Encyclopedia of Surgery

(22 Volume Set)

Andreas Lehrer • Kristin Mueller
Editors

Nova Medicine & Health

NOVA

ENCYCLOPEDIA OF SURGERY

VOLUME 1

(22 VOLUME SET)

No part of this digital document may be reproduced, stored in a retrieval system or transmitted in any form or by any means. The publisher has taken reasonable care in the preparation of this digital document, but makes no expressed or implied warranty of any kind and assumes no responsibility for any errors or omissions. No liability is assumed for incidental or consequential damages in connection with or arising out of information contained herein. This digital document is sold with the clear understanding that the publisher is not engaged in rendering legal, medical or any other professional services.

SURGERY – PROCEDURES, COMPLICATIONS, AND RESULTS

Additional books and e-books in this series can be found
on Nova's website under the Series tab.

SURGERY – PROCEDURES, COMPLICATIONS, AND RESULTS

ENCYCLOPEDIA OF SURGERY

VOLUME 1

(22 VOLUME SET)

ANDREAS LEHRER
AND
KRISTIN MUELLER
EDITORS

nova
Medicine & Health
New York

Copyright © 2020 by Nova Science Publishers, Inc.

All rights reserved. No part of this book may be reproduced, stored in a retrieval system or transmitted in any form or by any means: electronic, electrostatic, magnetic, tape, mechanical photocopying, recording or otherwise without the written permission of the Publisher.

We have partnered with Copyright Clearance Center to make it easy for you to obtain permissions to reuse content from this publication. Simply navigate to this publication's page on Nova's website and locate the "Get Permission" button below the title description. This button is linked directly to the title's permission page on copyright.com. Alternatively, you can visit copyright.com and search by title, ISBN, or ISSN.

For further questions about using the service on copyright.com, please contact:
Copyright Clearance Center
Phone: +1-(978) 750-8400 Fax: +1-(978) 750-4470 E-mail: info@copyright.com.

NOTICE TO THE READER

The Publisher has taken reasonable care in the preparation of this book, but makes no expressed or implied warranty of any kind and assumes no responsibility for any errors or omissions. No liability is assumed for incidental or consequential damages in connection with or arising out of information contained in this book. The Publisher shall not be liable for any special, consequential, or exemplary damages resulting, in whole or in part, from the readers' use of, or reliance upon, this material. Any parts of this book based on government reports are so indicated and copyright is claimed for those parts to the extent applicable to compilations of such works.

Independent verification should be sought for any data, advice or recommendations contained in this book. In addition, no responsibility is assumed by the Publisher for any injury and/or damage to persons or property arising from any methods, products, instructions, ideas or otherwise contained in this publication.

This publication is designed to provide accurate and authoritative information with regard to the subject matter covered herein. It is sold with the clear understanding that the Publisher is not engaged in rendering legal or any other professional services. If legal or any other expert assistance is required, the services of a competent person should be sought. FROM A DECLARATION OF PARTICIPANTS JOINTLY ADOPTED BY A COMMITTEE OF THE AMERICAN BAR ASSOCIATION AND A COMMITTEE OF PUBLISHERS.

Additional color graphics may be available in the e-book version of this book.

Library of Congress Cataloging-in-Publication Data

Names: Lehrer, Andreas, editor. | Mueller, Kristin, editor.
Title: Encyclopedia of surgery / Andreas Lehrer and Kristin Mueller.
Description: New York : Nova Science Publishers, [2020] | Series: Surgery - procedures, complications, and results | Includes bibliographical references and index. |
Identifiers: LCCN 2020031392 (print) | LCCN 2020031393 (ebook) | ISBN 9781536183290 (hardcover) | ISBN 9781536183887 (adobe pdf)
Subjects: LCSH: Surgery--Encyclopedias.
Classification: LCC RD17 .E53 2020 (print) | LCC RD17 (ebook) | DDC 617.003--dc23
LC record available at https://lccn.loc.gov/2020031392
LC ebook record available at https://lccn.loc.gov/2020031393

Published by Nova Science Publishers, Inc. † New York

CONTENTS

Preface **xli**

VOLUME 1

Chapter 1 Limb Lengthening by Combined Technique (External Fixator and Flexible Intramedullary Nailing): Experimental Studies **1**
Dmitry Popkov and Arnold Popkov

Chapter 2 Influence of the Transphyseal Sliding Nailing on Longitudinal Growth of the Tibia: Experimental Studies **13**
Dmitry Popkov, Natalia Kononovich, Roman Shutov and Dominique Barbier

Chapter 3 Lengthening and Deformity Correction of Lower and Upper Limbs **29**
Pierre Lascombes, Arnold Popkov, Pierre Journeau and Dmitry Popkov

Chapter 4 Influence of Lengthening on the Residual Limb Growth **51**
Pierre Journeau, Dmitry Popkov and Pierre Lascombes

Chapter 5 Bioactive Implants in Reconstructive Orthopedics **69**
Arnold Popkov

Chapter 6 Use of Intramedullary Bioactive Nailing in Deformity Correction in Patients with X-Linked Hereditary Hypophosphatemic Rickets **89**
Arnold Popkov

Chapter 7 Hybrid Technologies in Spinal Deformity Surgery **103**
Sergey Ryabykh

Chapter 8 Management of Posttraumatic Nonunions and Bone Defects by Combined Techniques (Ilizarov External Fixation and Interlocking Intramedullary Nailing). Experimental Studies and Clinical Practice **121**
Dmitry Borzunov, Alexander Mitrofanov, Sergey Kolchin, Andrey Emanov and Elena N. Gorbach

Chapter 9 Complications of Bariatric Surgery, Improvement of Comorbidities and Impact on Quality of Life **137**
Jaime Ruiz-Tovar and Carolina Llavero

Chapter 10 Adjustable Gastric Banding Surgery: Impact on Inflammation and Iron Metabolism **163**
Cristina Catarino, Susana Coimbra, Luís Belo, Luís Monteiro, Elísio Costa and Alice Santos-Silva

Chapter 11 Long Term Diabetes Outcomes after Bariatric Surgery **185**
Richard W. Carroll, Jeremy D. Krebs and Rinki Murphy

Chapter 12 Anesthesia Consideration and Management for Bariatric Surgery **209**
Antoni Sabaté and Sandra Llaurado

Chapter 13 Small Intestinal Bacterial Overgrowth after Bariatric Surgery **219**
Iman Andalib, Naveen Gara, Bikram S. Bal, Timothy R. Shope and Timothy R. Koch

Chapter 14 Optimal Physical Activity and Exercise Following Bariatric Surgery **235**
Matthew D. Barberio, Rosemary Lu and Monica J. Hubal

Chapter 15 Pregnancy after Bariatric Surgery **253**
Catarina Policiano, Alexandre Valentim Lourenço, Luísa Pinto and Luís Mendes Graça

Chapter 16 History and Development of Percutaneous Vertebral Augmentation Procedures **267**
Vincenzo Salini and Francesco Saverio Sirabella

Chapter 17 Thoraco-Lumbar Spine Anatomy **271**
Rosa M. Mirapeix

Chapter 18 Etiopathogenesis of Pathological and Traumatic Vertebral Fractures **277**
Vincenzo Levi and Mauro Pluderi

Chapter 19 Biomechanical Evaluation **281**
Daniele Vanni and Vincenzo Salini

Chapter 20 Epidemiology of Adult Thoracolumbar Fractures **285**
Luigi Aurelio Nasto and Enrico Pola

Chapter 21 Surgical Options for Thoracolumbar Vertebral Fractures **289**
Daniele Vanni, Vincenzo Magliani and Renato Galzio

Chapter 22 Vertebroplasty and Kyphoplasty: Role and Limits **295**
Daniele Vanni, Vincenzo Magliani and Renato Galzio

Chapter 23 Types, Morphology and Function of the New Devices **299**
Daniele Vanni and Vincenzo Magliani

Chapter 24 VBS: Evaluation and Indications **305**
Daniele Vanni and Vincenzo Magliani

Chapter 25 Spine Jack: Evaluation and Indications **313**
Daniele Vanni, Vincenzo Magliani and Vincenzo Salini

Chapter 26 Osseofix: Evaluation and Indications **321**
Marcello Bartolo, Giovanni Grillea and Giovanni Nano

VOLUME 2

Chapter 27 Surgical Technique **329**
Daniele Vanni, Vincenzo Magliani and Renato Galzio

Chapter 28 Alternatives to PMMA for Vertebral Augmentation Procedures **343**
Daniele Vanni and Vincenzo Salini

Chapter 29 Stem Cells and Biotechnologies for Vertebral Augmentation Procedures **349**
Andrea Pantalone, Matteo Guelfi and Vincenzo Salini

Chapter 30 Brow Lift **353**
Richard Baker and Afshin Mosahebi

Chapter 31 Blepharoplasty **377**
Mano Sira

Chapter 32 Facelift **393**
Fulvio Urso-Baiarda and Rajiv Grover

Chapter 33 Rhinoplasty **421**
Samuel Hahn and Oren Friedman

Chapter 34 Mastopexy **453**
Daniel Marsh and Niri Niranjan

Chapter 35 Breast Augmentation **469**
Patrick Mallucci and Olivier Alexandre Branford

Chapter 36 Breast Reduction **495**
Gurjinderpal Singh Pahal and Venkat Ramakrishnan

Chapter 37 Liposuction **517**
Reza Nassab

Chapter 38 Botulinum Toxin **537**
Darren J. McKeown

Chapter 39 Facial Fillers **559**
Darren J. McKeown

Chapter 40 Body Contouring Using Implant Prostheses **579**
Daniel Saleh and Mohammed Riaz

Chapter 41 Cosmetic Surgery in the Adolescent Patient **593**
Kelsey Larson, Sidhi Gosain and Arun Gosain

Chapter 42 Hand Rejuvenation **611**
Kuen Chin and Fulvio Urso-Baiarda

Chapter 43 Body Dysmorphic Disorder **631**
Valerie Picavet and Peter Hellings

Chapter 44 Development of a Surgical Navigation System Based on 3D Slicer Using Augmented Reality (AR) Technology **645**
Xiaojun Chen and Lu Xu

VOLUME 3

Chapter 45 Application of Navigation System in Bimaxillary Surgery **665**
Sun Yi and Constantinus Politis

Chapter 46 Computer-Assisted Minimally Invasive Surgery: Image-Guided Interventions and Robotic Surgery **679**
Francisco M. Sánchez Margallo and Juan A. Sánchez Margallo

Chapter 47 Modified Methods of Setting Up the Spinal Navigation System **719**
Sang Hoon Jang and Ho-Yeon Lee

Chapter 48 Ultrasound Imaging for Robotic Orthopedic Surgery: A Survey **727**
Pedro M. B. Torres and Paulo J. S. Gonçalves

Chapter 49 Development of Scrub Nurse Robot (SNR) Systems for Laparoscopic Surgery **737**
Kitaro Yoshimitsu

Chapter 50 T-Cell Shape Variation with Intra-Cellular Ca2+ Concentration: A Joint Image and Shape Study **749**
Yi Gao, Wei Chen, Baoyu Liu, Allen Tannenbaum and Cheng Zhu

Chapter 51 Revisional Bariatric Surgery for Weight Regain: A Programmatic Approach **757**
Eric J. DeMaria and Meredith A. Grzybowski

Chapter 52 Metabolic Failures and Bariatric Procedures **763**
Pedro Paulo Caravatto, Tarissa Zanata Petry and Ricardo Cohen

Chapter 53 Diagnostic Tools in Failed Bariatric Procedures **773**
Rudolf Weiner, Islam A. El-sayes and Sylvia Weiner

Chapter 54 Adjustable Gastric Band Failures **799**
J. W. M. Greve

Chapter 55 Failed Sleeve Gastrectomy **811**
Ricard Corcelles and Antonio Lacy

Chapter 56 Reoperations for Roux-en-Y Gastric Bypass Failures **821**
Jacques M. Himpens and Ramon Vilallonga

Chapter 57	Failed Minigastric Bypass: Surgical Strategies *Jean-Marc Chevallier*	**843**
Chapter 58	Surgical Procedures for Failure of Biliopancreatic Diversion with Duodenal Switch (BPD-DS) *Simon Marceau, Simon Biron, Frédéric-Simon Hould, Stefane Lebel, Odette Lescelleur, Laurent Biertho and Picard Marceau*	**861**
Chapter 59	Failed BPD *Giuseppe Maria Marinari, Vincenzo Borrelli and Luc Lemmens*	**869**
Chapter 60	History of Subarachnoid Haemorrhage *Dieter H. Woischneck*	**877**
Chapter 61	Arterial and Venous Vascularisation of the Brain *Horst Claassen*	**885**
Chapter 62	Neuropathologie of Subarachnoid Haemorrhage *Angelika Scheuerle*	**905**
Chapter 63	Subarachnoid Haemorrhage *Stefan Röhrer*	**913**
Chapter 64	Risk Factors: Formation, Growth, Rupture *Karl-Michael Schebesch and Petra Schödel*	**917**
Chapter 65	Scales *Petra Schödel and Karl-Michael Schebesch*	**921**
Chapter 66	Symptoms, Extracranial Manifestations *Petra Schödel and Karl-Michael Schebesch*	**927**
Chapter 67	Admission, Diagnostic Imaging, Acute Hydrocephalus *Thomas Schmidt*	**931**
Chapter 68	Endovascular Treatment of Aneurysms. Pre-, Peri- and Post- Interventional Management *G. Friedrich Götz*	**945**
Chapter 69	Aneurysms: Surgical Therapy *Ralph König*	**957**
Chapter 70	Decompressive Craniectomy and Aneurysmal Subarachnoid Haemorrhage *Stefan Röhrer*	**967**
Chapter 71	Intensive Therapy I for SAH *Thomas Kerz*	**971**
Chapter 72	Neuroprotection: DCI, Vasospasm, Nimodipine *Christian Heinen*	**979**

VOLUME 4

Chapter 73	Intensive Care: Monitoring *Werner Klingler and Dirk Repkewitz*	**991**
Chapter 74	Endovascular Treatment Options for Cerebral Vasospasm after Spontaneous Subarachnoid Haemorrhage *Yigit Ozpeynirci and Bernd Schmitz*	**1001**
Chapter 75	Chronic Hydrocephalus after Subarachnoid Haemorrhage *Alexandra Huthmann and Christoph A. Tschan*	**1019**
Chapter 76	Epileptic Seizures in Association with Spontaneous Subarachnoid Haemorrhage *Sarah Jesse*	**1027**
Chapter 77	Neurorehabilitation after Subarachnoid Haemorrhage *Martin Schorl and Michael Hartwich*	**1035**
Chapter 78	Cognitive Plasticity after Spontaneous Subarachnoid Haemorrhage *Christine Brand*	**1057**
Chapter 79	Health-Related Quality of Life Following Spontaneous Subarachnoid Haemorrhage as an Assessment Criterion for Therapeutic Outcome *Thomas Kapapa*	**1063**
Chapter 80	Experimental Models for the Study of Subarachnoid Haemorrhage *Nicole A. Terpolilli*	**1069**
Chapter 81	Vascular Imaging *Athanasios Saratzis*	**1079**
Chapter 82	The Role of Imaging in Colorectal Surgery *M. G. Pramateftakis, A. Kalogera-Fountzila, K. Sapalidis and E. Kotidis*	**1091**
Chapter 83	The Role of Imaging in Breast Surgery *Vasileios N. Papadopoulos*	**1109**
Chapter 84	The Role of Imaging in Neurosurgery *Savvas Grigoriadis, Christine Karatziou, Maria Sidiropoulou, Athanasia Anastasiou, Eleni Tsatsali and Georgios Giakoumettis*	**1159**
Chapter 85	The Role of Imaging in Parathyroid Surgery *I. Koutelidakis, A. Doundis, A. Ananiadis, S. Kalaitzis, T. Kaltsikis and V. Papaziogas*	**1193**
Chapter 86	The Role of Imaging in Adrenal Surgery *K. Sapalidis, I. Anastasiadis, E. Kotidi, M. G. Pramateftakis and I. Chrysogonidis*	**1207**
Chapter 87	The Role of Imaging in Hepatobiliary Surgery *Polyxeni Agorastou, Andreas Tooulias and Georgios Tsoulfas*	**1223**

Chapter 88 The Role of Imaging in Pancreatic Surgery **1233**
A. Mastoraki, N. Economopoulos, I. Papanikolaou and N. Arkadopoulos

Chapter 89 The Role of Imaging in Esophageal Surgery **1295**
Efstathios Kotidis, Konstantinos Sapalidis and Manos-Georgios Pramateftakis

VOLUME 5

Chapter 90 The Role of Imaging in Gastric Surgery **1323**
Efstathios Kotidis, Manos-Georgios Pramateftakis and Nikolaos Michalopoulos

Chapter 91 The Role of Imaging in Urology **1341**
Michelle Kim, Douglas A. Mata and Dicken S. C. Ko

Chapter 92 The Role of Imaging in Plastic Surgery **1357**
Alexandros Mekras and Vasileios Kalles

Chapter 93 Wrist Fractures in Adults: What Should a Medical Student Know? **1369**
Fares E. Sayegh

Chapter 94 Minimally Invasive Midface Lift Using Absorbable Sutures with Cones: A Step by Step Procedure **1377**
M. Goisis, A. Di Petrillo, L. Rosset, A. Kunderfranco, S. Mele, E. Stella and S. Khabouri

Chapter 95 Free Flap Breast Reconstruction: New Updates and Refinements on a Well Established Technique **1405**
Cedric L. Hunter and Gordon K. Lee

Chapter 96 New Materials and Techniques in General and Digestive Ambulatory Surgery **1429**
J. M. Suárez Grau, Dra. S. García Ruiz, Dra. C. Mendez García, C. Rubio Chaves and F. Docobo Durántez

Chapter 97 Ambulatory Surgery: Anesthetic Management and Complications **1443**
Monica del-Rio-Vellosillo and Jose Javier Garcia-Medina

Chapter 98 Ambulatory Surgery in Orthopaedics: Prevalence, Complications and Long-Term Outcomes **1463**
Omar Faour Martín and Miguel Ángel Martín Ferrero

Chapter 99 Advances in Surgical Procedures Thyroid Goitres: Surgery for Large and Difficult Goitres **1473**
Yassar A. Qureshi and Fiona McClenaghan

Chapter 100 Electrical Stimulation for Improving Physical Fitness Pre- and Postoperatively after Abdominal Surgery **1485**
Artur Marc Hernández

Chapter 101 Scenario Based MCQs in Oral Surgery **1513**
Arun Priya Srinivasan, Namdeo Prabhu and Mohammed Kassab

Chapter 102 The Role of Surgery in the Treatment of OSAS **1533**
F. Lorusso, A. Battaglia, A. Mistretta and S. Gallina

Chapter 103 Laparoscopic Surgery In Situs Inversus **1559**
Pankaj Kumar, Tushar S. Mishra and Siddhant Sarthak

Chapter 104 Management of Surgical Wounds Infections in Spine Surgery **1569**
M. Dobran, D. Nasi, S. Veccia and A. Giacometti

Chapter 105 Historical Evolution of Conservative Surgery of Breast Cancer **1577**
Maria Antonia Vaquero-Pérez, Jesus S. Torres-Jimenez and José Manuel Ramia-Ángel

Chapter 106 Surgery of Colorrectal Liver Metastases Involving the Inferior Vena Cava **1587**
Mario Serradilla-Martín, Pablo Ruíz-Quijano, Ana Palomares-Cano and José M. Ramia-Ángel

Chapter 107 Multidisciplinary Approach to Gender Reassignment Surgery in a DSD 46XX Patient with Delayed Diagnosis of Congenital Adrenal Hyperplasia: A Case Report **1599**
K. Sumapradja, R. A. Putri, A. K. Harzif, C. L. Sukasah and S. D. Elvira

Chapter 108 Cerebrovascular Bypass Surgery in the Treatment of Brain Aneurysms **1609**
Goran Mrak, Jakob Nemir and Hrvoje Barić

Chapter 109 Indocyanine Green Video-Angiography with FLOW 800 Analysis: Applications in Neuro-Oncological Surgery **1631**
Morgan Broggi, Jacopo Falco, Costanza M. Zattra, Marco Schiariti, Ignazio G. Vetrano, Giovanni Tringali, Giovanni Broggi, Paolo Ferroli and Francesco Acerbi

VOLUME 6

Chapter 110 The Application of Indocyanine Green Videoangiography as an Adjunct for Arteriovenous Malformation Surgery **1653**
Ann Knoll, Dara Sam Farhadi, Megan Cadigan, Joseph Georges and Peter Nakaji

Chapter 111 Current Trends in Functional Muscle Transfer to Improve Outcomes in Facial Reanimation Surgery **1665**
Ioana Lese and Adriaan O. Grobbelaar

Chapter 112 The Role of Endoscopic Sinus Surgery in Pediatric Patients **1679**
Marco Berlucchi and Michele Tomasoni

Chapter 113 Femtosecond Laser-Assisted Refractive Surgery **1709**
Hui Sun

Chapter 114 Surgery in Malignant Pleural Mesothelioma:
Extra-Pleural Pneumonectomy – A Critical Appraisal **1721**
Luca Bertolaccini and Lorenzo Spaggiari

Chapter 115 Guided Tissue Regeneration in Maxillofacial Surgery **1729**
Francine Benetti, João E. Gomes-Filho,
Gustavo Sivieri-Araújo, Rogério de C. Jacinto,
Elói Dezan-Júnior and Luciano T. A. Cintra

Chapter 116 How to Prevent Orthopedic Complications and Early Surgery
in CP Children: Role of Botulinum Toxin Therapy **1753**
Vera Zmanovskaya, Elena Levitina and Svetlana Ushakova

Chapter 117 Nutritional Care in Children with Cerebral Palsy.
Perioperative Management of Patients with Cerebral Palsy
Undergoing Orthopedic Surgery **1765**
Anna Shaitarova, Olga Perfilova and Elena Khramova

Chapter 118 Single-Event Multilevel Orthopedic Surgery in Children
with True Equinus Gait and Jump Knee Gait **1779**
Sergey Leonchuk, Georgy Chibirov, Tamara Dolganova,
Dmitry Dolganov and Dmitry Popkov

Chapter 119 Distal Rectus Femoris Transfer as a Part of Single-Event
Multilevel Orthopedic Surgery **1793**
Georgy Chibirov, Orhan Gatamov, Tamara Dolganova,
Dmitry Dolganov and Arnold Popkov

Chapter 120 Single-Event Multilevel Orthopedic Surgery in CP Patients
with Natural and Iatrogenic Crouch Gait **1801**
Tamara Dolganova, Georgy Chibirov, Orhan Gatamov,
Dmitry Dolganov and Dmitry Popkov

Chapter 121 Reconstructive Hip Surgery as a Part of Multilevel Surgery
in Non-Ambulant CP Children. Hip Development
after Reconstructive Surgery **1815**
Ahmed Tomov, Georgy Chibirov, Sinisa Ducic,
Arnold Popkov and Anna Aranovich

Chapter 122 Percutaneous Endoscopic Gastrostomy: Historical Perspective **1831**
Jeffrey L. Ponsky

Chapter 123 Indications, Contraindications, Decision Making
and Informed Consent **1837**
Robert D. Fanelli and Josephine A. Fanelli

Chapter 124 Palliative Considerations of Gastrostomy **1847**
Julie L. Mitchell and Susan A. Glod

Chapter 125 Preoperative Management **1861**
Valerie Wu Chao Ying and Jose M. Martinez

Chapter 126 Anesthesia for PEG Tube Placement **1871**
S. William Hazard, III

Chapter 127 Diagnostic Endoscopy during PEG **1885**
Susan M. Wetzel, Mei Chris Huang and John D. Mellinger

Chapter 128 Percutaneous Endoscopic Gastrostomy: The 'Pull' Technique **1907**
Kyle L. Kleppe and Melissa Phillips LaPinska

Chapter 129 Percutaneous Endoscopic Gastrostomy: The 'Push' Technique **1921**
Keyur Parikh and Richard C. K. Wong

Chapter 130 Percutaneous Endoscopic Gastrostomy: Introducer Technique **1931**
Sean B. Orenstein

Chapter 131 Direct Percutaneous Endoscopic Jejunostomy **1947**
Mena Boules, Andrew Strong and Matthew Kroh

Chapter 132 PEG with Jejunal Extension Tube **1957**
Ryan R. Gaffney and Matthew T. Moyer

Chapter 133 Alternative Gastric Access Methods: SLiC and PTEG **1973**
Adrian B. Dobrowolsky and Bipan Chand

VOLUME 7

Chapter 134 'Assisted' PEG Placement **1983**
Salvatore Docimo, Jr. and Eric M. Pauli

Chapter 135 PEG and PEJ in the Post-Bariatric Surgery Patient **1995**
Ryan M. Juza and Ann M. Rogers

Chapter 136 Alternative Uses of Percutaneous Endoscopic Gastrostomy **2009**
Heidi J. Miller and Jeffrey M. Marks

Chapter 137 Postoperative Management **2023**
Fazia A. Mir, Douglas L. Nguyen and Matthew L. Bechtold

Chapter 138 Prevention of Peristomal PEG Infection **2039**
Iruru Maetani

Chapter 139 Acute Complications of PEG **2055**
Lava Y. Patel and Michael B. Ujiki

Chapter 140 Chronic Complications of PEG **2077**
Faris M. Murad and Jeffrey A. Blatnik

Chapter 141 Endoscopic Management of PEG Related Complications **2091**
Joshua S. Winder and Eric M. Pauli

Chapter 142 Gastric Bypass Surgery and the Skin **2103**
Katherine Fiala and Ryan Batson

Chapter 143 Treating the Obese Patient with Type 2 Diabetes Post-Bariatric Surgery **2119**
Steven K. Malin, Jennifer L. Kirby and Peter T. Hallowell

Chapter 144 Gastrointestinal Hormones and Roux-en-Y Gastric Bypass **2139**
Deniz Atalayer

Chapter 145 Bariatric Surgery Alters Gut Metabolism: Role in Obesity and Type 2 Diabetes Resolution **2173**
Steven K. Malin

Chapter 146 CT Scan and 3D Applications for Hip Surgery **2189**
T. Robba, D. Molino, D. Martorano and A. Borre

Chapter 147 3D Fluoroscopy and Its Applications in Hip Surgery **2211**
Matteo Giachino, Alessandro Aprato, Claudio Degiorgis, Luigi Conforti, Giuseppe Massazza and Alessandro Massè

Chapter 148 MRI and 3D Applications for Hip Surgery **2227**
M. Busso, M. Falco, E. Shaipi, G. Gallo, P. Arnoffi and A. Veltri

Chapter 149 A Virtual Model in Hip Preserving Surgery **2249**
Paolo Di Benedetto, Michele Mario Buttironi and Araldo Causero

Chapter 150 The Limits and Future of Collision Models **2267**
Alessandro Aprato, Filippo Palmesino, Luca Ulrich, Enrico Vezzetti, Matteo Giachino and Alessandro Massè

Chapter 151 3D Customizing in Complex Primary Hip Replacement **2275**
Alessandro Aprato, Simone De Vivo, Francesco Marra, Alberto Nicodemo, Alessandro Bistolfi and Alessandro Massè

Chapter 152 3D Customizing in Revision Hip Replacement **2293**
A. Aprato, A. D'Amelio, F. Marra, M. M. Favuto, D. Mellano and A. Massè

VOLUME 8

Chapter 153 3D Customizing in Oncologic Hip and Pelvic Surgery **2311**
Michele Boffano, Pietro Pellegrino, Nicola Ratto and Raimondo Piana

Chapter 154 The Role of Surgical Resection in Hepatocellular Carcinoma: Anatomic versus Parenchyma-Sparing Resection and Their Oncological Outcomes **2333**
Simone Famularo, Alessandro Giani, Fabio Uggeri, Cristina Ciulli, Luca Nespoli, Giulia Lo Bianco, Luca Arzuffi, Luca Gianotti and Fabrizio Romano

Chapter 155 Laparoscopic Liver Resection for Hepatocellular Carcinoma Patients: Indications and Benefits **2363**
Zenichi Morise

Chapter 156 Post-Craniotomy Temporomandibular Dysfunction: Pathophysiology, Diagnosis and Treatment **2379**
Thiago Martinelli, Fernando Akio Maeda, Claudio Fróes de Freitas and Andre Luiz Ferreira Costa

Chapter 157 Medical and Surgical Advances in Bronchoscopy **2389**
Jack A. Kastelik, Mahmoud Loubani, Kate Dixon and Keyvan Moghissi

Chapter 158 Canine Fossa Puncture for the Management of Maxillary Sinusitis **2403**
Federico Sireci, Francesco Martines, Francesca De Bernardi, Salvatore Poma, Francesco Dispenza, Bruno Galletti, Francesco Galletti and Frank Rikki Canevari

Chapter 159 Complications and Their Management in Endoscopic Sinus Surgery (ESS) **2409**
Federico Sireci, Francesco Martines, Pietro Salvago, Claudio Sbacchi, Vincenzo Immordino, Francesco Galletti, Bruno Galletti, Giovanni Cimino, Francesco Dispenza and Frank Rikki Canevari

Chapter 160 Surgical Corridors in the Transphenoidal Skull Base Surgery **2419**
Federico Sireci, Giulia Danè, Francesco Martines, Francesco Dispenza, Francesco Galletti, Giorgio Peretti, Matteo Vitali and Frank Rikki Canevari

Chapter 161 The Role of Endoscopic Sinus Surgery in Pediatric Patients with Cystic Fibrosis **2427**
Marco Berlucchi, Vittorio Rampinelli, Marco Ferrari, Piercarlo Poli, Luigi Fomasi, Silviana Timpano and Rita Padoan

Chapter 162 Postoperative Pancreatic Fistula Following Distal Pancreatectomy **2441**
Jennifer L. Olson and Richard J. Bold

Chapter 163 Mininvasive Surgical Approach in Endoscopic Sinus Surgery (ESS) **2455**
Federico Sireci, Francesco Galletti and Frank Rikki Canevari

Chapter 164 Powered Adenoidectomy **2461**
Max M. April

Chapter 165 Intracapsular Tonsillectomy: My Surgical Approach (Max M. April, MD, FAAP, FACS) **2471**
Max M. April

Chapter 166 Intracapsular Tonsillectomy: My Surgical Approach (Robert F. Ward, MD, FACS) **2483**
Robert F. Ward

Chapter 167 Intracapsular Tonsillectomy: My Surgical Approach (John P. Bent, MD) **2487**
John P. Bent

Chapter 168 Extracapsular Tonsillectomy in 2017 **2493**
Lyuba Gitman and Nira A. Goldstein

Chapter 169 Coblation Intracapsular Tonsillectomy **2513**
Sophie Shay and Nina L. Shapiro

Chapter 170 The Results of Intracapsular vs. Extracapsular Tonsillectomy **2519**
Benjamin J. Rubinstein and Craig S. Derkay

Chapter 171 The Management of Post-Tonsillectomy Pain in Children **2529**
David E. Tunkel and Grace X. Tan

Chapter 172 Conclusion and Future Questions **2543**
Max M. April

Chapter 173 DIEP Flap Breast Reconstruction: Technical Tips to Optimize Outcomes and Avoid Complications **2551**
Koichi Tomita and Kenji Yano

Chapter 174 Effect of Radiotherapy on Implant-Based Immediate Breast Reconstruction with or without Acellular Collagen Matrix: Potential Strategies to Improve Outcome **2565**
Baek Kim and Rajgopal Achuthan

Chapter 175 Patient Satisfaction Following Autologous or Heterologous Breast Reconstruction **2583**
Laura Sita-Alb, Laura Duta and Lucian Fodor

Chapter 176 What Comes after a Free Flap Failure for Breast Reconstruction? **2607**
Lucian Fodor, Raluca Sobec, Laura Sita and Dragos Zamfirescu

Chapter 177 Reconstruction of the Nipple-Areolar Complex **2615**
Dragos Zamfirescu, Lucian Fodor, Matei Iordache and Andreea Bularda

Chapter 178 Dealing with Complications after Free Flap Breast Reconstruction **2635**
Raluca Sobec, Ioana Tichil and Lucian Fodor

VOLUME 9

Chapter 179 Managing Complications in Free-Flap Breast Reconstruction **2649**
Gordon K. Lee, Jarom N. Gilstrap and Jennifer E. Cheesborough

Chapter 180 The Effect of Sleeve Gastrectomy on Metabolic Comorbidities **2677**
Jaime Ruiz-Tovar and Carolina Llavero

Chapter 181 The Left-Handed Sleeve Gastrectomy: The Technique to Avoid Postoperative Gastric Stenosis or Gastric Twist **2683**
Pierre Blanc and Christophe Breton

Chapter 182 Weight Regain Following Sleeve Gastrectomy **2689**
Melanie Lauti, Andrew G. Hill and Andrew D. MacCormick

Chapter 183 The Utilisation of Enhanced Recovery after Surgery Programmes in Sleeve Gastrectomy **2713**
Daniel P. Lemanu, Andrew G. Hill and Andrew D. MacCormick

Chapter 184 Laparoscopic Duodenojejunal Bypass with Sleeve Gastrectomy **2729**
Chih-Kun Huang, Michelle Bernadette C. Lim-Loo, Thakoon Poonthananiwatkul, Vivek Kulkarni and Abhishek Katakwar

Chapter 185 Laparoscopic Sleeve Gastrectomy: Paying Attention to the Detail **2749**
F. Frattini, M. Lavazza, V. Quintodei, R. Delpini, F. Martignoni, A. Bacuzzi, E. Piantanida, S. Rausei, L. Boni and G. Dionigi

Chapter 186 Laparoscopic Experimental Surgery Models **2761**
Natalie Bath, Demetrius Litwin and Paulo N. Martins

Chapter 187 Experimental Models of Sepsis **2795**
Norbert Nemeth, Mihai Oltean and Bela Fulesdi

Chapter 188 Bariatric Experimental Surgery Models **2831**
Osman Bilgin Gulcicek

Chapter 189 Animal Models of Heart Failure **2839**
Mouer Wang

Chapter 190 Hepatopancreatobiliary Surgery Experimental Models **2865**
Paulo N. Martins, Natalie Bath and Adel Bozorgzadeh

Chapter 191 Animal Models of Acute Graft-Versus-Host and Host-Versus-Graft Responses and Disease **2915**
Abraham Matar and Raimon Duran-Struuck

Chapter 192 Microfluidic Devices and Micro-Dissected Tissue to Predict Therapeutic Response in Patients with Prostate Cancer **2939**
Robin Guay-Lord, Muhammad Abdul Lateef, Kayla Simeone, Benjamin Péant, Jennifer Kendall-Dupont, Anne-Marie Mes-Masson, Thomas Gervais and Fred Saad

Chapter 193 Of Mice and Rats: Animal Models for Use in Laparoscopy and Laparotomy with Human Ovarian Cancer Cell Line Intraperitoneal Xenografts **2967**
Philippe Sauthier, Anne-Marie Mes-Masson, Louise Champoux, Michèle Bally and Diane M. Provencher

VOLUME 10

Chapter 194 Organ Bioengineering through Decellularization and Recellularization Approaches **2983**
Maria Jaramillo and Basak E. Uygun

Chapter 195 Wound Healing and Scarring **3009**
A. Samandar Dowlatshahi

Chapter 196 Organ Preservation **3023**
Cheng Yang, Jiawei Li and Ruiming Rong

Chapter 197 Machine Organ Preservation **3043**
Hazel L. Marecki, Isabel Brüggenwirth and Paulo N. Martins

Chapter 198 Microcirculation **3073**
Norbert Nemeth and Andrea Szabo

Chapter 199 Experimental Gene Therapy Using Naked DNA **3115**
Eiji Kobayashi

Chapter 200 Robotic Surgery in Experimental Medicine **3129**
Sandra S. Y. Kim, David Ian Harriman and Christopher Nguan

Chapter 201 History, Development and the Importance of Experimental Surgery **3159**
Huifang Chen and Pierre Daloze

Chapter 202 The Discovery, Development and Patent Protection of New Drugs in Experimental and Clinical Research **3201**
Anlun Ma

Chapter 203 Ethical, Legal and Educational Issues in Experimental Surgery **3237**
Kupa Bilolo

Chapter 204 Veterinary Care and Management of Rodent and Large Animal Models in Transplantation Research **3259**
Patrick Lester, James Marx, Portia S. Allen, Bram V. Lutton and Raimon Duran-Struuck

Chapter 205 Pre-Operative and Postoperative Care in Experimental Surgery **3303**
Yanxin Hu

VOLUME 11

Chapter 206 Fluid, Electrolytes, and Acid-Base Balance in Experimental Surgery **3313**
Kupa Bilolo

Chapter 207 Imagery Techniques in Experimental Surgery **3337**
Junzheng Peng and Huifang Chen

Chapter 208 Telemetry Applications in Experimental Animals for Studying Human Diseases **3375**
Junzheng Peng and Huifang Chen

Chapter 209 Small Animals as Experimental Models **3413**
Rebekah Wilson, Adrien Kissenpfennig and James McDaid

Chapter 210 Large and Translational Animal Models in Experimental Surgery **3427**
Kupa Bilolo

Chapter 211 Cardiovascular Biomechanical Models **3449**
Ethan Kung

Chapter 212 Isolated Kidney Perfusion Models **3479**
Isabel M. A. Brüggenwirth, Henri G. D. Leuvenink and Paulo N. Martins

Chapter 213 Isolated Liver Perfusion Systems **3509**
Isabel Brüggenwirth, Hazel Marecki and Paulo N. Martins

Chapter 214 Experimental Models of Cartilage Repair **3537**
Jakub Zafar Qazi, Huifang Chen and Muhammad Zafarullah

Chapter 215 Experimental Models of Fracture Repair **3557**
Jakub Zafar Qazi, Huifang Chen and Muhammad Zafarullah

Chapter 216 Experimental Solid Organ Transplantation in Small Animals **3583**
Hao Dun

Chapter 217 Large Animal Models in Organ Transplantation **3611**
Babak Movahedi, Maria Lucia Madariaga, Sebastian Michel, Adel Bozorgzadeh and Paulo N. Martins

VOLUME 12

Chapter 218 Experimental Composite Tissues and Soft Tissues Transplantation **3647**
Hao Wang

Chapter 219 Ischemia-Reperfusion Injury Animal Models **3665**
Junzheng Peng and Huifang Chen

Chapter 220 Encapsulated Islet Transplantation: From Allogeneic to Xenogeneic Transplantation **3721**
Kun Ho Yoon, Eun Young Lee, Jun-Seop Shin, Byoung-Hoon Min, Jong-Min Kim and Chung-Gyu Park

Chapter 221 Hepatocyte Transplantation **3745**
Nalu Navarro Alvarez and Paulo Martins

Chapter 222 Preclinical Models of Decompressive Craniectomy: Lessons from Experimental Traumatic Brain Injury and Other Disease Models **3765**
E. G. Hayman, M. J. Kole and J. M. Simard

Chapter 223 Impaired Cerebral Energy Metabolism Following Traumatic Brain Injury Contributes to Poor Outcomes and Limits the Effectiveness of Decompressive Craniectomy **3781**
Courtney L. Robertson and Gary M. Fiskum

Chapter 224 Multimodal Monitoring in Decompressive Craniectomy for Traumatic Brain Injury and Stroke **3799**
Masoom Desai, Corey Lewis and Neeraj Badjatia

Chapter 225 Decompressive Craniectomy: The Effects on Neurochemistry and Brain Oxygen Delivery **3835**
Anna Teresa Mazzeo, Ashley Ralston, Deepak Gupta and Ross Bullock

Chapter 226 Medical Management of Intracranial Hypertension and Indications for Secondary Decompressive Craniectomy **3851**
G. Schwartzbauer and D. Stein

Chapter 227 Preoperative and Postoperative Nursing Care of Patients Undergoing Decompressive Craniectomy **3875**
Karen A. McQuillan and Tya Schoppe

Chapter 228 Decompressive Laparotomy to Treat Intracranial Hypertension and Multiple Compartment Syndrome **3917**
Margaret H. Lauerman and Thomas M. Scalea

Chapter 229 Decompressive Craniectomy in Ischemic Stroke **3931**
Matthew Jaffa, Carolyn A. Cronin and Barney J. Stern

Chapter 230 Decompressive Craniectomy in Diffuse Injury: Interpretation and Implications of the International DECRA Randomized Trial **3949**
D. J. Cooper, A. Udy, A. Nichol, J. V. Rosenfeld and M. Hunn

Chapter 231 Decompressive Craniectomy for Refractory Posttraumatic Intracranial Hypertension: Interpretation and Implications of the International RESCUEicp Randomized Trial **3957**
Tamara Tajsic, Angelos G. Kolias, Hadie Adams, Ivan Timofeev, David K. Menon and Peter J. Hutchinson

Chapter 232 Outcome Following Decompressive Craniectomy for Managing High Intracranial Pressure in Traumatic Brain Injury Patients: A Systematic Review **3967**
Juan Sahuquillo and Jane A. Dennis

VOLUME 13

Chapter 233 Decompressive Craniectomy in Pediatric TBI **3991**
David S. Hersh and Mari L. A. Groves

Chapter 234 Early Decompressive Craniectomy for Blast and Penetrating Brain Injury in War: Lessons for Civilian Surgeons **4011**
Jeffrey V. Rosenfeld, Randy S. Bell and Rocco Armonda

Chapter 235 Decompressive Craniectomy in Casualties from OIF and OEF: Management after Evacuation from the War Zone **4033**
Chris J. Neal, Randy S. Bell, Nicholas Szuflita and Rocco Armonda

Chapter 236 Guidelines for the Management of Severe Traumatic Brain Injury: Recommendations from the 2017 Fourth Edition **4045**
Kevin Kwan, Jamie S. Ullman, Julia Schneider, Gregory W. J. Hawryluk, Annette Totten and Jamshid Ghajar

Chapter 237 Decompressive Craniectomy: Surgical Indications in Developed versus Developing Countries **4055**
Franco Servadei, Corrado Iaccarino, Edoardo Picetti, Davide Nasi and Stephen Honeybul

Chapter 238 Timing and Technique of Cranioplasty **4071**
Gabriel F. Santiago, Judy Huang and Chad R. Gordon

Chapter 239 Complications of Decompressive Craniectomy **4081**
M. J. Kole, D. S. Hersh and G. Schwartzbauer

Chapter 240 Decompressive Craniectomy: Prognosis and Communication with Patient Families **4091**
O. Ugochukwu, D. Stein and S. Honeybul

Chapter 241 Ethical Considerations in Decompressive Craniectomy **4107**
Stephen Honeybul, Franco Servadei, Kwok Ming Ho, Luca Longhi and Grant Gillett

Chapter 242 The Prognostic Value of Traumatic Brainstem Injury on Magnetic Resonance Imaging: A Systematic Review **4119**
B. Aarabi, A. Wessell, N. Pratt, T. Chryssikos, M. Scarboro, C. Diaz Lomangino and C. Aresco

Chapter 243 Robotic Portal Lung Resection **4141**
Roman V. Petro, Charles T. Bakhos and Abbas E. Abbas

Chapter 244 Robotic-Assisted Mediastinal Mass Resection **4153**
Wissam Raad and Faiz Bhora

Chapter 245 Robotic Assisted Minimally Invasive Esophagectomy for Esophageal Cancer **4159**
Matthew C. Black, James D. Luketich and Inderpal S. Sarkaria

Chapter 246 Fundamental Approaches and Challenges to Benign Esophageal Robotic Surgery **4171**
Caitlin Wahl and John F. Lazar

Chapter 247 Robotic Mitral Valve Replacement and Repair **4187**
T. Sloane Guy, Lucas B. Ohmes and Ahmed A. Abouarab

Chapter 248 Robotic Coronary Revascularization **4201**
Philip Erwin, Sharon Ben-Or and Eric J. Lehr

Chapter 249 Robotic Approaches for Rectal Cancer **4219**
Kevin T. Behm and David W. Larson

Chapter 250 Robotic-Assisted Abdominal Wall Hernia Repair **4237**
Paul A. R. Del Prado and James G. Bittner, IV

Chapter 251 Robotic Hepatobiliary and Pancreatic Surgery **4261**
Sushruta S. Nagarkatti and John B. Martinie

Chapter 252 Robotic-Assisted Bariatric Surgery **4291**
Matthew Sharbaugh and Christopher You

VOLUME 14

Chapter 253 Robotic Urologic Surgery for Benign Disease **4317**
Aryeh Keehn and Daniel Eun

Chapter 254 Robotic Surgery for Urologic Malignancies **4345**
Jay D. Raman

Chapter 255 Applications of Robotic-Assisted Surgery in Urogynecology **4367**
Sarah A. Huber and Patrick J. Culligan

Chapter 256 Robotic Surgery: Clinical Perceptions, Approaches, and Challenges in Gynecologic Oncology **4397**
Tommaso Grassi, Valentina Zanfagnin, Stephanie R. DeJong, Jvan Casarin and Andrea Mariani

Chapter 257 Transoral Robotic Surgery: Treatment of Head and Neck Disease **4447**
Changxing Liu, Mark Swanson and Niels Kokot

Chapter 258 Robotic Surgery: Evolution, Challenges and the Future **4463**
Richard S. Lazzaro, Byron Patton, Landon Guntman and Faiz Bhora

Chapter 259 Robotic Surgery in Benign Gynecology **4471**
Yonghee K. Cho and Gerald Harkins

Chapter 260 Antibiotic Prophylaxis in Bariatric Surgery **4499**
Andrés García-Marín and Mercedes Pérez-López

Chapter 261 Thromboembolic Prophylaxis **4505**
Jaime Ruiz-Tovar and Carolina Llavero

Chapter 262 Antiemetic Prophylaxis **4511**
Esther García Villabona, Carmen Vallejo Lantero and Graciela García Villabona

Chapter 263 Nutritional Prophylaxis: Weight Loss for the Reduction of Surgical Risk **4527**
Irene Portero Larragueta

Chapter 264 Prophylaxis of Postoperative Cholelithiasis **4537**
Dennis Cesar Levano-Linares, Patricia Sanchez-Salcedo, Gustavo Díaz García, David Alías Jimenez, Manuel Durán Poveda and Jaime Ruíz-Tovar

Chapter 265 Prophylactic Measures to Reduce Staple Line Leaks and Bleeding **4545**
Irene Ortega-Vázquez

Chapter 266 Postoperative Ileus Prophylaxis:
Enhanced Recovery after Surgery (ERAS) **4555**
Pablo Royo-Dachary and Helen Almeida-Ponce

Chapter 267 Prophylaxis of Stress Ulcers, Anastomotic Ulcers
and Gastroesophageal Reflux Disease **4569**
Pablo Priego

Chapter 268 Postoperative Pain Prophylaxis and Management **4587**
Carmen Vallejo Lantero and Esther García Villabona

Chapter 269 The Use of Prophylactic Mesh in Open
and Laparoscopic Bariatric Surgery **4595**
Montiel Jiménez-Fuertes

Chapter 270 Prophylaxis of Internal Hernias **4603**
Manuel Ferrer-Márquez and Maria José Solvas-Salmerón

Chapter 271 Epidemiology of Surgical Site Infection **4611**
Pablo Priego

Chapter 272 Adequate Nutritional Support for the Prophylaxis
of Surgical Site Infection **4623**
Andrei Sarmiento, Grace Amesquita and Ramiro Carbajal

Chapter 273 Preoperative Bath and Shave **4633**
Cristina Bernabeu Herraiz and Lorena Rodríguez Cazalla

Chapter 274 Mechanical Bowel Preparation **4637**
Andrés García Marín and Mercedes Pérez López

Chapter 275 Antibiotic Prophylaxis **4641**
Noel Rojas-Bonet and Maria del Mar García-Navarro

Chapter 276 Hands and Skin Preparation **4647**
Lorena Rodríguez Cazalla and Cristina Bernabeu Herraiz

VOLUME 15

Chapter 277 Hyperoxygenation, Hypothermia Prevention,
Normoglycemia and Normovolemia **4653**
Esther García Villabona and Carmen Vallejo Lantero

Chapter 278 Adhesives and Wound Protectors **4663**
Dennis César Lévano-Linares and Patricia Sanchez-Salcedo

Chapter 279 Wound Irrigation **4671**
Gilberto González Ramírez

Chapter 280 Topical Intraperitoneal Irrigation **4687**
Jaime Ruiz-Tovar and Carolina Llavero

Chapter 281 Prophylactic Vacuum Therapy **4693**
Montiel Jiménez-Fuertes

Chapter 282 Antimicrobial Sutures **4701**
Jaime Ruiz-Tovar and Carolina Llavero

Chapter 283 Wound Cover: Topical Antibiotics or Antiseptics **4709**
Helen Almeida Ponce and Pablo Royo Dachary

Chapter 284 Clinical Examination, Imaging and Basic Surgical Techniques **4721**
Peter Stefanic

Chapter 285 Aortic Arch and Supraaortic Branches **4753**
František Sabol

Chapter 286 Descending and Thoracoabdominal Aorta **4781**
Tomáš Toporcer

Chapter 287 Abdominal Aorta, Iliac, and Splanchnic Arteries **4811**
Vladimir Sihotsky

Chapter 288 Carotid and Vertebral Arteries **4849**
Vladimir Katuch

Chapter 289 Peripheral Arterial Disease: Upper Extremity Artery Disease, Lower Extremity Artery Disease, Acute Limb Ischemia **4871**
Mária Kubíková

Chapter 290 Vascular Trauma **4911**
Ivan Kopolovets

Chapter 291 Vascular Access for Hemodialysis, Venous Insufficiency, and Its Treatment **4933**
Norbert Torma

VOLUME 16

Chapter 292 Complications and Recovery in Vascular Surgery **4975**
Peter Berek

Chapter 293 Laparoscopic Sleeve Gastrectomy **5015**
Pablo Priego

Chapter 294 Laparoscopic Adjustable Gastric Banding **5045**
Marta Cuadrado Ayuso, Rocio Franco Herrera and Jesús Lago Oliver

Chapter 295 Laparoscopic Nissen-Sleeve Gastrectomy **5063**
Alejandro Garcia Muñoz-Najar, Camilo Castellon Pavon, Manuel Duran and Jaime Ruiz-Tovar

Chapter 296 Laparoscopic Roux-en Y Gastric Bypass with Linear Stapled Anastomoses **5085**
Camilo J. Castellón Pavón, Alejandro García Muñoz-Najar, Jaime Ruiz-Tovar and Manuel Durán Poveda

Chapter 297 Laparoscopic Roux-en-Y Gastric Bypass: Circular Anastomosis **5101**
Maria Posada, Gabriel Salcedo, Jose Ramon Torres and Peter Vorwald

Chapter 298 Laparoscopic Roux-en-Y Gastric Bypass with Hand-Sewn Gastrojejunal Anastomosis **5141**
Alejandro Garcia Muñoz-Najar, Manuel Medina Garcia, Leire Zarain Obrador and Manuel Duran Poveda

Chapter 299 Laparoscopic Mini-Gastric Bypass **5163**
Dennis Cesar Levano-Linares, Patricia Sanchez Salcedo, Irene Grao, Manuel Duran Poveda, David Alías Jiménez and Jaime Ruiz-Tovar

Chapter 300 Laparoscopic One-Anastomosis Gastric Bypass (OAGB-BAGUA) **5179**
Jaime Ruiz-Tovar, Alejandro Garcia, Camilo Castellon, Manuel Duran and Carolina Llavero

Chapter 301 Laparoscopic Duodenal Switch **5203**
Nieves Perez-Climent, Carlos Serra, Miriam Ortin, Rafael Bou and Aniceto Baltasar

Chapter 302 Laparoscopic Biliopancreatic Diversion **5229**
Alberto Pagan

Chapter 303 Introduction to NAFLD and NASH: Etiopathogenesis **5247**
Soledad García-Gómez-Heras, Julio Paredes-González and Raquel Franco-Rodríguez

Chapter 304 Epidemiology and Relevance of NASH in Patients with Morbid Obesity **5265**
Leire Zarain-Obrador and Manuel Duran-Poveda

Chapter 305 Fatty Liver Development: Imbalance between Acquisition and Removal of Lipids **5273**
Lorea Zubiaga

Chapter 306 Histopathology of NAFLD and NASH **5287**
Soledad García-Gómez-Heras

VOLUME 17

Chapter 307 Liver Biopsy as the "Gold Standard" in NASH Diagnosis **5301**
Soledad García-Gómez-Heras, Julio Paredes-González and Raquel Franco-Rodríguez

Chapter 308 Conventional Imaging Tests for the Evaluation of NASH **5331**
Luis Tomás Ocaña Wilhelmi, Bruno Ramos Molina and Enrique Glückmann Maldonado

Chapter 309 MR Spectroscopy and Quantification of Intrahepatocitary Lipid Content **5343**
Jaime Ruiz-Tovar and Carolina Llavero

Chapter 310 Biochemical Markers **5351**
Soledad García-Gómez-Heras

Chapter 311 Evolution of Liver Steatosis after Sleeve Gastrectomy **5357**
Ramiro Carbajal Nicho, Andrei Sarmiento Alarcón, Nestor Palacios Bran and Jorge Orrego Peche

Chapter 312 Liver Steatosis and Roux-en-Y Gastric Bypass (RYGB) **5365**
Luciano Deluca, Liliana Parasporo, Patricio Cal and Ezequiel Fernández

Chapter 313 Liver Steatosis Regression after One Anastomosis Gastric Bypass **5373**
Luciano Antozzi, Miguel Angel Carbajo, Priscila Antozzi and Carlos Martin Esquivel

Chapter 314 SADI-S: Characteristics and Results of a Novel Bariatric Surgery Technique. The Role in NAFLD and NASH **5389**
Esteban Martin-Antona, Oscar Cano-Valderrama, Ester Martin Garcia-Almenta, Miguel Josa and Antonio J. Torres

Chapter 315 Simultaneous Liver Transplantation and Bariatric Surgery **5399**
David Calatayud, Eva María Montalvá, Javier Maupoey, Andrea Boscá and Rafael López-Andújar

Chapter 316 Non-Surgical Treatment of NASH: The Other Options **5419**
Raúl Bernal-Reyes and Daniel Bernal-Serrano

Chapter 317 The Use of Groin Flap for Upper Extremity Coverage in Electrical Burn Patients: Evidence-Based Case Reports **5431**
Nathania Pudya, Aditya Warhana and Erythrina Permatasari

Chapter 318 Autopsy of Aortic Dissection after TEVAR Installation: A Case Report **5441**
Yuli Budiningsih and Insil P. Hariyani

Chapter 319 Rare Occurrence of Secondary Extracranial Sinonasal Meningioma: A Case Report **5449**
Renindra Ananda Aman, Adhitya Syahada, Aryandhito Widhi Nugroho, David Tandian, Samsul Ashari, Syaiful Ichwan and Setyo Widi Nugroho

Chapter 320 Thoracic Epidural Analgesia in a Critically Ill Patient with Acute Pancreatitis **5457**
Dita Aditianingsih, Raden Besthadi Sukmono, Oryza Eureka, Willy Yant Kartolo and Erika Sasha Adiwongso

Chapter 321 Preoperative Therapeutic Plasma Exchange with Hypofibrinogenemia Complication in ABO-Incompatible Living Donor Kidney Transplantation **5463**
Dita Aditianingsih, Rudyanto Soedono, Endang Susalit, Willy Yant Kartolo and Erika Sasha Adiwongso

Chapter 322 Symmetrical Bilateral Keystone Perforator Island Flaps for Vulvar Reconstruction after Oncological Resection: A Case Report **5471**
Indri Aulia, Chaula Luthfia Sukasah and Eva Chintia Yessica

Chapter 323 Reconstruction of Auricle after Wide Excision of Giant Multiple Congenital Melanocytic Nevus of the Ear: A Rare Case Report **5475**
Dini Widiarni Widodo and Ferucha Moulanda

Chapter 324 Deviated Nose in a Patient with Parry–Romberg Syndrome: A Case Report **5481**
Mirta Hediyati Reksodiputro, Dewi Puspito Sari, Iris Rengganis, Endi Novianto and Dini W Widodo

Chapter 325 Use of Nasolabial and Nasal Septal Flaps for Unilateral Lower-Third Nasal Defects **5487**
Mirta H. Reksodiputro, Satria Dipo Putra Asmoro, Dini W. Widodo and Trimartani Koento

Chapter 326 Supernumerary Nostril: A Rare Congenital Anomaly **5493**
Dini Widiarni Widodo and Rindy Yunita Pratamisiwi

Chapter 327 Objective Measures in Functional Septorhinoplasty: Two Case Reports of Nasal Form and Nasal Valve Reconstruction **5499**
Trimartani Koento, Tiara Melati and Mirta H. Reksodiputro

Chapter 328 The Role of Voice Therapy in Reducing Voice-Related Symptoms in Laryngopharyngeal Reflux Evaluated by Reflux Symptom Index, Voice Handicap Index, and Laryngovideostroboscopy **5505**
Elvie Zulka Kautzia Rachmawati, Yonian Gentilis, Rahmanofa Yunizaf, Susyana Tamin, Fauziah Fardizza and Luh Karunia Wahyuni

Chapter 329 Maxillary Fibrous Dysplasia Reconstruction after Maxillectomy **5515**
Dini Widiarni Widodo and Razki Yorivan

Chapter 330 Cleft Palate with Velopharyngeal Insufficiency: A Case Report **5537**
Mirta H. Reksodiputro, Shally Adhina Putri, Dini W. Widodo and Trimartani Koento

Chapter 331 Tongue Edema after Palatoplasty: A Case Report **5543**
Rahendra, Pradini

Chapter 332 Non-Syndromic Unilateral Tessier No. 3 Facial Cleft: A Rare Congenital Disease **5549**
Mirta H. Reksodiputro, Tara C. Mariska, Dini W. Widodo and Trimartani Koento

Chapter 333 Outcomes of Resection Arthrodesis for Knee Malignancies **5557**
Yogi Prabowo, Afif Alhadi and Adisa Yusuf Reksoprodjo

Chapter 334 Total Sacrectomy and Spinopelvic Reconstruction of Sacrococcygeal Chordoma **5563**
Yogi Prabowo, Afif Alhadi and Rizky Priambodo Wisnubaroto

Chapter 335 Low Back and Leg Pain Induced by Dural Scar Formation after Laminectomy for Lumbar Canal Stenosis: Case Report and Literature Review **5571**
Ahmad Jabir Rahyussalim, Aria Adhitya, Tri Kurniawati and Khairul Hukmi

Chapter 336 Functional and Radiological Outcomes in Patients with Spondylitis Tuberculosis and Kyphotic Deformity Treated Using a Two-Stage Correction Procedure: A Case Series **5577**
Ifran Saleh and Auliya Akbar

Chapter 337 Management of Neglected Conus Medullaris Syndrome with Lumbar Canal Stenosis **5585**
Ahmad Jabir Rahyussalim, Sammy Saleh Alhuraiby, Tri Kurniawati and Khairul Hukmi

Chapter 338 Anterior Innominate Osteotomy for Closure of Neglected Bladder Exstrophy: A Report of Two Cases and a Brief Review of the Literature **5593**
Aryadi Kurniawan and Andi Praja Wira Yudha Luthfi

Chapter 339 Successful Treatment of Fracture at the Base of the Proximal Phalanx Using Extra-Articular Percutaneous K-Wiring with the Consideration of Safe Portals: A Case Report **5601**
Wahyu Widodo and Andi Praja Wira Yudha Luthfi

Chapter 340 The Role of Acupuncture in a Breast Cancer Patient with Cancer-Induced Bone Pain **5609**
Kemas Abdurrohim, Irma Nareswari and Diana Oei

Chapter 341 A Rare Case of CD8-Negative Monomorphic Epitheliotropic Intestinal T-Cell Lymphoma **5617**
Agnes Stephanie Harahap, Lydia Kencana, Maria Francisca Ham, Budiana Tanurahardja and Endang S. R. Hardjolukito

Chapter 342 A Rare Case of Clear Cell Papillary Renal Cell Carcinoma **5631**
Fili Sufangga and Budiana Tanurahardja

VOLUME 18

Chapter 343	Rare Case of Myelolipomatous Metaplasia within an Adrenocortical Adenoma *Monik Ediana Miranda, Maria Francisca Ham, Agnes Stephani Harahap and Benyamin Makes*	**5641**
Chapter 344	Chronic Myeloid Leukemia in a BCR-ABL1-Positive Patient with Pancytopenia and Excessive Fibrosis *Dian Sari Oethia Vathonati and Agnes Stephanie Harahap*	**5653**
Chapter 345	Clear Cell Chondrosarcoma: A Case Report *Ros Nirmawati, Evelina Kodrat and Errol Untung Hutagalung*	**5665**
Chapter 346	Hürthle Cell Carcinoma: A Rare Case with Unique Morphological Features *Familia Bella Rahadiati, Agnes Stephanie Harahap and Maria Fransiska Ham*	**5675**
Chapter 347	Invasive Breast Carcinoma Mimicking Secretory Carcinoma: A Case Report *Patricia Fransisca Julianty, Primariadewi Rustamadji and Hartono Tjahjadi*	**5689**
Chapter 348	Langerhans Cell Histiocytosis with Unusual Nodular Pattern *Imelda Setiana Silitonga and Endang Sri Roostini Hardjolukito*	**5701**
Chapter 349	Pitfalls in the Histopathological Diagnosis of Sclerosing Rhabdomyosarcoma *Fetisari Kurniawan, Nurjati Chairani Siregar, Ludi Dhyani Rahmartani, Marcel Prasetyo and Kshetra Rinaldhy*	**5711**
Chapter 350	Primary Malignant Giant Cell Tumor of Proximal Right Tibia: A Rare Case Report *Mirna Albertina Wijaja, Nurjati Chairani Siregar, Evelina Kodrat, Yogi Prabowo and Thariqah Salamah*	**5721**
Chapter 351	Secondary Malignant Giant Cell Tumor of the Bone: A Case Report and Rare Experience *Fadhlina Muharmi Harahap, Nurjati Chairani Siregar, Yogi Prabowo and Thariqah Salamah*	**5731**
Chapter 352	Segmental Absence of Intestinal Musculature: Case Report of a Rare Cause of Neonatal Intestinal Obstruction *Ignasia Andhini Retnowulan and Nur Rahadiani*	**5741**
Chapter 353	Hemangioma-Like Vessels in the Resection Margin of Giant Hemangiomas of the Liver as a Possible Cause of Recurrence: A Case Series and Literature Review *Marini Stephanie, Ening Krisnuhoni, Diah Rini Handjari and Nur Rahadiani*	**5751**

Chapter 354 46, XX Ovotesticular Disorder of Sex Development, Histopathological View: Report of a Rare Case **5757**
Intan Nevita Oktamiya Bernanthos and Budiana Tanurahardja

Chapter 355 A 56-Year-Old Woman with an Elevated Parathormone Level after the Surgery for Secondary Hyperparathyroidism **5773**
Caglar Keskin and Mustafa Şahin

Chapter 356 Epilepsy Surgery and Technical Aspects of Invasive Monitoring **5775**
Jorge A. González-Martínez

Chapter 357 Perioperative Visual Loss after Spine Surgery **5787**
Mariel Manlapaz and Sree Kolli

Chapter 358 Surgery for Intrahepatic Cholangiocarcinoma **5799**
Kelly Olino and Michael D'Angelica

Chapter 359 Surgery for Hilar Cholangiocarcinoma **5819**
Daniel Seehofer and Peter Neuhaus

Chapter 360 Surgery for Distal Cholangiocarcinoma **5833**
Salvatore Paiella, Stefano Andrianello, Giovanni Marchegiani, Roberto Salvia and Claudio Bassi

Chapter 361 Intraocular Surgery in Kyphosis **5849**
Mohannad Qasim Albdour and Karanjit S. Kooner

Chapter 362 Surgery of Thymomatous Myasthenia Gravis **5857**
Cameron D. Wright

Chapter 363 Palliative Hip Surgery in Patients with Cerebral Palsy **5867**
Julio Duart-Clemente and Serafín García-Mata

Chapter 364 Application to Cardiovascular Surgery **5881**
Shohei Miyazaki, Keiichi Itatani, Sachi Koyama, Kouki Nakashima, Tetsuya Horai, Norihiko Oka, Tadashi Kitamura and Kagami Miyaji

Chapter 365 Transfusion Practices in Cardiac Surgery **5909**
Surendra Kumar Agarwal, Gauranga Majumdar, Shantanu Pande and Siddartha Churchigundi Rudrappa

Chapter 366 Foregut Surgery **5939**
Emily S. Reardon, Daniel Mansour and Stephen M. Kavic

Chapter 367 Small Bowel Surgery **5949**
Eric Wise, Stephen P. Gadomski, II and Stephen M. Kavic

VOLUME 19

Chapter 368 Colon Surgery **5981**
William A. Teeter and Andrea C. Bafford

Chapter 369 Complications of Surgery **6001**
Sarwat Ahmad and Stephen M. Kavic

Chapter 370 Assessment of Ovarian Reserve before and after Gynecologic Surgery **6029**
Akira Iwase

Chapter 371 Follow-Up after Treatment of Localized Renal Tumor (Surgery, Surveillance, Ablative Therapies) **6045**
Francisco Javier Perez Garcia

Chapter 372 Video-Assisted Thoracic Surgery **6061**
Hirochika Matsubara and Diego Marquez-Medina

Chapter 373 Surgery for Early Non-Small Cell Lung Cancer **6073**
Masafumi Yamaguchi and Diego Marquez-Medina

Chapter 374 Vascular Anatomy of the Sellar Region and Complications during Endoscopic Endonasal Transsphenoidal Surgery for Pituitary Adenomas **6089**
Yasuhiko Hayashi

Chapter 375 Transsphenoidal Surgery for Pituitary Adenomas Guided by Intraoperative Magnetic Resonance Imaging (iMRI) **6109**
Sven Berkmann and Javier Fandino

Chapter 376 Inguinal Hernia Surgery in Patients with Liver Cirrhosis **6133**
Roberto De la Plaza-Llamas, José M. Ramia, Vladimir Arteaga-Peralta, Jhonny D. Gonzales-Aguilar, Cristina García-Amador and Aylhin J. López-Marcano

Chapter 377 Erectile Function after Female-to-Male Transsexual Surgery **6147**
Borko Stojanovic, Marta R. Bizic and Miroslav L. Djordjevic

Chapter 378 Failed Back Surgery Syndrome and Spinal Cord Stimulation **6161**
Ferdinand Iannaccone, Neil Majmundar and Vanny Le

Chapter 379 Complication Avoidance and Revision Surgery **6171**
Sameah A. Haider, Meghan E. Wilock and Julie G. Pilitsis

Chapter 380 Efficacy of Post-Operative Oral Tramadol and Diclofenac Sodium on Pain Relief Following Mandibular Third Molar Surgery: A Double Blind, Randomized Controlled Trial **6191**
M. Nabeel Nazar and Ashok K. Ramadorai

Chapter 381 Management of Failed Back Surgery Syndrome and Related Disorders **6203**
Angelo Rafael Cunha de Azevedo and William Omar Contreras Lopez

Chapter 382 Hemodynamic Complications Associated with Prone Positioning in Lumbar Spinal Surgery **6215**
Alessandra D'Ambrosi and Francesco Fedele

Chapter 383 Open Surgery in the Osteoporotic Spine **6221**
Demo Eugenio Dugoni

Chapter 384 Principles of Fracture Fixation in Orthopaedic Trauma Surgery **6229**
Wasim Khan, Mamun Al-Rashid and Kishan Vemulapalli

Chapter 385 Surgery in Elderly Patients with Hip Fractures **6239**
J. White, P. Smitham and W. S. Khan

Chapter 386 Arthroscopic Knee Surgery: An Evidence-Based Practice **6251**
Christopher Onyema, Emeka Oragui, Jonathan White and Wasim S. Khan

Chapter 387 The Role of Navigation in Total Knee Replacement Surgery **6263**
James Min-Leong Wong, Wasim S. Khan and Joyti Saksena

Chapter 388 Splenectomy as Part of Cytoreductive Surgery for Advanced Stage and Relapsed Ovarian Cancer **6277**
N. Bacalbasa and Irina Balescu

Chapter 389 Liver Surgery in Ovarian Cancer Liver Metastases **6301**
N. Bacalbasa and Irina Balescu

VOLUME 20

Chapter 390 Best Practice in Informed Consent in Oral Surgery **6325**
Aida Gutiérrez-Corrales, Gonzalo Ruiz-de-León-Hernández, Rand Alsheikh, Marisa Heras-Meseguer, Concepción Recio-Lora, Esther Hernández-Pacheco, Daniel Torres-Lagares and José-Luis Gutiérrez-Pérez

Chapter 391 Zinc Deficiency after Bariatric Surgery: Etiology, Health Implications and Management **6345**
Jaime Ruiz-Tovar and Carolina Llavero

Chapter 392 Mechanisms of Zinc Deficiency and Its Clinical Significance after Bariatric Surgery **6351**
Anand Nath, Hiral Shah, Bikram S. Bal, Timothy R. Shope and Timothy R. Koch

Chapter 393 The Perception of the Body: Quantitative Methods for Self-Evaluation of the Body in Plastic, Reconstructive and Aesthetic Surgery **6373**
Paolo Persichetti, Annalisa Cogliandro and Mauro Barone

Chapter 394 Leadership, Ethics, and the Adoption of Evidence Based Medicine among Leaders of Internal Medicine and Surgery **6381**
Ronald Bogdasarian

Chapter 395 Application of da Vinci® Robot in General Surgery: A Cost Assessment **6393**
Ioannis D. Gkegkes and Christos Iavazzo

Chapter 396 Therapeutic Potential of Adipose-Derived Stromal Cells in Wound Healing, Anti-Aging, and Plastic Surgery **6411**
Changyue Xue and Guo Li

Chapter 397 Speedy and Easy Techniques in Facial Palsy Surgery **6433**
A. Di Stadio

Chapter 398 Setting Up a Minimally Invasive Aortic Valve Surgery Program **6453**
Hunaid A. Vohra and Christopher P. Young

Chapter 399 CT Imaging and Echocardiography for Minimally Invasive Aortic Valve Surgery **6461**
Gabriel Loor and Eric E. Roselli

Chapter 400 Anaesthesia and Fast-Tracking in Minimally Invasive Aortic Valve Surgery **6475**
Ben Gibbison

Chapter 401 Cannulation and Cardio-Pulmonary Bypass for Minimally Invasive Aortic Valve Surgery **6485**
Martin Andreas, Guenther Laufer and Alfred Kocher

Chapter 402 Mini-Sternotomy Aortic Valve Surgery **6499**
Jared P. Beller and Gorav Ailawadi

Chapter 403 Mini-Thoracotomy Aortic Valve Surgery **6509**
Mattia Glauber, Antonio Miceli and Antonio Lio

Chapter 404 Re-Operative Minimally Invasive Aortic Valve Surgery **6519**
Mauro Del Giglio and Elisa Mikus

Chapter 405 Totally Endoscopic and Robotically-Enhanced Minimally Invasive Aortic Valve Surgery **6527**
Marco Vola and Antoine Gerbay

Chapter 406 Rapid Deployment Aortic Valves and Minimally Invasive Surgery **6537**
Kevin Phan and Tristan D. Yan

Chapter 407 Minimally Invasive Aortic Surgery **6551**
Tristan D. Yan

Chapter 408 The Effects of Dexamethasone in Pre and Post Operative Surgery **6569**
Jun-Beom Park

Chapter 409 Quality of Life Changes Relevant to Extent of Thyroid Surgery **6573**
Fatima Z. Syed

Chapter 410 Biological Characteristics, Clinical Classification, and Spasm of Arterial Grafts and Antispastic Management in Coronary Artery Bypass Grafting Surgery **6581**
Guo-Wei He

Chapter 411 Cardio Thoracic Surgery Approach to Cardiac Resynchronization Therapy: Implant Techniques, Advantages and Limitations **6611**
Nicola Testa, Paola Spatuzza, Carlo Maria De Filippo and Celestino Sardu

Chapter 412 Surgical Strategies to Push Up Resection Limits in Liver Disease and Liver Failure after Surgery **6621**
F. Romano, S. Famularo, R. A. Pellegrino, L. V. Gianotti, F. Uggeri, E. Pinotti, R. Corso, D. Ippolito, C. Talei and D. Fior

VOLUME 21

Chapter 413 Minimally Invasive Craniosynostosis Surgery **6665**
Jordan A. Magarik and Christopher M. Bonfield

Chapter 414 Raising the Bar on Pterygium Surgery **6687**
Arun C. Gulani and Parth G. Patel

Chapter 415 Relevance of C Reactive Protein Levels in Morbidly Obese Patients and after Bariatric Surgery **6699**
Jaime Ruiz-Tovar and Carolina Llavero

Chapter 416 Polytetrafluoroethylene Patches for Shoulder Surgery **6707**
Michael Nagra and Manit Arora

Chapter 417 Anaesthesia for Minimally Invasive Mitral Valve Surgery **6713**
Ben Gibbison and Amit Ranjan

Chapter 418 Minimally Invasive Approaches to Mitral Valve Surgery **6727**
Kasra Shaikhrezai and Steven Hunter

Chapter 419 Cannulation and Cardio-Pulmonary Bypass for Minimally Invasive Mitral Valve Surgery **6743**
M. Pozzi and J. F. Obadia

Chapter 420 Mini-Sternotomy Mitral Valve Surgery **6751**
Ludwig C. Müller

Chapter 421 Totally Endoscopic Mitral Valve Surgery **6757**
Martin Misfeld and Friedrich W. Mohr

Chapter 422 Robotic Assisted Mitral Valve Surgery **6773**
Arman Arghami, Richard C. Daly, Simon Maltais and Joseph A. Dearani

Chapter 423 Redo Minimally Invasive Mitral Valve Surgery **6787**
Marco Solinas and Michele Murzi

Chapter 424 Valve Repair Techniques in Minimally Invasive Mitral Surgery **6799**
Loris Salvador and Tommaso Hinna Danesi

Chapter 425 Minimally Invasive Tricuspid Valve and AF Ablation Surgery **6825**
Chawannuch Ruaengsri, Matthew R. Schill and Ralph J. Damiano, Jr.

Chapter 426 Contemporary Results in Minimally Invasive Mitral Valve Surgery **6845**
Daniel Pereda and José L. Pomar

Chapter 427 Echocardiographic Predictors of Early Postoperative Atrial Fibrillation in Coronary Artery Bypass Surgery Patients **6859**
Iana Simova, Tzvetana Katova, Anelia Nesheva, Krasimira Hristova, Velislava Kostova, Lyudmil Boyadzhiev and Nikolay Dimitrov

Chapter 428 Cytoreductive Surgery and Hyperthermic Intraperitoneal Chemotherapy for Mucinous Tumors of the Gastrointestinal Tract **6869**
Amanda K. Arrington and Joseph Kim

Chapter 429 Exfoliation Syndromeand Exfoliative Glaucoma: From Genetics to Surgery **6881**
Gábor Holló and Andreas Katsanos

Chapter 430 IgG4-Related Sclerosing Cholangitis in the Early Postoperative Period after Hepato-Biliary-Pancreatic Surgery: Screening Using Magnetic Resonance Cholangiography and Serum IgG4 Values **6901**
David Padilla-Valverde, Pedro Villarejo-Campos, Carlos Marcote-Ibañez, Mercedes Molina, Elena Buces, Francisco J. Redondo and Maitane Múgica

Chapter 431 The Impact of Social Media in Medicine: An Examination of Orthopaedic Surgery **6919**
Sergio M. Navarro, Heather S. Haeberle, Mary M. Cornaghie, Hafsah A. Hameed and Prem N. Ramkumar

Chapter 432 Quality of Life Changes Relevant to Extent of Thyroid Surgery **6931**
Fatima Z. Syed

Chapter 433 Robotic Surgery for Prostate Cancer: Functional and Oncological Outcomes in a Last Generation Referral Center **6939**
Elio Mazzone, Riccardo Bientinesi, Carlo Gandi, Pier Francesco Bassi and Emilio Sacco

Chapter 434 Intrathecal Baclofen Pumps in Spinal Deformity and Orthopedic Surgery **6955**
Jonathan Weyhenmeyer and Albert Lee

Chapter 435 Conservation Surgery: Open Partial Laryngectomy **6965**
Alfredo Quintin Y. Pontejos, Jr., Daryl Anne A. del Mundo, Soon Sue Rene, Andrea De Vito and Sheng-Po Hao

Chapter 436 Effect of Bariatric Surgery on Weight and Diabetes **6977**
Natalia R. Moreno-Castellanos

Chapter 437 Bariatric Surgery: Postoperative Complications **6995**
Carlos J. Ferrigni González, J. Ruiz-Tovar, J. González, A. Garcia and M. Duran Poveda

VOLUME 22

Chapter 438 Food Choices after Bariatric Surgery: Are There Changes in Oral Medium Characteristics and Food Perception? **7009**
Elsa Lamy, Fernando Capela e Silva and Isabel do Carmo

Chapter 439 Integrative Virtual Reality Therapy Produces Lasting Benefits for a Young Woman Suffering From Chronic Pain and Depression Post Cancer Surgery: A Case Study **7037**
Gregory House, Grigore C. Burdea, Namrata Grampurohit, Kevin Polistico, Doru Roll, Frank Damiani, Jasdeep Hundal and Didier Demesmin

Chapter 440 Is Minimally Invasive Parathyroidectomy Feasible in Patients with Previous Ipsilateral Thyroid Surgery? **7051**
Roberto de la Plaza Llamas, José Manuel Ramia Ángel, Vladimir Arteaga Peralta, Cristina García Amador, Aylhín Joana López Marcano, Aníbal Armando Medina Velasco and Begoña González Sierra

Chapter 441 Postoperative Cognitive Dysfunction in Cardiac Surgery: The Selection of Tests and Statistical Issues **7057**
Anna G. Polunina and Elena Z. Golukhova

Chapter 442 Current Anesthesia Concepts in Strabismus Surgery **7081**
Monica del-Rio-Vellosillo and Jose Javier Garcia-Medina

Chapter 443 Brain Mapping and Neuro-Monitoring in Low Grade Glioma Surgery: Current Challenges and Future Perspectives **7097**
Christian Brogna, Noemia Pereira, Eduardo C. Ribas, Holly Jones, Francesco Vergani, Sanj Bassi, Keyoumars Ashkan and Ranj Bhangoo

Chapter 444 The Effects of Lipoic Acid on Wound Healing in a Uterine Injury Rat Model: Clinical Perspectives in Obstetric Surgery **7117**
Asli Goker and Naci Kemal Kuscu

Chapter 445 Sex Differences in Terms of Eating Behaviors, Biological and Psychological Features: A Review in the Bariatric Surgery Population **7129**
Gabriela S. Figueiredo, Marta F. Lourdes, Paulo P. P. Machado and Eva M. Conceição

Chapter 446 The Lean Six Sigma Methodology: Applications in Thoracic Surgery **7151**
Luca Bertolaccini, Barbara Bonfanti, Jury Brandolini, Francesca Calabrese, Sergio Nicola Forti Parri, Kenji Kawamukai, Nicola Lacava and Piergiorgio Solli

Chapter 447 Mechanical Ventilation in Patients after Cardiac Surgery **7157**
Javier Barrenechea Gutiérrez, Pía Antequera Gorrini and Max Varela González

Chapter 448 Improvement of Cardiovascular Risk Factors after Bariatric Surgery **7169**
Jaime Ruiz-Tovar and Carolina Llavero

Chapter 449 The Effects of Exercise Programs on Cardiovascular Risk Factors in Patients Undergoing Bariatric Surgery **7177**
Artur Marc Hernández and Jaime Ruiz-Tovar

Chapter 450 Near-Infrared Spectroscopy as a Tool to Detect Cerebral Ischemia during Carotid Surgery **7209**
Bozidarka L. Zaric, Milan Obradovic, Dragana Unic-Stojanovic, Ayman El-Menyar, Hassan Al-Thani, Djordje Radak and Esma R Isenovic

Chapter 451 Intraoperative and Postoperative Analgesic Schemes in Bariatric Surgery **7229**
Esther García Villabona, Carmen Vallejo Lantero and Graciela García Villabona

Chapter 452 Multimodal Analgesia and Adjuvant Analgesic Treatment in Bariatric Surgery **7237**
Carmen Vallejo Lantero and Esther García Villabona

Chapter 453 Implications of Laparoscopic Approach on Postoperative Pain after Bariatric Surgery **7247**
Pablo Priego

Chapter 454 Peritoneal Lavage and Laparoscopic Sleeve Gastrectomy Surgery **7255**
Lorea Zubiaga and Jaime Ruiz-Tovar

Chapter 455 Prophylaxis of Deep-Vein Thrombosis in Bariatric Surgery **7263**
Jaime Ruiz-Tovar and Carolina Llavero

Chapter 456 Anesthetic Considerations in Pediatric Cardiac Surgery **7269**
Carolina Passos Diniz and Juliana Torres Pacheco

Chapter 457 Cardiac Surgery Postoperative Arrhythmias **7279**
Carla Daina, Joan Sanchez-de-Toledo and Lucas Saenz

Chapter 458 Aviation and Cardiac Surgery: Review of Their Relationships. Implication on Complexity Theory and Ethical Considerations **7295**
Roberto Battellini, Michael S. Firstenberg and Mauricio Perez-Martinez

Chapter 459 The Early History of Treatment of Keratoconus by Surgery **7311**
T. Jurkiewicz, C. Fabio and A. S. Marty

Chapter 460 The Retrosigmoid Approach:
From the Microsurgical Anatomy to the Surgery **7319**
Francesca Graziano, Enrico Lo Bue, Lara Brunasso, Alessia Lombardo, Rosario Maugeri and Domenico G. Iacopino

Chapter 461 Facial Nerve Restoration after Vestibular Schwannoma Surgery **7333**
S. Taliente, M. Maruccia, R. Guarino, R. Elia, G. Giudice and Nicola Quaranta

Index **7345**

PREFACE

Encyclopedia of Surgery organizes researchers from around the world in surgery and related disciplines and maintains an up-to-date reference work for readers worldwide.

In: Encyclopedia of Surgery (22 Volume Set)
Editors: Andreas Lehrer and Kristin Mueller
ISBN: 978-1-53618-329-0
© 2020 Nova Science Publishers, Inc.

Chapter 1

LIMB LENGTHENING BY COMBINED TECHNIQUE (EXTERNAL FIXATOR AND FLEXIBLE INTRAMEDULLARY NAILING): EXPERIMENTAL STUDIES

Dmitry Popkov [*] ***and Arnold Popkov***
Scientific and Clinical Laboratory for Deformity Correction and Limb Lengthening.
Federal Russian State-Financed Ilizarov Scientific Center for Restorative Traumatology and Orthopaedics, Kurgan, Russia

ABSTRACT

The experimental results of application of bioinert and bioactive intramedullary nailing in tibial lengthening in mongrels are presented in Chapter I. Basing on data of radiologic, angiographic and morphologic investigations, the advantages of combination of circular external fixation and flexible intramedullary nailing in a gradual limb lengthening are proved from the point of view of stimulation of the osteogenesis and accelerated formation of the distraction regenerate.

Keywords: combined technique of limb lengthening, experimental study

1.1. TIBIAL LENGTHENING WITH FLEXIBLE INTRAMEDULLARY INERT NAILING

Introduction

Based on our extensive experience with the Ilizarov lengthening method, we have demonstrated that one of its fundamentals is preservation of periosteum and intramedullary circulation. Furthermore, quality of the regenerate depends on the lengthening rate, which can

[*] Corresponding Author's Email: dpopkov@mail.ru.

be individualized [2]. Automatic high-frequency lengthening and compression of the regenerate immediately after the lengthening period provide optimal conditions for tissue regeneration, and result in significant reduction of the external fixation period [3]. Works have been done to demonstrate the prominent role of periosteum in distraction osteogenesis [4, 5]. Intramedullary nailing provides a strong elastic frame, which enhances the formation of periosteal callus. Additionally, as the two intramedullary nails do not completely fill the medullary cavity, endosteal callus formation is not inhibited. We have worked on the FIN concept to ensure compatibility with the Ilizarov method for limb lengthening. The following study conducted in dogs allows better understanding of our philosophy, and evaluating all the benefits of this combined method.

Materials and Methods

This study was conducted in 14 dogs of various breeds, aged 1 to 4 years, with the average weight of 18.8 kg. The mean length of tibia was 187 mm. The applied Ilizarov fixator consisted of two distal rings and two proximal three-quarter rings, connected by threaded rods. Both, percutaneous osteotomy of the fibula and osteoclasis of the tibia were performed in the middle third of the diaphysis. The FIN construct used two 1.5 mm nails with opposing curves (Figure 1). Both nails were sharply contoured, and their tips bent to 30–40° over a length of 2–3 mm. Their initial curves were identical, with apex located in the midsection. Both nails had blunt tips. Two slightly oblique entry holes were made with an awl in the superior portion of the proximal metaphysis. The first nail was hand pushed into the medullary canal, then across the osteoclasis and down to the distal metaphysis, as far as possible into the cancellous bone. The second nail was inserted in the same manner, on the opposite side of the bone. The final construct consisted of two nails with opposing curves positioned in the same plane. The free ends (trailing ends) of the nails were cut relatively short and bent to about 45–60° to prevent nail migration during distraction. The skin was closed in one layer. Distraction was initiated on the fifth day in all dogs (Figure 1). Duration of lengthening was 28 days. Mean distraction rate was 1 mm/day (in four steps) (Table 1).

However, as control X-rays showed extensive bone regenerate, the distraction speed had to be increased on D 8 in 4 dogs, D 15 in 3, and D 21 in 1. Early healing occurred twice in about 21 days of lengthening, and twice in about 28 days: in two cases, distraction resulted in fracture of the regenerate that had already consolidated (Figure 2), whereas in the other two cases, the newly regenerated bone was already very strong. The 28-day lengthening period was followed by the external fixation period. The external fixator was removed after 15 days (sixth week) in eight dogs and 30 days (eighth week) in four. All the dogs could bear weight right after removal of the external fixator without any limb protection.

Results were evaluated according to the radiographic appearance of the regenerate. Control X-rays were performed on a weekly basis throughout the distraction period, and thereafter, at 45 days, 60 days, and after removal of the intramedullary nails. Arteriographies were performed in some dogs after sacrifice: at D 5, 39, and 63. Additionally, bone regenerates were histologically studied.

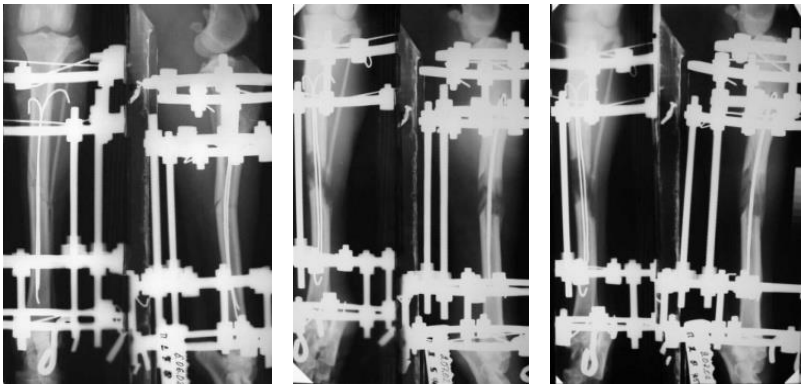

(a) (b) (c)

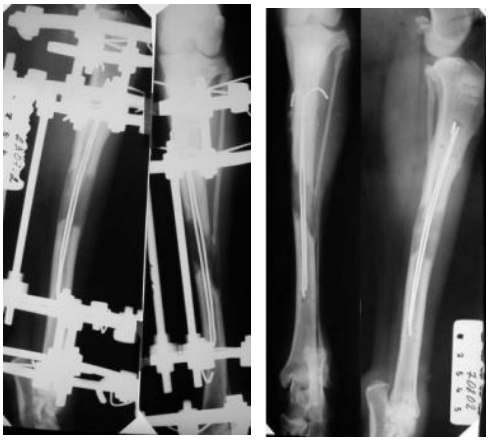

(d) (e)

Figure 1. Radiograph of the right tibia.Tibial lengthening by combined Ilizarov/FIN: Ilizarov fixator and intramedullary nails in place, osteoclasis of the tibia(a); X-ray taken after 21 days of lengthening(b); X-ray taken after 28 days of lengthening (end of lengthening period) (c). Note the intense and extensive periosteal reaction, and a growth zone with numerous bone trabeculae. Thirty millimeter lengthening: Complete healing achieved after 14 days of external fixation (d); external fixator removed (e); X-ray taken 15 days (D 63) after removal of the external fixator and resumption of weight bearing.

Table 1. Duration of the lengthening and external fixation

Period	Osteoclasis, Ilizarov +FIN	Distraction (lengthening)	External fixation	Removal of external fixation
Date	Day 0	Days 5-33	Days 34-49=6 dogs Days 34-63=8 dogs	Days 49=6 dogs Day 63=8 dogs

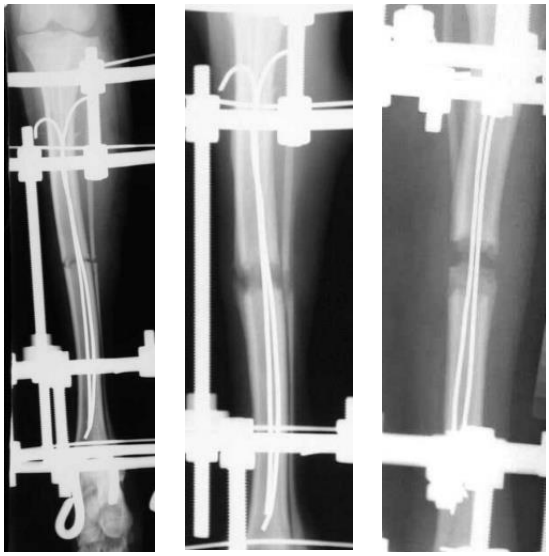

(a) (b) (c)

Figure 2. Healing status after 14 days of tibial lengthening using combined Ilizarov/FIN: Ilizarov fixator and two intramedullary nails in place, closed osteoclasis of the tibia (a); X-ray taken after 14 days of lengthening at a rate of 1.75 mm/day (b); X-ray taken after 21 days of lengthening, fracture of the regenerate (c).

Results

Radiological changes proved intense and extensive bone regeneration, it forced us to increase the distraction speed in some dogs. Newly formed bone was visible on radiographs after 7 days of lengthening. At this stage, the regenerate had an inhomogeneous structure with localized areas of increased bone density. Extensive periosteal reaction (21.6 mm long, 0.5–2.0 mm thick) could be noted along the bone fragments. At 2 weeks, the regenerate was well structured and filled completely the interfragmentary gap. The growth zone contained numerous bone trabeculae. Periosteal reaction was 24–26 mm long and 2–3 mm thick. The regenerate was larger than the tibia. In 15 days of fixation (D 48), the regenerate was completely consolidated in all the animals. Cortical bone was reconstructed. Continuity of three or four cortices was reestablished along the regenerate. The growth zone had disappeared. A denser periosteal reaction was noted. In 30 days of fixation (D 63), the medullary canal was already formed in three out of four dogs. No fracture or deformity occurred after removal of the external fixator because the regenerates had already consolidated, and also because the bones were protected by FIN.

After 15 days of external fixation, histology showed cortical continuity, fully interconnected cancellous trabeculae, and disappearance of the fibrous layer surrounding the new bone (Figure 3a). As a matter of fact, consolidation took place during the fixation period and lasted 2 weeks.

Thirty days after removal of the external fixator, the cortices were thicker. Remodeling of the medullary canal was under way. We were happy to note extensive tissue regeneration along the intramedullary nail (Figure 3b).

(a) (b)

Figure 3. Histologic sections (tibia): specimen at D 49 (fixator removed), cortices were present along the regenerate and continuity was re-established. Growth zone was no longer visible (a); specimen at D 88, 25 days after removal of the external fixator, intramedullary nails were removed just before sacrifice (b). Regenerate consisted of cortical and cancellous bone tissue. The medullary canal was patent. Ossification was present along the intramedullary nails.

(a) (b)

Figure 4. Arteriography: the medullary artery was patent (tibia-dog): Arteriography (AP and lateral) of specimen after removal of the intramedullary nails on the 6th day of the fixation period (D 39) (a); arteriography (AP and lateral) after 30 days of fixation (D 63) (b).

This structure can be compared to a stainless steel lead pencil.

Arteriographies performed at the initiation of lengthening, after 6 days of external fixation, and immediately after removal of the intramedullary nails (Figure 4), showed that the medullary artery had remained patent all the time.

No implant migration or skin problems occurred. We found that proper nail contouring ensured stability of bone fragments during lengthening.

Discussion

The Ilizarov lengthening method has revolutionized the biology of bone and bone growth. Preservation of bone environment, periosteum, and particularly, the medullary vascularization, respect of the biological rate of bone growth, use of automatic high-frequency lengthening, preservation of stability and elasticity (provided by the rings): everything works together to provide good to excellent tissue regeneration [3]. The more stable the lengthening site is, the faster it will heal. Though Professor Ilizarov claimed the major role of the bone marrow in new bone formation, a certain number of works disputed the paramount qualitative role of periosteum in distraction osteogenesis [4, 5].

FIN has a proven track record of over 25 years of effective fracture treatment in children based on animal experimentation [1] and above all, on the outstanding experience of the Pediatric Orthopedic Department, Surgical Clinic, Nancy (France). According to data, FIN builds a strong elastic frame that enhances biological effect of redistribution of blood flow to the periosteal structures through cortical canals, thus stimulating formation of periosteal callus. FIN is a semi-rigid elastic nailing system, that allows cyclic micro-scale plastic deformations which is most beneficial for healing. Also, as the two intramedullary nails do not fill in the medullary cavity completely, endosteal callus formation is not inhibited.

We had the idea to combine both elastic systems, Ilizarov and FIN, for limb lengthening [6]. Our animal experiments prove that contoured intramedullary nails do not inhibit endosteal bone formation. On the contrary, despite partial destruction of the bone marrow, the preserved intramedullary circulation stimulates tissue regeneration to such an extent that it becomes necessary to increase the distraction speed to avoid premature consolidation of the regenerate during lengthening.

The biological effect of redistribution of intramedullary blood flow to the periosteal structures stimulates formation of periosteal callus, resulting in extensive periosteal reaction, both along the bone fragments and at the diastasis. FIN provides increased stability at the diastasis by resisting translation motion (essentially) in the plane of the nails. Gradual stretching or sliding of the intramedullary nails through the regenerate during lengthening seems to enhance the regeneration process. However, the mechanism of biological stimulation of endosteal bone formation remains unexplained. Controlled bone marrow irritation by an intramedullary nail is known to produce localized new bone formation [1]. It has been confirmed in animals, when intramedullary nails positioned at the periphery of the regenerate and gradually pulled have shown to accelerate the formation of new bone [7].

Conclusion

FIN can be used together with external fixation for bone lengthening. Combined use of these two methods allows to stimulate both endosteal and periosteal bone formation. FIN improves stability of the bone fragments at the diastasis, and does not inhibit intramedullary circulation. In bone lengthening, FIN is the only internal fixation method that provides the same optimal conditions for bone regeneration as the Ilizarov method. That is why combined Ilizarov/FIN yields such a good outcome. The results of this experimental study have been, in our Kurgan clinic, a determining factor for the use of combined Ilizarov/FIN method in bone

lengthening and correction of bone deformities in patients with limb length discrepancy (LLD) and skeletal pathologies such as hereditary hypophosphatemic rickets.

1.2. TIBIAL LENGTHENING WITH FLEXIBLE INTRAMEDULLARY NAILING WITH HYDROXYAPATITE COATING

As mentioned in the previous chapter, the combined technique of lengthening (external fixator+FIN) boosts bone consolidation. Obviously, it is provided by mechanical peculiarities of osteosynthesis: increase of stability of bone fragments and gradual traction of intramedullary nails along the medullary cavity. This effect manifests only if the intramedullary blood supply is preserved – a fundamental condition of the Ilizarov method.

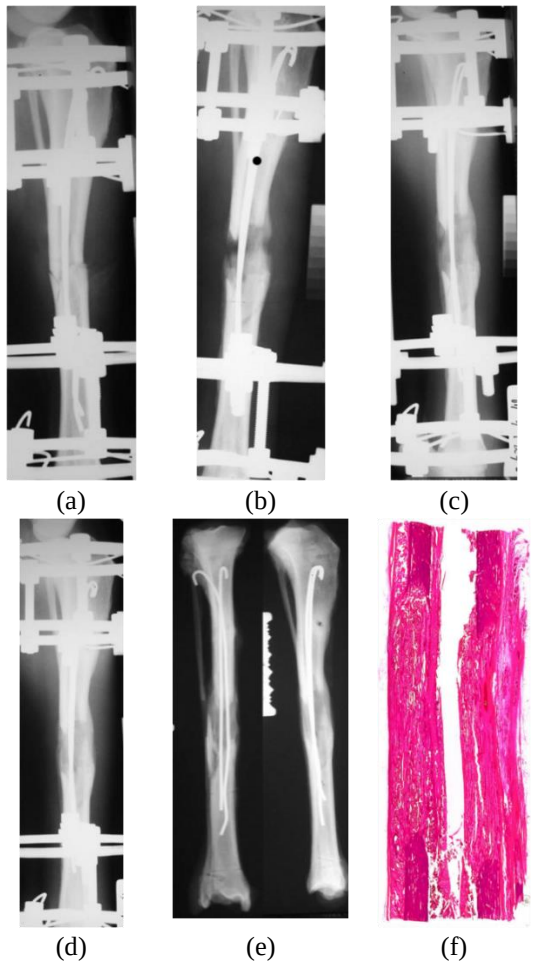

Figure 5. Radiograph of the *right tibia*.Tibial lengthening by combined Ilizarov/FIN: Ilizarov fixator and intramedullary nails in place, osteoclasis of the tibia(a); X-ray taken after 28 days of lengthening (end of lengthening period) (b); X-ray taken after 7 days (D 40) of fixation period (c). Complete healing achieved after 14 days of fixation period (D 48)(d); external fixator removed (e). Histologic sections (tibia): specimen at D 49 (fixator removed), cortices were present along the regenerate and continuity was re-established.

It is well-known that implants with hydroxyapatite coating, like prosthetic stems, have better adhesion with bone tissue because of biologic reaction of bone formation immediately on the implant without an intermediate fibrous layer. In other words, surfaces of such implants reveal osteoconductive features [8-12].

We held an experiment in dogs, when nails covered with hydroxyapatite were inserted in the medullary canal for tibial lengthening by the combined technique.

The results are presented in this chapter.

Materials and Methods

This study was conducted in 12 dogs of various breeds, aged from 1 to 4 years, with the average weight of 18.2 kg. The mean length of tibia was 181 mm. The applied Ilizarov fixator consisted of two distal rings and two proximal three-quarter rings, connected by threaded rods (Figure5). The only difference from the series with bioinert intramedullary nails described in the previous chapter was application of lesser number of wires in the Ilizarov fixator. The upper and lower systems contained only three wires each. There was no other difference between the surgical techniques.

Distraction was initiated on the fifth day in all dogs (Figure 5). The mean distraction rate at the beginning was 1 mm/day. Duration of lengthening was 28 days. A 28-day- lengthening period was followed by external fixation period. The external fixator was removed after 15 days of fixation (D 48) in all dogs. All the dogs could bear weight right after removal of the external fixator without any limb protection.

Results were evaluated according to the radiographic appearance of the regenerate. X-ray control was performed weekly throughout the distraction and fixation periods and after frame removal. Additionally, bone regenerates were histologically studied after sacrifice: at D 48 and D 63.

Results

As in the first series, radiological changes indicated intense and extensive bone regeneration, that forced us to increase the distraction speed in some dogs. Newly formed bone was visible on radiographs after D 7 of lengthening. At this stage, the regenerate had an inhomogeneous structure with localized areas of increased bone density. An intensive periosteal reaction (15–54 mm long and 3-10 mm thick) developed by the 2nd-3rd week of distraction period. It caused significant enlargement of bone cross-sectional dimensions (Figure 6).

As control X-rays revealed extensive bone regenerate, the distraction speed had to be increased in 7 dogs. Early healing occurred in four dogs by the 14th-21st day of lengthening. The following lengthening did not resulted in rupture of the regenerate that had already consolidated (Figure 7). After 15 days of fixation (D 48), the regenerate was completely healed in all the animals. Cortical bone was reconstructed. Continuity of three or four cortices was reestablished along the regenerate. The growth zone had disappeared. A denser periosteal reaction was noted. No fracture or deformity occurred after removal of the external fixator because the regenerates had already consolidated, besides the bones were protected by FIN.

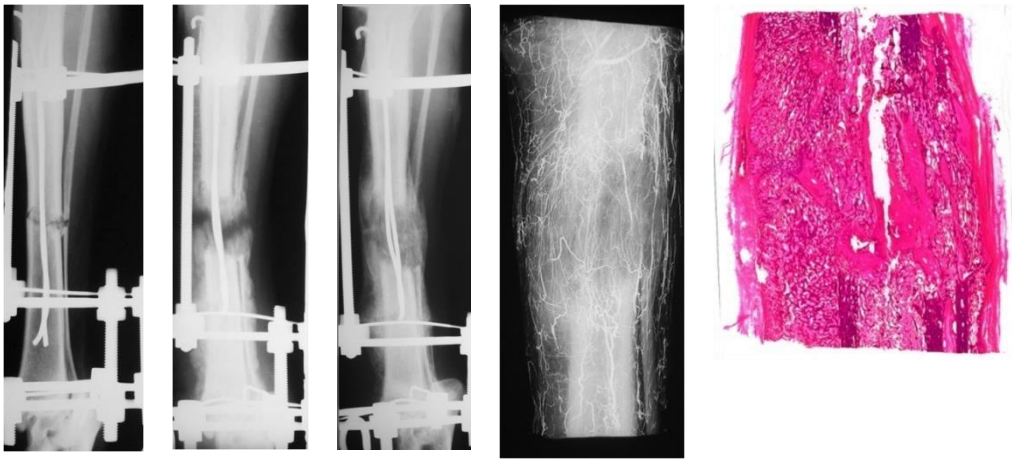

(a) (b) (c) (d) (e)

Figure 6. Intensive periosteal reaction: Ilizarov fixator and intramedullary nails in place, osteoclasis of the tibia(a); by the end of distraction (D 33) an intensive periosteal reaction developed at a level of the gap and adjacent bone fragments (b); bone consolidation was defined in two weeks of fixation (D 47), bone diameter doubled at a level of lengthening (c); arteriography by the sacrifice revealed a significant osteogenesis in periosteal and endosteal parts of new bone (d). Histologic sections: specimen at D 49 (fixator removed), cortices were present along the regenerate and continuity was re-established. Regenerate consisted of cortical and cancellous bone tissue. The medullary canal was patent. Ossification was present along the intramedullary nails. Periosteal reaction resulted in doubled bone diameter at a level of lengthening (e).

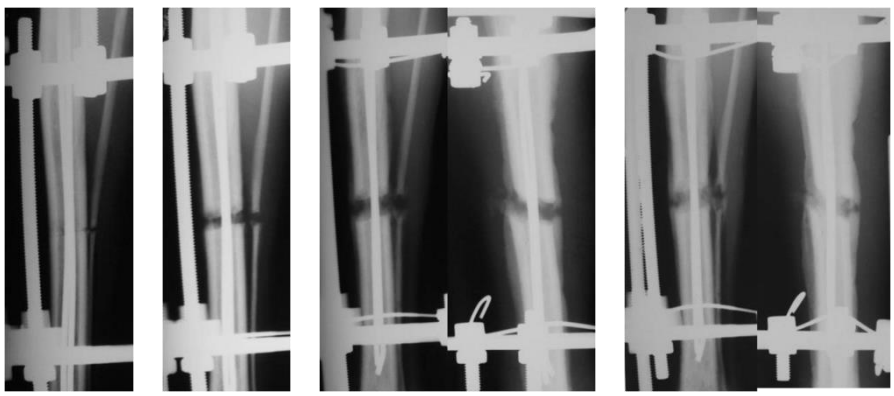

(a) (b) (c) (d)

Figure 7. Healing status after 14 days of tibial lengthening using combined Ilizarov/FIN: Ilizarov fixator and two intramedullary nails in place, closed osteoclasis of the tibia (a); X-ray taken after 7 days of lengthening (b); X-ray taken after 14 days of lengthening, the gap size did not correspond to the duration of distraction, the bone regenerate is uninterrupted, a continued periosteal reaction at the level of lengthening and bone fragments - consolidation (c); X-ray taken after 28 days of lengthening, no separation of bone fragments (the gap did not increased), wires of the Ilizarov fixator did not gain in curve, the regenerate did not ruptured (d).

At the same time, a histological study showed cortical continuity, fully interconnected cancellous trabeculae and disappearance of the fibrous layer surrounding the new bone

(Figure 5f, 6e). In fact, consolidation happened during the fixation period and lasted 2 weeks. Similar to bioinert intramedullary nails, the extensive tissue regeneration along the intramedullary nail was noted (Figure 5f, 6e).

Arteriographies, performed immediately after removal of the intramedullary nails (Figure 6d), showed exuberant formation of the vascular net in the regenerate and periosteal structures.

Besides, no implant migration, septic complications, secondary displacement of bone fragments or skin problems were observed. An ensured stability of bone fragments during lengthening was noted applying the flexible intramedullary nails with hydroxyapatite coating even if the number of wires in the Ilizarov frame was diminished.

Discussion

Preservation of bone environment, periosteum and, particularly, the medullary vascularization, respect of the biological rate of bone growth, preservation of stability and elasticity (provided by the rings) - all these work together to ensure excellent tissue regeneration [13,14].

Our previous animal experiments prove that contoured titanium intramedullary nails do not inhibit endosteal bone formation. On the contrary, despite partial destruction of the bone marrow, the preserved intramedullary circulation stimulates tissue regeneration.

Mechanical impact of gradual traction of flexible nails in the medullar cavity and increased stability at the diastasis by resisting translation motion (essentially) in the plane of the nails as demonstrated before [14] induce stimulation of the regeneration process.

The added bioactive intramedullary element in this situation appeared to to increase a favorable effect of the FIN.

Hydroxyapatite-coated intramedullary nails were chosen because of osteoconductive features of this mineral [15,16]. The fact of solid adhesion between bone and hydroxyapatite implants [8,9,12] was proved. Hydroxyapatite coating provides an early fixation of an implant without a fibrous layer between bone and implant. Soballe et al. [17] demonstrated that the fibrous tissue beneath HA interface contains collagen fibers which are usually perpendicular to the implant surface and can guide bony ongrowth.

Hydroxyapatite-coated intramedullary nails used in the experiment intensified formation of bone distraction regenerate. It ensured consolidation of bone fragments within two weeks after the end of distraction in all cases. The combined technique of distraction osteosynthesis with bioactive implants was performed with a lightened variant of the external osteosynthesis (fewer wires in the Ilizarov fixator).

We believe that use of hydroxyapatite-coated intramedullary nails in combination with external fixation can be indicated in systemic skeletal diseases, associated with disorders of bone tissue formation, impaired metabolism of Ca and P resulted in low bone mineral density.

Thus, the combined technique of lengthening with bioactive intramedullary implants respects all the favorable aspects of mechanical stimulation of bone formation. The use of hydroxyapatite-coated intramedullary nails allows to decrease the number of wires or half-pins of the external fixator with no harm to stability of osteosynthesis. Besides, the bone healing is achieved in the shortest period.

REFERENCES

[1] Téot, L. (1987). L'enclouage centromédullaire élastique stable chez l'enfant. Cahier d'enseignement de la SOFCOT no 28. Expansion Scientifique Française, Paris, 71–90.

[2] Lascombes, P., Membre, H., Prévot, J. & Barat, E. (1991). Histomorphométrie du régénérat osseux dans les allongements des membres selon la technique d'Ilizarov. *Rev Chir Orthop*., *77*, 141–150.

[3] Shevtsov, V. I., Popkov, A. V., Popkov, D. A. & Prévot, J. (2001). Réduction de la durée du traitement dans les allongements osseux progressifs. *Rev Chir Orthop*., *87*, 248–256.

[4] Kojimoto, H., Yasui, N., Goto, T., Matsuda, S. & Shimomura, Y. (1988). Bone lengthening by callus distraction. The role of periosteum and endosteum. *J Bone Joint Surg*., *70B*, 543–549.

[5] Yasui, N., Kojimoto, H., Sasaki, K., Shimizu, H. & Shimomura, Y. (1991). The effects of distraction upon bone, muscle and periosteum. *Orthop Clin North Am.*, *22*, 563–567.

[6] Shevtsov, V. I., Popkov, A. V., Popkov, D. A., Yerofeev, S. A., Prévot, J. & Lascombes, P. (2004). Embrochage centromédullaire dans les allongements osseux selon Ilizarov. *Rev Chir Orthop*., *90*, 399–410.

[7] Launay, F., Jouve, J. L., Guillaume, J. M., Viehweger, E., Jacquemier, M. & Bollini, G. (2001). Les allongements progressifs de l'avantbras chez l'enfant. À propos d'une série de 14 cas. *Rev Chir Orthop.*, *87*, 786–795.

[8] Dumbleton, J. & Manley, M. T. (2004). Hydroxyapatite-coated prostheses in total hip and knee arthroplasty. *J Bone Joint Surg (Am), 86-A*, 2526-2540.

[9] Chatelet, J-C. & Setiey, L. (2004). Comportement osseux à long terme après implantation d'un pivot fémoral totalement revêtu d'hydroxyapatite. *Rev Chir Orthop*, *90*, 628-635.

[10] Kold, S., Rahbek, O., Zippor, B., Bechtold, J. E. & Søballe, K. (2005). Bone compaction enhances fixation of hydroxyapatite-coated implants in a canine gap model. *J Biomed Mater Res B Appl Biomater*., *75*(1), 49-55.

[11] Rahbek, O., Kold, S., Bendix, K., Overgaard, S. & Søballe, K. (2005). Superior sealing effect of hydroxyapatite in porous-coated implants: experimental studies on the migration of polyethylene particles around stable and unstable implants in dogs. *Acta Orthop*, *76*(3), 375-385.

[12] Epinette, J. A. & Manley, M. T. (2007). Hydroxyapatite-coated total knee replacement: clinical experience at 10 to 15 years. *J Bone Joint Surg Br*, *89*(1), 34-38.

[13] Shevtsov, V. I., Popkov, A. V., Popkov, D. A. & Prévot, J. (2001). Réduction de la durée du traitement dans les allongements osseux progressifs. *Rev Chir Orthop*, *87*, 248–256.

[14] Popkov D., Popkov A., Haumont T., Journeau P. & Lascombes P. (2010). Flexible intramedullary nail use in limb lengthening. *J Pediatr Orthop*, *30*(8), 910-918.

[15] Hacking, S. A., Tanzer, M., Harvey, E. J., Krygier, J. J. & Bobyn, J. D. (2002). Relative contributions of chemistry and topography to the osseointegration of hydroxyapatite coatings. *Clin Orthop Relat Res*, *405*, 24-38.

[16] Popkov, A. V. & Popkov, D. A. (2012). Bioactive implants in traumatology and orthopaedics. *Irkutsk: SCRRS SB RAMS*., 438 p.

[17] Soballe, K., Hansen, E. S., Rasmussen, H. B. & Bunger, C. (1995) Fixation of porous coated versus HA coated implants. In: Epinette J-A: Geesink RGT: eds. *Hydroxyapatite coated hip and knee arthroplasty*. Vol *51*. Paris: Expansion Scientifique Francaise.

In: Encyclopedia of Surgery (22 Volume Set)
Editors: Andreas Lehrer and Kristin Mueller
ISBN: 978-1-53618-329-0
© 2020 Nova Science Publishers, Inc.

Chapter 2

INFLUENCE OF THE TRANSPHYSEAL SLIDING NAILING ON LONGITUDINAL GROWTH OF THE TIBIA: EXPERIMENTAL STUDIES

Dmitry Popkov[1,*], Natalia Kononovich[1], Roman Shutov[1] and Dominique Barbier[2]

[1]Scientific and Clinical Laboratory for Deformity Correction and Limb Lengthening. Federal Russian State-Financed Ilizarov Scientific Center for Restorative Traumatology and Orthopaedics, Kurgan, Russia

[2]Pediatric Orthopedic Surgery Department, Nancy University Hospital Center, Children's Hospital, Vandoeuvre, France

ABSTRACT

Transphyseal sliding nailing of the right intact tibia with thin steel rods was performed in six mongrel dogs at the age of six months. The contralateral segment served as a control. In series II the transphyseal sliding nailing was performed in a fractured tibia also in six dogs. Modifications of residual growth and natural shape-formation of proximal and distal epiphyses of the tibia were observed in the experiment in conditions influenced by the transphyseal rods.

Keywords: growth, tibia, transphyseal sliding nailing.

INTRODUCTION

Skeletal systemic diseases inhibiting strength properties of bone tissue, osteogenesis imperfecta in particular, are very often complicated by pathological fractures, deformities and limb length discrepancy. In 1952, Sofield proposed to perform transphyseal intramedullary reinforcement in order to correct deformities in osteogenesis imperfecta [1]. In this case,

* Corresponding Author's Email: dpopkov@mail.ru.

intramedullary material stay inside for the whole period of growth serving as an internal device during bone fragment union, as well as preventing the development of new deformities. Further development of the technique of transphyseal reinforcement allowed Bayley to create a specific system of transphyseal intramedullary telescopic osteosynthesis [2-6]. In 1987 Métaizeau proposed to use intramedullary sliding transphyseal elastic nailing not only for treatment of common shaft fractures in children, but also to prevent deformities in skeletal systemic diseases accompanied by bone tissue fragility [7].

There are many recent publications which highlight advantages of the telescopic intramedullary transphyseal systems in prevention of fractures and deformities in children affected with osteogenesis imperfecta [8-10]. In 2004, Boutaud and Laville reported fewer complications comparing to use of telescopic rods in their study of intramedullary transphyseal sliding reinforcement in 14 children with osteogenesis imperfecta (36 segments) [11]. Another advantage of elastic nails is a possibility of applying in any medullary canal diameter that is particularly important for children up to the age of 6 years.

As Salter and Harris demonstrated, the growth cartilage is known to be one of the most important anatomic structures in pediatric orthopedic practice [12]. However, there is no clinical or experimental research of the effect of prolonged transphyseal reinforcement with elastic nails on the growth of involved segment.

Thus, the purpose of this study was to evaluate the influence of transphyseal elastic nailing on the residual growth of intact tibia (series I) or on the tibia with transverse shaft fracture (series II).

MATERIALS AND METHODS

Experiments were performed observing 12 mongrel dogs in the period of growth (at the age of six months). The animals were divided in two experimental series (six animals in each). Littermate puppies were used in each separate series. Preoperative X-ray examination confirmed the presence of open tibial proximal and distal growth plates in all the dogs.

The sliding bipolar transphyseal elastic intramedullary nailing of the right intact tibia was performed in the first series (Figure 1) [13]. The left limb served as a control.

Protocol of surgery. Thiopental intravenous anesthesia was used for all the interventions. A proximal titanium nail of 1.8 mm of diameter and 10 cm in length, pre-curved at 40° was inserted from the approach of 2 cm medially to the proper patellar ligament. Preliminarily, an entry hole towards the medullary canal transphyseally by a single maneuver uwith a surgical awl of 3-mm diameter in the position of the knee flexion. It is through this channel the bent nail was inserted.

A distal nail was inserted retrogradely at the level of medial malleolus also transphyseally. Free ends of the nails were U-bent and impacted into epiphyses in order to prevent their migration inside the bone during residual growth of the segment. Wounds sutured by layers with interrupted stitches. Thus, preventive intramedullary transphyseal osteosynthesis applied for osteogenesis imperfecta was simulated in this series.

In the second series a transverse osteotomy was performed subperiosteally with a vibro-saw at the level of middle third of the tibial shaft from 2-cm antero-internal approach before insertion of intramedullary titanium nails (Figure 2). Fibular shaft integrity was broken by

transcutaneous osteotomy with a chisel. The technique of intramedullary nail insertion was similar to those of the first series, however, the nails were inserted along the entire length of the medullary canal. Thus, in this series intramedullary transphyseal elastic nailing was simulated for pathologic bone fracture in osteogenesis imperfecta.

Postoperative wounds were systematically treated in the postoperative period. The animals were anesthetized using non-steroid anti-inflammatory preparations during the first three days twice a day. Additional immobilization of the operated limb was not performed. The animals moved with full weight-bearing of the operated limb without limitation.

The growth of leg bones in created conditions was studied according to X-ray examination of both legs in AP and lateral views. X-rays were taken on the day of surgery and then once a month for six months (up to the closure of tibial growth plates). Radiography was performed at standard focal distance securing the examined limb with "VEP X Technology Premium VET" radiological device.

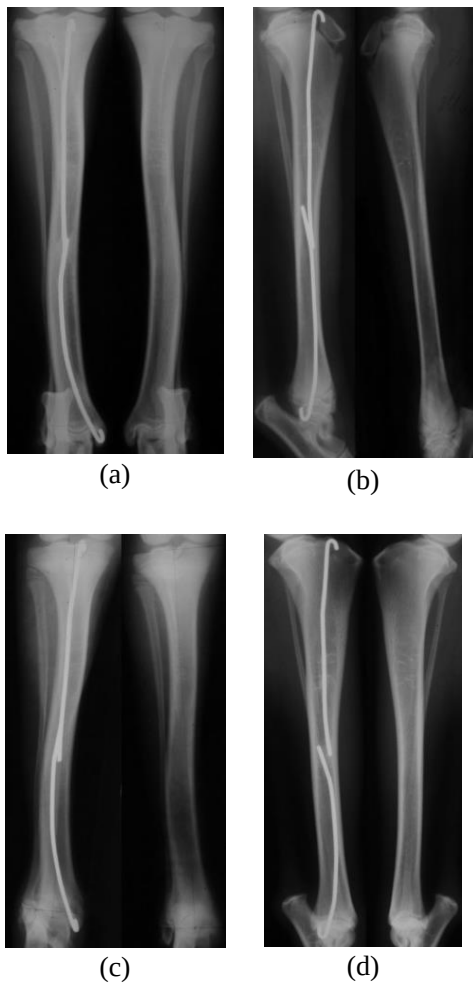

Figure 1. Series I: X-rays (D 0, AP view) of the right and left tibiae (**a**); X-rays (D 0, lateral view) of the right and left tibiae (**b**); X-rays (M 6, AP view) of the right and left tibiae (**c**); X-rays (M 6, lateral view) of the right and left tibiae (**d**).

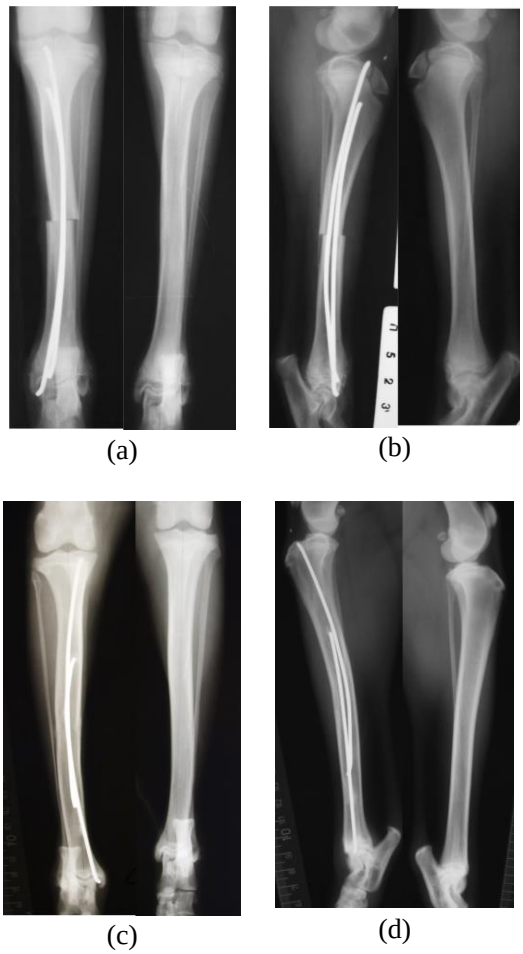

Figure 2. Series II: X-rays (D 0, AP view) of the right and left tibiae (**a**); X-rays (D 0, lateral view) of the right and left tibiae (**b**); X-rays (M 6, AP view) of the right and left tibiae (**c**); X-rays (M 6, lateral view) of the right and left tibiae (**d**).

The following parameters were evaluated monthly:

- tibial length was measured by X-rays in the lateral projection of segment axis from tibial condylar articular surface to the ankle gap. The change in tibial length was calculated, as well as the growth length loss comparing with the left tibia (mm and %), the growth for the observation period of the segment final length, and the relative loss of length comparing with the left tibia;
- the amount of crossing of the proximal and distal nails in the medullary canal;
- the diameter of tibial shaft in the middle third (by AP and lateral views of X-rays);
- the mechanical Medial Proximal Tibial Angle (mMPTA) was measured between the mechanical axis of segment and the line connecting two points (tops) of the concave articular surfaces of tibial condyles;
- the mechanical Lateral Distal Tibial Aangle (mLDTA) formed by the mechanical axis of segment and the ankle articular line;

- the location of elastic nails at the level of physes relative to their median axes in the sagittal and frontal planes.

Moreover, in series II the time of bone fragment consolidation was evaluated, as well as possible segment deformities resulted from secondary displacement. Statistical analysis included descriptive statistics: mean values (M) and standard deviation (SD). Comparative studies were carried out with Student's t-test and Wilcoxon test for independent and paired samples. Differences in values considered significant at $p<0.05$. AtteStat 13.1 Program was used to calculate the statistical parameters.

Comparing values within the series were as follows:

- D 0 (day of surgery) vs M 6 (six months after the experiment start) for the right limb,
- D 0 (day of surgery) vs M 6 (six months after the experiment start) for the left limb,
- D 0, the right limb, vs D 0, the left limb,
- M 6, the right limb, vs M 6, the left limb,

The experiments were made in accordance with the requirements of "European Convention for the protection of vertebrate animals used for experimental and other scientific purposes", and it was approved by Ethics Committee of the Ilizarov Center.

RESULTS

No infectious and neurological complications were observed in any case. Additional surgeries were not required. In all cases the puppies began moving with full weight-bearing of the operated limb in 2-3 days after surgery.

The position of nails relative to physes centers in each series is illustrated in Figure 3. The passage of the nails at the level of distal growth plate was markedly medial due to their insertion through medial malleolus. The nail occupied 0.63±0.03% of metaphysis area in this zone.

At the level of proximal physis the position of the nails was more central, but also, in most cases, with a tendency to 1-5-mm displacement in the medial direction with respect to bone longitudinal axis. The nail occupied 0.32±0.03% of the area of proximal metaphysis. The analysis of the tibial residual growth demonstrated in Table 1.

As seen from the data, the growth continued in the dogs of all series. Difference between the initial length and the length of tibiae (of the right and left limbs) by the end of the experiment are statistically significant in all the series. However, a smaller longitudinal increase of the operated tibia is also characteristic for the both series of the experiment, but they are not statistically significant. The value of longitudinal growth loss during the experiment is the least. Itamounted to 1-7 mm (from 1 to 5.4%) in series I and from 5 to 17 mm (from 2.8 to 9.5%) in series II, but the growth acceleration of the operated leg was observed in one dog, and the difference in length by the end of the experiment amounted to 5 mm (2.7%).

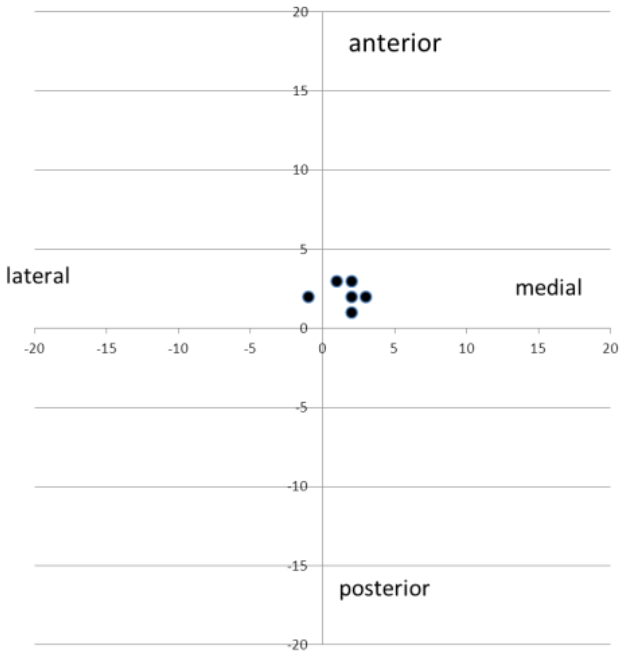

(a)

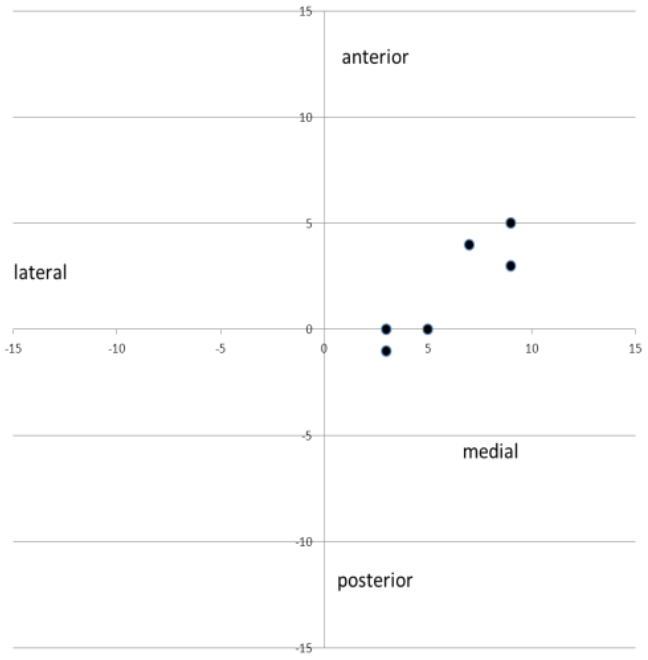

(b)

Figure 3. (Continued).

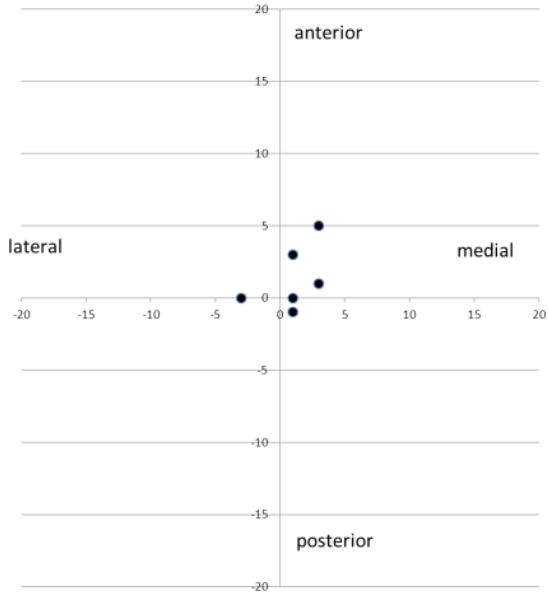

(c)

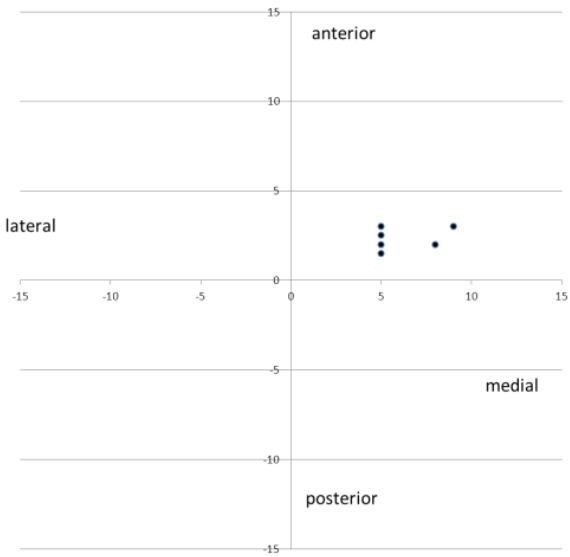

(d)

Figure 3. Location of elastic nails at the level of physes relative to their median axes in the sagittal and frontal planes: proximal tibial physis, series I (**a**); distal tibial physis, series I (**b**); proximal tibial physis, series II (**c**); distal tibial physis, series II (**d**).

When analyzing directly the value of tibial gain for D 0 - M 6 period in all the series, a 15-18% decrease of this parameter in the operated segment was determined comparing with the control one.

Table 1. The tibial longitudinal residual growth (M±SD)

	Total length of tibia (mm)				The loss of total length of "R" in comparison to final length of "L" in M6 period		The growth in length for D 0 – M 6 period		
	D 0		M 6				Of segment total length for M6 (%)		The loss of length of "R" in comparison to "L" (%)
	«R»	«L»	«R»	«L»	mm	%	«R»	«L»	
Series 1	136.5±39.5	136.7±39.4	152.7±36.7[1]	156.5±37.3[1]	3.8±2.9	2.5±2.1	11.5±5.0	13.6±4.6	17±12.3
Series 2	139.2±9.5	139.2±9.5	172.5±9.8[1]	180.3±8.5[1]	7.8±8.0	4.3±4.3	19.3±3.6	22.8±3.7	14.9±14.0

Note: [1] – statistically significant differences with the initial values of this series;
«R» – right tibia; «L» – left tibia.

Table 2. Values of proximal medial tibial angle (mMPTA)

		D 0		M 6		M 6 – D 0
		M ± SD (min-max)	P_1	M ± SD (min-max)	P_2	P_3 / P_4
Series 1	Right tibia	91.7°±2.4 (87°-96°)	P^t=0.914	90.8°± 2.1 (88°-94°)	P^t=0.642	P^t=0.306
	Left tibia	90.9°±2.8 (84°-95°)		93.4°±2.3 (90°-99°)		P^t=0.101
Series 2	Right tibia	92.3°±2.1 (90°-95°)	P^t=0.481	91.8 ± 1.9 (90°-95°)	P^t=0.079	P^t=0.675
	Left tibia	91.5±1.9 (89°-94°)		90.0 ± 1.1 (89°-92°)		P^t=0.128

Note: P^1= p-values when compared the right and left side for D0; P^2= p-values when compared the right and left side for M6; P^3= p-values of the right side values for D 0 vs M 6; P^4= p- values of the left side values for D0 vs M6; P^t : p-values for Student's test.

Table 3. Values of lateral distal tibial angle (mLDTA)

		D 0		M 6		M 6 – D 0
		M ± SD (min-max)	P_1	M ± SD (min-max)	P_2	P_3 / P_4
Series 1	Right tibia	85.2°±3.1 (81°-89°)	P^t=0.563	88.2° ± 5.3 (84°-96°)	P^t=0.023 P^w=0.045	P^t=0.267
	Left tibia	84.2±2.7 (79-87)		81.2° ± 2.8 (76°-84°)		P^t=0.088
Series 2	Right tibia	87.7° ± 2.1 (86°-91°)	P^t=0.718	84.2° ± 6.4 (78°-96°)	P^t=0.691	P^t=0.251
	Left tibia	87.2° ± 2.6 (84°-91°)		83°±2.5 (80°-85°)		P^t=0.016 P^w=0.026

Note: P^1= p-values when compared the right and left side for D0; P^2= p-values when compared the right and left side for M6; P^3= p-values of the right side values for DS vs M6; P^4= p-values of the left side values for D0 vs M6; P^t: p-values for Student's test; P^w : p-values for non-parametric Wilcoxon test.

Table 4. Diameter (mm) at the level of middle third in the tibial shaft

	D 0 (AP view)		M 6 (AP view)		D 0 (lateral view)		M 6 (lateral view)	
	right	left	Right	left	right	left	right	left
Series 1	11.3±0.82	11.3±0.82	13.2±0.84[1]	13.2±0.84[1]	10±1.55	10±1.55	11.8±1.72	11.2±1.47
Series 2	12.2±1.17	12.2±1.17	17.2±1.94[1]	14.3±1.21[1 2]	11.2±1.17	11.2±0.75	17.2±1.83[1]	13.3±1.21[2]

Note: [1] – significant differences D 0 vs M 6 for this series,
[2] – significant differences between right and left sides at M 6.

When measuring the extent of overlapping of nails in the medullary canal, it progressively decreased only as long as the tibia grew. In average the decrease of crossing was 13.4±0.9 mm in the first seriesand 15.6±5.7 mm in the second series by the end of the experiment. There was no significant difference between the series. Migration of the proximal nail inside the bone should be mentioned in two cases of 19 mm and 25 mm in series II. We did not observe the cases of nail inward migration during segment growth in series I.

No reliable differences in mMPTA values of the experimental segment were revealed between themselves and comparing with the preoperative level at different stages of the experiment (Table 2). Slightly marked changes of this value were found in the left (control) segment. However, these changes were statistically doubtful regarding the experimental segment in four cases. Apparently, the transphyseal insertion of elastic nails close to the center of growth plate doesn't significantly influence the mMPTA value

By the end of the experiment mLDTA values of the experimental (right) segment didn't change statistically significantly among themselves and comparing with the preoperative level in all the series. It can be mentioned that this value had a tendency to increase in the first series for the right limb, and that to some reduction – in the second series. As for the control segment, a reliable decrease in the mLDTA angle was revealed by the end of growth comparing with the preoperative values in the both series (Table 3).

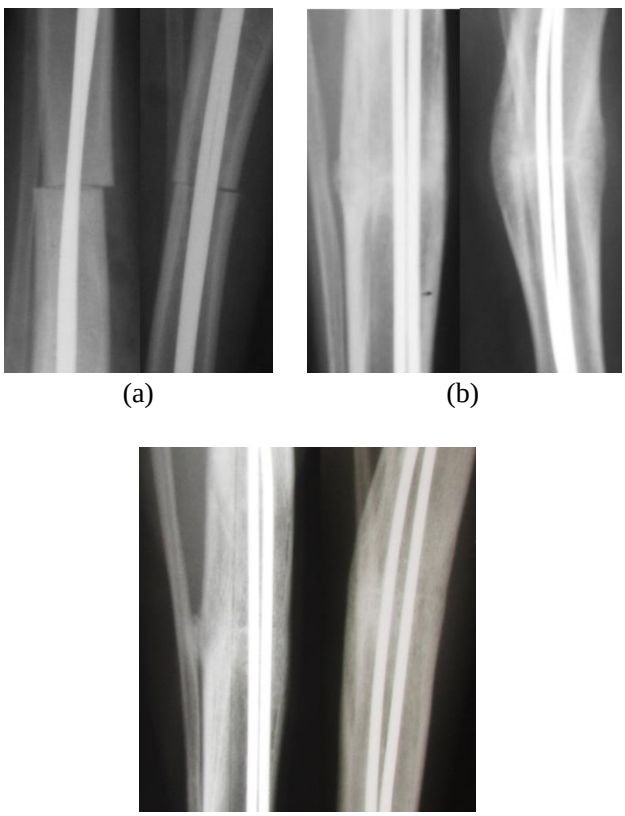

Figure 4. Bone consolidation (X-rays, AP and lateral views), series II: D 0 (**a**); M 2 (**b**); M 6 (**c**).

Thus, in our experiment the transphyseal insertion of elastic nails through the medial malleolus resulted in significant slowing down of the physiological decrease of mLDTA angle (physiological valgus deviation of the ankle) in series II.

The change in the values of tibial outer diameter in the middle third occurred upwards in the right and left limbs of all the animals. Significant difference between D 0 and M 6 were observed in series I and II. According to Table 4 data, the increase of shaft diameter was the same for operated and intact limb in series I. As we believe, it points out to an immaterial impact of intramedullary elastic nails on the functional activity of both endosteal lining and periosteum.

The X-ray signs of bone consolidation (disappearance of fracture line, continuity of cortical plates) in series II were observed in all the cases by the end of the second month of the experiment (Figure 4). Secondary displacement of fragments was observed in one animal only being characterized by 7˚ antecurvation deformity. A significant increase of bone diameter in the animals of this series was observed by the end of the experiment, if we compare both with the initial data and between the control and experimental limbs (Table 4). It is interesting that the most marked periosteal reaction and, consequently, cortical plate thickening occurred on the posterior surface of tibia. It is obvious that osteotomy is a prerequisite for periosteal reaction development under the conditions of the study.

DISCUSSION

Reconstructive orthopaedic interventions in the limbs for the systemic diseases accompanied by bone tissue fragility are intended to prevent deformities or to correct them. A positive effect of such surgeries on patients' functional condition and increase of their motor activity is indisputable [9,10,14-16]. Boutaud and Laville [11] consider that using of intramedullary sliding transphyseal elastic nailing for these purposes is preferable than telescopic rods: no problems with moving elastic nails apart, less total number of complications than with other systems, less incidence of implant migration . Many colleagues performing reconstructive surgeries in children with osteogenesis imperfecta note the common difficulties and/or disadvantages of telescopic systems: need to replace them as far as the child grows, migration of rods or their parts (e.g., threaded ones) when "anchoring" it to the bone (10.5% - 23.7%), telescopic rod deformation (up to 18.8%), the rod fails to elongate (up to 2.1%), the rod's damage (up to 6.9%) [8,17-21]. Thus, the problem of improving telescopic transphyseal systems remains relevant. Moreover, none of clinical studies assesses quantitatively the effect of transphyseally inserted elements on the limb's longitudinal growth, formation of the reinforced segments' epiphyses, or development of angular deformity.

The results of experimental studies on the effect of partial damage of the growth plates varied, but few in number. A negative effect of reaming of the transphyseal canal on the growth function of cartilage was observed in experimental studies of the proximal tibial physis when they simulated the anterior ligament reconstruction of the tibia. Thus, Chudik [22] and Ono [23] performing the anterior cruciate ligament reconstruction in puppies and rabbits found a statistically significant shortening of the operated segment by the end of natural growth. On the other hand, the straight transphyseally inserted wires of 1.3-2 mm in

diameter left in place for less than 12 weeks didn't cause growth dysfunction and consequently shortening in rabbits [24-28]. Epiphyseodesis with this size of wires was observed within the period of 12-24 weeks of transphyseal placement of implants [25,27]. Epiphysiodesis was observed if the wires' diameter exceeded 3.2-3.5 mm [27,28]. Finally, Mäkelä [28] found that injury of over 7% of the growth plate area led to an irreversible epiphysiodesis and segment shortening. On the other hand, the use of biodegradable transphyseal thin rods in rats doesn't lead to epiphysiodesis [29].

In clinical practice, especially in traumatology, the authors' opinion about the effect of transphyseal wire insertion on the growth cartilage function varies. For example, Horn J. et al. describe partial epiphysiodesis and development of angulation during fracture treatment in children [30]. In turn, Yung and Langenhan do not observe the effect of transphyseally inserted Kirschner wires on further growth of the operated limb [31,32].

In our study the injury of physis area was below 6% when the implants remained in place for 25 weeks, and they didn't cause irreversible epiphysiodesis and formation of statistically significant segment shortening. However, the mean length loss was 3.8 mm in series I, and 7.8 mm – in series II. Transphyseal reinforcement with osteotomy (series II) caused a greater shortening of the operated segment. The loss of residual growth of the operated segment was from 14% to 18%. Thus, the growth retardation was found in all the series of our study.

In our study, intramedullary sliding transphyseal nailing influenced the formation of the angle of inclination of the distal tibial articular surface. Eccentric placement of intramedullary nails through the medial malleolus led either to the ankle varus deviation (in series I) with a significant difference between the control limb and experimental one by the end of growth, or, as in series II, to significant inhibition of physiological valgus deviation (mLDTA decrease).

Central transphyseal placement of the nails didn't cause significant angular deviation in any series of the study. Studies of other authors confirm the fact of angular deviation in case of eccentric injury of the growth plate. In 1994 Guzzanti found two cases of knee valgus development because of lateral location of transphyseal canal and tendon insertion into it in their experimental series of the anterior cruciate ligament plasty in 21 rabbits [33]. Seil did not observe angular deviation during residual growth of the segment following a centrally located channel in 18 lambs [34]. The above mentioned studies and our own data confirm the position of Ford [35], that the central injury of the growth plate doesn't cause angular deformities, but can contribute to segment shortening formation, and peripheral epiphyseodesis leads to angular deformity development.

It is important to mention that long presence of the implant is essential for growth function modification in addition to topography and extent of growth plate injury. There are several studies, which demonstrated that acute forming of the transphyseal canel without wire or tendon placement doesn't lead to epiphyseodesis, as well as doesn't cause any disorders of longitudinal bone growth [36,37]. While formation of a narrow epiphyseodesis zone surrounding the permanently present implant is an irreversible cause of growth inhibition in this part of physis [38,39]. At the same time, just a relatively small size of epiphysiodesis (below 7%) allows spontaneous desepiphysiodesis in the process of active growth [28]. We think that repeated epiphysiodeses and spontaneous desepiphysiodeses explain local inhibition of physis function resulting in growth retardation, but not in arrest of growth immediately after surgery.

Both endosteal and periosteal reactions observed during experimental fracture treatment using intramedullary elastic nails are described in some studies [13,40]. The reasons are those referred to the mechanical irritation of medullary canal inner surface on one hand, and those referred to the redistribution of cortical plate blood flow to peripheral structures on the other hand. The endosteal and periosteal reactions in our experimental series were observed as well. However, there was no periosteal reaction in the first series, and the marked endosteal osteogenesis at the level of the contact with nail ends contributed to cortical plate thickening and bone envelope formation around the intramedullary nails. The periosteal reaction was noted in the second series, where bone integrity damage and periosteum detachment were produced. Thus, we believe that it was just a direct mechanical impact that initiated endosteal and periosteal osteogenesis in our study.

It should be mentioned, that we didn't observe disorders of wires moving apart during growth in the medullary canal in the first series, where the segment preventive reinforcement was imitated. These data confirmed the results reported by Boutard and Laville [11], and they demonstrated the advantages of intramedullary sliding elastic nailing over the telescopic rods from this point of view. However, locking of the elastic nail sliding was observed in three cases when bone fracture was simulated (series II). In our opinion, blocking of the nails with endosteal callus at the level of osteotomy may be an obstacle to moving the rods apart.

The intramedullary elastic osteosynthesis for treatment of shaft fractures in children, including pathological ones, is the most common and reliable surgical method used by pediatric orthopedists of many countries [13,41]. It is quite natural that consolidation of bone fragments took place in all the cases and within usual delay in series II of our study.

The encouraging results of using bisphosphonates [22,26,39] and/or implants with bioactive coating [43] in patients with osteogenesis imperfecta encourages us to hope that combination of therapeutic and surgical methods of treatment will contribute to improve the outcomes in terms of both anatomical (longitudinal growth of segments and prevention of deformities) and functional results of treatment.

CONCLUSION

This experimental study has demonstrated that transphyseal elastic osteosynthesis influences on the segment longitudinal growth. The least length loss was observed in the intramedullary sliding transphyseal nailing simulating preventive osteosynthesis.

The eccentric insertion of transphyseal nails causes angular deformity development or slows down the physiological orientation of articular surface. Thus, transphyseal telescopic systems should provide positioning of implant elements in the center of growth plates only.

Endosteal and periosteal reactions to intramedullary implant insertion lead to increase of cortical plate thickness and bone diameter, that may be benificial in case of combined treatment of osteogenesis imperfecta by pharmacological and surgical methods.

REFERENCES

[1] Sofield, H. A. & Millar, E. A. (1959). Fragmentation, realignment, and intramedullary rod fixation of deformities of the long bones in children. *J Bone Joint Surg Am*., *41*, 1371–1391.

[2] Bailey, R. W. & Cole, W. G. (1993). Early surgical management of severe forms of osteogenesis imperfecta. *Am J Med Genet*., *45*. 270-274.

[3] Bailey, R. W. & Dubow, H. I. (1963). Studies of longitudinal bone growth resulting in an extensible nail. *Surg Forum*., *14*, 455‑458.43. Popkov A., Popkov D. (2012). Bioactif Implants in Traumatology and Orthopaedics [in russian]. Irkutsk., Russia: *NSRS SO RAMN*., 438p.

[4] Ryöppy, S., Alberty, A. & Kaitila, I. (1987). Early semiclosed intramedullary stabilization in osteogenesis imperfecta. *J Pediatr Orthop.*, *7*(2), 139‑144.

[5] Tiley, F. & Albright, J. A. (1973). Osteogenesis imperfecta: treatment by multiple osteotomy and intramedullary rod insertion. Report on thirteen patients. *J Bone Joint Surg Am*., *55*(4), 701‑713.

[6] Williams, P. F. (1965). Fragmentation and rodding in Osteogenesis Imperfecta. *J Bone Joint Surg Br*., *47*, 23‑31.

[7] Metaizeau, J. P. (1987). Sliding centro-medullary nailing. Application to the treatment of severe forms of osteogenesis imperfecta. *Chir Pediatr*., *28*, 240-243.

[8] El-Adl, G., Khalil, M. A., Enan, A., Mostafa, M. F.,& El-Lakkany, M. R. (2009). Telescoping versus non-telescoping rods in the treatment of osteogenesis imperfecta. *Acta Orthop Belg.*, *75*(2), 200-208.

[9] Ruck, J., Dahan-Oliel, N., Montpetit, K., Rauch, F. & Fassier, F. (2011). Fassier-Duval femoral rodding in children with osteogenesis imperfecta receiving bisphosphonates: functional outcomes at one year. *J Child Orthop.*, *5*(3), 217‑224.

[10] Wirth, T. (2012). Osteogenesis imperfecta. *Orthop.*, *41*(9), 773‑782.

[11] Boutaud, B. & Laville, J. M. (2004). L'embrochage centromédullaire coulissant dans l'ostéogenèse imparfaite. *Rev Chir Orthop.*, *90*, 304-311.

[12] Salter, R. B. & Harris, W. R. (1963). Injuries involving the epiphyseal plate. *J Bone Jt Surg.*, *45*(3), 587‑622.

[13] Lascombes, P. (2010). *Flexible intramedullary nailing*. Springer-Verlag Berlin Heidelberg.

[14] Esposito, P. & Plotkin, H. (2008). Surgical treatment of osteogenesis imperfecta: current concepts. *Curr Opin Pediatr.*, *20*, 52–57.

[15] Khoshhal, K. I. & Ellis, R. D. (2001). Functional outcome of Sofield procedure in the upper limb in osteogenesis imperfecta. *J Pediatr Orthop.*, *21*(2), 236‑237.

[16] Porat, S., Heller, E., Seidman, D. S. & Meyer S. (1991). Functional results of operation in osteogenesis imperfecta: elongating and nonelongating rods. *J Pediatr Orthop.*, *11*, 200–203.

[17] Gamble, J. G., Strudwick, W. J., Rinsky, L. A. & Bleck, E. E. (1988). Complications of intramedullary rods in osteogenesis imperfecta: Bailey-Dubow rods versus nonelongating rods. *J Pediatr Orthop.*, *8*, 645‑649.

[18] Glorieux, F. H. (2007). Treatment of osteogenesis imperfecta: who., why., what? *Horm Res.*, *68*, Suppl 5, 8-11.

[19] Glorieux, F. H. (2008). Osteogenesis imperfecta. *Best Pract Res Clin Rheumatol*., *22*, 85–100.

[20] Monti, E., Mottes, M., Fraschini, P., Brunelli, PC., Forlino, A., Venturi, G., Doro, F., Perlini, S., Cavarzere, P. & Antoniazzi. (2010). Current and emerging treatments for the management of osteogenesis imperfecta. *Ther Clin Risk Manag.*, *6*, 367–381.

[21] Zionts, L. E., Ebramzadeh, E. & Stoot, N. S. (1998). Complications in the use of the Bailey-Dubow extensible wire. *Clin Orthop. 18*, 102-109.

[22] Chudik, S., Beasley, L., Potter, H., Wickiewicz, T., Warren, R. & Rodeo, S. (2007). The influence of femoral technique for graft placement on anterior cruciate ligament reconstruction using a skeletally immature canine model with a rapidly growing physis. *Arthrosc J Arthrosc Relat Surg Off Publ Arthrosc Assoc North Am Int Arthrosc Assoc.*, *23*(12), 1309-1319.

[23] Ono, T., Wada, Y., Takahashi, K., Tsuchida, T., Minamide, M. & Moriya, H. (1998). Tibial deformities and failures of anterior cruciate ligament reconstruction in immature rabbits. *J Orthop Sci Off J Jpn Orthop Assoc.*, *3*(3), 150‑155.

[24] Boelitz, R., Dallek, M., Meenen, N. M. & Jungbluth, K. H. (1994). Reaction of the epiphyseal groove to groove-crossing bore-wire osteosynthesis. Results of a histomorphologic small animal study. *Unfallchirurgie.*, *20*(3), 131-137.

[25] Cady, R. B., Siegel, J. A., Mathien, G., Spadaro, J. A. & Chase, S. E. (1999). Physeal response to absorbable polydioxanone bone pins in growing rabbits. *J Biomed Mater Res.*, *48*(3), 211-215.

[26] Hajdu, S., Schwendenwein, E., Kaltenecker, G., László, I., Lang, S., Vécsei, V. & Sarahrudi, K. (2011). The effect of drilling and screw fixation of the growth plate - an experimental study in rabbits. *J Orthop Res.*, *29*(12), 1834-1839.

[27] Kameyama, M. (1993). An experimental study on injuries to the growth plate - effects on the growth of long bones following placement of smooth pins across the growth plate of immature rabbits. *Nihon Seikeigeka Gakkai Zasshi.*, *67*(7), 662-676.

[28] Mäkelä, E. A., Vainionpää, S., Vihtonen, K., Mero, M. & Rokkanen, P. (1988). The effect of trauma to the lower femoral epiphyseal plate. An experimental study in rabbits. *J Bone Joint Surg Br.*, *70*(2), 187‑191.

[29] Fischerauer, S., Kraus, T., Wu, X., Tandl, S., Sorantin, E., Hanzi, A. C., Loffler, J. F., Uggowitzer, P. J. & Weinberg, A. M. (2013). In vivo degradation performance of micro-arc-oxidized implants: a micro-CT study in rats. *Acta Biomater*, 2013., *9*(2), 5411-5420.

[30] Horn, J., Kristiansen, L. P. & Steen, H. (2008). Partial physeal arrest after temporary transphyseal pinning. A case report. *Acta Orthop.*, *79*(6), 867-869.

[31] Langenhan, R., Baumann, M., Hohendorff, B., Probst, A. & Trobisch, P. (2013). Arthroscopically assisted reduction and internal fixation of a femoral anterior cruciate ligament osteochondral avulsion fracture in a 14-year-old girl via transphyseal inside-out technique. *Strategies Trauma Limb Reconstr*., *8*(3), 193–197.

[32] Yung, P. S., Lam, C. Y., Ng, B. K., Lam, T. P. & Cheng, J. C. (2004). Percutaneous transphyseal intramedullary Kirschner wire pinning: a safe and effective procedure for

treatment of displaced diaphyseal forearm fracture in children. *J Pediatr Orthop.*, *24*(1), 7-12.

[33] Guzzanti, V., Falciglia, F., Gigante, A. & Fabbriciani, C. (1994). The effect of intra-articular ACL reconstruction on the growth plates of rabbits. *J Bone Joint Surg Br.*, *76*(6), 960‑963.

[34] Seil, R., Pape, D. & Kohn, D. (2008). The risk of growth changes during transphyseal drilling in sheep with open physes. *Arthrosc J Arthrosc Relat Surg Off Publ Arthrosc Assoc North Am Int Arthrosc Assoc.*, *24*(7), 824‑833.

[35] Ford, L. T. & Key, J. A. (1956). A study of experimental trauma to the distal femoral epiphysis in rabbits. *J Bone Joint Surg Am*. *38*-A(1), 84‑92.

[36] Campbell, C. J., Grisolia, A. & Zanconato, G. (1959). The effects produced in the cartilaginous epiphyseal plate of immature dogs by experimental surgical traumata. *J Bone Joint Surg Am*., 41-A, 1221‑1242.

[37] Nordentoft, E. L. (1969). Experimental epiphyseal injuries. Grading of traumas and attempts at treating traumatic epiphyseal arrest in animals. *Acta Orthop Scand.*, *40*(2), 176‑192.

[38] Babu, L. V., Evans, O., Sankar, A., Davies, A. G., Jones, S. & Fernandes, J. A. (2014). Epiphysiodesis for limb length discrepancy: a comparison of two methods. *Strategies Trauma Limb Reconstr*., *9*(1), 1–3.

[39] Stevens, P. M. (2006). Guided growth: 1933 to the present. *Strategies Trauma Limb Reconstr*., *1*(1), 29–35.

[40] Téot, L. (1987). L'enclouage centromédullaire élastique stable chez l'enfant. Cah Enseign SOFCOT. Elsevier Masson. Paris. 71‑90.

[41] Knorr, P., Schmittenbecher, P. P. & Dietz, H. G. (1996). Treatment of pathological fractures of long tubular bones in childhood using elastic stable intramedullary nailing. *Unfallchirurg*., *99*(6), 410-414.

[42] el-Sobky, M. A., Hanna, A. A., Basha, N. E., Tarraf, Y. N. & Said, M. H. (2006). Surgery versus surgery plus pamidronate in the management of osteogenesis imperfecta patients: a comparative study. *J Pediatr Orthop, B*. *15*(3), 222-228.

In: Encyclopedia of Surgery (22 Volume Set)
Editors: Andreas Lehrer and Kristin Mueller
ISBN: 978-1-53618-329-0
© 2020 Nova Science Publishers, Inc.

Chapter 3

LENGTHENING AND DEFORMITY CORRECTION OF LOWER AND UPPER LIMBS

Pierre Lascombes[1], PhD, MD, Arnold Popkov[2], PhD, MD, Pierre Journeau[3], PhD, MD and Dmitry Popkov[2,*], PhD, MD

[1]Pediatric Orthopedic Surgery Dept, Geneva University Hospitals, Children's Hospital, Geneva, Switzerland

[2]Scientific and Clinical Laboratory for Deformity Correction and Limb Lengthening. Federal Russian State-Financed Ilizarov Scientific Center for Restorative Traumatology and Orthopaedics, Kurgan, Russia

[3]Pediatric Orthopedic Surgery Department, Nancy University Hospital Center, Children's Hospital, Vandoeuvre, France

ABSTRACT

Background. The aim of this study is to evaluate the influence of the external fixation associated with intramedullary nailing on the healing index in limb lengthening.

Material and Methods. This study was based on a series of patients with lower and upper limb length discrepancy of different etiologies. We evaluated results of treatment in patients undergoing limb lengthening with the combination of an external circular fixator and intramedullary nailing (154 cases). The Ilizarov frame (133 cases) or Taylor Spatial Frame (21 cases) were used in combination with flexible intramedullary nailing.

Results. In all the groups of patients we observed a significant reduction of the Healing Index – inferior to 30 days/cm. There were 117 complications but only 10 of them influenced on results of treatment. Finally, results are distributed according to categories: I category – 114 cases (74%), IIa – 27 cases (17.5%), IIb – 3 cases (1.9%), IIIa – 9 cases (5.7%), IVa – 1 case (0.9%).

Conclusion. Flexible intramedullary nailing provides multiple advantages to a method of limb lengthening. Flexible Intramedullary Nailing, when correctly applied, respects the bone biological features which are essential for successful limb lengthening. The major effect of application of the combination of external circular fixation with FIN is significant decrease of external osteosynthesis duration.

[*] Corresponding Author's Email: dpopkov@mail.ru.

Keywords: bone lengthening, Ilizarov method, flexible intramedullary nailing, Taylor spatial frame

INTRODUCTION

Gradual lengthening is the most reliable method in treatment of length discrepancy of upper and lower limb segments. Since the 80-s of the 20th century various changes of operative technique have been introduced aiming to improve the anatomic and functional results and to reduce duration of external fixation: lengthening in automatic mode, stimulation by acute compression of the regenerate, bifocal and polysegmental lengthening [1-3].

Actually, there are two possibilities to combine external fixation and intramedullary nailing in bone lengthening. The first one is presented by an association of external fixator and rigid intramedullary nail of 10 mm and more in diameter [4-6]. The second type of combined technique unites the external fixation and *flexible* intramedullary nailing [3, 7-9].

The experimental study described in the first chapters of this book proved that use of flexible intramedullary nails provides a favourable effect on formation of distraction regenerate. Encouraged by the experimental series, a clinical study was launched, in 2001 in an adolescent affected with a congenital shortening of a lower limb. Currently our technique takes a reliable and important place in the therapeutic arsenal of pediatric orthopedics.

The aim of this study is to demonstrate how the flexible intramedullary nailing influences the outcome in lengthening of upper and lower limbs.

MATERIALS AND METHODS

We have studied results of 154 limb lengthenings in patients of the age between 3 to 22 years old (the mean age at the beginning of lengthening was 11.2±0.17). Lengthening was performed in 79 cases in girls and in 75– in boys.

Lengthening was performed with the Ilizarov fixator (121 cases) or Taylor Space Frame (TSF®) (33) during the period 2001 - 2008 in two clinics: in the Ilizarov Scientific Center for Restorative Traumatology and Orthopaedics (Kurgan, Russia) and in the Children's Hospital of Nancy University Hospital Center (Nancy, France). Surgery was performed by the authors of this study during the years 2001 - 2010.

An inclusion criterion was upper or lower limb lengthening performed with the combined technique if results could be assessed in 12 months minimum after frame removal.

The distribution of cases according to the aetiology, type of distraction osteosynthesis, mean age at the beginning of lengthening is presented in Tables 1 and 2.

It is worth of mentioning that in the group of acquired discrepancy the limb length inequality developed as a result of post-traumatic epiphysiolysis or the physis damaged by the hematogenous osteomyelitis or osteoarthritis. Sequela of hematogenous osteomyelitis caused the lower limb length discrepancy in 15 cases, premature posttraumatic closure of the growth plate in 13 cases. Among the upper limb length discrepancy, sequela of osteomyelitis was observed in 12 children, consequences of the physis lesion – in 7 cases. For the group of

paralytic shortening the reason of length inequality of lower limbs (2 pts) was poliomyelitis, of upper limbs (4 pts) – the obstetrical trauma of a brachial plexus.

Table 1. Variants of distraction osteosynthesis in lower limb lengthening

Segment	Type of distraction osteosynthesis	Congenital		Acquired		Paralytic		Ollier disease		Neurofibromatosis, fibrous dysplasia	
		Nb	Mean age	Nb	Mean age	Nb	Age	Nb	Mean age	Nb	Age
Femur	Monofocal+ FIN	19	12.5± 0.98	9	13.7± 0.9	1	16	4	12.5±1.9	1	8
	Biforal+FIN	7	11.2± 1.7	5	12.2± 0.6						
Tibia	Monofocal+ FIN	22	11.3± 1.17	6	9± 1.5	1	15	1	11		
	Biforal+FIN	7	11.7± 2.1	2	15± 1.0						
Femur+ Tibia	Polysegmental+FIN	13	13.2± 0.8	6	11.7± 1.4			2	16.5±3.2	1	14
Total		68		28		2		7		2	

Table 2. Variants of distraction osteosynthesis in upper limb lengthening

Segment	Type of distraction osteosynthesis	Congenital		Acquired		Paralytic		Exostotic disease	
		Nb	Mean age	Nb	Mean age	Nb	Mean age	Nb	Mean age
Humerus	Monofocal+FIN	3	10± 6.0	3	9.7± 2.19	2	11.5± 3.5		
	Bifocal+FIN			13	13± 0.59	1	16		
Forearm	Monofocal+FIN	18	9.9± 1.04	3	13± 0.58	1	16	2	6.5±0.5
Humerus+Forearm	Polysegmental+FIN	1	7						
Total		22		19		4		2	

Monosegmental monofocal osteosynthesis in combination with FIN of the femur or tibia was done in 64 cases. Monosegmental bifocal distraction osteosynthesis of the femur or tibia was applied in 21 cases. Polysegmental distraction osteosynthesis of the lower limb was applied in 22 patients.

Monosegmental osteosynthesis in combination with FIN of the humerus was done in 8 cases. Bifocal distraction osteosynthesis of the humerus was applied in 14 cases. Monosegmental osteosynthesis of the forearm was used in 24 cases. Polysegmental distraction osteosynthesis of the upper limb was applied in only 1 patient.

Surgical Technique

The first stage of the surgery, a classical procedure, consists of application of the external fixator followed by the osteotomy via a percutaneous incision that preserves the periosteum and intramedullary vascularization [10, 11].

The second stage is application of FIN: through two incisions of 1 to 2 cm in the metaphyseal area two entry holes are made in the bone very oblique to the osteotomy by means of the trocar of 3-4 mm in diameter at a distance of 1.5 to 3 cm from the growth plate. For the femoral lengthening FIN is retrograde, starting from the distal metaphysis, if the lengthening is performed in the lower third of the segment. For the tibia (Figure 1), it is antegrade through the proximal metaphyseal approach. As for the humerus, the approach is distal at the level of the lateral supracondylar area with a retrograde FIN.

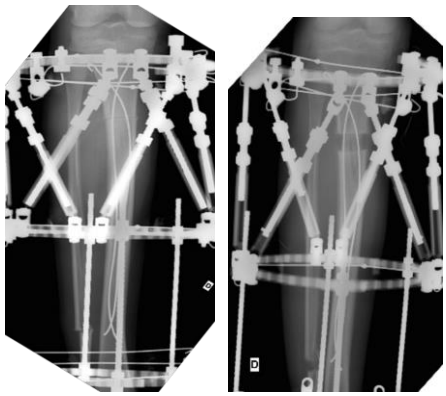

(a) (b)

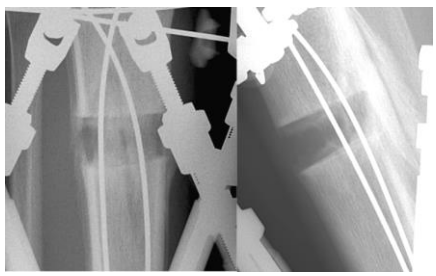

(c)

(d)

Figure 1. Surgical technique. Application of two Ilizarov rings, tibial osteoclasia and intramedullary nails. The two curved nails are inserted into the intramedullary canal in anterograde direction. The maximum curves are above the osteoclasia site. Their distal ends are bent (**a)**. During the lengthening the nails slide with the proximal fragment (**b**). Note: significant periosteal reaction both at the level of diastasis and at the adjacent bone fragments, regenerate is dense and significant (**c**), after frame removal (**d)**.

Two steel or titanium nails of the diameter from 1.5 to 2.5 mm are pre-curved with the ray of curvature about 40 to 60º and their tips of 1.5 to 3 mm are curved at 30 to 40º. The tip of every nail is blunt. The nails must be bent in a way that allows assembling two intersecting arches. The two nails opposed to each other are situated in the same plane creating the same geometric system - elastic and resistant, which is the same for a diaphyseal fracture. An important difference is that the nails have a smaller diameter in comparison to those used for fracture management.

We used intramedullary nails of 20 to 25% of medullary canal diameter in order to avoid its blocking by external fixator wires or half-pins during distraction period.

The two nails must be carefully introduced one by one up to the osteotomy site, then pushed through it until they finally reach the opposite metaphysis. Rotation of the curved blunt tip allows to avoid the half-pins and wires of external fixator, while inserting a nail along medullary canal, straight or deformed. The maximum curve should be placed near the osteotomy site in the diaphyseal part that enables to cross the nails above the osteotomy. In these conditions the lengthening slowly moves the apex of the nail curvature and it is situated at the level of the growing zone of the regenerate by the end of lengthening period (Figure 1).

If a bone segment is straight, the initial curvature of both nails must be identical. In a case of bone deformity, the arch of one nail can be more curved for maintaining a permanent tension that helps the angular correction during the lengthening. Another solution is to reorient both nails, opposing their concavity to the bone deformity.

External tips of intramedullary nails are bent at over 90º to avoid their migration into the medullary canal during the distraction period, and then they are cut as usually 5 to 10 mm from the bone. The skin is sutured.

The bifocal lengthening can also be associated with FIN. In this case a bipolar variant of nailing is more appropriate. Thus, for example, for the tibia, one antegrade nail is inserted through the proximal metaphysis, while the distal retrograde nail is inserted through the distal metaphysis (Figure 2). During the lengthening period the implants slide along one another in the same way as in a technique for the osteogenesis imperfecta. After the frame removal both regenerates remain reinforced at least by one intramedullary nail curved and oriented in a way opposing the natural tendency of the secondary deformity.

In a case of forearm lengthening we use a tension assembling with a nail in the radial bone, which concavity is oriented to the ulna, and vice versa in the ulna bone. In all the cases the nailing is retrograde in the radius, inserted through an incision of 1.5-2 cm above the distal physis, avoiding superficial nerves and veins, and it is antegrade in the ulna, inserted through a posterior-lateral approach of the olecranon (Figures 3, 4).

A distinction of the external fixator associated with FIN is an ability to attach additional wires or a half-pin after insertion of intramedullary nails. It concerns the frontal wire at a level of the distal femur or proximal tibia or also certain wires of the intermediate ring in the bifocal lengthening. Thus, all the external wires which can interfere the passage of the intramedullary nails in the medullary canal are inserted after FIN.

Lengthening begins on the 4-6th day after the surgery. Limb function is preserved by an early articular mobilization and weight bearing according to usual indications of the lengthening method.

(a) (b)

(c) (d)

(e)

Figure 2. (Continued).

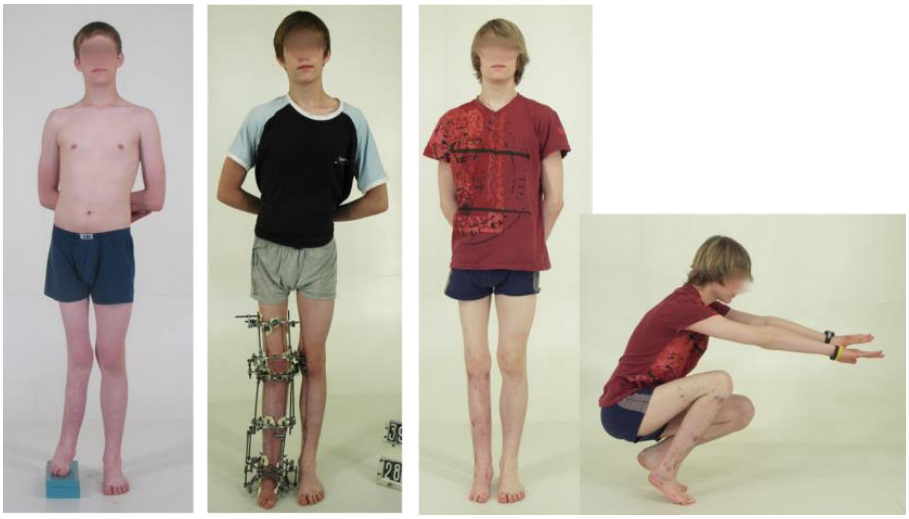

(f)

Figure 2. Bifocal lengthening of tibia: X-rays of the tibia before surgery (**a**), on the 30th day of distraction period (**b**), by the end of fixation period (6 weeks), cortical continuity, disappearance of growth zone of regenerate (**c**), after frame removal, amount of lengthening – 7 cm, HI – 15.6 d/cm (**d**), FIN removal performed in 5 months (**e**), patient before, during and after treatment (**f**).

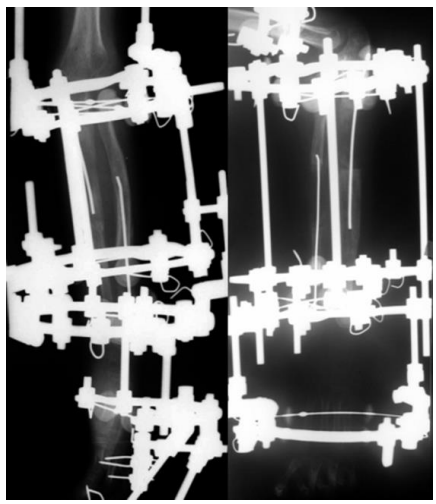

Figure 3. Exemple of forearm lengthening: nailing is retrograde in the radius and antegrade in the ulna.

Combined deformities are progressively corrected in all the patients during the lengthening period. With the Ilizarov technique, hinges are positioned according to the center of rotation of angulations CORA [12]. With the TSF®, the correction is progressively obtained simultaneously with lengthening following the instructions of the computerized program [13, 14].

Implants are removed in two steps. The external fixator can be removed at the beginning of bone consolidation according to radiographs and clinical test. A precise date is difficult to determine: when the “growth zone” has disappeared and the radiographic continuity of at

least 3 of 4 cortices is observed. Total weight bearing is allowed by the end of six weeks after Ilizarov fixator removal but a semicircular plaster cast is permanently applied for the period of 2 to 4 weeks. The removal of nails is possible in 2 to 8 months after frame removal.

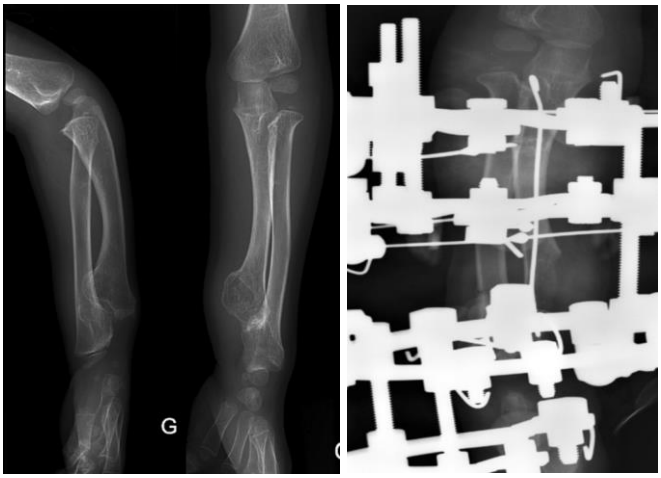

(a) (b)

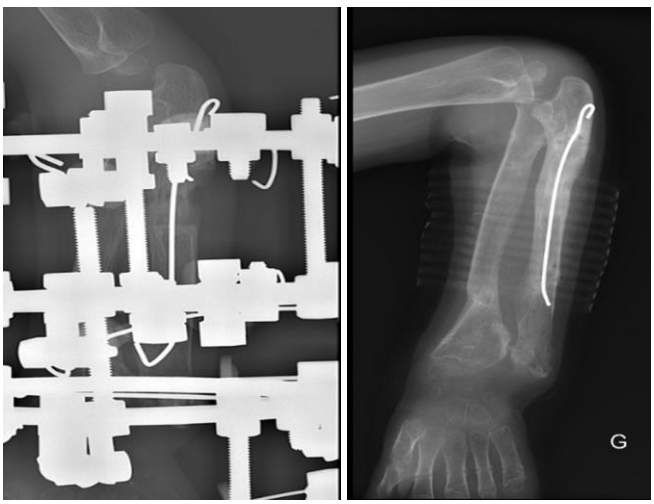

(c) (d)

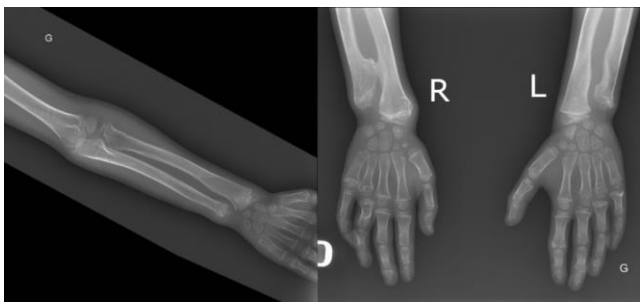

(e)

Figure 4. (Continued).

(f)

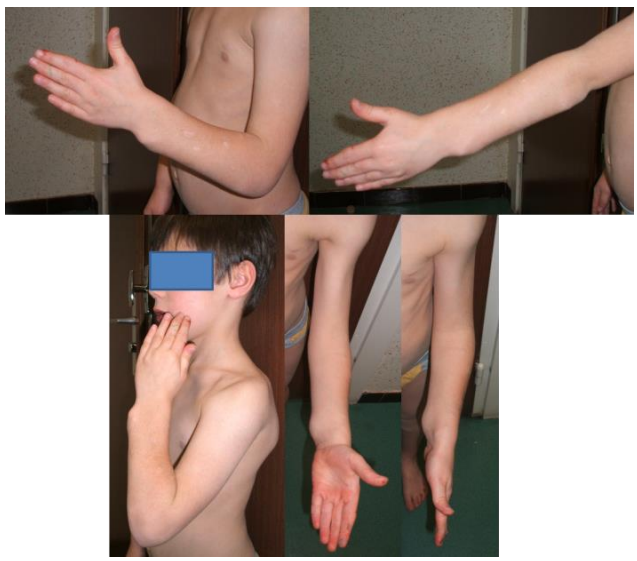

(g)

Figure 4. Forearm lengthening and cubital club hand deformity correction in a boy 6 y.o. with multiple exostoses: X-rays before surgery (**a**), in the beginning of the distraction period, the lengthening of ulna will be performed with intramedullary nailing, the deformity of the distal radius will be without lengthening (**b**), after correction, the first days of fixation period (**c**), after frame removal, gain of lengthening – 4 cm, HI – 22.3 d/cm (**d**), in a year after frame removal et 6 months after FIN removal (**e**), patient before and during treatment (**f**), functional outcome in a year after frame removal (**g)**.

A general classification of results of bone lengthening [15] is applied to evaluate the outcomes.

This classification (Table 3) is based on the respecting of a triple contract (gain of lengthening, projected treatment duration, and functional outcome):

- grade I: the triple contract is fulfilled, procedures are undertaken under local anesthesia and/or medical treatments are necessary but no intervention under general anesthesia is undertaken;
- grade II: the triple contract is also fulfilled but unscheduled intervention(s) under general anesthesia are necessary. These procedures can take place before the end of the lengthening program (grade II-a) or after the end of this program (grade II-b) without changing the date of external fixator removal;
- grade III: pursuing treatment is necessary beyond the planned period to obtain bone union, but at term, no alteration of function is observed. The HI is therefore lengthened with the external fixator removal or total weight bearing delayed beyond the scheduled time. In grade III-a, the length gain is greater than or equal to 75% of the initial objective, whereas a gain less than 75% is classified as grade III-b. It is possible in grade III-b that bone union takes place within the normal time delay with a HI less than 45 days/cm, but since the scheduled correction has not been obtained, the patient, who desires so, could request a new surgery; this can result in a new therapeutic period;
- grade IV: despite the different treatments, sequelae exist at the final evaluation when the gain is 75% or higher (grade IV-a) or less than 75% (grade IV-b). Whether or not the initial objective of treatment is met, loss of function means worsening of the earlier functional state.

Table 3. Description of the four-grade classification

Grade	I	II-a	II-b	III-a	III-b	IV-a	IV-b
Surgery with general anesthesia	No	Yes before[a]	Yes after[a]	Possible	Possible	Possible	Possible
Planned length gain obtained	Yes	Yes	Yes	Yes	No	Yes	No
Planned duration respected	Yes	Yes	Yes	No	No	Yes/no	Yes/no
Function respected	Yes	Yes	Yes	Yes	Yes	No	No

[a] Removal of external fixator.

Statistical analysis was performed using the software AtteStat®.

RESULTS

The average amount of lengthening was 5.1±0.2 cm, the relative average amount of lengthening made 20.3% of the initial length of a segment. It is important to assess the relative lengthening for each segment separately, including polysegmental lengthening.

Radiographic evaluation revealed the following features of formation of the distraction regenerate. In our series the regenerate was always dense and significant. In the majority of cases starting from the third week of lengthening the regenerate was well structured and filled the entire gap between the bone fragments. Its "growth zone" was 2 to 5 mm and abundantly filled with bone trabeculae, while the periosteal reaction increased. The diameter of the regenerate exceeded the diameter of bone fragments by 2 to 6 mm because of the periosteal reaction at the level of diastases and adjacent bone fragments as well (Figure 1).

Tables 4, 5 and 6 present the gain of lengthening and healing index in groups of patients differed by type of external osteosynthesis and etiology of limb length discrepancy (Figures 5 and 6). It is important to note that in all the groups the HI was inferior to 30 days/cm. We can take it as reference data to compare our results with the HI published by other colleagues in "Discussion". Only in one case the HI was 33.2 days/cm in 16 y.o. patient presented paralytic lower limb length discrepancy: monofocal tibial lengthening was performed in sequelae of poliomyelitis.

(a) (b)

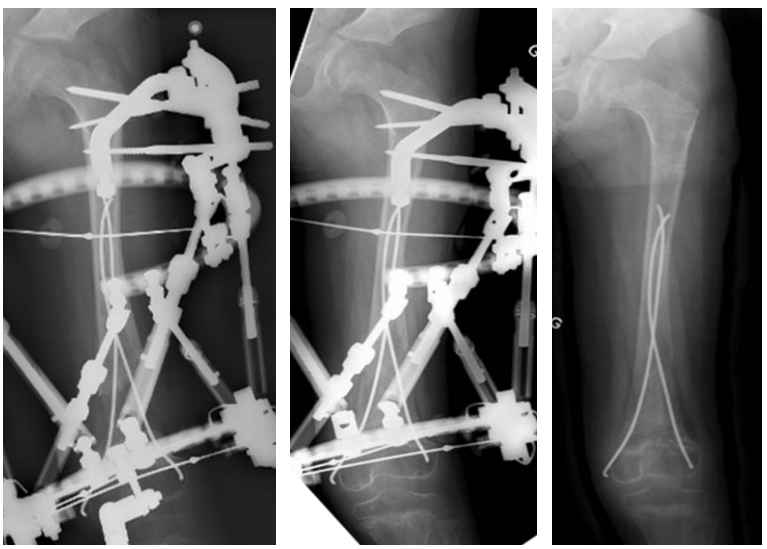

(c) (d) (e)

Figure 5. (Continued).

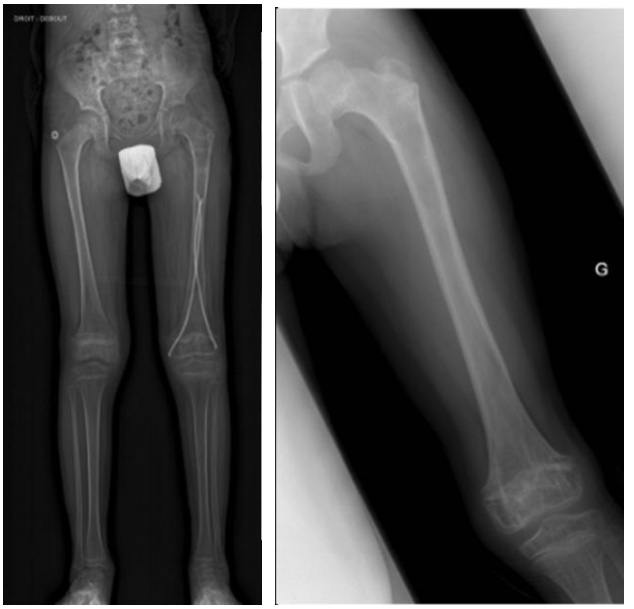

(f)

Figure 5. Femoral monofocal lengthening in a boy presenting posttraumatic lower limb length discrepancy: X-rays before surgery (**a**), on the 7th day of distraction period (**b**), on the 30th day of distraction period (**c**), at the end of distraction period (58 days) (**d)**, after frame removal, gain of lengthening – 6 cm, HI – 20.5 d/cm (**e**), in 7 months after frame removal, FIN removal performed (**f**).

(a) (b)

Figure 6. (Continued).

(c) (d) (e)

(f)

Figure 6. Polysegmental lower limb lengthening in a girl with congenital lower limb length discrepancy: X-rays before surgery (**a**), on 21st day of distraction period (**b**), fixation period (**c**), after frame removal, total gain of lengthening – 6 cm, HI – 15.8 d/cm (**d**), FIN removal performed in 4 months (**e**), patient before, during and after lengthening of the left leg (**f**).

Table 4. Duration of osteosynthesis, amount of lengthening and healing index in lower limb lengthening

Etiology	Segment	Parameters	Monofocal+FIN	Bifocal+FIN
Congenital	Femur	Osteosynthesis duration; days Lengthening; cm Healing index	91.4± 6.74 4.4± 0.36 21.2± 1.34	117± 7.5 7.0± 0.63 17.6± 2.38
	Tibia	Osteosynthesis duration; days Lengthening; cm Healing index	95.4± 3.65 3.9± 0.31 26.1± 1.74	136.8± 13.95 8.3± 0.802 16.3± 1.97
Acquired	Femur	Osteosynthesis duration; days Lengthening; cm Healing index	74.3± 7.88 4.2± 0.93 18.7± 1.96	98.8± 19.04 8.1± 0.51 12.99± 2.52
	Tibia	Osteosynthesis duration; days Lengthening; cm Healing index	108.7± 7.54 4.5± 0.29 24.3± 1.85	162.5± 39.5 8.5± 0.5 18.9± 3.51
Paralytic	Femur	Osteosynthesis duration; days Lengthening; cm Healing index	145 4.5 29	
	Tibia	Osteosynthesis duration; days Lengthening; cm Healing index	83 25 33.2	
Ollier disease	Femur	Osteosynthesis duration; days Lengthening; cm Healing index	129.1±17.4 5.6±0.62 23.3±2.2	
	Tibia	Osteosynthesis duration; days Lengthening; cm Healing index	112 5 22.4	
Neurofibromatosis	Femur	Osteosynthesis duration; days Lengthening; cm Healing index	96 4.5 21.3	

Table 5. Duration of osteosynthesis, amount of lengthening and healing index in upper limb lengthening

Etiology	Segment	Parameters	Monofocal+FIN	Bifocal+FIN
Congenital	Humerus	Osteosynthesis duration; days Lengthening; cm Healing index	90.5± 11.5 5± 1.0 19.4± 6.15	
	Forearm	Osteosynthesis duration; days Lengthening; cm Healing index	121.6± 8.79 5.96± 0.36 21.3± 1.53	
Acquired	Humerus	Osteosynthesis duration; days Lengthening; cm Healing index	88.3± 17.95 5.7± 0.88 15.8± 2.31	103.8± 6.9 9.1± 0.59 11.97± 1.29
	Forearm	Osteosynthesis duration; days Lengthening; cm Healing index	85.3± 12.99 3.8± 1.36 26.03± 6.23	
Paralytic	Humerus	Osteosynthesis duration; days Lengthening; cm Healing index	81.5± 2.5 5± 0.0 16.3± 0.5	109 6 18.2
	Forearm	Osteosynthesis duration; days Lengthening; cm Healing index	88 3 29.3	
Hereditary Multiple Exostoses	Forearm	Osteosynthesis duration; days Lengthening; cm Healing index	114.7±7.9 4.1±1.5 27.9±4,3	

Table 6. Duration of osteosynthesis, amount of lengthening and healing index in polysegmental limb lengthening

Etiology	Limb	Parameters	Fixator+FIN
Congenital	Upper	Osteosynthesis duration; days Lengthening; cm Healing index	112 5.5 20.4
	Lower	Osteosynthesis duration; days Lengthening; cm Healing index	125± 8.7 7.7± 0.6 16.5± 1.24
Acquired	Lower	Osteosynthesis duration; days Lengthening; cm Healing index	115.3± 8.72 6.8± 0.17 16.9± 1.28
Ollier disease	Lower	Osteosynthesis duration; days Lengthening; cm Healing index	138.2±14.8 12.5±0.5 11.6±0.7
Fibrous dysplasia	Lower	Osteosynthesis duration; days Lengthening; cm Healing index	98 5 19.6

Complications were noted in 103 patients (66.9% of cases). The Table 7 presents all the complications observed in our series as well as the treatment applied.

It should be noted that complications were of I, II-a or II-b categories in 107 cases, meaning the final results of treatment were not compromised and the planned therapeutic objectives were achieved without any sequelae.

We want to emphasize, there were no pathologic fractures after frame removal in patients presenting bone diseases with fragility (Ollier disease, fibrous dysplasia) (Figure 7).

(a) (b)

Figure 7. Use of combined technique of limb lengthening in the patient with fibrous dysplasia: bifocal femoral lengthening and deformity correction by hybrid external fixator (Ilizarov+TSF) associated with FIN (**a**), after frame removal FIN remained in place (**b**).

Table 7. List of complications according to severity grade

Complications	Treatment	Number
Grade I: gain, HI, and function fulfilled - intervention without GA		77
Local infection with pins or wires	Local care ± antibiotic therapy	55
Paresthesia, temporary paralysis	Surveillance, removal of wire in contact, no GA	9
Threat of early bone union	Acceleration of elongation speed	6
Delay in appearance of bone regenerate	Slowing down of elongation speed	2
Migration of FIN	Percutaneous nail pushing, no GA	5
Grade II-a: gain, HI, and function fulfilled - intervention with GA before end of lengthening program		27
Local infection with pins or wires	Pin or wire removal and replacement	7
Migration of FIN nails	Cutting, nail pushing or early removal of FIN nails	7
Problems with ExFix: deviation of assemble, cutaneous contact, instability	Revision of ExFix with GA	4
Breakage of ExFix material, screws	Material removal with GA	5
Early union of regenerate	New osteotomy	3
Infection of osteotomy hematoma	Surgical cleansing and antibiotic therapy	1
Grade II-b: gain, HI, and function fulfilled - intervention with GA after the end of the lengthening program		3
Migration of FIN nails	Early removal of FIN nails	3
Grade III-a: gain and function fulfilled, HI > 45 days/cm		9
Joint stiffness	Mobilization with GA, tendon elongation	6
Fracture and deformity after EF removal	Immobilization cast, epiphysiodesis or osteosynthesis	3
Grade III-b: function fulfilled, gain not obtained, HI > 45days/cm		0
Grade IV-a: function not fulfilled (sequelae), gain obtained		1
Posterior knee subluxation	Secondary progressive correction with EF	1
Grade IV-b: function not fulfilled (sequelae), gain not obtained		0

In the majority of cases (143 pts) the intramedullary nails were removed in 3-8 months after removal of the external fixator.

Prior to analysis of treatment results according to the principles of Lascombes classification [15], it is important to mention that 14 patients developed two complications. In such situation a more severe complication has been taken into consideration in assessment of the final result (Figure 8).

Thus, the results were categorized: I – 114 cases (74%), II-a – 27 cases (17.5%), IIb – 3 cases (1.9%), III-a – 9 cases (5.7%), IV-a – 1 case (0.9%).

(a) (b)

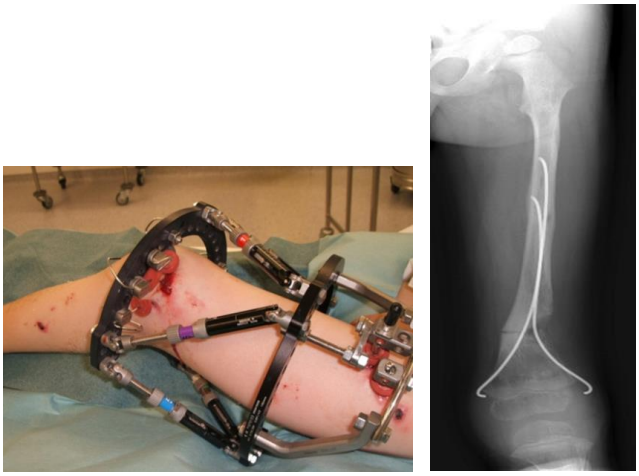

(c) (d)

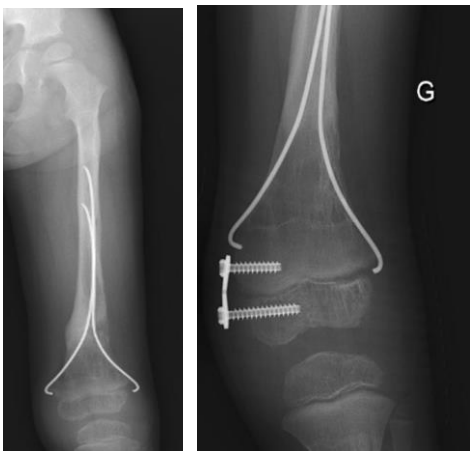

(e) (f)

Figure 8. (Continued).

(g) (h)

Figure 8. Patient T., 7 y.o., neurofibromatosis, type I: X-rays of lower limbs and foot of the patient before treatment (**a**), X-rays of the lengthened femur, fixation period (**b**), local infection near two wires in the distal ring caused their removal (**c**), fracture at the level of regenerate in 3 days after frame removal (**d**), bone consolidation obtained with valgus deformity (**e**), internal distal hemiepiphysiodesis by 8-plat (**f**), correction of the valgus deformity achieved in 14 months (**g**), X-rays after plate and FIN removal (**h**).

DISCUSSION

Improvement of bone lengthening procedure by means of external fixation remains topical. The duration of fixator wearing is often long because of the healing index, that makes from 35 days/cm to 65 days/cm according to several publications [7, 16-19]. It may cause multiple complications. Eralp et al. [205] mention the index of 1.65 month/cm in lengthening of the tibia by the Ilizarov fixator, and Sluga et al. [14] in application of the TSF – 48.4 days/cm. The index of consolidation usually obtained by conventional Ilizarov method is 24 to 30 days/cm in femoral or tibial lengthening and 30 to 40 days/cm in the forearm [3].

According to data of Donnan et al. [21] the HI makes 46.4 days/cm in femoral lengthening and 37.3 days/cm in tibial one when applying monolateral fixators of the Orthofix type. After McAndrew et al. [22] – 40.8 days/cm. Besides, the authors mix all the etiologies including achondroplasia, congenital, post-traumatic discrepancy and so on, that we consider unjustified. In some publications analyzing the treatment period one can find the authors' opinion on influence of various factors on the period of consolidation. Thus, Matsubara et al. [5] precise that the HI decreases to 42.5 days/cm in combination of gradual lengthening by the Ilizarov fixator or TSF with the gradual correction of associated deformities in comparison to the acute correction in the beginning of lengthening, when the HI makes 58.6 days/cm. El-Mowafi et al. [23] describe a favourable effect of low-frequency

stimulation of bone regeneration with the ultrasound: the HI reduces from 48 to 30 days/cm of lengthening. Finally Kim et al. [4] state that the nailing of a lengthened tibia with a nail of a diameter of 10 mm allowed to decrease the HI to 40.53 days/cm. In simultaneous ipsilateral femoral and tibial lengthening with the Ilizarov method, Curran observed in 4 patients the average femoral healing index of 28 days/cm and the average tibial healing index of 29 days/cm [16].

Besides, some acceleration of treatment can be achieved by different ways [2, 11, 24]. In addition to known methods of lengthening, we propose to unite two methods for the limb lengthening: the gradual distraction with the Ilizarov fixator or TSF and FIN [3, 25]. This combination enables to add certain advantages of the elastic intramedullary nailing to all the improvements of the distraction osteosynthesis.

Our previous comparative studies have shown that the combined technique (circular ExFix+FIN) allows the mean HI reduction of 7 days/cm or to decrease the distraction-consolidation time by 20% in limb lengthening [3, 25].

Other authors also reported this effect of HI reduction using a ring fixator with FIN [7, 8]. Furthermore, accelerated bone consolidation was observed in a short series of femur lengthening, where the monolateral Orthofix fixator was applied with FIN [9].

In contrast to combined methods of distraction osteosynthesis using intramedullary rigid nail [4-6], application of elastic nail reveals an advantage to combine lengthening with progressive deformity (axial and/or rotational) correction. This approach makes additional prealignment procedure unnecessary [3, 25, 26]. The second undisputable advantage of our method is a possibility to perform it in children without any risk to damage the physis. Clearly, an insertion of a rigid nail cannot avoid partial destruction, at least, of one growth zone.

Besides, the benefit of a reduced HI is a low rate of complications. We observed a significant decrease, even absence of those complications which are caused by long distraction-consolidation delay: pin/wire site infection, joint stiffness, hemorrhagic complications at pin site, as well as complications caused by low rate of bone regeneration: delayed consolidation (HI superior to 45 days/cm), deformity or fracture after frame removal [17, 27-29]. FIN left in situ allowed to minimize and even eradicate such specific problems as pathologic fractures at the level of fibrous or cartilaginous zone in our series of patients presenting diseases associated with bony fragility (fibrous dysplasia, Ollier disease) [30, 31].

So, the demonstrated and prooved advantages of the combined method for limb lengthening (ExFix+FIN) are reduction of HI, low rate of septic, articular and bony complications, prevention of pathologic fractures. Finally, we observed the good and excellent results in 93.5% of cases in this series.

The results are scored as good or excellent only if the planned length gain was achieved, planned duration of treatment was respected, there was no any complication impairing functional outcome, e.g. without sequelae.

It is worth of mentioning that only perfect performing of FIN associated with the Ilizarov fixator allows to respect all the obligatory conditions of the distraction osteosynthesis (Ilizarov method), namely, preservation of the bone surrounding, periosteum and especially intramedullary vascularization, respecting of biological rates of lengthening, preservation of the function by an early articular mobilization and weight bearing, respecting certain biomechanical rules. So, all the conditions are united in a way that enables association of indisputable advantages of FIN with the Ilizarov method of lengthening by means of the

Ilizarov frame itself or TSF. Nevertheless, the result depends first of all on the personal experience of the surgeon in both the limb lengthening technique and the flexible intramedullary nailing [3, 25].

CONCLUSION

The flexible intramedullary nailing, a low invasive and elegant method, allows to add multiple advantages to the method of limb lengthening with the external fixator. This combination seems to us well proved and logic. FIN, when correctly applied, respects the bone biological features which are essential for successful limb lengthening. The major effect of application of the combination of external circular fixation with FIN is a significant decrease of duration of the external osteosynthesis.

REFERENCES

[1] Gubin AV, Borzunov DY, Malkova TA (2013) The Ilizarov paradigm: thirty years with the Ilizarov method, current concerns and future research. *Int Orthop.* 37(8):1533-1539.

[2] Shevtsov VI, Popkov AV, Popkov DA, Prevot J (2001) Réduction de la durée du traitement dans les allongements osseux progressifs. *Rev Chir Orthop.* 87:248-256.

[3] Popkov D, Popkov A, Haumont Th, Journeau P, Lascombes P (2010) Flexible intramedullary nail use in limb lengthening. *J Pediatr Orthop.* 30:910-918.

[4] Kim H, Lee SK, Kim KJ, et al. (2009) Tibial lengthening using a reamed type intramedullary nail and an Ilizarov external fixator. *Int Orthop.* 33:835–841.

[5] Matsubara H, Tsuchiya H, Sakurakichi K, Watanabe K, Tomita K (2006) Deformity correction and lengthening of lower legs with an external fixator. *International orthopaedics.* 30 (6): 550-554.

[6] Paley D, Herzenberg JE, Paremain G, et al (1997) Femoral lengthening over an intramedullary nail. A matched-case comparison with Ilizarov femoral lengthening. *J Bone Joint Surg Am.* 79:1464–1480.

[7] Launay F, Jouve JL, Guillaume E, Viehweger, Jacquemier M, Bollini G (2001) Les allongements progressifs de l'avant-bras chez l'enfant. A propos d'une série de 14 cas. *Rev Chir Orthop.*87:786-795.

[8] Bukva B, Brdar R, Nikolic D, Petronic I, Ducic S, Abramovic D (2013) Combined external fixation and intramedullary alignment in correction of limb length discrepancies. *Acta Orthop Belg.* 79(4):411-416.

[9] Lampasi M, Launay F, Jouve JL, Bollini G (2009) Femoral lengthening over elastic stable intramedullary nailing in children using the monolateral external fixator. *Chir Organi Mov.* 93(2): 57-64.

[10] Ilizarov GA (1990) Clinical application of the tension-stress effect for limb lengthening. *Clin. Orthop.* 250:8-26.

[11] Ilizarov GA (1992) *Transosseous ostheosynthesis*, Berlin: Springer-Verlag.

[12] Paley D, Herzenberg JE, Tetsworth K, McKie J, Bhave A (1994) Deformity planning for frontal and sagittal plane corrective osteotomies. *Orthop Clin North Am.*3:425-465.

[13] Paley D. Correction of limb deformities in the 21st century (2000) *J Pediatr Orthop.* 20:279-281.

[14] Sluga M, Pfeiffer M, Kotz R, Nehrer S (2003) Lower limb deformities in children: two-stage correction using Taylor spatial frame. *J Pediatr Orthop* B. 12:123-128.

[15] Lascombes P, Popkov D, Huber H, Haumont T, Journeau P (2012) Classification of complications after progressive long bone lengthening: proposal for a new classification. *Orthop Traumatol Surg Res.* 98(6):629-637.

[16] Curran AR, Kuo KN, Lubicky JP (1999) Silmultaneous ipsilateral femoral and tibial lengthening with the Ilizarov method. *J Pediatr Orthop.* 19:386-390.

[17] Glorion C, Pouliquen JC, Langlais J, Ceolin JL, Kassis B (1995) Allongement de fémur par callotasis. Etude d'une série de 79 cas chez l'enfant et l'adolescent. *Rev Chir Orthop.* 81:147-156.

[18] Song HR, Myrboh V, Oh CW, Lee ST, Lee SH (2005) Tibial lengthening and concomitant foot deformity correction in 14 patients with permanent deformity after poliomyelitis. *Acta Orthop.* 76 (2):261-269.

[19] Stanitski DF, Shahcheraghi H, Nicker DA, Armstrong PF (1996) Results of tibial lengthening with the Ilizarov technique. *J Pediatr Orthop.* 16:168-172.

[20] Eralp L, Kocaoğlu M, Ozkan K, Türker M (2004) A comparison of two osteotomy techniques for tibial lengthening. *Archives of orthopaedic and trauma surgery.* 124 (5): 298-300.

[21] Donnan LT, Saleh M, Rigby AS (2003) Acute correction of lower limb deformity and simultaneous lengthening with a monolateral fixator *JBJS* (B). 85:254-260.

[22] McAndrew AR, Saleh M (2007) Limb lengthening by Villarubias method: the Sheffield Children's Hospital experience. *J Pediatr Orthop* B. 16:233-235.

[23] El-Mowafi H, Mohsen M (2005) The effect of low-intensity pulsed ultrasound on callus maturation in tibial distraction osteogenesis. *Int Orthop.* 29(2):121-124.

[24] Shevtsov VI, Popkov AV (1995) Automatic distractional osteosynthesis. *Hospital Management International.* 265-269.

[25] Lascombes P (2010) *Flexible intramedullary nailing in children.* Berlin Heidelberg: Springer-Verlag.

[26] Popkov D, Lascombes P, Popkov A, Journeau P, Haumont T (2012) Role of the flexible intramedullary nailing in limb lengthening in children: comparative study based on the series of 295 lengthenins. *Europ Orthop Traum.* 3:17-24.

[27] Popkov AV (1991) Errors and complications of operative lengthening of the lower extremities in adults by the Ilizarov method. *Vestn Khir I I Grek.* 1:113-116.

[28] Rybka V, Richtr M (1989) The index of relative prolongation in leg lengthening. *Min Orthop Traumatol.* 40:443-444.

[29] Launay F, Younsi R, Pithioux M, Chabrand P, Bollini G, Jouve JL (2013) Fracture following lower limb lengthening in children: a series of 58 patients. *Orthop Traumatol Surg Res.*99(1):72-79.

[30] Jesus-Garcia R, Bongiovanni JC, Korukian M, Boatto H, Seixas MT, Laredo J (2001). Use of the Ilizarov external fixator in the treatment of patients with Ollier's disease. *Clin Orthop Relat Res.* 382:82-86.

[31] Popkov D, Journeau P, Popkov A, Haumont T, Lascombes P (2010) Ollier's disease limb lenghtening: Should intramedullary nailing be combined with circular external fixation? *Orthop Traumatol Surg Res.* 96:348-353.

In: Encyclopedia of Surgery (22 Volume Set)
Editors: Andreas Lehrer and Kristin Mueller
ISBN: 978-1-53618-329-0
© 2020 Nova Science Publishers, Inc.

Chapter 4

INFLUENCE OF LENGTHENING ON THE RESIDUAL LIMB GROWTH

Pierre Journeau[1], Dmitry Popkov[2,*] and Pierre Lascombes[3]

[1]Pediatric Orthopedic Surgery Dept, Nancy University Hospital Center, Children's Hospital, Vandoeuvre, France
[2]Scientific and Clinical Laboratory for Deformity Correction and Limb Lengthening, Federal Russian State-Financed Ilizarov Scientific Center for Restorative Traumatology and Orthopaedics, Kurgan, Russia
[3]Pediatric Orthopedic Surgery Dept, Geneva University Hospitals, Children's Hospital, Geneva, Switzerland

ABSTRACT

Introduction. Prognosis of limb length discrepancy in children affected by congenital abnormality remains a subject of concern. Therapeutic strategy must take length prediction into account in order to adapt equalization techniques and the timing of treatment. Initial prognosis, however, may need revising after completion of one or several surgical interventions on the pathologic limb.

The aim of this study was to determine different types of growth response that a bone segment can present after progressive lengthening in case of congenital limb length discrepancy.

Materials and methods. Treatment results were analyzed in 150 patients with congenital lower limb length discrepancy, who underwent surgery at age from 2 to 15 years old. Bone segment growth rates were measured before lengthening, during the first year after frame removal and, finally, over long-term follow-up, calculating the ratios of radiological bone length to the number of months between two measurements. Mean follow-up was 5.1±1.3 years.

Results. Changes in short- and long-term growth rate distinguished five patterns of bone behavior after lengthening, ranging from growth acceleration to total inhibition.

* Corresponding Author's Email: dpopkov@mail.ru.

Discussion and Conclusion. These five residual growth patterns depended on certain factors causing acceleration or, on the contrary, slowing down of growth: age at the lengthening surgery, percentage of lengthening and minimal period between two lengthenings. These criteria help to optimize conditions for resumed growth after progressive segmental lengthening, avoiding conditions liable to induce slowing down or inhibition, and providing a planning aid in multi-step lengthening programs.

Keywords: congenital lower limb length discrepancy, bone lengthening, residual growth

INTRODUCTION

One of the major issues of the long-term follow up after limb lengthening remains the change of longitudinal growth function of the operated segment.

Residual growth after progressive lengthening has been the focus of several studies [1-9], but the evolution of congenital lower-limb length discrepancy in children undergoing progressive lengthening remains unforeseeable and the factors relevant to bone segment activity in these cases remain undetermined. Both slowing and boosted growth patterns have been reported, independently of the lengthening technique employed (Judet, Wagner, Callotasis or Cauchoix) [2-6], other authors finding no change in growth rates [7-9].

The present retrospective study sought to identify factors affecting residual growth after progressive lengthening: age at lengthening, percentage of lengthening, and single- or multistep strategy.

MATERIALS AND METHODS

We studied outcomes in 150 patients with congenital unilateral limb length discrepancy (girls/boys=79/71), to whom Ilizarov lower limb lengthening was performed at age from 2 to 15 years old (the average 8.3±2.9 years old). The series was homogeneous for etiology and surgical procedure. In total the patients underwent 207 stages of surgical segment lengthening. In 42 cases the segment was lengthened twice and in 15 – thrice.

Femoral lengthening gain ranged from 1.5 to 7 cm reaching the average of 4.2±1.43 cm or 17.3%±12.18% of the initial segment length. The index of fixation ranged from 2 to 47.3 days/cm (the mean 15.2±12.03 days/cm), the healing index – from 11.8 d/cm to 66 d/cm (the average 29.9±17.56 d/cm)

Tibial lengthening gain ranged from 2 to 7 cm reaching the average of 4.8±2.38 cm or 19.3%±11.04% of the initial segment length. The index of fixation ranged from 3.3 to 44.3 d/cm (the mean 15.7±10.41 d/cm), the healing index – from 10 to 73.3 d/cm (the average 28.6±13.0 d/cm).

In this series of patients the natural growth of a shortened limb was assessed before surgical treatment, in 1-3, 6-8, 9-12 months after the treatment and during 3-7 years of the long-term follow up.

Hechard-Carlioz charts [10] were used for monitoring femoral and tibial longitudinal growth. Preoperatively, predicted limb-length discrepancy and final segment length were

assessed with multiplier method [11] taking into account that, without treatment, the natural growth of a malformed segment is linear, with a constant rate, so that change in percentage discrepancy will likewise be linear [12].

To investigate possible growth-rate change after lengthening, whether stimulation, transitory slowing of growth during the first year or definitive cessation of growth, the following index was calculated at end of growth phase:

$$RGG\ (\%) = (PFSSD - (LG \pm FRSD)) \times 100\% / FLSL$$

where: RGG = residual growth gain; PFSSD = predicted final spontaneous segmental discrepancy (mm); LG = length gain achieved by external fixation (mm); FRSD = final residual segmental discrepancy (mm: healthy segment length minus lengthened segment length); and FLSL = final lengthened segment length (mm).

This index represents the change in spontaneous growth after progressive lengthening with respect to the final length of the lengthened segment; it may be positive (growth stimulation), neutral (no change) or negative (slowing of spontaneous growth).

RESULTS

Observing the longitudinal growth we distinguished the following types of change of the growth rate of the operated segment in short and long-term follow up.

Type I – increased growth rate by the end of lengthening progressively decreasing by the 9-12th month after the end of treatment, but the growth rate remains higher than initial during the long-term follow up (Figures 1, 5 and 6).

Type II - increased growth rate returning to the initial one by the 9-12th month after frame removal. In the long-term follow up the growth rate is close to preoperative (Figure 2).

Type III – growth rate increase is observed during the first postoperative year but in the long-term follow up the growth rate is slower than initial (Figure 3).

Type IV – immediate inhibition or absence of longitudinal growth of the segment is observed till the 6-8th month after the end of surgical lengthening followed by returning to the initial growth rate (Figure 4).

Type V – progressive decrease of the growth rate after the treatment down to full stop for several months followed by stabilization of the growth rate at values inferior to initial (Figure 4).

Tables 1 and 2 demonstrate change of the mean growth rate of lengthened femur and tibia in various groups of patients.

Comparing various groups to each other according to the relative amount of lengthening and healing index, no statistically significant difference was found. Choice of a method for femoral or tibial lengthening also had no significant influence on change of the following growth type. Distribution of cases between the groups of patients is of a proportional character. Reconstructive surgery on foot bones is of a great importance whether performed simultaneously with tibial lengthening or during the long-term follow up. In such cases the

tibial growth rate is slower than initial. This correlation was noticed even in the primary lengthening: two patients with growth rate of type II and III and four patients with type V.

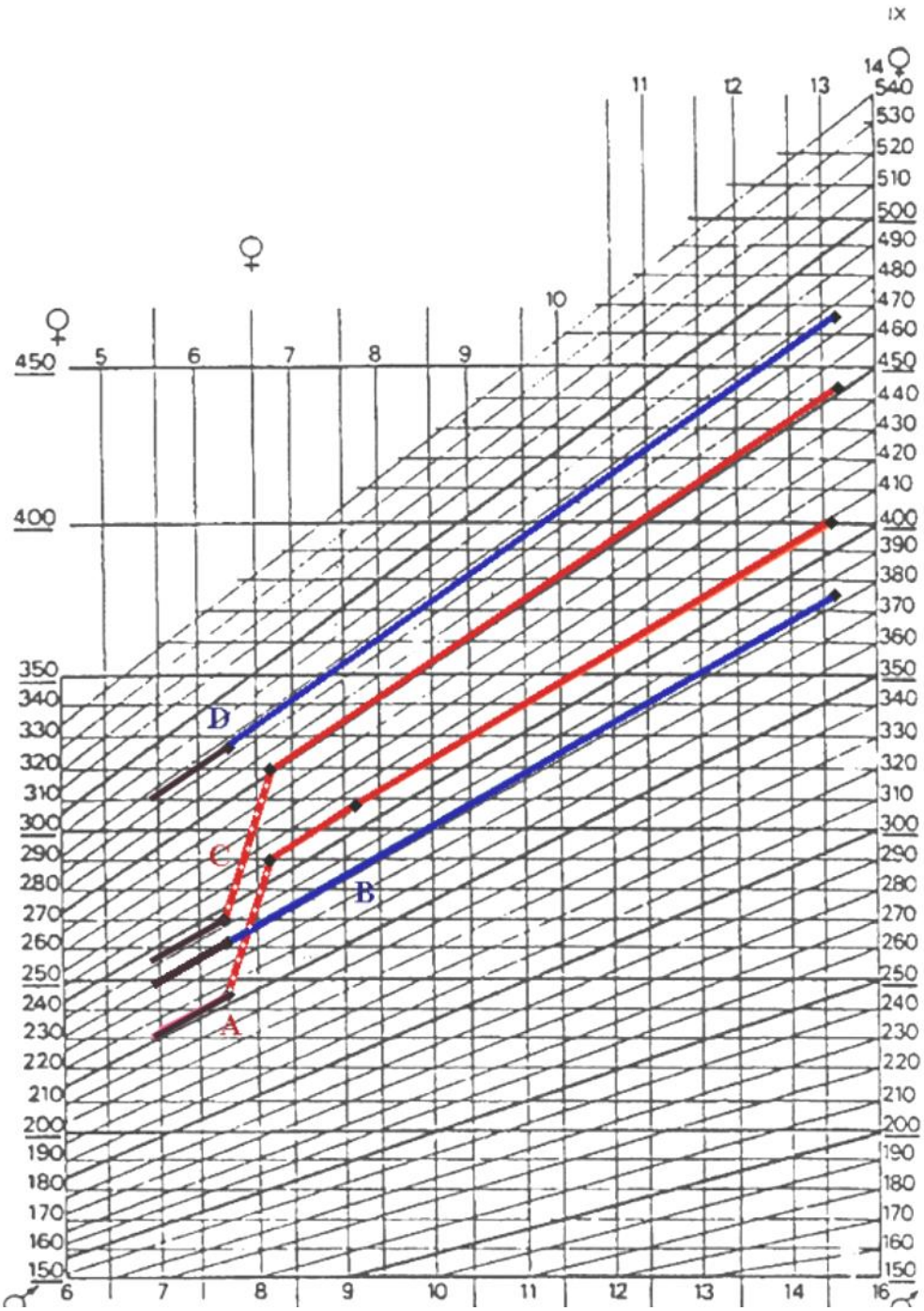

Figure 1. Diagram of segment growth (dotted line corresponds to bone lengthening, A – growth of short tibia, B – growth of normal tibia, C – growth of short femur, D – growth of normal femur): type I of residual growth of lengthened segments.

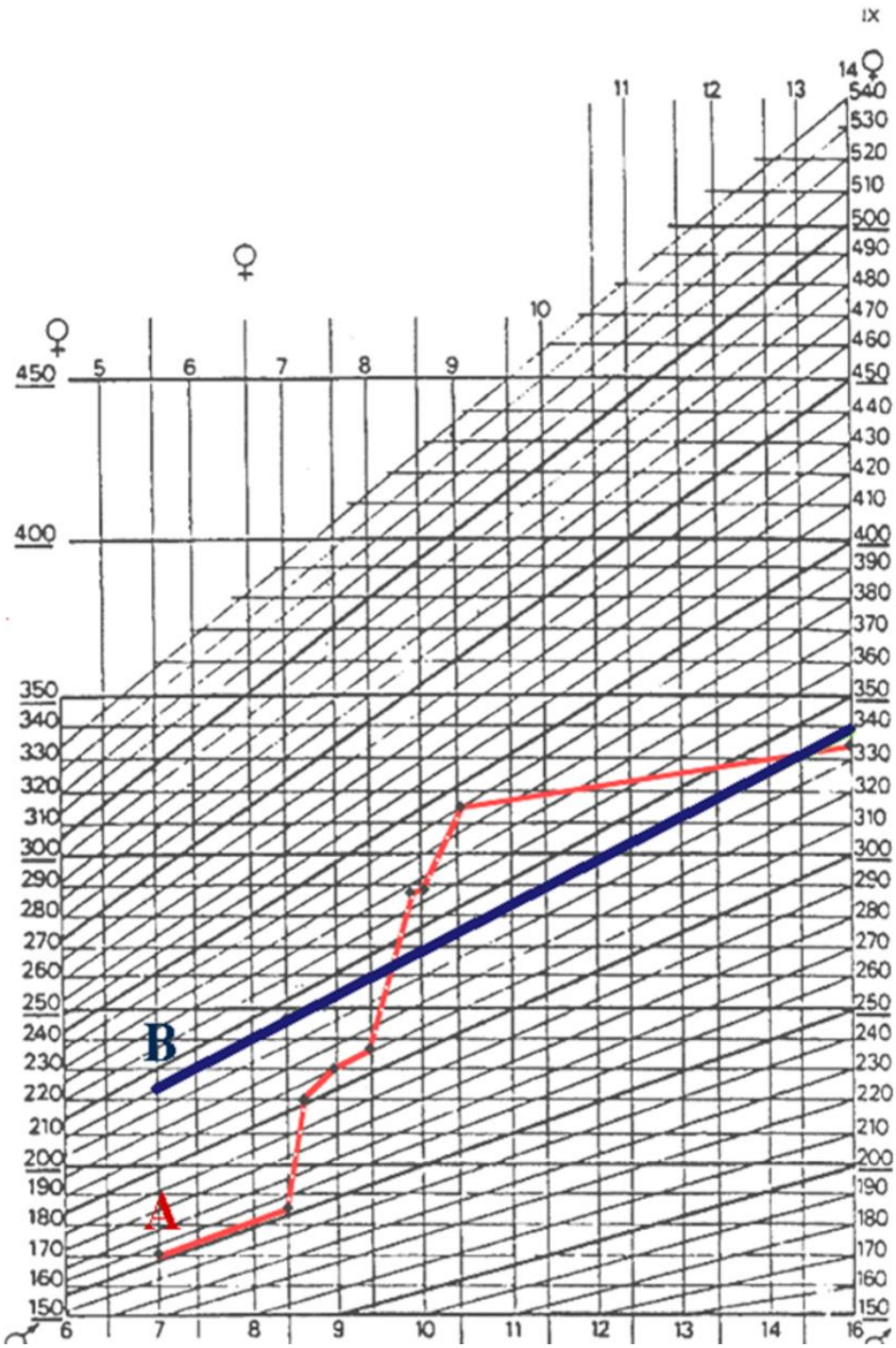

Figure 2. Diagram of segment growth (dotted line corresponds to bone lengthening, A – growth of short tibia, B – growth of normal tibia, C – growth of short femur, D – growth of normal femur):
type II of residual growth after the first lengthening, type V after iterative lengthening.

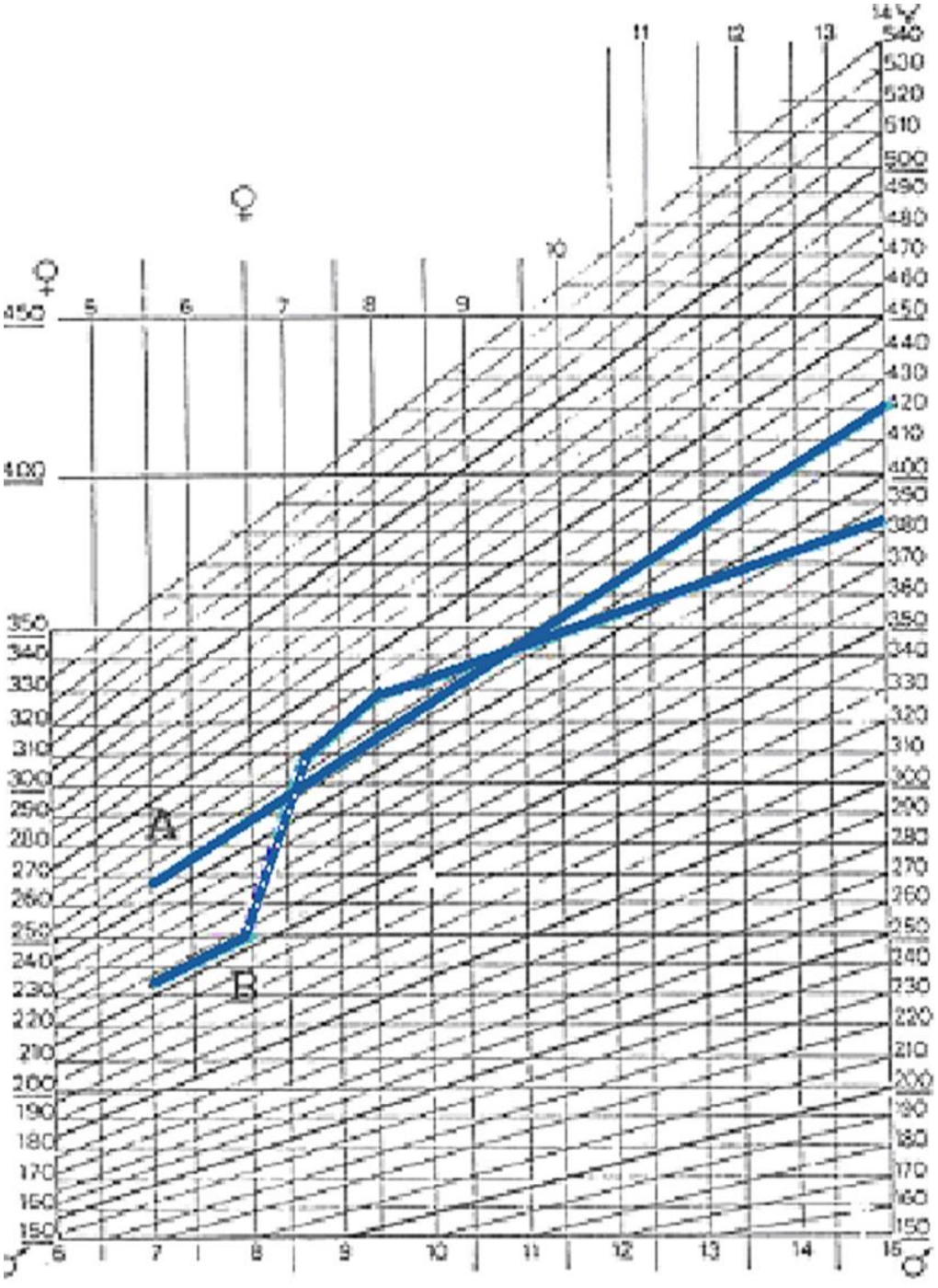

Figure 3. Diagram of segment growth (dotted line corresponds to bone lengthening, A – growth of normal tibia, B – growth of short tibia): type III of the residual growth.

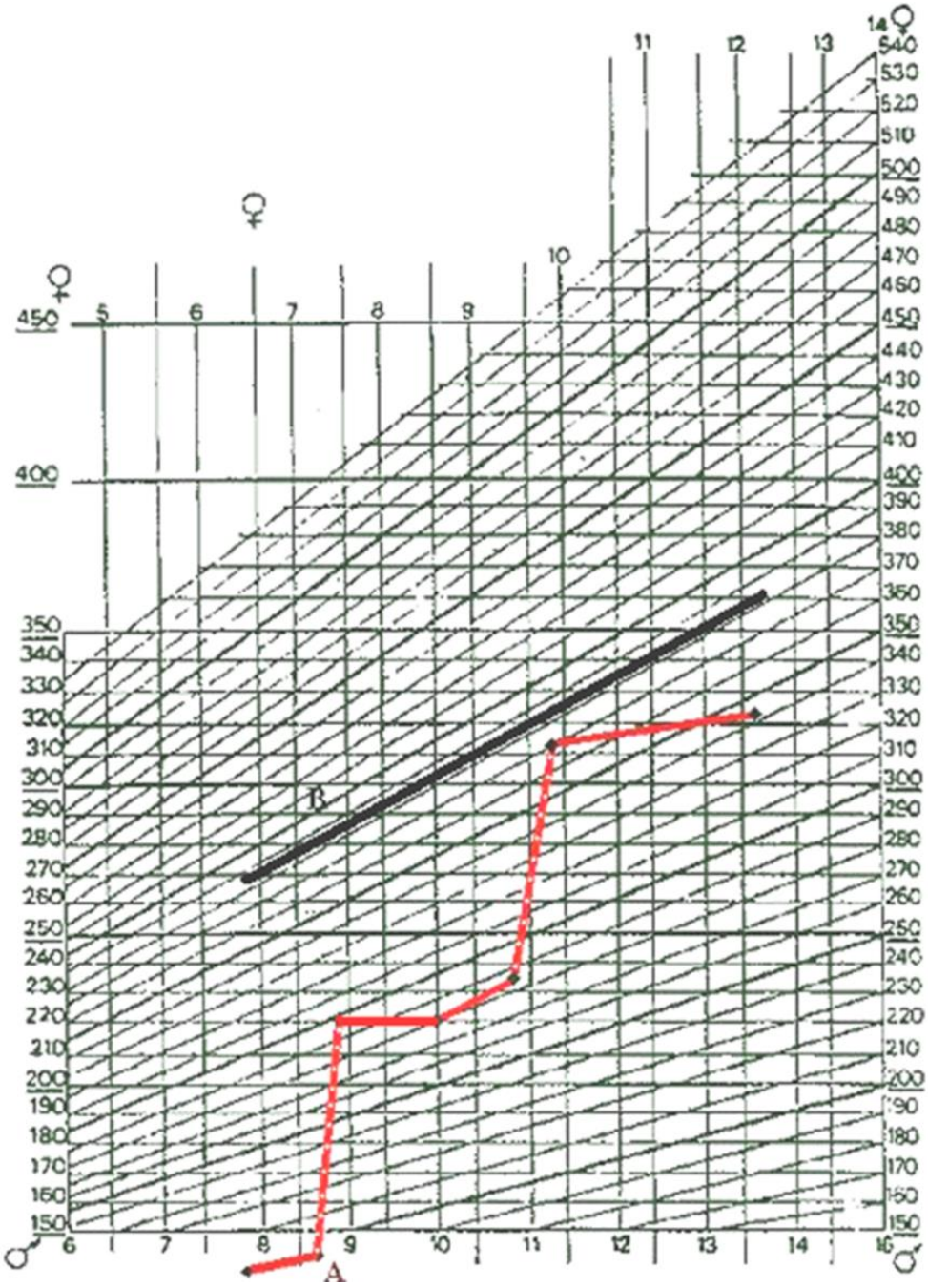

Figure 4. Diagram of segment growth (dotted line corresponds to bone lengthening, A – growth of short tibia, B - growth of normal tibia): type IV of the residual growth after the first lengthening,
Type V – after iterative lengthening.

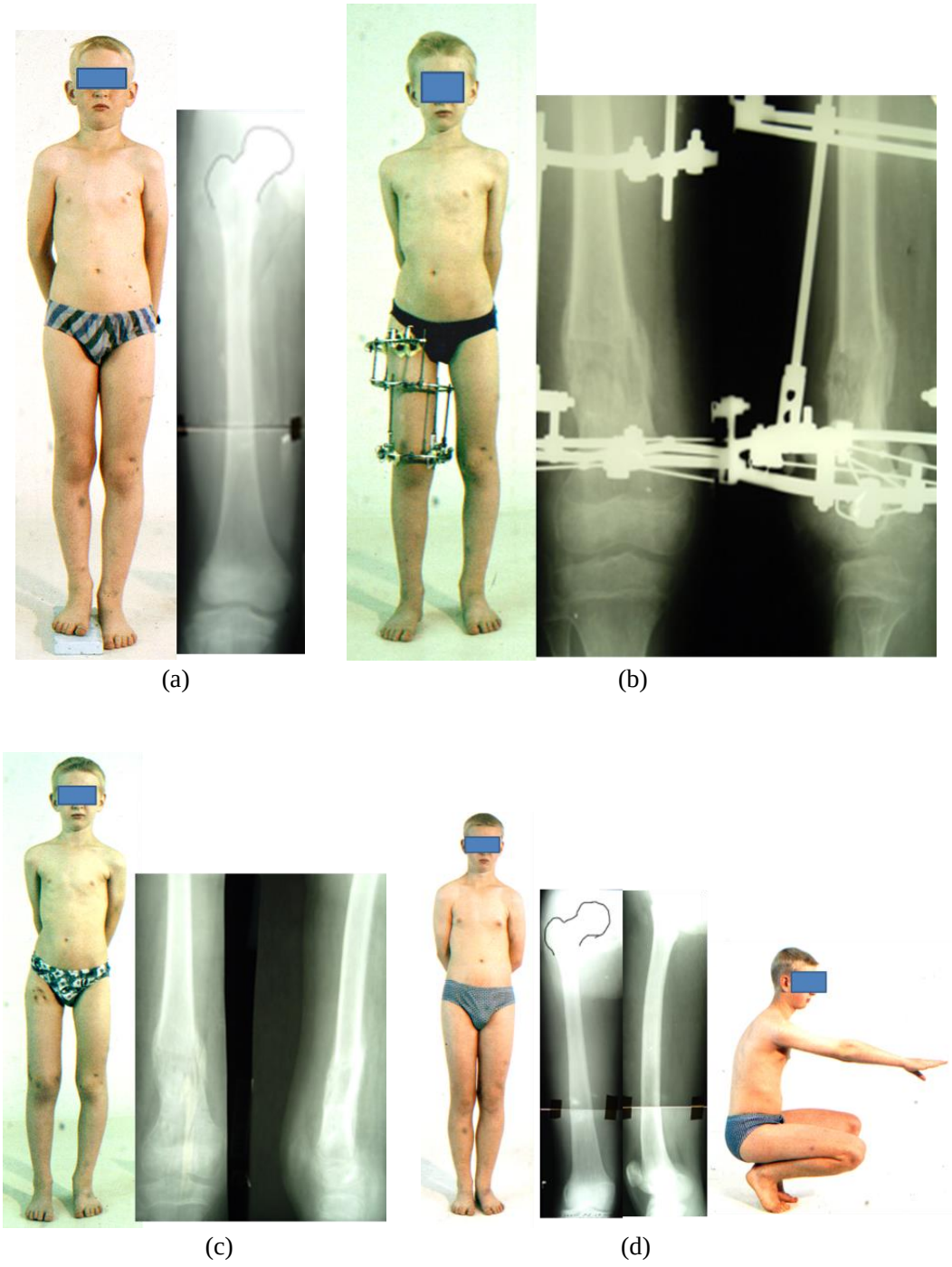

Figure 5. Case of femoral lengthening: photo of patient K., 11 y.o., X-rays of short femur, before treatment, (a); during lengthening (b); after frame removal, HI – 21.9 d/cm (c); photo of the patient at the age of 15 years and X-rays of lengthened femur (d).

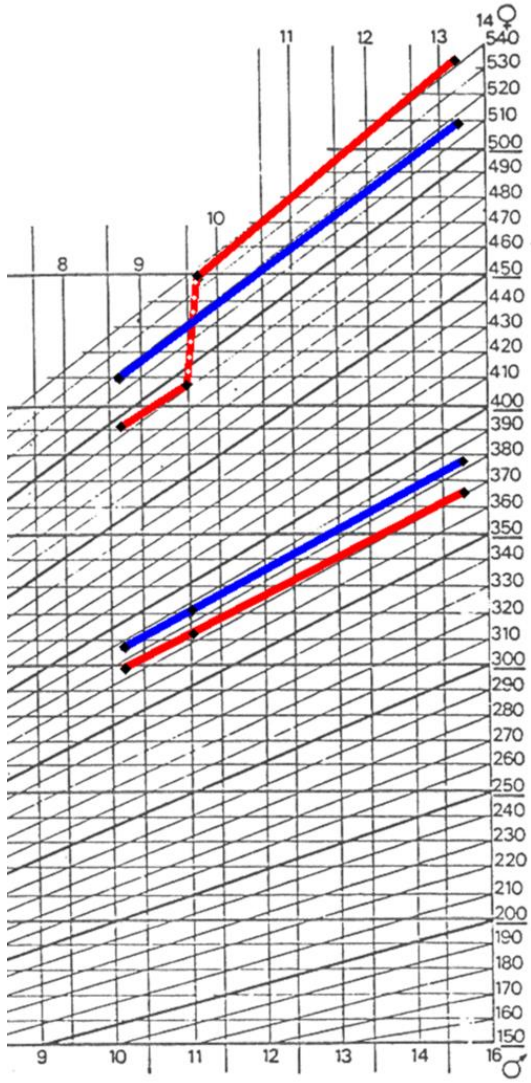

Figure 6. Diagram of the segment growth of the patient K (from figure 5).

Table 1. The mean values of growth rate in lengthened femur at different periods of observation

Groups of patients according to the growth type	Femoral growth rate at different periods of observation; mm/month				
	Before surgery	2-3 months	6-8 months	9-12 months	Long-term follow up
I	1.38±0.47	3.05±1.84	2.8±0.86	2.3±0.94	1.6±0.60
II	1.35±0.20	1.53±0.41	1.36±1.19	1.3±0.21	1.37±0.10
III	1.4±0.33	1.59±0.29	1.3±0.37	1.15±0.62	0.9±0.20
IV	1.26±0.30	0.22±0.37	0.55±0.48	2.03±1.02	1.8±0.64
V	1.27±0.74	0.43±0.62	0.33±0.58	0.42±0.40	0.24±0.65

Table 2. The mean values of growth rate in lengthened tibia at different periods of observation

Groups of patients according to the growth type	Tibial growth rate at different periods of observation; mm/month				
	Before surgery	2-3 months	6-8 months	9-12 months	Long-term follow up
I	1.13±0.29	2.6±0.96	1.51±0.68	1.8±0.53	1.48±0.27
II	1.24±0.31	2.7±2.03	-	1.25±0.25	1.25±0.35
III	1.1±0.46	3.7±2.43	2.1±0.56	0.76±0.37	0.73±0.28
IV	1.16±0.30	0.21±0.32	1.20±1.56	1.3±1.29	1.7±0.48
V	1.18±0.50	0.34±0.49	0.4±0.42	0.43±0.43	0.6±0.40

Comparison of group I and group V according to the data presented in Table 3 allows the statement that second and third stage of femoral lengthening necessitates inhibition of a natural segment growth. On the other hand, it is the primary surgical lengthening of the segment that stimulates the following growth.

Table 3. Distribution of femoral growth types according to the stage of lengthening; number of observations

Growth type	Primary lengthening	Second lengthening	Third lengthening
I	49	1	0
II	18	0	0
III	12	3	0
IV	5	0	0
V	6	20	7

Table 4. Distribution of tibial growth types according to the stage of lengthening; number of observations

Growth type	Primary lengthening	Second lengthening	Third lengthening
I	59	0	0
II	21	2	2
III	5	0	0
IV	11	4	0
V	8	24	11

In tibial lengthening we also observed inhibition of natural growth after consecutive lengthening (Table 4). After primary lengthening the decrease of longitudinal growth rate was noticed in presence of severe malformation of a proximal femur or if the lengthening was performed at age of 13-15 years old, i.e., prior to the end of natural growth. Reconstructive osteotomies on foot bones in 4 cases were associated with inhibition of longitudinal tibial growth in the long-term follow up even after the first lengthening.

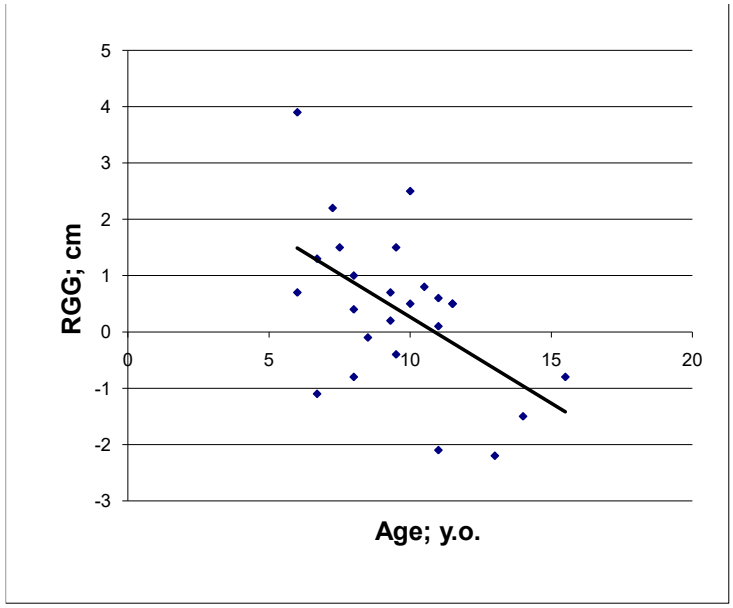

(a)

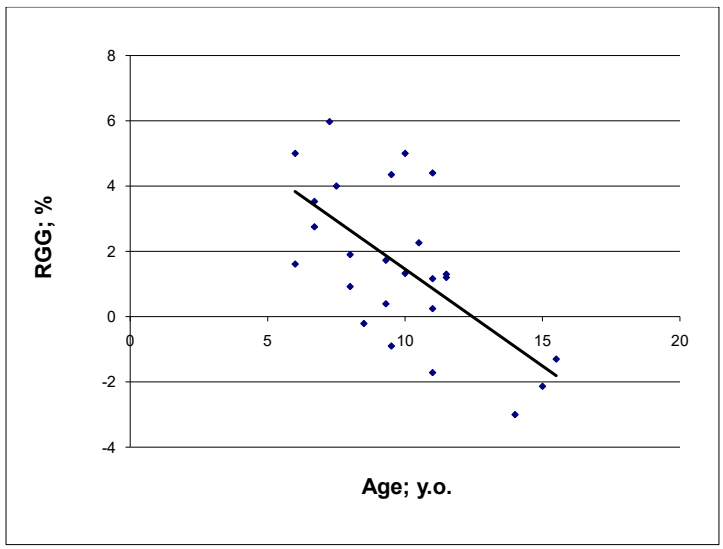

(b)

Figure 7. Relations between RGG (in boys) and age of lengthening, in cm (a) and % (b).

Figures 7 and 8 shows correlation between the age at the beginning of treatment and residual growth gain in the first stage of lower limb lengthening. Since the bone age of 8.5-9 years in girls and 12 years in boys the stimulation of longitudinal growth of the lengthened segment is not observed.

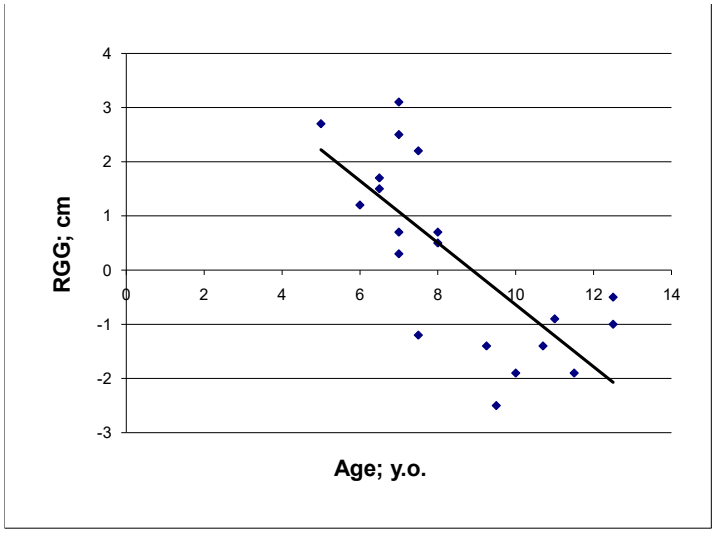

(a)

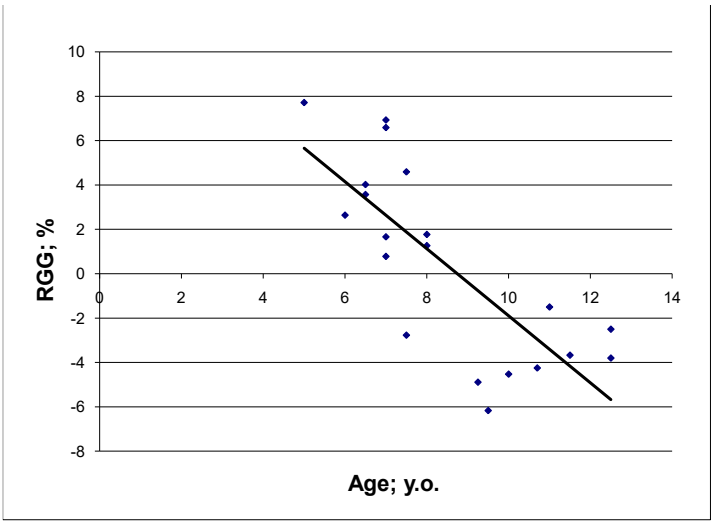

(b)

Figure 8. Relations between RGG (in girls) and age of lengthening, in cm (a) and % (b).

Besides, the age at the beginning of the second stage of lengthening and delay between stages are important for the following growth of segment. Figure 9 demonstrates influence of the age at the beginning of the second stage of lengthening and the time period between the stages on the following longitudinal growth of segment.

According to the above mentioned data it is obvious that in order to prevent the inhibition of the following growth, the second stage of lengthening should be performed before prepubertal growth acceleration and the most favorable delay between the lengthening stages of the same segment is about four years.

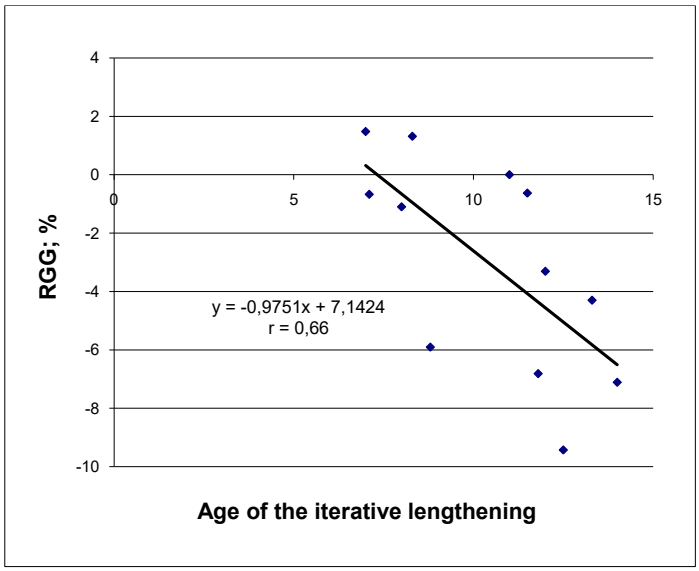

(a)

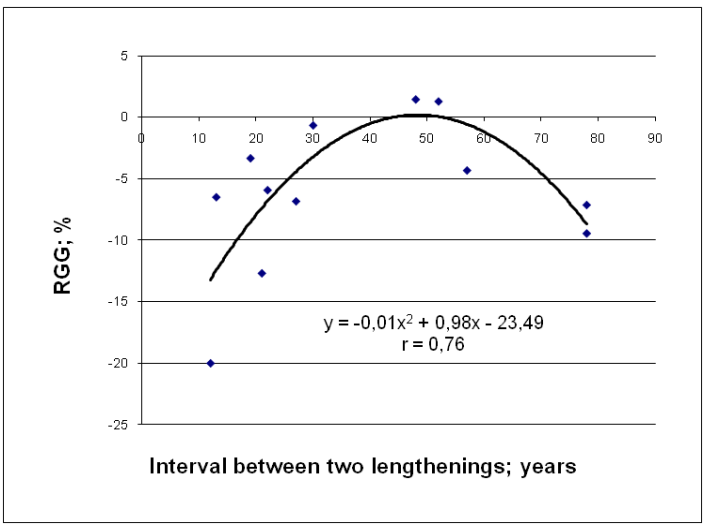

(b)

Figure 9. Relations between RGG and age of iterative lengthening (a) or RGG and delay between two lengthenings of the same segment (b).

If the same segment was lengthened trice, all patients manifested inhibition of longitudinal growth with negative value of residual growth gain. Absolute length loss was 5.0±1.27 cm, relative – 11.9±2.84%. Thereat, total amount of lengthening in femur was 15±2.25cm and in tibia – 13.8±1.92 cm. Thus, triple lengthening of a segment during the period of natural growth is considered inexpedient.

DISCUSSION

In congenital lower-limb length discrepancy, lengthening procedures often need to be performed before the end of spontaneous growth, due to the functional and psychological impact of the discrepancy on child and family. Prognosis of the growth of an operated limb is an important component of lengthening strategy.

The present series exclusively included congenital pathology, making it homogeneous. As congenital discrepancies show a percentage length difference that remains stable over growth in absence of treatment, we accepted the hypothesis that any observed change in growth pattern would be identical across all congenital etiologies, independently of segment location.

Growth stimulation following a first Ilizarov lengthening procedure was systematic when bone age was less than 12 years in boys or 9 years in girls.

This mechanism may be explained by stimulation due to increased vascularization during lengthening, or by a mechanical cause [5]. Some reports stressed the importance of having a correct biomechanical axis and of functional loading to minimize disturbance of conjunctive cartilage growth over periods exceeding 2 years [13,14]. Experimental studies showed that cell number per column in the growth area depends on the forces acting on the cartilage, increasing with increased loading. The greater the number of cells, the more active the cartilage [15]. Antonov demonstrated the growth-stimulating effect of functional forces under dynamic loading [13]. Absence of functional weight-bearing can slow down the longitudinal growth. It explains inhibition of tibial growth while reconstructive surgeries on foot simultaneously with tibial lengthening. External fixation allows all deformities to be progressively corrected, avoiding impairment of joint range of motion during lengthening and ensuring a perfect biomechanical axis in three dimensions [16-18].

Penneçot et al. [2] reported a significant impact on the growth plate after progressive bone lengthening by Judet distractor. The harmful effects of hyperpressure on the conjunctive cartilage, impaired vascularization and the resultant shaft ischemia may account for subsequent slowing of growth. However, the 1-2 mm initial joint-line distraction reported by Oostenbroek et al. was probably insufficient to prevent contact between the joint surfaces and avoid shaft compression [19]. Joint bridging avoids inducing subluxation and hyperpressure threatening the conjunctive cartilage. In the present series, there was no significant difference in residual growth rate associated with bridging of the knee, and no conclusion can thus be drawn as to whether bridging, performed basically to avoid joint impairment, also protects the tibial shaft.

The reduction in growth observed, however, was not necessarily related to the hyperpressure effects described by the above authors. Obtaining and maintaining a normal axis during the lengthening procedure seems to us to be a necessary but not sufficient condition for growth to be conserved.

Percentage lengthenings emerged as one of the main factors impacting residual growth. An experimental study, however, reported that a lengthening of 30% did not affect longitudinal tibial growth [20]; these conclusions were drawn from morphological results at only 5 weeks' follow up. Clinical data, in contrast, demonstrate the negative impact of such a length gain. Viehweger et al. [6], in series of 34 children, reported a clear impact on residual growth following lengthening exceeding 30% using a unilateral external fixator. One of our

studies [21] demonstrates that single-step lengthening of more than 30% of initial segment length is to be avoided in congenital lower-limb length discrepancy, as it may impair resumption of growth.

Osseous age at time of lengthening is a factor to be taken into account in treatment planning in congenital lower-limb abnormality. Pouliquen et al. [3] reported that lengthening performed before the age of 11 years induced growth disorder; this series, however, included only six children with congenital discrepancy. The present results, on the contrary, showed greater growth stimulation gain in children aged less than 8 years at time of procedure. These findings are in agreement with those of Suva et al. [5], who reported accelerated growth of a mean 2.5% in all children treated at less than 6 years of age.

In our study has shown that lengthening performed after the start of the pubertal growth boost (here taken as after 12 years' bone age in boys and 10 in girls, due to the impossibility of having a reliable physiological estimate of pubertal maturity) led to a negative RGG and all the more so in the early phases of puberty.

The exact mechanism of slowed growth can only be guessed at. During the intense pubertal spontaneous growth phase, the soft tissue of the lengthened segment cannot adapt to the change in length, which may result in hyper pressure on the growth plate. Suva et al. [5] suggest a phenomenon of growth capital exhaustion to account for slowing.

It also emerged that iterative lengthening of the affected segment induced negative RGG when conducted at close intervals (of less than 3 years). These findings may guide planning length equalization when the discrepancy prognosis requires iterative lengthening: iterative lengthening of a segment should be undertaken before the beginning of the pubertal growth boost but more than 3 years after the first procedure. The alternative is to perform the second lengthening around the end of spontaneous growth. This program can thus be applied to manage severe femoral or tibial hypoplasia.

CONCLUSION

Our results prove that the primary lengthening of lower limb segments in congenital length discrepancy, which is performed before the prepubertal growth acceleration, can be a factor stimulating the following natural growth.

The second stage of lengthening of the segment leads to inhibition of growth of the operated segment. The least inhibition is noted when the delay between two stages of lengthening of the same segment is about 4 years. Another unfavorable factor is performance of reconstructive surgeries on foot both simultaneously with tibial lengthening and during the long-term follow up.

Triple lengthening of the segment during the natural growth should not be performed at all.

All these data should be considered while planning the strategy of surgical treatment of children with congenital lower limb length discrepancy.

REFERENCES

[1] Dutoit M, Rigault P, Padovani JP, Finidori J, Touzet P, Durand Y (1990) The fate of children undergoing bone lengthening in congenital hypoplasia of the legs. *Rev Chir Orthop.* 76:1-7.

[2] Penneçot GF, Herman S, Pouliquen JC (1983). Effects of progressive lengthening on the growth cartilage. Value of measurement of the torque. *Rev Chir Orthop.* 69:623-627.

[3] 3 Pouliquen JC, Beneux J, Mener G, Penneçot GF (1979) Etude de la croissance du membre inférieur après allongement segmentaire chez l'enfant. *Ann Orthop Ouest.* 11:95-98.

[4] Sharma M, MacKenzie WG, Bowen JR (1996) Severe tibial growth retardation in total fibular hemimelia after limb lengthening. *J Pediatr Orthop.* 16:438-444.

[5] Suva D, Naccarato LH, Heripret G, Cauchoix J, Morel G (1984) An unknown after surgical lengthening of the femur in children: spontaneous postoperative parasitic lengthening. *Rev Chir Orthop.* 70:631-636.

[6] Viehweger E, Pouliquen JC, Kassis B (1998) Bone growth after lengthening of the lower limb in children. *J Pediatr Orthop B.* 7:154-157.

[7] Hope PG, Crawfurd EJ, Catterall A (1994) Bone growth following lengthening for congenital shortening of the lower limb. *J Pediatr Orthop.* 14:339-342.

[8] Sabharwal S, Paley D, Bhave A, Herzenberg JE (2000) Growth patterns after lengthening of congenitally short lower limbs in young children. *J Pediatr Orthop.* 20:137-145.

[9] McCarthy JJ, Kim H, Saluan P, Karsky D, Davidson RS (2003) The effects of limb lengthening on growth. *J Pediatr Orthop B.*12:328-331.

[10] Hechard P, Carlioz H (1978) Practical method of prediction of leg length inequality. *Rev Chir Orthop.* 64:81-87.

[11] Paley D, Bhave A, Herzenberg JE, Bowen JR (2000) Multiplier method for predicting limb-length discrepancy. *J Bone Joint Surg.* 82-A:1432-1446.

[12] Shapiro F (1982) Developmental patterns in lower-extremity length discrepancies. *J Bone Joint Surg.* 64-Am:639-651.

[13] Antonov SG (1979) Effect of physical loading on the state of the metaepiphyseal cartilage of the femoral bones and on the growth of these bones in length. *Arkh Anat Histol Embriol.* 76:75-81.

[14] Chargorodsky VS, Iljin LA (1972) Distribution of tension at the level of distal femoral physics. *Orthop Traum Protez.*1:33-38.

[15] Damsin JP, Djenadi K, Josset P, Wioland M (1996) Cartilage de croissance et croissance en orthopédie. *EMC Appareil locomoteur.* 14-009-A-10:13.

[16] Popkov D, Popkov A, Haumont Th, Journeau P, Lascombes P (2010) Flexible intramedullary nail use in limb lengthening. *J Pediatr Orthop.* 30:910-918.

[17] Catagni MA, Radwan M, Lovisetti L, Guerreschi F, Elmoghazy NA (2011) Limb lengthening and deformity correction by the Ilizarov technique in type III fibular hemimelia: an alternative to amputation. *Clin Orthop Relat Res.* 469(4):1175-1180.

[18] Hamdy RC, Makhdom AM, Saran N, Birch J (2014) Congenital fibular deficiency. *J Am Acad Orthop Surg.* 22(4):246-55.

[19] Oostenbroek HJ, Brand R, Van Roermund PM (2009) Growth rate after limb deformity correction by the Ilizarov method with or without knee joint distraction. Lengthening in 30 children followed for at least 2 years. *Acta Orthop.* 80:338-343.

[20] Gang C, Coulton L, Lang Y, Saleh M (2005) The effect of diaphyseal lengthening on the tibial growth plate. *J Bone Joint Surg.* 87-B (Suppl. III):316.

[21] Popkov D, Journeau P, Popkov A, Pedeutour B, Haumont T, Lascombes P (2012) Analysis of segmental residual growth after progressive bone lengthening in congenital lower limb deformity. *Orthop Traumatol Surg Res.*98(6):621-628.

In: Encyclopedia of Surgery (22 Volume Set)
Editors: Andreas Lehrer and Kristin Mueller
ISBN: 978-1-53618-329-0
© 2020 Nova Science Publishers, Inc.

Chapter 5

BIOACTIVE IMPLANTS IN RECONSTRUCTIVE ORTHOPEDICS

Arnold Popkov*, PhD, MD
Scientific and Clinical Laboratory for Deformity Correction
and Limb Lengthening. Federal Russian State-Financed Ilizarov Scientific
Center for Restorative Traumatology and Orthopaedics, Kurgan, Russia

ABSTRACT

Detailed description of methods of external circular osteosynthesis in association with flexible intramedullary nails with bioactive coating in deformity correction are presented in Chapter V. It is concerned with surgical treatment of orthopedic disorders in such diseases as osteogenesis imperfecta. In this part of the monograph we describe various currently existing bioactive coatings of implants, used in orthopedic practice and new developing trends of this field.

Keywords: flexible intramedullary bioactive coating, implants, intramedullary nailing

1. TYPES OF BIOACTIVE COATINGS AND IMPLANTS

Reconstruction of organs or skeletal parts affected by trauma or disease still remains quite challenging for the state-of-the-art traumatology and orthopedics. There are two different approaches to resolving of this problem nowadays: 1) simple substitution of an affected bone by an implant of mechanical integration or 2) creating the conditions for bone regeneration with spontaneous total recovery or by means of an implant of biological integration.

Analysis of the contemporary reference data proves that both trends are related to bioceramics. Perspectives of use of bioceramics are determined first of all by the possibility to change mechanical and biologic features of implants and their approaching to the bone

* Corresponding Author's Email: apopkov.46@mail.ru.

tissue. We recall that the bone has complicated structure and diverse tissue constitution. Mechanical characteristics of the compact bone are determined by specific 3D position of its structural components – bone lamellae of 3-10 mkm thick [1,2]. Bone matrix (collagen) makes up about 20-25% of total weight of bone, non-organic component (Ca phosphates) - 60-65%, content of water reaches 9-10%. Besides, there are small amounts of other organic compounds (proteins, other than collagen, polysaccharoses, lipids).

Organic bone matrix and non-organic components create a specific composition material. Contemporary bioengineering is not yet able to reproduce artificially the morphology of bone tissue in detail, thus, to achieve the same combination of biologic and mechanical features as of the bone. Nevertheless, biomaterials acting as implants should meet the following requirements:

1) Chemical features - absence of unwelcome chemical reactions with tissues and intertissue liquid, absence of corrosion;
2) Mechanical features of biomaterial should be close to those of the bone – strength (flexibility) and resistance to fatigue deformities and fractures;
3) Bioactivity of the material – absence of reaction of the immune system, osteoconductivity (ability to develop microvessels on the material surface and then ostegenic cells with formation of the bone tissue, also inside transverse pores of the optimal dimension) and osteoinductivity (ability of the material for adhesion and differentiation of mesenchymal stem cells including osteoblasts and stimulation of their osteogenic function). Osteogenity and osteoinductivity provide biointegration of implants.

Bioinert metals and alloys with ceramic coating on the bases of Ca phosphates (especially hydroxyapatite) are supposed to be the best for creating orthopedic implants for the locomotor system going through strong mechanical stresses. These materials provide biologic compatibility and significant biologic activity in bone formation around the metal.

Practical application and improvement of those implants are developed in the following directions:

1) Design of joint replacement implants: their metal load-bearing element is covered with hydroxyapatite aiming to create excessive bony sleeve providing secure contact of the metal with the bone tissue along the maximum surface, which exclude insufficient fixation of joint elements on the bone for long term.
2) Design of intramedullary implants for substitution of vast bone tissue defects resulted from trauma or radical excision in orthopedic or oncologic surgeries.
3) The reconstructive combined surgery definitely involves the second direction. As the contemporary ceramics is fragile, it covers metal layer (usually in a form of titanium, stainless steel nails of 1.5-3 mm diameter). Such covering is capable to induce reparative osteogenesis around the implant promoting bone defect substitution. Thus, a sleeve, formed along the entire implant, provides optimal conditions for healing bone fractures or pseudoarthroses, for formation of distraction regenerate in limb lengthening.

A weak point of those implants is necessity of a secondary surgery for their removal in 3-6 months after fracture consolidation, healing of bone fragments. This disadvantage is supposed to be conventional as removal of the implant is not obligatory.

Definitely, the solution of this problem suggests itself as to create an intramedullary implant made of solid composite material, which is progressively resorbed while the defect is getting filled with a newly formed bone. The first ones of those implants are composites of "hydroxyapatite – polymer" type, they manifest mechanical features similar to the bone and highly bioactive.

Development of those materials started by the end of 70s of the previous century, aiming to create artificial bone substitutes. In 1980s W. Bonfield et al. developed a composite consisted of hydroxyapatite particles and high density polyethylene [3]. Hydroxyapatite particles of 4 μm diameter were dispersed and uniformly distributed in the polymer *matrix*. Polyethylene is a typical material known for its consistency and rigidity, but manifesting no bioactivity. On the contrary, HA possesses bioactivity, but not consistency. Uniting these two materials results in products possessing consistency and bioactivity at the same time.

It was determined that if HA has a higher Young's modulus of elasticity than polyethylene, thus, this modulus of the composite "hydroxyapatite-polyethylene" rises with increase of volume ratio of HA-filler and can reach the modulus of cortical bone [3]. Nevertheless, composites lose consistency and become fragile when HA-content exceeds 45%. Y.Wang et al. also studied influence of dimension of HA-particles on mechanical properties of this composite material [4,5]. It turned out that composites with a lesser size of particles possess a higher modulus of torsion and extension and a higher tensile modulus of elasticity. The surgeon can easily pre-shape the composite during surgery, which is also an advantage of the material.

As polyethylene is not bioactive, so, when implanted, it is encapsulated with fibrous tissue and isolated from surrounding tissues. To provide bioactive properties, the content of HA particles should exceed 20% [3]. Exposure of HA-particles on the composite surface is necessary for providing bioactivity, as there should be direct contact between bioactive particles and surrounding tissues to induce the effect of osteoconductivity.

Thus, the "hydroxyapatite-polyethylene" composites with HA-content rate of 20-40% possess the consistency and Young's modulus similar to the ones of natural bone and the bioactivity. A combination of hydroxyapatite and polyethylene proposes a new material for bone substitution close to the bone by its mechanical properties. It is already used in orbital floor fractures to build up volume, and as a material for middle ear implants.

Other composites were composed of polyethylene and Bioglass® [5]. Bioglass® is bioactive glass revealing high level of bioactivity with both hard and soft tissues. In those composites the Young's modulus and microhardness grow with increase of Bioglass® content, though breaking tensile strength and strain to failure decrease. The composites build a layer of bone-like apatite on their surface [6,7].

Juhasz et al. reported about glass-ceramic A-W-polyethylene composites [8]. Glass-ceramics is distinguished for its high mechanical strength and bioactivity [7], that is why it is supposed to be an effective filler in bioactive composites. Increasing the A-W glass-ceramics content in those composites causes an increase in Young's modulus, yield strength and bending strength, and a decreased strain to failure [9]. The composites demonstrate high ability to produce apatite in simulated interstitial fluid, also increasing with increase of A-W glass-ceramics volume.

Composites “hydroxyapatite – poly-L-lactide” (u-HA-PLLA) contain poly-L-lactide (PLLA). This biodegradable polymer is used in fabrication of medical devices applied in clinical practice in orthopedic, cranio-maxillofacial surgery. Those devices have some weak points, like lesser strength than of the natural cortical bone, slow rate of degradation and no osteoconductivity. In order to improve bioactivity and mechanical strength of the polymer, its combination with bioactive ceramic fillers were developed. Some authors reported about composites with Ca phosphate fibers or particles of baked hydroxyapatite which are dispersed in biodegradable organic polymers. Though, those materials could not be resorbed completely. Other attempts were to add resorbable polymer to bioceramics, but those materials had low mechanical strength [10].

Shikinami et al. [11] reported development of composites “HA – PLLA”, when hydroxyapatite requires no thermal processing. Unbaked powder of hydroxyapatite (u-HA) was prepared by reaction between calcium hydrogen phosphate anhydride ($CaHPO_4$) and calcium carbonate. It resulted in carbonate containing hydroxyapatite. HA congeries were broken and sifted to receive particles of a diameter rang 0.3-20 μm, in average - 3 μm. U-HA particles were dispersed in polymer PLLA-matrix to fabricate composites “u-HA - PLLA”. The given composite possessed high mechanical strength. U-HA particles were uniformly distributed in matrix and exposed on the surface providing bioactivity. Bending strength of the material increases with increase of u-HA content. It reaches about 270 MPa with a 30 vol% u-HA filler content. This value is higher than in PLLA samples without filler and much higher than in human compound bone. Bending strength of the composite is also a little higher than in PLLA samples without u-HA and close to the value of human compound bone. Impact index of the composite with a 30 vol% u-HA filler content is much higher than the one of PLLA samples without u-HA or of human compound bone [12].

Biological properties of composites “u-HA – PLLA” were studied *in vitro* and *in vivo*. *In vitro* tests showed formation of bone-like apatite on the surface within 3 days after soaking in simulated body fluid. It suggests that the composites are bioactive. *In vivo* tests of implantation in bones of animals revealed that devices made of composites demonstrate more affinity to the bone than those made of PLLA: fibrous tissue formed on surfaces of the latter, while using of composites resulted in formation of bone-like apatite and direct contact with the bone. Histological study showed that new bone formation occurred in 2 weeks after implantation. Such bioactivity of those composites induces an early position stability of implant in bone. Gradual degradation of the implanted composite in the bone defect was observed to result in replacement of the composite by bone tissue. When the u-HA - PLLA composite rods were implanted in a subcutaneous layer, their bending strength preserved 85% of the initial value in 8 weeks and 80% in 25 weeks, while the molecular weight of the rods reduced to 20% of the initial value over the same period [13,14].

Healing of a fractured human bone normally requires over 8-12 weeks, though the healing period is determined by various parameters, like fracture location, stability of bone fragments, patient’s age. Stability of osteosynthesis is believed to be a very important factor during healing, so, in order to maintain stable fixation during this period, the mechanical strength of an intramedullary or on-bone device should be preserved. Despite the fact that the u-HA – PLLA composite demonstrated a faster degradation in bone defects than PLLA alone, fabricated with the same technique, but devices made of this composite preserve mechanical firmness during the entire period of fracture healing.

Shukinami et al. reported total degradation of rods for bone fixation made of "u-HA – PLLA" composite in approximately 4.5-5 years after being implanted: passages created in the distal femoral condylar for implanting were almost totally filled in with new bone [11]. There was no inflammatory response to biodegradation or bone defect substitution.

Thus, analysis of literature revealed that research in ceramics-polymer composites creation reached the level of commercially affordable proposals and the concept of combining of non-organic and organic components seems to be logic in developing material for bone reconstruction.

Choice of this or that material depends on medical-biologic characteristics of the bone defect as well as on a concrete clinical case. So, solution of this problem is possible upon availability of the whole range of biomaterials. Choosing the most appropriate material for the concrete case allows to the surgeon to shift from reconstructive-substitutive principle of treatment to a higher level of bioengineering.

Currently, tissue engineering is one of the youngest branches of medicine, it is based on the principles of molecular biology and genetic engineering. A multidisciplinary approach used in this sphere is aimed to create new biocomposite materials for recovery of lost functions of certain tissues or organs [15,16].

Basic principles of this approach are development and implantation of bases made of biodegradable material into the damaged organ or tissue, which are used in association with donor cells and/or bioactive materials. In the latest years, new technologies allow to extract bone morphogenic proteins (BMPs/BMP-2 and BMP-7) and use them in clinical practice.

Recombinant human osteogenic Protein-1 (rhOP-1), inducing *in vivo* formation of new bone tissue and possessing specific activity similar to natural osteogenic protein, stimulates proliferation and differentiation of osteoblasts *in vitro*. It is able to induce formation of bone tissue by stimulation of mesenchymal stem cells and their following differentiation into precursor osteogenic cells. Administration of rhOP-1 into the bone defect gap and fracture site provides total recovery of the bone in 30 months.

One of the major tasks of tissue engineering in treatment of bone pathologies is creation of synthetic composites which are able in combination with bioactive molecules to induce osteogenesis as well as chondrogenesis in reconstruction of joint surfaces (the latter has not found a practical application yet). Besides, such materials should possess certain properties of the bone [17,18,19]:

- to scaffold the defect volume,
- to possess osteoinductive capacity,
- to be biocompatible, i.e., to be able to biodegrade and not to provoke inflammatory response of the recipient.

All those properties together allow to such materials along with a supportive function to provide biointegration – ingrowth of cells and vessels into the implant structure, and stimulate bone tissue formation around the implant.

Tissue engineering implies using of cells in complex with biologic or artificial matrixes which conduct cells in the process of reparation. Implant fabrication should be rather cheap and clinical application with osteoinductive capacities should guarantee consolidation of injured bone in the shortest period possible: consolidation of a simple fracture of long bones

should not exceed 3-4 weeks, as for formation of the distraction regeneration in bone lengthening, the time of regenerate mineralization allowing to remove the external fixator should tend to zero (the process of mineralization must coincide with the process of formation of organic matrix).

Currently, the intramedullary implant in a shape of a titanium HA-coated wire meets all the requirements: production is rather cheap, practical application does not require use of expensive donor cells and artificial bioactive materials (OP-1, rhOP-1). Intramedullary space, bone marrow and endostium contain the entire set of morphogenetic proteins, ferments and growth factors, a great number of mesenchymal stem cells and endosteal osteogenic cells, needed for differentiation to osteoblasts and proliferation of the bone substance around the intramedullary nails.

Concept of Bone Tissue Formation on the Intramedullary Implant Surface

Nowadays, understanding of basics of the reparative regeneration in “skeletal tissues” provides development of tissue engineering in orthopedics and traumatology, first of all because of unsatisfactory time and results of fracture healing. When the contemporary science states that fractures require at least 12 weeks for healing and real time of patient’s rehabilitation takes 10-12 months, when the healing index in limb lengthening 45 days/cm [20-22], the situation naturally needs development of medical technologies stimulating the reparative process.

The Ilizarov scientific school always held to the concept of sufficiency of proper body reserve for healing of limb fractures and maintenance of optimal conditions for reparative bone regeneration that means:

- thorough, preferably close reduction of bone fragments,
- stable fixation of bone fragments,
- low invasive surgery,
- adequate blood supply of the fracture or limb lengthening site,
- optimal rate and rhythm of distraction,
- functional weight bearing of the limb during treatment.

Economic expediency is the basis of elaboration of the method of transosseous osteosynthesis aimed to osteogenetic induction. In 2001 D. Popkov suggested to lengthen long tubular bones by means of flexible intramedullary nailing. First, Ilizarov Scientific Center (Kurgan, Russia) started to apply the technique, then Pediatric Orthopedic Center (Nancy, France). As a result, reinforcement of reparative osteogenesis around flexible nails and reduction of healing time were noted [23-25].

In our opinion, the intramedullary osteosynthesis by nails with bioactive coating performs two functions – provides additional stability of bone fragments as well as all osteoconductive and osteoinductive conditions for reparative bone tissue regeneration characteristic to HA-based materials.

From the economic point of view, the production technology of nails with bioactive calcium phosphate coating is an inexpensive process [26,27], and intramedullary positioning

of the implant excludes necessity of additional cultivation of high-cost growth and cell factors.

Titanium nails are coated with biologic or synthetic hydroxyapatite produced by low temperature method [28]. According to the results of electronic microscopy, the present HA sample is a powder mixture with pallets inclusions of nanoscale structure of 10-100 nm diameter. According to X-ray phase analysis, the powder is a heterogeneous hydroxyapatite mixture of hexagonal and monoclinal structure with the internal surface area over 70 m^2/g. The coating technology of titanium nails of 1.8mm diameter is based on electrochemical deposition. In average the coating thickness is 85±3.0 μm, surface roughness – 5.5±0.01 μm. According to the results of AFM of fine resolution, the coating pattern consists of nodules of approximately 100 nm diameter, of approximately 35 nm height, and flaky fragments. They form spherulites of about 5 μm in diameter and up to 300 nm in height. In the middle of spherulites and in between them there are transverse pores of the diameter below 1-2 μm reaching metal base surface. Electronographic image of titanium coating of nails viewed micropore diameter of 2 to 5 μm (Figure 1).

The flexible intramedullary nailing with bioactive HA-coating allows to influence on the bone marrow activity stimulating endosteal bone formation by the very presence of the nail. Its internal stress induces the function of mesenchymal tissue of the bone marrow (mechanoinduction of osteogenesis). This method of osteoinduction is characterized by low traumatism, it preserves the nutrient artery, and excludes possibility of delayed consolidation.

Formation of bone tissue on the ceramic implant surface requires adhesion of certain molecules. The bone structure is hierarchically organized in various ranges of length – from macro- to nanoscale, thus, the implant structure also should be hierarchically organized in three levels: macro- , micro- and nano-. Besides, nano surface pattern should be approximately 100 nm in order to conform with cell receptors and the pores are needed of micro- and macro dimensions. The recommended dimension of micro pores is at least 300 μm which provides nutrition and cell distribution on the implant surface as well as formation of capillaries in it.



(a) (b)

Figure 1. Surface of the intramedullary titanium nail (scanning electron microscope) x1500 (a); x5000 (b).

Studies of ectopic osteogenesis on the ceramic implant surface showed that bone tissue formation is obligatory preceded by cell migration and angiogenesis which are observed only

if there is a sufficient amount of micropores, otherwise, ectopic formation of the new bone can slow down or fail. It is well known that not porous materials don't manifest osteoinductive properties.

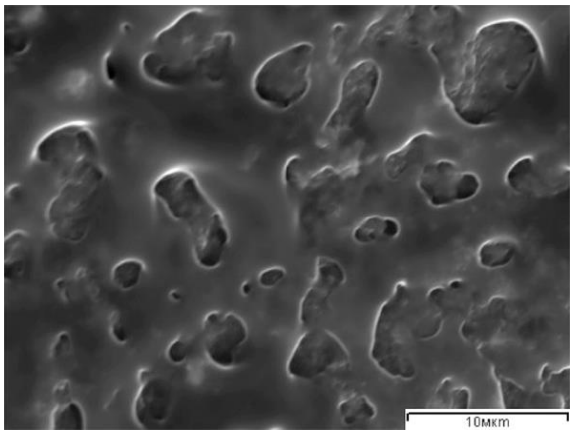

Figure 2. Surface of an intramedullary nail at 26th day of experimental study (scanning electron microscope, x3000). Through holes in the protein film can be seen the hydroxyapatite coating.

We determined that immediately after implantation of biomaterial, proteins of blood and extracellular matrix (Figure 2) – fibronectin, osteocalcin, bone sialoproteins, immune-globulin, albumin, etc. – are absorbed on the biomaterial surface.

We believe that osteoinduction is related both to the design of the implant surface pattern and to a biological phenomenon of inflammatory response developing after implanting of biomaterials [29,30]. Caplan A.I. and Boyan B.D. [31] hypothesized that initial inflammatory response to implanting of biomaterials stimulated factors attracting mesenchymal stem cells. One of them can be prostaglandin E2 (PGE2) produced by macrophages accumulated around biomaterials during the inflammatory phase [32,33]. The microrough surface, unique for osteoinductive materials, reported to stimulate production of PGE2 by macrophages [32] and PGE2 possesses hemotoxic features towards human mesenchymal stem cells and stimulates their osteogenic differentiation.

As a result of flexible intramedullary nailing, a certain bony sleeve forms around the nail because of inducing of the local osteogenesis. Figure 3 demonstrates CT images of dog's tibiae – intact and undergone intramedullary osteosynthesis. Shades of bony sleeve around the canal of intramedullary nail are clearly seen inside the marrow cavity. Thickness of a mineralized wall of this "sleeve" ranges from 1 to 3 mm. The bone tissue ingrows into pores of the implant surface and rapidly fills in all the space of marrow cavity firmly uniting nails with endosteum (Figure 3). Cancellous bone forms as a natural bone scaffold in fracture.

Osteoconductive and osteoinductive properties of flexible implants, that we developed, provide directional growth of new bone tissue in the fracture site, as well as in the limb lengthening gap, in correction of systemic diseases (osteogenesis imperfecta, Ollier disease, fibrous osteodysplasia, rickets-like diseases), in substitution of bone cysts; they also favor finishing of bone histogenesis in postnatal period in place of cartilaginous or connective matrix [34].

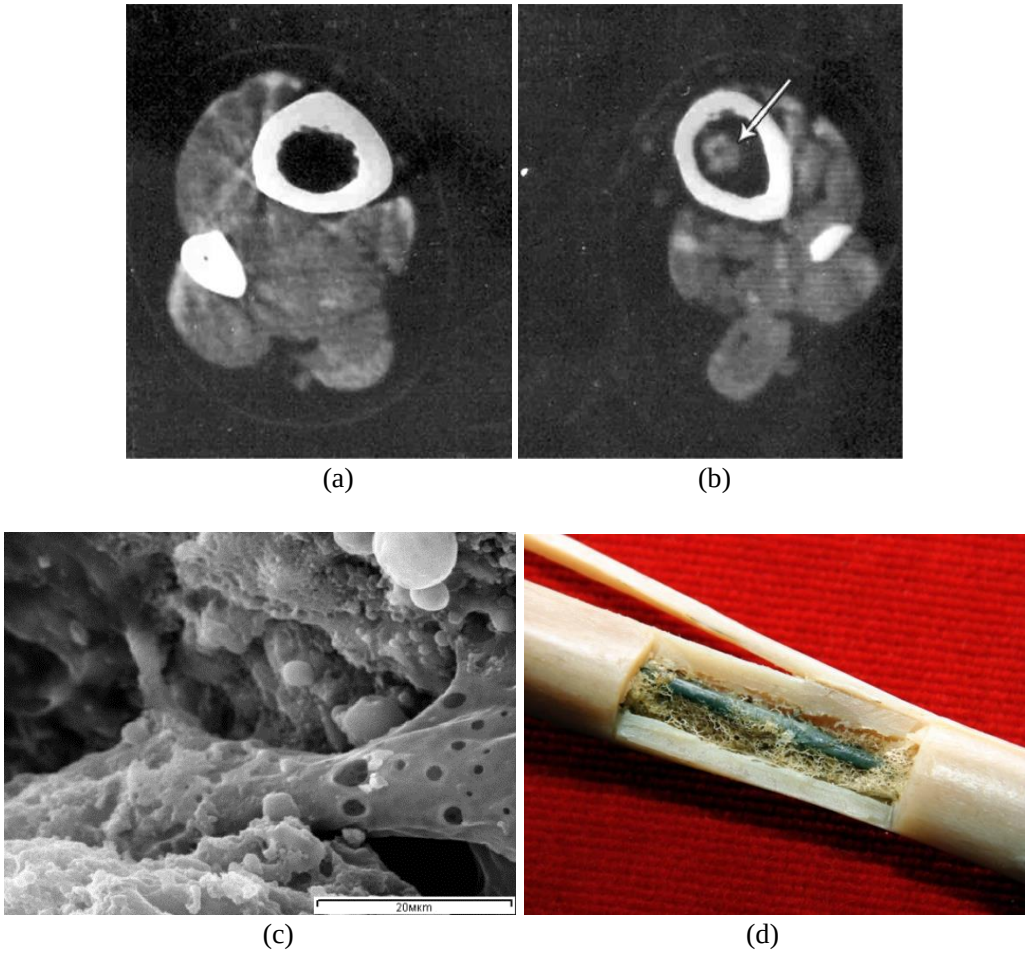

Figure 3. The bone tissue formation around intramedullary nail: intact tibia, computed tomography (a); lengthened tibia, after nail removal (b); bone trabeculae formation on the HA-coated surface of intramedullary nail (c); cancellous bone tissue filled in the space around the intramedullary nail (d).

2. Use of Intramedullary Bioactive Nailing in Osteogenesis Imperfecta

Deformity Correction and Intramedullary Telescopic Constructions

Basic surgical methods of treatment of deformities in children affected with osteogenesis imperfecta are corrective osteotomies and a basic mode of osteosynthesis is intramedullary [35-41,45,51,52,54]. Considering the fact that in OI all the limbs are involved, it is recommended to use reference data for treatment planning [41,42,49]. When levels and amount of deformity correction are determined, a number of required osteotomies and amount of correction at each level is calculated [44,47]. It is important to correct all the deformity components of the entire limb within one surgical session, as the deformities are often counter-directed and compensate the above and below segment axis [40,44,54]. Preventive

osteosynthesis of long bones as well as osteosynthesis in fractures are performed using intramedullary telescopic transphyseal constructions [37,46,51,53,54].

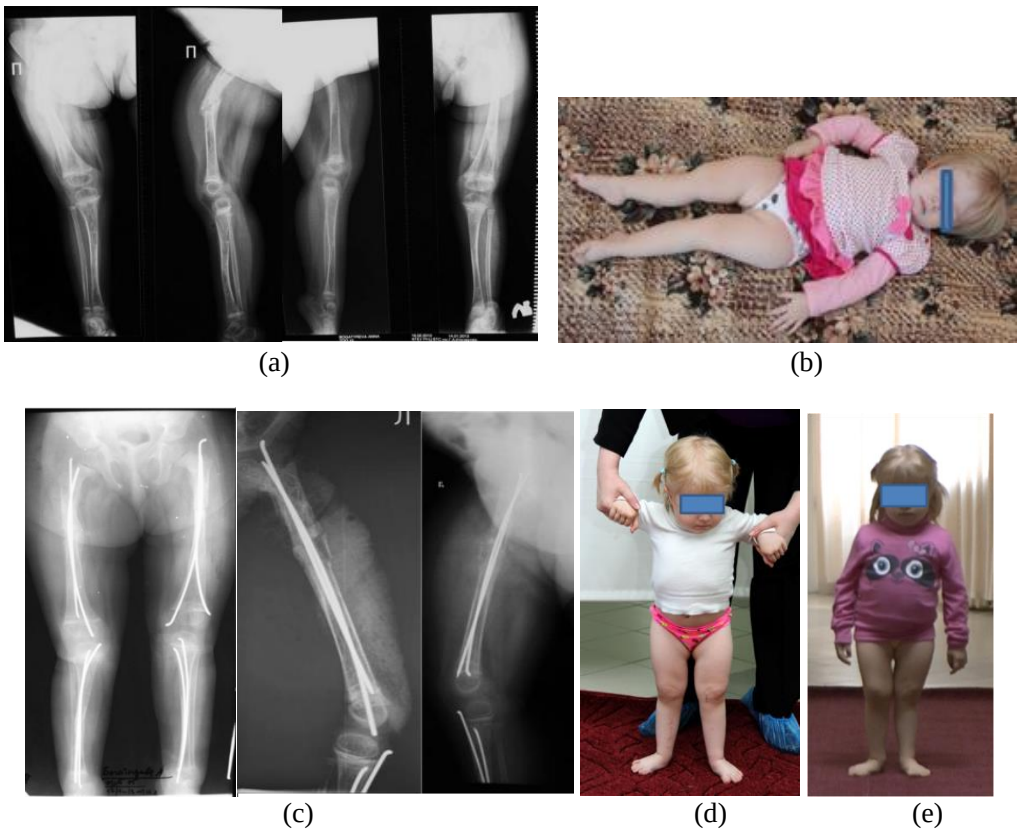

Figure 4. Application example of intramedullary transphyseal flexible osteosynthesis in a two-year-old female patient: X-rays of right and left lower limbs before treatment (a), photo of the patient (b); before surgery the child could not walk and stand. AP X-rays of limbs, lateral X-rays of femurs after insertion of flexible nails (c), the child began to stand with weight bearing on limbs in 3 months (d) and to walk independently in 5 months (e).

Among the basic intramedullary telescopic constructions there are

1. Flexible intramedullary nailing (FIN) [38,44];
2. Telescopic Bailey-Dubow nail [35-37];
3. Telescopic Fassier-Duval nail [41,48,54].

But the use of those telescopic systems is not devoid of complications [43,55].

We have developed and use transphyseal osteosynthesis with HA-coated bioactive intramedullary nails. Specific features of the coating providing osteoconductive and osteoinductive characteristics [48,50] are described in the previous chapter.

The procedure (Figure 4) starts with insertion of elastic, pre-curved along the entire length, mostly titanium nails of 1.5 to 4 mm diameter. The nails are smoothly contoured that produces two opposing curves. They are inserted towards each other from the opposite epiphyses or apophyses transphyseally. An important aspect of the passage through the physis

is use of a trocar or a surgical awl and performance of this maneuver at a single-attempt in order to avoid excessive trauma of the growth zone.

The nails can be advanced through the medullary canal to the opposite epiphysis without prior reaming. If the canal is very narrow or absent at all, the reaming of these parts of the bone is performed through the same approaches as osteotomies. Very often realignment osteotomies require one or several incisions to advance the wire under visual control.

FIN is the most effective method of osteosynthesis in deformity correction of the upper limbs. Indications for the surgical treatment are more frequent in forearm deformities, impairing use of the upper extremity in daily routine [40,53]. It is the small diameter of forearm bones that implies application of intramedullary nails of the 1.5-3 mm diameter for osteosynthesis of bone fragments after corrective osteotomies (Figure 5).

(a) (b)

Figure 5. Example of forearm deformity correction: X-rays of the forearm before surgery (a), after deformity correction and intramedullary flexible nailing (b).

Strong and Weak Points of This Method of Osteosynthesis

HA-coated FIN definitely preserves all advantages of the intramedullary elastic osteosynthesis with titanium or steel nails [38,44]. This method of osteosynthesis can be used almost in all bone dimensions.

Besides, if the marrow cavity is obliterated, preliminary reaming of fragments, even moderate, allows to insert elastic nails of a small diameter. This method of osteosynthesis permits to stabilize bone fragments in multilevel osteotomies. Elasticity of osteosynthesis provides distribution of the weight bearing along the entire medullar canal which is favorable for bone consolidation and does not impair strength properties of cortical plates. Intramedullary telescopic constructions prevent secondary fractures, even if they occur, bone fragments remain stable without significant displacement. Also, telescopic character of FIN scaffolds the bone while it is growing; stabilizing features of intramedullary nails are preserved if they overlap each other by 30% of their proper length and more. Besides, the HA-coating dramatically decreases nail migration in the long-term follow-up.

Results of assessment of how hydroxyapatite coating influences on preservation of mineral density in the operated segment are presented below.

A disadvantage of the technique is exclusion and then restriction within several weeks of the total weight bearing on the operated limb. Such a motion behavior causes decrease of the bone mineral density. In the long-term follow-up it is necessary to change nails while the bone growing in length and in diameter.

Combined Technique

In the Ilizarov Center we use combined osteosynthesis (external fixation and flexible intramedullary nailing) for severe multilevel deformities [48].

The technique is supposed for correction of deformities of lower limbs in children affected with osteogenesis imperfecta. It is based on a combined application of the transosseous osteosynthesis with the Ilizarov device and intramedullary osteosynthesis with bioactive HA-coated nails which provide prophylactics of deformity relapse. Application of the Ilizarov fixator allows to start weight-bearing on the operated limb from first post-operative days and to prevent secondary torsion deformities.

Technical Performance in Limb Deformities

Taking into consideration that lower limb deformities involve, as a rule, both the femur and tibia, polysegmental osteosynthesis of the limb is recommended, i.e., both segments should be operated simultaneously. Surgical procedure can be monofocal or bifocal in each segment depending on extensivity and amount of the deformity (Figure 6).

The surgery begins with insertion of intramedullary titanium nails with bioactive coating. In order to perform it, an oblique tunnel is made through a cortical layer into medullary cavity via a cutaneous incision of 8-10 mm long on lateral and medial surfaces of the metaphysis by means of a 4-5 mm diameter awl. An HA-coated nail is inserted through the tunnel. The nail diameter (2-3.5 mm) depends on the diameter of the intramedullary canal. In this pathology the marrow canal is often irregular or even absent at some locations, thus, insertion of nails is challenging for a surgeon and requires specific instruments.

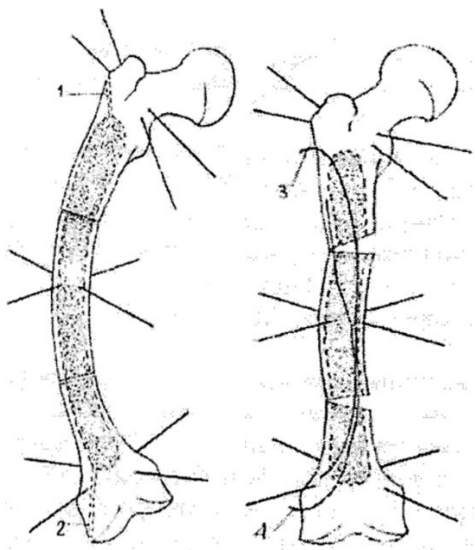

(a) (b)

Figure 6. Bone segment scheme of application of intramedullary nails in the combines technique: the segment before deformity correction (a), 1 and 2 - canals for intramedullary nail insertion; the segment after deformity correction and intramedullary nail insertion (b), 3 and 4 - inserted intramedullary nails into the medullary cavity.

A special device (Figure 7) can be used to guide and ensure a necessary direction for insertion of the nail according to the shape of medullary canal and bone deformity. It is also important, if the medullary cavity is absent (eburnation) or of a small diameter and needed to be drilled with a wire.

A flexible curved nail is inserted in the medullary cavity via guide. If the medullary cavity is patent, the nail is usually easy to introduce manually up to the opposite metaphysis. When the guide is taken out, a free nail end is cut and bent. A U-shaped bend should prevent nail migration into the medullary cavity during distraction, and, at the same time, make it possible to grip the tip with a special instrument for removal in several months after limb lengthening.

If there are small thin bone trabeculae crossing the medullary cavity and the surgeon does not intend to traumatize the canal by drilling, a special pusher (Figure 8) is used.

A severe bone deformity associated with osteoporosis usually renders impossible to insert the nail by the full length of the medullary canal at one time (as the nail easily perforates the bone cortex), so at the level of deformity apex (if angulation is up to 20°) a corrective hinge osteotomy should be performed. Then, having performed an acute axial alignment of the limb, the nail is introduced in the proximal bone fragment. If the deformity exceeds 20°, the intramedullary nailing is technically feasible only after closing wedge osteotomy at the deformity apex and its acute correction.

When the nails are inserted, then the soft tissues are sutured and transosseous osteosynthesis of a shorten limb segment is performed with Ilizarov fixator assembled according to the goals of the surgeon. A clinical case illustrating this surgical technique is presented below.

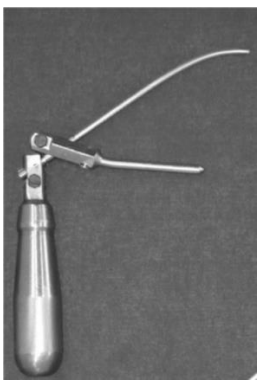

(a)

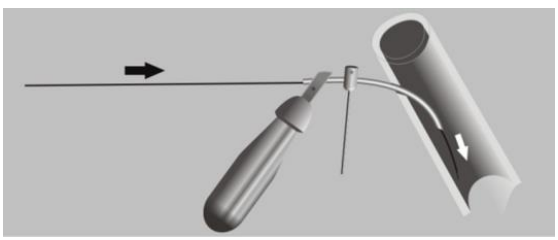

(b)

Figure 7. Tubular guide for intramedullary nails: photo (a), scheme of positioning in bone (b), the nail in the canal.

(a)

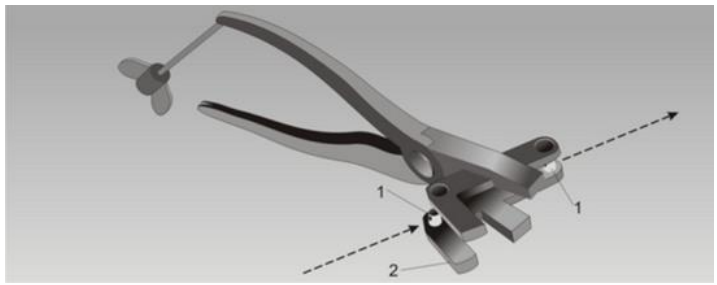

(b)

Figure 8. Special pusher for longitudinal nail insertion: photo (a), scheme (b), 1 - guides, 2 - hammer spot.

A Clinical Case

A female patient K., 6 years old. Diagnosis: osteogenesis imperfecta, combined deformities of lower limbs and contractures of hip and knee joints (Figure 9a,b). In anamnesis: multiple close fractures of lower limb bones treated conservatively.

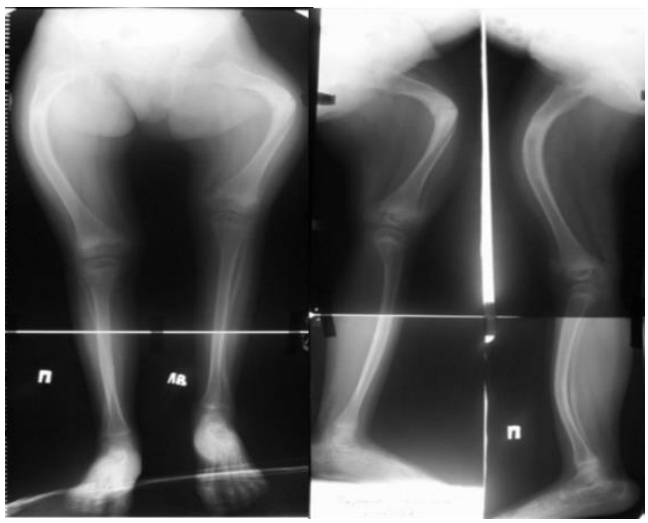

(a)

(b)

Figure 9. (Continued).

(c) (d)

(e)

Figure 9. Female patient K., 6 years old, osteogenesis imperfecta: X-rays of lower limbs before treatment (a), photo before treatment (b), photo during deformity correction with Ilizarov device (c), X-rays of lower limbs after treatment (d), photo and functional abilities of lower limbs in one year after treatment (e).

The patient underwent a consecutive deformity correction of lower limbs and flexible intramedullary nailing with HA-coating (Figure 9c,d). Rehabilitation took an average recovery time, control of long-term follow-up revealed complete functional recovery of the limbs and no deformity relapse in 18 months after treatment (Figure 9e).

Bone Mineral Density Study Results

In twenty patients of the age range from 4 to 27, who underwent polysegmental combined osteosynthesis with the Ilizarov frame and HA-coated flexible intramedullary nailing, bone mineral density was assessed (dual-photon bone densitometer “GE Lunar Corp”, USA) at the metaphyseal level of operated segments. Also measurements were taken at L2, L3, L4 levels. Assessments were done in 30 and 60 days after surgery, in 6 and 12 months after removal of the Ilizarov device.

The aim of study was to evaluate dynamics of bone mineral density of operated segments and lumbar vertebrae in conditions of an early activation of patients in postoperative period and using bioactive implants. It is worth of mentioning, that during the study period the patients were not administrated bisphosphonates.

Before surgery the bone mineral density value was 53.6% ($p<0.001$) of the value of healthy people in a proximal femoral metaphysis, where nail insertion was planned (Table 1). By the 30th postoperative day the bone mineral density increased by 9.6% ($p<0.05$) of the initial one. By the time of Ilizarov frame removal (60 days) it reached 19.5% ($p<0.001$). In 6 and 12 months the bone mineral density value always remained higher then initial.

Such a bone mineral density dynamics is noted in a distal femoral metaphysis (Table 2), a proximal tibial metaphysis (Table 3).

Table 1. Mineral density in a proximal femoral metaphysis (*M*±*SD*)

Period	Mineral density, g/cm^2	
	Metaphysis	Cortices
Normal value	1.570±0.108	1.680±0.101
Before surgery	0.841±0.059	1.277±0.102
After surgery		
D 30	0.922±0.054*	1.433±0.086*
D 60	1.005±0.080*	1.519±0.106*
After frame removal		
6 months	1.051±0.079*	1.289±0.104*
12 months	1.062±0.069*	1.340±0.094*

Note: * significant difference ($p<0.05$, Student's t-test) in comparison to the initial value.

Total amount of mineral substance in L2, L3, L4 vertebrae (Table 4) in patients before treatment was in average by 20% less than in healthy people. By the 30th postoperative day there was a tendency to bone mineral density increase, in average by 3.8% ($p<0.05$). In 60 days after surgery the increase reached 12.1% and became statistically significant in comparison to the preoperative bone mineral density level ($p<0.05$). Ilizarov frame removal did not influence on mineral substance content in the spine. During the following year of follow-up its amount did not change.

Table 2. Mineral density in a distal femoral metaphysis (*M*±*SD*)

Period	Mineral density, g/cm^2	
	Metaphysis	Cortices
Normal value	1.410±0.098	1.546±0.106
Before surgery	0.635±0.051	0.983±0.079
After surgery		
D 30	0.710± 0.046*	1.079±0.086*
D 60	0.786± 0.044*	1.167±0.070*
After frame removal		
6 months	0.785±0.058*	1.168±0.064*
12 months	0.797±0.048*	1.174±0.094*

Note: * significant difference ($p<0.05$, Student's t-test) in comparison to the initial value.

Table 3. Mineral density in a proximal tibial metaphysis (*M*±*SD*)

Period	Mineral density, g/cm^2	
	Metaphysis	Cortices
Normal value	1.571±0.094	1.736±0,127
Before surgery	0.705±0.049	1.043±0,073
After surgery		
D 30	0.854±0.068*	1.172±0.082*
D 60	0.874±0.070*	1.211±0.073*
After frame removal		
6 months	0.885±0.071*	1.218±0.085*
12 months	0.890±0.053*	1.215±0.079*

Note: * significant difference ($p<0.05$, Student's t-test) in comparison to the initial value.

Table 4. Amount of mineral substances in L2, L3, L4 vertebrae (*M* ± *SD*)

Period	Amount of mineral substances; g
Normal value	59.10 ± 4.10
Before surgery	47.30 ± 2.84
After surgery	
D 30	49.10 ± 2.71
D 60	53.0 ± 2.82*
After frame removal	
6 months	54.60 ± 2.64*
12 months	54.80 ± 3.12*

Note: * significant difference ($p<0.05$, Student's t-test) in comparison to the initial value.

CONCLUSION

Thus, we can remark, that combined techniques of osteosynthesis with application of bioactive implants used in patients with osteogenesis imperfecta for limb deformity correction enable to achieve a secure orthopedic outcome: correction of both angular and torsion deformities in femur and tibia simultaneously. Duration of external fixation does not exceed 1.5-2 months. Combined osteosynthesis used at the beginning of treatment in deformity correction becomes the intramedullary one after removal of the external fixator and prevents deformity relapse.

Combined osteosynthesis allowing to weight-bearing on the operated limb and mobilization of patients from first postoperative days allows to preserve and even to increase bone mineral density. First, this effect results from an early verticalization of patients and correspondingly an early weight-bearing on operated limbs. The second important element is HA-coated intramedullary nailing. Hypothetically, applying it, we can suggest an effect of decreasing or even excluding of mobilization of skeleton calcium repository (of intact and operated bones). The third factor is biointegration of implants [48,50]. It provides an increased stability of osteosynthesis of bone fragments, which advances bone consolidation and frame removal. All together these factors promote motion activity of a patient, necessary for preserving skeletal mineral density.

REFERENCES

[1] Ripamonti U, Crooks J, Khoali L, Roden L (2009) The induction of bone formation by coral-derived calcium carbonate/hydroxyapatite constructs *Biomaterials.* 30(7):1428–1439.

[2] Rivera EM, Araiza M, Brostow W et al (1999) Synthesis of hydroxyapatite from eggshells. *Matter Lett*. 41:128-134.

[3] Bonfield W, Wang. M, Tanner KE (1998) Interfaces in analogue biomaterials. *Acta Mater*. 46(7):2509–2518.

[4] Wang J, Layrolle P, Stigter M, de Groot K (2004) Biomimetic and electrolytic calcium phosphate coatings on titanium alloy: physicochemical characteristics and cell attachment. *Biomaterials.* 25:583–592.

[5] Wang Y, Khor KA, Cheang P (1998) Thermal Spraying of Functionally Graded Calcium Phosphate Coatings for Biomedical Implants. *J. Therm. Spray Technol*. 3:50–57.

[6] Kokubo T, Kushitani H, Sakka S et al (1990) Solutions able to reproduce in vivo surface-structure changes in bioactive glass-ceramic A-W. *J. Biomed. Mater Res.* 24:721–734.

[7] Kokubo T, Takadama H (2006) How useful is SBF in predicting in vivo bone bioactivity? *Biomaterials.* 27:2907–2915.

[8] Juhasz JA, Best SM, Bonfield W, Kawashita M, Miyata N, Kokubo T, Nakamura T (2003) Apatite-forming ability of glass-ceramic apatite-wollastonite - polyethylene composites: effect of filler content. *J. Mater Sci. Mater Med*. 14(6):489-495.

[9] Juhasz JA, Best SM, Brooks R, Kawashita M, Miyata N, Kokubo T, Nakamura T, Bonfield W (2004) Mechanical properties of glass-ceramic A-W-polyethylene composites: effect of filler content and particle size. *Biomaterials.* 25(6):949-955.

[10] Verheyen CC, de Wijn JR, van Blitterswijk CA, de Groot K (1992) Evaluation of hydroxylapatite/poly (L-lactide) composites: mechanical behavior. *J. Biomed. Mater Res*. 26(10):1277-1296.

[11] Shikinami Y, Matsusue Y, Nakamura T (2005) The complete process of bioresorption and bone replacement using devices made of forged composites of raw hydroxyapatite particles/poly l-lactide (F-u-HA/PLLA). *Biomaterials.* 26:5542-5551.

[12] Shikinami Y, Okuno M (1999) Bioresorbable devices made of forged composites of hydroxyapatite (HA) particles and poly-L-lactide (PLLA): Part I. Basic Characteristics. *Biomaterials.* 20(9):859-877.

[13] Furukawa T, Matsusue Y, Yasunaga T, Nakagawa Y, Shikinami Y, Okuno M, Nakamura T (2000) Bone bonding ability of a new biodegradable composite for internal fixation of bone fractures. *Clin. Orthop. Relat. Res.* 379:247-258.

[14] Furukawa T, Matsusue Y, Yasunaga T, Shikinami Y, Okuno M, Nakamura T (2000) Biodegradation behavior of ultra-high-strength hydroxyapatite/poly (L-lactide) composite rods for internal fixation of bone fractures. *Biomaterials.* 21(9):889-898.

[15] Langer R, Vacanti JP (1993) Tissue engineering. *Science.* 260:920–926.

[16] Spector M (1999) *Basis Principles of Tissue Engineering in Tissue Engineering Application in Maxillofacial Surgery and Periodontics*. Ed. S. Lynch; Quintessence Publishing Co. Inc: pp3–17.

[17] Yannas IV, Hansbrough J, Ehrlich N (1984) What criteria should be used for designing artificial skin replacements and how well do the current grafting materials meet these criteria? *J. Trauma*. 24:29.

[18] Reddi AH, Weintroub S, Muthukumaran N (1987) Biological principles of bone induction. *Orthop Clin N Amer*. 18:207–212.

[19] Reddi AH (1998) Role of morphogenetic proteins in skeletal tissue engineering and regeneration. *Nat. Biotechnol*. 16(3) :247–252.

[20] Caton J (1994) *Comment établir un plan d'égalisation? Eléments du choix. In: Les inégalités de longueur des membres*: sous la direction de A. Diméglio et al; Paris–Milan–Barcelone: MASSON. pp174–176.

[21] Glorion Ch (2000) Complications des allongements des membres. *Cahiers d'enseignement de la SOFCOT*; Elsevier. pp165–182.

[22] Launay F, Jouve JL, Guillaume E et al (2001) Les allongementsprogressifs de l'avant-bras chez l'enfant. A propos d'une série de 14 cas. *Rev. Chir. Orthop*. 87:786–795.

[23] Popkov D, Popkov A, Haumont T, Journeau P, Lascombes P (2010) Flexible intramedullary nail use in limb lengthening. *J. Pediatr Orthop.* 30:910-918.

[24] Popkov D, Journeau P, Popkov A, Haumont T, Lascombes P (2010) Ollier's disease limb lenghtening: Should intramedullary nailing be combined with circular external fixation? *Orthop. Traumatol. Surg. Res*. 96:348-353.

[25] Popkov D, Lascombes P, Popkov A, Journeau P, Haumont T (2012) Role of the flexible intramedullary nailing in limb lengthening in children: comparative study based on the series of 295 lengthenins. *European Orthopaedics Traumatology*. 3:17-24.

[26] Guseev VV, Tretiakova EM, Ivanova LR (2000) Ceramic materials reinforced with phosphate binders [in russian]. *Glass and ceramics.* 3:36–38.

[27] Guseeva TI, Guseev VV, Leonova LA (2009) Preparation of hydroxyapatite powder in the liquid-phase synthesis [in russian]. *News of Tomsk polytechnic university*. 315(3):47-50.

[28] Talashova IA, Silantieva TA (2007) The laboratory excretion of calcium phosphate compounds from the bone tissue of cattle and the determination of their composition by the method of electrone-probe microanalysis [in russian]. *Genij ortopedii*. 4:71–75.

[29] Popkov AV, Osipenko AV (2008) *Tissue regeneration in limb lengthening* [in russian]. Moscow, GEOTAR-Media. 239p.

[30] Le Nihouannen D, Daculsi G, Saffarzadeh A et al (2005) Ectopic bone formation by microporous calcium phosphate ceramic particles in sheep muscles. *Bone.* 36:1086–1093.

[31] Caplan AI, Boyan BD (1994) Endochondral Bone Formation: The Lineage Cascade. *Bone.* 8(1):1–46.

[32] Thomsen P, Gretzer C (2001) Macrophage interactions with modified material surfaces. *Curr. Opin Solid State a Mater Sci*. 5(2–3):163–176.

[33] Refai AK, Textor M, Brunette DM, Waterfield JD (2004) Effect of titanium surface topography on macrophage activation and secretion of proinflamatory cytokines and chemokines. *J. Biomed. Mater Res. A.* 70:194–205.

[34] Popkov A, Popkov D (2012) Bioactif Implants in Traumatology and Orthopaedics [in russian]. Irkutsk, Russia: NSRS SO RAMN, 438p.

[35] Bailey Cole WG (1993) Early surgical management of severe forms of osteogenesis imperfecta. *Am. J. Med. Genet*. 45:270–274.

[36] Bailey RW, Dubow HI (1981) Evolution of the concept of an extensible wire accomodating to normal longitudinal bone growth: clinical considerations and implications. *Clin. Orthop*. 159:157–170.

[37] Bilsel N, Beyzadeoglu T, Kafadar A (2000) Application of Bailey–Dubow rods in the treatment of Osteogenesis Imperfecta. *Eur. J. Orthop. Surg. Traumatol*. 10:183–187.

[38] Boutaud B, Laville JM (2004) L'embrochage centromédullaire coulissant dans l'ostéogenèse imparfaite. *Rev. Chir. Orthop*. 90:304–311.
[39] Cole WG. Early surgical management of severe forms of osteogenesis imperfect (1993) *Am. J. Med. Genet*. 45:270–274.
[40] Esposito P, Plotkin H (2008) Surgical treatment of osteogenesis imperfecta: current concepts. *Curr. Opin. Pediatr*. 20:52–57.
[41] Fassier F, Glorieux F (1999) Osteogeneis imperfecta in the child. *Cahiers d'enseignement de la SOFCOT*. Paris:Expansion Scientifique Française. pp235–252.
[42] Glorieux FH. Osteogenesis imperfecta (2008) *Best Pract. Res. Clin. Rheumatol.* 22:85–100.
[43] Larson T, Brighton B, Esposito P et al (2010) High reoperation rate and failed expansion in lower extremity expandable rods in osteogenesis imperfecta. In: *Proceedings of the Annual Meeting of the Pediatric Orthopaedic Society of North America (POSNA)*, Waikoloa, Hawaii.
[44] Lascombes P (2010) *Flexible intramedullary nailing*. Springer-Verlag Berlin Heidelberg.
[45] McHale KA, Tenuata TJ, Tosi LL, McKay DW (1994) Percutaneous intramedullary fixation of long bone deformity in severe osteogenesis imperfecta. *Clin. Orthop*. 305:242–248.
[46] Popkov DA, Kononovich NA, Shutov RB (2014) The effect of tibial transphyseal reinforcement on the growth and leg tissues. *Russian Journal of Physiology*. 100(7):81-90.
[47] Popkov D, Lascombes P, Berte N, Hetzel L, Ribeiro Baptista B, Popkov A, Journeau P (2014) The normal radiological anteroposterior alignment of the lower limb in children. *Skeletal Radiol*. DOI: 10.1007/s00256-014-1953-z.
[48] Popkov A, Popkov D (2012) *Bioactif Implants in Traumatology and Orthopaedics* [in russian]. Irkutsk, Russia: NSRS SO RAMN.
[49] Rauch F, Glorieux FH (2004) Osteogenesis imperfecta. *Lancet.* 363:1377–1385.
[50] Ripamonti U (2000) Smart biomaterials with intrinsic osteoinductivity: geometric control of bone differentiation. *Bone Engineering*; Ed. J.M. Davies. Toronto: Em Squared Inc.
[51] Ruck J, Dahan-Oliel N, Montpetit K, Rauch F, Fassier F (2011) Fassier-Duval femoral rodding in children with osteogenesis imperfecta receiving bisphosphonates: functional outcomes at one year. *J. Child Orthop*. 5(3):217-224.
[52] Stockley I, Bell M, Sharrard WJ (1989) The role of expanding intramedullary rods in osteogenesis imperfecta. *J. Bone Joint Surg.* 71B:422–427.
[53] Sułko J, Radło W (2005) Operative management of long-bone of the upper limb in children with osteogenesis imperfecta. *Chir. Narzadow Ruchu Ortop. Pol*. 70:195–199.
[54] Zeitlin L, Fassier F, Glorieux FH (2003) Modern approach to children with osteogeneis imperfecta. *J. Pediatr Orthop*. 12B:77–87.
[55] Zionts LE, Ebramzadeh E, Stoot NS (1998) Complications in the use of the Bailey-Dubow extensible wire. *Clin. Orthop*. 18:102–109.

In: Encyclopedia of Surgery (22 Volume Set)
Editors: Andreas Lehrer and Kristin Mueller
ISBN: 978-1-53618-329-0
© 2020 Nova Science Publishers, Inc.

Chapter 6

USE OF INTRAMEDULLARY BIOACTIVE NAILING IN DEFORMITY CORRECTION IN PATIENTS WITH X-LINKED HEREDITARY HYPOPHOSPHATEMIC RICKETS

Arnold Popkov*, PhD, MD
Scientific and Clinical Laboratory for Deformity Correction and Limb Lengthening. Federal Russian State-Financed Ilizarov Scientific Center for Restorative Traumatology and Orthopaedics, Kurgan, Russia

ABSTRACT

Introduction. X-linked hereditary hypophosphatemic rickets (XHPR) is the most common form of the hypophosphatemic rickets caused by renal phosphate wasting. The operative procedures to correct multiplanar bone deformities may be indicated for prevention of secondary orthopedic complications.

The aim of this retrospective study was comparison of results of correction in short and long term follow-up in children with XHPR who underwent the treatment with either the Ilizarov device alone or a combined technique consisting of the Ilizarov fixator and FIN.

Material and methods. We retrospectively analyzed 47 cases of surgical treatment in children affected by XHPR. Simultaneous deformity correction in femur and tibia was performed with the Ilizarov device (group I) or the combined method (group II).

Results. A monofocal bisegmental transosseous osteosynthesis was performed in group I on 24 limbs, a polyfocal bisegmental transosseous osteosynthesis was performed in 20 cases. In group II the monofocal polysegmental transosseous osteosynthesis was performed in 30 extremities, the polyfocal bisegmental – in 20 limbs.

The duration of external fixation was noted to be considerably shorter applying the combined technique: 124.7±14.9 days (group I) vs 87.4±13.2 days (group II).

In both groups deformity correction was achieved with a proper alignment and normal orientation of the knee joint. Nevertheless, while a child keep on growing in long

* Corresponding Author's Email: apopkov.46@mail.ru.

term follow-up, deviations of the mechanic axis from the center of the knee joint have been developing again and values of mLDFA, mMPTA have become pathologic in the most of cases. In group I location of a newly developed deformity resembled to a preoperative one, i.e., both, diaphyseal and metaphyseal parts were deformed. It is worth of mentioning that in group II in all the cases an apex of deformity (CORA) was located in distal metadiaphyseal zone of the femur and proximal metadiaphyseal zone of the tibia. It is important that all of them in group II were out of zone of the intramedullary nail tracks, in other words it is possible to prevent deformity recurrence with FIN.

Conclusion. The deformities of lower limbs in children with XLHR should be operatively corrected. Application of a combined osteosynthesis allows to considerably reduce the duration of external fixation, decrease the number of infectious complications, avoid secondary displacement of fragments. There were no recurrent deformities in parts of bone reinforced by intramedullary nails.

Keywords: X-linked hereditary hypophosphatemic rickets, combined surgical technique

INTRODUCTION

X-linked hereditary hypophosphatemic rickets (XHPR) is the most common form of the hypophosphatemic rickets caused by renal phosphate wasting, impaired renal production of 1.25-dihydroxyvitamin D3 and abnormal bone mineralization [1,2,3]. Clinical orthopedic features become obvious since the beginning of ambulating and are manifested by varus or valgus deformities of the lower limb, torsion deformities, impaired gait, short stature, pathologic fractures [2,4,5,6]. The conservative treatment is not always successful. In such cases, operative procedures for correction multiplanar bone deformities may be indicated to prevent secondary orthopedic complications like pain, pathologic fractures, degenerative arthropathy; or for cosmetic reasons [7-9].

Patients with deformities have been treated by various methods of corrective osteotomy and fixation devices, such as Kirschner wires, plates, temporary epiphysiodesis, Ilizarov devices and intramedullary nailing devices [8,9-12]. Different problems related to surgical correction were reported, among them increased rate of non-union after osteotomies, delayed union, recurrent deformity, deep intramedullary infection, refracture, nerve palsy and pin tract infection [13-15].

In our opinion, the Ilizarov method remains the most efficient technique from the point of view of multi-planar and multi-apical deformity correction. Application of a circular external device is crucial for orthopedic surgeons in particular [8,11,12]. A combination of external fixation and intramedullary rigid osteosynthesis allows to reduce the period of external fixation [13]. Nevertheless, in pediatric practice such combination is not applicable; on the other hand, the deformity correction should be performed in childhood in order to prevent development of early arthrosis.

Results of deformity correction were compared in two groups of patients differentiated by use of the external fixator alone (group 1) and application of the combined technique (external fixator and intramedullary nails with bioactive coating, group 2). Criteria of comparison were efficiency of the procedure, duration of external fixation and occurred complications.

MATERIALS AND METHODS

We retrospectively analyzed 47 medical charts of children affected with XHPR and hospitalized for correction of developed deformities of the lower limb. Criteria of inclusion were: deformities of two segments (femur and tibia) on both limbs, age under 18 years old, simultaneous deformity correction in femur and tibia on one limb with the Ilizarov device (group I) or the combined method (the Ilizarov device and intramedullary nailing – group II).

Diagnostics of all the patients was based on the typical laboratory finding of hypophosphatemia, elevated alkaline phosphatase activity in combination with presence of limb deformities, low stature and beginning of deformity development in average at 2-year-old age.

All the children received adequate oral phosphate and calcitriol therapy. In all the cases drug-resistant deformities were detected, which induced the lower limb deformities requiring operative correction [9].

Criteria of assessment were as follows:

- mechanical axis deviation (MAD), mechanical lateral distal femoral angle (mLDFA), mechanical medial proximal tibial angle (mMPTA), angulations at a level of femoral and tibial diaphysis [15,16], torsions;
- type of operation, number and levels of osteotomies, immediate or gradual character of corrections;
- duration of the external osteosynthesis;
- complications, their outcome;
- classification of results according to Lascombes [17] was used in 10-12 months after treatment.

Weight bearing full-length anteroposterior radiographs of the entire lower extremities were taken in a standing position with the patella centered forward, and lateral radiographs of each segment with adjacent joints were obtained. Radiologic indices (MAD, mMPTA, mLDFA) were measured preoperatively, after frame removal and in 10-12 months after treatment.

Surgical correction procedures were planned according to the patient's clinical assessment and radiographic data. Principles of deformity correction with the Ilizarov fixator considering CORA and ACA were strictly respected in all cases [12,16]. Taking into consideration systemic involvement of limbs, i.e., there were no intact limb for reference in planning of the correction gain, the average statistic radiologic values normal for the age were used [15].

The first surgical step was standard in both groups: it consisted of application of the external fixator, followed by percutaneous osteotomies. Frame assembly (rings and half-rings), position of olive wires and hinge elements were dictated by anatomic location and severity of the deformities in both groups. If the deformity was located at only one level of the bone segment, one single osteotomy was performed through a 10–15 mm longitudinal incision centered over the metaphyseal, metadiaphyseal or diaphyseal region. If the deformities were more severe, the double percutaneous osteotomies were done. In tibia the osteotomy of the fibula was performed in the lower third or between the middle-lower thirds

of the shaft. In all the cases the operation was performed on both segments of the lower limb simultaneously under one general anesthesia.

In group II the second step was FIN with chitosan-hydroxyapatite (HA)-coated titanium nails. In cases of monofocal correction two entry holes at metaphysis level were created with an awl in an oblique direction toward the osteotomy, at some distance from the growth plate. We recommend to select the closest metaphysis to the osteotomy in order to facilitate insertion of the intramedullary nails and proper orientation after intraoperative correction. The 1.8–2 mm nails were contoured to achieve a curvature of about 50–60°. Nails must be carefully advanced one at a time following the natural bow of the diaphysis, pushed across the osteotomy site and directed to the opposite metaphysis. After the nails have been inserted, they were reoriented so, that their concavities were oriented toward the convexity of the deformity. Once the nails were in place, the deformities were immediately corrected - totally or partially depending on the angulation. Generally, the acute total correction was used in deformities inferior to 30°. Obviously, a proper FIN construct facilitated realignment and prevented undesirable displacement of bone fragments. The free ends of nails were bent outside the bone to prevent migration during realignment. Then, they were trimmed, leaving approximately 5–10 mm from the bone surface. The skin was closed in one layer.

In cases of bifocal correction of a complex deformity, bipolar combined FIN was more appropriate. The intramedullary nails were inserted towards each other from opposite metaphyses. This principal of FIN positioning was used in diseases associated with extreme bone fragility or in bifocal limb lengthening [18,19]. Insertion and orientation of intramedullary nails were performed according to the above mentioned steps.

Finally, the additional wires/half-pins were inserted with the FIN construct in place: in the proximal and distal rings (short arches) and/or some middle-ring wires in bifocal correction.

Corrections of angular and rotational deformities were performed either in the acute or the gradual setting, depending on the severity of the deformity. Deformities of 30° and more were corrected partially at once, residual deformities – gradually. In case of gradual correction the lengthening of 1-2 cm was gained. Gradual correction can be initiated on the 5th postoperative day. In all cases we strived to eliminate the present deformities and to prevent under- or overcorrection, which is known to be fraud with relapse of deformations [7,10]. Once the external fixator has been removed, regenerates remained protected by at least one intramedullary nail in group II. In all the patients of group II the intramedullary nails stayed in their place for the whole follow-up period. By the end of operative treatment all the patients continued receiving oral phosphate and calcitriol therapy.

RESULTS

The mean age of patients in group I was 10.7±2.4 years, in the group II - 8.9±2.1 years. In both groups varus limb deformity was more frequent: 40 limbs in the first group and 46 – in the second. Valgus deformity was faced only in 4 patients, 2 in each group.

Considering the location of deformities, the monofocal bisegmental transosseous osteosynthesis (one osteotomy of femur and one of tibia) was performed in group 1 on 24 limbs, a polyfocal (double osteotomy of at least one of the segments) bisegmental

transosseous osteosynthesis was performed in 20 cases. In group 2 the monofocal polysegmental transosseous osteosynthesis was performed on 30 extremities, polyfocal bisegmental – in 20 limbs (Figures 1 and 2).

Duration of the external fixation period with the traditional Ilizarov technique vs HA-coated titanium nails is presented in Table 1. It is obvious that the duration of external fixation in group 2 was considerably shorter, which can be explained by stimulation of bone formation by means of bioactive implans in the osteotomy site [26-28].

(a) (b)

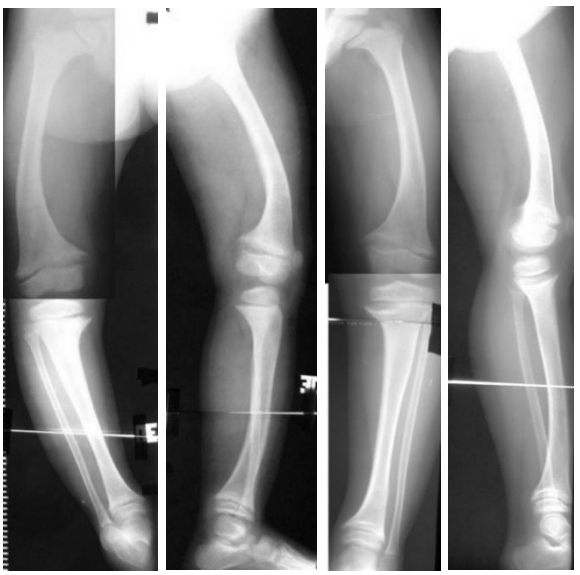

(c) (d) (e) (f)

Figure 1. (Continued).

(g)

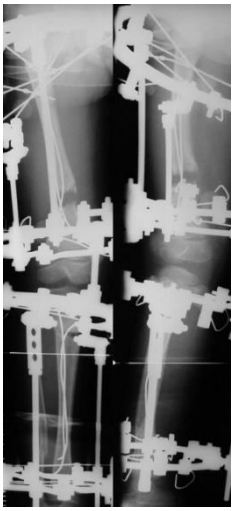

(h)

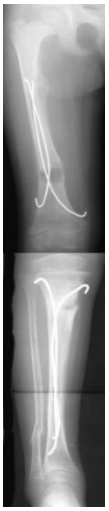

(i)

(j)

(k)

(l)



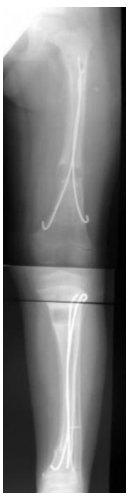

(m) (n) (o)

Figure 1. (Continued).

(p) (q) (r)

Figure 1. A 5-year-old girl with hypophosphatemic rickets. Before surgery: clinical appearance (a, b); AP and lateral X-rays, right side (c, d), left side (e, f). Ilizarov fixator in place for multisegmental correction of the right lower limb : clinical appearance (g), X-rays (h). Note the orientation of intramedullary nails to counter varus forces. View of the right lower limb 2 weeks after removal of the external fixator: biomechanical axis of the lower extremity was restored (i). Clinical appearance 1 year after removal of the external fixator (right side) and before surgery of the left lower limb (j, k). Surgical treatment of the left lower limb ; intraoperative X-ray immediately after insertion of intramedullary nails (l), AP and lateral X-rays: combined multisegmental external fixation/flexible intramedullary nailing (FIN). The biomechanical axis of the lower extremity was restored (m, n). X-ray of the left lower limb 10 days after removal of the external fixator (o). Patient 1 year after removal of the external fixator (left side) (p). Fixation period for the left side was 48 days. X-rays of the right lower limb 1 year after removal of the external fixator. Axial alignment still satisfactory (q, r). *NB! This figure has been originally published in Flexible Intramedullary Nailing in Children. 2010, pp 291-299 Use of FIN for Correction of Deformities in Children with Familial Hypophosphatemic Rickets Author: Dimitri Popkov © Springer-Verlag Berlin Heidelberg 2010 Material Requested: Fig.23.1 p. 292 With kind permission of Springer Science+Business Media.*

Table 1. Duration of the external fixation (days)

	Group I	Group II
Varus deformity of lower limb	124.7±14.9	87.4±13.2*
Valgus deformity of lower limb	137.8±13.6	111.3±7.4*

*Significant difference (P<0.05, Student t test) in comparison with the group I.

Table 2 presents values of MAD, mLDFA, mMPTA before treatment, after frame removal, by the beginning of weight-bearing and in a year follow-up.

In both groups deformity correction was achieved with a proper alignment and normal orientation of the knee space according to mechanic axes of segments. The results of correction remained preserved during the first year after treatment.

Table 2. Values of MAD, mLDFA, mMPTA

		Before treatment			At the beginning of full weight bearing after frame removal			In 10-12 months after frame removal		
		MAD	mLDFA	mMPTA	MAD	mLDFA	mMPTA	MAD	mLDFA	mMPTA
Group 1	Initial varus deformity of limb	40.8± 9.95	100.5± 3.8	77.7±3.5	0.9± 4.0	88.2±1.6	89.3±1.7	11.5± 5.3	92.5± 11.3	88.1±7.3
	Initial valgus deformity of limb	39.8± 4.1	68.5± 2.6	103.3± 3.5	5.1± 0.96	89± 1.8	92±1.6	6.7±3.1	8.9±7.5	91.3±5.3
Group 2	Initial varus deformity of limb	40.2± 9.2	100.4± 3.9	77.1±3.8	0.7±3.9	88.6±1.6	89.3±2.1	4.9±8.2	90.1±6.1	89.1±7.9
	Initial valgus deformity of limb	42.5± 4.9	67.3± 1.7	106.3± 3.1	3.3±1.3	88.3±0.5	89.8± 0.96	5.6±2.9	87.3±7.5	89.6± 10.2

The following complications were observed in group I: pin track infection in 24 cases (in 4 cases it required changing of wires under general anesthesia); transient sciatic or peroneal nerve palsy - 6 cases; displacement of bone fragments in postoperative period requiring adjustment of the Ilizarov fixator under general anesthesia – 8 cases; in 2 cases a plastic deformity at a level of correction occurred during the first week after frame removal, it required redressment of the deformity under general anesthesia and immobilization in a new plaster cast. In group II pin track infection was noted in 16 cases (in two cases wires were removed and reinserted); 7 cases of sciatic or peroneal nerve palsy with complete regression; in two cases intramedullary nails were insufficiently cut off and their free ends irritated soft tissues.

(a)

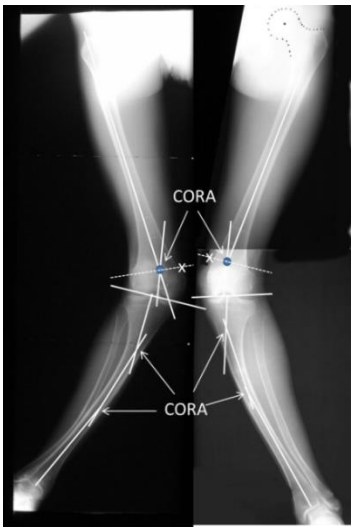

(b)

(c)

Figure 2. (Continued).

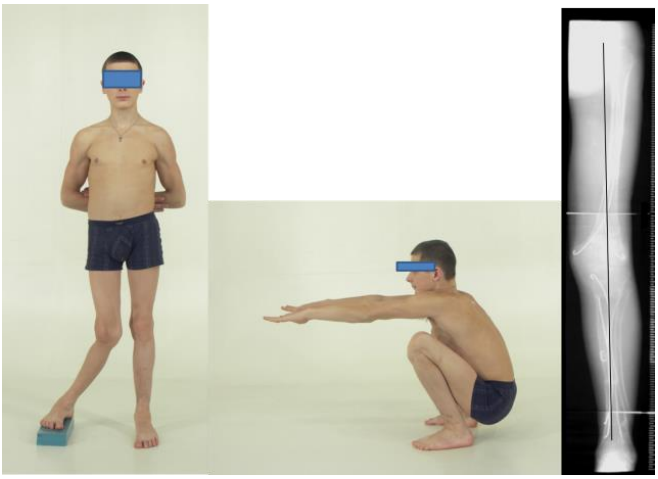

(d)

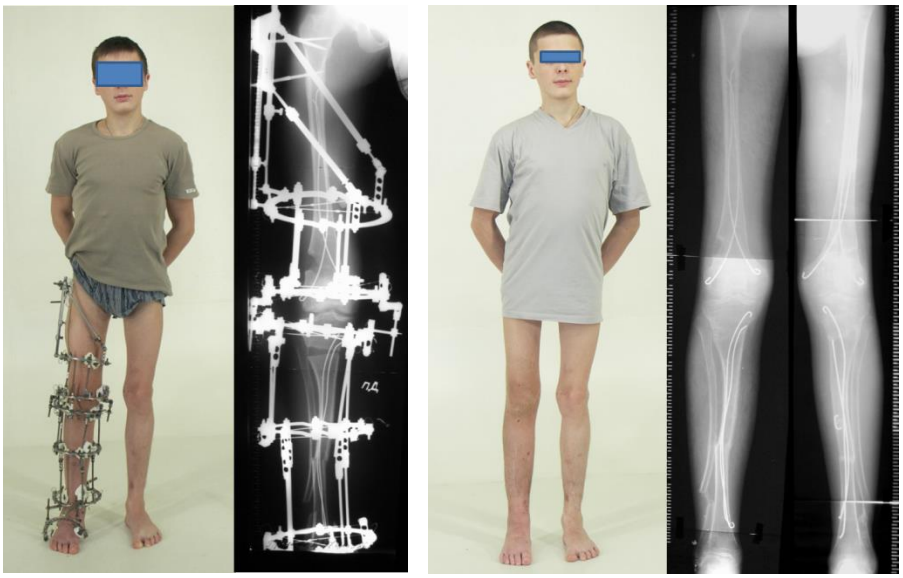

(e) (f)

Figure 2. A 17-year-old boy with hypophosphatemic rickets. Before surgery: clinical appearance (a); AP X-rays, illustration of preoperative planning, defining CORA and ACA (axis of correction of angulation, marked X) (b); Ilizarov fixator in place for multisegmental correction of the left lower limb: clinical appearance and, X-rays, duration of external fixation 91 days (c); clinical appearance et X-rays 1 year after removal of the external fixator (left side) and before surgery of the right lower limb (d); Ilizarov fixator in place for multisegmental correction of the right lower limb: clinical appearance and, X-rays, duration of external fixation 97 days (e); clinical appearance and X-rays 1 month after frame removal (f).

Thus, the results in group I were classified according to Lascombes [18] as follows: category I in deformity correction – 30 extremities, IIa – 12 limbs, IIb – 2 limbs. In group II : I – 46 limbs, IIa – 4 limbs. It is worth of mentioning that complications with sequelae (III, IV categories) were not observed in any patient of both groups.

DISCUSSION

Orthopedic complications of the X-linked hereditary hypophosphatemic rickets - severe deformities of lower limbs – develop in young age, so indications for operative treatment appear rather early [2,5,20]. Series of studies were published describing performed surgical treatment even when a patient's resistance to conservative treatment was stated [5,8,10]. Studies revealed that excess of fibroblast growth factor 23 action results in hypophosphatemic disease because it suppresses the expression of sodium-phosphate cotransporters in the proximal tubules of kidneys, which mediate physiological phosphate reabsorption [21-23]. Imel et al [3] discovered a significant increasing of circulating FGF23 concentrations while phosphate and calcitriol therapy, which can be a cause of resistance of patients with X-linked hereditary hypophosphatemic rickets to conservative treatment.

The developed deformities of lower limbs should be surgically corrected in order to maintain normal biomechanic conditions for ambulating, for cosmetic reasons and to prevent early severe arthrosis of hip and knee joints [12,13,23].

Various methods are used for fixation of bone fragments after performed osteotomies as plaster cast, K-wires, bone plates, external fixators, intramedullary nails [4,5,7,9,10,12]. It goes without saying that application of intramedullary locked nails in pediatric orthopedics is restricted.

Circular devices of external fixation with parallel or hexapodal position of connecting rods [8,11,13] provide the best conditions from the point of view of accuracy of deformity correction, abilities of gradual controlled correction of all deformity components in a postoperative period at a level of femur and tibia simultaneously, absence of interference in growth cartilages, absence of inhibition of the following segment growth in length.

In our study in both groups of patients the required correction was achieved simultaneously in femur and in tibia using the Ilizarov fixator and principles of Ilizarov method. Difference between the groups was in duration of fixation, number and severity of complications.

A general problem of external fixation remains a long period of fixation: from 4 months or 146 days in average [8,11] to 6 months [7]. There is a possibility to reduce considerably the duration of external fixation reported by Kocaoglu et al [5]. The external device was removed either after acute correction and introducing the intramedullary nail or by the end of distraction period. That approach allowed to reduce the duration of external fixation considerably, to prevent recurrent deformities and to preserve the accuracy of correction peculiar to application of circular fixators [12,13,15]. But the application of locked intramedullary nails is inadvisable in children and it requires another approach.

Considering advantages of FIN [18,19,24], we applied this type of osteosynthesis with elastic intramedullary nails coated with a bioactive layer in children affected by XHPR, who underwent acute correction on femur and tibia. It allowed to decrease the mean duration of external fixation to 87.4 days in deformity correction in varus limb axis and to 111.3 days in valgus limb axis (in average by 37 and 26 days correspondingly).

A prolonged period of external fixation can be associated with a high risk of complications. Petje et al [8] reported about one episode minimum of infectious complication around wires or half-pins in every patient while deformity correction with an external fixator. Song et al [13] noted in 20 patients 18 major complications (recurrent deformity, fracture

after frame removal, peroneal nerve palsy) and 13 minor complications. In the series of Fucentese et al [7] development of contractures of the knee joint and infection were observed.

In our study the FIN application allowed to decrease infectious complications and to avoid any secondary displacement of bone fragments during gradual correction, fractures and deformities at the level of correcting osteotomies after removal of external fixators. No complications concerning migration of intramedullary nails with bioactive coating were also noted.

In general, a high rate of deformity relapse is observed during the long term follow-up after operative correction in children with this pathology. Song et al [13] observed complications (recurrent deformity or fracture at a level of correction) in 10 patients out of 21, Rubinovitch et al [4] reported relapse of deformity in 27% of cases. Petje et al [8] observed up to 90% of recurrent deformities after primary correction and up to 60% after secondary surgeries, besides the rate of relapses reduced after the age of 14 years old. There is no data yet of development or relapse of the deformity of lower limbs in long term follow up (5-7 years) after surgical correction of deformities in children with XHPR and after the end of natural growth. It requires a longer period of follow up.

CONCLUSION

Nevertheless, advantages of combined osteosynthesis (circular external fixator and FIN with bioactive coating) can be already stated as shorter duration of external fixation, decrease of infectious complications and absence of secondary displacement of fragments during correction or deformities at the osteotomy level after frame removal.

REFERENCES

[1] Albright F, Butler AM, Bloomberg E (1937) Rickets resistant to vitamin D therapy. *Am. J. Dis. Child*. 54:529-547.

[2] Cho HY, Lee BH, Knag JH, Ha IS, Cheong HI, Choi Y (2005) A clinical and molecular genetic study of hypophosphatemic rickets in children. *Pediatr Res*. 58:329–333.

[3] Imel EA, DiMeglio LA, Hui SL, Carpenter TO, Econs MJ (2010) Treatement of X-linked hypophosphatemia with calcitriol and phosphate increases circulating fibroblast growth factor 23 concentrations. *J. Clin. Endocrinol. Metab.* 95(4):1846-1859.

[4] Rubinovitch M, Said SE, Glorieux FH, Cruess RL, Rogala E (1988) Principles and results of corrective lower limb osteotomies for patients with vitamin D-resistant hypophosphatemic rickets. *Clin. Orthop Relat.* Res. 237:264–270.

[5] Kocaoglu M, Bilen FE, Sen C, Eralp L, Balci HI (2011) Combined technique for the correction of lower-limb deformities resulting from metabolic bone disease. *J. Bone Joint Surg. Br*. 93(1):52-56.

[6] Zivičnjak M, Schnabel D, Billing H, Staude H, Filler G, Querfeld U, Schumacher M, Pyper A, Schröder C, Brämswig J, Haffner D (2011) Hypophosphatemic Rickets Study Group of the "Arbeitsgemeinschaft für Pädiatrische Endokrinologie" and "Gesellschaft

für Pädiatrische Nephrologie". *Pediatr Nephrol*. Age-related stature and linear body segments in children with X-linked hypophosphatemic rickets. 26(2):223-231.

[7] Fucentese SF, Neuhaus TJ, Ramseier LE, Ulrich Exner G (2008) Metabolic and orthopedic management of X-linked vitamin D-resistant hypophosphatemic rickets. *J. Child Orthop*. 2:285-291.

[8] Petje G, Meizer R, Radler C, Aigner N, Grill F (2008) Deformity correction in children with hereditary hypophosphatemic rickets. *Clin. Orthop. Relat. Res*. 466:3078-3085.

[9] Evans GA, Arulanantham K, Gage JR (1980) Primary hypophosphatemic rickets: effect of oral phosphate and vitamin D on growth and surgical treatment. *J. Bone Joint Surg. Am*. 62:1130–1138.

[10] Eyres KS, Brown J, Douglas DL (1993) Osteotomy and intramedullary nailing for the correction of progressive deformity in vitamin D-resistant hypophosphataemic rickets. *J. R. Coll. Surg. Edinb*.38:50–54.

[11] Matsubara H, Tsuchiya H, Kabata T, Sakurakichi K, Watanabe K, Tomita K (2008) Deformity correction for vitamin D-resistant hypophosphatemic rickets of adults. *Arch. Orthop. Trauma Surg.* 128(10):1137-1143.

[12] Choi IH, Kim JK, Chung CY, Cho TJ, Lee SH, Suh SW, Whang KS, Park HW, Song KS (2002) Deformity correction of knee and leg lengthening by Ilizarov method in hypophosphatemic rickets: outcomes and significance of serum phosphate level. *J. Pediatr Orthop*. 22(5):626-631.

[13] Song HR, Soma Raju VV, Kumar S, Lee SH, Suh SW, Kim JR, Hong JS. Deformity correction by external fixation and/or intramedullary nailing in hypophosphatemic rickets (2006) *Acta Orthop*. 77(2):307-314.

[14] Ferris B, Walker C, Jackson A, Kirwan E (1991) The orthopaedic management of hypophosphataemic rickets. *J. Pediatr Orthop.* 11(3):367–373.

[15] Popkov D, Lascombes P, Berte N, Hetzel L, Ribeiro Baptista B, Popkov A, Journeau P (2015) The normal radiological anteroposterior alignment of lower limb in children. *Skeletal Radiol*. 44(2):197-206.

[16] Paley D, Herzenberg JE, Tetsworth K, McKie J, Bhave A (1994) Deformity planing for frontal and sagittal plan corrective osteotomies. *Orthop. Clin. North Am*. 25:425–465.

[17] Lascombes P, Popkov D, Huber H, Haumont T, Journeau P (2012) Classification of complications after progressive long bone lengthening: proposal for a new classification. *Orthop. Traumatol. Surg. Res.* 98(6):629-637.

[18] Popkov D, Popkov A, Haumont T, Journeau P, Lascombes P (2010). Flexible intramedullary nail use in limb lengthening. *J. Pediatr Orthop.* 30:910-18.

[19] Lascombes P. Flexible Intramedullary Nailing in Children: *The Nancy University Manual* (2010) Springer.

[20] Petersen DJ, Boniface AM, Schranck FW, Rupich RC, Whyte MP (1992) X-linked hypophosphatemic rickets: a study (with literature review) of linear growth response to calcitriol and phosphate therapy. *J. Bone Miner Res*. 7(6):583–597.

[21] Ozono K. Bone and joint diseases in children (2010) Phosphaturic hormone, FGF23 and bone metabolism. *Clin Calcium*. 20(6):896-903.

[22] Shimada T, Yamazaki Y,Takahashi M, Hasegawa H et al (2005) Vitamin D receptor-independent FGF23 actions in regulating phosphate and vitamin D metabolism. *Am. J. Physiol. Renal Physol*. 289(5):1088-1095.

[23] Larson AN, Trousdale RT, Pagnano MW, Hanssen AD, Lewallen DG, Sanchez-Sotelo J (2010) Hip and knee arthroplasty in hypophosphatemic rickets. *J. Arthroplasty*. 25(7):1099-1103.

[24] Popkov D, Journeau P, Popkov A, Haumont T, Lascombes P (2010) Ollier's disease limb lenghtening: Should intramedullary nailing be combined with circular external fixation? *Orthop. Traumatol. Surg. Res.* 96:348—353.

[25] Chatelet JC, Setiey L (2004) Comportement osseux à long terme après implantation d'un pivot fémoral totalement revêtu d'hydroxyapatite. *Rev Chir. Orthop Reparatrice Appar Mot*. 90(7):628-635.

[26] Popkov D (2010) Use of FIN for correction of deformities in children with familial hypophosphatemic rickets. In : Lascombes P. *Flexible Intramedullary Nailing in Children*. Springer. pp291-299.

[27] Harrell RM, Lyles KW, Harrelson JM, Friedman NE, Drezner MK (1985) Healing of bone disease in X-linked hypophosphatemic rickets/osteomalacia: induction and maintenance with phosphorus and calcitriol. *J. Clin. Invest*. 75:1858–1868.

In: Encyclopedia of Surgery (22 Volume Set)
Editors: Andreas Lehrer and Kristin Mueller
ISBN: 978-1-53618-329-0
© 2020 Nova Science Publishers, Inc.

Chapter 7

HYBRID TECHNOLOGIES IN SPINAL DEFORMITY SURGERY

Sergey Ryabykh*, PhD, MD
Clinical Laboratory of Axial Skeleton Pathology and Neurosurgery,
Federal Russian State-Financed Ilizarov Scientific Center for Restorative Traumatology and Orthopaedics, Kurgan, Russia

ABSTRACT

Chapter V is a review of contemporary techniques of osteosynthesis of the spine. Advantages and disadvantages of modern internal systems of spinal correction and fixation are assessed, variants of combination of external and internal osteosynthesis of the spine are presented. There will be demonstrated variants, methodology and advantages of state-to-art methods of external spinal fixation and combined approaches associating merits of the external fixation and Cotrel-Dubousset systems. Abilities and advantages of the technique are analyzed and clinical observations with analysis of efficiency of correction are presented.

Keywords: combined technique, spine surgery

INTRODUCTION

Spinal deformity is one of the most frequent and leading syndrome of complex vertebrogenic pathology, congenital anomalies of vertebrae and ribs, systemic and neuromuscular diseases, posttraumatic modifications, idiopathic scoliosis and often their combination. The most important features of spinal deformity are the rate of progression and amount of deformity. These same features influence on cosmetic and functional outcome and, as a result, on quality and length of life.

* Corresponding Author's Email: rso_@mail.ru.

Surgical treatment of patients with a spinal deformity is supposed to solve the following problems: to stop deformity progression, to perform its maximum possible correction and to provide conditions for preserving the result. Despite of various manifestations of the disease, patients with spinal deformities are united by one common group of problems, they are variability of neurologic deficit, body balance disorder, persistent progression, functional degradation of cardiopulmonary system, unsatisfactory appearance and low quality of patients' life [2, 7, 8, 9]. Surgical treatment of patients with deformities over 100° is characterized by a high intraoperative risk and a high rate of complications in the postoperative period [2, 9, 10, 11].

All the methods used for spinal deformity correction can be subdivided in 2 groups: basic techniques, i.e., standard techniques of acute correction using widely spread implants; hybrid approach, i.e., combination of mobilizing methods (variants of traction and methods of vertebrotomy) with methods of distraction, derotation and reclination (in kyphosis) by means of external and internal fixation devices.

This chapter deals with indications and techniques of external fixation in children and adults, their combination with methods of spine mobilization in severe deformities and internal instrumental fixation. In severe forms of idiopathic scoliosis in children it is conventional to use tactics of preliminary traction for spine deformity correction, cranio- or halo-pelvic traction or traction with external fixation systems. Application of methods of preoperative halo-traction allows manipulating the major deformity arch indirectly by means of the most mobile spine regions, that considerably reduces this influence [3, 11]. Systems of external transpedicular fixation remain applicable, they possess mechanical advantage from the point of view of application of corrective efforts to major deformity arch while gradual correction, preserving patient's mobility and monitoring of neurologic and somatic status of the patient [1, 4, 5, 6, 10].

Despite many unsolved problems for the moment, we have tried to disclose the author's view on tactical issues of surgical treatment, such as possibility to perform simultaneously a neurosurgical and vertebrologic stages, a type of fixation, its extension, indications and techniques of combining of instrumentation methods, indications and application possibilities for corrective and shortening vertebrotomies. Also, the treatment outcome and complications are analyzed.

METHODS OF EXTERNAL FIXATION

Halo-Pelvic System

One of the most expanded types of spinal external fixation is halo-pelvic traction. The method is widely used for correction of severe spinal deformities of any etiology, including atypical (cervical and cervical-thoracic) locations. In our practice, we use this technique independently. The technique is applied as a variant of traction during the first stage of surgical correction, it is also combined with methods of mobilization of the major arch. The second stage is transpedicular fixation of the spine. Besides, this technique is used as a variant of a "lifeboat" in pressure sores at the apex of kyphosis of any etiology. The variant of

extrafocal fixation allows to create a reserve of soft tissues for wound healing by means of stabilization and distraction efforts [3].

Figure 1. Patient's image after deformity correction by Ilizarov halo-pelvic system.

The halo-pelvic device is assembled of Ilizarov set components (Figure 1) or the module halo-pelvic apparatus is applied (Patent RF utility model N 124137 dtd 20.01.2013) (Figure 2).

Figure 2. Halo-pelvic apparatus of the module type.

The device is applied to the patient lying in the supine position under general anesthesia with. Primary distraction for construction tension is performed on the operating table. Then starting from the 2nd day of the postoperative period the distraction along the axial rods is administrated at the rate of 0.5 cm per day within 7-21 days. Dressing with monitoring of wounds is performed in two days. The time of traction is determined empirically according to rigidity of the deformity and degree of the device tension. The traction longer than 3 weeks is not recommended because of the risk of infection complications. During the distraction period the patients can take care of themselves independently, clinical control of neurologic and somatic complications is extremely important. If the latter ones occurred, the distraction efforts are reduced by 1-2 cm following by dorsal transpedicular fixation.

Device for the External Transpedicular Fixation

This type of external fixation is used in spinal deformities over 100° of thoracic and lumbar location, as well as in inflammatory processes of soft tissues of the back on the background of unstable lesions of vertebrae [5, 6]. It is not used independently, it is applied as a traction technique to prepare to dorsal instrumental fixation.

The surgery is performed under narcosis with the patient in the prone position. The frame assembling depends on the amount and 3D orientation of deformity arches. Threaded rods are inserted by pairs into the vertebra arch pedicles through the micro incisions up to 0.5 cm. They form support units (Figure 3a). Every unit contains 3-4 segments depending on anatomical features of the patient's spine. If fixation of the pelvis is required, two pairs of threaded rods are inserted in the wings of iliac bones bilaterally.

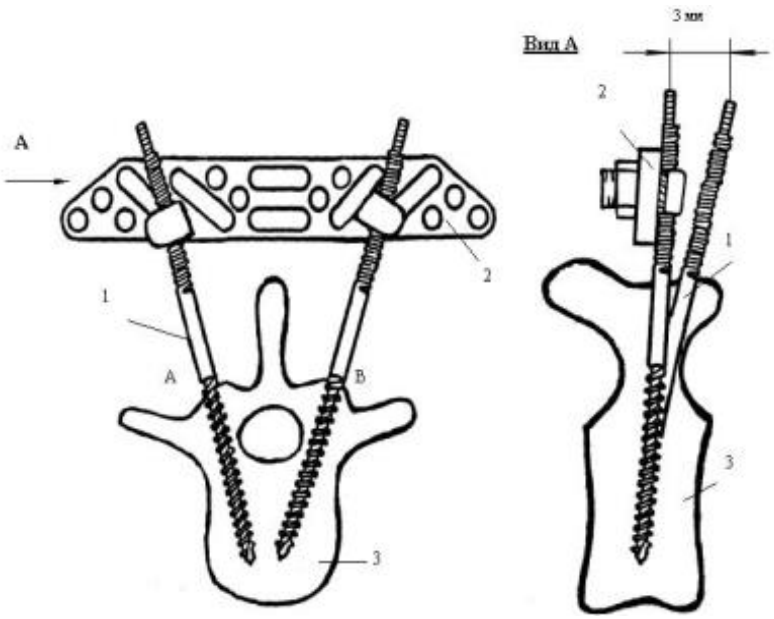

Figure 3. Assembling stages of the device for external fixation in severe idiopathic scoliosis (Lenke 3C+): insertion scheme of Schantz screws (a), connection of support units (b).

Then units are connected with longitudinal rods. Partial acute correction of the spinal deformity is performed on the operating table followed by antiseptic dressing (Figure 3b). Maximum possible correction of the spine is achieved during the postoperative period with monitoring of the neurologic status and X-ray control.

Dressings are changed every 3rd day. By the end of 10-14 days of correction in the frame at the rate of 0.5 cm/day the final open transpedicular instrumental correction and fixation of achieved spinal deformity correction is performed simultaneously with formation of posterior spondilodesis. This technique provides good and satisfactory treatment results (correction over 70%) minimizing the risk of neurologic and somatic complications.

External Transpedicular – Pelvic Fixation

Combined technique is also used as a lifeboat technology in inflammatory processes of soft tissues at the deformity apex of the lumbar spine. The technique unites advantages of transpedicular spinal fixation with pelvic screw fixation and localizes mechanical efforts in the lumber department. Besides, the technique can be used as preparation for the major stage of correction.

Figure 4. External transpedicular-pelvic fixation as a method of extrafocal fixation for pressure sore healing at the apex of deformity in congenital kyphosis on the myelocele background in a 9-year-old female.

The surgery is performed from a dorsal approach. Administration of narcosis and assembling of units don't vary. A distinctive feature is assembling of a transversal rod between pelvic units and their connection by two longitudinal rods with a spinal unit. It allows to build a united trapeze of rigidity (Figure 4). Dressing mode and distraction rate are the same.

COMBINED METHODS

Combination of Halo-Pelvic and Posterior Instrumental Fixation

"Connector"- type systems are used in actively growing children. This method is favorable for patients with severe spinal deformity and high risk of somatic and neurologic complications [11]. The external fixation is aimed to control somatic and neurologic status.

Let us review this technique on the example of a patient with severe progressing cervical-thoracic scoliosis in systemic pathology, who has not received an adequate well-timed orthopedic care for a long period. By the age of 11 he was already affected by serious stato-dynamic and functional disorders, which impair his life quality and even threaten his life. Obviously, the very patient's existence was challenged without solving the orthopedic problem.

The male patient, 11 years old, was first seen for spinal deformity by a spinal surgeon in July 2011. The anamnesis revealed that the patient has been followed by an orthopedists since the age of one, when the deformities of limbs appeared. He was administrated a conventional treatment as massage of limbs and orthopedic shoes. The diagnosis of Ollier disease was verified by geneticist in 2001. The spinal deformity has been persisting for the last 2 years. Orthopaedic status showed disproportionate stature, evident cachexia with a weight of 18 kg, decompensated rigid extended right-side cervico-thoracic scoliosis with deviated torso to the right and head to the left up to 90° of Cobb's angle, gibbus on the right, hypertrophic muscles of the neck being more severe on the right, clinodactyly and hypertrophied phalanges of the fingers, and grade I funnel chest deformity (Figure 5a,b). The traction test proved apparent rigidity of the deformity. Minimal exercise (walk up to 20 m distance) caused growing respiratory insufficiency. The lower limbs muscle strength in neurologic status was reduced to 3 according to ASIA score. No sensory impairment and pelvic organ dysfunction were detected. The patient developed quick fatigue with episodes of hypoxia (falling asleep).

(a) (b) (c)

Figure 5. (Continued).

(d)

(e)

(f)

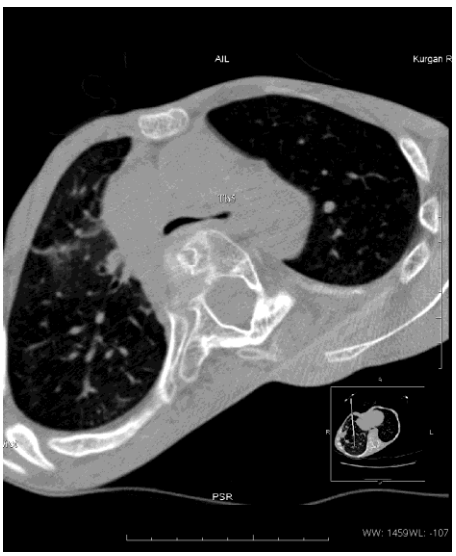

(g)

Figure 5. Image and data of X-ray investigation of the 11-year-old patient: photo of the patient in the intensive care unit: clinical torso deformation and cachexia (a), photo and X-ray of the left hand (b), X-ray of the spine (c), CT of the neck and thorax, Volume Reformation Tomography: severe rotation of cervical vertebrae (d), CT of the thorax, axial plane: signs of pneumofibrosis (e).

X-ray investigation displayed atypical spinal deformity with the apex of the major arch at the C_6-C_7 level, absence of vertebral-medullary conflict and fibrous modifications of pulmonary tissue (Figure 5c,d). Hospitalization to the Kurgan Ilizarov Center was recommended for additional assessment and considering possible surgical correction. Though, admission to the clinic was postponed because of viral respiratory infection. Emergency admission to the regional children's hospital was required on August 01, 2011 for a severe condition with complaints of spitting up blood, coughing, frequent episodes of sleep apnea up to 1 min long. Probably, the VRI caused complications of respiratory insufficiency on the background of severe restrictive lung affection. Mechanical lung ventilation, antibacterial and syndrome–based therapy were performed at the intensive care unit. The reduced mechanical ventilation parameters led to higher levels of hypercapnia.

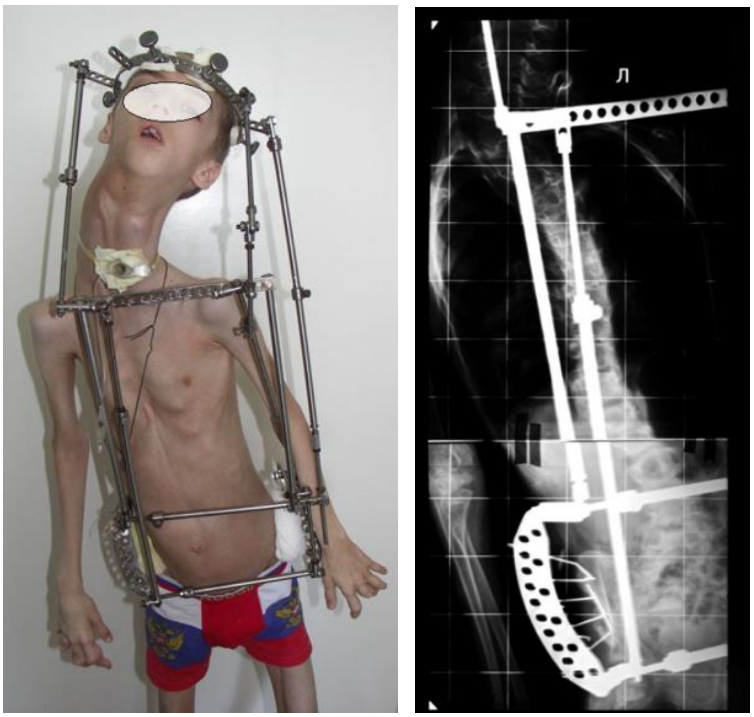

(a) (b)

Figure 6. Photo (a) and X-ray of the spine (b) of the 11-year-old patient after deformity correction with the halo-pelvic system using the Ilizarov set components.

The boy was examined by a team of spinal surgeons of the Kurgan Ilizarov Centre on August 05, 2011. Considering his severe syndrome of respiratory insufficiency on the background of significant decompensated scoliotic deformity, it was decided to correct the deformity by halo–pelvic device as the less invasive, simple and adequate method for stabilization of the patient's condition. External fixation device was applied for halo–pelvic traction on August 05, 2011. The frame was set up in the distraction mode of 6 cm to correct spinal deformity and create favorable conditions for lung excursion (Figure 6). The surgery lasted 35 minutes. The volume of blood loss was up to 20 ml. Saturation normalized within 24 postoperative hours. However, tracheostomy was performed due to progression of

respiratory failure on August 16, 2011. The patient's condition stabilized and he was transferred to autonomous breathing with *tracheostomy* in 2 days and transported to a somatic department in 7 days (on August 25, 2011).

The patient was referred from the regional children hospital to neurosurgery department of FSBI "Russian Ilizarov Scientific Centre "Restorative Traumatology and Orthopaedics" on September 27, 2011. The diagnosis on admission indicated the Ollier disease with multiple deformities of axial skeleton, severe combined scoliosis with underlying systemic pathology and disturbed cervical spine formation, progressing muscular dystrophy, pneumofibrosis of the right lung, myocardiodystrophy, grade 3 cachexia, tracheostomy, condition after frame application for halo-pelvic traction.

On admission to the Centre the patient was able to stand independently for 10 minutes and walk with a support for 6 minutes without respiratory imbalance, and he needed help with his meals and getting up. His torso balance improved in the coronal plane with persisted decompensation, but sagittal balance was compensated (Figure 6a). Deformity correction in the frame was observed at the level of major cervical-thoracic arch up to 32° (-31°), at the level of minor lumber arch - 10° (-2°) (Figure 6b). Spirometry revealed decrease of lung capacity to 43%.

Operative intervention performed on September 29, 2011 included correction and multi-support instrumentation fixation of C_2-Th_9 segments with combined connector-type system, posterior local spondylodesis, dismantling halo-pelvic traction system (Figure 4). Loss of blood volume was 200 ml (5% of the total blood volume).

Satisfactory functional and cosmetic effect was obtained (Figure 7). Functional result assessed in a month after the surgery showed increased vital capacity of 56% according to spirometry findings and improved respiratory function with pulmonary stress test. The patient could walk with a support during 30 minutes without respiratory imbalance, eat food and stand up by himself, with torso balance in the coronal and sagittal planes being compensated (Chapter 6, Figure 2a). The patient's weight was 21 kg (+3 kg). Checkup radiographs showed adequate screw position, spinal deformity correction achieved at the level of major cervicothoracic curve to 12° (-51°), at the level of accompanying lumbar arch to 10° (-2°) (Figure 7b). Therefore, the spinal correction was 81% and 17%, correspondingly. Neurologic assessment demonstrated positive dynamics in improving lower extremity muscular strength graded 4. The child was discharged on November 04, 2011 in 95 days after urgent hospitalization, and tracheostomy was removed on November 23, 2011.

This case demonstrates capacity of surgical orthopedic care, aimed to stabilize functional condition of the child and to improve his life quality. Absolute indications for the surgery were life threatening disorders caused by scoliosis. The halo-pelvic device was chosen because of its features as minimal surgical aggression, gradual distraction and neurologic control. Besides, we always consider this method as the method of choice for patients with severe deformities in life threatening conditions as demonstrated in the previous case. When somatic status is stabilized, the spinal departments are fixated with posterior internal multi-support system. This strategy is substantiated by severe functional disorders, related to major disease as well as to spinal deformity and high risk of neurologic and vital complications caused by its correction.

(a) (b) (c)

Figure 7. Photo (a) and radiographs (b, c) of the patient prior to discharge. Major arch of the deformity corrected to 12°.

Method of 4-staged correction are performed in two surgeries. The first surgery is anterior multilevel vertebrotomy, formation of interbody spondylodesis, closed osteosynthesis with external transpedicular fixator. The second surgery is Smith-Petersen osteotomy, correction and stabilization of the deformity with a transpedicular system forming posterior spondylodesis.

Aggressiveness of this technique determines the spectrum of its application – extremely severe spinal deformities of any etiology (scoliotic deformity with Cobb angle over 100°, Aaro-Dahlborn apical torsion over 60°, mobility of the major spinal deformity curve according to functional X-rays not exceeding 5% of the initial deformity) associated with progressing functional, neurologic and static-dynamic deficiency. Potentially, indications for the surgical treatment for those patients are vital, because of dramatic impairment of functions (especially the function of external respiration – FER). Surgical interference is based on the low-invasive principal for the segment being operated as well as for the organs involved in the surgical approach. That is why posterolateral thoracotomy and transpleural approach are not used in this group of patients. It can cause lungs collapse and turn severe FER deficiency into irreversible.

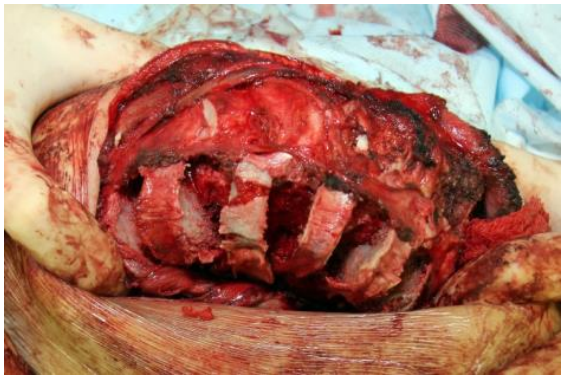

Figure 8. Apex of the major deformity arc after extensive anterior release.

The first stage is performing of an extensive anterior release at the level of 4-7 vertebrae-mobile segments of a concave side of the deformity apex, similar to anterior multilevel osteotomy at 270°. It differs from a standard technique of anterior release by an incision, which is performed parallel to the major arch along the posterior axillary line. It is convenient, as a severe torsion forms "vertebral" pleural sinus with no pulmonary tissue. After exposing posterior rib complex, 5-6 rib sectors are excised from midaxillary line with exarticulation of ribs, it provides effect of mobilization by decreasing rigidity of the thorax and a cosmetic effect at the same time. Then, extrapleural or transpleural approach to the vertebral bodies is performed. It is important to exclude a direct contact with lungs. Excision of intervertebral disks and epiphyseal plates is followed by a wedge adaptive resection of apical 4-7 vertebral bodies to correct their wedge shape. Anterior and posterior longitudinal ligaments are resected with visualization of the dural sac at 4-7 levels (Figure 8).

The second stage of the first surgical session is application of the external transpedicular fixator (Figure 9). In 10-14 days by the end of correction, a posterior extensive Smith-Petersen osteotomy at the deformity apex, application of transpedicular screws are performed followed by corrective maneuvers. The procedure is ended by formation of the posterior bone-plastic spondylodesis.

Combination of external fixation methods (halo-pelvic, external transpedicular fixation device) with variants of corrective vertebrotomy (spondylectomy through the root of vertebral arch or VCR), correction and posterior instrumental fixation of the spine, 360° bone graft spondylodesis.

Indications for this technique are deformities of a severe and extremely severe degree complicated with inflammation of soft tissues (Figure 9a,b).

The first stage is removal of implants from a dorsal approach, if necessary, wound debridement, stabilization with external fixation systems (halo-pelvic, external transpedicular fixation device, external transpedicular fixation – pelvic device) (Figures 9c, 10c) aimed to extra-focal correction stabilization of the deformity. Extra-focal external fixation provides favorable conditions for healing of soft tissues. The second stage is performed when the wound is healed. Its volume depends on the amount of deformity, its rigidity, neurologic deficiency. In our practice the second stage varied from the posterior instrumental correction and stabilization to VCR vertebrotomy (Figures 10 and 11).

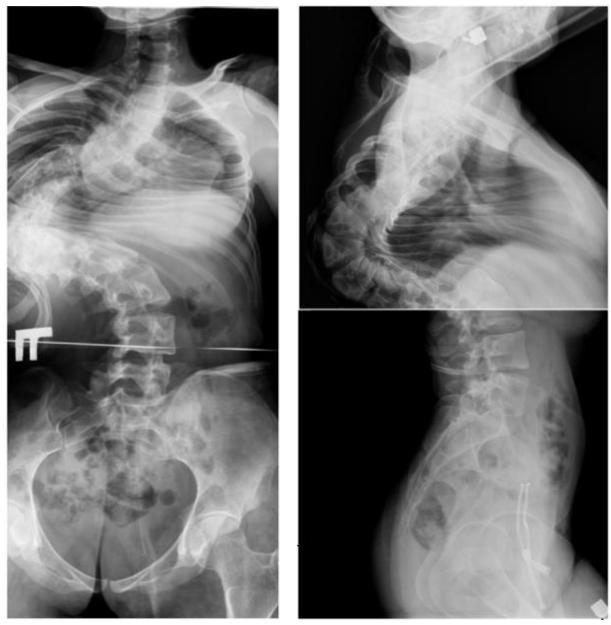

(a) (b)

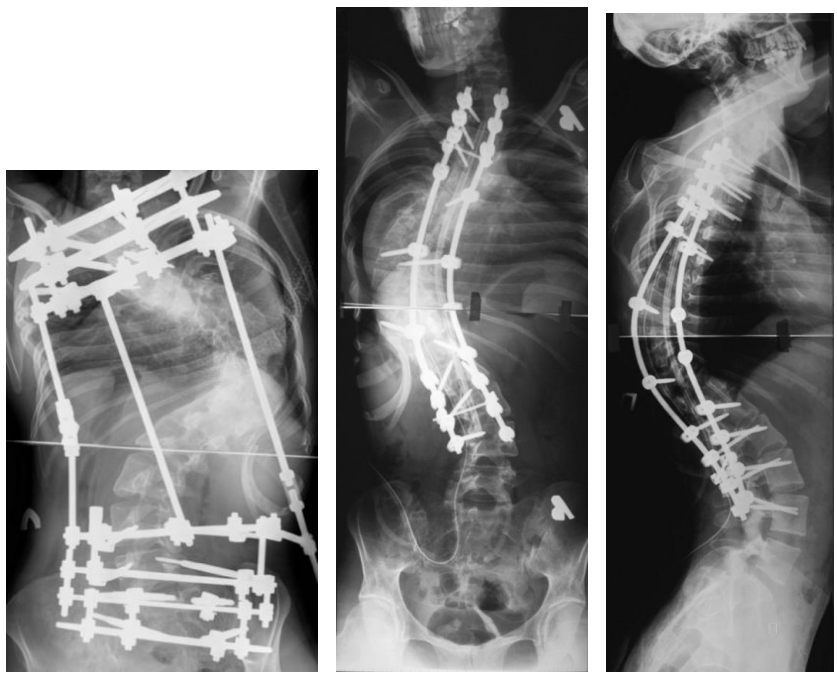

(c) (d) (e)

Figure 9. X-rays of a 14-year-old patient with typical idiopathic kyphoscoliosis of an extremely severe degree (Lenke 3C+): before treatment, scoliosis Cobb - 132°, kyphosis Cobb - 145° (a, b), in external fixator after anterior multilevel osteotomy (**c**), after removal of external transpedicular fixator, posterior extensive Smith-Petersen osteotomy at the $Th_{7\text{-}11}$ level, correction, posterior instrumental fixation and posterior spondylodesis: scoliosis Cobb - 64°, kyphosis Cobb - 82°. Correction rate is 52% and 45% correspondingly (d, e).

(a)

(b)

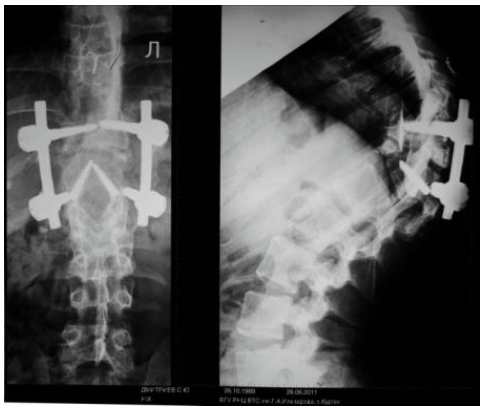

(c)

(d)

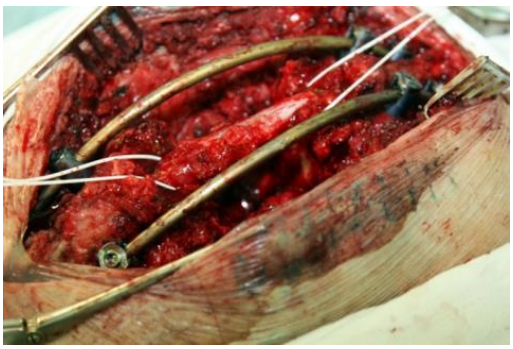

(e)

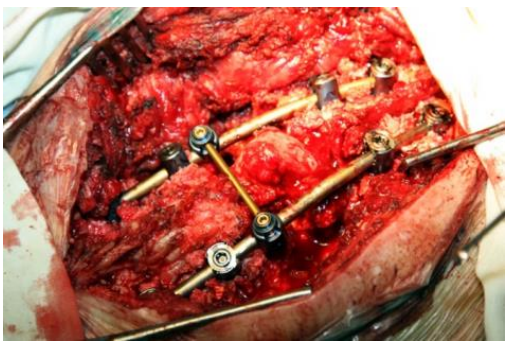

(f)

Figure 10. (Continued).

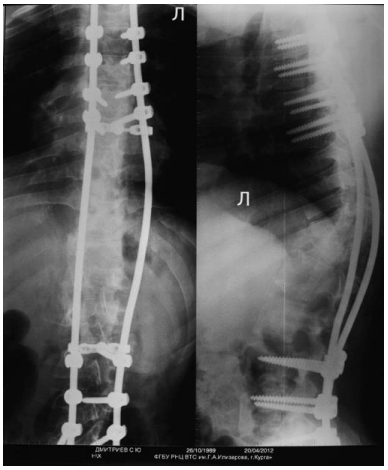

(g)

Figure 10. Photo and X-rays of a 22-year-old male patient. Spinal cord injury, late period. Sequelae of Th_{11} burst fracture-luxation with spinal cord compression. Lower spastic paraplegia. Disfunction of pelvic organs. Post-operative condition. Complications: Unstable construction. Infection of postoperative wound: patient's photo at admission (infected pressure sores in projection of screws) (a,b), X-rays at admission (**c**), Image of the patient after the 1st stage of treatment (removal of implants, wound debridement, stabilization in ExTrFix device (d), surgical steps of corrective shortening vertebrotomy with a block (e, f), X-rays after surgical treatment (g).

RESULTS

Spinal surgery using external fixation is "a surgery of complications" as it is aimed to cure complicated process of spinal column deformities. Basic indications for use of external fixation techniques are extremely severe spinal deformities (Table 1) and local wound process.

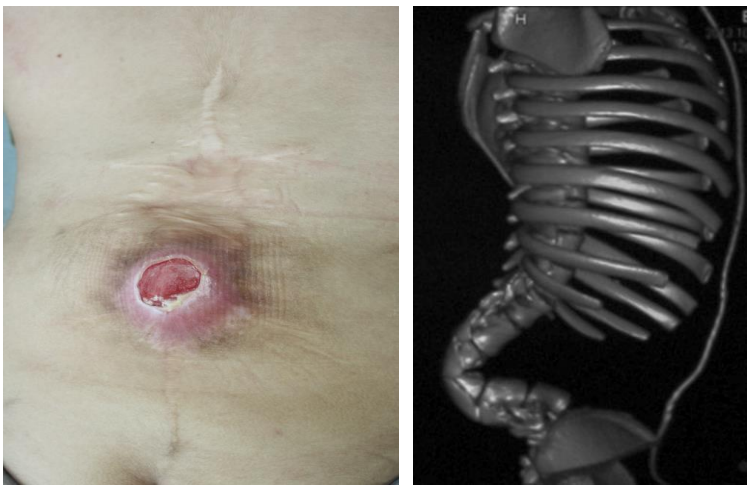

(a) (b)

Figure 11. (Continued).

(c)

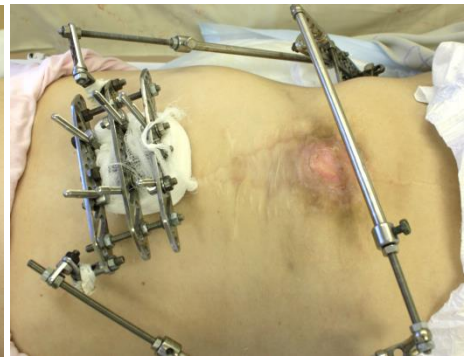

(d)

(e)

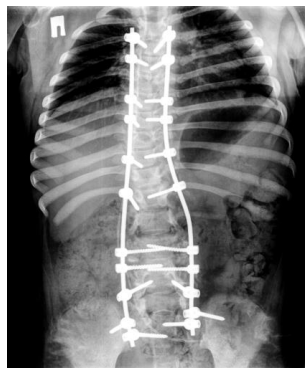

(f)

(g)

Figure 11. Photo and X-rays of a 9-year-old female patient with congenital kyphosis in myelocele with infected pressure sore at the deformity apex (a), 3D CT Volume Reformation Tomography of the spine in sagittal plane: myelodysplasia, dysraphy with hypogenesis of the posterior column and secondary structural wedge transformation of lumbar vertebral bodies (b), application of ExTrFix – pelvic device for wound healing by means of extrafocal fixation (c, d), surgery (e) and X-rays after corrective vertebrotomy and posterior instrumental fixation (f, g). Deformity correction of 84%.

Table 1. Influence of the deformity amount on the choice of a method of surgical treatment in scoliotic and kyphoscoliotic deformities of severe and extremely severe degree

Amount of deformity	Surgery		
	Mobilization	Correction	Fixation
70-100° * Mobile	• No • Smith-Petersen Osteotomy	Correction and Posterior Instrumental Fixation (PIF)	
70-100° * Rigid	• Anterior open or endoscopic release • Smith-Petersen Osteotomy	*Possible* Traction with ExTrFix or halo-pelvic device	PIF
Over 100° *	• Anterior multilevel osteotomy • Pedicle Subtraction Osteotomy • Vertebral Column Resection • Smith-Petersen Osteotomy	Traction with ExTrFix or halo-pelvic device	PIF

* EMG control is obligatory.

Though, analyzing the structure of complications in application of hybrid techniques, three groups can be distinguished: wound infection, implant instability and neurologic complications. Despite the external fixation, cases of wound infection in the structure of surgery of severe spinal deformities varied within the limit of 5%, which reflects average number of general surgical complications. Instability of construction, provoked by the bone resorbtion, despite its rareness was more often observed in young patients. It can be explained by bone-cartilaginous model of vertebrae and pelvis. Malposition and fracture of screws were in correlation with the scoliosis degree and torsion amount and ranged within 5-9%. Use of combined techniques in spinal deformity surgery allowed to decrease the rate of severe neurologic complications from 40% to 7%. It can be concluded that the method has average but controlled rate of complications.

DISCUSSION

Choice of tactics for correction of the spinal deformity of a severe degree is defined by mobility of arches. If deformities are rigid in any plane, many authors recommend mobilization of anterior and posterior departments in combination with external traction [3, 4, 6, 11].

Several authors tend to use external fixators. As major advantages the authors highlight possibility of a gradual, controlled correction, both, an isolated one followed by inversion to internal fixation and an associated one combined with anterior release at the deformity apex [3, 10, 11]. Nevertheless, this method is quite demanding to a close technique of screw insertion, biomechanically substantiated design of fixator and postoperative control [1, 3, 4, 10].

CONCLUSION

Planning of surgical treatment of spinal deformities is very individual. If spinal deformities are complicated with soft tissue inflammation at the deformity apex or there are severe functional disorders, indications for surgical treatment should be considered as vital and hybrid treatment methods must be applied using external fixation systems stage by stage.

REFERENCES

[1] Khudaev AT, Prudnikova OT, Kovalenko PI, Mushtaeva JuA (2008) Possibilities of the external transpedicular fixationin scoliotic deformity correction [in russian]. *Traumatology and Orthopaedics of Russia.* 3: 119-120.

[2] Lebedeva MN (2008) *Severe scoliotic deformities* [in russian]. Spine surgery. 4: 65-71.

[3] Ryabykh SO, Savin DM, Medvedeva SN, Gubina EB (2013) Our experience in treatment of neurogenic spinal deformities [in russian]. *Genij ortopedii.* 1: 87-92.

[4] Shevtsov VI, Khudaev AT, Kovalenko PI, Lulin SV (2004) Transosseous osteosynthesis in scoliosis [in russian]. *Spine surgery*. 2: 8-11.

[5] Wang W, Yao N, Song X, Yan Y, Wang C (2011) External spinal skeletal fixation combination with percutaneous injury vertebra bone grafting in the treatment of thoracolumbar fractures. *Spine.* 36(9):606-611.

[6] Magerl F (1982) External skeletal fixation of the lower thoracic and the lumbar spine. In: Current concepts of external fixation of fractures. *Springer Berlin Heidelberg.* pp 353-366.

[7] Kim YJ, Lenke LG, Bridwell KH, Kim KL, Steger-May K (2005) Pulmonary function in adolescent idiopathic scoliosis relative to the surgical procedure. *J Bone Joint Surg Am.* 87(7): 1534-1541.

[8] Goldberg CJ, Gillic I, Connaughton O, Moore DP, Fogarty EE, Canny GJ, Dowling FE (2003) Respiratory function and cosmesis at maturity in infantile-onset scoliosis. *Spine.* 28(20): 2397-2406.

[9] Benson ER, Thomson JD, Smith BJ, Banta JV (1998) Results and morbidity in a consecutive series of patients undergoing spinal fusion for neuromuscular scoliosis. *Spine.* 23: 2308-2317.

[10] Reyes-Sanchez A, Rosales LM, Miramontes V (2005) External fixation for dynamic correction of severe scoliosis. *Spine J.* 5: 418-426.

[11] Ryabykh SO, Gubin AV, Prudnikova OG, Kobyzev AE (2012) Treatment of combined spinal deformity in Ollier disease in a patient with abnormal verteblal formation. *Global Spine J.*1: 1-6.

In: Encyclopedia of Surgery (22 Volume Set)
Editors: Andreas Lehrer and Kristin Mueller
ISBN: 978-1-53618-329-0
© 2020 Nova Science Publishers, Inc.

Chapter 8

MANAGEMENT OF POSTTRAUMATIC NONUNIONS AND BONE DEFECTS BY COMBINED TECHNIQUES (ILIZAROV EXTERNAL FIXATION AND INTERLOCKING INTRAMEDULLARY NAILING). EXPERIMENTAL STUDIES AND CLINICAL PRACTICE

Dmitry Borzunov, PhD, MD*, Alexander Mitrofanov, PhD, MD, Sergey Kolchin, MD, Andrey Emanov, PhD, and Elena N. Gorbach, PhD

Russian Ilizarov Scientific Center for Restorative
Traumatology and Orthopaedics,
Kurgan, Russia

ABSTRACT

This chapter presents the results of an experimental study of the Ilizarov external fixation combined with intramedullary nailing in the management of long bone nonunions accompanied by anatomical shortening. These results were used in clinical practice. Combination of external fixation and nailing showed to be efficient in regenerate formation and nonunion healing in experimental settings that was proven by radiographic and histological studies. In clinical settings, such an approach to patients' rehabilitation was also efficient in achieving orthopedic goals and in reduction of in-patient treatment time.

Keywords: bone defect, nonunion, Ilizarov apparatus, nailing

* Corresponding Author's Email: borzunov@bk.ru.

INTRODUCTION

The incidence of long bone nonunions and defects due to failed fracture repair is not high. However, these complications are a challenge for orthopedic management and patients' rehabilitation [1, 2].

Management of nonunions is based on the principles that are already known. The main principles are stable fixation and compression at the docking site of bone fragments [3].

The Ilizarov method of distraction osteogenesis that is based on the use of external fixators provided the surgeons with new ways of treating this pathology [4].

However, a long period of external fixation, the bulky size of the apparatus, pin-tract infection along wires, and the necessity of multistage operative treatment are the disadvantages of the method [3, 5, 6].

On the other hand, intramedullary nailing is considered nowadays to be an optimal osteosynthesis method for the diaphysis of long bones. The technique is low invasive, provides good stability and more comfort for early rehabilitation [7, 12].

Combining the Ilizarov external fixation and nailing allows surgeons improve patient's rehabilitation and their quality of life.

Our study was aimed at revealing the biological aspects of bone reparation and the technical advantages of combining Ilizarov external fixation and nailing. It presents experimental findings and clinical outcomes of using this combined technique for bone nonunion and defect management.

EXPERIMENTAL STUDY

Materials and Methods

A canine model was used for this experiment which was carried out on eight mongrel dogs in the age from one to four years, weighing between 14 and 25 kg and whose tibia length was from 180 to 240 mm. The experiment was performed according to the requirements of the European Convention for the Protection of Experimental Animals (1986, Strasbourg).

Bone defect of the tibia was modeled in the upper third of the tibial shaft and measured 2 cm. The nutrient artery was affected and blood supply was impaired due to the defect. The next step was the mounting of the Ilizarov apparatus which consisted of proximal and middle proximal three-quarter rings and one full distal ring with wires in each of the supports that were all connected by threaded rods (Figure 1a). The gap formed between the bone fragments due to the defect modeled was reduced gradually by daily 2-mm compression with the Ilizarov fixator during one week. When the gap had been reduced to 4 or 5 mm, fixation with the Ilizarov apparatus continued for two months in order to obtain nonunion (Figure 1b).

Next, the Ilizarov apparatus was dismounted in order not to hinder nailing. Intramedullary nailing using the I-Loc system (BioMedtrix, USA) was performed through the entry point in the tibial plateau. Reaming of the medullary canal destructed the cartilaginous tissue at the nonunion level. After insertion, the nail was locked proximally.

The Ilizarov apparatus in the same assembly as for the nonunion model was applied again. Osteotomy of the distal fragment was performed. Compression at the nonunion level was produced. Distraction was initiated on the fifth day. The distraction rate was 0.75 mm per day made with six steps. Lengthening continued 28 days. Supportive compression at the level of the nonunion was carried out weekly. Average tibial lengthening achieved was 11.3±0.3%.

On days 7 to 10 after limb lengthening, two distal interlocking screws were inserted. Then, the external fixator was removed. The experiment was completed when radiographic consolidation was visualized (on average 45 days after completion of lengthening).

Evaluation of defect compression, nonunion, bone formation and consolidation was based on radiographic examination. Anteroposterior (AP) and lateral views were taken preoperatively, after the tibial defect was modeled, every two weeks during compression for obtaining nonunion, after osteotomy, every week during distraction, seven days after the start of fixation, and every 14 days after the external fixator removal.



(a) (b)

Figure 1. X-ray of the tibia in anteroposterior and lateral views: a - after bone defect modeling; b - after 2 months.

Histological study was carried out with the method of light microscopy (Nikmed-5, LOMO, St. Petersburg, Russia) of celloidin histotopographic sections of the tibial regenerate callus. Microphotos were taken with the DiaMorph complex (Moscow, Russia).

All animals could bear weight on the 14th day of lengthening. There were no skin problems, implant instability or other complications. Early external fixator removal did not cause regenerated bone fracture or deformity.

RADIOGRAPHIC AND HISTOLOGICAL RESULTS

The gap had inhomogeneous structure and partial closure of the medullary canal after two months (Figure 1b). The histological study confirmed the nonunion formed (Figure 2a). The interfragmentary layer contained vascularized fibrous tissue and groups of adipose cells (Figure 2b). The medullary canal of each fragment was closed by lamellar bone end plates with fibrous cartilaginous tissue on their surface (Figure 2c). The fibrous cords in the gap were united with the periosteum. They covered the bone fragments along the periphery but separated them from each other in the center (Figure 2a).

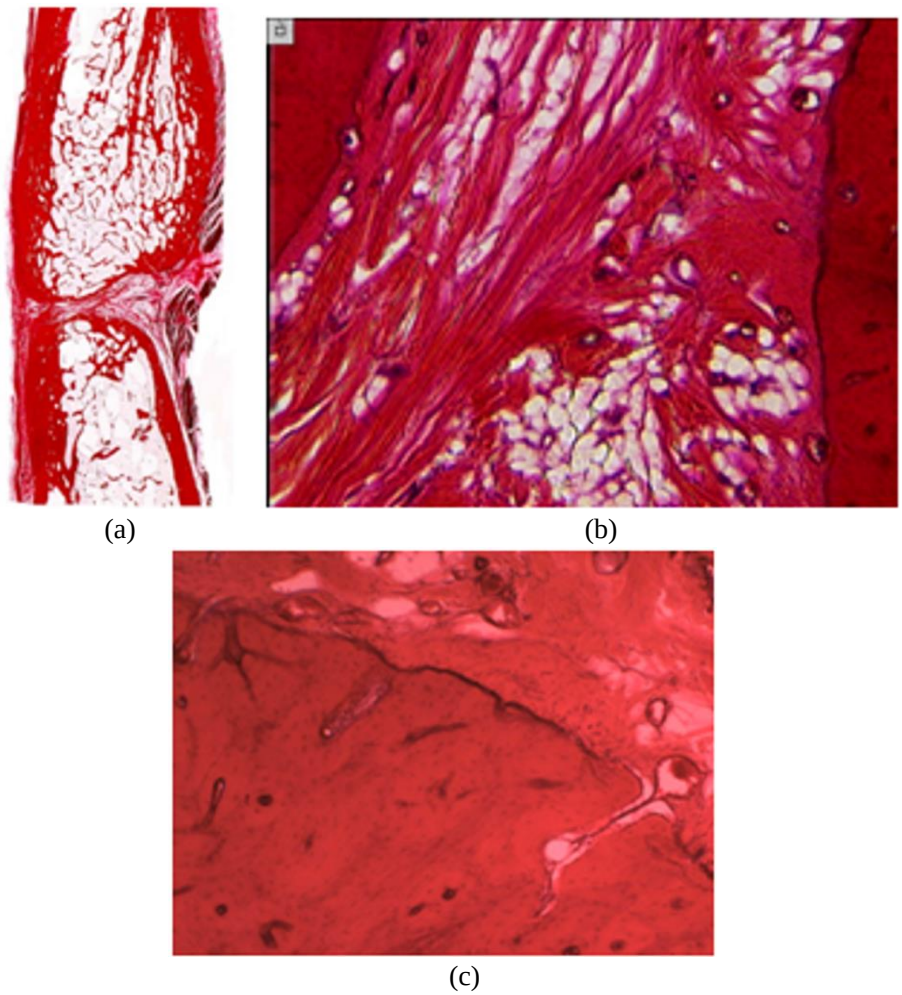

Figure 2. Histological structure of the gap between the bone fragments at 63 days of the experiment: (a) separated bone fragments of the non-union (histotopogram, Van Gieson staining, mag.x1.5); (b) fibrous connective tissue in the gap (picrofuchsin Van Gieson staining, mag. X 25); (c) lamellar bone tissue at the end of the proximal bone fragment and fibrous cartilaginous tissue on its surface (hematoxilin and eosin staining, mag. X 40).

On day 14 of lengthening, the interfragmentary gap at the osteotomy level measured 10±0.3 mm. The diastasis at the nonunion docking site was slightly visualized. In five dogs

the endosteal regenerate was 3 mm long, and the periosteal layer was 0.5 mm thick and up to 15 mm long (Figure 3a). The other three dogs had inhomogeneous regenerate structure within the nonunion diastasis. The periosteal layer was 3 mm thick (Figure 3b). Mild osteoporosis was seen in all cases.

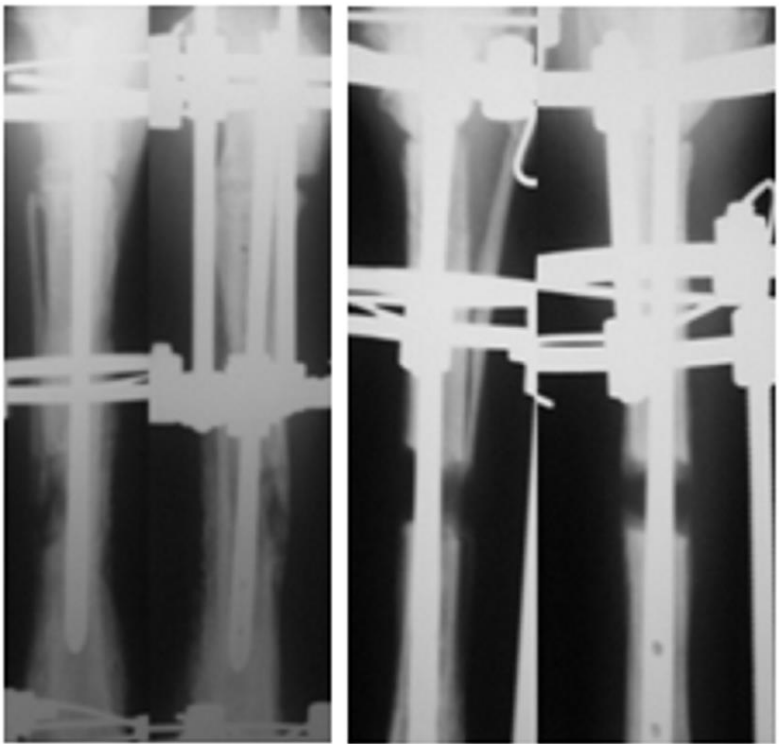

(a) (b)

Figure 3a, b. X-rays of the tibia taken after 14 days of tibial lengthening in the conditions of combined fixation;

From day 7 to 10 after completion of distraction, remodeling of the periosteal layer at the nonunion level started in five cases. Distraction regeneration still featured inhomogeneous structure but the cortices were undergoing formation (Figure 4a).

On day 30 after completion of distraction, the nonunion healed in six cases. Fully interconnected cancellous trabeculae were formed in the distraction gap with continuous cortices (Figure 4b). Similar condition of bone regeneration in the distraction gap was revealed by day 45 after completion of distraction in other two dogs.

On day 30 after completion of distraction, the histological study of the tissue at the level of pseudoarthrosis revealed union through hypertrophic callus (Figure 5a) with cortical continuity and interconnected cancellous bone (Figure 5b). Osteoclasts were attached to the periosteal tissue and indicated bone remodeling (Figure 5c). The endosteal tissue was presented by interspersed bone tissue and vascularised reticular tissue (Figure 5d). The endosteal area had a hollow canal after nailing. The walls of this canal consisted of fibrous tissue containing capillary vessels (Figure 5e).

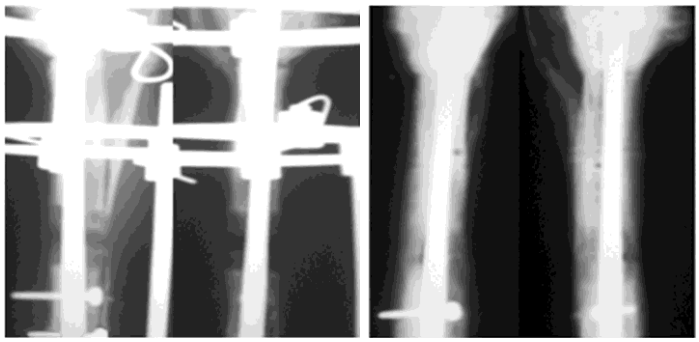

(a) (b)

Figure 4. Fragments of x-rays of the tibia: (a) combined fixation on 7th day; (b) continuity of cortices all over the tibia 30 days after lengthening.

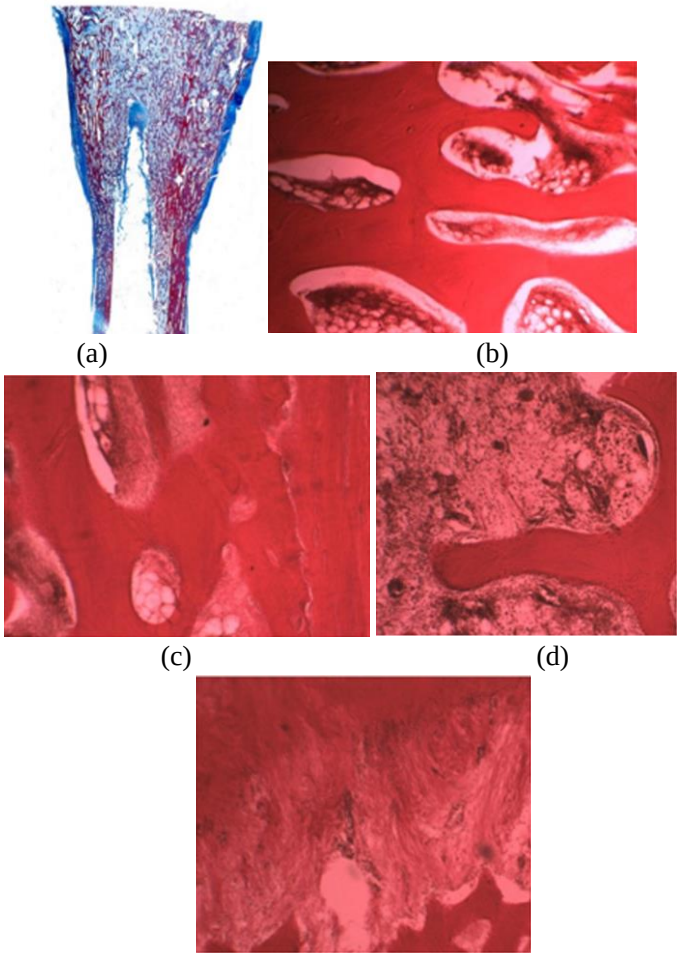

(a) (b)

(c) (d)

(e)

Figure 5. Morphological characteristics of the callus formed in the defect of the tibia after 30 days of lengthening: (a) histotopogram of the regeneration callus; (b) bone tissue part of the intermediary zone between the fragments; (c) periosteal bone tissue and osteoclasts; (d) reticular tissue with areas of hemopoesis ; (e) a layer of vascularized loose fibrous tissue on the internal wall of the canal formed by the nail. Masson staining (a), Hematoxilin and eosin staining (b-e); mag. x1.5 (a), x25 (b), x63 (c-e).

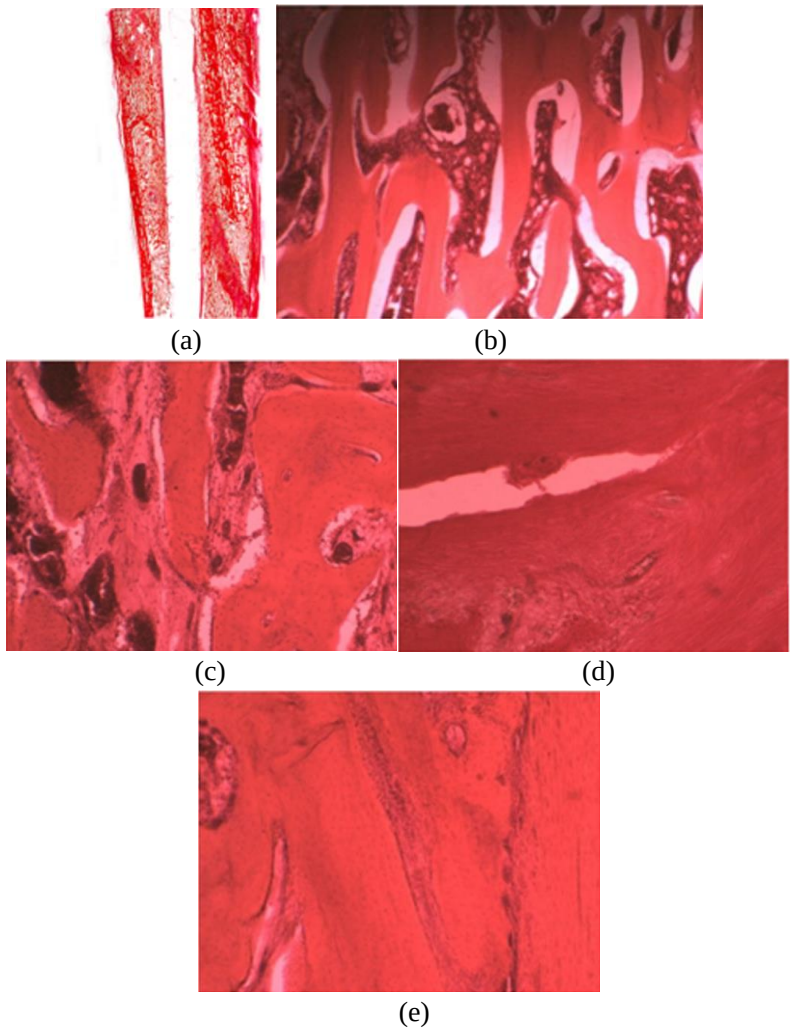

Figure 6. Histological picture of the distraction regenerate 20 days after the Ilizarov fixator was removed: (a) histotopogram; (b) part of cancellous bone tissue in the intermediary callus; (c) reticular fibrous tissue containing capillary blood vessels with hyperemia; (d) fibrous tissue; (e) osteoclastic resorption on the periosteal callus. Van-Giseon staining (a), Hematoxilin and eosin staining (b-e); mag x1.5 (a), x25 (b), x63 (c-e).

The distraction regenerate had features of a newly formed bone in the diastasis (Figure 6a). The cancellous bone tissue was in the intermediary area. The cortices were denser on the periosteal level. Bone tissue was formed of cancellous bone that contained areas of reticular tissue (Figure 6b). The periosteal callus was more pronounced on the side where the nail was closer to the cortex. On the contrary, the endosteum was more developed on the side where the cortex was at a greater distance from the implant (Figure 6a). Sinusoidal blood vessels between bone trabeculae were located both in the endosteal and periosteal tissues (Figure 6c). The medullary canal in the center was inane after nail as well as at the level of the pseudoarthrosis. The internal surfaces of the canal were presented by fibrous tissue and the external ones by trabecullar bone united with endosteal bone tissue (Figure 6d). Osteoclastic resorption was noted on the periosteal callus (Figure 6e).

CLINICAL APPLICATION

Combined Ilizarov External Fixation and Nailing for Nonunion Accompanied by Limb Shortening and Segmental Bone Defects

Preoperative Planning

Operative planning does not differ much from planning other orthopedic operations. It includes an accurate study of the anamnesis, careful general and local physical examination, and radiographic study. However, several issues require special attention. Evaluation of the true bone defect is a primary point because it determines the future lengthening amount to be achieved. Bone defect includes anatomical shortening as compared with the contralateral limb, interfragmentary diastasis, and the size of bone resection at the docking site (in case it is necessary). Basing on the defect assessment, the level of osteotomy, assembly of the external fixator and the distraction regenerate length are determined. The rings for the Ilizarov fixator are chosen individually. The nail of the optimal size must be prepared in view of future lengthening. Patient's preparation and anesthesia do not differ from the standard procedures before the Ilizarov osteosynthesis [8].

Surgical Technique

Step 1

The patient is positioned supine on a radiolucent table. The pelvis may be elevated with a firm cushion to make the placement of the external fixator easier. Any implant in place after previous operations should be removed in a minimally invasive manner. The entry point for nailing is produced under the control of an X-ray image intensifier (XRII). The skin incision should be minimal (two or 3 cm). Reaming of the medullary canal can be produced both with standard or rigid reamers (Figure 7). The diameter of the latter reamer type must exceed the diameter of the selected nail by 2 mm to prevent difficulties during distraction and implant instability after external fixator removal. Insertion of the nail is performed till the level of the future osteotomy under XRII control. Osteotomy is also performed under radiographic control from a small skin incision. Upon its completion, nailing is continued in the regular manner along with the insertion of static interlocking screws into the bone fragment that is to be lengthened.

The wounds are closed in a regular manner. The insertion of wires follows. The XRII use in this case is a personal preference of the surgeon. Positioning of wires or screws is standard for each anatomical segment [9]. Wires must be drilled into the bone as far as possible from the nail to prevent possible deep infection due to skin inflammation in the postoperative period [10]. A sufficient number of wires or screws in each ring or half-ring necessary only for distraction must be inserted, as the Ilizarov fixator will be removed after lengthening. Mounting of the external fixator supports, wire fixation and their tensioning, connection of the supports with threaded rods follows. At this stage, central position of the limb axis in the frame is paramount because it determines the success of distraction in future. The operation is completed by applying aseptic dressings and radiographic control (Figure 8).

Figure 7. Rigid reaming rods. Rigid reamers may be an alternative to the standard ones in case of sclerotic obliteration of the medullary canal.

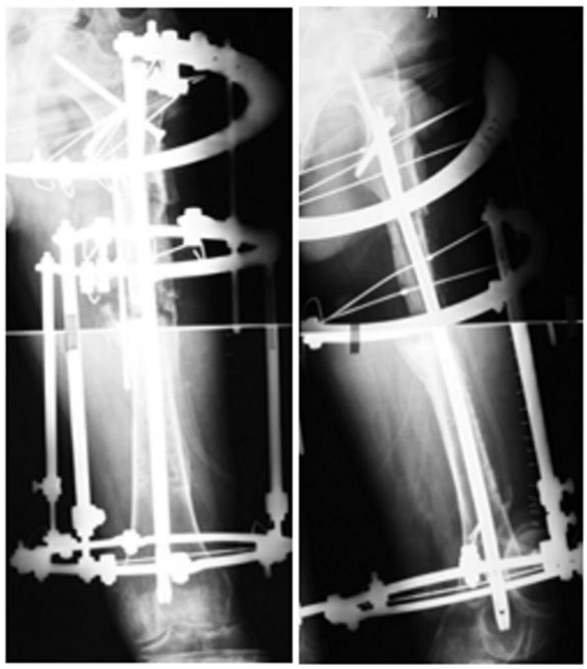

Figure 8. X-ray of the femur in anteroposterior and lateral view after step 1. Threaded rods are parallel to the bone axis and nail – optimal condition for future lengthening.

Postoperative Management and Care after Step 1

Aseptic dressings must be changed on the first postoperative day. Patient can start weight bearing and walking with crutches. On the third day after the operation, motion exercises are allowed. Distraction must start on the fifth postoperative day. The mean rate of distraction is 1 mm per day made with four steps. Radiographic checking is carried out on the tenth day of

distraction. In cases when bone fragments at the nonunion docking site have contact with each other, supportive compression (1 mm every 10 days) at this level is necessary to increase stability. In our opinion, the total time with the Ilizarov fixator on the limb should not exceed one or 1.5 months for prevention of deep infection around the implant. However, if orthopedic goals require a longer external fixation period and inflammatory skin problems appear, the solution is the use of antibiotics, wire care or even the removal of problematic wires or pins.

Step 2

Full contact of bone fragments at the docking level and limb length restoration are indications for the second step (removal of the external fixator and insertion of the distal locking screws).

Patient's preparation and positioning on the radiolucent table are the same as described previously. Preparation of the operation field must be very careful, especially for the external fixator. First of all, distal locking by a freehand technique must be performed. The number and positioning of screws are defined by the size of the bone fragment, nail design and surgeon's preferences. Type of fixation of the bone fragment which was transported is a specific choice for every case. Different techniques are used: plating, cerclage suture or a locking screw placed into a special hole in the nail [11]. The first and second variants make surgery more aggressive while the third one requires a specific design of the nail. Preference is given to the screw positioned in both cortices tangentionally to the nail. It makes the surgery less invasive and provides enough stability if the position of the screw is properly chosen (Figure 9).

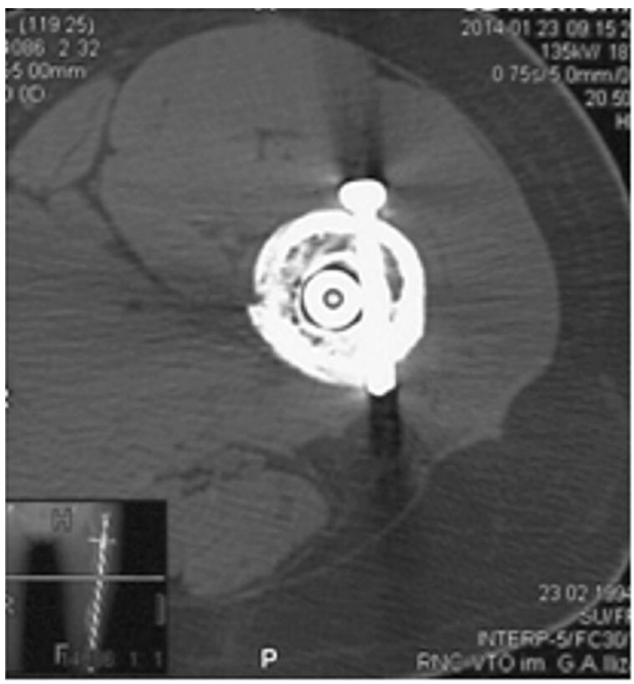

Figure 9. Fragment of the CT scan of the femur. The blocking screw inserted correctly.

Biomechanical grounding of this technique is based on that fact that prevention of the transported fragment from axial dislocation is provided by the friction forces between the screw and the nail as well as by the opposite side of the nail that contacts with the bone due to the screw [14]. When the nail is locked, the Ilizarov apparatus can be removed. Wounds are closed in a regular manner. The surgery is finished by applying aseptic dressings.

Postoperative Care after Step 2

On the first postoperative day, aseptic dressings must be changed. X-rays of the limb are taken. Patients can walk with crutches but due to static locking of the nail weight bearing is limited to 20 or 30% of the body mass, especially in obese patients. On the third day, joint motion exercises may be started. Subsequent radiographic examinations are performed in one, three, and six months. In delayed union, dynamisation of the nail is an option of choice. But it is expedient only after the distraction regenerate has fully remodeled to prevent limb shortening.

MATERIALS AND METHODS

Between 2011 and 2014, this technique was used for management of nonunions accompanied by anatomical shortening of the femur in nine patients (two females, seven males, mean age 32.75 years). In all the cases, the initial injuries were closed fractures of the femoral shaft managed with the following techniques: plating in one case (11%), interlocking nailing in four cases (44.5%), and non-interlocking nailing in four cases (44.5%). Nonunions in two patients (one after non-locking and one after interlocking nails) had been treated by reamed interlocking nailing prior to our operation, but union of the femur was not achieved. The mean time passed from the initial injury till our combined fixation was 2 years and 9 months.

Before treatment, all the patients (100%) walked with crutches and experienced pain in the femur after physical activity. The mean anatomical shortening of the limb was 3.71±0.66 cm. The mean bone loss before treatment was 7.86±1.37 % as compared with the contralateral limb.

Radiographic study before treatment showed hypertrophic nonunions of the femoral shaft. That was reason not to use any bone grafting in the nonunion area. Only reaming during nailing was used. X-rays were taken in the AP and lateral views after the first surgery (step 1), every 10 days during distraction, after the second surgery (step 2), and in the rehabilitation period (one month, three and six months after the Ilizarov fixator removal). CT was performed twice: after the Ilizarov fixator was removed and 6 months later for union verification and assessment of distraction regenerate remodeling.

The technique described above was used in all the patients. Distraction was initiated on the fifth day with the rate 1.5 mm per day in six steps, for creating tension forces at the level of the osteotomy. Once the diastasis between the bone fragments was seen on day 10, distraction was continued with the rate of 1 mm per day in four steps. During the entire period of external fixation, supportive compression at the docking site was produced with 1 or 1.5 mm in one step every 7 or 10 days.

Upon limb length equalization, the Ilizarov apparatus was removed and interlocking screws were inserted (step 2).

External fixation index (defined as the duration of external fixation in days divided by the total amount of lengthening in centimeters) and the average rate of distraction were evaluated. All the patients were available for follow-ups (6-12 months) after the external fixator had been removed.

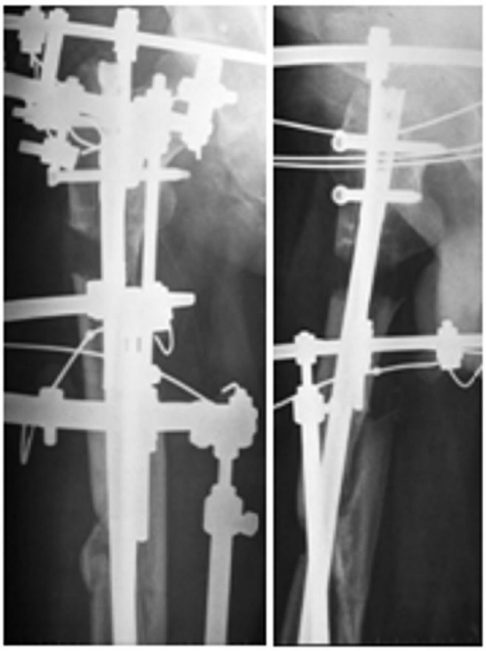

Figure 10. X-ray of the femur in anteroposterior and lateral views. 20 days of distraction. Distraction regenerate with inhomogeneous structure.

RESULTS

On day 10 of distraction, the radiographic examination showed the diastasis that measured 10±1.5 mm in eight cases. In one case, distraction with an advanced rate (1.5 mm per day) continued for five days, and the same radiographic diastasis was achieved.

Regenerate formation was visible by day 20 of distraction. The regenerate had inhomogeneous structure, presented both by periosteal and endosteal reactions (Figure 10). CT scans after step 2 showed that the regenerated bone was continuous, had a cylindrical shape, and zonal structure. Mean bone density was 50.5±16.3 HU (Figure 11).

Mean rate of distraction was 1.25 mm per day. External fixation index was 10.2±0.78 days/cm. Such a short duration of the external fixation can be explained by the fact that the Ilizarov apparatus was used only during distraction. Fixation after lengthening continued with the nail.

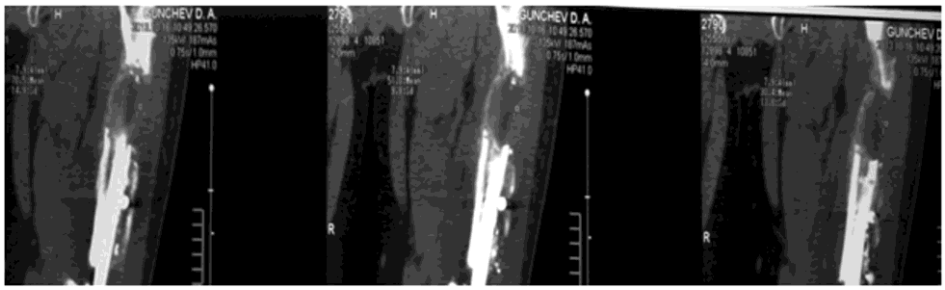

Figure 11. Fragments of the CT scan of the femur. Continuous distraction regenerate after step 2.

Figure 12. X-ray of the femur in anteroposterior and lateral view. Outcome in 5 months.

Inflammatory skin problems round two wires were observed in one case during distraction. Those wires were removed and new wires were inserted. Deep infection did not develop. Combined Ilizarov external fixation and nailing allowed us to achieve restoration of the limb length in all the cases. Consolidation of the distraction regenerate was achieved within five to 6 months after the Ilizarov apparatus had been removed. Nonunion healed after five or 6 months in eight cases. On the X-rays, continuity of three or four cortices at the nonunion level and along the regenerate area was seen (Figure 12). CT scans performed at that period showed the density values of 810-950 HU on both levels. In one case, a delayed union was diagnosed at a 6-months' follow-up. Distal interlocking screws were removed in this case, and three months later the bone united. Instability of the nail did not develop. Once the nonunion had healed, all the patients could walk without crutches bearing full weight on the limb.

DISCUSSION

Ilizarov's contribution [4] into the management of bone nonunions and defects is considered to be one of the most important developments in the orthopedics of the XX century [3]. Distraction osteogenesis is still the main method in the treatment of the patients with large bone defects and deformities [9]. Orthopedic problems that cannot be corrected simultaneously have a chance to be eliminated by gradual distraction. However, a long postoperative period with the external fixator on the limb forced the surgeons to search for the ways to shorten that period and improve patients' quality of life. Interlocking nailing was first described by G. Kuentscher. It has evolved to a method with biological justification and worldwide practice in fracture treatment [12]. Reaming of the medullary canal has several biologic effects. One of them is a strong hyperaemic reaction which results in revascularization of the bone cortex [13]. As the area of pseudoartrosis has a poor blood supply, this effect serves to success in nonunion treatment with nailing [7]. Analyzing all the pros and cons of external fixation and intramedullary nailing, we combined these techniques. Our experimental study has shown that the process of distraction regeneration features the typical pattern, even in the conditions of impaired blood supply. Revascularization after reaming and nail insertion results in an expressed periosteal reaction, both in the nonunion and distraction regenerate areas. Such a periosteal reaction is a sign of adequate blood supply from the periosteum and surrounding soft tissues. It is not caused by instability between bone fragments. In clinical settings, such an approach to nonunion treatment provided the conditions for early rehabilitation and allowed the patients to fulfill more physical activities. Moreover, external fixation period reduced, in-patient stay decreased, and postoperative recovery was faster as compared with the traditional Ilizarov method [10].

CONCLUSION

Intramedullary nailing can be used in combination with the Ilizarov external fixation for management of nonunions accompanied by limb shortening. The combined use of these two techniques allows stimulation of bone formation in the conditions of impaired blood supply. Intramedullary nailing improves the stability of the transported bone fragment and provides an opportunity to remove the Ilizarov apparatus earlier. We conclude that the combined Ilizarov external fixation and nailing is a highly efficient technique to obtain good outcomes in the management of this pathology.

REFERENCES

[1] Saleh KJ, Hak DJ, Nierengarten MB (2001) Socioeconomic burden of traumatic tibial fractures: non union or delayed union. *MedScape Orthopaedics Clinical* updates, pp 1–22.

[2] Heppenstall RB (ed) (1980) *Fracture treatment and healing*. WB Saunders, Philadelphia.

[3] Marti RK, Kloen P (2011) *Concepts and cases in non-union treatment*. AO Foundation, Switzerland.

[4] Ilizarov GA (1992) Transosseous osteosynthesis. Springer-Verlag, Heidelberg. Green SA (1984) Complications of external fixation. *AAOS Instr. Course Lect*. 33:138–143.

[5] Paley D (1991) Problems, obstacles and complications of limb lengthening. In: Bianchi Maiocchi A, Aronson J (eds) *Operative principles of Ilizarov*. Williams and Wilkins, Baltimore, pp 352–366.

[6] Hierholzer C, Glowalla C, Herrler M, von Rüden C, Hungerer S, Bühren V, Friederichs J (2014) Reamed intramedullary exchange nailing: treatment of choice of aseptic femoral shaft nonunion. *J. Orthop. Surg. Res*. 2014 Oct 10;9(1):88.

[7] Mazzarello F, Puncuh F, Lampugnani E et al (1997) *Limb external devices application: anesthetic procedures comparison*. Gaslini 29:55–60.

[8] Solomin L (2012) *The Basic Principles of External Skeletal Fixation Using the Ilizarov and Other Devices*. 2nd rev. Springer, 1593 p.

[9] Paley D, Herzenberg JE, Paremain G, Bhave A (1997) Femoral lengthening over an intramedullary nail: a matched-case comparison with Ilizarov femoral lengthening. *J. Bone Joint Surg. Am.* 79(10):1464–1480.

[10] Raschke MJ, Mann JW, Oedekoven G, Claudi BF (1992) Segmental transport after undreamed intramedullary nailing/ Preliminary report of a "Monorail" system. *Clin. Orthop. Relat. Res*. 282:233-240.

[11] Vécsei V, Hajdu S, Negrin LL (2011) Intramedullary nailing in fracture treatment: history, science and Küntscher's revolutionary influence in Vienna, Austria. Injury. 2011 Sep;42 *Suppl* 4:S1-5.

[12] Klein MP, Rahn BA, Frigg R, Kessler S, Perren SM (1990) Reaming versus non-reaming in medullary nailing: interference with cortical circulation of canine tibia. *Arch. Orthop. Trauma Surg*. 109:314-316.

[13] Stedtfeld HW, Mittlmeier T, Landgraf P, Ewert A (2004) The logic and clinical applications of blocking screws. *J. Bone Joint Surg Am*. 86-A Suppl 2:17-25.

In: Encyclopedia of Surgery (22 Volume Set)
Editors: Andreas Lehrer and Kristin Mueller
ISBN: 978-1-53618-329-0
© 2020 Nova Science Publishers, Inc.

Chapter 9

COMPLICATIONS OF BARIATRIC SURGERY, IMPROVEMENT OF COMORBIDITIES AND IMPACT ON QUALITY OF LIFE

Jaime Ruiz-Tovar[1,*], MD, PhD and Carolina Llavero[2,†]
[1]Department of Surgery. General University Hospital Elche, Spain
[2]Department of Surgical Nursery. Sureste Hospital, Madrid, Spain

ABSTRACT

More than 2/3 of the U.S, population is overweight or obese. Obesity is on the rise and the incidence is increasing most rapidly in the morbidly obese population, i.e., those with a BMIs exceeding 40 kg/m^2. Epidemiological studies estimate the prevalence of morbid obesity around 0.5%, but this rate is probably underestimated, as many morbidly obese subjects are not under any medical control. Only surgery results in substantial, long-term weight loss for obese individuals. Therefore, the performance of bariatric procedure has increased exponentially in the last 2 decades; from less than 9,000 procedures in 1993 to a high of over 115,000 in 2004. Actually, the number of bariatric procedures performed is even higher.

Despite nowadays most bariatric techniques are performed laparoscopically, the complications rate still represents a challenge for many surgeons. Complications associated to these approaches are often life-threatening conditions. Morbidly obese patients are high risk subjects and therefore, bariatric surgery must be considered a high risk procedure though the patients are operated for a benign condition. Complications include medical (deep vein thrombosis, pulmonary embolism, atelectasia, pneumonia,..) and surgical items (anastomotic leak, bleeding, surgical site infection,…).

Even considering the surgical risk, bariatric surgery has demonstrated much more advantages than disadvantages. Bariatric surgery can solve many comorbidities, such as diabetes mellitus, hypertension, dyslipidemia, pulmonary disorders, osteoarthritis,…, and reduces significantly the risk of developing new health problems, such as cardiovascular or neoplastic events. Altogether, this leads to a significant improvement of the quality of life. The patients feel healthier and this has a positive psychological impact. There are many scales available to evaluate quality of life, but all of them coincide in that bariatric

* Corresponding Author's Email: jruiztovar@gmail.com.
† Carolina Llavero, RN.

surgery achieves a significant improvement in the quality of life of morbidly obese patients.

INTRODUCTION

More than 2/3 of the U.S, population is overweight or obese. Obesity is on the rise and the incidence is increasing most rapidly in the morbidly obese population, i.e., those with BMIs exceeding 40 kg/m^2. Epidemiological studies estimate the prevalence of morbid obesity around 0.5%, but this rate is probably underestimated, as many morbidly obese subjects are not under any medical control. Only surgery results in substantial, long-term weight loss for obese individuals. Therefore, the performance of bariatric procedure has increased exponentially in the last 2 decades; from less than 9,000 procedures in 1993 to a high of over 115,000 in 2004. It is estimated that 220,000 weight-loss surgeries were performed in 2008. Actually, the number of bariatric procedures performed is even higher. [1]

COMPLICATIONS OF BARIATRIC SURGERY

Complications following surgical treatment of severe obesity vary based upon the procedure performed and can be as high as 40%. Due to the high surgical volume, improving the safety of these operations has become a high priority, leading to the development of strict criteria for center accreditation, guidelines for safe and effective bariatric surgery, and careful monitoring of surgical outcomes. [1,2] Operating on obese patients is challenging because of anatomic and physiologic characteristics and comorbidities of obese patients. However, the risk of serious intra-operative and in-hospital complications and mortality rates are relatively low when the surgery is performed by experienced surgeons with an institutional investment in bariatric programs.

Postoperative complication rates vary with surgical approach, such as fewer complications with the laparoscopic approach than the open approach. Complications also vary based upon type of procedure, such as fewer complications with the adjustable gastric band (AGB) than the laparoscopic Roux-en-Y gastric bypass (LRYGB). [1-3]

ADVERSE INTRA-OPERATIVE EVENTS (AIE)

The adverse intra-operative event (AIE) rate varies with the complexity of the procedure, ranging in contemporary reports from <1% to 5%. [3] The most common AIE in laparoscopic surgery include:

- Anesthesia events (1%)
- Instrument/equipment failure (0.8 %)
- Bowel injury (0.8 %)
- Hepatic injury (0.4 %)
- Anastomosis revision (0.3 %)

- Splenic injury (0.2 %)
- Major blood vessel injury (0.1 %)

In addition, previous intra-abdominal operations can create extensive adhesions, and abdominal wall procedures (i.e., abdominoplasty) can restrict insufflation and reduce the visible surgical field.

Trocar placement, blind insertion of the laparoscopic instruments, thermal injury or excess traction/manipulation of organs can contribute to some of the more common intra-operative laparoscopic complications.

Trocar Related Injuries

Peritoneal access by precise placement of the trocar and Veress needle is technically challenging in the patient with a thick abdominal wall; however, all types of entry access (e.g., open, closed, or optical view) can be safely performed by experienced surgeons. There is no statistical difference in the rates of major complications (e.g., vascular or solid organ injury) for open, closed, or optical view laparoscopic entry techniques. [4]

Spleen Injury

The spleen can be injured during weight-loss surgery, especially during a Laparoscopic sleeve gastrectomy (LSG), but bleeding can usually be controlled with hemostatic agents, and splenectomy is rarely required. [5]

Portal Vein, Inferior Vena Cava Injuries

Intra-operative injury to the portal vein and inferior vena cava is rare during bariatric operations, but can lead to rapid exsanguination. If thrombosis of the portal vein occurs following an injury, these patients require liver transplantation. [6]

Bowel Ischemia

During the performance of RYGB or BPD-DS procedures in particular, ischemia of the bowel may result if the root of the mesentery containing the mesenteric vessels is compromised or undermined during transection of the small bowel. [7]

Bowel ischemia may occur during bariatric operations in the following cases:

- Twisting the mesentery and/or mesenteric root while performing a retrocolic anastomosis for a RYGB
- Creating tension on the Roux-en-Y limb when performing a gastrojejunal anastomosis

- Incising the mesentery of the biliopancreatic limb or Roux limb at an angle such that blood flow to an end of intestinal limb is compromised.
- Closing the mesenteric defect with overly generous amounts of tissue between sutures
- Internal hernias at Petersen's defect (between the Roux limb mesentery and the transverse colon mesentery), through the transverse mesocolon itself in a retrocolic anastomosis, or the jejunojejunostomy site can also lead to ischemia and, therefore, these defects must be closed. An antecolic limb does not rule out the possibility of a future internal hernia through this potential space, but this is not likely to occur early after a RYGB.

Solid Viscus Organs

The liver can be injured during bariatric surgical procedures because of its close proximity to the stomach, especially during vertical sleeve gastrectomy. Bleeding can usually be controlled with hemostatic agents and a partial hepatectomy is rarely required. [4]

Hollow Viscus Organs

Bowel injury, such as a puncture or laceration, can occur with insertion of a Veress needle, trocar, lysis of adhesions, or dissection. [4]

Misconstruction

Misconstruction of a Roux-en-Y bypass or a biliopancreatic diversion–duodenal switch (BPD-DS) can occur during a laparoscopic or open approach. Proper bowel orientation must be maintained to avoid misconstruction. Misconstructions of the Roux-en-Y bypass with an anastomosis between the distal aspect of the biliopancreatic limb and the gastric pouch have been reported and lead to chronic bilious vomiting ("Roux-en-O"). Other examples of misconstruction include Roux limb inversion and short Roux limb. [8]

IN-HOSPITAL POSTOPERATIVE MORBIDITY

The risk of a major complication immediately after the operation ranges from approximately 0.2% to 10% in contemporary series, depending upon patient comorbid illnesses, type of procedure, surgical approach (laparoscopic or open), and surgeon expertise.

Anastomotic Leak

The anastomotic leak remains the most dreaded technical complication of bariatric surgery and is one of the most challenging complications of weight-loss surgery. The risk of a

leak ranges from 0.8% to 6%. The risk approaches 35% in revisional bariatric surgery. Most leaks occur early, generally within the first week after surgery but can occur up to a month after the operation. [9-11]

The clinical presentation is subtle and requires vigilance for signs such as low-grade fevers, respiratory compromise, and/or unexplained tachycardia greater than 120 bpm. These signs may also be present in the setting of pulmonary embolism. A leak may be radiographically confirmed by barium swallow or contrast computed tomography (CT). If a leak is suspected clinically, emergent surgical exploration should be performed, even if the imaging is negative, given the rapid progression to sepsis in the severely obese patient with comorbidities. A negative exploration that does not reveal a leak should not be considered a complication but rather evidence of good surgical judgment. Multiple studies have shown that re-exploration is safe when compared with missing or delaying the treatment of a leak. In experienced hands, surgical exploration and management of a leak is often feasible via a laparoscopic approach.

The surgical principles in treating a leak include:

- Broad-spectrum antibiotic coverage
- Identification and repair of the defect
- Irrigation and control of contamination
- Wide external drainage of the contaminated area
- Enteral access for feeding, most commonly a gastric feeding tube placed in the gastric remnant

Percutaneous drainage of a contained fluid collection may be an option in patients who are stable. Surgical therapies for persistent gastric leak are technically difficult and often unsuccessful. New approaches using minimally invasive endoscopic repair techniques appear safe and effective in some patients. These include use of glue, or placement of covered stents across the leak. Many different intraoperative techniques have been used to decrease the incidence of leaks. Over-sewing staple lines, buttressing materials for the staple line and fibrin glue have been used, but there is no evidence that these methods reliably decrease the leak rate after bypass surgery. [12,13]

Hemorrhage

Significant bleeding after gastric bypass has been described in 0.4% to 4% of patients. Bleeding can occur from the gastric or short gastric vessels during dissection of the greater curve. Most of the bleeding problems associated with a sleeve gastrectomy occur from the staple line after transection of the stomach. The bleeding is most likely a result of the large staples used for the thick tissue in the distal stomach. Large staples are not adequate to seal small vessels. This has led many surgeons to reinforce the staple line by over-sewing, buttressing, or both. [14]

Early bleeding typically can also occur from an anastomosis; more commonly, intraluminal bleeding occurs. Patients frequently present with tachycardia, a decreased hematocrit, and melena. Such bleeding typically resolves without surgical intervention, but may require transfusion of blood products and reversal of anticoagulation. Careful endoscopic

examination and therapy is appropriate for ongoing bleeding with high transfusion requirements. Surgery is reserved for hemodynamic instability, intraluminal bleeding not amenable to endoscopic therapy (e.g., staple line of the excluded stomach), or continued bleeding despite restoration of normal coagulation status. [15,16]

Venous Thromboembolism/Pulmonary Embolism

The overall incidence of a venous thromboembolism (VTE)/pulmonary embolism (PE) is approximately 0.4%. The incidence is around 0.3% for laparoscopic procedures and 1.2% for open procedures.

The most common risk factors associated with fatal PE include severe venous stasis disease, BMI >60, truncal obesity, and obesity-hypoventilation syndrome. [17]

Optimal strategies for preventing VTE/PE in the bariatric surgery setting have not been established. Most bariatric surgeons use both pneumatic compression devices in conjunction with subcutaneous unfractionated or low molecular weight heparin. The current American Society of Bariatric and Metabolic Surgeons (ASMBS) guidelines regarding VTE prophylaxis state that all bariatric patients receive mechanical prophylaxis and are ordered for early ambulation. Additionally, the surgeon may routinely use chemical prophylaxis of either low molecular weight heparin or unfractionated heparin. [18]

Preoperative risk stratification may be a useful tool for identifying high-risk patients for more aggressive prophylaxis. In patients identified preoperatively as high risk for PE, due to previous medical history of VTE, PE, or venous stasis disease, or inability to ambulate (i.e., wheelchair-bound), perioperative chemoprophylaxis of low molecular weight heparin or unfractionated heparin may be prescribed for an extended period even after discharge from the hospital. [19]

Myocardial Infarction

The incidence of a postoperative MI after a bariatric operation is approximately 0.2%. [1]

Pulmonary Complications

Major postoperative pulmonary complications include pneumonia and acute respiratory failure. Atelectasis is common after all types of surgery that require general anesthesia, and is more prevalent in the morbidly obese. The overall incidence of postoperative pneumonia is around 0.4%. The overall rate of acute respiratory failure (ARF) is 1.3%. The incidence is higher with an open compared with a laparoscopic procedure, gastric bypass procedures compared with restrictive procedures and for patients with preoperative heart failure, chronic renal failure, peripheral vascular disease, chronic obstructive pulmonary disease (COPD), tobacco smoking, and diabetes. ARF is associated with a significantly higher in-hospital mortality rate compared with those who do not develop the complication.

Early ambulation and incentive spirometry after surgery are important to decrease the incidence of pulmonary complications. Preoperative identification of the presence of

significant obstructive sleep apnea and initiation of continuous positive airway pressure (CPAP) therapy also reduce the risk of pulmonary complications in the postoperative period. CPAP should be used in the early postoperative period if it is clinically necessary. [20]

Surgical Site Infections

Surgical site infections (SSIs), which often are localized to the incision but can extend into deeper tissues, are the most common nosocomial infection, and are found in 2% to 5% of surgical operations in the United States. SSIs are associated with substantial morbidity, mortality, prolonged hospital stay, and increased cost of care. An overall incidence of SSIs of 1.1% has been described for bariatric surgery. Rates of wound infection are significantly greater for open procedures (10 – 15%) compared with laparoscopic (3 - 4%) procedures. Among laparoscopic techniques, rates of wound infection vary depending upon the technique used, with a higher rate of wound infections associated with the use of circular stapling devices to create the gastrojejunostomy. [21]

Signs of wound infections include unexplained fever, fluctuance, erythema, or drainage. Treatment consists of opening the affected area for drainage of infected fluid or pus, debridement of any devitalized tissue, and antibiotics if the surrounding skin suggests signs of cellulitis. The incidence of SSIs can be decreased by perioperative administration of antibiotics. [22]

In-Hospital Mortality

The intra-operative mortality is dependent upon multiple factors, including the technical difficulty of selected procedure (for example, BPD-DS technically more difficult than LAGB), patient selection (e.g., body habitus), presence of comorbid illnesses (e.g., COPD, congestive heart failure), skill of the surgeon (learning versus expert), institutional resources, and volume of procedures performed. While there are limited data available, the overall intra-operative mortality rates that are reported as well as the overall in-hospital mortality rates are typically <1% in most contemporary series. [23]

Pulmonary embolism (PE) remains the most common cause of mortality in the perioperative period after bariatric surgery, and accounts for approximately 30 – 50% of deaths. The mortality rate of a pulmonary embolism is dependent upon the severity of presentation and time to diagnosis/treatment, and widely varies from 1% to 95%. The majority of deaths occur within the first one to two hours after the embolism. [24]

Other common, serious causes of in-hospital mortality include cardiac events (12-17%), respiratory failure (11%), and septic complications related to an anastomotic leak (15%). [24]

30 DAYS MORBIDITY AND MORTALITY

Early morbidity and mortality rates that occur ≤30 days after the operation are generally low and vary with surgical approach, such as fewer complications and less mortality with the

laparoscopic than the open approach. Most patients have been discharged from the hospital during this one-month interval after the operation. Serious complications that occur during the in-hospital admission can also occur after discharge, such as a pulmonary embolus or myocardial infarction. The overall morbidity rate for serious complications ranges from approximately 3.4% to 12%, and varies with operative procedure (e.g., RYGB, LAGB), operative approach (open versus laparoscopic), patient age, body mass index (BMI), and comorbid illnesses. The morbidity associated with LAGB appears to be less than is seen with laparoscopic Roux-en-Y gastric bypass (LRYGB). The biliopancreatic diversion with duodenal switch (BPD-DS) appears to be the riskiest procedure with the highest 30-day mortality of 1.2%, and the one associated with the most complications and highest morbidity rates. [25-26]

Marginal Ulcers

Marginal ulcers typically occur within 30 days after the RYGB operations at the gastrojejunal anastomosis and at the gastroileal junction following a BPD-DS, despite bypass or removal of most of the acid secreting cells of the stomach. The risk of a marginal ulcer following bariatric operations varies between 1.2%and 12%. The clinical presentation of marginal ulcers includes melena, hematochezia, hematemesis, or pain and obstructive symptoms as the swollen mucosa can occlude the anastomosis to the small intestine. Early ulceration most likely is related to ischemia, too large of a pouch, or undiagnosed *Helicobacter pylori* (*H. pylori)* infection. [27]

Risk factors for late presentation of a marginal ulcer include smoking, nonsteroidal antiinflammatory drugs (NSAID), or gastrogastric fistula formation. Lifetime avoidance of smoking and NSAIDS is advised. If NSAIDS are necessary, a concomitant use of a proton pump inhibitor is advised. [28]

Stenosis

Stenosis occurs when the gastrojejunal anastomosis of a RYGB or gastroileal anastomosis of a BPD-DS becomes occluded secondary to tissue edema or a narrow anastomosis. Following a LSG, stenosis can occur if the sleeve narrows, kinks, or twists. A retrospective review of 230 patients found that the risk of stenosis following a LRYGB, BPD-DS, or LSG is approximately 3.3%, 1.2%, and 3.5%, respectively. [29]

The clinical presentation is consistent with an obstruction and includes nausea, vomiting, abdominal pain, and dysphagia. Endoscopic balloon dilation of the stenotic structure is the first management option.

Stomal Obstruction

Acute stomal obstruction is an early complication that can occur in up to 14% of LAGB patients. Obstruction is usually caused by inclusion of excess perigastric fat, use of a band of insufficient diameter for the thickness of the tissue, or significant tissue edema. Patients

usually present with persistent nausea, vomiting, and inability to tolerate secretions or oral intake. The diagnosis is confirmed with an upper gastrointestinal series demonstrating no passage of contrast beyond the band.

Acute stomal obstruction due to edema can initially be treated conservatively with nasogastric tube decompression until the edema subsides, although a potential for aspiration pneumonia and gastric ischemia exists. Persistent obstruction requires surgical revision or removal of the band. Meticulous removal of excess perigastric fat at the time of initial band placement may help prevent this complication. The use of larger diameter bands may also help to reduce the incidence of acute postoperative obstruction. [30]

30 Days Mortality

The overall 30-day postoperative mortality rate is generally less than 1% in most contemporary series. Mortality rates are higher for patients undergoing more complex operative procedures, or who sustain adverse intra-operative events or serious in-hospital complications (such as PE or acute respiratory failure [ARF]) as well as those with a BMI ≥50 kg/m^2, older age, and medical comorbidities. the mortality rate was greater for patients undergoing an open procedure compared with a laparoscopic procedure (0.79% versus 0.17%). The most common causes of death varied with the series but generally include pulmonary embolism, sepsis, complications of anastomotic leak, cardiac events, and small bowel obstruction.

Specific risk factors for mortality are male gender, older age (>65 years), excessive obesity (BMI ≥50 kg/m^2), comorbid illnesses, poor functional status, low-volume surgeons and hospitals (<100 procedures/year). [31,32]

LATE COMPLICATIONS

Complications of bariatric surgery that occur after 30 days include cholelithiasis, nutritional deficiencies, and neurologic and psychiatric complications.

Cholelithiasis

Cholelithiasis develops in as many as 38% of patients within six months of surgery, and up to 41% of such patients become symptomatic. Rapid weight loss can also contribute to the development of gallstones by increasing the lithogenicity of bile. The high frequency of cholelithiasis can be reduced to as low as 2% percent with a six month course of ursodeoxycholic acid given prophylactically after weight-loss surgery. The decision to perform a cholecystectomy at the time of bariatric surgery is controversial. Some surgeons recommend performing cholecystectomy at the same time if a patient has symptomatic gallstones preoperatively. The surgical opinion about asymptomatic gallstones is more divided, and studies have failed to demonstrate a benefit for simultaneous cholecystectomy for incidental gallstones.

Patients can also develop choledocholithiasis, which can be difficult to treat in the postoperative course of RYGB. Diagnosis of choledocholithiasis can be confirmed by ultrasound or magnetic resonance cholangiopancreatography (MRCP); however, endoscopic intervention and management can be difficult because of the relative inaccessibility to the duodenum due to the altered anatomy of the Roux-en-Y configuration. As a result, successful endoscopic retrograde cholangiopancreatography (ERCP) with cannulation of the papilla is very difficult to perform. Thus, treatment of choledocholithiasis may require surgery or transhepatic percutaneous access. [33,34]

Ventral Incisional Hernia

Ventral incisional hernias occur with a frequency of 0 - 1.8% in laparoscopic series and as high as 24% in open series, underscoring a clear advantage of the laparoscopic approach in this regard. Incisional hernias present with an enlarging bulge, pain, or obstructive symptoms. Severe obesity is associated with increased intra-abdominal pressure and thus, a high risk of hernia development after a laparotomy. Many surgeons postpone a formal repair until significant weight loss occurs (>1 year). Indications for early surgical repair include significant pain, bowel obstruction, and rapid enlargement of the hernia. [35]

COMPLICATIONS OF SPECIFIC BARIATRIC PROCEDURES

Roux-En-Y Gastric Bypass

Gastric Remnant Distension

Gastric remnant distension is a rare but potentially lethal complication following gastric bypass. The gastric remnant is a blind pouch and may become distended if paralytic ileus or distal mechanical obstruction occurs postoperatively. Iatrogenic injury to vagal fibers along the lesser curvature may also contribute, possibly by leading to impaired emptying of the bypassed stomach. Progressive distension can ultimately lead to rupture, spillage of massive gastric contents, and subsequent severe peritonitis. The combination of the large size of inoculum (liters) and the injurious contents (acid, bile, pancreatic enzymes, and bacteria) makes this complication much more serious than leakage occurring at the gastrojejunostomy.

Clinical features include pain, hiccups, left upper quadrant tympany, shoulder pain, abdominal distension, tachycardia, or shortness of breath. Radiographic assessment may demonstrate a large gastric air bubble.

Treatment consists of emergent operative decompression with a gastrostomy tube or percutaneous gastrostomy. Immediate operative exploration and decompression are required if percutaneous drainage is not feasible, or if perforation is suspected. Although gastrostomy is not performed routinely by most surgeons at the initial gastric bypass operation, drainage of the gastric remnant can prevent this rare but sometimes fatal complication. Routine gastrostomy should be considered in the elderly, super-obese patients, patients with diabetic gastropathy and as part of revisional surgeries where gastric emptying may be delayed. [36]

Dumping Syndrome

Dumping syndrome can occur in up to 50% of postgastric bypass patients when high levels of simple carbohydrates are ingested. Dumping may contribute to weight loss in part by causing the patient to modify the eating habits.

There are two types of dumping syndrome: early and late. [37]

- Early dumping syndrome — Early dumping syndrome has a rapid onset, usually within 15 minutes. It is the result of rapid emptying of food into the small bowel. Due to the hyperosmolality of the food, rapid fluid shifts from the plasma into the bowel occur, resulting in hypotension and a sympathetic nervous system response. Patients often present with colicky abdominal pain, diarrhea, nausea, and tachycardia. Patients should avoid foods that are high in simple sugar content and replace them with a diet consisting of high fiber, complex carbohydrate, and protein rich foods. Behavioral modification, such as small, frequent meals, and separating solids from liquid intake by 30 minutes, are also advocated. Usually, early dumping is self-limiting and resolves within 7 to 12 weeks.
- Late dumping syndrome — Late dumping syndrome is a result of the hyperglycemia and the subsequent insulin response leading to hypoglycemia that occurs 2 to 3 hours after a meal. Patients present with dizziness, fatigue, diaphoresis and weakness. The treatment is similar to early dumping syndrome.

Metabolic and Nutritional Derangements

Metabolic and nutritional derangements are common in severely obese patients and can be exacerbated following after bariatric surgery, making postoperative life-long compliance with appropriate dietary choices and vitamin supplementation imperative. Decreased oral intake as well as altered absorption of food from the stomach and small bowel reduces absorption of various micronutrients, particularly iron, calcium, vitamin B12, thiamine and folate. Hyperoxaluria and nephrolithiasis have been reported following Roux-en-Y gastric bypass surgery.

Change in Bowel Habits

Loss stool and diarrhea are more common after BPD and RYGB. Constipation is more common after gastric banding. Steatorrhea and more frequent stools can occur with excessive fat intake. In addition, these symptoms can be due to subclinical lactose intolerance, which is only recognized when dairy products are used in an effort to achieve adequate protein intake after bariatric surgery. [38]

Failure to Lose Weight and Weight Regain

Failure to lose weight following Roux-en-Y gastric bypass is rare, and is often due to maladaptive eating patterns during the early postoperative period. On the other hand, significant late weight regain occurs in up to 20% of patients, especially those with super-obesity (BMI >50 kg/m2) at the time of the initial operation. It is often due to progressive noncompliant eating and other behavioral habits, development of a functional gastrogastric fistula, gradual enlargement of the gastric pouch, or dilatation of the gastrojejunal anastomosis. [39]

Gastric Banding

Band Erosion

Band erosion through the wall of the stomach has been reported in up to 7% of GB patients, and it is thought to occur as a result of either gastric wall ischemia from an excessively tight band, mechanical trauma related to the band buckle or thermal trauma from electrosurgical energy sources used during band placement. Band erosion is a late complication and occurs at a mean of 22 months after surgery.

Clinical signs of band erosion include infection, failure of weight loss, or nausea and vomiting. Epigastric pain and hematemesis can also signal erosion of the lap band into the left gastric artery. This can happen when the lap band erodes into the posterior part of the stomach near the cardioesophageal junction. This complication can be avoided by careful placement during the initial surgery, making sure not to include the ascending branch of the left gastric artery during band placement.

Band erosion can be diagnosed by endoscopy and treatment involves removal of the band, which can be done laparoscopically. It is generally recommended that revision to another bariatric procedure be delayed for at least 2 to 3 months after an episode of band erosion, as the complication rate with immediate revision is increased. [40]

Band Slippage and Gastric Prolapse

Band slippage involves prolapse of part of the stomach through the band, with varying degrees of gastric obstruction. Slippage rates can be as high as 24%.

- Anterior prolapse involves migration of the band cephalad which creates an acute angle with the stomach pouch and esophagus, resulting in obstruction.
- Posterior gastric prolapse occurs when the stomach migrates cephalad, displacing the band caudally and creating a new pouch

Gastric prolapse is characterized by food intolerance, epigastric pain, and acid reflux. Diagnosis is confirmed with an upper gastrointestinal series demonstrating either malposition of the band or dilatation and prolapse of the gastric pouch.

Surgery is required urgently or emergently, depending on the presentation. Repair of the prolapse can sometimes be accomplished by repositioning the band, but often the band needs to be replaced or removed altogether, especially if significant inflammation is found. [41]

Port Malfunction

Port malfunction results if the tubing disconnects, subcutaneous port flips, or leakage within the system occurs. Such problems lead to inability to titrate the instilled volume of saline in the system. Reported incidence of port and tubing malfunction ranges from 0.4% to 7%. These problems usually become evident as an inability to access port and maintain band volume, or the development of weight gain. These complications require surgical repair or exchange of the hardware to attain band adjustability. Port dislocation can be reduced by attaching the port to a broad surface mesh first before anchoring to the rectus fascia. [42]

Esophagitis

Esophagitis and reflux are infrequent complications following Lap-Band. Deflation of the band and acid-suppression therapy are the mainstays of treatment. However, if intractable to medical therapy, band removal or conversion to other procedure such as RYGB may be necessary. [43]

Esophageal Dilatation

Esophageal dilatation proximal to the band device has been observed in as many as 10% of patients. This so-called "pseudoachalasia syndrome" may develop when the band is excessively inflated or in the setting of excessive amounts of food intake. Pouch dilatation has also been associated with a history of binge eating behavior. Patients often present with food and saliva intolerance, reflux and epigastric discomfort. The diagnosis can be confirmed with an upper gastrointestinal series.

The initial treatment should be removal of all the fluid from the band and behavioral diet modifications. This is usually successful in reversing esophageal dilatation. However, persistent dilatation may require replacement of the band in a new location on the stomach or conversion to a different procedure.

Deflation of the band alone is usually successful in reversing esophageal dilatation. However, persistent dilatation may require replacement of the band to a new location on the stomach or conversion to a different procedure. [44]

Hiatus Hernia

Hiatus hernia is often a pre-existing but unrecognized condition in patients undergoing bariatric surgery**.** This can lead to ongoing intractable reflux necessitating reoperation or band removal. Thus, a simple crural repair can be performed at the initial operation to avoid these complications. [45]

Sleeve Gastrectomy

Bleeding

Bleeding can occur from the gastric or short gastric vessels during dissection of the greater curve. Most of the bleeding problems associated with SG occur from the staple line after transection of the stomach. The bleeding is most likely a result of the large staples used for the thick tissue in the distal stomach. Large staples are not adequate to seal small vessels. This has led many surgeons to reinforce the staple line by over-sewing, buttressing or both. [46]

Stenosis

Narrowing or stenosis can create gastric outlet obstruction. The presentation varies depending on the severity of the obstruction and can include dysphagia, vomiting, dehydration and the inability to tolerate an oral diet.

The gastroesophageal junction and the incisura angularis are the two most common areas where stenosis occurs, and this can be diagnosed by an upper gastrointestinal series.

The most common reasons for the development of narrowing or stenosis are over-sewing the staple line and using a bougie that is too small. The preferable bougie size is currently debated in the literature and can range from 30 to 60 French. In most cases, surgeons use a 36 to 40 French bougie for the sleeve construction and the larger sizes of bougies are reserved for when SG is being performed as part of a staged procedure.

Management of stenosis primarily consists of endoscopic dilation. If the area of stenosis is too long, surgical intervention may be necessary with conversion to a RYGB, gastric stricturoplasty or resection with gastrogastrostomy. [47]

Gastric Leaks

Gastric leaks after SG are one of the most serious complications and can occur in up to 5.3% of patients.

Most leaks are due to local factors at the site of the staple line, such as inadequate blood supply and oxygenation, which impede the healing process. Leaks can also be due to gastric-wall heat ischemia, a consequence of the heat generated by the cautery used during dissection of the greater curve. Although the blood supply to the stomach is robust, the gastroesophageal junction tends to be an area of decreased vascularity and thus more prone to leaks. Additionally, the stomach tends to be thinner at the angle of His and some authors suggest that the large staple height used by many surgeons may not adequately seal this area of the stomach.

Some surgeons recommend leaving a small portion of stomach distal to the angle of His and then imbricating with a running suture. However, clinical studies have not provided evidence that reinforcing the suture line decreases the rate of leak after sleeve gastrectomy. Sleeve gastrectomy produces high intragastric pressure, which can affect the healing process and lengthen the amount of time for a leak to close. [48,49]

Reoperation with primary repair during the early postoperative course is the best option for a leak following SG. Clinically stable patients may be able to undergo percutaneous drainage, antibiotic therapy, and parenteral nutrition until the leak is healed. Endoscopic therapy with the use of stents has also been employed for management of leaks, but migration of the stents has been a problem. Early diagnosis, adequate drainage and gastric decompression are the mainstay of treatment for leaks. [50]

Reflux

Gastroesophageal reflux after SG presents with classic symptoms such as burning pain, heartburn, and regurgitation. It can occur as an early and late complication. The first-line treatment is antireflux medical therapy. GERD unresponsive to antireflux medical therapy with no clear anatomic abnormalities, such as stoma stenosis or a hiatal hernia, can be effectively treated by conversion to RYGB. [51]

Pure Malabsorptive Procedures (Biliopancreatic Diversion and Duodenal Switch)

Electrolyte Imbalances

Over half of the patients who underwent, malabsorptive procedures developed diarrhea and electrolyte imbalances, and these problems could persist more than five years after

surgery. Arthritis, protein malnutrition, vitamin deficiencies, cirrhosis, nephrolithiasis with oxalate stones and renal failure have also been associated. [52]

Renal Failure

Increased absorption of calcium oxalate leads to deposition in the renal parenchyma. This can lead to a postobstruction nephropathy and renal failure, which has been described in up to 20% of patients. Conversion to a gastric bypass or reversal should be considered in patients with metabolic complications. [53]

Cirrhosis

Hepatic abnormalities that may lead to cirrhosis can occur in up to 40% of patients and may persist or progress despite reversal in more than one-third of patients. Some patients have progressed to decompensated cirrhosis requiring transplantation. Progressive liver injury appears histologically as increasing steatosis, lobular lymphocytic inflammation, pericellular fibrosis, Mallory bodies, and deranged architecture, all features resembling those seen in alcoholic liver disease. [54]

IMPROVEMENT OF COMORBIDITIES

Weight Loss

Excess Body Weight

Excess body weight is defined as the amount of weight that is in excess of the ideal body weight. Ideal body weight is conventionally determined by the body mass index (BMI) <25 kg/m^2.

Based upon prospective studies and a randomized trial, the rate of weight loss varies with the specific bariatric procedures, as illustrated:

- For patients undergoing a Roux-en-Y Gastric Bypass (RYGB) or a sleeve gastrectomy (SG), weight loss occurs rapidly over the first few months, then continues over the next year to year and a half until weight loss reaches a plateau. During the first six months after RYGB, the average weight loss is 4.5 to 7 kg per month. Thus, average weight loss at the six-month follow up visit is 27 to 36 kg. Thereafter, the rate of weight loss tends to slow down to 2 to 3 kg per month, and total weight loss reaches a peak at 12 months postoperatively, averaging 45 to 54 kg.
- For patients who undergo an adjustable gastric band (AGB) procedure, weight loss is slower, with an anticipated one pound per week weight loss until stabilization is reached at approximately two years. Although most patients do well initially, some ultimately fail to sustain their improvement. Some AGB patients may not ever achieve significant weight loss. This highlights the importance of establishing a fundamental life-style change during the first one to two years after surgery in order to achieve long-term success in maintaining weight loss. [55-57]

Medical Comorbidities

Diabetes Mellitus

Bariatric surgical procedures are effective interventions for treating type 2 diabetes. Improvement in metabolic control is often evident within days to weeks following bariatric procedures, most likely reflecting an alteration in metabolism that is independent of weight loss. [58]

Three randomized trials illustrate the efficacy of weight loss surgery versus medical therapy alone:

- Obese patients with uncontrolled type II diabetes undergoing a RYGB or a SG plus medical therapy were significantly more likely to achieve the main outcome of a glycated hemoglobin level of 6.0 percent or less at 12 months compared with patients managed by intensive medical therapy alone (42% versus 37% versus 12%, respectively). [59]
- A randomized trial of 60 patients also found that obese diabetic patients undergoing a bariatric operation had better control than medical management alone. Obese patients (BMI ≥35) with a history of diabetes for five or more years and a glycated hemoglobin level ≥7.0 percent undergoing a RYGB or biliopancreatic diversion (BPD) were significantly more likely to achieve the study endpoint of remission of diabetes at two years compared with patients managed by medical therapy alone (75% versus 95% versus 0%, respectively). [60]
- A randomized trial that included 120 patients demonstrated that a RYGB procedure was superior to intensive medical management alone in achieving the main outcome measure of a glycated hemoglobin level of less than 7%. (75% versus 32%). [61]

Results following RYGB operation are promising and several trials are in progress to evaluate the procedure for patients with BMI <35 and poorly controlled type 2 diabetes. [62,63] Efficacious control of type 2 diabetes has also been demonstrated following a SG or an AGB.

In 2011, the American College of Surgeons Bariatric Surgery Center Network (ACS-BSCN) found that the remission or improvement was for patients undergoing RYGB, SG, and AGB. In a prospective, longitudinal study that included bariatric-specific data from more than 100 participating institutions and 28,616 obese diabetic patients, remission or improvement in diabetes at 12 months was achieved in 83 percent of patients undergoing a RYGB, 55 percent undergoing SG, and 44 percent undergoing an AGB. [64] This result has been corroborated by other studies demonstrating one-year remission or improvement of diabetes in 40% to 75% of patients who underwent a SG or an AGB. [27,28,65,66]. SG is an alternative procedure to RYGB for patients with BMI <50, the extremes of ages, and smokers.

In addition to glycemic control, improvement in distal peripheral neuropathy was identified following RYGB. An improvement or normalization of the Neuropathy Symptom Score (NSS) and the Neuropathy Deficit Score (NDS) in all patients has been found. [67]

Hypertension

The association between obesity and the development of hypertension is well established. Weight loss, whether by an intensive lifestyle-medical modification program or a bariatric operation, improves obesity-linked hypertension or contributes to remission. Patients undergoing a bariatric surgery plus intensive lifestyle medical management were able to achieve a similar reduction in systolic blood pressure at 12 months compared with patients managed with lifestyle medical modification alone. [68] While intensive lifestyle modification resulting in weight loss appears beneficial for resolution of hypertension, this is unfortunately not feasible for all patients, due to reasons such as lack of motivation or inability to exercise.

Data are unclear as to whether or not RYGB offers the highest resolution or reduction of hypertension of bariatric operations, as illustrated by several studies. [64,69]

Dyslipidemia

Obesity-linked dyslipidemia is a well-established risk factor for cardiovascular disease. [70] The most commonly encountered dyslipidemias in obese individuals include hypertriglyceridemia, decreased HDL-cholesterol values, and increased LDL-cholesterol particles. [71] Multiple studies have demonstrated improved lipid profiles following bariatric procedures. The most extensively studied procedure is the RYGB. Mean total cholesterol levels decreased by 16%, triglyceride levels decreased by 63%, LDL- cholesterol levels decreased by 31%, total cholesterol/HDL-cholesterol risk ratio decreased by 60%, and HDL-cholesterol levels increased by 39%. In addition, over 80% of patients requiring lipid-lowering medications preoperatively no longer required medical therapy. [72] Malabsorptive procedures obtain at least similar results of improvement of dyslipidemia. A recent study of our group has demonstrated that after SG, HDL-cholesterol values increase and Triglycerides levels decreased significantly. However, total and LDL-cholesterol remained unaltered of present nonsignificant improvements. Notwithstanding, mainly based on the HDL-cholesterol increase, the cardiovascular risk index present a significant improvement after surgery. [73]

Obstructive Sleep Apnea

An increased prevalence of obstructive sleep apnea in the obese population is well established. [74] Weight loss decreases apnea hypopnea index (AHI, the number of apneas and hypopneas per hour of sleep). In addition, weight loss achieved from bariatric operations also reduces AHI and appears to be similar to the efficacy of behavioral modification weight loss. However, a meta-analysis of 69 studies performed in 2013 identified a high rate of resolution or improvement in OSA following bariatric procedures. [75]

Gastroesophageal Reflux Disease

Obesity is a well-established risk factor for the development of gastroesophageal reflux disease (GERD). The impact of bariatric surgery on development, resolution, or exacerbation of GERD is an evolving topic of debate. Improvement of GERD may be dependent upon the type of bariatric procedure performed. RYGB may improve or ameliorate GERD symptoms. In addition, there is a significant improvement in esophagitis, presence of extraesophageal syndromes, use of proton pump inhibitors, and decreased total acid exposure. [76]

There are conflicting and inconclusive data on the association between AGB and prevalence of postoperative GERD. A systematic review that included 20 studies and 3307 obese patients undergoing AGB found a decrease in prevalence of postoperative GERD compared with the prevalence of preoperative one (7.7% versus 32.9%. In addition, the rate of use of anti-reflux medications decreased in the AGB postoperative period, the prevalence of pathologic reflux also decreased in the postoperative period, and the lower esophageal pressures improved after AGB. However, reflux symptoms developed in the postoperative period in 15% of patients who were asymptomatic preoperatively, and the rate of esophageal dysmotility increased following AGB. Based upon this review, it appears that AGB may have anti-reflux properties for some obese patients, but the procedure may also be associated with the development or worsening of reflux symptoms. [77]

While also highly debated, SG may be the least efficacious procedure to reduce postoperative GERD. In a systematic review of 11 prospective and retrospective studies that included 1058 patients, seven studies identified a decrease in GERD prevalence and four studies found an increase in GERD. [78] This lack of consensus regarding the association between SG and GERD was again reiterated during the 2011 International Sleeve Gastrectomy Expert Panel Consensus Statement where no consensus was reached regarding performance of sleeve gastrectomy in patients with gastric reflux. [79] Based on these data, we consider that preoperative GERD is a relative contraindication for undergoing a SG and in such cases we prefer performing a RYGB. [73]

Polycystic Ovary Syndrome

Polycystic ovarian syndrome (PCOS) is found in 30% to 70% of obese women of reproductive age and is associated with a high risk of infertility. [80] Weight reduction through diet and exercise and lifestyle modification can improve the hyperandrogenemic symptoms and insulin resistance associated with PCOS. Bariatric surgery is an alternative strategy for weight loss in women with PCOS. Obese women who effectively achieved weight loss following a RYGB had restored menstrual cycles at approximately three to four months following the operation, marked lessening of hirsutism and hyperandrogenemia at eight months, and an increased ability to conceive within two years of surgery. Similar studies have not been published for adjustable gastric band or sleeve gastrectomy. [81,82]

Oncologic

The association between obesity and certain cancers, such as breast, endometrial, colon, renal, and pancreatic cancers has been well established. Obesity also increases the likelihood of worse oncologic outcomes. The impact of bariatric surgery on oncologic outcome is difficult to assess in a short-term time frame, as longer time intervals are necessary to establish true risk reduction. [83-85]

Nonalcoholic Fatty Liver Disease (NAFLD)

Nonalcoholic fatty liver disease (NAFLD) is one of the most common causes of chronic liver disease worldwide, and morbid obesity is strongly associated with its development. [86] NAFLD is subdivided into nonalcoholic fatty liver (NAFL), hepatic steatosis without inflammation, and nonalcoholic steatohepatitis (NASH), which is associated with inflammation and can be indistinguishable histologically from alcoholic steatohepatitis.

The general approach to the overweight or obese patient with NAFLD or NASH is lifestyle modification and weight loss. [87] Histologic improvement has also been observed in some patients with NAFLD or NASH after bariatric surgery. At this time, it is not advised to perform a bariatric operation specifically for the purpose of improving NAFLD or NASH, nor is the optimal bariatric procedure yet identified. Given the potential for worsening fibrosis in some patients following bariatric surgery, patients should continue to have liver function tests monitored closely. [88]

PSYCHOSOCIAL EFFECT AND IMPACT ON QUALITY OF LIFE

Psychological Impact

Effective outcomes following bariatric surgery include psychosocial improvements. [89] There is a general tendency for patients with psychopathologic disorders to improve or normalize after bariatric surgery. [89-93] This may occur because patients take an active role in changing their lives, even while they are still overweight. [94-95]

- A prospective study that included 200 patients undergoing gastric bypass surgery found postoperative improvement at 20, 40, and 92 weeks in health-related (Short-Form 36) and weight-related (Impact of Weight on Quality of Life) quality of life surveys compared with the preoperative responses. [96]
- The Body Shape Questionnaire (BSQ) measures preoccupation with one's body shape and the Shape and Weight Concern subscales of the Eating Disorder Examination-Questionnaire (EDE-Q) assesses dissatisfaction, preoccupation, discomfort, and overvaluation of body shape. For 109 patients undergoing RYGB, responses to BSQ and EDE-Q surveys at 6 months and 12 months after RYGB were improved compared with preoperative responses. [97] In addition, over 80% of female patients had body image scores comparable with published normal values.

There are, at present, no data from prospective studies that assess the psychosocial impact of a sleeve gastrectomy (SG). Based upon the studies that show improvement with weight loss associated with RYGB and AGB, it is reasonable to surmise that patients undergoing a SG would also experience a similar benefit.

However, not all patients experience psychosocial improvement following bariatric surgery. Lack of improved psychosocial function may accompany lack of postoperative weight loss, some may initially improve but later experience declines of function even with maintenance of weight, and others lag behind functioning of normal patients. [89,92,94]

Impact on Quality of Life

Altogether, the improvement of most comorbidities associated with morbid obesity, and the increasing self-esteem based on esthetic reasons, leads to a significant improvement of the quality of life. The patients feel healthier and this has a positive psychological impact. There are many scales available to evaluate quality of life, but all of them coincide in that bariatric

surgery achieves a significant improvement in the quality of life of morbidly obese patients. [92-94]

REFERENCES

[1] Encinosa WE, Bernard DM, Du D, Steiner CA. Recent improvements in bariatric surgery outcomes. *Med Care* 2009; 47:531-5.

[2] Longitudinal Assessment of Bariatric Surgery (LABS) Consortium, Flum DR, Belle SH, et al. Perioperative safety in the longitudinal assessment of bariatric surgery. *N Engl J Med* 2009; 361:445-54.

[3] Lancaster RT, Hutter MM. Bands and bypasses: 30-day morbidity and mortality of bariatric surgical procedures as assessed by prospective, multi-center, risk-adjusted ACS-NSQIP data. *Surg Endosc 2008*; 22:2554-63.

[4] Ahmad G, Duffy JM, Phillips K, Watson A. Laparoscopic entry techniques. *Cochrane Database Syst Rev* 2008; :CD006583.

[5] Peters TG, Steinmetz SR, Cowan GS Jr. Splenic injury and repair during bariatric surgical procedures. *South Med J* 1990; 83:166-9.

[6] Huerta S, Li Z, Livingston EH. Outcome of portal injuries following bariatric operations. *Obes Surg* 2006; 16:105-9.

[7] Al-Khyatt W, Thomas JD, Humes DJ, Lobo DN. Intestinal ischemia following laparoscopic surgery: a case series. *J Med Case Rep* 2013; 7:25.

[8] Mitchell MT, Gasparaitis AE, Alverdy JC. Imaging findings in Roux-en-O and other misconstructions: rare but serious complications of Roux-en-Y gastric bypass surgery. AJR *Am J Roentgenol* 2008; 190:367-73.

[9] Stroh C, Köckerling F, Weiner R, et al. Are there gender-specific aspects of sleeve gastrectomy-data analysis from the quality assurance study of surgical treatment of obesity in Germany. *Obes Surg* 2012; 22:1214-9.

[10] Gentileschi P, Camperchioli I, D'Ugo S, et al. Staple-line reinforcement during laparoscopic sleeve gastrectomy using three different techniques: a randomized trial. *Surg Endosc* 2012; 26:2623-9.

[11] Lim RB, Blackburn GL, Jones DB. Benchmarking best practices in weight loss surgery. *Curr Probl Surg* 2010; 47:79-174.

[12] Madan AK, Stoecklein HH, Ternovits CA, et al. Predictive value of upper gastrointestinal studies versus clinical signs for gastrointestinal leaks after laparoscopic gastric bypass. *Surg Endosc* 2007; 21:194-6.

[13] Gonzalez R, Sarr MG, Smith CD, et al. Diagnosis and contemporary management of anastomotic leaks after gastric bypass for obesity. *J Am Coll Surg* 2007; 204:47-55.

[14] Wittgrove AC, Clark GW. Laparoscopic gastric bypass, Roux-en-Y- 500 patients: technique and results, with 3-60 month follow-up. *Obes Surg* 2000; 10:233-9.

[15] Frezza EE, Reddy S, Gee LL, Wachtel MS. Complications after sleeve gastrectomy for morbid obesity. *Obes Surg* 2009; 19:684-7.

[16] Lalor PF, Tucker ON, Szomstein S, Rosenthal RJ. Complications after laparoscopic sleeve gastrectomy. *Surg Obes Relat Dis* 2008; 4:33-8.

[17] Winegar DA, Sherif B, Pate V, DeMaria EJ. Venous thromboembolism after bariatric surgery performed by Bariatric Surgery Center of Excellence Participants: analysis of the Bariatric Outcomes Longitudinal Database. *Surg Obes Relat Dis* 2011; 7:181-8.

[18] American Society for Metabolic and Bariatric Surgery Clinical Issues Committee. ASMBS updated position statement on prophylactic measures to reduce the risk of venous thromboembolism in bariatric surgery patients. *Surg Obes Relat Dis* 2013; 9:493-7.

[19] Caruana JA, Anain PM, Pham DT. The pulmonary embolism risk score system reduces the incidence and mortality of pulmonary embolism after gastric bypass. *Surgery* 2009; 146:678-83.

[20] Masoomi H, Reavis KM, Smith BR, et al. Risk factors for acute respiratory failure in bariatric surgery: data from the Nationwide Inpatient Sample, 2006-2008. *Surg Obes Relat Dis* 2013; 9:277-81.

[21] Nelson DW, Blair KS, Martin MJ. Analysis of obesity-related outcomes and bariatric failure rates with the duodenal switch vs gastric bypass for morbid obesity. *Arch Surg* 2012; 147:847-54.

[22] Bohdjalian A, Langer FB, Kranner A, et al. Circular- vs. linear-stapled gastrojejunostomy in laparoscopic Roux-en-Y gastric bypass. *Obes Surg* 2010; 20:440-6.

[23] Buchwald H, Avidor Y, Braunwald E, et al. Bariatric surgery: a systematic review and meta-analysis. *JAMA* 2004; 292:1724-37.

[24] Stephens DJ, Saunders JK, Belsley S, et al. Short-term outcomes for super-super obese (BMI > or =60 kg/m2) patients undergoing weight loss surgery at a high-volume bariatric surgery center: laparoscopic adjustable gastric banding, laparoscopic gastric bypass, and open tubular gastric bypass. *Surg Obes Relat Dis* 2008; 4:408-15.

[25] Blackstone RP, Cortés MC. Metabolic acuity score: effect on major complications after bariatric surgery. *Surg Obes Relat Dis* 2010;6:267-73.

[26] Prachand VN, Davee RT, Alverdy JC. Duodenal switch provides superior weight loss in the super-obese (BMI > or =50 kg/m2) compared with gastric bypass. *Ann Surg.* 2006;244:611-9.

[27] Csendes A, Burgos AM, Altuve J, Bonacic S. Incidence of marginal ulcer 1 month and 1 to 2 years after gastric bypass: a prospective consecutive endoscopic evaluation of 442 patients with morbid obesity. *Obes Surg* 2009; 19:135-8.

[28] Azagury DE, Abu Dayyeh BK, Greenwalt IT, Thompson CC. Marginal ulceration after Roux-en-Y gastric bypass surgery: characteristics, risk factors, treatment, and outcomes. *Endoscopy* 2011; 43:950-4.

[29] Parikh A, Alley JB, Peterson RM, et al. Management options for symptomatic stenosis after laparoscopic vertical sleeve gastrectomy in the morbidly obese. *Surg Endosc* 2012; 26:738-46.

[30] Gravante G, Araco A, Araco F, et al. Laparoscopic adjustable gastric bandings: a prospective randomized study of 400 operations performed with 2 different devices. *Arch Surg* 2007; 142:958-61.

[31] Ballantyne GH, Belsley S, Stephens D, et al. Bariatric surgery: low mortality at a high-volume center. *Obes Surg* 2008; 18:660-7.

[32] Nguyen NT, Masoomi H, Laugenour K, et al. Predictive factors of mortality in bariatric surgery: data from the Nationwide Inpatient Sample. *Surgery* 2011; 150:347-51.

[33] Villegas L, Schneider B, Provost D, et al. Is routine cholecystectomy required during laparoscopic gastric bypass? *Obes Surg* 2004; 14:206-11.
[34] Hamad GG, Ikramuddin S, Gourash WF, Schauer PR. Elective cholecystectomy during laparoscopic Roux-en-Y gastric bypass: is it worth the wait? *Obes Surg* 2003; 13:76-81.
[35] Lee S, Carmody B, Wolfe L, et al. Effect of location and speed of diagnosis on anastomotic leak outcomes in 3828 gastric bypass cases. *J Gastrointest Surg* 2007; 11:708-13.
[36] Nguyen NT, Ho HS, Palmer LS, Wolfe BM. A comparison study of laparoscopic versus open gastric bypass for morbid obesity. *J Am Coll Surg* 2000; 191:149-55.
[37] Ukleja A. Dumping syndrome: pathophysiology and treatment. *Nutr Clin Pract* 2005; 20:517-25.
[38] Potoczna N, Harfmann S, Steffen R, et al. Bowel habits after bariatric surgery. *Obes Surg* 2008; 18:1287-96.
[39] Kalarchian MA, Marcus MD, Wilson GT, et al. Binge eating among gastric bypass patients at long-term follow-up. *Obes Surg* 2002; 12:270-5.
[40] Brown WA, Egberts KJ, Franke-Richard D, et al. Erosions after laparoscopic adjustable gastric banding: diagnosis and management. *Ann Surg* 2013; 257:1047-52.
[41] Abuzeid AW, Banerjea A, Timmis B, Hashemi M. Gastric slippage as an emergency: diagnosis and management. *Obes Surg* 2007; 17:559-61.
[42] Fabry H, Van Hee R, Hendrickx L, Totté E. A technique for prevention of port complications after laparoscopic adjustable silicone gastric banding. *Obes Surg* 2002; 12:285-8.
[43] Rubenstein RB. Laparoscopic adjustable gastric banding at a U.S. center with up to 3-year follow-up. *Obes Surg* 2002; 12:380-4.
[44] Poole N, Al Atar A, Bidlake L, et al. Pouch dilatation following laparoscopic adjustable gastric banding: psychobehavioral factors (can psychiatrists predict pouch dilatation?). *Obes Surg* 2004; 14:798-801.
[45] Gulkarov I, Wetterau M, Ren CJ, Fielding GA. Hiatal hernia repair at the initial laparoscopic adjustable gastric band operation reduces the need for reoperation. *Surg Endosc* 2008; 22:1035-41.
[46] Frezza EE, Reddy S, Gee LL, Wachtel MS. Complications after sleeve gastrectomy for morbid obesity. *Obes Surg* 2009; 19:684-7.
[47] Dapri G, Cadière GB, Himpens J. Laparoscopic seromyotomy for long stenosis after sleeve gastrectomy with or without duodenal switch. *Obes Surg* 2009; 19:495-9.
[48] Arias E, Martínez PR, Ka Ming Li V, et al. Mid-term follow-up after sleeve gastrectomy as a final approach for morbid obesity. *Obes Surg* 2009; 19:544-8.
[49] Burgos AM, Braghetto I, Csendes A, et al. Gastric leak after laparoscopic-sleeve gastrectomy for obesity. *Obes Surg* 2009; 19:1672-7.
[50] Oshiro T, Kasama K, Umezawa A, et al. Successful management of refractory staple line leakage at the esophagogastric junction after a sleeve gastrectomy using the HANAROSTENT. *Obes Surg* 2010; 20:530-4.
[51] Langer FB, Bohdjalian A, Shakeri-Leidenmühler S, et al. Conversion from sleeve gastrectomy to Roux-en-Y gastric bypass--indications and outcome. *Obes Surg* 2010; 20:835-40.
[52] Markowitz JS, Seu P, Goss JA, et al. Liver transplantation for decompensated cirrhosis after jejunoileal bypass: a strategy for management. *Transplantation* 1998; 65:570-2.

[53] Requarth JA, Burchard KW, Colacchio TA, et al. Long-term morbidity following jejunoileal bypass. The continuing potential need for surgical reversal. *Arch Surg* 1995; 130:318-25.

[54] Dean P, Joshi S, Kaminski DL. Long-term outcome of reversal of small intestinal bypass operations. *Am J Surg* 1990; 159:118-23.

[55] *BMI classification*. World Health Organization. apps.who.int/bmi/index.jsp?intro Page=intro_3.html (Accessed on August 29, 2013).

[56] Cunneen SA. Review of meta-analytic comparisons of bariatric surgery with a focus on laparoscopic adjustable gastric banding. *Surg Obes Relat Dis.* 2008;4:S47-55.

[57] Ballantyne GH. Measuring outcomes following bariatric surgery: weight loss parameters, improvement in co-morbid conditions, change in quality of life and patient satisfaction. *Obes Surg* 2003; 13:954-64.

[58] Rubino F. Is type 2 diabetes an operable intestinal disease? A provocative yet reasonable hypothesis. *Diabetes Care* 2008; 31 Suppl 2:S290-6.

[59] Schauer PR, Kashyap SR, Wolski K, et al. Bariatric surgery versus intensive medical therapy in obese patients with diabetes. *N Engl J Med* 2012; 366:1567-76.

[60] Mingrone G, Panunzi S, De Gaetano A, et al. Bariatric surgery versus conventional medical therapy for type 2 diabetes. *N Engl J Med* 2012; 366:1577-85.

[61] Ikramuddin S, Korner J, Lee WJ, et al. Roux-en-Y gastric bypass vs intensive medical management for the control of type 2 diabetes, hypertension, and hyperlipidemia: the Diabetes Surgery Study randomized clinical trial. *JAMA* 2013; 309:2240.-9

[62] Rubino F, Kaplan LM, Schauer PR, et al. The Diabetes Surgery Summit consensus conference: recommendations for the evaluation and use of gastrointestinal surgery to treat type 2 diabetes mellitus. *Ann Surg* 2010; 251:399-405.

[63] Kenngott HG, Clemens G, Gondan M, et al. DiaSurg 2 trial - surgical vs. medical treatment of insulin-dependent type 2 diabetes mellitus in patients with a body mass index between 26 and 35 kg/m2: study protocol of a randomized controlled multicenter trial - DRKS00004550. *Trials* 2013; 14:183.

[64] Hutter MM, Schirmer BD, Jones DB, et al. First report from the American College of Surgeons Bariatric Surgery Center Network: laparoscopic sleeve gastrectomy has morbidity and effectiveness positioned between the band and the bypass. *Ann Surg* 2011; 254:410-20.

[65] Dixon JB, O'Brien PE, Playfair J, et al. Adjustable gastric banding and conventional therapy for type 2 diabetes: a randomized controlled trial. *JAMA* 2008; 299:316-23.

[66] Ahn SM, Pomp A, Rubino F. Metabolic surgery for type 2 diabetes. *Ann N Y Acad Sci* 2010; 1212:E37-45.

[67] Müller-Stich BP, Fischer L, Kenngott HG, et al. Gastric bypass leads to improvement of diabetic neuropathy independent of glucose normalization--results of a prospective cohort study (DiaSurg 1 study). *Ann Surg* 2013; 258:760-5.

[68] Ikramuddin S, Korner J, Lee WJ, et al. Roux-en-Y gastric bypass vs intensive medical management for the control of type 2 diabetes, hypertension, and hyperlipidemia: the Diabetes Surgery Study randomized clinical trial. *JAMA* 2013; 309:2240-9.

[69] Zhang N, Maffei A, Cerabona T, et al. Reduction in obesity-related comorbidities: is gastric bypass better than sleeve gastrectomy? *Surg Endosc* 2013; 27:1273-80.

[70] Anderson KM, Castelli WP, Levy D. Cholesterol and mortality. 30 years of follow-up from the Framingham study. *JAMA* 1987; 257:2176-80.

[71] Joshi AV, Day D, Lubowski TJ, Ambegaonkar A. Relationship between obesity and cardiovascular risk factors: findings from a multi-state screening project in the United States. *Curr Med Res Opin* 2005; 21:1755-61.
[72] Nguyen NT, Varela E, Sabio A, et al. Resolution of hyperlipidemia after laparoscopic Roux-en-Y gastric bypass. *J Am Coll Surg* 2006; 203:24-9.
[73] Ruiz-Tovar J, Oller I, Tomas A, et al. Midterm impact of sleeve gastrectomy, calibrated with a 50-Fr bougie, on weight loss, glucose hemostasis, lipid profiles and comorbidities in morbidly obese patients. *Am Surg* 2012;78:969-74.
[74] Redline S, Budhiraja R, Kapur V, et al. The scoring of respiratory events in sleep: reliability and validity. *J Clin Sleep Med* 2007; 3:169-200.
[75] Sarkhosh K, Switzer NJ, El-Hadi M, et al. The impact of bariatric surgery on obstructive sleep apnea: a systematic review. *Obes Surg* 2013; 23:414-23.
[76] Madalosso CA, Gurski RR, Callegari-Jacques SM, et al. The impact of gastric bypass on gastroesophageal reflux disease in patients with morbid obesity: a prospective study based on the Montreal Consensus. *Ann Surg* 2010; 251:244-8.
[77] de Jong JR, Besselink MG, van Ramshorst B, et al. Effects of adjustable gastric banding on gastroesophageal reflux and esophageal motility: a systematic review. *Obes Rev* 2010; 11:297-305.
[78] Chiu S, Birch DW, Shi X, et al. Effect of sleeve gastrectomy on gastroesophageal reflux disease: a systematic review. *Surg Obes Relat Dis* 2011; 7:510-5.
[79] Rosenthal RJ, International Sleeve Gastrectomy Expert Panel, Diaz AA, et al. International Sleeve Gastrectomy Expert Panel Consensus Statement: best practice guidelines based on experience of >12,000 cases. *Surg Obes Relat Dis* 2012; 8:8-19.
[80] Vrbikova J, Hainer V. Obesity and polycystic ovary syndrome. *Obes Facts* 2009; 2:26-35.
[81] Eid GM, Cottam DR, Velcu LM, et al. Effective treatment of polycystic ovarian syndrome with Roux-en-Y gastric bypass. *Surg Obes Relat Dis* 2005; 1:77-80.
[82] Escobar-Morreale HF, Botella-Carretero JI, Alvarez-Blasco F, et al. The polycystic ovary syndrome associated with morbid obesity may resolve after weight loss induced by bariatric surgery. *J Clin Endocrinol Metab* 2005; 90:6364-9.
[83] Raghavendra RS, Kini D. Benign, premalignant, and malignant lesions encountered in bariatric surgery. *JSLS* 2012; 16:360-72.
[84] Basen-Engquist K, Chang M. Obesity and cancer risk: recent review and evidence. *Curr Oncol Rep* 2011; 13:71-6.
[85] Bardou M, Barkun AN, Martel M. Obesity and colorectal cancer. *Gut* 2013; 62:933-47.
[86] Hafeez S, Ahmed MH. Bariatric surgery as potential treatment for nonalcoholic fatty liver disease: a future treatment by choice or by chance*? J Obes* 2013; 2013:839275.
[87] Day CP. Non-alcoholic fatty liver disease: current concepts and management strategies. *Clin Med* 2006; 6:19-25.
[88] Tai CM, Huang CK, Hwang JC, et al. Improvement of nonalcoholic fatty liver disease after bariatric surgery in morbidly obese Chinese patients. *Obes Surg* 2012; 22:1016-21.
[89] van Hout GC, Boekestein P, Fortuin FA, et al. Psychosocial functioning following bariatric surgery. *Obes Surg* 2006; 16:787-94.
[90] Mamplekou E, Komesidou V, Bissias Ch, et al. Psychological condition and quality of life in patients with morbid obesity before and after surgical weight loss. *Obes Surg* 2005; 15:1177-84.

[91] Green AE, Dymek-Valentine M, Pytluk S, et al. Psychosocial outcome of gastric bypass surgery for patients with and without binge eating. *Obes Surg* 2004; 14:975-85.
[92] Papageorgiou GM, Papakonstantinou A, Mamplekou E, et al. Pre- and postoperative psychological characteristics in morbidly obese patients. *Obes Surg* 2002; 12:534-9.
[93] van Hout GC, van Oudheusden I, van Heck GL. Psychological profile of the morbidly obese. *Obes Surg* 2004; 14:579-88.
[94] Guisado JA, Vaz FJ. Personality profiles of the morbidly obese after vertical banded gastroplasty. *Obes Surg* 2003; 13:394-8.
[95] Buddeberg-Fischer B, Klaghofer R, Sigrist S, Buddeberg C. Impact of psychosocial stress and symptoms on indication for bariatric surgery and outcome in morbidly obese patients. *Obes Surg* 2004; 14:361-9.
[96] Sarwer DB, Wadden TA, Moore RH, et al. Changes in quality of life and body image after gastric bypass surgery. *Surg Obes Relat Dis* 2010; 6:608-14.
[97] Hrabosky JI, Masheb RM, White MA, et al. A prospective study of body dissatisfaction and concerns in extremely obese gastric bypass patients: 6- and 12-month postoperative outcomes. *Obes Surg* 2006; 16:1615-21.

In: Encyclopedia of Surgery (22 Volume Set)
Editors: Andreas Lehrer and Kristin Mueller
ISBN: 978-1-53618-329-0
© 2020 Nova Science Publishers, Inc.

Chapter 10

ADJUSTABLE GASTRIC BANDING SURGERY: IMPACT ON INFLAMMATION AND IRON METABOLISM

Cristina Catarino[1,2], Susana Coimbra[2,3], Luís Belo[1,2], Luís Monteiro[4], Elísio Costa[1,2] and Alice Santos-Silva[1,2]

[1]Laboratório de Bioquímica, Departamento de Ciências Biológicas, Faculdade de Farmácia, Universidade do Porto (FFUP), Porto, Portugal
[2]Instituto de Biologia MolecuIar e Celular, IBMC, Universidade do Porto, Porto, Portugal
[3]CESPU, Instituto de Investigação e Formação Avançada em Ciências e Tecnologias da Saúde, GRD-Paredes, Portugal
[4]Hospital da Prelada-Dr. Domingos Braga da Cruz, Porto, Portugal

ABSTRACT

Obesity is increasing all over the world both in developed and underdeveloped countries and is known to be associated with inflammatory changes, insulin resistance and with a hyperlipidemic state. The adipocyte is an important source of adipokines, such as adiponectin, leptin, interleukin (IL)-6 and tumor necrosis factor alpha, and their levels are significantly altered in the plasma of obese patients. Some of these adipokines are known to be associated with dyslipidemia, insulin resistance, vascular dysfunction, and inflammation, and seem to contribute to the development of cardiovascular disease (CVD). Moreover, some inflammatory markers, such as C-reactive protein (CRP), show an independent positive association with body mass index (BMI), and with increased CVD risk.

Cardiovascular morbidity and mortality is associated with the classic risk factors, dyslipidemia, hypertension and impaired glucose metabolism. More recently, inflammatory mechanisms have been accepted as important players in the development of atherosclerotic vascular disease. Obesity, an inflammatory condition, is also an important CVD risk factor.

Recently, it was found that the adipose tissue also expresses hepcidin, and, therefore, may have a direct involvement in iron metabolism. Indeed, obesity is also known to be associated with iron deficiency. The synthesis of hepcidin, an acute phase protein that regulates iron availability, is enhanced in obesity, through IL-6 and leptin secretion by adipose tissue, and may lead to iron deficiency.

Gastric band surgery is a safe surgical procedure for the treatment of morbid obesity, almost without mortality in the perioperative period and a low long-term mortality rate from unrelated causes. Using laparoscopic surgery a gradual, continuous and well-programmed weight loss, is achieved, as well as, a post-operative increasing quality of life and the co-morbidities associated with obesity are also reduced in 75% of patients.

In this book chapter, we will focus on the relationship between obesity, adipose tissue, inflammation and iron metabolism, and we will discuss the impact of gastric banding in the cross-talk between these important factors in obesity.

INTRODUCTION

According to the World Health Organization (WHO), obesity affects 35% of the population, [1] and its prevalence is rapidly increasing worldwide, both in developed and underdeveloped countries. Its development has been associated with genetic and environmental factors. Considering that eating habits, with high caloric diets, sedentary lifestyle and reduced levels of physical activity contribute significantly for weight gain, and that the genetics of populations did not change significantly in the last years, the environmental component appears to be very important for the actual obesity prevalence.

Body mass index (BMI) is a simple index, commonly used to classify underweight, overweight and obesity in adults. According to a recent study, [2] individuals with a BMI of 22.5–25.0 kg/m^2 had a normal survival, while individuals with moderate (BMI of 30.0-35.0 kg/m^2) and extreme obesity (BMI of 40.0-50.0 kg/m^2) presented a reduction in life expectancy of 3 and 10 years, respectively. There are several measurements for abdominal adiposity, namely, waist circumference (WC), [3] waist:hip ratio [4]and waist:height ratio. [5] The BMI might be misleading when measuring abdominal adiposity as individuals with a normal BMI may present a large WC. The evaluation of abdominal adiposity is important due to its association with several metabolic dysfunctions, such as, glucose intolerance, reduced insulin sensitivity and adverse lipid profiles.

Actually, obesity, especially abdominal obesity, is considered a strong risk factor for insulin resistance and, as a consequence, for type 2 diabetes *mellitus* (T2DM), [6] as well as, for cardiovascular disease (CVD) events. [7] Obesity has been associated also with inflammatory changes and an hyperlipidemic state, besides insulin resistance, and with an increased risk of CVD events. A hallmark of aging in humans is an increase of adipose mass, especially visceral adipose mass, which is an independent risk factor for chronic heart failure in older people. [8] Moreover, obesity increases the risk of ischemic heart disease, stroke, hypertension, obstructive sleep apnea, degenerative joint conditions, and multiple cancers. [9]

Cardiovascular morbidity and mortality is associated with the classic risk factors, namely dyslipidemia, hypertension and impaired glucose metabolism. However, more recently, inflammatory mechanisms were recognized as playing a vital role in initiation, maintenance and progression of atherosclerotic vascular disease. Atherosclerosis is an inflammatory disease with the participation of leukocytes and several cytokines.

Adipose tissue is an active endocrine organ that secretes several cytokines, known as adipokines. Most of these adipokines are known to interfere with insulin resistance, glucose and lipid metabolism and with the inflammatory process, [10] favoring CVD. Moreover, obesity usually presents a low-grade chronic inflammation, with increased levels of several

pro-inflammatory cytokines and acute phase reactants, such as tumour necrosis factor (TNF)-α, interleukin (IL)-1, IL-6 and C-reactive protein (CRP), that are positively correlated with BMI. [11, 12] Therefore, the prevention of obesity assumes a particular importance in human health, quality of life and longevity.

OBESITY AND ADIPOKINES

Adipokines contribute to appetite regulation and energy expenditure and play an important role in insulin sensitivity, oxidative capacity and lipid uptake. However, in obesity, the amount and characteristics of the adipose tissue is altered, promoting changes in adipokine profile. With obesity, the adipocytes become hypertrophic, inducing hypoxia and an inflammatory response. Moreover, the enhancement of adipose tissue leads to increased macrophage infiltration. Macrophages of the adipose tissue are likely to be an important source of pro-inflammatory cytokines, such as TNF-α and IL-6. [13, 14] It is known that expansion of the adipose tissue during weight gain leads to a recruitment of macrophages into the adipose tissue. [15] Apparently, macrophage infiltration of the white adipose tissue increases with BMI and with adipocyte hypertrophy. [16, 17] The increase in fat mass is associated with alterations in the adipokine profile, favoring hypertension, insulin resistance, dyslipidemia, inflammation and atherogenesis (Figure 1). Herein we will review some of the adipokines, especially their role in inflammation, iron metabolism and CVD risk.

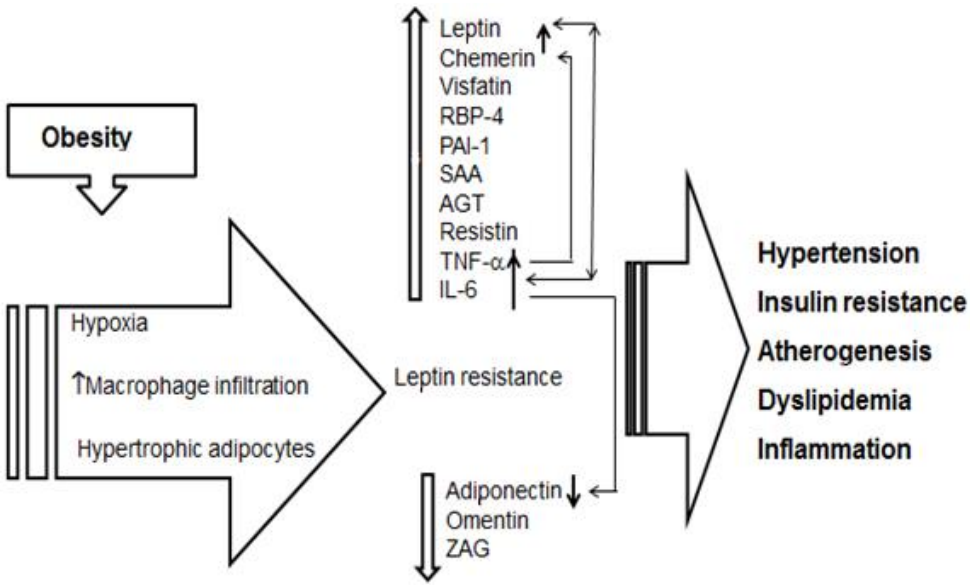

Figure 1. Obesity, adipokine profile and related comorbidities. (AGT, angiotensinogen; IL, interleukin; PAI-1, plasminogen activator inhibitor-1; RBP-4, retinol biding protein-4; SAA, serum amyloid A; TNF-α, tumor necrosis factor-α; ZAG, zinc-α2-glycoprotein).

Leptin controls adipose tissue growth via its central nervous system. Leptin controls food intake, by reducing appetite, body weight and fat stores; their blood levels increase with body fat mass. High levels of leptin enhance T-helper (Th)1 immune responses, suppress Th2

immune responses and increase macrophage activity, with production of different cytokines, namely, TNF-α and IL-6, [18] contributing to the low grade inflammatory state, commonly associated with obesity. It also interferes with antioxidant capacity, increasing reactive oxygen-species (ROS) production and inducible nitric oxide-synthase (iNOS) synthesis. Reduction in leptin activity leads to severe insulin resistance and vascular dysfunction. [18, 19] Leptin levels are known to be enhanced in obesity, [20] however, it seems that a resistance to leptin develops, explaining its reduced activity in obesity. [20] Leptin resistance can be explained by several mechanisms, including defects in leptin transport across the blood–brain barrier, impaired neuronal leptin signaling in target neurons or altered signaling in downstream target cells and neurocircuits. [21]

Chemerin is also an adipose tissue cytokine that has been associated with inflammation, adipogenesis, and with glucose and lipid metabolisms. [22, 23] It has a crucial role in adipocyte differentiation and development, and it may act as a modulator of different metabolic pathways in the mature adipocyte. [23, 24] Chemerin appears to act as modulator of the expression of adipocyte genes involved in glucose and lipid homeostasis. [23] Moreover, chemerin has been associated with several metabolic syndrome markers, namely, increased BMI, triglycerides, blood pressure and insulin resistance. [25] Furthermore, it was recently observed that insulin resistance seems to be a predictor of chemerin levels, independently of BMI. [26]

Visfatin is mainly produced by visceral white adipose tissue. Plasma visfatin is increased in subjects with obesity, T2DM, metabolic syndrome and CVD. [27] Circulating visfatin was positively associated with insulin resistance and hyperglycemia. On the other hand, visfatin appears atherogenic because it contributes to leukocyte adhesion [28] and to atherogenic plaque instability, [29] and may have a direct role in vascular dysfunction and inflammation through iNOS upregulation. [30]

Retinol-binding protein-4 (RBP-4), belongs to the lipocalin family, contributes to insulin resistance and it has been reported that it is increased in human obesity, T2DM and in subclinical atherosclerosis. [31] A positive relationship was found with insulin-resistance severity in obesity, with glucose-intolerance and type 2 diabetes, as well as, with a strong family background for T2DM in non-obese subjects. [32, 33] Lipocalin-2, another lipocalin family member, is an adipokine that has a potential role in insulin resistance and atherosclerosis. [31] The gene and protein expressions of lipocalin-2 in visceral adipose tissue is associated positively with inflammation. [34]

Plasminogen activator inhibitor (PAI)-1 is responsible for decreased fibrinolytic capacity and is, therefore, a cardiovascular risk factor. Ma et al. [35] showed that PAI-1 is increased in obesity and may have a direct role in obesity and in insulin resistance.

Serum amyloid A (SAA), an adipokine released primarily by adipocytes, is significantly increased in obesity and is associated with systemic inflammation and atherosclerosis. [36, 37]

Angiotensinogen undergoes two sequential cleavages by renin and angiotensin converting enzyme to produce angiotensin I and angiotensin II, which plays a major role in blood pressure regulation through salt reabsorption in renal tubules and vasoconstriction. Adipose-derived angiotensinogen is substantially increased in obese humans, [38] explaining the relationship between systemic hypertension and obesity.

Apelin is an adipokine with a favourable effect on metabolism, due to its positive effect on blood pressure and cardiac contractility. [39] Its secretion appears to be linked to insulin

secretion; actually, peripheral apelin injection in obese insulin-resistant mice improved insulin sensitivity and glucose uptake in skeletal muscle. [40] However, increased plasma concentrations of apelin were found in obese hyperinsulinemic and T2DM. [41] Moreover, circulating apelin concentration is not correlated to BMI, [42] suggesting that obesity is not the main determinant to increase plasma apelin. Inflammation and oxidative stress may explain the changes in plasma apelin observed in obesity. [41]

Adipocyte-fatty acid binding protein seems to play a crucial role in diabetes and atherosclerotic disease progress; it is, therefore, proposed as a predictor of the metabolic syndrome [43] and of CVD. [44]

Resistin is expressed by cells of the stromal compartment of the adipose tissue, particularly, by macrophages and by peripheral monocytes that are up-regulated during their differentiation to macrophages. It was named for its ability to induce insulin resistance [45] and some studies support also the association of resistin with obesity. [46] High resistin levels are reported to be associated with atherosclerosis, and it has been shown that resistin increases the expression of several pro-inflammatory cytokines, including TNF-α and IL-6. [47] The correlation between BMI and resistin levels [48] is weak; nonetheless, the proportion of mononuclear leucocytes within adipose tissue correlates well with BMI. [15]

The pro-inflammatory state and the impaired immunity in obesity contribute to increase the levels of several cytokines, such as TNF-α and IL-6. TNF-α is known as a key player in inflammatory cell activation and recruitment. [49] It has been linked to insulin resistance in skeletal muscle and adipose tissue, [50] and it seems to favor atherosclerosis through induction of adhesion molecule expression in endothelial and vascular smooth muscle cells. [51] Moreover, TNF-α induces a strong activation of NF-KB (nuclear factor kappa-light-chain-enhancer of activated B cells), a vital transcription factor that regulates an array of genes associated with inflammation. [52] It was reported that obese individuals, as compared with non-obese, present higher blood levels of TNF-α and soluble TNF-α receptors. The subsets of T cell populations and their function may be reduced in human obesity, and this may be related, at least in part, to the increased TNF-α production. [53]

In the absence of inflammation, the adipose tissue seems to contribute to 15–30% of circulating IL-6. [54] IL-6 impairs insulin stimulation, induces liver production of CRP, and associates with obesity-related hypertriglyceridemia by stimulating hepatic secretion of very low-density lipoproteins. [55, 56] The production of CRP, one of the most sensitive markers of inflammation, results from the interaction of pro-inflammatory cytokines (especially, IL-6, TNF-α and IL-1) with their receptors and inhibitors. Raised concentrations of CRP are thought to be emerging risk factors for CVD. [57] CRP levels are also raised in obesity, and weight loss usually leads to a reduction in CRP. [58]

Obesity associates with increased levels of some adipokines, but also with a decrease in the production of others. Adiponectin has anti-inflammatory activity and a protective role against insulin resistance. Adiponectin is inversely associated with the adhesion molecule expression and the transformation of macrophages into foam cells. It seems to protect against metabolic diseases and also against atherosclerosis. [59, 60] However, the protective role for CVD is controversial, with several data reporting a positive association of adiponectin with risk for all-cause and cardiovascular mortality. [61-63] Higher adiponectin levels were strongly associated with a lower risk of impaired glucose metabolism and T2DM, suggesting that adiponectin is involved in their pathophysiology, linking obesity to T2DM. [64] The

obese patients, especially those with visceral obesity, seem to present decreased plasma concentrations of adiponectin. [65, 66] This, suggests the existence of a feedback inhibition process, working when the total body fat mass increases, and inducing an increase in the secretion of other adipokines or a decrease in the metabolic function of the adipocyte. [67]

Omentin is strongly expressed in stromal vascular cells of adipose tissue, and seems to have a role in modulating insulin action. [68] It appears to have anti-inflammatory ability, reducing endothelial dysfunction and atherosclerosis. [69] Obese or overweight individuals have lower plasma omentin levels when compared with lean subjects [70] and its levels are inversely correlated with BMI, WC and circulating leptin. [70, 71] Omentin is also decreased in patients with coronary artery disease. [72]

Zinc-α2-glycoprotein (ZAG) seems to correlate inversely with markers of obesity such as BMI and WC. [73, 74] Although the factors that down-regulate ZAG are not well understood, obesity-related inflammation could be involved in its regulation. ZAG may act like adiponectin in protecting against the obese state. [75, 76]

Vaspin (visceral adipose tissue-derived serine protease inhibitor) is an adipokine expressed in visceral white adipose tissue. Fat mass expansion has been associated with increased expression of vaspin and its circulating levels. [77, 78] In obese subjects, serum vaspin decreases following a modest weight loss, which is accompanied by improvement in insulin resistance. [79] However, the mechanisms by which vaspin secretion is linked to glucose metabolism and to insulin sensitivity are not entirely understood. Administration of vaspin to obese mice improves glucose tolerance, insulin sensitivity, and reduces food intake. Until now molecular target(s) of vaspin and its mode of action are unknown. [80]

Some adipokines interfere in the regulation of each other's. For instance, TNF-α and IL-6 are involved in the regulation of other adipokines, such as adiponectin; [81] leptin and chemerin production is stimulated by TNF-α. [82]

In summary, in obesity, there is hypoxia, increased macrophage infiltration and adipocytes are hypertrophic and resistant to leptin and insulin action. Although the role of some adipokines is not completely known, the adipokine profile in obesity changes, usually presenting an increase in the levels of leptin, chemerin, visfatin, RBP-4, PAI-1, SAA, angiotensinogen, resistin, TNF-α and IL-6, and a reduction in adiponectin, omentin and ZAG (Figure 1). These changes seem to favor hypertension, insulin resistance, atherogenesis, dyslipidemia and inflammation.

THE IMPACT OF GASTRIC BANDING SURGERY IN OBESITY AND RELATED COMORBIDITIES

According to the current guidelines, bariatric surgery is recommended for patients with a BMI > 40 kg/m^2 and for patients with a BMI 35-40 kg/m^2, when presenting serious comorbidities associated with obesity, such as hypertension, diabetes or hyper-cholesterolemia. [83, 84]

Laparoscopic adjustable gastric banding (LAGB), sleeve gastrectomy and Roux-en-Y gastric bypass are techniques used in bariatric surgery; this surgery has been very successful in morbid obesity as it has been shown to be more effective than lifestyle intervention (physical activity, diet and weight reducing drugs). [85]

Using LAGB surgery a gradual, continuous and well-programmed weight loss, is achieved; moreover, it increases the quality of life of the patients and reduces co-morbidities in over 75% of patients, including the systemic inflammatory response. [86] Laparoscopic surgery, compared with the conventional open method, is mini-invasive and has decreased postoperative pain and length of hospitalization. It is associated with lower rates of complications, lower hospital readmission, and lower mortality. [87, 88]

LAGB is the most common surgery, as it is the easiest surgical technique. It involves the placement of an adjustable gastric band around the upper stomach. The gastric band is connected to an inflatable balloon that can be adjusted by adding or removing saline via a small subcutaneous access port. A loss of 47% excess weight may be maintained for about 15 years, as it shows a substantial long-term weight loss, which is similar to other bariatric procedures. [89] Several studies showed that the laparoscopic gastric band surgery in morbidly obese patients lead to a significant weight loss, [90, 91] even after a short period of one month. [90] Moreover, several authors documented a medium to long-term sustained weight loss with laparoscopic adjustable band gastric. [92-96]

Some authors reported [97] that the other bariatric techniques provide a higher degree of weight loss, however, LAGB seems to be associated with less and fewer severe complications. [98, 99] Significant improvements in health-related quality of life (HRQOL) have been reported, even in the first year after LAGB. [100] A poor baseline HRQOL, a high efficacy of the banding in controlling eat disorders, and a higher weight loss, are believed to be important factors to improve HRQOL of the patients. [100]

Resolution of obesity-related comorbidities depends on significant and sustained weight loss and on excess weight loss. [101, 102] According to Brancatisano et al., [103] weight loss, after Swedish adjustable gastric band placement, is an effective treatment of T2DM in morbidly obese patients. In this case, an early intervention offers the greatest chance of remission. The authors suggested that it might even prevent the occurrence of T2DM in patients with impaired glucose tolerance. [103] Indeed, it was reported that the extensive weight loss in formerly obese women, after Swedish adjustable gastric band surgery, was accompanied by an increase in insulin sensitivity, as showed by fasting insulin and the HOMA index; these favorable metabolic changes were also observed in women after a successful weight loss, by diet alone but were less pronounced. [104] The LAGB induces a substantial sustained positive effect on diabetes in morbidly obese patients, with a significant reduction in glycated hemoglobin (HbA1c) levels and a combined improvement/remission rate of 80%. [105]

THE IMPACT OF LAGB IN ADIPOKINES AND IN THE INFLAMMATORY STATE

As already referred, obesity is characterized by a low grade inflammatory process, involving several inflammatory mediators, produced by the adipose tissue. Conservative weight management techniques, including medication, often fail to achieve substantial and prolonged weight loss and reduction of inflammation in morbid obese individuals, explaining the increase success of bariatric surgery.

Table 1. Main findings reported in studies in obese patients after laparoscopic adjustable gastric banding (LAGB) surgery

Study	Obese Subjects	Follow up after LAGB surgery	Main Findings (*)	
Hanusch-Enserer et al. (2004) [121]	18 patients (15 F / 3 M)	6 months	↓ BMI, WC, DBP, SBP, glucose, C-peptide, TG, leptin, insulin	
		12 months	↓ BMI, WC, DBP, SBP, C-peptide, TG, GPT, γ-GT, leptin, insulin	↑ ghrelin
Coupaye et al. (2005) [144]	36 women	12 months	↓ fat mass, lean body mass, leptin	
Ram et al. (2005) [111]	23 patients (15 F / 8 M)	6 months	↓ BMI, insulin, proinsulin, leptin	
		14 months	↓ BMI, insulin, proinsulin, leptin	
Diker et al. (2006) [145]	23 patients (15 F / 8 M)	6 months	↓ BMI	↑ adiponectin
		14 months	↓ BMI	↑ adiponectin
Gasteyger et al. (2006) [129]	36 women (premenopausal) LAGB + Swedish LAGB	6 months	↓ BMI, fat, fat free mass, DBP, SBP, glucose, TChol, TG	↑ MCV; No alteration: iron and ferritin
		12 months	↓ BMI, fat, fat free mass, DBP, SBP, glucose, TChol, TG	↑ HDLc, MCV; No alteration: iron and ferritin
		18 months	↓ BMI, fat, fat free mass, DBP, SBP, glucose, TChol, TG, Hb	↑ HDLc; No alteration: iron and ferritin
		24 months	↓ BMI, fat, fat free mass, DBP, SBP, glucose, TChol, TG, Hb	↑ HDLc; No alteration: iron and ferritin
Anty et al. (2008) [143]	55 female patients "Roux en Y" gastric bypass + vertical calibrated gastroplasties + LAGB	6 months	↓ BMI, CRP, Orosomucoid	↑ TrSat
Shak et al. (2008) [112]	24 patients (14F / 10M)	6 months	↓ BMI, leptin	No alteration: total ghrelin, acylated ghrelin, insulin
		12 months	↓ BMI, leptin	No alteration: total ghrelin, acylated ghrelin, insulin

Study	Obese Subjects	Follow up after LAGB surgery	Main Findings (*)	
Korner et al. (2009) [114]	15 patients (11 F / 4 M)	2 weeks	↓ leptin, insulin, glucose, HOMA-IR	No alteration: PYY, ghrelin, GLP-1
		12 weeks	↓ leptin	No alteration: PYY, ghrelin, GLP-1
		26 weeks	↓ leptin, insulin, glucose, HOMA-IR	No alteration: PYY, ghrelin, GLP-1
		52 weeks	↓ leptin, insulin, glucose, HOMA-IR	No alteration: PYY, ghrelin, GLP-1
Moschen et al. (2009) [113]	30 patients (24 F / 6 M)	6 months	↓ BMI, glucose, insulin, HOMA-IR, CRP, TNF-α, leptin, PBEF/Nampt/visfatin	↑ adiponectin, resistin
		12 months	↓ BMI, glucose, insulin, HOMA-IR, CRP, TNF-α, leptin, resistin, PBEF/Nampt/visfatin	↑ adiponectin
Ramalho et al. (2009) [126]	32 women	1 month	↓ BMI, CRP, haptoglobin, transferrin, LDLc, TChol	↑ Alfa-1 antitrypsin, ferritin, sTFR, HDLc
		18 months	↓ BMI, glucose, CRP, haptoglobin, ferritin, sTFR	↑ Alfa-1 antitrypsin, transferrin, LDLc, TChol, HDLc
Trakhtenbroit et al. (2009)106	5 women	3 months	↓ insulin, HOMA-IR	No alteration: glucose
		9 months	↓ insulin, HOMA-IR	No alteration: glucose
		24 months		No alteration: glucose, insulin, HOMA-IR
Moschen et al. (2010) [128]	20 severely patients (13 F / 7 M)	6 months	↓ BMI, glucose, insulin, HOMA-IR, TChol, TG, CRP, IL-6	No detectable: TNF-α
Tussing-Humphreys et al. (2010) [109]	20 women LAGB + LSG	6 months	↓ BMI, WC, sTFR, hepcidin, HOMA-IR, CRP, IL-6, EPO	↑Hb, Ht
Benedix et al. (2011) [146]	Obese patients (7 F / 7 M)	6 months	↓ BMI, glucose, insulin	↑ adiponectin; No alteration: insulin, salivary ghrelin
		12 months	↓ BMI, glucose	↑ adiponectin; No alteration: insulin, salivary ghrelin
Marantos et al. (2011)110	20 women LAGB (13) + LSG (7)	12 months	↓ BMI, leptin, resistin, IL-6	↑ adiponectin
Plum et al. (2011) [107]	8 Obese patients (7 F / 1 M)		↓ BMI, insulin, HOMA-IR, c-peptide, leptin, HDLc	

Table 1. (Continued)

Study	Obese Subjects	Follow up after LAGB surgery	Main Findings (*)	
Bradley et al (2012) [108]	10 patients (9 F / 1 M)	22 ± 7 weeks	↓ BMI, glucose, insulin, HOMA-IR, c-peptide, leptin, CRP	↑ adiponectin
Cugno et al. (2012) [127]	25 women	3 months	↓ BMI, CRP, PAI-1, fibrinogen, VWF	
		6 months	↓ BMI, CRP, PAI-1, fibrinogen, VWF	
		12 months	↓ BMI, CRP, PAI-1, fibrinogen, VWF	
Gelisgen et al. (2012) [91]	21 patients (12 F / 9 M)	6 months	↓ BMI, insulin, HOMA-IR;	↑ acylated ghrelin; No alteration: glucose
Hady et al. (2012) [122]	100 patients (66 F / 34 M)	7 days	↓ BMI, insulin,	No alteration: glucose, HOMA-IR, HDLc
		1 month	↓ BMI, ghrelin, insulin,	
		3 months	↓ BMI, ghrelin, insulin, T Chol, LDL, TG	
		6 months	↓ BMI, insulin, T Chol, LDL, TG	
Krieger et al. (2012) [115]	30 patients (20 F / 10 M)	12 months	↓ BMI, leptin	No alteration: ghrelin
Cigdem et al. (2013) [90]	20 patients	1 month	↓ BMI, leptin, orexin-A, insulin resistance	↑ ghrelin
Samaras et al. (2013) [130]	15 patients	2 weeks	↓ BMI, SBP, glucose, insulin, HbA1C, TChol, TG, HDLc, LDLc	
		12 weeks	↓ BMI, SBP, glucose, HbA1C, TG	
Visockiene et al. (2013) [147]	90 patients (61 F / 29 M)	12 months	↓ BMI, fat mass, glucose, HbA1C, TG	↑ HDLc
Santos et al. (2014) [86]	46 patients (40 F / 6 M)	3 months	↓ hsCRP, neutrophil count, TG, transferrin	↑ transferrin saturation; No alteration: iron, ferritin

F, female; M, male

BMI, body mass index; CRP, C-reactive protein; DBP, diastolic blood pressure; EPO, erythropoietin; GLP-1, Glucagon-like peptide-1; GPT, glutamic pyruvic transaminase; Hb, hemoglobin; HbA1C, glycated hemoglobin; HDLc, high-density lipoprotein cholesterol; HOMA-IR, homeostasis model assessment of insulin resistance; hsCRP, high-sensitivity CRP; Ht, hematocrit; IL, interleukin; LDLc, low-density lipoprotein cholesterol; LSG, laparoscopic sleeve gastrectomy; MCV, mean corpuscular volume; PAI-1, plasminogen activator inhibitor-1; PBEF, pre-B cell enhancing factor; PYY, peptide YY; SBP, systolic blood pressure; sTfR, soluble transferrin receptor; TChol, Total cholesterol; TG, Triglycerides; TNF-α, tumor necrosis factor- α; TrSat, transferrin saturation; VWF, von Willebrand factor; WC, waist circumference; γ-GT; γ-glutamyl transferase.

(*) Findings compared to baseline.

In Table 1 are summarized the main findings observed in follow up studies in obese patients, after LAGB surgery.

In general, a marked decrease in weight of morbid obese patients occurs after LAGB surgery. Only a small number of studies focused on the inflammatory profile, adipokines levels or iron status, after LAGB surgery, and most of them provide very limited results. The small sample size is the most frequent limitation of the studies. [106-108] Comparisons between studies are difficult, as they present different periods of follow-up and, sometimes, the follow-up period was insufficient to confirm the long-term effects of bariatric surgery.

Furthermore, some studies cannot be used for comparisons as they included subjects submitted to two different surgery techniques. [109, 110]

Leptin is one of the adipokines that has been studied in obese patients after LAGB surgery. A decrease in leptin levels has been reported, [90, 108, 111-116] as soon as one month after laparascopic gastric band. [90] Ritt et al. [104] reported that women after Swedish adjustable gastric band, showed a significant reduction in leptin, while TNF-α serum levels increased, compared with dietary-treated obese patients.

Few studies exist concerning the changes induced in the novel adipokines, apelin, resistin, RBP-4, vaspin and visfatin, after bariatric surgery. Inconclusive results are described for resistin concentrations; indeed, obese patients, after LAGB surgery, presented higher resistin levels 6 months after surgery; [113] nevertheless, 12 months after surgery resistin levels decreased significantly. [110, 113]

Botella-Carretero et al. [117] reported an increase in visfatin concentration in obese patients after gastric bypass and biliopancreatic diversion surgery. Plasma visfatin levels are also increased in severely obese patients after intestinal bypass. [118]

In summary, more studies are needed to understand the relationship between weight loss imposed by LAGB and the secretion of adipokines, namely of novel adipokines, by the reduced adipose tissue.

Ghrelin, which stimulates appetite and food intake, enhancing fat mass deposition and weight gain, [119] is down-regulated in obesity. [120] Nevertheless contradictory results are reported concerning ghrelin levels after LAGB surgery; while some authors reported an increase in ghrelin [90, 121] and acylated ghrelin levels, [91] others described lower levels [122] or no alteration in ghrelin [114, 115] and acylated ghrelin [112] concentration.

Surgical injury induces a systemic inflammatory metabolic-endocrine response that is proportional to the severity of the surgical stress. The systemic inflammatory response was evaluated at 6 and 12 hours after laparoscopic adjustable gastric banding (were significantly reduced compared with those) and after open stoma-adjustable silicone band application, and it was reported that the inflammatory response was significantly lower for LAGB. [123]

A positive effect on fibrinolytic function, oxidative stress and antioxidant activity, which are associated to obesity, has been achieved with both open and laparoscopic gastric band interventions. Moreover, postoperative BMI, lipid profile, malondialdehyde (MDA), oxidized low-density lipoprotein (oxLDL), leptin and PAI-1 decreased significantly after both surgeries, while paraoxonase activity increased and was negatively correlated with BMI, MDA, oxLDL, leptin and PAI-1. [116] These studies suggest that several positive effects are observed as a result of weight loss after surgery.

After bariatric surgery, the visceral adipose expression of macrophage and T cell markers, by defining the adipose expression of TNF-α and IL-1 receptor antagonist, contribute to the systemic levels of TNF-α and IL-6. A higher inflammatory state of the

adipose tissue seems to predict a lower BMI reduction after surgery, notably at early stages after surgery. [124]

Indeed, there is some controversial data about the reduction in the inflammatory profile after gastric band surgery; Keogh et al, reported a 40% reduction in CRP levels one year after Swedish adjustable gastric band surgery. [125]

Other studies showed that as soon as 1 month after LAGB surgery, the obese patients present an improvement in the inflammatory profile, with a reduction in CRP and haptoglobin levels [126] that remain low for 18 months after surgery. Cugno et al. [127] observed a reversion of the low-grade inflammation at 3 months after bariatric surgery. Several other studies reported a reduction in the inflammatory process after weight loss by LAGB surgery, as shown by a decrease in CRP [86, 113, 127] and IL-6 levels. [110, 128]

Besides the improvement in the inflammatory state, insulin resistance and adipokine levels, several studies reported an improvement in the lipid profile [122, 129, 130] and in glucose related markers. [111, 113, 114, 121, 128, 130]

OBESITY, IRON STATUS AND THE IMPACT OF LAGB ON IRON METABOLISM

Iron deficiency is the most prevalent worldwide nutritional problem, [131] having significant public health implications. The development of iron deficiency occurs in two stages, starting by depletion of iron stores, followed by depletion of iron containing proteins and enzymes, including hemoglobin, which leads to an overt iron deficiency anemia. Data confirmed an association between obesity and hypoferremia in children, adolescents, adult men and women, and post-menopausal women, in both developed and transitional countries. [132-135] Considering that iron deficiency seems to diminish cognitive function and exercise performance, the association with obesity may represent a poor prognostic for a healthy physical and psychological condition.

The mechanisms that link iron status and obesity are still poorly clarified. The most accepted hypothesis is that iron deficiency is a consequence of the chronic low-grade inflammation state in obesity.

Hepcidin is a major regulator of iron availability for erythropoiesis. It inhibits iron intestinal absorption and reduces the flux of iron from splenic and hepatic macrophages, [136] as it binds to the cellular iron export channel ferroportin-1, present in enterocytes, hepatocytes and macrophages; ferroportin is needed for iron absorption and iron mobilization. The linkage of hepcidin to ferroportin induces ferroportin internalization and degradation, reducing iron availability. [137] The hepatic transcription of hepcidin is up-regulated by pro-inflammatory cytokines, bone morphogenetic proteins (BMP) and iron overload, and is down-regulated by iron deficiency, ineffective erythropoiesis and hypoxia. [138]

Besides the liver, hepcidin is also expressed in other tissues, namely in the adipose tissue. [139] Indeed, data suggest that adipocytes are capable of producing hepcidin, and this production is probably triggered by inflammatory stimuli. [140, 141] It seems that inflammatory changes in the adipose tissue increase hepcidin expression, which might contribute to the erythropoietic disturbances resulting from changes in iron metabolism that could, ultimately, lead to iron deficiency. [141] However, there are still controversies

concerning the contribute of adipocytes to the circulating levels of hepcidin, its importance in obesity and its linkage to erythropoietic disturbances. In healthy individuals, the hepatic hepcidin expression is higher than the adipocyte hepcidin expression; however, in obesity the adipose tissue mass increases and is higher than liver mass; [133] thus, in obesity, the hepcidin secreted by the adipose tissue, may be relevant for iron status and erythropoiesis. Hemojuvelin, which enhances hepcidin expression in the liver, is also expressed in adipocytes and highly increased in adipose tissue from obese. [142] Actually, blood concentrations of soluble hemojuvelin were significantly increased in obese patients, as compared to controls, suggesting that the adipose tissue may have a role in iron homeostasis in obesity and in erythropoiesis. More studies that contribute to clarify the interplay between protein expression-iron status-erythropoiesis are required.

There are few studies concerning the effects of LAGB surgery on iron metabolism. According to Anty et al. [143] bariatric surgery improved iron status in obese patients, as it corrected iron depletion, alongside with the reduction in adipose mass, and inflammation in the patients; Anty et al. [143] also observed a reversion of iron depletion in obese patients 6 months after bariatric surgery; apparently, bariatric surgery improved iron status by reducing chronic inflammation. Actually, they found a significant negative correlation between CRP levels and transferrin saturation; nevertheless, considering that the bariatric surgery included different techniques, namely vertical calibrated gastroplasties, LAGB and "Roux en Y" gastric bypass, it was difficult to analyze the relationship between iron status and the type of bariatric surgery.

Another study, by performing a follow-up of 3 months after LAGB surgery, reported also an increased in iron availability, as shown by an increase transferrin saturation in obese patients. [86]

In opposition to these findings, a follow up study reported that no alterations were observed in iron and ferritin levels 24 months after LAGB. [129]

CONCLUSION

LAGB associates with a successful decrease in body weight, an improvement in inflammatory markers, insulin resistance and lipid profile. Regarding adipokines, LAGB induces a decrease in leptin and an increase in adiponectin levels; however, there is a lack in data studying the effect of LAGB in novel adipokines. Concerning iron bioavailability, further studies are needed to understand the role of the adipose tissue in iron metabolism, in obesity, and the influence of weight loss, imposed by LAGB.

REFERENCES

[1] WHO. Obesity: Preventing and managing the global epidemic. *Report of a WHO Consultation on Obesity*; Geneve: WHO; 2000

[2] Whitlock G, Lewington S, Sherliker P, et al. Body-mass index and cause-specific mortality in 900 000 adults: collaborative analyses of 57 prospective studies. *Lancet*. 2009;373(9669):1083-96.

[3] Wei M, Gaskill SP, Haffner SM, Stern MP. Waist circumference as the best predictor of noninsulin dependent diabetes mellitus (NIDDM) compared to body mass index, waist/hip ratio and other anthropometric measurements in Mexican Americans--a 7-year prospective study. *Obes Res*. 1997;5(1):16-23.

[4] Welborn TA, Dhaliwal SS. Preferred clinical measures of central obesity for predicting mortality. *Eur J Clin Nutr*. 2007;61(12):1373-9.

[5] Ashwell M, Hsieh SD. Six reasons why the waist-to-height ratio is a rapid and effective global indicator for health risks of obesity and how its use could simplify the international public health message on obesity. *Int J Food Sci Nutr*. 2005;56(5):303-7.

[6] Koh-Banerjee P, Wang Y, Hu FB, Spiegelman D, Willett WC, Rimm EB. Changes in body weight and body fat distribution as risk factors for clinical diabetes in US men. *Am J Epidemiol*. 2004;159(12):1150-9.

[7] Walker SP, Rimm EB, Ascherio A, Kawachi I, Stampfer MJ, Willett WC. Body size and fat distribution as predictors of stroke among US men. *Am J Epidemiol*. 1996;144(12):1143-50.

[8] Nicklas BJ, Cesari M, Penninx BW, et al. Abdominal obesity is an independent risk factor for chronic heart failure in older people. *J Am Geriatr Soc*. 2006;54(3):413-20.

[9] Haslam DW, James WP. Obesity. *Lancet*. 2005;366(9492):1197-209.

[10] Rondinone CM. Adipocyte-derived hormones, cytokines, and mediators. *Endocrine*. 2006;29(1):81-90.

[11] Wellen KE, Hotamisligil GS. Obesity-induced inflammatory changes in adipose tissue. *J Clin Invest*. 2003;112(12):1785-8.

[12] Panagiotakos DB, Pitsavos C, Yannakoulia M, Chrysohoou C, Stefanadis C. The implication of obesity and central fat on markers of chronic inflammation: The ATTICA study. *Atherosclerosis*. 2005;183(2):308-15.

[13] Fain JN, Madan AK, Hiler ML, Cheema P, Bahouth SW. Comparison of the release of adipokines by adipose tissue, adipose tissue matrix, and adipocytes from visceral and subcutaneous abdominal adipose tissues of obese humans. *Endocrinology*. 2004;145(5):2273-82.

[14] Bruun JM, Lihn AS, Madan AK, et al. Higher production of IL-8 in visceral vs. subcutaneous adipose tissue. Implication of nonadipose cells in adipose tissue. *Am J Physiol Endocrinol Metab*. 2004;286(1):E8-13.

[15] Curat CA, Wegner V, Sengenes C, et al. Macrophages in human visceral adipose tissue: increased accumulation in obesity and a source of resistin and visfatin. *Diabetologia*. 2006;49(4):744-7.

[16] Curat CA, Miranville A, Sengenes C, et al. From blood monocytes to adipose tissue-resident macrophages: induction of diapedesis by human mature adipocytes. *Diabetes*. 2004;53(5):1285-92.

[17] Weisberg SP, McCann D, Desai M, Rosenbaum M, Leibel RL, Ferrante AW, Jr. Obesity is associated with macrophage accumulation in adipose tissue. *J Clin Invest*. 2003;112(12):1796-808.

[18] Santos-Alvarez J, Goberna R, Sanchez-Margalet V. Human leptin stimulates proliferation and activation of human circulating monocytes. *Cell Immunol*. 1999;194(1):6-11.

[19] Zhang Y, Proenca R, Maffei M, Barone M, Leopold L, Friedman JM. Positional cloning of the mouse obese gene and its human homologue. *Nature*. 1994;372(6505):425-32.

[20] Enriori PJ, Evans AE, Sinnayah P, Cowley MA. Leptin resistance and obesity. *Obesity* (Silver Spring). 2006;14 Suppl 5:254S-8S.

[21] Coppari R, Bjorbaek C. Leptin revisited: its mechanism of action and potential for treating diabetes. *Nat Rev Drug Discov*. 2012;11(9):692-708.

[22] Bozaoglu K, Bolton K, McMillan J, et al. Chemerin is a novel adipokine associated with obesity and metabolic syndrome. *Endocrinology*. 2007;148(10):4687-94.

[23] Goralski KB, McCarthy TC, Hanniman EA, et al. Chemerin, a novel adipokine that regulates adipogenesis and adipocyte metabolism. *J Biol Chem*. 2007;282(38):28175-88.

[24] Roh SG, Song SH, Choi KC, et al. Chemerin--a new adipokine that modulates adipogenesis via its own receptor. *Biochem Biophys Res Commun*. 2007;362(4):1013-8.

[25] Stejskal D, Karpisek M, Hanulova Z, Svestak M. Chemerin is an independent marker of the metabolic syndrome in a Caucasian population--a pilot study. *Biomed Pap Med Fac Univ Palacky Olomouc Czech Repub*. 2008;152(2):217-21.

[26] Chakaroun R, Raschpichler M, Kloting N, et al. Effects of weight loss and exercise on chemerin serum concentrations and adipose tissue expression in human obesity. *Metabolism*. 2012;61(5):706-14.

[27] Chang YH, Chang DM, Lin KC, Shin SJ, Lee YJ. Visfatin in overweight/obesity, type 2 diabetes mellitus, insulin resistance, metabolic syndrome and cardiovascular diseases: a meta-analysis and systemic review. *Diabetes Metab Res Rev*. 2011;27(6):515-27.

[28] Kim SR, Bae YH, Bae SK, et al. Visfatin enhances ICAM-1 and VCAM-1 expression through ROS-dependent NF-kappaB activation in endothelial cells. *Biochim Biophys Acta*. 2008;1783(5):886-95.

[29] Dahl TB, Yndestad A, Skjelland M, et al. Increased expression of visfatin in macrophages of human unstable carotid and coronary atherosclerosis: possible role in inflammation and plaque destabilization. *Circulation*. 2007;115(8):972-80.

[30] Romacho T, Azcutia V, Vazquez-Bella M, et al. Extracellular PBEF/NAMPT/visfatin activates pro-inflammatory signalling in human vascular smooth muscle cells through nicotinamide phosphoribosyltransferase activity. *Diabetologia*. 2009;52(11):2455-63.

[31] Xiao Y, Xu A, Hui X, et al. Circulating lipocalin-2 and retinol-binding protein 4 are associated with intima-media thickness and subclinical atherosclerosis in patients with type 2 diabetes. *PLoS One*. 2013;8(6):e66607.

[32] Graham TE, Yang Q, Bluher M, et al. Retinol-binding protein 4 and insulin resistance in lean, obese, and diabetic subjects. *N Engl J Med*. 2006;354(24):2552-63.

[33] Hammarstedt A, Graham TE, Kahn BB. Adipose tissue dysregulation and reduced insulin sensitivity in non-obese individuals with enlarged abdominal adipose cells. *Diabetol Metab Syndr*. 2012;4(1):42.

[34] Catalan V, Gomez-Ambrosi J, Rodriguez A, et al. Increased adipose tissue expression of lipocalin-2 in obesity is related to inflammation and matrix metalloproteinase-2 and metalloproteinase-9 activities in humans. *J Mol Med* (Berl). 2009;87(8):803-13.

[35] Ma LJ, Mao SL, Taylor KL, et al. Prevention of obesity and insulin resistance in mice lacking plasminogen activator inhibitor 1. *Diabetes*. 2004;53(2):336-46.
[36] Zhao Y, He X, Shi X, et al. Association between serum amyloid A and obesity: a meta-analysis and systematic review. *Inflamm Res*. 2010;59(5):323-34.
[37] Johnson BD, Kip KE, Marroquin OC, et al. Serum amyloid A as a predictor of coronary artery disease and cardiovascular outcome in women: the National Heart, Lung, and Blood Institute-Sponsored Women's Ischemia Syndrome Evaluation (WISE). *Circulation*. 2004;109(6):726-32.
[38] Yasue S, Masuzaki H, Okada S, et al. Adipose tissue-specific regulation of angiotensinogen in obese humans and mice: impact of nutritional status and adipocyte hypertrophy. *Am J Hypertens*. 2010;23(4):425-31.
[39] Kleinz MJ, Davenport AP. Emerging roles of apelin in biology and medicine. *Pharmacol Ther*. 2005;107(2):198-211.
[40] Yue P, Jin H, Aillaud M, et al. Apelin is necessary for the maintenance of insulin sensitivity. *Am J Physiol Endocrinol Metab*. 2010;298(1):E59-67.
[41] Yu S, Zhang Y, Li MZ, et al. Chemerin and apelin are positively correlated with inflammation in obese type 2 diabetic patients. *Chin Med J* (Engl). 2012;125(19):3440-4.
[42] Leal VO, Lobo JC, Stockler-Pinto MB, et al. Apelin: a peptide involved in cardiovascular risk in hemodialysis patients? *Ren Fail*. 2012;34(5):577-81.
[43] Xu A, Tso AW, Cheung BM, et al. Circulating adipocyte-fatty acid binding protein levels predict the development of the metabolic syndrome: a 5-year prospective study. *Circulation*. 2007;115(12):1537-43.
[44] Chow WS, Tso AW, Xu A, et al. Elevated circulating adipocyte-fatty acid binding protein levels predict incident cardiovascular events in a community-based cohort: a 12-year prospective study. *J Am Heart Assoc*. 2013;2(1):e004176.
[45] Chen BH, Song Y, Ding EL, et al. Circulating levels of resistin and risk of type 2 diabetes in men and women: results from two prospective cohorts. *Diabetes Care*. 2009;32(2):329-34.
[46] Owecki M, Miczke A, Nikisch E, Pupek-Musialik D, Sowinski J. Serum resistin concentrations are higher in human obesity but independent from insulin resistance. *Exp Clin Endocrinol Diabetes*. 2011;119(2):117-21.
[47] Bokarewa M, Nagaev I, Dahlberg L, Smith U, Tarkowski A. Resistin, an adipokine with potent proinflammatory properties. *J Immunol*. 2005;174(9):5789-95.
[48] Kaser S, Kaser A, Sandhofer A, Ebenbichler CF, Tilg H, Patsch JR. Resistin messenger-RNA expression is increased by proinflammatory cytokines in vitro. *Biochem Biophys Res Commun*. 2003;309(2):286-90.
[49] Clark IA. How TNF was recognized as a key mechanism of disease. *Cytokine Growth Factor Rev*. 2007;18(3-4):335-43.
[50] Lorenzo M, Fernandez-Veledo S, Vila-Bedmar R, Garcia-Guerra L, De Alvaro C, Nieto-Vazquez I. Insulin resistance induced by tumor necrosis factor-alpha in myocytes and brown adipocytes. *J Anim Sci*. 2008;86(14 Suppl):E94-104.
[51] Choy JC, Granville DJ, Hunt DW, McManus BM. Endothelial cell apoptosis: biochemical characteristics and potential implications for atherosclerosis. *J Mol Cell Cardiol*. 2001;33(9):1673-90.

[52] Antunes F, Han D. Redox regulation of NF-kappaB: from basic to clinical research. *Antioxid Redox Signal*. 2009;11(9):2055-6.

[53] Tanaka S, Isoda F, Ishihara Y, Kimura M, Yamakawa T. T lymphopaenia in relation to body mass index and TNF-alpha in human obesity: adequate weight reduction can be corrective. *Clin Endocrinol (Oxf)*. 2001;54(3):347-54.

[54] Mohamed-Ali V, Goodrick S, Rawesh A, et al. Subcutaneous adipose tissue releases interleukin-6, but not tumor necrosis factor-alpha, in vivo. *J Clin Endocrinol Metab*. 1997;82(12):4196-200.

[55] Nieto-Vazquez I, Fernandez-Veledo S, de Alvaro C, Lorenzo M. Dual role of interleukin-6 in regulating insulin sensitivity in murine skeletal muscle. *Diabetes*. 2008;57(12):3211-21.

[56] Sparks JD, Cianci J, Jokinen J, Chen LS, Sparks CE. Interleukin-6 mediates hepatic hypersecretion of apolipoprotein B. *Am J Physiol Gastrointest Liver Physiol*. 2010;299(4):G980-9.

[57] Helfand M, Buckley DI, Freeman M, et al. Emerging risk factors for coronary heart disease: a summary of systematic reviews conducted for the U.S. Preventive Services Task Force. *Ann Intern Med*. 2009;151(7):496-507.

[58] Tzotzas T, Evangelou P, Kiortsis DN. Obesity, weight loss and conditional cardiovascular risk factors. *Obes Rev*. 2011;12(5):e282-9.

[59] Tilg H, Moschen AR. Role of adiponectin and PBEF/visfatin as regulators of inflammation: involvement in obesity-associated diseases. *Clin Sci (Lond)*. 2008;114(4):275-88.

[60] Okamoto Y, Arita Y, Nishida M, et al. An adipocyte-derived plasma protein, adiponectin, adheres to injured vascular walls. *Horm Metab Res*. 2000;32(2):47-50.

[61] Laughlin GA, Barrett-Connor E, May S, Langenberg C. Association of adiponectin with coronary heart disease and mortality: the Rancho Bernardo study. *Am J Epidemiol*. 2007;165(2):164-74.

[62] Wannamethee SG, Whincup PH, Lennon L, Sattar N. Circulating adiponectin levels and mortality in elderly men with and without cardiovascular disease and heart failure. *Arch Intern Med*. 2007;167(14):1510-7.

[63] Pilz S, Mangge H, Wellnitz B, et al. Adiponectin and mortality in patients undergoing coronary angiography. *J Clin Endocrinol Metab*. 2006;91(11):4277-86.

[64] Snijder MB, Heine RJ, Seidell JC, et al. Associations of adiponectin levels with incident impaired glucose metabolism and type 2 diabetes in older men and women: the hoorn study. *Diabetes Care*. 2006;29(11):2498-503.

[65] Bahceci M, Gokalp D, Bahceci S, Tuzcu A, Atmaca S, Arikan S. The correlation between adiposity and adiponectin, tumor necrosis factor alpha, interleukin-6 and high sensitivity C-reactive protein levels. Is adipocyte size associated with inflammation in adults? *J Endocrinol Invest*. 2007;30(3):210-4.

[66] Hotta K, Funahashi T, Arita Y, et al. Plasma concentrations of a novel, adipose-specific protein, adiponectin, in type 2 diabetic patients. *Arterioscler Thromb Vasc Biol*. 2000;20(6):1595-9.

[67] Oh DK, Ciaraldi T, Henry RR. Adiponectin in health and disease. *Diabetes Obes Metab*. 2007;9(3):282-9.

[68] Yang RZ, Lee MJ, Hu H, et al. Identification of omentin as a novel depot-specific adipokine in human adipose tissue: possible role in modulating insulin action. *Am J Physiol Endocrinol Metab*. 2006;290(6):E1253-61.

[69] Zhong X, Li X, Liu F, Tan H, Shang D. Omentin inhibits TNF-alpha-induced expression of adhesion molecules in endothelial cells via ERK/NF-kappaB pathway. *Biochem Biophys Res Commun*. 2012;425(2):401-6.

[70] Auguet T, Quintero Y, Riesco D, et al. New adipokines vaspin and omentin. Circulating levels and gene expression in adipose tissue from morbidly obese women. *BMC Med Genet*. 2011;12:60.

[71] Shibata R, Ouchi N, Takahashi R, et al. Omentin as a novel biomarker of metabolic risk factors. *Diabetol Metab Syndr*. 2012;4(1):37.

[72] Zhong X, Zhang HY, Tan H, et al. Association of serum omentin-1 levels with coronary artery disease. *Acta Pharmacol Sin*. 2011;32(7):873-8.

[73] Gong FY, Zhang SJ, Deng JY, et al. Zinc-alpha2-glycoprotein is involved in regulation of body weight through inhibition of lipogenic enzymes in adipose tissue. *Int J Obes (Lond)*. 2009;33(9):1023-30.

[74] Selva DM, Lecube A, Hernandez C, Baena JA, Fort JM, Simo R. Lower zinc-alpha2-glycoprotein production by adipose tissue and liver in obese patients unrelated to insulin resistance. *J Clin Endocrinol Metab*. 2009;94(11):4499-507.

[75] Bing C, Mracek T, Gao D, Trayhurn P. Zinc-alpha2-glycoprotein: an adipokine modulator of body fat mass? *Int J Obes (Lond)*. 2010;34(11):1559-65.

[76] Leal VO, Lobo JC, Stockler-Pinto MB, et al. Is zinc-alpha2-glycoprotein a cardiovascular protective factor for patients undergoing hemodialysis? *Clin Chim Acta*. 2012;413(5-6):616-9.

[77] Youn BS, Kloting N, Kratzsch J, et al. Serum vaspin concentrations in human obesity and type 2 diabetes. *Diabetes*. 2008;57(2):372-7.

[78] Chang HM, Park HS, Park CY, Song YS, Jang YJ. Association between serum vaspin concentrations and visceral adipose tissue in Korean subjects. *Metabolism*. 2010;59(9):1276-81.

[79] Chang HM, Lee HJ, Park HS, et al. Effects of weight reduction on serum vaspin concentrations in obese subjects: modification by insulin resistance. *Obesity* (Silver Spring). 2010;18(11):2105-10.

[80] Bluher M. Vaspin in obesity and diabetes: pathophysiological and clinical significance. *Endocrine*. 2012;41(2):176-82.

[81] Bruun JM, Lihn AS, Verdich C, et al. Regulation of adiponectin by adipose tissue-derived cytokines: in vivo and in vitro investigations in humans. *Am J Physiol Endocrinol Metab*. 2003;285(3):E527-33.

[82] Wang B, Trayhurn P. Acute and prolonged effects of TNF-alpha on the expression and secretion of inflammation-related adipokines by human adipocytes differentiated in culture. *Pflugers Arch*. 2006;452(4):418-27.

[83] Sjostrom L, Lindroos AK, Peltonen M, et al. Lifestyle, diabetes, and cardiovascular risk factors 10 years after bariatric surgery. *N Engl J Med*. 2004;351(26):2683-93.

[84] Kulick D, Hark L, Deen D. The bariatric surgery patient: a growing role for registered dietitians. *J Am Diet Assoc*. 2010;110(4):593-9.

[85] Gloy VL, Briel M, Bhatt DL, et al. Bariatric surgery versus non-surgical treatment for obesity: a systematic review and meta-analysis of randomised controlled trials. *BMJ*. 2013;347:f5934.

[86] Santos J, Salgado P, Santos C, et al. Effect of bariatric surgery on weight loss, inflammation, iron metabolism, and lipid profile. *Scand J Surg*. 2014;103(1):21-5.

[87] Parikh MS, Laker S, Weiner M, Hajiseyedjavadi O, Ren CJ. Objective comparison of complications resulting from laparoscopic bariatric procedures. *J Am Coll Surg*. 2006;202(2):252-61.

[88] Flum DR, Belle SH, King WC, et al. Perioperative safety in the longitudinal assessment of bariatric surgery. *N Engl J Med*. 2009;361(5):445-54.

[89] O'Brien PE, MacDonald L, Anderson M, Brennan L, Brown WA. Long-term outcomes after bariatric surgery: fifteen-year follow-up of adjustable gastric banding and a systematic review of the bariatric surgical literature. *Ann Surg*. 2013;257(1):87-94.

[90] Cigdem Arica P, Kocael A, Tabak O, Taskin M, Zengin K, Uzun H. Plasma ghrelin, leptin, and orexin-A levels and insulin resistance after laparoscopic gastric band applications in morbidly obese patients. *Minerva Med*. 2013;104(3):309-16.

[91] Gelisgen R, Zengin K, Kocael A, et al. Effects of laparoscopic gastric band applications on plasma and fundic acylated ghrelin levels in morbidly obese patients. *Obes Surg*. 2012;22(2):299-305.

[92] Caiazzo R, Arnalsteen L, Pigeyre M, et al. Long-term metabolic outcome and quality of life after laparoscopic adjustable gastric banding in obese patients with type 2 diabetes mellitus or impaired fasting glucose. *Br J Surg*. 2010;97(6):884-91.

[93] Himpens J, Cadiere GB, Bazi M, Vouche M, Cadiere B, Dapri G. Long-term outcomes of laparoscopic adjustable gastric banding. *Arch Surg*. 2011;146(7):802-7.

[94] Ray JB, Ray S. Safety, efficacy, and durability of laparoscopic adjustable gastric banding in a single surgeon U.S. community practice. *Surg Obes Relat Dis*. 2011;7(2):140-4.

[95] te Riele WW, Boerma D, Wiezer MJ, Borel Rinkes IH, van Ramshorst B. Long-term results of laparoscopic adjustable gastric banding in patients lost to follow-up. *Br J Surg*. 2010;97(10):1535-40.

[96] Cobourn C, Chapman MA, Ali A, Amrhein J. Five-year weight loss experience of outpatients receiving laparoscopic adjustable gastric band surgery. *Obes Surg*. 2013;23(7):903-10.

[97] Miller K, Pump A, Hell E. Vertical banded gastroplasty versus adjustable gastric banding: prospective long-term follow-up study. *Surg Obes Relat Dis*. 2007;3(1):84-90.

[98] Kasza J, Brody F, Vaziri K, et al. Analysis of poor outcomes after laparoscopic adjustable gastric banding. *Surg Endosc*. 2011;25(1):41-7.

[99] Chakravarty PD, McLaughlin E, Whittaker D, et al. Comparison of laparoscopic adjustable gastric banding (LAGB) with other bariatric procedures; a systematic review of the randomised controlled trials. *Surgeon*. 2012;10(3):172-82.

[100] Pilone V, Mozzi E, Schettino AM, et al. Improvement in health-related quality of life in first year after laparoscopic adjustable gastric banding. *Surg Obes Relat Dis*. 2012;8(3):260-8.

[101] Dixon JB, O'Brien PE, Playfair J, et al. Adjustable gastric banding and conventional therapy for type 2 diabetes: a randomized controlled trial. *JAMA*. 2008;299(3):316-23.

[102] Dixon JB, O'Brien PE. Health outcomes of severely obese type 2 diabetic subjects 1 year after laparoscopic adjustable gastric banding. *Diabetes Care*. 2002;25(2):358-63.
[103] Brancatisano A, Wahlroos S, Matthews S, Brancatisano R. Gastric banding for the treatment of type 2 diabetes mellitus in morbidly obese. *Surg Obes Relat Dis*. 2008;4(3):423-9.
[104] Ritt M, Piza H, Rhomberg M, Aigner F, Lechleitner M. Metabolic risk factors in formerly obese women--effects of a pronounced weight loss by gastric band operation compared with weight loss by diet alone. *Diabetes Obes Metab*. 2005;7(3):216-22.
[105] Sultan S, Gupta D, Parikh M, et al. Five-year outcomes of patients with type 2 diabetes who underwent laparoscopic adjustable gastric banding. *Surg Obes Relat Dis*. 2010;6(4):373-6.
[106] Trakhtenbroit MA, Leichman JG, Algahim MF, et al. Body weight, insulin resistance, and serum adipokine levels 2 years after 2 types of bariatric surgery. *Am J Med*. 2009;122(5):435-42.
[107] Plum L, Ahmed L, Febres G, et al. Comparison of glucostatic parameters after hypocaloric diet or bariatric surgery and equivalent weight loss. *Obesity* (Silver Spring). 2011;19(11):2149-57.
[108] Bradley D, Conte C, Mittendorfer B, et al. Gastric bypass and banding equally improve insulin sensitivity and beta cell function. *J Clin Invest*. 2012;122(12):4667-74.
[109] Tussing-Humphreys LM, Nemeth E, Fantuzzi G, et al. Decreased serum hepcidin and improved functional iron status 6 months after restrictive bariatric surgery. *Obesity* (Silver Spring). 2010;18(10):2010-6.
[110] Marantos G, Daskalakis M, Karkavitsas N, Matalliotakis I, Papadakis JA, Melissas J. Changes in metabolic profile and adipoinsular axis in morbidly obese premenopausal females treated with restrictive bariatric surgery. *World J Surg*. 2011;35(9):2022-30.
[111] Ram E, Vishne T, Maayan R, et al. The relationship between BMI, plasma leptin, insulin and proinsulin before and after laparoscopic adjustable gastric banding. *Obes Surg*. 2005;15(10):1456-62.
[112] Shak JR, Roper J, Perez-Perez GI, et al. The effect of laparoscopic gastric banding surgery on plasma levels of appetite-control, insulinotropic, and digestive hormones. *Obes Surg*. 2008;18(9):1089-96.
[113] Moschen AR, Molnar C, Wolf AM, et al. Effects of weight loss induced by bariatric surgery on hepatic adipocytokine expression. *J Hepatol*. 2009;51(4):765-77.
[114] Korner J, Inabnet W, Febres G, et al. Prospective study of gut hormone and metabolic changes after adjustable gastric banding and Roux-en-Y gastric bypass. *Int J Obes* (Lond). 2009;33(7):786-95.
[115] Krieger AC, Youn H, Modersitzki F, et al. Effects of laparoscopic adjustable gastric banding on sleep and metabolism: a 12-month follow-up study. *Int J Gen Med*. 2012;5:975-81.
[116] Uzun H, Zengin K, Taskin M, Aydin S, Simsek G, Dariyerli N. Changes in leptin, plasminogen activator factor and oxidative stress in morbidly obese patients following open and laparoscopic Swedish adjustable gastric banding. *Obes Surg*. 2004;14(5):659-65.
[117] Botella-Carretero JI, Luque-Ramirez M, Alvarez-Blasco F, Peromingo R, San Millan JL, Escobar-Morreale HF. The increase in serum visfatin after bariatric surgery in

morbidly obese women is modulated by weight loss, waist circumference, and presence or absence of diabetes before surgery. *Obes Surg*. 2008;18(8):1000-6.

[118] Garcia-Fuentes E, Garcia-Almeida JM, Garcia-Arnes J, et al. Plasma visfatin concentrations in severely obese subjects are increased after intestinal bypass. *Obesity* (Silver Spring). 2007;15(10):2391-5.

[119] De Vriese C, Delporte C. Ghrelin: a new peptide regulating growth hormone release and food intake. *Int J Biochem Cell Biol*. 2008;40(8):1420-4.

[120] Tschop M, Weyer C, Tataranni PA, Devanarayan V, Ravussin E, Heiman ML. Circulating ghrelin levels are decreased in human obesity. *Diabetes*. 2001;50(4):707-9.

[121] Hanusch-Enserer U, Cauza E, Brabant G, et al. Plasma ghrelin in obesity before and after weight loss after laparoscopical adjustable gastric banding. *J Clin Endocrinol Metab*. 2004;89(7):3352-8.

[122] Hady HR, Dadan J, Golaszewski P. 100 obese patients after laparoscopic adjustable gastric banding - the influence on BMI, gherlin and insulin concentration, parameters of lipid balance and co-morbidities. *Adv Med Sci*. 2012;57(1):58-64.

[123] Zengin K, Taskin M, Sakoglu N, Salihoglu Z, Demiroluk S, Uzun H. Systemic inflammatory response after laparoscopic and open application of adjustable banding for morbidly obese patients. *Obes Surg*. 2002;12(2):276-9.

[124] Lasselin J, Magne E, Beau C, et al. Adipose inflammation in obesity: relationship with circulating levels of inflammatory markers and association with surgery-induced weight loss. *J Clin Endocrinol Metab*. 2014;99(1):E53-61.

[125] Keogh JB, Brancatisano A, Taylor SF, et al. Evaluation of the Swedish adjustable gastric band VC (SAGB-VC) in an Australian population: early results. *Can J Surg*. 2013;56(1):15-20.

[126] Ramalho R, Guimaraes C, Gil C, Neves C, Guimaraes JT, Delgado L. Morbid obesity and inflammation: a prospective study after adjustable gastric banding surgery. *Obes Surg*. 2009;19(7):915-20.

[127] Cugno M, Castelli R, Mari D, et al. Inflammatory and prothrombotic parameters in normotensive non-diabetic obese women: effect of weight loss obtained by gastric banding. *Intern Emerg Med*. 2012;7(3):237-42.

[128] Moschen AR, Molnar C, Geiger S, et al. Anti-inflammatory effects of excessive weight loss: potent suppression of adipose interleukin 6 and tumour necrosis factor alpha expression. *Gut*. 2010;59(9):1259-64.

[129] Gasteyger C, Suter M, Calmes JM, Gaillard RC, Giusti V. Changes in body composition, metabolic profile and nutritional status 24 months after gastric banding. *Obes Surg*. 2006;16(3):243-50.

[130] Samaras K, Viardot A, Botelho NK, Jenkins A, Lord RV. Immune cell-mediated inflammation and the early improvements in glucose metabolism after gastric banding surgery. *Diabetologia*. 2013;56(12):2564-72.

[131] Tulchinsky TH. Micronutrient deficiency conditions: global health issues. *Publ Health Rev*. 2010;32:243 - 55.

[132] Nead KG, Halterman JS, Kaczorowski JM, Auinger P, Weitzman M. Overweight children and adolescents: a risk group for iron deficiency. *Pediatrics*. 2004;114(1):104-8.

[133] Yanoff LB, Menzie CM, Denkinger B, et al. Inflammation and iron deficiency in the hypoferremia of obesity. *Int J Obes* (Lond). 2007;31(9):1412-9.

[134] Lecube A, Carrera A, Losada E, Hernandez C, Simo R, Mesa J. Iron deficiency in obese postmenopausal women. *Obesity* (Silver Spring). 2006;14(10):1724-30.

[135] Zimmermann MB, Zeder C, Muthayya S, et al. Adiposity in women and children from transition countries predicts decreased iron absorption, iron deficiency and a reduced response to iron fortification. *Int J Obes* (Lond). 2008;32(7):1098-104.

[136] Lee PL, Beutler E. Regulation of hepcidin and iron-overload disease. *Annu Rev Pathol*. 2009;4:489-515.

[137] Nemeth E, Tuttle MS, Powelson J, et al. Hepcidin regulates cellular iron efflux by binding to ferroportin and inducing its internalization. *Science*. 2004;306(5704):2090-3.

[138] Nicolas G, Chauvet C, Viatte L, et al. The gene encoding the iron regulatory peptide hepcidin is regulated by anemia, hypoxia, and inflammation. *J Clin Invest*. 2002;110(7):1037-44.

[139] Collins JF, Wessling-Resnick M, Knutson MD. Hepcidin regulation of iron transport. *J Nutr*. 2008;138(11):2284-8.

[140] Bekri S, Gual P, Anty R, et al. Increased adipose tissue expression of hepcidin in severe obesity is independent from diabetes and NASH. *Gastroenterology*. 2006;131(3):788-96.

[141] Vokurka M, Lacinova Z, Kremen J, et al. Hepcidin expression in adipose tissue increases during cardiac surgery. *Physiol Res*. 2010;59(3):393-400.

[142] Luciani N, Brasse-Lagnel C, Poli M, et al. Hemojuvelin: a new link between obesity and iron homeostasis. *Obesity* (Silver Spring). 2011;19(8):1545-51.

[143] Anty R, Dahman M, Iannelli A, et al. Bariatric surgery can correct iron depletion in morbidly obese women: a link with chronic inflammation. *Obes Surg*. 2008;18(6):709-14.

[144] Coupaye M, Bouillot JL, Coussieu C, Guy-Grand B, Basdevant A, Oppert JM. One-year changes in energy expenditure and serum leptin following adjustable gastric banding in obese women. *Obes Surg*. 2005;15(6):827-33.

[145] Diker D, Vishne T, Maayan R, et al. Impact of gastric banding on plasma adiponectin levels. *Obes Surg*. 2006;16(8):1057-61.

[146] Benedix F, Westphal S, Patschke R, et al. Weight loss and changes in salivary ghrelin and adiponectin: comparison between sleeve gastrectomy and Roux-en-Y gastric bypass and gastric banding. *Obes Surg*. 2011;21(5):616-24.

[147] Visockiene Z, Brimas G, Abaliksta T, Siauliene L, Liakina V, Strupas K. Metabolic changes one year after laparoscopic adjustable gastric banding operation in morbidly obese subjects. *Wideochir Inne Tech Malo Inwazyjne*. 2013;8(1):13-21.

In: Encyclopedia of Surgery (22 Volume Set)
Editors: Andreas Lehrer and Kristin Mueller
ISBN: 978-1-53618-329-0
© 2020 Nova Science Publishers, Inc.

Chapter 11

LONG TERM DIABETES OUTCOMES AFTER BARIATRIC SURGERY

Richard W. Carroll[1,2], Jeremy D. Krebs[1,2] and Rinki Murphy[3]
[1]Centre for Endocrine, Diabetes, and Obesity Research, Wellington Regional Hospital, Wellington, New Zealand
[2]Department of Medicine, University of Otago, New Zealand
[3]Department of Medicine, University of Auckland, New Zealand

ABSTRACT

Bariatric surgery was developed primarily as a therapy to induce weight loss. Indeed, those with type 2 diabetes were originally not considered surgical candidates due to the perceived high risk nature of surgery in these individuals. However, significant post-operative improvements in diabetes control were noted early in the history of bariatric surgery. Multiple retrospective and prospective studies have since supported this finding, including a number of high quality randomised trials. Variable definitions of diabetes outcomes are used within the published literature complicating comparative analysis. This chapter will review the published literature on glycaemic outcomes at least 12 months following bariatric surgery, and discuss the importance of a consistent set of definitions when reporting on diabetes outcomes.

INTRODUCTION

Bariatric surgery was developed to induce weight loss, and was not originally proposed as a treatment for type 2 diabetes. Indeed, the majority of bariatric surgeons considered a diagnosis of type 2 diabetes to be a contraindication to bariatric surgery, due to a perception of increased surgical risk. Nonetheless, early pioneers of bariatric surgery recognised the early and sustained glycaemic benefits that those with pre-operative type 2 diabetes appeared to gain from surgery. Whilst the mechanism of this effect remains to be completely clarified, the concept of a surgical procedure as an appropriate and effective therapy for type 2 diabetes has been accepted following the publication of an increasing number of studies reporting

superior outcomes in those undergoing surgery when compared to optimal lifestyle and medical treatment. Thus, in 2011, the International Diabetes Federation published a position statement on the place of bariatric surgery in the treatment armoury for type 2 diabetes. [1] This concluded by acknowledging that bariatric surgery should be considered earlier in the management of obese persons with type 2 diabetes. In this chapter, we discuss a number of recent studies that have contributed to this opinion.

The published literature on diabetes outcomes following bariatric surgery is extensive, and the quality of study methodology is variable. For the purposes of this chapter, a systematic literature search was performed to capture all studies published up to mid-2014. Search terms included 'bariatric surgery', 'gastric banding', 'sleeve gastrectomy', 'gastric bypass' 'biliopancreatic diversion', and 'diabetes'. In addition, the reference lists in included studies along with recent review articles were screened for appropriate studies not detected by the search. [2] Studies of bariatric surgery versus a non-surgical group or alternative bariatric procedures, that reported glycaemic outcomes at least 12 months following surgery were selected for discussion. The design of each of these studies varies, and the list includes prospective randomised controlled studies, and prospective and retrospective case controlled studies. Additionally, a number of meta-analyses including data from smaller, uncontrolled studies are discussed. A summary of the included studies is presented in table 1.

DEFINITION OF DIABETES OUTCOME

The state of diabetes following bariatric surgery and the definition of this has been highly controversial. A number of descriptions of glycaemic outcome to encompass varying degrees of diabetes resolution are utilised within the bariatric surgery literature. However, use of terms such as 'cure', 'resolved' or 'remission' in this context are controversial for a number of reasons. Most importantly, fasting glucose concentrations in the population are a continuous variable and the diagnosis of diabetes itself is based on a somewhat arbitrary threshold above which there is an increased risk of microvascular complications. It is not yet known whether these thresholds remain true in a post-bariatric surgery population, and consequently diagnostic criteria validated for a non-surgical population may be misleading when applied to those who have undergone bariatric surgery. Secondly, the concept of "glycaemic memory" is well established, and relates to the latent effect that periods of hyperglycaemia may have on outcomes later life, irrespective of changes in glycaemic control in the intervening period. [3]

The UKPDS trial illustrated this concept most vividly. Participants randomised to the intensive treatment arm of the study had significantly improved glycaemic control over the 13 years of the study in comparison to those receiving standard treatment. [4] Participants were subsequently followed up 10 years after the completion of the study. Over this 10 year period glycaemic control, as measured using HbA1c, became comparable in the two groups. Despite this those who had been initially randomised to the intensive therapy arm maintained significantly lower rates of microvascular complications and cardiovascular mortality. This strongly argues that the period of early improved glycaemic control had a long term benefit on cardiovascular disease.

Table 1. Summary of discussed studies. Diabetes outcomes reported by each included study are presented, although the reader should note the different definitions utilized

Study	Intervention 1	Intervention 2	Duration of follow up	Study design	Definition of diabetes outcome	Diabetes at baseline (%)		Diabetes outcome at study end (%) based on study specific definition[1]	
						Intervention 1	Intervention 2	Intervention 1	Intervention 2
Hofso [6]	Gastric bypass	Lifestyle	12 months	Prospective case control	Complete = FG <5.6 mmol/L, and 2HrG of <7.8 mmol/L, and HbA1c of < 6.2% (44 mmol/mol) in the absence of glucose lowering therapy. Partial = FG <7.0 mmol/L, and 2HrG<11.1 mmol/L, and HbA1c < 6.5% (47 mmol/mol).	26	29	55 (70) [2]	0 (33)
Ikramuddin [7]	Gastric bypass	Lifestyle	12 months	Randomised	HbA1c <7% (53 mmol/L)	100	100	75	32
Kashyap et [12]	Gastric bypass/ Sleeve gastrectomy	Medical therapy	12 months	Randomised	HbA1c <6.0% (42 mmol/mol)	100	100	44 / 23	6
Lee [9]	Gastric bypass	Sleeve gastrectomy	12 months	Randomised	FG <126 mg/dl (7.0 mmol/L) and HbA1c of <6.5% (47 mmol/mol) in the absence of glucose lowering medications	100	100	93	47

[1] Figures in parentheses represent number achieving partial/incomplete control as per study specific definitions, unless otherwise indicated
[2] Diabetes outcome inclusive of participants who achieved either complete or partial remission.

Table 1. (Continued)

Study	Intervention 1	Intervention 2	Duration of follow up	Study design	Definition of diabetes outcome	Diabetes at baseline (%)		Diabetes outcome at study end (%) based on study specific definition[3]	
						Intervention 1	Intervention 2	Intervention 1	Intervention 2
Schauer [10]	Gastric bypass/ sleeve gastrectomy	Lifestyle	12 months	Randomised	HbA1c <42 mmol/mol with or without the use of diabetes medications	100	100	42 / 37[4]	12
Scopinaro [11]	Biliopancreatic diversion	Medical therapy	12 months	Prospective historical case control	FG <126mg/dl (7.0 mmol/L) and HbA1c <6.0% (42 mmol/mol) in the absence of glucose lowering medications	100	100	30 (83[5])	0
Serrot [8]	Gastric bypass	Medical therapy	12 months	Retrospective case control	HbA1c <5.7% (39 mmol/mol) in the absence of glucose lowering medications for remission, HbA1c <6.5% (47 mmol/mol) in the absence of glucose lowering medications for control	100	100	24 / 41	NR
Vidal [11]	Gastric bypass	Sleeve gastrectomy	12 months	Prospective comparison	FG <126 mg/dl (7.0 mmol/L), and HbA1c 3.4-5.5% (14-36 mmol/mol) in the absence of glucose lowering medications	100	100	85	85

[3] Figures in parentheses represent number achieving partial/incomplete control as per study specific definitions, unless otherwise indicated
[4] 5/18 in SG arm reported as achieving diabetes remission remained on diabetes medications, whilst none of those in remissionin RYGB arm did
[5] Inclusive of participants who were deemed to have achieved diabetes control defined as an HbA1c <7.0% (53 mmol/mol) in the absence of glucose lowering medication

Study	Intervention 1	Intervention 2	Duration of follow up	Study design	Definition of diabetes outcome	Diabetes at baseline (%)		Diabetes outcome at study end (%) based on study specific definition[6]	
						Intervention 1	Intervention 2	Intervention 1	Intervention 2
Adams [15]	Gastric bypass	Referred for but did not undergo surgery/ Population control	24 months	Prospective comparison	Hba1c and fasting glucose within the normal reference range	NR	NR	75	7 / 6
Dixon [16]	Laparoscopic adjustable gastric band	Lifestyle	24 months	Randomised	FG <126 mg/dl (7.0 mmol/L) and Hba1c <6.2% (44 mmol/mol) in the absence of glucose lowering therapy	100	100	73	23[7]
Kashyap [12]	Gastric bypass / Sleeve gastrectomy	Medical therapy	24 months	Randomised	HbA1c <6.0% (42 mmol/mol)	100	100	33 / 11	6
Leslie [14]	Gastric bypass	Medical therapy	24 months	Retrospective case control	Composite end point of ADA defined treatment goals (HbA1c<7.0% (53 mmol/mol), LDL<100mg/dl, SBP<130mmHg)	100	100	38	17
Mingrone [18]	Gastric bypass/ biliopancreatic diversion	Medical/ Lifestyle	24 months	Randomised	FG < 100 mg/dl (5.6 mmol/L) and HbA1c level < 6.5% (45 mmol/mol) for at least 1 year without active pharmacologic therapy	100	100	75 / 95	0

[6] Figures in parentheses represent number achieving partial/incomplete control as per study specific definitions, unless otherwise indicated

[7] Assuming that all those not available for follow up at study end (n=4) achieved diabetes remission. Diabetes remission achieved by 11% if each of these participants failed to achieved diabetes remission

Table 1. (Continued)

Study	Intervention 1	Intervention 2	Duration of follow up	Study design	Definition of diabetes outcome	Diabetes at baseline (%)		Diabetes outcome at study end (%) based on study specific definition[8]	
						Intervention 1	Intervention 2	Intervention 1	Intervention 2
Sjostrom [17]	Bariatric surgery[9]	Medical/Lifestyle[10]	24 months	Prospective case control	FG < 7.0 mmol/L or the use of glucose lowering medication	100	100	72	21
Pournaras [22]	Gastric bypass	Gastric band	36 months	Prospective comparison	FG <7.0 mmol/L and 2hrG <11.1 mmol/L and HbA1c <42 mmol/mol in the absence of glucose lowering medication for > 3 months	100	100	72	17
Schauer [23][11]	Gastric bypass/ sleeve gastrectomy	Lifestyle	36 months	Randomised	HbA1c <42 mmol/mol with or without the use of diabetes medications	100	100	38 / 24	5
Pinheiro [21]	Gastric bypass [12]	Gastric bypass [13]	48 months	Randomised	Normal range glucose levels in the absence of glucose lowering medication	100	100	93	58

[8] Figures in parentheses represent number achieving partial/incomplete control as per study specific definitions, unless otherwise indicated
[9] Inclusive of gastric banding, sleeve gastrectomy, and gastric bypass
[10] Medical/lifestyle arm was not standardised
[11] Further follow up of participants reported earlier by Schauer et al. 91% of participants available for this further analysis
[12] Biliary limb of 50cm, Roux limb of 150cm
[13] Biliary limb of 100cm, Roux limb of 250cm

Study	Intervention 1	Intervention 2	Duration of follow up	Study design	Definition of diabetes outcome	Diabetes at baseline (%)		Diabetes outcome at study end (%) based on study specific definition[14]	
						Intervention 1	Intervention 2	Intervention 1	Intervention 2
Pontiroli [20]	Laparoscopic adjustable gastric band	Offered but declined laparoscopic adjustable gastric band	48 months	Prospective case control	FG < 6.1 mmol/L, and 2hrG <7.8 mmol/L in the absence of glucose lowering medications[15]	100	100	45	4
Adams [15]	Gastric bypass	Referred for, but did not undergo surgery/ Population control	72 months	Prospective case control	Hba1c and fasting glucose within the normal reference range	NR	NR	62	8 / 6
Iaconelli [19]	Biliopancreatic diversion	Medical therapy	120 months	Prospective case control	Not specified – implied that contemporary criteria for the diagnosis of diabetes used	100	100	100	45[16]
Sjostrom [17]	Bariatric surgery[17]	Medical/Lifestyle[18]	120 months	Prospective case control	FG < 7.0 mmol/L or the use of glucose lowering medication	100	100	36	13

[14] Figures in parentheses represent number achieving partial/incomplete control as per study specific definitions, unless otherwise indicated.
[15] Definition not defined in manuscript – implication that remission is defined by fasting and 2 hour OGTT glucose levels below contemporary diagnostic thresholds for dysglycaemia.
[16] Remission rate at 12 months – 120 month figure not provided, although mean HbA1c at that stage was 62 mmol/mol.
[17] Inclusive of gastric banding, sleeve gastrectomy, and gastric bypass.
[18] Medical/lifestyle arm was not standardized.

Therefore it cannot be assumed that if a person with diabetes has "normal" glucose metabolism following bariatric surgery, that their risk of micro and macro vascular disease is the same as a person who has never had a diagnosis of diabetes. It is highly plausible, and indeed worthy of study, that the glucose burden pre bariatric surgery confers an increased risk of micro and macrovascular disease later in life, even if normal glucose levels are restored following surgery. Furthermore, progressive decline in pancreatic beta cell function over time is characteristic of type 2 diabetes and it is unknown whether bariatric surgery alters this process. Thirdly, use of the term "cure" for a chronic disease mediated predominantly by lifestyle may not be helpful in encouraging longer term compliance to favourable dietary and exercise strategies. Regardless of these caveats, a better understanding of glycaemic outcomes following bariatric surgery is important for pre-operative patient counselling as to the likely glycaemic benefits from the procedure.

In the absence of definitive evidence addressing each of the issues above, the literature reporting diabetes outcomes following bariatric surgery is notable for the degree of variability with which diabetes remission is defined. This is confusing, and has possibly contributed to the delays seen for bariatric surgery to be accepted as an appropriate therapeutic option in the management of obese persons with type 2 diabetes. An agreed set of definitions of diabetes outcomes would ideally be used when reporting on bariatric surgery outcomes, and thus the American Diabetes Association (ADA) released a consensus statement in 2009 providing recommendations on the definition of glycaemic outcomes post bariatric surgery.[5] This suggested the use of the terms "partial remission" (HbA1C<6.5% (47 mmol/L), fasting glucose 100-125 mg/dl (5.6 – 6.9 mmol/L)), and "complete remission" (HbA1c "in the normal range", fasting glucose <100mg/dl (5.6 mmol/L)) provided that each of these assessments were persistent for at least 1 year duration, and in the absence of active pharmacologic therapy or ongoing procedures. Additionally, the ADA defined prolonged remission as the thresholds required for satisfaction of complete remission, maintained for at least 5 years. The definition of diabetes outcomes used by each study discussed below is variable, and the reader is therefore advised to consider the effect the chosen definition may have on outcome interpretation. Furthermore, comparison of bariatric surgery with non-surgical intensive medical management can only rely on achievement of similar glycaemic targets rather than diabetes remission as defined by achieving such glycaemic targets in the absence of glucose lowering therapy.

REVIEW OF DIABETES OUTCOMES FOLLOWING BARIATRIC PROCEDURES

The literature reporting on diabetes outcomes following bariatric surgery is extensive and ranges from small case series through to high quality randomised controlled studies. A number of excellent meta-analyses have attempted to address this diversity of study quality, and some of these publications are discussed later in this chapter. Here, we selected only those studies that included a comparison or control group, either an alternative bariatric procedure or lifestyle/medical therapies, and reported on outcomes at 12 months or beyond.

Studies Reporting Diabetes Outcomes at 12 Months

Gastric Bypass Versus Lifestyle/Medical Therapy

Three studies were identified reporting diabetes outcomes at 12 months following gastric bypass.[6-8] Diabetes control was achieved by 41-75% of those in the gastric bypass arm in these studies. The variability is likely due to differences in the definitions utilised to define diabetes outcomes in each study and in the baseline characteristics of the participants. The study by Ikramuddin and colleagues defined only diabetes control and accepted a higher HbA1c threshold (<7.0% (53 mmol/mol)) than the other two studies; thus, this study reported the highest rates of diabetes control. The studies by Hofso and Serrot both reported diabetes remission, requiring absence of glucose lowering medications, and control defined by a lower HbA1c level, a higher mean age of participant in the surgical arm (56 vs 42 years), and a higher HbA1c at baseline (8.2 vs 7.1% (66 vs 54 mmol/mol)).

Hofso and colleagues performed a comparison study of gastric bypass versus a lifestyle based intervention in 146 morbidly obese adults (mean BMI 45.6 kg/m2) and reported outcomes at 12 months.[6] The study was not randomised as the study authors considered this to be unethical on the basis of clear local guidelines on selecting bariatric interventions for obese patients. Those in the gastric bypass arm of the study received a low calorie diet for 3 to 6 weeks prior to surgery, and were seen by a dietitian in group sessions every 3 months during the study period. The lifestyle intervention in this study was significant; each participant in this arm was referred to a specialist inpatient weight loss centre and had four stays within the centre during the 12 month study period. Each admission was for between 1 and 4 weeks. Participants received numerous interventions during each stay including input from a medical doctor, a nurse, a physiotherapist, and a specialist trained nurse. Physical activity was increased, and all participants were provided with education on a healthy diet, which they were encouraged to follow. Group sessions focused on the psychosocial and emotional aspects of obesity and weight loss. Weight loss drugs were not used. Phone contact was maintained fortnightly while participants were away from the weight loss centre. In addition to fasting bloods, a 75g 2 hour oral glucose tolerance test was used to define both diabetes at study entry and diabetes outcomes. 26% and 29% of participants in the gastric bypass and lifestyle intervention arms respectively had type 2 diabetes at baseline. Diabetes remission was defined as a fasting glucose <5.6 mmol/L, and a 2 hour glucose of <7.8 mmol/L, and an HbA1c of < 6.2% (44 mmol/mol) in the absence of glucose lowering therapy. In addition, the study authors defined partial diabetes remission as glucose levels below the diagnostic thresholds at baseline (<7.0 and 11.1 mmol/L for fasting and 2 hour glucose respectively) and an HbA1c < 6.5% (47 mmol/mol) without the use of glucose lowering therapy.

The study authors elected to report diabetes remission rates at 12 months, including participants who had achieved either complete or partial remission. Thus, the overall diabetes remission rate by this criteria was significantly greater in the gastric bypass arm versus those in the lifestyle intervention arm (70 vs 33%, OR 4.7 (1.2–18.4). However, none of the participants in the lifestyle intervention arm achieved complete diabetes remission, whilst 11 out of the 14 participants (55% of those with type 2 diabetes at baseline) achieved complete diabetes remission at 12 months follow up.

Ikramuddin and colleagues performed a 12 month randomised study of intensive medical management versus intensive medical management plus Roux-en-Y gastric bypass.[7] 120 obese participants (BMI 30-39 kg/m2) with type 2 diabetes were recruited, and a primary composite outcome incorporating achievement of diabetes, blood pressure and lipid control targets was reported. Intensive medical management included a reduced energy diet for all participants with the aim of weight loss in the order of 1-2 pounds per week. Increased physical activity was encouraged, and each participant had regular face to face contact with a study interventionist to discuss behavioural and social issues around weight loss. Orlistat, and Sibutramine prior to withdrawal from the US market, were available for use by those in the lifestyle arm if agreed weight loss targets were not met. The contemporary American Diabetes Association guidelines for the management of type 2 diabetes were followed for the medical management of each participant in the study. 75% of those randomised to gastric bypass achieved diabetes control (defined solely as an HbA1c of <7% (53 mmol/L)) at 12 months versus 32% of those randomised to intensive medical management only (OR, 6.0; 95% CI, 2.6-13.9). Whilst the primary composite outcome was achieved in 49% (versus 19%) of those undergoing gastric bypass, there was no difference between the two arms when blood pressure and lipid outcomes were assessed as independent outcomes.

Serrot and colleagues performed a retrospective case control study of obese (BMI 30-35 kg/m2) participants with type 2 diabetes who had undergone gastric bypass in their institution versus a control group (BMI matched persons with type 2 diabetes from a primary care database).[8] Of nearly 3000 gastric bypass procedures performed over an 8 year period, 20% had preoperative type 2 diabetes and of these, 17 participants had a BMI of 30-35 kg/m2. Each surgical participant was matched with one control subject. Diabetes remission was defined as an HbA1c <5.7% (39 mmol/mol) in the absence of glucose lowering medications, whilst diabetes control was defined as an HbA1c <6.5% (47 mmol/mol) in the absence of glucose lowering medications. At the 12 month follow up assessment 4/17 (24%) of surgical participants had achieved diabetes remission and a further 7 (41%) of participants had achieved diabetes control. Classification outcomes in the control group were not reported. The mean HbA1c in those who had undergone surgery fell from a baseline level of 8.2% ((66 mmol/mol) ± 2.0%) to 6.1% ((43 mmol/mol) ± 2.7%), but did not change significantly in the control group ((7.0 (53 mmol/mol) ± 0.7% to 7.1 (54 mmol/mol) ± 1.8%).

Gastric Bypass Versus Sleeve Gastrectomy

Two randomised controlled studies and one prospective non-randomised study reported outcomes at 12 months following either gastric bypass or sleeve gastrectomy, with 2 of these studies including a lifestyle/medical arm.[9-11] In addition, a further randomised controlled study primarily reporting on 24 month outcomes, presented 12 month outcomes.[12] Whilst each study used stringent criteria for diabetes remission/control, it should be noted that participants in the study by Lee and colleagues demonstrating superior efficacy of GBP compared to SG, these participants were Taiwanese and had significantly lower BMI at baseline versus those in the studies by Schauer and Vidal which both showed similar efficacy of GBP compared to SG. The apparent marked increase in surgical participants achieving diabetes remission in the study by Vidal when compared to those in the study by Schauer (85% versus 40%) is of interest. Despite a similar age at surgery (mean approximately 48 years), participants in the Schauer study were not as obese, had a longer pre-operative

duration of diabetes, and a 4 fold higher pre-operative use of insulin. This may indicate less beta cell reserve, and thus reduced likelihood of resolution of diabetes even with substantive weight loss and improved insulin sensitivity.

Lee and colleagues reported 12 month diabetes outcomes following randomisation to gastric bypass or sleeve gastrectomy in 60 overweight (BMI 25-35 kg/m2) Taiwanese participants with sub-optimally controlled type 2 diabetes.[9] Diabetes remission was defined as a fasting glucose of <126 mg/dl (7.0 mmol/L) and HbA1c of <6.5% (47 mmol/mol) and the absence of diabetes medications. Participants were assessed by an extensive multidisciplinary team prior to surgery but the study does not report on medical interventions used in the post-operative period. 93% of those randomised to gastric bypass achieved diabetes remission at 12 months versus 47% of those who had undergone sleeve gastrectomy.

Schauer and colleagues first reported on diabetes outcomes of overweight and obese American participants (BMI 27-43 kg/m2) and type 2 diabetes at 12 months of follow up.[10] 150 participants were recruited and randomised in equal numbers to one of 3 interventional arms (intensive medical therapy, gastric bypass plus intensive medical management, and sleeve gastrectomy plus intensive medical management). Diabetes control/remission, defined as an HbA1c <42 mmol/mol with or without the use of diabetes medications, was achieved by 12% of those randomised to medical therapy only, 42% of those randomised to the gastric bypass arm, and 37% of those randomised to the sleeve gastrectomy arm. The definition of diabetes remission utilised for this study was clearly limited by the acceptance of an HbA1c < 42 mmol/mol as evidence for remission even in the context of ongoing diabetes medication use. It could be argued that those who required ongoing glucose lowering therapy should be defined as being, at best, partial responders. However, all of those in the gastric bypass arm who achieved diabetes remission did so without the ongoing use of diabetes medications, whilst 28% of those in the sleeve gastrectomy arm who were reported as achieving diabetes remission continued to require glucose lowering therapy; all of those in the medical management alone arm who achieved the primary endpoint remained on glucose lowering therapy.

Vidal and colleagues performed a non-randomised prospective study comparing outcomes of severely obese (BMI >35kg/m2) participants with type 2 diabetes (n=91) who underwent either gastric bypass (n=52) or laparoscopic sleeve gastrectomy (n=39).[11] The groups were matched at baseline for duration, control, and treatment of diabetes. Diabetes remission was defined as a fasting glucose <126 mg/dl (7.0 mmol/L) and an HbA1c within the normal range (3.4-5.5% (14-37 mmol/mol)) in the absence of glucose lowering medications. At 12 months following surgery diabetes remission had been achieved by 84.6% of those who had undergone gastric bypass and 84.6% of those who had undergone laparoscopic sleeve gastrectomy. Interestingly, the study authors found no relationship between weight loss and diabetes remission, but did note a significant association between duration and severity (treatments required, HbA1c at baseline) of diabetes and diabetes remission.

Biliopancreatic Diversion Versus Lifestyle/Medical Therapy

Scopinaro and colleagues performed a prospective, case controlled study of biliopancreatic diversion surgery versus medical management in overweight or obese persons (BMI 25-34.9 kg/m2) with type 2 diabetes.[13] Participants who underwent biliopancreatic

diversion surgery had a mean age of 56 years and established diabetes (mean duration of diabetes = 11 years, mean HbA1c at baseline = 78 mmol/mol, 12/30 participants requiring insulin therapy at baseline). Controls were selected from an historical registry. The study authors defined 3 categories of diabetes outcomes. Diabetes remission was defined as a fasting glucose <126 mg/dl (7.0 mmol/L), and an HbA1c ≤6.0% (42 mmol/mol) without the use of glucose lowering medications; controlled diabetes was defined as an HbA1c ≤7.0% (53 mmol/mol) in the absence of glucose lowering medication; improved diabetes was defined as a >1% (10-11 mmol/mol) reduction in Hba1c levels when compared to baseline. No participants in the historical control group achieved diabetes remission or diabetes control during 1 year of treatment (mean HbA1c at baseline = 8.8% (73 mmol/mol)). Whilst two thirds of participants required an increase in their medication doses during this 12 month period, no participant was able to reduce medication doses. In contrast, diabetes remission was achieved by 30% of those who had undergone biliopancreatic diversion, and diabetes control by a further 53% (83% total). However, 5 participants (out of 12) who required insulin therapy at baseline remained on insulin therapy at 12 months following biliopancreatic surgery.

The relative low rate of diabetes remission following biliopancreatic diversion in this study, in contrast to very high rates more commonly reported following this procedure, may be explained by the baseline characteristics of the study cohort. Specifically, this was an older cohort than other studies discussed above (mean age = 56.4 years), and participants had both a longer duration of diabetes (mean = 11.2 years) and a higher Hba1c (mean = 9.6% (81 mmol/mol)) at baseline.

Studies Reporting on Outcomes from 12 to 24 Months

Gastric Bypass Versus Lifestyle/Medical Therapy

Two study of gastric bypass versus lifestyle medical therapy were identified that reported on outcomes at 24 months.[14,15] The study by Adams and colleagues continued to follow up their cohort for a total of 72 months and is therefore discussed in the following section. Leslie and colleagues performed a retrospective case control study of outcomes following gastric bypass versus medical managements for obese persons with type 2 diabetes.[14] Rather than define diabetes outcomes using simply glycaemic markers, the study authors elected to use a composite end point of treatment goals as recommended by the American Diabetes Association for the management of type 2 diabetes (HbA1c <7.0% (53 mmol/mol), low-density lipoprotein <100mg/dl, systolic blood pressure <130mmHg). 152 and 115 participants who had undergone gastric bypass or medical therapy alone respectively were included in the analysis. The percentage of participants satisfying the ADA treatment goals who had undergone gastric bypass was 10.5% at baseline, increasing to 38.2% at 24 months follow up. A smaller, non-significant increase was noted in the medical therapy group (13.9% at baseline versus 17.4% at 24 months).

Laparoscopic Adjustable Gastric Band Versus Lifestyle/Medical Therapy

One study was identified that reported on diabetes outcomes 24 months following laparoscopic adjustable gastric banding. Dixon and colleagues reported diabetes outcomes at

24 months on 60 obese participants (BMI 30-40 kg/m2, age range 20-60 years) with type 2 diabetes randomised to either laparoscopic adjustable gastric banding or an intensive lifestyle program without the use of bariatric surgery.[16] The lifestyle program was comprehensive and administered via a multidisciplinary team consisting of a physician, dietitian, and diabetes nurse via face to face meetings at 6 week intervals. A low energy diet with reduced saturated fats was prescribed along with increased exercise activity; very low calorie diets and/or weight loss pharmaceutical agents were also available for use. Diabetes remission was defined as a fasting glucose level of <126 mg/dl (7.0 mmol/L) and an Hba1c <6.2% (44 mmol/mol) in the absence of glucose lowering therapy, and was achieved by 73% of those who in the laparoscopic adjustable gastric band arm versus 11-23% (based on the assumption that diabetes remission was/was not achieved by 4 participants randomised to the lifestyle arm who did not complete the study). Furthermore, improvement in diabetes control was evident in those who underwent gastric banding with 26/30 participants not requiring glucose lowering therapy at study end (versus 2 at baseline).

The percentage of participants who achieved diabetes remission in the surgical arm of this study was high, and particularly notable given that the mean age at which participants underwent surgery (46.6 years), the mean HbA1c at baseline (7.8% (62 mmol/mol)), and a mean BMI at surgery (37.0 kg/m2) was comparable to baseline characteristics of cohorts in other studies discussed in this chapter following gastric bypass or biliopancreatic diversion surgery. However, only one participant in the surgical group used insulin therapy at baseline, and although duration of diabetes at surgery was not reported, the exclusion of participants with evidence of microvascular complications is likely to result in the selection of those with a more recent diagnosis of diabetes.

Bariatric Surgery Versus Lifestyle/Medical Therapy

Three studies were identified that reported on outcomes in studies incorporating two or more bariatric surgery modalities.[12,17,18] The Swedish Obesity Study (SOS) reported on outcomes at 24 months in addition to those at 120 months and is thus discussed in the section below.[17] The studies by Kashyap and Mingrone both included a gastric bypass arm but reported markedly different diabetes outcomes at 24 months (33 versus 75% respectively). The authors used significantly different definitions of diabetes outcomes that could potentially result in discordant outcomes. However, whilst Kashyap elected to simply use HbA1c, Mingrone utilised seemingly more stringent criteria including a fasting glucose and HbA1c threshold, and the absence of glucose lowering medication. It should be noted though that Mingrone accepted an HbA1c of <6.5% (47 mmol/mol) as evidence of diabetes remission. The discordance between these studies is also not easily explained by differing baseline characteristics; whilst the two cohorts undergoing gastric bypass were of similar ages at operation (mean = 47.9 years and 43.9 years for the Kashyap and Mingrone studies respectively), and had a similar duration and control of diabetes at baseline (7.4/6.0 years, 9.0%(75 mmol/mol)/8.5%(69 mmol/mol) respectively), participants in the Mingrone study had a significantly higher BMI (44.6 versus 36.1 kg/m2). Additionally, differences in the medical/lifestyle program, prescribed for those in the surgical arms alongside surgery, do not appear likely to be a factor in this anomaly. None of the medical/lifestyle arm of the Mingrone study achieved diabetes remission, in comparison to 6% of participants in the equivalent arm of the Kashyap study.

Kashyap and colleagues undertook a prospective randomised study of optimal medical therapy versus either gastric bypass or sleeve gastrectomy in 60 moderately obese (mean BMI =36.1 kg/m2) participants with type 2 diabetes at baseline.[12] All patients received intensive medical therapy as recommended by the American Diabetes Association, including dietary modifications, increased frequency of capillary glucose measurements, and the use of all available glucose lowering agents. In addition, each participant received nutritional counselling by a study dietitian and underwent a psychological assessment, in part to assess suitability for bariatric surgery. Participants were then randomly allocated to either ongoing medical therapy alone, gastric bypass surgery, or sleeve gastrectomy. Diabetes remission was defined as an HbA1c of less than 42 mmol/mol (6.0%). 44% and 26% of those who had undergone gastric bypass and sleeve gastrectomy respectively had an HbA1c of <6.0% (42 mmol/mol) at 12 months follow up, compared with 6% of those who had received medical therapy alone. However, a reduction in the number of participants satisfying criteria for diabetes control at 24 months was evident (33, 11, and 6% for gastric bypass, sleeve gastrectomy, and medical therapy respectively).

Mingrone and colleagues performed a single centre randomised controlled study of gastric bypass versus biliopancreatic diversion versus medical/lifestyle therapy only.[18] 60 participants (age 30-60, BMI >35 kg/m2) were recruited, each of whom had had type 2 diabetes for at least 5 years and had a current HbA1c of >7.0% (53 mmol/mol). Each participant had visits with a multidisciplinary team (including a diabetologist, dietitian, and study nurse) at baseline and then 1, 3, 6, 9, 12 and 24 months following commencement of the intervention. A low-fat, high fibre diet and ≥30 minutes of brisk walking every day was prescribed to those in the medical arm and diabetes medications were adjusted based on regular HbA1c measurements. In keeping with the definition suggested by the American Diabetes Association, diabetes remission was defined as a fasting plasma glucose level < 100 mg/dl (5.6 mmol/L) and an HbA1c level < 6.5% (45 mmol/mol) for at least 1 year without active pharmacologic therapy. Diabetes remission was achieved by 95% of those in the biliopancreatic diversion arm, 75% of those in the gastric bypass arm, and none of those in the medical arm. Biliopancreatic diversion and gastric bypass were associated with an odds ratio of diabetes remission of at least 9.5 (95% CI, 2.54 to 35.51; P<0.001) and 7.5 (95% CI 1.97 to 28.61; P<0.001) respectively when compared with medical therapy alone.

As noted earlier, the 95% diabetes remission rate in the biliopancreatic diversion arm of the above study by Mingrone and colleagues is significantly higher than the 30% at 12 months seen in the study by Scopinaro discussed in the section above. Again, this is likely to be explained by the older age at surgery, and longer duration of diabetes of participants in the Scopinaro study.

Studies Reporting on Outcomes Beyond 2 Years

Bariatric Surgery Versus Lifestyle/Medical Therapy

Adams and colleagues performed a prospective study recruiting obese adults (BMI>35kg/m2) who underwent gastric bypass surgery over a 10 year period (n=418).[15] 2 control groups were included, the first of which included participants who had sought but not undergone gastric bypass surgery (n=417), and a second group comprised of obese adults

selected from a regional registry (n=321). An explanation as to why each of the participants in the first control group had not undergone gastric bypass was not provided in the manuscript. The prevalence of diabetes within each group at baseline was not presented, although the mean HbA1c was 42 mmol/mol or less in each group. Diabetes at baseline was defined as a fasting glucose of >126mg/dl (7.0 mmol/l), and/or an HbA1c of >6.5% (47 mmol/mol), and/or the use of glucose lowering medications, whilst remission of diabetes was defined as an Hba1c and fasting glucose within the normal reference range (absolute figures not provided) in the absence of ongoing glucose lowering therapy. Using these definitions, diabetes remission was achieved by 75% (95% CI, 63%-87%) and 62% (95% CI, 49%-75%) at 2 and 6 years post-surgery respectively in the gastric bypass group. Diabetes remission rates at 6 years were significantly lower in those who had either sought gastric bypass but not undergone surgery (8%; 95%CI,0%-16%, OR, 16.5 versus gastric bypass) and population controls (6%; 95% CI, 0%-13%, OR, 21.5). The study authors also noted a significantly lower incidence of new diagnoses of diabetes during 6 year follow up in the gastric bypass group (2%; 95% CI, 0%-4%) in comparison to those in the first control group (17%; 95% CI 10%-24%, OR 0.11 favouring gastric bypass; 95% CI 0.04- 0.34) and those in the population control group (15%; 95% CI 9%- 21%, OR 0.21 favouring gastric bypass; 95% CI, 0.06-0.67).

Iaconelli and colleagues performed a prospective case controlled study of conventional lifestyle and medical therapy versus biliopancreatic diversion in obese participants with type 2 diabetes.[19] Diabetes outcomes were reported at 10 years. The study authors note the initial study design of a randomised controlled trial was declined by their ethics regulatory committee partly on the basis of the required long duration of follow up. Instead the study team enrolled 110 obese participants with type 2 diabetes and initiated a 3 month run-in intervention comprising dietary optimisation. At the end of the run-in period, participants who met the inclusion criteria for the study (age 25-60 years, BMI >35 kg/m2, and a residual diagnosis of type 2 diabetes on the basis of standard criteria, n=50) were offered either conventional lifestyle and medical therapy alone, or conventional therapy plus biliopancreatic diversion surgery (n=28 and 22 respectively). Conventional therapy included dietary, exercise and medication optimisation as per current American Diabetes Association guidelines. Diabetes remission was actually a secondary endpoint in the study, with the authors choosing instead change in the glomerular filtration rate from baseline to study end as their primary end point. The authors did not specify the definition used for diabetes remission in the study, although it is implied that diagnostic thresholds commonly used at the initiation of the study (fasting glucose >7.0 mmol/L (on 2 occasions) and/or a 2 hour glucose > 11.1 mmol/L following a 75g oral glucose tolerance test) were utilised to assess diabetes outcome. The manuscript provides no information on whether ongoing use of glucose lowering therapy was accounted for. Allowing for these limitations, diabetes remission was achieved by 100% of participants at 12 months by those who had undergone biliopancreatic diversion surgery; the authors noted that none of these participants redeveloped diabetes during the remainder of follow up to 10 years. The mean HbA1c at 10 years in the conventional treatment and biliopancreatic diversion surgery arms was 7.8% (62 mmol/mol) and 4.9% (30 mmol/mol) respectively.

Pontiroli and colleagues performed a prospective case controlled study of outcomes following laparoscopic adjustable gastric banding versus optimisation of lifestyle and medical therapies.[20] The study investigators recruited 122 sequential patients (age range 18-66)

referred for the management of obesity, who met contemporary criteria for bariatric surgery (BMI > 40 kg/m2, or BMI > 35 kg/m2 in the presence of obesity related co-morbidities). The absence or presence of type 2 diabetes was clarified through an oral glucose tolerance test based on standard diagnostic criteria. The participants were then followed within two intervention studies; the primary intervention study assessed the effect of laparoscopic adjustable gastric banding on the prevention of type 2 diabetes, whilst the secondary intervention study assessed the effect on those with established type 2 diabetes. Thus, 37 participants with established type 2 diabetes were enrolled in the secondary intervention section of the study. Each of these participants was offered laparoscopic adjustable gastric banding; 17 consented to surgery with the remainder wishing to utilise lifestyle/medical options. The applied definition of diabetes remission was not specifically provided in the published manuscript, although it is implied that contemporary diagnostic criteria for the diagnosis of thresholds of dysglycaemia were utilised. Thus, diabetes remission would be diagnosed on the basis of a fasting glucose level <6.1 mmol/L, and a 2 hour post glucose level of <7.8 mmol/L (presumably also in the absence of glucose lowering medications). HbA1c measurements were recorded but are not specifically reported in the context of diabetes remission. Using this definition, diabetes remission was achieved by 45% at 4 years by those who had undergone laparoscopic adjustable gastric banding, and 4% of those who had declined surgery. Of note, none of those who had undergone laparoscopic adjustable gastric banding as a part of the primary prevention component of the study developed diabetes during the 4 years of follow up, whilst 17% of those who declined surgery did so.

Studies Comparing Different Forms of Bariatric Surgery

Pinheiro and colleagues performed a randomised study of two types of Roux-en-Y gastric bypass in 105 participants with type 2 diabetes and severe obesity (BMI >50kg/m2).[21] The diagnosis of diabetes and diabetes outcomes was defined on the basis of diagnostic thresholds. The primary intent of the study was to assess the varying effect of the resulting length of both the biliary and Roux limb of the gastric bypass. In group 1, the biliary and Roux limbs were 50 and 150 cm respectively, whilst in group 2 the biliary and Roux limbs were 100 and 250cm respectively (so called long-long limb Roux-en-Y gastric bypass). At 48 months follow up, diabetes control (glycaemic markers below diabetes diagnostic thresholds in the absence of glucose lowering medication) was achieved in 58% of those in group 1 and 93% of those in group 2. A statistically higher proportion of participants in group 2 had improvement of dyslipidaemia, whilst there was no difference in the improvement in hypertension seen.

Pournaras et al performed a prospective comparison study of gastric bypass (n=22) versus gastric banding (n=12) in severely obese participants with type 2 diabetes.[22] The study design allowed for an assessment of diabetes outcomes, along with exploration of the mechanism underlying the expected improvements in diabetes control. The study investigators defined diabetes remission based on contemporary diagnostic thresholds; a fasting plasma glucose <7 mmol/L in the absence of medical treatment for at least 3 days, and a 2-hour plasma glucose <11.1 mmol/L following an oral glucose tolerance test (OGTT). In addition, an HbA1c <6.0% (42 mmol/mol) after 3 months without the use of glucose lowering medication was required. Participants had established diabetes at baseline with a mean

duration of diabetes of >5 years; 55% of those who underwent gastric bypass and 30% of those who underwent gastric banding required insulin therapy prior to surgery. 68% of those in the gastric bypass arm had achieved diabetes remission at 12 months of follow up versus none in the gastric banding arm despite similar weight loss (20-25% body weight) at that assessment. At 36 months follow up, the percentage of those in diabetes remission had increased to 72% and 17% for gastric bypass and gastric banding respectively.

Following publication of diabetes outcome results after bariatric surgery at 12 months,[10] Schauer and colleagues performed a further analysis of follow up outcomes at 36 months.[23] 137 (91%) of the original 150 randomised participants (randomised in equal numbers to intensive medical therapy, gastric bypass plus intensive medical therapy, and sleeve gastrectomy plus intensive medical therapy) were evaluated. As in the original study, diabetes remission was defined as an HbA1c of <42 mmol/mol with or without the use of diabetes medications, and was achieved by 38% and 24% of those who had undergone gastric bypass and sleeve gastrectomy respectively (versus 5% of those randomised to intensive medical therapy alone). Glycaemic relapse (defined as satisfying criteria for diabetes remission at 12 months but not at 36 months) was seen in 80% of participants in the medical therapy group, 24% of those who had undergone gastric bypass group, and 50% of those who had undergone sleeve gastrectomy. Decrease in BMI following surgery (odds ratio, 1.33 for every 1 unit (mg/m2); 95% CI, 1.15 to 1.56; P<0.001) and the pre-surgical duration of type 2 diabetes (duration <8 versus >8 years; odds ratio, 3.3; 95% CI, 1.2 to 9.1; P = 0.02) were the only two predictors of diabetes outcome following either bariatric surgery.

The Swedish Obese Subjects Study (SOS study) was a very large prospective non-randomised study performed in Sweden between 1987 and 2000.[17] Following a large scale national recruitment drive, 4047 participants who met the study criteria (BMI >34 kg/m2 for men, BMI >38 kg/m2 for women, age 37-60 years) were recruited and offered either non-surgical or, if appropriate, surgical interventions. Surgery was performed at 25 national centres and included gastric banding, sleeve gastrectomy, and gastric bypass. Each participant who had chosen bariatric surgery was matched at the time of surgery to a participant who had elected medical therapy only (based on 18 variables including demographic, metabolic, psychosocial, and personality parameters). Medical and lifestyle therapies were not standardised for this trial. The intervention for both the surgically treated participant, and their match medical therapy only control, was considered to have commenced on the day of surgery.

Outcomes following 10 years of follow up were reported in 2004 and included data on 4047 participants with at least 2 years of follow up data available (all those enrolled in the SOS study) and 1703 participants who had 10 years of follow up data available. The study authors reported both diabetes incidence (compared with baseline) and diabetes outcomes. The majority of enrolled participants did not have type 2 diabetes at baseline, although the study authors were still able to report on approximately 200 participants who did and had follow up data extending to 10 years. The criteria used to define both disease and disease outcome were the same, and were reflective of contemporary diabetes diagnostic thresholds. Thus, diabetes remission was defined as a fasting glucose of <7.0 mmol/L (126 mg/dl) in the absence of glucose lowering medications.

590/4047 and 202/4047 participants had type 2 diabetes at baseline and 2 or 10 years of follow up data available respectively. Of those with 2 years of follow up data, 246/342 (72%) of surgical participants and 52/248 (21%) of control participants had achieved diabetes

remission (Odds ratio 8.42 95%CI 5.68-12.5). Over the same period, 8% of control participants who did not have diabetes at baseline (n=1402) developed type 2 diabetes, compared to 1% of those who had undergone bariatric surgery (n=1489). Of those with 10 years of follow up data, 42/118 (36%) of surgical participants and 11/84 (13%) of control subjects had achieved diabetes remission (Odds ratio 3.45 95%CI 1.64-7.28). As expected the incidence of new diabetes in those who did not have type 2 diabetes at baseline, had increased further at 10 years such that 24% and 7% of control and surgical participants respectively had developed diabetes.

Recently, the SOS study authors have reported on further long term outcomes at greater than 15 years.[31] These data provide further evidence that bariatric surgery has a favourable and durable effect on obesity and the risk of developing type 2 diabetes or related complications. Surgery reduced the risk of developing type 2 diabetes by 78% at 15 years, and reduced overall mortality by 29% (HR=0.71, 95%CI 0.54-0.92) at 16 years of follow up. Bariatric surgery was associated with a 53% reduction in the risk of fatal cardiovascular events (adjusted HR=0.47, 95%CI 0.29-0.78), and a 33% reduction in total cardiovascular events (HR=0.67, 95%CI 0.54-0.83) at up to 18 years of follow up. A reduction in the incidence of a new diagnosis of cancer following surgery (HR=0.67, 95%CI 0.53-0.85) was also demonstrated. On the basis that obesity is a known risk factor for cancer, this raises the possibility that intentional weight loss achieved by bariatric surgery may protect against this association although further research is required.

META-ANALYSES OF STUDIES REPORTING ON DIABETES OUTCOMES FOLLOWING BARIATRIC SURGERY

A large number of meta-analyses using a diverse range of selection criteria have been published. The majority report on weight or short term outcomes only and are therefore beyond the scope of this chapter. The reader is directed towards meta-analyses performed by Lai, Maggard-Gibbons, and Gloy and colleagues which all included either studies discussed in the paragraphs above, or studies reporting on diabetes outcomes <12 months following surgery.[24-26] In addition, Parikh and colleagues have recently published a meta-analysis of 39 studies reporting on diabetes outcomes in subjects with a BMI <35kg/m2.[27]

The largest meta-analysis thus far published reporting outcomes of bariatric surgery (gastric banding, gastroplasty, RYGB and biliopancreatic diversion/duodenal switch (BD/DS)) included all studies published between 1990 and 2006, and updated a previous meta-analysis by the same group.[28,29] The meta-analysis included 621 studies, within which 103 arms specifically reported on diabetes outcomes (3188 subjects). All study designs were included, with each study was assigned a level of evidence. 22.3% of the cohort (30,160/135,246 subjects) had pre-operative diabetes. Weight loss across the whole cohort, expressed as excess body weight lost (EBWL%), was 48.98, 56.48, 63.25, and 73.72% at ≥ 2 year follow up for gastric banding, gastroplasty, RYGB, and BD/DS respectively, although the majority of subjects remained obese (Mean pre-operative BMI 47.86, mean post-operative BMI 33.89kg/m2). Weight loss assessed at ≥ 2 years exceeded that reported at shorter post-operative intervals for each modality. Weight loss in patients with pre-operative diabetes was similar with 67.1 and 58.01% EBWL at <2 or ≥ 2 year follow up respectively when all

surgical modalities were included (67.10 and 64.7% for RYGB specifically). Analysis of the subjects with diabetes included in the meta-analysis revealed that resolution of diabetes (defined as cessation of diabetes medications and either normal fasting glucose (<100 mg/dl (5.5 mmol/L)) or an HbA1c < 6% (42 mmol/mol) across the whole cohort was 78.1% (80.27 and 74.59% at <2 and ≥ 2 year follow up respectively), whilst resolution or improvement (defined as a reduction in number or dose of diabetes medications, or an improvement in fasting glucose to between 100-125 mg/dl (5.5 - 6.9 mmol/L)) was seen in 86.61% (86.0 and 87.24% respectively). Further assessment based on surgical procedure revealed that resolution of diabetes was seen in 56.73% (54.99 and 58.29% at <2 and ≥ 2 year follow up respectively) following gastric banding, 79.74% (81.44 and 77.46%) following gastroplasty, 80.28% (81.60 and 70.90%) following RYGB, and 95.05% (94.0 and 95.85%) following BD/DS.

In addition the authors performed a sub-analysis on 12 studies that included only subjects with diabetes (n=963) and reported overall resolution of diabetes in 79.29% (81.81 and 62.08%), and resolution or improvement in 98.91% (98.56 and 100%). It should be noted however that data for ≥ 2 year follow up in studies that recruited only those with diabetes included only 48 subjects (31 who underwent RYGB and 17 who underwent gastric banding). Of those who underwent RYGB, 80.65% remained in remission from diabetes at ≥2 years whilst all patients had experienced at least improvement in glycaemic control. Less impressively, only 41% (7/17 subjects) who had undergone gastric banding remained in remission from diabetes at 2 years. Additionally, the definition of resolution or improvement of diabetes, or even the diagnosis of diabetes itself, varied significantly across the included studies. Overt diabetes was generally defined as an HbA1c of > 53 mmol/mol (7%) whilst most international organisations that accept HbA1c as a diagnostic tool currently suggest cut off values of between 45 and 50 mmol/mol, with a lower range reflective of less severe abnormalities in glucose homeostasis. Secondly, resolution of diabetes was confirmed in some studies on the basis of a measured fasting glucose without the requirement of either further testing or perhaps more robust HbA1c assessments. Improvements in diabetes control was also defined biochemically as a reduction of fasting glucose to between 5.5 -6.9 mmol/L irrespective of HbA1c. As the rationale behind glucose lowering in patients with diabetes is to prevent longer term micro and macrovascular complications, and HbA1c correlates best with the risk of these complications irrespective of day to day fluctuations in plasma glucose measurements, this approach may incorrectly attribute improvement to an otherwise unaltered state. The authors acknowledge that only 4.7% of the contributing studies were randomised controlled trials, and the level of evidence was generally poor (1.6% (10/621) studies assessed as contributing class 1 evidence as per CEBM criteria).

Yip and colleagues performed a large meta-analysis including all studies that reported on diabetes outcomes following either gastric bypass or sleeve gastrectomy.[30] Inclusion criteria used to identify suitable studies were the recruitment of patients aged 18 years or over, the presence of type 2 diabetes prior to bariatric surgery, participants undergoing either gastric bypass or sleeve gastrectomy, and the reporting of glycaemic outcomes with specified criteria at comparable time points of assessment. On this basis, 2655 studies were assessed, of which 33 were considered appropriate for inclusion. The majority of these (30, 18 prospective and 12 retrospective) were not randomised, and 31/33 studies compared either gastric bypass or sleeve gastrectomy against a lifestyle/medical therapy “control” group. 2 of the randomised controlled studies compared gastric bypass against sleeve gastrectomy. Reflective of the available literature reporting on diabetes outcomes following bariatric surgery, only 8/35

studies of outcomes following gastric bypass and 1/16 studies of outcomes following sleeve gastrectomy had a duration of follow up of >12 months. Reported definitions of glycaemic outcome required an HbA1c level below a specified threshold in the absence of glucose lowering therapy.

Using this definition, diabetes remission was achieved by 67% and 56% in those who had undergone gastric bypass and sleeve gastrectomy respectively at 3 months, 76% and 68% at 12 months, and 81% and 80% at 36 months. The authors noted that the differing definition of diabetes remission used had a significant effect on reported outcomes; in those participants who had undergone sleeve gastrectomy, collective studies that defined diabetes remission as an HbA1c <6.0% (42 mmol/mol), <6.5% (47 mmol/mol) or <7.0% (53 mmol/mol) reported diabetes remission in 44.0%, 67.8% and 75.8% of participants respectively.

CONCLUSION

Early improvements in glucose homeostasis were noted soon after the first bariatric procedures were performed, and a huge volume of evidence validating this phenomenon has since been published. Whilst the study quality and design has varied considerably, the overall assessment of this literature strongly supports bariatric surgery as valid treatment option for obese persons with type 2 diabetes. Indeed, in well designed randomised controlled trials, bariatric surgery is far superior to conventional lifestyle and medical therapy in terms of achieving improvements in glycaemic status alone. Studies presented in this chapter that included a lifestyle/medical arm illustrate the difficulty in achieving improvements in diabetes control that could constitute remission even in a research setting; when stringent criteria for diabetes remission were applied, on average 10% or less of participants in these arms achieved diabetes remission. These findings are clearly of high importance when considering the relative benefit of bariatric surgery in comparison to other treatment options for the management of type 2 diabetes in obese persons.

The marked study heterogeneity with respect to criteria and severity of type 2 diabetes at recruitment, BMI at baseline, specific bariatric procedure performed (even amongst studies purportedly studying the same bariatric modality), definitions of glycaemic outcomes utilised, and concurrent use of medical/lifestyle therapies, means that an absolute stratification of each bariatric procedure to the relative impact on glycaemic control is not possible. Nonetheless, the suggestion of a trend of increasing benefit on glycaemic control with gastric banding (diabetes remission/control at greater than 12 months follow up, seen in 17-73% of included studies), sleeve gastrectomy (11-85%), gastric bypass (24-93%), and biliopancreatic diversion (30-100%) is in keeping with the increasing weight loss seen respectively with each of these procedures in the published literature. In many respects, the interest lies in the analysis of studies reporting on sleeve gastrectomy and gastric bypass as these two procedures are perhaps more comparable than other bariatric procedures. With one exception (Vidal et al, where 85% diabetes remission rates were seen in both arms), all other studies that included both gastric bypass and sleeve gastrectomy, showed improved rates of diabetes remission in those who had undergone gastric bypass. Indeed, this relationship was preserved when one considers outcomes at each follow up interval with improved diabetes remission rates following gastric bypass at 12 months (42-93% versus 23-85% in those undergoing gastric

bypass and sleeve gastrectomy respectively), 24 months (33 versus 11%, one study reported [12]) and greater than 24 months (38 versus 24%, one study reported [23]). Whether this apparent benefit on glycaemic outcome of gastric bypass against sleeve gastrectomy translates into clinically meaningful improvements remains to be clarified, as significant reductions in body weight alone are seen following either procedure.

Understandably, many physicians treating patients with type 2 diabetes have historically been reluctant to refer these patients for bariatric surgery, given a paucity of published data on longer term outcomes. This is especially true of younger patients, where the expected long lifespan following surgery clearly increases the risk that any longer term consequences of surgery may negatively affect outcomes. The studies presented above go some way to providing reassurance in this respect, and whilst well designed studies assessing the longer term effect of bariatric surgery on glycaemic complications such as nephropathy, retinopathy, cardiovascular disease are needed, longer term effects on glycaemic status alone are clearly impressive when compared with other currently available therapies. Many authors feel that the more pertinent contemporary question is not if bariatric surgery should at the forefront of therapeutic strategies for obese persons with type 2 diabetes, but at how early it should be performed. Inclusion criteria for many publically funded bariatric surgery programmes internationally select on the presence of more rather than fewer obesity or diabetes related complications; increasing evidence as to the long term efficacy and safety of bariatric procedures would surely therefore require that this approach is reassessed.

In summary, whilst the degree of improvement varies across the published literature, in part because of consistent inconsistencies in the definitions used, the evidence thus far supports a significant and clinically important durable effect of bariatric surgery on glycaemic status. Control groups included in these studies highlight the difficulty in achieving these results without bariatric surgery, even in the context of intensive research based lifestyle and medical interventions. Further research is required to assess the longterm impact on other diabetes related outcomes, but, as per recent statements from the International diabetes federation (IDF), bariatric surgery should now be considered early in the management of obese persons with type 2 diabetes. [1]

REFERENCES

[1] Zimmet P, Alberti KGMM, Rubino F, Dixon JB. IDF's view of bariatric surgery in type 2 diabetes. *Lancet.* 2011;378(9786):108–10.

[2] Dixon JB, Roux CW, Rubino F, Zimmet P. Bariatric surgery for type 2 diabetes. *Lancet.* 2012;379(9833):2300–2311.

[3] Ihnat M, Thorpe JE, et al. Hypothesis: the "metabolic memory", the new challenge of diabetes. *Diabet Med.* 2007;24(6):582–6.

[4] Holman RR, Paul SK, Bethel MA, Matthews DR, Neil HAW. 10-Year Follow-Up of Intensive Glucose Control in Type 2 Diabetes. *N Engl J Med*. 2008;359(15):1577–89.

[5] Buse JB, Caprio S, Cefalu WT et al. How do we define cure of diabetes? *Diabetes care*. 2009;32(11):2133-2135

[6] Hofsø D, Nordstrand N, Johnson LK, et al. Obesity-related cardiovascular risk factors after weight loss: a clinical trial comparing gastric bypass surgery and intensive lifestyle intervention. *Eur J Endocrinol.* 2010;163(5):735–45.

[7] Ikramuddin S, Korner J, Lee W-J, et al. Roux-en-Y Gastric Bypass vs Intensive Medical Management for the Control of Type 2 Diabetes, hypertension, and hyperlipidaemia. *JAMA*. 2013;309(21):2240–2249..

[8] Serrot FJ, Dorman RB, Miller CJ, et al. Comparative effectiveness of bariatric surgery and nonsurgical therapy in adults with type 2 diabetes mellitus and body mass index <35 kg/m2. *Surgery*. 2011;150(4):684–91.

[9] Lee W-J, Chong K, Ser K-H, et al. Gastric Bypass vs Sleeve Gastrectomy for Type 2 Diabetes Mellitus. *Arch Surg*. 2011;146(2):143–148.

[10] Schauer PR, Kashyap SR, Wolski K, et al. Bariatric Surgery versus Intensive Medical Therapy in Obese Patients with Diabetes. *N Engl J Med*. 2012:1–10.

[11] Vidal J, et al. Type 2 Diabetes Mellitus and the Metabolic Syndrome Following Sleeve Gastrectomy in Severely Obese Subjects. *Obes Surg.* 2008;18(9):1077-1082

[12] Kashyap SR, Bhatt DL, Wolski K, et al. Metabolic Effects of Bariatric Surgery. *Diabetes care.* 2013;36:2175–2182.

[13] Scopinaro N, Adami GF, Papadia FS, et al. Effects of biliopanceratic diversion on type 2 diabetes in patients with BMI 25 to 35. *Ann Surg.* 2011;253(4):699–703.

[14] Leslie DP, et al. Efficacy of the Roux-en-Y Gastric Bypass Compared to Medically Managed Controls in Meeting the American Diabetes Association Composite End Point Goals for Management of Type 2 Diabetes Mellitus. *Obes Surg*. 2012;22(3):367-374

[15] Adams TD, Davidson LE, Litwin SE, et al. Health Benefits of Gastric Bypass Surgery After 6 Years. *JAMA.* 2012;308(11).

[16] Dixon JB, O'Brien PE, Playfair J, et al. Adjustable gastric banding and conventional therapy for type 2 diabetes: a randomized controlled trial. *JAMA.* 2008;299(3):316–323.

[17] Sjöström L, Lindroos A, Peltonen M. Lifestyle, diabetes, and cardiovascular risk factors 10 years after bariatric surgery. *N Engl J Med.* 2004;351(26):2683–2693.

[18] Mingrone G, Panunzi S, Gaetano A De, et al. Bariatric Surgery versus Conventional Medical Therapy for Type 2 Diabetes. *N Engl J Med*. 2012:1–9.

[19] Iaconelli A, Panunzi S, De Gaetano A, et al. Effects of bilio-pancreatic diversion on diabetic complications: a 10-year follow-up. *Diabetes Care.* 2011;34(3):561–7..

[20] Pontiroli A, Folli F, Paganelli M, et al. Laparoscopic Gastric Banding Prevents Type 2 Diabetes and Arterial Hypertension and Induces Their Remission in Morbid Obesity. *Diabetes Care*. 2005;28(11):2703–2709.

[21] Pinheiro JS, et al. Long-long limb Roux-en-Y gastric bypass is more efficacious in treatment of type 2 diabetes and lipid disorders in super-obese patients. *Surg Obes Relat Dis.* 2008, 4(4), 521-525

[22] Pournaras DJ, Osborne A, Hawkins SC, Royce P. Remission of Type 2 Diabetes After Gastric Bypass and Banding. *Ann Surg.* 2010;252(6):1–6.

[23] Schauer PR, Bhatt DL, Kirwan JP, et al. Bariatric Surgery versus Intensive Medical Therapy for Diabetes - 3-Year Outcomes. *N Engl J Med*. 2014:1–12.

[24] Li J-F, Lai D-D, Ni B, et al. Comparison of laparoscopic Roux-en-Y gastric bypass with laparoscopic sleeve gastrectomy for morbid obesity or type 2 diabetes mellitus : a meta-analysis of randomized controlled trials. *J Can Chir*. 2013;56(6):158–164.

[25] Maggard-gibbons M, Maglione M, Livhits M, Ewing B, Maher AR. Bariatric Surgery for Weight Loss and Glycemic Control in Nonmorbidly Obese Adults with Diabetes. *JAMA*. 2013;309(21):2250–2261.

[26] Gloy VL, Briel M, Bhatt DL, et al. Bariatric surgery versus non-surgical treatment for obesity : a systematic review and meta-analysis of. *BMJ* 2013;347(October):1–16.

[27] Parikh M, Issa R, Vieira D, et al. Role of bariatric surgery as treatment for type 2 diabetes in patients who do not meet current NIH criteria: a systematic review and meta-analysis. *J Am Coll Surg*. 2013;217(3):527–32.

[28] Buchwald H, Estok R, Fahrbach K, Banel D, et al. Weight and Type 2 Diabetes after Bariatric Surgery : Systematic Review and Meta-analysis. *AJM*. 2009;122(3):248–256.

[29] Buchwald H, Avidor Y, Braunwald E, et al. Bariatric Surgery: A Systematic Review and Meta-analysis. *JAMA*. 2004;292(14):1724–1737.

[30] Yip S, Plank L, Murphy R. Gastric bypass and sleeve gastrectomy for type 2 diabetes: a systematic review and meta-analysis of outcomes. *Obes Surg* 2013:23(12), 1994-2003

[31] Sjostrom L. Review of the key results from the Swedish Obese Subjects (SOS) trial – a prospective controlled intervention study of bariatric surgery. *J Intern Med* 2013; 273: 219–234.

In: Encyclopedia of Surgery (22 Volume Set)
Editors: Andreas Lehrer and Kristin Mueller
ISBN: 978-1-53618-329-0
© 2020 Nova Science Publishers, Inc.

Chapter 12

ANESTHESIA CONSIDERATION AND MANAGEMENT FOR BARIATRIC SURGERY

Antoni Sabaté[1,*], MD, PhD and Sandra Llaurado[2], MD
[1]Department of Anesthesia, Reanimation and Pain Clinic,
Hospital Universitari de Bellvitge, Universitat de Barcelona Health Campus,
Hospitalet, Barcelona, Spain
[2]Department of Anesthesia, Reanimation and Pain Clinic,
Hospital Universitari de Bellvitge, Universitat de Barcelona Health Campus,
Hospitalet, Barcelona, Spain

ABSTRACT

Morbidly obese patients are already at high risk for cardiovascular and respiratory functional overload related to varying degrees of metabolic syndrome. Most of patients request for bariatric surgery in an early stage of the disease, therefore low rates of mortality and morbidity are the standard. Even that, perioperative complications are related to previous comorbidity, age, body mass index and type of bariatric surgery. Restrictive procedures are not expected to have mortality, but all complication rates are 3.2%, and readmission rate is 4.3%. For gastric bypass procedures, the complication rate is 16%, the readmission rate of 6.6% and mortality around 0.4%, which account intra operatively in 0.18%. of patients. Consequently, anesthetic management of morbid obese patients is a challenge, even to an experienced anesthesiologist and to do that effectively, these key points have to be considered:

ABBREVIATIONS

BMI	body mass index
OSA	obstructive sleep apnea
TOFr	the train of four stimulus ratio

* Corresponding Author's Emails: asabatep@bellvitgehospital.cat; asabatep@ub.edu; Fax: 34-3-260 7998.

1. Safety in Airway Procurement at Anesthesia Induction

In order to facilitate oxygenation and the airway management, patients are placed in semi-sitting position and oxygen is administered to increase tolerance to apnea.

Because neck fat accumulation, difficult tracheal intubation is present in around 10% of patients.

Awake intubation is indicated when a limited mandible advancement is associated to a short tyromental distance [< 6 cm] and a Mallampati class 2/3/4. This conservative approach try to reduce the “can ventilate and can't intubate” crisis, noticed in a range of 0.3-1.2% of patients.

Awake tracheal intubation with videolaringoscope is a good alternative to fiber optical intubation. The introduction of sugammadex, which is able to quickly reverse a neuromuscular blockade of any depth and ensure complete recovery of pharyngeal muscles, have displaced the use of succinylcholine for the patients in whom a general anesthesia induction is planned.

2. Maintenance of Anesthesia during Laparoscopic Procedures

In laparoscopic surgery a deep neuromuscular blockade facilitates ventilation and ensures an adequate surgical field. From a clinical point of view, although neuromuscular monitoring is not widely used, it is therefore advisable. In relation to ventilation strategies during surgery, there is some evidence that recruitment maneuvers added to positive expiratory pressure improved intraoperative oxygenation; but, there is no evidence of any difference between modes of ventilation. Both, desflurane and sevoflurane are suitable for maintenance of anesthesia, and patients are fully awake in a few minutes after switched off the vaporizer. Moreover, both reversal of neuromuscular blockade and consciousness are necessary for a safe tracheal extubation at the end of anesthesia.

Neuromuscular monitoring of depth is necessary in the morbidly obese to dose neuromuscular blockade antagonist to prevent residual paralysis, which affects genioglossus muscle activity during deep inspiration, causing retroglossal and retropalatal narrowing. These effects are particularly dangerous in morbidly obese patients because of the possible presence of obstructive sleep apnea syndrome.

The dose of sugammadex must be sufficient to affect the gradient between the peripheral and central compartments and more is required when repeated doses or continuous infusion of rocuronium.

3. Postoperative Management

Even if most patients are managed in ward, close supervision during 4-6 hour after surgery is mandatory. Postoperative continuous mechanical ventilation is necessary in less than 1% of patients; at risk are those affected by more severe hypoventilation syndrome or

when hemorrhage or leaks are present. On the contrary, obstruction of upper airway and the limited functional respiratory capacity in morbid obese patients are common and facilitate hypoxemic episodes after bariatric surgery. To prevent it, reintroduction of continuous positive airway pressure is crucial. Also, a multimodal analgesia without opioid is preferable. Sitting bed patient position and early mobilization helps to fast-track process that will take 2-4 days.

1. Anesthesia Consideration and Management for Bariatric Surgery

The prevalence of morbid obesity has multiplied in the last fifteen years, and it has been associated with higher mortality in comparison with non obese population. Morbidly obese patients are at high risk of cardiovascular and respiratory functional overload related to varying degrees of metabolic syndrome. Most of the patients need bariatric surgery in an early stage of the disease to ensure low rates of mortality and morbidity are the standard. Because of that, a composite measure, which will involve combining serious complications, reoperations, and readmissions, is advisable to predict performance of the surgery. It is important to note that cardiovascular disorders are no longer a contraindication of surgery, and therefore, major postoperative complication and mortality can occur more frequently as morbid obese patient are accepted for any type of surgery.

Perioperative complications are related to the type of bariatric surgery. Restrictive procedures are not expected to have mortality, but all complication rates are 3.2%, and readmission rate is 4.3%. [1] For gastric bypass procedures, the complication rate is 16%, the readmission rate of 6.6% and mortality around 0.4%, which account intra operatively in 0.18% of patients. [1] Sleeve gastrectomy is performed in those high risk patients as an intermediate stage to definitive bypass procedure. Risk stratification predictors are: age, male sex, body mass index (BMI) and comorbidities [diabetes, obesity hypoventilation syndrome and heart disease]. [2-4] Adverse anesthesia intraoperative events [multiple tracheal intubation attempts, sustained dysrhythmia and hypotension and hypercarbia] occurred in 0.9% of the patients. [3].

The whole bariatric population should be screened for obstructive sleep apnea (OSA) through the application of the Epworth sleepiness scale, Stop-band score or a clinical history of nocturnal snoring, morning headache or a large neck circumference, and if some of them are positive, a polysomonography study is mandatory as well as arterial blood gases for those patients affected by hypoventilation syndrome. Smoking cessation and pretreatment with non invasive positive airway pressure ventilation facilitate optimization previous to surgery. The patients with severe hypertension [those on two or more antihypertensive drugs], or history of acute heart disease should undergo cardiovascular evaluation from time to time, and a special attention has to be paid to those super obese patients (BMI > 70 $kg.m^{-1}$). Anesthetic treatment of morbid obese patients is a challenge, even to an experienced anesthesiologist, and to do that effectively some intraoperative key points have to be considered.

1.1. Safety in Airway Procurement at Anesthesia Induction

In order to facilitate oxygenation and the airway management, patients are placed in semi-sitting position and oxygen is administered to them to increase tolerance to apnea.

Because of neck fat accumulation, difficult tracheal intubation is present in around 10% of patients. [5-7]. For obese patients in ramped position, Airtraq™ have a faster tracheal intubation than the Macintosh laryngoscope. [8] It is a general opinion that, awake intubation should be indicated when any element of the triple airway maneuver [mandible advancement, neck extension, and mouth opening] is limited in patients with severe OSA. From our experience, [9] awake intubation is indicated when a limited mandible advancement is associated with a short tyromental distance (<6cm) and a Mallampati class 2/3/4. This conservative approach tries to reduce the “can ventilate and can't intubate” crisis, noticed in a range of 0.3-1.2% in our series of patients. [9] Awake tracheal intubation with videolaringoscope is a good alternative to fiber optical intubation [10-15]. The introduction of sugammadex, which is able to reverse quickly a neuromuscular blockade of any depth and ensure complete recovery of pharyngeal muscles [16], has displaced the use of succinylcholine for the rest of patients in whom a general anesthesia induction is planned. The outcome of that is a better oxygenation provided by rocuronium in comparison with succinylcholine [17] and a quicker recovery of spontaneous ventilation with rocuronium when high dose of both drugs are used. [18]. In a case report, the administration of sugammadex in a 'can't ventilate' scenario allowed return of spontaneous breathing before the development of hypoxia [19].

It is important to say that the reversal of neuromuscular blockade is not enough to obtain adequate ventilation, which also requires that the patient regain consciousness in order to avoid airway collapse caused by hypnotic drugs. [20]

The dose of propofol for anesthesia induction depends on the weight of the patient, consequently, some adjust to a large dose has to be made if ideal body weight is used to calculate the dose. On the contrary, neuromuscular blocker drugs can be dose by using ideal body weight. However, a rapid sequence induction is advisable for morbid obese patients.

1.2. Maintenance of Anesthesia during Laparoscopic Procedures

It was found that obesity caused a statistically significant increase in respiratory resistance and an increase in inspiratory pressure and a decrease in dynamic respiratory compliance when mechanical ventilation was started in laparoscopic surgery. In non obese patients, a definite plateau in the total exhaled carbon dioxide per minute was observed within 20 minutes from the start of pneumoperitoneum; on the contrary, the total exhaled carbon dioxide per minute increases during the whole surgery in the morbidly obese patients. [21] After disinflation, the total exhaled carbon dioxide per minute returned more rapidly to the baseline values in the non obese patients. [21]

In relation to ventilation strategies during surgery, there is some evidence that recruitment maneuvers added to positive expiratory pressure improves intraoperative oxygenation without changes in blood pressure; but, there is no evidence of any difference between pressure controlled ventilation and volume controlled ventilation. [22] A deep neuromuscular blockade facilitates ventilation and ensures an adequate surgical field facilitating the surgical procedure. From a clinical point of view, although neuromuscular monitoring is not widely used, it is therefore advisable to use it in all patients, being the train of four stimulus ratio [TOFr] at abductor pollicis the recommended monitor.

End-tidal of sevoflurane leading to a BIS value below 50 in 50% of the morbid obese patient has been observed in 1.6%, higher than that previously reported in non obese patients,

0.97%, and less than that reported in children, 2.8%. [23]. Both, desflurane and sevoflurane are suitable for maintenance of anesthesia, although. desflurane increased intestinal motility and decreased surgeon satisfaction compared with sevoflurane. [24].

Both, reversal of neuromuscular blockade and consciousness are necessary for a safe tracheal extubation at the end of anesthesia. On the basis of the awareness of residual neuromuscular blockade and its clinical implications, drug used during anesthesia should be considered in the morbidity risk analysis.

Neuromuscular monitoring of depth is necessary in the morbidly obese patients to dose neuromuscular blockade antagonist so as to prevent residual paralysis, that affects genioglossus muscle activity during deep inspiration, and causes retroglossal and retropalatal narrowing, with airway flow limitation; [25-27] changes also occur in swallowing as well as in inspiratory capacity and ventilatory response to hypoxia, which are reduced. [28, 29] These effects are particularly dangerous in morbidly obese patients because of the possible presence of obstructive sleep apnea syndrome. [30] Also at higher risk of upper airway collapse during the perioperative period, these patients should be fully awake and the neuromuscular blockade fully reversed before tracheal extubation is attempted. [31]

In contrast to anticholinesteric agent, sugammadex is able to reverse intense neuromuscular blockade, in a first step, and captures free rocuronium, leading to release of rocuronium from cell receptors. Even though the pharmacokinetic profile of sugammadex is affected by age and renal function, quick reversal (<2 minutes) occurs in lean patients after a sugammadex dose of 2 mg.kg-1 [moderate blockade] or 4 mg.kg-1 (deep blockade), either with propofol or sevofluorane for anesthesia maintenance. [32] The dose of sugammadex must be sufficient to affect the gradient between the peripheral and central compartments and more is required with repeated doses or continuous infusion of rocuronium. Overdoses will which result from using real body weight in morbidly obese patients in the standard calculations will be costly and ineffective in a high number of patients given the ceiling effect. Moreover, the safety and efficacy of sugammadex dose based on the ideal body weight has been questioned.

Table 1. Dose of Sugammadex. Summary of data reported in bariatric surgery

	Dose mg/kg Real body weight	Time to TOF 0.9 [sc]	Time to tracheal extubation [sc]
Moderate blockade [T2]			
Standard Patients	2 mg/Kg	90 sc	
Obese Patient			
Van Lancker [33]	1.34 mg/kg	120 sc	255 sc
Van Lancker [33]	2 mg/Kg	128 sc	326 sc
Gaszynski [34]	1.29 mg/Kg	167 sc (265 sc)	-
Llaurado [35]	1.23 mg/Kg	113 sc (300 sc)	220 sc
Sanfilippo [36]	1.075 mg/Kg	151 ± 44 sc	
Sanfilippo [36]	2 mg/Kg	121 ± 21 sc	
Deep Blockade			
Standard Patient	4 mg/kg	90 sc	
Obese Patient			
Llaurado [35]	2.3 mg/Kg	167 sc (460 sc)	586 sc

Many morbid obese patients on sugammadex have different types of responses or reactions depending on the type of anesthesia, the total dose of neuromuscular blockade drug and time from the last dose of rocuronium.

Table 1 represent a summary of sugammadex dose studies. [33-36] We can identify patients who are likely to exhibit more variability of response by monitoring nerumuscular blockade. In one study, [37] the risk of TOF ratio <0.9 in tracheal extubation after sugammadex remains as high as 9.4% in a clinical setting in which neuromuscular monitoring was not used.

Likewise, the percentage of patients requiring an additional dose of sugammadex tended to be larger in the deep neuromuscular blockade at the end of procedure. [35] It is also interesting that time until extubation was much longer in patients with deep blockades. [35] The short interval between the administration of the last doses of rocuronium and sugammadex were associated with a higher incidence of postoperative residual weakness. [37] Again, some case reports advice on resistance to sugammadex. [38-39].

1.3. Postoperative Management

Even if most patients are treated in ward, in a setting of fast-track surgery [40] close supervision from 4-6 hour after surgery is mandatory, because morbid obese patients carry significantly increased risk of extubation failure and are frequently associated with difficult airway management. Extubation failure is caused by loss of upper airway patency; edema, soft tissue collapse, and laryngospasm which are among the most frequent mechanisms of upper airway obstruction.[41] Anesthesia induced atelectasis occurs in nearly all anesthetized patients; even if reversible after bariatric surgery, and hypoventilation syndrome determine respiratory complications in the postoperative period. [42] The reasons for abnormalities in regional ventilation produced during anesthesia and surgery are: hypoventilation due to pain or residual anesthetics, lung edema due to fluid overload and exacerbation of chronic obstructive pulmonary disease. [43] A clinically relevant fade in forced vital capacity is produced as a consequence of residual neuromuscular blockade. [44] Therefore, strategies to prevent respiratory complication or improve ventilation such as multimodal analgesia without opioid, sitting bed patient position and early mobilization, have to be implemented to help fast-track process that will take 2-4 days. [45]

Postoperative continuous mechanical ventilation is necessary in less than 1% of the patients; at risk are those affected by more severe hypoventilation syndrome or those with hemorrhage or leaks. Obstruction of upper airway and the limited functional respiratory capacity in morbid obese patients are the consequences of hypoxemic episodes after bariatric surgery. [46] To prevent it, reintroduction of continuous positive airway pressure is crucial, as well as adequate reversal of neuromuscular blockade. [47, 48] Fewer episodes of postoperative oxygen desaturation [46] and less likely associated with X-ray results are consistent with postoperative complete reversal of neuromuscular blockade. [47, 48]

2. New Insights in Morbid Obese Patients' Management

A recent systematic review of medical journals concluded that there is no adequate information to make strong recommendations regarding appropriate selection of the obese

patients scheduled for ambulatory surgery. However, the super obese patient (BMI>50 kg/ m) do present an increased risk for perioperative complications. [49] Patients affected by obstructive sleep apnea may be accepted for ambulatory surgery if they are able to use a continuous positive airway pressure device in the postoperative period and pain can be managed without opioid drugs. [50] A recent report indicates safety of performance of bariatric restrictive procedures in ambulatory regimen, 0.8 % of patients were transferred from the Ambulatory centre to a hospital and 3.6% of patients were readmitted within 30 days. [51] By using laryngeal mask instead of tracheal intubation, the requirements for neuromuscular blockade drugs were reduced and time to discharge the patients from both the postanesthesia care unit and the hospital also was reduced; [52] however, in two patients laryngeal mask had to be removed because of initial placement failed and in one patient a laryngospasm occurred after removal, which represent 8% of the failures.

For those patients with recurrent episodes of pulmonary thrombi embolism or with the contraindication of prophylaxis, the use of vena cava filters will remain controversial, even though its use continues to rise. [53] Thrombosis of vena cava related to filters is uncommon, but it may be present in at least 3% of the patients.

REFERENCES

[1] American Association of Clinical Endocrinologist. The Obesity Society and American Society for Metabolic and Bariatric Surgery Medical. Guidelines for clinical practice for perioperative nutritional, metabolic and nonsurgical support of the bariatric surgery patient. *Surgery for Obesity and Related Diseases* 2008; 4: S109-S184.

[2] De Maria EJ, Portenier D, Wolfe L. Obesity surgery mortality risk score: proposal for a clinically useful score to predict mortality risk in patients undergoing gasgtric bypass. *Surg. Obes. Relat. Dis*. 2007; 3: 134-140.

[3] Marti Valeri C, Sabate A, Masdevall C, Camprubí I, Dalmau A, Gracia T, Koo M, Sanzol R, Suárez M, Montero A. Influencia del grado de obesidad en la morbimortalidad operatoria de la cirugia bariatrica. *Rev. Esp. Anestesiol. Reanim.* 2004; 51: 44-46.

[4] Maciejewski ML, Winegar DA, Farley JF, Wolfe BM, De Maria EJ. Risk stratification of serious adverse events alter bypass in the Bariatric Outcome Longitudinal Database. *Sur. Obes. Relat. Dis*. 2012; 8: 671-677.

[5] Brodsky JB, Lemmens HJM, Vierra M, Saidman LJ. Morbid obesity and tracheal *Intubation Anesth. Analg.* 2002; 94:732–6.

[6] Lavi R, Segal D, Ziser A. Predicting difficult airways using the intubation difficulty scale: a study comparing obese and non-obese patients. *J. Clin. Anesth*. 2009; 21: 264-7.

[7] Juvin P, Lavaut E, Dupont H, Lefevre P, Demetriou M, Dumoulin JL, et al. Difficult tracheal intubation is more common in obese than in lean patients. *Anesth. Analg*. 2003; 97: 595-600.

[8] Andersen LH, Rovsing L, Olsen KS. GlideScope videolaryngoscope vs. Macintosh direct laryngoscope for intubation of morbidly obese patients: a randomized trial. *Acta Anaesthesiol. Scand.* 2011; 55: 1090-7.

[9] Montealegre-Angarita MC, Llauradó-Paco S, Sabaté A, Ferreres E, Cabrera A, Camprubí I. Analysis of difficult intubation factors in bariatric surgery. Influence of the choice of neuromuscular blocker on the availability of sugammadex. *Rev. Esp. Anestesiol. Reanim*. 201; 60:434-9.

[10] Abdallah R, Galway U, You J, Kurz A, Sessler DI, Doyle DJ. A randomized comparison between the Pentax AWS video laryngoscope and the Macintosh laryngoscope in morbidly *Anesth. Analg*. 2011; 113:1082-7.

[11] Ydemann M, Rovsing L, Lindekaer AL, Olsen SK. Intubation of the morbidly obese patient: GlideScope vs. Fastrach. *Acta. Anaesthesiol. Scand*. 2012; 56: 755–761.

[12] Ranieri D, Filho SM, Batista S, do Nascimento P. Comparison of Macintosh and Airtraq TM laryngoscopes in obese patients placed in the ramped position. *Anaesthesia* 2012; 67: 980–985.

[13] Moore AR, Schricker T, Court O. Awake videolaryngoscopy-assisted tracheal intubation of the morbidly obese. *Anaesthesia* 2012; 67: 232–5. 23.

[14] Wender R, Goldman AJ. Awake insertion of the fibreoptic intubating LMA C Trach in three morbidly obese patients with potentially difficult airways. *Anaesthesia* 2007; 62: 948-51.

[15] Dimitriou VK, Zogogiannis ID, Liotiri DG. Awake tracheal intubation using the Airtraq laryngoscope: a case series. *Acta Anaesthesiologica Scandinavica* 2009; 53: 964–7. 5.

[16] Lee C, Jahr JS, Candiotti KA, Warriner B, Zornow MH, Naguib M. Reversal of profound neuromuscular block by sugammadex administered three minutes after rocuronium. *Anesthesiology* 2009; 110: 1020-5

[17] Tang L, Li S, Huang S, Ma H, Wang Z. Desaturation following rapid sequence induction using succinylcholine vs rocuronium in overweight patients. *Acta Anaesthesiol Scand* 2011; 55: 203-8.

[18] Sørensen MK, Bretlau C, Gatke R, Sørensen MA, Rasmussen LA. Rapid sequence induction and intubation with rocuronium-sugammadex compared with succinylcholine: a randomized trial. *Br. J. Anaesth.* 2012; 108: 682-9 22.

[19] Paton L, Gupta S, Blacoe D. Successful use of sugammadex in a 'can't ventilate' scenario. *Anaesthesia*. 2013; 68:861-4.

[20] Isono S. Obstructive sleep apnea of obese adults: pathophysiology and perioperative airway management. *Anesthesiology* 2009; 110:908 –21.

[21] Perilli V, Vitale F, Modesti C, Ciocchetti P, Sacco T, Sollazzi L Carbon dioxide elimination pattern in morbidly obese patients undergoing laparoscopic surgery *Surg. Obes. Relat. Dis*. 2012; 8: 590-4.

[22] Aldenkortt M, Lysakowski C, Elia N, Brochard L, Tramèr MR. Ventilation strategies in obese patients undergoing surgery: a quantitative systematic review and meta-analysis *Br. J. Anaesth*. 2012;109: 493-502.

[23] Zeidan A, Mazoit JX. Minimal alveolar concentration of sevoflurane for maintaining bispectral index below 50 in morbidly obese patients. *Acta Anaesthesiol. Scand*. 2013; 57:474-9.

[24] De Corte W, Delrue H, Vanfleteren LJ, Dutré PE, Pottel H, Devriendt DK, Van Rooy FH, D'Hondt M, Carlier S, Desmet MB. Randomized clinical trial on the influence of anaesthesia protocol on intestinal motility during laparoscopic surgery requiring small bowel anastomosis *Br. J. Surg*. 2012; 99: 1524-9.

[25] Eikermann M, Zaremba S, Malhotra A, Jordan AS, Rosow C, Chamberlin NL. Neostigmine but not sugammadex impairs upper airway dilator muscle activity and breathing. *Br. J. Anaesth* 2008; 101: 344-9.

[26] Herbstreit F, Peters J, Eikermann M. Impaired upper airway integrity by residual neuromuscular blockade. *Anesthesiology* 2009; 110: 1253-60.

[27] Eikermann M, Vogt FM, Hersbstreit F, Vahit-Dastgerdi M, Zenge MO, Ochterbeck C de Greiff A, Peters J. The predisposition to inspiratory upper airway collapse during partial neuromuscular blockade. *Am. J. Respir. Crit. Care Med*. 2007; 175: 9-15.

[28] Sundman E, Witt H, Olsson R, Ekberg O, Kuylenstierna R, Eriksson Ll. The incidence and mechanisms of pharyngeal and upper esophageal dysfunction in partially paralyzed humans. *Anesthesiology* 2000; 92: 977-84.

[29] Eriksson Ll, Sundman E, Olsson R, Nilsson L, Witt H, Ekberg O, Kuylenstierna R. Functional assessment of the pharynx at rest and during swallowing in partially paralyzed humans. *Anesthesiology* 1997; 87:1035-43.

[30] Schumann R, Jones SB, Ortiz VE, Connor K, Istvan P, Ozawa ET, Harvey AM, Carr DB. Best practice recommendations for anesthetic perioperative care and pain management in weight loss surgery. *Obesity Research* 2005; 13: 254-66.

[31] Frey WC, Pilcher J. Obstructive sleep-related breathing disorders in patients evaluated for bariatric surgery. *Obes. Surg*. 2003; 13: 676-83.

[32] Kleijn HJ, Zollinger DP, van den Heuvel MW, Kerbusch T. Population pharmacokinetic-pharmacodynamic analysis for sugammadex-mediated reversal of rocuronium induced neuromuscular blockade. *Br. J. Clin. Pharmacol.* 2011; 72: 415-33.

[33] Van Lancker P, Dillemans B, Bogaert T, Muller JP, De Kock M, Haspeslagh M. Ideal versus corrected body weight for dosage of sugammadex in morbidly obese patients. *Anaesthesia* 2011; 66: 721-5. 17.

[34] Gaszynski T, Szewczyk T, Gaszynski W. Randomized comparison of sugammadex and neostigmine for reversal of rocuronium-induced muscle relaxation in morbidly obese undergoing general anaesthesia *Br. J. of Anaesth.* 2012; 108: 236–9.

[35] Llaurado S, Sabaté A, Ferreres E, Camprubi I, Cabrera A. Sugammadex ideal body weight dose adjusted by level of neuromuscular blockade in laparoscopic bariatric surgery. *Anesthesiology* 2012; 117: 93-8.

[36] Sanfilippo M, Alessandri F, Wefki Abdelgawwad Shousha AA, Sabba A, Cutolo A. Sugammadex and ideal body weight in bariatric surgery. *Anesthesiol. Res. Pract*. 2013.

[37] Kotake Y, Ochiai R, Suzuki T, Ogawa S, Takagi S, Ozaki M, Nakatsuka I, Takeda J. Reversal with sugammadex in the absence of monitoring did not preclude residual neuromuscular block. *Anesth. Analg*. 2013; 117: 345-51.

[38] Grandjean B, Guerci P, F Vial, Raft J, Fuchs-Buder T, Bouaziz H. Sugammadex and profound rocuronium neuromuscular blockade induced by magnesium sulphate *Ann. Fr. Anesth. Reanim.* 2013; 32: 378-9.

[39] Murata T, Kubodera T, Ohbayashi M, Murase K, Adachi YU, Matsuda N. Recurarization after sugammadex following a prolonged rocuronium infusion for induced hypothermia. *Can. J. Anaesth*. 2013;60: 508-9.

[40] Carron M, Veronese S, Foletto M, Ori C. Sugammadex allows fast-track bariatric surgery. *Obes. Surg*. 2013; 23:1558-63.

[41] Cavallone LF, Vannucci A; American Society of Anesthesiologists Task Force on Management of the Difficult Airway. Review article: Extubation of the difficult airway and extubation failure. *Anesth. Analg*. 2013; 116: 368-83.

[42] Martí-Valeri C, Sabaté A, Masdevall C, Dalmau A. Improvement of associated respiratory problems in morbidly obese patients after open Roux-en-Y gastric bypass. *Obes Surg.* 2007; 17:1102-10.

[43] Tusman G, Bohm SH, Warner DO, Sprung J. Atelectasis and perioperative pulmonary complications in high-risk patients. *Curr. Opin. Anesthesiol* 2012, 25:1–10.

[44] Eikermann M, Blobner, M, Groeben, H, Rex, Ch, GroteT, Neuhauser M, Beiderlinden, M, Peters, JD. Postoperative upper airway obstruction after recovery of the train of four ratio of the adductor pollicis muscle from Neuromuscular Blockade. *Anesth. Analg.* 2006; 102: 937-4.

[45] Güldner A, Pelosi P, de Abreu MG. Non ventilatory strategies to prevent postoperative pulmonary complications. *Curr. Opin. Anaesthesiol*. 2013; 26:141-51.

[46] Sasaki N, Meyer MJ, Eikermann M. Postoperative respiratory muscle dysfunction: pathophysiology and preventive strategies.*Anesthesiology*. 2013; 118: 961-78.

[47] Ledowski T, Hillyard S, O'Dea B, Archer R, Vilas-Boas F, Kyle B. Introduction of sugammadex as standard reversal agent: Impact on the incidence of residual neuromuscular blockade and postoperative patient outcome. *Indian J. Anaesth*. 2013; 57:46-51.

[48] Llauradó S, Sabaté A, Ferreres E, Camprubí I, Cabrera A. Postoperative respiratory outcomes in laparoscopic bariatric surgery: Comparison of a prospective group of patients whose neuromuscular blockade was reverted with sugammadex and a historical one reverted with neostigmine. *Rev. Esp. Anestesiol Reanim*. 2014 Jan 8. doi: 10.1016/j.redar.2013.11.009.

[49] Joshi GP, Ahmad S, Riad W, Eckert S, Chung F. Selection of obese patients undergoing ambulatory surgery: a systematic review of the literature. *Anesth. Analg*. 2013 117:1082-91.

[50] Joshi GP, Ankichetty SP, Gan TJ, Chung F Society for Ambulatory Anesthesia consensus statement on preoperative selection of adult patients with obstructive sleep apnea scheduled for ambulatory surgery. *Anesth. Analg*. 2012; 115: 1060-8.

[51] Billing PS, Crouthamel MR, Oling S, Landerholm RW. Outpatient laparoscopic sleeve gastrectomy in a free-standing ambulatory surgery center: first 250 cases. *Surg. Obes. Relat. Dis*. 2013; 17: S1550-7289.

[52] Carron M, Veronese S, Gomiero W, Foletto M, Nitti D, Ori C, Freo U. Hemodynamic and hormonal stress responses to endotracheal tube and ProSeal Laryngeal Mask Airway™ for laparoscopic gastric banding. *Anesthesiology*. 2012;117: 309-20.

[53] Sing RF, Fischer PE. Inferior vena cava filters: indications and management. *Curr. Opin. Cardiol.* 2013;28:625-31.

In: Encyclopedia of Surgery (22 Volume Set)
Editors: Andreas Lehrer and Kristin Mueller
ISBN: 978-1-53618-329-0
© 2020 Nova Science Publishers, Inc.

Chapter 13

SMALL INTESTINAL BACTERIAL OVERGROWTH AFTER BARIATRIC SURGERY

Iman Andalib[1], MD, Naveen Gara[1], MD, Bikram S. Bal[2], MD, Timothy R. Shope[3], MD, and Timothy R. Koch[1,*], MD

[1]Section of Gastroenterology and Hepatology, Washington, DC, US
[2]Center for Gastrointestinal and Liver Diseases, Centra Southside, Farmville, VA, US
[3]Department of Surgery, MedStar-Washington Hospital Center and Georgetown University School of Medicine, Washington, DC, US

ABSTRACT

Worldwide, the prevalence of obesity continues to rise. Attempts at modification of diet and lifestyle often fail to prevent the medical complications of obesity. Bariatric surgery is being increasingly utilized for treatment of obesity. Despite being a gold standard therapy for management of medically-complicated obesity, bariatric surgery has been associated with multiple complications including nutritional deficiencies, bloating, and dyspepsia. Ongoing clinical research has shown that bariatric surgery can lead to postoperative small intestinal bacterial overgrowth with its related nutritional deficiencies. Bacterial overgrowth may result from alteration of the host defense mechanisms, including loss of gastric acid or diminished exposure to bile acids, and altered upper gastrointestinal motility. Other co-morbid disorders, including diabetes mellitus, chronic narcotic use, use of proton pump inhibitors and antidepressants appear to play a role in the development of bacterial overgrowth. Although microbial investigation of jejunal aspirates is the gold standard for detecting bacterial overgrowth, glucose-hydrogen breath testing is increasingly becoming the test of choice for this diagnosis. The treatment for bacterial overgrowth can be very challenging and can include treatment of the underlying disease, correction of vitamin deficiencies, and discontinuation of motility-altering medications. Antibiotics are effective, but only a few studies concerning choice of and duration of antibiotic therapy exist. Herein, we describe the potential mechanisms for the development of small intestinal bacterial overgrowth,

[*] Corresponding Author's Email: timothy.r.koch@medstar.net; Fax: +1-877 6808198.

the effects of bacterial overgrowth on nutrients, the methods of diagnosis of bacterial overgrowth, and treatment options for this disorder.

INTRODUCTION

Microbiota of the Alimentary Tract

Small intestinal bacterial overgrowth (SIBO) results in a malabsorption syndrome due to an increase in and/or alteration of microorganisms within the upper gastrointestinal tract. It is a condition in which there is an expansion of bacteria in the small intestine resulting in excessive fermentation and malabsorption, which can significantly impair an individual's quality of life.

This is not a new surgical disorder. In a 1955 publication, Dr. James Halsted commented that: "intestinal anastomosis leading to stasis of intestinal contents, with overgrowth of bacteria, may cause vitamin B12 deficiency through bacterial interference" [1]. Early work demonstrated that concentrations of the bacterial flora in the gastrointestinal tract normally vary along the length of the gastrointestinal tract [2].

In human physiology, bacterial fermentation is limited to the distal gut as well as to the large intestine. The duodenum and jejunum are relatively sterile. Therefore, colonization of bacteria in the upper gut is abnormal. In this syndrome of SIBO, the flora of the proximal small intestine begin to resemble the flora of a healthy subject's colon, developing high concentrations of anaerobic bacteria. In patients who have undergone bariatric surgery, it would be reasonable to expect that the altered upper gut flora would resemble species present in mouth flora since individuals are frequently swallowing fluids (including saliva). This assumption however has not been confirmed by studies involving subjects after bariatric surgery.

Bacterial concentrations in the upper small intestine typically are low due to effects of gastric acid, gastric emptying, and normal small intestinal motility. The concentration of bacteria in the cecum is usually $10^{10\text{-}12}$ colony forming unit (cfu)/ml; in the ileum bacterial concentrations drop to $10^{5\text{-}8}$ cfu/ml, and in the jejunum and the duodenum bacterial concentrations further drop to $10^{0\text{-}4}$ cfu/ml [3-5]. Therefore, for fermentation to occur, food must normally reach the distal gut anaerobic bacteria. Expansion of bacterial populations in the upper gut can be blocked by several defense mechanisms, including the intestinal immune system, gastric acid, gastric emptying, pancreatic enzymes, intraluminal bile, and small intestinal motility (see Table 1). If any of these mechanisms fail, SIBO could then develop [6]. In addition, in the small intestine, the cleansing action of peristalsis especially the interdigestive migrating motor complex (termed MMCs) is important for the propulsion of bacteria into the colon [7]. Therefore, conditions that result in dysmotility of the small intestine could lead to upper gut bacterial overgrowth.

Table 1. Defense factors preventing small intestinal bacterial overgrowth

Intestinal Immune System
Gastric Acid Production
Gastric Emptying
Pancreatic Enzymes
Intraluminal Bile
Small Intestinal Motility
-Interdigestive Migrating Motor Complexes
-Small Intestinal Liquid and Solid Transit

Predisposing Factors

The etiologies of SIBO are complex and are summarized in Table 2. The origin of SIBO includes clinical disorders and anatomical abnormalities such as bariatric surgery, partial gastrectomy with Billroth II reconstruction, small intestinal diverticulosis, small intestinal stricture (due to Crohn's disease, radiation enteritis, or focal segmental ischemia), fistulae, or previous resection of the ileocecal valve. Other predisposing factors involve disorders of protective antibacterial mechanisms including the presence of pancreatic insufficiency or achlorhydria [7]. Motility disorders that can induce SIBO include scleroderma, diabetes mellitus with autonomic neuropathy, or chronic idiopathic intestinal pseudo-obstruction. Other disorders associated with SIBO include celiac disease, chronic pancreatitis, and radiation enteritis [7-9].

Table 2. Clinical conditions and the development of small intestinal bacterial overgrowth

Anatomical Alteration
Bariatric Surgery
Small Intestinal Diverticulosis
Intestinal Stricture (Benign, Malignant, Radiation-Induced or Crohn's disease)
Fistula (Gastrocolic or Jejunocolic; Crohn's disease)
Resection of Ileocecal Valve
Altered Gastric Acid Production
Post-Surgical Gastrectomy or Vagotomy
Chronic *Helicobacter pylori* gastritis
Proton Pump Inhibitor
Dysmotility Disorders
Gut Autonomic Neuropathy (Diabetes Mellitus)
Scleroderma
Motility-Altering Medications (Narcotics, Anti-Depressants, or Calcium-Channel Antagonists)
Medical Disorders
Immunodeficiency Disorders
Celiac Disease
Chronic Pancreatitis

There are reports in the literature that use of chronic narcotics, proton pump inhibitors, and antidepressants could increase the likelihood of developing SIBO, but these factors have not been extensively studied [10].

We have evaluated the association between medication use and SIBO in patients after Roux-en-Y gastric bypass [11]. In a retrospective study that included 206 patients who underwent Roux-en-Y gastric bypass at our institution from 1999-2007, all patients were required to take a daily multivitamin with minerals. A serum folate level above the upper limit of normal was considered to be elevated and therefore consistent with a diagnosis of SIBO [12-13]. There were 115 patients (97 females and 18 males; average age: 46 years-old; average BMI: 53 kg/m^2) who had serum folate levels measured. Medication lists for these patients after gastric bypass were reviewed, and short-term narcotic use in the immediate post-operative period was excluded. There were 58 patients with chronic narcotic use of whom 51 had elevated serum folate levels; in a control group of 32 patients who received no motility-altering medication, only 10 patients had elevated serum folate levels (Chi-squared 2x2: $p<.0001$). This result supported the strong relationship between chronic narcotic usage and SIBO. Among the 25 remaining patients, 13 of 13 patients (100%) who were receiving an anti-depressant medication had elevated serum folate levels, 8 of 9 patients (89%) who were receiving a proton pump inhibitor had elevated serum folate levels, and 2 of 3 patients (67%) who were receiving a calcium channel antagonist had elevated serum folate levels. These results support the concern that patients after bariatric surgery may be at risk for development of SIBO during concomitant intake of narcotics, proton pump inhibitors, anti-depressants, or calcium-channel antagonists.

SIBO has been identified by clinical evidence and abnormal glucose-breath tests in patients who have undergone Roux-en-Y gastric bypass (as discussed above), vertical sleeve gastrectomy, and adjustable gastric banding.

It has been suggested that inadequate small intestinal motility may result in the presence of residual food particles or residue in the small intestine, a potential culture media for bacteria. Specifically, a reduction in the frequency or occurrence of interdigestive (fasting) migrating motor complexes (MMC) could result in the development of small bowel bacterial overgrowth. However, a study from the Mayo Clinic (Rochester, MN) reported however significant increases in the frequency of phase III MMCs in individuals who had undergone partial gastrectomy with either Billroth II reconstruction or Roux-en-Y reconstruction [14].

By contrast, investigators at the University of Copenhagen (Denmark) studied 17 individuals after Roux-en-Y gastric bypass and compared their results to 9 controls [15]. Small intestinal transit was examined using gamma camera images in individuals receiving mixed isotope solid-liquid meals. The passage of solid isotope, but not liquid isotope, was significantly prolonged through the small intestine in individuals who had undergone Roux-en-Y gastric bypass. Slowed passage of solids through the small intestine could be an important factor promoting the overgrowth of upper gut bacteria.

Advanced age may be an independent risk factor for SIBO [16]. However, the incidence of SIBO may be underestimated, since many of these patients are asymptomatic. The underlying mechanism has been proposed to be due to age-related dysmotility or achlorhydria (possibly caused by atrophic gastritis induced by chronic gastric *Helicobacter pylori* infection). Further studies are needed to determine the actual incidence of SIBO in this population.

Mechanisms of Malabsorption

Proposed mechanisms of malabsorption in individuals with SIBO are summarized in Table 3. Bacteria in the small intestine can interrupt the metabolism and absorption of many bioactive compounds including monosaccharides, lipids, proteins and vitamins [1, 13, 17, 18].

Table 3. Proposed mechanisms of malabsorption induced by small intestinal bacterial overgrowth

Bacterial Deconjugation of Bile Salts
Reduced Brush Border Disaccharidases
Carbohydrate Fermentation by Bacteria
Formation of Short-Chain Organic Acids
Utilization of Protein by Bacteria
Altered Gut Permeability
Utilization of Vitamins by Bacteria
Interference with the Cobalamin-Intrinsic Factor Complex

Fat malabsorption in SIBO has been proposed to result from bacterial deconjugation of bile salts in the proximal gut. Conjugated bile salts are required for micelle formation (containing lipids and fat-soluble vitamins A, D, E and K) prior to micelle absorption in the terminal ileum. However, in individuals with SIBO, bacteria in the small intestine deconjugate bile salts forming free bile acids, which can interfere with formation of mixed micelles. Furthermore, deconjugated bile acids formed by bacterial activity may induce mucosal damage, and thus contribute to patchy submucosal lesions identified in individuals with SIBO.

Although malabsorption of lipophilic vitamins (vitamins A, D, E, and K) may also occur as a result of altered micelle absorption, vitamin K levels are generally normal in patients with SIBO due to the production of vitamin K by luminal bacteria [17-19].

Carbohydrate malabsorption is also common in SIBO. This phenomenon has been proposed to be the result of reduced brush border disaccharidase levels (due to digestion by bacterial proteases) as well as carbohydrate fermentation by the bacteria, itself. In addition, small intestinal and colonic bacteria can metabolize these malabsorbed carbohydrates to form short-chain organic acids, which leads to increased osmolarity of the intestinal fluid and thus results in diarrhea [17, 20].

Protein malabsorption has been proposed to be the consequence of utilization of protein by the bacteria. Another proposed mechanism may be the enterocyte injury which alters the gut permeability leading to the development of a protein-losing enteropathy [21].

The postoperative development of vitamin B12 deficiency induced by SIBO has a complex pathophysiology. In a healthy proximal small intestine, intrinsic factor normally binds to vitamin B12. This complex will facilitate cobalamin absorption in the distal ileum. In the presence of SIBO, the colonized bacteria including anaerobes and facultative gram-negative aerobes utilize or consume vitamin B12 making it less available for absorption. In SIBO, bacteria can interfere with the formation of the cobalamin-intrinsic factor complex. Interestingly, enteric bacteria do biosynthesize cobalamin. However, this cobalamin is not available for absorption by the host as it is retained by the bacteria [3, 17, 22].

Effects of Small Intestinal Bacterial Overgrowth on Nutrition

Small intestinal bacterial overgrowth may include a catabolic process that could lower serum albumin levels. The preoperative prevalence of hypoalbuminemia in patients seeking bariatric surgery is reported to be 1.1% [23]. Clinicians in Brazil have reported two patients who developed hypoalbuminemia after Roux-en-Y gastric bypass [24]. Hydrogen breath testing supported a diagnosis of bacterial overgrowth. Each patient was treated with oral ciprofloxacin for two weeks and one patient in addition received a two week course of oral tetracycline. One patient had a rise in serum albumin from 2.4 g/dl pre-treatment to 3.3 g/dl post-treatment, while in the second patient, the serum albumin pre-treatment was 2.3 g/dl but the post-treatment level was only 2.7 g/dl (normal range is 3.5 to 5.0 g/dl).

Upon examination of patients who underwent Roux-en-Y gastric bypass surgery at our institution from 1999-2007, we identified 115 individuals who had both serum folate and serum albumin levels obtained [25]. A serum folate level above the upper limit of normal was considered to be an indirect measure of small intestinal bacterial overgrowth [12, 13], and a serum albumin level below the lower limit of normal was considered to be low. In this study, 42 patients with an abnormal glucose-hydrogen breath test, consistent with SIBO, were treated with oral antibiotics. There was no relationship identified between SIBO and low serum albumin levels (Chi-squared 2x2: $p=0.8$). Among 42 patients with abnormal glucose-hydrogen breath test, 14 patients (33%) had low serum albumin levels and 42% of these patients achieved normal serum albumin levels after antibiotic treatment for SIBO (see Figure 1). Thus, there was no evidence that SIBO induced hypoalbuminemia; treatment of SIBO did not improve serum albumin levels in the majority of patients after Roux-en-Y gastric bypass.

In an attempt to suppress the development of SIBO, Woodard and associates followed 44 patients after Roux-en-Y gastric bypass who were randomized to receive either a control (placebo) or 2.4 billion Lactobacillus species daily [26]. At 6 months, individuals who received daily Lactobacillus had reduced breath hydrogen levels, supporting suppression of upper gut bacterial overgrowth. However, there were no differences in weight loss when comparing the two groups of patients at 6 months. It was noted that gastrointestinal quality of life surveys had improved in both groups, supporting the importance of gastric bypass surgery in improving patients' quality of life.

In examination of the effect of SIBO on vitamin B12, SIBO classically causes megaloblastic anemia [1]. Cobalamin (vitamin B12) deficiency can occur as a result of utilization of the vitamin by the bacteria before it can be absorbed. This deficiency is improved after antibiotic administration, but cannot be corrected by addition of intrinsic factor.

We have reported the effect of SIBO on vitamin B1 (thiamine) levels after Roux-en-Y gastric bypass [13]. There was a significant relationship between the presence of SIBO and whole blood thiamine diphosphate levels that were below the lower limit of normal.

Twenty one patients were also evaluated who had thiamine diphosphate levels below the lower limit of normal and abnormal glucose-hydrogen breath tests, consistent with SIBO [13]. Fifteen patients received oral thiamine supplements, but repeat whole blood thiamine levels remained low in all 15. Nine of these patients then received oral antibiotic therapy. Determination of repeat thiamine levels revealed that all 9 patients had normalized their whole blood thiamine levels. These results support the hypothesis that SIBO induces thiamine deficiency after gastric bypass surgery in obese patients. Patients after gastric bypass surgery

who develop thiamine deficiency may require antibiotic treatment of SIBO in order to normalize their whole blood thiamine levels.

MANAGEMENT

Clinical Features

As discussed above, SIBO is generally considered to be a malabsorption disorder. The clinical consequences of SIBO are similar regardless of the underlying predisposing factors (see Table 4). Patients with SIBO may be asymptomatic or may have symptoms that resemble the irritable bowel syndrome, including diarrhea, abdominal bloating, abdominal cramps, or flatulence. These symptoms are usually followed by the development of malabsorption. In patients with short bowel syndrome, inflammatory bowel diseases, scleroderma, radiation enteritis or diabetes, it may be difficult to determine whether the symptoms are due to the primary disease, or SIBO itself [3].

Many patients with SIBO fulfill Rome I criteria for a clinical diagnosis of irritable bowel syndrome, because the symptoms of SIBO and irritable bowel syndrome overlap to a large degree. Pimentel et al. [3] have reported that among 202 patients meeting Rome I criteria for IBS, 78% had abnormal breath tests, supporting the presence of SIBO. In their reports, successful eradication of SIBO after antibiotic treatment was associated with significant relief of abdominal symptoms [27].

One of the late features of SIBO is development of anemia. It is usually due to vitamin B12 deficiency, which results in macrocytic and megaloblastic anemia. In prolonged cases of malabsorption, cobalamin deficiency can lead to subacute combined degeneration of the spinal cord and/or peripheral neuropathy. In other severe cases, symptoms such as night blindness (nyctalopia) due to vitamin A deficiency, osteomalacia due to vitamin D deficiency, or vitamin E deficiency syndromes (retinopathy, anemia, ataxia, myopathy, or dysarthria) can occur. Protein malabsorption in SIBO can lead to hypoalbuminemia, which can induce peripheral edema [3].

Table 4. Clinical features of small intestinal bacterial overgrowth

Diarrhea
Abdominal Bloating
Abdominal Cramps
Flatulence
Macrocytic Anemia
Subacute Combined Degeneration
Peripheral Neuropathy
Nyctalopia
Osteomalacia
Peripheral Edema

Diagnosis

A patient with symptoms of diarrhea, abdominal bloating/pain, or steathorrhea with a coexisting predisposition to SIBO should prompt the clinician to consider testing for small intestinal bacterial overgrowth, especially if there has been no response to empiric treatment. The "Gold Standard" for the diagnosis of a SIBO is a quantitative microbial investigation of a jejunal aspiration [6, 28]. However, this test has fallen out of favor since it has major limitations. First, in order for this quantitative test to be diagnostic, a duodenal aspirate must be obtained and then should be immediately cultured in order to identify the presence of at least 10^6 cfu/mL [29]. Second, the distribution of bacterial overgrowth might be restricted to one particular area of intestine, which may not be within the reach of a gastroscope. Since a gastroscope reaches only the upper portion of small intestine, there could be potentially high false-negative rate when using this approach for the diagnosis of SIBO [3, 30]. Since this quantitative test is invasive, time-consuming, and may be altered by contamination, breath tests such as the xylose breath test and the hydrogen breath test have been developed.

However, there is presently no general agreement as to which test is superior for the diagnosis of SIBO. ^{14}C-cholylglycine or bile acid breath test was the first encouraging breath test for the diagnosis of SIBO [31]. The test was based on the deconjugation of the bile salt by small bowel bacteria, before reaching colonic bacteria. However, it was shown that the test had a high false-negative rate of 30% to 40% with only moderate sensitivity. In addition, there was a concern of falsely positive test results in patients with ileal resection, since the unabsorbed bile salt would reach the colonic bacteria and would be deconjugated [21, 32]. With the development of newer tests, the bile acid test has fallen out of favor.

The ^{14}C-D-xylose breath test is another test with higher sensitivity and specificity. This test depends on the ability of catabolization of xylose by the high concentration of small intestine bacteria with production of $^{14}CO_2$. One of the advantages of this test is the absorption of both $^{14}CO_2$ that is produced as well as uncatabolized xylose by the proximal small bowel. These dual measurements could potentially decrease the number of false positive results caused by catabolization of xylose by colonic bacteria [7, 33]. As previously mentioned, studies have shown that the sensitivity and specificity of this test are superior to those of the ^{14}C-bile acid test [34]. Therefore, the ^{14}C-D-xylose test replaced the bile-acid breath test and became a popular test for evaluation of bacterial overgrowth. However, other investigators questioned the accuracy of this test [35], and so additional studies are needed to evaluate the efficacy of this test in patients who have undergone bariatric surgery.

Additional tests have been developed based upon the metabolic activity of upper gut bacteria. As shown in Table 5, metabolic products produced by bacteria include hydrogen, methane, ammonia, d-lactic acid and folate [13]. The pulmonary clearance of methane and hydrogen forms the pathophysiological basis for the glucose-hydrogen breath test. The glucose-hydrogen breath test has become one of the most important diagnostic methods for SIBO, with a reported sensitivity of 62.5% and a specificity of 82% [6, 28]. As shown in Figure 2 in an individual with post-prandial abdominal pain after Roux-en-Y gastric bypass, the diagnosis of a positive or abnormal glucose breath test is supported both by a high fasting breath level of methane as well as by fermentation of glucose to produce hydrogen, which is then measured in the breath.

Table 5. Metabolic products of bacteria

Methane
Hydrogen
Ammonia
d-Lactic Acid
Folic Acid

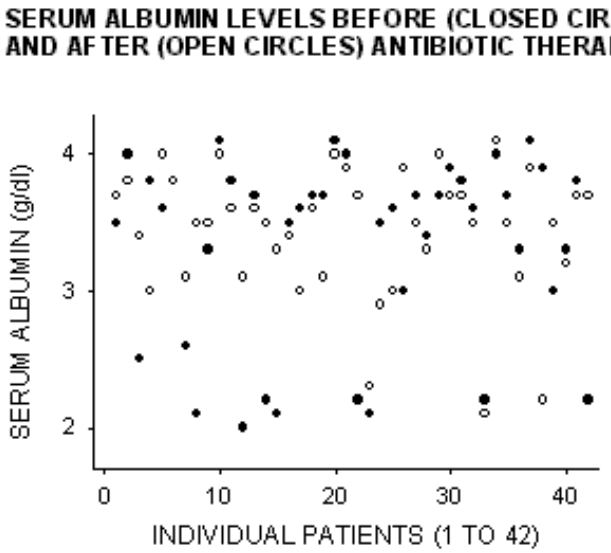

Figure 1. Effect of antibiotic therapy on serum albumin in forty two patients after Roux-en-Y gastric bypass.

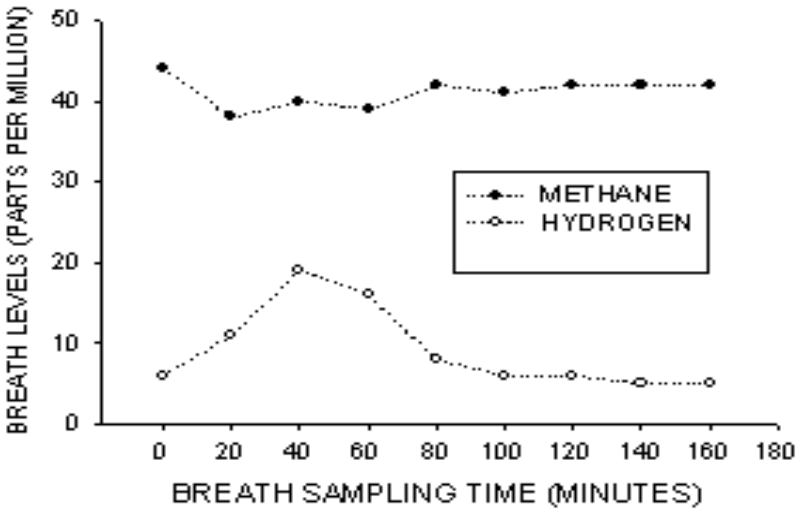

Figure 2. Gastric bypass patient with abdominal pain: breath hydrogen/methane levels after 25 grams of oral glucose.

However, there are several limitations when using the glucose-hydrogen breath test, including determination of cut-off points to define a positive test. A positive or abnormal glucose breath test in an individual who has fasted for at least 10 hours is supported by either: i. a fasting breath hydrogen or methane level that is >10 parts per million or, ii. after oral ingestion of 50 grams of glucose, an increase in breath hydrogen or methane of >14 parts per million above the baseline breath hydrogen or methane values. Furthermore, since glucose is almost completely absorbed in the proximal small intestine, this test may not be reliable for the diagnosis of SIBO of the distal small intestine. In patients with rapid transit (oral-cecal transit time of less than 75 minutes), the breath test may not be useful since it could result in false positive results [36]. As another potential downside to this test, after Roux-en-Y gastric bypass, the bypassing of duodenum and proximal jejunum could reduce absorption of glucose by the small intestine, leading to a higher percentage of patients with an abnormal breath test. Nonetheless, this test is one of the most useful methods for the diagnosis of SIBO.

Finally, the lactulose-hydrogen breath test is another test that has been examined in patients with potential SIBO, but its validity has also been questioned. In studies, it has been shown that the lactulose-hydrogen breath test has a sensitivity of 17-68% and specificity of 44-70%; therefore this test may not be useful for the diagnosis of SIBO [5].

Treatment Options

The treatment of SIBO can be complex and multifactorial. The treatment of SIBO essentially should focus on: 1) treatment of the underlying disease; 2) modification of the diet, such as a trial of a lactose-free diet; 3) discontinuation of acid-lowering or motility-altering medications; 4) correction of vitamin deficiencies and nutritional support as indicated; 5) treatment of potential dysmotility disorders; and 6) antibiotic treatment targeting the bacteria that cause SIBO.

Individuals with SIBO may be asymptomatic. However, if symptoms of malabsorption such as diarrhea and bloating occur in the presence of a positive breath test result, the clinician may decide to start antibiotic therapy for SIBO (see Table 6). There have been many studies examining different antibiotics, but no guidelines have been published with regards to the choice of antibiotics or the duration of the treatment for management of recurrent SIBO. This is partly due to the difficulty in acquiring a culture of bacteria from the small intestine, as well as determining its antibiotic susceptibility. Generally, empiric antimicrobial agents are used that have both aerobic and anaerobic coverage. Cycling of antibiotics involves utilization of an antibiotic for 7 to 14 days, with consideration of a repeat course of antibiotic in 1 to 3 months (depending upon the timing for a return of abdominal symptoms). In addition, long-term treatment is not optimal as it might be associated with other problems such as development of antibiotic-associated diarrhea, *Clostridium difficile* colitis, and resistance to antibiotics. Also the recurrence rate of SIBO is high.

In a major meta-analysis of antibiotic treatment of SIBO, Shah and associates [37] identified 1356 articles. As their primary outcome, the authors chose normalization of post-treatment breath testing. Their secondary outcome was post-treatment clinical response. Only 10 studies met inclusion criteria. Among these 10 studies, rifaximin was studied in 8 of the studies. This meta-analysis showed that antibiotics were more effective than placebo, and that the clinical response paralleled the results obtained from breath testing.

Table 6. Antibiotic therapy for small intestinal bacterial overgrowth

ANTIBIOTIC	DOSAGE	TIMING
Metronidazole	250-500 mg	2 to 3 Times Daily
Doxycycline	100 mg	1 to 2 Times Daily
Cefaclor	250 mg	3 Times Daily
Amoxicillin-Clavulanic Acid	250-500 mg/62.5-125 mg	2 to 3 Times Daily
Ciprofloxacin	250-500 mg	Twice Daily
Norfloxacin	400 mg	Twice Daily
Rifaximin	200-550 mg	1 to 2 Times Daily
Trimethoprim-Sulfamethoxazole	160/800 mg	1 or 2 Times Daily
Clindamycin*	150 mg	2 to 4 Times Daily

* High risk of pseudo-membranous colitis.

In older literature, the treatment of choice for SIBO was tetracycline, taken by mouth four times a day, with presumed resolution of symptoms within one week. However, new studies have shown that almost half of the patients with SIBO do not respond to this therapy, probably because tetracycline does not have a direct activity against anaerobic bacteria. Eradication rates with tetracycline were also shown to be as low as 40%.

Metronidazole has also been used for treatment of SIBO, but data are scarce with regards to this antibiotic. Metronidazole does provide coverage against anaerobic bacteria. As a potential risk factor, it has been reported that enzymatic conversion of metronidazole produces an analog of thiamine [38]. It is therefore possible that metronidazole could exacerbate thiamine deficiency induced by bacterial overgrowth in patients who have undergone bariatric surgery.

Other antibiotics such as amoxicillin–clavulanic acid have been used previously for empiric treatment of SIBO due to convenience of dosing [7]. Attar and associates compared the treatment of 10 patients with amoxicillin–clavulanic acid, norfloxacin and *Sacchromyces boulardii*. These authors identified significant improvement of symptoms with both amoxicillin–clavulanic acid (60%) and norfloxacin (90%), but no symptomatic improvement with the use of *Sacchromyces boulardii* [39].

There are additional studies which have evaluated the efficacy of non-absorbable antibiotics, including neomycin and rifaximin, to decrease the potential side effects noted with the use of systemic antibiotics. These studies have shown that rifaximin, which has bactericidal activity directed against both aerobic and anaerobic bacteria, led to the normalization of breath testing and the resolution of symptoms of malabsorption [40]. Rifaximin has also been shown to have a very low toxicity, since only < 0.4% of the drug is absorbed [41]. Neomycin has also been studied in older literature. It did not show significant clinical benefit for the treatment of SIBO, and it had no significant side effects.

Given the limited information with regards to the treatment of SIBO, there is no conclusive data to assist our understanding which antibiotics have the most efficacy. Clinicians should consider the risks of long-term systemic antibiotic therapy, costs, and the likelihood of recurrence of SIBO before choosing antibiotic treatment.

Prokinetic agents have also been evaluated due to their potential benefit for propulsion of bacteria through the small intestine. One study of 5 individuals with SIBO demonstrated a decrease in symptoms of bloating and nausea, and normalization of breath tests after nightly administration of low dose Octreotide [42]. Therefore, this agent could be an important option

in those individuals who do not respond to or are intolerant to systemic antibiotics. However, this study included relatively few subjects. Additional studies are required to address questions of the effects of Octreotide, the duration of treatment with Octreotide, and whether its combination with antibiotic therapy could be beneficial to individuals with SIBO.

Although the primary goal of treatment of SIBO is to control the overgrowth of bacteria in the upper gut, nutritional support is an important component for proper management of patients with SIBO. Some of these patients have vitamin deficiencies and some patients have protein-calorie malnutrition. Therefore, appropriate nutritional supplementation with micronutrients and macronutrients is a crucial component of the treatment of SIBO.

The initial goal for treatment of protein malnutrition is the daily intake of 60 to 80 grams of protein. Multiple sources of liquid protein supplementation are commercially available. Vitamin B12 deficiency can be treated with intramuscular vitamin B12 1000 mcg once monthly. Severe vitamin B12 deficiency is treated with intramuscular vitamin B12 500-1000 mcg once daily for 7 days, then once weekly for 3 weeks, and then once monthly. In patients with control of SIBO by antibiotics, vitamin B12 deficiency may respond to oral vitamin B12 500 to 1000 mcg daily. Vitamin B1 (thiamine) deficiency can be treated with 200 mg intramuscularly once monthly. Severe thiamine deficiency (visual loss, Psychosis, or Wernicke's disease) requires 250 mg of thiamine either intramuscularly or intravenously (infusion over 3 to 4 hours) once daily for a minimum of 3 to 5 days. In patients with control of SIBO by antibiotics, vitamin B1 deficiency may respond to oral vitamin B1 100 to 250 mg twice daily.

CONCLUSION

Small intestinal bacterial overgrowth is a malabsorption syndrome which can lead to significant consequences such as deficiencies of macro- and micro-nutrients. It is commonly associated with other disorders and the use of acid-reducing and motility-altering medications. As the rates of bariatric surgeries rise, the risk of developing of bacterial overgrowth increases. Therefore, clinicians should always consider bacterial overgrowth in their differential as a cause of malabsorption. Due to the high incidence of bacterial overgrowth and the difficulty controlling its associated symptoms, further clinical research is warranted regarding antibiotic therapy for bacterial overgrowth. Since indefinite use of antimicrobials is not ideal therapy, further studies are needed to evaluate alternative therapies for the treatment of small intestinal bacterial overgrowth.

REFERENCES

[1] Halsted, JA. Megaloblastic anemia: associated with surgically produced gastrointestinal abnormalities. *California Med* 1955; 83(3): 212-217.

[2] Finegold, SM. Intestinal bacteria: the role they play in normal physiology, pathologic physiology, and infection. *California Med* 1969; 110(6): 455-59.

[3] Lin, HC. Small intestinal bacterial overgrowth: a framework for understanding irritable bowel syndrome. *JAMA* 2004; 292(7): 852-858.

[4] Wilson, KH. The gastrointestinal biota. In: Yamada T, Alpers DH, Laine L, Owyang C, Powell DW, eds. *Textbook of Gastroenterology*. Philadelphia, PA; Williams & Wilkins; 1999; 624-636.

[5] Vanner, S. The small intestinal bacterial overgrowth irritable bowel syndrome hypothesis: implications for treatment. *Gut* 2008; 57: 1315-1321.

[6] Bures, J; Cyrany, J; Kohoutova, D; et al. Small intestinal bacterial overgrowth syndrome. *World J Gastroenterol* 2010; 16(24): 2978-2990.

[7] Singh, VV; Toskes, PP. Small bowel bacterial overgrowth: presentation, diagnosis, and treatment. *Curr Gastro Rep* 2003; 5: 365-372.

[8] Gregg, CR; Toskes, PP. Enteric bacterial flora and small bowel bacterial overgrowth syndrome. In *Sleisenger and Fordtran's Gastrointestinal and Liver Disease*, ed 7. Philadelphia, PA; WB Saunders; 2002; 1783–1793.

[9] Husebye, E; Skar, V; Hoverstad, T; et al. Abnormal intestinal motor patterns explain enteric colonization with gram-negative bacilli in late radiation enteropathy. *Gastroenterology* 1995; 109: 1078–1089.

[10] Fried, M; Siegrist, H; Frei, R; et al. Duodenal bacterial overgrowth during treatment in outpatients with omeprazole. *Gut* 1994; 35: 23–26.

[11] Bal, B; Shah, HN; Finelli, FC; Kirkpatrick, JR; Koch, TR. Risk factors associated with small intestinal bacterial overgrowth after Roux-en-Y gastric bypass surgery. *Am J Gastroenterol* 2008; 103 (S1): S97-8.

[12] Camilo, E; Zimmerman, J; Mason, JB; Golner, B; Russell, R; Selhub, J; Rosenberg, IH. Folate synthesized by bacteria in the human upper small intestine is assimilated by the host. *Gastroenterology* 1996; 110(4): 991-8.

[13] Lakhani, SV; Shah, HN; Alexander, K; Finelli, FC; Kirkpatrick, JR; Koch, TR. Small intestinal bacterial overgrowth and thiamine deficiency after Roux-en-Y gastric bypass surgery in obese patients. *Nutr Res* 2008; 28(5): 293-298.

[14] Fich, A; Neri, M; Camilleri, M; Kelly, KA; Phillips, SF. Stasis syndromes following gastric surgery: Clinical and motility features of 60 symptomatic patients. *J Clin Gastroenterol* 1990; 12(5): 505-12.

[15] Dirksen, C; Damgaard, M; Bojsen-Moller, KN; et al. Fast pouch emptying, delayed small intestinal transit, and exaggerated gut hormone responses after Roux-en-Y gastric bypass. *Neurogastroenterol Motil* 2013; 25: 346-e255.

[16] Saltzman, JR; Kowdley, KV; Pedrosa, MC; et al. Bacterial overgrowth without clinical malbsorption in elderly hypochlorhydric patients. *Gastroenterology* 1994; 106: 615–623.

[17] Koch, TR; Finelli, FC. Postoperative metabolic and nutritional complications of bariatric surgery. *Gastroenterol Clin North Am* 2010; 39(1): 109-124.

[18] Bal, B; Koch, TR; Finelli, FC; Sarr, MG. Managing medical and surgical disorders after divided Roux-en-Y gastric bypass surgery. *Nat Rev Gastroenterol Hepatol* 2010; 7: 320-324

[19] Wanitschke, R; Ammon, HV. Effects of dihydroxy bile acids and hydroxyl fatty acids on the absorption of oleic acid in the human jejunum. *J Clin Invest* 1978; 61:178–186.

[20] Giannella, RA; Rout, WR; Toskes, PP. Jejunal brush border injury and impaired sugar and amino acid uptake in the blind loop syndrome. *Gastroenterology* 1974; 67: 965–974.

[21] King, CE; Toskes, PP. Protein-losing enteropathy in the human and experimental rat blind loop syndrome. *Gastroenterology* 1981; 80: 504–509.

[22] Welkos, SA; Toskes, PP; Baer, H; et al. Importance of anaerobic bacteria in the cobalamin malabsorption of experimental rat blind loop syndrome. *Gastroenterology* 1981; 80: 313–320.

[23] Flancbaum, L; Belsley, S; Drake, V; Colarusso, T; Tayler, E. Preoperative nutritional status of patients undergoing Roux-en-Y gastric bypass for morbid obesity. *J Gastrointest Surg* 2006; 10(7): 1033-7.

[24] Machado, JDC; Campos, CS; Silva, CLD; et al. Intestinal bacterial overgrowth after Roux-en-Y gastric bypass. *Obes Surg* 2008; 18: 139-43.

[25] Bal, B; Shah, HN; Finelli, FC; Kirkpatrick, JR; Koch, TR. Hypoalbuminemia after Roux-en-Y gastric bypass surgery is not related to small intestinal bacterial overgrowth. *Am J Gastroenterol* 2008; 103 (S1): S103.

[26] Woodard, GA; Encarnacion, B; Downey, JR; et al. Probiotics improve outcomes after Roux-en-Y gastric bypass surgery: a prospective randomized trial. *J Gastrointest Surg* 2009; 13(7): 1198-204.

[27] Pimentel, M; Chow, E; Lin, HC. Eradication of small intestinal bacterial overgrowth reduces symptoms in irritable bowel syndrome. *Am J Gastroenterol* 2000; 95: 3503-3506.

[28] Gasbarrini, A; Laurittano, EC; Gabrielli, M; et al. Small intestinal bacterial overgrowth: diagnosis and treatment. *Dig Dis* 2007; 25: 237-240.

[29] Corazza, GR; Menozzi, MG; Strocchi, A; Rasciti, L; Vaira, D. The diagnosis of small bowel bacterial overgrowth: Reliability of jejunal culture and inadequacy of breath hydrogen testing. *Gastroenterology* 1990; 98: 302-309.

[30] Rumessen, JJ; Gudmand-Hoyer, E; Bachmann, E; Justesen, T. Diagnosis of bacterial overgrowth of the small intestine: comparison of the 14C-D-xylose breath test with jejunal cultures in 60 patients. *Scand J Gastroenterol* 1985; 20: 1267-1275.

[31] Fromm, H; Hofmann, AF. Breath test for altered bile acid metabolism. *Lancet* 1971; 2(7725): 621-625.

[32] Ferguson, J; Walker, K; Thomson, AB. Limitations in the use of ^{14}C-glycocholate breath and stool bile acid determinations in patients with chronic diarrhea. *J Clin Gastroenterol* 1986; 8: 258–262.

[33] King, CE; Toskes, PP. Comparison of the 1-gram [^{14}C]xylose, 10-gram lactulose-H_2, and 80-gram glucose-h_2 breath tests in patients with small intestinal bacterial overgrowth. *Gastroenterology* 1986; 91: 1447–51.

[34] Toskes, PP. The changing nature of small intestine bacterial overgrowth. Curr *Gastroenterol Rep* 1999; 1: 267–268.

[35] Lewis, SJ; Young, G; Mann, M; et al. Improvement in specificity of [^{14}C]d-xylose breath test for bacterial overgrowth. *Dig Dis Sci* 1997; 42:1587–1592.

[36] Kerlin, P; Wong, L. Breath hydrogen testing in bacterial overgrowth of the small intestine. *Gastroenterology* 1988; 95(4): 982-988.

[37] Shah, SC; Day, LW; Somsouk, M; Sewell, JL. Meta-analysis: antibiotic therapy for small intestinal bacterial overgrowth. *Aliment Pharmacol Ther* 2013; 38(8): 925-34.

[38] Alston, TA; Abeles, RH. Enzymatic conversion of the antibiotic metronidazole to an analog of thiamine. *Arch Biochem Biophys* 1987; 257(2): 357-62.

[39] Attar, A; Flourie, B; Rambaud, JC; Franchissuer, C; Ruszniewski, P; Bouhnik, Y. Antibiotic efficacy in small intestinal bacterial overgrowth-related chronic diarrhea: a crossover randomized trial. *Gastroenterology* 1999; 117: 794–797.

[40] Scrapellini, E; Gabrielli, M; Lauritano, CE; Lupascu, A; et al. High dosage rifaximin for the treatment of small intestinal bacterial overgrowth. *Aliment Pharmacol Ther* 2007; 25: 781-786.

[41] Pimentel, M; Park, S; Mirocha, J; Kane, SV; Kong, Y. The effect of a nonabsorbed oral antibiotic (rifaximin) on the symptoms of the irritable bowel syndrome. *Ann Intern Med* 2006; 145: 557-563.

[42] Soudah, HC; Hasler, WL; Owyang, C. Effect of octreotide on intestinal motility and bacterial overgrowth in scleroderma. *N Engl J Med* 1991; 325: 1461–1467.

In: Encyclopedia of Surgery (22 Volume Set)
Editors: Andreas Lehrer and Kristin Mueller
ISBN: 978-1-53618-329-0
© 2020 Nova Science Publishers, Inc.

Chapter 14

OPTIMAL PHYSICAL ACTIVITY AND EXERCISE FOLLOWING BARIATRIC SURGERY

Matthew D. Barberio, PhD, Rosemary Lu, and Monica J. Hubal*, PhD
Department of Integrative Systems Biology
George Washington University School of Medicine
Research Center for Genetic Medicine
Children's National Medical Center, Washington, DC, US

ABSTRACT

Bariatric surgery typically results in health improvements across multiple obesity-related comorbidities, in addition to losses of excess weight. It is commonly believed that weight loss following surgery would improve physical activity (PA) levels as movement becomes less difficult, resulting in increased cardiorespiratory (CR) fitness. Increased physical activity levels post-surgery would help optimize and sustain weight loss and other co-morbidity improvements. However, evaluation of fitness and PA levels after surgery-induced weight loss is a nascent field without consensus about the efficacy of current surgical programs to evoke increased fitness and PA changes. Few studies to date have measured changes in different types of fitness, from musculoskeletal function to cardiorespiratory endurance. Furthermore, the limited available research suggesting significant increases in self-reported physical activity following surgery have used objective PA measures, making interpretation difficult. The goal of this chapter is to review existing literature regarding fitness and PA changes following weight-loss surgery. As part of this goal, we will briefly review some basic tenets of physical fitness related to activity and exercise. We will also relate fitness and PA changes to sustained weight-loss and reduced health risks following surgery. Finally, we will highlight gaps in the literature and suggest specific research topics needed to address these relationships, so that optimal bariatric surgery programs can be designed to maximize improvements in fitness.

* Corresponding Author's Email: mhubal@childrensnational.org; Fax: 202.476.6014.

GLOSSARY OF TERMS

Physical activity	Bodily movements produced by skeletal muscle that result in an increase in energy expenditure.
Exercise	A form of physical activity that is structured with planned sequences of repetitive body movements with the goal of maintenance or improvements in physical fitness.
Physical fitness	Ability to carry out daily tasks with vigor and alertness, without undue fatigue and with ample energy to enjoy leisure-time pursuits and to meet unforeseen emergencies
Overload	Physical activity and exercise that an individual is unaccustomed to presents a positive stressor to various physiological systems.
Adaptation	Molecular, structural, and mechanical changes in physiological systems so that subsequent stressors are adequately handled by the systems.
Injury	Damage done to various tissues or various physiological systems as a result of physical stress.
Cardiorespiratory fitness	The capability of circulatory and respiratory systems ability to deliver fuel during sustained physical activity and to remove metabolic waste products.
Muscular strength	The amount of external force a muscle or a muscle group can exert.
Muscular endurance	The ability of a muscle or muscle groups to repetitively produce external force without undue fatigue.
Body composition	The measurement of the relative amounts of body fat, lean tissue (i.e., muscle), bone, and other vital organs.
Flexibility	The ability to move a joint about its full range of motion.

INTRODUCTION

In response to rapidly increasing rates of obesity, bariatric weight loss surgeries have increased worldwide, reaching approximately 341,000 procedures in 2011 [1]. Bariatric surgery is a major medical intervention with the primary goals of chronically reducing excess weight loss, decreasing incidence and severity of obesity related co-morbidities, and overall improvement in quality of life. Despite widespread evidence of bariatric surgery effectiveness on excess weight loss and resolution of co-morbidities, the effects of weight loss surgery on overall cardiorespiratory fitness and physical activity levels (two critical components of overall health) have yet to be defined.

Increased physical activity is associated with reduced incidences of chronic disease and all-cause mortality [2-4]. Physical activity generally improves overall physical fitness, including its underlying components, including cardiorespiratory, muscular, and metabolic fitness, though specific benefits will vary based on the type and amount of activities done.

While the main goal of weight loss surgery is the reduction of excess weight, improvements in other lifestyle choices (such as physical activity levels) are essential to overall improvements in quality of life [5]. Despite this, very little research is available regarding post-operative improvements in physical fitness or the various components that make up overall physical fitness [6]. A key remaining question is the identification of independent and interactive effects of surgery and weight loss on cardiorespiratory fitness? Another question is whether spontaneous physical activity increases following substantial weight loss. Further investigations regarding changes in physical fitness following surgery are needed for the appropriate exercise prescription for the post-operative populations.

Physical activity plays vital roles in long term excess weight loss and improvements in quality of life following surgery. In previous investigations, those considered to be morbidly obese cite reductions in mobility and physical activity, as a negative impact of their excess weight [7]. This reduced PA can compound the obese state by further reducing energy expenditure. Increased physical activity can positively impact outcomes following weight loss surgery by elevating energy balance both acutely (i.e., during physical activity) and chronically (i.e., elevated resting metabolic rate, maintenance of lean body mass, etc.). However, investigations into the ability of weight loss surgeries to result in improvements in physical activity levels are scarce and inconclusive. Additionally, investigations into optimal strategies for structured/prescribed physical activity recommendations in the weight loss surgery population are lacking.

The purpose of this chapter is to first provide a short primer on fitness and physical activity, followed by a summarization of the literature to date regarding changes in cardiorespiratory fitness and physical activity following bariatric surgery. We will also highlight relationships between enhanced physical activity and fitness and reductions in health risks and obesity related co-morbidities. Finally, we will identify specific areas that warrant further investigation to better understand the relationships between weight loss surgery and improvements in overall health.

EXCESS WEIGHT LOSS EFFICACY FOLLOWING BARIATRIC SURGERY

Most recent estimates indicate that approximately 341,000 metabolic/bariatric surgical procedures occurred worldwide in 2011, of which the Roux-ex-Y gastric bypass (RYGB) accounted for 47%, sleeve gastrectomy (SG) 28%, adjustable gastric banding (AGB) 18%, and biliopancreatic diversion/duodenal switch (BPD/DS) 2.2% of total procedures [1]. These values are estimated from voluntary survey participation of over 50 countries/regions represented in the International Federation for Surgery of Obesity and Metabolic Disorders (IFSO) and may under-represent precise totals.

The most recognizable goal of weight loss surgery is to induce chronic reductions in excess weight, defined as the difference between preoperative weight and the ideal weight and often represented as a percentage (% excess weight loss = (weight lost/ preoperative excess weight)*100). The most recent meta-analysis of available data (1990 – 2004) indicates that patients lost an average of 61.2% of excess weight following surgery, regardless of the type of procedure performed [8]. Resolution of obesity related comorbidities in patients following surgery were as follows: 76.8% diabetes; 61.7% hypertension; 85.7% sleep apnea

and; hyperlipidemia improved in 70% of patients, regardless of procedure type [8]. There is significant variance in these outcomes based on procedure. We refer readers to Buchwald et al. (2004) for a more complete analysis of the successes of individual procedure types. It is important to point out that most (if not all) of these co-morbidities are also significantly affected by physical activity, meaning that resolution following surgery is affected both by surgery and each patient's physical activity pattern.

While it is has widely been shown that bariatric weight loss surgery is successful in acutely reducing excess weight, a growing concern regarding long-term (> 5 yrs.) excess weight reduction and maintenance exists, as well as interest in long-term health improvements [9-11]. A key debate in this area is whether co-morbidity resolution is weight-loss dependent or independent, and to what extent resolution is driven by weight loss itself. As long-term weight loss is augmented by adopting positive lifestyle strategies following surgery, research in fitness and PA changes post-surgery are essential to the success of bariatric surgery programs.

PHYSICAL ACTIVITY, EXERCISE, AND PHYSICAL FITNESS

Before moving on to review the literature on fitness and PA changes following surgery, we feel it is beneficial to provide a short primer on exercise physiology for the current reader. Physical activity and physical fitness have been defined and discussed in detail previously, but here we seek to briefly discuss and summarize these key concepts [12, 13].

Physical fitness is defined as "the ability to carry out daily tasks with vigor and alertness, without undue fatigue and with ample energy to enjoy leisure-time pursuits and to meet unforeseen emergencies" [12]. Evidence overwhelmingly supports a positive relationship between physical fitness levels and health-related risks factors [3]. *Physical activity* is defined as bodily movements produced by skeletal muscle that results in an increase in energy expenditure [12]. Physical activity encompasses many day-to-day activities (such as walking or cooking), as well as participation in planned events such as recreational sports. *Exercise* is a specific form of physical activity that is structured with planned sequences of repetitive body movements with the goal of maintenance or improvements in physical fitness [14].

Physically-active lifestyles delay all-cause mortality, as well as reduce the risk of developing Type 2 diabetes mellitus, coronary heart disease, and multiple forms of cancer [4]. Evidence largely supports a dose-response relationship between the amount of physical activity and health-related outcomes [4, 15], though data regarding the quantities of physical activity required for such benefits is not clear and is likely specific to each outcome. Most large epidemiological studies have found that a minimum of approximately 150 $min \cdot wk^{-1}$ (~1000 $kilocalories \cdot wk^{-1}$) is sufficient for health-related benefits [3]. However, few studies have addressed this PA level cutoff, and other lifestyle interventions, in severely obese populations [16].

Physical fitness cannot be described as a singular phenotype, but instead can be divided into five health-related components that can be individually evaluated [3, 17]. Below we discuss the five health-related components of physical fitness, describe how they are clinically evaluated, and note the impact of a physically active lifestyle on each component. For the purposes of this chapter, we will focus most heavily on cardiorespiratory fitness.

Principals of Training and Adaptation

Before discussing the health-related components of physical fitness, it is important to note the basic principles underlying how physical activity and exercise improve physical fitness. The general adaptation syndrome, developed by Dr. Hans Selye, describes three stages of a stress response: alarm and reaction, development of resistance, and finally exhaustion [18]. This model is easily applied to physical activity and exercise to describe how they promote health improvement:

1. **Overload** (alarm and reaction) – physical activity and exercise that an individual is unaccustomed to presents a positive stressor to various physiological systems.
2. **Adaptation** (resistance development) – continual overload applied to a system results in adaptations (i.e., molecular, structural, and mechanical) so that subsequent stressors are adequately handled by the system.
3. **Injury** (exhaustion) – if the overload of the applied stressors from physical activity and exercise is too great or the appropriate adaptations have not occurred, then injuries such as muscle strains, ligament tears, and bone fracturing may result.

Providing adequate overload (without going so far as to evoke a significant injury response) to physiological systems is essential to promotion of positive beneficial adaptations of these systems. Physical activity and exercise have the benefit of being quantifiable and easily adjusted so that the appropriate stressor is achieved and risk of injury reduced. For instance, the intensity of an exercise is easily changed by adjusting the pace (i.e., intensity) at which one walks or runs, while in resistance training the amount of resistance used can be increased or decreased. Another important variable in determining overload is the amount (i.e., dose) of any given physical activity or exercise that is performed. This is easily change by altering the amount of time spent doing any particular endurance exercise or by decreasing the amount of repetitions during resistance training. Lastly, the frequency at which one participates in any form of physical activity is important to determining the amount of overload that is applied.

A final important principle for physical activity and exercise is specificity. The principle of specificity states that all adaptations will be specific to the applied stressor. Thus, it is important that any exercise or physical activity be planned in accordance with the outcome goal. For instance, if increased muscular strength is desired, resistance-type exercise as opposed to endurance training is indicated. Later in this chapter, we will discuss the recommended amounts, intensities, and frequency of exercise and physical activity to promote health and well-being for specific health-related components following intervention such as surgery.

Cardiorespiratory Fitness

Cardiorespiratory fitness is defined as the capability of circulatory and respiratory systems ability to deliver energy during sustained physical activity and to remove metabolic waste products [12]. Alternatively, it may also be defined as the ability to sustain moderate-to-high intensity exercise for prolonged periods of time [14]. Traditionally, maximal

cardiorespiratory fitness has been determined by a maximal progressive incremental exercise test performed on a cycle ergometer or treadmill, in which the maximal rate of oxygen consumption (VO_{2max}; ml $O_2 \cdot kg^{-1}$ body mass $\cdot$ min^{-1}) is measured by indirect calorimetry. It may also be predicted by the utilization of a submaximal exercise test from which the results are extrapolated to estimate maximal ability [14] via equation.

Regular moderate-vigorous physical activity and exercise result in increased cardiorespiratory fitness [3]. Current recommendations of the American College of Sports Medicine (ACSM), American Heart Association (AHA), and the *2008 Physical Activity Guidelines for Americans* prescribe at least 30 $min \cdot d^{-1}$ of moderate intensity exercise on at least 5 $d \cdot wk^{-1}$ [15, 19, 20]. Research also indicates that more vigorous physical activity requires less time and results in similar, and potentially greater, cardiorespiratory benefits [3], though this relationship will be specific to each element underlying cardiorespiratory fitness.

Routine participation in cardiorespiratory exercise (also commonly referred to as aerobic or endurance exercise training) results in various physiological adaptations in the heart, vasculature, and skeletal muscle that promote increases in cardiorespiratory fitness. One major structural change that occurs during training is an increase in the volume of the left ventricle. This adaptation reduces the energetic costs of the heart by increasing stroke volume, reducing resting heart rate, and reducing submaximal exercise heart rate.

Skeletal muscle also undergoes significant adaptations that promote an increase in cardiorespiratory fitness. First, an increase in vascularization of the skeletal muscle occurs as more capillaries form around individual fibers. This increase in capillarity results in a greater perfusion of the skeletal muscle, especially during exercise, increasing oxygen delivery to and extraction by the fibers. Skeletal muscle also undergoes various metabolic adaptations, including increase in mitochondrial content of the individual fibers, as well as increases in various key enzymes important for the uptake and oxidation of glucose and triglycerides.

Collectively, these adaptations are essential to the favorable changes that occur in various cardiometabolic risk factors that are associated with physical activity and exercise. Improvements in blood lipid profiles, reductions in insulin resistance, and reductions in systemic markers of inflammation have routinely been found as a result of regular physical activity, independent of weight loss [3].

Muscular Strength and Endurance

Muscular strength and muscle endurance have been combined to describe muscular fitness [13]. *Muscular strength* is related to the amount of external force a muscle or a muscle group can exert. Standard measurement of muscular strength requires the use of dynamometers or tensiometers to measure force produced during an isometric (non-shortening) contraction. Other tests, such as a 1-repition maximum (1-RM) are more commonly used to determine this value, and measure dynamic, rather than static, strength. The 1-RM is defined as "the greatest resistance that can be moved through a full range of motion in a controlled manner" [14]. Muscular strength should always be measured in the muscle group of interest to a particular task. *Muscular endurance* is defined as the ability of a muscle or muscle groups to repetitively produce external force without undue fatigue. The standard of measure is through use of isokinetic dynamometer, but is more often determined

through tests such as sit-ups, sit-and-stand, push-ups, and pull-ups. Dynamic tests using free weights may also be used to determined absolute muscular endurance (total number of repetitions at a given resistance) or the relative muscular endurance (total number of repetitions at a resistance equal to percentage of 1-RM).

Resistance training promotes skeletal muscle hypertrophy and increased skeletal muscle fiber size through an increase in protein synthesis. Resultant increases in muscle fiber size and fiber density result in an increased muscular strength and muscular endurance. This also can result in increased lean body mass and a greater percentage of lean body mass to overall mass. Regular resistance training can also result in increased neural motor unit firing rates, recruitment of higher threshold motor units, and more synchronous motor unit firing [21]. In fact, these neural adaptations are largely responsible for early increases in muscular strength and endurance, as individuals adapt to the complex movements of resistance training.

Because adaptation is specific to the applied exercise stressor, strategies to promote muscular strength and muscular endurance are distinct. For promoting increases in muscular endurance the American College of Sports Medicine (ACSM) recommends a minimum of 10-15 repetitions for each major muscle group 2-3 days per week ($d \cdot wk^{-1}$) [17]. For increases in muscular strength, it is recommended that a minimum of 1-3 sets consisting of 8-12 repetitions at 70-85% of 1-RM be performed 2-3 $d \cdot wk^{-1}$[17]. It is important to progressively increase the resistance so that a continual overload is applied to the muscle as adaptations occur. Resistance training can be completed through the use of specialized machinery, which assists movements, or free weights, and the choice of equipment should be based on experience level of the individual.

Body Composition

Another component of fitness is *body composition;* defined as the measurement of the relative amounts of body fat, lean tissue (i.e., muscle), bone, and other vital organs. These values are all obtainable through dual-energy X-ray absorptiometry (DEXA) or other scanning technologies. However, other more cost- and time-effective measurements (such as multiple site skinfolds and body mass index) are more commonly used as indices of body composition. Skinfolds assume that approximately 1/3 of all body fat is located subcutaneously, but this is largely influenced by race, ethnicity, and age [22]. To account for these variables, specific regression equations can be used to determine the percentage of body fat from skinfolds [23], though anthropomorphic equations always contain some amount of error. Body mass index (BMI) is a commonly used calculation to assess body mass (in kg) relative to height (in meters) of an individual. Naturally, the calculated BMI values cannot distinguish between lean body mass and fat mass, but a BMI ≥ 30 $kg \cdot m^2$ is associated with an increase in health related risk factors [24].

Flexibility

Flexibility is also a component of overall fitness and is defined as the ability to move a joint about its full range of motion [12, 14]. Flexibility can be separated into two specific

types: static and dynamic. Static flexibility is ability to reach a specific point in the range of motion of a joint whereas dynamic flexibility is the ability to move quickly throughout the entire range of motion without resistance [21]. Good flexibility is an important to improving quality of life and mitigating join pain and injuries, especially in aging populations.

Standard laboratory methods are used to determine flexibility, measured in degrees, through the use of goniometers. Less accurate methodology using tape-measures (i.e., sit and reach tests) are often used to evaluate flexibility at the hip clinically [14]. Just as muscular strength is specific to muscle groups, flexibility is joint specific and can be influenced by joint type and muscle "tightness" [14].

Here we have introduced and briefly discussed physical fitness, the underlying health-related components of physical fitness, and some standard measurement procedures. For more thorough discussion regarding these topics, we suggest you consult the appropriate citations or exercise science textbooks. For the purposes of this chapter, we will now focus mainly on the effects bariatric weight loss surgery's effect on changes in cardiorespiratory outcomes.

BARIATRIC WEIGHT LOSS SURGERY, CARDIORESPIRATORY FITNESS, AND PHYSICAL ACTIVITY

Low cardiorespiratory fitness results in increased incidences of cardiovascular disease, all-cause mortality, and an increased relative risk of death similar to those associated with diabetes and tobacco use [2, 9, 25-31]. Furthermore, post-surgery complications and 30-day readmission rates were significantly related to cardiorespiratory fitness levels prior to surgery [32]. However, very few studies have analyzed changes in cardiorespiratory fitness following surgery. Also concerning is evidence that a significant portion (~30%) of weight loss may be due to loss of fat free mass [33, 34]. In the following section, we will discuss the limited available evidence regarding changes in cardiorespiratory fitness, changes in physical activity fitness, and the relationship between long-term weight loss and physical activity following weight loss surgery.

Does Weight Loss Surgery Result Enhance Cardiorespiratory Fitness?

de Souza et al. (2010) showed that VO_{2max} was significantly increased (22.1 ± 2.1 vs. 15.8 ± 2.1 ml· kg^{-1}·min^{-1}) 12 months following RYGBP. Reductions in BMI in this cohort were also significantly correlated to exercise capacity [6]. To date, this is the only investigation to study bariatric surgery and changes in cardiorespiratory fitness through indirect calorimetry. Leite et al. (2013) found similar results using the six-minute walk (6MWT), an indirect surrogate for cardiorespiratory fitness in which individuals walk for 6 minutes and try to cover as much distance as possible. Sixty-five individuals who had undergone surgery in the previous 24 months and had a current BMI < 30 kg/m^2 covered similar distances in the 6MWT to that of non-obese controls and significantly more than individuals who had undergone surgery but were still considered obese with a BMI > 30 kg/m^2 [35]. Similar results were found by Varga et al. (2013), in which reduction in BMI correlated with significantly increased 6MWT three months following surgery [36].

Interestingly, two studies by the same group have studied the effect of weight loss surgery on functional measures of pulmonary function. Only one study found an increased lung volume (3.5%), increased expiratory reserve volume (88.9%), and decreased inspiratory reserve volume (-20.4%) 12 months following RYGBP [35, 37]. More controlled analyses will be required, but these data indicate that bariatric weight loss surgery may result in significant positive cardiorespiratory benefits.

Does Weight Loss Surgery Result in Spontaneous Increases in Physical Activity?

Reduction in weight following surgery presents the opportunity for individuals to increase physical activity levels, as physical limitations are eased. Available evidence indicates that patients routinely report increased levels of physical activity through the use of various lifestyle questionnaires (Table 1). However, self-reporting physical activity levels using questionnaires was recently brought into question by Bond et al. (2010). Their investigation found that patients significantly over-estimated the amount of time spent doing moderate-to-vigorous physical activity (MVPA; defined as a metabolic equivalent (MET) ≥ 3) and compliance (55% vs. 5%) with the recommended 150 $min \cdot wk^{-1}$ of physical activity when reported levels were compared to the use of accelerometers [38], which provide objective measures of PA.

Evidence from Structured Exercise Interventions Following Weight Loss Surgery

Even though these findings regarding over reporting are concerning, reported increases in post-operative physical activity levels have been associated with enhanced outcomes. A recent meta-analysis of 17 observational studies by Egberts et al. (2011) found that increased post-operative physical activity resulted in an average of 3.62 kg greater weight loss than those who had minimal physical activity. Of these 17 survey studies, 15 showed a positive relationship between physical activity levels and weight loss [52]. Mundi et al. (2013) and Josbeno et al. (2011) both found MVPA levels to be greater in those who lost ≥ 50% excess weight from pre-surgery baseline. Other studies have found that self-reported levels of physical activity have been associated with successful weight loss [40, 43-45, 47, 53, 54], BMI reductions [40, 41, 50], decreased fat mass [50], and increased lean body mass [50]. Even in patients who have regained a significant amount of weight, physical activity has been associated with lower long-term weight regain [10]. It is likely that altered physical activity levels, along with other lifestyle modifications such as nutritional and psychosocial, play a crucial role in maximizing the long-term success of post-operative excess weight loss. Future objective studies that explore whether bariatric weight loss surgery leads to spontaneous increases in regular physical activity will be crucial to understanding the role of physical activity in successful long-term weight loss.

Table 1. Effect of physical activity on bariatric weight-loss surgery outcomes

Study		Surgery Type	Prescribed or Spontaneous	Physical Activity Reporting	Follow-up Duration (mo)	% EWL	P-value	ΔBMI (kg/m^2)	P-value
Boan et al. 2004	[39]	RYGBP	Spontaneous	BQA	6	26.7[¥]	<0.0001	-14.0	<0.0001
Bond et al. 2004	[40]	GBP Control	Spontaneous	Self-report Self-	24	68.2 ± 17.4	<0.0081[∞]	-31.5	0.0011[∞]
			Sedentary	report	24	63.9 ± 19.5		-33.0	
Silver et al. 2006	[41]	RYGBP	Spontaneous	BRFSS	24.2 ± 7.9	55.8 ± 15.2[€]	N/A	N/A	N/A
Mathus-Vliegen	[42]	LAGB &	Spontaneous	HRQL	12	42.1 ± 17.9	N/A	-11.5	<0.001
and de Wit 2007		OAGB			30	42.2 ± 22.8	N/A	-11.6	<0.001
					60	41.6 ± 26.2	N/A	-11.4	<0.001
Welch et al. 2008[#]	[43]	RYGBP	Spontaneous	BSSQ	<6	35.9 ± 13.7	N/A	-17.5[§]	N/A
					6 to 12	50.8 ± 15.0			N/A
					12 to 18	66.9 ± 41.1	N/A		N/A
					>18	65.7 ± 16.6	N/A		N/A
Colles et al. 2008[#]	[44]	LAGB	Spontaneous	BPAQ	4	32.2 ± 13.0	NS	-6.0	<0.001
					12	50.0 ± 20.7	<0.001	-9.3	<0.001
Bond et al. 2009[#]	[45]	RYGBP	Spontaneous[£]	IPAG-short	12	71.5 ± 15.5	0.049	-18.9 ± 4.6	0.013
						69.8 ± 14.1		-18.3 ± 4.6	
						63.1 ± 16.6		-16.9 ± 4.2	
Livhits et al. 2010[#]	[46]	RYGBP	Spontaneous	IPAG-short	40.1 ± 15.3	52.6 ± 22.4	<0.01	N/A	N/A
Forbush et al.	[47]	RYGBP	Spontaneous	AAF	12	82.7 ± 27.3	<0.01	-17.6[§]	N/A
2011[#]					24	82.7 ± 23.2			
					36	84.0 ± 24.0			
					48	77.8 ± 26.8			
					60	76.0 ± 20.8			
Shah et al. 2011[#]	[48]	RYGBP	Prescribed	Supervision	1.5	2.1[€]		N/A	N/A
		and GB		and diary	3	4.2[€]	<0.01	N/A	N/A
		Control	N/A	N/A	1.5	1.8[€]		N/A	N/A
					3	4.7[€]	<0.01	N/A	N/A

Study		Surgery Type	Prescribed or Spontaneous	Physical Activity Reporting	Follow-up Duration (mo)	% EWL	P-value	ΔBMI (kg/m^2)	P-value
Josbeno et al. 2011[#]	[49]	RYGBP	Spontaneous	SWPro	24	72.8 ± 10.8	0.02	-19.8	N/A
					36	53.0 ± 17.6		-12.7	N/A
					48	60.1 ± 21.5		-14.4	N/A
					60	58.0 ± 28.4		-16.9	N/A
Freire et al. 2012	[10]	RYGBP	Spontaneous	Self-report	<24	59.1 ± 20.3[§]	NS	-17.5	N/A
					25 to 60			-22.3	N/A
					>61			-17.1	N/A
Vatier et al. 2012	[50]	RYGBP	Spontaneous	MAQ	6	25.9 ± 19.7[€]	<0.0001	-9.1	<0.0001
					12	37.1 ± 20.5[€]	<0.0001	-13.0	<0.0001
Mundi et al. 2013[#]	[51]	Non-lap band	Spontaneous	IPAG-short	12	33.2 ± 9.4	<0.001	-14.3	0.001
						67.1 ± 8.8	<0.001	-15.2	

RYGBP; Roux-en-Y gastric bypass. GBP; Gastric bypass. LAGB; Laparoscopic adjustable gastric banding. OAGB; Open adjustable gastric banding. GB; Gastric banding. BQA; Baseline Questionnaire of Activity. BRFSS; Behavioral Risk Factor Surveillance System Questionnaire. HRQL; Health Related Quality of Life Questionnaire. BSSQ; Bariatric Surgery Self-Management Questionnaire. SF-36; Medical Outcomes Trust Short Form-36. BPAQ; Baecke Physical Activity Questionnaire. IPAG-short; International Physical Activity Questionnaire short form. AAF, Arizona Activity Frequency Questionnaire. MAQ, Modifiable Activity Questionnaire. SWPro; BodyMedia SenseWear® Pro armband. P values represent significance for pre to postoperative values unless otherwise noted. [∞] P value represents significance between physical activity group and sedentary group. [#] Study identified physical activity as a significant determinant of weight loss. [£] Study separated patients into inactive/active, active/active, inactive/inactive groups based on pre/post-surgery physical activity levels. [¥] Mean % total weight loss. [€] Mean of total absolute weight loss (kg). [§] Mean all time points combined.

While the previous section highlighted a lack of consensus about spontaneous PA changes with surgery, there is also a lack of consensus regarding routine structured exercise. Routine structured PA is largely considered to be beneficial to overall health outcomes for the general population, though very few studies have examined appropriate strategies for severely obese populations and post-surgical patients [16, 55-57]. Thus, investigations regarding prescribed exercise following bariatric weight loss surgery are scarce.

Shah et al. (2011) randomized individuals at least three months post-surgery into a high volume exercise program (HVEP) or control group. The HVEP consisted of 12 weeks of aerobic exercise at 60-70% of VO_{2max} with a weekly goal of ≥2,000 kcal/week expenditure. Despite significant increased total energy expenditure ($kcal \cdot kg^{-1} \cdot day^{-1}$), HVEP did not show significantly altered outcomes for cardiorespiratory fitness, changes in LBM, reductions in fat mass, or reductions in BMI as compared to the non-exercising controls [48]. Interestingly, individuals in the HVEP did have a beneficial change in post-prandial blood glucose response to an oral glucose tolerance test [48]. Castello et al. (2011) also studied the effects of prescribed aerobic training at four months post-surgery. Individuals exercised for 12 weeks at 50-70% of peak heart rate 3 $d \cdot wk^{-1}$ for 1 $h \cdot day^{-1}$ [58]. The aerobic training group saw similar reductions in weight loss and reductions in BMI but significant increase in the 6MWT as compared to the non-exercising control group [58]. A combination of resistance training (2 sets, 15 reps, 60-75% 1-RM) and aerobic training (30 $min \cdot d^{-1}$, 60-75% heart rate reserve; HHR: defined as difference between resting heart rate and peak heart rate) was completed 3 $d \cdot wk^{-1}$ for 12 weeks in surgery patients in the study by Stegan et al. (2011). Both the training group and non-exercising controls saw similar improvements in body weight, BMI, and aerobic capacity [59]. However, the combination training prevented reductions in muscle strength of major muscle groups as compared to non-exercising controls [59].

Together these studies do not show significant enhancements of surgical outcomes (excess weight loss and BMI reductions) with the addition of a post-operative exercise regimen. This may be due to the large reductions in weight already associated with weight loss surgery, which may confound each study's ability to identify significant differences. Furthermore, these studies follow these individuals for only 12 weeks, in which the time frame may not be long enough to identify the long-term benefits of exercise interventions in these populations. However, enhancements in glucose tolerance [48] and maintenance of muscle mass [59] was seen within these time frames, indicating positive health benefits.

OPTIMIZATION OF EXERCISE STRATEGIES FOLLOWING SURGERY

Until exercise specialists have more data concerning the effects of weight loss surgery on fitness and physical activity patterns, it is difficult to effectively prescribe exercise plans during the post-surgical period, either acutely or over the long-term. In general, addition of overall PA via increased aerobic exercise should facilitate fat loss while maintaining lean mass. Sufficient doses of aerobic exercise should also improve cardiorespiratory and cardiometabolic fitness. Accentuation of this prescription with some resistance training may ameliorate the losses in muscle mass seen in some post-bariatric surgery patients.

Current American College of Sports Medicine recommendations suggest 30 $min \cdot d^{-1}$ on 5 $d \cdot wk^{-1}$ at a moderate to vigorous (60-75% maximal capacity) for enhancements of

cardiorespiratory fitness [3, 14]. Maximal capacity may be determined in a variety of ways such as the VO_{2max}, maximal predicted heart rate (HR_{max}; HR_{max} = 220 – Age), or the heart rate reserve (HRR; HRR= Maximal heart rate – resting heart rate). However, evidence suggests that 150 min·wk^{-1} of moderate to vigorous physical activity is effective at preventing weight gain, while additional amounts of time (~250 min·wk^{-1}) can result in modest weight loss [60]. Exercise amounts greater 250 min· wk^{-1} may be required for prevention of weight regain in the previously overweight [60]. Until more controlled randomized trails regarding various exercise interventions exploring the amounts, durations, intensities, and modalities of exercise strategies are available, further recommendations for cannot be prescribed.

Until more precise studies are done in severely obese populations, a general recommendation would be the addition of 1-3 sets of resistance exercise to the aerobic exercise described above. This would consist of 8-12 repetitions at 70-85% of 1-RM performed 2-3 d·wk^{-1} in all major muscle groups [17]. The goal of these exercises should be prevention of decrements in muscle strength and muscle mass that are prevalent following weight loss surgery.

CONSIDERATIONS FOR FUTURE INVESTIGATIONS

We have highlighted two general areas in which further studies are needed using well-controlled designs and objective measures. The first of these is the assessment of overall physical fitness. More studies are needed using techniques such as graded exercise testing to identify the individual and interactive effects of surgery and weight loss on various aspects of overall fitness such as cardiorespiratory fitness. In addition, there is considerable interest in the loss of lean body mass in certain patients following weight loss surgery, such that body composition longitudinal assessments are warranted, rather than relying on BMI (which does not speak to composition) to indicate morphologic changes. Fitness changes in patients are likely also modified by a litany of factors, including gender, age, and race, as well as baseline levels for fitness and history of physical activities. The second area we highlighted as needing more study is changes in physical activity levels after surgery-induced weight loss. While we reviewed a number of studies in the literature concerning physical activity in post-surgical patients, there is a severe lack of both objectively-measured general physical activity levels and purposeful prescribed exercise intervention studies to see how exercise affects tissues in the time period after weight loss surgery. Together, these data can be integrated to provide more precise exercise prescriptions post-surgery to facilitate health improvements.

REFERENCES

[1] Buchwald H, Oien DM. Metabolic/bariatric surgery worldwide 2011. *Obesity Surgery.* 2013;23(4):427-36.

[2] Blair SN, Kohl HW, 3rd, Barlow CE, Paffenbarger RS, Jr., Gibbons LW, Macera CA. Changes in physical fitness and all-cause mortality. A prospective study of healthy and unhealthy men. *JAMA.* 1995;273(14):1093-8.

[3] American College of Sports Medicine Position Stand. Quantity and quality of exercise for developing and maintaining cardiorespiratory, musculoskeletal, and neuromotor fitness in apparently healthy adults: guidance for prescribing exercise. *Medicine and science in sports and exercise.* 2011;43(7):1334-59.

[4] Physical Activity Guidelines Advisory Committee report, 2008. To the Secretary of Health and Human Services. Part A: executive summary. *Nutrition reviews.* 2009;67(2):114-20.

[5] Kolotkin RL, LaMonte MJ, Litwin S, Crosby RD, Gress RE, Yanowitz FG, et al. Cardiorespiratory fitness and health-related quality of life in bariatric surgery patients. *Obesity surgery.* 2011;21(4):457-64.

[6] de Souza SA, Faintuch J, Sant'anna AF. Effect of weight loss on aerobic capacity in patients with severe obesity before and after bariatric surgery. *Obesity Surgery.* 2010;20(7):871-5.

[7] Kolotkin RL, Head S, Hamilton M, Tse CK. Assessing Impact of Weight on Quality of Life. *Obesity Research.* 1995;3(1):49-56.

[8] Buchwald H, Avidor Y, Braunwald E, Jensen MD, Pories W, Fahrbach K, et al. Bariatric surgery: a systematic review and meta-analysis. *JAMA.* 2004;292(14):1724-37.

[9] Magro DO, Geloneze B, Delfini R, Pareja BC, Callejas F, Pareja JC. Long-term weight regain after gastric bypass: a 5-year prospective study. *Obesity surgery.* 2008;18(6):648-51.

[10] reire RH, Borges MC, Alvarez-Leite JI, Toulson Davisson Correia MI. Food quality, physical activity, and nutritional follow-up as determinant of weight regain after Roux-en-Y gastric bypass. *Nutrition.* 2012;28(1):53-8.

[11] Faria SL, de Oliveira Kelly E, Lins RD, Faria OP. Nutritional management of weight regain after bariatric surgery. *Obesity surgery.* 2010;20(2):135-9.

[12] Caspersen CJ, Powell KE, Christenson GM. Physical activity, exercise, and physical fitness: definitions and distinctions for health-related research. *Public health reports.* 1985;100(2):126-31.

[13] Corbin CB, Pangrazi, R.P., Franks, D.B.,. Definitions: Health, Fitness, and Physical Activity. *Research Digest.* 2000:11.

[14] Pescatello LS, American College of Sports Medicine. *ACSM's guidelines for exercise testing and prescription.* 9th ed. Philadelphia: Wolters Kluwer/Lippincott Williams & Wilkins Health*;* 2014. xxiv, 456 p. p.

[15] Haskell WL, Lee IM, Pate RR, Powell KE, Blair SN, Franklin BA, et al. Physical activity and public health: updated recommendation for adults from the American College of Sports Medicine and the American Heart Association. *Medicine and Science in Sports and Exercise.* 2007;39(8):1423-34.

[16] Goodpaster BH, Delany JP, Otto AD, Kuller L, Vockley J, South-Paul JE, et al. Effects of diet and physical activity interventions on weight loss and cardiometabolic risk factors in severely obese adults: a randomized trial. *JAMA.* 2010;304(16):1795-802.

[17] American College of Sports M. American College of Sports Medicine Position Stand. Progression models in resistance training for healthy adults. *Medicine and Science in Sports and Exercise.* 2009;41(3):687-708.

[18] Selye H. Stress and the general adaptation syndrome. *British Medical Journal.* 1950;1(4667):1383-92.

[19] Nelson ME, Rejeski WJ, Blair SN, Duncan PW, Judge JO, King AC, et al. Physical activity and public health in older adults: recommendation from the American College of Sports Medicine and the American Heart Association. *Circulation.* 2007;116(9):1094-105.

[20] United States. Department of Health and Human Services. *2008 physical activity guidelines for Americans: be active, healthy, and happy!* Washington, DC: U.S. Dept. of Health and Human Services; 2008. ix, 61 p. p.

[21] Brooks GA, Fahey TD, Baldwin KM. *Exercise physiology: human bioenergetics and its applications.* 4th ed. Boston: McGraw-Hill; 2005. xxi, 876, 7, 22 p. p.

[22] Roche AF, Heymsfield S, Lohman TG. *Human body composition.* Champaign, IL: Human Kinetics; 1996. x, 366 p. p.

[23] Pollack ML, Schmidt DH, Jackson AS. Measurement of cardio-respiratory fitness and body composition in the clinical setting. *Comprehensive Therapy.* 1980;6(9):12-27.

[24] Rimm EB, Stampfer MJ, Giovannucci E, Ascherio A, Spiegelman D, Colditz GA, et al. Body size and fat distribution as predictors of coronary heart disease among middle-aged and older US men. *American Journal of Epidemiology.* 1995;141(12):1117-27.

[25] Alexander JK. Obesity and Cardiac Performance. *The American Journal of Cardiology.* 1964;14:860-5.

[26] Barlow CE, Kohl HW, 3rd, Gibbons LW, Blair SN. Physical fitness, mortality and obesity. *International journal of obesity and related metabolic disorders: Journal of the International Association for the Study of Obesity.* 1995;19 Suppl 4:S41-4.

[27] Ekelund LG, Haskell WL, Johnson JL, Whaley FS, Criqui MH, Sheps DS. Physical fitness as a predictor of cardiovascular mortality in asymptomatic North American men. The Lipid Research Clinics Mortality Follow-up Study. *The New England Journal of Medicine.* 1988;319(21):1379-84.

[28] Laukkanen JA, Lakka TA, Rauramaa R, Kuhanen R, Venalainen JM, Salonen R, et al. Cardiovascular fitness as a predictor of mortality in men. *Archives of Internal Medicine.* 2001;161(6):825-31.

[29] Salvadori A, Fanari P, Fontana M, Buontempi L, Saezza A, Baudo S, et al. Oxygen uptake and cardiac performance in obese and normal subjects during exercise. *Respiratio.* 1999;66(1):25-33.

[30] Sandvik L, Erikssen J, Thaulow E, Erikssen G, Mundal R, Rodahl K. Physical fitness as a predictor of mortality among healthy, middle-aged Norwegian men. *The New England Journal of Medicine.* 1993;328(8):533-7.

[31] Wei M, Kampert JB, Barlow CE, Nichaman MZ, Gibbons LW, Paffenbarger RS, Jr., et al. Relationship between low cardiorespiratory fitness and mortality in normal-weight, overweight, and obese men. *JAMA.* 1999;282(16):1547-53.

[32] McCullough PA, Gallagher MJ, Dejong AT, Sandberg KR, Trivax JE, Alexander D, et al. Cardiorespiratory fitness and short-term complications after bariatric surgery. *Chest.* 2006;130(2):517-25.

[33] Chaston TB, Dixon JB, O'Brien PE. Changes in fat-free mass during significant weight loss: a systematic review. *International Journal of Obesity.* 2007;31(5):743-50.

[34] Tamboli RA, Hossain HA, Marks PA, Eckhauser AW, Rathmacher JA, Phillips SE, et al. Body composition and energy metabolism following Roux-en-Y gastric bypass surgery. *Obesity.* 2010;18(9):1718-24.

[35] Leite FS, Barbalho-Moulim MC, Soares KK, Dias F, D., Peixoto-Souza FS, Costa D. Evaluation of functional capacity, body composition and pulmonary function after bariatric surgery. *Health.* 2013;5(8A3):7.

[36] Vargas CB, Picolli F, Dani C, Padoin AV, Mottin CC. Functioning of obese individuals in pre- and postoperative periods of bariatric surgery. *Obesity Surgery.* 2013;23 (10):1590-5.

[37] Barbalho-Moulim MC, Miguel GP, Forti EM, Campos Fdo A, Peixoto-Souza FS, Costa D. Pulmonary Function after Weight Loss in Obese Women Undergoing Roux-en-Y Gastric Bypass: One-Year Followup. *ISRN Obesity.* 2013;2013:796454.

[38] Bond DS, Jakicic JM, Unick JL, Vithiananthan S, Pohl D, Roye GD, et al. Pre- to postoperative physical activity changes in bariatric surgery patients: self report vs. objective measures. *Obesity.* 2010;18(12):2395-7.

[39] Boan J, Kolotkin RL, Westman EC, McMahon RL, Grant JP. Binge eating, quality of life and physical activity improve after Roux-en-Y gastric bypass for morbid obesity. *Obesity Surgery.* 2004;14(3):341-8.

[40] Bond DS, Evans RK, Wolfe LG, Meador JG, Sugerman HJ, Kellum JM, et al. Impact of self-reported physical activity participation on proportion of excess weight loss and BMI among gastric bypass surgery patients. *The American Surgeon.* 2004;70(9):811-4.

[41] Silver HJ, Torquati A, Jensen GL, Richards WO. Weight, dietary and physical activity behaviors two years after gastric bypass. *Obesity Surgery.* 2006;16(7):859-64.

[42] Mathus-Vliegen EM, de Wit LT. Health-related quality of life after gastric banding. *The British Journal of Surgery.* 2007;94(4):457-65.

[43] Welch G, Wesolowski C, Piepul B, Kuhn J, Romanelli J, Garb J. Physical activity predicts weight loss following gastric bypass surgery: findings from a support group survey. *Obesity Surgery.* 2008;18(5):517-24.

[44] Colles SL, Dixon JB, O'Brien PE. Hunger control and regular physical activity facilitate weight loss after laparoscopic adjustable gastric banding. *Obesity Surgery.* 2008;18(7):833-40.

[45] Bond DS, Phelan S, Wolfe LG, Evans RK, Meador JG, Kellum JM, et al. Becoming physically active after bariatric surgery is associated with improved weight loss and health-related quality of life. *Obesity.* 2009;17(1):78-83.

[46] Livhits M, Mercado C, Yermilov I, Parikh JA, Dutson E, Mehran A, et al. Behavioral factors associated with successful weight loss after gastric bypass. *The American Surgeon.* 2010;76(10):1139-42.

[47] Forbush S, Nof L, Echternach J, Hill C, Rainey J. Influence of activity levels and energy intake on percent excess weight loss after Roux-en-Y gastric bypass. *Obesity Surgery.* 2011;21(11):1731-8.

[48] Shah M, Snell PG, Rao S, Adams-Huet B, Quittner C, Livingston EH, et al. High-volume exercise program in obese bariatric surgery patients: a randomized, controlled trial. *Obesity.* 2011;19(9):1826-34.

[49] Josbeno DA, Kalarchian M, Sparto PJ, Otto AD, Jakicic JM. Physical activity and physical function in individuals post-bariatric surgery. *Obesity Surgery.* 2011;21(8):1243-9.

[50] Vatier C, Henegar C, Ciangura C, Poitou-Bernert C, Bouillot JL, Basdevant A, et al. Dynamic relations between sedentary behavior, physical activity, and body composition after bariatric surgery. *Obesity Surgery.* 2012;22(8):1251-6.

[51] Mundi MS, Lorentz PA, Swain J, Grothe K, Collazo-Clavell M. Moderate physical activity as predictor of weight loss after bariatric surgery. *Obesity Surgery.* 2013;23(10):1645-9.

[52] Egberts K, Brown WA, Brennan L, O'Brien PE. Does exercise improve weight loss after bariatric surgery? A systematic review. *Obesity Surgery.* 2012;22(2):335-41.

[53] Evans RK, Bond DS, Wolfe LG, Meador JG, Herrick JE, Kellum JM, et al. Participation in 150 min/wk of moderate or higher intensity physical activity yields greater weight loss after gastric bypass surgery. *Surgery for Obesity and Related Diseases.* 2007;3(5):526-30.

[54] Chevallier JM, Paita M, Rodde-Dunet MH, Marty M, Nogues F, Slim K, et al. Predictive factors of outcome after gastric banding: a nationwide survey on the role of center activity and patients' behavior. *Annals of Surgery.* 2007;246(6):1034-9.

[55] Anderson JW, Brinkman VL, Hamilton CC. Weight loss and 2-y follow-up for 80 morbidly obese patients treated with intensive very-low-calorie diet and an education program. *The American Journal of Clinical Nutrition*. 1992;56(1 Suppl):244S-6S.

[56] Ryan DH, Johnson WD, Myers VH, Prather TL, McGlone MM, Rood J, et al. Nonsurgical weight loss for extreme obesity in primary care settings: results of the Louisiana Obese Subjects Study. *Archives of Internal Medicine.* 2010;170(2):146-54.

[57] Samaha FF, Iqbal N, Seshadri P, Chicano KL, Daily DA, McGrory J, et al. A low-carbohydrate as compared with a low-fat diet in severe obesity. *The New England Journal of Medicine.* 2003;348(21):2074-81.

[58] Castello V, Simoes RP, Bassi D, Catai AM, Arena R, Borghi-Silva A. Impact of aerobic exercise training on heart rate variability and functional capacity in obese women after gastric bypass surgery. *Obesity Surgery.* 2011;21(11):1739-49.

[59] Stegen S, Derave W, Calders P, Van Laethem C, Pattyn P. Physical fitness in morbidly obese patients: effect of gastric bypass surgery and exercise training. *Obesity surgery.* 2011;21(1):61-70.

[60] American College of Sports Medicine Position Stand. Appropriate physical activity intervention strategies for weight loss and prevention of weight regain for adults. *Medicine and Science In Sports and Exercise. 2*009;41(2):459-71.

In: Encyclopedia of Surgery (22 Volume Set)
Editors: Andreas Lehrer and Kristin Mueller
ISBN: 978-1-53618-329-0
© 2020 Nova Science Publishers, Inc.

Chapter 15

PREGNANCY AFTER BARIATRIC SURGERY

Catarina Policiano, Alexandre Valentim Lourenço, Luísa Pinto and Luís Mendes Graça
Department of Obstetrics and Gynecology, University Hospital of Santa Maria, Centro Hospitalar Lisboa Norte, Lisbon, Portugal

OBESITY EPIDEMIC AND ITS IMPACT ON PREGNANCY

Obesity rates and its serious comorbidities have been rising worldwide resulting in a significant loss of life expectancy [1, 2]. Women of reproductive age are generally healthy and metabolic disorders in this age group are uncommon. However they account for a large group of the obese population and pre-pregnancy Body Mass Index (BMI) has been strongly associated with an increased risk of diabetes, hypertension and dyslipidemia, not only during pregnancy but also in the following decades of life. Pre-pregnancy overweight and obesity are also independent risk factors for serious comorbid cardiovascular events (ischemic heart disease, cardiac heart failure) even in the absence of metabolic syndrome [3-5].

The Impact on Fertility

The excess of adipose tissue has been demonstrated to be associated with increased secretion of a wide variety of cytokines and hormone-like factors, such as leptine and acute-phase proteins [6, 7]. The proinflammatory state and the metabolic dysfunction may justify the higher rates of infertility in obese women, particularly in the case of polycystic ovary syndrome (PCOS). The pathophysiology of PCOS is unclear and this entity is commonly defined as oligo- or anovulation, hyperandrogenism, and polycystic ovaries. This condition affects 6-25% of reproductive-age women and at least half of the women with PCOS are obese, representing potential bariatric surgery patients [8].

There are various reports of the negative impact of obesity on the success of assisted-reproductive technology (ART) [9]. Hirshfeld-Cytron et al. described a case of a woman that had been submitted to a gastric bypass with the loss of approximately 79 Kg and who

presented for controlled ovarian hyperstimulation, which resulted in an empty follicle syndrome, resolved by changing the route of administration of human chorionic gonadotropin (hCG). The authors hypothesized that in the setting of dramatic weight loss after bariatric surgery, skin redundancy may limit the bioavailability of subcutaneous hCG. This limitation was overtaken by changing the route of administration to intramuscular [10]. Several publications have also discussed the role of weight loss in obese women with infertility, in particular the specific role in improving the rates of conception and live births [11]. Nonetheless, the heterogeneity of the samples and of the outcomes in the published studies resulted in no consensus on the effect of maternal weight on the outcomes of ART [12].

Obesity and Pregnancy

Obesity in pregnancy is defined as a pre-pregnancy BMI $\geq$ 30 Kg/m^2 [13]. BMI is an independent predictive risk factor of maternal-fetal adverse outcomes [14-16]. The recommended total weight gain for overweight (BMI 25-30 Kg/m^2) and obese women is 7.0-11.5 kg and 5.0-9.0 kg, respectively, based on the guidelines of the Institute of Medicine [17]. Extreme obesity (BMI $\geq$ 50 Kg/m^2) imparts a significant increase of obstetric complications such as hypertensive disorders of pregnancy and gestational diabetes, macrosomia, shoulder dystocia, perineal trauma at birth and higher rates of cesarean deliveries, compared to all-other obese and non-obese women. Furthermore, neonates from extremely obese women are more likely to have metabolic disturbances and to be admitted to the Neonatal Intensive Care Unit (NICU) [18-20].

Regarding the higher risk of diabetes, it is generally accepted that the underlying mechanism consists on an exaggerated insulin resistance that is characteristic both of the pregnant and of the obese woman [21].

Obese women are prone to develop metabolic syndrome with all its typical components such as hypertension. Hypertensive disorders including preeclampsia (association between hypertension and proteinuria during pregnancy or in the postpartum period) and eclampsia (preeclampsia with convulsions) are more frequent in the obese population. It is hypothesized that obesity in pregnant women predisposes to preeclampsia due to an up-regulated systemic inflammatory reaction and hyperlipidemia [22, 23].

Obesity: Difficulty of Ultrasound Screening and Risk of Malformations

Obesity in pregnancy poses difficulties in the ultrasonographic diagnosis of fetal anomalies even for experienced sonographers [24]. Images are more difficult to interpret because of abdominal adiposity. A recent report has found higher number of ultrasound evaluations in this population. Among obese women, 48% had five or more ultrasound scans compared to 25% in the nonobese group ($p < 0.05$) [25]. Despite the technical difficulties, literature points out an increased ultrasound detection of specific structural anomalies, such as neural tube defects, cardiovascular, face and limb anomalies, when comparing to average-weight women [26, 27]. Some recent studies in animal models have demonstrated that maternal obesity may not only be associated with lifelong deleterious metabolic effects on the developing child such as all the underlying comorbidities (diabetes, hypertension…space

removed) but may also imply future neurologic disorders. The explanation of the investigators relies on alterations on neuronal proliferation, maturation and migration in association with the abnormal hormonal and inflammatory environment characteristic of obesity [28, 29].

Maternal obesity has been associated with increased risk of developing asthma during childhood. Furthermore, children´s overweight is also an important predisposing factor and in both cases the mechanism that justifies the relationship between obesity and asthma seems to be an excess of inflammatory reaction [30].

Obese women have a higher incidence of dizygotic twin gestation when compared to average weight women. The possible explanation for this association relies on the elevated follicle-stimulating hormone levels [31].

A large study from Sweden including 1,599,551 deliveries, demonstrated that maternal overweight and obesity were associated with higher rates of spontaneous and medically indicated preterm deliveries, especially extremely preterm compared to normal weight women. [32]

Regarding the route of delivery, pre-pregnancy obesity imparts a higher risk of cesarean section. A systematic review on the risk for cesarean deliveries in obese nulliparous women demonstrated that the risk for cesarean delivery is increased by 50% in overweight women and is more than double for obese women compared with women with normal BMI [33]. Longer first stage of labor and higher rate of fetal heart rate abnormalities are contributors to the increased rate of cesarean deliveries [34-35]. Moreover, a cesarean section in an obese woman is associated with more frequent perioperative morbidities, such as longer operative times, excessive blood loss, anesthetic difficulties (epidural failure, difficult intubation), infectious and thromboembolic events. Obesity is also associated with short-term perinatal risks of macrosomia, birth trauma and shoulder dystocia [35, 36].

Lifestyle interventions (diet, exercise) in overweight and obese pregnant women give important contributions in reducing maternal complications such as hypertensive disorders, diabetes and shoulder dystocia. It is absolutely essential to encourage weight loss at the pre-conception counseling appointments since it has been proven that the pregravid excess of weight implies a higher risk pregnancy compared to the excessive weight gained during pregnancy. All the comorbidities that have been described above will result in longer hospital stay leading to increased overall healthcare costs compared to average weight women. Unfortunately lifestyle interventions are frequently ineffective in the long-term achievement and maintenance of weight loss. Furthermore, there are no truly effective pharmacological agents to treat obesity, especially morbid obesity [37-38].

TYPES OF BARIATRIC SURGERY: ADVANTAGES AND LIMITATIONS FOR PREGNANT WOMEN

Bariatric surgery is recommended for the treatment of morbid obesity (BMI $\geq$ 40Kg/m^2) or class II obesity (BMI $\geq$ 35Kg/m^2 with associated co-morbidities) and it is an increasingly selected option for obesity refractory to lifestyle intervention and medical treatment. It is the most effective approach to these situations, resulting in partial or complete resolution of co-morbidities associated with obesity and improving the quality of life of the patients.

Epidemiological studies report that women of reproductive age account for about half of the patients that have been submitted to bariatric surgery [39, 40].

Bariatric surgery comprises two major types of surgeries according to the main mechanism of weight loss: restrictive or malabsorptive. Restrictive procedures, such as adjustable gastric band, contribute to the limiting of caloric intake by reducing gastric volume, implying only mild nutritional deficiencies. Malabsorptive surgeries, such as biliopancreatic diversion, induce weight loss by generating an asynergy between the bolus and the biliopancreatic secretions, subsequently implying a higher protein and micronutrients (iron, calcium, vitamin B12, folate and vitamin D) deficiency compared to exclusively restrictive procedures. Gastric bypass, the most common weight loss surgery performed worldwide, is a technique that comprises both mechanisms of weight loss but is predominantly malabsorptive. Comparing the two most commonly used methods, laparoscopic adjustable gastric banding and Roux-en-Y gastric bypass, the last one is considered the most effective in terms of weight loss. Despite the longer operative time and the higher rate of perioperative morbidity associated with gastric bypass, in the long-term follow up, gastric banding requires more frequently reoperation. The majority of bariatric surgeries may be performed by laparoscopy with safer and less invasive procedures [41].

In nonpregnant obese patients, bariatric surgery contributes to reverse, eliminate or to improve many serious comorbid illnesses of the metabolic syndrome, such as impaired glucose tolerance, dyslipidemia and hypertension, leading in the long-term to an increase in life expectancy by decreasing the related deaths due to cardiovascular disease and complications. According to Buchwald et al., more than three quarters of patients with type 2 diabetes experience complete resolution of the disease after bariatric surgery. Of those patients who fail to achieve complete resolution, more than half showed demonstrable improvement. Thus, about 85% of patients with diabetes experienced improvement in their diabetes evolution after bariatric surgery [42]. Other medical conditions caused or aggravated by obesity, such as sleep apnea, daytime sleepiness, asthma, and gastroesophageal reflux are also significantly improved by the weight reduction after bariatric surgery. Moreover there is significant improvement in the quality of life and psychosocial wellbeing of morbidly obese patients [43]. Hormonal and mechanical factors of pregnancy alter the structure and function of the normal physiological barriers to reflux of gastric contents into the esophagus, and overweight is an aggravating factor that predisposes to complaints refractory to lifestyle and medical treatment. Thus, bariatric surgery as an effective promoter of weight reduction contributes to avoid the aggravating effect of obesity in physiological changes that are characteristic of pregnancy and otherwise would be symptomatic and difficult to control.

Several studies report an important improvement in fertility after bariatric surgery, particularly in hyperandrogenic and anovulatory women, independently of the type of bariatric surgery [40].

Potential complications such as micronutrient deficiencies are more commonly associated with malabsorptive surgery than with restrictive bariatric surgery. Restrictive procedures such as adjustable gastric band may be loosened during pregnancy permitting the individualization of caloric and gastric volume reduction. These surgeries are also less frequently responsible for late surgical complications than predominantly malabsorptive surgeries, such as gastric bypass. The band consists of an inflatable balloon whose diameter can be adjusted in ambulatory care by adding or removing saline solution via a reservoir port positioned beneath the skin. The bands are adjustable to allow the size of the gastric outlet to be modified as

needed in order to be adequate for gestational age weight gain. There are no randomized trials comparing elective deflation versus indicated deflation of the gastric band during pregnancy in terms of maternal-fetal outcomes. A recent retrospective study suggested that band loosening should be reserved for symptomatic patients in order to avoid excessive weight gain [44].

Pregnancy should be postponed until at least 12 to 18 months after bariatric surgery in an attempt to avoid the theoretical potential adverse effect of the intense nutritional deficiencies that may affect both fetus and mother during the rapid weight loss phase. If this vulnerable time period coincides with the time of elevated nutritional needs of a pregnancy, some reports highlight the possibility of a malnourished fetus and of potential complications such as low birth weight and malformations [45, 46]. Despite the inconsistent scientific evidence that supports the need to postpone pregnancy for a specific period after bariatric surgery and the lack of randomized trials showing significant differences in maternal-fetal morbidity and mortality, a recent retrospective cohort study, that compared pregnancy outcomes between women who conceived less than two years and more than two years after bariatric surgery, found that in the first group there were higher rates of gestational diabetes and lower weight loss [46]. Nonetheless, in case of pregnancy in the first year after surgery, women should be reassured that there is no scientific evidence of increased adverse neonatal outcomes. [47].

The American College of Obstetricians and Gynecologists (ACOG) recommends effective non-oral contraception, especially in women that have undergone malabsorptive surgery and do not pretend or have formal contraindications to get pregnant [48]. Oral contraception, especially after malabsorptive surgeries, may suffer a limited and irregular absorption leading to unreliable pharmacological effectiveness.

Regarding anatomic gastrointestinal complications, data from several reports suggest that they are more frequently associated with malbsorptive surgeries such as gastric bypass. Dumping syndrome consists on the effect of fast absorption carbohydrates that are rapidly emptied into the small bowel causing an osmotic shift of excessive fluid from the intravascular compartment to the small bowel lumen. This will cause abdominal cramping, bloating, nausea, vomiting and diarrhea. Symptoms of tachycardia, palpitations, anxiety and diaphoresis may be due not only to intravascular depletion but also to the secondary hypersecretion of insulin, which results in hypoglycemia. As a result, patients develop an aversion to high-carbohydrate foods, which leads to major changes in their diet and eating habits. Pregnant women submitted to bariatric surgery usually do not tolerate the standard oral glucose tolerance test for screening of gestational diabetes. An alternative method that has been suggested includes the outpatient evaluation of fasting capillary blood glucose and a 2-hour postprandial sample for 1 week between 24-28 weeks of gestation (the gestational age recommended for the standard evaluation). Women with previous restrictive surgeries, such as adjustable gastric band, rarely develop dumping syndrome and usually tolerate the standard glucose challenge test [48].

Understanding the underlying mechanism of each type of bariatric surgery is critical for an adequate counseling of patients. Pregnancy after bariatric surgery is associated with significant decreased rates of hypertensive disorders and gestational diabetes as well as lower rates of fetal macrosomia, comparing to obese women who have not undergone bariatric surgery [47].

Concise guidelines for counseling and management of reproductive-aged women that have undergone bariatric surgery are lacking. Moreover, there is neither consensus on the

adequate management of pregnant women previously submitted to bariatric surgery nor specific recommendations on the role of the bariatric surgeon. Nonetheless, several international societies and committees recommend tight monitoring of maternal nutrition and vitamin supplementation as well as close supervision with the collaboration of the bariatric surgeon and nutritionist [48].

Nutritional Deficiencies

As mentioned above, nutritional derangements can occur after bariatric surgery. These are particularly severe and frequent after malaborptive procedures. Macronutrient deficiencies such as protein–calorie malnutrition and fat malabsorption, deficiencies in fat-soluble vitamins in association with deficit of several micronutrients and minerals, particularly iron, folate, vitamin B12, vitamin D and calcium may occur after gastric bypass. Absorption of iron and folate are diminished because of reduced availability of acid in the gastric pouch and also due to the bypass of the duodenum, the major site for the absorption of these two micronutrients [40, 42].

Patients with morbid obesity (usually the population submitted to bariatric surgery) may develop secondary hyperparathyroidism and vitamin D deficiency. The abrupt weight loss imparted by bariatric surgery is frequently accompanied by the regression of secondary hyperparathyroidism and the improvement of vitamin D deficiency and bone turnover. Dietary calcium is mainly absorbed in the duodenum. After Roux-en-Y gastric bypass, food stream bypasses the majority of the stomach and duodenum, causing chronic calcium deficiency which may result in secondary hyperparathyroidism and vitamin D deficiency, counteracting the improvement caused by weight loss. There are reports of osteopenia and metabolic bone disease after bariatric malabsorptive surgery. Supplementation with vitamin D and calcium is recommended in these cases [49].

Absorption of food vitamin B12 occurs in the terminal ileum. However the absorption requires an adequate gastric acid secretion and the prior combination with intrinsic factor, which is produced in the gastric mucosa, and may be deficient in women previously submitted to gastric bypass.

Laparoscopic adjustable gastric band has been only associated with folate deficiency. The importance of normal levels in prenatal and first trimester assessments in order to avoid neural tube defects makes it fundamental to routinely monitor the levels of folate before and during pregnancy.

The absence of an adequate multivitamin supplementation may have important negative consequences for the fetus such as: cerebral hemorrhages due to vitamin K deficiency; microcephaly, hypotonia, microphthalmia and permanent retinal damage due to vitamin A deficiency; anemia due to vitamin B12 and iron deficiency and fetal deaths [50].

Pregnant women previously submitted to a bariatric operation should have a nutritional assessment preconception and during pregnancy for deficiencies of micronutrients. There is no consensus on the adequate nutritional supplementation during pregnancy and the daily doses are mainly extrapolated from observational studies and expert opinions. Vitamin B12 storage is enough for about 12 to 18 months. If replacement is needed, a daily oral dose of 500 mcg is recommended. However the lack of intrinsic factor may prevent intestinal absorption and weekly intramuscular injections of 1000 mcg are usually more effective. In

order to prevent anemia and neural tube defects, Beard et al. recommend that folate (400 mcg) and iron (50-100 mg daily) should be routinely supplemented during pregnancy. Furthermore, at least 1,000 mg calcium (maximum of 1,500 mg) is also recommended [50]. Vitamin A supplementation should be limited to 5000 IU per day in order to avoid retinoid embryopathy [48].

Nutritional monitoring should continue in puerperal women who are breastfeeding [48].

High restriction of the daily intake of calories or proteins is not recommended in the case of pregnancy after bariatric surgery, even if there is persistence of a high BMI, because caloric restriction may impair fetal growth.

MATERNAL-FETAL OUTCOMES AFTER BARIATRIC SURGERY

Despite the lack of rigorous randomized studies, pregnant women who have been submitted to bariatric surgery have lower rates of many adverse maternal and neonatal outcomes compared to pregnant women who are obese without bariatric surgery and pregnancy outcome is similar to that in the general population [47].

Pregnancy after Malabsorptive vs after Restrictive Surgeries

Pregnancy after gastric bypass is more consistently reported in the literature in association with serious complications such as bowel obstruction, dumping syndrome, hemorrhage and herniation compared to restrictive surgeries. Gastrointestinal complaints may mimic non-specific symptoms of pregnancy such as hyperemesis, esophageal reflux and uterine contractions, requiring a high index of suspicion in order to disclose them. Misdiagnosis or delayed diagnosis may lead to maternal morbidity and mortality. Recently, a cohort study showed an incidence of 1% of internal herniation during pregnancy, which is a potentially serious complication that requires immediate surgical intervention even in the absence of typical findings on imaging exams [51]. The enlarging gravid uterus imposes an increased abdominal pressure and cephalad displacement of the bowel, contributing to herniation, obstruction, potentially life-threatening bowel strangulation and sepsis, which may be lethal to both mother and fetus [47].

Gastrointestinal complications in pregnant women with previous insertion of a gastric band are rarer than after gastric bypass but some serious complications such as gastric ulceration, band erosion and slippage have been reported in the literature. [52-54].

Pregnancy increases the risk of gallstone disease due to decreased gallbladder emptying and motility as well as changes in the chemical components of bile (increased cholesterol saturation and decreased bile acid content). Acute cholecystitis is the second most common nonobstetrical surgical emergency during pregnancy, after acute appendicitis. The frequency of symptomatic gallstones after malabsorptive surgery is significantly higher than after restrictive procedures. This difference has been attributed to the rapid weight loss after malabsorptive techniques, which is thought to be an important factor in inducing gallstones formation postoperatively. Thus, the occurrence of pregnancy during the postoperative period

of maximum weight loss is an additional risk factor for cholelithiasis and its complications, such as cholecystitis and pancreatitis [55].

Fetal Outcomes after Bariatric Surgery

Obese pregnant women have higher rates of extremes of growth disorders - low birth weight and macrosomia -, probably due to higher rates of vascular complications and gestational diabetes, respectively. After bariatric surgery, all the metabolic changes related to nutritional deficiencies impart a decrease in the mean birth weight, consequently decreasing the rate of macrosomia and increasing the number of small for gestational age neonates compared not only to obese women without bariatric surgery but also in comparison to the general population [56]. Weintraub et al. compared pre- and post-bariatric pregnancies and reported more than 50 percent decrease in the risk of macrosomia [57]. Regarding the rate of fetal growth restriction there is no consensus in the literature. The role of nutritional deficiency as an important risk factor that may induce poor fetal growth may be balanced by the decreased risk of preeclampsia after bariatric surgery that may account for lower cases of fetal growth restriction in this context.

Fetal adverse outcomes include the risk of small for gestation age due to chronic nutrient malabsorption as well as the acute metabolic consequences of maternal fasting in case of prolonged symptoms of gastrointestinal obstruction. We have recently reported a clinical case of gastric rupture finding during a cesarean section in a woman with an adjustable gastric band [58]. Despite the obvious maternal morbidity with the need of partial gastrectomy, we discussed the fetal repercussion of the hemoperitoneum from gastric rupture as well as the effect of prolonged maternal fasting and metabolic acidosis. The poor nutritional status of the mother can be exacerbated by vomiting or nausea during pregnancy. When inadequately corrected during pregnancy, serious health problems may occur in the fetus, such as growth retardation and electrolyte imbalances. Probably too restrictive bariatric surgeries with an exaggerated limitation of nutrient intake would result in maternal malnutrition or starvation. Consequently the accumulation of ketone bodies would condition in extreme situation a fasting acidemia. It is still not known the exact effect of maternal acidemia on fetal acid base balance.

Multidisciplinary management of pregnancy with an active role of the bariatric surgeon is essential to disclose the need for immediate surgical intervention. Adjustable gastric band is a reversible bariatric surgery and deflation is a possible solution for women with gastric obstruction symptoms. It is absolutely essential to evaluate the effectiveness of this intervention and if symptoms persist after removal of fluid of the band it may suggest band slippage or gastric prolapse. With these suspicions surgical exploration should be a first option. Imaging exams should not be avoided with the fear of fetal harm, since the correct diagnosis of an obstruction or herniation may prevent fetal morbidity and death. Case reports of maternal deaths have been described in the literature, mainly due to a delayed diagnosis [59, 60].

Previous bariatric surgery is not an indication for the anticipation of delivery or for a cesarean section and both decisions should be made in accordance with standard obstetric criteria [48]. The increased rate of cesarean deliveries in some observational studies of pregnant women after bariatric surgery is associated with obesity, gastrointestinal

complications and medically indicated preterm delivery [61]. The bariatric surgery is not an established independent risk factor for cesarean section [56].

There is no evidence of increased delivery complications in pregnancy after bariatric surgery, such as low Apgar scores, meconium-stained amniotic fluid, NICU admission, perinatal mortality rate, congenital malformations. Moreover, there is also no difference in neonatal outcomes between malabsorptive and restrictive surgeries [62].

CONCLUSION

Prepregnancy obesity is a significant and independent risk factor for both adverse maternal and perinatal outcomes with an increased risk for gestational hypertensive disorders and diabetes. The combination of pregestational metabolic syndrome with the physiological changes of pregnancy imparts an increased risk for maternal disease such as chronic cardiac dysfunction. During labor, obesity increases the risk for cesarean delivery and the associated complications of anesthesia, infection, wound disruption and thromboembolism.

Diet, behavioral therapy, exercise and pharmacological treatment usually yield only modest results and weight loss is frequently regained in a short to medium period of time. Bariatric surgery is a promising treatment for morbidly obese women or in case of failure of lifestyle interventions and medical treatment. Weight loss after these surgeries is associated with an increase in fertility for obese women of reproductive age, especially if there is an anovulatory dysfunction. Pregnancy after bariatric surgery is safe and women are not at increased risk for adverse maternal and perinatal outcomes. Moreover, the major risks for many obesity-related gestational complications are decreased, especially the development of hypertensive disorders and gestational diabetes, as long as appropriate monitoring, nutritional control and efficient prenatal care are provided. Non-oral contraception is recommended during the period of maximum postoperative weight loss (12-18 months) in order to avoid potential risks of complications secondary to poor maternal nutritional status during this period. The most common pregnancy complications after bariatric surgery are nutritional deficiencies, which are easily treated with adequate supplementation. Multidisciplinary surveillance with the collaboration of bariatric surgeon, nutritionist and close obstetrical monitoring are needed to an early detection of any maternal or fetal complications related to previous bariatric surgery. Both obstetricians and surgeons have to consider these pregnant women as high-risk pregnancies, with the need of special care for nutritional assessment and supplementation, and monitoring for adequate weight management.

It is crucial for the obstetrician to know specifically which bariatric procedure the pregnant women had undergone in order to effectively make preconception counseling as well as to prevent and manage potential complications. Malabsorptive interventions impart higher nutritional deficiencies and more frequently are associated with gastrointestinal complications while restrictive procedures such as gastric banding are reversible and adaptable during pregnancy and may be loosened and adjusted to facilitate adequate gestational weight gain. Gastrointestinal complications during pregnancy after bariatric surgery may have only mild and nonspecific symptoms and may also overlap with common obstetric complaints. Late recognition may be life-threatening for both the mother and fetus.

In conclusion, pregnancy in women previously submitted to bariatric surgery is usually safe for the mother and the fetus provided that there is an adequate collaboration between high-risk obstetrician and bariatric surgeon.

REFERENCES

[1] Pi-Sunyer F. X. The obesity epidemic: Pathophysiology and consequences of obesity. *Obes Res.* 2002; 10:97-104.

[2] National Task Force on the Prevention and Treatment of Obesity. Overweight, obesity, and health risk. *Arch Intern Med.* 2000; 160:898-904.

[3] Schmiegelow M. D., Andersson C., Køber L., Andersen S. S., Norgaard M. L., Jensen T. B., Gislason G., Berger S. M., Torp-Pedersen C. Associations between body mass index and development of metabolic disorders in fertile women: A nationwide cohort study. *J Am Heart Assoc.* 2014. doi: 10.1161/JAHA.113.000672.

[4] Schmiegelow M. D., Andersson C., Køber L., Andersen S. S., Olesen J. B., Jensen T. B., Azimi A., Nielsen M. B., Gislason G., Torp-Pedersen C. Prepregnancy obesity and associations with stroke and myocardial infarction in women in the years after childbirth: a nationwide cohort study. *Circulation.* 2014; 129:330-7.

[5] Thomsen M., Nordestgaard B. G. Myocardial infarction and ischemic heart disease in overweight and obesity with and without metabolic syndrome. *JAMA Intern Med.* 2014; 174:15-22.

[6] Calabrò P., Golia E., Maddaloni V., Malvezzi M., Casillo B., Marotta C., Calabrò R., Golino P. Adipose tissue-mediated inflammation: The missing link between obesity and cardiovascular disease? *Intern Emerg Med.* 2009; 4:25-34.

[7] Calabro P., Yeh E. T. Obesity, inflammation, and vascular disease: The role of the adipose tissue as an endocrine organ. *Subcell Biochem.* 2007; 42:63-91.

[8] Setji T. L., Brown A. J. Polycystic ovary syndrome: update on diagnosis and treatment. *Am J Med.* 2014. doi: 10.1016/j.amjmed.2014.04.017.

[9] Moragianni V. A., Jones S. M., Ryley D. A. The effect of body mass index on the outcomes of first assisted reproductive technology cycles. *Fertil Steril.* 2012; 98:102-8.

[10] Hirshfeld-Cytron J., Kim H. H. Empty follicle syndrome in the setting of dramatic weight loss after bariatric surgery: case report and review of available literature. *Fertil Steril.* 2008; 90:1199.e21-3.

[11] Kort J. D., Winget C., Kim S. H., Lathi R. B. A retrospective cohort study to evaluate the impact of meaningful weight loss on fertility outcomes in an overweight population with infertility. *Fertil Steril.* 2014. doi: 10.1016/j.fertnstert.2014.01.036.

[12] Maheshwari A., Stofberg L., Bhattacharya S. Effect of overweight and obesity on assisted reproductive technology: A systematic review. *Hum Reprod Update.* 2007; 13:433-44.

[13] American College of Obstetricians and Gynecologists. ACOG Committee opinion no. 549: Obesity in pregnancy. *Obstet Gynecol.* 2013; 121:213-7.

[14] Chung J. H., Melsop K. A., Gilbert W. M., Caughey A. B., Walker C. K., Main E. K. Increasing prepregnancy body mass index is predictive of a progressive escalation in adverse pregnancy outcomes. *J Matern Fetal Neonatal Med.* 2012; 25:1635-9.

[15] Crane J. M., White J., Murphy P., Burrage L., Hutchens D. The effect of gestational weight gain by body mass index on maternal and neonatal outcomes. *J Obstet Gynaecol Can.* 2009; 31:28-35.

[16] Scott-Pillai R., Spence D., Cardwell C. R., Hunter A., Holmes V. A. The impact of body mass index on maternal and neonatal outcomes: a retrospective study in a UK obstetric population, 2004-2011. *BJOG.* 2013; 120:932-9.

[17] Rasmussen Z. M., Yaktine A. L. *Weight gain during pregnancy: Reexamining the guidelines.* Institute of Medicine, National Academy of Sciences, National Academies Press, Washington, 2009.

[18] Alanis M. C., Goodnight W. H., Hill E. G., Robinson C. J., Villers M. S., Johnson D. D. Maternal super-obesity (body mass index > or = 50) and adverse pregnancy outcomes. *Acta Obstet Gynecol Scand.* 2010; 89:924-30.

[19] Crane J. M., Murphy P., Burrage L., Hutchens D. Maternal and perinatal outcomes of extreme obesity in pregnancy. *J Obstet Gynaecol Can.* 2013; 35:606-11.

[20] Blomberg M. Maternal obesity, mode of delivery, and neonatal outcome. *Obstet Gynecol.* 2013; 122:50-5.

[21] Catalano P. M., Kirwan J. P., Haugel-de Mouzon S., King J. Gestational diabetes and insulin resistance: role in short- and long-term implications for mother and fetus. *J Nutr.* 2003; 133:1674-83.

[22] Bodnar L. M., Ness R. B., Harger G. F., Roberts J. M. Inflammation and triglycerides partially mediate the effect of prepregnancy body mass index on the risk of preeclampsia. *Am J Epidemiol.* 2005; 162:1198-206.

[23] Rebelo F., Schlüssel M. M., Vaz J. S., Franco-Sena A. B., Pinto T. J., Bastos F. I., Adegboye A. R., Kac G. C-reactive protein and later preeclampsia: Systematic review and meta-analysis taking into account the weight status. *J Hypertens.* 2013; 31:16-26.

[24] Chung J. H., Pelayo R., Hatfield T. J., Speir V. J., Wu J., Caughey A. B. Limitations of the fetal anatomic survey via ultrasound in the obese obstetrical population. *J Matern Fetal Neonatal Med.* 2012; 25:1945-9.

[25] Zozzaro-Smith P., Bacak S., Park J., Spall M., Glantz J. C., Thornburg L. L. Association between obesity during pregnancy and the use of prenatal services. *Obstet Gynecol.* 2014; 123 Suppl 1:80S. doi: 10.1097/01.AOG.0000447404.93680.48.

[26] Stothard K. J., Tennant P. W., Bell R., Rankin J. Stothard K. J., Tennant P. W., Bell R., Rankin J. Maternal overweight and obesity and the risk of congenital anomalies: A systematic review and meta-analysis. *JAMA.* 2009; 301:636-50.

[27] Waller D. K., Shaw G. M., Rasmussen S. A., Hobbs C. A., Canfield M. A., Siega-Riz A. M., Gallaway M. S., Correa A.; National Birth Defects Prevention Study. Prepregnancy obesity as a risk factor for structural birth defects. *Arch Pediatr Adolesc Med.* 2007; 161:745-50.

[28] Stachowiak E. K., Oommen S., Vasu V. T., Srinivasan M., Stachowiak M., Gohil K., Patel M. S. Maternal obesity affects gene expression and cellular development in fetal brains. *Nutr Neurosci.* 2013; 16:96-103.

[29] Stachowiak E. K., Srinivasan M., Stachowiak M. K., Patel M. S. Maternal obesity induced by a high fat diet causes altered cellular development in fetal brains suggestive of a predisposition of offspring to neurological disorders in later life. *Metab Brain Dis.* 2013; 28:721-5.

[30] Ekström S., Magnusson J., Kull I., Lind T., Almqvist C., Melén E., Bergström A. Maternal BMI in early pregnancy and offspring asthma, rhinitis and eczema up to 16 years of age. *Clin Exp Allergy.* 2014. doi: 10.1111/cea.12340.

[31] Reddy U. M., Branum A. M., Klebanoff M. A. Relationship of maternal body mass index and height to twinning. *Obstet Gynecol.* 2005; 105: 593-7.

[32] Cnattingius S., Villamor E., Johansson S., Edstedt Bonamy A. K., Persson M., Wikström A. K., Granath F. Maternal obesity and risk of preterm delivery. *JAMA.* 2013; 309:2362-70.

[33] Poobalan A. S., Aucott L. S., Gurung T., Smith W. C., Bhattacharya S. Obesity as an independent risk factor for elective and emergency caesarean delivery in nulliparous women--systematic review and meta-analysis of cohort studies. *Obes Rev.* 2009; 10:28-35.

[34] Norman S. M., Tuuli M. G., Odibo A. O., Caughey A. B., Roehl K. A., Cahill A. G. The effects of obesity on the first stage of labor. *Obstet Gynecol.* 2012; 120:130-5.

[35] Chauhan S. P., Magann E. F., Carroll C. S., Barrilleaux P. S., Scardo J. A., Martin J. N Jr. Mode of delivery for the morbidly obese with prior cesarean delivery: Vaginal versus repeat cesarean section. *Am J Obstet Gynecol.* 2001; 185:349-54.

[36] Perlow J. H., Morgan M. A. Massive maternal obesity and perioperative cesarean morbidity. *Am J Obstet Gynecol.* 1994; 170:560-5.

[37] Thangaratinam S., Rogozińska E., Jolly K., Glinkowski S., Duda W., Borowiack E., Roseboom T., Tomlinson J., Walczak J., Kunz R., Mol B. W., Coomarasamy A., Khan K. S. Interventions to reduce or prevent obesity in pregnant women: A systematic review. *Health Technol Assess.* 2012; 16:1-191.

[38] Oteng-Ntim E., Varma R., Croker H., Poston L., Doyle P. Lifestyle interventions for overweight and obese pregnant women to improve pregnancy outcome: Systematic review and meta-analysis. *BMC Med.* 2012; 10:47. doi: 10.1186/1741-7015-10-47.

[39] Santry H. P., Gillen D. L., Lauderdale D. S. Trends in bariatric surgical procedures. *JAMA.* 2005; 294:1909-17.

[40] Shekelle P. G., Newberry S., Maglione M., Li Z., Yermilov I., Hilton L., Suttorp M., Maggard M., Carter J., Tringale C., Chen S. Bariatric surgery in women of reproductive age: special concerns for pregnancy. *Evid Rep Technol Assess* (Full Rep). 2008; 169:1-51.

[41] Tice J. A., Karliner L., Walsh J., Petersen A. J., Feldman M. D. Gastric banding or bypass? A systematic review comparing the two most popular bariatric procedures. *Am J Med.* 2008; 121:885-93.

[42] Buchwald H., Avidor Y., Braunwald E., Jensen M. D., Pories W., Fahrbach K., Schoelles K. Bariatric surgery: A systematic review and meta-analysis. *JAMA.* 2004; 292:1724-37.

[43] Brancatisano A., Wahlroos S., Brancatisano R. Improvement in comorbid illness after placement of the Swedish Adjustable Gastric Band. *Surg Obes Relat Dis.* 2008; 4:S39-46.

[44] Pilone V., Hasani A., di Micco R., Vitiello A., Monda A., Izzo G., Iacobelli L., Villamaina E., Forestieri P. Pregnancy after laparoscopic gastric banding: Maternal and neonatal outcomes. *Int J Surg.* 2014. doi: 10.1016/j.ijsu.2014.05.027.

[45] Magdaleno R. Jr., Pereira B. G., Chaim E. A., Turato E. R. Pregnancy after bariatric surgery: A current view of maternal, obstetrical and perinatal challenges. *Arch Gynecol Obstet.* 2012; 285:559-66.

[46] Parikh R., Lavoie M., Wilson L., Maranda L., Leung K., Simas T. M. Timing of pregnancy after bariatric surgery. *Obstet Gynecol.* 2014; 123. doi: 10.1097/01.AOG. 0000447168.75769.f7.

[47] Kjaer M. M., Nilas L. Pregnancy after bariatric surgery: A review of benefits and risks. *Acta Obstet Gynecol Scand.* 2013; 92:264-71.

[48] American College of Obstetricians and Gynecologists. ACOG practice bulletin no. 105: Bariatric surgery and pregnancy. *Obstet Gynecol.* 2009; 113:1405-13.

[49] De Prisco C., Levine S. N. Metabolic bone disease after gastric bypass surgery for obesity. *Am J Med Sci.* 2005; 329:57-61.

[50] Beard J. H., Bell R. L., Duffy A. J. Reproductive considerations and pregnancy after bariatric surgery: Current evidence and recommendations. *Obes Surg.* 2008; 18:1023-7.

[51] Andreasen L. A., Nilas L., Kjær M. M. Operative Complications during Pregnancy after Gastric Bypass: A Register-Based Cohort Study. *Obes Surg.* 2014 Mar 23 Epub ahead of print.

[52] Suffee M. T., Poncelet C., Barrat C. Gastric band slippage at 30 weeks' gestation: Diagnosis and laparoscopic management. *Surg Obes Relat Dis.* 2012; 8:366-8.

[53] De Nino W. F., Zubarik R. S., Forgione P. M. Laparoscopic gastric band slippage diagnosed with esophagogastroduodenoscopy in a 12-week gestation nulliparous patient. *Surg Obes Relat Dis.* 2011; 7:225-6.

[54] Erez O., Maymon E., Mazor M. Acute gastric ulcer perforation in a 35 weeks' nulliparous patient with gastric banding. *Am J Obstet Gynecol.* 2004; 191:1721-2.

[55] Moon R. C., Teixeira A. F., DuCoin C., Varnadore S., Jawad M. A. Comparison of cholecystectomy cases after Roux-en-Y gastric bypass, sleeve gastrectomy, and gastric banding. *Surg Obes Relat Dis.* 2014; 10:64-8.

[56] Kjær M. M., Lauenborg J., Breum B. M., Nilas L. The risk of adverse pregnancy outcome after bariatric surgery: a nationwide register-based matched cohort study. *Am J Obstet Gynecol.* 2013; 208:464.e1-5.

[57] Weintraub A. Y., Levy A., Levi I., Mazor M., Wiznitzer A., Sheiner E. Effect of bariatric surgery on pregnancy outcome. *Int J Gynaecol Obstet.* 2008; 103:246-51.

[58] Policiano C., Rocha P., Catanho M. C., Pinto L., Valentim-Lourenço A., Graça L. M. Acute fetal asphyxia after gastric rupture in a pregnant patient with a gastric band. *Acta Obstet Gynecol Scand.* 2013; 92:1419-21.

[59] Loar P. V. 3rd, Sanchez-Ramos L., Kaunitz A. M., Kerwin A. J., Diaz J. Maternal death caused by midgut volvulus after bariatric surgery. *Am J Obstet Gynecol.* 2005; 193:1748-9.

[60] Moore K. A., Ouyang D. W., Whang E. E. Maternal and fetal deaths after gastric bypass surgery for morbid obesity. *N Engl J Med.* 2004; 351:721-2.

[61] Roos N., Neovius M., Cnattingius S., Trolle Lagerros Y., Sääf M., Granath F., Stephansson O. Perinatal outcomes after bariatric surgery: Nationwide population based matched cohort study. *BMJ.* 2013; 347: doi: 10.1136/bmj.f6460.

[62] Ducarme G., Parisio L., Santulli P., Carbillon L., Mandelbrot L., Luton D. Neonatal outcomes in pregnancies after bariatric surgery: A retrospective multi-centric cohort study in three French referral centers. *J Matern Fetal Neonatal Med.* 2013; 26:275-8.

In: Encyclopedia of Surgery (22 Volume Set)
Editors: Andreas Lehrer and Kristin Mueller
ISBN: 978-1-53618-329-0
© 2020 Nova Science Publishers, Inc.

Chapter 16

HISTORY AND DEVELOPMENT OF PERCUTANEOUS VERTEBRAL AUGMENTATION PROCEDURES

***Vincenzo Salini*[1,*]**
and Francesco Saverio Sirabella*[2], *MD
[1]Orthopaedic and Traumatology Department, "G. d' Annunzio" University,
Chieti, Italy. Orthopaedic and Traumatology Residency,
"G. d'Annunzio" University, Chieti, Italy
[2]Orthopaedic and Traumatology Department,
"G. d'Annunzio" University, Chieti, Italy

The first percutaneous vertebral augmentation was performed by Galibert and Deramond [1, 2, 3] in 1984 at the University Hospital of Amiens, France. In this case, polymethylmethacrylate (PMMA) was injected into the C2 vertebral body for a painful hemangioma, under fluoroscopic control, become successful in relieving chronic pain of the patient. This procedure began to be known as "Vertebroplasty", a fluoroscopic-guided therapeutic technique consisting of introduction of a trocar into a vertebral body, followed by injection of an acrylic polymer to give a greater resistance to the vertebral body. This procedure was allowed to treat vertebral fractures or vertebral body collapses due to tumors or metabolic disorders. In 1987 Deramond and Galibert [4,5] published a report of a small number of patients affected by painful hemangiomas of the vertebral body treated with Vertebroplasty, with satisfactory pain control. The first use of this technique for the treatment of painful osteoporotic vertebral compression fractures (VCFs), was published in 1991. Vertebroplasty was little known in the United States until 1993, when the procedure was shown at the American Society of Neuroradiology annual meeting. After a year, Dion and Jensen [6] successfully treated the first patient in the United States, at the Virginia University. However, the first article about this procedure was published in 1997: 29 patients with osteoporotic vertebral compression fracture, showed an effective relief of painful symptoms in 90% of cases after treatment with Vertebroplasty [7, 8]. As published by the SIR (Society of Interventional Radiology) in 2003, the main indications for Vertebroplasty include: osteoporotic vertebral compression fracture older than 2 weeks and refractory to medical therapy, painful vertebra with extensive osteolysis or invasion secondary to benign or

* Corresponding Author's Email: v.salini@unich.it.

malignant tumor and painful vertebral fractures associated to osteonecrosis. The contraindications are absolute and reklative as: asymptomatic vertebral body compression fractures, active osteomyelitis of the target vertebra, coagulopathy, allergy to bone cement, patient condition improving upon medical therapy, prophylaxis in osteoporotic patients, and myelopathy originating at the fracture level [9, 10, 11] . The official practice guidelines for vertebroplasty were collectively prepared in 2009 by the Society of Interventional Radiology (SIR), the American College of Radiology (ACR), the American Society of Neuroradiology (ASNR), the Society of Neurointerventional Surgery (SNIS) and the American Society of Spine Radiology (ASSR). However, one of the most important problem related to Vertebroplasty is that this technique is not able to restore vertebral height. As a solution to this issue, a procedure called "Kyphoplasty", also known as "Balloon-Assisted Vertebroplasty", was introduced by Dr. Mark Reiley in 1990 [12] as an alternative vertebral augmentation technique, able to restore the height and angle of kyphosis of a fractured vertebra, followed by its stabilization injecting bone cement. The procedure consists in the use of a small balloon that is inflated in the vertebral body, in order to create a void within cancellous bone, followed by cement injection as PMMA. Subsequently, Kyphoplasty was proposed as an alternative procedure to Vertebroplasty, since Kyphoplasty is capable of correcting and preventing deformity of the spine and having a lower rate of cement extrusion. One of the most important trial was done by Wardlaw and al. in 2009 [13]. It was a randomized controlled trial (FREE): 300 patients, affected by one to three acute vertebral fractures, were divided into two groups. The firs group (149 patients) was treated by Kyphoplasty whereas the second control group (151 patients) was treated conservatively. The results demonstrated that balloon Kyphoplasty was a safe and effective technique in case of acute vertebral fractures, usable especially as early treatment option. In a prospective randomized study, Liu et al. (2010) [14] randomly assigned 100 patients with osteoporotic vertebral compression fracture to either Kyphoplasty or Vertebroplasty and followed them for six months. The main results from this study was that there was a little difference between Kyphoplasty and Vertebroplasty in terms of pain reduction, but Kyphoplasty increased vertebral body height and reduced kyphotic wedge angle more than Vertebroplasty. In 2012 Ma et al. [15] in a systematic review and meta-analysis concluded that "*Kyphoplasty and Vertebroplasty are both safe and effective surgical procedures for treating osteoporotic vertebral compression fractures. Kyphoplasty may be superior to Vertebroplasty in patients with large kyphosis angles, vertebral fissures, fractures in the posterior edge of the vertebral body or significant height loss in the fractured vertebrae*". Vertebroplasty and kyphoplasty are both excellent percutaneous surgical technique, capable to provide short-term pain relief and to improve physical functionality in patients with osteoporotic or tumor-associated vertebral fractures [16]. However, none of these two techniques is not free from complications such as symptomatic cement leakage, cement embolism, pulmonary embolism, hematomas, spinal cord compression, radiculopathy, infection and adjacent vertebral fracture (domino effect). This is one of the several issues that must be resolved [17]. Therefore, alternative percutaneous vertebral augmentation procedures become necessary. For these reasons nowadays the "third generation" of percutaneous vertebral augmentation procedures is started [18].

REFERENCES

[1] Percutaneous vertebroplasty: history, technique and current perspectives. Hide IG, Gangi A. *Clin. Radiol*. 2004 Jun;59(6):461-7.

[2] Vertebroplasty. Anderson SR. *Pain Pract.* 2001 Jan;1(1):46-52.

[3] Percutaneous vertebroplasty. Kallmes DF, Jensen ME. *Radiology.* 2003 Oct;229(1):27-36.

[4] Preliminary note on the treatment of vertebral angioma by percutaneous acrylic vertebroplasty. Galibert P, Deramond H, Rosat P, Le Gars D. *Neurochirurgie* 1987, 33:166-168.

[5] Percutaneous vertebroplasty with polymethylmethacrylate. Technique, indications, and results. Deramond H, Depriester C, Galibert P, *Le Gars D: Radiol Clin. North Am.* 1998, 36:533-546.

[6] Percutaneous polymethacrylate vertebroplasty in the treatment of osteoporotic vertebral body compression fractures: technical aspects. Jensen ME, Evans AJ, Mathis JM, Kallmes DF, Cloft HJ, Dion JE. *Am. J. Neuroradiol.* 1997;18:1897–904.

[7] Vertebroplasty and kyphoplasty. Lavelle W, Carl A, Lavelle ED, Khaleel MA. *Anesthesiol. Clin*. 2007 Dec;25(4):913-28.

[8] Percutaneous vertebroplasty. Hurley MC, Kaakaji R, Dabus G, Shaibani A, Walker MT, Fessler RG, Bendok BR. *Neurosurg. Clin. N Am*. 2009 Jul;20(3):341-59.

[9] Advances in surgical treatment of osteoporotic fractures of the spine. Goh LH, Tan SB, Liaw JS. *Ann. Acad. Med. Singapore*. 2002 Sep;31(5):623-30.

[10] Use of percutaneous kyphoplasty and vertebroplasty in spinal surgery. Marlin E, Nathoo N, Mendel E. *J. Neurosurg. Sci*. 2012 Jun;56(2):105-12.

[11] Vertebral compression fractures in the elderly. Old JL, Calvert M. *Am. Fam. Physician*. 2004 Jan 1;69(1):111-6.

[12] New Technologies in Spine: Kyphoplasty and Vertebroplasty for the Treatment of Painful Osteoporotic Compression Fractures. Garfin SR, Yuan HA, Reiley MA, *Spine* 2001; 26 (14): 1511–1515.

[13] Efficacy and safety of balloon kyphoplasty compared with non-surgical care for vertebral compression fracture (FREE): a randomised controlled trial. Wardlaw D, Cummings SR, Van Meirhaeghe J, Bastian L, Till- man JB, Ranstam J, Eastell R, Shabe P, Talmadge K, Boonen S. *Lancet* 2009. 373:1016 –24.

[14] Kyphoplasty for chronic painful osteoporotic vertebral compression fractures via unipedicular versus bipedicular approachment: a comparative study in early stage. Chen C, Chen L, Gu Y, Xu Y, Liu Y, Bai X, Zhu X, Yang H. *Injury.* 2010;41(4):356-9.

[15] Balloon kyphoplasty versus percutaneous vertebroplasty in treating osteoporotic vertebral compression fracture: grading the evidence through a systematic review and meta-analysis Ma XL, Xing D, Ma JX, Xu WG, Wang J, Chen Y. *Eur. Spine J.* (2012) 21:1844–1859.

[16] The technological development of minimally invasive spine surgery. Snyder LA, O'Toole J, Eichholz KM, Perez-Cruet MJ, Fessler R. Biomed Res Int. 2014;2014:293582. Neurosurgery. 2002 Nov;51(5 Suppl):S1-14. History of minimally invasive spine surgery. *Jaikumar S1*, Kim DH, Kam AC.

[17] The technological development of minimally invasive spine surgery. Snyder LA, O'Toole J, Eichholz KM, Perez-Cruet MJ, Fessler R. *Biomed. Res. Int.* 2014;2014:293582.

[18] New perspective for third generation percutaneous vertebral augmentation procedures: Preliminary results at 12 months. Vanni D, Pantalone A, Bigossi F, Pineto F, Lucantoni D, Salini V. *J. Craniovert Jun. Spine* 2012;3:47-51.

In: Encyclopedia of Surgery (22 Volume Set)
Editors: Andreas Lehrer and Kristin Mueller
ISBN: 978-1-53618-329-0
© 2020 Nova Science Publishers, Inc.

Chapter 17

THORACO-LUMBAR SPINE ANATOMY

Rosa M. Mirapeix*, MD, PhD
Human Anatomy and Embryology Unit
Department of Morphological Sciences
Autonomous University of Barcelona, Spain

INTRODUCTION

A good knowledge of the anatomical characteristics of the spine is essential to understand and to anticipate any problems that might occur during surgical practice. Moreover, the awareness of the normal relationships between the spine and the surrounding elements is becoming increasingly important in clinical practice, since surgeons are often asked to use advanced imaging procedures during surgery. Percutaneous vertebral procedures require, on the one hand, an accurate localization of the bone region to be treated and, on the other hand, a careful identification of the trajectory that must be followed for safe device insertion. The normal anatomic structures and variations that affect the spine must be understood in order to accomplish this goal.

The human spine is a complex unit made up of 24 vertebrae (7 cervicals, 12 thoracics and 5 lumbars), the sacrum (5 fused vertebrae) and the coccyx (4 fused vertebrae with Co1 often not fused).

The thoracolumbar vertebrae can be divided into the vertebral body, the pedicles, posterior elements and the transverse processes (these have a slightly different embryological origin and are not anatomically regarded as part of the posterior elements) (Figure 1).

The vertebrae progressively enlarge from the cervical through the lumbar region in all three planes despite finding variations in its size at any particular level, depending on individual's size, age and gender.

* Corresponding Author's Email: Rosa.Mirapeix@uab.cat.

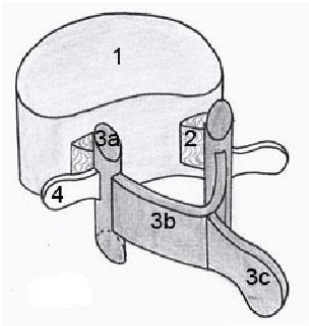

Figure 1. Parts of the vertebrae. 1- vertebral body; 2- pedicles; 3- posterior elements: articular processes (3a), laminae (3b) and spinous process (3c); 4- transverse processes.

THE VERTEBRAL BODY

The anterioposterior length of the thoracolumbar spine gradually increases caudally, whereas the transverse width decreases from T1 to T4 (from 30 mm to 25 mm) and then progressively increases until L5 (55 mm) [1].

The anterior surface of the vertebral body is slightly concave and it relates to the prevertebral muscles, the descending aorta and the inferior vena cava. From the posterior wall of the descending aorta, a paired branches that supply the thoracic and lumbar spine arise. These arteries run around the vertebral body towards the intervertebral foramina, giving off ascending and descending branches (radicular arteries), which anastomise with similar branches arising from the adjacent vertebral arteries from above and below. The anterolateral surface, as well as, the greater part of the superior and inferior surfaces of each vertebral body is perforated by tiny holes which are occupied by nutrient intraosseous arteries coming from the deep surface of each radicular artery. Accompanying the arteries that supply the vertebral spine and surrounding the vertebral body, there is an external vertebral venous plexus. This plexus has numerous connections along the trunk with the intercostal and lumbar veins. Intercostal veins connect with the hemiazygos and azygos venous system that finally drains into the superior vena cava, while lumbar vertebral veins drain into the inferior vena cava. These connections must be taken into consideration in order to prevent or diagnose local and distance side effects related to surgical procedures.

The posterior surface of the body has one or more large nutrient foramina which are occupied by nutrient arteries and the basivertebral veins. This surface of the vertebral body relates to the vertebral canal, which is occupied by the spinal cord, which is surrounded by the meninges. The space between the outer meninx (the dura mater) and the vertebra is called the epidural space. In the trunk, this epidural space is quite wide and is occupied by internal vertebral venous plexus and fat. The internal vertebral venous plexus is connected longitudinally along the entire vertebral spine. This valveless plexus consists of two venous groups (anterior and posterior), which communicate by a series of venous rings [2]. The anterior epidural network of veins is much more prominent than the posterior and it is related to the posterior longitudinal ligament, while the posterior epidural network of veins is related to the ligamentum flavum. The internal vertebral venous plexus drains into the external vertebral venous plexus though radicular veins at the intervertebral foramina region. The

existence of this epidural space should be borne in mind when invasive procedures are performed.

THE POSTERIOR ELEMENTS

The posterior elements of a vertebra are the laminae, the articular processes and the spinous processes (Figure 1). All these elements provide areas for muscle attachment.

The Laminae

The laminae (right and left) connect in the midline and close the vertebral canal posteriorly. In the lower thoracic spine, its thickness decreases slightly while its height increases, being T11 the tallest. In the lumbar spine, the thickness and width increases (L5 has the greatest width) [3]. In the thoracic spine, a degree of laminar overlap between the level above and the level below exists. In contrast, in the lumbar spine, the laminae have a wider interlaminar space; therefore the ligamentum flavum has a greater length. The portion of the lamina located between the superior and inferior articular processes and just below the level of the pedicle is called isthmus or pars interarticularis. This is the most common site of stress fractures [4].

The Articular Processes

Related to the lamina and located above and below the posterior end of the pedicles, there are four articular processes (two superiors and two inferiors). The articular processes of two consecutive vertebrae interlock at the facet joints. In the thoracic region, the articular facets are coronally aligned and markedly oblique (on average at 65º to the plane of the intervertebral discs), whereas in the lumbar spine these joint surfaces are more vertical and sagitally aligned. In the posterior edge of each of the superior articular processes of lumbar vertebrae, there is another small bump called *mammillary process*.

The Spinous Process

Projecting posteriorly from the junction of the two laminae we find the spinous process. Its length increases from T1 to T7 and decreases downwards. The tip of each spinous process, from T1 to T3 projects over the upper half of the underlying vertebra; from T4 to T6 it lies over the lower half of the underlying vertebra; from T7 to T9 it projects over the upper half of the subjacent vertebra, and from T10 to T12, the tip of the spinous process is at the level of the subjacent intervertebral space [1]. In the lumbar spine, the spinous processes are shorter and horizontally orientated. They are quadrangular and thickened along its posterior and inferior borders. The interspinous and supraspinous ligaments connect to adjacent spinous processes.

TRANSVERSE PROCESSES

They extend laterally from the junction of the pedicle and the lamina on each side as a flat rectangular bar of bone. In the thoracic region, the tip of each transverse process from T1 to T10 bears oval costal facets while T11 and T12 do not have costal facet since they do not articulate with the ribs. In the lumbar spine, near its attachment to the pedicle, each transverse process bears on its posterior surface a small, irregular bony prominence called the *accessory process* (identifiable as the only bony projection from the back of the proximal end of the transverse process). The length of the transverse processes progressively decreases from T1 to T12. The transverse processes of L4 are the smallest, thus allowing identification of a transitional vertebra [1].

PEDICLES

The pedicles are two pillars of bone extending backwards from the superior half of the posterior margin of the vertebral bodies. It is the only connection between the posterior elements and the vertebral bodies (Figure 1). Pedicles are designed to transmit the tension and bending forces sustained by any of the posterior elements to the anterior part of the vertebra. They have thick bone walls while their inner cores are filled with cancellous bone. The medial cortical wall is 2-3 times thicker than the lateral cortical wall [5].

In the thoracic spine, pedicles are ovoid in shape; their sagittal diameter is slightly larger than the transverse diameter [6]. Pedicle height increases from 9 to 16 mm [7], while pedicle width decreases from T1 to T10 (the narrowest between T3-T10) and has a mild increase from T10 to T12 with sizes ranging from 4 to 8 mm depending on the level [8]. In lumbar spine, pedicle height is fairly constant being 15 mm on average [9] while pedicle width increases progressively until L5, which is twice as wide as L1 [10]. Thus, in the thoracic spine the pedicles are narrower whereas in the lumbar spine they are wider.

Pedicles cannot be visualized directly from a posterior view. The location of the pedicle is inferred by identifying bony landmarks such as the transverse processes and the superior articular facets. Pedicles are in the horizontal plane, at the same level than the transverse processes. Thus, the midline of the transverse process corresponds to the mid-pedicle height. In the coronal plane, the pedicles are located anteriorly to the inferior half of the superior articular facet and to the isthmus of the lamina. Furthermore, the lumbar pedicles are located medially to the mammillary processes.

The direction of the pedicles from posterior to anterior varies along the thoracolumbar spine not only in the transverse plane but also in the sagittal plane (Figure 2).

In a transverse plane, the thoracic pedicles are almost parallel, running forward 0º, whereas in the lumbar spine they have a slight medial inclination (Figure 2A). From T12 to L5, one should aim 5º more medially for each level [6, 9] (Figure 2B). Thus, at the L5 level the orientation must be approximately 30º medially (the direction being from posterolateral to anteromedial). The interpeduncular distance normally decreases progressively from the level of T1 through T6 and then increases gradually from T6 to L5 [11] due to the transverse width of the vertebral body along the thoracolumbar spine.

In a sagittal plane, the pedicles exhibit varying angles based on both their anatomical characteristics and the amount of physiological lordosis found in each vertebral level. Lumbar pedicles are neutral (90º) for most of the lumbar spine except at L5, where they have a slightly cranial orientation [6] (Figure 2C).

Pedicles have important relations medially, superiorly and inferiorly. The vertebral canal is located medially to the pedicles. It is occupied by the spinal cord. It should be taken into consideration that they are in contact with the epidural space, which contains fat and an inner vertebral venous plexus. The distance from the medial pedicle wall to the lateral border of the dura mater is greater in lumbar spine (approximately 1.5 mm) than in the thoracic spine [12]. Superiorly and inferiorly, pedicles form the inferior and superior margins of the intervertebral foramina respectively. The distance between the nerve root and the superior pedicle wall varies from 1.9 to 3.9 mm in the thoracic spine and from 4.1 to 5.5 mm in the lumbar spine, while the distance between the nerve root and the inferior pedicle wall varies from 1.7 to 2.8 mm in the thoracic spine and from 1.3 to 1.5 mm in the lumbar spine [12, 13]. The spinal ganglion is located below the pedicle, on which it sometimes leaves its imprint [14].

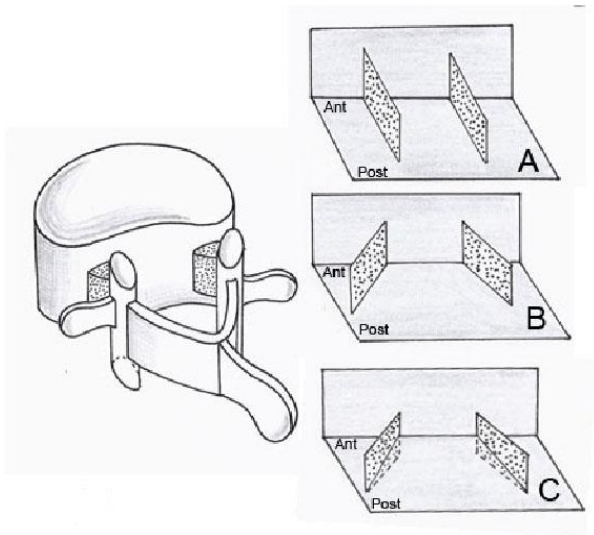

Figure 2. Orientation of the pedicles. *A) Thoracic spine*. The thoracic pedicles run forward 0º. They are almost parallel. B) *Lumbar spine*. The lumbar pedicles run from posterolateral to anteromedial. C) *The L5 pedicles* have a slightly cranial orientation.

THE INTERVERTEBRAL FORAMINA

The intervertebral foramina are bounded above and below by the pedicles, anteriorly by the posterior surface of the discs and body vertebra and posteriorly by the zygopophysial joints. There is, however, a great variation in their size during movements. The foramen is larger in flexion and smaller in extension, being a difference of about a 20% between both situations. In extreme flexion, the pedicles move apart from each other and the disc's convexity is minimal due to the tension of the posterior longitudinal ligament [14]. During extension, all the diameters decrease: the pedicles move closer to each other, reducing the

height of the foramen. In the thoracic region, the heads of the ribs occlude the inferior part of this foramen. In the lumbar region, the intervertebral foramina are oval with a large vertical axis. The L5-S1 foramen is the roundest and the smallest [14].

In adults, the 7-22% of the intervertebra foramina are occupied by the radicular arterioles, the foraminal veins, the lymph vessels, fat and the spinal nerve which maintains a relatively constant location in the anterior superior portion of the foramen [6].

REFERENCES

[1] René Louis. Surgery of the spine. *Surgical Anatomy and Operative Approaches*. Springer-Verlag Berlin Heidelberg 1983 pp: 28-34.

[2] Groen JM, Du Toit DF, Phillips FM, Hoogland PVJM, Kuizenga K, Coppes MH, Muller CJF, Grobbelaar M, Mattyssent J. Anatomical and pathological considerations in percutaneous vertebroplasty and kyphoplasty: A reappraisal of the vertebral venous system. *Spine* 2004; 29(13): 1465-1471.

[3] Xu R, Burgar A, Ebraheim NA, Yeasting RA. The quantitative anatomy of the laminas of the spine. *Spine* (Phila Pa 1976) 1999; 24(2): 107-113.

[4] Ebraheim EA, Hassan A, Lee M, Rongming Xu. Functional anatomy of the lumbar spine. *Seminars in pain medicine*. 2004; 2: 131-137.

[5] Kothe R, O'Holleran JD, Liu W, Panjabi M. Internal architecture of the thoracic pedicle. An anatomic study. *Spine* (Phila Pa 1976) 1996; 21(3): 264-270.

[6] Rabinowitz RS, Currier BL. Transpedicular screw fixation of the lumbar spine: review and technique. *Operative techniques in orthopaedics* 1997; 7(1): 71-78.

[7] Panjabi MM, Takata K, Goel V. Thoracic human vertebrae. Quantitative three-dimensional anatomy. *Spine* (Phila Pa 1976) 1991; 16(8): 888-901.

[8] Cinotti G, Gumina S, Ripani M. Pedicle instrumentation in the thoracic spine. A morphometric and cadaveric study for placement of screws. *Spine* (Phila Pa 1976) 1999; 24(2): 114-119.

[9] Ouellet JA, Vincent A. Surgical anatomy of the pelvis, sacrum and lumbar spine relevant to spine surgery. *Seminars in spine surgery* 2004; 16: 91-100.

[10] Panjabi MM, Goel V, Oxland T. Human lumbar vertebrae. Quantitative three-dimensional anatomy. *Spine* (Phila Pa 1976) 1992; 17(3): 299-306.

[11] Anderson MW. Imaging of thoracic and lumbar spine fractures. *Seminars in spine surgery* 2010, 22: 8-19.

[12] Ebraheim NA, Janbaly G, Xu R. Anatomic relations between the thoracic pedicle to the adjacent neural structures. *Spine* (Phila Pa 1976) 1997; 22(14): 1553-1556.

[13] Ebraheim NA, Xu R, Darwing M. Anatomic relations between the lumbar pedicle and adjacent neural structures. S*pine* (Phila Pa 1976) 1997; 22(20): 2338-2341.

[14] Demondion X, Lefebvre G, Fisch O, Vanderbussche L, Cepparo J, Balbi V. Radiographic anatomy of the intervertebral cervical and lumbar foramina (vessels and variants). *Diagnostic and interventional imaging* 2012; 93: 690-697.

In: Encyclopedia of Surgery (22 Volume Set)
Editors: Andreas Lehrer and Kristin Mueller
ISBN: 978-1-53618-329-0
© 2020 Nova Science Publishers, Inc.

Chapter 18

ETIOPATHOGENESIS OF PATHOLOGICAL AND TRAUMATIC VERTEBRAL FRACTURES

Vincenzo Levi*, MD and Mauro Pluderi, MD
Neurosurgery Department, IRCSS Ca' Granda - Ospedale Maggiore Policlinico, "Milan University", Milan, Italy

INTRODUCTION

Fractures of the thoracolumbar spine are the most common fractures of the spinal column. They are usually provoked by compression forces, though flexion/distraction, hyperextension and rotation are the main mechanisms responsible for high instable lesions. Epidemiologic data on thoracolumbar fractures are not uniform worldwide. In Western countries, more than 160,000 thoracolumbar fractures occur every year .The estimated prevalence among the adult population is approximately 1% , but this percentage increases up to 2-3% considering subjects older than 80 years. The sequelae of the damage caused by a vertebral fracture in the thoracolumbar segment of the spine may be devastating, including severe neurologic deficits as paraplegia, pain and secondary spine deformity.

Thoracolumbar fractures may be divided in pathological and traumatic fractures, depending on the etiology of the lesion. The former are usually the consequence of alteration of the vertebral bone's normal structure. They are sustained by different pathological conditions, such as osteoporosis, infections or tumours, and may lead to spontaneous fracture or collapse of the vertebra.

Traumatic fractures, instead, are often provoked by high-energy injuries, such as motor vehicle accidents and falls from height. They occur predominantly in the young and are responsible for the most unstable and severe lesions.

Aim of this chapter is to analyse the underling mechanisms responsible for thoracolumbar fractures formation, both pathological and traumatic. Before discussing this topic, however, it is necessary to review few but essential anatomic and biomechanical concepts regarding the thoracolumbar region of the vertebral column.

* Corresponding Author's Email: vincenzolevi@me.com.

ANATOMIC AND BIOMECHANICAL CONSIDERATIONS

As it is well known, each segment of the spine may be schematically divided in three columns (Denis, 1983):

- Anterior column: includes the anterior half of the disc and vertebral body and the anterior longitudinal ligament.
- Middle column: consists of the posterior half of the disc and vertebral body plus posterior longitudinal ligament and pedicles.
- Posterior column: encloses vertebral posterior arch and interposed posterior ligamentous complex (supraspinous and interspinous ligament, facet joins and capsule, ligament flavus).

At the time of trauma, compressive and/or distraction forces act on one or more of these columns, producing bony and ligamentous damage, that in some cases (when two column are involved at least) may lead to acute instability and consequently neurological deficits.

The thoracolumbar region, moreover, is more susceptible to fractures because of the following anatomical reasons:

- At the transition T11–12 the spine curvature switches from a relatively rigid thoracic kyphosis to a more mobile lumbar lordosis.
- The lowest thoracic ribs (T11 and T12) are free floating, providing less stability at the thoracolumbar junction.
- Different joint range of motion on the antero-posterior and lateral planes between the thoracic and lumbar region, mainly due to the diverse facet joints orientation. The thoracic facet joints, infact, are mostly oriented in the coronal plane, in opposition to the lumbosacral segment where they are oriented in a more sagittal alignment, increasing in this way the degree of potential flexion and extension at the expense of limiting lateral bending and rotation.

The thoracolumbar segment, therefore, represents a point of great transition between the stiff thoracic cage and the more mobile lumbar spine. This basically explains why the thoracolumbar region is most commonly involved with traumatic spinal fractures.

PATHOLOGICAL THORACOLUMBAR SPINAL FRACTURES

Pathological fractures of the thoracolumbar spine may be caused by several diseases, as bone infections (osteomyelitis, tuberculosis),metabolic bone (osteoporosis, osteomalacia, hyperparathyroidism) and tumours (multiple myeloma, primitive and metastatic tumours).

Among these entities, the osteoporosis results to be the most common cause of pathological thoracolumbar spinal fractures. In the European Union, in 2000, the number of osteoporotic fractures was estimated at 3.79 million, whereas the incidence in women older than 50 years is greater than 10 per 1000 per year and is three times higher after the age of 75

years. Considering these data, 30–50% of women and 20–30% of men will develop vertebral fractures during their life.

Osteoporosis generally produces a kind of fracture that is referred as compression or wedge –shaped fracture, defined as a vertebral body height reduction at least of 15%. A wedge compression fracture is generally a mechanically stable fracture pattern.

Unlike traumatic fractures in which pain decreases with time as the fracture heals, pathologic fractures secondary to bone infection, tumor or osteoporosis usually have pain that worsens over time.

TRAUMATIC THORACOLUMBAR SPINAL FRACTURES

The thoracolumbar region of the spinal column represents the most common site of traumatic vertebral fractures. In a cohort of 965 patients admitted for traumatic spine injuries to the Emergency Department in the Australian State of Victoria, Tee et al has recently found the incidence of thoracolumbar spine injuries to be more than 60%, with compression fractures being the most common injury morphologically.

In literature, neurological deficiencies has been reported in a range of 20% and 30% of the cases, depending most of all on the fracture type and the trauma severity. Approximately, 60% of traumatic fractures occur at the thoracolumbar junction (T11–L2), whereas 30% and 10% affect the thoracic and lumbosacral segment of the spine respectively.

Motor vehicle accidents results to be the main cause of vertebral injury in the young population (50%). The remaining fractures are secondary to falls from height and sports and recreational activities.

The most relevant forces that may be implied in the pathophysiology of thoracolumbar trauma and fractures are:

1. *Axial compression*: if it is the only force implied in the trauma, it causes an isolated failure of the anterior column, usually leaving posterior column elements intact. The consequence is a loss of integrity of the vertebral endplate, which may be followed by vertebral body compression and then by typical burst fracture. Depending on the energy of the trauma, the axial load may produce an incomplete or complete burst fractures. Whether severe compression occurs, instead, significant disruption of posterior elements may arise as well. Wedge compression fractures, conversely, are the result of the combination of an axially compressive force plus an eccentric compressive force anterior to the axis of rotation.
2. *Flexion/distraction*: when a flexion/distraction force is applied to the spine, the axis of flexion is moved anteriorly (towards the anterior abdominal wall), producing large tensile forces on the vertebral body and posterior arch. The consequent structural damage may interest all the elements of the spine (osseous structures, ligamentous apparatus, soft tissues).

Chance fracture is a typical distraction fracture that involves a horizontal fracture, which begins in the spinous process, progresses through the lamina, transverse processes, and pedicles, and extends into the vertebral body. The cause is usually a motor vehicle accident

with the victim wearing a lap seat belt.

1. *Hyperextension*: Hyperextension produces an extremely unstable injury pattern that may be biomechanically considered the reverse of that seen with flexion. Tension, infact, is applied anteriorly to the strong anterior longitudinal ligaments and anterior portion of the anulus fibrosus, which are usually severely damaged, whereas compression forces are transmitted to the posterior elements. This mechanism results in a rupture from anterior to posterior and may result in facet, lamina, and spinous process fractures.
2. *Rotation*: both compressive forces and flexion-distraction mechanisms may be combined with rotational forces and lead to rotational fracture dislocations. In this case, the anterior and posterior elements may be completely pulled away. This pattern of fracture is highly instable. Rotational forces may further be combined with shearing forces and lead to even more unstable fractures (slice fractures, Holdsworth).

REFERENCES

Boos F, Aebi M (2008) *Spinal Disorders: Fundamental of diagnosis and treatment.* Springer-Verlag Berlin Heidelberg.

Denis F (1983) The three column spine and its significance in the classification of acute thoracolumbar spinal injuries. *Spine* 8:817–31.

El-Khoury GY, Whitten CG (1993) Trauma to the upper thoracic spine: anatomy, biomechanics, and unique imaging features. *AJR Am J Roentgenol* 160:95–102.

Gertzbein SD. (1992) Scoliosis Research Society. Multicenter spine fracture study. *Spine Phila Pa* 1992;17:528–40.

Holdsworth F (1970) Fractures, dislocations, and fracture-dislocations of the spine. *J Bone Joint Surg Am* 52:1534–51.

Kim DH, Silber JS, Albert TJ (2003) Osteoporotic vertebral compression fractures. *Instr Course Lect* 52:541–50.

Magerl F, Aebi M, Gertzbein SD, Harms J, Nazarian S (1994) A comprehensive classificationof thoracic and lumbar injuries. *Eur Spine J* 3:184–201.

Reginster JY, Burlet N (2006) Osteoporosis: a still increasing prevalence. *Bone* 38:S4–9.

Roaf R (1960) A study of the mechanics of spinal injuries. *J Bone Joint Surg Br* 42B:810–23.

In: Encyclopedia of Surgery (22 Volume Set)
Editors: Andreas Lehrer and Kristin Mueller
ISBN: 978-1-53618-329-0
© 2020 Nova Science Publishers, Inc.

Chapter 19

BIOMECHANICAL EVALUATION

Daniele Vanni[1,*], MD and Vincenzo Salini[2]

[1] Orthopaedic and Traumatology Department, "G. d'Annunzio" University, Chieti, Italy. Neurosurgery Spine Department, Asl Chieti, Italy

[2]Department Chief of Orthopaedic and Traumatology Department, "G. d' Annunzio" University, Chieti, Italy. Orthopaedic and Traumatology Residency, "G. d'Annunzio" University, Chieti, Italy

The spine acts as a pillar, since it supports the weight of the upper part of the body, by transferring the load on the lower limbs through the pelvis [1]. The spine is conceptually divided into several Spinal Functional Units (SFU). Each SFU is composed of two vertebrae and the disc in between them. Each SFU could be divided intro three columns: anterior, middle and posterior. The anterior and middle columns sustain the axial compressive loads that become progressively more important cranio-caudally. A complex load resulting from an anterior bending moment and an axial compression, due to the specific location of center of gravity of human body , that is situated anteriorly to the spine [1,2]. For these reason, tensile forces along the posterior column are necessary in order to keep the spine erect. This forces act on the medial column, that represents the fulcrum of the spine, while the anterior column has to resist the compression forces. Consequently to the anterior flexion, center of gravity of human body moves more anteriorly, increasing the bending moment on the vertebral column and the compressive stresses on the anterior column. Bending over to pick up a load not only moves the center of gravity anteriorly, but also it increases the magnitude of the anteriorly load, which combined with the increased moment arm, greatly increases the compressive stresses on the anterior column. This biomechanical condition is responsible of the anterior overload, especially in the older people with camptocormic posture , further overloading the anterior column.

Vertebral body is formed by cancellous bone biomechanically characterized by high bone turnover (80%) and lower calcified volume (20%). Therefore, this tissue withstands the dynamic stresses, deforming itself without breaking. Vertebral body resists the compressive forces, although this function depends on age, posture and loading history. Resistance to

* Corresponding Author's Email: danielevannimd@libero.it

compression is attributable to the dense trabecular network. Infact, the structure of a vertebral body does not weaken greatly even after removal of the outer shell of cortical bone,. On the osteoporotic vertebrae, the cortex resists 15% of the compressive load close to the endplates, and 45% at midbody height. The supporting role of the cortex increases in vertebra of older patients. In fact they lose bone faster from the trabeculae that from the cortex. The anterior cortex is thicker and less porous than the posterior one. Probably this is due to the need to resist to the higher forces during the forward flexion movements. The trabeculae of the vertebral bodies tend to be denser in the posterior part of the vertebral body, compared to the anterior part. The trabeculae are more dense in the inferior part than the upper half, perhaps because they are reinforced by the trabecular arcades from the pedicles. Degenerative disc disease and senile neuromotor and neurosensory decay, are associated with progression of kyphosis resulting in anterior translation of gravitational axis, progressive distraction of posterior ligaments and compression of anterior column. In case of osteoporosis, the trabecular thinning results in reduction of strength of vertebral body.. In relation to the gravitational force, the fracture of the body induces reduction of height of vertebral body and progression of kyphosis, especially at the level of the anterior spinal column [4]. The more involved vertebrae are T7 and T8 at the middle thoracic column and T12 and L1 at the thoracolumbar transition which is subjected to great flexion (Figure 1). The thoracolumbar hinge is subjected to most stress being a junction of different curves. The progression of kyphotic curve and forward displacement of gravitational axis lead to an increase in flexion, causing new fracture. Infact, the risk of another vertebral fracture increases 5 fold after the first event ('domino-effect') (Figure 2).

These conditions, must be considered in case of open approach, especially in identifying the level of junction and the location and surgery instrumentation, considering the increased fixation failure risk.

Images:

Group	CPS group	PMMA-PS group	EPS group
BMD (g/cm^2)	0.68+/-0.06	0.71+/-0.08	0.66+/-0.007
F_{max} (N)	751.50+/-251.37	1521.70+/-513.27	1175.20+/-396.51
E (J)	1.47+/-0.51	3.09+/-0.93	2.46+/-0.69

BMD, Fmax and E in CPS group, PMMA-PS group and EPS group

Figure 1. Different characteristics of transpedicular screw fixation systems.

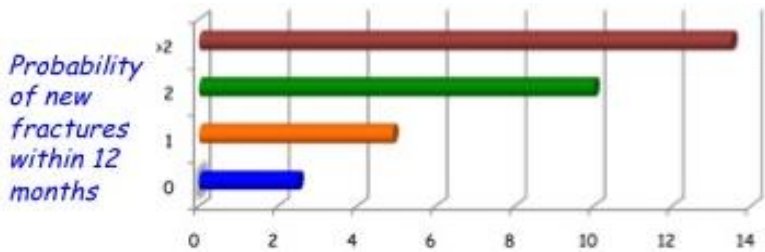

Figure 2. Probability of new vertebral fractures within 12 months from the first.

REFERENCES

[1] Biomechanics of vertebral fractures and the vertebral fracture cascade. Christiansen BA, Bouxsein ML. *Curr Osteoporos Rep*. 2010;8(4):198-204.

[2] Mechanisms of initial endplate failure in the human vertebral body. Fields AJ, Lee GL, Keaveny TM. *J. Biomech.* 2010;1;43(16):3126-31

[3] Biomechanics of thoracolumbar burst fractures: Methods of induction and treatments. Fakurnejad S, Scheer JK, Patwardhan AG, Havey RM, Voronov LI, Smith ZA. *J. Clin. Neurosci*. 2014 Jun 25

[4] Endplate deflection is a defining feature of vertebral fracture and is associated with properties of the underlying trabecular bone. Jackman TM, Hussein AI, Adams AM, Makhnejia KK, Morgan EF. *J. Orthop. Res.* 2014 Jul;32(7):880-6.

[5] Dynamics of interpedicular widening in spinal burst fractures: an in vitro investigation. Brandolini N, Kapur N, Hall RM. *Spine J.* 2014 Feb 6. pii: S1529-9430(14)00135-1.

[6] The influence of distraction force on the intradiscal pressure gradient in the bridged lumbar spine: a biomechanical investigation using a calf model. Spiegl U, Pätzold R, Glasmacher S, Stephan D, Josten C, Bühren V, Gonschorek O, Augat P. *Spine* (Phila Pa 1976). 2014 Apr 1;39(7):E427-33.

[7] Lumbar trabecular bone mineral density distribution in patients with and without vertebral fractures: a case-control study. Giambini H, Salman Roghani R, Thoreson AR, Melton LJ 3rd, An KN, Gay RE. *Eur. Spine J.* 2014 Jun;23(6):1346-53.

[8] Biomechanics of human thoracolumbar spinal column trauma from vertical impact loading. Yoganandan N, Arun MW, Stemper BD, Pintar FA, Maiman DJ. *Ann. Adv. Automot. Med*. 2013;57:155-66.

[9] Biomechanics of thoracolumbar junction vertebral fractures from various kinematic conditions. Fradet L, Petit Y, Wagnac E, Aubin CE, Arnoux PJ. *Med. Biol. Eng. Comput*. 2014 Jan;52(1):87-94.

[10] Biomechanics of vertebral compression fractures and clinical application. Adams MA, Dolan P. *Arch. Orthop. Trauma Surg*. 2011 Dec;131(12):1703-10.

[11] Biomechanics of back pain. Adams MA. *Acupunct. Med*. 2004 Dec;22(4):178-88. Review.

[12] Cortical and trabecular load sharing in the human vertebral body. Eswaran SK, Gupta A, Adams MF, Keaveny TM. N. *J. Bone Miner Res.* 2006 Feb;21(2):307-14.

In: Encyclopedia of Surgery (22 Volume Set)
Editors: Andreas Lehrer and Kristin Mueller
ISBN: 978-1-53618-329-0
© 2020 Nova Science Publishers, Inc.

Chapter 20

EPIDEMIOLOGY OF ADULT THORACOLUMBAR FRACTURES

Luigi Aurelio Nasto [*] ***and Enrico Pola***
Department of Orthopaedic Surgery, Catholic University of Rome School of Medicine,
"A. Gemelli" University Hospital, Rome, Italy

INTRODUCTION

Data on incidence of thoracolumbar (TL) fractures in adult population are sparse and varies with countries and population analysed. Reported incidence ranges from 23 to 90 cases per 100,000 inhabitants per year.[1-3] However, available data are either retrospective case series from different centres or small population cohort studies, i.e., the Framingham study which included 5,209 patients with a reported prevalence of vertebral fractures of 14%.[4]

Thoracolumbar fractures classically exhibit a bimodal distribution, with peaks among males under 30 years of age and in the geriatric population.[5] Thoracolumbar fractures occurring in young and middle-age patients (less than 60 years old) result from a medium to high-energy trauma, such as motor vehicle accidents, falls from height, and sports-related injuries. In particular, motorcycle riders are more likely to sustain severe spinal fractures; nevertheless, in recent years the incidence of thoracolumbar fractures resulting from gunshot wounds and other projectiles has been increasing as well. [6, 7] The rate of TL fractures in patients admitted to the hospital because of blunt trauma has been reported to be as high as 2-4%. In an observational study of 2400 trauma patients scanned for TL fractures, a total of 260 injuries were identified in 152 patients (6.3%). Forty-two (16.2%) fractures occurred at L1, 38 (14.6%) at L2, 29 (11.1%) at L3, and 27 (10.4%) at T12; the higher thoracic spine (T1-T7) accounted for 13.5% of the fractures, making the thoracolumbar junction the most frequently involved segment.[8] TL injuries occur most frequently in men (2/3) than in women (1/3) and some neurological deficit occurs in about 10 – 20% of traumatic spinal fractures, accounting for some 11,000 new spinal cord injuries occurring each year in the United States. In a recent longitudinal prospective study on 13,496 admitted patients in Sweden, incidence of TL

[*] Corresponding Author's Email: luigiaurelionasto@yahoo.it.

fractures in patients younger than 60 years old was 13 per 100,000 per year, and twice as high in men as in woman. Fifteen percent (15%) of these patients required surgery with a 30 day case fatality rate of 0.7% and a 90 day case fatality rate of 1.4%. [9] Despite the relatively low mortality rate of TL fractures in young patients without neurological injury, the 1-year mortality rate for patients with paraplegia or other catastrophic spinal cord injuries approaches 7%.[10]

Isolated thoracolumbar fractures are also frequently seen in elderly women. Because of their poor bone density and declining mental status, elderly people may develop TL fractures after a fall from a standing height or minor trauma. TL wedge compression fractures account for the most frequent osteoporotic fractures. They often occur at the midthoracic (T7-T8) spine and the thoracolumbar junction (T12-L1) and, despite being associated with significant pain and morbidity, remain frequently undiagnosed.[11, 12] Reported incidence of TL fractures in elderly patients rises sharply with age ranging from 570 to 1070 per 100,000 inhabitants per year, in men and women respectively. [13] Osteoporosis is the single most important risk factor for TL fractures in elderly patients, therefore TL fracture epidemiology is strictly dependent on the incidence of osteoporosis in general population. It is currently estimated that over 200 million people suffer from this disease worldwide.[14] This figure is expected to rise in the following years because of the alarming trend of an increasingly aging population in western countries.[15] Osteoporotic TL fractures also carry and extra burden of increased morbidity and mortality in elderly patient. In a recent long-term (12 to 22 years) follow-up study on 257 patients presence of an osteoporotic TL fracture strongly correlated with higher prevalence of back pain, impaired health status, and increased 10-year mortality rate. Mortality rate among female patients with a TL fracture was 95,1 per 1,000 inhabitant-years, whilst it was only 62,0 per 1,000 inhabitant-years among an age-matched control population.[16] TL fractures in elderly patients are associated with chronic pain, decreased physical function, deformity, and potentially social isolation, all of which negatively impact individual quality of life. [17] Nevertheless, a direct connection between TL fractures and specific causes of death have not been identified. This suggests an indirect association between osteoporosis, TL fractures, and other comorbidities eventually leading to a decreased life expectancy for elderly patients. [18]

Direct and indirect costs of TL fractures in general population have been studied by many authors but figures are different according to the country and the study population analyzed.[19-22] In a recent study by the researchers of the VU University Medical Centre in Netherlands, a total of 200 patients were retrospectively reviewed and assessed. Average cost of conservative treatment for stable TL fracture without neurological deficit was € 5,100. Surgical treatment of unstable fractures had an average cost of € 12,500, whereas TL fractures with neurological deficit accounted for € 31,900 of extra costs. [23] However, estimates of costs for osteoporotic TL vertebral fractures are even higher. A recent study from researchers at Hannover University has shown an extra average cost of € 8,200 per year per newly diagnosed fracture in patients ≥ 60 years of age.[24] The annual number of fractures in the EU will rise from 3,5 million in 2010 to 4,5 million in 2025, corresponding to an increase of 28% with a total cost, in 2010, of € 37 billion (of which 66% spent for direct treatment of the incident fractures, 5% for pharmacological prevention, and 29% for long-term fracture care).[25] With these figures in mind, it is reasonable to assume that the prevention, treatment, and long-term follow-up of TL fractures in Europe and worldwide will became a major issue for modern healthcare systems.

REFERENCES

[1] Belmont, Jr.P. J. et al. (2001). Incidence, epidemiology, and occupational outcomes of thoracolumbar fractures among U.S. Army aviators. *J Trauma,*. *50*(5) 855-61.

[2] Cooper, C., et al. (1992). Incidence of clinically diagnosed vertebral fractures: a population-based study in Rochester, Minnesota, 1985-1989. *J Bone Miner Res,*. *7*(2),221-7.

[3] Kanis, J.A., et al. (2000). Long-term risk of osteoporotic fracture in Malmo. *Osteoporos Int*, *11*(8), 669-74.

[4] Samelson, E. J., et al. (2006). Incidence and risk factors for vertebral fracture in women and men: 25-year follow-up results from the population-based Framingham study. *J Bone Miner Res*, *21*(8), 1207-14.

[5] Gertzbein, S.D. (1992). Scoliosis Research Society. Multicenter spine fracture study. *Spine* (Phila Pa 1976),. *17*(5), 528-40.

[6] Robertson, A., et al., (2002). Spinal injury patterns resulting from car and motorcycle accidents. *Spine* (Phila Pa 1976). *27*(24), 2825-30.

[7] Bono, C.M. and R. F. Heary. (2004). Gunshot wounds to the spine. *Spine J,*. *4*(2), 230-40.

[8] Holmes, J.F., et al. (2001). Epidemiology of thoracolumbar spine injury in blunt trauma. *Acad Emerg Med*, *8*(9), 866-72.

[9] Jansson, K.A., et al., (2010). Thoracolumbar vertebral fractures in Sweden: an analysis of 13,496 patients admitted to hospital. *Eur J Epidemiol*, *25*(6), 431-7.

[10] Shikata, J., et al. (1990). Surgical treatment for paraplegia resulting from vertebral fractures in senile osteoporosis. *Spine* (Phila Pa 1976), *15*(6), 485-9.

[11] Nevitt, M. C., et al. (1998). The association of radiographically detected vertebral fractures with back pain and function: a prospective study. *Ann Intern Med,*. *128*(10), 793-800.

[12] Melton, L.J., 3rd and D.F. Kallmes, (2006). Epidemiology of vertebral fractures: implications for vertebral augmentation. *Acad Radiol,*. *13*(5), 538-45.

[13] Felsenberg, D., et al. (2002). Incidence of vertebral fracture in europe: results from the European Prospective Osteoporosis Study (EPOS). *J Bone Miner Res,*. *17*(4), 716-24.

[14] Cooper, C., Campion, G. & Melton, L. J. 3rd. (1992). Hip fractures in the elderly: a world-wide projection. *Osteoporos Int,*. *2*(6), 285-9.

[15] Reginster, J.Y. &Burlet, N.(2006) *Osteoporosis: a still increasing prevalence.Bone*, *38*(2 Suppl 1), S4-9.

[16] Hasserius, R., et al. (2005). Long-term morbidity and mortality after a clinically diagnosed vertebral fracture in the elderly--a 12- and 22-year follow-up of 257 patients. *Calcif Tissue Int*, *76*(4) 235-42.

[17] Riggs, B.L. & Melton, L. J.3rd. (1995). The worldwide problem of osteoporosis: insights afforded by epidemiology. *Bone*, *17*(5 Suppl) 505S-511S.

[18] Kado, D.M., et al. (1999). Vertebral fractures and mortality in older women: a prospective study. Study of Osteoporotic Fractures Research Group. *Arch Intern Med*, *159*(11),1215-20.

[19] Bleibler, F., et al. (2014). Expected lifetime numbers and costs of fractures in postmenopausal women with and without osteoporosis in Germany: a discrete event simulation model. *BMC Health Serv Res*, *14*, p. 284.

[20] Svedbom, A., et al. (2014). Epidemiology and economic burden of osteoporosis in Switzerland. *Arch Osteoporos*, *9*, 187.

[21] Qu, B., et al. (2014). The economic burden of fracture patients with osteoporosis in western China. *Osteoporos Int*, *25*(7), 1853-60.

[22] Si, L., Winzenberg, T. M.& Palmer, A. J. (2014). A systematic review of models used in cost-effectiveness analyses of preventing osteoporotic fractures. *Osteoporos Int*, *25*(1), p. 51-60.

[23] van der Roer, N., et al. (2005). Direct medical costs of traumatic thoracolumbar spine fractures. *Acta Orthop*, *76*(5), 662-6.

[24] Lange, A., Zeidler, J.,& Braun, S.(2014). One-year disease-related health care costs of incident vertebral fractures in osteoporotic patients. *Osteoporos Int*, 2014.

[25] Hernlund, E., et al. (2013).Osteoporosis in the European Union: medical management, epidemiology and economic burden. A report prepared in collaboration with the International Osteoporosis Foundation (IOF) and the European Federation of Pharmaceutical Industry Associations (EFPIA). *Arch Osteoporos*, *8*(1-2), p. 136.

In: Encyclopedia of Surgery (22 Volume Set)
Editors: Andreas Lehrer and Kristin Mueller
ISBN: 978-1-53618-329-0
© 2020 Nova Science Publishers, Inc.

Chapter 21

SURGICAL OPTIONS FOR THORACOLUMBAR VERTEBRAL FRACTURES

Daniele Vanni[1,*], Vincenzo Magliani[1] and Renato Galzio[2]
[1]Orthopaedic and Traumatology Department, "G. d'Annunzio" University, Chieti, Italy.
Neurosurgery Spine Department, Asl Chieti, Italy
[2]Neurosurgery Department, "L'Aquila University", L'Aquila, Italy.
Neurosurgery Residency "L'Aquila University", L'Aquila, Italy

The surgical management of the thoraco-lumbar vertebral fractures is a difficult topic. Sometimes they can be treated conservatively, but in case of complications, such as neurological deficit or progression of the segmental kyphosis, surgical treatment becomes mandatory. Furthermore, it must be considered that some complications [1] can also occur after a correct surgical treatment, especially, in case of an osteoporotic spine. Osteoporotic vertebral injuries are divided into several types [2,3]: A) wedge-type compression fracture exhibiting progressive kyphosis, B) flat-type fracture with osteonecrosis or pseudarthrosis often exhibiting intravertebral cleft formation; C) concave or H-shaped fracture associated with anterior spur or sclerotic changes.

The best results can be found in patients treated for wedge-type lesions. The presence of an anterior bone spur in H-shaped fractures may help to stabilize the collapsed vertebra. Therefore, a posterior approach must be performed in the cases of the concave fracture or H-shaped fracture. An anterior procedure might invalidate the stabilization produced by the bone spur. Moreover, in cases of flat-type lesions, the eggshell procedure is an excellent option. [4, 5, 6].

On the contrary, the anterior surgical approaches are performed to decompress the spinal canal and to release the posterior structures, especially in the case of a severe segmental kyphosis. However, the anterior instrumentation is associated with a high rate of failure when it is used alone [7, 8, 9, 10, 11, 12]. Therefore, a combined anterior and posterior procedure may maximize the chances for a successful fusion. However, a simple augmentation of the vertebral body,if possible, represents the easiest mode to obtain the reconstruction of the

* Corresponding Author's Email: danielevannimd@libero.it.

anterior column.[13-14]. Anterior approach is not at all easy to perform, especially in elderly patients, due to their comorbidities [8, 9]. Therefore, posterior approach is the best choice in order to obtain decompression of the neural elements, fixation of the vertebral column and correction of the deformity [11, 15, 16].

Fixation failure and loss of correction are two most fearful complications, especially in osteoporotic spine[11]. For these reasons it is necessary to obtain very stable constructs.

The problem of each instrumentation is the difference between the hardness of the osteoporotic bone and the stiffness of the implant. The pedicle screws may damage the bone, causing a screw loosening, while the cages may penetrate into the vertebral body.

In case of anterior approach, in osteoporotic spine, it is mandatory to avoid collapse of the bone graft or subsidence of the cage during the procedure of correction of the deformity, especially in postoperative period. In fact, progression of segmental kyphosis requires a combined anterior and posterior procedure.

In case of posterior instrumentation, it is mandatory to perform a stabilization involving at least two vertebrae above and two vertebrae below the fracture. Regarding the choice of the implants, pedicle screws are the best system. Sublaminar hooks were also used in the past, but the risk of laminar fracture and migration of the hook is very high, especially in osteoporotic spine. However, sublaminar hooks (or wires) can be used together with the pedicle screws, placing them at the proximal or distal edge of the constructs.

Nevertheless, the most common complication is the cement leakage into the adjacent structures. Although the rate of symptomatic clinically leaks is low, severe complications may occur, mainly spinal cord or nerve root compression, pulmonary embolism, paraplegia or death.

When the conservative treatment is not possible and open posterior fixation become an overtreatment, a minimally invasive percutaneous approach is a good alternative [17]. The minimally invasive approach allows a tissue-sparing surgery, reduces blood loss and postoperative pain. The patients affected with osteoporotic vertebral fractures, often have multiple co-morbidities and they are subjected to multidrug medical therapy. Therefore, whenever possible, it better to use this approach. Although an accurate patient selection is necessary. The percutaneous posterior stabilization, used as internal fixation system, should be reserved for stable vertebral fractures only [18].

This technique involves, through mini-incisions, the insertion of pedicle screws with two external tubes and a targeting system. It possible to insert a connecting rod, stabilizing the upper and lower vertebrae.

NEW PERSPECTIVES FOR SCREW FIXATION

From a biomechanical point of view, the pedicle provides a strong fixation for the screws in the healthy bone. But, in osteoporotic vertebra, the trabecular and cortical bone of the pedicle can be reduced by up to 50% [18]. The instrumentation of the osteoporotic spine, especially in posterior stabilization, results in failure in 12% of cases, due to loosening of the screws [19, 20, 21, 22, 23], and poor rigidity of the bone–screw contact. The correction of failure or nonunion requires a surgical revision. Therefore, different designs and methods of augmentation of the screws should be available [24]. Various methods were developed to

increase the fixation strength of the screw in case of bone deficiency. Perforated screws with vertebroplasty augmentation, solid screws with vertebroplasty augmentation and solid screws with balloon kyphoplasty augmentation are actually used. Alternatively, it is possible to combine sublaminar hooks, wires, conical screws, iliac screws or expandable screws [25, 26], but with higher strength and higher risk [27, 28]. Brantley et al. [29] suggested that there is an interaction between increase in diameter and increase in length. Polly et al. [30] reported that increasing the length of the screw alone or increasing the diameter of the screw less than 2 mm do not improve screw stability. The depth of the screw insertion plays a significant role. Screws implanted deeper than 50% into the vertebral body or bicortical screws perforating anterior vertebral cortex can enhance the bone anchorage [31, 32]. However, the bicortical fixation was avoided because of the risk of anterior leakage. The cement augmentation is regarded as an efficient system to enhance the strength of the screw in the osteoporotic bones, transferring the bio-mechanical load anteriorly from the pedicle to the vertebral body [33]. The higher strength of screw can be obtained with the larger amount of injected cement. There could be potential problems like, risk of cement leakage and difficulty of the removal of the screw. Cook et al. [34] reported that PMMA injection through the expanded screw increased the pullout strength by 250% when compared with the non-cemented expandable screw [35]. In both the techniques, cement is injected prior to insertion of the screw. Researchers designed an expandable pedicle screw (EPS) which is able to improve screw stability without harming the pedicle, avoiding the risk of pedicle fracture and vascular or visceral injuries caused by larger or longer screws. Many biomechanical studies have demonstrated that pedicle screw fixation is highly correlated with the bone density [35]. In fact the mechanical load influences the bone tissue according to Wolff's law [36]. As a result, the density of bone surrounding the expandable portions of the EPS becomes higher. The expansion of the EPS should also improve fixation strength by allowing greater bone contact, without an increase in the insertion diameter or in the screw length. EPS enhances the strength of the fixation like the traditional method of PMMA screw augmentation [37]. In conclusion, the expandable pedicle screw is an effective, safe and easy method.

REFERENCES

[1] Spinal cord compression. Schiff, D. *Neurol Clin*, 2003, 21, 67–86.

[2] The three column spine and its significance in the classification of acute thoracolumbar spinal injuries. Denis, F. *Spine*, 8, 817–831, 1983

[3] Percutaneous vertebroplasty for severe osteoporotic vertebral body compression fractures. Peh, WC; Gilula, LA; Peck, DD. *Radiology*, 223, 121–126, 2002

[4] Transpedicular decompression and pedicle subtraction osteotomy (eggshell procedure): a retrospective review of 59 patients. Murrey, DB; Brigham, CD; Kiebzak, GM; Finger, F; Chewning, SJ. *Spine* (Phila Pa 1976). 2002, 27(21), 2338-45.

[5] The eggshell technique for prevention of cement leakage during kyphoplasty. Greene, DL; Isaac, R; Neuwirth, M; Bitan, FD. *J Spinal Disord Tech*., 2007, 20(3), 229-32.

[6] Surgical correction of lumbar kyphotic deformity: posterior reduction "eggshell" osteotomy. Danisa, OA; Turner, D; Richardson, WJ. *J Neurosurg*., 2000 Jan, 92(1 Suppl), 50-6.

[7] Spinal cord anterior decompression for delayed spinal cord paralysis after osteoporotic vertebral compression fracture: application of thoracoscopic approach. Hiraizumi Y. *Chir Narzadow Ruchu Ortop Pol*., 2008, Jan-Feb, 73(1), 67-73.

[8] Anterior thoracolumbar reconstruction surgery for late collapse following vertebroplasty: report of three cases. Miyagi, R; Sakai, T; Bhatia, NN; Sairyo, K; Katoh, S; Chikawa, T. *J Med Invest*., 2011 Feb, 58(1-2), 148-53.

[9] Anterior expandable strut cage replacement for osteoporotic thoracolumbar vertebral collapse. Uchida, K; Kobayashi, S; Nakajima, H; Kokubo, Y; Yayama, T; Sato, R; Timbihurira, G; Baba, H. *J Neurosurg Spine*., 2006, 4(6), 454-62.

[10] Two in vivo surgical approaches for lumbar corpectomy using allograft and a metallic implant: a controlled clinical and biomechanical study. Huang, P; Gupta, MC; Sarigul-Klijn, N; Hazelwood, S; *Spine, J*. 2006, 6(6), 648-58.

[11] Relationship between New Osteoporotic Vertebral Fracture and Instrumented Lumbar Arthrodesis. Kim, BH; Choi, DH; Jeon, SH; Choi, YS. *Asian Spine J*., 2010 Dec, 4(2), 77-81.

[12] Posterior instrumented fusion without neural decompression for incomplete neurological deficits following vertebral collapse in the osteoporotic thoracolumbar spine. Ataka, H; Tanno, T; Yamazaki, M. *Eur Spine J*., 2009 Jan, 18(1), 69-76. Epub 2008 Nov 13.

[13] Combined posteroanterior surgery for osteoporotic delayed vertebral fracture and neural deficit in patients with Parkinson's disease. Nakashima, H; Yukawa, Y; Ito, K; Horie, Y; Machino, M; Kato, F. *Orthopedics*., 2009, 32(10).

[14] Vertebroplasty-augmented short-segment posterior fixation of osteoporotic vertebral collapse with neurological deficit in the thoracolumbar spine: comparisons with posterior surgery without vertebroplasty and anterior surgery. Uchida, K; Nakajima, H; Yayama, T; Miyazaki, T; Hirai, T; Kobayashi, S; Chen, K; Guerrero, AR; Baba, H. *J Neurosurg Spine*., 2010 Nov, 13(5), 612-21.

[15] Anterior versus posterior surgery for osteoporotic vertebral collapse with neurological deficit in the thoracolumbar spine. Uchida, K; Kobayashi, S; Matsuzaki, M; Nakajima, H; Shimada, S; Yayama, T; Sato, R; Baba, H. *Eur Spine J*., 2006 Dec, 15(12), 1759-67. Epub 2006 May 5.

[16] Anterior-posterior surgery versus posterior closing wedge osteotomy in posttraumatic kyphosis with neurologic compromised osteoporotic fracture. Suk, SI; Kim, JH; Lee, SM; Chung, ER; Lee, JH. *Spine* (Phila Pa 1976). 2003, 28(18), 2170-5.

[17] Minimal access surgical techniques in the management of the painful lumbar motion segment. German, JW. *Foley Spine* (Phila Pa 1976). 2005, 30(16 Suppl), S52-9. KT.

[18] Biomechanical study of pedicle screw fixation in severely osteoporotic bone. Cook, SD; Salkeld, SL; Stanley, T; Faciane, A; Miller, SD. *Spine J*., 2004, 4(4), 402-8.

[19] Influence of bone mineral density on the fixation of thoracolumbar implants. A comparative study of transpedicular screws, laminar hooks, and spinous process wires. Coe, JD; Warden, KE; Herzig, MA; McAfee, PC. *Spine*, 1990, 15(9), 902–907.

[20] Effects of bone mineral density on pedicle screw fixation. Halvorson, TL; Kelley, LA; Thomas, KA; Whitecloud, TS 3rd, Cook, SD. *Spine*, 1994, 1, 19(21), 2415–2420

[21] Caudo-cephalad loading of pedicle screws: mechanisms of loosening and methods of augmentation. Law, M; Tencer, AF; Anderson, PA. *Spine*, 1993 18(16):2438–2443

[22] Influence of bone mineral density on pedicle screw fixation: a study of pedicle screw fixation augmenting posterior lumbar interbody fusion in elderly patients. Okuyama, K; Abe, E; Suzuki, T; Tamura, Y; Chiba, M; Sato, K. *Spine J*, 2001,1(6), 402–407

[23] An experimental study on transpedicular screw fixation in relation to osteoporosis of the lumbar spine. Soshi, S; Shiba, R; Kondo, H; Murota, K. *Spine*, 1991, 16(11), 1335–1341.

[24] Assessment of different screw augmentation techniques and screw designs in osteoporotic spines. Becker S; Chavanne A; Spitaler R; Kropik, K; Aigner, N; Ogon, M; Redl, H. *Eur Spine J*., 2008, 17(11), 1462-9.

[25] Surgical Treatment of Osteoporotic Thoracolumbar Compressive Fractures with Open Vertebral Cement Augmentation of Expandable Pedicle Screw Fixation: A Biomechanical Study and a 2-Year Follow-up of 20 Patients. Wu, ZX; Gao, MX; Sang, HX; Ma, ZS; Cui, G; Zhang, Y; Lei, W. *J Surg Res*., 2010.

[26] Biomechanical and histological evaluation of an expandable pedicle screw in osteoporotic spine in sheep. Wan, S; Lei, W; Wu, Z; Liu, D; Gao, M; Fu, S. *Eur Spine J*., 2010, 19(12), 2122-9.

[27] Effects of bone mineral density on pedicle screw fixation. Halvorson, TL; Kelley, LA; Thomas, KA; Whitecloud, TS 3rd; Cook, SD. *Spine*, 1994; 1 19(21), 2415–2420

[28] Increased pedicle screw pullout strength with vertebroplasty augmentation in osteoporotic spines. Sarzier, JS; Evans, AJ; Cahill, DW. *Neurosurg*, 2002, 96(3 Suppl), 309–312

[29] The effects of pedicle screw fit. *An in vitro study*. Brantley, AG; Mayfield, JK; Koeneman, JB. Spine 1994, (Phila Pa 1976) 19, 1752–1758

[30] Revision pedicle screws. Bigger; longer shims—what is best? Polly, DW Jr; Orchowski, JR; Ellenbogen, RG. *Spine*, 1998 (Phila Pa 1976) 23, 1374–1379

[31] Radiculopathy caused by osteoporotic vertebral fractures in the lumbar spine. Sasaki, M; Aoki, M; Nishioka, K; Yoshimine, T. *Neurol Med Chir* (Tokyo). 2011, 51(7), 484-9.

[32] Vertebral fracture. Griffith, JF; Guglielmi, G. *Radiol Clin North Am*., 2010, 48(3), 519-29. Review.

[33] Biomechanical study of pedicle screw fixation in severely osteoporotic bone. Cook, SD; Salkeld, SL; Stanley, T. *Spine J*, 2004, 4, 402–408

[34] Biomechanical comparison of different techniques in primary spinal surgery in osteoporotic cadaveric lumbar vertebrae: expansive pedicle screw versus polymethylmethacrylate-augmented pedicle screw. Liu, D; Wu, ZX; Pan, XM; Fu, SC; Gao, MX; Shi, L; Lei, W. *Arch Orthop Trauma Surg*., 2011

[35] Influence of screw positioning in a new anterior spine fixator on implant loosening in osteoporotic vertebrae. Reinhold, M; Schwieger, K; Goldhahn, J; Linke, B; Knop, C; Blauth, M. *Spine* (Phila Pa 1976)2006; 31, 406–413

[36] The biology of bone graft repair. Burchardt, H. *Clin Orth Rel Res*., 1983, 174, 28–42.

[37] Minimally invasive lumbar fusion. Foley, KT; Holly, LT; Schwender, JD. *Spine* (Phila Pa 1976). 2003, 28(15 Suppl), S26-35. Review.

In: Encyclopedia of Surgery (22 Volume Set)
Editors: Andreas Lehrer and Kristin Mueller
ISBN: 978-1-53618-329-0
© 2020 Nova Science Publishers, Inc.

Chapter 22

VERTEBROPLASTY AND KYPHOPLASTY: ROLE AND LIMITS

Daniele Vanni[1]*, MD, Vincenzo Magliani[2], MD and Renato Galzio[3]

[1]Orthopaedic and Traumatology Department,
"G. d'Annunzio" University, Chieti, Italy.
Neurosurgery Spine Department, Asl Chieti, Italy
[2]Neurosurgery Spine Department, Asl Chieti, Italy,
Spine Trauma at Orthopaedic and Traumatology Residency,
"G. d'Annunzio" University, Chieti, Italy.
[3]Neurosurgery Department, "L'Aquila University", L'Aquila, Italy
Neurosurgery Residency "L'Aquila University", L'Aquila, Italy

At the moment there is not a single guideline about the management of vertebral fractures, both traumatic and pathological [1,2]. Timing and the indications for the conservative treatment are not clear. In addition, the surgical criteria are also poorly defined. In the past, a conservative treatment for at least 30 days was considered as proper treatment for the majority of the fractures, especially in case of osteoporosis vertebral fractures (OVF). Surgical solutions were necessary if pain persisted-vertebroplasty for vertebral fractures with loss of height less than 30%, kyphoplasty for the ones with height loss greater than 30%. The conservative treatment avoids surgical risks. However, it forces the patient to a poor quality of life and it does not stop the domino effect, with poor results. Vertebral augmentation procedures are fast, performed in general anesthesia and percutaneously. Therefore, a standing radiography is necessary in patients with acute, severe back or low back pain and a risk profile (age >65 years, positive anamnesis for previous vertebral fractures, metabolic diseases, renal failure, and prolonged therapy with the corticosteroids or antiepileptic, body mass index <20). CT scan is performed in order to characterize the fracture personality, to obtain more detailed information about fracture type and to distinguish between a simple compression fracture from a more complex lesion. MRI shows signs of spinal cord and/or

* Corresponding Author's Email: danielevannimd@libero.it.

dural sac compression, radicular conflict, and also allows to distinguish between new and old fractures, according to signal intensity in TSE (Turbo Spin Echo) T2 weighted sequences. This is the most important aspect according to which surgical indication and eventually the vertebral height recovery entity are established. The more recent the fracture, the greater is the possibility of recovery of height.

Percutaneous surgery with VP or KP [3] is necessary in case of persistent pain or contraindications to use of orthosis (e.g. intolerance, restrictive respiratory failure).

VP is recommended for patients with persistent pain and vertebral collapse less than 30% until 1 month after the fracture or after 3 months.

KP is indicated in case of vertebral collapse persistent pain with high body reduction equal or higher than 30%, between 1 and 3 months. [1,2].

Only PMMA administration could be used for VP, allowing vertebral body reinforcement without restoration of vertebral body height KP provides a partial correction of vertebra body height through an " expandable balloon". KP is a more biomechanically valid process. This technique provides for the stabilization of the fracture after reduction. In addition, the creation of an intrasomatic cavity filled with PMMA reduces the risk of cement leakage. [3, 4, 5]

Although the majority of PMMA leakages are asymptomatic, adverse effects of VP include localized bleeding, infection, mediastinitis, pain, neurological symptoms (neuropathic pain and paraplegia) and pulmonary embolism following leakage of injected material [6, 7, 8, 9, 10].

PMMA leakage has been reported into the venous plexus, inferior vena cava, the epidural space in the spinal canal, neural foramina, intravertebral disk space, and paraspinal soft tissue. Adjacent vertebral fracture is a possible complication, due to a major cement stifness compared to the vertebrae one. (Fribourg et al. 2004). PMMA is contraindicated during infections. Hypotensive reactions may occur between 10 to 165 seconds from bone cement application. They could last from 30 seconds to 5 minutes or more, inducing cardiac arrest.

Percutaneous vertebral augmentation procedures (PVAP) are based on the cement injection into the vertebral body. These techniques have achieved great success in recent years as they allow an efficient OVF management; stabilizing the vertebra, especially the anterior column. they also ensure a rapid pain resolution. The pain in fact, is due to micro-motion fragments at the fracture site. Treatment of OVF has been radically changed in the last three decades. The first generation mini-invasive surgery for treatment of VCF - vertebral compression fracture by percutaneous injection of bone cement (PMMA) was described by Galibert et al. in 1987; this surgical procedure goes by the name of vertebroplasty. [5] This technique produced excellent results in terms of pain relief. However, unfortunately, it appears incomplete in several aspects. In fact, the vertebroplasty does not allow recovery of vertebral body height. Therefore, vertebral body remains collapsed and so the spinal biomechanic is altered . There is not possibility to stop the domino effect. Additionally, it is necessary to inject a very low viscosity and high pressure cement, with risk of leakage of around 30%. These problems led to the creation of second-generation PVAP. The balloon kyphoplasty [5] is a recent change to percutaneous vertebroplasty, conducted for the first time by Reiley in 1998; this procedure involves the inflation of a balloon catheter in the collapsed vertebral body to restore its height before the stabilization with bone cement. The use of the balloon can create a cavity inside the vertebral body; in this way, the cement can be injected with less pressure and greater viscosity, considerably reducing the risk of leakage. [11-16] Reducing the relevance of cement as the primary stabilizer in vertebral compression fractures

may reduce or eliminate concerns about cement leakage.[17,18] Unfortunately, recovery of vertebral body height is temporary. In fact, as soon as the balloon is deflated, there is often a new total or partial vertebral body collapse.[19-22] This has led to creation of a new device. They obtain recovery of vertebral height. However, they must not be removed from the vertebral body to allow the injection of PMMA. Therefore, the conventional balloon can be replaced by equivalent mechanical systems:[23,24] third generation PVAP.

REFERENCES

[1] Cortet B, Blotman F, Debiais F, Huas D, Mercier F, Rousseaux C, Berger V, Gaudin AF, Cotté FE. Management of osteoporosis and associated quality of life in post menopausal women. *BMC Musculoskelet Disord*. 2011;12:7.

[2] Rao RD, Singrakhia MD. Painful osteoporotic vertebral fracture. Pathogenesis, evaluation and roles of vertebroplasty and kyphoplasty in its management. *J. Bone Joint Surg* 2003;85-A(10): 2010– 2022.

[3] Dionyssiotis Y. Management of osteoporotic vertebral fractures. *Int. J. Gen. Med*. 2010;21;3:167- 71.

[4] Hardouin P, Fayada P, Leclet H, Chopin D. Kyphoplasty. *Joint Bone Spine*. 2002;69(3):256- 61.Review.

[5] McGirt MJ, Parker SL, Wolinsky JP, Witham TF, Bydon A, Gokaslan ZL. Vertebroplasty and kyphoplasty for the treatment of vertebral compression fractures: an evidenced-based review of the literature. *Spine J*. 2009;9(6):501-8.Review.

[6] Yang SC, Chen WJ, Yu SW, Tu YK, Kao YH, Chung KC. Revision strategies for complications and failure of vertebroplasties *Eur. Spine J.* 2008;17(7):982-8.

[7] Chen C, Chen L, Gu Y, Xu Y, Liu Y, Bai X, Zhu X, Yang H. Kyphoplasty for chronic painful osteoporotic vertebral compression fractures via unipedicular versus bipedicular approachment: a comparative study in early stage. *Injury*. 2010;41(4):356-9.

[8] Song BK, Eun JP, Oh YM. Clinical and radiological comparison of unipedicular versus bipedicular balloon kyphoplasty for the treatment of vertebral compression fractures. *Osteoporos Int*. 2009;20(10):1717-23.

[9] Oh GS, Kim HS, Ju CI, Kim SW, Lee SM, Shin H. Comparison of the results of balloon kyphoplasty performed at different times after injury. *J. Korean Neurosurg. Soc*. 2010;47(3):199-202.

[10] Voggenreiter G. Balloon kyphoplasty is effective in deformity correction of osteoporotic vertebral compression fractures. *Spine* 2005; 30:2806–2812.

[11] Luo J, Adams MA, Dolan P. Vertebroplasty and Kyphoplasty Can Restore Normal Spine Mechanics following Osteoporotic Vertebral Fracture. *J. Osteoporos*. 2010;2010:729257.

[12] Garfin SR, Yuan HA, Reilley MA. Kyphoplasty and vertebroplasty for the treatment of painful osteoporotic compression fractures. *Spine* 2001;26(14):1511–1555.

[13] Mathis JM, Orlando Ortiz A, Zoarski G. Vertebroplasty versus Kyphoplasty: a comparison and contrast. *Am. J. Neuroradiol.* 2004; 25:840–845.

[14] Felder-Puig R, Piso B, Guba B, Gartlehner G. Kyphoplasty and vertebroplasty for the management of osteoporotic vertebral compression fractures: a systematic review". *Orthopade.* 2009;38(7):606-15. Review.

[15] Khurjekar K, Shyam AK, Sancheti PK, Sonawane D. Correlation of kyphosis and wedge angles with outcome after percutaneous vertebroplasty: a prospective cohort study. *J. Orthop. Surg.* 2011;19(1):35-40.

[16] Bula P, Lein T, Strassberger C, Bonnaire F. Balloon kyphoplasty in the treatment of osteoporotic vertebral fractures: indications - treatment strategy – complications. *Z. Orthop Unfall*. 2010;148(6):646-56.

[17] Minenna G, D'Amore S, D'Amore M.Recenti Complication after vertebroplasty in patient with senile osteoporosis: strategical therapy to revise. *Prog. Med*. 2006;97(7-8):389-92.

[18] Al-Nakshabandi NA. Percutaneous vertebroplasty complications. *Ann. Saudi Med*. 2011;31(3):294-7.

[19] Feltes C, Fountas KN, Machinis T, Nikolakakos LG, Dimopoulos V, Davydov R, Kassam M, Johnston KW, Robinson JS Immediate and early postoperative pain relief after kyphoplasty without significant restoration of vertebral body height in acute osteoporotic vertebral fractures. *Neurosurg. Focus* 2005;18:5.

[20] Rotter R, Martin H, Fuerderer S, Gabl M, Roeder C, Heini P. Vertebral body stenting: a new method for vertebral augmentation versus kyphoplasty Thomas Mittlmeier *Eur. Spine J. 2*010;19:916–923.

[21] Ishiguro S, Kasai Y, Sudo A, Iida K, Uchida A. Percutaneous vertebroplasty for osteoporotic compression fractures using calcium phosphate cement. *J Orthop Surg* (Hong Kong). 2010;18(3):346-51.

[22] Heini PF, Teuscher R. Vertebral body stenting / stentoplasty. *Swiss Med. Wkly*. 2012;142.

[23] Fields AJ, Lee GL, Keaveny TM. Mechanisms of initial endplate failure in the human vertebral body. *J. Biomech*. 2010;1;43(16):3126-31.

[24] Noriega D, Ardura F, Beyerlein J, Hansen-Algenstaedt N. Clinical results for the use of a new extensible cranio-caudal implant for the treatment of vertebral compression fractures; results of a prospective, multicentre study after 1 year of follow-up. *Eur. Spine J*. 2012;21:1415-1439.

In: Encyclopedia of Surgery (22 Volume Set)
Editors: Andreas Lehrer and Kristin Mueller
ISBN: 978-1-53618-329-0
© 2020 Nova Science Publishers, Inc.

Chapter 23

TYPES, MORPHOLOGY AND FUNCTION OF THE NEW DEVICES

Daniele Vanni[1]*, MD and Vincenzo Magliani[2], MD
[1]Orthopaedic and Traumatology Department, "G. d'Annunzio" University, Chieti, Italy.
Neurosurgery Spine Department, Asl Chieti, Italy
[2]Neurosurgery Spine Department, Asl Chieti, Italy
Spine Trauma at Orthopaedic and Traumatology Residency,
"G. d'Annunzio" University, Chieti, Italy

There are different systems and devices available for PVAP, with similar characteristics, although they are different for many features :

Spine Jack® [1] [Figure 1] is a new device for mechanical kyphoplasty. It is a titanium implant designed to restore vertebral height through a distraction effect via bilateral transpedicular minimally invasive approach, the device is inserted into the vertebral body (from T10 to L5) [Figure 2] and gradually expanded like a little jack [Figure 3] [2] . The distraction exerted by the device allows fracture reduction that occurs by ligamentotaxis on the anterior longitudinal ligament. Spine Jack® is equipped with a mechanical and not a hydraulic opening; this ensures a gradual and controlled vertebral fracture reduction. This feature allows to recover the collapsed vertebra and to provide the primary support 3D to the structure in order to mechanically stabilize the vertebrae in axial compression [3]. Once this step has been completed, bone cement is injected into the restored vertebra in order to secure the vertebral structure, and relieve the patient's pain. The presence of two symmetrical devices into the vertebral body allows also a polymethylmethacrylate (PMMA) homogeneous spreading. The expansion of the device creates a high-viscosity cement preferential flow direction, also reducing the risk of leakage . When injected, cement inter-digitation creates a large contact area below the midline: This helps to provide stability to the obtained vertebral body reduction. Although, the technique was developed for osteoporotic fractures, it could be used in traumatic fractures of the thoracolumbar vertebrae.

* Corresponding Author's Email: danielevannimd@libero.it.



Figure 1. Spine Jack System® (From: Vanni et al. [3] J Craniovert Jun Spine 2012).

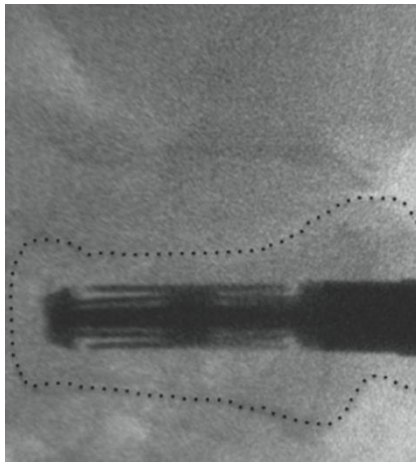

Figure 2. Spine Jack® insertion (From: Vanni et al. [3] J Craniovert Jun Spine 2012).

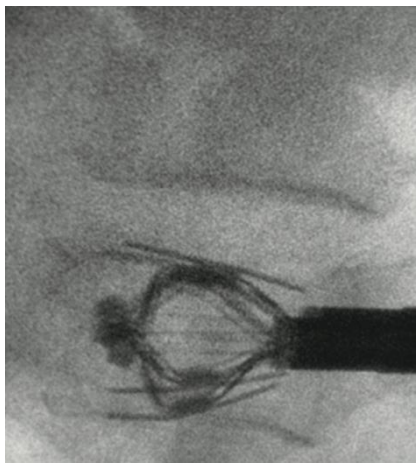

Figure 3. Spine Jack® opening (From: Vanni et al. [3] J Craniovert Jun Spine 2012).

OsseoFix Spinal Fracture Reduction System® [Figure 4,5]: It is intended for the minimally invasive percutaneous treatment of vertebral fractures in the region T10-L5 due to

osteoporotic collapse [4]; it facilitates the correction/reduction of OVF using a titanium implant with PMMA cement [4,5]. The cylindrical titanium implants, once inserted into the vertebral body, restores the height of the vertebral body in question and immediately stabilize a vertebral fracture; the space created by the installation of titanium stent in the vertebral body (which remains in situ) is filled with PMMA [4,5,6].

VBS-Vertebral Body Stenting System® [Figure 6,7]: The VBS is a titanium device, intended for the reduction of painful vertebral compression fractures and/or creation of a void in cancellous bone in the spine for the treatment of levels ranging from Th5-L5 [7,8]. It is intended to be used in combination with a legally-marketed PMMA based bone cement adequately indicated for use in vertebroplasty or kyphoplasty procedures [9,10]. The VBS stents are introduced percutaneously into the vertebral body with only a stab incision required to place the access instruments. Expanding the VBS stents inside the collapsed vertebra offers height restoration and conservation. The mechanical construct restores the height while at the same time offering a cavity for injection of highly viscous PMMA[11, 12, 13].

Figure 4. OsseoFix Spinal Fracture Reduction System®: cylindrical titanium implants.

Figure 5. OsseoFix Spinal Fracture Reduction System®: opening.



Figure 6. VBS-Vertebral Body Stenting System® (From Klezl et al. [13] Injury. 2011).

Figure 7. VBS-Vertebral Body Stenting System®: opening (From Klezl et al. [13] Injury. 2011).

It is possible to affirm that, although the different devices have the same purposes of usage, they have technical characteristics that make them different one from each other. Therefore, it is appropriate to evaluate them in detail, in order to understand how to use them to the properly[14, 15]. In other words, we can say that, depending on different parameters, including the etiopathogenesis of the fracture, its morphological characteristics and the age of the patient, it may be more correct to use one specific device rather than another[16, 17].Considering different experiences of several surgeons, we will discuss in detail the various devices, rationality of their use and we will try to draw a guide line of treatment that could help to choice the more proper and appropriate device for the particular type of vertebral fracture [14, 15, 16, 17].

REFERENCES

[1] Clinical results for the use of a new extensible cranio-caudal implant for the treatment of vertebral compression fractures results of a prospective, multicentre study after 1

year of follow-up. Noriega D, Ardura F, Beyerlein J, Hansen-Algenstaedt N. *Eur. Spine J.* 2012;21:1415-39.

[2] Differences in the restoration of vertebral height after treatment of osteoporotic vertebra compression fractures: Cadaver study. Krüger A, Oberkircher L, Flossdorf F, Ruchholtz S. *Eur. Spine J.* 2012;21:1415-9.

[3] New perspective for third generation percutaneous vertebral augmentation procedures: Preliminary results at 12 months. Vanni D, Pantalone A, Bigossi F, Pineto F, Lucantoni D, Salini V. *J. Craniovert Ju.n Spine* 2012;3:47-51.

[4] Osseofix® system for percutaneous stabilization of osteoporotic and tumorous vertebral compression fractures - clinical and radiological results after 12 months. Ender SA, Gradl G, Ender M, Langner S, Merk HR, Kayser R. *Rofo.* 2014 Apr;186(4):380-7.

[5] Percutaneous Stabilization System Osseofix® for Treatment of Osteoporotic Vertebral Compression Fractures - Clinical and Radiological Results after 12 Months. Ender SA, Wetterau E, Ender M, Kühn JP, Merk HR, Kayser R. *PLoS One*. 2013 Jun 26;8(6):e65119. Print 2013

[6] Cementless Fixation of Osteoporotic VCFs Using Titanium Mesh Implants (OsseoFix): Preliminary Results. Eschler A, Ender SA, Ulmar B, Herlyn P, Mittlmeier T, Gradl G. *Biomed Res Int*. 2014;2014:853897.

[7] Cement Augmentation in a Thoracolumbar Fracture Model: Reduction and Stability Following Balloon Kyphoplasty Vs. Vertebral Body Stenting. Disch AC, Schmoelz W. *Spine* (Phila Pa 1976). 2014 Jun 11.

[8] Radiographic and safety details of vertebral body stenting: results from a multicenter chart review. Diel P, Röder C, Perler G, Vordemvenne T, Scholz M, Kandziora F, Fürderer S, Eiskjaer S, Maestretti G, Rotter R, Benneker LM, Heini PF. *BMC Musculoskelet Disord.* 2013 Aug 8;14(1):233.

[9] Vertebral body stenting versus kyphoplasty for the treatment of osteoporotic vertebral compression fractures: a randomized trial. Werner CM, Osterhoff G, Schlickeiser J, Jenni R, Wanner GA, Ossendorf C, Simmen HP. *J. Bone Joint Surg. Am*. 2013 Apr 3;95(7):577-84.

[10] Vertebral body stenting / stentoplasty. Heini PF, Teuscher R. *Swiss Med. Wkly*. 2012 Aug 6;142:w13658.

[11] Vertebral Body Stenting System for the Treatment of Osteoporotic Vertebral Compression Fracture: Follow-up at 12 Months in 20 Cases. Muto M, Greco B, Setola F, Vassallo P, Ambrosanio G, Guarnieri G. *Neuroradiol. J*. 2011 Aug 31;24(4):610-9.

[12] Vertebral body stenting. A method for repositioning and augmenting vertebral compression fractures. Fürderer S, Anders M, Schwindling B, Salick M, Düber C, Wenda K, Urban R, Glück M, Eysel P. *Orthopade.* 2002 Apr;31(4):356-61.

[13] Early results after vertebral body stenting for fractures of the anterior column of the thoracolumbar spine. Klezl Z, Majeed H, Bommireddy R, John J. *Injury*. 2011 Oct;42(10):1038-42.

[14] Causes of late revision surgery after bone cement augmentation in osteoporotic vertebral compression fractures. Ha KY, Kim YH, Chang DG, Son IN, Kim KW, Kim SE. *Asian Spine J.* 2013 Dec;7(4):294-300.

[15] Single centre prospective study of the efficacy of percutaneous cement augmentation in the treatment of vertebral compression fractures. Joseph RN, Swift AJ, Maliakal PJ. *Br. J. Neurosurg*. 2013 Aug;27(4):459-64.

[16] Height restoration of osteoporotic vertebral compression fractures using different intravertebral reduction devices: a cadaveric study. Krüger A, Oberkircher L, Figiel J, Floßdorf F, Bolzinger F, Noriega DC, Ruchholtz S. *Spine J.* 2013 Nov 4. pii: S1529-9430(13)01216-3.

[17] Treatment options for vertebral fractures an overview of different philosophies and techniques for vertebral augmentation. Bornemann R, Koch EM, Wollny M, Pflugmacher R. *Eur. J. Orthop. Surg. Traumatol.* 2014 Jul;24 Suppl 1:S131-43.

In: Encyclopedia of Surgery (22 Volume Set)
Editors: Andreas Lehrer and Kristin Mueller
ISBN: 978-1-53618-329-0
© 2020 Nova Science Publishers, Inc.

Chapter 24

VBS: EVALUATION AND INDICATIONS

Daniele Vanni[1,*], MD and Vincenzo Magliani[2], MD
[1]Orthopaedic and Traumatology Department, "G. d'Annunzio" University, Chieti, Italy.
Neurosurgery Spine Department, Asl Chieti, Italy
[2]Neurosurgery Spine Department, Asl Chieti, Italy.
Spine Trauma at Orthopaedic and Traumatology Residency,
"G. d'Annunzio" University, Chieti, Italy

Symptomatic vertebral compression fracture can negatively impact health and quality of life by causing substantial pain and severe disability [1, 2]. These vertebral fractures may result from trauma but they can be also incidental to osteoporosis or tumors. In the latter case, they usually represent a secondary localization of tumor disease [3, 4]. Regardless of the cause, restoration of height and realignment of the vertebral bodies are mandatory in order to prevent the progression of the deformity and the commensurate deterioration of quality of life [1, 2, 3, 4]. Vertebral Body Stenting (V.B.S.) is a specific third generation intrasomatic expandible device for percutaneous vertebral augmentation. It represents an available option to alleviate pain but especially to restore the height of the fractured vertebra, as well as the normal curvature of the spine [5]. This aspect is important in order to prevent postural abnormalities and pain caused by pathological progressive kyphosis. In 1958, the AO formulated four basic principles, which have become the guidelines for internal fixation. They can be summarized in: 1) anatomic reduction of the fracture 2) immediate and effective primary stability 3) preservation of blood supply and 4) Early and active mobilization [6]. At the beginning, these criteria had been established for the treatment of long bones fractures, but fundamental aims of fracture treatment in the limbs and fusion of the spine are the same. In particular, the specific goal of spine treatment is to restore as much function as possible to the injured neural elements. Therefore, the AO principles, modified for the vertebral fractures [7, 8] surgical treatment are [9]: - anatomical reduction: reinstatement of spine alignment improves spine biomechanics. It allows the vertebral column to perform properly its protective function and it is responsible for the clinical improvement and reduction of pain. - stable internal fixation: it allows to maintain not only the integrity of the spinal functional

* Corresponding Author's Email: danielevannimd@libero.it.

unit, but also it provides the balance and the physiologic three-dimensional form of the spine. - preservation of blood supply: an ideal surgical technique for treatment of vertebral fractures, should be able to minimize the damage of anatomical structures and to reduce the disturbance of nerve roots and dura. It should be the as atraumatic as possible, trying not to compromise the vascular supply. - early and active mobilization: restoration of normal spinal anatomy allows immediate pain reduction and early patient mobilization. It is possible only if stable spine is achieved.

VBS [10, 11] enables a minimally invasive surgical treatment of vertebral fractures, fully satisfying these four fundamental principles. In fact VBS [Figure 1] is introduced percutaneously into the vertebral body with only a stab incision required to place the access instruments. The system is made of titanium and it works like a real stent. In fact, using a balloon (the same that was employed to perform the classic kyphoplasty), the device is expanded inside the vertebral body, ensuring, by ligamentotaxis, an "effective reduction", restoring the correct vertebral morphology and allowing restoration and conservation of height of vertebral body while at the same time offering a cavity for injection of highly viscous PMMA based bone cement [Figure 2] [12, 13]. VBS offers an expansion ratio of 400%: this is fundamental for reconstruction of collapsed vertebral body**.** After the expansion phase, the balloon can be deflated and definitively removed, without the risk of loss of reduction , since the device is crushproof and it remains into the vertebral body, overcoming the problem of partial height loss after removal of the balloon. The cavity, obtained through the device expansion, is then filled with PMMA based bone cement, providing additional primary stability.

VBS is intended for the reduction of painful vertebral compression fractures and/or creation of a void in cancellous bone in the spine for the treatment of levels ranging from Th5-L5 [Figure 3, 4, 5, 6] [12, 13 ,14].

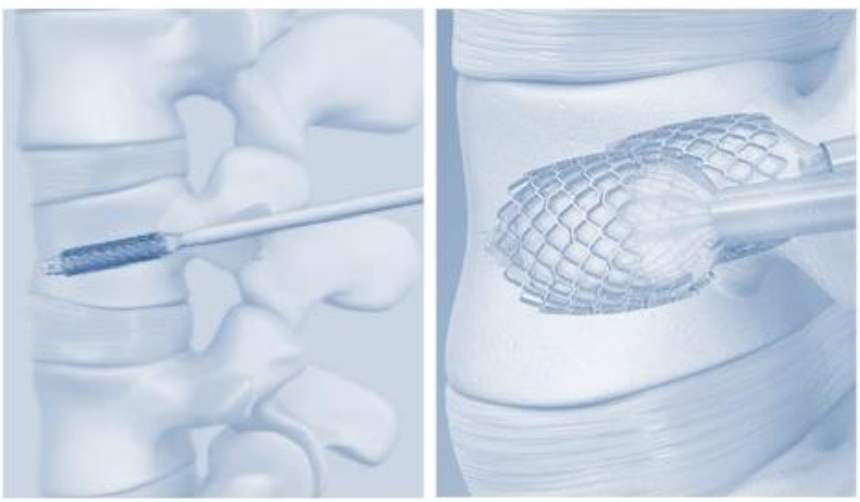

Figure 1. Vertebral Body Stenting: implant.

Figure 2. Vertebral Body Stenting: PMMA injection.

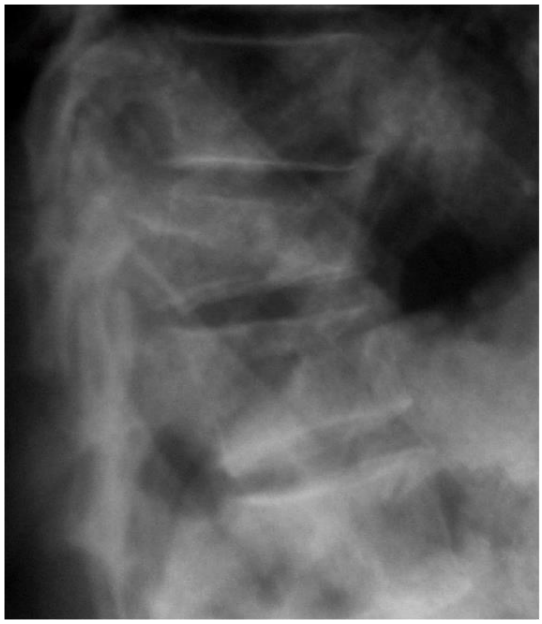

Figure 3. Vertebral fractures: Rx imaging.

The indications are: - osteoporotic vertebral compression fractures from Th10-L5 without involvement of the posterior vertebral edge classified after Genant, Grade 2 and Grade 3 with a kyphotic angulation of more than 15° [15, 16]. ; - fractures without the involvement of the posterior vertebral edge, classified according to AO classification in [7, 8, 9]:

A1.1 Endplate impaction

A1.2 Wedge impaction fracture

A1.3 Vertebral body collapse

A3.1 Incomplete burst fracture; (depending on the degree of posterior wall involvement, internal fixation must be used in addition)

– In combination with internal fixation

A3.1 Incomplete burst fracture

A3.2 Burst-split fracture; in these cases the extent of the gap width should not be too wide

B1.2 Posterior disruption predominantly ligamentous associated with type A fracture of the vertebral body

B2.3 Posterior disruption predominantly osseous with type A fracture of the vertebral body

The contraindications are: fractures that need internal fixation: (A2 split fractures, A3.3 complete burst fracture, B1.1 posterior disruption predominantly ligamentous with transverse disruption of the disc, B2.1 transverse bicolumn fracture, B2.2 posterior disruption predominantly osseous with disruption of the disc, B3 anterior disruption through the disc and all C types. Extensive mechanical and biomechanical testing has been performed to characterize the mechanical behavior and performance of the VBS [17]. The preclinical testing of the VBS was designed to evaluate all relevant loading conditions that may impact the device to demonstrate a reasonable assurance of safety. These biomechanical tests demonstrated a significant decrease of height loss after balloon deflation using VBS compared to balloon kyphoplasty. For instance, VBS was able to significantly maintain the pre-fracture height and avoid a loss of reduction which has been measured with balloon deflation in kyphoplasty. If compared with balloon kyphoplasty, it has been demonstrated that VBS showed positive clinical results allowing to obtain a significant level of pain relief and functional improvement.

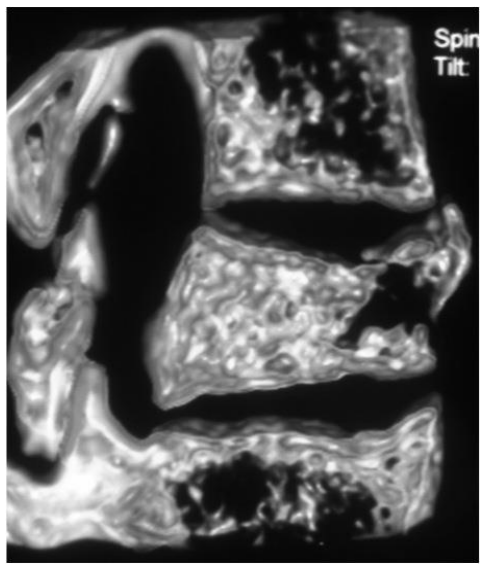

Figure 4. Vertebral fractures: 3D TC imaging.

Figure 5. Vertebral fractures: Post-op control.

Figure 6. Vertebral fractures: Post-op control.

VAS and ODI score were reduced by 6.4 points and 41.7% respectively at 12 months. In addition, a substantial improvement of the vertebral body height to 15.3% at 12 months was also demonstrated, as well as a good kyphosis correction to 4.5° at 12 months [Figure 7]. Risk of adjacent vertebral fracture was estimated to be 9%, which seems similar or somewhat lower than the rates reported in the literature for balloon kyphoplasty. VBS could be considered to be a safe and effective surgical technique to treat vertebral fractures and osteoporotic vertebral compression fractures with a low rate of adverse effects. The proper

atraumatic technique enables minimal retraction or disturbance of the nerve roots and dura, and maintains the stability of the facet joints. The ideal surgical technique and implant design minimize damage to anatomical structures, i.e., facet capsules. keeps the soft tissue attachment intact, and creates a physiological environment that facilitates healing. This specific treatment usually leads to an immediate pain relieve and allows for an early mobilisation and return to normal activity [18, 19].

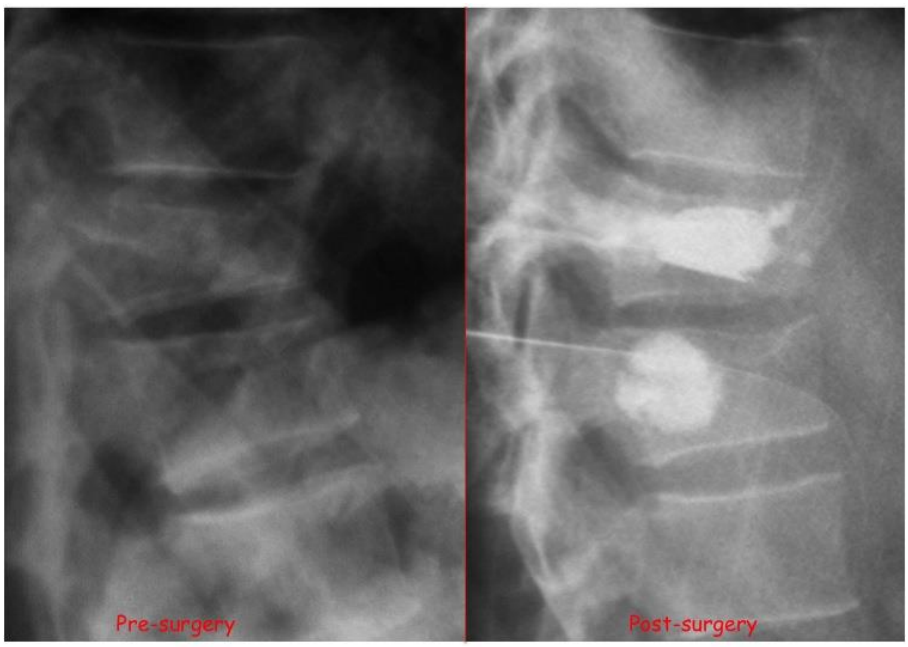

Figure 7. Vertebral fractures: pre-surgery and post-surgery comparison.

REFERENCES

[1] Fractures and mortality in relation to different osteoporosis treatments. Yun H, Delzell E, Saag KG, Kilgore ML, Morrisey MA, Muntner P, Matthews R, Guo L, Wright N, Smith W, Colón-Emeric C, O'Connor CM, Lyles KW, Curtis JR. *Clin. Exp. Rheumatol*. 2014 Jul 28.

[2] Prevention and treatment of multiple osteoporotic compression fracture. Park YS, Kim HS. *Asian Spine J*. 2014 Jun;8(3):382-90. doi: 10.4184/asj.2014.8.3.382. Epub 2014 Jun 9.

[3] Osteoporosis and fragility fractures: Vertebral fractures. Gerdhem P. *Best Pract. Res. Clin. Rheumatol*. 2013 Dec;27(6):743-55.

[4] Other non-vertebral fractures. Hagino H. *Best Pract Res Clin Rheumatol.* 2013 Dec;27(6):731-41.

[5] Vertebral body stenting versus kyphoplasty for the treatment of osteoporotic vertebral compression fractures: a randomized trial. Werner CM, Osterhoff G, Schlickeiser J, Jenni R, Wanner GA, Ossendorf C, Simmen HP. *J. Bone Joint Surg. Am.* 2013 Apr 3;95(7):577-84.

[6] Callus distraction with the AO tubular fixator--principles, techniques and clinical examples. Rüter A, Wagner S, Brutscher R. *Zentralbl. Chir*. 1994;119(8):573-8.

[7] AO spine classification system for thoracolumbar fractures. Aebi M. *Eur. Spine J*. 2013 Oct;22(10):2147-8.

[8] Relationships between the Arbeitsgemeinschaft für Osteosynthesefragen Spine System and the Thoracolumbar Injury Classification System: an analysis of the literature. Joaquim AF, Patel AA. *J. Spinal Cord Med*. 2013 Nov;36(6):586-90.

[9] Injury characteristics and surgical treatment of lower lumbar vertebral burst fractures. Zeng ZY, Wu P, Zhang JQ, Tang HC, Song YX, Yan WF, Han JF, Jin CY. *Zhongguo Gu Shang*. 2014 Feb;27(2):112-7.

[10] Cement Augmentation in a Thoracolumbar Fracture Model: Reduction and Stability Following Balloon Kyphoplasty Vs. Vertebral Body Stenting. Disch AC, Schmoelz W. *Spine* (Phila Pa 1976). 2014 Jun 11

[11] Radiographic and safety details of vertebral body stenting: results from a multicenter chart review. Diel P, Röder C, Perler G, Vordemvenne T, Scholz M, Kandziora F, Fürderer S, Eiskjaer S, Maestretti G, Rotter R, Benneker LM, Heini PF. *BMC Musculoskelet Disord*. 2013 Aug 8;14(1):233.

[12] Vertebral body stenting / stentoplasty. Heini PF, Teuscher R. *Swiss Med. Wkly*. 2012 Aug 6.

[13] Vertebral Body Stenting System for the Treatment of Osteoporotic Vertebral Compression Fracture: Follow-up at 12 Months in 20 Cases. Muto M, Greco B, Setola F, Vassallo P, Ambrosanio G, Guarnieri G. *Neuroradiol. J*. 2011 Aug 31;24(4):610-9. Epub 2011 Sep 2.

[14] Early results after vertebral body stenting for fractures of the anterior column of the thoracolumbar spine. Klezl Z, Majeed H, Bommireddy R, John J. *Injury*. 2011 Oct;42(10):1038-42.

[15] Comparisons of noninvasive bone mineral measurements in assessing age-related loss, fracture discrimination, and diagnostic classification. Grampp S, Genant HK, Mathur A, Lang P, Jergas M, Takada M, Glüer CC, Lu Y, Chavez M. *J. Bone Miner Res*. 1997 May;12(5):697-711.

[16] Comparison of semiquantitative visual and quantitative morphometric assessment of prevalent and incident vertebral fractures in osteoporosis The Study of Osteoporotic Fractures Research Group. Genant HK, Jergas M, Palermo L, Nevitt M, Valentin RS, Black D, Cummings SR. *J. Bone Miner Res*. 1996 Jul;11(7):984-96.

[17] Vertebral body stenting: a new method for vertebral augmentation versus kyphoplasty. Rotter R, Martin H, Fuerderer S, Gabl M, Roeder C, Heini P, Mittlmeier T. *Eur. Spine J*. 2010 Jun;19(6):916-23.

[18] Percutaneous vertebroplasty in patients with intractable pain from osteoporotic or metastatic fractures: A prospective study using quality-of-life assessment. Cheung G, Chow E, Holden L, Vidmar M, Danjoux C, Yee AJ, Connolly R, Finkelstein J. *Can Assoc. Radiol. J*. 2006 Feb;57(1):13-21.

[19] Sagittal range of motion after a spinal fracture: does ROM correlate with functional outcome? Post RB, Leferink VJ. *Eur. Spine J*. 2004 Oct;13(6):489-94. Epub 2004 Apr 9.

In: Encyclopedia of Surgery (22 Volume Set)
Editors: Andreas Lehrer and Kristin Mueller
ISBN: 978-1-53618-329-0
© 2020 Nova Science Publishers, Inc.

Chapter 25

SPINE JACK: EVALUATION AND INDICATIONS

Daniele Vanni[1]*, MD, Vincenzo Magliani[2], MD and Vincenzo Salini[3]

[1]Orthopaedic and Traumatology Department, "G. d'Annunzio" University, Chieti, Italy.
Neurosurgery Spine Department, Asl Chieti, Italy
[2]Neurosurgery Spine Department, Asl Chieti, Italy
Spine Trauma at Orthopaedic and Traumatology Residency,
"G. d'Annunzio" University, Chieti, Italy
[3]Orthopaedic and Traumatology Department, "G. d' Annunzio" University, Chieti, Italy.
Orthopaedic and Traumatology Residency,
"G. d'Annunzio" University, Chieti, Italy

At the moment there is no single guideline for management of osteoporosis vertebral fractures (OVF) [1,2].Timing and the indications for the conservative treatment are not clear; The surgical criteria are also poorly defined. In the past, a conservative treatment for at least 30 days was considered the proper treatment for the majority of the fractures. If the pain persisted, a surgical solution was needed: Vertebroplasty is for OVF with loss of height less than 30%, while kyphoplasty is for OVF with loss of height greater than 30%. The conservative treatment avoids surgical risks. However, it forces the patient to a poor quality life and it does not stop the the domino effect, causing poor results. Vertebral augmentation procedures are fast, performed in general anesthesia and percutaneously. Therefore, a standing radiography is necessary in patients with acute, severe back or low back pain and a risk profile (age >65 years, positive anamnesis for previous vertebral fractures, metabolic diseases, renal failure, and prolonged therapy with the corticosteroids or antiepileptic, body mass index <20). CT scan is performed in order to characterize the fracture personality, in order to obtain more detailed information about fracture type and to distinguish between a simple compression fracture from a more complex lesion. MRI shows signs of spinal cord and/or dural sac compression, radicular conflict, and also allows to distinguish between new

* Corresponding Author's Email: danielevannimd@libero.it.

and previous fractures, according to signal intensity in TSE (Turbo Spin Echo) T2 weighted sequences. This is the most important aspect according to which surgical indication and eventually the recovery of vertebral height entity are established. The more recent the fracture, the greater is the possibility of height recovery. Percutaneous vertebral augmentation procedures (PVAP) are based on the cement injection into the vertebral body. These techniques achieved great success in recent years as they allow an efficient OVF management; by stabilizing the vertebra, especially the anterior column, they ensure a rapid pain resolution. The pain in fact, is due to micro-motion between the fragments at fracture site. Treatment of OVF has radically changed in the last three decades. The first generation mini-invasive surgery for treatment of VCF - vertebral compression fracture by percutaneous injection of bone cement (PMMA) was described by Galibert et al. in 1987; this surgical procedure goes by the name of vertebroplasty.[3] This technique produced excellent results in terms of pain relief. However, unfortunately, it appears incomplete in several aspects. In fact, the vertebroplasty does not allow any recovery of vertebral body height . Therefore, vertebral body remains collapsed and so the spinal biomechanics is altered There is no possibility to stop the domino effect. Additionally, it is necessary to inject a very low viscosity and high pressure cement, with a risk of leakage of around 30%. These problems led to the creation of second-generation PVAP. The balloon kyphoplasty [4] is a recent change to percutaneous vertebroplasty, conducted for the first time by Reiley in 1998; this procedure involves the inflation of a balloon catheter in the collapsed vertebral body to restore its height before the stabilization with bone cement. The use of the balloon can create a cavity inside the vertebral body. In this way, the cement can be injected with less pressure and greater viscosity, considerably reducing the risk of leakage.[5-10] Reducing the relevance of cement as the primary stabilizer in vertebral compression fractures may reduce or eliminate concerns about cement leakage.[11-17] Unfortunately, recovery of height recovery is. In fact, as soon as the balloon is deflated, there is often a new total or partial vertebral body collapse.[18-21] This has led to research for creation of new devices. They allow recovery of the vertebral height. However, they must not be removed from the vertebral body to allow the cementing. Therefore, the conventional balloon can be replaced by equivalent mechanical systems:[22,23] Third generation PVAP.



Figure 1. Spine Jack System®.

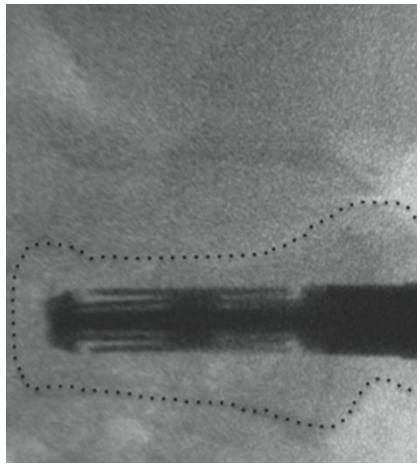

Figure 2. Spine Jack® insertion.

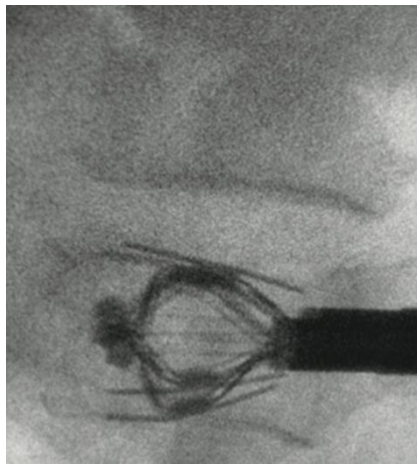

Figure 3. Spine Jack® opening.

Spine Jack® [23,24] [Figure 1] is a new device for mechanical kyphoplasty. It is a titanium implant designed to restore vertebral height through a distraction effect via bilateral transpedicular minimally invasive approach, the device is inserted into the vertebral body (from T10 to L5) [Figure 2] and gradually expanded like a little jack [Figure 3]. The distraction exerted by the device allows fracture reduction that occurs by ligamentotaxis on the anterior longitudinal ligament. Spine Jack® is equipped with a mechanical rather than a hydraulic opening; this ensures a gradual and controlled reduction of vertebral fracture . This feature allows to recover the collapsed vertebra and to provide the primary support to the structure in order to mechanically stabilize the vertebrae in axial compression. Once this step has been completed, bone cement is injected into the restored vertebra in order to secure the vertebral structure, and relieve the pain. The presence of two symmetrical devices into the vertebral body also allows a homogeneous spreading of polymethylmethacrylate (PMMA). Expansion of the device creates a preferential flow direction of high-viscosity cement, also reducing the resk of leakage. When injected, cement inter-digitation creates a large contact area below the midline: This helps to add stability to the obtained vertebral body reduction.

Although, the technique was developed for osteoporotic fractures, it could be used in traumatic fractures of the thoracolumbar vertebrae.

This technique allows a good reconstruction of the anterior column, restoring vertebral height. Another feature to highlight is the advantage of preventing cement leak into intervertebral disc space, which could increase the risk of adjacent vertebral body fractures in OVF. In fact, the device has a security system: If the load forces concentrated on the devices are too high, the system automatically blocks itself; a further expansion of the device does not occur, thus reducing the risk of breakage of vertebral endplates . Furthermore, an excellent reduction of superior endplate may have the potential benefit of better future performance of injured disc.

Figure 4. Vertebral fracture in patient with osteoporosis.

Vanni et al. showed that Spine Jack® represents a safe and effective system for treatment of OVF . In this study, Spine Jack® and kyphoplasty were compared, creating two groups of evaluation. Spine Jack® and kyphoplasty groups did not differ significantly in age, gender distribution, location of OVF, duration between injury and surgery, pre-operative VAS pain score, vertebral body height, or kyphotic wedge angle [Figure 4 and 5]. The degree of anterior column injury is best assessed using the McCormack and Gaines load sharing classification. The safe indication would be at 3 points and limited to approximately 4-5 points. Patients underwent a clinical follow-up (using VAS and Oswestry disability index [ODI]) and post-operative standing plain radiogram of the spine at 1, 6, and 12 months. The radiographic parameters taken into account were: Post-operative anterior vertebral body height, preoperative anterior vertebral body height, cephalic anterior vertebral body height, and caudal anterior vertebral body height. The fractured vertebral body height restoration was calculated according to the following equation: 2 ×(post-operative anterior vertebral body height-pre-operative anterior vertebral body height)/ (cephalic anterior vertebral body height + caudal anterior vertebral body height) × 100%.[25] Vertebral height was measured immediately before and after PVAP, in order to assess restoration of vertebral height.

Figure 5. Pre-operative nuclear magnetic resonance.

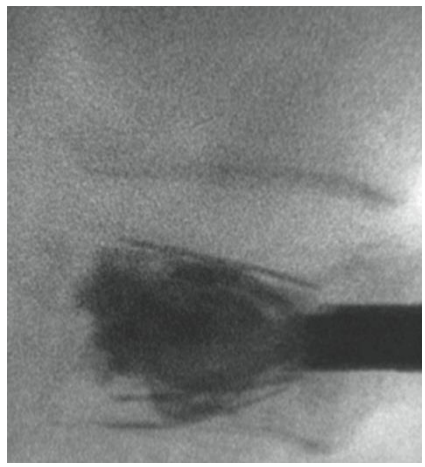

Figure 6. Final intra-operative control.

A semi-quantitative assessment of recovery of vertebral height was performed and three assessment degrees were identified: Grade 0 (no change), grade 1 (below 50%) and grade 2 (greater than 50%). Compared to the Spine Jack® group, the kyphoplasty group required a little longer operation time (an average of 40 min vs. 45 min, $P < 0.05$), and a greater amount of PMMA (4.0 vs. 5.0 mL, $P < 0.05$). The post-operative increase in vertebral body height was greater in the Spine Jack® group than in the kyphoplasty group ($P < 0.05$). The 85% of the patients who underwent PVAP using the Spine Jack® system has returned to the assessment degree 2 [Figures 6 and 7], 12% in 1 and 3% in 0. The 58% of the patients who underwent PVAP using balloon kyphplasty returned to the assessment degree 2, 26% in 1 and 16% in 0. There was no statistical difference in VAS pain scores and in the ODI between the treatment groups at any stages from the pre-operative period, through the post-operative period, to the final follow-up. In group A, there were not leakage events, nor device loosening. In the group B, there were 20 but not clinically significant leakage events. In both

groups, there was no iatrogenic vertebral endplates fractures or fractures of the vertebra above or below. Neurological defects, radicular symptoms, and pulmonary embolism have never occurred.

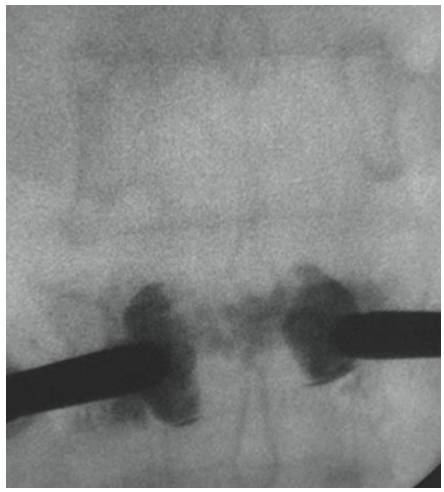

Figure 7. Final intra-operative control.

Finally, it is mandatory to highlight that Spine Jack® is useful not only for treatment of OVF, but also in case of vertebral fractures, although they could be not recent. In fact the the device is able to perform a significant force of elevation, and also able to reduce not very "fresh" fractures. Only the third generation device for PVAP able to treat this type of fractures.

Figure 8. Radiographic post-operative control.

In conclusion, it is possible to affirm that Spine Jack® is able to determine a safe restoration of vertebral body height, if compared to the conventional balloon kyphoplasty. This is due to the efficient mechanical characteristic of Spine Jack® system, and above all, it is due to the possibility of leaving the devices into the vertebral body. This avoids vertebral body recollapsing before cement injection. [Figure 8]. Spine Jack® has the advantage to restore, according to the "fracture freshness," the vertebral height and the normal spine

biomechanic and stability. The restoration of normal spine biomechanics results in an interruption of the domino effect and in a reduction of the risk of new vertebral fractures. [26].

REFERENCES

[1] Dionyssiotis Y. Management of osteoporotic vertebral fractures. *Int. J. Gen. Med.* 2010;3:167-71.

[2] Cortet B, Blotman F, Debiais F, Huas D, Mercier F, Rousseaux C, et al. Management of osteoporosis and associated quality of life in post menopausal women. *BMC Musculoskelet Disord* 2011;12:7.

[3] Galibert P, Deramond H, Rosat P, Le Gars D. Preliminary note on the treatment of vertebral angioma as well as painful and debilitating diseases. *Neurochirurgie* 1987; 33:166—168.

[4] Hardouin P, Fayada P, Leclet H, Chopin D. Kyphoplasty. *Joint Bone Spine* 2002;69:256-61.

[5] McGirt MJ, Parker SL, Wolinsky JP, Witham TF, Bydon A, Gokaslan ZL. Vertebroplasty and kyphoplasty for the treatment of vertebral compression ractures: An evidenced-based review of the literature. *Spine J.* 2009;9:501-8. 13.

[6] Luo J, Adams MA, Dolan P. Vertebroplasty and Kyphoplasty Can Restore Normal Spine Mechanics following Osteoporotic Vertebral Fracture. *J. Osteoporos* 2010;2010:729257.

[7] Garn SR, Yuan H A, Reiley M A. New technologies in spine: Kyphoplasty and vertebroplasty for the treatment of painful osteoporotic compression fractures. *Spine* (Phila Pa 1976) 2001;26:1511-5.

[8] Mathis JM, Ortiz AO, Zoarski GH. Vertebroplasty versus kyphoplasty: A comparison and contrast. *AJNR Am. J. Neuroradiol.* 2004;25:840-5.

[9] Felder-Puig R, Piso B, Guba B, Gartlehner G. Kyphoplasty and vertebroplasty for the management of osteoporotic vertebral compression fractures: A systematic review. *Orthopade* 2009;38:606-15.

[10] Khurjekar K, Shyam AK, Sancheti PK, Sonawane D. Correlation of kyphosis and wedge angles with outcome after percutaneous vertebroplasty: A prospective cohort study. *J. Orthop. Surg.* (Hong Kong) 2011;19:35-40.

[11] Bula P, Lein T, Strassberger C, Bonnaire F. Balloon kyphoplasty in the treatment of osteoporotic vertebral fractures: Indications-treatment strategy-complications. *Z Orthop. Unfall* 2010;148:646-56.

[12] Minenna G, D'Amore S, D'Amore M. Complication after vertebroplasty in patient with senile osteoporosis: Strategical therapy to revise? *Recenti Prog. Med.* 2006;97:389-92.

[13] Al-Nakshabandi NA. Percutaneous vertebroplasty complications. *Ann. Saudi Med.* 2011;31:294-7.

[14] Yang SC, Chen WJ, Yu SW, Tu YK, Kao YH, Chung KC. Revision strategies for complications and failure of vertebroplasties. *Eur. Spine J.* 2008;17:982-8. 22.

[15] Chen C, Chen L, Gu Y, Xu Y, Liu Y, Bai X, et al. Kyphoplasty for chronic painful osteoporotic vertebral compression fractures via unipedicular versus bipedicular approachment: A comparative study in early stage. *Injury* 2010;41:356-9.

[16] Song BK, Eun JP, Oh YM. Clinical and radiological comparison of unipedicular versus bipedicular balloon kyphoplasty for the treatment of vertebral compression fractures. *Osteoporos Int* 2009;20:1717-23.

[17] Oh GS, Kim HS, Ju CI, Kim SW, Lee SM, Shin H. Comparison of the results of balloon kyphoplasty performed at different times after injury. *J. Korean Neurosurg. Soc* 2010;47:199-202.

[18] Voggenreiter G. Balloon kyphoplasty is effective in deformity correction of osteoporotic vertebral compression fractures. *Spine* (Phila Pa 1976) 2005;30:2806-12.

[19] Feltes C, Fountas KN, Machinis T, Nikolakakos LG, Dimopoulos V, Davydov R, et al. Immediate and early postoperative pain relief after kyphoplasty without signi□cant restoration of vertebral body height in acute osteoporotic vertebral fractures. *Neurosurg Focus* 2005;18:e5.

[20] Rotter R, Mar tin H, Fuerderer S, Gabl M, Roeder C , Heini P, et al. Vertebral body stenting: A new method for vertebral augmentation versus kyphoplasty. *Eur. Spine J.* 2010;19:916-23.

[21] Ishiguro S, Kasai Y, Sudo A, Iida K, Uchida A. Percutaneous vertebroplasty for osteoporotic compression fractures using calcium phosphate cement. *J. Orthop. Surg.* (Hong Kong) 2010;18:346-51.

[22] Fields AJ, Lee GL, Keaveny TM. Mechanisms of initial endplate failure in the human vertebral body. *J. Biomech.* 2010;43:3126-31.

[23] Noriega D, Ardura F, Beyerlein J, Hansen-Algenstaedt N. Clinical results for the use of a new extensible cranio-caudal implant for the treatment of vertebral compression fractures results of a prospective, multicentre study after 1 year of follow-up. *Eur. Spine J.* 2012;21:1415-39.

[24] Krüger A, Oberkircher L, Flossdorf F, Ruchholtz S. Differences in the restoration of vertebral height after treatment of osteoporotic vertebra compression fractures: Cadaver study. *Eur. Spine J.* 2012;21:1415-9.

[25] Yeh JH, Yang SC, Kao YH, Ma CH, Yu SW, Tu YK. Clinical and radiographic evaluation of balloon kyphoplasty using VCFX for osteoporotic vertebral compression fracture. *Formos J. Musculoskelet Disord* 2011;2:94-8.

[26] Vanni D, Pantalone A, Andreoli E, Salini V. Surgical treatment of osteoporotic 46 vertebral fractures: State of the art. *J. Orthop. Transl. Res. Clin. Appl.* 2012;4:35-46.

In: Encyclopedia of Surgery (22 Volume Set)
Editors: Andreas Lehrer and Kristin Mueller
ISBN: 978-1-53618-329-0
© 2020 Nova Science Publishers, Inc.

Chapter 26

OSSEOFIX: EVALUATION AND INDICATIONS

Marcello Bartolo[1], MD, Giovanni Grillea[2,*], MD and Giovanni Nano[2], MD

[1]Diagnostic and Terapeutic Neuroradiology Unit.
IRCCS INM Neuromed, Pozzilli, Isernia, Italy
[2]Diagnostic and Terapeutic Neuroradiology Unit. IRCCS INM Neuromed,
Pozzilli, Isernia, Italy

INTRODUCTION

Vertebral compression fractures represent one of the most common complications of osteoporosis. In western countries the prevalence of vertebral compression fractures is constantly increasing because of aging population. Consequently the morbidity and mortality burden related to their effects, mainly represented by pain and kyphotic deformities, is also increasing. This leads to deep social and economical costs.[1]. Vertebral augmentation of acute collapses is a minimally invasive treatment option with proved effectiveness in reducing pain and improving quality of life of the affected patients whose symptoms were refractory to medical treatment [2, 3, 4, 5]. Since its introduction in medical practice in the nineties for the treatment of aggressive vertebral angioma, vertebral augmentation with polymethyl-methacrylate (PMMA), till today the most widely employed filler material, has evolved rapidly. Currently it is considered an effective option also for the treatment of osteoporotic and non-osteoporotic collapses, with reported success rates of 80-95% and 70-92% respectively [6, 7, 8]. In the late nineties kyphoplasty was introduced as an alternative procedure to traditional vertebroplasty with the speculated advantage of reduction of kyphotic deformities owing to the creation of a cavity inside the vertebral body then filled with PMMA [9, 10]. Although is still a matter of debate which procedure, traditional vertebroplasty over kyphoplasty, bear the best absolute advantage in pain improvement, both them share some rare complications. Some complications, like cement leakage/embolism, are mainly related to the procedure itself, while other, as thermal/chemical/mechanical injuries, are mainly related

* Corresponding Author's Email: grillea@hotmail.com.

to the polymerization characteristics of the PMMA and to its intrinsic high stiffness [11, 12, 13]

Vertebroplasty and kyphoplasty can be considered safe procedures if properly performed by skilled and prudent operators, and their risks can be considered acceptable if the right indications are met [13]. Several efforts have been made to further decrease the occurrence of these complications. In recent years some companies have focused on the development of non-toxic resorbable cements, while other on the development of devices able to control or reduce cement spread inside the vertebral body, like curved injection needles or expandable containers. [14, 15, 16]

DEVICE CHARACTERISTICS AND INDICATIONS

Recently a new expandable titanium device, OsseoFix® (AlphaTec Spine Inc. Carlsbad CA), has been developed for treatment of osteoporotic vertebral compression fractures. It is composed of a titanium mesh that, once implanted bilaterally inside the vertebral body through both pedicles, is expanded with the aims of decreasing the kyphotic deformity, stabilizing the collapse compacting the surrounding trabecular bone and reducing the amount of cement required with the potential following risk of leakages through any way.

OsseoFix® implant is intended for use inside vertebral bodies from level T6 through level L5. It is available in three measures according to the width of the pedicles involved. OsseoFix® implantation is usually indicated in patient with painful stable vertebral fractures type A1.1 to A1.3 or A3.1, according to AO classification, dating at least three weeks and refractory to conservative treatment, in which intravertebral edema is evident on magnetic resonance imaging (MRI), i.e., bone hypointensity on T1 weighted images and/or equivalent hyperintensity on T2 weighted fat saturated images. Other two remarkable cases in which OsseoFix® is indicated, which represent an extension of the usual indications typical of traditional vertebroplasty, are represented by acute stable traumatic vertebral collapses of the above mentioned type occurred in young patients and vertebral collapses secondary to osteoporosis dating back more than three weeks and up to 9 months, also known as "inveterate" collapses, in which signs of bone marrow edema are still detected on MRI.

The contraindications do not differ from the standard ones working for traditional vertebroplasty. The main contraindications are the following: vertebral compression fracture with evidence of retropulsed fragment impinging dura mater or spinal cord; previous treatment at the same level; ongoing systemic or local infections; history of severe anaphylactic reactions to iodine based compounds; body mass index over 30; known illnesses such cancer; irreversible coagulopathies; pre-existing calcium disorders; renal failure; psychiatric disorders of any kind.

TECHNIQUE AND DISCUSSION

OsseoFix® deployment does not significantly differ from the deployment of any other expandable intravertebral device. Here we report what we do at our Institution; all the phases of the procedure are guided by fluoroscopy. The patient lie prone over the fluoroscopic table

under local anesthesia and mild sedation. We usually use only mild sedation, unless the anesthetist believe the clinical conditions of the patient require general anesthesia, a very rare occurrence. All the following steps are performed bilaterally on each peduncle. Once the skin over the involved level is prepped in a sterile fashion, several mL of lidocaine are injected subcutaneous in order to accomplish local anesthesia. Under fluoroscopic guidance two 22 G spinal needles are then inserted down to the posterior elements of the vertebral body and periosteal local anesthesia is accomplished injecting several mL of naropine. The OsseoFix® Spine Fracture Reduction System is composed of a tunneling cannula, whose diameter fit with that of the device chosen varying from 10G to 13G, that is introduced inside the pedicle up to its junction with the vertebral body, with the aim to create a working channel through the pedicle. The stylet of the working cannula is then retracted and a kirschner wire is introduced inside the vertebral body. Coaxially to the working cannula and over the kirschner wire a tapper is introduced up to the anterior wall of the vertebral body. The tapper, with diameter varying according to the device chosen, must be screwed while advancing it in order to create a channel in which the device will be fitted. The tapper is then changed with the device that is coaxially introduced and advanced inside the vertebral body targeting its tip to the anterior third of the vertebral body itself. Once on the fluoroscopy checks the position is considered correct the operator expand the device acting on the screw handle. The device is lodged at the tip of the introducer and is locked between two vise-like ends that approximate each other acting on the screw handle. The approximation of the ends shortens the device that is so forced to expand. The shortening and expansion range vary with the measure of the device chosen, as shown in Figure 1. This operation leaves little room to the operator discretion, thus providing a guarantee for controllability and reproducibility (Figure 2).

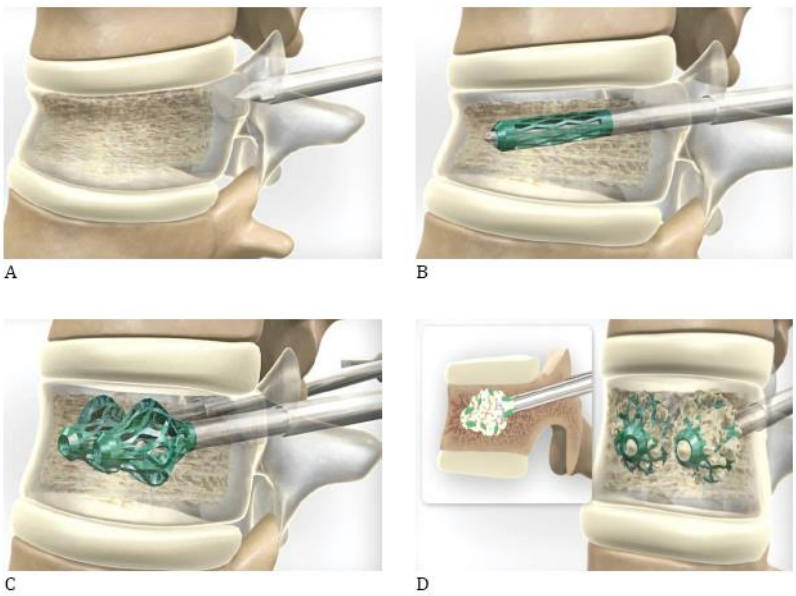

Figure 1. Drawing A shows the working cannula inside the pedicle with the tip up to the pedicle/vertebral body junction. Drawing B shows the OsseoFix unexpanded implant in correct position with the tip at the anterior third of the vertebral body. Drawing C shows both the implant expanded before cement injection. Drawing D shows both the implants injected with cement; the detail on the left shows the interdigitations of cement and trabecular bone through the cells of the titanium mesh.

The cavity created following the expansion of the device is stable because, in contrast with kyphoplasty or other balloon assisted stentoplasty, the expanded device remains in place stabilizing the cavity itself. There are some reports about the use of this device with in vitro specimen without injection of any cement at all [17]. In these cases no significant difference in strength and stiffness was found between the specimens with and without cement injected, leading to a speculated remarkable advantage of lack of complications related to the cement injection. However these were only in vitro findings that necessitate further study but that look promising.

The surrounding collapsed trabecular bone is compacted outward during device expansion and some of it is squeezed through the cells of the titanium mesh. A double advantage follows this operation, on one side the compaction of the trabecular bone lead to an increase of the vertebral body height, hence reducing kyphotic deformity, and on the other side the interdigitation of trabecular bone occurring through the cells of the mesh stabilize the device in place. At the end of the expansion PMMA cement is injected inside the expanded device. The cement employed with the device is composed of 95%wt PMMA and 5%wt hydroxyapatite (HA). The HA promote the biocompatibility of the cement. The overall volume of PMMA is significantly reduced compared to the amount required by traditional kyphoplasty, only about 1 mL for each device suffices. Also the cement interdigitates through the cells of the titanium mesh further stabilizing the device (Figure 3). The compacted trabecular bone surrounding the device decrease the number and width of that small bone channels through which cement can leaks, that is another remarkable advantage.

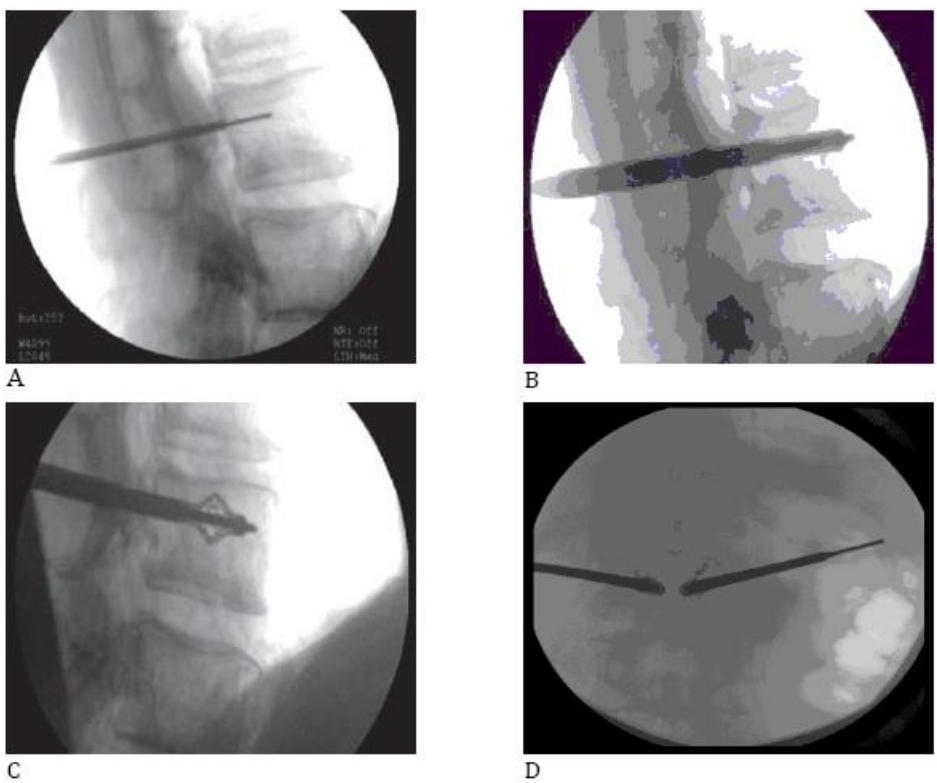

Figure 2. (Continued).

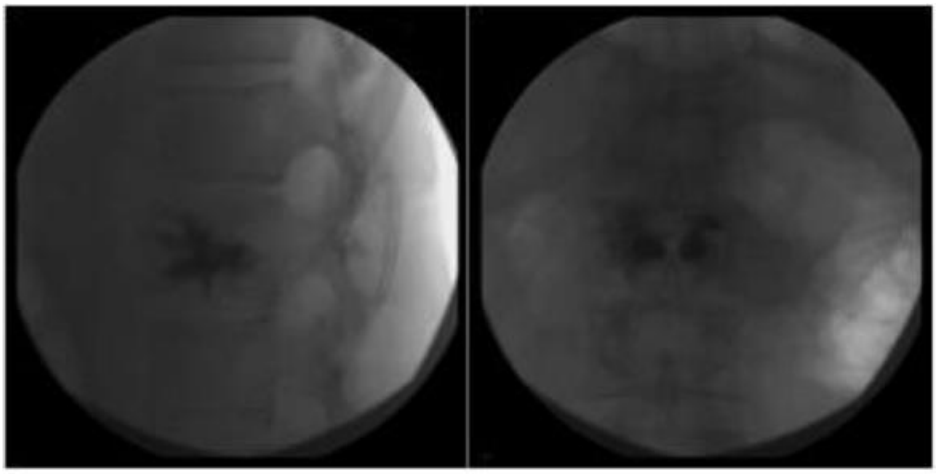

E

Figure 2. Intraoperative fluoroscopic views showing the kirschner wire in place (A), the unexpanded device in place (B), the device expanded before cement injection (C), both devices in place at the end of the cement injection (D) and two end-procedure latero-lateral and antero-posterior views showing both devices in place correctly positioned and filled with cement (E).

At our Institution we are using OsseoFix® Spine Fracture Reduction System since 2011. Up to the time we are writing more than 120 patients have undergone the implantation with over 200 overall levels treated. In many cases the procedure was accomplished on two or more consecutive levels and in a few cases there were two or more levels treated with a healthy vertebra in between (sandwich). All procedures have been accomplished successfully without any complication both during and after the procedure. The follow-up interval is over one year for most of these patients.

A B

Figure 3. Picture A shows the device expanded and filled with cement removed from an in vitro specimen with evidence of interdigitation of trabecular bone and cement through the cells of the titanium mesh. Picture B shows another similar specimen dissected on its major axis in which such interdigitations are well rendered.

We found in all cases a significant and stable improvement of pain that, like traditional vertebroplasty, is almost always immediate. The reduction of kyphotic deformities has also been found significant in all cases, particularly in patients with multiple levels treated. In no case there have been adjacent fractures, finding particularly remarkable in cases of double level treated with healthy sandwich vertebral bodies in between. Failure of the device has not occurred in any case.

CONCLUSION

OsseoFix® Spine Fracture Reduction System provide both immediate and long term effectiveness in reducing pain and kyphotic deformities secondary to vertebral compression fractures. It is a new device that bears in it several advantages over the traditional kyphoplasty and vertebroplasty, mainly the consistence of the increase of vertebral body height and the almost absent risk of cement leakages through any way.

REFERENCES

[1] Riggs BL, Melton LJ 3rd (1995) The worldwide problem of osteoporosis: insights afforded by epidemiology. *Bone* 17 (5 Suppl):505S–511S.

[2] Gangi A, Clark WA (2010) Have recent vertebroplasty trials changed the indications for vertebroplasty? *Cardiovasc. Intervent. Radiol.* 33(4):677–680

[3] McGirt MJ, Parker SL, Wolinsky JP et al (2009) Vertebroplasty and kyphoplasty for the treatment of vertebral compression fractures: an evidenced-based review of the literature. *Spine J.* 9(6):501–508, Epub 2009 Feb 28

[4] McKiernan F, Faciszewski T, Jensen R (2004) Quality of life following vertebroplasty. *J .Bone Joint. Surg. Am.* 86-A(12):2600–2606

[5] Phillips FM (2003) Minimally invasive treatments of osteoporotic vertebral compression fractures. *Spine* (Phila Pa 1976) 28(15 Suppl):S45–S53, 1.

[6] Galibert P, Deramond H, Rosat P, Le Gars D. [Preliminary note on the treatment of vertebral angioma by percutaneous acrylic vertebroplasty]. *Neurochirurgie.* 1987;33(2):166-8. French.

[7] Jensen ME, McGraw JK, Cardella JF et A. Position statement on percutaneous vertebral augmentation: a consensus statement developed by the American Society of Interventional and Therapeutic Neuroradiology, Society of Interventional Radiology, American Association of Neurological Surgeons/Congress of Neurological Surgeons, and American Society of Spine Radiology. *AJNR Am. J. Neuroradiol.* 2007 Sep;28(8):1439-43.

[8] McGirt MJ, Parker SL, Wolinsky JP, Witham TF, Bydon A, Gokaslan ZL. Vertebroplasty and kyphoplasty for the treatment of vertebral compression fractures: an evidenced-based review of the literature. *Spine J.* 2009 Jun;9(6):501-8. doi: 10.1016/j.spinee.2009.01.003. Epub 2009 Feb 28. Review.

[9] Garfin SR, Yuan HA, Reiley MA. New technologies in spine: kyphoplasty and vertebroplasty for the treatment of painful osteoporotic compression fractures. *Spine* (Phila Pa 1976). 2001 Jul 15;26(14):1511-5.

[10] Lieberman IH, Dudeney S, Reinhardt MK, Bell G. Initial outcome and efficacy of "kyphoplasty" in the treatment of painful osteoporotic vertebral compression fractures. *Spine* (Phila Pa 1976). 2001 Jul 15;26(14):1631-8.

[11] Papanastassiou ID, Phillips FM, Van Meirhaeghe J, Berenson JR, Andersson GB, Chung G, Small BJ, Aghayev K, Vrionis FD. Comparing effects of kyphoplasty, vertebroplasty, and non-surgical management in a systematic review of randomized and non-randomized controlled studies. *Eur. Spine J.* 2012 Sep;21(9):1826-43. Epub 2012 Apr 29. Review.

[12] Jensen ME, Evans AJ, Mathis JM, Kallmes DF, Cloft HJ, Dion JE. Percutaneous polymethylmethacrylate vertebroplasty in the treatment of osteoporotic vertebral body compression fractures: technical aspects. *AJNR Am. J. Neuroradiol*. 1997 Nov-Dec;18(10):1897-904.

[13] Mathis JM. Percutaneous vertebroplasty: complication avoidance and technique optimization. *AJNR Am. J. Neuroradiol*. 2003 Sep;24(8):1697-706.

[14] Masala S, Nano G, Marcia S, Muto M, Fucci FP, Simonetti G. Osteoporotic vertebral compression fractures augmentation by injectable partly resorbable ceramic bone substitute (Cerament™|SPINE SUPPORT): a prospective nonrandomized study. *Neuroradiology*. 2012 Jun;54(6):589-96.

[15] Saxena A, Hakimelahi R, Jha RM, Hirsch AE, Growney M, Yoo AJ. The safety and effectiveness of a curved needle for vertebral augmentation: comparison with traditional techniques. *J. Vasc. Interv. Radiol.* 2010 Oct;21(10):1548-53.

[16] Flors L, Lonjedo E, Leiva-Salinas C, Martí-Bonmatí L, Martínez-Rodrigo JJ, López-Pérez E, Figueres G, Raoli I. Vesselplasty: a new technical approach to treat symptomatic vertebral compression fractures. *AJR Am. J. Roentgenol*. 2009 Jul;193(1):218-26.

[17] Ghofrani H, Nunn T, Robertson C, Mahar A, Lee Y, Garfin S. An evaluation of fracture stabilization comparing kyphoplasty and titanium mesh repair techniques for vertebral compression fractures: is bone cement necessary? *Spine* (Phila Pa1976). 2010 Jul 15;35(16):E768-73.

In: Encyclopedia of Surgery (22 Volume Set)
Editors: Andreas Lehrer and Kristin Mueller
ISBN: 978-1-53618-329-0
© 2020 Nova Science Publishers, Inc.

Chapter 27

SURGICAL TECHNIQUE

Daniele Vanni[1,*], MD, Vincenzo Magliani[2], MD and Renato Galzio[3]

[1]Orthopaedic and Traumatology Department,
"G. d'Annunzio" University, Chieti, Italy
Neurosurgery Spine Department, Asl Chieti, Italy
[2]Neurosurgery Spine Department, Asl Chieti, Italy.
Spine Trauma at Orthopaedic and Traumatology Residency,
"G. d'Annunzio" University, Chieti, Italy
[3]Neurosurgery Department, "L'Aquila University", L'Aquila, Italy
Neurosurgery Residency "L'Aquila University", L'Aquila, Italy

Although some differences could exist among the various devices, for example, the dimension and the diameter of the device or the amount of PMMA that could be used, surgical technique is the same for all the third generation systems. The different steps, that are mandatory, take place from the patient evaluation, pre-operative planning, patient position, recruitment of anatomical landmarks , surgical access, introduction of the device and expansion before PMMA injection [1, 2].

PATIENT ASSESSMENT

Before surgery, it is mandatory to dispose of [2, 3, 4, 5]:

- Current X-ray images, in standing position, of the thoracic and lumbar spine, in two planes, in order to assess the fracture and the spinal alignment;
- A spiral CT and MRI scan of the painful region of the spine;
- If an MRI scan is contraindicated, a bone scan may identify an acute fracture;
- Ruling out another cause of pain;
- Feasibility of surgery and use of anaesthesia.

* Corresponding Author's Email: danielevannimd@libero.it.

Planning of Stent Placement

The placement of the stents should be planned based on the AP image which gives hints for the route of insertion [6, 7, 8].

Pre-Planning of Stent Size

The stent size for the procedure can roughly be planned preoperatively by CT scan [9].

Intraoperative X-Ray Imaging

The device must be implanted using X-ray on both planes, using two C-arms, or with one freely mobile C-arm [10].

Anatomical Landmarks

For percutaneous vertebral augmentation procedures, two stents per vertebra should be placed in a symmetrical, paramedian position within the affected vertebral body to achieve optimum reduction of the spinal fracture without damaging the lateral vertebral body edges. Ideally, the distance from the compressed endplate to the stents should be about 5 mm [Figure 1] [11, 12].

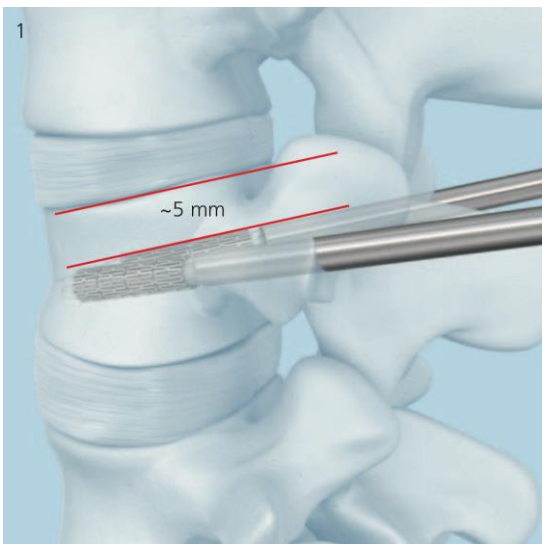

Figure 1.

The position of the stents needs to be planned evaluating pre-operative images.
The following landmarks have to be defined on the spine [13, 14, 15]:

- -Both pedicles
- Spinous process
- Endplates
- Posterior wall of vertebral body

PATIENT POSITIONING

The patient must be placed in prone position on a lumbar support. The table must be radiolucent in both planes [Figure 2, 3].

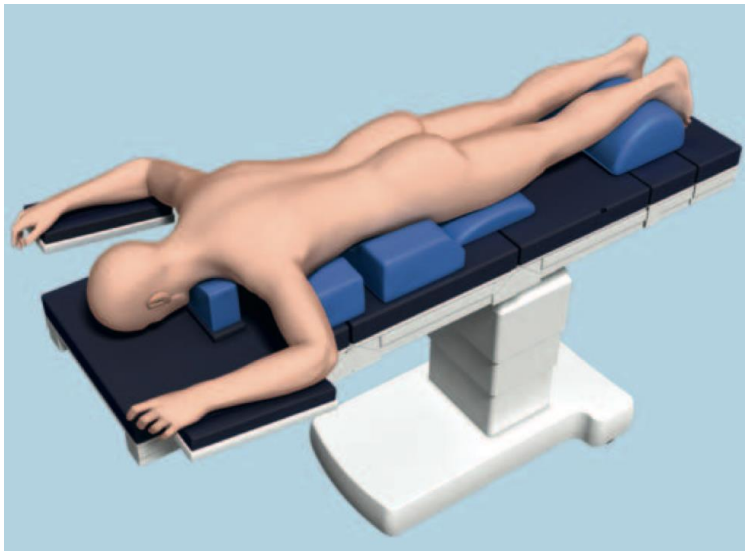

Figure 2.

Figure 3.

The table should allow free manipulation of the C-arm over the operative site in both planes [Figure 4].

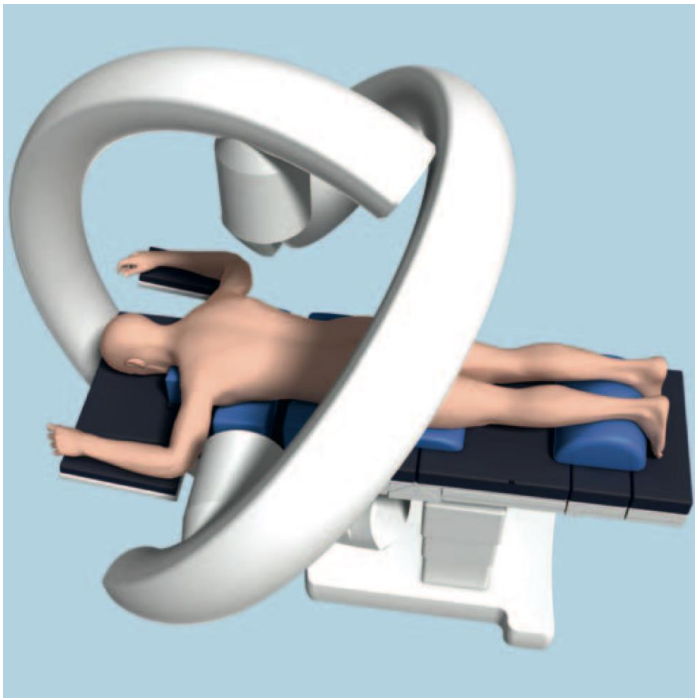

Figure 4.

ACCESS OPTIONS

There are two access options to the targeted vertebral body, depending on its anatomy [16, 17, 18, 19]:

1. Transpedicular access

As a general rule, the bilateral skin incisions for the transpedicular approach are 1–2 cm lateral and up to 1 cm cranial to the centre of the pedicle [Figure 5]. It is also important to remember that this entry point could slightly change in case of obese patient, or in case of very tall or very short people [20, 21] .

2. Extra-/Parapedicular access

The bilateral skin incisions for the extra-/parapedicular technique are planned according to the anatomical situation [Figure 6]. In patients with small pedicles, especially in the higher thoracic spine, an extrapedicular approach is preferable [22, 23] .

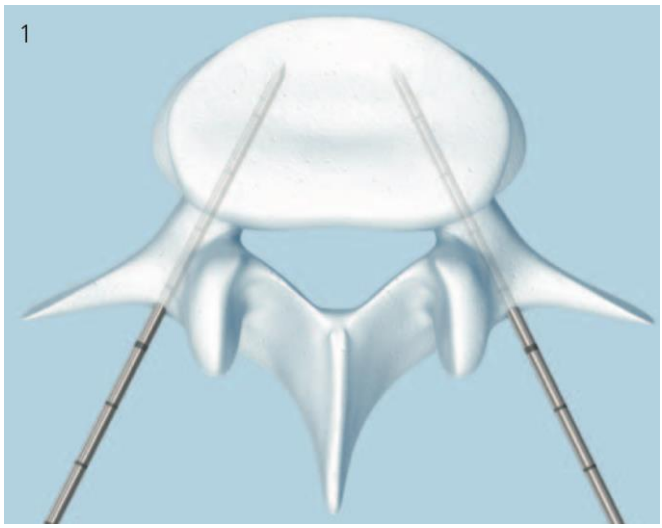

Figure 5.

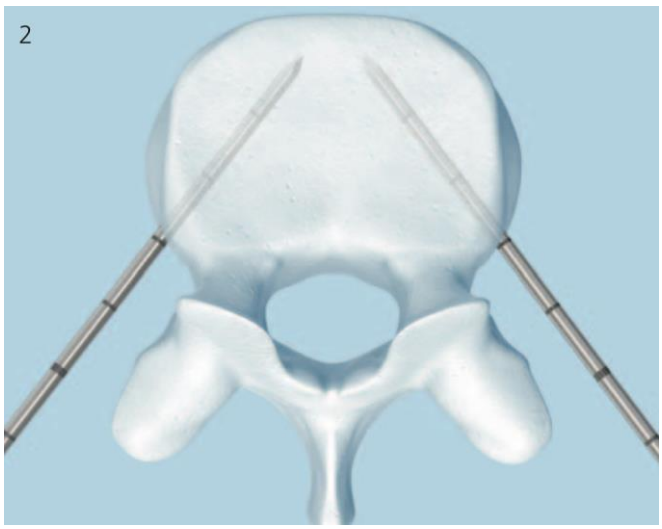

Figure 6.

INSTRUMENT POSITIONING WITH A GUIDE WIRES

First the guide wires are positioned. The other instrumentation follows the path created by the guide wires. Once the anatomical landmarks are detected, the guide wires can be percutaneously introduced through skin incisions using X-ray control (AP and lateral).

Either a transpedicular or extra-/parapedicular access may be selected depending on the anatomy of the vertebral body to be treated [24].

Note: With either access technique it is important to place the two devices symmetrically towards the midline and the anterior wall of the vertebral body at a medial location. In this

position the devices have room to expand without pressing against either the lateral wall, or the other device [Figure 7] .

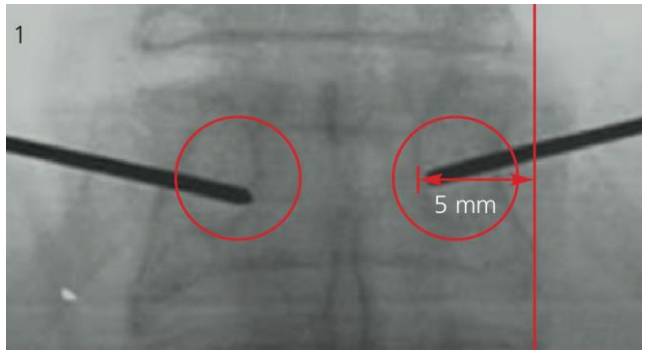

Figure 7.

TRANSPEDICULAR ACCESS

Position Guide Wires

Under AP and lateral X-ray control the guide wires must be inserted to the superior outer pedicle quadrant using slight manual pressure. Once the guide wires touch the bone the outlines of the lateral pedicle are reached. Both guidewires are driven with controlled blows from a hammer through the cortex [25, 26]. Cautiously the guide wires are advanced into the center of the vertebral body. It is very important to highlight that the tips of the guide wires should be about and not closer than 5 mm to the anterior wall of the vertebral body.

Figure 8.

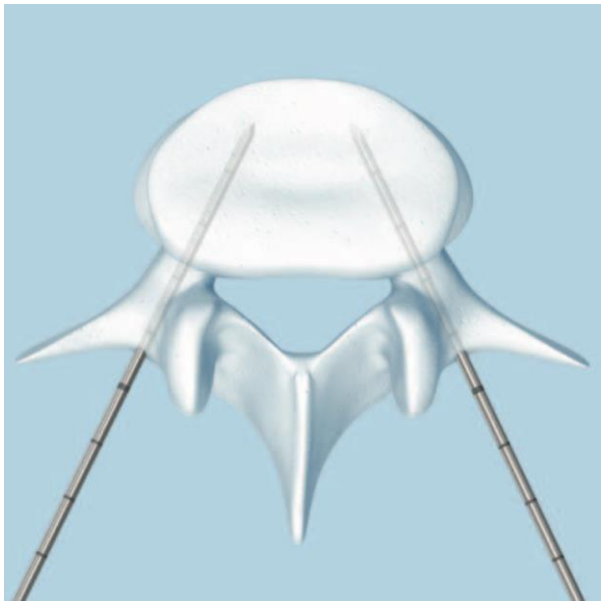

Figure 9.

They should be positioned symmetrically and aligned in both AP and lateral views [Figure 8, 9] [27]. The tips of the guide wires must not pass the midline in AP view until they have passed the posterior wall in the lateral view. When the guide wires are advanced, it is important to ensure that they are not inserted too far medially, in order to avoid penetration into the spinal canal. It is also essential to avoid overdrive the guide wires into vascular structures beyond the anterior cortical wall [28] .

Position Working Sleeves over Guide Wires

The instrument assembly of working sleeve, side-opening cannula and cannulated trocar is used. The instrument assembly is pushed with a counterclockwise turning motion over the first guide wire.

It is mandatory not to insert the working sleeve into the bone without the side-opening cannula. This could damage the working sleeve and obstruct stent insertion. Do not hammer on the side-opening cannula, cannulated trocar and working sleeve. The working sleeve can also be placed without the mounted cannulated trocar (working sleeve with side-opening cannula over guide wire). If this method is chosen, there is more clearance between the diameter of the guide wire and the side-opening cannula to allow for minor correction in the trajectory when positioning the working sleeve. This can lead to a slight resistance while penetrating the bony vertebral body surface [29]

Placement working sleeve must be evaluated under lateral X-ray control. It is mandatory to ensure that the tip of the working sleeve has passed the pedicle and is positioned inside the vertebral body.

When the working sleeve is inserted, the position of the guide wire must be monitored in order to confirm that it is not advancing forward. It is possible to pull back the side-opening

cannula to verify the positioning of the working sleeve. All this procedure must be repeated on the controlateral side. Once both working sleeves are in place, the side-opening cannulae with the inserted cannulated trocar and the guide wires can be removed [30].

The working sleeves remain in the vertebral body. It is important to advance the instrument assembly carefully in order to avoid any injury to the physician's hand. Since the guide wire is longer than the combined length of the pre-mounted working sleeve with the side-opening cannula with cannulated trocar, it will protrude through the handle of the side-opening cannula.

EXTRA-/PARAPEDICULAR ACCESS

Position Guide Wires

Guide wires are inserted using slight manual pressure under AP and lateral X-ray control.

Both the guide wires is inserted up to the vertebral body and they are driven with controlled blows from a hammer through the cortex. Should you touch bone before reaching the vertebral body, the outline of the lateral pedicle has been reached [Figure 10]. The guide wires must be cautiously advanced and, if it is necessary, it must be redirected in order to reach the center of the vertebral body [31] . The tips of the guide wires should be about and not closer than 5 mm to the anterior wall of the vertebral body.

The tips of the guide wires must not pass the midline in AP view until they have passed the posterior wall in the lateral view. When advancing the guide wires, it is mandatory to ensure that they are not inserted too far medially, to avoid penetration into the spinal canal. It is also essential to avoid overdriving the guide wires into vascular structures beyond the anterior cortical wall [32] .

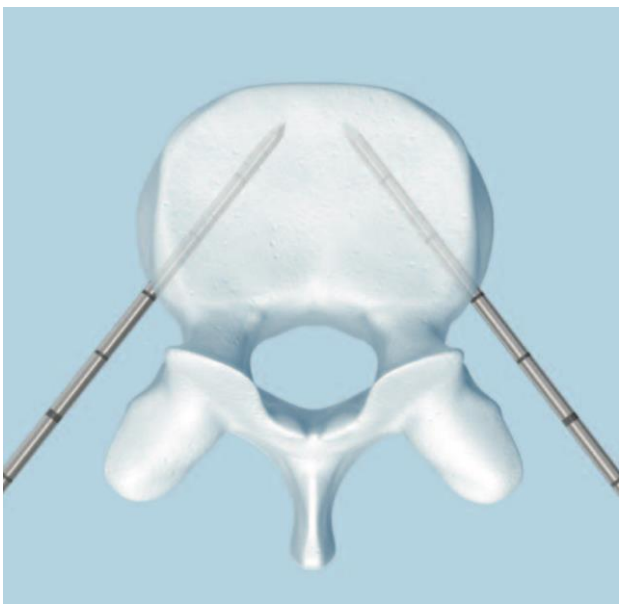

Figure 10.

Positioning Working Sleeves over Guide Wires

The instrument assembly of working sleeve, side-opening cannula and cannulated trocar is used. The instrument assembly is pushed with a counterclockwise turning motion over the first guide wire. The working sleeve must not be inserted into the bone without the side-opening cannula. This could damage the working sleeve and obstruct stent insertion. It is mandatory not to hammer on the side-opening cannula, cannulated trocar and working sleeve.

The working sleeve can also be placed without the mounted cannulated trocar (working sleeve with side-opening cannula over guide wire). Then, there is more clearance between the diameter of the guide wire and the side-opening cannula in order to allow for minor correction in the trajectory when positioning the working sleeve. This can lead to a slight resistance when penetrating the bony vertebral body surface. Working sleeve placement must be monitored under lateral X-ray control [33]. The tip of the working sleeve must be advanced until it has penetrated the cortex and it is tightly seated into the bone.

When the working sleeve is inserted, the position of the guide wire must be carefully monitored, in order to confirm that it is not advancing forward [34]. It possible to pull back the side-opening cannula in order to verify the positioning of the working sleeve. The same procedure must be repeated on the controlateral side. Once both working sleeves are in place, the side-opening cannulae with the inserted cannulated trocar and the guide wires must be removed. The working sleeves remain in the vertebral body. It is important to advance the instrument assembly carefully in order to avoid any injury to the physician's hand. The guide wire is longer than the combined length of the instrument assembly of working sleeve and the side-opening cannula and cannulated trocar will protrude through the handle of the side-opening cannula.

When using trocars for instrument positioning, creating the pathway and positioning of the instrumentation is achieved in one step. Either a transpedicular or extra-/parapedicular access may be selected depending on the anatomy of the vertebral body to be treated. With either access technique it is important to plan to place the two stents symmetrically towards the midline [35].

CREATE ACCESS CHANNEL

Drill [Figure 11] followed by blunt plunger [Figure 12] are used through the working sleeves to create an access channel for the stents. It is important to use lateral X-ray intensification in order to avoid the penetration into the anterior cortex of the vertebral body [36]. It is essential to avoid overdriving these instruments into vascular structures beyond the anterior cortical wall. For the same reasons, it is mandatory not to use a hammer to drive the drill forward [37]. The drill may aggressively advance with rotation. The plunger can be driven forward with light hammer blows. It is mandatory to ensure that the hammer blows hit the protruding metal pin and not the plastic handle. While using drill or plunger, it is important to ensure that the working sleeves are not moving [38]. The drill or plunger must not be used for manipulating or correcting the direction of the working sleeve. The same procedure must be repeated on the controlateral side.

In general, these are the same steps for each type of third generation device for percutaneous vertebral augmentation procedure. From this point, the difference is the type and the shape of the device. But, anyway the last step that is common for each device is the PMMA injection.

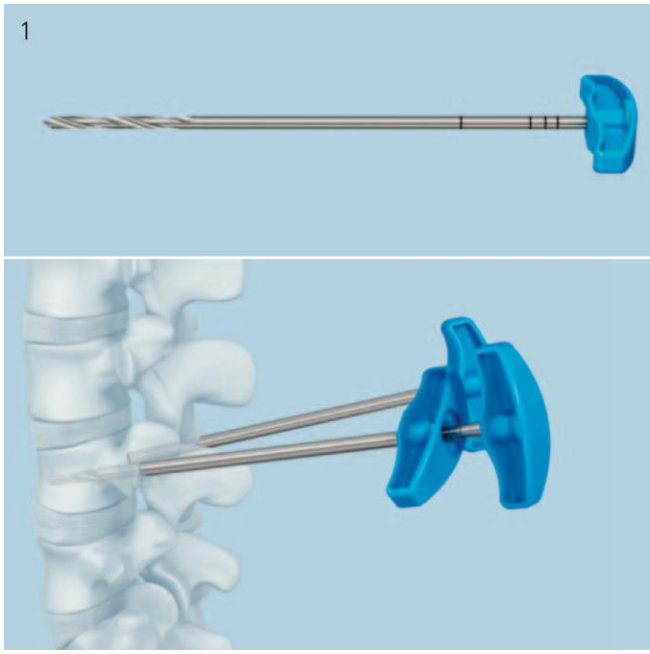

Figure 11.

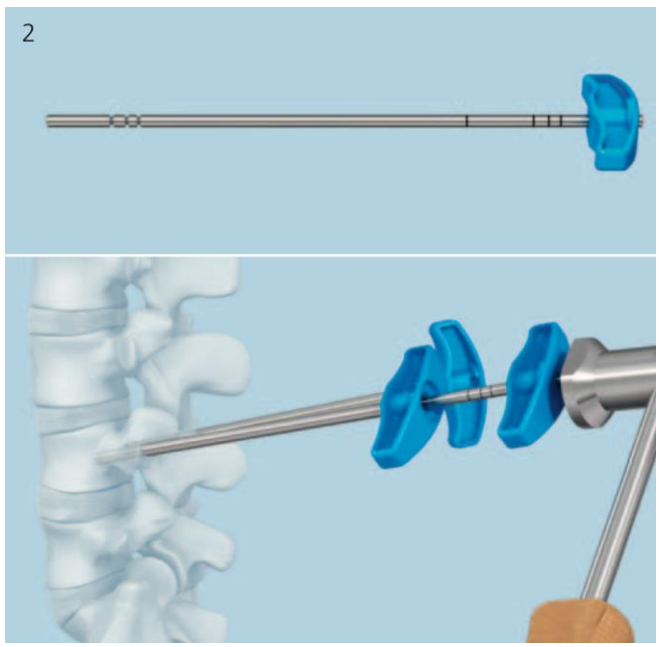

Figure 12.

There are different type of cement formulas. They have an different radiopacity and different working time and viscosity. Some of these cements are ready for immediate injection, others require several minutes before they can be used. It is mandatory to consider the temperature of the setting time because it could influence the cement properties, like the viscosity that is a fundamental for cement leakage controlling. If a cement has a low-viscosity, it should not be injected. In addition, small syringes or plunger technique seem to be the best system to inject cement because in this way it is possible to have a direct feedback during cement injection and to provides the best way of injecting high-viscosity cement [39].

The fundamental steps of a correct cement injection are [40, 41, 42]:

- The cement must be prepared but it can be injected only when it has reached the correct viscosity
- Cement injection must be controlled under lateral x-ray vision and with intermittent AP checks.
- The injection must stopped if any cement leakage is observed. On the basis of the cement type, the injection can be resumed after 35 o to 160 seconds.
- The filling procedure can be completed until the vertebral body is supported from the upper to the lower endplate respectively
- After the cement injection, the cannula can be removed when the cement has set.
- The maximum amount of cement that can be injected safely in one session is about 25 cc

REFERENCES

[1] Balloon kyphoplasty is effective in deformity correction of osteoporotic vertebral compression fractures. Voggenreiter G. *Spine* 2005, 30(24):2806 –12

[2] Percutaneous kyphoplasty: new treatment for painful vertebral body fractures. Masala S, Cesaroni A, Sergiacomi G, Fiori R, Massari F, Manenti G, Nardi P, Simonetti G. *In Vivo* 2004, 18(2):149 –53

[3] An Ex Vivo Evaluation of an Inflatable Bone Tamp Used to Reduce Fractures Within Vertebral Bodies Under Load. Belkoff T, Jasper LE, Stevens SS. *Spine*. 1999, 27(15): 1640–1643

[4] Preliminary experience with balloon kyphoplasty for the treatment of painful osteoporotic compression fractures. Wilhelm K, Stoffel M, Ringel F, Rao G, Rosseler L, Urbach H, Meyer B. *Rofo* 2003, 175(12):1690 – 6

[5] Percutaneous cementing techniques of the spine – chances and limits. Berlemann U, Muller CW, Krettek C. *Orthopäde* 2004, 33(1):6 –12

[6] Vertebroplasty and kyphoplasty: a systematic review of 69 clinical studies. Hulme PA, Krebs J, Ferguson SJ, Berlemann U. *Spine* 2006, 31(17):1983–2001

[7] Sagittal alignment of spine and pelvis regulated by pelvic incidence: stan- dard values and prediction of lordosis. Boulay C, Tardieu C, Hecquet J, et al. *Eur. Spine J.* 2006, 15:415–22

[8] Kyphoplasty-minimally invasive vertebral compression fracture repair. Erickson K, Baker S, Smith J. *AORN J.* 2003, 78(5):766 –73;quiz 777– 80

[9] Efficacy and safety of balloon Kyphoplasty in the treatment of vertebral compression fractures: a systematic review.Bouza C, López T, Magro A, Navalpotro L, Amate JM. *Eur. Spine J.* 2006, 15(7):1050 –1067

[10] Balloon kyphoplasty in the treatment of back pain. Nöldge G, DaFonseca K, Grafe I, Libicher M, Hillmeier J, Meeder PJ, Kauffmann GW, Kasperk C. *Radiologe* 2006, 46(6): 506 –12

[11] Vertebroplasty and kyphoplasty for the treatment of vertebral compression fractures: an evidenced- based review of the literature. McGirt MJ, Parker SL, Wolinsky JP, Witham TF, Bydon A, Gokaslan ZL. *The Spine Journal* 2009, 9:501–508

[12] Kyphoplasty: an assessment of a new technology. *AJNR Am J Neuroradiol*. Cloft HJ, Jensen ME. 2007, 28(2):200 –3

[13] Comparison of vertebroplasty and balloon kyphoplasty for treatment of vertebral compression fractures: a meta-analysis of the literature. Eck JC, Nachtigall D, Humphreys SC, Hodges SD. *The Spine Journal* 2008, 8:488 – 497

[14] Balloon kyphoplasty in the management of vertebral compression fractures: an updated systematic review and meta-analysis. Taylor RS, Fritzell P, Taylor RJ. *Eur. Spine J.* 2007, 16:1085 –1100

[15] *Percutaneous cementing techniques in treatment of osteoporotic spinal sintering*. Berlemann U, Heini PF. Unfall- chirurg. 2002, 105(1):2– 8

[16] Balloon kyphoplasty in traumatic fractures of the thoracolumbar junction: Preliminary experience in 12 cases. De Falco R, Scarano E, Di Celmo D, Grasso U, Guarnieri L. *J. Neurosurg. Sci.* 2005, 49:147–153

[17] Kyphoplasty: 2 years of experience in a neurosurgery department. Atalay B, Caner H, Gokce C, *Altinors N. Surgical Neurology*. 2005, 64: S2:72–S2:76

[18] Incidence of subsequent vertebral fracture after kyphoplasty. Fribourg D, Tang C, Sra P, Delamarter R, Bae H. *Spine* 2004, 29(20):2270–6; discussion 2277

[19] Vertebral Fracture Assessment Using a Semiquantitative Method. Genant HK, Wu CY, Van Kuijk C, Nevitt MC. *J. Bone Miner Res.* 1993, 8(9):1137–1148

[20] In Vivo Intradiscal Pres- sure Measurement in Healthy Individuals and in Patients With Ongoing Back Problems. Sato K, Kikuchi S, Yonezawa T. *Spine* 1999, 24(23): 2468–2474

[21] Combined percutaneous transpedicular tumor debulking and kyphoplasty for pathological compression fractures. Technical note. Gerszten PC, Welch WC. *J. Neurosurg. Spine* 2007, 6(1):92–5

[22] Changes of pulmonary function for patients with osteoporotic vertebral compression fractures after kyphoplasty. Yang HL, Zhao L, Liu J, Sanford CG, Chen L, Tang T, Ebraheim NA. *J. Spinal Disord. Tech.* 2007, 20(3):221– 225

[23] Reduction of pain and fracture incidence after kyphoplasty:1-year outcomes of a prospective controlled trial of patientswith primary osteoporosis. Grafe IA, Da Fonseca K, Hillmeier J, Meeder PJ, Libicher M, Nöldge G, Bardenheuer H, Pyerin W, Basler L, Weiss C, Taylor RS, Nawroth P, Kasperk C. *Osteoporos Int.* 2005, 16(12):2005 –12

[24] *Extended kyphoplasty indications for stabilization of osteoporotic vertebral compression fractures*. Unfallchirurg. Boszczyk B, Bierschneider M, Potulski M, Robert B, Vastmans J, Jaksche H. 2002, 105(10):952–7

[25] Minimally invasive therapy of painful osteoporotic vertebral fractures. Krepler P, Grohs JG. *Radiologe* 2003, 43(9): 718 –22

[26] Conservative and minimally invasive treatment modalities at the spine. Berlis A. *Med. Monatsschr Pharm* 2007, 30(1):17–24

[27] The current treatment–a survey of osteo- porotic fracture treatment. Osteoporotic spine fractures: the spine surgeon's perspective. Heini PF. *Osteoporos Int*. 16 Suppl 2: S85–92

[28] New technologies in spine: kyphoplasty and vertebroplasty for the treatment of painful osteoporotic compression fractures. Garfin SR, Yuan HA, Reiley MA. *Spine* 2001, 26(14):1511– 5

[29] Severe thoracolumbar osteoporotic burst fractures: Treatment combining open kyphoplasty and short- segment fixation. Blondel B, Fuentes S, Metellus P, Adetchessi T, Pech-Gourg G, Dufour H. *Orthopaedics & Traumatology: Surgery & Research*. 2009, 95(5):359 –364

[30] Initial outcome and efficacy of "kyphoplasty" in the treatment of painful osteoporotic vertebral compression fractures. Lieberman IH, Dudeney S, Reinhardt MK, Bell G. *Spine* 2001, 15 26(14):1631– 8

[31] A comprehensive classification of thoracic and lumbar injuries. Magerl F, Aebi M, Gertzbein SD, Harms J, Nazarian S. *Eur. Spine J.* 1994, 3:184-201

[32] Vertebral body stenting. A method for repositioning and augmenting vertebral body compression fractures. Fürderer S, Anders M, Schwindling B, Salick M, Dűber C, Wenda K, Urban R, Glück M, Eysel P. *Orthopäde.* 2002, 31:356 –361

[33] Percutaneous Techniques in the Treatment of Spine Tumors. Mendel E, Bourekas E, Gerszten P, Golan JD. *Spine* 2009, 34(22S):S93–S100

[34] Vertebral body stenting: a new method for vertebral augmentation versus kyphoplasty. Rotter R, Martin H, Fuerderer S, Gabl M, Roeder C, Heini P, Mittlmeier T. *Eur. Spine J.* 2010, 19:916 –923

[35] Balloon Kyphoplasty and Vertebroplasty for Vertebral Compression Fractures: A Comparative Systematic Review of Efficacy and Safety. Taylor RS, Taylor RJ, Fritzell P. *Spine* 2006, 31(23):2747–2755

[36] Efficacy and safety of balloon kyphoplasty compared with non-surgical care for vertebral compression fracture (FREE): a randomised controlled trial. Wardlaw D, Cummings SR, Van Meirhaeghe J, Bastian L, Tillman JB, Ranstam J, Eastell R, Shabe P, Talmadge K, Boonen S. *Lancet* 2009, 373:1016 –24

[37] Kyphoplasty and vertebroplasty in fractures in the elderly: effort and effect. Meeder PJ, Da Fonseca K, Hillmeier J, Grafe I, Noeldge G, Kasperk C. *Chirurg* 2003, 74(11):994 – 9

[38] Treatment of painful osteoporotic vertebral fractures with percutaneous vertebroplasty or kyphoplasty. Watts NB, Harris ST, Genant HK. *Osteoporos Int*. 2001, 12(6):429 –37

[39] New In Vivo Measurements of Pressures in the Intervertebral Disc in Daily Life. Wilke T, Neef P, Caimi M, Hoogland T, Claes LE. *Spine* 1999, 24(8): 755–762

[40] Comparison of 5766 Vertebral Compression Fractures Treated With or Without Kyphoplasty. Zampini JM, White AP, McGuire KJ. *Clin. Orthop. Relat. Res.* 2010, 468(7):1773-1780

[41] Vertebroplasty and kyphoplasty in the fractured osteoporotic spine. Ohlin A, Johnell O. *Clin. Calcium* 2004, 14(1):65 – 9

[42] Biomechanical evaluation of vertebroplasty and kyphoplasty with polymethyl methacrylate or calcium phosphate cement under cyclic loading. Wilke HJ, Mehnert U, Claes LE, Bierschneider MM, Jaksche H, Boszczyk BM. *Spine* 2006, 31(25):2934–41

In: Encyclopedia of Surgery (22 Volume Set)
Editors: Andreas Lehrer and Kristin Mueller
ISBN: 978-1-53618-329-0
© 2020 Nova Science Publishers, Inc.

Chapter 28

ALTERNATIVES TO PMMA FOR VERTEBRAL AUGMENTATION PROCEDURES

***Daniele Vanni*[1,*] *and Vincenzo Salini*[2]**

[1]Orthopaedic and Traumatology Department, "G. d'Annunzio" University, Chieti, Italy.
Neurosurgery Spine Department, Asl Chieti, Italy
[2]Orthopaedic and Traumatology Department, "G. d' Annunzio" University, Chieti, Italy

The acrylic bone cement plays an important in spine surgery. The polymethylmethacrylate (PMMA) has been extended from the field of ophthalmology and dentistry to the orthopaedics, as acrylic cement is used for prosthetic implants fixation, for osteoporotic, tumoral or metastatic remodeling areas and for vertebral fractures treatment [1, 2].

The PMMA bone cement was also found to be a good carrier for the antibiotic release at the infection site. PMMA is the gold standard for treatment of painful vertebral fractures by percutaneous vertebral augmentation procedures, but significant drawbacks are associated with its use, i.e., pulmonary embolism, toxicity of the methylmethacrylate monomer, heat generated during curing, and increased stress on adjacent vertebra [3]. In recent years the scientific advancement and research in the field of biomaterials have been an essential boost to search for alternatives to the PMMA. Over the past 20 years, the experimental study of acrylic biomaterials like bone cement, bioglass, cement additives, cement absorbable antibiotic, has become particularly significant, suggesting the evaluation of numerous models and projects [4]:

- the study of composite materials, formed by low polymerization temperature bone cement and bioglass fibers, with the aim to create a bioactive surface in contact with the bone
- a bone cement with sodium fluoride in order to provide a controlled release pharmacological system, able to prevent bone resorption.

[*] Corresponding Author's Email: danielevannimd@libero.it.

- measurement of superoxide anion in cultured human leukocytes, as an indicative parameter of the materials reactivity.
- evaluate the tolerance and activity of the fluoride added cement, in cultured adult human osteoblastic cells, with particular attention to the actual availability of fluoride in the time of contact with the surface containing the additive compound , evaluating the biocompatibility and the osteoconductive capacity of a new acrylic bone cement.

PMMA is commonly used as a filler material, but unfortunately a range of issues to be resolved are associated with its use.

In fact, the PMMA has a modulus of elasticity and stiffness different from that of the vertebral column and it use could change the normal biomechanic of the spine, resulting in subsequent fractures of the vertebrae, above or below[5, 6, 7, 8, 9].

The "adjacent level insufficiency fractures", following percutaneous vertebral augmentation procedures seem to be due to the abnormal stresses that are generated when a "super vertebrae" is created. Especially in case of osteoporotic vertebral fractures, the "non-augmentated vertebrae" have lower structural integrity, that is due to disease. Reports of up to 52% of osteoporotic spines treated with either vertebroplasty or kyphoplasty sustained adjacent level fractures within a 7-year period [10]. Deramond and Mathis [11] report a significative increase of "adjacent vertebrae fractures", probably resulting from a shift in the normal load transmission through the spine following percutaneous vertebral augmentation procedures. Lieberman et al. [12] shows an abnormal load and motion distribution in vertebral segments treated with percutaneous vertebral augmentation procedures. In addition Farooq et al. [13] reports that percutaneous vertebral augmentation procedures reduce annulus and neural arch stress concentrations: as a result there is a greater compressive stress concentration on the intervertebral disc and on the adjacent vertebral bodies. In addition, the PMMA reaches a high polymerization temperature and this can represent a problem when it is used near very delicate structures, such as meninges and spinal cord. Though the PMMA is able to provide an immediate and good primary stability, since it acts as an inert material, it cannot be reabsorbed over the time nor it has the ability to biointegrate with bone tissue around. This has therefore led to the search for alternatives to PMMA. The goal is to find materials capable of providing an immediate absolute stability during vertebral augmentation procedures, without presenting the problems of the high polymerization temperatures. It should also be capable of bone bio-integration, over the time.

For these reason, it is fundamental to evaluate the biomechanical properties of different vertebral augmentation agents in a reproducible vertebral body model, able to mimic the physiological conditions in a reproducible way. In addition, it is mandatory to describe the biomechanical effects of these agents on the surrounding spinal column through comparative analysis.

Until now, four different filler materials seem to be usable: (1) SRS-tricalcium phosphate cement; (2) MIIG X3 HiVisc, calcium sulfate cement; and (3) BoneSource, calcium phosphate cement. In the study of Clint Hill et al. [14] the same amount of liquid (5 mL) was used in each augmentation and each vertebra was augmented bilaterally via injection of two 2.5 mL volumes of the investigated material [15]. The vertebrae were then tested in the lab through mechanical testing load frame. Each vertebra was compressed under a stroke-controlled loading regime in order to evaluate the construct's elastic modulus in compression. Mechanical testing was stopped in case of a compressive displacement of 6 mm or

mechanical failure (denoted by a rapid decrease in the measured compressive load, greater than 15% of the current load) [16, 17, 18]. From the study of Clint Hill et al. the mean modulus of elasticity for the control group vertebrae was 92.44 ± 19.28 MPa; SRS-tricalcium phosphate group was 79.14 ± 20.20 MPa ; BoneSource group was 57.49 ± 8.35 MPa. The mean modulus of elasticity was highest in the PMMA group (195.47 ± 2.33 MPa) and lowest in the MIIG group (25.79 ± 4.77 MPa). On the basis of these data it is possible to establish that PMMA is stiffer than the other materials. Calcium phosphate and calcium sulfate revealed a similar modulus of elasticity to the nonaugmented vertebrae and they are not stiff as PMMA but they are able to sustain significant loads. These data suggest that the characteristic of the filler materials may influence the "adjacent segment fracture phenomenon" resulting from percutaneous vertebral augmentation procedures [19, 20, 21, 21, 23, 24]. However, although alternative osteoconductive filler materials might prevent subsequent vertebral compression and fractures because they are less stiff than PMMA, without causing exothermic effects, [25, 26, 27], they may not provide enough initial stiffness. Therefore, according to D. H. Heo et al. [28] recollapse may occur 1 year after in the CaP-augmented vertebrae [29]. A newly available alternative to PMMA is a containment system that enables percutaneous bone graft augmentation of the fractured vertebra.

Minimally invasive percutaneous vertebral augmentation with intravertebral polyethylene mesh sac is a new system used in the minimally invasive biologic vertebral reconstruction procedures [30]. It consists of a polyethylene mesh sac, introduced into the vertebral body and filled with morcelized bone allograft. Bone graft is able to create a hyperdense pack, reducing the fracture and restoring vertebral height. Osteoconductive and osteoinductive properties allow a biologic vertebral reconstruction. The adjacent vertebrae should be more protected by a construct with a similar elasticity and physical characteristics of the morcelized bone. In fact the use of bone tissue (autologous / homologous) is still considered the "gold standard" in spinal instrumentation surgical techniques in order to facilitate spinal arthrodesis formation. Autologous bone has the greatest osteogenic potential, but its availability is limited and its use may be associated with painful long-term complications. The use of homologous bone is an important option in case of bulk or structural graft. Bone graft augmentation offers fracture reduction and trabecular stabilization. Long-term findings suggest that bone graft augmentation in osteoporotic patients yields a stable yet less rigid segment, which may reduce the risk of adjacent level fracture. For younger people, the potential now exists for biologic fracture repair. The limitations of the autologous bone substitutes, make it necessary to search for alternatives. Till date, the synthetic bone substitutes represent a partial solution, because they provide some bone mechanical properties such as osteoinductivity and osteoconductivity, but this features remain largely dependent on the presence of vital periosteum and bone [31]. The advent of bone substitutes and composites of biological factors represents a promising development in the search for synthetic bone grafts that are able to substitute the mechanical and osteogenic properties of the bone tissue.

SE SERVE PUOI AGGIUNGERE…..

A promising alternative is resorbable, nano-crystalline calcium phosphate cement (CPC), which is biocompatible, biomimetic and having extensive clinical history. Additionally, these

CPCs can be used as delivery vehicles for bioactive molecules to accelerate healing and treat osteoporosis which is typically the root cause of the vertebral fractures.

However, use of pure CPC in vertebral augmentation has been limited due to reports of cardiovascular deterioration. This effect has been associated with cement extravisation leading to pulmonary embolism stimulating thrombosis. In order to minimize these risks, a new class of combination CPCs have been developed with enhanced viscosity, cohesiveness and improved radiographic visualization. Unlike other CPCs discussed in the literature, these combination CPCs do not initiate a thrombotic response.

RESULTS

Results of human cadaver vertebral injections testing are summarized in Table 1. Overall, nano-crystalline CPC combination biomaterials were easy to inject and visualize under fluoroscopy. Individual formulations were resistant to leakage and exhibited symmetrical, well defined flow characteristics. Conversely, the PMMA controls exhibited finger-like protrusions indicative of poor resistance to leakage (Figure 1). From an initial 13 formulations, 8 (62%) could be injected easily, 100% were resistant to leakage and exhibited symmetrical and well defined flow characteristics. It was observed that cement injection force, leakage and dispersion were related to CPC formulation design (molecular weight of the viscosity modifier, weight percent of the modifier, ratio of liquid to powder) but not by the nature and concentration of contrast agents.

DISCUSSION

This new class of modified CPCs were easy to inject and visualize. Many formulations exhibited improved resistance to leakage and dispersion relative to PMMA. Injection force, leakage and dispersion were related to CPC formulation and can be tailored for optimal performance. Additionally, these CPCs did not exhibit a tendency to initiate thrombosis. These combination formulations may significantly reduce the risks historically associated with CPC and are an attractive alternative to PMMA due to their biocompatibility, mechanical properties and resorbability.

REFERENCES

[1] Treatment options for vertebral fractures an overview of different philosophies and techniques for vertebral augmentation. Bornemann, R; Koch, EM; Wollny, M; Pflugmacher, R. *Eur J Orthop Surg Traumatol*., 2014 Jul, 24 Suppl 1, S131-43.

[2] Percutaneous vertebroplasty in the treatment of pain caused by metastatic tumor. Togao, O; Mihara, F; Yoshiura, T; Noguchi, T; Kuwabara, Y; Yoshimitsu, K; Honda, H. *Fukuoka Igaku Zasshi*., 2005 Apr, 96(4), 93-9.

[3] Current concepts and techniques in percutaneous vertebroplasty. Heran, MK; Legiehn, GM; Munk, PL. *Orthop Clin North Am*., 2006 Jul, 37(3), 409-34.

[4] Bone substitutes in vertebroplasty. Heini, PF; Berlemann, U. *Eur Spine J*. 2001 Oct, 10 Suppl 2, S205-13. Review.

[5] Vertebroplasty versus Kyphoplasty: a comparison and contrast. Mathis, JM; Orlando Ortiz, A; Zoarski, G. *Am J Neuroradiol*, 2004, 25, 840–845

[6] Kyphoplasty. Hardouin, P; Fayada, P; Leclet, H; et al. *J Bone Spine*, 2002, 69(3), 256–261

[7] Management of osteoporotic vertebral fractures. Dionyssiotis Y. *Int J Gen Med*. 2010, 21, 3,167-71.

[8] Kyphoplasty and vertebroplasty for the management of osteoporotic vertebral compression fractures: a systematic review". Felder-Puig, R; Piso, B; Guba, B; Gartlehner, G. *Orthopade*., 2009, 38(7), 606-15.

[9] Kyphoplasty for chronic painful osteoporotic vertebral compression fractures via unipedicular versus bipedicular approachment: a comparative study in early stage. Chen, C; Chen, L; Gu, Y; Xu, Y; Liu, Y; Bai, X; Zhu, X; Yang, H. *Injury*. 2010, 41(4), 356-9.

[10] Osteoporosis prevalence and fracture characteristics in elderly female patients with fractures. Augat, P; Weyand, D; Panzer, S; Klier, T. *Arch Orthop Trauma Surg*., 2010, Nov, 130(11), 1405-10.

[11] Characteristics of a prevalent vertebral deformity predict subsequent vertebral fracture: results from the European Prospective Osteoporosis Study (EPOS)". Lunt, M; O'Neill, TW; Felsenberg, D; Reeve, J; Kanis, JA; Cooper, C; Silman, AJ. European Prospective Osteoporosis Study Group. *Bone*. 2003, 33(4), 505-13

[12] Biomechanics of vertebral fractures and the vertebral fracture cascade. Christiansen, BA; Bouxsein, ML. *Curr Osteoporos Rep*., 2010, 8(4), 198-204.

[13] Mechanisms of initial endplate failure in the human vertebral body. Fields, AJ; Lee, GL; Keaveny, TM. *J Biomech*., 2010, 1, 43(16), 3126-31

[14] Vertebral compression model and comparison of augmentation agents. Hill, C; Wingerter, S; Parsell, D; McGuire, R. *Evid Based Spine Care J*. 2011 Feb, 2(1), 23-7.

[15] Biomechanical evaluation of an injectable calcium phosphate cement for vertebroplasty. Lim, TH; Brebach, GT; Renner, SM; Kim, WJ; Kim, JG; Lee, RE; Andersson, GB; *An HS. Spine* (Phila Pa 1976). 2002 Jun 15, 27(12), 1297-302.

[16] Differential blood contamination levels and powder-liquid ratios can affect the compressive strength of calcium phosphate cement (CPC): a study using a transpedicular vertebroplasty model. Kiyasu, K; Takemasa, R; Ikeuchi, M; Tani, T. *Eur Spine J*., 2013 Jul, 22(7), 1643-9.

[17] Biomechanical study of vertebroplasty with geneX(®) cement augmentation in a calf osteoporotic vertebral compression fracture model. Zhang, S; Jiang, J; Zhu, Q; Huang, Z. *Nan Fang Yi Ke Da Xue Xue Bao*. 2012, Jun, 32(6), 843-6.

[18] Bone healing using a bi-phasic ceramic bone substitute demonstrated in human vertebroplasty and with histology in a rabbit cancellous bone defect model. Hatten, HP Jr; Voor, MJ. *Interv Neuroradiol*. 2012 Mar, 18(1), 105-13. Epub 2012 Mar 16.

[19] Effectiveness of a bone substitute (CERAMENT™) as an alternative to PMMA in percutaneous vertebroplasty: 1-year follow-up on clinical outcome. Marcia, S; Boi, C; Dragani, M; Marini, S; Marras, M; Piras, E; Anselmetti, GC; Masala, S. *Eur Spine J*., 2012 May, 21 Suppl 1, S112-8.

[20] In silico evaluation of stress distribution after vertebral body augmentation with conventional acrylics; composites and glass polyalkenoate cements. Dickey, BT; Tyndyk, MA; Doman, DA; Boyd D. *J Mech Behav Biomed Mater*., 2012 Jan, 5(1), 283-90.

[21] Evaluation of two novel aluminum-free; zinc-based glass polyalkenoate cements as alternatives to PMMA bone cement for use in vertebroplasty and balloon kyphoplasty. Lewis, G; Towler, MR; Boyd, D; German, MJ; Wren, AW; Clarkin, OM; Yates, A. *J Mater Sci Mater Med*., 2010 Jan, 21(1), 59-66.

[22] Suitability of a calcium phosphate cement in osteoporotic vertebral body fracture augmentation: a controlled, randomized, clinical trial of balloon kyphoplasty comparing calcium phosphate versus polymethylmethacrylate. Blattert, TR; Jestaedt, L; Weckbach, A. *Spine* (Phila Pa 1976). 2009 Jan 15, 34(2), 108-14.

[23] Calcium-phosphate and polymethylmethacrylate cement in long-term outcome after kyphoplasty of painful osteoporotic vertebral fractures. Grafe, IA; Baier, M; Nöldge, G; Weiss, C; Da Fonseca, K; Hillmeier, J; Libicher, M; Rudofsky, G; Metzner, C; Nawroth, P; Meeder, PJ; Kasperk, C. *Spine* (Phila Pa 1976). 2008 May 15, 33(11), 1284-90.

[24] Comparison of an experimental bone cement with surgical Simplex P; Spineplex and Cortoss. Boyd, D; Towler, MR; Wren, A; Clarkin, OM. *J Mater Sci Mater Med*., 2008 Apr, 19(4), 1745-52.

[25] Complication after vertebroplasty in patient with senile osteoporosis: strategical therapy to revise. Minenna, G; D'Amore, S; D'Amore M. *Recenti Prog Med*., 2006, 97(7-8), 389-92.

[26] Percutaneous vertebroplasty complications. Al-Nakshabandi, NA. *Ann Saudi Med*., 2011 May-Jun, 31(3), 294-7.

[27] Epidural cement leakage through pedicle violation after balloon kyphoplasty causing paraparesis in osteoporotic vertebral compression fractures - a report of two cases. Park, SY; Modi, HN; Suh, SW; Hong, JY; Noh, W; Yang, JH. *J Orthop Surg Res*., 2010 Aug 6, 5, 54.

[28] Biomechanical comparison of unipedicular versus bipedicular kyphoplasty. Steinmann, J; Tingey, CT; Cruz, G; Dai, Q. *Spine* (Phila Pa 1976). 2005, 15, 30(2), 201-5.

[29] Comparison of the results of balloon kyphoplasty performed at different times after injury. Oh, GS; Kim, HS; Ju, CI; Kim, SW; Lee, SM; Shin, H. *J Korean Neurosurg Soc*., 2010 Mar, 47(3), 199-202

[30] 3Balloon kyphoplasty in the treatment of osteoporotic vertebral fractures: indications - treatment strategy – complications. Bula, P; Lein, T; Strassberger, C; Bonnaire, F. *Z Orthop Unfall*., 2010,148(6), 646-56.

[31] Biomechanical, histological and histomorphometric analyses of calcium phosphate cement compared to PMMA for vertebral augmentation in a validated animal model. Galovich, LA; Perez-Higueras, A; Altonaga, JR; Orden, JM; Barba, ML; Morillo, MT. *Eur Spine J*., 2011 Aug, 20 Suppl 3, 376-82.

In: Encyclopedia of Surgery (22 Volume Set)
Editors: Andreas Lehrer and Kristin Mueller
ISBN: 978-1-53618-329-0
© 2020 Nova Science Publishers, Inc.

Chapter 29

STEM CELLS AND BIOTECHNOLOGIES FOR VERTEBRAL AUGMENTATION PROCEDURES

Andrea Pantalone*, MD, Matteo Guelfi, MD and Vincenzo Salini
Orthopaedic and Traumatology Department, "G. d'Annunzio" University, Chieti, Italy

INTRODUCTION

Regenerative medicine is recently developed into a multidisciplinary branch aimed to replace or restore normal function of cells, tissues, and organs that are damaged by disease. Unlike conventional surgical therapies, which, although including some element of reconstruction, they remain predominantly ablative for most diseases.

Regenerative medicine incorporates the fields of tissue engineering, cell biology, nuclear transfer and materials science to allow a truly regenerative approach by reconstructing, repairing, or replacing missing or damaged tissue to a state as close as possible to its native architecture and function [1, 2].

In the last two decades, regenerative medicine has shown the potential for ''bench-to-bedside'' translational research in specific clinical settings. A crucial point in regenerative medicine is represented by the cell type to be transplanted (stem cells) in the affected patients, alone or in conjunction with specific biomaterials (scaffold) [3, 4]. Stem cells have been proposed as a powerful tool in the treatment of several human diseases, both for their ability to represent a source of new cells to replace those lost due to tissue injuries or degenerative diseases, and for the ability of produce trophic molecules able to minimize damage and promote recovery in the injured tissue [5, 6].

Different cell types (embryonic, fetal or adult stem cells), human fetal tissues and genetically engineered cell lines have been tested for their ability to replace damaged cells and to restore the tissue function after transplantation [7].

Based on their origin, whether from the individual to be treated or from a donor, these cells can be defined as autologous or allogenic. Autologous cells would represent the ideal

* Corresponding Author's Email: pantaloneandrea@libero.it.

transplantation source, since they are not rejected by the immune system, avoiding the use of immunosuppressant drugs.

Nevertheless, the use of these cells is limited by their low "ex vivo" expansion abilities, particularly in cases of patients with end-stage organ disease who do not produce enough cells for transplantation [8].

In these cases, the use of allogenic cells may represent an advantage, but this may require the creation of specific cell banks, able to provide a large number of samples from different donors immunologically matched with the potential patients [9].

Spinal surgery is a field that is rapidly changing and evolving; the use of biologics (stem cells) has now become widespread. Actually autologous (bone marrow aspirate and mesenchymal stem cells, adipose stem cells) or allogenic stem cells are not yet in routine clinical use in spine surgery but these approaches have also been studied for achieving spinal fusion in order to treat degenerative and traumatic spine diseases [10].

Barbanti Brodano G. et al. (2012) demonstrated that human mesenchymal stem cells obtained from the bone marrow in combination with bioceramics (bone substitutes composed of calcium and phosphate complex salt derivatives) seem to be an alternative to the autologous or allogenic bone fusion in spine surgery [11].

This *in vitro* study shows how stem cells, together with a scaffold, should enable in reaching successful spinal fusion according to the correct principles of regenerative medicine and bypassing the drawbacks of traditional treatment (autologous bone grafts and allografts), including limited availability, donor site morbidity, risk of disease transmission and reduced osteogenicity [12, 13].

In order to be used for regenerative medicine on a large scale in spinal surgery, 'the perfect cells' (autologous or allogenic) to be transplanted must show the following features [14]:

- *Accessibility*: the collection of cells should not require the use of invasive procedures;
- *Availability*: the cells should be readily available in large number for transplantation;
- *Plasticity*: the cells should be able to differentiate in different cell types;
- *Mitotic stability*: the cells should retain a stable karyotype along several cell divisions;
- *Low* risk: the use of the cells should not induce transplanted related diseases, such as immunoreaction and cancer;
- *Ethical acceptability*: the use of the cells should avoid ethical concerns.

In future stem cells could become the gold standard strategy for achieving spinal fusion [15].

REFERENCES

[1] Astori G, Soncin S, Lo Cicero V, Siclari F, Sürder D, Turchetto L, Soldati G, Moccetti T. Bone marrow derived stem cells in regenerative medicine as advanced therapy medicinal products. *Am J Transl Res* 2010; 2 (3): 285-295.

[2] Bajada S, Mazakova I, Richardson JB, Ashammakhi N. Updates on stem cells and their applications in regenerative medicine. *J Tissue Eng Regen Med* 2008; 2 (4): 169-183.

[3] Alvarez A, Unda F, Cañavate ML, Hilario E. Stem cell and regenerative medicine. *Curr Stem Cell Res Ther*. 2009, 4 (4): 287-97.

[4] Pneumaticos SG, Triantafyllopoulos GK, Chatziioannou S, Basdra EK, Papavassiliou AG. Biomolecular strategies of bone augmentation in spinal surgery. *Trends Mol Med*. 2011 Apr; 17(4):215-22.

[5] Caplan A I. Adult mesenchymal stem cells for tissue engineering versus regenerative medicine. *J Cell Physiol* 2007; 213 (2): 341-347.

[6] Gardner R L. Stem cells and regenerative medicine: principles, prospects and problems. *C R Biol* 2007; 330 (6-7): 465-473.

[7] Goldschlager T, Oehme D, Ghosh P, Zannettino A, Rosenfeld JV, Jenkin G. Current and future applications for stem cell therapies in spine surgery. *Curr Stem Cell Res Ther*. 2013 Sep;8(5):381-93.

[8] Hipp J, Atala A. Sources of stem cells for regenerative medicine. *Stem Cell Rev*. 2008; 4: 3-11.

[9] Mason C, Dunnill P. Assessing the value of autologous and allogeneic cells for regenerative medicine. *Regen Med* 2009; 4 (6): 835-853.

[10] Miyazaki M, Tsumura H, Wang JC, Alanay A. An update on bone substitutes for spinal fusion. *Eur Spine J* 2009;18:783–99.

[11] Barbanti Brodano G, Mazzoni E, Tognon M, Griffoni C, Manfrini M. Human mesenchymal stem cells and biomaterials interaction: a promising synergy to improve spine fusion. *Eur Spine J*. 2012 May;21 Suppl 1:S3-9.

[12] Orlando G, Baptista P, Birchall M, De Coppi P, Farney A, Guimaraes-Souza NK, Opara E, Rogers J, Seliktar D, Shapira-Schweitzer K, Stratta RJ, Atala A, Wood KJ, Soker S. Regenerative medicine as applied to solid organ transplantation: current status and future challenges. *Transpl Int.* 2011;24(3):223-32.

[13] Cui Q, Ming Xiao Z, Balian G, Wang GJ. Comparison of lumbar spine fusion using mixed and cloned marrow cells. *Spine* 2001;26:2305–10.

[14] Andersson, E. R, Lendahl U. Regenerative medicine: a 2009 overview. *J Intern Med* 2009, 266 (4): 303-310.

[15] Peterson B, Iglesias R, Zhang J, et al. Genetically modified human derived bone marrow cells for posterolateral lumbar spine fusion in athymic rats: beyond conventional autologous bone grafting. *Spine* 2005;30:283–9; discussion 289–90.

In: Encyclopedia of Surgery (22 Volume Set)
Editors: Andreas Lehrer and Kristin Mueller
ISBN: 978-1-53618-329-0
© 2020 Nova Science Publishers, Inc.

Chapter 30

BROW LIFT

Richard Baker[1,*] and Afshin Mosahebi[2,†]
[1]Broomfield Hospital, Chelmsford, UK
[2]Royal Free Hospital, London UK

KEY POINTS

- Aesthetic results are equivalent between open brow lift (OBL) and endoscopic brow lift (EBL) (level III evidence).
- Complication rates are low for both procedures (level III evidence).
- Patient satisfaction is high for both procedures (level IV evidence).
- Scalp sensation is impaired to a greater degree in OBL in the short term but in the long-term this difference diminishes (level III evidence).
- Temporary change in scalp sensation is a significant symptom for patients in both groups (level IV evidence)

INTRODUCTION

The forehead occupies a prominent position in the upper third of the face and is often the first site for the appearance of rhytids. Many people choose to improve forehead rhytids with the use of botulinum toxin, the soaring demand for which reflects the aesthetic importance of the forehead. However, brow lift procedures reduce rhytids more and improve brow position with much greater longevity. In 2011, 47,000 brow lifts were performed in the United States (up from 42, 000 the previous year [1]) and 1500 were performed in the UK [2]. Female patients currently outnumber males by ten to one, but as the demand for male cosmetic surgery increases the difference is likely to reduce. The concept of forehead rejuvenation dates back over 100 years in the literature [3]. Hunt described elevation of the eyebrows using direct, coronal and anterior hairline (pretrichial) skin excisions in 1926 [4].

[*] Corresponding Author's Email: richhjbaker@gmail.com.
[†] Corresponding Author's Email: info@londonplasticsurgerycentre.com.

Gonzalez-Ulloa in 1962 and Loeb in 1970 described the modern coronal brow lift combined with a facelift using a continuous incision [5, 6]. Marino and Godolpho (1964) and more recently Adamson et al. (1985) introduced the concept of brow muscle modification to reduce forehead rhytids [7, 8]. New approaches to the open brow lift (OBL) such as transblepharoplasty and lateral approaches have since been presented, all possible planes of dissection – subcutaneous, subgaleal, subperiosteal, biplanar – have been described and many methods of fixation attempted [9]. The endoscopic brow lift (EBL) was introduced by Isse in 1994 and has since been popularised by Ramirez [10]. Both open and endoscopic procedures, and their variants, are currently widely practised and no consensus has emerged regarding the superiority of any one.

LITERATURE OVERVIEW

Publications looking at brow lift procedure were identified using a PubMed search and the search term 'forehead [MeSH] OR brow [MeSH] AND 'lift' [MeSH] in October 2012. Hits were filtered for those specific to brow lift, and the relevant papers reviewed and assigned a level of evidence (LOE) adapted from the American Society of Plastic Surgeons (ASPS) Scales for Rating Levels of Evidence (Appendix) from which graded recommendations were derived.

The literature search yielded 492 hits, of which 485 were relevant to brow lifting. Ten non-English language papers were excluded. Dates of publication ranged from 1972 to September 2012. There was one study of Level II evidence, fourteen at Level III, 117 papers at Level IV and 163 papers at Level V evidence. The manuscripts comprised fifty reviews, ninety discussions and comments on points of technique, and sixty case series. Endoscopic brow lift (EBL) was exclusively addressed by 79 publications. Other popular topics were anatomy and aesthetics (21 papers) and fixation devices (44 papers).

ANATOMY AND AESTHETICS

The literature referring to anatomy and aesthetics of the brow is composed completely of anatomical live patient and cadaver studies and thus amounts to level V evidence.

Skin and underlying muscle contribute to forehead rhytids. Forehead muscles have a superficial, intermediate and deep layer, with an anatomically distinct depressor superciliary muscle and a brow fat pad that allows movement of the eyebrows [11].

The wide mobility of the scalp and forehead is due to an anatomical gap in the deep layer of the subcutaneous fascia [12]. This anatomy accounts for the brow lifting effect of division of the corrugator supercilii and procerus muscles.

Aesthetically pleasing brows (Figure 1) are usually described as having a lateral peak located at the junction of its medial two-thirds and lateral third, or alternatively the lateral limbus of the iris [13].

However, an observational study comparing eyebrow peaks with anatomical landmarks in fifty subjects found that the deep temporal fusion line is the most reliable landmark in both males and females [14].

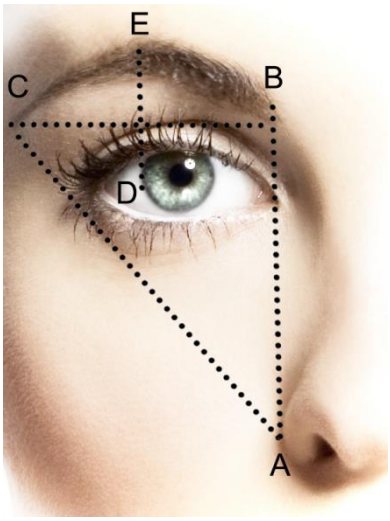

Data from McCord CD Jr, Codner MA. *Eyelid and Periorbital Surgery*. St Louis: Quality Medical Publications; 2008.

Figure 1. The aesthetic brow. The medial extent of the brow (B) is vertically aligned with the lateral aspect of the ala (A). The lateral extent of the brow (C) is horizontally aligned with the medial extent (B) and along a line formed by the ala and lateral canthus of eye. The lateral edges of the limbus (D) is vertically aligned with the brow's highest point (E).

An anatomical study in twelve cadavers suggests the characteristic shape of the brow has a ligamentous basis [15]. There are three retaining ligaments medially and one laterally, beginning approximately one centimetre from the midline and one centimetre above the supraorbital rim. The medial three ligaments extend from the cranium into the forehead musculature, whereas the lateral ligament extends in a sheet-like fashion across the lateral aspect of the supraorbital rim.

Ageing is accompanied by relatively greater descent of the lateral brow. A study measuring the brows of seventy volunteers determined that, counterintuitively, it is higher in fifty to sixty year-olds than twenty to thirty year-olds at all points along its length but significantly so at the medial and mid-brow points [16]. Knize postulates in a study of forty cadaver half heads that relative lateral brow descent is due to a greater effect of descending forces on the lateral eyebrow (gravity, corrugator supercilii and lateral orbicularis oculi) compared with elevating forces (frontalis muscle resting tone) [17]. This helps to account for the observation that selective elevation of the lateral brow has a rejuvenating effect whilst over-elevation of the medial brow imparts an unaesthetic surprised appearance.

The supraorbital, supratrochlear and frontal branch of the facial nerve must be avoided during brow lift surgery. In a study of 75 cadavers, Cuzalina et al. located the supraorbital nerve within an average 0.56mm +/- 0.7mm of a line extending from the medial iris vertically upwards (rather than along the oft-quoted mid-pupillary line) and the supratrochlear nerve an average of 9mm medial to it [18]. In an examination of fifty skulls by Miller et al. the supratrochlear nerve was never closer than 1.6cm to the midline at the level of the supraorbital ridge, and there were no supratrochlear foramina [19]. Theoretically sensory nerve injury is less likely if corrugator supercilii, procerus and orbicularis oculi muscles are disinserted rather than resected. Hafezi et al. found rates of permanent sensory loss following EBL with conventional muscle resection versus EBL with muscle disinsertion of 13.6% and

4.5% respectively [20]. However, muscle resections were performed early in the series and the disinsertions later, so there is the possibility of a learning curve effect.

Based on a study of 26 cadavers by Liebman et al., the frontal branch of the facial nerve runs *within* the superficial musculoaponeurotic system (SMAS), which in the brow becomes the temporoparietal fascia [21]. Caution must be taken in interpreting the findings from the cadaver studies described as the anatomy can vary modestly from the *in vivo* setting.

OPEN BROW LIFT TECHNIQUES

Modern open brow lift techniques vary in two principal ways: the pattern of skin incisions/excisions; and the plane in which the forehead flap is elevated.

Incision Type

Multiple incisions are described for OBLs, aiming either to reduce specific complications or enhance certain effects (Figure 2). In 1962 Gonzalez-Ulloa described a straight coronal incision, followed in 1972 by Regnault's combined coronal and facelift incisions [5, 22]. Gleason in 1973 described two temporal incisions specifically to elevate the lateral brows [23]. Ortiz-Monasterio in 1978 described the classic wavy coronal incision brow lift [24]. The main incisions in use today are: direct; (bi)coronal; pretrichial/trichophytic and lateral (the terms 'bicoronal' and 'coronal' are used interchangeably in the literature in the context of brow lifting).

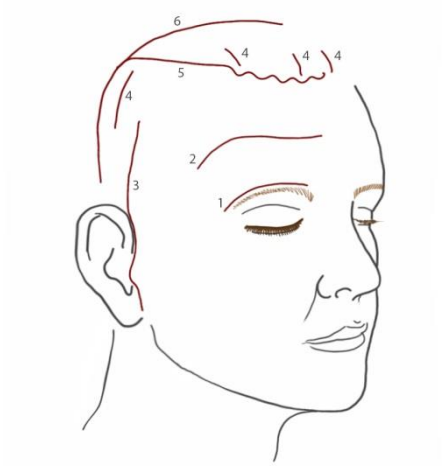

Modified from Guillot JM, Rousso DE, Replogle W. Forehead and scalp sensation after brow-lift: a comparison between open and endoscopic techniques. *Arch Facial Plast Surg*. 2011;13(2):109-16.

Figure 2. Incisions for brow lifts: 1. Direct; 2. Mid-forehead; 3. Temporal/cheek; 4. Endoscopic; 5. Trichophytic; and 6. Coronal.

Direct Brow Lift

The direct brow lift, in which a melon slice of skin is excised directly above the eyebrows within a relaxed skin tension line, is technically straightforward and predictably elevates the eyebrows although with poorly concealed scars [25]. It is better suited to men owing to their thicker skin, straighter brows, higher and/or thinner hairlines and lower aesthetic demand. In a retrospective questionnaire study of 28 patients (43 brows) of both genders, a 'happy' or 'very happy' response was given by 81% for cosmesis and by 74% for the degree of lift attained [26]. However, paraesthesia or numbness was noted postoperatively in 51% of brows. All procedures were performed for facial nerve palsies or involutional changes and it is for these patients rather than cosmetic patients that direct brow lifts are recommended [26].

Bicoronal and Pretrichial Brow Lift

The bicoronal incision placed within the hairline is the conventional OBL incision. Since this results in excision of hair-bearing scalp, in patients with receding hairlines it can be brought forward to the anterior hairline border to enable excision of non-hair-bearing skin. The latter excision is termed 'pretrichial' or 'trichophytic', although 'tricophytic' can also refer to a particular type of camouflaging closure technique (described later).

After measuring the foreheads of fifty volunteers, McKinney et al. concluded that a bicoronal incision is better for brows shorter than 5cm in height whilst a pretrichial incision is ideal for taller brows [27].

Cilento and Johnson found low complication rates in their retrospective review of 1,004 OBLs using both coronal and trichophytic incisions, and a questionnaire returned by 416 patients (64%) demonstrated a 99% satisfaction rate [28]. Unfortunately there was no comparison of the outcomes for coronal and pretrichial incisions [28].

A series of 600 OBLs utilising a coronal incision in the subgaleal plane revealed a 4% overall complication rate after five years follow-up, the most common of which was persistent scalp paraesthesia [29]. Table 1 compares complication rates from series of coronal and pretrichial OBLs. Whilst differences between publications in defining or detecting complications preclude statistical comparison of this data, on the whole complication rates appear to be low for either procedure. Table 2 compares satisfaction rates for the three main OBL incisions. Few papers report patient satisfaction rates and those that do either do not state how it is measured or use methods that have no reference to previous literature. Frequently papers state that 'patient satisfaction was very high' with no numerical evidence. However, what little evidence there is suggests that patient satisfaction is high with all three procedures. Revision rates are very rarely mentioned. Those reported are 0.57% (bicoronal and pretrichial), 0.83% (bicoronal) and 0% (pretrichial) [28, 29, 30].

The primary disadvantages of the coronal and pretrichial approaches are the long incisions and consequent scars, and the risk to sensory nerves. A strategy used to reduce scar visibility is to conceal it with hair regrowth. Traditionally incisions were bevelled parallel with the hair follicles preserving the maximum numbers of hair shafts to subsequently cover the scar. An alternative approach is the trichophytic incision in which the bevel is perpendicular to the hair shafts. This transects the hair follicles just deep to the epidermis such that subsequent hair growth is through the scar [34]. Camirand and Doucet compared the two types of incision in a prospective randomised controlled trial (RCT) in thirty patients

[35]. In each patient one half of the incision was parallel to the hair shafts and in the other half the incision was perpendicular to the hair shafts (trichophytic).

Table 1. Comparison of complication rates between bicoronal and pretrichial OBLs from published case series

Complication	Coronal (%)	Pretrichial (%)
Hematoma	0 [28] <1 [29]	0 [28] 2 [30] 3.7 [32]
Permanent numbness or dysaesthesia	1.2 [28] <3 [29]	0 [31, 32] 1.2 [28] 10 [30]
Permanent alopecia	0.7 [28] <1 [29]	0 [31, 32] 0.7 [28] 12 [30]
Permanent frontal branch weakness	0 [28, 29]	0 [28, 30, 31]
Ocular irritation	0 [29] 7.4 [28]	0 [30, 31] 7.4 [28]
Poor scarring	<1 [29]	10 [30] 1.6 [31] 0 [32]
Overall complication rate	4 [29]	2.2 [31], 3.7 [30]

Table 2. Comparison of satisfaction rates between bicoronal, pretrichial and lateral OBLs

	n	Follow-up (yrs)	Bicoronal (%)	Pretrichial (%)	Lateral (%)
Cilento and Johnson 2009 [28]	416	5	99.5	99.5	
Freidland et al. 1996 [29]	600	5	98		
Vogel and Hoopes 1992 [30]	50	7.5		90	
Fogli 2003 [33]	270	5.5			88

In 95% of patients the trichophytic scar was significantly better in terms of visibility, nonlinearity, absence of hypopigmentation and the abundance of hair into and in front of the scar [35].

Lateral Brow Lift

The lateral brow lift avoids a coronal incision altogether by confining incisions to the temporal regions. Proponents argue that the technique is simple, yields an efficient lift without elevating the medial brow, may improve the hairline and reduces wrinkling of the medial forehead [36]. Knize's variation of the lateral brow lift uses two temporal scalp incisions to elevate and suspend the lateral eyebrows and two upper blepharoplasty incisions to access the procerus and corrugator muscles [37]. In a 140 patient case series 'most' patients experienced scalp dysaesthesia that typically recovered by six to twelve weeks [37].

Complication rates presented in lateral brow lift series are summarised in Table 3. Notable is the three to five percent incidence of temporary frontal branch palsy, considerably higher than that reported for other types of brow lift.

Dysaesthesia remains troublesome as in other OBLs although the assessment of this symptom clearly varies significantly, with Fogli reporting no occurrences whilst Knize says most of his patients develop temporary dysaesthesia [33, 37].

Table 3. Complication rates in published series of lateral brow lifts

	n	Mean follow-up (yrs)	Dysaesthesia (%)	Frontal branch palsy (%)	Alopecia (%)	Longevity (yrs)
Knize 1996 [37]	140	0.25 - 4	'Most'*	5*	>2	-
Fogli et al. 2003 [33]	270	5.5	0	3*	1.5	-
Badin et al. 2010 [38]	44	3	18.2	4.5*	0	3

-not stated; *temporary.

Fogli's case series measures outcome by surgeon assessment (using a three point scale) of three criteria: distance between eyelashes and brow; improvement of crow's feet; and improvement of lower eyelid and malar wrinkling [33]. 81% of patients were judged to have very good or good aesthetic results [33]. Badin et al. measure the brow lifts at 1.5 and three years by calculating ratios of mid-pupil to lateral canthal distance to the vertical distance to the eyebrow [38]. However, insufficient data is provided to convert this into a simple brow elevation distance in millimetres that can be compared with other series. Whilst it does demonstrate a statistically significant elevation at postoperative follow-up, its aesthetic significance is hard to judge [38].

Planes of Dissection

The forehead flap has been elevated in various planes, aiming to improve the magnitude and longevity of lift whilst reducing rates of flap necrosis, hypertrophic scarring, scalp dysaesthesia and alopecia. The subcutaneous and subgaleal planes are the most commonly used in OBLs (EBL uses the subperiosteal plane) although most techniques incorporate a subperiosteal plane just above the supraorbital rim to avoid the supraorbital and supratrochlear nerves and give greater mobility to the brow. Superficial transverse rhytids can be more easily addressed in the subcutaneous plane because it allows greater stretch of the skin whilst also posing less risk of transecting sensory nerves. However, the subcutaneously elevated flap has a poorer blood supply than the thicker subgaleal flap, which may affect viability. Despite this, Wolfe and Baird found no wound healing problems in 27 female patients who had subcutaneous OBL, no alopecia and only temporary loss of scalp sensation posterior to the incision [32]. The technique produced long-term (mean follow-up of 7.5 years) patient-assessed wrinkle reduction in a retrospective review of fifty patients [30].

Pollock and Pollock used progressive tension sutures between the skin flap and galea in a series of eighty patients to sustain brow elevation [39]. Although there were no relapses, average follow-up was only 13.5 months [39]. Niamtu reported high patient satisfaction in a case series of fifty patients who underwent subcutaneous brow lift, although without explaining how this was assessed [4].

Dissecting the frontal flap in a subperiosteal plane with release of the orbital rim periosteum has the advantage of reducing the risk to the sensory nerves and frontal branches of the facial nerve [43]. In his series of 92 patients undergoing bicoronal subperiosteal OBL with up to seven year follow-up, Ramirez presented two cases of alopecia, no 'significant' cases of scalp dysaesthesia, no recurrent brow ptosis, maintenance of brow position and 'extremely high' patient satisfaction [42].

Table 4. Complication rates for case series of OBLs using different planes of dissection

Series	Type	n	Follow-up (yrs)	Delayed healing (%)	Poor scarring (%)	Partial flap necrosis (%)	Alopecia (%)	Scalp dysaethesia (%)	Relapse rate (%)	Revision rate (%)
Wolfe and Baird 1989 [32]	PT, BC, SC	27	X	0	0	3.7	0	100 (T)	0	0
Vogel and Hoopes 1992 [30]	PT, SC	50	7.5	0	<10	0	12 (T); 12 (P)	10	0	0
Pollock and Pollock 2007 [39]	PT, SC	80	1.1	1.3	0	1.3	1.3	0	0	1.3
Niamtu et al. 2008 [40]	PT, SC	50	2.5	0	0	4	0	0	0	0
Friedland et al. 1996 [29]	BC, SG	600	5	0	<1	0	<1	<3	0	<1
Troilius 1999 [41]	BC, SG	60			6.7		10 (T)	X		
Fogli 2003 [33]	L, SG	270	5.5	0	0	0	1.5 (T)	0	0	0
Knize 1996 [37]	L, SP	140	0.25 - 4	0	0	0	>2	'Most'(T)	3.5	5.7
Guyuron and Rowe 2008 [31]	PT, SG	297	1-8	2.2	0	0	0	0	-	-
Ramirez 1995 [42]	BC, SP	92	Up to 7	0	0	0	2	0	-	-

PT = pretrichial; SG = subgaleal; L = lateral; BC = bicoronal; SC = subcutaneous; SP = subperiosteal; T = transient; P = permanent; X = not recorded.

Complication rates for OBL using different dissection planes from various case series are summarised in Table 4. Rates are mostly below five percent but range from from zero to twelve percent for permanent alopecia and 0-100% for transient dysaesthesia. This probably represents differences in the definition of these complications rather than true differences. Definitions are typically not provided so this cannot be verified.

Several authors have combined dissection planes (biplanar lifts) aiming to achieve the benefits of each, such as greater flap mobility, less risk of sensory disturbance and longer lasting results. Ramirez used his biplanar brow lift in 24 patients with high foreheads with a mean follow-up of ten months [44]. It begins with a pretrichial incision and subcutaneous dissection followed by subperiosteal dissection with endoscopic control from the mid-forehead onwards. Ramirez reported one incidence of superficial forehead flap necrosis and two hematomas. Numbness was found in the area of subcutaneous dissection in all patients for up to twelve months but sensation posterior to the incision was preserved [44]. Although the aesthetic results are described as 'very satisfactory', no objective measures are given.

Aldo Mottura uses a bicoronal incision with dissection in the subcutaneous and subgaleal planes. In a series of fifty patients with up to four years follow-up, episodes of postoperative paraesthesia resolved spontaneously, there were no wound healing problems and brow elevation was as effective as with frontal lifts with galea transection (an historical control group) [45].

A similar technique involving temporoparietalis fascial, galeal, and periosteal imbrication without division of the galea achieved an average of 5mm of lateral brow elevation with partial relapse in five cases and transient alopecia in six cases (six to eight months) in a case series of 32 patients [46]. Karabulut and Tümerdem combined subperiosteal and subgaleal dissection planes, describing a coronal incision, subgaleal elevation until 2.5cm from the supraorbital rim and subperiosteal dissection thereafter [47]. No patient showed significant brow descent over an average of 34 months follow-up [47].

There is evidence that the greater mobility of biplanar flaps enables more skin resection. Marshak et al. used biplanar dissection of the skin and SMAS in the temporal region in their lateral brow lift in 37 patients, excising more skin using the biplanar technique compared with the control uniplanar subSMAS group (mean 21.8mm versus 15.1mm respectively) [48].

Open Brow Lift Combined with Other Procedures

For the purposes of research it is optimal to perform OBL in isolation to avoid the complexities of estimating competing effects of different procedures. However, in practice many patients request and surgeons perform simultaneous procedures, summarised in Table 5. The commonest combination is with upper blepharoplasty. As this procedure may exacerbate a compensated brow ptosis, it is advisable to perform the brow lift first [49, 50]. In their 600 patient case series, Friedland et al. reported combined upper blepharoplasty and brow lift with aesthetic results reported as excellent in 100% of patients, although no supportive data was included [29].

Similarly, Fogli performed simultaneous lower blepharoplasties in 241 patients with subjectively satisfactory results [33]. Dempsey et al. combined OBL with midface lifts in 130 patients to (subjectively) produce a natural and long-lasting result [51].

Other techniques that can be combined with OBL to improve aesthetic results include release of upper midface ligamentous structures, wide undermining of orbicularis oculi and suspension sutures to improve the lateral brow and elevate cheek fat [52].

ENDOSCOPIC BROW LIFT

There are 79 papers that discuss EBL from 1994 onwards. EBL was first described in the literature by Isse following presentation of the work in 1992 [10]. This was a 58 patient case series in which some of the EBL procedures were combined with endoscopic face lifts. The overall complication rate was 18% including seromas, ecchymosis and prolonged numbness (two patients) [10]. This procedure used a subperiosteal dissection plane with release of the periosteum from the orbital rim. The need to resect certain muscles – corrugators, procerus, orbicularis and even the frontal muscle – was soon recognized [54]. Excess skin is accommodated by dissecting the scalp posteriorly and various methods of securing the scalp flap to the skull have been described and are detailed later [55].

Proponents of EBL over OBL feel that it has less risk of alopecia, reduced tissue trauma, small camouflaged scars, less bleeding and oedema, improved postoperative comfort and faster recovery.

Table 5. Proportion of OBLs in published case series combined with other procedures

Case series	n	Upper bleph (%)	Lower Bleph (%)	Facelift (%)
Ramirez 1995 [42]	92			100
Friedland et al. 1996 [29]	600	100	0	86
Troilius 1999 [41]	60	50		
Fogli 2003 [33]	270	93	89	63
De Cordier et al. 2002 [53]	400	50	50	86

For these reasons Ramirez predicted as early as 1997 that EBL would become the first line choice for forehead rejuvenation [56]. The main disadvantage of the endoscopic approach is that excess skin cannot be resected thus potentially raising the hairline [57].

A survey of 21 New York plastic surgeons in 2001 with an 84% response rate (21 of 25 surgeons contacted) found that seventy percent of patients but only fifty percent of surgeons were satisfied with the long-term results [58]. Complications included alopecia, hairline changes, infected hardware, brow asymmetry requiring revision, prolonged brow or forehead dysaesthesia, and frontal branch nerve paralysis. Interestingly, the number of EBLs being performed by these surgeons was declining significantly [58]. The authors postulate that this may be due to refinement of indications, the growth of alternative means of rejuvenation such as botulinum toxin and concerns about the procedure's efficacy [58].

Several studies (Table 6) demonstrate the efficacy of EBL in terms of brow elevation. This data is infrequently included in case series and comparison between series is difficult as measurement is non-standardised. Follow-up times vary and are often ambiguous. Furthermore, some papers document brow elevation at rest and during active elevation whilst other papers make no distinction. However, the papers all agree that EBL achieves an immediate postoperative brow lift of somewhere between four and twelve millimetres. The longevity of this effect is poorly recorded but there is consensus that the lift relaxes with time (from as early as four to six weeks in a minority of patients), lasts at least two years and declines in a linear fashion by approximately 1mm per year [59, 60, 61]. For example, Papadopulos et al. found mean elevation of eight millimetres at two years dropping to 5.6mm at five years in 143 patients, with 63% saying they would be likely to repeat the procedure [61]. Reliable reduction in transverse and vertical rhytids is claimed in both a 67 patient and 400 patient case series, although without objective measurement [57, 53].

Complication rates from several EBL case series are summarised in Table 7. Alopecia and dysaesthesia are the commonest reported complications, ranging from 0-19% and 0-57% respectively. Poor scarring seems to be relatively uncommon - less than five percent in most series, although as high as 24% in that of Papadopulos [61]. Transient mild sensory symptoms appear common but permanent sensory disturbance occurs in less than five percent of cases. Palsy of the frontal branch of the facial nerve is inconsistently mentioned but ranges from 0-2.5%. For example, in Marchac's series of 206 EBLs there were five cases of frontal branch palsy, all resolving by six months [63]. Permanent palsy appears to be rare and is not usually reported. However, across all complications the distinction between transient and permanent is often not made.

Complication rates also vary according to how the data is collected. In the series of Withey et al. data is derived from a patient survey and considerably higher complication rates are recorded than those based on surgeons' assessments quoted in other papers [64].

Table 6. Elevation of the brow achieved with EBL in several case series

	n	Follow-up (months)	Midpupil to brow (mm)	Mean brow elevation (mm)		Duration (yrs)
				Medial	Lateral	
De la Fuente and Santamaría 2002 [60]	207	12	8	2	10	-
Papadopulos et al. 2012 [61]	143	38	5.6	5.3	5	↓1mm/yr
Troilius 1999 [41]	60	12	6.7	6.3	5.6	
Jones and Grover 2004 [62]	189	9.4	3.79 (glue) 6.16 (PDS)	-	-	-
McKinney and Sweis 2001 [27]	24	9	4.13	-	-	-
Graf et al. 2008 [59]	72	5	3.2	4.2	3	>1

Table 7. Complication rates of EBL case series

Study	n	Median age	Follow-up (months)	Complications (%)				
				Poor Scarring	Alopecia	Dysaesthesia	Overall	Revisions
Byrd 1997 [65]	42	-	6-18	-	-	2.4	4.8	-
Marchac et al. 1997 [63]	206	-	6	-	-	-	7.8	6
Jones and Grover 2004 [62]	538	50	9.4	0.7	1.4		2.2	0.2
Sidle et al. 2005 [66]	80	-	7-12	-	-	-	-	1.25
Withey et al. 2002 [64]	100	53	17	0	24 (T)	57 (T)	-	3 relapses
De la Fuente and Santamaria 2002 [60]	207	48	6+	-	2.8	-	4.3	-
Sozer and Biggs 2000 [67]	128	53	60		4.7	0.8		
Romo et al. 1999 [68]	259	49	21		7.3	3.5		
Papadopulos et al. 2012 [61]	98		38					
De Cordier et al. 2002 [53]	400	55	19.5	0.75	0.25	2		1.8
Patrocinio et al. 2006 [69]	67	48	6			20		3.3
Roberts and Ellis 1998 [70]	30	61	6	3.3		0		

T= temporary.

The distinction between side effect and complication, particularly in relation to scalp sensation and scarring, is rarely discussed and adds further imprecision to the documenting of complication rates.

Methods of Brow Fixation

The early brow lifts, such as Regnault's complete face and forehead lift with undermining and direct closure of the galea without cortical fixation, utilised subgaleal dissection [22]. However, as EBL came to the fore in the 1990s the plane of dissection changed to subperiosteal, thus mandating a method of cranial suspension. Since the first paper in 1994, considerable innovation has led to development of both permanent and bioabsorbable cranial fixation techniques (Table 8). Securing the elevated brow to the pericranium (rather than skull) has been achieved using sutures (absorbable and non-absorbable), electrocautery and glue [71, 72, 73, 62]. An absorbable subperiosteal suture achieved long-term (up to six years) brow elevation in a 300 patient case series [74]. Percutaneous fixation of supraorbital adhesions to the deep temporal fascia, specifically to address the lateral brow, maintained brow elevation at three years follow-up in 44 patients [38]. Imbrication of a temporoparietalis fascia/galeal/periosteal flap achieved an average of five millimetres lateral brow elevation in 32 patients [46].

The skull has the advantage of non-elasticity and is therefore commonly used in most EBL techniques. McKinney and Sweis described sculpted outer cortical tunnels and sutures for brow fixation with elevation maintained at five years [27]. Jones and Grover retrospectively compared fibrin glue periosteal fixation in 189 patients with PDS sutures tied through cortical tunnels in 349 patients and found significantly increased stability of brow elevation in the latter group [62]. Average brow elevation was 5.9mm at one month in the fibrin glue group, falling to 3.8mm beyond four months. In the cortical tunnels group the equivalent figures were each 6.2mm [62]. In both groups overall, there were two cases of significant although temporary alopecia and three cases of minor alopecia, four scar revisions and one reoperation for relapse [62]. Marchac et al. reported 86% good or excellent results (subjective assessments by surgeons) in their 206 patient case series using fibrin glue with a 7.8% complication rate [63].

Several permanent fixation methods have been described including posts and K-wires, but hardware palpability, technical risks of cortical drilling, postoperative alopecia and poor reliability prompted the development of bioabsorbable brow fixation devices [75, 76]. In 1996, Pakkanen and coworkers described their biodegradable polylactide pericranial pins and several similar devices have since emerged [77].

Benito et al. found fixation with bioabsorbable polylactic acid copolymer screws gave equivalent outcomes and fewer complications compared to stainless steel screws in their study of 99 patients [78]. Polylactic acid tacks reportedly gave satisfactory results in fifty patients, albeit with a mean follow-up of only five months [79].

The bioabsorbable Endotine device, a polylactide homopolymer, was first described in 2003 by Stevens et al. in a series of nine patients, which showed that that the device provided rapid and secure fixation with apparently fewer complications than other fixation techniques, but was still palpable at six months [80].

Chowdhury et al. reported their experiences with the Endotine device in 31 patients [81]. They achieved a mean brow lift of 2.8mm, with no recurrences up to 22 months [81]. The problems they encountered were palpability, tenderness and numbness, visible lumps, device mobility and exacerbation of a high hairline [81].

However, patient satisfaction was high, with 95% of patients self-reporting as 'happy' or 'very happy' and 81% saying they would recommend Endotine fixation to others [81].

Table 8. Summary of different brow fixation fixation techniques from published case series

Series	n	Fixation method	Mean follow-up (yrs)	Brow elevation at last follow-up (mm)	Complications, comments
McKinney and Sweis 2001 [27]	93	Bone tunnels and absorbable suture	5	4	No relapses
Jones and Grover 2004 [62]	349	PDS and bone tunnels	0.75	6.16	
Jones and Grover 2004 [62]	189	Fibrin glue	0.75	3.79	1 revision for relapse
Foustanos et al. 2006 [71]	300	Absorbable subperiosteal suture	4	Not stated	No recurrences
Tuccillo et al. 2007 [46]	32	Galeal/periosteal flap imbrication	1.25	5 (lateral)	Partial relapse in 5 patients
Chowdhury et al. 2007 [81]	31	Endotine	2	2.8	No relapses
Honig et al. 2008 [82]	25	Cortical bone tunnels	1	3 (lateral)	2mm relapse between 6 and 12 months
Honig et al. 2008 [82]	22	Endotine	1	4 (lateral)	2mm relapse between 6 and 12 months

In a case controlled study of 47 patients by Hönig et al., the Endotine device was compared to conventional single point tissue fixation with sutures anchoring the galea and periosteum to cortical bone tunnels [82]. In both groups the lateral brow position became depressed in the first six months after surgery but the medial third position was better maintained with the Endotine device, although this was not statistically significant [82]. Pascali et al. maintain that lateral brow ptosis and temporal laxity correction is difficult with the Endotine device and therefore trialled the so-called Endotine Ribbon™ (Coapt Systems), a flexible polylactic acid ribbon with multi-point fixation [83]. They reported 'satisfactory' lateral brow lifting in a case series of thirty patients using this new device [83]. Problems of persistent palpability and sensitivity with the Endotine prompted fabrication of the Ultratine using a second-generation polymer, polylactic acid and polyglycolic acid that dissolves more quickly [84].

Brow elevations achieved with different fixation techniques are summarised in Table 8. The studies have varying durations of follow-up and methods of measuring brow elevation, so it is impossible to assign superiority to any technique.

A prospective randomised controlled trial with long-term follow-up would address this question but could prove practically challenging.

Nonetheless, the Endotine device seems to be as effective as any other and has grown in popularity because of its combination of multi-point fixation, cortical attachment and slow absorption.

Variations of Endoscopic Brow Lift

Three variations of the EBL deserve brief mention for their ingenuity although they are not routinely practised - the transblepharoplasty EBL, the extended EBL and EBL combined

with the CO_2 laser. In 1996 Ramirez described the transblepharoplasty forehead lift in fourteen patients, achieving upper face rejuvenation solely via upper blepharoplasty incisions with the use of an endoscope [85]. Its application is limited to patients with male pattern baldness, high foreheads and relatively mild lateral brow ptosis who are also having simultaneous upper blepharoplasties. In a subsequent case series of 43 patients lateral brow elevation was maintained in 36 patients for up to seven years [86].

Byrd described the extended brow lift, using an endoscope to dissect into the midface to reposition the orbital orbicularis oculi, malar fat pad and nasolabial folds [65]. Satisfactory aesthetic results were reported in 42 patients over six to eighteen months follow-up, although no methodology was given for this assessment [65]. There was one case of transient frontal branch palsy [65]. Ramirez took the concept further to include subperiosteal endoscopic dissection of the central oval of the face to give a 'tridimensional' endoscopic rejuvenation which, in his series of 500 patients, produced excellent aesthetic results with minimal sequelae or complications [87].

Eight case controlled studies and case series were published in the 1990s advocating simultaneous EBL and laser resurfacing but discussion is notably absent in the literature since then. The rationale is that the CO_2 laser can target the deep vertical and transverse forehead rhytids that EBL can't address. Several small series claim low complication rates and good aesthetic results although with little objective assessment [88, 89]. In the biggest case controlled study of 174 patients, Roberts and Yokoo found signs of periorbital ageing such as altered pigmentation and crow's feet were improved in the EBL plus laser resurfacing group but not in the OBL without laser resurfacing group [90]. Although low complication rates are quoted in these papers, the lack of uptake of this procedure suggests that the risks of flap necrosis, poor scarring, prolonged erythema and additional costs have dissuaded most practitioners.

OPEN VERSUS ENDOSCOPIC BROW LIFT

A survey in 2001 by Elkwood et al., completed by almost 600 members of the American Society of Plastic Surgeons (ASPS) and representing data on almost 7,000 brow lifts, addressed the aesthetic outcomes, longevity of effects and the incidence and severity of complications for OBL and EBL [91]. The two types of brow lift were performed in similar numbers and patient satisfaction was over 98% for both procedures. Surgeons found OBL to be more effective in terms of brow elevation, reduction of transverse rhytids and glabellar lines (Figure 3) [91].

Other studies appear to favour EBL over OBL. A retrospective comparison of 120 patients having either procedure found that one year after OBL there was no significant difference from the preoperative brow position, whereas the brow was seven millimetres higher in the EBL group [41].

With an open approach division of cutaneous sensory nerves is inevitable and one would expect better preservation of scalp sensation in EBL at least in the short term. In a prospective, non-randomised controlled comparative study of eleven patients undergoing EBL versus ten undergoing OBL, both demonstrated subjectively and objectively decreased scalp sensibility postoperatively. However, compared to the EBL group the OBL group

showed significantly less scalp sensibility up to fourteen weeks, although by 24-26 weeks there was no difference [92]. Sensation was measured objectively (mechanoceptive and thermoceptive) and subjectively (visual analog scale).

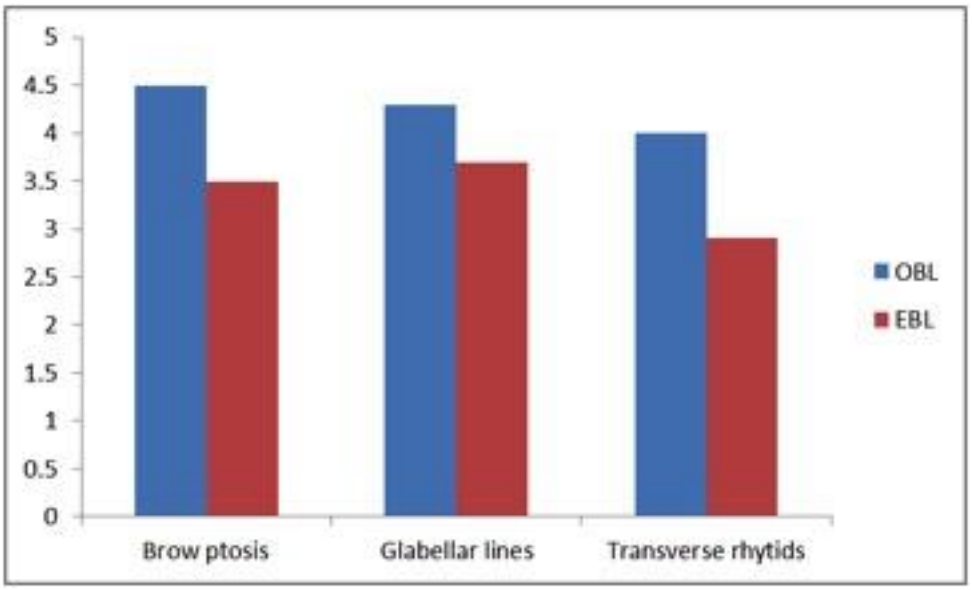

Rating scale is 0 (not efficacious) to 5 (fully attaining aesthetic goals) [91].

Figure 3. Aesthetic results of OBL versus EBL according to a survey of 600 ASPS surgeons (7000 brow lifts).

Of 58 patients who were retrospectively enrolled in the same study, scalp sensitivity was reduced in all but significantly more so in the OBL group between six and eighteen months, with the difference disappearing beyond this point [92]. Interestingly, 57 of the 58 patients found that their scalp numbness was bad enough to deter them from undergoing the surgery again regardless of the technique of brow lift used [92].

Complication rates, efficacy and patient satisfaction data presented in case series of both OBL and EBL are summarised in Tables 9, 10 and 11. Although not a formal meta-analysis, the total number of patients represented is 5500 and two thirds of series have over eighteen months follow-up. Few studies include objective measures of brow lift in terms of absolute brow elevation or reduction in rhytids. Results are frequently in the form of subjective assessments by surgeons and patients making it difficult to compare one study with another. As the number of empty boxes illustrate, it is difficult to extract a complete set of comparative complication rates from each series and typically references to complications are brief and lacking in raw data. Furthermore, the definitions of the different complications are inconsistent, particularly in relation to dysaesthesia and alopecia and whether they are transient or permanent. Nonetheless, the figures suggest similar complication rates for both procedures with neither appearing strikingly superior.

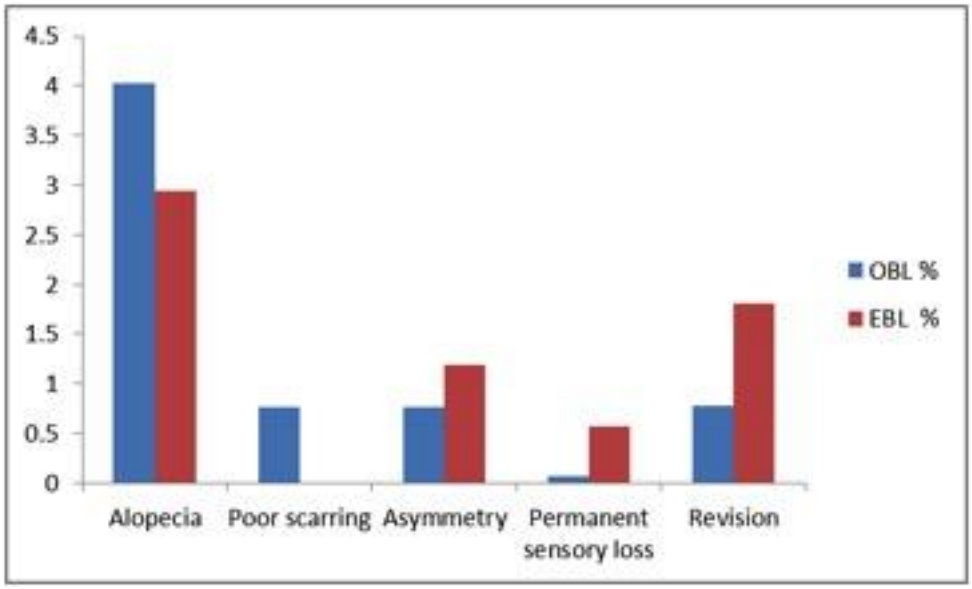

Figure 4. The complication rates of OBL versus EBL from a survey of 600 ASPS surgeons [91].

It is difficult to determine from the literature which procedure has greater efficacy (Table 10) or patient satisfaction (Table 11). A minority of studies objectively assess aesthetic results whereas the majority claim very high patient satisfaction without describing how this was ascertained or giving figures. Those few studies that do compare OBL and EBL have found little difference in aesthetic results. Tabatabai and Spinelli retrospectively compared their limited incision OBL (93 patients) with EBL (100 patients) with up to five years follow-up [93]. No significant difference was found in average brow elevation between the two groups (four millimetres). Patient satisfaction was equivalent in both groups although the figures are not given [93]. A retrospective comparison of 84 patients undergoing either coronal, trichophytic or endoscopic brow lifts did not find a statistical difference in elevation at nineteen months follow-up (3.5, 3.4 and 3.2mm respectively) [94]. The brows in all groups maintained elevation at long-term follow-up (35 to 56 months) with no statistically significant difference between them [94].

In Guyuron and Rowe's series of 755 patients, 438 had endoscopic forehead lifts, 297 had pretrichial lifts and twenty had major scalp advancements [31]. Complications were remarkably rare, the commonest being delayed healing (2.2% in the OBL group) with no permanent dysaethesias. Successful forehead rejuvenation was apparently achieved in both groups but no data is given to support this assertion [31]. Dayan et al. compared endoscopic and coronal approach brow lifts in a 140-patient case comparative study, with 121 patients having OBL versus nineteen EBLs and found no significant difference between the groups in postoperative brow position at twelve months [95]. Elkwood's survey of 600 ASPS surgeons suggests that the complication rate is equally low for either procedure, the most frequent complication in both being alopecia (Figure 4) [91]. However, these figures rely on surgeon recall rather than rigorous assessment of medical records or prospective data entry and are therefore subject to recall bias. Supporting this, the rate of permanent sensory loss in the OBL group was unusually low at 0.07% [91].

A meta-analysis of fifteen well designed studies selected from 189 articles concluded that there was no clear evidence indicating superiority of either technique in terms of brow elevation or complication rates [96].

As with many other aesthetic procedures the truth may be that OBL and EBL are both superior for different patient groups. Guyuron and Rowe select OBL or EBL according to the height of the forehead, recommending EBL for those with mild elongation, OBL for moderate elongation and open forehead shortening using a pretrichial incision for those with severe forehead elongation [3].

Table 9. Complication rates from case series of open and endoscopic brow lifts

Study	n	Brow lift type	Age	Follow-up (months)	Complications (%)				
					Poor scarring	Alopecia	Dysaesthesia	Overall	Revision
Wolfe and Baird 1989 [32]	27	O	-	-	0	0	100 (T)	-	-
Vogel and Hoopes 1992 [30]	50	O	53	90	<10	12	10		
Isse 1994 [10]	61	O	33-72	11			3.3	18	
Hamas 1995 [97]	35	E	26-55	12-18					
Friedland et al. 1996 [29]	600	O	58	60	<1	<1	<3	<4	0.8
Byrd 1997 [65]	42	E		6-18			2.4		
Marchac et al. 1997 [63]	206	E		6					
Robert and Ellis 1998 [70]	26	O	55	6	11.5		19		
Roberts and Ellis 1998 [70]	30	E	61	6	3.3		0		
Guyuron et al. 1999 [98]	180	O	-	80	1.7	0.5	0	-	1.7
Marten 1999 [99]	27	O	-	60	3.7	0	3.7	-	3.7
Romo et al. 1999 [68]	259	E	49	21		7.3	3.5		
Sozer and Biggs 2000 [67]	128	E	53	60		4.7	0.8		
Withey et al. 2002 [64]	100	E	53	17	0	24 (T)	57 (T)	84	3 relapses
De la Fuente and Santamaria 2002 [60]	207	E	48	6+	-	2.8	-	4.3	-
De Cordier et al. 2002 [53]	400	E	55	19.5	0.75	0.25	2		1.8
Fogli 2003 [33]	270	O	45	66	0	1.5	0	>6	<5
Jones and Grover 2004 [62]	538	E	50	9.4	0.7	1.4		2.2	0.2
Sidle et al. 2005 [66]	80	E		7-12					1.25
Mottura 2006 [45]	50	O	-	48	6		0		2
Patrocinio et al. 2006 [69]	67	E	48	6			20		3.3
Guyuron and Rowe 2008 [31]	297	O	-	12-144	2.2	0	0	-	-
Foustanos 2008 [74]	350	E							
Guyuron and Rowe 2008 [31]	438	E	-	10-144	0	0	0	-	-
Papadopulos et al. 2012 [61]	98	E		38					

O = open; E = endoscopic; T = transient.

Table 10. Case series and controlled trials comparing OBL and EBL

Study	n	Difference in	
		complications	brow elevation
Troilius 1999 [41]	OBL = 60 EBL = 60	Poorer scars and more transient alopecia in OBL (not significant)	Loss of elevation 1 year after OBL vs. 7mm elevation after EBL
Dayan et al. 2001 [95]	OBL = 121 EBL = 19	Not recorded	No difference at one year, brow position lower in OBL group at 5 years
Elkwood et al. 2001 [91]	OBL = 3500 EBL = 3500 (approx.)	Permanent loss of sensation 0.57% (EBL) vs. 0.07% (OBL)	
Puig and LaFerriere 2002 [94]	OBL = 46 EBL = 38	Not recorded	No difference
Guyuron and Rowe 2008 [31]	OBL = 297 EBL = 438	2.2% delayed healing (OBL) vs. 0% (EBL)	Not measured
Guillot et al. 2011 [92]	EBL = 36 OBL = 22	No difference in scalp sensation after 18 months	Not measured

Table 11. Patient satisfaction rates following OBL and EBL

	Patient Satisfaction (%)	
	OBL	EBL
Papadopulos et al. 2012 [61]		71
Cilento and Johnson 2009 [28]	99	
Chowdury et al. 2007 [81]		95
Patrocinio et al. 2006 [69]		93
Fogli 2003 [33]	88	
Chiu and Baker 2003 [58]		70
Withey et al. 2002 [64]		84
Roberts and Ellis 1998 [70]	88.5	
Roberts and Ellis 1998 [70]		100
Freidland et al. 1996 [29]	98	
Vogel and Hoopes 1992 [30]	90	

CONCLUSION

The published literature regarding brow lifting is mainly in the form of case series (level IV) and ranges from level V to level II evidence. The anatomy of the brow has been well elucidated and is fairly constant. Both OBL and EBL reliably elevate the brow for at least 24 months. However there is a gradual loss of effect with time and no evidence that either procedure has greater efficacy. Both procedures have equivalent low complication rates and are associated with very high patient satisfaction. There is no proven superiority of one incision or plane of dissection in OBL or one method of cranial suspension in EBL.

In short, brow lift is a relatively safe and modestly effective procedure with several variations that can be tailored to suit different patients.

REFERENCES

[1] www.plasticsurgery.org/News-and -Resources/2011-Statistics-.html.

[2] www.baaps.org.uk.

[3] Miller, C. C. *The correction of featural imperfections*. 2nd Edition. Chicago: Oak Printing Co. 1908.

[4] Hunt, H. L. *Plastic Surgery of the Head, Face, and Neck.* Philadelphia, PA Lea and Febiger 1926.

[5] Gonzalez-Ulloa, M. Facial wrinkles. Integral elimination. *Plast. Reconstr. Surg. Transplant Bull.* 1962; 29:658-73.

[6] Loeb, R. Technique for preservation of the temporal branches of the facial nerve during face-lift operations. *Br. J. Plast. Surg.* 1970; 23(4):390-4.

[7] Marino, H., Gandolfo, E. Treatment for wrinkles of the forehead. *Prensa Med. Argent.* 1964; 51:1368-71.

[8] Adamson, P. A., Johnsoncm Jr, Anderson, J. R., Dupin, C. L. The forehead lift. A review. *Arch. Otolaryngol.* 1985; 111(5):325-9.

[9] Paul, M. D. Subperiosteal transblepharoplasty forehead lift. *Aesthetic Plast. Surg.* 1996; 20 (2):129-34.

[10] Isse, N. G. Endoscopic facial rejuvenation: endoforehead, the functional lift. Case reports. *Aesthetic Plast. Surg.* 1994; 18(1):21-9.

[11] Daniel, R. K., Landon, B. Endoscopic forehead lift: anatomic basis. *Aesthet. Surg. J.* 1997; 17(2):97-104.

[12] Abramo, A. C. Forehead rhytidoplasty: endoscopic approach. *Aesthetic Plast. Surg.* 1995; 19(5):463-7.

[13] *Grabb and Smith's Plastic Surgery*. 6th edition, LWW; 2006.

[14] Pham, S., Wilhelmi, B., Mowlavi, A. Eyebrow peak position redefined. *Aesthet. Surg. J.* 2010; 30(3):297-300.

[15] Sullivan, P. K., Salomon, J. A., Woo, A. S., Freeman, M. B. The importance of the retaining ligamentous attachments of the forehead for selective eyebrow reshaping and forehead rejuvenation. *Plast. Reconstr. Surg.* 2006; 117(1):95-104.

[16] Matros, E., Garcia, J. A., Yaremchuk, M. J. Changes in eyebrow position and shape with aging. *Plast. Reconstr. Surg.* 2009; 124(4):1296-301.

[17] Knize, D. M. An anatomically based study of the mechanism of eyebrow ptosis. *Plast. Reconstr. Surg.* 1996; 97(7):1321-33.

[18] Cuzalina, A. L., Holmes, J. D. A simple and reliable landmark for identification of the supraorbital nerve in surgery of the forehead: an in vivo anatomical study. *J. Oral Maxillofac. Surg.* 2005 Jan.; 63(1):25-7.

[19] Miller, T. A., Rudkin, G., Honig, M., Elahi, M., Adams, J. Lateral subcutaneous brow lift and interbrow muscle resection: clinical experience and anatomic studies. *Plast. Reconstr. Surg.* 2000; 105(3):1120-7.

[20] Hafezi, F., Naghibzadeh, B., Nouhi, A., Naghibzadeh, G. Eliminating frown lines with an endoscopic forehead lift procedure (corrugator muscle disinsertion). *Aesthetic Plast. Surg.* 2011; 35(4):516-21.

[21] Liebman, E. P., Webster, R. C., Berger, A. S., DellaVecchia, M. The frontalis nerve in the temporal brow lift. *Arch. Otolaryngol.* 1982; 108(4):232-5.

[22] Regnault, P. Complete face and forehead lifting, with double traction on "crow's-feet". *Plast. Reconstr. Surg.* 1972; 49(2):123-9.
[23] Gleason, M. C. Brow lifting through a temporal scalp approach. *Plast. Reconstr. Surg.* 1973; 52(2):141-4.
[24] Ortiz-Monasterio, F., Barrera, G., Olmedo, A. The coronal incision in rhytidectomy--the brow lift. *Clin. Plast. Surg.* 1978; 5(1):167-79.
[25] Rafaty, F. M., Goode, R. L., Abramson, N. R. The brow-lift operation in a man. *Arch. Otolaryngol.* 1978 Feb.; 104(2):69-71.
[26] Booth, A. J., Murray, A., Tyers, A. G. The direct brow lift: efficacy, complications and patient satisfaction. *Br. J. Ophthalmol.* 2004; 88(5):688-91.
[27] McKinney, P., Sweis, I. An accurate technique for fixation in endoscopic brow lift: a 5-year follow-up. *Plast. Reconstr. Surg*. 2001; 108(6):1808-10.
[28] Cilento, B. W., Johnsoncm, Jr. The case for open forehead rejuvenation: a review of 1004 procedures. *Arch. Facial Plast. Surg.* 2009; 11(1):13-7.
[29] Friedland, J. A., Jacobsen, W. M., TerKonda, S. Safety and efficacy of combined upper blepharoplasties and open coronal browlift: a consecutive series of 600 patients. *Aesthetic Plast. Surg.* 1996; 20(6):453-62.
[30] Vogel, J. E., Hoopes, J. E. The subcutaneous forehead lift with an anterior hairline incision. *Ann. Plast. Surg.* 1992; 28(3):257-65.
[31] Guyuron, B., Rowe, D. J. How to make a long forehead more aesthetic. *Aesthet. Surg. J*. 2008; 28(1):46-50.
[32] Wolfe, S. A., Baird, W. L. The subcutaneous forehead lift. *Plast. Reconstr. Surg.* 1989; 83 (2):251-6.
[33] Fogli, A. L. Temporal lift by galeapexy: a review of 270 cases. *Aesthetic Plast. Surg.* 2003; 27(3):159-65.
[34] Mayer, T. G., Fleming, R. W. Hairline aesthetics and styling in hair replacement surgery. *Head Neck Surg.* 1985; 7(4) 286-302.
[35] Camirand, A., Doucet, J. A comparison between parallel hairline incisions and perpendicular incisions when performing a face lift. *Plast. Reconstr. Surg*. 1997; 99 (1): 10-5.
[36] Miller, T. A. Lateral subcutaneous brow lift. *Aesthet. Surg. J*. 2003; 23(3):205-10.
[37] Knize, D. M. Limited-incision forehead lift for eyebrow elevation to enhance upper blepharoplasty. *Plast. Reconstr. Surg.* 1996; 97(7):1334-42.
[38] Badin, A. Z., Bittencourt, L. M., Balderrama, C. R. Lateral brow fixation in endoscopic forehead lift: long-term results with braided nylon percutaneous sutures. *Aesthetic Plast. Surg*. 2010 Feb.; 34(1):78-87.
[39] Pollock, H., Pollock, T. A. Subcutaneous brow lift with precise suture fixation and advancement. *Aesthet. Surg. J*. 2007; 27(4):388-95.
[40] Niamtu, J. 3rd. The subcutaneous brow- and forehead-lift: a face-lift for the forehead and brow. *Dermatol. Surg.* 2008; 34(10):1350-61.
[41] Troilius, C. A comparison between subgaleal and subperiosteal brow lifts. *Plast. Reconstr. Surg.* 1999; 104(4):1079-90.
[42] Ramirez, O. M. The anchor subperiosteal forehead lift. *Plast. Reconstr. Surg*. 1995; 95 (6):993-1003.
[43] Toranto, I. R. The subperiosteal forehead lift. *Clin. Plast. Surg.* 1992; 19(2):477-85.

[44] Ramirez, O. M. Endoscopically assisted biplanar forehead lift. *Plast. Reconstr. Surg.* 1995; 96(2):323-33.
[45] Aldo Mottura, A. Open frontal lift: a conservative approach. *Aesthetic Plast. Surg.* 2006; 30(4):381-9.
[46] Tuccillo, F., Jacovella, P., Zimman, O., Repetti, G. An alternative approach to brow lift fixation: temporoparietalis fascia, galeal, and periosteal imbrication. *Plast. Reconstr. Surg.* 2007; 119(2):692-702.
[47] Karabulut, A. B., Tümerdem, B. Forehead lift: a combined approach using subperiosteal and subgaleal dissection planes. *Aesthetic Plast. Surg.* 2001; 25(5):378-81.
[48] Marshak, H., Morrow, A. A., Morrow, D. M. Biplanar temple lift for lateral brow ptosis: comparison with uniplanar dissection technique. *Aesthetic Plast. Surg.* 2008; 32 (3):517-22.
[49] Riefkohl, R., Kosanin, R., Georgiade, G. S. Complications of the forehead-brow lift. *Aesthetic Plast. Surg.* 1983; 7(3):135-8.
[50] Rafaty, F. M., Brennan, H. G. Current concepts of browpexy. *Arch. Otolaryngol.* 1983; 109(3):152-4.
[51] Dempsey, P. D., Oneal, R. M., Izenberg, P. H. Subperiosteal brow and midface lifts. *Aesthetic Plast. Surg.* 1995; 19(1):59-68.
[52] Namazie, A. R., Keller, G. S. Current practices in endoscopic brow and temporal lifting. *Facial Plast. Surg. Clin. North Am.* 2001; 9(3):439-51.
[53] De Cordier, B. C., de la Torre, J. I., Al-Hakeem, M. S., Rosenberg, L. Z., Gardner, P. M., Costa-Ferreira, A., Fix, R. J., Vasconez, L. O. Endoscopic forehead lift: review of technique, cases, and complications. *Plast. Reconstr. Surg.* 2002; 110(6):1558-68.
[54] Chajchir, A. Endoscopic subperiosteal forehead lift. *Aesthetic Plast. Surg.* 1994 Summer; 18(3):269-74.
[55] Vasconez, L. O., Core, G. B., Gamboa-Bobadilla, M., Guzman, G., Askren, C., Yamamoto, Y. Endoscopic techniques in coronal brow lifting. *Plast. Reconstr. Surg.* 1994; 94(6):788-93.
[56] Ramirez, O. M. Why I prefer the endoscopic forehead lift. *Plast. Reconstr. Surg.* 1997; 100 (4):1033-9.
[57] Taylor, C. O., Green, J. G., Wise, D. P. Endoscopic forehead lift: technique and case presentations. *J. Oral Maxillofac. Surg.* 1996; 54(5):569-77.
[58] Chiu, E. S., Baker, D. C. Endoscopic brow lift: a retrospective review of 628 consecutive cases over 5 years. *Plast. Reconstr. Surg.* 2003; 112(2):628-33.
[59] Graf, R. M., Tolazzi, A. R., Mansur, A. E., Teixeira, V. Endoscopic periosteal brow lift: evaluation and follow-up of eyebrow height. *Plast. Reconstr. Surg.* 2008; 121(2):609-16.
[60] De la Fuente, A., Santamaría, A. B. Endoscopic forehead lift: is it effective? *Aesthet. Surg. J.* 2002; 22(2):113-20.
[61] Papadopulos, N. A., Eder, M., Weigand, C., Biemer, E., Kovacs, L. A review of 13 years of experience with endoscopic forehead-lift. *Arch. Facial Plast. Surg.* 2012; 14 (5):336-41.
[62] Jones, B. M., Grover, R. Endoscopic brow lift: a personal review of 538 patients and comparison of fixation techniques. *Plast. Reconstr. Surg.* 2004 Apr. 1; 113(4):1242-50.

[63] Marchac, D., Ascherman, J., Arnaud, E. Fibrin glue fixation in forehead endoscopy: evaluation of our experience with 206 cases. *Plast. Reconstr. Surg*. 1997; 100(3):704-12.

[64] Withey, S., Witherow, H., Waterhouse, N. One hundred cases of endoscopic brow lift. *Br. J. Plast. Surg.* 2002; 55(1):20-4.

[65] Byrd, H. S. The extended browlift. *Clin. Plast. Surg.* 1997; 24(2):233-46.

[66] Sidle, D. M., Loos, B. M., Ramirez, A. L., Kabaker, S. S., Maas, C. S. Use of BioGlue surgical adhesive for brow fixation in endoscopic browplasty. *Arch. Facial Plast. Surg*. 2005; 7(6):393-7.

[67] Sozer, O., Biggs, T. M. Our experience with endoscopic brow lifts. *Aesthetic Plast. Surg*. 2000; 24(2):90-6.

[68] Romo, T. 3rd, Sclafani, A. P., Yung, R. T. Endoscopic foreheadplasty: temporary vs. permanent fixation. *Aesthetic Plast. Surg*. 1999; 23(6):388-94.

[69] Patrocinio, L. G., Patrocinio, J. A. Forehead-lift: a 10-year review. *Arch. Facial Plast. Surg.* 2008 Nov.-Dec.; 10(6):391-4.

[70] Roberts, T. L. 3rd, Ellis, L. B. In pursuit of optimal rejuvenation of the forehead: endoscopic brow lift with simultaneous carbon dioxide laser resurfacing. *Plast. Reconstr. Surg*. 1998; 101(4):1075-84.

[71] Foustanos, A., Zavrides, H. An alternative fixation technique for the endoscopic brow lift. *Ann. Plast. Surg.* 2006; 56(6):599-604.

[72] Loomis, M. Endoscopic brow fixation without bolsters or miniscrews. *Plast. Reconstr. Surg.* 1996; 98:373.

[73] Ellenbogen, R., Youn, A., Svehlak, S., Yamini, D. Transcoronal brow lift fixation: a 2-point dermis-to-skull fibrous scar adhesion. *Aesthet. Surg. J.* 2004; 24(3):261-4.

[74] Foustanos, A. Suture fixation technique for endoscopic brow lift. *Semin. Plast. Surg*. 2008; 22(1):43-9.

[75] Pozner, J. N. Simplified fixation for endoscopic brow lifts: self-tapping, drill-free posts. *Plast. Reconstr. Surg.* 1999; 103:1326.

[76] Chasan, P. E., Kupfer, D. M. Direct K-wire fixation technique during endoscopic brow lift. *Aesthetic Plast. Surg.* 1998; 22(5):338-40.

[77] Pakkanen, M., Salisbury, A. V., Ersek, R. A. Biodegradable positive fixation for the endoscopic brow lift. *Plast. Reconstr. Surg*. 1996; 98(6):1087-91.

[78] Benito, J., Camargo, V. J., Torres, A. Absorbable screws in endoscope-assisted forehead lifting. *Aesthetic Plast. Surg*. 2003; 27(1):63-7.

[79] Landecker, A., Buck, J. B., Grotting, J. C. A new resorbable tack fixation technique for endoscopic brow lifts. *Plast. Reconstr. Surg*. 2003; 111(2):880-6.

[80] Stevens, W. G., Apfelberg, D. B., Stoker, D. A., Schantz, S. A. The endotine: a new biodegradable fixation device for endoscopic forehead lifts. *Aesthet. Surg. J*. 2003; 23 (2):103-7.

[81] Chowdhury, S., Malhotra, R., Smith, R., Arnstein, P. Patient and surgeon experience with the endotine forehead device for brow and forehead lift. *Ophthal. Plast. Reconstr. Surg.* 2007; 23(5):358-62.

[82] Hönig, J. F., Frank, M. H., Knutti, D., de La Fuente, A. Video endoscopic-assisted brow lift: comparison of the eyebrow position after Endotine tissue fixation versus suture fixation. *J. Craniofac. Surg*. 2008; 19(4):1140-7.

[83] Pascali, M., Gualdi, A., Bottini, D. J., Botti, C., Botti, G., Cervelli, V. An original application of the Endotine Ribbon device for brow lift. *Plast. Reconstr. Surg*. 2009; 124 (5):1652-61.

[84] Berkowitz, R. L., Apfelberg, D. B. Preliminary evaluation of a fast-absorbing multipoint fixation device. *Aesthet. Surg. J*. 2008; 28(5):584-8.

[85] Ramirez, O. M. Transblepharoplasty forehead lift and upper face rejuvenation. *Ann. Plast. Surg*. 1996; 37(6):577-84.

[86] Niechajev, I. Transpalpebral browpexy. *Plast. Reconstr. Surg*. 2004; 113(7):2172-80.

[87] Ramirez, O. M. The central oval of the face: tridimensional endoscopic rejuvenation. *Facial Plast. Surg*. 2000; 16(3):283-98.

[88] Citarella, E. R., Sterodimas, A., Condé-Green, A. Endoscopically assisted limited-incision rhytidectomy: a 10-year prospective study. *J. Plast. Reconstr. Aesthet. Surg.* 2010; 63(11):1842-8.

[89] Ramirez, O. M., Pozner, J. N. Laser resurfacing as an adjunct to endoforehead lift, endofacelift, and biplanar facelift. *Ann. Plast. Surg*. 1997; 38(4):315-21.

[90] Roberts, T. L. 3rd, Yokoo, K. M. In pursuit of optimal periorbital rejuvenation:laser resurfacing with or without blepharoplasty and brow lift. *Aesthet. Surg. J*. 1998; 18 (5): 321-32.

[91] Elkwood, A., Matarasso, A., Rankin, M., Elkowitz, M., Godek, C. P. National plastic surgery survey: brow lifting techniques and complications. *Plast. Reconstr. Surg*. 2001; 108 (7):2143-50.

[92] Guillot, J. M., Rousso, D. E., Replogle, W. Forehead and scalp sensation after brow-lift: a comparison between open and endoscopic techniques. *Arch. Facial Plast. Surg.* 2011; 13(2):109-16.

[93] Tabatabai, N., Spinelli, H. M. Limited incision nonendoscopic brow lift. *Plast. Reconstr. Surg.* 2007; 119(5):1563-70.

[94] Puig, C. M., LaFerriere, K. A. A retrospective comparison of open and endoscopic brow-lifts. *Arch. Facial Plast. Surg*. 2002; 4(4):221-5.

[95] Dayan, S. H., Perkins, S. W., Vartanian, A. J., Wiesman, I. M. The forehead lift: endoscopic versus coronal approaches. *Aesthetic Plast. Surg*. 2001; 25(1):35-9.

[96] Graham, D. W., Heller, J., Kurkjian, T. J., Schaub, T. S., Rohrich, R. J. Brow lift in facial rejuvenation: a systematic literature review of open versus endoscopic techniques. *Plast. Reconstr. Surg.* 2011; 128(4):335e-341e.

[97] Hamas, R. S. An endoscopic brow lift that does not raise the hairline. *Aesthet. Surg. J*. 1997; 17(2):127-9.

[98] Guyuron, B., Behmand, R. A., Green, R. Shortening of the long forehead. *Plast. Reconstr. Surg.* 1999; 103(1):218-23.

[99] Marten, T. J. Closed, nonendoscopic, small-incision forehead lift. *Clin. Plast. Surg*. 2008; 35(3):363-78.

In: Encyclopedia of Surgery (22 Volume Set)
Editors: Andreas Lehrer and Kristin Mueller
ISBN: 978-1-53618-329-0
© 2020 Nova Science Publishers, Inc.

Chapter 31

BLEPHAROPLASTY

Mano Sira*
Western Eye Hospital, Imperial College NHS Trust, London

KEY POINTS

- Consider eyebrow and eyelid position to plan appropriate adjunctive procedures such as brow lift or ptosis repair.
- Address risk factors for dry eye. Evidence supports the use of omega 3 and phytoestrogen supplements in dry eye.
- Skin incision using radiofrequency does not appear to offer any benefit compared with traditional knife incision.
- There is a trend towards orbital fat preservation rather than resection.
- Eyelid laxity must be avoided
- Consider the need for lateral canthal support.
- Lower eyelid swelling is more frequent in the transconjunctival approach to blepharoplasty.

INTRODUCTION

Blepharoplasty has been the subject of extensive publications in the surgical literature - a literature search for 'blepharoplasty' yields more than 2400 hits. This chapter therefore does not set out to be an exhaustive summary of the evidence base but rather addresses the main areas of concern encountered by the surgeon undertaking blepharoplasty surgery.

* Corresponding Author's Email: manosira@doctors.net.uk.

LITERATURE SEARCH

A comprehensive review of the blepharoplasty literature in 2013, including PubMed, the Cochrane Library, EMBASE and CINAHL reveals that most publications are of level IV and V evidence (Appendix), with a lack of high quality Level I or II evidence.

In evaluating the current best available evidence the following terms were combined as appropriate: blepharoplasty; upper eyelid; lower eyelid; Asian; surgery; technique; preoperative assessment; postoperative; individual complications (including the terms dry eye, haematoma, blindness, ectropion, retraction, lid malposition, scleral show, scarring, chemosis, infection, inflammation, suture abscess, granuloma, post-blepharoplasty ptosis and lagophthalmos); outcomes; eyelid analgesia; and pain control/management. Medical Subject Headings (MeSH terms) were used if available, the search was limited to publications in English and additional references were included if appropriate.

AESTHETICS AND THE AGEING EYELID

There is no consensus on the perfect eyelid aesthetic since personal preference, racial differences and overall harmony of the facial subunits are very individual. The patient attending for upper periorbital rejuvenation may be offered brow lift surgery by one surgeon or upper blepharoplasty by another. There is inherent inconsistency because of the difficulty in determining to what degree each feature has changed. Obeying certain parameters, however, aids the surgeon in their surgical plan.

The following changes known to occur to the upper eyelid/periorbita have an ageing effect on the appearance[1]:

Loss of volume due to thinning of the skin with associated fat and muscle atrophy. This often results in the deep upper eyelid sulcus seen in older patients.

A raised upper eyelid skin crease, increasing the pretarsal show. This is due, in part, to involutional ptosis and dehiscence of the levator aponeurosis and its insertion in to the subdermal tissues, which create the crease.

The lateral brow/eyelid junction is convex with a gentle arc in youth (Figure 1), becoming less convex and flatter due to volume deflation and descent respectively [2] (Level V).

In the lower eyelid, rounding of the lateral canthal angle [3] (due to dehiscence of the lateral canthal tendon), lower eyelid laxity, orbital fat prolapse at the insertion of a lax orbicularis-retaining ligament and volume deflation of the malar region (SOOF) resulting in a tear trough/naso-jugal groove all contribute to an aged appearance.

Figure 1. The attractive youthful upper eyelid/brow junction exhibits a gentle convex arc.

THE ASIAN EYELID

Anatomy of the Asian versus Caucasian Eyelid

With the possible exception of the presence of an epicanthal fold, the lack of an upper eyelid skin crease is the most striking point of difference between the Asian and Caucasian upper lid. When present it is formed by the anterior inserton of levator aponeurosis fibres into the subdermal tissues the pretarsal skin and is most evident on eye opening when the lid is retracted. The skin that folds over the supratarsal crease is described as the double eyelid fold. The pretarsal skin visible just below the double eyelid fold is referred to as the pretarsal show.

Comparative studies between Asian and Caucasian upper eyelids show that the Asian single eyelid (with an absent or low crease) exhibits fusion of the orbital septum to the levator aponeurosis below the superior tarsal border, whereas this fusion is above the superior tarsal border in Caucasians (Figure 2). The preaponeurotic fat pad therefore descends anteriorly to the tarsal plate in the Asian single eyelid and a thick subcutaneous fat layer prevents levator fibres from extending toward the skin near the superior tarsal border. Structural differences relating to increased fat in the Asian upper eyelid include the presence of a pretarsal fat pad and a moderate fat increase in the double Asian eyelid [4] (Level III).

In contrast, cadaveric dissection by Kakizaki [5] (Level V) describes how the orbital septum attachment on the levator aponeurosis in Asians seems to be situated above the superior tarsal plate border in vivo, but the preaponeurotic fat extends beyond the distal end of the anterior layer of the levator aponeurosis (DEALLA), sometimes reaching the tarsal plate. The Asian upper eyelid crease is thus lower and less distinctly defined than in Caucasians due to the inferior extension of the preaponeurotic fat which can interrupt the superficially extending, skin crease defining, levator aponeurosis fibres. In addition the tarsal plate is shorter and pretarsal suborbicularis tissue is thicker in Asian than Caucasian upper eyelids.

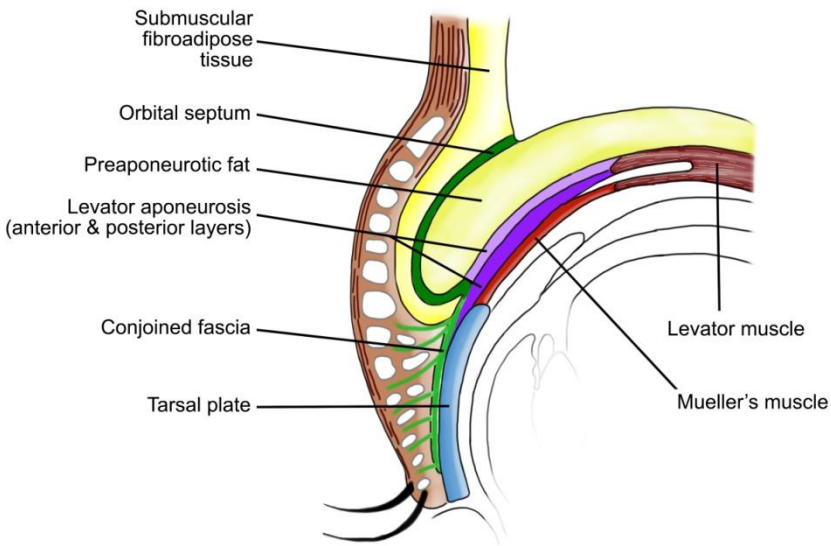

Figure 2. Anatomy of the Asian upper eyelid, (after Kakizaki (5)).

Aesthetics of the Asian versus Caucasian Eyelid

An interesting study recently compared composite images created by digital morphing of faces from different racial origins to analyse contributors to faces being deemed average and attractive [6] (Level I). They discovered that attractive Korean faces have relatively wide-set eyes and that the medial and lateral eye fissure height (as measured at the midpoint of medial and lateral eye fissures, respectively) were greater than in average Korean faces. The median eye fissure height (palpebral fissure height vertically from pupillary centre) was also greater in attractive Asian faces than average Asian faces. Attractive Korean or Asian faces did not have an epicanthus and exhibited more exposure sclera in the medial and lateral area of the eyes. Attractive Asian faces had a less steeply slanted palpebral fissure compared to average Asian faces, but attractive Caucasian and African faces had a steeper palpebral than their average counterparts. Finally, attractive Caucasian and African faces had a relatively narrower palpebral fissure height and width than average Caucasian and African faces. Regardless of race, attractive faces had wide-set eyes and a lower brow position than average faces. These interesting observations might suggest that attractiveness occurs through some form of 'convergence to the ethnic mean', at least for some morphologic features, although the researchers did not explore this.

THE NEGATIVE VECTOR

The position of the globe relative to the orbital rim will affect the success of blepharoplasty. A constellation of features contributes to the ‘morphologically prone eye’ [7] (Figure 3). It is useful to exclude horizontal lid laxity with a preoperative ‘snap test', since blepharoplasty carried out on a lax lower eyelid can result in inferior scleral show and/or ectropion. A negative vector, in which the apex of the cornea is anterior to the inferior orbital rim, can result in the lid slipping under the globe following blepharoplasty, thus worsening inferior scleral show. Patients with a negative vector orbit should be counselled of this risk and, should they wish to proceed, the addition of lateral canthopexy/canthoplasty is highly recommended [8] (Level III). The vertical height of the eyelid must also be taken into consideration [9] (Level V).

A negative vector can be a sign of maxillary hypoplasia. Associated features include inferior scleral show, prominent medial fat and a prominent nasojugal crease. Pessa et al. [11] (Level III) showed that the craniofacial skeleton remodels throughout adulthood, the orbital rim moving posteriorly relative to the anterior cornea with advancing age. Thus over-resection of orbital fat during lower blepharoplasty can emphasise the relative proptotic appearance of the eye that occurs naturally with age due to orbital remodelling. Pessa et al. also found that with age there is a tendency for the cheek mass to move posteriorly relative to the corneal apex (see Chapter 32).

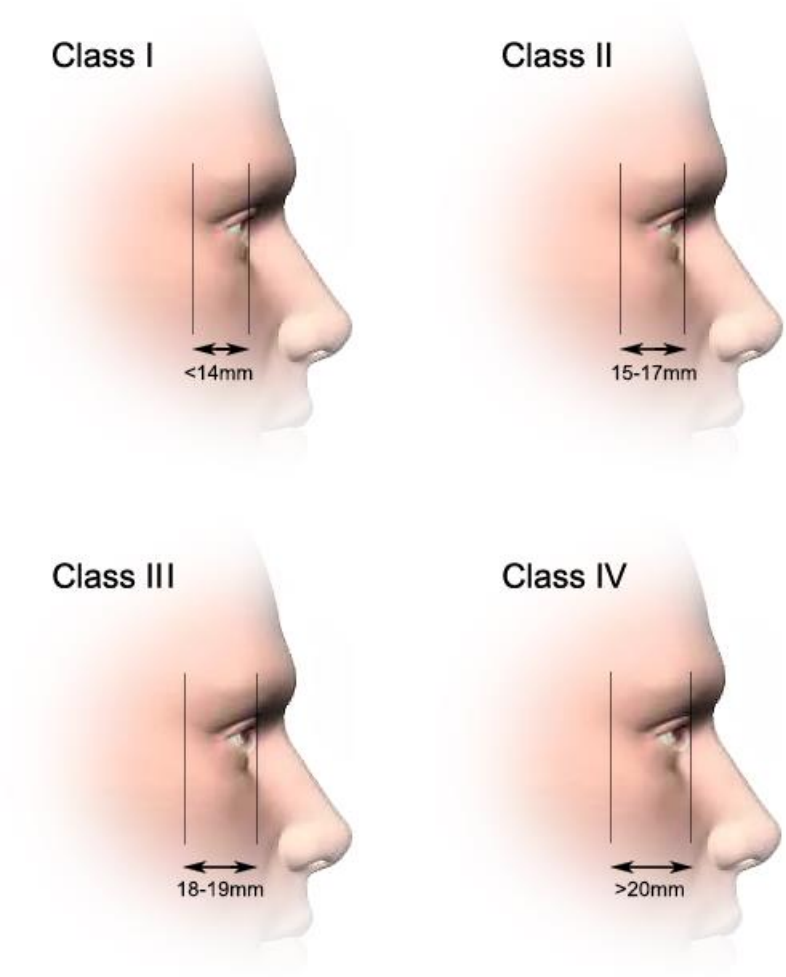

Figure 3. Morphological classification of globe/bony orbit relationships and corresponding exophthalmometry measurements (in millimetres). Data from Hirmand et al.[10].

AVOIDING THE DRY EYE

Peri-operative and postoperative complications can be minimised by recognising and addressing the following risk factors: refractive corneal surgery [12] (Level IV); diabetes [13] (Level V); smoking [14] (Level II); previous eyelid surgery; bleeding disorders and anti-coagulant use, preoperative brow position [15] (Level III), ptosis, the presence or absence of an upgoing Bell's reflex and orbicularis oculi function (i.e., lagophthalmos).

Hamawy and coworkers [16] (Level III) retrospectively examined 202 patients undergoing upper and/or lower blepharoplasty and found dry eye persisted for over two weeks in 10% of patients. They provide an algorithm for preventing and managing dry eye.

The preoperative assessment should screen the patient for symptoms of dry eye, such as burning, itching, a foreign body sensation, watering, aching and generally tired eyes. If these

symptoms are made worse by activities of reduced blinking such as computer use or long periods of reading, the patient is likely to have evaporative dry eye.

Reduced tear break up time (TBUT) is a good indicator of evaporative dry eye and is improved with oral omega-3 supplementation. In their double masked study Kangari and colleagues [17] (Level I) randomised 64 patients into two groups, receiving either placebo (two medium-chain triglyceride oil capsules daily) or omega-3 (one capsule of each of 180mg eicosapentaenoic acid (EPA) and 120mg docosahexaenoic acid (DHA) daily) for thirty days in each case. Repeated-measures analysis of variance showed that improvements in TBUT, Ocular Surface Disease Index (OSDI), and Schirmer's scores were significantly better in the treatment than the placebo group.

Signs and symptoms of dry eye syndrome can also be improved by phytoestrogen supplementation in postmenopausal women [18] (Level I) recruited 66 postmenopausal women, all with low sex hormone levels correlated with high tear film osmolarity values, in their double-masked cross-over placebo study. Subjects were randomised into two study groups receiving either phytoestrogen or placebo. After thirty days of therapy, assessment of Schirmer test and TBUT showed the treatment group had significantly decreased tear osmolarity and increased tear production compared with the placebo group.

Whilst high level evidence does not exist, there is expert opinion and surgical consensus that patients who have undergone corneal refractive surgical correction should wait at least six months before undergoing blepharoplasty, chiefly because of the effects on corneal sensation, tear production and tear film alteration [19] (Level V).

AMOUNT OF SKIN EXCISION

The degree of skin excision in blepharoplasty should be tailored to the individual, for instance using the popular skin pinch method [20, 21] (Level IV). Halvorson et al. [22] (Level III) describe the pinch technique used in 476 patients over ten years (Figure 4): a line is drawn at 45° from the medial and lateral ends of the supratarsal crease ending 6mm from the angular vein of the nose (visible as a blue line) and 12mm from the lateral palpebral fissure respectively. The inferior marking follows the existing or desired supratarsal crease (typically 8-10mm above the lid margin) and the superior marking is based on the skin excision determined by the pinch test, keeping at least 10mm from the infrabrow supratarsal eyelid skin.

TRANSCUTANEOUS V TRANSCONJUNCTIVAL APPROACHES

Taban et al. [23] (Level IV) retrospectively compared twenty patients (forty eyes) with 25 patients (fifty eyes), undergoing transconjunctival lower eyelid blepharoplasty with and without skin pinch (as described by Parkes et al. [24]) respectively. They concluded that the pinch method of skin excision minimises the risk of postoperative eyelid malposition by avoiding violation of orbital septum and orbicularis muscle. When lower blepharoplasty requires both fat and skin excision, the skin pinch technique with transconjunctival fat excision allows for stable postoperative lower eyelid position.

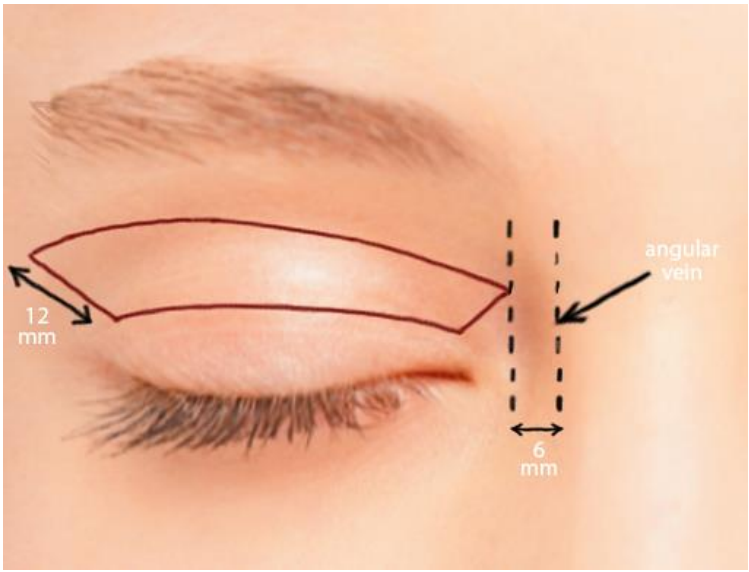

Figure 4. Skin markings for upper blepharoplasty. The incision starts medially 6mm from the angular vein and ends laterally 12mm from the palpebral fissure. At each end, incisions are extended superiorly at a 45° angle. After Halvorson [22].

Netscher et al. [25] (Level II) performed a non-randomised study on lower lid blepharoplasty via transcutaneous and transconjunctival approaches on the left and right eyelids respectively in ten consecutive patients. The authors commented that patients had predominantly lower lid fat problems with little or no skin excess. Outcome measures included standardised photographic evaluation by independent masked observers assessing for differences in scleral show, visible scarring, swelling or ectropion. Subjective patient evaluation was also carried out by questionnaire. There were no significant differences in aesthetic outcome and patient acceptance was equal between the two techniques. Transient lower lid swelling was more likely in the transconjunctival group but scleral show occurred with equal frequency and severity between the groups. External scarring using the transcutaneous technique was not a perceived problem in the subjective patient assessment and was not statistically different between the techniques as determined by photographic analysis.

ORBICULARIS MUSCLE RESECTION

Damasceno et al. [26] (Level II) compared pinch upper blepharoplasty with or without orbicularis excision (the muscle resection being equivalent to the amount of skin removed) in a randomised, double-masked, left-right study of fifteen consecutive female patients. Patients scored differences in oedema, haematoma, itching and pain between both sides on the seventh, thirteenth and nineteenth days and three masked oculoplastic surgeons analysed aesthetic outcomes using a visual analogue scale. They concluded that upper blepharoplasty causes more postoperative symptoms and presents worse initial aesthetic outcome when the preseptal orbicularis oculi muscle is excised, but the final aesthetic outcome is the same

whether preseptal orbicularis oculi is excised or preserved. However, the small study may have lacked the statistical power to detect a modest, but potentially significant, difference in outcome.

CREATING A DOUBLE EYELID CREASE

The creation of a 'double eyelid' is one of the most commonly requested cosmetic procedures in East and Southeastern Asian countries [27]. There are essentially two methods of creating an upper eyelid fold - the incisional fixation technique and the non-incisional suture method.

There is little evidence to guide selection of the surgical technique. The incisional method has been well described in the literature (Park and Park [27] (Level V)). The upper lid is everted and a caliper used to measure the vertical height of the central portion of the tarsal plate, which is usually 6.5 to 7.5mm in Asians. The lid is returned to its normal position and a mark is made at the central point of the crease incision at a height corresponding to that of the tarsus. If the crease shape chosen was a nasally tapered crease, the crease marking is merged toward the medial canthus. For a parallel crease shape design, the surgeon should make a conscious effort to stay parallel to the lash line as the mark approaches the medial canthus. A second line that demarcates the superior incision is made two millimetres above the inferior mark centrally, 2.5mm laterally, and one millimetre medially where the two lines converge [28, 29] (Level IV and Level V).

Following the skin crease incision, the orbital septum is opened over the preaponeurotic fat pad in order to avoid damage to the levator aponeurosis and muscle. A 6/0 or 7/0 nylon suture is then passed through the edge of the strip of pretarsal orbicularis from the under surface of the muscle and engaging the distal edge of the levator aponeurosis. The suture is tightened just enough to approximate muscle and aponeurosis without strangulation of the tissues. The fixation point in the levator aponeurosis determines the tightness of the pretarsal skin and the height of the supratarsal crease. This technique can elevate the upper eyelid (by effectively plicating the levator aponeurosis) thus widening the palpebral aperture.

LATERAL CANTHAL SUPPORT

Horizontal lower eyelid laxity is a significant cause of post-blepharoplasty lower eyelid ectropion/retraction. Whilst eyelid laxity is often obvious preoperatively, sometimes it is sub clinical and diagnosed retrospectively. In recent years routine lateral canthal support has been advocated to reduce the incidence of post-blepharoplasty lower eyelid malposition. Codner et al. [30] (Level III) reviewed 264 patients undergoing lower blepharoplasty with routine lateral canthal support (canthopexy, canthoplasty or orbicularis suspension, Figure 7) over a ten-year period. Lid malposition requiring correction occurred in 3.5% of cases compared to rates of between 5-30% in standard lower blepharoplasty. The authors conclude that this technique allows more aggressive tightening of the anterior lamella whilst preserving the preoperative eye shape.

Despite this conclusion, there appear to be situations in which additional lateral canthal support can worsen unwanted post-blepharoplasty sequelae, such as inferior scleral show in cases of prominent globes in the negative vector configuration. Goldberg [9] (Level V) provides reasoned argument for an individualised approach to providing lateral canthal support. Whilst lateral canthopexy/horizontal eyelid shortening has a powerful role where there is lower eyelid laxity, it will not elevate the eyelid in cases of postoperative (iatrogenic) vertical shortening of the lower eyelid, and can in fact worsen the situation.

MANAGEMENT OF ORBITAL FAT

Recent years have seen a paradigm shift in lower lid blepharoplasty with regards the management of orbital fat, favouring fat preservation rather than resection of prolapsed intraorbital fat. In his series of 152 patients Hamra [31] (Level IV) described a method of repositioning subseptal fat beyond the infraorbital rim and under the repositioned orbicularis muscle.

Parsa et al. [32] (Level III) provide long-term (mean 11.3 years, range 1-16) follow up data in 26 patients comparing fat removal with preservation using the technique first described by de la Plaza [33] (Level V), in which capsulopalpebral fascia is approximated to the arcus marginalis after repositing the herniated fat to the infraorbital compartment. Outcome measures assessed by the operating surgeon were time to palpebral bag recurrence, lower lid hollowing, lid malposition and eyelid dysmobility. The author concluded that fat preservation resulted in significantly less recurrence of palpebral bags (7.7% in the fat preservation group versus 30% in the fat removal group) [32].

SKIN INCISION AND CLOSURE

Skin incision and closure have been addressed by robust studies. Kashkouli et al. [34] (Level I) randomised 46 eyelids to compare eyelid skin incisions made with a scalpel in one eyelid versus a radiofrequency (RF) device in the other. Around six months postoperatively a masked observer assessed scarring using a visual analogue scale and a Cochet-Bonnet filament-type aesthesiometer, finding no significant difference in scar appearance or sensory recovery. The zone and depth of tissue damage on histopathologic examination was higher in the radio-frequency group but this did not appear to be clinically significant.]

Table 1. Visual analogue scale for blepharoplasty scar assessment: 0 (best) to 10 (worst), from Kashkouli [34])

	A. Colour	B. Surface	C. Contour	D. Distortion	E. Texture
1	Perfect	Matte	Flush	None	Normal
2	Slight mismatch	Shiny	Slightly proud/indented	Mild	Just palpable
3	Obvious mismatch		Hypertrophy	Moderate	Firm
4	Gross mismatch		Keloid	Severe	Hard

Kouba et al. [35] (Level I) conducted a randomised, split-eyelid, single-masked, prospective study comparing the efficacy of 6/0 polypropylene, 6/0 fast-absorbing gut, and ethylcyanoacrylate (ECA) tissue adhesive on 36 consecutive upper lid blepharoplasties. Patients' subjective outcomes of closure technique and cosmetic evaluation (thickness, width, texture, colour change, overall cosmetic outcome) were assessed at one and three months. Objective outcomes (cosmetic outcome of wound closure technique using standardised photographs) were assessed by a masked physician. Scoring was performed on a scale of one (excellent wound healing, scar matches surrounding skin) to five (poor scar wound healing, does not match surrounding skin). The researchers concluded that sutured epidermal closure and tissue adhesive are highly efficacious for upper eyelid blepharoplasty but that cosmesis using ECA was superior to that of fast-absorbing gut by three months after surgery - although the result did not reach statistical significance.

Greene et al. [36] (Level I) performed a prospective, randomised, single-masked study in twenty subjects (forty eyelids) undergoing upper eyelid blepharoplasty, closing one eyelid with octyl-2-cyanoacrylate and the other with suture. In contrast to the study of Kouba [35] and coworkers they found no difference in final incision appearance by four weeks after surgery, and also found wound complications and duration of healing to be similar. Whilst Kouba et al. [35] felt that tissue adhesive improved cosmesis compared with absorbable suture material over short and intermediate term follow-up, they did not find any advantage of tissue adhesive over non-absorbable (polypropylene) sutures. The evidence provided by the two randomised studies therefore shows no clear advantage of either closure technique overall.

LACRIMAL GLAND PROLAPSE

Massry [37] (Level III) reports the incidence of lacrimal gland prolapse in 57 patients with an average age of 78 years to be 60% after a mean follow up of twelve months. The author repositioned the prolapsed gland by suturing its anterior capsule to the arcus marginalis (just anterior to the lacrimal gland fossa) with 4/0 prolene suture. Six patients required further lacrimal gland suture repositioning due to prolonged swelling and three required suture repositioning of the lacrimal gland due to pain. This prospective study was undertaken in cases of functional blepharoplasty but may have application in cosmetic practice.

COMPLICATIONS

Lower Eyelid Retraction

Various methods exist to correct lower eyelid retraction following blepharoplasty. Simon et al. [38] (Level III) reviewed 43 cases of subperiosteal midface lift with and without hard palate grafts to correct lower eyelid retraction related to previous blepharoplasty or thyroid eye disease. They found that the addition of hard palate grafts was superior, reducing the inferior marginal distance by 2.2mm compared with 1.1mm without hard palate graft.

A technique that permits smaller degrees of elevation of a retracted lower eyelid without the need for grafted tissue has been described [39] (Level III). This involves preseptal/suborbicularis dissection and release of the orbito-malar ligament followed by recession of the septum and inferior lower eyelid retractors as a composite. The mean elevation in lower eyelid height in 26 eyes was 1.4mm.

Swelling & Bruising

Reducing oedema and bruising has been attempted by introducing autologous platelet concentrate in to eyelid incisions. In a prospective, randomised, controlled trial [40] (Level II). Thirty-three patients received autologous platelet concentrate in the eyelid incisions of one side during bilateral blepharoplasty surgery (either upper, lower or four lid blepharoplasty). The untreated contralateral eye was used as a control and did not receive any placebo treatment. Platelet-rich plasma was mixed with thrombin and applied topically to the wound on a randomly selected side before wound closure. Patients were examined and completed a questionnaire at postoperative days one, three, seven and thirty. A masked oculoplastic surgeon assessed photographs for bruising and oedema. Patients reported a statistically significant decrease in oedema at thirty days compared to the untreated eye. There was subjective reduction in bruising on the treated side although this difference was not statistically significant.

Retrobulbar Haematoma

Complications of blepharoplasty include haematoma which, if retrobulbar, can be sight threatening due to optic nerve compression [41] (Level V). Acute management involves immediate lateral canthotomy and intravenous steroid to relieve intraorbital pressure and inflammation. This is supported by widespread clinical experience, and the lack of high quality evidence is more a feature of an ethical inability to design a study around this than representing any doubt as to proper clinical management.

Chemosis

Chemosis due to dessication of pouting conjunctiva, can be treated with lubrication, topical steroid preparations, ocular decongestants, direct pressure and temporary tarsorrhaphy [42] (Level IV). Again, this is poorly supported by high level evidence but is considered standard practice.

Other

Pacella and Codner [43] and Hartstein and Kikkawa [44] provide excellent review articles of complications and their management following blepharoplasty.

CONCLUSION

The evidence base for blepharoplasty surgery is limited mainly to studies of Level III and below.

As for any surgery, meticulous patient selection and thorough preoperative assessment minimises postoperative complications. Particular attention should be paid to the brow and eyelid position so that adjunctive surgery such as brow lift or ptosis repair can be considered. Eyelid laxity should be identified and routine lateral canthal support has been advocated but remains contentious (Level III). Risk factors for dry eye should be addressed (Level III). Omega 3 and phytoestrogen supplements have high levels of evidence supporting their use in dry eye (Level I). There is no evidence comparing skin pinch excision techniques versus measured skin excision and both methods appear equally effective (Level III, IV). Similarly transconjunctival and transcutaneous approaches to lower blepharoplasty are both efficacious but lower lid swelling is more frequent after the transconjunctival approach. Transcutaneous techniques are not a perceived problem in terms of subjective scarring (Level II). There is an increasing tendency towards orbital fat preservation rather than resection during blepharoplasty (Level III). Skin incision with radiofrequency is no better than cold steel (Level I) but scar cosmesis may be superior with tissue adhesives compared with resorbable sutures (Level I). Excising preseptal orbicularis oculi muscle when performing upper blepharoplasty causes more postoperative symptoms and presents worse initial aesthetic outcome, but the final aesthetic outcome is the same whether the muscle is excised or preserved (Level II). Finally in cases of persistent postoperative lower eyelid retraction, the use of hard palate grafts as a spacer should be considered unless very modest elevation is required (Level III).

REFERENCES

[1] Truswell WH 4th. Aging changes of the periorbita, cheeks, and midface. *Facial Plast. Surg*. 2013 Feb;29(1):3-12.

[2] Fezza JP.The sigmoid upper eyelid blepharoplasty: redefining beauty. *Ophthal. Plast. Reconstr. Surg*. 2012 Nov-Dec;28(6):446-51.

[3] Chong KK, Goldberg RA Lateral canthal surgery. *Facial Plast. Surg*. 2010 Aug;26(3):193-200.

[4] Jeong S, Lemke BN, Dortzbach RK, Park YG, Kang HK. The Asian upper eyelid: an anatomical study with comparison to the Caucasian eyelid. *Arch. Ophthalmol.* 1999 Jul;117(7):907-12.

[5] Kakizaki H, Leibovitch I, Selva D, Asamoto K, Nakano T. Orbital septum attachment on the levator aponeurosis in Asians: in vivo and cadaver study. *Ophthalmology*. 2009 Oct;116(10):2031-5.

[6] Biometric study of eyelid shape and dimensions of different races with references to beauty. Rhee SC, Woo KS, Kwon B. *Aesthetic. Plast. Surg*. 2012 Oct;36(5):1236-45.

[7] Rees TD, LaTrenta GS. The role of the Schirmer's test and orbital morphology in predicting dry-eye syndrome after blepharoplasty. *Plast. Reconstr. Surg*. 1988 Oct;82(4):619-25.

[8] Glat PM, Jelks GW, Jelks EB, Wood M, Gadangi P, Longaker MT. Evolution of the lateral canthoplasty: techniques and indications. *Plast. Reconstr. Surg*. 1997 Nov;100(6):1396-405.

[9] Goldberg RA. Review of Prophylactic Lateral Canthopexy in Lower Blepharoplasties. *Arch. Fac. Plas.* 2003 May/June (5):272-275.

[10] Hirmand H, Codner MA, McCord CD, Hester TR Jr, Nahai F. Prominent eye: Operative management in lower lid and midfacial rejuvenation and the morphologic classification system. *Plast. Reconstr. Surg.* 2002;110:620-628.

[11] Pessa JE, Desvigne LD, Lambros VS, Nimerick J, Sugunan B, Zadoo VP. Changes in ocular globe-to-orbital rim position with age: implications for aesthetic blepharoplasty of the lower eyelids. *Aesthetic Plast. Surg.* 1999 Sep-Oct;23(5):337-42.

[12] Korn BS, Kikkawa DO, Schanzlin DJ. Blepharoplasty in the post-laser in situ keratomileusis patient: preoperative considerations to avoid dry eye syndrome. *Plast. Reconstr. Surg*. 2007 Jun;119(7):2232-9.

[13] Kronish JW, McLeish WM. Eyelid necrosis and periorbital necrotizing fasciitis. Report of a case and review of the literature. *Ophthalmology*. 1991 Jan;98(1):92-8.

[14] Altinors DD, Akìa S, Akova YA, Bilezikìi B, Goto E, Dogru M, Tsubota K. Smoking associated with damage to the lipid layer of the ocular surface. *Am. J. Ophthalmol.* 2006 Jun;141(6):1016-1021.

[15] Prado RB, Silva-Junior DE, Padovani CR, Schellini SA. Assessment of eyebrow position before and after upper eyelid blepharoplasty. *Orbit.* 2012 Aug;31(4):222-6.

[16] Hamawy AH, Farkas JP, Fagien S, Rohrich RJ. Preventing and managing dry eyes after periorbital surgery: a retrospective review. *Plast. Reconstr. Surg.* 2009 Jan;123(1):353-9.

[17] Scuderi G, Contestabile MT, Gagliano C, Iacovello D, Scuderi L, Avitabile T. Effects of phytoestrogen supplementation in postmenopausal women with dry eye syndrome: a randomised clinical trial. *Can. J. Ophthalmol.* 2012 Dec;47(6):489-92.

[18] Lee WB, McCord CD Jr, Somia N, Hirmand H. Optimizing blepharoplasty outcomes in patients with previous laser vision correction. *Plast. Reconstr. Surg*. 2008 Aug;122(2):587-94.

[19] Rosenfield LK. The pinch blepharoplasty revisited. *Plast. Reconstr. Surg*. 2005 Apr 15;115(5):1405-12; discussion 1413-4.

[20] Parkes M, Fein W, Brennan HG. Pinch technique for repair of cosmetic eyelid deformities. *Arch. Ophthalmol.* 1973 Apr;89(4):324-8.

[21] Halvorson EG, Husni NR, Pandya SN, Seckel BR. Optimal parameters for marking upper blepharoplasty incisions: a 10-year experience. *Ann. Plast. Surg.* 2006 May;56(5):569-72.

[22] Taban M, Taban M, Perry JD. Lower eyelid position after transconjunctival lower blepharoplasty with versus without a skin pinch. *Ophthal. Plast. Reconstr. Surg.* 2008 Jan-Feb;24(1):7-9.

[23] Parkes M, Fein W, Brennan HG. Pinch technique for repair of cosmetic eyelid deformities. *Arch. Ophthalmol*. 1973 Apr;89(4):324-8.

[24] Netscher DT, Patrinely JR, Peltier M, Polsen C, Thornby J. Transconjunctival versus transcutaneous lower eyelid blepharoplasty: a prospective study. *Plast. Reconstr. Surg.* 1995 Oct;96(5):1053-60.

[25] Damasceno RW, Cariello AJ, Cardoso EB, Viana GA, Osaki MH. Upper blepharoplasty with or without resection of the orbicularis oculi muscle: a randomised double-blind left-right study. *Ophthal. Plast. Reconstr. Surg.* 2011 May-Jun;27(3):195-7.

[26] Park JI, Park MS. Double-eyelid operation: orbicularis oculi-levator aponeurosis fixation technique. *Facial Plast. Surg. Clin. North Am*. 2007 Aug;15(3):315-26.

[27] Chen WP. Asian blepharoplasty. Update on anatomy and techniques. *Ophthal. Plast. Reconstr. Surg.* 1987;3(3):135-40.

[28] Chen WP, Park JD. Asian upper lid blepharoplasty: an update on indications and technique. *Facial Plast. Surg.* 2013 Feb;29(1):26-31.

[29] Codner MA, Wolfli JN, Anzarut A. Primary transcutaneous lower blepharoplasty with routine lateral canthal support: a comprehensive 10-year review. *Plast. Reconstr. Surg*. 2008 Jan;121(1):241-50.

[30] Hamra ST. Arcus marginalis release and orbital fat preservation in midface rejuvenation. *Plast. Reconstr. Surg.* 1995 Aug;96(2):354-62.

[31] Parsa AA, Lye KD, Radcliffe N, Parsa FD. Lower blepharoplasty with capsulopalpebral fascia hernia repair for palpebral bags: a long-term prospective study. *Plast. Reconstr. Surg.* 2008 Apr;121(4):1387-97.

[32] de la Plaza R, Arroyo JM. A new technique for the treatment of palpebral bags. *Plast. Reconstr. Surg.* 1988 May;81(5):677-87.

[33] Kashkouli MB, Kaghazkanai R, Mirzaie AZ, Hashemi M, Par-varesh MM, Sasanii L. Clinicopathologic comparison of radiofrequency versus scalpel incision for upper blepharoplasty. *Ophthal. Plast. Reconstr. Surg.* 2008;24:450-453.

[34] Kouba DJ, Tierney E, Mahmoud BH, Woo D. Optimizing closure materials for upper lid blepharoplasty: a randomised, controlled trial. *Dermatol. Surg.* 2011 Jan;37(1):19-30.

[35] Greene D, Koch RJ, Goode RL. Efficacy of octyl-2-cyanoacrylate tissue glue in blepharoplasty: A prospective controlled study of wound-healing characteristics. *Arch. Facial Plast. Surg.* 1999;1:292-296.

[36] Massry GG. Prevalence of lacrimal gland prolapse in the functional blepharoplasty population. *Ophthal. Plast Reconstr. Surg.* 2011;27: 410-413.

[37] Ben Simon GJ, Lee S, Schwarcz RM, McCann JD, Goldberg RA. Subperiostealmidface lift with or without a hard palate mucosal graft for correction of lower eyelid retraction. *Ophthalmology* 2006;113:1869-1873.

[38] Norris JH, Malhotra R. Composite septo-retractor recession; a surgical technique for lower-eyelid retraction and review of the literature. *Ophthal. Plast. Reconstr. Surg.* 2011 Nov;27(6):447-52.

[39] Vick VL, Holds JB, Hartstein ME, Rich RM, Davidson BR. Use of autologous platelet concentrate in blepharoplasty surgery. *Ophthal. Plast. Reconstr. Surg*. 2006;22:102-104.

[40] Cruz AA, Ando A, Monteiro CA, Elias J Jr. Delayed retrob- ulbar hematoma after blepharoplasty. *Ophthal. Plast. Reconstr. Surg*. 2001;17:126-130.

[41] Weinfeld AB, Burke R, Codner MA. The comprehensive management of chemosis following cosmetic lower blepha- roplasty. *Plast. Reconstr. Surg.* 2008;122:579-586.

[42] Pacella SJ, Codner MA. Minor complications after blepha- roplasty: Dry eyes, chemosis, granulomas, ptosis, and scleral show. *Plast. Reconstr. Surg.* 2010;125:709-718.

[43] Hartstein ME, Kikkawa D. How to avoid blepharoplasty complications. *Oral. Maxillofac. Surg. Clin. North Am*. 2009 Feb;21(1):31-41.

In: Encyclopedia of Surgery (22 Volume Set)
Editors: Andreas Lehrer and Kristin Mueller
ISBN: 978-1-53618-329-0
© 2020 Nova Science Publishers, Inc.

Chapter 32

FACELIFT

Fulvio Urso-Baiarda[1,*] and Rajiv Grover[2]
[1]Wexham Park Hospital, Slough, UK
[2]King Edward VII's Hospital Sister Agnes, London, UK

KEY POINTS

- There is no clear evidence that one face-lift technique is significantly better than any other.
- Preinfiltration is carried out almost unanimously, but the composition of infiltrate has not been subjected to rigorous investigation and remains a matter for debate, although there is some evidence that the omission of adrenaline may reduce the rate of postoperative haematoma.
- Fibrin tissue adhesives may confer some benefit, mostly in terms of bruising and swelling, but the clinical importance of such benefit is debatable, particularly when considered against cost and the risk of transmissible disease.
- The benefit of suction drains is most probably similarly minor, but the risk-benefit balance is more favourable owing to their low cost with no increased risk of disease transmission.
- The overall published haematoma rate following face-lift is around 3.5%, but the risk is much greater if surgery is combined with anterior platysmaplasty or if the patient is male, smokes, takes blood-thinning agents or has uncontrolled hypertension. Smoking also risks vascular compromise and wound impair men.

INTRODUCTION

The face is the major focus of social encounters, second to none. It projects a first impression to the outside world of our character, health, energy, vigour and youthfulness. The

* Corresponding Author's Email: fulvio@doctors.org.uk.

desire for that impression to be positive is reflected in an unremitting demand for facial rejuvenation.

In a very early account of facial cosmetic surgery, Pangman and Wallace [1] expressed their opinion that:

> "there is no field which requires more exacting technique, more highly developed esthetic sense, greater human understanding, and which causes more trial and tribulation than does cosmetic surgery".

The procedures offering to achieve a patient's aims are myriad and can be baffling – not just to the patient. By way of a background to understanding the contemporary techniques in use, this chapter shall describe some of the changes that take place in the ageing face, provide a historical account of the techniques that have arisen to deal with them, and consider the relevant refinements in our anatomical understanding of the region. This is followed by consideration of the currently available evidence on technique selection, efficacy and longevity, as well as the development and avoidance of complications.

HOW DOES THE FACE AGE?

The classic description of changes taking place in the ageing face was provided by Gonzalez-Ulloa [2], based on observations of the relationships between various soft tissue landmarks correlated with radiographic views of the underlying skeleton. This was in broad agreement with Pitanguy's [3] later quantification of ageing changes in women. Quantitative comparison of patients with historical photographs by Yousif and colleagues [4] revealed a progressive deepening of the nasolabial fold accompanied by inferior, lateral and anterior migration of the soft tissues of the cheek, the latter most likely causing the former [5].

Whilst descent undoubtedly does take place in the ageing face, other authors place greater emphasis on the contributions of progressive soft tissue and skeletal deflation. Pessa [6] used three-dimensional stereolithography and laser polymerization modelling of the facial skeletons of twelve young and old men to analyse ageing skeletal changes, concluding that the facial skeleton continues to grow during adulthood and facial structures rotate downward and inward with respect to the cranial base. The author speculated that such changes may be responsible for some well-recognised stigmata of ageing – the tear trough deformity [7] and the negative vector orbit [8].

Little9 echoes such views in his summary of the features of youth and ageing (Figure 1). In his view, facial ageing occurs gradually as a transition from a heart to rectangular to pear-shaped face, due to gradual soft-tissue descent. Rejuvenation is therefore best achieved by redistribution rather than excision of tissues. Perhaps surprisingly, the same study has not been carried out in men, in whom a rectangular face does not appear stigmatic of ageing but can be consistent with rugged youthfulness. A tendency towards squaring off of the lower face in either gender could be responsible for the occasionally stated impression that 'men age better than women'.

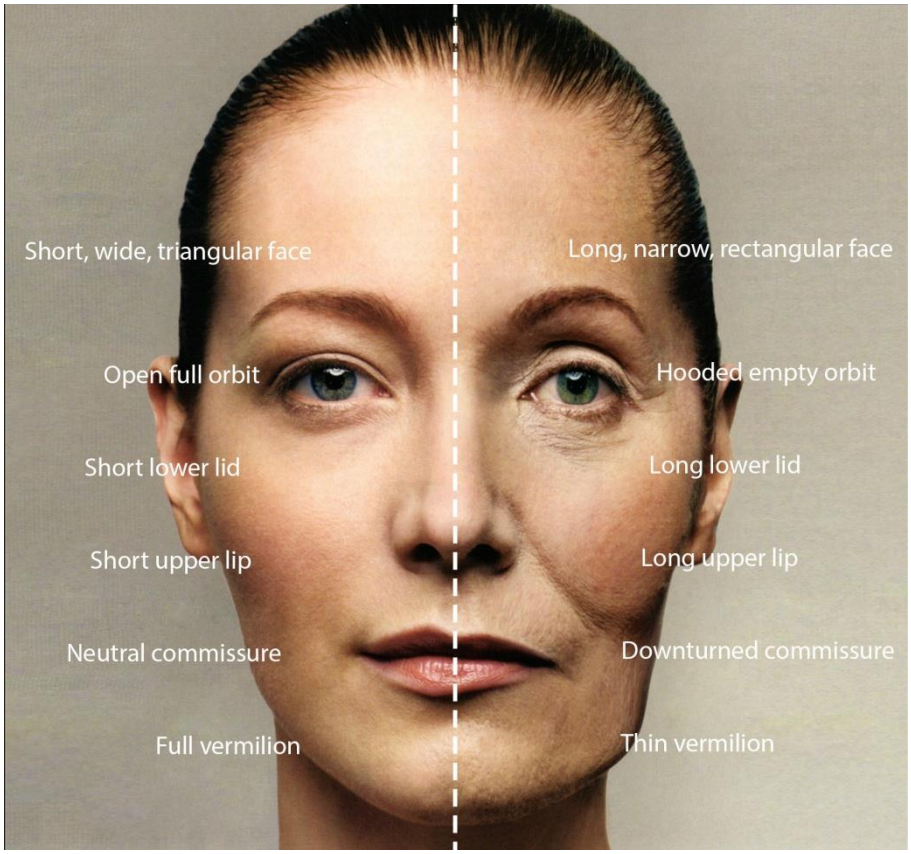

Figure 1. Features of an aged versus a youthful face orbit and mouth. Adapted From Little (2000).

On a histological level, skin creases can result from a number of different mechanisms [10]. Wrinkles can be considered dynamic or static, resulting respectively from the effect of muscle insertions or from intrinsic skin changes, such as elastosis and epidermal atrophy combined with the progressive effects of gravity. Light and electronic microscopic study has failed to reveal any consistent structural change associated with wrinkles, and Kligman and colleagues [11] concluded that they are a mechanical phenomenon taking place in areas of mobility. Subsequent similar analysis revealed elastotic swelling on either side of a wrinkle – thus the wrinkle itself may represent a strip of normal tissue within a region of swollen dermis [10]. In support of this, Chatterjee's [12] study of wrinkling in the UVB-radiated hairless mouse concluded that elastosis-associated skin swelling combined with reducing collagen content permitted a fracture in the dermal collagen layer in response to mechanical trauma. One may speculate that stretch marks could result from a similar process subjected to tension rather than flexion.

CHANGING PRIORITIES FOR FACIAL REJUVENATION

Aims of facial rejuvenation have evolved with improved understanding of the ageing processes in the face and refinements in concepts of beauty. Developments in surgical

technique have broadly mirrored those developments. Thus a preoccupation with effacement of nasolabial and labiomandibular folds has given way to correction of both tissue atrophy and downward migration. Some previously observed sequelae of ageing – jowls, deepened nasolabial folds – are now conceptualised as shelving of descending soft tissues over fixed areas, therefore representing a need for resuspension rather than a large wrinkle in need of flattening.

In his analysis of ageing changes in the face and strategies for effective rejuvenation, Little [9] lists his order of priorities as: first, restoration of the facial ogee; second, periorbital and perioral improvement; and third, nasolabial fold effacement. This reverses the common primacy of nasolabial fold obliteration as a key end point in facial rejuvenation. The ogee is an architectural term referring to two opposing sigmoid forms, a very common aesthetic detail (Figure 2). Little observes that a correctly aligned oblique facial photograph shows an ogee with a zygomatic peak in youth but not in senescence, attributing this to tissue atrophy and descent, and identifying its restoration as critical to rejuvenation [9].

There are several interesting consequences of a model of ageing by soft tissue atrophy and descent. Firstly, in the mid and lower face, changes are both additive and subtractive, whereas in the neck they are purely additive. Little believes this partly accounts for the success of the reductive surgical techniques in use (liposuction, platysma retensioning) to rejuvenate the neck but failure of such techniques to rejuvenate the upper midface. Since atrophy is a continuing process, fat stores should be preserved and redistributed rather than excised where possible [9].

Figure 2. The ogee is an architectural form consisting of two opposing arcs. The youthful facial ogee is evident in oblique view, and its loss is perceived as unattractive.

Another consequence of a volumetric model of facial ageing is to render tension-based rejuvenation strategies conceptually flawed, since tension across a deformable tissue will flatten it. An unnatural 'windswept' appearance can be a consequence of a purely tension-based rejuvenation strategy:

> "excessive tension on deformable tissues… produces an appearance of tightness, an attribute that occurs in neither the aged nor the youthful face, but only in the postsurgical face."[9]

IMPORTANT ANATOMICAL CONCEPTS

The Superficial Musculo Aponeurotic System (SMAS)

At the direction of their tutor Paul Tessier, who was aware of Tord Skoog having used a combined flap of skin and a subcutaneous fascial structure, Mitz & Peyronie [13] provided the first detailed description of the SMAS in their landmark paper. The description of SMAS, as an investing layer for mimetic muscles, continuous inferiorly with platysma and superiorly with superficial temporal fascia, lead the way to face-lift procedures based on SMAS dissection. Use of SMAS is associated with two main benefits - avoidance of excessive skin tension by basing midfacial resuspension on the SMAS layer; and permitting different vectors of closure of skin and SMAS flaps. Comparisons of the biomechanical properties of dermis and SMAS excised during face-lift indicate that SMAS exhibits less stress relaxation and creep [14,15]. These observations would explain clinical observations of improved longevity of SMAS-based face-lifts.

Mitz & Peyronie also described important relations between SMAS and nerves in the region - crucially, that motor nerve branches run deep to it and only sensory branches superficial. Although this formal description of SMAS came somewhat late historically – after, for instance, the Skoog face-lift which appeared to make use of it – a superficial fascia of the face was referred to much earlier in Gray's Anatomy of the Human Body (1859) [16].

Retaining Ligaments of the Face

Furnas [17] described areas of adhesion, or "ligaments", between the dermis and the skeleton at the zygoma and mandible, and fibrous connections from platysma to dermis (Figure 3). Their description was accompanied by the realisation that ligament release was crucial for facial rejuvenation to transmit force exerted through SMAS tension more distantly, and was subsequently incorporated into various forms of face-lift.

Stuzin, Baker and Gordon [18] described similar areas of dermal attachment to relatively fixed structures other than periosteum (parotid gland, anterior border of masseter).

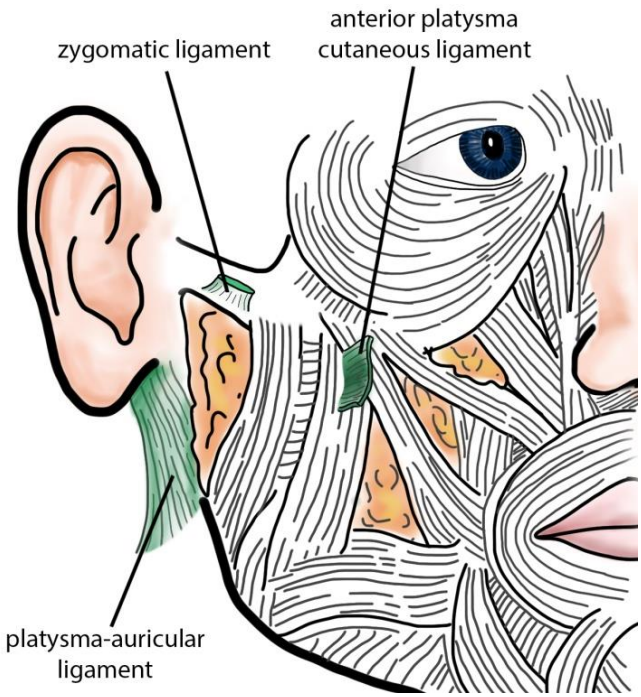

Figure 3. Furnas described retaining ligaments of the cheek at the zygoma ('McGregor patch') and the mandible, plus two further condensations of platysma to dermis – the platysma-auricular ligament and the anterior platysma cutaneous ligament. (After Furnas 1989).

The Platysma

Cadaveric and clinical examinations of platysma demonstrate normal anatomic variability that could explain why certain ageing changes occur in some individuals and not others. A study of fourteen cadaveric and 21 clinical cases found demonstrated decussation of platysma across the midline in just under two thirds of cases, whereas in the remainder there were free medial edges [19]. These free edges can lead to platysma bands and permit submental fat pseudoherniation into the interval between them - the so-called 'turkey gobbler' deformity.

The Facial Nerve

Knowledge of the location of the facial nerve and its variations is central to safe face-lift surgery. A technique for preoperative percutaneous facial nerve mapping has been described20 but has not become established in clinical practice, probably due to the additional operative time necessary. Most surgeons continue to rely on techniques based on operating in facial regions and planes which anatomical knowledge tells us do not contain branches of the facial nerve. The relationships of nerve branches to SMAS as described by Mitz and Peyronie is very useful in this regard13.

Following approximately two thousand facial nerve dissections for parotidectomy, Baker noted that frontal and mandibular divisions of the facial nerve are usually terminal, whereas

the remaining facial nerve divisions usually ramify widely and exhibit crossover communications [21]. Thus the functional consequences of frontal or mandibular nerve injury are likely to be more profound and less likely to recover. Other dissections have shown that the depth of the facial nerve at the anterior parotid is usually nine to ten millimetres below the skin surface [22].

The course of the frontal branch of the facial nerve is summarised in the classic paper of Pitanguy and Silveira Ramos [23] as approximating a line drawn from five millimetres below the tragus to fifteen millimetres above the lateral eyebrow (Figure 4). The important relationships of this branch to the temporal fascia were described by Stuzin and colleagues [24] as follows: the temporal fascia is arranged in three laminae, the temporoparietal fascia most superficially, and superficial and deep laminae of the deep temporal fascia. The frontal branch passes superiorly along the underside of the temporoparietal fascia. Thus the plane deep to the superficial lamina of the deep temporal fascia represents a safe dissection plane in this region. During a subcutaneous dissection in the temporal region, care must be taken not to penetrate superficial temporal fascia to avoid injury to the frontal branch of the facial nerve.

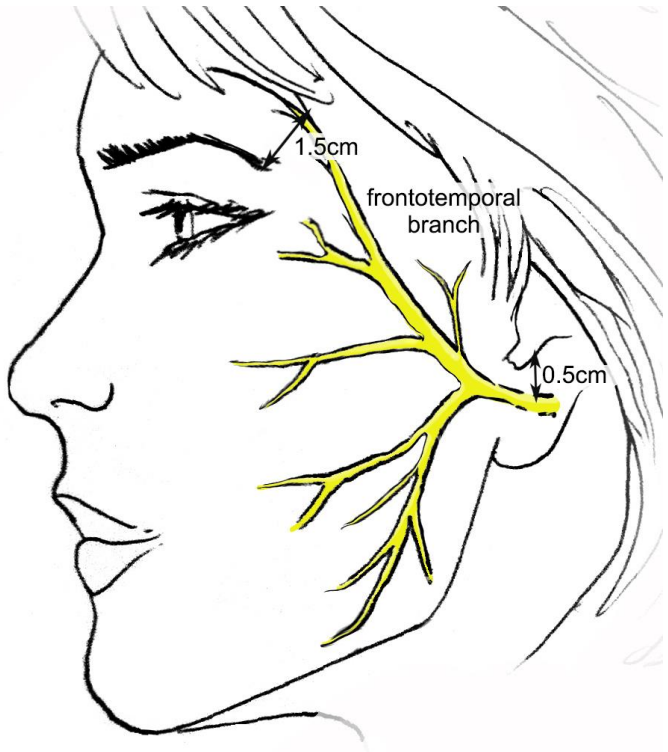

Figure 4. Location of the frontotemporal branch of the facial nerve. (Data from Pitanguy I, Silveira Ramos A: The frontal branch of the facial nerve: The importance of its variations in face-lifting. *Plast Reconstr Surg* 38:352, 1966.)

In the lateral cheek the buccal branches of the facial nerve are protected between superficial and deep lobes of the parotid gland, but anteriorly lie directly beneath a fragile layer of SMAS [13].

In a study of 100 dissections of the mandibular ramus of the facial nerve [25], laterally (posterior to the facial artery) the branch dipped as much as one centimetres below the edge of the mandible in almost one fifth of cases. Anterior to the facial artery the nerve was always above the lower border of mandible.

Cervical Sensory Nerves

The great auricular nerve is at risk during the postauricular and cervical dissection of face-lift procedures. To assist in its preservation, its course was delineated by McKinney and Katrana [26], who state it: a) crosses the belly of sternomastoid at its midpoint 6.5cm below the external auditory canal; and b) runs close to the external jugular vein just beneath the skin and SMAS. McKinney and Gottlieb [27] felt that the safest place to incise SMAS/platysma is immediately anterior to sternomastoid, where the great auricular nerve passes deep into the parotid. Izquierdo and colleagues [28] observed that its postauricular branches extend no further than 1.5cm posterior to the ear lobule, therefore recommending placement of mastoid tacking sutures more posterior than this.

The lesser occipital nerve can have greater significance during face-lift surgery than may be credited. Pantaloni and Sullivan [29] found that it innervated the superior third of the ear and mastoid in around sixty percent of cases, the superior two thirds of the ear in twenty percent of specimens, and almost the entire ear except the lobe in five percent. Although it usually travelled over sternomastoid fascia beneath SMAS, it sometimes ran subcutaneously, placing it at significant risk of division during face-lift. Patients should be counselled accordingly. We are not aware of studies demonstrating the frequency of a coexistent dominant (innervating most of the ear) and superficial (subcutaneous) lesser occipital nerve – the most concerning anatomical variation for those performing face-lifts that included a postauricular dissection.

FACE-LIFT TECHNIQUES

There have been three broad historical schools of thought regarding face-lift techniques. These are: face-lifts based exclusively on skin flaps; face-lifts based on skin flaps with manipulation of underlying SMAS, without SMAS dissection; and face-lifts in which skin and SMAS flaps are raised and mobilised independently. Within each group, evolution and modification has resulted in the current diversity of practice.

The earliest face-lifts were skin-only procedures. At simplest, these consisted of skin excision with direct closure. In the year of his death in 1932, Holländer described having performed a face-lift in Berlin on a Polish aristocrat in 1901. This was at her apparently determined insistence and following her "feminine persuasion" [30]. She presented Holländer with a drawing showing that the removal of facial skin from in front of the ear would improve her nasolabial folds and elevate the corners of her mouth.

Although apparently successful, such techniques gave way to raising and redraping superficial skin flaps. Bettman can be credited in 1920 [31] both with publishing the first pre-

and postoperative photographs following face-lift surgery and with combining two separate (occipital and temporal) incisions into a single incision more similar to those in current use.

Skoog (1974) is usually credited with first raising and redraping skin and SMAS (termed 'superficial fascia') as a single unit [32], although there are similarities to the earlier account of Pangman and Wallace [1]. Skoog certainly popularised the approach, which represented a major advance by taking wound tension off the skin and transferring it to SMAS, hitched onto deep temporal fascia above the zygomatic arch. However, the midface correction achieved was probably limited by failure to release the zygomatic and upper masseteric retaining ligaments of the cheek, which, in addition to the SMAS itself, were still to be described. Since platysma is often less lax than neck skin, mobilising a skin/platysma flap also often did not satisfactorily deal with redundancy in the neck.

In response to failure of the traditional Skoog face-lift to correct malar fat descent, Hamra [33] developed the deep-plane face-lift. This elevated malar fat over zygomaticus major along with the Skoog (SMAS and skin) face-lift flap, and a skin/platysma flap inferiorly. A few years later Hamra further modified this technique, as the composite face-lift, to deal with poor upper midface rejuvenation [34]. In the latter technique, a composite flap including orbicularis oculi in addition to SMAS/platysma and malar fat was elevated. Hamra warns the reader that an extraordinary (author's own emphasis) amount of tension is necessary to reposition the composite flap of skin, SMAS/platysma and orbicularis and produce adequate rejuvenation.

SMAS techniques rely on the dissection, tightening and redraping of skin and SMAS/platysma as separate flaps. Many authors describe variations in skin incision, degree of flap mobilisation and flap tensioning/insetting. However, in general there is a continuous temporal, preauricular, postauricular and occipital incision, from which a subcutaneous flap is elevated to varying extents. Baker elevates skin up to a few centimetres lateral to the nasolabial fold, and from postauricularly to the anterior midline of neck. SMAS is elevated to the anterior border of parotid and tensioned posterosuperiorly, and skin redraped without tension, excising the excess.

Daniel Baker [35] questioned whether the high rate of transient facial nerve palsy in published series of deep-dissection face-lift was justified by any additional benefit. The development of his limited-incision face-lift with lateral SMASectomy was driven by a desire for less invasive face-lifting with less morbidity, and has proven a popular and reproducible technique incorporating some interceding anatomical principles – SMAS resuspension, different vectors for skin and SMAS, and retaining ligament release. After elevating subcutaneous flaps, Baker described excision of an oblique strip of SMAS from near the angle of the mandible to the malar prominence and reapproximation of the remaining SMAS. The excision is at the junction of fixed (lateral) and mobile (anterior) SMAS, so this manoeuvre exerts a posterosuperior vector of pull on the anterior midface. In thin faces the SMAS can instead be plicated to preserve volume, increasingly recognised as a feature of youthfulness. This procedure was originally developed for younger female patients with earlier ageing changes. More significant facial descent, as in the type III or IV patient of his classification (Table 1), may mandate an additional retroauricular incision to correct dog-ear formation.

Table 1. Classification of face-lift patients, modified from Baker (1997)

Type	Age	Characteristics
I – ideal candidate	40's	Slight cervical laxity with good elasticity Early jowls + Submental/submandibular fat + Microgenia
II – good candidate	Late 40s – late 50s	Moderate cervical laxity Moderate jowls Submental/submandibular fat + Microgenia
III – fair candidate	Late 50s – early 70s	Moderate cervical laxity Significant jowls Submental/submandibular fat + Microgenia Platysma bands with animation
IV – poor candidate	60s – 70s	Poor cervical elasticity Significant jowls Submental/submandibular fat + Microgenia Platysma bands with animation Skin folds below cricoid Deep cervical creases

There followed a period of popularity of limited incision surgery accompanied by SMAS manipulation with minimal dissection, usually in the form of plication or imbrication. The important difference between such techniques and those involving SMAS flap surgery is that the latter involves mobilisation of SMAS and surgical release of areas of ligamentous fixation, whereas the former does not.

Following the description of an S-shaped preauricular face-lift incision by Ansari [36], Saylan (1999) described his classic S-lift [37] - today perhaps credited more with being the predecessor to the 'minimal access cranial suspension' (MACS) lift [38] than in its own right. In the S-lift, a two centimetre sigmoid skin excision is marked and a subcutaneous plane immediately beneath hydrodissected by tumescent infiltration, after which subcutaneous tunnels are created with a liposuction cannula. There follows limited blunt subcutaneous dissection of the cheek, skin and SMAS excision, and so-called 'U' and 'O' purse-string sutures to suspend and plicate mobile SMAS and platysma to mastoid periosteum and zygomatic arch fascia using, as originally described, prolene suture. A later modification of the procedure - the S-Plus lift - extended the SMAS flap further into the midface, used two SMASectomies, purse-string imbrication of SMAS and malar cheek resuspension [39] (Figure 5).

Feeling that most patients with early midface ptosis requested a vertical facial elevation rather than the posterosuperior pull offered by conventional face-lifts, Tonnard and co-workers [38] modified the S-lift incision and points of fixation to describe the MACS lift. This is, strictly-speaking, a short scar procedure rather than a minimal access one (although 'MACS' is admittedly a punchier name than 'SSCS') which uses an inverted L preauricular and temporal incision and purse string sutures to achieve midface-lift. In keeping with the rejuvenation philosophies espoused by Little, Tonnard felt that the superior vector provides

facial and cervical rejuvenation whereas a lateral vector merely flattens the face. Other differences from the S-lift were tailoring, rather than predetermining, the extent of initial skin excision, and use of deep temporal fascia rather than zygomatic arch periosteum for fixation. U- and O-shaped purse-string sutures are used in a simple MACS-lift to tighten SMAS and lift jowls, and a third suture to the malar fat pad is used in an extended MACS-lift.

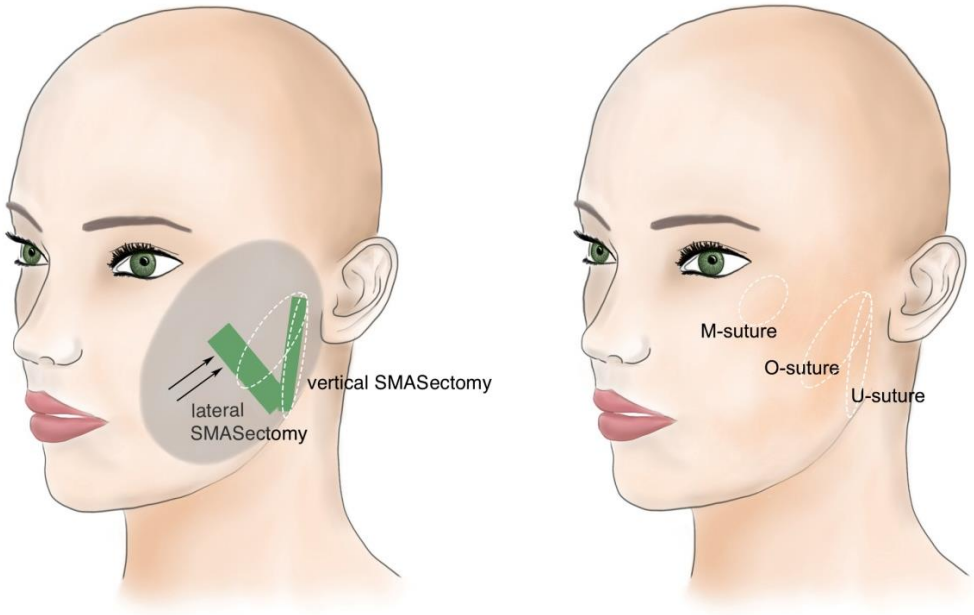

Figure 5. (LEFT) The S-plus lift: extent of subcutaneous flap undermining (grey) and SMAS excision (green). Mobile SMAS is elevated towards the fixed SMAS, lifting the midface and flattening the nasolabial folds (arrows). (RIGHT) The placement of purse-string U-, O- and M-sutures. The U- and O-sutures are imbrication sutures which close vertical and lateral SMASectomy. The M-suture is designed to lift the malar fat pad and cheek soft tissues vertically to produce midface fullness and lifting (after Hopping 2010).

Various surgeons are more or less aggressive in their facial dissections. Mendelson extends his beyond the zygomatic Iigament, releases SMAS from zygomaticus major and sutures SMAS to zygomatic periosteum. Stuzin recommends extending the SMAS dissection over zygomaticus major, manoeuvre that relies on innervation of most facial muscles coming from their deep surface. Debate rages as to the optimal balance between surgical aggressiveness, safety and relative efficacy.

IS ANY FACE-LIFT TECHNIQUE SUPERIOR?

With a number of differing philosophies to facial rejuvenation surgery, from each of which has arisen various improvements and variations, naturally the question of whether any one represents a marked improvement over the others crops up.

The main proponents of each technique have all reported satisfactory results in their respective series. Hamra and Lennon published a large favourable experience of over 500

Skoog face-lifts (Hamra and Lennon, 1984), before moving on to similar series of deep plane and composite face-lift procedures. Positive results were reported in 403 patients undergoing the deep-plane technique, complications including one percent major (requiring evacuation) haematoma and one percent transient lip paresis. Kamer's [40] prospective questionnaire evaluation of 100 patients six months after deep-plane face-lift demonstrated that 97% of patients were pleased with their outcome. The haematoma rate was 2.8% and there were few other identified complications.

In his experience of 167 composite face-lifts, Hamra [34] encountered one cervical haematoma requiring evacuation and no facial nerve injuries. He warned that malar tenderness and swelling might persist for several months after the procedure. The actual aesthetic outcome was not formally assessed, but Hamra criticised previous SMAS face-lifts for producing an 'operated look' resulting from good neck rejuvenation despite a deep nasolabial crease, and felt that the composite face-lift produced a more harmonious result.

Baker [41] reported his series of lateral SMASectomy in over 1500 patients, finding it most beneficial in early ageing (types I and II of his classification, Table 1), but also applicable to types III and IV when modified to improve jowl elevation and a traditional incision used to deal with a retroauricular dog ear. However, he felt the technique was less well suited to male patients owing to thicker skin and muscle of the neck. The commonest complication was the need for neck revision (four percent), although Baker noted a similar experience with traditional face-lift and the observation appears just as relevant today [42]. He additionally reported three percent temporal hairline scar revisions, two percent earlobe scar revisions, two percent secondary mini-lift after one year, 1.5% hematoma and 0.1% facial nerve weakness. Massiha [43] also noted high patient satisfaction in his series of "several hundred" short-scar lateral SMASectomies similar to Baker's. Outcomes were not quantified, but there were no reported instances of nerve injury or skin necrosis, and complications were described as rare and minimal.

In his description of the technique, Saylan (2002) gave an account of his experience of S-lift in 250 patients. Complications included transient facial nerve palsy (1.2%), minor haematoma (0.8%), and self-limiting pretragal tension (17.6%). A majority of patients (76%) experienced dimpling beneath the ear lobe due to traction on the platysma, which could be improved by liposuction with a sharp cannula (presumably to produce soft tissue tunnelling and distribute or attenuate the tension). Saylan felt the procedure was best suited to younger patients with good skin quality and early ageing changes (Baker type 1 patients). Again outcomes were not formally quantified.

Tonnard and co-workers [44] reported on over 450 MACS-lifts on patients with a mean age of 57. Dog-ears were not chased and all settled by two months. Short recovery was cited as an advantage of this technique, the authors reporting most patients being able to return to normal activity after one week, with none requiring camouflage make-up beyond two weeks. Two per cent of patients required evacuation of haematoma. Adequate facial suspension was maintained by eighteen months, which was the longest follow-up in the series, although five percent required revision surgery to correct the neck.

In a review of 54 patients undergoing short scar volumetric face-lift [45], three independent surgeons graded preoperative and three month postoperative photographs of a random sample of 25 of those patients. The authors reported no significant complications, aesthetic outcomes were generally rated as ‘Good’ (with none rated ‘Poor’) and improvements in malar eminence soft tissue volume, the nasolabial fold, jowls and the

cervicomental angle. The authors concluded that short scar volumetric malar imbrication face-lift was a straightforward, safe and effective procedure for improving early ageing.

Various other studies express their opinions on the effectiveness of individual techniques. For instance: one case series review of 539 patients concluded that less invasive procedures resulted in less morbidity, durable results and high patient satisfaction [46]; another retrospective review of 83 patients concluded that a short incision and limited subcutaneous dissection face-lift resulted in high levels of satisfaction with a low complication rate47; a review of 135 patients undergoing minimally invasive endolaser face-lift combined with suture suspension, cutaneous laser therapy and fat grafting concluded that results were satisfactory [48]. However, interpretation of all these uncontrolled studies is difficult. For example, close analysis of the latter study revealed an 18.5% complication rate, and the study was diminished by lack of quantification, indication of length of follow up, no control group and the difficulty in assessing the relative contributions of the various adjunctive therapies.

Despite these extensive series representing a significant body of experience of prominent surgeons, none are controlled comparative studies. The differences in methodologies, including patient populations, operating surgeons, anaesthesia, and outcome intervals and assessments, make comparison of the different techniques almost impossible. Several investigators have therefore attempted to make direct comparisons between types of facial rejuvenation procedure in order to address whether one is better than any other. In assessing the evidence presented, we have adhered to the Level of Evidence classifications adopted by the American Society of Plastic Surgeons (Appendix)

Table 2. Summary of studies directly comparing midface-lift procedures. See text for explanation

Author	Procedures	Study size	Summary	Evidence Level
Ivy et al. (1996)	lateral SMASectomy/ conventional SMAS vs. extended SMAS/ composite face-lift	21	Procedures equivalent after 24 hours.	II
Kamer & Frankel (1998)	SMAS vs. deep plane face-lift	634	Fewer 'tucks' following deep plane.	III
Litner & Adamson (2006)	SMAS plication vs. imbrication vs. deep plane	32	Best intraoperative lift with deep plane.	II
Prado et al. (2006)	MACS vs. lateral SMASectomy	82	No difference in cosmetic outcome or satisfaction.	III
Antell and Orseck (2007)	Combinations of skin only vs. conventional SMAS vs. lateral SMASectomy vs. SMAS plication	16 (8 twins)	No discernible difference.	III

The relevant studies are summarised in Table 2. Litner and Adamson (2006) carried out a prospective study comparing limited versus extended face-lift techniques. Each hemiface of 32 patients underwent a progressively more extensive face-lift procedure (SMAS plication, then imbrication, then deep plane face-lift) and data was collected intraoperatively (Evidence Level II). The authors concluded that a superior intraoperative lift wad obtained using the deep plane technique, but the study design did not permit any comparison of longevity. This is important since other work suggests that such early differences may not correlate with longer-term outcome.

For instance, Ivy and colleagues (1996) carried out a split-hemiface prospective randomised controlled trial comparing more conservative (either lateral SMASectomy or conventional SMAS lift) with more extensive (extended SMAS or composite face-lift) surgery (Evidence Level II). In this analysis of 21 patients, assessments were made intraoperatively and at 24 hours, and were reviewed by six surgeons using postoperative photographs at six months and one year. Greatest intraoperative changes determined by SMAS overlap, nasolabial fold effacement and midface movement were achieved with the more extensive procedures, but this difference was lost at 24 hours and subsequent time points. The possibility remained that more extensive surgery produced a result of similar magnitude but greater longevity compared with conservative surgery, but the maximum follow up of one year was unable to demonstrate this.

Prado and co-workers (2006) retrospectively compared two minimal incision procedures (MACS lift and SMASectomy) in 82 patients (Evidence Level III). Patients and two independent plastic surgeons assessed postoperative photographs at one month and two years. The MACS procedure was quicker to perform but was associated with more postoperative pain. However, the cosmetic outcome and patient and surgeon satisfaction were similar for either procedure. Overall there was no clear benefit to one procedure over the other.

Antell and Orseck (2007) published an interesting series of eight pairs of twins who had undergone various face-lift procedures: skin only; conventional SMAS; Baker-type SMASectomy; and SMAS plication. Follow up photographs taken between thirteen and sixty months postoperatively were evaluated by four blinded Plastic Surgeons. Again, the authors concluded that no one technique was superior to any other. Although the occurrence of eight pairs of monozygotic twins who had all had face-lifts in a single series was noteworthy, the chance nature of these comparisons was evident. For instance, four siblings (two twin pairs) underwent the same procedure and could justifiably have been excluded from the series. There was no standard follow-up interval across twin pairs, and even within twin pairs it is unclear whether assessment always took place at the same postoperative follow-up interval. These factors, combined with the (understandably) small series, make data interpretation problematic.

Due to inherent difficulties in making aesthetic judgements of the outcomes of different techniques, Kamer & Frankel (1998) attempted to assess the efficacy of SMAS versus deep plane face-lift techniques objectively by retrospectively evaluating the need for revision procedures within eighteen months ('tuck rate') in 634 patients. They found that such procedures were performed significantly less frequently following deep-plane face-lift (3.3% vs. 11.4%). However, the indications listed for determining the need for a tuck (inelastic skin, deep nasolabial folds, jowl, cheek or malar redundancy, and patient dissatisfaction) were themselves subjective, so the objectivity of the rate of revision surgery can be questioned. Additionally, since SMAS procedures were carried out early in the series whereas deep plane face-lifts were performed in the latter half, the declining revision rate could be commensurate with increasing experience.

In conclusion, there remains no clear evidence of greater effectiveness of any particular technique over any other, although no study has really effectively addressed the question. It is a difficult one to address objectively due to differences in preoperative patient desires, variations in anatomy, variations between surgeons and intrinsic subjectivity of aesthetic outcome assessment. Nonetheless, there appears to be some convergence in techniques towards the common themes of decreasing reliance on skin tension through SMAS

manipulation, increasing use of vertical vectors of resuspension rather than purely lateral ones, and the recognition of the importance of volume preservation in many patients.

Adjunctive Measures, Complications & Their Avoidance

1. Preinfiltration

Following the successful use of tumescent anaesthesia to reduce blood loss in liposuction, Brody [49] attempted a similar strategy for face-lift surgery after a run of haematomas. He reported "impressive results" with greatly reduced intraoperative bleeding, easier tissue dissection, reduced operative time and no further haematomas. This lead to the widespread adoption of preinfiltration prior to face-lift surgery, although formal evidence did not yet exist.

This was addressed ten years later in a study by Jones & Grover [50], who studied the effect of tumescent infiltration on postoperative complications. Using a retrospective comparative study design in a cohort of 678 patients (Evidence Level III), the first 449 patients, who did not receive tumescence, was compared with the next 229 who did. Tumescent solutions consisted of local anaesthetic, adrenaline, hyaluronidase and corticosteroid, and procedures were performed under hypotensive general anaesthesia by an experienced anaesthetist. The investigators found that use of tumescent anaesthesia reduced postoperative swelling, oozing, skin necrosis, alopecia, hypertrophic scarring and scar stretch, and noted that tumescence made dissection of skin flaps easier, particularly in the neck. Interestingly, tumescent infiltration did not significantly alter the rates of major or minor haematoma – indeed there was a non-significant increase in haematoma rate in the group who received tumescence.

A mechanism by which tumescent preinfiltration may reduce the complications noted in this study is not immediately obvious. The authors speculated that the key mechanism might have been reduced skin flap tension, resulting either from intraoperative tissue expansion (a mechanical effect of the infiltrate) or from reduced postoperative swelling (a pharmacological effect of locally administered corticosteroid) [50]. An alternative mechanism could simply have been facilitated dissection of an optimal skin flap plane by preoperative hydrodissection.

Preinfiltration has become an established routine for most face-lift surgeons. The composition and relative concentrations of the tumescent solution is far less ubiquitous, however, and there is little strong evidence to guide this. Two early reports of preoperative infiltration for face-lifting used only dilute lidocaine and adrenaline [49,51]. Other surgeons add varying amounts of triamcinolone and hyaluronidase [52]. In Brody's opinion, the composition of infiltrate is not important, it being simply necessary to infiltrate a substantial volume; he wondered whether saline alone might have a similar effect.

One study looking at the composition of infiltration [50] compared tumescence with and without adrenaline in a case-control study of 910 patients, finding a significant reduction in both major (from 4.8% to no events) and minor (from 2.6% to 0.4%) haematomas when adrenaline was omitted. Other measures – dressings, drains, fibrin glue and tumescence – did not affect haematoma occurrence. The authors concluded that adrenaline should be omitted from preinfiltration solutions prior to face-lift. Adrenaline use could increase the rate of postoperative haematoma formation by temporary vasoconstriction (its desired intraoperative

effect) making it more difficult to identify bleeding vessels and perform effective surgical haemostasis. Knize {Knize:2004ch} felt that the increased speed of surgery associated with adrenaline-containing tumescence increased the risk of reactive vasodilatation.

To our knowledge, little other evidence on the composition of tumescent infiltration prior to face-lifting exists, although anecdotally most practitioners agree that tumescent infiltration itself is a useful, or indeed mandatory, adjunct.

2. Fibrin Tissue Adhesives

There is an unusual amount of good evidence assessing the use of fibrin glue in face-lifting (summarised in Chapter 30, Table 1,), possibly due to acceptability to patients and surgeons of split-hemiface double-blind randomised controlled trials with or without tissue sealants, for which there may be equipoise regarding efficacy and only minor concerns of adverse events. The main theoretical advantages are a haemostatic effect with reduced haematoma rates, and reduced incidence of seroma or prolonged drainage by closing dead space from dissected tissue planes. Potential disadvantages include cost, the risk of transmissible disease (with the use of donor rather than autologous fibrin), allergy and, importantly, unproven efficacy.

Table 3. Studies examining the influence of fibrin tissue adhesive on the postoperative course of face-lift surgery. (* = statistically insignificant or no statistical scrutiny; X = not assessed)

	n	Effect of fibrin on		
		haematoma	bruising/ swelling	other
Bruck (1982)	82	X	↓ swelling	↓ operating time
Marchac et al. (1987)	65	X	↓	-
Flemming (1992)	?	↓	↓ swelling	↓ operative time, faster recovery, ↓ need for drains
Marchac & Sandor (1994)	100	↓ major	↓ ecchymosis	-
Oliver (2001)	20	X	X	↓ drainage
Powell (2001)	8	X	↓	Autologous platelet gel
Man, Plosker & Winland Brown (2001)	20	X	↓swelling*	↓ operative time*, faster recovery*, ↓ need for drains*
Grover, Jones & Waterhouse (2001)	1078	No effect	X	X
Fezza (2002)	48	↓ major*	↓	-
Jones & Grover (2004)	678	No effect	X	-
Marchac & Greensmith (2005)	30	No effect	No effect	Small ↓ drainage
Kamer & Nguyen (2007)	200	↓*	↓	↓ seroma
Zoumalan & Rizk (2008)	605	↓ minor	X	-
Lee et al. (2009)	9	↓ minor*	↓	-
Por (2009)	Meta-analysis; 58 cumulative	X	↓ bruising*	↓ drainage*
Mustoe (2011)	120	↓ haematoma/ seroma	X	↓ drainage

Marchac and co-workers [53] examined the effect of fibrin tissue adhesive in 65 patients undergoing face-lift with a hybrid uncontrolled and split-hemiface study. For the ten patients in the split-hemiface part of the study there was no difference between the two sides in five cases and the glued side was judged superior in the remainder. Overall Marchac felt that the tissue adhesive had a beneficial effect.

Oliver and co-workers' experience was broadly similar to that of Marchac [54]. Their prospective double-blind randomised controlled trial of twenty patients undergoing face-lift with bilateral drainage and fibrin glue to one side only (Evidence Level II) demonstrated significantly reduced drain output at 24 hours (ten millilitres versus thirty millilitres) on the fibrin side. The researchers felt that this difference could be enough to replace the use of drains.

One objection to donor derived blood products such as fibrin – potential disease transmission - is obviated by use of autologous products. Man and colleagues [55] enrolled twenty patients for their study into the effect of autologous fibrin, derived from platelet-poor plasma, on postoperative outcome following face-lift and/or neck lift, breast augmentation or mastopexy. They observed that the fibrin rapidly stopped intraoperative capillary bleeding and felt that it reduced operating times, reduced postoperative swelling, shortened recovery and avoided drain use. However, none of the results were quantified and there was no control group in this study, making objective interpretation of the data difficult. The same year, Powell [56] investigated the efficacy of autologous platelet gel in a prospective randomised controlled trial of eight patients undergoing deep plane face-lift, comparing treated and untreated hemifaces by means of blinded postoperative photographs (Evidence Level II). Platelet gel was found to reduce bruising and swelling.

Fezza [57] carried out a prospective clinical trial comparing the use of drains alone after face-lift in 24 patients with fibrin glue and no drains in the next 24 (Evidence Level II) - essentially, a comparison of fibrin glue versus drainage. Use of fibrin was associated with less bruising and swelling as determined by nurse observers from pre- and postoperative photographs, a thirteen minute shorter operative time, subjectively 'faster healing' and fewer complications (zero versus 8.3% haematoma requiring evacuation). The latter was not significant however, corresponding to zero versus two actual haematoma events in the fibrin and non-fibrin groups respectively. Although common, sequential analysis can produce bias resulting from an advancing learning curve, in that late results tend to be superior to earlier ones. This effect is most relevant when using outcome measures such as operative time, which is highly dependent on experience and less apparent for very experienced practitioners whose technical improvement may have levelled. The observation of reduced operative time in the fibrin study group is difficult to explain - it cannot be accounted for by the time taken to insert drains, and haemostasis should be similarly rigorous whether fibrin is used or not. A potential explanation could be an active learning curve within this series.

In their series of face-lift patients, Grover & Jones [58] sprayed fibrin glue beneath the skin flaps in 412 patients, and in 266 patients, no glue was used. There was an overall haematoma rate of 4.1% and the use of fibrin glue did not have any effect on this. This was in keeping with their earlier multivariate analysis of risk factors for haematoma following facelift in 1078 patients [59], which found that Tisseal had no beneficial effect (haematoma rates of 4.4% and 4.0% with and without use of Tisseal respectively).

The prospective unblinded split hemiface randomised controlled trial of Marchac and Greensmith is widely cited [60]. The authors compared the use of fibrin glue with none at the

end of face-lift surgery in thirty patients (Evidence Level II). Surgical drains were also used and drain output at 24 hours taken as one outcome measure. Whilst there was a statistically significant reduction in drain output with the use of fibrin glue (26ml vs. 34ml), the authors felt the magnitude of that difference was clinically irrelevant, in contrast to the earlier study of Oliver [54]. Subjective assessment of oedema and ecchymosis at days one and eight also revealed no striking difference between hemifaces, and the authors disagreed with Fezza's determination that the use of fibrin glue reduced operative time [57]. In contrast, they argued that its use added a further operative step, and since meticulous haemostasis was not obviated by use of fibrin glue the net effect was to increase the length of the whole procedure. One haematoma in the study (on an unglued side) did not permit statistically meaningful comment. Overall, the authors believed that drains were more important than fibrin glue, and since adopting the use of the former no longer required the latter.

Kamer & Nguyen carried out a case-control study prospectively evaluating the outcomes of deep plane face-lift using fibrin glue in 100 patients, compared with the retrospective outcomes of 100 patients without use of fibrin (Evidence Level III) [61]. Whilst the authors felt the use of fibrin conferred a number of benefits, the only ones achieving statistical significance were a reduction in prolonged induration, oedema and ecchymosis, from 22% to no instances. Reductions in the instances of expanding haematoma (from three to one percent) and seroma (from seven to one percent) were not statistically significant, but the authors nonetheless believed them to be 'clinically significant'.

Zoumalan and Rizk [62] conducted a retrospective case-control study of the impact of fibrin glue and no drains in 605 patients undergoing either deep-plane or (in a minority) lateral SMASectomy face-lifts. In their series, no patient experienced major haematoma but the minor haematoma rate was significantly reduced by the use of fibrin (3.4% vs. 0.4%). Most minor haematomas occurred in men, consistent with their greater risk noted elsewhere [59], and a significant protective effect of fibrin was only apparent in the male subgroup. The authors noted that almost a third of haematomas were associated with postoperative vomiting and recommended prevention and prompt treatment of nausea.

In their small split-hemiface randomised controlled trial comparing fibrin sealant versus none in nine patients, Lee and colleagues [63] found tissue sealant significantly reduced bruising and swelling at days three and seven (Evidence Level II), as judged by five blinded independent observers. Whilst there appeared to be a beneficial effect of the tissue sealant on the prevention of small haematomas (22% vs. 0% in the untreated and treated groups respectively), the study lacked sufficient power to show statistical significance. There were no major haematomas in the study.

Por and colleagues (2009) [64] performed a small meta-analysis into the use of tissue sealants in face-lift (Evidence Level 1). This was based on the pooled data of the randomised controlled trials of Marchac60, Oliver54 and Powell56. Tissue sealants produced a non-significant trend towards reduced drainage. There was no effect on ecchymosis or oedema.

In their prospective split hemiface randomised controlled trial of 120 patients, Mustoe and co-workers65 found fibrin tissue sealant significantly reduced the rate of seroma/haematoma and the volume of drain output formation following face-lift.

An overall view of the literature therefore suggests some benefit of fibrin glue in terms of bruising, swelling and possibly early drain output. However, benefit in terms of haematoma risk reduction is demonstrated inconsistently, and if there is such an effect at best it is likely to be small. In view of this, the potential (admittedly small) risk of disease transmission, and

the additional cost of using the product, there does not appear to be overwhelming support for the use of fibrin glue.

3. Drains

Opinion differs regarding the use of drains following face-lift surgery. Huang and colleagues [66] investigated use of suction drains in 46 patients, comparing sixteen in whom a drain was placed on the left side, fourteen in whom it was placed on the right and sixteen in whom no drain was used. All drains were removed after 24 hours irrespective of drain output. The single haematoma that occurred in the study was on a drained side following its removal, although the study size is too small to draw any meaningful inference. Huang felt that each hemiface in unilaterally drained sides was identical, and that these patients were postoperatively indistinguishable from those who received no drains, concluding that drains were probably unnecessary.

In contrast, Perkins' group [67] felt that drainage had some benefits following face-lift. They retrospectively reviewed 222 face-lifts performed by one surgeon using the same technique, half with and half without drains, measuring the occurrence of haematoma or seroma within 24 hours. Their series contained several minor haematomas - needing aspiration only - and seromas. Drainage appeared to reduce seroma frequency significantly (15% vs. 37%) although it had no significant affect on haematoma rate (7% vs. 8%). As previously discussed, Marchac [60] decided to discontinue the use of fibrin tissue adhesive after introducing drains into his practice, feeling that they achieved similar functions - reducing the dead space of elevated flaps - but that drains were more important.

Aiming to address conflicting opinions regarding drain usage, Jones and colleagues [68] carried out a split-hemiface prospective randomised controlled trial of the use of Medinorm low suction Bellows drains following face-lift surgery, in which one half of the face was drained and the other acted as control, in fifty patients (Evidence Level II). Patient and clinician assessment at one day and approximately one week postoperatively found no effect on postoperative oedema or haematoma rate with the use of drains. There was, however, a reduction in postoperative bruising associated with their use, and consequently a speedier return to normal activities.

The use of drains following face-lift surgery remains a matter of individual surgeon preference, opponents citing little benefit, and proponents citing some benefit with little downside.

4. Haematoma

Haematoma is the commonest complication of face-lift, the literature quoting rates of two to nine percent (Table 4). Large haematomas can compromise skin flap perfusion and, unless treated expediently, result in skin necrosis. Small haematomas may have little immediate impact, only being detected after initial swelling has subsided, but can lead to contour irregularities, altered skin pigmentation, infection, persistent postoperative oedema and prolonged convalescence.

Kamer & Song [69] retrospectively investigated 451 deep plane face-lifts, establishing a rate of major and minor haematoma of 2.2% and 6.65% respectively. Haematomas occurred much more frequently in men, in keeping with other studies (five versus two percent for major and twelve versus six percent for minor) and all haematomas occurred in the

subcutaneous dissection plane used in the neck, rather than the deep plane of dissection used in the face. The authors commented that the latter plane is relatively avascular and, in their view, less likely to produce haematoma than raising a subcutaneous flap.

Table 4. Reported incidence of haematoma following face-lift. (Adapted from Grover & Jones 2001)

Study	n=	% haematoma
Rees et al. (1973)	806	3.3
Straith et al. (1977)	500	2.6
Leist et al. (1977)	324	3.4
Perkins et al. (1997)	222	7.5
Kamer (1998)	100	2.8
Rees et al. (1994)	1236	1.9
Marchac & Sandor (1994)	200	2-9
Jones (1995)	137	3.6
Grover & Jones (2001)	1078	4.2
Durnig & Jungwirth (2006)	126	5.6

Grover and colleagues (2001) investigated preoperative and intraoperative risk factors for haematoma following face-lift in a large case-control study of 1078 patients (Evidence Level III) [59]. Since risk factors commonly coexisted, multivariate analysis was used to identify independent risk factors and their individual relative risks.

The findings were surprising (Table 5). Against an overall haematoma rate of 4.2%, the risk factor most strongly related to haematoma formation was concurrent anterior platysmaplasty, which had not previously been identified. Next were uncontrolled systolic hypertension, male gender, aspirin or non-steroidal use, and smoking. The type of face-lift, whether it was primary or secondary, patient age, use of fibrin sealant, and cardiovascular or pulmonary comorbidity, did not affect haematoma rate. Relative risk for each significant risk factor was calculated (Table 6), aiming to guide preoperative patient counselling. Risk factors are cumulative - thus a male smoker taking aspirin would have a 7.2 times increased haematoma risk.

On the basis of this study, preexisting hypertension should be treated, the patient should be counselled on smoking cessation if relevant, and if medically permissible aspirin or NSAIDs should be discontinued. Whilst anteriorly platysmaplasty is still commonly carried out, the surgeon should be aware of the increased risk of haematoma and be particularly diligent with regards haemostasis.

The same study suggested that the increased haematoma risk from aspirin/NSAIDs more or less normalised within two weeks of their discontinuation. This conclusion was formed from comparison of the NSAID/aspirin users in the haematoma (14/45) and non-haematoma (31/1033) groups: nine of the fourteen NSAID/aspirin users in the haematoma group had discontinued the medication within two weeks of surgery, whereas 26 of the 33 NSAID/aspirin users in the non-haematoma group has discontinued more than two weeks before their face-lift.

Table 5. Significant and non-significant factors for the development of postoperative haematoma following face-lift (data from Grover et al. 2001)

Significant factors (Relative risk)	Non-significant factors
Anterior platysmaplasty (4.3)	Type of facelift
Preoperative SBP>150mmHg (3.6)	Primary or secondary procedure
Male gender (2.8)	Cardiovascular/pulmonary comorbidity
Use of aspirin/NSAIDs (2.3)	Use of fibrin tissue adhesive
Smoking (2.1)	Operating surgeon
	Patient age

5. Smoking

Krueger & Rohrich [70] reviewed the effects of cigarette smoking on plastic surgery procedures. The many inhaled products of tobacco smoke influence wound healing via several pathways, including direct microvascular injury, inhibition of the function and proliferation of inflammatory cells, stimulation of hormones that retard epithelialisation, cutaneous vasoconstriction and competitive binding of toxins to haemoglobin. In addition, increases in platelet adhesiveness, plasma fibrinogen concentration and blood viscosity combined with altered red blood cell rheology predispose to occlusive microvascular thrombosis, which can have a more chronic impact on the response to injury. Delayed healing, wound dehiscence, postoperative infection and poor scarring are therefore all more likely in a patient who smokes.

Rees and colleagues reported their retrospective observation following 1186 face-lifts that smokers were more than twelve times more likely to suffer skin slough postoperatively [71]. Riefkohl and colleagues [72] subsequently carried out a prospective comparative study into the effect of smoking on occlusive vascular disease and skin slough after face-lift, by comparing histological assessment of excised preauricular skin and rates of skin slough in active smokers, ex-smokers and non-smokers (Evidence Level 2). In total 83 patients were assessed, and there were nine cases of skin slough, with a frequency of five percent in non-smokers and twenty percent in active smokers. Whilst striking, this difference was not statistically significant. However, occlusive vascular disease was increasingly noted with advancing age and smoking, and there was a significant association between severe occlusive vascular disease and skin slough. Amongst smokers, there was also a significant association between skin slough and postoperative failure to abstain from smoking.

We are only aware of one study examining the effects of smoking on the outcome of face-lift surgery that failed to find an adverse effect. Webster and co-workers [73] reported no skin sloughs in their population of 407 patients undergoing skin slough, of whom 32.4% were active cigarette smokers. However, this group raised facial flaps more conservatively specifically with a view to designing a procedure that was relatively safe in smokers.

Smoking is implicated in the study of Grover and co-workers [59] investigating haematoma after face-lifts, who found it to be a risk factor. 6.1% of patients with a positive smoking history sustained a haematoma compared with 3.7% of non-smokers. Although smoking has an overall prothrombotic effect, such a relationship could arise from, for example, impaired mucous clearance and increased coughing in the convalescent period, dislodging thrombin clots.

The optimal period of smoking cessation, or the degree of smoking reduction required to normalise risk levels, are not known. Consensus opinion cannot be derived from the literature, with recommendations ranging from cessation one day to four weeks preoperatively and five days to four weeks postoperatively. Haematological parameters - blood and plasma viscosities, haematocrit, blood cell filterability, plasma fibrinogen levels, and total white blood cell count - normalise over a period of around eight weeks [74].

6. Hilotherapy

Cooling devices designed for use after facial injuries are commercially available and used by some practitioners following face-lift surgery, although little evidence exists for that indication. Research has demonstrated that cooling with gel packs and ice bags reduces pain, bruising and eyelid swelling after craniotomy [75], and that a Hilotherm cooling face mask reduces pain and swelling compared with cold compresses after mandibular fracture fixation [76] or dental extraction [77]. However, a literature review found study data regarding the benefits of cooling after oral surgery to be inconclusive [78].

Jones and coworkers [79] randomised fifty patients to either standard dressings or hilotherapy following face-lift (to assess bruising, swelling and haematoma) and a further fifteen to hilotherapy cooling on one side of the face only (to allow more accurate comparison of an effect on postoperative pain). Surprisingly the researchers found significantly increased postoperative swelling in patients who received cold therapy, with no statistically significant effect on bruising, haematoma or postoperative pain. Whilst evidence is currently exceptionally sparse, there exists none at present that would encourage the use of hilotherapy after face-lift.

7. Thromboprophylaxis

Low molecular weight heparin is commonly used in the postoperative period of many surgical procedures to reduce the risk of thromboembolic disease, based on effectiveness shown in multiple studies addressing general, orthopaedic and urological surgery [80]. In the United Kingdom, the regimen of mechanical and chemical thromboprophylaxis is determined by patient risk stratification [81]. The majority of patients undergoing face-lift would be considered moderate risk - aged over forty, undergoing surgery longer than thirty minutes duration, without additional risk factors. Recommendations for such patients are to receive 2000-3000IU of heparin per day until mobile [82].

Despite this, Durnig and Jungwirth argue against LMWH thromboprophylaxis following face-lift83. In their retrospective comparative study of 126 patients (Evidence Level III), 89 received only perioperative compression stockings, early mobilisation and analgosedation and the remainder also received LMWH. There were no instances of symptomatic thrombosis or pulmonary embolism. However, sixteen percent of patients from the LMWH group experienced postoperative bleeding compared with one percent of patients not receiving LMWH. Based on this, the authors felt that patients should not routinely receive LMWH following face-lift. They reserved chemoprophylaxis for patients with known risk factors such as prothrombotic conditions, relevant past history and use of the contraceptive pill.

Durnig and Jungwirth felt that their use of analgosedation rather than general anaesthesia was relevant to their low rate of postoperative thrombosis, based on a survey by Reinisch and colleagues [84] in which 0.35% of their sample of 9937 face-lift patients developed deep vein

thrombosis, but 84% of thromboembolic events occurred in association with general anaesthesia. Thus their conclusions regarding the need for heparin chemoprophylaxis may not apply to patients undergoing face-lifting under general anaesthesia.

8. Hair Loss

Hair loss can result from face-lift surgery either from excision of hair-bearing skin (causing posterior or superior retraction of the hairline, particularly around the sideburn or temporal area), as a result of scar alopecia from incisions placed within hair-bearing scalp, or through damage to hair follicles on the underside of elevated skin flaps (e.g. resulting from diathermy). The former is a consequence of incision design and vector of skin redraping, and as such should be explicitly controllable by the surgeon.

To minimise scar alopecia, there have been differing opinions as to whether to bevel scalp incisions so they are parallel to hair follicles (minimising the number of follicles injured) or perpendicular to them (leaving the possibility of hairs growing through and disguising the scar). Camirand states he was inspired to attempt the latter by the success he had observed of follicular grafts in treating alopecia, conceptualising the bevelled scar containing deep hair follicles essentially as follicular flaps which could permit hair growth into the overlying scar [85].

Camirand and co-workers therefore compared scars resulting from these alternative incision designs as part of a double-blind comparison in which eighteen patients acted as their own controls, and four observers were asked to state which side had the more aesthetic scar [85]. There was a significant preference for the side with the perpendicular bevelled scar and the author was able to demonstrate hair growth through the scars on the perpendicular side as intended. Moreover, Camirand points out it is actually easier to perform a perpendicular bevelled scar rather than a parallel one matching the constantly changing direction of hair follicle growth.

HOW LONG DOES A FACE-LIFT LAST?

It seems appropriate to end an overview of face-lift surgery with consideration of how long the procedure will last for - a question commonly asked by patients considering whether to embark on the process, and one which has recently been addressed. Jones & Lo [42] carried out a retrospective assessment of the outcome of face-lift, performed by SMASectomy/SMAS plication and lateral platysmaplasty or using the volumetric approach of Little [86], on standardised photographs taken prospectively over the previous ten years. Software was used to measure the movement of key facial points in the early and late (5.5 years) postoperative period.

At the late time point the researchers found good maintenance of correction of the jowl, nasolabial fold and marionette regions, but significant relapse of the neck. Global subjective assessment determined that three quarters of patients looked younger after 5.5 years than at the time of presentation, and adverse stigmata of face-lift did not occur. Thus the post-facelifted patient ages differentially, losing neck correction sooner than elsewhere. Overall, the authors concluded, patients could be reassured of the longevity of their aesthetic gains.

CONCLUSION

The face is of unique importance both to self image and the image projected to others. Advances in our understanding of the interaction between anatomy and ageing have fuelled changes in face-lift techniques that have been, at times, stepwise and at other time more significant sea changes. Despite the existence of enthusiasts for one technique or another, and a fair body of research seeking a technique that is better than the rest, there is at present no clear winner. A skilled surgeon carrying out a technique with which they are experienced in an appropriately selected patient is likely to achieve a satisfactory result, which an overall view of the literature suggests would most likely be indistinguishable from a different but equally applicable procedure carried out by a similarly experienced surgeon. The importance of patient selection cannot be overemphasised, and published series cannot take into account those patients turned away as physically or psychologically unsuitable for surgery.

REFERENCES

[1] Pangman, W. J. W. & Wallace, R. M. R. Cosmetic surgery of the face and neck. *Plast. Reconstr. Surg. Transplant. Bull.* 27, 544–550 (1961).

[2] Gonzalez-Ulloa, M. & Fores, E. S. Senility of the face -- basic study to understand its causes and effects. *Plastic and Reconstructive Surgery* 36, 239–246 (1965).

[3] Pitanguy, I. I. et al. Numerical modeling of facial aging. *Plastic and Reconstructive Surgery* 102, 200–204 (1998).

[4] Yousif, N. J., Gosain, A., Sanger, J. R., Larson, D. L. & Matloub, H. S. The nasolabial fold: a photogrammetric analysis. Plastic and Reconstructive Surgery 93, 70–77 (1994).

[5] Yousif, N. J. N. Changes of the midface with age. *Clinics in Plastic Surgery* 22, 213–226 (1995).

[6] Pessa, J. E. An algorithm of facial aging: verification of Lambros's theory by three-dimensional stereolithography, with reference to the pathogenesis of midfacial aging, scleral show, and the lateral suborbital trough deformity. *Plastic and Reconstructive Surgery* 106, 479–490 (2000).

[7] Flowers, R. S. Tear trough implants for correction of tear trough deformity. *Clinics in Plastic Surgery* 20, 403–415 (1993).

[8] Jelks, G. W. G. & Jelks, E. B. E. Preoperative evaluation of the blepharoplasty patient. Bypassing the pitfalls. *Clinics in Plastic Surgery* 20, 213–224 (1993).

[9] Little, J. W. Volumetric perceptions in midfacial aging with altered priorities for rejuvenation. *Plastic and Reconstructive Surgery* 105, 252–66– discussion 286–9 (2000).

[10] Tsuji, T. T., Yorifuji, T. T., Hayashi, Y. Y. & Hamada, T. T. Light and scanning electron microscopic studies on wrinkles in aged persons' skin. *Br. J. Dermatol.* 114, 329–335 (1986).

[11] Kligman, A. M., Zheng, P. & Lavker, R. M. The anatomy and pathogenesis of wrinkles. *Br. J. Dermatol*. 113, 37–42 (1985).

[12] Chatterjee, R. R., Benzinger, M. J. M., Ritter, J. L. J. & Bissett, D. L. D. Chronic ultraviolet B radiation-induced biochemical changes in the skin of hairless mice.

Photochem. Photobiol. 51, 91–97 (1990).
[13] Mitz, V. & Peyronie, M. The superficial musculo-aponeurotic system (SMAS) in the parotid and cheek area. *Plastic and Reconstructive Surgery* 58, 80–88 (1976).
[14] Har-Shai, Y. Y. et al. Viscoelastic properties of the superficial musculoaponeurotic system (SMAS): a microscopic and mechanical study. *Aesth. Plast. Surg*. 21, 219–224 (1997).
[15] Saulis, A. S., Lautenschlager, E. P. & Mustoe, T. A. Biomechanical and viscoelastic properties of skin, SMAS, and composite flaps as they pertain to rhytidectomy. *Plastic and Reconstructive Surgery* 110, 590–600 (2002).
[16] Gray, H. & Goss, C. M. *Gray's anatomy* (1985).
[17] Furnas, D. W. D. The retaining ligaments of the cheek. *Plastic and Reconstructive Surgery* 83, 11–16 (1989).
[18] Stuzin, J. M., Baker, T. J. & Gordon, H. L. The relationship of the superficial and deep facial fascias: relevance to rhytidectomy and aging. *Plastic and Reconstructive Surgery* 89, 441–441 (1992).
[19] Vistnes, L. M. L. & Souther, S. G. S. The anatomical basis for common cosmetic anterior neck deformities. *Annals of Plastic Surgery* 2, 381–388 (1979).
[20] Park, J. I. Preoperative percutaneous facial nerve mapping. *Plastic and Reconstructive Surgery* 101, 269–277 (1998).
[21] Baker, D. C. & Conley, J. Avoiding facial nerve injuries in rhytidectomy. Anatomical variations and pitfalls. *Plastic and Reconstructive Surgery* 64, 781–795 (1979).
[22] Rudolph, R. R. Depth of the facial nerve in face lift dissections. *Plastic and Reconstructive Surgery* 85, 537–544 (1990).
[23] Pitanguy, I. & Ramos, A. S. The frontal branch of the facial nerve: the importance of its variations in face lifting. *Plastic and Reconstructive Surgery* 38, 352–356 (1966).
[24] Stuzin, J. M., Wagstrom, L., Kawamoto, H. K. & Wolfe, S. A. Anatomy of the frontal branch of the facial nerve: the significance of the temporal fat pad. *Plastic and Reconstructive Surgery* 83, 265–271 (1989).
[25] Dingman, R. O. R. & Grabb, W. C. W. Surgical anatomy of the mandibular ramus of the facial nerve based on the dissection of 100 facial halves. *Plast. Reconstr. Surg. Transplant. Bull.* 29, 266–272 (1962).
[26] McKinney, P. & Katrana, D. J. Prevention of injury to the great auricular nerve during rhytidectomy. Plastic and Reconstructive *Surgery* 66, 675–679 (1980).
[27] McKinney, P. P. & Gottlieb, J. J. The relationship of the great auricular nerve to the superficial musculoaponeurotic system. *Annals of Plastic Surgery* 14, 310–314 (1985).
[28] Izquierdo, R. R., Parry, S. W. S., Boydell, C. L. C. & Almand, J. J. The great auricular nerve revisited: pertinent anatomy for SMAS-platysma rhytidectomy. *Annals of Plastic Surgery* 27, 44–48 (1991).
[29] Pantaloni, M. M. & Sullivan, P. P. Relevance of the lesser occipital nerve in facial rejuvenation surgery. *Plastic and Reconstructive Surgery* 105, 2594–2593 (2000).
[30] Panfilov, D. E. & Larkin, G. *Cosmetic Surgery Today*. (Thieme, 2005).
[31] Bettman, A. G. A classic reprint: Plastic and cosmetic surgery of the face. *Aesth. Plast. Surg*. 12, 5–7 (1988).
[32] Skoog, T. G. *Plastic surgery.* (W.B. Saunders Company, 1974).
[33] Hamra, S. T. S. The deep-plane rhytidectomy. *Plastic and Reconstructive Surgery* 86, 53–53 (1990).

[34] Hamra, S. T. S. Composite rhytidectomy. *Plastic and Reconstructive Surgery* 90, 1–13 (1992).
[35] Baker, D. C. Deep dissection rhytidectomy: a plea for caution. *Plastic and Reconstructive Surgery* 93, 1498–1499 (1994).
[36] Ansari, P. Ansari: Neue Methode der Gesichts-und Halsstraffung. *Kosmetik J.* (1983).
[37] Saylan. The S-lift: Less Is More. *Aesthetic Surgery Journal.* 19, 4–4 (1999).
[38] Tonnard, P. et al. Minimal access cranial suspension lift: a modified S-lift. *Plastic and Reconstructive Surgery* 109, 2074–2086 (2002).
[39] Hopping, S. B., Janjanin, S., Tanna, N. & Joshi, A. S. The S-Plus lift: a short-scar, long-flap rhytidectomy. *Ann. R. Coll. Surg. Engl.* 92, 577–582 (2010).
[40] Kamer, F. M. One Hundred Consecutive Deep Plane Face-lifts. *Arch. Otolaryngol. Head Neck Surg.* 122, 17–22 (1996).
[41] Baker, D. C. Lateral SMASectomy. *Plastic and Reconstructive Surgery* 100, 509–513 (1997).
[42] Jones, B. M. & Lo, S. J. How Long Does a Face Lift Last? Objective and Subjective Measurements over a 5-Year Period. *Plastic and Reconstructive Surgery* 130, 1317–1327 (2012).
[43] Massiha, H. Short-Scar Face Lift with Extended SMAS Platysma Dissection and Lifting and Limited Skin Undermining. *Plastic and Reconstructive Surgery* 112, 663–669 (2003).
[44] Tonnard, P. L., Verpaele, A. & Gaia, S. Optimising Results from Minimal Access Cranial Suspension Lifting (MACS-Lift). *Aesth. Plast. Surg.* 29, 213–220 (2005).
[45] Jones, B. M., Marucci, D. D. & Ross, G. L. Volumetric short scar rhytidectomy–indications, technique and outcomes. *Journal of Plastic Reconstructive …* 61, 736–743 (2008).
[46] del Campo, A. F. Update on minimally invasive face lift technique. *Aesthetic Surgery Journal* 28, 51–62 (2008).
[47] Ellenbogen, R., Youn, A., Yamini, D. & Svehlak, S. The volumetric face lift. *Aesthet. Surg. J.* 24, 514–522 (2004).
[48] Badin, A. Z. D. et al. Minimally Invasive Facial Rejuvenation Endolaser Mid-Face Lift. *Aesth. Plast. Surg.* 25, 447–453 (2001).
[49] Brody, G. S. The tumescent technique for face lift. *Plastic and Reconstructive Surgery* 94, 407–407 (1994).
[50] Jones, B. M. B. & Grover, R. R. Avoiding hematoma in cervicofacial rhytidectomy: a personal 8-year quest. Reviewing 910 patients. *Plastic and Reconstructive Surgery* 113, 381–390 (2004).
[51] Schoen, S. A., Taylor, C. O. & Owsley, T. G. Tumescent technique in cervicofacial rhytidectomy. *Journal of Oral and Maxillofacial Surgery* 52, 344–347 (1994).
[52] Hoefflin, S. M. S. The extended supraplatysmal plane (ESP) face lift. *Plastic and Reconstructive Surgery* 101, 494–503 (1998).
[53] Marchac, D., Pugash, E. & Gault, D. The use of sprayed fibrin glue for face lifts. *Eur. J. Plast. Surg.* 10, 139–143 (1987).
[54] Oliver, D. W., Hamilton, S. A., Figle, A. A., Wood, S. H. & Lamberty, B. G. *A prospective, randomized, double-blind trial of the use of fibrin sealant for face lifts*. 1–5 (2001).

[55] Man, D., Plosker, H. & Winland-Brown, J. E. The use of autologous platelet-rich plasma (platelet gel) and autologous platelet-poor plasma (fibrin glue) in cosmetic surgery. *Plastic and Reconstructive Surgery* 107, 229–37– discussion 238–9 (2001).

[56] Powell, D. M., Chang, E. & Farrior, E. H. Recovery From Deep-Plane Rhytidectomy Following Unilateral Wound Treatment With Autologous Platelet Gel. *Archives of Facial Plastic Surgery* 3, 245–250 (2001).

[57] Fezza, J. P., Cartwright, M., Mack, W. & Flaharty, P. The use of aerosolized fibrin glue in face-lift surgery. *Plastic and Reconstructive Surgery* 110, 1–7 (2002).

[58] Jones, B. M. B. & Grover, R. R. Reducing complications in cervicofacial rhytidectomy by tumescent infiltration: a comparative trial evaluating 678 consecutive face lifts. *Plastic and Reconstructive Surgery* 113, 398–403 (2004).

[59] Grover, R. R., Jones, B. M. B. & Waterhouse, N. N. The prevention of haematoma following rhytidectomy: a review of 1078 consecutive facelifts. *British Journal of Plastic Surgery* 54, 6–6 (2001).

[60] Marchac, D. & Greensmith, A. L. Early Postoperative Efficacy of Fibrin Glue in Face Lifts: A Prospective Randomized Trial. *Plastic and Reconstructive* Surgery 115, 911–916 (2005).

[61] Kamer, F. M. & Nguyen, D. B. Experience with Fibrin Glue in Rhytidectomy. *Plastic and Reconstructive Surgery* 120, 1045–1051 (2007).

[62] Zoumalan, R. & Rizk, S. S. Hematoma Rates in Drainless Deep-Plane Face-lift Surgery With and Without the Use of Fibrin Glue. *Archives of Facial Plastic Surgery* 10, 103–107 (2008).

[63] Lee, S., Pham, A. M., Pryor, S. G., Tollefson, T. & Sykes, J. M. Efficacy of Crosseal fibrin sealant (human) in rhytidectomy. *Arch. Facial. Plast. Surg*. 11, 29–33 (2009).

[64] Por, Y. C., Shi, L., Samuel, M., Song, C. & Yeow, V. K.-L. Use of tissue sealants in face-lifts: a metaanalysis. *Aesth. Plast. Surg*. 33, 336–339 (2009).

[65] Mustoe, T., Silvati-Fidell, L. & Desmond, J. Reduced Hematoma/Seroma Occurrence with Use of Fibrin Sealant during Facial Rhytidectomy: Results of an Integrated Analysis of Phase 2 and Phase 3 Study Data. *Plastic and …* (2011).

[66] Huang, T. T., Blackwell, S. J. & Lewis, S. R. Routine use of a suction drain in facial rhytidoplasty. *Annals of Plastic Surgery* 18, 30–33 (1987).

[67] Perkins, S. W. S., Williams, J. D. J., Macdonald, K. K. & Robinson, E. B. E. Prevention of seromas and hematomas after face-lift surgery with the use of postoperative vacuum drains. Arch. *Otolaryngol. Head Neck Surg*. 123, 743–745 (1997).

[68] Jones, B. M., Grover, R. & Hamilton, S. The Efficacy of Surgical Drainage in Cervicofacial Rhytidectomy: A Prospective, Randomized, Controlled Trial. *Plastic and Reconstructive Surgery 120*, 263–270 (2007).

[69] Kamer, F. M. & Song, A. U. Hematoma formation in deep plane rhytidectomy. *Archives of Facial Plastic Surgery* 2, 240–242 (2000).

[70] Krueger, J. K. & Rohrich, R. J. Clearing the smoke: the scientific rationale for tobacco abstention with plastic surgery. *Plastic and Reconstructive Surgery* 108, 1063–73; discussion 1074–7 (2001).

[71] Rees, T. D. T., Liverett, D. M. D. & Guy, C. L. C. The effect of cigarette smoking on skin-flap survival in the face lift patient. *Plastic and Reconstructive Surgery* 73, 911–915 (1984).

[72] Riefkohl, R., Wolfe, J. A., Cox, E. B. & McCarty, K. S. *Association between cutaneous occlusive vascular disease, cigarette smoking, and skin slough after rhytidectomy*. 1–4 (2006).

[73] Webster, R. C., Kazda, G., Hamdan, U. S., Fuleihan, N. S. & Smith, R. C. Cigarette smoking and face lift: conservative versus wide undermining. *Plastic and Reconstructive Surgery* 77, 596–604 (1986).

[74] Ernst, E. E. & Matrai, A. A. Abstention from chronic cigarette smoking normalizes blood rheology. *Atherosclerosis* 64, 75–77 (1987).

[75] Shin, Y. S., Lim, N. Y., Yun, S.-C. & Park, K. O. A randomised controlled trial of the effects of cryotherapy on pain, eyelid oedema and facial ecchymosis after craniotomy. *J. Clin. Nur*s. 18, 3029–3036 (2009).

[76] Rana, M. et al. 3D evaluation of postoperative swelling in treatment of bilateral mandibular fractures using 2 different cooling therapy methods: A randomized observer blind prospective study. *J. Craniomaxillofac. Surg*. – (2012). doi:10.1016/j.jcms.2012.04.002

[77] Rana, M. et al. Three-Dimensional Evaluation of Postoperative Swelling After Third Molar Surgery Using 2 Different Cooling Therapy Methods: A Randomized Observer-Blind Prospective Study. *Journal of Oral and Maxillofacial Surgery* 69, 7–7 (2011).

[78] Greenstein, G. G. Therapeutic efficacy of cold therapy after intraoral surgical procedures: a literature review. *J. Periodontol.* 78, 790–800 (2007).

[79] Jones, B. M. B., Grover, R. R. & Southwell-Keely, J. P. J. Post-operative hilotherapy in SMAS-based facelift surgery: A prospective, randomised, controlled trial. *British Journal of Plastic Surgery* 64, 6–6 (2011).

[80] Collins, R. R., Scrimgeour, A. A., Yusuf, S. S. & Peto, R. R. Reduction in fatal pulmonary embolism and venous thrombosis by perioperative administration of subcutaneous heparin. Overview of results of randomized trials in general, orthopedic, and urologic surgery. *N. Engl. J. Med.* 318, 1162–1173 (1988).

[81] Bick, R. L. R. & Haas, S. S. Thromboprophylaxis and thrombosis in medical, surgical, trauma, and obstetric/gynecologic patients. *Hematol. Oncol. Clin. North Am*. 17, 217–258 (2003).

[82] Haas, S. S. European consensus statement on the prevention of venous thromboembolism. European Consensus Conference, Windsor, U.K., November, 1991. in *Blood Coagul Fibrinolysis* 4 Suppl 1, S5–10 (1993).

[83] Durnig, P. & Jungwirth, W. Low-Molecular-Weight Heparin and Postoperative Bleeding in Rhytidectomy. *Plastic and Reconstructive Surgery* 118, 502–507 (2006).

[84] Reinisch, J. F. J., Bresnick, S. D. S., Walker, J. W. J. & Rosso, R. F. R. Deep venous thrombosis and pulmonary embolus after face lift: a study of incidence and prophylaxis. *Plastic and Reconstructive Surgery* 107, 1570–1577 (2001).

[85] Camirand, A. A. & Doucet, J. J. A comparison between parallel hairline incisions and perpendicular incisions when performing a face lift. *Plastic and Reconstructive Surgery* 99, 10–15 (1997).

[86] Little, J. W. Three-dimensional rejuvenation of the midface: volumetric resculpture by malar imbrication. *Plastic and Reconstructive Surgery* 105, 267–85– discussion 286–9 (2000).

In: Encyclopedia of Surgery (22 Volume Set)
Editors: Andreas Lehrer and Kristin Mueller
ISBN: 978-1-53618-329-0
© 2020 Nova Science Publishers, Inc.

Chapter 33

RHINOPLASTY

Samuel Hahn*, MD and Oren Friedman, MD
Department of Otolaryngology - Head and Neck Surgery,
University of Pennsylvania, Philadelphia, PA, US

KEY POINTS

- Understanding anatomic distribution of the soft tissue envelope and osseocartilaginous structure, specifically the nasal valves, is critical to successful surgical planning in rhinoplasty.
- Careful assessment of nasal function prior to rhinoplasty is important, however subjective and objective measures may not correlate; a graded approach should be used to help guide management
- Management of the upper third of the nasal vault requires judicious use of osteotomies for control of the nasal bones. Both continuous and perforating methods of osteotomies provide excellent control and outcomes but studies show that perforating osteotomies may result in less postoperative edema.
- Spreader grafts are widely used in cosmetic rhinoplasty; despite lack of well-designed studies, there appears to be ample clinical studies suggesting that spreader grafts are beneficial in improving nasal aesthetics and function.
- Literature supports the use of irradiated homologous costal cartilage (IHCC) as a viable option for grafts in rhinoplasty. Postoperative complication rates using IHCC were comparable to autogenous cartilage grafts
- A graded approach in tip refinement that focuses on tip stabilization and maintaining and/or augmenting supportive structures of the tip is necessary to produce successful long lasting results
- Perioperative dose of steroid may help decrease postoperative periorbital edema and ecchymosis

* Corresponding Author's Email: Samuel.Hahn@uphs.upenn.edu.

INTRODUCTION

Rhinoplasty can be one of the most technically challenging cosmetic operations. Successful rhinoplasty requires a thorough understanding of both structural and aesthetic components of the nose as well as the face. The surgeon must carefully evaluate not only the patient's nasal anatomy and function but also understand their motivation and desired outcome of surgery. This complete knowledge will help the surgeon balance the form and function of the nose necessary for successful long-term results.

While the basic components of rhinoplasty have not significantly changed over the years, there have been many differing opinions of surgical approaches and contouring techniques. Much of the evidence supporting rhinoplasty techniques has been based on retrospective case series with validated outcome measures being regularly implemented only in the recent past [1]. Due to the varying degrees of subjective influence on the rhinoplasty outcomes, i.e., patient satisfaction in appearance and functionality of the nose, it is important to understand the available techniques and expected outcomes based on patient anatomy and physiology. Having an evidence-based approach to rhinoplasty will help the rhinoplasty surgeon achieve optimal success.

NASAL ANATOMY AND FUNCTION

Thorough understanding of nasal anatomy is essential for successful nasal surgery. The human nose is a complex three-dimensional structure comprised of the external skin and soft tissue envelope, an osseo-cartilaginous framework and an internal mucosal lining. It is important to understand the relationships between the anatomic components that give each patient a distinct appearance. Congenital and acquired nasal deformities present surgical challenges that require application of demanding technical manoeuvres to the anatomical components to enhance nasal appearance and function safely and effectively [2-4].

Externally, the nose is covered by the skin and soft tissue envelope. This is composed, in increasing depth, of epidermis, dermis, subcutaneous fat, fibromuscular tissue, the deep fatty vascular layer, loose areolar tissue and periostium/perichondrium. The nasal musculature lies within the fibromuscular layer of the nose within the superficial musculoaponeurotic system (SMAS). An appreciation of the skin is essential in preoperative surgical assessment and intraoperative surgical execution as skin quality plays a significant factor in the final aesthetic result and the surgical technique chosen for rhinoplasty will depend on individual skin quality, thickness and texture for each patient [3-5]. For example, providing definition of the nasal tip often requires significantly greater tip support in thick-skinned individuals compared with thin-skinned ones; whereas use of a camouflaging onlay soft tissue graft is required more often in thin-skinned patients.

The structural framework of the nose is composed of paired bony and cartilaginous elements. Successful surgical outcomes depend on proper maintenance and restoration of this framework. The nose can be divided into upper, middle and lower vaults (Figure 1). These vaults provide the structural support and three-dimensional height and projection of the nose. The upper (bony) vault is comprised of the paired nasal bones and the paired ascending processes of the maxilla. The middle (cartilaginous) vault is composed of the upper lateral cartilages and the cartilaginous dorsal septum.

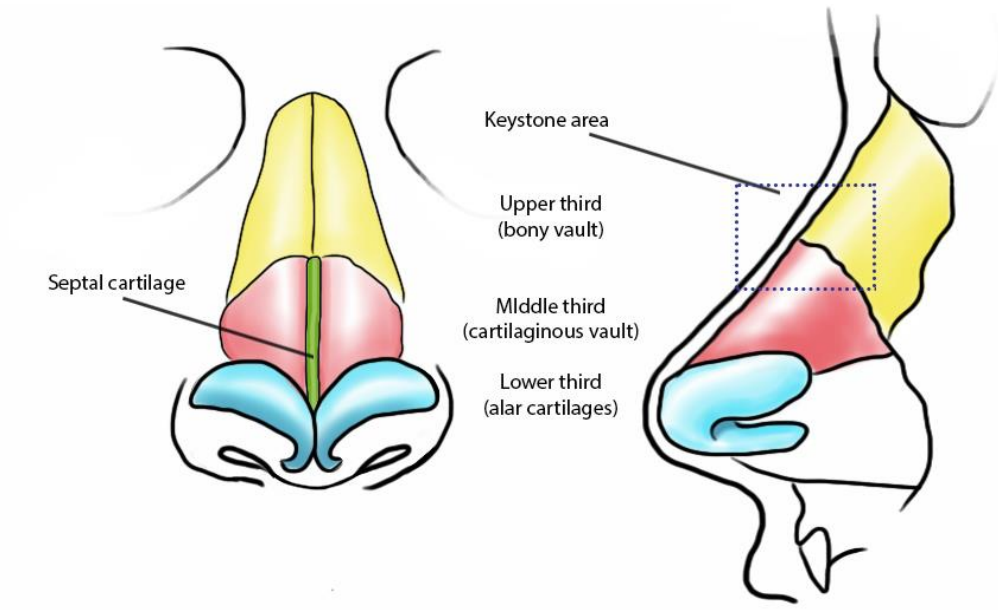

Figure 1. Thirds of the nose and the keystone area. The upper third is comprised of the bony structures whereas middle and lower thirds are cartilaginous structures. The "keystone" area (dotted box) is the site of convergence of the nasal bones, the perpendicular plate of the ethmoid bone, the upper lateral cartilages and the cartilaginous septum.

The point of transition from the bony upper vault to the cartilaginous middle vault is the rhinion. It is here the upper lateral cartilage and perichondrium inserts on the undersurface of the nasal bone. This region is also referred to as the keystone area and represents the site of convergence of the caudal margin of the nasal bones, the perpendicular plate of the ethmoid bone, the superior margin of the upper lateral cartilages and the cartilaginous septum (Figure 1). It is important to understand the relationship between the nasal bone and upper lateral cartilage in order to perform nasal surgery safely. Disruption of the keystone area can lead to a collapsed internal nasal valve, saddle nose, inverted V deformity and dorsal nasal irregularities [6]. Therefore, care must be taken when performing dorsal reduction and osteotomies to preserve the keystone area.

The lower vault consists of cartilaginous structures, primarily the lower lateral cartilages and caudal septum. The lower vault defines the nasal tip and changes in the angle and convexity of the domal segments will affect its appearance. Nasal tip stability is dependent on suspensory ligaments between the medial crus and the upper and lower lateral cartilages (so called scroll region) as well as the lower lateral cartilage attachments to the caudal septum at the membranous septum and the inherent strength and shape of the lower lateral cartilages. Anderson's tripod model of the nasal tip, with the lateral crura representing two legs of the tripod and the paired medial crura composing the central leg, is helpful in visualizing the affects that manipulation of the alar cartilages have on the nasal tip (Figure 2) [7]. The nasal tip can be manipulated in any three dimensional direction by altering one or more of the tripod limbs. Shortening a limb will result in rotation of the tip towards the ipslateral side as well as deprojecting the tip. While this analogy may be oversimplified, this concept helps surgeons conceptualise maneuvers that alter the shape and position of the tip, including rotation and projection of the tip.

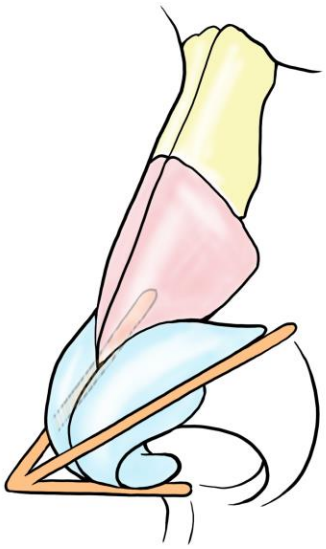

Figure 2. The Anderson tripod model – the medial and lateral crurae of the lower lateral cartilages create a tripod which can effectively dictate tip position depending on changing one or more legs of the tripod.

Understanding the structural framework of the nose is essential in shaping the nose in a stable and functional manner. Additionally, this knowledge allows the surgeon to be cognizant of preserving and improving upon the nasal airway during rhinoplasty. Nasal valves are the narrowest portions of the nasal airway, accounting for over half of the total nasal airway resistance (Figure 3). The area defined as the "internal nasal valve" is the narrowest portion of the nasal airway and it is therefore the primary regulator of nasal airflow. It is the area bound by the nasal septum medially, the caudal edge of the upper lateral cartilage laterally, the floor of the nose inferiorly and the head of the inferior turbinate inferolaterally. The normal angle between the upper lateral cartilage and nasal septum is ten to fifteen degrees and the cross-sectional area of this region is approximately 55–64 square millimeters [8]. A smaller cross-sectional area or a narrowed angle between the upper lateral cartilage and nasal septum may contribute to increased airway resistance and the sensation of nasal airway obstruction.

The "external nasal valve" is located in the nasal vestibule and is bound by the alar rim and columella, including the medial crus, nasal spine and soft tissues covering the nasal sill and floor. The external valve may be narrowed either at rest (i.e., vestibular stenosis) or may have a floppy and weak lateral component (i.e., alar rim) which narrows under the influence of negative pressure during nasal inspiration [9]. In a systematic review of 44 journal articles spanning 25 years addressing nasal valve repair, Rhee et al. showed that correction of nasal valve compromise through rhinoplasty is effective in improving both nasal airflow and quality of life [10]. Understanding the anatomy of the nasal valves and the consequences of their compromise will help surgeons achieve maximal patient satisfaction.

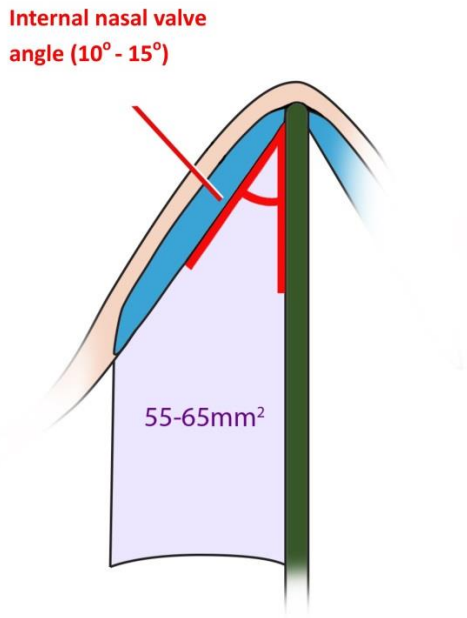

Figure 3. The internal nasal valve. The internal nasal valve is the narrowest area of the nasal airway - the normal angle between the upper lateral cartilage and nasal septum is ten to fifteen degrees, with a cross-sectional area in the range of 55–64 mm^2.

PATIENT EVALUATION

Proper preoperative evaluation and care is an integral component of the patient's surgical experience and successful outcome [11]. A thorough evaluation of the patient is necessary to maximise the success of surgery. The evaluation process is not merely a physical assessment of the nasal deformity but an opportunity to get to know the patient, their motivations, concerns and expectations. Establishing trust and rapport early is key to successful surgery as it will help the surgeon and patient define realistic expectations and goals of rhinoplasty. Understanding the patient's perception of their nose and its desirable and undesirable qualities will help the surgeon develop a framework for surgical planning. Open communication regarding the patient's motivation for undergoing rhinoplasty is important to establish the psychological and emotional maturity of the patient. A patient's reluctance to openly participate in discussion may signify potential underlying psychological issues that may result in an unhappy patient following what may have been a perfect technical operation [12].

It is important to note that while the surgeon and patient may agree on an aesthetically pleasing nose, many patients may not be able to articulate their preferences or desires satisfactorily [13]. Some surgeons have found the use of photograph editing software to be useful in demonstrating outcomes of rhinoplasty and improving communication of the steps and expectations from surgery. Mehta and colleagues performed a retrospective quantitative analysis of accuracy of preoperative computer images in primary and revision rhinoplasty patients [14]. The investigators demonstrated moderate overall accuracy of preoperative computer imaging, accuracy being greatest along the upper third and worst in demonstrating

supratip height and fullness. Not surprisingly there was a correlation between patient satisfaction and accuracy of preoperatively edited images. Despite the differences in accuracy, most patients found the computer imaging helpful. This result supports a study by Sharp et al. showing significant improvement in satisfaction of patients undergoing cosmetic rhinoplasty following computer imaging compared to those without preoperative imaging [15]. Additionally, a full medical and surgical history is a requisite part of patient evaluation prior to undergoing any surgical planning.

The physical examination of the patient should start with inspection and palpation of the nose to appreciate specific anatomical irregularities. Surgeons must train themselves to look at the patient's nasal surface in the office and identify the underlying osseocartilaginous structures and positions. In addition to the aesthetic qualities of the nose, its functionality should be analyzed during the preoperative examination. The function of the nose as a conduit for respiration should not be overlooked and preserving or improving nasal patency should be a goal in any rhinoplasty procedure. Nasal examination may incorporate anterior rhinoscopy, nasal endoscopy (which may be aided with decongestant spray to assess turbinate hypertrophy) and the Cottle maneuver or external nasal dilator strips for evaluation of nasal valve compromise [16]. Additional objective tests including rhinomanometry, to measure nasal cavity pressure and airflow, and acoustic rhinometry, to analyze nasal cross-sectional area along the length of the nasal airway, may be performed to assess nasal function. Although these steps may help identify possible areas of obstruction, studies have shown that there is not a clear correlation between objective tests such as rhinomanometry or acoustic rhinometry and subjective presence of nasal obstruction or severity of airway obstruction [17]. Therefore, surgical practice cannot be based purely on objective measures such as rhinomanometry and acoustic rhinometry. A graded approach guided by subjective patient complaints along with objective data to guide and measure postoperative success is most beneficial1, [18].

STRUCTURAL ASSESSMENT

During examination the thickness of skin and soft tissues should be carefully assessed by visualization and palpation. The thickness of skin, subcutaneous fat and nasal muscle are unique to each individual, as shown in cadaveric dissections performed by Anderson [17]. In patients with very thin skin, even minor irregularities of the osseocartilaginous framework of the nose will be easily noticeable, mandating extreme care with skeletal reconstruction to avoid step offs or sharp protrusions. After surgery an unnatural and angular appearance of the nose can occur due to buckling cartilaginous structures under the forces of wound contracture. In contrast, thicker nasal skin with increased sebaceous gland and soft tissues thickness will mask most skeletal imperfections along the dorsum and nasal tip, but may obscure the delicate qualities of the nasal framework resulting in an amorphous appearance, prolonged postoperative inflammation and unsatisfactory long-term outcomes [18]. Thick skin is often associated with a weak and under-projected cartilaginous framework that can make refinement of the nasal tip challenging [19]. It is important to preserve and strengthen the nasal framework in these patients in order to create a desirable and lasting postoperative appearance.

Clinical examination should assess structural integrity of the nose. The nasal tip should be palpated for recoil and cartilaginous integrity. A weak nasal tip suggesting brittle or floppy lower lateral or columellar support will require reinforcement during surgery, whereas a stiff nasal tip may be able to handle more aggressive modifications. Additionally, the length of the nasal bones, the intrinsic strength of the upper lateral cartilages, the support given to the middle third by the upper lateral cartilages and nasal septum and non-visible dorsal irregularities should all be assessed with palpation.

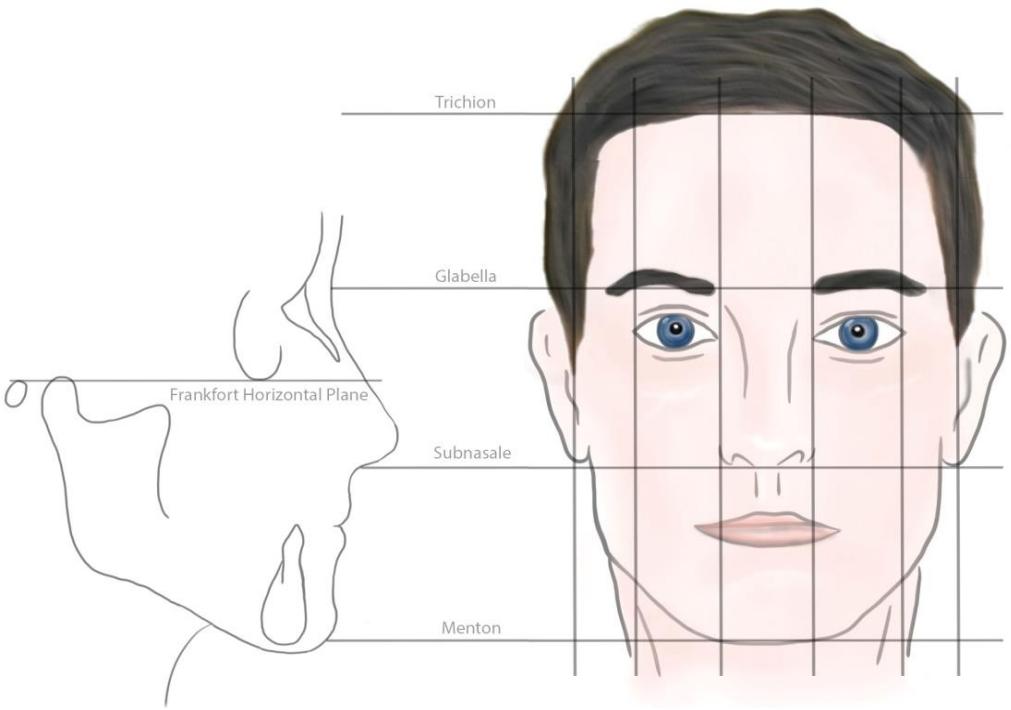

Figure 4. Horizontal thirds and vertical fifths of the face. Each vertical fifth is equal to the width of an eye. The Frankfort horizontal line is a reference line drawn from the superior point of the external auditory canal to the inferior aspect of the infraorbital rim. Horizontal thirds are formed from lines parallel to the Frankfort line at the trichion, glabella, subnasale, and menton.

While rhinoplasty is indeed part art, problem areas of the nose can be defined and structural components analysed in a systematic manner to assess for factors that may lead to real or perceived incongruity or asymmetry [3-20].

The principle of evaluating facial features by division into horizontal thirds and vertical fifths is a useful one (Figure 4). The Frankfort horizontal line, drawn from the superior point of the external auditory canal to the inferior aspect of the infraorbital rim, allows the surgeon to divide the face into three anatomic units by drawing parallels to this line at the trichion, glabella, subnasale and menton (Figure 4). For patients with receded hairlines the middle third is used as the main unit of reference. Vertical fifths are divided with vertical parallel lines, each fifth being equal to the width of an eye. The width of the nasal base should equal a vertical fifth. These reference units are important in noting imbalances that may affect the perception of the nose in relation to the face.

The unique three-dimensional projection of the nose means the rhinoplasty surgeon must study it from multiple angles to understand the interrelationship of structures and the consequences of their manipulation. Viewing the nose from different angles also permits appreciation of the nuanced twists and bumps that may otherwise be missed. It is therefore important to analyze features of the nose thoroughly using standardised views.

STANDARDISED PHOTOGRAPHIC VIEWS

Frontal View

The frontal view permits the best assessment of nasal straightness. A line drawn along the midline from the glabella to the menton should bisect the nose. The brow-tip aesthetic line, which follows the medial eyebrow, curves down the lateral nasal wall and ends at the ipsilateral tip-defining point, should be a smooth symmetric continuous line (Figure 5). Disruption of this curvilinear line will be evident in a crooked or twisted nose [4]. The width of the nose is also best seen on the frontal view. Using the principle of vertical fifths, the alar base should equal one reference unit or the intercanthal distance. The base of the nasal bones should be about three-quarters the width of the alar base.

The frontal view also allows clear assessment of nasal tip shape and symmetry. The nasal tip can present some of the most challenging deformities to correct in rhinoplasty. There are several characteristics that make up complex three-dimensional shape of the tip including the tip volume, definition, width, shape, projection, position and rotation. Patients with excessive tip volume will have a bulbous nasal tip. The vertical and horizontal components of the bulbous tip should be identified. Skin and soft tissue thickness may contribute to nasal tip volume, especially at the alar lobule. Thick sebaceous skin or soft tissue fullness in the interdomal region can give the nasal tip a bulbous appearance.

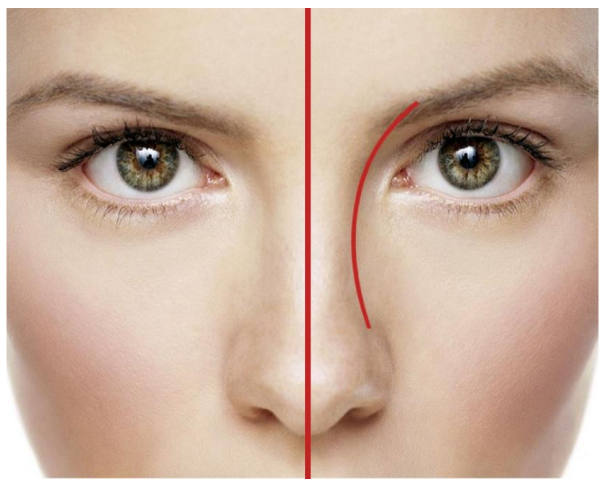

Figure 5. A line drawn along the midline from the glabella to the menton should bisect the nose. The brow-tip aesthetic line along the medial eyebrow to the ipsilateral tip-defining point should be a smooth continuous line.

The size and shape of the lower lateral cartilages can significantly impact tip bulbosity as well. A bifid nasal tip, excessive lateral crural length, vertical or horizontal convexity of the lateral crura and vertical malpositioning of the lateral crura can all contribute to a bulbous nasal tip. Hafezi and colleagues noted that over forty percent of the 286 rhinoplasty patients in their study had a dome shaped, hemispheric appearance to the lower lateral cartilage at the scroll region which correlated to a strong bulbous nasal tip and nostril flaring [21]. A boxy nasal tip can result from an excessive angle of divergence (greater than 30º) between the two domes, increased domal arch length (greater than 4mm), or a combination of both resulting in widening of the tip defining points (>5mm) [22]. In patients with thin skin, prominent lower lateral cartilage convexity, and wide angle of divergence, a bifid tip may be seen in addition to single tip bulbosity (Figure 6).

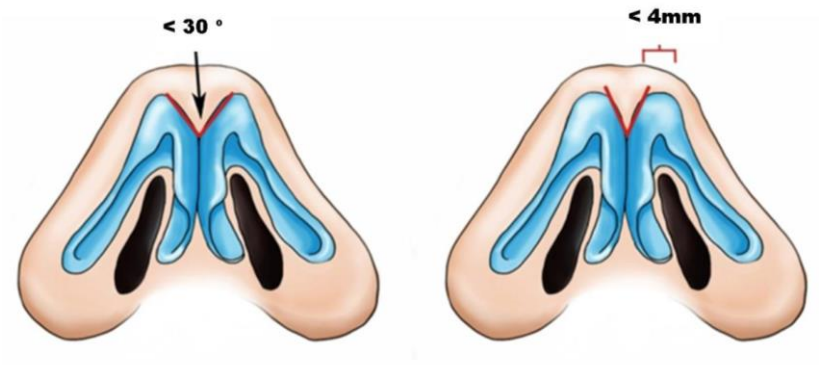

Figure 6. The ideal nasal tip should have an angle of divergence less than thirty degrees and interdomal distance of less than four millimetres. Greater angles or distance will result in a bulbous nasal tip.

Finally, the frontal view shows the relationship between the alar rim and infratip lobule, which should resemble a “gull-in-flight” [3]. Asymmetry of the alar rim could suggest alar retraction or malpositioned lateral crura. The relationship of the columella to the alar rim can also be identified from the frontal view, although the lateral view is helpful in this regard.

Lateral View

The lateral or profile view provides important information on tip projection and rotation, dorsal height and profile, alar-columellar proportions and nasal length. Nasal tip projection can be measured as a “3-4-5” right angled triangle as described by Crumley; “3” representing the distance from nasal tip to alar crease, “4” that from alar crease to nasion and “5” that from nasal tip to nasion (Figure 7a), to create a balanced nose [23]. Adequate nasal projection may also be measured using Goode’s method, drawing a perpendicular line to Frankfort’s horizontal plane along the alar crease with second line drawn from the nasal tip perpendicular to this line. The length from alar crease to nasal tip line is divided by the length from the nasion to the nasal tip which should equal 55-60% (Figure 7b) [24]. A third method of assessing projection involves measuring a 1:1 ratio of the distance from the base of the columella to the nasal tip and that of the height of the upper lip from subnasale to the upper

lip vermilion border (Figure 7c) [25]. When assessing nasal tip projection, its relation to other aesthetic facial features such as forehead, cheek and chin projection must also be considered as these may alter the perception of tip projection. Evaluating other facial angles such as Powell and Humphrey's aesthetic triangle (nasofacial, nasofrontal and nasomental angles) will be useful in assessing the true nasal projection compared to the perceived nasal projection relative to other facial features [26].

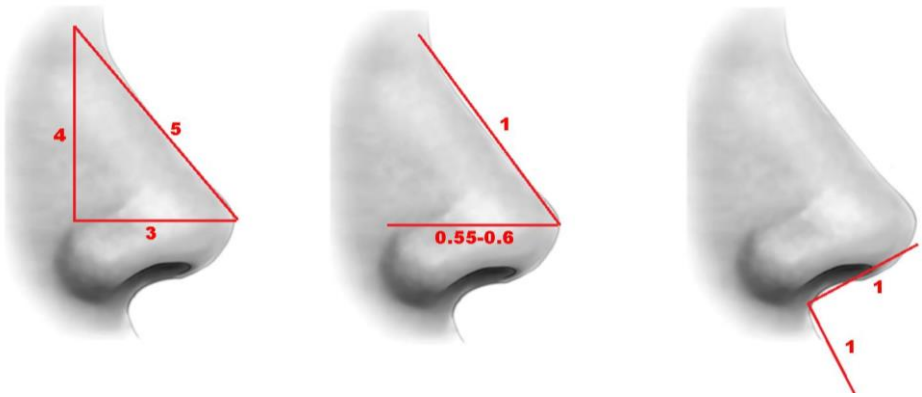

Figure 7. Nasal tip projection can be analysed using various methods such as those of (a) Crumley, (b) Goode, and (c) Simons.

Rotation is assessed by the nasolabial angle, which is defined by the bisection of a line drawn from the subnasale to the columellar root and a line from subnasale to labrale superius. The ideal angle is typically considered to be 90-100º for males and a more rotated 100-115º for females. Interestingly, Guyuron's studies showed that the ideal nasolabial angle may be more acute and less discrepant between genders than anticipated [29, 30]. Two studies analyzing the aesthetic appearance of nasal tip rotation by altering the nasolabial angle, one surveying the general population and another surveying rhinoplasty surgeons, showed consistent results for the ideal nasolabial angle between both groups: 96º for males and 98º for females, which are more acute than the generally accepted values. The nasolabial angle may be affected by anatomic variables unrelated to the nasal tip such as a prominent anterior nasal spine or maxillary protrusion, so some surgeons prefer to determine tip rotation by measuring the angle between the Frankfort horizontal plane and the long axis of the nostril [28]. Using this measurement, the aesthetic ideal angle ranges from 0-10º in men and 10-25º in women (Figure 8). Abnormalities in nasal tip rotation, especially a ptotic tip, are common indications for tip rhinoplasty. Using the tripod analogy introduced earlier, abnormalities in nasal tip rotation can occur when the strength and integrity of the lateral and medial crura of the lower lateral cartilage is compromised. Additionally, excessive length of the lateral crura or caudal projection of the cartilaginous septum can result in a ptotic tip. The inverse would naturally result in an overly rotated nose. One must be mindful of the attachment of the lower lateral cartilage to the upper lateral cartilage and septum as well as the nasal spine and other minor support structures, which can all, alter tip rotation.

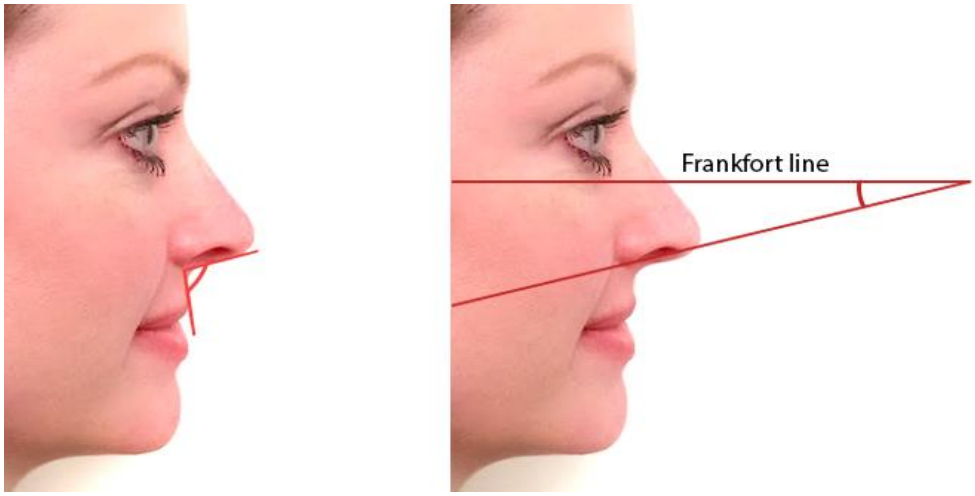

Figure 8. Nasal tip rotation can be determined using the nasolabial angle or nasal-Frankfort horizontal angle.

Continued assessment of the nasal tip should include assessment of the supratip break, tip-defining points and infratip break (Figure 9). There should be a gentle transition between these points. The columella has a double break, the break occurring at the infratip lobule and the second reflecting the columella. These breaks usually mark the junction of the medial and intermediate crus. The lateral view allows for assessment of the alar-columellar relationship (Figure 9). The various relationships between the ala and columella were presented by Gunter et al. [29], who identified positioning of the ala and columella in relation to a line drawn through the long axis of the nose. Ideally, about two to four millimeters of the columella should be visible below the alar margin.

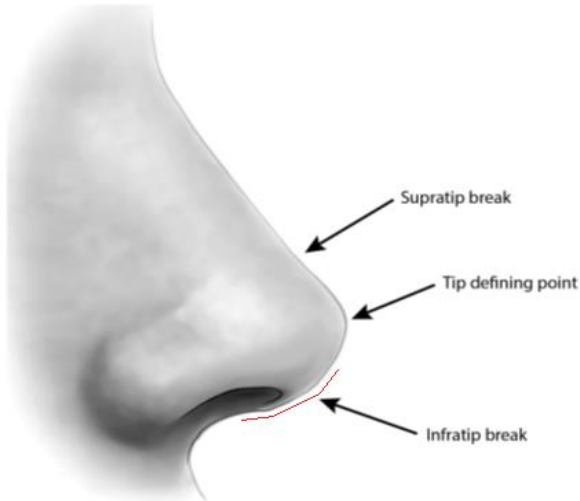

Figure 9. Nasal tip anatomy showing the supratip break, tip defining point and infratip break. Note the double break of the columella (red line): the initial break is at the transition from the nasal tip to the infratip lobule and the second break is at the junction of the intermediate crura and medial crura of the lower lateral cartilages.

Continued evaluation of the nose using the profile view will lead to the assessment of nasal dorsal profile and length. Nasal dorsal assessment should identify any concavity, convexity or contour irregularity along the course of the nose. An aesthetically pleasing nasal dorsum should be a straight line about one to two millimeters posterior to a line drawn from the nasal tip to the nasion. Just superior to the tip defining points should be a slight gentle, one or two millimetre depression corresponding to the supratip [30]. Abnormalities of the nasal dorsum can be due to cartilaginous or bony defects that affect the nasal width, straightness, curvature and projection.

Byrd identified the appropriate aesthetic proportions for nasal length as two thirds of the mid facial height and equal to the chin vertical based on direct clinical measurements taken from 87 models (Figure 10) [31]. However, the length of the nose can be difficult to define due to the many contributing factors that can influence perceived length. The nasofrontal angle converges at the nasion and is typically between 115-130º, with a more obtuse or acute angle more appealing in female and male noses respectively. It is important to remember that a more acute angle may give the appearance of a shorter nose while a shallow angle may appear to lengthen the nose. It is critical to identify the position and height of the nasion to interpret nasal length appropriately. Mowlavi and colleagues [32] surveyed 150 Caucasians on the ideal position of the nasion. For both males and females, the ideal nasion was ten millimetres in height (i.e., anterior to the anterior corneal plane) and positioned above the level of the lower limbus on profile view (Figure 11). A nasion positioned higher will give the appearance of a longer nose while a lower one will give the appearance of a shorter nose with a dorsal hump. Additionally, the relationship of the nasal tip and surrounding facial structures may alter the appearance of nasal length.

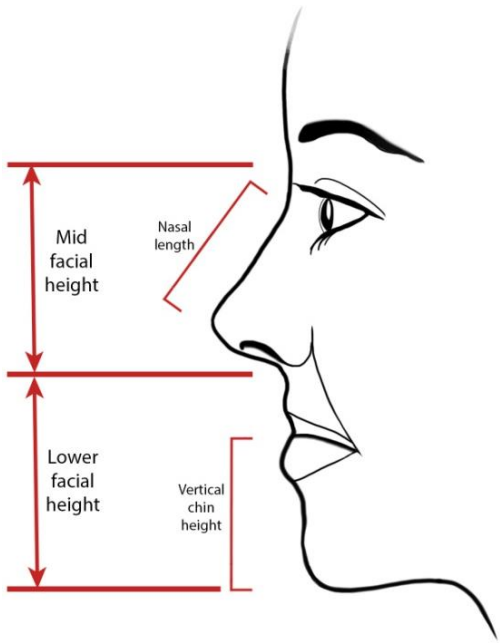

Figure 10. Nasal length, as described by Byrd and Hobar, can be characterised as 2/3 the midface height and equal to the vertical chin height.

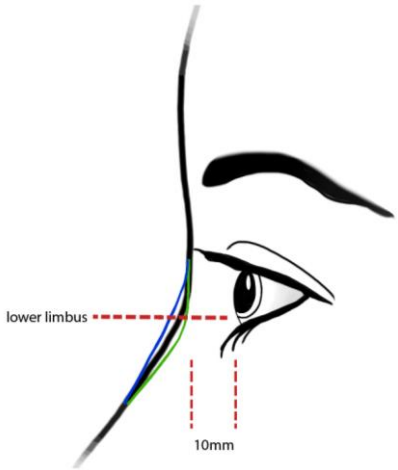

Figure 11. Nasion placement is ideally above the level of the lower limbus in both males and females, according to Mowlavi et al.). A nasion positioned higher will give the appearance of a longer nose (blue line) whereas a lower one will give the appearance of a shorter nose with a dorsal hump (green line).

Basal View

The basal view allows evaluation of the nostrils, columella, infratip lobule and alar base. When viewed from the base, the nose can be seen as an isosceles triangle as described by Crumley, which can be divided into thirds [23]. The anterior third is the infratip lobule and the posterior two thirds are the columella and nostrils (Figure 12). The angle of divergence can be measured from this view by identifying the angle between the two domal segments. This is approximately thirty degrees or less. A bulbous or boxy nose would result in a more trapezoidal shape. The basal view allows for another opportunity to assess the symmetry of the lower lateral cartilages by viewing the curvature of the alar rim. The nostrils should be symmetric and shaped like a pear oriented 30-45º from the midline. Asymmetry of the nostrils may suggest domal irregularities or crural height discrepancies. The medial crura of the lower lateral cartilages and the caudal septum can be evaluated for flaring or deviations that may be narrowing the nostril causing airway obstruction. The width of the alar base can be noted from this view and should be approximately equal to the intercanthal distance.

Figure 12. The basal view permits evaluation of the nostrils, columella, infratip lobule and alar base. The nose can be regarded as a truncated isosceles triangle divided into thirds (Crumley). The anterior third is the infratip lobule and the posterior two thirds are the columella and nostrils.

Oblique View

The oblique or three-quarter view is less important for critical structural assessment of the nose but complements the aforementioned views in providing a complete picture of the nose and its relation to other facial structures. Often, patients will consider the oblique view as their profile view when they look in the mirror. On this view, nuances of the nasal dorsal height, length and contour, tip projection and bulbosity and aesthesic brow-tip line may be reassessed.

Using a standardised approach to assessment of the nose will allow the surgeon to thoroughly evaluate all components of the nose to plan a surgery that will help balance the nose with the face. It is important to remember that while there are longstanding ideals for nasal angles, lengths and shapes, studies show that there is variability to these standards and that personal and ethnic considerations must be observed.

RHINOPLASTY APPROACH

Rhinoplasty can be achieved through two main surgical approaches: the endonasal or closed approach; or the external or open approach. Both share many of the same incisions and surgical principles. Incisions include the transcartilaginous or cartilage-splitting, intercartilaginous, marginal and transcolumellar types, and can be used alone or combined to provide the necessary exposure. While there are proponents of each approach, there have been few studies comparing them and surgeons should be familiar with both. Experienced rhinoplasty surgeons understand that successful rhinoplasty depends not on the surgical approach used but on understanding of the anatomic diagnosis and preservation of supportive structures [33].

MANAGEMENT OF THE BONY UPPER NASAL VAULT AND NASAL DORSAL REDUCTION

Congenital or traumatic deformities of nasal bones, commonly evident as nasal deviation and dorsal humps, are amongst the most common indications for rhinoplasty. As with much of rhinoplasty there is a paucity of prospective data comparing management of these deformities or surgical techniques.

OSTEOTOMY

Control of the bony nasal dorsum and upper vault often requires osteotomy, to 1) alter the width of the nasal base, 2) close an open roof following dorsal reduction or trauma, or 3) reconcile length and contour differences of the nasal bones [34]. Lateral, medial and intermediate osteotomies are used to manipulate the nasal bones (Figure 13). The ideal osteotomy should be precise, reproducible, safe, and afford maximal aesthetic and functional

results. Additionally, it should limit the postoperative sequelae of edema, ecchymosis and nasal bone instability [35].

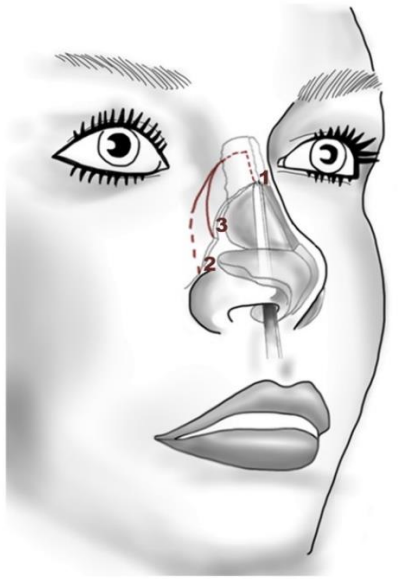

Figure 13. Medial (1), lateral (2) and intermediate (3) osteotomies can be used to manipulate the nasal bones.

Lateral osteotomies are the most commonly used in both functional and aesthetic correction of nasal deformities. Two basic techniques in performing lateral osteotomies have become accepted over the years: continuous and perforating. Both techniques aim to mobilise the lateral upper nasal vault through a "high-to-low-to-high" approach described by Webster, maximizing nasal bone mobility while maintaining structural integrity of the nasal airway [36]. The continuous lateral osteotomy is performed endonasally starting at the pyriform aperture, creating a single fracture line along the ascending process of the maxilla and nasal bone. The perforating osteotomies are performed through a percutaneous external or transnasal internal approach by creating multiple postage stamp-like osteotomies along the intended line of mobilization. The fracture is completed by digital or instrument assisted mobilization of the nasal bones.

There have been multiple studies comparing the two techniques of lateral osteotomies. Zoumalan et al. quantitatively evaluated the effects of both continuous and perforating lateral osteotomies on nasal bone narrowing, showing no statistical difference in the dorsal or ventral nasal bone width following narrowing. Thus both methods are able to achieve satisfactory control of the upper vault. Gryskiewicz and Gryskiewicz performed a prospective, randomised, partially blinded study of 75 patients comparing postoperative ecchymosis and edema between perforating and continuous lateral osteotomies, showing statistically significant differences favoring perforating osteotomies [38]. Additionally, a cadaveric study of nasal mucosal trauma following lateral continuous osteotomy compared to percutaneous external osteotomy by Rohrich et al. showed that there was nearly a seven-fold increase risk of mucosal injury using the continuous approach [39]. It is important to note that while osteotomy technique and size of osteotome are contributing factors to postoperative edema

and ecchymosis, these are not the only factors. Critics of the perforating lateral osteotomies argue of the risk of perceptible cutaneous scarring following surgery. Gryskiewicz [40] and Hinton et al. [41] showed that visible scarring occurred in up to six percent of patients six months to one year following surgery with one patient (two percent) requiring additional scar revision. A critical review of these studies shows that both methods provide excellent mobilization of the bony nose with no significant differences in aesthetic or functional outcomes but perforating osteotomies may provide decreased postoperative sequelae of edema and ecchymosis with little risk of perceptible scarring.

Medial osteotomies may be required in cases of significant bony deviation or when the width of the nasal dorsum requires complete mobilization of the nasal bones. The osteotomy frees the nasal bone from the bony septum medially and the nasal root superiorly by either directly intersecting with the fracture line of the lateral osteotomy or creating a fault along the nasal bone that will result in a predictable fracture following lateral osteotomy. The medial osteotomy can be performed in a straight, oblique, or perforating manner. Harshbarger and Sullivan suggest performing medial osteotomies at fifteen degrees laterally of the midline to follow the natural break-line of the nasal bones [42]. Care must be taken during medial osteotomy to avoid superior extension into the thick bone at the nasofrontal suture line, which can cause a rocker deformity requiring further osteotomies to correct.

Intermediate osteotomies may be required in cases of severe concavity and convexity or significant length discrepancy resulting in deviation of the nasal bones. If required, the intermediate osteotomies should be performed prior to mobilizing the nasal bones through lateral osteotomies. These osteotomies are usually performed in a continuous fashion from caudal to cranial along the region of greatest deformity. In laterally occurring deformities, the intermediate osteotomies may be performed through a percutaneous external approach as described by Westreich and Lawson [43].

NASAL DORSAL HUMP REDUCTION

The surgical technique chosen for hump removal is determined by the degree and location of dorsal hump projection. Often the dorsal hump has a cartilaginous and bony component. Dorsal hump reduction of the bony nasal dorsum is usually performed with an osteotome or rasp, and use of an ultrasonic bone aspirator has also been described [44]. The cartilaginous nasal dorsum is generally reduced and contoured using a scalpel and/or osteotome. Lee et al. performed a systematic review of nasal dorsal reduction surgery showing only retrospective evidence over the past decade [45]. No consensus methodology for removing the dorsal hump emerged from the eleven studies reviewed, with most surgeons using multiple surgical techniques including reductive osteotomies and rasping. Surgeons reported good outcomes and minor complication rates of 0-26% - mostly prolonged edema and hump underresection [45]. Dorsal hump reduction can be performed en bloc or as a split approach addressing cartilaginous and bony portions individually. Care must be taken not to disrupt the upper lateral cartilage attachment to the caudal nasal bone during the reduction in order to avoid postoperative complications of inverted-V deformity and nasal sidewall instability. The technically challenging aspect of dorsal reduction is achieving the ideal nasal profile with respect to the patient’s face while maintaining key structural support of the nose.

MANAGEMENT OF THE MIDDLE NASAL VAULT AND NASAL DORSAL AUGMENTATION

The middle nasal vault houses the upper lateral cartilage and cartilaginous septum. Surgical techniques aimed at management of deformities of the middle nasal vault have evolved over the past ten to fifteen years due to an increased awareness of function of the internal nasal valve as a regulator of airflow [46-51]. Maintaining the stability of the middle nasal vault is imperative in any rhinoplasty procedure. The integrity of the connections between the upper lateral cartilage and the dorsal septum medially, the nasal bone at the keystone region and the lower lateral cartilage at the scroll region will help avoid postoperative complications such as saddle nose deformity, inverted-V deformity, hourglass deformity, dorsal irregularities, or nasal valve collapse. Many of the surgical techniques that have been described for management of the middle nasal vault have focused on secondary nasal surgery to improve nasal function following rhinoplasty [49, 52-54]. The overall goal of rhinoplasty addressing the middle nasal vault is to strengthen the structural support elements and balance the aesthetic requirements with nasal function.

SPREADER GRAFTS AND FLAPS

In the 1980's Sheen popularised the use of spreader grafts as a means of reconstructing the internal nasal valve and contouring the nasal dorsum of the middle nasal vault [54]. Since then, spreader grafts have become widely used in primary and secondary rhinoplasty to widen the internal nasal valve in static or dynamic nasal valve collapse, prevent nasal valve collapse following dorsal hump reduction and recontouring or straightening the nasal dorsum [54, 55]. The spreader grafts should be placed under the nasal bones and cover the keystone area and be long enough to extend to the caudal edge of the upper lateral cartilage. Spreader grafts may be made from septal cartilage, but in cases of previous surgery where inadequate septal cartilage remains, conchal cartilage or rib cartilage may be used (Figure 14). Alternatively, in patients with a prominent dorsum who are undergoing dorsal reduction, the upper lateral cartilage excess may be folded on itself to lie between the septum and upper lateral cartilage to serve as an "auto-spreader graft", or so-called "spreader flap" [56, 57]. Occasionally, wider grafts may be required due to insufficiency of lateral cartilage or nasal deviation in which case multiple pieces of cartilage may be layered to provide adequate thickness for appropriate nasal contouring and support.

While the use of spreader grafts is widespread, there remains a lack of strong supportive evidence for their use in rhinoplasty. Rhee et al. noted through systematic review that most studies on the management of nasal valve collapse, including the use of spreader grafts, were uncontrolled case series [10]. However, despite the lack of well-designed studies, there appears to be an abundance of anecdotal clinical evidence suggesting that spreader grafts are beneficial in improving nasal aesthetics and function [58]. Spreader grafts have been shown to improve both objective and subjective measures of nasal airflow as assessed by rhinomanometry, acoustic rhinometry and validated outcome measures including the Nasal Obstruction Symptom Evaluation (NOSE) scale and Visual analog scale (VAS) [56, 59-62].

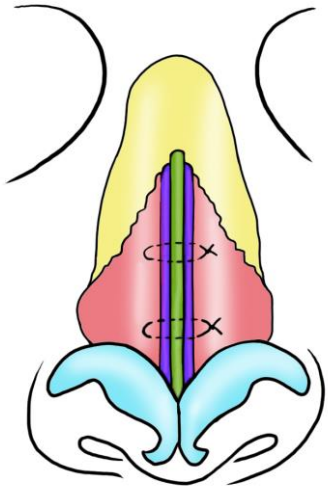

Figure 14. Spreader grafts are essential in supporting and reconstructing the middle nasal vault. They may be fashioned in strips from autologous cartilage and placed between the upper lateral cartilage and nasal septum.

INTERNAL NASAL VALVE SURGERY AND FUNCTIONAL RHINOPLASTY

The internal nasal valve is of great significance to rhinoplasty involving manipulation of the middle nasal vault. Since the introduction of the spreader graft many other techniques have been reported. In 2004 Andre et al. presented the endonasal placement of spreader grafts which may have some advantages in certain patient populations due to its limited invasiveness, but no studies comparing the open and endonasal approach have been performed [63]. Other variations of the spreader graft including spreader flaps [56], auto-spreader grafts [64] and mini-spreader flap [61] techniques have all been shown subjectively to relieve nasal obstruction and objectively to increase nasal airflow on by increasing the nasal valve angle.

The ability of spreader grafts to support and lateralise the lateral nasal wall may be limited in patients with weak nasal sidewalls. In such patients a lateral crural strut graft or alar batten graft may be required, as reported by Faris et al., to add stability and support of the lateral nasal wall (Figure 15) [65]. In cases of significant lateral nasal sidewall instability or need for additional nasal valve support, the alar batten graft can be used with good success. Toriumi first described the use of the alar batten graft, placement of small strips of cartilage in subcutaneous pockets, to strengthen the lateral nasal wall [66]. There have been numerous retrospective studies looking at subjective assessment of nasal patency following rhinoplasty with alar batten graft for management of nasal valve collapse, showing an overall 96-100% improvement in subjective nasal airflow over a one to five year follow-up period [62,66-68]. The alar batten graft has become a widely used adjunct to the spreader graft in management of nasal valve collapse in rhinoplasty with good functional and aesthetic outcomes.

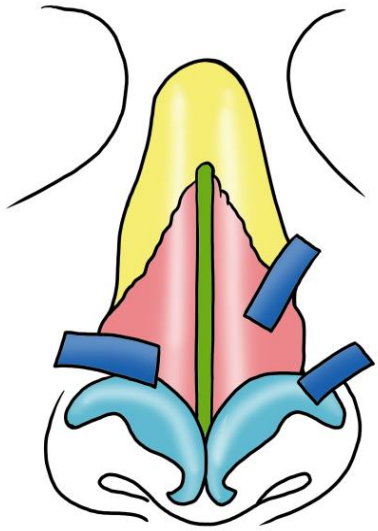

Figure 15. Patients with weak nasal sidewalls may require additional structural grafts for support. Batten grafts, shown in various positions here, can provide strength and stability to the nasal sidewall and prevent dynamic collapse on inspiration.

The upper lateral cartilage splay graft initially described by Guyuron in 1998, which uses conchal cartilage placed over the dorsum of the septum and under the upper lateral cartilage, can also be used to reconstruct the middle vault and give significant support to the internal nasal valve [69]. Additionally, the butterfly graft, introduced by Clark and Cook, using conchal cartilage as an onlay graft secured to the caudal margin of the upper lateral cartilage, can help spring open the internal nasal valve [53]. Friedman and Cook [70] reviewed 100 primary rhinoplasty patients with internal nasal valve collapse who had undergone conchal butterfly grafts. Internal nasal valve collapse was identified by preoperative relief of nasal obstruction via Cottle maneuver or application of an external nasal dilator, collapse of nasal sidewall on inspiration, or weak upper lateral cartilage support on palpation. The investigators found that over 90% of patients reported subjective improvement in breathing and 88% of the patients were happy with their postoperative appearance.

While studies looking at the splay and butterfly grafts were retrospective and did not use validated outcome measures, they appears to be a viable option for functional rhinoplasty in appropriate patients. However these grafts can significantly widen the middle vault, resulting in unacceptable cosmetic results. Deylaminour reported as many as twenty percent of patients being unhappy with their cosmetic outcome from this maneuver suggesting conscientious patient selection for this grafting technique [71].

Flaring sutures described by Park [72], thrown from one upper lateral cartilage to the other and tied tightly over the nasal dorsum, or nasal valve suspension sutures as described by Paniello [48], anchoring the collapsed nasal valve to the inferior orbital rim, can be used alone or in conjunction with other techniques to widen the internal nasal valve [72]. Schlosser and Park [76] investigated the effects of spreader grafts, flaring sutures or a combination of both on the nasal airway of six cadavers, using acoustic rhinometry to measure the nasal airway before and after treatment. Both techniques in isolation failed to have a statistically significant impact on minimal cross-sectional area of the nasal valve (5.4% for spreader graft

and 9.1% for flaring sutures) but a combination of the two significantly increased minimal cross-sectional area by 18.7% ($p<0.05$). This finding was consistent with retrospective reviews by Sciuto and Bernardeschi [77] and Park [75], showing that patients with internal nasal valve collapse who underwent rhinoplasty with combined spreader grafts and suture techniques experienced improved postoperative subjective nasal patency.

Armed with a better understanding of the nasal valve, recent refinements in surgical techniques and an accompanying thorough preoperative evaluation, surgeons will be able to identify and treat nasal valve collapse. Carefully selected functional nasal surgery with correction of nasal valve dysfunction has been shown to improve quality of life significantly in patients complaining of nasal obstruction with preoperative findings of nasal valve collapse [59,75].

NASAL DORSAL AUGMENTATION

Nasal dorsal augmentation can be a challenging problem to address in the middle nasal vault. A wide array of techniques have been implemented in dorsal augmentation including en bloc cartilaginous augmentation, diced cartilage with fascial or alloplastic grafts, soft tissue augmentation and alloplastic implantation. Generally, autogenous cartilage grafts either from the nasal septum, ear or costal cartilage is preferred over irradiated rib cartilage or alloplastic grafts due to perceived resistance to resorption and warping. However, the data supporting these perceptions were based on low-level evidence with small data pools, inconsistent study designs and limited follow-up [76]. Lee et al. showed in their systematic review of nasal dorsal augmentation that graft resorption, infection and revision rates were comparable regardless of donor cartilage used [45]. Kriedel and colleagues [80] performed a long-term study of 357 patients who underwent primary or revision rhinoplasty with 1025 irradiated homologous cartilage grafts (IHCC) and 218 autogenous cartilage grafts. The total complication rate, including warping, infection, and resorption related to the irradiated homologous cartilage grafts, was 3.25% and the overall comparative resorption rate between autologous cartilage versus irradiated homologous cartilage was nearly identical (1.37% to 1.01% respectively). It was not methodologically possible to compare complication rates of IHCC and autogenous cartilage groups directly as both types were often used together (the authors attributing all infections to have arisen from the IHCC graft in such cases).

Literature supports the use of irradiated homologous cartilage graft as a viable option to autogenous cartilage grafts for nasal dorsal augmentation.

ALLOPLASTIC IMPLANTS

Synthetic implants have long been a topic of controversy in rhinoplasty. Critics cite concerns with the introduction of foreign material and risks of inflammation, infection and extrusion. Peled et al. reported their findings from a meta-analysis of the three most commonly used implants in rhinoplasty - silicone, expanded polytetrafluoroethylene (Gore-Tex) and porous high-density polyethylene (Medpor), showing that silicone had twice the rate of implant removal compared to polytetrafluroethylene and high-density polyethelene (6.5%

vs. 3.1%) [78]. Other studies have shown that complication rates were low but not negligible - for instance, extrusion (1-10.7%), infection (1-6.25%) and displacement (1-3%), and were higher in revision rhinoplasty cases [79-85]. Recently, more literature has appeared supporting the use of resorbable synthetic material, specifically, polydioxanone (PDS) plates in septal reconstruction. James and Kelly reported on 58 primary and secondary rhinoplasties using the PDS plate in conjunction with autogenous cartilage grafts for floating columellar strut, septal extension grafts and alar batten grafts, showing good postoperative results [86]. Only minor complications of infection (1.7%) and partial extrusion (1.7%) were noted after a mean follow-up period of eighteen months. An additional retrospective study of 400 patients by Boenisch in the use of PDS plates for reconstruction of severe septal deformity showed that nearly ninety percent subjectively maintained a straight nasal septum after twelve months, correlating with over eighty percent objective improvement in nasal rhinomanometry [87]. There appears to be retrospective evidence supporting the use of resorbable PDS plates in septal reconstruction. However, alloplastic implants will continue to be a topic of controversy that requires more prospective data and better long-term evidence. In the future, new synthetic materials may become available for implantation that will continue to evolve the field of nasal augmentation.

MANAGEMENT OF THE LOWER NASAL VAULT AND NASAL TIP SURGERY

The lower nasal vault consists of the lower lateral cartilage and caudal nasal septum forming the nasal tip. The complex three-dimensional nature of the nasal tip makes it one of the most challenging aspects of rhinoplasty. Tip projection, rotation and refinement are frequently discussed in rhinoplasty literature with a myriad of surgical techniques and management philosophies. As with most of rhinoplasty, strong evidence does not exist for the many different suture and grafting techniques for tip rhinoplasty and most of the available data is in the form of retrospective series.

Over the years, nasal tip surgery has moved away from reductive techniques such as cartilage morselization, scoring and resection and focused on tip stabilization and maintaining or augmenting supportive structures of the nasal tip as surgeons have realised the long-term consequences of wound contracture and gravity. Suturing and grafting techniques to help contour and stabilise the nasal tip have been evolving and are widely used by rhinoplasty surgeons.

Tip suture techniques can effectively control the shape and curvature of the lateral cartilages while maintaining their structural integrity. Variations of the transdomal and interdomal suturing techniques have been described to address the bulbous tip [88, 89]. Gruber proposed a step-wise suturing algorithm based on 150 rhinoplasty cases for the bulbous nasal tip in which cephalic resection, transdomal and interdomal sutures, lateral crural matress sutures and columella-septal suture are placed to create tip contour and address tip bulbosity [90].

Tip grafting techniques can be used in instances where greater projection of the nasal tip is required than can be produced with suture techniques, when camouflage of persistent

asymmetry is needed, when added bulk is required at the infratip lobule region, or when greater refinement of the lobule is required than conventional techniques can provide [91].

Prior to working on the nasal tip, the nasal base should be assessed for stability to ensure a solid foundation for the lower nasal vault and prevent postoperative loss of tip projection and/or rotation [92]. If needed, a columellar strut or caudal extension graft should be implemented to support the medial crura of the lower lateral cartilage. Additionally, based on a review of 100 consecutive primary rhinoplasty patients, Constantian [93] purports that rhinoplasty surgeons should identify two key anatomical characteristics that will ensure successful tip surgery and avoid secondary deformities: 1) whether there is adequate tip projection and 2) whether the lateral crura are malpositioned. He noted that over sixty percent of patients required increased tip support and projection and nearly half (46%) had anatomical variants of alar cartilage positioning [93]. Therefore preoperative identification and surgical planning to support and reinforce the nasal tip is important for long-term surgical success.

TIP REFINEMENT

The bulbous or amorphous nasal tip will require refinement techniques to achieve satisfactory contouring. The shape and position of the lower lateral cartilages along with the thickness of the overlying skin and soft tissue envelope determine tip width and bulbosity. The thickness of the skin will heavily influence the choice of surgical technique. Due to the complex nature of the tip bulbosity, a graduated approach to nasal tip refinement should be used. The surgical approaches to addressing the cartilaginous components of a bulbous tip include cephalic resection, suture techniques to refine the tip and flatten the lateral crura, grafting techniques to mask or augment the nasal tip, domal or lateral crural division and lateral crural repositioning.

Patrocinio et al. retrospectively reviewed 641 rhinoplasty cases over a three year period to present a graduated approach to tip rhinoplasty based on the level of tip bulbosity comparing methods of tip refinement including cephalic trim, interdomal suturing with or without lateral crural steal, shield grafting and vertical dome division [94]. They reported an overall patient satisfaction rate of 95.6% and revision rate of 5.6%. Patients with mild tip bulbosity but excellent medial and lateral tip support did well with conservative cephalic trim without delayed postoperative loss of tip projection. Patients with an abnormally large angle of divergence between the medial and intermediate crura (more than thirty percent) or excessive interdomal width (more than four millimetres) required interdomal suture techniques [95]. Patients with thick skin and weak lower lateral cartilages required extended shield grafts to achieve satisfactory refinement, while thick skinned patients with strong lower lateral cartilages benefited from dome division techniques. The study demonstrated a graded approach to the nasal tip that could help surgeons achieve optimal long-term success in tip refinement.

POSTOPERATIVE CARE

Appropriate postoperative care is essential for proper healing and successful long-term outcomes after rhinoplasty. Appropriate care involves nasal splinting, taping and packing, nasal hygiene, perioperative antibiosis and strategies to minimise edema. There have been many methods of postoperative external nasal splinting that have been described using different material including aluminum, plaster and dental compounds [96, 97]. Regardless of the material used, the primary goal of external nasal splinting is to provide a secure bolster for the nasal framework and soft tissue envelope following rhinoplasty [98]. Prior to application of the external nasal splint, the nasal dorsum is taped to limit postoperative edema and prevent irritation from the splinting material. There are proponents of endonasal septal splints or packing for patients who have had septoplasty as part of their rhinoplasty procedure to help with septal mucosal flap approximation and prevent recurrent/secondary septal deviation, septal hematoma or synechiae formation [99,100]. However, Cook et al. showed in a prospective study of 100 patients undergoing septoplasty that patients who were randomised to have silicone septal splints did not demonstrate any such benefits but did have significantly increased postoperative discomfort [101]. The use of septal splints following septorhinoplasty is therefore not universally recommended and the decision should be made on a case by case basis.

Nasal hygiene is imperative in maintaining a clean surgical site. This will help prevent nasal crusting and infection, which can lead to inflammation and scarring. Use of nasal saline spray will help maintain a moist nasal airway to promote healthy mucosal healing. Although there is a lack of evidence supporting the use of nasal saline following rhinoplasty, there is abundant empirical evidence supporting its use. Shone et al. [102] showed persistent decreased mucocilary clearance three weeks after septoplasty and Tomooka and colleagues' found a statistically significant improvement in nasal symptoms amongst patients with nasal dysfunction using nasal saline irrigation [103]. Thus there is indirect support for the use of nasal saline following rhinoplasty.

Postoperative edema is inevitable after rhinoplasty. There is conflicting data on the efficacy of routine systemic corticosteroid administration for prevention and mitigation of postoperative edema. Kara and Gokalan conducted a double-blind, randomised controlled trial with placebo control to evaluate the effects of single-dose dexamethasone on eyelid edema and ecchymosis following rhinoplasty [104]. They determined that single-dose dexamethasone had a significant effect in decreasing upper and lower eyelid edema and upper eyelid ecchymosis for the first two days. Hoffman and colleagues showed in their randomised, double-blind study of intraoperative intravenous dexamethasone plus a five day postoperative course of oral prednisone following rhinoplasty that there was significantly less postoperative eyelid and paranasal edema during the first four days after surgery in those patients receiving steroids [105]. A meta-analysis performed by Hatef et al. concluded that preoperative steroid dosing is superior to postoperative dosing and extended dosing superior to a single dose in reducing periorbital edema and ecchymosis after rhinoplasty [106].

While steroids may decrease early facial edema, they appear less effective in reducing nasal edema. A study conducted by Berinstein et al. did not show any significant improvement in nasal edema, determined using magnetic resonance imaging, after rhinoplasty with osteotomies in patients who received steroids preoperatively versus those who did not

[107]. Thus although evidence suggests that perioperative and postoperative corticosteroids decrease early facial edema, the effects appear short-lived and do not translate to intranasal swelling. Given the inherent risks of corticosteroid use, surgeons should weigh their risks and benefits for individual patients prior to administration following rhinoplasty.

Whether an open or closed approach is used for rhinoplasty, proper care of the incision site will decrease the risk of infection and help minimise scar formation. Topical and systemic antibiotics are frequently used postoperatively in rhinoplasty. Bandhauer et al. showed topical antibiotic ointment to decrease the growth of potentially infectious nasal flora and *Staphylococcus aureus* in patients with nasal packing [108]. Randomised, controlled trials have shown that prophylactic systemic antibiotics within two hours of the start of surgery have been effective in preventing postoperative infections in various surgical procedures [109]. There are no guidelines regarding routine postoperative systemic antibiotics after nasal surgery. However, most rhinoplasty surgeons prefer to give postoperative antibiotics to prevent toxic-shock syndrome in the setting of intranasal splints or packing, the exposure of soft tissues to the nasal airway and the use of devascularised cartilage or synthetic grafts during rhinoplasty [110].

COMPLICATIONS OF RHINOPLASTY

Careful preoperative and intraoperative assessment and patient education will optimise the surgical outcome. As with all surgical procedures, complications may occur following rhinoplasty. Surgical experience will help the surgeon anticipate which intraoperative maneuvers may lead to postoperative issues. In addition, a thorough awareness and knowledge of the possible complications allow the surgeon to identify and treat them should they arise. Postoperative complications of rhinoplasty may be categorised as either early (up to six weeks postoperatively), or late (occurring after six weeks).

Intraoperatively the surgeon may be faced with unexpected excessive bleeding, which may be due to inadequate local hemostatic injections, intraoperative hypertension, undisclosed use of anti-platelet or anti-thrombotic agents, or underlying coagulopathy. Careful use of electrocautery and topical vasoconstrictive medication may be required. Care must be taken during elevation of the skin and soft tissue, especially in thin-skinned patients. Inadvertent violation of the skin can lead to unsightly and act as a conduit for infection.

Complications can arise from manipulation of weak or unstable osseocartilaginous structures, including collapse of the bony pyramid or disarticulation of the upper lateral cartilages from the nasal bone. Careful reapproximation and use of grafts to provide support to these structures may be necessary. Improperly placed or inadequate osteotomies can lead to deformities such as the rocker deformity (following incomplete medial osteotomies), requiring percutaneous completion of the osteotomy and careful alignment of the nasal bones; the open roof deformity (from incomplete joining of medial and lateral osteotomies); and step deformities (due to misplaced lateral osteotomies) [111, 112]. The surgeon must also be mindful of the vital surrounding structures (i.e., orbit, nasolacrimal system, cranium) that may be injured during osteotomies [113].

In the early postoperative period the surgeon should be aware of potential bleeding and infectious risks [114]. Nasal packing and postoperative antibiotics may be used to avoid some

of these early complications. In cases of infection, early treatment with systemic antibiotics and incision and drainage of any abscesses are important in preventing serious complications. Some nasal edema and ecchymosis may be expected after nasal surgery. Careful taping and splinting of the nose will help minimise nasal edema. Cold compresses, postoperative head elevation and hypertensive control can all help decrease the severity and length of edema and ecchymosis postoperatively. In instances of severe edema, postoperative oral and injectable steroids may be useful.

Early postoperative success unfortunately does not always portend long-term success. Late complications occurring after six weeks postoperatively can manifest as a functional and/or cosmetic failure. Late complications often arise as sequelae of the healing process including scar formation and bony and cartilaginous remodeling and resorption [115]. Overly aggressive resection of the bony or cartilaginous structures during rhinoplasty may result in a weakened and malpositioned framework.

Late complications can be considered based on the respective nasal vaults involved. The bony nasal vault may exhibit asymmetry or widening due to inadequate or misaligned osteotomies, saddling due to over-reduction of the dorsal nasal bone, persistent dorsal hump, step deformity and open-roof deformity [116]. Middle third deformities include the inverted-V deformity from disarticulated or weakened upper lateral cartilages, pollybeak deformity from soft tissue edema or hypertrophy or loss of tip projection, saddle nose deformity from over-resection of the dorsal septum, and nasal asymmetry [116, 117]. Late complications of the lower third or nasal tip may present as tip distortions including tip asymmetry, bossa formation, tip widening or pinching and tip over- or under-rotation. The aesthetic relationship between the ala and columella may be affected (i.e., alar notching, hanging columella, etc.) by the over- or underresection of the lateral crura of the lower lateral cartilage and the caudal septum [118, 119]. Furthermore, the functionality of the nose may be compromised with late complications such as internal and external nasal valve collapse (static or dynamic) due to over-resection or inadequate support [120, 121]. Additionally, septal perforations, synechiae/webbing and nasal stenosis can have disastrous late consequences in nasal functionality and cosmesis [121, 122].

Late postoperative complications usually require revision rhinoplasty to correct the nasal deformities. Therefore, care must be taken during the primary surgery to consider and address potential pitfalls and long-term sequelae of each surgical maneuver. The downstream effect of each maneuver on the functionality and cosmesis of the nose must not be overlooked and will be better understood as the surgeon critically appraises their own experience over the years.

CONCLUSION

Rhinoplasty is a complex procedure involving a balance between form and function. The primary goal is to achieve the patient's desired aesthetic outcome while maintaining or improving nasal breathing. To achieve satisfactory outcomes, a thorough understanding of the patient's nasal anatomy and the surgical techniques needed to correct the irregularities is essential. The most important advice is perhaps to manage the patient's expectations before and after surgery by maximizing the time spent in the office counselling the patient and minimizing the complexity of the surgical intervention required to achieve the patient's

desired outcome. It is important to develop excellent rapport with the patient to develop a clear, common vision of the final surgical outcome. Proper preparation and patient evaluation allows one to choose the most appropriate surgical approach and technique to achieve a desirable outcome. Finally, meticulous surgical execution that is grounded in clinical evidence will allow for the best long-term outcome. While much of rhinoplasty is based on historical retrospective data, improvements in outcomes research of patient satisfaction based on validated outcome measures along with improved study design and prospective, long-term data will help rhinoplasty surgeons continue to evolve and perfect their craft.

REFERENCES

[1] Cannon DE, Rhee JS: Evidence-based practice: functional rhinoplasty. *Otolaryngologic clinics of North America* 2012, 45(5):1033-1043.

[2] Toriumi DM, Mueller RA, Grosch T, Bhattacharyya TK, Larrabee WF, Jr.: Vascular anatomy of the nose and the external rhinoplasty approach. *Arch. Otolaryngol. Head Neck Surg.* 1996, 122(1):24-34.

[3] Tardy ME: *Rhinoplasty: The Art and Science*. Philadelphia: WB Saunders; 1997.

[4] Tardy ME, Brown R.: *Surgical anatomy of the nose*. New York: Raven Press; 1990.

[5] Branham GH: *Facial soft tissue reconstruction: Thomas procedures in facial plastic surgery*. Shelton, Conn.: People's Medical Pub. House; 2011.

[6] Toriumi DM: Management of the middle nasal vault. *Operative Techniques in Plastic and Reconstructive Surgery* 1995, 2(1):16-30.

[7] Anderson JR: The dynamics of rhinoplasty. In: *Proceedings of the Ninth International Congress of Otorhinolaryngology: 1969; Mexico City*; 1969.

[8] Bridger GP: Physiology of the nasal valve. *Arch Otolaryngol* 1970, 92(6):543-553.

[9] Constantian MB: The incompetent external nasal valve: pathophysiology and treatment in primary and secondary rhinoplasty. *Plast. Reconstr. Surg.* 1994, 93(5):919-931; discussion 932-913.

[10] Rhee JS, Arganbright JM, McMullin BT, Hannley M: Evidence supporting functional rhinoplasty or nasal valve repair: A 25-year systematic review. *Otolaryngology--head and neck surgery: official journal of American Academy of Otolaryngology-Head and Neck Surgery* 2008, 139(1):10-20.

[11] Swamy RS, Most SP: Preoperative, anesthetic and postoperative care for rhinoplasty patients. *Facial plastic surgery clinics of North America* 2009, 17(1):7-13, v.

[12] Picavet VA, Gabriels L, Grietens J, Jorissen M, Prokopakis EP, Hellings PW: Preoperative symptoms of body dysmorphic disorder determine postoperative satisfaction and quality of life in aesthetic rhinoplasty. *Plastic and reconstructive surgery* 2013, 131(4):861-868.

[13] Shipchandler TZ, Sultan B, Ishii L, Boahene KD, Capone RB, Kontis TC, Papel ID, Byrne PJ: Aesthetic analysis in rhinoplasty: surgeon vs. patient perspectives: a prospective, blinded study. *Am. J. Otolaryngol.* 2013, 34(2):93-98.

[14] Mehta U, Mazhar K, Frankel AS: Accuracy of preoperative computer imaging in rhinoplasty. *Arch. Facial. Plast. Surg.* 2010, 12(6):394-398.

[15] Murrell GL: Components of the Nasal Examination. *Aesthet. Surg. J.* 2013, 33(1):38-42.
[16] Kim DW, Rodriguez-Bruno K: Functional rhinoplasty. *Facial plastic surgery clinics of North America* 2009, 17(1):115-131, vii.
[17] Anderson KJ, Henneberg M, Norris RM: Anatomy of the nasal profile. *Journal of anatomy* 2008, 213(2):210-216.
[18] Cho GS, Kim JH, Yeo NK, Kim SH, Jang YJ: Nasal skin thickness measured using computed tomography and its effect on tip surgery outcomes. *Otolaryngology-head and neck surgery: official journal of American Academy of Otolaryngology-Head and Neck Surgery* 2011, 144(4):522-527.
[19] Toriumi DM: New concepts in nasal tip contouring. *Arch. Facial. Plast. Surg.* 2006, 8(3):156-185.
[20] Ridley MB: Aesthetic facial proportions. In: *Facial plastic and reconstructive surgery.* edn. Edited by Papel ID, Nachlas, N.E. Philadelphia: Mosby Year Book; 1992: 99-109.
[21] Hafezi F, Naghibzadeh B, Nouhi AH: Applied anatomy of the nasal lower lateral cartilage: a new finding. *Aesthetic plastic surgery* 2010, 34(2):244-248.
[22] Rohrich RJ, Adams WP, Jr.: The boxy nasal tip: classification and management based on alar cartilage suturing techniques. *Plastic and reconstructive surgery* 2001, 107(7):1849-1863; discussion 1864-1848.
[23] Crumley RL, Lanser M: Quantitative analysis of nasal tip projection. *The Laryngoscope* 1988, 98(2):202-208.
[24] Powell N, Humphreys B: *Proportions of the aesthetic face*. New York: Thieme-Stratton; 1984.
[25] Simons RL: Nasal tip projection, ptosis and supratip thickness. *Journal of Ear, Nose, & Throat* 1982, 61(8):452-455.
[26] Powell N, Humphreys B.: *Proportions of the aesthetic face*. New York: Thieme-Stratton; 1984.
[27] Brown M, Guyuron B: Redefining the ideal nasolabial angle: part 2. Expert analysis. *Plastic and reconstructive surgery* 2013, 132(2):221e-225e.
[28] Kim DW, Egan KK: Metrics of nasal tip rotation: a comparative analysis. *The Laryngoscope* 2006, 116(6):872-877.
[29] Gunter JP, Rohrich RJ, Friedman RM: Classification and correction of alar-columellar discrepancies in rhinoplasty. *Plastic and reconstructive surgery* 1996, 97(3):643-648.
[30] Stucker FJ, Souza, C., Kenyon, G.S., Lian, T.S., Draf, W., Shick, B.: *Rhinology and Facial Plastic Surgery*: Springer; 2009.
[31] Byrd HS, Hobar PC: Rhinoplasty: a practical guide for surgical planning. *Plastic and reconstructive surgery* 1993, 91(4):642-654; discussion 655-646.
[32] Mowlavi A, Meldrum DG, Wilhelmi BJ: Implications for nasal recontouring: nasion position preferences as determined by a survey of white North Americans. *Aesthetic plastic surgery* 2003, 27(6):438-445.
[33] Becker DG: Anatomy, Incisions and Approachs: Open and Closed Rhinoplasty. In: *Rhinoplasty Archive.* Edited by Becker DG, Palma, P.; 2011.
[34] Cochran CS, Ducic Y, Defatta RJ: Rethinking nasal osteotomies: an anatomic approach. *The Laryngoscope* 2007, 117(4):662-667.
[35] Bloom JD, Immerman SB, Constantinides M: Osteotomies in the crooked nose. *Facial plastic surgery: FPS* 2011, 27(5):456-466.

[36] Webster RC, Davidson TM, Smith RC: Curved lateral osteotomy for airway protection in rhinoplasty. *Arch. Otolaryngol.* 1977, 103(8):454-458.
[37] Zoumalan RA, Shah AR, Constantinides M: Quantitative comparison between microperforating osteotomies and continuous lateral osteotomies in rhinoplasty. *Archives of facial plastic surgery* 2010, 12(2):92-96.
[38] Gryskiewicz JM, Gryskiewicz KM: Nasal osteotomies: a clinical comparison of the perforating methods versus the continuous technique. *Plastic and reconstructive surgery* 2004, 113(5):1445-1456; discussion 1457-1448.
[39] Rohrich RJ, Minoli JJ, Adams WP, Hollier LH: The lateral nasal osteotomy in rhinoplasty: an anatomic endoscopic comparison of the external versus the internal approach. *Plastic and reconstructive surgery* 1997, 99(5):1309-1312; discussion 1313.
[40] Gryskiewicz JM: Visible scars from percutaneous osteotomies. *Plastic and reconstructive surgery* 2005, 116(6):1771-1775.
[41] Hinton AE, Hung T, Daya H, O'Connell M: Visibility of puncture sites after external osteotomy in rhinoplastic surgery. *Archives of facial plastic surgery* 2003, 5(5):408-411.
[42] Harshbarger RJ, Sullivan PK: The optimal medial osteotomy: a study of nasal bone thickness and fracture patterns. *Plastic and reconstructive surgery* 2001, 108(7):2114-2119; discussion 2120-2111.
[43] Westreich RW, Lawson W: Perforating double lateral osteotomy. *Archives of facial plastic surgery* 2005, 7(4):257-260.
[44] Pribitkin EA, Lavasani LS, Shindle C, Greywoode JD: Sonic rhinoplasty: sculpting the nasal dorsum with the ultrasonic bone aspirator. *The Laryngoscope* 2010, 120(8):1504-1507.
[45] Lee MR, Unger JG, Rohrich RJ: Management of the nasal dorsum in rhinoplasty: a systematic review of the literature regarding technique, outcomes and complications. *Plastic and reconstructive surgery* 2011, 128(5):538e-550e.
[46] Akcam T, Friedman O, Cook TA: The effect on snoring of structural nasal valve dilatation with a butterfly graft. *Arch. Otolaryngol. Head Neck Surg.* 2004, 130(11):1313-1318.
[47] Kern EB: Surgical approaches to abnormalities of the nasal valve. *Rhinology* 1978, 16(3):165-189.
[48] Paniello RC: Nasal valve suspension. An effective treatment for nasal valve collapse. *Archives of otolaryngology--head & neck surgery* 1996, 122(12):1342-1346.
[49] Stucker FJ, Hoasjoe DK: Nasal reconstruction with conchal cartilage. Correcting valve and lateral nasal collapse. *Arch. Otolaryngol. Head Neck Surg.* 1994, 120(6):653-658.
[50] Gassner HG, Friedman O, Sherris DA, Kern EB: An alternative method of middle vault reconstruction. *Arch. Facial Plast. Surg.* 2006, 8(6):432-435.
[51] Menger DJ: Lateral crus pull-up: a method for collapse of the external nasal valve. *Arch. Facial Plast. Surg.* 2006, 8(5):333-337.
[52] Stucker FJ, Lian T, Sanders K: Management of severe bilateral nasal wall collapse. *Am. J. Rhinol.* 2002, 16(5):243-248.
[53] Clark JM, Cook TA: The 'butterfly' graft in functional secondary rhinoplasty. *Laryngoscope* 2002, 112(11):1917-1925.
[54] Sheen JH: Spreader graft: a method of reconstructing the roof of the middle nasal vault following rhinoplasty. *Plastic and reconstructive surgery* 1984, 73(2):230-239.

[55] Ingels KJ, Orhan KS, van Heerbeek N: The effect of spreader grafts on nasal dorsal width in patients with nasal valve insufficiency. *Arch. Facial. Plast. Surg.* 2008, 10(5):354-356.

[56] Gruber RP, Park E, Newman J, Berkowitz L, Oneal R: The spreader flap in primary rhinoplasty. *Plastic and reconstructive surgery* 2007, 119(6):1903-1910.

[57] Byrd HS, Meade RA, Gonyon DL, Jr.: Using the autospreader flap in primary rhinoplasty. *Plast. Reconstr. Sur.g* 2007, 119(6):1897-1902.

[58] Antunes MB, Goldstein SA: Surgical approach to nasal valves and the midvault in patients with a crooked nose. *Facial plastic surgery: FPS* 2011, 27(5):422-436.

[59] Most SP: Analysis of outcomes after functional rhinoplasty using a disease-specific quality-of-life instrument. *Archives of facial plastic surgery* 2006, 8(5):306-309.

[60] Constantian MB, Clardy RB: The relative importance of septal and nasal valvular surgery in correcting airway obstruction in primary and secondary rhinoplasty. *Plastic and reconstructive surgery* 1996, 98(1):38-54; discussion 55-38.

[61] Boccieri A, Macro C, Pascali M: The use of spreader grafts in primary rhinoplasty. *Annals of plastic surgery* 2005, 55(2):127-131.

[62] Khosh MM, Jen A, Honrado C, Pearlman SJ: Nasal valve reconstruction: experience in 53 consecutive patients. *Archives of facial plastic surgery* 2004, 6(3):167-171.

[63] Andre RF, Paun SH, Vuyk HD: Endonasal spreader graft placement as treatment for internal nasal valve insufficiency: no need to divide the upper lateral cartilages from the septum. *Archives of facial plastic surgery* 2004, 6(1):36-40.

[64] Yoo S, Most SP: Nasal airway preservation using the autospreader technique: analysis of outcomes using a disease-specific quality-of-life instrument. *Archives of facial plastic surgery* 2011, 13(4):231-233.

[65] Faris C, Koury E, Kothari P, Frosh A: Functional rhinoplasty with batten and spreader grafts for correction of internal nasal valve incompetence. *Rhinology* 2006, 44(2):114-117.

[66] Toriumi DM, Josen J, Weinberger M, Tardy ME, Jr.: Use of alar batten grafts for correction of nasal valve collapse. *Archives of otolaryngology--head & neck surgery* 1997, 123(8):802-808.

[67] Becker DG, Becker SS: Treatment of nasal obstruction from nasal valve collapse with alar batten grafts. *Journal of long-term effects of medical implants* 2003, 13(3):259-269.

[68] Millman B: Alar batten grafting for management of the collapsed nasal valve. *The Laryngoscope* 2002, 112(3):574-579.

[69] Guyuron B, Michelow BJ, Englebardt C: Upper lateral splay graft. *Plastic and reconstructive surgery* 1998, 102(6):2169-2177.

[70] Friedman O, Cook TA: Conchal cartilage butterfly graft in primary functional rhinoplasty. *The Laryngoscope* 2009, 119(2):255-262.

[71] Deylamipour M, Azarhoshangh A, Karimi H: Reconstruction of the internal nasal valve with a splay conchal graft. *Plastic and reconstructive surgery* 2005, 116(3):712-720; discussion 721-712.

[72] Park SS: The flaring suture to augment the repair of the dysfunctional nasal valve. *Plastic and reconstructive surgery* 1998, 101(4):1120-1122.

[73] Sciuto S, Bernardeschi D: Upper lateral cartilage suspension over dorsal grafts: a treatment for internal nasal valve dynamic incompetence. *Facial plastic surgery: FPS* 1999, 15(4):309-316.

[74] Schlosser RJ, Park SS: Surgery for the dysfunctional nasal valve. Cadaveric analysis and clinical outcomes. *Archives of facial plastic surgery* 1999, 1(2):105-110.

[75] Rhee JS, Poetker DM, Smith TL, Bustillo A, Burzynski M, Davis RE: Nasal valve surgery improves disease-specific quality of life. *Laryngoscope* 2005, 115(3):437-440.

[76] Angelos PC, Been MJ, Toriumi DM: Contemporary review of rhinoplasty. *Archives of facial plastic surgery* 2012, 14(4):238-247.

[77] Kridel RW, Ashoori F, Liu ES, Hart CG: Long-term use and follow-up of irradiated homologous costal cartilage grafts in the nose. *Archives of facial plastic surgery* 2009, 11(6):378-394.

[78] Peled ZM, Warren AG, Johnston P, Yaremchuk MJ: The use of alloplastic materials in rhinoplasty surgery: a meta-analysis. *Plastic and reconstructive surgery* 2008, 121(3):85e-92e.

[79] Lam SM, Kim YK: Augmentation rhinoplasty of the Asian nose with the "bird" silicone implant. *Annals of plastic surgery* 2003, 51(3):249-256.

[80] Zeng Y, Wu W, Yu H, Yang J, Chen G: Silicone implants in augmentation rhinoplasty. *Aesthetic plastic surgery* 2002, 26(2):85-88.

[81] Wang JH, Lee BJ, Jang YJ: Use of silicone sheets for dorsal augmentation in rhinoplasty for Asian noses. *Acta oto-laryngologica Supplementum* 2007(558):115-120.

[82] Lohuis PJ, Watts SJ, Vuyk HD: Augmentation of the nasal dorsum using Gore-Tex: intermediate results of a retrospective analysis of experience in 66 patients. *Clinical otolaryngology and allied sciences* 2001, 26(3):214-217.

[83] Inanli S, Sari M, Baylancicek S: The use of expanded polytetrafluoroethylene (Gore-Tex) in rhinoplasty. *Aesthetic plastic surgery* 2007, 31(4):345-348.

[84] Wang TD: Multicentre evaluation of subcutaneous augmentation material implants. *Archives of facial plastic surgery* 2003, 5(2):153-154.

[85] Baran CN, Tiftikcioglu YO, Baran NK: The use of alloplastic materials in secondary rhinoplasties: 32 years of clinical experience. *Plastic and reconstructive surgery* 2005, 116(5):1502-1516.

[86] James SE, Kelly MH: Cartilage recycling in rhinoplasty: polydioxanone foil as an absorbable biomechanical scaffold. *Plastic and reconstructive surgery* 2008, 122(1):254-260.

[87] Boenisch M, Nolst Trenite GJ: Reconstruction of the nasal septum using polydioxanone plate. *Archives of facial plastic surgery* 2010, 12(1):4-10.

[88] Tardy ME, Jr., Cheng EY, Jernstrom V: Misadventures in nasal tip surgery. Analysis and repair. *Otolaryngologic clinics of North America* 1987, 20(4):797-823.

[89] Papel ID: Interlocked transdomal suture technique for the wide interdomal space in rhinoplasty. *Archives of facial plastic surgery* 2005, 7(6):414-417.

[90] Gruber RP, Friedman GD: Suture algorithm for the broad or bulbous nasal tip. *Plastic and reconstructive surgery* 2002, 110(7):1752-1764; discussion 1765-1758.

[91] Kridel RW, Soliemanzadeh P: Tip grafts in revision rhinoplasty. *Facial plastic surgery clinics of North America* 2006, 14(4):331-341, vi.

[92] Toriumi DM: Structure approach in rhinoplasty. *Facial plastic surgery clinics of North America* 2005, 13(1):93-113.
[93] Constantian MB: The two essential elements for planning tip surgery in primary and secondary rhinoplasty: observations based on review of 100 consecutive patients. *Plastic and reconstructive surgery* 2004, 114(6):1571-1581; discussion 1582-1575.
[94] Patrocinio LG, Patrocinio TG, Maniglia JV, Patrocinio JA: Graduated approach to refinement of the nasal lobule. *Archives of facial plastic surgery* 2009, 11(4):221-229.
[95] Pedroza F: A 20-year review of the "new domes" technique for refining the drooping nasal tip. *Archives of facial plastic surgery* 2002, 4(3):157-163.
[96] Ahn MS, Maas CS, Monhian N: A novel, conformable, rapidly setting nasal splint material: results of a prospective study. *Archives of facial plastic surgery* 2003, 5(2):189-192.
[97] Cunningham MW, Yousif NJ, Sanger JR, Gingrass RP, Matloub HS: Aquaplast for nasal splinting. *Annals of plastic surgery* 1984, 13(4):357-358.
[98] Cochran CS, Ducic Y, DeFatta RJ: Current concepts in the postoperative care of the rhinoplasty patient. *Southern medical journal* 2008, 101(9):935-939.
[99] Guyuron B: Is packing after septorhinoplasty necessary? A randomized study. *Plastic and reconstructive surgery* 1989, 84(1):41-44; discussion 45-46.
[100] Guyuron B, Vaughan C: Evaluation of stents following septoplasty. *Aesthetic plastic surgery* 1995, 19(1):75-77.
[101] Cook JA, Murrant NJ, Evans KL, Lavelle RJ: Intranasal splints and their effects on intranasal adhesions and septal stability. *Clinical otolaryngology and allied sciences* 1992, 17(1):24-27.
[102] Shone GR, Yardley MP, Knight LC: Mucociliary function in the early weeks after nasal surgery. *Rhinology* 1990, 28(4):265-268.
[103] Tomooka LT, Murphy C, Davidson TM: Clinical study and literature review of nasal irrigation. *The Laryngoscope* 2000, 110(7):1189-1193.
[104] Kara CO, Gokalan I: Effects of single-dose steroid usage on edema, ecchymosis and intraoperative bleeding in rhinoplasty. *Plastic and reconstructive surgery* 1999, 104(7):2213-2218.
[105] Hoffmann DF, Cook TA, Quatela VC, Wang TD, Brownrigg PJ, Brummett RE: Steroids and rhinoplasty. A double-blind study. *Archives of otolaryngology--head & neck surgery* 1991, 117(9):990-993; discussion 994.
[106] Hatef DA, Ellsworth WA, Allen JN, Bullocks JM, Hollier LH, Jr., Stal S: Perioperative steroids for minimizing edema and ecchymosis after rhinoplasty: a meta-analysis. *Aesthetic surgery journal / the American Society for Aesthetic Plastic surgery* 2011, 31(6):648-657.
[107] Berinstein TH, Bane SM, Cupp CL, DeMarco JK, Hunsaker DH: Steroid use in rhinoplasty: an objective assessment of postoperative edema. *Ear, nose, & throat journal* 1998, 77(1):40-43.
[108] Bandhauer F, Buhl D, Grossenbacher R: Antibiotic prophylaxis in rhinosurgery. *American journal of rhinology* 2002, 16(3):135-139.
[109] Classen DC, Evans RS, Pestotnik SL, Horn SD, Menlove RL, Burke JP: The timing of prophylactic administration of antibiotics and the risk of surgical-wound infection. *The New England journal of medicine* 1992, 326(5):281-286.

[110] Perrotti JA, Castor SA, Perez PC, Zins JE: Antibiotic use in aesthetic surgery: a national survey and literature review. *Plastic and reconstructive surgery* 2002, 109(5):1685-1693; discussion 1694-1685.
[111] Conrad K, Gillman G: Refining osteotomy techniques in rhinoplasty. *J. Otolaryngol.* 1998, 27(1):1-9.
[112] Goldfarb M, Gallups JM, Gerwin JM: Perforating osteotomies in rhinoplasty. *Arch. Otolaryngol. Head Neck Surg.* 1993, 119(6):624-627.
[113] Thomas JR, Griner NR, Remmler DJ: Steps for a safer method of osteotomies in rhinoplasty. *Laryngoscope* 1987, 97(6):746-747.
[114] Tamerin JA: Management of hemorrhage post rhinoplasty. *N. Y. State J. Med.* 1967, 67(4):550-551.
[115] Adamson PA, Smith O, Tropper GJ: Incision and scar analysis in open (external) rhinoplasty. *Arch. Otolaryngol. Head Neck Surg.* 1990, 116(6):671-675.
[116] Padovan IF, Jugo SB: The complications of external rhinoplasty. *Ear Nose Throat J.* 1991, 70(7):454-456.
[117] Tardy ME, Jr., Kron TK, Younger R, Key M: The cartilaginous pollybeak: etiology, prevention and treatment. *Facial Plast. Surg.* 1989, 6(2):113-120.
[118] Gillman GS, Simons RL, Lee DJ: Nasal tip bossae in rhinoplasty. Etiology, predisposing factors and management techniques. *Arch. Facial. Plast. Surg.* 1999, 1(2):83-89.
[119] Kamer FM, Churukian MM, Hansen L: The nasal bossa: a complication of rhinoplasty. *Laryngoscope* 1986, 96(3):303-307.
[120] Beekhuis GJ: Nasal obstruction after rhinoplasty: etiology and techniques for correction. *Laryngoscope* 1976, 86(4):540-548.
[121] Adamson P, Smith O, Cole P: The effect of cosmetic rhinoplasty on nasal patency. *Laryngoscope* 1990, 100(4):357-359.
[122] Sulsenti G, Palma P: Complications and sequelae of nasal base and tip surgery. *Facial Plast. Surg.* 1997, 13(1):25-43.

In: Encyclopedia of Surgery (22 Volume Set)
Editors: Andreas Lehrer and Kristin Mueller
ISBN: 978-1-53618-329-0
© 2020 Nova Science Publishers, Inc.

Chapter 34

MASTOPEXY

Daniel Marsh [*] ***and Niri Niranjan***
St Andrews Centre for Plastic Surgery, Broomfield Hospital,
Chelmsford, UK

KEY POINTS

- The mastopexy procedure is a compromise between the final aesthetic result and scarring that is acceptable to the patient.
- In choosing a mastopexy technique the surgeon must account for the parenchymal distribution in relation to the inframammary fold and the quality of the overlying skin envelope.
- If considering a periareolar technique do not attempt to lift the nipple more than four centimetres.
- From his large series of vertical scar mastopexy procedures, Lassus suggests a superior pedicle is acceptable if moving the nipple nine centimetres or less, otherwise a lateral pedicle should be used.
- Mastopexy augmentation is a difficult procedure accompanied by an 8-23% reoperation rate (in two large single surgeon series) and an 11-17% complication rate.

INTRODUCTION

Literally ‘breast fixing’, mastopexy refers to the surgical technique for uplifting the breast. This chapter reviews the background and evidence for common mastopexy procedures.

[*] Corresponding Author’s Email: Dan.marsh@nhs.net.

HISTORY

There are numerous descriptions of mastopexy techniques in the literature dating back to Schwarzmann [1] who described the dermal pedicle for breast reduction and Lamont [2] who in 1946 described a two-stage mastopexy for markedly enlarged breasts. Considering all the available mastopexy techniques, the choice of which to use depends on the degree of ptosis, amount of available breast tissue/skin excess and a compromise between eventual cosmetic result and the degree of scarring acceptable to the patient. Here we will review the most common mastopexy procedures divided into type by incisions used and the evidence behind their use.

Although many mastopexy procedures have evolved from breast reduction techniques, especially in terms of preserving the blood supply to the nipple with various designs of pedicle, mastopexy is distinct from breast reduction in that the aim is to preserve as much parenchymal tissue as possible.

ANATOMY

The footprint of the breast on the chest wall typically sits between the sternal edge and the mid axillary line and from the second to the sixth rib. The mammary gland sits in a relatively avascular plane superficial to the anterior thoracic wall. The gland itself consists of between fifteen and twenty lobes of varying numbers of lobules each with a single lactiferous duct opening into the nipple. The lobes are separated by fibrous septae running from pectoral fascia to the dermis of the skin envelope. In the upper portion of the breast these septae are known as the suspensory ligaments of Astley Cooper and help suspend the breast on the chest wall. A non-lactating breast consists of fibrous fatty tissue held between the fibrous septi running between the pectoralis fascia and the skin envelope. After lactation and the menopause there is resorption of the glandular tissues, which is one of the causes of breast ptosis. The breast is supplied by perforating vessels from the internal mammary artery, the lateral thoracic artery and intercostal vessels (Figure 1). Venous drainage of the breast is through vessels accompanying the arteries - mainly internal mammary and lateral thoracic veins.

Any mastopexy procedure that lifts the nipple requires separation of the nipple from the surrounding skin on a dermal or parenchymal pedicle, and the design of the pedicle must take into consideration the source of the blood supply to the nipple. If the mastopexy procedure uses a superior or lateral pedicle the nipple blood supply will be from the thoracoacromial and/or lateral pectoral vessels. A medial pedicle utilises the blood supply from the internal mammary vessels and a central or inferior pedicle the intercostal perforators.

The nerve supply to the breast is derived from the second to sixth intercostal nerves [3], with the nipple and areola consistently innervated by the lateral and anterior cutaneous branches of the third, fourth and fifth intercostal nerves (Figure 2). In a cadaveric study looking at breast specimens of 28 females the most constant innervation pattern was by the 4th lateral cutaneous branch (79%) and by the third and fourth anterior cutaneous branches (57%) [4]. Sensation to the upper pole of the breast is from supraclavicular branches of the cervical plexus.

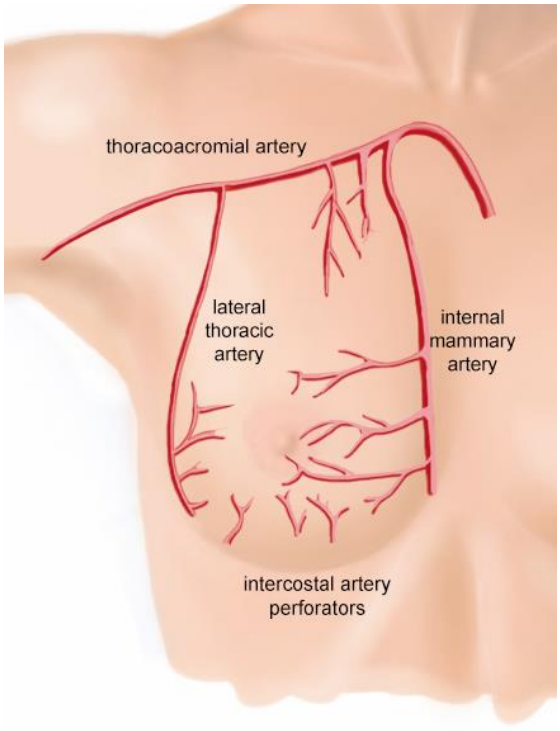

Figure 1. The arterial supply of the breast.

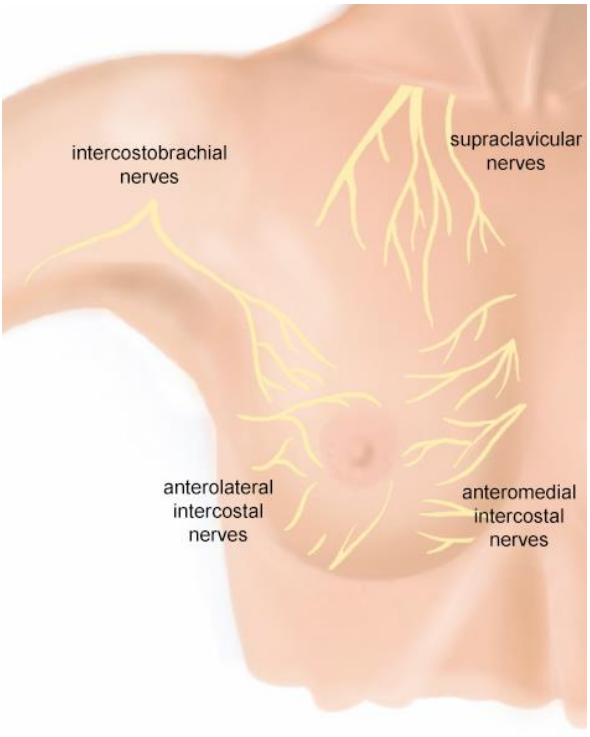

Figure 2. Innervation of the breast.

The 'perfect breast' was defined in 1955 by Penn [5] as having a sternal notch to nipple distance of 21cm which is also equal to the distance between the nipples. The nipple to inferior mammary fold distance was defined as 6.8cm and the areolar diameter 3.8-4.5cm. Although these measurements are still oft quoted, it should be remembered that this study was based on measurements taken from only twenty women whom the author determined had 'aesthetically perfect' breasts. Clearly these measurements cannot be applied across all cultures and to women from all societies as the 'perfect breast' in one culture may be viewed as too large or small in another.

A sound knowledge of breast anatomy is essential when considering patients for a mastopexy procedure which requires uplift of the nipple-areola complex to its normal position, rearrangement of breast parenchyma and redraping of the breast skin over the breast mound after resection of any excess skin.

INDICATIONS FOR MASTOPEXY

One of the most common indications is the post childbirth/breast feeding breast when the breast may be drooping and appear deflated as compared to the prepregnancy state. Other indications are simple ageing of the breast, the effects of gravity and weakening of the supporting tissues of the breast.

In more recent times patients who have had gastric banding procedures leading to massive weight loss commonly request mastopexy and these can be some of the most challenging cases as the nipple can be as much as forty centimetres below the sternum. Further, with the improvement in breast cancer survival there is an increasing patient population who require contra lateral symmetrising mastopexy procedures following breast reconstruction.

Patients with congenital breast deformities such as breast asymmetry or the tuberous breast could also be considered as requiring a mastopexy procedure where the shape of the breast is altered. Further, mastopexy procedures may also be combined with augmentation of the breast – the so called 'mastopexy-augment', commonly referred to as 'the most difficult procedure in aesthetic breast surgery' with a reputation for being the 'most frequently litigated operation in plastic surgery' [6].

CLASSIFICATION OF BREAST PTOSIS

The aim of mastopexy is to address breast ptosis as originally described by Regnault [7] who graded breast ptosis depending on the relationship between the nipple and the inframammary fold (IMF) (Figure 3).

Grade 1 – nipple at the level or just inferior to the IMF
Grade 2 – nipple is 1-3cm below the IMF
Grade 3 – nipple is more than 3cm below the IMF

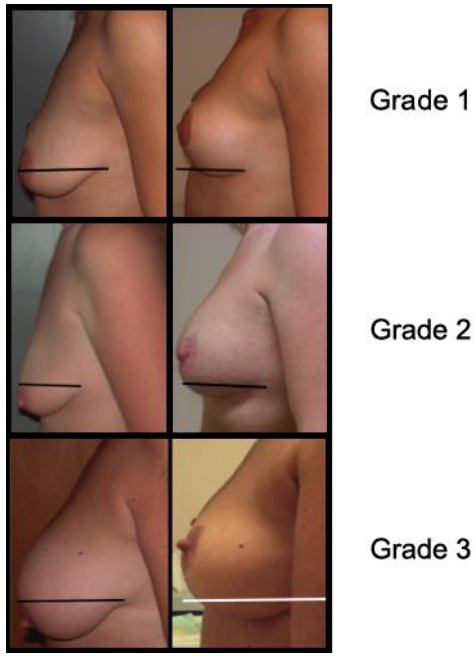

Figure 3. Breast ptosis according to Regnault 1976, before and after mastopexy.

Since 1976 the category of pseudoptosis has been added to Regnault's original grading system referring to the situation where the nipple is at or above the IMF but the majority of breast tissue is below the IMF.

Brink [8] recognised the importance of both the breast parenchyma and the nipple position in his classification of ptosis into glandular ptosis, true ptosis, pseudoptosis and parenchymal maldistribution (Figure 4).

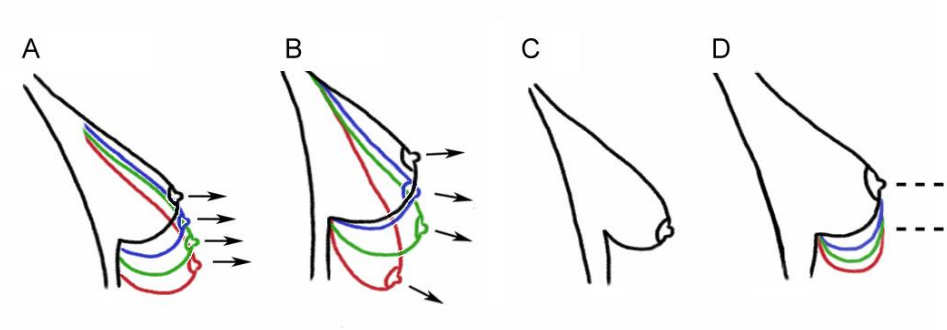

Figure 4. Classification of breast ptosis according to Brink: A) glandular ptosis; B) true ptosis; C) parenchymal maldistribution; and D) pseudoptosis.

When considering the degree of ptosis and the appropriate mastopexy technique, the position of the inframammary fold should also be taken into account as true breast ptosis involves three elements: skin laxity, migration of the nipple areolar complex and the position of the inframammary fold – that is, the IMF itself can be adjusted which will also have an effect on ptosis.

APPRAISAL OF THE EVIDENCE LEVEL FOR MASTOPEXY

When examining the evidence for surgical techniques, it would be preferable to use at least Level II evidence (see Appendix). This level of evidence is too sparse for mastopexy procedures and there are certainly no randomised controlled studies or meta-analysis of randomised controlled studies (Level I). Level III evidence is defined as that which is obtained from well-designed non-experimental descriptive studies such as comparative studies, correlation studies and case studies; Level IV evidence is that from expert opinions and clinical experience of respected authorities.

A search of the Cochrane database in February 2013 using the term 'mastopexy' produced only two studies, one comparing two types of local anaesthetic [9] and the other looking at occurrence of sebaceous cysts at the incision site of mastopexy procedures [10]. Entering the term 'mastopexy' into Pubmed produced 424 results; applying the filters 'clinical trial', 'comparative study', 'controlled clinical trial', 'multicentre study', 'randomised controlled trial' reduced the 424 results down to twenty results, of which only one by Swanson [11] was reporting on mastopexy, the other studies being about breast reduction, mastectomy and simple augmentation. Thus we cannot use level I or II evidence. Adding the filter 'case report' (Level III evidence) produced a total of 61 results of which only seven were concerned with mastopexy techniques and outcomes. For this reason, the level of evidence for this chapter was set at level IV to allow inclusion of the opinions of respected names in breast surgery.

EVIDENCE FOR MASTOPEXY PROCEDURES

Periareolar Mastopexy

As with all aesthetic surgical procedures there is a trade-off between the stigmata of surgery – that is, surgical scars - and optimising the aesthetic outcome. Mastopexy is a prime example of this and the periareolar mastopexy attempts to disguise the surgical incisions around the areolar at the expense of limiting surgical access and exposure to the breast. The periareolar mastopexy is ideally suited to women with mild to moderate ptosis who have adequate breast parenchymal tissue to support the redraped skin. The incision around the areola may be doughnut or crescent shaped and the procedure can include the use of a breast implant if the underlying breast tissue is of inadequate volume and requires augmentation.

The periareolar mastopexy can be skin only ('concentric') excision where a donut of skin is de-epithelialised around the nipple and the outer skin is sutured around the nipple using a non-absorbable suture before the edge of the nipple and the breast tissue is closed with a skin suture as described by Rees and Aston [12].

Critics of the original description for concentric mastopexy argue that the periareolar scars can become widened and the areola stretched, with the breast's overall appearance being flattened. Other complications of the periareolar incision can arise from incorrect placement of the periareolar scar and Spear et al. [13] discuss a series of rules to minimise these complications (Figure 5).

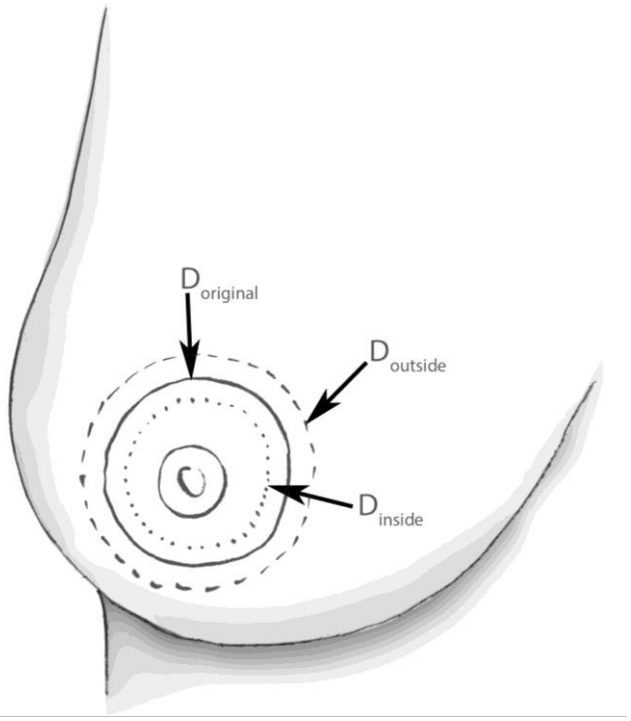

Figure 5. Rules for periareolar mastopexy: 1) $D_{outside} \leq D_{original} + (D_{original} - D_{inside})$; 2) $D_{outside} \leq 2$ X D_{inside}; 3) $D_{final} = ½ (D_{outside} + D_{inside})$. Data from Spear et al. [13].

Spear has presented the results of concentric mastopexy following his guidelines, showing that for the 31 patients he operated on (21 with simultaneous augmentation) all healed with minimal excessive scarring, although four required 'minor' periareolar scar revision; the conclusion was that concentric mastopexy was a safe procedure when using Spear's guidelines [13].

In 2001, Spear revisited his original description of the concentric mastopexy, commenting on the increased popularity of the technique and the benefit of using a non-absorbable purse string suture around the areola to counteract the tendency of the areola to dilate [14]. Spear also commented that in his experience if the nipple is to be elevated more than three or four centimetres, a periareolar mastopexy becomes more risky and in women with small nipple areola complex, the chance of developing a widened scar was also increased. On reviewing his original second rule - that D outside should be no more 2 x D inside - Spear suggests that using a non-absorbable blocking periareolar suture allows this rule to be modified to 3 x D inside, although this was not supported by a presentation of his results.

Alternatively, the Benelli mastopexy [15] addresses the skin and glandular tissue separately with a teardrop shaped skin excision and then an inverted T type gland resection through the periareolar incision.

A further alternative to skin only or Benelli type periareolar mastopexy is the use of a prosthetic Vicryl and Dacron mesh used as an internal bra to support the lower pole of the breast as described by Goes. Goes has published a seven-year experience of his technique [16] in 254 mastopexy patients in which he used a periareolar approach and overlapped de-

epithelialised skin with a synthetic mesh between the skin layers for extra support. Complications from Goes' technique are reported by the author as 1.5% seroma rate, 1% haematoma rate and a 4% loss of areolar sensitivity.

Crescenteric Periareolar Mastopexy

Puckett [17] described a technique of crescent mastopexy and augmentation for use in women with ptosis where the nipple is at the inframammary fold – a position they termed 'grade 1½ ptosis'. In a case series of 26 patients with a follow up of six months to four years Puckett commented that 'the lift appeared to be sustained over this period'. However twelve of the 26 patients had scar widening of five millimetres or more and five were left with oval areolas.

Short Scar Periareolar Inferior Pedicle Reduction (SPAIR) Mastopexy

Hammond [18] described a mastopexy technique based on his method of breast reduction using an inferior pedicle for the nipple and a circumvertical skin excision to address any excess skin. The proposed benefit of this technique is that it allows direct control of the volume of upper pole of the breast (termed 'auto-augmentation'), which is often deficient in patients requesting mastopexy. The inferior pedicle and the periareolar incision allow access to the pectoralis fascia to which the pedicle is sutured, thereby 'fixing' and uplifting the breast. Hammond describes this technique in 474 patients of which eight were mastopexy only, the remainder being breast reduction patients.

Vertical Scar Mastopexy

This technique is suitable for women with moderate to severe ptosis and poor skin quality who require some breast tissue to be excised to achieve an acceptable cosmetic result. The payoff is greater, more visible scarring compared to the periareolar technique, but in our opinion a more satisfactory 'fixing' of the breast can be achieved in these women who present with a greater degree of ptosis.

One of the original proponents of the vertical scar technique was Lassus [19] who described a technique that involves breast reduction with excision of glandular tissue, areolar transposition and no skin undermining, performed through an incision that closes with a vertical scar. In our experience, this technique is generally agreed to be most suitable for young women with firm glandular tissue, moderate ptosis and a skin envelope of decent quality. In 1996 Claude Lassus [20] reviewed his personal series of 710 patients, 1350 breasts operated on of which mastopexy was performed in 439 breasts using a vertical scar technique. In this series, two patients had total and eleven had partial nipple loss. In his review paper, Lassus comments that surgeons should use a lateral pedicle if moving the nipple more than nine centimetres, otherwise using a superior pedicle. He reports four cases of 'terrible hypertrophic scars' and sixteen 'severe' scars. Critics of the Lassus technique argue that

patients are left with an unacceptable bunching of the skin along the vertical scar that will take several months to settle down and some women are unable to accept this.

Moving forward from the Lassus technique, Lejour [21] modified the vertical scar technique to include undermining of the skin envelope, overcorrection of the breast deformity to account for later recurrence of ptosis and liposuction as necessary to further reduce the breast volume (Figures 6 and 7). Lejour has published large series of her results [22] showing the technique can be used for large volume breast reduction as well as mastopexy procedures. As with the Lassus technique, there is significant skin excess in the vertical scar that is accounted for by wrinkling the scar and by allowing time for the wrinkling to settle.

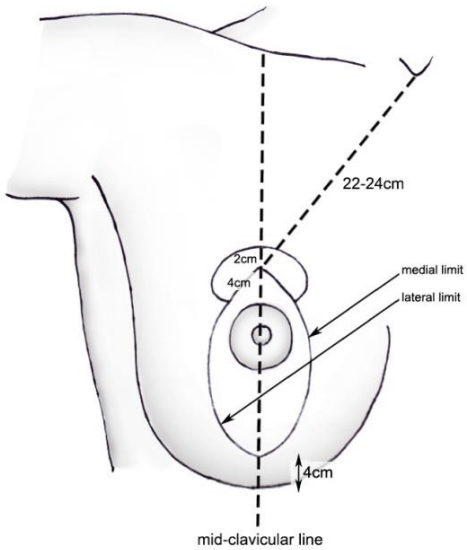

Figure 6. Markings for Lejour mastopexy. Adapted from Lejour M. 'Vertical mammaplasty and liposuction of the breast' [22].

Figure 7. Right-sided Lejour style mastopexy for breast asymmetry with left sided expander implant.

In 1999 Madeline Lejour published results from her own series of 250 consecutive patients (476 breasts) [23, 24] in which she stated she used the vertical scar mastopexy technique for every case except for women whose breasts were very small, who were undergoing augmentation mastopexy procedures and for those with tuberous breasts, in whom she used a periareolar approach. Complications of the Lejour technique reported by the author from the 476 operated breasts were two cases of partial nipple necrosis, a 5% seroma rate and a 1.2% haematoma rate.

L –Shaped Scar Mastopexy

Chiari [25] has described a further modification of the vertical scar technique by adding a single sided lateral horizontal component to the scar resulting in an L or J shaped scar. This technique was described for patients with moderate breast ptosis mainly due to skin excess but otherwise with a reasonable amount of breast tissue. Chiari advocates this technique over the standard vertical scar/inverted T techniques as the improved cosmetic results are immediately evident rather than having to wait three months, the breast retains projection, the areolar remains undistorted and is said to be less flattened in the inferior pole.

In 2012, Chiari published a prospective study of 125 breasts looking at breast sensitivity before and after L scar mammaplasty [26]. Breast sensitivity was tested using the Semmes-Weinstein esthesiometer preoperatively and six and twelve months postoperatively. Of the 125 breasts tested, 62 had tissue resection less than 200g and could be considered a mastopexy rather than formal breast reduction. In Chiari's study, using the L shaped scar, there was a return to preoperative sensation of the skin, areola and nipple by six to twelve months postoperatively in all cases where the resection weight was less than 200g.

Vertical Scar with Short Horizontal Component

Daniel Marchac (1982) described an adaption of the vertical scar technique mastopexy whereby he added a short horizontal component to excise excess skin and minimise wrinkling of the vertical scar seen with the Lassus/Lejour techniques [27]. This technique is most suited to women with a reasonable quality skin envelope requiring resection of a moderate amount of beast tissue to achieve a pleasing cosmetic outcome. Proponents of Marchac's technique argue that the vertical scar is the most visible breast scar whereas the horizontal scar is the least visible. Adding a short horizontal component is therefore a small price to pay for an immediately superior cosmetic result compared with the patience required following other vertical scar techniques.

Inverted-T (Wise Pattern)

This technique as described by Wise in 1956 [28] is commonly performed for breast reduction but is equally suitable for mastopexy procedures in patients with moderate to severe ptosis requiring minimal glandular resection and excision of a large amount of skin. Advantages of this technique are that the surgeon is most often familiar with the markings,

has good control over the amount of skin/breast tissue resected and can shape the breast so the result is immediately visible. Again the pay off for this type of procedure is that the scarring is greater than with periareolar or vertical scar techniques, but it is our view that for certain patients with significant ptosis this is a sensible approach if a large amount of skin resection is required.

Augmentation Mastopexy

Commonly women requesting augmentation post childbirth may require both lifting of the breast through a mastopexy procedure and augmentation of the breast as they feel they have lost breast volume. The mastopexy augment is therefore an attractive option, as the implant will fill out a previously stretched skin envelope. However this benefit must be weighed against the risks of wound breakdown due to increased tension on suture lines from the implant and potential of over resection of skin flaps during the mastopexy. Augmentation mastopexy leaves the surgeon the choice of any mastopexy procedure (except liposuction alone) as they all allow access to the chest for placement of the breast implant, and the choice of procedure should be tailored to the individual patient.

Calobrace [29] retrospectively reviewed his own five-year series 332 patients who underwent simultaneous augmentation mastopexy. The approach used by Calobrace varied depending on the degree of ptosis, and he employed periareolar (twenty percent), short scar (forty percent) and Wise pattern (forty percent) skin incisions as the degree of ptosis increased. Follow up ranged from one to six years with a mean of 1.5 years. Of the 332 patients operated on, 77 required reoperation, the most common indications being capsular contracture (11/332), poor scarring (11/332) and recurrent ptosis (11/332). There was no correlation between reoperation rate and the mastopexy approach used. Calobrace further comments that a poor cosmetic result was seen in 23.2% of augmentation mastopexy patients. When considering Calobrace's results, it should be remembered that there are many reasons patients may undergo repeat operations or indeed may choose not to have an operation even if it is indicated. Reoperation rate as an outcome measure is subjected to bias from many factors including patient psychology, surgeon preferences, economics, patient demographics – e.g. employment/childcare issues, fitness for further surgery, all of which can influence whether a patient proceeds to reoperation. As such it may not be sensitive indicator of patient satisfaction or dissatisfaction with surgery.

Scott Spear [30] has published results from his series of 53 bilateral and seven unilateral mastopexy augment patients with mean follow up of twelve months, in which he used both periareolar and vertical scar approaches. In his paper Spear states that primary simultaneous augmentation mastopexy has an early revision rate of eight percent and a complication rate of seventeen percent with many patients commenting postoperatively that they still desired a greater degree of lift. These findings can be placed in context when comparing results from primary breast augmentation, which is associated with a 1.7% revision rate.

Others have published their retrospective case series of augmentation mastopexy, including Cannon and Lindsey [31] who reviewed their results of 100 consecutive augmentation mastopexies performed via the periareolar approach only. Operated patients had either grade two ptosis (76%), grade three ptosis (16%) or tuberous breasts (8%) and follow-up averaged 8.3 months. In this series of periareolar mastopexies the overall

complication rate was eleven percent. There were three instances of moderate hypertrophic scarring, six of mild hypertrophic scaring and one partial nipple necrosis, the latter occurring in a patient with grade three ptosis requiring a seven-centimetre nipple lift.

Based on this experience, Cannon and Lindsey [31] have defined favourable patient factors they consider important for success in periareolar mastopexy:

1. Flaccid empty breasts
2. Small to moderate implant size (<360mls)
3. Planned nipple elevation of 4cm or less
4. Lighter skin tones
5. Absence of stretch marks

Stevens et al. [32] published their retrospective review of 321 consecutive single stage augmentation mastopexies in 617 individual breasts with an average follow up of forty months using inverted T (60%), periareolar (21%), vertical (15%) and crescent (4%) scars. The surgical revision rate was 14.6%, most often for implant related issues. The highest overall revision rate was in patients who underwent a periareolar mastopexy (it would be worth going into this in more detail – e.g. relative reoperation rates of periareolar versus other augmentation mastopexies, perhaps in the form of a table). As a comparison, Stevens et al. reviewed their own series of 150 mastopexy only patients and found this group had an 8.6% revision rate, which was twice the tissue related revision rate in their mastopexy-augment group. These mastopexy-augment figures can be compared to a large prospective study published by the breast implant manufacturer Mentor looking at augmentation-only patients (as opposed to augmentation mastopexy patients), which showed a reoperation rate of 13.2% at three years and 20% at five years [33].

Rod Rohrich [34] surveyed 1500 US Board-Certified plastic surgeons, receiving 487 replies (a 32.5% response rate). Questions included the surgeon's choice of mastopexy technique, their own satisfaction with their results, patient satisfaction and mastopexy complication rates. The most popular technique was inverted T (45.8%) followed by the SPAIR technique (32.6%) and then periareolar (30.6%); interestingly 71% of respondents used only one technique. Physicians were also asked to report patient satisfaction with the results of their surgery on a scale from one (unsatisfied) to five (very satisfied). Half of respondents reported patients rated their surgery at 4/5 and 40.9% at 5/5.

Most respondents reported a less than five percent complication rate, the most commonly (across all types of mastopexy) being suture spitting, poor scarring and bottoming out. Comparing types of mastopexy, the inverted T group had significantly greater incidence of bottoming out and the periareolar group had a significantly greater need for revision compared to other groups. Clearly there is significant potential for reporting bias in questionnaire surveys, in particular when asking surgeons to report recalled patient satisfaction with their surgery and the complication rate of five percent is much lower than that reported in other large mastopexy series discussed above.

Swanson [35] published a photometric study in which he analysed frontal and lateral images of pre- and postoperative mastopexy patients from 82 international publications on mastopexy and breast reduction. Swanson grouped the publications and photographs presented in them according to the mastopexy technique used.

Using simple measurements including upper pole, lower pole and total breast area, Swanson found that none of the techniques actually improved breast projection and, with the exception of the vertical technique, breast projection was actually reduced after mastopexy. Further, Swanson states that based on his analysis of photographs of mastopexy patients, no mastopexy technique produced a significant increase in upper pole projection and the use of fascial sutures did not have any lasting effect on upper pole fullness. The 82 papers examined included mastopexies carried out using inverted T, superior or medial pedicle, inverted T central pedicle, inverted T inferior pedicle, vertical scar, periareolar and intramammary approaches. Commenting on areolar shape, Swanson found that in 84.2% of all mastopexy studies, use of a Wise pattern or Lejour 'mosque dome' pattern resulted in an un-appealing inverted teardrop areolar shape. This finding Swanson attributes in the Lejour markings to the creation of a dog ear superiorly when the vertical ellipse is closed and with Wise pattern markings being due to the unpredictable topography of the local skin around the new areolar. To maintain a circular areolar shape longterm, Swanson advocates using a closed technique whereby the areolar markings are not drawn preop but are marked later once the mastopexy has been completed, as advocated by Pitanguy [36].

CONCLUSION

This review of the evidence available for mastopexy procedures confirms the dearth of high-level evidence available for cosmetic surgery procedures, which means surgeons must rely on retrospective case series reviews and comments from respected sources. For a topic as large and complex as mastopexy there are good papers available including personal series of large numbers of patients with adequate follow-up. It is important to note that for younger surgeons beginning their careers they may not be able to match the results of more experienced surgeons as undoubtedly there are the numerous small steps included in mastopexy procedures by the 'big names' in breast surgery that are not commented on in these review papers and that contribute to the success of the described mastopexy procedures.

This chapter has covered the anatomy of the breast, as a clear comprehension of the blood and nerve supply to the breast is a prerequisite for performing a successful mastopexy procedure and for designing a safe pedicle for the nipple to be maintained on. The technique used to address skin excess is dependent on the degree of ptosis and the distance the nipple is to be elevated which in turn determines the eventual postoperative scarring. Of equal importance is the parenchymal distribution and breast volume preoperatively as the rearrangement of this tissue determines the eventual shape of the breast after mastopexy and influences the decision on whether to use an implant or not to augment the breast.

A striking finding on reviewing the available evidence is that there is no single mastopexy procedure that produces the desired long-term effect of a breast lift and adequate upper pole fullness. What is also clearly apparent is the high revision rate associated with all types of mastopexy procedure, which may well be a reflection of the complex nature of the problem and the high demands of this particular patient population.

REFERENCES

[1] Schwarzman, E.: Über eine neue Methode der Mammaplastik. *Wien. Med. Wochenschr*. 86:100–102, 1936.

[2] Lamont ES. A Two-Stage Mastopexy in Plastic Surgery of Markedly Enlarged Breasts. *Ann. Surg*. 1946 Jul;124(1):111-7.

[3] Sarhadi NS, Shaw Dunn J, Lee FD, Soutar DS. An anatomical study of the nerve supply of the breast, including the nipple and areola. *Br. J. Plast Surg*. 1996 ;49(3):156-64.

[4] Schlenz I, Kuzbari R, Gruber H, Holle J. The sensitivity of the nipple-areola complex: an anatomic study. *Plast Reconstr. Surg*. 2000 Mar;105(3):905-9.

[5] Penn J. Breast reduction. *Br. J. Plast Surg*. 1955;7:357–371.

[6] Gorney M. Ten years' experience in aesthetic surgery malpractice claims. *Aesthetic Surg J*. 2001;21:569–571.

[7] Regnault P. Breast ptosis. Definition and treatment. *Clin. Plast Surg.* 1976;3:193.

[8] Brink RR. Management of true ptosis of the breast. *Plast Reconstr. Surg.* 1993;91(4):657-62.

[9] Kakagia D, Fotiadis S, Tripsiannis G. Levobupivacaine versus ropivacaine infiltration analgesia for mastopexy: a comparative study of 2 long-acting anesthetic drugs in infiltrative anesthesia for mastopexy. *Annals of Plastic Surgery*, 2005, 55(3), 258.

[10] Mu D, Luan J, Mu L, Xin M. The relationship between the thickness of de-epithelialization and occurrence of sebaceous cysts at the incision site after mastopexy and reduction mammaplasty. *Annals of plastic surgery*, 2010, 65(4), 389.

[11] Swanson E. A retrospective photometric study of 82 published reports of mastopexy and breast reduction. *Plast Reconstr Surg*. 2011 Dec;128(6):1282-301.

[12] Rees TD and Aston SJ 'The tuberous breast' *Clin. Plast. Surg*. 1976;3:339.

[13] Spear SL, Kassan M, Little JW. Guidelines in concentric mastopexy. *Plast Reconstr Surg.* 1990;85:961.

[14] Spear SL, Giese SY, Ducic I. Concentric mastopexy revisited. *Plast Reconstr. Surg*. 2001;107:1294.

[15] Benelli L. A new periareolar mammaplasty: the "round block" technique. *Aesthetic Plast Surg.* 1990;14:93.

[16] Goes JCS. Periareolar mammaplasty: double skin technique with application of polyglactine or mixed mesh. *Plast Reconstr Surg* 1996;97:959.

[17] Puckett, C. Crescent mastopexy and augmentation. *Plast. Reconstr. Surg*. 75: 533, 1985.

[18] Hammond DC, Alfonso D, Khuthaila DK. Mastopexy using the short scar periareolar inferior pedicle reduction technique. *Plast Reconstr Surg*. 2008 May;121(5):1533-9.

[19] Lassus C. Breast reduction: evolution of a technique. A single vertical scar. *Aesthetic Plast Surg*. 1987;11:107.

[20] Lassus C. A 30-year experience with vertical mammaplasty. *Plast. Reconstr. Surg*. 1996 Feb;97(2):373-80.

[21] Lejour, M., Abboud, M., Declety, A., and Kertesz, P. Réduction des cicatrices de plastie mammaire: de l'ancre courte à la. *Ann. Chir. Plast. Esthet*. 35: 369, 1990.

[22] Lejour M. Vertical mammaplasty and liposuction of the breast. *Plast Reconstr Surg* 1994;94:100.

[23] Lejour M. Vertical mammaplasty: update and appraisal of late results. *Plast Reconstr Surg* 1999;104:771.

[24] Lejour M. Vertical mammaplasty: early complications after 250 personal consecutive cases. *Plast Reconstr Surg*. 1999 Sep;104(3):764-70.

[25] Chiari AJ. The L short scar mammaplasty: a new approach. *Plast Reconstr Surg* 1992;90:233.

[26] Chiari A Jr, Nunes TA, Grotting JC et al. Breast sensitivity before and after the L short-scar mammaplasty. *Aesthetic Plast Surg*. 2012 Feb;36(1):105-14.

[27] Marchac D, Olarte G. Reduction mammaplasty and correction of ptosis with a short inframammary scar. *Plast Reconstr Surg* 1982;69:45.

[28] Wise RJ. A preliminary report on a method of planning the mammaplasty. *Plast Reconstr Surg*. 1956;17:367.

[29] Calobrace MB, Herdt DR, Cothron KJ. Simultaneous augmentation/mastopexy: a retrospective 5-year review of 332 consecutive cases. *Plast Reconstr. Surg*. 2013 Jan;131(1):145-56.

[30] Spear SL, Boehmler JH 4th, Clemens MW. Augmentation/mastopexy: a 3-year review of a single surgeon's practice. *Plast Reconstr. Surg.* 2006 Dec;118(7 Suppl):136S-147S.

[31] Cannon CL 3rd, Lindsey JT. Conservative augmentation with periareolar mastopexy reduces complications and treats a variety of breast types: a 5-year retrospective review of 100 consecutive patients. *Ann. Plast. Surg*. 2010 May;64(5):516-2.

[32] Stevens WG, Freeman ME, Stoker DA, et al. One-stage mastopexy with breast augmentation: a review of 321 patients. *Plast Reconstr Surg*. 2007 Nov;120(6):1674-9.

[33] Mentor Corporation. *Saline-Filled Breast Implant Surgery: Making an Informed Decision*. Santa Barbara, Calif.: Mentor Corporation, updated January 2004.

[34] Rohrich RJ, Gosman AA, Brown SA, Reisch J. Mastopexy preferences: a survey of board-certified plastic surgeons. *Plast Reconstr. Surg*. 2006 Dec;118(7):1631-8.

[35] Swanson E. A retrospective photometric study of 82 published reports of mastopexy and breast reduction. *Plast Reconstr. Surg*. 2011 Dec;128(6):1282-301.

In: Encyclopedia of Surgery (22 Volume Set)
Editors: Andreas Lehrer and Kristin Mueller
ISBN: 978-1-53618-329-0
© 2020 Nova Science Publishers, Inc.

Chapter 35

BREAST AUGMENTATION

Patrick Mallucci[1,*] and Olivier Alexandre Branford[2,#]
[1]The Cadogan Clinic, London, UK and
Royal Free Hospital, London, UK
[2]Imperial College Healthcare NHS Trust, London, UK

KEY POINTS

- Breast augmentation must be seen as a process in order to achieve optimal results with a low complication rate and reoperative requirement
- The goals of breast augmentation are: to enhance the breast, producing a result that is pleasing and in proportion with the individual; to minimise distortion through careful implant selection; to avoid complications through good technique; and to achieve results with longevity
- Comprehensive patient education is key, providing them with the knowledge to make sound decisions about their breast augmentation
- Tissue based preoperative planning is a crucial part of the process of breast augmentation
- An understanding of the importance of aesthetic goals is crucial to achieving consistently attractive results and satisfied patients

BACKGROUND

Breast augmentation is currently the most frequently performed cosmetic surgical procedure, a position held since 2006, with the figures for 2013 being up one percent on the previous year [1]. Breast augmentation has traditionally been seen as an isolated simple surgical procedure. Evidence has shown that this philosophy is outdated and leads to poor

* Corresponding Author's Email: pat.mallucci@googlemail.com (personal); narin@patrickmallucci.co.uk (secretary)
# Corresponding Author's Email: olivier.branford@totalise.co.uk.

results, excessive complications and unhappy patients, requiring repeated postoperative consultations and resulting in reoperation rates of around twenty percent at three years, as shown in successive premarket approval studies [2, 3]. In this chapter we delineate an evidence-based systematic approach to consistently achieving the best possible results in breast augmentation, with the lowest possible complication rate and reoperative requirement.

This chapter deals with breast augmentation using breast implants since the safety of widespread use of injectables remains controversial. A brief review of fat transfer is included at the end of the chapter examining the latest evidence for its use in breast augmentation.

LITERATURE SEARCH

For the purposes of this chapter a comprehensive analysis of relevant evidence-based studies related to breast augmentation was made. The source for these articles was MEDLINE. We have emphasised evidence-based guidelines and primary research studies, rather than other review articles, unless they were systematic reviews, where possible. However due to the paucity of high level evidence related to some areas of the decision making process in aesthetic surgery we have also acknowledged lower level studies, controversies, recent developments, other viewpoints, and any apparent conflicts of interest or instances of bias that might affect the strength of the evidence presented where appropriate. Only 2.2% of articles have been shown to be level I evidence in plastic surgery [4]. This may be in part due to the inherent difficulties in surgery in performing randomised blinded trials. Individual case series, case reports, and expert opinion (levels III through V) can address some subtleties of surgical technique that are valuable to the practicing surgeon but not currently amenable to prospective, controlled, randomised trials[5]. Where appropriate these have been critically appraised and the level of evidence for key clinical recommendations indicated using the American Society of Plastic Surgeons (ASPS) Levels of Evidence Rating Scale for Therapeutic Studies (Appendix) [5].

Based on our findings we have provided an evidence-based step-wise process-based approach to the management of breast augmentation patients.

THE PROCESS OF BREAST AUGMENTATION

Definition

A process may be defined as a “Group of practices that are completed successfully to reach a goal” [6]. Adams and Mallucci have produced a comprehensive overview of breast augmentation and have recognised the importance of the process in achieving optimal results. [7] Adams has conducted a level II prospective cohort study in 300 breast augmentation patients to examine outcome following introduction of a comprehensive and defined process with a mean follow up of 2.1 years and overall reoperation rate of only 3.7 % [6]. In addition Adams analyzed two subcohorts within his study: saline and form-stable gel implants, comparing the process between these two groups, although he supplied no statistics in this part of the assessment. The respective reoperation rates were 4.7% and 2.9% for the saline

and form-stable implants. Adams [2, 3] validated his process for breast augmentation by comparing his data to Mentor and Inamed clinical trials data: when breast augmentation is seen as an isolated procedure there is a 15-24% reoperation rate.

Goals of the Process

Adams and Mallucci have clearly set out the goals for the process of breast augmentation [7]:

- To enhance the breast, producing a result that is pleasing and in proportion with the individual
- To minimise distortion through careful implant selection
- To avoid complications through good technique
- To achieve results with longevity

Tebbetts has succinctly stated in *primary* breast augmentation, the tissue environment and the decision processes by patient and surgeon are very different compared with breast reconstruction: in reconstruction, tissues are, by definition, already compromised or destroyed; a primary objective in primary augmentation is to avoid tissue compromise, reoperation, and deformities resulting from a primary, medically unnecessary operation [8].

In this chapter we will set out how to achieve these goals by respecting the natural proportions of the breast.

Primary Subprocesses

Adams and Mallucci have cited four primary goals for patient care in a recent CME article [7]:

1. Comprehensive Patient Education

The authors recommend that this should be performed by a patient education specialist prior to surgical consultation that enhances subsequent informed consent.

The principles of implant selection should be explained.

All attempts to ensure that patients have realistic expectations should be made.

Patients should be told that there is preoperative and postoperative asymmetry in 100% of patients [6].

Patients should understand the limitations of the procedure.

Patients should be provided with the knowledge for them to make sound decisions about their breast augmentation.

Rohrich and colleagues have published a retrospective study of 100 randomly selected patients assessed for nipple, breast mound and chest wall asymmetries by four independent physicians using standardised preoperative photographs [9]. They found significant asymmetries in all parameters, with nipple-areola complex position asymmetry in 53%, nipple-areola size asymmetry in 24%, mound asymmetry in 44%, inframammary fold position asymmetry in thirty percent and chest wall asymmetry in nine percent. Overall 88% of women exhibited some asymmetry, with 65% having more than one parameter of

asymmetry. The results of the study support the patient education recommendations by Adams and Mallucci with respects to preoperative counselling in terms of asymmetry.

2. Tissue-Based Preoperative Planning Evaluation

This is a crucial part of the process and is based on work by Tebbetts and Adams [6, 10, 11]. The basis of this approach is to use quantitative, objective data to enable objective rather than subjective decisions to be made with respect to preoperative planning. A number of systems have been described. In Europe Allergan has devised a computerised Biodynamic system: measurements are entered by the surgeon and the software computes a best fit implant. The drawback of this technique is that it uses external sizers tried on by patient, making it subjective. In the US Tebbetts and Adams have classified available tissue-based assessment systems into three generations as shown in Table 1 [12].

Table 1. US tissue-based assessment systems

Generation	Details of System
First	BioDimensional System (Inamed Corp.) Choosing an implant that forced tissues to match it
Second [11]	TEPID system: characteristics of breast Tissue, Envelope, Parenchyma, Implant, and implant Dynamics Defined measurements to match the implant to the patient's tissue characteristics and breast dimensions, instead of forcing tissues to a desired result
Third [12]	Key decision parameters and data from more than 2300 primary breast augmentations planned using the TEPID system were analyzed to define the five most critical decisions that affect reoperation rates and risks of uncorrectable deformities Uses 5 critical decisions to define a decision support process using five critical measurements

Tebbetts and Adams examined 1664 cases of breast augmentation planned using the TEPID system with up to seven years follow-up (although mean follow-up was not stated) in a level IV case series [12]. The overall reoperation rate was three percent, and reoperation rate for implant size exchange was 0.2 %. The junior author's (Adams) clinical experience included more than 300 augmentations with up to six years of follow-up using this system, with an overall reoperation rate of 2.8 %, relative to reoperation rates of seventeen percent rates in data from Mentor and McGhan which were submitted for their saline premarket approval studies in 2000 [13, 14]. As a result of this study the authors described five critical decisions in breast augmentation, which are shown in Table 2. The article provides a good system for implant choice, is quantifiable and had good numbers included in the study with good outcomes. The authors recommend their third generation published tissue-based system as the only one that uses measurements to determine optimal fill volume and an implant that fits the breast. In this part of the process observed dimensions are more important than volume, and these guide appropriate choice of implant. In this way it is possible to identify 'best fit' for the breast template causing as little distortion to the breast as possible, resulting in optimal fill while respecting natural boundaries.

3. Refined Surgical Technique

The surgical plan should be developed preoperatively following the surgeon's consultation. The authors recommend creating implant pockets under direct vision using careful prospective haemostasis techniques with no blunt dissection to minimise tissue trauma and ensure a rapid recovery [7, 15, 16].

Table 2. The five critical decisions in tissue-based preoperative planning

Decision	Measurement/ Comments
Implant plane	Determines soft-tissue coverage Determined by soft tissue pinch thickness
Implant volume	This is based on predicted tissue-based optimal fill volume of the breast: this is determined by breast base width with adjustments for skin stretch, and minor adjustments for nipple to inframammary fold distance and for estimates of parenchyma to stretched envelope fill (although this last parameter appears difficult to achieve in a fully quantitative way)
Implant type, size and dimensions	Based on discussion between patient and surgeon Base width of the implant selected should not exceed the base width of the patient's existing breast For ptotic breasts it is advisable to favor higher profile anatomical implants to inflate lower pole Where skin is poor and there is little parenchyma lower profile anatomical implants are the best choice
Optimal location of IMF	If the recommended intraoperative nipple to inframammary fold distance for the planned volume implant is greater than the patient's preoperative nipple to inframammary fold distance under maximal stretch, the surgeon should consider lowering the fold to the recommended level If the recommended nipple to inframammary fold distance is the same or longer than the patient's preoperative nipple to inframammary fold distance under maximal stretch, no lowering of the fold is indicated
Incision site	Based on patient preference and surgeons preference and skill set Inframammary, axillary, periareolar or umbilical

4. Strictly Defined Postoperative Plan

All patients should be given detailed defined postoperative instructions with respect to wound care, avoiding underwired bras, the need to keep mobile and when to commence light aerobic activity and more strenuous exercise.

BREAST AESTHETICS

When planning breast augmentation it is essential to have an aesthetic goal. Penn described a triangle of aesthetic proportion in relation to breast reduction [17]. However, it would be possible to have Penn dimensions and an unattractive breast due to the article lacking important definitions of proportion. Other authors have tried to recommend various proportions to define ideal breast proportions but have used random populations of women not chosen for the attractiveness of their breasts and made no attempts to define attractiveness [18].

We have recently identified four key parameters that may be using to assess good results in breast augmentation and as a guide in the design of aesthetic breast surgery [19]. In a quantitative observational study of 100 topless models chosen by the editors of mass print media for the attractiveness of their breasts, we identified specific proportions that were common to all of them (Figure 1, Table 3).

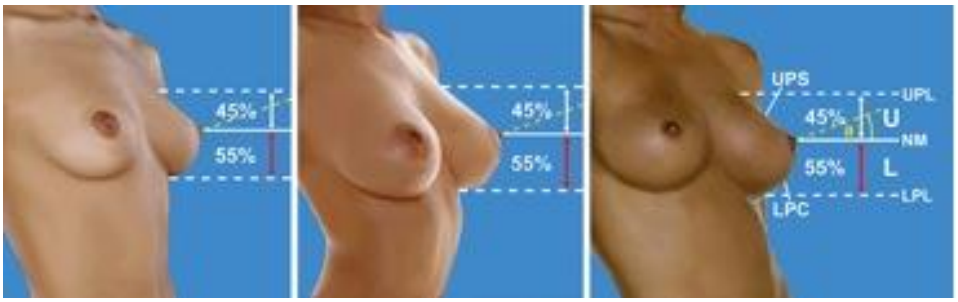

Figure 1. Three quarter profile view with standard breast parameters: U:L proportion, nipple angulation, contour of upper and lower poles. These images show three different breast sizes: all 3 models have a U:L ratio of 45:55, straight or concave upper poles, 20º upward angle of nipple pointing, and convex lower poles. U = Upper pole, L = Lower pole, UPL = Upper Pole Line, LPL = Lower Pole Line,nm = Nipple Meridian, UPS = Upper Pole Slope, LPC = Lower Pole Convexity, a = nipple angulation. [19]

Table 3. Results of analysis of breasts for four key features in 100 models [19]

Parameter	Result (n = 100)
Vertical Height of Upper Pole: Vertical Height of Lower Pole	45:55
Nipple Pointing from Horizontal	20º upwards
Upper Pole Contour (%) Concave: Straight: Convex	61:33:6
Lower Pole Convexity	Smooth convex curve in 100%

Our analysis revealed that the lower pole of the breasts was invariably fuller than the upper pole. The nipple meridian lay at a point such that on average the proportion of breast above it was 45% and below it 55%: the so called 45:55 ratio. In the vast majority of breasts the upper pole was either straight or concave (61% and 33% of cases respectively). The upper pole was convex in only six percent of cases. The angulation of the nipple was upwards from the horizontal at a mean angle of twenty degrees. In all cases the breasts demonstrated a tight convex lower pole. No ptotic breasts were seen. The results of our study may be used to guide implant selection, incision placement and pocket dissection in breast augmentation, to achieve consistently attractive aesthetic proportions. The aesthetic vocabulary generated by this study may also be used, for the first time, to quantitatively assess good and bad results in aesthetic surgery.

The importance of nipple position in determining breast attractiveness has also been suggested by other authors, although they did not define what the ideal nipple position should be, and they did not define attractiveness as the study examined just ten patients out of a random selection of volunteers [20].

PREOPERATIVE ASSESSMENT

It is extremely important to identify, record and point out asymmetries to patients preoperatively. Structural asymmetries should be noted, including pectus excavatum/ pectus carinatum, sternal rotation, scoliosis and thoracic hypoplasia, which is the most common abnormality. The lie of the breast on chest wall should be recorded, especially lateralisation of the nipple and breast, as the postoperative intermammary distance is determined by the preoperative state.

The minimum recommended preoperative measurements are shown in Table 4.

It is also useful to make as assessment of parenchymal fill as percentage of volume of skin envelope, although this is difficult to do in a quantitative way.

The most important of these parameters in determining implant selection is breast width, with skin stretch of envelope being the next most important factor[12]. The other dimensions will further guide the selection process but to a lesser extent. Chest wall shape and anomalies will determine implant height and projection.

Table 4. Recommended preoperative breast measurements in breast augmentation

Measurements	Comments
Soft-tissue pinch thickness:	Pinch with index and thumb and measure using other hand using calipers
Of upper pole	If <2cm then choose dual plane or partial retropectoral [15]
Of lower pole (at inframammary fold)	If <0.5 cm, surgeon preserves intact pectoralis muscle origins along IMF for additional coverage, creating a partial retropectoral pocket (compared with a dual-plane pocket) [15]
Breast base width	Using calipers From parasternal origin of pectoralis major to lateral aspect of breast
Degree of skin stretch	Done by measuring the forward displacement of areolar skin during maximal pull Care must be taken not to cause discomfort
Nipple to sternal notch	
Breast height	
Nipple to inframammary fold distance	On maximum stretch
Intermammary distance	

CONSENT AND COMPLICATIONS

The complications that should be discussed preoperatively have been succinctly summarized by Adams and Mallucci (Table 5) [7]:

Table 5. Complications in breast augmentation

Complication
Bleeding/hematoma (1% risk)
Infection (should be 1% risk)
Use of drains
Seroma
Sensory changes to the nipple and or breast (common in the short term)
Scarring
Asymmetry
Implant visibility/palpability
Implant rippling
Malposition of the implant
Implant rupture (1-2% at 10 years)
Implant rotation (anatomical) (2%)
Soft-tissue stretch (stretch marks)
Glandular atrophy (over time)
Galactorrhea
Capsular contracture (5% for textured silicone)
Anaplastic large cell lymphoma (implant related) (see below)
Need for reoperation at some stage in the future (approximately 20% at 10 years)
Mammography plus breast cancer detection
Silicone controversy
Financial implications for the future

Anaplastic Large Cell Lymphoma

Jewell and colleagues have reviewed the current evidence relating to possible associations between breast implants and Anaplastic Large Cell Lymphoma (ALCL), a rare non-Hodgkin's lymphoma [21]. They found eighteen publications describing 27 cases of ALCL in breast implant recipients: 78% of cases had an indolent course. There is no prospective epidemiological study in the literature linking implants and ALCL although there are seven such studies that suggested that the observed non-Hodgkin's lymphoma cases were comparable to expected non-Hodgkin's lymphoma cases based on population rates.

In a Level III systematic review Kim and colleagues found that when ALCL does occur around breast implants it seems to develop in the capsule surrounding the breast implant and/or presents as an unexplained seroma or mass and may only require removal of the implant and capsulectomy, with clinical follow up. This may simply reflect a different pattern of breast cancer seen in breast implant patients rather than an increase in the condition. Ultimately, understanding the biology, treatment, and prognosis of implant-associated ALCL will require substantial research efforts, such as in vitro experiments using immortalised implant-associated ALCL cell lines, collection of detailed clinical information in breast implant registries, and well-designed epidemiologic studies [22]. ALCL remains a rare

association without evidence of causation, occurring at a frequency of one in one million women with and without breast implants [23].

In a more recent Level V article by Kim and colleagues conducted a structured expert consultation process consisting of a multidisciplinary panel of ten experts, selected based on nominations from national specialty societies, academic department heads, and recognised researchers in the United States [24]. The panellists agreed that:

There is a positive association between breast implants and ALCL development but likely under recognition of the true number of cases.

A recurrent, clinically evident seroma occurring six months or more after breast implantation should be aspirated and sent for cytologic analysis.

Anaplastic lymphoma kinase-negative ALCL that develops around breast implants is a clinically indolent disease with a favourable prognosis that is distinct from systemic anaplastic lymphoma kinase-negative ALCL.

Management should consist of removal of the involved implant and capsule, which is likely to prevent recurrence, and evaluation for other sites of disease.

Adjuvant radiation or chemotherapy should not be offered to women with capsule-confined disease.

Little agreement, however, was found regarding etiologic risk factors for implant-associated ALCL and further research is needed to improve our understanding of the epidemiology, clinical aspects, and biology of this disease.

CHOICE OF IMPLANT

Filler

Saline vs. Silicone

Saline implants exhibit several problems, such as palpability, underfilling, overfilling, deflation and they have a firmer consistency and unnatural feel, compared with silicone implants [25]. The saline vs silicone debate has a long history based more on a series of unfounded health scares and high profile media cases under the auspices of biased regulatory bodies than patient satisfaction with their implants. Anecdotal data and individual case reports of possible systemic symptoms that were associated with patients who had received silicone breast implants led to a reclassification of this type of implant by the FDA in 1988. This reclassification and the FDA requirement that manufacturers obtain premarket approval of the implant before making it available for widespread sales generated a public controversy in 1990 and 1991. The result of the controversy was a ban of the silicone gel implant for augmentation mammaplasty in the US and a restriction of its use to mastectomy reconstruction to patients who were enrolled in a restrictive trial protocol entitled the "Silicone Gel Adjunct Study". The moratorium on use of silicone implants lasted between 1992 and 2006.

Silicone implants have been approved for general use since the 2006 following Food and Drug Administration (FDA) clinical trials and panel hearings. Over 25 Level II and III scientific studies, some involving up to several hundred thousand subjects each, and over ten Level I meta-analyses (quantitative systematic reviews) show no link between breast

augmentation and autoimmune connective tissue disease [26]. Court-appointed national science panels [27] and the Institute of Medicine report entitled "Safety of Silicone Breast Implants" [28] also found no evidence that systemic disease is associated with breast implants. Despite this almost unequivocal evidence there is still some resistance from anti-implant groups, supported by repeated FDA scares often based on conjecture, anecdotal or individual case reports relating to different aspects of breast augmentation, prior to studies being developed to show that these are frequently unfounded concerns in the clinical setting. It is clear from the evidence that the burden of proof lies heavily with the profession and not with regulatory authorities, and may be related more to the FDAs fear of litigation than their scientific objectivity [29, 30].

There have been problems with junk science, sensationalist media, and legal battles based on lawyers playing on the emotion of juries rather than scientific method [31]. However, regardless of the level of regulation, the plastic surgical profession does need to play a role in auditing outcomes and contribute to research into new implants [32]. In this way problems such as have been seen with a higher than expected rupture rates associated with the use of poor quality implants such as the Poly Implant Prothése (PIP) implants, with unauthorised industrial grade silicone as a filler material, manufacturing defects, shell thickness variation and inadequate quality control [33], will be detected more rapidly. It would be best for patients if regulatory bodies and governments work together with surgeons with the common goal of achieving consistent results with optimum safety

Silicone implants are used in Europe and the rest of world outside the United States due to their superior feel and durability. The silicone gel in these implants has been made to be progressively more cohesive by cross-linking of silicone. This gives the implants a firmer consistency, making them form-stable: the implants maintain their shape without collapsing and are resistant to deformation by the surrounding soft tissue envelope and capsular contracture. The gel in such implants does not extrude from the implant through violations of envelope integrity. However, due to these reasons of resistance to deformation, the use of form-stable implants requires an even more careful evaluation of the patient's chest dimensions to determine the appropriate style of implant in order to avoid distortion [25].

Other Implant Fillers

Trilucent (soybean oil) implants have also been used and were vigorously marketed as having the advantages of a natural composition and radiographic translucency. These were withdrawn from use due to elevated carcinogen levels being detected in the breakdown product of soya Hydrogel implants. The Medical Devices Agency in 2000 recommended that all Trilucent breast implants should be removed from patients. The safety of the implants were questioned in two cases where Trilucent implants caused symptomatic local tissue reactions and capsule histology showed inflammatory changes [34]. Rizkalla and colleagues found in a Level IV case series that free oil was found around the implant in 34% of patients, concluding that the implants tended to bleed [35]. Kirkpatrick and Jones examined 51 explanted Trilucent implants and two factory-retained prostheses, and found that the soybean oil in all of these had undergone peroxidation, yielding potentially genotoxic aldehyde by-products [36]. The concentrations were 1000 times that thought to be potentially genotoxic. In a more recent multicentre study to assess the potential hazards from exposure to these lipid peroxidation products Williams and colleagues found although explanted Trilucent implant

soybean oil filler contained substantial levels of genotoxic lipid peroxidation products, particularly malondialdehyde, no progenitors of breast carcinoma were seen. Further, the location of the implants precluded these products from reaching the mammary epithelial cells which are progenitors of breast carcinoma [37]. The authors also found that blood levels of the peroxidation products were not elevated.

Hydrogel breast implants were withdrawn from use in the UK in 2000 due to concerns about the metabolic fate of the implant filler material, the hydrogels polyvinylpyrrolidine (PVP) and guar gum. In a retrospective audit of 66 women Hardwicke and colleagues reported that the implants also had double the implant rupture rate of saline-filled implants. The authors hypothesised that an osmotic gradient occurred due to the hydrogel filler causing the implants to swell and weaken the elastomer shell, leading to the observed implant rupture. A vigorous inflammatory tissue reaction was seen when PVP and guar gum filler were released into the subcutaneous tissues, causing pain and swelling [38].

As a result none of these implants using alternate implant fillers are in current use.

Surface Texturing

Smooth vs. Textured

Surface textured implants were designed to mimic the polyurethane implant rough porous surface and two percent capsular contracture rate [39]. Textured implants come at a cost of more visible rippling and greater palpability, as well as greater cost for the implants [25]. However, the most important difference between smooth and textured implants is with respect to the associated rates of capsular contracture. In an early retrospective level III study Ersek showed compared the rate and incidence of capsular contracture of smooth and textured silicone breast implants, showing that moderate to severe capsular contracture occurs in up to 45% of patients for smooth implants and five percent for textured implants [40].

Level I studies have not supported surface texture reducing capsular contracture in the subpectoral plane, although there may be benefit in the subglandular plane [41-43]. In a level I meta-analysis of seven randomised controlled trials Barnsley and colleagues found that only three of these studies found significantly reduced rates of capsular contracture with the use of textured implants [44]. However the authors found that when all seven studies were pooled there was a protective effect for surface texturing on the rate of capsular contracture with an odds ratio of 0.19. Again the authors found that there was no significant difference when comparing contracture rates between smooth and textured implants in the submuscular plane, although this subgroup was from a single study that was underpowered. These findings may be attributable to capsular contracture being more difficult to appreciate in the deeper submuscular plane or textured surface implants having no impact on capsular contracture when placed submuscularly. Similarly, in another level I systematic review, Wong and colleagues examined six randomised controlled trials and found that the relative risk of capsular contracture when comparing smooth and textured implants was four at one year, seven at three years and three at seven years [41].

Shape

Customization of implants by implant companies allows for different projections for a given volume. Published series indicate that moderate projection devices have the lowest reoperation rates and rates of uncorrectable deformities [11, 12, 15, 45]. Tebbetts has warned against the use of high- or extra-high-projection implants for primary breast augmentation and that a wide range of primary augmentation can be adequately treated with moderate projection devices [8].

Implants may be round or anatomical (also known as "tear-drop" or shaped implants). These latter are devices where the vertical axis is different in dimension than the horizontal axis [25]. Anatomic implants allow for even greater variability in implant selection allowing for choice of width, height and projection. For example, tall teardrop shapes are best suited for patients with a long chest or low breast position [25], and a "reduced height"–shaped device creates a relatively exaggerated width with abbreviated height to decrease upper-pole fullness [46].

There has been controversy as to whether anatomic implants are really anatomic and whether round implants behave anatomically *in vivo*. In a review article on breast augmentation Spear has stated that overall with an anatomically shaped implant there is a diminished tendency toward upper-pole bulges, roundness, or distortion and greater volume support for the lower breast, particularly in thin patients, those with a high inframammary crease, ptotic patients, and those with a vertically or horizontally deficient chest [25].

The indications for implant shape have been succinctly summarised by Adams and Mallucci [7]:

Round
Fuller appearance
Small volumes (less impact at small volumes)
Good anatomy and skin quality
Previous rotation
Athletic individuals (rotation)
Certain breast/chest wall shapes

Anatomical
Desire for natural appearance (Figure 2 and Figure 3) and implant that 'fits' their breast
Constricted lower pole
Thoracic hypoplasia
Breast reconstruction
Mild ptosis or pseudoptosis

In addition in a recent study by Cárdenas-Camarena and Encinas-Brambila examining whether round or anatomical implants should be chosen the authors concluded that specific clinical features should determine implant selection [47].

Figure 2. Preoperative anteroposterior view and three quarter views of patient requesting breast augmentation.

Figure 3. Postoperative anteroposterior view and three quarter views of patient from Figure 2 post symmetrical anatomical breast augmentation demonstrating an attractive natural appearance with upward pointing nipples, a slight concavity to the upper pole and a full convex lower pole as described in our recent study [19].

They suggested that anatomical implants should be used for patients with significant differences in chest height and width measurements, for cases of significant mammary asymmetry, for patients with a small breast volume, and for breasts with a significant deficit of inferior mammary volume or significant shortening of the breast. The authors recommended round implants for patients with a superior pole deficit or moderate breast pseudoptosis, for patients with a breast that will cover the implant, and for patients with a small asymmetry.

It would follow that for patients with breast asymmetry where one breast fits into the first clinical category and the other into the second that these patients should be treated with an anatomical implant on one side and a round implant on the other. We have reported a case of

breast asymmetry where the principles of biodimensional implant selection have been used resulting in selection of a round implant on one side and an anatomical implant on the other side in the same patient [48]. To our knowledge, prior to our case, a round implant and an anatomical implant have not been previously employed in the same patient to correct asymmetry. We simply chose the best fit based on breast and chest wall dimensions, choosing asymmetric (different volume) asymmetric (different shaped) implants. The same biodimensional approach should be applied to both round and anatomical implants. Surgeons should have the confidence in being able to step between the two implant shapes based on dimension rather than compartmentalizing them away from each other: In this case we have crossed the boundary between anatomical and round implant selection.

Generations of Breast Implants

Cronin and Gerow were the first to use a silicone prosthesis for breast augmentation in 1961 [49], replacing the antecedent, less well tolerated practice of injecting silicone directly into breasts targeted for augmentation. There has been an evolution in every aspect of the devices (Table 6).

Table 6. Generations of breast implants [7]

Implant Generation	Production Period	Characteristics
First	1960s	Thick shell (0.25-mm average); thick, viscous gel; Dacron patch
Second	1970s	Thin shell (0.13-mm average); less viscous gel; no patch
Third	1980s	Thick, silica-reinforced, barrier coat shells
Fourth	1992–present	Stricter manufacturing standards; refined third-generation devices
Fifth	1993–present	Cohesive silicone gel–filled devices; form-stable devices

The current breast implants are fifth generation: the Style 410 implant being the first of the fifth-generation implants, distinguished by its highly cohesive, form-stable, silicone gel filler. The extent of cross linking of the silicone polymers during the manufacturing process is what determines the firmness of the silicone gel. As mentioned previously, when the filler crosslinking occurs to the degree that the silicone gel breast implant will maintain its dimensions and form (i.e., gel distribution within the shell) in any position, the cohesive gel implant is said to be form-stable [50]. In a Level II prospective, multicentre, non-randomised Investigational Device Exemption study with three-year follow-up data Bengtson and colleagues examined clinical outcomes and patient satisfaction in 941 patients undergoing highly cohesive anatomical silicone breast implantation (492 subjects underwent primary breast augmentation) and found that the Allergan Style 410 has low complication rates and high satisfaction rates. [51] Implant malposition was the most common complication (2.6%) and all other complications occurred in less than two percent of augmentation subjects, with Baker grade III and IV capsular contracture in 1.9%, and implant rupture occurring in 0.7%.

The risk of reoperation, another key safety endpoint, was 12.5%, with the primary reason being implant malposition. More than half of patients having their implants removed did so to change the size or style. This study reaffirms the safety of modern implants, and highlights the importance of careful preoperative planning in order to reduce reoperation rates. Hedén reported similar results in an earlier study of 1676 implants, the largest series in the world, using the Inamed Style 410 Matrix implant system, with four percent capsular contracture, less than one percent rotation, and less than one percent device rupture [52]. Not all form-stable implants are equal: in a Level II prospective cohort study comparing highly cohesive, form-stable breast implants Jewell and Jewell showed that rippling was significantly lower for the Allergan Natrelle 410 implant relative to the Mentor Contour Profile Gel, with rates of 7.6% and 37.3% respectively [53].

PREOPERATIVE MARKING

Preoperative markings are shown in Figure 4 in a patient with significant chest wall and breast asymmetry. Anteroposterior preoperative (Figure 5) and postoperative (Figure 6) photographs of the same patient are also shown.

Mark midline, inframammary folds (IMFs) and orientation marks (medial line on areola).

Once the implant dimension and nipple to IMF distance are known the surgeon can decide on the location of the inframammary incision – if the nipple to IMF distance is shorter than the implant dimension the incision will be below IMF so that it will lie in the IMF postoperatively.

Mark a 4-4.5cm incision commencing 1cm medial to areola going laterally.

Mark medial and lateral width of pocket using callipers to delineate this on the skin.

Mark height of pocket based on implant height going up from level of incision.

Figure 4. Preoperative skin markings in a patient with significant chest wall and breast asymmetry showing midline, inframammary fold, pocket size and incision markings.

Figure 5. Preoperative anteroposterior view of patient marked in Figure 2 showing significant asymmetry.

Figure 6. Postoperative anteroposterior view of patient marked in Figure 2 following asymmetric anatomical implant insertion.

INCISION PLACEMENT

Choices for incisions in breast augmentation are inframammary, periareolar, transaxillary, and transumbilical. In addition, an endoscope may be used for assistance [54]. In general, the inframammary and periareolar approaches will provide improved access as compared with the axillary or transumbilical approaches [25, 55]. However, there are other factors that may certainly influence the choice of incision. A very thin Asian patient without significant breast tissue, lacking a defined inframammary fold, may be at risk for increased prominence of an inframammary scar. An extremely small areola may limit the access

potential through this approach in these patients. Such factors should be taken into account when considering incision choices [56]. Adams and Mallucci have succinctly summarised the advantages and disadvantages of the various different incisions as shown in Table 7 [7].

Table 7. Advantages and disadvantages of incisions [7]

Incision	Advantages	Disadvantages
Inframammary	Most control Ability to manipulate/set inframammary fold Least implant effects (trauma and contamination)	Scar not ideal unless planned properly
Periareolar	Good access to breast Scar can be very well disguised usually	Can result in poor scarring; higher capsular contracture rates Contamination theory Nipple-areola complex sensitivity more affected
Transaxillary	No scar on breast	Remote from pocket; tends to promote blunt dissection Less controlled pectoralis major release unless endoscopically assisted Dual-plane dissection not possible

THE IMPLANT POCKET

Pocket Choice

Implant placement may be subglandular, subpectoral, total submuscular, or "dual plane". Tebbetts has summarised the tradeoffs and potential benefits of each pocket type, as shown in Table 8 [15]. The patient's breast habitus, including shape and tissue characteristics, should also be considered when making this choice. In a level III retrospective comparative analysis Biggs and Yarish shown that submuscular placements, whether partial or total, have a lower capsular contracture rate than subglandular placements [57].

In addition, the subglandular position places the implant closer to the skin surface, thereby increasing the potential for palpable or visual irregularities, particularly in patients with a paucity of breast tissue. The submuscular (or subpectoral) plane is preferable in achieving accurate mammography [58].

Currently, the total submuscular position for implant placement in breast augmentation is used infrequently. It requires a subserratus anterior dissection for a portion of the pocket development, which is an unnatural plane. Other potential disadvantages are disruption of the inframammary fold and a distortion of lower pole shape [56].

Table 8. Choice of pocket

Pocket	Tradeoffs	Potential Benefits
Subglandular/ Retromammary (when pinch test >2-3 cm)	• Increased risk of edge visibility or palpability. • Possible increased interference with mammography. • Possible increased incidence of capsular contracture.	• Increased control of breast shape. • Usually a more rapid postoperative recovery. • Minimal or no distortion with pectoralis contraction. • Increased control of inframammary fold position and shape.
Partial retropectoral (without dividing pectoralis origins along the inframammary fold)	• Lateral implant displacement over time, widening the space between the breasts. • Less control of upper medial fill. • More postoperative tenderness and a more prolonged recovery. • Distortion of breast shape with pectoralis contraction. • Less precise control of inframammary fold position, depth, and configuration. This potential tradeoff is minimised or eliminated by division of pectoralis origins along the inframammary fold in patients who have adequate soft-tissue coverage. • Increased risk of superior implant malposition or displacement (when inferior pectoralis origins across inframammary fold are not divided). • Longer time required for deepening of the inframammary fold (when pectoralis origins along the inframammary fold are not divided	• Muscle coverage mandatory if pinch thickness <2cm above breast parenchyma. • Possibly more accurate mammograms. • Less risk of palpable or visible implant edges. • Possible decreased risk of capsular contracture (small difference with saline-filled implants, greater difference with silicone gel-filled implants).
Total submuscular	• All tradeoffs listed above for partial retropectoral, plus: • Highest risk of superior implant displacement or malposition. • Longer operative time. • Longest postoperative recovery and morbidity. • Least accurate and predictable • inframammary fold and longest to achieve depth. • Greatest risk of inframammary fold irregularities, lateral flattening, and fold level inaccuracies.	• Possible increased coverage inferolaterally but clinically no significant additional cover long-term.

Tebbetts has described a dual plane technique in a level II prospective comparative study [15]:

Definition: Implant lies partially behind the pectoralis major muscle *and partially behind the* breast parenchyma.

Totally divide specific origins of pectoralis major to reposition the muscle relative to implant.

Parenchyma-muscle interface is specifically altered to change implant-parenchymal dynamics. Parenchymal attachments to muscle are freed by dissecting in retromammary plane to different degrees depending on breast type as set out in Table 9.

Table 9. The Dual Plane technique [15]

Plane	Dissection
Dual plane I	Division of inferior pectoral origins only with no division of pectoral origin along the sternum
Dual plane II	Division of inferior origins with no division of pectoral origin along the sternum + release of anterior pectoral fascial attachments to gland with rotation upwards of inferior origin to level of inferior areolar border
Dual plane III	Division of inferior origins with no division of pectoral origin along the sternum + release of anterior pectoral fascial attachments to gland with rotation upwards of inferior origin to level of upper areolar border

The advantages of the dual plane technique as stated by Tebbetts are shown in Table 10. While good numbers were included in this study 468 patients (936 breasts), the distribution of patients to dual-plane type was not randomised but based on breast type. In addition the approach and implant type was not randomised but based on patient preference. Tebbetts did not say whether the results were graded by independent observers or the author, although patient satisfaction was assessed. No statistical or significance data was provided in this study.

Table 10. Advantages of dual plane technique [15]

Advantages
Good upper pole/medial cover
Improved draping of lower pole of breast over implant
Reduction in pectoralis animation
Lower capsular contracture rates [59]
Good mammographic visibility of the breast
Maximises benefits of retromammary and partial retropectoral approaches while minimizing tradeoffs
May be used in wide range of breast types
Adjusts implant-soft-tissue relationships to ensure adequate soft-tissue coverage while optimizing implant-soft-tissue dynamics
Adds options for treating breasts with highly mobile parenchyma, glandular ptotic breasts and constricted lower pole breasts

Pocket Dissection

This has been elegantly described by Tebbetts, Adams and Mallucci [7, 15]:

Start medially then sweep laterally.

Identify pectoralis major/pectoralis minor division in upper third of pocket and serratus anterior muscle.

Come medially superiorly again and divide and accessory medial pectoral origins, but not the main origin.

'Prospective haemostasis' and diathermy perforators before cutting them. Adams uses monopolar forceps to do the dissection.

Pocket Preparation and Irrigation

Burkhardt and colleagues conducted two prospective controlled blinded clinical studies on the use of a povidone-iodine containing solution irrigation of the pocket [60, 61]. In the first of these studies the authors failed to show a reduction in the risk of capsular contracture [60]. However in a later study Burkhardt and colleagues showed a significant reduction in class III-IV capsular contracture from saline-irrigated implant to implants irrigated with Betadine solution (27% vs. 10% respectively) [60, 61]. However, the results may have been influenced by the fact that more of the Betadine-irrigated devices were textured, which may have reduced capsular contracture rates, favourably distorting the results. Also, using the smooth, saline-irrigated implants as their standard the authors failed to show that the Betadine solution alone (or texturization alone) was able to significantly reduce capsular contracture rates, however when combined this did significantly improve outcomes as a cumulative effect.

Adams conducted a level IV prospective case series [62] demonstrating a low incidence of capsular contracture using triple antibiotic breast irrigation in 165 patients undergoing primary breast augmentation. They showed a Grade III/IV capsular contracture of 1.8% compared with 9% in other published reports [63-65]. However the authors changed their antibiotic regime half way through the study (from povidone-iodine/cefazolin/gentamicin to bacitracin/cefazolin/gentamicin) due to the U.S. Food and Drug Administration's ban on povidone-iodine use during placement of breast prostheses (this ban was introduced despite the absence of any evidence that extraluminal povidone-iodine contributes to implant shell failure). The study had a mean follow-up of only fourteen months, although the authors noted that all contractures occurred within one year of surgery.

Pajkos and colleagues conducted a level II comparative prospective, blinded, clinical study of implants and capsules removed from patients with or without significant capsular contracture to investigate the association of biofilm contamination, breast implants, and capsular contracture [66]. They tested the capsule and implant samples by routine microbiological culture, sensitive broth culture and scanning electron microscopy. They found that routing swab cultures were negative in all samples. The sensitive broth culture samples were positive in seventeen of nineteen samples from patients with significant contractures, compared with only one out of eight samples obtained for patients with minimal or no contracture, a highly significant difference. Fourteen of the seventeen positive cultures from significantly contracted breasts yielded coagulase-negative staphylococci, mainly species of the *Staphylococcus epidermidis* group.

Taken together these reports add to the theory that the biofilm is implicated in the pathogenesis of contracture, and that steps should be taken to prevent its formation [66, 67].

POSTOPERATIVE MANAGEMENT

There is little evidence-based support for any specific postoperative recommendation, but general recommendations include mobilizing the patients early to reduce the incidence of complications and wearing a non-underwired supportive/sports bra six weeks postoperatively. Spear recommends the use of a support brassiere with a binder strip placed across the superior pole for ten to fourteen days to minimise the risk of rotation when using anatomic implants [25].

FAT TRANSFER AND BREAST AUGMENTATION

The use of fat injection to the breast as an alternative to the use of implants in breast augmentation remains controversial [68, 69]. Khouri and colleagues have advocated the use of a bra-like vacuum-based external tissue expander, the Brava device, prior to and following fat transfer, reporting highly significantly improved mean augmentation volumes (233ml versus 134ml) and graft survival (82% vs. 55%) in a level IV prospective multicentre study which was compared with a meta-analysis of six published reports [70].

Fat transfer for breast augmentation is being used increasingly and a large number of studies have appeared in the scientific literature, some with a large number of patients and with relatively long follow up for at least a proportion of those patients studied [68]. Delay and colleagues retrospectively examined their patients in a level IV study undergoing 880 procedures over ten years [71]. Breast reconstruction procedures accounted for 734 of these procedures and 30 were for aesthetic breast surgery. The authors found no increased risk of local recurrence of breast cancer or development of a new cancer in their first patients with ten-year oncological follow up. A number of studies appear to have settled the debate over whether breast augmentation with autologous fat leads to calcifications and cysts that might hinder mammographic examinations for the detection of breast cancer [68]. The postoperative radiologic appearance is usually that of normal breasts, sometimes showing images of fat necrosis that will not confuse the differential diagnosis of cancer for radiologists experienced in breast imaging [71]. Delay and colleagues acknowledged that for their study this finding was in a group of patients who had been treated by a surgical team that had completed its learning curve with modern approaches to fat transfer and with good communication with specialised radiologists familiar with the images produced by fat transfer. The authors advocated that in the context of fat injection for aesthetic surgery the principal radiologic risk is that a breast cancer may occur at the same time as lipomodelling. They recommended that in order to reduce this risk, imaging investigations (mammography and ultrasound) should be carried out before lipomodelling by a specialised radiologist in order to ascertain the absence of a suspicious lesion. The authors advocated that if there is any doubt, lipomodelling is deferred or contraindicated. The authors also advised a one-year postoperative radiological assessment. They felt that sufficient volume could be obtained for lipoaugmentation to be effective in patients requesting a natural appearance with a moderate increase in volume, with sufficient donor adiposity. Delay also advocated fat transfer as an adjunctive treatment for the imperfections and complications of implants.

In a recent level V prospective case series in twelve patients using pre- and postexplantation three-dimensional imaging Del Vecchio has shown that fat transfer may be used in combination with preexpansion of the breast subcutaneous tissue (the "third space") to achieve comparable breast volumes in patients requesting removal of their implants in a single stage [72]. However the theoretical risk of promoting breast malignancy or recurrence remains, mediated by mechanisms such as the expression of protumorigenic factors (such as aromatase) by cells within the graft, angiogenesis and the transformation of stem cells within the graft [73]. The concerns regarding aromatase may be reduced by injection into subcutaneous tissue or under the gland rather than into the parenchyma, and angiogenesis is only transient following fat grafting [68]. There is currently no laboratory evidence that cells present within the adipose tissue graft represent any meaningful risk of malignancy [68]. Although it is difficult to extrapolate the results of laboratory studies to the clinical setting, it is unlikely that fat transfer will be adopted universally until longer term clinical studies have provided a more definitive answer. However, the fact that published clinical studies describing outcomes of fat grafting to the breast in more than 2000 patients have not reported any increase in new or recurrent cancers is encouraging [68].

In a level IV study Rigotti and colleagues evaluated 137 patients treated with autologous fat grafting for cosmetic defects or following modified radical mastectomy [74]. All patients had at least three years of follow-up after fat grafting with a median follow-up of 7.6 years. The study evaluated local recurrence of breast cancer during two periods: the period between initial surgery and fat grafting, and the period between fat grafting and follow-up. The breast cancer local recurrence rate during the pregraft period was 9.1 cases per 1000 patient-years compared with 7.2 cases per 1000 patient-years in the period after fat grafting, with no statistical significance between the groups. The outcomes of definitive larger, prospective, multicentre randomised controlled clinical studies and or a robust international registry with long-term follow up with adequate serial pre- and posttreatment radiological examination are eagerly awaited by both patients and the plastic surgical community. Until then, it should be advised that lipofilling should be performed only in experienced hands in the context of cautious oncologic follow-up [75].

CONCLUSION

In this chapter we have demonstrated using the best available evidence that breast augmentation is a process, and that if it is approached with the principles that we have delineated, patients are likely to be highly satisfied, with improved outcomes including the lowest possible complication rate and reoperative requirement.

REFERENCES

[1] American Society of Plastic Surgeons. *2013 plastic surgery procedural statistics*. Available at: http://www.plasticsurgery.org/news/plastic-surgery-statistics/2013.html.

[2] Mentor Corp. Silicone gel and Saline Implant PMA Clinical Trials. Available at: http://www.fda.gov/cdrh/breastimplants/index.html.

[3] Inamed Corp. *Silicone gel and Saline Implant PMA Clinical Trials.* Available at: http://www.fda.gov/cdrh/breastimplants/index.html.
[4] Sinno H, Neel OF, Lutfy J, Bartlett G, Gilardino M. Level of evidence in plastic surgery research. *Plast Reconstr Surg*.127:974-980.
[5] Sullivan D, Chung KC, Eaves FF, 3rd, Rohrich RJ. The level of evidence pyramid: indicating levels of evidence in Plastic and Reconstructive Surgery articles. *Plast Reconstr Surg*.128:311-314.
[6] Adams WP, Jr. The process of breast augmentation: four sequential steps for optimizing outcomes for patients. *Plast Reconstr Surg*. 2008;122:1892-1900.
[7] Adams WP, Jr., Mallucci P. Breast augmentation. *Plast Reconstr. Surg*. 2012;130:598e-612e.
[8] Tebbetts JB, Teitelbaum S. High- and extra-high-projection breast implants: potential consequences for patients. *Plast Reconstr Surg*.126:2150-2159.
[9] Rohrich RJ, Hartley W, Brown S. Incidence of breast and chest wall asymmetry in breast augmentation: a retrospective analysis of 100 patients. *Plast Reconstr Surg.* 2006;118:7S-13S; discussion 14S, 15S-17S.
[10] Tebbetts JB, Adams WP. Five critical decisions in breast augmentation using five measurements in 5 minutes: the high five decision support process. *Plast Reconstr Surg*. 2005;116:2005-2016.
[11] Tebbetts JB. A system for breast implant selection based on patient tissue characteristics and implant-soft tissue dynamics. *Plast Reconstr Surg*. 2002;109:1396-1409; discussion 1410-1395.
[12] Tebbetts JB, Adams WP. Five critical decisions in breast augmentation using five measurements in 5 minutes: the high five decision support process. *Plast Reconstr Surg*. 2006;118:35S-45S.
[13] McGhan Medical Corporation. *Saline-Filled Breast Implant Surgery: Making an Informed Decision*. Santa Barbara CMMC, 2000. Pp. 10–18.
[14] Mentor Corporation. *Saline-Filled Breast Implant Surgery: Making an Informed Decision*. Santa Barbara CMC, 2000. Pp. 11–19.
[15] Tebbetts JB. Dual plane breast augmentation: optimizing implant-soft-tissue relationships in a wide range of breast types. *Plast Reconstr Surg*. 2001;107:1255-1272.
[16] Tebbetts JB. Achieving a predictable 24-hour return to normal activities after breast augmentation: Part II. Patient preparation, refined surgical techniques, and instrumentation. *Plast Reconstr Surg*. 2002;109:293-305; discussion 306-297.
[17] Penn J. Breast reduction. *Br. J .Plast Surg.* 1955;7:357-371.
[18] Hauben DJ, Adler N, Silfen R, Regev D. Breast-areola-nipple proportion. *Ann. Plast Surg.* 2003;50:510-513.
[19] Mallucci P, Branford OA. Concepts in aesthetic breast dimensions: analysis of the ideal breast. *J. Plast Reconstr Aesthet. Surg*. 2012;65:8-16.
[20] Fabie A, Delay E, Chavoin JP, Soulhiard F, Seguin P. [Plastic surgery application in artistic studies of breast cosmetic]. *Ann. Chir Plast Esthet.* 2006;51:142-150.
[21] Jewell M, Spear SL, Largent J, Oefelein MG, Adams WP, Jr. Anaplastic large T-cell lymphoma and breast implants: a review of the literature. *Plast Reconstr Surg*.128:651-661.
[22] Kim B, Roth C, Chung KC, et al. Anaplastic large cell lymphoma and breast implants: a systematic review. *Plast Reconstr Surg*.127:2141-2150.

[23] de Jong D, Vasmel WL, de Boer JP, et al. Anaplastic large-cell lymphoma in women with breast implants. *JAMA*. 2008;300:2030-2035.
[24] Kim B, Roth C, Young VL, et al. Anaplastic large cell lymphoma and breast implants: results from a structured expert consultation process. *Plast Reconstr Surg*.128:629-639.
[25] Spear SL, Bulan EJ, Venturiml. Breast augmentation. *Plast Reconstr Surg.* 2006;118:188S-196S; discussion 197S-198S.
[26] Janowsky EC, Kupper LL, Hulka BS. Meta-analyses of the relation between silicone breast implants and the risk of connective-tissue diseases. *N. Engl. J. Med.* 2000;342:781-790.
[27] Tugwell P, Wells G, Peterson J, et al. Do silicone breast implants cause rheumatologic disorders? A systematic review for a court-appointed national science panel. *Arthritis Rheum*. 2001;44:2477-2484.
[28] Marwick C. Are they real? IOM report on breast implant problems. Institute of Medicine. *JAMA*. 1999;282:314-315.
[29] Macklin R. Ethics, epidemiology, and law: the case of silicone breast implants. *Am. J. Public Health*. 1999;89:487-489.
[30] Annas GJ. Burden of proof: judging science and protecting public health in (and out of) the courtroom. *Am. J. Public Health*. 1999;89:490-493.
[31] Angell M. What's really behind the attack on silicone breast implants. *Med Econ*. 1996;73:131-133, 136, 139-140 passim.
[32] Berry MG, Stanek JJ. The PIP mammary prosthesis: a product recall study. *J. Plast Reconstr Aesthet Surg*.65:697-704.
[33] Swarts E, Kop AM, Nilasaroya A, Keogh CV, Cooper T. Rupture of Poly Implant Prothese (PIP) Silicone Breast Implants: An Implant Retrieval Study. *Plast Reconstr Surg.*
[34] Choudhary S, Cadier MA, Cottrell BJ. Local tissue reactions to oil-based breast implant bleed. *Br. J. Plast Surg*. 2000;53:317-318.
[35] Rizkalla M, Webb J, Chuo CB, Matthews RN. Experience of explantation of Trilucent breast implants. *Br. J. Plast Surg*. 2002;55:117-119.
[36] Kirkpatrick WN, Jones BM. The history of Trilucent implants, and a chemical analysis of the triglyceride filler in 51 consecutively removed Trilucent breast prostheses. *Br. J. Plast Surg.* 2002;55:479-489.
[37] Williams GM, Caldwell J, Armstrong D, et al. Multicentre study to assess potential hazards from exposure to lipid peroxidation products in soya bean oil from Trilucent breast implants. *Regul Toxicol Pharmacol*. 2009;53:107-120.
[38] Hardwicke J, Gaze NR, Laitung JK. A retrospective audit of Novagold 'hydrogel' breast implants. *J. Plast Reconstr Aesthet Surg*. 2007;60:1313-1316.
[39] Pennisi VR. Long-term use of polyurethane breast prostheses: a 14-year experience. *Plast Reconstr Surg*. 1990;86:368-371.
[40] Ersek RA. Rate and incidence of capsular contracture: a comparison of smooth and textured silicone double-lumen breast prostheses. *Plast Reconstr Surg*. 1991;87:879-884.
[41] Wong CH, Samuel M, Tan BK, Song C. Capsular contracture in subglandular breast augmentation with textured versus smooth breast implants: a systematic review. *Plast Reconstr Surg.* 2006;118:1224-1236.

[42] Asplund O, Gylbert L, Jurell G, Ward C. Textured or smooth implants for submuscular breast augmentation: a controlled study. *Plast Reconstr Surg.* 1996;97:1200-1206.

[43] Collis N, Coleman D, Foo IT, Sharpe DT. Ten-year review of a prospective randomized controlled trial of textured versus smooth subglandular silicone gel breast implants. *Plast Reconstr Surg*. 2000;106:786-791.

[44] Barnsley GP, Sigurdson LJ, Barnsley SE. Textured surface breast implants in the prevention of capsular contracture among breast augmentation patients: a meta-analysis of randomized controlled trials. *Plast Reconstr Surg*. 2006;117:2182-2190.

[45] Tebbetts JB. Achieving a zero percent reoperation rate at 3 years in a 50-consecutive-case augmentation mammaplasty premarket approval study. *Plast Reconstr Surg*. 2006;118:1453-1457.

[46] Spear SL. Breast augmentation with reduced-height anatomic implants: the pros and cons. *Clin Plast Surg*. 2001;28:561-565.

[47] Cardenas-Camarena L, Encinas-Brambila J. Round gel breast implants or anatomic gel breast implants: which is the best choice? *Aesthetic Plast Surg.* 2009;33:743-751.

[48] Mallucci P, Branford OA. Asymmetric implants for breast asymmetry. *J. Plast Reconstr Aesthet Surg*.65:1580-1583.

[49] Cronin TD, Gerow FJ. Augmentation mammaplasty: A new "natural feel" prosthesis. In: *Transactions of the Third International Congress of Plastic Surgery*, Amsterdam, The Netherlands; October 13-18, 1963, Excerpta Medica Foundation; 1963:41-49., 1963.

[50] Brown MH, Shenker R, Silver SA. Cohesive silicone gel breast implants in aesthetic and reconstructive breast surgery. *Plast Reconstr Surg*. 2005;116:768-779; discussion 780-761.

[51] Bengtson BP, Van Natta BW, Murphy DK, Slicton A, Maxwell GP. Style 410 highly cohesive silicone breast implant core study results at 3 years. *Plast Reconstr Surg*. 2007;120:40S-48S.

[52] Heden P, Jernbeck J, Hober M. Breast augmentation with anatomical cohesive gel implants: the world's largest current experience. *Clin. Plast Surg.* 2001;28:531-552.

[53] Jewell ML, Jewell JL. A comparison of outcomes involving highly cohesive, form-stable breast implants from two manufacturers in patients undergoing primary breast augmentation. *Aesthet Surg J*.30:51-65.

[54] Tebbetts JB. Axillary endoscopic breast augmentation: processes derived from a 28-year experience to optimize outcomes. *Plast Reconstr Surg*. 2006;118:53S-80S.

[55] Hidalgo DA. Breast augmentation: choosing the optimal incision, implant, and pocket plane. *Plast Reconstr Surg*. 2000;105:2202-2216; discussion 2217-2208.

[56] Alpert BS, Lalonde DH. MOC-PS(SM) CME article: breast augmentation. *Plast Reconstr Surg*. 2008;121:1-7.

[57] Biggs TM, Yarish RS. Augmentation mammaplasty: a comparative analysis. *Plast Reconstr Surg*. 1990;85:368-372.

[58] Angell M. Shattuck Lecture--evaluating the health risks of breast implants: the interplay of medical science, the law, and public opinion. *N Engl. J. Med*. 1996;334:1513-1518.

[59] Spear SL, Carter ME, Ganz JC. The correction of capsular contracture by conversion to "dual-plane" positioning: technique and outcomes. *Plast Reconstr Surg*. 2006;118:103S-113S; discussion 114S.

[60] Burkhardt BR, Demas CP. The effect of Siltex texturing and povidone-iodine irrigation on capsular contracture around saline inflatable breast implants. *Plast Reconstr Surg*. 1994;93:123-128; discussion 129-130.

[61] Burkhardt BR, Eades E. The effect of Biocell texturing and povidone-iodine irrigation on capsular contracture around saline-inflatable breast implants. *Plast Reconstr Surg*. 1995;96:1317-1325.

[62] Adams WP, Jr., Rios JL, Smith SJ. Enhancing patient outcomes in aesthetic and reconstructive breast surgery using triple antibiotic breast irrigation: six-year prospective clinical study. *Plast Reconstr Surg*. 2006;118:46S-52S.

[63] Mentor Corp. *saline implant premarket approval*. Available at www.fda.gov/cdrh/ breastimplants/2000 Accessed November 15.

[64] Inamed Corp. *saline implant premarket approval*. Available at www.fda.gov/ cdrh/ breastimplants/2000<http://www.fda.gov/cdrh/breastimplants/2000>. Accessed November 15.

[65] *2003 and 2005 silicone breast implant PMA information*. Available at www.fda.gov/cdrh/breastimplants. Accessed November 15.

[66] Pajkos A, Deva AK, Vickery K, Cope C, Chang L, Cossart YE. Detection of subclinical infection in significant breast implant capsules. *Plast Reconstr Surg*. 2003;111:1605-1611.

[67] Wiener TC. The role of betadine irrigation in breast augmentation. *Plast Reconstr Surg*. 2007;119:12-15; discussion 16-17.

[68] Fraser JK, Hedrick MH, Cohen SR. Oncologic risks of autologous fat grafting to the breast. *Aesthet Surg J*.31:68-75.

[69] Pearl RA, Leedham SJ, Pacifico MD. The safety of autologous fat transfer in breast cancer: lessons from stem cell biology. *J. Plast Reconstr Aesthet Surg*. 2012;65:283-288.

[70] Khouri RK, Eisenmann-Klein M, Cardoso E, et al. Brava and autologous fat transfer is a safe and effective breast augmentation alternative: results of a 6-year, 81-patient, prospective multicentre study. *Plast Reconstr Surg*.129:1173-1187.

[71] Delay E, Garson S, Tousson G, Sinna R. Fat injection to the breast: technique, results, and indications based on 880 procedures over 10 years. *Aesthet Surg J*. 2009;29:360-376.

[72] Del Vecchio DA. "SIEF"-Simultaneous Implant Exchange with Fat: A New Option in Revision Breast Implant Surgery. *Plast Reconstr Surg*.130:1187-1196.

[73] Mojallal A, Saint-Cyr M, Garrido I. Autologous fat transfer: controversies and current indications for breast surgery. *J. Plast Reconstr Aesthet Surg*. 2009;62:708-710.

[74] Rigotti G, Marchi A, Stringhini P, et al. Determining the oncological risk of autologous lipoaspirate grafting for post-mastectomy breast reconstruction. *Aesthetic Plast Surg*. 34:475-480.hal

[75] Petit JY, Lohsiriwat V, Clough KB, et al. The oncologic outcome and immediate surgical complications of lipofilling in breast cancer patients: a multicentre study--Milan-Paris-Lyon experience of 646 lipofilling procedures. *Plast Reconstr Surg*. 128:341-346.

In: Encyclopedia of Surgery (22 Volume Set)
Editors: Andreas Lehrer and Kristin Mueller
ISBN: 978-1-53618-329-0
© 2020 Nova Science Publishers, Inc.

Chapter 36

BREAST REDUCTION

Gurjinderpal Singh Pahal* *and Venkat Ramakrishnan*
St. Andrews Centre for Plastic Surgery, Broomfield Hospital, Chelmsford UK

KEY POINTS

- Reduction mammaplasty remains a frequently performed plastic surgical procedure with consistently high patient satisfaction scores.
- Functional disability and impaired quality of life resulting from macromastia can be improved by reduction mammaplasty.
- Postoperative ability to lactate is similar whether a superior, medial, or inferior full-thickness nipple pedicle is used for reduction mammaplasty.
- The risk of post-operative complications is doubled in active smokers.
- Mammographic screening saves 2-2.5 lives for every over diagnosed case overall. In those who are under forty, it is recommended for patients at high risk of breast cancer.
- The evidence currently suggests only a single pre-operative dose of intravenous antibiotic is needed to reduce infection rates.
- The use of adrenaline-containing local anaesthetic solutions decreases significant blood loss and provides analgesia for the patient.
- Vertical scar reduction is associated with a higher surgical revision rate compared with a Wise pattern reduction.
- The majority of members of the American Society for Aesthetic Plastic Surgery use only an inferior pedicle and Wise pattern technique for breast reduction.
- Use of drains does not alter haematoma rate, but in practice most breast reductions have drains placed and nearly half of surveyed surgeons always use them.

"There is no better beginning to the saga of mammaplasties than 'Once Upon a Time…' and at its source lies women's eternal dream – beautiful, firm and harmoniously

* Corresponding Author's Email: drgsp@doctors.org.uk.

> proportioned breasts – a dream that has inspired painting, sculpture and literature since the dawn of mankind…"
>
> Lalardrie & Mouly, 1978[1]

INTRODUCTION

In what could be the first recorded 'breast reduction' aimed at improving function, Hippocrates (460–370 B.C.) narrates the legend of Shi'ite women having their right breast amputated by cauterization so that

> "...all their strength and power was concentrated in the right shoulder and arm, thus permitting them to handle their swords better" [2].

Byzantine physician Paulus of Aegina (Alexandria, 625-690 AD) used a crescenteric inframammary incision with resection of skin in pendulous cases for "effeminacy of men", or male breast reduction [3]. In 1848 Dieffenbach was probably the first to perform a reduction mammaplasty in a female by reducing the lower two-thirds of the breasts and posterior segment, leaving the scar in the inframammary fold [4].

Reduction mammaplasty remains a frequently performed plastic surgical procedure today. Common indications include bilateral macromastia and for symmetrisation following developmental asymmetry or contralateral post-mastectomy reconstruction. It consistently rates highly for patient satisfaction with 93% of women reporting they would undergo the surgery again [5], and it has been shown to improve body self-image [6].

This chapter aims to present the most up-to-date scientific evidence available for breast reduction surgery rather than to provide the reader with detailed technical guidance. The evidence behind the most popular approaches to these procedures and the opinions of respected experts in the field shall also be presented.

To research this topic, a Medline literature search was performed using the terms 'reduction mammaplasty', 'reduction mammoplasty' or 'breast reduction'. Limiting the search to level I evidence (Appendix 1), whilst academically ideal, would identify few publications and exclude many of the most influential practitioners. Therefore papers of all evidence levels have been assessed based as much on their importance as their scientific methodology.

PATHOPHYSIOLOGY

Women with breast hypertrophy have oestrogen levels within normal laboratory limits and a normal number of oestrogen receptors [7], suggesting that some women may be hypersensitive to circulating oestrogens and/or demonstrate an abnormal end-organ response to it. Thelarche, pregnancy and menopause may also be responsible for hypermastia, further supporting the oestrogen-sensitivity theory. In addition, the global obesity epidemic has resulted in breast hypertrophy secondary to increased adipose tissue rather than glandular hyperplasia, and fat now accounts for 48-61% of breast reduction specimens [8, 9]. Finally, a rare but important condition to consider is juvenile virginal hypertrophy of the breast

(gigantomastia), for which definitions vary but include resections specimens of more than 1800g per breast or of 3% total body weight [10, 11].

SURGICAL ANATOMY

Comprehensive knowledge of the neurovascular anatomy of the breast is prerequisite to understanding the design choices available for reduction mammaplasty and to minimise nipple areolar complex (NAC) necrosis and sensory loss.

The breast is a superficial ectodermal structure with a rich blood supply, receiving contributions from the internal mammary artery medially, the thoracoacromial and thoracodorsal arteries superiorly, branches of the lateral thoracic artery and multiple deep intercostal perforators through and below the pectoralis musculature [12] (Chapter 34, Figure 1).

Taylor et al. described the breast as having a predominantly superficial arterial supply and venous drainage through the subdermal plexus [13], reinforcing the importance of a maintained dermal connection to the nipple-areolar complex (NAC) pedicle. Hall-Findlay [14] also describes a superficial arterial input to the breast with the exception of one large deep perforator arising from the internal mammary artery at the level of the fifth or sixth intercostal space. It usually perforates the pectoralis musculature medial to the breast meridian slightly above the infra-mammary fold (IMF) and carries venae commitantes with it.

There is at present a lack of literature comparing the vasculature of different NAC–bearing pedicles in detail. O'Dey et al. [15] examined the architecture of the arteries supplying the breast and their contribution to the blood supply of the NAC on seven female cadavers (fourteen breasts) following vessel filling. Four arterial sources were found to be primarily responsible for the blood supply to the NAC. In descending order of reproducibility these were branches originating from the lateral thoracic artery, the internal mammary artery, the anterior branches of the intercostal arteries and those deriving from the highest thoracic arteries.

The NAC is usually innervated by the 3rd, 4th and 5th anterior cutaneous nerves and the 4th and 5th lateral cutaneous nerves [16] (Chapter 34, Figure 2). The lateral cutaneous branch of the 4th intercostal nerve is considered uniquely responsible for NAC sensation [17] (Figure 1). The deep branch of the lateral 4th intercostal nerve has been shown in cadaveric studies to run medially above the pectoralis fascia until the mid-portion of the breast, where it then runs superiorly towards the NAC [18]. Maintaining a full thickness medial pedicle and not exposing the pectoralis fascia may therefore explain why the medial pedicle technique maintains nipple sensation equivalent to that of the lateral pedicle technique [13].

The subcutaneous layer of adipose tissue in the breast is traversed by Cooper's suspensory ligaments. These are the connective tissue support structures within the breast and extend obliquely to the skin surface from the deep pectoral fascia. The attachments stretch with pregnancy, obesity and aging, resulting in excess breast mobility and ptosis. Finally, as a mammary gland, the breast comprises lactiferous ducts each supplied by glandular breast parenchyma and draining into the nipple.

AIMS OF SURGERY

In 1928 Biesenberger [19] outlined eight aims of reduction mammaplasty that remain relevant today. They are:

1. The breast should be lifted to a youthful and natural form in proportion to other parts of the body.
2. The two breasts should be symmetrical.
3. The nipple and areola should be translocated to an appropriate location.
4. The blood supply to nipple and areola should not be jeopardized.
5. The function of the breast should be preserved.
6. The scars should not be visible through normal clothing or be above the areola.
7. The operation must be applicable to all forms of deformity.
8. The procedure should be a one-stage operation.

Reduction mammaplasty aims to improve symptoms by decreasing the volume of breast tissue. The technique should yield a predictable and improved breast shape whilst providing parenchymal support to enable longevity of the result. Vascular and neural integrity of the NAC should be maintained and the NAC should be repositioned to its anatomically correct position.

SURGICAL INDICATIONS AND PATIENT SELECTION

Disproportionate upper body weight resulting from breast hypertrophy can cause functional disability and adversely affect quality of life. Multiple studies have shown that reduction mammaplasty provides symptomatic relief and improves the quality of life for patients with macromastia [20]. Such women often have a poor posture and complain of musculoskeletal symptoms such as neck, back and shoulder pain, as well as heaviness of the anterior chest wall. They may have shoulder indentations and ulceration from the strap of the brassiere due to the weight of their breasts and sometimes suffer from intertrigo, acne and inframammary hidradenitis.

Hypertrophic breasts themselves may be ptotic and exhibit prominent veins, stretch marks and an enlarged NAC. Occasionally the patient may complain of upper limb paraesthesiae, particularly in the ulnar nerve distribution, secondary to pressure on the brachial plexus.

The social stigma of breast hypertrophy should not be underestimated. Inability to participate in sport and exercise, sexual harassment and ill-fitting clothing are common complaints. The psychological benefits of restoring proportion between the breasts and overall physique are difficult to quantify, but many surgeons believe they are considerable and numerous patient satisfaction studies of reduction mammaplasty have documented favorable results [21-28].

In North America most insurance carriers will not reimburse for reduction mammaplasties in which less than 1000g tissue is resected. Spector et al. [29] examined the effect of smaller reduction mammaplasties on symptoms and quality-of-life. A total of 59

patients underwent reduction mammaplasty of less than 1000g, and all patients were given a questionnaire designed to evaluate macromastia-related symptoms and quality-of-life issues, preoperatively and three to twelve months postoperatively.

The investigators found that smaller reduction mammaplasties significantly reduced all macromastia-related symptoms assessed, including pain in the upper and lower back, neck, arms, shoulders, hands and breasts, as well as reducing headaches, rashes, itching and painful bra strap grooving. Furthermore, reduction mammaplasty resulted in significant improvement in all quality-of-life factors analyzed, including difficulty buying clothes and bras, difficulty participating in sports and difficulty running. The authors concluded that reimbursement for reduction mammaplasty of less than 1000g was justified.

Thoma et al. [30] assessed the health-related quality of life experienced by 52 breast reduction patients using four reliable and validated health-related quality-of-life measures completed at one week and one day before surgery and at one, six, and twelve months afterwards. For all patients, mean scores for all quality-of-life instruments increased from the preoperative assessments to the postoperative assessments. The effect of surgery was equivalent to an expected lifetime gain of 5.3 quality-adjusted life years (equivalent to each patient living an additional 5.3 years in perfect health). The authors concluded that there was no justification for the ongoing restriction or denials of third-party payments based on body mass index.

PREOPERATIVE ASSESSMENT

General

As well as a standard medical and surgical history, a history of bleeding tendency and of factors that may compromise wound healing, such as smoking and diabetes, should be noted and measures taken to optimise preoperative physiology. Use of hormone-based medications, blood-thinning agents and the presence of any allergies should be documented. Importantly, the patient's expectations of surgery and desired post-operative bra size should be explored so that unrealistic expectations can be addressed at this stage.

General examination of pertinent systems is followed by a tailored breast examination with the patient standing and arms hanging by the sides at ease. Particular attention should be paid to breast asymmetry, chest wall abnormalities, kyphosis or scoliosis, breast lumps, masses, scars, skin dimpling, nipple discharge, and the grade of breast ptosis. The axillae and supraclavicular areas should be palpated for lymphadenopathy and accessory breast tissue and the rest of the abdomen and pelvis examined for accessory breasts.

Important measurements to note include bra size, sternal notch to nipple distance, nipple to inframmammary fold (IMF) distance, width of the nipple areolar complex (NAC) and BMI. Any subjective alterations in nipple sensation should be documented. Finally, sequelae of macromastia such as poor posture, notching or ulceration of the shoulders from the straps of the brassiere and submammary intertrigo should be noted. Pre-operative photographs from the neck to the waist in three views (head on, oblique and lateral) complete the pre-operative consultation.

Age

Shermak et al. [31] investigated the impact of age on the outcome of breast reduction using multiple logistic regression analysis in 1192 consecutive patients (2156 breast reductions) with an average age of 36, performed over ten years by seventeen plastic surgeons at one institution. Women older than fifty years were significantly more likely to experience infection (odds ratio 2.7) with non-significant trends toward wound healing problems (odds ratio 1.6) and re-operative wound debridement (odds ratio 5.1). There was no association between age and the development of fat necrosis or seroma. They concluded that patients older than fifty have impaired breast reduction outcomes, particularly infection, that may negatively impact wound healing, and postulate that hormonal deficiency may partially account for this finding.

However, as highlighted by Alderman et al. [32], several other surgeon and patient factors that could be correlated with post-operative infections were not included, such as use of peri-operative antibiotics, length of surgery, patient temperature, operating room traffic, the individual surgeon, type of reduction technique and reduction volume, and it is unclear why this information was omitted from the analysis.

Obesity

The effect of obesity on complication rates following reduction mammaplasty is unclear from the literature. Four retrospective studies (a total of 1033 women) concluded that obesity had no impact on the risk of complications [33-36] whereas four other retrospective studies (a total of 1514 women) concluded that increasing obesity lead to increased complication rates [37-40].

The Maintenance of Certification (MOC) program encourages surgeons to engage in, and measure up to, a comprehensive set of standards designed to help them maintain high professional standing, participate regularly in continuing medical education, remain current in critical knowledge areas, and perform well in their surgical practices. Since 2007, the American Board of Plastic Surgery has accumulated data on 606 surgeons, reporting on 6461 breast reductions. Most recently, Kerrigan et al. [41] have analysed the MOC data set using logistical regression. They conclude that a BMI of over thirty is a significant predictor of adverse events and parenchymal resection of 1301-1900g was also a significant predictor of increased complications. Obesity with a BMI exceeding forty carried a significant risk of re-operation.

Smoking

According to Bartsch et al. [42], an active smoking history doubles the risk of developing post-operative wound healing problems, defined in their study as the absence of a stable dry non-inflamed wound requiring no dressings within ten days of surgery. Padubidri et al. [43] reports an overall breast reconstruction complication rate in smokers of 39%, compared with 25% in ex-smokers and 26% in non-smokers. Complications were significantly more frequent

in smokers, and smokers undergoing mammaplasty should be urged to stop smoking for at least three weeks prior to surgery.

Ability to Breast-Feed

The reproductive history of the patient is important, noting whether the patient succeeded in breast-feeding previously and any possible wish to do so in future. It should be explained that any significant resection of sub-areolar breast tissue will decrease the amount of breast tissue that can contribute to lactation. Studies have demonstrated that approximately seventy percent of patients can breast-feed after breast reduction but that only thirty percent do, similar to the rates in a population that has never had surgery.

Using a patient-completed questionnaire, Cruz Korchin et al. [44] compared ability to breast-feed in 164 patients who had undergone mammaplasty with different pedicle types (48 superior, 59 medial, and 57 inferior full-thickness dermoglandular pedicles) with a control group of 151 women of child-bearing age with macromastia but no prior breast surgery. They found no significant difference between any of the groups - successful breast-feeding, defined as breast-feeding for two weeks or more, was observed in 62% of the control group versus 62% for superior pedicle, 65% for medial pedicle and 64% for inferior pedicle breast reductions.

The ability to lactate (i.e., produce milk) and the ability to breast-feed successfully (i.e., satiate the feeding demands of an infant) should be distinguished. Reassuringly, no significant difference was found between any of the mammaplasty groups and the control group in the need to supplement breast-feeding (34% in the control group versus 38%, 38% and 35% in the superior, medial and inferior pedicle techniques respectively). Finally, it is worth emphasising that Cruz Korchin specifically refers to *dermoglandular pedicles* in this study, and it is unlikely that *dermal* pedicle breast reductions will retain much breast-feeding potential.

Screening Mammography

It is accepted that screening mammography guidelines should be followed in the pre-operative course of patients undergoing reduction mammoplasty. Such guidelines, however, remain controversial in the general female population and false-positive findings can result in overdiagnosis, necessitating additional imaging, biopsies and needless harm [42]. The American Cancer Society [45] and the American Congress of Obstetrics and Gynaecologists [46] recommend annual mammography in women over forty years old. The US Preventive Services Taskforce[47] advises against routine annual screening in women aged 40-49 and advocates biennial screening mammography for women aged 50-74 years. The NHS Breast Screening Programme provides free breast screening every three years for all women aged fifty and over. The programme is now phasing in an extension of the age range of women eligible for breast screening to those aged 47 to 73. In September 2000, research was published which demonstrated that the NHS Breast Screening Programme had lowered mortality rates from breast cancer in the 55-69 age [48]. In 2010, Duffy et al. [49]

demonstrated that the benefit of mammographic screening (lives saved) exceeded harm caused (overdiagnosis), with 2-2.5 lives saved for every overdiagnosis.

The lifetime risk of breast cancer is one in eight, and occult carcinoma has been detected in 0.06% to 0.4% of breast reduction specimens despite normal preoperative mammography. For instance, Colwell et al. [50] examined the incidence of breast cancer in breast reductions specimens in one institution over a fourteen-year period. Six cancers were detected from 800 reduction mammaplasties performed between 1988 and 2001 (0.8%). Three were invasive (0.4%) and three were ductal carcinoma in situ (0.4%). Thus, a thorough breast history must be obtained including family history of breast cancer, previous open or percutaneous biopsies or surgery to the breast, previous abnormal mammograms, history of nipple discharge and any recent change in breast shape.

Some practitioners take the view that, since a large proportion of their patients will go on to develop cancer, it is worthwhile using the resection specimens opportunistically to establish that cancer was not present at the time of surgery, thereby avoiding a future possible claim of negligence for failing to diagnose cancer at the earliest opportunity.

SURGICAL TECHNIQUE

The nomenclature used for reduction mammaplasty techniques can be confusing. A clear distinction should be made between the skin resection pattern (e.g., vertical, inverted 'T' periareolar, limited horizontal scar, no vertical scar etc.) and the choice of pedicle used to maintain the neurovascular supply to the NAC (which ultimately governs the parenchymal excision). Each may be selected independently. Whilst reducing breast volume to improve symptoms is the desired goal, this should be achieved by utilising a technique that maintains blood and neural supply to the skin and NAC of the breast, preserves the ability to breast feed and ultimately results in a cosmetically pleasing breast shape that is maintained over time. Literature review does not point to any right or wrong answer as to which technique to use under particular circumstances; instead it is evident that patient selection combined with surgeon's expertise are both key to success.

Use of Infiltration

The use of adrenaline-containing local anaesthetic solutions appears to decrease blood loss and the need for blood transfusion, as well as providing analgesia for the patient. Noone [51], Thomas [52] and Metaxotos [53] advocate the use of adrenaline-containing local anaesthetics. Thomas et al. compared outcomes with or without preoperative infiltration of 180-200ml normal saline containing 1:500,000 adrenaline in a series of 100 breast reductions (fifty patients), with groups matched for age and co morbidity. Blood loss, measured by the fall in postoperative haemoglobin, was significantly less when infiltration was used. The clinical significance of this finding, however, is unclear as the authors do not correlate the fall in haemoglobin with their patients' cardiovascular parameters.

Metaxotos et al. conducted a randomised, double-blind, placebo–controlled trial to evaluate the effect of preoperative adrenaline-containing local anaesthesia infiltration on peri-

and postoperative bleeding and postoperative pain in 24 consecutive patients undergoing breast reduction. One breast was infiltrated with bupivicaine and adrenaline solution, and the other with the same volume of normal saline. Peri-operative blood loss was calculated by weighing swabs, and the postoperative drainage from suction drains was measured at 3, 24 and 48 hours. Postoperative pain was assessed using visual analogue scales and verbal response scores at three, six, ten and 24 hours post-infiltration. There was a significant reduction in both peri- and postoperative blood loss ($p < 0.01$ and $p < 0.05$ respectively) and pain on the side receiving infiltration ($p < 0.01$).

Use of Antibiotic Prophylaxis

Several studies have yielded contradictory findings as to the benefit of antibiotics in breast reduction. Ahmadi et al. [54] prospectively compared microbiology cultures from fifty reduction mammaplasty patients divided into three groups: those who received no antibiotics, a single dose of preoperative antibiotics or both pre- and postoperative antibiotics. Patients were generally young (average age 34 years), the average body mass index (BMI) was 32 and patients had no history of diabetes mellitus, peripheral vascular disease, previous breast surgery or use of steroids or tobacco.

On microbiological culture, 55% of patients exhibited growth in one or both breasts, most commonly of Staphylococcus epidermis (90%) followed by Corynebacterium diphtheria (7%), and Enterobacter (3%). Patients with positive cultures were more likely to have active infection than those with a negative culture, but there was no significant difference in infection rate between any of the groups. There was, however, a significant reduction in the occurrence of delayed wound healing in the group that received preoperative antibiotics only, and there was a significant association between delayed wound healing and infection. The authors concluded that prophylactic antibiotic use in breast reduction does not significantly alter infection rate, but a single preoperative dose significantly improves wound healing (presumably through an effect on subclinical infection).

Veiga-Filho et al. [55] prospectively randomized 100 women to receive either no antibiotics or preoperative antibiotics and a six-day post-operative course, with the same operative parameters as Ahmadi et al. (surgery performed by the same surgical team under general anaesthesia, using a Wise pattern scar incision and no drains). All patients were discharged on the first postoperative day and followed up weekly for thirty days by a surgeon blinded to the study group.

They found that the infection rate was significantly lower in the study group receiving antibiotics (2% vs. 14%), but the study had several limitations: for instance, the non-antibiotic group consisted of older patients with a higher total resection weight, either of which could have contributed to the infection rate. Despite this, and combined with the previous study, it seems appropriate to give patients a single pre-operative dose of intravenous antibiotic. It is clear that future randomized controlled trials are needed to confirm the efficacy and cost-effectiveness of antibiotic use in reduction mammaplasty, since injudicious use can suppress natural host flora, result in microbial resistance and have implications on cost and potential allergic reactions.

The Wise Pattern Reduction Mammaplasty

The inverted–T, or Wise pattern, skin excision pattern can be used with any pedicle. It is most commonly combined with the inferior pedicle technique, as described by Robbins in 1977 [56], although the senior author's preference is for a superomedial pedicle (Figure 1). Advantages of the inferior pedicle technique include a predictably reliable pedicle, ease of teaching and versatility, ranging from very small reductions/mastopexies to larger reductions [57-60]. This has made it the preferred method of breast reduction worldwide for the past forty years [61-64].

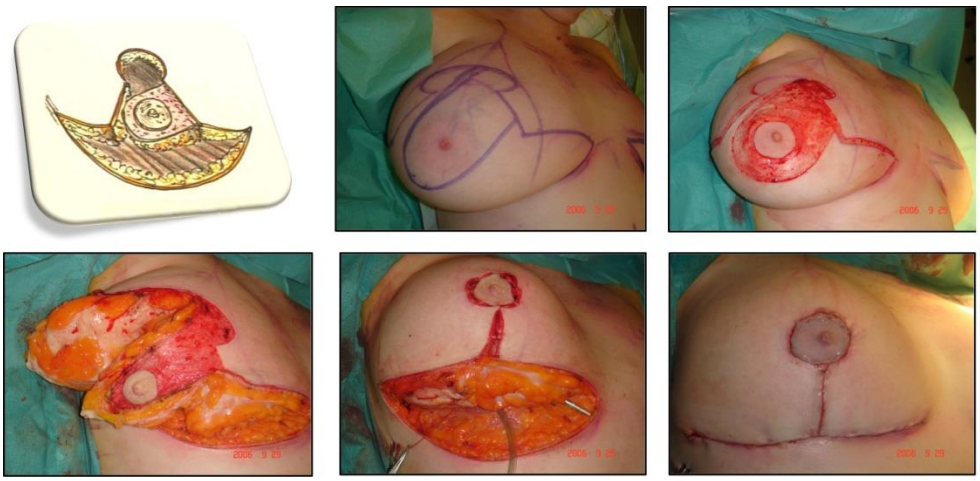

Figure 1. Surgical sequence for Wise pattern reduction mammaplasty with a superomedial pedicle. The markings are determined preoperatively with the patient standing. The pedicle is deepithelialised, inferior medial and lateral wedges excised and medial and lateral breast pillars reapproximated to create a pleasing breast cone, prior to final closure.

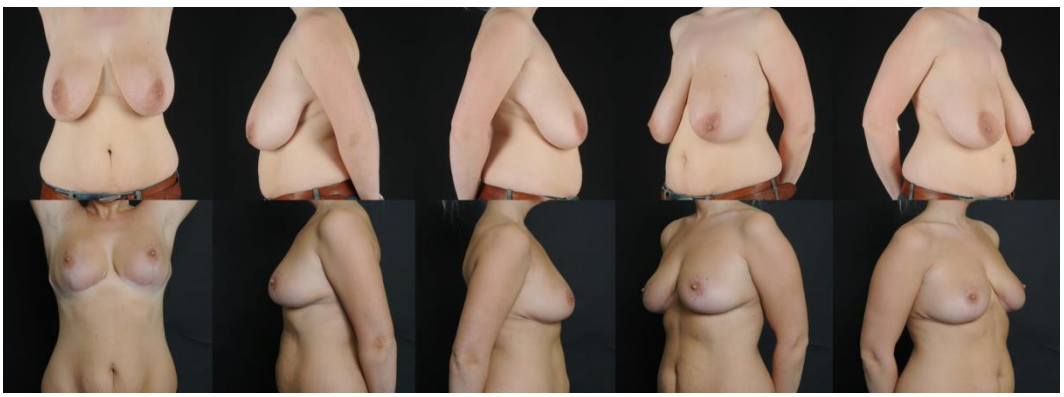

Figure 2. Pre- and post-operative appearance of Wise pattern inferior pedicle breast reduction.

The technique does have drawbacks, however, including a large inframammary scar (which may become stretched or hypertrophic) and the phenomenon of 'bottoming-out' or pseudoptosis [65] referred to by Claude Lassus as "*Sein en Sabot"* or *"clog aspect"*.

According to Hall-Findley [14], the inverted-T techniques usually rely on the skin brassiere to shape the breast, undermining the skin and leaving behind the heavy inferior pole of the breast that invariably bottoms-out as the skin stretches.

Niranjan modifies the technique by use of a 'dermal hammock' that is a triangular-shaped dermal extension of the inferior pedicle. This is secured to the pectoralis fascia to support the pedicle and theoretically prevent bottoming out. There is, however, no long-term published data to support this modification at present.

Cruz-Korchin et al. [66] prospectively compared the outcomes of 208 patients randomised to undergo either inferior pedicle Wise pattern reductions (group I) or medial pedicle vertical pattern reductions (group II) in moderate resections averaging 500g per breast. Outcome measures were self-assessed patient satisfaction six months postoperatively, revision rates and complication rates.

There was no significant difference between the groups in age, body mass index or the amount of tissue excised. Group I required no surgical revisions, whereas there was an eleven percent revision rate for dog-ears in Group II. Other complications occurred with similar frequency in both groups. Patients' evaluations of breast size, shape, symmetry, nipple sensation, symptom relief, ease of brassiere/clothing fitting, and overall satisfaction were similar. The vertical mammaplasty was rated significantly higher by patients with regard to scars and overall aesthetic results. The authors concluded that patients are less disappointed with the scars following a vertical scar breast reduction but are more likely to require surgical revision than those who have a Wise pattern reduction.

Okoro et al. [67] surveyed 5112 members of the American Society of Plastic Surgeons on their preferences, practices and opinions of various breast reduction techniques. Around half of those surveyed responded. Most used preoperative antibiotics (93%), intra-operative deep venous thrombosis prophylaxis (92%), general anaesthesia (97%), an inferior pedicle (69%), and usually (more than 75% of the time) performed surgery on an outpatient basis (61%). The authors concluded that the inferior pedicle Wise pattern remained the most popular but use of other techniques was increasing. They also concluded that plastic surgeons were increasingly aware of the risks of deep venous thrombosis.

Rohrich et al. [68] surveyed 1500 members of the American Society for Aesthetic Plastic Surgery, of whom 554 responded. A little over half (56%) of their respondents used only the inferior pedicle and Wise pattern techniques, whereas 6.9% of the respondents used only limited incision techniques. Most surgeons reported that they did not anticipate changing their practices to accommodate advances in limited incision techniques, although 89% believed that newer limited incision and liposuction techniques were trends that would be here to stay.

The Vertical Scar Reduction Mammaplasty

In 1964 Claude Lassus designed the vertical scar incision pattern, subsequently reported in 1970 as *'A technique for breast reduction'* [69]. He modified the technique in 1986 and again the next year to achieve a skin excision pattern that left a single vertical scar above the IMF [70, 71]. A similar skin incision is used in the Lejour vertical mammaplasty, and some authors credit Lejour for bringing the vertical mammaplasty concept into the mainstream of plastic surgery [65]; in 1994 she published her results on 153 reduction mammaplasties using

this technique combined with liposuction, and in 1999 she updated her experience on 324 reductions performed in 167 patients [72].

Advocates of the vertical scar technique combined with a superomedial pedicle list the benefits as a shorter scar with decreased scar hypertrophy, retained upper pole fullness, more extensive lateral parenchymal resection (avoiding axillary fullness) and a more desirable surgical result with greater projection and longevity [73]. The breast is coned rather than being pushed up and flattened and the vertical elliptical excision means that the medial and lateral pillars are brought together. Approximation of the parenchymal pillars rather than reliance on the skin envelope results in, it is claimed, longevity and a more aesthetic shape to the reduced breast. However, no long-term studies compare the longevity and shape of one technique with the other.

The superomedial vertical scar technique has been criticised for being restricted to cases of mild to moderate mammary hypertrophy and is considered less intuitive and difficult to learn when compared with inverted-T scar reduction mammaplasties. Surgeons report increased complication rates with higher volume parenchymal resection and some remain hesitant to apply the superomedial pedicle vertical scar technique to large volume mammaplasties [74-76]. Furthermore, concern over NAC vascular compromise during pedicle rotation has prompted some surgeons to limit this technique to reductions less than 1000g[75,77].

Lista et al. [78] reported the largest series (250 consecutive patients) of vertical scar reduction mammaplasties performed by a single surgeon over a three-year period. A ‘mosque dome’ skin-marking pattern was used with transposition of the NAC on a superior or medial dermoglandular pedicle. The average reduction per breast (including liposuction) was 636g (range 60 to 2020 g) and complications were minimal (5.6% of breasts), with no nipple loss, attesting to the safety of this technique. They conclude that this technique has been applied to breast reductions of all sizes and has consistently produced good breast shape, with an operation that is quicker to perform and leaves less scarring than standard breast reductions.

Hall-Findlay [73] concludes that medial or superomedial pedicle vertical breast reduction is simple, efficient and reliable and the desirable superior portion of the breast is preserved whilst the undesirable inferior and lateral portion of the breast is removed. The result is a shorter scar and a post-operative breast that maintains an aesthetic shape over time by relying on the healing medial and lateral breast pillars for shape rather than the skin brassiere.

Choice of Pedicle

A variety of pedicles have been described over the years that use the inverted-T shape scar pattern, including the lateral pedicle of Skoog [79], Strombeck’s horizontal bipedicle and lateral pedicle [80], the vertical bipedicle of McKissock [81], the inferior pedicle as already discussed and Weiner’s superior pedicle [82]. It is clear, however, that the inferior and central mound techniques have stood the test of time and remain safe and reliable, albeit with their own aesthetic limitations.

Nipple sensation is derived laterally from the fourth intercostal nerve. As previously discussed, the deep branch of the lateral fourth intercostal nerve runs across the breast above the pectoralis fascia until the mid-portion of the breast, where it travels superiorly towards the NAC. This may explain why full thickness pedicles other than the lateral pedicle can also

successfully preserve nipple sensation, so long as exposure of the pectoralis fascia is avoided [18]. Davidson et al. [83] compared safety, reliability and operative time of the superomedial and inferior pedicle techniques amongst 215 patients with an average BMI of 29. There were no cases of nipple loss and no significant difference in operating time.

Septum-Based Mammoplasty

The septum-based mammaplasty is an evolution of the lateral and medial pedicle techniques to improve sensitivity of the NAC after reduction mammaplasty and to enhance blood supply to the pedicle by preserving intercostal perforators within the septum [84]. The pedicle is based on a horizontal septum described by Würinger [85,86], which attaches the NAC to the thoracic wall at the level of the fifth rib (Figure 3). Branches and perforators from the intercostal, thoracoacromial, and lateral thoracic vessels as well as the deep branch of the fourth intercostal nerve are included within this septum.

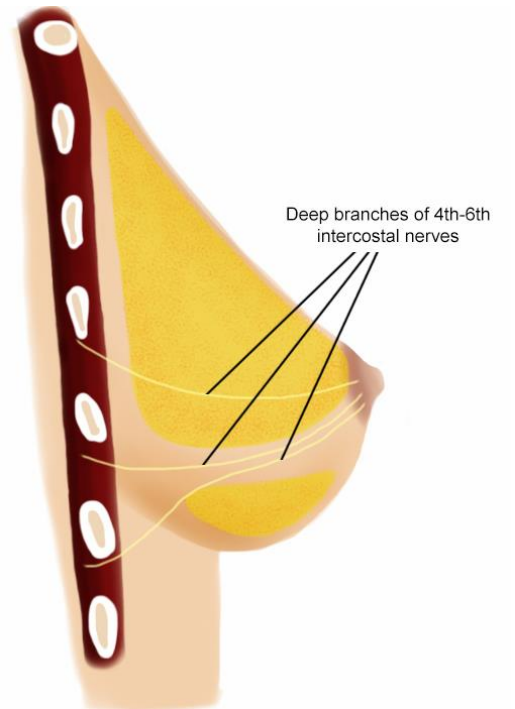

Figure 3. The septum-based mammoplasty aims to preserve the deep branch of the 4th intercostal nerve along with its horizontal vascular pedicle.

As Hamdi states,

> "It is very difficult to invent a new technique in plastic surgery, and it is said that something new is something old that has been forgotten, so we still adopt and improve old ideas in order to incorporate them into our contemporary techniques" [87]

Thus, the contribution of Skoog merits particular recognition as the first to describe the lateral dermoglandular pedicle.

In Hamdi's series [88], 110 consecutive patients underwent septum-based breast reduction over a seven-year period. The mean nipple-to-sternal notch distance was 33cm (range 22 to 45 cm), mean resection was 658g (range 160 to 1980g) and nipple elevation averaged nine centimetres (range three to seventeen centimetres). Complications included a retroareolar hematoma in three breasts and total areola necrosis in one (0.5%) as a result of an infection in a diabetic patient. Limited wound dehiscence occurred in fifteen breasts (7.7%), secondary scar revision was needed in ten (9%) and one patient required a revision. Most of the complications occurred in the first fifteen patients and was attributed to the learning curve of the procedure.

Use of Surgical Drains

Two important studies show that the incidence of adverse events is not significantly altered by the use of drains. Collins et al.[89] randomly drained one breast in 150 patients undergoing bilateral breast reduction. The majority (141) of patients had inferior pedicle reductions. There was no mention of antibiotic use or whether the infiltrate contained epinephrine. Haematomas occurred in seven patients (4.6%) and there was no difference between the drained and undrained sides.

Similarly, Corion et al. [90] randomised 107 patients undergoing bilateral breast reduction to have bilateral drains (55 patients) or no drains (52 patients). Neither antibiotics nor wetting solution were used. Again, their rates of adverse events were similar in each group. Despite this evidence, a recent review of practice reported in the MOC shows that over half of all breast reductions performed had drains placed and 44% of surgeons always use drains, whereas 31% never use them [41].

EXAMINATION OF HISTOPATHOLOGICAL SPECIMENS

Breast reduction specimens are routinely sent for histopathological analysis but there is little evidence to guide best practice [91]. The lifetime risk of breast cancer is one in eight, and it is not uncommon for invasive or in-situ carcinoma to be detected in reduction mammaplasty specimens despite normal mammograms [41]. The most recent analysis of the largest series of breast reduction specimens by Kerrigan et al. [92-97] concludes that 0.5-4% of surgical specimens result in a diagnosis that may initiate further treatment; breast reduction specimens from women older than forty years, as well as higher risk women of any age (*BRCA* genes, positive family history of breast cancer) should be studied microscopically.

The rate of abnormal findings depends on the extent of pathological examination. Nielsen et al. [98] performed extensive pathological examinations (three millimetre cuts, with 200 or more blocks per specimen) on autopsy breast specimens, finding a 14-16% incidence of unsuspected invasive breast cancer or ductal carcinoma in situ. Pathologic findings appeared related both to age and the extent of histologic investigation. Examination of three areas of tissue rather than one demonstrated a higher rate of pathologic findings in women older than

forty years but not in younger women. Bondeson et al. [99] reviewed pathologic findings in breast specimens from women younger than thirty years and found no significant abnormality. They suggested that microscopic examination was unnecessary in this group.

In five separate cohorts containing breast reduction specimens from 560, 562, 800, 813, 866 and 2488 patients respectively, between 0.5 and 4% of surgical specimens contained a diagnosis that could initiate further treatment [92-97]. Colwell et al.[93] examined the incidence of breast cancer in 800 reduction mammaplasties performed at their institution over a fourteen-year period. Six cancers were detected (0.8%) of which three were invasive (0.4%) and three were ductal carcinoma in situ (0.4%). Stratified by indication for surgery, there was a trend toward higher detection rates in the reconstruction group – that is, patients having symmetrising breast reduction following a previous breast reconstruction for cancer - compared with the macromastia or congenital asymmetry groups (1.2% vs. 0.7% vs. 0% respectively). Preoperative mammography was negative for masses and suspicious microcalcification in all patients. They conclude that reduction mammaplasty involved a small but definite risk of detecting previously undetected cancer in the resection specimen.

Clark et al. [97] conducted a single-centre retrospective chart review examining the incidence of benign and precancerous lesions in breast reduction specimens over a five-year period. Of the 562 patients who underwent reduction mammaplasty, 53% had non-proliferative or proliferative breast lesions (non-proliferative disease is not associated with an increased risk of breast cancer, whereas proliferative disease without atypia results in a small increase in risk – RR 1.5-2). A further 25 patients (4.4%) had a specimen containing atypical ductal or lobular hyperplasia (proliferative disease with atypical hyperplasia is associated with a greater risk of cancer development - RR 4-5), six patients (1.1%) had ductal carcinoma in situ and four patients (0.7%) had lobular carcinoma in situ. No occult invasive breast cancer was identified in the breast reduction specimens, but one patient with ductal carcinoma in situ was found to have invasive breast cancer on completion mastectomy (0.2%). Their study demonstrates the importance of systematic analysis of breast reduction specimens to help identify and guide the management of patients with increased risk of breast cancer following reduction mammaplasty.

CONCLUSION

This chapter offers the reader a comprehensive appraisal of the current evidence-based literature available for reduction mammoplasty. As well as including the highest quality evidence, as defined by accepted ‘level one’ research standards, the opinions of experts in the reduction mammaplasty arena have been included. Having appraised the evidence in detail, it is apparent that advocates of one preferred technique over another have years of experience, as well as evidence, to support their decision. The common goals of breast reduction remain the same however – to yield aesthetically pleasing breasts with minimal scarring, using a technique that will preserve nipple sensitivity, respect breast anatomy and offer longevity as far as shape is concerned.

As with all plastic surgical procedures, surgery should be bespoke to suit the needs of the patient, as well as satisfying realistic expectations. Aside from the pedicle and skin pattern choice, evidence for and against the use of drains, antibiotics and adrenaline-containing

infiltration has been discussed at length, and patient factors that point towards unfavorable outcomes, such as smoking, obesity and age, have also been deliberated. The plethora of available evidence is reassuring to a degree, however it also indicates the learning curves, both initial and ongoing, that plastic surgeons face throughout training and beyond.

REFERENCES

[1] Lalardrie, JP; Mouly, R. History of mammaplasty. *Aesthetic Plast Surg*, 1978 Dec; 2(1), 167-76.

[2] *Hippocrates Octoginta Volumina*. Francisci Minitii Calvi, Roma (1525).

[3] Adams, F. *The seven books of Paulus Aegineta*. Volumes I-III. London: Sydenham Society, 1844.

[4] Dieffenbach, JF. *Die Operative Chirurgie*. Vol 2. Leipzig, Brockhaus (1848) p 370.

[5] Lassus C. A 30-year experience with vertical mammaplasty. *Plast Reconstr Surg*, 97: 373, 1996.

[6] Lejour, M. Vertical mammaplasty and liposuction of the breast. *Plast Reconstr Surg*, 94, 100, 1994.

[7] Jabs, AD; et al. Mammary hypertrophy is not associated with increased estrogen receptors. *Plast Reconstr Surg*, 86, 64, 1990.

[8] Lejour, M. Evaluation of fat in breast tissue removed by vertical mammaplasty. *Plast Reconstr Surg*, 99, 386, 1997.

[9] Cruz-Korchin, N; Korchin, L; Gonzalez-Keelan, C; et al. Macromastia: how much of it is fat? *Plast Reconstr Surg*, 109, 64,

[10] Netscher, DT; Mosharrafa, AM; Laucirica, R. Massive asymmetric virginal breast hypertrophy. *South Med J*, 89, 434, 1996.

[11] Gliosci, A; Presutti, F. Virginal gigantomastia: validity of combined surgical and hormonal treatments. *Aesthetic Plast Surg*, 17, 61, 1993.

[12] Hester, TR; Jr. Bostwick, J; 3rd. Miller, L; et al. Breast reduction utilizing the maximally vascularized central breast pedicle. *Plast Reconstr Surg*, 1985, 76, 890-900

[13] Reid, CD; Taylor, GI. The vascular territory of the acromiothoracic axis. *Br J Plast Surg*. 1984 Apr, 37(2), 194-212.

[14] Elizabeth, J. Hall–Findlay. Vertical Reduction Mammaplasty. *Grabb and Smith's Plastic Surgery*, Sixth Edition by Charles H. Thorne.

[15] O'Dey, D; Prescher, A; Pallua, N. Vascular Reliability of Nipple-Areola Complex–Bearing Pedicles: An Anatomical Microdissection Study. *Plast Reconstr Surg*, 119(4), 1167-1177, April 1, 2007.

[16] Craig, RDP; Sykes, PA. Nipple sensitivity following reduction mammaplasty. *Br J Plast Surg*, 23, 165, 1970.

[17] Courtiss, EH; Goldwyn, RM. Breast sensation before and after plastic surgery. *Plast Reconstr Surg*, 58, 1, 1976.

[18] Schlenz, I; Kuzbari, R; Gruber, H; Holle, J. The sensitivity of the nipple-areola complex: an anatomic study. *Plast Reconstr Surg*, 105(3), 905-9, 2000.

[19] Biesenberger, H. Eine neue Methode der mammaplastik. *Zentralbl Chir*., 55, 2382, 1928.

[20] Chao, JD; Memmel, HC; Redding, JF; et al. Reduction mammaplasty is a functional operation, improving quality of life in symptomatic women: a prospective, single-center breast reduction outcome study. *Plast Reconstr Surg*, 110(7), 1644-1652, December 2002.

[21] Miller, AP; Zacher, JB; Berggren, RB; et al. Breast reduction for symptomatic macromastia: can objective predictors for operative success be identified? *Plast Reconstr Surg*, 95, 77, 1995.

[22] Klassen, A; Fitzpatrick, R; Jenkinson, C; Goodacre, T. Should breast reduction surgery be rationed? A comparison of the health status of patients before and after treatment, postal questionnaire survey. *BMJ*, 313, 454, 1996.

[23] Klassen, A; Jenkinson, C; Fitzpatrick, R; Goodacre, T. Patients' health related quality of life before and after aesthetic surgery. *Br J Plast Surg*, 49, 433, 1996.

[24] Dabbah, A; Lehman, JA, Jr; Parker, MG; et al. Reduction mammoplasty: an outcome analysis. *Ann Plast Surg*, 35, 337, 1995.

[25] Boschert, MT; Barone, CM; Puckett, CL. Outcome analysis of reduction mammaplasty. *Plast Reconstr Surg*, 98, 45, 1996.

[26] Maxwell, DG; Ringler, SL; Short, K; et al. Reduction mammoplasty: long-term efficacy, morbidity, and patient satisfaction. *Plast Reconstr Surg*, 96, 1106, 1995.

[27] Raispis, T; Zehring, RD; Downey, DL. Long-term functional results after reduction mammaplasty. *Ann Plast Surg*, 34, 113, 1995.

[28] Gonzalez, F; Walton, RL; Shafer, B; et al. Reduction mammaplasty improves symptoms of macromastia. *Plast Reconstr Surg*, 91, 1270, 1993.

[29] Spector, JA; Karp, NS. Reduction mammaplasty: a significant improvement at any size. *Plast Reconstr Surg*, 120(4), 845-850, September 15, 2007.

[30] Thoma, A; Sprague, S; Veltri, K. A prospective study of patients undergoing breast reduction surgery: health-related quality of life and clinical outcomes. *Plast Reconstr Surg*, 120(1), 13-26, July 2007.

[31] Shermak, MA; Chang, D; Buretta, K. More Increasing age impairs outcomes in breast reduction surgery. *Plast Reconstr Surg*, 128(6), 1182-1187, December 2011.

[32] Alderman, AK; Kulkarni, AR. Discussion: increasing age impairs outcomes in breast reduction surgery. *Plast Reconstr Surg*. Dec, 128(6), 1188-90, 2011.

[33] Zubowski, R1; Zins, JE; Foray-Kaplon, A; et al. Relationship of obesity and specimen weight to complications in reduction mammaplasty. *Plast Reconstr Surg*. 2000 Oct, 106(5), 998-1003.

[34] Wagner, DS; Alfonso, DR. The influence of obesity and volume of resection on success in reduction mammoplasty: an outcomes study. *Plast Reconstr Surg*. Apr, 115(4), 1034-8, 2005.

[35] Roehl, K; Craig, ES; Gómez, V; Phillips, LG. Breast reduction: safe in the morbidly obese? *Plast Reconstr Surg*. Aug, 122(2), 370-8, 2008.

[36] Setälä, L; Papp, A; Joukainen, S; et al. Obesity and complications in breast reduction surgery: are restrictions justified? *J Plast Reconstr Aesthet Surg*. Feb, 62(2), 195-9, 2009.

[37] Stevens, WG; Gear, AJ; Stoker, DA; et al. Outpatient reduction mammoplasty: an eleven-year experience. *Aesthet Surg J*. 2008 Mar-Apr, 28(2), 171-9.

[38] Gamboa-Bobadilla, GM; Killingsworth, C. Large-volume reduction mammaplasty, the effect of body mass index on postoperative complications. *Ann Plast Surg*., 2007 Mar, 58(3), 246-9.

[39] Shah, R; Al-Ajam, Y; Stott, D; Kang, N. Obesity in mammoplasty: a study of complications following breast reduction. *J Plast Reconstr Aesthet Surg*., 2011 Apr, 64(4), 508-14.

[40] Chun, YS; Schwartz, MA; Gu, X; et al. Body mass index as a predictor of postoperative complications in reduction mammaplasty. *Plast Reconstr Surg*., 2012 Feb, 129(2), 228e-233e.

[41] Kerrigan, CL; Slezak, SS. Evidence-based medicine: reduction mammaplasty. *Plast Reconstr Surg*., 2013 Dec, 132(6), 1670-83.

[42] Bartsch, RH; Weiss, G; Kästenbauer, T; et al. Crucial aspects of smoking in wound healing after breast reduction surgery. *J Plast Reconstr Aesthet Surg*., 2007, 60(9), 1045-9.

[43] Padubidri, AN; Yetman, R; Browne, E; et al. Complications of postmastectomy breast reconstructions in smokers, ex-smokers, and nonsmokers. *Plast Reconstr Surg*., 2001 Feb, 107(2), 342-9.

[44] Cruz, NI; Korchin, L. Lactational performance after breast reduction with different pedicles. *Plast Reconstr Surg*., 2007 Jul, 120(1), 35-40.

[45] *American Cancer Society Guidelines for the Early Detection of Cancer: Breast cancer* http://www.cancer.org/healthy/findcancerearly/cancerscreeningguidelines/american-cancer-society-guidelines-for-the-early-detection-of-cancer.

[46] *American Congress of Obstetrics and Gynaecologists* http: //www.acog.org/About-ACOG/News-Room/News-Releases/2011/Annual-Mammograms-Now-Recommended-for-Women-Beginning-at-Age-40.

[47] US Preventive Services Task Force. Screening for Breast Cancer: U.S. Preventive Services Task Force Recommendation Statement. *Ann Intern Med*, 2009, 151, 716-726.

[48] Miller, A. Effect of NHS breast cancer screening programme on mortality from breast cancer in England and Wales, 1990-8: comparison of observed with predicted mortality. *BMJ*, 2000, 321, 665-669.

[49] Duffy, SW; Tabar, L; Olsen, AH; et al. Absolute numbers of lives saved and overdiagnosis in breast cancer screening, from a randomized trial and from the Breast Screening Programme in England. *J Med Screen*, 2010, 17, 25–30.

[50] Colwell, AS; Kukreja, J; Breuing, KH; et al. Occult breast carcinoma in reduction mammaplasty specimens: 14-year experience. *Plast Reconstr Surg*, 2004 Jun, 113(7), 1984-8.

[51] Noone, RB. An evidence-based approach to reduction mammaplasty. *Plast Reconstr Surg*., 2010 Dec, 126(6), 2171-6.

[52] Thomas, SS; Srivastava, S; Nancarrow, JD; Mohmand, MH. Dilute adrenaline infiltration and reduced blood loss in reduction mammaplasty. *Ann Plast Surg*., 1999 Aug, 43(2), 127-31.

[53] Metaxotos, NG; Asplund, O; Hayes, M. The efficacy of bupivacaine with adrenaline in reducing pain and bleeding associated with breast reduction: a prospective trial. *Br J Plast Surg*., 1999 Jun, 52(4), 290-3.

[54] Ahmadi, AH; Cohen, BE; Shayani, P. A prospective study of antibiotic efficacy in preventing infection in reduction mammaplasty. *Plast Reconstr Surg*., 2005, 116, 126–131.

[55] Veiga-Filho, J; Veiga; DF; Sabino-Neto, M; et al. The role of antibiotics in reduction mammaplasty. *Ann. Plast Surg*, 65, 144-146, 2010.

[56] Robbins, TH. A reduction mammaplasty with the areola-nipple based on a inferior dermal pedicle. *Plast Reconstr Surg*., 1977, 59, 64–7.

[57] Spear, SL; Howard, MA. Evolution of the vertical reduction mammaplasty. *Plast Reconstr Surg*., 2003 Sep, 112(3), 855-68.

[58] Chen, CM; White, C; Warren, SM; et al. Simplifying the vertical reduction mammaplasty. *Plast Reconstr Surg*., 2004 Jan, 113(1), 162-72.

[59] McCulley, SJ; Hudson, DA. Short-scar breast reduction: why all the fuss? *Plast Reconstr Surg*., 2001 Apr 1, 107(4), 965-9.

[60] Davison, SP; Mesbahi, AN; Ducic, I et al. The versatility of the superomedial pedicle with various skin reduction patterns. *Plast Reconstr Surg*. 2007 Nov, 120(6), 1466-76.

[61] Wise, RJ; Gannon, JP; Hill, JR. Further Experience with Reduction Mammaplasty. *Plast Reconstr Surg*., 1963 Jul, 32, 12-20.

[62] Wise, RJ. A preliminary report on a method of planning the mammaplasty. *Plast Reconstr Surg*, (1946). 1956 May, 17(5), 367-75.

[63] Courtiss, EH; Goldwyn, RM. Reduction mammaplasty by the inferior pedicle technique. An alternative to free nipple and areola grafting for severe macromastia or extreme ptosis. *Plast Reconstr Surg*., 1977 Apr, 59(4), 500-7.

[64] Georgiade, NG; Serafin, D; Morris, R; Georgiade, G. Reduction mammaplasty utilizing an inferior pedicle nipple-areolar flap. *Ann Plast Surg*., 1979 Sep, 3(3), 211-8.

[65] Hammond, DC; Loffredo, M. Breast Reduction. *Plast Reconstr Surg*., 2012 May, 129(5), 829e-39e.

[66] Cruz-Korchin, N; Korchin, L. Vertical versus Wise pattern breast reduction: patient satisfaction, revision rates, and complications. *Plast Reconstr Surg*., 112(6), 1573-1578, November 2003.

[67] Okoro, SA; Barone, C; Bohnenblust, M; et al. Breast reduction trend among Plastic Surgeons: a national survey. *Plastic & Reconstructive Surgery*. 122(5), 1312-1320, November 2008.

[68] Rohrich, RJ; Gosman; AA; Brown, SA; et al. Current preferences for breast reduction techniques: a survey of board-certified Plastic Surgeons 2002. *Plastic & Reconstructive Surgery*., 114(7), 1724-1733, December 2004.

[69] Lassus, C. A technique for breast reduction. *Int Surg*., Jan 1970, 53(1), 69-72.

[70] Lassus, C. An "all-season" mammoplasty. *Aesthetic Plast Surg*., 1986, 10(1), 9-15.

[71] Lassus, C. Breast reduction: evolution of a technique--a single vertical scar. *Aesthetic Plast Surg*., 1987, 11(2), 107-12.

[72] Lejour, M. Vertical mammoplasty: early complications after 250 personal consecutive cases. *Plast Reconstr Surg*., Sep 1999, 104(3), 764-70.

[73] Hall-Findlay, EJ. Pedicles in vertical breast reduction and mastopexy. *Clin Plast Surg*. 2002, 29, 379–391.

[74] Landau, AG1; Hudson, DA. Choosing the superomedial pedicle for reduction mammaplasty in gigantomastia. *Plast Reconstr Surg*., 2008 Mar, 121(3), 735-9.

[75] Nahabedian, MY1; McGibbon, BM; Manson, PN. Medial pedicle reduction mammaplasty for severe mammary hypertrophy. *Plast Reconstr Surg*., 2000 Mar, 105(3), 896-904.

[76] Neaman, KC; Armstrong, SD; Mendonca, SJ; et al. Vertical reduction mammaplasty utilizing the superomedial pedicle: is it really for everyone? *Aesthet Surg J*., 2012 Aug, 32(6), 718-25.

[77] Finger, RE; Vasquez, B; Drew, GS; Given, KS. *Superomedial pedicle technique of reduction mammaplasty*., 1989 Mar, 83(3), 471-80.

[78] Lista, F; Ahmad, J. Vertical scar reduction mammaplasty: a 15-year experience including a review of 250 consecutive cases. *Plast Reconstr Surg*., 117(7), 2152-2165, June 2006.

[79] Skoog, T. A technique for breast reduction: transposition of the nipple on a cutaneous vascular pedicle. *Acta Chir Scand*, 1963, 126, 453.

[80] Strombeck, JO. Mammaplasty: report of a new technique based on the two pedicle procedure. *Br J Plast Surg*, 1960, 13, 79.

[81] McKissock, P. Reduction mammaplasty with a vertical dermal flap. *Plast Reconstr Surg*, 1972, 49, 245.

[82] Weiner, DL; Aiache, AE; Silver, L; Tittiranonda, T. A single dermal pedicle for nipple transposition in subcutaneous mastectomy, reduction mammaplasty or mastopexy. *Plast Reconstr Surg*, 1973, 51, 115.

[83] Davison, SP; Mesbahi, AN; Ducic, I. The Versatility of the Superomedial Pedicle with Various Skin Reduction Patterns. *Plastic & Reconstructive Surgery*., 120(6), 1466-1476, November 2007.

[84] Würinger, E; Mader, N; Posch, E; Holle, J. Nerve and vessel supplying ligamentous suspension of the mammary gland. *Plast Reconstr Surg*., 1998 May, 101(6), 1486-93.

[85] Würinger, E. Refinement of the central pedicle breast reduction by application of the ligamentous suspension. *Plast Reconstr Surg*., 1999 Apr, 103(5), 1400-10.

[86] Wueringer, E; Tschabitscher, M. New aspects of the topographical anatomy of the mammary gland regarding its neurovascular supply along a regular ligamentous suspension. *Eur J Morphol*. 2002 Jul, 40(3), 181-9.

[87] *Vertical Scar Mammaplasty*. Springer 2005, Eds: Hamdi M, Hammond DC, Nahai F.

[88] Hamdi, M; Van, Landuyt, K; Tonnard, P. Septum-Based Mammaplasty: A Surgical Technique Based on Würinger's Septum for Breast Reduction *Plastic & Reconstructive Surgery*., 123(2), 443-454, February 2009.

[89] Collis, N; McGuiness, CM; Batchelor, AG. Drainage in breast reduction surgery: a prospective randomised intra-patient trail. *Br J Plast Surg*., 2005 Apr, 58(3), 286-9.

[90] Corion, LU; Smeulders, MJ; van Zuijlen, PP; van der Horst, CM. Draining after breast reduction: a randomised controlled inter-patient study. J. *Plast. Reconstr*. *Aesthet. Surg*., 62, 865-868, 2009.

[91] American Society of Plastic Surgeons 2010, *Plastic Surgical Procedural Statistics*. http://www.plasticsurgery.org/news/plastic-surgery-statistics/2010-plastic-surgery-statistics.html

[92] Petit, JY; Rietjens, M; Contesso, G; et al. Contralateral mastoplasty for breast reconstruction: a good opportunity for glandular exploration and occult carcinomas diagnosis. *Ann Surg Oncol*., 1997 Sep, 4(6), 511-5.

[93] Colwell, AS; Kukreja, J; Breuing, KH; et al. Occult breast carcinoma in reduction mammaplasty specimen: 14-year experience. *Plast Reconstr Surg*., 2004 Jun, 113(7), 1984-8.

[94] Slezak, S; Bluebond-Langner, R. Occult carcinoma in 866 reduction mammaplasties: preserving the choice of lumpectomy. *Plast Reconstr Surg*., 2011 Feb, 127(2), 525-30.

[95] Pitanguy, I; Torres, E; Salgado, F; et al. Breast pathology and reduction mammaplasty. *Plast Reconstr Surg*., 2005 Mar, 115(3), 729-34.

[96] Ishag, MT; Bashinsky, DY; Beliaeva, IV; et al. Pathologic findings in reduction mammaplasty specimens. *Am J Clin Pathol*., 2003 Sep, 120(3), 377-80.

[97] Clark, CJ; Whang, S; Paige, KT. Incidence of precancerous lesions in breast reduction tissue: a pathologic review of 562 consecutive patients. *Plast Reconstr Surg*., 2009 Oct, 124(4), 1033-9.

[98] Nielsen, M; Jensen, J; Andersen, J. Precancerous and cancerous breast lesions during lifetime and at autopsy. A study of 83 women. *Cancer*., 1984 Aug 15, 54(4), 612-5.

[99] Bondeson, L; Linell, F; Ringberg, A. Breast reductions: what to do with all the tissue specimens? *Histopathology*., 1985 Mar, 9(3), 281-5.

In: Encyclopedia of Surgery (22 Volume Set)
Editors: Andreas Lehrer and Kristin Mueller
ISBN: 978-1-53618-329-0
© 2020 Nova Science Publishers, Inc.

Chapter 37

LIPOSUCTION

Reza Nassab*
Lancashire Teaching Hospitals NHS Foundation Trust, UK

KEY POINTS

- Wetting solutions have allowed more extensive liposuction without the associated blood loss. The tumescent and superwet techniques both have an estimated blood loss volume of one percent of the aspirated volume, compared to reported rates of 20-45% for the dry technique.
- The main techniques are suction (SAL), power (PAL), ultrasound (UAL) and laser assisted (LAL) liposuction.
- PAL has been shown to be quicker to perform with less pain, bruising and oedema when compared with SAL.
- UAL has been shown to result in less blood loss than SAL.
- A small number of case series have shown the potential benefit of skin retraction following LAL.
- Despite the variety of liposuction techniques, almost all comparative studies of the liposuction assisted devices revealed no significant difference in terms of aesthetic outcome.

HISTORY OF BODY CONTOURING AND LIPOSUCTION

On February 28, 1926, the French surgeon Charles Dujarier attempted to remove fat from the legs of one Suzanne Geoffre, a fashion designer who was unhappy with the heaviness of her calves. For the first time, ladies fashion exposed legs below the knees, and slender calves and ankles became highly sought after. The attempt, however, tragically resulted in amputation of a limb, and it was fifty years before the procedure resurfaced again.

* Corresponding Author's Email: rsnassab@gmail.com.

In the early 1970s, Schrudde described 'lipexeresis,' which was a technique of creating subcutaneous tunnels with scissors and then removing fat with curettes and suctioning the remaining particles after irrigation. In 1976, Fischer and Fischer developed the addition of suction to extract subcutaneous fat with the use of sharp cannulas[1]. Dr Illouz introduced the blunt cannula for fat removal in France in 1977[1,2]. The next important milestone in liposuction was the use of wetting solutions by Dr Illouz, which heralded lower blood loss and removal of larger amounts of fat[1,2]. The technique of liposuction was introduced to the United States in the early 1980s[3]. In 1987, Klein introduced the tumescent technique of liposuction that allowed liposuction to be performed under local anaesthesia with reduced blood loss[2]. Since the advent of traditional suction assisted liposuction (SAL) there have been a number of advances in techniques and technologies to assist the procedure, including power-, laser-, ultrasound and radiofrequency-assisted devices.

In 2011, the International Society for Aesthetic Plastic Surgery reported that over 1.2 million lipoplasty procedures had been performed globally, making it the most common cosmetic procedure worldwide[4]. Liposuction is also the most commonly performed cosmetic surgical procedure in the United States according to the American Society for Aesthetic Plastic Surgery (ASAPS)[5].

This chapter explores the various facets of liposuction and reviews the evidence supporting the different techniques that are commonly used.

LITERATURE SEARCH

A search for relevant studies was undertaken using Pubmed up to January 2013. The medical subject headings or MeSH terms used for the search included: liposuction; lipoplasty; lipolysis; infiltration; suction assisted; power assisted; laser assisted; ultrasound assisted; water assisted; radiofrequency assisted and VASER. Combinations of these terms were also used to maximise the return of results. The studies identified were then classified according to the level of evidence for key clinical recommendations using the American Society of Plastic Surgeons Levels of Evidence Rating Scale for Therapeutic Studies (Appendix) [6]. The studies with the highest level of evidence have been included in this review.

KEY STEPS

The process of liposuction may be considered as a number of key steps, which include:

- Preoperative assessment and marking
- Anaesthesia
- Infiltration using wetting solutions
- Incisions
- Liposuction, fat fragmentation and emulsification using various devices
- Closure and dressings
- Postoperative care

Anaesthesia

The introduction of tumescent infiltration allowed liposuction to be performed without general anaesthesia. Liposuction is commonly performed using both general and local anaesthesia with or without sedation. There has also been a move to perform liposuction as an office-based procedure in many parts of the world. Since the original suction lipoplasty was described there have been a number of devices developed to assist with liposuction. The lipoaspirate comprises of a supernatant fat layer and infranatant aspirate. We shall review these in detail and highlight the evidence behind their use. We also review the evidence behind new approaches to body contouring such as water assisted liposuction and radiofrequency liposuction. We conclude by reviewing some special considerations in liposuction such as large volume liposuction and combination procedures.

Infiltration and Wetting Solutions

The introduction of wetting solutions in lipoplasty is credited to Dr Illouz [1,2] and has become standard practice for liposuction. Numerous studies in the literature explore the various solutions used in practice.

Dry

The dry technique, popularised by Fournier and Otteni [2], was the first method of liposuction, in which patients underwent insertion of the liposuction cannula under general anaesthesia without any infiltration. The aspirate would typically contain approximately 20-45% blood, thus limiting the amount of fat that could be removed without the need for transfusion [7]. Triana et al. conducted a large retrospective series comprising more than 26,000 patients undergoing various types of liposuction. In their series, anaemia (which was not defined) was found in two thirds of patients (4760 of 7140 patients) undergoing dry liposuction compared to 0.08% of those having tumescent liposuction [*Level IV Evidence*][8]. Consequently dry liposuction is not frequently used today due to the significant associated blood loss.

Wet

In 1983 Illouz reported his series of over 3000 cases of ‘wet’ liposuction, infiltrating with hypotonic hyaluronidase solution to emulsify fat and facilitate aspiration[9]. The technique consisted of infusion of 100-300ml of fluid into each treatment site regardless of the intended volume of fat removal, and had the effect of reducing the aspirated blood volume to 10-25%[7]. In 1984, Hetter added low-dose epinephrine to the wetting solution in order to reduce blood loss to less than five percent [10].

Superwet

Fodor introduced the concept of the ‘superwet’ technique, which uses an infiltration to aspiration ratio of 1:1[11] – that is, one millilitre of infiltrate is infused for every millilitre of fat to be aspirated. The reported blood loss with this technique ranges from one to four percent of the aspirate[7].

Tumescent

In 1987, Klein described the tumescent technique, which uses larger volumes of infiltrate prior to liposuction [12]. Typically, three to four millilitres of infiltrate would be used for every millilitre of aspirate. In a series of 112 patients, Klein reported that the haematocrit would drop by one percentage point for each litre of fat removed using the tumescent technique [13].

Local Anaesthesia in Wetting Solutions

Numerous studies have explored the safe dose of lidocaine that can be administered during liposuction. In general, the usual recommended maximum dose for lidocaine with epinephrine is 7 mg/kg [7,14], but published reviews have demonstrated safe use of wetting solutions utilizing much higher doses [14]. In liposuction there are a number of factors that contribute to the safe use of higher doses of lidocaine. Firstly, systemic absorption from fat is intrinsically slow. Secondly, absorption is further slowed by vasoconstriction caused by use of epinephrine-containing solutions. Finally, some of the wetting solution is re-aspirated during liposuction. The current recommended safe limit in liposuction is 35 mg/kg of lidocaine when used with epinephrine, although safe use of doses up to 64 mg/kg have been reported [14-16].

A comparative study by Perry et al. assessed the effectiveness of lidocaine on postoperative analgesia. In their ten patients liposuction was performed using a wetting solution that contained lidocaine for one side and a solution with no lidocaine for the contralateral side. No difference was found postoperatively in terms of pain level between the two sides. This study suggests that the lidocaine does not provide postoperative analgesia although the study size was small [*Level II Evidence*] [17].

In summary, wetting solutions have allowed more extensive liposuction whilst reducing associated blood loss. Table 1 summarises the estimated blood loss associated with the various wetting solutions. There still remains much debate on the use of superwet versus tumescent solution in liposuction. Rohrich et al. reviewed the literature on wetting solutions and recommended the use of the superwet technique. They found no evidence for any benefit of using tumescent solutions in terms of safety or efficacy. The superwet technique had comparable blood loss to tumescent liposuction but without the risks of fluid overload and congestive heart failure [14]. Perry et al. have recommended that no lidocaine is required in patients undergoing the procedure under general anaesthesia [17].

Liposuction Techniques

Fischer and Fischer were the first to use suction for aspiration of fat [2]. Further advances in lipoplasty have come from the development of devices to assist in the fragmentation of fat to allow easier removal. A survey of ASAPS members revealed SAL to be the preferred method amongst 51% of respondents. Power- and ultrasound-assisted liposuction (PAL and UAL) were preferred by 23% and 21% respectively. Laser assisted lipoplasty (LAL) was only preferred by 4% of the respondents [18].

Table 1. Estimated blood loss using various wetting solutions [7]

Wetting Solution	Estimated blood loss as% of volume
Dry	20-45%
Wet	4-30%
Superwet	1%
Tumescent	1%

Suction Assisted Lipoplasty (SAL)

SAL relies on the mechanical motion of the cannula to disrupt and avulse adipocytes, which are then aspirated via tubing connected to suction. The suction pressure was classically described to be one atmosphere (760 mmHg), although these days the pressure varies from about 300-600 mmHg [19]. SAL remains the most commonly used technique and is often the benchmark against which other techniques are compared.

Syringe Aspiration

In 1986, Fournier described the use of syringes for fat aspiration [20]. The same year, Toledo began using syringe liposuction combined with fat grafting, which he termed 'syringe liposculpture' 21]. These and other authors have presented their series but only a small number of comparative studies have been performed analysing syringe and suction liposuction. Lewis et al. compared syringe and suction pump aspiration in a small series of six patients. They reported less bruising and less blood loss with the use of the syringe for aspiration [*Level II Evidence*] [22]. This was confirmed by another small comparative study of ten patients [23]. The main advantages of the syringe technique are reported as accurate fat removal, precise quantification, less blood loss, less pain and preservation of adipocytes. The major disadvantage, however, is a significantly lengthened operative time [*Level II Evidence*] [23]. The negative pressure generated by various syringes appears to be primarily related to the volume aspirated and independent of the syringe calibre. Table 2 illustrates the negative pressure generated with varying amounts of aspiration. The negative pressure achieved with 60ml of aspiration is similar to that expected for a SAL device [*Level V Evidence*] [24]. The role of syringe aspiration of fat has recently seen a renaissance with the rising popularity of lipomodelling.

Table 2. Negative pressure generated using various syringe sizes [24]

Volume aspirated (ml)	Negative pressure generated (mmHg)	Negative pressure generated (atm)
1	-165	-0.21
3	-349	-0.45
10	-559	-0.735
30	-667	-0.877
60	-718	-0.944

Power Assisted Lipoplasty (PAL)

PAL refers to the use of a reciprocating cannula attached to a suction source. The MicroAire device, approved by the FDA in 1998, has a cannula that reciprocates at 2000-4000 cpm with a two millimetre stroke [25]. Fodor and Vogt performed a pilot study in thirty patients comparing PAL with traditional SAL [26]. Patients served as their own controls having one side treated with PAL and the other with SAL. There was no difference between sides in terms of pain, oedema or ecchymosis but PAL was reportedly better at breaking up fibrous fatty areas and superficial layer liposuction. The other main advantage of PAL was reduced surgeon fatigue. Disadvantages included expense and some degree of surgeon discomfort due to vibration of the instrument [*Level II Evidence*] [25,26].

Katz et al. performed a comparative study of PAL versus SAL in 21 patients under tumescent anaesthesia, patients again serving as their own controls. The mean aspirated volume was 1400ml and the amounts of supernatant and infranatant aspirate were similar in both groups. Compared with SAL, PAL was carried out 35% quicker and was associated with 45% less intraoperative and 38% less postoperative pain. Ecchymosis and oedema were also 37% and 32% less on the PAL side respectively [*Level II Evidence*]. No complications were reported in this series [27].

Scuderi et al. confirmed these findings in their series of fifteen patients comparing PAL, SAL, and UAL [28]. PAL reduced operative times by almost 50% compared to UAL and 25% compared to SAL. PAL and UAL had significantly lower mean haemoglobin concentrations in the lipoaspirate compared with SAL, suggesting it produced less trauma. No differences were found in terms of aesthetic outcome between the three methods of liposuction. The investigators also noted more surgeon distress with the PAL device due to the vibration of the reciprocating cannula [*Level II Evidence*] [28]. A further study of fifteen cases confirmed the superiority (in terms of total amount of fat removed) of PAL over SAL in the treatment of more fibrous areas [*Level II Evidence*] [29].

Ultrasound Assisted Lipoplasty (UAL)

The use of ultrasound in body contouring is often credited to Zocchi in 1980s. In his 1992 paper entitled ‘ultrasonic liposculpting’ he described the theory underlying the use of ultrasound and the technique of UAL [30]. The potential benefits of UAL as described by Zocchi are summarised in Table 3 [30].

The fragmentation of fat using ultrasound is thought to occur by three main mechanisms: cavitation, thermal effects and mechanical effects [30]. The first-generation devices used solid blunt probes of four to six millimetre diameter to deliver a continuous ultrasound. This caused fragmentation of fat that subsequently required aspiration. Second-generation devices, such as the Lysonix (Lysonix Inc.), allow simultaneous ultrasound delivery and aspiration. Its probes are about five millimetres in diameter with only a two millimetre lumen for aspiration, resulting in a significant amount of time required for aspiration. The ultrasound delivery is also continuous and the necessary incisions are in the region of 1cm to allow for instrumentation and the use of skin protectors [31].

Although UAL has been described for some time there were few who used it in view of the high complication rates reported with early devices. There have been numerous papers in the literature reporting a range of complications.

Zocchi published his initial series of 280 patients treating over 1000 areas. He reported no complications apart from incision site skin distress prior to the introduction of skin port protectors [*Level IV Evidence*] [30].

Table 3. The potential benefits of UAL [30]

Potential Benefits of Ultrasound Assisted Liposuction
Selective destruction of fat whilst respecting surrounding tissues
Smoother/more regular skin surfaces, caused by elimination of the fluid part of the adipose tissue whilst retaining higher density structures (adipocyte wall, intracellular substance and thick cellular residue)
Potential for skin tightening by stimulation of the deep dermis
Potential to treat cellulite and peau d'orange skin
Reduced physical exertion for the surgeon

Maxwell and Gingrass reported their experience with some first and second-generation UAL devices in 250 patients. In this series, the average volume aspirated was 3940ml with an average fat content of the aspirate of 63%. There were three cases (1.2%) of significant abdominal skin necrosis and 28 seromas (11.2%) [*Level IV Evidence*]. They preferred a deeper plane of UAL to Zocchi who described superficial use to stimulate the dermis [32].

In 1998, Fodor et al. performed a comparative study of UAL with SAL in 100 patients. Patients had UAL performed on one side and SAL on the contralateral side using a superwet infiltration. The supernatant fat averaged 75% of the total volume of aspirate in UAL but was not stated for SAL. The lipocrits from the infranatant aspirate were found to be less than one percent in both SAL and UAL, signifying a very low blood content within the aspirate. No significant differences were found in terms of satisfaction, ecchymosis and swelling. Relative procedure times were not recorded. The authors did not observe any significant advantage in terms of skin retraction using the UAL. No complications were reported in either group [*Level II Evidence*] [33].

Scuderi et al. compared UAL with SAL and PAL in 45 patients, each treatment group comprising of fifteen patients. The UAL group was found to have a significantly higher supernatant fat content than in PAL and SAL (eighty percent compared with fifty percent). The mean triglyceride concentration in the lipoaspirate in the UAL was also much higher than PAL and SAL, thought to be due to the specific adipocyte disruption caused by sonication. The aesthetic outcome was similar amongst the three treatment groups, but both the cost and the operative time of UAL was significantly greater than PAL and SAL [*Level II Evidence*] [28].

A large series of 660 patients undergoing UAL reported a complication rate of 1.8%, the main complications being two episodes of hypotension, three seromas, three cases of contact dermatitis and one haemorrhage [*Level IV Evidence*] [34]. In the large series of various techniques by Triana et al. there was a significantly higher rate of both seromas and skin necrosis following UAL than either SAL or LAL [*Level IV Evidence*] [8]. UAL has also been compared to surgical lipectomy in a study of forty patients (with half undergoing each intervention) demonstrating that UAL took almost double the operative time but was associated with a five times shorter hospital stay. The surgical lipectomy group had no complications, whereas the UAL group, experienced ecchymosis (80%), orthostatic

hypotension (75%), cellulitis (75%), and epidermal loss in a small area (10%) [*Level II Evidence*] [35]. Although the sample size is small (n=20), the high prevalence of cellulitis as a complication in the UAL group is striking.

The evidence for the first- and second-generation UAL devices reveals variable complication rates. The main comparative trials have failed to show any significant benefit of UAL over SAL in terms of aesthetic outcomes [*Level II Evidence*] [28,33]. Renewed interest in UAL has been stimulated by the production of a new generation of devices.

Vibration Amplification of Sound Energy at Resonance (VASER)

The current third generation ultrasound devices, such as the VASER (Vibration Amplification of Sound Energy at Resonance), differs from earlier devices in a number of ways: VASER uses 2.9-3.7mm solid probes with grooves near the tip, which transfer some ultrasound energy to adjacent areas; ultrasound energy delivery can be pulsed rather than continuous, reducing heat production; and, according to some data, the VASER probe may be more effective at fragmentation and emulsification at half the energy settings of earlier UAL devices (Figure 1) [31,36]. The VASER requires an alternative device for the aspiration of the fat.

Jewell et al. first reported a pilot study of 77 patients undergoing VASER lipoplasty in 2002. They reported that the supernatant fat exceeded 80% of the total volume in all their cases and no complications [*Level IV Evidence*] [36]. In 2004, Fodor et al. confirmed the safety and efficacy of the VASER device in 400 patients [*Level IV Evidence*] [37].

A multicentre, prospective, randomised, single blind controlled trial comprising twenty females compared VASER and SAL, showing that VASER was associated with significantly less blood loss and better skin retraction. However no difference was detected at follow-up in terms of patient and surgeon satisfaction [*Level I Evidence*] [38].

A comparative study of lipoplasty aspirates from SAL and a third generation UAL revealed that the SAL aspirate had a 7.5 times higher haemoglobin content and a 6.5 times higher haematocrit. The study concluded that the third generation UAL device was associated with significantly less blood loss than SAL [*Level III Evidence*] [39].

Hoyos has refined the use of VASER in liposculpture with an approach referred to as ‘VASER assisted high definition liposculpture’ [40]. This builds on the Mentz technique of abdominal etching to produce the appearance of highly developed musculature (Figure 2) [41]. Hoyos et al. published a series of 306 patients undergoing high definition VASER from 2005 to 2007. They noted that 84% of their 257 were satisfied with their results. The main complications included: seroma (6.5%); port site burns (2.9%), prolonged swelling (1.6%), pigmentary changes (0.65%); and, cellulitis (0.65%) [*Level IV Evidence*].[40] The reported seroma rate in this series was higher than described by Jewell et al. (of zero) but this was attributed to superficial layer liposuction performed by Hoyos [36]. This seroma rate was significantly lower than other UAL devices [*Level IV Evidence*]. The VASER, due to the lower energy used, did not produce any distant necrosis or skin necrosis unlike the early generation UAL devices.

Laser Assisted Liposuction (LAL)

Laser assisted liposuction (LAL) relies on the principle of selective photothermolysis to target specific chromophores at certain wavelengths [42]. The theoretical mechanisms of action and benefits for laser lipolysis are summarised in Table 4 [42].



Figure 1. Illustration of 3.7mm and 2.9mm VASER cannulas.

Figure 2. VASER assisted high definition liposculpture used to produce abdominal etching. Images courtesy of Dr Ravi Jain, Riverbanks Clinic, Harpenden.

The most commonly used laser liposuction devices are Neodymium:Yttrium Aluminium Garnet (Nd:YAG) lasers with a wavelength of 1064 nm. Use of the sequential 1064/1320nm Nd:YAG laser [43] and diode lasers of varying wavelengths [44,45] have also been reported.

Table 4. The mechanisms and benefits of LAL [42]

Liquefaction of adipocytes due to photothermal injury
Disruption of adipocytes assisting suctioning
Thermal energy resulting in improved haemostasis
Small access incisions typically of approximately 2mm

1064nm Nd:YAG LAL

In 2002, Badin et al. presented the first clinical series of 245 patients using the 1064nm Nd:YAG LAL. Reported benefits included skin retraction, reduced swelling and good contouring, and the authors recommended LAL in circumstances where conventional liposuction techniques could leave undesirable skin redundancy. The main disadvantages were the cost of the device, learning curve and increased operative time. They reported no complications in their series [*Level IV Evidence*] [46]. Fakhouri et al. have reviewed and summarised a number of case series reporting the use of 1064nm lasers in treating various areas [43].

In 2006, Prado et al. performed a prospective, randomised, double-blind controlled trial comparing SAL and LAL. They recruited 25 patients who were randomly assigned to undergo SAL on one side of the body and LAL on the other side. There were no reported complications in either group. No significant differences in cosmetic outcome were found between SAL and LAL using an objective grading system. Overall, patients reported more pain following SAL. LAL resulted in significantly lower lipocrits when compared to SAL. Histologically LAL resulted in ninety percent disruption of adipocyte architecture and rupture of the nuclear cellular membrane, whereas SAL resulted in 90% preservation of the adipocyte architecture with intact cellular membranes [*Level I Evidence*] [47].

Skin tightening is considered one of the main benefits of LAL. A large series compared a variety of liposuction techniques over a 25-year period, finding that LAL resulted in better skin retraction in areas such as the axillae, submental region and inner thighs. This effect was better than tumescent liposuction alone but was not significantly different from UAL. The authors did not describe how they measured skin retraction and it may have been a subjective assessment. They did not comment on the duration of these effects either [*Level IV Evidence*] [8].

Sequential 1064/1320nm Nd:YAG LAL

Histological and laboratory studies have shown that the 1320nm wavelength laser targets collagen (dermal and subcutaneous) and collagen-bound water more effectively than the 1064nm wavelength [*Level V Evidence*] [48]. Therefore, the 1320nm wavelength may be more efficient in fat disruption and result in better skin contraction [*Level V Evidence*] [49].

Woodhall et al. conducted a comparative study of the 1064 nm, 1320nm and combined 1064/1320nm Nd:YAG lasers. The first part of the study revealed no difference in fat reduction or skin retraction when comparing the 1064nm laser to tumescent liposuction alone in eight patients. The second study of ten patients showed no difference when comparing the 1064nm and 1032nm lasers. The third study, in which twenty patients underwent treatment with the combined 1064/1320nm multiplex laser, reported improvement in skin laxity when compared to the individual wavelength lasers. Thermal burns were reported in two patients (ten percent) using the multiplex device [*Level II Evidence*] [50].

A small series using a laser device with sequential firing of 1064 and 1320nm wavelengths demonstrated an average of 22% and 17% skin shrinkage respectively after one and three months [*Level IV Evidence*] [51]. This study comprised of only five patients but used tattoo markings to measure subsequent skin retraction accurately. A further study by DiBernardo on ten patients comparing SAL and LAL in a randomised split abdomen study revealed minimal difference between the two techniques at one month. At three months, however, a 62% improvement in skin tightening (again measured in terms of skin tightening) was noted on the side of the abdomen treated with LAL compared to only five percent on the SAL side [*Level II Evidence*] [52].

Diode LAL

Neira has described the technique of a low-level laser liposuction, which he has called the Neira 4L technique. This procedure uses a 635nm diode laser applied externally to the treatment areas for periods of six to twelve minutes. This low level laser causes liquefaction of the fat, which is then aspirated using SAL. Neira and coworkers reported a series of 700 patients in whom the average aspirate was five litres. They reported a patient satisfaction rate of 93% and a seroma rate of 40%. Other complications included asymmetries (3%), haematomas, bruising (5%), and infection (0.3%) [*Level IV Evidence*] [53].

The efficacy of 635nm diode low-level laser without liposuction has been investigated as a non-invasive method of body contouring. In a double-blind, randomised placebo-controlled trial, 67 patients underwent thrice weekly treatment using laser or placebo for two weeks. Measurements were taken of the waists, hips and thighs before the start of treatment and then at one, two and four weeks after starting treatment. Their results showed a statistically significant reduction in the measurements at two and four weeks compared with those at baseline in the treatment group but not the placebo group. However, some relapse was evident in hip measurements from two to four weeks suggesting that the effect could have been transient (Figure 3). Longer term follow-up would be needed to assess whether the benefits were maintained in the long-term [*Level I Evidence*] [54].

The 980nm diode laser has been used for lipolysis in view of its continuous wave emission and high power settings making it useful for large areas that require high cumulative energy. The use of 924nm and 975nm diode devices has also been reported. These are primarily small case series with no high level evidence available for these devices [43].

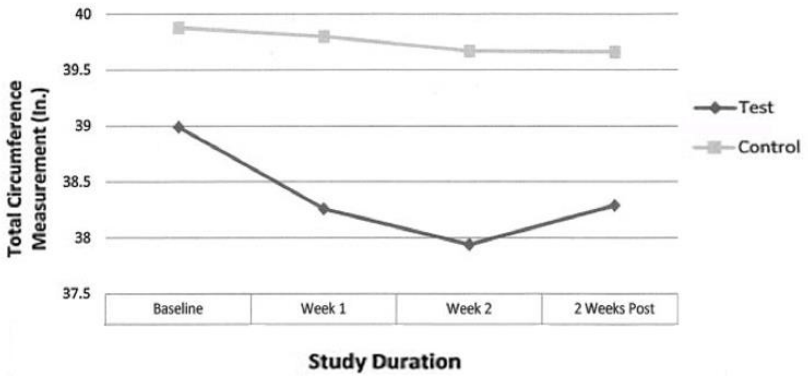

Figure 3. Circumference measurements of the waist (top) and hip (bottom) at each evaluation point for all participants (n=67). Modified from Jackson [54].

In summary, although numerous case series address the safety and efficacy of the 1064nm Nd:YAG laser, the only comparative study is that of Prado et al., showing no difference in aesthetic outcome between LAL and SAL [*Level I Evidence*] [47]. A number of case series with other lasers, such as the diode and 1064/1320nm multiplex, indicate some benefits in terms of skin retraction. A small randomised controlled trial showed short-term benefit of a diode laser on skin retraction [*Level I Evidence*] [54]. No long-term studies are available to assess the longevity of skin retraction. Some authors with vast experience of liposuction have reported little benefit of laser-assisted methods over tumescent suction liposuction techniques [*Level V Evidence*] [55].

THE FUTURE OF LIPOLYSIS AND BODY CONTOURING

There are continual developments in the field of body contouring. A few recent developments include water- and radiofrequency-assisted liposuction.

Water Assisted Lipoplasty (WAL)

The WAL device uses a dual-purpose cannula that produces a fan-shaped jet of tumescent infiltrate whilst simultaneously suctioning the instilled fluid and aspirated fat. The infiltration process comprises of two phases using different solutions. The first is preinfiltration with tumescent solution to produce anaesthesia and vasoconstriction in the treatment area. The second phase is simultaneous irrigation and aspiration using an infiltration solution with a lower local anaesthetic concentration than used in the first phase. The benefits of this technique include the use of a water jet to loosen adipocytes whilst preserving surrounding structures such as nerves and vessels [56]. Stutz et al. demonstrated histologically and immunohistologically in thirty lipoedema patients undergoing WAL that adipocytes largely survived and there was no evidence of damage to lymphatics [*Level V Evidence*] [57]. This has led to it being considered for fat harvesting in lipomodelling. A case series exploring the safety and efficacy of WAL in 41 consecutive patients for body

contouring and lipoharvesting found it to be safe with minimal blood loss and lipocrits estimated at less than one percent. The investigators found ninety percent of adipocytes were viable using special staining techniques in five patients [*Level IV Evidence*] [58].

Araco et al. conducted a randomised trial comparing WAL and traditional liposuction. In their study of sixty patients (28 traditional vs. 32 WAL), those undergoing WAL had pain scores 4.8 times less than traditional liposuction, which was statistically significant. In the WAL group, 87% were pain free after four days compared to only 3.6% in the traditional group. The WAL group also had significantly less ecchymosis. There was no significant difference in aesthetic outcome between the two procedures [*Level I Evidence*] [59].

There remains little evidence in the literature for the use of WAL in body contouring and lipomodelling at present. The few small case series do, however, provide interesting results and highlight this as an interesting technology for further research.

Radiofrequency Assisted Liposuction (RFAL)

The radiofrequency assisted liposuction (RFAL) device comprises a bipolar radiofrequency (RF) probe in which an internal electrode is inserted into adipose tissue and an external electrode applied to the skin surface (Figure 4). The internal RF probe then emits RF current through a small conductive tip [60]. Potential benefits of RFAL are summarised in Table 5.



Figure 4. Radiofrequency assisted liposuction.

Table 5. The benefits of radiofrequency assisted liposuction [60]

The Benefits of Radiofrequency Assisted Liposuction
Faster treatment
Reduced tissue trauma
Improved safety
Uniform heating of skin and subcutaneous tissues
Potential for skin retraction

Paul and Mulholland presented their experience of the RFAL device in a series of twenty patients. Compared with a LAL device the time taken to heat a treatment zone was significantly faster and heat distribution was more uniform with RFAL. Histological analysis following RFAL revealed extensive destruction and coagulation of adipocytes and adipose tissue, along with coagulation of small to medium sized blood vessels and preservation of the subdermal plexus. There was also coagulation of deep, reticular dermal collagen suggesting

the potential for skin retraction. There were no reported complications of the treatment [*Level IV Evidence*] [60].

There have been a number of other case studies using the RFAL device in the literature. Blugerman et al. presented 23 patients with an average aspiration of 2404ml. The series demonstrated significant reductions in weight and circumference measurements at six weeks and three months follow up, and the authors commented on significant skin tightening following treatment. There were no reported complications in the series [*Level IV Evidence*] [61]. These findings have since been confirmed by Hurwitz et al. [*Level IV Evidence*][62] and Ion et al. [*Level IV Evidence*] [63].

Theodorou et al. performed RFAL in 97 patients with an average aspiration of 1146 cc. They reported rates of major and minor complications of 6.25% and 8.3% respectively. The overall patient satisfaction was 82% for skin tightening and 85% for body contouring [*Level IV Evidence*] [64].

These initial series have shown some promising results, but no comparative studies or randomised clinical trials have been performed to date.

LARGE VOLUME LIPOSUCTION

Large volume liposuction has been defined as the removal of 5000ml or more of total aspirate (that is, fat plus re-aspirated infiltrated solutions) during a single procedure [15]. The literature does not provide clear evidence for the maximum safe volume of aspiration, but higher complication rates and death have been reported when larger volumes or more anatomical sites are treated [66,70].

Rohrich et al. reviewed over 200 patients undergoing aspirations exceeding five litres and gave recommendations for fluid resuscitation: when less than five litres is aspirated the maintenance fluid plus the volume of subcutaneous wetting solution is adequate resuscitation; whereas when more than five litres is aspirated, an additional 0.25ml of crystalloid for every 1ml of aspirate over five litres is given [*Level IV Evidence*] [14].

In 1999, Albin et al. reported a series of 181 patients undergoing liposuction of more than five litres. In this series, seven patients underwent aspiration of over twenty litres, of whom one had a deep venous thrombosis and one a pulmonary embolus [*Level IV Evidence*] [65]. In a larger series of 631 patients over twelve years, Commons reviewed patients undergoing liposuction of more than three litres. They highlighted the low complication rates in their patients and overall safety of large volume liposuction [*Level IV Evidence*] [66]. They also recommended overnight monitoring in such large volume liposuction patients. In 2008, Choudry et al. published their series of 62 patients undergoing large volume liposuction. They found five patients with symptomatic postoperative anaemia requiring blood transfusion and one patient with a haematoma requiring operative evacuation [*Level IV Evidence*] [67].

COMBINED LIPOSUCTION AND ABDOMINOPLASTY

The concept of liposuction combined with abdominoplasty has been around since the mid-1980's. There were a few reports of cases where combinations of procedures were

undertaken with varying degrees of skin resection from mini- to full-abdominoplasty. There were initial concerns regarding higher complications with combined procedures focussing on the viability of the abdominal skin flaps following liposuction [68]. Matarasso has described safe areas for combined lipoabdominoplasty based on the blood supply of the abdominal wall (Figure 5) [68,69]. An ASAPS survey explored the liposuction morbidity and mortality of its members. The survey found that the mortality rate associated with liposuction alone was 0.0021%. When liposuction was combined with abdominoplasty, however, the mortality rate rose to 0.0305%, which was fourteen times more than liposuction alone [70].

There have been a number of studies exploring the safety and efficacy of lipoabdominoplasty since that survey. Vila-Rovira described a series of 48 patients in whom extensive liposuction with minimal dissection abdominoplasty was performed. This method utilises the Avelar technique that uses liposuction of the upper and lower abdomen to allow the skin to be advanced without undermining the skin flaps. Minimal undermining creating a tunnel from the umbilicus to xiphoid whilst preserving the perforators and Scarpa's fascia is performed. In this series, complications included: seromas (ten percent); small areas of skin necrosis (ten percent); haematomas (two percent); cutaneous irregularities (twenty percent); secondary liposuction (ten percent); and scar revisions (ten percent) [*Level IV Evidence*] [71].

Heller et al. described a comparative study in which 114 patients underwent various body contouring procedures. They found that the lowest complication rate (at five percent) was in the liposuction only group. The traditional W-pattern and modified low transverse abdominoplasty procedures had overall complication rates of 42% and 17%, respectively. The combined lipoabdominoplasty group had a significantly lower complication rate of 9% [*Level III Evidence*] [72].

In 2010, Weiler et al. reported a series of 173 patients undergoing lipoabdominoplasty. In this series complications included partial dehiscence or skin necrosis (6.9%), infection (7.5%), seroma (3.4%), major fat necrosis (0.5%) and skin flap necrosis (1.1%). Systemic complications included deep venous thrombosis (2.8%) and pulmonary embolism (1.1%) [*Level IV Evidence*] [73].

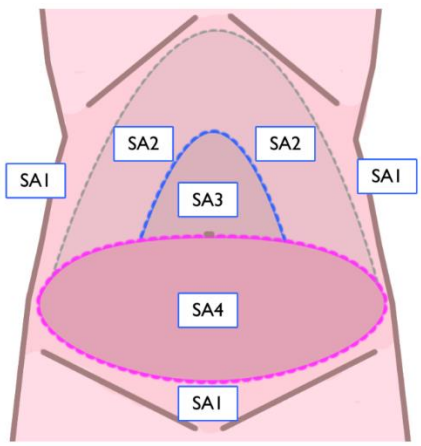

Figure 5. Anatomic areas for safe suction in combined abdominoplasty-liposuction [68,69].

Most recently, a prospective outcome study of 360 patients treated with liposuction, lipoabdominoplasty or abdominoplasty was reported [*Evidence Level II*]. In this study, lipoabdominoplasty and abdominoplasty patients experienced significantly more pain and complications than liposuction alone. The complication rates were 3.7% for liposuction only, 21.9% for lipoabdominoplasty, and 15.4% for abdominoplasty alone. However the highest level of patient satisfaction (99.2%) was from the combined lipoabdominoplasty procedure. The lipoabdominoplasty group also reported the most improvement in quality of life, self-esteem and self-confidence [*Level II Evidence*] [74].

In summary, combined liposuction and abdominoplasty carries a higher complication rate but the patient reported outcomes in this group are significantly better than liposuction alone.

CONCLUSION

There has been a huge increase in demand for liposuction, currently making it the most popular cosmetic surgical procedure globally. Early concerns about the safety of the procedure have been alleviated by the use of wetting fluids and the associated reduction in blood loss, but this has introduced new issues with fluid balance. Safety issues were also raised when large volume liposuction was performed but recommendations and guidelines have been reported to reduce adverse events in these cases. There have been considerable developments technologically in the production of devices to assist with liposuction. We have seen that there are, however, only a very small handful of high-level evidence based studies available in the field of liposuction. The majority of the literature comprises case series' of variable size based on personal experience. There is a need for more randomised controlled trials and comparative studies in liposuction to help elucidate the effectiveness of new emerging technologies.

REFERENCES

[1] Fodor, PB. Reflections on lipoplasty: History and personal experience. *Aesthetic Surg J*, 2009, 29, 226-231.

[2] Ahern, RW. The history of liposuction. *Semin Cutan Med Surg*, 2009, 28, 208-211.

[3] Lewis, CM. Early history of lipoplasty in the United States. *Aesthetic Plast Surg*, 1990, 14, 123-126.

[4] International Society of Aesthetic Plastic Surgery. *ISAPS International Survey on aesthetic/cosmetic procedures in 2011*. http://www.isaps.org/isaps-global-statistics.html

[5] American Society for Aesthetic Plastic Surgery. *ASAPS Statistics*. http://www.surgery.org/media/statistics.

[6] American Society of Plastic Surgeons. *ASPS Scales for Rating Levels of Evidence*. http://www.plasticsurgery.org/x3136.xml

[7] Rohrich, RJ; Beran, SJ; Fodor, PB. The role of subcutaneous infiltration in suction-assisted lipoplasty: A review. *Plast Reconstr Surg*, 1997, 99, 514-519.

[8] Triana, L; Triana, C; Barbato, C; Zambrano, M. Liposuction: 25 years of experience in 26, 259 patients using different devices. *Aesthetic Surg J*, 2009, 29, 509-12.

[9] Illouz, YG. Body contouring by lipolysis: A 5-year experience with over 3000 cases. *Plast Reconstr Surg*, 1983, 72, 591-597.
[10] Hetter, GP. The effect of low-dose epinephrine on the haematocrit drop following lipolysis. *Aesthetic Plast Surg*, 1984, 8, 19-21.
[11] Fodor, PB. Wetting solutions in aspirative lipoplasty: A plea for safety in liposuction. *Aesthetic Plast Surg*, 1995, 19, 379-380.
[12] Klein, JA. Tumescent technique for regional anaesthesia permits lidocaine doses of 35mg/kg for liposuction. *J Dermatol Surg Oncol*, 1990, 16, 248-263.
[13] Klein, JA. Tumescent technique for local anaesthesia improves safety in large-volume liposuction. *Plast Reconstr Surg*, 1993, 92, 1099-1100.
[14] Rohrich; RJ; Kenkel; JM; Janis; JE; et al. An update on the role of subcutaneous infiltration in suction-assisted lipoplasty. *Plast Reconstr Surg*, 2003, 111, 926-927.
[15] Haeck, PC; Swanson, JA; Gutowski, KA; et al. Evidence-based patient safety advisory, Liposuction. *Plast Reconstr Surg*, 2009, 124, 28S-44S.
[16] Wells, JH; Hurvitz, KA. An evidence-based approach to liposuction. *Plast Reconstr Surg*, 2011, 127, 949-954.
[17] Perry, AW; Petti, C; Rankin, M. Lidocaine is not necessary in liposuction. *Plast Reconstr Surg*, 1999, 104, 1900-1902.
[18] Ahmad, J; Eaves, FF, 3rd; Rohrich, RJ; Kenkel, JM. The American Society for Aesthetic Plastic Surgery (ASAPS) survey: current trends in liposuction. *Aesthetic Surg J*, 2011, 31, 214-224.
[19] Berry, MG; Davies, D. Liposuction: A review of principles and techniques. *J Plast Reconstr Aesthetic Surg*, 2011, 64, 985-992.
[20] Fournier, PF. Who should do syringe liposculpturing. *J Dermatol Surg Oncol*, 1988, 14, 1055-1056.
[21] Toledo, LS. Syringe liposculpture:A two-year experience. *Aesthetic Plast Surg*, 1991, 15, 321-326.
[22] Lewis, CM. Comparison of the syringe and pump aspiration methods of lipoplasty. *Aesthetic Plast Surg*, 1991, 15, 203-208.
[23] Mandel, MA. Syringe liposculpture revisited. *Aesthetic Plast Surg*, 1993, 17, 199-203.
[24] Rodriguez, RL; Conde-Green, A. Quantification of negative pressures generated by syringes of different calibers used for liposuction. *Plast Reconstr Surg*, 2012, 130, 383-384.
[25] Fodor, P. Power-assisted lipoplasty. *Aesthetic Surg J*, 2001, 21, 90-92.
[26] Fodor, PB; Vogt, PA. Power-assisted lipoplasty (PAL), A clinical pilot study comparing PAL to traditional lipoplasty (TL). *Aesthetic Plast Surg*. 1999, 23, 379-385.
[27] Katz, BE; Bruck, MC; Coleman, WP, III. The benefits of powered liposuction versus traditional liposuction: A paired comparison analysis. *Dermatol Surg*, 2001, 27, 863-867.
[28] Scuderi, N; Paolini, G; Grippaudo, FR; Tenna, S. Comparative evaluation of traditional, ultrasonic, and pneumatic assisted lipoplasty: analysis of local and systemic effects, efficacy, and costs of these methods. *Aesthetic Plast Surg*, 2000, 24, 395-400.
[29] Scuderi, N; Tenna, S; Spalvieri, C; De Gado, F. Power-assisted lipoplasty versus traditional suction-assisted lipoplasty: comparative evaluation and analysis of output. *Aesthetic Plast Surg*, 2005, 29, 49-52.
[30] Zocchi, M. Ultrasonic liposculpturing. *Aesthetic Plast Surg*, 1992, 16, 287-298.

[31] Man MW, Palm MD, Sengelmann RD. New advances in liposuction technology. *Semin Cutan Med Surg*, 2008, 27, 72-82.
[32] Maxwell, GP; Gingrass, MK. Ultrasound-assisted lipoplasty: a clinical study of 250 consecutive patients. *Plast Reconstr Surg*, 1998, 101, 189-202.
[33] Fodor, PB; Watson, J. Personal experience with ultrasound-assisted lipoplasty: A pilot study comparing ultrasound-assisted lipoplasty with traditional lipoplasty. *Plast Reconstr Surg*, 1998, 101, 1103-1116.
[34] Roustaei, N; Masoumi, Lari, SJ; Chalian, M; et al. Safety of ultrasound-assisted liposuction: a survey of 660 operations. *Aesthetic Plast Surg*, 2009, 33, 213-8.
[35] Omranifard M. Ultrasonic liposuction versus surgical lipectomy. *Aesthetic Plast Surg* 2003, 27, 143-145.
[36] Jewellml; Fodor, PB; de, Souza, Pinto, EB; Al, Shammari, MA. Clinical application of VASER--assisted lipoplasty: a pilot clinical study. *Aesthet Surg J*, 2002, 22, 131-46.
[37] Fodor, PB. Personal experience with ultrasound-assisted lipoplasty: a pilot study comparing ultrasound-assisted lipoplasty with traditional lipoplasty. *Plast Reconstr Surg*, 2004, 113, 1852-4.
[38] Nagy, MW; Vanek, PF; Jr. A multicenter, prospective, randomized, single-blind, controlled clinical trial comparing VASER-assisted lipoplasty and suction-assisted lipoplasty. *Plast Reconstr Surg*, 2012, 129, 681e-689e.
[39] Garcia, O; Jr. Nathan, N. Comparative analysis of blood loss in suction-assisted lipoplasty and third-generation internal ultrasound-assisted lipoplasty. *Aesthet Surg J* 2008, 28,430-5.
[40] Hoyos, AE; Millard, JA. VASER-Assisted high-definition liposculpture. *Aesthetic Surg J*, 2007, 27, 594-604.
[41] Mentz; H; Gilliland, M; Patronella, C. Abdominal etching: differential liposuction to detail abdominal musculature. *Aesthetic Plast Surg*, 1993, 17, 287-290.
[42] Palm, MD; Goldman, MP. Laser lipolysis: Current practices. *Semin Cutan Med Surg*, 2009, 28, 212-219.
[43] Fakhouri, TM; El, Tal, AK; Abrou, AE; et al. Laser-assisted lipolysis: A review. *Dermatol Surg*, 2012, 38, 155-69.
[44] Neira, R; Toledo, L; Arroyave, J; et al. Low-level laser-assisted liposuction: the Neira 4 L technique. *Clin Plast Surg*, 2006, 33, 117-127.
[45] Wolfenson, M; Norberto, dos, Santos, Filho, FC. Skin tightening in lipoplasty following security parameters for use of the diode laser with double wavelength 924nm and 975 nm. *Plast Reconstr Surg*, 2012, 130, 235e-236e.
[46] Badin, AZD; Moraes, LM; Gondek, L; et al. Laser lipolysis: Flaccidity under control. *Aesthetic Plast Surg*, 2002, 26, 335-339.
[47] Prado, A; Andrades, P; Danilla, S; et al. A prospective, randomized, double-blind, controlled clinical trial comparing laser-assisted lipoplasty with suction-assisted lipoplasty. *Plast Reconstr Surg*, 2006, 118, 1032-1045.
[48] Reszko, AE; Magro, CM; Diktaban, T; et al. Histological comparison of 1064nm Nd:YAG and 1320nm Nd:YAG laser lipolysis using an ex vivo model. *J Drugs Dermatol*, 2009, 8, 377-382.
[49] Khoury, JG; Saluja, R; Keel, D; et al. Histological evaluation of interstitial lipolysis comparing a 1064, 1320 and 2100nm laser in ex vivo model. *Lasers Surg Med*, 2008, 40, 402-406.

[50] Woodhall, KE; Saluja, R; Khoury, J; Goldman, MP. A comparison of three separate clinical studies evaluating the safety and efficacy of laser-assisted lipolysis using 1,064, 1,320 nm, and a combined 1,064/1,320nm multiplex device. *Lasers Surg Med*, 2009, 41, 774-8.

[51] DiBernardo, BE; Reyes, J. Evaluation of skin tightening after laser-assisted liposuction. *Aesthet Surg J*, 2009, 29, 400-7.

[52] DiBernardo, BE. Randomized, blinded split abdomen study evaluating skin shrinkage and skin tightening in laser-assisted liposuction versus liposuction control. *Aesthet Surg J*, 2010, 30, 593-602.

[53] Neira, R; Ortiz-Neira, C. Low-level laser-assisted liposculpture: clinical report of 700 cases. *Aesthet Surg J*, 2002, 22, 451-5.

[54] Jackson, RF; Dedo, DD; Roche, GC; et al. Low-level laser therapy as a non-invasive approach for body contouring: A randomized, controlled study. *Lasers Surg Med*, 2009, 41, 799-809.

[55] Coleman, WP; III. Lasers for liposuction: No benefit over tumescent liposuction. *Dermatol Surg*, 2012, 38, 170.

[56] Man, D; Meyer, H. Water jet-assisted lipoplasty. *Aesthet Surg J*, 2007, 27, 342-346.

[57] Stutz, JJ; Krahl, D. Water jet-assisted liposuction for patients with lipoedema: histologic and immunohistologic analysis of the aspirates of 30 lipoedema patients. *Aesthetic Plast Surg*, 2009, 33, 153-162.

[58] Sasaki, GH. Water-assisted liposuction for body contouring and lipoharvesting: Safety and efficacy in 41 consecutive patients. *Aesthet Surg J*, 2011, 31, 76-88.

[59] Araco, A; Gravante, G; Araco, F; et al. Comparison of power water-assisted and traditional liposuction: a prospective randomized trial of postoperative pain. *Aesthetic Plast Surg*, 2007, 31, 259-265.

[60] Paul, M; Mulholland, RS. A new approach for adipose tissue treatment and body contouring using radiofrequency-assisted liposuction. *Aesthetic Plast Surg*, 2009, 33, 687-694.

[61] Blugerman, G; Schavelzon, D; Paul, MD. A safety and feasibility study of a novel radiofrequency-assisted liposuction technique. *Plast Reconstr Surg*, 2010, 125, 998-1006.

[62] Hurwitz, D; Smith, D. Treatment of overweight patients by radiofrequency-assisted liposuction (RFAL) for aesthetic reshaping and skin tightening. *Aesthetic Plast Surg*, 2012, 36, 62-71.

[63] Ion, L; Raveendran, SS; Fu, B. Body contouring with radiofrequency-assisted liposuction. *J Plast Surg Hand Surg*, 2011, 45, 286-293.

[64] Theodorou, SJ; Paresi, RJ; Chia, CT. Radiofrequency-assisted liposuction device for body contouring: 97 patients under local anaesthesia. *Aesthetic Plast Surg*, 2012, 36, 767-779.

[65] Albin, R; de Camp, T. Large-volume liposuction in 181 patients. *Aesthetic Plast Surg* 1999, 23, 5-15.

[66] Commons, GW; Halperin, B; Chang, CC. Large-volume liposuction: a review of 631 consecutive cases over 12 years. *Plast Reconstr Surg*, 2001, 108, 1753-1763.

[67] Choudry; UH;, Hyza, P; Lane, J; et al. The importance of preoperative hemoglobin evaluation in large volume liposuction: Lessons learned from our 15-year experience. *Ann Plast Surg*, 2008, 61, 230-234.

[68] Matarasso, A. Liposuction as an adjunct to full abdominoplasty. *Plast Reconstr Surg*, 1995, 95, 829-836.
[69] Matarasso, A. Liposuction as an adjunct to full abdominoplasty revisited. *Plast Reconstr Surg*, 2000, 106, 1197-1202.
[70] Hughes, CE; III. Reduction of lipoplasty risks and mortality: An ASAPS survey. *Aesthetic Surg J*, 2001, 21, 120-125.
[71] Vila-Rovira, R. Lipoabdominoplasty. *Clin Plast Surg*, 2008, 35, 95-104.
[72] Heller, JB; Teng, E; Knoll, BI; et al. Outcome analysis of combined lipoabdominoplasty versus conventional abdominoplasty. *Plast Reconstr Surg*, 2008, 121, 1821-1829.
[73] Weiler, J; Taggart, P; Khoobehi, K. A case for the safety and efficacy of lipoabdominoplasty, A single surgeon retrospective review of 173 consecutive cases. *Aesthetic Surg J*, 2010, 30, 702-713.
[74] Swanson, E. Prospective outcome study of 360 patients treated with liposuction, lipoabdominoplasty, and abdominoplasty. *Plast Reconstr Surg*, 2012, 129, 965-978.

In: Encyclopedia of Surgery (22 Volume Set)
Editors: Andreas Lehrer and Kristin Mueller
ISBN: 978-1-53618-329-0
© 2020 Nova Science Publishers, Inc.

Chapter 38

BOTULINUM TOXIN

Darren J. McKeown*
Aesthetic Medicine Institute, Glasgow, UK

KEY POINTS

Botulinum toxins exert their effect by blocking the action of acetylcholine, a neurotransmitter involved in neuromuscular and neuroglandular signalling.

Dosage units of different brands of botulinum toxin type A are not always equivalent. Botox and Xeomin have a roughly 1:1 dose conversion rate whereas Botox:Dysport conversion ratios of 1:2 to 1:5 have been suggested.

Using a Botox:Dysport conversion ratio of 1:2.5, Dysport appears to last longer, produce greater reduction of dynamic lateral canthal rhytids, be associated with greater patient satisfaction and be more cost-effective. Dysport appears to have a greater range of diffusion, which may be an advantage or disadvantage.

Reconstituted products remain effective for at least several weeks if refrigerated, contrary to manufacturer's guidance.

There is no evidence of an adverse effect of prolonged regular use of botulinum toxin for control of dynamic rhytids, although no very long-term studies exist.

INTRODUCTION

At no time in the history of aesthetic practice can a drug be said to have made more impact than botulinum toxin. Since Jean and Alastair Carruthers described the aesthetic benefits of this new class of drug in 1987, the use of botulinum toxin products has expanded year on year to become the most popular aesthetic treatment in both the UK and the USA, with the use of these drugs now dominating the management of many signs of ageing that were traditionally considered a surgical problem.

* Corresponding Author's Email: drdarrenmckeown@gmail.com.

Botulinum toxins have been more significant to aesthetic practice than simply an extra tool for the practitioner. This class of drugs has paved the way for the increasing trend for non-surgical treatment and has shifted the goals of aesthetic practice from ‘cure’ to ‘prevention’.

Whilst botulinum toxins are best utilised for rejuvenation of the upper face, they also play a role in the lower face and neck, particularly in combination with other non-surgical techniques such as soft tissue fillers, chemical peels, lasers and other light devices for skin rejuvenation. These non-surgical techniques in combination now form a critical part of modern aesthetic practice.

MECHANISM OF ACTION

Botulinum toxin is a potent neurotoxin produced by Clostridium botulinum. There are seven known serotypes [1], each produced by a different strain of the bacterium and labelled A to G. The human body is susceptible to five of these subtypes – except for types C and D [1]. Only types A and B are currently available as commercial drug preparations and in aesthetic practice only type A has proven to be clinically useful [1].

Botulinum toxins exert their effect by blocking the action of acetylcholine, a neurotransmitter involved in neuromuscular and neuroglandular signalling. Depending on the serotype, the toxin binds selectively and irreversibly to a particular surface protein on the presynaptic nerve terminal that subsequently prevents release of acetylcholine into the synaptic cleft.

Type A botulinum toxin consists of one heavy (147kD) and one light chain (52kD) [1]. The heavy chain gains access to the cell by binding to its membrane whereas the light chain cleaves synaptosomal associated protein-25 (SNAP-25) on the membrane’s cytosolic surface. SNAP-25 is normally responsible for allowing intracellular acetylcholine containing vesicles in the nerve terminal to fuse with the cell membrane and discharge their contents into the synaptic cleft[1]. Since the binding of botulintum toxin type A to SNAP-25 is an irreversible process, cell signalling can only recommence when the nerve endings sprout new nerve terminals, a process that takes several months to occur and accounts for the prolonged results achieved after botulinum toxin treatment.

ANTIDOTE

An antidote is available for botulinum toxin but it must be administered within four hours to be effective. This is clinically impractical as it takes several days for any adverse events to be observed.

NOMENCLATURE

There are currently three commercial preparations of botulinum toxin type A available in the UK and USA. The proprietary and non-proprietary naming of the different preparations is

complex, with different proprietary and non-proprietary names being used on either side of the Atlantic, and recent changes in the proprietary labelling of botulinum toxin products in the USA and non-proprietary labelling in the UK add to the potential for confusion.

The first botulinum toxin type A to be licensed in the United States was manufactured by Allergan and known by the proprietary name of botulinum toxin A and the non-proprietary name Botox. It was approved in 1989 for the treatment of strabismus, blepharospasm and hemifacial spasm and was later granted a license by the USA Food and Drug Administration (FDA) for the treatment of moderate to severe glabellar rhytids under the separate non-proprietary name of Botox Cosmetic in 2002.

In the UK, Botox was licensed for medical use in 1994 and subsequently granted a cosmetic license under the non-proprietary name of Vistabel in 2006. In November 2011, however, the UK Medicines and Healthcare products Regulatory Agency (MHRA) granted Botox a license for treating glabellar rhytids and Vistabel was subsequently withdrawn from the market. Now, all Allergan botulinum toxin products in the UK are simply known as Botox.

Dysport was originally licensed in the UK for the treatment of blepharospasm and hemifacial spasm in 1990. Although the drug was widely used for cosmetic indications from that time, it was not until 2009 that it was granted a cosmetic license under the separate name of Azzalure. In the same year, Dysport was licensed in the US for the treatment of cervical dystonias and glabellar rhytids under the trade name of Reloxin.

Dysport and Botox have significantly different dosing requirements and injection techniques. To avoid confusion, when Dysport was licensed in America the FDA changed the proprietary name of Botox from botulinum toxin type A to onabotulinumtoxinA and Dysport was given the proprietary name of abobotulinumtoxinA. In the UK however, the proprietary name for both preparations remains botulinum toxin type A.

Most recently, Xeomin, which has a similar dosing regimen to Botox, was granted a license for treatment of blepharospasm in the UK in 2007. The same drug was also granted a license to treat moderate to severe glabeller rhytids under the separate name of BoCouture in the UK in 2010. The FDA approved Xeomin in 2010 for the treatment of glabellar rhytids, cervical dystonia and blepharospasm all under the one name. In the US, the proprietary name for this product is incobotulinumtoxinA.

Where a cosmetic license has been granted to a botulinum toxin type A product – both in the UK and in the USA – the license at the time of writing only includes the treatment of moderate to severe glabellar rhytids. Although other indications are regularly treated, this is on a ‘off label’ basis and patients must be consented as such prior to treatment.

DOSE CONVERSION BETWEEN BRANDS

The dosage units of different brands of botulinum toxin type A products are not always equivalent and care must be taken when converting between them. Despite earlier reports otherwise, Botox and Xeomin have a roughly 1:1 dose conversation rate and as a general rule, doses can be used interchangeably [2].

Dysport, however, has a very different dosing regimen, and conversion ratios of Botox:Dysport from 1:2 to 1:5 have been suggested. In clinical practice a conversion ratio of 1:2.5 to 1:3 appears to be optimal (Wohlfarth 2001).

CLINICAL EFFICACY COMPARISON OF BOTULINUM TOXIN TYPE A BRANDS

There is much debate over which brand of botulinum toxin is superior in terms of efficacy of wrinkle reduction and longevity of results. Much of the literature compares Botox with Dysport since they have been available the longest. Early work comparing Botox and Dysport suggested that Botox was superior in terms of duration of effect [3,4]. However, these studies used relatively low doses of both drugs that were out of keeping with clinical practice, whilst more recent studies using higher doses of both drugs indicate that the relationship between the two is not simple.

In a study comparing Botox 30U and Dysport 75U injected at five injection points in the glabella (i.e., a conversion ratio of 1:2.5), both drugs had similar efficacy in terms of wrinkle reduction and duration of effect. When the conversion ratio was increased to 1:4U, comparing 64U of Botox with 256U of Dysport, Dysport was significantly more effective [5].

Nestor compared 10U Botox with 25U Dysport on contralateral sides of the same forehead (i.e., a conversion ratio of 1:2.5). In this study, Dysport lasted significantly longer than Botox [6]. At the lateral canthus, Nettar compared 10U of Botox on one side to 30U of Dysport on the other side, finding that Dysport resulted in a significantly greater reduction in dynamic rhytids and greater patient satisfaction[7]. There is also some evidence that Dysport has a more rapid onset of action than Botox and may be more cost effective [2,8].

ZONE OF DIFFUSION

There is evidence to suggest that Dysport has a greater zone of diffusion around injection points than the other two brands of botulinum toxin. This can be used at the surgeon's discretion to assist in achieving aesthetic objectives. For example, a diffuse effect may be desirable when treating a broad, flat muscle such as frontalis, whereas a more localised effect is preferable when treating smaller muscles. In the latter instance Botox may be the preferable brand [9].

RECONSTITUTION AND STORAGE

As a general rule, manufacturers recommended reconstitution and storage guidelines are not backed by scientific evidence and are excessively restrictive. Manufacturers of Botox, Dysport and Xeomin each recommend their product should be used within 24 hours of reconstitution, although the literature suggests that the products remain stable and efficacious for several weeks or months after reconstitution provided they are maintained in refrigerated conditions [10-12].

The volume of saline used for reconstitution can safely be varied depending on the preferences of the practitioner. Clinically useful reconstitution guidelines for aesthetic indications are summarised in Table 1.

It is desirable to keep dilution low and drug concentration high to reduce the volume of injectate and minimise immediate unsightly subcutaneous swelling, allowing patients to resume their daily activities straight away. Nonetheless, the use of higher dilution volumes is safe, does not impact the effectiveness of the drug and does not increase the incidence of diffusion related complications [13].

Concern has been expressed that the foaming resulting from excessively rapid injection of saline during botulinum toxin reconstitution could cause denaturation of the protein. A randomised clinical trial has shown these concerns to be unjustified [14].

CONTRAINDICATIONS TO TREATMENT

Botulinum toxin injections should not be performed at the site of an active infection. Patients should not be treated if they are currently pregnant or nursing a child, although there have been no reports of teratogenicity in cases of inadvertent treatment under such circumstances. Caution should be exerted in treating patients who have peripheral nerve disorders or neuromuscular disorders such myasthenia gravis or Eaton-Lambert syndrome. Aminoglycosides appear to have an acetylcholine blocking action that may potentiate the effects of botulinum toxin and so caution should be exerted in patients who are concurrently taking these antibiotics [15].

INJECTION TECHNIQUE

Botulinum toxins should be injected using either a 30G or 32G insulin syringe in an effort to minimise discomfort and to allow the most accurate control of dosing. Injections are placed either subcutaneously on the surface of the muscle or within the muscle belly. There is no need to touch periosteum and inject on withdrawal as has previously been suggested.

PAIN MANAGEMENT

To meet the high expectations of aesthetic patients, treatment with botulinum toxin needs to be quick, easy and pain-free, or at least associated with minimal discomfort. A number of techniques have been described to assist with this objective.

The use of topical anaesthetic cream [16] and prior skin cooling with ice [17] can reduce the pain associated with botulinum toxin injections. In practice however, these steps are rarely undertaken as it makes the procedure more time-consuming and inconvenient and are usually only accepted by the most pain intolerant patients.

Reconstitution of botulinum toxin with preserved saline rather than the manufacturer's recommended non-preserved saline causes significantly less pain and is a useful strategy to make the experience more comfortable without any additional inconvenience [18].

Table 1. Reconstitution guidelines for aesthetic use of botulinum toxins

Drug	Units per vial	Reconstitution volume	Units per 0.1ml
Botox / Xeomin	100	2.50ml	4
Dysport	300	1.50ml	20
Dysport	125	0.63ml	20

CLINICAL APPLICATION OF BOTULINUM TOXIN

There are three basic principles of muscular physiology relevant to treatment with botulinum toxin. Consideration of these key principles, and their aesthetic implications, is useful when planning a series of injections.

1. There is an inverse relationship between muscle tension and length. A muscle treated with botulinum toxin becomes relaxed and so lengthens perpendicular to the direction of the overlying rhytids. This can be clinically troublesome, for example when treating the horizontal rhytids in the forehead: after treatment, the vertical length of the muscle is increased, resulting in an apparent lengthening of the forehead and depression of the brow.
2. Each muscle of facial expression affects the appearance of the overlying skin. When a muscle of facial expression is paralysed, this will have the opposite effect on the position of the overlying skin. For example, the corrugator supercilli depresses the brow medially upon contraction. When this muscle is treated with botulinum toxin the result is lateral deviation of the brow.
3. When a section of muscle is paralysed, the surrounding musculature will often overact in a compensatory mechanism. This can be especially relevant when the central two thirds of the frontalis are treated, preserving the lateral one-sixth on either side. Compensatory overactivity of the untreated area will result in unnatural flaring of the outer third of the brow.

By anticipating these unwanted effects it is possible to preempt and avoid them, maximising the aesthetic outcome of the treatment.

TREATMENT AREAS

Treatment with botulinum toxin is best considered in terms of individual treatment areas. These can be broadly grouped into those of the upper face, the lower face and the neck. As a general rule, treatment of the upper face achieves the most consistent results and practice is best supported by evidence. In the lower face, treatment outcomes are less predictable and the evidence is less complete.

Upper Face

Glabella

As the only facial area licensed for the cosmetic use of botulinum toxins at the present time, there exists the most published evidence relating to treatment of the glabella.

Anatomical Injection Sites

The glabella muscle complex consists of the procerus muscle centrally and the corrugator supercilli muscles laterally on either side. In addition, depressor supercilli may contribute to the dynamics of this region. The standard injection pattern for treating the glabella includes five injection points: one central injection in procerus and two laterally on either side in the corrugators (Figure 1a) [15]. Whilst this this usually sufficient, in some – particularly male - patients with a broader and bulkier muscle, more injections may be necessary [15] (Figure 1b).

Procerus is a small pyramidal shaped muscle that originates from the nasal bones and superior border of the upper lateral cartilages and inserts into the forehead skin between the eyebrows. It is a depressor of the medial forehead. The bulk of the muscle is easy to palpate and a single injection at the level of the nasion usually treats it adequately [15].

The Botox product insert pack recommends two injection sites in either corrugator supercilli muscle. The medial injection is recommended at the level of the inner canthus one centimetre above the eyebrow and the lateral injection point is recommended 1cm above the eyebrow, just medial to the mid-pupillary line. These anatomical landmarks do not correspond to the underlying anatomy, however. Guyuron has shown in a cadaver study that the origin of the corrugator supercilli lies approximately two millimetres lateral to the nasion at the level of the orbital rim [19]. Injection one centimetre above the eyebrow is likely to miss the targeted muscle and result in overtreatment of the inferior and central portion of the frontalis. This results in an unattractively depressed medial brow.

At the central origin, corrugator supercilli lies deep to the frontalis, adherent to the underlying periosteum. As the muscle travels laterally towards its insertion in the skin above the medial third of the brow it becomes progressively more superficial. Anatomically precise injection therefore requires a two plane injection technique with a deep injection medially and a more superficial injection laterally above the medial third of the brow [20] (Figure 2c).

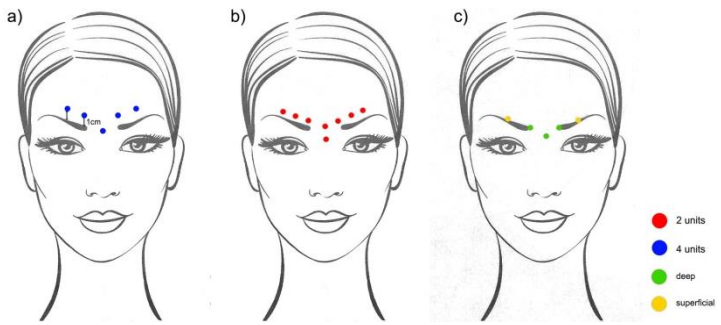

Figure 1. Left: Standard injection pattern of botulinum toxin for treating the glabella; Middle: Injection pattern for patients with bulkier muscle; Right: planes for botulinum toxin injections.
Doses are for Botox.

Depressor supercilli is a contentious muscle. Whilst some have argued that it merely represents the superomedial aspect of the orbicularis occuli muscle, a cadaver study reports it as a distinct muscle originating from the superior process of the maxilla approximately ten millimetres above the medial canthus and inserting to the skin fourteen millimetres superior to the canthus [21]. It is rarely of clinical importance the first time the glabella is treated but can become clinically relevant later on when the patient is still able to depress the brow despite other muscles of the glabellar complex being paralysed. In such situations, a small dose directed into depressor supercilli will cure this.

Optimal Dosage

The licensed dose of Botox and Xeomin to treat the glabella is 20U, and that of Dysport is 50U. However the optimal dose to treat this region has been the subject of a number of studies. Carruthers and colleagues carried out a multicentre, double-blind placebo controlled trial of 20U of Botox injected at five injection points in patients with moderate to severe glabellar rhytids. Patients experienced a reduction in the appearance of rhytids lasting up to 120 days. This study was the basis for Botox receiving its cosmetic license in the USA [22].

The same group subsequently published a dose ranging study comparing the efficacy of four doses of Botox in the treatment of the glabella in female patients [23], comparing 10U, 20U, 30U and 40U of Botox using five injection points in the glabella. Patients who received the three higher doses had a significantly greater response compared with the group who received 10U. There were no statistically significant differences between the 20U, 30U and 40U groups at any time, indicating that higher doses do not result in more prolonged effects [23]. This may be due to saturation of the nerve terminals at 20U, beyond which additional product has no additional benefit.

Carruthers also completed a dose ranging study comparing 20U, 40U, 60U and 80U in male patients, again finding that the higher three doses (40U, 60U and 80U) were significantly more effective than 20U. The investigators therefore recommended a starting dose of 40-80U in male patients [24].

Brandt and colleagues carried out a randomised, placebo controlled trial of 50U of Dysport. They found an 89.5% response rate in the treatment group compared with a 7.5% response rate in the placebo group, indicating that 50U Dysport is an effective dose in a majority of patients. Ascher and colleagues compared three doses of Dysport for the treatment of glabellar rhytids: 25U, 50U and 75U injected at five sites in the glabella [25]. They found that both 50U and 75U provided significant improvements in the appearance of glabellar rhytids for up to three months and was superior to 25U.

Horizontal Forehead Rhytids

Treatment of horizontal forehead rhytids with botulinum toxin is one of the most technically challenging areas and is associated with the greatest risk of patient dissatisfaction.

Anatomy of Injections

The frontalis is a broad, flat muscle overlying the frontal bone. It has no bony attachments. Inferiorly its medial fibres are continuous with procerus, intermediate fibres interdigitate with corrugator supercilli and orbicularis occuli, and lateral fibres interdigitate with orbicularis occuli. Superiorly it is continuous with the galea aponeurotica below the coronal suture. The medial borders of the muscle on either side are continuous for a variable

distance above the nasion before becoming separated by a portion of galea. Its extent is easy to determine simply by asking the patient to elevate his or her eyebrows and observing the wrinkling pattern in the overlying skin (Figure 2).

Before treating frontalis it is vital to consider whether it is actually aesthetically desirable to do so. The frontalis is the only brow elevator and paralysing it will almost always produce some brow ptosis [26]. The surgeon must anticipate the extent of brow ptosis and whether it will be aesthetically acceptable prior to undertaking treatment. In general, younger patients with minimal skin excess of the forehead and upper eyelid will suffer little or no significant ptosis, and the frontalis may safely be treated in its entirety. In contrast, older patients with a hyperfunctional frontalis (compensated upper lid excess/brow ptosis) will always suffer from clinically significant brow ptosis and should not be treated. Between these spectra lie a majority of patients in whom it may be safe to treat a portion of the frontalis but not the entire muscle.

In patients where there is concern regarding the degree of brow ptosis it is possible to treat only a section of the frontalis. Some have suggested treating only the central two thirds of the muscle, sparing the regions lateral to the mid-pupillary line on either side. In practice, however, this causes depression of the medial brow and flaring of the lateral brow, producing a very unnatural brow contour. When it is undesirable to paralyse the entire frontalis muscle the author prefers to inject its entire width, placing the injections higher up on the forehead (at least three to four centimetres above the eyebrow). This leaves an inferior band of functioning muscle that can support the brow. Although this leaves some rhytids above the eyebrows it is preferable to an unnatural brow contour. Whenever treating the forehead in this high-risk group of patients it is essential that the brow depressor muscles are treated simultaneously.

Injection sites should be placed along the entire width of the muscle, approximately two to three centimetres apart as far as the lateral extent of the horizontal forehead rhytids on either side. For most forehead sizes this will result in a row of four to six injection sites. If the patient has a tall forehead, more likely in male patients, then it may be necessary to carry out two separate rows of injections in order to achieve a satisfactory result. In some patients there may be no muscle in the centre of the forehead in which case there is no need to inject in this area (Figure 3).

Figure 2. The extent of frontalis can be determined by asking the patient to elevate their brows.

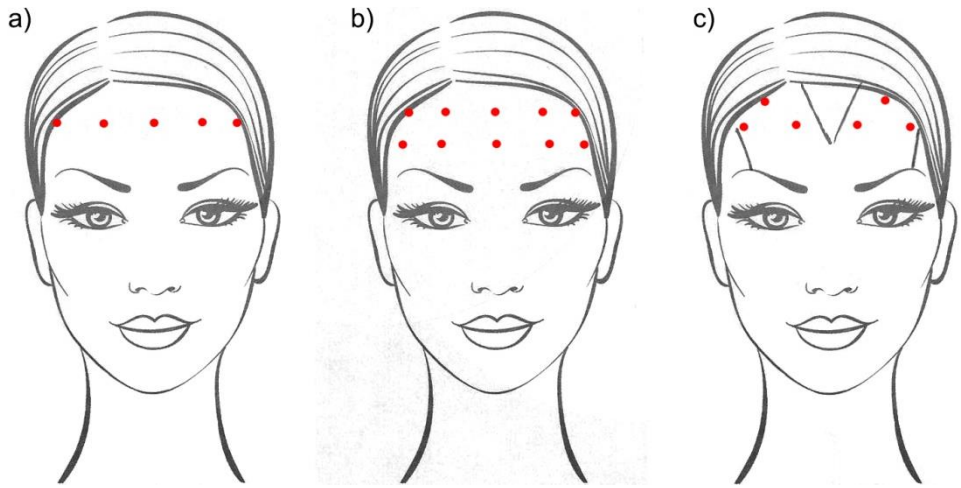

Figure 3. Injection pattern for treatment of frontalis with botulinum toxin. a) Standard injection pattern; b) injection pattern in patients with a tall forehead; c) injection pattern for patients with frontalis divarication. All points represent injections of 2U Botox.

Dosage

There is a paucity of high quality data regarding the optimal dose of botulinum toxins for use in the forehead. Carruthers carried out a double-blind, randomised dose ranging study to investigate the optimal dosage of Botox to use in the forehead in female patients. Patients were randomised to receive 16U, 32U or 48U of Botox. Half of this dose was injected to the frontalis (i.e., 8U, 16U and 24U respectively) and the other half injected into the brow depressors. They found significant dose-response trends, with greater wrinkle reduction and longer lasting results in the patients who received higher doses [27].

Ultimately, the total injection dose will vary depending on the size of the patient's forehead, the extent of the frontalis muscle and the portion of the muscle that is desirable to paralyse. As a starting guide, each injection point should receive either 2U of Botox or 5-6U of Dysport.

Lateral Canthal Rhytids (Crows Feet)

Treatment of the lateral canthal rhytids with botulinum toxin is one of the earliest described indications of the drug and can provide some of the most satisfying results.

Anatomy of Injections

Orbicularis oculi is a sphincteric muscle responsible for closing the eyelids. It originates medially near the inner canthus and its fibres pass laterally across the eyelids with the lateral portion of the muscle extending towards the temple and the upper part of the cheek. On eyelid closing, laughing or smiling the lateral part of the muscle is responsible for creating the dynamic rhytids that appear at the lateral canthus as the so-called 'crows feet'.

In most cases, three or four injections are necessary in this area (Figure 4). The first is placed 1cm lateral to the lateral canthus, taking care to remain distant from the orbital rim to prevent product diffusion into extraocular muscles. The next is placed 1-1.5cm above this point, and a further one or two injections are placed below it, also 1–1.5cm apart, depending on the extent of the rhytids.

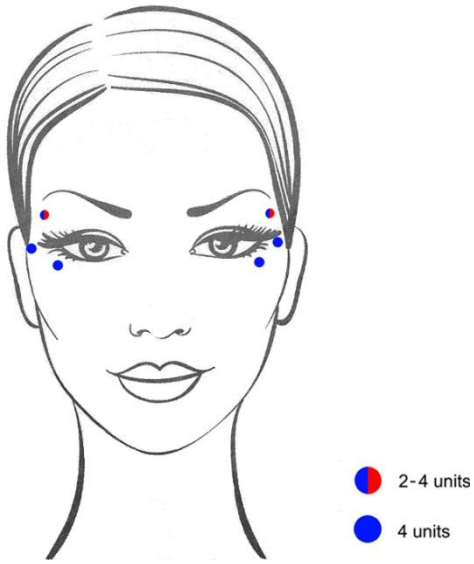

Figure 4. Botulinum toxin injection pattern and dose for treatment of lateral canthal rhytids. Doses refer to injections of Botox.

Dose

The Botox Facial Aesthetic Study Team carried out a double-blind, randomised, placebo controlled dose response study of Botox in the treatment of lateral canthal rhytids. Patients were randomised to receive 3, 6, 12 or 18U of Botox on one side and placebo on the other. All doses resulted in an improvement compared with placebo, but higher doses achieved greater wrinkle ablation and longer lasting results. There was no difference between the 12U and 18U groups so the authors concluded that the optimal dose for treating lateral canthal rhytids was 12U per side [4].

Ascher and colleagues [28] carried out a double-blind, placebo-controlled dose ranging study to identify the optimal dose of Dysport in the treatment of lateral canthal rhytids. Patients were randomised to receive 15, 30 or 45U of Dysport on one side and placebo on the other. Again all doses produced an improvement compared with placebo, but there was a significant dose response relationship with 30U and 45U delivering longer lasting results.

Lower Lid

Flynn and Carruthers demonstrated that a single injection of 2U Botox at the lower eyelid midpupillary line resulted in a reduction in lower eyelid dynamic rhytids and an increase in the palpebral aperture [29]. The same authors later performed a dose finding study, comparing 4U with 8U Botox in the lower eyelid. The incidence of complications increased at the higher dose, with all patients complaining of eyelid oedema and incomplete sphincter function. Consequently the authors recommended lower doses of 2U or 4U of Botox in the lower eyelid [30].

In the lower eyelid the orbicularis occuli muscle has a role in maintaining the position of the infraorbital fat pad in addition to its sphincter function. Paralysis of this muscle can result in herniation of the fat, resulting in a lower eyelid bag [31]. In clinical practice it is

impossible to identify preoperatively who will be affected by this complication and the author rarely uses this technique due to its inherent unpredictability.

The Botox Brow Lift

Eyebrow elevation by means of botulinum toxin injection has been well described in the literature and is very commonly practiced [32-38]. Careful and detailed aesthetic evaluation of the face is crucial before undertaking this procedure. All too often it is undertaken unnecessarily and results in an inadvertently aged and unnatural appearance.

In the lower face and neck, descent of the soft tissues is a characteristic feature of ageing. In the brow however, there is a paradoxical elevation in eyebrow position with age secondary to a hyperfunctioning frontalis muscle [39]. Brow lifting should only be undertaken in patients with genuine brow ptosis as a feature of ageing. This group of patients should be the minority.

The Botox brow lift takes advantage of the dynamic interplay of the muscles of facial expression in determining the position of the overlying skin. Broadly speaking, the muscles of facial expression can be divided into elevators and depressors. To create the Botox brow lift it is necessary to reduce the impact of the brow depressors, thereby potentiating the effect of the brow elevators.

The brow depressors are procerus, corrugator supercilii, depressor supercillii and the superolateral part of orbicularis occuli. The only brow elevator is frontalis, which must therefore be preserved when trying to create a chemical brow lift (Figure 5).

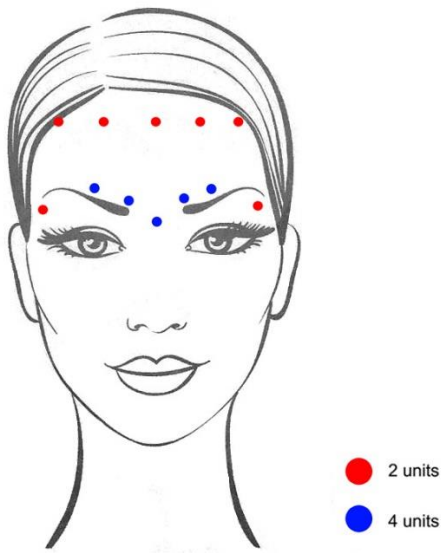

Figure 5. Injections points for chemical brow lift: injections to the high forehead, glabella and superolateral orbicularis. Doses refer to Botox.

Frankel [38] described the impact on eyebrow position of injecting 20U of Botox in the glabella in a standard five-point injection technique. He noted that, although this resulted in some medial brow elevation, maximal elevation was observed at the outer third of the brow. Ahn [36] subsequently documented the effect of injecting 7-10U of Botox into the lateral

orbicularis oculi fibres superior and lateral to the orbital rim. This resulted in a 1mm elevation in brow height medially and a 4.8mm elevation laterally. In practice, a combination of glabella and lateral orbicularis injections are normally used to achieve a brow lift [40].

Lower Face

The use of botulinum toxin products in the lower face and neck has been well described in recent years, although the results are not always as predictable and satisfying as in the upper face.

Neck

The early literature on botulinum toxin in the neck focused on injecting platysmal bands. Brandt and Bellman reported the first use of botulinum toxin in the neck in 1998. In his paper he described injecting platysmal bands with 50–100U of Botox, which he claimed resulted in a reduction in the appearance of horizontal rhytids as well as a tightening of the skin of the neck [41].

The following year Kane published a series of fifty patients in whom platysmal bands were treated with five to twenty units each, depending on the thickness of each band. All patients showed some degree of improvement in neck contour, although the author conceded that the improvement was limited by redundant skin (Kane 1999).

A multi-practice case series of 1500 treatments of the platysmal bands was published in the same year [42]. The treatment was carried out on the anterior platysmal bands bilaterally with three to five injections per band, generally with a dose of up to 100U per patient – although some received up to 250U of Botox. The authors subjectively reported satisfactory outcomes in 98.5% of patients. Adverse events included one percent of patients reporting neck weakness and one case of dysphagia that resolved with conservative management.

In 2007 Levy described a departure from injection of platysmal bands, which he called the Nefertiti neck lift after the ancient Egyptian Goddess depicted with a sharply defined neck and jawline. The theory underlying the technique is that platysma exerts a negative force on the lower face and neck, so paralysing it should create the opposite effect resulting in an upward lift to the neck and lower face. Levy described injecting five sites 1–1.5cm apart along the inferior border of the mandible and two injection sites in the superior pole of the posterior platysmal band. Each site was injected with two to three units of Botox, for a total dose of fifteen to twenty units per side. According to the author all patients had a noticeable improvement in the contour of their jawline and elevation of the skin. The technique had a favourable side effect profile, which the authors attributed to the lower doses used in comparison with other papers [43].

Oral Commissures

Traditionally, down turning of the corners of the mouth has been considered a surgical problem to be addressed by facelift surgery. In more recent years, facial fillers and fat augmentation have played an increasing role. Injection of botulinum toxin to the depressor anguli oris muscle can also help provide an elevation in this area [44]. A single injection of

two to five units of Botox or six to fifteen units of Dysport is placed in the most inferior and posterior part of the muscle to avoid diffusion into the nearby depressor labii inferioris [45].

In this area the results of botulinum toxin alone are modest and it is better to combine with other treatment modalities. When combined with filler injections, the overall result and duration of action is greater than when either technique is performed alone (Carruthers 2010, Custis 2010).

Chin

Over activity of the mentalis muscle can produce an unattractive peau d'orange dimpling on the chin. This can be managed effectively with 5U of Botox delivered through a single injection point at the level of the mental prominence [15].

Nose

Dynamic rhytids of the nose can be treated successfully with injection of three units of Botox into nasalis bilaterally [46]. Dynamic drooping of the nasal tip can also be corrected by injecting three units into depressor septi nasi at the base of the columella.

Lips

Injection of botulinum toxin can reduce the appearance of perioral lines ("smokers lines"). Treatment of these lines has the simultaneous benefit of providing an increase in lip eversion and the appearance of enhanced volume [47].

One study compared a total dose of 7.5U with 12U Botox, injected at four equally divided injection sites on the upper lip. Both doses produced a satisfactory appearance, although the higher dose resulted in a longer lasting result [48].

Gummy Smile

The gummy smile is characterised by excessive gingival show on smiling and is associated with an unattractive appearance. This can be corrected by injecting a small dose (usually two to three units) of Botox into the levator labii superioris alaequae nasi muscle on either side [49].

Masseter

The ideal female jaw is narrow and delicate in contrast with the male jaw, which is broad and defined. It is possible to reduce the jaw angle width by injecting botulinum toxin into the masseter muscle, which results in muscle atrophy and a reduction in the width of the jaw angle. Doses of 30-50U in two to three injection points per muscle have been reported to be successful [50, 51].

TREATING MALE PATIENTS

As a general rule, men can be treated using the same basic principles as women. Male patients tend to require higher doses and more injection sites, however, to account for their greater muscle mass and broader muscle sizes[52]. Little evidence-based guidance exists, but

from clinical experience doses of twenty to fifty percent higher than corresponding female doses are a useful starting point depending on muscle thickness.

COMBINATION THERAPY

Optimal management of the ageing face is achieved by combination therapy. This includes treating multiple areas of the face with botulinum toxin, combination of botulinum toxin with other non-surgical techniques and, where appropriate, combination of non-surgical with surgical techniques [53].

COMPLICATIONS

Complications following botulinum toxin treatment are generally uncommon, mild and self-limiting. They can occur either from a general reaction to the drug or by the spread of the toxin beyond the intended treatment site. Generalised reactions that have been reported include nausea, fatigue, malaise, flu-like symptoms and rashes at sites distant to the injection [54]. The effect of spread beyond the treatment zone will depend on which area is being treated and which muscle has been unintentionally affected.

Upper Lid Ptosis

When treating the glabella, diffusion of the toxin through the orbital septum into the levator palpebri superioris results in an upper lid ptosis, which can last anywhere from two weeks to three months. It is difficult to quantify the precise risk of blepharoptosis. In earlier studies using Botox the rate of upper lid ptosis was reported to be as high as 5.4% [22]. However, as experience and injection techniques have developed more recent studies have not reported any incidence of eyelid ptosis using both Botox and Dysport [25]. In practice the actual rate of eyelid ptosis is probably greater than zero, although an estimate of less than one percent would seem reasonable when counselling patients. When ptosis does occur, its course can be improved with 0.5% apraclonidine eye drops three times per day which causes contraction of Müllers muscle and allows temporary reprieve until the effects of the drug wear off.

Brow Ptosis

Brow ptosis is a consequence of treatment of the frontalis muscle. If actively sought, it will be found to occur in the majority of patients undergoing treatment of the forehead [26]. It is incumbent upon the practitioner to anticipate the degree of brow ptosis that treatment of the forehead rhytids will create, discuss this with the patient and make a clinical decision of risk versus benefit to treating this area.

Strabismus

Strabismus is a potential complication of injections at the lateral or medial canthus where there is diffusion of toxin within the bony orbit. It is a rare complication and as such is difficult to quantify from the available literature. Where it has been reported it has generally settled with conservative management over a period of several weeks, but all cases should be referred for an ophthalmology opinion.

Upper Lip Ptosis

Injection sites placed too inferior from the lateral canthus can cause diffusion into the zygomaticus major muscle, which causes upper lip ptosis and an asymmetric smile. In one large study the incidence of this was approximately 0.2% [55].

Lower Lip Incompetence

Lower lip incompetence can result from inadvertent treatment of the depressor labii inferioris when targeting the depressor anguli oris muscle.

Neck Weakness, Hoarseness and Dysphagia

In the largest case series of treatments of the neck, 10% of patients reported transient neck pain. One per cent of patients reported neck weakness and 0.07% reported transient dysphagia [42].

Muscle Atrophy

Long-term repeated use of botulinum toxin will lead to disuse atrophy. The precise implications of this condition and the timescale over which it develops are yet to be fully described.

LONG-TERM FOLLOW UP

Despite the widespread practice of injecting botulinum toxin for over two decades now, there remains a lack of long-term prospective data in the scientific literature to document long-term outcomes and best practice treatment guidelines to optimise long-term outcomes.

Bulstrode and Grobbelaar [26] described their experience of patients receiving regular treatment with botulinum toxin over sixteen months, shown it was safe and effective over this time scale.

Rubin described a series of 311 patients who had well tolerated repeated treatments of 50U Dysport into the glabella [56]. A similar study by the Reloxin Investigational Group examining 50U of Dysport in up to six treatment cycles with an average follow up of seventeen months found a low incidence of adverse events, concluding that repeat treatments were safe and well tolerated [57].

Dailey treated a group of toxin naïve women with 20U of Botox in the glabella at four-month intervals over a period of two years. At the end of the study the researchers found that the effects of treatment remained evident at six months follow up, implying that results eventually last longer with longer-term treatment [58].

Binder (2006) described a case of identical twins, one of whom had been treated regularly with Botox for the last thirteen years and her sister who had not. In the sister who had not received treatment, visible lines were present on her face, even at rest. The sister who had regular treatment however did not display any resting rhytids.

TOPICAL APPLICATION OF BOTULINUM TOXIN – THE FUTURE?

There is currently much interest in producing a topically applied botulinum toxin formulation for the treatment of patients who are averse to needles and injections. A major barrier to this development has been creating a formulation that can be absorbed through skin and penetrate to muscle in a precise fashion. One formulation has been developed that appears to overcome this problem, with early clinical trials showing promising results in the treatment of lateral canthal rhytids [59,60]. Should this or any similar product make it to market, it is likely to be a prescription only medication expertly applied in a medical aesthetic clinic, rather than a more widely available over the counter product.

CONCLUSION

There can be little doubt as to the impact botulinum toxin drugs have had on aesthetic practice. Treatment with botulinum toxin has been demonstrated to be safe, effective, associated with minimal complications and reliably delivers a high degree of patient and surgeon satisfaction. Much progress has been made over the preceding two decades with regards to optimising injection techniques and dosing, but there still remain some important unanswered questions that need to be addressed by further studies, particularly with regards to the long-term management of patients with botulinum toxin.

At the current time there is plenty of anecdotal evidence to suggest that, used judiciously, the long-term aesthetic results of botulinum toxin are favourable. However, this has yet to be adequately quantified and important variables such as the optimal age to begin treatment, how regularly treatment should be repeated and for how long treatments should be repeated remains to be determined.

It is well documented that in the long-term the anti-wrinkle effect of botulinum toxins last progressively longer with each cycle. At some point it is likely that, even on discontinuing treatment, patients skin will not return to its pretreatment condition and at least some of the effects can be considered permanent. At what point this occurs, and how the management

should proceed thereafter is still unclear. It may be that in the long-term treatment is no longer necessary or perhaps should be continued on a less frequent 'maintenance' basis.

There is currently a trend towards utilizing botulinum toxins in very young patients who have yet to develop signs of ageing as a 'preventative' to stop wrinkles developing. There is a lack of evidence to support this practice and a great deal of consideration is required before this could be encouraged. In the long-term, muscle atrophy resulting from excessive repeated treatments leads to loss of volume from loss of muscle bulk. This can be particularly evident around eye area where the bony outline of the orbital rim becomes obvious from excessive treatment of the orbicularis oculi, resulting in an unnatural and inadvertently aged appearance.

It is likely that for the foreseeable future the use of botulinum toxins will continue to expand and as we learn more about long-term outcomes. Our approach to using these drugs will continue to evolve with a generally more conservative approach and a trend towards greater combination therapies with other non-surgical techniques in order to optimise long-term results.

REFERENCES

[1] Carruthers, A. et al. (2013). The convergence of medicine and neurotoxins: a focus on botulinum toxin type A and its application in aesthetic medicine--a global, evidence-based botulinum toxin consensus education initiative: part I: botulinum toxin in clinical and cosmetic practice. *Dermatol Surg*, *39*, 493–509.

[2] Jandhyala, R. (2012). Relative potency of incobotulinumtoxinA vs onabotulinumtoxinA a meta-analysis of key evidence. *J Drugs Dermatol*, *11*, 731–736.

[3] Lowe, P. L., Patnaik, R. & Lowe, N. J. (2005). A Comparison of Two Botulinum Type A Toxin Preparations for the Treatment of Glabellar Lines: Double-Blind, Randomized, Pilot Study. *Dermatol Surg.*

[4] Lowe, N. J. et al. (2005). Double-blind, randomized, placebo-controlled, dose-response study of the safety and efficacy of botulinum toxin type A in subjects with crow's feet. *Dermatol Surg*, *31*, 257–262.

[5] Lowe, N. J., Shah, A., Lowe, P. L. & Patnaik, R. (2010). Dosing, efficacy and safety plus the use of computerized photography for botulinum toxins type A for upper facial lines. *J Cosmet Laser Ther*, *12*, 106–111.

[6] Nestor, M. S. & Ablon, G. R. (2011). Duration of action of abobotulinumtoxina and onabotulinumtoxina: a randomized, double-blind study using a contralateral frontalis model. *J Clin Aesthet Dermatol*, *4*, 43–49.

[7] Nettar, K. D. K., Yu, K. C. Y. K., Bapna, S. S., Boscardin, J. J. & Maas, C. S. C. (2011). An internally controlled, double-blind comparison of the efficacy of onabotulinumtoxinA and abobotulinumtoxinA. *Archives of Facial Plastic Surgery*, *13*, 380–386.

[8] Yu, K. C. Y., Nettar, K. D., Bapna, S., Boscardin, W. J. & Maas, C. S. (2012). Split-face double-blind study comparing the onset of action of onabotulinumtoxinA and abobotulinumtoxinA. *Archives of Facial Plastic Surgery*, *14*, 198–204.

[9] Hexsel, D. D. et al. (2012). Field effect of two commercial preparations of botulinum toxin type A: a prospective, double-blind, randomized clinical trial. *J. Am. Acad. Dermatol.*, *67*, 226–232.

[10] Liu, A. A. et al. (2012). Recommendations and current practices for the reconstitution and storage of botulinum toxin type A. *J. Am. Acad. Dermatol.*, *67*, 373–378.

[11] Yang, G. C., Chiu, R. J. & Gillman, G. S. (2008). Questioning the need to use Botox within 4 hours of reconstitution: a study of fresh vs 2-week-old Botox. *Archives of Facial Plastic Surgery*, *10*, 273–279.

[12] Hui, J. I. & Lee, W. W. (2007). Efficacy of fresh versus refrigerated botulinum toxin in the treatment of lateral periorbital rhytids. *Ophthal Plast Reconstr Surg*, *23*, 433–438.

[13] Carruthers, A., Bogle, M. & Carruthers, J. (2007). A randomized, evaluator-blinded, two-center study of the safety and effect of volume on the diffusion and efficacy of botulinum toxin type A in the treatment of lateral orbital rhytides. *Dermatol Surg*, *33*, 567-71.

[14] De Almeida, A. R. T., Kadunc, B. V., Di Chiacchio, N. & Neto, D. R. (2003). Foam during reconstitution does not affect the potency of botulinum toxin type A. *Dermatol Surg*, *29*, 530–532.

[15] Carruthers, J., Fagien, S., Matarasso, S. L. & Group, B. C. (2004). Consensus Recommendations on the Use of Botulinum Toxin Type A in Facial Aesthetics. *Plastic and Reconstructive Surgery*, *114*, 1S–22S.

[16] Eppley, B. L. Easing Botox administration with EMLA cream. (2004). *Aesthet Surg J*, *24*, 79–81.

[17] Seo, D. W. & Hong, J. P. (2009). The use of a topical skin cooling device to achieve relief of injection-induced pain. *Plastic and Reconstructive Surgery*, *123*, 111e–112e.

[18] Allen, S. B. & Goldenberg, N. A. (2012). Pain difference associated with injection of abobotulinumtoxinA reconstituted with preserved saline and preservative-free saline: a prospective, randomized, side-by-side, double-blind study. *Dermatol Surg*, *38*, 867–870.

[19] Janis, J. E., Ghavami, A., Lemmon, J. A., Leedy, J. E. & Guyuron, B. (2007). Anatomy of the Corrugator Supercilii Muscle: Part I. Corrugator Topography. *Plastic and Reconstructive Surgery*, *120*, 1647–1653.

[20] Ozsoy, Z. Z., Gözü, A. A. & Genç, B. B. (2004). Two-plane injection of botulinum exotoxin A in glabellar frown lines. *Aesth Plast Surg*, *28*, 114–115.

[21] Cook, B. E., Lucarelli, M. J. & Lemke, B. N. (2001). Depressor supercilii muscle: anatomy, histology, and cosmetic implications. *Ophthal Plast Reconstr Surg*, *17*, 404–411.

[22] Carruthers, J. A. et al. (2002). A multicenter, double-blind, randomized, placebo-controlled study of the efficacy and safety of botulinum toxin type A in the treatment of glabellar lines. *J. Am. Acad. Dermatol.*, *46*, 840–849.

[23] Carruthers, A., Carruthers, J. & Said, S. (2005). Dose-ranging study of botulinum toxin type A in the treatment of glabellar rhytids in females. *Dermatol Surg*, *31*, 414–22– discussion 422.

[24] Carruthers, A. & Carruthers, J. (2005). Prospective, double-blind, randomized, parallel-group, dose-ranging study of botulinum toxin type A in men with glabellar rhytids. *Dermatol Surg*, *31*, 1297–1303.

[25] Ascher, B. et al. (2004). A multicenter, randomized, double-blind, placebo-controlled study of efficacy and safety of 3 doses of botulinum toxin A in the treatment of glabellar lines. *J. Am. Acad. Dermatol.*, *51*, 223–233.
[26] Bulstrode, N. & Grobbelaar, A. (2002). Long-Term Prospective Follow-Up of Botulinum Toxin Treatment for Facial Rhytides. *Aesth Plast Surg*, *26*, 356–359.
[27] Carruthers, A., Carruthers, J. & Cohen, J. (2003). A prospective, double-blind, randomized, parallel- group, dose-ranging study of botulinum toxin type a in female subjects with horizontal forehead rhytides. *Dermatol Surg*, *29*, 461–467.
[28] Ascher, B., Rzany, B. J. & Grover, R. (2009). Efficacy and safety of botulinum toxin type A in the treatment of lateral crow's feet: double-blind, placebo-controlled, dose-ranging study. *Dermatol Surg.*
[29] Flynn, T. C., Carruthers, J. A. & Carruthers, J. A. (2001). Botulinum-A toxin treatment of the lower eyelid improves infraorbital rhytides and widens the eye. *Dermatol Surg*, *27*, 703–708.
[30] Flynn, T. C., Carruthers, J. A. & Carruthers, J. A. (2003). Botulinum A Toxin. Lower Eyelid: Dose-Finding Study. *Dermatol Surg*, *29*, 943-50.
[31] Paloma, V. & Samper, A. (2001). A complication with the aesthetic use of Botox: herniation of the orbital fat. *Plastic and Reconstructive Surgery*, *107*, 1315.
[32] Foster, J. A., Proffer, P. L., Proffer, L. H., Wulc, A. E. & Perry, J. D. (2005). Modifying brow position with botulinum toxin. *Int Ophthalmol Clin*, *45*, 123–131.
[33] Klein, A. W. (2004). Botox for the eyes and eyebrows. *Dermatol Clin*, *22*, 145–9– vi
[34] Chen, A. H. & Frankel, A. S. Altering brow contour with botulinum toxin. (2003). *Facial Plastic Surgery Clinics of NA*, *11*, 457–464.
[35] Fagien, S. (2003). Botulinum toxin type A for facial aesthetic enhancement: role in facial shaping. *Plastic and Reconstructive Surgery*, *112*, 6S–18S– discussion 19S–20S.
[36] Ahn, M. S., Catten, M. & Maas, C. S. Temporal brow lift using botulinum toxin A. (2000). *Plastic and Reconstructive Surgery*, *105*, 1129–35– discussion 1136–9.
[37] Huang, W., Rogachefsky, A. S. & Foster, J. A. (2000). Browlift with botulinum toxin. *Dermatol Surg*, *26*, 55–60.
[38] Frankel, A. S. & Kamer, F. M. (1998). Chemical browlift. *Arch Oto Head Neck Surg 124*, 321-3.
[39] Matros, E., Garcia, J. A. & Yaremchuk, M. J. (2009). Changes in eyebrow position and shape with aging. *Plastic and Reconstructive Surgery*, *124*, 1296–1301.
[40] Lee, C. J., Kim, S. G. & Yi Han, J. (2006). The Results of Periorbital Rejuvenation with Botulinum Toxin A Using Two Different Protocols. *Aesth Plast Surg*, *30*, 65–70.
[41] Brandt, F. S. & Bellman, B. (1998). Cosmetic use of botulinum A exotoxin for the aging neck. *Dermatol Surg*, *24*, 1232–1234.
[42] Matarasso, A., Matarasso, S. L., Brandt, F. S. & Bellman, B. (1999). Botulinum A exotoxin for the management of platysma bands. *Plastic and Reconstructive Surgery*, *103*, 645–645.
[43] Levy, P. M. (2007). The 'Nefertiti lift': a new technique for specific re-contouring of the jawline. *J Cosmet Laser Ther*, *9*, 249–252.
[44] (2001). CarruthersCarruthers. BOTOX use in the mid and lower face and neck. *Semin Cutan Med Surg*, *20*, 8–8.
[45] Goldman, A. & Wollina, U. (2010). Elevation of the corner of the mouth using botulinum toxin type a. *J Cutan Aesthet Surg*, *3*, 145–150.

[46] Tamura, B. M., Odo, M. Y., Chang, B., Cucé, L. C. & Flynn, T. C. (2005). Treatment of nasal wrinkles with botulinum toxin. *Dermatol Surg*, *31*, 271–275.

[47] Semchyshyn, N. & Sengelmann, R. D. (2003). Botulinum toxin A treatment of perioral rhytides. *Dermatol Surg*, *29*, 490–5– discussion 495.

[48] Cohen, J. L., Dayan, S. H., Cox, S. E., Yalamanchili, R. & Tardie, G. (2012). OnabotulinumtoxinA dose-ranging study for hyperdynamic perioral lines. *Dermatol Surg*, *38*, 1497–1505.

[49] Polo, M. (2008). Botulinum toxin type A (Botox) for the neuromuscular correction of excessive gingival display on smiling (gummy smile). *Am J Orthod Dentofacial Orthop*, *133*, 195–203.

[50] Adriaens, J., van Loon, B., Ingels, K. J., Bergé, S. J. & Maal, T. J. (2012). Three-dimensional stereophotogrammetric method of quantifying the effect of botulinum toxin type A injections on masseter hypertrophy. *Plastic and Reconstructive Surgery*, *130*, 376e–378e.

[51] (2010). Evaluation and selecting indications for the treatment of improving facial morphology by masseteric injection of botulinum toxin type A. *63*, 2026–2031.

[52] Flynn, T. C. (2007). Botox in men. *Dermatol Ther*.

[53] Carruthers, A., Carruthers, J. & Monheit, G. D. (2010). Multicenter, randomized, parallel-group study of the safety and effectiveness of onabotulinumtoxinA and hyaluronic acid dermal fillers (24-mg/mL smooth, cohesive …. *Dermatologic …*

[54] Klein, A. W. (2001). Complications and adverse reactions with the use of botulinum toxin. *Semin Cutan Med Surg*, *20*, 109–120.

[55] Matarasso, S. L. & Matarasso, A. (2001). Treatment guidelines for botulinum toxin type A for the periocular region and a report on partial upper lip ptosis following injections to the lateral canthal rhytids. *Plastic and Reconstructive Surgery*, *108*, 208–207.

[56] Rubin, M., Dover, J., Maas, C. & Nestor, M. (2009). An analysis of safety data from five phase III clinical trials on the use of botulinum neurotoxin type A-ABO for the treatment of glabellar lines. *Aesthet Surg J*, *29*, S50–6.

[57] Monheit, G. D., Cohen, J. L. (2009). Reloxin Investigational Group. Long-term safety of repeated administrations of a new formulation of botulinum toxin type A in the treatment of glabellar lines: interim analysis from an open-label extension study. *J. Am. Acad. Dermatol.*, *61*, 421–425.

[58] Dailey, R. A., Philip, A. & Tardie, G. (2011). Long-term treatment of glabellar rhytides using onabotulinumtoxina. *Dermatol Surg.*

[59] Brandt, F., O'Connell, C., Cazzaniga, A. & Waugh, J. M. (2010). Efficacy and safety evaluation of a novel botulinum toxin topical gel for the treatment of moderate to severe lateral canthal lines. *Dermatol Surg*, *36* Suppl *4*, 2111–2118.

[60] Glogau, R. R. et al. (2012). Results of a randomized, double-blind, placebo-controlled study to evaluate the efficacy and safety of a botulinum toxin type A topical gel for the treatment of moderate-to-severe lateral canthal lines. *J Drugs Dermatol*, *11*, 38–45

In: Encyclopedia of Surgery (22 Volume Set)
Editors: Andreas Lehrer and Kristin Mueller
ISBN: 978-1-53618-329-0
© 2020 Nova Science Publishers, Inc.

Chapter 39

FACIAL FILLERS

Darren J. McKeown*
Aesthetic Medicine Institute, Glasgow, UK

KEY POINTS

Ageing is characterised by soft-tissue loss of volume and ptosis. There is also loss of facial skeletal support with age.

Fillers are most usefully classified as temporary, semi-permanent or permanent.

Collagen fillers have been largely superseded by hyaluronic acid owing to enzymatic reversibility, longer duration of action and a more favourable side-effect profile of the latter.

There is a high reported incidence of nodule formation following the use of hydroxyapatite and poly-l-lactic acid-based fillers.

Polymethylmethacrylate is the only permanent filler licensed by the FDA. Anecdotal evidence suggests complications are not uncommon and can be difficult to manage.

Blindness is a rare serious complication of filler injection, occurring most frequently when the filler material is autologous fat and the anatomical location is the nose.

INTRODUCTION

The last decade has seen dramatic advancement in our understanding of facial ageing. Thanks to a series of revolutionary anatomical studies, our traditional two-dimensional view of the ageing face has been firmly replaced by a more sophisticated three-dimensional model, at the heart of which lies the concept of volume loss. As the face ages, global loss and redistribution of volume occurs in both hard and soft tissues.

With an evolving understanding of facial ageing has come an appreciation of the importance of restoring volume in facial rejuvenation. Dermal fillers have assisted the therapeutic approach of plastic surgeons by providing a minimally invasive technique for

* Corresponding Author's Email: drdarrenmckeown@gmail.com.

volume restoration without the risks associated with traditional surgical approaches of structural fat grafts and implants.

Since the early days of collagen fillers, great advances in dermal filler technology now allow surgeons to produce consistent, reproducible and long lasting results. The contemporary aesthetic practitioner can choose from a wide range of filler products that can be tailored to suit individual indications.

FACIAL AGEING AND VOLUME LOSS

It was traditionally assumed that subcutaneous facial fat consisted of a single, uniform layer. More recent cadaver studies have instead revealed that subcutaneous fat is partitioned into discrete anatomic compartments and a significant proportion of facial ageing is due to characteristic changes that occur within each compartment. Cheek fat, also referred to as the malar fat pad, has three distinct compartments: medial, middle and lateral-temporal cheek fat. The forehead similarly contains three distinct fat compartments: medial, middle and lateral-temporal cheek fat that also extends to the cheek. Nasolabial fat exists as a distinct fat compartment. Subcutaneous orbital fat also consists of three separate compartments: superior, inferior and lateral determined by septal borders, whilst jowl fat is the most inferior fat compartment.

It has also been determined by cadaveric injection dye studies that distinct vascularised membranes define each fat compartment anatomically. Each compartment has its own identifiable blood vessel that carries the perforator blood supply to the overlying skin [1].

A German group studied age related changes to facial fat compartments by carrying out CT scans of unfixed cadaver heads. They demonstrated a general inferior shift and inferior volume redistribution of facial fat compartments with age. In addition, they noted compartment-specific changes including volume loss of the deep medial fat compartment in the cheek and in the buccal extension of the buccal fat pad. The implications of this study, whilst significant, need to be tempered against the age of the cadaver heads since a group of 54-75 years was compared with a group of 75-104 years, older than the typical aesthetic patient [2].

Volumetric contour changes are not limited to facial fat. Significant bony changes to the facial skeleton also take place with advancing age. In the upper face there is an increase in circumference of both the inferior and superior orbital rims, with a corresponding increase in the orbital aperture. In the midface there is an increase in the pyriform aperture, with a decrease in the glabellar and maxillary angles. In the lower face there is a reduction in the height of the body and ramus of the mandible, reduction in length of the mandibular body and widening of the mandibular angle [3].

Such anatomic studies demonstrate that facial ageing is a complex three-dimensional process. It is characterised not only by soft tissue volume loss but also by three-dimensional re-distribution of the soft and hard tissues of the face. The modern aesthetic practitioner's approach to anti-ageing therapy has therefore shifted focus to the restoration of facial volume and re-creation of more youthful facial contours.

CLASSIFICATION OF DERMAL FILLERS

There are currently over 150 dermal filler materials on the worldwide market. It is beyond the scope of this text to cover each material in detail. Instead, we will focus on those fillers that have been approved by the Food and Drug Administration (FDA) in America. There are fifteen such approved products at the time of writing. That is not to say there are no other useful fillers available elsewhere in the world, nor is it to say that all FDA fillers should be recommended. FDA approval does however serve as a useful benchmark in determining a minimum standard of research. Furthermore, the FDA list includes the most commonly used and clinically relevant products worldwide.

Dermal fillers can be variously classified (for instance by duration of effect, depth of implantation, composition material and stimulatory effect on the skin) but the duration of effect provides the most clinically useful classification, into: temporary, semi-permanent or permanent.

Temporary fillers such as collagen and hyaluronic acid (HA) gels have the benefit of allowing great flexibility and reversibility. They can be reversed by injection of collagenase or hyaluronidase respectively, allowing the surgeon the option of a 'get out of jail' card in the event of a serious adverse event. Semi-permanent and permanent fillers offer the promise of long lasting or even permanent correction. However, this needs to be balanced against a lack of predictability and control over the final result and the risk of long-term complications, which can be difficult, and in some cases impossible, to correct.

Temporary Fillers

Collagen

The first collagen products to be introduced were of bovine origin, available commercially as Zyderm and Zyplast (Allergan, Irvine, Ca). The FDA licensed Zyderm in 1981, whilst Zyplast was approved in 1985. The main difference between the two was that Zyplast contained cross-linked collagen, designed for deeper implantation within the dermis for the correction of deeper wrinkles, whilst Zyderm was non-cross-linked and suited to more superficial implantation. A multicentre study spanning six years and more than 5000 patients revealed the product to be safe, associated with only minor self-limiting complications [4].

Due to its bovine origin, however, hypersensitivity reactions were common and a skin test was mandatory prior to treatment. Hypersensitivity reactions nonetheless occurred after a negative skin test and were a major limitation of the early collagen products. To address this, the manufacturer developed synthetic human collagen under the trade names of Cosmoderm and Cosmoplast. The FDA approved these with no clinical trials as they were considered a simple source change to the original Zyderm and Zyplast products (that were subsequently withdrawn from the market by the manufacturer). Consequently there have never been substantial clinical trials on Cosmoderm or Cosmoplast, both of which are no longer available since the advent of HA fillers.

Two other porcine-derived collagen products have been approved by the FDA and produced under the trade names of Evolence (Colbar Lifescience, Herzliya, Isreal) and Fibrel (Mentor Corp, Goleta, Ca). Neither product is commercially available any longer.

Collagen was once considered the gold standard filler material and was a revolutionary product in its day. It was the first 'off the shelf' product to allow instant volume replacement and wrinkle reduction in a reliable and safe manner. However, injectable collagen had a relatively short duration of effect, results typically lasting just three to four months [5]. Since the introduction of hyaluronic acid, with its longer duration of effect and favourable side effect profile, collagen has been largely superseded and interest in it as a filler is now primarily historic.

Properties of commonly used collagen fillers are summaried in Table 1.

Hyaluronic Acid

The introduction of HA fillers has revolutionised the dermal filler market. HA is a polysaccharide found naturally within the skin, whose main function is to provide structure and maintain hydration within the dermis. There are a number of currently available HA products that have been approved by the FDA. These can be categorised according to the source of HA (animal or non-animal), concentration of HA within the product, degree of cross-linking, and their particulate or homogenous nature.

Restylane

Restylane was the first HA filler to be approved by the FDA in 2003. It is a non-animal sourced particulate gel containing 20mg/ml HA stabilised using BDDE (1.4-butaediol diglycidyl ether). Restylane contains 100,000 particles per millilitre. Its sister product, Restylane Perlane, contains 10,000 larger particles per millilitre and is designed for deeper implantation within the dermis for the correction of deeper lines and wrinkles.

The first large scale clinical trial of 158 patients injected with Restylane published in 1998 showed that effects persisted at eight months in over eighty percent of patients [6]. Another group reported their series of 1446 patients who underwent treatment of various facial areas with Restylane and found that 61% of patients remained satisfied with the results after nine months. They noted that the duration of effect appeared to vary depending on the area treated, with treatment of the nasolabial fold and glabella generally lasting longer than the lips [7].

Table 1. Summary of collagen fillers

Brand name	Source	Concentration	Cross linked	Commercially available
Zyderm	Bovine	35mg/ml	No	No
Zyplast	Bovine	35mg/ml	Yes	No
Cosmoderm	Human	35mg/ml	No	No
Cosmoplast	Human	35mg/ml	Yes	No
Evolence	Porcine	35mg/ml	Yes	No
Fibrel	Porcine	35mg/ml	Yes	No

A multicentre, randomised controlled trial comparing Restylane with bovine collagen (Zyplast) for the correction of nasolabial folds randomised 138 patients to receive Restylane or collagen to contralateral nasolabial folds [8]. The authors found that Restylane required less volume of product to achieve an optimal cosmetic result. Results were assessed at six months according to the degree of improvement on the Winkle Severity Rating Scale, demonstrating a superior result in nasolabial folds treated with Restylane and fewer side effects such as lumpiness or nodules. This study was the basis of Restylane obtaining FDA approval in America.

Hylaform

Hylaform was the first FDA-approved animal-based HA filler. It contains 5.5mg/ml avian-sourced HA and in unpublished – and therefore not peer reviewed - clinical data submitted to the FDA, was found to be equivalent in efficacy to bovine collagen (www.fda.gov). However bacterial-sourced HA (Perlane) has been found to be more efficacious in the ablation of wrinkles (as measured by the Wrinkle Severity Score) and was significantly longer lasting [9].

Juvederm

Juvederm contains bacterial-sourced HA and was first approved in 2006. Unlike the Restylane family of products in which product consistency is varied by changing particle size, Juvederm's consistency is varied by altering the concentration of HA and its degree of cross-linking. In the US, it is available in two formulations: Juvederm Ultra and Juvederm Ultra Plus. Both contain 24 mg/ml HA but the Ultra Plus product is more highly cross-linked.

A randomised, double-blind multicentre trial of 292 patients comparing Juvederm with bovine collagen (Zyplast) in the correction of nasolabial folds found clinically significant wrinkle reduction persisted at nine months in the Juvederm group but not the collagen group. Moreover, 78% of patients treated with Juvederm had a clinically significant improvement that persisted beyond one year [10]. A further comparison of Juvederm and. Zyplast randomised 87 patients to receive each on contralateral nasolabial folds. In the Juvederm group, 96% of patients maintained their result at 24 weeks and 81% retained their result at one year. Conversely only 41% of patients maintained their results at 24 weeks in the Zyplast group. When patients were re-treated at the end of the study, less than half of the original volume of filler was required to achieve an optimal result [11].

Superior efficacy of Juvederm over Zyplast was confirmed in a further multicentre, double-blind, randomised trial comparing the two in the correction of moderate or severe nasolabial folds. In the study of 439 patients, Juvederm lasted considerably longer than Zyplast, with 88% of subjects preferring Juvederm [12].

Newer formulations of Juvederm containing lidocaine aim to reduce the procedural discomfort. During the first injection, pain is felt as the needle pierces the skin. The pain of product insertion is then less and subsequent injections in the same area are pain free as the initial dose of anaesthetic takes effect. There appear to be no associated increase in adverse events with this formulation [13,14].

Restylane vs. Juvederm

A randomised controlled trial of Restylane Perlane with Juvederm Ultra Plus compared treatment with each product on contralateral randomised nasolabial folds. After six months 70% of Juvederm treated folds maintained correction compared with 45% of Restylane Perlane treated folds. At twelve months, 71.4% of patients preferred the effects of Juvederm. The results were highly statistically significant [15].

Other Hyaluronic Acid products

Belotero is a bacterial-sourced HA filler approved by the FDA in 2011. It consists of 22.5mg/ml HA and, according to the manufacturer, is better able to fill dermal defects because of its 'dynamic, double cross-linking technology'. One randomised controlled trial, funded by the manufacturer, appears to show equivalent longevity to Restylane and Juvederm [16]. Captique was produced by the same manufacturer as Hylaform (Allergan, Irvine, Ca) and was identical except for the source of HA, which was bacterial rather than avian. Neither Hylaform nor Captique are available commercially any longer.

Prevelle (Mentor Corp, Santa Barba, Ca) is bacterial-sourced HA, similar to Captique and Hylaform except with more cross-linking to increase its durability. It is commercially available at present. There is little peer-reviewed literature to support its use.

Elevess is a non-animal sourced HA filler approved by the FDA in 2006. There is little clinical evidence to support this product and there are a number of case reports of serious adverse events including persistent swelling, pain and nodule formation [17].

Duration of Effect of Hyaluronic Acid

Although the effects of HA are generally described as lasting six to twelve months, in practice the effects can remain visible for much longer. Individual case reports indicate clinical improvement persisting up to five years [18-20]. Evidence from histological studies indicates that the mechanical stretching effect of HA fillers on the dermis activates dermal fibroblasts to synthesise collagen de novo, which may account for the prolonged results often observed [21]. Recognition of a potentially very prolonged effect of HA is important to avoid unnecessary repeat treatments resulting in overcorrection and an unnatural result. The decision to carry out a repeat treatment should therefore be based on the findings of clinical examination rather than simply the chronology of previous injections.

Re-Treatment Intervals for Hyaluronic Acid

One study examined the effect of different re-treatment intervals to the nasolabial folds, with two groups of patients randomised to retreatment after either 4.5 or nine months. At eighteen months follow up, both groups maintained a similar degree of clinical improvement on the wrinkle severity rating scale, indicating that prolonged results were achieved regardless of the interval to initial re-treatment [22].

Safety

Initial safety data for Restylane prior to 2000 indicated an adverse event rate of one in 650 patients treated (0.15%). The majority of these were temporary events including localised granulomatous reactions, bacterial infection and acneiform or cystic lesions. Subsequently a manufacturing refinement, reducing the trace amounts of protein within the filler, reduced

adverse events to one in 1800 patients, with hypersensitivity occurring in one in every 5,000 patients treated [23].

There have been at least ten case reports of a granulomatous reaction to injectable HA [24-33]. There has also been a case report of severe angioedema acute hypersensitivity following injection of HA (Restylane) into the lips [34].

Properties of commonly used HA fillers are summaried in Table 2.

Semi-Permanent Fillers

Calcium Hydroxyapatite

Calcium hydroxyapatite (CaHA), is available under the trade name of Radiesse (Bioform Medical, San Mateo, Ca, USA). The product consists of calcium hydroxyapatite microspheres of 25-45μm diameter suspended in an aqueous gel carrier composed of caboxymethylcellulose, glycerine and water [35]. In an evaluator blinded randomised controlled trial comparing Radiesse with bovine collagen in the treatment of nasolabial folds on contralateral sides of the same patient, Radiesse provided a longer lasting correction with less volume of product required, albeit at the expense of prolonged oedema [35]. In comparison with HA fillers, CaHA has greater viscosity and elasticity which some users feel offers enhanced filling properties [36]. Due to the calcium hydroxyapatite content, Radiesse has often been promoted for the correction of bony defects such as nasal bridge deficiency [37].

One randomised study compared patient satisfaction following treatment with CaHA with two brands of HA (Restylane and Juvederm). The investigators found a greater patient satisfaction with the outcome of treatment from CaHA [38], although it is worth noting the study was funded by Bioform Medical.

CaHA does not come without its fair share of problems, particularly nodule formation and inflammatory reactions. One study of 609 patients demonstrated a 12.4% incidence of nodule formation following treatment of the lips using CaHA [39]. A further multicentre study of 113 patients primarily being treated for nasolabial folds and perioral rejuvenation found two patients required intralesional steroid injections for nodule formation and a further two required a course of oral steroids for ongoing inflammatory reactions [40]. There have also been case reports of nodule formation at sites distant to the injection site [41] as well as intraoral foreign body granulomatous nodules associated with injection in the facial soft tissues [42].

Poly-L-Lactic Acid (PLLA)

Poly-L-Lactic Acid (Sculptra) produces long-term volume enhancement by initiating a foreign body reaction and inflammatory response. Patients are typically treated with a series of three to four injections at one-month intervals. Over a nine-month period the PLLA is reabsorbed and replaced by a matrix of new collagen and proteoglycans [43]. Although the initial product is fully reabsorbed within the first year, the clinical appearance of enhanced volume typically persists for up to three years [44-46].

Table 2. Summary of HA fillers

Brand name	Source	Concentration	Cross linked	Commercially available
Restylane	Bacterial	20mg/ml	Yes	Yes
Perlane	Bacterial	20mg/ml	Yes	Yes
Hylaform	Avian	5.5mg/ml	Yes	No
Juvederm Ultra	Bacterial	24mg/ml	Yes	Yes
Juvederm Ultra plus	Bacterial	24mg/ml	Highly	Yes
Belotero	Bacterial	22.5mg/ml	Yes	Yes
Captique	Bacterial	5.5mg/ml	Yes	No
Prevelle	Bacterial	5.5mg/ml	Highly	Yes
Elvess	Bacterial	28mg/ml	Yes	Yes

PLLA was initially marketed under the trade name of New Fill (Sanofi-Aventis, US), but this was subsequently removed from the market due to a high incidence of granulomatous reactions. The same product was reintroduced as Sculptra with different dilution and injection guidelines (Lowe NJ 2006).

In an FDA approval study, 233 patients were randomised to receive PLLA (Sculptra) and human collagen (CosmoPlast) on contralateral nasolabial folds. The effects of PLLA were maintained up to thirteen months, in comparison to three months for human collagen.

Despite the longer lasting results, the initial problems of New Fill have (perhaps unexpectedly) not gone away. In one large series of 210 cases, almost twenty percent of patients developed nodules. The researchers felt that the majority of these were clinically insignificant because they were only obvious on palpation. In the author's experience, however, patients continue to feel such irregularities when applying cosmetics and as such they remain a constant source of patient dissatisfaction. As well as the high incidence of palpable nodules, five patients required intralesional steroids and two required surgical excision of nodules, accepting the associated permanent scarring in approximately one percent of cases [47].

A further series of 100 cases was reported with eighteen serious adverse events. These included twelve cases of granuloma formation that were clinically significant, five cases of infection and three of long-term allergy [48]. There have also been numerous reports of late onset infections and granulomas [49-52]. Periorbital and temporal injection of PLLA has resulted in orbital infarction and permanent loss of vision [53].

In the author's experience, the volume enhancement produced by Sculptra is not youthful soft, supple skin but firm, fibrous tissue more reminiscent of extensive subcutaneous scarring.

Permanent Fillers

Polymethylmethacrylate

Polymethylmethacrylate (PMMA) is the only permanent filler to have been licensed by the FDA. A similar preparation has been available commercially under the trade names of Arteplast, Artecol and most recently Artefil. This family of products all contain approximately twenty percent PMMA suspended in an eighty percent bovine collagen matrix, which is gradually reabsorbed in the first three months allowing the PMMA particles to elicit

a foreign body reaction and generate new collagen or scar tissue [43]. Each generation of these fillers have been the result of manufacturing refinements, in particular avoiding particles of less than twenty microns in diameter. It has been hypothesised that smaller particles can be phagocytosed by macrophages and result in prolonged inflammatory reactions to the product [54].

Lemperle, the inventor of Artecol/Artefil, published the results of a postal survey of 950 patients conducted one to two years after treatment with PMMA. He reported a 91% patient satisfaction rate and a three percent complication rate [55].

In an FDA approval study, patients were randomised to receive either PMMA or collagen. At twelve months follow up, 86.7% of the PMMA group demonstrated continued augmentation with a similar rate of adverse events as the collagen control group [56]. In a further five year follow up study, funded by the product manufacturers, the same group were able to reassess half of the initial cohort treated with PMMA. They claimed there were no serious, unexpected long-term complications [54].

Other authors have disputed these findings, claiming a much higher personal complication rate with adverse events including serious granulomatous reactions occurring three or four years following treatment [48]. In one case series alone, PMMA was associated with 32 serious complications including infection, necrosis, granuloma, inflammatory reactions, hardening, stiffening and tissue immobility. The authors reported that these complications were, in general, very difficult and, in some cases, impossible to manage [57].

INJECTION AREAS

Perioral Rhytids

Lines and wrinkles in the perioral area - including the nasolabial folds, marionette lines and radial rhytids on the lips (“smokers lines”) - are the commonest anatomical target for injectable fillers. Lines and wrinkles in this area form a single aesthetic unit and are usually treated in combination at the same treatment session. Product guidelines suggest that filler should be placed within the dermis in the area around the mouth. The dermis in this region is relatively thin, however, making true intradermal injection difficult. One histological study of nasolabial fold Juvederm injection found that the filler was actually located in the subcutaneous tissue, despite attempted intradermal injection and a satisfactory cosmetic outcome [58].

In one study of twenty patients using both Restylane and Perlane, investigators used an average of 5.6ml of HA to achieve optimal correction of the perioral area including nasolabial folds, marionette lines, oral commissures and radial lip lines [59]. In the author’s practice a more conservative approach is taken in this region, with volumes of two to four millilitres of filler more typical. When injecting this area it is essential to envisage the region as a three dimensional, dynamic structure and to appreciate that overcorrection can inhibit the dynamics of the region and result in an unnatural appearance.

Lips

The lips are often described as the most 'sensual' feature on the face. Full lips are associated with youth and beauty, and lip augmentation is frequently requested by patients presenting to cosmetic clinics. A multicentre randomised, single blinded controlled trial comparing lip augmentation using injectable HA with no treatment found that HA injection produced significant improvements on a validated lip augmentation scale [60]. The results of lip augmentation with HA typically lasted six months or more.

HA injection into the lip is an exquisitely painful procedure and adequate anaesthesia is a prerequisite for a slow, controlled and precise injection. Anaesthesia is best achieved using infraorbital and mental nerve blocks, approached through the upper and lower buccal sulci respectively. There is little evidence to support the optimal anatomical layer of filler injection. Some prefer to inject the filler material deep within the muscle layer of the lip. It is the author's opinion that this can create an unnatural and lumpy result when the lip moves and it is therefore better to place the filler material more superficially in the potential space between mucosa and the muscle.

Injections can be carried out in an antegrade or retrograde manner, although again little evidence supports either technique. It is the author's preference to use an antegrade flow technique, which allows the filler to dissect its own way forward in the natural tissue space. Once the tip of the needle is located in the correct plane the injected filler creates its own natural dissection plane and avoids multi-level product placement. The needle can be inserted in a lateral to medial direction or vertically in a superior to inferior direction, which is the author's preference. This technique encourages the product to flow not only laterally along the border of the lip, but inferiorly in to the red part of the lip, which produces a more harmonious and natural augmentation.

Tear Trough

The tear trough, or nasojugal grove, extends inferolaterally from the medial canthus towards the mid-pupillary line and denotes the junction between the lower eyelid and the upper cheek [61]. A true osseocutaneous ligament, termed the tear trough ligament, has recently been identified in this region [62]. With advancing age the tear trough becomes deeper as volume is lost from the midface and orbital rim.

Injection of HA filler to augment and rejuvenate the tear trough was first described in 2005 [63]. The author described superficial injections of Restylane with a high patient satisfaction rating of 92%, although few others have been able to replicate these results. Lambros described a deeper plane of injection on either the suborbicularis or supraperiosteal plane with firm massage to ensure a smooth result, using 0.2-0.4ml of filler per side. He noted that very often the filler seemed to last much longer in this region [64].

One group attempted to quantify filler longevity in the tear trough using volumetric 3D image analysis. The average filler volume was 0.21ml per side with no patients receiving more than 0.5ml per side. At 14.4 months average follow up, 85% of the initial filler volume persisted [65]. Indeed, there have been clinical reports of HA persisting for five years in the tear trough. Some have attributed the longer lasting result in this region to the relative lack of tissue mobility [20].

It would therefore appear that a small injection volume in a deep plane produces effective and long-lasting correction of the tear trough deformity. The tear trough is a difficult area to treat, with minor irregularities in the surface of the filler being apparent through the thin overlying skin creating a visual deformity. Experienced injectors only should therefore attempt tear trough injections.

Cheeks

Volume restoration to the cheeks and midface can be one of the most gratifying minimally invasive aesthetic procedures, associated with a high degree of patient satisfaction and reported to enhance the patient's own feelings of attractiveness [66].

As a general rule, high viscosity HA fillers are ideal for cheek augmentation [67]. The cheek can be filled using a linear threading or serial puncture injection technique [68] although the author's preferred technique is to use a blunt-tipped cannula from a single point inferior and lateral to the outer canthus. A sharp-tipped needle is used to create a small stab incision for entry of the cannula. This allows access to the entire cheek and midfacial area with a single needle point, minimizing the risk of bruising and swelling post-treatment. A small (0.1ml) injection of two percent lidocaine with 1:200,000 adrenaline at the planned site of cannula entry is sufficient to ensure a pain-free procedure and reduce the risk of entry site bleeding or bruising.

Overcorrection of the cheek should be avoided at all costs. In some younger patients as little as 0.4ml per side will provide enough augmentation whilst maintaining a natural look (Figure 1). Overcorrection in the cheek may appear acceptable in a resting patient but becomes immediately obvious and unnatural when the patient animates in laughing or smiling. It is therefore always best to undercorrect the cheek, review the patient two weeks later and make a decision on whether to add further volume at that stage.

Figure 1. Before (left) and after (right) 0.4cc hyaluronic acid in each cheek plus 0.3cc to the right and 0.5cc hyaluronic acid to the left nasolabial fold. The patient also underwent botulinum toxin injections to the glabella and forehead.

Treatment of the cheek area is almost always combined with treatment of other areas in the adjacent aesthetic units, in particular the nasolabial fold and tear trough. In some cases, injection of filler into the deep medial fat compartment of the cheek alone will provide enough correction of the tear trough deformity without formal treatment of the tear trough itself (Figure 2).

Volume restoration in the cheek usually lasts for a prolonged period of time in clinical practice, with most patients opting to have it performed once per year. A three-dimensional volume analysis found that 65.8% of the initial filler volume was still present in the cheek after six months [69]. If a patient therefore returns to the clinic requesting further augmentation before the full effects have worn off, it is important to reduce the injection volume from the first treatment record to avoid over-correction.

Temples

Hollowing of the temporal fossa, due to loss of volume from the lateral temporal subcutaneous fat pad or atrophy of the temporal extension of the buccal fat pad, contribute to the appearance of ageing in the upper face. Volume restoration in this area with HA can provide an effective rejuvenation of the upper face.

In a study of twenty patients undergoing temple injections of Restylane Perlane to the temples, Ross & Malhotra recorded an 81% patient satisfaction rate. Most patients received one millilitre of filler per side, except one patient who received three millilitres due to severe asymmetry [70]. In an effort to enhance patient satisfaction and avoid contour irregularities sometimes seen when injecting the thin skin of the temple, Lambros described a technique of diluting filler on a 2:1 diluent (normal saline or lidocaine) to filler ratio. The author claimed this technique, “the dilution solution”, resulted in a smoother look and improved patient satisfaction [71].

Figure 2. Before (left) and after (right) 2ml hyaluronic acid injected in the deep medial fat compartment bilaterally, demonstrating effacement of the tear trough deformity without any injections in the tear trough itself. The patient also had 2.4ml hyaluronic acid injected in the perioral rhytids and botulinum toxin injections in the glabella and forehead.

COMPLICATIONS

The advent of minimally invasive aesthetic medicine has reduced the risk of major complications compared with invasive surgical techniques, but adverse events have not been eliminated and vary according to the product used, its indication and the skill and experience of the injector. Practitioners should fully understand and appraise their patients of the risk of adverse events. Most are minor and self-limiting but serious life-changing complications can occur and it is vital that this is communicated to the prospective patient.

Localised Adverse Reactions

The majority of adverse events are localised reactions such as erythema, bruising, pain and swelling. These are to be expected but their incidence can be reduced by careful injection technique. Injections that increase dissection of the subdermal plane (fan like needle use, rapid injection, rapid flow rate and higher injection volumes) increase the risk of localised adverse events, although multiple small volume injections and depth of injection do not appear to have any impact [72].

Granuloma

Foreign body granulomas have been reported after use of every type of dermal filler [24,73,74]. The precise incidence of granuloma formation is difficult to quantify since it is typically a late event occurring months or years after the initial treatment and as such is often under-reported. The incidence varies depending on the nature of the filler, its surface structure and properties, content of impurities but not its primary biocompatibility or the volume injected [75]. Due to the relatively low incidence of granuloma formation there is a lack of good quality clinical trials on how best to manage them, so management is based on expert opinion rather than evidence. As a general rule most untreated granulomas will grow to approximately the size of a bean and eventually resolve in one to five years, although experts advocate the use of intralesional and oral steroid treatment to expedite the resolution [75].

Necrosis

Necrosis is a potential complication where any foreign material has been injected into the skin or subcutaneous tissue [76]. It can result from arterial embolisation of filler material or as a result of swelling around the filler material causing occlusion of the arterial supply distally. Again the precise risk is difficult to quantify due to the event being relatively rare. Nonetheless one large case series of bovine collagen injections found a necrosis incidence of approximately 0.1% [77]. It is likely that other fillers with a similar mode of action have a similar risk profile.

Where a permanent or semi-permanent filler material has been used there can be little meaningful intervention to prevent the development of necrosis after the initial signs of arterial occlusion have developed. If a HA has been used, however, prompt recognition of the signs of arterial occlusion – pale skin and disproportionate pain – and immediate injection of hyaluronidase to dissolve the filler may prevent progression to necrosis and avoid the scarring and reconstructive defect [78,79].

Blindness

One of the most serious complications of dermal filler injections is permanent visual loss resulting from inadvertent injection into a branch of the ophthalmic artery, retrograde embolisation and occlusion of the retinal artery. This is a rare but devastating complication of any filler injection in the upper face and scalp.

There have been at least 34 case reports published in the medical literature documenting blindness following filler injections. Fifteen cases have been reported after fat injections, nineteen following injection of other materials including steroids (four cases), collagen (three cases), silicone (three cases), PLLA (two cases), HA (two cases), CaHA (one case), paraffin (one case), PMMA (two cases) and one case of an unknown substance (Table 3).

Table 3. Cases of blindness by filler material

Filler material	Cases of blindness
Fat	15
Steroids	4
Collagen	3
Silicone	3
PLLA	2
Hyaluronic acid	2
PMMA	2
Calcium hydroxyapatite	1
Paraffin	1
Unknown	1

Table 4. Injection sites for synthetic materials to result in blindness

Injection site	Reports of blindness
Nose	7
Glabella	4
Scalp	3
Forehead	2
Temple	2
Peri-orbital	1

The injection sites that have resulted in blindness have included the nose (seven cases), glabella (four cases), scalp (three cases), forehead (two cases), temple (two cases) and one case of peri-orbital injection (Table 4). Given that the most commonly reported injection site

causing blindness is itself one of the least commonly injected areas - the nose - this may be a particularly high-risk region, and this should be discussed with patients at the pretreatment consultation [80].

CONCLUSION

Modern dermal filler technology provides a means of addressing many signs of facial ageing through a relatively quick and easy injection. Using dermal fillers it is possible to address many signs of ageing that have been traditionally considered a 'surgical' problem, whilst minimizing the risk of side effects and complications.

As dermal filler treatment has evolved to become a normal part of life for many men and women, the market has expanded and the number of potential filler materials available internationally has increased exponentially. In an under-regulated field of medical practice it is essential that physicians take the lead in demanding high quality products from drug companies and only offer patients products that are supported by solid clinical evidence.

As the field of minimally invasive aesthetic medicine becomes a mainstream part of life, it is easy for physicians and patients to forget that such procedures constitute real, medical procedures with a risk of side effects and complications. To minimise the risks of such complications and to ensure prompt recognition and initiation of side effect management it is essential that only appropriately trained and experienced physicians should carry out this work. As well as being able to reduce the risk of side effects through proper training and experience, physicians should also be able to recognise the early signs of complications and initiate prompt treatment to minimise the risk of long-term consequences.

As the demand for minimally invasive procedures continues to rise, and our understanding of facial ageing continues to evolve, it is becoming increasingly clear that the best results in anti-ageing therapy are achieved through a combined approach. The consulting physician should not be focused on one single treatment modality but consider a combination of treatment approaches in order to optimise results. Topical products, botulinum toxins, platelet rich plasma, chemical peels, laser, IPL and surgical intervention should all be considered. By combining strategies, we can continue to offer our patients the most effective solutions to their aesthetic concerns.

REFERENCES

[1] Schaverien, M. V., Pessa, J. E., Saint-Cyr, M. & Rohrich, R. J. (2009). The Arterial and Venous Anatomies of the Lateral Face Lift Flap and the SMAS. *Plastic and Reconstructive Surgery*, *123*, 1581–1587.

[2] Gierloff, M. M. et al. (2012). Aging changes of the midfacial fat compartments: a computed tomographic study. *Plastic and Reconstructive Surgery*, *129*, 263–273.

[3] Shaw, R. B. & Kahn, D. M. (2007). Aging of the midface bony elements: a three-dimensional computed tomographic study. *Plastic and Reconstructive Surgery*, *119*, 675–81– discussion 682–3.

[4] Cooperman, L. S., Mackinnon, V., Bechler, G. & Pharriss, B. B. (1985). Injectable collagen: a six-year clinical investigation. *Aesth Plast Surg*, *9*, 145–151.

[5] Matarasso, S. L. (2007). Injectable collagens: lost but not forgotten--a review of products, indications, and injection techniques. *Plastic and Reconstructive Surgery*, *120*, 17S–26S.

[6] Duranti, F., Salti, G., Bovani, B., Calandra, M. & Rosati, M. L. (1998). Injectable hyaluronic acid gel for soft tissue augmentation. A clinical and histological study. *Dermatol Surg*, *24*, 1317–1325.

[7] Bosniak, S., Cantisano-Zilkha, M. & Glavas, I. P. (2004). Nonanimal stabilized hyaluronic acid for lip augmentation and facial rhytid ablation. *Archives of Facial Plastic Surgery*, *6*, 379–383.

[8] Narins, R. S., Brandt, F., Leyden, J. & Lorenc, Z. P. (2003). A randomized, double-blind, multicenter comparison of the efficacy and tolerability of Restylane versus Zyplast for the correction of nasolabial folds. *Dermatologic …*,

[9] RAO, J., Chi, G. C. & Goldman, M. P. (2005). Clinical comparison between two hyaluronic acid-derived fillers in the treatment of nasolabial folds: hylaform versus restylane. *Dermatol Surg*, *31*, 1587–1590.

[10] Pinsky, M. A., Thomas, J. A., Murphy, D. K. & Walker, P. S. (2008). Juvéderm injectable gel: A multicenter, double-blind, randomized study of safety and effectiveness. *Aesthetic Surgery Journal*, *28*, 17–23.

[11] Lupo, M. P., Smith, S. R., Thomas, J. A., Murphy, D. K. & Beddingfield, F. C. (2008). Effectiveness of Juvéderm Ultra Plus dermal filler in the treatment of severe nasolabial folds. *Plastic and Reconstructive Surgery*, *121*, 289–297.

[12] Baumann, L. S., Shamban, A. T. & Lupo, M. P. (2007). Comparison of smooth-gel hyaluronic acid dermal fillers with cross-linked bovine collagen: a multicenter, double-masked, randomized, within-subject study. *Dermatologic …*,.

[13] Weinkle, S. H. et al. (2009). A multi-center, double-blind, randomized controlled study of the safety and effectiveness of Juvéderm injectable gel with and without lidocaine. *J Cosmet Dermatol*, *8*, 205–210.

[14] Levy, P. M., De Boulle, K. & Raspaldo, H. (2009). A split-face comparison of a new hyaluronic acid facial filler containing pre-incorporated lidocaine versus a standard hyaluronic acid facial filler in the treatment of naso-labial folds. *J Cosmet Laser Ther*, *11*, 169–173.

[15] Goodman, G. J. et al. (2011). A comparison of the efficacy, safety, and longevity of two different hyaluronic acid dermal fillers in the treatment of severe nasolabial folds: a multicenter, prospective, randomized, controlled, single-blind, within-subject study. *Clin Cosmet Investig Dermatol*, *4*, 197–205.

[16] Prager, W. et al. (2012). A prospective, split-face, randomized, comparative study of safety and *12*-month longevity of three formulations of hyaluronic acid dermal filler for treatment of nasolabial folds. *Dermatol Surg*, *38*, 1143–1150.

[17] Van Dyke, S. S., Hays, G. P. G., Caglia, A. E. A. & Caglia, M. M. (2010). Severe Acute Local Reactions to a Hyaluronic Acid-derived Dermal Filler. *J Clin Aesthet Dermatol*, *3*, 32–35.

[18] Liew, S. & Nguyen, D. Q. A. (2011). Nonsurgical Volumetric Upper Periorbital Rejuvenation: A Plastic Surgeon's Perspective. *Aesth Plast Surg*, *35*, 319–325.

[19] Choi, H. S. H. et al. (2011). Modifying the upper eyelid crease in Asian patients with hyaluronic acid fillers. *Plastic and Reconstructive Surgery 127*, 844–849.

[20] Dayan, S. H., Arkins, J. P. & Somenek, M. (2012). Restylane persisting in lower eyelids for 5 years. *J Cosmet Dermatol*, *11*, 237–238.

[21] Wang, F. F. et al., In vivo stimulation of de novo collagen production caused by cross-linked hyaluronic acid dermal filler injections in photodamaged human skin. *Arch Dermatol 143*, 155–163. (2007).

[22] Narins, R. S., Dayan, S. H., Brandt, F. S. & Baldwin, E. K. (2008). Persistence and improvement of nasolabial fold correction with nonanimal-stabilized hyaluronic acid 100,000 gel particles/mL filler on two retreatment schedules: results up to 18 months on two retreatment schedules. *Dermatol Surg*, *34*, Suppl 1, S2–S8.

[23] Friedman, P. M., Mafong, E. A., Kauvar, A. N. B. & Geronemus, R. G. (2002). Safety data of injectable nonanimal stabilized hyaluronic acid gel for soft tissue augmentation. *Dermatol Surg*, *28*, 491–494.

[24] Sage, R. J., Chaffins, M. L. & Kouba, D. J. (2009). Granulomatous foreign body reaction to hyaluronic acid: report of a case after melolabial fold augmentation and review of management. *Dermatol Surg*, *35*, Suppl 2, 1696–1700.

[25] Raulin, C., Greve, B., Hartschuh, W. & Soegding, K. (2000). Exudative granulomatous reaction to hyaluronic acid. (Hylaform). *Contact Dermatitis*, *43*, 178–179.

[26] Fernández-Aceñero, M. J., Zamora, E. & Borbujo, J. (2003). Granulomatous foreign body reaction against hyaluronic acid: report of a case after lip augmentation. *Dermatol Surg*, *29*, 1225–1226.

[27] Honig, J. F., Brink, U. & Korabiowska, M. Severe granulomatous allergic tissue reaction after hyaluronic acid injection in the treatment of facial lines and its surgical correction. *J Craniofac Surg*, *14*, 197–200. (2003).

[28] Al-Shraim, M., Jaragh, M. & Geddie, W. (2007). Granulomatous reaction to injectable hyaluronic acid. (Restylane) diagnosed by fine needle biopsy. *J. Clin. Pathol.*, *60*, 1060–1061.

[29] Bardazzi, F., Ruffato, A., Antonucci, A., Balestri, R. & Tabanelli, M. (2007). Cutaneous granulomatous reaction to injectable hyaluronic acid gel: another case. *J Dermatolog Treat*, *18*, 59–62.

[30] Pinheiro, M. V. B., Bagatin, E., Hassun, K. M. & Talarico, S. (2005). Adverse effect of soft tissue augmentation with hyaluronic acid. *J Cosmet Dermatol*, *4*, 184–186.

[31] Edwards, P., Fantasia, J. & Iovino, R. (2005). Foreign Body Reaction to Hyaluronic Acid. (Restylane): An Adverse Outcome of Lip Augmentation. *Oral Surg Oral Med Oral Pathol Oral Radiol Endod*, *100*, 186–186.

[32] Ghislanzoni, M., Bianchi, F., Barbareschi, M. & Alessi, E. (2006). Cutaneous granulomatous reaction to injectable hyaluronic acid gel. *Br J Dermatol*, *154*, 755–758.

[33] Jordan, D. R. (2005). Delayed Inflammatory Reaction to Hyaluronic Acid. (Restylane. (R)). *Ophthal Plast Reconstr Surg*,.

[34] Leonhardt, J. M., Lawrence, N. & Narins, R. S. (2005). Angioedema acute hypersensitivity reaction to injectable hyaluronic acid. *Dermatol Surg*, *31*, 577–579.

[35] Smith, S., Busso, M., McClaren, M. & Bass, L. S. (2007). A randomized, bilateral, prospective comparison of calcium hydroxylapatite microspheres versus human-based collagen for the correction of nasolabial folds. *Dermatol Surg*, *33*, Suppl 2, S112–S121.

[36] Sundaram, H., Voigts, B., Beer, K. & Meland, M. (2010). Comparison of the rheological properties of viscosity and elasticity in two categories of soft tissue fillers: calcium hydroxylapatite and hyaluronic acid. *Dermatol Surg*, *36* Suppl 3, 1859–1865.

[37] Siclovan, H. R. & Jomah, J. A. (2009). Injectable Calcium Hydroxylapatite for Correction of Nasal Bridge Deformities. *Aesth Plast Surg*, *33*, 544–548.

[38] Moers-Carpi, M. et al. (2007). A multicenter, randomized trial comparing calcium hydroxylapatite to two hyaluronic acids for treatment of nasolabial folds. *Dermatol Surg 33* Suppl 2, S144–S151.

[39] Jansen, D. A. & Graivier, M. H. (2006). Evaluation of a calcium hydroxylapatite-based implant. (Radiesse) for facial soft-tissue augmentation. *Plastic and Reconstructive Surgery*, *118*, 22S–33S.

[40] Sadick, N. S., Katz, B. E. & Roy, D. (2007). A multicenter, 47-month study of safety and efficacy of calcium hydroxylapatite for soft tissue augmentation of nasolabial folds and other areas of the face. *Dermatol Surg*, *33* Suppl 2, S122–6– discussion S126–7.

[41] Beer, K. R. (2007). Radiesse nodule of the lips from a distant injection site: report of a case and consideration of etiology and management. *J Drugs Dermatol*, *6*, 846–847.

[42] Daley, T., Damm, D. D., Haden, J. A. & Kolodychak, M. T. (2012). Oral lesions associated with injected hydroxyapatite cosmetic filler. *Oral Surg Oral Med Oral Pathol Oral Radiol*, *114*, 107–111.

[43] Lemperle, G., Morhenn, V. & Charrier, U. (2003). Human Histology and Persistence of Various Injectable Filler Substances for Soft Tissue Augmentation. *Aesth Plast Surg*, *27*, 354–366.

[44] Valantin, M.-A. et al. (2003). Polylactic acid implants. (New-Fill) to correct facial lipoatrophy in HIV-infected patients: results of the open-label study VEGA. *AIDS*, *17*, 2471–2477.

[45] Moyle, G. J. G., Brown, S. S., Lysakova, L. L. & Barton, S. E. S. Long-term safety and efficacy of poly-L-lactic acid in the treatment of HIV-related facial lipoatrophy. *HIV Med*, 7, 181–185. (2006).

[46] Salles, A. G., Lotierzo, P. H., Gimenez, R., Camargo, C. P. & Ferreira, M. C. (2008). Evaluation of the poly-L-lactic acid implant for treatment of the nasolabial fold: 3-year follow-up evaluation. *Aesth Plast Surg*, *32*, 753–756.

[47] Lowe, N. J., Maxwell, C. A., Lowe, P., Shah, A. & Patnaik, R. (2009). Injectable poly-l-lactic acid: 3 years of aesthetic experience. *Dermatol Surg*, *35* Suppl 1, 344–349.

[48] Saylan, Z. (2003). Facial Fillers and Their Complications. *Aesthetic Surgery Journal*, *23*, 221–224.

[49] Dijkema, S. J., van der Lei, B. & Kibbelaar, R. E. (2005). New-fill injections may induce late-onset foreign body granulomatous reaction. *Plastic and Reconstructive Surgery*, *115*, 76e–78e.

[50] Apikian, M., Roberts, S. & Goodman, G. J. (2007). Adverse reactions to polylactic acid injections in the periorbital area. *J Cosmet Dermatol*, *6*, 95–101.

[51] Hamilton, D. G., Gauthier, N. & Robertson, B. F. (2008). Late-onset, recurrent facial nodules associated with injection of poly-L-lactic acid. *Dermatol Surg*, *34*, 123–126.

[52] Goldan, O., Bank, J., Regev, E., Haik, J. & Winkler, E. (2008). Epidermoid Inclusion Cysts After APTOS Thread Insertion: Case Report with Clinicopathologic Correlates. *Aesth Plast Surg*, *32*, 147–148.

[53] Roberts, S. A. I. & Arthurs, B. P. (2012). Severe visual loss and orbital infarction following periorbital aesthetic poly-(L)-lactic acid. (PLLA) injection. *Ophthal Plast Reconstr Surg*, *28*, e68–e70.

[54] Cohen, S. R., Berner, C. F., Busso, M. & Clopton, P. (2007). Five-Year Safety and Efficacy of a Novel Polymethylmethacrylate Aesthetic Soft Tissue Filler for the Correction of Nasolabial Folds. *Dermatologic …*,

[55] Lemperle, G., Gauthier-Hazan, N. & Lemperle, M. (1998). PMMA-Microspheres. (Artecoll) for long-lasting correction of wrinkles: refinements and statistical results. *Aesth Plast Surg*, *22*, 356–365.

[56] Cohen, S. R. & Holmes, R. E. (2004). Artecoll: a long-lasting injectable wrinkle filler material: Report of a controlled, randomized, multicenter clinical trial of 251 subjects. *Plastic and Reconstructive Surgery*, *114*, 964–969.

[57] Salles, A. G. et al. (2008). Complications after polymethylmethacrylate injections: report of *32* cases. *Plastic and Reconstructive Surgery*, *121*, 1811–1820.

[58] Arlette, J. P. & Trotter, M. J. (2008). Anatomic location of hyaluronic acid filler material injected into nasolabial fold: a histologic study. *Dermatol Surg*, *34* Suppl 1, S56–62– discussion S62–3.

[59] Brandt, F., Bassichis, B., Bassichis, M., O'Connell, C. & Lin, X. (2011). Safety and effectiveness of small and large gel-particle hyaluronic acid in the correction of perioral wrinkles. *J Drugs Dermatol*, *10*, 982–987.

[60] Glogau, R. G. et al. (2012). A randomized, evaluator-blinded, controlled study of the effectiveness and safety of small gel particle hyaluronic acid for lip augmentation. *Dermatol Surg 38*, 1180–1192.

[61] Flowers, R. S. (1993). Tear trough implants for correction of tear trough deformity. *Clinics in Plastic Surgery*, *20*, 403–415.

[62] Wong, C.-H., Hsieh, M. K. H. & Mendelson, B. (2012). The tear trough ligament: anatomical basis for the tear trough deformity. *Plastic and Reconstructive Surgery*, *129*, 1392–1402.

[63] Kane, M. A. C. (2005). Treatment of Tear Trough Deformity and Lower Lid Bowing with Injectable Hyaluronic Acid. *Aesth Plast Surg*, *29*, 363–367.

[64] Lambros, V. S. (2007). Hyaluronic acid injections for correction of the tear trough deformity. *Plastic and Reconstructive Surgery*, *120*, 74S–80S.

[65] Donath, A. S., Glasgold, R. A., Meier, J. & Glasgold, M. J. (2010). Quantitative evaluation of volume augmentation in the tear trough with a hyaluronic Acid-based filler: a three-dimensional analysis. *Plastic and Reconstructive Surgery*, *125*, 1515–1522.

[66] Taub, A. F. (2012). Cheek augmentation improves feelings of facial attractiveness. *J Drugs Dermatol*, *11*, 1077–1080.

[67] DeLorenzi, C., Weinberg, M., Solish, N. & Swift, A. (2009). The long-term efficacy and safety of a subcutaneously injected large-particle stabilized hyaluronic acid-based gel of nonanimal origin in esthetic facial contouring. *Dermatol Surg*, *35* Suppl 1, 313–321.

[68] Carruthers, J., Rzany, B., Sattler, G. & Carruthers, A. (2012). Anatomic guidelines for augmentation of the cheek and infraorbital hollow. *Dermatol Surg*, *38*, 1223–1233.

[69] Kestemont, P. P. et al. (2012). Sustained efficacy and high patient satisfaction after cheek enhancement with a new hyaluronic acid dermal filler. *J Drugs Dermatol*, *11*, s9–16.

[70] Ross, J. J. & Malhotra, R. (2010). Orbitofacial rejuvenation of temple hollowing with Perlane injectable filler. *Aesthetic Surgery Journal*.

[71] Lambros, V. (2011). A technique for filling the temples with highly diluted hyaluronic acid: the "dilution solution". *Aesthetic Surgery Journal*, *31*, 89–94.

[72] Glogau, R. G. & Kane, M. A. C. (2008). Effect of injection techniques on the rate of local adverse events in patients implanted with nonanimal hyaluronic acid gel dermal fillers. *Dermatol Surg*, *34* Suppl 1, S105–S109.

[73] Azizzadeh, B. (2009). Late-onset infections and granuloma formation after facial polylactic acid. (new-fill) injections in women who are heavy smokers. *Plastic and Reconstructive Surgery*, *124*, 316–318.

[74] Goulart, J. M., High, W. A. & Goldenberg, G. (2011). Evidence of calcium hydroxylapatite migration: distant nodule formation in the setting of concurrent injection with nonanimal stabilized hyaluronic acid. *J. Am. Acad. Dermatol.*, *65*, e65–6.

[75] Lemperle, G., Gauthier-Hazan, N. & Wolters, M. (2009). Foreign body granulomas after all injectable dermal fillers: part 1. Possible causes. *Plastic and …*,

[76] Kassir, R. R., Kolluru, A. A. & Kassir, M. M. (2011). Extensive necrosis after injection of hyaluronic acid filler: case report and review of the literature. *J Cosmet Dermatol*, *10*, 224–231.

[77] Hanke, C. W. (2002). A New ePTFE Soft Tissue Implant for Natural-Looking Augmentation of Lips and Wrinkles. *Dermatol Surg*,

[78] Hirsch, R. J., Lupo, M., Cohen, J. L. & Duffy, D. (2007). Delayed presentation of impending necrosis following soft tissue augmentation with hyaluronic acid and successful management with hyaluronidase. *J Drugs Dermatol*, *6*, 325–328.

[79] Hirsch, R. J., Cohen, J. L. & Carruthers, J. D. A. (2007). Successful management of an unusual presentation of impending necrosis following a hyaluronic acid injection embolus and a proposed algorithm for management with hyaluronidase. *Dermatol Surg*, *33*, 357–360.

[80] Lazzeri, D. et al. (2012). Blindness following cosmetic injections of the face. *Plastic and Reconstructive Surgery*, *129*, 995–1012.

In: Encyclopedia of Surgery (22 Volume Set)
Editors: Andreas Lehrer and Kristin Mueller
ISBN: 978-1-53618-329-0
© 2020 Nova Science Publishers, Inc.

Chapter 40

BODY CONTOURING USING IMPLANT PROSTHESES

***Daniel Saleh**[*] and Mohammed Riaz*[†]
Castle Hill Hospital, Cottingham, UK

KEY POINTS

- The largest experience of implant placement for augmentation gluteoplasty is intramuscular.
- Complications of augmentation gluteoplasty appear to be high but the incidence and outcomes of salvage surgery are unclear.
- The preferred plane of calf augmentation is subaponeurotic.
- Male pectoral augmentation is an uncommon procedure but subjective patient satisfaction is high.
- Upper limb contour augmentation, although uncommon, is most commonly performed for posttraumatic deformity with acceptable outcomes.
- No validated aesthetic outcomes have been reported for gluteal, calf, pectoral or upper limb implant augmentation. No comparisons to alternate methods of augmentation are available in the current literature.

INTRODUCTION

Alloplastic implants have been used in a number of guises to enhance the aesthetic appearance of body parts. The largest worldwide experience is of the use of breast implants for aesthetic augmentation. Numerous other implants now exist and are used to enhance the limbs and trunk. Practices vary between cultures and gender, as evident in the current literature. This chapter focuses on the use of implants in the limbs and trunk and excludes the breast, which is dealt with separately in Chapter 6.

[*] Corresponding Author's Email: dansaleh@doctors.org.uk.
[†] Corresponding Author's Email: mrmriaz@hotmail.com.

GLUTEAL AUGMENTATION

The gluteal region of men and women is considered an important aesthetic element in all cultures, although there is cultural diversity as to what constitutes an attractive buttock. Most published work originates from South America. Cuenca-Guerra and colleagues were the first to scrutinise over 1200 photographs of young female adult buttocks [1], assessing standard posterior, three-quarter profile and full lateral views. Six plastic surgeons separately analysed these images for specific features of beauty [1]. A validated scale does not exist but four features were consistent among the assessors that were felt to contribute to beautiful buttocks (Table 1). [1] They subsequently proposed a classification of buttock morphology primarily based on antero-posterior projection and gluteal and peri-gluteal fat volume [1] that was correlated to methods of augmentation (Table 2).

Table 1. Ideal gluteal aesthetic components identified by Cuenca-Guerra et al. [1]

Anatomical feature	Description
Lateral gluteal depression	Hollowing at the lateral buttock between insertion of Gluteus medius superiorly and vastus lateralis inferiorly
Infragluteal fold	Horizontal fold at the inferomedial buttock. Formed by insertion of Semitendinosus and biceps femoris into the ischial tuberosity.
Supra-gluteal fossettes	Formed by the posterior superior iliac spines (PSIS)
"V-shaped" crease	A fold at the cranial end of the medial buttock where the two sides of the "v" point toward the fossettes.

Table 2. Type classification of buttock according to morphology as described by Cuenca-Guerra et al.

Type	Morphology	Surgical correction
1	Excess gluteal and lumbar fat	Liposuction
2	Excess supra- and subgluteal fat only (flat buttock)	Small based round high profile implants for projection
3	Lumbo-sacral hyperlordosis (exaggerated A-P projection)	Almond shaped wide based low profile implants
4	Limited gluteal fat, poor gluteal projection	Wide based high profile implants
5	Ptotic buttocks of older persons	Skin excision +/- implant id required.

Bartles was the first to augment the buttock (using a breast prosthesis) [2] and the number of buttock augmentations performed within the Americas increased sixfold between 2002 and 2008. [3] Four planes have been described for implant placement: subcutaneous, intramuscular and submuscular and sub-fascial (the gluteal fascia).

EVOLUTION OF TECHNIQUES

Gonzalez-Ulloa described the subcutaneous pocket for implant augmentation [4] and his subsequent report [5] showed the procedure was reproducible. The method did not become

popular, since division of the aponeurotic and fascial attachments between the skin, subcutaneous fascia and underlying gluteal muscle left the implant mobile within its dissected pocket. Therefore potential implant visibility, palpability, ptosis and/or displacement and seroma were common. Evidence for this is anecdotal as no long-term data has been reported after Gonzalez-Ulloa's description and ten-year report, which did not discuss postoperative results. However, it appears that surgeons had poor early results and abandoned the subcutaneous plane.

Robles and co-workers provided the first description of subgluteus maximus (submuscular) implant placement. [6] Proponents cited decreased implant displacement, seroma and ptosis, and felt that submuscular placement would provide better aesthetic results versus subcutaneous placement. Hidalgo has reported the most comprehensive analysis of submuscular implant placement, and overall five percent of 97 patients augmented required reoperation for complications. A further thirteen percent of this cohort experienced minor complications that did not mandate reoperation, including one seroma. [7] Nonetheless detractors of submuscular placement cited particular disadvantages related to the limits of the submuscular pocket: it cannot be dissected beyond the inferior margin of the pyriformis muscle since operative injury or latent implant pressure could disturb the sciatic nerve. A potential consequence of this is a "high riding" prosthesis leaving the inferior pole of the buttock relatively empty, resulting in unsatisfactory aesthetic outcomes. [8] No further series of submuscular implant placement have been reported and none offer formal aesthetic evaluation.

Following Roble's submuscular description, Vergara and colleague described the intramuscular pocket for buttock augmentation. [9] Following anatomical evaluation they advocated the use of an intragluteus maximus plane to avoid sciatic nerve injury (allowing dissection beyond the inferior limit of the pyriformis), provide complete implant coverage with muscle, prevent ptosis and migration due to muscle support, and protect the implant from wound dehiscence. [9] The anatomical study showed there to be a natural intramuscular plane that could be bluntly dissected to provide a larger and more easily identifiable pocket than the submuscular space. [9] A subsequent report of 160 cases exhibited a complication rate of ten percent [10] including implant asymmetry (2.5%), capsular contracture (2%) and rupture (0.5%), with no infections. Haematoma rates were not clearly documented. Reoperation was required in four percent of cases and no patients experienced sciatic nerve injury or dysfunction. [9] Mendieta summarised a case series of 73 patients in whom there were no sciatic nerve sequelae or capsular contractures, but wound dehiscence occurred in thirty percent [11], all in the second postoperative week, thought to be related to patient mobilisation. Relatively high dehiscence rates were thought to have been due to a combination of bilateral tension on the intergluteal wound, relative poor vascularity of the midline incision and use of large implants. However in the majority of cases implant removal was not needed because muscle coverage of the prosthesis remained intact. [11] Interestingly the same author subsequently adopted a paragluteal crease incision and reported only one dehiscence in a cohort of eighteen patients using that approach. [12] Again, no sciatic nerve injuries were observed and implant migration was diagnosed in two percent of cases. [12]

Gonzalez provided a detailed report of a novel method for optimizing the surgical dissection of the intramuscular pocket. [8] In the largest series to date, 746 patients had gluteoplasty, 650 patients were primary aesthetic augmentation cases and the remainder were reconstructive cases such as poliomyelitis deformity correction. Although the results were not

subdivided to permit focus on the aesthetic cases, complications were uncommon overall [8]: no capsular contractures or nerve injuries were observed; infection occurred in four cases; one seroma required drainage; and there were two cases of implant migration requiring re-operation. However, the wound dehiscence rate was 14%. [8] Serra and colleagues detailed 105 intramuscular gluteoplasties in which there were nine percent seroma, five percent dehiscence and one percent infection rates. [13] However the seroma rate decreased to two percent overall once the surgical dead space was routinely closed with placating sutures and implant migration was eliminated. [13] Serra and co-workers have subsequently modified their technique for intramuscular augmentation to try reduce the complication rate. [14] The supra-gluteal fascia pocket created to allow intramuscular dissection was reduced in size, without undermining the skin flap in the midline. [14] This modified technique reduced the overall complication rate from 35% to 5%. However, the majority of patients that had the modified technique also had liposuction and it is unclear what effect, if any, this may have had on overall outcomes. [14]

The most recent series of intramuscular (including 154 subfascial and 46 intramuscular) gluteoplasties reported a 5.5% infection rate and 3% implant migration, [13] the author going on to adopt the subfascial method described by de la Pena. [3, 15] Like other authors, this change was driven by the significant degree of postoperative pain after muscular dissection, a slow return to ambulation and subjective difficulty in maintaining lower gluteal fullness. [3,8,10,12] Interestingly none of the reports for intramuscular augmentation include consistent reporting of all types of pertinent postoperative sequelae. In addition no authors have used objective surgeon or patient assessment of aesthetic outcomes for defined periods postoperatively. However, Serra et al. did perform postoperative computed tomographic (CT) scans to assess muscle atrophy and implant position for intramuscular augmentation. [16] The implants did not have physical sequelae for the patients, but muscle atrophy was consistent. All oval implants had re-orientated from vertical placement into an oblique position in line with the muscle fibres [16] but this had no effect on the aesthetic outcome.

The subfascial gluteoplasty is the latest surgical modification for implant insertion. Despite its relatively recent description in 2004, this method had been deployed by De La Pena for “years”. [17] A subfascial implant is attractive because theoretically it may reduce postoperative pain as no muscular dissection is carried out. The thick gluteal fascia (aponeurosis) can maintain implant position as demonstrated in a cadaveric study. [18] De la Pena and co-workers advocate this particular method of gluteoplasty for thin, young patients of a generally athletic build. [15] This group state a less than one percent deep infection rate in their experience and no seromas or haematomas [15], however a definitive case series is not provided in the report and rates of capsular contracture, implant migration and aesthetic evaluation objectively are not published. Although subfascial gluteoplasty carried a similar overall complication rate (of thirteen percent) versus intramuscular procedures performed by the same surgeon, the author believes subfascial placement carries better aesthetic outcomes and an easier postoperative course for the patient. [3] The exact complication rate is difficult to ascertain but has been reported as in the region of 32%; predominantly dehiscence and seroma formation were reported. [19] A smaller series with a similar operative technique and incision demonstrated a 51% complication rate for 31 patients using the same prostheses as De La Pena. [15,19] The majority of these were wound dehiscence and seroma formation. [19] Major complications were observed in 35% of cases, 15% of these were secondary to implant migration, rotation, flipping and patient dissatisfaction. Furthermore 19% of the

major complications were related to seroma formation. [19] However this study did report a 100% rate of palpable implant at the lower pole of the buttock, which has not been the case for intra and submuscular placement of prostheses.

A recent survey of American society of plastic surgeons that assessed data submitted for 2226 gluteal augmentations, showed the preferred plane of implant placement was intramuscular (68%). [20] Although complication rates for different planes were not directly compared, the overall complication rate was 38%, the most common being wound dehiscence (7.9%). [20] Although reporting of complications is not consistent for augmentation gluteoplasty, intramuscular implant placement appears to carry less overall complications.

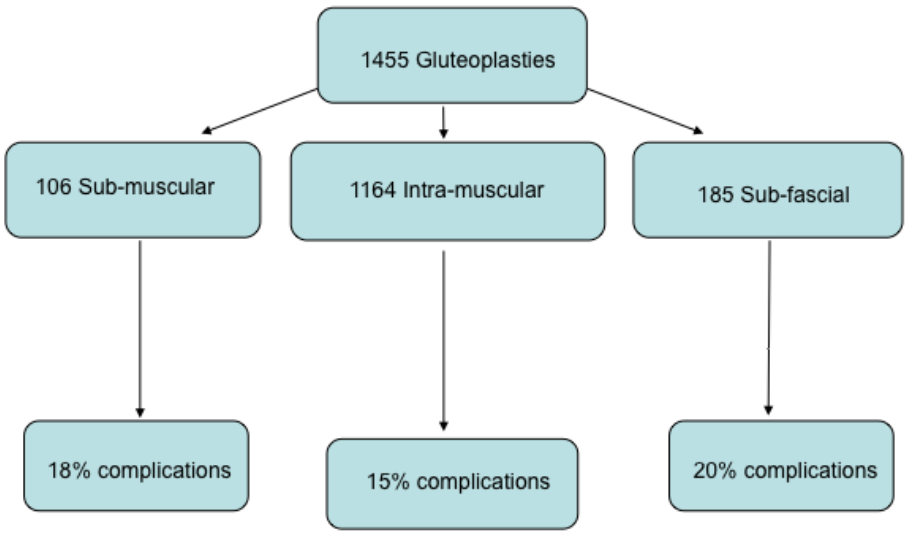

Figure 1. Summary of the complication rates presented in the literature for gluteal augmentation in submuscular, intramuscular or subfascial planes to date.

Breast implants were first used to augment the gluteal region. The heterogeneous nature of reporting means exact complication rates cannot be accurately correlated to implant type used. The current implants available can be broadly grouped as custom made solid silicone, silicone gel and silicone cohesive gel. Some authors prefer either gel or cohesive gel because they afford softer feel. [6,15] Implants are also available in round or anatomic (oval) shape. Round implants probably provide better posterior projection although this is not a validated observation. There are a number of manufacturers providing various sized implants, and the cohesive gel implants can be textured which may contribute to prevention of implant migration. It is possible different implant types have distinct complication profiles. This has not been assessed in any trials and was not objectively scrutinised in the survey performed by Mofid and colleagues. [20]

There is a paucity of objective aesthetic assessment across all methods described and studied for gluteoplasty. The largest cumulative experience is with intramuscular implantation and despite there being only case series evidence, they appear to carry less complications versus subcutaneous, submuscular and subfascial prosthetic placement. Unfortunately stratification of minor and major complications is inconsistent in this body of literature and it is unclear whether certain infections were deep or superficial. Despite the volume of gluteal

augmentations performed, patient satisfaction and aesthetic outcome studies are yet to be forthcoming and should be a priority in future study for this procedure. Figure 1 summarises the cumulative published experience.

IMPLANT PREPARATION

Preparation of the implant and pocket before implant insertion is important given the proximity of the anus and sexual organs. Although there is no evidence of a higher commensal bacterial count in the gluteal region compared to other body regions, it is logical to ensure great care during implant handling and insertion.

De la Pena advocates plugging the anus with a povidone soaked swab at the time of skin preparation. Once the pocket is fashioned the selected implant is soaked in an antibiotic solution and inserted with a "no touch" technique familiar to insertion of breast implants. [17] Rather than soak the implant, Mendieta prefers to wash the pocket out with antibiotic solution (the antimicrobial agent is not specified). [11] No infections were reported in this series despite 30% dehiscence rate treated with antibiotics. Vergara also isolates the anus by suturing a swab in place but no local antibiotic therapy was used. However an intraoperative and one week course of intravenous and oral antibiotics were routinely used and no infections were reported. [9]

The most comprehensive preparation was described by Senderoff. [3] The anus was covered with a povidone soaked swab and the implant was soaked in povidone and saline. The intergluteal region was then re-prepped in a standard fashion ready for implant insertion. Later in this authors experience patients were routinely provided antiseptic wash to use the night before and morning of surgery.

The remaining series discussed do not specify an antimicrobial regimen or particular method of implant and/or pocket preparation. We believe it is unlikely these investigators do not have a routine practice and it is probable some form of particular implant preparation exists. There is no one study that has compared methods of improving sterility to infection rates. Moreover it is hard to directly compare these series given the heterogeneous methods used, which have probably evolved from their preferred methods of breast implant preparation. This is exemplified by Mofid and co-workers' survey that showed not all surgeons use postoperative drains and the majority irrigate the implant pocket with antibiotics. [20]

The use of suction drainage placed in the plane of the implant is more consistent and used by nearly all authors. [3,5,6,8-11,13,17] Hidalgo explicitly does not use drains and only reported one seroma in his series of 97 patients. [7] Most authors place drains because unlike augmentation mammaplasty the dissection within or around the gluteus muscle can be extensive, perhaps inciting a potentially larger seroma formation. However there is no correlation in the literature presented between drain use, seroma rate and infection.

CALF AUGMENTATION

The posterior leg is not defined as a secondary sexual characteristic but calves do have an important place in cultural perceptions of beauty. With the advent of prosthetic enhancement it could be argued a natural progression to calf augmentation was inevitable. Unlike other body contouring procedures with implants, men, particularly body builders, primarily seek calf implants. The first implant to be used for the purpose of augmenting the posterior leg was carried out by Carlsen. [21]

Numerous studies have assessed the outcomes of this procedure with different surgical approaches. It is evident from the available body of literature that confusing terms of implant placement have been used. On scrutiny of the surgical techniques provided, the plane of dissection and implant placement have been re-named in this text for the sake of clarity. The implant pockets are described as subcrural which refers to the plane deep to the crural or popliteal fascia overlying the fascia/aponeurosis of the gastrocnemius muscle. Subfascial describes a plane deep to the gastrocnemius fascia overlying the muscle proper and in this text will be referred to as subaponeurotic to avoid confusion. 'Submuscular' is in the areolar plane between gastrocnemius and soleus muscles and 'supraperiosteal' lies anterior to the posterior tibial periosteum, completely submuscular. However, surgical exposure is more constant and all authors have preference for an incision through the medial popliteal crease.

The particular aesthetic ideals were first delineated through photographic and anatomical analysis by Ceunca-Guerra and co-worker. [22] Eight surgeons independently rated the ideal aesthetics of the calf region. The standard photograph set included a posterior, lateral and three quarter posterior view of the calf. The group of surgeon assessors highlighted five distinct types of posterior leg that were aesthetically deficient with particular attention to anteroposterior and laterolateral projections. [22] It is unclear whether the ratings were adjusted for intraobserver errors and validated. The published evidence that has followed this description has not however grouped patients using this method. This may be because of the heterogeneity of this anatomical site or that surgeons do not feel the exact morphology of the posterior leg dictates the approach to augmentation. Muscle bulk, subcutaneous fat and skin quality can differ widely. Generally most surgeons aspire to create greater laterolateral width together with medial antero-posterior projection. [22]

Von Szalay reported the first series of subaponeurotic implants but did not accurately quantify the cohort size stating “more than 25 cases”. [23] Of these cases one patient experienced deep sepsis and one requested implant removal giving at most a re-operation rate of 8% and 4% incidence of capsular contracture [23] A larger series of 121 subaponeurotic patients reported a re-operation rate of 7% due to one haematoma, two deep infections, four capsular contractures and one implant migration. Aesthetic outcomes were reported as high, but not qualified by the author. [24] Montellano also augmented patients using a subaponeurotic method in 68 cases, emphasizing a successful surgical technique but no stratification of patient outcomes or complications was provided. [25] Lemperle offered a more comprehensive assessment of 14 subaponeurotic implant patients reporting satisfactory outcomes with re-operation in 14%; one seroma and one visible implant. [26] None of these studies have reported objective or subjective patient satisfaction rates.

Felicio reported a cohort of 100 cases of augmentation, ninety of which were for pure aesthetic purposes and included cases of subcrural and subaponeurotic implant placement.

[27] Although the surgical groups were not discussed separately, an overall complication rate of seven percent was observed and three percent required re-operation. Two patients were unhappy with aesthetic outcomes and one implant migrated superiorly necessitating removal. A small, subsequent cohort of eleven patients experienced no re-operations and no complications for implants placed in the subaponeurotic plane. [28]

Kalixto and colleagues presented eight cases, including three revision cases from previous aesthetic augmentation using a novel surgical approach. [29] A submuscular plane was used citing a safer dissection in the avascular areolar plane, no potential injury to neurovascular structures and avoidance of implant visibility were cited as advantages. However, prior to this series there was no clear consensus in the literature that implant visibility has been reported by patients as undesirable in other planes of placement. The authors concluded that patients experienced greater postoperative pain due to the intermuscular dissection and no data was published for complications or aesthetic outcomes. [29] The submuscular approach was also advocated recently by Ceunca-Guerra et al. also stating this reduces implant show and seroma but results of their clinical experience were not included. [22] Nunes and colleagues are the only team to describe the supra-periosteal placement of prostheses. [30] This unique experience used a total supra-periosteal plane for augmentation with closed fasciotomy of the posterior compartment to increase muscle herniation hence reducing the size of prosthesis required and decreasing implant show. [30] No complications at all were reported and no aesthetic evaluation was presented. [30]

The most recent cohorts have been subaponeurotic augmentations. Niechajev presented fourteen cases with only one re-operation for patient dissatisfaction. [31] In the only study to examine patient perceptions of their aesthetic outcome, Pereira et al. assessed 53 subaponeurotic augmentations and showed more than seventy percent of patients felt their aesthetic appearance was very good, whereas two percent had poor appearance. [32] No infections, capsular contractions or implant displacements were observed, although six percent required operative drainage of seroma. Furthermore eight percent of the cohort developed hypertrophic scars. A series of 63 patients who all had subaponeurotic bilateral calf implants reported a similar complication profile. [33] Early postoperative pain was experienced by 11%, seroma in 21% and dehiscence in 7%. One patient required explantation for infection, two implants ruptured and four implants had significant capsular contracture. Revision surgery for these complications did not result in recurrent problems but follow-up thereafter is unclear. The authors did try to assess aesthetic outcomes using a non-validated scale questionnaire. The mean aesthetic index was 9.8, indicating high satisfaction.

Overall the current evidence lacks detailed aesthetic evaluation of postoperative appearance and follow-up durations are scantily reported. The majority of cases are subaponeurotic and appear to offer relatively low complications rates. In particular there is little reference to problems such as implant show, yet authors who prefer submuscular or supraperiosteal placement anecdotally refer to this as a significant issue associated with subcrural or aponeurotic augmentation. Furthermore there is only one report of implant displacement using the subaponeurotic plane. Currently the majority of experience is with a subaponeurotic approach and until large series or a randomised series is devised with patient aesthetic evaluation a superior method cannot be determined.

PECTORAL AUGMENTATION

Implants have also been used for body contouring of the male chest. The first series of implants for chest wall deformities (including female radiation necrosis) used custom made silicon prostheses placed subcutaneously. [34] Four males had correction of anterior thoracic wall abnormalities. Although there was no between groups analysis, 35% of the seventeen patients treated by this method experienced complications related to the prosthesis. Two extrusions, two implant migrations and a capsular contracture were reported, yet only two implants required explantation.

Isolated case reports of custom moulds for pectoral enhancement and pectus excavatum followed until Aiache described a subpectoral placement of soft silicone implants in males via a transaxillary approach. [35] Other authors also use this technique and stress the importance of not releasing the pectoral attachments to the chest, thus preventing implant migration inferomedially or laterally. [36] No breakdown of implant related complications, if any were provided.

Horn believed maintaining implant position was key to longstanding results and used textured, cohesive silicon implants for his cohort of male pectoral augmentation. [37] In twelve patients there was a subjective high patient satisfaction and no complications. [37]

A cohort of sixteen patients had no major complications following transaxillary pectoral implantation. [38] Three patients required drainage of a unilateral seroma. However there was no re-operation, capsular morbidity, infections or haematomas.

A more recent, larger cohort described the three typical presentations for pectoral enhancement; body builders with pectoral injuries and secondary asymmetry, hypoplastic pectoral deformity and those that cannot obtain the desired pectoral projection with regular exercise. [39] The authors described measurements to help aid implant size selection in those with a pectoralis major muscle (the majority). These measurements described were; infraclavicular width and height of the mid-portion of the muscle between the clavicle and its lower border, plus the distance between the axillary fold and the lateral edge of the sternum. The subsequent implant size and pocket is approximately two centimetres shorter than these dimensions. In 21 patients no complications were reported, however follow-up duration was not documented. Of interest it was the authors opinion that custom made implants, whilst a better “fit”, could be less desirable than textured cohesive implants for bodybuilder/athletic patients. Patients have reported dissatisfaction with pectoral implants because they can restrict exercise and intense exercise can displace implants. [40] There is no validated questionnaire or study to support this but it was felt custom implants are harder and restrict exercise whereas the textured prosthesis is more pliant.

There is a relative lack of study into male chest enhancement, most likely because it is not a common procedure. There are no large case series. The current literature would suggest it is a relatively safe procedure because few complications have been reported with subjectively high patient satisfaction.

UPPER LIMB AUGMENTATION

Upper limb enhancement is useful to restore symmetry where rupture or denervation of muscle has occurred. Deltoid enhancement following axillary nerve injury has been described. Custom-made silicone implants modelled on the contralateral normal deltoid contour were implanted. All implants were submuscular overlying the humeral periosteum/glenohumeral joint. The exact number of deltoid enhancements performed is unclear but no patients experienced any complications and follow-up totalled four years. [41]

The same author also enhanced an unknown number of biceps deformities by placing implants in a subbrachialis pocket. [41] Appearances at rest were reported as good by the operator but this tight submuscular pocket allows no implant movement and the dynamic movement of a visible biceps muscle cannot be recreated. No complications were reported although the total follow-up period was not stated. Chugay recently described placement of silicone implants in the sub-bicipital plane, through an axillary incision. [42] In the cohort of 94 patients there were three major complications: one seroma requiring serial drainage; one implant migration requiring revision surgery; and one compartment syndrome following concomitant biceps and triceps implantation. [42] There were two cases of medial antebrachial neurapraxia, but no infections, capsule morbidity or functional impairments were reported.

Triceps enhancement has been used to enhance size post-trauma and for individuals with poor muscle bulk. Hodgkinson found the medial head of triceps rupture in bodybuilders to cause significant asymmetry that cannot be corrected by exercise alone. [41] He described a distal arm approach through a transverse incision within the superior posterior elbow creases. [41] In cases of traumatic medial head rupture, the distal radial nerve is protected and the detached muscle fibres are removed medially, to make a sub-triceps space. Hodgkinson reported no infections, extrusions or capsule morbidity for a small undefined cohort. However, one patient experienced bilateral radial nerve neurapraxia (wrist drop). Calf implants were used in patients who were not posttraumatic. In contrast, Chugay used an axillary approach to create an implant pocket beneath the long head of triceps and now prefers a subfascial pocket in the posterior arm for tricep augmentation. [43] Fourteen patients had implantation of custom-made solid silicone prostheses. Two patients required revision surgery for implant migration and one patient experienced an ulnar nerve neurapraxia that resolved.

It is likely the number of upper limb enhancement procedures will increase in coming years given the global trend of males increasingly seeking cosmetic procedures. There is very little evidence measuring the effect, if any, that upper limb enhancement has on patients. Large series, possibly through collaboration, with meticulous reporting of adverse sequelae and validated patient outcomes will help determine the best surgical approach.

CONCLUSION

At present intramuscular gluteoplasty appears to have the most reproducible outcomes in terms of complication rate. Refinement of other techniques may enable the surgeon to be patient specific with the implant placement. In conjunction with this objective patient

satisfaction will be required in future series to accurately correlate, if possible, patient outcome and surgical approach and complication rate. The optimal site for calf implantation is not clear. Objective patient evaluation will aid the future direction of this surgery given that there are relatively low complications reported for the various planes of implantation.

The smallest cumulative experience exists for pectoral and upper limb enhancement. It is probable this group are the most heterogeneous given that many cases reported have a pathological cause for the alteration in body parts. Restoration of other body parts, such as the face following trauma/paralysis of muscle is common. We believe there is an element of taboo amongst surgeons and patients when offering/asking for prosthetic restoration of the upper limb or chest. Once this is overcome collaboration will hopefully concentrate experience and allow accurate assessment of outcomes and patient satisfaction.

REFERENCES

[1] Cuenca-Guerra, R. & Lugo-Beltran, I. Beautiful Buttocks: Characteristics and Surgical Techniques. *Clinics in Plastic Surgery* 33, 321–332 (2006).

[2] Bartles, R. J., O'Maley, J. E. & Douglas, W. M. Bartles: An unusual use of the Cronin breast prosthesis - Google Scholar. *Plast Reconstr Surg* (1969).

[3] Senderoff, D. M. Buttock augmentation with solid silicone implants. *Aesthetic Surgery Journal* 31, 320–327 (2011).

[4] Gonzalez-Ulloa, M. Torsoplasty. *Aesth Plast Surg* 3, 357–368 (1979).

[5] Gonzalez-Ulloa, M. Gluteoplasty: a ten-year report. *Aesth Plast Surg* 15, 85–91 (1991).

[6] Robles, J. M., Tagliapietra, J. C. & Grandi, M. [CITATION][C]. *Cir Plast Iberolatinoamericana* (1984).

[7] Hidalgo, J. E. Submuscular Gluteal Augmentation: 17 Years of Experience With Gel and Elastomer Silicone Implants. *Clinics in Plastic Surgery* 33, 435–447 (2006).

[8] Gonzalez, R. Augmentation Gluteoplasty: The XYZ Method. *Aesth Plast Surg* 28, 417–425 (2004).

[9] Vergara, R. & Marcos, M. Intramuscular gluteal implants. *Aesth Plast Surg* (1996).

[10] Vergara, R. & Amezcua, H. Intramuscular gluteal implants: 15 Years' experience. *Aesthetic Surgery Journal* 23, 86–91 (2003).

[11] Mendieta, C. G. Gluteoplasty. *Aesthetic Surgery Journal* (2003).

[12] Mendieta, C. G. Intramuscular Gluteal Augmentation Technique. *Clinics in Plastic Surgery* 33, 423–434 (2006).

[13] Serra, F., Aboudib, J. H. & Cedrola, J. Gluteoplasty anatomic basis and technique. *Aesthetic Surgery …* (2010).

[14] Serra, F., Aboudib, J. H. & Marques, R. G. Reducing wound complications in gluteal augmentation surgery. *Plastic and Reconstructive Surgery* 130, 706e–713e (2012).

[15] la Peña, de, J. A., Rubio, O. V., Cano, J. P., Cedillo, M. C. & Garcés, M. T. Subfascial Gluteal Augmentation. *Clinics in Plastic Surgery* 33, 405–422 (2006).

[16] Serra, F., Aboudib, J. H. & Marques, R. G. Intramuscular technique for gluteal augmentation: determination and quantification of muscle atrophy and implant position by computed tomographic scan. *Plastic and Reconstructive Surgery* 131, 253e–259e (2013).

[17] la Peña, de, J. A. Subfascial technique for gluteal augmentation. *Aesthetic Surgery Journal* 24, 265–273 (2004).
[18] Hwang, S. W., Nam, Y. S., Hwang, K. & Han, S. H. Thickness and tension of the gluteal aponeurosis and the implications for subfascial gluteal augmentation. *J Anat* 221, 69–72 (2012).
[19] Bruner, T. W., Roberts Iii, T. L. & Nguyen, K. Complications of Buttocks Augmentation: Diagnosis, Management, and Prevention. *Clinics in Plastic Surgery* 33, 449–466 (2006).
[20] Mofid, M. M. *et al.* Buttock augmentation with silicone implants: a multicenter survey review of 2226 patients. *Plastic and Reconstructive Surgery* 131, 897–901 (2013).
[21] Carlsen, L. N. Calf augmentation--a preliminary report. *Annals of Plastic Surgery* 2, 508–510 (1979).
[22] Cuenca-Guerra, R., Daza-Flores, J. L. & Saade-Saade, A. J. Calf Implants. *Aesth Plast Surg* 33, 505–513 (2009).
[23] Szalay, von, L. Calf augmentation: a new calf prosthesis. *Plastic and Reconstructive Surgery* 75, 83–87 (1985).
[24] Aiache, A. E. Calf implantation. *Plastic and Reconstructive Surgery* 83, 488–493 (1989).
[25] Montellano, L. Calf augmentation. *Annals of Plastic Surgery* 27, 429–438 (1991).
[26] Lemperle, G. & Kostka, K. Calf augmentation with new solid silicone implants. *Aesth Plast Surg* (1993).
[27] Felício, Y. Calfplasty. *Aesth Plast Surg* 24, 141–147 (2000).
[28] Dini, M., Innocenti, A. & Lorenzetti, P. Aesthetic calf augmentation with silicone implants. *Aesth Plast Surg* 26, 490–492 (2002).
[29] Kalixto, M. A. & Vergara, R. Submuscular Calf Implants. *Aesth Plast Surg* 27, 135–138 (2003).
[30] Nunes, G. & Garcia, D. Calf Augmentation with Supraperiostic Solid Prosthesis Associated with Fasciotomies. *Aesth Plast Surg* 28, 1–3 (2004).
[31] Niechajev, I. Calf Augmentation and Restoration. *Plastic and Reconstructive Surgery* 116, 295–305 (2005).
[32] Pereira, L. H., Nicaretta, B. & Sterodimas, A. Bilateral Calf Augmentation for Aesthetic Purposes. *Aesth Plast Surg* 1–8 (2011). doi:10.1007/s00266-011-9799-4
[33] la Peña-Salcedo, de, J. A., Soto-Miranda, M. A. & Lopez-Salguero, J. F. Calf implants: a 25-year experience and an anatomical review. *Aesth Plast Surg* 36, 261–270 (2012).
[34] Lavey, E. *et al.* Customized silicone implants of the breast and chest. *Plastic and Reconstructive Surgery* 69, 646–651 (1982).
[35] Aiache, A. E. Male chest correction. Pectoral implants and gynecomastia. *Clinics in Plastic Surgery* 18, 823–828 (1991).
[36] Novack, B. H. Alloplastic implants for men. *Clinics in Plastic Surgery* 18, 829–855 (1991).
[37] Horn, G. A New Concept in Male Chest Reshaping: Anatomical Pectoral Implants and Liposculpture. *Aesth Plast Surg* 26, 23–25 (2002).
[38] Pereira, L. H., Sabatovich, O., Santana, K. P. & Picanço, R. Pectoral Muscle Implant: Approach and Procedure. *Aesth Plast Surg* 30, 412–416 (2006).
[39] Benito-Ruiz, J., Raigosa, J. M., Manzano-Surroca, M. & Salvador, L. Male Chest Enhancement: Pectoral Implants. *Aesth Plast Surg* 32, 101–104 (2008).

[40] Mentz, H. A., Ruiz-Razura, A., Newall, G., Patronella, C. K. & Miniel, L. A. Pectoral etching: a method for augmentation, delineation, and contouring the thoracic musculature in men. *Plastic and Reconstructive Surgery* 120, 2051–2055 (2007).

[41] Hodgkinson, D. J. Contour Restoration of the Upper Limb Using Solid Silicone Implants. *Aesth Plast Surg* 30, 53–58 (2006).

[42] Chugay, N. V. & Chugay, P. N. Chugay: Bicipital augmentation: a retrospective review... - Google Scholar. *American Journal of Cosmetic Surgery* (2009).

[43] Chugay, N. V. & Chugay, P. N. Triceps augmentation: early experience with the procedure. *American Journal of Cosmetic Surgery* (2010).

In: Encyclopedia of Surgery (22 Volume Set)
Editors: Andreas Lehrer and Kristin Mueller
ISBN: 978-1-53618-329-0
© 2020 Nova Science Publishers, Inc.

Chapter 41

COSMETIC SURGERY IN THE ADOLESCENT PATIENT

***Kelsey Larson*[*], *Sidhi Gosain*[†] *and Arun Gosain*[‡]**
Cleveland Clinic Foundation, Cleveland OH, US

KEY POINTS

- As the number of adolescent individuals seeking cosmetic surgical procedures continues to grow, it is important for practitioners to understand the unique considerations for this patient population.
- Since adolescents may still be completing their growth, it is important to consider the normal development of these individuals with relation to the surgical procedure at hand.
- More research is needed to understand what, if any, influence that surgery has on final stages of growth and development in adolescent patients. In addition, it is important to be upfront with patients on this uncertainty.
- Adolescents often require more in-depth screening and discussions preoperatively to determine appropriate candidates for surgery and to ensure patients, parents, and surgeons agree on reasonable, clear goals for the procedure.

INTRODUCTION

Adolescents (younger than eighteen years old) represent a small percentage of patients undergoing cosmetic surgery (approximately two percent) [1,2] with this percentage remaining steady over the last decade. However, as the total number of individuals seeking cosmetic surgery overall grows yearly (increasing by approximately six percent from 2010 to 2011) [1,2,3] so too does the number of adolescents seeking aesthetic procedures. While many European plastic and aesthetic surgical societies collect and report yearly data on

[*] Corresponding Author's Email: ker20@case.edu.
[†] Corresponding Author's Email: sidhigosain@gmail.com.
[‡] Corresponding Author's Email: ArGosain@luriechildrens.org.

cosmetic surgery procedures, the most detailed European data readily available, reported by the British Association of Aesthetic Plastic Surgeons (BAAPS), [3] does not report by age group. Thus the exact number of adolescents presenting for cosmetic surgery in the UK or Europe as a whole is unclear. This data is available for the United States, however, and shows that around 230,000 adolescents had cosmetic surgical procedures in 2011, with approximately 76,800 of these (33%) being surgical operations (as opposed to minimally invasive/procedural) (Table 1). [1]

As the number of adolescent individuals seeking cosmetic surgical procedures continues to grow, it is important for practitioners to understand the unique considerations for this patient population. This chapter, expanded from a previously-published paper, [4] seeks to provide information on psychological considerations and cultural influences affecting adolescents presenting for plastic surgery; procedure-specific considerations for the most commonly performed operations; and comment on patient selection and trends relating to adolescents. For the purpose of this chapter, specifically surgical operations (not minimally invasive office-based procedures) will be addressed.

When considering the number of surgeries noted throughout this chapter, it is important to remember that the data presented represents a select group of societies that report patient statistics in readily available format. However is in no means inclusive of all adolescent patients who present to surgeons for consideration of cosmetic surgery, or even of all teens who undergo cosmetic procedures.

Table 1. Estimation of cosmetic surgical procedures in one year. ASPS [1] data for all age groups (total) and 13-19 year age group (teen). BAAPS [3] and ISAPS [5] data reflects total procedures performed across all ages, neither organisation providing data divided by age group

	ASPS (teens)	ASPS (total)	BAAPS	ISAPS
Rhinoplasty	33,892	243,773	4,518	985,325
Breast Augmentation	8,892	307,180	10,015	1,506,475
Breast Reduction	*	*	4,501	549,994
Gynaecomastia	14,371	19,766	790	235,947
Chin Augmentation	1,809	20,680	**	108,178
Blepharoplasty	1,881	196,286	6,057	1,085,153
Liposuction	3,248	204,702	3,581	2,174,803
Otoplasty	7,489	26,433	1,170	242,271

*ASPS does not report breast reduction numbers for cosmetic versus reconstructive patients. However, ASAPS [2] indicates 2,944 patients <18 years old and 112,964 patients across all age groups underwent breast reduction.

**Unlisted in BAAPS data. (ASPS - American Society of Plastic Surgeons;
BAAPS - British Association of Aesthetic Plastic Surgeons;
ISAPS - International Society of Aesthetic Plastic Surgeons;
ASAPS - American Society of Aesthetic Plastic Surgery).

PSYCHOLOGICAL CONSIDERATIONS

Body Image Development and Relationship to Cosmetic Surgery

Understanding and addressing body image with adolescent surgery patients is a critical component of interacting with this group of individuals. During puberty especially, significant transitions in the patient's physical appearance and interest in peers' opinions lends to major changes in body image. Body image, the "subjective perception of the body as it is seen through the mind's eye," [5] was first described by Schilder in the 1930s. [6] He postulated that overall life satisfaction, body image, and self-esteem combine to influence a person's confidence and outlook on life. Recent work on the connection between body image and cosmetic surgery centres on four basic principles: the physical reality of appearance, the perception of appearance, the importance of appearance, and the degree of dissatisfaction with appearance. [7] These concepts form a continuum of body image satisfaction, from overly-assured or arrogant about oneself to pathologic dissatisfaction such as with body dysmorphic disorder (BDD). [8] A complete review of cosmetic surgery patients, body image, and body image development in adolescents is outside the scope of this chapter; however, it is important to consider where on the spectrum of body image satisfaction each adolescent patient lies when selecting an appropriate candidate for surgical intervention.

In the past, both proponents and opponents of cosmetic surgery in adolescents have used the rapid change in body image to argue their opinion on the topic. In the 1980s, a Dutch study demonstrated linear improvement in body image as adolescents grow up, regardless of cosmetic surgery status. [9] This *idea of improvement in body image with age without surgical intervention* was initially a leading piece of data which opponents of adolescent cosmetic surgery used in evaluation patients and conducting further research. However, more recent data found that the improvement in body attitude in adolescent cosmetic surgery patients exceeds the previously reported natural improvement in body image as the patients aged. [10] Teenagers in the cosmetic surgery group postoperatively reported significant decrease in appearance-related burdens and significant improvement in self-image compared with non-surgical controls.

Opponents to cosmetic surgery for teens also argued that teenagers were presenting with unrealistic concerns for their appearance and thus surgical intervention would be counter-indicated. To address this concern, researchers published a study in the British Journal of Plastic Surgery demonstrating that adolescents presenting for consideration of cosmetic surgery had a realistic view of their body compared to the assessment of the parent and surgeon. [11] Furthermore, parents and teens had similar assessment of the psychological and social burdens relating to the cosmetic concern, and surgeons confirmed realistic/reasonable flaws in these adolescents. Additional studies have demonstrated no difference in self-confidence or mental health measures when comparing teenagers presenting for cosmetic surgery versus age-matched controls, but rather demonstrated specific dissatisfaction with a particular aspect of their physical appearance. [9,12]

Plastic surgeons need to continue strict screening of their patients (see "Patient Selection" discussion later in the chapter) including screening for pathologic body image disorders. The ongoing body image development of adolescents presenting for cosmetic surgery should be

considered, but evidence indicates that this factor alone should not be a deterrent to considering surgical options for them.

Gender Considerations

Many speculate that adolescent girls and boys presenting for cosmetic surgery have different goals for surgery and/or different postoperative satisfaction. In adults, male cosmetic surgery patients account for approximately ten percent of procedures performed; it is likely this number is larger in the adolescent population given gynaecomastia operation in boys alone already accounts for eighteen percent of total cosmetic surgeries in 13-19 year-olds. [1] Studies specifically addressing male versus female adolescent patients note that boys were overall more satisfied with their appearance, but that girls' appearance evaluation tends to naturally become more positive over time (versus boys' appearance evaluations which tend to remain the same). [13] Evaluation of adolescents following cosmetic surgery demonstrates no significant differences in postoperative satisfaction (92% for girls versus 80% for boys) and low rate of desire for additional surgery with the majority of patients reporting very good (60.5%) or good (33.3%) results. [14] More studies are needed to fully elicit the differences, if any, between adolescent girls and boys who present for cosmetic surgery.

CULTURAL INFLUENCE

Sociocultural attitudes towards appearance questionnaires-3 (SATAQ-3) around the world support the intuitive notion that adolescent females are tremendously affected by cultural ideals of beauty. [15,16] Why the obsession? As Freud put it, "the enjoyment of beauty, has a peculiar, mildly intoxicating quality of feeling. Beauty has no obvious use - yet civilization could not do without it." [17] Though cultural standards may differ, there appears to be a universal hierarchy in which beauty is one's key to upward mobility.

Studies done internationally indicate that biologically-based factors such as averageness, symmetry, and sexual dimorphism influence attractiveness, but experience and, consequently, familiarity do as well. [18] This technical research explains why not many people prize their unique noses as an emblem of individuality and instead view them as a hindrance to social acceptance. Therefore the primary aim of cosmetic surgery across cultures entails a dichotomy that is particularly influential during the psychosocial development of the adolescent years. Individuals wish to "fit in" while simultaneously standing out in features they believe will be perceived positively by their peers.

What cultures across the globe do not share, however, is the conventionally American inclination towards "quick fixes" in the pursuit of happiness. Several hospitals around the world have implemented their own version of psychological screenings that must be "passed" in order for the patient to undergo cosmetic. [19] However, the subjectivity of these screenings suggests that the validity of the parameters being screened may be of questionable validity. At this time, a validated, easy to administer psychological survey is unavailable to practitioners. Each surgeon's screening methods vary greatly, establishing the possibility of inconsistent conclusions as to the psychological status of patients. Further research to build a

universal, validated, easy to administer survey is ongoing and would help create objective assessments for those countries that use psychological screening routinely for their patients.

While no study can truly represent the view of an entire continent (i.e., the "European look") or even a nation (i.e., the "French look"), international media aids in revealing general beauty trends and how a similar look might be acquired. In the words of French actress Juliette Binoche (at the 2010 Cannes Film Festival):

"In France, beauty is much more subtle…we think it's more about looking after yourself than going down the artificial route."

In addition, although he does mention the "booming" of the cosmetic surgery industry in France, Parisian plastic surgeon Bernard Mole says "The aesthetic goals of cosmetic patients in France are geared towards more subtle changes (than those in the United States)". [20] Debra Ollivier, an American author who married and raised two children in Paris, agrees. In her book, [21] she explains how in France, peculiarities tend to be valued over conformity with respect to aesthetics, as they preserve an individual's uniqueness and personal flair. While beautiful models are still prized at face value, they have not gathered a following comparable to that in the U.S., where their admirers are often willing to undergo surgical procedures in order to emulate these models. [21] This difference may in part be due to the economic affluence of the U.S. combined with family values that accept appearance to be an essential factor for success.

More cultural factors exist behind differing psychology of cosmetic surgery patients. A 2009 study in Norway found that both education and quality of relationship with parents were negative predictors of cosmetic surgery in young women. [22] The same study listed being teased as a positive predictor of cosmetic surgery. According to Debra Ollivier, the French family unit is very tight-knit, while its American counterpart is better described as "dysfunctional". [21] This comparison may provide further insight as to why teenagers in America opt to change their looks as opposed to modifying behaviour or developing other skills that may help them to succeed. Once again a "quick fix" is employed in an attempt to ameliorate a situation; if strong parental bonds do not exist, teens may turn to cosmetic surgery to fit in with peers.

Adolescents' hopes and primary objectives of cosmetic surgery, however, seem to be more or less the same across the globe: improved body image and self-esteem, which in turn usher forth higher social status and quality of life. [23] While looks are by no means a final marker of potential to succeed in life, it is impossible to remove society's affinity for the aesthetically blessed.

Youths who are teased for being ugly are unlikely to apply themselves in school or otherwise; meanwhile, those at the opposite end of the spectrum might not apply themselves because of their preoccupation with themselves, not realizing that their looks may one day fade as well.

The central dilemma cosmetic plastic surgeons continue to face is where to set the limit on what operations will benefit the patient enough to outweigh the emotional, financial, and any ethical costs that may accompany cosmetic surgery performed in adolescents.

PROCEDURE-SPECIFIC CONSIDERATIONS

Since adolescents may still be completing their growth, it is important to consider the normal development of these individuals with relation to the surgical procedure at hand. Details of each operative procedure can be found in the corresponding chapters of this textbook, with the following discussion aimed at specific considerations in adolescents.

Nasal

Rhinoplasty is one of the most common cosmetic procedures performed world-wide, with international data estimating rhinoplasty to be the fourth most common cosmetic procedure, [24] British data estimating it to be the fifth most common cosmetic procedure (approximately 4500 operations) [3] and American (ASPS) data estimating rhinoplasty to the second most common cosmetic procedure. [1] Importantly, ASPS data demonstrates rhinoplasty is consistently the most common procedure in thirteen to nineteen year-olds, accounting for approximately 44% of cosmetic surgeries performed in this age group.

Nasal growth continues up to the age of eighteen years when the overall facial growth is complete. [25] The various components of the nose develop from their own unique embryologic origins [26] with numerous possibilities for congenital malformations. [27] In general, periods of slower and faster changes occur along a similar timeline as overall body growth of the individual. The authors recommend consideration of cosmetic rhinoplasty in girls from thirteen years or in boys from fifteen years of age, as the nose has completed approximately 90% of its development by this time.

When addressing rhinoplasty in adolescents, surgeons must take into account the critical nasal components, specifically the lacrimal bone and enclosing sutural tissue. This area is the single growth centre that should not be disturbed before nasal development is complete as it is primarily responsible for stabilizing the horizontal and vertical growth of the nasomaxillary complex. In general, nasal osteotomies are contra-indicated until after sixteen to eighteen years of age for the above reason.

While there has been limited information on rhinoplasty under twelve years of age, [28] multicentre studies with large patient numbers and long follow-up for complete assessment have not been done. Numerous publications with recommendations for rhinoplasty to correct severe functional difficulties or posttraumatic injuries in children focus on restoring anatomic relationships, especially of the septum, to promote wound-healing and normal development. [29,30,31] These authors also promote open over closed rhinoplasty in an effort to preserve, as much as possible, the integrity of the cartilaginous skeleton.

With respect to purely cosmetic rhinoplasty, limited data is available as most surgeons recommend waiting until after the completion of facial growth before proceeding to surgery. Chauhan et al. [29] has published the most complete paper detailing not only the surgical changes but also the psychosocial considerations for adolescents undergoing aesthetic nasal surgery. This group recommends avoiding elective rhinoplasty until the following criteria can be met: at least one year after menarche for women, stable growth of the individual for a minimum of one year, psychological readiness, and parental support. This study's use of validated questionnaires to assess overall, social and health-related benefits, combined with a

follow-up of three years with good results, provides the strongest assessment of adolescent rhinoplasty. Patients in this study were between thirteen and nineteen years old, with a mean age of seventeen years, in line with previously stated age guidelines.

Breast

Breast development during puberty typically begins between the ages of nine and thirteen years old in girls, with average age in multiple studies in various countries around twelve or thirteen years old. [33] The stage of development, determined by the Tanner staging system, clearly defines the clinical process. Stage 5, completion of development, is characterised by breast reaching final adult size, the areola returning to contour of surrounding breast with a central papilla extending slightly above contour. Fourteen years old is the most common estimate of the age of Tanner stage 5, with ranges from twelve to sixteen years old. [34] Complete and final breast growth and development, however, can persist into a woman's early twenties.

Breast Augmentation

Breast augmentation is the second most common procedure performed worldwide, [24] and the most common cosmetic surgery procedure in Britain [3] and the US [1] each year. ASPS data indicates it is the third most common aesthetic surgery in adolescents, accounting for approximately 11.5% of all cosmetic surgery procedures on those thirteen to nineteen years old. [1] Of those in this age group who undergo breast augmentation, 44% is for purely cosmetic reasons. [2]

In the US, saline implants for purely cosmetic breast augmentation are approved by the FDA for women eighteen years and older, while silicone implants are approved for women 22 years of age or older. [35] Younger individuals may have these implants placed for cosmetic augmentation, but this would be considered an "off label" use for the implants. If the augmentation, however, is for reconstruction (tuberous breast deformity or Poland syndrome), either style of implant is then considered approved by the FDA. Age limitations are imposed due to the theory that breast development continues into the early twenties and due to maturity concerns relating to informed decision-making. In Europe, definitive age recommendations regarding approval for breast augmentation is not as strict as in the US.

For all young women, it is important to be upfront with patients regarding the unknown effect of cosmetic breast augmentation on further development and future breast health. Specifically, patients should be informed that long-term follow-up studies of women who undergo cosmetic breast augmentation as an adolescent are not available. Data extrapolated from adult breast augmentation patients may or may not be applicable. In addition, adolescents should be clearly informed of the life span of breast implants, typically quoted about ten years, and the likely future need for re-operation (replacement, adjustments, or removal) given the young age at initial operation.

Breast Reduction

Breast reduction is the sixth most common cosmetic surgical procedure throughout the world, [5] third most common in Britain [3] and ninth most common in the US. [2] Reduction

is a bit of a grey area in terms of breast surgery, sometimes being classified under cosmetic or aesthetic operations and sometimes under reconstructive operations. Often reduction is accompanied by a breast lift for improved cosmetic outcome, with inclusion of these patients again changing the number and percentile of reported procedures. Breast reduction accounted for just fewer than three percent of the total cosmetic surgeries performed on under eighteen year-olds in the US. [2]

Typical patients presenting for discussion of breast reduction note complaints such as back or neck pain, worsening body posture, dermatitis or other skin irritations under their breasts, shoulder indentations from bra straps, and limitation of physical activity. Following breast reduction, studies have demonstrated improved psychological scores for women in the areas of body image, self-esteem, and relationships. [36,37,38,39]

Despite numerous studies demonstrating benefits in patients undergoing breast reduction, there is limited evidence on adolescents who undergo breast reduction. Small series indicate mammaplasty is well tolerated in teenagers with normal or elevated BMIs with low reported complications. [40] Sustained relief of symptoms for several years has been reported in limited patient populations. [41,42] However, as with breast augmentation, long-term follow-up of teenagers who undergo breast reduction and its effect on development, need for future surgical intervention, and lasting effect of relief of symptoms has not been completely explored. In the author's limited experience with breast reduction in adolescents, patients do, at least initially, report definitive relief of symptoms.

Gynaecomastia

Surgical treatment for gynaecomastia was the tenth most common cosmetic surgical procedure world-wide, [5] second most common in British men [3] and fourth most common in US men. [1] Even more importantly, it was the second most common cosmetic surgical procedure performed on thirteen to nineteen year-olds in the US, accounting for almost nineteen percent of aesthetic operations in adolescents. [1] This number is likely underestimated given that paediatric surgeons and breast surgeons who report in different databases are also performing these procedures.

Adolescents presenting for discussion of surgery are often obese or overweight, although almost one quarter of patients have causes other than weight-related factors as an explanation. [43] It is recommended that adolescents who present with gynaecomastia during puberty are observed for six to twelve months since further growth and/or weight loss can affect body contour and the relative prominence of the breast. However, should gynaecomastia persist beyond this period of observation and affect the self-esteem of the child, surgical intervention should be considered. Often adolescents with gynaecomastia are so troubled by their figure that they are reluctant to participate in sports or change in public locker rooms so that their deformity is not noticed by their peers, making weight loss even more challenging. Understandably, obese adolescents require more extensive operations, but are equally satisfied and have similar postoperative complications rates as their average weight counterparts. [24] The majority of patients (approximately 75%) undergo bilateral surgeries with peri-areolar skin incisions and bipedicle techniques to minimise nipple-areolar complex necrosis. [24,44,45,46] Most articles report almost 100% satisfaction rates postoperatively, although extensive postoperative follow-up using validated questionnaires is missing. One study noted about twelve percent of individuals contacted postoperatively were "not satisfied"

but details as to what contributed to postoperative dissatisfaction were not provided. [25] In contrast to many studies in adolescents, adults with gynaecomastia are usually a difficult patient population to please. This difference in satisfaction postoperatively is unclear, and likely represent a combination of the limited studies in adolescents, the psychological differences between adults and adolescents, and the primary reasons for desiring surgery in the first place. In the authors' experience, young men who seek surgery have experienced ridicule regarding their appearance and report very positive changes in postoperative self-esteem and confidence.

Similar to young women presenting for breast surgery, it is important to counsel young men presenting with gynaecomastia as to the limited long-term follow-up data for corrective surgery. It is unclear what effect, if any, such surgery has on further development. During the operation, the most important point is to ensure as complete removal of breast tissue as possible. Any tissue left behind could grow in the future leading to recurrence of the original condition or area of concern. Overall, life-long recurrence rate specifically for adolescents who undergo cosmetic surgery for gynaecomastia is unknown, and long-term patient satisfaction has not been studied.

Chin

Chin augmentation is less common than previously discussed cosmetic surgical procedures, only fourteenth most common internationally [5] and is not listed as one of the most common cosmetic surgeries in the BAAPS audit. [3] ASPS data also indicates mentoplasty as a relatively uncommon procedure, accounting for only two percent of thirteen to nineteen year-old cosmetic surgery patients. [1] These numbers represent purely cosmetic mentoplasty and exclude those patients with developmental conditions such as craniofacial microsomia who have specific underlying pathologic conditions. Individuals with these conditions are best addressed via evaluation with a team-based approach including paediatric craniofacial surgeons and orthodontists who can address the complex nature of patients' situations.

Given the small number of adolescents each year who undergo simple cosmetic-driven mentoplasty, the paucity of published material on this topic is not surprising. Final growth of the mandible, similar to the rest of the facial skeleton, continues until a person's mid-teenage years. In the authors' opinion, mentoplasty using chin implant provides a safer alternative than sliding genioplasty in adolescents as their facial features are still undergoing some final development. Over the late teenage and early twenties, the optimum chin shape and projection for the individual's face is likely to change slightly as he or she undergoes further maturation into adulthood, and implants allow for easier repeat operations for fine-tuning at an older age compared to the more permanent sliding genioplasty.

Eye

Blepharoplasty is the third most common cosmetic surgery around the world, second most common in Britain [3] and fourth most common in the US. [1] However, in adolescents thirteen to nineteen years old, blepharoplasty is relatively uncommon, representing only two

percent of cosmetic surgeries in this age group. [1] While the exact characteristics of these patients has not been published, adolescent blepharoplasty patients tend to have a history of craniofacial deformities or traumatic injuries which lead to soft tissue deformities requiring correction. Indication for purely cosmetic blepharoplasty in one's teen years without underlying craniofacial or traumatic aetiologies is unusual.

Body

Liposuction is the most common cosmetic surgical procedure on an international basis, [5] sixth most common cosmetic surgical procedure in Britain [3] and third most common in the US. [1] Many would be surprised that liposuction is the fifth most common cosmetic surgery in thirteen to nineteen year-olds, although this is only four percent of procedures in these adolescents. [1] Similar to adults who present requesting liposuction, adolescents should be evaluated for their understanding of the goals of the procedure (to improve contour and minimise disproportionate areas) and the understanding of what the procedure cannot accomplish (significant weight loss in obese individuals). It is important to re-enforce to adolescents that the procedure is not a substitution for a well-rounded diet and exercise, and further encourage these healthy habits at a young age. Good adolescent candidates for liposuction are those with a specific area of unnatural and/or asymmetric fat deposition, especially if it is interfering with activity level or lifestyle. Similar to adults, teenagers who continue to have excessive fat deposits despite demonstrating a commitment to exercise and appropriate eating are stronger applicants for surgical intervention. For the typical adolescent patient who presents for discussion of liposuction, lifestyle changes should take precedence over surgical intervention.

Otoplasty

Otoplasty is the ninth most common cosmetic surgical procedure on an international basis [5] and the tenth most common cosmetic surgical procedure in Britain. [3] However, adolescents make up a significant number of the total patients undergoing this procedure, with approximately 7400 operations on US adolescents in 2011, accounting for 28% of total procedures on this age group. [1] In the United States, otoplasty is increasingly viewed by insurance carriers to be a cosmetic procedure as opposed to correction of a congenital deformity. In the author's practice of plastic surgery in the paediatric and adolescent population, otoplasty and correction of gynaecomastia are the procedures most commonly not routinely covered by insurance carriers.

Secondary Cleft

Adolescents with secondary cleft deformities represent a unique subset of patients presenting for discussion of rhinoplasty and/or lip revisions. These patients do not fit clearly into the cosmetic surgery category as their area of concern stems from a primary developmental problem, but many no longer consider surgery for secondary cleft deformities

reconstructive as the primary cleft problem has already been corrected. In the US, more of these adolescents are meeting resistance from insurance companies when they present for rhinoplasty or other surgical procedures to correct aesthetic concerns.

Previous studies evaluating the overall psychological status of cleft lip/cleft palate patients have found increased rates of depression and anxiety as adults, [47,48] elevated concern for abnormalities in nose and dentition, [28] problems with body image, and lower self-confidence. [49] Surveys of adult patients demonstrate that those who did not seek secondary treatment reported lower quality-of-life scores with almost 63% of women surveyed expressing desire for further correction of upper-lip and nose concerns. [50,51]

While numerous researchers have attempted to follow-up with patients using a variety of questionnaires, [52] it has not been until recently that a focused, validated survey specifically addressing the unique concerns of cleft lip / cleft palate patients has been developed. Klassen et al. [53] have begun to develop a CLEFT-Q - a validated quality of life questionnaire for cleft lip / cleft palate patients similar to that of the BREAST-Q in place for breast surgery patients. [54] Research which follows from this questionnaire will provide further insight into adolescents dealing with these conditions, and will serve as an example of projects which are needed to address aesthetic adolescent surgery in general.

PATIENT SELECTION

As in all areas of cosmetic surgery, patient selection and preoperative evaluation/ assessment is of utmost importance. The American Society of Plastic Surgeons suggested points to consider when evaluating an adolescent presenting for cosmetic surgery (paraphrased below) [55], with further details provided in the authors' opinions.

Patient Is the Primary Person Who Desires Surgery and Initiates Discussion

As surgeons assess whether or not a request is medically appropriate, they should also ask why the individual is interested in the procedure. Adolescents who indicate that a family member or friend has suggested cosmetic surgery but do not clearly state why they want the procedure for themselves are at risk of regretting the decision or being unhappy with results.

Further, patients who acknowledge internal motivators tend to be more in touch with their sense of self, demonstrate more maturity, and be happier with outcomes. Examples of internal motivators include ideas such as "I would be more confident if I was not worried about the appearance of my nose" or "I would be much happier and less critical of how I look in photos." Examples of external motivators include ideas such as "I would become more popular" or "Boy/girls would like me more." Internal goals relate to sense of self and body image and tend to be reasonably met following surgery. One can understand how, if a person is less preoccupied with a perceived flaw, he or she will demonstrate more confidence. However, external goals are often unreasonable to achieve as they rely on obtaining the approval of others. Postoperatively, when a more streamlined nose does not lead directly to the popular crowd, the patient is likely to be disappointed and hypercritical of the surgical outcome. Whereas assessment of motivators can be applied to many cosmetic surgical

patients, this assessment is even more crucial when evaluating the adolescent patient. Adolescents are at a particular time of their life where external motivators tend to be more highly valued and the opinion, or presumed opinion, of others tends to be held in higher regard.

Patient Has Reasonable Goals, and Understands the Benefits and Risks

Adolescents with a clear, defined request and reasonable goals are more likely to be satisfied postoperatively than those teenagers with vague expectations. A young woman concerned over a hump in her nose and requesting a more linear profile provides a surgeon with a clear goal when counselling, discussing outcomes, and reviewing risks/benefits. On the other hand, a teenager requesting a "cuter nose" does not give a clear picture of her expected outcome. Often adolescent individuals have a more difficult time articulating their exact concern compared to their adult cosmetic surgery counterparts. It is thus important to spend additional time with these individuals to make sure that patient, parents, and surgeon are on the same page prior to proceeding to surgery. Teenagers often require multiple appointments to fully explore the surgical risks/benefits, give accurate information on how they want their appearance to change, and ensure that all questions have been answered.

Adolescents tend to see circumstances in black and white more so than adults, with outcomes viewed as perfect or disastrous. It is the surgeon's job to clearly define what will happen pre- and postoperatively and to be exceptionally honest with the patient as to whether or not their goals can be achieved. Plastic surgeons have a responsibility to turn down cosmetic surgical requests from teenagers especially if they do not feel the goals of the patient can be met or desired outcomes from the procedure can be reasonably achieved.

Patient Demonstrates Maturity Toward Decision Making and Dealing with Postoperative Discomforts or Less Than Perfect Outcome

The initial assessment of adolescent maturity comes with the above patient interactions. At the very minimum, the teenage patient should be able to calmly and sensibly have the above discussions with his or her parent and surgeon, including dealing with questions or concerns that arise. Surgeons also need to explore how the adolescent will cope with postoperative discomfort, complications, or poor outcomes. This issue can be addressed with direct questions ("How will you handle peers who notice you look different?" or "How would you deal with this complication?") or with indirect links ("What is a difficult situation you've been in, and what did you do to resolve it?"). The questions not only allow the surgeon to assess the teenager's maturity, but also encourage the patient to consider in advance how he or she would deal with possible postoperative issues and hopefully initiate a discussion between the patient and parent on such a topic.

As part of a routine preoperative work-up, a psychological history should also be obtained. Anyone with a known psychopathologic condition or anyone the surgeon is concerned about coping with postoperative difficulties should be evaluated by a psychologist or psychiatrist prior to surgical intervention, with postoperative care and follow-up coordinated with this support system as well.

TRENDS IN COSMETIC SURGERY IN ADOLESCENTS

In the past several years, the number of cosmetic plastic surgery procedures has increased by approximately five to six percent overall from one year to the next [1,3] with teenagers steadily accounting for about two percent of this total year by year with increasing gross numbers in keeping with those of the adult cosmetic surgery population. Of the most common cosmetic surgery procedures in this age group, rhinoplasty, breast augmentation and gynaecomastia surgery have remained approximately steady in terms of numbers with the same ranking of popularity of procedures.

Reasons why more adolescents are seeking cosmetic surgery are beginning to become evident as researchers focus more attention on this specific group of individuals. Survey results of high school students demonstrate that two thirds of students knew someone who had undergone cosmetic surgery but only one third would be interested in such surgery for themselves. [56] Interest was most commonly expressed in liposuction, rhinoplasty, breast augmentation and breast reduction, somewhat in keeping with the popularity of procedures reported in annual statistics. Importantly, teens who expressed interest in aesthetic procedures described cosmetic surgery patients as "motivated," while those who did not express interest felt these patients were "vain." Not surprisingly but unfortunately, 96% of high school students surveyed reported primary source of information on cosmetic surgery as magazines or television rather than physician or other health-care source. Similar survey results from college-age students illustrate the link between greater internalization of mass media images of beauty and more positive attitudes toward aesthetic surgery. [57]

As adolescents become increasingly ensconsed in the digital era, media, marketing and associated celebrities are more commonly encountered each day via the ever-increasing use of the Internet, social networking sites, smart phones and other digital devices. Numerous studies have demonstrated a link between more intense celebrity admiration and drive for cosmetic surgery procedures, [58] with experts suggesting a link to ever increasing unrealistic societal beauty ideals. [59] As noted in the above study, magazines and television are the main sources adolescents use to learn about cosmetic surgery, so with increasing mainstream information via these resources, more and more teenagers are likely to consider aesthetic surgery. In addition, as the number of procedures rises each year, more postoperative patients are discussing cosmetic surgery with their peers, generating further interest. Minimally invasive procedures are also becoming popularised, making prior deterrents from surgery (scar formation, pain, longer recovery) less important considerations.

CONCLUSION

It is clear that in the coming years, the total number of individuals seeking cosmetic surgery will continue to increase, and along with it the number of adolescents requesting such procedures. Plastic surgeons must understand that these individuals are not just small adults, as is often quoted in paediatric surgery, but also that they have specific psychological and developmental concerns unique to their age group. Going forward, additional research is needed to understand the effect of surgery on end-stages of growth and development into adulthood and the long-term outcomes obtained from procedures during the adolescent years.

REFERENCES

[1] American Society of Plastic Surgeons. *2011 Plastic Surgery Statistics Report*. ASPS National Clearing House of Plastic Surgery Procedural Statistics. Available at: www.plasticsurgery.org. Accessed August 1st, 2012.

[2] American Society for Aesthetic Plastic Surgery. *Cosmetic Surgery National Databank Statistics: Expanded data for 2011*. Available at: http://www.surgery.org. Accessed August 1st, 2012.

[3] British Association of Aesthetic Plastic Surgeons. *BAAPS 2011 Annual Audit*. Available at: http://www.baaps.org.uk/about-us/audit. Accessed August 1st, 2012.

[4] Larson K, Gosain A. Cosmetic Surgery in the Adolescent Patient. *Plastic and Reconstructive Surgery*. 2012; 129:135e-141e.

[5] McGrath MH, Mukerji S. Plastic surgery and the teenage patient. *J Pediatr Adolesc Gynecol*. 2000; 13:105-118.

[6] Schilder P. Localization of the body image (postural model of the body). Res Publ Assoc *Nerv Ment Dis*. 1934; 13: 466-585.

[7] Sarwer DB, Pertschuk M, Wadder T. Psychological Investigations in Cosmetic Surgery: a look back and a look ahead. *PRS*. 1998; 101:1136-1142.

[8] Sarwer DB, Wadden TA, Pertschuk MJ, Whitaker LA. The psychology of cosmetic surgery: a review and reconceptualization. *Clinical Psychology Review*. 1998; 18(1): 1-22.

[9] Rauste-von Wrightml. Body image satisfaction in adolescent girls and boys: a longitudinal study. *J Youth Adolesc*.1989; 18:71-83.

[10] Semis KJ, Hovious SE, de Beaufort ID, Verhulst FC et al. After plastic surgery: Adolescent reported appearance ratings and appearance-related burdens in patients and general population groups. *PRS*. 2002; 109: 9-17.

[11] Simis KJ, Koot JM, et al. Assessing adolescents and young adults for plastic surgical intervention: pre-surgical appearance ratings and appearance-related burdens as reported by adolescents and young adults, parents and surgeons. *British Journal of Plastic Surgery*. 2000; 53: 593-600.

[12] Simis KJ, Verhulst FC, et al. Body Image, Psychosocial Functioning, and Personality: Are Adolescents and Young Adults Applying for Plastic Surgery? *J Child Psychol. Psychiatr*. 2001; 42(5): 669-678.

[13] Gillen MM, Lefkowitz ES. Gender and racial/ethnic differences in body image development among college students. *Body Image*. 2012; 9:126-130.

[14] Kamburoglu HO, Ozgur F. Postoperative Satisfaction and the Patient's Body Image, Life Satisfaction, and Self-Esteem: a retrospective study comparing adolescent girls and boys after cosmetic surgery. *Aesth. Plast Surg*. 2007; 31:739-745.

[15] Stefanile C, Matera C, Nerini A, et al. Validation of an Italian version of the SATAQ-4 on adolescent girls. *Body Image* 2011; 8:432-436.

[16] Knauss C, Paxton SJ, Alsaker. Validation of the German version of SATAQ-G. *Body Image* 2009; 6:113-120.

[17] Freud S. *Civilization and Its Discontents*. 1930

[18] Rhodes G. The Evolutionary Psychology of Facial Beauty. *Annual Rev Psychol*. 2006; 57:199-226.

[19] Rumsey N and Clarke A. *New Psychological Screening for Plastic Surgery Patients in UK*. Online article from American Society for Aesthetic Plastic Surgery (www.surgery.org) and Phys.org (phys.org/wire-news). Article date June 2012. Accessed October 2012.

[20] Petrou I. French Plastic surgeon compares practices in his country to those in US. *Cosmetic Surgery Times*. Dec 1, 2011. Accessed online, 10/1/2012. http://www.modernmedicine.com/modernm edicine/article/articleDetail.jsp?id=750219

[21] Ollivier D. *What French Women Know: About Love, Sex, and other Matters of the Heart and Mind*. GP Putnam's Sons, 2009.

[22] Javo IM, Sorlie T. Psychosocial predictors of an interest in cosmetic surgery amount young Norwegian women: a population based study. *Plastic Reconstructive Surgery* 2009 Dec; 124(6):2142-2148.

[23] Ramaye A, Walburg V, Charbrol H. The attitudes of French teenagers toward plastic surgery. *Ann Chir Plast Esthet* 2008 Oct; 53(5): 457-458.

[24] *International Survey on Aesthetic/Cosmetic Procedures*, 2010. Available at: http://www.isaps.org. Accessed August 15th, 2012.

[25] Enlow DH, Hans MG. *Essentials of Facial Growth*. Philadelphia: Saunders; 1996.

[26] Gupta A, Malhotra G, Akadiri O, Jackson IT. Chapter 18: Head and Neck Embryology and Anatomy. Plastic and Reconstructive Surgery, MZ Siemionow and M Eisenmann-Klein (eds), *Springer Specialist Surgery Series*, 2010.

[27] Elluru RG, Wooten CT. Chapter 188: Congenital Malformations for the Nose. *Cummings Otolaryngology – Head and Neck Surgery*, 5th Edition. PW Flint, BH Haughey, et al. (eds). Philadelphia: Elsevier, 2010.

[28] Ortiz-Monasterio F, Olmedo A. Corrective rhinoplasty before puberty: A long-term follow-up. *PRS*. 1981; 68:381-391.

[29] Verwoerd CDA, Verwoerd-Verhoef HL. Rhinosugery in Children: Basic Concepts. *Facial Plastic Surgery*. 2007; 23(4): 219-230.

[30] Dennis SCR, den Herder C, et al. Open Rhinoplasty in Children. *Facial Plastic Surgery*. 2007; 23(4): 259-266.

[31] Shandilya M, den Herder C, et al. Pediatric Rhinoplasty in an Academic Setting. *Facial Plastic Surgery*. 2007; 23(4): 245-257.

[32] Chauhan N, Warner J, Adamson PA. Adolescent Rhinoplasty: Challenges and Psychosocial and Clinical Outcomes. *Aesthetic Plastic Surgery*. 2010; 34:510-516.

[33] Parent AS, Teilmann G, Juul A, Skakkebaek NE, et al. The Timing of Normal Puberty and the Age Limits of Sexual Precocity: Variations around the World, Secular Trends, and Changes after Migration. *Endocrine Reviews*. 2003; 24(5):668-693.

[34] Susman EJ, Houts RM, Steinberg L et al. Longitudinal Development of Secondary Sexual Characteristics in Girls and Boys between ages 9½ and 15½ Years. *Arch Pediatr Adolesc Med*. 2010; 164(2): 166-173.

[35] US Food and Drug Administration. *Implants and prosthetics: Breast implants*. Available at: http://www.fda.gov. Accessed August 15th, 2012.

[36] Rogliani M, Gentile P, Labardi L, Donfranseo et al. Improvement of psychical and psychologic symptoms after breast reduction. *J Plastic Reconstructive Aesthetic Surgery*. 2009; 62: 1647-1649.

[37] Saariniemi KM, Keranen, UH, Salminen-Peltola PK, et al. Reduction mammoplasty is effective treatment according to two quality of life instruments: a prospective randomized clinical trial. *PRS*. 2008; 61:1472-1478.

[38] Glatt BS, Sarwer DM et al. A retrospective study of changes in physical symptoms and body image after reduction mammoplasty. *PRS*. 1999: 103:76-82.

[39] Mellow AA, Domingos NA, Miyazaki MC. Improvement in quality of life and self-esteem after breast reduction surgery. *Aesthetic Plastic Surgery*. 2010; 34: 59-64.

[40] Webbml, Cerrato F, et al. Effect of Obesity on Early Outcomes in Adolescents Undergoing Reduction Mammaplasty. *Annals of Plastic Surgery*. 2012; (68)3: 257-260.

[41] McMahan JD, Wolfe JA, Cromer BA, Ruberg RL. Lasting success in teenage reduction mammoplasty. *Annals of Plastic Surgery*. 1995; 35(3):227-231.

[42] Lee MC, Lehman JA, Tantri MD, Parker MG, Wagner DS. Bilateral reduction mammoplasty in an adolescent population. *J Craniofacial Surg*. 2003; 14(5):691-695.

[43] Rosen H, Webbml, et al. Adolescent Gynaecomastia: not only an obesity issue. *Ann Plast Surg*. 2010; 64(5): 688-690.

[44] Gabra HO, Morabito A, Bianchi A, BowenJ. Gynaecomastia in the adolescent: a surgically relevant condition. *Eur J Pediatric Surg*. 2004; 14(1): 3-6.

[45] Peters MD, Vastine V, Knox L, Morgan RF. Treatment of adolescent gynaecomastia using a bipedicle technique. *Ann Plast Surg*. 1998; 40(3):241-245.

[46] Laituri CA, Garey CL, Ostlie DJ et al. Treatment of Adolescent Gynaecomastia. *J Pediatric Surgery*. 2010; 45: 650-654.

[47] Marcusson A, Paulin G, Ostrup I. Facial appearance in adults who had cleft lip and palate treated in childhood. *Scand J Plast Reconstr Surg Hand Surg*. 2002; 36:16-23.

[48] 1 Ramstad T, Otten E, Shaw WC. Psychosocial adjustment in Norwegian adults who had undergone standardized treatment of complete cleft lip and palate: II. Self-reported problems and concerns with appearance. *Scand J Plast Reconstr Surg Hand Surg*. 1995: 29: 329-336.

[49] Bernstein NR, Kapp K. Adolescents with cleft palate: Body-image and psychosocial problems. *Psychosomatics*. 1981; 22:697-703.

[50] Sinko K, Jagsch R et al. Evaluation of esthetic, functional, and quality of life outcome in adult cleft lip and palate patients. *Cleft Palate Craniofac J*. 2005; 42(4): 355-361.

[51] Hunt O, Burden D, Hepper P, Johnston C. The psychosocial effects of cleft lip and palate: a systemic review. *Eur J Orthod*. 2005; 27(3):274-285.

[52] Eckstein DA, Wu RL, Akinbiyi T, Silver L, Taub PJ. Measuring quality of life in cleft lip and palate patients: currently available patient-reported outcomes measures. *PRS*. 2011; 128(5): 518e-526e.

[53] Klassen AF, Tsangaris E, Forrest CR, Wong KWY et al. Quality of life of children treated for cleft lip and/or palate: a systematic review. *J Plastic Reconstructive Aesthetic Surgery*. 2012; 65(5): 547-557.

[54] Cano SJ, Klassen AF, Scott M, et al. The BREAST-Q: further validation in independent clinical samples. *PRS*. 2012; 129(2): 293-302.

[55] American Society of Plastic Surgeons. *Plastic Surgery for Teenagers Briefing Paper*. Available at: http://www.plasticsurgery.org/News-and-Resources/Briefing-Papers.html. Accessed August 1st, 2012.

[56] Pearl A, Weston J. Attitudes of Adolescents about Cosmetic Surgery. Ann Plast Surg. 2003; 50:628-630.

[57] Sarwer DB, Cash TC et al. Female college students an cosmetic surgery: an investigation of experiences, attitudes, and body image. *PRS*. 2005; 115:931-938.

[58] Maltby J, Day L. Celebrity Worship and Incidence of elective cosmetic surgery: evidence of a link among young adults. *Journal of Adolescent Health*. 2011: 49:483-489.

[59] Hargreaves DA, Tiggmann M. Idealized media images and adolescent body image: "comparing" boys and girls. *Body Image*. 2004;1:351-361.

In: Encyclopedia of Surgery (22 Volume Set)
Editors: Andreas Lehrer and Kristin Mueller
ISBN: 978-1-53618-329-0
© 2020 Nova Science Publishers, Inc.

Chapter 42

HAND REJUVENATION

Kuen Chin[1,*] and Fulvio Urso-Baiarda[2]
[1]Ninewells Hospital, Dundee, UK
[2]Wexham Park Hospital, Slough, UK

KEY POINTS

- It is possible to judge a person's age based solely on the appearance of their hands. This combined with the increasing popularity of facial rejuvenation may have resulted in the observed increase in requests for hand rejuvenation in recent years. The overall evidence basis for these procedures is scant.
- Features of ageing hands include skin laxity, actinic skin changes, soft tissue atrophy and the development of venous prominence. Rejuvenation modalities may address some or all of these.
- No modalities addressing skin laxity are supported by strong evidence. The least invasive modality is medical needling, which has a good safety profile when used elsewhere but lacks safety and efficacy data for use in the hand.
- Venous prominence has been addressed by sclerotherapy and endovenous laser therapy, neither of which is backed by strong evidence. From what literature is available their efficacy seems similar, but laser treatment may have a more favourable safety profile.
- In contrast to the other treatment modalities, volume enhancing hand rejuvenation treatments are supported by reasonable evidence. Autologous fat grafts appear to survive at least into the early (five month) postoperative period, after which one would expect longer-term survival from our experience elsewhere. There are few studies directly comparing non-autologous fillers, but HA appears to be most consistently favoured in terms of safety and efficacy.
- Fractional photothermolysis and Plasma Skin Resurfacing are the modalities targeting actinic skin changes of the hands that are supported by the highest quality

* Corresponding Author's Email: andycky@doctors.org.uk.

evidence (a single Evidence Level 2 study each). These small studies have demonstrated safety and short-term efficacy but no follow-up data beyond three months exists for either modality.

- Many authors have provided anecdotal reports of the use of combination therapies for hand rejuvenation, which appears to be a popular practice, but it has not yet been the subject of a high quality study.

INTRODUCTION

There has been much interest in hand rejuvenation in recent years. The discrepancy between the apparent age of a celebrity's hands and that of their face is the subject of regular media broadcasts. In a single year, one newspaper published the headlines: "Why do Madonna's hands look older than her face?" [1], "Even with muscles like these, Madonna can't beat the hands of time" [2] and "She's so vein... Madonna's hands look worse than ever" [3]. Whether cause or consequence, such articles reflect increasing preoccupation with senescent hands and how to disguise them.

Several authors have speculated as to why the hands might attract such attention. They are the second most exposed body part after the head and neck [4], making them both socially visible and highly susceptible to environmental and sun-induced ageing [5-7]. The ability of untrained observers to estimate age just by looking at a pair of hands [8] could readily subvert an individual's efforts to disguise the sequelae of facial ageing.

Whatever the origin for the demand for hand rejuvenation, a market has sprung up to supply it and, according to some sources, has more than trebled in recent years [1,9]. Although practitioners offer a plethora of hand rejuvenation procedures, their evidence basis is not always clear. This chapter aims formally to review the current literature and assess levels of evidence for current practice, to identify consensus opinion (both positive and negative) and those areas that warrant future investigation.

To do this, publications looking at hand rejuvenation procedures were identified with a PubMed search of the term: *("Esthetics"[Mesh] OR "Rejuvenation"[Mesh]) AND "Hand"[Mesh]* (searched March 2012). Hits were filtered for relevance and their citation lists manually searched, until no more relevant articles could be found. Papers were assigned a level of evidence (LOE) derived from the American Society of Plastic Surgeons (ASPS) Scales for Rating Levels of Evidence.

OVERVIEW OF THE LITERATURE

The literature search yielded 191 hits, of which 29 were relevant to hand rejuvenation and another 28 identified manually from their citations. Eight of those were excluded as they were not peer-reviewed [10-14], not in English [15] or were unobtainable [16,17].

The 49 included publications consisted of those considering normal hand aesthetics and/or the changes that take place in ageing [5,8,18,19], complications of hand rejuvenation [20] or various hand rejuvenation modalities. The latter consisted of modalities addressing

skin excess, venous prominence [21-26], volume loss [7,27-41], skin quality [42-48] or a combination of those features [6,49-55].

THE AGEING HAND

Bains and co-workers [8] analysed factors contributing to a young or old hand appearance by comparing the age attributed to images of female hands before or after digital manipulation of features such as veins, blemishes, wrinkles makeup and jewellery. They found that an observer could accurately estimate age from isolated images of hands and that old hands were characterised by wrinkles, veins, prominent joints, thin skin, deformity and spots. Conversely young-appearing hands exhibited tissue fullness and a lack of veins or wrinkles. The single most ageing factor was the appearance of veins. Added nail varnish or jewellery could not disguise old-looking hands.

These findings were generally supported by a subsequent observational analysis of age-related changes in the hands [5] (LOE-4)., except that tortuous veins were considered a better marker of ageing than veins per se, since athletic hands could display prominent (but straight) veins whilst remaining youthful and attractive. The study also found a gender difference in the ideal hand aesthetic, with most women preferring their non-dominant hand but most men preferring their dominant one. The authors speculated that this could reflect a more general difference between the sexes in preferring slenderness or muscularity. It is an important finding since most studies assessing patient satisfaction after hand rejuvenation have a mostly or wholly female subject population, and results may not be applicable to men.

Most studies addressing hand rejuvenation therapies use quantitative or semi-quantitative outcomes, but Carruthers [18] (LOE-3) wanted to make assessments of hand ageing more objective by defining a photonumeric rating scale (Table 1). To validate it, images of different aged hands were independently rated, and the inter- and intrarater agreement was found to be good. Surprisingly though, there was no attempt to correlate the scale with the actual age of the photographed hand, the scale only considered changes related to soft tissue loss, and the researchers stated that it had been validated for photographic but not live hand assessments. Those limitations would significantly impact the usefulness of the scale, and it does not appear to be in widespread use.

Table 1. Five-point photonumeric scale (modified from Carruthers 2008)

0	no loss of fatty tissue
1	mild loss, slight visibility of veins
2	moderate loss, mild visibility veins & tendons
3	severe loss, moderate visibility of veins and tendons
4	very severe loss, marked visibility of veins and tendons

In a literature review addressing normal hand aesthetics, Jakubietz and colleagues [56] concluded that normal anatomy and proportions were prerequisites for beauty, and that a long slender hand was generally considered elegant and beautiful. Consistent with earlier work, prominent veins could be considered attractive in male hands but less prominent vasculature was preferred in females. A youthful appearance was also attractive, and ageing could be

classified as extrinsic or intrinsic (Table 2). Procedures that reversed either type of ageing could rejuvenate hands and therefore beautify them.

Table 2. Signs of extrinsic and intrinsic hand ageing (Jakubietz 2005) [56]

Extrinsic ageing	Intrinsic ageing
Actinic keratosis	Wrinkles
Solar lentigines	Dermal atrophy
Punctate hypopigmentation	Fat atrophy
Solar purpura	Visible colour of tendons
Grouped, flesh-coloured papules	Prominent veins
	Visible bony contour

HAND REJUVENATION MODALITIES

Rejuvenation options for the hand can be divided into those addressing skin changes (either skin excess or photoageing), protruberant veins or soft tissue atrophy [50], any of which may be present to varying extents.

a) Skin Excess

The 'distal dorsal superior extremity plasty' was described by Wendt in 2000 [4] (LOE-4). It is a technique that aims to improve hand contour by excising 'redundant' skin from the dorsum via a transverse skin excision. Resectable skin is marked as an ellipse centred over the dorsal wrist crease with the wrist fully flexed, and the procedure is performed under local anaesthetic. Risk of transection of the dorsal branch of ulnar or superficial branch of radial nerves was pointed out by the author, although no complications were reported in the very small series (six procedures in two patients) and the need for multiple procedures per patient was not accounted for. Others have commented that such an approach could have a paradoxical pro-ageing effect by making veins and tendons appear more visible [31], and safety in terms of nerve injury, long-term scar stretch and stiffness have not been determined in any large study.

The technique has been modified recently [57] (LOE-4) to limit the scar to the ulnar side of the dorsum. The excess skin identified using the pinch test is marked in the dorsal carpal region preoperatively. Under local anaesthetic, intravenous sedation and tourniquet control, a flap is mobilised along a vector line between the second metacarpophalangeal joint and the caput ulnae. The author stressed restricting the extent of undermining to the ulnar and middle third of the dorsum as more extensive undermining caused 'dog-ears' that would necessitate a longer incision. The resultant scar is an S-shaped scar with a distal curve at the inferior border of the caput ulnae, extending in a radial and ulnar direction (Figure 1). At fourteen to twenty months follow-up of eleven patients undergoing bilateral surgery, the author found 60-75% reduction of excess skin (determined using the pinch test and verified with callipers), and in two patients the tightened skin also reduced venous prominence bilaterally.

Figure 1. The S-shaped incision line curves around the distal border of the caput ulnae, ending in a horizontal direction in the relaxed skin tension lines in the ulnar as well as radial direction.
After Handle et al. 2011 [57].

A less invasive technique to address wrinkles and skin excess carried out by Aust [58] (LOE-4) used percutaneous collagen induction therapy. This treatment, also known as medical needling, is carried out by rolling a needling device (in this case an Environ Medical Roll) on the dorsum of the hand, creating thousands of closely neighbouring microwounds under regional anaesthesia. The resulting dermal inflammation triggers the release of growth factors including epidermal growth factor, fibroblast growth factor and transforming growth factor leading to improved collagen deposition – essentially an inflammatory response. The author reported improved skin texture, skin tightening, dermal neovascularisation and no change in pigmentation. However, no measurements of improvement were given.

b) Venous Prominence

Whilst marketing material aimed directly at patients refers to three modalities - sclerotherapy, endovenous laser therapy and phlebectomy - to rectify prominent hand veins, the latter does not appear to be the subject of any high quality peer-reviewed publication. One brief correspondence suggests it may be a useful treatment but the author notes it is technically demanding [25] (LOE-5). Of the remaining publications addressing venous prominence in the hand, those currently in print for sclerotherapy or endovenous laser therapy are of evidence level 4.

The main pieces of work on hand sclerotherapy are by Bowes & Goldman [21] (LOE-4) and Duffy [23] (LOE-4). Bowes described his experience of sclerotherapy in seven female patients (fourteen hands) using sodium tetradecyl sulfate sclerosant. Hand appearance was photographed preoperatively, postoperatively and at final follow-up an average of 3.2 years later. Efficacy was rated using a defined semi-quantitative score, according to which a 90-100% improvement was observed (that is, minimally apparent residual vessels or complete disappearance). The authors' reported '97.8% average improvement' has little meaning since mathematical transformations (such as mean averages) cannot validly be applied to semi-

quantitative scores, but the overall impression was that sclerotherapy achieved the task of obliterating the appearance of dorsal hand veins. No serious complications were observed, with mild swelling and erythema resolving quickly.

Duffy compared his retrospective eleven-year experience of hand sclerotherapy of 100 female patients, using either high or low concentrations of sclerosant (sodium tetradecyl sulfate or polidocanol in either group). One vein was spared (for future emergency venous access rather than for venous drainage) and treatment was repeated weekly if the response was inadequate.

High concentrations of either sclerosant were found to be more efficacious than low concentrations. In an earlier paper Duffy commented that smaller veins in younger patients can be more resistant [22] (LOE-5). Accordingly in this report the author recommended high concentrations in young patients but indicated that low concentrations may be adequate to treat the more fragile veins of elderly patients.

Postoperative thrombi were almost ubiquitous (occurring in 95% patients) and were treated by microthrombectomy. Additionally, 82% of patients developed mild upper limb oedema and 7.5% developed severe swelling. Half the patients experienced moderate discomfort (related to thrombi) and this was severe in a further twenty percent. A single patient developed paraesthesia in the distribution of the superficial branch of radial nerve, presumably resulting from trauma during attempted cannulation, and fourteen percent underwent some recurrence due to neovascularisation. The safety and long-term efficacy of this procedure has therefore not been adequately demonstrated.

Endovenous laser therapy was examined in a study of 54 hands in 28 patients [26] (LOE-4), although this was essentially a description of the author's experience without defined outcome measures. It was performed reportedly with no significant problems in an outpatient setting using tumescent anaesthesia, which provided anaesthesia, vasoconstriction, venous compression and a heat sink. Around two thirds of patients also received midazolam sedation.

The laser fibre was introduced to the veins via a sheath and an average of four veins treated per patient. The author used a 940nm diode laser and a 600μm fibre, delivering 7W power and pulling the fibre back through the vein at a rate of two millimetres per second. Total operative time was 45±20 minutes per hand. A compressive dressing was applied postoperatively. Eighteen of 28 patients received treatment to both hands simultaneously, the remainder undergoing either staged or unilateral therapy. The authors reported that patients tolerated the procedure well, with no specific comments regarding patients who had bilateral simultaneous procedures. Patients were told they could resume usual activities immediately if they had not received sedation or the following day if sedation had been administered.

After a mean of thirteen months follow-up, one postoperative complication was reported - a small skin burn at a laser exit site, left to heal conservatively. All patients experienced ecchymosis and hand swelling for around two weeks, and two patients required postoperative oral analgesia. All patients were reportedly satisfied with their results although no attempt was made to quantify this formally. Shamma considered this a superior technique to sclerotherapy, which in the upper limb required higher concentrations of sclerosant than in the leg and, as noted elsewhere, can result in a tender, phlebitic cord [26].

From the little evidence available, whilst efficacies of sclerotherapy and endovenous laser therapy appear similar, sclerotherapy appears to be associated with a higher incidence of significant complications such as severe postoperative pain and swelling. However, start-up costs for laser therapy may be prohibitive, and any modality aiming to ablate dorsal hand

veins (even if the practitioner seeks to preserve one) inevitably restricts future options for intravenous access.

c) Volume Replacement

Several volumetric hand rejuvenation procedures have been reported, but only one study has investigated their anatomical basis. Using histologic analysis and confirmed by duplex ultrasound scanning, Bidic [27] (LOE-4) described three distinct fatty areolar laminae and three fascial layers. The superficial lamina in more obese cadavers appeared to have more fat cells to obscure the appearance of veins, tendons and bones. Dorsal hand veins and sensory nerves were present in the intermediate lamina, and extensor tendons were found in the deep lamina. The author suggested that fat grafts or fillers injected into the superficial lamina could be carried out without jeopardizing the dorsal veins, sensory nerves or extensor tendons. Volar to dorsal adhesions from fascial sheaths surrounding perforating arteries and veins were identified using lead oxide injection [27] and could account for the lumpy compartmentalisation sometimes seen with injection of filler. The authors suggested aggressive massage to distribute injected filler evenly while preserving perforating vessels.

Volume-enhancing hand rejuvenation modalities are supported by the best (LOE-2) evidence available in this field, both using autologous fat [29,30] and non-autologous filler material [37]. Five further level 4 papers support the use of both autologous and non-autologous fillers for hand rejuvenation.

Autologous Fat Grafting

In 1985, Pierre Fournier presented a modified fat grafting technique which he called ‘microlipoinjection’, in which 13-gauge needles attached to ordinary syringes could be used to harvest fat for transplantation [59]. Grafting of fat took place by bolus injection and massage distribution.

This was followed some years later by Lauber, Abrams and William Coleman [36] (LOE-5), who harvested graft material using tumescent liposuction and reinjected it to the dorsum of the hand as a mound to be redistributed by massage. An assessment of graft longevity was not given.

Sydney Coleman has popularised ‘modern’ autologous fat grafting in all body locations, including in the dorsum of hand. Coleman (LOE-4) gives a clear description of the technique for autologous fat grafting [31], in which intact fat cells are harvested from donor sites tumesced with local anaesthetic and adrenaline, using a syringe and blunt cannula and avoiding excessive negative pressure (which could damage fat cells both mechanically and through lowering the boiling point of fat towards room temperature). Centrifugation of the harvested fatty material (3000 rpm for three minutes) yields a three-layer centrifugate. The uppermost oil from ruptured fat cells is decanted and wicked, the lowermost aqueous portion drained out, and the remaining middle portion consists of live, donor fat cells.

Currently the most accepted technique for injecting fat grafts aims to maximise contact between fat cells and recipient tissue. To achieve this, small aliquots or fat parcels are deposited in various directions and, if possible, planes. The alternative technique described earlier, of injecting a single dorsal fat lump and dispersing it by massage, would leave all but

a rim of outermost fat cells without the potential for revascularisation, potentially leading to poor graft survival, contour irregularities, fat necrosis and oil cysts. Coleman acknowledges that hand rejuvenation by fat grafting is not 'anatomical', in the sense that an attractive young hand is not fat, but instead fat is used to simulate thicker skin and subcutaneous tissue, soften the colour and definition of extensor tendons and veins, and support the skin [31].

Butterwick's studies on hand rejuvenation by fat grafting examine operative technique using a double-blind randomised controlled trial and side-by-side two-hand model. Low study numbers prevent these well-designed studies from attaining level 1 evidence. The first [29] (LOE-2) compared survival of centrifuged versus uncentrifuged fat grafts for dorsal hand augmentation, using aesthetics, venous prominence and depth of metacarpal space as surrogate markers. Fourteen patients were evaluated up to five months after injection of ten millilitres of centrifuged or non-centrifuged fat. Surprisingly there was a preference for the non-centrifuged side at one month follow-up, but this was replaced by a preference for centrifuged fat at three and five months in all patients.

Butterwick's second randomised controlled trial [30] (LOE-2) was a similar study in terms of design and outcome measures, this time comparing the survival of fresh or frozen fat grafts (fast frozen to -40°C, and slow thawed prior to use). Surgical technique was generally similar to that of Coleman [31]. Interestingly, at all time points there was a strong consistent aesthetic preference for frozen fat, and venous prominence and metacarpal space depth was also lower in that group. Whilst a physiological basis for improved survival of pre-frozen fat grafts is difficult to explain, this study indicates that frozen fat grafts appear to be at least as effective as fresh graft. This offers the potential for a single modest volume harvest followed by repeated small volume transfers of fresh followed by frozen fat.

Butterwick acknowledged that the follow-up interval was short in these studies. Moreover, the subject of investigation in the earlier trial - fat graft centrifugation - is less a matter of debate now than it was at the time, since either centrifugation or filtration of harvested fat has become accepted and standard practice as a means of improving survival of fat graft injectate. Regarding the second study, freezing of harvested fat in the United Kingdom would be governed by legislation proscribing the storage of human tissue [60], and in practice would be difficult to carry out. Therefore these high quality studies have little practical relevance to current practice, except perhaps to document that autologous fat grafting in general (irrespective of trial study group) appears an effective means of hand volume replacement.

Non-Autologous Fillers

Soft tissue augmentation of the dorsum of hands is probably carried out more commonly using non-autologous fillers than autologous fat (owing to the reduced cost and facility requirements of the former), although comparative data does not exist. Fillers described for this purpose in the literature include hyaluronic acid (HA), collagen, poly-l-lactic acid (PLLA), polymethylmethacrylate (PMMA) and calcium hydroxyapatite (CaHA), but few are the subjects of high level evidence studies.

Hyaluronic Acid and Collagen

However, one small but otherwise well-designed double-blind randomised controlled trial [37] (LOE-2) compared the use of 1.4ml HA (Restylane) and 2ml collagen (Cosmoplast) fillers for dorsal hand soft tissue augmentation in opposing hands of ten female patients.

Serial photographs obtained at one week and one, three and six months were scored by two blinded physicians for rhytid clearance, vein clearance, bony prominence and soft tissue atrophy. Additionally, patients scored each side for tolerability and satisfaction with the outcome.

Injections of HA filler were rated as significantly more painful, possibly because the collagen filler formulation included 0.3% lidocaine. There was a modest, non-significant, higher patient satisfaction following use of HA. However, physician evaluators rated HA as significantly superior to collagen using the indices of soft tissue augmentation at all time points. Side effects noted by the study were generally mild: pain, tingling and bruising following injection. One patient - in the collagen filler group - experienced nodule formation. Overall the authors favoured the use of HA over collagen filler.

Other evidence relating to these fillers is of lower level evidence. Hartmann [34] (LOE-5) reported the use of stabilised HA (Macrolane™ VRF290, Restylane Vital and Restylane Vital Light) in two patients. In one, Macrolane™ was injected subcutaneously in a fan-shaped pattern using a blunt 18-gauge cannula through a small incision made centrally in the proximal dorsum of the hand. In the other, Restylane Vital and Vital Light was injected more superficially (dermal to sub dermal level) with a 30-gauge needle using a tunnelling and tenting technique for fine correction or to correct less severe lipoatrophy. After injection, the material was massaged in. Both procedures were carried out under topical local anaesthesia and the patient treated with Macrolane™ received additional local anaesthetic injections at the incision site. Outcomes were clinician-recorded subjective observations, finding improved appearance with reduced visibility of veins and tendons and symmetrically filled interphalangeal spaces. No complications were reported, although as a two-patient study the power to detect complications would be very low.

A larger series of twelve patients treated with porcine collagen (Dermicol-P35 30G) for volume replacement in the hands (bilaterally) was published the same year [35] (LOE-5). Ten women and two men had the treatment carried out under topical anaesthesia using serial puncture or the linear threading technique, followed by firm massage to evenly distribute the filler. At 8-24 weeks, patients were ‘very satisfied’ with 23 out of 24 hands and ‘satisfied’ with one out of 24. Minimal to no swelling, mild discomfort lasting one to two days and minor bruising (two hands) were reported. At three months 22 out of 24 hands maintained cosmetic improvement. Comparison of the results of the two latter papers cannot be made as there were no standardised measurements of improvement. Both Hartmann and Inglefield reported good patient tolerance to the treatments, with early return to normal activities.

Poly-l-Lactic Acid

The use of PLLA as a semipermanent dorsal hand filler receives sparse attention in the literature. Whilst none of the three existing publications provide sufficiently high quality evidence to either promote or refute this indication, the reports are generally not encouraging. In a retrospective review of its use in 26 patients, Sadick [40] (LOE-4) described high patient satisfaction in "the majority of patients", although this was not quantified and no formal outcomes were defined. 'Few adverse events' took place according to the authors, but this corresponded to a reported 11.4% complication rate after excluding pain and swelling.

Redaelli [39] (LOE-4) retrospectively reported the outcome of injecting PLLA filler in 27 patients using a satisfaction scoring system (based on patient satisfaction score, physician’s satisfaction score and photograph score) taken before the first treatment and after the last

treatment given. Scores of one to ten were given by the patient, physician and for the pictures (although the basis for this scoring was not given) and the average of these termed the 'definitive graduated score' (DGS). The mean DGS was 6.55, with 22.2% of patients having unsatisfactory results (of less than five). The authors explained that most of these patients had been treated early in the series using too dilute solutions. Since then, a protocol had been set up comprising:

> First session: 2ml for hands using a 5ml dilution (with 0.5ml 3% carbocain and water) of polylactic acid bottles.
>
> Subsequent sessions: 1.5-2ml per hand using a 6-8ml dilution of polylactic acid bottles.

There were reportedly "no important side effects". However, soft tissue irregularity was suggested in one patient ('small nodulation unnoticed by the patient).

The most recent report of the use of PLLA for hand rejuvenation in a single patient (Randon 2010, LOE-5) recounts the author's experience but otherwise adds little more to the evidence. Thus the literature is weak in this area, but hints at a treatment that commonly requires multiple treatments, is frequently uncomfortable and sometimes has little perceptible benefit.

Calcium Hydroxyapatite

Radiesse was approved for the treatment of severe lines and wrinkles of the face in 2006[32]. In 2007, Busso and Applebaum (LOE-5) reported their use of this CaHA filler (with the addition of lidocaine) for hand recontouring [28].

Edelson [32] (LOE-5) recommended mixing Radiesse (1.3ml in Luer-Lok syringe) with 0.5mls of 2% plain lidocaine (in 3ml Luer-Lok syringe) using a Luer-Lok to Luer-Lok connector prior to injection, reducing its viscosity and extrusion force. In his description of technique and experience, the author presented pre- and posttreatment (up to 28 weeks) images of two patients, with the effects of rejuvenation still evident at 28 weeks. Adverse effects other than transient hand swelling were considered infrequent, although no objective comment could be made from this very limited series.

In a short communication, Gargasz [33] (LOE-5) described their technique of subcutaneously injecting Radiesse into the dorsal hands of their patients using a similar technique of bolus and massage dispersal, except under field infiltration local anaesthetic (0.5ml of lidocaine). The author recommended limiting injections to one or two to decrease the chance of irritation to subcutaneous tissue. Patients were allowed to return to normal activities as soon as they felt comfortable. Similar to Edelson, reported adverse effects were limited to local mild swelling and bruising which resolved in one to two weeks [33]. Patients were reviewed two weeks after treatment for more volume injection if required. No objective results of their treatment were reported.

Sadick [41] (LOE-4) used topical anaesthesia prior to injecting CaHA into the dorsum of hands by retrograde delivery. In their case series of ten patients assessing the safety and efficacy of this hand rejuvenation technique, patients, principle investigator and an independent evaluator evaluated wrinkle severity and improvement. The effects of treatment were still present at twelve months, with sixty percent of patients giving satisfactory ratings at this period, with improvement in dorsal hand wrinkles.

d) Skin Changes

Multiple modalities aimed at rejuvenating skin have been described, but relatively few of these have been given specific attention in the literature for rejuvenating the skin of the hand. Dorsal hand skin differs from that of the face, for example, in having thinner dermis, an inferior blood supply and fewer appendages [48]. Descriptions of skin rejuvenation at other sites may therefore not be safely extrapolated to the hands.

The only reasonably high evidence level papers published for rejuvenation of dorsal hand skin relate to fractional photothermolysis [44] (LOE-2) and Plasma Skin Resurfacing (PSR) [42] (LOE-2). Other modalities have been considered at lower evidence level, including the Erbium:YAG laser [14,45] (both LOE-4), salicylic acid peel [17,48] (both LOE-4) and IPL [43] (LOE-4).

Fractional photothermolysis uses a mid-infrared laser to produce discrete thermal injuries, termed microscopic treatment zones (MTZs) surrounded by spared areas from which regeneration takes place. Jih [44] (LOE-2) carried out a prospective randomised study comparing fractional photothermolysis with no treatment in the randomised hands of ten patients (who underwent symmetrisation after the study). Patients with Fitzpatrick skin type V or above were excluded. On the treated side, five treatments were carried out at two to three week intervals using a 1550nm diode-pumped erbium fibre laser, providing 8-9mJ/MTZ and a treatment density of 2500MTZ/cm^2 achieved with ten passes, under topical anaesthesia.

Photographs and skin biopsies were obtained before treatment and one & three months afterwards. Photographs were assessed subjectively by investigator and patient for skin roughness, wrinkling and pigmentation; biopsies were examined histologically. Photographs showed improvement in skin roughness, skin wrinkling & pigmentation at one & three month time points (although physician assessors felt there to be some loss of improvement in pigmentation by three months points), and biopsies demonstrated thickening of epidermis and increased dermal collagen density, as would be expected in response to injury. All patients tolerated the procedure and rated pain as mild to moderate. Unwanted effects appeared limited to transient erythema and swelling.

Plasma skin resurfacing (PSR) uses ultrahigh energy radiofrequency to convert nitrogen to plasma, which is directed to skin via a handpiece, transferring heat and producing its clinical effect. Alster [42] (LOE-2) investigated ten patients undergoing PSR to the hands, neck or chest under topical anaesthesia. Energies were set at 1.0, 1.5 or 1.8J with 10-20% pulse overlap, 1-4Hz pulse repetition and a single pass. Standardised photos obtained before treatment and at days four, seven, fourteen, thirty and ninety were used by independent medical assessors to evaluate texture, pigmentation and wrinkle severity according to a standardised grading scale, and blinded histological comparison was also made of punch biopsies taken before and ninety days after treatment.

Following PSR there was 48% mean improvement in rating scale measurements in treated hands. Statistically significant reductions were seen in wrinkle severity (4.1 to 2.4) and hyperpigmentation (1.8 to 0.4), both at ninety days. Histologically all specimens exhibited epidermal thickening, decreased solar elastosis and increased dermal collagen deposition. All patients experienced erythema, swelling and desquamation in response to PSR, but there was no infection, unwanted scarring or hypopigmentation. The authors felt that higher energy settings produced greater clinical benefit, although the size of the study precluded meaningful subgroup analysis so this was a clinical impression. The disadvantage

of higher energy settings was felt to be prolonged healing time (fourteen versus seven days), and the recommendation given was for more treatment sessions of lower energy.

The Er:YAG laser is marketed as safe for resurfacing photo damaged hand skin, prompting Jimenez [45] (LOE-4) to investigate its use in seven patients. A five millimetre spot size at one joule (5J/cm^2) energy over two to three passes resulted in mostly 'poor' cosmetic improvement at follow up six months later. Two patients developed bacterial infections during healing, and healing was alarmingly prolonged (two to three weeks), exceeding what would be expected in the face using similar treatment parameters. The latter suggests that poor efficacy did not result from undertreatment (in terms of energy delivery). Despite this the authors concluded that Er:YAG laser resurfacing could safely be performed in the hands, apparently disregarding their 29% significant wound infection rate or the fact that 43% of patients said they would not have the treatment again or recommend it to others.

The only other study involving Er:YAG treatment to the hands [46] (LOE-4) adds little additional information. This is a seemingly larger prospective study of 21 patients, although only three of those received laser treatment to the hands (the others receiving it to the face or neck). Inclusion criteria were relatively minor skin changes - superficial fine lines with fine surface textural or pigmentary changes, and at 2.5J/cm^2 the energy density was half that in Jimenez's study. It is unclear how the authors rated photographs obtained at various time points, up to two months post procedure - their methodology states only that *"blinded objective grading of photographs was performed by four aesthetic surgeons using matched and morphed two month postoperative digital images."* Thus the outcome, that there was 48% improvement in the appearance of the dorsal hands, is difficult to interpret. Unwanted outcomes again included erythema and swelling, along with crusting, pain and one Staphylococcal infection. Complications were not subdivided by anatomical site of laser delivery so it is not known which of these related specifically to the dorsal hands.

Salicylic acid peels for rejuvenation of dorsal hand skin has been the subject of two publications, but we could not find strong evidence supporting its use. One paper could not be obtained[17] but reference to it elsewhere [61] indicates that the author presented experience of fifty percent salicylic acid ointment in 81 patients to treat freckling, pigmentation and ageing changes of hands and arms, with apparently excellent results reported. No further information about methodology or results analysis is known.

Swinehart [48] (LOE-4) presented an uncontrolled retrospective review of experience of pretreatment combined with 50% salicylic acid peel to the dorsum of the hands in eleven patients. 0.1% tretinoin was used to inhibit melanogenesis and loosen epidermal attachments, thought to enhance subsequent penetration of peel. 20% tricarboxylic acid (TCA) was used to pretreat actinic keratoses, seborrhoeic keratoses or lentigines. During the peel itself, salicylic acid paste was applied and the treated area dressed with cling film and Kerlix. Dressings were changed at 48 hours and as required thereafter. Desquamation was usually complete by day ten and erythema subsided over three to four weeks.

The follow-up period or quantification method, if any, was not stated in this paper, and there was no control group. Nonetheless the author stated that all patients "experienced excellent results", there being "effective removal of ninety percent or more of cutaneous lesions." Without more methodological detail it is difficult to substantiate those views. Side effects included a burning sensation lasting two days and salicylism resulting from excessive systemic absorption, resulting in tinnitus or muffled hearing, which was self-limiting.

Goldman [43] (LOE-4) presented the use of intense pulsed light (IPL) to rejuvenate aged hand skin in 23 patients of Fitzpatrick skin types I and II presenting with solar lentigines and 'poor skin texture' (presumably rhytids). Four IPL sessions were performed at three to four week intervals using a 550nm filter, 6-9J/cm^2 fluence, 15-20ms delay and pulse duration of 4.2-4.5ms. No topical anaesthesia was necessary, patients receiving only cold dressings before and after treatment. Semi-quantitative assessment of colour, extent and density of solar lentigines was then carried out by the physician four weeks after the procedure. Patients also rated their satisfaction with the outcome.

Despite poor skin texture being an inclusion criterion for the study, no assessment of outcome with regards skin texture was made. Outcome assessment was subjective and there was no control group. The authors' conclusions, that there was improvement in lesion clearance and skin texture with high patient satisfaction, therefore cannot be substantiated. More patients than physicians rated their outcome as 'satisfactory' (rather than 'excellent' or 'good'), indicating they were less impressed with the results. The published case photographs appear to show fading of solar lentigines but the hands nonetheless appeared to retain an aged appearance after IPL treatment.

Hexsel and colleagues[62] (LOE-4) carried out a comparative study between cryotherapy and dermabrasion for the treatment of solar lentigo of the back of the hands. A total of ten patients were treated with cryotherapy in their left hand and dermabrasion in the right hand without anaesthesia. The authors found that stinging during the procedure was more intense with cryotherapy. Three months post procedure, hyperpigmentation was more common in the hands treated with dermabrasion and hypopigmentation more common in the hands treated with cryotherapy. At six months, the treatment modalities exhibited similar rates of hyperpigmentation but hypopigmentation remained more common in the cryotherapy treated hands (55.55% vs. 11.11%). Recurrence rate at nine months was similar between both treatments at 55.55%.

e) Combination Therapies

Several authors have discussed the need for combination therapy to address the different components of ageing that take place in the hand. Almost all have considered the need for fat grafting (addressing volume, skin laxity and visible veins and tendons) in addition to other treatments, such as rhytidoplasty [49] (LOE-4), tricarboxylic acid (TCA) chemical peel [53] (LOE-5), laser therapy [6] (LOE-5) and dermabrasion [54] (LOE-5). Several reviewers have also summarised the multimodal therapies available for hand rejuvenation [50-52,55].

Aboudib Júnior considered fat grafting the most effective modality for hand rejuvenation, although his technique differed somewhat from that popularised by Coleman - in using high pressure suction for fat graft harvest, washing harvested fat in saline rather than centrifuging, and distributing injected fat by massage rather than deposition of multiple small parcels. His case series [49] (LOE-4) presented experience of combining fat grafting with rhytidoplasty (presumably of the hands, although this was not actually explicitly stated) in 47/72 patients, the remainder having fat grafting alone. However some methodological vagueness limits the usefulness of that series as evidence. Outcome quantification was not described so the very precisely attributed patient satisfaction of 98.6% is difficult to corroborate or comprehend. Other measures were imprecise (e.g. that oedema lasted *'about thirty days'* postoperatively),

subjective (e.g. that there was moderate tissue absorption at one year *'without involving the cosmetic result'*) or prone to recall bias (e.g. *that 'no complaints of pain were recorded'*).

From our contemporary understanding of fat grafting we would anticipate poorer survival and higher rates of resorption, fat necrosis and lipid cyst formation from the technique described. Fournier, who uses a similar method of fat grafting by bolus injection and massage distribution, has recently described his experience and long-term outcomes, estimating that approximately 10% patients develop dorsal hand fat cysts, that 25-50% of injected fat is viable, and that some patients exhibit total graft resorption.

The few reviews of hand rejuvenation outline a number of therapeutic options for hand rejuvenation, including topical retinoids, alpha-hydroxy acids, bleaching agents, microdermabrasion, chemical peels, cryotherapy, IPL, laser, photodynamic therapy, autologous and non-autologous fillers and combination therapies. However little data is presented in these reviews and most of the citations do not provide evidence specific to hand rejuvenation [51,52,63].

CONCLUSION

Surgery for hand rejuvenation is controversial. Medical students are taught that there is no such thing as aesthetic hand surgery – function is paramount. For a growing number of practitioners and patients this no longer appears to be the case. Irrespective of their ranking as (only) the second most aesthetically important body part, however, the prime contribution of hands to daily life is unquestionably functional. In this context it is difficult to justify any risk to personal livelihood, self-care and the pursuit of normal life that could result from hand surgery performed for non-functional reasons. As such, an acceptable rejuvenation modality must exhibit an exemplary risk profile. A significant proportion of plastic surgeons would probably consider no degree of adverse risk acceptable for the purpose of hand rejuvenation.

Despite this, hand rejuvenation is requested by patients and offered by practitioners, and as modalities for rejuvenating the rest of the body become more sophisticated, the disparity between senescent hands and a youthful face will increase. Thus we anticipate the demand for hand rejuvenation to continue and expand. Objective assessment of the safety and efficacy of these procedures may take on increasing importance in years to come.

Practitioners wishing to carry out evidence-based hand rejuvenation face several challenges. In general there is a paucity of clinical evidence and practically no such evidence of very high quality. Many reports are anecdotal, based on surgeons' experience or preference, or applied to the hands from rejuvenation procedures used in other anatomical sites without specific evidence. Quantification of outcomes is carried out inconsistently or not at all, and series are generally too small to preclude meaningful statistical analysis. With the current state of the literature it is not possible to provide definitive evidence-based guidance on hand rejuvenation.

Despite this, some trends can cautiously be discerned from an overall view of the literature. Firstly, it appears that ageing of the hands follows several distinct processes - venous prominence, skin excess, skin photo-ageing and volume loss - which may occur to a greater or lesser degree in different individuals. Of these, venous prominence is the single change found, in one study, to confer the greatest appearance of ageing.

Ageing changes can be addressed individually or using combination modalities to tackle several sequelae at once. Some individual modalities address more than one sign of hand ageing - for instance, treatments correcting volume loss also reduce venous prominence.

Skin excess has been addressed by open excision, either through a dorsal wrist crease scar [2,4] or an ulnar scar [3,57] or percutaneous needle collagen induction therapy [4,58]. On empiric grounds the excisional techniques would be expected to have a higher risk profile than percutaneous needle therapy - particularly in terms of nerve injury, swelling, haematoma and stiffness. Thus one should actively seek evidence that decisively refutes the suspicion of harm resulting from these excisional treatments. In the absence of such robust safety data, they are not currently recommended. There is insufficient data for any of these modalities to conclude on either their safety or efficacy.

Venous prominence has been treated by sclerotherapy, endovenous laser therapy and phlebectomy, although the latter is almost completely unreferenced in the medical literature. The largest series of sclerotherapy to the hands showed higher concentrations of sodium tetradecyl sulfate or polidocanol sclerosant to be more efficacious than lower concentrations [5-7,23]. However, microthrombi (treated by thrombectomy) were almost universal and upper limb oedema very common, being severe in 7.5% cases. Half the patients experienced moderate and twenty percent experienced severe discomfort; one patient experienced superficial branch of radial nerve distribution paraesthesia and fourteen percent had recurrence due to neovascularisation. On the basis of admittedly weak evidence, the safety and long-term efficacy of this technique is dubious. It should therefore be approached cautiously and outcomes carefully scrutinised. Similar precautions should be applied to the use of endovenous laser therapy, the efficacy of which has not been quantified formally - a retrospective review of experience in 54 hands reported only that all patients were ‘satisfied’. In this series complications were relatively minor, the most severe being one exit wound burn, which healed conservatively. One cannot accurately determine safety and efficacy based on this study. At very least, these destructive techniques necessarily reduce future options for intravenous access, which may be relevant to the administration of medical treatment (including anaesthesia) to a population who, by self-selection, one must presume are entering a stage of life in which medical comorbidity becomes more common.

Hand rejuvenation by volume enhancement – both autologous [8,29,30] and non-autologous [37] - is supported by the best level evidence in this field. Butterwick carried out double-blind randomised controlled trials to investigate, separately, survival of centrifuged versus uncentrifuged fat grafts, and survival of fresh or frozen fat grafts. Thorough outcome quantification included aesthetics, vein prominence and depth of metacarpal space. More important than the outcomes of the study comparisons (favouring centrifuged fat at the longest follow-up points, and favouring frozen fat at all time points) these studies show that autologous fat grafting as performed using Butterwick’s documented method survives for at least five months, and that volume replacement and aesthetic improvement both occur as a result. The author herself acknowledges that the follow-up period was too short to assess long-term survival, and patient numbers were relatively small. The best available study of non-autologous fillers for hand rejuvenation [37] slightly favoured HA over collagen. This study was also limited by study size and short follow-up.

The best available evidence for rejuvenation of dorsal hand skin relates to fractional photothermolysis [44] and PSR [42]. Photographs and skin biopsies one & three months after fractional photothermolysis showed improvement in skin roughness, skin wrinkling &

pigmentation. However, there was a loss in physician-rated improvement in pigmentation by three months, and no further time points were sampled, reminding the reader of the possibility of a transient response. PSR resulted in improved wrinkle severity and hyperpigmentation associated with epidermal thickening, decreased solar elastosis and increased dermal collagen without major adverse events, in a small series of ten patients. The longevity of the treatment is not known, and larger supportive studies do not exist.

Whilst there exists no high level evidence regarding the Er:YAG laser for rejuvenation of dorsal hand skin, the experience of Jimenez [45] (LOE-4) appears not to support its use both on grounds of safety and efficacy. Cosmetic improvement was rated as 'poor' in six of seven patients at six months, noting (despite the small series) cases of bacterial infection and prolonged healing. At best one could state that there exists no high level definitive evidence, and patients should be counselled accordingly.

REFERENCES

[1] *Daily Mail*. (2006). at <http://www.dailymail.co.uk/health/article-392693/Why-Madonnas-hands-look-older-face.html>

[2] *Daily Mail*. (2006). at <http://www.dailymail.co.uk/tvshowbiz/article-392504/Even-muscles-like-Madonna-beat-hands-time.html>

[3] *Daily Mail*. (2007). at <http://www.dailymail.co.uk/tvshowbiz/article-484060/Shes-vein--Madonnas-hands-look-worse-ever.html>

[4] Wendt, J. R. J. Distal, dorsal superior extremity plasty. *Plastic and Reconstructive Surgery* 106, 210–213 (2000).

[5] Jakubietz, R. G., Kloss, D. F., Gruenert, J. G. & Jakubietz, M. G. The ageing hand. A study to evaluate the chronological ageing process of the hand. *Journal of Plastic, Reconstructive & Aesthetic Surgery* 61, 681–686 (2008).

[6] Abergel, R. P. & David, L. M. Aging hands: a technique of hand rejuvenation by laser resurfacing and autologous fat transfer. *J. Dermatol. Surg. Oncol.* 15, 725–728 (1989).

[7] Abrams, H. L. & Lauber, J. S. Hand rejuvenation. The state of the art. *Dermatol Clin* 8, 553–561 (1990).

[8] Bains, R. D., Thorpe, H. & Southern, S. Hand aging: patients' opinions. *Plastic and Reconstructive Surgery* 117, 2212–2218 (2006).

[9] *Hand Rejuvenation Is the New Must-Have Procedure*. www.plasticsurgerypractice.com 1–1 (2007). at <http://www.plasticsurgerypractice.com/news/18362-hand-rejuvenation-is-the-new-must-have-procedure>

[10] Ganske, M. G. Time on your hands: New ways to keep it from showing. *Longevity* (1993).

[11] Goren, G. *Ambulatory Phlebectomy*. (1995).

[12] Goldberg, D. J. Goldberg: Treatment of neck and hand photoaged skin... - Google Scholar. *Lasers Surg Med* (1998).

[13] Manske, P. R. Aesthetic hand surgery. *The Journal of Hand Surgery* 27, 383–384 (2002).

[14] McDaniel, D. H., Ash, K. & Lord, J. McDaniel: The erbium: Yag laser: a review and follow-up... - Google Scholar. *Lasers Surg Med* (1998).

[15] Jakubietz, R., Grünert, J. G., Kloss, D. F., Meffert, R. & Schmidt, K. Alterung und ideale Ästhetik der Hand. *Der Hautarzt* (2009).
[16] Welch, H. J. & Villavicencio, J. L. Primary varicose veins of the upper extremity: a report of three cases. *J. Vasc. Surg.* 20, 839–843 (1994).
[17] Aronsohn, R. B. Aronsohn: Hand chemosurgery - Google Scholar. *Am J Cosmet Surg* (1984).
[18] Carruthers, A. *et al.* A Validated Hand Grading Scale. *Dermatol Surg* 34, S179–S183 (2008).
[19] Jakubietz, R. G., Jakubietz, M. G., Kloss, D. & Gruenert, J. G. A New Simple Method Used to Prepare Fat for Injection. *Aesth Plast Surg* 29, 546–551 (2005).
[20] Al-Qattan, M. M. Complications related to Artecoll injections for soft tissue augmentation of the hand: 3 case reports. *The Journal of Hand Surgery* 36, 994–997 (2011).
[21] Bowes, L. E. L. & Goldman, M. P. M. Sclerotherapy of reticular and telangiectatic veins of the face, hands, and chest. *Dermatol Surg* 28, 46–51 (2002).
[22] Duffy, D. M. The role of sclerotherapy in the rejuvenation of aging hands. *Cosmet Dermatol* 8, 10 (1995).
[23] Duffy, D. M. D., Garcia, C. C. & Clark, R. E. R. The role of sclerotherapy in abnormal varicose hand veins. *Plastic and Reconstructive Surgery* 104, 1474–1471 (1999).
[24] Duffy, D. M. The Role of Sclerotherapy in Abnormal Varicose Hand Veins. *Plastic and Reconstructive Surgery* 106, 228 (2000).
[25] Lee, B. J. The role of sclerotherapy in abnormal varicose hand veins. *Plastic and Reconstructive Surgery* 106, 227–229 (2000).
[26] Shamma, A. R. & Guy, R. J. Laser Ablation of Unwanted Hand Veins. *Plastic and Reconstructive Surgery* 120, 2017–2024 (2007).
[27] Bidic, S. M., Hatef, D. A. & Rohrich, R. J. Dorsal Hand Anatomy Relevant to Volumetric Rejuvenation. *Plastic and Reconstructive Surgery* 1 (2010). doi:10.1097/PRS.0b013e3181da86ee
[28] Busso, M. & Applebaum, D. Hand augmentation with Radiesse (Calcium hydroxylapatite). *Dermatol. Ther.* 20, 385–387 (2007).
[29] Butterwick, K. J. K. Lipoaugmentation for aging hands: a comparison of the longevity and aesthetic results of centrifuged versus noncentrifuged fat. *Dermatol. Surg.* 28, 987–991 (2002).
[30] Butterwick, K. J., Bevin, A. A. & Iyer, S. Fat Transplantation Using Fresh Versus Frozen Fat: A Side-by-Side Two-Hand Comparison Pilot Study. *Dermatol. Surg.* 32, 640–644 (2006).
[31] Coleman, S. R. S. Hand rejuvenation with structural fat grafting. *Plastic and Reconstructive Surgery* 110, 1731–1737 (2002).
[32] Edelson, K. L. K. Hand recontouring with calcium hydroxylapatite (Radiesse). *J. Cosmet Dermatol* 8, 44–51 (2009).
[33] Gargasz, S. S. & Carbone, M. C. Hand rejuvenation using Radiesse. *Plastic and Reconstructive Surgery* 125, 259e–60e (2010).
[34] Hartmann, V. *et al.* Hand augmentation with stabilized hyaluronic acid (Macrolane™ VRF20 and Restylane ®Vital, Restylane ®Vital Light). *Journal der Deutschen Dermatologischen Gesellschaft* (2009). doi:10.1111/j.1610-0387.2009.07271.x

[35] Inglefield, C. Nonsurgical hand rejuvenation with Dermicol-P35 30G. *Aesthetic Surgery Journal* 29, S19–S21 (2009).
[36] Lauber, J. S. J., Abrams, H. L. H. & Coleman, W. P. W. Application of the tumescent technique to hand augmentation. *J. Dermatol. Surg. Oncol.* 16, 369–373 (1990).
[37] Man, J., Rao, J. & Goldman, M. A Double-Blind, Comparative Study of Nonanimal-Stabilized Hyaluronic Acid versus Human Collagen for Tissue Augmentation of the Dorsal Hands. *Dermatol Surg* 34, 1026–1031 (2008).
[38] Puwanant, A., Evangelisti, S. M. & Griggs, R. C. Treating the chief complaint: hand rejuvenation for Hirayama disease. *Neurology* 77, 190–191 (2011).
[39] Redaelli, A. Cosmetic use of polylactic acid for hand rejuvenation: report on 27 patients. *J. Cosmet Dermatol* 5, 233–238 (2006).
[40] Sadick, N. S., Anderson, D. & Werschler, W. P. Addressing volume loss in hand rejuvenation: A report of clinical experience. *J Cosmet Laser Ther* 10, 237–241 (2008).
[41] Sadick, N. S. A 52-week study of safety and efficacy of calcium hydroxylapatite for rejuvenation of the aging hand. *J. Drugs Dermatol* 10, 47–51 (2011).
[42] Alster, T. S. & Konda, S. Plasma skin resurfacing for regeneration of neck, chest, and hands: investigation of a novel device. *Dermatol Surg* 33, 1315–1321 (2007).
[43] Goldman, A. A., Prati, C. C. & Rossato, F. F. Hand rejuvenation using intense pulsed light. *J. Cutan Med. Surg* 12, 107–113 (2008).
[44] Jih, M. H., Goldberg, L. H. & Kimyai-Asadi, A. Fractional Photothermolysis for Photoaging of Hands. *Dermatol Surg* 34, 73–78 (2007).
[45] Jimenez, G. & Spencer, J. M. Erbium:YAG laser resurfacing of the hands, arms, and neck. *Dermatol Surg* 25, 831–835 (1999).
[46] McDaniel, D. H., Ash, K., Lord, J., Newman, J. & Zukowski, M. The erbium: YAG laser: a review and preliminary report on resurfacing of the face, neck, and hands. *Aesthetic Surgery Journal* 17, 157–164 (1997).
[47] Slavin, J. W. Rejuvenation of the hand: Alternative treatments for lightening the dorsal skin. *Aesthetic Surgery Journal* 20, 72–73 (2000).
[48] Swinehart, J. M. Salicylic acid ointment peeling of the hands and forearms. Effective nonsurgical removal of pigmented lesions and actinic damage. *J Dermatol Surg Oncol* 18, 495–498 (1992).
[49] Júnior, J. H. J. A., de Castro, C. C. C. & Gradel, J. J. Hand rejuvenescence by fat filling. *Annals of Plastic Surgery* 28, 559–564 (1992).
[50] Butterwick, K. J. K. Rejuvenation of the aging hand. *Dermatol Clin* 23, 515–vii (2005).
[51] Levit, E., Daly, D., Scarborough, D. & Bisaccia, E. A Profile of Hand Rejuvenation Options. *Cosmetic Dermatology* 47–53 (2001).
[52] Shamban, A. T. Combination Hand Rejuvenation Procedures. *Aesthetic Surgery Journal* 29, 409–413 (2009).
[53] Teimourian, B., Adham, M. Rejuvenation of the hand: fat injection combined with TCA peel. *Aesthetic Surgery Journal* 20, 70–71 (2000).
[54] Vida, V. T. Lipoinjection and aging hands: the combination of dermabrasion, chemical peel, and lipoinjection for the aesthetic improvement of aging hands. *Am J Cosmet Surg* 6, 27–32 (1989).
[55] Scarborough, D., johnson, B., Lugo, A. & Bisaccia, E. Exploring aesthetic interventions, Part X: rejuvenation options for aging hands. *Skin & Aging* 13, 66–74 (2005).

[56] Jakubietz, R. G., Jakubietz, M. G., Kloss, D. & Gruenert, J. G. Defining the Basic Aesthetics of the Hand. *Aesth Plast Surg* 29, 546–551 (2005).
[57] Handle, M. M., Bonfatti-Ribeiro, L. M. L., Barcaro-Machado, B. H. B. & Pitanguy, I. I. Minimal-scar handlift: a new surgical approach. *Aesthetic Surgery Journal* 31, 953–962 (2011).
[58] Aust, M. C. *et al.* Percutaneous Collagen Induction: Minimally Invasive Skin Rejuvenation without Risk of Hyperpigmentation—Fact or Fiction? *Plastic and Reconstructive Surgery* 122, 1553–1563 (2008).
[59] Fournier, P. F. Microlipoextraction et microlipoinjection. *Rev Chir Esthet Lang Franc* (1985).
[60] Act, H. T. Human Tissue Authority. Human Tissue Act 2004. *London, UK: Human Tissue Authority. URL: http://www. hta. gov. uk/[accessed 22 February 2011]* (2004).
[61] Tosti, A., Grimes, P. E. & De Padova, M. P. *Color atlas of chemical peels*. (2006).
[62] Hexsel, D. M., Mazzuco, R., Bohn, J., Borges, J. & Gobbato, D. O. Clinical comparative study between cryotherapy and local dermabrasion for the treatment of solar lentigo on the back of the hands. *Dermatol Surg* 26, 457–462 (2000).
[63] Scarborough, D., Johnson, B., Lugo, A. & Bisaccia, E. *Exploring aesthetic interventions, Part X: rejuvenation options for aging hands*. 13, 66–74 (2005).

In: Encyclopedia of Surgery (22 Volume Set)
Editors: Andreas Lehrer and Kristin Mueller
ISBN: 978-1-53618-329-0
© 2020 Nova Science Publishers, Inc.

Chapter 43

BODY DYSMORPHIC DISORDER

Valerie Picavet and Peter Hellings*
University Hospitals Leuven, Belgium

KEY POINTS

- Body dysmorphic disorder represents a new name for an old syndrome [1]. Its recognition is critical since an unrecognised preoperative BDD patient may become a severely, and sometimes dangerously, dissatisfied postoperative patient. All plastic surgeons should know about BDD [1-4].
- The psychological impact of nasal deformities and its surgical correction cannot be underestimated [5] and cosmetic rhinoplasty is suspected of being the most frequently requested and performed surgical procedure in this population [6,7]. Unsatisfied patients despite a good cosmetic rhinoplasty result have been reported for as long as the procedure itself [5,8,9]. This chapter aims to explore BDD in general, as well as addressing the particular concerns of BDD in the rhinoplasty population.

HISTORY AND DEFINITION

In 1886, Morselli introduced the term "dysmorphophobia" in the European medical literature [10]. Etymologically this term derives from the Greek "dysmorphia" meaning ugliness, specifically of the face and "phobos" meaning fear. Dysmorphia first appeared in "the histories of Herodotus", referring to the myth of the ugliest girl in Sparta [11]. In the medical literature dysmorphophobia has mostly been defined as the subjective feeling of ugliness or physical defect despite a normal appearance [10,12]. Since the introduction of dysmorphophobia, similar symptoms have been categorised under a variety of names. In the beginning of the twentieth century Janet reported cases of l'obsession de la honte du corps (obsession with shame of the body) and classified it within a large class of syndromes similar to obsessive-compulsive disorder [13]. Similar, Kraepelin described a dysmorphophobic

* Corresponding Author's Email: Peter.Hellings@med.kuleuven.be.

syndrome and urged it to be classified as a compulsive neurosis [14]. One of psychiatry's most famous patients, Freud's Wolf-Man with "hypochondrial paranoia", represents a classic case of dysmorphophobia in the psychoanalytic literature. This patient was convinced he was victim of a nasal injury caused by dermatological treatment of obstructive sebaceous glands, ruining its nasal contour. Brunswick, the Wolf Man's second psychoanalyst, wrote "he neglected his daily life and work because he was engrossed to the exclusion of all else, in the state of his nose" and "his life was centred on the little mirror in his pocket and his fate depended on what it revealed or was about to reveal" [15]. In the 1930s "beauty hypochondria" (Schönheitshypochondrie") and "one who is worried about being ugly" ("Hässlichkeitskummer") are other colourful labels to describe BDD-like preoccupations with imagined defects in appearance [16].

Whereas dysmorphophobia has a clear presence in the European literature, the disorder was only rarely mentioned in the American literature [1]. Moreover, cases of this disorder may first have appeared in the cosmetic and dermatology literature, describing the "minimal deformity" and "insatiable" patient [17,18]. Only in 1980, dysmorphophobia entered the U.S. psychiatric nosology in the Diagnostic and Statistical Manual of Mental Disorders- third edition (DSM-III). It was categorised as an example of an atypical somatoform disorder [19]. With the publication of the DSM-III-revised in 1987, dysmorphophobia achieved diagnostic status and was officially termed "body dysmorphic disorder" [20]. Currently, BDD is categorised as a somatoform disorder [21]. This classification has been criticised, however, asserting that it should be considered as an obsessive-compulsive spectrum disorder or an affective spectrum disorder [22].

The present definition of BDD in the DSM-IV-Text-Revision requires three diagnostic criteria: (A) a preoccupation with an imagined defect in appearance (or if a slight defect is present, the persons' concern is excessive); (B) the preoccupation causes significant distress or impairment in one or more important areas of functioning and (C) the preoccupation is not better accounted for by another psychiatric disorder [21].

CLINICAL FEATURES

Preoccupations with Appearance

The hallmark characteristic of BDD is a preoccupation with some aspect of the appearance. BDD patients are convinced that some aspect of their appearance is unattractive or deformed. In reality, the area of concern appears normal or the flaw is minimal. Any part of the body may be the focus of concern. However the most common areas involved are the hair, skin and face, in particularly the nose [16,23,24]. The complaint about the appearance can be specific or vague and most BDD patients are concerned with more than one body part. Moreover, concerns might shift to another feature over time [16]. The preoccupations with appearance are difficult to resist or control, and on average consume three to eight hours a day [25]. They are often associated with fears of rejection and feelings of low self-esteem, shame, embarrassment, unworthiness, and being unlovable [25].

Intrusive Thoughts

BDD patients typically experience uncontrollable, intrusive thoughts about their appearance. They describe being unable to stop thinking about the perceived defect, some to the extent that they are able to focus on little else. These thoughts may increase in situations in which the person expects to be scrutinized [23]. Many BDD patients are unable to recognise that their concerns are excessive and nearly half of patients are delusional (i.e., certain that their view of the 'defect' is accurate) [25,26]. In addition, most BDD sufferers have delusions of reference, thinking that others take special notice of the 'defect', perhaps staring at it, talking about it, or mocking it [25].

Compulsive Behaviors

In an attempt to calm anxieties concerning appearance, or to avoid the feared ridicule or rejection of others, BDD patients frequently engage in time-consuming repetitive and compulsive behaviours. Common behaviours include comparing with others, mirror checking, excessive grooming, camouflaging and excessive reassurance seeking about their appearance [16,22,23]. For example, Phillips and Diaz found in their evaluation of 188 subjects with BDD that 87% reported excessively checking their appearance in mirrors and other reflective surfaces; 88% also reported camouflaging behaviours such as using a hat or one’s hand to hide the perceived facial defect [27]. Moreover, BDD sufferers frequently avoid situations and clothing that might expose their defect, such as examining oneself in mirrors, swimming or dating [16]. Compulsive behaviours are thought to contribute to the maintenance of BDD, as they prevent sufferers from habituating to the sight of their appearance and keep attention focused on the feature of concern [28]. However, many BDD patients feel that they cannot resist engaging in some of these behaviours, even when the behaviours themselves may worsen the defect, for example in skin picking.

Impairment in Functioning

Intrusive thoughts and compulsive behaviours may consume several hours each day and may lead to significant impairment in social and or occupational life [16,22,23]. 98% out of 188 BDD patients reported interference with their social and occupational life, and approximately thirty percent reported becoming housebound as a result of their condition [27]. Similarly, Phillips and colleagues reported in their study of 200 BDD patients that in the previous month, 36% (n=63) had been absent from work, and 32% (n=56) had skipped school because of the disorder [29]. Moreover, they reported that eleven percent had permanently left school [29].

Reduced Quality of Life and Emotional Distress

Quality of life in BDD patients is low. Phillips investigated the quality of life in 176 BDD sufferers using the Medical Outcomes Study 36-item Short-Form health Survey (SF-36) [30]. BDD patients scored markedly lower in all areas of mental health related quality of life compared to the U.S. normal and compared to patients with type II diabetes, with a recent myocardial infarct and with depression [30]. Moreover, more severe BDD symptoms were significantly correlated with poorer functioning and quality of life[30]. The emotional distress in BDD sufferers ranges from mild distress to severe and disabling emotional pain, leading to suicidal ideation and attempts [16,23,24,31].. Available evidence indicates that approximately 80% of individuals with BDD experience lifetime suicidal ideation and 24% to 28% have attempted suicide [32]. In addition, people with BDD have higher levels of hostility compared to healthy controls [16]. Anger has many sources: frustration over looking abnormal, not being able to improve one's appearance, lack of control, and feelings of being rejected by others or that others are mocking the defect [16]. Not infrequently, anger and violence are directed toward the surgeon or dermatologist who provided unsatisfying treatment [16]. Several cases of BDD patients who threatened, stalked, attempted to kill, or actually killed their dermatologist or plastic surgeon have been reported [9,16]. Finally, for some patients, the emotional desperation to improve the perceived defect can lead to self-harm. For example, the use of abrasive chemicals or razor blades to correct blemishes of the skin is not uncommon [33]. Moreover, some patients even perform their own surgery [7]. Veale described nine patients that performed "Do It Yourself" procedures in an attempt to alter their appearance [7]. This was either in desperation after being declined or unable to afford cosmetic surgery. For example, he reported a female patient, preoccupied by the ugliness of multiple areas of her body, who desired liposuction but could not afford it. Subsequently, she used a knife to cut her thighs in order to squeeze out the fat [7]. Similarly, Phillips described a patient who attempted to perform a rhinoplasty, by opening the nose with a razor blade and replacing the nasal cartilage with chicken cartilage in the desired shape [16].

Co-Morbid Psychopathology

Co-morbid psychopathology occurs frequently in BDD patients. Most common co-occurring disorders are (major) depression, social phobia, substance abuse, obsessive-compulsive disorder and personality disorders [25,27,33]. Depression has the highest rate of co-occurrence, with a lifetime rate of eighty percent and a current rate of 60% [34]. The onset of depression in patients with BDD tends to be either concurrent with or subsequent to the onset of BDD [29].

PREVALENCE AND DEMOGRAPHIC FEATURES OF BDD

Body dysmorphic disorder is not considered rare. The prevalence of BDD in the general community has been reported as 0.7-3%, with a higher prevalence in adolescents and young adults [35-38]. These prevalence rates may be underestimates as BDD is often present in a

hidden state [16,23,35]. BDD patients are embarrassed and reluctant to discuss their concerns. Veale and colleagues reported that 38% of their sample (of fifty patients) would not disclose their concerns to their general practitioners for fear of embarrassment, being misunderstood or not taken seriously [36]. Of the remaining 68% who did mention their concerns to their general practitioner, 83% were dissatisfied with the response [36]. Moreover co-morbid psychopathology might explain to a certain extent the under-recognition of BDD, even in a psychiatric setting. Finally, patients frequently show impaired judgment regarding the psychiatric origin of their concerns and often seek cosmetic treatment because they are convinced they warrant medical, rather than psychiatric attention [16,23]. Therefore, the prevalence of BDD in a cosmetic setting is suspected to be much higher with rates of 6-54% being reported [37-39].

The mean age of onset of BDD is late adolescence, however, BDD is usually diagnosed years later [16]. Although the gender ratio has varied in some clinical samples, BDD appears to affect men and women equally [21,27]. Information on ethnicity and BDD symptoms is rare. It has been shown that Afro-Americans of both genders are less dissatisfied with their bodies than Caucasians, Asians, and Hispanics, suggesting that ethnic background contributes to a person's vulnerability and risk for BDD [40]. However, BDD has been reported in numerous countries and continents around the world [25]. These case reports and series suggest that BDD's clinical features are generally similar across cultures, but that culture may produce nuances and accents [25].

COSMETIC TREATMENT IN BDD PATIENTS

For patients with BDD the treatment of choice is psychiatric pharmacological and/or cognitive-behavioural therapy [16]. The primary treatment for BDD does not consist of surgery. Nevertheless the literature reports that 50-76% of BDD patients sought and up to 66% received cosmetic treatment [2,6,41]. Patients refused by a cosmetic surgeon often engage in “doctor-shopping” until they find a provider who is willing to perform the desired treatment [16]. Therefore it has been suspected that the prevalence rate of BDD in a cosmetic setting is much higher than in the general population. In cosmetic settings rates ranging from six to fifteen percent have been reported [35,37,38], with some smaller studies mentioning rates as high as 54% [39,41]. The wide variety in reported prevalence is due to the application of different diagnostic tools and defect severity rating scales. It reflects the lack of a standardised approach for proper identification of BDD patients in this particular setting. Moreover, it raises questions regarding the utility of the present definition of BDD in a cosmetic surgery setting [42,43]. The first criterion of BDD refers to a preoccupation with “an imagined or slight defect in physical appearance”. Cosmetic surgery patients often present with relatively slight defects in appearance, presumably consistent with the diagnosis of BDD. Such minimal flaws in appearance, however, are frequently judged as observable and correctable by the plastic surgeon, falsely excluding patients to meet the diagnostic criteria of BDD. In addition, in cosmetic patients dissatisfaction with an aspect of appearance serves as a motivational component for pursuit of cosmetic surgery [4,44]. Judgment of degree of dissatisfaction and preoccupation is therefore highly subjective [42,43]. Similarly assessing the resulting disruption in daily functioning as defined in the second criterion of BDD-

diagnosis is not straightforward [43]. Nevertheless, it has been suggested that the degree of emotional distress and behavioural impairment are more accurate indicators of BDD in a cosmetic surgery population than the size or nature of the physical defect [41,43].

BDD is reported in a wide variety of cosmetic procedures, but dermatological and facial plastic procedures seem to be most frequently sought by BDD patients [10,32,45], of which rhinoplasty appears to be the most commonly sought facial plastic procedure [6,7].

There is a general consensus that BDD should be considered a contraindication to cosmetic treatments [6,24,46,47]. Clinical reports and retrospective studies reveal that the vast majority of patients with BDD do not benefit from cosmetic surgery. After surgery, they show a low degree of satisfaction, a deterioration of BDD symptoms and may even become violent towards themselves and/or their surgeon [24,26,46]. Unfortunately, only very few prospective studies investigating the impact of BDD on satisfaction after cosmetic surgery are available [41,48,49]. Tignol et al. evaluated the effect of cosmetic surgery in 24 patients with a minimal defect in appearance, with (n=10) and without (n=14) BDD, five years after their request for cosmetic surgery [48]. Seven out of ten BDD patients had undergone cosmetic treatment, confirming that the majority of BDD patients receive cosmetic treatment. BDD patients were significantly younger at the time of cosmetic surgery compared to non-BDD subjects. Surprisingly, patient satisfaction with the intervention was high in both groups. However, six of the seven BDD operated patients still had a BDD diagnosis and exhibited higher levels of disability and psychiatric comorbidity compared to their non-BDD counterparts [48]. Similarly, Veale et al. found in their study of 29 patients seeking cosmetic rhinoplasty, that "possible BDD" patients (n=6) were no less satisfied with the outcome after rhinoplasty at either three or nine months compared to "non-BDD patients" [41]. The authors presumed that they might have identified a group of patients with subclinical or very mild BDD who are satisfied with cosmetic surgery. The weak methodologies of these studies make it difficult to draw firm conclusions. However, patient's declared satisfaction with cosmetic treatment may explain to a certain extent why some plastic surgeons are convinced that BDD should not always be considered as a contraindication for aesthetic surgery [9,48]. On the other hand, a survey conducted among members of the American Society for Aesthetic Plastic Surgery (ASAPS) conducted in 2001 brought to light that 29% of aesthetic surgeons had been threatened legally and 2% physically by a patient with BDD [9]. Furthermore, cases of BDD patients suing their cosmetic surgeon for operating on them, instead of recognizing BDD, have been reported. These cases bring to light additional concerns associated with treating BDD patients and highlight the importance of proper identification of BDD patients in this particular setting.

RHINOPLASTY AND BDD

The central role of the nose in the face makes the nose one of the most common areas of concern in patients with BDD [16,23,26]. As a result, cosmetic rhinoplasty is suspected to be one of the most frequently requested and performed surgical procedures in this population [6,7]. In a study of 200 patients with BDD, Crerand et al. found that rhinoplasty was the most frequent sought (n=33 patients) and performed (n=23) cosmetic surgical procedure [6]. Similarly, Veal et al. found in their analysis of 25 BDD patients with a history of aesthetic

surgery that seventeen underwent cosmetic rhinoplasty [7]. Moreover, in this retrospective study rhinoplasty had the highest level of dissatisfaction after cosmetic surgery [7]. Interestingly, previous research with rhinoplasty patients has found no correlation between the perceived degree of nasal deformity and the amount of psychological disturbance [41,50]. These findings suggest that in this population, the amount of distress and psychological functional impairment may be better indicators of BDD than the degree of nose imperfection [43,50].

To our knowledge there are only three prospective studies investigating BDD in a cosmetic rhinoplasty setting [41,49,50]. Veale and colleagues investigated the prevalence of BDD in 29 patients seeking cosmetic rhinoplasty and evaluated its impact on surgery [41]. In the first stage of the study they found that six patients (21%) had a possible diagnosis of BDD based on a screening questionnaire [41]. This screening tool, the Body Dysmorphic Disorder Questionnaire (BDDQ), had however not yet been validated in a cosmetic surgery population. There were neither significant differences on the depression or anxiety scores, nor on the rating of the nose imperfection in "possible BDD" patients and "no BDD" patients. Furthermore, "possible BDD" patients were no less satisfied with the postoperative result three and nine months after surgery [41]. As mentioned previously, the authors presumed that they might have identified a group of patients with subclinical or very mild BDD who are satisfied with cosmetic surgery. The authors subsequently compared the patients without BDD undergoing rhinoplasty and BDD patients with nasal preoccupations seen in a psychiatric setting. They found that the latter were younger, more depressed, more anxious and more preoccupied with their nose [41]. Moreover they were significantly less functional at work, in their social life and in relations. Finally BDD patients were more convinced that their life would dramatically change after rhinoplasty [41]. The small scale of this study, however, questions its validity.

We previously performed an observational study in 226 patients undergoing rhinoplasty [50] and found that 43% of aesthetic rhinoplasty patients showed moderate to severe BDD symptoms, defined as impairing and distressing thoughts and behaviour concerning their appearance [50]. In contrast, patients undergoing functional rhinoplasty or presenting to the ENT outpatient clinic for general ENT or otological concerns exhibited a moderate to severe BDD symptoms in only twelve percent and two percent of cases respectively [50]. Nevertheless, whereas 43% of aesthetic rhinoplasty patients showed moderate to severe BDD symptoms, only 2% met the diagnostic criteria for BDD. This rate, consistent with BDD rates reported in community samples, but much lower than the prevalence of BDD reported in cosmetic surgery patients, probably underestimates the true prevalence of BDD. Indeed, in the other patients, the nasal deformity was judged as observable and correctable by the aesthetic surgeon, excluding them to meet the diagnostic criteria for BDD [50]. This highlights the shortcoming of the present definition of BDD in a cosmetic setting, where the judgment of a slight defect in appearance seems to be highly subjective and may falsely exclude patients to meet the diagnostic criteria for BDD. This observational study also found a positive correlation between BDD symptom severity and the number of previous rhinoplasties and psychiatric history [50]. The latter emphasises the importance of a thorough preoperative assessment of cosmetic rhinoplasty patients, including a psychiatric history, as it might be an indicator for latent BDD. There was no significant correlation between age, gender, marital status, ethnicity, previous aesthetic surgery other than rhinoplasty, referral pattern, motivation for surgery and severity of BDD symptoms [50].

According to these findings, the first three items in the well-known acronym SIMON (single, immature, male, overly expecting and narcissistic) are not associated with an increased risk of BDD symptoms. In accordance to previous studies there was no correlation between the patients´ and surgeons' evaluation of the nasal shape [43]. Moreover, whereas an inverse correlation between the severity of BDD symptoms and the patients' evaluation of his or her nose was found, there was no correlation between the observers' evaluation of the nasal shape and the severity of BDD symptoms [50]. This confirms that the degree of psychological distress is not related to the actual physical deformity but that it is related to and influences the patients' perception of his or her nasal shape. Finally, this observational study demonstrated that BDD symptoms have a clearly negative effect on daily functioning. Patients with more severe BDD symptoms had significant lower generic QoL and exhibited significantly more appearance-related disruption to everyday living, lower self-esteem, more difficulties with personal relations and emotional distress [50].

Only recently a large scale, prospective study in 166 patients seeking cosmetic rhinoplasty provided the first profound evidence that preoperative BDD symptoms have a clearly negative impact on the subjective outcomes after aesthetic rhinoplasty in terms of satisfaction with the final result and daily functioning [49]. Patients with more severe BDD symptoms before surgery, as assessed with the Yale-Brown Obsessive Compulsive Scale Modified for BDD (BDD-YBOCS), were significantly less satisfied with the final result after surgery. Moreover, after surgery, the subgroup of patients with moderate to severe BDD symptoms experienced significantly more impairment in daily functioning compared to patients with less severe or no BDD symptoms[49]. On the other hand, there was no correlation between patients' and surgeons' appraisal of nasal shape before or three months after surgery [49].

These findings confirm the long-standing impression that the prevalence of BDD and excessive BDD symptoms is much higher in patients presenting for aesthetic rhinoplasty, compared to that reported in the general population. Moreover, in every patient with excessive BDD symptoms, the indication of aesthetic rhinoplasty should be carefully evaluated, even when according to the aesthetic surgeon a nasal deformity is present, as it may result in a severely dissatisfied patient after the intervention.

RECOGNIZING BDD IN A COSMETIC SETTING

Literature on BDD and the awareness of aesthetic surgeons of this disorder have increased over the past decades. Nevertheless, diagnosing BDD during a preoperative consultation remains challenging. An electronic survey of the American Society for Aesthetic Plastic Surgery (ASAPS) demonstrated that 84% of plastic surgeons had treated a patient whom they believed was appropriate for surgery, only to realise after operation that the patient might have had BDD and was not a good candidate [9]. The same survey revealed that surgeons estimated that only two percent of patients seen for primary cosmetic surgery suffer from BDD. This rate, consistent with the prevalence of BDD in the general population but much lower than the prevalence of BDD reported in cosmetic surgery patients, suggests that most surgeons underestimate the prevalence of BDD in their patient population [9].

Missed diagnoses of BDD may be due to the lack of validated, easy-to-use screening tools for BDD in patients seeking aesthetic surgery [51]. We previously performed a systematic review trough Medline and Embase to identify the existing screening tools for BDD in a cosmetic surgery setting[51]. In the majority of cases, general information and questions that might help in the identification of patients at risk for BDD [47,52,53] were provided. Only thirteen studies used a screening tool for diagnosing BDD in patients seeking cosmetic treatment. We identified six different screening tools. Two of them had been validated in a cosmetic dermatology setting: the Body Dysmorphic Disorder Questionnaire - Dermatology Version (BDDQ-DV) and the Dysmorphic Concern Questionnaire (DCQ) [51]. Both BDDQ-DV and DCQ are self-report tools that demand only limited effort of patients and therefore seem suitable for clinical use and large-scale research.

The BDDQ-DV is a modification of the Body Dysmorphic Disorder Questionnaire (BDDQ), a brief screening questionnaire for BDD that has been developed based on the definition of BDD in the Diagnostic and Statistical Manual of Mental Disorders, 4th Edition (DSM-IV)[16]. The BDDQ has been demonstrated to have a good sensitivity (100%) and specificity (89%) in a psychiatric setting[16]. Dufresne and Phillips modified this questionnaire for use in a dermatologic surgery setting (the BDDQ-DV) and tested its psychometric properties in this specific population [53]. The screening questionnaire was compared with the BDD-Diagnostic Manual and was used in combination with a five-point Likert defect rating scale (1: no defect - 5: severe defect). A positive screening for BDD was obtained if the patient acknowledged a preoccupation with his or her appearance and at least moderate (Likert rating scale ≥ 3) distress or impairment in functioning. A 100% sensitivity and 92.3% specificity was found in this particular population. The positive predictive value was 70% and the negative predictive value was 100% [53]. However, the validation process had several limitations. Firstly, the number of patients included was small (n=46), with seven patients diagnosed with BDD according to the BDD-DM. In a later stage, the BDDQ-DV was used in a larger cosmetic surgery population, but was no longer assessed against the gold standard for diagnosing of BDD, giving no further psychometric information of the BDDQ-DV [54]. A second limitation is that a dermatological surgeon and no mental health care worker confirmed the diagnosis of BDD.

The Dysmorphic Concern Questionnaire (DCQ) was constructed by Oosthuizen et al. (1998), based on the General Health Questionnaire (GHQ) [55]. It is a self-report instrument that consists of seven statements asking the respondent to rate their concern about their physical appearance and their attempts to deal with the problem relative to others (0=no concern, 3= much more than other people). The DCQ was originally developed to assess concern over physical appearance without the intent to diagnose BDD [55]. Stangier et al. evaluated the validity and reliability of the DCQ as a screening instrument for BDD in female dermatological outpatients [56]. In this study, the DCQ was assessed against the BDD-DM and the BDD-YBOCS. They found a high sensitivity when used in combination with an assessment of severity of the defect [56]. A cut-off value of greater than or equal to eleven appeared to be most suitable to recognise and screen for BDD (kappa coefficient 0.72, $p<0.001$, 100% sensitivity), whereas a cut-of value of more than or equal to fifteen appeared to be more appropriate to estimate the prevalence of BDD in a specific population (kappa coefficient 0.61, $p<0.001$, 100% specificity) [56]. According to the present instructions, both screening questionnaires should be used in combination with a defect rating scale, assessing the severity of the deformity. However, as mentioned previously, the judgment of a slight

defect in appearance is highly subjective in a cosmetic surgery setting. As a result, the outcome of both screening tools is also subject to interrater variability. Until now, no investigator independent screening tool has been developed. Moreover, no screening tool for BDD has been validated in a non-dermatological cosmetic surgery setting [51].

In two large-scale studies, the Yale-Brown Obsessive Compulsive scale Modified for BDD (BDD-YBOCS) was used to determine BDD symptom severity in patients seeking rhinoplasty [49,50]. This fully validated instrument represents the gold standard to assess the severity of BDD symptoms and consists of ten items rating BDD-related thoughts and behaviours [16,57]. Patients with moderate to severe BDD symptoms (i.e., BDD-YBOCS-score $\geq$ 16) were significantly less satisfied after cosmetic rhinoplasty and had more impairment in daily life compared to patients with no to mild BDD symptoms (i.e., BDD-YBOCS-score < 16), regardless of the objective deformity of nasal shape [50]. Therefore the BDD-YBOCS also seems to be appropriate to for use in the preoperative evaluation of aesthetic patients.

Finally, the use of computerised visual imaging might be helpful in the identification of patients with pathological body image, such as in BDD. Until now, no studies that determine the additional value of computerised visual imaging in patient selection have been performed.

CONCLUSION

BDD is a well-established psychiatric disorder that should be considered as a contraindication for cosmetic rhinoplasty. Given the high prevalence of BDD (symptoms) in a cosmetic rhinoplasty population and its clearly negative influence on the subjective outcomes after surgery, rhinoplasty surgeons should be familiar with BDD. In order to prevent patients from undergoing unsatisfying surgery and in the context of the increasing importance of medico-legal arguments, screening for BDD (symptoms) should be an integral part of the preoperative evaluation of cosmetic rhinoplasty patients.

REFERENCES

[1] Phillips, K. A. (1991). Body dysmorphic disorder: the distress of imagined ugliness. *Am J Psychiatry*, *148*, 1138–1149.

[2] Honigman, R. J., Phillips, K. A. & Castle, D. J. (2004). A Review of Psychosocial Outcomes for Patients Seeking Cosmetic Surgery. *Plastic and Reconstructive Surgery*, *113*, 1229–1237.

[3] Phillips, K. A., Grant, J., Siniscalchi, J. & Albertini, R. S. (2001). Surgical and nonpsychiatric medical treatment of patients with body dysmorphic disorder. *Psychosomatics*, *42*, 504–510.

[4] Sarwer, D. B., Wadden, T. A., Pertschuk, M. J. & Whitaker, L. A. (1998). The psychology of cosmetic surgery: a review and reconceptualization. *Clin Psychol Rev*, *18*, 1–22.

[5] Amodeo, C. A. (2007). The Central Role of the Nose in the Face and the Psyche: Review of the Nose and the Psyche. *Aesth Plast Surg*, *31*, 406–410.

[6] Crerand, C. E., Phillips, K. A., Menard, W. & Fay, C. (2005). Nonpsychiatric medical treatment of body dysmorphic disorder. *Psychosomatics*, *46*, 549–555.
[7] Veale, D. (2000). Outcome of cosmetic surgery and DIY' surgery in patients with body dysmorphic disorder. *Psychiatr Bull R Coll Psychiatr*, *24*, 218–220
[8] Sarwer, D. B. et al. (2005). A prospective, multi-site investigation of patient satisfaction and psychosocial status following cosmetic surgery. *Aesthetic Surgery Journal*, *25*, 263–269.
[9] Sarwer, D. B. (2002). Awareness and identification of body dysmorphic disorder by aesthetic surgeons: Results of a survey of american society for aesthetic plastic surgery members. *Aesthetic Surgery Journal*, *22*, 531–535
[10] Morselli, E. (1886). Sulla dismorfofobia e sulla tanatofobia [On dysmorphophobia and on being buried alive]. *Bolletina Accad. Med. Genova*, *6*, 110–119.
[11] Philippopoulos, G. S. (1979). The analysis of a case of dysmorfophobia. *Can J Psychiatry*, *24*, 397–401.
[12] Munro, A. & Stewart, M. (1991). Body dysmorphic disorder and the DSM-IV: the demise of dysmorphophobia. *Can J Psychiatry*, *36*, 91–96.
[13] Janet, P. (1903). Raymond. *Les Obsessions Et la Psychasthenie*.
[14] Kraepelin, E. (1909). *Psychiatrie: ein Lehrbuch fu˜r Studierende und Arzte* / Vol. I.
[15] Freud, S. (2001). *An infantile neurosis*.
[16] Phillips, K. A. *The broken mirror: understanding and treating body dysmorphic disorder*. (New York: Oxford University Press, 1996).
[17] Edgerton, M. T., Jacobson, W. E. & Meyer, E. (1960). Surgical-psychiatric study of patients seeking plastic (cosmetic) surgery: ninety-eight consecutive patients with minimal deformity. *British Journal of Plastic Surgery*, *13*, 136–145.
[18] Knorr, N. J., Edgerton, M. T. & Hoopes, J. E. (1967).The 'insatiable' cosmetic surgery patient. *Plastic and Reconstructive Surgery*, *40*, 285–289
[19] Association, A. P. (1980). *Diagnostic and Statistical Manual of Mental Disorders*, (DSM-III).
[20] Association, A. P. (1987). [CITATION][C]. Dc: Author.
[21] Association, A. P. (2000). Diagnostic And Statistical Manual Of Mental Disorders DSM-IV-TR Fourth Edition (Text Revision) Author: *American Psychiatr*.
[22] Phillips, K. A., McElroy, S. L., Hudson, J. I. & Pope, H. G. (1995). Body dysmorphic disorder: an obsessive-compulsive spectrum disorder, a form of affective spectrum disorder, or both? *J Clin Psychiatry*, *56*, Suppl 4, 41–51– discussion 52.
[23] Crerand, C. E., Franklin, M. E. & Sarwer, D. B. (2006).Body Dysmorphic Disorder and Cosmetic Surgery. *Plastic and Reconstructive Surgery*, *118*, 167e–180e.
[24] Pavan, C. et al. (2008). Psychopathologic Aspects of Body Dysmorphic Disorder: A Literature Review. *Aesth Plast Surg*, *32*, 473–484.
[25] Phillips, K. A. (2004). Body dysmorphic disorder: recognizing and treating imagined ugliness. *World Psychiatry*, *3*, 12–17.
[26] Phillips, K. A., McElroy, S. L., Keck, P. E., Pope, H. G. & Hudson, J. I. (1993). Body dysmorphic disorder: 30 cases of imagined ugliness. *Am J Psychiatry*, *150*, 302–308
[27] Phillips, K. A. & Diaz, S. F. (1997). Gender differences in body dysmorphic disorder. *J Nerv Ment Dis*, *185*, 570–577.
[28] Rosen, J. C., Reiter, J. & Orosan, P. (1995). Cognitive-behavioral body image therapy for body dysmorphic disorder. *J Consult Clin Psychol*, *63*, 263–269.

[29] Phillips, K. A., Menard, W., Fay, C. & Weisberg, R. (2005). Demographic characteristics, phenomenology, comorbidity, and family history in 200 individuals with body dysmorphic disorder. *Psychosomatics*, *46*, 317–325
[30] Phillips, K. A., Menard, W., Fay, C. & Pagano, M. E. (2005). Psychosocial functioning and quality of life in body dysmorphic disorder. *Compr Psychiatry*, *46*, 254–260
[31] Phillips, K. A. & Menard, W. (2006). Suicidality in body dysmorphic disorder: a prospective study. *Am J Psychiatry*, *163*, 1280–1282
[32] Phillips, K. A. (2007). Suicidality in body dysmorphic disorder. *Primary psychiatry.*
[33] Phillips, K. A. & Taub, S. L. (1995). Skin picking as a symptom of body dysmorphic disorder. *Psychopharmacol Bull*, *31*, 279–288.
[34] Hodgkinson, D. J. (2005). Identifying the Body-Dysmorphic Patient in Aesthetic Surgery. *Aesth Plast Surg*, *29*, 503–509.
[35] Altamura, C., Paluello, M. M., Mundo, E., Medda, S. & Mannu, P. (2001). Clinical and subclinical body dysmorphic disorder. *Eur Arch Psychiatry Clin Neurosci*, *251*, 105–108.
[36] Veale, D. et al. (1996). Body dysmorphic disorder. A survey of fifty cases. *Br J Psychiatry*, *169*, 196–201.
[37] Ishigooka, J. J. et al. (1998). Demographic features of patients seeking cosmetic surgery. *Psychiatry Clin Neurosci*, *52*, 283–287.
[38] Aouizerate, B. et al. (2003). Body dysmorphic disorder in a sample of cosmetic surgery applicants. *Eur Psychiatry*, *18*, 365–368.
[39] Vindigni, V., Pavan, C., Semenzin, M. & Granà, S. (2002). *The importance of recognizing body dysmorphic disorder in cosmetic surgery patients: do our patients need a preoperative psychiatric evaluation?* … of Plastic Surgery.
[40] Mayville, S., Katz, R. C., Gipson, M. T. & Cabral, K. (1999). Assessing the Prevalence of Body Dysmorphic Disorder in an Ethnically Diverse Group of Adolescents. *J Child Fam Stud*, *8*, 357–362.
[41] Veale, D., De Haro, L. & Lambrou, C. (2003). Cosmetic rhinoplasty in body dysmorphic disorder. *British Journal of Plastic Surgery*, *56*, 546–551.
[42] Sarwer, D. B., Crerand, C. E. & Didie, E. R. (2003). Body dysmorphic disorder in cosmetic surgery patients. *Facial Plast Surg*.
[43] Sarwer, D. B., Wadden, T. A., Pertschuk, M. J. & Whitaker, L. A. (1998). Body image dissatisfaction and body dysmorphic disorder in 100 cosmetic surgery patients. *Plastic and Reconstructive Surgery*, *101*, 1644–1649.
[44] Sarwer, D. B., Pertschuk, M. J., Wadden, T. A. & Whitaker, L. A. (1998). Psychological investigations in cosmetic surgery: a look back and a look ahead. *Plastic and Reconstructive Surgery*, *101*, 1136–1142.
[45] Bohne, A. et al. (2002). Prevalence of body dysmorphic disorder in a German college student sample. *Psychiatry Res*, 109, 101–104.
[46] Sarwer, D. B. (1997). The‘ obsessive’ cosmetic surgery patient: a consideration of body image dissatisfaction and body dysmorphic disorder. *Plastic Surgical Nursing*.
[47] Sarwer, D. B. & Crerand, C. E. (2008). Body dysmorphic disorder and appearance enhancing medical treatments. *Body Image*, *5*, 50–58.
[48] Tignol, J., Biraben-Gotzamanis, L., Martin-Guehl, C., Grabot, D. & Aouizerate, B. (2007). Body dysmorphic disorder and cosmetic surgery: evolution of 24 subjects with

a minimal defect in appearance 5 years after their request for cosmetic surgery. *Eur Psychiatry*, *22*, 520–524.

[49] Picavet, V. A. et al. (2013). Preoperative symptoms of body dysmorphic disorder determine postoperative satisfaction and quality of life in aesthetic rhinoplasty. *Plastic and Reconstructive Surgery*, *131*, 861–868.

[50] Picavet, V. A., Prokopakis, E. P., Gabriëls, L., Jorissen, M. & Hellings, P. W. (2011). High Prevalence of Body Dysmorphic Disorder Symptoms in Patients Seeking Rhinoplasty. *Plastic and Reconstructive Surgery*, *128*, 509–517.

[51] Picavet, V. V., Gabriëls, L. L., Jorissen, M. M. & Hellings, P. W. P. (2011). Screening tools for body dysmorphic disorder in a cosmetic surgery setting. *Laryngoscope*, *121*, 2535–2541

[52] Jakubietz, M., Jakubietz, R. J., Kloss, D. F. & Gruenert, J. J. (2007). Body Dysmorphic Disorder: Diagnosis and Approach. *Plastic and Reconstructive Surgery*, *119*, 1924–1930

[53] Phillips, K. A. & Dufresne, R. G. (2000). Body dysmorphic disorder. A guide for dermatologists and cosmetic surgeons. *Am J Clin Dermatol*, *1*, 235–243.

[54] Dufresne, R. G., Jr, Wilkel, C. S. & Vittorio, C. C. (2000). Rate of body dysmorphic disorder in dermatology patients. *Journal of the American*, …

[55] Oosthuizen, P. P., Lambert, T. T. & Castle, D. J. D. (1998). Dysmorphic concern: prevalence and associations with clinical variables. *Aust N Z J Psychiatry*, *32*, 129–132.

[56] Stangier, U., Janich, C. & Adam-Schwebe, S. (2003). Screening for body dysmorphic disorder in dermatological outpatients. *Dermatology and …*

[57] Phillips, K. A. et al. (1997). A severity rating scale for body dysmorphic disorder: development, reliability, and validity of a modified version of the Yale-Brown Obsessive Compulsive Scale. *Psychopharmacol Bull*, *33*, 17–22.

In: Encyclopedia of Surgery (22 Volume Set)
Editors: Andreas Lehrer and Kristin Mueller
ISBN: 978-1-53618-329-0
© 2020 Nova Science Publishers, Inc.

Chapter 44

DEVELOPMENT OF A SURGICAL NAVIGATION SYSTEM BASED ON 3D SLICER USING AUGMENTED REALITY (AR) TECHNOLOGY

Xiaojun Chen*, PhD and Lu Xu
Institute of Biomedical Manufacturing and Life Quality Engineering,
School of Mechanical Engineering, Shanghai Jiao Tong University, Shanghai, China

ABSTRACT

Over the past decades, the field of computer-aided surgery has experienced tremendous development due to the rapid growth of computing power and the improvements in imaging modalities [1]. Based on the guidance of preoperative planning with CT, magnetic resonance imaging (MRI), or other volumetric image data associated with the patient, surgical navigation system is being widely used in various surgeries (ear, nose, oral implantology, etc.) for minimizing the risks and improving the precision of the surgeries [2]. Although some commercially-available surgical navigation systems have been approved for clinical applications, these systems are expensive and not open to the public. 3D Slicer is a free open source software platform for the research community of computer-aided surgery. In this contribution, a loadable module based on Slicer to support surgical navigation has been developed and validated. This research module allows reliable calibration of the surgical instruments, point-based registration and surface matching registration, so that the position and orientation of the surgical instrument can be tracked and displayed on the computer screen in real time to reduce the surgical risks. Furthermore, this module could be shared with global research community and be extended to various surgeries. On the other hand, Augmented Reality (AR)-based surgical navigation is a promising technology for clinical applications. For example, virtual anatomical structures such as soft tissues, blood vessels and nerves can be integrated with the real-world scenario in real time. In this study, an AR-based surgical navigation module (AR-SNS) is developed using an optical see-through HMD (head-mounted display), aiming at improving the safety and reliability of the surgery. With the use of this system, including the calibration of instruments, registration, and the calibration of HMD, the 3D virtual critical anatomical structures are aligned with the

* Corresponding Author's Email: xiaojunchen@163.com; Fax: (+86)21-34206847.

actual structures of patient in real-world scenario during the intra-operative motion tracking process.

Keywords: computer-aided surgery, 3D Slicer, augmented reality, optical see-through HMD

1. INTRODUCTION

Percutaneous sacroiliac joint screw fixation is a kind of minimally invasive surgery for the clinical treatment of posterior pelvic ring injury. Compared with the traditional open reduction and internal fixation, the advantage of the screw insertion technique is that it brings less trauma, less intra-operative blood loss, low infection rate and necrosis rate, quick recovery, etc. However, in order to avoid injuring the peripheral nerves, blood vessels and soft tissues, it is important to control the position and orientation of screw through the intra-operative guidance. Currently, the major techniques include the X-ray C-arm system and computer-aided surgical navigation. Compared with the traditional X-ray C-arm system, the 2D or 3D computer-aided navigation system can improve the safety of sacroiliac joint screw insertion significantly and reduce the intra-operative X-ray fluoroscopy time.

Over the past decades, the field of computer-aided surgery has experienced tremendous development due to the rapid growth of computing power and the improvements in imaging modalities [1]. Based on the guidance of preoperative planning with CT, magnetic resonance imaging (MRI), or other volumetric image data associated with the patient, surgical navigation system is being widely used in various surgeries (ear, nose, oral implantology, etc.) for minimizing the risks and improving the precision of the surgeries [2]. Although some commercially-available surgical navigation systems have been approved for clinical applications such as Kick (Brainlab, Germany), StealthStation (Medtronic, USA), eNLight and NavSuite (Stryker Corporation, USA), Navigation Panel Unit (Storz, Germany) and etc., [3], the disadvantages include high-cost of the whole system and failure to clarify the several apparent issues pertaining to the calibration of the surgical instrument, registration, intra-operative motion tracking, etc. [2] In 2012, Daniel Behrendt (University of Leipzig, Germany), Martin Koestler (BrainLAB, Germany), et al. [4] evaluated 2D-navigaion and 3D-navigation for iliosacral screw fixation using the commercial computer-aided navigation systems (BrainLAB Trauma 2.6 and BrainLAB Spine & Trauma Fluoro-3D 1.6.0). However, the high cost of this navigation system restricts its wide clinical applications since it is not open to the public.

In this study, a powerful software package for visualization and medical image computing called Slicer, or 3D Slicer (Brigham Women's Hospital, Boston, MA) was used as a platform for developing a surgical navigation system. Unlike general commercial workstation, 3D Slicer is a free, open source software and is not required to specific hardware. The purpose of this study is to develop and evaluate a new loadable module named "Surgical Navigation System" (SNS) based on Slicer so that the risks of percutaneous implantation of sacroiliac joint screw surgery can be reduced in anatomically complex operation sites.

On the other hand, all of the traditional navigation systems use computer screen to render the navigation information such as the real-time position and orientation of the surgical instrument, virtual path of preoperative surgical planning, and etc., so that the surgeons have

to switch between the actual operation site and computer screen which is inconvenient and impact the continuity of surgery.

In recent years, due to the great development of Augmented Reality (AR) technology, more and more wearable AR devices have appeared like Google Glass, Skully AR-1 (An AR motorcycle helmet) [5], and etc. AR is an integrated technique of image processing, and in AR system, real objects and virtual (computer-generated) objects are combined in a real environment. Furthermore, real and virtual objects are aligned with each other, and run interactively in real time [6, 7]. Due to the advantages of AR visualization, developing a surgical navigation system based on AR is a significant challenge for the next generation. For example, after the registration of the preoperative CT in relation to the intra-operative realistic scene, surgeons can superimpose the virtual CT data onto the patient's anatomy [8]. In 2010, Liao et al. [9, 10] developed a 3-D augmented reality navigation system for MRI-guided surgery by using auto-stereoscopic images, and the system creates a 3D image, fixed in space, which is independent of viewer pose. In addition, Navab et al. [11] from Technical University of Munich have demonstrated a very practical application of AR. They developed an X-ray C-arm system equipped with a video camera, so that a fused image that combines a direct video view of a patient's elbow with the registered X-ray image of the humerus, radius, and ulna bones was produced.

This study also presents an AR-based surgical navigation module (AR-SNS) using an optical see-through HMD (head-mounted display), which encompasses the preoperative surgical planning, registration, and intraoperative tracking. With the aid of AR-SNS, the surgeon wearing the HMD can obtain a fused image that virtual anatomical structures such as soft tissues, blood vessels and nerves integrated with the intra-operative real-world scenario, so that the safety and reliability of the surgery can be improved.

2. MATERIALS AND METHODS

2.1. Surgical Navigation System Based on 3D Slicer

2.1.1. The Navigation Software Workflow Based on Slicer

Figure 1 shows the workflow and functions of the surgical navigation software based on Slicer (green) and the supporting algorithms and techniques (yellow). With the support of "SNS" module (pink) and some relevant modules from Slicer (blue), the 3D medical modeling, preoperative surgical planning, calibration of surgical instruments, registration, and intraoperative tracking can be realized. The framework of the software starts with loading of the preoperative CT data, and ends with the real-time navigation and its details described as follows:

1) Loading of the original CT data: The patient is imaged in the CT scanner, and the acquired images are automatically transferred to the Slicer interface via the "DICOM" module since Slicer allows loading images in DICOM format from disk or directly from the clinical Picture Archiving and Communication System (PACS).

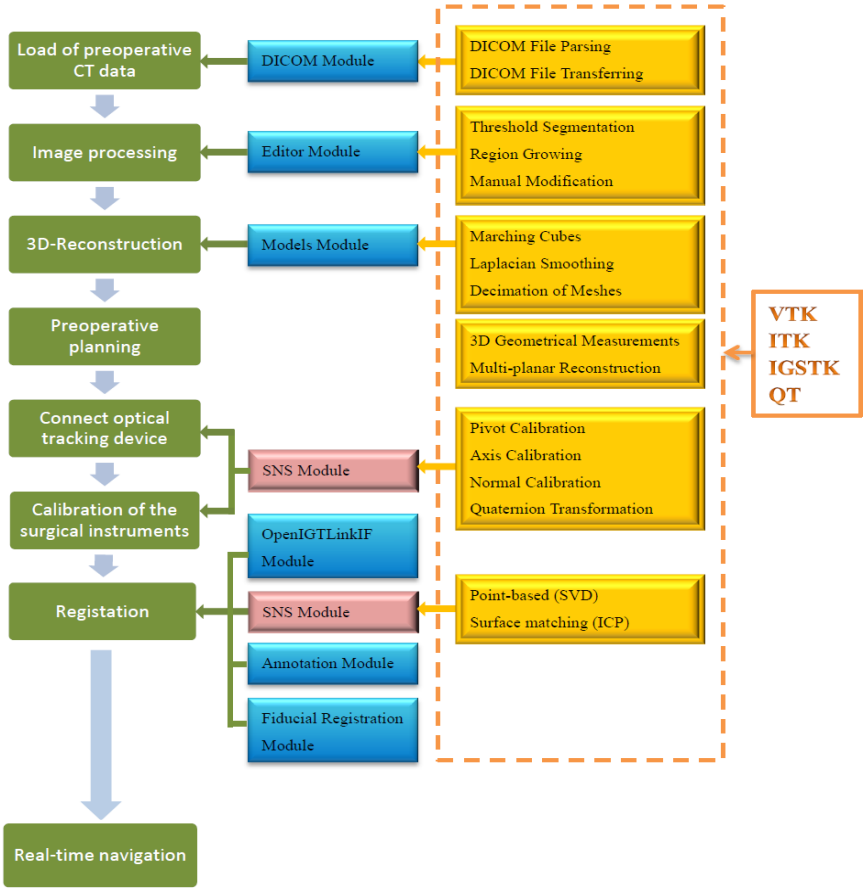

Figure 1. The workflow and functions of surgical navigation software based on Slicer.

2) Image processing: Based on the CT data, each image can be segmented via the "Editor" module. Slicer provides different image segmentation methods for satisfying different requirements such as threshold segmentation and manual modification, so that the hard tissues and soft tissues can be marked.
3) 3D-Reconstruction: After image segmentation, a 3D surface model is reconstructed using the Marching Cubes algorithm [12]. All of the 3D modeling in this step is processed through the "Models" module of 3D Slicer.
4) Preoperative planning: Then, on the basis of these CT images and the 3D model, the user can implement preoperative surgical planning and 3D geometrical measurement via the Slicer ruler. When one target point and one entry point are selected, user can create a trajectory that connects these two points and adjust it in real-time. The virtual optimal path will be rendered on all of the 2D/3D views.
5) Communicate with optical tracking device: The Polaris Vicra optical tracking device can be activated and initialized via the "SNS" module.
6) Calibration of the surgical instruments: Since the Polaris optical tracking system only localizes the reference frame with mounted sphere-shaped retro-reflective markers, it is necessary to determine the spatial relationship between the surgical instrument and the reference frame (this procedure is also called as

"calibration"). Figure 2 shows a simulated surgical drill and a simulated surgical saw used in this research and the coordinate systems for the instrument and the reference frame are respectively established. The calibration encompasses three sections, "Pivot Calibration", "Axis Calibration of surgical drill" and "Surface Calibration of surgical saw", so that the movements of the reference frame can represent those of the surgical instrument.

7) Registration: The basic requirement of any navigation technique is the registration, which is the process of bringing two coordinate systems into spatial alignment [1]. In the most common clinical scenario, patient's position must be registered (aligned) with preoperative image data set on the procedure table. There are a variety of registration methods including paired points [13-15] and surface matching [16, 17] concepts, which are proposed in this study. The details of registration are described below.

2.1.2. Calibration of the Surgical Instruments

The "Pivot Calibration" is to calculate the offset values of the tip point of the instrument. This procedure can be realized through the following method. Pivot the surgical instrument slowly around the tip for about half a minute in the Polaris optical tracking system. Then, on the basis of the collected data of about 250 frames regarding to the movements of the reference frame, the offset values can be calculated. As for the detailed description of the involved algorithms during this procedure, please refer to Ref. [18]. An open-source C++ software library named Image-Guided Surgery Toolkit (IGSTK) providing classes for implementing the standard "Pivot Calibration" [19, 20] is applied to "SNS" module, and the calibration data is automatically saved into an XML file. The orientation of the surgical drill is very important to the surgeons. Figure 3 shows a calibration tool used in this study for carrying out the "Axis Calibration of surgical drill". There is a series of axial holes matched to the different drills. During the calibration process, the surgical drill is inserted into the matched axial hole, and the direction vector (u,v,w) of surgical drill relative to the coordinate system of reference frame can be obtained with the support of the tracking device (shown in Figure 4). According to (1), T1 and T2 are, respectively, the translation matrices of surgical drill's reference frame and calibration tool relative to the tracking system, and (1,0,0)T is the direction vector of axial hole in the coordinate system of calibration tool.

$$(u,v,w)^T = T_1^{-1}T_2\begin{bmatrix}1\\0\\0\end{bmatrix} \tag{1}$$

As for the "Surface Calibration of surgical saw", Figure 5 shows the calibration. The handpiece of the saw lies on the two v grooves, and the blade is inserted into the slot of the calibration tool. The axial vector of the v groove and normal vector of the slot under the coordinate system of calibration tool are all known, and with the support of the tracking device, the normal vector $(u_x, v_x, w_x)^T$ and axial vector $(u_y, v_y, w_y)^T$ of surgical saw relative to the reference frame can be calculated as follows:

$$(u_x, v_x, w_x)^T = T_1^{-1}T_2\begin{bmatrix}1\\0\\0\end{bmatrix} \tag{2}$$

$$(u_y, v_y, w_y)^T = T_1^{-1}T_2\begin{bmatrix}0\\1\\0\end{bmatrix} \tag{3}$$

According to (2) and (3), T_1 and T_2 are, respectively, the translation matrices of surgical saw's reference frame and calibration tool relative to the tracking system. $(1,0,0)^T$ and $(0,1,0)^T$ are, respectively, the normal vector of slot and axial vector of v groove in the coordinate system of calibration tool.

Since the quaternion is used in the XML file to presents the axial offset values while the initial calibrated results are vectors, we need to transform the vectors to a quaternion before running the tracking system. Based on the extension of Euler's formula, a quaternion (shown in (5)) can represents any rotation in three dimensions with an angle of rotation of θ around the axis defined by a unit vector see (4).

$$\underset{u}{\rightarrow} = (u_x, u_y, u_z) = u_x\mathrm{i} + u_y\mathrm{j} + u_z\mathrm{k} \tag{4}$$

$$\mathrm{q} = \cos\frac{1}{2}\theta + (u_x\mathrm{i} + u_y\mathrm{j} + u_z\mathrm{k})\sin\frac{1}{2}\theta \tag{5}$$

Suppose $\underset{v}{\rightarrow}$ is the obtained vector value when calibration step is completed:

$$\underset{v}{\rightarrow} = (\underset{v_x}{\rightarrow}\ \underset{v_y}{\rightarrow}\ \underset{v_z}{\rightarrow}) \tag{6}$$

And in this study, a 3D simulated instrument model is built along the negative direction of Z axis; thus:

$$\underset{z}{\rightarrow} = \left(\underset{z_x}{\rightarrow}\ \underset{z_y}{\rightarrow}\ \underset{z_z}{\rightarrow}\right) = (0, 0, -1) \tag{7}$$

Since the unit vector $\underset{u}{\rightarrow}$ equals the cross product of vector $\underset{v}{\rightarrow}$ and $\underset{z}{\rightarrow}$, based on the (8):

$$\underset{u}{\rightarrow} = \underset{z}{\rightarrow} \times \underset{v}{\rightarrow} = \begin{vmatrix}\mathrm{i} & \mathrm{j} & \mathrm{k}\\ z_x & z_y & z_z\\ v_x & v_y & v_z\end{vmatrix}$$
$$= \begin{vmatrix}z_y & z_z\\ v_y & v_z\end{vmatrix}\mathrm{i} - \begin{vmatrix}z_x & z_z\\ v_x & v_z\end{vmatrix}\mathrm{j} + \begin{vmatrix}z_x & z_y\\ v_x & v_y\end{vmatrix}\mathrm{k} \tag{8}$$

Hence:

$$\cos\theta = \frac{\vec{z}\cdot\vec{v}}{\|\vec{z}\|\,\|\vec{v}\|} = \frac{\underset{z_x}{\rightarrow}\underset{v_x}{\rightarrow} + \underset{z_y}{\rightarrow}\underset{v_y}{\rightarrow} + \underset{z_z}{\rightarrow}\underset{v_z}{\rightarrow}}{\sqrt{z_x^2+z_y^2+z_z^2}\times\sqrt{v_x^2+v_y^2+v_z^2}} \tag{9}$$

So according to (8) and (9), $\underset{u}{\rightarrow}$, $\cos\frac{1}{2}\theta$, $\sin\frac{1}{2}\theta$ are all known , substitution of these results into (5) leads to the value of q. And the quaternion q can be finally written into the XLM file and be read when the Polaris optical tracking system is running.



a) the coordinate systems of surgical drill and the reference

b) the coordinate systems of surgical saw and the reference

Figure 2. The simulated surgical instruments used in this research.



Figure 3. The calibration tool.

Figure 4. The calibration for the surgical drill axis.

Figure 5. The calibration for the surgical saw surface.

2.1.3. Registration

Figure 6 shows the establishment of coordinate systems for real-time tracking in Slicer. There are four 3D coordinate systems, respectively, world coordinate system XYZ determined by the optical tracing system; virtual coordinate system $X_0Y_0Z_0$ (also referred as to the image coordinate system) determined by Slicer; reference coordinate system 1 $X_1Y_1Z_1$ (also referred as to the patient coordinate system) determined by the reference frame fixed on the patient; reference coordinate system 2 $X_2Y_2Z_2$ determined by the position probe. A1 and A2 are the transformation matrices with which Reference Coordinate System 1-2 can be, respectively, transformed to world coordinate system, and are all known through the Polaris optical tracking system. A0 and A10 are the registration transformation matrices with which world coordinate system and reference coordinate system 1 can be, respectively, transformed to virtual coordinate system, and can be obtained through singular value decomposition (SVD) algorithm. Therefore, the spatial relationship among the various coordinate systems in navigation system can be determined, so that the movements of the patient and surgical instruments can be rendered in the preoperative image coordinate system in real time. As for the detailed principle of the point-based registration, please refer to [21].

In Slicer, the point-based registration step is accomplished using the “OpenIGTLinkIF”, “SNS”, “Annotation” and “Fiducial Registration” modules in 3D Slicer. The “OpenIGTLinkIF” module is a program module for network communication with external software/hardware using OpenIGTLink protocol. Therefore, with the support of this module, the optical tracking device can be connected, and it can implement the import and export of position, linear transform and image data between OpenIGTLinkIF-compliant software and MRML scene [22]. MRML scene is a coherent internal data structure that maintains the links between the individual medical image data types, their visualization and any other steady state of the application and modules. While the tracking device Polaris Vicra is communicated with Slicer through the “OpenIGTLinkIF”, the “SNS” will help the user to

obtain a list of fiducial coordinates in the realistic world that matched with the fiducials picked on the virtual image. Based on the two matched lists of fiducials in "Annotation", the fiducial registration can be completed and the position and orientation of the surgical instrument model varies on the computer screen in real time so that the navigation procedure is realized.

Paul J. Besl and Neil D. Mckay [23] described a general-purpose, representation-independent method based on the iterative closest point (ICP) algorithm for registration of 3-D shapes, which is widely used in the field of medical image registration. Therefore, in order to improve the registration precision, surface-based registration based on ICP is realized in "SNS" module. The principle of this method is seeking the closest measured point corresponding with target point set though the repeated iteration. It is an optimal matching algorithm based on the least square method, and the registration is accomplished while the value of objective function that residual sum of squares formed is less than the preset threshold. Figure 7 shows the point cloud on the STL model for surface registration which is collected on the pelvic model surface of patient by using the positioning probe.

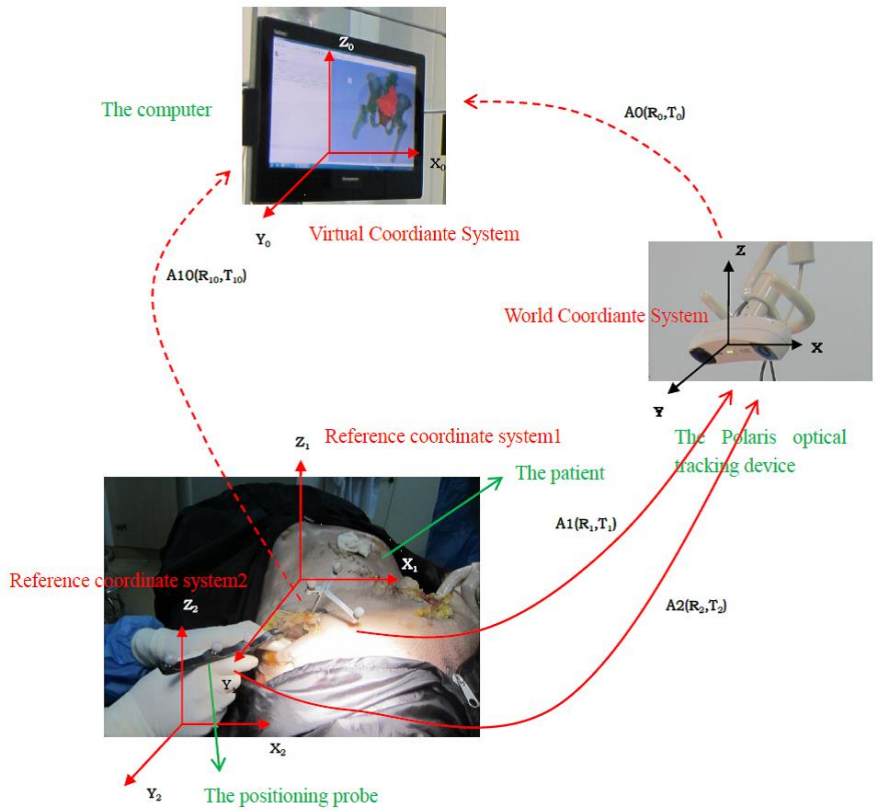

Figure 6. The establishment of coordinate systems for real-time tracking in Slicer.

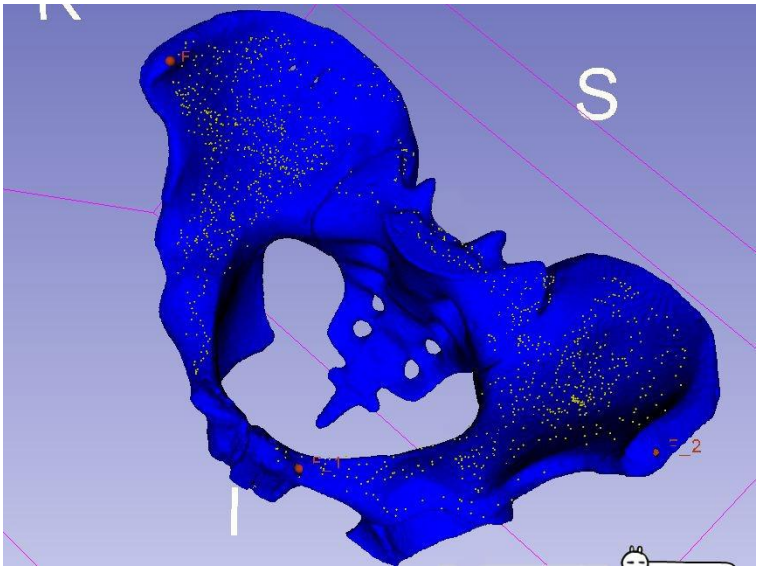

Figure 7. The point cloud for surface registration.

Figure 8. Using a positioning probe to collect the coordinates of the fiducial points.

2.1.4. Phantom Experiment

In order to evaluate the feasibility of the navigation system, a rapid plastic pelvis model is used for conducting a phantom experiment. First, a 3D model was reconstructed through the "Models" module based on the CT data. Then, the calibration of instruments including the positioning probe and the surgical drill were completed in the "SNS" module. After the Polaris optical tracking device was communicated with Slicer through the "OpenIGTLinkIF" module, the operator created a list in "Annotation" module including three fiducials whose coordinates were all initially at origin of a virtual coordinate system (VCS). Meanwhile, with the application of the Polaris and the positioning probe (shown in Figure 8), the coordinates

of the fiducials under the reference coordinate system (RCS) which was determined by the reference frame fixed on the pelvis model were also obtained. Using this two paired list of fiducial points (shown in Figure 9), a registration transformation matrix can be generated through the "Fiducial Registration" module and the movements of the surgical instruments now can be rendered in the preoperative image coordinate system in real time (see Figure 10). In addition, the "Volume Reslice Driver" module can reslice a volumetric image of the patient with the plane along the surgical tool and visualize the sectional image on the 2D and 3D viewer on the 3D Slicer window, which is particularly useful for stereotactic surgical navigation (also see Figure 10).

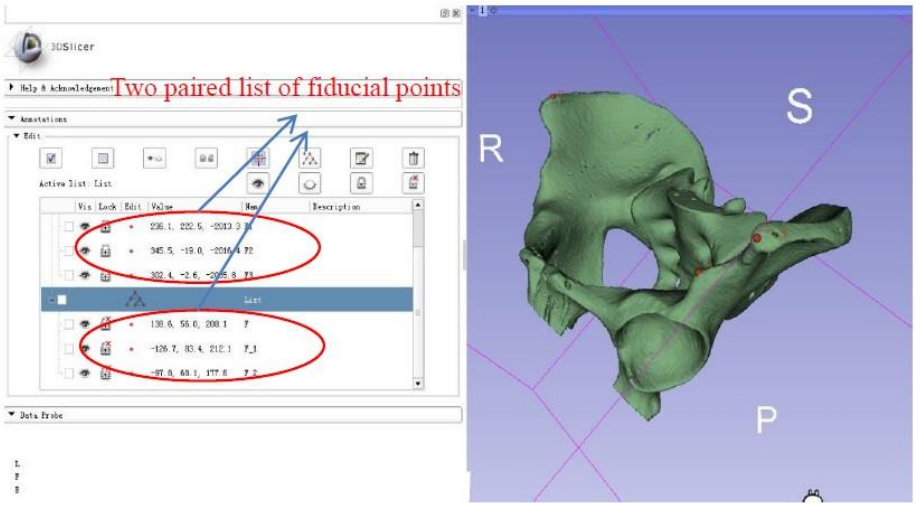

Figure 9. Two paired list of fiducial points.

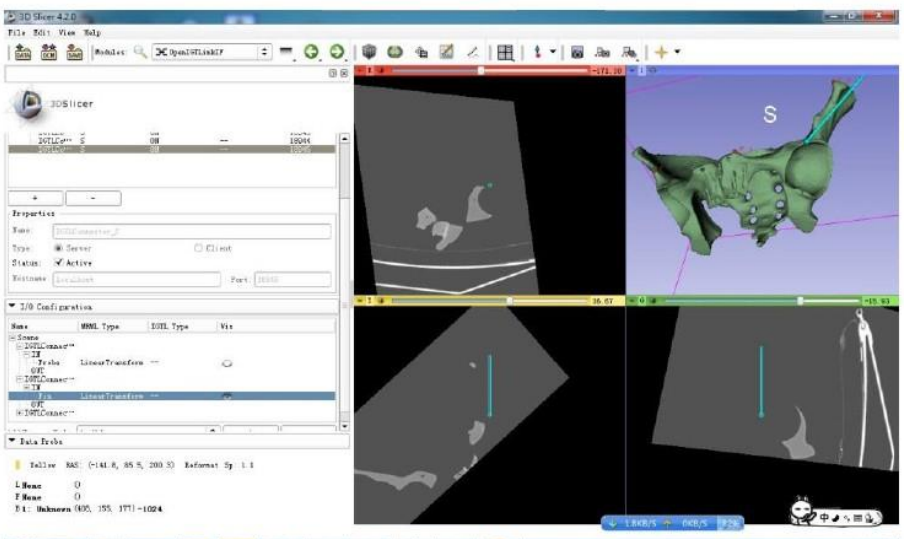

Figure 10. The position of the drill is tracked and rendered on the computer screen.

2.2. The AR-Based Surgical Navigation Module (AR-SNS)

2.2.1. The Hardware Architecture of AR-SNS

The AR-SNS is constructed based on a high-performance graphical workstation (HP), a 2D LCD monitor (G2200W, BenQ), an optical tracking device (Polaris Vicra, NDI Inc., Canada) and an optical see-through HMD (nVisor ST60, NVIS, United States) (Shown in Figure 11). The workstation is equipped with a 4GB memory card, a core i7 CPU and an nVIDIA Quadro FX4800 graphic card, running on the windows 7 operating system. As for HMD, it uses high-resolution microdisplays featuring 1280×1024 24-bit color pixels per eye, for vivid visual rendering and integration with reality.

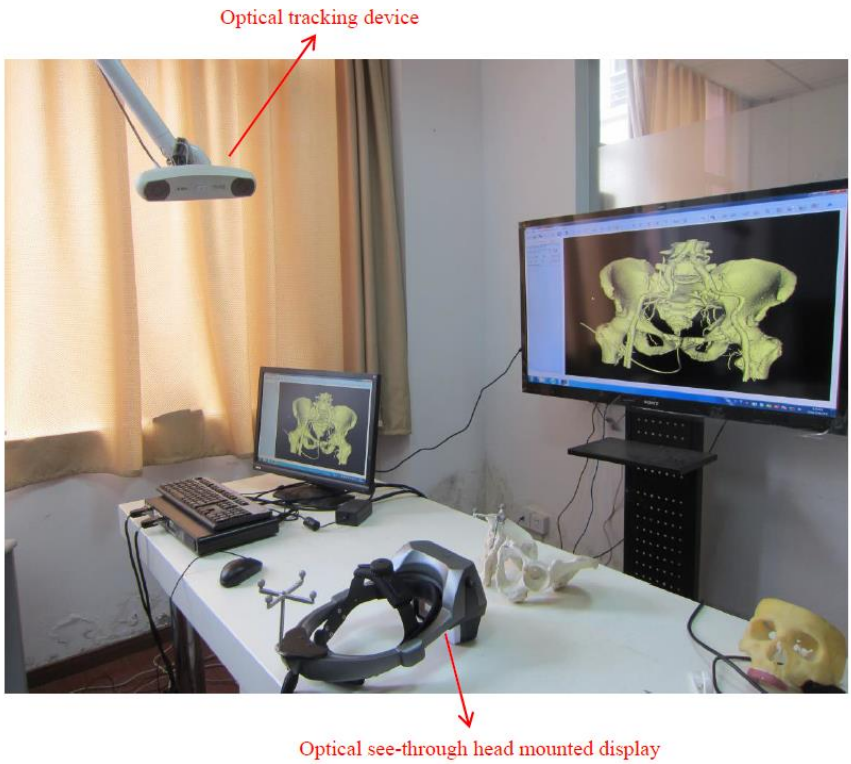

Figure 11. The hardware of AR-SNS.

2.2.2. 3d-Reconstruction and Preoperative Surgical Planning

Based on the original CT data, the segmentation of the hard tissue is conducted by using a threshold and region growing combined method, and for the soft tissue in each image, semi-automatic region growing method is adopted, and if it is over-segmented or under-segmented, manual modification is also used. Then, 3D surface models can be reconstructed through the marching cubes algorithm [12]. Figure 12 shows a 3D pelvis model and a bladder imported into AR-SNS after the 3D-reconstruction. All of the work including the image segmentation and 3D modeling is realized.

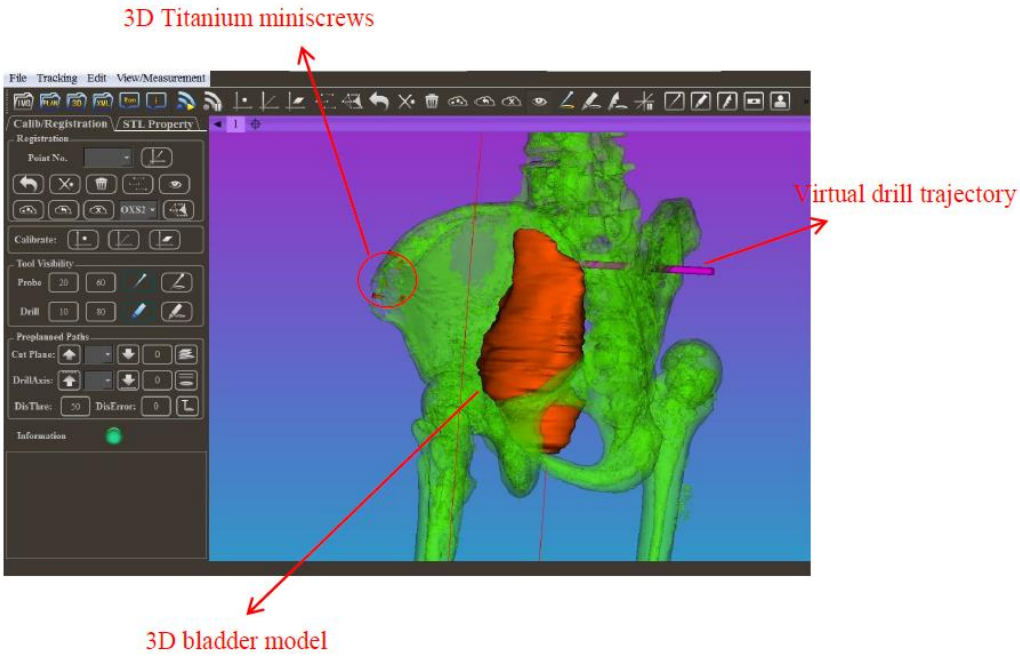

Figure 12. A 3D pelvis model and a bladder imported into the AR-SNS.

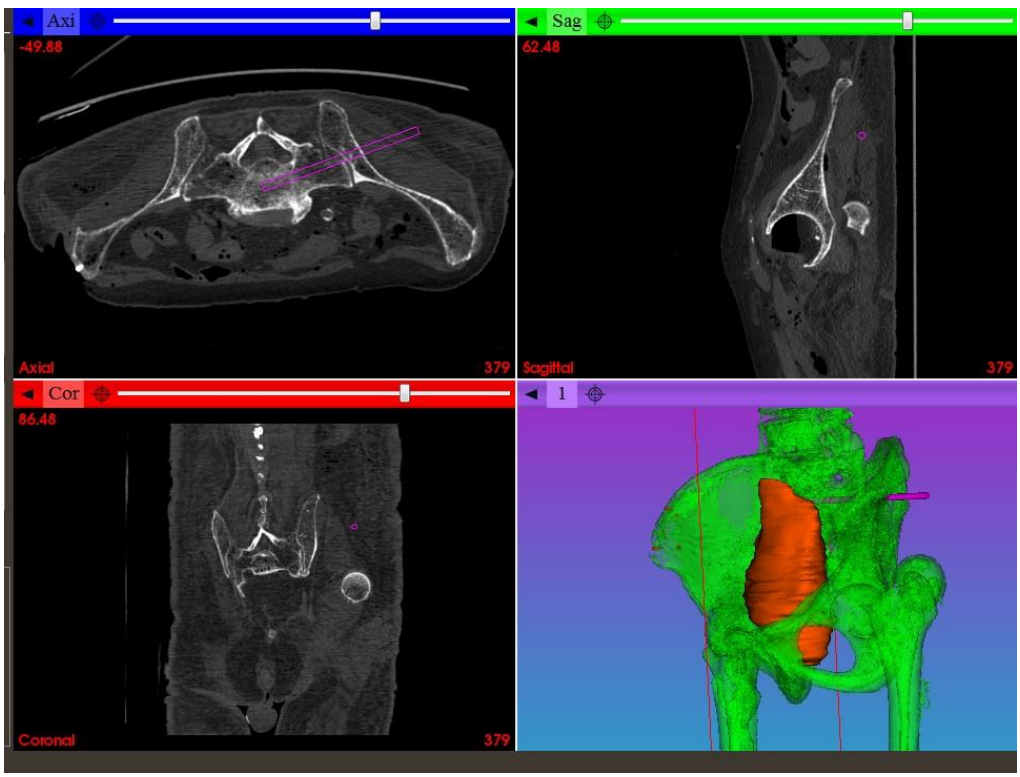

Figure 13. A virtual path for the surgical drill rendering on all of the 2D/3D views.

On the basis of these CT images and the 3D model, the procedure of preoperative planning can be implemented and is describe as follows: percutaneous implantation of sacroiliac joint screw is a very common surgery in orthopedics. And, in order to avoid injuring the important anatomical structures like soft tissues, blood vessels and nerves, a virtual path for the surgical drill should be created and will be rendered on all of the 2D/3D views. An example for a preoperative surgical planning is shown in Figure 13, so that the precision, safety and reliability of the implant surgery can be enhanced.

2.2.3. Calibration of the Patient's Position in Relation to the HMD

After registration, the preoperative images in HMD are aligned with the patient on the procedure table. Then, the calibration of HMD needs to be done. In the AR-SNS, the basic requirement is the calibration of the patient's position in relation to the HMD, which means the movement of the patient or the HMD will not affect the initial correspondence of VCS and RCS. The principle is described as follows: first of all, two reference frames are respectively mounted on the HMD and patient. Then, in order to obtain the calibration matrix after the initial registration of the patient's position in relation to the image data set, we built the transformation relationship shown in Figure 14. Suppose:

R is the initial transformation matrix of VCS to reference frame coordinate system2;

A_1 and A_2 are respectively the transformation matrix of reference frame coordinate system1 to the World Coordinate System before and after movement of the user head;

A_3 and A_4 are respectively the transformation matrix of reference frame coordinate system2 to the World Coordinate System before and after movement of the patient;

B_1 is the matrix of virtual model under the VCS before movement;

B_2 is the calibration transformation matrix of virtual model under the VCS;

Since the relative position of one point on the computer virtual image is fixed before and after movement, setting X as the coordinate of this point in computer virtual image coordinate system. Then, X_1 is the coordinate of X in VCS (also referred as the computer screen coordinate system) before movement and X_2 is the coordinate of X in VCS after movement. Equations (1) and (2) demonstrate the transformational relation:

$$RB_1X = X_1 \tag{1}$$

$$RB_2X = X_2 \tag{2}$$

The purpose is to maintain the relative position of this point in patient coordinate system unchanged before and after movement, so setting X3 as the coordinate of X in reference frame coordinate system2. Equations (3) and (4) show the transformational relation before and after movement:

$$(A_3)^{-1}A_1X_1 = X_3 \tag{3}$$

$$(A_4)^{-1}A_2X_2 = X_3 \tag{4}$$

Thus, based on Equations (1), (2), (3) and (4):

$$B_2 = [(A_4)^{-1}A_2R]^{-1}(A_3)^{-1}A_1RB_1 \tag{5}$$

In the polaris optical tracking system, seven elements representing the unit quaternion and the translation vector, are used to describe the transformation of a rigid body under world coordinate system. Therefore, A1, A2, A3, and A4 can be calculated on the basis of each rigid body's seven elements provided by the Polaris, and R can be calculated through the point-based registration and surface registration respectively under patient coordinate system and virtual coordinate system.

Since A_1, A_2, A_3, A_4, R, B_1 (which can be supposed as an identity matrix) are all known, the calibration transformation matrix B_2 can be calculated according to equation (5). As a result, the position and orientation of the virtual model will change with corresponds to the movement of HMD and patient, and match the real anatomical structures during intra-operative navigation procedure.

The setup of the AR-SNS and the actual view seen from the HMD is also illustrated in Figure 15.

2.2.4. Phantom Experiment and Cadaver Experiment

A phantom experiment was first conducted. With the original CT data (0.625 mm slice thickness, 512×512 matrix), a 3D pelvis model was reconstructed through the threshold segmentation, and fabricated using 3D printing technology. Then, the critical anatomical structures (especially the soft tissues, blood vessels and nerves) can be segmented using the manual modification method. In this experiment, a 3D bladder and some blood vessels and nerves were reconstructed. After calibration and registration, the AR-based surgical navigation was realized. Seen through the HMD, the 3D virtual anatomical structures were aligned with the real plastic pelvis model in any time regardless of the movement of HMD and model. (see Figure 15)

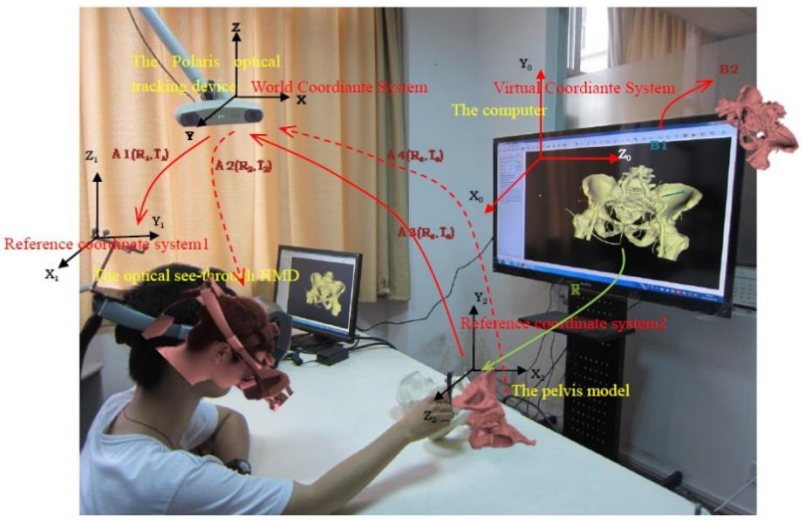

Figure 14. The establishment of coordinate systems in AR-SNS.

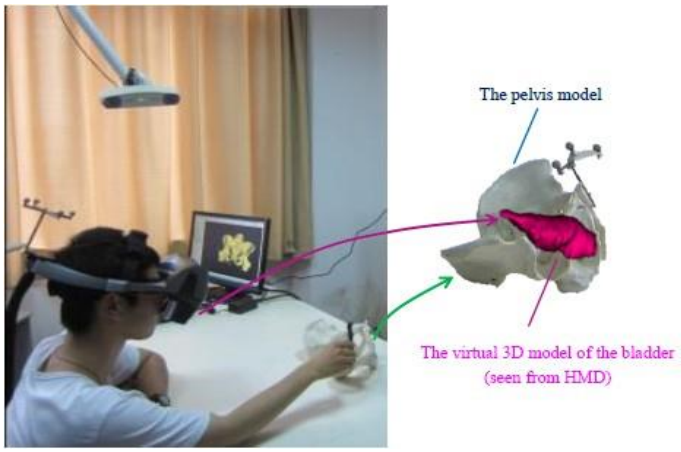

Figure 15. Wearing HMD to conduct a phantom experiment.

Figure 16. The panoramic view of the operating room for a cadaver experiment.

Researchers have also conducted a cadaver experiment for percutaneous implantation of sacroiliac joint screw in an operating room. First of all, five titanium miniscrews were inserted into the pelvis before CT scanning for fiducial point registration. Then, based on the CT data, 3D-reconstruction and preoperative surgical planning were conducted, and the data were imported to AR-SNS. Figure 12 shows the 3D- reconstruction, including a pelvis model, a bladder model and titanium miniscrews models. In addition, the optimization design of a virtual drill trajectory is the preoperative planning result. (see Figure 13) Then, in order to show the position and orientation of the surgical drill model correctly, point calibration and axis calibration were carried out. After point-based and surface matching registration and calibration of the HMD, the 3D virtual bladder was aligned with the real cadaveric pelvis during the intra-operative, and the 3D instrument model is displaying in HMD in real time, so that the operator can implant the sacroiliac joint screw into the pelvis along with the preoperative planned trajectory. (see Figure 16)

CONCLUSION

Nowadays, the minimally invasive surgery is becoming more and more popular in orthopaedics. Percutaneous implantation of sacroiliac joint screw is a typical surgery to treat the posterior pelvic ring injury. Nevertheless, due to the anatomic intricacies of the pelvis and the screw length, it is still a challenge to control the intra-operative position and orientation of the screw for avoiding damaging the surrounding critical anatomical structures. Furthermore, the radiation exposure of the conventional technique using intra-operative X-ray C-arm system is excessive. In the past years, an image-guided system developed by the Brainlab AG company was performed and evaluated on the transiliosacral screw fixation surgery, aiming at minimizing the surgical risks. However, this commercial navigation system is expensive and the lack of software expandability is obvious. As a result, the individual requirements of the surgeons cannot be met. Compared with some commercial visualization and medical image processing software, 3D Slicer (or just Slicer) is a free open source software platform for the community of computer-aided surgery, and it supports the development of extension modules. Although many researcher groups have presented the surgical navigation systems based on Slicer for various surgeries in the literature, their applications in percutaneous sacroiliac joint screw fixation are rarely reported.

In this contribution, a new loadable module ("SNS" module) based on Slicer was developed to achieve computer-aided navigation, aiming at improving the safety of percutaneous sacroiliac joint screw fixation surgery. The presented software module allows the calibration of surgical tools including "Pivot Calibration", "Axis Calibration of surgical drill" and "Surface Calibration of surgical saw", high-accuracy registration (point-based and surface matching), intra-operative motion tracking and virtual intra-operative CT imaging. The implementation and workflow of the designed Slicer module has been described in detail and validated through a cadaver experiment. With the support of other modules like "Editor", "Models", "OpenIGTLinkIF", "Fiducial Registration", etc., image segmentation, 3D-reconstruction, preoperative surgical planning, registration and intra-operative motion tracking can all be realized in Slicer. In addition, the "SNS" module can also be extended to various surgeries such as ear, nose, throat and oral implantology, and will be open-sourced to the global research community.

On the other hand, the Augmented Reality technology has great potential to apply to the computer-aided surgical navigation system. Some examples of AR-based surgical applications have been presented in the literature, for example, a hybrid tracking method for surgical augmented reality (University of Tubingen, Germany), an integral videography system (University of Tokyo, Japan), an alternative biopsy guidance system (University of Pittsburgh, America), an X-ray C-arm system (Technical University of Munich, Germany), etc. In addition, the calibration of AR device is also introduced in some reports. For instance, Falko Kellner (University of Kiel, Germany) et al. proposed a calibration approach with optical see-through head mounted displays to improve the average distance judgment of users in 2012, but, there is a significant underestimation of distances in the virtual environment [24]. Yakup Genc (Siemens Corporate Research Imaging and Visualization Department, America) et al. developed a method to calibrate stereoscopic optical see-through HMDs based on the 3D alignment of a target in the physical world with a virtual object in user's view [25]. However, the calibration algorithm was only validated on a video see-through system, and the

researchers did not validate it for the optical see-through system. Stuart J. Gilson (Department of Physiology, United Kingdom) placed a camera inside an optical see-through HMD to take pictures simultaneously of tracked object and features in the HMD display for performing camera calibration [26]. In this study, a method for calibrating an optical see-through HMD is introduced and validated on an optical see-through system, and a surgical navigation system based on AR has been developed.

With the use of this system, including 3D-reconstruction, preoperative planning, registration, and calibration of HMD, the 3D virtual critical anatomical structures are aligned with the actual structures of patient in real-world scenario during the real-time motion tracking process. Therefore, some disadvantages of the traditional surgical navigation (For example, surgeon is no longer obliged to switch between the real operation scenario and computer screen) are overcome, and the safety, accuracy, and reliability of the surgery may be improved. The cadaver experiment validates the feasibility of AR-SNS. However, it is just a pilot study and still under development. Furthermore, some other experiments will be conducted to test the accuracy and efficiency of this system. The typical method is to measure the average distance deviations between the preoperative surgical planning trajectory and postoperative CT data. The researchers from Germany recently have compared the accuracy of a navigation system for oral implantology using either a head-mounted display or a monitor as a device for visualization. The results show that using of an HMD has no major disadvantages compared to the monitor setting [27].

ACKNOWLEDGMENTS

This study was supported by Natural Science Foundation of China (Grant No.: 81171429), Shanghai Pujiang Talent Program (Grant No.: 13PJD018) and Medical and Technological Joint Science Research Fund of Shanghai Jiao Tong University (Grant No.:YG2011ZD05 and YG2012MS18).

REFERENCES

[1] Cleary, K. and Peters, T. M., Image-guided interventions: Technology review and clinical applications. *Annu. Rev. Biomed. Eng.*, no.12, pp. 119-42, Apr. 2010.

[2] Hong, J., Matsumoto, N., Ouchida, R., Komune, S. and Hashizume, M., Medical navigation system for otologic surgery based on hybrid registration and virtual intraoperative computed tomography. *IEEE Trans. Biomed. Eng.*, vol. 56, no. 2, pp. 426-432, Feb. 2009.

[3] (2014, April 11). [Online]. Available: http://en.wikipedia.org/wiki/Computer-assisted_surgery.

[4] Behrendt, D., Mütze, M., Steinke, H., Koestler, M., Josten, C. and Böhme, J., Evaluation of 2D and 3D navigation for iliosacral screw fixation. *Int. J. CARS*, vol. 7, pp. 249-255, 2012.

[5] (2014, June 10). [Online]. Available: http://www.skullysystems.com/# home

[6] Azuma, R., Baillot, Y., Behringer, R., Feiner, S., Julier, S. and MacIntyre. B., Recent advances in augmented reality. *IEEE Computer Graphics and Applications.* 21: 34-47, 2001.

[7] Yang, M. D., Chao, C. F., Huang, K. S., Lu, L. Y. and Chen, Y. P., Image-based 3D scene reconstruction and exploration in augmented reality. *Automation in Construction.* 33: 48-60, 2013.

[8] Navab, N., Traub, J., Sielhorst, T., Feuerstein, M. and Bichlmeier, C., Action- and workflow-driven augmented reality for computer-aided medical procedures. *IEEE Computer Society.* 27: 10-14, 2007.

[9] Liao, H., Dohi, T. and Iwahara, M., Improved viewing resolution of integral videography by use of rotated prism sheets. *Opt. Express.* 15: 4814-4822, 2007.

[10] Liao, H., Inomata, T., Sakuma, I. and Dohi, T., 3-D augmented reality for MRI-Guided surgery using integral videography autostereoscopic image overlay. *IEEE Trans. on Biomed. Eng.* 57: 1476-1486, 2010.

[11] Navab, N., Heining, S. M. and Traub, J., Camera augmented mobile C-arm (CAMC): calibration, accuracy study and clinical applications. *IEEE Trans. Med. Imaging.* 29: 1412-1423, 2010.

[12] Lorensen, W. E. and Cline, H. E., Marching cubes: A high resolution 3D surface construction algorithm. *ACM Computer Graphics*, vol. 21, pp. 38-44, 1987.

[13] Fitzpatrick, J. M., West, J. B. and Maurer, C. R., Predicting error in rigid body point-based registration. *IEEE Trans. Med. Imag.*, vol. 17, no. 5, pp. 694-702, Oct. 1998.

[14] West, J. B., Fitzpatrick, J. M., Toms, S. A., Maurer, C. R. and Maciunas, R. J., Fiducial point placement and the accuracy of point-based rigid body registration. *Neurosurgery*, vol.48, pp. 810-816, Apr. 2001.

[15] Claes, J., Koekelkoren, E., Wuyts, F. L., Claes, G. M. E., Van Den Hauwe, L. and Van de Heyning, P. H., Accuracy of computer navigation in ear, nose, throat surgery-The influence of matching strategy. *Otolaryngol. Head Neck Surg.*, vol. 126, pp. 1462-1466, Dec. 2000.

[16] Schicho, K., Figl, M., Seemanm, R., Donat, M., Pretterklieber, M. L., Birkfellner, W., Reichwein, A., Wanschitz, F., Kainberger, F., Bergmann, H., Wagner, A. and Ewers, R., Comparison of laser surface scanning and fiducial marker-based registration in frameless stereotaxy. *J. Neurosurg.*, vol. 106, pp. 704-709, Apr. 2007.

[17] Caversaccio, M., Zulliger, D., Bachler, R., Nolte, L. P. and Hausler, R., Practical aspects for optimal registration (matching) on the lateral skull base with an optical frameless computer-aided pointer system. *Amer. J. Otol.*, vol. 21, pp. 863-870, Nov. 2000.

[18] Chen, X. J., Lin, Y. P., Wu, Y. Q. and Wang, C. T., Real-time motion tracking in image-guided oral implantology. *Int. J. Med. Robotics Comput. Assist Surg.*, vol. 4, pp. 339-347, Sep. 2008.

[19] Cleary, K., Cheng, P., Enquobahrie, A. and Yaniv, Z., *IGSTK: The Book*. Signature Book Printing, Gaithersburg, Maryland, 2009.

[20] Maurer, C. R., Fitzpatrick, J. M., Wang, M. Y., Galloway, R. L., Maciunas, R. J. and Allen, G. S., Registration of head volume images using implantable fiducial markers. *IEEE Trans. Med. Imaging*, vol. 16, pp. 447-462, Aug. 1997.

[21] Chen, X. J., Ye, M., Lin, Y. P., Wu, Y. Q. and Wang, C. T., Image guided oral implantology and its application in the placement of zygoma implants. *Computer Methods and Programs in Biomedicine*, vol. 93, pp. 162-173, 2009.

[22] (2013, June 14). [Online]. Available: http://www.slicer.org/slicerWiki /index.php/ Documentation/Nightly/Modules/OpenIGTLinkIF

[23] Besl, P. J. and Mckay, N. D., A method for registration of 3-D shapes. *IEEE Trans. Pattern Anal. Machine Intell.*, vol. 14, pp. 239-256, Feb. 1992.

[24] Kellner, F., Bolte, B., Bruder, G., Rautenberg, U., Steinicke, F., Lappe, M. and Koch, R., Geometric calibration of head-mounted displays and its effects on distance estimation. *IEEE. Trans. on Visualization and Computer Graphics.* 18: 589-596, 2012.

[25] Genc, Y., Sauer, F., Wenzel, F., Tuceryan, M. and Navab, N., Optical see-through HMD calibration: A stereo method validated with a video see-through system. *IEEE and ACM Int. Symposium on Augmented Reality.* 165-174, 2000.

[26] Gilson, S. J., Fitzgibbon, A. W. and Glennerster, A., Spatial calibration of an optical see-through head mounted display. *J. Neurosci Methods.* 173: 140-146, 2008.

[27] Vigh, B., Muller, S., Ristow, O., Deppe, H., Holdstock, S., Hollander, J. D., Navab, N., Steiner, T. and Hohlweg-Majert, B., The use of a head-mounted display in oral implantology: a feasibility study. *Int. J. CARS.* 9: 71-78, 2014.

In: Encyclopedia of Surgery (22 Volume Set)
Editors: Andreas Lehrer and Kristin Mueller
ISBN: 978-1-53618-329-0
© 2020 Nova Science Publishers, Inc.

Chapter 45

APPLICATION OF NAVIGATION SYSTEM IN BIMAXILLARY SURGERY

Sun Yi and Constantinus Politis*
Stomatology and Maxillofacial Surgery,
KU Leuven University

ABSTRACT

Perioperative navigation is an upcoming tool in orthognathic surgery. This chapter contains two parts. The aim of this chapter is to evaluate the accuracy of image-guided maxillary positioning in the sagittal and vertical directions. 18 patients (12 males, 6 females) underwent bimaxillary surgery with the use of perioperative navigation. During Le Fort I osteotomy, the KolibriTM surgical navigation system was used to control movement of the maxilla at the edge of the central upper incisor in the sagittal (buccal surface) and vertical (incisal edge) direction. At one week after surgery, a postoperative lateral cephalogram was taken and was registered to the preoperative lateral cephalogram to identify the actual surgical movement of the maxilla. Student's two-tailed paired t-test was used to evaluate differences between the planned and actual surgical movement of the maxilla, which were 0.63 ± 0.50 mm ($p = 0.12$) in the sagittal direction and 0.57 ± 0.37 mm ($p = 0.45$) in the vertical direction. Our findings show that the navigation system is a useful perioperative tool to control the surgical change of the maxilla in bimaxillary surgery.

Keywords: perioperative navigation, anatomic landmark-based registration, accuracy of image-guided maxillary positioning

INTRODUCTION

Precise positioning of the maxilla is an important determinant of the aesthetic and functional outcomes of orthognathic surgery. Bimaxillary surgery is usually performed in two

* Corresponding Author's Email: constantinus.politis@uzleuven.be.

phases to achieve proper positioning: the preoperative surgical planning and intermediate splint construction, followed by the precise positioning of the maxilla during surgery with the help of the pre-fabricated intermediate and final splints.

Previous studies have shown that a number of inaccuracies can occur during facebow registration, transferring the facebow data to the articulator, and model surgery to fabricate the intermediate splint. Several different methods have been introduced to improve the accuracy of the intermediate splint [1, 2, 5, 6, 16, 17, 25, 26]. Recently, the concept of computer-assisted virtual surgical planning has been introduced. Different methods have been developed to simulate the cut of the jaws, and to virtually place the upper and lower jaws into the desired position [4, 13, 23, 24, 27]. The digital intermediate splint and the final splint are then fabricated through CAD/CAM technology. These rapid prototyping splints have a high degree of accuracy compared to conventional manually fabricated splints [8].

The principle behind the surgical technique has not changed over the past twenty years. During bimaxillary surgery, when the maxilla is mobilized first, the vertical change of the maxilla can be controlled using an intraoral reference point (IRP) [10] or an extraoral reference point (ERP) [7, 9, 11, 15, 18, 19]. Both methods have been proven to have good accuracy in the vertical direction. Regarding the transversal plane , precision relies on the use of the intermediate splint to position the maxilla as planned. The mobility of the temporomandibular joint (TMJ) can potentially lead to inaccuracies, especially in the sagittal direction, and it is sometimes very difficult to achieve full control of, e.g., a multi-segmented maxilla in all dimensions. Therefore, even a good intermediate splint is not always sufficient to precisely position the maxilla in the sagittal direction. There is currently no simple perioperative tool that allows the surgeon to control the surgical change of the maxilla during the operation, especially in the sagittal direction.

Navigation systems are widely used in the operating room to improve surgical accuracy. Bell [3] previously reported the clinical outcome of image-guided orthognathic surgery; however, the accuracy of the surgery was not quantified. The purpose of this chapter is to evaluate the accuracy of image-guided maxillary repositioning in the sagittal and vertical directions.

MATERIALS AND METHODS

18 patients (12 males, 6 females) underwent bimaxillary surgery with perioperative use of the Kolibri™ navigation system (Brainlab AG, Feldkirchen, Germany). A preoperative lateral cephalogram was obtained four weeks before the operation. Surgical treatment was planned based on cast model study, clinical examination and lateral cephalogram tracing. All patients were scheduled for a one-piece Le Fort I osteotomy with a bilateral sagittal split osteotomy (BSSO) of the lower jaw as a second step during the bimaxillary procedure. Wax bite registrations were taken with the teeth in centric relation, followed by facebow registration. Model surgery following the surgical treatment plan was performed on the ARH articulator (Dentatus, Spanga, Sweden). One week before surgery, an intermediate splint was manually fabricated, which was placed inside the patient's mouth on the evening before the operation to ensure that it correctly fit on the occlusal surface.

Each patient was scanned using a SkyView (Cefla dental, Imola, Italy) cone beam computed tomography (CBCT) scanner four weeks before the operation using the following parameters: 9-inch field of view and dentition mode. Each slice was composed of 512 × 512 pixels, and the voxel size was 0.3 × 0.3 × 0.3 mm. The DICOM (Digital Image Communications in Medicine) data was imported into the iPlan ENT 3.0.0 surgical planning software (Brainlab AG, Feldkirchen, Germany). In this program, the Frankfort horizontal plane (FHP) was orientated as the X-Y plane and the nasion perpendicular plane was orientated as the Y-Z plane. The following six anatomical landmarks were selected for point-based registration: the left and right infraorbital foramen, the anterior nasal spine, the tips of the left and right upper canines, and the mesial contact points of the left and right upper incisors (Figure 1). The prepared surgical planning was transferred to the navigation system via USB stick.

The navigation system was set up in a standard operating room. The preoperative CBCT images were displayed on the monitor of the navigation system. With the patient under general anesthesia, the reference star array was securely attached to the patient's skull with a fixation screw (Figure 2). At the beginning of the operation, an experienced surgeon performed patient-to-image registration, following the protocol described by Sun et al [22]. After patient-to-image registration, when the tip of the VectorVision^2 Pointer (Brainlab AG, Feldkirchen, Germany) was placed on a specific anatomic landmark, the position of the pointer tip in the patient space was calculated automatically through the navigation system and transferred to the corresponding position in the preoperative CBCT image space. The position of the pointer tip was projected on the preoperative CBCT image as a green cross.

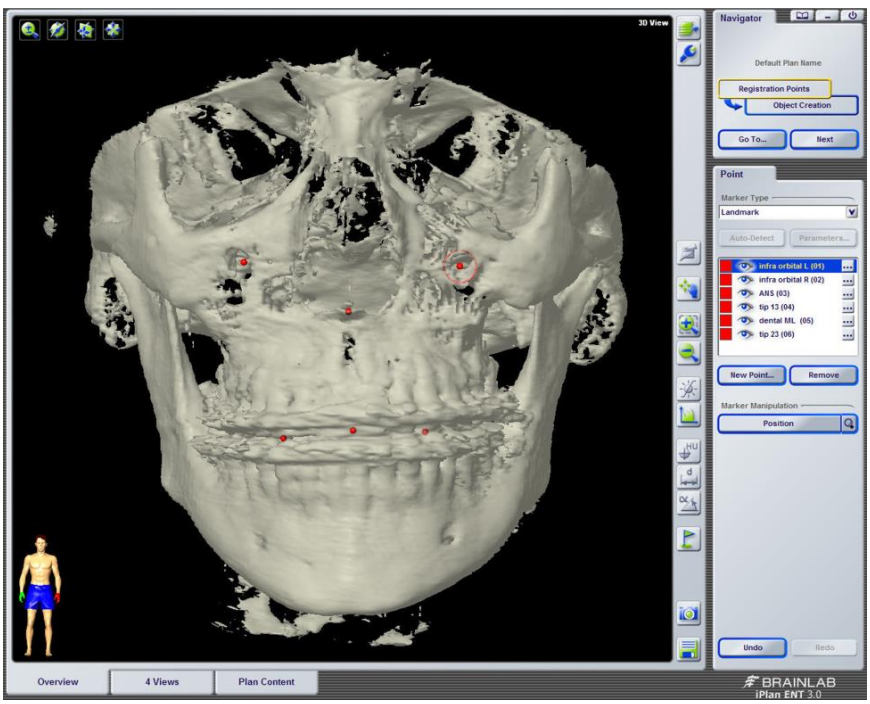

Figure 1. Six anatomical landmarks were indicated in the planning software (iPlan ENT 3.0.0): the left and right infraorbital foramen, the anterior nasal spine, the tips of the left and right upper canines, and the mesial contact point of the left and right upper incisors.

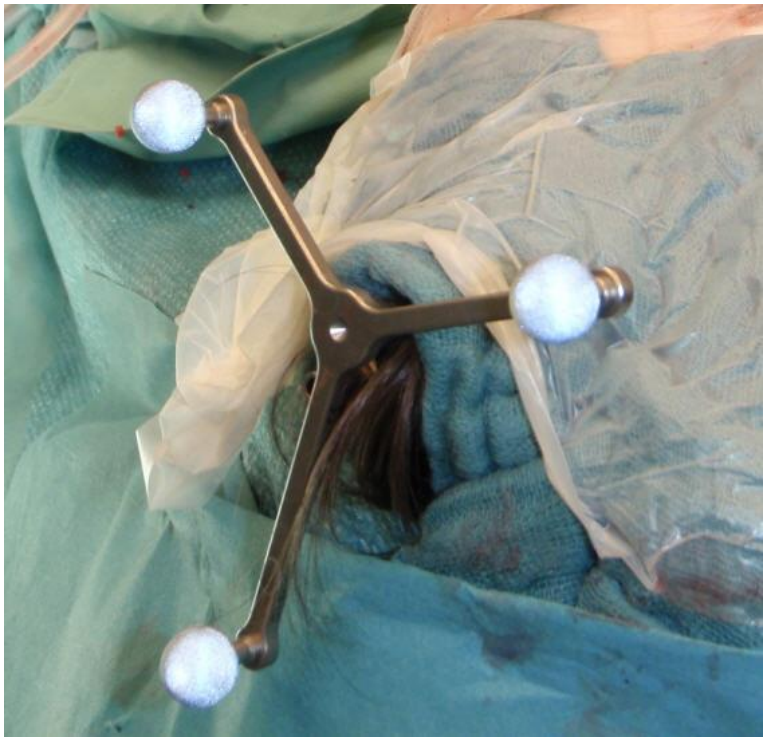

Figure 2. The reference star array was securely attached to the skull of the patient.

The VectorVision^2 Pointer was used to ensure the accuracy of the registration on the following anatomic points: the tips of the left and right upper canines and the upper incisors. The VectorVision^2 Pointer was also used to mark a reference point at the tip of the central upper incisor, which appeared as blue dot on the CBCT image in the navigation system. Registration was accepted if no discrepancy was observed between pointer position in the surgical field and the position of the green cross in the CBCT dataset.

A Tekka screw was inserted at the base of nose. After the down-fracture of the maxilla, intermaxillary fixation was applied using the intermediate splint to reposition the maxillary teeth in the desired occlusion. While the intermediate splint allowed the surgeon to place the maxilla at the desired position in the transversal and sagittal planes, the vertical position was dictated, not by the intermediate splint, but rather by manual intrusion or extrusion rotation on the condyle of the mandible. The vertical change of the maxilla was first controlled using a caliper by repeated measurement of the distance between the Tekka screw and the edge of the upper incisor before and after maxillary positioning.

The VectorVision^2 Pointer was then used to check the vertical change at the edge of the upper central incisor. The pointer was physically positioned at the edge of the central incisor. The axis of the pointer was then orientated perpendicular to the FHP. On the preoperative CBCT image, coming from the green cross, which represented the pointer tip, an offset along the vertical direction was set until it (red cross) reached the edge of the upper central incisors (Figure 3).

The amount of the offset was noted as the surgical change in the vertical direction. The minimum offset was 1 mm. When there was a discrepancy between the vertical measurements from the caliper and the pointer, the measurement of the navigation system was preferred.

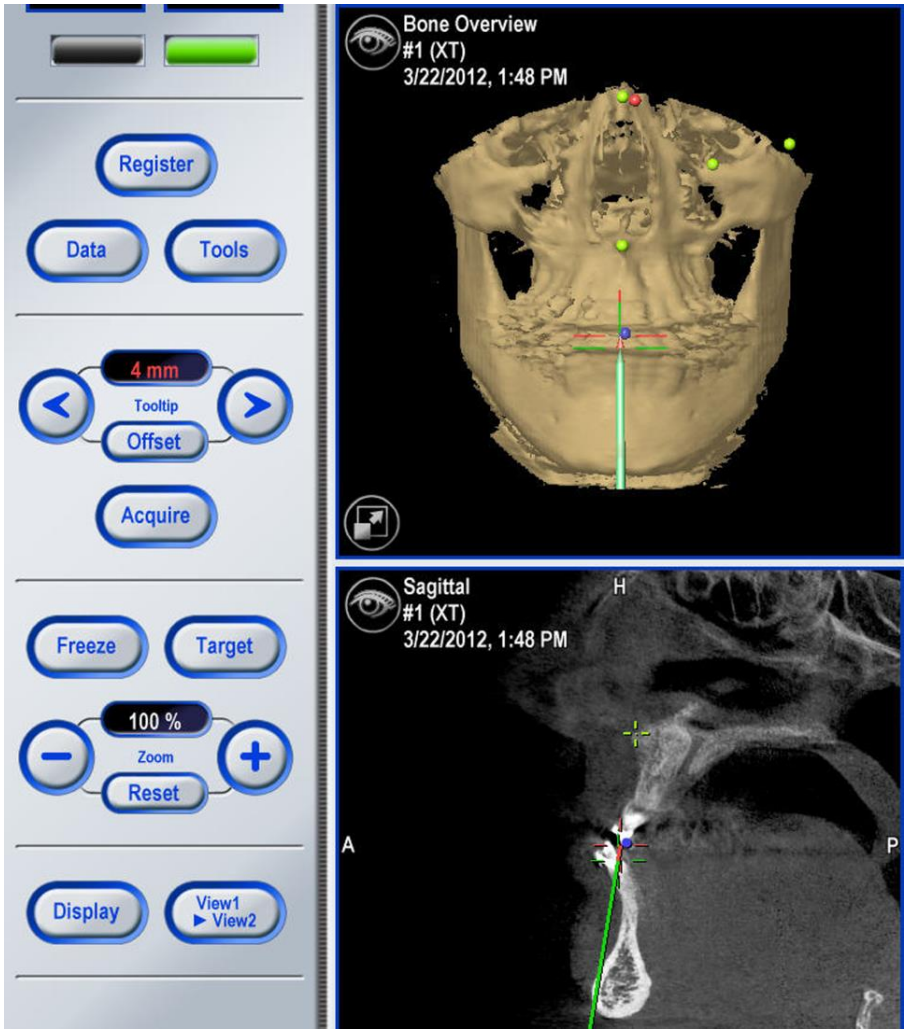

Figure 3. The blue point was acquired at the edge of the upper central incisor after the patient-to-image registration. After Le Fort I osteotomy, to measure the vertical movement of the maxilla using the navigation system, the pointer tip was physically positioned at the edge of the upper central incisor. The axis of the pointer was orientated perpendicular to the FHP. In this example, the pointer tip was projected on the preoperative CBCT image as green cross. The pointer offset was 4 mm along the vertical direction until it (red cross) reached the edge of the upper central incisor in the preoperative CBCT image. The figure illustrated that the surgical change in the vertical direction was 4mm. (From Sun Y, Luebbers HT, Agbaje JO, Lambrichts I, Politis C. The accuracy of image-guided navigation for maxillary positioning in bimaxillary surgery. *J Craniofac Surg* 2014;25(3):1095-9).

To check the surgical movement of the maxilla in the sagittal direction, the pointer was physically positioned at the edge of the central incisor. The axis of the pointer was then orientated parallel to the FHP. On the preoperative CBCT image, coming from the green cross, which represented the pointer tip, an offset along the sagittal direction was set until it (red cross) reached the edge of the upper central incisors (buccal surface) (Figure 4).

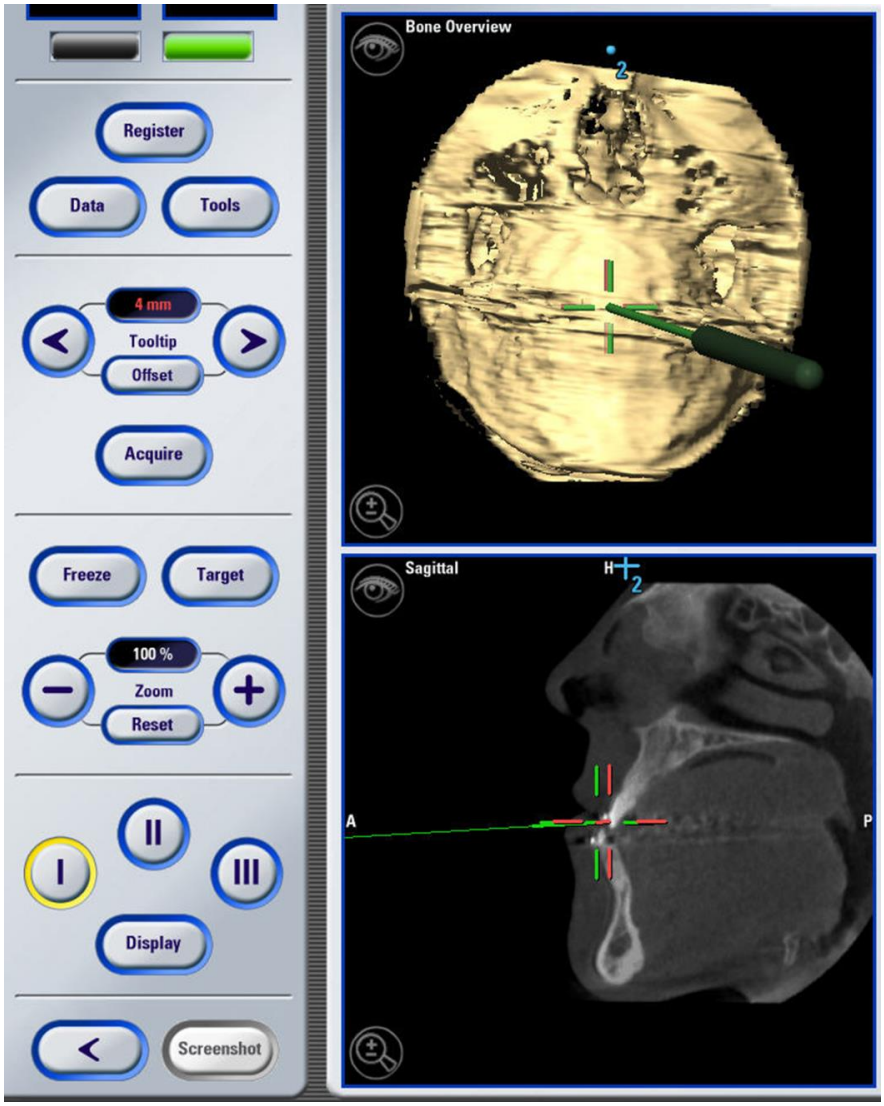

Figure 4. After Le Fort I osteotomy, to measure the sagittal movement of the maxilla using the navigation system, the pointer tip was physically positioned at the edge of the upper central incisor. The axis of the pointer was orientated parallel to the FHP. In this example, pointer tip was projected on the preoperative CBCT image as green cross. The pointer offset was 4 mm along the sagittal direction until it (red cross) reached the edge of the upper central incisor (buccal surface) in the preoperative CBCT image. The figure illustrated that the surgical change in the sagittal direction was 4mm. (From Sun Y, Luebbers HT, Agbaje JO, Lambrichts I, Politis C. The accuracy of image-guided navigation for maxillary positioning in bimaxillary surgery. *J Craniofac Surg* 2014;25(3):1095-9).

The amount of the offset was noted as the surgical change in the sagittal direction. The minimum offset was 1 mm. Since the sagittal position of the maxilla is also determined by the manual compression exerted on the condyle during maxillary repositioning over the intermaxillary fixation, small sagittal corrections could be made until the pointer indicated that the preplanned sagittal position of the upper incisor was reached. The maxilla was then held in the desired position and stabilized with four osteosynthesis plates, which were adapted

to allow for passive placement without displacement of bone during fixation of the osteosynthesis screws. Once the upper jaw was stabilized, the navigation system was used to re-check the surgical movement in the sagittal and vertical directions at the edge of the upper central incisors. This final measurement from the navigation system was recorded for each patient.

At one week after surgery, a postoperative lateral cephalogram was obtained. Surgically unaffected structures of the skull base were used to superimpose the preoperative cephalogram tracing onto the postoperative lateral cephalogram image. The sagittal direction was defined by the preoperative FHP. The vertical direction was perpendicular to the FHP. The actual surgical movement at the edge of central incisor point of the maxilla was measured separately in the sagittal and vertical directions. These measurements were repeated four weeks later by the same observer. For each patient, the actual surgical movement was calculated over these two measurements.

Statistical analysis was performed using MedCalc (MedCalc Software bvba, Belgium). Student's two-tailed paired *t*-test was performed to determine intra-observer reliability; as well as to make comparisons between the planned and the actual surgical movement of the maxilla in the sagittal and vertical directions, and between the measurement results from the navigation system and the actual surgical movement in the sagittal and vertical directions. Differences were considered statistically significant if $p \leq 0.05$.

RESULTS

The preoperative surgical planning included movement of 2 to 6.5 mm in the sagittal direction (defined as advancement/setback) and movement of −8.5 to 4.5 mm in the vertical direction (defined as intrusion/extrusion), with advancement and extrusion represented by movement in the positive direction.

Patient-to-image registration was successful and uneventful in all patients. Evaluation of intra-observer reliability revealed no significant differences between the two measurements based on cephalographic images: sagittal ($p = 0.27$) and vertical ($p = 0.14$). The absolute mean differences between the first and the second measurements were 0.14 mm and 0.16 mm in the sagittal and vertical directions, respectively. In the sagittal direction, the absolute mean difference between the planned and the actual surgical change was 0.63 ± 0.50 mm (0.1–2.1 mm; $p = 0.12$). The absolute mean difference between the measurement result from the navigation system and the actual surgical change was 0.47 ± 0.33 mm (0.1–1.27 mm; $p = 0.19$). The absolute mean difference between the preoperative surgical planning and the measurement result from the navigation system was 0.33 ± 0.45 mm (0–1 mm) (Table 1).

In the vertical direction, the difference between the measurement with the caliper and the measurement from the navigation system was more than 1 mm in two out of 18 patients. The absolute mean difference between the planned and the actual surgical change was 0.57 ± 0.37 mm (0–1.1 mm; $p = 0.45$). The absolute mean difference between the measurement result from the navigation system and the actual surgical change was 0.64 ± 0.41 (0–1.54 mm; $p = 0.94$). The absolute mean difference between the preoperative surgical planning and the measurement result from the navigation system was 0.17 ± 0.30 mm (0–1 mm) (Table 2).

Table 1. Distribution of the differences between the surgical treatment plan, measurement results from the navigation system, and actual surgical change at the edge of the upper central incisor in the sagittal direction (n = 18)

	Range (mm)				Absolute mean ± SD (range) in mm
	0–0.5	0–1	0–1.5	>1.5	
Planned - actual	10 (55.6%)	15 (83.3%)	17 (94.4%)	1 (5.6%)	0.63 ± 0.50 (0.1–2.1)
Navigation - actual	12 (66.7%)	16 (88.9%)	18 (100%)	0 (0%)	0.47 ± 0.33 (0.1–1.27)
Planned - navigation	13 (72.2%)	18 (100%)	18 (100%)	0 (0%)	0.33 ± 0.45 (0–1)

Table 2. Distribution of the differences between the surgical treatment plan, measurement results from the navigation system, and the actual surgical movement at the edge of the upper central incisor in the vertical direction (n = 18)

	Range (mm)				Absolute mean ± SD (range) in mm
	0–0.5	0–1	0–1.5	>1.5	
Planned - actual	8 (44.4%)	17 (94.4%)	18 (100%)	0 (0%)	0.57 ± 0.37 (0–1.1)
Navigation - actual	6 (33.3%)	17 (94.4%)	17 (94.4%)	1 (5.6%)	0.64 ± 0.41 (0–1.54)
Planned - navigation	17 (94.4%)	18 (100%)	18 (100%)	(0 %)	0.17 ± 0.30 (0–1)

DISCUSSION

Successful orthognathic surgery requires repositioning the maxilla as precisely as possible in accordance with the preoperative surgical planning. The surgical accuracy at the anterior maxilla, especially at the incisor tip, is very important for aesthetic reasons, as small inaccuracies of the upper incisor position can affect the patient's satisfaction, particularly if they occur in the vertical position.

The ERP technique used to control the vertical change of maxillary repositioning is highly precise, with previous studies reporting maxillary positioning vertical deviations of between 0.37 and 1 mm [7, 11, 15, 18, 19]. In our study, the surgical change of the maxilla was controlled by the navigation system, and we observed a variation of 0.57 ± 0.37 mm in the vertical direction between the preoperative surgical plan and the actual surgical movement, which was comparable to previous studies using the ERP method.

A most recent study by Gil et al., [9] reported an even better accuracy of 0.3 ± 0.20 mm in the vertical direction using medial canthal region as an ERP. In another study [10], where an improved internal reference point (IRP) technique was applied, 81% of the patients showed a variation of within 0.4 mm in the vertical direction.

There is typically a larger deviation in the sagittal direction. Polido et al [19] reported that the average deviation of sagittal maxillary positioning was about 1.7 mm, which was greater than the deviation in the vertical positioning (1 mm). Ong et al., [15] reported a mean difference of 0.85 mm between the planned and the actual surgical movement in the sagittal direction. Similarly, Kretschmer et al., [11] found a median difference of 1 mm between the planned and the actual surgical movement in the sagittal direction. Deviation in the sagittal direction is likely due to several sources of error: errors associated with the facebow recording, transferring face bow to the articulator, model surgery to fabricate the intermediate splint and the mobility of the TMJ [20, 28]. The present study showed that image guidance improved the deviation in the sagittal direction to a mean of 0.63 mm (0.1–2.1 mm). Omura et al. [14] described another method of joint fixation with positioning plates to improve the accuracy of the maxillary positioning; however, this technique required an additional surgical procedure and it is difficult to manage during surgery. Kretschmer et al., [11] mentioned the clinical outcome of a similar technique, in which 75.2% of the deviations were within 1 mm in both the sagittal and vertical directions. In our study, 83.3% of the patients showed a variation of within 1 mm between the planned and the actual movement of the maxilla in the sagittal direction. This finding was comparable to those mentioned by Kretschmer et al [11] and was better than those reported by Polido et al., [19] (39%) and Stanchina et al., [21] (65%).

In our study, the average deviations between the measurement results from the navigation system and the actual surgical movement were within 0.65 mm in both the sagittal and vertical directions. There were no significant differences between the measurement results of the navigation system and the actual surgical movements in both the sagittal and vertical directions. These findings prove that the navigation system can directly assess the surgical movement of the maxilla in the operating room, and thus has the potential to eliminate the errors associated with facebow recording, transferring face bow to the articulator, model surgery to fabricate the intermediate splint and the mobility of the TMJ.

It must be noted that image-guided surgery can introduce additional errors. Firstly, the navigation system only reports the Euclidian distance between the tip position of the pointer in the world space and the target label in the imaging space. This direct measurement provides no clinically relevant information, it is more important to know the surgical change in sagittal/vertical direction respectively. To identify the surgical change in the sagittal direction, it is necessary to orientate the axis of the pointer parallel to the FHP. Similarly, to evaluate the vertical change of the maxilla, the axis of the pointer needs to be orientated perpendicular to the FHP. Because of the limited space in the oral cavity, it is almost impossible to perfectly measure the sagittal and vertical changes through the pointer, especially in the posterior regions of the maxilla. Additionally, during the operation, the minimum offset unit of the pointer is 1 mm. The surgeon can only estimate the surgical change to up to half of the minimum offset unit, meaning that the maximum accuracy of the measurement is 0.5 mm.

Human-related errors can occur in image-guided surgery, because it is difficult to keep the maxilla stable during maxilla fixation. Even under the guidance of the navigation system, it is difficult to avoid maxillary positioning errors during fixation of the osteosynthesis plates when eccentric drilling occurs or if the plates are not perfectly adapted to the bone in a passive way. Such error may reduce the accuracy of maxillary positioning in the sagittal direction. In our study, the maximum difference between the preoperative planning and the final measurement from the navigation system was within 1 mm.

Finally, the accuracy of the image-guided surgery is mainly defined by the target registration error (TRE). In our study, six anatomic landmarks were selected for patient-to-image registration, and we found maximum differences between the measurement results from the navigation system and the actual surgical movement of 1.27 mm and 1.54 mm in the sagittal and vertical directions, respectively. Sun et al [22] used this method in an *in vitro* study with the same anatomic landmarks selected for paired point-based registration; similar to our findings, they found the mean TRE in the region of the maxilla to be 0.93 ± 0.31 mm, and the maximum TRE observed was 1.6 mm in the region of frontal maxilla. The TRE is one factor that limits the accuracy of image-guided surgery. In an ideal situation where physical error sources can be eliminated, the navigation system can give the surgeon confidence that the deviation between the planned and the actual surgical movement can be controlled within the range of the maximum TRE. To improve the accuracy of maxillary repositioning, other image registration techniques could be applied to diminish the TRE, e.g., template-based registration or fiducial screws can be inserted in the maxilla for point-based registration. Luebbers et al [12] reported a maximum TRE of 0.9 mm in the periorbital region using a maxillary splint with only two fiducial screws inserted percutaneously on the lateral orbital rim. This registration technique is the most accurate among all previously studied techniques; however, additional surgical work is required and the procedure causes pain and discomfort to the patient.

The following issues should be considered when performing image-guided surgery: the set-up and use of the image-guided navigation system added 30–45 minutes to the surgical treatment time. The navigation star array is fixed on the skull and could possibly cause infection after the operation, although this seems unlikely.

CONCLUSION

In conclusion, our study demonstrates that intraoperative computer navigation combined with the use of intermediate splint is a useful additional tool for controlling the surgical change of the maxilla in bimaxillary surgery, enabling precise positioning of the maxilla during bimaxillary surgery. Overall, we find that a navigation system might be helpful for controlling the final surgical outcome during the operation, especially for non-experienced surgeons.

REFERENCES

[1] Akram, A., Collin, J., Postlethwaite, K., Sweeney, G., Planned to perfection? Use of the model repositioning instrument to plan maxillary movements for orthognathic surgery. *Orthodontics (Chic.)* 12:130-133, 2011.

[2] Anwar, M., Harris, M., Model surgery for orthognathic planning. *Br J Oral Maxillofac Surg* 28:393-397, 1990.

[3] Bell, R. B., Computer planning and intraoperative navigation in orthognathic surgery. *J Oral Maxillofac Surg* 69:592-605, 2011.

[4] Choi, J. Y., Hwang, J. M., Baek, S. H., Virtual model surgery and wafer fabrication using 2-dimensional cephalograms, 3-dimensional virtual dental models, and stereolithographic technology. *Oral Surg Oral Med Oral Pathol Oral Radiol* 113:193-200, 2012.

[5] Cottrell, D. A., Wolford, L. M., Altered orthognathic surgical sequencing and a modified approach to model surgery. *J Oral Maxillofac Surg* 52:1010-1021, 1994.

[6] Ellis, E., 3rd., Accuracy of model surgery: evaluation of an old technique and introduction of a new one. *J Oral Maxillofac Surg* 48:1161-1167, 1990.

[7] Ferguson, J. W., Luyk, N. H., Control of vertical dimension during maxillary orthognathic surgery. A clinical trial comparing internal and external fixed reference points. *J Craniomaxillofac Surg* 20:333-336, 1992.

[8] Gateno, J., Xia, J., Teichgraeber, J. F., Rosen, A., Hultgren, B., Vadnais, T., The precision of computer-generated surgical splints. *J Oral Maxillofac Surg* 61:814-817, 2003.

[9] Gil, J. N., Campos, F. E., Claus, J. D., Gil, L. F., Marin, C., de Freitas S. F., Medial canthal region as an external reference point in orthognathic surgery. *J Oral Maxillofac Surg* 69:352-355, 2011.

[10] Gil, J. N., Claus, J. D., Manfro, R., Lima, S. M., Predictability of maxillary repositioning during bimaxillary surgery: accuracy of a new technique. *Int J Oral Maxillofac Surg* 36:296-300, 2007.

[11] Kretschmer, W. B., Zoder, W., Baciut, G., Baciut, M., Wangerin, K., Accuracy of maxillary positioning in bimaxillary surgery. *Br J Oral Maxillofac Surg* 47:446-449, 2009.

[12] Luebbers, H. T., Messmer, P., Obwegeser, J. A., Zwahlen, R. A., Kikinis, R., Graetz, K. W., Matthews, F., Comparison of different registration methods for surgical navigation in cranio-maxillofacial surgery. *J Craniomaxillofac Surg* 36:109-116, 2008.

[13] Metzger, M. C., Hohlweg-Majert, B., Schwarz, U., Teschner, M., Hammer, B., Schmelzeisen, R., Manufacturing splints for orthognathic surgery using a three-dimensional printer. *Oral Surg Oral Med Oral Pathol Oral Radiol Endod* 105:e1-7, 2008.

[14] Omura, S., Kimizuka, S., Iwai, T., Tohnai, I., An accurate maxillary superior repositioning technique without intraoperative measurement in bimaxillary orthognathic surgery. *Int J Oral Maxillofac Surg* 41:949-951, 2012.

[15] Ong, T. K., Banks, R. J., Hildreth, A. J., Surgical accuracy in Le Fort I maxillary osteotomies. *Br J Oral Maxillofac Surg* 39:96-102, 2001.

[16] Paul, P. E., Barbenel, J. C., Walker, F. S., Khambay, B. S., Moos, K. F., Ayoub, A. F., Evaluation of an improved orthognathic articulator system. 2. Accuracy of occlusal wafers. *Int J Oral Maxillofac Surg* 41:155-159, 2012a.

[17] Paul, P. E., Barbenel, J. C., Walker, F. S., Khambay, B. S., Moos, K. F., Ayoub, A. F., Evaluation of an improved orthognathic articulator system: 1. Accuracy of cast orientation. *Int J Oral Maxillofac Surg* 41:150-154, 2012b.

[18] Perkins, S. J., Newhouse, R. F., Bach, D. E., A modified Boley gauge for accurate measurement during maxillary osteotomies. *J Oral Maxillofac Surg* 50:1018-1019, 1992.

[19] Polido, W. D., Ellis, E., 3rd, Sinn, D. P., An assessment of the predictability of maxillary repositioning. *Int J Oral Maxillofac Surg* 20:349-352, 1991.

[20] Sharifi, A., Jones, R., Ayoub, A., Moos, K., Walker, F., Khambay, B., McHugh, S., How accurate is model planning for orthognathic surgery? *Int J Oral Maxillofac Surg* 37:1089-1093, 2008.

[21] Stanchina, R., Ellis, E., 3rd, Gallo, W. J., Fonseca, R. J., A comparison of two measures for repositioning the maxilla during orthognathic surgery. *Int J Adult Orthodon Orthognath Surg* 3:149-154, 1988.

[22] Sun, Y., Luebbers, H. T., Agbaje, J. O., Schepers, S., Vrielinck, L., Lambrichts, I., Politis, C., Validation of anatomical landmarks-based registration for image-guided surgery: an in-vitro study. *J Craniomaxillofac Surg* 41:522-526, 2013.

[23] Swennen, G. R., Mollemans, W., De Clercq, C., Abeloos, J., Lamoral, P., Lippens, F., Neyt, N., Casselman, J., Schutyser, F., A cone-beam computed tomography triple scan procedure to obtain a three-dimensional augmented virtual skull model appropriate for orthognathic surgery planning. *J Craniofac Surg* 20:297-307, 2009.

[24] Tsuji, M., Noguchi, N., Shigematsu, M., Yamashita, Y., Ihara, K., Shikimori, M., Goto, M., A new navigation system based on cephalograms and dental casts for oral and maxillofacial surgery. *Int J Oral Maxillofac Surg* 35:828-836, 2006.

[25] Walker, F., Ayoub, A. F., Moos, K. F., Barbenel, J., Face bow and articulator for planning orthognathic surgery: 1 face bow. *Br J Oral Maxillofac Surg* 46:567-572, 2008a.

[26] Walker, F., Ayoub, A. F., Moos, K. F., Barbenel, J., Face bow and articulator for planning orthognathic surgery: 2 articulator. *Br J Oral Maxillofac Surg* 46:573-578, 2008b.

[27] Xia, J. J., Gateno, J., Teichgraeber, J. F., New clinical protocol to evaluate craniomaxillofacial deformity and plan surgical correction. *J Oral Maxillofac Surg* 67:2093-2106, 2009.

[28] Zizelmann, C., Hammer, B., Gellrich, N. C., Schwestka-Polly, R., Rana, M., Bucher, P., An evaluation of face-bow transfer for the planning of orthognathic surgery. *J Oral Maxillofac Surg* 70:1944-1950, 2012.

In: Encyclopedia of Surgery (22 Volume Set)
Editors: Andreas Lehrer and Kristin Mueller
ISBN: 978-1-53618-329-0
© 2020 Nova Science Publishers, Inc.

Chapter 46

COMPUTER-ASSISTED MINIMALLY INVASIVE SURGERY: IMAGE-GUIDED INTERVENTIONS AND ROBOTIC SURGERY

Francisco M. Sánchez Margallo [*] ***and Juan A. Sánchez Margallo***
Jesús Usón Minimally Invasive Surgery Centre, Cáceres, Spain

ABSTRACT

Laparoscopic surgery represents one of the main evolutions of surgical techniques. However, this leads to some challenges that can be reduced through computer technology. This chapter presents a review of the state of the art of current methods for computer-assisted in laparoscopic surgery. Surgical navigation systems have the potential to improve information on the exact place of key anatomical structures such as vessels and tumors within the surgical field. With the support of navigation systems surgeons can potentially improve clinical outcomes of image-guided interventions. The use of image guidance methods such as augmented reality and near infrared fluorescence enhances visual information to supplement the two-dimensional imaging and the absence of tactile feedback in laparoscopic surgery. In the field of robotic surgery, robotic systems enable surgeons to perform advanced laparoscopic procedures with greater visualization and dexterity than traditional laparoscopic technology. Image-guided robots can be inserted into the patient's body by using real-time feedback from different imaging techniques. Recent developments in minimally invasive techniques have led to laparoendoscopic single-site surgery (LESS), which has a great potential in patient outcomes but remains technically challenging. Several robotic-assisted systems have been applied to single-site surgery to deal with these limitations. This has resulted in a new kind of surgery, robotic LESS or R-LESS. This work gives an overview of current developments in image-guided laparoscopic interventions regarding navigation systems and image guidance methods, as well as in new systems and applications of robotic surgery, especially in novel surgical techniques such as LESS and NOTES.

[*] Corresponding Author's Email: msanchez@ccmijesususon.com.

Keywords: laparoscopic surgery, image-guided interventions, augmented reality, robotic surgery

ABBREVIATIONS

5-ALA	5-aminolevulinic acid
AESOP	Automated Endoscopic System for Optimal Positioning
AR	Augmented reality
CAS	Computer-assisted surgery
CT	Computed tomography
DARPA	Defense Advanced Research Projects Agency
DOF	Degrees of freedom
FDA	Food and Drug Administration
ICG	Indocyanine green
IGS	Image-guided surgery
LESS	Laparo-endoscopic single-site surgery
MDCT	Multiple detector computed tomography
MIS	Minimally invasive surgery
MRI	Magnetic resonance imaging
NASA	National Aeronautics and Space Administration
NIRF	Near-infrared fluorescence
NOTES	Natural orifice transluminal endoscopic surgery
NSF	National Science Foundation
PDD	Photodynamic diagnostic
PpIX	Protoporphyrin IX
PUMA	Programmable Universal Machine for Assembly
RAL	Robotic-assisted laparoscopic
SPS	Surgical planning system
SRI	Stanford Research Institute
TEM	Transanal endoscopic microsurgery
TRUS	Transrectal ultrasound
US	Ultrasound
UVA	Ultraviolet A
VR	Virtual reality

1. INTRODUCTION

The introduction of minimally invasive surgery (MIS) has been one of the greatest advances in the surgical field in recent times. This kind of surgery tries to reduce the invasiveness for the patients, providing them with several benefits such as reduction of tissue trauma and postoperative pain, better aesthetic results, and less operative periods with the consequence reduction of the healthcare costs. These benefits have made these surgical techniques the focus of attention and the choice in many surgical procedures, which usually

have been performed by open surgery. However, they have some limitations that should be addressed. In minimally invasive procedures the depth perception is lost, and surgeons have to perform the intervention using a two-dimensional (2D) interpretation of the surgical field. Besides, they have to use new surgical instruments that in most cases limit their surgical skills and hamper the ergonomic conditions during surgery. All the previous restrictions entail a steep learning curve for the surgeon.

Continuous advances in computer science make computer-assisted surgery (CAS) a new powerful way for addressing some of the aforementioned limitations, increasing and expanding surgeon's perceptions. The broad range of CAS represents the integration of computer technology in surgical procedures for presurgical planning, surgical guiding as well as surgical manipulation. Within the field of CAS, image-guided surgery (IGS) and surgical robots are the most challenging fields. Image-guided surgery provides surgeons with tools to apply preoperative information from the patient during the surgical performance as well as the possibility of preoperative planning. This allows the surgeon to determine the best way to tackle an operation and to treat a disease, and later use this information as support during the course of the intervention. Similarly, advances in robot technology have enabled the development of robotic surgical systems and devices for surgical assistance. These systems are created as tools to solve certain technical difficulties during the performance of some MIS techniques, providing three-dimensional (3D) view of the surgical field, improvement of the surgical instruments, increased surgical skills, improving ergonomics, and even providing tactile feedback during surgery. The objective of this chapter is to review the history and current status of computer-assisted in MIS. The chapter is organized into two main sections, which are focused on IGS and robotic-assisted surgery, as main components of CAS.

2. IMAGE-GUIDED SURGERY

In order to cope with some of the limitations in MIS and guide the surgeon during a surgical procedure, systems for IGS have been developed. The lack of tactile feedback and 3D sensation in video-assisted surgery accelerated the need for these systems. In addition, for the human eye, several pathologies, such as the presence of non-superficial tumors, are not easily distinguishable from surrounding normal tissue. This make, in some occasions, decision making during surgery a very difficult process. During IGS preoperative imaging data is used in conjunction with images from the operative field to improve the localization and targeting of pathologies, as well as monitor and control treatments. Several advanced in imaging technologies are used for IGS such as magnetic resonance imaging (MRI), computed tomography (CT), and even positron emission tomography (PET), which replace or complement direct visualization. The combination of tracking technologies for recording the position of the patient and the surgical instruments with preoperative and intraoperative images provides a comprehensive assistance tool for guiding any MIS intervention. Image-guided procedures are substantially less invasive than traditional surgery. Image-guided technology allows for more precise and accurate procedures and surgeons can decide the best approach to address a specific disease before the intervention, which may reduce the operating times as well as the number of surgical ports needed.

In general, there are some common steps followed to carry out an image-guided surgical intervention [1,2]. Initially, the patient undergoes diagnostic imaging, in most cases CT or MRI. These images are then converted and processed into a 3D model of the patient's anatomy. This information is subsequently used for preoperative surgical planning and/or intraoperative surgical decision making. During the operation, the virtual model and the surgical planning are used as a guide for navigating into the patient anatomy. During this process, the surgical instruments are tracked and mapped with respect to the virtual model to increase the accuracy during the procedure and minimize damage to normal tissues. This 3D navigation helps a surgeon to better visualize and understand the internal anatomy of the patient during each surgical step.

2.1. Components of Image-Guided Surgery

IGS integrates three major technologies: imaging, tracking, registration and visualization technologies. Each of these components will be described in more detail below.

2.1.1. Image Acquisition and Rendering

The fundamental basis of IGS is diagnostic imaging, and its progress primarily depends on technological advances in this field. No unique imaging system is exclusively used for diagnostic imaging, many different imaging modalities have been used for IGS, including ultrasound (US), MR and X-Ray imaging. All diagnostic imaging modalities have been used to guide procedures with or without some modification or adjustment. However, most image-guided navigation systems used CT or MRI systems. This is because they can provide a good quality 3D map of the anatomy, especially in the case of CT imaging. While most image-guided navigation systems are based on preoperative imaging, there is an increasing interest in using intraoperative imaging for navigation [3].

Once diagnostic imaging data of the patient has been recorded, this information needs to be processed. The goal of medical image processing is to extract quantitative information from the diagnostic images to better diagnose, localize, monitor, and treat surgical pathologies. Currently there are a large number of software tools to delineate, reconstruct and visualize patient organs and pathologies in 3D models obtained from medical imaging before surgery such as Myrian® from Intrasense, Ziostation® from Ziosoft, Synapse® Vincent from Fujinon, Iqqa® Liver from Edda Technology, Scout® Liver from Pathfinder, among others.

One of the main steps in image processing is the image segmentation. This is defined as structuring an image into different regions that are identified by signal intensities, textures, lines, or shapes. The resulting virtual model is defined by the different relevant anatomical structures that will take part during the surgical intervention [3]. Medical image segmentation is a challenging process. In diagnostic images not all the anatomical structures of interest are homogeneous and clearly separable from the surroundings. In some cases their grayscale value is not constant, and strong edges may not be present around borders. Additionally, image segmentation algorithms may not work well in the presence of poor image contrast, significant noise, and unclear anatomical boundaries. For this reason, in certain cases it is needed the intervention of an expert human operator to guide the process, which could be tedious and prone to error. Image segmentation is a fundamental step to support the surgical

treatment of tumors or in case some critical anatomical structures should be avoided during the surgical intervention.

2.1.2. Tracking Technologies

In IGS it is crucial to record the 3D position and orientation of both the patient and the surgical instruments during the intervention. These positions will be mapped later on with the 3D model obtained from preoperative imaging (registration process), to precisely visualize the instrument motion with respect to the surrounding anatomical structures. Surgical navigation systems provide surgeons with a better visualization of the anatomical structures inside the body in relation to the actual position of surgical instruments, minimizing damage of surrounding health tissues.

Currently there are different tracking technologies that are commonly used for IGS such as optical videometric (Figure 1), optical active and passive infrared, and electromagnetic [4]. Among them, optical tracking systems are the most used. They are generally highly spatially accurate (more precise than 1 mm), but suffer from the line-of-sight restrictions between the tracking device and the object to be tracked and have some limitations to track flexible instruments. Electromagnetic tracking systems do not have this line-of-sight constraint and are capable of tracking flexible objects inside the body such as catheters and the instrument tip [5].

2.1.3. Registration

Registration is another essential component for IGS; with this process the real patient and the image-based model (virtual model) are co-registered in the same reference frame. The simplest registration method is to manually match a paired-point landmark, such as the umbilicus or a nipple, between the actual organ and the overlaying image [6]. In the most common clinical scenario, radiopaque markers are attached on the patient's skin to be registered in the preoperative CT or MRI studies. Although this method is useful when superimposed on skin or bone, it is not sufficient for complex soft intraabdominal organs (non-rigid registration).

Figure 1. Videometric tracker with pattern-marked markers (Claron Technology Inc.,Toronto, ON, Canada).

Registration can be broadly classified into two types: rigid registration or non-rigid registration [3]. Image registration is rigid when images are assumed to be solid and only need rotation and/or translation to be matched with each other. In commercial IGS, only rigid registration is used [4]. However, most of the anatomical structures presented in MIS are not rigid, and therefore deformations of these structures during surgery require the application of non-rigid registration algorithms, updating the anatomical changes in the intraoperative images [7,8]. Imaging data acquired by US and intraoperative CT have been specially utilized in cases requiring renewed real-time data for intraoperative deformation [9,10].

2.1.4. Visualization

The visualization techniques used to display the results during IGS can be categorized into three main types: projected images, additional monitor or transparent monitor [11,12]. The first method consists of projecting the virtual model directly onto the patient or the target organ [6]. However, in this visualization method the projector light beam may be interrupted by the surgical staff or equipment. Moreover, image deformations can occur when the images are projected onto irregular surfaces. The second method, which is the most used, makes use of an additional monitor to display the virtual model and additional information, in which the typical visualization is a four-quadrant presentation that usually consists of three orthogonal 2D images and a 3D rendering. The third method uses a transparent monitor or plate between the target organ and the surgeon's line of vision. In this case, the virtual model is superimposed on the actual real view through the transparent surface [13]. Additionally, there is a hybrid solution, which is the use of a video head-mounted display. In this case, the images from the IGS are displayed on a small video monitor mounted in front of one or both eyes using a head-mounted video camera.

2.2. Surgical Planning Systems

Surgical planning systems (SPS) use the 3D virtual models of a patient to develop a treatment plan and predefine the surgical steps. The 3D models of the patients are usually obtained from their CT or MRI preoperative imaging. These planning systems allow surgeons to interact with the virtual model of the patient, so that they can understand more in depth his/her anatomy and define the best operative strategy. SPS are excellent tools for assessing the patient's pathology and for preoperative decision-making (Figure 2). Preoperative surgical planning may improve the efficiency of MIS procedures thanks to better learning of patient anatomy and real preoperative training [14]. Therefore, using SPS surgeons can establish an improved diagnosis and a better planning of the best-suited therapy for each surgical case [15]. However, apart from all these positive implications, one limitation of these systems is the surgeon's learning curve.

Some of the features that typically include SPS are semi-automated or automated segmentation of relevant anatomical structures, identification of the lesion margins, accurate 3D model generation from the segmented data, selective visualization and transparency transforms [15,16]. These systems are particularly important for procedures where surgeons will be working close to nerves or vulnerable anatomical structures that could lead to

significant consequences during surgery. The next step will be to transfer the previous surgical planning to the patient by means of a surgical navigation system.

Figure 2. Example of a surgical planning system for intraabdominal surgery.

2.3. Surgical Navigation Systems

Surgical navigation systems (SNS), in which patient's preoperative information is used during the surgical intervention as a surgical decision-making tool, has been clinically applied in many fields to improve the safety, accuracy, and efficiency of surgeries. In MIS, due to surgeon has less visual and tactile perception than in open surgery, image assistance may be increasingly helpful for 3D understanding of the surgical target. The main aim of SNS is to specifically target an anatomical structure during surgery in safer and less invasive ways. Commercial based SNS are most widely used in neurosurgery [17], otolaryngology [18], and orthopedics [19], in which the target organs are assumed to be rigid and to have a constant spatial relationship to anatomical landmarks [20,21]. In more recent works, image-guided navigation has been extended to soft tissue applications like the liver and other abdominal organs [22,23]. However, the use of these systems in abdominal surgery is still a challenging task.

The basic setup of a SNS consists of a preoperative image data, a tracking system, a computer platform with screen, and the respective navigation software [4]. Navigation in general uses preoperative image data for example form CT or MRI images, which are used for navigation in the OR (image acquisition). Before surgery, surgical strategy, steps, paths

for the surgical instruments, and objects and areas of interest may be planned using a virtual model obtained from the preoperative images (planning). During surgery, the preoperative image data need to be matched to the current patient position by means of the tracking systems (registration). If required, the surgeon may obtain additional images during the surgery and register and include them in the running navigation.

2.3.1. Augmented Reality

The use of SNS allows surgeons to see patient's anatomical structures obtained from preoperative imaging or a prior surgical planning. However, when this information is displayed on an independent monitor, a distance between this visual information and the actual patient surgical field is created. In order to eliminate this gap, augmented reality (AR) applied to the surgical navigation is developed. Navigation surgery using AR consists in superimposing the preoperative 3D patient modeling onto the real intraoperative view of the patient [14,24], thus augmenting the real view with virtual information. AR has the potential to enhance the understanding of the pathological and surrounding anatomy during surgery by means of projecting the 3D model of the interested region. From the patient's medical images such as US, CT or MRI, AR techniques increase the surgeon's intraoperative vision by providing a virtual transparency of the patient [14]. Fine definition of dissection planes, resection margins and avoidance of injury to invisible structures are substantial applications of AR in abdominal surgery [9,25].

AR is based on two major processes: 3D modeling and visualization of anatomical or pathological structures appearing in the medical image, and the registration of this visualization onto the real patient [14]. The preoperative reconstructed images are registered with anatomic landmarks or artificial markers on the patient and then these images are tracked with regard to the patient's position, intraoperative images, as well as instruments and camera movements. Best preoperative imaging modalities are usually offered by CT and MRI, but one of the main constraints is that surgical anatomy changes drastically during surgery. Therefore, one of the most challenging aspects of AR applied to surgery is to register and merge preoperative and intraoperative images, where tracking devices are the principal protagonists in order to relate these two concepts [26]. Tracking devices link spatial information from imaging modalities, anatomical landmarks, instruments, by representing these in one common coordinate system and establishing a simple registration [26,27]. Among intraoperative imaging, US has been the most widely used image acquisition.

Surgical navigation based on AR could be defined as the next step in IGS. However, this imaging technique remains currently limited by the registration of organs deformation during surgery, the lack of studies to prove its usefulness, and the portability and cost of the required equipment [11]. The use of AR navigations systems has been extensively used in neurosurgery, otolaryngology, orthopedics, and maxillofacial surgery [21]. These surgeries allow for precise registration thanks to rigid organs and bone structures. In the case of abdominal surgery the use of AR is more challenging. One of the main problems is the need to provide a real-time updating of the changes that occur in intraabdominal structures caused by breathing, heartbeat, patient movement and interactions by the surgeons. In order to deal with these problems, soft tissue navigation methods are being developed.

Marescaux et al. [28] reported the first use of an AR-assisted intervention for adrenalectomy without a tracking system for the laparoscope. The virtual model was obtained

from a CT scan of the patient. Then, segmentation of the intraabdominal organs and 3D reconstruction of the lesion were performed. During surgery, an operator adapted manually the virtual model to the real laparoscopic images by using 7 different visible landmarks on the skin (right costal margin and 3 trocar sites) and inside the abdomen (inferior vena cava and 2 laparoscopic tools). These AR images were displayed on an independent monitor.

An intraoperative navigation system, which incorporated a port placement planning, using overlay intraperitoneal images on the patient's abdominal wall was developed by Sugimoto et al. [6]. Raw data of the preoperative patient information obtained via multiple detector computed tomography (MDCT) were used to volume rendering using OsiriX (OsiriX Fundation, Geneva, Switzerland). In order to simultaneously display the target organ and blood vessels, they injected carbon dioxide into the gastrointestinal tract and pancreatobiliary duct, and at the same time administering a rapid intravenous injection of contrast agent, then scanning, enabling the simultaneous display of the gastrointestinal tract and pancreatobiliary duct with associated blood vessels. For registration, the 3D model was set to reproduce the patient body surface, and the positional coordinates of the umbilicus, left and right nipples, and the inguinal region were fixed as physiological markers on the body surface. This registration process was non-invasive and markerlesss, and was completed within 5 min. They used the navigation system during seven surgeries, including three cholecystectomies, two gastrectomies and two colectomies. During surgery, 3D volume-rendering reconstructions of the gastrointestinal tract, blood vessels and soft tissue were projected on the patient’s abdomen, and therefore unexpected organ injury could be avoided when the port was inserted. In laparoscopic biliary surgery, the displayed virtual cholangiography with surrounding vessel anatomy on the abdominal wall reduced the number of ports during surgery.

A real-time AR navigation system to be used in an open MRI operating theater was presented by Tsutsumi et al. [29]. The system was used during a laparoscopic cholecystectomy in three patients and during a laparoscopic ventral hernia repair in two patients. The operating theater was equipped with a 0.4-T open MRI, an optical tracking system and MR-compatible equipment such as a surgical bed, surgical lights, a respirator, a display monitor, and vital monitoring systems. To perform the laparoscopic interventions they used MR-incompatible surgical instruments, but out of the 5G restriction area as much as possible. For each patient, they place six to nine skin-affixed MRI-visible markers on the patient abdomen as well as the surgical ports. Then, an initial MRI scan was performed under the pneumoperitoneum, so that they can obtain the 3D model of the anatomical structures with the possible deformations caused by the pneumoperitoneum. Registration between the patient and the MRI images was performed by recording the space location of the skin-affixed markers on the patient using a handle probe registered by the optical tracker. Then, to the position of the laparoscope was also recorded, so that the virtual model was updated in real time with regard to the laparoscope’s movement. The navigation frame rate was 8 frames per min. Laparoscopic cholecystectomy was successfully performed in three patients and laparoscopic ventral hernia repair in two patients. During the operations, the laparoscopic monitor clearly showed the AR models of the intraperitoneal structures, such as the common bile ducts and the urinary bladder (Figure 3), as well as the proper positions of the prosthesis.

Simpfendorfer et al. [30] developed an AR system that could fuse 3D models from transrectal US (TRUS) with a real laparoscopic video during radical prostatectomy. For registration of both image modalities (3D-2D), the system used custom-developed needles

with colored heads that were inserted into the prostate using conventional laparoscopic instruments. Once the navigations aids were inserted, the 3D TRUS data was acquired. These navigations aids were segmented in the 3D model as well as in the 2D video images recorded from the laparoscope. By means of this registration the system was able to compensate the organ and/or camera movements. The virtual model was superimposed on the laparoscopic video stream defining the dissection borders for the prostate, the nerves and vessels. In order to avoid the risk of spreading tumor cells, the navigation aids were removed with the prostate inside the specimen bag. The initial test of the navigation system in an in vivo human patient was successfully performed and with no complications [30]. The setup of the navigation system took approximately 12 minutes in total, including the insertion of the navigation aids, the intraoperative US image acquisition, and the creation of the models. This AR method has been also used in a partial nephrectomy [9].

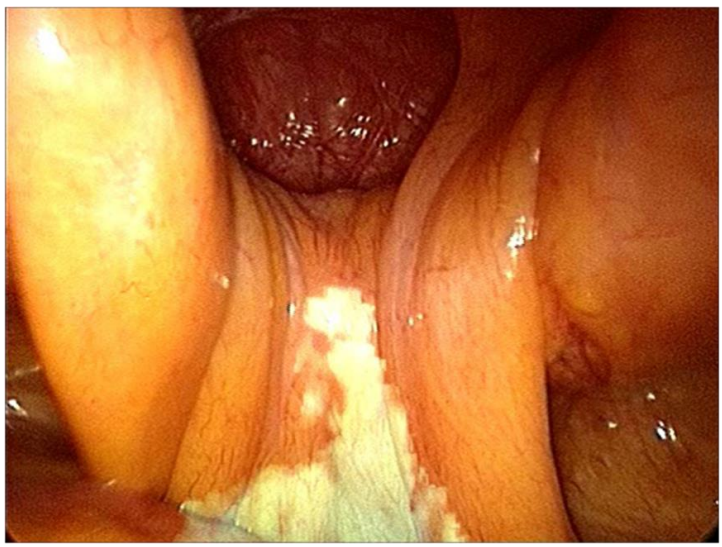

Figure 3. View of the laparoscopic monitor with overlaid polygon of the urinary bladder (Courtesy of Prof. M. Hashizume, Department of Advanced Medical Initiatives, Kyushu University, Fukuoka, Japan).

Soler et al. proposed an interactive AR method for liver resection [14]. In this case, the 3D model of the patient was adapted manually to the real model, modifying its position, scale and orientation so that visible landmarks coincided both on the 3D model and the real view of the patient. Therefore, a continuous interaction of the surgeon to update the 3D model with regard to possible intraoperative alterations was needed. Besides, this system provided resection tools for virtually resecting the 3D model during the surgical intervention. This system used CT imaging data to carry out the three steps that form the entire process: 3D patient modeling, preoperative patient visualization and virtual surgical planning and intraoperative AR assistance. For the 3D patient modeling they proposed an automatic method based on hierarchical segmentation of visible organs, from the easiest to the most complex one, using the software VR-Anat©IRCAD 2011. This interactive AR system has been applied on 40 surgical oncological procedures for liver, adrenal gland, pancreas, and

parathyroid tumor resection. However, more quantitative information is needed to validate its efficiency during surgical interventions.

An AR navigation system for laparoscopic splenectomy based on preoperative MDCT was proposed by Leiri et al. [31]. For the intervention they previously segmented some important anatomical structures in the patient's 3D model such as the spleen, accessory spleen, vascular structures and pancreas, and a color-code was defined for each of them. For the registration process, five multimodality markers were placed on the patient's body, and then the MDCT scan was obtained. After scanning, the artificial markers on the patient were registered with regard to the volume image by means of an optical tracking system (Polaris, Northern Digital Inc., Ontario, Canada). After pneumoperitoneum and insertion of the scope, the registration between the spleen surface and the 3D volume was adjusted. To record the movements of the laparoscopic camera during the intervention, and therefore update the overlay images, visible infrared markers were placed on it. The overlay images were updated with about 10 fps. However, this AR navigation system does not take into account respiratory motion, pneumoperitoneum, or organ deformation. The system was used during six cases of laparoscopic splenectomy in children and all the interventions were carried out successfully. None of the cases required conversion to open surgery. During surgery, the splenic artery, splenic vein, and pancreas were fused onto laparoscopic images.

2.4. Fluorescence-Guided Surgery

Another technique for IGS is the fluorescence-guided surgery (FGS), which is an imaging technique that enables to detect anatomical structures that are fluorescently labeled during surgery. This technique allows surgeons to visualize some intraabdominal structures that are not visible with a conventional laparoscope under white light, providing an additional diagnosis tool during the intervention. FGS has the potential to improve cancer surgery outcomes, minimize the time under anesthesia and reduce health-care costs by means of its improved contrast and depth of tissue penetration compared to visible light [32]. There are different fluorescent contrast agents described in the scientific literature that can be used for near-infrared fluorescence (NIRF) imaging as a tool for photodynamic diagnostic (PDD) during MIS such as indocyanine green (ICG), fluorescein or 5-aminolevulinic acid (5-ALA) [33].

Fluorescence imaging can support the diagnosis in surgical procedures such as laparoscopic hepatectomy. This procedure has some limitations compared to open hepatectomy such as the limited possibility to visualize and palpate liver surfaces that may lead to miss some subcapsular lesions during surgery. Kudo et al. [34] used this diagnostic technique in 17 patients who underwent laparoscopic hepatectomy. To this end, a dose of 0.5 mg/kg of ICG was administered intravenously within the 2 weeks prior to surgery. ICG is a fluorescent tricarbocyanine dye that absorbs near infrared light and subsequently emits light at slightly longer wavelengths. Since ICG is retained in cancerous tissues and/or non-cancerous compressed liver parenchyma around tumors, it was used during surgery as a fluorescence source. The laparoscopic fluorescence imaging system used consisted of a commercial camera (Olympus Medical Systems, Tokyo, Japan) and a cutoff filter on the camera head. Additionally, an intraoperative ultrasonography with a flexible laparoscopic probe (BK Medical, Herlev, Den-mark, or Hitachi-Aloka Medical, Tokyo, Japan) was also

used to screen the whole liver. Results reported that using fluorescence imaging they were able to identify 12 hepatocellular carcinomas of the 16 cases identified (75%) and 11 liver metastases of the 16 cases identified (69%). In a study with 6 pigs, the ICG fluorescent agent was also used to detect the ischemic areas in a laparoscopic mesenteric ischemia model [35]. They injected intravenously a dose of 0.5 mg/kg 15 min after ischemia of a small bowel loop. The ICG fluorescence signal was detected using the D-Light-P laparoscope imaging system (Karl Storz GmbH & Co. KG, Tüttlingen, Germany).

Mohsen et al. [36] reported the first use in humans of fluorescein to improve visualization of biliary topography during laparoscopic cholecystectomy. This technique took advantage of the fact that the liver excretes fluorescein and ultraviolet A (UVA) excites fluorescein causing it to emit green light. A custom-made UVA source of light was used to induce fluorescence of bile. This device had an external rod with 11 mm of diameter so that it could be inserted in a 12 mm surgical port. The technique was applied to 5 patients who had symptomatic gallstones and who underwent a laparoscopic cholecystectomy. After induction of pneumoperitoneum, fluorescein sodium at 7.5 mg/kg was injected intravenously. Then, the UVA lighting device was introduced through the epigastric port and the white light from the laparoscope was reduced. In all cases the bile ducts started to show fluorescence under UVA light within 4 to 5 minutes after fluorescein injection. During the operation, the UVA light was used in three main occasions: for an initial visualization, before clipping the cystic duct and at the end, to detect possible leakage of fluorescent bile. No leakage was reported at the end of the operation. This technique allowed better and earlier real-time visualization of biliary anatomy than conventional white light. This method could be a complementary imaging technique of intraoperative cholangiography or intraoperative US. Schols et al. [37] also obtained a successful fluorescence delineation of both the cystic duct and artery using both fluorophores intravenous ICG and CW800-CA, and a commercially available laparoscopic fluorescence imaging system (Karl Storz GmbH & Co. KG). They tested the technique during a laparoscopic cholecystectomy performed in six pigs.

The use of fluorescence imaging techniques has also applied to detection of peritoneal metastasis in human colorectal cancer [38]. In this study 5-ALA was used as a fluorescent contrast agent. In cancer cells, 5-ALA causes the increase in activity of porphobilinogen deaminase and the decrease in activity of ferrochelatase, which leads to intracellular accumulation of protoporphyrin IX (PpIX). PpIX emits red fluorescence with a blue-violet light excitation (380-430 nm). This technique was tested in twelve patients with colorectal cancer. For these interventions 5-ALA hydrochloride dissolved in 20 ml of 50% glucose solution was orally administered 3 h before surgery at a dose of 15-20 mg/kg, ≤1 g per patient. At the beginning of the intervention, the abdominal cavity was observed in white light image as well as fluorescence image under excitation with blue-violet light and using a long pass filter on the laparoscopic camera. Peritoneal dissemination was observed in 8 patients with conventional white light observation, which were also detected with fluorescence image. A small, flat lesion was only detected using fluorescence imaging in one patient. This imaging technique has been also used as PDD in neurosurgery and urology [39, 40].

The use of infrared fluorescence imaging as PDD may help to achieve maximal nephron preservation during partial nephrectomy, and therefore avoid possible complications associated with renal insufficiency. In a study with 77 patients who underwent a laparoscopic partial nephrectomy, orally administrated 5-ALA was used for intraoperative PDD of tumor type and resection margins [41]. As imaging systems they used the D-Light-P laparoscope

(Karl Storz GmbH & Co. KG). Results showed that PDD using 5-ALA was highly sensitive detecting renal cell carcinoma in dissected tumors. This diagnostic technique was able to predict the type of the lesion with an accuracy of 94% and with a positive predictive value of 98%. In another study, 2 patients underwent a laparoscopic partial nephrectomy and 17 patients a robot-assisted partial nephrectomy using ICG for PDD [42]. Before surgery, patients received intravenous injections of ICG, which was diluted to a 2.5mg/ml solution and the total doses ranged from 5mg to 25 mg until obtaining the optimal fluorescence. The intraoperative ICG fluorescence signal was visualized using the Endoscopic SPY® Imaging System (Novadaq Inc., Missisaugua, Ontario, Canada). Final results reported that 13 patients had malignant lesions, where the tumor margin demarcation was most apparent with NIRF imaging. Specifically, malignant renal tumors were visualized as hypofluorescent compared with the surrounding normal renal parenchyma.

Recently, Hockenberry et al. [43] described a novel use of NIRF imaging without ICG or other injectable contrast agents to identify otherwise obscured intraluminal areas of interest during robotic-assisted laparoscopic (RAL) surgery marked by the white light of endoscopic instruments. They used the NIRF imaging system provided by the da Vinci® Surgical System (Intuitive Surgical, Inc., Sunnyvale, CA) by means of the FireFly® integrated system (Novadaq®; Mississauga, Ontario, CA). They applied this imaging technique in five patients during different urologic RAL interventions. Using this NIRF imaging, intraoperative ureteroscopy was used to identify the extent of a ureteral stricture in a patient undergoing RAL partial ureterectomy. Cystoscopy was used to identify bladder diverticula and tumor locations in three patients undergoing RAL partial cystectomy with or without diverticulectomy and the ureteral orifice in another patient undergoing RAL nephroureterectomy. In particular, during the RAL partial ureterectomy, by filtering light wavelengths below near-infrared and accentuating the near-infrared spectrum, the intraluminal white light of the ureteroscope appears green while the surrounding structures remain visible for the laparoscopic camera, which allowed surgeons to easily identify the ureteral stricture.

3. ROBOT-ASSISTED INTERVENTIONS

Compared with traditional laparoscopic surgery, robotic-assisted interventions offer advantages such as higher range of motion, 3D visualization, and scaling of movements [44]. The first robotic-assisted surgeries on humans were conducted at the beginning of 1985 using the Programmable Universal Machine for Assembly (PUMA®) model 200 developed by Unimation Company to perform CT-guided intracranial neurological biopsies. The PUMA® 200 is an industrial servo-controlled robotic arm with six degrees of freedom (DOF) that was adapted for stereotactic surgery [45,46]. Robot-assisted surgery is becoming the gold standard for urological surgeries including prostatectomy, and it seems that gynecology is the next main focus. With the continuous advances in surgical techniques and surgical robotics, it is expected that in the future all surgical treatments can be performed by endoscopic procedures or by robot-assisted surgery. However, at the moment, a robotic surgical operation is too far to be performed entirely without human control. Surgical robots are generally used for specific surgical tasks such as supporting and improving the intracorporeal suture, holding the

laparoscopic camera or taking a biopsy. Although, there are some more complex robotic platforms, as the da Vinci® Surgical System, that can be used as a support to complete the entire surgical procedure.

Despite their wide benefits there are some problems that remain to be solved in robotic surgery such as the price of surgical robots and their maintenance, the size, the lack of training for surgeons, and the few available studies that confirm the improved performance and outcomes of robotic-assisted surgical procedures.

3.1. Surgical Robots for MIS

In this section, some of the most popular robotic surgical systems for MIS, which are commercially available or in their last stages of development prior commercialization, are described.

3.1.1. Automated Endoscopic System for Optimal Positioning (AESOP®)

The earliest commercial system for robotic laparoscopic surgery which was accepted by the surgical community was the Automated Endoscopic System for Optimal Positioning (AESOP®). This system was developed by Computer Motion (Santa Barbara, CA, USA), a company that was founded with grants from National Aeronautics and Space Administration (NASA) and the National Science Foundation (NSF). The AESOP® system was able to control automatically the motion of a laparoscopic camera attached to its robotic arm. This support system allows for more precise and consistent movements of the laparoscopic camera, providing surgeons with a steadier view and filling the needs for holding the camera by a surgical staff during the entire procedure. Additionally, the AESOP® system controls the motion of the camera by means of surgeon's commands transmitted by either foot pedals or voice [47]. This system was cleared by the Food and Drug Administration (FDA) in 1994 to assist surgeons in MIS.

The AESOP® camera holder has been used during routine gynecological endoscopic surgical procedures [48]. The previous study reported that the voice-controlled AESOP® works more efficiently and faster than the hand or foot control. This device has been also used during laparoscopic radical prostatectomy [49] and laparoscopic cholecystectomy, among others minimally invasive surgical procedures.

3.1.2. ZEUS® Surgical System

After the initial success with AESOP®, Computer Motion decided to develop an entire robotic surgical system with surgical manipulators based on three AESOP® arms, the ZEUS® Surgical System. Two arms were designed to host the surgical instruments and one for the laparoscopic camera. The ZEUS® Surgical System is a master-slave system with remote manipulators controlled by means of a console. The surgeon seated at the console should wear polarized glasses to perceive the 3D image form the flat monitor. In 2001 the FDA cleared Computer Motion's ZEUS® Robotic Surgical System for use in abdominal operations [50]. This surgical system provided tremor filtering and scaling function. In 2003 Computer Motion was acquired by Intuitive Surgical, discontinuing the commercialization of both AESOP® and ZEUS® robotic systems.

This surgical platform was originally designed for minimally invasive procedures such as beating heart, coronary artery bypass grafting and mitral valve repairs [51]. ZEUS® has been used to harvest internal mammary arteries [52] and to perform in 1998 the world's first robotically-assisted minimally invasive coronary artery bypass grafting at the University Hospital Munich-Grosshadern in Germany [53]. ZEUS® is also well-known for the "Lindbergh" surgery in 2001 where a surgeon in New York, USA, performed a laparoscopic cholecystectomy in Strasbourg, France, demonstrating for the first time the feasibility of telepresence surgery [50,54].

3.1.3. The da Vinci® Surgical System

The emergence of laparoscopic surgery, combined with the interest of the US Army to operate on severely wounded soldiers directly in the battlefield or in the route to a field hospital led the NASA and the Stanford Research Institute (SRI) to focus their research programs on telesurgery [55]. This initiative was significantly supported by the Defense Advanced Research Projects Agency (DARPA). Their efforts were eventually very fruitful and the research produced a robotic endoscopic surgical system. However, limitations in telecommunication and funding prevented its implementation in the battlefield. Instead, the robotic platform was adapted for civilian and commercialized by Intuitive Surgical Incorporation (Sunnyvale, CA, USA) as the da Vinci® Surgical System [56].

The da Vinci® Surgical System was first launched in 1999. The main purpose of this robotic surgical system has been to provide a reliable, intuitive, surgical platform that brings the benefits of MIS to the patient while the surgeon is performing the procedure with similar conditions to open surgery such as higher dexterity, better ergonomic conditions and 3D visualization. Initially, the ability of this surgical platform to manipulate delicate tissues was applied to cardiac surgery. Subsequently, the benefits of this surgical robotic platform were extended to other surgical disciplines.

Figure 4. The da Vinci® Si System in an OR with the double console (©2014 Intuitive Surgical, Inc.).

Nowadays, the da Vinci® Surgical System is the only commercially available master-slave robotic system. At the end of 2012, there were more than 2,500 da Vinci® Surgical Systems installed in over 2,000 hospitals worldwide [56]. Therefore, at present this surgical robotic system is the most commonly used for performing minimally invasive laparoscopic surgery in humans (Figure 4).

One of the main features of this surgical system is its EndoWrist® surgical instruments (Intuitive Surgical, Inc.; Sunnyvale, CA, USA) that translate the movements of the instrument handle to the remote tip in an intuitive manner, avoiding the fulcrum effect. The end effector of these instruments mimic human hand motion by a mechanical articulation, providing surgeons with additional three DOF (seven in total) and about 90° of articulation in the wrist. These features provide surgeons with a full range of motion during the performance of minimally invasive procedures. However, not all the provided instruments are wristed such as the Harmonic® ACE and the single-site instruments. Additionally, the da Vinci® Surgical System is equipped with tremor filtering, scaling function, and alignment of the eyes and hands with the provided image of the instruments tip. The surgical image is displayed in real time through a high-quality 3D endoscope into the stereo viewer. Besides, this stereo viewer allows for additional visual information such as CT or US images.

There have been four commercial models of the da Vinci Surgical System: the da Vinci® Standard System, the da Vinci® S System (released in 2006), the da Vinci® Si Surgical System (released in 2009), and the most current version, the da Vinci® Xi System (released in 2014). The da Vinci® Standard System has been discontinued from sale and is no longer supported by Intuitive Surgical. The second version, the da Vinci® S Surgical System, was designed to facilitate surgical setup through a slimmer arm design and the addition of a fourth robotic arm. The da Vinci® Si version was equipped with a 3D full high-definition vision system, a second console for training, the availability to perform single-site surgery, and the integration of laser technology to allow for fluorescent imaging [56]. One of the most remarkable advances of the latest version, the da Vinci® Xi Surgical System, is that it allows for multi-quadrant surgery that can be performed without repositioning the system. Additionally, this version provides smaller and thinner arms as well as the ability to attach the endoscope to any arm. At the moment, Intuitive Surgical remains the market leader for robotic MIS by holding the license of more than 1,000 patents that cover the fundamental aspects of the da Vinci® Surgical System's technology such as the surgical console, the vision system and the wristed instruments. This hampers the development of new robotic surgical systems.

This surgical platform has been successfully used in a wide range of abdominal [57] and thoracic procedures [58]. In addition, it has been applied to other emerging procedures such as single-site surgery [59, 60] and Natural Orifice Transluminal Endoscopic Surgery (NOTES) [61,62] in an attempt to further reduce the invasiveness of surgery. Although this is a system for telesurgery and all robotic arms are controlled remotely from the surgical console, its installation, removal, and exchange of the camera as well as the instruments should be performed by a bedside assistant. Besides, for some interventions installation of the system is time-consuming considering that for some procedures time is a critical issue. Although the latest version, the da Vinci® Xi System, seems to have improved this limitation.

3.1.4. Amadeus® Surgical System

Similar to the da Vinci® Surgical System, another project that is currently under development is the Amadeus® system (Titan Medical Inc., Toronto, Canada), which is a 4-armed robotic surgical platform for MIS with snakelike multiarticulating arms for improved maneuverability and obstacle avoidance [63]. As the da Vinci® Surgical System this surgical platform consists of a master-salve robotic system with a workstation that allows surgeon to control remotely the robotic surgical instruments. This workstation also provides surgeon with 3D endoscopic view of the surgical field and a set of instruments for single-site surgery. In addition, this system includes force feedback for detection of tissue-level forces, which allows surgeons to feel how hard they are pulling on tissues, sutures, or other structures, minimizing tissue damage. Currently, the company has put the Amadeus system on the back burner to focus their efforts on developing and commercializing a new robotic platform for Single-Site Surgery, the Titan's Single Port Orifice Robotic Technology (SPORT™) surgical system.

3.2. Robotic Surgery in MIS

The introduction of laparoscopic surgery came with some technical limitations including mirroring of instrument movements, limited articulation, two-dimensional (2D) visualization and poor ergonomics, which may lead to some surgical complications [64]. These technical limitations of laparoscopic surgery significantly influenced the development of robotic surgical systems as a means to improve the control of laparoscopic instruments, providing wider maneuverability in complex procedures, and improve visualization of the surgical field. Some advantages of robotic surgical systems include 3D vision, increased precision and dexterity, and ergonomic conditions for the surgeon that may lead to less muscle fatigue. However, in order to ensure the success of a robotic procedure, a variety of factors must be taken into account such as the surgical system to be used, the appropriate selection of surgical equipment as well as patient and procedural considerations.

3.2.1. Robotic-Assisted Urological Surgery

Robotic was first introduced in urological surgery in 1991 to conduct a transurethral resection of the prostate using the robotic system Probot® (Imperial College, London, UK), a resection device with seven DOF. For this procedure, the surgical robot was used to insert into the patient a cutting device for removing the prostatic tissue. This system possesses a transurethral ultrasonographic probe at its tip to measure the gland at the beginning of the procedure, providing an intraabdominal model of the prostate in which the surgeon can define the area to be removed. Then, the robotic system computes the trajectories of resection for the surgical tool and follows them during the intervention [65].

There are a substantial number of studies on performing complex urological procedures with robotic assistance in humans that has documented their safety, efficacy, and feasibility [66]. These studies have applied robotic-assisted surgery to several urological domains such as localized prostate cancer (radical prostatectomy), bladder cancer (radical cystectomy and urinary diversion for muscle-invasive bladder cancer), kidney surgery (nephrectomy, donor

nephrectomy, partial nephrectomy), pyelo-ureteric junction obstruction (pyeloplasty), and adrenal surgery [67].

The first successful laparoscopic radical prostatectomy was performed by Schuessler in 1991 [68]. However, due to its technical difficulty, this operation was not widely carried out until the da Vinci® surgical system appeared. The miniature tools with EndoWrist® technology offer a potential advantage over standard laparoscopic instruments in the accuracy of movements and suturing along with high-magnification 3D view. This ensures preservation of the lateral prostatic fascia, which may result in better erectile function postoperatively as compared to conventional open surgery [69,70]. RAL radical prostatectomy seems to reduce the blood loss, risk of intraoperative transfusion, and anastomotic strictures in comparison with retropubic radical prostatectomy [71]. Consequently, this new technology has spread rapidly, and in 2009 about 85 % of all radical prostatectomies in the USA were performed by assistance of the da Vinci® surgical system [67,72].

In the case of partial nephrectomy, although open approach remains the reference standard for the treatment of small renal tumors, laparoscopic partial nephrectomy is constantly evolving. However, this is a challenging approach due to its steep learning curve and technical requirements. To cope with some of these limitations, robotic technology has recently been applied to laparoscopic partial nephrectomy with the goal of providing a safe and effective alternative to laparoscopic partial nephrectomy [73]. The first robot-assisted partial nephrectomy was described by Gettman et al. [74] in 2004. Some studies suggested that RAL partial nephrectomy offers equivalent oncological control to open and laparoscopic partial nephrectomy while reporting shorter hospital stay, less intraoperative blood loss, shorter operating room time and shorter warm ischemia time [73,75,76].

3.2.2. Robotic-Assisted Cardiac Surgery

The application of laparoscopic techniques to cardiac surgery entails some difficulties such as the lack of dexterity using the conventional laparoscopic instrumentation that is required for delicate cardiac surgical procedures and the loss of depth perception due to the 2D vision. The application of robotic technology has overcome some of these limitations, providing new approaches to minimally invasive cardiac surgery.

In 1998 Stephenson et al. [77] reported the first robot-assisted totally endoscopic coronary anastomosis on twenty-five isolated porcine hearts placed inside a thoracic trainer, using an arterial conduit to the left anterior descending artery. The procedure was performed endoscopically using the ZEUS® Surgical System [77]. All the 25 surgeries were successfully completed and showed good probe patency. The lack of tremor and motion scaling allowed for the precise movements required to complete the endoscopic microvascular anastomosis. Loulmet et al. applied the first robotic totally endoscopic coronary artery bypass grafting in humans in 1998 [78]. This intervention was performed in 4 male patients with the indication of grafting the left internal thoracic artery to the left anterior descending coronary artery. The da Vinci® Surgical System was used to perform the surgery and the Heartport® system (Heartport, Inc, Redwood City, USA) was used for arresting the heart during the anastomosis. Carpentier et al. [79] performed the first robotic mitral valve repair using an early prototype of the da Vinci® Surgical System in 1998.

The FDA approved the da Vinci® Surgical System for mitral valve surgery in 2002 and in 2004 for use in coronary anastomosis during cardiac revascularization. Some of the most common applications of robot-assisted cardiac surgery are the mitral valve repair [80] and endoscopic coronary artery bypass grafting [81,82]. Over 1,700 robotic cardiac operations per year are currently performing in the USA and the numbers are increasing each year [83].

The CardioARM® is one of the latest surgical robots that have being introduced is in the field of cardiac surgery. CardioArm® was developed at Carnegie Mellon University (Pittsburgh, USA). This system consists of a slim snakelike manipulator designed to perform minimally invasive epicardial interventions through a subxiphoid approach. The CardioARM® was developed in an effort to provide dedicated intrapericardial therapeutic delivery with single port access. One of the main advantages of this design is the ability to preserve its previous configuration and shape in intraabdominal space during navigation or to become completely flexible if necessary [84].

3.2.3. Robotic-Assisted Thoracic Surgery

The application of MIS to thoracic surgery has been slow mainly due to some difficulties that entail this type of surgery such as the limited thoracic space, the ribs restrictions, the heartbeat and the breathing [85]. The initial application of video-assisted thoracic surgery was only as a diagnostic tool. The development of specific thoracoscopic instruments led to more complex procedures such as pulmonary lobectomy. Apart from its technical demand, thoracoscopic surgery has a steep learning curve because of the unergornomic position and two-dimensional view. In this sense, advances in robotic surgery have tried to solve some of these limitations.

Several cases have been reported in which robotic-assisted thoracoscopic surgery has been performed for the early-stages of lung cancer [86,87]. Jang HJ et al. [88] compared the results of forty cases of robot-assisted lobectomy (RAL) with forty cases of video-assisted thoracic surgery lobectomy (VAL) for lung cancer. Results showed no conversions to open thoracotomy in RAL against 2% for the VAL group. The operative time for both surgical techniques was similar, but the rate of postoperative complications in the RAL group (n = 4) was significantly lower than that of the VAL group (n = 13). Additionally, postoperative stay was significantly shorter for the RAL (6 vs 9 days). Park et al. [89] reported that the cost in the USA of video-assisted or robotic-assisted thoracic surgery for lung cancer was lower than open thoracotomy due to the longer hospital stay than this later required.

The mediastinum, especially the upper part, is a delicate and difficult anatomical area to be reached through thoracoscopy mainly because this anatomical area has large and fragile vessels and nerves. Thoracoscopic surgery has some limitations that make those maneuvers more difficult such as the 2D view of the surgical field and the lack of DOF of the surgical instruments that limit the maneuverability. The thoracoscopic thymectomy is considered a technically challenging operation that requires a long learning curve [90]. The introduction of robotic surgical system has dealt with some of the aforementioned problems, mainly the increasing in maneuverability compared to conventional thoracoscopy [85]. However, the lack of tactile feedback of most of the current robotic systems may increase the risk to damage the tumor tissue, increasing the possibility of tumor seeding.

3.2.4. Robotic-Assisted Gynecological Surgery

Since its approval for use in gynecologic surgery by the FDA in 2005, the da Vinci® Surgical System has been widely adopted by hospitals and gynecologic surgeons [91]. At the moment, it is the only commercially available robotic surgical platform for gynecologic surgery in the US. The application of robotic technology has had a strong impact in abdominal and pelvic surgery. One of the most influential results is a decrease in the number of procedures performed by laparotomy, even in the case of obesity, which leads to a reduction in blood loss, shorter hospitalization, and shorter recovery to normal activities [92,93]. Magrina et al. [92] reported a 3% of conversion rate with robotic surgery for endometrial cancer in comparison to 10% for laparoscopic patients. Robotic-assisted surgery has been extensively applied in gynecological surgery in benign gynecology as well as gynecologic oncology. Robotic-assisted surgery allows gynecologists to perform minimally invasive hysterectomies [94], myomectomies [95], and lymph node biopsies [96] without the need for large abdominal incisions.

3.3. Robotic Single-Site Surgery

Since the introduction of laparoscopy, MIS has experienced great advances and innovation, in the pursuit of the final objective to eliminate or keep invisible all scars after surgery. In this sense, laparoendoscopic single-site surgery (LESS) is now consolidated as a real alternative to conventional laparoscopic surgery, with numerous studies sustaining its feasibility and therapeutic safety [97-99]. In this new approach, articulated or prebent instruments are introduced into the abdominal cavity through specific multichannel ports or conventional low profile laparoscopic trocars, placed in close proximity through one single incision. If the surgical procedure is performed with an additional transperitoneal port, it is referred to as hybrid LESS. This way, and still lacking scientific proof, single incision offers various theoretical or potential advantages, such as better cosmetic results, lower incidence of incisional pain, and faster recovery. This surgical technique particularly contributes to excellent cosmesis results mainly because of the surgical scars are often undetectable, especially when the surgical entrance is through the umbilicus.

Apart from its benefits, LESS surgery presents some specific difficulties, which include the reduction in freedom of movement, inline vision with loss of triangulation [100], and closer proximity of instruments, leading to external and intraabdominal clashing and crossing [101], and the deficient ergonomy for the operating surgeon [102]. Clashing of instruments could be partially avoided by using prebent, articulated or instruments of different lengths. Additionally, when using flexible instruments, the size and weight of tissue that can be held are limited owing to the insufficient force transmitted through the instruments.

In an attempt to overcome these problems, new specifically designed instruments and devices are being developed. In this regard, robotic systems for LESS may improve the ability to maneuver within the abdominal cavity due to the possibility of use articulated robotic instruments and with higher number of DOF. This has led to a new kind of surgery, robotic LESS or R-LESS. R-LESS promises to overcome the limitations of laparoscopic single-site surgery by eliminating instrument clashing and reproducing conventional triangulation in a

single incision environment. However, further developments are needed in order to optimize the current robotics systems to single-site surgery.

3.3.1. da Vinci® Surgical System

The first application of single-site robotics in gynecology was reported by Escobar et al. using standard EndoWrist® instruments directed through a GelPort® (Applied Medical; Rancho Santa Margarita, USA) through the umbilicus [103]. Also Kaouk et al. reported the first clinical cases in humans of robotic single-site surgery for radical prostatectomy, radical nephrectomy, and dismembered pyeloplasty using the da Vinci® S Surgical System [104]. In July 2009, White et al. [105] mentioned the first clinical cases of R-LESS uretral reimplant and sacral colpopexy. The first application of R-LESS in digestive surgery was reported by Ostrowitz et al. [106]. Romanelli et al. [107] mentioned the first R-LESS cholecystectomy and Allemann et al. [108] reported the performance of a Nissen fundoplication on 18 pigs either with R-LESS or LESS.

In 2009, Intuitive Surgical Inc. released the third generation of da Vinci® Surgical System, the da Vinci® Si System, which included a wide range of specialized instruments for single-site surgery, a surgical simulator and near-infrared imaging capabilities [109]. The da Vinci® Single-Site Instrumentation kit contains material that has been specifically designed to enable robotic surgery through a single incision of 2-2.5 cm. These surgical instruments are inserted thorough curved trocars, and therefore avoiding collisions between the robotic arms. Additionally, the robotic system can switch the instruments in the right and left side on the control panel, which allows the surgeon to manipulate the instruments on the console as they were not crossed [44]. These new instruments for LESS have been tested for cholecystecmy [59], pyeloplasty [60] and nephrectomies procedures [109], amount others.

However, the flexible instruments for R-LESS provided by Intuitive Surgical are not wristed, and therefore the surgical performance is as if straight-stick conventional laparoscopy instruments were using. In addition, the flexible instrument shafts, necessary for instrument delivery through curved cannulas, limit the tolerance for load of the instruments, causing the shaft could be bent when it has excessive load.

3.3.2. Single-Port Laparoscopy Bimanual Robot (SPRINT®)

The SPRINT® is a master-slave teleoperated robotic platform developed for bimanual interventions by means of single access port. This system consists of two robotic arms with a maximum diameter of 18 mm and a stereoscopic camera (Karl Storz GmbH & Co. KG). This device mounts two graspers that differ in shape and size, which are controlled using a wire-driven mechanism (Figure 5). Each grasper can applied up to 5 N of force. Each robotic arm has embedded the motors and gear boxes, which provide them six DOF. The surgeon's console consists of two manipulators for each of the robotic arms, one pedal and a 3D Full-HD vision system with polarized glasses. Two Phantom Omni haptic devices (Sensable Technologies Inc., Woburn, USA) are used as manipulator, thus enabling to control all six DOF of each robotic arm. This robotic system is still in the prototype phase and still presents some mechanical constraints [110].

The initial tests of this surgical system have been carried out on an in vivo animal model. A midline laparotomy of (approximately 10 cm) was performed and the abdominal cavity was exposed by means of a fixed retractor. The robotic system was fixed to the OR table and

suspended over the incision made in the abdomen of the patient. A surgeon controlled remotely both arms of the robotic system during the performance of a small-bowel enteroenterostomy [111].

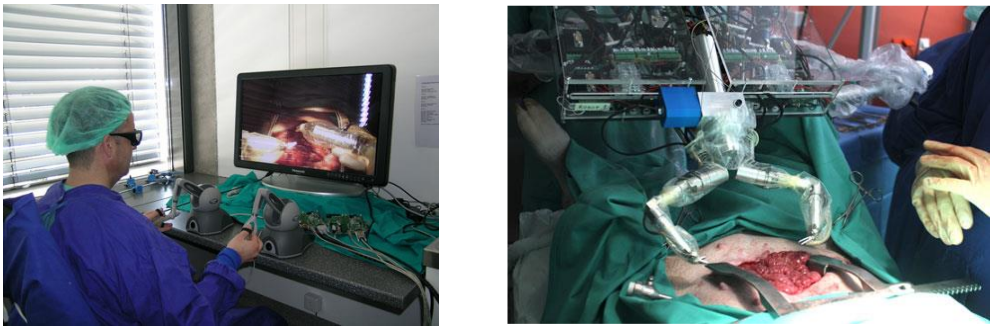

(a) (b)

Figure 5. SPRINT® robot for single-site surgery. (a) Surgeon console with the manipulators and the 3D monitor. (b) SPINT® robot setup in the OR (Images from [111]. Reprinted with permission).

3.3.3. Plate- Spring Mechanism-Based Laparoscopic Surgery Robot (PLAS®)

The PLAS® prototype consists of two flexible arms assembled in a Y-shaped design [112]. Unlike the traditional wire- or link-driven mechanisms used to move the instrument arms [111], this device uses a novel plate-spring mechanism, which provides more than 14 N force transmission. This high force transmission allows for performing a wide range of surgical procedures through single port access. In contrast to the bulkiness of gearboxes and the weaknesses of wired systems, plate springs can deal with these limitations. The movements of both arms could achieve a total of 12 DOF. This feature could be one of the most competitive with regard to the other similar robotic systems, allowing the device to reach a wide workspace inside the abdominal cavity. This system has been only experimentally tested on in vivo animal models. During these experiments, a surgeon performed a liver dissection using PLAS®, determining that it has sufficient force transmission capability to handle the organs during surgery [112].

Nevertheless, the current version of PLAS® does not have an additional supporting structure to hold the endoscope and tool change is not possible. Therefore, several ports and forceps might be required to perform an entire procedure. In addition, this device does not provide haptic feedback from the end effectors to the user's manipulators.

3.4. Robotic Natural Orifice Transluminal Endoscopic Surgery

The concept of natural orifice transluminal endoscopic surgery, most commonly known as NOTES, constitutes a new surgical approach that combines aspects of flexible endoscopy and laparoscopy, where the ultimate goal is to ensure the absence of scars in the skin of the patient. NOTES can be performed as a hybrid procedure, in case surgeon requires laparoscopic assistance or as a pure procedure, if no accessory trocar through the patient’s abdominal wall is needed.

This type of surgical approach avoids the need to make any abdominal incisions, which may correlate with fewer wound infections and a faster recovery and return to daily life. Available literature confirms the feasibility and security in the short term of a variety of transluminal procedures, including cholecystectomy, appendectomy, tubal ligation, gastrojejunostomy, nephrectomy, pancreatectomy and splenectomy [113-115]. The body's orifices are considered natural routes, and reported entrances to the abdominal cavity include transgastric, transcolonic, transvaginal and transvesical. Once the transluminal procedures are completed, the endoscope is withdrawn through the natural orifice and the incision is closed by using clips or endoscopic suturing devices.

Some of the limitations of this technique include inefficient tissue traction, inadequate triangulation of instruments, and existing risk of abdominal infections due to an incorrect disinfection or visceral closing. In NOTES, to perform the surgical procedures, surgeons have to manipulate endoscopic forceps through the flexible endoscopic channel, which in some cases it does not provide the degree of maneuverability required to perform the procedure without complications. Additionally, current endoscopes and instruments remain inadequate to perform complex surgeries by NOTES approach. NOTES itself requires the acquisition of new equipment and surgical skills for deployment in the surgery, which demands for the development of specific training programs.

To overcome the aforementioned limitations, the use of robotic technology could provide a potential solution to increase the dexterity in manipulating the endoscopic forceps in a narrow visual field and a small cavity. This leads to the concept of robotic natural orifice transluminal surgery (R-NOTES).

3.4.1. da Vinci® Surgical System

The use of the da Vinci® Surgical System for robotic-assisted NOTES has been reported in animal and cadaveric models, but not in the case of human patients. The initial experience with robotic natural orifice transluminal surgery (R-NOTES) using the da Vinci® Surgical System was reported by Haber et al. [116] for reconstructive urology. In this study, they performed 10 robotic-assisted hybrid transvaginal NOTES pyeloplasties, 10 radical and 10 partial nephrectomies in 10 in vivo porcine models. For performing these procedures, the robotic laparoscope and the first robotic arm were placed through a single umbilical incision by means of a single-port multicannula, and the second robotic arm was placed through the vagina. All the procedures were performed successfully without any open conversion or additional laparoscopic port. In a study with 3 female cadavers, two different approaches for retroperitoneal transvaginal R-NOTES nephrectomy were reported using the da Vinci® Si System in a 3-arm configuration [61]. In the first approach, the peritoneal cavity was accessed in the lithotomy position and in the prone jackknife position during the second approach. Access to the peritoneal cavity was obtained by means of a single-port device inserted through the vagina. The results showed that the first approach could not be successfully performed due to collision of the robotic arms against the legs and limited bowel retraction. During the second approach, in one of the subjects there was a rectal injury during the access and the procedures could not be completed because they could not reach the kidney with the robotic instruments due to the height of the subject. Using also a cadaveric model, Eyraud et al. [62] completed successfully a transrectal hybrid R-NOTES nephrectomy and adrenalectomy.

Demura et al. [117] analyzed the feasibility of using the da Vinci® Surgical System for a transrectal small intestinal anastomosis and closure of the rectal anterior wall incision in a porcine ex vivo model. A Tuebingen MIC trainer (Richard Wolf GmbH, Knittlingen, Germany) was used as surgical setting, in which the ex vivo small vowel segments were place. Surgical performance using the R-NOTES approach was compared with traditional transabdominal robot-assisted surgical approach as well as using transanal endoscopic microsurgery instruments (TEM NOTES). For the R-NOTES procedure, two 8-mm robotic arms were inserted through the anterior rectal wall orifice of the box trainer and placed horizontally, and a 12-mm camera was inserted through the same orifice and placed above the two arms. The number of experiments with each approach was 12. Results showed that the mean burst pressures in the transrectal R-NOTES group and the transabdominal robotic group were significantly higher than in the TEM NOTES group. Besides, the surgical time was shorter in the R-NOTES group than in the TEM NOTES group, but longer than the transabdominal robotic group.

Although the use of the da Vinci® Surgical System provides several benefits for the surgeon such as the increase dexterity, multiple DOF and 3D vision, using this robotic system for NOTES is still technically challenging. For this reason, further refinements of this technique as well as development of new surgical instruments and devices should be done. On the other hand, novel surgical devices and prototypes focus on providing new alternatives for R-NOTES are described below.

3.4.2. Endoscopic Surgical Robot for Tele-NOTES

In 2009 Suzuki et al. [118] reported the first telesurgery experiment by performing a NOTES procedure (Tele-NOTES). In this experiment they used an endoscopic surgical robot inserted through the esophagus to perform surgeries in the upper gastric tubes and the abdominal cavity through the stomach wall. Therefore, this surgical robot was able to perform intraabdominal surgeries without any external incision on the patient. The robotic system consisted of one central camera and two robotic arms, which were controlled by means of a wire-driven mechanism. The surgeon controlled the system from a surgical console, which consisted of two haptic devices (PHANTOM Omni, SensAble Technologies Inc., MA, USA) for the manipulation of forceps (Figure 6). The robot could perform grasping, incising and clipping of soft tissue using the cooperative action of left and right robotic arms.

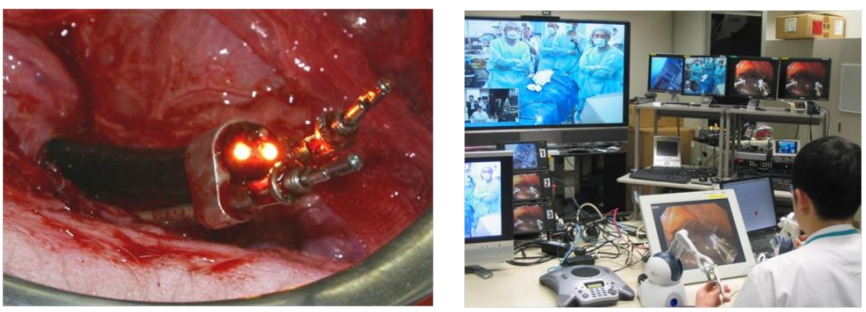

(a) (b)

Figure 6. Endoscopic surgical robot for Tele-NOTES. (a) Surgical robot inside the abdominal cavity. (b) Remote operation unit to control the robotic arms (Courtesy of Prof. M. Hashizume, Department of Advanced Medical Initiatives, Kyushu University, Fukuoka, Japan).

The system has been previously used for endoscopic mucosal resection in stomach, and NOTES procedures on liver, gall bladder, small intestine and oviduct in animal models [118]. For the Tele-NOTES experiment they performed a lymph node dissection between Japan and Thailand (distance of about 3,750 km) using a human soft cadaver. The robotic system was controlled by the cooperative direction of a surgeon and an endoscopist. The surgeon was placed on the surgical console in Japan, who was in charge of manipulating the robotics arms. The endoscopist was on the patient side in Thailand controlling the endoscope.

3.4.3. EndoSAMURAI®

The EndoSAMURAI® (Olympus Corp., Tokyo, Japan) is a prototype platform consisting mainly of an endoscope and a control console. This endoscopic platform has two independent end effectors with five DOF, a third conventional working channel, and an ergonomic user interface [119]. The main advantage is that the console has similar actuators used in conventional laparoscopic surgery, thereby adapting to the use of the system is usually less complex and more intuitive for a laparoscopist. The two articulating working arms can be moved out of the original diameter of the scope and therefore provide more triangulation. However, this may reduce the maneuverability in tight spaces lumen such as in the oesophagus or small bowel. The system has some similar functions to a traditional endoscope such as the light source and insufflation of gas, but also standard functions for suction and the possibility of rinsing the endoscopic lens. Exchangeable instruments via the working channels of the scope allow for a variety of working functions including grasping, retracting, tissue cutting, coagulation, hemostasis, and suturing with a needle holder. In general, the system is operated by two individuals: the main surgeon placed at the workstation and the camera assistant who guides the endoscope within the abdominal cavity [120].

This device has been compared in a benchtop simulation with a conventional dual-channel endoscope during the performance of bimanual coordination tasks such as suturing and knot-tying [119]. Results showed better results for the novel device in time and accuracy. Recently, the EndoSAMURAI® has been tested in an experimental in vivo porcine model by performing a transgastric small bowel segmental resection with acceptable quality and within a reasonable time (110 min) [120].

3.4.4. Master and Slave Transluminal Endoscopic Robot (MASTER®)

Another robotic prototype for NOTES that is used with a conventional endoscope is the MASTER® (Nan Yang Technological University, Singapore). This consists of two small cable-driven flexible arms with nine DOF located at the tip of the endoscope. These cables have the enough size to be inserted through the channels of a conventional flexible endoscope with double channels. Moreover, this robotic platform provides a console for the manipulation of the surgical tools in a more intuitive manner. This console is adapted to the surgeon's needs allowing for a more ergonomic position during the intervention. The master controller is attached to the wrist and fingers of the operator and connected to the manipulator by electrical and wire cables [121]. The robotic arms allow for tissue manipulation, triangulation, off-axis forces and monopolar cautery. This system also requires an endoscopist as well as a robotic operator to perform a surgical intervention. However, there are some limitations that should be improved in future versions such as automation of camera control and an easier exchange of instrument.

This device has already been tested in ex vivo and in vivo animal models for endoscopic submucosal dissection. The novel device has been shown to have faster learning curve than using conventional endoscopic equipment to complete the procedure [121]. Recently, Phee et al. [122] performed the same procedure in 5 human patients with early-stage gastric neoplasia, limited to the mucosa. After markings and circumferential mucosal incision, all submucosal dissections were performed using the MASTER® system. All surgeries were successfully performed with no residual or recurrent tumors. Additionally, the MASTER® system has been used to perform wedge hepatic resection through the transgastric route on two female pigs. Results showed that the procedure using the novel device was accomplished successfully in both patients without the need for assistance using laparoscopic instruments [123].

3.4.5. Miniature Robot for NOTES

The robotic systems for NOTES based on the endoscope that use cable-driven arms are prone to generate friction during wire actuation inside the endoscopic channels. This may cause significant amount of hysteresis and ineffective force transmission, thus resulting in lack of instrument responsiveness and accuracy [124]. An alternative to this problem is to use systems that do not require cable-driven mechanism as the miniature robot for NOTES developed at the University of Nebraska-Lincoln (Lincoln, USA) [125]. This device, with tubular shape, consists of two arms connected to a central body by a rotational joint. This miniature robot has two remotely controlled actuators with six DOF, stereovision and ultra bright LED lighting. Both cautery and forceps are the end-effectors provided by this device. The actuators are remotely controlled by the surgeon using an external console, which consists of two joysticks for controlling the robotic arms and a TFT color LCD monitor located between the two joysticks to display the video from the endoscopic camera.

In order to be introduced into the peritoneal cavity through the esophagus by means of a standard therapeutic endoscope, this system acquires initially a linear configuration. Once the system is inside the abdominal cavity it is restructured again into three parts using an external magnetic handle that interacts with magnets housed in the robot body. The exterior magnet handle can be moved along the outer surface of the abdomen for repositioning the robot throughout the procedure. This robotic system has been tested for an abdominal exploration, a bowel manipulation, and a cholecystectomy in three ex vivo porcine models [125]. Results of this study reported that the robot has the sufficient flexibility for transgastric insertion while providing a stable platform for tissue manipulation and visualization of the surgical field. Besides, the robotic arms were able to provide the sufficient force for tissue retraction and dissection during the procedures. However, this system experienced some problems during the execution of some of these surgical procedures. In one case, the robotic device did not have the enough magnetic coupling for attaching the robot to the interior abdominal wall and, in another procedure, there was a mechanical failure in one of its shoulder joints.

3.5. Image-Guided Robotic Surgery

The principal disadvantage of the conventional endoscopic technique is that it is difficult to maintain precise control of the endoscopic instruments because of limited range of

movements of the surgical instruments, heartbeat, breathing movements, instable visualization of the operative field, and haptic input. These limitations make difficult to perform some procedures that need for high precise movements such as tumor resection or cardiac surgery. In this sense, robotic technology along with image-guided techniques is a feasible solution to cope with these surgical requirements. Needles, slender probes or other instruments can be inserted into the body using real-time feedback of different imaging modalities, such as CT, MRI, US and fluoroscopy [27]. In this sense, we will focus our attention on robotic systems that are placed in imaging devices using them during the curse of the intervention.

3.5.1. Tumor Therapy

One of the most popular robotic platform for tumor ablation is the CyberKnife® system (Accuray, Inc., Sunnyvale, USA), which was the first image-guided robotic system for noninvasive radiation procedures. This robotic system was developed in 1987 as an interventional radiological robot and received the FDA approval in 2001. It consists of a large robotic arm that can quickly and accurately deliver targeted radiation with converged beams from multiple angles, reducing radiation exposure to surrounding tissue [126]. Before the intervention, a CT scan of the patient is imported into the treatment planning system. Then, the robotic manipulator automatically follows a fixed preplanned path to target the lesion, but this path can be modified automatically along the treatment on the basis of possible patient displacement. Because the patient is in continuous motion and the interior of the human body is an unstable scenario, CyberKnife® updates its spatial registration of the patient prior to each dose using an X-ray imaging system and a respiratory tracking system to track and anticipate respiratory motion [127,128]. The X-ray images are used during the treatment to compute the changes in position of the patient using the CT images as baseline, and therefore making continuous adjustments for movement. This image-guided robotic system has been used for radiotherapy of brain tumors, lesions of the spine, lung, pancreas, liver, and prostate [126].

In 2012 The Indian Perfint Healthcare Corporation (Chennai, India) released the MAXIO® system, which is an integrated planning, navigation and robotic targeting system for CT-guided tumor ablation. The use of this platform can be divided into four phases: Image registration, planning, treatment and verification. Once the CT images have been obtained, the next step is the image segmentation using a semi-automatic segmentation method. After the image segmentation has been performed and the tumor has been localized, surgeons can plan the interventional procedure in 3D by selecting the target and entry point. In this phase, the clinician can analyze the best approach to reach the tumor. Once the planning is done, clinicians can uses the MAXIO®'s robotic targeting system to support them to reach the tumor safely and as planned, and then proceed to deliver the thermal or other energy beams to blast the tumor. Finally, the visualization tools help clinicians to verify and extend the procedure if needed. The robotic platform has been tested using abdominal phantoms [129]. Initial experiences with the system reported that it improves the accuracy of needle placement, reduce number of needle passes, and significantly reduce the total radiation dose to the patients [130].

3.5.2. Cardiac Surgery

Robots have been also applied to support the intravascular procedures. In this sense, Hansen Medical (Mountain View, CA, USA) developed the Sensei® robotic catheter, which is a master-slave system that allows surgeon to control remotely a fluoroscopically guided catheter. This system prevents the exposure to radiation by the cardiologist. Sensei® received the FDA clearance in 2007. This robotic system has a workstation with an intuitive interface that translates the surgeon's hands movements to a robotically steered guided catheter using advanced robotic technology (Artisan® Control Catheter). The combination of outer and inner guide motion allows the catheter to easily acquire any curved shape. The workstation provides the fluoroscopic view of the catheter as well as the 3D model of it. Sensei® is compatible with multiple imaging systems including fluoroscopy as well as 3D mapping systems. This system also provides force feedback thanks to a force sensor at the tip of the catheter that registers the information regarding the contact between the catheter and the tissue [131]. These features allow surgeons to navigate flexible catheters with greater stability and control during complex cardiac arrhythmia procedures. This system has been used extensively for catheter ablation of atrial fibrilation [132,133]. Studies reported that the use of this system reduces fluoroscopy times in catheter ablation of atrial fibrilation, resulting in reduced X-ray exposure for patients and other surgical staff in the OR [133,134].

Another feasible option for remote catheter navigation and ablation is the use of remote magnetic navigation technology. This technology is used by the Niobe® Navigation System (Stereotaxis, St. Louis, MO, USA), which was designed for cardiac interventions. This system consists of two permanent magnets positioned at either side of the fluoroscopy table creating a spherical uniform magnetic field, which can apply a low-intensity magnetic field to the patient. The system uses a special catheter containing small magnetic implants, which are aligned with regard to the magnetic field applied. The workstation of this robotic platform is able to integrate real-time imaging data to produce 3D magnetic vectors. This allows the cardiologist to guide the tip of the catheter though the major vessels and heart of the patient by changing the orientation of the magnetic field. The Niobe® system has been proven safe and effective in the treatment of different types of supraventricular and ventricular arrhythmias [135-137].

3.5.3. MRI-Compatible Robots

In 2008 Hashizume et al. [138] presented a MR image-guided surgical robotic system for MIS. The system consists of MR image guidance, an MRI-compatible operating table, an MRI-compatible master-slave surgical manipulator, and an open-bone MRI scanner (Figure 7). The master-slave robotic system is made of MRI-compatible material, and enables each manipulator to be attached to any position on the guide rail of the operating table. The manipulator system has four arms: one holds the endoscope while the other three arms hold the robotic forceps or other surgical instruments such as ablation needle, grasper, scissors or needle holder. All of them are MRI-compatible. The surgeon controls remotely the slave manipulators by means of a console, which also provides the image-guidance system and the endoscopic view. The image-guidance system allows surgeon to make a preoperative plan using the 3D anatomical images and see in real time the navigation images during the intervention in order to reach easily the target.

They performed in vivo experiments with MR image-guided laparoscopic radiofrequency ablation for liver tumors on three pigs, using mimic tumors made of agarose gel and with a diameter of approximately 2cm. In order to plan the puncture path, the surgeon segmented the target and defined the entry point on the abdominal wall using the MRI data on the preoperative planning system. Then, during the intervention the tumor was punctured using the MR image-guided surgical robotic system. The surgeon succeeded in puncturing safely all liver targets on each subject while maintaining the operative field with the robotic forceps [138].

Figure 7. MRI-guided surgical robotic system. The photograph shows an open-bone MR scanner in the top left, the MRI-compatible operating table with the compact MRI-compatible surgical manipulator (slave) in the upper right, and the surgical console with the manipulator (master) at the bottom (Courtesy of Prof. M. Hashizume, Department of Advanced Medical Initiatives, Kyushu University, Fukuoka, Japan).

Another MRI-compatible system for MIS is the MrBot® (Johns Hopkins Bayview Medical Center, Baltimore, USA). This is a fully-actuated robot for image-guided access of the prostate gland. The robot was customized for transperineal needle insertion and designed to be MRI-compatible. To achieve it the robot was made of nonmagnetic and dielectric materials such as plastics, ceramics, and rubbers and it is electricity free. The robot implements a pneumatic actuator to avoid electricity use. The robotic system consists of a controller unit located outside the imager's room, which has all the electric components, and the robot. The robot's end-effector has six DOF to be placed and oriented. This end-effector has an additional DOF to set the depth of needle insertion and three DOFs to manipulate a titanium needle. This robotic system has been designed to accommodate various needle drivers for different percutaneous interventions such as biopsy, thermal ablations, or brachytherapy. However, to date only the needle driver for the transperineal seed brachytherapy has been implemented. The tip of the robot has a MRI-visible set of markers to

register the position of the robot. Planning software is used for organ segmentation and defining the needle path. Dose constraints and organ contours are used by the planning software to determine the optimal location for the seeds. Needle penetration and source delivery are automated and controlled remotely by the surgeon [139]. This system was experimentally tested in 4 male dogs for prostate brachytherapy [140]. Results showed a mean placement error of the seeds of 3.32±2.77 mm.

CONCLUSION

The introduction of computer-assisted surgery, including image-guided surgery and robot-assisted surgery, to support surgical interventions has provided surgeons with new assistance tools to address some limitations of MIS as well as improve the clinical outcomes. In general terms, the magnified operative field and the increased surgical dexterity result in a low conversion rate and reduced tissue trauma. With improved computer and imaging technologies, navigation systems are quickly becoming an integral part in the surgical routine in hospitals. These systems improve the surgeon perception of the patient anatomy and provide tools to analyze in advance the most suited approach to carry out a surgical intervention. In this sense, AR offers a suitable way to enhance the common view of the surgical field with useful information as preoperative images and virtual models. Although this technology is well established for rigid anatomy, further work has to be done for a full integration with deformable anatomical models. Continuous technological advances in robotic-assisted surgery have led to potential improvements in the development of MIS procedures such as 3D vision, increased precision and dexterity, and ergonomic conditions for the surgeon. Besides, novel robotic prototypes are being developed for recent MIS approaches such as LESS and NOTES. New dexterous and micro-robotic systems are able to enter the body via a LESS or NOTES approach, providing assistance during the surgical intervention. However, there is currently no ideal platform for these surgeries. Each kind of procedure may require a customized solution to provide a feasible surgical robotic system.

REFERENCES

[1] Galloway R, Peters T. Overview and History of Image-Guided Interventions. In: *Image-guided interventions: technology and applications*. 2008. Springer New York.

[2] Jolesz FA. *Introduction. In: Intraoperative Imaging and Image- Guided Therapy.* Jolesz FA, editor. 2014. Springer New York.

[3] Kapur T, Egger J, Jayender J, Toews M, Wells WM. Registration and Segmentation for Image-Guided Therapy. In: *Intraoperative Imaging and Image- Guided Therapy.* Jolesz FA, editor. 2014. Springer New York.

[4] Cleary K, Wilson E, Ordas S, Banovac F. Navigation. In: *Intraoperative Imaging and Image- Guided Therapy.* Jolesz FA, editor. 2014. Springer New York.

[5] Sánchez-Margallo JA, Sánchez-Margallo FM, Oropesa I, Gómez EJ. Systems and technologies for objective evaluation of technical skills in laparoscopic surgery. *Minim Invasive Ther Allied Technol* 2014;23(1):40–51.

[6] Sugimoto M, Yasuda H, Koda K, Suzuki M, Yamazaki M, Tezuka T, et al. Image overlay navigation by markerless surface registration in gastrointestinal, hepatobiliary and pancreatic surgery. *J Hepatobiliary Pancreat Sci.* 2010;17:629–36.

[7] Oguro S, Tokuda J, Elhawary H, Haker S, Kikinis R, Tempany CM, Hata N. MRI signal intensity based B-spline nonrigid registration for pre- and intraoperative imaging during prostate brachytherapy. *J Magn Reson Imaging* 2009;30(5):1052–8.

[8] Archip N, Tatli S, Morrison P, Jolesz F, Warfi eld SK, Silverman S. Non-rigid registration of pre-procedural MR images with intra-procedural unenhanced CT images for improved targeting of tumors during liver radiofrequency ablations. *Med Image Comput Comput Assist Interv* 2007;10(Pt 2):969–77.

[9] Teber D, Guven S, Simpfendörfer T, Baumhauer M, Güven EO, Yencilek F, Gözen AS, Rassweiler J. Augmented reality: a new tool to improve surgical accuracy during laparoscopic partial nephrectomy? Preliminary in vitro and in vivo results. *Eur Urol* 2009;56(2):332-8.

[10] Shekhar R, Dandekar O, Bhat V, Philip M, Lei P, Godinez C, et al. Live augmented reality: a new visualization method for laparoscopic surgery using continuous volumetric computed tomography. *Surg Endosc* 2010;24(8):1976–85.

[11] Okamoto T, Onda S, Yanaga K, Suzuki N, Hattori A. Clinical application of navigation surgery using augmented reality in the abdominal field. *Surg Today* 2014. [Epub ahead of print].

[12] Pieper SD. Visualization and Display for Image-Guided Therapy. In: *Intraoperative Imaging and Image- Guided Therapy.* Jolesz FA, editor. 2014. Springer New York.

[13] Liao H, Inomata T, Sakuma I, Dohi T. 3-D augmented reality for MRI-guided surgery using integral videography autostereoscopic image overlay. *IEEE Trans Biomed Eng* 2010;57(6):1476–86.

[14] Soler L, Nicolau S, Pessaux P, Mutter D, Marescaux J. Real-time 3D image reconstruction guidance in liver resection surgery. *Hepatobiliary Surg Nutr* 2014;3(2):73–81.

[15] Soler L, Forest C, Nicolau S, Vayssiere C, Wattiez A, Marescaux J. Computer-assisted operative procedure: from preoperative planning to simulation. *Eur Clin Obstet Gynaecol* 2006;2(4):201–8.

[16] Gering DT, Nabavi a, Kikinis R, Hata N, O'Donnell LJ, Grimson WE, et al. An integrated visualization system for surgical planning and guidance using image fusion and an open MR. *J Magn Reson Imaging* 2001;13(6):967–75.

[17] Ferroli P, Tringali G, Acerbi F, Schiariti M, Broggi M, Aquino D, Broggi G (2013) Advanced 3-dimensional planning in neurosurgery. *Neurosurg Suppl* 1:A54–A62.

[18] Stelter K, Ertl-Wagner B, Luz M, Muller S, Ledderose G, Siedek V, Berghaus A, Arpe S, Leunig A. Evaluation of an image-guided navigation system in the training of functional endoscopic sinus surgeons. A prospective, randomised clinical study. *Rhinology* 2011;49(4):429-37.

[19] Wilson DA, Astephen Wilson JL, Richardson G, Dunbar MJ. Changes in the functional flexion axis of the knee before and after total knee arthroplasty using a navigation system. *J Arthroplasty* 2014;29(7):1388-93

[20] Hong J, Matsumoto N, Ouchida R, Komune S, Hashizume M. Medical navigation system for otologic surgery based on hybrid registration and virtual intraoperative computed tomography. *IEEE Trans Biomed Eng* 2009;56(2):426–432.

[21] Mezger U, Jendrewski C, Bartels M. Navigation in surgery. *Langenbecks Arch Surg.* 2013;398:501–14.

[22] Wood BJ, Kruecker J, Abi-Jaoudeh N, Locklin JK, Levy E, Xu S et al. Navigation systems for ablation. *J Vasc Interv Radiol.* 2010;21(8):S257–63.

[23] Beyar R. Navigation within the heart and vessels in clinical prac-tice. *Ann N Y Acad Sci.* 2010;1188(1):207–13.

[24] Baumhauer M, Feuerstein M, Meinzer HP et al. Navigation in endoscopic soft tissue surgery: perspectives and limitations. *J Endourol* 2008;22:751–766.

[25] Ukimura O, Gill IS (2008) Imaging-assisted endoscopic surgery: cleveland clinic experience. *J Endourol* 22:803–810.

[26] Birkfellner W, Hummel J, Wilson E, Cleary K. Tracking Devices. In: Peters T, Cleary K, editors. *Image-guided interventions: technology and applications.* Springer New York; 2008.

[27] Micali S, Pini G, Teber D. New trends in minimally invasive urological surgery. What is beyond the robot?. *World J Urol* 2013;31(3):505–13.

[28] Marescaux J, Rubino F, Arenas M, Mutter D, Soler L. Augmented-reality-assisted laparoscopic adrenalectomy. *JAMA* 2004;292:2214–5.

[29] Tsutsumi N, Tomikawa M, Uemura M, Akahoshi T, Nagao Y, Konishi K, et al. Image-guided laparoscopic surgery in an open MRI operating theater. *Surg Endosc* 2013;27(6):2178–84.

[30] Simpfendörfer T, Baumhauer M, Müller M, Gutt CN, Meinzer HP, Rassweiler JJ, et al. Augmented reality visualization during laparoscopic radical prostatectomy. *J Endourol.* 2011;25:1841–5.

[31] Ieiri S, Uemura M, Konishi K, Souzaki R, Nagao Y, Tsutsumi N, et al. Augmented reality navigation system for laparoscopic splenectomy in children based on preoperative CT image using optical tracking device. *Pediatr Surg Int* 2012;28(4):341–6.

[32] Vahrmeijer AL, Hutteman M, van der Vorst JR, van de Velde CJ, Frangioni JV. Image-guided cancer surgery using near-infrared fluorescence. *Nat Rev Clin Oncol* 2013;10(9):507-18.

[33] Nguyen QT, Tsien RY. Fluorescence-guided surgery with live molecular navigation--a new cutting edge. *Nat Rev Cancer* 2013;13(9):653–62.

[34] Kudo H, Ishizawa T, Tani K, Harada N, Ichida A, Shimizu A, et al. Visualization of subcapsular hepatic malignancy by indocyanine-green fluorescence imaging during laparoscopic hepatectomy. *Surg Endosc* 2014;28(8):2504–8.

[35] Diana M, Noll E, Diemunsch P, Dallemagne B, Benahmed M a, Agnus V, et al. Enhanced-reality video fluorescence: a real-time assessment of intestinal viability. *Ann Surg* 2014;259(4):700–7.

[36] Mohsen A, Elbasiouny MS, Fawzy YS. Fluorescence-guided laparoscopic cholecystectomy: a new technique for visualization of biliary system by using fluorescein. *Surg Innov* 2013;20(2):105–8.

[37] Schols RM, Lodewick TM, Bouvy ND, van Dam DA, Meijerink WJ, van Dam GM, Dejong CH, Stassen LP. Near-infrared fluorescence laparoscopy of the cystic duct and artery in pigs: performance of a preclinical dye. *J Laparoendosc Adv Surg Tech A* 2014;24(5):318-22.

[38] Kondo Y, Murayama Y, Konishi H, Morimura R, Komatsu S, Shiozaki A, et al. Fluorescent detection of peritoneal metastasis in human colorectal cancer using 5-aminolevulinic acid. *Int J Oncol* 2014;45(1):41–6.

[39] Jichlinski P, Forrer M, Mizeret J, Glanzmann T, Braichotte D, Wagnieres G, Zimmer G, Guillou L, Schmidlin F, Graber P, van den Bergh H and Leisinger HJ: Clinical evaluation of a method for detecting superficial surgical transitional cell carcinoma of the bladder by light induced fluorescence of protoporphyrin IX following the topical application of 5-aminolevulinic acid: preliminary results. *Lasers Surg Med* 1997;20: 402-408.

[40] Friesen SA, Hjortland GO, Madsen SJ, Hirschberg H, Engebraten O, Nesland JM and Peng Q: 5-Aminolevulinic acid-based photo-dynamic detection and therapy of brain tumors (review). *Int J Oncol* 2002;21: 577-582.

[41] Hoda MR, Popken G. Surgical outcomes of fluorescence-guided laparoscopic partial nephrectomy using 5-aminolevulinic acid-induced protoporphyrin IX. *J Surg Res* 2009;154(2):220–5.

[42] Tobis S, Knopf JK, Silvers C, Messing E, Yao J, Rashid H, et al. Robot-assisted and laparoscopic partial nephrectomy with near infrared fluorescence imaging. *J Endourol* 2012;26(7):797–802.

[43] Hockenberry MS, Smith ZL, Mucksavage P. A novel use of near-infrared fluorescence imaging during robotic surgery without contrast agents. *J Endourol* 2014;28(5):509-12.

[44] Ohuchida K, Hashizume M. Overview of Robotic Surgery. In: Watanabe G, editor. *Robotic Surgery*. Tokyo: Springer Japan; 2014.

[45] Benabid AL, Cinquin P, Lavalle S, Le Bas JF, Demongeot J, de Rougemont J. Computer-driven robot for stereotactic surgery connected to CT scan and magnetic resonance imaging. Technological design and preliminary results. *Appl Neurophysiol* 1987; 50:153–154.

[46] Kwoh YS, Hou J, Jonckheere EA, Hayati S. A robot with improved absolute positioning accuracy for CT guided stereotactic brain surgery. *IEEE Trans Biomed Eng* 1988; 35:153–160.

[47] Wedmid A, Llukani E, Lee DI. Future perspectives in robotic surgery. *BJU Int* 2011;108(6 Pt 2):1028–36.

[48] Mettler L, Ibrahim M, Jonat W. One year of experience working with the aid of a robotic assistant (the voice-controlled optic holder AESOP) in gynaecological endoscopic surgery. *Hum Reprod* 1998;13(1O):2748-50.

[49] Wagner AA, Varkarakis IM, Link RE, Sullivan W, Su LM. Comparison of surgical performance during laparoscopic radical prostatectomy of two robotic camera holders, EndoAssist and AESOP: a pilot study. *Urology* 2006;68(1):70-4.

[50] Ewing DR, Pigazzi a., Wang Y, Ballantyne GH. Robots in the Operating Room The History. *Surg Innov* 2004;11(2):63–71.

[51] Satava RM. Robotic surgery: from past to future: a personal journey. *Surg Clin North Am* 2003; 83:1491–1500.

[52] Kiaii B, Boyd WD, Rayman R, et al. Robot-assisted computer enhanced closed-chest coronary surgery: preliminary experience using a harmonic scalpel and Zeus. *Heart Surg Forum* 2000;3:194-197.

[53] Boehm DH, Reichenspurner H, Detter C, et al. Clinical use of a computer-enhanced surgical robotic system for endoscopic coronary artery bypass grafting on the beating heart. *J Thorac Cardiovasc Surg* 2000;48:198-202.

[54] Marescaux J, Leroy J, Gagner M, Rubino F, Mutter D, Vix M et al. Transatlantic robot- assisted telesurgery. *Nature* 2001; 413(6854):379–380.

[55] Satava RM. Surgical robotics: the early chronicles: a personal historical perspective. *Surg Laparosc Endosc Percutan Tech* 2002; 12:6–16.

[56] Hagen ME, Curet MJ. The da Vinci Surgical® Systems. In: Watanabe G, editor. *Robotic Surgery*. Tokyo: Springer Japan; 2014.

[57] Hagen ME, Pugin F, Chassot G, Huber O, Buchs N, Iranmanesh P, Morel P. Reducing cost of surgery by avoiding complications: the model of robotic Roux-en-Y gastric bypass. *Obes Surg* 2012; 22(1):52–61.

[58] Augustin F, Bodner J, Wykypiel H, Schwinghammer C, Schmid T. Perioperative results of robotic lung lobectomy: summary of literature. *Surg Endosc* 2012; 26:1190–1191.

[59] Morel P, Buchs NC, Iranmanesh P, Pugin F, Buehler L, Azagury DE, Jung M, Volonte F, Hagen ME. Robotic single-site cholecystectomy. *J Hepatobiliary Pancreat Sci* 2014;21(1):18-25.

[60] Tobis S, Houman J, Thomer M, Rashid H, Wu G. Robot-assisted transumbilical laparoendoscopic single-site pyeloplasty: technique and perioperative outcomes from a single institution. *J Laparoendosc Adv Surg Tech A* 2013;23(8):702-6.

[61] Laydner H, Autorino R, Isac W, Khalifeh A, Panumatrassamee K, Kassab A, et al. Robotic retroperitoneal transvaginal natural orifice translumenal endoscopic surgery (NOTES) nephrectomy: feasibility study in a cadaver model. *Urology* 2013;81 (6):1232–7.

[62] Eyraud R, Laydner H, Autorino R, Hillyer S, Long J-A, Panumatrassamee K, et al. Robot-assisted transrectal hybrid natural orifice translumenal endoscopic surgery nephrectomy and adrenalectomy: initial investigation in a cadaver model. *Urology* 2013;81(5):1090–4.

[63] Olanrewaju OA, Faieza AA, Syakirah K. Current trend of robotics application in medical. In: *IOP Conference Series: Materials Science and Engineering. Vol*. 46. IOP Publishing. 2013.

[64] Connor S, Garden OJ. Bile duct injury in the era of laparoscopic cholecystectomy. *Br J Surg* 2006; 93:158–168.

[65] Bann S, Khan M, Hernandez J, Munz Y, Moorthy K, Datta V, et al. Robotics in surgery. *J Am Coll Surg* 2003;196(5):784–95.

[66] Autorino R, Zargar H, Kaouk JH. Robotic-assisted laparoscopic surgery: recent advances in urology. *Fertil Steril* 2014 [Epub ahead of print].

[67] Tachibana M, Yoshioka K. Robotic Surgery in Urology. In: Watanabe G, editor. *Robotic Surgery*. Tokyo: Springer Japan; 2014.

[68] Schuessler WW, Schulam PG, Clayman RV, Kavoussi LR. Laparoscopic radical prostatectomy: initial short-term experience. *Urology* 1997; 50(6):854–857.

[69] Krambeck AE, DiMarco DS, Rangel LJ, Bergstralh EJ, Blute ML, Gettman MT. Radical prostatectomy for prostatic adenocarcinoma: a matched comparison of open retropubic and robot-assisted techniques. *BJU Int* 2009; 103(4):448–453.

[70] Richards KA, Hemal AK, Kader AK, Pettus JA. Robot assisted laparoscopic pelvic lymphadenectomy at the time of radical cystectomy rivals that of open surgery: single institution report. *Urology* 2010; 76:1400–1404.

[71] Coelho RF, Rocco B, Patel MB, Orvieto MA, Chauhan S, Ficarra V et al. Retropubic, laparoscopic, and robot-assisted radical prostatectomy: a critical review of outcomes reported by high-volume centers. *J Endourol* 2010; 24:2003–2015

[72] Orvieto MA, Patel VR. Evolution of robot-assisted radical prostatectomy. *Scand J Surg* 2009; 98(2):76–88.

[73] Hanzly M, Fredrick A, Creighton T, Attwood K, Mehedint D, Kauffman E, Kim HL, Schwaab T. Learning Curves for Robotic-Assisted and Laparoscopic Partial Nephrectomy. *J Endourol* 2014;11 [Epub ahead of print].

[74] Gettman MT, Blute ML, Chow GK, Neururer R, Bartsch G, Peschel R. Robotic-assisted laparoscopic partial nephrectomy: technique and initial clinical experience with daVinci robotic system. *Urology* 2004; 64:914–918.

[75] Brandina R, Aron M. Laparoscopic partial nephrectomy: advances since 2005. *Curr Opin Urol* 2010; 20:111–118.

[76] Haseebuddin M, Benway BM, Cabello JM, Bhayani SB. Robot-assisted partial nephrec- tomy: evaluation of learning curve for an experienced renal surgeon. *J Endourol* 2010; 24:57–61.

[77] Stephenson ER, Sankholkar S, Ducko CT, Damiano RJ. Robotically assisted microsurgery for endoscopic coronary artery bypass grafting. *Ann Thorac Surg* 1998; 66:1064–1067.

[78] Loulmet D, Carpentier A, d' Attelis N et al. Endoscopic coronary artery bypass grafting with the aid of computer-assisted instruments. *J Thorac Cardiovasc Surg* 1999;48:4–10.

[79] Carpentier A, Loulmet D, Aupècle B, et al. Computer assisted open heart surgery. First case operated on with success. *C R Acad Sci III* 1998;321:437-42

[80] Chi NH, Huang CH, Huang SC, Yu HY, Chen YS, Wang SS, Wu IH. Robotic mitral valve repair in infective endocarditis. *J Thorac Dis* 2014;6(1):56-60.

[81] Srivastava S, Gadasalli S, Agusala M, Kolluru R, Naidu J, Shroff M, Barrera R, Quismundo S, Srivastava V. Use of bilateral internal thoracic arteries in CABG through lateral thoracotomy with robotic assistance in 150 patients. *Ann Thorac Surg* 2006; 81:800–806.

[82] Watanabe G. Cardiac Surgery: Overview. In: Watanabe G, editor. *Robotic Surgery*. Tokyo: Springer Japan; 2014.

[83] Robicsek F. Robotic cardiac surgery: time told! *J Thorac Cardiovasc Surg* 2008;135:243–246.

[84] Ota T, Degani A, Schwartzman D, Zubiate B, McGarvey J, Choset H, Zenati MA. A highly articulated robotic surgical system for minimally invasive surgery. *Ann Thorac Surg* 2009; 87:1253–1256.

[85] Lee HS, Jang HJ. Robotic Surgery in General Thoracic Surgery. In: Watanabe G, editor. *Robotic Surgery*. Tokyo: Springer Japan; 2014.

[86] Nasir BS, Bryant AS, Minnich DJ, Wei B, Cerfolio RJ. Performing robotic lobectomy and segmentectomy: cost, profitability, and outcomes. *Ann Thorac Surg* 2014;98(1):203-8; discussion 208-9.

[87] Melfi FM, Fanucchi O, Davini F, Romano G, Lucchi M, Dini P, Ambrogi MC, Mussi A. Robotic lobectomy for lung cancer: evolution in technique and technology. *Eur J Cardiothorac Surg* 2014;9 [Epub ahead of print].

[88] Jang HJ, Lee HS, Park SY, Zo JI. Comparison of the early robot-assisted lobectomy experience to video-assisted thoracic surgery lobectomy for lung cancer: a single-institution case series matching study. *Innovations* 2011; 6(5):305–310.

[89] Park BJ, Flores RM. Cost comparison of robotic, video-assisted thoracic surgery and thoracotomy approaches to pulmonary lobectomy. *Thorac Surg Clin* 2008;18(3):297–300.

[90] Toker A, Erus S, Ozkan B, Ziyade S, Tanju S. Does a relationship exist between the number of thoracoscopic thymectomies performed and the learning curve for thoracoscopic resection of thymoma in patients with myasthenia gravis? *Interact Cardiovasc Thorac Surg* 2011; 12 (2):152–155.

[91] Díaz-Montes TP, Tanner EJ, Fader AN. Instrumentation, Platforms, and Basic Principles of Robotics. In: Escobar P, Falcone T, editors. *Atlas of Single-Port, Laparoscopic, and Robotic Surgery.* Springer New York; 2014.

[92] Magrina JF, Zanagnolo V, Giles D, Noble BN, Kho RM, Magtibay PM. Robotic surgery for endometrial cancer: comparison of perioperative outcomes and recurrence with laparoscopy, vaginal/laparoscopy and laparotomy. *Eur J Gynaecol Oncol* 2011;32:476–80.

[93] Orady M. Robotic-Assisted Total Laparoscopic Hysterectomy. In: Escobar P, Falcone T, editors. *Atlas of Single-Port, Laparoscopic, and Robotic Surgery*. Springer New York; 2014.

[94] Magrina JF, Kho R, Magtibay PM. Robotic radical hysterectomy: technical aspects. *Gynecol Oncol* 2009;113:28–31.

[95] Hsiao SM, Lin HH, Peng FS, Jen PJ, Hsiao CF, Tu FC. Comparison of robot-assisted laparoscopic myomectomy and traditional laparoscopic myomectomy. *J Obstet Gynaecol Res* 2013;39(5):1024-9.

[96] Holloway RW, Bravo RA, Rakowski JA, James JA, Jeppson CN, Ingersoll SB, Ahmad S. Detection of sentinel lymph nodes in patients with endometrial cancer undergoing robotic-assisted staging: a comparison of colorimetric and fluorescence imaging. *Gynecol Oncol.* 2012;126(1):25-9.

[97] Emami CN, Garrett D, Anselmo D, Nguyen NX. Pediatric single incision laparoscopic cholecystectomy: lessons learned in the first 25 cases. *Pediatr Surg Int* 2011; 27:743–746.

[98] Park HS, Kim TJ, Song T, Kim MK, Lee YY, Choi CH, Lee JW, Kim BG, Bae DS. Single-port access (SPA) laparoscopic surgery in gynecology: a surgeon's experience with an initial 200 cases. *Eur J Obstet Gynecol Reprod Biol* 2011; 154:81–84

[99] Gaujoux S, Kingham TP, Jarnagin WR, D'Angelica MI, Allen PJ, Fong Y. Single-incision laparoscopic liver resection. *Surg Endosc* 2011; 25:1489–1494.

[100] White MA, Haber G-P, Kaouk JH. Robotic single-site surgery. *Curr Opin Urol* 2010; 20(1): 86-91.

[101] Islam A, Castellvi AO, Tesfay ST, Castellvi AD, Wright AS, Scott DJ. Early surgeon impressions and technical diffi- culty associated with laparoendoscopic single-site surgery: a Society of American Gastrointestinal and Endoscopic Surgeons learning center study. *Surg Endosc* 2011; 25:2597–2603.

[102] Pérez-Duarte FJ, Lucas-Hernández M, Matos-Azevedo A, Sánchez-Margallo JA, Díaz-Güemes I, Sánchez-Margallo FM. Objective analysis of surgeons' ergonomy during laparoendoscopic single-site surgery through the use of surface electromyography and a motion capture data glove. *Surg Endosc* 2014;28(4):1314–20.

[103] Escobar PF, Fader AN, Paraiso MF, Kaouk JH, Falcone T. Robotic-assisted laparoendoscopic single- site surgery in gynecology: initial report and technique. *J Minim Invasive Gynecol* 2009;16:589–91.

[104] Kaouk JH, Goel RK, Haber GP, Crouzet S, Stein RJ. Robotic single-port transumbilical surgery in humans: initial report. *BJU Int* 2009; 103(3):366–369.

[105] White WM, Haber G-P, Goel RK, et al. Single-port urological surgery: single-center experience with the first 100 cases. *Urology* 2009 Oct; 74(4): 801–804.

[106] Ostrowitz MB, Eschete D, Zemon H, DeNoto G. Robotic-assisted single-incision right colectomy: early experience. *Int J Med Robot* 2009 Dec; 5(4): 465–470.

[107] Romanelli JR, Roshek TB 3rd, Lynn DC, Earle DB. Single-port laparoscopic cholecystectomy: initial experience. *Surg Endosc* 2010 Jun; 24(6): 1374–1379.

[108] Allemann P, Leroy J, Asakuma M, et al. Robotics may overcome technical limitations of single-trocar surgery. *Arch Surg* 2010 Mar; 145(3): 267–271.

[109] Haber G-P, White MA, Autorino R, et al. Novel robotic da Vinci instruments for laparoendoscopic single-site surgery. *Urology* 2010 Dec; 76(6): 1279–1282.

[110] Petroni G, Niccolini M, Menciassi A, Dario P, Cuschieri A. A novel intracorporeal assembling robotic system for single-port laparoscopic surgery. *Surg Endosc* 2013;27(2):665–70.

[111] Petroni G, Niccolini M, Caccavaro S, Quaglia C, Menciassi A, Schostek S, et al. A novel robotic system for single-port laparoscopic surgery: preliminary experience. *Surg Endosc* 2013;27(6):1932–7.

[112] Cheon B, Gezgin E, Ji DK, Tomikawa M, Hashizume M, Kim H-J, et al. A single port laparoscopic surgery robot with high force transmission and a large workspace. *Surg Endosc* 2014;28(9):2719–29.

[113] Sanchez-Margallo FM, Perez FJ, Sanchez MA, Asencio JM, del Carmen Tejonero M, Moreno C, Noguera J. Hybrid notes cholecystectomy in an experimental model of laparoscopic acute cholecystitis. *Surg Laparosc Endosc Percutan Tech* 2011;21(2):e65-9.

[114] Noguera JF, Cuadrado A, Sánchez-Margallo FM, Dolz C, Asencio JM, Olea JM, Morales R, Lozano L, Vicens JC. Emergency transvaginal hybrid natural orifice transluminal endoscopic surgery. *Endoscopy* 2011;43(5):442-4.

[115] Bulian DR, Runkel N, Burghardt J, Lamade W, Butters M, Utech M, Thon KP, Lefering R, Heiss MM, Buhr HJ, Lehmann KS. Natural Orifice Transluminal Endoscopic Surgery (NOTES) for colon resections--analysis of the first 139 patients of the German NOTES Registry (GNR). *Int J Colorectal Dis* 2014;29(7):853-61.

[116] Haber GP, Crouzet S, Kamoi K, Berger A, Aron M, Goel R et al. Robotic NOTES (natural orifice translumenal endoscopic surgery) in reconstructive urology: initial laboratory experience. *Urology* 2008; 71:996–1000.

[117] Demura Y, Ishikawa N, Hirano Y, Inaki N, Matsunoki A, Watanabe G. Transrectal robotic natural orifice translumenal endoscopic surgery (NOTES) applied to intestinal anastomosis in a porcine intestine model. *Surg Endosc* 2013;27(12):4693–701.

[118] Suzuki N, Hattori A, Ieiri S, Konishi K, Maeda T, Fujino Y, et al. Tele-control of an endoscopic surgical robot system between Japan and Thailand for tele-NOTES. *Stud Health Technol Inform* 2009;142:374–9.

[119] Spaun GO, Zheng B, Swanström LL. A multitasking platform for natural orifice translumenal endoscopic surgery (NOTES): a benchtop comparison of a new device for flexible endoscopic surgery and a standard dual-channel endoscope. *Surg Endosc* 2009;2720–7.

[120] Fuchs K-H, Breithaupt W. Transgastric small bowel resection with the new multitasking platform EndoSAMURAI™ for natural orifice transluminal endoscopic surgery. *Surg Endosc* 2012;26(8):2281–7.

[121] Phee SJ, Low SC, Huynh V a, Kencana a P, Sun ZL, Yang K. Master and slave transluminal endoscopic robot (MASTER) for natural orifice transluminal endoscopic surgery (NOTES). Conf. Proc. *IEEE Eng Med Biol Soc* 2009;1192–5.

[122] Phee SJ, Reddy N, Chiu PWY, Rebala P, Rao G V, Wang Z, et al. Robot-assisted endoscopic submucosal dissection is effective in treating patients with early-stage gastric neoplasia. *Clin Gastroenterol Hepatol* 2012;10(10):1117–21.

[123] Phee SJ, Ho KY, Lomanto D, Low SC, Huynh V a, Kencana a P, et al. Natural orifice transgastric endoscopic wedge hepatic resection in an experimental model using an intuitively controlled master and slave transluminal endoscopic robot (MASTER). *Surg Endosc* 2010;24(9):2293–8.

[124] Yeung BPM, Gourlay T. A technical review of flexible endoscopic multitasking platforms. *Int J Surg* 2012;10(7):345–54.

[125] Lehman AC, Dumpert J, Wood N a, Redden L, Visty AQ, Farritor S, et al. Natural orifice cholecystectomy using a miniature robot. *Surg Endosc* 2009;23(2):260–6.

[126] Dieterich S, Gibbs IC. The CyberKnife in clinical use: current roles, future expectations. *Front Radiat Ther Oncol* 2011;43:181–94.

[127] Adler JR Jr, Chang SD, Murphy MJ, Doty J, Geis P, Hancock SL. The Cyberknife: a frameless robotic system for radiosurgery. *Stereotact Funct Neurosurg* 1997; 69:124–128.

[128] Adler JR Jr, Murphy MJ, Chang SD, Hancock SL. Image-guided robotic radiosurgery. *Neurosurgery* 1999; 44:1299–1306, Discussion 1306-7.

[129] Koethe Y, Xu S, Velusamy G, Wood BJ, Venkatesan AM. Accuracy and efficacy of percutaneous biopsy and ablation using robotic assistance under computed tomography guidance: a phantom study. *Eur Radiol* 2014;24(3):723–30.

[130] Abdullah BJ, Yeong CH, Goh K, Yoong B, Ho G, Kulkarni A. Early experience of a commercial available robot (Maxio) for CT-guided radiofrequency ablation of liver tumours. *Insights Imaging* (2014) 5 (Suppl 1):S162.

[131] Di Biase L, Natale A, Barrett C, Tan C, Elayi CS, Ching CK, et al. Relationship between catheter forces, lesion characteristics, "popping," and char formation: experience with robotic navigation system. *J Cardiovasc Electrophysiol* 2009;20(4):436-40.

[132] Hlivák P, Mlčochová H, Peichl P, Cihák R, Wichterle D, Kautzner J. Robotic navigation in catheter ablation for paroxysmal atrial fibrillation: midterm efficacy and predictors of postablation arrhythmia recurrences. *J Cardiovasc Electrophysiol* 2011;22(5):534-40.

[133] Thomas D, Scholz EP, Schweizer PA, Katus HA, Becker R. Initial experience with robotic navigation for catheter ablation of paroxysmal and persistent atrial fibrillation. *J Electrocardiol* 2012;45(2):95-101.

[134] Steven D, Servatius H, Rostock T, Hoffmann B, Drewitz I, Müllerleile K, Sultan A, Aydin MA, Meinertz T, Willems S. Reduced fluoroscopy during atrial fibrillation ablation: benefits of robotic guided navigation. *J Cardiovasc Electrophysiol* 2010;21(1):6-12.

[135] Schmidt B, Chun KRJ, Tilz RR, Koektuerk B, Ouyang F, Kuck K-H. Remote navigation systems in electrophysiology. *Europace* 2008;10(Suppl 3):iii57–61.

[136] Arya A, Zaker-Shahrak R, Sommer P, Bollmann A, Wetzel U, Gaspar T, et al. Catheter ablation of atrial fibrillation using remote magnetic catheter navigation: a case–control study. *Europace* 2011;13:45–50.

[137] Lüthje L, Vollmann D, Seegers J, Dorenkamp M, Sohns C. Hasenfuss Get al. Remote magnetic versus manual catheter navigation for circumferential pulmonary vein ablation in patients with atrial fibrillation. *Clinical Research in Cardiology* 2011;100:1003–1011.

[138] Hashizume M, Yasunaga T, Tanoue K, Ieiri S, Konishi K, Kishi K, et al. New real-time MR image-guided surgical robotic system for minimally invasive precision surgery. *Int J Comput Assist Radiol Surg* 2008;2(6):317–25.

[139] Cunha JA, Hsu I-C, Pouliot J, Roach Iii M, Shinohara K, Kurhanewicz J, et al. Toward adaptive stereotactic robotic brachytherapy for prostate cancer: demonstration of an adaptive workflow incorporating inverse planning and an MR stealth robot. *Minim Invasive Ther Allied Technol* 2010;19(4):189–202.

[140] Stoianovici D, Song DY, Petrisor D, Mozer P, Armour E, Vigaru B, Muntener M, Patriciu A, Schar M. MRI-compatible pneumatic robot (MRBot) for prostate brachytherapy: Preclinical assessment of accuracy and execution of dosimetric plans. *International Journal of Radiation Oncology Biology Physics* 2008;72(1):S306-S307.

In: Encyclopedia of Surgery (22 Volume Set)
Editors: Andreas Lehrer and Kristin Mueller
ISBN: 978-1-53618-329-0
© 2020 Nova Science Publishers, Inc.

Chapter 47

MODIFIED METHODS OF SETTING UP THE SPINAL NAVIGATION SYSTEM

Sang Hoon Jang [*] ***and Ho-Yeon Lee***
Department of Neurosurgery, Gang-buk Wooridul Spine Hospital,
Seoul, Korea

ABSTRACT

There are many reports about accuracy and efficacy of the spinal navigation system but most of their topics are limited to spinal instrumentation. For minimally invasive surgery, important things are how to set up navigation system fast and efficiently without interference of surgical flow, and how to use the navigation system within a small working field. Our team has already introduced a skin fixed dynamic reference frame (DRF) into mini open transforaminal lumbar interbody fusion (TLIF) and recently examined the accuracy of skin-fixed DRF in the anterior cervical foraminotomy. Both methods require only few minutes to set up and do not prohibit the natural movement of the surgeon during the operation. We want to share detailed methods about setting up the navigation system and the knowhow of using navigation systems, especially in minimally invasive spinal surgeries.

Keywords: spinal navigation system, skin fixed dynamic reference frame

1. INTRODUCTION

Recently a number of different manufacturers offer spinal navigation systems, which utilize preoperative CT scans to intraoperative 3D images, which are widely used in spinal surgeries [1-5]. Although there are some differences in hardware and software functions, these systems basically enable surgical instruments to be shown in reference to the displayed imaging anatomy in real time. Therefore, a more precise and delicate operation, after minimal exposure of the spinal structures could even be possible in deformed or severely degenerated

[*] Corresponding Author's Email: iamleesol@gmail.com.

spines [6]. There is a steep learning curve in using the navigation system, which is difficult and requires a significant amount of time, especially in the case of early experience of image guided surgery, even in a simple procedure [3-5]. Among every step of introducing the navigation system, the most important thing is the registration process for matching the image anatomy to the surgical anatomy. Setting reliable reference frames have an important role in reducing registration inaccuracy. Usually, setting up the navigation system is done with the fixed reference frame (FRF), which is attached to a head rest or operation table. But in this circumstance, the positioning change of the patient, on the operation table, can cause significant errors in the navigation system.

A dynamic reference frame (DRF) is firmly attached to the patient's body, which helps to overcome these weak-points. Bone fixed DRF usually requires another separate skin incision, or a longer incision, and occasionally interferes surgeon's movement. Skin fixed DRF can be a solution to these problems, and are designed as a fast and efficient method for minimal invasive surgery without interference of surgical flow and within a small working field.

2. MATERIALS AND METHODS

2.1. Indication

- Minimal invasive anterior foraminotomy in cervical spine
- Multilevel oblique corpectomy of cervical spine in case of ossified posterior longitudinal ligament (OPLL) or cervical spondylotic myelopathy (CSM)
- Minimal invasive posterior cervical foraminotomy
- Posterior cervical instrumentation
- Thoracic posterior decompression surgery using a tubular retractor
- Pedicle screw insertion in thoracic spine
- Paraspinal decompression for extraforaminal lumbar disc herniation,
- Mini open transforaminal lumbar interbody fusion (TLIF).

2.2. Instrumentations

- Cone beam CT(O arm® Medtronic Sofamor Danek, Memphis, TN) (Figure 1)
- Navigation system (Stealthstation® Medtronic Sofamor Danek, Memphis, TN) (Figure 2).
- Incised surgical film (OPSITE® Smith & Nephew, Hull, UK) (Figure 3).
- Dynamic reference frame (DRF) (Figure 4)

2.3. Procedures

Anesthesia

General anesthesia with single lumen endotracheal tube

If a monitoring system for motor and somatosensory evoked potentials is required, set up prior to positional change

Figure 1. Cone beam CT(O arm® Medtronic Sofamor Danek, Memphis, TN)

Figure 2. Navigation system (Stealthstation® Medtronic Sofamor Danek, Memphis, TN).

Figure 3. Incised surgical film (OPSITE® Smith & Nephew, Hull, UK)

Figure 4. Dynamic reference frame (Stealthstation® Medtronic Sofamor Danek, Memphis, TN)

Localization of the level and entry point

Localization is done with portable radiograph.

Introduction of navigation system is done after bony exposure of index level because skin incision and muscle dissection can cause anatomical deformation of skin surface. It is closely associated with accuracy of skin fixed DRF.

Cervical spine

Mark index level with two 18-gauze needles on the skin crease of the anterior neck.

Thoracic spine

Mark index level with 18-gauze needle and place 3-4 more needles at regular intervals to the sacral spine

Lumbar spine

Mark index level with 18-gauze needle

Set up the navigation system

Cervical spine

Supine position

While draping the patient, expose forehead widely and cover with transparent surgical film (OPSITE® Smith & Nephew, Hull, UK). Mount DRF on the skin surface of forehead and fixed firmly with incised surgical film (OPSITE® Smith & Nephew, Hull, UK) (Figure 5-7).

Figure 5. During the draping, expose forehead and eyes of the patient and cover eyebrows with sterile gauze to protect them from adhesive surgical film.

Figure 6. Exposed forehead is covered by transparent surgical film.

Figure 7. Mount the DRF cutaneously, overlying the draped forehead and fix it firmly with incised surgical film.

Thoracic spine

Prone position

While draping the patient, expose the skin surface widely to the lumbar spine and cover with transparent surgical film (OPSITE® Smith & Nephew, Hull, UK). Mount DRF on the skin surface, 5-6 levels below the surgical point, and fix firmly with incised surgical film (OPSITE® Smith & Nephew, Hull, UK)

Lumbar spine

Prone position

While draping the patient, expose the skin surface widely to the sacral hiatus area. Cover with transparent surgical film (OPSITE® Smith & Nephew, Hull, UK). Mount dynamic reference frame on the skin surface of sacral hiatus, and fix firmly with transparent surgical tape (OPSITE® Smith & Nephew, Hull, UK) (Figures 8-10).

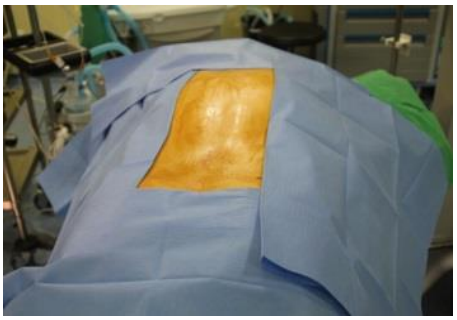

Figure 8. During the draping, expose skin surface widely to the sacral hiatus area.

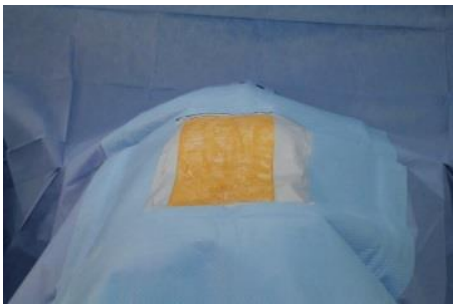

Figure 9. Exposed sacral region is covered by transparent surgical film.

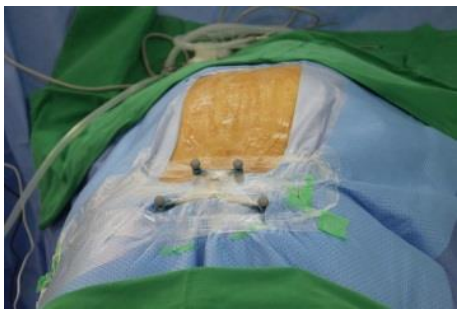

Figure 10. Mount the DRF cutaneously overlying the draped sacral hiatus area and fix it firmly with incised surgical film.

2.4. Outcomes

From June 2009 to Dec. 2009, 20 patients underwent mini-open TLIF with skin fixed DRF [7]. Mean age was 55.9 years (range: 34–74 years) and mean BMI was 24.4 (range: 19.9–28.6).

Five patients were diagnosed with spondylolytic spondylolisthesis, and the remaining fifteen patients were diagnosed with degenerative spondylolisthesis. Nineteen patients underwent single level surgery and 1 patient underwent two level surgery. A total of 82 screws were inserted under navigation guidance with skin fixed DRF. The mean time duration to set up the navigation system with skin fixed DRF was 8.5 ± 6.5 min (range: 10–30 min). The second O-arm scan, after pedicle screw insertion, revealed eight pedicle breaches (4 grade I, 2 grade II, and 2 grade III) [8]. Among them, the two grade III screws were reinserted and confirmed to be in the proper position with a third O-arm scan. Despite the eight pedicle perforations, there were no major complications such as nerve injury, unintended durotomy, or malposition of the final construct.

Cervical Spine

From September 2012 to May 2013, 31 patients underwent minimally invasive anterior cervical surgery. A single level surgery was done in 10 patients; two level surgeries in 11; and three level surgeries in 10. The mean time duration to set up navigation system with skin fixed DRF was 4.8 ± 3.5 min. (range: 8–20 min). 48 Caspar pins were inserted into each cervical vertebra. The validity of the navigation was then assessed by comparing the differences between the actual positions of the inserted Caspar pin, based on the second O-arm scan and the recorded images of the navigation probe. The mean horizontal error was 0.49 ± 0.71 mm. The mean vertical error was 0.88 ± 0.93 mm. And the mean angular deviation in the sagittal plane was 0.59 ± 0.55°. ICC value was 0.74 for intra-observer reliability. And there were no major complications or revision surgeries due to the navigational error. But unintended durotomy developed in 3 cases without any neural injury; all of them had severe space-occupying calcified OPLL, however, in all cases, in-situ dura repair was done with artificial dura.

CONCLUSION

With development of the navigation system, the spine surgeon can perform complex and minimal invasive surgery successfully without radiation hazard, but many surgeons are still do not favor the navigation system and don’t trust it, due to the complex methods for registration and the set up process, learning curve, and the interruption of work flow. This modified method will be one part of the solution to overcome these kinds of problems.

REFERENCES

[1] Acosta, F. L., Jr., Thompson, T. L., Campbell, S., Weinstein, P. R., Ames, C. P., Use of intraoperative isocentric C-arm 3D fluoroscopy for sextant percutaneous pedicle screw placement: case report and review of the literature. *The spine journal: official journal of the North American Spine Society* 5 (3):339-343. doi:10.1016/j.spinee.2004.09.012.

[2] Fritsch, E., Duchow, J., Seil, R., Grunwald, I., Reith, W., Accuracy of fluoroscopic navigation of pedicle screws. CT-based evaluation of bone screw placement. *Der Orthopade* 31 (4):385-391, 2002.

[3] Holly, L. T., Foley, K. T., Intraoperative spinal navigation. *Spine* 28 (15 Suppl):S54-61. doi:10.1097/01.brs.0000076899.78522.d9, 2003.

[4] Tjardes, T., Shafizadeh, S., Rixen, D., Paffrath, T., Bouillon, B., Steinhausen, E. S., Baethis, H., Image-guided spine surgery: state of the art and future directions. *European spine journal: official publication of the European Spine Society, the European Spinal Deformity Society, and the European Section of the Cervical Spine Research Society* 19 (1):25-45. doi:10.1007/s00586-009-1091-9, 2010.

[5] Holly, L. T., Foley, K. T., Image guidance in spine surgery. *The Orthopedic clinics of North America* 38 (3):451-461; abstract viii. doi:10.1016/j.ocl.2007.04.001, 2007.

[6] Moses, Z. B., Mayer, R. R., Strickland, B. A., Kretzer, R. M., Wolinsky, J. P., Gokaslan, Z. L., Baaj, A. A., Neuro-navigation in minimally invasive spine surgery. *Neurosurgical focus* 35 (2):E12. doi:10.3171/2013.5.focus13150, 2013.

[7] Cho, J. Y., Chan, C. K., Lee, S. H., Lee, H. Y., The accuracy of 3D image navigation with a cutaneously fixed dynamic reference frame in minimally invasive transforaminal lumbar interbody fusion. *Computer aided surgery: official journal of the International Society for Computer Aided Surgery* 17 (6):300-309. doi:10.3109/ 10929088. 2012.728625, 2012.

[8] Rajasekaran, S., Vidyadhara, S., Ramesh, P., Shetty, A. P., Randomized clinical study to compare the accuracy of navigated and non-navigated thoracic pedicle screws in deformity correction surgeries. *Spine* 32 (2):E56-64. doi:10.1097/01.brs.0000252094. 64857.ab, 2007.

In: Encyclopedia of Surgery (22 Volume Set)
Editors: Andreas Lehrer and Kristin Mueller
ISBN: 978-1-53618-329-0
© 2020 Nova Science Publishers, Inc.

Chapter 48

ULTRASOUND IMAGING FOR ROBOTIC ORTHOPEDIC SURGERY: A SURVEY

Pedro M. B. Torres* and Paulo J. S. Gonçalves
Polytechnic Institute of Castelo Branco, School of Technology,
Castelo Branco, Portugal
LAETA, IDMEC, Instituto Superior Técnico, Universidade de Lisboa,
Lisboa, Portugal

ABSTRACT

Robotic surgeries are performed by classical techniques, purely mechanical and their success essentially depends on the surgeon's experience. However, surgeons are increasingly receptive to new technologies and search new tools that help them improve their performance. Increasing advances in robotics have allowed the emergence of new systems dedicated to surgery, which began to be a valid option in surgical aid. The computer-assisted surgery (CAS) and particularly the robot-assisted surgery, improves accuracy and precision of procedures, allowing more reliable and reproducible outcomes, minimizing the invasiveness of surgical procedures and improving patient outcomes by reducing complications and improving patient safety compared with conventional techniques. The increasing evolution of surgical robotic systems has also been accompanied for significant evolution in surgical navigation systems.

Actual systems, commonly used in the operating room, employ markers placed on the human for tracking bones or other body parts. Ultrasound images are on the rise, and under strong development for use in surgeries, allowing low-cost and non-invasive real-time navigation systems.

These navigation systems will be used in the near future in CAS and robotic surgery. The chapter will review the current approaches in robotic surgery, where ultrasound based navigation is used, with a special care on orthopedics.

Keywords: ultrasound imaging, robotics, surgical robotics

* Corresponding Author's Email: paulo.goncalves@ipcb.pt.

1. INTRODUCTION

Increasing advances in robotics have allowed the emergence of new systems dedicated to surgery, which began to be a valid option in surgical aid. The computer-assisted surgery (CAS) [1] and particularly the robot-assisted surgery [2, 3] improves accuracy and precision of procedures, besides producing more reliable and reproducible outcomes, minimizing the invasiveness of surgical procedures improving patient outcomes by reducing complications and improving patient safety compared with conventional orthopedic techniques.

The use of robots to automate medical tasks increases its reliability, accuracy and is an excellent contribution to Minimal Invasive Surgery (MIS). MIS is becoming more and more common nowadays in hospitals. These procedures through tiny incisions are performed instead of one large opening. Because the incisions are small, patients trend to have quicker recovery times and less discomfort than with conventional surgery. Last thirty years have been marked by the development of robotic systems for MIS. In 1985 a robot, The PUMA 560 [4] was used to place a needle for a brain biopsy using CT guidance. Three years later the same machine was used to perform a transurethral resection. In 1987 robotics was used in the first Laparoscopy surgery, a cholescystecotomy. In 1988, PROBOT, [5] developed at Imperial College London, was used to perform prostatic surgery.

More recently appeared the following surgical systems: ZEUS, DaVinci and DLR MIRO. The ZEUS robotic surgical system, initially developed in 1995 for endoscopic microsurgery (including general surgery, thoracic surgery, gynaecology, urology), was the robotic system used in the first transatlantic surgical intervention performed on a human, in 2001 between New York and Strasbourg, France, at 15000 km of distance [6]. The DaVinci Surgical System enables surgeons to operate through a few tiny incisions with dramatically enhanced vision, precision and control. State-of-the-art DaVinci Surgery helps surgeons to minimize the pain and risk associated with traditional surgery, while increasing the chances for a fast recovery and excellent clinical outcomes.DLR MIRO [7–9] is a compact, slim and LightWeight Robot (LWR) robotic system versatile for various existing and future medical robotic procedures. It can be used in orthopedics for setting holes for bone screws, robot-assisted endoscope guidance and on to the multi-robot concept for (endoscopic) minimal invasive surgery.

2. ORTHOPEDIC ROBOTIC SURGERY

In orthopedics several solutions have emerged, such as ROBODOC® [10], for the planning and performance of total hip and knee replacement, CASPAR® [9], developed for the same purpose of ROBODOC®, Acrobot Sculptor [11, 12], used in knee surgery, or the RIO robotic arm (MAKOplasty) [13], the latest developed system for orthopedics.The Robodoc® surgical system consisted of the Orthodoc® [14], pre-surgical planner and the Robodoc® as the surgical tool. The Robodoc system comprises a five-axis Sankyo-Seiki industrial robot with a six degree-of-freedom force-sensor. The Orthodoc® describes the three-dimensional geometry of the femur from CT data and the geometry of the implant.The MAKO system consists of the well known general purpose WAM - Whole Arm Manipulator from Barrett Technology [15], for bone deburring and an optical navigation system consisting of stereo infrared cameras, and marker arrays attached to the tibia and femur. On the other

hand, the Acrobot system uses their special purpose robot manipulator, while the tibia and femur are immobilized with bone clamps which are fixed through small skin incisions.

These first systems evolved with the massive usage of the computer in the operating room, as presented in the following section.

3. COMPUTER AIDED ORTHOPEDIC SURGERY

The increasing evolution of surgical robotic systems has also been accompanied by significant evolution in the surgical navigation systems [16]. Of the several systems that have appeared in the market are highlighted the OrthoPilot [17], (http://www.orthopilot.com) and the BrainLAB systems [18], (https://www.brainlab.com). Both systems employ markers placed on the femur for tracking the bone movements [19].

The incisions performed to place these markers can leave serious injury to the patient and there are many cases of complaints of pain at the implant site after Surgery. Studies on the patients reported persistent severe pain at the site of pin implantation, after surgery, caused by the injuries to the nerves, caused by fiducial markers [20].

Surgical navigation systems allow the surgeon to perform surgical actions in real time using information conveyed through a virtual world, which consist of computer-generated models of surgical instruments and the virtual representations of the anatomy being operated. Virtual representations can be generated from data obtained through Computer Tomography scans, ultrasound images, amongst others. Image-guided surgical navigation is on the rise in many different areas of medicine, with strong growth in orthopedic surgery.

The use of visual information obtained from medical images is widely used in Computer Aided Orthopedic Surgery (CAOS) (www.caos-international.org). CAOS systems are increasingly available, with several commercial and research systems now well established. These systems assist surgeons in preoperative planning and simulation, from the obtained bone model, and in intra-operative navigation, using tracking systems with fiducial markers attached to the patient bone, and in the robotic execution of the surgical procedure. From the fiducial markers the position and orientation of the bone in the intra-operative scenario relative to the robot frame is obtained in the state-of-the-art systems, e.g., the Brain Lab System or Orthopilot.

Much research has been developed in order to find new solutions and explore alternatives to avoid the fiducial markers in surgical navigation, [21, 22]. The use of Ultrasound (US) images has gained high relevance in Image-guided surgeries, [23, 24], since it is a non-invasive modality and provides real-time images, which are used to plan a surgical procedure and guide surgical instruments during surgery. The ultrasound based 3D bone surfaces are located by placing markers in the US probe to track them and generating a 3D bone surface that can be registered with a model preconceived through a 3D image modality, as Computed Tomography (CT) or Magnetic Resonance Imaging (MRI).

4. TOWARDS ULTRASOUND IMAGING IN ORTHOPEDIC SURGERY

Recently, much scientific research work has been developed, with the purpose of eliminating fiducial markers in orthopedic surgery [25, 26], and the main guidelines of research focuses on the use of intra-operative Ultrasound (US) images and pre-operative computed tomography (CT) to provide real time surgical guidance. In [27], it is presented a semi-automatic bone detection approach for US via registration with CT datasets pre-operatively acquired. The CT data is used to create a patient-specific bone model, and rigid transformation from US to CT is estimated by the Iterative Closest Point (ICP) algorithm, from a initializing of three points in the datasets. The three correspondence points, define the principal axis and orientation of the bone in both modalities. In [28] is proposes a point-based registration algorithm based on unscented Kalman filter (UKF) to estimate the rigid transformation parameters between the bone surfaces obtained from US and CT data, less sensitive to outliers compared with ICP.

Both methods are based on features of the datasets (feature-based), but there are also methods that use the image intensity information (intensity-based) directly in order to avoid extraction of bone surfaces. In [29] was used the normalized cross-correlation as a similarity metric for registering CT and US images. Prior to registration, both datasets were converted to bone probability images using gradient, bone intensity and US shadowing artifact information. More recently, in [30] it is proposed a rigid registration method where the translation parameters are estimated from the projections of local phase volumes in frequency domain. Bone surfaces were automatically extracted directly from 3D US and CT volumes based on 3D local image features calculated using 3D Log-Gabor filter.

After its incipient first experiments, guiding a robot using ultrasound images, i.e., ultrasound based visual servoing, has recently gained new interest due to the establishment of visual servoing.

Initial works consisted in the use of robot arms that manipulated an ultrasound probe for medical diagnoses [31, 32]. The use of ultrasound also found its way into orthopedics as a non-invasive radiation-free navigation system for surgeon operated, interventions [33]. This is particularly valuable when the bones to be operated are so small, that it is not possible to attach heavy tracking targets onto them. For interventions cooperated by robot arms, effective applications using ultrasound guidance are not yet available, but an intense race involving research centers and industry is currently taking place.

Guiding a robot in positioning tasks through visual information using uncalibrated visual servoing systems is a very active research topic due to the complexity of real applications and workspace scenarios such as an operating room. The operating room can unpredictably change during a surgery, causing calibration errors. In [34], uncalibrated visual servoing was proposed, where the inverse system Jacobean was estimated on-line, thus immune to camera miss-calibration. It presents a very promising solution for the operating room, where it is also desired to minimize calibration time. Furthermore, this approach will give added robustness to a medical setting where the environment is calibrated, but redundancy is necessary for safety reasons. This work has been further extended to a more general case in [35], where the uncalibrated model can evolve during the tasks to be performed. In [36], tools for ultrasound based 3D Bone model reconstruction; registration and visualization are presented, which are currently being developed by the research team, in order to introduce ultrasound feedback in

the visual control loop. In [37], was proposed and approach to obtain the position and orientation of a bone based in it's 3D model obtained from Computed Tomography images (in the preoperative scenario) and the registration of ultrasound images to it (in the intra-operative scenario). More recently, in [38], was proposed a vision system for robotic ultrasound guided orthopedic surgery. This system, during surgery, acquires a 3D US bone surface from a sequence of US images. Later, that bone surface will then be registered to the pre-operative 3D bone model, for a precise knowledge of the bone position and orientation. The system then allows bone tracking during surgeries based on ultrasound images of bones, without the use of fiducial markers, diminishing invasiveness, is briefly presented in the next section.

5. ULTRASOUND BASED NAVIGATION FOR ORTHOPEDIC SURGERY

For navigation, the system presented in [38], during surgery, acquires a 3D US bone surface from a sequence of US images. This bone surface will then be registered to the pre-operative bone model, for a precise knowledge of the bone position and orientation. This registration is performed in two steps. Firstly a global registration is performed, before the surgical procedure, to exactly register the bone. The second step is to locally register the bone, which is faster and more suitable for tracking the bone movements. To update the bone´s drilling position and orientation, the robot manipulator uses the measured bone movement. Figure 1 shows an overview of the HipRob navigation system [38].

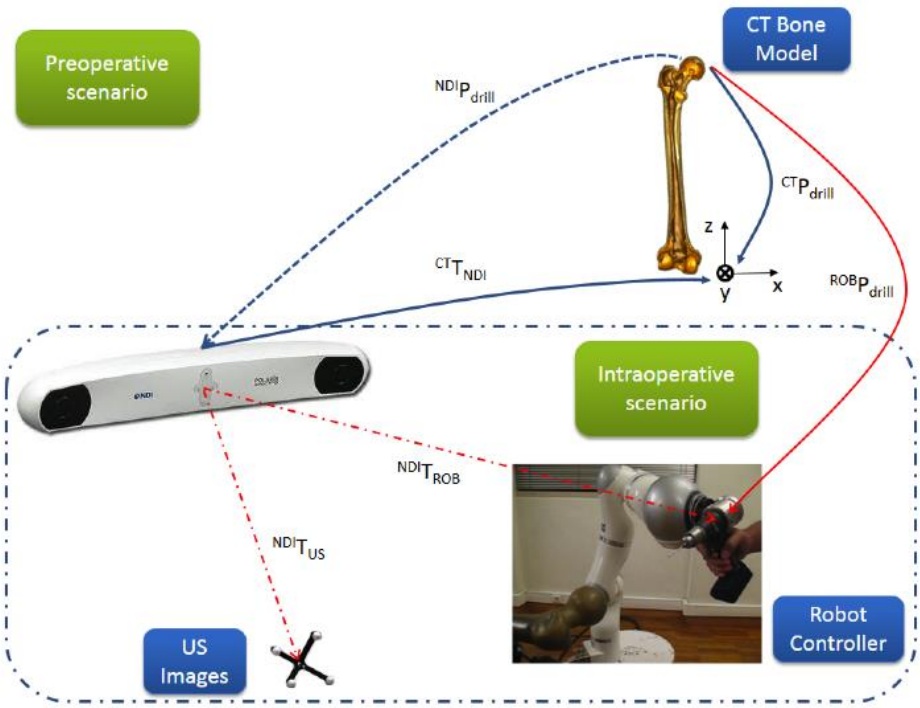

Figure 1. Overview of the hardware setup and frames transformations of HipRob navigation system [38].

The avoidance of fiducial markers implies that the US probe is referenced to the optical measurement system (NDI - Polaris) (\http://www.ndigital.com/medical/products/polaris-family). Placing on marker in the US probe makes the referencing. From this moment, also the images and features are referenced to the tracker. The pose of the robot end-effector also has to be referenced by the Navigation system to inform the robot controller of its location. The ideal drilling point is obtained pre-operatively in the CT reference frame. Inside the operating room, an initial calibration (${}^{CT}T_{NDI}$) between the tracker and CT is needed to localize the femur. After calibration, the main goal consists in to determine at each instant, the drilling point in the robot reference frame (${}^{ROB}P_{drill}$) and track the bone movements with the robot.

CONCLUSION

The present chapter presented the most important steps that surgical robotics are performing towards a common use in the operating room. The control of robots is evolving at an enormous pace and is strongly pushed by the recent advances in medical imaging. Ultrasound imaging plays a decisive role in robotic surgery because it is noninvasive and widely used by medical doctors. The main drawback is the precision of the measurements taken from US images. It was shown that this error is less than 2 [mm] nowadays, which allows its use in the operating room during surgeries. These types of systems are still slow, and cannot be operated in real-time, although they can give a measure to correct the robot trajectory. Future developments in this field will surely take care of diminishing the computational time, and also the precision of the system.

The HipRob navigation system was applied with real results in a femur phantom developed by the authors, assuring a precise calibration scheme, below 2 [mm] error, [35] which allows the ultrasound system to track the femur movements.

ACKNOWLEDGMENT

This work is partially supported by FCT, through IDMEC, under LAETA Pest-OE/EME/LA0022.

REFERENCES

[1] Adams, L., Krybus, W., Meyer-Ebrecht, D., Rueger, R., Gilsbach, J.M., Moesges, R., Schloendorff, G., (1990). Computer-assisted surgery, *IEEE Computer Graphics and Applications*. 10(3), 43-51.

[2] Kather, J., Hagen, M.E., Morel, P., Fasel, J., Markar S, Schueler M., (2010). Robotic hip arthroscopy in human anatomy, *Int J Med Robot*. 6(3), 301-305.

[3] Mantwill, F., Schulz, A.P., Faber, A., Hollstein, D., Kammal, M., Fay, A., Ju, Ch., (2005). Robotic systems in total hip arthroplasty - is the time ripe for a new approach?, *Int J Med Robot*. 1(4), 8-19.

[4] Satava, R.M., (2002). Surgical robotics: the early chronicles: a personal historical perspective, *Surg Laparosc Endosc Percutan Tech*. 12, 6-16.

[5] Harris, S.J., Arambula-Cosio F., Mei, Q., Hibberd, R.D., Davies, B.L., Wickham, J.E., Nathan, M.S., Kundu, B. (1997). The Probot - an active robot for prostate resection, *Proc Inst Mech Eng H*, 211(4), 317-325.

[6] Marescaux, J., Leroy, J., Gagner, M., Rubino, F., Mutter, D., Vix, M., Butner, S.E., Smith, M.K., (2001). Transatlantic robot-assisted telesurgery, *Nature*, 413, 379-380.

[7] Konietschke, R., Hagn, U., Nickl, M., Jorg, S., Tobergte, A., Passig, G., Seibold, U., Le-Tien, L., Kubler, B., Groger, M., and Frohlich, F., and Rink, C., and Albu-Schaffer, A., and Grebenstein, M., and Ortmaier, T., Hirzinger, G., (2009). The DLR MiroSurge - A robotic system for surgery, *IEEE International Conference on Robotics and Automation*, 1589—1590.

[8] Hagn, U., Nickl, M., Jorg, S., Passig, G., Bahls, T., Nothhelfer, A., Hacker, F., Le-Tien, L., Albu-Schaffer, A., Konietschke, R., Grebenstein, M., Warpup, R., Haslinger, R., Frommberger, M., Hirzinger, G., (2008). The DLR MIRO: a versatile lightweight robot for surgical applications, *Industrial Robot: An International Journal*, 35(4), 324-336.

[9] Ryan, A. B., (2012). Medical Robots: Current Systems and Research Directions, *Journal of Robotics*.

[10] Kazanzides, P., Mittelstadt, B.D., Musits, B.L., Bargar, W.L., Zuhars, J.F., Williamson, B., Cain, P.W., Carbone, E.J., (1995). An integrated system for cementless hip replacement, *IEEE Engineering in Medicine and Biology Magazine*, 14(3), 307 -313.

[11] Cobb, J.P., Henckel, J., Gomes, M.P.S.F., Barrett, A.R.W., Harris, S.J., Jakopec, M., Rodriguez, F.M., Davies, B.L., (2006). Hands-on robotic unicompartmental knee replacement: a prospective, randomised controlled study of the acrobot system, *The Journal of Bone and Joint Surgery B*, 88(2), 188 -197.

[12] Davis, E.T., Gallie, P., Macgroarty, K., Waddele, J.P., Schemitsch, E., (2007). The accuracy of image-free computer navigation in the placement of the femoral component of the Birmingham Hip Resurfacing, *The Bone & Joint Journal*, 89(4), 557-560.

[13] Pearle, A. D., Kendoff, D., Stueber, V., Musahl, V., Repicci, J. A., (2009). Perioperative management of unicompartmental knee arthroplasty using the MAKO robotic arm system (MAKOplasty), *American Journal of Orthopedics*, 38(2), 16-19.

[14] Paul, H.A., Bargar, W.L., Mittlestad, B., Musits, B., Taylor, R.H., Kazanzides, P., Zuhars Willliamson, B., Hanson W., (1992). Development of a surgical robot for cementless total hip arthroplasty, *Clinical Orthopedics*, 285, 57-66.

[15] Rooks, B., (2006). The harmonious robot, *Industrial Robot: An International Journal*, 33(2), 125-130.

[16] Stiehl, J.B., Konermann, W.H., Haaker, R.G., DiGioia, A.M., (2007). *Navigation and MIS in Orthopedic Surgery*, Springer.

[17] Miehlke, R.K., Haaker, R.G., Konermann, W.H., (2004). Navigation and Robotics in Total Joint and Spine Surgery, *Navigation and Robotics in Total Joint and Spine Surgery*, 242-247.

[18] Gumprecht, H.K., Widenka, D.C., Lumenta, C.B., (1999). BrainLab VectorVision Neuronavigation System: technology and clinical experiences in 131 cases, *Neurosurgery*, 44(1), 97-104.

[19] Schulz, A.P., Faber, A., and Meiners, J., (2007). Determination of optimal non-invasive patient fixation methods for use in robotic hip replacement surgery - an in vitro study, *Int J Med Robot.* 3(2), 135--139.

[20] Nogler, M., Maurer, H., Wimmer, C., Gegenhuber, C., Bach, C., Krismer, M., (2001). Knee pain caused by a fiducial marker in the medial femoral condyle: a clinical and anatomic study of 20 cases, *Acta orthopaedica Scandinavica.* 72(5), 477-480.

[21] Barratt, D., Penney, G., Chan, C., Slomczykowski, M., Carter, T., Edwards, P., Hawkes, D., (2006). Self-calibrating 3d-ultrasound-based bone registration for minimally invasive orthopedic surgery, *IEEE Transactions on Medical Imaging*. 25(3), 312–323.

[22] Talib, H., Styner, M., Rudolph, T., Gonzalez Ballester, M., (2007). Dynamic registration using ultrasound for anatomical referencing, *4th IEEE International Symposium on Biomedical Imaging*, 1164–1167.

[23] Daanen, V., Tonetti, J., Troccaz, J., (2004). An information fusion method for the automatic delineation of the bone-soft tissues interface in ultrasound images, *Computer Vision and Mathematical Methods in Medical and Biomedical Image Analysis*, *LNCS*, 3117, 218–229.

[24] Hacihaliloglu, I., Abugharbieh, R., Hodgson, A., Rohling, R., (2008) Bone segmentation and fracture detection in ultrasound using 3d local phase features, Medical Image Computing and Computer-Assisted Intervention, *LNCS*, 5241, 287–295.

[25] Amiot, L., Poulin, F., (2004). Computed tomography-based navigation for hip, knee, and spine surgery, *Clin. Orthop. Relat. Res.* 421, 77-86.

[26] Nabeyama, R., Matsuda, S., Miura, H., Mawatarim, T., Kawano, T., Iwamoto, Y. (2004). The accuracy of image-guided knee replacement based on computed tomography, *Journal of Bone and Joint Surgery*. 86-B, 366-371.

[27] Beitzel, J., Ahmadi, S.A., Karamalis, A., Wein, W., Navab, N. (2012). Ultrasound bone detection using patient-specific CT prior, *International Conference of the IEEE Engineering in Medicine and Biology Society*. 2664-2667.

[28] Moghari, G.P., Barratt, D.C., Chan, C.S.K., Slomczykowski, M., Carter, T.J., Edwards, P.J., Hawkes, D.J., (2007). Point-Based Rigid-Body Registration Using an Unscented Kalman Filter, *IEEE Transactions on Medical Imaging.* 26(12), 1708-1728.

[29] Penney, M.H., Abolmaesumi, P., (2006). Cadaver validation of intensity-based ultrasound to CT registration, *Medical Image Analysis.* 10(3), 385-395.

[30] Hacihaliloglu, I., Wilson, D.R.. Gilbart, M., Hunt, M.A., Abolmaesumi, P., (2013). Non-iterative partial view 3D ultrasound to CT registration in ultrasound-guided computer-assisted orthopedic surgery, *International Journal of Computer Assisted Radiology and Surgery*. 8(2), 157-168.

[31] Abolmaesumi, P., Salcudean, S.E., Wen-Hong Z., Sirouspour, M.R., DiMaio, S.P., (2002). Image-guided control of a robot for medical ultrasound, *IEEE Transactions on Robotics and Automation.* 18(1), 11-23.

[32] Krupa, A., Chaumette, F., (2006). Guidance of an ultrasound probe by visual servoing, *Advanced Robotics.* 20(11), 1203-1218.

[33] Chen, T., Abolmaesumi, P., Pichora, D.R., Ellis, R.E., (2005). A System for Ultrasoundguided Computer-assisted Orthopaedic Surgery, *Journal of Computer Aided Surgery*. 10(5-6), 281-292.

[34] Goncalves, P.J.S., Mendonca, L.F., Sousa, J.M.C., Caldas Pinto, J.R., (2008). Uncalibrated Eye-to-Hand Visual Servoing using Inverse Fuzzy Models, *IEEE Transactions on Fuzzy Systems.* 16(2), 341-353.

[35] Goncalves, P.J.S., Sousa, J.M.C., Caldas Pinto, J.R., (2008). Evolving Fuzzy Modeling of an Uncalibrated Visual Servoing System, In *Lecture Notes in Computer Science*, Springer-Verlag Berlin. 5112, 1041-1050.

[36] Goncalves, P.J.S., Fernandes, J.M., (2008). Tools for an Ultrasound Based 3D Bone Model Reconstruction, Registration and Visualization System, Euromedia 2008, *Workshop on Medical Imaging Systems*, Porto, Portugal.

[37] Goncalves, P.J.S., Carvalho, M. V., Mateus, D., Torres P.M.B., (2009). Registo de Imagens Ecográficas com Modelo 3D de Ossos - aplicação ao fémur, *Revista Ibérica de Sistemas e Tecnologias de Informação.* 4, 43-56.

[38] Gonçalves, P.J.S., Torres, P.M.B., Santos, F. and António, R., Catarino, N., Martins, J.M.M., (2014). A Vision System for Robotic Ultrasound Guided Orthopedic Surgery, *Journal of Intelligent & Robotic Systems.* 1-13.

In: Encyclopedia of Surgery (22 Volume Set)
Editors: Andreas Lehrer and Kristin Mueller
ISBN: 978-1-53618-329-0
© 2020 Nova Science Publishers, Inc.

Chapter 49

DEVELOPMENT OF SCRUB NURSE ROBOT (SNR) SYSTEMS FOR LAPAROSCOPIC SURGERY

Kitaro Yoshimitsu*

Institute of Advanced Biomedical Engineering and Science (TWIns),
Faculty of Advanced Techno-Surgery (FATS), Tokyo Women's Medical University,
Tokyo, Japan

ABSTRACT

There is currently a chronic shortage of scrub nurses to exchange surgical instruments with operating surgeons. Smooth instrument exchange maintains a surgeon's operating rhythm and can be limited by the availability of skilled scrub nurses. To compensate for this shortage, we propose a scrub nurse robot (SNR), which will achieve an efficacy at the level of a skilled human scrub nurse during laparoscopic surgery. In this paper, we developed a new SNR with a novel function: automatic insertion of a surgical instrument to achieve a smooth instrument exchange with the expectation that the higher functional ability would increase surgical operation efficacy. First, we developed the first version of the SNR, which was composed of two separate robots called R-1and R-2. The R-1 was designed to have two arms to handle an electric knife and a blood aspirator, which are the instruments that are most frequently used during laparoscopic surgery. The R-2 has a horizontal arm and two hands. The R-2 also has a tool changer that stores other instruments. After the basic validation study of the first SNR, the second version of the SNR was developed and achieved smooth and wide movement of its arms, each with four degrees of freedom (DOF). The second SNR is able to speak several sentences and recognize some words, as well as the names of surgical instruments, and is also capable of recognizing a surgeon's intraoperative actions by a real-time visual recognition system (RTVRS). The RTVRS is basically composed of both a commercially available three-dimensional (3D) position-tracking system and the algorithm that we developed to recognize the surgeon's actions during the exchange of instruments from the aforementioned positional data. Considering the results from the validation study of the second SNR, the third version of the SNR, which is able to insert the tip of the instrument into a small-caliber trocar cannula penetrating a patient's abdominal wall, was developed.

* Corresponding Author's Email: yoshimitsu.kitaro@twmu.ac.jp.

This function is called the automatic instrument inserting function (AIIF). The AIIF's algorithm, which is called kinematic-based feedback control, enables the arm instead of a surgeon to insert the instrument into the cannula. We validated that it was quicker to use the third SNR to help the surgeon's stand-ins to exchange instruments in a laboratory using the second SNR compared to human scrub nurses in real surgical operations. We defined the time spent exchanging surgical instruments as the *targeting time*. The results of the evaluation showed that it was possible to exchange instruments 1.69 s faster than in a clinical operating room between a human scrub nurse and a surgeon and 2.8 s faster than using the second SNR.

Keywords: laparoscopic surgery, robotic scrub nurse, automatic instrument inserting function

1. INTRODUCTION

Large hospitals continue to face a chronic shortage of nurses. The shortage is especially dire for scrub nurses who assist surgeons by exchanging surgical instruments [1, 2]. A scrub nurse is required to hand a surgical instrument to an operating surgeon as soon as it is requested. It may cause a distraction during the overall procedure if the scrub nurse spends too much time looking for the instrument. This lag may place an unnecessary burden on the surgeon, possibly reducing the quality and efficacy of the operation. To avoid such delays, the scrub nurse needs to be fully attentive to the activity in the operative field and also accurately anticipate what instrument a surgeon might need in the next procedure. For this to be possible, the scrub nurse needs to know the surgical procedure and the surgeon and also must be highly disciplined. An ideal scrub nurse is defined as someone who is able to meet the aforementioned requirements; as such, ideal scrub nurses are scarce. To compensate for the severe shortage of scrub nurses, a scrub nurse robot (SNR) system has been proposed. The goal of this research project was to develop an SNR capable of acting like the aforementioned skilled scrub nurse. The SNR was designed to adapt to surgeons with various levels of skill and different personalities. Three versions of SNR systems have already developed for endoscopic and laparoscopic surgery. The target for this SNR system is laparoscopic surgery because it is not too complicated for the SNR to follow, and surgeons performing endoscopic and laparoscopic surgery do not use as many types of surgical instruments as in conventional surgery in which the abdominal or thoracic wall is cut open widely [3].

Robotic scrub nurses to pass surgical instruments have been extensively proposed and investigated. The Penelope Surgical Instrument Server (SIS) is a robotic scrub nurse that has been used in clinical cases [4]. It can hand surgical instruments to surgeons per voice commands. This robot seems to be designed for so-called minor surgeries. Takashima et al. [5] have developed an interface between their own developed robotic scrub nurse and a surgeon, although the system has not yet been used in actual clinical cases. However, the SNR system that is proposed herein is intended to be used during major surgery such as abdominal, thoracic, and cardiac surgery. Moreover, the goals of the SNR are for it to be able to accurately anticipate which instrument the surgeon will request for the next step of surgery and to hand this to the surgeon in a timely fashion.

2. METHODS

2.1. First Version Of SNR

Figure 1 shows the first version of the SNR: R-1 and R-2 [6, 7].

The specifications of the R-1 (Figure 1a) were determined from analysis of the intraoperative motions of a surgeon and a scrub nurse in laparoscopic surgery [2]. In the preliminary investigation of a laparoscopic cholecystectomy, an electric knife and a blood aspirator were used very frequently (for approximately 40–50% of the duration of the laparoscopic procedure). The analysis of the intraoperative motion data indicated the necessity for the robot, which handles only an electric knife and a blood aspirator, and it was decided to divide the required tasks into two robots. The R-2 (Figure 1b) was designed to handle other instruments. The total number of instruments was, at the most, 15 in a routine laparoscopic cholecystectomy. Further details about the R-1 and R-2 are described in the next chapter.



(a) (b)

Figure 1. The first version of the SNR: R-1 and R-2.

The R-1 has a linear actuator inside its main body to lift the arm up and down to the height position of the surgeon's hand. A rotary actuator is located on this linear actuator to move the shoulders. In the wrist section, in order to realize a smooth transfer of instruments, a rotary actuator is fitted for each wrist. In the fingers, pneumatic robotic hand actuators are used to tightly grasp instruments. The R-1 has six degrees of freedom (DOF). Motor drivers and power supplies that control the actuators are located in the head section.

Figure 1b shows the R-2. The R-2 has a tool changer component and an arm component side by side. The tool changer holds a laparoscope, forceps, and the other instruments, and the

arm component hands over and receives the instruments with its two hands. The tool changer has a pneumatic latch rotor actuator to transfer the instruments to the hand. The arm turns 180 degrees to pass them to the surgeon after retrieving the instrument from the tool changer. The fingers of the R-2 are moved by the same air-powered mechanism as that of the R-1 to tightly grasp instruments. The tool changer and arm components both have linear actuators for height adjustment according to the hand position of the surgeon. The R-2 has nine DOF.

Figure 2. The second version of the SNR: ASULA.

2.2. Second Version of SNR

Considering the results from the validation study, a second version of the SNR—termed the advanced surgical unit in laparoscopic area (ASULA)—was developed. Figure 2 shows the ASULA. The biggest change from the first version of the SNR was that the separate robots were combined into one ASULA because the first SNR was too large for ordinary operating rooms. Therefore, the working space for an SNR in an operating room is expected to be decreased, and the dangers of interference with other surgical systems and instruments could be reduced. In order to abandon the R-2's main component of the tool changer—a surgical tray, which generally holds sterilized surgical instruments—was located at the side of the ASULA. The number of DOF in the arm sections was increased to four. While the arms were now freer, use of the rotary and linear actuators was maintained. Therefore, in the second version of the SNR, a reduction by five DOF from the first version of the SNR was incorporated to offer a total of 10 DOFs. This means that even if by any chance a malfunction should occur in the SNR, safety would be improved because of the expected greater simplicity of the control program. As for the user interface, in addition to foot switches that

were already installed in the first version of the SNR, a speech recognition system (Voice Key ver. 1.4) was employed to improve human adaptation.

2.3. Real-Time Visual Recognition System for Second Version of SNR

We intended to develop an SNR that was capable of providing the correct instrument without any verbal requests from the surgeon and without any delay. For this to be possible, the SNR needed a real-time visual recognition system (RTVRS) to detect the characteristics of surgeons' motions when exchanging instruments, especially to detect the moment when they draw out an instrument after use.

First, we defined and divided the intraoperative actions of a surgeon into two groups: *working* and *exchanging* actions. The *working* action means that a surgeon is doing some kind of surgical procedure with a surgical instrument, and the *exchanging* action means that he or she is replacing the surgical instrument after use with the instrument that is needed next. During this exchanging action, a scrub nurse must help the surgeon in an accurate and timely manner. The exchanging action was, for the purpose of convenience, further subdivided into five key actions: (1) pulling an instrument after use through a trocar cannula; (2) returning the instrument; (3) waiting for an instrument that the surgeon has requested; (4) receiving it; and (5) inserting it into the trocar cannula.

An algorithm capable of detecting and distinguishing the surgeon's motions observed during the action of exchanging instruments was developed [8, 9]. Reflective markers were attached to the surgeon's wrist, elbow, shoulder, and chest. These markers were captured by two digital video cameras set up in the operating room. We verified whether the algorithm was capable of detecting and distinguishing the six motions observed during the aforementioned five actions. As a result, the algorithm correctly captured each motion in real surgical operations [8, 9]. The entire procedural model of an endoscopic and laparoscopic surgery was constructed for the actions of a surgeon, a scrub nurse, and the possible statuses of a patient [2, 8, 9, 10] using the extended timed-automata formalism of UPPAAL [11, 12]. This surgical model installed into the SNR can enable the SNR to know which procedure is occurring to confirm which action a surgeon is now conducting and possibly to recognize what type of surgery is happening. The aforementioned surgeon's actions can be constructed by extended timed-automata modeling, as shown in Figure 3.

The composition of the first version of the RTVRS for the SNR was aimed at detecting surgeons' motions during the exchange of instruments, although the goal for the RTVRS for the SNR is to establish a visual system that enables the SNR to recognize surgical personnel actions and surgical instruments' positions in real time. First, in order to obtain real-time positional data of a surgeon's body parts, a commercially available real-time three-dimensional (3D) position-tracking system was utilized. This consists of high-speed digital video cameras with a sampling rate of 60 frames/s and QuickMag IV, which is capable of automatically tracking colored markers and outputting their 3D coordinates. More than two digital video cameras must be used in order to provide 3D positional data. Second, we modified the aforementioned algorithm for offline analysis of a surgeon's motions in order for the SNR to recognize the surgeon's actions in real time from the 3D positional data output by the QuickMag IV. One of the main modifications was that the modified algorithm detected only two out of the six actions shown in Figure 3: extracting and inserting [13].

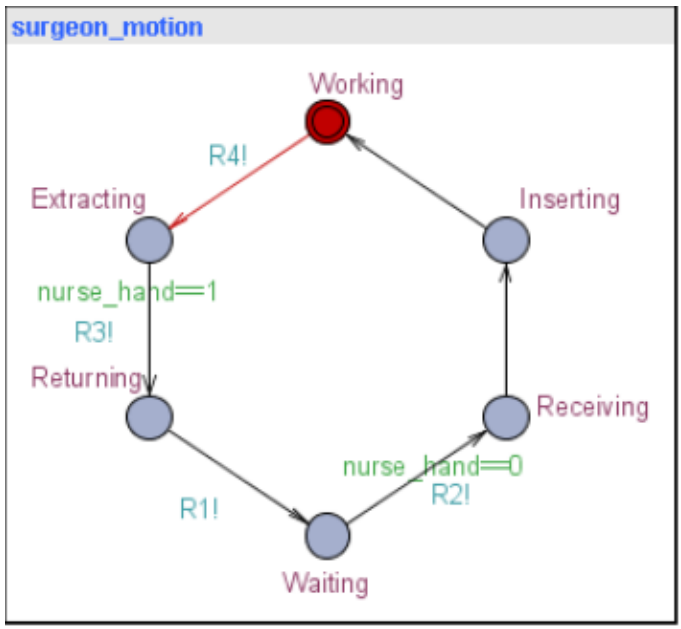

Figure 3. The aforementioned surgeon's actions during laparoscopic surgical procedure.

2.4. Third Version Of SNR

Precise analysis during endoscopic and laparoscopic surgery provided us with various types of intraoperative information and findings. For example, the exchange of surgical instruments is repeated 60 to 150 times in a single laparoscopic cholecystectomy, and each action of exchanging surgical instruments takes quite a long time—on average, 4–5 s. As mentioned in the previous section, we further investigated the surgeon's actions of exchanging instruments by dividing these into five subactions, such as extracting an instrument, returning it, waiting for the next instrument, getting it from a scrub nurse, and inserting it through a trocar cannula into the operative field. We found that an older, more highly skilled surgeon spent more time inserting a surgical instrument into an inlet of a small-caliber trocar cannula than a younger novice surgeon did, although he finished the surgical operation much more quickly [7]. The action of inserting instruments into small-caliber trocar cannulas can be stressful for older surgeons because they must repeat this action many times. This action can also be unfavorable for young surgeons, although they are able to finish this action in shorter periods of time because they repeat this action many more times—sometimes amounting to 150 times in a single operation—than older, more highly skilled surgeons. Then, we came up with an idea for a new function of the SNR: an automatic instrument inserting function (AIIF). Namely, we considered that the SNR would be extremely helpful for all surgeons if the SNR instead of surgeons could insert surgical instruments into trocar cannulas. We also noticed another unfavorable action during endoscopic and laparoscopic surgery. The action of exchanging surgical instruments forces surgeons to shift their eyes from the endoscope monitor displaying the operative field. This action—called *eye-off* action—is distracting to surgeons because they like to keep their attention on the operative field. This aforementioned new feature of the SNR may eliminate

this unfavorable action because surgeons will not need to look at the inlet of the trocar cannula.

According to the concept of the new feature, we developed the third version of the SNR (Figure 4). The SNR is composed of three parts: an arm, a tool changer, and a body. The arm handles an instrument and guides the tip to the entry point of a cannula. The tool changer locates the upper part of the body with the tool stage. Each holder on the tool stage grasps a surgical instrument. The body contains a power supply, electric air valves, and motor drivers in a control box at the bottom of the body.

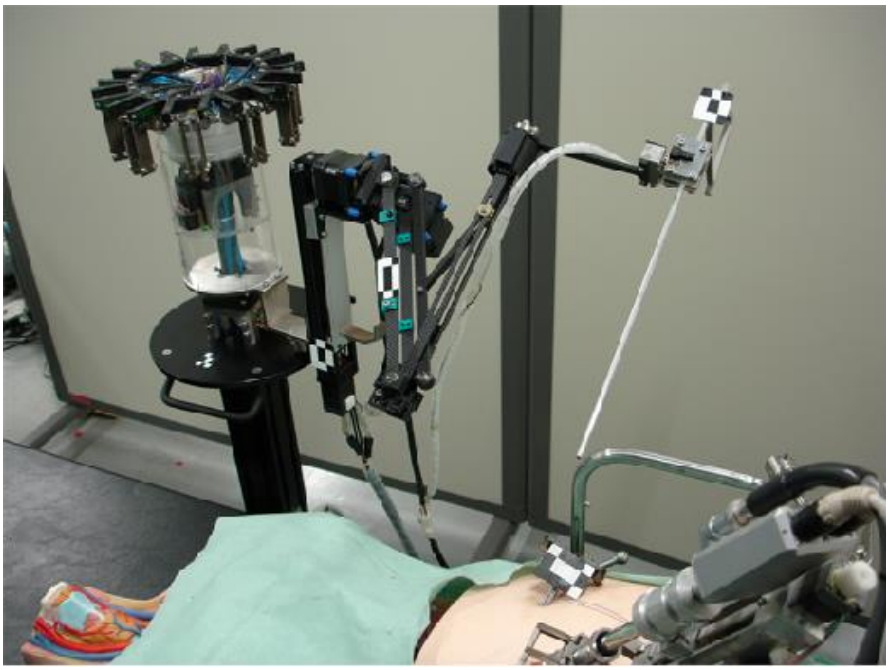

Figure 4. The third version of the SNR.

The entire arm can be detached at the shoulder by sliding respective counterparts in or out that are mutually complementary in shape. Two pneumatic actuators are used on the detachable section instead of an electric actuator in order to be sterilized. One of the actuators has two fingers and is used with a hand part to grasp an instrument with a 10-mm stroke. An infrared sensor is located on this actuator to detect objects between the fingers. The other pneumatic actuator is located at the wrist part. This actuator is used to retrieve an instrument from the tool changer. Electric drive actuators are used for the reaching mechanism, and a rotating mechanism is located at the shoulder. The shoulder rotation is correctly transmitted by using concavo-convex parts. The main shafts of the arm are made of carbon materials that are rigid and light. Every joint is made of an aluminum alloy with a black alumite treatment to prevent corrosion. Shafts in the joints are made of stainless steel with oil-less bearings. The tool changer has 10 tool holders that are positioned circularly, facing outward. This holder is designed to be detachable, similar to the arm. Each holder is composed of a pneumatic actuator and an infrared sensor to detect an instrument that is returned between the fingers. Stainless steel plates are affixed to the tip of the actuator to tightly hold an instrument. The tool stage on the tool changer is made of white MC nylon. Air pressure and electric supply for

the pneumatic actuators are supplied from the control box at the bottom. At the connecting part between the tool stage and the tool changer, we used air and electric connectors to transfer air pressure and electric signals. Thus, the tool stage can also be easily detached, much like the arm.

2.5. AIIF

The greatest characteristic of the third SNR is the AIIF of its arm. The arm inserts the tip of an instrument into the entrance of the trocar cannula instead of a surgeon. The AIIF has two purposes. One of these is reducing the waiting time; this forces a surgeon to wait for the next instrument until a scrub nurse hands it to him or her—1.71 s on average. The other purpose is decreasing the eye-off time, which takes 1.41 s on average when a surgeon inserts an instrument into the trocar cannula. Inserting an instrument with a length of approximately 400 mm into a 5-mm-diameter trocar cannula can be a difficult task, especially for older surgeons. If this annoying task were done automatically by the SNR, the operating procedure would be expected to become much smoother. To achieve this feature, a 3D coordinate measurement system named Micron Tracker 2 (Claron Technology Inc.) was used as the position feedback sensor. This system obtains the 3D coordinate and angle values of specific predefined markers. In this paper, we propose kinematic-based feedback control as a controlling algorithm for the AIIF. To achieve this idea, the original position of the SNR coordinate system was set as an absolute coordinate system; reference vectors were also created, as shown in Figure 5.

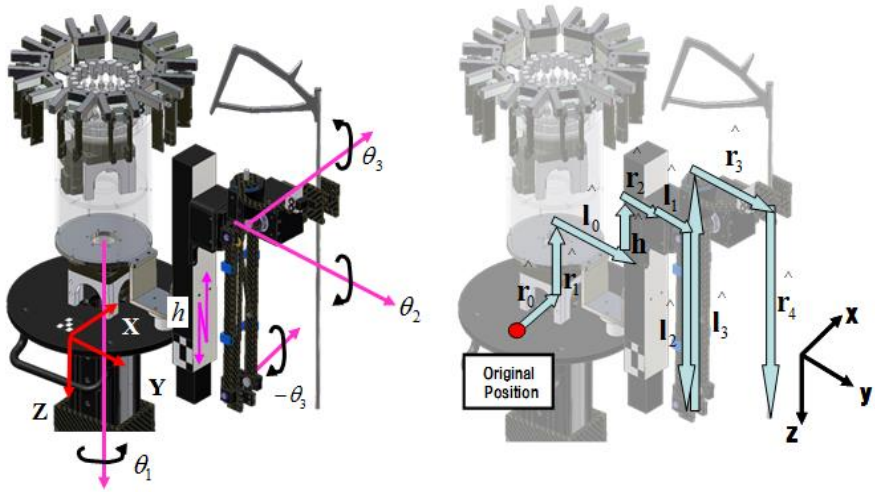

Figure 5. A controlling algorithm for the AIIF.

The AIIF was executed as follows:

- First, for the direct kinematic analysis, we described the 3D position of the tip of the instrument, as shown in Equation (1).

- Second, the 3D position of the tip of an instrument and the entrance of the trocar cannula were fed back by the Micron Tracker 2 and assigned to P_x, P_y, and P_z and P_x', P_y', and P_z', respectively.
- Third, Equation (1) was solved for simultaneously. To solve the simultaneous equations, the value of was fixed as 45 degrees.
- Finally, the values that should be controlled by each actuator were calculated via Equations (2)–(4) by using the solutions of Equation (1).

$$\begin{cases} (P_x, P_x') = \mathbf{r}_0 - S_1(\mathbf{l}_0 + \mathbf{r}_2) + (S_1S_3 + S_2C_1C_3)\mathbf{l}_2 - S_1\mathbf{r}_3 + S_2C_1(\mathbf{r}_4 - \mathbf{l}_3) \\ (P_y, P_y') = C_1(\mathbf{l}_0 + \mathbf{r}_2) + (-S_3C_1 + S_1S_2C_3)\mathbf{l}_2 + C_1\mathbf{r}_3 + S_1S_2(\mathbf{r}_4 - \mathbf{l}_3) \\ (P_z, P_z') = -\mathbf{r}_1 - \mathbf{h} + C_2C_3\mathbf{l}_2 + C_2(\mathbf{r}_4 - \mathbf{l}_3) \end{cases} \quad (1)$$

$$\theta_1 = {}^{SNRbody}_{Cannula}\theta_1' - {}^{SNRbody}_{Tooltip}\theta_1 \quad (2)$$

$$\theta_3 = {}^{SNRbody}_{Cannula}\theta_3' - {}^{SNRbody}_{Tooltip}\theta_3 \quad (3)$$

$$h = {}^{SNRbody}_{Cannula}h' - {}^{SNRbody}_{Tooltip}h \quad (4)$$

2.6. Evaluation of Third SNR Compared with Previous Version

In this section, we tested how fast the SNR inserts the tip of an instrument into the entrance of the trocar cannula. Four students were used as the surgeon's stand-ins in this experiment. They were all familiar with the role of a surgeon. We measured the time that was taken for the AIIF and defined this time as the *targeting time*. This targeting time starts from the moment when the tip of instrument is extracted from the entrance of the cannula. Measurement is finished at the moment when the tip of the next instrument is inserted into the cannula.

The SNR started moving from its waiting position. The signal from the infrared sensor was the trigger signal for starting the AIIF. After insertion, the surgeon's stand-ins could recognize the end of the targeting motion from a beeping sound from the computer. Then, they pushed the foot switch next to their feet. Finally, the SNR released the instrument and moved back to its original position, ready for the next motion.

The results are shown in Table I; Figure 6 shows the time taken for each segmented action. We segmented these actions based on the following definitions:

Returning: The moment from when the tip of the instrument is extracted to the moment when the surgeon releases the instrument.

Waiting: The moment from when the surgeon releases the instrument that he or she has finished using to the moment when the surgeon receives the instrument that he or she requested for the next operating procedure.

Targeting at the entrance of the cannula: The moment from when the surgeon receives the instrument that he or she will use in the next operating procedure to the moment when the surgeon inserts the tip of the instrument into the entrance of the cannula.

Mechanical movement: The moment from when the infrared sensor recognizes the extraction and the SNR starts moving to the moment when the SNR inserts the tip of the instrument into the entrance of the cannula.

Table 1. Time for targeting an instrument (in seconds)

Average	±Standard deviation	Maximum	Minimum
Surgeon: real nurses (*N* = 128)	3.72 ± 2.19	17.70	1.77
Stand-ins: second SNR (*N* = 27)	4.80 ± 0.90	6.60	2.93
Stand-ins : third SNR (*N* = 20) (Kinematic-based feedback control)	2.03 ± 0.10	2.24	1.86

The targeting time in the case of the laboratory was considerably shorter and more stable than in the case when the second SNR was used, even compared to real operations. In particular, we determined that the third SNR finished its targeting motion 1.69 s faster than clinical cases under kinematic-based feedback control. We also observed that three-fourths of the stand-ins quickly adjusted to exchanging instruments with the SNR. Afterward, most of the time, they had already or concurrently grasped the handle of the instrument when the AIIF finished. Thus, all they had to do was quickly slide in the instrument as soon as the AIIF had finished. Therefore, if this arm is introduced in clinical operating rooms, we can expect that surgeons would concentrate more on the operating procedures because the SNR would enable them not to have to pay attention to confirming the position of the entrance of the trocar cannula as surgeons do currently.

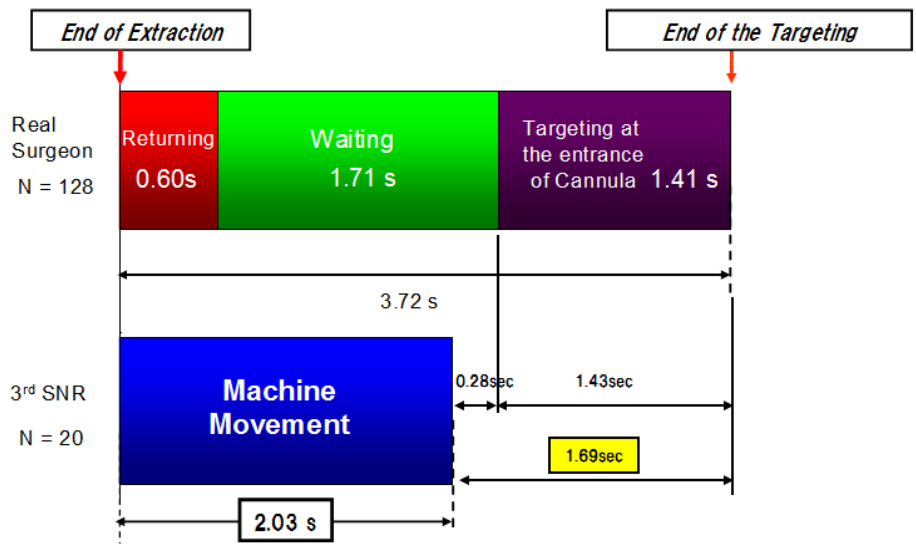

Figure 6. The time taken for each segmented action.

CONCLUSION

To compensate for the severe and chronic shortage of scrub nurses, we have proposed an SNR system that is capable of functioning as a skilled human scrub nurse in endoscopic and laparoscopic surgery. We have proposed and developed three versions of this system. In this paper, we describe these three versions of the SNR and its features. The first SNR, which was composed of two separate robots called R-1 and R-2, was designed as a prototype. After the basic evaluation of the first SNR, we developed the second version of the SNR, which has a voice recognition system as a user interface and achieved smooth and wide movement of its arms, each with four DOF. The second SNR was able to speak several sentences and recognize some words, as well as the names of surgical instruments, and was also capable of recognizing a surgeon's intraoperative actions by its RTVRS. Concerning the results from the evaluation of the second SNR, we developed the third version of the SNR, which has an AIIF. This function (instead of a surgeon) correctly inserts the next instrument into the cannula. We constructed two types of algorithms for AIIF control and evaluated how well the third SNR worked in a laboratory compared to human scrub nurses in real operations and compared to the second SNR. We discovered two remarkable results from the third SNR. One is the targeting time, which is defined as the moment from the end of extraction to the insertion of the next instrument. The third SNR was 1.69 s faster than human scrub nurses in presenting surgical instruments under the kinematic-based feedback control. Currently, we are researching how to control the SNR based on the surgical operating model that we have constructed with UPPAAL [8, 12]. By including this surgical model in the SNR system, it will be able to predict the next instrument that should be used in the next surgical procedure and also be able to work better to provide the best support for high-quality surgical operations.

REFERENCES

[1] Bower, F. L., and McCullough, C., Nurse shortage or nursing shortage: Have we missed the real problem? *Nurs. Econ.*, 22(4):200-203, 2004.

[2] Miyawaki, F., Masamune, K., Suzuki, S., Yoshimitsu, K., and Vain, J., Scrub nurse robot system—Intraoperative motion analysis of a scrub nurse and timed-automata-based model for surgery. *IEEE Trans. Ind. Electron.*, 52(5):1227-1235, 2005.

[3] Hashimoto, D., *Advanced Techniques in Gasless Laparoscopic Surgery*, 1995.

[4] Robotic Surgical Tech, Inc., http://www.roboticsurgicaltech.com/ index.html

[5] Takashima, K., Nakashima, H., Mukai, T., and Hayashi, S., Scrub nurse robot for laparoscopic surgery. *Adv. Robotics*, 22(13-14):1585-1601, 2008.

[6] Yoshimitsu, K., Tanaka, T., Ohnuma, K., Miyawaki, F., Hashimoto, D., and Masamune, K., Prototype development of scrub nurse robot for laparoscopic surgery, *Proceedings of Computer Assisted Radiology and Surgery*, 845-850, 2005.

[7] Yoshimitsu, K., Masamune, K., Tanaka, T., Ohnuma, K., Hashimoto, D., and Miyawaki F., Development of human adaptive scrub nurse robot for laparoscopic surgery, *Proceedings of the 3rd COE Workshop on Human Adaptive Mechatronics (HAM)*, 149-152, 2006.

[8] Ohnuma, K., Masamune, K., Yoshimitsu, K., Vain, J., Fukui, Y., and Miyawaki, F., Analysis and recognition of a surgeon's motions in laparoscopic cholecystectomy giving a scrub nurse robot suitable timings for instrument exchange, *Proceedings of the 3rd COE Workshop on Human Adaptive Mechatronics (HAM)*, 219-223, 2006.

[9] Ohnuma, K., Masamune, K., Yoshimitsu, K., Sadahiro, T., Vain, J., Fukui, Y., and Miyawaki, F., Timed-automata based model for laparoscopic surgery and intraoperative motion recognition of a surgeon as the interface connecting the surgical scenario and the real operating room, *Proceedings of Computer Assisted Radiology and Surgery*, 1(Suppl. 1):442-445, 2006.

[10] Miyawaki, F., Masamune, K., Suzuki, S., Yoshimitsu, K., and Vain, J., Intraoperative motion analysis of surgical staff and timed automata based model of surgery to develop scrub nurse robot system, *Proceedings of the 2nd COE Workshop on Human Adaptive Mechatronics (HAM)*, 65-70, 2005.

[11] Hune, T., Larsen, K., and Pettersson, P., Guided synthesis of control programs using UPPAAL, *Proceedings of the IEEE ICDCS International Workshop on Distributed Systems Verification and Validation*, E15-E22, 2000. Wang, J., Fundamentals of erbium-doped fiber amplifiers arrays, IEEE J. Quantum Electron., submitted for publication.

[12] http:// www.uppaal.com.

[13] Miyawaki, F., Ohnuma, K., Sadahiro, T., Yoshimitsu, K., Masamune, K., and Fukui, Y., Development of real-time visual recognition system (RTVRS) for SNR and assessment of performance of RTVRS-driven SNR during exchange of surgical instruments, *Proceedings of the 4th COE Workshop on Human Adaptive Mechatronics (HAM)*, 25-30, 2007.

In: Encyclopedia of Surgery (22 Volume Set)
Editors: Andreas Lehrer and Kristin Mueller
ISBN: 978-1-53618-329-0
© 2020 Nova Science Publishers, Inc.

Chapter 50

T-CELL SHAPE VARIATION WITH INTRA-CELLULAR Ca^{2+} CONCENTRATION: A JOINT IMAGE AND SHAPE STUDY

***Yi Gao*[1,*], *Wei Chen*[2,3], *Baoyu Liu*[2], *Allen Tannenbaum*[4] *and Cheng Zhu*[2]**
[1]Stony Brook University, Department Biomedical Informatics, Stony Brook, NY, US
[2]Georgia Institute of Technology, Department Biomedical Engineering, Atlanta, GA, US
[3]School of Medicine, Zhejiang University, Hangzhou, China
[4]Stony Brook University, Departments Computer Science and Applied Mathematics/Statistics, Stony Brook, NY, US

Abstract

Ca^{2+} signaling is of major importance for a wide range of intra- and inter-cellular processes. In particular, for the immune system, Ca^{2+} regulation is crucial for mast cell degranulation, lysis of infected cells, and essentially all responses initiated by T-cell, B-cell, and Fc receptors. The introduction of the Ca^{2+} indicators, such as the fura-2 and indo-1, by Roger Tsien and collaborators, enables the in-vivo and real time imaging of the intracellular Ca^{2+} concentration. In this work, we utilize active contour and optimal mass transport techniques to collectively estimate the intracellular Ca^{2+} concentration and quantify the shape variations in the T-cells. Our results indicate an potentially interesting positive correlation between the intracellular Ca^{2+} concentration with the variations in T-cell shape.

1. INTRODUCTION

Ca^{2+} signaling is crucial for a wide range of intra- and inter-cellular processes including those of the immune system. Indeed, Ca^{2+} regulation is central for mast cell degranulation, lysis of infected cells, and just about all responses initiated by T-cell, B-cell, and Fc

*Corresponding Author's Email: gaoyi@gatech.edu.

receptors [1]. Since the 1980s, the introduction of the Ca^{2+} indicators such as the fura-2 and indo-1 by Roger Tsien and collaborators [2], enables the in-vivo and real time measurement of the intracellular Ca^{2+} concentration. As a result, researchers are now able to capture the fluorescent images as well as videos, and quantitatively estimate the dynamics of intracellular Ca^{2+} concentration.

In this note, we utilize the 340nm/380nm two channel fluorescent images by collectively analyzing the Ca^{2+} concentration as well as the variation of the shape of the T-cell. Using the active contour method [3], we automatically identify and track the T-cell within the high-speed camera video. After that, based on the optimal mass transport theory [4], we formulate a metric to quantify the "distance" between cell shape configurations. The resulting time-varying Ca^{2+} concentration and the shape metric curves shows an interesting positive correlation, which may provide insight into the study of immunological function of the T-cell.

2. METHOD

In this section, we first describe how to extract and segment a given cell from the 380nm fluorescent image. Then, based on the segmentation, we estimate the Ca^{2+} concentration and the shape change in the cell, and determine the correlation between them.

2.1. Cell Extraction and Tracking

In order to estimate the intra cellular Ca^{2+} concentration as well as to compute the shape of the cell, we have to extract the boundary of the cell from the video. To that end, denote the i-th frame as $I : \Omega \to \mathbb{R}^+$. It can be observed, for example in Figure 2 in Section 3 below, that the cells appear brighter in the image than their background region. Therefore, we opt to use the region based active contour method (Chan-Vese model)[3] for the cell segmentation due to its ability of both extracting the bright region as well as keeping the boundary relative regular/smooth. Mathematically, the contour is modeled as a simple closed curve in Ω, $C : [0, 1] \to \Omega$ with $C(0) = C(1)$. The extraction of the cell boundary is accomplished by computing the curve C minimizing the energy functional $E(C)$ given as [3]:

$$E(C) := \int_{\text{inside } C} |I(x,y) - \mu_1|^2 \, dxdy + \int_{\text{outside } C} |I(x,y) - \mu_2|^2 \, dxdy + \lambda \int_C ds \tag{1}$$

where μ_1 (μ_2) is the average image intensity inside (outside) the close contour C, respectively. The λ is a positive parameter that controls the smoothness of the resulting contour: large positive λ will result in a smooth cell boundary whereas a small positive λ will capture all the boundary details, at the risk of being influenced by the image noise.

The contour C which gives the minimal $E(C)$ is obtained by solving the variational problem under the level set framework [5]. Specifically, in order to achieve fast processing speed, we used the sparse field level set implementation for the level set evolution [6].

2.2. Ca^{2+} Concentration Estimation

The intra-cellular Ca^{2+} is estimated as the cell image intensity ratio between the 340nm channel and the 380nm channel [2]. Assuming that the cells have been extracted via the preceding segmentation procedure, this can be computed as:

$$a = \int_{\text{inside } C} \frac{I_{340nm}(x,y)}{I_{380nm}(x,y)} dxdy \Big/ \int_{\text{inside } C} 1 dxdy \tag{2}$$

After this, we compute the temporal shape variation and find interesting correlation with the shape of the cell, which are detailed below.

2.3. Shape Metric and Correlation with Ca^{2+} Concentration

In order to compare the shapes of the cell at different time points, we have to formalize the definition of the concept of "shape". We adopt the definition of "shape" which measures the geometric property of the object after certain global similarity transformation is removed [7, 8]. Due to the motion of the cell mounting device, such global transformation should be removed from the shape metric computation. After that, the "distance" between two shapes are defined. Various definition for the shape metric have been proposed [9, 10, 11], in this work, the Wasserstein 2-metric derived from the optimal mass transport is used. Mathematically,

$$d(C_1, C_2) = \min_T (W(R_1, T \circ R_2)) \tag{3}$$

where

$$\hat{R}_i(x,y) = \begin{cases} 1 & \text{if } (x,y) \text{ inside } C_i \\ 0 & \text{otherwise} \end{cases}$$
$$R_i(x,y) = \frac{\hat{R}_i(x,y)}{\int_\Omega \hat{R}_i(x,y) dxdy} \tag{4}$$

and T is the optimal similarity transformation aligning R_1 with R_2. It is computed as:

In the equation, the $W(\cdot,\cdot)$ indicates the Wasserstein distance defined as follows. First, we call a diffeomorphism $\mu : \Omega \to \Omega$ *mass preserving* (MP) if $\forall D \subseteq \Omega$ with $(x,y) = \mu(u,v)$, we have:

$$\int_{\mu^{-1}(D)} R_1(u,v) dudv = \int_D R_2(x,y) dxdy. \tag{5}$$

Via change of variables, this can be rewritten as

$$\det(J_\mu(x,y)) R_2(\mu(x,y)) = R_1(x,y), \forall (x,y) \in \Omega \tag{6}$$

where $J_\mu(x,y)$ is the Jacobian of μ at (x,y). This is referred to as the *Jacobian equation*. This equation is highly nonlinear, and may have many solutions. The objective here is to

compute the following distance and find the corresponding optimal transportation map (if it exists), defined in terms of the L^p Kantorovich-Wasserstein functional [4]:

$$W(R_1, R_2) = \inf_{\mu \in MP} \left(\int_\Omega |\mu(x,y) - (x,y)|^p R_1(x,y) dxdy \right) \tag{7}$$

The minimization problem defined Equation (7) is highly non-linear and is difficult to solve. The quadratic version of this problem ($p = 2$ in Eq. (7)) has been extensively studied and has a number of approaches devoted to its numerical solution; see [12, 13, 14, 15] and the references therein. Previously, by representing the masses as sum of Dirac delta functions, the linear programming can then be employed in solving the problem [12]. Such scheme is also used to model cell nuclei evolution [15]. However, for 2D images of the size $N \times N$, the complexity of such scheme is $O(N^4)$, which is computationally very heavy for large N. Benamou and Brenier took a different path by casting the original problem to a computational fluid mechanics one [13]. Also in the continuum, Haker *et al.* [14] took another approach. They first constructed a mass preserving map μ_0 not necessarily minimizing the cost in Equation 7. Then, such initial map was iteratively processed so as to remove its curl component accomplished via a non-local first order partial differential equation. For a given mass-preserving initial mapping, the solution of the equation does indeed asymptotically converge to the optimal map [16], but numerically may have a problem that if the initial mapping is "far" from the final optimal mapping. In such a case, the scheme may require many iteration steps to sufficiently reduce the curl. To address such problems, Haber *et al.* discretized the problem first and then formulated a consistent numerical scheme in the discrete domain using sequential quadratic programming [17].

In the quadratic case, one can show that there exists a unique strictly convex function $\tilde{\Psi} : \Omega \to \Omega$ such that the optimal mapping $\tilde{\mu}$ is the gradient of $\tilde{\Psi}$, i.e., $\tilde{\mu} = \nabla\tilde{\Psi}$ [18]. Plugging this into Equation 6 we have:

$$\det(H_{\tilde{\Psi}}(x,y)) R_2(\nabla\tilde{\Psi}(x,y)) = R_1(x,y), \quad \forall (x,y) \in \Omega \tag{8}$$

where $H_{\tilde{\Psi}}$ is the Hessian of $\tilde{\Psi}$ and Equation 8 is the Monge-Ampere equation. Following [19], $\tilde{\Psi}$ can be solved iteratively by:

$$\frac{\partial \Psi}{\partial t} = \log \left(\frac{\det(H_{\tilde{\Psi}}(x,y)) R_2(\nabla_{(x,y)}\Psi(x,y))}{R_1(x,y)} \right) \tag{9}$$

When Ψ converges to $\tilde{\Psi}$, we have the optimal mapping $\tilde{\mu} = \nabla_{(x,y)}\Psi$, where $\nabla_{(x,y)}$ is the spatial gradient operator.

2.4. Overall Algorithm

Given a series of images (video), we present the overall algorithm for the entire processing pipeline as shown in Figure 1. Specifically, the input to the processing pipeline consists of two video sequences $I_{340nm}(x,y,t)$ and $I_{380nm}(x,y,t)$ (340 nm and 380 nm channels, respectively). The cell segmentation algorithm in Section 2.1 is used to extract the T-cells in each frame of the two video sequences. Then, the Ca^{2+} concentration in each frame is computed and is denoted by $a(t)$. In parallel, the shape of the T-cell in each subsequent frame

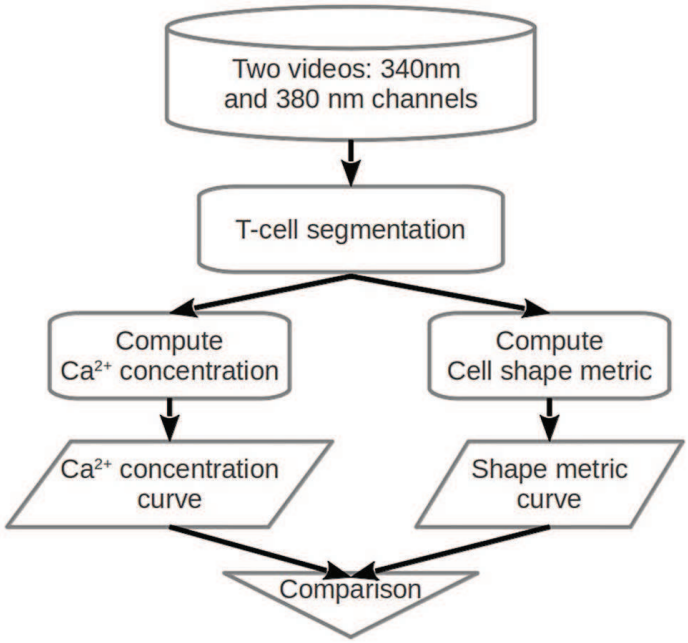

Figure 1. Overall flow chart of the proposed algorithm.

is compared with that in the first frame, and is denoted as $S(t) := W(R(t), R(t_0))$. Since we are interested in the trends of $a(t)$ and $S(t)$, not their absolute values, they are normalized by dividing their respective ranges (the difference between maximum and minimum values). Finally, the normalized $a(t)$ and $S(t)$ are compared to show the correlation.

3. Experimental Results

3.1. Cell Extraction

We show in Figure 2 several frames from the video indicating the image condition, cell extraction results, and the shape variance between frames.

3.2. Shape and Ca^{2+} Correlation

The algorithm is tested on a total of 20 data cases. Among them, three results are picked at random and are shown below. From these figures and similarly on others not shown here because of lack of space, we can observe a positive correlation between the two curves. Moreover, it is interesting to observe that the Ca^{2+} concentration change often precedes the shape change. This is more evident when there is a relatively significant change in both curves, such as in Figure 3 around 270-th frame and Figure 4 around 110-th frame.

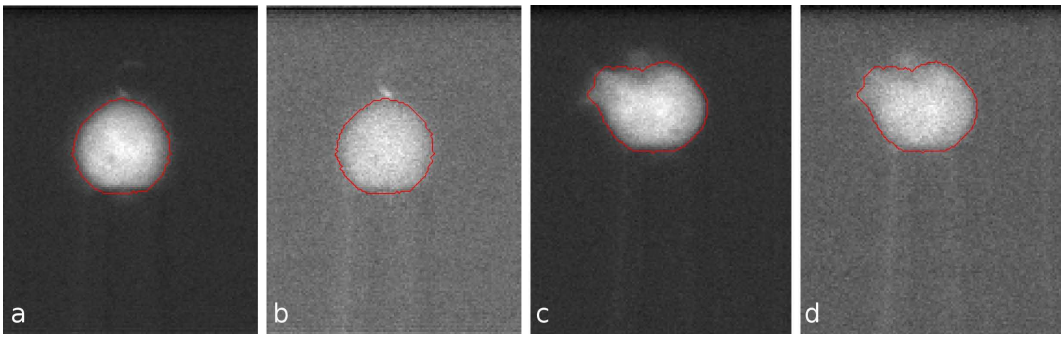

Figure 2. Frame 10 or 380nm (a) and 340nm (b) channels. Frame 115 or 380nm (c) and 340nm (d) channels. The red contours indicate the extracted cell boundaries. Note that the bright spot on top of the cell is glass beads and is correctly excluded from the cell region. The significant shape change between the frames can be observed.

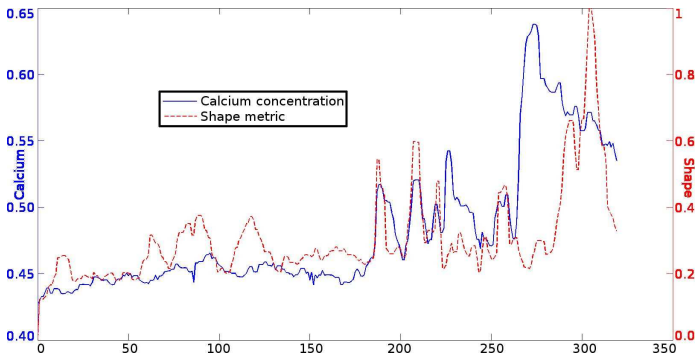

Figure 3. The Ca^{2+} (red) and shape metric (blue) curves and their respective regression lines. Case 1.

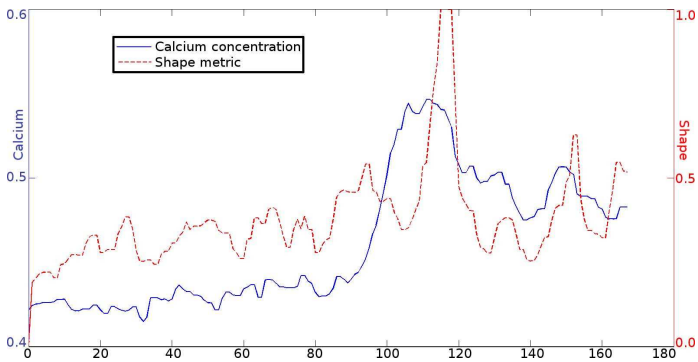

Figure 4. The Ca^{2+} (red) and shape metric (blue) curves and their respective regression lines. Case 2.

Conclusion and Discussion

In this work we proposed a complete pipeline for image and shape analysis for the fluorescent T-cell images. In particular, we have used the Wasserstein 2-metric to measure the

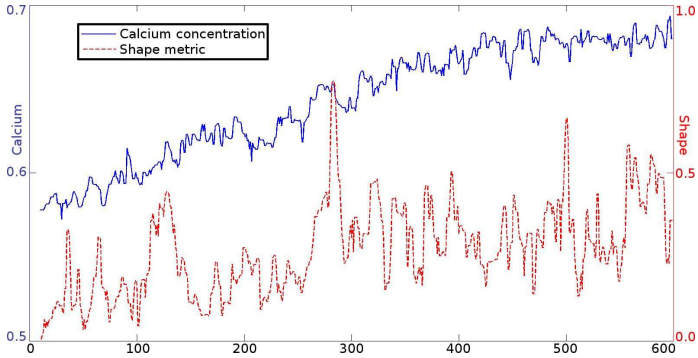

Figure 5. The Ca^{2+} (red) and shape metric (blue) curves and their respective regression lines. Case 3.

shape variation of the T-cells, which shows an interesting correlation with the intracellular calcium concentration.

It is also noted that since both the Ca^{2+} concentration and the shape metric computation depends upon the segmentation of the T-cells, we must consider the question of whether the correlation between the two measures is caused by the common segmentation upon which they are based. One possible way to verify this is to utilize other methods to compute the Ca^{2+} concentration so that the generation of the two curves are decoupled. In this manner, we plan to further examine the correspondence found in this work. Another future research direction involves the quantitative analysis of the correlation between the Ca^{2+} concentration and the shape metric.

REFERENCES

[1] Patrick G Hogan, Richard S Lewis, and Anjana Rao. Molecular basis of calcium signaling in lymphocytes: Stim and orai. *Annual review of immunology*, 28:491, 2010.

[2] Grzegorz Grynkiewicz, Martin Poenie, and Roger Y Tsien. A new generation of ca2+ indicators with greatly improved fluorescence properties. *Journal of Biological Chemistry*, 260(6):3440–3450, 1985.

[3] T.F. Chan and L.A. Vese. Active contours without edges. *Image Processing, IEEE Transactions on*, 10(2):266–277, 2001.

[4] Cédric Villani. *Optimal Transport: Old and New*, volume 338. Springer, 2008.

[5] S. Osher and J.A. Sethian. Fronts propagating with curvature-dependent speed: algorithms based on hamilton-jacobi formulations. *Journal of computational physics*, 79(1):12–49, 1988.

[6] Ross T Whitaker. A level-set approach to 3d reconstruction from range data. *International Journal of Computer Vision*, 29(3):203–231, 1998.

[7] C.G. Small. *The statistical theory of shape*. Springer Verlag, 1996.

[8] I.L. Dryden and K.V. Mardia. *Statistical shape analysis*. John Wiley & Sons, 1998.

[9] M.I. Miller. Computational anatomy: shape, growth, and atrophy comparison via diffeomorphisms. *NeuroImage*, 23:S19–S33, 2004.

[10] Y. Gao, T. Riklin-Raviv, and S. Bouix. Shape analysis, a field in need of careful validation. *Human Brain Mapping*, 2014.

[11] Y. Gao and S. Bouix. Signed Poisson map for shape analysis. In *Proceedings of the International Symposium on Biomedical Imaging (ISBI)*, 2014.

[12] T. Kaijser. Computing the Kantorovich distance for images. *Journal of Mathematical Imaging and Vision*, 9(2):173–191, 1998.

[13] J.D. Benamou and Y. Brenier. A computational fluid mechanics solution to the Monge-Kantorovich mass transfer problem. *Numerische Mathematik*, 84(3):375–393, 2000.

[14] S. Haker, L. Zhu, A. Tannenbaum, and S. Angenent. Optimal mass transport for registration and warping. *International Journal of Computer Vision*, 60(3):225–240, 2004.

[15] Wei Wang, John A Ozolek, Dejan Slepcev, Ann B Lee, Cheng Chen, and Gustavo K Rohde. An optimal transportation approach for nuclear structure-based pathology. *IEEE Transactions on Medical Imaging*, 30(3):621–631, 2011.

[16] S. Angenent, Haker S., and Tannenbaum A. Minimizing flows for the monge–kantorovich problem. *SIAM J. Math. Analysis*, 35:61–97, 2003.

[17] E. Haber, T. Rehman, and A. Tannenbaum. An efficient numerical method for the solution of the l2 optimal mass transfer problem. *SIAM Journal on Imaging Science*, 32(1):197–211, 2010.

[18] Y. Brenier. Polar factorization and monotone rearrangement of vector-valued functions. *Comm. on pure and applied mathematics*, 44(4):375–417, 1991.

[19] M.M. Sulman, JF Williams, and R.D. Russell. An efficient approach for the numerical solution of the monge-ampère equation. *Applied Numerical Mathematics*, 61(3):298–307, 2011.

In: Encyclopedia of Surgery (22 Volume Set)
Editors: Andreas Lehrer and Kristin Mueller
ISBN: 978-1-53618-329-0
© 2020 Nova Science Publishers, Inc.

Chapter 51

REVISIONAL BARIATRIC SURGERY FOR WEIGHT REGAIN: A PROGRAMMATIC APPROACH

Eric J. DeMaria[1,*], MD
and Meredith A. Grzybowski[2]
[1]Maryview Medical Center, Suffolk, Virginia
[2]Maryview Medical Center, Bon Secours Health System, Portsmouth, Virginia

ABSTRACT

Revisional bariatric surgery is a significant endeavor because of higher operative risks and poorer weight loss outcomes than primary procedures. The decision to carry out such surgery must be taken by a multidisciplinary team that confirms that the outcomes of the primary procedure actually are not sufficient and, if this is the case, thoroughly analyzes the causes of failure of the initial procedure. Causes for failure include anatomical factors such as initially poorly performed constructions or, conversely, acquired changes that counteract the activity of a correctly performed surgical procedure. Evaluation of the anatomical imperfection requires specific radiological and endoscopic techniques. Depending on the objective findings in combination with the subjective complaints of the patient an adequate surgical strategy can be searched for.

More often than not however behavioral/dietary flaws constitute the essential part of the failure and must be addressed by patient re-education and behavior modification.

OVERVIEW

Revisional bariatric surgery is a complex and evolving area of traditional bariatric surgery. Although bariatric surgery provides a permanent tool to treat obesity for the majority of patients, we are seeing a growing number return with issues that need to be addressed by multidisciplinary comprehensive treatment strategies. Although there may be surgical

* Corresponding Author's Email: ejdemaria@gmail.com.

options, often the procedures are difficult and often carry greater risk than the primary operation. [1] More importantly, the benefit of the various surgical intervention have not been proven in large cohort studies.

Our primary philosophy is to evaluate the patient's anatomy while asking the question "does this procedure look like it is supposed to look?" In years past, our approach was different in that we, and many others, considered only major technical complications, like staple line disruption, to be of significance. Now we are considering the patient in a comprehensive manner evaluating their eating behavior and whether or not they still receive feedback from their surgical 'tool'. Patients who do not receive feedback from a primarily restrictive procedure such as gastroplasty, gastric bypass, or gastric banding are considered likely to have anatomic changes that have led to a suboptimal result. This hypothesis is further investigated by endoscopy and imaging studies as well as comprehensive behavioral evaluation. This information is collated and used to discuss treatment strategies and recommend options.

It is important to remember that, while bariatric surgery leads to complex physiologic changes including changes in gut hormones such as ghrelin, altered metabolic responses including a cancer-cachexia like syndrome, etc. revisional surgery is not undertaken to restore or augment these responses. Despite experience with many hundreds of revisional procedures, we do not know if these procedures manipulate the physiology. Our focus is on the traditional concepts of how bariatric surgery works, i.e., we manipulate restriction and/or malabsorption. It is important to approach a planned revisional intervention in these terms.

CANDIDATES

Patients seek out revisional bariatric surgery for a multitude of reasons, some because they have regained weight, some because they believe their surgery has failed, and some because they experience physical problems that they believe may be related to having bariatric surgery. [2] What is constant, is that nearly all the patients that come to see the bariatric unit are unsatisfied with their current weight and are looking for help to obtain a certain weight loss goal or improve current comorbidities. We primarily see patients with previous gastric bypass since that procedure has been performed open or laparoscopically in our region of the United States for the past 20 plus years. Therefore most of our review will cover our approach to the struggling gastric bypass patient and how we evaluate them.

EDUCATION

Patients start the process by calling our program and are scheduled to attend a bariatric revision seminar. They are then sent a packet of information and paperwork to fill out and return. In addition to a health questionnaire and release of medical information form used to obtain the initial surgery operative note, the paperwork they are asked to fill out also contains a revision testimonial in which we ask patients to describe in their own words why they feel they need a revision of their bariatric surgery. Bariatric revision seminars are held once per month and give patients general information on what to expect with the evaluation process,

types of testing performed, and surgical and non-surgical options for revisional bariatric surgery such as reversal, revision, conversion, and endoscopic procedures. Patients are also provided with information from our program dietician about the nutritional evaluation and key diet principles that bariatric patients should be aware of and follow. Patients are then scheduled for an initial evaluation with the bariatric surgeon.

INITIAL EVALUATION

During the initial evaluation appointment we take the patient's past bariatric history including what type of surgery was performed, what the approach was (open or laparoscopic), when the surgery was done, and who performed the surgery. We also want to know what their initial pre-operative weight was and the lowest weight they obtained post operatively. This is followed up by asking the patient if they experienced any post operative complications, if they still feel the effects of their surgery, if they ever had dumping syndrome, if they continue to have dumping syndrome now, and if they are currently experiencing symptoms of GERD. Often times, patients do not understand when asked if they feel the effect of their surgery and we have to go into further detail asking if they have any sense of restriction with eating, what types of foods they eat, and the quantity and quality of foods they are able to consume. We also often run across patients who do not know what dumping is or who were never educated post operatively on the type of diet they were expected to follow. It follows a common pattern that the further out patients are from initial surgery, the less likely they were to be educated on diet, exercise, side effects, and overall what was expected of them postoperatively. Another factor that is very common among patients seeking out revisional bariatric surgery is the lack of follow up that they had with their initial bariatric program. It would be safe to say that all of the patients we have seen seeking revision have had as little as a 2 year to as much as 25 year gap in follow up.

The most prominent reason for seeking revisional bariatric surgery in the patients we have seen is weight regain, but one patient's regain is not always the same as another. In the initial evaluation appointment we have to evaluate further the factors behind the weight regain. We have seen patients come in with as little as a 20 pound weight regain or patients who have regained past their preoperative weight (>100 lbs.). Another variable is the amount of time in which patients gained the weight. This can vary from less than 6 months to over 10 years.

Much of the time we find that the patient’s weight regain has resulted from behavioral factors, but even these can be variable. Some patients developed reactive hypoglycemia that was never diagnosed and are driven to eat whatever is available due to alarmingly low blood sugars. Maladaptive eating is a commonly seen issue among our patient population. Some patients have issues with strictures, marginal ulcers, or chronic nausea and vomiting leading them to eat foods that will easily pass through their pouch and gastrojejunostomy. However, more often than not, many patients are uncomfortable with the feeling of restriction from their initial surgery and try to eat foods that will bypass this restrictive sensation. We have met many patients who honestly believe something is wrong with their surgery because they have an uncomfortable feeling in their chest when they eat certain foods such as meat, bread, or pasta. We often have to remind the patient of the sensation of fullness they experienced in the

immediate post-operative period and relate that to what they are feeling now. Many realize that it is the exact same feeling and that they have been trying to avoid that feeling by eating "slider foods" and foods that will bypass the restrictive nature of their surgery.

ANATOMIC EVALUATION

At their initial evaluation appointment, patients are scheduled for three specific tests which are usually performed within the following 2-3 weeks. These consist of an endoscopic evaluation of the gastric anatomy, barium upper GI, and nutritional laboratory evaluation. If nutritional intake concerns were noted in the patient interview, nutritional evaluation with the dietician is required. For those patients with laparoscopic adjustable bands, an upper GI, to evaluate for band slippage, hiatal hernia, or esophageal dilation, and nutritional lab work is performed. Occasionally endoscopy is used to evaluate for band erosion, but that is often not necessary [3].

The endoscopy is performed by the bariatric surgeon to evaluate the patient's gastric anatomy. Precise measurement of the various key anatomic aspects of bariatric anatomy has been a challenge as we do not have adequate measuring tools such as stick/ruler that can be inserted and used to make measurements during the procedure. One such instrument was previously sold commercially but is no longer available. Currently, measurements are specifically taken during the endoscopy as to the distance from the patient's incisors to the level of the z-line and to the level of the gastrojejunostomy in order to estimate gastric pouch length. We attempt to determine if the pouch is long and narrow (cylindrical) or wide (spherical) in order to make approximate volume calculations. With narrow pouches we estimate pouch width to be the same as gastrojejunostomy diameter and estimate volume in cm^3 according to the formula for the volume of a cylinder, i.e., $\pi r^2 l$. We estimate the diameter of the gastrojejunostomy, typically be retroflexing the scope in the Roux limb and photographing the scope passing across the anatomosis. The scope diameter is used as an internal standard to allow us to estimate the anastomotic diameter, e.g., 2-fold, 3-fold, 4-fold, etc. versus scope diameter (10mm). The surgeon also evaluates the pouch for evidence of hiatal hernia, ulcers, or a gastrogastric fistula, and for potential afferent limb elongation.

A barium upper GI with air contrast is ordered with the additional request of ingestion of a barium tablet and barium meal ingestion at the end of the study. Patients are told to bring 6-8 ounces of cottage cheese with them to the study for preparation of the barium meal. A standard barium upper GI is performed followed by an evaluation using powdered barium mixed with the cottage cheese at a 1:1 concentration that the patient is asked to ingest until feeling full. While patients are often able to ingest between 4 and 6 ounces, sometimes up to 12 total ounces of the barium cottage cheese mixture are actually consumed. A final abdominal x-ray is performed to capture the volume and possible dilation of the pouch with the barium meal. We have tried chunky applesauce as an alternative for those patient that are unable to tolerate cottage cheese due to allergy, lactose intolerance, or refusal due to taste/texture, but the applesauce barium mixture appears to move too quickly through the pouch into the efferent limb before volume estimation can be obtained. There have also been several patients whose gastrojejunostomy was dilated to an extent that the barium cottage cheese mixture emptied too rapidly into the efferent limb and pouch volume estimation was

inaccurate. Overall, this test has been beneficial in providing information on GERD, presence of hiatal hernia, ulcer, possible esophageal dysmotility issues, gastric pouch enlargement and volume, gastrojejunostomy enlargement, and possible afferent limb syndrome due to elongation of the blind end of the Roux limb (candy cane) seen with side to side gastrojejunostomy anastomosis.

SURGICAL STRATEGIES

Patients are brought back into the office after the testing is completed to review their results and determine what options are available to them. If their anatomy is intact, then we refer them for nutritional counseling with our dietician to get back on track with healthy eating habits and continue to follow them on a regular basis for bariatric follow up [1-4].

Patients are treated on an individual basis and plans are made with each patient depending on what was found during testing. Many patients are found to have a sliding hiatal hernia, a dilated gastric pouch, or a dilated gastrojejunostomy and frequently some combination of the 3 is found. At times, additional testing is necessary to determine a course of action for the patient. If significant GERD symptoms are found, esophageal manometry testing may confirm that the lower esophageal sphincter is hypotensive. In that case hiatal hernia repair and modified Dor, Toupet, or Nissen fundoplication may be performed with the degree of fundoplication decided during surgery depending on the technical issues found. Hiatal repair with fundoplication has also proved to be a valuable intervention in American patients whose individual health insurance does not cover any further bariatric treatments as the diagnosis being treated by this intervention is gastroesophageal reflux disease. Patients presenting combination of a dilated gastric pouch and dilated gastrojejunostomy usually continue with the evaluation process for the potential of complete revision of their gastric bypass versus laparoscopic adjustable band placement over their existing bypass. Those patients with dilated gastrojejunostomy alone are considered for revision versus endoscopic plication of the gastrojejunostomy. In laparoscopic band patients suffering significant symptoms of excessive restriction with reflux and typical findings on upper GI the band is often completely deflated in the office. Mostly these patients choose to continue with evaluation for conversion to sleeve gastrectomy or roux-en-y gastric bypass.

BEHAVIOR MODIFICATION

As most patients have regained some amount of weight, whether it be due to maladaptive eating, hypoglycemia, or old habits returning, we require all patients to go through a nutritional evaluation with our dietician. Even if the patient's insurance company does not require a weight loss trial, we will often require patients to complete a minimum of 3 months in a weight loss class to relearn healthy eating habits and behaviors. We have come to require that a patient desiring surgical intervention for weight regain in the absence of a surgical complication must demonstrate a 10% total body weight loss during this time to confirm compliance and behavior change. Healthy eating habits and behaviors are essential for a

successful revisional bariatric surgery, and patients are informed that their compliance with diet and exercise is essential in order to achieve positive results.

SUMMARY

Overall weight loss is less with revisional bariatric surgery and requires more effort on the patient's behalf. Patient selection for bariatric revisional surgery is key for both patient and programmatic success. With a multidisciplinary team and good communication between the patient and that team, success is possible.

REFERENCES

[1] Brethauer SA, Kothari S, Sudan R, Williams B, English WJ, Brengman M, Kurian M et al. Systematic review on reoperative bariatric surgery: American Society for Metabolic and Bariatric Surgery Revision Task Force. *Surg. Obes. Relat. Dis*. 2014;10:952-72.

[2] Johnson WH, Fernanadez AZ, Farrell TM, Macdonald KG, Grant JP, McMahon RL, Pryor AD, Wolfe LG, DeMaria EJ. Surgical revision of loop ("mini") gastric bypass procedure: multicenter review of complications and conversions to Roux-en-Y gastric bypass. *Surg. Obes. Relat. Dis.* 2007;3:37-41.

[3] Kellogg TA. Revisional bariatric surgery. *Surg. Clin. North Am.* 2011;91:1353-71.

[4] Zundel N, Hernandez JD. Revisional surgery after restrictive procedures for morbid obesity. *Surg. Laparosc. Endosc. Percutan. Tech*. 2010;20:338-43.

In: Encyclopedia of Surgery (22 Volume Set)
Editors: Andreas Lehrer and Kristin Mueller
ISBN: 978-1-53618-329-0
© 2020 Nova Science Publishers, Inc.

Chapter 52

METABOLIC FAILURES AND BARIATRIC PROCEDURES

Pedro Paulo Caravatto*, Tarissa Zanata Petry and Ricardo Cohen
Center for Obesity and Diabetes, Hospital Alemão Oswaldo Cruz,
São Paulo, Brazil

ABSTRACT

There is an increasing body of evidence that bariatric surgery leads to higher remission rates of type 2 diabetes mellitus (T2DM) than any other medical treatment or lifestyle intervention. Several trials published so far comparing the effect of bariatric surgery and best medical treatment on diabetic obese patients have shown that T2DM reached up to 75-80% at the end of the study in the surgical group, although most studies have shown a relatively short period of follow-up.

There is no doubt that bariatric procedures, primarily Roux-en-Y gastric bypass, are more effective at inducing T2DM remission. However, there is a lack of information regarding long-term results for disease control. In this chapter, the authors present long-term results of bariatric surgery over metabolic diseases remission.

INTRODUCTION

During the past decades, the number of individuals with type 2 diabetes (T2DM) in the United States (U.S.) has more than doubled, showing that we are in the midst of an epidemic. Approximately 25.8 million Americans were diagnosed with diabetes (nearly 8.3% of the population), and by 2050 as many as one in three U.S. adults could have diabetes [1-2]. Furthermore, T2DM is the leading cause of kidney failure, non-traumatic lower-limb amputations, coronary heart disease, stroke, and visual impairments among adults in the U.S. [3].

* Corresponding Author's Email: pcaravatto@haoc.com.br.

Aside from high morbidity and premature mortality, T2DM imposes a substantial burden on the economy because of its significant medical costs and indirect costs that are the result of work absenteeism, reduced productivity and unemployment from chronic disability. In 2012, the American Diabetes Association (ADA) estimated that the total national cost of diabetes in the U.S. was $245 billion, of which more than 70% represented direct health expenditures [1]. This represents a 41% increase when compared to a previous estimate published in 2008 [4]. In addition, there has been a significant increase in health resources usage by people with diabetes. For example, diabetics incur approximately 25% of all U.S. hospital inpatient days, almost one third of all nursing/residential facilities days, and around half of all physician office, emergency department, and hospital outpatient visits. An even worse scenario is reported when analyzing data for a specific age, in particular the elderly [1]. For these reasons, it is estimated that health expenditures for diabetics are 2.3 times higher than they would be in the absence of T2DM.

Prospective longitudinal studies have shown that bariatric surgery is the most effective intervention for obesity and its associated diseases, in particular T2DM, reducing the long-term mortality rate of morbidly obese patients when compared to clinical treatment [5-6].

The improvement of metabolic control in bariatric patients was observed as early as days or weeks after surgical procedure, long before considerable weight loss occurred, indicating a direct anti-diabetic effect of the procedure. Consequently, some operations began to be considered as an option to treat less obese patients with uncontrolled T2DM [7]. As expected, good results regarding metabolic control were obtained in this patient group without significant weight loss, particularly after Roux-en-Y gastric bypass (RYGB) [8-9]. Treatment goals are outlined in Table 1. Nonetheless, only limited information is available regarding long-term effects, recurrence or worsening of metabolic diseases years after surgery, and factors associated with their re-emergence.

Table 1. Treatment goals for T2DM patients

Partial remission	Complete remission
At least 1 year's duration	At least 1 year's duration
No active pharmacologic therapy or ongoing procedures	No active pharmacologic therapy or ongoing procedures
HbA1c < 6.5%	HbA1c 4.5 – 6%
FPG 100 – 125 mg/dL	FPG < 100 mg/dL
Secondary goals include: LDL < 100 mg/dL and blood pressure < 130x80 mmHg	

*HbA1c – glycated hemoglobin.
FPG – fasting plasma glucose.
LDL – low-density lipoprotein.

EFFECTS IN TERMS OF GLYCEMIC CONTROL

We recently published the largest and longest-term study to date to examine the safety and efficacy of RYGB in T2DM patients with BMI between 30 and 35 kg/m^2. All patients were followed from 1 to 6 years (median 5 years). Main outcomes were safety and T2DM remission, defined as glycated hemoglobin (HbA1c) < 6.5% without medication. All patients had uncontrolled T2DM, despite appropriate lifestyle modifications and use of antidiabetic

medications including or not insulin for at least 1 year. Mean pre-op HbA1c was 9.7% and mean duration of disease was 12.5 years.

T2DM remission was observed in 88% of patients, with a significant reduction of HbA1c (9.7 to 5.9%), despite diabetes medication cessation in the majority of cases.

Improvement of diabetes (HbA1c < 7% with lower doses of oral diabetes medications and no insulin) was achieved in 11% of patients. Only one patient in the entire cohort had no changes in diabetes evolution. All patients experienced significant weight loss at 5 years, however there was no correlation between the amount of weight loss and levels of fasting plasma glucose or HbA1c for the first 5 years.

Beta cell function significantly improved as measured by C-peptide response to glucose load. No mortality, major surgical complication or massive weight loss were reported [9].

At 8 years follow-up, 11 (16.5%) patients with previous T2DM remission were back on antidiabetic drugs, 10 were using metformin alone and 1 patient was using a combination of vildagliptin and metformin. There was no correlation between T2DM recurrence and weight regain. Excess weight loss at 8 years was 69% for this series.

During hospital admission and after discharge, all patients had their T2DM managed according to the following protocols adopted by our institution (Tables 2, 3 and 4).

Table 2. Management of T2DM in the perioperative care (NPO status)

BLOOD GLUCOSE (mg/dL) FROM	BLOOD GLUCOSE (mg/dL) TO	INSULIN (UI)	IV GLUCOSE (g)	ACTION
0	69		10	IV glucose G50% 20mL Capillary blood glucose: 6am, 12pm, 6pm and 12am
180		9		Long-acting insulin once a day
70	99	0		Fast-acting insulin
100	149	0		Fast-acting insulin
150	199	1		Fast-acting insulin
200	249	3		Fast-acting insulin
250	299	5		Fast-acting insulin
300	349	7		Fast-acting insulin
350		8		Fast-acting insulin

A retrospective analysis by Di Giorgi et al. reporting on 42 post RYGB diabetic patients with a medium follow-up of 3 years showed resolution of diabetes in 64% at 6 months, while all patients had their diabetes improved. Pre-operative data showed that mean BMI was 51.4 kg/m^2 and 34% of the participants were using insulin. At 3 years diabetes recurrence was experienced by 26% of patients with initial resolution and by 20% of patients with initial improvement. This group had lower preoperative BMI compared to those who did not recur. Such findings were not observed in our series, where correlation to weight regain was not observed [10].

Table 3. In-hospital management of T2DM in postoperative care (patients in liquid diet)

1. Metformin 2 g per day (optimized)				
2. DPP4 inhibitors				
BLOOD GLUCOSE (mg/dL) FROM	*BLOOD GLUCOSE (mg/dL) TO*	*INSULIN (UI)*	*IV GLUCOSE (g)*	*ACTION*
0	69		10	IV glucose G50% 20mL
180		*		Capillary blood glucose before breakfast, lunch, dinner and before 10 pm Long-acting insulin once a day (bed-time)
70	99	5		Fast-acting insulin before breakfast, lunch and dinner
100	149	6		Fast-acting insulin before breakfast, lunch and dinner
150	199	7		Fast-acting insulin before breakfast, lunch and dinner
200	249	9		Fast-acting insulin before breakfast, lunch and dinner
250	299	11		Fast-acting insulin before breakfast, lunch and dinner
300	349	13		Fast-acting insulin before breakfast, lunch and dinner
350		14		Fast-acting insulin before breakfast, lunch and dinner
(*) If patient is under insulin treatment prior to surgery, reintroduce 50-70% usual dose of insulin and titrate according to fasting capillary blood glucose (target < 120 mg/dL) and postprandial capillary blood glucose (target < 180 mg/dL)				

* DPP4 - dipeptidyl peptidase 4.

Table 4. Outpatient T2DM management (long-term follow-up)

1. Metformin 2 g per day (optimized)
2. DPP4 inhibitors
3. Insulin If patient is under insulin treatment prior to surgery, maintain same dose used at hospital discharge and titrate according to fasting capillary blood glucose (target < 120 mg/dl) and postprandial capillary blood glucose (target < 180 mg/dl). Clinical practice shows that it usually takes 21 days to withdraw insulin therapy in patients with preserved beta cell function.

* DPP4 - dipeptidyl peptidase 4.

Chikunguwo et al. retrospectively studied 177 patients with T2DM who had undergone RYGB. Patients were followed-up from 5 to 16 years (mean 8.6 years). Complete T2DM remission was observed in 88.7% patients, but 43.3% recurred. In this study, T2DM recurrence was correlated with weight regain. The authors found that percentage of weight

loss, gender, age and severity of T2DM were independent predictors of recurrence. Strongest predictors were insulin therapy and gender [11].

EFFECTS IN TERMS OF LIPIDS CONTROL AND CARDIOVASCULAR OUTCOMES

Metabolic surgery benefits that go beyond glucose control include a positive effect on lipid profile. Increases in high-density lipoprotein (HDL) cholesterol have already been reported one year after RYGB [12, 13], however data are still limited to non-controlled studies in morbidly obese patients. Although the actual role played by HDL in the reduction of cardiovascular risk is still unclear [14], there is some evidence that increase in HDL is associated with a reduced progression of atherosclerosis and hence better cardiovascular outcomes, which constitutes a major benefit from metabolic surgery [15, 16].

We examined other cardiovascular risk factors in diabetic patients with low BMI submitted to RYGB and found that hypertension resolved in 58%, hypercholesterolemia in 64%, and hypertriglyceridemia in 58%. For the entire cohort, mean blood pressure progressively decreased over the course of six years [9]. There was also a significant improvement over the six years in lipid parameters, with progressive reductions in total cholesterol, LDL cholesterol and triglycerides, and increase in HDL cholesterol. These changes led to a 10-year decrease in fatal and non-fatal stroke and myocardial infarction numbers.

Other studies have shown beneficial effects of gastric bypass on diabetes and reduced mortality from heart disease in morbidly obese subjects [16, 17]. A recent report from the Swedish Obese Subjects (SOS) study [18] demonstrated the reduction of myocardial infarction incidence in obese diabetic patients following bariatric surgery. We reported the favorable outcomes of metabolic surgery in low BMI patients that go beyond glycemic control, as indicated by the substantial reductions in hypertension and dyslipidemia, yielding major improvements in predicted CV risk. Our results are similar to small, observational studies from India, China and South America [19, 20, 21], although follow-up in these studies was relatively short.

WHAT IS THE ROLE OF WEIGHT LOSS IN THE INCIDENCE OF CARDIOVASCULAR EVENTS?

Lifestyle interventions to prevent T2DM have not avoided cardiovascular events, including in long-term follow up [22, 23]. Sjostrom et al. [15], in the Swedish Obese Subjects study, a non-randomized prospective study, concluded that, compared to usual care, bariatric surgery leads to a reduced number of cardiovascular events and deaths. One of the most important findings in the Swedish study was the lack of correlation between BMI and cardiovascular mortality and/or events. And, conversely, a positive correlation with fasting plasma insulin levels. The Look AHEAD study [24] showed that intensive lifestyle modification may induce significant improvements in intermediate health indicators, such as body weight, fitness, blood pressure, glycemic control, and lipids. These improved risk factor

profiles, however, did not translate into lower rates of non-fatal myocardial infarction, non-fatal stroke, hospitalization for angina, or death compared with conventional diabetes treatment [25]. Look AHEAD found that people who are obese and suffer from T2DM can lose weight and maintain weight loss with a lifestyle intervention. Although the study found that weight loss had many positive health benefits for patients with T2DM, it did not reduce the number of cardiovascular events. Evidence is increasing that metabolic surgery is more effective than medical or lifestyle interventions for weight loss and diabetes remission. In a recent analysis by Arterburn et al. [26] of severely obese patients with diabetes, the adjusted probability of initial remission was 12 to 24 times greater for the 1395 patients who had bariatric surgery than for the 62322 who received usual medical care alone.

In a recent editorial, the same author [27] stated that the benefits of intensive lifestyle treatment for T2DM were more prominent in patients with early stage diabetes, similar to what was reported in bariatric surgery, showing better results in milder, earlier stage disease. Consequently, a strong argument can be made for considering earlier surgical intervention in moderately obese patients (BMI <30 kg/m^2) with early stage diabetes, in particular in those with severe insulin resistance, higher cardiovascular risk and uncontrolled disease. This argument backs up the 2011 International Diabetes Federation (IDF) statement on new perspectives on surgical treatment of uncontrolled T2DM in patients with BMIs between 30 and 35 kg/m^2 [28].

Timing of metabolic surgery is of the utmost importance for T2DM remission. In a retrospective study, Arterburn et al. [27] found that almost 35% of the patients who went into remission following RYGB redeveloped T2DM within five years of surgery. Predictor factors were poor preoperative glycemic control, insulin use and longer diabetes duration, indicating that the earlier the intervention takes place the better [26]. From the above, one may conclude that the Look AHEAD study fundamentally shows that weight loss does not appear to reduce T2DM-associated cardiovascular disease, but rather enhances the benefit of interventions aimed at improving diabetes (diet, surgery etc.).

IS THERE A SURGICAL TREATMENT OPTION FOR PATIENTS WITH TYPE 2 DIABETES RECURRENCE?

Over recent years, the aim of metabolic/bariatric surgery has changed from weight loss only to metabolic control. So far, there is no recognized definition of what constitutes failure of metabolic surgery, much less an accepted standard of care for patients who fall into this category.

Table 5. Definitions for T2DM recurrence

Partial recurrence	Complete recurrence
HbA1c 6.5-7%, but higher than lowest level reported after surgery	HbA1c > 7% and higher than lowest level reported after surgery
Addition of 1 oral antidiabetic agent	Addition of 2 or more oral antidiabetic agents and/or insulin

*HbA1c – glycated hemoglobin.

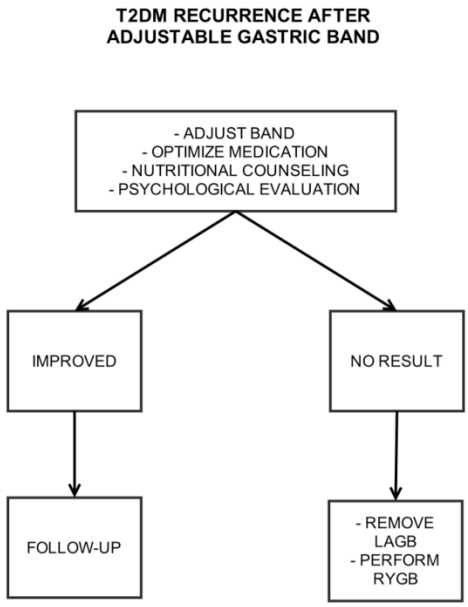

Figure 1. T2DM recurrence after laparoscopic adjustable gastric band (LAGB).

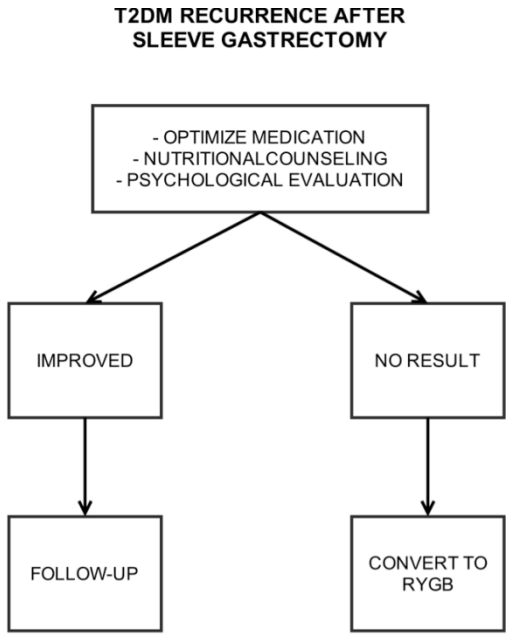

Figure 2. T2DM recurrence after sleeve gastrectomy.

Arterburn et al. proposed the following criteria for T2DM relapse after bariatric/metabolic surgery. One or more of the following conditions should be fulfilled: (a) restarting diabetes medication; (b) one or more HbA1c readings ≥ 6.5%; and/or (c) one or more fasting glucose values ≥ 126 mg/dl [26]. Interestingly, the authors examined the T2DM relapse rate only among subjects who initially experienced a diabetes remission after surgery (partial or complete).

In this chapter, we propose new criteria for patients who do not fall into the remission category but who had their metabolic conditions improved after surgery and, for unknown reasons, later experienced worsening of their metabolic status. These patients should be considered as suffering from T2DM recurrence (and not relapse), and may be divided into two categories (Table 5).

Patients with T2DM recurrence may be candidates for revisional surgery after optimized clinical treatment (Figures 1, 2, 3).

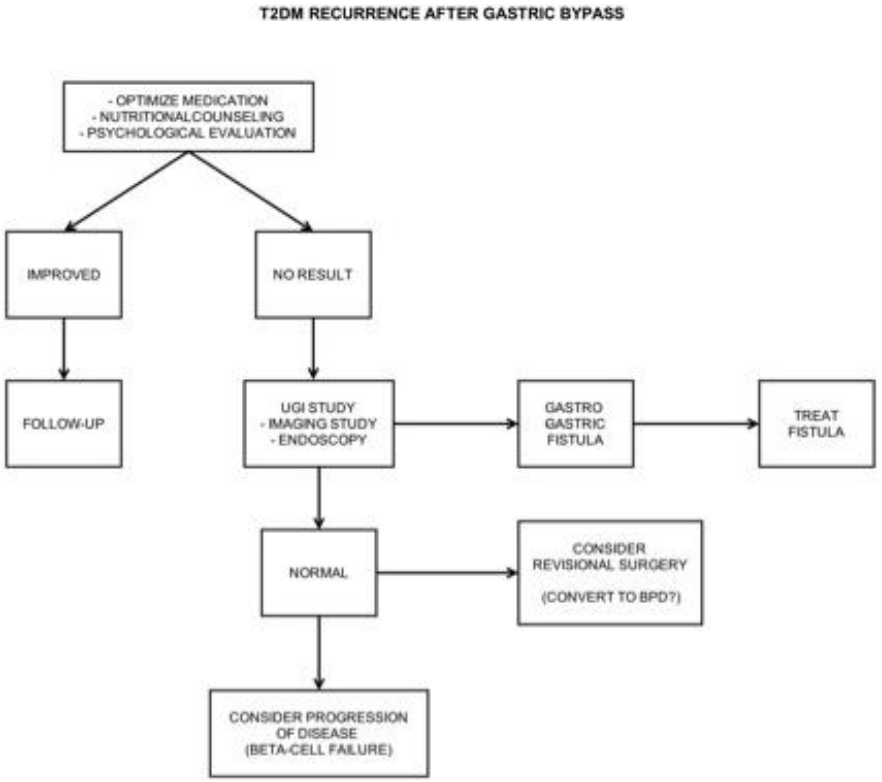

Figure 3. T2DM recurrence after gastric bypass.

CONCLUSION

When offering surgical treatment aiming at durable diabetes remission, patient selection and counseling are of the utmost importance. We found that patients with a longer history of diabetes and those under insulin treatment were more likely to relapse than those who were not using insulin or who had had diabetes for less than 10 years. However, not all patients receiving insulin failed to achieve diabetes remission. An earlier surgical intervention clearly appears to be preferable. However, more severely affected and insulin-dependent diabetic patients may benefit from surgery as well, since these patients, although unable to interrupt diabetic medication, may experience improvement in retinopathy, nephropathy, and other diabetes-related conditions. Furthermore, these patients may benefit from a significant improvement in quality of life and experience remission of other metabolic diseases. It is also

believed that an aggressive glycemic control may induce beneficial "metabolic memory" – be it transiently – as reported in the UKPDS study, and reduce the incidence of microvascular complications [29]. Therefore, patients with T2DM recurrence after metabolic surgery may still continue to experience reduced microvascular and macrovascular complications in the long-term when compared to those who never had their disease controlled.

REFERENCES

[1] American Diabetes Association. Economic Costs of Diabetes in the U.S. in 2012. *Diabetes Care* 2013, 36:1033-46.

[2] Boyle JP, Thompson TJ, Gregg EW, Barker LE, Williamson DF. Projection of the year 2050 burden of diabetes in the US adult population: dynamic modeling of incidence, mortality, and prediabetes prevalence. *Popul. Health Metr* 2010, 8: 29.

[3] Lebovitz HE. Science, clinical outcomes and the popularization of diabetes surgery. *Current Opinion in Endocrinology, Diabetes and Obesity* 2012, 19: 359–66.

[4] American Diabetes Association. Economic costs of diabetes in the U.S. in 2007. *Diabetes Care* 2008; 31: 596–615.

[5] Sjöström L, Lindroos A-K, Peltonen M et al. Lifestyle, diabetes and cardiovascular risk factors 10 years after bariatric surgery. *New Engl. J. Med.* 2004, 351: 2683-93.

[6] Sjöström L, Narbro K, Sjöström CD et al. Effects of bariatric surgery on mortality in Swedish obese subjects. *New Engl. J. Med.* 2007, 357: 741-52.

[7] Rubino F. Is type 2 diabetes an operable intestinal disease? A provocative yet reasonable hypothesis. *Diabetes Care* 2008, 31: S290-6.

[8] Schauer PR, Burguera B, Ikramuddin S et al. Effect of laparoscopic Roux-en Y gastric bypass on type 2 diabetes mellitus. *Ann. of Surg.* 2003, 238: 467–84.

[9] Cohen RV, Pinheiro JC, Schiavon CA et al. Effects of gastric bypass surgery in patients with type 2 diabetes and only mild obesity. *Diabetes Care* 2012, 35: 1420–8.

[10] DiGiorgi M, Rosen D J, Choi J J, et al. Re-emergence of diabetes after gastric bypass in patients with mid- to long-term follow-up. *Surg. Obes Relat. Dis.* 2010; 6: 249-53.

[11] Chikunguwo S M, Wolfe L G, Dodson P, et al. Analysis of factors associated with durable remission of diabetes after Roux-en-Y gastric bypass. *Surg. Obes. Relat. Dis.* 2010; 6: 254-9.

[12] Kim S, Richards WO. Long-term follow-up of the metabolic profiles in obese patients with type 2 diabetes mellitus after Roux-en-Y gastric bypass. *Ann. Surg.* 2010; 251: 1049-55.

[13] Asztalos BF, Swarbrick MM, Schaefer EJ, et al. Effects of weight loss, induced by gastric bypass surgery, on HDL remodeling in obese women. *J. Lipid Res.* 2010; 51: 2405-12.

[14] Voight BF, Peloso GM, Orho-Melander M, et al. Plasma HDL cholesterol and risk of myocardial infarction: a Mendelian randomisation study. *Lancet* 2012; 380: 572-80.

[15] Sjöström L, Peltonen M, Jacobson P, et al. Bariatric surgery and long-term cardiovascular events. *JAMA* 2012; 307: 56–65.

[16] Adams TD, Gress RE, Smith SC et al. Long-term mortality after gastric bypass surgery. *N. Engl. J. Med.* 2007; 357: 753-61.

[17] Carlsson LM; Peltonen M, Ahlin S et al. Bariatric surgery and prevention of type 2 diabetes in Swedish obese subjects. *N. Engl. J. Med.* 2012; 367: 695-704.

[18] Romeo S, Maglio C, Burza MA, et al. Cardiovascular events after bariatric surgery in obese subjects with type 2 diabetes. *Diabetes Care* 2012; 35: 2613-7.

[19] Shah SS, Todkar JS, Shah PS, et al. Diabetes remission and reduced cardiovascular risk after gastric bypass in Asian Indians with body mass index <35 kg/m^2. *Surg. Obes. Relat. Dis.* 2010; 6: 332–8.

[20] Cohen R, Caravatto PP, Correa JL, et al. Glycemic control after stomach-sparing duodenal-jejunal bypass surgery in diabetic patients with low body mass index. *Surg. Obes. Relat. Dis.* 2012; 8: 375–80.

[21] Schauer PR, Kashyap SR, Wolski K et al. Bariatric surgery vs. intensive medical therapy in obese patients with diabetes. *New Engl. J. Med.* 2012, 366: 1567-76.

[22] Yamaoka K, Tango T. Efficacy of lifestyle education to prevent type 2 diabetes: a meta-analysis of randomized controlled trials. *Diabetes Care* 2005; 28: 2780–6.

[23] Li Q, Chen L, Yang Z, et al. Metabolic effects of bariatric surgery in type 2 diabetic patients with body mass index <35 kg/m^2. *Diabetes Obes Metab.* 2011; 14: 262–70.

[24] Look AHEAD Research Group, Wing RR. Long-term effects of a lifestyle intervention on weight and cardiovascular risk factors in individuals with type 2 diabetes mellitus: four-year results of the Look AHEAD trial. *Arch. Intern. Med.* 2010, 170: 1566– 75.

[25] Gregg EW, Chen H, Wagenknecht LE et al. Association of an intensive lifestyle intervention with remission of type 2 diabetes. *JAMA* 2012; 308: 2489–96.

[26] Arterburn D, Bogart A, Coleman KJ et al. Comparative effectiveness of bariatric surgery vs. nonsurgical treatment of type 2 diabetes among severely obese adults. *Obes Res Clin Pract* 2013, 7: e258-68.

[27] Arterburn DE, O'Connnor PJ. A look ahead at the future of diabetes prevention and treatment. *JAMA* 2012, 308: 2517-9.

[28] Dixon JB, Zimmet P, Alberti KG, Rubino F. Bariatric surgery: an IDF statement for obese Type 2 diabetes. *Diabet. Med.* 2011, 28: 628-42.

[29] Murray P, Chune GW, Raghavan VA. Legacy effects from DCCT and UKPDS: what they mean and implications for future diabetes trials. *Curr. Atheroscler Rep.* 2010; 12:432–9.

In: Encyclopedia of Surgery (22 Volume Set)
Editors: Andreas Lehrer and Kristin Mueller
ISBN: 978-1-53618-329-0
© 2020 Nova Science Publishers, Inc.

Chapter 53

DIAGNOSTIC TOOLS IN FAILED BARIATRIC PROCEDURES

Rudolf Weiner[1,*], MD, PhD, Islam A. El-sayes[1,†], MD and Sylvia Weiner[2,‡], MD

[1]Center for Surgery for Obesity and Metabolic Diseases
(Center of Excellence)
Universitary Hospital Sana Klinikum Offenbach,
Clinic for Obesity and Metabolic Surgery, Starkenburgring,
Offenbach am Main, Germany
[2]Department for General, Visceral and Minimally Invasive Surgery
Krankenhaus Nordwest, Frankfurt am Main, Germany

ABSTRACT

Worldwide, there is an evident increase in the incidence and accordingly in the prevalence of obesity. Current estimates postulate that the incidence of obesity will reach about 40% of the adult population by the year 2030. Importantly, developing countries do not seem to be immune against this epidemic. Accordingly, the worldwide performance of bariatric procedures is showing a corresponding yearly increase. Recent procedures such as sleeve gastrectomy are currently replacing old standard techniques. The increase in bariatric surgery numbers is unfortunately associated with complications that cannot be under estimated and that have been reported with all procedures. That is why timely diagnosis and management of these complications is an integral part of bariatric practice. Complications or (failures) can be broadly divided in early and late complications. Although readily reported, failure does not have a standardized definition. Gastric band has a special foreign body-associated nature and will therefore be separately discussed.

* Corresponding Author's Email: profweiner@gmail.com.
† Corresponding Author's Email: islam_sayes@yahoo.com.
‡ Corresponding Author's Email: sylvia.weiner@gmx.de.

Acute failures or complications can be detected through reliable clinical symptoms and signs summarized in this chapter. Radiological studies and diagnostic laparoscopy are essential diagnostic and therapeutic tools.

Late complications or failures will be thoroughly discussed. Standardized techniques play the main role in the diagnosis of failure after bariatric intervention. These techniques can be implemented in all procedures. All these techniques will be discussed with their possible pros and cons. Diagnostic techniques include: radiological studies, endoscopy and diagnostic laparoscopy. Radiological studies include for example contrast-enhanced upper GI series, computed tomography and three-dimensional tomographic reconstructions. The role of endoscopy and diagnostic laparoscopy will also be highlighted.

INTRODUCTION

In 2005, 23.2% (937 million) of the world's adult population was overweight, and 9.8% (396 million) was obese. According to current projections, from 2005 to 2030 the number of overweight individuals will increase by 44%, to reach a total of 2.16 billion, corresponding to 38% of the world's adult population [1]. During the same interval, the number of obese individuals will increase by 45% to reach a total of 1.12 billion (20% of the world's adult population). In 2005, the prevalence of overweight was higher in economically developed countries compared to developing countries (35.2 vs 19.6%). Similarly, the prevalence of obesity was higher in developed countries compared to developing ones (20.3 vs 6.7%). However, growth in population size, aging, and urbanization of lifestyle will all contribute to an epidemic of overweight and obesity in developing regions in the next few decades [1]. This overwhelming increase in the prevalence of morbid obesity with its associated comorbidities pushed institutions worldwide to search for new minimally invasive modalities to face this epidemic. Over the past years, standard procedures like biliopancreatic diversion (BPD), duodenal switch (DS), gastric banding (LAGB), and Roux-en-Y gastric bypass (RYGB) established their position in the armamentarium of bariatric procedures. Other procedures such as sleeve gastrectomy and mini-gastric bypass are also partially replacing old standard procedures. More recently, newer surgical as well as endoscopic bariatric procedures started to compete with these standard procedures.

However, this increasing number of performed bariatric interventions does not come without complications, either acute early complications or late complications (failures) [2]. Unsatisfactory gastrointestinal manifestations were reported in 16.9% of patients who underwent RYGB, 7.8% of LAGB and 37.7% of BPD patients [2]. Reflux was reported by 10.9% of RYGB, and 4.7% of LASGB patients. Stomal stenosis was present in 4.6% of RYBG patients. Even sleeve gastrectomy, although one of the most recent procedures, suffers failures and complications as reported in many reviews [3, 4]. These complications attributed to bariatric interventions may be indications for operative revisions. In addition to these (anatomical) failures, another very important cause of failure indicating revision is weight gain after bariatric intervention. Some reports postulated that the most common cause for revision after a bariatric intervention is weight regain or insufficient primary weight loss after the intervention [5, 6]. Gagner reported that weight regain was the main cause of re-operation in about 90% of patients in his series [6]. The consideration of an intervention as failing needs

an adequate definition and a standardized diagnostic approach in order to correctly diagnose and then treat a failure when it occurs.

DEFINITION OF A FAILED BARIATRIC PROCEDURE

Controversy exists regarding the definition of a failed bariatric procedure. The wide spectrum of bariatric procedures performed worldwide and the lack of standardized criteria to define success or satisfactory outcome following a procedure plays a role. Another factor is the variation in the expected weight loss results following each procedure. Baltasar in a recent meta-analysis proposed that sleeve gastrectomy achieves the greatest mean BMI reduction (12-17 units) while gastric banding produces the least satisfactory outcome in terms of weight loss [7].

Another factor leading to the lack of definition of failure is the indication for revision after a (possibly) failed procedure. Failure or revision after most procedures is mainly due to inadequate weight loss. In the specific field of LAGB migration or slippage are important indications contributing to the consideration of gastric band as a (failed) procedure. This issue has been addressed in a recent systematic review by Mann and his colleagues [8]. Although Body Mass Index Loss is the most accurate interpretation tool for a successful or a failed procedure, still other indices are being used by other authors, for example percentage of total body weight, or change in BMI [8, 9].

The most frequent cited definition for failure after bariatric surgery as reported by Mann et al. was: <50% of excess weight lost (EWL), with or without residual BMI of greater than 35 kg/m^2, at 18 months post-operation.

The second most frequently cited definition was: <25% of excess weight lost (without a time-frame specified). However, in all the reviewed studies, there was surprisingly no comment on the effect of the primary procedure on the associated metabolic status of the patient. Consequently, remission or persistence of the associated primary metabolic impairment (diabetes and hypertension in the first place) was not listed as factor in assessing whether this procedure was successful or failed.

Additionally, most of the reviewed studies failed to report the selection criteria for failure. In our opinion, factors such as patient dissatisfaction with the procedure, food intolerance, and impairment of a healthy life style should also be part of the consideration of the procedure as a failed procedure.

In summary, a consensus for standardization of the definition of failure after bariatric procedure is still lacking.

SPECTRUM OF FAILURE OF A BARIATRIC PROCEDURE

A pitfall in most currently implemented definitions for a failed procedure is, in our opinion, the concentration on a long-term failure, and ignoring the acute or short-term failure. A failed procedure is also a procedure which can, in the early post-operative course, be associated with complications. Accordingly, early leakage or bleeding should also be counted as acute failures and should be timely and thoroughly diagnosed and accordingly managed.

Hence, we would like to classify failures broadly as: acute failures (can also be referred to as: acute complications) and long-term failures.

ACUTE FAILURE, DIAGNOSIS AND POSTULATED ALGORITHM (FOR ALL PROCEDURES OTHER THAN GASTRIC BANDING)

To be considered successful a bariatric intervention requires thorough understanding of the associated anatomical and physiological changes. Consequently it is preferably performed by a highly experienced team, that can diagnose and timely manage any deviation from the normal postoperative course. Otherwise, potentially devastating outcomes may occur. Recent data from the USA have reported postoperative complication rates ranging between 2.2-10.8 percent [10-12]. Retrospective analysis of our unit's data revealed an early postoperative morbidity rate of 7.1 percent [13].

Early postoperative failure includes, primarily, leakage and bleeding. In order to prevent and timely manage these events, a triad of adequate preoperative preparation, adoption of standardized operative technique and meticulous postoperative care is strongly recommended. During the early postoperative phase, persistent unexplained tachycardia of more than 100 beats/min, fever (≥38.5°C), abdominal pain, tachypnea (>20 breaths/min) or decreased urinary output despite good hydration must induce a high index of suspicion. Laboratory findings of C-reactive protein (CRP) >150 mg/L, leukocytosis >11,000 cells/ml or a drop in plasma hemoglobin of more than 2 gram/dl also suggest the development of complications.

We recommend CRP level and complete blood count to be routinely checked on the first and fifth postoperative day. Diagnostic radiological and endoscopic tools should also be readily available but they are not routinely used in uncomplicated cases. In our center, all patients are discharged on the fifth postoperative day, as long as the postoperative course is smooth. Our experience suggests that postoperative hospital stay of up to five days ensures adequate perioperative patient assessment, unless postoperative complications necessitating a prolonged hospital stay are encountered.

Accurate diagnosis and timely management of acute failure of a bariatric intervention can be highly challenging. Particular care must be given to this high-risk patient group, where results of laboratory parameters may be misleading. Reliable clinical evaluation and interpretation of radiological studies pose another challenge. Thus, diagnosis and management of post-operative complications require an integrated teamwork approach that analyzes the triad of clinical suspicion, altered laboratory profile and abnormal radiological studies. More importantly, to date, we lack a consensus for sound management of those complications.

HOW TO DIAGNOSE A POSSIBLE EARLY COMPLICATION?

1. Laboratory Parameters

Routine postoperative check of patient's laboratory profile (full blood count and CRP) should be a standard practice. Any deviation from the normal values should be strictly

monitored. CRP and leukocyte count play a major role in the early detection of postoperative complications, especially staple line disruption and leakage [14] Analysis of our data showed that elevated CRP and leukocytosis were detected in 18 patients (36.5 percent) out of 49 patients and 31 patients (47%) out of 66 patients with early complications after RYGB and sleeve gastrectomy respectively, including 19 patients (86.3%) and 12 patients (100 percent) who developed early postoperative leakage after those procedures [13].

Postoperative check of hemoglobin level is also mandatory. A drop of more than two grams/dl should warrant further work up, especially if combined with tachycardia, evidence of gastrointestinal bleeding or excessive bloody drain effluent.

2. Clinical Symptoms and Signs

Abdominal pain, nausea and vomiting requiring excessive analgesic or antiemetic treatment should raise the suspicion of possible complications. Hypotension, tachycardia, fever, tachypnea, dyspnea, low urinary output and abnormal color or increased volume of drain effluent should also be handled with a high index of suspicion [15]. Additionally, hematemesis or melena raise the suspicion of staple line bleeding. To date, the sensitivity and specificity of these parameters have not been well studied. Tachycardia seems to be correlated with the highest sensitivity and specificity amongst the other parameters [16, 17]. In our center, tachycardia was found in five patients (42%) and seven patients (37%) who developed early post-operative leakage and bleeding respectively [13].

3. Radiological Studies

Extravasation of gastrointestinal contents can be diagnosed radiologically by contrast-enhanced computed tomography (CT) scans with oral contrast (Figure 1a) or by gastrograffin swallow studies (Figure 1b).

The presence of an abscess cavity, air foci (Figure 1a) in the vicinity of the operative field or stranding in the mesentery on CT scans raise the possibility of leakage. Pleural effusion or pneumonia may also be suggestive of an underlying leak [18]. Intra- as well as extra-luminal bleeding can be diagnosed by CT scans. [19, 20]. The same applies to abdominal wall bleeding and intraoperatively inflicted solid organ injury.

Some authors perform routine postoperative gastrograffin upper GI series for all their patients due to simplicity and relatively low cost of the procedure [21]. Negative studies should however not mislead the surgeon in the presence of a strong clinical suspicion [15]. Mittermair et al. [22] reported complete inadequacy of gastrograffin series to detect leakages in their patients. Such data together with the radiation exposure accompanying these diagnostic modalities questions the necessity of their routine postoperative use.

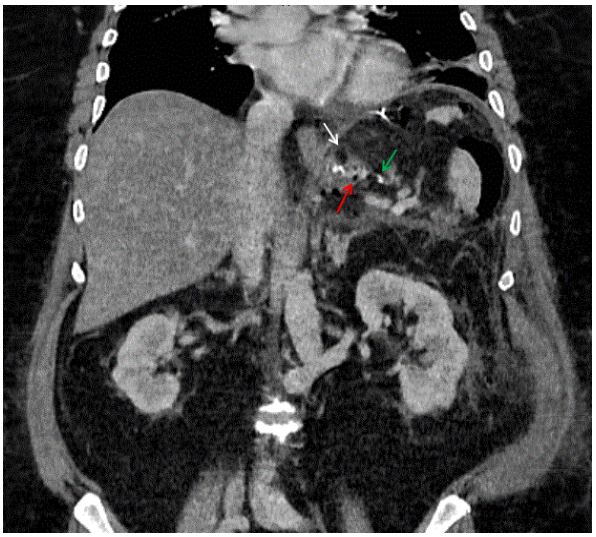

(a)

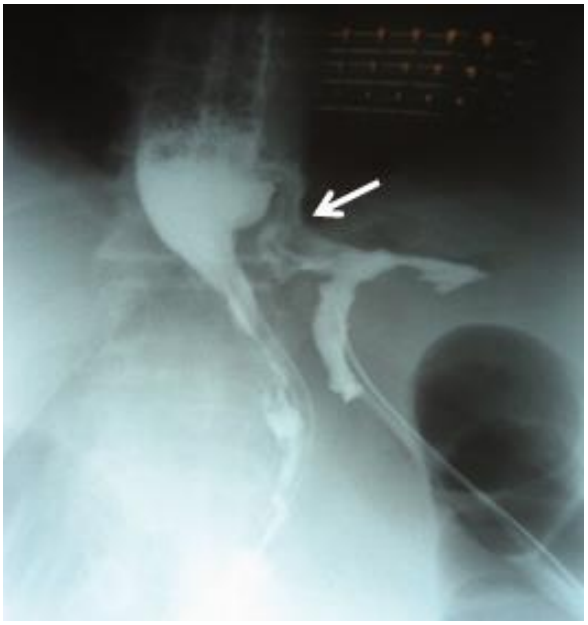

(b)

Figure 1a,b. Extravasation of gastrointestinal contents can be diagnosed radiologically by contrast-enhanced computed tomography (CT) scans with oral contrast (a) or gastrografin swallow studies (b).

4. Diagnostic Laparoscopy (DL)

DL is the most reliable tool to confirm or rule out serious early postoperative issues including leakage and extra-luminal bleeding in patients with suspicious clinical, laboratory or radiological findings.

In our personal series, we have observed a 100% specificity for DL in 23 patients with complicated sleeve gastrectomy: DL confirmed complicated post-LSG course (13 patients with bleeding, nine with leakage and one with trocar-site hernia). This observation should be compared with the findings with RYGB: a specificity of only 70 percent in 33 patients with suspected complications. DL confirmed complications suspected by routine postoperative check in only 23 patients (12 patients with leakage, seven with bleeding, three with trocar site hernia, and one with small bowel obstruction) whereas it was negative in 10 patients (Table 1).

Table 1. Value of diagnostic laparoscopy (DL) in patients with a suspicious (*) post-operative course after LSG vs. LRYGB

First detected indication for DL	LSG N=23		LRYGB N=33	
	Diagnosis confirmed by positive DL	Negative DL	Diagnosis confirmed by positive DL	Negative DL
Elevated CRP	Leakage: 7	0	Leakage: 9 Trocar site hernia: 2	4
Tachycardia	Bleeding: 9 Leakage: 1	0	Bleeding: 6 Leakage: 3	4
Abdominal pain	Bleeding: 3 Trocar site hernia: 1	0	Bleeding: 1 Trocar site hernia: 1 SBO: 1	2
Suspicious CT scan	Bleeding: 1 Leakage: 1	0		0
Total number (%)	23 (100%) ($p<0.05$)	0 (0%)	23 (70%)	10 (30%)

LRYGB: laparoscopic Roux-en-Y gastric bypass, SBO: small bowel obstruction.

Values refer to number of patients in whom DL was done and confirmed or excluded a suspected acute post-LSG complication.

* Suspicious means: Persistent unexplained tachycardia of more than 100 beats/min, fever (≥38.5 C), a more than routinely-encountered post-operative abdominal pain, tachypnea (>20 breaths/min), or decreased urinary output despite good hydration, C-reactive protein (CRP) >150 mg/l, leukocytosis >11,000 cells/μl or a suspicious CT scan.

The discrepancy between RYGB and sleeve gastrectomy may be attributed to the fact that DL can miss some complications such as transient internal herniation, twisted gastro-jejunal or entero-enteral anastomotic reconstruction, intussusception or anastomotic ulcer post-RYGB. These factors that can lead to transient deviation from normal post-RYGB course are not encountered after LSG. The results are currently under further analysis for future publication. The incidence of bleeding after obesity surgery ranges from 0.6 to 4 percent [23, 24]. Stapling through highly vascular tissues can be followed by considerable amount of intra- as well as extra-luminal (intra-peritoneal) bleeding. Bleeding should be controlled by surgical intervention (hematoma evacuation, over-sewing, and drainage) when patients are hemodynamically unstable. In hemodynamically stable patients, we usually resort to conservative methods with fluid resuscitation, blood transfusion (if necessary) and careful observation. We propose the following algorithm (Algorithm 1) for possible diagnosis and management of acute failures after bariatric intervention.

LATE FAILURE AFTER BARIATRIC INTERVENTION; SPECTRUM OF DIAGNOSTIC MODALITIES

After briefly discussing the acute failure of a bariatric procedure, we would like to address the long-term failure of a bariatric procedure, which is a failure occurring after an uneventful early post-operative phase. All bariatric procedures can be subjected to long-term failure.

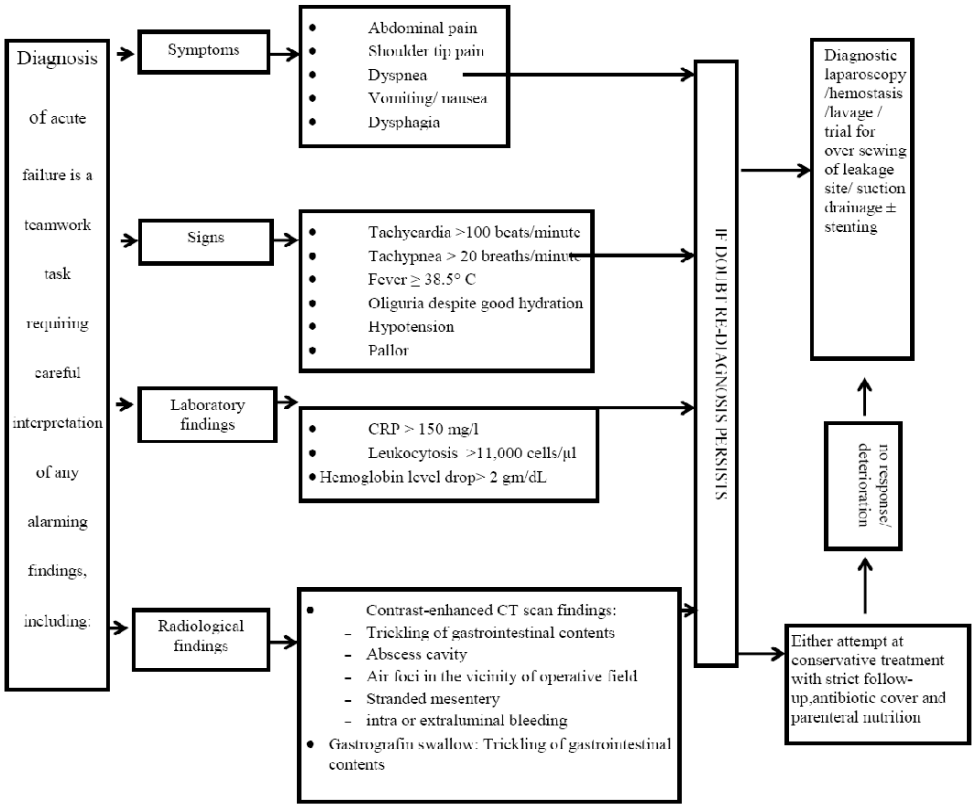

Algorithm 1. Management of patients with suspected acute leakage after bariatric intervention.

In our opinion LAGB should be separately discussed because of the specific nature of this foreign body-associated procedure. In addition to the common causes of long-term failures encountered with other procedures (weight regain, reflux, hiatal herniation, ulceration,…..) and urgent band-related conditions (gastric perforation, volvulus, abscess formation,….), LAGB can cause two special conditions or causes of failure, namely: band slippage and band migration.

Diagnosis of Band Slippage

Band slippage is encountered in 4-13% of patients [25]. Patients with slipped band usually present with manifest upper abdominal pain and acute upper obstructive manifestation. If neglected these can progress to gastric gangrene by strangulation of the

blood supply of the pouch. Band slippage is usually an acute condition, and should be timely diagnosed and properly managed.

Band slippage is often recognized on gastrografin upper abdominal series. The slipped band tends to be more horizontally placed [26]. Through the weight of the herniated stomach, the anterior and posterior band margins are no longer opposed and give the so called O sign [27]. Because of the progressive obstruction and strangulation, an air-fluid level may appear in the proximal gastric pouch.

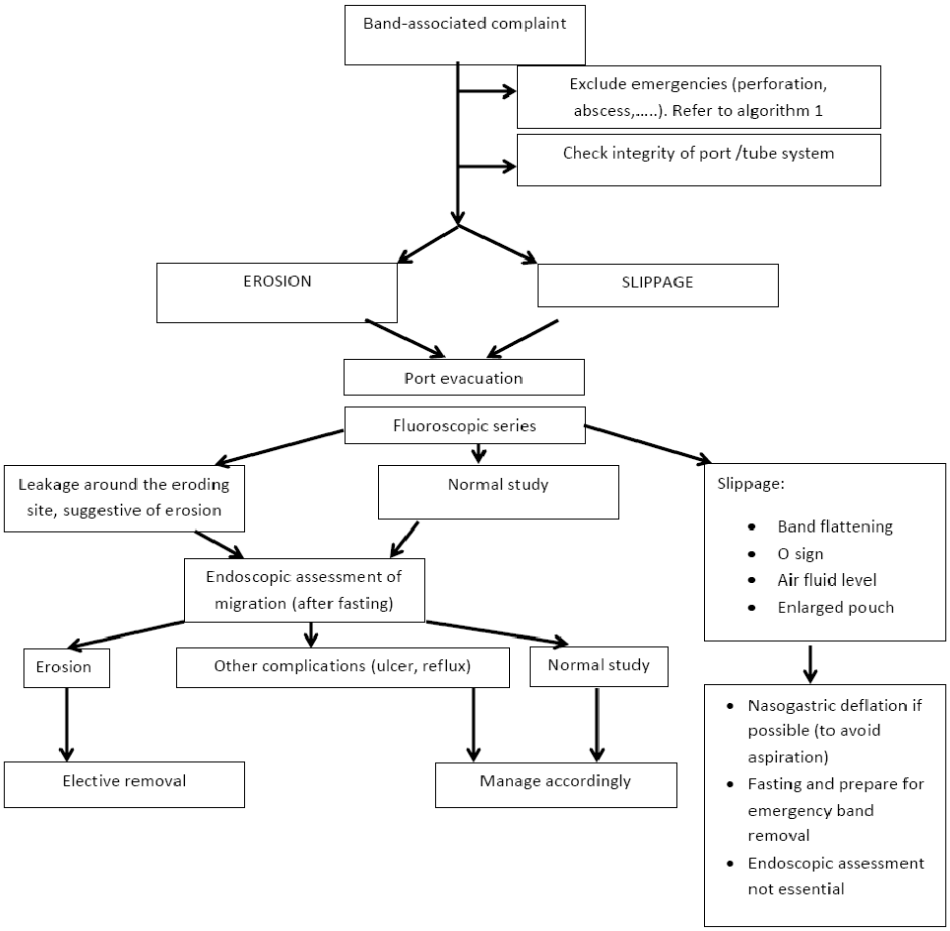

Algorithm 2. How to manage a failed band.

Diagnosis of Band Erosion

Band erosion is usually a gradual process that can progress from incomplete to complete intra luminal band migration. Band migration usually presents with vague manifestations, including loss of restriction (with possible weight gain), upper abdominal pain and port site pain or port site infection. Band erosion is typically detected by gastroscopy. A systematic review of band erosion in 15,775 patients revealed 231 cases of erosion (1.46%) in 15,775 all detected by gastroscopy [28]. This experience should not understate the role of radiological

interventions in the diagnosis of this event. In fluoroscopic series, a leak of contrast around the eroding location of the band can be detected. CT scans can also detect a completely migrating band, with more certainty than incomplete erosion [29].

Port-Related Complications

Two important port-related complications are port inversion and tubing defect or disconnection. Port displacement can be readily detected in abdominal radiographs. Tubing system defect or disconnection can be diagnosed by water soluble contrast material injection in the port system.

We propose an algorithm for rapid assessment and diagnosis of gastric band failures (algorithm 2)

RADIOLOGICAL DIAGNOSTIC TOOLS FOR A FAILED BARIATRIC INTERVENTION

Fluoroscopy (Upper GI Series)

Water-soluble contrast upper GI series have commonly been used to show the pathway constructed by a bariatric procedure, be it restrictive or malabsorptive. In sleeve gastrectomy, the currently most commonly performed restrictive procedure, different patterns of the residual stomach have been described by Werquin et al. [30]: a tubular pattern (66%) with a uniform caliber, the superior pouch pattern (26%, with a wide superior component of the retained fundus that gradually fills), the inferior pouch pattern (8%, with a wide residual distal component), the superior-inferior pouch pattern (both proximal and distal pouches), the pseudodiverticular pattern with a diverticular dilatation of the lesser curve. Other rare patterns, such as the corkscrew have also been reported [31].

Long-term failure of sleeve gastrectomy can be seen in fluoroscopic upper GI series, where gastric dilatation or stenosis can be diagnosed. Gastric dilatation is usually suspected in fluoroscopy by loss of the normal tubular pattern of the sleeve and pouch enlargement. Stenosis can be readily seen by impaired distal contrast flow, and may be associated with proximal gastric dilatation (Figure 2), gastro-oesophageal reflux and hiatal herniation.

Upper GI series play also a significant role in failed malabsorptive procedures. Assessment of the proximal pouch, the alimentary limb and the site of the gastro-eneterostomy can be accomplished by fluoroscopic series. Gastric pouch size can be readily assessed by upper GI series, especially if compared with immediate post-operative series. Shah et al. [32] described that the size of the gastric pouch after RYGB should be the same as that of lower thoracic or lumbar vertebral body.

Upper GI series by their dynamic nature allow to demonstrate stenosis of the gastroenterostomy. Pouch distension and delayed passage of contrast through a smooth narrowing are highly suggestive for this condition [32].

Although not typically diagnosed in upper GI series, a stenosis of the entero-enteral (JJ) anastomosis can also be shown on these series. If stenosis is associated with significant stasis

at the pancreaticobiliary limb, symptoms may include pancreatitis and biliary stasis. The stasis may be severe enough to induce gastrogastric fistulation or rupture (blow out) in acute cases. This situation may be diagnosed on dynamic series by stasis of contrast flow, retrograde passage in the biliopancreatic limb or reflux in the alimentary limb. Plain abdominal films may also show fluid level formation.

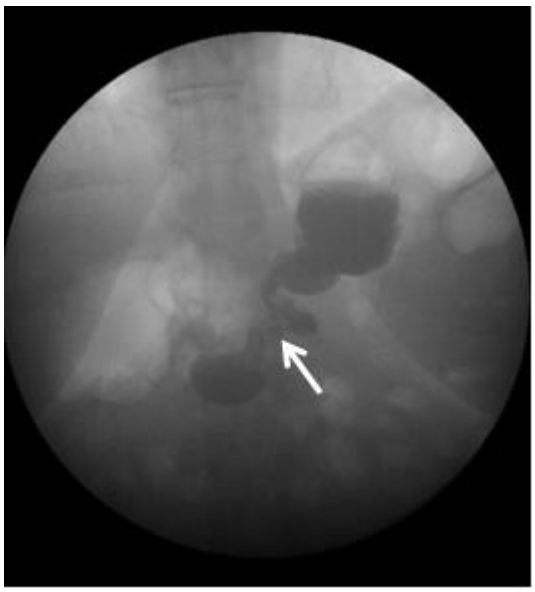

Figure 2. Stenosis can be associated with proximal gastric dilatation.

In malabsorptive procedures a specific cause of failure is blind loop formation. This formed sac acts as a reservoir or a second stomach, which overtime may lead to loss of the restrictive element of the procedure. Late evacuation of its contents is in our opinion another cause for late dumping symptoms. Additionally, recurrent abdominal colics and bacterial overgrowth may be associated with blind loop sac formation.

Marginal ulcers developing at the gastroenerostomy site are an important cause of failure after bariatric procedures, usually presenting with vague upper abdominal complaints (Pain, nausea, vomiting, etc.). Smoking and chronic acid exposure are possible precipitating factors. In upper GI series these ulcers can be seen as ulcer niches at the anastomosis site or in the proximal part of the alimentary limb [33].

Another condition that may occur after bypass procedures is internal herniation, a situation linked tot the creation of peritoneal defects. This condition can also be detected in GI series when small bowel limbs containing contrast in their lumens are seen within the hernia space [34, 35].

Dynamic upper GI series may also help in the diagnosis of gastro-gastric fistulation, when contrast flows in the distal pouch.

Despite the value of fluoroscopy in obesity practice, practical difficulty in performing the study may influence interpretation [36]. Practical difficulties include for example fluoroscopy table weight limit. Most currently used static tables tolerate not more than 550 pounds (400 pounds for movable tables). However, larger capacity systems are now available with weight limits up to 600 pounds for static tables and 500 pounds for movable tables. The problem of

poor interpretation can be overcome by performing the study in supine position with lateral spread of weight, leading to decreased thickness of abdominal wall tissues and accordingly better interpretation of the study with a lower dose of radiation. Another issue is the distance between the table and the radiation source, which typically ranges from 45 to 49 cm, and reaches in recent devices up to 60 cm. Performing the study in supine position may allow a better accommodation of the patient in the device. A third problem is the width of the table, which if insufficiently wide, may lead to patient instability during the examination. A fourth problem is the need for a higher dose of radiation to penetrate through a relatively thicker abdominal wall.

In fluoroscopic diagnostic studies we prefer to use water soluble contrast (Gastrograffin). This avoids the risk of barium induced peritonitis and at the risk of impaction at any stenotic site. An important precaution point is to allow for a reasonable period of fasting after gastrografin intake in cases where an operation is indicated. Alternatively, gastric decompression should be tried. Several reports documented the irritating hypertonic effect of gastrografin on bronchial epithelium, and the occurrence of marked pulmonary oedema and even death in case of aspiration [37].

Apart from 3D gastric pouchography, which is of utmost importance in follow-up of all bariatric interventions, conventional abdominal CT scans (enhanced by oral and intravenous contrast) are also of value in assessing failure or complications after bariatric interventions. Because we are focusing in this chapter on long-term failures after bariatric interventions we will not discuss the major role of CT scans in assessing acute complications after surgical interventions. Instead, we will mention some possible causes of failure, that can be diagnosed on routine CT scans.

Recurrent weight gain or insufficient weight loss can result from enlargement of the constructed pouch and/or the alimentary limb. This can be easily detected on abdominal CT scans. After sleeve gastrectomy, loss of the normal tubular shape of the constructed pouch denotes a possible cause of insufficient weight loss. After malabsorptive procedures, pouch enlargement, distension of the alimentary limb, or widening of the anastomosis play a similar role.

Measuring the diameter of the gastroenterostomy during examination should be a routine part of interpretation of CT scans in patients who underwent malabsorptive bariatric interventions. In these scans, administration of an oral contrast material just prior to the examination helps to diffentiate the gastric pouch, gastroenterostomy and alimentary limb (which are opacified) from the biliopnacreatic limb and enteroenterostomy (non opacified). This is essential for adequate interpretation of the cause of failure and also for detecting potential events like internal herniation. Distention of the gastric pouch and collapse of the distal pouch are also important features. The normal peristaltic movements of the biliopancreatic limb protects from retrograde passage of contrast material or gases in this limb [29, 38]. Through oral contrast intake, conditions such as gastrogastric fistulation can be detected by abnormal flow of contrast in the distal gastric pouch. Similarly, with adequate localization of the gastric pouch and alimentary limb, blind loop formation (also at the site of the enteroenterostomy) may be seen. Although not typically diagnosed, marginal ulcerations have been reported to be detected on CT abdominal scans [39].

THREE DIMENSIONAL CT ASSESSMENT

A corner stone in accurate assessment of failure after bariatric intervention is the proper outlining of anatomical changes in the gastro-intestinal tract, which allows to choose the best management or revisional modality. Previous studies reported that accurate assessment of pouch size enables the surgeon to design the best strategy and perform the best available intervention [40]. Here, we think that 3D pouch construction provides the best aid to the treating team.

Despite reports that endoscopy, upper GI series and CT scans are the most commonly used assessment modalities [41-45], we believe that they don't offer sufficient data. Endoscopy is to some extent operator-dependent and routine CT is of a higher value in the evaluation of acute complications. Endoscopy is more invasive and is not free of complications. Moreover, insufflation of air during endoscopy may lead to over-distension of the gastric pouch [40]. The classical upper GI series can be useful in providing approximative data for pouch volumes. Langer and his colleagues postulated that a sleeve wider than 4 cm is considered to be dilated, but they did not estimate the sleeve volumes [46].

Three dimensional CT gastric reconstruction (together with alimentary limb reconstruction) represents in our opinion the best investigative modality for pouch and alimentary limb. Based on our experience, we affirm that this modality of investigation gives the most accurate reconstruction of the actual intra-abdominal anatomy. Sets required for this investigative modality should be an integral part of any center practicing obesity surgery.

Although there were reports [47] comparing the accuracy of pouch measurements after gastric bypass using gastroscopic assessment versus those using 3D pouchography did not find statistically significant difference between both measurements, we still stress on the superior value of 3D pouchography. As mentioned, interpretation of endoscopic findings can be operator dependent. Many authors support our opinion regarding the value of 3D gastric pouchography [48].

Technically, 3D pouchography entails drinking a powder or effervescent granules diluted with water after overnight fasting. Ingestion allows stomach distension with air. This distension helps in obtaining an actual picture for the current gastric (and alimentary limb) anatomy. Addition of a spasmolytic agent is indicated. Some authors prefer glucagon [47], others tend to use Buscopan® [40]. Thin slice scans (1 mm) are taken and three dimensional volume-rendering images created in a 3D workstation. The modality is described in different techniques using different contrast agents. [40, 47, 48] Some authors tend to use iodine containing contrast agents [40], others prefer effervescent granules without the use of iodine-containing oral contrast agents [47].

Some authors [47] resort to 3D pouchography to obtain base line data for future comparison in patients with non-satisfactory results after bariatric intervention. Through this modality a large and sufficient deal of information can be available which, if properly analyzed, usually allows for the best intervention to overcome the encountered failure after a bariatric intervention. A large pouch can be easily assessed (Figure 3).

Other abnormalities such as loop formation, a wide gastroenterostomy and a twisted pouch (Figure 4) can be readily diagnosed [40]. In addition, hiatal herniation, a common cause for complaints after bariatric intervention can be adequately diagnosed (Figure 5).

Other less readily detected pathologies, e.g. gastro-gastric fistulation are also readily seen in 3D pouchographies. Reports from different centers on cases of fistulation that failed to be diagnosed despite several gastroscopies and upper GI series have been published [40].

Moreover, computed tomography with 3D imaging has been shown to be of reasonable value in patients with previous gastric banding, because it allows to delineate the entire band, location and orientation, as well as related complications such as erosion, slippage and infection. Port-related complications may also be detected [49].

A possible limitation of this modality is ist inherent radiation exposure [50], although low dose exposure with a highly preserved quality can be achieved in recent stations [48, 51]. Some assume that the radiation dose used in 3D CT imaging does not exceed the radiation dose in conventional CT scans [48].

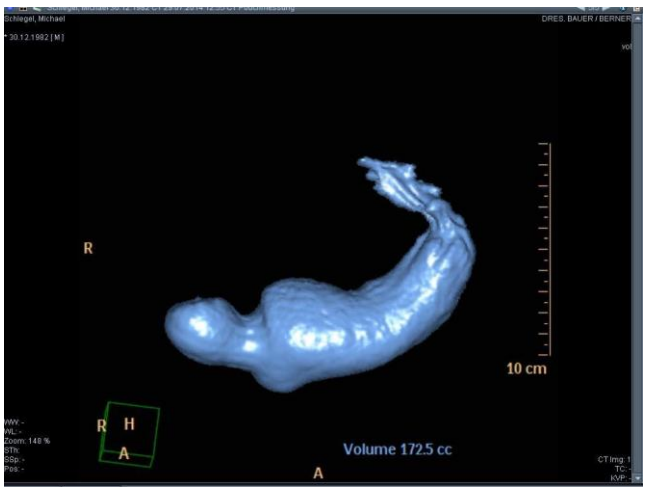

Figure 3. A large pouch after sleeve gastrectomy seen on CT pouchography.

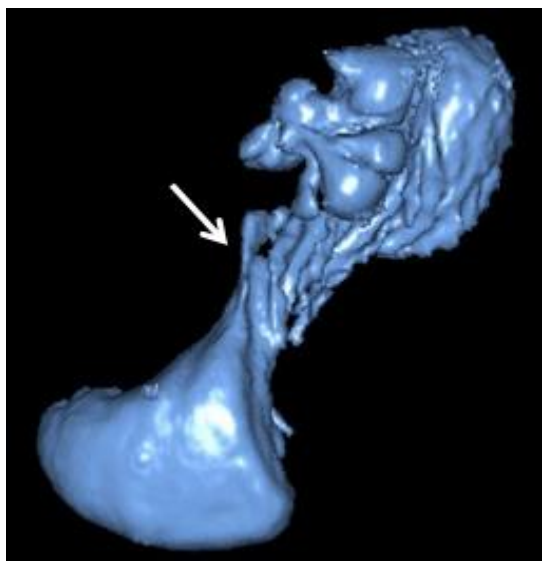

Figure 4. A twisted pouch after sleeve gastrectomy.

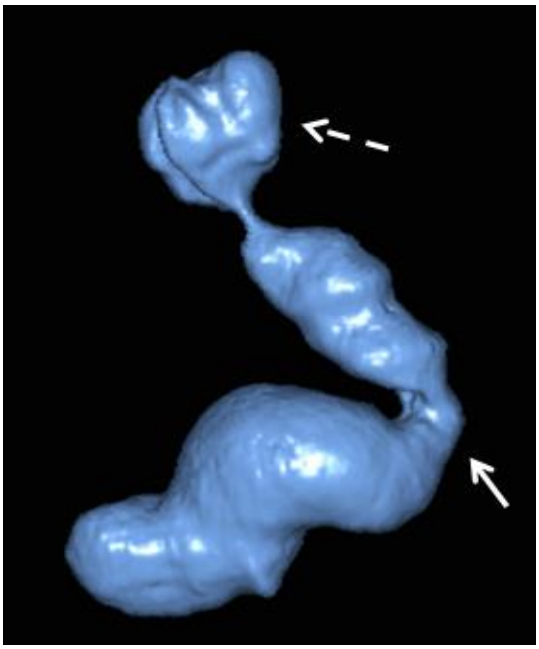

Figure 5. Hiatal herniation, a common cause for complaints after bariatric intervention can be adequately diagnosed on CT pouchography.

Blanchet et al. mentioned additional limitations of this technique [48] i.e., the need for a recently equipped station, and the learning curve required for performing the study and interpreting its findings (although the latter usually does not exceed 10 minutes after achieving an adequate learning curve). Inadequate fasting or failure of adequate oral intake of the contrast agent [40], leads to incomplete distension of the pouch and inadequate interpretation of the results.

ROLE OF ENDOSCOPY IN FOLLOW-UP AND DETECTION OF FAILURES OR COMPLICATIONS AFTER BARIATRIC INTERVENTIONS

Endoscopy plays a major role in the bariatric field in that it allows evaluation of symptoms attributed to complications or failures after surgery. In an analysis of more than 7,000 restrictive and malabsorptive procedures 4 main complications were reported after restrictive prrocedures; pouch or stoma dilatation (2.4%), stomal stenosis (2.2%), staple line failure (1.5%) and stomach erosions (1.2%). These complications were also reported after malabsorptive procedures with incidences of 0.47%, 2.7%, 5.9% and 1.2% respectively. These figures denote the importance of follow-up endoscopy in assessing failures and complications after bariatric interventions [52]. That is why we recommend a scheduled follow-up endoscopy regimen after bariatric interventions. The diagnostic spectrum of gastroscopy in patients with failed bariatric surgery is very broad and better to be illustrated based upon which procedure is performed and its possible causes of failure or complications.

Follow-Up Endoscopy after Roux-En-Y Gastric Bypass

Patients with nausea, vomiting or dysphagia after RYGB should have a gastroscopic evaluation to rule out conditions like marginal ulceration in 27-52% of patients followed by stomal stenosis in 4 -39% [53, 54, 55].

Stomal Stenosis

An anastomosis is considered stenotic if the normal 9.5 mm endoscope cannot readily bypass it [56]. Stenosis has a reported incidence of 5-12% after LRYGB [57, 58]. Possible underlying factors for a stenotic gastrojejunostomy include local ischemia, the use of a circular stapler and local inflammation (by smoking for example) [56].

In case of stenosis in the presence of active marginal ulceration ulcer treatment should be initiated prior to dilatation of the stenosis to avoid inadvertent perforation during the dilatation sessions [56]. An intended diameter of dilatation to avoid symptomatic recurrence is 15 mm [59]. An important point to be considered here is to adequately assess the proximal part of the alimentary limb to rule out any associated pathology or active ulceration.

Endoscopic dilatation can be safely started 4 weeks post-operatively [59, 60] and is usually performed using balloon dilatation through a bougie passed over a guide wire. Guide wire guidance is essential when a bougie cannot be readily passed through a stenotic stoma [56]. Torsion, angulation of the stoma and marginal ulceration are all underlying factor for failed dilatation.

Marginal Ulceration

This condition is reported to vary in incidence from 0.6-16% [45]. Marginal ulcers are asymptomatic in more than 20% of cases [58]. Ulcer development is limited to the intestinal side of the anastomosis [56].

An important predisposing factor for marginal ulceration and pouch inflammation is *H.Pylori* infection. Although not highly sensitive, mucosal biopsies should be taken prior to and during every follow-up endoscopic session after RYGB, and the same applies to all bariatric interventions. A proved infection should be thoroughly treated and follow-up endoscopy after eradication is a routine practice in our patients.

Other factors than *H. Pylori* infection have been strongly linked to marginal ulceration. These factors may be either intrinsic or extrinsic. The former include pouch acid production, pouch ischemia and gastrogastric fistula due to retrograde passage of acid produced from the distal pouch into the constructed pouch and subsequently over the site of the anastomosis. The latter include smoking and alcohol consumption.

Pouch and Stomal Dilatation and Blind Loop Formation

This triad represents an important cause of failure after RYGB. In this case failure is determined by insufficient weight loss or weight gain. Through any of those three causes, an abnormally large amount of food will be ingested and rapidly dumped distally. This can simply be explained by loss of restriction. During endoscopy, length of the pouch (distance between the gastro-oesophageal junction and the stoma) can be readily measured. Despite the

fact that the diameter of the stoma can be assessed by experience of the endoscopist, it cannot be actually measured. Thanks to the advances in interventional endoscopic techniques, the spectrum of endoscopic applications exceeds the diagnostic level and reaches the therapeutic level. Techniques as the endoscopic overstitch are currently practiced in our clinic, but results are still in the evaluation phase.

Gastro Gastric Fistulation

An important cause of failure after RYGB is the formation of a gastrogastric fistula. A channel is gradually formed between the proximal and distal gastric pouches. This condition has two effects. First, the restrictive effect of RYGB is lost due to the passage of food stuffs from the proximal pouch into the distal pouch which causes the patients to tolerate larger volumes of meals. Second, the retrograde passage of acid from the distal into the proximal pouch results in exaggerated effect of gastric acid on the constructed stoma, with consequent oedema, ulceration and stenosis. This event is not easily found during routine endoscopy performed by non-experienced personnel. As previously mentioned, pouchography plays a major role here. Still, besides its possible therapeutic role, endoscopy can assess this situation, and get access to the distal stomach pouch.

Follow-Up Endoscopy after Sleeve Gastrectomy: (Figure 6)

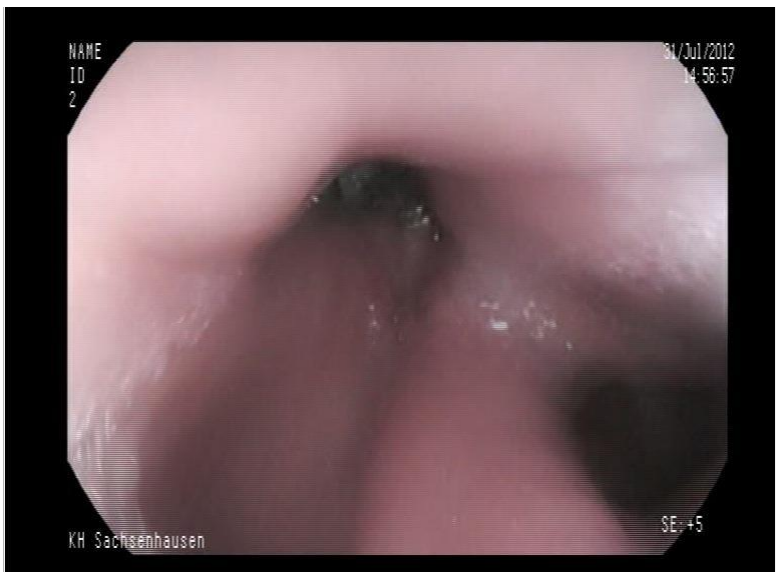

Figure 6. Follow-up endoscopy after sleeve gastrectomy showing a gastric fistula.

Stenosis of the Sleeve

Although uncommon, stenosis is a serious complication after sleeve construction. We experienced cases with severe nutritional impairment due to sleeve stenosis, up to Beri Beri and Wernicke's encephalopathy. Stenosis is most common at the incisura angularis. In our opinion, gastroscopy can help in evaluation of a stenotic sleeve. It is noteworthy that the stenotic segment can be overlooked when the endoscope, when it crosses the stenosis thanks

to its mere weight. This is why we recommend pouchography for the accurate assessment of the stenotic segment before ruling out sleeve stenosis. (Figures 7a,b,c)

(a)

(b)

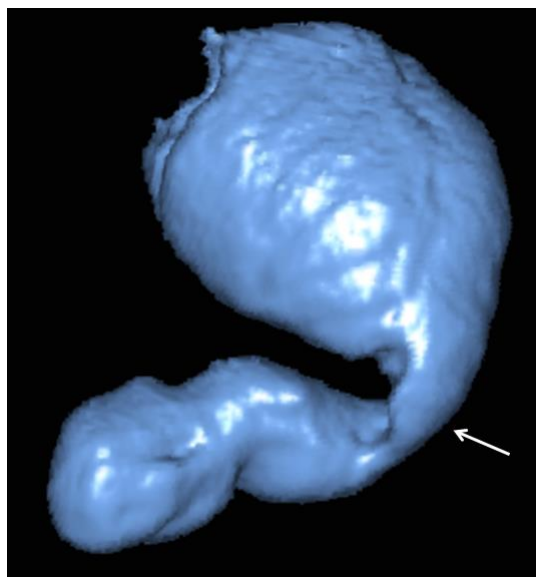

(c)

Figures 7a,b,c. Sleeve stenosis as seen on CT pouchography.

Sleeve Dilatation

Long-term results after sleeve gastrectomy are not universally satisfactory in terms of weight loss and weight regain has been reported in 75% of the cases [61]. This finding has been correlated with increased sleeve volume. Consequently assessment of the sleeve volume in late follow-up sessions is of utmost importance. Patients presenting for evaluation of

weight regain or non-satisfactory weight loss undergo a standardized assessment that mainly includes endoscopic assessment followed by pouchography.

During endoscopy, a wide sleeve, allowing swift retroflexion or inversion of the gastroscope, usually indicates an increased sleeve volume. Accurate measurement of the sleeve volume and shape however cannot be accomplished by endoscopy. The full assessment usually proceeds to pouchography to delineate the new sleeve shape.

Follow-Up Procedures after Malabsorptive Procedures (Biliopancreatic Diversion, BPD)

As for RYGB, pouch assessment (whether a large pouch of 200-500 ml size in BDP Scopinaro or a tubular sleeve in duodenal switch) and stomal inspection can be endoscopically performed. Biopsies from a marginal ulcer or for detection of *H. Pylori* gastritis, or from ileal mucosa can be easily achieved. Conditions involving stomal stenosis, pouch dilatation or blind loop formation are very amenable.

Follow-Up Procedures after Vertical Banded Gastroplasty

Vertical banded gastroplasty is no longer a common bariatric practice. This procedure remains interesting because of the common presentation of patients with history of vertical banded gastroplasty who suffer from problems related to the functional failure of this procedure. A high pressure created by a stenotic distally applied ring or mesh is cranially propagated. This leads to a common triad of presentations; gastro-oesophageal reflux, pouch enlargement (new stomach) and gastro-gastric fistula. The latter two phenomena are associated with loss of restriction with resultant weight gain. All these changes can be detected endoscopically. Again, the accurate volumetric assessment is better achieved by pouchography.

Follow-Up Procedures after Gastric Banding

At endoscopy a normally functioning non-complicated band in retroflexion appears as a belt surrounding the gastroscope. However, two important conditions have to be carefully assessed after gastric banding; band erosion and band slippage. We discussed before band slippage, a condition that as mentioned before is better assessed by upper GI series. Band erosion is also diagnosed by upper GI series, but endoscopy here seems to be a better diagnostic tool. Band erosion has been reported in rates ranging up to 2.8%. [62] Band erosion is a gradual process involving penetration of the tight band into the gastric wall. The blackish discoloration of the eroding segment is pathognomonic and is possibly due to the burning effect of gastric acid on this segment. Patients suffering from band erosion usually present with a gradual loss of the restricting effect of the gastric band. Sometimes the first manifestation of erosion is tenderness or infection of the port of the migrating band, due to ascending infection along the tubing system. Endoscopy can be both diagnostic and

therapeutic in these cases, as band extraction can be completed endoscopically provided more than 50% of the band circumference is eroding inside the stomach lumen [56].

Endoscopy and Hiatal Hernia after Bariatric Intervention

A commonly encountered event after bariatric intervention is hiatal herniation. Either this herniation was already present at the time of the primary intervention, or it developed by disappearance of the fat pad surrounding the cardia as a part of weight loss after bariatric surgery. This leads to the classical symptoms of hiatal herniation presenting as epigastric discomfort, dysphagia or reflux manifestations. Endoscopy has been broadly used in the diagnosis of this type of sliding hiatal herniation. Herniation can be assessed by one of two methods [63]: either by measuring the distance between the squamocolumnar transition and the diaphragmatic impression (usually considered when more than 3 cm), or by inspecting the impression of a patulous diaphragmatic sphincter by a retroflexed endoscope).

Endoscopy and Reflux Disease after Bariatric Intervention

Another important cause of failure or dissatisfaction after bariatric intervention is the development of gastrooesophageal reflux disease. Patients usually present with typical manifestations including dull aching upper abdominal pain, heart burn, vomiting and dysphagia with in extreme cases reflux of gastric juice through the nose. We saw many cases presenting with intolerable reflux manifestations, mainly after sleeve gastrectomy. That is why diagnosis of gastro-esophageal reflux disease should be a routine part of follow-up after bariatric intervention. Differential diagnostic points include other medically-treatable causes (e.g.: *H. Pylori* induced gastritis and marginal ulceration, etc.). After ruling out all medical causes, and after failure of medical management of reflux, a surgical approach may be required, for example conversion of a sleeve into RYGB. The role of endoscopy in this condition should be respected. The presentation with the typical findings of reflux on endoscopy is diagnostic with a specificity of about 95% [64, 65].

Role of Diagnostic Laparoscopy in Assessment of Failure after Bariatric Intervention: (Figure 8A,B)

Laparoscopy constitutes one of the best diagnostic (and at the same time therapeutic) modalities. Some patients are presented with failures or complications after bariatric interventions that remain unexplined despite a full diagnostic work-up.

Conditions such as extensive adhesions, blind loop formation, twisted pouches or sleeves, hernitations (whether internal or hiatal) may escape diagnosis by the routinely available techniques. This is a frequent event. In these patients, diagnostic laparoscopy gives the highest level of accuracy and offers at the same time a simultaneous therapeutic option. (See before also, the role of diagnostic laparoscopy in the assessment of acute failures after bariatric interventions)

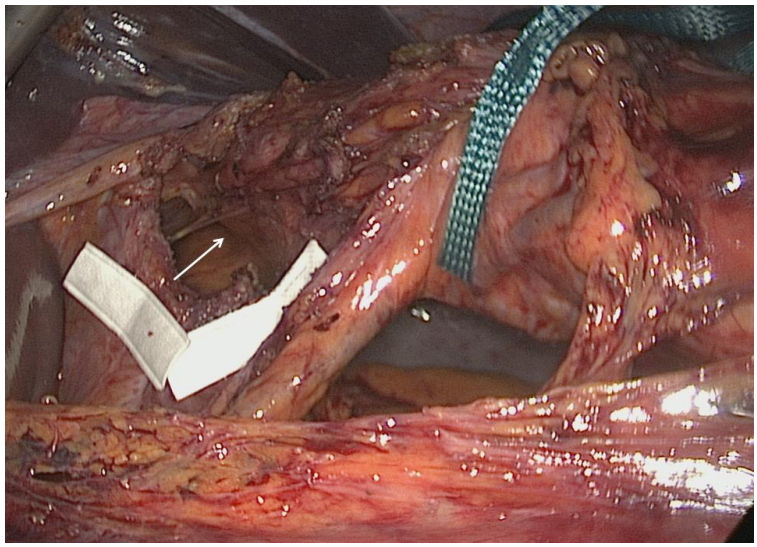

(a)

(b)

Figure 8a,b. Diagnostic laparoscopy offers the best sensitivity for complications or failures after bariatric intervention. See the hiatal herniation (a) and the extensive adhesions (b) which may cause failure after bariatric interventions.

REFERENCES

[1] Kelly T, Yang W, Chen CS, Reynolds K, He J. Global burden of obesity in 2005 and projections to 2030. *Int J Obes* (Lond). 2008 Sep;32(9):1431-7.

[2] Maggard MA, Shugarman LR, Suttorp M, Maglione M, Sugerman HJ, Livingston EH, Nguyen NT, Li Z, Mojica WA, Hilton L, Rhodes S, Morton SC, Shekelle PG. Meta-analysis: surgical treatment of obesity. *Ann Intern Med.* 2005 Apr 5;142(7):547-59.

[3] Aurora AR, Khaitan L, Saber AA. Sleeve gastrectomy and the risk of leak: a systematic analysis of 4,888 patients. *Surg Endosc*. 2012 Jun;26(6):1509-15.

[4] Parikh M, Issa R, McCrillis A, Saunders JK, Ude-Welcome A, Gagner M. Surgical strategies that may decrease leak after laparoscopic sleeve gastrectomy: a systematic review and meta-analysis of 9991 cases. *Ann Surg.* 2013 Feb;257(2):231-7.

[5] Gawdat K. Bariatric re-operations: are they preventable? *Obes Surg*. 2000 Dec;10(6):525-9.

[6] Gagner M, Gentileschi P, de Csepel J, Kini S, Patterson E, Inabnet WB, Herron D, Pomp A. Laparoscopic reoperative bariatric surgery: experience from 27 consecutive patients. *Obes Surg.* 2002 Apr;12(2):254-60.

[7] Chang SH, Stoll CR, Song J, Varela JE, Eagon CJ, Colditz GA. The effectiveness and risks of bariatric surgery: an updated systematic review and meta-analysis, 2003-2012. *JAMA Surg*. 2014 Mar;149(3):275-87.

[8] Mann JP, Jakes AD, Hayden JD, Barth JH. Systematic Review of Definitions of Failure in Revisional Bariatric Surgery. *Obes Surg*. 2014 Dec 17. [Epub ahead of print]

[9] Baltasar A, Perez N, Serra C, Bou R, Bengochea M, Borrás F. Weight loss reporting: predicted body mass index after bariatric surgery. *Obes Surg.* 2011 Mar;21(3):367-72.

[10] Hutter MM, Schirmer BD, Jones DB, Ko CY, Cohen ME, Merkow RP, et al. First report from the American College of Surgeons Bariatric Surgery Center Network: laparoscopic sleeve gastrectomy has morbidity and effectiveness positioned between the band and the bypass. *Ann Surg.* 2011 Sep;254(3):410-22.

[11] Birkmeyer NJ, Dimick JB, Share D, Hawasli A, English WJ, Genaw J, et al. Hospital complication rates with bariatric surgery in Michigan. *JAMA.* 2010 Jul 28;304(4):435-42.

[12] DeMaria EJ, Pate V, Warthen M, Winegar DA. Baseline data from American Society for Metabolic and Bariatric Surgery-designated Bariatric Surgery Centers of Excellence using the Bariatric Outcomes Longitudinal Database. *Surg Obes Relat Dis*. 2010 Jul-Aug;6(4):347-55.

[13] Weiner RA, El-Sayes IA, Theodoridou S, Weiner SR, Scheffel O. Early post-operative complications: incidence, management, and impact on length of hospital stay. A retrospective comparison between laparoscopic gastric bypass and sleeve gastrectomy. *Obes Surg*. 2013 Dec;23(12):2004-12.

[14] Albanopoulos K, Alevizos L, Natoudi M, Dardamanis D, Menenakos E, Stamou K, et al. C-reactive protein, white blood cells, and neutrophils as early predictors of postoperative complications in patients undergoing laparoscopic sleeve gastrectomy. *Surg Endosc.* 2013 Mar;27(3):864-71.

[15] Herron D, Roohipour R. Complications of Roux-en-Y gastric bypass and sleeve gastrectomy. *Abdom Imaging*. 2012 Oct;37(5):712-8.

[16] Gagnière J, Slim K. Don't let obese patients be discharged with tachycardia after sleeve gastrectomy. *Obes Surg*. 2012 Sep;22(9):1519-20.

[17] Cottam D, Qureshi FG, Mattar SG, Sharma S, Holover S, Bonanomi G, et al. Laparoscopic sleeve gastrectomy as an initial weight-loss procedure for high-risk patients with morbid obesity. *Surg Endosc*. 2006 Jun;20(6):859-63.

[18] De Aretxabala X, Leon J, Wiedmaier G, Turu I, Ovalle C, Maluenda F, et al. Gastric leak after sleeve gastrectomy: analysis of its management. *Obes Surg*. 2011 Aug;21(8):1232-7.

[19] Car Peterko A, Kirac I, Gaurina A, Diklić D, Bekavac-Bešlin M. Diagnosis and Management of Acute and Early Complications of/after Bariatric Surgery. *Dig Dis*. 2012 ;30(2):178-81.

[20] Silecchia G, Catalano C, Gentileschi P, Elmore U, Restuccia A, Gagner M, et al. Virtual gastroduodenoscopy: a new look at the bypassed stomach and duodenum after laparoscopic Roux-en-Y gastric bypass for morbid obesity. *Obes Surg*. 2002 Feb;12(1):39-48.

[21] Triantafyllidis G, Lazoura O, Sioka E, Tzovaras G, Antoniou A, Vassiou K, et al. Anatomy and complications following laparoscopic sleeve gastrectomy: radiological evaluation and imaging pitfalls. *Obes Surg.* 2011 Apr;21(4):473-8.

[22] Mittermair R, Sucher R, Perathoner A. Results and complications after laparoscopic sleeve gastrectomy. *Surg Today*. 2014 Jul;44(7):1307-12.

[23] Bakhos C, Alkhoury F, Kyriakides T, Reinhold R, Nadzam G. Early postoperative hemorrhage after open and laparoscopic roux-en-y gastric bypass. *Obes Surg*. 2009 Feb;19(2):153-7.

[24] Schauer PR, Ikramuddin S, Gourash W, Ramanathan R, Luketich J. Outcomes after laparoscopic Roux-en-Y gastric bypass for morbid obesity. *Ann Surg*. 2000 Oct;232(4):515-29.

[25] Blachar A, Blank A, Gavert N, Metzer U, Fluser G, Abu-Abeid S. Laparoscopic adjustable gastric banding surgery for morbid obesity: imaging of normal anatomic features and postoperative gastrointestinal complications. *AJR Am J Roentgenol*. 2007 Feb;188(2):472-9.

[26] Mehanna MJ, Birjawi G, Moukaddam HA, Khoury G, Hussein M, Al-Kutoubi A. Complications of adjustable gastric banding, a radiological pictorial review. *AJR Am J Roentgenol.* 2006 Feb;186(2):522-34.

[27] Pieroni S, Sommer EA, Hito R, Burch M, Tkacz JN. The "O" sign, a simple and helpful tool in the diagnosis of laparoscopic adjustable gastric band slippage. *AJR Am J Roentgenol*. 2010 Jul;195(1):137-41.

[28] Brown WA, Egberts KJ, Franke-Richard D, Thodiyil P, Anderson ML, O'Brien PE. Erosions after laparoscopic adjustable gastric banding: diagnosis and management. *Ann Surg*. 2013 Jun;257(6):1047-52.

[29] Sonavane SK, Menias CO, Kantawala KP, Shanbhogue AK, Prasad SR, Eagon JC, Sandrasegaran K. Laparoscopic adjustable gastric banding: what radiologists need to know. *Radiographics.* 2012 Jul-Aug;32(4):1161-78.

[30] Werquin C, Caudron J, Mezghani J, Leblanc-Louvry I, Scotté M, Dacher JN, Savoye-Collet C. Early imaging features after sleeve gastrectomy. *J Radiol.* 2008 Nov;89(11 Pt 1):1721-8.

[31] Goitein , Goitein O, Feigin A, Zippel D, Papa M. Sleeve gastrectomy: radiologic patterns after surgery. *Surg Endosc*. 2009 Jul;23(7):1559-63.

[32] Shah S, Shah V, Ahmed AR, Blunt DM. Imaging in bariatric surgery: service set-up, post-operative anatomy and complications. *Br J Radiol.* 2011 Feb;84(998):101-11.

[33] Sapala JA, Wood MH, Sapala MA, Flake TM Jr. Marginal ulcer after gastric bypass: a prospective 3-year study of 173 patients. *Obes Surg*. 1998 Oct;8(5):505-16.

[34] Carucci LR, Turner MA, Yu J. Imaging evaluation following Roux-en-Y gastric bypass surgery for morbid obesity. *Radiol Clin North Am*. 2007 Mar;45(2):247-60.

[35] Carucci LR, Turner MA, Shaylor SD. Internal hernia following Roux-en-Y gastric bypass surgery for morbid obesity: evaluation of radiographic findings at small-bowel examination. *Radiology*. 2009 Jun;251(3):762-70.

[36] Carucci LR. Imaging obese patients: problems and solutions. *Abdom Imaging*. 2013 Aug;38(4):630-46.

[37] Trulzsch DV, Penmetsa A, Karim A, Evans DA. Gastrografin-induced aspiration pneumonia: a lethal complication of computed tomography. *South Med J*. 1992 Dec;85(12):1255-6.

[38] Mortelé KJ, Pattijn P, Mollet P, Berrevoet F, Hesse U, Ceelen W, Ros PR. The Swedish laparoscopic adjustable gastric banding for morbid obesity: radiologic findings in 218 patients. *AJR Am J Roentgenol*. 2001 Jul;177(1):77-84.

[39] Ni Mhuircheartaigh J, Abedin S, Bennett AE, Tyagi G. Imaging features of bariatric surgery and its complications. *Semin Ultrasound CT MR*. 2013 Aug;34(4):311-24.

[40] Karcz WK, Kuesters S, Marjanovic G, Suesslin D, Kotter E, Thomusch O, Hopt UT, Felmerer G, Langer M, Baumann T. 3D-MSCT gastric pouch volumetry in bariatric surgery-preliminary clinical results. *Obes Surg.* 2009 Apr;19(4):508-16.

[41] Varghese JC, Roy-Choudhury SH. Radiological imaging of the GI tract after bariatric surgery. *Gastrointest Endosc.* 2009 Dec;70(6):1176-81.

[42] Prosch H, Tscherney R, Kriwanek S, Tscholakoff D. Radiographical imaging of the normal anatomy and complications after gastric banding. *Br J Radiol.* 2008 Sep;81(969):753-7.

[43] Blachar A, Federle MP, Pealer KM, Abu Abeid S, Graif M. Radiographic manifestations of normal postoperative anatomy and gastrointestinal complications of bariatric surgery, with emphasis on CT imaging findings. *Semin Ultrasound CT MR*. 2004 Jun;25(3):239-51.

[44] Trenkner SW. Imaging of morbid obesity procedures and their complications. *Abdom Imaging.* 2009 May-Jun;34(3):335-44.

[45] Obstein KL, Thompson CC. Endoscopy after bariatric surgery (with videos). *Gastrointest Endosc*. 2009 Dec;70(6):1161-6.

[46] Langer FB, Bohdjalian A, Felberbauer FX, Fleischmann E, Reza Hoda MA, Ludvik B, Zacherl J, Jakesz R, Prager G. Does gastric dilatation limit the success of sleeve gastrectomy as a sole operation for morbid obesity? *Obes Surg*. 2006 Feb;16(2):166-71.

[47] Alva S, Eisenberg D, Duffy A, Roberts K, Israel G, Bell R. Virtual three-dimensional computed tomography assessment of the gastric pouch following laparoscopic Roux-Y gastric bypass. *Obes Surg*. 2008 Apr;18(4):364-6.

[48] Blanchet MC, Mesmann C, Yanes M, Lepage S, Marion D, Gelas P, Gouillat C. 3D gastric computed tomography as a new imaging in patients with failure or complication after bariatric surgery. *Obes Surg.* 2010 Dec;20(12):1727-33.

[49] Kawamoto S, Fishman EK. Adjustable laparoscopic gastric banding: demonstrated on multidetector computed tomography with multiplanar reformation and 3-dimensional imaging. *J Comput Assist Tomogr*. 2009 Mar-Apr;33(2):288-90.

[50] Oei TN, Shyn PB, Govindarajulu U, Flint R. Diagnostic medical radiation dose in patients after laparoscopic bariatric surgery. *Obes Surg.* 2010 May;20(5):569-73.

[51] Gleeson TG, Byrne B, Kenny P, Last J, Fitzpatrick P, O'Gorman P, Eustace SJ. Image quality in low-dose multidetector computed tomography: a pilot study to assess

feasibility and dose optimization in whole-body bone imaging. *Can Assoc Radiol J*. 2010 Dec;61(5):258-64.

[52] Monteforte MJ, Turkelson CM. Bariatric surgery for morbid obesity. *Obes Surg*. 2000 Oct;10(5):391-401.

[53] Huang CS, Farraye FA. Endoscopy in the bariatric surgical patient. *Gastroenterol Clin North Am*. 2005 Mar;34(1):151-66.

[54] Marano BJ Jr. Endoscopy after Roux-en-Y gastric bypass: a community hospital experience. *Obes Surg*. 2005 Mar;15(3):342-5.

[55] Wilson JA, Romagnuolo J, Byrne TK, Morgan K, Wilson FA. Predictors of endoscopic findings after Roux-en-Y gastric bypass. *Am J Gastroenterol.* 2006 Oct;101(10):2194-9.

[56] Mathus-Vliegen EM. The cooperation between endoscopists and surgeons in treating complications of bariatric surgery. *Best Pract Res Clin Gastroenterol.* 2014 Aug;28(4):703-25.

[57] Kumar N, Thompson CC. Endoscopic management of complications after gastrointestinal weight loss surgery. *Clin Gastroenterol Hepatol.* 2013 Apr;11(4):343-53.

[58] Csendes A, Burgos AM, Burdiles P. Incidence of anastomotic strictures after gastric bypass: a prospective consecutive routine endoscopic study 1 month and 17 months after surgery in 441 patients with morbid obesity. *Obes Surg.* 2009 Mar;19(3):269-73.

[59] Barba CA, Butensky MS, Lorenzo M, Newman R. Endoscopic dilation of gastroesophageal anastomosis stricture after gastric bypass. *Surg Endosc.* 2003 Mar;17(3):416-20.

[60] Nguyen NT, Stevens CM, Wolfe BM. Incidence and outcome of anastomotic stricture after laparoscopic gastric bypass. *J Gastrointest Surg.* 2003 Dec;7(8):997-1003.

[61] Himpens J, Dobbeleir J, Peeters G. Long-term results of laparoscopic sleeve gastrectomy for obesity. *Ann Surg*. 2010 Aug;252(2):319-24.

[62] Di Lorenzo N, Lorenzo M, Furbetta F, Favretti F, Giardiello C, Boschi S, Alfredo G, Micheletto G, Borrelli V, Veneziani A, Lucchese M, Boni M, Civitelli S, Camperchioli I, Pilone V, De Luca M, De Meis P, Cipriano M, Paganelli M, Mancuso V, Gardinazzi A, Schettino A, Maselli R, Forestieri P. Intragastric gastric band migration: erosion: an analysis of multicenter experience on 177 patients. *Surg Endosc*. 2013 Apr;27(4): 1151-7.

[63] Kahrilas PJ, Kim HC, Pandolfino JE. Approaches to the diagnosis and grading of hiatal hernia. *Best Pract Res Clin Gastroenterol*. 2008;22(4):601-16.

[64] Moayyedi P, Talley NJ. Gastro-oesophageal reflux disease. *Lancet.* 2006 Jun 24;367(9528):2086-100.

[65] Richter JE. Diagnostic tests for gastroesophageal reflux disease. *Am J Med Sci*. 2003 Nov;326(5):300-8.

In: Encyclopedia of Surgery (22 Volume Set)
Editors: Andreas Lehrer and Kristin Mueller
ISBN: 978-1-53618-329-0
© 2020 Nova Science Publishers, Inc.

Chapter 54

ADJUSTABLE GASTRIC BAND FAILURES

J. W. M. Greve*
Dutch Obesity Clinic South,
Department of Surgery, Zuyderland Medical Center Heerlen
and Orbis Medical Center Sittard, Heerlen, the Netherlands

ABSTRACT

The adjustable gastric band is a good treatment option but requires a strict follow up and good compliance of the patient. Despite good results failures do occur either due to technical failures or patient non-compliance. Failure can also be a result of band complications.

In many cases surgical revision is possible either by repositioning of the band or replacement of the band. A back on track program and band adjustments can also result inrecovering an initial good result.

In case of band failure conversion to another technique is shown to be safe and effective. A good treatment strategy is based on the conclusions of a mandatory multidisciplinary team.

Failure of an initially successful band is rather a phase in a lifelong obesity treatment program and not a disqualification of the band as valid treatment option.

1. INTRODUCTION

In search for a safe and effective surgical treatment for morbid obesity the idea of an adjustable band was developed. As early as 1982 a first paper on adjustable gastric banding was published and mid eighties of the past century a workable device was constructed and used clinically [1, 2]. Laparoscopic placement made it a very successful and frequently used device (Cadiere, Belachew) [3, 4]. Many types of the adjustable silicone gastric band (ASGB) have been developed over the years. The most important improvement was a change from low volume high-pressure bands to high volume low-pressure bands, which reduced the risk

* Corresponding Author's Email: j.greve@atriummc.nl.

of erosion significantly. Placement of the band in the early days was peri-gastric creating the retro gastric tunnel by dissecting at the lesser curve of the stomach. This technique had a significant erosion rate probably due to micro lesions of the stomach wall. Moreover due to placement through the lesser sac with a relatively large pouch slippage and pouch dilation were a frequent problem. These problems were significantly reduced by introduction of the pars flaccida technique [5].

Over the years it has been shown that follow up is crucial in a successful treatment program in patients with an adjustable gastric band. There is a significant correlation between frequency of follow up and weight loss as was shown by Ren and colleagues [6]. Several algorithms have been proposed to improve outcome, in particular on when and how to adjust the band. The green zone concept by O'Brien based on clinical parameters is the most effective, but other options are available such as adjustments based on balloon pressure as proposed by Fried [7]. When all criteria are fulfilled (correct placement, correct type of band and an optimal follow up program) good long term results (>5 years) can be achieved that are comparable to the gastric bypass [8, 9].

Currently however, most bariatric surgeons no longer consider the adjustable band as a viable treatment option. Long term results from early series with inferior band types and poor follow up programs show very poor results with a high percentage of revisions and band removals and few patients with sufficient long-term weight loss. Poor results and the introduction of "easy, no worry, procedures" such as the gastric sleeve resection has resulted in dramatic reduction of band placements, partly under pressure of the public opinion. Nevertheless with a good patient selection and a good follow up program the adjustable band is still a very valid treatment option.

As all bariatric procedures the adjustable band is not flawless. Even in good programs problems may occur that need correction. Moreover more than 800,000 bands have been placed worldwide which means that, even with low failure rates, there will be a significant number of patients that may need a revision or conversion of the procedure.

2. BAND FAILURES

Failures of the band can be divided in several categories. Primary failures pertain to patients who never reach a desired weight loss, which can be due to a technical problem (high band position, large size of the band, malposition of the band, mechanical defect of the band etc.) or due to non-compliance of the patient (poor diet habits, failure to adhere to the follow program). A second category consists of the patients who had a successful weight loss but then regained weight. This can be due to a mechanical failure (band leakage, tubing or port disconnection, tubing breakage), slippage of the band or pouch dilation or changed dietary habits of the patient while some patients develop band intolerance. A third category consists of the patients with a band complication, a condition that often needs acute intervention. Examples are acute herniation of the stomach through the band, acute obstruction, erosion of the band, internal herniation of bowel around the tubing but also severe reflux and/or esophagus dilatation.

3. General Considerations in Revision or Conversion

When a surgical procedure is required to improve the outcome of the patient this can either be a revision/correction of the current procedure (e.g., band reposition, band replacement, port revision etc.) or a conversion to a different type of procedure [10]. Reversal is in itself an easy procedure but should only be considered on explicit patient request or under rare circumstances. Just removing the band will without exception result in weight regain and loss of the positive effect on the co-morbidities. If a band is removed it is advisable to take down the entire plication (gastro-gastric sutures) in case the patient reconsiders and comes back for a new bariatric procedure.

In all patients careful evaluation by a multidisciplinary team including a dietician, psychologist and bariatric surgeon is mandatory. This may help to identify patients who have a deteriorated eating pattern or inappropriate life style changes. In these patients a "back on track" program and careful adjustment of the band may be sufficient. However multidisciplinary team evaluation can also assist in the decision on which strategy to follow when a revisional procedure or a conversion to another technique is required. Next to evaluation of patient behavior upper gastrointestinal X-ray and or endoscopy are required to detect technical failures or band complications. The final decision for an intervention should always be based on evaluation of all results by the multidisciplinary team.

4. Primary Failure

Primary failure as a result of a technical failure should be evaluated carefully. In all patients dietary counseling is mandatory as well as evaluation of filling volume of the band. Life style modifications need to be recorded as well. Diagnosis based on these results is a multidisciplinary team effort. X-ray and or endoscopy are required to exclude a technical problem. If there is a band malfunction (leakage, band not closed) or malposition of the band (band not around the stomach) a revision of the band is required by either replacement of the band or repositioning. In case of a high band position (no stomach above the band, Figure 1C) successful reposition of the band is unlikely and conversion to another procedure is required.

Available options are Roux en Y gastric bypass (RYGB), sleeve gastrectomy (SG), biliopancreatic diversion (BPD), duodenal switch (DS) or omega loop gastric bypass. More recently some surgeons have added a gastric plication to the band but long term results are not available yet [11]. Conversion of a failed restrictive procedure to a new type of restrictive procedure is less likely to be successful. However, several authors have reported good outcomes of conversion to a SG. Nevertheless, in most series conversion to a RYGB is considered the gold standard and good outcomes are reported [10, 12]. Optionally conversion to RYGB can be done while leaving the band in place for future adjustments (adjustable banded RYGB) [13]. Although BPD and DS are feasible not many surgeons are in favor of this options [14, 15]. This is also true for the so called "Bandinaro" in which the band is left in place [9].

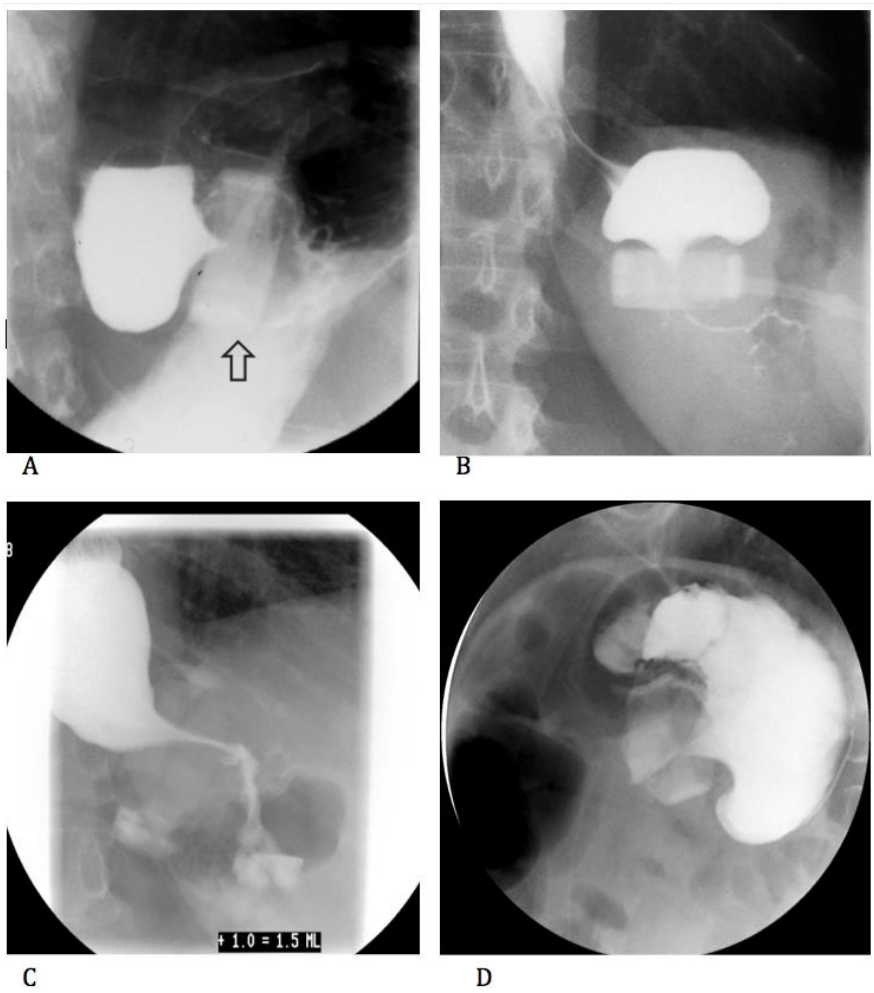

Figure 1. Upper GI X-ray of band related complications. A: posterior slippage with vertical band position. B: anterior slippage with horizontal band position. C: primary failure with high band position (no gastric pouch). D: acute herniation of the stomach through the band.

4.1. Conversion to Sleeve Gastrectomy

Since its introduction the nowadays very popular SG procedure is being used as rescue operation for the ASGB. It has been shown to be feasible and relatively safe although severe complications have been reported with a significant percentage of leaks and fistulas that are difficult to treat [16]. The procedure can be done in 1 or 2 stages with a lower reported complication rate in the latter strategy [17, 18]. Successful weight loss is reported ranging between 31-60 %EWL however there is an increased complication rate with leaks in up to 6% [10]. In a paper by the group of Rosenthal et al. comparing RYGB with SG after band it was found that in non-responders (primary failure) conversion to RYGB was more successful than SG [19].

4.2. Conversion to RYGB

Most reported series on treatment of a failing ASGB treat conversion to RYGB. In particular, in primary failures (non-responders) successful treatment is more likely with a bypass [19]. Similar to conversion to a SG a 2-stage procedure may be more safe but a large number of publications have shown the efficacy and safety of conversion to a RYGB in 1 stage [12]. Outcome after conversion to RYGB is comparable to the results of a primary RYGB with similar or slightly higher complication rates [12, 20].

4.3. Conversion to Adjustable Banded RYGB

Restriction is an important part of the working mechanism of a RYGB. Several studies have shown a benefit for a non-adjustable band placed around the pouch of the RYGB as reported by Fobi in open RYGB and more recently by Bessler in laparoscopic procedures [21, 22].

Furthermore, placement of an adjustable band around the gastric pouch of RYGB patients with weight regain was shown to be a valid option [23]. In patients with banded pouch after SAGB, all studies reported further weight loss, varying from 55.9%–94.2% excess body mass index loss (EBMIL) after 12–42 months of follow-up (Figure 2). With these considerations in mind a logical step was to leave the band in place when conversion to a RYGB was indicated, to prevent pouch dilation and to add the option for adjustments. Feasibility of this strategy has been demonstrated but larger studies with long term follow up are needed [13]. Potential problem with this treatment mode is that the band may add complications to a regular gastric bypass such as slippage, infection and erosion of the band. Most important is to protect the band from contact with the small bowel as was shown in the past with the adjustable RYGB.

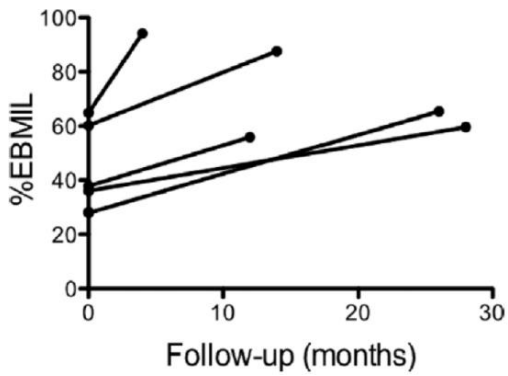

Figure 2. Salvage of failing RYGB with an adjustable band on the pouch. Excess body mass index loss (%EBMIL) after revision. Values shown for follow-up (in months) after revisional surgery (t _ 0) [23].

This was a procedure in which the pouch above the band (allowing access to the remnant stomach by opening the band) was used to anastomose the jejunum to (Figure 3). This resulted in a high erosion rate into the small bowel and the procedure was abandoned after careful evaluation [24].

In conversion of a band to adjustable band RYGB the excluded stomach can be used to create a Nissen like plication distal to the band (Greve plication) to prevent slippage and avoid contact of the SAGB with the small bowel (Figure 4).

Figure 3. Functional or adjustable gastric bypass. A procedure with a high risk of band erosion to the small bowel [24].

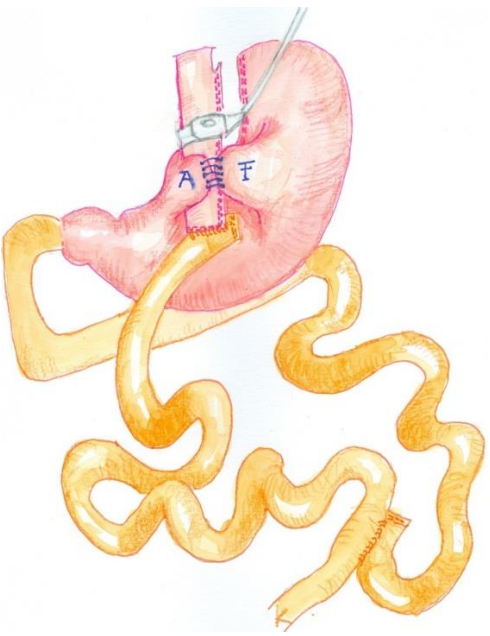

Figure 4. In conversion of a band to adjustable RYGB the excluded stomach can be used to create a Nissen like plication distal to the band (Greve plication) to prevent slippage and contact of the SAGB with the small bowel.

5. SECONDARY FAILURE

Secondary failure is defined when patients who had an initial good weight loss and resolution of co-morbidities experience significant weight regain. Causes can be patient related (diet, life style) or due to a technical problem. Minor problems such as port dislocation or port disconnection are not discussed here, as the solution is simple. The majority of secondary failures are related to pouch dilation or band slippage. In early series pouch dilation or slippage was a frequent problem in up to 40% of the patients [25]. Introduction of the pars flaccida technique has significantly reduced the incidence of slippage to 6.5% and less [8, 25].

5.1. Failure Due to Patient Compliance or Due to Band Intolerance

In patients with insufficient follow up or incorrect band adjustments (too tight or not tight enough) a "back on track" program and proper adjustment of the band may be an option. In particular a too tight band will result in wrong eating habits.

These patients can develop reflux like symptoms and often are permanently hungry due to lack of satiety. Opening the band and re-education of the patient may work. However most patients will need a conversion to a different procedure. Options are discussed in subsection 4.

5.2. Mechanical Failure of the Band

Although the adjustable bands are made of durable silicone, technical failures can occur. Breakage or unlocking of the band will result in loss of restriction and weight regain. Another cause of loss of restriction is breakage of the tubing, which is often due to material fatigue. Inserting a connecting piece can fix breakage of the tubing but it is probably better to replace the band as is the case with a broken band. Leakage of the balloon can also occur. In particular in some of the older band types (Swedish band) a fold in the balloon could cause a perforation of the balloon at inflation.

5.3. Pouch Slippage or Dilation

Definition of slippage versus pouch dilation is difficult and not relevant for the treatment. After counseling by the multidisciplinary team and proper diagnosis by radiology initial treatment can be band deflation. If there is a spontaneous reposition gradual insufflation of the band can be attempted [26]. Failure of reposition after deflation or recurrence of slippage is an indication for band reposition in patients with good weight loss. Good results have been reported also on the long term with this policy [27, 28]. In the early days posterior slippage (band in a vertical position, Figure 1A) was a frequently encountered problem with the perigastric technique. Replacing the band using the pars flaccida approach can solve this issue. In the more common anterior slippage (band in a horizontal position, Figure 1B)

laparoscopic repositioning is in general successful. An important technical aspect is the release of all gastro-gastric sutures and the gastric plication all the way to His' angle. In most cases the band can be opened and re-used. After correction of the position, fixation of the band by plication of the fundus to the pouch with a minimum of 4 non-absorbable sutures is required. Symmetrical pouch dilation probably requires conversion to RYGB because successful repositioning is less likely [26].

5.4. Gastro-Esophageal Reflux (GERD)

Secondary GERD is usually a result of a too tight band with stasis and regurgitation of food into the esophagus. Opening the band may resolve this condition. In some patients a hiatal hernia may have developed de novo or was missed during band placement. Correction by closing the hiatus and repositioning of the pouch is an option [29]. However, in general in patients with severe reflux symptoms conversion to a RYGB with, if applicable, repair of the hiatal hernia is considered to be the best option [30].

6. Band Complications and Technical Failures

6.1. Revision after Band Erosion

Band erosion can be early or late. Early erosion is most likely due to a lesion of the stomach wall at insertion or a secondary infection of the band. Late erosion can be due to over-inflation of the band but often no clear explanation is found. Symptoms are upper abdominal pain, loss of restriction and sometimes the opposite, food intolerance. Fever may occur and inflammation around the port of the band is often a first symptom of band erosion. Diagnosis is confirmed by gastroscopy, followed by CT scan that can be helpful to identify a large inflammatory mass. Treatment strategy is manifold. Once the diagnosis is confirmed the band can be removed (endoscopically or surgically). Endoscopic band cutting tools can be used for endoscopic removal but in that situation the port of the band needs to be removed first [31].

Port removal is in general advised to prevent complications due to the tubing when the band migrates in total to the stomach with the port still attached. Surgical removal is the most used option, the laparoscopic approach being the preferred one. It is possible to immediately convert to another procedure such as repair of the gastric wall defect and placement of a new band or conversion to gastric bypass [32, 33]. Alternatively after removal of the band and closure of the defect a biliopancreatic diversion can be constructed in the same session, avoiding an anastomosis in an infected and inflamed area. However, in most cases band removal and revision some 3-6 month later is preferred.

When the patient benefited from successful weight loss with the band, re-banding may be attempted. After band erosion, conversion to RYGB is nevertheless preferred and, as mentioned before, long-term results are good. In fact a 2-stage procedure allows conversion to any type of bariatric procedure later on. A 1-stage conversion to SG or RYGB is not advised because of the high complication risk, in particular leakage.

6.2. Band Obstruction

Obstruction of the band may be due to a large food particle, a bezoar or may be due to acute herniation of the stomach (see below). Symptoms are food intolerance, inability to drink and regurgitation of saliva. Occlusion of the outlet can be solved by deflation of the band or by endoscopic removal of the foreign body or food particle. Bezoar is rare but can be more problematic and, if large, may even need surgical removal. Prevention by avoiding the ingestion of indigestible fibers (asparagus, oranges etc.) is key.

6.3. Acute Herniation of the Stomach

When a patient after ASGB develops sudden food intolerance and epigastric pain he/she should be considered an emergency. When a significant part of the stomach herniates through the band incarceration of the stomach can occur with high risk of necrosis and perforation. An upper GI contrast study or even a plain abdominal X-ray is diagnostic (Figure 1D). Immediate deflation of the band followed by emergency laparoscopy is needed. At laparoscopy the band can be opened and the stomach, when ischemic but not necrotic, can be left in place for a re-laparoscopy and repositioning of the band several days later. Alternatively the band can be removed and the patient planned for elective conversion to another procedure.

CONCLUSION

There is a distinct group of patients that can effectively be treated with an adjustable silicone gastric band, which remains a safe and effective operation. However, as there is not one single surgical procedure that will be permanently effective in any patient, revisions and conversions will be required.

Patients who had a good result with the SAGB but who have either a mechanical failure or a secondary pouch problem can be treated effectively by surgical correction. It is also shown that when a band fails conversion to another technique is safe and effective. It is obvious that revisions and conversions need to be done in centers of excellence and by experienced surgeons as these procedures can be complex and do carry a slightly higher risk.

REFERENCES

[1] Forsell, P., D. Hallberg, and G. Hellers, Gastric Banding for Morbid Obesity: Initial Experience with a New Adjustable Band. *Obes. Surg.,* 1993. 3(4): p. 369-374.

[2] Kuzmak, L.I., A Review of Seven Years' Experience with Silicone Gastric Banding. *Obes. Surg., 1991*. 1(4): p. 403-408.

[3] Favretti, F., G.B. Cadiere, G. Segato, G. Bruyns, F. De Marchi, J. Himpens, C. Belluco, and M. Lise, Laparoscopic Placement of Adjustable Silicone Gastric Banding: Early Experience. *Obes. Surg.,* 1995. 5(1): p. 71-73.

[4] Belachew, M., M.J. Legrand, T.H. Defechereux, M.P. Burtheret, and N. Jacquet, Laparoscopic adjustable silicone gastric banding in the treatment of morbid obesity. A preliminary report. *Surg. Endosc.*, 1994. 8(11): p. 1354-6.

[5] O'Brien, P.E., J.B. Dixon, C. Laurie, and M. Anderson, A prospective randomized trial of placement of the laparoscopic adjustable gastric band: comparison of the perigastric and pars flaccida pathways. *Obes. Surg.*, 2005. 15(6): p. 820-6.

[6] Shen, R., G. Dugay, K. Rajaram, I. Cabrera, N. Siegel, and C.J. Ren, Impact of patient follow-up on weight loss after bariatric surgery. *Obes. Surg.*, 2004. 14(4): p. 514-9.

[7] Fried, M., The current science of gastric banding: an overview of pressure-volume theory in band adjustments. *Surg. Obes. Relat. Dis.*, 2008. 4(3 Suppl): p. S14-21.

[8] O'Brien, P.E., L. MacDonald, M. Anderson, L. Brennan, and W.A. Brown, Long-term outcomes after bariatric surgery: fifteen-year follow-up of adjustable gastric banding and a systematic review of the bariatric surgical literature. *Ann. Surg.*, 2013. 257(1): p. 87-94.

[9] Favretti, F., G. Segato, D. Ashton, L. Busetto, M. De Luca, M. Mazza, A. Ceoloni, O. Banzato, E. Calo, and G. Enzi, Laparoscopic adjustable gastric banding in 1,791 consecutive obese patients: 12-year results. *Obes. Surg.*, 2007. 17(2): p. 168-75.

[10] Brethauer, S.A., S. Kothari, R. Sudan, B. Williams, W.J. English, M. Brengman, M. Kurian, M. Hutter, L. Stegemann, K. Kallies, N.T. Nguyen, J. Ponce, and J.M. Morton, Systematic review on reoperative bariatric surgery: American Society for Metabolic and Bariatric Surgery Revision Task Force. *Surg. Obes. Relat. Dis.*, 2014. 10(5): p. 952-972.

[11] Zagzag, J., B.F. Schwack, H. Youn, C.R. Fielding, G.A. Fielding, and M.S. Kurian, Does adding a lesser-curvature gastrogastric plication suture reduce the need for revision after laparoscopic adjustable gastric band placement? *Surg. Endosc.*, 2012. 26(2): p. 514-7.

[12] Coblijn, U.K., C.J. Verveld, B.A. van Wagensveld, and S.M. Lagarde, Laparoscopic Roux-en-Y gastric bypass or laparoscopic sleeve gastrectomy as revisional procedure after adjustable gastric band--a systematic review. *Obes. Surg.*, 2013. 23(11): p. 1899-914.

[13] Meesters, B., G. Latten, L. Timmermans, R. Schouten, and J.W. Greve, Roux-en-Y gastric bypass as revisional procedure after gastric banding: leaving the band in place. *Surg. Obes. Relat. Dis.*, 2012. 8(6): p. 717-22.

[14] Slater, G., J. Duncombe, and G.A. Fielding, Poor weight loss despite biliopancreatic diversion and subsequent revision to a 30-cm common channel after initial laparoscopic adjustable gastric banding: an analysis of 8 cases. *Surg. Obes. Relat. Dis.*, 2005. 1(6): p. 573-9.

[15] Topart, P., G. Becouarn, and P. Ritz, Biliopancreatic diversion with duodenal switch or gastric bypass for failed gastric banding: retrospective study from two institutions with preliminary results. *Surg. Obes. Relat. Dis.*, 2007. 3(5): p. 521-5.

[16] Moszkowicz, D., R. Arienzo, I. Khettab, G. Rahmi, F. Zinzindohoue, A. Berger, and J.M. Chevallier, Sleeve gastrectomy severe complications: is it always a reasonable surgical option? *Obes. Surg.*, 2013. 23(5): p. 676-86.

[17] Silecchia, G., M. Rizzello, F. De Angelis, L. Raparelli, F. Greco, N. Perrotta, M.A. Lerose, and F.C. Campanile, Laparoscopic sleeve gastrectomy as a revisional procedure

for failed laparoscopic gastric banding with a "2-step approach": a multicenter study. *Surg. Obes. Relat. Dis.*, 2014. 10(4): p. 626-31.

[18] Stroh, C., D. Benedix, R. Weiner, F. Benedix, S. Wolff, C. Knoll, T. Manger, and C.N.O. Obesity Surgery Working Group, Is a one-step sleeve gastrectomy indicated as a revision procedure after gastric banding? Data analysis from a quality assurance study of the surgical treatment of obesity in Germany. *Obes. Surg.*, 2014. 24(1): p. 9-14.

[19] Marin-Perez, P., A. Betancourt, M. Lamota, E. Lo Menzo, S. Szomstein, and R. Rosenthal, Outcomes after laparoscopic conversion of failed adjustable gastric banding to sleeve gastrectomy or Roux-en-Y gastric bypass. *Br. J. Surg.*, 2014. 101(3): p. 254-60.

[20] te Riele, W.W., Y.K. Sze, M.J. Wiezer, and B. van Ramshorst, Conversion of failed laparoscopic gastric banding to gastric bypass as safe and effective as primary gastric bypass in morbidly obese patients. *Surg. Obes. Relat. Dis.*, 2008. 4(6): p. 735-9.

[21] Fobi, M.A. and H. Lee, SILASTIC ring vertical banded gastric bypass for the treatment of obesity: two years of follow-up in 84 patients [corrected]. *J. Natl. Med. Assoc*. 1994. 86(2): p. 125-8.

[22] Bessler, M., A. Daud, T. Kim, and M. DiGiorgi, Prospective randomized trial of banded versus nonbanded gastric bypass for the super obese: early results. *Surg. Obes. Relat. Dis.*, 2007. 3(4): p. 480-4; discussion 484-5.

[23] Vijgen, G.H., R. Schouten, N.D. Bouvy, and J.W. Greve, Salvage banding for failed Roux-en-Y gastric bypass. *Surg. Obes. Relat. Dis.*, 2012. 8(6): p. 803-8.

[24] Greve, J.W., F. Furbetta, G. Lesti, R.A. Weiner, J.M. Zimmerman, and L. Angrisani, Combination of laparoscopic adjustable gastric banding and gastric bypass: current situation and future prospects -- routine use not advised. *Obes. Surg.*, 2004. 14(5): p. 683-9.

[25] Schouten, R., D. Japink, B. Meesters, P.J. Nelemans, and J.W. Greve, Systematic literature review of reoperations after gastric banding: is a stepwise approach justified? *Surg. Obes. Relat. Dis.*, 2011. 7(1): p. 99-109.

[26] Ooi, G., P. Burton, C. Laurie, G. Hebbard, P.E. O'Brien, and W.A. Brown, Nonsurgical Management of Luminal Dilatation After Laparoscopic Adjustable Gastric Banding. *Obes. Surg.*, 2013.

[27] Schouten, R., F.M. van Dielen, and J.W. Greve, Re-operation after laparoscopic adjustable gastric banding leads to a further decrease in BMI and obesity-related co-morbidities: results in 33 patients. *Obes. Surg.*, 2006. 16(7): p. 821-8.

[28] Vijgen, G.H., R. Schouten, L. Pelzers, J.W. Greve, S.H. van Helden, and N.D. Bouvy, Revision of laparoscopic adjustable gastric banding: success or failure? *Obes. Surg.*, 2012. 22(2): p. 287-92.

[29] Dolan, K., R. Finch, and G. Fielding, Laparoscopic gastric banding and crural repair in the obese patient with a hiatal hernia. *Obes. Surg.*, 2003. 13(5): p. 772-5.

[30] Rogers, A.M., Improvement of esophageal dysmotility after conversion from gastric banding to gastric bypass. *Surg. Obes. Relat. Dis.*, 2010. 6(6): p. 681-3.

[31] El-Hayek, K., P. Timratana, S.A. Brethauer, and B. Chand, Complete endoscopic/transgastric retrieval of eroded gastric band: description of a novel technique and review of the literature. *Surg. Endosc.*, 2013. 27(8): p. 2974-9.

[32] Abu-Abeid, S., D. Bar Zohar, B. Sagie, and J. Klausner, Treatment of intra-gastric band migration following laparoscopic banding: safety and feasibility of simultaneous laparoscopic band removal and replacement. *Obes. Surg.*, 2005. 15(6): p. 849-52.

[33] Suter, M., V. Giusti, E. Heraief, and J.M. Calmes, Band erosion after laparoscopic gastric banding: occurrence and results after conversion to Roux-en-Y gastric bypass. *Obes. Surg.*, 2004. 14(3): p. 381-6.

In: Encyclopedia of Surgery (22 Volume Set)
Editors: Andreas Lehrer and Kristin Mueller
ISBN: 978-1-53618-329-0
© 2020 Nova Science Publishers, Inc.

Chapter 55

FAILED SLEEVE GASTRECTOMY

Ricard Corcelles*, MD, PhD
and Antonio Lacy†, MD, PhD
Insititute of Digestive and Metabolic Diseases. Gastrointestinal Surgery Department, Hospital Clinic Barcelona, Barcelona, Spain

ABSTRACT

In the last 15 years, LSG has become increasingly popular as a primary procedure because of its simplicity, relative safety, and effectiveness to achieve sustained weight loss over time. LSG has demonstrated its effectiveness in achieving weight loss and resolution of obesity related co-morbidities. Despite good success rates, it may occasionally be associated with failure. LSG failure is defined by insufficient weight loss, weight regain, surgical complications, and poor control of comorbidities such as gastro-esophageal reflux disease (GERD). As demand for LSG increases, so will the need for revisional surgeries. The incidence of revision varies according to the studies analyzed but revision rate following primary LSG is reported to be between 5-30%. Revisional surgery is technically more demanding, and associated with higher complications and mortalities compared to primary bariatric procedures. Complication rates between 0 and 46% have been reported after these reoperations. In this chapter, we will analyze the potential causes of LSG failure as well as the suggested revision surgeries.

1. INTRODUCTION

Sleeve Gastrectomy was first created by Hess and Marceau in 1998 as the first part of the duodenal switch (DS) operation [1, 2]. In high risk and super-super obese patients, the gastric sleeve part of the DS operation was often performed alone in an attempt to reduce morbidity and mortality, and to facilitate the laparoscopic approach [3].

* Corresponding Author's Email: rcorcelles@hotmail.es.
† Corresponding Author's Email: alacy@clinic.ub.es.

Owing to the relative technical ease, low complications rates and good weight loss results, it was found that laparoscopic sleeve gastrectomy (LSG) could be performed in many cases as a stand-alone bariatric operation [4]. Technical details of LSG vary, but the ultimate goal of the procedure is to remove the vast majority of the stomach, especially the fundus, leaving only a thin gastric tube from the esophagus to the duodenum. The absence of gastro-intestinal anastomosis during the operation, and leaving patients with an intact gastrointestinal (GI) tract are other potential benefits of this relatively new technique.

In the last 15 years, LSG has become increasingly popular as a primary procedure because of its simplicity, relative safety, and effectiveness to achieve sustained weight loss over time. A recent meta-analysis data by Buchwald and colleagues suggests LSG is the second leading bariatric operation in the world, only surpassed by laparoscopic Roux-en-Y gastric bypass (LRYGB) [5]. As demand for LSG increases, so will the need for revisional surgeries. In this chapter, we will analyze the potential causes of LSG failure as well as the suggested revision surgeries.

2. LAPAROSCOPIC SLEEVE GASTRECTOMY (LSG) FAILURE

LSG has demonstrated its effectiveness in achieving weight loss and resolution of obesity related co-morbidities [6]. Despite good success rates, it may occasionally be associated with failure. LSG failure is defined by insufficient weight loss, weight regain, surgical complications, and poor control of comorbidities such as gastro-esophageal reflux disease (GERD) [7, 8]. LSG patients appear to be subjected to weight regain after more than 3 years. Himpens et al., noted that more than 30% of the LSG patients had inadequate weight loss or weight regain, requiring an additional procedure [9]. This is similar to what has been reported with other restrictive weight loss operations such as the adjustable gastric band (AGB), or the vertical banded gastroplasty (VBG) [10, 11]. Several factors may be responsible for late weight regain after sleeve gastrectomy. These factors include dietary factors, and changing eating habits to high caloric meals. Long term anatomic changes with the sleeved stomach dilatation might allow the patient to consume larger amounts of food, thus contributing to weight regain as well [12]. Furthermore, loss of patient follow-up and counseling, may also play an important role in weight regain. Surgical complications after LSG can lead to procedural failure [8]. A recent systematic review of the literature on LSG including a total of 15 studies (n = 940 patients) revealed overall complication rates of 12.1%. Reported complications include bleeding or leakage from the staple line, strictures, delayed gastric emptying, gastric dilation, and vomiting [13]. LSG failure is however multifactorial and finds a feeding ground in patient's poor adherence, procedure failure, and surgeon error.

3. REVISIONAL SURGERY AFTER LSG FAILURE

The prevalence of revisional surgery increases as the number of LSG procedures rises. The incidence of revision varies according to the studies analyzed but revision rate following primary LSG is reported to be between 5% and 30% [9].

Revisional surgery is technically more demanding, and associated with higher complications and mortality compared to primary bariatric procedures. Complication rates between 0 and 46% have been reported after these procedures [7]. Revision of previous bariatric operations carries a higher overall risk of leakage. A review of revisional bariatric surgeries conducted by Jones et al., (n = 838 patients) reported a 14% (n = 118) major complication rate and 0.8% (n = 7) mortality rate. The study also noted that complication rates were lower in the laparoscopic patients with no mortalities in this group [14]. This challenging scenario obligates bariatric surgeons to have solid options in revisional surgery after LSG failure [15-19]. Revisions are technically demanding due to the increased tissue fibrosis and the altered anatomy following the primary procedure [20]. The currently accepted alternatives for the patients who require revisional surgery for failed LSG are detailed as follows.

3.1. Laparoscopic Re-Sleeve Gastrectomy (LRSG)

Laparoscopic re-sleeve gastrectomy (LRSG) was initially reported in 2003 as revision for poor weight loss after DS [21]. Since its first description by Gagner et al., several case series have been published [13]. Baltasar et al., showed feasibility of LRSG in the super-super obese patients, when the resulting gastric pouch is too large or dilated after the original LSG [12]. Another retrospective study included 13 patients with ineffective weight loss (%EWL < 50%) or weight regain who underwent LRSG. All patients underwent a preoperative upper GI series showing persistent fundus at the time of revision. Weighted mean preoperative body mass index (BMI) and excess weight were 44.6 kg/m^2 and 61.8 kg, respectively. After 12 months follow-up, mean BMI, percent of EWL, and percent of BMI loss decreased to 27.5 kg/m^2, 71.4%, and 82.8%, respectively. There was no morbidity reported [16]. However, LRSG results are far from being complications free, and complications at time may be severe in nature [22]. Within a smaller case series study (n = 7) of patients undergoing LRSG Dapri et al., reported one leak at the angle of His, and less successful weight loss than for primary cases [15]. Interestingly, Rebibo et al., retrospectively evaluated outcomes in 15 patients having LRSG after failure of LSG [18]. These patients were matched (age, gender, BMI, and co-morbidities) 1:2 with patients undergoing first line LSG. The mean operating time was longer in the LRSG (116 vs. 86 min; $p \leq 0.01$), and postoperative complications were higher in the re-sleeved patients. Two patients experienced leakage and one died. At 12 months the EWL was 66% for the LRSG and 77% for the primary LSG group ($p = 0.05$) [18].

The results of the above mentioned studies suggest that LRSG can achieve significant short-term weight loss at 24 months follow-up but at the cost of substantial peri-operative complications.

3.2. Laparoscopic Gastric Bypass (LRYGBP) or Omega Loop Mini Gastric Bypass (LMGB)

The conversion of a failed LSG to laparoscopic gastric bypass (LGB), considered by many the “gold standard” bariatric procedure, has been accepted as a revisional option because of the reasonable balance between weight loss and complications.

A recently published systematic review of revisional surgery following failed primary LSG reported weight loss improvement in more than 100 patients (6 studies) with laparoscopic gastric bypass (LGB) (laparoscopic Roux en Y gastric bypass (LRYGB) or omega loop mini gastric bypass (LMGB)) as a revisional procedure [23]. Mean preoperative BMI was 41.9 kg/m^2, which decreased after conversion to 38.9 kg/m^2 at 3 months, 36.5 kg/m^2 at 6 months, 33.7 kg/m^2 at 12 months, and 35.7 kg/m^2 at 24 or more months of follow-up. Percentage of EWL was 48% over the last follow-up period (i.e., 24 months). Similar trends in weight loss results have been recently published with 21 patients undergoing LMGB; a single gastro-jejunal bypass anastomosis connecting the gastric sleeve to a jejunal loop (200 cm downstream from the ligament of Treitz). Mean BMI at 12 and 24 months after LMGB was 34.6 kg/m^2 and 35.7 kg/m^2, respectively [24].

The Fourth International Consensus Summit on Sleeve Gastrectomy [25], a recent survey of 88 bariatric surgeons experienced in LSG (average of 295 operations per surgeon), reported that LRYGB was the preferred option if a second operation is required for weight regain after LSG [25]. Twenty % consider LRSG, 46% conversion to LRYGB and 24% conversion to BPDDS.

However, strong evidence suggests weight loss outcomes after LGB are similar to those after LRSG. Cheung et al., [23], reported short-term weight loss outcomes after failed LSG. At 24 months, mean BMI and percentage EWL were 35.7 kg/m^2 and 48%, for the LGB group (n = 114) vs. 35.3 kg/m^2 and 44%, for the LRSG group (n = 45). The article review concludes there are no significant differences in weight loss improvement between both procedures. Langer et al., reported satisfactory results of 8 patients converted to LGB because of insufficient weight loss and severe reflux disease [17]. Interestingly, the authors emphasized that patients undergoing conversion to LGB after LSG could be more prone to regain weight.

Perioperative complications after LGB as revisional procedure have also been reported. Moszkowicz et al., described a morbidity rate of 9.5% after LMGB [24]. A prospective case series study from the Netherlands (n = 18 patients) reported successful results within the LGB as a revision procedure in terms of weight loss, GERD, and dysphagia [19].

However, associated peri-operative complications were significantly high and included anastomotic leakage (n = 2), intra-abdominal bleeding (n = 2), splenectomy, wound infection, and cardiac decompensation.

LSG has been reported to carry a risk of GERD. A retrospective study (n = 30) evaluated long term side effects after LSG. More than 20% of patients in the study reported severe GERD or vomiting at 6 years after the procedure [9]. Weiner et al., reports a 15% incidence of GERD in a cohort of 76 subjects, which was improved by conversion to LGB [26].

In this clinical situation, conversion to LGB is a consistent option for management of GERD related complications after LSG (Figures 1-4).

3.3. Laparoscopic Biliopancreatic Diversion with Duodenal Switch (BPDDS)

Sleeve gastrectomy was primarily planned as the first stage of a two stage duodenal switch, hence making the BPDDS a logical candidate for revisional surgery after SG. However, patients who underwent LSG, as a premeditated and planned strategy for eventually performing BPDDS should not be considered as benefiting from a “true revisional procedure” for failure and are not analyzed in this chapter.

Figure 1. Conversion from LSG to LGB.

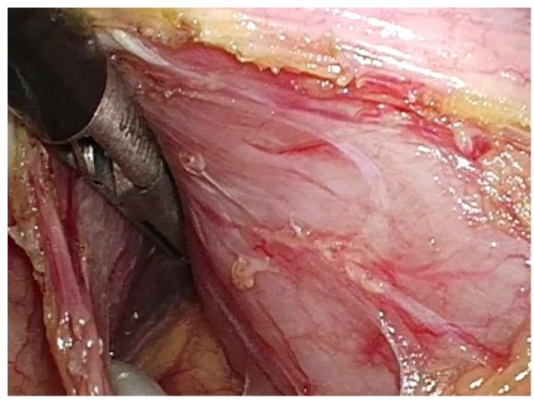

Figure 2. Conversion from LSG to LGB; gastric sleeve dissection.

LSG conversion to BPDDS has some potential advantages. There is no need to dissect and manipulate the stomach, which may ultimately decrease gastric leak rates, and other peri-operative complications compared to those observed in a primary BPDDS procedure.

Single-stage BPDDS has been reported to have higher complications rates [27]. Iannelli et al., retrospectively compared 110 super-obese patients (BMI $\geq$ 50 kg/m^2) undergoing the two staged DS with 110 patients (matched for age, gender and BMI) undergoing the single-stage DS [28]. The postoperative complication rate was 8.2% in the staged approach and 15.5% in the single-stage DS group. Multivariate analysis showed that single-stage DS was the only predictive factor of complications (odds ratio 2.36; 95% confidence interval 1.001-5.61) [28]. A small study evaluated outcomes in 9 patients with failed LSG converted to DS [15].

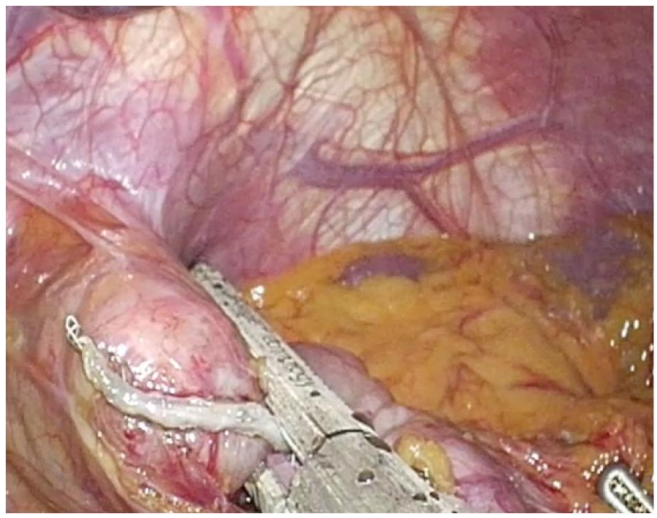

Figure 3. Conversion from LSG to LGB; gastric pouch transaction.

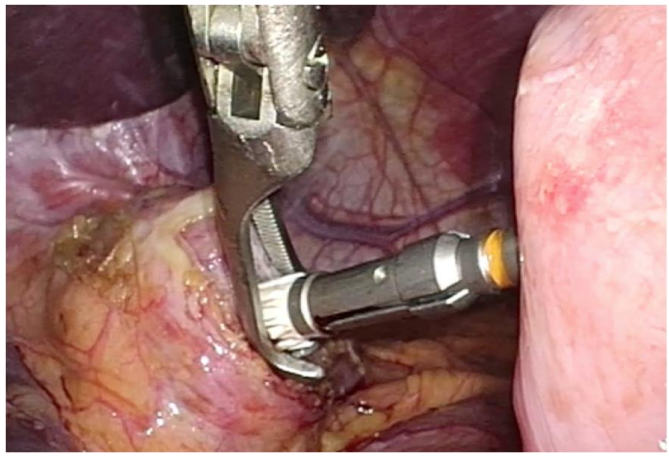

Figure 4. Conversion from LSG to LGB; gastrojejunal anastomosis.

There were no conversions in the study but operative time was considerably long (mean 152.6 ± 54.3 minutes). Complications included one patient with bleeding, one patient with a duodenoileostomy leak, and one with a duodenoileostomy stenosis. Weight loss at 25 months follow-up was successful; mean 25 month BMI and percent EWL was 27.3 ± 5.2 kg/m^2 and 73.7 ± 27.7%. During follow-up, 2 patients required revision due to hypoproteinemia and diarrhea (feeding jejunostomy tube) [15].

Thus, BPDDS as revisional surgery after LSG failure, promotes substantial weight loss improvement but at the cost of relatively high complication rates.

3.4. Miscellanea of Revisional Procedures

After failed sleeve gastrectomy, some alternative procedures have been described in an attempt to minimize surgical complications and improve weight loss outcomes.

Among these, single anastomosis duodenoileal bypass [29], plication of the sleeve [30], banded sleeve [31], butterfly gastroplasty (micro funnel shaped pouch) [32], and side to side jejunoileal anastomosis, are the most important.

Results however continue to remain limited to case reports, and very small case series, hence no conclusions can be drawn.

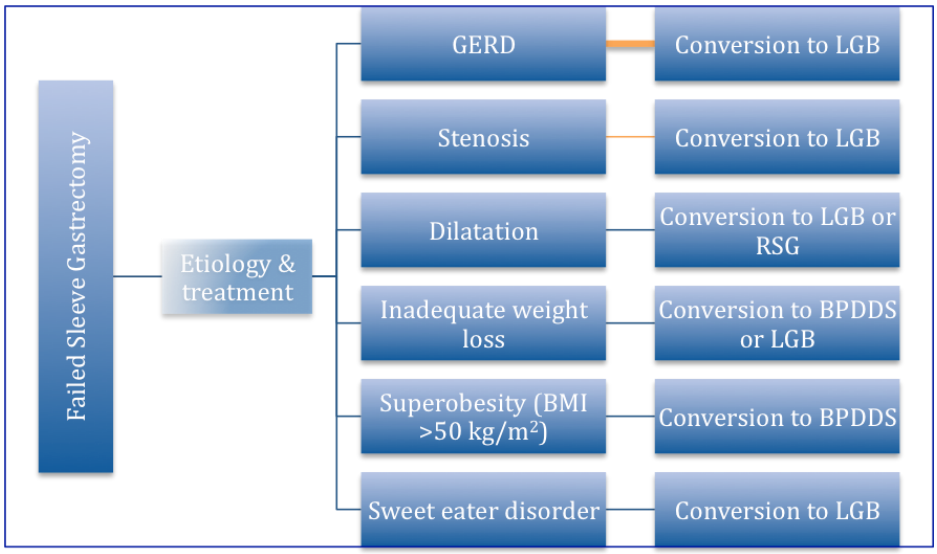

Figure 5. Proposed algorithm of treatment after LSG failure.

Table 1. Failed Primary Laparoscopic Sleeve Gastrectomy Studies

Author	Year of publication	Type of study	n (size)	Age (years)	Pre-op BMI (kg/m^2)	Revisional Procedure
Abdel-Galil*	2013	Case series	40	32	48	Butterfly gastroplasty
Chevallier	2013	Case series	38	49.5	44	LMGB
Dapri	2011	Case control	7	44	38.9	LRSG
Dapri	2011	Case control	19	47.2	36.9	BPDDS
Gautier	2013	Case series	15	39.7	40.9	LRYGB
Iannelli	2011	Case series	13	40.3	34.9	LRSG
Langer	2010	Case series	8	35.8	47	LRYGB
Lech*	2013	Case series	10	n/a	n/a	LRSG
Nienhuijs	2011	Case series	29	n/	45	LRYGB and open
Rebibo	2012	Case series	15	47	41.5	LRSG
Van Rutte	2012	Case series	18	46.5	32.3	LRYGB
Wadhawan	2013	n/a	6	42	38	LRYGB

*only abstract available.

CONCLUSION

In general, revisional surgery is technically more demanding than primary bariatric procedures, and must be performed with extreme care. Such operations should be carried out in tertiary centers with experienced bariatric surgery programs that can limit the incidence and severity of peri-operative complications.

Furthermore, the selected type of revisional procedure should take three different considerations into account: the individual patient history and cause of failure, the difficulty of the revisional procedure, and the bariatric surgeon's experience.

After thorough revision of the available literature, it appears that revisional surgery for LSG failure overall offers weight loss improvement at 24 months. In summary: while LRSG, and LGB appear to be reasonable options with well-adjusted results and complication rates, the conversion to a BPDDS appears to create an increased weight loss but at the cost of major morbidity. LGB can effectively manage intractable GERD after LSG. Unfortunately, the data in revisional sleeve gastrectomy is limited, and long term randomized controlled studies are required to compare weight loss outcomes and complication rates.

REFERENCES

[1] Hess, D. S., Hess, D. W. Biliopancreatic diversion with a duodenal switch. *Obes. Surg*. 1998 Jun;8(3): 267-821. PMID: 9678194.

[2] Marceau, P., Biron, S., St Georges, R., Duclos, M., Potvin, M., Bourque, R. A. Biliopancreatic Diversion with Gastrectomy as Surgical Treatment of Morbid Obesity. *Obes. Surg*. 1991 Dec;1(4):381-387. PMID: 10775939.

[3] Regan, J. P., Inabnet, W. B., Gagner, M., Pomp, A. Early experience with two-stage laparoscopic Roux-en-Y gastric bypass as an alternative in the super-super obese patient. *Obes. Surg*. 2003 Dec;13(6):861-4. PMID: 14738671.

[4] Franco, J. V., Ruiz, P. A., Palermo, M., Gagner, M. A review of studies comparing three laparoscopic procedures in bariatric surgery: sleeve gastrectomy, Roux-en-Y gastric bypass and adjustable gastric banding. *Obes. Surg*. 2011 Sep;21(9):1458-68. PMID: 21455833.

[5] Buchwald, H., Oien, D. M. Metabolic/bariatric surgery worldwide 2011. *Obes. Surg*. Apr;234. PMID: 23338049.

[6] Yang, X., Yang, G., Wang, W., Chen, G., Yang, H. A meta-analysis: to compare the clinical results between gastric bypass and sleeve gastrectomy for the obese patients. *Obes. Surg*. 2013 Jul;23(7):1001-10. PMID: 23595210.

[7] Lim, C. S., Liew, V., Talbot, M. L., Jorgensen, J. O., Loi, K. W. Revisional bariatric surgery. *Obes. Surg*. 2009 Jul;19(7):827-32. PMID: 18972173.

[8] Lacy, A., Ibarzabal, A., Pando, E., Adelsdorfer, C., Delitala, A., Corcelles, R., Delgado, S., Vidal, J. Revisional surgery after sleeve gastrectomy. *Surg. Laparosc. Endosc. Percutan. Tech*. 2010 Oct;20(5): 351-6. PMID: 20975509.

[9] Himpens, J., Dobbeleir, J., Peeters, G. Long-term results of laparoscopic sleeve gastrectomy for obesity. *Ann. Surg*. 2010 Aug;252(2):319-24. PMID: 20622654.

[10] Scozzari, G., Farinella, E., Bonnet, G., Toppino, M., Morino, M. Laparoscopic adjustable silicone gastric banding vs laparoscopic vertical banded gastroplasty in morbidly obese patients: long-term results of a prospective randomized controlled clinical trial. *Obes. Surg*. 2009 Aug; 19(8):1108-15. PMID: 19513797.

[11] Camerini, G., Adami, G., Marinari, G. M., Gianetta, E., Pretolesi, F., Papadia, F., Marini, P., Murelli, F., Carlini, F., Stabilini, C., Sormani, M. P., Scopinaro, N. Thirteen years of follow-up in patients with adjustable silicone gastric banding for obesity: weight loss and constant rate of late specific complications. *Obes. Surg*. 2004 Nov-Dec; 14(10):1343-8. PMID: 15603649.

[12] Baltasar, A., Serra, C., Perez, N., Bou, R., Bengochea, M. Re-sleeve gastrectomy. *Obes. Surg*. 2006 Nov;16(11):1535-8. PMID: 17132421.

[13] Shi, X., Karmali, S., Sharma, A. M., Birch, D. W. A review of laparoscopic sleeve gastrectomy for morbid obesity. *Obes. Surg*. 2010 Aug;20(8):1171-7. PMID: 20379795.

[14] Jones, K. B., Jr. Revisional bariatric surgery--potentially safe and effective. *Surg. Obes. Relat. Dis*. 2005 Nov-Dec;1(6):599-603. PMID: 16925301.

[15] Dapri, G., Cadiere, G. B., Himpens, J. Laparoscopic repeat sleeve gastrectomy versus duodenal switch after isolated sleeve gastrectomy for obesity. *Surg. Obes. Relat. Dis*. 2011 Jan-Feb;7(1):38-43. PMID: 21115409.

[16] Iannelli, A., Schneck, A. S., Noel, P., Ben Amor, I., Krawczykowski, D., Gugenheim, J. Re-sleeve gastrectomy for failed laparoscopic sleeve gastrectomy: a feasibility study. *Obes. Surg*. 2011 Jul;21(7):832-5. PMID: 20924713.

[17] Langer, F. B., Bohdjalian, A., Shakeri-Leidenmuhler, S., Schoppmann, S. F., Zacherl, J., Prager, G. Conversion from sleeve gastrectomy to Roux-en-Y gastric bypass--indications and outcome. *Obes. Surg*. 2010 Jul;20(7):835-40. PMID: 20393810.

[18] Rebibo, L., Fuks, D., Verhaeghe, P., Deguines, J. B., Dhahri, A., Regimbeau, J. M. Repeat sleeve gastrectomy compared with primary sleeve gastrectomy: a single-center, matched case study. *Obes. Surg*. 2012 Dec;22(12):1909-15. PMID: 23001573.

[19] van Rutte, P. W., Smulders, J. F., de Zoete, J. P., Nienhuijs, S. W. Indications and short-term outcomes of revisional surgery after failed or complicated sleeve gastrectomy. *Obes. Surg*. 2012 Dec;22(12):1903-8. PMID: 23001572.

[20] Khaitan, L., Van Sickle, K., Gonzalez, R., Lin, E., Ramshaw, B., Smith, C. D. Laparoscopic revision of bariatric procedures: is it feasible?. *Am. Surg*. 2005 Jan;71(1): 6-10. PMID: 15757050.

[21] Gagner, M., Rogula, T. Laparoscopic reoperative sleeve gastrectomy for poor weight loss after biliopancreatic diversion with duodenal switch. *Obes. Surg*. 2003 Aug;13(4): 649-54. PMID: 12935370.

[22] Trelles, N., Gagner, M., Palermo, M., Pomp, A., Dakin, G., Parikh, M. Gastrocolic fistula after re-sleeve gastrectomy: outcomes after esophageal stent implantation. *Surg. Obes. Relat. Dis*. 2010 May-Jun;6 (3):308-12. PMID: 20060368.

[23] Cheung, D., Switzer, N. J., Gill, R. S., Shi, X., Karmali, S. Revisional bariatric surgery following failed primary laparoscopic sleeve gastrectomy: a systematic review. *Obes. Surg*. 2014 Oct;24(10):1757-63. PMID: 24927693.

[24] Moszkowicz, D., Rau, C., Guenzi, M., Zinzindohoue, F., Berger, A., Chevallier, J. M. Laparoscopic omega-loop gastric bypass for the conversion of failed sleeve gastrectomy: early experience. *J. Visc. Surg*. 2013 Dec;150(6):373-8. PMID: 24139677.

[25] Gagner, M., Deitel, M., Erickson, A. L., Crosby, R. D. Survey on laparoscopic sleeve gastrectomy (LSG) at the Fourth International Consensus Summit on Sleeve Gastrectomy. *Obes. Surg*. 2013 Dec;23(12):2013-7. PMID: 23912263.

[26] Weiner, R. A., Theodoridou, S., Weiner, S. Failure of laparoscopic sleeve gastrectomy--further procedure?. *Obes. Facts*. 2011;4 Suppl. 1: 42-6. PMID: 22027290.

[27] Buchwald, H., Estok, R., Fahrbach, K., Banel, D., Sledge, I. Trends in mortality in bariatric surgery: a systematic review and meta-analysis. *Surgery*. 2007 Oct;142(4): 621-32. PMID: 17950357.

[28] Iannelli, A., Schneck, A. S., Topart, P., Carles, M., Hebuterne, X., Gugenheim, J. Laparoscopic sleeve gastrectomy followed by duodenal switch in selected patients versus single-stage duodenal switch for superobesity: case-control study. *Surg. Obes. Relat. Dis*. 2013 Jul-Aug;9(4):531-8. PMID: 22498357.

[29] Sanchez-Pernaute, A., Rubio, M. A., Perez Aguirre, E., Barabash, A., Cabrerizo, L., Torres, A. Single-anastomosis duodenoileal bypass with sleeve gastrectomy: metabolic improvement and weight loss in first 100 patients. *Surg. Obes. Relat. Dis*. 2013 Sep-Oct;9(5):731-5. PMID: 22963820.

[30] Abdelbaki, T. N., Huang, C. K., Ramos, A., Neto, M. G., Talebpour, M., Saber, A. A. *Gastric plication for morbid obesity: a systematic review*. 2012 Oct;22(10):1633-9. PMID: 22960951.

[31] Karcz, W. K., Karcz-Socha, I., Marjanovic, G., Kuesters, S., Goos, M., Hopt, U. T., Szewczyk, T., Baumann, T., Grueneberger, J. M. To band or not to band--early results of banded sleeve gastrectomy. *Obes. Surg*. 2014 Apr;24(4):660-5. PMID: 24464518.

[32] Abdel-Galil, E. S. A. Laparoscopic butterfly gastroplasty after failed sleeve gastrectomy in morbidly obese patient. Only abstract available. *Obes. Surg*. 2013; 238.

In: Encyclopedia of Surgery (22 Volume Set)
Editors: Andreas Lehrer and Kristin Mueller
ISBN: 978-1-53618-329-0
© 2020 Nova Science Publishers, Inc.

Chapter 56

REOPERATIONS FOR ROUX-EN-Y GASTRIC BYPASS FAILURES

Jacques M. Himpens[1,*], MD, PhD
and Ramon Vilallonga[†], MD, PhD
[1]Division of Bariatric Surgery, Chief of Department
AZ St-Blasius, Division of Bariatric Surgery,
Dendermonde, Belgium
[2]Endocrine, bariatric and metabolic Unit,
General Surgery and robotic Department, Consultant surgeon
Universitary Hospital Vall Hebron, Universitat Autònoma de Barcelona,
Endocrine, bariatric and metabolic Unit, General Surgery Department,
Barcelona, Spain

ABSTRACT

The Roux-en-Y gastric bypass procedure is considered by many the "state of the art" bariatric intervention. Nevertheless, as any other weight loss/ metabolic operation it requires a strict follow up and good patient compliance to avoid the development of poor dietary habits. The most dreaded dietary flaw is without doubt sweets eating, which constitutes the ruin for all bariatric procedures. Poor weight loss outcomes may however be the consequence of anatomical aberrations of the bypass construction as well. In addition, surgical complications may arise all along the postoperative course of the bypass patients. Complications and anatomical flaws may warrant surgical intervention to correct the anatomy, or, in some occasions, to radicalize the bypass or to convert the bypass to another type of bariatric/metabolic procedure.

The decision to surgically re-intervene must be backed up by the conclusions of a multidisciplinary consultation.

[*] Corresponding Author's Email: jacques_himpens@hotmail.com.
[†] Corresponding Author's Email: vilallongapuy@hotmail.com.

INTRODUCTION

The Roux-en-Y gastric bypass (RYGB) is considered the gold standard for bariatric ("metabolic") surgery. The procedure existed long before the laparoscopic infatuation and survived the rise of several upcoming fashionable operations such as the adjustable band (AGB) and the previously abandoned vertical banded gastroplasty (VBG) (the latter witnessed a revival because of the laparoscopic approach [1])

RYGB has undergone a substantial evolution over the years, both with the open, "classic" or the minimally invasive approach. In its initial embodiment RYGB as proposed by Mason [2] involved the creation of a horizontal stomach pouch, which, consequently, comprised a significant portion of the stomach fundus. With time, it became clear that the construction with horizontal stomach pouch was quite sensitive to dilation and subsequent failure. Newer versions of the RYGB, involving the use of the lesser curvature part of the cardia for pouch creation were popularized by surgeons such as Griffen [3]. With the advent of laparoscopy the technically quite complex RYGB procedure experienced a drop in popularity to the benefit of LAGB. In 1994 however Allan Wittgrove [4] and colleagues succeeded in performing a full- laparoscopic RYGB (LRYGB). Nevertheless, it took several years before the laparoscopic procedure benefited from general acceptance by the surgical community. Recently, the laparoscopic version of RYGB regained the pole position in terms of most popular and most performed bariatric operation [5]. Presently LRYGB is usually performed according to a few technical variations. Whereas initially the alimentary limb (AL) (Figure 1) was constructed some 150 cm long and the biliopancreatic limb (BPL) was kept rather short (which would allow endoscopic access to the excluded duodenum, stomach and biliary tree), more recently there is a tendency to reduce the length of the AL and to lengthen the BPL [6].

This new modification allegedly increases weight loss and enhances the metabolic impact of the construction.

In terms of anastomotic technique in RYGB, some surgeons prefer the handsewn technique [7], in contrast with others who choose the circular stapled technique [8] or the linear stapled technique [9]. Most surgeons by now close the potential hernia defects (Figure 2), but others claim that closure is not necessary [10]

Despite the popularity of LRYGB, many surgical teams recently made the switch to supposedly simpler procedures including the sleeve gastrectomy (LSG) and the mini gastric bypass (MGB), often called the omega loop or single anastomosis gastric bypass (OLGB, respectively SAGB). Of note, the "newer" procedures have not yet sustained the test of time and little is known about the long-term outcomes.

Over the years it has been shown that follow-up is crucial for a successful gastric bypass. Adequate follow-up with periodical blood analysis is necessary, not only to dietary flaws (especially the abuse of carbohydrates and simple sugars), but also to detect the development of vitamin, mineral and protein deficiencies [11].

As all bariatric procedures LRYGB has some drawbacks. Even with good follow-up, problems may occur that need correction. Consequently, considering the high number of patients who have undergone LRYGB, it is inevitable that some individuals will need correction of the bypass construction for different reasons. It is the aim of this chapter first to analyze possible complications or unwanted side effects (such as insufficient weight loss and

weight regain) that will need correction, and, second, to provide solutions to address this issue.

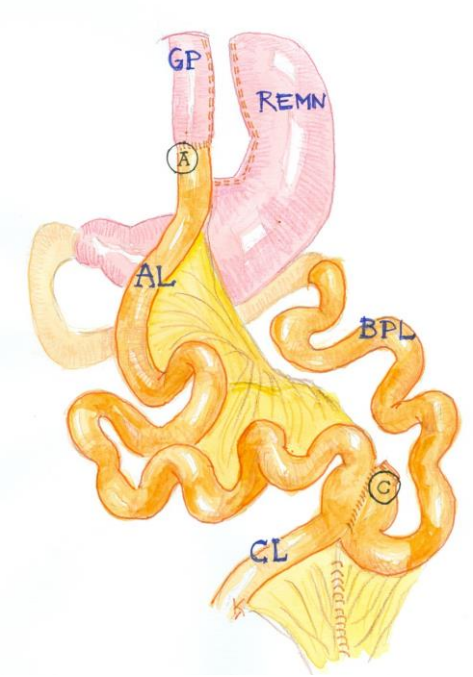

Figure 1. The typical "old fashioned" Roux-en-Y gastric bypass with relatively short biliopancreatic limb (BPL). The small gastric pouch (GP) is anastomosed to the alimentary limb (AL) that lies anterior to the stomach remnant (REMN) and the colon. The junction of AL and BPL results in the common limb (CL).

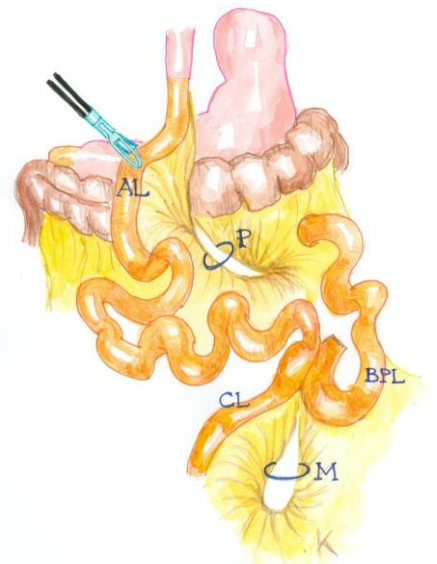

Figure 2. The 2 most important defects created by the Roux construction: Petersen's defect (P) between the mesentery of the alimentary limb (AL) and the transverse mesocolon and the mesenteric gap situated between the mesenteries of the biliopancreatic (BPL) and the common limb (CL).

1. Types of Failures

Failures of gastric bypass can be divided into several categories:

- Some patients never reach sufficient weight loss, which may be due to anatomical reasons or to lack of discipline of the patient (poor diet habits, failure to adhere to the follow-up program). These failures are considered *primary failures*.
- Some patients initially did experience successful weight loss but subsequently suffered weight regain. This evolution may be due to anatomical reasons (such as pouch dilation or gastrogastric fistula), but is most often caused by changed dietary habits of the patient. These failures are called *secondary failures.*
- Some patients suffer a *complication* that demands surgical correction. Examples of complication are intractable gastro-esophageal reflux (GERD), with or without hiatal hernia (HH), herniation of the gastric remnant through the hiatus, food intolerance because of long-term anastomotic stenotic problems, ulceration of the anastomosis, ulceration in the gastric remnant, blind loop symptoms at the level of the gastro-enteral or the entero-enteral (jejunojejunal or JJ) anastomosis, internal herniation with obstruction of the AL, the BPL or the common limb (CL), intussusception at the level of the alimentary-biliopancreatic confluent, trocar incision herniation, and problems concerning glucose metabolism, such as neuroglycopenia.

2. General Considerations in Revision or Conversion

As in every bariatric-metabolic procedure it is essential to analyze the cause of failure of LRYGB,. Analysis must involve thorough evaluation of the anatomical integrity of the bypass construction. Anatomical alterations often may remain silent and not interfere with the clinical outcome. In face of poor clinical results, however, anatomical alterations should be addressed. Alterations may be situated in any of the components (i.e., the gastric pouch, shape or volume, the diaphragmatic hiatus, the length of the limbs). In some occasions the aberrant anatomy may be deemed too complicated and conversion to a different type of procedure (e.g. conversion to a distal RYGB) while keeping the gastric pouch and anastomosis as they are may be preferred. The most radical conversion procedure consists of reversal but should only be considered under rare circumstances.

Simple reversal will most likely result in weight regain and resurgence of co-morbidities. Consequently, reversal procedures will most often be combined with conversion to a restrictive construction such as SG.

Whenever a substantial change in anatomical construction is anticipated, a multidisciplinary team should be consulted to address all the aspects of the required therapeutic change. In our practice, the multidisciplinary team consists of a dietitian, a psychologist, a gastroenterologist, an endocrinologist, and, last but not least, the bariatric surgeon. Multidisciplinary evaluation is organized by the *bariatric coordinating nurse*, who because she personally knows the patients can best evaluate the capacity of the patient to deal with newly induced dietary restrictions, lifestyle changes, compliance with supplementation and medication and acceptance of a proposed new operation. The *psychologist*'s task is to

evaluate how the patient has progressed since the preoperative assessment. In some instances the patient will demonstrate a psychological incapacity or refusal to deal with the characteristics of the bypass. In contrast, sometimes the patient may have developed unrealistic expectations and must be taught to accept the actual outcome of the LRYGB in terms of weight loss, even when the outcome does not match his/her expectations. The patient must also be educated about the impact of a new surgical procedure that may, for example, significantly impair the capacity of ingesting food. This impairment may in some occasions surpass the psychological capacities of the individual. The *dietitian* analyzes the patient's dietary response to the bypass itself. When restriction is still active, some patients overcome the imposed small size of meals by increasing the frequency of meals (polyphagia). When restriction has weaned off, patients often experience the tendency to increase the size of their meals (hyperphagia) [12]. Alternatively, some subjects no longer observe the strict dietary restrictions such as the abstinence from sugars that were imposed at the time of surgery. Typically, some patients will preferably choose carbohydrates, especially liquid ones, because they no longer experience any dumping sensation - the alleged primary deterrent from ingesting sweets [13]. Typically, sweets eating will not warrant a surgical solution, because, as demonstrated by Scopinaro, this evolution is resistant to all bariatric constructions [14]. Consequently, the dietitian's main task consists of putting the patient back on the "right track".

The *gastroenterologis*t and the *radiologis*t evaluate the shape and volume of the different bypass components and will in addition check for possible significant changes such as marginal ulcers, HH, or gastrogastric fistula. Besides confirming the diagnosis made by the radiologist, the endoscopist may attempt to correct some of the detected anatomical aberrations and proceed to reducing the size of the pouch or trying to close a gastrogastric fistula. Interventional endoscopy has recently gained an important position in the correction of bypass failures but because of the novelty of the technique and lack of mid- to long-term outcome reports this aspect will not be further addressed in the present chapter.

The e*ndocrinologis*t investigates the possible insufficient improvement or resurgence of comorbidities, and, depending on the severity of the findings, may orient towards a surgical solution to address this issue. Conditions amenable to improvement with operative treatment include dyslipidemia, arterial hypertension (AHT) and type 2 diabetes (T2DM). When the aforementioned diseases have not substantially improved, or have re-emerged after initial remission or improvement either the patient's dietary compliance or the team's choice for the bypass procedure itself may be questioned.

The *bariatric surgeon* must evaluate the safety of an anticipated re-intervention, taking the specific history of the patient into account. Patients who postoperatively suffered a leak at the gastro-enterostomy for instance may not be ideal candidates for undergoing procedures involving the pouch part of the RYGB construction. Depending on the indication, the surgeon may decide to opt for a procedure that will influence the length of the limbs rather than to alter the volume of the pouch.

The final decision for any bariatric reintervention should always be based on evaluation of all results by the *multidisciplinary team*.

3. Primary Failure

Primary failures are rare after RYGB. Except for the cases where the patient displays an outrageous lack of dietary discipline, primary failures should always raise the suspicion of anatomical causes. In primary failures the most obvious culprit for poor weight loss is a poorly designed gastric pouch, that may have been constructed too large, or that has been made of parts of the stomach that are too distensible. Several strategies have been described to address this issue.

3.1. Reshaping the Pouch

A poorly constructed gastric pouch (i.e., too large a pouch, or a pouch including the fundus) may be found, usually in patients who previously underwent another bariatric procedure such as LAGB or LSG, and in whom poor dissection of the apical part of the stomach results in the keeping of a large pouch, usually located posteriorly. Another possible anatomical cause for poor weight loss is the presence of a gastrogastric fistula, a condition that results in the abolition of the bypass physiology. The gastrogastric fistula may sometimes be the result of an imperfect transection of the stomach, usually located at the uppermost part of the staple line [15], but is most often caused by a perforating marginal ulcer, that connects the staple line of the anastomosis with the horizontal staple line on the remnant stomach [16]. Diagnosis and treatment strategy are based on a multidisciplinary approach. It is however noteworthy that in some occasions a gastrogastric fistula will only be discovered at surgical re-exploration. Correction of too large a pouch consists of extensive dissection of the gastric pouch, but only on the left sided part of the latter to avoid ischemic problems, because the blood supply essentially is provided by the vessels at the lesser curvature side of the stomach pouch. Usually the anastomosis itself can be kept as is. After complete dissection of the gastric pouch a re-resection can be performed under safe conditions, guided by a large bore gastric tube introduced by the anesthesiologist and kept in close contact with the lesser curvature of the stomach pouch. The resection of the pouch is best performed with a linear stapler with green or black load because the tissues invariably will be thickened. Alternatively, the fully dissected lateral aspect of the gastric pouch can be imbricated (or plicated), which has the advantage of being cheaper and possibly reduces the risk of fistula caused by staple line dehiscence. During reshaping of the pouch we usually perform dissection and resection of the fundic part of the remnant as well, in an effort to rule out all possible hidden gastrogastric fistula [17]. Typically, resection of the remnant will be carried out from the top down to the level of the antrum, i.e., to the right of the alimentary limb, because as mentioned above, a gastrogastric fistula of the posterior aspect of the gastro-enteral anastomosis (GEA) is always possible. Dissection of the part of the remnant lying across the anastomosis is obscured by the mesentery of the alimentary limb and must be performed, at the risk of devascularizing that part of the remnant, which is another reason why we do not hesitate to perform resection of its fundic part.

3.2. Banding the Pouch

RYGB is commonly seen as a mixed procedure (mixed restrictive and malabsorptive). Even with a correctly constructed pouch and gastro-enterostomy (GEA) the restrictive aspect may not suffice in some instances and may find benefit from additional measures. These

measures include the placement of a non-adjustable band around the bypass pouch as reported by Fobi in open RYGB [18], and more recently by Bessler in laparoscopic procedures [19]). In our [20] (and in others') experience the secondary placement of a band is however fraught with a high erosion rate (in our experience up to 20%). Another, perhaps better option for addressing poor weight loss after RYGB consists of the placement of an adjustable band (AGB) around the gastric pouch as described by Bessler [21].

After banding the pouch with an AGB, further weight loss, varying from 55.9%–94.2% excess body mass index loss (EBMIL) has been documented after respectively 12–42 months of follow-up [22]. While theoretically the incidence of erosion after placement of an adjustable band should be lower than with a non-adjustable (Fobi) ring, adjustable band-specific complications such as slippage, infection and erosion of the band may appear. In case of one of the aforementioned mishaps it is better to remove the band (=foreign object), if at all possible by endoscopic technique, and to trim the pouch over a large bore tube.

3.3. Longitudinal Partial Resection of Pouch and Alimentary Limb (Gagner Technique)

Michel Gagner's team developed an interesting technique to influence the volumes involved in the bypass in an effort to resume weight loss without using a foreign object [23]. The technique consisted of reducing the gastric pouch together with the proximal part of the antimesenteric edge of the AL with a linear stapler. Long-term weight loss outcomes of this ingenious technique were however disappointing, both in Gagner's and in our experience. Rather than resecting the pouch and the AL longitudinally, we also attempted to reduce both by plication around a 34 Fr orogastric tube, quite similarly to the newly described technique that mimicks SG [24]. Unfortunately, here as well, midterm outcomes concerning weight loss were rather poor.

3.4. Endoscopic Trimming of Pouch and Gastro-Enteral Anastomosis

Recently, several techniques have been described to reduce the size and/or the compliance of the gastric pouch and to reduce the size of the GEA. As previously mentioned, these techniques are beyond the scope of this chapter.

3.5. Reversal and Conversion to Sleeve Gastrectomy

When all possible correctible causes for primary failure of the RYGB have been ruled out the multidisciplinary team may conclude that the choice for RYGB was not the correct one and may decide to reverse the bypass. See below (4.2).

4. Secondary Failure

Secondary failure occurs when patients who initially experienced good weight loss and resolution of co-morbidities suffer a significant weight regain and resurgence of the comorbidities. This evolution indicates that the procedure most likely was indeed correctly chosen and well carried out (as demonstrated by the initial success), but that some unwanted evolution did interfere with continued weight loss. Causes of weight regain may well be patient related (diet, life style) or may be linked with anatomical changes that have developed

over the years. There are conflicting data in the literature concerning the importance of the secondary dilation of the pouch, and of the dilation of the GEA [25, 26]. Based on the (poor) experience gathered with pouch trimming and anastomotic reshaping performed for primary failure, we cannot recommend a surgical re-intervention that limits itself to these objectives. In secondary failures the pouch can be banded (by adjustable or non-adjustable band) as well, but, as mentioned before, this strategy does carry its own complications. In addition, patients who got used to the quite comfortable eating conditions secondary to the RYGB more often than not will only reluctantly accept a new significant reduction.

4.1. Distalization of RY Gastric Bypass

The RYGB being a mixed restrictive-malabsorptive procedure, the malabsorption may be enhanced as well. Malabsorption can be augmented by increasing the length of the bypassed bowel. Consequently, the conventional "proximal" bypass may be converted into a "distal bypass". Because of the substantial number of severe complications described in the literature, distalization of the bypass is only performed in well-compliant individuals who nevertheless developed weight regain after initial good weight loss. The best candidates are the patients who did not dilate their gastric pouch (hence cannot eat large volumes), but who developed a grazing (or polyphagic) eating pattern.

Lengthening the AL to 200 or even 250 cm has proven useless on the long term for patients who failed the RYGB [27]. Conversely, "true" distal gastric bypass has been proposed several years ago as active remedial operation for failed RYGB. While extremely effective in terms of weight loss, the side effects of the distal construction however have proven too significant to allow general acceptance of the procedure. In the initial description by Sugerman, who used the distalization principle in patients who did poorly after (open) proximal bypass, the metabolic consequences were considerable and some patients died [28]. Brolin [29] found that only half of the patients had clear benefits from the conversion of a regular to a distal RYGB. However, Brolin described a particular type of distal bypass, with a very long alimentary channel and a very short (75 cm) common channel. Our technique of bypass distalization much more resembles the open operation described by Rawlins et al. [30], who reported good results in compliant patients with a construction of a 100 cm long CL and a 150 cm AL. We actually maintain a length of 150 cm both for the AL and the CL, the BPL not being routinely measured [31].

This technique has the practical advantage that mostly the alimentary limb had been constructed some 150 cm long, hence that all that needs to be done is to transect the alimentary flush with the entero-enteral anastomosis and to reimplant the alimentary limb on the common some 150 cm proximal to the ileocecal valve. Thus, the sum of AL + CL is approximately 300 cm, the minimum length to avoid protein malnutrition according to Scopinaro [14]. With our distalization strategy, besides inducing good additional weight loss in a good number of individuals, we managed to "cure" a patient from insulinodependent T2DM, despite a weight loss of approximately 50% EBMIL obtained by the "regular" RYGB. It is clear however that after distalization patients become at high risk to develop deficiencies including protein malnutrition, hence the obligation to select the patients in terms of compliance (as demonstrated by their behavior after the initial RYGB) and the commitment of both patient and multidisciplinary team to zealously follow-up the patient at regular intervals.

4.2. Reversal (Figure 3-11) and Conversion to Sleeve Gastrectomy (as First Step of a Duodenal Switch or DS)

For some individuals the RYGB induces dietary restrictions -such as the interdiction of ingesting sugar- that proved too hard to keep. Non-compliance to the diet however results in an array of undesired symptoms including hypoglycemia and eventually weight regain.

For these patients, the RYGB appears to represent a "wrong choice" on the long-term and it might consequently be better to change the metabolic-surgical strategy overall. Converting one procedure to another or even simple reversal of a procedure nowadays is less of a challenge than in the open surgery era, because laparoscopy causes far less adhesions. In order to allow more than one final choice it is an acceptable policy to initially reconvert the bypass anatomy to a normal situation. We described the technique in 2006 [32] and reported on our patients' outcomes a few years later [33].

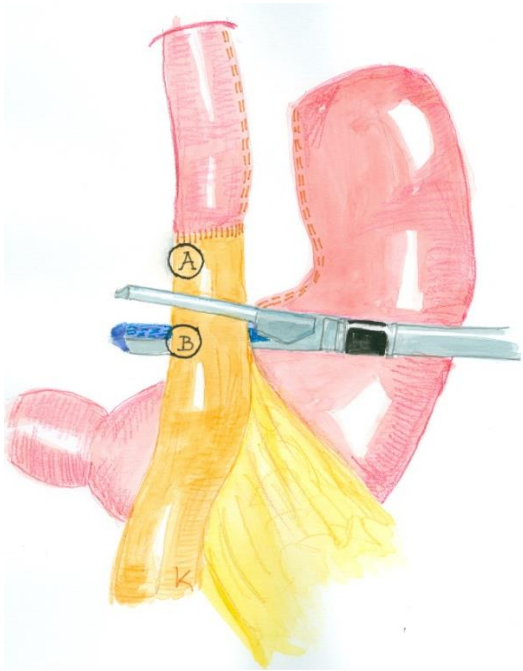

Figure 3. The gastro-enteral anastomosis must be taken down, uniting the gastric pouch (A) and the proximal part of the alimentary limb (AL). The gastro-enteral anastomosis is being transected (separation of A and B). Transection is performed just distal to the anastomosis to create ischemic discoloration of the most proximal part of the AL, which facilitates identification of the gastric pouch part at the anastomosis. Thanks to the ischemic discoloration of the most proximal part of the transected AL the trimming-of the gastric pouch can be kept minimal.

Obviously, reconversion to a normal anatomy will not likely improve weight loss. However, starting from the newly re-obtained normal anatomy, a LSG can be constructed, either immediately during the reversal or with some delay to give the patient the occasion to accommodate to the new situation [34]. A ''sleeve-like'' gastrectomy can be performed over a 34-French bougie to calibrate the new stomach. (Figure 10), while imbricating ("plicating") the middle part of the sleeve proximal to the antrum of the stomach. (Figure 11).

It appears that in some cases LSG is actually superior to RYGB, possibly because of the preservation of the antrum and pyloric sphincter, with subsequent enhanced gastric emptying [35] and inhibition of the orexogenic Ghrelin hormone [36]. In addition, in cases in which the restriction created by the sleeve does not suffice, the "natural complement" of the LSG, i.e., a DS may be carried out. DS is a typical biliopancreatic diversion, and has been shown to be the most active procedure in terms of T2DM remission rates [37]. In addition, because of the preservation of an acceptable stomach volume (i.e., the sleeved stomach), unlike with the distal gastric bypass, the DS might be safer than the distal RYGB.

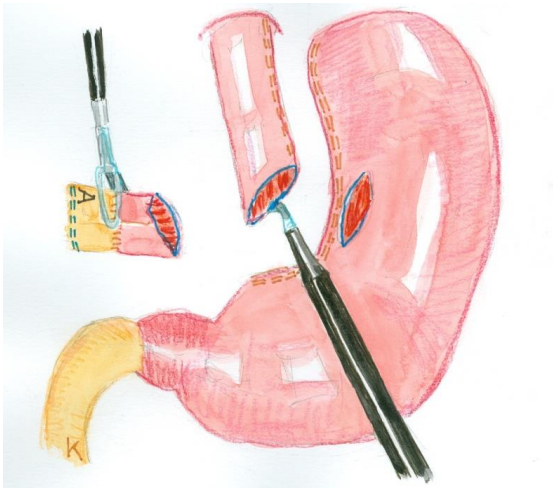

Figure 4. A gastrotomy is performed in the remnant vis-à-vis the distal part of the pouch, that is opened in its distal part at this time.

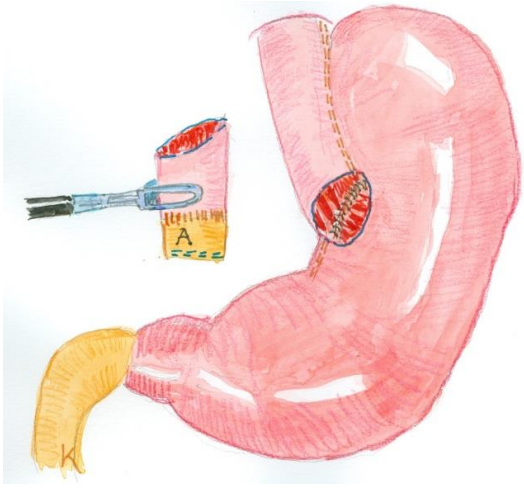

Figure 5. Anastomosis is performed between the open pouch and the remnant (Posterior layer). A manual anastomosis is preferred. Please note that the vertical part of the pouch and the corresponding part of the remnant are not opened, but rather sutured together to restore a fundus-like structure to avoid reflux.

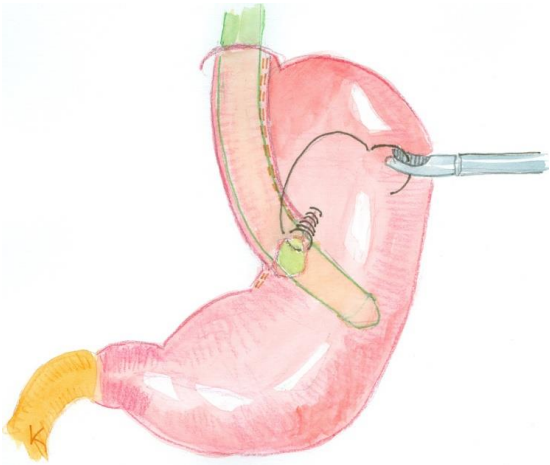

Figure 6. Anastomosis is performed between the open pouch and the remnant (Anterior layer). A manual anastomosis is preferred. Please note that the vertical part of the pouch and the corresponding part of the remnant are not opened, but rather sutured together to restore a true fundus to avoid reflux.

Figure 7. The JJ anastomosis is being transected at C, separating the BPL from the AL-CL confluent. Note that first the original mesenteric defect must be recreated and that the linear stapler is placed slightly on the BPL side of the anastomosis to avoid narrowing at the AL-CL junction. A rim of ischemic tissue may thus be left on the AL-CL side of the anastomosis, but this has no clinical significance.

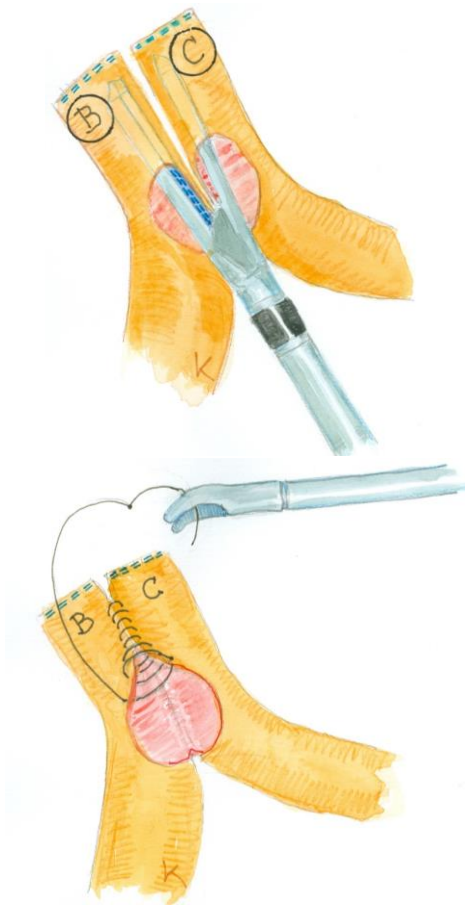

Figure 8 and 9. Anastomosis between B (previously the proximal AL) and C (previously the BPL), restoring the continuity of the small bowel. Care must be taken not to twist the mesenteries of the 2 small bowel loops. With the technique usually chosen for RYGB the mesenteric defect at this anastomosis should be quite small.

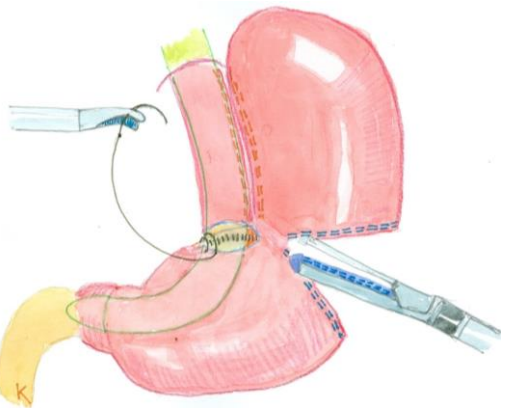

Figure 10. A ‘‘sleeve-like’’ gastrectomy can be performed by the use of a 34-French bougie to calibrate the new stomach. The technique starts by devascularizing and resecting the fundus, ending a few cm proximal to the level of the newly fashioned anastomosis.

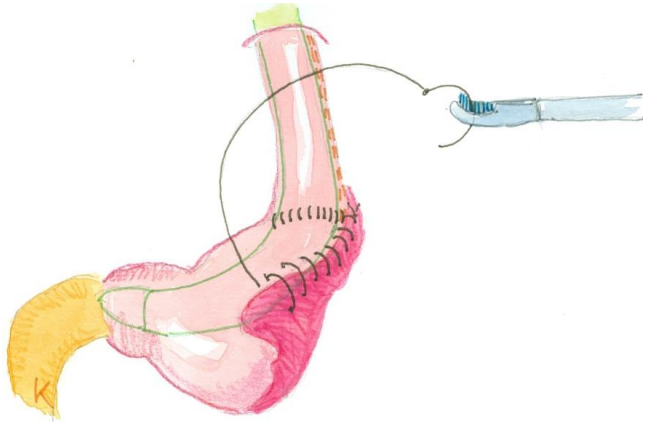

Figure 11. Plication of the middle part of the sleeve proximal to the antrum of the stomach.

5. Revisional Procedures after RYGB for Complications Interfering with the Outcome

5.1. Hiatal Hernia and Gastro-Esophageal Reflux (GERD)

Despite the recognized efficacy of the RYGB anatomy in abolishing GERD, reflux symptoms may complicate even RYGB. Usually, reflux will be alkaline, but acid reflux is possible as well, perhaps as a result of too large a gastric pouch or too a short an AL, or, more frequently, as a result of an abnormal communication between the bypassed gut and the pouch or the AL as seen in gastrogastric fistula. Alternatively, an obstruction may be causing acid reflux, as in cases with severe adhesions impacting on the CL or in trocar orifice herniation.

In case of alkaline reflux, a Hiatal Hernia (HH) must be ruled out.

HH can be highly symptomatic after RYGB, not only in terms of GERD, but in terms of dysphagia as well. The latter condition may induce excessive weight loss, which may warrant reintervention. Rarely, HH involves herniation of the excluded stomach, a situation that requires immediate reoperation because of the risk of strangulation.

Figure 12. Our personal technique of crural repair. While the fully dissected distal esophagus (ESO) is reclined anteriorly, the posterior closure of the hiatal crura is performed by at least one figure of 8 stitch of polypropylene material buttressed by cellulose acetate pledgets.

When performing hiatal exploration a thorough circular exploration of the crura must be performed as well as dissection/liberation of the distal esophagus, the latter being important to rule out epiphrenic diverticula and to provide sufficient slack for the intra-abdominal esophagus, an essential condition in avoiding recurrence [38]. In our experience, crural repair is best performed by posterior placement of non-absorbable, deep stitches, that are then tied over pledgets (we usually use cellulose acetate pledgets) [39] (Figure 12). The use of prosthetic mesh is best avoided because of the risk of erosion in a previously dissected area.

5.2. Issues at the Gastro-Enteral Anastomosis

A dreaded problem at the GEA is the anastomotic or marginal ulcer, a condition that occurs in up to 50 % of the cases [40]. Causative factors include excessive acid production as with a large pouch (but again, a gastrogastric fistula must be ruled out), ischemia, and the persistence of foreign material (staples or non-absorbable sutures). Marginal ulceration appears more frequently in smokers. When conservative management including the use of large doses of proton pump inhibitors (PPI) fails, surgical treatment may be considered. In case of perforation, surgical treatment must be performed immediately.

5.2.1. Elective Treatment of Marginal Ulceration

The first treatment of chronic marginal ulcer is the cessation of cigarette smoking. Smoking is a leading cause of recurrent anastomotic ulceration.

Surgical exploration should aim at reducing the acid production, e.g. by reducing the size of the pouch, by performing vagotomy, or, more radically, by performing remnant gastrectomy to permanently reduce gastrin and subsequent acid production. Even in the presence of small pouches, in case of chronic marginal ulcer, we usually resect the GEA together with a chunk of pouch, care being taken not to induce ischemia.

To avoid vascularity issues, dissection at the lesser curve is kept minimal and transection (either stapled or preferably manual, with the coagulating hook) performed at an angle, keeping the greater curvature part of the pouch substantially shorter than the lesser curvature. Reanastomosis is preferably performed manually to avoid ulcer-inducing staples. We usually perform resection of the fundus as well, with the purpose to allow better visualization of the greater curvature side of the pouch, and to reduce systemic acid production overall.

5.2.2. Emergency Treatment of Marginal Ulceration

When faced with perforated anastomotic ulceration, the surgical treatment should be confined to dealing with the acute situation, i.e., the perforation itself. Trimming of the edges of the ulcer and suture closure covered by an omental patch is probably the best initial treatment. Because of the invariably present concomitant peritonitis, it is preferable to delay more extensive treatment such as described in 5.2.1. (the search for a gastro-gastric fistula, trimming of the pouch and total reconstruction of the GEA) to a later date, when septic symptoms and acute inflammatory changes have subsided.

In exceptional cases the perforation involves the remnant part and a bulbar ulcer may be found. Treatment should be as for any perforated duodenal ulcer.

5.3. Other Circumstances Amenable to Surgical Correction

5.3.1. Blind Loop Syndrome (Candy Cane Deformation at the GEA, "Cloaca" Formation at the JJ Anastomosis)

Not infrequently patients who underwent LRYGB several months to years previously complain of abdominal pain confined to the left upper quadrant together with severe nausea and sometimes dysphagia. This condition is pathognomonic for blind loop syndrome. Diagnosis can be made by barium swallow (to identify a "candy cane" deformation of the blind end of the AL) and/or by CT scan (to diagnose a "cloaca" formation at the level of the Y anastomosis).

Treatment is surgical (laparoscopic) and consists of stapled resection of the redundant part (Figure 13). Care must be taken to avoid excessive narrowing of the lumen, which especially at the GEA may result in increased dysphagia. Stenosis may cause staple line leakage as well.

Figure 13. The candy cane deformity of the blind end at the alimentary limb may become highly symptomatic and demand resection. It is important to pull the uppermost part of the "candy cane" cephalad and to the left rather than to pull on the staple line. Note the presence of a large bore orogastric tube to prevent stenosis.

5.3.2. Intussusception at the JJ Anastomosis

An unusual cause of obstruction is the intussusception at the level of the JJ anastomosis. Mostly the condition consists of the retrograde invagination of the CL into itself and into the JJ anastomosis [41].

The cause is unclear, but one hypothesis is the existence of an active pacemaker in the distal small bowel that sends impulses in a retrograde fashion. Typically these patients will present a typical "target sign" at the abdominal CT scan.

Treatment is surgical (laparoscopic) and quite urgent to avoid necrosis. The best approach consists of plication, or, better, resection and redo of the JJ anastomosis, because simple reduction and fixation is fraught with a high incidence of recurrences.

5.3.3. Internal Hernia

Internal hernia (IH) is a common cause of chronic pain after RYGB. Typically the patient suffers crampoid pain, comparable to contraction pains during labour, most often occurring after a meal. Some patients become emaciated because of this condition.

It is noteworthy that previous closure of the mesenteric and Petersen defect (Figure 2) does not provide fool-proof warranty for absence of IH. In a recent retrospective study performed 9 years after the LRYGB [42], we found that the incidence of small bowel occlusion including IH was a frightening 9%, despite our policy of systematically closing all the defects with non-absorbable suture. Obviously, technical flaws may be responsible for this finding, but it is possible as well that the sometimes massive weight loss creates gaps in an initially well performed closure. Diagnosis in the acute setting is merely clinical: a patient with excruciating pain should be taken to the operating room for emergency laparoscopic exploration. When the cause of the acute abdomen is indeed found to be an IH, some bowel loops will appear dusky (or black!). Often a substantial quantity of intraperitoneal milky-white fluid may be noted, corresponding to chyle, produced by the chronic hyperpressure in the lymphatics of the small bowel.

When reduction of an IH is attempted it is wise to start exploration at the ileo-cecal transition and to gently pull the bowel, passing it from the grasper in one hand to the other, going cephalad, until a "snap" is felt which indicates the reduction of the herniated part. Closure of the defect that caused the IH is usually straightforward after adequate reduction and should be performed by a running suture of non-resorbable suture material.

5.3.4. Excessive Weight Loss and Protein Malnutrition

This condition is quite rare after "regular" RYGB. However, malnutrition is occasionally encountered in some patients who skipped the scheduled follow-up visits, neglected their complaints (of nausea, e.g.) or developed extremely poor eating habits consisting of exclusively ingesting carbohydrates for example. These patients may lose excessive weight and/or develop hypoproteinemia. These individuals invariably present a significantly impaired healing capacity because of malnourishment and are therefore initially best treated by the laparoscopic placement of gastrostomy in the excluded stomach (food stuffs administered via this route will be fully absorbed). After recovery of their metabolic balance these patients will require extensive counseling to address their poor dietary habits, and sometimes will need to undergo corrective surgery which may consist of reversal of their procedure.

5.3.5. Hypoglycemia and Neuroglycopenia

The dramatic impact of RYGB on glucose metabolism, even in the absence of T2DM is well documented. Recently, some attention has been paid to the hypoglycemia syndrome, a condition appearing some 2 to 3 years after the RYGB procedure and characterized by the apparition of hypoglycemia some 90 minutes to 2 hours after a meal (especially after a meal rich in carbohydrates). Hypoglycemia may be accompanied by vague symptoms of light-

headedness, fatigue, exhaustion and marked tremor, but syncopes and epileptic insults are relatively common as well. When neurological symptoms of hypoglycemia become apparent, the syndrome is referred to as neuroglycopenia. This clinical condition is remarkably underestimated and is often confused with "chronic fatigue", fibromyalgia, or organic central neurological aberrations.

5.3.5.1. Diagnosis

The diagnosis of the hypoglycemia syndrome is essential because this condition may cause car accidents, accidents on the work floor, or in the household. The clinical aspect differs from the dumping syndrome because individuals suffering from hypoglycemia very rarely mention pain and/or diarrhea. Also, the chronology of events differs, the symptoms with the hypoglycemia syndrome occurring later after a meal than with dumping.

Initial diagnosis can be made by a tolerance test with a standard meal or with oral glucose. It is important to record the clinical symptoms that go together with the biochemical hypoglycemia during the test, because some patients do not suffer any symptoms despite plasma glucose values as low as 30 mg/dl. Once the diagnosis of hypoglycemia, which is secondary to an exaggerated insulin response to carbohydrates and sugars, has been made [43], the possibility of an insulin producing pancreatic tumor must be ruled out. The most accurate test available is the sampling of plasma insulin after selective intra-arterial peripancreatic Calcium injections. Intra-arterial Calcium elicits a pancreatic insulin response when a secreting tumor is present. The selectivity of the test allows to detect the approximate location of the tumor in the pancreas. Additional diagnostic tools are the Magnetic Resonance Scan and the Octreotide inhibition test.

5.3.5.2. Treatment

The first treatment of the hypoglycemia syndrome is dietary: patients should refrain from all intake of simple sugars and limit the ingestion of carbohydrates. The requested change in eating behavior is a considerable task, because most patients go through an acute withdrawal phase when kept away from carbohydrates and sugars.

Medical treatment consists of oral acarbose, diazoxide or parenteral octreotide but these treatment modes are expensive and not very efficient [44].

Surgical Treatment

The most effective treatment is surgery. Three types of operations have been described:

- the placement of a band or ring around the pouch to slow down gastric emptying
- pancreatectomy.
- reversal of the procedure

1. Placement of Band around the Stomach Pouch

This treatment was proposed more specifically to address the problem of postprandial dumping [45]. Despite quite good outcomes in terms of dumping reduction, this technique faces the relatively high incidence of complications we already mentioned. Moreover, the technique does not appear to be effective in true postprandial hypoglycemia.

2. Pancreatectomy

Theoretically, pancreatectomy makes sense because it removes the source of insulin secretion. This strategy was first described by Service et al. [46].

Despite good short-term outcomes this very aggressive surgical procedure however does not appear to keep its promises on the long term.

3. Reversal (as mentioned before)

Reversal of the bypass construction is logical because it addresses the alleged cause of insulin hypersecretion, i.e., the bypass of the duodenum, causing an imbalance in incretin production. Some reports however question this approach [47].

There is quite a simple strategy to avoid reversing a bypass for hypoglycemia syndrome in vain. This strategy consists of placing a gastrostomy tube in the remnant stomach, either laparoscopically, or percutaneously, under CT guidance. The patient hereafter is fed exclusively through the gastrostomy. When hypoglycemia clearly regresses (which can be documented by an oral tolerance test through the gastrostomy tube), reversal may safely be attempted. We try to perform full reversal rather than a functional reversal, which may be obtained by gastro-gastrostomy uniting pouch and remnant. Rather, we perform transection of the GEA and of the JJ anastomosis at the level of the BPL ending. The blind end of the AL and of the BPL are reanastomosed, hereby restoring small bowel continuity. Finally, the pouch and remnant are reanastomosed as well, which concludes reversal to a normal anatomy (and may be complemented by sleeve-like gastrectomy). (Figures 3-11)

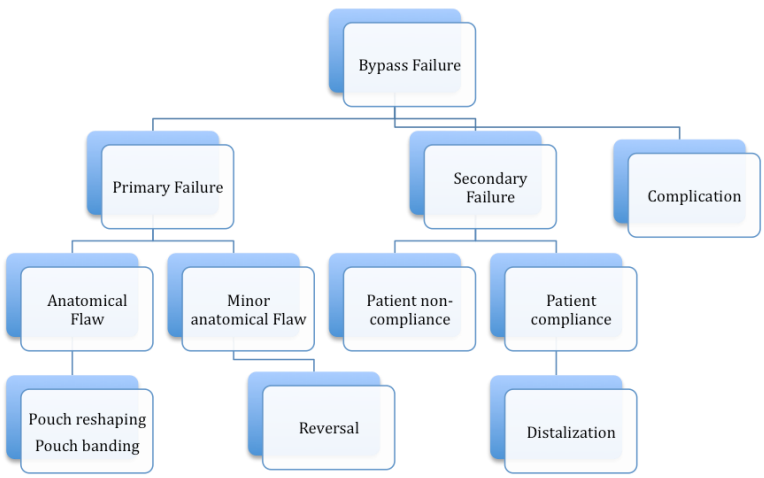

Figure 14. Algorithm showing the surgical management for Roux-en-Y gastric bypass failures.

CONCLUSION

The laparoscopic Roux-en-Y gastric bypass has passed the test of time and a number of patients have now undergone the procedure more than 10 years ago. Even though the overall

outcomes are excellent, not unexpectedly, some late complications do arise, creating weight problems or other conditions that may be significant in terms of patient comfort and even safety. This chapter attempted at describing the most common problematic issues occurring occasionally after (laparoscopic) Roux-en-Y gastric bypass and to come up with an acceptable strategic approach. (Figure 14).

REFERENCES

[1] Scozzari G, Toppino M, Famiglietti F, Bonnet G, Morino M. 10-year follow-up of laparoscopic vertical banded gastroplasty: good results in selected patients. *Ann Surg*. 2010;252(5):831-9.

[2] Mason EE, Ito C. Gastric bypass in obesity. Surg Clin North Am 1967;47(6):1345-51 Kuzmak, L.I., *A Review of Seven Years' Experience with Silicone Gastric Banding. Obes Surg.*1991;1(4): p. 403-408.

[3] Griffen WW Jr. Gastric Bypass for morbid obesity. *Surg Clin North Am* 1979;59(6):1103-12.

[4] Wittgrove AC, Clark GW, Tremblay LJ. Laparoscopic Gastric Bypass, Roux-en-Y: Preliminary Report of Five Cases. *Obes Surg.* 1994;4(4):353-357.

[5] Buchwald H, Oien DM. Metabolic/bariatric surgery worldwide 2011. *Obes Surg*. 2013;23(4):427-36.

[6] Nergaard BJ1, Leifsson BG, Hedenbro J, Gislason H. Gastric bypass with long alimentary limb or long pancreato-biliary limb--long-term results on weight loss, resolution of co-morbidities and metabolic parameters. *Obes Surg.* 2014;24(10):1595-602.

[7] Higa KD, Ho T, Boone KB. Laparoscopic Roux-en-Y gastric bypass: technique and 3-year follow-up. *J Laparoendosc Adv Surg Tech A.* 2001;11(6):377-82.

[8] Jacob BP, Gagner M. New developments in gastric bypass procedures and physiological mechanisms. *Surg Technol Int.* 2003;11:119-26)

[9] Lönroth H, Dalenbäck J, Haglind E, Lundell L. (Laparoscopic gastric bypass. Another option in bariatric surgery. *Surg Endosc.* 1996;10(6):636-8).

[10] Cho M, Pinto D, Carrodeguas L, Lascano C, Soto F, Whipple O, Simpfendorfer C, Gonzalvo JP, Zundel N, Szomstein S, Rosenthal RJ. Frequency and management of internal hernias after laparoscopic antecolic antegastric Roux-en-Y gastric bypass without division of the small bowel mesentery or closure of mesenteric defects: review of 1400 consecutive cases. *Surg Obes Relat Dis.* 2006;2(2):87-91.

[11] Dogan K, Aarts EO Koehestanie P, Betzel B, Ploeger N, de Boer H,Aufenacker TJ, van Laarhoven KJ, Janssen IM, Berends FJ. Optimization of vitamin suppletion after Roux-en-Y gastric bypass surgery can lower postoperative deficiencies: a randomized controlled trial. *Medicine* (Baltimore). 2014;93(25):e169.

[12] Himpens J, Coromina L, Verbrugghe A, Cadière GB. Outcomes of revisional procedures for insufficient weight loss or weight regain after Roux-en-Y gastric bypass. *Obes Surg*. 2012; 22(11): p. 1746-54.

[13] Sugerman HJ, Starkey JV, Birkenhauer R. A randomized prospective trial of gastric bypass versus vertical banded gastroplasty for morbid obesity and their effects on sweets versus non-sweets eaters. *Ann Surg.* 1987;205(6):613-24.

[14] Scopinaro N. Thirty-five years of biliopancreatic diversion: notes on gastrointestinal physiology to complete the published information useful for a better understanding and clinical use of the operation. *Obes Surg* 2012;22(3):427-32.

[15] Yao DC, Stellato TA, Schuster MM, Graf KN, Hallowell PT. Gastrogastric fistula following Roux-en-Y bypass is attributed to both surgical technique and experience. *Am J Surg*. 2010;199(3):382-5.

[16] Moon RC, Teixeira AF, Goldbach M, Jawad MA. Management and treatment outcomes of marginal ulcers after Roux-en-Y gastric bypass at a single high volume bariatric center. *Surg Obes Relat Dis.* 2014;10(2):229-34.

[17] Salimath J, Rosenthal RJ, Szomstein S. Laparoscopic remnant gastrectomy as a novel approach for treatment of gastrogastric fistula. *Surg Endosc.* 2009;23(11):2591-5.

[18] Fobi, M.A. and H. Lee, SILASTIC ring vertical banded gastric bypass for the treatment of obesity: two years of follow-up in 84 patients [corrected]. *J Natl Med Assoc*, 1994; 86(2):125-8.

[19] 19Bessler, M., Daud A, Kim T , and DiGiorgi M, Prospective randomized trial of banded versus nonbanded gastric bypass for the super obese: early results. *Surg Obes Relat Dis*, 2007. 3(4): 480-4; discussion 484-5.

[20] Dapri G, Cadière GB, Himpens J. Laparoscopic placement of non-adjustable silicone ring for weight regain after Roux-en-Y gastric bypass. *Obes Surg* 2008;19(5):650-4.

[21] Bessler M, Daud A, DiGiorgi MF, Olivero-Rivera L, Davis D. Adjustable gastric banding as a revisional bariatric procedure after failed gastric bypass. *Obes Surg* 2005;15(10):1443-8t.

[22] Bessler M, Daud A, DiGiorgi MF, Inabnet WB, Schrope B, Olivero-Rivera L, Davis D. Adjustable gastric banding as revisional bariatric procedure after failed gastric bypass--intermediate results. *Surg Obes Relat Dis.* 2010;6(1):31-5.

[23] Gagner M. Laparoscopic jejunal sleeve: a simple and ideal new technique for revision of Roux-en-Y gastric bypass after weight regains technical aspects. *Surg Technol Int.* 2010;20:147-52.

[24] Broderick RC, Fuchs HF, Harnsberger CR, Sandler BJ, Jacobsen GR. Comparison of bariatric restrictive operations: laparoscopic sleeve gastrectomy and laparoscopic gastric greater curvature plication. *Surg Technol Int.* 2014;25:82-9.

[25] Heneghan HM, Yimcharoen P, Brethauer SA, Kroh M, Chand B. Influence of pouch and stoma size on weight loss after gastric bypass. *Surg Obes Relat Dis.* 2012;8(4):408-15.

[26] Topart P, Becouarn G, Ritz P. Pouch size after gastric bypass does not correlate with weight loss outcome. *Obes Surg.* 2011;21(9):1350-4.

[27] Christou NV, Look D, Maclean LD. Weight gain after short- and long-limb gastric bypass in patients followed for longer than 10 years. *Ann Surg*. 2006;244(5):734-40.

[28] Sugerman HJ, Kellum JM, DeMaria EJ. Conversion of proximal to distal gastric bypass for failed gastric bypass for superobesity. *J Gastrointest Surg.* 1997;1(6):517-24.

[29] Brolin RE, Cody RP. Adding malabsorption for weight loss failure after gastric bypass. *Surg Endosc* 2007;21(11): 1924-6.

[30] Rawlins ML, Teel D 2nd, Hedgcorth K, Maguire JP Revision of Roux-en-Y gastric bypass to distal bypass for failed weight loss. *Surg Obes Relat Dis.* 2011;7(1):45-9.

[31] Dapri G, Cadière GB, Himpens J. Laparoscopic conversion of Roux-en-Y gastric bypass to distal gastric bypass for weight regain. *J Laparoendosc Adv Surg Tech A*. 2011;21(1):19-23.

[32] Himpens J, Dapri G, Cadière GB. Laparoscopic conversion of the gastric bypass into a normal anatomy. *Obes Surg*. 2006;16(7):908-12.

[33] Dapri G, Cadière GB, Himpens J. Laparoscopic reconversion of Roux-en-Y gastric bypass to original anatomy: technique and preliminary outcomes. *Obes Surg.* 2011;21(8):1289-95.

[34] Vilallonga R, van de Vrande S, Himpens J. Laparoscopic reversal of Roux-en-Y gastric bypass into normal anatomy with or without sleeve gastrectomy. *Surg Endosc*. 2013;27(12):4640-8.

[35] Melissas J, Daskalakis M. Gastric emptying after sleeve gastrectomy. *Obes Surg.* 2011;21(11):1810-1; author reply 1812-3.

[36] Cummings BP, Bettaieb A, Graham JL, Stanhope KL, Kowala M, Haj FG, Chouinard ML, Havel PJ. Vertical sleeve gastrectomy improves glucose and lipid metabolism and delays diabetes onset in UCD-T2DM rats. *Endocrinology*. 2012;153(8):3620-32.

[37] Yu J1, Zhou X, Li L, Li S, Tan J, Li Y, Sun X. The long-term effects of bariatric surgery for type 2 diabetes: systematic review and meta-analysis of randomized and non-randomized evidence. *Obes Surg.* 2015;25(1):143-58.

[38] Nason KS, Luketich JD, Witteman BP, Levy RM. The laparoscopic approach to paraesophageal hernia repair. *J Gastrointest Surg*. 2012 Feb;16(2):417-26.

[39] Kang T, Urrego H, Gridley A, Richardson WS. Pledgeted repair of giant hiatal hernia provides excellent long-term results. *J Laparoendosc Adv Surg Tech A.* 2014;24(10):684-7.

[40] Gilmore MM, Kallies KJ, Mathiason MA, Kothari SN. Varying marginal ulcer rates in patients undergoing laparoscopic Roux-en-Y gastric bypass for morbid obesity versus gastroesophageal reflux disease: is the acid pocket to blame? *Surg Obes Relat Dis.* 2013;9(6):862-6.

[41] Stephenson D, Moon RC, Teixeira AF, Jawad MA. Intussusception after Roux-en-Y gastric bypass. *Surg Obes Relat Dis*. 2014;10(4):666-70.

[42] Himpens J, Verbrugghe A, Cadière GB, Everaerts W, Greve JW. Long term results of laparoscopic Roux-en-Y gastric bypass: evaluation after 9 years. *Obes Surg* 2012;22(10):1586-93.

[43] Goldfine AB, Mun EC, Devine E, Bernier R, Baz-Hecht M, Jones DB, Schneider BE, Holst JJ, Patti ME. Patients with neuroglycopenia after gastric bypass surgery have exaggerated incretin and insulin secretory responses to a mixed meal. *J Clin Endocrinol Metab*. 2007;92(12):4678-85.

[44] Cui Y, Elahi D, Andersen DK. Advances in the etiology and management of hyperinsulinemic hypoglycemia after Roux-en-Y gastric bypass. *J Gastrointest Surg*. 2011;15(10):1879-88.

[45] Z'graggen K1, Guweidhi A, Steffen R, Potoczna N, Biral R, Walther F, Komminoth P, Horber F Severe recurrent hypoglycemia after gastric bypass surgery. *Obes Surg.* 2008;18(8):981-8.

[46] Service GJ, Thompson GB, Service FJ, Andrews JC, Collazo-Clavell ML, Lloyd RV. Hyperinsulinemic hypoglycemia with nesidioblastosis after gastric-bypass surgery. *N Engl J Med*. 2005;21;353(3):249-54.

[47] Mala T. Postprandial hyperinsulinemic hypoglycemia after gastric bypass surgical treatment. *Surg Obes Relat Dis*. 2014;10(6):1220-5).

In: Encyclopedia of Surgery (22 Volume Set)
Editors: Andreas Lehrer and Kristin Mueller
ISBN: 978-1-53618-329-0
© 2020 Nova Science Publishers, Inc.

Chapter 57

FAILED MINIGASTRIC BYPASS: SURGICAL STRATEGIES

Jean-Marc Chevallier*
Department of Bariatric Surgery, Hôpital
Européen Georges Pompidou, Paris, France

ABSTRACT

Against morbid obesity MGB is an alternative to RYGB with less morbidity and same long-term efficiency because it involves just one anastomosis. But the presence of bile in the afferent limb and the 200 cm long bypass imply that MGB failure reoperations must be approached differently than after RYGB. Revision rate is between 0.8 and 4.7% in the literature, 2% in our experience (20/1000).

Revisions are performed for complication (leaks, biliary reflux or marginal ulcer), inadequate weight loss or malnutrition. Leaks after MGB can lead to biliary peritonitis and must be treated quickly by conversion from MGB to RYGB. Intractable bile reflux is rare (0.9%) and must be treated by conversion of the MGB to RYGB, provided the common limb length down to the ileocecal valve is longer than three meters. Insufficient weight loss or weight regain (4.9%) require a multidisciplinary assessment to evaluate eating disorders and to appreciate if there is a true pouch dilatation. If the patient remains morbidly obese and the gastric pouch appears dilated a revision with pouch trimming might be efficient. If the pouch is not dilated a band can be placed around the gastric tube in order to add more restriction.

MGB is more malabsorptive than RYGB but the rate of malnutrition appears low (between 0.3 and 1.28% in the literature). In case of alarming malnutrition a revision can be decided after preparation. Restoration of a normal anatomy can easily be performed after MGB. The conversion of the MGB to a sleeve gastrectomy has a substantial leakage rate but it obviously allows the patient to keep thin.

With experience MGB appears to have a small reoperation rate, to be easily converted or reversible if necessary. It should thus be considered in the armamentarium of bariatric surgeons.

* Corresponding Author's Email: jean-marc.chevallier@egp.aphp.fr.

INTRODUCTION

Morbid obesity has become a public health problem in most countries. It leads to a high incidence of complications that decrease life expectancy, even in young adults. Medical treatment of obesity is known to bring disappointing results; however, bariatric surgery has been proved to be efficient for the treatment of morbid obesity, and for decreasing even mortality and complication rates [1]. Our surgical team has 20 years of experience in laparoscopic bariatric surgery. We used to perform the Laparoscopic Roux-en-Y gastric bypass (RYGB) using the Lonröth technique, which consists of an omega loop raised up to the gastric pouch, in which both anastomoses are created and then separated by a section converting the omega into a Roux-en Y gastric bypass [2]. The Laparoscopic Minigastric Bypass or One Anastomosis Gastric bypass (MGB) is a modification of this omega loop bypass, with only one anastomosis, namely the gastrojejunostomy. In 2005, a prospective randomized trial compared MGB to RYGB and showed better outcomes for MGB at 2 years [3]. However MGB has raised criticism and controversy, especially regarding its potential risk of biliary reflux [4]. More recently, some long-term series on MGB have shown promising results in terms of security and efficiency [5-9]. After having published the outcomes of our first 100 MGB procedures [10], we have recently reported on our first 1000 MGB procedures over a 7-year period [11]. We compared these results to the literature and focused in this chapter on surgical strategies in case of MGB failure.

1. THE MGB PROCEDURE (FIGURES 1-2)

All surgical procedures were carried out by six different surgeons using the same standardized technique (Figure 1). Details of the surgical procedure have been published previously [10], and are similar to those described by Rutledge [12].

Figure 1. One anastomosis gastric bypass.

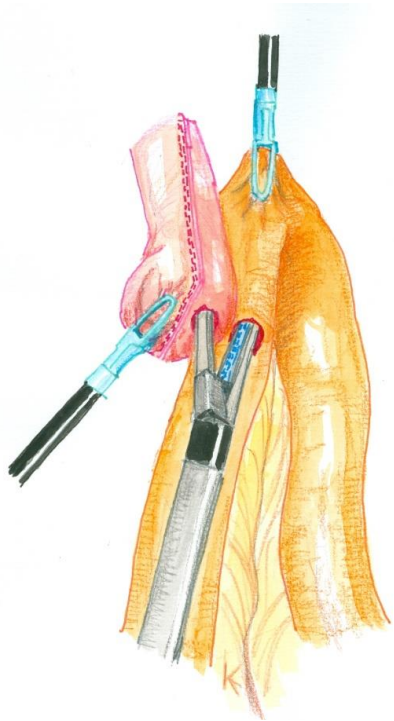

Figure 2. Linear stapled gastrojejunal anastomosis.

A long and narrow gastric tube was created by applying one horizontal 45-mm roticulator Endo-GIA® stapler (Covidien, Cincinnati, OH, US) at the angle of lesser curvature, just above the left branch of the crow's foot, and then four to five vertical 60-mm roticulator Endo-GIA® staple cartridges upward to the angle of His, calibrated along a 32-Fr bougie, similar to the vertical part of a sleeve gastrectomy. No reinforcement was done on the staple line. Section of the greater omentum in bivalve was performed.

The jejunum was mounted antecolically at 200 cm down from the ligament of Treitz, and a side-to-end anastomosis (Figure 2) was performed with the gastric tube using a posterior 45-mm Endo-GIA® stapler and an anterior running suture.

A nasogastric tube was passed into the efferent loop, and a closed vacuum drain was placed behind the anastomosis. The anastomosis was finally checked using an intraoperative methylene blue test.

2. Definition of Failure; Revision of an MGB

In most series weight loss was determined as changes in mean BMI and mean percent Excess Body-Mass Index loss (%EBMIL), with BMI 25 as the upper limit of normal according to the actually adopted standard measure [13].

Failure can be due to complication (marginal ulcer or intractable bile reflux), insufficient weight loss (defined by a %EBMIL of < 25%) or on the opposite, excessive weight loss with malnutrition (%EBMIL > 100% with albuminemia < 30 g/L). Table 1 summarizes late revisions after MGB in four long-term studies.

Table 1. Late revisions after MGB in the literature

	Lee 2012 [14]	Musella [8]	Noun [6]	Chevallier [11]
Inadequate WL	10 (0.9%)	1		4
Bile reflux	4 (0.3%)		4	7
malnutrition	10 (0.9%)	1	4	2
Obstruction	1	1	33 (open)	5
Internal hernia	0	0	0	0
Marginal ulcer	7	4	6	2
stricture	1	0	0	0
TOTAL	33/1322 (2.8%)	7/818 (0.8%)	47/1000 (4.7%)	20/1000 (2%)

WL = weight loss.

Revision rate was between 0,8 and 4.7%. Lee published in 2011 a revision rate of 1.7% on 1322 MGB at 9 years follow up [14]; these data have been updated in 2012 in comparison to RYGB [7]. In this latter paper the two most common reasons for revision were malnutrition and inadequate weight loss in 10 (30,3%), marginal ulcer in 7 (21,2%) and intractable bile reflux in 4 (12,1%) patients. Revisional surgery performed was RYGB in 11 (47.8%), Sleeve Gastrectomy in 10 (43.5%) and conversion to a normal anatomy in 2 (8.6%) patients. In our recently published experience [11] we had to revise 20 patients (2%): 7 for intractable reflux (35%), 5 for intestinal obstruction, 4 for inadequate weight loss, 2 for marginal ulcer, and 2 for malnutrition. The chapter will be divided in three parts: revision for complication, inadequate weight loss and malnutrition.

3. REVISION FOR COMPLICATION

The early complication rate was 6% in the metaanalysis [15], 51 leaks (1%), 2.8% marginal ulcers, 4.2% anemia. Late complications leading to revision are collected in Table 1.

3.1. Leaks

Our 0.6% rate of leakage is low, and is similar to other series [5-9]: this may be because a good blood supply was preserved in the thinner gastric tube and jejunal loop without mesenteric interruption. After MGB leak at the gastrojejunostomy leads to a biliary peritonitis. As for every bariatric procedure in case of leakage the reoperation must be decided as soon as possible, but in the case of MGB it is even more important because of the presence of bile. If the reoperation has been decided soon enough the treatment of the leak can actually be a simple suture, but it has to be accompanied by the conversion of the MGB to a RYGB in order to move the bile away from the gastrojejunostomy (see below).

3.2. Biliary Reflux

Critics of the MGB procedure compare it to the first bypasses performed by Mason in 1969 [16], which consisted of horizontal sectioning of the proximal part of the stomach and

then raising the bowel loop to form an omega shape. The proximity of the anastomosis to the esophagus caused incapacitating biliary reflux, which led the author to abandon the omega procedure for the Roux-en-Y procedure.

Symptomatic biliary reflux is not frequent after MGB and most of the time can be cured medically. In a recent publication [17] we compared postoperative GIQLI (GastroIntestinal Quality of Life Index) 5 years after MGB with preoperative GIQLI. Interestingly we found no significant differences in the GERD symptoms (Regurgitation, heartburn, nausea, belching) between the two groups. Lee reported intractable bile reflux in four cases [7]. In our experience 11 cases of biliary reflux so far necessitated us to convert to a RYGB at ~2 years post-MGB in patients who had lost all their excess weight. The conversion had a spectacular effect on biliary reflux, and patients also maintained their weight loss.

However, GERD is rarely a problem in MGB because the anastomosis is placed low in the stomach. Although it is common to find bile around the anastomosis in the medium- and long-term, it is rarely seen as far up as the esophagus.

MGB actually creates an anatomy where reflux is intuitively promoted, as opposed to the standard RYGB. This is one of the major criticisms raised against the MGB: unfortunately, our data were insufficient to determine if this criticism is unfounded. We can only mention that among the post-operative gastroscopic biopsies conducted, we found foveolar hyperplasia, a sign of biliary reflux, in only 13/76 (17.1%) cases at 2 years and in 2/43 (4.6%) cases at 4 years, with no dysplasia or metaplasia [18].

We have no experience of the anti-reflux technique, as described by others [19]. In our technique the gastric pouch must be long and narrow. Stapling must be vertical, perpendicular to the incision in the pouch, and above the posterior surface of the stomach so that the afferent loop comes from the back, and is higher than the efferent loop. If biliary reflux ever becomes intractable, conversion to RYGB is still a valid and effective straightforward option.

3.3. Marginal Ulcer

One of the classic concerns with a gastrojejunal bypass is the occurrence of marginal ulcers at the edge of the gastrojejunal anastomosis, a condition that is caused by the small gastric pouch continuing to secrete acid. In a recent meta-analysis collecting 5095 cases operated between 1997 and 2011 in seven different centers [15] the marginal ulcer rate was 2.8%. Most of the marginal ulcers appear to be curable medically.

In our experience two ulcers were revealed by symptoms of peritonitis late in follow-up. Both patients were heavy smokers; they had lost all their excess weight, and had stopped taking proton-pump inhibitors. Overall, the number of marginal ulcers (2%) was however low and equivalent to that found after RYGB [20]. The rate of ulcers was probably low because of our policy of preoperatively screening for Helicobacter Pylori and eradicating whenever present. The small size of gastric pouches with our technique, and the routine prescription of proton-pump inhibitors most likely helped keeping the incidence as low as well. A larger gastric pouch in MGB (likely producing more acid) might increase the incidence of ulcers; a pouch must be long and narrow to keep the acid secreting volume low. The bile in contact with the anastomosis may actually buffer the ulcerogenic effect of acid on the anastomosis [21].

As for RYGB smoking was a risk factor for marginal ulcers throughout this series We think that patients who continue smoking after an omega-loop bypass need to keep taking proton-pump inhibitors.

3.4. Conversion of MGB to RYGB (Figure 3)

In case of leak or intractable bile reflux MGB can be converted to RYGB.
Two techniques are available to convert MGB to RYGB:

- to perform a latero-lateral jejunojejunostomy 70 cm distal to the gastrojejunostomy (Figure 3 A)
- to staple the afferent loop just between both anastomosis (Figure 3B)
- to close the mesenteric defect (Figure 3C)

This technique was proposed by Lee [14] but might be dangerous: because the bypass is already 200 cm long, adding 70 cm results in a 270 cm, which could be too long and lead to malnutrition (see below).

The best approach is to measure the total limb length down from the gastrojejunostomy. If it is more than 3 meters long, Lee's technique may be performed with security. If limb length is less, the following second option should be used.

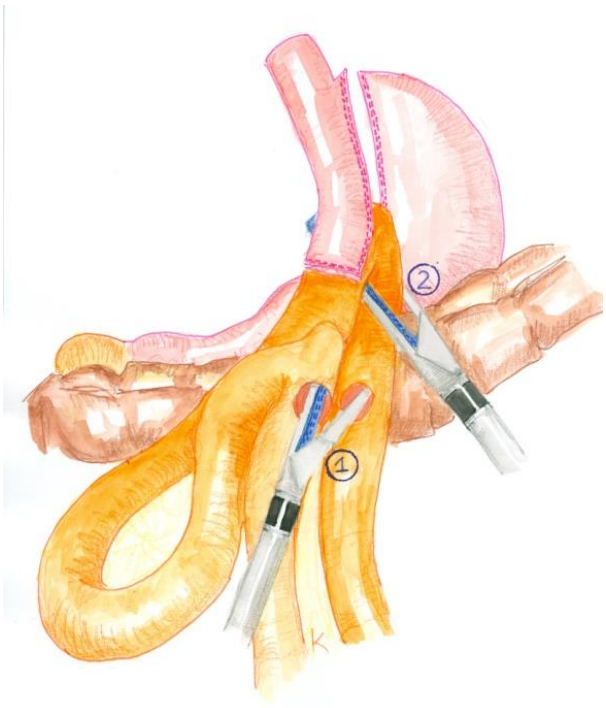

Figure 3. Conversion MGB to RYGB: easy way (1: jejunojejunostomy, 2: section between both anastomosis).

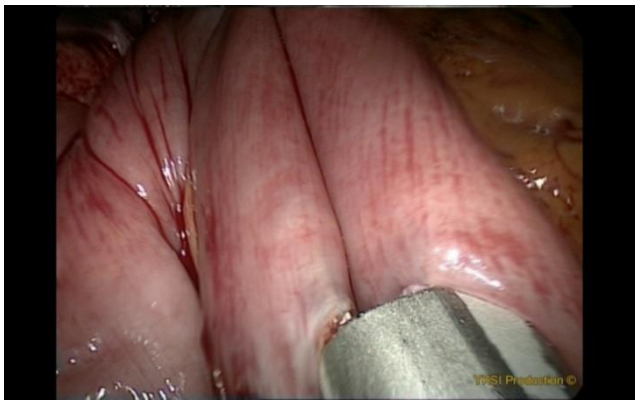

Figure 3A. Jejuno-jejunostomy (70 cm distal from gastrojejunal anastomosis).

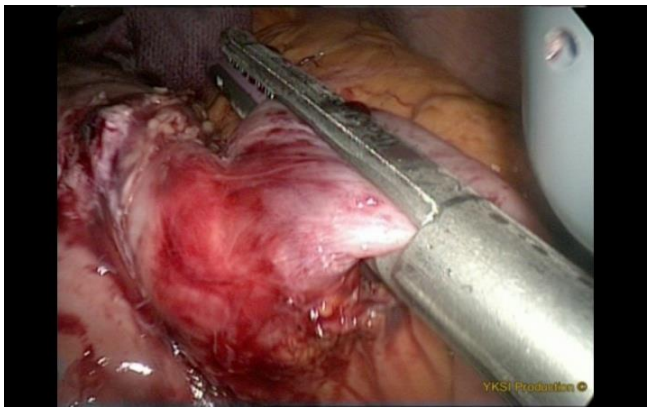

Figure 3B. Section between both anastomosis.

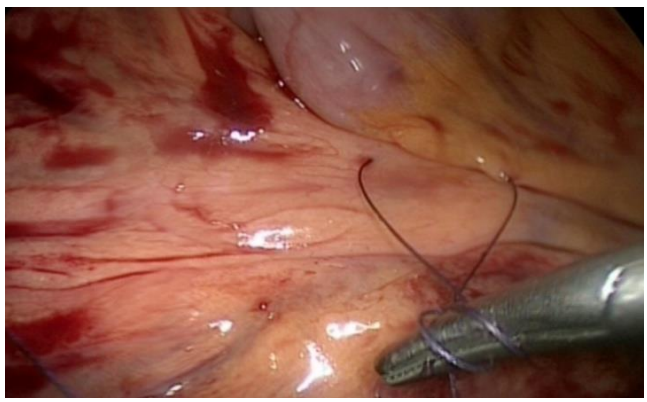

Figure 3C. Closure of mesenteric defect.

- Resection of the anastomosis
- restoration of the digestive tract by a linear side-to-side enteroenterostomy
- then performing a regular RYGB by transecting the gastric pouch more proximally and constructing a 1.5-meter long alimentary limb (Figure 4).

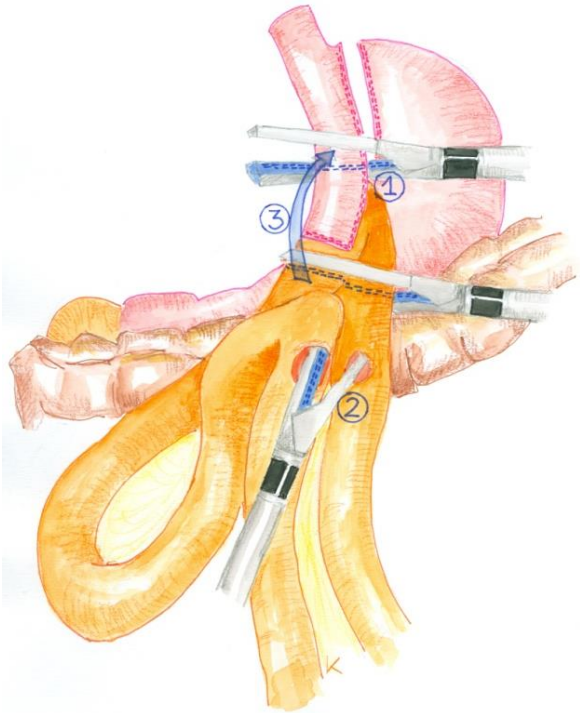

Figure 4. Conversion MGB to RYGB: regular RYGB. 1: resection of GJ anastomosis. 2: enteroenterostomy. 3: regular RYGB.

4. Revision for Inadequate Weight-Loss

Five percent (n = 49) of patients had a ≤ 25% EBMIL and had to be considered weight-loss failures [11]. In this population, the mean preoperative BMI was 42.5 ± 6.4 kg/m^2 and the %EBMIL was 13.8 ± 12.6% at 5 years. Noteworthy, 40% of these patients previously had had a gastric banding (LAGB).

Dilatation of the gastric pouch occurred in four patients, which caused excessive weight regain by 24 months post MGB. The dilatation was assessed by an upper GI series. Redo surgery was done by pouch trimming using a calibration tube for all patients, at ~4 years post MGB, when patients had a mean BMI of 39.3 kg/m^2 and a mean %EBMIL of 40.3%. There was no per- or post-operative morbidity.

At 5 years, these patients' mean BMI was 35.9 kg/m^2 and %EBMIL was 55.7%. Three of these four patients had had LAGB before MGB.

In front of inadequate weight loss the first question is: is it primary weight loss or weight regain? A psychological and dietetical assessment is mandatory. The multidisciplinary team has to be consulted for an unanimous decision before considering reoperation.

The discussion about weight regain after MGB is not very different from the one after RYGB. Revisional procedures can be either endoscopic or laparoscopic. Considering the potential risk of redo surgery, an endoscopic procedure should be the first choice to improve weight loss. Unfortunately these advanced endoscopic procedures are still under evaluation and not significantly efficient so far [22].

Consequently most of the cases actually are treated by redo surgery.

The choice of the type of surgery should be guided by different factors to limit complications. It has actually been proven that the risk of leakage is more important after redo surgery than after the primary bypass [23].

The local anatomical conditions might influence the decision: previously dissected tissues, sclerosis caused by postoperative leakage can lead the surgeon to avoid stapling or resection. Diabetes resurgence may invite for a more malabsorptive radical solution, such as a distal bypass or a duodenal switch. Conversely, patients who regain weight after initial good weight loss have, most of the time, lost the restrictive part of the bypass.

A regular upper GI series or a 3-D CT-scan volumetry will then assess a pouch dilatation. A pouch over 200 cm3 is considered the threshold to reoperate [24].

Two options are available: pouch trimming or banding.

4.1. Pouch Trimming after MGB Failure (Figure 5)

The restrictive action of MGB is due to a long and narrow gastric pouch, which recently has been considered as the most efficient form of pouch even in RYGB [25]. As with RYGB, pouch trimming may be considered when there is an actual pouch dilatation. If pouch dilatation was due to a technical mishap in the previous operation (incomplete section of the upper fundus too far away from the EG junction) (primary dilatation) trimming the pouch is worthwhile. If dilatation occurred after the operation (secondary dilatation), because of inadequate eating behavior the decision to reoperate is highly dependent on the psycho-dietetical evaluation. Outcomes of reoperation have been reported as good with a primary dilatation, but moderately good after a secondary dilatation.

Reoperation begins by complete adhesiolysis with clear identification of the anastomosis, the biliary and alimentary limbs. The gastric pouch must be dissected off the remnant stomach with freeing of all adhesions of the greater omentum. This usually allows to appreciate the magnitude of the pouch dilatation. The gastric tube has then to be separated from the excluded stomach and the omentum up to the left diaphragmatic crus.

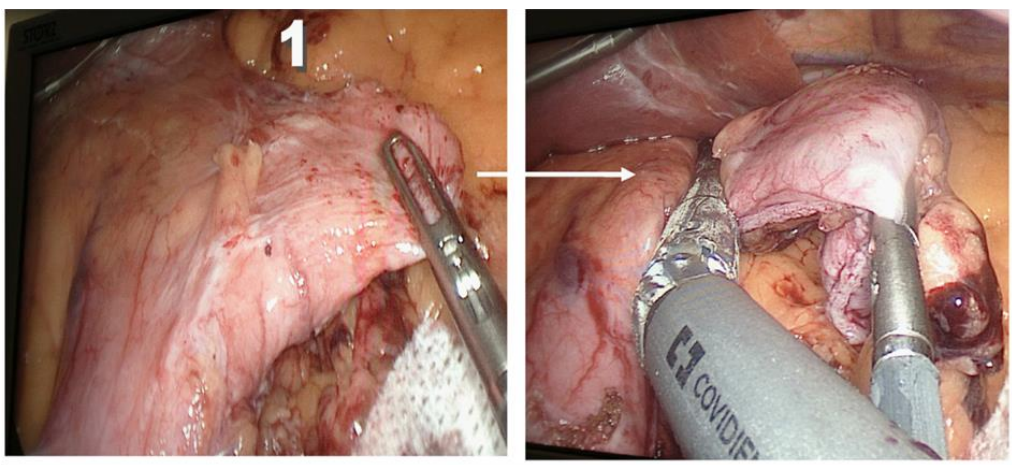

Figure 5. Pouch trimming for weight regain.

This exposes the pouch that can now be resected upwards by a linear Stapler exactly like a "re-sleeve." As in every redo gastric resection it could be advisable to use higher staples (especially in the higher fundus) and/or reinforcement material. A methylene blue test can also be performed to check the staple line.

4.2. To Band a MGB (Figure 6)

If a bypass failure is due to a failure of the restrictive part it is also possible to add some restriction by putting a band around the gastric pouch. This has been reported for RYGB failures and led also Mal Fobi to propose a non-adjustable banded bypass, which led to prolonged weight loss [26].

Some series have shown that putting an adjustable band around the gastric pouch after a RYGB can lead to better weight loss afterwards [27]. Even though this has not been published yet it seems particularly suitable to put a band around the tube of a MGB because this tube is long and even in case of dilated tube there is always room enough to put the band around the stomach above the anastomosis.

The technique is exactly the same as putting a primary band through the pars flaccida. After having opened the pars flaccid of the little omentum, the peritoneal sheet is cut along the edge of the right crus and a retrogastric tunnel is dissected. The posterior dissection reaches the left crus and the band is placed at the upper part of the gastric tube far away from the anastomosis. As there is no longer a lesser sac, the band is not fixed posteriorly. It is then advisable to fix the band to the excluded stomach by three stitches: one above and two beneath the band.

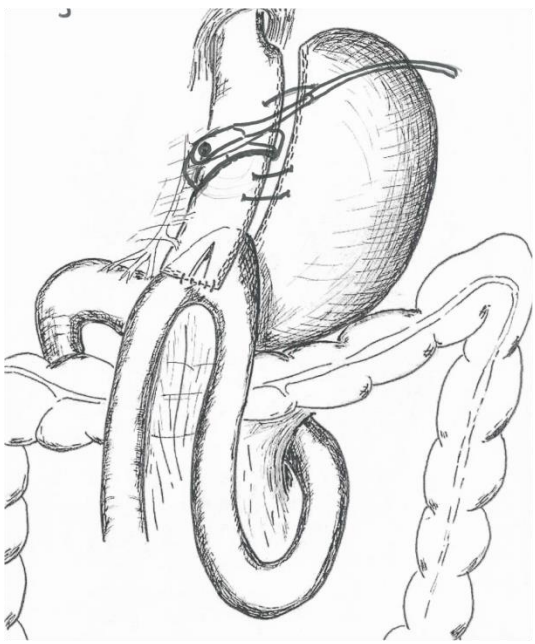

Figure 6. Band on MGB.

5. REVISION FOR MALNUTRITION

Excessive weight loss can be considered as %EBMIL > 100% and albuminemia < 30 g/l.

Rutledge observed malnutrition in 31/2401 patients [12], Noun in 4/1000 [6] and Lee in 9/1322 [14]. In our experience malnutrition occurred in three patients [11]. Their mean BMI at 5 years was 19 kg/m^2 and %EBMIL was 124% and 122%.

After treatment in a specialized medical unit with parenteral alimentation and psychiatric support, they recently had a reversion of the SAGB into a normal anatomy. The potential risk of malnutrition after MGB occurs because of the long bypassed biliary limb, with consequences depending on the length of the common limb.

5.1. Considerations on "Normal" Limb Length

The "normal" efferent limb length is 592 cm (extremes: 380-790). This means that the length of the intestine can be very variable [28]. It is usually considered that an effective and safe bypass must bypass 1/3 of the total limb length. The regular MGB bypasses 200 cm.

This is adapted if the total limb length is 600 cm. If the efferent limb is only 380 cm long (lowest extreme), this means that the remaining common limb will only be 180 cm long (less than 50% of the efferent limb) which could lead to protein deficiency or malnutrition. If the limb is 790 cm long (highest limit), the bypass will be around ¼, which could be not enough and may lead to insufficient weight loss.

These considerations highlight the fact that it is important, when performing a malabsorptive procedure like MGB, to measure the whole intestinal length from the ileocaecal valve upwards or at least to check that there are still three more meters down from the anastomosis. This also explains why a regular RYGB (which bypasses 150 cm) can lead to failure if the total limb length is 790 cm.

All these considerations do not take into account the villi's surface for each cm^2 that could be different from one patient to another and decreases with age.

5.2. MGB 'S Risk of Malnutrition

Too short a common limb can lead to protein deficiency and malnutrition whatever the patient eats. One of the criticisms about MGB is that patients may complain of frequent stools, bowel urgency or diarrhea.

Lee [7] reported that, when compared with RYGB, MGB patients had a similar QOL at five years and experienced less abdominal pain but higher stool frequency.

In our experience [17], patients usually have 3 to 4 stools per day during the first 3 months after MGB, and then the rhythm slows down to one or 2 unless when patients continue to consume fats. We compared postoperative GIQLI five years after MGB with preoperative GIQLI.

Interestingly, as demonstrated by Lee, we found no significant differences in diarrhea symptoms between the preoperative and the 5-year's groups. According to the literature the rate of malnutrition after MGB could be between 0.3 and 1.3% (Table 2).

5.3. When to Reoperate?

After a period of incapacitating diarrhea, the albuminemia level falls under 30 g/L. It is important to check the serum prealbumin, showing the lack of protein pooling. The patient has to be hospitalized in a medical unit to check the whole gut and use parenteral nutrition. Most of the time this period of parenteral nutrition improves the nutritional status but when the patient comes back home there may be further deterioration. The recurrence of protein deficiency is an indication to reoperate, especially because parenteral feeding often leads to venous catheter infection.

5.4. Which Revision?

In case of malnutrition after MGB the patient's situation becomes dangerous. The debate is whether it is better to restore the normal anatomy (exposing the patient to return to morbid obesity) or if it is possible to let a secure part of a bariatric procedure (convert the MGB to a Sleeve gastrectomy).

5.4.1. Restoration to a Normal Anatomy (Figure 7)

The MGB can be considered as easily reversible. The restoration of a normal anatomy can be performed by the following consecutive steps:

1. Section of the stomach above the anastomosis (Figure 7 A)
2. Creation of a vertical gastro-gastrostomy (Figure 7B)
3. Restoration of the digestive tract by a linear enteroenterostomy (Figure 7C)
4. Resection of the anastomosis (Figure 7D)

5.4.2. Conversion of a MGB to a Sleeve Gastrectomy

This conversion has been described by Himpens et al., for a RYGB [29]. The difference is that with RYGB a handsewn gastrogastric anastomosis must be performed between the pouch and the part of the stomach just distal to the horizontal stapling line. This leaves a stomach volume that can be resected at the end of the procedure aided by the use of a 32 or 32-Fch bougie to calibrate the new stomach.

CONCLUSION

MGB is an alternative to RYGB with less morbidity and same long-term efficiency because it involves only one anastomosis.

Table 2. risk of malnutrition after MGB according to literature

	Rutledge [12]	Noun [6]	Lee [7]	Chevallier [11]
N	31/2401	4/1000	9/1322	3/1000
%	1.28%	0,4%	0.6%	0.3%

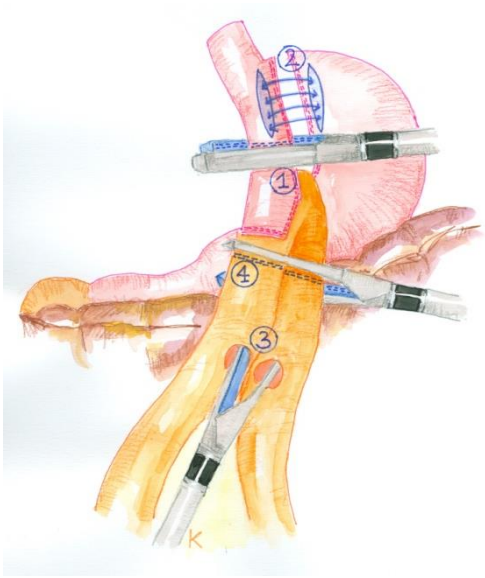

Figure 7. Restoration of a normal anatomy. (1: section above the gastrjejunostomy, 2: gastrogastric anastomosis, 3: jejunojejunostomy, 4: resection of GJ anastomosis).

Figure 7A. Section above the gastrojejunostomy.

Figure 7B. Gastrogastric anastomosis.

Figure 7C. Jejuno-jejunostomy.

Figure 7D. Resection of gastrojejunal anastomosis.

Nevertheless, the presence of bile in the afferent limb and the 200 cm long bypass imply that MGB failure reoperations must be discussed somehow differently than after RYGB.

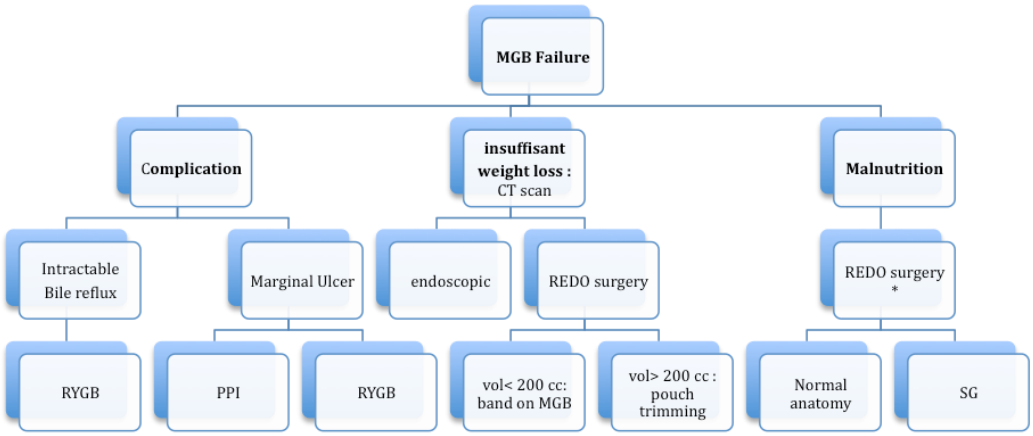

*After ressuscitation, SG = sleeve gastrectomy, PPI: proton pomp inhibitors.

Figure 8. Algorithm for revisional surgery after failed MGB.

Leaks can lead to biliary peritonitis and must be treated by conversion from MGB to RYGB. Intractable bile reflux is rare and must be treated by conversion of the MGB to RYGB, but the common limb length must be longer than 3 meters down to the ileocecal valve. Insufficient weight loss or weight regain may happen. A multidisciplinary assessment must be evaluated if there is pouch dilatation. If the patient remains morbidly obese and the gastric pouch appears dilated, a revision with pouch trimming might be efficient. If the pouch is not dilated, a band can be placed around the gastric tube to add more restriction.

MGB is more malabsorptive than RYGB, but the risk of malnutrition is less than 4%. If the patient is at danger, a revision can be decided after preparation. Restoration of a normal anatomy can easily be performed after MGB.

The conversion of the MGB to a sleeve gastrectomy allows the patient to keep thin but has a higher leakage rate. See algorithm Figure 8. With experience, MGB actually appears to have a small reoperation rate to be easily converted or reversible. It should then be considered in the armamentarium of bariatric surgeons.

REFERENCES

[1] Sjostrom, L., Narbro, K., Sjostrom, D., Karason, K., Larsson, B., Wedel, H., et al., Effect of bariatric surgery on mortality in Swedish obese subjects. *NEJM*. 2007; 357: 741-52.

[2] Lönroth, H., Dalenbäck, J., Hagling, E., Lundell, L. Laparoscopic Gastric bypass. *Surg. Endos*. 1998; 10:636-38.

[3] Lee, W. J., Yu, P. J., Wang, W., et al., Laparoscopic Roux-en-Y versus mini-gastric bypass for the treatment of morbid obesity. *Ann. Surg*. 2005; 242:20-28.

[4] Fisher, B. L., Buchwald, H., Clark, W., Champion, J. K., Fox, S. R., MacDonald, K. G., Mason, E. E., Terry, B. E., Schauer, P. R., Sugerman, H. J. Mini-gastric bypass controversy. *Obes. Surg*. 2001; 11: 773-777.

[5] Carbajo, M., Garcia-Caballero, M., Toledano, M., Osorio, D., Garcia-Lanza, C., Carmona, J. A. One-anastomosis gastric bypass by laparoscopy: results of the first 209 patients. *Obes. Surg*. 2005;15(3): 398-404.

[6] Noun, R., Skaff, J., Riachi, E., Daher, R., Antoun, N. A., Nasr, M. One thousand consecutive mini-gastric bypass: short- and long-term outcome. *Obes. Surg*. 2012;22 (5):697-703.

[7] Lee, W. J., Ser, K. H., Lee, Y. C., Tsou, J. J., Chen, S. C., Chen, J. C. Laparoscopic Roux-en-Y vs mini-gastric bypass for the treatment of morbid obesity: a 10-year experience. *Obes. Surg*. 2012; 22(12):1827-34.

[8] Musella, M., Susa, A., Greco, F., De Luca, M., Manno, E., Di Stefano, C., et al., The laparoscopic mini-gastric bypass: the Italian experience: outcomes from 974 consecutive cases in a multicenter review. *Surg. Endos*. 2014; 28(1):156-63.

[9] Kular, K. S., Manchanda, N., Rutledge, R. A 6-Year Experience with 1,054 Mini-Gastric Bypasses- First Study from Indian Subcontinent. *Obes. Surg*. 2014; 24:1430-5.

[10] Chakhtoura, G., Zinzindohoué, F., Ghanem, Y., Ruseykin, I., Dutranoy, J. C., Chevallier, J. M. Primary results of laparoscopic mini-gastric bypass in a French obesity-surgery specialized university hospital. *Obes. Surg*. 2008; 18:1130-1133.

[11] Chevallier, J. M., Arman, G. A., Guenzi, M., et al., One thousand single anastomosis (omega loop) gastric bypasses to treat morbid obesity in a 7-year period: outcomes show few complications and good efficacy. *Obes. Surg*. 2015 (in press).
[12] Rutledge, R. The mini-gastric bypass: experience with the first 1,274 cases. *Obes. Surg*. 2001; 11:276-280.
[13] Deitel, M., Gawdat, K., Melissas, J. Reporting weight loss 2007. *Obes. Surg.* 2007;17: 565-8.
[14] Lee, W.-J., Lee, Y.-C., Ser, K.-H., et al., Revisional surgery for laparoscopic minigastric bypass. *Surg. Obes. Relat. Dis*. 2011; 7:486-92.
[15] Mahawar, K. K., Jennings, N., Brown, J., Gupta, A., Balupuri, S., Small, P. K. "Mini" gastric bypass: systematic review of a controversial procedure. *Obes. Surg*. 2013; 23 (11): 1890-8.
[16] Mason, E. E., Ito, C. Gastric bypass in obesity. *Surg. Clin. North Am*. 1967; 47:1345-1350.
[17] Bruzzi, M., Rau, C., Voron, T., Guenzi, M., Berger, A., Chevallier, J. M. Single anastomosis or mini-gastric bypass: long-term results and quality of life after a 5-year follow-up. *Surg. Obes. Relat. Dis*. 2015 (in press).
[18] Chevallier, J. M., Trelles, N., Arienzo, R., Jamal, W., Chakhtoura, G., Zinzindohoué, F. Endoscopic findings after laparoscopic omega loop gastric bypass. *Obes. Surg*. 2011; 21:956.
[19] Garcia-Caballero, M., Carbajo, M. One anastomosis gastric bypass, safe and efficient surgical procedure for treating morbid obesity. *Nutr. Hosp*. 2004; 19(6): 372-5.
[20] Su-Hsin Chang, Stoll, C., Jihyun Song, Varela, E., Eagon, C., Colditz, G., The Effectiveness and Risks of Bariatric Surgery, an Updates Systematic Review and Meta-analysis. *JAMA Surg*. 2014; 149(3):275-287.
[21] Rieu, P. N., Jansen, J. B., Biemond, I., Offerhaus, G. J., Joosten, H. J., Lamers, C. B. Short-term results of gastrectomy with Roux-en-Y or Billroth II anastomosis for peptic ulcer. A prospective comparative study. *Hepatogastroenterology* 1992; 39(1): 22-6.
[22] Ryou, M., Ryan, M. B., Thompson, C. C. Current status of endoluminal bariatric procedures for primary and revisional indications. *Gastrointest. Endosc. Clin. N. Am*. 2011, Apr; 21(2): 315-33.
[23] Patel, S., Szomstein, S., Rosenthal, R. J. Reasons and Outcomes of reoperative bariatric surgery for failed and complicated procedures. *Obes. Surg*. 2010, Jul. 30.
[24] Robert, M., Pechoux, A., Marion, D., Laville, M., Gouillat, C., Disse, E. relevance of Roux-en-Y gastric bypass volumetry using 3-dimensional gastric computed tomography with gas to predict weight loss at 1 year. *Surg. Obes. Relat. Dis*. 2014 May 23. pii: S 1550-7289(14)00216-0. doi: 10 1016/j. soard 2014.05.014.
[25] Iannelli, A., Kassir, R., Gugenheim, J. The Long and Narrow Pouch for Laparoscopic Roux-en Y Gastric Bypass. *Obes. Surg*. 2014:24; 1744-45.
[26] Fobi, M. Banded gastric bypass: combining two principles. 2004 ASBS Consensus Conference. *Surg. Obes. Relat. Dis*. 2005 May-june; 1(3): 304-9.
[27] Irani, K., Youn, H. A., Ren-Fielding, G. A., et al., Mid-term results for gastric banding as salvage procedure for patients with weight loss failure after Roux-en-Y gastric bypass. *Surg. Obes. Relat. Dis*. 2011 mar-Ap; 7(2):219-24.

[28] Betty, M. L., Underhill, M. B. Intestinal length in man. *Br. Med. J*. 1955; 19:1243-46.
[29] Himpens, J., Dapri, G., Cadière, G. B. Laparoscopic conversion of the gastric bypass into a normal anatomy. *Obes. Surg*. 2006 Jul; 16(7): 908-12.

In: Encyclopedia of Surgery (22 Volume Set)
Editors: Andreas Lehrer and Kristin Mueller
ISBN: 978-1-53618-329-0
© 2020 Nova Science Publishers, Inc.

Chapter 58

SURGICAL PROCEDURES FOR FAILURE OF BILIOPANCREATIC DIVERSION WITH DUODENAL SWITCH (BPD-DS)

Simon Marceau*, MD, Simon Biron#, MD,
Frédéric-Simon Hould†, MD, Stefane Lebel‡, MD,
Odette Lescelleur¶, MD, Laurent Biertho•, MD,
and Picard Marceau%, MD, PhD
Bariatric Surgeon, IUCPQ, Laval University
Québec (Québec), Canada

ABSTRACT

We are presenting our experience in dealing with patients on whom BPD-DS has caused either excessive malabsorption or insufficient weight loss.

We discuss the decision making to proceed with changing the architecture of the intestinal bypass and what procedure was used to resolve the problem. Suggestions are given on how each procedure was performed and the results obtained from each of these.

In conclusion failure after BPD-DS is relatively rare and revision for denutrition is usually simple and efficient. A complete reversal of the procedure is also feasible.

* Corresponding Author's Email: mirsim@videotron.ca.
# Corresponding Author's Email: simon.biron@chg.ulaval.ca.
† Corresponding Author's Email: Frederic.hould@chg.ulaval.ca.
‡ Corresponding Author's Email: stefanelebel@gmail.com.
¶ Corresponding Author's Email: odette.lescelleur@chg.ulaval.ca.
• Corresponding Author's Email: laurent.biertho@chg.ulaval.ca.
% Corresponding Author's Email: picard.marceau@chg.ulaval.ca.

INTRODUCTION

BPD-DS is a safe and very efficient procedure when follow-up is appropriate. It can but rarely fail by causing either excessive malabsorption or not enough weight loss and will require revisional surgery.

Recently we reported a review of 2615 consecutive patients submitted to a BPD-DS between 1992 and 2010. 95% of these patients were followed up with a visit or blood work within the last 2 years with a mean follow-up of 9.6 years (range 2 to 20 years) [Ref].

We reported that 2.9% (n:78) of these patients required the intestinal diversion be restored either for excessive malabsorption (n:37) or for insufficient weight loss (n:41).

In the present chapter we will focus on these patients and will discuss the type of procedure used. We will first present the possible revisions for malabsorption and then the revisions for insufficient weight loss.

Revision for Malabsorption

BPD-DS by decreasing bile contact with food permanently compromises absorption of fat, liposoluble vitamins and calcium. This is usually easily compensated with appropriate supplements. However by shortening the functional intestine by about half, it temporarily compromises protein absorption in about 20% of the patients for the first year. This is followed by spontaneous recovery for the great majority of patients particularly with appropriate treatment. In a few patients, protein absorption remains under normal levels, and resists to medical treatment. A decision needs to be taken to modify the architecture of the bypass. Circumstances dictate the timing to do so. There is not one perfect timing for reoperation, since it depends on patients' collaboration, easiness of follow-up and severity of patients' symptoms. One needs to keep in mind the risk of hypoalbuminemia on the liver, which may be life threatening when hypoalbuminemia reaches levels below 25g/l. We report our own experience hereunder.

Patient Characteristics

During our 20-years of experience with BPD-DS, a decision was made to modify the bypass in 28 patients and to completely reverse the bypass in 9 (for a prevalence of revision for malabsorption of 1.4%). The reasons that forced the decision to modify the bypass were complex but the dominant factor was recurrent protein deficiency in 15; diarrhea in 8; abdominal pain in 4; persistent anorexia in 7 and persistent asthenia in 3. There were also aggravating factors complicating the situation.

Nine patients were drug addicts, 5 presenting with psychiatric problems, 4 with excessive use of alcohol and in 4 the situation was aggravated by the appearance of concomitant diseases (2 cancers, 1 lupus and 1 cirrhosis). The bypass was almost completely dismantled in 9 patients. This group was younger (38 vs 51 years old) and the decision was delayed (8 vs 4 yrs.) compared to the group whose bypass was only lengthened.

Surgical Approach

In 80% of patients measures of the intestinal segments before revision were found to be within 10% the expected length: Total Alimentary Channel (TAC) 250 cm and Common Channel (CC) 100 cm. In 20% it was found to be longer, with variation in the 50 to 100% range for the TAC and between 100 and 175% for the CC. None of the patients were found with channels shorter than expected. Isolated lengthening of the CC (which is rarely done for diarrhea), can be realized by moving the the ileo-ileal anastomosis upward at the desired level on the TAC channel (Figure 1).

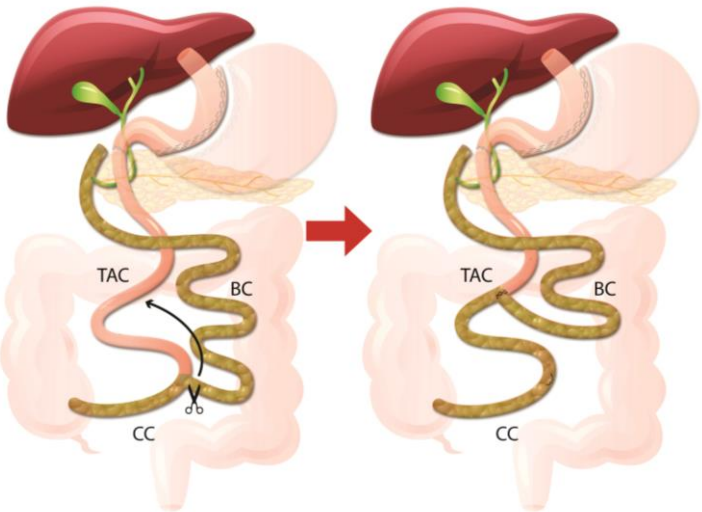

Figure 1. Lengthening only the Common channel. To lengthen only the common channel for controlling diarrhea, the ileo-ileostomy can be displaced more proximally on the total alimentary channel. It implies a mesenteric closure and a new end to side ileo-ileostomy. TAC: Total Alimentary Channel; CC: Common Channel; BC: Biliary Channel.

For lengthening both the TAC and the CC one can either move the distal end of the strict alimentary channel to an appropriate level on the biliary channel (BC) requiring one closure and one anastomosis (Figure 2) or use a "kissing anastomosis method" (side to side) without any closure, between TAC and BC. This technique is easier but leaves a loop in place (Figure 3). In our experience, the lengthening varied from 50 to 300cm for a mean of 100 cm.

On the other hand, 3 different techniques are available to completely or almost completely reverse the intestinal bypass. For complete reversal it is possible to take down the duodeno-ileostomy and to do a new duodeno-duodenal anastomosis with the duodenal-stump, and complete the procedure by replacing the previous latero lateral anastomosis for a new end to end ileo-ileostomy. It requires a closure of the mesenteric window, and 2 new anastomosis (Figure 4). To avoid dissecting the duodenal area and to do an almost complete reversal is possible through two methods.

One technique is to do an end to side ileo-jejunostomy as close as possible from both the duodenal area and the Angle of Treitz at ±20 cm from each one and replace the initial ileo-ileostomy by a new end to end ileo-ileostomy. It requires a closure of the mesenteric window and 2 anastomosis.

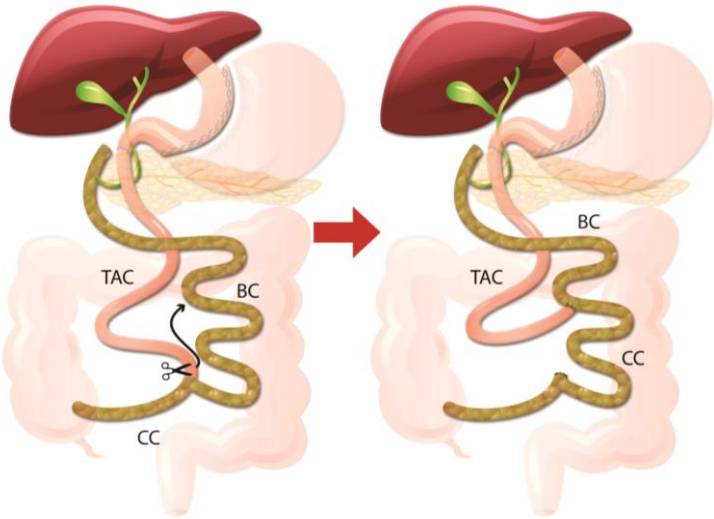

Figure 2. Lengthening both the total alimentary and common channels. The total alimentary channel (TAC) is transected with a mechanical device above the ileo-ileostomy and reanastomosed at an appropriate level on the biliary channel (BC). Both TAC and Common Channel (CC) are lengthened for an equivalent length. The same method can be used for a "nearly complete reversal" if the reanastomosis between the proximal TAC and the proximal jejunum is done as close as possible to the ligament of Treizt.

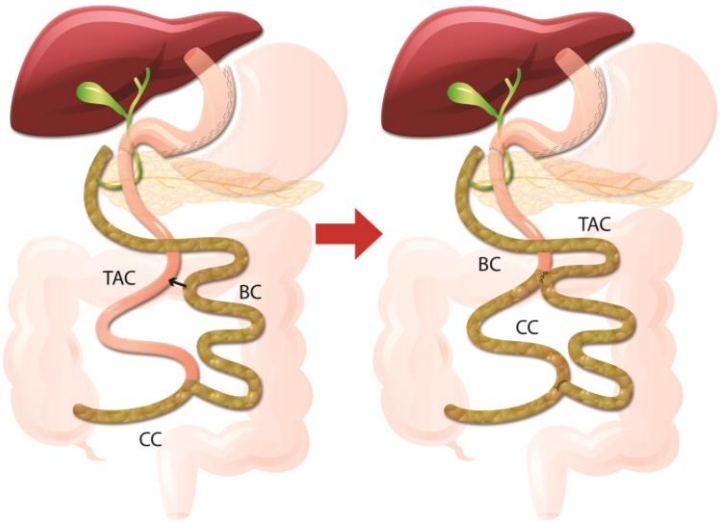

Figure 3. Kissing anastomoses for lengthening both TAC and CC. A kissing anastomosis (side to side) between TAC and BC forming a loop will lengthen both TAC and BC for an equivalent length. This is the simplest technique and requires only one anastomosis. TAC: Total Alimentary Channel; CC: Common Channel; BC: Biliary Channel.

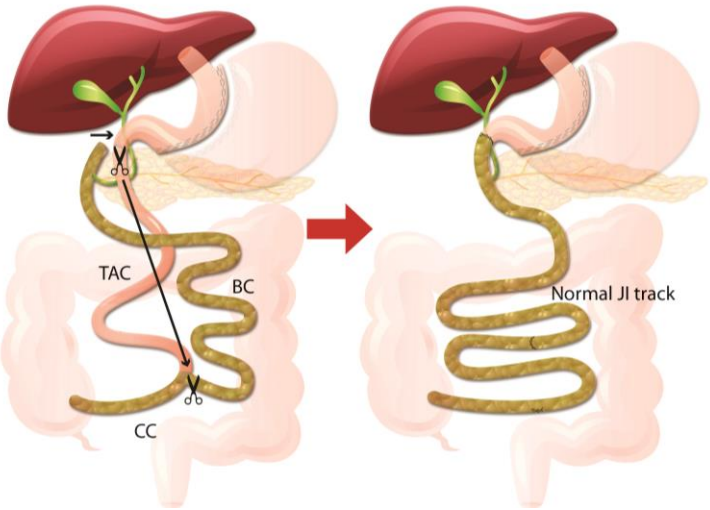

Figure 4. Complete reversal. The duodeno-ileal anastomosis is taken down and a new duodeno-duodenal anastomosis is done with the duodenal stump. The end of the previous biliary channel is then connected to the origin of the previous total alimentary channel. It requires a mesenteric closure and 2 anastomosis. TAC: Total Alimentary Channel; CC: Common Channel; BC: Biliary Channel.

The other technique consists of using the same approach as for lengthening both the TAC and CC (Figure 2) and to do the reconnection as high as possible to the proximal jejunum close to the angle of Treitz. This requires only one mesenteric window closure and a single anastomosis. With these 3 different methods patients end up with a sleeve gastrectomy with either a normal intestinal tract; or with about 40 to 150 cm biliary bypass. This last method is obviously easier and requires only one small bowel anastomosis. The long-term risk of peptic ulcer is considered negligible.

Results

The lengthening of the intestinal segments was efficient to correct the malabsorption in 80% of the patients. The remaining 20% of patients required re-lengthening or complete reversal of the duodenal switch. In terms of weight gain there was none in one third of the patients, and the other two-third gained 8 to 45 kg. There was one operative death in this group of 37 patients. The mean follow-up after revision was 5.5 years. Late unrelated death was not different than for the whole group. There were 2 suicides (1 and 8 years after revision) and 2 deaths from pulmonary insufficiency (2 and 4 years after revision).

After complete or nearly complete reversal malabsorption ceased and a mean 32 kg weight regain occurred (range: 18 to 74 kg). When the decision for reversal was triggered by the presence of chronic abdominal pain (n:4) this symptomology persisted despite complete revision. There was no major complication following reversal.

Conclusion in Regard to Revision for Malabsorption

The need to surgically correct BPD-DS for excessive weight loss and/or malnutrition was rare (1.4%). It usually occurred in patients presenting with other aggravating factors making the evaluation and the follow-up difficult. It was also precipitated by the appearance of unexpected associated disease. The decision between lengthening the non-bypassed bowel versus a complete reversal depends on the severity of the malnutrition and the difficulty of follow-up. When lengthening is done, it should be done at the expense of the biliary limb and both the common channel and alimentary channel are lengthened: The kissing anastomosis technique is easier because it limits the procedure to only one new anastomosis but the long term risk of creating a loop has not yet been demonstrated.

Lengthening of the alimentary tract usually does not result in major weight gain and relieves the malabsorption in 80% of the patients. A complete reversal removed the malabsorption but was also followed by major weight regain. The surgical technique consisting in joining the distal end of TAC (transected above the ileo-ileostomy) to the proximal jejunum (end-to-side) is easier and leaves the patient with only a duodenal diversion and a 150 cm short bypass.

REVISION FOR INSUFFICIENT WEIGHT LOSS

Patient Characteristics

Definition of "insufficient weight loss" after bariatric surgery is not yet clearly defined. It is generally agreed that a BMI ≥40 represents a handicap sufficient in itself to justify surgery, hence we consider failure when a patient with an initial BMI greater than 50 does not reach a BMI below 40 or when a patient with an initial BMI less than 50 does not reach BMI less than 35. This goal is reached in almost 90% of cases after BPD-DS with a mean weight loss of 55 kg. The decision to proceed with a revision for insufficient weight loss depends essentially on patients themselves in relation to the risk involved. In this series, 40 patients required a revision for insufficient weight loss. Revision was performed at a mean 8 years after the primary surgery (range: 1 to 15 years). Overall the group had lost a mean of 31.5 kg; their BMI was 40.3 ±5.7; the gender ratio (f/m) was 31/9 and their mean age 47 years old. Two of them were patients with Prader-Willi syndrome.

Surgical Procedure

In 8 patients, before revision was done, the measurement of both the alimentary and common channel were found to be as expected (250/100 cm); in 14 they were elongated by 20 to 80% and in the other 18, the measures were not reported.

In 13 patients, it was decided to do only a shortening; in 18 only a re-sleeve and in 9 a re-sleeve plus a shortening was performed. When shortening was done the goal was to restore the initial intestinal length (250/100 cm). A segment of the TAC was resected including the

ileo-ileal anastomosis, and a new end to end ileo-ileostomy and a new end to side ileo-ileal anastomosis at 100 cm from the ileo-ceacal valve were performed.

RESULTS

One patient suffering from Prader-Willi died early after re-sleeve and shortening. There were 4 late deaths from unrelated causes: (trauma after 10 years, cancer after 16 and 20 years, cerebral vascular accident after 20 years).

After shortening (n:13) an additional 14 kg weight loss (range: 3-38 kg) was obtained, with a follow-up of 8 years and a final total weight loss of 49 kg and final BMI of 34 without protein malabsorption. Only one patient required a second shortening.

Re-sleeve only (n: 18) resulted in additional weight loss similar to shortening of the intestine (19 vs 14 kg) ($p=0.18$). Intestinal shortening accompanied by regastrectomy did not increase weight loss but this addition was undertaken in patients who had already shown greater resistance to weight loss after the initial procedure having lost only 22 kg versus 35 kg for the others. Furthermore this latest group remained with a greater BMI (42 vs 34 kg/m^2) and a lower percent excess weight loss (35 vs 63), at a mean 16 years after the initial surgery, confirming their weight loss resistance.

Conclusion Regarding Reoperation to Add Weight Loss

Revision for insufficient weight loss is rarely necessary after BPD-DS (1.6%). If intestinal segments are found within the expected length, a simple regastrectomy would seem the procedure of choice with better additional weight loss. For patients who initially show resistance to weight loss, the addition of a regastrectomy together with shortening of the bowel will almost double the initial weight loss without protein malabsorption. With this strategy a second attempt gave an additional 14 kg weight loss.

CONCLUSION

Lengthening the functional intestine will be efficient to cure protein malabsorption in 80%, and cause minimal weight gain. However 20% of the patients will eventually require a total reversal. For increasing weight loss, regastrectomy was more efficient than shortening of the functional intestine but we believe that when the channels are found to be 50% longer than expected, they should also be shortened and if there is evidence of resistance to weight loss, an attempt to restore the proper length of the bypass is indicated.

ACKNOWLEDGMENTS

Sincere thanks to Paule Marceau, databank manager who assisted for the collection of data and to Helene Trudel from the department of Audiovisual for the figures.

REFERENCE

Marceau P, Biron S, Marceau S, Hould FS, Lebel S, LeScelleur O, Biertho L, Simard Serge, Kral JG. Long-Term Metabolic Outcomes 5 to 20 Years after Biliopancreatic diversion. *Obes Surg* doi 10.1007/s/1695-015-1599-5.

In: Encyclopedia of Surgery (22 Volume Set)
Editors: Andreas Lehrer and Kristin Mueller
ISBN: 978-1-53618-329-0
© 2020 Nova Science Publishers, Inc.

Chapter 59

FAILED BPD

Giuseppe Maria Marinari[1,*], Vincenzo Borrelli[1] and Luc Lemmens[2]
[1]Humanitas Gavazzeni, Bariatric Unit, Bergamo, Italy
[2]AZ Nikolaas, Sint-Niklaas

ABSTRACT

The failure in weight loss after BPD is an unpleasant event and it is poorly described in the literature: little has been written on the rate of inadequate weight loss, and how to handle it. From the limited available data it seems that after BPD weight loss is less than 50% of the excess weight in about 10% of cases. The solution to this issue varies depending on the eating habits of the patients and on their tolerance to side effects and diet that BPD entails. Surgery can be an eventual solution to weight loss failure but patients should be informed of the small size of the data on which to decide.

1. INTRODUCTION

Insufficient weight loss and weight regain constitute an important problem for all bariatric procedures. The percentages of these problems will vary depending on the different procedures: 50 % or more for adjustable gastric banding (AGB), 20 to 30 % for the standard gastric bypass (SGB), 30 to 50 % for the sleeve gastrectomy (SG). BPD or BPD-DS are still considered the most powerful operation in terms of weight loss, weight maintenance and resolution of co-morbidities. Nevertheless this procedure is not free of failures. There are few data published on this topic, but failures occurred in 8 - 10 % of our patients.

Because of their efficacy malabsorptive procedures are actually considered the most powerful procedure, not only as a primary but especially as a redo procedure after the failure of a restrictive operation [1, 2, 3]. In the author's series weight loss after BPD can be considered very good: at two years a mean BMI of 27 is reached, and the weight loss is sustained, leading to a mean BMI of 28 in the long term. Nevertheless, even BPD can fail in

* Corresponding Author's Email: giuseppe.marinari@gavazzeni.it.

some cases, particularly in long term follow up: since few papers face this problem, it is difficult to estimate at which percentage a failure can happen. In the few papers available the failure rate varies from 1.5% [4] to 10% [5]: as far author's unpublished data, in GMM - VB series in 2.1% of cases the weight loss was less than 25% of the excess weight (EW) and in 8.1% the weight loss was less than 50% of the EW, whilst in LL series, in 2.3% of cases the BMI remained over 35, and 8% regained weight (unpublished data). Goal of this chapter is trying to determine an algorithm to manage a malabsorption failure.

2. REASONS FOR FAILURE

There are three main reasons for failure to loose sufficient weight or for weight regain after BPD.

1. Sweet eating is a pitfall for all type of procedures. Although BPD is a malabsorptive procedure, simple sugars absorption is preserved and there is no restriction in the food intake. This may lead to an extra absorption of hundreds of calories per day, particularly when these sweets are taken in between meals. This drawback must be explained to patients before the operation and must be repeated later during consultation: unfortunately, people sometimes become sweet eater after surgery.
2. Hunger. As in other bariatric procedures, in very early follow up the hunger feeling is diminished after BPD due to the reduced gastric volume and to the change in gut hormones. In contrast with other procedures, while BPD patients are able to eat normal meals early after the operation they usually manage to keep their weight loss. It has been shown that after BPD a threshold mechanism of absorption for fat and starch [6] should allow to eat great amount of food at a stable weight, provided it happens in three-four meals per day. Per meal only 300 til 500 Kcal can be absorbed. Extra meals or grazing will jeopardize this mechanism of weight maintenance: in a BPD series of 15 subjects with Prader Willi Syndrome, where a compulsive hyperphagia is present, half of the patients were failures [7]. After a longer period of follow-up some patients will start to complain of a significant increase in the hunger feeling with polyphagia and hyperphagia, and therefore of weight regain as a consequence. This must be highlighted, because compulsiveness and eating disorders have been suggested as particular indications to BPD, but at the same time they can be reason of a BPD failure.
3. Intestinal adaptation [8], can be a reason of weight regain in a few patients. The diagnosis is difficult and can only be made after exclusion of other reasons (i.e., sweet eating or grazing) of weight regain. It should only occur several years after the operation.

3. TREATMENT

The first step in tackling weight issues after BPD is always an in-depth nutritional counseling in order to evaluate:

1) Daily simple sugar intake
2) Daily protein intake
3) Number of meals per day
4) Presence of compulsive hyperphagia

Different causes of weight regain will need different solutions.

a) Sweet eating. There is no surgical solution in case of pure sweet eating: if the patient cannot control it, the help of a dietician and a psychological support can be offered. Results are strongly dependent on patient compliance
b) Compulsive hyperphagia. Patients can become very hungry several years after BPD and some of them will start eating several times per day and even during the night. These patients may complain of frequent large stools and weight regain will be an important problem. Psychological support can be offered , but results are in most of the cases disappointing. In case of polyphagia with enough protein intake (> 150 g per day) and normal albuminemia, a surgical solution may be proposed. The resection of the stomach fundus (Figure 1), similar to Sleeve Gastrectomy, can decrease the ghrelin's levels and therefore may induce weight loss (9). Literature is sparse and inaccurate: it is impossible to predict how much of the excess weight can be lost with this type of revisional surgery. The risk of protein malnutrition should always be kept in mind: in this case a further revision to gastric bypass will still be possible. Nevertheless, in LL unpublished data, this type of revision has led to a good weight loss (about 10 points of BMI). In 19 patients the BMI had initially decreased from 46,3 to 27,7 after the BPD. On the long run there was a weight regain to a BMI of 36,3 and a fundus resection was performed. After revision there was an average BMI loss of 10 points down to 25,9. Three patients suffered from protein deficiency and 2 of them needed TPN. Also other authors suggest a secondary Sleeve Gastrectomy as a solution after BPD failure [9].
c) Intestinal (over)adaptation. When there is no sweet eating, protein intake is adequate (80-100 g/day), eating habits are regular (3, maximal 4 meals per day), and volumes unchanged intestinal (over)adaptation must be ruled out. The solution one may offer is a limb length revision, with shortening of both the alimentary and the common limb. Unfortunately, there is no literature on this subject. There was only a short experience of one of the authors (GMM) at University of Genoa School of Medicine with Scopinaro's series. Shortening the limb length was attempted in 4 cases. The revision was practically ineffective in 3 long term patients and led to a small BMI loss in 1 patient, who had been operated on elsewhere just 18 months before, and in whom the limbs were too long. In analogy with previous reoperations performed for incisional hernias years after standard BPD (alimentary limb cm 200, common limb cm 50) in patients with good weight loss (> 70% of EW) and good nutritional status, in whom the length of the alimentary and of the common limb was found to be cm 240 and cm 70 respectively, in the 4 cases cited above, the alimentary and the common limb length was shortened to cm 240 and to cm 70 respectively (Figure 2). Revision was uneventful both on bowel movements and on protein levels. Shortening the alimentary and the common limb in order to provide a better weight loss is a big

challenge: an aggressive revision could lead to protein malnutrition and excessive bowel movements, whilst a limited shortening will be ineffective.

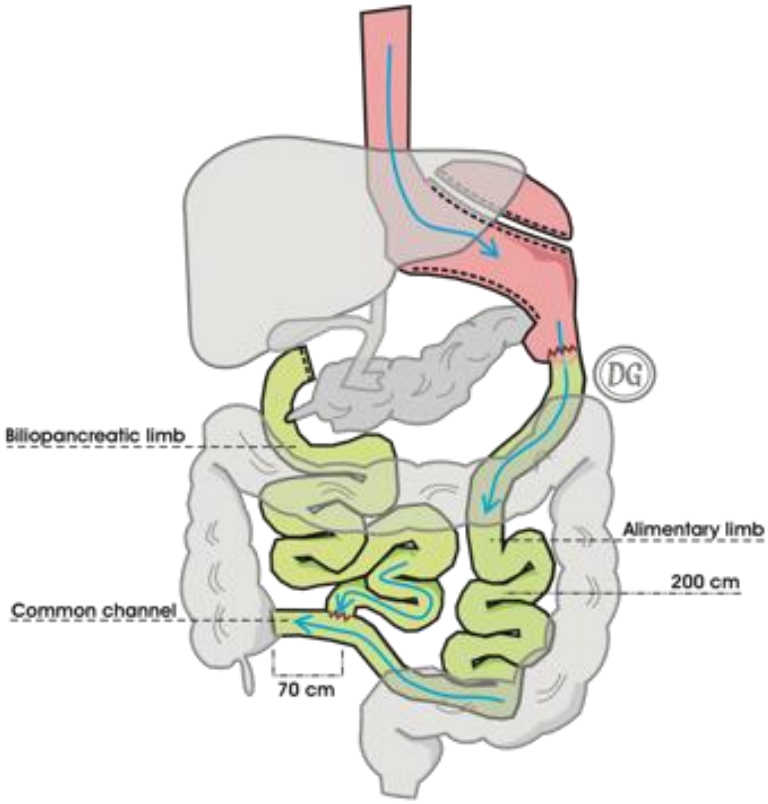

Figure 1. Resection of the stomach fundus.

d) In case of unsatisfactory weight loss in BPD patient with low tolerance, i.e., excessive bowel movements or protein deficiency, a conversion to gastric bypass is feasible (Figure 3). This is quite a drastic intervention since BPD must be taken down altogether and converted into a regular gastric bypass. This includes a subtotal gastrectomy, which makes the operation irreversible. Patients with an intestinal (over)adaptation may be converted into a gastric bypass as well. The early results of conversion are good with an acceptable weight loss, normalization of bowel movements and normalization of vitamin A, E and K; in case of protein malnutrition, serum proteins levels will come to normal values. However, in the longer follow-up, in comparison with a primary gastric bypass, a higher risk of weight regain has been observed. For this reason one of the authors (LL) suggests now a banded gastric bypass, with a silicone ring of 6.5 or 7 cm. Nevertheless, conversion into a gastric bypass is the best solution for patients with BPD side effects: protein malnutrition, excessive bowel movements, vitamin deficiencies, odor problems, other. This conversion can easily be done by laparoscopy, especially in case of previous laparoscopic BPD. In the medium term follow-up the authors found a loss of about 5 points in BMI.

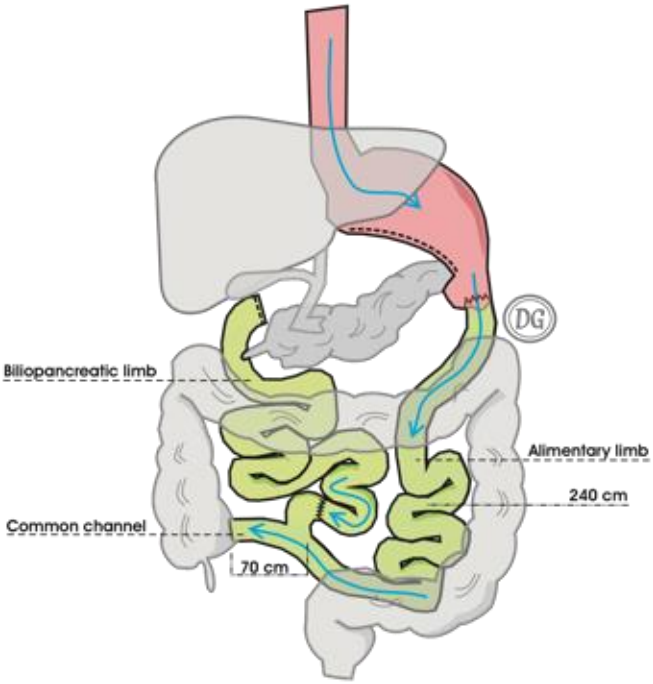

Figure 2. Shortening of the alimentary limb and of the common channel.

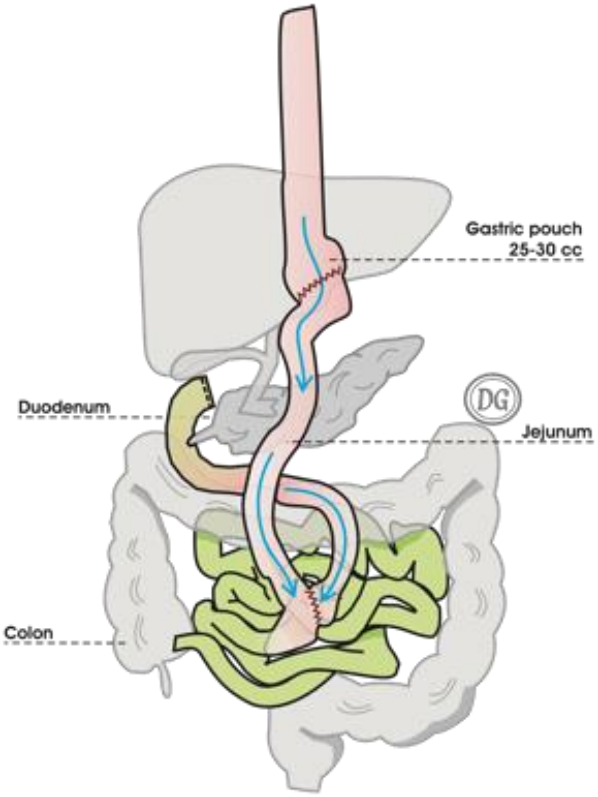

Figure 3. Conversion to Roux-en-Y gastric bypass.

CONCLUSION

About 10% of patients after BPD will have an insufficient weight loss or a weight regain. Because of the large burden of nutritional consequences and side effects that malabsorption entails, the number of failures should be reduced by selecting and directing sweet eaters to strategies other than BPD. Nevertheless, some patients will fail in any case, due to compulsive hyperphagia or intestinal adaptation. The first step in finding a solution is a thorough nutritional counseling, and only in very selected cases can a surgical revisio be suggested. Compulsive hyperphagia with high daily protein intake can be addressed by a stomach fundus resection, whilst regular eating habits and low tolerance for BPD side effects or for high-protein diet can be addressed by conversion of BPD into a gastric bypass (see Algorithm in Figure 4).

Figure 4. Algorithm for the management of BPD failure.

Before surgical revision of the biliopancreatic diversion patients should be fully informed that:

1. very few data are available on BPD revision;
2. in case of stomach fundus resection the reduced intake of food could lead to protein malnutrition;
3. the conversion to gastric bypass involves a subtotal gastrectomy.

Conversion to gastric bypass is an effective solution for BPD side effects but very little is known about weight effect in the long term.

REFERENCES

[1] Elnahas A, Graybiel K, Farrokhyar F, Gmora S, Anvari M, Hong D. Revisional surgery after failed laparoscopic adjustable gastric banding: a systematic review. (2013) *Surg. Endosc.*; 27:740-5.

[2] Daskalakis M, Scheffel O, Theodoridou S, Weiner RA. (2009) Conversion of failed vertical banded gastroplasty to biliopancreatic diversion, a wise option. *Obes. Surg.*; 19:1617-23.

[3] Keshishian A, Zahriya K, Hartoonian T, Ayagian C. (2004) Duodenal switch is a safe operation for patients who have failed other bariatric operations. *Obes. Surg.*; 14:1187-92.

[4] Marceau P, Biron S, Hould FS, Lebel S, Marceau S, Lescelleur O, Biertho L, Simard S. (2007) Duodenal switch: long-term results. *Obes. Surg.*; 17:1421-30.

[5] Slater G, Duncombe J, Fielding GA. (2005) Poor weight loss despite biliopancreatic diversion and subsequent revision to a 30-cm common channel after initial laparoscopic adjustable gastric banding: an analysis of 8 cases. *Surgery for Obesity and Related Diseases*; 1: 573 – 579.

[6] Scopinaro N, Marinari GM, Pretolesi F, Papadia F, Murelli F, Marini P, Adami GF. (2000) Energy and nitrogen absorption after biliopancreatic diversion. *Obes. Surg.*; 10:436-41.

[7] Marinari GM, Camerini G, Novelli GB, Papadia F, Murelli F, Marini P, Adami GF, Scopinaro N. (2001) Outcome of biliopancreatic diversion in subjects with Prader-Willi Syndrome. *Obes. Surg.*; 11:491-5.

[8] Friedman D, Marinari G, Camerini G, Baschieri G, Simonelli A, Scopinaro N. (1997) Morpho-functional adaptation and motility of the small intestine and colon after extensive intestinal exclusions *G Chir.;* 18:785-91.

[9] Gagner M. (2010) Laparoscopic revisional surgery after malabsorptive procedures in bariatric surgery, more specifically after duodenal switch. *Surg. Laparosc. Endosc. Percutan .Tech.*; 20: 344-347.

In: Encyclopedia of Surgery (22 Volume Set)
Editors: Andreas Lehrer and Kristin Mueller
ISBN: 978-1-53618-329-0
© 2020 Nova Science Publishers, Inc.

Chapter 60

HISTORY OF SUBARACHNOID HAEMORRHAGE

Dieter H. Woischneck
Neurosurgical Department, Hospital Landshut, Landshut, Germany

ABSTRACT

The modern definition of an "aneurysm" as being the "dilatation of a weakened artery" originated in 1728 (Lancisis). Cerebral aneurysms were further described by Morgagni (1761) and Biumi (1778) in the 18th century. Beadles (1907) noticed that cerebral aneurysms could in almost all cases only be diagnosed post-mortem. Air encephalography also did nothing to increase diagnostic confidence: the invention of cerebral angiography would be the answer in 1926 (E. Monitz). Seldinger's catheter method pushed the technology further in1953. In 1911, Cushing developed a clip for securely occluding inaccessible tumour vessels. McKenzie modified this silver clip and in 1937 Walter Dandy was the first surgeon to treat an intracranial aneurysm with a clip. The first embolisation treatments of intracranial malformations thus resulted in the 1960s and 70s. As a result of international norms the further developments were standardised.

Keywords: history, intracranial aneurysm, subarachnoid hemorraghe, surgical equipment, interventional radiography

Cerebral aneurysms were first described by Morgagni (1761) and Biumi (1778) in the 18th century. The authors had by that time already surmised that subarachnoid haemorrhage was the result of perforated blood vessels. Evidence for this affliction came in 1859: during post-mortem examinations of young men after their sudden deaths, Sir William Gull found haemorrhages in the meshes of the pia mater that had developed as a result of a ruptured aneurysm. However, despite studying these developments methodically the classic triad of symptoms eluded him. The solution was found by Charles Symonds in 1823/24. At the beginning of the 20th century, there then developed a great source of frustration: Beadles (1907) noticed that cerebral aneurysms could in almost all cases only be diagnosed post-mortem. At this stage, surgeons performing craniotomy were by chance confronted with intracranial aneurysms, especially when treating sellar masses. This is evidenced by a report

from Sir Victor Horsley of an incidental finding of an aneurysm in the optic nerve, which he treated with bilateral ligation of the cervical portion of the carotid artery. As the former foremost expert in pituitary gland surgery, Harvey Cushing came across numerous such cases, opening up the sacs (aneurysms) and filling them with muscle tissue. Air encephalography also did nothing to increase diagnostic confidence: the invention of cerebral angiography would be the answer.

About the Invention and Establishment of Cerebral Angiography

In 1926 the Portuguese neurologist Egas Moniz carried out initial experiments into cerebral angiography on dogs, using lithium and strontium bromide as contrast media. When first used in humans this method was by no means successful, causing some patients to die. Surgical exposure of the carotid artery with subsequent direct puncture was carried out for the first time on Patient 6. The examination was technically successful but this patient also died from complications. Cerebral angiography was first survived by a patient on 28 June 1927. The method was published in 1927, and a monograph by the inventor with 180 cases appeared in 1931. Sodium iodide was replaced as a contrast medium in 1931 by Thorotrast. In 1934, Moniz described the four angiographic phases. In 1933, Lima and Caldas published the first results of serial angiography. The angiographic findings for intracranial tumours (Lima) and cerebrovascular aneurysms (Cairns, Dott and Jefferson) were presented at a meeting of the British Society of Neurological Surgeons in 1935.

By the mid-30s, Bergstrand, Olivecrona and Tönnis were presenting angiographic images of arteriovenous malformations. In 1936, percutaneous carotid angiography was described by Lomann and Myerson and disseminated by Shimidzu. In 1940, Takahashi published a study on percutaneous vertebral artery puncture. In Europe, angiography was universally accepted relatively quickly, while in the USA the method was initially received with much scepticism due to issues with the employed contrast agents. This situation was improved through the introduction of tri-iodinated contrast media, leading to widespread use of the method from 1945 onwards. In 1944 Dandy pronounced ambivalent: “There is no doubt whatever of the excellent demonstrations of aneurysms by this method; it is unquestionably the most important, if not the only function that this procedure serves.” Even pioneers did not seem to be able to predict the future.

Seldinger’s catheter method pushed the technology further (1953). The first embolisation treatments of intracranial malformations thus resulted in the 1960s and 70s. In 1973, computer tomography (CT) was also introduced as a cerebral diagnostic method. First attempts at CT-DSA by Oldendorf (1978) passed off initially without repercussions, and the method became established by the beginning of the 80s.

The History of Surgery on Cerebral Aneurysms

As is often the case, it was in ancient times, around 2725 BC, that Imhotep became somewhat well-known: for arterial aneurysm. There was no further mention until Galen (200

AD). The modern definition of an "aneurysm" as being the "dilatation of a weakened artery" originated in 1728 (Lancisis). The attempt to treat aneurysms through ligation of the proximal artery also dates from this period. In 1760, Jean-Louis Petit reported an aneurysm of the carotid bifurcation that spontaneously healed as a result of thrombosis. These observations led John Hunter, in around 1800, to systematically treat aneurysms by afferent artery ligation with the aim of inducing thrombosis. The method is named "Hunterian Ligation" in his honour. In 1885, Sir Victor Horsley used this principle to treat an aneurysm of the intracranial carotid artery, discovered by chance during a craniotomy, with ligation of the extracranial internal carotid artery. However, the outcomes of incidental findings in the era of carotid ligation that was now beginning were poor. In 1931, Normann Dott was the first surgeon in history to attack a suspected aneurysm after SAH in a planned and targeted way using frontal craniotomy. He had found an aneurysm of the internal carotid artery that he covered with muscle tissue. In the 1930s Harvey Cushing, in particular, attempted to strengthen the wall of the aneurysm ("wrapping") by removing muscle tissue from the leg. The Silverstone clamp, with which the carotid artery could be gradually closed at the neck, provided an interlude. The aim was to achieve collateral circulation via the circle of Willis prior to final vascular occlusion and thus prevent ischaemic complications of the carotid ligature.

Running parallel to these attempts was the development of aneurysm clips. Initially, it was once again Norman Dott who attempted to ligate intracranial aneurysms through a surgical suture at the neck. This method was favoured time and again up until the late 60s (Brake and Anmacher, 1969). In 1911, Cushing developed a clip for securely occluding inaccessible tumour vessels. McKenzie modified this silver clip and in 1937 Walter Dandy was the first surgeon to treat an intracranial aneurysm with a clip: he treated a 43-year-old, alcoholic man with oculomotor nerve palsy for internal carotid artery aneurysm. The surgical procedure went well, as Cushing reported, even through the brain atrophy. The patient did not have an angiogram prior to surgery. The door was therefore open to the development of ever more specialised clips.

THE DEVELOPMENT OF ANEURYSM CLIPS

The development of clips has repeatedly been referred to as an evolution. The literature certainly gives the impression of a teleological development, which is not exactly evolution. In 1840, in France, the toolmaker Joseph Charrière devised vascular clips that intersected, opened in response to pressure and closed as the pressure decreased. This principle was adopted in the emerging field of neurosurgery: Olivecrona had the idea of attaching further posterior winged blades to the so-called Dandy clip so that the clip could be opened and repositioned. Schwartz developed miniaturised spring forceps as clips. Mayfield continued to develop Schwartz's inventions in the 1950s by adding a grooved clip surface, kinked introducer and continuing miniaturisation. Together with Kees, an engineer, Mayfield developed a whole range of individual clips. He persuaded seven volunteers to undergo a temporal craniotomy procedure so that he could test his clips in vivo. As far as we know from what has been written, there were no deaths. In subsequent years, many details and specifications concerning the clips were presented: The Drake clip had fenestrations for efferent vessels. Mayfield devised clips with arms that did not intersect when closed so that

they would not act like scissors. McFadden devised round clip arms with blunt tips. Heifetz attempted specifically to devise a clip with an additional spring for secure closure. The next generation of clips was then made to the specifications of microneurosurgery (Yasargil, Sugita, Spetzler). Clips were also developed that permit examinations with magnetic resonance imaging.

The success story of clips has also had its darker sides: new developments were often made by companies that had no knowledge of biocompatibility or metallurgy. There were catastrophic results due to clips rusting in the body or lethal complications from magnetic resonance imaging. That improved with the introduction of national standards.

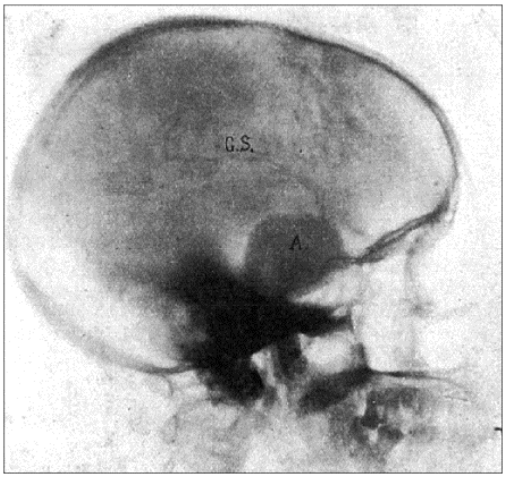

(a)

(b)

Figures 1a and 1b. Cerebral angiography illustrating a giant aneurysm of the internal carotid artery. Patient with oculomotor nerve palsy. Original images from the book: Trobosis y otras obstrucccciones de las carotidas. By Dr. Egas Moniz. In: Manuales de medicina practica. Salvat Editores, S.A. Barcelona – Buenos Aires. 1941.

THE INVESTIGATION OF CEREBRAL VASOSPASM

Sir William Gull, who, as already mentioned, was one of the first physicians to attribute SAH to a ruptured aneurysm, was also the first to describe secondary deterioration as a result of cerebral infarctions: 150 years ago, he reported the case of a young woman who fell into a coma five days after suffering SAH, developed wide and fixed pupils, and subsequently died. The post-mortem examination uncovered a ruptured aneurysm of the middle cerebral artery, a blood clot around the vessel and focal softening in the cortex.

THE EXISTENCE OF CEREBRAL VASOSPASM

Physiologists gathered the next findings en route to the discovery of vasospasm: in 1925, Florey described cerebral vasospasms in cats, caused by mechanical and electrical stimulation of the cerebral vessels. In 1944, Zucker found evidence of spasmogenic substances in the serum of laboratory animals. In 1949, Jackson injected blood into the cisterna magna of dogs and assumed that the resulting vasospasm was caused by the components of the red blood cells. The clinical breakthrough in defining "spasm" was made in 1951 by Ecker and Riemenschneider: they detected a spasm in humans using angiography, which was at its strongest at the site of the largest collection of blood, i.e., near the aneurysm. They described the time limitation, reporting that no spasms occurred after day 26 post SAH. This dependence on time led to the realisation by Allcock and Drake in 1965 that the spasm was particularly frequent and pronounced in the first three days after SAH and that the timing of surgery should account for the frequency of the spasm. During this period, Kennedy was the first to develop the theory that a surgical reduction of the SAH volume could lead to spasm prophylaxis. In the 1970s, the existence of cerebral vasospasm and its basic clinical features were recognised, and research into prophylaxis and treatment began:

ABOUT THE PROPHYLAXIS AND TREATMENT OF CEREBRAL VASOSPASM

As early as the 1960s, there were initial clinical recommendations to avoid an excessive drop in blood pressure, even after SAH, in order to improve cerebral perfusion. In 1972, Wise recommended a systolic pressure of 150-170, and a diastolic pressure of 85-100 mm Hg. In the next few years, however, consideration was given to increasing the central venous pressure so as to improve the neurological outcome. The administration of whole blood, plasma or albumin was recommended. Triple-H therapy was in its infancy. In 1979, Allen described the positive effect of calcium antagonists on a vasospasm induced in an experiment on dogs. Allen was also the initiator of nimodipine tests. From then on, treatment of vasospasm played a very influential role in the development of intensive therapy (and vice versa). Questions related to the ventilation strategy and the use or otherwise of invasive neuromonitoring continue to dominate discussions to this day and run parallel to the other major issue of neurosurgical intensive care - neurotraumatology.

In the late 1970s, Weir, Suzuki and Hashimoto established a link between surgical timing and spasm prophylaxis, which is acknowledged today: operations in the first few days after SAH have been found to deliver a better outcome, as the spasm was not yet formed – they are now also regarded as a means of preventing and treating spasms:

SURGICAL TIMING OVER THE DECADES

Until well into the 1950s, the management of ruptured aneurysms was based on case-by-case decisions and personal opinions: in 1951, Slosberg observed that the surgical occlusion of ruptured aneurysms was about as effective as reducing blood pressure with drugs. In 1963, Merritt wrote that ruptured aneurysms should only be approached when operating on space-occupying haematomas. Among the first to recommend surgery, at least for patients in good condition, were Hunt and Hess in 1968. Consequently, they developed a scale for assessing patients after SAH which would make the decision to operate easier. Throughout the 1970s, it was then recognised that after a period of bed rest, drug treatment and stabilisation, better long-term outcomes were achieved with, rather than without surgery. The high rate of later second bleeds could thus be reduced.

In the 1980s, a number of pioneers in aneurysm surgery (Dott, Drake, Yasargil) were still recommending surgery after stabilising the patient, with clipping proving to be significantly better than the wait-and-see attitude alone. However, many patients died while waiting for surgery – not only due to the vasospasm as first described in 1951, but also because of recurring haemorrhages. The improved outcomes of aneurysm surgery were therefore the result of a bias, since the patients with worse baseline conditions or complications were not included in the statistics reported by the surgeons. That was the dichotomy of the 80s: Kasel and Drake complained that although the surgical outcomes had improved, the management outcomes in terms of SAH symptoms had not. Suzuki, Yoshimoto and Norden achieved good surgical outcomes even with early surgery. The International Cooperative Study on the Timing of Aneurysm Surgery recommended early surgery in patients in good condition. It certainly would not have done any harm. In the 90s, early surgery was carried out in patients whose baseline status was poor. Some of the trailblazers of cerebral aneurysm surgery were poor statisticians and fell short with a view to the overall patient population. Retrospectively, this blinkered view of surgical outcomes alone has hampered the advancement of aneurysm treatment. The next expansion of the therapeutic spectrum is also attributable to neurosurgery:

THE DEVELOPMENT OF INTERVENTIONAL NEURORADIOLOGY

The neurosurgeon Luessenhop carried out the first attempts at embolisation on malformations in Washington in 1960. Lehmann used an adhesive substance (cyanoacrylate) for the first time in 1967. In 1973, Djindjian described the embolisation of extracranial tumours and vascular malformations. The rapid technological advancement in X-ray diagnostics was the driving force for interventional neuroradiologists: the ability to visualise the smallest of blood vessels using digital subtraction angiography, “online” imaging in two planes and the development of the flow- or guidewire-directed microcatheter. The wheel of

time is turning very quickly in this medical field: 20 years ago interventional procedures were a rarity, 10 years ago detachable coils did not exist, and five years ago today's stents were a distant reality. The two trailblazers of this technology and their background are presented below:

Fedor Andreevich Serbinenko (1928 – 2002) was a pioneer of embolisation treatment. After completing his studies, Serbinenko joined the N.N. Burdenko Neurosurgery Institute in Moscow in 1954, which was being established at that time as a neurocentre. Supported by the then luminaries of Russian neurosurgery (Shlykov, Salazzkin), he focused his attention on percutaneous angiography. In 1959, during the May Day celebrations in Red Square, he observed how children were playing with helium-filled balloons and trying to steer them like kites on long strings. And so the idea of endovascular balloon embolisation was born. In 1964, his first attempt at balloon occlusion of an intracranial vessel was successful, and in 1969 or 1970 the first permanent occlusion in the case of a malformation was achieved. By 1962, 162 embolisations had taken place, with a valve being developed to prevent spontaneous emptying. Later, Serbinenko worked with Alexander Luria to carry out psychological tests after experimental vascular occlusion. Despite Cold War restrictions, the techniques became more widespread and continued to be developed elsewhere, particularly as doctors from abroad were invited to visit the institute in Moscow. There was one overriding goal: greater individual adaptation to the aneurysm with the embolic agent than with the balloon. It is at this point that the second greatest pioneer in the field appeared: the neurosurgeon Guido Guglielmi, born in Rome in 1948. He took Mullen's idea from the 1960s of using electrolysis to detaching a metallic coil from the catheter, developing it further. Because of its elasticity (memory effect), the coil assumes its original shape and so several coils can be packed into the aneurysm. Stasis and thrombosis occur in the aneurysm as an immediate effect. Epithelialisation to achieve an intact vascular wall is the long-term effect. Guglielmi began his work in Rome in 1976. In 1983, he began working with Fernando Vinuela in London. After many years of correspondence, Vinuela invited him to the UCLA in Los Angeles in 1989, where the GDC (Guglielmi Detachable Coil) was ultimately developed. Guglielmi is now back at work in Rome.

With the dual approach of surgery and embolisation, an interest developed in obtaining more detailed information on a patient's progress in order to achieve a better prediction. The search began for criteria as to which patient would benefit more from which treatment. Attempts then began to describe treatment outcomes on an individual level:

THE EXPLORATION OF HEALTH-RELATED QUALITY OF LIFE

Whilst until the 1990s the treatment outcome of SAH was given as mortality or, more specifically, was categorised according to the Glasgow Outcome Score, since the start of the new millennium many working groups have been exploring health-related quality of life. The quality-of-life research that has now been ongoing for 15 years pursues two goals: 1) The search for sophisticated predictors with which treatment can be optimised individually (intervention yes or no, operation or coiling, expansion or reduction of intensive therapy) and 2) an estimation of the extent to which rehabilitation is feasible. At the beginning of the 2000s, quality-of-life scales from internal medicine or neurotraumatology were used one-for-

one to this end in SAH research. In the last few years, there have been attempts to develop specific tools for measuring the symptoms. What complicates matters is that a lot of statistical data on SAH is subsumed in health and disease registries under the keyword “stroke”, leading to a loss of information on the particular features of the clinical condition. In rehabilitation research, scales are also traditionally used for SAH patients which originate from stroke research and are presumably inadequate.

CONCLUSION

The first modern descriptions of SAH as a pathological condition and cerebrovascular aneurysms were formulated by the neurologists of the 19th century. With the development of neurosurgery in the first half of the 20th century, SAH became a preserve of this new discipline. Hence, therapies were introduced that had been developed from neurosurgery and subsequently opened out into their own disciplines – special intensive therapy and interventional neuroradiology are perfect examples. Neurosurgeons have relinquished their powers at the expense of more individualised treatment. Despite all the medical and technological advances, the clinical experience endemic to neurology and neurosurgery must not be overlooked.

REFERENCES

Heros RC, Morcos JJ. Cerebrovascular surgery: past, present, and future. *Neurosurgery.* 2000; 47: 1007-1033.

Louw D.F., Louis D.F., Asfora W.T., Sutherland G.R. A brief history of aneurysm clips. *Neurosurgical Focus.* 2001; 11: 1-4.

Polevaya N.V., Kalani M.Y., Steinberg G.K., Tse V.C. The transition from hunterian ligation to intracranial aneurysm clips: a historical perspective. *Neurosurgical Focus.* 2006; 20: E3.

Prestigiacomo C.J. Historical perspectives: the microsurgical and endovascular treatment of aneurysms. *Neurosurgery.* 2006; 59: 39-4.

Rahimi S.Y., Brown J.H., Macomson S.D., Jensen M.A., Alleyne C.H. Jr. Evolution of the treatment of cerebral vasospasm. *Neurosurgical Focus.* 2006; 20: E4.

Stein S.C. Brief history of surgical timing: surgery for ruptured intracranial aneurysms. *Neurosurgical Focus.* 2001; 11: E3.

Teitelbaum G.P, Larsen D.W., Zelman V. Lywsachev A.FG., Likhterman L.B. A tribute to Dr. Fedor A. Serbinenko, founder of endovascular neurosurgery. *Neurosurgery* 2000; 46: 462-469.

In: Encyclopedia of Surgery (22 Volume Set)
Editors: Andreas Lehrer and Kristin Mueller
ISBN: 978-1-53618-329-0
© 2020 Nova Science Publishers, Inc.

Chapter 61

ARTERIAL AND VENOUS VASCULARISATION OF THE BRAIN

Horst Claassen
Institute of Anatomy and Cell Biology,
Martin Luther University Halle-Wittenberg
Halle (Saale), Germany

ABSTRACT

This chapter has been written especially for neurosurgeons currently in training. To begin with, a description is provided of the cerebral arteries and veins as well as their relevant ramifications. The symptoms of ischaemia will also be mentioned. Thereafter, the neighbouring structures of the cerebral arteries will be described specifically in relation to the surgical treatment of aneurysms. Current textbooks on the subject of anatomy provide functional descriptions of structures often to the detriment of topography, or the two topics are covered together without making any identifiable distinction. In the surgical treatment of aneurysms in particular, it is important to be aware of and possibly avoid damaging the tracts and structures in the immediate vicinity.

Keywords: cerebral arteries, cerebral veins, aneurysms, functional anatomy, topographical anatomy

1. INTRODUCTION

Life-threatening subarachnoid haemorrhage is often the result of a ruptured aneurysm. This type of aneurysm often develops at the bifurcations of the cerebral arteries. Aneurysms, or arterial outpouchings, usually develop due to a congenital structural abnormality of the arterial walls, particularly of the tunica media, or due to the excessive pressure arising from hypertension (Drenckhahn 2004; Bähr and Frotscher 2014). The arteries most commonly affected by such outpouchings are the anterior communicating artery, followed by the internal

carotid artery (Paulsen and Waschke 2010). Post-mortem examinations have revealed the following incidence of aneurysms with advancing age: 4.1% at 20-29 years of age, 11% at 30-49, 8.4% at 50-69, and 20% over the age of 90.

As a preventative measure, aneurysms can be secured with a clip. Otherwise they have to be occluded with a clip if acute subarachnoid haemorrhage occurs. Alternatively, endovascular catheter treatment can be undertaken, by inserting platinum-coated metal coils. This causes a thrombus to form in the saccular bulge of the aneurysm, thereby preventing rupture of the bulging arterial wall. This novel concept is called endovascular coiling. In all cases it is essential to consider the surrounding anatomic structures when performing surgery.

2. Arterial Blood Supply to the Brain

The brain is supplied by two arterial territories, namely the internal carotid artery and the vertebral artery (Figure 1). Corrosion casts of the cerebral arteries illustrate this quite clearly (Tillmann 1997). The cerebral part of the internal carotid artery divides into the anterior and middle cerebral arteries. The intracranial part of the vertebral artery first gives rise to the posterior spinal artery, then the posterior inferior cerebellar artery, and finally the anterior spinal artery. The vertebral arteries then join from both sides to form the basilar artery, from which in each case two further cerebellar arteries emerge: the anterior inferior arteries and the superior cerebellar arteries. Having emitted the superior cerebellar arteries, the basilar artery branches off into the two posterior cerebral arteries.

The posterior communicating artery, which is the penultimate branch of the internal carotid artery, usually anastomoses with the posterior cerebral artery to connect the anterior carotid territory with the posterior vertebral territory. The two anterior cerebral arteries are likewise joined together by a connecting artery, namely the anterior communicating artery. The resulting structure is a closed arterial loop, known as the *circle of Willis,* which encircles the optic chiasm, infundibulum and mamillary bodies (Figure 1). Out of 1,000 brains, however, the circle of Willis as described in textbooks is found only in 53.8% (Leonhardt 1988). Variations appear in 46.2%, often involving the communicating arteries, with the posterior communicating arteries differing more frequently than the anterior communicating artery.

Below is a description of the branches of the major cerebral arteries and the territories they supply, based largely on the observations of Töndury et al. (1987) presented in the Textbook and Atlas of Human Anatomy by Rauber/Kopsch (*Lehrbuch und Atlas der Anatomie des Menschen* Volume III, 1987). The three cerebral arteries are in each case divided into segments, as is customary in neurosurgery. Corning (1923) distinguished between two types of branches in the case of cerebral arteries: 1. The cortical branches which supply blood to the grey matter of the cerebral and cerebellar cortex, and partly ensure perfusion of the semioval centre. 2. The basal branches are small branches that enter the brain vertically and perfuse the “central grey matter”, i.e., the basal ganglia, internal capsule, thalamus, cranial nerve nuclei as well as parts of the semioval centre. An analysis of the structure of the cerebral arteries, including phylogenetic aspects, has been provided by Lasjaunias and colleagues (2001). Yasargil (1969) describes the fine structure of the cerebral arteries. Based on his observations, the middle layers of the intracranial arteries contain far

fewer collagen fibres than the extracranial arteries. This is possibly a factor that predisposes to aneurysms.

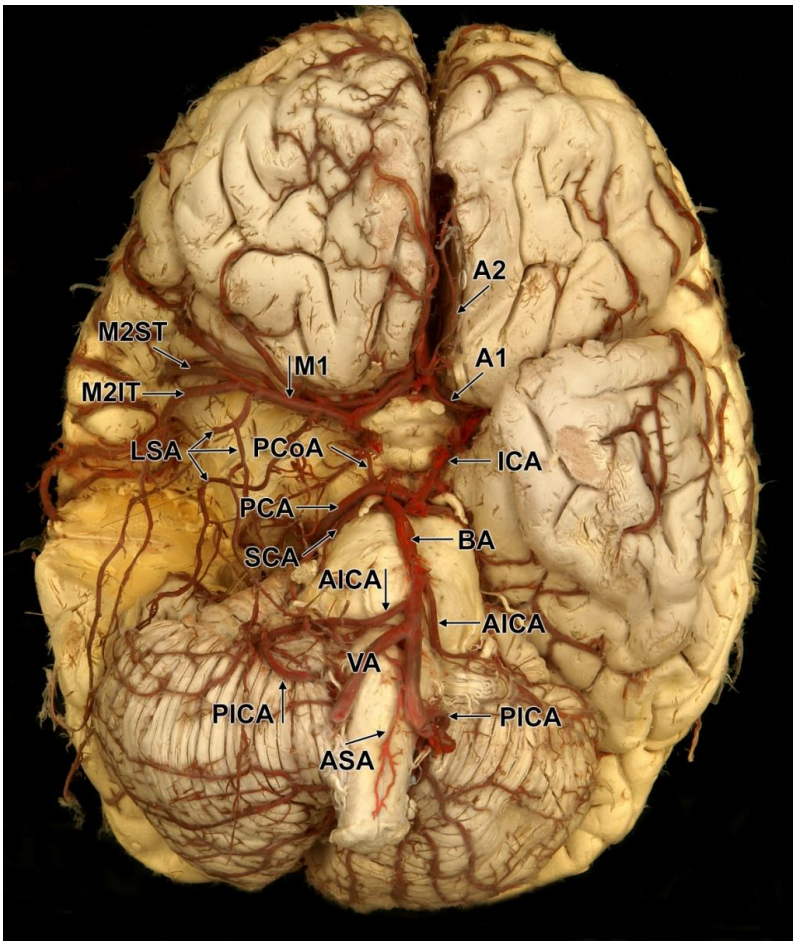

Figure 1. Injected specimen showing the arteries of the brain – basal aspect. The blood is supplied to the brain by the internal carotid artery (ICA) and vertebral artery (VA). The two circulations are connected by the posterior communicating arteries (PCOA). The resulting structure is the circle of Willis, which surrounds the optic chiasm, infundibulum and mamillary bodies. The anterior half of the right temporal lobe has been removed from the specimen. The lenticulostriate arteries (LSA), which supply the basal ganglia and internal capsule, are therefore exposed. Note that the lenticulostriate arteries, due to the special preparation technique, hang down from the M1 segment of the middle cerebral artery. These arteries would normally permeate the cerebral matter and ascend toward their supply territories in a formation similar to an onion skin. Also note the ascending posterior inferior cerebellar artery (PICA) on the right, versus the descending posterior inferior cerebellar artery (PICA) on the left. The following major arteries and arterial branches are visible: A1 – A2 = segments of the anterior cerebral artery, AICA = anterior inferior cerebellar artery, ASA = anterior spinal artery, BA = basilar artery, ICA = internal carotid artery, LSA = lenticulostriate artery, M1 – M2 = segments of middle cerebral artery, M2ST = middle cerebral artery of superior trunk, M2IT = middle cerebral artery of inferior trunk, PCA = posterior cerebral artery, PCoA = posterior communicating artery, PICA = posterior inferior cerebellar artery, SCA = superior cerebellar artery, VA = vertebral artery. Image of a wet specimen (1933, Trautmann preparative technique) in a jar (W/D/H 21 x 10 x 26 cm) from the Meckel Collections of the Institute of Anatomy and Cell Biology of Martin Luther University Halle-Wittenberg.

2.1. Branches of the Internal Carotid Artery

The *internal carotid artery* supplies the cerebrum, pituitary gland, orbital content, forehead, as well as the mucous membranes of the frontal sinus cavity, ethmoidal sinuses and anterior nasal cavity. It runs parallel to the pharynx as far as the base of the skull and passes through the carotid canal of the petrosal bone, entering the middle cranial fossa at the pyramidal apex. The artery then traverses the carotid sulcus on both sides of the body of the sphenoid bone and passes through the cavernous sinus. After penetrating the dura mater anteriorly at the sella turcica, it branches off on reaching the subarachnoid space. Next to the sella turcica, the artery curves to form an S shape which is referred to as the "carotid siphon" (Sobotta/Becher 1973). As it carries on, the artery is divided into the following segments:

Cervical Part

At the neck, the interior carotid artery initially lies posterior and lateral to the external carotid artery, but then winds in a more medial direction on its ascent. Immediately before it enters the carotid canal, the artery forms a medial convexity.

Petrous Part

At its petrous part, the interior carotid artery ramifies to supply the tympanic cavity (caroticotympanic arteries). The artery of the pterygoid canal also emerges here, and is anastomosed with the artery of the same name arising from the maxillary artery.

Cavernous Part

At this point the internal carotid artery is surrounded by the venous blood of the cavernous sinus. It releases the following branches:

- Tentorial basal branch
- Tentorial marginal branch
- Meningeal branch to the dura mater of the anterior cranial fossa
- Cavernous branch
- Inferior hypophysial artery
- Branch to trigeminal ganglion
- Branches to cranial nerves IV and V

Cerebral Part

The cerebral part, as it is called, is reached on penetration of the dura mater. It is here where the following arteries emerge, the supply territories of which are described below: superior hypophysial artery, clivus branches, ophthalmic artery, posterior communicating artery, anterior choroidal artery, anterior cerebral artery, middle cerebral artery.

- The superior hypophysial artery leads to the pituitary stalk and the basal hypothalamus.
- The clival branches supply the meninges at the clivus.

- The ophthalmic artery supplies the tear ducts, the eye and the choroid, the ciliary body and iris, as well as the eyelids.
- The posterior communicating artery anastomoses with the posterior cerebral artery and forms part of the cerebral arterial circle (of Willis). The branches of the following are emitted: optic chiasm, oculomotor nerve, thalamus, hypothalamus, tail of caudate nucleus.
- Anterior choroidal artery, runs beneath the optic tract past the lateral geniculate body, arriving at the choroid line through the choroidal fissure of the inferior horn of the lateral ventricle. In vertebrates, this artery once played a pivotal role due to its vast vascular territory. The anterior choroidal artery in humans also has numerous branches, the failure of which, if diagnosable, is not without its problems.

The *anterior choroidal artery* is the final branch of the internal carotid artery before it divides into the anterior and middle cerebral artery. It covers an expansive territory, including parts of the choroid plexus of the lateral ventricle and the third ventricle, the basal ganglia, internal capsule, parts of the diencephalon with the junction boxes for the auditory and optic tracts, as well as portions of the mesencephalon. Damage to the anterior choroidal artery will lead to motor, sensory and visual deficits (Deller 2015). Branches of the anterior choroidal artery:

- Choroidal branches to lateral ventricle, forming the choroid plexus in the inferior horn of the lateral ventricle.
- Choroidal branches to third ventricle, supplying the choroid plexus of the third ventricle.
- Branches to anterior perforated substance, passing through the anterior perforated substance to the genu of the internal capsule.
- Branches to optic tract.
- Branches to lateral geniculate body, the fourth synapse in the visual pathway.
- Branches to internal capsule, leading to the posterior limb of the internal capsule where the pyramidal, optic and auditory pathways, amongst others, are located.
- Branches to globus pallidus, a basal ganglion that is responsible, amongst others, for "more mobility".
- Branches to tail of caudate nucleus, a basal ganglion.
- Branches to tuber cinereum.
- Branches to hypothalamic nuclei.
- Branches to substantia nigra, a brainstem nucleus that degenerates in the presence of Parkinson's disease.
- Branches to red nucleus, which plays a central role in extrapyramidal motor function.
- Branches to amygdaloid body, a basal ganglion.
- Anterior cerebral artery = *anterior terminal branch* of the internal carotid artery.
- Middle cerebral artery = *lateral terminal branch* of and continuation of the internal carotid artery.

2.1.1. Anterior Cerebral Artery

A distinction is made between two segments (Figure 1, 2): the precommunicating part (Pars praecommunicalis, or A1 segment) at the base of the brain, and the postcommunicating part (Pars postcommunicalis, or A2 segment) emerging behind the anterior communicating artery.

2.1.1.1. Precommunicating Part (A1 Segment)

- Short central arteries (lateral group): 8-12 branches permeate the medial anterior perforated substance and supply the anterior hypothalamus, column of fornix, anterior commissure, head of caudate nucleus, globus pallidus and anterior limb of the internal capsule.
- Long central artery (recurrent artery of Heubner): this artery leads back to the lateral anterior perforated substance. It supplies the head of the caudate nucleus, the anterior third of the lentiform nucleus, and anterior limb of the internal capsule. *Clinical features:* Long central artery dysfunction can result in aphasia, hemiparesis and paralysis of the muscles of the face and tongue. The artery should be spared when clipping aneurysms (Lang and Wachsmuth 1979).

2.1.1.2. Anterior Communicating Artery

- Short central arteries (anterior group): the anterior group of these arteries form 6-7 narrow ramifications that perfuse the optic chiasm.

2.1.1.3. Postcommunicating Part (A2 Segment)

The postcommunicating part winds around the genu of the corpus callosum, ramifying onto the medial frontal lobe and the cingulate gyrus. Above the corpus callosum, the A2 segment divides into the pericallosal and callosomarginal arteries (Figure 2).

- Pericallosal artery (Figure 2): supplies the corpus callosum and anastomoses at the splenium of the corpus callosum with the posterior cerebral artery.
- Callosomarginal artery (Figure 2): passes over the cingulate gyrus in the cingulate sulcus, ramfiying onto the medial surface of the hemisphere.

The cortical branches of the A2 segment not only supply the medial surface of the hemisphere, but also a narrow strip on the lateral surface of the cortex. Close to the superior margin of the cerebral hemisphere, the branches of the A2 segment anastomose with the middle cerebral artery. *Clinical features:* Owing to the described anastomotic processes, both anterior cerebral arteries can, if necessary, be occluded distal to the anterior communicating artery.

2.1.2. Middle Cerebral Artery

The middle cerebral artery (Figure 1) is divided into two segments: the sphenoid part (M1 segment) running parallel to the lesser wing of the sphenoid, and the insular part (M2 segment) ascending in the lateral sulcus. In rare cases, the middle cerebral artery may be

duplicated. Adachi (1928) observed a duplicated middle cerebral artery five times (3%) in 166 hemispheres of donated Japanese bodies.

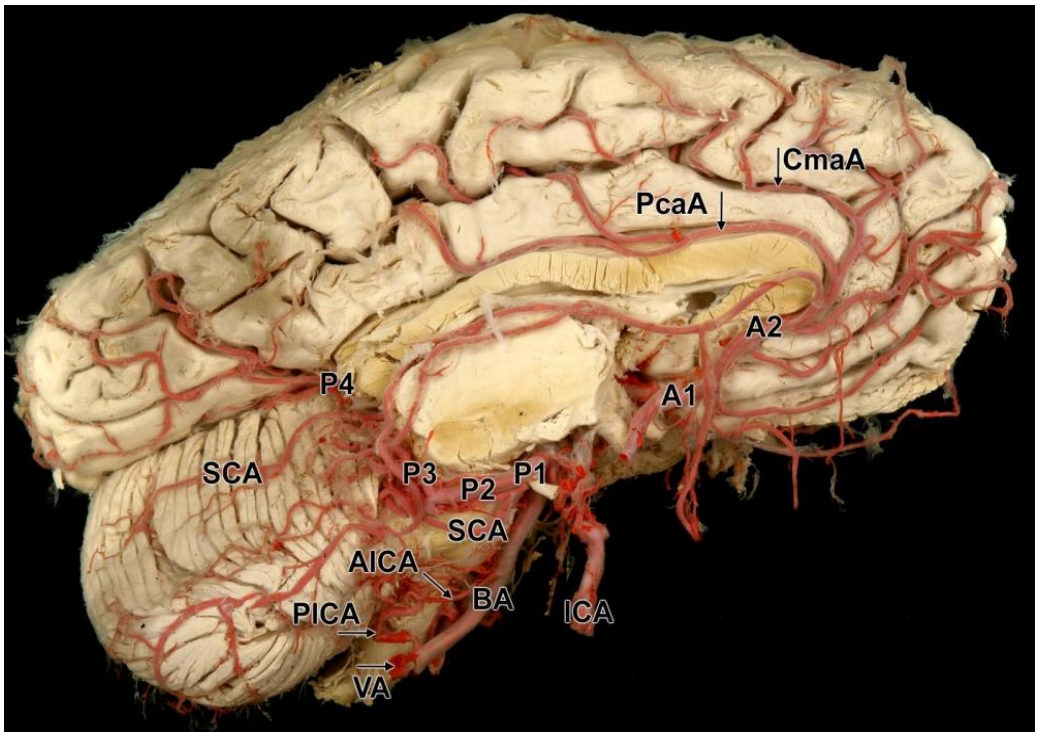

Figure 2. Injected specimen of the arteries of the brain – medial section. Caudally, the stumps of the internal carotid artery (ICA) and vertebral artery (VA) are visible. The brain is supplied with blood by these two arteries and their ramifications. Note how the supply territories of the anterior cerebral artery (A1 – A2) and posterior cerebral artery (P1 – P4) are connected by the pericallosal artery (PcaA). The following major arteries and arterial branches are identifiable: A1 – A1 = segments of the anterior cerebral artery, AICA = anterior inferior cerebellar artery, SCA = superior cerebellar artery, BA = basilar artery, CmaA = callosomarginal artery, ICA = internal carotid artery, P1 – P4 = segments of the posterior cerebral artery, PcaA = pericallosal artery, PICA = posterior inferior cerebellar artery, VA = vertebral artery. Image of a wet specimen (1957, Trautmann preparative technique) in a jar (W/D/H 22 x 10 x 25 cm) from the Meckel Collections of the Institute of Anatomy and Cell Biology of Martin Luther University Halle-Wittenberg.

2.1.2.1. Sphenoid Part (M1 Segment)

- Anterolateral central arteries (lenticulostriate arteries, Figure 2): these arteries infiltrate the lateral half of the anterior perforated substance, ascending cranially and supplying the putamen, internal capsule, as well as the head and body of the caudate nucleus. *Clinical features:* One branch ascending at the outer aspect of the putamen is referred to as the "artery of cerebral haemorrhage".

2.1.2.2. Insular Part (M2 Segment)

The M2 segment bifurcates at the limen insulae, or insular threshold, into a superior and inferior trunk (Figure 3).

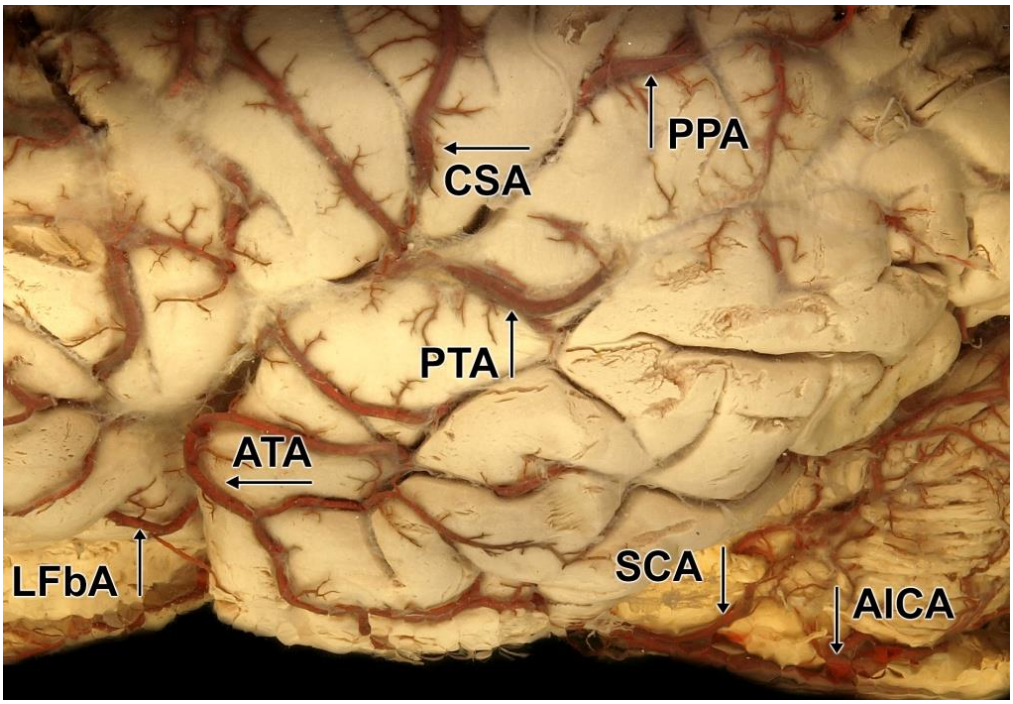

Figure 3. Injected specimen of the arteries of the brain – lateral view. The branches of the M2 segment of the middle cerebral artery are visible. The M2 segment passes through the Sylvian fissure. The branches of the M2 segment supply, among others, the motor speech centre (Broca's area), the sensorimotor cortex, the primary auditory centre, and the sensory speech centre (Wernicke's area). The following major arteries and arterial branches are visible: AICA = anterior inferior cerebellar artery, ATA = anterior temporal artery, CSA = central sulcal artery, LFbA = lateral frontobasal artery, PTA = posterior temporal artery, SCA = superior cerebellar artery, PPA = posterior parietal (supramarginal) artery. Image of a wet specimen (1957, Trautmann preparative technique) in a jar (W/D/H 22 x 10 x 25 cm) from the Meckel Collections of the Institute of Anatomy and Cell Biology of Martin Luther University Halle-Wittenberg.

- Superior trunk: The arteries of the precentral sulcus, central sulcus (Figure 3) and postcentral sulcus are ramifications of the superior trunk, perfusing the convolutions of the sensorimotor cortex. Further branches supply Broca's area, the motor centre for speech. The supramarginal arteries (Figure 3) and angular gyri lead to Wernicke's area.
- Inferior trunk: The branches of the inferior trunk supply the lateral gyri of the temporal lobe and the primary auditory centre in Heschl's convolutions. The terminal branch of the M2 segment is the posterior temporal artery (Figure 3), which perfuses the majority of Wernicke's area. *Clinical features:* The middle cerebral artery is the largest branch and the continuation of the internal carotid artery. Hence, embolisms from the distal territory of the internal carotid artery are often deposited in the middle cerebral artery (Clara 1959). Occlusion of the posterior temporal artery can affect the sensory speech centre. This artery is therefore also referred to as the "artery of Wernicke's aphasia".

2.2. Branches of the Vertebral Artery

The **vertebral artery** (Figure 1, 2) travels through the foramen of the transverse process of the cervical spine to the atlas, entering the skull through the foramen magnum. Its branches supply blood to the brain stem, cerebellum, the auditory and vestibular system, as well as, via the posterior cerebral artery, the occipital lobe of the telencephalon with visual centre.

2.2.1. Posterior Spinal Artery

The posterior spinal artery is the first intracranial branch of the vertebral artery. It supplies the core areas of the spinobulbar tract.

2.2.2. Posterior Inferior Cerebellar Artery

The posterior inferior cerebellar artery (Figures 1, 2) is the largest branch of the vertebral artery. It supplies the majority of the inferior aspect of the cerebellar hemisphere, the inferior portion of the vermis and core areas of the medulla oblongata. The terminal segment emits the choroidal branch to the fourth ventricle for the choroid plexus of the fourth ventricle.

- Arteries of posterolateral sulcus: the arteries of this lateral vascular system supply parts of the medulla oblongata with the trigeminal nerve nucleus (V) as well as the solitary, ambiguus and dorsal nuclei of the vagus nerve (X) and hypoglossal nucleus. *Clinical features:* A deficit in the lateral vascular system will lead to the development of Wallenberg's syndrome, which is characterised by dysphonia (nerve X), dysphagia (IX), gustatory anaesthesia (VII, IX, X), sensory disorders in the face (V), vertigo and nystagmus (medial longitudinal fasciculus).

2.2.3. Anterior Spinal Artery

The anterior spinal artery (Figure 1) emerges shortly before the confluence of the two vertebral arteries that forms the basilar artery. The pyramidal arteries arising from the anterior spinal artery perfuse the medullary pyramids.

2.2.4. Basilar Artery

At the lower aspect of the pons, the basilar artery (Figures 1, 2) bifurcates, giving way to the anterior inferior cerebellar arteries. Once the superior cerebellar arteries have been discharged at the upper aspect of the pons, the artery divides into a pair of posterior cerebral arteries. The following arteries also emerge:

- Artery of the anterior median fissure: The anterior segment of the pyramidal tract in the lower ventral medulla oblongata is supplied by this artery.
- Medial medullary branches of the anterior median fissure artery: perfusion of the area of the medial longitudinal fasciculus and tectospinal tract in the upper ventral portion of the medulla oblongata.
- Median pontine branches: enter the pons and supply the area of the medial longitudinal fasciculus, tectospinal tract, medial and lateral lemniscus pathways as well as trigeminal lemniscus.

- Short pontine branches: travel into the region of the pontine nuclei and corticospinal tract.
- Labyrinthine artery (though only in 15%; see below).

2.2.5. Anterior Inferior Cerebellar Artery

The anterior inferior cerebellar artery (Figures 1, 2) perfuses the flocculonodular lobe of the cerebellum, and emits a branch to supply the choroid plexus of the fourth ventricle.

- Labyrinthine artery: the artery supplying the auditory and vestibular system is in 85% of cases a branch of the anterior inferior cerebellar artery. Only in 15% of cases does this artery originate from the basilar artery.
- Long pontine branches: lead to the superior cerebellar peduncle as well as to the area of the anterior spinocerebellar tract and the motor nucleus of trigeminal nerve V in the pons.

2.2.6. Superior Cerebellar Artery

The superior cerebellar artery (Figures 1-3) is the largest of the three cerebellar arteries. It supplies the entire superior surface of the cerebellar hemisphere and superior aspect of the vermis. The artery anastomoses with the branches of the inferior cerebellar arteries, and with the posterior cerebral artery in the area of the quadrigeminal bodies.

2.2.7. Posterior Cerebral Artery

The posterior cerebral artery (Figures 1, 2) is divided into four segments. The precommunicating part (P1) is located in front of the posterior communicating artery, with the postcommunicating part (P2) behind. The P2 segment extends as far as the origin of the posterior inferior temporal branch. The quadrigeminal part (P3) begins here, ascending to the quadrigeminal bodies. The terminal part (P4), which winds its way towards the occipital pole, begins at the level of the quadrigeminal bodies.

2.2.7.1. Precommunicating Part (P1 Segment)

- Interpeduncular perforating arteries (posterolateral central arteries): these arteries supply the posterior limb of the internal capsule, the thalamus and hypothalamus, as well as the territories of Perlia's nucleus (oculomotor nerve, III), Edinger-Westphal nucleus and medial longitudinal fasciculus in the mesencephalon. *Clinical features:* A deficit in this arterial segment is described as a peduncular syndrome: homolateral paresis of the eye muscles, contralateral hemianaesthesia, impaired coordination of the eye movements.

2.2.7.2. Postcommunicating Part (P2 Segment)

- Short circumferential arteries: responsible for supplying the red nucleus and substantia nigra.
- Quadrigeminal artery: supplies the quadrigeminal bodies.
- Thalamogeniculate artery: supplies the posterolateral portion of the thalamus.

- Anterior and posterior inferior temporal branches: supply the basal gyri of the temporal lobe. At the hippocampal sulcus, the branches of these arteries form a T-shape bifurcation, thus supplying the hippocampus and dentate gyrus with tiny branches that form an arcade-like pattern. *Clinical features:* Given the vascular architecture, the CA1 region (cornu ammonis 1, Sommer sector) is more susceptible to ischaemia than CA2/CA3 (cornu ammonis 2/3, Spielmeyer sector).

2.2.7.3. Quadrigeminal Part (P3 Segment)

- Lateral and medial posterior choroidal arteries: perfuse the choroid plexus of the third ventricle.

2.2.7.4. Terminal Part (P4 Segment)

- Lateral occipital artery: this artery contributes to the perfusion of the basal surface of the occipital lobe and posterior segments of the temporal lobe.
- Medial occipital artery: the parieto-occipital branch of this artery leads to the superior aspect of the cuneus belonging to the occipital lobe, and the calcarine branch to the pole of the occipital lobe. The visual cortex is perfused in 42% of cases exclusively by the parieto-occipital branch, in 23% by the calcarine branch, and in 31% by both.

3. Aneurysms and Neighbouring Structures of the Intracranial Arteries

3.1. Internal Carotid Artery

Aneurysms of the internal carotid artery (Figures 1, 2) can occur where the artery passes through the cavernous sinus (cavernous part of internal carotid artery) (Duus 1993). The artery curves at this point to form an S shape (carotid siphon) and is surrounded by venous blood. In the immediate vicinity, the following nerves, listed in caudal to cranial order, traverse the sinus wall: maxillary, ophthalmic, trochlear and oculomotor nerves (Sobotta/Becher 1983; Leonhardt 1988). The abducens nerve passes immediately below the artery. A caudally positioned aneurysm will exert pressure on cranial nerves V1, V2, IV and VI. Paraesthesias in the upper and mid face, as well as abducens nerve palsy, can develop as a result. An orally located aneurysm will more likely affect the oculomotor nerve. This can be manifested as a cranial and lateral shift in the position of the eyeball as well as double vision. In addition, the parasympathetic fibres of cranial nerve III may be affected. The pupils will then dilate (mydriasis). An arteriovenous fistula will result from a ruptured aneurysm. In this case, arterial blood will spread via the sphenoparietal and superior petrosal sinuses to more distant sinus cavities.

Aneurysms develop more frequently in the cerebral part of the internal carotid artery, known as the supraclinoid segment (30% according to Bähr and Froscher 2014). These arterial bulges are found near to the ophthalmic or posterior communicating artery

(ophthalmic and posterior communicating aneurysm). Given the proximity to the anterior clinoid process and to the cavernous sinus, it is difficult to operate on such aneurysms (Kyoshima et al. 2006). Secondary involvement of the optic nerve, optic chiasm, or optic tract in the aneurysmal process is possible. If the decussating fibres of the optic chiasm are affected, the nasal fields of the retina, which represent the temporal fields of vision, can be impaired (heteronymous hemianopsia). The field of vision is thus laterally disturbed on both sides. Unilateral impairment of an optic tract will lead to homonymous hemianopsia, causing dysfunction in one temporal and one nasal field of vision.

3.2. Anterior Cerebral Artery

Aneurysms of the anterior cerebral artery (Figures 1, 2) affect the anterior communicating artery in 40%-45% of cases (anterior aneurysm). This artery forms the border between the A1 and A2 segments. An anterior aneurysm is located in front of the optic chiasm. It usually projects superiorly or anteriorly, and less often inferiorly or posteriorly (Sanches-Mejia et al. 2006). Sections of the rhinencephalon such as the olfactory tract and anterior perforated substance are in close proximity. Basal sections of the frontal lobe, such as the rectal gyrus and orbital gyri, likewise border the anterior communicating artery. When operating on this area, it is important to spare the short central arteries and long central artery (both from the A1 segment), which supply the basal ganglia and the internal capsule. Furthermore, the short central arteries (from the anterior communicating artery) supply the optic chiasm. Subarachnoid haemorrhage resulting from a ruptured anterior aneurysm can spread ventrally into the pericallosal cistern and dorsally into the chiasmatic cistern via the cistern of lamina terminalis, which is traversed by the anterior cerebral artery.

3.3. Middle Cerebral Artery

In approx. 20% of cases aneurysms of the middle cerebral artery (Figures 1-3) affect the beginning of the M2 segment (MCA aneurysms according to Bähr and Frotscher 2014). Here, the artery divides into a superior and an inferior trunk. The MCA aneurysm, measuring 2-14 mm, is larger than other types of aneurysm (Rinne et al. 2006). Due to subarachnoid haemorrhage, a ruptured MCA aneurysm more often results in death than other types of ruptured aneurysms. The bleeding may be associated with intraventricular haemorrhage. The inferior horn of the lateral ventricle is affected in such cases. MCA aneurysm is related to the parahippocampal gyrus, as part of the limbic system, and to the amygdala, a basal ganglion. Aneurysmal subarachnoid haemorrhage will spread in the cistern of the lateral fissure, since the M2 segment of the artery passes through the Sylvian fissure (Figure 3). Consideration must therefore be given to the proximity of important telencephalic centres, such as the motor speech centre (Broca's area) in the inferior frontal gyrus, the primary auditory centre in the Heschl convolutions of the superior temporal gyrus, and the sensory speech centre (Wernicke's area) in the supramarginal and angular gyri. On surgical intervention, care must also be taken not to interfere with the branches of the M2 segment that supply the motor and premotor cortex as well as the sensory cortex. Ultimately, the artery does not only bifurcate, namely into the superior and the inferior trunks (Figure 1), but multiple divisions also occur

(Lang and Wachsmuth 1979). If MCA aneurysms are to be occluded, it is important to know about a potential bi-, tri- quad- or pentafurcation so that branches concealed by the side of the aneurysm facing away from the surgeon are not also occluded.

3.4. Posterior Cerebral Artery

Aneurysms of the posterior cerebral artery (Figures 1, 2) are rare and usually affect the postcommunicating P2 segment. This type of aneurysm is found near the oculomotor nerve. Also in close proximity are the cerebral crura of the mesencephalon and parahippocampal gyrus, as part of the limbic system. A subarachnoid haemorrhage will spread into the ambient cistern, which is traversed by the superior cerebellar artery (Figure 2) and the trochlear nerve. Trochlear nerve palsy causes the eyeball to deviate inward and downward.

3.5. Basilar Artery

Basilar artery aneurysms (Figures 1, 2) occur at a rate of 10% (Bähr and Frotscher 2014) in the so-called basilar tip (basilar tip aneurysms), at the upper margin of the pons. The basilar artery divides at this point into the two superior cerebellar arteries and the two posterior cerebral arteries. Immediately ventral to this aneurysm are the mamillary bodies, infundibulum and floor of the hypothalamus. Dorsolaterally, the aneurysm meets with the oculomotor nerve and the fine arteries of the P1 segment (Figure 2) of the posterior cerebral artery that supply the internal capsule and thalamus. A haemorrhage will also spread into the ambient cistern via the interpeduncular cistern. Liliequist's membrane, which extends between the two temporal lobes, prevents the haemorrhage from crossing into the chiasmatic cistern. A basilar tip aneurysm is a space-occupying process in the region of the tentorial incisure (Lang 1985). Compression of the oculomotor nerve is therefore to be expected. The aneurysm can moreover displace the cerebral aqueduct dorsally, and the posterior wall of the third ventricle superiorly (Lang 1985). Intraoperative complications can entail unintentional injury to the fine arteries of the P1 segment of the posterior cerebral artery (Hernesniemi et al. 2006). Damage to one of the small-calibre interpeduncular perforating arteries running through the posterior perforated substance alone can have drastic consequences for the patient (Lawton 2011).

Aneurysms occur less often at the junction of the middle to lower third of the artery, roughly at the level of the origin of the anterior inferior cerebellar artery (1%-2%, according to Bähr and Frotscher 2014), than at the basilar tip (Figure 1). The abducens nerve is found dorsal, and the trigeminal nerve lateral to such aneurysms. Any haemorrhage will spread via the medial pontine cistern into the pontocerebellar cistern, located in the cerebellopontine angle, through which the facial and vestibulocochlear nerves pass. The lateral aperture of the fourth ventricle (Luschka) discharges into the pontocerebellar cistern; adhesion can occur in the event of bleeding. Internal hydrocephalus can result.

Basilar artery aneurysms are difficult to treat surgically on account of the fact that the neighbouring structures of this artery, namely the brain stem, territory of the clivus and tentorial incisure, are very hard to reach from lateral access points in the middle or posterior cranial fossa (Pernkopf 1957). Pterional (where the frontal bone, parietal bone, squamous

bone and greater wing of the sphenoid bone converge), subtemporal and suboccipital approaches are suggested (Hernesniemi et al. 2006). Using modern surgical techniques, such as endovascular coiling of the aneurysm as mentioned at the start, treatment outcomes have improved.

3.6. Anterior Inferior Cerebellar Artery

Aneurysms of the anterior inferior cerebellar artery (Figures 1-3) are rare and are usually found close to the origin of the basilar artery. The abducens nerve is located near to such an aneurysm. The artery runs through the pontocerebellar cistern together with the facial and vestibulocochlear nerves, as well as the labyrinthine artery. The foramen of Luschka also passes into this cistern. Hence, a subarachnoid haemorrhage would also prevent CSF from exiting the lateral aperture of the fourth ventricle (foramen of Luschka). Internal hydrocephalus would be the result.

3.7. Posterior Inferior Cerebellar Artery

Aneurysms of the posterior inferior cerebellar artery (Figures 1, 2) are also rare. They mostly develop where the given artery emerges from the vertebral artery (Figure 1). A distinction is made between the descending and the ascending posterior inferior cerebellar artery (Figure 1). In both cases, the aneurysm is located near the inferior olive and is linked with cranial nerves IX, X, XI and XII (Pernkopf 1957). A subarachnoid haemorrhage will spread into the lateral cerebellomedullary cistern, on the posterolateral aspect of the medulla oblongata. Corresponding membranes separating the adjacent cisterns probably prevent the haemorrhage from infiltrating the pontocerebellar and cerebellomedullary cisterns. During surgical treatment of an aneurysm of the posterior inferior cerebellar artery, occlusion of the small arteries involved in supplying the caudal cranial nerves can occur (Bertalanffy et al. 2006). Wallenberg's syndrome would be the result.

4. VENOUS DRAINAGE OF THE BRAIN

The description of the major cerebral veins and their branches is provided, as with the arteries, on the basis of the relevant chapter by Töndury et al. in the Textbook and Atlas of Human Anatomy by Rauber/Kopsch (1987). With thin walls and no valves, the cerebral veins drain into the dural venous sinuses. They are distributed independently of the arteries and can be divided into two main groups: 1) Superficial cerebral veins: The superficial cerebral veins transport the blood of the cerebral cortex to the superior sagittal sinus and basal sinus. 2) Deep cerebral veins: The deep cerebral veins transport blood from the medulla, basal ganglia and diencephalon to the great cerebral vein (or vein of Galen).

4.1. Superficial Cerebral Veins

The venous blood in the upper half of the outer surface of the cerebral hemispheres flows through the ascending, i.e., superior cerebral veins, into the superior sagittal sinus, and that in the lower half through the descending, i.e., inferior cerebral veins, into the transverse and sphenoparietal sinus. The superficial middle cerebral vein transports venous blood from both territories to the sphenoparietal sinus. Ultimately, the superficial cerebral veins also include the veins of the medial and basal aspects of the cerebral hemisphere.

4.1.1. Superior Cerebral Veins

These are 6-12 ascending veins that can be divided into four groups: frontal, frontoparietal, parietal and occipital veins. The frontal veins drain the blood from the gyri of the frontal lobe. The triad of frontoparietal veins (veins of Rolando) is made up of the precentral, central and postcentral veins. These veins lead into the sulci of the same names and transport the blood away from the precentral and postcentral gyri. The parietal and superior veins transport blood from the parietal lobe and the upper occipital lobe. Characteristically, the frontal veins drain in the direction of the blood flow, whereas the parietal and occipital veins drain in the opposite direction to the flow of the venous blood into the superior sagittal sinus.

4.1.2. Inferior Cerebral Veins

These comprise the inferior temporal and inferior occipital veins, which transport venous blood from the temporal lobe and from the lower occipital lobe down to the transverse sinus. The superficial middle cerebral vein, moreover, which descends through the lateral sulcus to the sphenoparietal sinus, carries blood out of the supramarginal and angular gyri.

The superficial cerebral veins on the outer aspect of the cerebral hemisphere are connected via two important anastomoses: 1. Superior anastomotic vein (vein of Trolard): This vein is formed from the postcentral vein and the superficial middle cerebral vein. It links the superior sagittal sinus to the sphenoparietal sinus. 2. Inferior anastomotic vein (vein of Labbé): This vein facilitates the anastomosis of the largest inferior temporal vein with the superficial middle cerebral vein. Via the vein of Trolard, the superior sagittal sinus is joined with the transverse sinus.

4.1.3. Veins of the Medial Surface

The frontopolar, medial anterior and posterior frontal, paracentral, precuneal veins, and the medial occipital veins drain blood from the territories of the frontal, parietal and occipital lobe belonging to the medial surface. The anterior cerebral (anterior limbic) vein and the dorsal (posterior limbic) vein of corpus callosum transport blood out of the corpus callosum and cingulate gyrus.

4.1.4. Veins of the Basal Surface

The anterior cerebral vein takes the same course as the artery of the same name. The deep middle cerebral artery is found deep in the lateral sulcus under the middle cerebral artery. The basal vein (of Rosenthal) emerges in the territory of the anterior perforated substance from the confluence of the anterior cerebral and deep middle cerebral veins. The vein travels dorsally

along the optic tract, ascending to the quadrigeminal bodies, and discharges into the great cerebral vein (of Galen).

The anterior cerebral veins, the anterior communicating vein, the basal segments of the basal veins and the interpeduncular veins with posterior communicating vein form a cerebral venous circle (also referred to as Trolard's hexagon) beneath the cerebral arterial circle (Figure 1).

4.2. Deep Cerebral Veins

The deep cerebral veins, i.e., the septum pellucidum, thalamostriate and superior choroid veins, drain the blood from the basal ganglia, internal capsule, semioval centre of the white matter and the choroid plexus of the lateral ventricle and third ventricle. They merge at the posterior margin of the interventricular foramen in the anterior venous confluence with the internal cerebral vein.

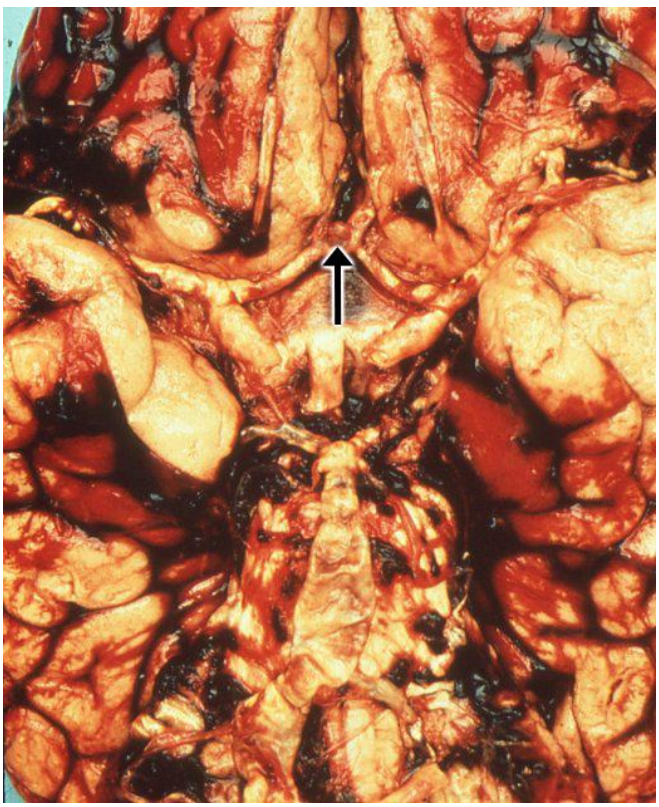

Figure 4. Aneurysm of the anterior communicating artery (anterior aneurysm). In 40%-45% of cases, the anterior communicating artery is affected. This artery forms the border between the A1 and A2 segments of the anterior cerebral artery. In this case the aneurysm (arrow) projects caudally, which tends to be rare. The aneurysm has ruptured. The subarachnoid haemorrhage has spread into the lamina terminalis cistern and, in particular, into the Sylvian, ambient and pontocerebellar cisterns. Image of an original specimen from a donated body, used in the Neuroanatomy Course at the Institute of Anatomy of Christian Albrechts University Kiel.

The vein of septum pellucidum transports blood from the genu of the corpus callosum, the head of the caudate nucleus and from the white matter of the frontal lobe. Unlike the name suggests, the thalamostriate vein does not drain blood from the thalamus, but rather from the striate body, the internal capsule and the white matter of the frontal and parietal lobe. The superior choroid vein removes blood from the hippocampus, fornix and corpus callosum.

The subependymal veins of the posterior and inferior horns drain blood from the white matter of the parietal and occipital lobe, and the temporal lobe and hippocampus, respectively, transporting it to the basal vein.

The internal cerebral vein takes venous blood from the thalamus, fornix, hippocampus, pineal body and quadrigeminal bodies. The largest thalamic vein, namely the superior thalamic vein, leads vertically into the middle of the internal cerebral artery. The interior cerebral veins on both sides unite via the pineal body to from the great cerebral vein (of Galen).

The great cerebral vein (of Galen) discharges into the right sinus immediately behind the confluence of the inferior sagittal sinus. It incorporates the caudally ascending basal vein (of Rosenthal) and the medial superior cerebellar vein. Furthermore, numerous smaller veins arrive at the great cerebral vein from the territories of the cuneus of the occipital lobe, epithalamus and quadrigeminal bodies.

4.3. Veins of the Cerebellum and Brain Stem

The cerebellar veins follow a similar pattern to the cerebral arteries, though they are independent of the latter. Their larger branches cross furrows and convolutions in a sagittal, and only rarely transverse direction. A differentiation is made between one medial and two lateral groups of veins. The medial veins drain blood from the vermis; the lateral veins remove blood from the cerebellar hemispheres.

The medial superior cerebellar vein carries blood from the upper part of the cerebellar vermis to the great cerebral vein; the medial inferior cerebellar vein transports blood from the inferior vermis to the transverse sinus. The lateral superior cerebellar vein carries the blood of the upper half of the hemisphere to the transverse sinus or straight sinus. The lateral inferior cerebellar vein drains blood from the lower half of the hemisphere, transporting it to the transverse sinus.

The superior petrosal (or Dandy's) vein ascends from the cerebellopontine angle along the trigeminal nerve to the superior petrosal sinus. It removes only a small amount of blood from the cerebellum, since it mainly drains the pons and medulla oblongata. However, this vein can also substitute the lateral superior and inferior cerebellar veins, among others. In this particular case, the superior petrosal vein drains almost the entire cerebellar hemisphere.

The veins of the brain stem are the continuation of the spinal veins, linking them to the basal cerebral veins. Caudally they create a longitudinal and transverse system in a similar way to the spinal veins. Topographically, the veins of the medulla oblongata and pons, like the cerebellar veins, are part of the infratentorial system.

Clinical features: The cerebral veins have specific source territories in which venous stasis can develop in the event of cerebral vein or sinus thrombosis, ultimately resulting in haemorrhagic infarcts in the cortex or medulla, as well as accompanying oedema. Cerebral venous and sinus thromboses are caused not only by thrombi rising from the pelvic and leg

veins, but also by cardiovascular disorders, trauma, tumours, and inflammatory processes in the brain, skull and paranasal sinuses.

Thrombosis leads to an increase in intracranial pressure, and in extreme cases to compression of the tentorium. The consequences are headaches, nausea, vomiting, disorders of consciousness and, depending on the localisation of the pathological process, motor and sensory deficits. Thrombosis of the superior cerebral veins can result in a haemorrhagic infarct, mostly accompanied by contralateral hemiparesis or hemiplegia. Thrombosis of the inferior cerebral veins leads to an infarct in the region of the temporal or basal occipital lobe. The resulting symptoms are aphasia or contralateral homonymous hemianopsia. Thrombosis of the deep cerebral veins causes clouding of consciousness that progresses rapidly and can result in coma.

5. Relevance of Cerebral Veins and Dural Venous Sinuses to Surgical Aneurysm Repair

5.1. Superficial Cerebral Veins

When taking a lateral approach, such as for middle cerebral artery aneurysms, attention must be paid to the veins of the Sylvian fissure. The superficial middle cerebral vein courses over the surface together with the branches of the M2 segment of the middle cerebral artery (Figure 3). The deep middle cerebral vein can be found deep in the lateral fissure. At the base of the brain it enters the basal vein (of Rosenthal) along with the anterior cerebral vein. The superficial veins that drain the Sylvian fissure are referred to as “guardians” (Lawton 2011). This structure can vary, draining superiorly, anteriorly or posteriorly (Lawton 2011). In case of superior drainage, the venous blood flows into the frontoparietal veins, the superior anastomotic vein (vein of Trolard), and the superior sagittal sinus. In case of anterior drainage, the blood is discharged into the sphenoparietal, cavernous, superior petrosal and inferior petrosal sinuses. Finally, if the blood is drained posteriorly, it is transported into the inferior temporal veins, inferior anastomotic vein (vein of Labbé), and the transverse sinus.

5.2. Veins of the Cerebellum and Brain Stem

If taking a posterolateral approach through the asterion (junction of the lambdoid, parietomastoid and occipitomastoid sutures), the proximity of the transverse and sigmoid sinuses must first be taken into consideration. The medial inferior and lateral superior cerebellar veins drain the blood from the cerebellar vermis and hemispheres into the transverse sinus. The superior petrosal vein transports blood from the pons and medulla oblongata to the superior petrosal sinus.

ACKNOWLEDGMENTS

I wish to thank Professor Dr. sc. med. R. Schultka, Director of the Meckel Anatomical Collections at the Institute of Anatomy and Cell Biology of Martin Luther University Halle-Wittenberg, for kindly loaning the injected specimens of the cerebral arteries for imaging purposes. I also thank Mr. G. Bothe, photographer at the Institute of Forensic Medicine of Martin Luther University Halle-Wittenberg for the excellent images and expert labelling of the collected specimens.

REFERENCES

Adachi B (1928): *Das Arteriensystem der Japaner*. Band I: A. pulmonalis, Aorta bis Arcus volaris profundus. Maruzen, Kyoto, S. 113.

Bähr M, Frotscher M (2014): *Neurologisch-topische Diagnostik*. 10. Auflage. Thieme, Stuttgart und New York, S. 521-527.

Bertalanffy H, Benes L, Heinze S, Tirakotai W, Sure U (2006): Surgical management of aneurysms of the vertebral and posterior inferior cerebellar artery complex. In: Schmidek HH, Roberts DW (Eds.), *Schmidek and Sweet's Operative Neurosurgical Techniques, Section XIII: Management of Intracranial Aneurysms*. 5th Edition, Saunders, Elsevier, pp 1209-1223.

Clara M (1959): *Das Nervensystem des Menschen*. 3. neubearbeitete Auflage. Johann Ambrosius Barth, Leipzig, S. 716.

Corning HK (1946): *Lehrbuch der topographischen Anatomie*. 23. Auflage. Springer, Berlin, S 36-42.

Deller T (2015): Hirngefäße. In: Waschke J, Böckers TM, Paulsen F (Hrsg.), *Anatomie – Das Lehrbuch – Sobotta*. 1. Auflage. Elsevier, Urban & Fischer, München, S. 623-644.

Drenckhahn (2004): Blutgefäße des Zentralnervensystems. In: Drenckhahn D (Hrsg.) *Benninghoff/Drenckhahn, Anatomie*, Band 2. 16. Auflage. Elsevier, Urban & Fischer, München, S. 621-648.

Duus P (1995): *Neurologisch-topische Diagnostik. 6*. Auflage. Thieme, Stuttgart und New York, S. 121, 439-441.

Herneshiemi J, Karatas A, Niemelä M, Ishii K, Peerless SJ, Drake CG (2006): Surgical techniques of terminal basilar and posterior cerebral artery aneurysms. In: Schmidek HH, Roberts DW (Eds.), *Schmidek and Sweet's Operative Neurosurgical Techniques, Section XIII: Management of Intracranial Aneurysms*. 5th Edition, Saunders, Elsevier, pp 1177-1191.

Kyoshima K, Shibuya M, Kobayashi S (2006): Surgical management of paraclinoid aneurysms. In: Schmidek HH, Roberts DW (Eds.), *Schmidek and Sweet's Operative Neurosurgical Techniques, Section XIII: Management of Intracranial Aneurysms.* 5th Edition, Saunders, Elsevier, pp 1099-1114.

Lang J und Wachsmuth W (1979): Lanz Wachsmuth, *Praktische Anatomie, Kopf – Teil 1B: Gehirn- und Augenschädel*. Springer, Berlin, Heidelberg und New York, S. 38-48, 123, 181-189.

Lang J (1985): Lanz Wachsmuth, *Praktische Anatomie, Kopf – Teil A: Übergeordnete Systeme,* Sonderausgabe 2004 der 1985 erschienenen 1. Auflage. Springer, Berlin, Heidelberg, New York et al., S. 438-439.

Lasjaunias P, Berenstein A, ter Brugge KG (2001): *Surgical Neuroangiography*. Vol. 1: Clinical vascular anatomy and variations. Second edition. Springer, Berlin und Heidelberg.

Lawton MT (2011): *Seven Aneurysms. Tenets and Techniques for Clipping.* Thieme, Stuttgart und New York.

Leonhardt H (1988): Kopf – Hals. In: Leonhardt H, Tillmann B, Zilles K (Hrsg.), Rauber/Kopsch, *Anatomie des Menschen, Lehrbuch und Atlas, Band IV, Topographie der Organsysteme, Systematik der peripheren Leitungsbahnen*. Thieme, Stuttgart und New York, S. 21-183.

Paulsen F, Waschke J (2010): Sobotta – *Atlas der Anatomie des Menschen. Kopf, Hals und Neuroanatomie*. 23. Auflage. Elsevier, Urban & Fischer, München, S. 266-269.

Pernkopf E (1957): *Topographische Anatomie des Menschen*. IV. Band, 1. Hälfte: Topographische und stratigraphische Anatomie des Kopfes. Urban & Schwarzenberg, München, Berlin und Wien. S. 193-227.

Rinne J, Ishii K, Shen H, Kivisaari R, Hernesniemi J (2006): Surgical Management of Aneurysms of the Middle Cerebral Artery. In: Schmidek HH, Roberts DW (Eds.), *Schmidek and Sweet's Operative Neurosurgical Techniques, Section XIII: Management of Intracranial Aneurysms*. 5th Edition, Saunders, Elsevier, pp 1144-1166.

Sanchez-Mejia RO, Quinones-Hinojosa A, Jun P, Lawton MT (2006): Microsurgical Management of Anterior Communicating Artery Aneurysms. In: Schmidek HH, Roberts DW (Eds.), *Schmidek and Sweet's Operative Neurosurgical Techniques, Section XIII: Management of Intracranial Aneurysms*. 5th Edition, Saunders, Elsevier, pp 1131-1143.

Sobotta/Becher (1973): *Atlas der Anatomie des Menschen*, Band 3. Ferner H, Staubesandt J (Hrsg.). 17. Auflage. Urban & Schwarzenberg, München, Berlin und Wien, S. 66-67.

Tillmann B (1997): *Farbatlas der Anatomie*. Zahnmedizin – Humanmedizin. Thieme, Stuttgart und New York, S. 240.

Töndury G, Kubik S, Krisch B (1987): Hirnhäute und Hirngefäße. In: Leonhardt H, Töndury G, Zilles K (Hrsg.), *Anatomie des Menschen, Lehrbuch und Atlas*, Band III, Nervensystem, Sinnesorgane Thieme, Stuttgart und New York, S. 175-233.

Yasargil MG (1969): Microsurgery applied to neurosurgery. *Chapter 4: Reconstructive and constructive surgery of the cerebral arteries in man.* Thieme, Stuttgart, New York und London, pp 82-95.

In: Encyclopedia of Surgery (22 Volume Set)
Editors: Andreas Lehrer and Kristin Mueller
ISBN: 978-1-53618-329-0
© 2020 Nova Science Publishers, Inc.

Chapter 62

NEUROPATHOLOGIE OF SUBARACHNOID HAEMORRHAGE

Angelika Scheuerle
Section Neuropathology, University Ulm, Günzburg, Germany

ABSTRACT

The resulting damages from subarachnoid haemorrhage has a complex pathogenesis encompassing various systems which nevertheless overlap when active simultaneously, consecutively or at staggered intervals. The precise interplay of different factors that lead to alternately pronounced, permanent damage to the central nervous system has not yet been completely and conclusively explained. However, the underlying mechanisms that are activated as a result of bleeding into the subarachnoid space from a blood vessel are presented.

Keywords: subarachnoid haemorrhage, pathogenesis, histology, aneurysm, early and delayed injury

The subarachnoid space is formed by a loosely arranged layer of cells in the pia mater lying next to the glia limitans which is divided by a basal membrane. The outer layer forms densely structured, flat to cuboidal arachnoid cells that are joined with each other by tight junctions. The arachnoid cells have projections which make contact with the pia mater and therefore permeate the space like a spider's web. Individual fibroblasts and collagen fibres, as well as medium-sized blood vessels are also found which, like the intracerebral vessels, have a blood-CSF barrier. The subarachnoid space contains cerebrospinal fluid (CSF) which is transported via the arachnoid villi (arachnoid granulations). If blood penetrates the subarachnoid space, an increase in intracranial pressure, initial vasoparalysis, and impaired CSF drainage will result depending on the extent and magnitude, which will reflect the size of the defect in the vessel. To maintain the cerebral blood flow, the blood pressure will increase along with vasodilation. This leads to an increase in the cerebral blood volume and further increase in intracranial pressure, even global cerebral ischaemia, since the intracranial

pressure will exceed the arterial perfusion pressure. This can be seen in the form of apoptosis but also necroses, both in animal experiments and in post-mortem examinations on humans, whereby apoptosis was not only detected in brain cells but also in vascular wall cells. Vascular wall damage causes a disturbance in the blood-brain barrier with subsequent cerebral oedema and a further increase in intracranial pressure. The death receptor, TNF-alpha, p53, and the Caspase cascade appear to play a crucial role in cell death induced by SAH.

If the acute phase of bleeding is survived, haematoma then develops with lysis of erythrocytes, precipitation of fibrin and infiltration of fibroblasts and sprouting of capillaries, from which granulation tissue forms. These organisational processes explain the course of temporal changes which are reflected in the (CSF "cancel") histological findings. These initially exhibit fresh blood with perfectly preserved erythrocytes, granulocytes and leukocytes in the same ratio as in a patient's peripheral blood count. After approx. 12 hours, the erythrocyte boundaries are more indistinct (blurred), and reactive pleocytosis begins. Oxyhaemoglobin and initial erythrophages emerge on the first day post haemorrhage. The breakdown of haemoglobin begins three to four days later with evidence of siderophages. As a result, haematoidin crystals may be visible if there is more pronounced haemorrhaging.

During haemoglobin release and haemoglobin breakdown, oxygen radicals develop, which activate adhesion molecules that attract macrophages and neutrophils. The potent vasoconstrictor leads to the increased detection of TNF-alpha during this phase. Erythrocyte breakdown products in the subarachnoid space can trigger so-called spreading depressions that are linked with the delayed onset of cerebral ischaemia which ensues 5-14 days after the haemorrhage. The slow spread of neuronal ("and glial" cancel) depolarisation detectable on electrophysiological testing can lead to cerebral ischaemia as a result of vasoconstrictive activity.

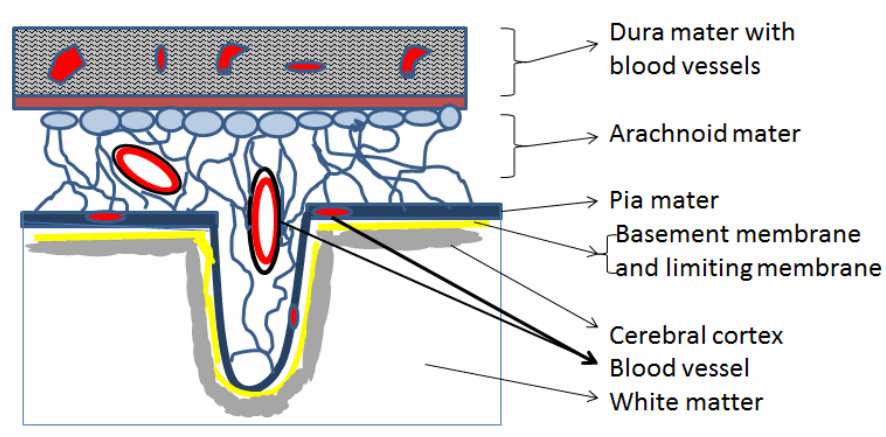

Figure 1. Structure of the subarachnoid space. From the outside inward, the dura mater is identifiable from the firm collagen/fibre-rich connective tissue with embedded blood vessels. Next is the arachnoid mater with dura-facing neurothelium (arachnoidal cells), from where delicate trabeculae traverse the subarachnoid space like a spider's web to reach the pia mater, a delicate layer of vascularised connective tissue.

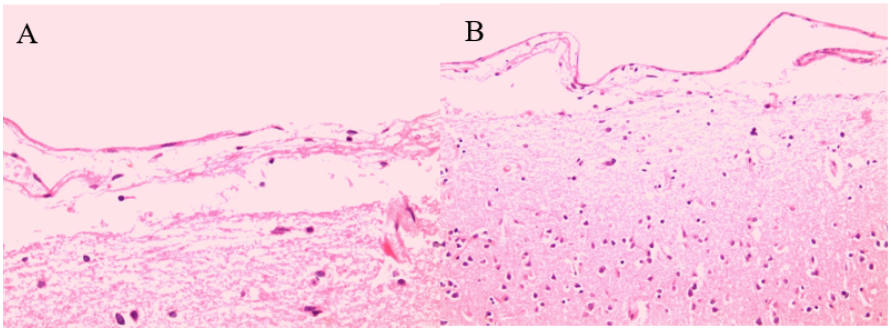

Figure 2. A) Delicate arachnoid mater with narrow, elongated, flat arachnoid cells and embedded blood vessel. B) An adjacent, external band of cortex.

CAUSES OF SAH

Aside from trauma, a ruptured aneurysm (85%) is the main cause of SAH. An aneurysm is the bulging of an arterial wall, the exact origin of which is not yet fully understood. As they are extremely rare in newborn babies and children with no apparent cause (trauma, infections, connective tissue diseases), it is assumed that the change in the vascular wall is acquired. Genetic factors are postulated, since apart from a familial predisposition aneurysms occur increasingly with congenital connective tissue diseases (polycystic kidney disease, Ehler-Danlos syndrome type IV, etc.). Forbes (1930) [1], and later Stehbens (1989) [2], have suggested that a defect appears in the muscle layer at the onset of an aneurysm. Other authors favour the theory that so-called intimal cushions reduced the elasticity locally. This causes increased pressure on the immediately adjacent wall, possibly leading to structural changes in the aneurysm. Calouhi et al. [3] see increasing evidence for an inflammatory event in the pathogenesis of a cerebral aneurysm. Back in 2010, Y. Kanematsu et al. [4] reported that macrophages and cytokines originating from the macrophages assume a key role in haemodynamic blebs. They are particularly effective during the constant remodelling of the wall following haemodynamic stress. It cannot yet be fully understood why some aneurysms rupture, while other aneurysms do not rupture throughout a person's life. Usually, the rupture is assumed to have an inflammatory origin. The risk of rupture grows with the size of the aneurysm, the location of the aneurysm in the posterior circulation, hypertension, alcohol and cocaine abuse.

Histologically, the aneurysm is characterised by the loss of the internal elastic lamina and a thinning or even missing middle coat in the arterial wall, resulting in the wall usually only consisting of collagen fibres, isolated smooth muscle cells and possibly individual elastic fibres. Ruptures usually occur at the dome of the aneurysm where blood and fibrin are deposited. Some fresh and partially organised thrombi are observed in the lumen. Arteriosclerotic changes can take place at the margins of usually fusiform aneurysms.

Aneurysms caused by inflammation are rare and usually accompanied by infectious endocarditis (bacterial or mycotic). Histologically, the bulge in the wall is accompanied by pronounced inflammatory cell infiltrates (granulocytes, lymphocytes).

Morphologically, arterial dissection reveals a tear in the intima and/or media with subsequent bleeding into the arterial wall which, as well as being caused by trauma, can also

be precipitated by amyloid angiopathy. Occasionally, especially in older people and sometimes due to genetic predisposition, deposits of amyloid are found in the walls of the small and medium-sized, mostly arterial blood vessels of the cortex and the leptomeninges. They can be accompanied by Alzheimer's type dementia.

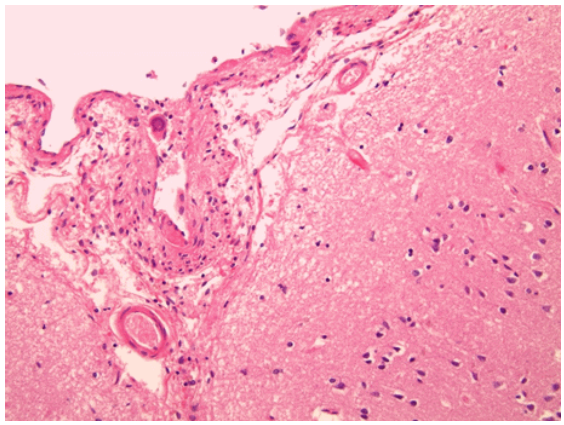

Figure 3. The arachnoid mater follows the invaginated sulcus of the superficial cortex, where it is somewhat fibrosed and the embedded blood vessels are more clearly visible. A small calcified psammoma body can be seen.

Non-aneurysmal perimesencephalic haemorrhage corresponds to bleeding into the basal interpedicular cisterns, anterior to the midbrain. It can occur in combination but also with no evidence of an aneurysm, and is more frequent in hypertensive patients. The patients have an excellent prognosis and require only a short period of convalescence. In particular, no cerebral ischaemia develops.

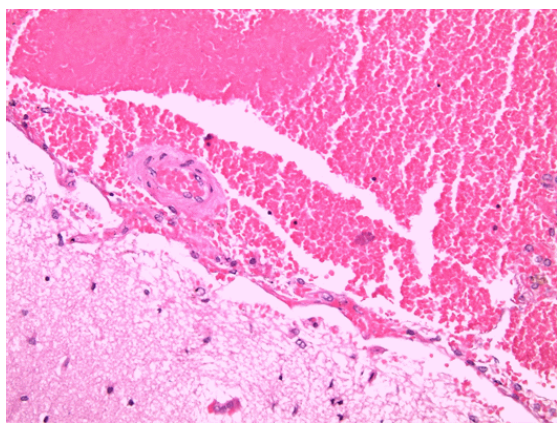

Figure 4. Recent subarachnoid haemorrhage with well-preserved erythrocytes and individual white blood cells, embedded subarachnoid arterial branch and basal outer cortex are also depicted.

Other rare causes of subarachnoid haemorrhage are arteriovenous malformations of the cerebral cortex which usually lead to an intracerebral haemorrhage and in >5% can bleed primarily into the subarachnoid space. Small aneurysmal bulges of delicate afferent and efferent arterial branches have been identified as a cause of haemorrhage. Cavernomas also more likely lead to intracerebral haemorrhage than to subarachnoid haemorrhage.

SAH develops in 30% of children and most adults with sickle cell disease (Cary et al., 1990) [5]. Other rare causes are venous thrombi, vasculitis, severe stenosis, coagulation disorders, inflammations as well as primary and secondary leptomeningeal tumours.

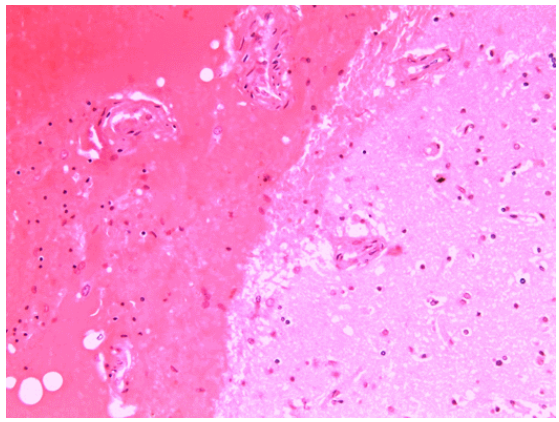

Figure 5. Less recent subarachnoid haemorrhage (approx. 1 day) with depleted erythrocytes that now have blurry contours.

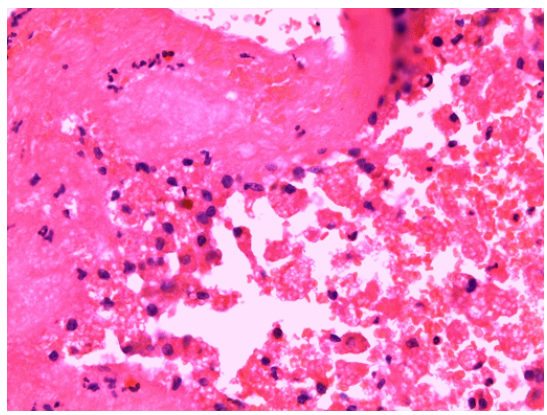

Figure 6. Incipient signs of organisation of a haemorrhage with erythrophages.

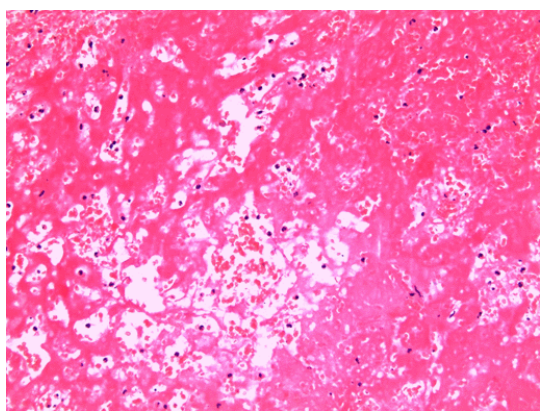

Figure 7. Approx. 1-2 day-old blood with fibrin precipitations, but still loosely distributed leukocytes and interspersed, still well-preserved erythrocytes.

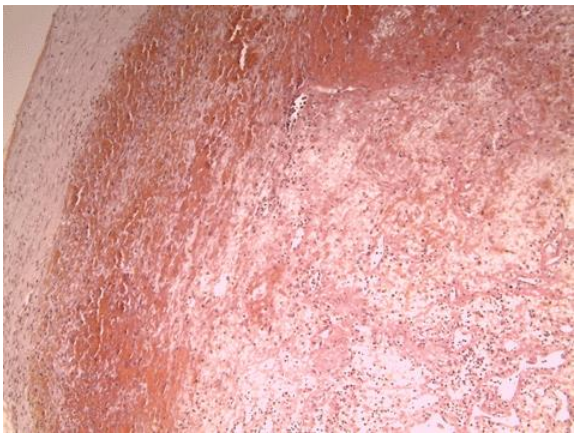

Figure 8. Aneurysm: Partially thrombosed aneurysm (VEG). To the left: sections of the fibrous aneurysm wall with adjacent fresh blood and well-preserved erythrocytes. To the right: advancing hypervascular granulation tissue, corresponding to organised thrombus (VEG staining).

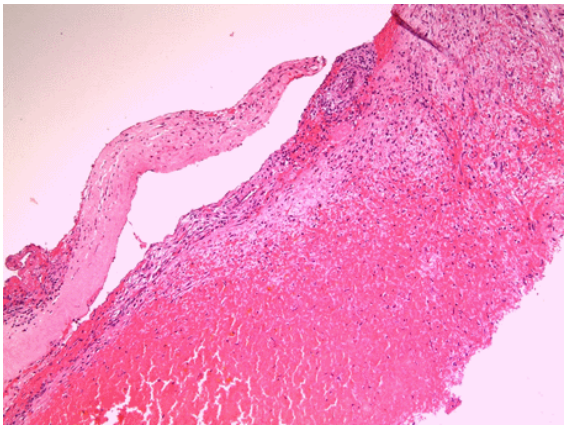

Figure 9. Rupture site of an aneurysm HE: Significantly narrowed aneurysm wall, consisting of rather hypocellular fibrous connective tissue (bottom left). Mononuclear round cells (top centre) at the rupture site. Top right: organised thrombus with fibroblasts and isolated vascular fissures.

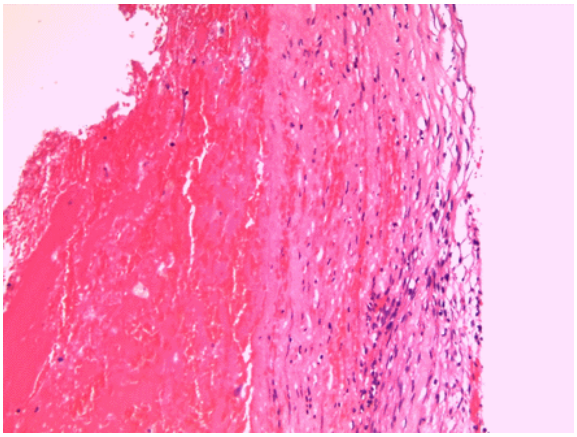

Figure 10. The fibrous wall segments adjacent to the aneurysm rupture site with fresh intramural haemorrhages (right). Left: lumen of the aneurysm sac filled with fresh blood.

REFERENCES

[1] van Gijn J, Rinkel GJ. Subarachnoid haemorrhage: diagnosis, causes and management. *Brain: a journal of neurology*. 2001 Feb;124(Pt 2):249-78. PubMed PMID: 11157554.

[2] Sabri M, Lass E, Macdonald RL. Early brain injury: a common mechanism in subarachnoid hemorrhage and global cerebral ischemia. *Stroke research and treatment*. 2013;2013:394036. PubMed PMID: 23533958. Pubmed Central PMCID: 3603523.

[3] Cahill J, Calvert JW, Zhang JH. Mechanisms of early brain injury after subarachnoid hemorrhage. *Journal of cerebral blood flow and metabolism: Official journal of the International Society of Cerebral Blood Flow and Metabolism.* 2006 Nov;26(11):1341-53. PubMed PMID: 16482081.

[4] Dreier JP, Woitzik J, Fabricius M, Bhatia R, Major S, Drenckhahn C, et al. Delayed ischaemic neurological deficits after subarachnoid haemorrhage are associated with clusters of spreading depolarizations. *Brain: a journal of neurology*. 2006 Dec;129(Pt 12):3224-37. PubMed PMID: 17067993.

[5] Ostergaard L, Aamand R, Karabegovic S, Tietze A, Blicher JU, Mikkelsen IK, et al. The role of the microcirculation in delayed cerebral ischemia and chronic degenerative changes after subarachnoid hemorrhage. *Journal of cerebral blood flow and metabolism: Official journal of the International Society of Cerebral Blood Flow and Metabolism*. 2013 Dec;33(12):1825-37. PubMed PMID: 24064495. Pubmed Central PMCID: 3851911.

In: Encyclopedia of Surgery (22 Volume Set)
Editors: Andreas Lehrer and Kristin Mueller
ISBN: 978-1-53618-329-0
© 2020 Nova Science Publishers, Inc.

Chapter 63

SUBARACHNOID HAEMORRHAGE

Stefan Röhrer
Department of Neurosurgery, University of Ulm, Ulm, Germany

ABSTRACT

The incidence of aneurysmal subarachnoid hemmorrhage is different in miscellaneous countries or regions. Exact global figures are not available. Reasons might be variable medical infrastructure in different countries such as availability of diagnostic methods. Subarachnoid hemorrhage thus could go undiagnosed and a patient may die without prior diagnosis. The common age for subarachnoid hemorrhage is between 40 and 60 years, and women are more affected. Additionally differences between races have been detected in terms of the occurrence of subarachnoid hemorrhage. So black people are statistically more affected. The risk factors for occur of subarachnoid hemorrhage can be separate in modifiable and non-modifiable factors. Examples for modifiable factors are smoking, arterial hypertension and excess alcohol consumption. Familial disposition or genetic diseases are non-modifiable factors.

Keywords: subarachnoid hemorrhage, epidemiology, cerebral aneurysm

EPIDEMIOLOGY OF ANEURYSMAL SUBARACHNOID HAEMORRHAGE

In the literature the incidence of aneurysmal subarachnoid haemorrhage (SAH) in Western countries is quoted as being 6-10 cases per 100,000 inhabitants a year [1, 2]. In some countries, such as Japan or Finland for example, the occurrence of SAH of unknown cause is significantly higher, reaching annual rates of up to 23 out of 100,000 inhabitants [1, 3]. Exact global figures are not available, as the care structure in the various countries does differ significantly. Not everywhere is a standard or emergency CT imaging method available for diagnosing SAH. SAH thus could go undiagnosed and a patient may die without prior diagnosis. An example of this would be Africa. In principle, an aneurysmal SAH can occur at any age, but tends to be more common in people between 40 and 60 years of age [4, 5].

Gender-specific comparison reveals that the ratio between women and men is 3:2 [1]. The risk of SAH was thereby found to be lower in women who do not give birth to their first child until after the age of 23, or who have had hormone replacement therapy but have never taken oral contraception [17].

Furthermore, differences between races have been identified in terms of the occurrence of SAH. Hence, the risk of spontaneous SAH has been found to be 2.1 times higher in black versus white people [6].

Intracranial aneurysms in children are very rare and constitute 1%-5% of all detected aneurysms [14, 15]. A ruptured aneurysm with consecutive aneurysmal SAH causes haemorrhagic stroke in 10%-15% of paediatric patients [16].

RISK FACTORS FOR ANEURYSMAL SUBARACHNOID HAEMORRHAGE

When it comes to the risk factors for aneurysmal SAH, a distinction is made between modifiable and non-modifiable factors.

The modifiable and treatable factors which increase the risk of SAH include smoking (1.9%), arterial hypertension (2.8%) and excess alcohol consumption (4.7%) [3]. The risk of spontaneous SAH is also increased by taking oral contraceptives [7]. As patients with these risk factors are increasingly affected by SAH, acquired damage of the internal elastic lamina appears to be the cause of aneurysm formation.

Predictor for ruptured aneurysm	Points
Hypertension	
No	0
Yes	1
Population	
North America, Europe	0
Japan	3
Finland	5
Age	
<70 years old	0
>70 years old	1
Aneurysm size	
< 7.0 mm	0
7.0-9.9 mm	3
10.0-19.9 mm	6
>20 mm	10
History of SAH from another aneurysm	
No	0
Yes	1
Location of aneurysm	
Internal carotid artery	0
Middle cerebral arteries	2
Anterior cerebral arteries/posterior cerebral arteries	3

Figure 1. PHASES Score.

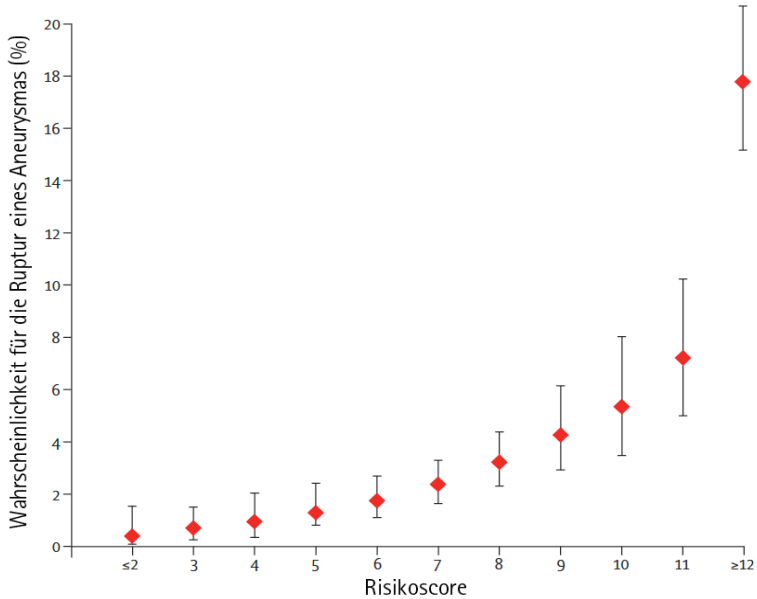

Figure 2. Five-year risk of a cerebral aneurysm rupturing according to the PHASES Score.

The non-modifiable factors include familial disposition, with 5%-20% of all patients having a positive family history of aneurysmal haemorrhage [8]. In particular, first-degree relatives of patients with aneurysmal SAH are found to have a 3-7 times higher risk of also experiencing such a haemorrhage. In contrast, the risk returns to normal in the second generation [9]. There are genetic factors, moreover, that are responsible for the development of aneurysmal SAH. Connective tissue diseases and polycystic kidney disease would be worth mentioning here [10]. In the case of the latter, mutations can be found on chromosomes 4 or 16, depending on the type. In contrast, Ehlers-Danlos syndrome and Marfan syndrome, which are often mentioned in relation to SAH, are only very rarely noted to be associated with a haemorrhage [11] and, in the case of Marfan Syndrome, studies have not established any relevant link [12].

In order to ascertain the five-year risk of a rupture in incidental cerebral aneurysms, the PHASES Score (following Chapter) was developed. To determine the risk of rupture, this score includes age, arterial hypertension, size and location of the aneurysm, previous history of SAH and the geographic location of the patient [13].

REFERENCES

[1] Linn F. H. H., Rinkel G. J., Algra A. et al. 1996. Incidence of subarachnoid hemorrhage. Role of region, year and CT scanning: A meta-analysis. *Stroke*, 27: 625-629.

[2] Broderick J. P., Brott T. G., Tomsick T. et al. 1993. Intracerebral hemorrhage more than twice as common as subarachnoid hemorrhage. *J Neurosurg*, 78: 188-191.

[3] Teunissen L. L., Rinkel G. J. E., Algra A., van Gijn J. 1996. Risk factors for subarachnoid hemorrhage: A systematic review. *Stroke*, 27: 544-549.

[4] Longstreth W. T. Jr., Nelson L. M., Koepsell T. D., van Belle G. 1993. Clinical course of spontaneous subarachnoid hemorrhage: a population-based study in King County, Washington. *Neurology*, 43: 712-718.

[5] Lanzino G., Kassel N. F., Germanson T. P., Kongable G. L., Truskowski L. L., Torner J. C. et al. 1996. Age and outcome after aneurysmal subarachnoid hemorrhage: why do older patients fare worse? *J Neurosurg*, 85: 410-418.

[6] Broderick J. P., Brott T. G., Tomsick T., Huster G., Miller R. 1992. The risk of subarachnoid and intracerebral hemorrhages in blacks as compared with whites. *N Engl J Med*, 326: 733-736.

[7] Johnston S. C., Colford J. M. Jr., Gress D. R. 1998. Oral contraceptives and the risk of subarachnoid hemorrhage: a meta-analysis. *Neurology*, 51: 441-418.

[8] Schievink W. I. 1997. Genetics of intracranial aneurysms (Review). *Neurosurgery*, 40: 651-662.

[9] Bromberg J. E. C., Rinkel G. J. E., Algra A., Greebe P., van Duyn C. M., Hasan D. et al. 1995. Subarachnoid haemorrhage in first and second degree relatives of patients with subarachnoid haemorrhage. *BMJ*, 311:288-289.

[10] Schievink W. I., Michels V. V., Piepgras D. G., Wiebers D. O. 1992. Saccular intracranial aneurysms in autosomal dominant polycystic kidney disease. *J Am Soc Nephrol*. 3: 88-95.

[11] Schievink W. I., Michels V. V., Piepgras D. G. 1994. Neurovascular manifestations of heritable connective tissue disorders. A review. *Stroke*, 25: 889-903.

[12] Van den Berg J. S., Limburg M., Hennekam R. C. 1996. Is Marfan syndrome associated with symptomatic intracranial aneurysms? *Stroke*, 27: 10-12.

[13] Gravin J. P. et al. 2014. Development of the PHASES score for prediction of risk of rupture of intracranial aneurysms: a pooled analysis of six prospective cohort studies. *The Lancet Neurology*, 13: 59-66.

[14] Herman J. M., Rekate H. L., Spetzler R. F. 1991. Pediatric intracranial aneurysms: simple and complex cases. *Pediatr Neurosurg*, 17: 66-72.

[15] Krishna H., Wani A. A., Behari S., Banerji D., Chhabra D. K., Jain V. K. 2005. Intracranial aneurysms in patients 18 years of age and under, are they different from aneurysms in adult population? *Acta Neurochir*, 147: 469-467.

[16] Jordan L. C., Johnston S. C., Wu Y. W., Sidney S., Fullerton H. J. 2009. The importance of cerebral aneurysms in childhood hemorrhagic stroke: a population-based study. *Stroke*, 49: 400-405.

[17] Mhurchu Cliona, Anderson Craig, Jamrozik Konrad, Hankey Graeme, Dunbabin David. 2011. Hormonal factors and risk of aneurysmal subarachnoid hemorrhage: an international population-based, case-control study. *Stroke*, 32: 606-612.

In: Encyclopedia of Surgery (22 Volume Set)
Editors: Andreas Lehrer and Kristin Mueller
ISBN: 978-1-53618-329-0
© 2020 Nova Science Publishers, Inc.

Chapter 64

RISK FACTORS: FORMATION, GROWTH, RUPTURE

Karl-Michael Schebesch and Petra Schödel
Neurochirurgische Klinik, University of Regensburg,
Regensburg, Germany

ABSTRACT

Aneurysms have a pathology that is certainly multifactorial and probably an expression of genetic predisposition. Their incidence is increased in the event of a family history, and they usually occur in considerable numbers with certain genetic diseases. Arterial hypertension, diabetes mellitus, smoking, drug abuse and connective tissue diseases with tunica media insufficiency are suspected risk factors for aneurysm formation. A distinction must be made between the factors that promote the development of cerebral aneurysms and those that cause them to rupture and lead to the occurrence of subarachnoid haemorrhage. In addition to age and sex, size, morphology, positive history of a previous ruptured aneurysm, as well as a positive family history are other significant contributory risk factors for a rupture.

FORMATION

Recent autopsy studies, along with radiological screening, have demonstrated that the prevalence of cerebral aneurysms is in some instances much higher than previously assumed [1, 2]. Aneurysms have a pathology that is certainly multifactorial and probably an expression of genetic predisposition [3, 4]. Their incidence is increased in the event of a family history, and they usually occur in considerable numbers with certain genetic diseases (polycystic kidneys, Marfan syndrome, Ehler's Danlos syndrome) [1, 5, 6]. The following factors are suspected to contribute to the development and growth of cerebral aneurysms: arterial hypertension, diabetes mellitus, smoking, drug abuse and connective tissue diseases with tunica media insufficiency [4, 5, 7].

Elaborate computer-based simulation studies, as well as physical wind tunnel experiments, have to date produced valuable yet inconsistent results which when combined, however, suggest that considerable influence is exerted by the properties of the vessel walls – such as shear stress in the vascular walls, the angle of the exiting vessels and the surrounding pressure. Pathohistological studies of aneurysm-carrying vessels have also demonstrated that a sometimes pronounced inflammatory reaction takes place in the vascular wall, accompanied by an influx of T cells and macrophages. It is therefore presumed that the localised weakening of the vessel wall, together with the flow characteristics of the blood, could result in the formation of cerebral aneurysms [8-10].

Table 1. Phases Score: Predicted risk of rupture in percent within the next 5 years. ICA = Internal Carotid Artery, MCA = Middle Cerebral Artery, ACA = Anterior Cerebral Artery, postCirc = posterior circulation including the posterior communicating artery, y = years, SAH = Subarachnoid Haemorrhage

Population in North America and Europe, excluding Finland												
	No hypertension, no history of SAH				Hypertension, no history of SAH				Hypertension and history of SAH			
Size, Age ≥ 70y	ICA	MCA	ACA	postCirc	ICA	MCA	ACA	postCirc	ICA	MCA	ACA	postCirc
≥ 20 mm	7	13	>15	>15	10	>15	>15	>15	14	>15	>15	>15
10-19.9 mm	2	4	6	7	3	5	8	9	4	7	11	13
7-9.9 mm	1	1	3	3	1	2	3	4	2	3	5	6
<7 mm	0	1	1	1	0	1	1	2	1	1	2	3
Size, Age <70y	ICA	MCA	ACA	postCirc	ICA	MCA	ACA	postCirc	ICA	MCA	ACA	postCirc
≥ 20 mm	5	9	15	>15	7	12	>15	>15	10	>15	>15	>15
10-19.9 mm	1	2	4	5	2	3	6	7	3	5	8	9
7-9.9 mm	1	1	2	2	1	1	2	3	1	2	3	4
<7 mm	0	0	1	1	0	1	1	1	0	1	2	2
Size, Age ≥ 70y	ICA	MCA	ACA	postCirc	ICA	MCA	ACA	postCirc	ICA	MCA	ACA	postCirc
≥ 20 mm	>15	>15	>15	>15	>15	>15	>15	>15	>15	>15	>15	>15
10-19.9 mm	5	10	>15	>15	7	13	>15	>15	10	>15	>15	>15
7-9.9 mm	2	4	7	8	3	5	9	11	4	8	13	15
<7 mm	1	2	3	4	1	2	4	5	2	3	6	7
Size, Age <70y	ICA	MCA	ACA	postCirc	ICA	MCA	ACA	postCirc	ICA	MCA	ACA	postCirc
≥ 20 mm	13	>15	>15	>15	>15	>15	>15	>15	>15	>15	>15	>15
10-19.9 mm	4	7	11	13	5	9	15	>15	7	13	>15	>15
7-9.9 mm	2	3	5	6	2	4	6	8	3	5	9	11
<7 mm	1	1	2	3	1	2	3	3	1	2	4	5

GROWTH AND RUPTURE

A distinction must be made between the factors that promote the development of cerebral aneurysms (see above) and those that cause them to rupture and lead to the occurrence of subarachnoid haemorrhage (SAH). As a condition, SAH peaks between the ages of 50 and 70 years, and affects women approx. 1.6 times more often than men. In addition to age and sex, however, there are other significant contributory factors, of which the following have been

frequently identified: size (craniocaudal diameter or largest diameter) depending on anatomic position (e.g., >5 mm ACOM, >7 mm ICA/MCA/PCOM), morphology (irregular, fusiform, blebs, blisters), positive history of a previous ruptured aneurysm, as well as a positive family history [7, 11-13].

The role of environmental factors such as the weather is not clear, whereas ethnicity has been confirmed as a definite and highly significant factor. Hence, the incidence of aneurysmal SAH in Asia, but also in Finland, is approximately three times higher than in Central and Western Europe [7, 11-13].

A practical risk stratification method for use in patients with cerebral aneurysm is the PHASES score, which accounts for the aforementioned variables and permits estimation of the haemorrhagic risk [14].

Mycotic aneurysms (following cerebral infections), dissecting aneurysms (usually caused by trauma) and giant aneurysms (>24.9 mm) are rare cerebral aneurysmal malformations. These three entities are to be viewed as having a distinct pathophysiology in terms of development and risk of rupture, and according to a number of authors are to be strictly separated from conventional cerebral aneurysms [6, 7, 12, 13].

REFERENCES

[1] Agarwal N, Gala NB, Choudhry OJ, Assina R, Prestigiacomo CJ, Duffis EJ, et al. Prevalence of asymptomatic incidental aneurysms: a review of 2,685 computed tomographic angiograms. *World neurosurgery.* 2014 Dec;82(6):1086-90. PubMed PMID: 23336985.

[2] Mostafazadeh B, Farzaneh Sheikh E, Afsharian Shishvan T, Seraji FN, Salmasian H. The incidence of berry aneurysm in the Iranian population: an autopsy study. *Turkish neurosurgery.* 2008 Jul;18(3):228-31. PubMed PMID: 18814108.

[3] Farlow JL, Lin H, Sauerbeck L, Lai D, Koller DL, Pugh E, et al. Lessons learned from whole exome sequencing in multiplex families affected by a complex genetic disorder, intracranial aneurysm. *PloS one.* 2015;10(3):e0121104. PubMed PMID: 25803036. Pubmed Central PMCID: 4372548.

[4] Sam C, Li FF, Liu SL. Inherited neurovascular diseases affecting cerebral blood vessels and smooth muscle. *Metabolic brain disease.* 2015 Apr 21. PubMed PMID: 25893882.

[5] Weir B. Unruptured intracranial aneurysms: a review. *Journal of neurosurgery.* 2002 Jan;96(1):3-42. PubMed PMID: 11794601.

[6] Wiebers DO, Whisnant JP, Huston J, 3rd, Meissner I, Brown RD, Jr., Piepgras DG, et al. Unruptured intracranial aneurysms: natural history, clinical outcome, and risks of surgical and endovascular treatment. *Lancet.* 2003 Jul 12;362(9378):103-10. PubMed PMID: 12867109.

[7] Suarez JI, Tarr RW, Selman WR. Aneurysmal subarachnoid hemorrhage. *The New England journal of medicine.* 2006 Jan 26;354(4):387-96. PubMed PMID: 16436770.

[8] Doenitz C, Schebesch KM, Zoephel R, Brawanski A. A mechanism for the rapid development of intracranial aneurysms: a case study. *Neurosurgery.* 2010 Nov;67(5):1213-21; discussion 21. PubMed PMID: 20948398.

[9] Hasan DM, Hindman BJ, Todd MM. Pressure Changes Within the Sac of Human Cerebral Aneurysms in Response to Artificially Induced Transient Increases in Systemic Blood Pressure. *Hypertension.* 2015 Aug;66(2):324-31. PubMed PMID: 26056344.

[10] Poelma C, Watton PN, Ventikos Y. Transitional flow in aneurysms and the computation of haemodynamic parameters. *Journal of the Royal Society, Interface / the Royal Society*. 2015 Apr 6;12(105). PubMed PMID: 25694540. Pubmed Central PMCID: 4387528.

[11] Bederson JB, Connolly ES, Jr., Batjer HH, Dacey RG, Dion JE, Diringer MN, et al. Guidelines for the management of aneurysmal subarachnoid hemorrhage: a statement for healthcare professionals from a special writing group of the Stroke Council, American Heart Association. *Stroke; a journal of cerebral circulation.* 2009 Mar; 40(3):994-1025. PubMed PMID: 19164800.

[12] Diringer MN. Management of aneurysmal subarachnoid hemorrhage. *Critical care medicine*. 2009 Feb;37(2):432-40. PubMed PMID: 19114880. Pubmed Central PMCID: 2820121.

[13] van Gijn J, Rinkel GJ. Subarachnoid haemorrhage: diagnosis, causes and management. *Brain: A journal of neurology.* 2001 Feb;124(Pt 2):249-78. PubMed PMID: 11157554.

[14] Greving JP, Wermer MJ, Brown RD, Jr., Morita A, Juvela S, Yonekura M, et al. Development of the PHASES score for prediction of risk of rupture of intracranial aneurysms: a pooled analysis of six prospective cohort studies. *The Lancet Neurology.* 2014 Jan;13(1):59-66. PubMed PMID: 24290159.

In: Encyclopedia of Surgery (22 Volume Set)
Editors: Andreas Lehrer and Kristin Mueller
ISBN: 978-1-53618-329-0
© 2020 Nova Science Publishers, Inc.

Chapter 65

SCALES

Petra Schödel and Karl-Michael Schebesch
Neurochirurgische Klinik,
University of Regensburg, Regensburg, Germany

ABSTRACT

There is a variety of scales that have been established specifically for grading Subarachnnoid Haemorrhage. Initial assessment of the level of consciousness is made by the Glasgow Coma Scale. The scales most commonly used for grading SAH are those by Hunt and Hess and the World Federation of Neurological Surgeons. Imaging-based classification systems are represented by the Fisher Rating Scale and Modified Fisher Rating Scale. Volume and distribution of the blood in the initial computed tomography are rated. To describe the outcome objectively, the Glasgow Outcome Score is often used.

The severity and the prognosis of subarachnoid haemorrhage are determined using a variety of scales that have been established specifically for grading SAH [1].

An initial preclinical assessment of the level of consciousness is made using the Glasgow Coma Scale (GCS, see Table 1) [2]. This scale was developed in 1974 by neurosurgeons Graham Teasdale and Bryan Jennett as a means of generally estimating the depth of unconsciousness, and has since become established in emergency medicine worldwide. Owing to its routine use, it is not only neurosurgeons that have become highly proficient in its application. The initially measured GCS score is integrated into other scores specific to SAH. Furthermore, by regularly measuring the GCS it is easy to detect a change in the level of consciousness, such as during the vasospastic phase.

The scales most commonly used for grading SAH are those by Hunt and Hess (HH, see Table 2) and the "World Federation of Neurological Surgeons" (WFNS, Table 3) [3, 4].

Table 1. Glasgow Coma Scale

Glasgow Coma Scale (GCS)		
Eye opening	Spontaneous	4
	In response to voice	3
	In response to painful stimulus	2
	No response	1
Verbal response	Oriented	5
	Confused	4
	Inappropriate words	3
	Incomprehensible sounds	2
	None	1
Motor response	Obeys commands	6
	Localised defence	5
	Withdrawal	4
	Flexion	3
	Extension	2
	None	1
Total (GCS score)		3-15

Table 2. Hunt and Hess Scale

Hunt and Hess grading		
Grade	*Consciousness*	*Clinical severity*
0	Awake	Asymptomatic, incidental
I	Awake	Asymptomatic, mild headache, discrete nuchal rigidity
Ia	Awake	Fixed neurological deficit with no further evidence of SAH
II	Awake	Severe headaches, nuchal rigidity, cranial nerve deficits, no further focal neurological deficit
III	Somnolent	Confusion, slight focal neurological deficit
IV	Soporific	Moderate to severe hemiparesis, onset of decerebrate rigidity, vegetative disorders
V	Deep coma	Signs of decerebrate rigidity

Table 3. World Federation of Neurological Surgeons Grading System (WFNS Scale)

World Federation of Neurological Surgeons Grading System		
Grade	*GCS*	*Motor deficit (hemiparesis, aphasia)*
I	15	No
II	13-14	No
III	13-14	Yes
IV	7-12	Yes/No
V	3-6	Yes/No

Hunt and Hess developed their classification system in 1968 based on 275 SAH patients, in whom they identified a correlation between the initial neurological condition and the severity of the disease course. The patients are stratified on the basis of their initial neurological symptoms, from asymptomatic, mild headache (HH I) to deep coma (HH V). Significant pre-existing conditions, as well as any vasospasm already detectable on an

angiogram, will lead to the patient being placed in the next highest HH category. The higher the Hunt and Hess score, the greater the probability of death and a poor neurological outcome, therefore. The original publication describes an increase in the mortality rate from 11% at grade HH I to 100% at HH V. Modern, rapid diagnostic tests and critical care have vastly improved the prognosis of patients whose baseline neurological condition is poor. A recent publication reports a good outcome in 26% of SAH cases rated WFNS V (see below) compared to a mortality rate of 30% in the past [5]. The Hunt and Hess Scale was modified in 1974 with the addition of grades HH 0 (unruptured aneurysm) and HH Ia (no meningeal reaction, but fixed neurological deficit, e.g., oculomotor nerve palsy) [6].

Table 4. Fisher Rating Scale

Fisher grading	
Group	*Evidence of blood on CCT*
1	No evidence of blood
2	Diffuse distribution of blood or evidence of blood in the subarachnoid space, including interhemispheric fissure, insular cisterns or ambient cisterns less than 1 mm thick
3	Localised blood clot and/or evidence of blood in the subarachnoid space more than 1 mm thick
4	Intracerebral or intraventricular blood with diffuse or no SAH

To improve the objective assessment of the severity of SAH, the WFNS Scale was developed in 1988. Stratification is achieved by grading the level of consciousness of the patient based on the GCS, as well as any possible motor deficit.

Table 5. Modified Fisher Rating Scale

Modified Fisher					
Group	No SAH	Focal or diffuse, thin SAH	Focal or diffuse, thick SAH	Intraventricular SAH	
0	+	-	-	-	No subarachnoid or intraventricular blood
1	-	+	-	-	Thin, diffuse or focal SAH, no intraventricular blood
2	-	+	-	+	Thin, diffuse or focal SAH with intraventricular blood
3	-	-	+	-	Thick, diffuse or focal SAH, no intraventricular blood
4	-	-	+	+	Thick, diffuse or focal SAH with intraventricular blood

In addition to rating SAH severity clinically, there are also imaging-based classification systems. Grading in this case is mostly undertaken using the Fisher Rating Scale (Table 4) and Modified Fisher Rating Scale (Table 5) [7, 8]. The volume and distribution of the blood in the initial CCT can certainly act as predictors for the occurrence of clinically relevant vasospasm, and thus correlate with a poor neurological outcome. Assignment to Fisher 4 with intraparenchymal or intraventricular blood thus implies the highest risk of vasospasm.

Table 6. Glasgow Outcome Scale

Glasgow Outcome Score		
Grade		Clinical description
1	Death	Severe injury or death without recovering consciousness
2	Persistent vegetative status	Severe damage with prolonged state of unresponsiveness and a lack of higher mental functions
3	Severe disability	Severe injury with permanent need for help with activities of daily living
4	Moderate disability	No need for assistance in everyday life, employment is possible but may require special equipment
5	(Almost) complete recovery	Slight damage with minor neurological and psychological deficits

To describe the outcome objectively, the Glasgow Outcome Score (GOS, see Table 6) is often used in patients with SAH as well as in other patients with brain injuries [9]. The degree of disability in the patient that results from the effects of SAH are thus described, but the neurological deficits are not precisely differentiated. Moreover, the GOS only inadequately determines psychological disorders and cognitive impairment.

In addition to the SAH classification systems described above, there are others which in everyday practice are used only seldom or only on a regional level. Those of particular interest are the Claassen CT Rating Scale, which describes the distribution of the blood on CCT in greater detail than the Fisher Grade and likewise permits estimation of the risk of vasospasm, and the SAH grading system developed by Ogilvy and Carter in 1998. Patient age, HH grade, Fisher grade and aneurysm size are thereby included in these assessments. Both scales permit a slightly more exact risk estimation but are far more complicated to use and to analyse [10, 11].

REFERENCES

[1] Rosen DS, Macdonald RL. Subarachnoid hemorrhage grading scales: a systematic review. *Neurocritical care.* 2005;2(2):110-8. PubMed PMID: 16159052.

[2] Teasdale G, Jennett B. Assessment of coma and impaired consciousness. A practical scale. *Lancet.* 1974 Jul 13;2(7872):81-4. PubMed PMID: 4136544.

[3] Hunt WE, Hess RM. Surgical risk as related to time of intervention in the repair of intracranial aneurysms. *J Neurosurg*. 1968 Jan;28(1):14-20. PubMed PMID: 5635959.

[4] Report of World Federation of Neurological Surgeons Committee on a Universal Subarachnoid Hemorrhage Grading Scale. *Journal of neurosurgery*. 1988 Jun;68(6):985-6. PubMed PMID: 3131498.

[5] Wostrack M, Sandow N, Vajkoczy P, Schatlo B, Bijlenga P, Schaller K, et al. Subarachnoid haemorrhage WFNS grade V: is maximal treatment worthwhile? *Acta neurochirurgica*. 2013 Apr;155(4):579-86. PubMed PMID: 23397308.

[6] Hunt WE, Kosnik EJ. Timing and perioperative care in intracranial aneurysm surgery. *Clinical neurosurgery*. 1974;21:79-89. PubMed PMID: 4608645.

[7] Fisher CM, Kistler JP, Davis JM. Relation of cerebral vasospasm to subarachnoid hemorrhage visualized by computerized tomographic scanning. *Neurosurgery*. 1980 Jan;6(1):1-9. PubMed PMID: 7354892.

[8] Frontera JA, Claassen J, Schmidt JM, Wartenberg KE, Temes R, Connolly ES, Jr., et al. Prediction of symptomatic vasospasm after subarachnoid hemorrhage: the modified fisher scale. *Neurosurgery*. 2006 Jul;59(1):21-7; discussion -7. PubMed PMID: 16823296.

[9] Jennett B, Bond M. Assessment of outcome after severe brain damage. *Lancet*. 1975 Mar 1;1(7905):480-4. PubMed PMID: 46957.

[10] Claassen J, Vu A, Kreiter KT, Kowalski RG, Du EY, Ostapkovich N, et al. Effect of acute physiologic derangements on outcome after subarachnoid hemorrhage. *Critical care medicine*. 2004 Mar;32(3):832-8. PubMed PMID: 15090970.

[11] Ogilvy CS, Carter BS. A proposed comprehensive grading system to predict outcome for surgical management of intracranial aneurysms. *Neurosurgery*. 1998 May;42(5):959-68; discussion 68-70. PubMed PMID: 9588539.

In: Encyclopedia of Surgery (22 Volume Set)
Editors: Andreas Lehrer and Kristin Mueller
ISBN: 978-1-53618-329-0
© 2020 Nova Science Publishers, Inc.

Chapter 66

SYMPTOMS, EXTRACRANIAL MANIFESTATIONS

Petra Schödel and Karl-Michael Schebesch
Neurochirurgische Klinik,
University of Regensburg, Regensburg, Germany

ABSTRACT

The sudden development of intense headache (thunderclap headache) is usually the first symptom of aneurysmal subarachnoid haemorrhage: "worst headache of my life." The headaches are often accompanied by clouding of consciousness and even coma. Loss of consciousness can be just temporary following Subarachnoid Haemorrahge, but can also result in persistent coma and even death. Nuchal rigidity is one of the key symptoms. Localised pressure resulting from a ruptured aneurysm as well as an innocent aneurysm can lead to cranial nerve deficits. Depending on its location and extent of an intracerebral haemorrhage it can lead to focal neurological deficits such as hemiparesis or aphasia, as well as epileptic seizures. However, there are a certain number of more rare extracranial symptoms.

The sudden development of intense headache (thunderclap headache) is usually the first symptom of aneurysmal subarachnoid haemorrhage [1]. This type of headache will even be described by migraine patients as the "worst headache of my life" or the "feeling that my skull is being split in two by an axe." Retrospectively, approximately 30%-40% of patients report headaches of increased intensity in the preceding weeks which are interpreted as being related to mild SAH ("warning bleed") or a growing aneurysm [2, 3]. In addition to a thunderclap headache, severe nuchalgia and occasionally back pain along the entire length of the spine can also develop.

The headaches are often accompanied by clouding of consciousness and even coma. They can be caused by increased intracranial pressure, acute hydrocephalus, direct parenchymal brain damage from intracerebral bleeding or ischaemia associated with SAH, or even seizures. This loss of consciousness can be just temporary following SAH, but can also result in persistent coma and even death. Secondary clouding of consciousness over the

course of the disease can be an expression of secondary haemorrhage, or also increased intracranial pressure with CSF stasis.

Clinical examination of the patient will usually reveal marked nuchal rigidity not long after SAH. Meningeal irritation is indicated by the patient's avoidance of light and sensitivity to noise. Nausea and vomiting can also occur. The Lasègue, Kernig and Brudzinski signs may be positive.

Given the close proximity of the cranial nerves and arteries of the circle of Willis, localised pressure resulting from a ruptured aneurysm as well as an innocent aneurysm can lead to cranial nerve deficits. There have been reports in particular of oculomotor nerve palsy from aneurysms in the left and right posterior communicating artery, abducens nerve palsy from aneurysms in the cavernous sinus, or scotomas from large aneurysms in the internal carotid artery or anterior communicating artery.

A ruptured aneurysm causes intracerebral bleeding, which depending on its location and extent can lead to focal neurological deficits such as hemiparesis or aphasia, as well as epileptic seizures.

Ocular bleeding, especially into the vitreous body, is likely to occur as a result of stasis in the intraocular veins which arises due to an increase in intracranial pressure during and after the aneurysm has ruptured. This condition, known as Terson syndrome, is found in approx. 10%-20% of all SAH patients and is associated with a higher rate of mortality. If visual disorders develop due to Terson syndrome, vitrectomy may be necessary over the course [4, 5].

In addition to all these symptoms, which result from changes in the brain and dura precipitated by the aneurysm and SAH, there are a certain number of more rare extracranial symptoms.

Cardiac problems of any nature are a secondary symptom of SAH and occur in approx. 14% of patients. From basic ECG changes to tachyarrhythmias and bradyarrhythmias, and even elevated troponin and heart attacks - anything is possible [6]. A rare cardiac complication is Takotsubo-like cardiomyopathy, which probably develops due to increased catecholamine release during the acute phase of SAH [7]. This left-ventricular dyskinesia abates as a rule after a few weeks. Neurogenic pulmonary oedema can develop from SAH-induced cardiac dysfunction, but also from treatment-related hypervolaemia. Furthermore, hyperglycaemia and marked electrolyte disorders, such as hyponatraemia and hypokalaemia, can result from SAH [8].

REFERENCES

[1] van Gijn J, Rinkel GJ. Subarachnoid haemorrhage: diagnosis, causes and management. *Brain : a journal of neurology*. 2001 Feb;124(Pt 2):249-78. PubMed PMID: 11157554.

[2] Verweij RD, Wijdicks EF, van Gijn J. Warning headache in aneurysmal subarachnoid hemorrhage. A case-control study. *Archives of neurology*. 1988 Sep;45(9):1019-20. PubMed PMID: 3274041.

[3] Juvela S. Minor leak before rupture of an intracranial aneurysm and subarachnoid hemorrhage of unknown etiology. *Neurosurgery*. 1992 Jan;30(1):7-11. PubMed PMID: 1738458.

[4] Stiebel-Kalish H, Turtel LS, Kupersmith MJ. The natural history of nontraumatic subarachnoid hemorrhage-related intraocular hemorrhages. *Retina*. 2004 Feb;24(1):36-40. PubMed PMID: 15076942.

[5] Wietholter S, Steube D, Stotz HP. [Terson syndrome: a frequently missed ophthalmologic complication in subarachnoid hemorrhage]. *Zentralblatt fur Neurochirurgie*. 1998;59(3):166-70. PubMed PMID: 9816667. Terson-Syndrom: Haufig ubersehene ophthalmologische Komplikation bei Subarachnoidalblutung.

[6] Ahmadian A, Mizzi A, Banasiak M, Downes K, Camporesi EM, Thompson Sullebarger J, et al. Cardiac manifestations of subarachnoid hemorrhage. Heart, lung and vessels. 2013;5(3):168-78. PubMed PMID: 24364008. *Pubmed Central* PMCID: 3848675.

[7] Inamasu J, Nakatsukasa M, Mayanagi K, Miyatake S, Sugimoto K, Hayashi T, et al. Subarachnoid hemorrhage complicated with neurogenic pulmonary edema and takotsubo-like cardiomyopathy. *Neurologia medico-chirurgica*. 2012;52(2):49-55. PubMed PMID: 22362283.

[8] Chen S, Li Q, Wu H, Krafft PR, Wang Z, Zhang JH. The harmful effects of subarachnoid hemorrhage on extracerebral organs. *BioMed research international.* 2014;2014:858496. PubMed PMID: 25110700. Pubmed Central PMCID: 4109109.

In: Encyclopedia of Surgery (22 Volume Set)
Editors: Andreas Lehrer and Kristin Mueller
ISBN: 978-1-53618-329-0
© 2020 Nova Science Publishers, Inc.

Chapter 67

ADMISSION, DIAGNOSTIC IMAGING, ACUTE HYDROCEPHALUS

Thomas Schmidt
Department of Neurosurgery, Evangelic Hospital Oldenburg,
Medical Campus University of Oldenburg, Germany

ABSTRACT

A patient with subarachnoid haemorrhage can be at extremely high risk on the clinical spectrum or appear to be almost asymptomatic on admission. Medical management must be able to quickly adapt to this clinical scenario and the rapid progression of the condition that under certain circumstances can occur. Therefore, the neurological and radiological scales for evaluating patients with subarachnoid haemorrhage should be used routinely. The life-threatening complications that accompany subarachnoid haemorrhage must be immediately identified, corrected, and avoided with a view to rebleeding from the ruptured haemorrhage. Modern methods of computed tomography permit diagnosis of subarachnoid haemorrhage in the first few hours after onset of the symptoms in particular. A non-aneurysmal cause for spontaneous subarachnoid haemorrhage is found in only 15% of cases.

Keywords: grading scales, diagnostic imaging, aneurysm rerupture, acute hydrocephalus, epileptic seizures

INITIAL NEUROCRITICAL CARE – MEDICAL EVALUATION

Patients with suspected or proven subarachnoid haemorrhage admitted to a neurovascular unit should immediately undergo targeted neurological evaluation to determine the scope and urgency of further diagnostic and therapeutic efforts. Initial management involves primary clinical stabilisation of the patient, ascertainment of the correct diagnosis, definitive treatment of the aneurysm and avoidance of complications. If patients have survived the first few hours of subarachnoid haemorrhage, they are subsequently at risk of three major neurological

complications: rebleeding of the ruptured aneurysm, acute hydrocephalus, and delayed cerebral ischaemia.

Once the patient has been admitted, attention should first be given to his/her level of consciousness and any neurological deficits. At this point about half of the patients are already comatose. [1, 2] The loss of consciousness at onset of the symptoms is also a strong indication of a ruptured aneurysm and does not typically occur in perimesencephalic subarachnoid haemorrhage. [3] These patients are at risk of respiratory failure. Intubation and mechanical ventilation should ensure adequate oxygenation, maintain the pH in the normal range and prevent hypercapnia.

Alert patients usually describe the headaches as the worst they have ever had in their lives, focussing in particular on their extremely sudden onset. A preceding "sentinel" headache is reported by 10% to 43% of patients. [4] The headaches are mostly associated with one or more concomitant symptoms including nausea and vomiting, meningism, temporary loss of consciousness, cranial nerve disorders and neurological deficits.

Grading Scales

The initial clinical severity of subarachnoid haemorrhage is in itself a significant predictor for the outcome of the condition. [5] The severity should therefore be clinically determined as soon as possible using the Glasgow Coma Scale [6], the Hunt and Hess Scale [7], and the WFNS Scale [8]. Whereas the GCS is used to judge the clinical level of consciousness regardless of the underlying cause, the HH and WFNS scales were developed specifically for clinically stratifying SAH (Following Chapter). Use of these scales provides a clear clinical determination of the patients condition, whilst the parameters of the HH Scale are influenced heavily by the examiner's subjective opinion.

The Fischer Scale [9] was developed as a means of assessing the risk of vasopasm and cerebral ischaemia from baseline CCT. The subsequently adapted and less subjective Modified Fisher Scale [10] evaluates the volume of cisternal and intraventricular blood more specifically as part of its risk assessment (following Chapter).

Epileptic Seizures and SAH

Epileptic seizures occur in approx. 8% of patients after subarachnoid haemorrhage, 90% of which are observed within the first 24 hours. [11-13] Epileptic seizures occur at a later stagme in 3% to 7% of patients. [14, 15] In retrospective studies, intracerebral haematoma, rebleeding, a ruptured aneurysm of the middle cerebral artery, the thickness of the subarachnoid blood clot, an unfavourable neurological status and cerebral infarction have been identified as risk factors for the occurrence of epileptic seizures in the early phase of subarachnoid haemorrhage. [14-18] The significance in terms of the impact on the prognosis of a patient with epileptic seizures in the early phase of subarachnoid haemorrhage is not clear. In some studies, epileptic seizures were not found to influence the outcome. [13, 15, 19] A correlation to a poor clinical outcome was established in a retrospective study, however. [20] Although prophylactic anticonvulsant medication after subarachnoid haemorrhage has not as yet been found to produce a favourable therapeutic outcome, prophylactic antiepileptic

treatment is used widely for preventing the risk of rebleeding from an untreated ruptured aneurysm during an epileptic seizure. This concept is furiously debated, meaning that a general recommendation for prophylactic anticonvulsant treatment cannot be pronounced [21].

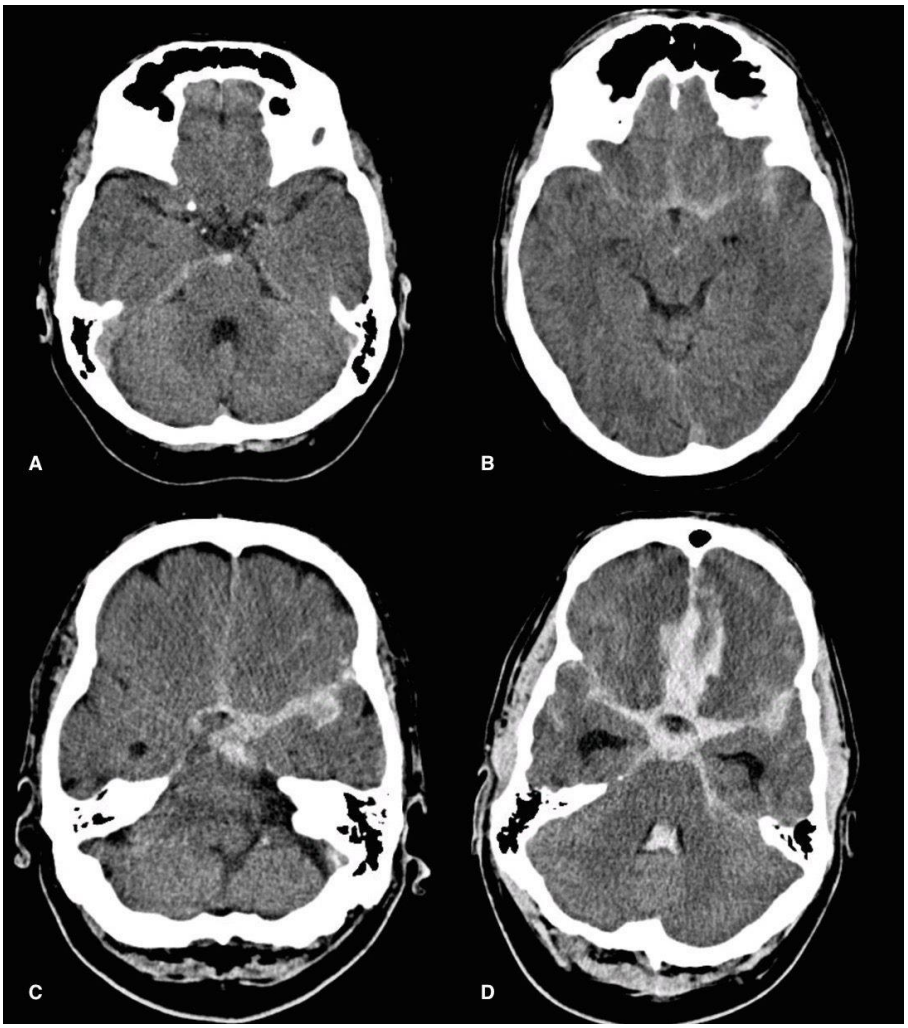

Figure 1. According to the modified Fisher scale the CT-Scans of four different patients with subarachnoid hemorrhage (A-D) demonstrate an increasing clot burden at the basal cisterns.
A: Grade I hemorrhage with minimal blood at the interpeduncular cistern. B: Also grade I haemorrhage, but significant more CSF-spaces are filled with blood. C: Subarachnoid haemorrhage grade IV with substantial blood in the sylvian fissure on the left. D: CT also reveals intraventricular blood and intraparenchymal hematoma corresponding grade V.

DIAGNOSTIC IMAGING

Once the patient with subarachnoid haemorrhage has received primary clinical care, appropriate diagnostic imaging should be arranged without further delay to detect the actual

cause of the given symptoms. In doing so, it is important not only to establish the diagnosis of subarachnoid haemorrhage in itself, but also to detect a life-threatening situation that could potentially exist due to space-occupying subdural or intracerebral haematoma, decompensated hydrocephalus or severe cerebral swelling.

Computed Tomography

Non-contrast computed tomography is the first examination when SAH is clinically suspected and is at the same time the diagnostic imaging method of choice. Hyperdense blood in the basal cisterns and fissures is a characteristic feature of SAH on cranial CT (CCT). However, the haemorrhage is not necessarily confined to the subarachnoid space, but can also involve the ventricles, subdural space and brain parenchyma, consistent with intracerebral haemorrhage (Figure 1). The sensitivity is affected by the volume of blood, the time since symptom onset, the scanner properties and the experience of the examining radiologist. CT produces false negative results in approx. 2.5% – 7% of aneurysmal SAHs. On the day the haemorrhage occurs, extravasal blood can be detected in more than 95% of patients. [22, 23] As blood can be flushed out of the cerebrospinal cavities relatively quickly, the sensitivity of cranial CT drops to 50% on the seventh day following the haemorrhage [24].

Lumbar Puncture

In a small group of patients with negative cranial CT and transient sudden headache, metabolites of haemoglobin can be identified within the first 12 hours by lumbar puncture and intracranial aneurysm, in fact, in a subsequent angiography. Therefore, a lumbar puncture is certainly indicated in patients with a clinical event and negative cranial CT, even when the cerebrospinal fluid findings are normal in a majority of the examinations. The puncture itself should be performed with great care and ensue within a suitable time frame, no earlier than six hours after the onset of symptoms. This seems to be easier than it is in reality in order to obtain reliable results. The traditional three-glass test is not considered appropriate in this regard [25].

Computed Tomographic Angiography (CTA)

CT angiography has now become more valuable in the first-line work-up of spontaneous SAH than catheter angiography. On the one hand, the sensitivity of CTA in detecting an intracranial aneurysm is the same as that of catheter angiography. [26, 27] In addition, CTA has other apparent advantages that have contributed to this development. These include its less invasive nature compared to DSA, lower costs, reduced time and effort, as well as the simultaneous ability to depict the bony structures at the base of the skull. However, despite the modern scanner technology, the negative predictive value is only 82% to 96% [28, 29], meaning that CTA cannot completely replace DSA even today. It is with aneurysms of less than 3 mm in size that the diagnostic confidence is reduced [30-32].

DSA and Three-Dimensional Rotational Angiography

Angiography of the cerebral arteries is not only intended to detect one or more aneurysms as the underlying cause of spontaneous SAH, but also provides further essential information about the exact configuration of the aneurysm and its adjacent angioarchitecture, which is needed in order to decide on the appropriate treatment option of surgical clipping and endovascular coiling. Even when a cerebral aneurysm was not detected in non-invasive diagnostic testing, DSA led to a change in treatment strategy in 19% to 30% of patients [33].

Angiography is invasive, however. The risk of transient or permanent neurological complications during an angiogram of the cerebral vessels after subarachnoid haemorrhage is 1.8%, [34] and that of intraprocedural rebleeding from the ruptured aneurysm 1%-2% [35, 36].

In approx. 15% of spontaneous subarachnoid haemorrhage cases, primary diagnostic testing including conventional angiography does not detect an aneurysm of the cerebral arteries. Repetition of conventional angiography after 10 to 14 days is mandatory in such a case, since in a substantial number of patients a missed aneurysm can be subsequently detected [37].

MRI

Because of the high diagnostic significance of computed tomography in the acute phase of subarachnoid haemorrhage, the shorter examination times and the simple workflow required for the intensive care patient, the number of MRI studies in the initial diagnostic testing of subarachnoid haemorrhage is very low. Fresh subarachnoid bleeding within the first 12 hours after symptom onset can be detected in FLAIR sequences. [38-40] MRI reaches a sensitivity comparable to that of CT [38, 40].

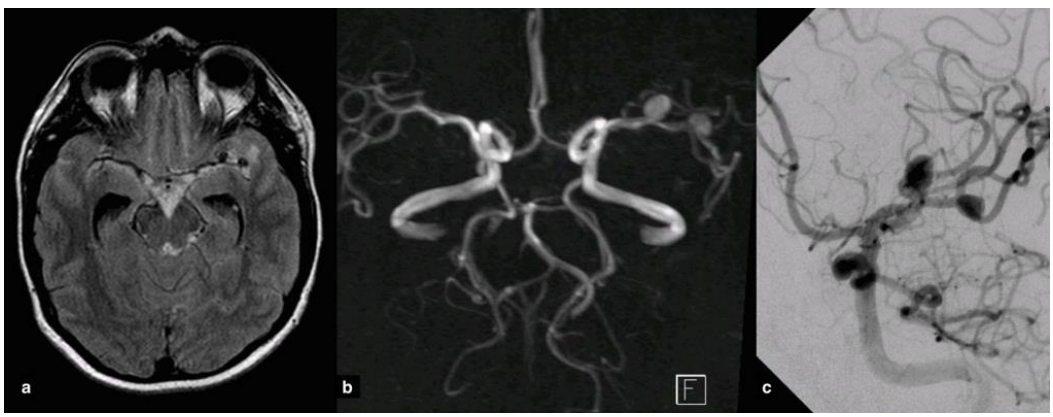

Figure 2. MRI of a 36-year-old women in the 22th week of pregnancy suffering by acute onset of severe headache and vomiting. In a fresh T2-hyperintensive subarachnoid haemorrhage in the basal cistern can be detected in FLAIR sequences. 3D-MIP reconstructed TOF-MRA (b) shows two saccular aneurysms at the M1- and M2-segment of middle cerebral artery on the left. Diagnosis was confirmed on DSA and aneurysm were successfully occluded by endovascular coiling subsequently.

Table 1. Non-aneurysmatic causes of spontaneous SAH

Cerebrovascular lesions
- Arterial dissection - Arteriovenous malformation (BAVM) - Dural arteriovenous fistula - Intracerebral cavernoma - Sinus vein thrombosis - Cerebral amyloid angiopathy - Moyamoya
Inflammatory vascular lesions
- Wegener's granulomatosis - Polyarteritis nodosa - Churg-Strauss syndrome - Behçet's disease - Other types of vasculitis - Mycotic aneurysms
Spinal vascular lesions
- Saccular aneurysm of the anterior spinal artery - Arteriovenous malformation (SAVM) - Dural arteriovenous fistula - Spinal cavernoma
Medicines
- Cocaine consumption - Overdose of anticoagulants
Other causes
- Sickle cell disease - Coagulopathies - Pituitary apoplexy - Meningeal carcinomatosis - Intracranial tumours

Due to the loss of hyperdensity of blood and signal intensity in CT in the days following SAH, the diagnostic significance of MRI in the detection of subarachnoid blood with FLAIR and T2* sequences increases and becomes better than with CT [41].

In avoiding exposure to radiation, MRI is thus a suitable alternative to CT in patients who during pregnancy experience subarachnoid haemorrhage. (Figure 2) In addition, a supplementary cranial and cervical MRI scan is necessary if in the initial diagnostic testing of spontaneous subarachnoid haemorrhage, including catheter angiography, no source of haemorrhage was detectable and other causes have to be ruled out. (Table 1) In approx. 14% of this patient population, other findings are compiled using MRI which substantially alter the further treatment plan in approx. 6% of patients [42].

PREVENTION OF REBLEEDING

Rebleeding from a ruptured aneurysm after subarachnoid haemorrhage is linked with a mortality of up to 74% [43, 44] and with a significantly poorer functional outcome in surviving patients. A significant factor in the acute phase of the illness is that the risk of

rebleeding is at its highest in the first 12 hours and occurs within the first 24 hours 13.6% to 48.6% of cases. [1, 45-48] In fact, about one third of recurrent haemorrhages occur within the first three hours and about one half within the first six hours. Rebleeding during this early time window also appears to have a more negative impact on the clinical outcome than rebleeding at a later stage. [48] After the first day, the further risk of rebleeding is evenly distributed and is about 2% per day, 40% after one month, [1] and 50% after six months [49].

Numerous factors have an influence on the risk of rebleeding. Poor neurological status on admission, [45, 50] initial loss of consciousness, the size of the aneurysm, [50-52] and hypertension above 160 mm Hg [45, 52] as well as a lengthy period until definitive aneurysm treatment increase the risk of rebleeding. Early treatment of the aneurysm can reduce the risk of rebleeding [53, 54].

Antifibrinolytic treatment with tranexamic acid or epsilon-aminocaproic acid has proven effective in protecting against rebleeding after an aneurysm has ruptured. [55-57] However, because of the increased risk of secondary vasospasm and cerebral ischaemia, the overall clinical outcome is not positively affected, [58, 59] meaning that this treatment has not found a place in clinical practice. Nevertheless, it may be feasible under certain circumstances [60].

ACUTE HYDROCEPHALUS

The occurrence of acute hydrocephalus as a result of subarachnoid haemorrhage is a frequent complication and in an initially awake patient typically causes subsequent gradual deterioration in the level of consciousness. Figures related to frequency vary between 15% and 87%. [60-62] An initial enlargement of the ventricles, especially the temporal horns, is frequently attempted but regresses within the first two days. In fact, in about 50% of patients with acute hydrocephalus the clinical symptoms regressed spontaneously in the first 24 hours without any specific intervention. [63] (Figure 3) Acute hydrocephalus is to be seen as an independent risk factor for a poor clinical outcome [64, 65].

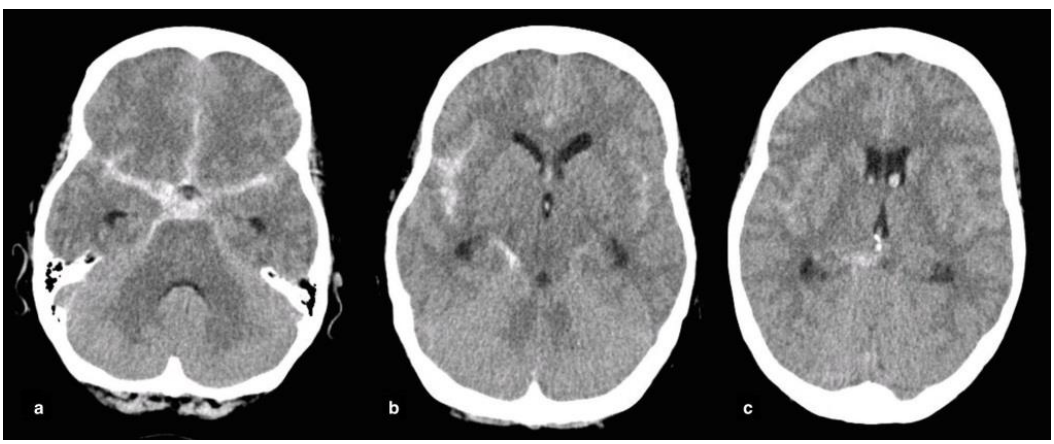

Figure 3. CT (a-c) demonstrates acute hydrocephalus of a 42-year-old individual following subarchnoid hemorrhage. However the were no significant clinical symptoms related to hydrocephalus and initial enlargement of the ventricles regresses within the first two days without any specific intervention.

Pathophysiologically, there are two mechanisms behind the development of acute hydrocephalus. Firstly, the circulation of cerebrospinal fluid is displaced into the ventricles and basal cisterns by intraventricular or subarachnoid blood, [66] and secondly, reabsorption of the cerebrospinal fluid at the level of the arachnoid granulations is decreased. In contrast, the later chronic hydrocephalus is the result of secondary, reactive fibrosis and adhesion of the leptomeninges, which restrict the CSF circulation. [67-70] The hypothesis that subarachnoid haemorrhage increases the production of cerebrospinal fluid is furiously debated in the literature and to date has not been proven with any certainty [71-74].

Risk factors for acute hydrocephalus from subarachnoid haemorrhage are intraventricular bleeding, a substantial volume of blood in the subarachnoid space, increasing loss of consciousness, increased patient age, and an aneurysm located in the posterior circulation [75, 76].

Proven and symptomatic hydrocephalus is treated with an external ventricular drain and more rarely in clinical practice with lumbar drainage or a series of lumbar punctures. After an external ventricular drain has been inserted, an improvement in the patient's neurological condition is generally seen due to the reduction in intracranial pressure. [77-79] A recently published prospective cohort study came to the conclusion that use of an external drain must be regarded as an independent risk factor for rebleeding. [80] In this context, preliminary retrospective studies also identified an increased risk of rebleeding. [79, 81] However, there are also studies that did not report an increased risk of rebleeding after placement of an external drain for treatment of hydrocephalus following subarachnoid haemorrhage [82, 83].

REFERENCES

[1] Brilstra EH, Rinkel GJ, Algra A, van Gijn J. Rebleeding, secondary ischemia, and timing of operation in patients with subarachnoid hemorrhage. *Neurology*. 2000 Dec 12;55 (11):1656–60.

[2] Fontanarosa PB. Recognition of subarachnoid hemorrhage. *Ann Emerg Med.* 1989 Nov;18 (11):1199–205.

[3] Dupont SA, Lanzino G, Wijdicks EFM, Rabinstein AA. The use of clinical and routine imaging data to differentiate between aneurysmal and nonaneurysmal subarachnoid hemorrhage prior to angiography. Clinical article. *J Neurosurg. American Association of Neurological Surgeons*; 2010 Oct;113 (4):790–4.

[4] Polmear A. Sentinel headaches in aneurysmal subarachnoid haemorrhage: what is the true incidence? A systematic review. *Cephalalgia.* 2003 Dec;23 (10):935–41.

[5] Rosen DS, Macdonald RL. Subarachnoid hemorrhage grading scales: a systematic review. *Neurocrit Care*. 2005;2 (2):110–8.

[6] Teasdale G, Jennett B. Assessment of coma and impaired consciousness. A practical scale. *Lancet.* 1974 Jul 13;2 (7872):81–4.

[7] Hunt WE, Hess RM. Surgical risk as related to time of intervention in the repair of intracranial aneurysms. *J Neurosurg. Journal of Neurosurgery Publishing Group;* 1968 Jan;28 (1):14–20.

[8] Report of World Federation of Neurological Surgeons Committee on a Universal Subarachnoid Hemorrhage Grading Scale. *J Neurosurg*. 1988 Jun;68 (6):985–6.

[9] Fisher CM, Kistler JP, Davis JM. Relation of cerebral vasospasm to subarachnoid hemorrhage visualized by computerized tomographic scanning. *Neurosurgery.* 1980 Jan;6 (1):1–9.

[10] Frontera JA, Claassen J, Schmidt JM, Wartenberg KE, Temes R, Connolly ES, et al. Prediction of symptomatic vasospasm after subarachnoid hemorrhage: the modified fisher scale. *Neurosurgery.* 2006 Jul;59 (1):21–7–discussion21–7.

[11] Hasan D, Schonck RS, Avezaat CJ, Tanghe HL, van Gijn J, van der Lugt PJ. Epileptic seizures after subarachnoid hemorrhage. *Ann Neurol.* Wiley Subscription Services, Inc., A Wiley Company; 1993 Mar;33 (3):286–91.

[12] Baker CJ, Prestigiacomo CJ, Solomon RA. Short-term perioperative anticonvulsant prophylaxis for the surgical treatment of low-risk patients with intracranial aneurysms. *Neurosurgery.* 1995 Nov;37 (5):863–70–discussion870–1.

[13] Rhoney DH, Tipps LB, Murry KR, Basham MC, Michael DB, Coplin WM. Anticonvulsant prophylaxis and timing of seizures after aneurysmal subarachnoid hemorrhage. *Neurology.* 2000 Jul 25;55 (2):258–65.

[14] Lin C-L, Dumont AS, Lieu A-S, Yen C-P, Hwang S-L, Kwan A-L, et al. Characterization of perioperative seizures and epilepsy following aneurysmal subarachnoid hemorrhage. *J Neurosurg. Journal of Neurosurgery Publishing Group*; 2003 Dec;99 (6):978–85.

[15] Choi K-S, Chun H-J, Yi H-J, Ko Y, Kim Y-S, Kim J-M. Seizures and Epilepsy following Aneurysmal Subarachnoid Hemorrhage : Incidence and Risk Factors. *J Korean Neurosurg Soc*. 2009 Aug;46 (2):93–8.

[16] Kvam DA, Loftus CM, Copeland B, Quest DO. Seizures during the immediate postoperative period. *Neurosurgery.* 1983 Jan;12 (1):14–7.

[17] Ukkola V, Heikkinen ER. Epilepsy after operative treatment of ruptured cerebral aneurysms. *Acta neurochirurgica*. 1990;106 (3-4):115–8.

[18] Huttunen J, Kurki MI, Und Zu Fraunberg von M, Koivisto T, Ronkainen A, Rinne J, et al. Epilepsy after aneurysmal subarachnoid hemorrhage: A population-based, long-term follow-up study. *Neurology.* Lippincott Williams & Wilkins; 2015 Jun 2;84 (22):2229–37.

[19] Fung C, Balmer M, Murek M, Z'Graggen WJ, Abu-Isa J, Ozdoba C, et al. Impact of early-onset seizures on grading and outcome in patients with subarachnoid hemorrhage. *J Neurosurg. American Association of Neurological Surgeons*; 2015 Feb;122 (2):408–13.

[20] Butzkueven H, Evans AH, Pitman A, Leopold C, Jolley DJ, Kaye AH, et al. Onset seizures independently predict poor outcome after subarachnoid hemorrhage. *Neurology.* 2000 Nov 14;55 (9):1315–20.

[21] Lanzino G, D'Urso PI, Suarez J, Participants in the International Multi-Disciplinary Consensus Conference on the Critical Care Management of Subarachnoid Hemorrhage. Seizures and anticonvulsants after aneurysmal subarachnoid hemorrhage. *Neurocrit Care.* 2011 Sep;15 (2):247–56.

[22] Boesiger BM, Shiber JR. Subarachnoid hemorrhage diagnosis by computed tomography and lumbar puncture: are fifth generation CT scanners better at identifying subarachnoid hemorrhage? *J Emerg Med.* Elsevier; 2005 Jul;29 (1):23–7.

[23] van der Wee N, Rinkel GJ, Hasan D, van Gijn J. Detection of subarachnoid haemorrhage on early CT: is lumbar puncture still needed after a negative scan? *J Neurol Neurosurg Psychiatr*. BMJ Group; 1995 Mar;58 (3):357–9.

[24] Edlow JA, Caplan LR. Avoiding pitfalls in the diagnosis of subarachnoid hemorrhage. *N Engl J Med*. 2000 Jan 6;342 (1):29–36.

[25] Buruma OJ, Janson HL, Bergh Den FA, Bots GT. Blood-stained cerebrospinal fluid: traumatic puncture or haemorrhage? J Neurol Neurosurg Psychiatr. *BMJ Group*; 1981 Feb;44 (2):144–7.

[26] Jayaraman MV, Mayo-Smith WW, Tung GA, Haas RA, Rogg JM, Mehta NR, et al. Detection of intracranial aneurysms: multi-detector row CT angiography compared with DSA. Radiology. *Radiological Society of North America*; 2004 Feb;230 (2):510–8.

[27] Villablanca JP, Jahan R, Hooshi P, Lim S, Duckwiler G, Patel A, et al. Detection and characterization of very small cerebral aneurysms by using 2D and 3D helical CT angiography. *AJNR Am J Neuroradiol*. 2002 Aug;23 (7):1187–98.

[28] Papke K, Kuhl CK, Fruth M, Haupt C, Schlunz-Hendann M, Sauner D, et al. Intracranial aneurysms: role of multidetector CT angiography in diagnosis and endovascular therapy planning. *Radiology. Radiological Society of North America;* 2007 Aug;244 (2):532–40.

[29] Li Q, Lv F, Li Y, Luo T, Li K, Xie P. Evaluation of 64-section CT angiography for detection and treatment planning of intracranial aneurysms by using DSA and surgical findings. *Radiology. Radiological Society of North America*, Inc; 2009 Sep;252 (3):808–15.

[30] McKinney AM, Palmer CS, Truwit CL, Karagulle A, Teksam M. Detection of aneurysms by 64-section multidetector CT angiography in patients acutely suspected of having an intracranial aneurysm and comparison with digital subtraction and 3D rotational angiography. *American Journal of Neuroradiology. American Society of Neuroradiology*; 2008 Mar;29 (3):594–602.

[31] Donmez H, Serifov E, Kahriman G, Mavili E, Durak AC, Menkü A. Comparison of 16-row multislice CT angiography with conventional angiography for detection and evaluation of intracranial aneurysms. *Eur J Radiol.* Elsevier; 2011 Nov;80 (2):455–61.

[32] Bechan RS, van Rooij SB, Sprengers ME, Peluso JP, Sluzewski M, Majoie CB, et al. CT angiography versus 3D rotational angiography in patients with subarachnoid hemorrhage. *Neuroradiology.* Springer Berlin Heidelberg; 2015 Sep 4;:1–8.

[33] Tomycz L, Bansal NK, Hawley CR, Goddard TL, Ayad MJ, Mericle RA. "Real-world" comparison of non-invasive imaging to conventional catheter angiography in the diagnosis of cerebral aneurysms. *Surg Neurol Int.* 2011;2 (1):134.

[34] Cloft HJ, Joseph GJ, Dion JE. Risk of cerebral angiography in patients with subarachnoid hemorrhage, cerebral aneurysm, and arteriovenous malformation: a meta-analysis. *Stroke.* 1999 Feb 1;30 (2):317–20.

[35] Saitoh H, Hayakawa K, Nishimura K, Okuno Y, Teraura T, Yumitori K, et al. Rerupture of cerebral aneurysms during angiography. *AJNR Am J Neuroradiol*. 1995 Mar;16 (3):539–42.

[36] Koenig GH, Marshall WH, Poole GJ, Kramer RA. Rupture of intracranial aneurysms during cerebral angiography: report of ten cases and review of the literautre. *Neurosurgery.* 1979 Sep;5 (3):314–24.

[37] Suarez JI, Tarr RW, Selman WR. Aneurysmal subarachnoid hemorrhage. *N Engl J Med*. 2006 Jan 26;354 (4):387–96.

[38] Noguchi K, Ogawa T, Seto H, Inugami A, Hadeishi H, Fujita H, et al. Subacute and chronic subarachnoid hemorrhage: diagnosis with fluid-attenuated inversion-recovery MR imaging. *Radiology*. 1997 Apr;203 (1):257–62.

[39] Küker W, Thiex R, Block F. Hyperacute perimesencephalic subarachnoid hemorrhage: demonstration of blood extravasation with MRI. *J Comput Assist Tomogr*. 1999 Jul;23 (4):521–3.

[40] Wiesmann M, Mayer TE, Yousry I, Medele R, Hamann GF, Brückmann H. Detection of hyperacute subarachnoid hemorrhage of the brain by using magnetic resonance imaging. *J Neurosurg. Journal of Neurosurgery Publishing Group*; 2002 Apr;96 (4):684–9.

[41] Mitchell P, Wilkinson ID, Hoggard N, Paley MN, Jellinek DA, Powell T, et al. Detection of subarachnoid haemorrhage with magnetic resonance imaging. *J Neurol Neurosurg Psychiatr*. BMJ Group; 2001 Feb;70 (2):205–11.

[42] Rogg JM, Smeaton S, Doberstein C, Goldstein JH, Tung GA, Haas RA. Assessment of the value of MR imaging for examining patients with angiographically negative subarachnoid hemorrhage. AJR American journal of roentgenology. *American Public Health Association*; 1999 Jan;172 (1):201–6.

[43] Juvela S. Rebleeding from ruptured intracranial aneurysms. *Surgical Neurology*. 1989 Nov;32 (5):323–6.

[44] Hijdra A, Vermeulen M, van Gijn J, van Crevel H. Rerupture of intracranial aneurysms: a clinicoanatomic study. *J Neurosurg*. 1987 Jul;67 (1):29–33.

[45] Ohkuma H, Tsurutani H, Suzuki S. Incidence and significance of early aneurysmal rebleeding before neurosurgical or neurological management. *Stroke*. 2001 May;32 (5):1176–80.

[46] Fujii Y, Takeuchi S, Sasaki O, Minakawa T, Koike T, Tanaka R. Ultra-early rebleeding in spontaneous subarachnoid hemorrhage. *J Neurosurg. Journal of Neurosurgery Publishing Group*; 1996 Jan;84 (1):35–42.

[47] Inagawa T, Kamiya K, Ogasawara H, Yano T. Rebleeding of ruptured intracranial aneurysms in the acute stage. *Surgical Neurology*. 1987 Aug;28 (2):93–9.

[48] Tanno Y, Homma M, Oinuma M, Kodama N, Ymamoto T. Rebleeding from ruptured intracranial aneurysms in North Eastern Province of Japan. A cooperative study. *J Neurol Sci*. Elsevier; 2007 Jul 15;258 (1-2):11–6.

[49] Jane JA, Kassell NF, Torner JC, Winn HR. The natural history of aneurysms and arteriovenous malformations. *J Neurosurg. Journal of Neurosurgery Publishing Group*; 1985 Mar;62 (3):321–3.

[50] Naidech AM, Janjua N, Kreiter KT, Ostapkovich ND, Fitzsimmons B-F, Parra A, et al. Predictors and impact of aneurysm rebleeding after subarachnoid hemorrhage. *Arch Neurol. American Medical Association;* 2005 Mar;62 (3):410–6.

[51] Boogaarts HD, van Lieshout JH, van Amerongen MJ, de Vries J, Verbeek ALM, Grotenhuis JA, et al. Aneurysm diameter as a risk factor for pretreatment rebleeding: a meta-analysis. *J Neurosurg*. 2015 Apr;122 (4):921–8.

[52] Guo L-M, Zhou H-Y, Xu J-W, Wang Y, Qiu Y-M, Jiang J-Y. Risk Factors Related to Aneurysmal Rebleeding. *World Neurosurgery*. 2011 Sep;76 (3-4):292–8.

[53] Kassell NF, Torner JC, Haley EC, Jane JA, Adams HP, Kongable GL. The International Cooperative Study on the Timing of Aneurysm Surgery. Part 1: Overall management results. *J Neurosurg. Journal of Neurosurgery Publishing Group;* 1990 Jul;73 (1):18–36.

[54] Diringer MN, Bleck TP, Claude Hemphill J, Menon D, Shutter L, Vespa P, et al. Critical Care Management of Patients Following Aneurysmal Subarachnoid Hemorrhage: Recommendations from the Neurocritical Care Society's Multidisciplinary Consensus Conference. *Neurocrit Care.* 2011 Jul 20;15 (2):211–40.

[55] Roos Y. Antifibrinolytic treatment in subarachnoid hemorrhage: a randomized placebo-controlled trial. STAR Study Group. *Neurology*. 2000 Jan 11;54 (1):77–82.

[56] Kassell NF, Torner JC, Adams HP. Antifibrinolytic therapy in the acute period following aneurysmal subarachnoid hemorrhage. Preliminary observations from the Cooperative Aneurysm Study. *J Neurosurg. Journal of Neurosurgery Publishing Group*; 1984 Aug;61 (2):225–30.

[57] Vermeulen M, Lindsay KW, Murray GD, Cheah F, Hijdra A, Muizelaar JP, et al. Antifibrinolytic treatment in subarachnoid hemorrhage. *N Engl J Med*. 1984 Aug 16;311 (7):432–7.

[58] Roos Y, Rinkel G, Vermeulen M, Algra A, van Gijn J. Antifibrinolytic therapy for aneurysmal subarachnoid hemorrhage: a major update of a cochrane review. *Stroke*. Lippincott Williams & Wilkins; 2003 Sep;34 (9):2308–9.

[59] Hillman J, Fridriksson S, Nilsson O, Yu Z, Saveland H, Jakobsson K-E. Immediate administration of tranexamic acid and reduced incidence of early rebleeding after aneurysmal subarachnoid hemorrhage: a prospective randomized study. *J Neurosurg. Journal of Neurosurgery Publishing Group;* 2002 Oct;97 (4):771–8.

[60] Connolly ES, Rabinstein AA, Carhuapoma JR, Derdeyn CP, Dion J, Higashida RT, et al. Guidelines for the Management of Aneurysmal Subarachnoid Hemorrhage: A Guideline for Healthcare Professionals From the American Heart Association/American Stroke Association. *Stroke*. 2012 May 25;43 (6):1711–37.

[61] Zaidi HA, Montoure A, Elhadi A, Nakaji P, McDougall CG, Albuquerque FC, et al. Long-term Functional Outcomes and Predictors of Shunt-Dependent Hydrocephalus After Treatment of Ruptured Intracranial Aneurysms in the BRAT Trial. *Neurosurgery*. 2015 May;76 (5):608–15.

[62] Shah AH, Komotar RJ. Pathophysiology of Acute Hydrocephalus After Subarachnoid Hemorrhage. *WNEU*. Elsevier Inc; 2015 Aug 22;80 (3-4):304–6.

[63] Suarez-Rivera O. Acute hydrocephalus after subarachnoid hemorrhage. *Surgical Neurology*. 1998 May;49 (5):563–5.

[64] Giraldo EA, Mandrekar JN, Rubin MN, Dupont SA, Zhang Y, Lanzino G, et al. Timing of clinical grade assessment and poor outcome in patients with aneurysmal subarachnoid hemorrhage. *J Neurosurg. American Association of Neurological Surgeons*; 2012 Jul;117 (1):15–9.

[65] Karamanakos PN, Und Zu Fraunberg von M, Bendel S, Huttunen T, Kurki M, Hernesniemi J, et al. Risk factors for three phases of 12-month mortality in 1657 patients from a defined population after acute aneurysmal subarachnoid hemorrhage. *WNEU*. Elsevier; 2012 Dec;78 (6):631–9.

[66] Hasan D, Tanghe HL. Distribution of cisternal blood in patients with acute hydrocephalus after subarachnoid hemorrhage. *Ann Neurol*. Wiley Subscription Services, Inc., A Wiley Company; 1992 Apr;31 (4):374–8.

[67] KIBLER RF, COUCH RS, CROMPTON MR. Hydrocephalus in the adult following spontaneous subarachnoid haemorrhage. *Brain*. 1961 Mar;84:45–61.

[68] Brydon HL, Bayston R, Hayward R, Harkness W. The effect of protein and blood cells on the flow-pressure characteristics of shunts. *Neurosurgery*. 1996 Mar;38 (3):498–504–discussion505.

[69] Blasberg R, Johnson D, Fenstermacher J. Absorption resistance of cerebrospinal fluid after subarachnoid hemorrhage in the monkey; effects of heparin. *Neurosurgery*. 1981 Dec;9 (6):686–91.

[70] Vermeij FH, Hasan D, Vermeulen M, Tanghe HL, van Gijn J. Predictive factors for deterioration from hydrocephalus after subarachnoid hemorrhage. *Neurology*. 1994 Oct;44 (10):1851–5.

[71] Kosteljanetz M. Cerebrospinal fluid production in subarachnoid haemorrhage. *Br J Neurosurg*. 1988;2 (2):161–7.

[72] Black PM, Tzouras A, Foley L. Cerebrospinal fluid dynamics and hydrocephalus after experimental subarachnoid hemorrhage. *Neurosurgery*. 1985 Jul;17 (1):57–62.

[73] Kanat A, Turkmenoglu O, Aydin MD, Yolas C, Aydin N, Gursan N, et al. Toward Changing of the Pathophysiologic Basis of Acute Hydrocephalus After Subarachnoid Hemorrhage: A Preliminary Experimental Study. *WNEU*. Elsevier Inc; 2015 Aug 22;80 (3-4):390–5.

[74] Niemela M, Marbacher S. Acute Hydrocephalus After Subarachnoid Hemorrhage—Can It Be Caused by Water Vesicles of Choroid Plexuses? *WNEU*. Elsevier Inc; 2015 Aug 22;80 (3-4):307–8.

[75] Graff-Radford NR, Torner J, Adams HP, Kassell NF. Factors associated with hydrocephalus after subarachnoid hemorrhage. A report of the Cooperative Aneurysm Study. *Arch Neurol*. 1989 Jul;46 (7):744–52.

[76] Mohr G, Ferguson G, Khan M, Malloy D, Watts R, Benoit B, et al. Intraventricular hemorrhage from ruptured aneurysm. Retrospective analysis of 91 cases. *J Neurosurg. Journal of Neurosurgery Publishing Group*; 1983 Apr;58 (4):482–7.

[77] Ransom ER, Mocco J, Komotar RJ, Sahni D, Chang J, Hahn DK, et al. External ventricular drainage response in poor grade aneurysmal subarachnoid hemorrhage: effect on preoperative grading and prognosis. *Neurocrit Care*. 2007;6 (3):174–80.

[78] Rajshekhar V, Harbaugh RE. Results of routine ventriculostomy with external ventricular drainage for acute hydrocephalus following subarachnoid haemorrhage. *Acta neurochirurgica*. 1992;115 (1-2):8–14.

[79] Hasan D, Vermeulen M, Wijdicks EF, Hijdra A, van Gijn J. Management problems in acute hydrocephalus after subarachnoid hemorrhage. *Stroke*. 1989 Jun;20 (6):747–53.

[80] van Donkelaar CE, Bakker NA, Veeger NJGM, Uyttenboogaart M, Metzemaekers JDM, Luijckx G-J, et al. Predictive Factors for Rebleeding After Aneurysmal Subarachnoid Hemorrhage: Rebleeding Aneurysmal Subarachnoid Hemorrhage Study. *Stroke*. Lippincott Williams & Wilkins; 2015 Aug;46 (8):2100–6.

[81] Paré L, Delfino R, Leblanc R. The relationship of ventricular drainage to aneurysmal rebleeding. *J Neurosurg. Journal of Neurosurgery Publishing Group;* 1992 Mar;76 (3):422–7.

[82] McIver JI, Friedman JA, Wijdicks EFM, Piepgras DG, Pichelmann MA, Toussaint LG, et al. Preoperative ventriculostomy and rebleeding after aneurysmal subarachnoid hemorrhage. *J Neurosurg. Journal of Neurosurgery Publishing Group;* 2002 Nov;97 (5):1042–4.

[83] Hellingman CA, van den Bergh WM, Beijer IS, van Dijk GW, Algra A, van Gijn J, et al. Risk of rebleeding after treatment of acute hydrocephalus in patients with aneurysmal subarachnoid hemorrhage. *Stroke*. Lippincott Williams & Wilkins; 2007 Jan;38 (1):96–9.

In: Encyclopedia of Surgery (22 Volume Set)
Editors: Andreas Lehrer and Kristin Mueller
ISBN: 978-1-53618-329-0
© 2020 Nova Science Publishers, Inc.

Chapter 68

ENDOVASCULAR TREATMENT OF ANEURYSMS. PRE-, PERI- AND POST-INTERVENTIONAL MANAGEMENT

G. Friedrich Götz
Medical School Hanover, Hanvover, Germany

ABSTRACT

Endovascular treatment is a minimally invasive procedure for occluding cerebral aneurysms. The number of aneurysms undergoing endovascular treatment in different hospitals and countries is astonishingly varied. The ISAT study has demonstrated that interventional treatment offers an advantage over surgical treatment in the management of ruptured intracranial cerebral aneurysms. In the treatment of unruptured intracranial aneurysms, surgical and endovascular procedures are equally effective, but in incidental middle cerebral artery bifurcation aneurysms clipping is superior. Continuing advances in interventional tools has resulted not only in a reduction of the complication rate, but also an expansion of the therapeutic spectrum to include complex aneurysms.

Keywords: subarachnoid haemorrhage (SAH), coils, balloon remodelling, intracranial stent, stent-assisted coiling, flow diverter, antiplatelet treatment, MR angiography, follow-up, ISAT, barrow institute study

Endovascular treatment is a minimally invasive procedure for occluding cerebral aneurysms, which can be space-occupying, symptomatic or incidental. This interventional procedure is the treatment of choice for aneurysms which in neurosurgical terms are difficult to reach – especially those at the basilar tip. The prospective, randomised ISAT study [1] has demonstrated that interventional treatment offers an advantage over surgical treatment in the management of ruptured intracranial aneurysms. Endovascular treatment leads more rarely to a slight drop in the post-therapeutic GCS and to post-therapeutic epilepsy [2]. In the treatment of unruptured intracranial aneurysms, surgical and endovascular procedures are equally effective, but in incidental MCA (middle cerebral artery) bifurcation aneurysms clipping is

superior [3, 4]. The number of aneurysms undergoing endovascular treatment in different hospitals and countries is astonishingly varied, however. Continuing advances in interventional tools has resulted not only in a reduction of the complication rate, but also an expansion of the therapeutic spectrum to include complex aneurysms. Endovascular treatment comprises a variety of different therapeutic approaches such as coil embolisation of the aneurysmal sac or other method of embolisation, flow modulation in the parent artery, as well as implantation of devices for bridging the aneurysm neck. Therapy can be customised by using varied combinations of these technical aids. Thanks to special interventional tools, continuing miniaturisation and optimised biocompatibility, and increasing experience worldwide, the number of aneurysms that cannot be treated interventionally has been minimised.

Proximal vessel occlusion and diversion of the blood flow in aneurysms of the intracranial vertebral artery and the cavernous internal carotid artery today represent an established, yet seldom employed therapeutic concept. The procedure can induce thrombosis of the aneurysm, and prevent both an increase in size and rupture. Interventional vascular occlusion with balloons, coils or, more effectively, so-called vascular plaques, is superior to surgical vessel ligation, since during angiography collateral cerebral perfusion can be evaluated.

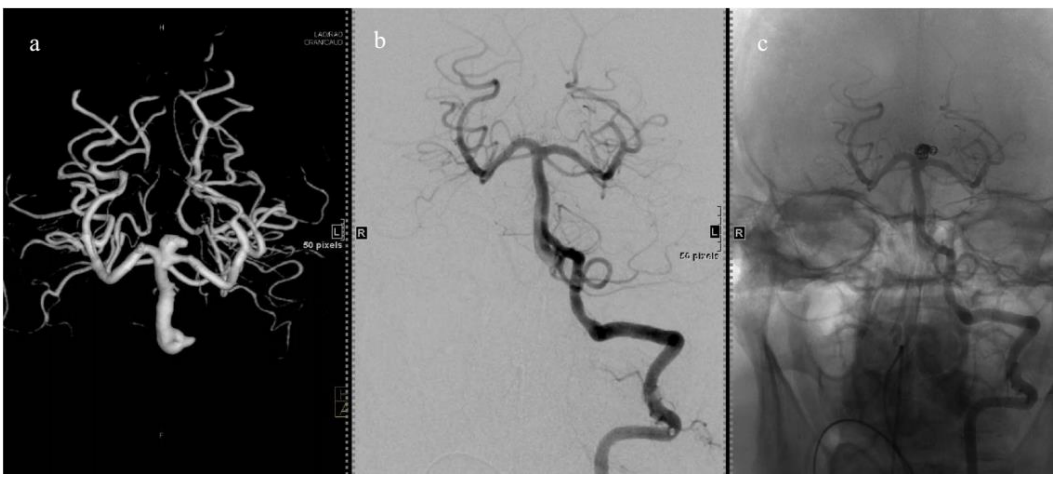

Figure 1. Endovascular treatment with coils: . 58 male with Subarachnoid Haemorrhage Hunt & Hess grade 2. a) 3D digital subtraction angiography, b + c) subtracted and unsubtracted frontal projection after embolisation with two coils.

Conventional endovascular treatment entails filling the lumen with coils to occlude the aneurysm. Berry-shaped aneurysms with a narrow neck (smaller than 4 mm) and favourable dome-to-neck ratio (larger than 1.4 mm), respectively, can be treated with coils only and without having to permanently modulate the coagulation. After carefully probing the aneurysm with a microcatheter the three-dimensional expanding coils are inserted in decreasing order of diameter. Small and short coils can be used to ensure that they fit snugly against the parent vessel. The aim is to pack the aneurysm as densely as possible with coils, reduce perfusion of the aneurysm to zero and thus induce thrombosis and subsequent fibrosis. The rate of complications from coil embolisation is less than 10%; this includes

thromboembolic and haemorrhagic complications at less than 5% and 2%, respectively. The permanent occlusion of an aneurysm depends not only on the density with which the implanted coils are packed (up to 40 % of the aneurysm lumen are filled with coils), but also on the flow properties in the parent vessel and stability of the wall. The occlusion rate is stratified in accordance with the Raymond classification into complete (class 1), residual perfusion of the aneurysm neck (class 2, equivalent to 90%-95%) and incomplete (class 3, marked remnant/reperfusion >90%) [5] (Figure 1).

The technique in use the longest for improving the treatment options for wide-necked intracranial aneurysms is remodelling [6]. It involves brief inflation of a balloon in the parent artery so as to stabilise the coils in the aneurysm. To use a balloon catheter and microcatheter simultaneously, a wide-bore or second distal access and/or guide catheter is required. Prior to balloon insufflation, a bolus dose of heparin is usually injected intravenously. This method, which requires considerable technical dexterity, permits dense packing of the coils and, as a result, safe and stable occlusion of broad-based aneurysms. Another advantage of this technique is that it provides protection for the efferent blood vessels in close proximity to the base of the aneurysm, especially at the MCA bifurcation, the A1/A2 junction, the posterior communicating artery and the basilar tip, and permits action to be taken immediately in response to a ruptured vessel (Figure 2).

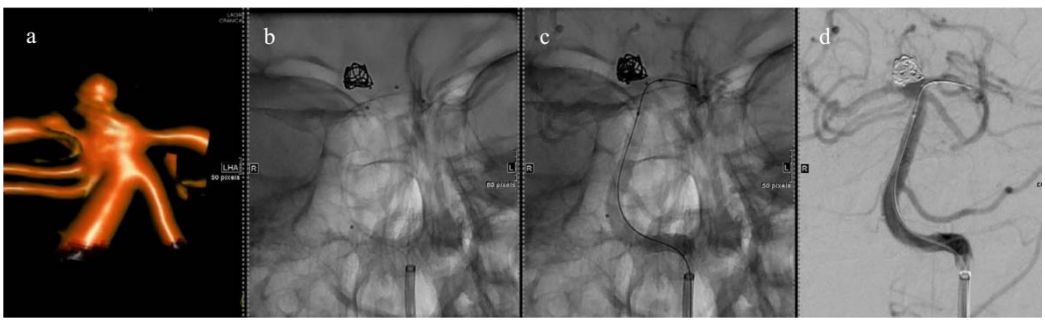

Figure 2. Balloon remodelling: 44 female with an aneurysm of the basilary tip and a history of Subarachnoid Haemorrhage Hunt & Hess Score 4 and of coil embolisation. Modified Rankin Scale 0. a) 3D DSA b) Working projection with balloon catheter (Eclipse 6 x 9, Balt®) at the aneurysm fundus (the markers indicate the length of the balloon) and microcatheter tip at the base of the aneurysm. c + d) unsubtracted and subtracted DSA. Embolisation of the basal reperfusion with a coil using balloon inflation for scaffolding.

Permanent implants in the parent artery generally necessitate modulation of coagulation over a prolonged period. This also applies to the latest generation of intracranial stents, the thrombogenicity of which is much lower than with older models. Hence, stent-protected coil embolisation as a treatment for ruptured aneurysms can only be recommended to a limited extent. Wherever possible, coils are used exclusively in the treatment of an acute aneurysm rupture.

The premedication used most commonly prior to permanent implantation of a device in the cerebral vasculature entails a daily dose of 100-300 mg aspirin and 75 mg clopidogrel for a minimum of five days, or a loading dose of 450 mg clopidogrel and 100 mg aspirin the evening beforehand. To monitor the regular intake and the efficacy of the medication, specific coagulation analysis is recommended immediately before the intervention. If the standard

medication does not satisfactorily modulate the coagulation, either an increased dose or alternative drug (e.g., ticagrelor) can be used.

The development of flexible intracranial stents, which are available in an open-cell or closed-cell design, and are interwoven or laser-cut, has expanded the endovascular possibilities for treating wide-necked, complex aneurysms. The stent mesh not only prevents the coils placed into the aneurysm from herniation into the parent artery, but also positively alters the flow properties at the neck of the aneurysm. This should help to reduce the number of aneurysms incompletely embolised at the base and, in turn, the frequency of recurrence. This theoretic advantage is certainly consistent with the results reported in numerous case studies, but has not yet been confirmed by a randomised prospective trial.

Elective stent-assisted coil embolisation necessitates modulation of the coagulation as described above. If emergency stent implantation is required to correct prolapsed coil loops or to treat peri-interventional vascular dissection, 500 mg of intravenous aspirin and an intravenously effective platelet aggregation inhibitor as a bolus and subsequent infusion should be administered during the procedure. Long-term medication should be initiated with a loading dose of clopidogrel (e.g., 450 mg via gastric tube) at the periprocedural stage.

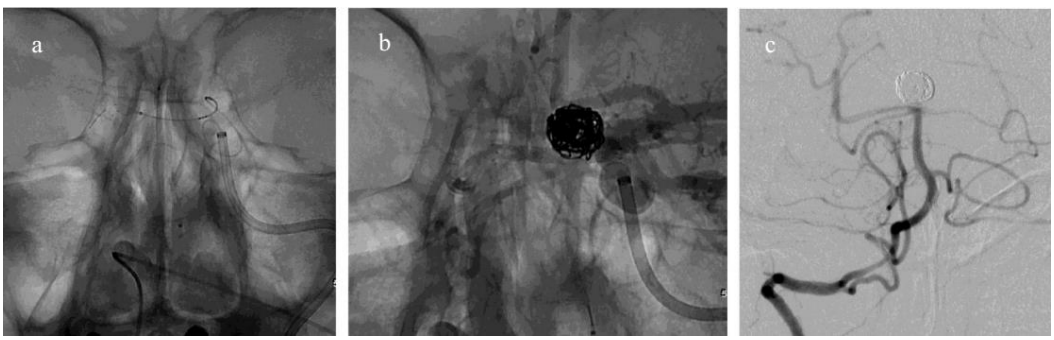

Figure 3. Stent assisted coiling: 66 male who presented with an incidental basilar tip aneurysm and vertebrobasilar arteriosclerotic stenosis. a) Stent implantation (LVIS junior 3.5 x 18 Microvention®) via the left posterior communicating artery into the right posterior cerebral artery b) Post coil embolization c) Treatment outcome after 6 months (subtracted DSA after right vertebral artery injection).

Coiling with stent assistance can be performed in one or two stages. To accurately deploy the stent, a stable access route is required – ideally consisting of a guide, distal coaxial and microcatheter. Using the jailing technique, the microcatheter placed in the aneurysm is fixed with the subsequently deployed stent and then carefully removed after coiling is complete. As with remodelling, this approach requires two microcatheters to be inserted simultaneously in the parent vessel. Alternatively, the stent can be implanted first and coiling performed six weeks later at the earliest. With this method, it is necessary to probe the aneurysm through the tines of the stent. This can be done even with small and flat aneurysms once the stent has stabilised. Sequential stent implantation and coiling during an intervention is less advisable, since probing the aneurysm can cause the stent to become misaligned if it has not yet stabilised (Figure 3).

Wide-necked aneurysms located in the carotid T, the MCA bifurcation or basilar tip have an unfavorable haemodynamic, the so called water hammer effect [7]. The recanalisation rate after coil embolisation, generally known to be high in these aneurysms, is induced by coil compaction and progressive aneurysmal growth. Reconstruction of the base of the aneurysm

and preservation of the efferent arteries pose a particular challenge. Special techniques and materials are required to treat such aneurysms.

The base of the aneurysm can be reconstructed by inserting two microstents to form an X or Y shape. The resulting haemodynamic effects vary depending on the design of the stent and implant geometry [7]. The stents can be implanted in two stages by probing the mesh once the first stent has stabilised, or in one procedure. Different technical variations for vascular reconstruction have been described [8]. The microcatheter for coil embolisation must either be navigated through the struts of the stent into the aneurysm, or be placed in the aneurysm using the jailing technique prior to deployment of the stent. Protection of the efferent arteries allows dense coil packing, which is necessary for preventing recanalization (Figure 4).

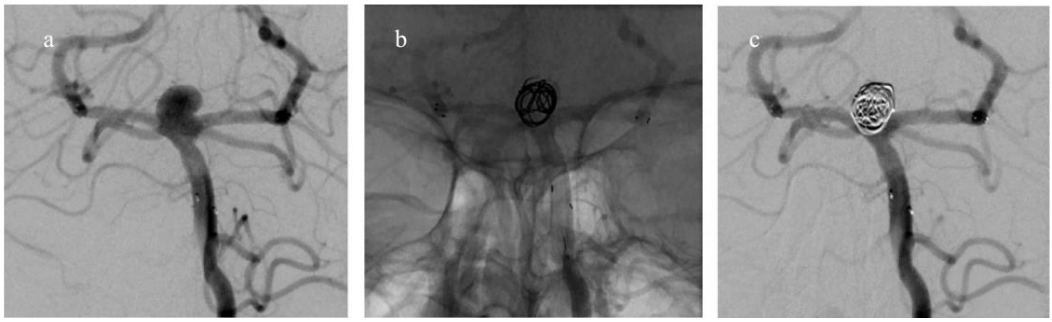

Figure 4. Y stenting: 46 female presenting with a wide-necked, incidental basilar tip aneurysm and a history of familial subarachnoid haemorrhage. a) frontal projection of an angiogram. Stent implantation firstly from the right, secondly on the left posterior cerebral artery to the basilar artery (Solitaire® 4 x 20), b) Unsubtracted DSA with Y- stenting in situ and the first coil inside the aneurysm. c) Subtracted DSA after embolisation with two coils.

Intra- and extra-aneurysmal placement of a stent and subsequent coil embolisation is referred to as the waffle-cone technique [9, 10]. The expandable end of the self-expanding microstent is designed for reconstructing and modelling the aneurysm fundus and stabilising the coil.

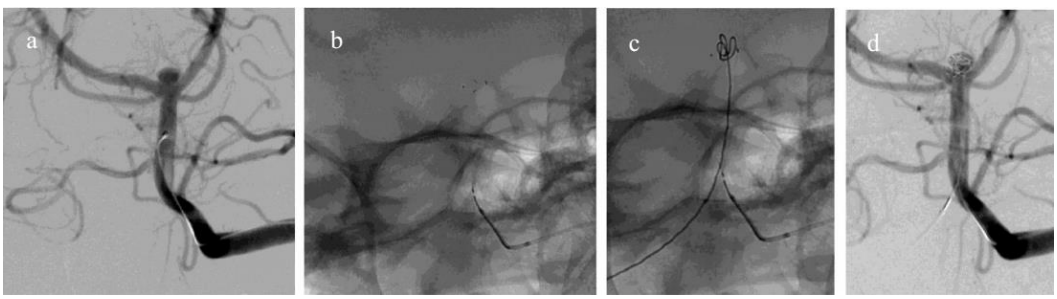

Figure 5. Waffle cone technique: 28 male with a wide-necked basilar tip aneurysm. Implantation of a pCONus (®) device and embolisation of the aneurysm with four coils. a) subtracted angiogram, working position. b) unsubtracted projection after expansion of the pCONus® 4-25-5 from the neck of the aneurysm to the basilar artery. c) unsubtracted projection with a second microcatheter placed inside the aneurysm d) subtracted angiogram after implantation of four coils, prior to detachment of pCONus.

A stent-like device with a distal portion that unfolds like a flower is suitable in particular for treating wide-necked bifurcation aneurysms [11, 12]. The distal end, which opens out into a disc shape, is used to secure the aneurysm fundus, whilst the proximal end ensures stabilisation in the parent artery. Stable anchorage facilitates probing of the aneurysm and coiling. Compared to X and Y stenting, the waffle-cone technique using the described device is easier to perform and is regularly done within one treatment procedure (Figure 5).

Flow diverters are flexible, self-expanding stent-like devices with a more dense wire mesh. They modulate the blood flow in the parent vessel, reduce inflow of blood into the aneurysm. Consequently they, or when Combined with loosely packed coils flow diverters promote occlusion of the aneurysm. The high mesh density of flow diverters results in low porosity of these implants. Porosity is a measure of permeability to liquid, and describes the ratio of the free surface not covered by struts to the total surface. A flow diverter is most effective if it is densely woven with as little material as possible. The goal is achieved technologically if the product offers low permeability combined with high flexibility and good wall apposition.

Compared to intracranial microstents, the denser wire mesh of flow diverters inevitably results in relatively high thrombogenicity. It is essential to adequately modulate the coagulation at the time of implantation. Following the intervention, treatment with aspirin and Plavix should continue for a minimum of 3-6 months. Since late thromboembolic complications have been reported [13, 14], consideration should be given to modulating the coagulation for an even longer period in individual cases.

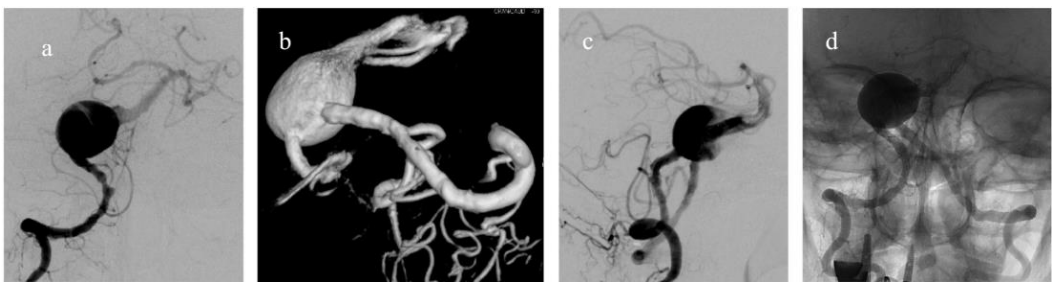

Figure 6. Arteriosclerotic fusiform vertebrobasilar aneurysm: 60 female with progressive brain stem symptoms. a) Angiogramm after injection of the right vertebral artery. b) 3D digital subtraction angiography. The terminal segments of both vertebral arteries and the basilar artery are incorporated in the aneurysm sac. c + d) Subtracted and unsubtracted DSA after implantation of a stent (Leo® 4.5 x 75) and a flow diverter (Silk® 5.5 x 50).

Flow diverters are suitible for the management of wide-necked and dysplastic aneurysms. They offer promise in the treatment of dissecting aneurysms and blood blister-like aneurysms that are extremely difficult to manage [15, 16]. Despite the initial euphoria, clinically viable therapeutic outcomes with fusiform aneurysms can only be expected if such treatment is strictly indicated. Large vertebrobasilar, fusiform aneurysms are a particular therapeutic challenge given the numerous efferent perforators, as well as the lack of mural stability and parietal thrombi. Vascular reconstruction with a stable, self-expanding stent and additional implantation of a flow diverter may be necessary in the treatment of extremely wide, fusiform aneurysms. Although causal therapy would appear to be possible with such a device, peri-

interventional mortality is significant and good long-term outcome has been achieved rarely (Figure 6).

A hazardous scenario arises if an aneurysm ruptures after implantation of a flow diverter [17]. This can possibly be caused by a small amount of blood continuing to flow into the aneurysm but the outflow being blocked, thus increasing the intra-aneurysmal pressure. This potential complication can probably be ameliorated by partially coiling the aneurysm. The rational use of flow diverters is hindered by the fact that the pathophysiological effects are not fully understood, combined with a lack of randomised studies [14, 18] as opposed to numerous case studies and small retrospective series.

A cork-like implant made of interwoven nitinol fibres that unfolds inside the aneurysm is also suitable for treating wide-necked aneurysms. The wire, ball-like device is selected in a suitable size based on the maximum transverse diameter of the aneurysm. It can be modelled to fit the wall to the parent artery perfectly prior to electrolytic detachment. Perfusion of the aneurysm often ceases immediately after the implant has unfolded. An advantage with this technique is the possibility to use it in the event of acute rupture of an aneurysm, since modulation of the coagulation is not essential [19, 20] (Figure 7).

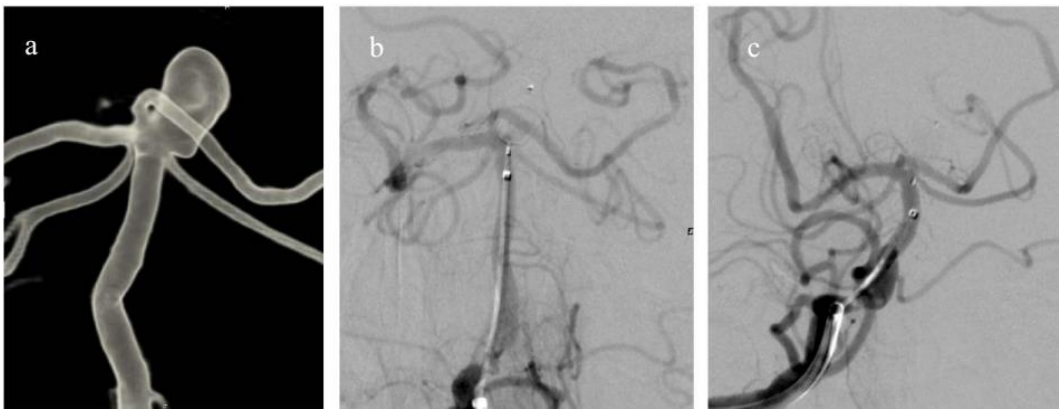

Figure 7. WEB® (woven endobridge): in superior cerebellar aneurysms. 59 female, history of sentinel bleeding and a wide-necked basilar artery aneurysm between the origin of the superior cerebellar and posterior cerebral arteries on the left. a) 3D digital subtraction angiography. b) DSA after implantation of a WEB® SL 2-8-S device. Immediate cessation of aneurysm perfusion. c) Angiogram after electrolytic detachment of the device and complete occlusion of the aneurysm.

POST-INTERVENTIONAL MEASURES

If coiling has been completed successfully without complications, post-interventional pharmacological modulation of the coagulation is not necessary. If individual tines prolapse into the carrier vessel, intravenous or subcutaneous heparin can be prescribed for five days; aspirin is likely to be equally effective.

Aspirin (100-300 mg) and clopidogrel (75 mg) are essential for modulating the coagulation when implanting stents and flow diverters. When prescribing dual antiplatelet therapy, additional gastric protection is usually recommended. After implanting intracranial

stents, drug therapy is switched no sooner than eight weeks later to long-term aspirin and is continued for a minimum of one year.

Dual antiplatelet therapy should last longer if a flow diverter has been implanted. Reports of late thromboembolic complications [12, 13] call the six-month limitation of intensive anticoagulation into doubt. It is therefore advisable to consider the benefits and risks in each individual case. Most authors recommend lifelong continuation of aspirin after dual antiplatelet therapy once a flow diverter has been implanted. The thrombogenicity of the implants can be expected to decrease in future thanks to improved surface technology.

MRI is used preferentially in the follow-up of aneurysms after coil embolisation [19-23]. High-resolution, thin-section 3D TOF sequences are used by most practitioners. Analysis must not be restricted to MIP reformations, but must account for the individual axial images.

The coil-filled aneurysm is displayed on 3D TOF MRA as a compact, attenuated signal. The contrast to the flow signal in the adjacent artery is high. Segments of the aneurysm that are still perfused and not excluded from the circulation exhibit a bright signal and can be identified precisely from the 3D TOF images. Visual assessment of the treatment outcome is most reliable if it is done by two examiners using a three-part scale [24] (Figure 8).

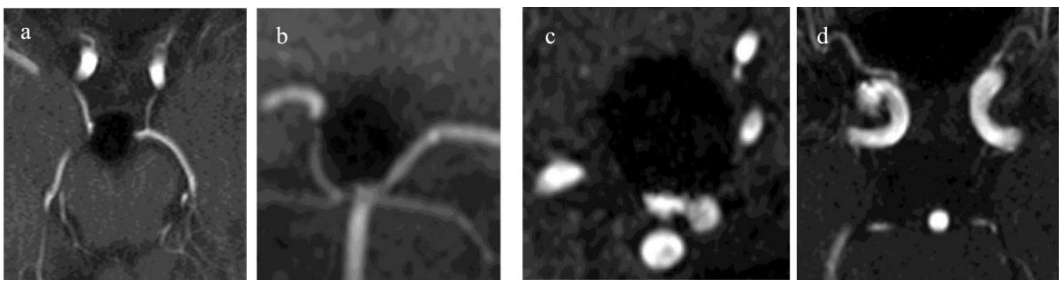

Figure 8. MRA after endovascular treatment: (a+b) 3D TOF MRA (3 Tesla) thick-slice MIP reformations complete exclusion with a homogenous signal void inside a basilar tip aneurysm post coiling. c + d) 3D TOF MRA (3 Tesla). Axial source images of a 72 male show an area of recurrence at the neck of an opthalmic ACI aneurysm on the right.

Contrast-enhanced head and neck angiography is less often used for post-interventional assessment of aneurysms. In the current literature, 3D TOF MR angiography is reported to offer greater sensitivity with rather than without contrast enhancement [21, 23]. The use of a contrast agent does not ensure that a distinction can be made between flow and a contrast-enhanced thrombus, however. In the authors' opinion the minimal gain in sensitivity is therefore accompanied by a decrease in specificity. Infectious complications or an inflammation of the aneurysm wall are absolute indications for the application of contrast agents.

Although all intracranial stents and flow diverters are MR-compatible, image distortion of varying degrees does occur with the individual implants. The implants of a number of manufacturers cause a large void in the signal [21] and hamper the assessment of the carrier vessel and aneurysm region. Others permit identification of the parent vessel, but might mistake the artefact of the device for stenosis. Artifacts also depend on the field strength of the used MRI system and can be so misleading that conventional DSA will be required in order to elucidate the situation. Despite the high material density, unexpectedly small artifacts occur with intrasaccular flow disrupters on MRI, meaning that in principle non-invasive

follow-up is possible. For the woven endobridge intra-arterial catheter angiography is recommended three months after implantation, since early reperfusion of aneurysms was not detected by MRI in all cases [20].

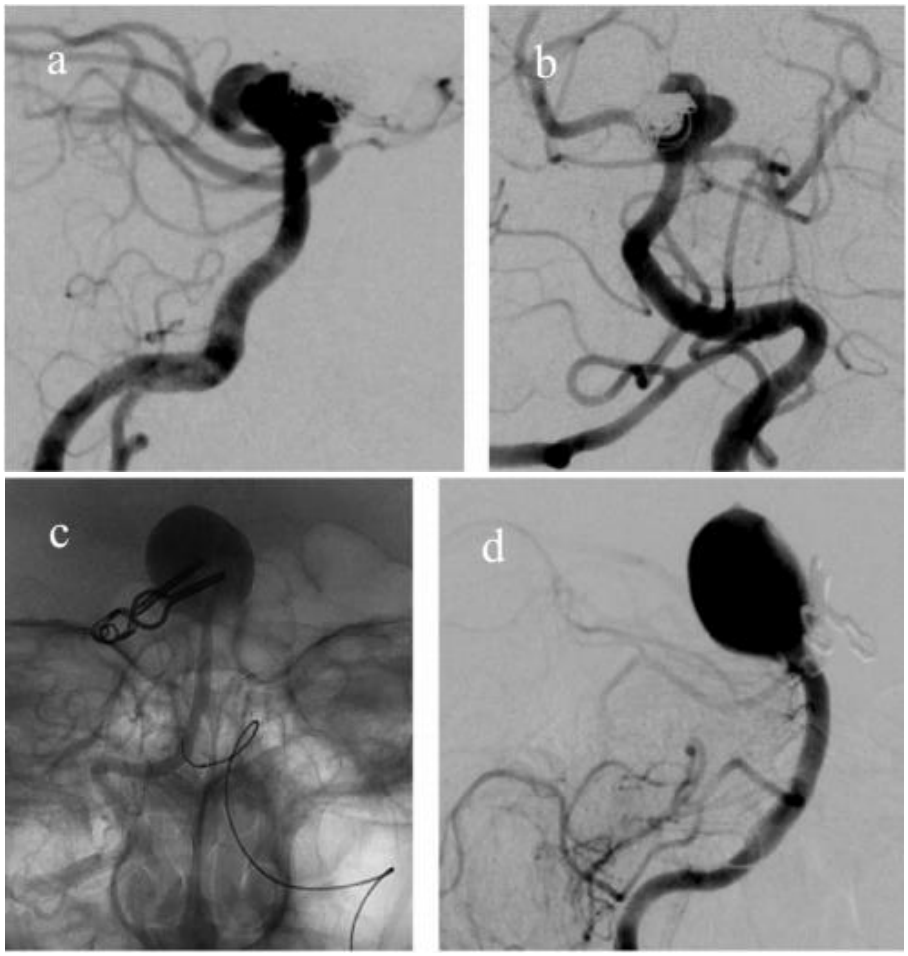

Figure 9. Recurrence after therapy: a+ b) 49 female with a history of SAH I and embolisation of a basilar tip aneurysm with coils . Recurrent SAH and regrowth of the aneurysm 9 years later. Digital subtraction angiography with frontal and lateral projection c + d) 52 male presents with headaches and aneurysm recurrence. History of SAH and clipping in 1992 for basilar tip aneurysm, no follow-up since.; Unsubtracted and subtracted DSA, frontal and lateral views, prior to stent assisted coiling.

The modified Raymond classification is often also applied in the evaluation of the treatment outcome after using other devices than coils. It can take up to six months to completely occlude a wide-necked aneurysm with a flow diverter. Therefore, the last angiogram taken on the day of the procedure to assess the therapeutic outcome will not be conclusive, since a further reduction as well as an increase in the perfusion of the aneurysm can result [15]. MRA usually is scheduled at 6-12 months after endovascular aneurysm treatment. The timing should be scheduled individually, however, depending on the course of the intervention and the implants used. If MRA follow-up reveals a change over the final angiogram taken at intervention, it is advisable to perform intraarterial DSA for confirmation

and to weigh up therapeutic consequences. In all cases in which stable occlusion of the aneurysm is achieved, cerebral catheter angiography is not necessary. Depending on the type of materials implanted, MRA may not be sufficient to reliably evaluate the therapeutic outcome.

The recanalisation rate after endovascular coiling is reported at up to 40% and is much higher than after clipping [2-4, 25, 26]. Remarkably, this treatment outcome evidently correlates only vaguely with the number of recurrent bleeds [26, 27]. Complete occlusion of an aneurysm with coils might be not necessary for cure and continuing protection against rebleeding. The decision whether reintervention for incompletely occluded aneurysms is indicated should be made on a personalized basis. As long as valid data on the long-term outcome of endovascular aneurysm treatment remain sparse [26, 27], follow-up examinations are still mandatory. Recommendations for follow-up also account for the occurrence of de novo aneurysms, which are reported at a rate of up to 1% per year.

Recurrence can occur after both endovascular and surgical treatment due to aneurysmal growth associated with arteriopathy (Figure 9). Recanalisation and recurrent SAH following endovascular treatment are observed more often in smokers than in non-smokers.

REFERENCES

[1] Molyneux A, Kerr R, International Subarachnoid Aneurysm Trial Collaborative G, Stratton I, Sandercock P, Clarke M, et al. International Subarachnoid Aneurysm Trial (ISAT) of neurosurgical clipping versus endovascular coiling in 2143 patients with ruptured intracranial aneurysms: a randomized trial. *Journal of stroke and cerebrovascular diseases: the official journal of National Stroke Association*. 2002 Nov-Dec;11 (6):304-14. PubMed PMID: 17903891.

[2] Ayling OG, Ibrahim GM, Drake B, Torner JC, Macdonald RL. Operative complications and differences in outcome after clipping and coiling of ruptured intracranial aneurysms. *Journal of neurosurgery*. 2015 Sep;123 (3):621-8. PubMed PMID: 26047409.

[3] Ruan C, Long H, Sun H, He M, Yang K, Zhang H, et al. Endovascular coiling vs. surgical clipping for unruptured intracranial aneurysm: A meta-analysis. *British journal of neurosurgery*. 2015 Aug;29 (4):485-92. PubMed PMID: 26037936.

[4] Smith TR, Cote DJ, Dasenbrock HH, Hamade YJ, Zammar SG, El Tecle NE, et al. Comparison of the Efficacy and Safety of Endovascular Coiling Versus Microsurgical Clipping for Unruptured Middle Cerebral Artery Aneurysms: A Systematic Review and Meta-Analysis. *World neurosurgery*. 2015 Oct;84 (4):942-53. PubMed PMID: 26093360.

[5] Raymond J, Guilbert F, Weill A, Georganos SA, Juravsky L, Lambert A, et al. Long-term angiographic recurrences after selective endovascular treatment of aneurysms with detachable coils. *Stroke; a journal of cerebral circulation.* 2003 Jun;34 (6):1398-403. PubMed PMID: 12775880.

[6] Pierot L, Cognard C, Spelle L, Moret J. Safety and efficacy of balloon remodeling technique during endovascular treatment of intracranial aneurysms: critical review of

the literature. *AJNR American journal of neuroradiology*. 2012 Jan;33 (1):12-5. PubMed PMID: 21349960.

[7] Kono K, Terada T. Hemodynamics of 8 different configurations of stenting for bifurcation aneurysms. *AJNR American journal of neuroradiology*. 2013 Oct;34 (10):1980-6. PubMed PMID: 23578668.

[8] Brassel F, Melber K, Schlunz-Hendann M, Meila D. Kissing-Y stenting for endovascular treatment of complex wide necked bifurcation aneurysms using Acandis Acclino stents: results and literature review. *Journal of neurointerventional surgery*. 2015 May 18. PubMed PMID: 25987589.

[9] Horowitz M, Levy E, Sauvageau E, Genevro J, Guterman LR, Hanel R, et al. Intra/extra-aneurysmal stent placement for management of complex and wide-necked-bifurcation aneurysms: eight cases using the waffle cone technique. *Neurosurgery*. 2006 Apr;58 (4 Suppl 2):ONS-258-62; discussion ONS-62. PubMed PMID: 16582648.

[10] Lee SM, Kim YJ, Ho Ko J. The effectiveness of the waffle-cone technique in treating complex intracranial aneurysms. *Interventional neuroradiology: journal of peritherapeutic neuroradiology, surgical procedures and related neurosciences*. 2015 Aug;21 (4):470-8. PubMed PMID: 26092438.

[11] Gory B, Aguilar-Perez M, Pomero E, Turjman F, Weber W, Fischer S, et al. pCONus Device for the Endovascular Treatment of Wide-Neck Middle Cerebral Artery Aneurysms. *AJNR American journal of neuroradiology*. 2015 Sep;36 (9):1735-40. PubMed PMID: 26206810.

[12] Henkes H, Weber W. The Past, Present and Future of Endovascular Aneurysm Treatment. *Clinical neuroradiology*. 2015 Oct;25 Suppl 2:317-24. PubMed PMID: 26031430.

[13] Rossen JD, Chalouhi N, Wassef SN, Thomas J, Abel TJ, Jabbour PM, et al. Incidence of cerebral ischemic events after discontinuation of clopidogrel in patients with intracranial aneurysms treated with stent-assisted techniques. *Journal of neurosurgery*. 2012 Nov;117 (5):929-33. PubMed PMID: 22957528.

[14] Shankar JJ, Tampieri D, Iancu D, Cortes M, Agid R, Krings T, et al. SILK flow diverter for complex intracranial aneurysms: a Canadian registry. *Journal of neuro-interventional surgery*. 2015 May 18. PubMed PMID: 25987591.

[15] Mpotsaris A, Skalej M, Beuing O, Eckert B, Behme D, Weber W. Long-term occlusion results with SILK flow diversion in 28 aneurysms: Do recanalizations occur during follow-up? *Interventional neuroradiology: journal of peritherapeutic neuroradiology, surgical procedures and related neurosciences*. 2015 Jun;21 (3):300-10. PubMed PMID: 26015522.

[16] Nossek E, Chalif DJ, Chakraborty S, Lombardo K, Black KS, Setton A. Concurrent use of the Pipeline Embolization Device and coils for intracranial aneurysms: technique, safety, and efficacy. *Journal of neurosurgery*. 2015 Apr;122 (4):904-11. PubMed PMID: 25658781.

[17] Turowski B, Macht S, Kulcsar Z, Hanggi D, Stummer W. Early fatal hemorrhage after endovascular cerebral aneurysm treatment with a flow diverter (SILK-Stent): do we need to rethink our concepts? *Neuroradiology*. 2011 Jan;53 (1):37-41. PubMed PMID: 20339842.

[18] Wakhloo AK, Lylyk P, de Vries J, Taschner C, Lundquist J, Biondi A, et al. Surpass flow diverter in the treatment of intracranial aneurysms: a prospective multicenter

study. *AJNR American journal of neuroradiology.* 2015 Jan;36 (1):98-107. PubMed PMID: 25125666.

[19] Behme D, Berlis A, Weber W. Woven EndoBridge Intrasaccular Flow Disrupter for the Treatment of Ruptured and Unruptured Wide-Neck Cerebral Aneurysms: Report of 55 Cases. *AJNR American journal of neuroradiology*. 2015 Aug;36 (8):1501-6. PubMed PMID: 25953761.

[20] Mine B, Tancredi I, Aljishi A, Alghamdi F, Beltran M, Herchuelz M, et al. Follow-up of intracranial aneurysms treated by a WEB flow disrupter: a comparative study of DSA and contrast-enhanced MR angiography. *Journal of neurointerventional surgery*. 2015 May 21. PubMed PMID: 25999378.

[21] Attali J, Benaissa A, Soize S, Kadziolka K, Portefaix C, Pierot L. Follow-up of intracranial aneurysms treated by flow diverter: comparison of three-dimensional time-of-flight MR angiography (3D-TOF-MRA) and contrast-enhanced MR angiography (CE-MRA) sequences with digital subtraction angiography as the gold standard. *Journal of neurointerventional surgery*. 2014 Oct 28. PubMed PMID: 25352582.

[22] Lane A, Vivian P, Coulthard A. Magnetic resonance angiography or digital subtraction catheter angiography for follow-up of coiled aneurysms: do we need both? *Journal of medical imaging and radiation oncology*. 2015 Apr;59 (2):163-9. PubMed PMID: 25857748.

[23] Levent A, Yuce I, Eren S, Ozyigit O, Kantarci M. Contrast-Enhanced and Time-of-Flight MR Angiographic Assessment of Endovascular Coiled Intracranial Aneurysms at 1.5 T. *Interventional neuroradiology: journal of peritherapeutic neuroradiology, surgical procedures and related neurosciences.* 2014 Dec;20 (6):686-92. PubMed PMID: 25496678. Pubmed Central PMCID: 4295240.

[24] Ernst M, Yoo AJ, Kriston L, Schonfeld MH, Vettorazzi E, Fiehler J. Is visual evaluation of aneurysm coiling a reliable study end point? Systematic review and meta-analysis. *Stroke; a journal of cerebral circulation*. 2015 Jun;46 (6):1574-81. PubMed PMID: 25944331.

[25] Mascitelli JR, Oermann EK, Mocco J, Fifi JT, Paramasivam S, Stapleton CJ, et al. Predictors of success following endovascular retreatment of intracranial aneurysms. *Interventional neuroradiology: journal of peritherapeutic neuroradiology, surgical procedures and related neurosciences.* 2015 Aug;21 (4):426-32. PubMed PMID: 26092439.

[26] Spetzler RF, McDougall CG, Zabramski JM, Albuquerque FC, Hills NK, Russin JJ, et al. The Barrow Ruptured Aneurysm Trial: 6-year results. *Journal of neurosurgery*. 2015 Sep;123 (3):609-17. PubMed PMID: 26115467.

[27] Molyneux AJ, Birks J, Clarke A, Sneade M, Kerr RS. The durability of endovascular coiling versus neurosurgical clipping of ruptured cerebral aneurysms: 18 year follow-up of the UK cohort of the International Subarachnoid Aneurysm Trial (ISAT). *Lancet.* 2015 Feb 21;385 (9969):691-7. PubMed PMID: 25465111. Pubmed Central PMCID: 4356153.

In: Encyclopedia of Surgery (22 Volume Set)
Editors: Andreas Lehrer and Kristin Mueller
ISBN: 978-1-53618-329-0
© 2020 Nova Science Publishers, Inc.

Chapter 69

ANEURYSMS: SURGICAL THERAPY

Ralph König
Department of Neurosurgery, University of Ulm,
Ludwig-Heilmeyer-Straße 2, Günzburg, Germany

ABSTRACT

The following chapter addresses several peculiarities with regard to surgery for ruptured intracranial aneurysms. Furthermore the chapter tries to give an insight in newer developments of neurovascular, especially aneurysm surgery: tailored approaches, retractorless neurosurgery, endoscopic and endoscope assisted aneurysm surgery. Furthermore it provides an overview of intraoperative imaging and electrophysiology in aneurysm surgery.

Keywords: aneurysm surgery, retractorless neurosurgery, tailored approaches, intraoperative angiography, intraoperative electrophysiology

INTRODUCTION

"Endovascular therapy has changed the practice of vascular neurosurgery forever" [1]. Albeit the subject of best treatment for ruptured aneurysms of the anterior circulation remains controversial [2-6] there is accumulating evidence that patients undergoing surgical clipping after acute subarachnoid hemorrhage (aSAH) demonstrate substantial postoperative decline of their clinical condition [7]. More precisely, Ayling [8], in a post hoc analysis of perioperative complications from the CONCIOUS-1 Study demonstrated a greater perioperative decline in GCS after clipping compared to coiling. Additionally patients clipped for ruptured aneurysms seem to have higher rates of delayed ischemic deficits (DCI) compared to those treated endovascularly [9, 10].

As a consequence of those data, particularly since the International Subarachnoid Hemorrhage Trial (ISAT) [11] the number of ruptured aneurysms treated endovascularly increased steadily. A paradigm shift in acute management of patients with ruptured

aneurysms occurred in many neurovascular centers around the world [12]. In spite of this general development one should not lose sight of the fact that the most appropriate treatment for an individual patient might be different in various treatment centers, as the level of endovascular or surgical experience varies. Furthermore in the presence of SAH endovascular procedures that require dual antiplatelet therapy (stent remodeling, flow diversion) should be avoided, as this has important ramifications for necessary subsequent surgical procedures (CSF-diversion, central venous lines, ICP measurement, tracheotomy).

Regardless of any further developments in endovascular therapy there will be ruptured aneurysms that require surgical treatment. Therefore aneurysm clipping will retain importance in the future. Also, more or less in obscurity and silent aneurysm surgery refined in the recent years:

- Application and adaption of tailored minimally invasive skull base approaches
- Retractorless surgery [13, 14]
- Endoscopic and endoscope-assisted techniques [15, 16]
- Intraoperative neuromonitoring [17, 18]
- Intraoperative imaging and visualization techniques [19] [20-22]

CLIPPING OF RUPTURED ANEURYSMS

Clipping of ruptured aneurysms is the other side of the same coin. Albeit the objective is the same, complete clipping of the aneurysm without a remnant and compromise of parent vessels, surgery for ruptured aneurysms has various specific characteristics compared to unruptured ones.

- First timing of treatment: Based on the results of the cooperative study the optimum time for definitive aneurysm treatment shifted from late (>7 days after aSAH) to early (<3 days after aSAH) (Kassell: 1990di; 23). Today, to further reduce the risk of recurrent haemorrhage from ruptured aneurysms a policy of urgent treatment within the first 24 hours after bleeding is pursued. But this might not be the end of the story as there seems to be some evidence for emergency treatment of ruptured aneurysms [24].
- Second, the “angry, red, swollen brain”: In the presence of SAH the brain is vulnerable and swollen, due to brain edema, acute hydrocephalus and potential intracerebral haemorrhage. The subarachnoid cisterns are filled up with clotted blood and anatomy might be distorted from space-occupying intracerebral hematoma. Therefore to gain space and to get access to the relevant pathology is hampered, particularly as premature intraoperative rupture threatens to complicate the procedure. Generous indication for CSF diversion, either by ventricular or lumbar drainage helps to relax the brain, as suction of CSF from the basal cisterns is made difficult by clotted blood. Further osmotic therapy administered by the anaesthetist may help to create a slack brain. Temporary mild hyperventilation may additionally help if the aforementioned measures fail [25].

- Third, temporary clipping: temporary clipping is used frequently especially during surgery for ruptured aneurysms. On the one hand it is used to deal with intraoperative rupture, which occurs between 7 and 35%, depending on various aneurysm and surgeon specific factors (Batjer: 1986wq; Fridriksson: 2002if; 26). On the other it is a helpful adjunct in the final dissection of the aneurysm dome and clip application, especially in larger aneurysms. Griessenauer, in the so far largest study about the effect of temporary clipping in ruptured aneurysms concluded, that limited temporary clipping did not affect clinical outcome in patients with aSAH [27]. Perfect interaction and communication between the between the anaesthesiological and surgical team helps to reduce potential harmful effects of temporary artery occlusion.
- Fourth, posthaemorrhagic hydrocephalus: surgery with or without opening of the lamina terminalis during the procedure does not have any positive effect on shunt dependency after aSAH, but on the contrary seem to result in an elevated risk for shunt dependency compared to endovascular therapy [28]. Apart from that aneurysm location, especially ruptured anterior cerebral artery ACA aneurysms, and the amount of blood are predictors for persistent posthaemorrhagic hydrocephalus.

MINIMALLY INVASIVE OR TAILORED APPROACHES TO ANEURYSMS

In public the term “minimal invasive surgery” unfortunately is connoted in particular with small skin incisions. This does not necessarily imply, that a minimal invasive procedure is minimal invasive in handling with crucial structures e.g., the brain. In this respect minimal invasive surgery may turn out to be rather invasive and harmful. Therefore the term keyhole approach (or tailored approach), as coined by Axel Perneczky [29] seems to be a more appropriate designation for the concept of moving away from standard approaches (“one size fits all”), but instead come down to small approaches, which take into account the individual anatomy and pathology of each case. e.g., a tailored approach for a ruptured ACM aneurysm with associated space occupying temporal intracerebral haemorrhage might not be a osteoplastic supraorbital craniotomy, but a decompressive craniectomy.

A crucial prerequisite for tailored approaches is excellent preoperative planning based on multimodal (e.g., MRI, CT, DSA) neuroradiological cross-sectional and 3D imaging. In order to realise multimodality planning for complex neurovascular procedures computerized planning is helpful. Meanwhile even coregistration of projectional DSA data with 3D datasets allows for 4-D planning, taking into account the fourth dimension: time (Smartbrush Angio, Brainlab AG, Feldkirchen). Based on 3-D imaging development of surgical simulation tools using virtual or physical models proceed [30]. Concerning to this especially 3D printing techniques appear as a promising tool in the future [31-33].

RETRACTORLESS SURGERY

By now the potentially harmful effects of static brain retraction have been well described and the underlying cellular and molecular mechanisms of injury were unveiled [34-37]. In their publication entitled “The quiet revolution: retractorless surgery for complex vascular

and skull base lesions", Spetzler and Sanai [13] described a technique to overcome fixed retraction by dynamic retraction with surgical instruments. Especially the sucker and suction hand play a critical role as a mobile, "roving retractor" [1]. The sucker complements the dissecting instrument providing e.g., countertraction while cutting arachnoid bands with microscissors. Along with an extensive arachnoidal dissection, careful patient positioning allowing for gravity retraction of the brain this technique allows for a limited retractor-induced tissue injury even in complex vascular and skull base lesions.

To put it in the right light: limited use of retractors, e.g., in the final stage of aneurysm clipping after careful dissection is not a problem. But use of fixed retraction should be reduced to the minimum.

INTRAOPERATIVE IMAGING AND VISUALIZATION

The idea of intraoperative angiography (IOA) goes back to almost 50 years now [38, 39]. The rationale is based on the studies of Drake [40], dealing with the "…late consequences of incomplete surgical treatment of cerebral aneurysms". The potential benefit is obvious: prompt and correctable detection of inadvertent aneurysm residuals and parent vessel or branch occlusion respectively.

In the so far largest contemporary study of IOA dealing with IOA performed during surgical treatment of 976 aneurysms Chalouhi et al. [19] described a clip revision rate of 8.2%. Reasons for clip readjustment were residual aneurysm in 54, 7%, parent vessel occlusion in 42.9% and a combination of both in 2.4% of cases.

Albeit the benefits of IOA seem to be clear the critique never silenced: besides safety concerns, accuracy, duration and costs appeared as main arguments against routine use of IOA in aneurysm surgery. Further the development of intraoperative microscope-based Indocyanine Green Angiography (ICG) seemed to make IOA superfluous.

- Safety concerns: Complications, especially permanent stroke rate due to IOA reported in the literature exceed by far that of routine cerebral angiography [41]. The prevailing mechanism thereby is vessel injury (dissection) on catheter access caused by distorted vessel anatomy due to patient positioning and thromboembolic events [42-44]. However, most of those publications date back 20 years. Further development and distribution of imaging technology e.g., enable intelligent catheter navigation from groin to neck, therefore reducing the risk of vessel injury. In their review of 1093 consecutive cases, Chalouhi et al. [19] for instance report about 0,99% of transient or minor complications, none resulting in permanent morbidity.
- Diagnostic accuracy: Diagnostic accuracy of IOA has always been one important criticism as the rate of false negative findings range up to 8.7%. Similar to complications ongoing technical development and integration of modern flat panel diagnostic imaging devices into the operation theatre with the possibility of 3D-rotational angiography helped to overcome that issue. Apart from very few exceptions image quality of IOA come about standard diagnostic angiography [45, 46].

- Duration and costs: in health care systems always under pressure to control costs IOA is not economically advantageous, as it extends operation time by at least 15 to 20 minutes. But, in a more comprehensive view calculating the incremental cost-utility ration for routine IOA Kallmes et al. [47] proved IOA to be cost-effective in a manner consistent with low morbidity as it helps prevent clinically relevant cerebral infarctions.
- IOA in the era of ICG: development of microscope-based ICG was an important landmark in neurovascular surgery [20]. ICG enables for simple, easy intraoperative control of vessel patency and aneurysm obliteration. However, thorough evaluation of ICG in aneurysm surgery yielded some disconcordance between ICG and intra- or postoperative control angiograms. Reasons include the "field of view" problem of ICG and its weakness for low-flow detection (e.g., residual inflow to an aneurysm) [48-50].

Devoid of intraoperative imaging modalities yielding comparable diagnostic accuracy, nowadays associated with a low complication rate IOA still remains a valuable tool in neurovascular surgery, especially in aneurysm surgery. Klopfenstein [51], in a comparison of routine and selective use of IOA during aneurysm surgery concluded, that "given the frequency of significant disease that remains undetected if IOA is used on a selective basis and the low complication rate associated with the procedure, the use of IOA should be considered in the majority of aneurysm cases". To put it into the right light: we are far away of considering IOA as a standard in aneurysm surgery. But it proves to be very helpful, especially in large aneurysms, tailored approaches and aneurysms previously treated endovascularly.

INTRAOPERATIVE ELECTROPHYSIOLOGY

In a series of 50 unruptured large and giant aneurysms Takebayashi [52] evaluated the utility of MEP monitoring (direct cortical stimulation) with a focus on the correlation of MEP changes during surgery and postoperative motor function. The study demonstrated a good correlation of MEP recordings and postoperative motor outcome: Preserved MEPs during surgery were always correlated with good motor outcome regardless of duration of temporary vessel occlusion. On the other hand permanent loss of MEPs during the surgical course was always followed by severe and permanent motor deficits.

Unfortunately the validity of intraoperative monitoring during vascular neurosurgical procedures is considered rather low compared to brain tumor surgery. Wicks et al. [53] for example, in a recent consecutive series of 691 patients determining accuracy of SSEP changes in predicting postoperative stroke rate reported positive and negative predictive values of 30% and 94% respectively. In Szelenyi's series using MEP recordings [54, 55] a relatively high rate of false negative results with motor evoked potentials (MEP) (postoperative motor deficits without intraoperative MEP changes) occurred. These findings were especially ascribed to delayed neurological deficits caused by lacunar infarction from perforating arteries. Hence development of lacunar infarcts may take longer than 12 hours [56] these could not be detected with intraoperative recordings.

Though intraoperative neuromonitoring during cerebral aneurysm surgery is not standard today, especially MEP recordings seem to be a rather robust prognostic factor for postoperative motor outcome. SEP´s and MEP´s may give real-time feedback regarding the individual ischemic tolerance e.g., during temporary clipping. Although not always possible, alterations in monitoring may initiate an alternative surgical strategy (e.g., clip alteration, additional bypass) and therefore have the potential to improve operative safety [54].

REFERENCES

[1] Lawton, MT. *Seven Aneurysms.*, 2011 Apr 19, 1–240.

[2] McDougall, CG; Spetzler, RF; Zabramski, JM; Partovi, S; Hills, NK; Nakaji, P; et al. The Barrow Ruptured Aneurysm Trial. *J Neurosurg.*, 2012 Jan, 116(1), 135–44.

[3] Spetzler, RF; McDougall, CG; Albuquerque, FC; Zabramski, JM; Hills, NK; Partovi, S; et al. The Barrow Ruptured Aneurysm Trial: 3-year results. *J Neurosurg.*, 2013 Jul, 119(1), 146–57.

[4] Spetzler, RF; McDougall, CG; Zabramski, JM; Albuquerque, FC; Hills, NK; Russin, JJ; et al. The Barrow Ruptured Aneurysm Trial: 6-year results. *J Neurosurg.*, 2015 Sep, 123(3), 609–17.

[5] Ayling, OGS; Ibrahim, GM; Drake, B; Torner, JC; Macdonald, RL. Operative complications and differences in outcome after clipping and coiling of ruptured intracranial aneurysms. *J Neurosurg.*, 2015 Sep, 123(3), 621–8.

[6] Moon, K; Levitt, MR; Almefty, RO; Nakaji, P; Albuquerque, FC; Zabramski, JM; et al. Treatment of Ruptured Anterior Communicating Artery Aneurysms: Equipoise in the Endovascular Era? *Neurosurgery*., 2015 Oct, 77(4), 566–71.

[7] Mahaney, KB; Todd, MM; Bayman, EO; Torner, JC. IHAST Investigators. Acute postoperative neurological deterioration associated with surgery for ruptured intracranial aneurysm: incidence, predictors, and outcomes. *J Neurosurg.*, 2012 Jun, 116(6), 1267–78.

[8] Ayling, OGS; Ibrahim, GM; Drake, B; Torner, JC; Macdonald, RL. Operative complications and differences in outcome after clipping and coiling of ruptured intracranial aneurysms. *J Neurosurg.*, 2015 Sep, 123(3), 621–8.

[9] Dehdashti, AR; Mermillod, B; Rufenacht, DA; Reverdin, A; de Tribolet, N. Does treatment modality of intracranial ruptured aneurysms influence the incidence of cerebral vasospasm and clinical outcome? *Cerebrovasc Dis*. Karger Publishers, 2004, 17(1), 53–60.

[10] Dorhout Mees, SM; Kerr, RS; Rinkel, GJE; Algra, A; Molyneux, AJ. Occurrence and impact of delayed cerebral ischemia after coiling and after clipping in the International Subarachnoid Aneurysm Trial (ISAT). *J Neurol.* Springer-Verlag, 2012 Apr, 259(4), 679–83.

[11] Molyneux, A; Kerr, R; Stratton, I; Sandercock, P; Clarke, M; Shrimpton, J; et al. International Subarachnoid Aneurysm Trial (ISAT) of neurosurgical clipping versus endovascular coiling in 2143 patients with ruptured intracranial aneurysms: a randomised trial. *Lancet.*, 2002 Oct 26, 360(9342), 1267–74.

[12] Lin, N; Cahill, KS; Frerichs, KU; Friedlander, RM; Claus, EB. Treatment of ruptured and unruptured cerebral aneurysms in the USA: a paradigm shift. *J Neurointerv Surg.* BMJ Publishing Group Ltd, 2012 May, 4(3), 182–9.

[13] Spetzler, RF; Sanai, N. The quiet revolution: retractorless surgery for complex vascular and skull base lesions. *J Neurosurg*., 2012 Feb, 116(2), 291–300.

[14] Lanzino, G. Retractorless brain surgery. *J Neurosurg*., 2012 Feb, 116(2), 290–0.

[15] Fischer, G; Oertel, J; Perneczky, A. Endoscopy in aneurysm surgery. *Neurosurgery*., 2012 Jun, 70(2 Suppl Operative), 184–90–discussion190–1.

[16] Yoshioka, H; Kinouchi, H. The Roles of Endoscope in Aneurysmal Surgery. *Neurol Med Chir (Tokyo)*., 2015, 55(6), 469–78.

[17] Yue, Q; Zhu, W; Gu, Y; Xu, B; Lang, L; Song, J; et al. Motor evoked potential monitoring during surgery of middle cerebral artery aneurysms: a cohort study. *WNEU*. Elsevier, 2014 Dec, 82(6), 1091–9.

[18] Nakaji, P. Motor-evoked potentials in cerebral aneurysm surgery. *WNEU*. Elsevier, 2015 Feb, 83(2), 162–3.

[19] Chalouhi, N; Theofanis, T; Jabbour, P; Dumont, AS; Fernando Gonzalez, L; Starke, RM; et al. Safety and efficacy of intraoperative angiography in craniotomies for cerebral aneurysms and arteriovenous malformations: a review of 1093 consecutive cases. *Neurosurgery*., 2012 Dec, 71(6), 1162–9.

[20] Raabe, A; Beck, J; Gerlach, R; Zimmermann, M; Seifert, V. Near-infrared indocyanine green video angiography: a new method for intraoperative assessment of vascular flow. *Neurosurgery*., 2003 Jan, 52(1), 132–9–discussion139.

[21] Raabe, A; Nakaji, P; Beck, J; Kim, LJ; Hsu, FPK; Kamerman, JD; et al. Prospective evaluation of surgical microscope-integrated intraoperative near-infrared indocyanine green videoangiography during aneurysm surgery. *J Neurosurg. Journal of Neurosurgery Publishing Group*, 2005 Dec, 103(6), 982–9.

[22] Raabe, A; Beck, J; Seifert, V. Technique and image quality of intraoperative indocyanine green angiography during aneurysm surgery using surgical microscope integrated near-infrared video technology. *Zentralbl Neurochir*. © Georg Thieme Verlag Stuttgart New York, 2005 Feb, 66(1), 1–6–discussion7–8.

[23] de Gans, K; Nieuwkamp, DJ; Rinkel, GJE; Algra, A. Timing of aneurysm surgery in subarachnoid hemorrhage: a systematic review of the literature. *Neurosurgery*., 2002 Feb, 50(2), 336–40–discussion340–2.

[24] Zipfel, GJ. Editorial: Ultra-early surgery for aneurysmal subarachnoid hemorrhage. *J Neurosurg*., 2015 Feb, 122(2), 381–2.

[25] Velly, LJ; Bilotta, F; Fàbregas, N; Soehle, M; Bruder, NJ; Nathanson, MH; et al. Anaesthetic and ICU management of aneurysmal subarachnoid haemorrhage: A survey of European practice. *Eur J Anaesthesiol*., 2015 Mar, 32(3), 168–76.

[26] Leipzig, TJ; Morgan, J; Horner, TG; Payner, T; Redelman, K; Johnson, CS. Analysis of intraoperative rupture in the surgical treatment of 1694 saccular aneurysms. *Neurosurgery*., 2005 Mar, 56(3), 455–68–discussion 455–68.

[27] Griessenauer, CJ; Poston, TL; Shoja, MM; Mortazavi, MM; Falola, M; Tubbs, RS; et al. Peer-Review Reports. *WNEU*. Elsevier Inc, 2013 Jun 17, 1–9.

[28] Yamada, S; Ishikawa, M; Yamamoto, K; Ino, T; Kimura, T; Kobayashi, S; et al. Aneurysm location and clipping versus coiling for development of secondary normal-

pressure hydrocephalus after aneurysmal subarachnoid hemorrhage: Japanese Stroke DataBank. *J Neurosurg*., 2015 Jul 31, 1–7.

[29] Perneczky, A; Kindel, S; Kanno, T; Tschabitscher, M; Reisch, R. *Keyhole Approaches in Neurosurgery*. *S*pringer Science & Business Media, 2009. 1 p.

[30] Marinho, P; Thines, L; Verscheure, L; Mordon, S; Lejeune, JP; Vermandel, M. Recent advances in cerebrovascular simulation and neuronavigation for the optimization of intracranial aneurysm clipping. *Computer Aided Surgery*., 2015 Apr 12, 17(2), 47–55.

[31] Abla, AA; Lawton, MT. Three-dimensional hollow intracranial aneurysm models and their potential role for teaching, simulation, and training. *WNEU*. Elsevier, 2015 Jan, 83(1), 35–6.

[32] Weinstock, P; Prabhu, SP; Flynn, K; Orbach, DB; Smith, E. Optimizing cerebrovascular surgical and endovascular procedures in children via personalized 3D printing. *J Neurosurg Pediatr. American Association of Neurological Surgeons*, 2015 Jul 31, 1–6.

[33] Aoun, RJN; Hamade, YJ; Zammar, SG; Patel, NP; Bendok, BR. Futuristic 3D Printing and Personalized Neurosurgery. *WNEU*. Elsevier, 2015 Aug 20, 0(0).

[34] Rosenørn, J; Diemer, NH. Reduction of regional cerebral blood flow during brain retraction pressure in the rat. *J Neurosurg. Journal of Neurosurgery Publishing Group*, 1982 Jun, 56(6), 826–9.

[35] Rosenørn, J; Diemer, NH. The influence of intermittent versus continuous brain retractor pressure on regional cerebral blood flow and neuropathology in the rat. *Acta Neurochir*., 1988, 93(1-2), 13–7.

[36] Rosenørn, J; Diemer, NH. The influence of the profile of brain retractors on regional cerebral blood flow in the rat. *Acta Neurochir*., 1987, 87(3-4), 140–3.

[37] Xu, W; Mellergård, P; Ungerstedt, U; Nordström, C-H. Local changes in cerebral energy metabolism due to brain retraction during routine neurosurgical procedures. *Acta Neurochir*. Springer-Verlag, 2002 Jul, 144(7), 679–83.

[38] Bartal, AD; Tirosh, MS; Weinstein, M. Angiographic control during total excision of a cerebral arteriovenous malformation. Technical note. *J Neurosurg*., 1968 Aug, 29(2), 211–3.

[39] Lazar, ML; Watts, CC; Kilgore, B; Clark, K. Cerebral angiography during operation for intracranial aneurysms and arteriovenous malformations. Technical note. *J Neurosurg*., 1971 May, 34(5), 706–8.

[40] Drake, CG; Vanderlinden, RG. The late consequences of incomplete surgical treatment of cerebral aneurysms. *J Neurosurg*., 1967 Sep, 27(3), 226–38.

[41] Chiang, VL; Gailloud, P; Murphy, KJ; Rigamonti, D; Tamargo, RJ. Routine intraoperative angiography during aneurysm surgery. *J Neurosurg*., 2002 Jun, 96(6), 988–92.

[42] Vitaz, TW; Gaskill-Shipley, M; Tomsick, T; Tew, JM. Utility, safety, and accuracy of intraoperative angiography in the surgical treatment of aneurysms and arteriovenous malformations. *AJNR Am J Neuroradiol*., 1999 Sep, 20(8), 1457–61.

[43] Martin, NA; Bentson, J; Viñuela, F; Hieshima, G; Reicher, M; Black, K; et al. Intraoperative digital subtraction angiography and the surgical treatment of intracranial aneurysms and vascular malformations. *J Neurosurg*., 1990 Oct, 73(4), 526–33.

[44] Martin, N; Doberstein, C; Bentson, J; Viñuela, F; Dion, J; Becker, D. Intraoperative angiography in cerebrovascular surgery. *Clin Neurosurg*., 1991, 37, 312–31.

[45] Schaller, K; Cabrilo, I; Pereira, VM; Bijlenga, P. [Hybrid operation theatre from the perspective of neurosurgery]. *Chirurg*., 2013 Dec, 84(12), 1041–7.

[46] Kotowski, M; Sarrafzadeh, A; Schatlo, B; Boex, C; Narata, AP; Pereira, VM; et al. Intraoperative angiography reloaded: a new hybrid operating theater for combined endovascular and surgical treatment of cerebral arteriovenous malformations: a pilot study on 25 patients. *Acta Neurochir*., 2013 Nov, 155(11), 2071–8.

[47] Kallmes, DF; Kallmes, MH. Cost-effectiveness of angiography performed during surgery for ruptured intracranial aneurysms. *AJNR Am J Neuroradiol*., 1997 Sep, 18(8), 1453–62.

[48] Caplan, JM; Sankey, E; Yang, W; Radvany, MG; Colby, GP; Coon, AL; et al. Impact of indocyanine green videoangiography on rate of clip adjustments following intraoperative angiography. *Neurosurgery*., 2014 Oct, 75(4), 437–43–disucssion444.

[49] Kulwin, C; Cohen-Gadol, AA. False-negative indocyanine green videoangiography among complex unruptured middle cerebral artery aneurysms: the importance of further aneurysm inspection. *Br J Neurosurg*., 2014 Oct, 28(5), 658–62.

[50] Sharma, M; Ambekar, S; Ahmed, O; Nixon, M; Sharma, A; Nanda, A; et al. The utility and limitations of intraoperative near-infrared indocyanine green videoangiography in aneurysm surgery. *WNEU*. Elsevier, 2014 Nov, 82(5), e607–13.

[51] Klopfenstein, JD; Spetzler, RF; Kim, LJ; Feiz-Erfan, I; Han, PP; Zabramski, JM; et al. Comparison of routine and selective use of intraoperative angiography during aneurysm surgery: a prospective assessment. *J Neurosurg*., 2004 Feb, 100(2), 230–5.

[52] Takebayashi, S; Kamiyama, H; Takizawa, K; Kobayashi, T; Saitoh, N. The Significance of Intraoperative Monitoring of Muscle Motor Evoked Potentials during Unruptured Large and Giant Cerebral Aneurysm Surgery. *Neurol Med Chir (Tokyo)*., 2014, 54(3), 180–8.

[53] Wicks, RT; Pradilla, G; Raza, SM; Hadelsberg, U; Coon, AL; Huang, J; et al. Impact of changes in intraoperative somatosensory evoked potentials on stroke rates after clipping of intracranial aneurysms. *Neurosurgery*., 2012 May, 70(5), 1114–24–discussion1124.

[54] Szelényi, A; Langer, D; Kothbauer, K; De Camargo, AB; Flamm, ES; Deletis, V. Monitoring of muscle motor evoked potentials during cerebral aneurysm surgery: intraoperative changes and postoperative outcome. *J Neurosurg. American Association of Neurological Surgeons*, 2006 Nov, 105(5), 675–81.

[55] Szelényi, A; Langer, D; Beck, J; Raabe, A; Flamm, ES; Seifert, V; et al. Transcranial and direct cortical stimulation for motor evoked potential monitoring in intracerebral aneurysm surgery. *Neurophysiol Clin*., 2007 Dec, 37(6), 391–8.

[56] Steinke, W; Ley, SC. Lacunar stroke is the major cause of progressive motor deficits. *Stroke*. Lippincott Williams & Wilkins, 2002 Jun, 33(6), 1510–6.

In: Encyclopedia of Surgery (22 Volume Set)
Editors: Andreas Lehrer and Kristin Mueller
ISBN: 978-1-53618-329-0
© 2020 Nova Science Publishers, Inc.

Chapter 70

DECOMPRESSIVE CRANIECTOMY AND ANEURYSMAL SUBARACHNOID HAEMORRHAGE

Stefan Röhrer
Department of Neurosurgery, University of Ulm, Ulm, Germeny

ABSTRACT

Cerebral vasospasm is a redoubtable complication of subarachnoid hemorrhage. Due to this cerebral infarction may be the consequence. At worst, a space-occupying infarct can develop and threaten patients life additionally which will necessitate decompressive craniectomy.

It is known that decompressive craniectomy can reduce the increased intracranial pressure, but this is often fraught with severe complications.

Keywords: cerebral vasospasm, subarachnoid hemorrhage, decompressive hemicraniectomy, cerebral oedema

PATHOPHYSIOLOGY OF CEREBRAL OEDEMA

Cerebral oedemas are categorised as being either cytotoxic or vasogenic. Pathophysiologically, cytotoxic cerebral oedema develops as a result of swollen glial cells, as well as disruption to the membranous ion pump (sodium-potassium pump) and intracellular autoregulation. The result is an enlargement of the intracellular space of the brain owing to an influx of sodium into the cells, with water and chloride ions being drawn into the intracellular environment. This type of cerebral oedema mostly occurs with intracerebral bleeding, and cerebral infarctions respectively. The worst possible consequence of the cerebral vasospasms that develop due to a ruptured cerebral aneurysm is cerebral hypoperfusion with consecutive cerebral infarctions. Such infarctions can lead to cytotoxic cerebral oedema, which in turn can result in life-threatening swelling of the brain. Conversely, vasogenic cerebral oedema develops from an impairment of the blood-brain barrier, as well as from increased permeability of the capillary vessels, which can cause the increased influx of fluid into the

interstitium and, in turn, to an enlargement of the extracellular space. This can be caused by traumatic brain injury, abscesses, or brain tumours.

INDICATION FOR DECOMPRESSIVE HEMICRANIECTOMY

In case of traumatic brain injury, decompressive hemicraniectomy is indicated in the event of space-occupying haemorrhage, and space-occupying cerebral oedema with a midline shift on CCT imaging of >5 mm respectively. It is indicated moreover for treating intracranial pressure that is increased to more than 25 mm Hg for 30 minutes and resistant to therapy, as well as cerebral perfusion pressure that is decreased to <50-60 mm Hg at the same time as rising intracranial pressure values.

In case of cerebral infarctions, decompressive craniectomy is indicated due to the development of a mass from secondary swelling of the infarcted cerebral tissue consistent with cytotoxic cerebral oedema. The positive clinical aspects were demonstrated by the DESTINY study.

Cerebral vasospasms with cerebral perfusion deficit can be a secondary consequence of aneurysmal subarachnoid haemorrhage. Cerebral infarctions are a tertiary complication here; at worst, a space-occupying infarct can develop which, depending on the size and the space consumed, will necessitate decompressive craniectomy.

It is known that decompressive craniectomy can reduce the increased intracranial pressure following traumatic brain injury [1] as well as after malignant middle cerebral artery infarctions [2, 3]. Cerebral oedema can accompany the initial bleed in the event of aneurysmal subarachnoid haemorrhage, but can also develop later as a result of cerebral vasospasms and consecutive infarctions. Irrespective of the point at which cerebral oedema occurs, it is known to worsen the outcome of the patient after subarachnoid haemorrhage [4, 5]. Treatment of this life-threatening form of oedema is essential, though this is often also fraught with severe complications such as infections, axonal injury or hygromas. Given that the functional outcome is unclear, especially with severe subarachnoid haemorrhage (WFNS IV-V) accompanied by extremely high intracranial pressure, aggressive therapy in the form of decompressive craniectomy is a topic of hot debate. Between 1999 and 2008, Güresir et al. studied a total of 939 patients with aneurysmal subarachnoid haemorrhage. Decompressive craniectomy was performed in 79 of these patients. The study concluded that decompressive craniectomy is an effective method of treatment for patients with increased intracranial pressure. It was also demonstrated that surgery to treat the pressure is indicated irrespective of the time at which it occurs. Such treatment can be undertaken regardless of the pathophysiology of the elevated intracranial pressure (haemorrhage, infarction or swelling) [6].

REFERENCES

[1] Bullock M. R., Chesnut R., Ghajar J., Gordon D., Hartl R., Newell D. W. et al. 2006. Surgical management of acute subdural hematomas. *Neurosurgery*, 58: 16-24.

[2] Schwab S., Steiner T., Aschoff A., Schwarz S., Steiner H. H., Jansen O. et al. 1998. Early hemicraniectomy in patients with complete middle cerebral artery infarction. *Stroke*, 29: 1888-1893.

[3] Vahedi K., Hofmeijer J., Juettler E., Vicaut E., George B., Algra A. et al. 2007. Early decompressive surgery in malignant infarction of the middle cerebral artery: a pooled analysis of three randomised controlled trials. *Lancet Neurol*, 6: 215-222.

[4] Broderick J. P., Brott T. G., Duldner J. E., Tomsick T., Leach A. et al. 1994. Initial and recurrent bleeding are the major causes of death following subarachnoid hemorrhage. *Stroke*, 25: 1342-1347.

[5] Ferguson S., Macdonald R. L. 2007. Predictors of cerebral infarction in patients with aneurysmal subarachnoid hemorrhage. *Neurosurgery*, 60: 658-667.

[6] Güresir E., Schuss P., Vatter H., Raabe A., Seifert V., Beck J. 2009. Decompressive craniectomy in subarachnoid hemorrhage; *Neurosurg Focus*, 26 E4.

In: Encyclopedia of Surgery (22 Volume Set)
Editors: Andreas Lehrer and Kristin Mueller
ISBN: 978-1-53618-329-0
© 2020 Nova Science Publishers, Inc.

Chapter 71

INTENSIVE THERAPY I FOR SAH

Thomas Kerz
Department of Neurosurgery, Johannes Gutenberg University of Mainz,
Mainz, Germany

ABSTRACT

There are special features of the intensive medical care of patients with SAH that are essential to outcome. American as well as European recommendations do exist, and the American Neurocritical Care Society has also published its own recommendations [1-3]. Nevertheless, a recently published survey revealed that treatments offered to such patients vary considerably. This chapter tries to summarize evidence-based recommendations relevant to therapy, sedation, blood pressure, fluids and electrolytes.

Keywords: subarachnoid haemorrhage, intensive care therapy, cerebral vasospasm, hyponatremia, cerebral blood flow

1. SEDATION

By minimising sedation in ventilated patients, the length of stay in intensive care and ventilation time can be reduced [4]. If sedation is too deep, clinical examination of neurological patients is difficult and important findings may be obscured. On the other hand, insufficient sedation can result in increased cerebral oxygen consumption and elevated intracranial pressure. Most studies and recommendations focus on patients in mixed intensive care units, whereas only few studies have been published in regard to sedated patients with neurological damage. Therefore and until further studies are available, the recommendations for patients in general ICUs should be followed. In patients in neurological intensive care, analgesia-based sedation (fentanyl or remifentanil) has achieved greater pain relief than sedatives (propofol or midazolam), albeit with an equal rate of unscheduled extubations [5]. Significant interindividual pharmacokinetic effects have been reported for midazolam in

neurological patients. In one study, midazolam or its active metabolite, 1-hydroxymidazolam glucuronide, was still detectable 67 h on average after ending the midazolam infusion. By measuring the concentrations, a higher percentage of patients with neurological damage could be distinguished from those with delayed recovery, since approx. three quarters of the patients with no measurable drug concentration died due to neurological damage or were severely affected, whereas approx. three quarters of the patients with measurable concentrations recovered completely [5].

In neurological patients without an increase in intracranial pressure requiring sedation for less than five days, daily neurological evaluation could be performed sooner after sedation with remifentanil, if necessary together with propofol or midazolam, than after analgesia with fentanyl or morphine [6]. In patients with increased intracranial pressure or those requiring deep sedation due to unstable intracerebral pathologies, conventional sedatives can be administered. In a meta-analysis, no single regimen was found to offer any particular benefit over another [7]. Ketamine is no longer contraindicated – in fact, the substance is beneficial due to its sedative and analgesic properties [8]. After termination of sedation, O_2 consumption and energy turnover each increase by about 50% [5]. Withdrawal delirium is observed in approx. 15%-50% of all patients on general intensive care units [9]. No information is available on its frequency in neurointensive care patients. If vigilance deteriorates, a cranial CT scan should generally be taken to investigate the cause (hydrocephalus, secondary haemorrhage, ischaemia, etc.).

A comparison of dexmedetomidine and propofol in patients with SAH revealed that the incidence of bradycardia and hypotension is identical [10]. Whereas dexmedetomidine is often used in awake operations and has been found to convey cerebroprotective effects in animal studies, its potentially negative effect on cerebral blood flow (CBF) in humans has not yet been fully explained. Hence, no firm recommendation can be made as to its use in sedating patients with neurological conditions [11].

Inhalational anaesthetics lead to decoupling of $CMRO_2$ (cerebral metabolic rate of oxygen) and CBF, by decreasing the former and increasing the latter. In doing so, they could play a protective role against vasospasm-induced ischaemia. Isoflurane has resulted in an insignificant increase in ICP, but significant decreases in mean arterial pressure (MAP) and cerebral perfusion pressure (CPP, 6.5 and 6.3 mm Hg, respectively), despite raising the vasopressor dose [12]. The mean blood flow rates in the middle cerebral artery remained unchanged. In another study that compared isoflurane with propofol, regional CBF measured by thermodiffusion was markedly increased [13]. In approximately one third of patients, sevoflurane resulted in severe adverse reactions, including an elevation in ICP and a drop in MAP and CPP, necessitating discontinuation of drug administration [14].

Conclusion: All sedatives conventionally used in intensive care patients can also be applied in SAH patients.

2. Blood Pressure and Fluids

Blood pressure and cardiac output play a pivotal role in terms of cerebral perfusion. Acute SAH is regularly associated with reduced cerebral autoregulation. Hence, CBF is directly related to MAP and cannot be maintained at a constant level by the cerebral vessels.

Triple H therapy, consisting of hypervolaemia, hypertension and haemodilution, has long been used as a means of increasing CBF in the presence of vasospasm. In the only available randomised study on this subject, however, hypervolaemia did not lead to an improvement either in CBF or the neurological outcome [5]. Prophylactic volume expansion and hyperdynamic therapy, even when introduced before development of vasospasm and after securing the aneurysm, also had no positive effect on CBF and no clinical benefit as compared to normovolaemia [15]. Only isolated case reports have demonstrated that such therapy is beneficial. The target values in such a case were a systolic pressure of 160 mm Hg before clipping the aneurysm and 240 mm Hg after, respectively [16]. However, significant adverse effects have also been reported: pulmonary oedema, hyponatraemia, secondary haemorrhage and coagulopathies. With respect to blood pressure management, randomised studies are lacking. Whereas dopamine was used in most of the earlier studies, phenylephrine, dobutamine or noradrenaline have been the focus of more recent studies, and vasopressin was also studied in another. Case series and cohort studies suggest that CBF is increased by approx. 10 ml · 100g-1 · ml-1 as a result of adjusting hypertensive blood pressure levels (systolic 160-200 mm Hg). Miller et al. reported an 88% improvement in the neurological deficits of their patients if hypertensive treatment was not commenced until after onset of the symptoms [17]. Neurological improvement was noted in 71% of patients in another study in which normovolaemic hypertension was modified to 25%-50% above the normal arterial systolic blood pressure by dopamine and dobutamine [18]. In line with these findings, CBF and cerebral oxygen tension ($PtiO_2$) increased as a result of hypertensive therapy [19], whilst hypervolaemia was associated with an increased rate of adverse reactions (pulmonary oedema, heart failure) [20]. Two studies have demonstrated that the CBF can be increased in patients with severe SAH by administering hypertonic saline [21, 22]. With respect to blood pressure and the treatment of concomitant Takotsubo cardiomyopathy [23, 24], levosimendan [25] or intra-aortic counterpulsation [26, 27] have been used in isolated cases. Therapeutic anticoagulation is necessary in case of the latter, however. In patients with further aneurysms in addition to a haemorrhaged and occluded aneurysm, induced hypertension with CPP values between 80 and 120 mm Hg (MAP 90-130 mm Hg) was not associated with an increased rate of bleeding [28]. Noradrenaline was mainly used in this study, if needed in combination with dopamine or dobutamine.

The study group of the Neurocritical Care Society recommends maintaining euvolaemia and avoiding prophylactic hypervolaemia. Isotonic solutions should be used for fluid replacement. If a negative fluid balance persists, hydrocortisone or fludrocortisone can be considered [2]. In general, higher blood pressure is accompanied by increased CBF; most studies noted an improvement in the neurological deficit in approx. two thirds of patients.

Conclusion: Isotonic solutions should be used for replacing fluids. Euvolaemia should be the goal.

3. ELECTROLYTES

Hyponatraemia is the most common form of electrolyte imbalance in SAH. It can occur with euvolaemia, hypervolaemia or hypovolaemia. The most common cause for euvolaemic or hypervolaemic hyponatraemia is the inadequate secretion of antidiuretic hormone (ADH).

Since it is not always possible to detect an excessive ADH concentration, the term “syndrome of inadequate antidiuresis” (SIAD) has been coined lately. Other signs are a urine osmolality of > 100 mOsm/kg and a urinary sodium concentration of > 30 mmol/L. The levels generally return to normal if water is restricted. To measure the increased reabsorption rate of sodium, fractional sodium excretion (> 0.5%) is appropriate but can be falsified by the administration of diuretics. Fractional uric acid excretion has a positive predictor rate for SIAD of 100% at a cut-off of > 12% and is not distorted by diuretics [5].

Hypovolaemic hyponatraemia thus is usually accompanied by a urinary sodium concentration of < 30 mmol/L, fractional sodium excretion of < 0.5%, and fractional uric acid excretion of < 12%. Differentiation is complicated, however, as excessive diuresis and excessive reabsorption of free water sometimes occur simultaneously [29].

Determination of volume status is crucial to therapy, since hypervolaemic patients require diuresis whereas in euvolaemia it would lead to unwanted fluid deficiency. Drug-wise, fludrocortisone and hydrocortisone can be administered. Hypertonic saline solutions or enteral administration of saline are likewise possible. Vasopressin receptor antagonists, such as tolvaptan, lead to ofree water clearance but can also cause excessive diuresis and therefore should only be used whilst closely monitoring the volume status [5].

Studies and meta-analyses have not found prophylactic treatment with magnesium to be beneficial in preventing a delayed ischaemic neurological deficit (DIND, [30]). The benefit in terms of avoiding hypomagnesaemia also has not been adequately demonstrated [31].

Conclusion: A thorough investigation of the causes and appropriate therapy are required if hyponatraemia is to be avoided. Magnesium replacement cannot be recommended.

REFERENCES

[1] Bederson JB, Connolly ES, Jr., Batjer HH, Dacey RG, Dion JE, Diringer MN, et al. Guidelines for the management of aneurysmal subarachnoid hemorrhage: a statement for healthcare professionals from a special writing group of the Stroke Council, American Heart Association. *Stroke*. 2009;40(3):994-1025.

[2] Diringer MN, Bleck TP, Claude Hemphill J, 3rd, Menon D, Shutter L, Vespa P, et al. Critical care management of patients following aneurysmal subarachnoid hemorrhage: recommendations from the Neurocritical Care Society's Multidisciplinary Consensus Conference. *Neurocrit Care.* 2011;15(2):211-40.

[3] Steiner T, Juvela S, Unterberg A, Jung C, Forsting M, Rinkel G, et al. European Stroke Organization guidelines for the management of intracranial aneurysms and subarachnoid haemorrhage. *Cerebrovasc Dis.* 2013;35(2):93-112.

[4] Velly LJ, Bilotta F, Fabregas N, Soehle M, Bruder NJ, Nathanson MH, et al. Anaesthetic and ICU management of aneurysmal subarachnoid haemorrhage: a survey of European practice. *Eur J Anaesthesiol*. 2015;32(3):168-76.

[5] Barr J, Fraser GL, Puntillo K, Ely EW, Gelinas C, Dasta JF, et al. Clinical practice guidelines for the management of pain, agitation, and delirium in adult patients in the intensive care unit. *Crit Care Med*. 2013;41(1):263-306.

[6] Egerod I, Jensen MB, Herling SF, Welling KL. Effect of an analgo-sedation protocol for neurointensive patients: a two-phase interventional non-randomized pilot study. *Crit Care*. 2010;14(2):R71.

[7] McKenzie CA, McKinnon W, Naughton DP, Treacher D, Davies G, Phillips GJ, et al. Differentiating midazolam over-sedation from neurological damage in the intensive care unit. *Crit Care*. 2005;9(1):R32-6.

[8] Karabinis A, Mandragos K, Stergiopoulos S, Komnos A, Soukup J, Speelberg B, et al. Safety and efficacy of analgesia-based sedation with remifentanil versus standard hypnotic-based regimens in intensive care unit patients with brain injuries: a randomised, controlled trial [ISRCTN50308308]. *Crit Care*. 2004;8(4):R268-80.

[9] Roberts DJ, Hall RI, Kramer AH, Robertson HL, Gallagher CN, Zygun DA. Sedation for critically ill adults with severe traumatic brain injury: a systematic review of randomized controlled trials. *Crit Care Med*. 2011;39(12):2743-51.

[10] Himmelseher S, Durieux ME. Revising a dogma: ketamine for patients with neurological injury? *Anesth Analg*. 2005;101(2):524-34, table of contents.

[11] Bruder N, Lassegue D, Pelissier D, Graziani N, Francois G. Energy expenditure and withdrawal of sedation in severe head-injured patients. *Crit Care Med*. 1994;22(7):1114-9.

[12] Jaber S, Chanques G, Altairac C, Sebbane M, Vergne C, Perrigault PF, et al. A prospective study of agitation in a medical-surgical ICU: incidence, risk factors, and outcomes. *Chest*. 2005;128(4):2749-57.

[13] Erdman MJ, Doepker BA, Gerlach AT, Phillips GS, Elijovich L, Jones GM. A comparison of severe hemodynamic disturbances between dexmedetomidine and propofol for sedation in neurocritical care patients. *Crit Care Med*. 2014;42(7):1696-702.

[14] Farag E. Dexmedetomidine in the neurointensive care unit. *Discov Med*. 2010;9(44):42-5.

[15] Bosel J, Purrucker JC, Nowak F, Renzland J, Schiller P, Perez EB, et al. Volatile isoflurane sedation in cerebrovascular intensive care patients using AnaConDa((R)): effects on cerebral oxygenation, circulation, and pressure. *Intensive Care Med*. 2012;38(12):1955-64.

[16] Villa F, Iacca C, Molinari AF, Giussani C, Aletti G, Pesenti A, et al. Inhalation versus endovenous sedation in subarachnoid hemorrhage patients: effects on regional cerebral blood flow. *Crit Care Med*. 2012;40(10):2797-804.

[17] Purrucker JC, Renzland J, Uhlmann L, Bruckner T, Hacke W, Steiner T, et al. Volatile sedation with sevoflurane in intensive care patients with acute stroke or subarachnoid haemorrhage using AnaConDa(R): an observational studydagger. *Br J Anaesth*. 2015;114(6):934-43.

[18] Lennihan L, Mayer SA, Fink ME, Beckford A, Paik MC, Zhang H, et al. Effect of hypervolemic therapy on cerebral blood flow after subarachnoid hemorrhage : a randomized controlled trial. *Stroke*. 2000;31(2):383-91.

[19] Egge A, Waterloo K, Sjoholm H, Solberg T, Ingebrigtsen T, Romner B. Prophylactic hyperdynamic postoperative fluid therapy after aneurysmal subarachnoid hemorrhage: a clinical, prospective, randomized, controlled study. *Neurosurgery*. 2001;49(3):593-605; discussion -6.

[20] Kassell NF, Peerless SJ, Durward QJ, Beck DW, Drake CG, Adams HP. Treatment of ischemic deficits from vasospasm with intravascular volume expansion and induced arterial hypertension. *Neurosurgery*. 1982;11(3):337-43.
[21] Miller JA, Dacey RG, Jr., Diringer MN. Safety of hypertensive hypervolemic therapy with phenylephrine in the treatment of delayed ischemic deficits after subarachnoid hemorrhage. *Stroke*. 1995;26(12):2260-6.
[22] Otsubo H, Takemae T, Inoue T, Kobayashi S, Sugita K. Normovolaemic induced hypertension therapy for cerebral vasospasm after subarachnoid haemorrhage. *Acta Neurochir* (Wien). 1990;103(1-2):18-26.
[23] Muench E, Horn P, Bauhuf C, Roth H, Philipps M, Hermann P, et al. Effects of hypervolemia and hypertension on regional cerebral blood flow, intracranial pressure, and brain tissue oxygenation after subarachnoid hemorrhage. *Crit Care Med*. 2007;35(8):1844-51; quiz 52.
[24] Raabe A, Beck J, Keller M, Vatter H, Zimmermann M, Seifert V. Relative importance of hypertension compared with hypervolemia for increasing cerebral oxygenation in patients with cerebral vasospasm after subarachnoid hemorrhage. *J Neurosurg*. 2005;103(6):974-81.
[25] Tseng MY, Al-Rawi PG, Czosnyka M, Hutchinson PJ, Richards H, Pickard JD, et al. Enhancement of cerebral blood flow using systemic hypertonic saline therapy improves outcome in patients with poor-grade spontaneous subarachnoid hemorrhage. *J Neurosurg*. 2007;107(2):274-82.
[26] Tseng MY, Al-Rawi PG, Pickard JD, Rasulo FA, Kirkpatrick PJ. Effect of hypertonic saline on cerebral blood flow in poor-grade patients with subarachnoid hemorrhage. *Stroke*. 2003;34(6):1389-96.
[27] Lee VH, Connolly HM, Fulgham JR, Manno EM, Brown RD, Jr., Wijdicks EF. Tako-tsubo cardiomyopathy in aneurysmal subarachnoid hemorrhage: an underappreciated ventricular dysfunction. *J Neurosurg*. 2006;105(2):264-70.
[28] Wybraniec MT, Mizia-Stec K, Krzych L. Neurocardiogenic injury in subarachnoid hemorrhage: A wide spectrum of catecholamin-mediated brain-heart interactions. *Cardiol J*. 2014;21(3):220-8.
[29] Busani S, Rinaldi L, Severino C, Cobelli M, Pasetto A, Girardis M. Levosimendan in cardiac failure after subarachnoid hemorrhage. *J Trauma*. 2010;68(5):E108-10.
[30] Apostolides PJ, Greene KA, Zabramski JM, Fitzgerald JW, Spetzler RF. Intra-aortic balloon pump counterpulsation in the management of concomitant cerebral vasospasm and cardiac failure after subarachnoid hemorrhage: technical case report. *Neurosurgery*. 1996;38(5):1056-9; discussion 9-60.
[31] Lazaridis C, Pradilla G, Nyquist PA, Tamargo RJ. Intra-aortic balloon pump counterpulsation in the setting of subarachnoid hemorrhage, cerebral vasospasm, and neurogenic stress cardiomyopathy. Case report and review of the literature. *Neurocrit Care*. 2010;13(1):101-8.
[32] Platz J, Guresir E, Vatter H, Berkefeld J, Seifert V, Raabe A, et al. Unsecured intracranial aneurysms and induced hypertension in cerebral vasospasm: is induced hypertension safe? *Neurocrit Care*. 2011;14(2):168-75.
[33] Fenske W, Stork S, Koschker AC, Blechschmidt A, Lorenz D, Wortmann S, et al. Value of fractional uric acid excretion in differential diagnosis of hyponatremic patients on diuretics. *J Clin Endocrinol Metab*. 2008;93(8):2991-7.

[34] Audibert G, Steinmann G, de Talance N, Laurens MH, Dao P, Baumann A, et al. Endocrine response after severe subarachnoid hemorrhage related to sodium and blood volume regulation. *Anesth Analg*. 2009;108(6):1922-8.

[35] Murphy T, Dhar R, Diringer M. Conivaptan bolus dosing for the correction of hyponatremia in the neurointensive care unit. *Neurocrit Care*. 2009;11(1):14-9.

[36] Reddy D, Fallah A, Petropoulos JA, Farrokhyar F, Macdonald RL, Jichici D. Prophylactic magnesium sulfate for aneurysmal subarachnoid hemorrhage: a systematic review and meta-analysis. *Neurocrit Care*. 2014;21(2):356-64.

[37] de Rooij NK, Rinkel GJ, Dankbaar JW, Frijns CJ. Delayed cerebral ischemia after subarachnoid hemorrhage: a systematic review of clinical, laboratory, and radiological predictors. *Stroke*. 2013;44(1):43-54.

In: Encyclopedia of Surgery (22 Volume Set)
Editors: Andreas Lehrer and Kristin Mueller
ISBN: 978-1-53618-329-0
© 2020 Nova Science Publishers, Inc.

Chapter 72

NEUROPROTECTION: DCI, VASOSPASM, NIMODIPINE

Christian Heinen
Department of Neurosurgery, Evangelical Hospital Oldenburg,
Steinweg 13-1726122 Oldenburg, Germany

ABSTRACT

Cerebral posthaemorrhagic vasospasm and delayed cortical ischaemia are dreaded complications associated above all with aneurysmal subarachnoid haemorrhage. These phenomena are also observed during traumatic SAH or inflammatory CNS disease [1]. Mortality in relation to SAH is approx. 50% and includes patients who die on the spot and do not reach a hospital. The mortality rate in patients receiving hospital treatment is still 25% regardless of all diagnostic and therapeutic options [2]. Vasopasms and delayed cortical ischaemia are entities that should each be considered individually. The clinical significance is the subject of much discussion.

Keywords: neuroprotection, delayed cortical ischemia, cerebral vasospasm

INTRODUCTION

In a meta-analysis, Frontera et al. reported that symptomatic vasospasms (clinical findings with no changes on imaging) occurred in 16% of patients, delayed cortical ischaemia (DCI) (clinical findings WITH changes on imaging) in 21%, angiographic vasospasms in 31% and on TCD in 45% [3]. This stresses the fact that morphological findings do not necessarily have to have a clinical impact and that there must be mechanisms which extend beyond simple vasospasm.

It is therefore important to be clear about the terms and to distinguish one from another.

CEREBRAL VASOSPASM - CVS

CVS basically means the pathological constriction of the cerebral arteries following SAH. In the literature, varying and sometimes contradictory forms of CVS, the clinical implications of which vary considerably, are grouped together under this generic term. Vasospasms detected on *angiography*, i.e., a decrease in the vascular cross-section compared to previous images, were described as early as 1951 [4]. The incidence is specified as 60%-70%. However, this is not necessarily associated with clinical deterioration. In contrast, CVS is found on *transcranial Doppler/Duplex* (TCD), and occurs in approx. 50% of all SAH patients. A relative constriction of the vessels is thereby measured indirectly from a change in blood flow velocity according to Poiseuille's Law. The difficulty with the term CVS is that, as already mentioned, it offers no indication of the clinical impact and refers merely to the vasoconstriction itself, without allowing for the other pathological mechanisms.

DELAYED CORTICAL ISCHAEMIA - DCI

The term delayed cortical ischaemia (DCI) was therefore introduced. Firstly, it refers to new changes revealed by CCT/MRI images e.g., constriction of the vessels, and also to ischaemia or perfusion deficits that were not identifiable on the initial scans. Secondly, symptoms of clinical deterioration are recorded. These include new-onset aphasia, unilateral symptoms, deterioration of the GCS (Glasgow Coma Score) by 2 points, neglect, or apraxia. The changes should last at least one hour, not have a direct temporal relationship to aneurysm treatment, and not be attributable to other diseases (infection/electrolyte imbalance/cardiac events, etc.) [5]. In 20%-30% of patients, DCI appears to be responsible for the severe neurological damage that develops as a secondary complication. In approx. 7%-10% this can even prove fatal [6], regardless of any particular treatment. The term DCI is therefore more broadly defined and does not focus on vasospasm alone.

The following sections provide a summary of the possible components that contribute to the development of DCI.

PATHOMECHANISM

A number of pathomechanisms are proposed as contributory factors in DCI. How it develops precisely, however, is still unclear. Besides disrupted autoregulation of the arterial system, inflammatory processes are of particular relevance. Ultimately, there is a preponderance of vasoconstrictive and obstructive agents with at the same time a significant reduction in antagonistic vasodilators. Basically, there are different phases of ischaemia in SAH.

The early phase ("early brain injury") occurs during acute rupture as global ischaemia due to the acute rise in intracranial pressure (ICP) with a consecutive decrease in cerebral perfusion pressure (CPP), and spans the first 72 hours after the bleeding occurs. It is posited that the consequences of this early damage sometimes are only seen over the course [7]. Acute vasospasm in response to the haemorrhagic extravasate has been described [8]. The

blood-brain barrier is permeated and autoregulation disrupted. During the *late phase*, a number of simultaneous processes takes place, leading to local structural change in the vascular wall with resulting intimal thickening and media proliferation [9].

In its physiological state *NO*, as a cGMP inducer, is an essential and potent vasodilator that is stored in pre- and postganglionic perivascular neurons.

However, NO has a high affinity to haemoglobin. The latter binds increasingly to NO during SAH decreasing signifantly NO-levels as a vasodilator. SAH also leads to neuron reduction with an emphasis on NO deficiency. *Endothelin-1* is the most potent vasoconstrictor known [10]. Increased concentrations are found both in the cerebrospinal fluid and in the plasma of SAH patients; clinically these closely correlate with the occurrence of CVS [11, 12]. Endothelin-1 usually appears in astrocytes, neurons, smooth muscle cells and the endothelium. As a result of activating leukocytes in the cerebrospinal fluid, SAH appears to increase the production and in turn the secretion of endothelin-1 [13]. Various degradation mechanisms release *free radicals*, which damage cell membranes in the endothelium, smooth muscle cells and in vasoregulatory neurons. Additional vasoconstrictive substances such as arachidonic acids may be released through these cascade with a dysregulated calcium influx being the consequence [14]. Moreover, the increased development of *microemboli* and *cortical spreading depression (CSD)* seems to play a part in the emergence of DCI. Cerebral ischaemia was found in 77% of post-mortem examinations without any angiographic evidence of vasospasms [15]. A combination of pathologically activated coagulation and simultaneously decreased fibrinolysis is believed to be responsible for the formation of *microemboli* [16].

CSD describes waves of depolarisation spreading through the grey matter.

This occurs spontaneously in SAH and lasts longer than the otherwise usual 5-15 minutes. In healthy individuals, vasoconstriction occurs shortly before CSD, followed by vasodilation during the CSD phase (spreading hyperperfusion) and a phase of reduced and delayed tissue perfusion during the recovery phase after the CSD wave [17]. However, the vascular reaction is altered in SAH patients. Therefore, the CSD can lead either to no change in the vascular width or to a pathological vasoconstriction known as *cortical spreading ischaemia* [18] without a relaxation phase. If CSD occur more and more frequently in quick succession, the affected areas of cortex cannot recover from the hypoperfusion. CSD occurs more often between day 5 and 7 post haemorrhage [19].

NEUROPROTECTION

Numerous strategies have arisen based on recent insights into the pathological mechanism. The therapeutic options that are actually available for treating or preventing DCI, however, are rather sobering. Despite all efforts, the calcium channel blocker nimodipine constitutes the drug with the only evidence to date of a significantly better outcome. An overview of the pharmacological and non-pharmacological options and their impact is provided in the following few paragraphs (see also Table 1 and 2).

Table 1. Overview substances and recommendation level

Substance	Mechanism of action	Indication	American Stroke Association recommendation
Ca^{++} blocker	Vasodilation/anti-inflammatory	Prevention and treatment of CVS/DCI	Yes
Mg^{++}	Vasodilation/(anti-inflammatory)	Prevention of CVS	No
Statins	Anti-inflammatory, improved endothelial function	Treatment of CVS	No
Anti-epileptics	Anticonvulsive/diminished cortical spreading depression	Treatment of convulsions	No
Aspirin	Platelet aggregation inhibition	Prevention of DCI	No
Glucocorticoids	Anti-inflammatory	Prevention of CVS	No
Enoxaparin	Antithrombotic	Prevention of DCI	No
Tirilazad	Membrane stabilisation	Treatment of CVS	No
Clazosentan	Vasodilation	Treatment of CVS	No

CVS: cerebral vasospasm DCI: delayed cerebral ischemia

PHARMACOLOGICAL

Nimodipine

Nimodipine is a dihydropyridine and therefore a selective Ca++ channel blocker. It binds to the voltage-dependent L-type Ca++ channels and appears to have an increased affinity to cerebral and renal vessels. In Europe both oral and intravenous pharmaceutical forms are available, whereas in the USA only oral administration is approved.

Intra-arterial administration via an intracranially placed microcatheter is also possible [20]. There have also been reports of intrathecal doses [21]. In comparative studies, the efficacy of intravenous and oral doses did not differ [22, 23]. Those studies that were able to demonstrate efficacy were based on oral intake [24]. It is important to mention that many of the nimodipine studies were carried out many years, sometimes decades ago, but the results are still valid in terms of clinical routine [24, 25]. The only larger-scale study to which reference is still made and which on meta-analysis suggests that nimodipine has a significantly better outcome, dates back to 1989 [26]!

Neuroprotection

The original assumption that the positive effect was derived merely from vasodilatation has more recently been revised. In contrast to other Ca++ channel blockers, nimodipine obviously has other neuroprotective properties, particularly after SAH. However, its exact mechanism of action has not yet been fully explained. Nimodipine plays a part in activating fibrinolysis, which may then attenuate the development of microthrombi [27]. It also prevents uncontrolled Ca++ influx into the neurons subsequent to an ischaemic event. This influx would normally lead to neuronal cell destruction [28]. In rat model nimodipine seemed also to attenuate CSD [29].

Intra-Arterial

Intra-arterial administration of nimodipine is considered in particular for refractory or rapidly recurring CVS and DCI [30, 31]. In addition to adverse drug reactions, the risks associated with the surgical procedure such as thrombosis, vascular perforations, air embolisms etc. must be taken into account [32].

Intrathecal

As early as 1982, Auer et al. described the local intrathecal use of nimodpine in the prevention of symptomatic vasospasm [33]. This idea was revisited over the course, whereby nimodipine was administered via lumbar drain and not locally as during clipping procedure [21].

However, the validity of the efficacy data is limited given that larger comparative studies are not available. Other Ca++ channel blockers have also been applied locally via an external ventricular drain, a catheter placed in the circle of Willis, or as pellets. There are no clear recommendations due to the lack of larger-scale randomised studies, however [34].

Adverse Reactions

The side effect profile of nimodipine is broad. Pulmonary arteriovenous shunts with consecutively impaired gas exchange, hypotension, thrombopenia, allergic reactions and gastroparesis can occur. Reciprocal interactions occur (according to the package leaflet from Bayer) with certain antibiotics (e.g., erythromycin, quinupristin/dalfopristin), HIV drugs (e.g., ritonavir), certain antimycotics (e.g., ketoconazole) and antidepressants (e.g., nefazodone, fluoxetine), antiepileptics (e.g., valproic acid).

Triple-H Therapy: Hypertension/Hypervolaemia/Haemodilution

The principle behind triple-H therapy is to maintain perfusion by increasing the arterial pressure and decreasing viscosity (according to Poiseuille's Law) in the case of vascular dysregulation [35]. This is based on the observation that SAH patients developed new neurological deficits in the event of hypotension. Responses to triple-H therapy were recorded as early as the 1950s [36]. This method was and remains widespread, although there is still no clear evidence of its effectiveness. Meta-analyses performed in 2004 and 2010 did not reveal advantage from either combined triple-H therapy or the individual components (hypervolaemia/hypertension only, etc.) [37]. In contrast, hypervolaemia would appear to result in more complications [38]. At present, euvolaemia and "mild hypertension" are therefore recommended [39].

Magnesium

Mg++ is a competitive blocker of voltage-dependent calcium channels. Its effect ranges from vasodilatation, inhibition of platelet aggregation, and improvement in erythrocyte elasticity, as far as stabilisation of the endothelium [34]. Other neuroprotective effects have been detected experimentally [40]. Interestingly, hypomagnesaemia occurs in approx. 50% of

all SAH patients. It can be used as a predictor of DCI, particularly between day 2 and 12 post haemorrhage [41]. Despite the high expectations for Mg++, no evidence of a positive effect on the outcome has been forthcoming – large-scale studies (e.g., MASH-II study) notwithstanding [42]. There is no clear recommendation for routine use in SAH [39].

Statins

As stabilisers of the endothelium, platelet adhesion/aggregation inhibitors and anti-inflammatory agents, statins seem predestined for neuroprotection. However, neither meta-analyses nor a large-scale, multicentre, randomised, double-blind phase 3 study managed to identify a significant difference between simvastatin and a placebo [43-45]. Statins thus are not used routinely at present.

Endothelin-1 Receptor Antagonists

As already mentioned, endothelin-1 (ET-1) is the most potent vasoconstrictor known. The first study used the non-selective ET-inhibitor TAK-044 [46], without achieving any significant improvement. Subsequently, other study groups demonstrated an improvement in the angiographic vasospasm and the occurrence of delayed ischaemic neurological deficits (DIND) with the specific ET-1-inhibitor clazosentan. However, outcome was not more favourable [10]. Moreover, significant adverse effects such as pulmonary oedema, anaemia and hypotension [47] occured, and the subset of clipped patients showed a poorer response. The study (CONSCIOUS-2) was discontinued and the planned follow-up study, CONSCIOUS-3, was not even started [35].

Other Substance Classes

There are numerous other literature references concerning neuroprotection in SAH. Various substances such as corticosteroids, radical scavengers (tirilazad), aspirin, low-molecular-weight heparins, metalloproteinases, progesterone/oestrogen, antiepileptics and antifibrinolytics, have been studied for their suitability as neuroprotective agents in SAB [47-49]. But, none of them proved satisfactory.

NON-PHARMACOLOGICAL

Interventional

Intracerebral

Aside from the intra-arterial administration of nimodipine discussed above, balloon dilatation in the treatment of refractory symptomatic vasospasms also plays an important role. The best outcomes are achieved if treatment ensues within two hours after onset of the

symptoms [50]. Because material from the coronary angiography had to be used in the initial phase, the material has improved considerably in the last few years. At the same time, growing expertise has helped to lower periprocedural complications and improve the results, even in the case of multiple treatments [51] (see Table 2).

Intra-Aortic Counterpulsation

As an adaptation of the treatment for cardiogenic shock, this method involves the intra-aortic insertion of a balloon proximal to the cerebral vessels. If the aortic valve closes, it is inflated so as to increase the diastolic cerebral arterial flow [50].

Hypothermia

Evidence was found that hypothermia has a positive effect on mean flow velocity in the middle cerebral artery in the case of both increased ICP and DCI. This is still to be confirmed by larger studies [52].

Stellate Ganglion Block (SGB)

The potential efficacy is based on the assumption that noradrenergic sympathetic innervation of the cerebral vessels originates largely from the superior cervical ganglion. Consequently, this system has a vasoconstrictive effect. Vasorelaxation is therefore achieved by blocking this ganglion. The technique is simple: infiltration at the transverse process of C6 using approx. 8-10 ml of a local anaesthetic. In spite of the vasodilation (measured indirectly from the TCD), autoregulation seems be preserved when blocking the stellate ganglion [53]. One study of clipped SAH patients (n = 15) revealed that both a clinical improvement and a drop in TCD flow rates were achieved [54]. Since larger studies have not yet been conducted, the role of such a concept cannot be reliably judged.

Table 2. Evidence level of measures in refractory cerebral vasospasm

	Administration	Effect	Evidence level
Hypertension	IV	MAP increase	B
Balloon angioplasty	IA (cerebral)	Mechanical dilatation	B
Drug-eluting angioplasty	IA (bolus/continuous)	Vasodilation/anti-inflammatory	C
Intra-aortic counterpulsation	IA extracerebral	Increased cerebral perfusion	C
Ca^{++} channel blockers	Intrathecal	Vasodilation/anti-inflammatory	D
NO	Intrathecal	Vasodilation	D
Hypothermia	Systemic		D
Stellate block	Stellate ganglion	Vasodilation	D

IV: intravenous MAP: middle arterial pressure IA: intra-arterial

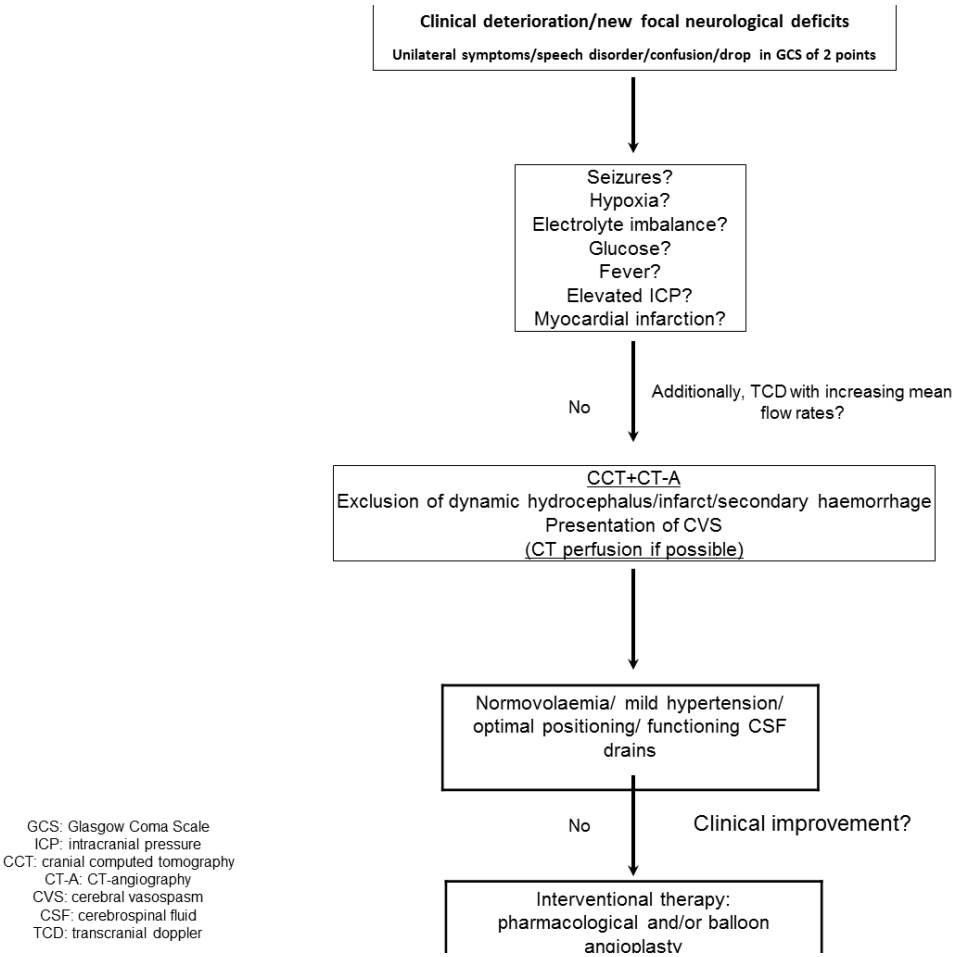

Figure 1. possible treatment algorithm.

CONCLUSION

There is no consistency in the terminology as regards CVS and DCI, meaning that vasospasm (on angiography/TCD), DIND and DCI are often used synonymously. DCI can also occur WITHOUT morphological changes, as various pathomechanisms occur simultaneously and do not necessarily lead to vasoconstriction. However, it is of utmost importance to recognize and treat these pathologies (see proposed treatment algorithm Figure 1). Despite intensive research at all levels, DCI therapy is still proving futile. Orally administered nimodipine is the only medicine to date that has exhibited a neuroprotective effect specifically in SAH. Hopefully, with growing knowledge of the pathophysiological background and translational studies, it will be possible to develop additional, effective treatment options. At the same time, it would be desirable to have reliable and easily detectable biomarkers for DCI with a view to establishing the diagnosis as well as monitoring treatment. Genetic factors that predispose patients to DCI may be the key to identifying and treating patients [55, 56] (Figure 1).

REFERENCES

[1] Eisenhut, M. Vasospasm in cerebral inflammation. *Int J Inflam*. Hindawi Publishing Corporation, 2014, 2014, 509707.

[2] van Gijn, J; Rinkel, GJ. Subarachnoid haemorrhage: diagnosis, causes and management. *Brain*., 2001 Feb, 124(Pt 2), 249–78.

[3] Frontera, JA; Fernandez, A; Schmidt, JM; Claassen, J; Wartenberg, KE; Badjatia, N; et al. Defining Vasospasm After Subarachnoid Hemorrhage: What Is the Most Clinically Relevant Definition? *Stroke*., 2009 May 22, 40(6), 1963–8.

[4] Ecker, A; Riemenschneider, PA. Arteriographic demonstration of spasm of the intracranial arteries, with special reference to saccular arterial aneurysms. *Journal of Neurosurgery*., 1951 Nov, 8(6), 660–7.

[5] Vergouwen, MDI; Vermeulen, M; van Gijn, J; Rinkel, GJE; Wijdicks, EF; Muizelaar, JP; et al. Definition of Delayed Cerebral Ischemia After Aneurysmal Subarachnoid Hemorrhage as an Outcome Event in Clinical Trials and Observational Studies: Proposal of a Multidisciplinary Research Group. *Stroke*., 2010 Sep 27, 41(10), 2391–5.

[6] Tjahjadi, M; König, R; Wirtz, CR; Woischneck, D; Kapapa, T. Cerebral Vasospasm and Health-Related Quality of Life After Subarachnoid Hemorrhage. *World Neurosurgery*. Elsevier Inc, 2013 Jul 8, 80(1-2), 113–20.

[7] Kusaka, G; Ishikawa, M; Nanda, A; Granger, DN; Zhang, JH. Signaling pathways for early brain injury after subarachnoid hemorrhage. *J Cereb Blood Flow Metab*., 2004 Aug, 24(8), 916–25.

[8] Macdonald, RL; Pluta, RM; Zhang, JH. Cerebral vasospasm after subarachnoid hemorrhage: the emerging revolution. *Nat Clin Pract Neurol*., 2007 May, 3(5), 256–63.

[9] Hughes, JT; Schianchi, PM. Cerebral artery spasm. A histological study at necropsy of the blood vessels in cases of subarachnoid hemorrhage. *Journal of Neurosurgery*., 1978 Apr, 48(4), 515–25.

[10] Kramer, A; Fletcher, J. Do Endothelin-Receptor Antagonists Prevent Delayed Neurological Deficits and Poor Outcomes After Aneurysmal Subarachnoid Hemorrhage? *A Meta-Analysis. Stroke*. 2009 Sep 25, 40(10), 3403–6.

[11] Fassbender, K; Hodapp, B; Rossol, S; Bertsch, T; Schmeck, J; Schütt, S; et al. Endothelin-1 in subarachnoid hemorrhage: An acute-phase reactant produced by cerebrospinal fluid leukocytes. *Stroke*., 2000 Dec, 31(12), 2971–5.

[12] Seifert, V; Löffler, BM; Zimmermann, M; Roux, S; Stolke, D. Endothelin concentrations in patients with aneurysmal subarachnoid hemorrhage. Correlation with cerebral vasospasm, delayed ischemic neurological deficits, and volume of hematoma. *Journal of Neurosurgery*., 1995 Jan, 82(1), 55–62.

[13] Yakubu, MA; Leffler, CW. Regulation of ET-1 biosynthesis in cerebral microvascular endothelial cells by vasoactive agents and PKC. *Am J Physiol*., 1999 Feb, 276(2 Pt 1), C300–5.

[14] Chaichana, KL; Pradilla, G; Huang, J; Tamargo, RJ. Role of inflammation (leukocyte-endothelial cell interactions) in vasospasm after subarachnoid hemorrhage. *World Neurosurgery*., 2010 Jan, 73(1), 22–41.

[15] Neil-Dwyer, G; Lang, DA; Doshi, B; Gerber, CJ; Smith, PW. Delayed cerebral ischaemia: the pathological substrate. *Acta Neurochir (Wien)*., 1994, 131(1-2), 137–45.

[16] Hirashima, Y; Nakamura, S; Endo, S; Kuwayama, N; Naruse, Y; Takaku, A. Elevation of platelet activating factor, inflammatory cytokines, and coagulation factors in the internal jugular vein of patients with subarachnoid hemorrhage. *Neurochem Res*., 1997 Oct, 22(10), 1249–55.

[17] Lauritzen, M; Dreier, JP; Fabricius, M; Hartings, JA; Graf, R; Strong, AJ. Clinical relevance of cortical spreading depression in neurological disorders: migraine; malignant stroke, subarachnoid and intracranial hemorrhage; and traumatic brain injury. *Journal of Cerebral Blood Flow &amp, Metabolism*. Nature Publishing Group, 2010 Nov 3, 31(1), 17–35.

[18] Dreier, JP; Major, S; Manning, A; Woitzik, J; Drenckhahn, C; Steinbrink, J; et al. Cortical spreading ischaemia is a novel process involved in ischaemic damage in patients with aneurysmal subarachnoid haemorrhage. *Brain*., 2009 Jun 24, 132(7), 1866–81.

[19] Bosche, B; Graf, R; Ernestus, RI; Dohmen, C; Reithmeier, T; Brinker, G; et al. Recurrent spreading depolarizations after subarachnoid hemorrhage decreases oxygen availability in human cerebral cortex. *Ann Neurol*. Wiley Subscription Services, Inc., A Wiley Company, 2010 May, 67(5), 607–17.

[20] Doukas, A; Petridis, AK; Barth, H; Jansen, O; Maslehaty, H; Mehdorn, HM. Resistant vasospasm in subarachnoid hemorrhage treated with continuous intraarterial nimodipine infusion. *Acta Neurochir Suppl*. Vienna: Springer Vienna, 2011, 112(Chapter 16), 93–6.

[21] Hänggi, D; Beseoglu, K; Turowski, B; Steiger, HJ. Feasibility and safety of intrathecal nimodipine on posthaemorrhagic cerebral vasospasm refractory to medical and endovascular therapy. *Clinical Neurology and Neurosurgery*., 2008 Sep, 110(8), 784–90.

[22] Kronvall, E; Undrén, P; Romner, B; Säveland, H; Cronqvist, M; Nilsson, OG. Nimodipine in aneurysmal subarachnoid hemorrhage: a randomized study of intravenous or peroral administration. *Journal of Neurosurgery*., 2009 Jan, 110(1), 58–63.

[23] Soppi, V; Karamanakos, PN; Koivisto, T; Kurki, MI; Vanninen, R; Jaaskelainen, JE; et al. A randomized outcome study of enteral versus intravenous nimodipine in 171 patients after acute aneurysmal subarachnoid hemorrhage. *World Neurosurgery*., 2012 Jul, 78(1-2), 101–9.

[24] SM, DM; GJE, R; VL, F; A, A; van den Bergh, WM; M, V; et al. Calcium antagonists for aneurysmal subarachnoid haemorrhage (Review). *Cochrane Library*., 2008 Jul, (2), 1–42.

[25] Feigin, VL; Rinkel, GJ; Algra, A; Vermeulen, M; van Gijn, J. Calcium antagonists in patients with aneurysmal subarachnoid hemorrhage: a systematic review. *Neurology*., 1998 Apr, 50(4), 876–83.

[26] Pickard, JD; Murray, GD; Illingworth, R; Shaw, MD; Teasdale, GM; Foy, PM; et al. Effect of oral nimodipine on cerebral infarction and outcome after subarachnoid haemorrhage: British aneurysm nimodipine trial. *BMJ*. BMJ Group, 1989 Mar 11, 298(6674), 636–42.

[27] Vergouwen, MDI; Vermeulen, M; de Haan, RJ; Levi, M; Roos, YB. Dihydropyridine calcium antagonists increase fibrinolytic activity: a systematic review. *J Cereb Blood Flow Metab*., 2007 Jul, 27(7), 1293–308.

[28] Pisani, A; Calabresi, P; Tozzi, A; D'Angelo V; Bernardi G. L-type Ca2+ channel blockers attenuate electrical changes and Ca2+ rise induced by oxygen/glucose deprivation in cortical neurons. *Stroke*., 1998 Jan, 29(1), 196–201–discussion202.

[29] Dreier, JP; Windmüller, O; Petzold, G; Lindauer, U; Einhäupl, KM; Dirnagl, U. Ischemia triggered by red blood cell products in the subarachnoid space is inhibited by nimodipine administration or moderate volume expansion/hemodilution in rats. *Neurosurgery*., 2002 Dec, 51(6), 1457–65–discussion1465–7.

[30] Wolf, S; Martin, H; Landscheidt, JF; Rodiek, SO; Schürer, L; Lumenta, CB. Continuous Selective Intraarterial Infusion of Nimodipine for Therapy of Refractory Cerebral Vasospasm. *Neurocrit Care*., 2009 Dec 22, 12(3), 346–51.

[31] Kim, JH; Park, IS; Park, KB; Kang, DH; Hwang, SH. Intraarterial Nimodipine Infusion to Treat Symptomatic Cerebral Vasospasm after Aneurysmal Subarachnoid Hemorrhage. *J Korean Neurosurg Soc*., 2009, 46(3), 239.

[32] Tsurushima, H; Kamezaki, T; Nagatomo, Y; Hyodo, A; Nose, T. Complications associated with intraarterial administration of papaverine for vasospasm following subarachnoid hemorrhage--two case reports. *Neurol Med Chir (Tokyo)*., 2000 Feb, 40(2), 112–5.

[33] Auer, LM; Ito, Z; Suzuki, A; Ohta, H. Prevention of symptomatic vasospasm by topically applied nimodipine. *Acta Neurochir (Wien)*., 1982, 63(1-4), 297–302.

[34] Westermaier, T. Neuroprotective Treatment Strategies for Delayed Cerebral Ischemia after Subarachnoid Hemorrhage – Review of Literature and Future Prospects. *J Neurol Neurophysiol*., 2013, 05(01), 1–8.

[35] Rowland, MJ; Hadjipavlou, G; Kelly, M; Westbrook, J; Pattinson, KTS. Delayed cerebral ischaemia after subarachnoid haemorrhage: looking beyond vasospasm. *Br J Anaesth*., 2012 Aug 9, 109(3), 315–29.

[36] DENNY-BROWN, D. The treatment of recurrent cerebrovascular symptoms and the question of "vasospasm". *Med Clin North Am*., 1951 Sep, 35(5), 1457–74.

[37] Dankbaar, JW; Slooter, AJ; Rinkel, GJ; Schaaf, ICVD. Effect of different components of triple-H therapy on cerebral perfusion in patients with aneurysmal subarachnoid haemorrhage: a systematic review. *Crit Care.* BioMed Central Ltd, 2010, 14(1), R23.

[38] Rinkel, GJE; Feigin, VL; Algra, A; van Gijn, J. Circulatory volume expansion therapy for aneurysmal subarachnoid haemorrhage. *Cochrane Database Syst Rev*., 2004, (4), CD000483.

[39] Connolly, ES; Rabinstein, AA; Carhuapoma, JR; Derdeyn, CP; Dion, J; Higashida, RT; et al. Guidelines for the management of aneurysmal subarachnoid hemorrhage: a guideline for healthcare professionals from the American Heart Association/american Stroke Association. *Stroke*. Lippincott Williams & Wilkins, 2012, pp, 1711–37.

[40] Dong, JF; Cruz, MA; Aboulfatova, K; Martin, C; Choi, H; Bergeron, AL; et al. Magnesium maintains endothelial integrity; up-regulates proteolysis of ultra-large von Willebrand factor; and reduces platelet aggregation under flow conditions. *Thromb Haemost*., 2008 Mar, 99(3), 586–93.

[41] van den Bergh, WM; Algra, A; van der Sprenkel, JWB; Tulleken, CAF; Rinkel, GJE. Hypomagnesemia after Aneurysmal Subarachnoid Hemorrhage. *Neurosurgery*., 2003 Feb, 52(2), 276–82.

[42] MD, SMDM; MD, PAA; MD, PWPV; van Kooten, MDF; MD, HAK; MD, JB; et al. Magnesium for aneurysmal subarachnoid haemorrhage (MASH-2): a randomised placebo-controlled trial. *The Lancet.* Elsevier Ltd, 2012 Jul 7, 380(9836), 44–9.

[43] Vergouwen, MDI; de Haan, RJ; Vermeulen, M; Roos, YBWEM. Effect of statin treatment on vasospasm, delayed cerebral ischemia, and functional outcome in patients with aneurysmal subarachnoid hemorrhage: a systematic review and meta-analysis update. *Stroke.* Lippincott Williams & Wilkins, 2010 Jan, 41(1), e47–52.

[44] Liu, J; Chen, Q. Effect of statins treatment for patients with aneurysmal subarachnoid hemorrhage: a systematic review and meta-analysis of observational studies and randomized controlled trials. *Int J Clin Exp Med*., 2015, 8(5), 7198–208.

[45] FMedSci, PJK; MSc, CLT, PhD, CS, FRCS, PPJH, PhD, PGDM, Collaborators, FTS. Simvastatin in aneurysmal subarachnoid haemorrhage (STASH): a multicentre randomised phase 3 trial. *Lancet Neurol.* Elsevier Ltd, 2014 Jun 10, 13(7), 666–75.

[46] Shen, J; Pan, JW; Fan, ZX; Xiong, XX; Zhan, RY. Dissociation of vasospasm-related morbidity and outcomes in patients with aneurysmal subarachnoid hemorrhage treated with clazosentan: a meta-analysis of randomized controlled trials. *Journal of Neurosurgery*., 2013 Jul, 119(1), 180–9.

[47] Young, AMH; Karri, SK; Helmy, A; Budohoski, KP; Kirollos, RW; Bulters, DO; et al. Pharmacologic Management of Subarachnoid Hemorrhage. *World Neurosurgery*. Elsevier In, 2015 Jul 1, 84(1), 28–35.

[48] Behrouz, R; Sadat-Hosseiny, Z. Pharmacological Agents in Aneurysmal Subarachnoid Hemorrhage. *Clinical Neuropharmacology*., 2015 May, 1–5.

[49] Mehta, V; Russin, J; Spirtos, A; He, S; Adamczyk, P; Amar, AP; et al. Matrix Metalloproteinases in Cerebral Vasospasm following Aneurysmal Subarachnoid Hemorrhage. *Neurology Research International*., 2013, 2013(7), 1–4.

[50] Findlay, JM; Nisar, J; Darsaut, T. Résumé. *Can J Neurol Sci*., 2015 Sep 2, 1–18.

[51] Chalouhi, N; Tjoumakaris, S; Thakkar, V; Theofanis, T; Hammer, C; Hasan, D; et al. Endovascular management of cerebral vasospasm following aneurysm rupture: outcomes and predictors in 116 patients. *Clinical Neurology and Neurosurgery*., 2014 Mar, 118, 26–31.

[52] Seule, M; Muroi, C; Sikorski, C; Hugelshofer, M; Winkler, K; Keller, E. Therapeutic Hypothermia Reduces Middle Cerebral Artery Flow Velocity in Patients with Severe Aneurysmal Subarachnoid Hemorrhage. *Neurocrit Care*., 2013 Oct 17, 20(2), 255–62.

[53] Naidu, RK. *A Review of the Stellate Ganglion Block/Cervical Sympathetic Block on the Prevention and Therapy of Cerebral Vasospasm After Subarachnoid Hemorrhage*. ICU Director. SAGE Publications, 2013 Jul 19, 4(4), 161–5.

[54] Dash, H; Chouhan, R; Jain, V; Rath, G; Bithal, P; Suri, A. Stellate ganglion block for treatment of cerebral vasospasm in patients with aneurysmal subarachnoid hemorrhage - A preliminary study. *J Anaesth Clin Pharmacol*., 2011, 27(4), 516–6.

[55] Rosalind Lai, PM; Du, R. Role of Genetic Polymorphisms in Predicting Delayed Cerebral Ischemia and Radiographic Vasospasm After Aneurysmal Subarachnoid Hemorrhage: A Meta-Analysis. *World Neurosurgery*., 2015 Jun 11.

[56] Baumann, A; Devaux, Y; Audibert, G; Zhang, L; Bracard, S; Colnat-Coulbois, S; et al. Gene Expression Profile of Blood Cells for the Prediction of Delayed Cerebral Ischemia after Intracranial Aneurysm Rupture: A Pilot Study in Humans. *Cerebrovasc Dis*. Karger Publishers, 2013, 36(3), 236–42.

In: Encyclopedia of Surgery (22 Volume Set)
Editors: Andreas Lehrer and Kristin Mueller
ISBN: 978-1-53618-329-0
© 2020 Nova Science Publishers, Inc.

Chapter 73

INTENSIVE CARE: MONITORING

Werner Klingler[1,2] and Dirk Repkewitz[2]
[1]Division of Neurophysiology, Ulm University, Ulm, Germany
[2]Department of Neuroanaesthesiology, Neurosurgical Ulm University Hospital, Guenzburg, Germany

ABSTRACT

Besides direct and indirect cerebral lesions, subarachnoid haemorrhage (SAH) may cause severe alterations of metabolism as well as cardiac, pulmonary and other medical complications. Specialized intensive care is required to improve neurological outcome and overall survival. This chapter covers monitoring of patients suffering from SAH in the intensive care unit (ICU). Prudent observation and evaluation of these parameters helps to manage the course of disease.

INTRODUCTION

Intensive care in specialized neurocritical care centers is associated with a lower mortality and better outcome in SAH compared to general ICU's (Kurtz et al. 2011). Multimodal cerebral monitoring including clinical examination, assessment of cerebral perfusion, intracranial pressure and other specific parameters is essential for an individualized treatment plan and for prevention of secondary brain injury (Figure 1). This chapter focuses on ICU monitoring after the initial SAH. In this critical time interval there is a high risk for re-bleeding, epileptic seizures and/or delayed cerebral ischemia (DCI) due to vasospasm. Indeed, vasospasm can occur up to roughly 20 days after the initial event and is associated to mortality, functional and cognitive disability (Le Roux et al. 2014, Lantigua et al. 2015).

Despite the brain weighs only roughly 2% of lean body mass, it is allocated 20% of cardiac output at rest. Perfusion and oxygenation are crucial for cerebral energy metabolism, which is primarily based on glucose degradation and the respiratory chain. Early detection of an imbalance between cerebral oxygen supply and demand is relevant to outcome in these patients (Diringer et al. 2009).

CLINICAL EXAMINATION

Whereas the initial presentation of SAH is characterized by severe headache, meningism and neurological impairment, the later course of symptoms varies significantly, most notably during ICU treatment. Here, detection of re-bleeding and vasospasm is of vital importance. Clinical examination of SAH patients is fast and focuses on vital signs, level of consciousness and motor responses. Asymmetric motor responses or partial epileptic seizures may be an indication of focal brain lesion hinting towards vasospasm. In awake patients one of the first signs of a developing vasospasm usually are cognitive deficits such as an attention deficit or change in conscious state. Quantification of the level of consciousness is best achieved by structured assessment of sedation and agitation. Several clinical grading scales have been developed. The Glasgow Coma Scale is widely known, however it is only validated for traumatic brain injury. Instead, the Richmond Agitation Sedation Scale (RASS) is designed for ICU use and has the advantage of a high validity and interrater reliability (Ely et al. 2003).

In unconscious patients, a key element is the examination of the pupillary light reflex, which integrates the optic and oculomotor nerves and brainstem nuclei. Instrument-based documentation of pupillary function is commercially available. The oculomotor nerve partially controls eye movements and activates the ciliary muscle, via parasympathetic fibers, i.e., miosis. The oculomotor nerve trails along the base of the brain and is especially vulnerable to direct pressure lesions or secondary damage. Up to one third of SAH patients show intraocular hemorrhage, known as Terson´s syndrome. This phenomenon likely occurs due to elevated ICP. Other symptoms of elevated ICP include cephalgia, nausea and vomiting including cranial nerve palsies. Indeed, persistent ocular divergence, ocular bobbing, lack of pupillary light reflex, unequal or irregular pupils are signs of severe brain damage and associated with poor neurological prognosis. Damage of the autonomous nuclei in the brainstem leads to pathological breathing patterns, cardiac arrhythmia and finally death (Miyata et al. 2014).

MONITORING OF THE INTRACRANIAL PRESSURE (ICP)

ICP monitoring allows an estimation of cerebral perfusion by calculating the perfusion pressure as the difference between mean arterial pressure and ICP (see chapter 13).

In over 90% of SAH patients some degree of elevated ICP is found, mainly within the first 8 days after the bleeding. The Hunt and Hess grade correlates with the degree of ICP elevation. Mortality is increased in those patients, which have significantly elevated post-SAH ICP levels (Lv et al. 2015). Hence, ICP monitoring is advisable in those patients showing clinical or radiographic signs and symptoms of elevated ICP, especially in sedated patients (chapter 9). Invasive ICP monitoring is used significantly more frequently in neurocritical care units compared to general ICU´s. Whether ICP-directed therapy is causative for better outcome in these specialized units has not been shown yet (Kurtz et al. 2011). There are several methods for assessment of ICP. Most centers use ventricular catheters, which have the advantage of potential use for CSF drain in order to reduce intracranial volume and also to obtain material for microbiological analysis. Other possibilities include the insertion of a

small pressure sensor via a small drill trepanation. The sensor can be placed in the epidural, subdural, subarachnoid or parenchymatous space (Diringer et al. 2011)

TRANSCRANIAL DOPPLER ULTRASONOGRAPHY (TCD)

Roughly 30 – 70% of SAH patients show radiographic evidence of vasospasm, but only half of those experience neurological symptoms. Clinical signs of vasospasm fluctuate and often are unspecific. The frequent use of sedatives in SAH patients further limits clinical evaluation (Kistka et al. 2013, Le Roux et al. 2014). Vasospasm is detected by cerebral angiography with high sensitivity and specificity. TCD bridges the gap between physiological and radiological examination. The main advantage of TCD is its non-invasive nature and bedside evaluation. However, analysis is limited to the blood supply originating from trunk of the middle cerebral artery. Technical problems such as inadequate insonation window or interrater variability account for moderate sensitivity, especially in the assessment of the outflow into the anterior cerebral artery. In other words, TCD is an easy applicable method with a high predictive value for vasospasm detection predominantly of the middle cerebral artery. Increased flow velocities (> 120cm/s), most notably in combination with clinical suspicion of vasospasm, should prompt additional investigations such as diagnostic imaging (see chapter 9).

Figure 1. Neurocritical care including intracranial pressure monitoring and brain oxygenation monitoring [1], processed EEG [2], continuous cardiac output monitoring [3], ECG, invasive blood pressure, SpO_2, pCO_2, temperature monitoring [4] and TCD [5].

NEAR-INFRARED SPECTROSCOPY (NIRS)

NIRS is another non-invasive method for estimation of cerebral perfusion. Absorption of specific near-infrared wavelengths (700-1000nm) depends on tissue oxygenation and mitochondrial oxygen metabolism. Thereby cerebral hypoperfusion, e.g., in carotid surgery or

temporary clipping, can be detected intraoperatively. In the ICU, NIRS may detect vasospasm but also impairment of cerebral autoregulation. However, NIRS electrodes mainly cover the frontal lobe and are vulnerable to sweat and other obstacles impairing electrical impedance (Zweifel et al. 2010).

BRAIN OXYGENATION MEASUREMENTS AND CEREBRAL MICRODIALYSIS

Even if cerebral perfusion pressure and other parameters are normal, neuronal metabolism may be impaired in SAH. In these conditions, an accumulation of acidic metabolites as well as a drop of brain tissue oxygenation ($ptiO_2$) and pH can be observed by tissue microdialysis. Several studies suggest a link between regional ptiO2 and vasospasm respectively impaired autoregulation. However, sample sizes are small and results not fully consistent (Kistka et al. 2012). Several metabolic markers can be measured using microdialysis. Glycolytic metabolites include glucose, lactate and pyruvate. Neuronal degradation goes along with an increase in glutamate, nitrite and taurine concentrations. These parameters as well as the lactate/pyruvate ratio may even be prognostic markers for neurological outcome (Sarrafzadeh et al. 2004). A pre-requisite and limitation is the necessity of an invasive implantation of a microcathether into the relevant brain region and the sensors are only monitoring a localized region of the brain. A modification of the above described microcatheters is a thermal diffusion flowmetry probe. This intracerebral microcathether contains a temperature sensitive electrode, which detects heat signals emitted by a gold electrode of the same device. The time delay is a measure for local cerebral blood flow (Kistka et al. 2013).

BIOMARKERS

The occurrence of neuronal degradation products, enzymes and specific proteins in the cerebro-spinal fluid (CSF) of SAH patients supports the concept of monitoring these biomarkers for prognostication and vasospasm detection. A well recognized feature of SAH is a centrally mediated sympathetic response. Indeed, increased CSF and blood levels of epinephrine are independent prognostic predictors of poor prognosis. One of the best studied biomarkers in SAH is the calcium-binding glial protein S100β. Brain lesions of various aetiology lead to release of S100β, which is not only found in elevated concentrations in the CSF but to a lesser extent also in peripheral blood. S100β may be a prognostic biomarker of SAH, but it does not seem to be a specific indicator for vasospasm or DCI. Neuro-inflammatory response is a key element in the pathophysiology of SAH. Indeed, acute phase proteins such as C-reactive protein or cytokines, e.g., TNF-α and IL-1β are variably and asynchronously upregulated in SAH. IL-1β and other cytokines are endogenous pyrogens that impair thermoregulation. Other proteins, which are released in brain damage, are for example neuron-specific enolase, apolipoprotein E, amyloid β protein and creatine kinase BB. High CSF concentrations of those proteins may indicate poor outcome. A promising approach is the investigation of vasogenic biomarkers because there are indications, that vascular

endothelial growth factor and the vasoconstrictive substance endothelin-1 is elevated in SAH (Hong et al. 2014). In conclusion, analysis of biomarkers may help for the differentiation between re-bleeding and vasospasm. Currently, its use in SAH is still limited due to the need for sophisticated laboratory technology and lack of point of care specificity.

ELECTROPHYSIOLOGICAL MONITORING

Vasospasm and non-convulsive epileptic seizures are frequent complications of SAH but difficult to detect in the unconscious patient. Electroencephalography (EEG) is a tool to assess electrical brain activity. The electrical signal of the EEG recording is based on summation of depolarization events in neighbouring brain cells, most notably of postsynaptic potentials of apical cortical neurons. In contrast to the ECG waveform, the registration is characterized by scattered potentials. Amplitude and and frequency of the EEG signal are indirect markers for synchronicity of neuronal excitation (Table 1). A decrease in the Alpha/Delta frequency band ratio is associated with delayed cerebral ischemia due to vasospasm (Claassen et al. 2004). EEG can also detect epileptic seizures, which in SAH patients are often a hint for aneurysmal re-bleeding. Non-convulsive seizures occur in 10-20% of comatose SAH patients and in some patients may explain unconsciousness (Kistka et al. 2013, Lantigua et al. 2015).

The question arises, whether the main goal for the prevention of DCI may be achieved by using modified EEG recordings, which are already in use for the analysis of the depth of sedation and have the advantage of easy interpretation. Processed EEG parameters, such as the bispectral index and the suppression ratio have been shown to have prognostic value concerning neurological outcome following hypoxic brain damage (Selig et al. 2014). Potential use of such devices in stroke/vasospasm detection is currently under investigation. Similarly the use of evoked potentials is still controversial for outcome prognosis or early detection of vasospasm in the ICU, although evoked potentials are frequently used during aneurysm surgery to indicate a loss of neuronal function respectively diminished local blood perfusion (Wachter et al. 2011). All discussed electrophysiological methods are difficult to integrate in the ICU due to technical pitfalls such as electrical noise fields, nursing care as well as requiring specific expertise for the application and interpretation of the complex signals (Le Roux et al. 2014).

Table 1. EEG-frequency bands and level of consciousness

Frequency range	Label	Symbol	Level of consciousness
0,5-4 Hz	Delta	δ	deep sedation, trance
4-8 Hz	Theta	θ	hypnosis
8-13 Hz	Alpha	α	awake, closed eyes
13-30 Hz	Beta	ß	awake, concentrated, REM sleeping cycle
30-42 Hz	Gamma	γ	high information flow

Reduced metabolic activity due to e.g., hypoxia or sedative drugs results in synchronisation of potentials and reduction of EEG frequency.

CARDIO-RESPIRATORY MONITORING

Arterial blood pressure is a hemodynamic index, most relevant for goal-directed therapy in SAH patients (chapter 13). Correct evaluation of blood pressure is not simple, there are pitfalls in the technical assessment but also since the pressure pulse waveform depends on the point of measurement. Invasive blood pressure monitoring is superior to non-invasive methods both in terms of accuracy and time restraints (Kim et al. 2014). The insertion of an arterial line is rarely associated with complications such as infection, bleeding or thrombosis. Non-invasive blood pressure readings disguise hypotensive intervals by overestimating systolic arterial blood pressure resulting in elevated ICU mortality compared to invasive blood pressure monitoring (Lehman et al. 2013).

Physiologically, systolic arterial blood pressure is roughly 20mmHg to 40mmHg higher in the legs than in the arms even in supine position. Systolic blood pressure rises and blood flow velocity decreases with increasing distance from the heart, which results in different pulse waveforms. Hence, the mean arterial pressure (MAP) as the geometric mean of the pulse wave is the best parameter for therapeutic decisions. Continuous cardiac output monitoring and evaluation of stroke volume variability may be helpful in some patients, most notably for evaluation of the dilemma volume versus adrenergic drugs (Lehman et al. 2013).

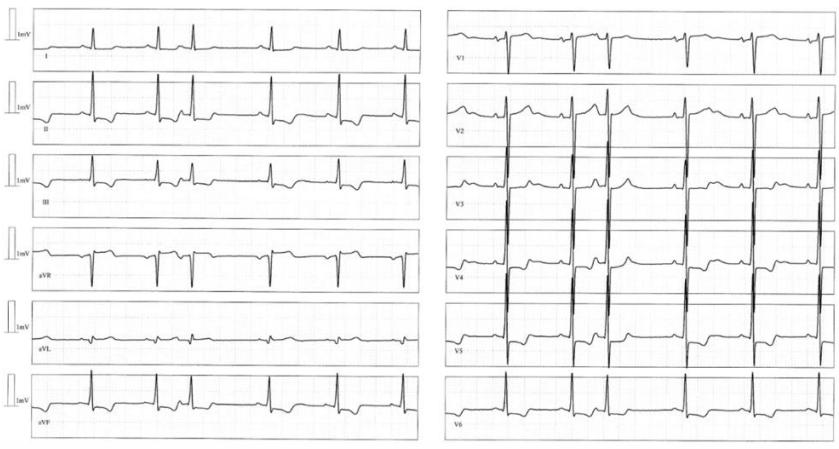

Figure 2. ECG alterations in SAH. Dysrhythmia and ST-segment abnormalities.

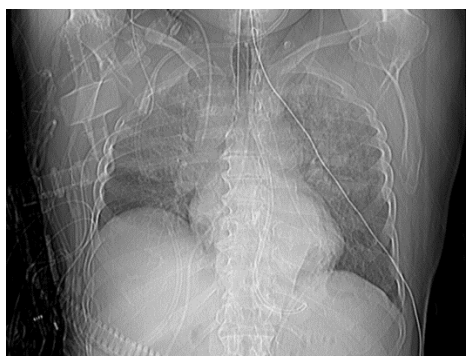

Figure 3. Neurogenic pulmonary edema.

ICU monitoring further requires continuous electrocardiographic (ECG) monitoring, because 50-100% of patients present cardiac arrhythmia and/or signs of myocardial ischemia as a consequence of the SAH induced adrenergic surge (Cushing´s reflex). ST-segment abnormalities (Figure 2) may be the primary reason for hospital admission. Myocardial stress markers, such as Troponin, N-terminal end of the prohormone brain natriuretic peptide (NTproBNP) and CK-MB may be elevated in SAH patients. Similarly, lung insufficiency of variable degree is a well recognized complication of SAH and causes up to 30% of deaths after SAH. Mascia (2009) introduced a double hit model of lung injury after severe brain lesion. The initial adrenergic reaction hits the lung by constriction of pulmonary veins resulting in pulmonary hypertension, increasing hydrostatic pressure, cardiac burden and ventilation/perfusion deficit. The second hit is mediated by a systemic inflammatory response syndrome, which not only causes an increase of the permeability in the blood-brain barrier, but also causes leaky lung capillaries. Inflammatory neuropeptides activate neutrophil infiltration into the lungs, which cause further deterioration of pulmonary function. The lungs are then even more vulnerable to mechanical stress of invasive ventilation. Apart from neurogenic pulmonary edema (Figure 3) there are other reasons impairing pulmonary function such as respiratory tract infections, aspiration, pulmonary embolisation and drugs influencing pulmonary shunt (Mascia 2009, Diringer et al. 2011, Lantigua et al. 2015). Vasodilating drugs, most notably nimodipine, hamper the physiological vasoconstriction of non- or low-ventilated alveoli, thus increasing pulmonary shunt. The above mentioned mechanisms might be one reason, why lungs are rarely viable for organ donation after severe brain injury Furthermore, pCO2 has to be monitored closely in SAH because of its key role in controlling cerebral blood flow (chapter 15).

GENERAL CONSIDERATIONS

General considerations in SAH include monitoring of hemoglobin and of the coagulation system for obvious reasons. A key factor in SAH monitoring are glucose levels, because there is strong evidence that hypo- as well as hyperglycemia is associated to poor neurological outcome. Further parameters include hormones and electrolyte levels (chapter 13). Tight monitoring of temperature in indispensable in SAH patients as thermoregulation is impaired in this group of patients. Neurogenic, non-infectious fever usually occurs within the first 3 days of admission and has a higher incidence poor grade SAH and in those patients with intraventricular bleeding. Common causes of infectious fever include cathether infections, respiratory tract infections or ventriculitis. Aggressive temperature control is indispensable and achieved by pharmacological and physical cooling including intravascular cooling cathethers. Surprisingly, therapeutic hypothermia has failed to show a benefit in SAH (Karnatovskaia et al. 2014). Other medical complications include thrombocytopenia, hepatic and renal dysfunction. The gastrointestinal function is often impaired due to adrenergic reflexes and neurogenic inflammatory response. Osmotic stimulation of peristalsis and early enteral nutrition is beneficial to prevent secondary complications as gastrointestinal bleeding or ileus (Diringer et al. 2011, Le Roux et al. 2014, Lantigua et al. 2015).

SUMMARY STATEMENT

Survival and neurological outcome after SAH depends on specific complications such as vasospasm and re-bleeding but also on a variety of general medical parameters. Specific monitoring is essential for management of SAH patients. Detection of vasospasm is essential but not trivial, because all discussed methods have limitations. Recognition and treatment of the typical medical complications of SAH is another key element in the management of SAH-patients. Hence, multimodal monitoring and specific neurocritical care is a decisive factor for overall outcome.

REFERENCES

Claassen, J; Hirsch, LJ; Kreiter, KT; Du, EY; Connolly, ES; Emerson, RG; Mayer, SA. Quantitative continuous EEG for detecting delayed cerebral ischemia in patients with poor-grade subarachnoid hemorrhage. *Clin Neurophysiol.*, 2004 Dec, 115(12), 2699-710.

Diringer, MN; Bleck, TP; Claude Hemphill, J; 3rd, Menon, D; Shutter, L; Vespa, P; Bruder, N; Connolly, ES; Jr, Citerio, G; Gress, D; Hänggi, D; Hoh, BL; Lanzino, G; Le Roux, P; Rabinstein, A; Schmutzhard, E; Stocchetti, N; Suarez, JI; Treggiari, M; Tseng, MY; Vergouwen, MD; Wolf, S; Zipfel, G. Neurocritical Care Society. Critical care management of patients following aneurysmal subarachnoid hemorrhage: recommendations from the Neurocritical Care Society's Multidisciplinary Consensus Conference. *Neurocrit Care.*, 2011 Sep, 15(2), 211-40

Ely, E; Truman, B; Shintani, A; Thomason, J; Wheeler, A; Gordon, S; Francis, J; Speroff, T; Gautam, S; Margolin, R; Sessler, C; Dittus, R; Bernard, G. Monitoring sedation status over time in ICU patients: reliability and validity of the Richmond Agitation-Sedation Scale (RASS). *JAMA.*, 2003 Jun 11, 289(22), 2983-91.

Hong, CM; Tosun, C; Kurland, DB; Gerzanich, V; Schreibman, D; Simard, JM. Biomarkers as outcome predictors in subarachnoid hemorrhage--a systematic review. *Biomarkers*, 2014 Mar, 19(2), 95-108.

Karnatovskaia, LV; Lee, AS; Festic, E; Kramer, CL; Freeman, WD. Effect of prolonged therapeutic hypothermia on intracranial pressure, organ function, and hospital outcomes among patients with aneurysmal subarachnoid hemorrhage. *Neurocrit Care.*, 2014 Dec, 21(3), 451-61.

Kim, SH; Lilot, M; Sidhu, KS; Rinehart, J; Yu, Z; Canales, C; Cannesson, M. Accuracy and precision of continuous noninvasive arterial pressure monitoring compared with invasive arterial pressure: a systematic review and meta-analysis. *Anesthesiology*, 2014 May, 120(5), 1080-97.

Kistka, H; Dewan, MC; Mocco, J. Evidence-based cerebral vasospasm surveillance. *Neurol Res Int.*, 2013, 2013, 256713.

Kurtz, P; Fitts, V; Sumer, Z; Jalon, H; Cooke, J; Kvetan, V; Mayer, SA. How does care differ for neurological patients admitted to a neurocritical care unit versus a general ICU? *Neurocrit Care.*, 2011 Dec, 15(3), 477-80. doi: 10.1007/s12028-011-9539-2.

Lantigua, H; Ortega-Gutierrez, S; Schmidt, JM; Lee, K; Badjatia, N; Agarwal, S; Claassen, J; Connolly, ES; Mayer, SA. Subarachnoid hemorrhage: who dies, and why? *Crit Care*., 2015 Aug 31, 19, 309.

Lehman, LH; Saeed, M; Talmor, D; Mark, R; Malhotra, A. Methods of Blood Pressure Measurement in the ICU. *Crit Care Med*., 2013 Jan, 41(1), 34–40.

Le Roux, P; Menon, DK; Citerio, G; Vespa, P; Bader, MK; Brophy, GM; Diringer, MN; Stocchetti, N; Videtta, W; Armonda, R; Badjatia, N; Böesel, J; Chesnut, R; Chou, S; Claassen, J; Czosnyka, M; De Georgia, M; Figaji, A; Fugate, J; Helbok, R; Horowitz, D; Hutchinson, P; Kumar, M; McNett, M; Miller, C; Naidech, A; Oddo, M; Olson, D; O'Phelan, K; Provencio, JJ; Puppo, C; Riker, R; Robertson, C; Schmidt, M; Taccone, F. Consensus summary statement of the International Multidisciplinary Consensus Conference on Multimodality Monitoring in Neurocritical Care: a statement for healthcare professionals from the Neurocritical Care Society and the European Society of Intensive Care Medicine. *Neurocrit Care*., 2014 Dec, 21 Suppl 2, S1-26.

Lv, Y; Wang, D; Lei, J; Tan, G. Clinical observation of the time course of raised intracranial pressure after subarachnoid hemorrhage. *Neurol Sci*., 2015 Jul, 36(7), 1203-10.

Mascia, L. Acute lung injury in patients with severe brain injury: a double hit model. *Neurocrit Care*., 2009 Dec, 11(3), 417-26.

Miyata, K; Mikami, T; Asai, Y; Iihoshi, S; Mikuni, N; Narimatsu, E. Subarachnoid hemorrhage after resuscitation from out-of-hospital cardiac arrest. *J Stroke Cerebrovasc Dis*., 2014 Mar, 23(3), 446-52.

Sarrafzadeh, AS; Haux, D; Lüdemann, L; Amthauer, H; Plotkin, M; Küchler, I; Unterberg, AW. Cerebral ischemia in aneurysmal subarachnoid hemorrhage: a correlative microdialysis-PET study. *Stroke*, 2004 Mar, 35(3), 638-43.

Selig, C; Riegger, C; Dirks, B; et al. Bispectral index and suppression ratio as an early predictor of unfavourable neurological outcome after cardiac arrest. *Resuscitation*, 2014, 85, 221-6.

Wachter, D; Christophis, P; Stein, M; Oertel, MF. Use of multimodal electrophysiological monitoring to predict outcome after subarachnoid hemorrhage? A prospective series. *J Neurosurg Sci*., 2011 Sep, 55(3), 179-87.

Zweifel, C; Castellani, G; Czosnyka, M; Carrera, E; Brady, KM; Kirkpatrick, PJ; Pickard, JD; Smielewski, P. Continuous assessment of cerebral autoregulation with near-infrared spectroscopy in adults after subarachnoid hemorrhage. 2010 *Stroke*, 41(9), 1963–1968.

In: Encyclopedia of Surgery (22 Volume Set)
Editors: Andreas Lehrer and Kristin Mueller
ISBN: 978-1-53618-329-0
© 2020 Nova Science Publishers, Inc.

Chapter 74

ENDOVASCULAR TREATMENT OPTIONS FOR CEREBRAL VASOSPASM AFTER SPONTANEOUS SUBARACHNOID HAEMORRHAGE

Yigit Ozpeynirci and Bernd Schmitz
Section Neuroradiology, University of Ulm, Günzburg, Germany

ABSTRACT

When vasospasm is suspected in a patient with subarachnoid haemorrhage, medical treatment is usually the first choice. Unfortunately, vasospasm is often refractory to medical therapy and, moreover, the percentage of patients who cannot tolerate mainstream non-invasive treatment, usually due to cardiopulmonary complications, is not minute. Early endovascular treatment appears to be the best alternative for this group of patients.

Endovascular treatment of cerebral vasospasm is divided into two categories: chemical dilatation of the spasm by intra-arterial administration of vasoactive drugs, and transluminal balloon angioplasty of spastic segments. Flow augmentation strategies involving aortic obstruction with balloons are being actively investigated. However, they have not yet found a place in current practice.

Keywords: vasospasm, endovascular, angioplasty

GENERAL INDICATIONS FOR AND TIMING OF INVASIVE INTERVENTIONAL MANAGEMENT

In their guidelines, the American Heart Association (AHA) and American Stroke Association (ASA) consider endovascular therapy as reasonable in patients with symptomatic cerebral vasospasm (CV), recommending it in particular for those who do not rapidly respond to hypertensive therapy (Class IIa; Level of Evidence B) [1].

Endovascular intervention is often performed in patients who, despite intensive medical therapy, have a diminishing neurological status, develop sudden focal neurological deficits or in whom there is concern regarding complications from medical management. In many poor grade SAHs, however, routine clinical examination is not sensitive to acute changes in neurological status, since most of these patients are already comatose. The same applies to intubated and sedated patients. In these patients, the physician therefore has to rely on serial non-invasive imaging studies and it would be wise to treat moderate to severe CV revealed by such studies and confirmed by digital subtraction angiography (DSA).

Transcranial Doppler ultrasound (TCD) is an easy-to-perform bedside method which can be used on a daily basis during the vasospasm-sensitive phase to detect rising flow velocities. It is also helpful in the follow-up of patients after treatment.

CT angiography (CTA) supported by CT perfusion (CTP) is more sensitive than TCD in the detection of CV. CTP is able to illustrate the perfusion at tissue level and thus is sensitive to CV of both proximal and distal arteries. It is a very helpful in demonstrating delayed cerebral ischaemia (DCI) and impending infarction in intubated patients or patients with low Glasgow Coma Scores (GCS) [9] (Figure 1).

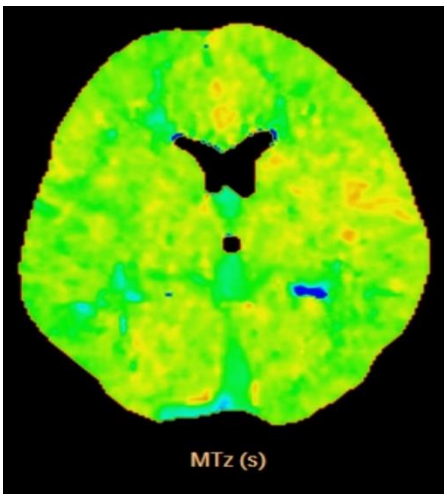

(A)

(B)

Figure 1. (Continued).

(C)

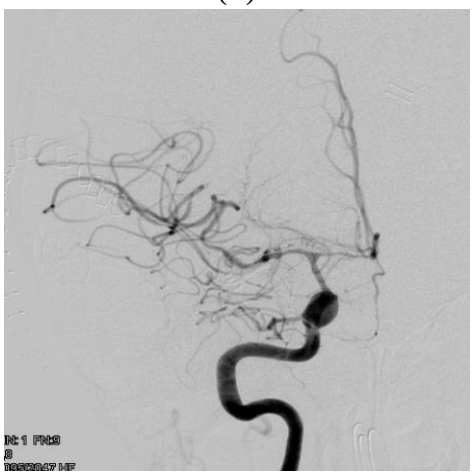

(D)

(E)

Figure 1. The Mean Transit Time (MTT) map (A) shows prolongation in both ACA territories and the right MCA territory without deficient perfusion on the CBV map (not shown). CTA demonstrates severe CV (B and C). DSA confirms the severe CV on the right (D). Control DSA 10 days after continuous IAIT with nimodipine reveals complete resolution of CV (E).

Angiographic findings of CV consist of decreased luminal calibre, increased cerebral circulation time and in severe cases retrograde filling of the affected vascular territory through leptomeningeal collaterals.

Studies suggest that there is a 2h time window after symptom onset in most patients during which endovascular therapy will be beneficial [2, 3, 4, 5, 6, 7, 8]. Thus it is reasonable to frequently check the neurological status of awake patients and assess the flow velocities of cerebral arteries via TCD in the patient with lower GCSs.

ENDOVASCULAR PROPHYLAXIS

As prophylactic transluminal balloon angioplasty (TBA) is related to very high mortality and has not been found to have a positive effect on outcome, and the therapeutic effects of all drugs administered IA are transient, CV prophylaxis is not recommended [1, 7].

INTRA-ARTERIAL INFUSION THERAPY (IAIT)

Several vasodilator agents have been infused intra-arterial (IA) through transarterial catheters to treat patients with CV. They include phosphodiesterase inhibitors (papaverine, milrinone and amrinone), calcium channel blockers (nimodipine, verapamil, nicardipine), protein kinase inhibitors (fasudil hydrochloride) and adenylyl cyclase activators (colforsin daropate hydrochloride) [5, 6]. The main effect is a temporary relaxation of smooth muscle cells in the vascular wall, causing vasodilatation.

There have been no randomised clinical trials to demonstrate the benefit of intra-arterial infusion therapy (IAIT) over medical therapy alone. The data is mostly based on large case series [10, 11, 12, 13, 14, 15, 16, 17, 18, 19, 20, 21, 22, 23]. Nimodipine is the most intensively studied, and only, drug approved by the US Food and Drug Administration for use in the treatment of CV. According to the studies. IA nimodipine is safe and effective in the treatment of CV. Angiographic improvement in up to 43% of interventions and clinical improvement in 76% of treated patients were achieved using IA nimodipine [12, 13, 23]. This so-called clinicoangiographic dissociation has been explained by the presumably neuro-protective effects of nimodipine.

The drugs can be injected through selective or superselective catheterisation. Super-selective catheterisation would only be prudent where two circulations are unevenly affected distal to a bifurcation. However, in most patients only selective catheterisation would be enough to effectively treat CV and the risk of thrombus formation in a superselectively catheterised vasospastic artery is very high.

The methods involve either slow bolus administration of drug or prolonged infusions lasting approximately 30 to 120 min, or a combination of the two methods. Follow-up angiography is usually performed 10-15 minutes after the injection. A typical IA infusion dose of nimodipine per vessel is 1 to 2 mg over 10 to 30 minutes (total dose not exceeding 4 to 5 mg). If a significant effect is observed, the procedure can be ended and the patient returns to the intensive care unit for further follow-up. When required, multiple sessions have to be performed in order to achieve a better outcome. Some authors therefore prefer to leave the

introducer sheath in the artery during the sensitive period to avoid multiple femoral punctures in case of recurrent CV. If a minor angiographic effect is seen, continuous infusion therapy could be considered. The catheter will be left in the artery and continuous infusion therapy initiated, starting from 2 hours and lasting up to 10 days. Depending on the duration of the therapy the infusion rates of nimodipine vary between 1 and 6 mg/h.

At our institution, we usually treat severe CV with IAIT via indwelling catheters. Mostly it takes 5-7 days to return the size of the cerebral arteries to normal, but we have had a few patients in whom the IA catheters remained *in situ* for 10 days without significant complications (Figures 2 and 3).

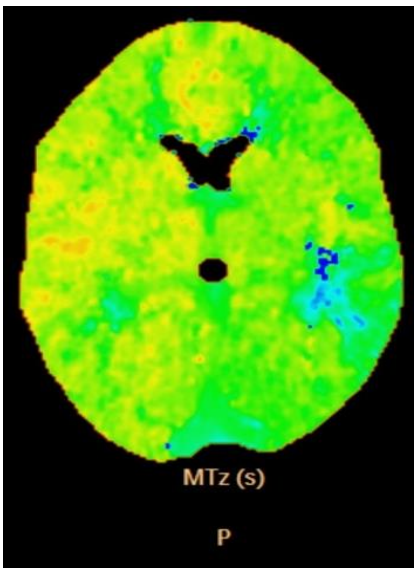

(A)

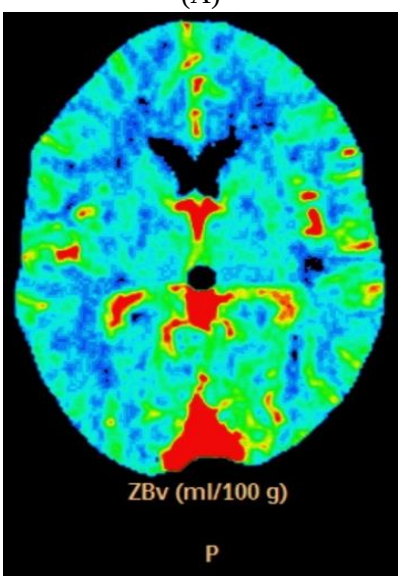

(B)

Figure 2. (Continued).

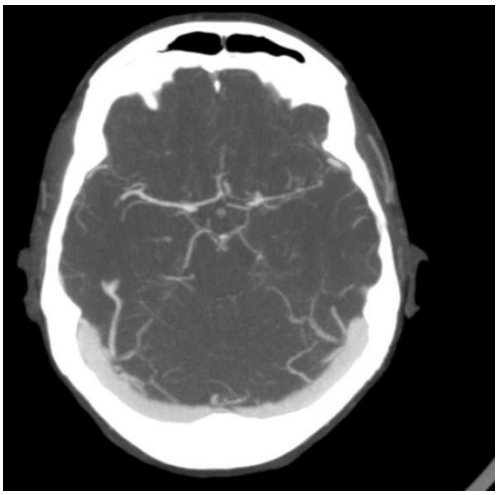

(C)

(D)

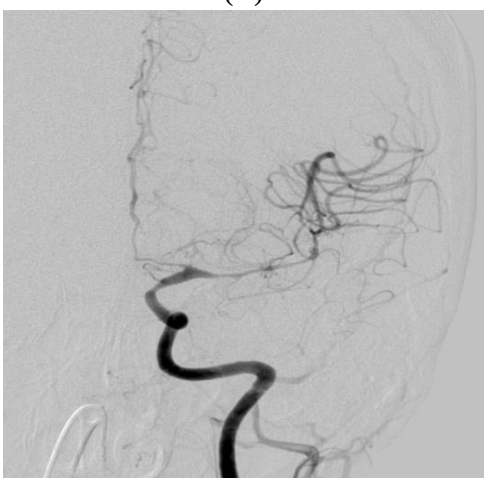

(E)

Figure 2. (Continued).

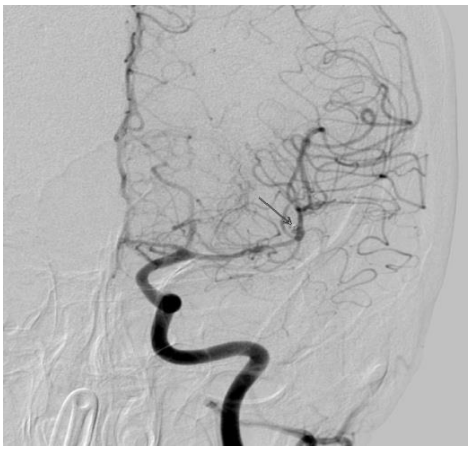

(F)

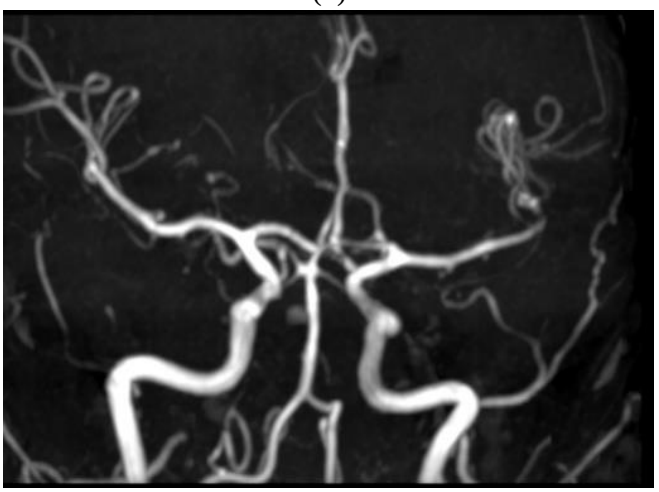

(G)

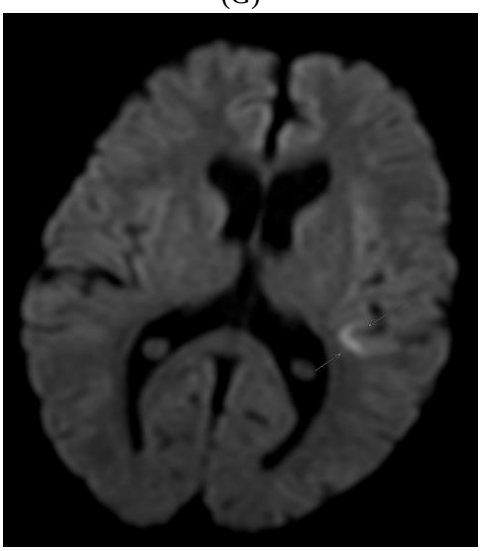

(H)

Figure 2. (Continued).

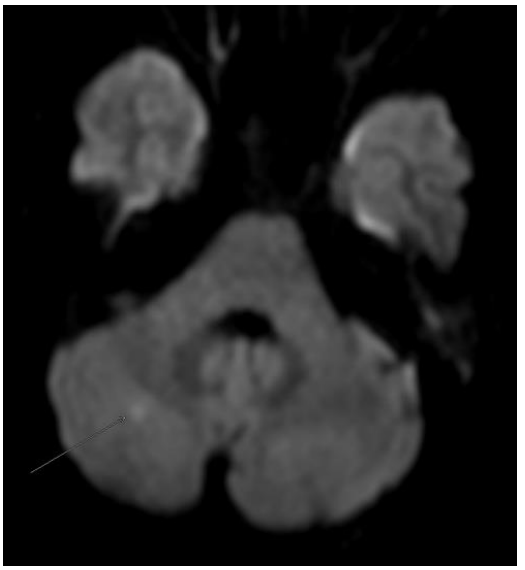

(I)

Figure 2. The Mean Transit Time (MTT) map (A) shows prolongation in the left MCA territory with deficient perfusion on the CBV map (B) in the posterior insula. CTA (C and D) and DSA (E) images confirm severe CV of the proximal and distal arteries on the left. DSA (F) performed after 8 days of continuous IAIT with nimodipine demonstrates significant regression of CV. The arrow indicates the ruptured and coiled aneurysm in the left MCA. MRA (G) 7 days after IAIT shows arteries of normal size. On DWI (arrows on H and I) the infarctions in the left posterior insula and right cerebellum are visible. No significant complications related to the treatment of CV.

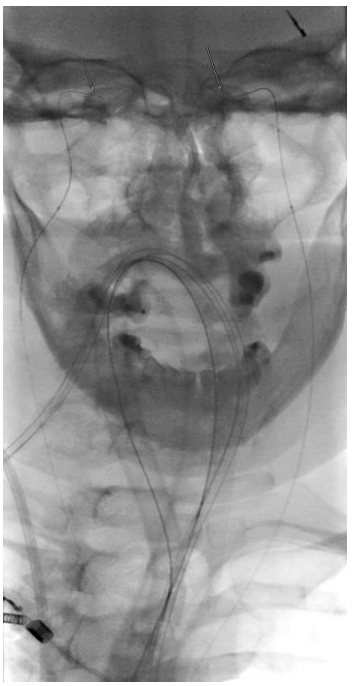

(A)

Figure 3. (Continued).

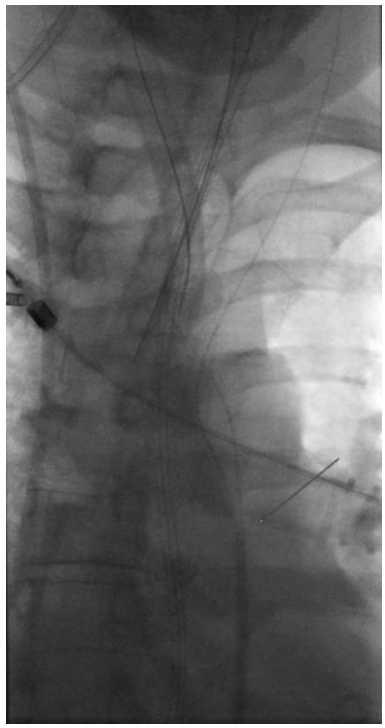

(B)

Figure 3. The distal markers of the indwelling microcatheters for continuous IAIT are illustrated (arrow on A). They lie in each petrous segment of the ICA. At B the distal tip of the guiding catheter can be seen in the descending aorta (arrow on B). The guiding catheter is usually placed at such a level to avoid injuring a vessel.

If no effect is observed, another therapy regimen should be considered.

The agents can be injected without danger to treat CV regardless of the vessel size and orientation. However, care should be taken when injecting Nimotop (Bayer, Leverkusen, Germany), since the solution contains 23.7vol% ethanol (alcohol) and interactions with alcohol-incompatible drugs can occur.

Verapamil and nicardipine are the next two drugs whose use is being increasingly reported in the literature [10, 14, 15].

SPECIFIC CONSIDERATIONS REGARDING IAIT

Delayed onset of action, a transient therapeutic effect and the potential increase in intracranial pressure (ICP) are some of the disadvantages of IAIT. IA nimodipine may increase the ICP by extravasation of fluid into the interstitial space in the brain or decrease the blood pressure through systemic vasodilation. Both have the potential to lower the cerebral perfusion pressure (CPP) with subsequent ischaemia in especially delicate vasospastic areas. Therefore, direct monitoring of ICP is necessary for excluding such a risk.

In order to prolong the effects of IAIT and avoid multiple sessions, nimodipine can be infused continuously via indwelling arterial microcatheters placed in the internal carotid

artery or vertebral artery. This therapy is especially useful in cases of severe proximal and distal CV [16, 18, 19, 20, 21, 22]. However, vessel wall dissection, catheter dislocation, thromboemboli and sepsis due to indwelling foreign material are risks which should be kept in mind (Figure 4). Aggressive measures to prevent thromboembolism should be undertaken which in turn could pose a problem in patients with severe SAH. At our institution, we usually give patients heparin and aspirin and routinely perform a Multiplate test (Roche, Basel, Switzerland) in each patient to exclude any unresponsiveness.

With a session-wise treatment strategy the delayed response to vasodilator infusion should be kept in mind before evaluating the therapeutic response and adjusting the drug dosage. Feng et al. demonstrated angiographic improvement when performing a control angiogram 10-15 minutes after treatment [14].

TRANSLUMINAL BALLOON ANGIOPLASTY (TBA)

TBA for CV is documented thoroughly in the literature [1, 3, 4, 5, 6, 7, 24, 25, 26, 27, 28]. TBA is currently performed with commercially available single and double-lumen over the wire balloon catheters. As with IAIT, TBA has never been investigated in a randomised controlled trial. Uncontrolled clinical case series have demonstrated its safety and technical efficacy, however. The technical efficacy of TBA for reversing CV ranges between 80% and 100%. Clinical success varies considerably, with reversal of DCI in 31% to 77% of patients [6, 7, 24, 25, 26, 27, 28]. Early treatment within 2 h from symptom onset makes a significant positive contribution toward clinical improvement.

When a balloon is inflated in the lumen of a spastic artery, it stretches and disrupts both the already contracted and degenerated muscle and the proliferative non-muscular components, mainly in the tunica media. It paralyses the vessel wall. Thus, the therapeutic effects of TBA are generally long-lasting and retreatment is rarely necessary.

(A)

Figure 4. (Continued).

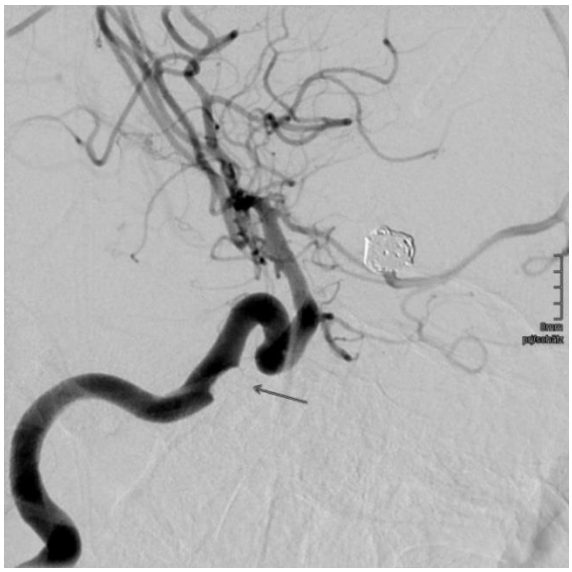

(B)

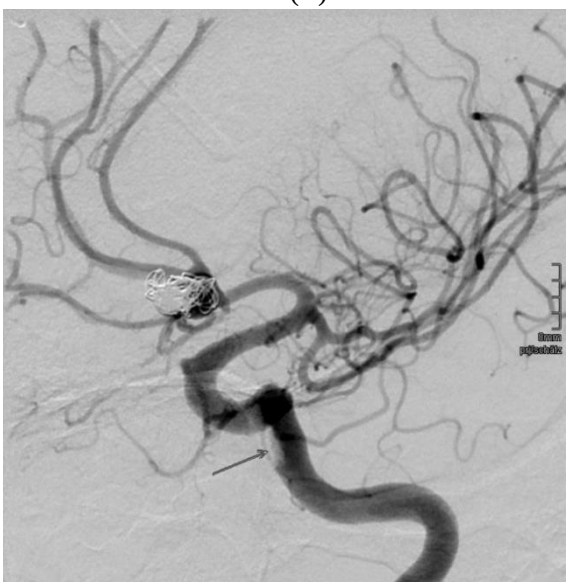

(C)

Figure 4. Thrombus formation in the internal carotid artery due to indwelling catheters without significant narrowing of the lumen. Arrows on CTA image (A) and on DSA images (B and C).

Many experts believe that an expanding balloon in a non-contracted vessel lumen would not achieve the same therapeutic effect. Therefore, many neurointerventionists choose to perform TBA before the initiation of IAIT when combined therapy is planned. With respect to catheterisation and introduction of a balloon catheter, however, it is sometimes necessary to prepare the target vessel with IAIT before TBA.

TBA has been graded as a Class IIb treatment with evidence level B according to guidelines published by the AHA and ASA [1].

SPECIFIC CONSIDERATIONS REGARDING TBA

TBA is usually limited to the proximal vessels of the circle of Willis with diameters greater than 2 mm. Distal balloon angioplasty is generally not recommended. Despite the recent advances in microcatheter technology, tortuous vessels and angioplasty of the anterior cerebral artery still remain technically challenging.

The rate of major complications is approx. 5%. TBA-related complications are vessel rupture, occlusion, dissection, distal embolism, reperfusion injury, displacement of surgical clips and rebleeding from uncontrolled aneurysms.

Prior to TBA, the anatomy of the target vessel before the spasm should be carefully reviewed in order to avoid overdilatation. In the absence of a baseline angiogram, it is often difficult to estimate the normal calibre of a spastic artery and dilatation of a hypoplastic or fenestrated artery may sometimes be encountered. This can be avoided by carefully scrutinising the available angiographic studies. When inflating the balloon, undersizing it to about 80% of the normal vessel diameter is advised. If planning multiple dilatations on a vessel, it is prudent to start distally and continue proximally in order to avoid crossing a fresh angioplasty site with the endovascular material (Figure 5). To avoid multiple dilatations, the balloon length should if possible correspond to the longest straight segment of the target vessel.

TBA is generally contraindicated if the patient has already developed a large infarction in the territory of the target vessel. The same principles of endovascular treatment for acute ischaemic stroke can be applied here. Attempts to restore tissue perfusion to a large infarcted area would increase the risk of reperfusion haemorrhage. Fatal cases of reperfusion haemorrhage have indeed been reported to occur up to 24 h after treating CV with TBA [29].

It is inadvisable to perform TBA adjacent to clipped ruptured aneurysms given that it has been associated with fatal rupture of the parent artery.

(A)

Figure 5. (Continued).

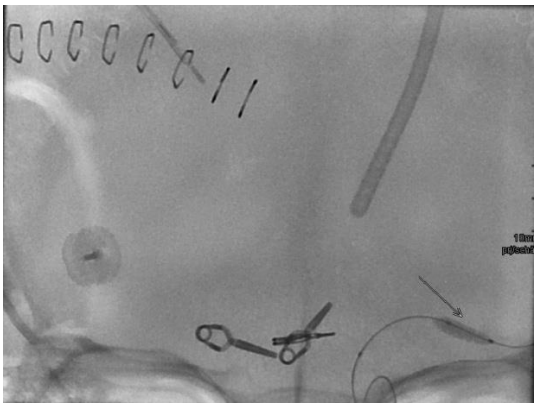

(B)

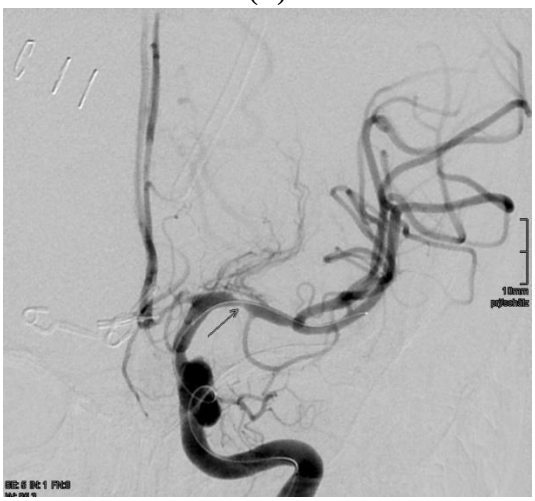

(C)

(D)

Figure 5. (Continued).

(E)

Figure 5. Severe CV of the proximal intracranial arteries (A). TBA performed from distal (C) to proximal. The inflated balloon can be seen (arrows on B and D). Control scan demonstrates good filling of the proximal MCA (E).

Permanent occlusion of the artery, endothelial injury inflicted by the balloon and other standard factors associated with any endovascular intervention mean that appropriate anticoagulation is necessary. Usually, bolus infusion of heparin at the beginning of the procedure followed by repeat doses according to the ACT level should suffice.

Although uncommon, vasospasm may also recur after angioplasty.

BRIEF DISCUSSION AND WRAP-UP

The endovascular therapy of CV consists of two different treatment modalities which can either be used separately or in a complementary fashion. IAIT procedures are generally used in the management of CV involving the distal arteries beyond the circle of Willis, whereas TBA is the treatment of choice for CV of the larger vessels.

IA administration of vasodilating drugs can be safely undertaken in awake patients. On the other hand, most interventionalists prefer to perform TBA on patients under general anaesthesia, because paralysis potentially lowers the risks of the procedure and offers better visibility of the balloon.

In cases of high-grade SAH and delayed presentation to the hospital, CV will often be encountered. If endovascular treatment is planned in such cases, CV can be managed in the same session with aneurysm embolisation [11, 30].

REFERENCES

[1] Connolly E. S. Jr., Rabinstein A. A., Carhuapoma J. R., Derdeyn C. P., Dion J., Higashida R. T., Hoh B. L., Kirkness C. J., Naidech A. M., Ogilvy C. S., Patel A. B., Thompson B. G., Vespa P.; American Heart Association Stroke Council; Council on

Cardiovascular Radiology and Intervention; Council on Cardiovascular Nursing; Council on Cardiovascular Surgery and Anesthesia; Council on Clinical Cardiology. Guidelines for the management of aneurysmal subarachnoid hemorrhage: a guideline for healthcare professionals from the American Heart Association/American Stroke Association. *Stroke*. 2012;43(6): 1711-37.

[2] Hayashi K., Hirao T., Sakai N., Nagata I.; JR-NET2 Study Group. Current status of endovascular treatment for vasospasm following subarachnoid hemorrhage: analysis of JR-NET2. *Neurol Med Chir* (Tokyo). 2014;54(2):107-12.

[3] Keyrouz S. G., Diringer M. N. Clinical review: Prevention and therapy of vasospasm in subarachnoid hemorrhage. *Crit Care*. 2007;11(4):220.

[4] Athar M. K., Levine J. M. Treatment options for cerebral vasospasm in aneurysmal subarachnoid hemorrhage. *Neurotherapeutics*. 2012;9(1):37-43.

[5] Durrant J. C., Hinson H. E. Rescue therapy for refractory vasospasm after subarachnoid hemorrhage. *Curr Neurol Neurosci Rep*. 2015;15(2): 521.

[6] Dabus G., Nogueira R. G. Current options for the management of aneurysmal subarachnoid hemorrhage-induced cerebral vasospasm: a comprehensive review of the literature. *Interv Neurol*. 2013;2(1):30-51.

[7] Abruzzo T., Moran C., Blackham K. A., Eskey C. J., Lev R., Meyers P., Narayanan S., Prestigiacomo C. J. Invasive interventional management of post-hemorrhagic cerebral vasospasm in patients with aneurysmal subarachnoid hemorrhage. *J Neurointerv Surg*. 2012;4(3):169-77.

[8] Lylyk P., Vila J. F., Miranda C., Ferrario A., Romero R., Cohen J. E. Partial aortic obstruction improves cerebral perfusion and clinical symptoms in patients with symptomatic vasospasm. *Neurol Res*. 2005; 27:129-35.

[9] Cremers C. H., Vos P. C., van der Schaaf I. C., Velthuis B. K., Vergouwen M. D., Rinkel G. J., Dankbaar J. W. CT perfusion during delayed cerebral ischemia after subarachnoid hemorrhage: distinction between reversible ischemia and ischemia progressing to infarction. *Neuroradiology*. 2015.

[10] Nogueira R. G., Lev M. H., Roccatagliata L., Hirsch J. A., Gonzalez R. G., Ogilvy C. S., Halpern E. F., Rordorf G. A., Rabinov J. D., Pryor J. C. Intra-arterial nicardipine infusion improves CT perfusion-measured cerebral blood flow in patients with subarachnoid hemorrhage- induced vasospasm. *AJNR Am J Neuroradiol*. 2009;30(1): 160-4.

[11] Oran I., Cinar C. Continuous intra-arterial infusion of nimodipine during embolization of cerebral aneurysms associated with vasospasm. *AJNR Am J Neuroradiol*. 2008; 29(2):291-5.

[12] Hänggi D., Turowski B., Beseoglu K., Yong M., Steiger H. J. Intra-arterial nimodipine for severe cerebral vasospasm after aneurysmal subarachnoid hemorrhage: influence on clinical course and cerebral perfusion. *AJNR Am J Neuroradiol*. 2008;29(6):1053-60.

[13] Biondi A., Ricciardi G. K., Puybasset L., Abdennour L., Longo M., Chiras J., Van Effenterre R. Intra-arterial nimodipine for the treatment of symptomatic cerebral vasospasm after aneurysmal subarachnoid hemorrhage: preliminary results. *AJNR Am J Neuroradiol*. 2004;25(6): 1067-76.

[14] Feng L., Fitzsimmons B. F., Young W. L., Berman M. F., Lin E., Aagaard B. D., Duong H., Pile-Spellman J. Intraarterially administered verapamil as adjunct therapy

for cerebral vasospasm: safety and 2-year experience. *AJNR Am J Neuroradiol*. 2002; 23(8):1284-90.

[15] Sehy J. V., Holloway W. E., Lin S. P., Cross D. T. 3rd, Derdeyn C. P., Moran C. J. Improvement in angiographic cerebral vasospasm after intra-arterial verapamil administration. *AJNR Am J Neuroradiol*. 2010; 31(10):1923-8.

[16] Ott S., Jedlicka S., Wolf S., Peter M., Pudenz C., Merker P., Schürer L., Lumenta C. B. Continuous selective intra-arterial application of nimodipine in refractory cerebral vasospasm due to aneurysmal subarachnoid hemorrhage. *Biomed Res Int.* 2014;2014:970741.

[17] Cho W. S., Kang H. S., Kim J. E., Kwon O. K., Oh C. W., Son Y. J., Know B. J., Jung C., Hang M. H. Intra-arterial nimodipine infusion for cerebral vasospasm in patients with aneurysmal subarachnoid hemorrhage. *Interv Neuroradiol*. 2011;17(2):169-78.

[18] Doukas A., Petridis A. K., Barth H., Jansen O., Mehdorn H. M. Continuous intra-arterial infusion of nimodipine at the onset of resistant vasospasm in aneurysmal subarachnoidal haemorrhage. Technical report. *Neurol Res*. 2011;33(3):290-4.

[19] Mayer T. E., Dichgans M., Straube A., Birnbaum T., Müller-Schunk S., Hamann G. F., Schulte-Altedorneburg G. Continuous intra-arterial nimodipine for the treatment of cerebral vasospasm. *Cardiovasc Intervent Radiol*. 2008;31(6):1200-4.

[20] Doukas A., Petridis A. K., Barth H., Jansen O., Maslehaty H., Mehdorn H. M. Resistant vasospasm in subarachnoid haemorrhage treated with continuous intraarterial nimodipine infusion. *Acta Neurochir Suppl*. 2011;112:93-6.

[21] Wolf S., Martin H., Landscheidt J. F., Rodiek S. O., Schürer L., Lumenta C. B. Continuous selective intraarterial infusion of nimodipine for therapy of refractory cerebral vasospasm. *Neurocrit Care*. 2010; 12(3):346-51.

[22] Musahl C., Henkes H., Vajda Z., Coburger J., Hopf N. Continuous local intra-arterial nimodipine administration in severe symptomatic vasospasm after subarachnoid hemorrhage. *Neurosurgery*. 2011;68(6): 1541-7.

[23] Hui C., Lau K. P. Efficacy of intra-arterial nimodipine in the treatment of cerebral vasospasm complicating subarachnoid haemorrhage. *Clin Radiol.* 2005;60(9):1030-6.

[24] Santillan A., Knopman J., Zink W., Patsalides A., Gobin Y. P. Transluminal balloon angioplasty for symptomatic distal vasospasm refractory to medical therapy in patients with aneurysmal subarachnoid hemorrhage. *Neurosurgery*. 2011;69(1):95-102.

[25] Mortimer A. M., Steinfort B., Faulder K., Bradford C., Finfer S., Assaad N., Harrington T. The detrimental clinical impact of severe angiographic vasospasm may be diminished by maximal medical therapy and intensive endovascular treatment. *J Neurointerv Surg*. 2014 pii: neurintsurg-2014-011403.

[26] Mortimer A. M., Steinfort B., Faulder K., Erho T., Dexter M., Assaad N., Harrington T. Institution of sustained endovascular treatment prior to clinical deterioration in patients with severe angiographic vasospasm: A retrospective observational study of clinico-radiological outcomes. *J Neuroradiol*. 2015;42(3):176-83.

[27] Chalouhi N., Tjoumakaris S., Thakkar V., Theofanis T., Hammer C., Hasan D., Starke R. M., Wu C., Gonzalez L. F., Rosenwasser R., Jabbour P. Endovascular management of cerebral vasospasm following aneurysm rupture: outcomes and predictors in 116 patients. *Clin Neurol Neurosurg*. 2014;118:26-31.

[28] Heit J. J., Choudhri O., Marks M. P., Dodd R. L., Do H. M. Cerebral angioplasty using the Scepter XC dual lumen balloon for the treatment of vasospasm following intracranial aneurysm rupture. *J Neurointerv Surg.* 2015;7(1):56-61.

[29] Higashida R. T., Halbach V. V., Cahan L. D. et al. Transluminal angioplasty for treatment of intracranial arterial vasospasm. *J Neurosurg* 1989;71:648-53.

[30] Cho Y. D., Han M. H., Ahn J. H., Jung S. C., Kim C. H., Kang H. S., Kim J. E., Lim J. W. Simultaneous endovascular treatment of ruptured cerebral aneurysms and vasospasm. *Korean J Radiol*. 2015;16(1):180-7.

In: Encyclopedia of Surgery (22 Volume Set)
Editors: Andreas Lehrer and Kristin Mueller
ISBN: 978-1-53618-329-0
© 2020 Nova Science Publishers, Inc.

Chapter 75

CHRONIC HYDROCEPHALUS AFTER SUBARACHNOID HAEMORRHAGE

Alexandra Huthmann [*] ***and Christoph A. Tschan*** [†]
Department of Neurosurgery, Ludmillenstift Meppen, Meppen, Germany

ABSTRACT

Subarachnoid haemorrhage (SAH) causes acute and chronic hydrocephalus. Treatment strategies and alternatives are described from clinical point of view. Modern therapy strategies of chronic hydrocephalus in SAH will be discussed. Treatment methods and modern strategies in daily clinical routine for acute and chronic hydrocephalus in SAH are demonstrated. Ventricular drainage, lumbar drainage, endoscopic third ventriculostomy, intraventricular fibrinolysis and different shunting procedures are focused. Ventricular drainage is gold standard for treatment of acute hydrocephalus in SAH. Additional or exchange to lumbar drainage is discussed to prevent cerebral vasospasm and chronic hydrocephalus. In case of chronic hydrocephalus ventriculoperitoneal shunting is necessary. Different shunt types and valves are available. To prevent overdrainage, a gravitational valve can be added to the differential pressure valve. Adjustable shunt valves allow optimizing pressure level and individual needs. In SAH early CSF drainage can avoid chronic hydrocephalus. Early lumbar drainage may reduce onset of cerebral vasospasm. In case of ventriculoperitoneal shunting adjustable differential pressure valves are effective. The combination with gravitational valves prevents overdrainage.

Keywords: SAH, ventricular drain, lumbar drain, ventriculoperitoneal shunt, gravitational valve, chronic hydrocephalus

The occurrence of disturbances in the circulation of cerebrospinal fluids (CSF) takes two forms: acute and chronic hydrocephalus [1]. The latter will be discussed in this chapter since the acute hydrocephalus was discussed in chapter nine.

[*] Corresponding Author's Email: Huthmann@Ludmillenstift.de.
[†] Corresponding Author's Email: Tschan@Ludmillenstift.de.

The initial therapy of disturbances in the circulation of CSF after subarachnoid haemorrhage is often managed by placement of an external ventricular drainage to manipulate the amount of CSF within the ventricular system. For this procedure a frontal burr hole is placed in order to insert a draining catheter into the anterior horn of the lateral ventricle [2, 3, 4]. In most cases a silicon catheter with a perforated tip is used. Within several minutes after insertion, physiological levels of intracranial pressure can be achieved by this measure; often pressure relief is necessary to achieve optimal conditions for potential aneurysm treatment. An alternative to a silicon catheter is a steel needle (Duisburger Needle) that is introduced through a pre-inserted bolt [5]. In the absence of occlusions in the cerebrospinal fluid circulation, single or repeated lumbar punctures or placement of a lumbar silicon catheter (lumbar drainage, LD) [6, 7] for continuous CSF drainage can be performed. Furthermore the removal of blood from subarachnoid space with a lumbar drainage (LD) may decrease development of cerebral vasospasm [8, 9, 10, 11]. In both cases (ventricular drainage, LD) the silicon catheter will be connected to a sealed draining system (Figure1) [3]. According to the principles of communicating tubes and containers, the amount of cerebrospinal fluid drained, and consequently the intracranial pressure may be adjusted by manipulating the height of the drainage system relatively to the head, or more specific to the ventricles [12].
In our hospital we set up the pressure level of the container 10 cm above the foramen Monroi level (approximately the level of the external auditory canal). Monitoring of the CSF outflow should be documented and in case of over or underdrainage pressure level needs to be readjusted. Maximum outflow in adults should be round about 200 ml in 24 hours.

Figure 1. Sealed draining systems for ventricular and lumbal drain.

The ventricular drain allows ICP monitoring. For this a Statham reservoir (pressure measurement chamber e.g., same system for blood pressure monitoring) has to be added to the system. In some systems the measure unit is integrated. To measure the correct ICP, the

drain has to be closed for a while in front of the container. Measurement in open systems or in case of overdrainage (slit ventricles) reveals wrong ICP values.

In case of severe intraventricular bleeding the drain can be occluded by clots. Sterile flushing is possible. Up to now there is no clear evidence for reducing the risk of chronic hydrocephalus development by using intraventricular fibrinolysis [13, 14].

Chronic hydrocephalus has an incidence of 25% to 37% [15, 16]. Unfortunately, the functionality of CSF circulation is not always restored with the resorption of subarachnoid blood. Additionally, it is quite difficult to identify a potential chronic hydrocephalus in progress by merely evaluating the imaging diagnostics while the drainage system is in function. One way to tackle this issue is by constant clinical and radiographic evaluation of the patient during gradual reduction of the CSF flow rate and subsequent removal of the catheter [17, 18, 19, 20, 21].

If follow up CT- or MRI-scans of the patient show an enlargement of the ventricular system with corresponding clinical deterioration, indicating a potential development of chronic hydrocephalus, a long-term treatment is indicated. A significantly higher rate for need of shunt-therapy was observed in older patients (> 65 years), poor initial neurological status and additional intraventricular haemorrhage [22, 23, 24].

CSF IL-6 values of ≥ 10,000 pg/ml in the early post-SAH period and assessment of S100B levels in CSF and serum may be useful as predictive parameters for shunt dependency in patients with hydrocephalus following aneurysmal SAH [25, 26].

The long-term treatment is commonly carried out by implantation of a ventriculoperitoneal shunt system (VP-shunt) [27]. Also the use of lamina terminalis fenestration and endoscopic third ventriculostomy is discussed, but both procedures remain to be of limited efficacy. Maybe ETV can be employed as a temporary intervention in certain conditions, such as during the waiting period for the clearance of CSF before inserting a VP-shunt or to treat an obstructive hydrocephalus in case of an additional intraventricular haemorrhage [28, 29, 30].

In our clinical routine CSF protein and cell count are used to decide the right moment for implantation of a VP-Shunt. CSF-Protein should be less than 1g to avoid valve obstruction and CSF samples should count less than 50 cells per µl and no microbiological activity.
The objective of the VP-shunt is to connect the ventricles with the peritoneal cavity (subcutaneously) to avoid excessive CSF accumulation in the ventricular system by draining according to the differential pressure gradient between the ventricle and the tip of the distal catheter.

Similar to the technique of implanting an external ventricular drainage, a common method to perform this task is to insert a silicon catheter with a multi-perforated proximal tip in one of the lateral ventricles (usually the right ventricle) through a frontal burr hole. This is connected within a few centimetres with a CSF-reservoir (Control Reservoir) and (a) pressure controlling valve(s). These parts are connected in turn with a distal silicon catheter that ends in the peritoneal cavity through subcutaneous tunnelling [31, 32].

The function of the CSF-reservoir (with unidirectional pump function) is to control the shunt's functionality and to access the CSF circulation if needed. To optimize the flow rate of the CSF, avoiding over- or underdrainage, adjustable differential pressure (DP) valves are used [33, 34, 35].

Figure 2. X-ray of the skull with implanted Miethke proSA®-Shunt system with upstream CSF Control-Reservoir, programmable differential pressure valve and programmable gravitational valve (Christoph Miethke GmbH & Co. KG, Aesculap AG, Germany) and telemetric ICP-probe (NEUROVENT®-P-tel, RAUMEDIC AG, Germany)

A common problem that mostly occurs during mobilization of shunted patients is overdrainage of CSF, which is poorly controlled by the DP valve. This led to the development of additional gravitational valves (Figure 2) that control flow in the upright position, eventually optimizing CSF flow in various postures, accounting for diurnal variations [36, 37, 38, 39]. Typical signs and symptoms of overdrainage include postural headaches in the upright position that are alleviated by lying down. A typical finding in radiographic scans of the brain (e.g., CT, MRI) is a pronounced reduction in the size of the ventricles (slit ventricles) or subdural hygroma.

Hydrocephalus might take weeks or even months after an instance of SAH to manifest itself, which is why a long-term intensive follow up of such patients is crucial [40, 41, 42]. For this reason diagnostic telemetric ICP-measurement and long-term monitoring are useful especially in difficult cases [43, 44].

REFERENCES

[1] Germanwala AV, Huang J, Tamargo RJ. Hydrocephalus after aneurysmal subarachnoid hemorrhage. *Neurosurg. Clin. N. Am*. 2010 Apr;21(2): 263-70. Review.

[2] Huyette DR, Turnbow BJ, Kaufman C, Vaslow DF, Whiting BB, Oh MY. Accuracy of the freehand pass technique for ventriculostomy catheter placement: Retrospective assessment using computed tomography scans. *J. Neurosurg.* 2008;108: 88–91.

[3] Quinones-Hinojosa A. Philadelphia, PA: Saunders; 2012. Schmidek and Sweet Operative Neurosurgical Techniques: *Indications, Methods, and Result.*

[4] Muralidharan R. External ventricular drains: Management and complications. *Surg Neurol Int.* 2015; 6(Suppl 6): S271–S274.

[5] Meyer B, Schaller K, Rhode V, Hassler W. Percutaneous needle trephination. Experience in 200 cases. *Acta Neurochir.* (Wien). 1994;127(3-4): 232-5.

[6] Hoekema D, Schmidt RH, Ross I. Lumbar drainage for subarachnoid hemorrhage: technical considerations and safety analysis. *Neurocrit. Care.* 2007;7(1): 3-9.

[7] Ormond DR, Dressler A, Kim S, Ronecker J, Murali R. Lumbar drains may reduce the need for permanent CSF diversion in spontaneous subarachnoid haemorrhage. *Br. J. Neurosurg.* 2013 Apr;27(2): 171-4.

[8] Park S, Yang N, Seo E. The effectiveness of lumbar cerebrospinal fluid drainage to reduce the cerebral vasospasm after surgical clipping for aneurysmal subarachnoid hemorrhage. *J. Korean Neurosurg. Soc.* 2015 Mar;57(3): 167-73.

[9] de Aguiar PH, Barros I, Paiva BL, Simm RF. Removal of clots in subarachnoid space could reduce the vasospasm after subarachnoid hemorrhage. *Acta Neurochir. Suppl.* 2013;115: 91-3.

[10] Kwon OY, Kim YJ, Kim YJ, Cho CS, Lee SK, Cho MK. The Utility and Benefits of External Lumbar CSF Drainage after Endovascular Coiling on Aneurysmal Subarachnoid Hemorrhage. *J. Korean Neurosurg. Soc.* 2008 Jun;43(6): 281-7.

[11] Klimo P Jr, Kestle JR, MacDonald JD, Schmidt RH. Marked reduction of cerebral vasospasm with lumbar drainage of cerebrospinal fluid after subarachnoid hemorrhage. *J. Neurosurg.* 2004 Feb;100(2): 215-24.

[12] Bisnaire D, Robinson L. Accuracy of levelling intraventricular collection drainage systems. *J. Neurosci. Nurs.* 1997 Aug; 29(4): 261-8.

[13] Gerner ST, Kuramatsu JB, Abel H, Kloska SP, Lücking H, Eyüpoglu IY, Doerfler A, Schwab S, Huttner HB. Intraventricular fibrinolysis has no effects on shunt dependency and functional outcome in endovascular-treated aneurysmal SAH. *Neurocrit Care.* 2014 Dec;21(3): 435-43.

[14] Kramer AH, Fletcher JJ. Locally-administered intrathecal thrombolytics following aneurysmal subarachnoid hemorrhage: a systematic review and meta-analysis. *Neurocrit. Care*. 2011 Jun;14(3):489-99. doi: 10.1007/s12028-010-9429-z. Review.

[15] Yoshioka H, Inagawa T, Tokuda Y, Inokuchi F. Chronic hydrocephalus in elderly patients following subarachnoid hemorrhage. *Surg. Neurol.* 2000 Feb;53(2): 119-24; discussion 124-5.

[16] Yang TC, Chang CH, Liu YT, Chen YL, Tu PH, Chen HC. Predictors of shunt-dependent chronic hydrocephalus after aneurysmal subarachnoid haemorrhage. *Eur Neurol*. 2013;69(5):296-303. doi: 10.1159/ 000346119. Epub 2013 Feb 26.

[17] Zolal A, Juratli T, Dengl M, Ficici KH, Schackert G, Sobottka SB. Daily drained CSF volume is a predictor for shunt dependence - A retrospective study. *Clin. Neurol. Neurosurg*. 2015 Aug 28; 138:147-150.

[18] Lewis A, Kimberly WT. A retrospective analysis of cerebrospinal fluid drainage volume in subarachnoid hemorrhage and the need for early or late ventriculoperitoneal shunt placement. *J. Neurosurg. Sci.* 2014 Dec 17.

[19] Lewis A, Irvine H, Ogilvy C, Kimberly WT. Predictors for delayed ventriculoperitoneal shunt placement after external ventricular drain removal in patients with subarachnoid hemorrhage. *Br. J. Neurosurg*. 2015 Apr;29(2): 219-24.

[20] Lewis A, Taylor Kimberly W. Prediction of ventriculoperitoneal shunt placement based on type of failure during external ventricular drain wean. *Clin. Neurol. Neurosurg*. 2014 Oct;125: 109-13.

[21] Klopfenstein JD, Kim LJ, Feiz-Erfan I, Hott JS, Goslar P, Zabramski JM, Spetzler RF.Comparison of rapid and gradual weaning from external ventricular drainage in patients with aneurysmal subarachnoid hemorrhage: a prospective randomized trial. *J. Neurosurg*. 2004 Feb;100(2): 225-9.

[22] Bae IS, Yi HJ, Choi KS, Chun HJ. Comparison of Incidence and Risk Factors for Shunt-dependent Hydrocephalus in Aneurysmal Subarachnoid Hemorrhage Patients. *J. Cerebrovasc. Endovasc. Neurosurg*. 2014 Jun;16(2): 78-84.

[23] Czorlich P, Ricklefs F, Reitz M, Vettorazzi E, Abboud T, Regelsberger J, Westphal M, Schmidt NO. Impact of intraventricular hemorrhage measured by Graeb and LeRoux score on case fatality risk and chronic hydrocephalus in aneurysmal subarachnoid hemorrhage. *Acta Neurochir.* (Wien). 2015 Mar;157(3): 409-15.

[24] Kwon JH, Sung SK, Song YJ, Choi HJ, Huh JT, Kim HD. Predisposing factors related to shunt-dependent chronic hydrocephalus after aneurysmal subarachnoid hemorrhage. *J. Korean Neurosurg. Soc.* 2008 Apr;43(4): 177-81.

[25] Wostrack M, Reeb T, Martin J, Kehl V, Shiban E, Preuss A, Ringel F, Meyer B, Ryang YM.Shunt-dependent hydrocephalus after aneurysmal subarachnoid hemorrhage: the role of intrathecal interleukin-6. *Neurocrit. Care*. 2014 Aug;21(1): 78-84.

[26] Brandner S, Xu Y, Schmidt C, Emtmann I, Buchfelder M, Kleindienst A. Shunt-dependent hydrocephalus following subarachnoid hemorrhage correlates with increased S100B levels in cerebrospinal fluid and serum. *Acta Neurochir. Suppl.* 2012;114:217-20.

[27] Kang S.Efficacy of lumbo-peritoneal versus ventriculo-peritoneal shunting for management of chronic hydrocephalus following aneurysmal subarachnoid haemorrhage. *Acta Neurochir.* (Wien). 2000;142(1): 45-9.

[28] Komotar RJ, Hahn DK, Kim GH, Starke RM, Garrett MC, Merkow MB, Otten ML, Sciacca RR, Connolly ES Jr. Efficacy of lamina terminalis fenestration in reducing shunt-dependent hydrocephalus following aneurysmal subarachnoid hemorrhage: a systematic review. Clinical article. *J. Neurosurg.* 2009 Jul;111(1): 147-54. Review.

[29] Fukuhara T, Shimizu T, Namba Y. Limited efficacy of endoscopic third ventriculostomy for hydrocephalus following aneurysmal subarachnoid hemorrhage. *Neurol. Med. Chir.* (Tokyo). 2009 Oct;49(10): 449-55.

[30] Obaid S, Weil AG, Rahme R, Bojanowski MW. Endoscopic third ventriculostomy for obstructive hydrocephalus due to intraventricular hemorrhage. *J. Neurol. Surg. A Cent. Eur. Neurosurg*. 2015 Mar;76(2):99-111. doi: 10.1055/s-0034-1382778. Epub 2014 Jul 21.

[31] Chalouhi N, Whiting A, Anderson EC, Witte S, Zanaty M, Tjoumakaris S, Gonzalez LF, Hasan D, Starke RM, Hann S, Ghobrial GM, Rosenwasser R, Jabbour P.

Comparison of techniques for ventriculoperitoneal shunting in 523 patients with subarachnoid hemorrhage. *J. Neurosurg.* 2014 Oct;121(4): 904-7.

[32] Greenberg MS. Handbook of Neurosurgery. 7th ed. New York: Thieme; 2010. *CSF diversionary procedures*; pp. 207–14.

[33] Lee L, King NK, Kumar D, Ng YP, Rao J, Ng H, Lee KK, Wang E, Ng I. Use of programmable versus nonprogrammable shunts in the management of hydrocephalus secondary to aneurysmal subarachnoid hemorrhage: a retrospective study with cost-benefit analysis. *J. Neurosurg*. 2014 Oct;121(4): 899-903.

[34] Kim KH, Yeo IS, Yi JS, Lee HJ, Yang JH, Lee IW. A pressure adjustment protocol for programmable valves. *J Korean Neurosurg Soc*. 2009 Oct;46(4):370-7. doi: 10.3340/jkns.2009.46.4.370. *Epub* 2009 Oct 31.

[35] Katano H, Karasawa K, Sugiyama N, Yamashita N, Ohkura A, Kamiya K. Clinical evaluation of shunt implantations using Sophy programmable pressure valves: comparison with Codman-Hakim programmable valves. *J. Clin. Neurosci.* 2003 Sep;10(5): 557-61.

[36] Aschoff A, Kremer P, Benesch C, Fruh K, Klank A, Kunze S. Overdrainage and shunt technology. A critical comparison of programmable, hydrostatic and variable-resistance valves and flow-reducing devices. *Childs Nerv. Syst.* 1995 Apr;11(4): 193-202.

[37] Czosnyka Z, Czosnyka M, Richards HK, Pickard JD.Posture-related overdrainage: comparison of the performance of 10 hydrocephalus shunts in vitro. *Neurosurgery*. 1998 Feb;42(2): 327-33; discussion 333-4.

[38] Kehler U, Kiefer M, Eymann R, Wagner W, Tschan CA, Langer N, Rohde V, Ludwig HC, Gliemroth J, Meier U, Lemcke J, Thomale UW, Fritsch M, Krauss JK, Mirzayan MJ, Schuhmann M, Huthmann A. PROSAIKA: A prospective multicenter registry with the first programmable gravitational device for hydrocephalus shunting. *Clin. Neurol. Neurosurg*. 2015 Oct;137: 132-6.

[39] Tschan CA, Antes S, Huthmann A, Vulcu S, Oertel J, Wagner W. Overcoming CSF overdrainage with the adjustable gravitational valve proSA. *Acta Neurochir* (Wien). 2014 Apr;156(4): 767-76; discussion 776.

[40] Walcott BP, Iorgulescu JB, Stapleton CJ, Kamel H. Incidence, Timing, and Predictors of Delayed Shunting for Hydrocephalus After Aneurysmal Subarachnoid Hemorrhage. *Neurocrit. Care*. 2015 Aug;23(1): 54-8.

[41] Yang TC, Chang CH, Liu YT, Chen YL, Tu PH, Chen HC. Predictors of shunt-dependent chronic hydrocephalus after aneurysmal subarachnoid haemorrhage. *Eur. Neurol.* 2013;69(5): 296-303.

[42] Wang YM, Lin YJ, Chuang MJ, Lee TH, Tsai NW, Cheng BC, Lin WC, Su BY, Yang TM, Chang WN, Huang CC, Kung CT, Lee LH, Wang HC, Lu CH. Predictors and outcomes of shunt-dependent hydrocephalus in patients with aneurysmal sub-arachnoid hemorrhage. *BMC Surg.* 2012 Jul 5;12: 12.

[43] Antes S, Tschan CA, Kunze G, Ewert L, Zimmer A, Halfmann A, Oertel J.Clinical and radiological findings in long-term intracranial pressure monitoring. *Acta Neurochir*. (Wien). 2014 May;156(5): 1009-19; discussion 1019.

[44] First clinical results with a new telemetric intracranial pressure-monitoring system. Welschehold S, Schmalhausen E, Dodier P, Vulcu S, Oertel J, Wagner W, Tschan CA. *Neurosurgery*. 2012 Mar;70 (1 Suppl. Operative): 44-9; discussion 49.

In: Encyclopedia of Surgery (22 Volume Set)
Editors: Andreas Lehrer and Kristin Mueller
ISBN: 978-1-53618-329-0
© 2020 Nova Science Publishers, Inc.

Chapter 76

EPILEPTIC SEIZURES IN ASSOCIATION WITH SPONTANEOUS SUBARACHNOID HAEMORRHAGE

Sarah Jesse
Department of Neurology, University of Ulm, Oberer Eselsberg, Ulm, Germany

ABSTRACT

Epileptic tonic-clonic seizures in relation to spontaneous subarachnoid haemorrhage (SAH) should be classified into initial seizures within the first 24 h after SAH, early seizures during the first 14 days, and late onset then with symptomatic epilepsy, given that the therapeutic approach and prognosis are correlated to such clinical stratification. Since randomised controlled and double-blind clinical trials into the management of epileptic seizures with SAH are lacking, therapeutic recommendations can only be made based on the guidance of the Neurocritical Care Society and American Stroke Association.

Initial seizures related to the manifestation of bleeding occur in up to 21%. Anticonvulsant medication should be administered until treatment of the aneurysm, albeit for a maximum of three days, preferably with non-enzyme inducers so as to avoid drug interactions with nimodipine. The incidence of early seizures within the following 14 days does not appear to differ between patients undergoing surgery and those receiving endovascular treatment for ruptured aneurysms (10%-11%). If there are risk factors, such as multiple epileptic seizures or the existence of parenchymal defects, drug therapy should be administered for 3-6 months. The late onset of epileptic seizures post SAH accounts for 12% of the patient population and should, as with any symptomatic form of epilepsy, be managed long-term with anticonvulsants. Non-convulsive seizures and non-convulsive status epilepticus occur in 18% and 13% of cases, respectively, and should be considered in particular in quantitative disorders of consciousness as well as diagnosed with the help of an EEG.

After neurovascular events, epilepsy – with a prevalence of 0.5%-1% – is the second most commonly occurring neurological disorder. It has an incidence of 46 in 100,000 per year and increases with age, and mostly results from symptomatic conditions such as intracerebral/subarachnoid bleeding, ischaemia or neoplasias. Irrespective of whether epilepsy

has been diagnosed, the lifetime prevalence in terms of a single epileptic seizure occurring in the normal population is > 10% [1].

In relation to spontaneous subarachnoid haemorrhage (SAH), (simple or complex) partial epileptic seizures generally occur, often with secondary generalisation. It is useful to differentiate between initial seizures within the first 24 h after SAH, early seizures during the first 14 days, and late onset then with symptomatic epilepsy, given that the therapeutic approach and prognosis are correlated to such clinical stratification.

INITIAL SEIZURE

In patients with SAH, 3%-21% initially exhibit tonic-clonic seizures at onset or within the first 24 hours of bleeding [2, 3], often if the patient is younger [4] as well as with a higher Fisher score, accompanied by localised cisternal, intraventricular or intraparenchymal bleeds [5]. The occurrence of these initial seizures is associated with a complicated stay in hospital and is often accompanied by further epileptic attacks, an increased rate of pneumonia, and delayed onset of cerebral ischaemia related to vasospasm [6]. Despite the higher risk of complications, the long-term prognosis of the patient does not appear to be adversely affected, particularly as after six months the functional outcome is no worse, mortality is not increased and the prevalence of epilepsy is no higher in those affected [6, 7]. Prophylactic anticonvulsant therapy at this stage is hotly debated, but would seem reasonable for spanning the period until treatment of the aneurysm [8] in light of the fact that the risk of rebleeding is known to be closely correlated with increased systolic blood pressure. Thus, further convulsive epileptic seizures in relation to an untreated aneurysm signify an indirect risk of secondary bleeding [9, 10], which itself is associated with a clinical outcome that is far worse [11]. As systematic studies into anticonvulsive therapy in this regard are still awaited, it is advisable – as recommended by the Guidelines of the Neurocritical Care Society and the American Stroke Association – to administer prophylactic drug therapy during the immediate posthaemorrhagic phase until surgical or endovascular treatment is carried out, albeit for a maximum of three days [12, 13].

EARLY SEIZURE

Epileptic seizures occurring within 14 days after the manifestation of SAH are referred to as early seizures. Data in the literature on ruptured aneurysms are inconsistent with respect to the periprocedural occurrence of epileptic seizures, which are reported at a rate of 13.6% and 8.3% for clipping versus coiling, respectively [14]; this relatively high incidence decreases over the subsequent five years to 9.6% and 6.4%, respectively. In this case younger age as well as a high Fischer or Hunt and Hess score, or delayed ischaemic complications, are also major risk factors/predictors for epilepsy [14, 15]. Contrary to these results, an international study in a total of more than 20,000 patients with spontaneous SAH detected no relevant difference as regards the occurrence of early seizures or epilepsy (10.0% versus 11.1%) between operation and intervention [16].

Postoperative prophylactic drug therapy is frequently administered despite the absence of prior epileptic seizures, but is also hotly debated in the light of recent study data. Randomised controlled trials into the safety and efficacy of anticonvulsant drugs for primary and secondary prophylaxis post SAH are lacking [17, 18]. Moreover, there are studies that have demonstrated an inferior outcome in those patients treated prophylactically with anticonvulsants [19, 20]. The literature available on this topic primarily addresses the use of phenytoin, and in rarer cases carbamazepine and phenobarbital. Apart from the typical side effects of the individual anticonvulsants in the treated populations, an increased number of neurological deficits was detected in particular on account of the higher incidence of ischaemia, possibly owing to the interaction between the given enzyme inducers and coadministration of nimodipine. Its plasma concentration is reduced by up to 70% due to induction of cytochrome p450 [21]. Few studies are available on levetiracetam, which compared to phenytoin does not trigger enzyme production; no difference in the outcome has been noted [22, 23], whilst tolerability with respect to side effects is improved overall [24].

In line with the recommendations of the Neurocritical Care Society (Guidelines 2011) and American Stroke Association (Guidelines 2012), therefore, it is in principle advisable to forgo prophylactic anticonvulsant therapy during the postoperative phase if there are no signs indicative of epileptic seizures. Administration of drug therapy for 3-6 months for early seizures, in the same way as for cerebral ischaemia, appears to be justified [25, 26] if epileptic seizures have already occurred and if, in particular, parenchymal damage has resulted from the SAH or secondary ischaemia [12, 13, 27, 28].

LATE SEIZURE

The long-term incidence of symptomatic epilepsy after spontaneous SAH is 8% during the first year post haemorrhage, and 12% during the subsequent five years. The probability of epilepsy occurring is associated with higher Hunt and Hess grades and with parenchymal damage [29, 30]. Additional risk factors appear to be early epileptic seizures [31] as well as a lower rating on the Glasgow Outcome Scale at hospital discharge [32]. With late-onset seizures carrying a higher risk of recurrence and usually being correlated with a parenchymal defect, a patient should be assumed to have symptomatic epilepsy that will then require treatment in accordance with the guidelines of the ILAE [1].

NON-CONVULSIVE SEIZURE

Non-convulsive seizures occur in 8%-18% of patients [33]. A number of studies that performed continuous EEG monitoring in SAH patients revealed an incidence of up to 18% for complex partial non-convulsive seizures and up to 13% for non-convulsive status epilepticus, which was associated with the increased age of the patients as well as higher mortality. Furthermore, delayed cerebral ischaemia could be predicted in one study based on specific EEG changes (reduced delta/alpha ratio, relative alpha variability and amplitude) [34]. As continuous EEG monitoring is not practicable in clinical routine, it certainly will not replace regular Doppler ultrasound in the detection of vasospasms. However, in patients with

persistent disorders of consciousness – whether in terms of quantity or quality – an EEG should be performed to rule out non-convulsive seizures or non-convulsive status epilepticus.

Epileptic activity as a differential diagnosis in localised subarachnoid signal alterations on CT and MRI.

Both computed tomography (as the "gold standard" for early diagnosis of SAH) and magnetic resonance imaging permit detection of signal alterations in the subarachnoid space which in addition to SAH are also attributable on differential diagnosis to other conditions, such as an inflammatory exudate in meningitis, meningeal spread, hypertension-induced exudate associated with posterior reversible encephalopathy syndrome, cerebral amyloid angiography, cortical venous thrombosis or vascular malformation [35]. Further differential diagnoses include reversible cerebral vasokonstriction syndrome, hyperanticoagulation with vitamin K antagonists, and angiitis [36]. In association with renal failure, localised subarachnoid exudate can also appear on follow-up imaging after administration of a contrast agent [37]. Another important factor to be considered in the differential diagnosis of spontaneous SAH, as well as vasospasm-induced ischaemia, is localised cortical and also subarachnoid signal alteration in the event of protracted or frequent seizures as well as (non-convulsive) status epilepticus [38] (Figure1).

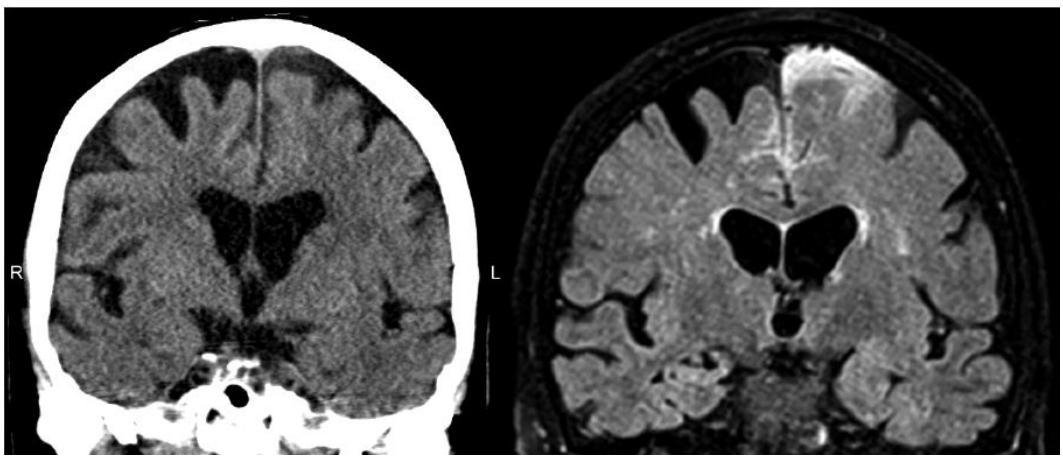

Figure 1. CT and MRI scans from a female patient with non-convulsive status epilepticus existing for several days. Evidence of localised subarachnoid hyperdensity/hyperintensity in the left upper frontal lobe consistent with protein-rich exudate. Courtesy of the Neuroradiological Department of Neurology, Rehabilitation Hospital Ulm, Ulm, Germany.

Summary of the major aspects of epileptic seizures in spontaneous SAH:

- Stratification of epileptic seizures into initial, early and late is reasonable given that treatment and prognosis are designed with these categories in mind.
- Since randomised controlled and double-blind clinical trials into the management of epileptic seizures with SAH are lacking, therapeutic recommendations can only be made based on the guidance of the Neurocritical Care Society and American Stroke Association.
- Initial cases related to the manifestation of bleeding occur in up to 21% of SAH cases and are associated with a complex hospital stay. Anticonvulsant medication should

be administered until treatment of the aneurysm, albeit for a maximum of three days, preferably with non-enzyme inducers so as to avoid drug interactions with nimodipine.

- The incidence of early seizures within the following 14 days does not appear to differ between patients undergoing surgery and those receiving endovascular treatment for ruptured aneurysms (10%-11%). If there are risk factors, such as multiple epileptic seizures or the existence of parenchymal defects, drug therapy should be administered for 3-6 months.
- The late onset of epileptic seizures post SAH accounts for 12% of the patient population and should, as with any symptomatic form of epilepsy, be managed long-term with anticonvulsants.
- Non-convulsive seizures and non-convulsive status epilepticus occur in 18% and 13% of cases, respectively, and should be considered in particular in quantitative disorders of consciousness as well as diagnosed with the help of an EEG.
- Subarachnoid signal alterations on CT and MRI can be indicative not only of SAH but also of other conditions, such as a protracted epileptic seizure or (non-convulsive) status epilepticus, and should be considered when deliberating the differential diagnosis.

REFERENCES

[1] Diener H-C, Weimar, C. *Leitlinien für Diagnostik und Therapie in der Neurologie*. Thieme-Verlag. 2012.

[2] Claassen J, Peery S, Kreiter KT, Hirsch LJ, Du EY, Connolly ES, et al. Predictors and clinical impact of epilepsy after subarachnoid hemorrhage. *Neurology*. 2003 Jan 28;60(2):208-14. PubMed. PMID: 12552032. Epub 2003/01/29. eng.

[3] Hasan D, Schonck RS, Avezaat CJ, Tanghe HL, van Gijn J, van der Lugt PJ. Epileptic seizures after subarachnoid hemorrhage. *Annals of neurology*. 1993 Mar;33(3):286-91. PubMed PMID: 8498812. Epub 1993/03/01. eng.

[4] Krishna H, Wani AA, Behari S, Banerji D, Chhabra DK, Jain VK. Intracranial aneurysms in patients 18 years of age or under, are they different from aneurysms in adult population? *Acta neurochirurgica*. 2005 May;147(5):469-76; discussion 76. PubMed PMID: 15812597. Epub 2005/04/07. eng.

[5] Guth JC, Gerard EE, Nemeth AJ, Liotta EM, Prabhakaran S, Naidech AM, et al. Subarachnoid extension of hemorrhage is associated with early seizures in primary intracerebral hemorrhage. *Journal of stroke and cerebrovascular diseases* : the official journal of National Stroke Association. 2014 Nov-Dec;23(10):2809-13. PubMed.PMID: 25194742. Epub 2014/09/10. eng.

[6] De Marchis GM, Pugin D, Lantigua H, Zammit C, Tadi P, Schmidt JM, et al. Tonic-clonic activity at subarachnoid hemorrhage onset: impact on complications and outcome. *PloS one*. 2013;8(8):e71405. PubMed PMID: 23951155. Pubmed Central PMCID: 3741137. Epub 2013/08/21. eng.

[7] Fung C, Balmer M, Murek M, Z'Graggen WJ, Abu-Isa J, Ozdoba C, et al. Impact of early-onset seizures on grading and outcome in patients with subarachnoid hemorrhage.

Journal of neurosurgery. 2015 Feb;122(2):408-13. PubMed PMID: 25479126. Epub 2014/12/06. eng.

[8] Lanzino G, D'Urso PI, Suarez J. Seizures and anticonvulsants after aneurysmal subarachnoid hemorrhage. *Neurocritical care*. 2011 Sep;15(2):247-56. PubMed PMID: 21751102. Epub 2011/07/14. eng.

[9] De Marchis GM, Lantigua H, Schmidt JM, Lord AS, Velander AJ, Fernandez A, et al. Impact of premorbid hypertension on haemorrhage severity and aneurysm rebleeding risk after subarachnoid haemorrhage. *Journal of neurology, neurosurgery, and psychiatry*. 2014 Jan;85(1):56-9. PubMed PMID: 23813741. *Epub* 2013/07/03. eng.

[10] Tang C, Zhang TS, Zhou LF. Risk factors for rebleeding of aneurysmal subarachnoid hemorrhage: a meta-analysis. *PloS one*. 2014;9(6):e99536. PubMed PMID: 24911172. Pubmed Central PMCID: 4049799. Epub 2014/06/10. eng.

[11] Park J, Woo H, Kang DH, Kim YS, Kim MY, Shin IH, et al. Formal protocol for emergency treatment of ruptured intracranial aneurysms to reduce in-hospital rebleeding and improve clinical outcomes. *Journal of neurosurgery*. 2015 Feb;122(2):383-91. PubMed PMID: 25403841. Epub 2014/11/19. eng.

[12] Connolly ES, Jr., Rabinstein AA, Carhuapoma JR, Derdeyn CP, Dion J, Higashida RT, et al. Guidelines for the management of aneurysmal subarachnoid hemorrhage: a guideline for healthcare professionals from the American Heart Association/american Stroke Association. *Stroke; a journal of cerebral circulation*. 2012 Jun;43(6):1711-37. PubMed PMID: 22556195. Epub 2012/05/05. eng.

[13] Rowe AS, Goodwin H, Brophy GM, Bushwitz J, Castle A, Deen D, et al. Seizure prophylaxis in neurocritical care: a review of evidence-based support. *Pharmacotherapy*. 2014;34(4):396-409. PubMed PMID: 24277723. *Epub* 2013/11/28. eng.

[14] Hart Y, Sneade M, Birks J, Rischmiller J, Kerr R, Molyneux A. Epilepsy after subarachnoid hemorrhage: the frequency of seizures after clip occlusion or coil embolization of a ruptured cerebral aneurysm: results from the International Subarachnoid Aneurysm Trial. *Journal of neurosurgery*. 2011 Dec;115(6):1159-68. PubMed PMID: 21819189. Epub 2011/08/09. eng.

[15] Raper DM, Starke RM, Komotar RJ, Allan R, Connolly ES, Jr. Seizures after aneurysmal subarachnoid hemorrhage: a systematic review of outcomes. *World neurosurgery*. 2013 May-Jun;79(5-6):682-90. PubMed PMID: 23022642. Epub 2012/10/02. eng.

[16] Hoh BL, Nathoo S, Chi YY, Mocco J, Barker FG, 2nd. Incidence of seizures or epilepsy after clipping or coiling of ruptured and unruptured cerebral aneurysms in the nationwide inpatient sample database: 2002-2007. *Neurosurgery*. 2011 Sep;69(3):644-50; discussion 50. PubMed PMID: 21499155. Epub 2011/04/19. eng.

[17] Marigold R, Gunther A, Tiwari D, Kwan J. Antiepileptic drugs for the primary and secondary prevention of seizures after subarachnoid haemorrhage. *The Cochrane database of systematic reviews*. 2013;6:CD008710. PubMed PMID: 23740537. Epub 2013/06/07. eng.

[18] Rhoney DH, Tipps LB, Murry KR, Basham MC, Michael DB, Coplin WM. Anticonvulsant prophylaxis and timing of seizures after aneurysmal subarachnoid hemorrhage. *Neurology*. 2000 Jul 25;55(2):258-65. PubMed PMID: 10908901. Epub 2000/07/26. eng.

[19] Naidech AM, Kreiter KT, Janjua N, Ostapkovich N, Parra A, Commichau C, et al. Phenytoin exposure is associated with functional and cognitive disability after subarachnoid hemorrhage. *Stroke; a journal of cerebral circulation*. 2005 Mar;36(3): 583-7. PubMed PMID: 15662039. Epub 2005/01/22. eng.

[20] Rosengart AJ, Huo JD, Tolentino J, Novakovic RL, Frank JI, Goldenberg FD, et al. Outcome in patients with subarachnoid hemorrhage treated with antiepileptic drugs. *Journal of neurosurgery*. 2007 Aug;107(2):253-60. PubMed PMID: 17695377. Epub 2007/08/19. eng.

[21] Tartara A, Galimberti CA, Manni R, Parietti L, Zucca C, Baasch H, et al. Differential effects of valproic acid and enzyme-inducing anticonvulsants on nimodipine pharmacokinetics in epileptic patients. *British journal of clinical pharmacology*. 1991 Sep;32(3):335-40. PubMed PMID: 1777370. Pubmed Central PMCID: 1368527. Epub 1991/09/01. eng.

[22] Milligan TA, Hurwitz S, Bromfield EB. Efficacy and tolerability of levetiracetam versus phenytoin after supratentorial neurosurgery. *Neurology*. 2008 Aug 26;71(9):665-9. PubMed PMID: 18725591. Epub 2008/08/30. eng.

[23] Murphy-Human T, Welch E, Zipfel G, Diringer MN, Dhar R. Comparison of short-duration levetiracetam with extended-course phenytoin for seizure prophylaxis after subarachnoid hemorrhage. *World neurosurgery*. 2011 Feb;75(2):269-74. PubMed PMID: 21492729. Epub 2011/04/16. eng.

[24] Karamchandani RR, Fletcher JJ, Pandey AS, Rajajee V. Incidence of delayed seizures, delayed cerebral ischemia and poor outcome with the use of levetiracetam versus phenytoin after aneurysmal subarachnoid hemorrhage. *Journal of clinical neuroscience* : official journal of the Neurosurgical Society of Australasia. 2014 Sep;21(9):1507-13. PubMed PMID: 24919470. Epub 2014/06/13. eng.

[25] Kwan J, Wood E. Antiepileptic drugs for the primary and secondary prevention of seizures after stroke. *The Cochrane database of systematic reviews*. 2010 (1):CD005398. PubMed PMID: 20091574. Epub 2010/01/22. eng.

[26] Leung H, Man CB, Hui AC, Kwan P, Wong KS. Prognosticating acute symptomatic seizures using two different seizure outcomes. *Epilepsia*. 2010 Aug;51(8):1570-9. PubMed PMID: 20002147. Epub 2009/12/17. eng.

[27] Diringer MN, Bleck TP, Claude Hemphill J, 3rd, Menon D, Shutter L, Vespa P, et al. Critical care management of patients following aneurysmal subarachnoid hemorrhage: recommendations from the Neurocritical Care Society's Multidisciplinary Consensus Conference. *Neurocritical care*. 2011 Sep;15(2):211-40. PubMed PMID: 21773873. Epub 2011/07/21. eng.

[28] Ibrahim GM, Fallah A, Macdonald RL. Clinical, laboratory, and radiographic predictors of the occurrence of seizures following aneurysmal subarachnoid hemorrhage. *Journal of neurosurgery*. 2013 Aug;119(2):347-52. PubMed PMID: 23581590. Epub 2013/04/16. eng.

[29] Grunwald IQ, Kuhn AL, Schmitt AJ, Balami JS. Aneurysmal SAH: current management and complications associated with treatment and disease. The *Journal of invasive cardiology*. 2014 Jan;26(1):30-7. PubMed PMID: 24402809. Epub 2014/01/10. eng.

[30] Huttunen J, Kurki MI, von Und Zu Fraunberg M, Koivisto T, Ronkainen A, Rinne J, et al. Epilepsy after aneurysmal subarachnoid hemorrhage: A population-based, long-term

follow-up study. *Neurology*. 2015 Jun 2;84(22):2229-37. PubMed PMID: 25948726. Epub 2015/05/08. eng.

[31] Serafini A, Gigli GL, Gregoraci G, Janes F, Cancelli I, Novello S, et al. Are Early Seizures Predictive of Epilepsy after a Stroke? Results of a Population-Based Study. *Neuroepidemiology*. 2015 Jul 28;45(1):50-8. PubMed PMID: 26227564. Epub 2015/08/01. Eng.

[32] Buczacki SJ, Kirkpatrick PJ, Seeley HM, Hutchinson PJ. Late epilepsy following open surgery for aneurysmal subarachnoid haemorrhage. *Journal of neurology, neurosurgery, and psychiatry*. 2004 Nov;75(11):1620-2. PubMed PMID: 15489400. Pubmed Central PMCID: 1738819. Epub 2004/10/19. eng.

[33] Gilmore E, Choi HA, Hirsch LJ, Claassen J. Seizures and CNS hemorrhage: spontaneous intracerebral and aneurysmal subarachnoid hemorrhage. *The neurologist*. 2010 May;16(3):165-75. PubMed PMID: 20445426. Epub 2010/05/07. eng.

[34] Kondziella D, Friberg CK, Wellwood I, Reiffurth C, Fabricius M, Dreier JP. Continuous EEG monitoring in aneurysmal subarachnoid hemorrhage: a systematic review. *Neurocritical care*. 2015 Jun;22(3):450-61. PubMed PMID: 25277888. Epub 2014/10/04. eng.

[35] Cucchiara B, Sinson G, Kasner SE, Chalela JA. Pseudo-subarachnoid hemorrhage: report of three cases and review of the literature. *Neurocritical care*. 2004;1(3):371-4. PubMed PMID: 16174937. Epub 2005/09/22. eng.

[36] Renou P, Tourdias T, Fleury O, Debruxelles S, Rouanet F, Sibon I. Atraumatic nonaneurysmal sulcal subarachnoid hemorrhages: a diagnostic workup based on a case series. *Cerebrovasc Dis*. 2012;34(2):147-52. PubMed PMID: 22890017. Epub 2012/08/15. eng.

[37] Morris JM, Miller GM. Increased signal in the subarachnoid space on fluid-attenuated inversion recovery imaging associated with the clearance dynamics of gadolinium chelate: a potential diagnostic pitfall. *AJNR American journal of neuroradiology*. 2007 Nov-Dec;28(10):1964-7. PubMed PMID: 17893215. Epub 2007/09/26. eng.

[38] Villalobos-Chavez F, Rodriguez-Uranga JJ, Sanz-Fernandez G. [Sequential changes in magnetic resonance in a limbic status epilepticus]. *Revista de neurologia*. 2005 Mar 16-31;40(6): 354-7. PubMed PMID: 15795872. Epub 2005/03/30. Cambios secuenciales en la resonancia magnetica en estado epileptico limbico. spa.

In: Encyclopedia of Surgery (22 Volume Set)
Editors: Andreas Lehrer and Kristin Mueller
ISBN: 978-1-53618-329-0
© 2020 Nova Science Publishers, Inc.

Chapter 77

NEUROREHABILITATION AFTER SUBARACHNOID HAEMORRHAGE

Martin Schorl and Michael Hartwich
Early Neurological/Neurosurgical Rehabilitation,
Asklepios Schlossbergklinik Bad König, Frankfurter Strasse 33,
Bad König, Germany

ABSTRACT

Neurorehabilitation after subarachnoid haemorrhage (SAH) is of major importance in all patients surviving the acute stage of their illness but remaining disabled. Neurorehabilitation aims at regaining self control in the activities of daily living in severely affected patients or the return to the workplace in moderate affected patients.

This chapter describes the German Phase model for neurorehabilitation after central nervous damage in general and focuses on the patients severely affected after SAH. Severely affected patients after central nervous system damage are treated by early neurological and neurosurgical rehabilitation as the link between acute care and rehabilitation. Early neurological and neurosurgical rehabilitation becomes increasingly specialized, nowadays integrating intensive care treatment modalities and rehabilitation. The aim was to minimise the need to return patients from early rehabilitation back to the emergency department and facilitate integrated rehabilitation treatment with accompanying treatment of the typical complications. For this to happen, a combination of multidisciplinary emergency and rehabilitative measures are usually needed which, depending on the respective medical situation, can be carried out in varying degrees of intensity and dominance.

The interdisciplinary approach of early neurological and neurosurgical rehabilitation is discussed in detail concerning the characteristics of the patients treated, the setting, the multidisciplinary treatment concept including the medical and therapeutic staff and the diagnostic equipment required.

Special aspects of neurorehabilitation after SAH are discussed in detail. Data concerning outcome are presented. Overall, they show the benefit of early neurological and neurosurgical rehabilitation both from the patient's and the society's perspective.

Keywords: neurorehabilitation, German phase model of neurorehabilitation, early neurological rehabilitation, early neurosurgical rehabilitation, interdisciplinary neurorehabilitation

DEVELOPMENT OF NEUROREHABILITATION AND LEGAL REGULATIONS

Early rehabilitation after stroke has proven superior to late rehabilitation [20]. Rehabilitation should therefore be commenced at the earliest opportunity in the acute phase during initial treatment so as to increase the chances of rehabilitation and not to lose any valuable time [4]. Since 2001, therefore, social law in Germany has included an entitlement to rehabilitation services during acute inpatient care (Section 27 of Social Security Code (SGB) IX).

However, the phase model for the rehabilitation of individuals with severe and very severe brain damage was inaugurated as early as 1995 by the Bundesarbeitsgemeinschaft Rehabilitation (BAR) [Federal Rehabilitation Council] [4]. The Bundesarbeitsgemeinschaft Rehabilitation is an amalgamation of different health insurance providers (umbrella organisations for health insurance, accident insurance, annuity insurance) with the participation of the Medical Review Board of the Statutory Health Insurance Funds, representatives of the federal states, medical societies and medical experts.

The aim of the phase model was to create an integrated treatment and rehabilitation chain targeted to the needs of patients and accounting for both medical and rehabilitative requirements.

Table 1. Phase model for neurorehabilitation of individuals with severe brain injury in Germany

Phase	Definition
A	Acute care including surgery, neurosurgery, interventional neuroradiology, neurointensive care.
B	Early post-acute rehabilitation treatment; intensive care facilities must be provided, may include mechanical ventilation.
C	Continuing rehabilitation. Vital signs are stable and the patient is able to participate actively in therapy, but requires some medical care. Partly dependent in activities of daily living (ADL).
D	Follow-up rehabilitation. Patients are mostly independent in ADL; medical therapies aimed at returning to work, may be performed on an outpatient rehabilitation basis.
E	Occupational retraining or reintegration.
F	Function-preserving nursing care and therapies for patients with disorders of consciousness or persistent, severe disabilities (e.g., occupational therapy, physiotherapy, oral tract therapy), either in specialized nursing homes or at home, sometimes with home ventilation therapy.

In this phase model, a distinction is made (Table 1) between an acute phase and several subsequent rehabilitation phases: ideally, once primary acute hospital treatment (Phase A) is complete, the patient initially receives care under Phase B (known as “early neurological rehabilitation”), then Phase C (continuing rehabilitation), and finally Phase D (follow-up rehabilitation). One or more of the above-mentioned phases can be skipped depending on the level of care required by the patient or the degree of independence achieved.

Occupational reintegration or retraining can take place in Phase E. If after early rehabilitation (Phase B) the level of independence is not sufficient to move on to the subsequent rehabilitation phases, out-of-hospital nursing care is introduced while continuing with the treatment programme (Phase F). The aim here is to at least maintain the level that has been achieved and avoid secondary complications.

With the introduction of a new hospital billing system (G-DRG) in 2001, early neurological rehabilitation is now predominantly funded through flat rates per case, which are based on the one hand on medical diagnoses and on the other hand on reimbursement-relevant procedures. The complex flat rate for "early neurological rehabilitation" (known as OPS 8-552) [7] can only be billed if certain qualitative structural and quantitative requirements are fulfilled. Therefore, among other things, at least 300 treatment minutes per patient per day must be provided and weekly team meetings with standardised assessments carried out.

In contrast to developments in other countries, where rehabilitation teams attend to severely affected patients during anaesthesiological and neurological/neurosurgical treatment (outreach rehabilitation), specialist clinics have been established in Germany that have the necessary medical and rehabilitative expertise along with the staff and equipment required to also deal with patients in critical condition who are still in need of intensive care immediately after undergoing emergency treatment. This enables rehabilitative approaches to be integrated into the treatment programme at the earliest opportunity.

As a result of neurorehabilitation becoming increasingly specialised in its position as the link between the acute disciplines of neurology and neurosurgery as well as rehabilitation, attempts have been made to introduce an additional qualification in neurorehabilitation or the separate title of specialist for neurorehabilitation into basic and advanced training. Relevant initiatives are also afoot internationally within the framework of the European Federation for NeuroRehabilitation (EFNR).

EARLY NEUROLOGICAL REHABILITATION/PHASE B ACCORDING TO THE PHASE MODEL

General Aspects

Patients

Among all patients in early neurological and neurosurgical rehabilitation, patients post subarachnoid haemorrhage (SAH) account for 7.5% to 28% [9, 12, 18] of total patient numbers depending on the specialisation of the hospital.

Patients in early neurological and neurosurgical rehabilitation are typically medically unstable over a lengthy period of time and may have a variety of complications ([3], Table 2). On the one hand, these are pre-existing comorbidities involving other organ systems, and on the other hand complications in the central and peripheral nervous system. A distinction is essentially made here between direct nervous system complications (e.g., epilepsy, critical illness polyneuropathy, hydrocephalus, sinking skin flap syndrome after decompressive craniectomy) or the impact of the symptoms of neurological damage on other organ systems (e.g., pneumonia following neurogenic dysphagia, electrolyte imbalance and arrhythmia as a result of central endocrine insufficiencies, intestinal motility disorders with vomiting as a result of autonomous functional disorders of the peripheral nervous system).

Table 2. Typical medical complications in early neurological/neurosurgical rehabilitation

Organ system	Symptom	
Central and peripheral nervous system	Meningitis/ventriculitis	
	Epileptic seizure	
	Convulsive and non-convulsive status epilepticus	
	Critical-illness polyneuropathy	
	Neurogenic dysphagia	
	Malresorptive hydrocephalus	
	Shunt dysfunction, shunt infection	
	Sinking skin flap syndrome	
Endocrine system	Diabetes insipidus	
	Cerebral salt-wasting syndrome	
	Syndrome of inappropriate ADH secretion	
	Electrolyte disorders	
	Acquired anterior pituitary insufficiency	
Vegetative system	Sympathicotonic dysregulation	Tachycardia
		Arterial hypertension
		Hyperhidrosis
		Tachypnoea
		Hyperthermia
	Gastrointestinal dysregulation	Vomiting
		Pylorospasm
		Reflux
		Diarrhoea
Cardiopulmonary system	Cardiac arrhythmias	
	Heart failure	
	Endocarditis	
	Takotsubo cardiomyopathy	
	Pneumonia	
	Bronchial obstruction	
	Thrombosis, pulmonary embolism	
	Pneumothorax	
	Pleural effusion	
	Pleuritis	
Gastrointestinal system	Gallstones, gallbladder sludge	
	Cholestasis	
	Cholecystitis	
	Hyperammonaemia	
	Gastritis, ventricular ulcer, duodenal ulcer	
	Ascites	
	Peritonitis	
Genitourinary system	Urinary tract infection	
	Renal failure	
	Nephrolithiasis	
	Haematuria	
	Incontinence	
Musculoskeletal system	Heterotopic ossification	
Bacteria requiring isolation	MRSA, 3-MRGN, 4-MRGN, clostridia, VRE	
Pre-existing diseases	Cancer	
	Coronary heart disease	
	Bronchial asthma	
	Mental illnesses	

Organ system	Symptom
	Infectious diseases (hepatitis, HIV)
	Parkinson's disease, Parkinson's syndrome, multiple sclerosis
	Inflammatory bowel diseases
Medication	Sedative effects (e.g., antidepressants, antiepileptics)
	Interactions
	Proconvulsive effects (e.g., theophylline, anti-infectives, activating substances)

The BAR defined the task of early rehabilitation, among other things, as "the medical diagnosis and curative medical treatment of underlying diseases and comorbidities from neurological damage" [4, point 3.1.3., page 10] and mentioned explicitly that "management of life-threatening complications and any complications occurring during mobilisation must be possible" [4, point 3.1.3., page 10].

The aim was thus to minimise the need to return patients from early rehabilitation back to the emergency department and facilitate integrated rehabilitation treatment with accompanying treatment of the typical complications. For this to happen, a combination of multidisciplinary emergency and rehabilitative measures are usually needed which, depending on the respective medical situation, can be carried out in varying degrees of intensity and dominance. Significant overarching tasks in early neurological and neurosurgical rehabilitation involve the continuation of the curative medical efforts initiated as part of acute treatment, support in the remission of CNS/PNS damage by promoting neuroplasticity (basal objectives: improved vigilance, cooperation, ability to communicate), implementation of compensatory and adaptive measures that reduce the need for assistance and increase quality of life, evaluation of the potential for rehabilitation, and the organisation of further care [3]. Ideally, patients can be transferred to continuing rehabilitation phases (Phase C) if there is a corresponding improvement in independence.

Nowadays, patients are transferred to early neurological and neurosurgical rehabilitation immediately on completion of neurological, neurosurgical, or interventional neuroradiological acute medical care. At such a time, many patients are still under analgosedation and mechanical ventilation, and often still have cerebrospinal fluid drains in situ. Medically speaking, the main objectives at this early phase are medical stabilisation, weaning from ventilation, tapering off the analgosedation and achieving an adequate rehabilitative capacity. Initial, mostly passive rehabilitation measures run parallel to this. Ideally, as treatment progresses, intensive care takes a back seat in favour of rehabilitation that takes an increasingly active approach.

To this end, drugs that influence the level of consciousness and stabilise the circulation must be tapered off. As vigilance improves, sympathicotonic dysregulation of the autonomic nervous system often comes to the fore which, given the tendency for tachycardia and hypertension to develop, can be detrimental to early mobilisation and, as a result of hyperhidrosis, can lead to fluid losses and electrolyte imbalances. Nursing care (e.g., from the concept of basal stimulation) and positioning concepts are incorporated in the multidisciplinary approach alongside drug therapies. To make patient mobilisation easier, formulations of substances administered via enteral feeding tube are to be preferred for drug treatment in contrast to substances requiring intravenous application. As a result, changes in medication must also be undertaken frequently during the initial phase.

In the event of severe damage to the central nervous system, or as a result of critical illness polyneuropathy often occurring as a complication in up to 69% [27], there is often evidence of neurogenic dysphagia. After appropriate diagnostic testing, usually involving endoscopy, this will necessitate the insertion, at least temporarily, of a tracheostoma for protection against aspiration as well as percutaneous feeding tubes. The improvement in swallowing function with the aim of decannulation in the tracheotomised patient is also one of the primary objectives of early neurological rehabilitation, which is why swallowing rehabilitation is initiated as a multidisciplinary approach from the time of admission onwards.

Setting

Appropriate equipment and staffing are indispensable to the above-mentioned diagnostic and therapeutic activities, as an accompaniment to intensive care treatment, if the patient is not to be subjected to the stresses of being transferred. The aim is to offer patients "one-stop" care. Otherwise, rehabilitation would in the worst-case scenario be repeatedly interrupted. Early neurological and neurosurgical rehabilitation is therefore carried out predominantly in specially dedicated clinics that in some cases also offer subsequent rehabilitation phases (see below), more rarely as a functional facility affiliated with acute hospitals. Early neurological and neurosurgical rehabilitation is to a large extent characterised by interdisciplinarity – not only from a medical point of view, but also from the perspective of nursing and therapy.

Multidisciplinary Treatment Concept

Early neurological and neurosurgical rehabilitation is carried out under the supervision of a neurologist and/or neurosurgeon with at least three years of experience in neurorehabilitation. Depending on (intensive care) orientation and equipment, as well as the available diagnostic and therapeutic services, the medical team usually consists not only of neurologists, but also physicians, general practitioners, rehabilitation and intensive care specialists. Since transfers to neurosurgery constitute the second most frequent type of transfer alongside transfers to internal medicine [30], some facilities do now employ neurosurgeons or collaborate with neurosurgical clinics in order to offer elective secondary surgical procedures in-house alongside rehabilitation. Expertise in neuroradiology is usually provided via links with (neuro) radiology practices or centres, where teleradiological concepts are increasingly ensuring widespread availability and results of high quality.

Care staff receive basic and advanced training both in intensive care and neurorehabilitation. This combination is of particular importance since patients should benefit as early as possible from neurorehabilitative nursing while on intensive care, and rehabilitative care has huge significance in neurorehabilitation beyond basic care and treatment. This results primarily from the fact that in severely affected patients a number of rehabilitative aspects are viewed within the context of activities of daily living. Catalogues of nursing services have been defined on this basis [11].

The primary objective in physiotherapy is initially to achieve early mobilisation and train the circulation with the aim of sufficient cardiopulmonary capacity and stability in the autonomic nervous system in readiness for the subsequent rehabilitation steps. At the early phase, close coordination with the intensive care specialists and the therapists' own expertise in intensive and respiratory medicine are always essential aspects that can help to interpret the reactions of patients. The purpose of early mobilisation is also to achieve the best possible physiological muscle tone, facilitate first movements, develop targeted motor skills and

incorporate them into activities of daily living, and improve postural control. An essential basis for improving motor skills on the one hand, and achieving progress in terms of dysphagia, level of consciousness and environmental interaction on the other, is verticalisation. Later on in the process of neurorehabilitation, the focus is then on change in position, transfers to a wheelchair, wheelchair locomotion and walking. In the case of very severely affected patients, efforts to influence pathologically affected muscle tone come to the fore.

In many early rehabilitation clinics, the therapeutic focus of occupational therapy is not only on motor rehabilitation of the upper extremities so as to restore the hand motor skills to a sufficient degree in everyday and professional life, but also dysphagia therapy, including tracheal cannula management and the reinstatement of an oral diet. This also requires specialist knowledge in respiratory therapy, instrumental diagnosis of dysphagia and close coordination with other therapeutic areas that frequently complement each other in their approaches to the problem (nursing, speech therapy).

The primary task of neuropsychology in early neurological and neurosurgical rehabilitation is on the one hand to diagnose and assess disorders of consciousness with regard to interpreting basic approaches of interaction and developing early communication methods for and with patients, and on the other hand to diagnose and treat the characteristic neuropsychological symptoms and syndromes. Supporting relatives is also very important, as is the advice and guidance of the therapeutic team in case of patients with mental (e.g., depression with suicidal tendency) or neuropsychological (e.g., organic brain syndrome with restlessness, aggressiveness and behaviour that is harmful to the self or others) disorders. Neuropsychology is often the discipline where first-line diagnosis and treatment of aphasic disorders are undertaken in the process of developing methods of communication.

Besides the diagnosis and treatment of aphasia and dysarthria, which are frequently limited in early neurological rehabilitation by concurrent neurocognitive deficits, the diagnosis and treatment of dysphagia is a further area of expertise covered by speech therapy.

Table 3 provides an overview of the respective treatment modalities.

In addition to these standard therapies, a variety of other treatments (e.g., music therapy, art therapy, animal-assisted therapy, physical therapy) are used in different combinations. Increasingly, modern (e.g., robot-assisted locomotion therapy) and evidence-based (e.g., constrained induced movement therapy) therapies find their way into early rehabilitation, sometimes adapted specifically to the patients.

The complexity of injury patterns in patients on the one hand and the variety of specialist disciplines involved in the treatment on the other hand rely on clear and thorough communication on the part of all those involved, and a flexible approach to planning with targeted selection and implementation of treatment. Regular interdisciplinary team meetings every week are therefore an opportunity to exchange information, focus on objectives and mutually agree on the treatment plan. Multidisciplinary treatment concepts (e.g., botulinum toxin injection into the salivary glands for reducing the amount of saliva in pseudohypersalivation with risk of aspiration following reduced swallowing frequency, thereby facilitating dysphagia therapy and extending tracheal cannula unblocking times) and concurrent programmes from various disciplines (e.g., physiotherapy for mobilisation into a sitting position and speech therapy for managing dysphagia in the achieved sitting position) are characteristic of the early neurological and neurosurgical rehabilitation activities that rely on considerable staff input.

Table 3. Overview of therapeutic treatments in Phase B

Nursing therapy 4-6 hr/d	• Diagnostics: Skin conditions, position tolerance, primary behavior observation, assessment of endurance • Basal stimulation: activating "guided" basic care, initiation of cooperation in mini-sequences in the ADL • Relaxing therapies in agitated phases: bathing, positions, communication, reduction of sedating medication
Physiotherapy 1-2 hr/d	• Diagnostics: muscular tone, joint flexibility, pathological movements • Prophylactic treatment to prevent complications: against contractures, pneumonia • Mobilisation (even if patients are on respiratortherapy): "Pilot"-seat, bed edge, wheel chair, improvement of circulatory endurance, initiation of first position and support reactions • Respiration therapy: assistance in weaning of respirator, secretion control • Multimodal stimulation for improvement of perception • Reduction of pathologically increased muscle tone: functional positioning, modified neurophysiologically orientated treatment procedures, casting • Regain of mobility: transfer and wheelchair training, treadmill training, balance training, walking with and without auxiliary devices
Occupational therapy 1-2 hr/d	• Diagnostics: swallowing function, secretion control, assessment of aspiration risk • Facio-oral tract (FOT) therapy: improvement of swallowing reflex, weaning from tracheal tube after successful weaning from the respirator, management of tracheal tube • Improvement of hand function: Reduction of pathological muscle tone, establishing first and functional movements, expansion of usage in activities of daily living, e.g., constraint induced movement therapy (CIMT), improvement of fine motor skills, reduction of apraxia and ataxia • Training of abilities in activities of daily living: bathing, clothing, eating • Improvement of multimodal perception • Adaption of auxiliary devices • Neurocognitive training: planning strategies, attention, memory
Neuropsychology 2-3 hr/wk	• Diagnostics: assessment of level of consciousness using standardized behavioral observation, scales and screenings • Recommendations for interaction with the patient • Daily scheduling based on endurance • Establishing communication: communication code, communication training • Family counseling
Speech therapy (complementary or as needed)	• Diagnostics: Different types of aphasia, dysarthria, swallowing disorders, evaluation of aspiration risk • Establishing communication communication code, auxiliary devices, communication training, compensation strategies • Facio-oral-tract-(FOT)-therapy • Training and improvement of swallowing and eating, compensation strategies • Management of tracheal tubes
Music therapy (as needed)	• Diagnostics: attempt to create musical contact in cases of severe disturbed consciousness • Establishing communication: relaxing or animating musical stimulation, musical communication code

Specific Aspects in Patients Post Subarachnoid Haemorrhage (SAH)

A few specific aspects must be considered in the neurorehabilitation of patients after SAH. These concern firstly the underlying condition, and secondly the characteristic symptoms and typical additional complications.

With regard to the underlying condition, the extent to which untreated, partially treated or fully treated aneurysms are to be given follow-up treatment and monitored must be agreed specifically with the neurosurgeons or neuroradiologists providing initial treatment. The modern interventional neuroradiological treatment procedures sometimes mean that anticoagulant therapy is necessary. This must be considered with respect to competing comorbidities and planning of the necessary secondary interventions (placement of percutaneous feeding tubes, elective neurosurgical secondary interventions). On the other hand, the anticoagulant therapy required for internal comorbidities can be hampered or prove impossible if the placement of a cerebrospinal fluid drain has to be performed repeatedly. As a result of the often early transfer of patients to early neurological and neurosurgical rehabilitation, vasospasm therapy or prophylaxis is also occasionally shifted to early rehabilitation, meaning that appropriate expertise and options for instrumental diagnosis must be available.

As occlusive hydrocephalus is initially common, and communicating hydrocephalus is not uncommon over the course, particularly in severe SAH, the diagnosis of hydrocephalus and indication for shunt placement is the preserve of early neurological and neurosurgical rehabilitation and must be closely coordinated with the neurosurgeon. Frequently, these patients are also transferred to early neurological and neurosurgical rehabilitation with cerebrospinal fluid drains still in situ. Handling these drains and weaning are also typically the responsibility of early rehabilitation.

The identification of absolute (e.g., occlusion) or relative (incorrect valve setting) shunt dysfunction in patients with implanted shunts is another issue to be managed as part of neurorehabilitative treatment. Clinically, these patients can usually only be assessed inadequately with regard to shunt dysfunction, as the symptoms of shunt dysfunction and primary damage overlap [5], are frequently only subtle, and merely cause the course of rehabilitation to stagnate [5]. Imaging procedures do not often sufficiently distinguish between shunt dysfunction and the consequences of the primary damage [5]. In recent years, there has been increased use of a gravitational unit (“shunt assistant”) combined with the shunt valve as a means of preventing overdrainage when the body is in the upright position. However, in patients who are predominantly bedridden they can lead to a relative shunt dysfunction due to underdrainage [14] and should therefore not be implanted in this patient group.

With the increasing use of decompressive hemicraniectomy as the treatment of last resort in treatment-resistant increased intracranial pressure with accompanying intracerebral haemorrhage and vasospastic infarctions, the diagnosis of a sinking skin flap syndrome [1, 24, 31] that may lastingly impair neurorehabilitation [24] and identification of the need for cranioplasty is very important. After cranioplasty it is essential to promptly diagnose as well as introduce appropriate treatment for complications such as aseptic bone necrosis following autologous cranioplasty with a risk of bone resorption or a sinking bone syndrome [8].

Epileptic seizures are a well-known consequence of focal brain damage. In the differential diagnosis of disorders of consciousness as a result of primary damage, non-

convulsive status is of particular significance. The preferred antiepileptics for treatment of symptomatic epilepsy are those that do not impair consciousness, have as little interaction potential as possible, and can be administered easily via a feeding tube. Given the difficulties of differential diagnosis in the case of disorders of consciousness (e.g., valproate-induced encephalopathy) and the potential of pharmacological interactions with loss of effectiveness (e.g., when administering the antibiotic meropenem, which is frequently used in intensive care), valproic acid should not be used as first-line treatment in these patients, which is in contrast to common therapy guidelines in epilepsy. In our own experience, lacosamide also leads to encephalopathy-type conditions time and again. In patients dependent on tube feeding, phenytoin is obsolete, as an effective drug level cannot be achieved [30, own experience].

Organic brain syndromes (OBS) with pronounced drive disorders are not unusual after SAH due to aneurysms commonly being found in the anterior communicating artery or the A1 and proximal A2 segment of the anterior cerebral artery [2]. Not uncommonly, like other neuropsychological symptoms, OBS are also crucial to the functional outcome [19] and can hinder rehabilitation. With regard to attempts at drug treatment, the differentiation of reactive depression, malresorptive hydrocephalus, a symptomatic sleep apnoea syndrome, endocrine problems and a non-convulsive status from organic brain syndromes with reduced drive is important. In the first instance, drug treatment to improve drive is attempted with amantadine, and also levodopa, drive-stimulating antidepressants, and more rarely with amphetamines. Our experience with modafinil is good, especially with simultaneously impaired vigilance. It is worth remembering that, apart from amantadine, the use of medication is beyond any approved indication and the relevant medicolegal aspects of off-label use should be considered. Amnestic syndromes are hardly accessible with drug therapy and require intensive neuropsychological treatment with development of compensation strategies and if necessary accommodation in a special setting (contained area).

At a rate of 47.5%, endocrine disorders of superordinate hypothalamic-pituitary hormone production occur more frequently after SAH than after traumatic brain injury (27.5%) [21]. Interestingly, the occurrence does not correlate with the severity of the subarachnoid haemorrhage [21]. They more often affect only one endocrine axis in isolation, and less often several at once [22]. Frequency figures fluctuate between 5.4% and 57.5% depending on the test procedures and their timing [22]. An essential problem results from a lack of reliable reference values for endocrine disorders in the early phase following brain damage.

Corticotropic insufficiency is of particular relevance to early neurological and neurosurgical rehabilitation, as it is aside from somatotropic insufficiency the most frequent insufficiency [22], often sidesteps routine laboratory tests (compared to thyrotropic insufficiency), is often difficult to diagnose on a clinical level as a result of the often unspecific or ambiguous symptoms, but in stressful situations (infections, operations) can even result in life-threatening Addisonian crisis. Furthermore, corticotropic insufficiency is usually only a relative one, with normal or borderline basal cortisol levels. Often, significantly higher substitution doses than usual are needed [26]. Other endocrine disorders in the form of diabetes insipidus (up to 3% [22]), syndrome of inappropriate ADH secretion or cerebral salt-wasting syndrome may occur.

As time goes on, spasticity frequently develops as a consequence of focal brain damage from concurrent bleeding or vasospastic infarctions, or herniation in severely affected patients. This often requires further therapy such as botulinum toxin injections, joint

mobilisation under anaesthetic and corrective cast treatment in addition to the basic measure of physiotherapy. Systemic antispastic agents should preferably be avoided because of frequently occurring cognitive and gastrointestinal side effects with at the same time a mostly inadequate effect on severe spasticity, even at high doses. In contrast, experience with intrathecal baclofen therapy is positive [30; own experience]. Appropriate multimodal therapy in the case of severe spasticity requires, time and again, a combination of all therapeutic aspects and options and is ideally only to be performed in the early neurological and neurosurgical rehabilitation setting.

Critical illness polyneuropathy (CIP) often develops over the further course and is of particular significance in the rehabilitation process. It has additional negative implications in terms of the patient's motor skills, often leads to neurogenic dysphagia, reduces physical resilience and prolongs the process of weaning off ventilation in a highly significant way [27]. Because the symptoms of central nervous and peripheral nervous damage overlap, the clinical diagnosis of CIP in patients post SAH is unreliable [13]. Using a standardised electrophysiological test, the incidence of critical illness polyneuropathy as a concomitant condition was found to be 69% in patients in early neurological and neurosurgical rehabilitation [27].

Haemorrhaging in the vitreous body of the eye (Terson syndrome) is not uncommon after subarachnoid haemorrhage. The reported incidence fluctuates between 12% and 50% [6, 10]. The resulting visual disturbances often have a lasting negative impact on rehabilitation, as they are often recognised only late on in patients whose communication is impaired. Especially in this condition, ocular ultrasound is a simple and safe screening method.

Other complications often emerge at the interface with other medical disciplines (e.g., neurourology in the case of neurogenic bladder disorders, psychiatry in the case of depression, cardiology in the case of stress-induced cardiomyopathy [Takotsubo cardiomyopathy] or unspecific ECG changes, pulmonology in the case of neurogenic pulmonary oedema, gastroenterology in the case of gastrointestinal motility disorders with gastroparesis, reflux and vomiting, infectiology in the case of central fever, etc.).

In addition, complications that develop with other diseases but are not typically associated with SAH can also occur of course during the rehabilitation of SAH patients (Table 2). Given that infections are a frequent complication, clinically-orientated, moderate antibiotic treatment is essential in view of the increasing problem of multidrug-resistant pathogens firstly to adequately treat the infection, and secondly to minimise the selection of multidrug-resistant pathogens. Eradication is often impossible in neurological rehabilitation due to various factors (e.g., long-term placement of cannulae, broad spectrum antibiotics often necessary, multiple antibiotic pre-treatments in long-term intensive therapy and ventilation, incontinence, limited cooperativeness). The necessary isolation limits rehabilitation options, and the chances of successful rehabilitation are therefore reduced. Therefore, in the case of elevated body temperature it is appropriate to differentiate between bacterial infection and a central fever.

Finally, it is worth mentioning that many pharmacological approaches constitute off-label use in accordance with current regulatory provisions. Alongside the increased need for a clear indication, additional information and accurate documentation occasionally off-label use brings with it problems in relation to the reimbursement of the costs for expensive treatments (e.g., botulinum toxin) since health insurers can deny payment in this context.

Outcomes of Early Neurological/Neurosurgical Rehabilitation

The individual federal states are responsible for defining health policy in Germany. Germany-wide data are therefore scarce or can only be compared to a limited extent due to distinctions between the states. To illustrate the outcomes, the data from the Quality Assurance Institute in Hessen and data from our own hospital (also located in Hessen) are presented and compared. With six million inhabitants, Hessen is the fifth largest federal state in Germany. All stroke patients and thus all patients with SAH are registered by the acute hospitals as a compulsory measure with the Hessen Quality Assurance Institute. As early neurological and neurosurgical rehabilitation is also assigned to the acute hospital sector according to social legislation (Section 39 SGB V), comprehensive data are also available on this topic.

In 2013, 487 patients with SAH were admitted to acute hospitals in Hessen. The mean inpatient stay for acute hospital treatment for all patients with SAH was 15.7 days (standard deviation: $\pm$10.9 days). 259 out of 487 (53.2%) patients were ventilated. The mean duration of ventilation was 13.3 days (standard deviation: $\pm$12.6 days). Concerning the duration of ventilation it should be noted that some of the patients (especially the more severely affected) were transferred to early neurological and neurosurgical rehabilitation in a ventilated state and therefore were excluded in the above mentioned analysis.

Table 4 illustrates the functional outcome at the end of acute treatment, classified according to the modified Rankin Scale.

Throughout Hessen, 175 out of 487 (35.9%) patients post SAH were transferred to early neurological and neurosurgical rehabilitation. Table 5 compares the relevant characteristics of the patients in Hessen and at our own hospital.

In Germany, the Barthel Index [15] was established as a standard tool for assessing functional independence, although it was originally designed for patients with quadri-/paraplegia and has some methodological weaknesses. Because of the severity of the damage and the resulting lack of independence, patients in early neurological and neurosurgical rehabilitation are not represented by the Barthel Index, or only late on in the course of the disease owing to the so-called floor effect. Therefore, in Germany, the Early Rehabilitation Barthel Index [23] was introduced to illustrate typical early rehabilitation items which better describe the severity of a patient's condition. Improvements in these items are therefore more appropriate than the Barthel Index for elucidating the advances in early rehabilitative treatment (Table 6).

Table 4. Functional outcome at the end of acute treatment (n = 487) based on the modified Rankin Scale

Scale	Definition	Number of patients	%
0	No symptoms	68	14.0
1	Symptoms with no relevant functional impairment	89	18.3
2	Mild functional impairment	30	6.2
3	Moderate functional impairment	39	8.0
4	Moderately severe functional impairment	57	11.7
5	Severe functional impairment	120	24.6
6	Death	84	17.2

Table 5. Comparison of relevant characteristics in all early rehabilitation patients post SAH in Hessen and our own hospital

Item	Hessen	Bad König
Patient number	175	46
Age [years] *	57.9 ± 11.9	56.2 ± 11.2
Age [years] **	57	53
Ratio men/women [n]	61/114	13/33
Ratio men/women [%]	34.9/65.1	28.3/71.7
Interval event – admission [days] *	45.7 ± 50.3	38.2 ± 46.4
Interval event – admission [days] **	28	23
Number of ventilated patients [n]	64/175	31/46
Number of ventilated patients [%]	36.6	67.4
Duration of ventilation [days] *	16.2 ± 21	10.4 ± 7.7
Duration of ventilation [days] **	11.5	8.5
Weaning ratio [n]	37/41	25/29
Weaning ratio [%]	90.2 %	86.2 %
Decannulation rate [n]	46/70	28/41
Decannulation rate [%]	65.7	68.3
Length of stay [days] *	52.6 ± 116.1	74.5 ± 71.6
Length of stay [days] **	38	37

*Mean + standard deviation, **median, n = number

Table 6. Early Rehabilitation Barthel Index compared between the start and end of early neurological/neurosurgical rehabilitation

Population	Hesse, total (n = 175)						Bad König (n = 46)					
Item *	Admission		Discharge		Difference**		Admission		Discharge		Difference**	
	n	%	n	%	n	%	n	%	n	%	n	%
Disorder requiring intensive medical monitoring	67	38.3	11	17.4	56/67	-83.6	36	78.3	8	17.4	28/36	-77.8
Tracheostoma requiring aspiration	70	40.0	24	28.3	46/70	-65.7	41	89.1	13	28.3	28/41	-68.3
Permanent/intermittent ventilation	41	23.4	4	9.7	37/41	-90.3	29	63.0	4	8.7	25/29	-86.2
Impaired orientation requiring supervision	44	25.1	21	30.4	23/44	-52.3	32	69.6	14	30.4	18/32	-56.3
Behavioural disorder requiring supervision	38	21.7	11	15.2	27/38	-71.1	23	50.0	7	15.2	16/23	-69.6
Severely impaired communication	85	48.6	48	37.0	37/85	-43.5	40	87.0	17	37.0	23/40	-57.5
Swallowing disorder requiring supervision	101	57.7	49	32.6	52/101	-51.5	43	93.5	15	32.6	28/43	-65.1

* Multiple answers possible, ** discharge vs admission

Length of Acute Hospital Stay (for Patients Transferred to Early Neurological/ Neurosurgical Rehabilitation)

The length of stay for primary acute hospital treatment until transfer to early neurological and neurosurgical rehabilitation was 45.7 ± 50.3 days (median 28 days) in Hessen as a whole and 38.2 ± 46.4 days (median 23 days) at our clinic, and thus can be easily compared against an earlier 2005 overview of unselected diseases with a latency of transfer to early neurological and neurosurgical rehabilitation treatment of 47.0 ± 90.2 days (median 27 days) [28]. As this value also includes diseases (cerebral infarction, hypoxia) that are typically associated with shorter acute hospital stays compared to SAH and traumatic brain injury, it can be assumed that the length of acute hospital stay for patients with SAH admitted to early neurological and neurosurgical rehabilitation has slightly decreased in acute medicine in the last ten years.

Percentage of Ventilated Patients Admitted to Early Neurological and Neurosurgical Rehabilitation

The percentage of patients admitted to early neurological and neurosurgical rehabilitation still in a ventilated state (unselected diseases) was 16.6% in 2002 [12] and 18.4% in 2005 [28]. An increase can be established in this regard, as the Hessen-wide percentage of 36.6% among all the SAH patients admitted to early rehabilitation shows (Table 5). The rate at early rehabilitation facilities with a strong intensive care focus is even higher - 61.4% [9] and at our own clinic 67.4% (Table 5).

The further development in early neurological and neurosurgical rehabilitation in relation to intensive care content and procedures facilitates the tendency towards shorter acute medical stays and eases the burden on intensive neurosurgical or anaesthesiological units caring for patients with SAH.

Weaning

Published weaning rates from early neurological and neurosurgical rehabilitation (unselected diseases) in Germany are 68.3% [17], 69.8% [16], 78% [3] and 90.5%, respectively [25]. The weaning rate for patients with SAH is between 86.2% and 90.2% (Table 5). The median duration of weaning was 11.5 and 8.5 days, respectively (Table 5). These values demonstrate that in early neurological and neurosurgical rehabilitation there is now a high level of expertise in respiratory medicine and that patients requiring ventilation after SAH have very good chances of being successfully weaned despite often running the gamut of possible complications.

Decannulation Rates

Even with successful weaning, many patients in early neurological and neurosurgical rehabilitation remain dependent on a tracheostoma, as neurogenic dysphagia frequently develops which due to the associated risk of aspiration can mean that a blocked tracheal cannula is needed. The percentage of tracheotomised patients in the last few years in early neurological and neurosurgical rehabilitation has increased from 40% [28] in an unselected population of patients to up to 89% in patients with SAH (Table 6). Decannulation rates of 65.7% and 68.3%, respectively, (Table 5) indicate that under intensive swallowing

rehabilitation over two thirds of patients with SAH can be weaned from the tracheal cannula, even if severely affected.

Length of Stay in Early Neurological/Neurosurgical Rehabilitation

The average length of stay in early neurological/neurosurgical rehabilitation for patients after SAH in 2013 was 62.6 ± 116.1 days (median 38 days) in Hessen as a whole and 74.5 + 71.6 days (median 37 days) at our own clinic. These values are highly consistent with those of other studies [3, 12, 18] in patients after SAH. Since 2002 there has been a gradual decrease in the lengths of stay for unselected patients, including patients post SAH, from 57 days in 2002 [12] to 37 and 38 days (Table 5) for SAH patients, in whom furthermore the course tends to be more fraught with complications. Alongside the increasing complexity and modalities of intensive therapy (e.g., ventilation), must also be considered. The reduction in the length of stay is most likely caused by the change in the billing system to flat rates per case and an increasingly restrictive attitude on the part of health insurers towards paying for the respective services.

Typical Early Rehabilitation Issues

Based on Schönle's Early Rehabilitation Barthel Index [23], Table 6 details the improvements in the respective items over the course of early rehabilitation therapy, which range from 43%-90% in Hessen as a whole and 56%-86% at our own clinic. It demonstrates that early neurological and neurosurgical rehabilitation, both in relation to medical stabilisation (e.g., termination of intensive care, weaning off ventilation, weaning off tracheostoma) and in relation to increased quality of life (e.g., improvement of swallowing disorders) and the establishment of conditions for further rehabilitation therapy or outpatient care (e.g., reducing orientation and behavioural disorders requiring supervision), constitutes a significant contribution in the care chain for patients after subarachnoid haemorrhage.

Transfer Rate in Subsequent Rehabilitation Phases

The reported transfer rates from early neurological and neurosurgical rehabilitation to subsequent rehabilitation phases are between 33.4% [28], 39.5% [18] and 55.4% [3] for unselected patient groups and 42.9% for patients post SAH [12]. However, agreements at the federal state level on phase transition should be considered here, meaning that the comparability of these figures is limited. At our own clinic, a comparable value of 43.5% is achieved (Table 7), whereas in Hessen as a whole it is somewhat lower (Table 7).

Table 7. Discharge from early neurological/neurosurgical rehabilitation

Population	Hesse, total (n = 175)		Bad König (n = 46)	
Goal of **transfer**	n	%	n	%
Home with non-professional assistance	6	3.4	2	4.4
Home with professional assistance	12	6.9	5	10.9
Inpatient rehabilitation (Phase C/D)	45	25.7	20	43.5
Alternative early rehabilitation	26	14.9	1	2.2
Transfer to acute hospital (subsequent readmission)	42 (28)	24.0	6 (4)	13.0
Care home	37	21.1	9	19.6
Deceased	7	4.0	3	8.7

Table 8. Functional outcome at the end of early neurological/neurosurgical rehabilitation based on the modified Rankin Scale

Population		Hessen, total (n = 175)		Bad König (n = 46)	
Score	Definition	n	%	n	%
0	No symptoms	3	1.7	0	0
1	Symptoms with no relevant functional deficit	2	1.1	0	0
2	Mild functional deficit	11	6.3	6	13.0
3	Moderate functional deficit	24	13.7	5	10.9
4	Moderately severe functional deficit	58	33.1	13	28.3
5	Severe functional deficit	72	41.1	19	41.3
6	Death	5	2.9	3	6.5

Transfer Rate in Care Facilities

The reported percentage of patients transferred to care facilities from early neurological and neurosurgical rehabilitation is between 16.2% [3] and 18.2% [18] in unselected patient groups and 21.9% in patients post SAH [12]. The rates in Hessen as a whole and at our own clinic are comparable at 21.1% and 19.6%, respectively (Table 7).

Return Transfer Rate in Acute Care Hospitals

The rate of return transfer from early neurological and neurosurgical rehabilitation is between 11.4% [28] and 27.6% [18] and ensues primarily as a result of internal or neurosurgical complications [30]. Evaluation of the data from 2013 reveals a retransfer rate in Hessen as a whole of 24% and 13% at our own clinic, where an appropriate team of staff and equipment for intensive care are in place (Table 7). This is readily comparable with earlier data for patients after SAH at 10.5% [12]. With an appropriate intensive care setting, retransfers are almost exclusively limited to elective neurosurgical secondary interventions [our own data]. This shows that it is possible, with an appropriately designed early neurological and neurosurgical rehabilitation concept, to guarantee “one-stop” treatment and minimise transfers which can be stressful to patients and to some extent put them at risk.

Functional Outcome at the End of Early Neurological and Neurosurgical Rehabilitation

The modified Ranking Scale (mRS) is a frequently used instrument for evaluating the outcome after stroke. To some degree it must be stressed from our own experience that external evaluation scales are highly problematic in the evaluation of outcome or even quality of life. Usually a score of 1-3 on the mRS scale is rated as a good outcome. A good 20% of patients after SAH therefore achieve a good outcome from early neurological and neurosurgical rehabilitation, both in Hessen as a whole and at our own clinic. This value, though apparently low, must be viewed from the angle of initial disease severity: only severely and very severely affected patients after SAH are admitted to early neurological and neurosurgical rehabilitation, bypassing more mildly affected patients who enter later phases of rehabilitation or at best remain asymptomatic.

CONTINUING REHABILITATION (PHASE C)

Phase C is the link between early neurological/neurosurgical (Phase B) and follow-up rehabilitation (Phase D). Those treated are patients who can already actively participate in the programme but must still receive curative medical treatment and require a lot of nursing attention [4, point 3.2., page 12].

The patients must meet the entry criteria for Phase C [4, point 3.2.1., page 12]:

- Alertness, able to comply with simple commands, sufficient ability to actively participate in the treatment measures of 30 minutes each
- Ability to communicate and interact
- Mobilised in a wheelchair for 2-4 hours at a time
- Vital signs and autonomic nervous system stable with no need for intensive medical supervision/treatment
- No further need for ventilation
- Comorbidities must not hinder mobilisation
- No danger to self/others and no severe disturbances to social behaviour in small groups

However, in contrast to rehabilitation during follow-up (Phase D), the patients to a large extent still depend on assistance in activities of daily living. The overriding aim of continuing rehabilitation is to improve independence in activities of daily living (ADL) and to restore the basic function of the nervous system through to the full capacity to act. Moreover, the further rehabilitation potential and long-term prospects should be clarified, a long-term treatment plan established, and continued care planned and introduced [4, point 3.2.2., page 13].

FOLLOW-UP REHABILITATION (PHASE D)

With growing independence in activities of daily living, but persistent motor deficits and mental disturbances that frequently interfere in working life and the daily routine, follow-up rehabilitation (Phase D) can begin upon achieving a Barthel Index score of approx. 65-70 points [29], indicating a general ability and willingness to cooperate as well as the capacity to act and learn. The main aim of Phase D is to achieve complete independence in everyday life and ideally facilitate the professional reintegration of those patients of working age.

PRESERVATIVE NON-HOSPITAL NURSING CARE (PHASE F)

If motor deficits in particular should limit activities of daily living, preservative non-hospital nursing care (Phase F) while continuing treatments on an outpatient basis is indicated. This nursing care can be carried out both at home and also in an institutional setting, such as in care homes or specialist nursing homes with treatments adapted to the patient's condition.

ACKNOWLEDGMENT

The authors wish to thank Dr. Med. B. Misselwitz, MPH, Head of the Institute of Quality Assurance Hessen at the Hessische Krankenhausgesellschaft e. V., Frankfurter Strasse 10 – 14, 65760 Eschborn for providing the data used in this article.

REFERENCES

[1] Annan, M; De Toffol, B; Hommet, C; Mondon, K. Sinking skin flap syndrome (or syndrome of the trephined): a review. *Br J Neurosurg*, 2015, 29, 314-318.

[2] Bader, P. Vaskuläre Erkrankungen. In: Müller F, Walther E, Herzog J, editors. *Praktische Neurorehabilitation*. 1. Aufl., Stuttgart: Kohlhammer, 2014. 35-42.

[3] Bertram, M; Brandt, T. Neurologisch-neurochirurgische Frührehabilitation. *Nervenarzt*, 2007, 78, 1160-1174.

[4] Bundesarbeitsgemeinschaft für Rehabilitation (BAR). Empfehlungen zur neurologischen Rehabilitation von Patienten mit schweren und schwersten Hirnschädigungen in den Phasen B und C. *Frankfurt: Bundesarbeitsgemeinschaft für Rehabilitation*, 1995.

[5] Chen, Z; Song, W; Du, J; Li, G; Yang, Y; Ling, F. Rehabilitation of patients with chronic normal-pressure hydrocephalus after aneurysmal hemorrhage benefits from ventricularperitoneal shunt. *Top Stroke Rehabil*, 2009, 16, 330-338.

[6] Czorlich, P; Burkhardt, T; Knospe, V; Richard, G; Vettorazzi, E; Wagenfeld, L; et al. Ocular ultrasound as an easy applicable tool for detection of Terson's syndrome after aneurysmal subarachnoid hemorrhage. *PLoS ONE*, 9(12), e114907. doi:10.1371/ journal. pone. 0114907.

[7] Deutsches Institut für Medizinische Dokumentation und Information (DIMDI), im Auftrag des Bundesministeriums für Gesundheit unter Beteiligung der Arbeitsgruppe OPS des Kuratoriums für Fragen der Klassifikation im Gesundheitswesen (KKG), (Hrsg.). OPS Version 2015 - Systematisches Verzeichnis. *Operationen- und Prozedurenschlüssel – Internationale Klassifikation der Prozeduren in der Medizin*. Köln: Deutscher Ärzteverlag; 2014. p 426. https:// www.dimdi.de/ static/ de/ klassi/ops/kodesuche/onlinefassungen/opshtml2015/block-8-55...8-60. htm, Zugriff am 28.06.2015.

[8] Di Rienzo, A; Iacoangeli, M; Alvaro, L; Colasanti, R; Dobran, M; Di Somma, LGM; et al. The sinking bone syndrome? *Neurol Med Chir*, 2013, 53, 329-335.

[9] Eifert, B; Maurer-Karattup, P; Schorl, M. Integration of intensive care treatment and neurorehabilitation in patients with disorders of consciousness: a program description and case report. *Arch Phys Med Rehabil*, 2013, 94, 1924-1933. DOI: 10.1016/j-apmr.2013.03.030.

[10] Hassan, A; Lanzino, G; Wijdicks, EF; Rabinstein, AA; Flemming, KD. Terson's syndrome. *Neurocrit Care*, 2011, 15, 554-558.

[11] Hagen, T; Bennefeld, H; Diepolder, V; Haase, I; Leidner, O; Miosge, W; et al. Entwicklung eines Kataloges pflegetherapeutischer Maßnahmen in der neurologischen Frührehabilitation (Phase B). *Neurol Rehabil*, 2007, 13, 151-158.

[12] Hoffmann, B; Karbe, H; Krusch, C; Müller, B; Pause, M; Prosiegel, M; et al. Patientencharakteristika in der neurologisch/neurochirurgischen Frührehabilitation (Phase B): Eine multizentrische Erfassung im Jahr 2002 in Deutschland. *Akt Neurol*, 2006, 33, 287-296.

[13] Hund, EF; Fogel, W; Krieger, D; De Geogia, M; Hacke, W. Critical illness polyneuropathy: clinical findings and outcomes of a frequent cause of neuromuscular weaning failure. *Crit Care Med*, 1996, 24, 1328-1333.

[14] Kaestner, S; Kruschat, T; Nitzsche, N; Deinsberger, W. Gravitational shunt units may cause under-drainage in bedridden patients. *Acta Neurochirurgica*, 2009, 151, 217-221.

[15] Mahoney, FI; Barthel, D. Functional evaluation: The Barthel Index. *Md State Med J*, 1965, 14, 56-61.

[16] Oehmichen, F; Ketter, G; Mertl-Rötzer, M; Platz, T; Puschendorf, W; Rollnik, JD. Beatmungsentwöhnung in neurologischen Weaningzentren. *Nervenarzt*, 2012, 83, 1300-1307.

[17] Rollnik, JD; Berlinghof, K; Lenz, O; Bertomeu, AM. Beatmung in der neurologischen Frührehabilitation. *Akt Neurol*, 2010, 7, 316-318.

[18] Rollnik, JD; Janosch, U. Current trends in the length of stay in neurological early rehabilitation. *Dtsch Ärztebl Int*, 2010, 107 (16), 286-292.

[19] Saciri, BM; Kos, N. Aneurysmal subarachnoidal haemorrhage: outcomes of early rehabilitation after surgical repair of ruptured intracranial aneurysms. *JNNP*, 2002, 72, 334-337.

[20] Salter, K; Jutai, J; Hartley, M; Foley, N; Bhogal, S; Bayona, N; et al. Impact of early vs delayed admission to rehabilitation on functional outcomes in persons with stroke. *J Rehab Med*, 2006, 38, 113-117.

[21] Schneider, HJ; Kreitschmann-Andermahr, I; Ghigo, E; Stalla, GK; Agha, A. Hypothalamo-pituitary dysfunction following traumatic brain injury and aneurysmal subarachnoid hemorrhage. *JAMA*, 2007, 298, 1429-1438.

[22] Schneider, M; von Rosen, F. Neuroendokrinologie. In: Müller F, Walther E, Herzog J, editors. Praktische Neurorehabilitation. *1. Aufl., Stuttgart, Kohlhammer*, 2014. 300-305.

[23] Schönle, PW. Der Frühreha-Barthelindex (FBI) – eine frührehabilitationsorientierte Erweiterung des Barthelindex. *Rehabilitation*, 1995, 4, 69-73.

[24] Schorl, M. Sinking Skin Flap Syndrome (SSFS) – Clinical Spectrum and Impact on Rehabilitation. *Cent Eur Neurosurg*, 2009, 70, 68-72.

[25] Schorl, M; Eifert, B. Weaning in der neurologischen Frührehabilitation: individuelles Vorgehen führt zu hohen Erfolgsquoten (Poster). 28. *Arbeitstagung für Neurologische Intensiv- und Notfallmedizin (ANIM)*, Leipzig, 12.01.-15.01.2011.

[26] Schorl, M; Flechsenhaar, D; Guthier, M; Imöhl, L; Hartwich, M. Ungewöhnliche Ursache rezidivierender Vigilanzminderungen bis zum Koma bei kompliziertem Verlauf nach Subarachnoidalblutung bei Ruptur eines Aneurysmas der A. communicans anterior (Poster). *Arbeitstagung Neurolointensivmedizin (ANIM)*, Berlin, 29.-31.01.2015.

[27] Schorl, M; Valerius-Kukula, S-J; Kemmer, TP. Critical-illness-polyneuropathy as sequelae of severe neurological illness: incidence and impact on ventilator therapy and rehabilitation. *Neurorehabilitation*, 2013, 32, 149-156. DOI: 10.3233/NRE-130832.

[28] Spranger, M; Hoffmann, B; Karbe, H; Krusch, C; Müller, B; Pause, M; et al. Der Stellenwert der neurologisch-neurochirurgischen Frührehabilitation in der

Versorgungskette von Patienten mit schweren neurologischen Erkrankungen. *Neurol Rehabil*, 2005, 11, 317-322.

[29] Stier-Jarmer, M; Koenig, E; Stucki, G. Strukturen der neurologischen Frührehabilitation (Phase B) in Deutschland. *Phys Med Rehab Kuror*, 2002, 12, 260-271.

[30] Von Wedel-Parlow, FK; Gehring, K; Kutzner, M. Neurologische Frührehabilitation. In: Frommelt P, Lösslein H, editors. *Neurorehabilitation*. Berlin, Heidelberg: Springer, 2010. 501-556.

[31] Yamaura, A; Makino, H. Neurological deficits in the presence of the sinking skin flap following decompressive craniectomy. *Neurol Med Chir*, 1977, 17, 43-53.

In: Encyclopedia of Surgery (22 Volume Set)
Editors: Andreas Lehrer and Kristin Mueller
ISBN: 978-1-53618-329-0
© 2020 Nova Science Publishers, Inc.

Chapter 78

COGNITIVE PLASTICITY AFTER SPONTANEOUS SUBARACHNOID HAEMORRHAGE

Christine Brand
Department of Neurosurgery, University of Ulm, Ulm, Germany

ABSTRACT

Patients who suffer spontaneous subarachnoid haemorrhage (SAH) often find themselves in the full swing of life, not only personally but also professionally. It is a radical event that has a dramatic effect on a patient's physical and psychological well-being. More than 50% of all SAH patients describe cognitive deficits that have a negative impact on quality of life. The exact causes of cognitive deficits are not yet known. However, patients develop everyday strategies with which to compensate for these deficits, such as writing themselves notes. One of the most reported impaired functions is working memory, irrespective of the time at which they were examined. Never the less, the ability of the brain to restore or compensate for functions that have been lost plays a very important role following spontaneous SAH. It is essential to the success of rehabilitation, as well as the social and professional reintegration of the patient to identify cognitive deficits and to train them.

Keywords: SAH, cognitive plasticity, quality of life, rehabilitation, cognitive deficits

Patients who suffer spontaneous subarachnoid haemorrhage (SAH) often find themselves in the full swing of life, not only personally but also professionally. It is a radical event that has a dramatic effect on a patient's physical and psychological well-being and thus has a negative impact on quality of life [1, 2]. Patients who outwardly appear to have achieved a good therapeutic outcome, implying that they have no obvious disorders such as palsy or speech defects, are often still burdened by less noticeable deficits. Such deficits are immediately apparent to patients themselves, of course, as well as to their family [3]. Patients very often describe deficits in terms of working memory, concentration and attention [4].

Conversations involving a number of people prove difficult to follow. Professionally they become less resilient, finding that their working lives are more of a strain than before the haemorrhage. Co-workers and superiors expect the same level of input from the patient, who is no longer written off sick and has no noticeable signs of illness. Cognitive deficits also lead to potential conflicts at home. Patients feel misunderstood and often become emotionally withdrawn.

After spending approx. two to four weeks under critical neurosurgical care, patients with spontaneous SAH are transferred for neurological follow-up treatment, which as a rule lasts three weeks. Following the inpatient stay, the patient is discharged to the care of his or her family doctor. In Germany, referral to a neuropsychologist is not current practice. Under normal circumstances, the patient undergoes gradual professional reintegration so as to resume work as before. In reality, this proves successful in only very few cases. Success is dependent firstly on the severity of the residual deficits, secondly on the demands of the patient's acquired skill.

The nature and intensity of cognitive deficits after spontaneous SAH have now been studied thoroughly [5-7]. Potential patient- and therapy-related influential factors have been described [7]. The progress over time, the potential for recovery, and with it plasticity, have been illustrated by diverse studies [5, 8, 9]. There is only speculation, however, as to the exact causes or pathogenesis. Awareness of the nature and scope, as well as the possible chances of improvement in the cognitive deficits, is essential for establishing a therapeutic basis for rehabilitation. Long-term morbidity can thus be minimised and at best prevented. The aim, however, should be to avoid cognitive deficits by administering optimised therapy. To achieve this, however, the causes must be known. Patient-related factors cannot be influenced by the treating physicians in the emergency department.

The aim of treating spontaneous SAH in the acute phase as well as later on during rehabilitation should therefore be to minimise the patient's cognitive deficits so as to prevent long-term morbidity.

SPECTRUM OF COGNITIVE DEFICITS FOLLOWING SPONTANEOUS SUBARACHNOID HAEMORRHAGE

More than 50% of all SAH patients describe cognitive deficits [1, 4, 7, 10, 11] that have a negative impact on quality of life. In the clinical routine, patients most often describe concentration-related deficits [4]. Difficulty concentrating is apparent not only during activities of daily living, but also at work. Diverse studies have examined the ability to concentrate following spontaneous SAH. Relevant concentration disorders were found in 11%-13% of the SAH patients studied [8, 12, 13]. Impaired memory, especially working memory, is the disorder that is most noticeable to the majority of patients after spontaneous SAH. Patients develop everyday strategies with which to compensate for these deficits, such as writing themselves notes. Various studies have reported working memory deficits in 28%-71% of all SAB patients, irrespective of the time at which they were examined [4, 7, 12, 14, 15]. Professionally, impaired concentration and memory deficits prove to be the biggest hurdle. Another area that can be affected is the speed of information processing, an issue that

has been found in 31%-65% of those affected [4, 7, 16]. In addition to the domains already mentioned, executive functions can also be impaired in SAH patients.

PLASTICITY AFTER SPONTANEOUS SUBARACHNOID HAEMORRHAGE

The ability of the brain to restore or compensate for functions that have been lost plays a very important role following spontaneous SAH. It is essential to the success of rehabilitation, as well as the social and professional reintegration of the patient. With today's ever-diminishing resources, the purpose and necessity for long inpatient stays, and thus costly inpatient rehabilitation programmes delivered by specially trained personnel, are called into question. Studies have been conducted to examine patients at varying times after spontaneous SAH in order to determine whether cognitive deficits have the potential to improve. It was demonstrated that skills in relation to speech comprehension, numeracy, verbal memory, attention, concentration and also executive functions do potentially improve [7, 8, 14]. The information processing rate appears to be a predictor for plasticity. The extent of the potential recovery depends on the severity of the bleeding and its localisation [17], as well as on patient-associated factors such as school education or age of the patient [7], and so cannot be influenced by the physician. Cognitive deficits can still improve even months after occurrence of the haemorrhage [7, 8, 16]. In practice this implies that one period of rehabilitation lasting several weeks is not sufficient. Specific, specialised outpatient follow-up care from a neuropsychologist is appropriate and necessary if an optimum outcome is to be achieved. This appears to be the only way to guarantee the best possible professional reintegration of the patient. Social integration could likewise be positively influenced in this manner. Long-term morbidity could thus be sustainably reduced.

FACTORS INFLUENCING COGNITIVE DEFICITS

To optimise therapy in the emergency department and create the best conditions for subsequent rehabilitation, the factors that influence cognitive performance and the quality of life of patients with spontaneous SAH have been examined [18-20]. In doing so, it is useful to divide these factors into two categories: patient-related and treatment-related factors. In the emergency setting, physicians cannot influence patient-related factors. School education, profession, laterality, pre-existing cardiac diseases, obesity, hyperlipidaemia, diabetes mellitus and nicotine abuse all appear to have a significant influence on the therapeutic outcome. Treatment-related factors are the primary focus of the attending physician. Some studies have looked at whether coiling or clipping of a ruptured aneurysm offers a better treatment outcome. The type of treatment does not appear to influence the cognitive treatment outcome, however [8]. Various conventional classification systems have been considered as potential prognostic tools. None could ultimately live up to expectations. Neither the Fisher score, which describes the extent of the bleeding based on diagnostic imaging, nor the Hunt and Hess scale, which documents the initial clinical condition, permitted a satisfactory estimation to be made of the treatment outcome [21]. Another popular system for grading the clinical condition is the Glasgow Outcome Score, though it does not describe the presence of

cognitive deficits. The localisation of the aneurysm also appears, moreover, to have no impact on the existence of cognitive deficits [8, 22, 23].

POSSIBLE CAUSES OF COGNITIVE DEFICITS, THERAPEUTIC STRATEGIES AND PROSPECTS

The exact causes of cognitive deficits are not yet known. Theories abound, however. It stands to reason that the bleeding itself is the cause of all evil [22]. On the one hand the haemorrhage causes localised damage, as well as deficits theoretically due to the effects of the bleeding. These include impaired CSF circulation, vasospasms and ischaemia. Or is the acute rise in intracranial pressure following rupture of the aneurysm responsible for the cognitive deficits [7]? It appears at least to explain why focal lesions also influence cognitive areas suspected to exist in other regions of the brain. From another angle, numerous functions such as memory may not be focussed on just one area of the brain. This subject certainly needs to be examined more closely.

In conclusion, it should be stated at least that cognitive deficits often develop in patients with spontaneous SAH and negatively influence quality of life in the long term. As a result, long-term morbidity increases. Cognitive deficits can be treated specifically by means of rehabilitation therapy. There is still a chance after several months that these deficits will improve. Outpatient follow-up care from a neuropsychologist subsequent to initial inpatient rehabilitation is therefore beneficial to the patient.

REFERENCES

[1] Kapapa T. Lebensqualität nach spontaner Subarachnoidalblutung- Analyse klinischer Variablen, welche die gesundheitsbezogene Lebensqualität nach spontaner Subarachnoidalblutung beeinflussen. *Neurologie und Rehabilitation*. 2005:21-8.

[2] Tjahjadi M, Heinen, C., König, R., Rickels, R., Wirtz, C.R., Woischneck, D., Kapapa, T. Health-related quality of life after spontaneous subarachnoid hemorrhage measured in a recent patient population. *World Neurosurg*. 2013;79:296-307. Epub 2012 Oct 6.

[3] Kapapa T, Woischneck, D., Tjahjadi, M. Long-term health-relates quality of life after spontaneous nontraumatic subarachnoid hemorrhage: self and proxy reports in a 10-year period. *World Neurosurg.* 2014;81:105-9. Epub 2012 Oct 6.

[4] Hutter BO, Gilsbach JM, Kreitschmann I. Quality of life and cognitive deficits after subarachnoid haemorrhage. *British journal of neurosurgery*. 1995;9(4): 465-75. PubMed PMID: 1.

[5] McKenna P, Willison JR, Phil B, Lowe D, Neil-Dwyer G. Cognitive outcome and quality of life one year after subarachnoid haemorrhage. *Neurosurgery*. 1989 Mar;24(3):361-7. PubMed PMID: 4.

[6] Madureira S, Canhao P, Guerreiro M, Ferro JM. Cognitive and emotional consequences of perimesencephalic subarachnoid hemorrhage. *Journal of neurology*. 2000 Nov;247(11):862-7. PubMed PMID: 16.

[7] Brand C, Alber, B., Fladung, A.K., Knauer, K., König, R., Oechsner, A. Schneider, I.L., Tumani, H., Widder, B. Wirtz, C.R., Woischneck, D., Kapapa T. Cognitive performance following spontaneous subarachnoid haemorrhage versus other forms of intracranial haemorrhage. *Br. J. Neurosurg.* 2014;28:68-80.

[8] Haug T, Sorteberg A, Sorteberg W, Lindegaard KF, Lundar T, Finset A. Cognitive outcome after aneurysmal subarachnoid hemorrhage: time course of recovery and relationship to clinical, radiological, and management parameters. *Neurosurgery*. 2007 Apr;60(4):649-56; discussion 56-7. PubMed PMID: 17415201. Epub 2007/04/07. eng.

[9] Hop JW, Rinkel GJ, Algra A, van Gijn J. Changes in functional outcome and quality of life in patients and caregivers after aneurysmal subarachnoid hemorrhage. *J. Neurosurg.* 2001 Dec;95(6): 957-63. PubMed PMID: 11765839.

[10] Kreiter KT, Copeland D, Bernardini GL, Bates JE, Peery S, Claassen J, et al. Predictors of cognitive dysfunction after subarachnoid hemorrhage. *Stroke*. 2002;33:200-9.

[11] Mayer SA, Kreiter KT, Copeland D, Bernardini GL, Bates JE, Peery S, et al. Global and domain-specific cognitive impairment and outcome after subarachnoid hemorrhage. *Neurology*. 2002 Dec 10;59(11):1750-8. PubMed PMID: 12473764. Epub 2002/12/11. eng.

[12] Hutter BO, Gilsbach JM. Which neuropsychological deficits are hidden behind a good outcome (Glasgow = I) after aneurysmal subarachnoid hemorrhage? *Neurosurgery*. 1993 Dec;33(6):999-1005; discussion -6. PubMed PMID: 8134014.

[13] Hutter BO, Gilsbach JM. Early neuropsychological sequelae of aneurysm surgery and subarachnoid haemorrhage. *Acta Neurochirurgica*. 1996;138(12):1370-8; discussion 8-9. PubMed PMID: 14.

[14] Al- Khindi T, Loch Macdonald R, Schweizer TA. Cognitive and functional outcome after aneurysmal subarachnoid hemorrhage. *Stroke*. 2010;41: 519-36.

[15] Hutter BO, Gilsbach JM. Das Aachener Lebensqualitätsinventar für Patienten mit Hirnschädigung: Entwicklung und methodische Gütekriterien. Möllers HJ, Engel RR, Hoff P (Hrsg) *Befunderhebnung in der Psychiatrie: Lebensqualität, Negativsymptomatik und andere aktuelle Entwicklungen* Springer, Wien New York. 1996:83-101.

[16] Egge A, Waterloo K, Sjoholm H, Ingebrigtsen T, Forsdahl S, Jacobsen EA, et al. Outcome 1 year after aneurysmal subarachnoid hemorrhage: relation between cognitive performance and neuroimaging. *Acta Neurol. Scand.* 2005 Aug;112(2):76-80. PubMed PMID: 16008531. Epub 2005/07/13. eng.

[17] Kwen PL, Pullicino, .P, Krenzer, R. . Reversible impairment in cognition and midbrain hematoma. *J. Neuroimaging.* 1998;8:54-5.

[18] Tidswell P, Dias PS, Sagar HJ, Mayes AR, Battersby RD. Cognitive outcome after aneurysm rupture: relationship to aneurysm site and perioperative complications. *Neurology*. 1995 May;45(5): 875-82. PubMed PMID: 7746400.

[19] Wermer MJH, Kool H, Albrecht KW, Rinkel GJE. Subarachnoid hemorrhage treated with clipping: long term effects on employment, relationships, personality and mood. *Neurosurgery*. 2007;60:91-8.

[20] Kapapa T, Tjahjadi, M., König, R., Wirtz, C.R., Woischneck, D. Which clinical variable influences health-realated quality of life the most after spontaneous subarachnoid hemorrhage? Hund and Hess scale, Fishe score, World Federation of

Neurosurgeons score, Brussels coma score, and Glasgow coma score compared. *World Neurosurg*. 2013;80: 853-8. Epub 2012 Sep 25.

[21] Cedzich C, Roth A. Neurological and psychosocial outcome after subarachnoid haemorrhage, and the hunt and hess scale as a predictor of clinical outcome. *Zentralblatt fur Neurochirurgie*. 2005 Aug;66(3):112-8. PubMed PMID: 18.

[22] Hutter BO, Kreitschmann-Andermahr I, Mayfrank L, Rohde V, Spetzger U, Gilsbach JM. Functional outcome after aneurysmal subarachnoid hemorrhage. *Acta Neurochir. Suppl.* 1999;72:157-74. PubMed PMID: 10337421. Epub 1999/05/25. eng.

[23] Ahola K, Vilkki, J., Servo, A. Frontal tests do not detect frontal infarctions after ruptured intracranial aneurysm. *Brain Cogn*. 1996;31: 1-16.

In: Encyclopedia of Surgery (22 Volume Set)
Editors: Andreas Lehrer and Kristin Mueller
ISBN: 978-1-53618-329-0
© 2020 Nova Science Publishers, Inc.

Chapter 79

HEALTH-RELATED QUALITY OF LIFE FOLLOWING SPONTANEOUS SUBARACHNOID HAEMORRHAGE AS AN ASSESSMENT CRITERION FOR THERAPEUTIC OUTCOME

Thomas Kapapa
Department of Neurosurgery, University of Ulm, Ulm, Germany

ABSTRACT

Health-related quality of life serves as a supplement to the clinical criteria for determining the outcome of therapy. The lack of a higher-level definition for the term quality of life, however, is still problematic, but there is a general consensus on the individual approach and understanding as to what the term entails. The aim of this chapter is to make it clear that a good or very good clinical treatment outcome is not to be regarded as equivalent to good or very good quality of life. The subjective perception and attitude of the patient towards his or her personal situation after the haemorrhage are equally important when it comes to evaluating the treatment outcome. The individual assessment of the treatment outcome also very much depends on the expectations and experience of the patient. This should be taken into account when determining the said outcome.

Keywords: outcome; rehabilitation; cognition, reintegration

Aristotle: “We are what we repeatedly do. Excellence, then, is not an act, but a habit!” But what happens when external or internal factors prevent us from continuing to do what we normally do so well? When is something new to be regarded as a habit? This rather philosophical approach in dealing with quality of life often cannot be reconciled with the concept of health-related quality of life. This is due on the one hand to the context within which quality of life needs to be understood. Terms such as lust for life, vitality, courage and trials of life are used synonymously. There are core intellectual elements such as political

philosophy, social philosophy, environmental philosophy and medical ethics that deal with the term quality of life. Time, in the context of the here and now as well as transition, is another important factor for determining quality of life. All the differences described here lead us to surmise that there is no all-encompassing definition for quality of life.

The author sees the approach to quality of life in the medical context as a means of optimising patient care. To the author, health-related quality of life represents a collection of criteria reflected by objectives, values and principles, such as the certainty and length of life and a defined level of health, the freedom to seize opportunities, or personal and social recognition. Yet to the author health-related quality of life also inevitably includes criteria with alternative approaches to quality of life, such as the existence of economic conditions for achieving an ideal situation as expected by a society or self-imposed goals [1-3]. With this theory in mind, clinical endpoints are to be understood in the context of subjective satisfaction, psychosocial interaction and forward-looking behaviour [4].

The advances in the treatment of this complex condition, already described in this book, are so effective that mortality now accounts for only roughly a third of patients after one month. Results from the 1960s came to far more inferior conclusions, namely that approx. 33% of patients died before reaching a hospital and 27% of patients died during treatment [5, 6]. The Glasgow Outcome Scale and Modified Rankin Scale are the methods most commonly used for assessing the treatment outcome [7-9]. Not only is the rate of those surviving spontaneous subarachnoid haemorrhage increasing, but also the number of patients with a good treatment outcome [10]. The outcome of treating spontaneous subarachnoid haemorrhage is often described as “good”, “moderate”, or “poor”. There has been a clear improvement in the survival rate to almost 50% of patients classified in line with general criteria as having a “good” or “very good” outcome from such an event [11-14]. These categories are consistent mostly with functional neurological deficits. Little consideration is given in these ratings to psychological, cognitive and social components. The quality of life of many patients, despite their physical well-being, may still be impaired [3, 15]. It is not unusual to find that such disorders are caused by neuropsychological and cognitive deficits [15-17]. It is generally agreed that spontaneous subarachnoid haemorrhage has a considerable impact on quality of life [14].

The treatment outcome has a more lasting and profound impact than the patient’s condition at discharge alone. It must be judged in the context of the patient’s normal family life, routine social ties and social participation, as well as usual physical and mental achievements. Clinical parameters do not suffice to describe this situation. It has long been known that a disease can alter the conditions and thus the quality of life over an extended period of time [18]. Accordingly, health-related quality of life can be judged as 1) quality of personal situation, 2) satisfaction with personal situation, or 3) a combination of both [18]. Hence, the clinical treatment outcome is always an integrated part of the individual personal situation. To gain an insight into such a situation, health-related quality of life is useful. It is an illustration of the disease, the clinical outcome of treatment and the personal situation. It places the “patient” above the “disease” as the objective, and also establishes a connection between the two. This provides the opportunity to compare rational health indications, objective clinical ratings and progress against the patient’s subjective views and treatment outcomes.

The prevailing method for measuring quality of life is the questionnaire or interview. Various quality-of-life questionnaires are available for collating information universally on

general characteristics, or specifically on disease-related characteristics [3, 14]. At present, there is no quality-of-life tool for the neurological/neurosurgical field that combines the objective and subjective indicators for satisfaction related to spontaneous subarachnoid haemorrhage.

Physical performance and role identity, i.e., the behavioural expectations (and behavioural codes) placed by others on the respective role holders, such as mother, father, employee, comforter, etc., are most affected by spontaneous subarachnoid haemorrhage and are reported in up to 60% of patients with diminished quality of life [19, 20]. Anxiety and depression are described by more than half of the patients with impaired quality of life [19, 20]. Both have a considerable influence on psychosocial interaction in the community. This is reflected in diminished vitality (43%) and emotions (40%) [19], and affects the ability to work. The ability of a patient to function socially after suffering spontaneous subarachnoid haemorrhage is influenced if physical identity as well as mental and emotional health are impaired [21]. A restriction to the quality of life after spontaneous subarachnoid haemorrhage may go unnoticed and untreated for a long time [2]. This situation is also unaffected by an improvement in residual physical deficits [22].

Descriptions of how the quality of life is influenced by clinical factors are inconsistent [14, 23]. The parameters most commonly reported, however, are age, sex, residual physical factors, neurological status on admission and Glasgow Outcome Score [14, 19, 22-29]. In this regard better scores are attained with the clinical factors, along with better results in terms of health-related quality of life. The Hunt & Hess Score and Fisher Score are seldom described as influential [27, 30].

In summary, it is evident that spontaneous subarachnoid haemorrhage has a lasting, negative impact on health-related quality of life. Such an influence is multifactorial, affecting several aspects of quality of life yet primarily the physical and emotional domains. Similarly, certain roles are affected which prove difficult to rehabilitate following critical care. It makes sense to document health-related quality of life three to six months after reintegrating the patient into his or her daily life. It is at this point that the implications of the haemorrhage can be evaluated and the therapeutic outcome can be further improved. Treatment of impaired health-related quality of life signals an improvement in the overall treatment outcome. Treatment is interdisciplinary, involving physical and occupational therapists, neuropsychologists and psychologists, and if necessary specialists in psychosomatic medicine and psychiatry, as well as social workers. It also engages the patient's entire family and circle of friends. If the improvement in the purely physical and clinical criteria of the treatment outcome following spontaneous subarachnoid haemorrhage comes to a standstill due to the fact e.g., that no new clips or coils, no new minimally invasive approach, and no new treatment for delayed cerebral ischaemia or hydrocephalus is forthcoming, another way in which to further enhance the treatment outcome is to define, document and instigate therapy with a view to health-related quality of life.

REFERENCES

[1] Kapapa T, Tjahjadi M, Konig R, Wirtz CR, Woischneck D. Which clinical variable influences health-related quality of life the most after spontaneous subarachnoid

hemorrhage? Hunt and Hess scale, Fisher score, World Federation of Neurosurgeons score, Brussels coma score, and Glasgow coma score compared. *World Neurosurgery*. 2013 Dec;80(6):853-8. PubMed PMID: 23022643.

[2] Kapapa T, Woischneck D, Tjahjadi M. Long-term health-related quality of life after spontaneous nontraumatic subarachnoid hemorrhage: self and proxy reports in a 10-year period. *World neurosurgery.* 2014 Jan;81(1):105-9. PubMed PMID: 23046914.

[3] Tjahjadi M, Heinen C, Konig R, Rickels E, Wirtz CR, Woischneck D, et al. Health-related quality of life after spontaneous subarachnoid hemorrhage measured in a recent patient population. *World Neurosurgery*. 2013 Feb;79(2):296-307. PubMed PMID: 23046917.

[4] Kapapa T, König K, Heissler H, Ly MP, Zumkeller M, Schneekloth C, et al. [Health-related quality of life as an addendum to clinical criteria of outcome measurement in neurosurgery]. *Neurol. Rehabil*. 2006; ;12(1):37-41.

[5] Locksley HB. Natural history of subarachnoid hemorrhage, intracranial aneurysms and arteriovenous malformations. *Journal of Neurosurgery*. 1966 Sep;25(3):321-68. PubMed PMID: 5921326.

[6] Locksley HB. Natural history of subarachnoid hemorrhage, intracranial aneurysms and arteriovenous malformations. Based on 6368 cases in the cooperative study. *Journal of Neurosurgery*. 1966 Aug;25(2):219-39. PubMed PMID: 5911370.

[7] Jennett B, Bond M. Assessment of outcome after severe brain damage. *Lancet.* 1975 Mar 1;1(7905):480-4. PubMed PMID: 46957.

[8] Rankin J. Cerebral vascular accidents in patients over the age of 60. II. Prognosis. *Scottish medical journal.* 1957 May;2(5):200-15. PubMed PMID: 13432835.

[9] van Swieten JC, Koudstaal PJ, Visser MC, Schouten HJ, van Gijn J. Interobserver agreement for the assessment of handicap in stroke patients. Stroke: *a Journal of Cerebral Circulation*. 1988 May;19(5):604-7. PubMed PMID: 3363593.

[10] Seule MA, Stienen MN, Cadosch D, Fournier JY, Lussmann R, Hildebrandt G, et al. [Aneurysmal subarachnoid hemorrhage - therapy and complications]. *Anasthesiol Intensivmed Notfallmed Schmerzther*. 2010 Jan;45(1):8-17. PubMed PMID: 20091471. Epub 2010/01/22. *Aneurysmatische Subarachnoidalblutung - Diagnostik und Therapie zerebraler und systemischer Komplikationen*. ger.

[11] Mocco J, Ransom ER, Komotar RJ, Sergot PB, Ostapkovich N, Schmidt JM, et al. Long-term domain-specific improvement following poor grade aneurysmal subarachnoid hemorrhage. *Journal of Neurology*. 2006 Oct;253(10):1278-84. PubMed PMID: 17063319.

[12] Mocco J, Zacharia BE, Komotar RJ, Connolly ES, Jr. A review of current and future medical therapies for cerebral vasospasm following aneurysmal subarachnoid hemorrhage. *Neurosurgical Focus.* 2006;21(3):E9. PubMed PMID: 17029348.

[13] Mocco J, Ransom ER, Komotar RJ, Schmidt JM, Sciacca RR, Mayer SA, et al. Preoperative prediction of long-term outcome in poor-grade aneurysmal subarachnoid hemorrhage. *Neurosurgery*. 2006 Sep;59(3):529-38; discussion -38. PubMed PMID: 16955034.

[14] Passier PE, Visser-Meily JM, Rinkel GJ, Lindeman E, Post MW. Determinants of health-related quality of life after aneurysmal subarachnoid hemorrhage: a systematic review. Quality of Life Research: *An International Journal of Quality of Life Aspects of*

Treatment, Care and Rehabilitationan. 2013 Jun; 22(5): 1027-43. PubMed PMID: 22956388.

[15] Brand C, Alber B, Fladung AK, Knauer K, Konig R, Oechsner A, et al. Cognitive performance following spontaneous subarachnoid haemorrhage versus other forms of intracranial haemorrhage. *British Journal of Neurosurgery*. 2014 Jan;28(1):68-80. PubMed PMID: 23879444.

[16] Hutter BO, Gilsbach JM. Which neuropsychological deficits are hidden behind a good outcome (Glasgow = I) after aneurysmal subarachnoid hemorrhage? *Neurosurgery*. 1993 Dec;33(6):999-1006. PubMed PMID: 8134014.

[17] Hutter BO, Gilsbach JM, Kreitschmann I. Quality of life and cognitive deficits after subarachnoid haemorrhage. *Br. J. Neurosurg.* 1995;9(4):465-75. PubMed PMID: 7576273.

[18] Felce D, Perry J. Quality of life: its definition and measurement. *Research in developmental disabilities*. 1995 Jan-Feb;16(1):51-74. PubMed PMID: 7701092.

[19] Katati MJ, Santiago-Ramajo S, Perez-Garcia M, Meersmans-Sanchez Jofre M, Vilar-Lopez R, Coin-Mejias MA, et al. Description of quality of life and its predictors in patients with aneurysmal subarachnoid hemorrhage. *Cerebrovasc Dis*. 2007;24(1):66-73. PubMed PMID: 17519546. Epub 2007/05/24. eng.

[20] Hackett ML, Anderson CS. Health outcomes 1 year after subarachnoid hemorrhage: An international population-based study. The Australian Cooperative Research on Subarachnoid Hemorrhage Study Group. *Neurology*. 2000 Sep 12;55(5):658-62. PubMed PMID: 10980729. *Epub* 2000/09/12. eng.

[21] van der Schaaf IC, Brilstra EH, Rinkel GJ, Bossuyt PM, van Gijn J. Quality of life, anxiety, and depression in patients with an untreated intracranial aneurysm or arteriovenous malformation. *Stroke*. 2002 Feb;33(2):440-3. PubMed PMID: 11823649. *Epub* 2002/02/02. eng.

[22] Hop JW, Rinkel GJ, Algra A, van Gijn J. Changes in functional outcome and quality of life in patients and caregivers after aneurysmal subarachnoid hemorrhage. *J. Neurosurg.* 2001 Dec;95(6):957-63. PubMed PMID: 11765839.

[23] Noble AJ, Schenk T. Which variables help explain the poor health-related quality of life after subarachnoid hemorrhage? A meta-analysis. *Neurosurgery*. 2010 Apr;66(4):772-83. PubMed PMID: 20190663. Epub 2010/03/02. eng.

[24] Agazzi S, de Tribolet N, Uske A, Regli L. Quality of life after aneurysmal subarachnoid hemorrhage in the elderly. *Cerebrovasc Dis*. 2004;18(2):174-5. PubMed PMID: 15256793. Epub 2004/07/17. eng.

[25] Cedzich C, Roth A. Neurological and psychosocial outcome after subarachnoid haemorrhage, and the Hunt and Hess scale as a predictor of clinical outcome. *Zentralbl Neurochir*. 2005 Aug;66(3):112-8. PubMed PMID: 16116553. Epub 2005/08/24. eng.

[26] Hutter BO, Kreitschmann-Andermahr I, Gilsbach JM. Health-related quality of life after aneurysmal subarachnoid hemorrhage: impacts of bleeding severity, computerized tomography findings, surgery, vasospasm, and neurological grade. *J Neurosurg*. 2001 Feb;94(2):241-51. PubMed PMID: 11213961. *Epub* 2001/02/24. eng.

[27] Hutter BO, Kreitschmann-Andermahr I, Mayfrank L, Rohde V, Spetzger U, Gilsbach JM. Functional outcome after aneurysmal subarachnoid hemorrhage. *Acta Neurochir. Suppl.* 1999;72:157-74. PubMed PMID: 10337421.

[28] Visser-Meily JM, Rhebergen ML, Rinkel GJ, van Zandvoort MJ, Post MW. Long-term health-related quality of life after aneurysmal subarachnoid hemorrhage: relationship with psychological symptoms and personality characteristics. *Stroke*. 2009 Apr;40(4):1526-9. PubMed PMID: 19095984. Epub 2008/12/20. eng.

[29] Wik KE, Lindegaard KF, Brunborg B, Bjork IT, Ruland C. [Life following acute subarachnoid haemorrhage]. *Tidsskr Nor Laegeforen*. 2005 Jan 20;125(2):152-4. PubMed PMID: 15665885. Epub 2005/01/25. Livet etter akutt hjernehinneblodning. nor.

[30] Kapapa T, Rickels E. Health-related quality of life after subarachnoid hemorrhage. *Neurol. Rehabil*. 2005;11(1):21-8.

In: Encyclopedia of Surgery (22 Volume Set)
Editors: Andreas Lehrer and Kristin Mueller
ISBN: 978-1-53618-329-0
© 2020 Nova Science Publishers, Inc.

Chapter 80

EXPERIMENTAL MODELS FOR THE STUDY OF SUBARACHNOID HAEMORRHAGE

Nicole A. Terpolilli
Department of Neurosurgery, Ludwig-Maximilians University of Munich,
Munich, Germany

ABSTRACT

Various animal models have been developed in order to study the pathophysiology of SAH and to evaluate possible pharmacological treatment strategies. The following chapter discusses the most widely used techniques and animal models.

Keywords: experimental SAH, animal models of SAH, MCA perforation model

Various experimental animal models of subarachnoid haemorrhage have been developed to investigate pathophysiological mechanisms and to trial possible new treatment strategies. The following chapter will explore the most frequently employed techniques. Haemorrhage is most commonly induced either by a single or multiple injection of blood into the subarachnoid space or by puncturing/perforating a vessel in the circle of Willis (CW). In the last 30 years experiments were frequently carried out on primates as their physiology and anatomy is similar to that of humans. This enabled the use of clinical examination methods such as digital subtraction angiography and CT angiography for measuring cerebral blood flow and detecting vasospasm. More recently, rodents are favoured as laboratory animals given the scarce availability of primates; besides animal welfare issues and ethical and financial motives, the mouse model in particular is gaining in importance because it offers the possibility of genetic modification, i. e. the creation of transgenic mice. Furthermore, improved *in vivo* imaging techniques, such as two-photon microscopy or magnetic resonance imaging, provide increasingly accurate insights into the processes of posthemorrhagic microcirculation, even when using small laboratory animals.

INJECTION MODELS

Bagley described an animal model for investigating subarachnoid haemorrhage as early as 1928: autologous venous blood was mixed with cerebrospinal fluid and injected into the cisterna magna of dogs [1], which triggered the typical cardiovascular/systemic consequences of human pathology; in some cases multiple injections were required to achieve this effect. Subsequently, the model was adapted for different species, injection sites and injection techniques. Heparinised or non-heparinised whole blood (autologous or heterologous) or haemolysate is injected. The cisterna magna injection model is used extensively in dogs [2-4], different monkey species [5-8], rats [9-12], and mice [13, 14]. Since in the majority of patients aneurysms, and therefore also the bulk of the haemorrhage, are located in the anterior portion of the circle of Willis, it has been suggested that animal models with injection into the anterior cisterns may be better suited to reproduce the clinical phenotype. While transfrontal or transorbital blood injection into the prechiasmatic cistern in monkeys [15, 16] or dogs [17] produced inconsistent results with regard to the development of vasospasm and neurological damage, the model of prechiasmatic blood injection in rats [18, 19] reliably produces subarachnoid haemorrhage with corresponding deficits in a minimally-invasive fashion and with negligible operative morbidity; in this frequently used model auto- or heterologous blood is injected stereotactically into the prechiasmatic cistern via a small frontal burrhole.

In summary, injection models are easy to standardise, particularly with regard to haemorrhage volume, technically easy to implement (compared to other techniques) and reliably result in a range of quantifiable secondary SAH complications, such as decreased cerebral blood flow, intracranial hypertension, neuronal damage, and secondary changes at the cellular and microcirculation levels.

However, injection techniques also have distinct disadvantages as not all aspects of the pathophysiology of SAH can be modelled. In particular, the kinetics of stereotactic volume injection, which usually is performed over minutes, do not correspond to those of a ruptured arterial vessel where haemorrhage happens within seconds with high pressure. Accordingly, intracranial pressure in injection models does not follow the same course as ICP in the human pathology, furthermore the decrease of cerebral blood flow after injection is only short-lived [20]. As the initial and sharp ICP peak and/or the consecutive global cerebral ischaemia are decisive factors for early pathophysiological changes (early brain injury, EBI), it is as yet unclear to what extent injection models are suited to investigating acute pathophysiological changes after subarachnoid haemorrhage.

To better adapt the dynamics of injection-induced subarachnoid haemorrhage to the real-life situation, arterio-intrathecal shunt models were developed. Steiner et al. developed a canine model with femoro-intrathecal shunt in 1975 [21, 22] in order to investigate the pathophysiology of acute mortality after subarachnoid haemorrhage. This approach was modified in the rabbit model by Marbacher et al. to create the so-called shunt model [23]: The cisterna magna of rabbits is transcutaneously cannulated and connected to a catheter that has already been placed in the subclavian artery. When this bypass - which is initially closed with a clip - is opened subsequently, blood enters the subarachnoid space proportional to and dependent on the arterial blood pressure. Afterwards, the shunt is sealed. Previous results with this model indicate that the acute phase of subarachnoid haemorrhage, which is characterised

by a CPP-independent decrease in cerebral blood flow [24, 25], may be better reproduced than in other injection models [26].

Re-bleedings which frequently occur and may complicate the clinical course are another factor that cannot be modelled using single injection techniques.

As the occurrence of (angiographically detectable) delayed vasospasm is associated with the extent of subarachnoid blood volume, the injection model may be carried out in a staged fashion, injecting twice or multiple times [27-31] thereby significantly increasing the severity of SAH and of all posthaemorrhagic complications. However, even after double blood injection, the acute decrease of cerebral blood flow is much less pronounced than the CBF drop observed in patients and in the perforation models described below [20, 32]. Lastly, vascular injury and/or endothelial damage, important pathophysiological features of aneurysmal subarachnoid haemorrhage, are missing in the injection model.

CIRCLE OF WILLIS: PERFORATION MODELS

In order to adequately model vascular injury and the arterial haemorrhage kinetics of subarachnoid haemorrhage in an experimental setup, large animal models were developed from the 1960s onwards; SAH was triggered by direct vascular puncture of the internal carotid artery [ICA, 33-35], middle cerebral artery [MCA, 36], or arteries of the posterior circulation [37-39]. Catheter-assisted [40] or endoscopic [41] procedures without craniotomy have also been described. In 1995, Bederson was the first researcher to describe the filament perforation model in rats [42]; in this non-invasive technique, a monofilament is introduced via the external carotid artery into the internal carotid artery and then advanced intracranially. The circle of Willis is perforated at the MCA bifurcation, the filament is then quickly removed. Over the years, several modifications of the MCA perforation model have been introduced: in order to control the intensity of haemorrhage, the common carotid artery was ligated [43]. However, this reduces global cerebral perfusion and leads to an increase in posthaemorrhagic global cerebral ischaemia. Use of different filament sizes (3-0, 4-0, 5-0) may be more suited to influence haemorrhage volume and, thus, severity [44]; moreover, replacing the polymer filament with Wolfram wire may help to reduce the perioperative complication rate [45]. Important pathophysiological features of SAH are reliably reproduced in the MCA perforation model: a sharp increase in ICP with simultaneous decrease in cerebral perfusion, the Cushing reflex, and numerous secondary complications such as brain oedema formation, (histologically detectable) neuronal damage and neurological deficits; re-bleeding intermittently occurs and can be quantified [46]. In the late 1990s, the endovascular filament perforation technique was first described in mice and thus could also be used in transgenic mouse models [47-49], but the reported mortality and secondary posthaemorrhagic damage showed wide variations. The routine use of laser Doppler flowmetry and intracranial pressure measurement during perforation helps to prove correct SAH induction and thereby enables a high level of standardisation of the method [50, 51]. Combining the perforation mouse model with transgenic alterations and improved *in vivo* imaging techniques such as intravital microscopy led to important insights into the pathophysiology of the early phase after subarachnoid haemorrhage. This early brain injury is characterised by a significant disturbances of the cerebral microcirculation, involving among other things microthrombosis

of cerebral vessels [52, 53], microvascular constrictions (so called microvasospasms) [54], and impaired cerebrovascular CO_2 reactivity [55].

The drawbacks of the perforation model are the challenging and complex surgical technique and the inability to fully control the blood volume. However, after an appropriate training phase, perioperative morbidity decreases significantly. By continuously monitoring intracranial pressure and cerebral blood flow during induction of SAH and at different time-points thereafter, standardisation of bleeding intensity can not only be guaranteed, but also documented. A further albeit minor point of criticism in the perforation model is the lack of a "non-haemorrhage" control group: sham operated animals, in which the filament is introduced but the circle of Willis is not punctured, usually are used as controls. Unlike in injection models, where sham-operated animals are injected saline to separate the effect of intracranial volume augmentation from the effect of blood components, these animals do not undergo any physiological changes. However, in summary, the perforation model of subarachnoid haemorrhage is a well-established tool for simulating most facets of SAH pathophysiology and - despite a few limitations and higher (technical and surgical) complexity than other techniques - the only SAH model that simulates mechanical trauma from vascular rupture. Most studies that address the mechanisms of early brain injury [56, 57] use this model.

OTHER SAH MODELS

Placement of blood clots onto or around the circle of Willis vessels leads to delayed vasospasm that is clearly detectable on angiography or by Doppler sonography; this technique has been frequently used for chronic SAH studies and drug trials [58-61] However, a craniotomy and invasive operative procedure are needed to position the blood clot, limiting the successful use of this method to larger species such as dogs and monkeys. The costly equipment and surgical expertise needed for large animal experiments, the increasing restrictions placed on primate experiments, and the shift in research focus to early disturbances in the cerebral microcirculation, have severely limited the dissemination of the clot model. Currently, the primate model is used in a few centres to investigate delayed vasospasms [62, 63].

Various studies report the successful and standardisable induction of intracranial aneurysms [64-66]; however, it has not yet been possible to reliably trigger subarachnoid haemorrhage in these models. Further development of this method or its combination with existing perforation techniques may make a model of aneurysmal subarachnoid haemorrhage feasible in the future.

CONCLUSION

There are a multitude of experimental techniques for inducing subarachnoid haemorrhage. All models have distinct advantages and disadvantages; given the complex human pathology no single model will adequately represent every nuance of the disease. Perforation models are technically complex and more surgically/manually challenging than

other techniques, but perforation-induced SAH appears to be most closely related to the kinetics of haemorrhage, vascular trauma in ruptures, elevated ICP, decreased CBF and other secondary posthaemorrhagic processes of human pathophysiology. In transgenic mouse models this method, combined with novel imaging and visualisation techniques, enables examination of all aspects of SAH pathophysiology, particularly in the early phase (<72 hours) after haemorrhage; if necessary, results obtained in the rodent model then can be tested/verified in clinically relevant, large animal models with respect to their suitability for use in SAH therapy.

REFERENCES

[1] Bagley, C. Jr. Blood in the cerebrospinal fluid: Resultant functional and organic alterations in the central nervous system - Part A: Experimental data. *Arch Surg* 1928;17(1):18-38.

[2] Kuwayama A., Zervas N. T., Belson R., Shintani A., Pickren K. A model for experimental cerebral arterial spasm. *Stroke* 1972 Jan;3(1):49-56.

[3] Mizuno T., Hamada J., Kai Y., Todaka T., Morioka M., Ushio Y. Single blood injection into the ventral cisterna magna through a microcatheter for the production of delayed cerebral vasospasm: experimental study in dogs. *AJNR Am J Neuroradiol* 2003 Apr; 24(4):608-12.

[4] Varsos V. G., Liszczak T. M., Han D. H., Kistler J. P., Vielma J., Black P. M. et al. Delayed cerebral vasospasm is not reversible by aminophylline, nifedipine, or papaverine in a "two-hemorrhage" canine model. *J Neurosurg* 1983 Jan;58(1):11-7.

[5] Chow R. W., Newton T. H., Smith M. C., Adams J. E. Cerebral vasospasm induced by subarachnoid blood and serotonin. An angiographic study. *Invest Radiol* 1968 Nov; 3(6):402-7.

[6] Martins A. N., Doyle T. F., Newby N., Kobrine A. I., Ramirez A. The effect of a simulated subarachnoid hemorrhage on cerebral blood flow in the monkey. *Stroke* 1975 Nov;6(6):664-72.

[7] Delgado-Zygmunt T. J., Arbab M. A., Shiokawa Y., Svendgaard N. A. A primate model for acute and late cerebral vasospasm: angiographic findings. *Acta Neurochir* (Wien) 1992;118(3-4):130-6.

[8] von M. C., Chang J. Y., Delgado T., Owman C., Sahlin C., Svendgaard N. A. Ultrastructural cerebrovascular changes in a model of subarachnoid hemorrhage in baboon based on triple cisternal blood injection. *Surg Neurol* 1990 Mar;33(3):195-201.

[9] Delgado T. J., Brismar J., Svendgaard N. A. Subarachnoid haemorrhage in the rat: angiography and fluorescence microscopy of the major cerebral arteries. *Stroke* 1985 Jul;16(4):595-602.

[10] Solomon R. A., Antunes J. L., Chen R. Y., Bland L., Chien S. Decrease in cerebral blood flow in rats after experimental subarachnoid hemorrhage: a new animal model. *Stroke* 1985 Jan;16(1):58-64.

[11] Doczi T., Joo F., Adam G., Bozoky B., Szerdahelyi P. Blood-brain barrier damage during the acute stage of subarachnoid hemorrhage, as exemplified by a new animal model. *Neurosurgery* 1986 Jun;18(6):733-9.

[12] Sobey C. G., Heistad D. D., Faraci F. M. Effect of subarachnoid hemorrhage on dilatation of rat basilar artery *in vivo*. *Am J Physiol* 1996 Jul;271(1 Pt 2):H126-H132.
[13] Lin C. L., Calisaneller T., Ukita N., Dumont A. S., Kassell N. F., Lee K. S. A murine model of subarachnoid hemorrhage-induced cerebral vasospasm. *J Neurosci Methods* 2003 Feb 15;123(1):89-97.
[14] Kamp M. A., Dibue M., Sommer C., Steiger H. J., Schneider T., Hanggi D. Evaluation of a murine single-blood-injection SAH model. *PLoS One* 2014;9(12):e114946.
[15] McIntyre J. W., Miller J. D., Weir B. K. Anaesthesia for cerebral angiography: cardiovascular and cerebrospinal fluid pressure observations in the monkey under pentobarbital-halothane anaesthesia. *Can Anaesth Soc J* 1969 Jul;16(4):309-15.
[16] Weir B., Erasmo R., Miller J., McIntyre J., Secord D., Mielke B. Vasospasm in response to repeated subarachnoid hemorrhages in the monkey. *J Neurosurg* 1970 Oct;33(4):395-406.
[17] Jakubowski J., McCleery W. N., Todd J. H. Proceedings: Acute haemorrhagic cerebral vasospasm in the dog: an experimental model. *Br J Anaesth* 1973 Dec;45(12):1235-6.
[18] Prunell G. F., Mathiesen T., Svendgaard N. A. A new experimental model in rats for study of the pathophysiology of subarachnoid hemorrhage. *Neuroreport* 2002 Dec 20;13(18):2553-6.
[19] Sabri M., Jeon H., Ai J., Tariq A., Shang X., Chen G. et al. Anterior circulation mouse model of subarachnoid hemorrhage. *Brain Res* 2009 Oct 27;1295:179-85.
[20] Prunell G. F., Mathiesen T., Svendgaard N. A. Experimental subarachnoid hemorrhage: cerebral blood flow and brain metabolism during the acute phase in three different models in the rat. *Neurosurgery* 2004 Feb;54(2):426-36.
[21] Steiner L., Lofgren J., Zwetnow N. N. Lethal mechanism in repeated subarachnoid hemorrhage in dogs. *Acta Neurol Scand* 1975 Oct;52(4): 268-93.
[22] Steiner L., Lofgren J., Zwetnow N. N. Characteristics and limits of tolerance in repeated subarachnoid hemorrhage in dogs. *Acta Neurol Scand* 1975 Oct;52(4):241-67.
[23] Marbacher S., Andereggen L., Neuschmelting V., Widmer H. R., von G. M., Takala J. et al. A new rabbit model for the study of early brain injury after subarachnoid hemorrhage. *J Neurosci Methods* 2012 Jul 15;208(2): 138-45.
[24] Schubert G. A., Seiz M., Hegewald A. A., Manville J., Thome C. Hypoperfusion in the acute phase of subarachnoid hemorrhage. *Acta Neurochir Suppl* 2011;110(Pt 1):35-8.
[25] Schubert G. A., Seiz M., Hegewald A. A., Manville J., Thome C. Acute hypoperfusion immediately after subarachnoid hemorrhage: a xenon contrast-enhanced CT study. *J Neurotrauma* 2009 Dec;26(12):2225-31.
[26] Marbacher S., Neuschmelting V., Andereggen L., Widmer H. R., von G. M., Takala J. et al. Early brain injury linearly correlates with reduction in cerebral perfusion pressure during the hyperacute phase of subarachnoid hemorrhage. *Intensive Care Med Exp* 2014 Dec;2(1):30.
[27] Raslan F., Albert-Weissenberger C., Westermaier T., Saker S., Kleinschnitz C., Lee J. Y. A modified double injection model of cisterna magna for the study of delayed cerebral vasospasm following subarachnoid hemorrhage in rats. *Exp Transl Stroke Med* 2012;4(1):23.
[28] Guresir E., Schuss P., Borger V., Vatter H. Rat cisterna magna double-injection model of subarachnoid hemorrhage - background, advantages/limitations, technical

considerations, modifications, and outcome measures. *Acta Neurochir Suppl* 2015;120: 325-9.

[29] Deinsberger W., Vogel J., Kuschinsky W., Auer L. M., Boker D. K. Experimental intracerebral hemorrhage: description of a double injection model in rats. *Neurol Res* 1996 Oct;18(5):475-7.

[30] Spallone A., Pastore F. S. Cerebral vasospasm in a double-injection model in rabbit. *Surg Neurol* 1989 Dec;32(6):408-17.

[31] Kikkawa Y. A rabbit cisterna magna double-injection subarachnoid hemorrhage model. *Acta Neurochir Suppl* 2015;120:331-5.

[32] Lee J. Y., Sagher O., Keep R., Hua Y., Xi G. Comparison of experimental rat models of early brain injury after subarachnoid hemorrhage. *Neurosurgery* 2009 Aug;65(2):331-43.

[33] Simeone F. A., Ryan K. G., Cotter J. R. Prolonged experimental cerebral vasospasm. *J Neurosurg* 1968 Oct;29(4):357-66.

[34] Frazee J. G. A primate model of chronic cerebral vasospasm. *Stroke* 1982 Sep;13(5): 612-4.

[35] Asano T., Sano K. Pathogenetic role of no-reflow phenomenon in experimental subarachnoid hemorrhage in dogs. *J Neurosurg* 1977 Apr; 46(4):454-66.

[36] Clower B. R., Smith R. R., Haining J. L., Lockard J. Constrictive endarteropathy following experimental subarachnoid hemorrhage. *Stroke* 1981 Jul;12(4):501-8.

[37] Barry K. J., Gogjian M. A., Stein B. M. Small animal model for investigation of subarachnoid hemorrhage and cerebral vasospasm. *Stroke* 1979 Sep;10(5):538-41.

[38] Jakubowski J., Bell B. A., Symon L., Zawirski M. B., Francis D. M. A primate model of subarachnoid hemorrhage: change in regional cerebral blood flow, autoregulation carbon dioxide reactivity, and central conduction time. *Stroke* 1982 Sep;13(5):601-11.

[39] Kuyama H., Ladds A., Branston N. M., Nitta M., Symon L. An experimental study of acute subarachnoid haemorrhage in baboons: changes in cerebral blood volume, blood flow, electrical activity and water content. *J Neurol Neurosurg Psychiatry* 1984 Apr; 47(4):354-64.

[40] Masuda T., Sato K., Yamamoto S., Matsuyama N., Shimohama T., Matsunaga A. et al. Sympathetic nervous activity and myocardial damage immediately after subarachnoid hemorrhage in a unique animal model. *Stroke* 2002 Jun;33(6):1671-6.

[41] Ergun R., Fernandez J., Misra M., Dujovny M. Endoscopic technique: a new model of subarachnoid hemorrhage in rats. *Neurol Res* 2001 Sep; 23(6):627-30.

[42] Bederson J. B., Germano I. M., Guarino L. Cortical blood flow and cerebral perfusion pressure in a new noncraniotomy model of subarachnoid hemorrhage in the rat. *Stroke* 1995 Jun;26(6):1086-91.

[43] Veelken J. A., Laing R. J., Jakubowski J. The Sheffield model of subarachnoid hemorrhage in rats. *Stroke* 1995 Jul;26(7):1279-83.

[44] Schwartz A. Y., Masago A., Sehba F. A., Bederson J. B. Experimental models of subarachnoid hemorrhage in the rat: a refinement of the endovascular filament model. *J Neurosci Methods* 2000 Mar 15;96(2): 161-7.

[45] Hollig A., Weinandy A., Nolte K., Clusmann H., Rossaint R., Coburn M. Experimental subarachnoid hemorrhage in rats: comparison of two endovascular perforation techniques with respect to success rate, confounding pathologies and early hippocampal tissue lesion pattern. *PLoS One* 2015;10(4):e0123398.

[46] Hockel K., Scholler K., Trabold R., Nussberger J., Plesnila N. Vasopressin V(1a) receptors mediate posthemorrhagic systemic hypertension thereby determining rebleeding rate and outcome after experimental subarachnoid hemorrhage. *Stroke* 2012 Jan;43(1):227-32.

[47] Kamii H., Kato I., Kinouchi H., Chan P. H., Epstein C. J., Akabane A. et al. Amelioration of vasospasm after subarachnoid hemorrhage in transgenic mice overexpressing CuZn-superoxide dismutase. *Stroke* 1999 Apr;30(4):867-71.

[48] Saito A., Kamii H., Kato I., Takasawa S., Kondo T., Chan P. H. et al. Transgenic CuZn-superoxide dismutase inhibits NO synthase induction in experimental subarachnoid hemorrhage. *Stroke* 2001 Jul;32(7):1652-7.

[49] Parra A., McGirt M. J., Sheng H., Laskowitz D. T., Pearlstein R. D., Warner D. S. Mouse model of subarachnoid hemorrhage associated cerebral vasospasm: methodological analysis. *Neurol Res* 2002 Jul; 24(5):510-6.

[50] Feiler S., Friedrich B., Scholler K., Thal S. C., Plesnila N. Standardized induction of subarachnoid hemorrhage in mice by intracranial pressure monitoring. *J Neurosci Methods* 2010 Jul 15;190(2):164-70.

[51] Scholler K., Feiler S., Anetsberger S., Kim S. W., Plesnila N. Contribution of bradykinin receptors to the development of secondary brain damage after experimental subarachnoid hemorrhage. *Neurosurgery* 2011 Apr;68(4):1118-23.

[52] Sehba F. A., Bederson J. B. Mechanisms of acute brain injury after subarachnoid hemorrhage. *Neurol Res* 2006 Jun;28(4):381-98.

[53] Sehba F. A., Mostafa G., Friedrich V., Jr., Bederson J. B. Acute microvascular platelet aggregation after subarachnoid hemorrhage. *J Neurosurg* 2005 Jun;102(6):1094-100.

[54] Friedrich B., Muller F., Feiler S., Scholler K., Plesnila N. Experimental subarachnoid hemorrhage causes early and long-lasting microarterial constriction and microthrombosis: an *in-vivo* microscopy study. *J Cereb Blood Flow Metab* 2012 Mar; 32(3):447-55.

[55] Friedrich B., Michalik R., Oniszczuk A., Abubaker K., Kozniewska E., Plesnila N. CO2 has no therapeutic effect on early microvasospasm after experimental subarachnoid hemorrhage. *J Cereb Blood Flow Metab* 2014 Aug;34(8):e1-e6.

[56] Sehba F. A., Hou J., Pluta R. M., Zhang J. H. The importance of early brain injury after subarachnoid hemorrhage. *Prog Neurobiol* 2012 Apr; 97(1):14-37.

[57] Sehba F. A., Pluta R. M., Zhang J. H. Metamorphosis of subarachnoid hemorrhage research: from delayed vasospasm to early brain injury. *Mol Neurobiol* 2011 Feb; 43(1):27-40.

[58] Shiokawa K., Kasuya H., Miyajima M., Izawa M., Takakura K. Prophylactic effect of papaverine prolonged-release pellets on cerebral vasospasm in dogs. *Neurosurgery* 1998 Jan;42(1):109-15.

[59] Fathi A. R., Bakhtian K. D., Marbacher S., Fandino J., Pluta R. M. Blood clot placement model of subarachnoid hemorrhage in non-human primates. *Acta Neurochir Suppl* 2015;120:343-6.

[60] Handa Y., Weir B. K., Nosko M., Mosewich R., Tsuji T., Grace M. The effect of timing of clot removal on chronic vasospasm in a primate model. *J Neurosurg* 1987 Oct; 67(4):558-64.

[61] Pluta R. M., Bacher J., Skopets B., Hoffmann V. A non-human primate model of aneurismal subarachnoid hemorrhage (SAH). *Transl Stroke Res* 2014 Dec;5(6):681-91.

[62] Fathi A. R., Pluta R. M., Bakhtian K. D., Qi M., Lonser R. R. Reversal of cerebral vasospasm via intravenous sodium nitrite after subarachnoid hemorrhage in primates. *J Neuro*surg 2011 Dec;115(6):1213-20.

[63] Pluta R. M., Dejam A., Grimes G., Gladwin M. T., Oldfield E. H. Nitrite infusions to prevent delayed cerebral vasospasm in a primate model of subarachnoid hemorrhage. *JAMA* 2005 Mar 23;293(12):1477-84.

[64] van Alphen H. A., Gao Y. Z., Kamphorst W. An acute experimental model of saccular aneurysms in the rat. *Neurol Res* 1990 Dec;12(4):256-9.

[65] Nishikawa M., Smith R. D., Yonekawa Y. Experimental intracranial aneurysms. *Surg Neurol* 1977 Apr;7(4):241-4.

[66] Morimoto M., Miyamoto S., Mizoguchi A., Kume N., Kita T., Hashimoto N. Mouse model of cerebral aneurysm: experimental induction by renal hypertension and local hemodynamic changes. *Stroke* 2002 Jul;33(7):1911-5.

In: Encyclopedia of Surgery (22 Volume Set)
Editors: Andreas Lehrer and Kristin Mueller
ISBN: 978-1-53618-329-0
© 2020 Nova Science Publishers, Inc.

Chapter 81

VASCULAR IMAGING

Athanasios Saratzis*, PhD
Department of Cardiovascular Sciences
and NIHR Cardiovascular Biomedical Research Unit,
University of Leicester, United Kingdom

ABSTRACT

Vascular imaging has seen a revolution over the last two decades, since the introduction of endovascular surgery, which has gradually become routine practice, and the development of advanced cross-sectional imaging modalities with higher fidelity and accuracy. Duplex ultrasound (US), computed tomography (CT), magnetic resonance imaging (MRI), and conventional digital subtraction angiography (DSA) are currently the main imaging modalities in the armamentarium of vascular surgery. Given the recent advances in software and imaging devices, DSA is now typically reserved for intervention rather than diagnosis. The modern vascular surgeon needs to be aware of the limitations and advantages of each imaging modality, and should be able to diagnose and plan therapeutic procedures, involving either open or endovascular reconstruction, independently. This chapter covers the basics behind the main imaging methods in contemporary vascular practice with an aim to aid diagnosis and management of the relevant pathologies.

INTRODUCTION

Vascular imaging has seen a revolution over the last two decades, since the introduction of endovascular surgery, which has gradually become routine practice, and the development of advanced cross-sectional imaging modalities with higher fidelity and accuracy [1]. Duplex ultrasound (US), computed tomography (CT), magnetic resonance imaging (MRI), and conventional digital subtraction angiography (DSA) are currently the main imaging modalities in the armamentarium of vascular surgery. Given the recent advances in software

* Corresponding Author's Email: as875@le.ac.uk.

and imaging devices, DSA is now typically reserved for intervention rather than diagnosis. The modern vascular surgeon needs to be aware of the limitations and advantages of each imaging modality, and should be able to diagnose and plan therapeutic procedures, involving either open or endovascular reconstruction, independently [2]. This chapter covers the basics behind the main imaging methods in contemporary vascular practice with an aim to aid diagnosis and management of the relevant pathologies.

CONTRAST IN VASCULAR IMAGING

The majority of the imaging modalities in vascular surgery require the administration of intra-arterial or intra-venous contrast agents to adequately picture the vasculature. Even ultrasound is now aided by the administration of contrast, to depict more complex anatomies, such as after endovascular interventions [3]. There are certain limitations and challenges associated with contrast administration that need to be discussed.

Several types of contrast media are available, based on the imaging modalities where they are used. Contrast media also differ in terms of molecular function and properties. Iodinated media are typically used in vascular imaging, and they may be either ionic or non-ionic. Non-ionic contrast is currently the most widely used medium, given the reduced risk for adverse reactions. Additionally, the vast majority of media used today are low or iso-osmolar, again due to reduced risk for anaphylaxis and nephropathy [4]. Any form of angiography, either CT or MR generated or conventional DSA, requires the administration of a contrast agent. That may lead to contrast induced nephropathy (CIN), which is an acute deterioration in renal function due to direct damage to the kidney, which happens at the level of the renal tubule [5]. CIN has conventionally been defined as an acute rise in serum creatinine levels of at least 25% compared to baseline and is associated with short and long term adverse outcomes [6-8]. Other definitions of acute kidney injury (AKI) have also been made available over the last decade, but are more applicable to interventions, such as endovascular aneurysm repair (EVAR), rather than diagnostic imaging modalities [5, 9]. Patients at increased risk for CIN or AKI after contrast administration include those with diabetes, hypertension, current smoking habit, critical limb ischaemia (especially in the case of existent tissue loss) and those with a baseline estimated glomerular filtration rate of less than 45ml/min/1.73m [5, 10]. The prevention of CIN and AKI in these patient groups is challenging and there are several proposed interventions with variable results, including the use of iso-osmolar contrast agents, adequate patient hydration using normal saline with or without sodium bicarbonate, premedication with N-acetylcysteine, ischaemic preconditioning, or angiography based on carbon dioxide contrast agents [5, 9]. Reno-protection should be guided by pre-existing risk-factors and most definitely contrast use should be avoided if possible. Gadolinium, a non-iodinate medium which is the contrast of choice in MR imaging, is less nephrotoxic but can also lead to a deterioration in renal function as well as interstitial nephritis and a rare type of nephropathy, gadolinium-induced nephrogenic systemic fibrosis, in high-risk patients – especially these with chronic kidney disease stage 3 and above at baseline [11-13]. MR-based angiography also requires fairly small doses of gadolinium (0.1mmol/kg), which may also explain the less pronounced impact on renal function. Carbon dioxide (CO_2) is an alternative contrast agent useful in both diagnostic and therapeutic procedures. Catheter-directed

injection of CO2 results in a negative contrast image within the target vessel [14]; CO2 is rapidly absorbed and is not nephrotoxic. However, it is very challenging to image below the knee lesions adequately [15] and most centres are not yet familiar with its use [14, 16]. Interestingly, several case-series of EVAR using CO2 as a contrast medium have recently been made available [17, 18].

Several ultrasound contrast media are currently available, most in the form of "micro-bubbles" and various are under developments, hopefully with less nephrotoxic properties. These agents typically consist of micro-bubbles encased in a biodegradable-shell. These are injected whilst an ultrasound probe is used to visualize the vessel in question. The subsequent risk of nephropathy is less. There are no large studies available with regards to usage of contrast-based Duplex ultrasonography in the diagnostic assessment of the peripheral vasculature; however, this modality has shown promising results in post-EVAR follow-up for endoleak [19, 20].

DIGITAL SUBTRACTION ANGIOGRAPHY

Conventional angiography involved the selective catheterisation of a target vessel or territory with an angiographic catheter, typically through a femoral (percutaneous) approach. Radiographic images are taken after contrast injection. Digital subtraction angiography (DSA) is almost always employed, which allows the subtraction of background tissue to provide a better picture of the vasculature, using simple software. DSA has been the gold standard for imaging the arterial and venous tree, but is currently being replaced in routine practice by more contemporary cross-sectional modalities that are less invasive and labour intensive. Given its invasive nature, DSA can be associated with access-related complications, such as haematoma, pseudoaneurysm formation, or inadvertent cannulation of an adjacent vessel [21]. To limit these, most interventionists will perform vessel-punctures under ultrasound guidance in contemporary practice. Other complications secondary to DSA include damage to the target vasculature, including dissection, thrombosis, vasospasm, and peripheral embolization or even rupture of the target vessel. Finally, there is an increased risk of CIN given that iodinated contrast is injected intra-arterially [5]. Given these risks, DSA is usually reserved for intervention or imaging of challenging anatomy, such as below the knee lesions or heavily calcified lesions where CT angiography and MR angiography may not be as sensitive. Additionally, DSA yields physiologic information, such as the measurement of pressure gradients across lesions and the ability to observe the flow of contrast through a vessel in real-time. This may particularly helpful in below the knee lesions and in patients where a low cardiac output does not allow adequate imaging with non-invasive modalities.

COMPUTED TOMOGRAPHY (CT)

Angiography based on images obtained by computed tomography (CT) has seen significant advances over the last three decades. The current modality of choice when using CT to image the vasculature is multi-detector CT angiography (MDCTA). Using intravenous contrast medium, multiple detectors travel in a helical orientation around the patient and

collect volumetric data (together with cross-sectional images), which are then displayed using relevant software. Typically, the volume of contrast required is 50 to 150 ml, depending on the patient's respiratory status, left ventricular function, localization of the disease, and the degree of anatomical detail that is necessary. Retrospective or prospective ECG synchronisation can be applied as well, which may be applicable especially when imaging the proximal aorta and dissections. The main differences between conventional spiral CT and MDCTA include the rapid acquisition speed for MDCTA and the fact that volumetric data are obtained, which allow in-depth analyses of the anatomy of the vessels. Reconstruction of the cross-sectional slices together with the volumetric data obtained via MDCTA is performed with relevant software using the following protocols: maximum intensity projection (MIP), vessel density ratio (VDR), and multi-planar reconstruction (MPR) [22]. Maximum intensity projection can provide pictures very similar to DSA but may exaggerate the degree of stenosis in the case of significant calcification; MPR cannot follow the tortuous course of certain arteries but it can very accurately depict intraluminal thrombus. Several solutions are being investigated to overcome these technical problems including curved MPR and digital subtraction imaging. Additionally, the latest generation devices provide even more detailed scanning and the subsequent quality of the images obtained is very similar to DSA. Another important advantage of MDCTA over DSA is the fact that the cross-sectional slices provide important information about the surrounding anatomy, which could not have been obtained using conventional angiography. Overall, MDCTA is a rapid and safe mode of imaging the vasculature. It has become the preferred method of imaging patients before EVAR (instead of DSA) [23] in order to plan the procedure and has largely replaced DSA as a diagnostic modality for peripheral arterial disease [24].

It has long been shown that EVAR can be safely planned using measurements obtained from reconstructed MDCTA images without the need for DSA. A typical EVAR protocol MDCTA scan includes acquisition of unenhanced, arterial contrast, and delayed post-contrast images. Unenhanced images provide a baseline examination against which apparent abnormalities in the arterial phase can be judged. Delayed images allow for the evaluation of slow endoleaks, especially type 2 endoleaks. MDCTA is in fact very accurate at depicting endoleaks, migration and other device-associated or anatomical complications following EVAR [25, 26]. Further classification with DSA may be necessary in the case of an endoleak, as up to 10% of endoleaks may not be classifiable based on CT reconstruction alone. However, most centres now employ MDCTA as the “gold-standard” in imaging endoleaks, at least at the first instance. Regarding routine post-EVAR follow-up, ultrasound has replaced MDCTA as the preferred modality for device surveillance given the as it is less expensive and does not involve contrast or radiation exposure. A recent meta-analysis has shown that unenhanced ultrasound has rather poor sensitivity for endoleak detection; however CEUS is highly sensitive [25].

MDCTA is also useful in the assessment and planning of peripheral arterial disease (PAD). In the evaluation of severe peripheral lesions, MDCTA has a sensitivity of 92% and a specificity of 97% when compared with DSA [27, 28]. When used after ultrasound imaging before intervention, it may lead to a change in the initial treatment strategy in up to 25% of cases. However, in contemporary practice, given the increasing accuracy of ultrasonography, planning of intervention based on ultrasound alone is acceptable in the majority of cases. MDCTA is associated with lower radiation dose than DSA, and consistency in treatment recommendations based on MDCTA is excellent [28]. Regarding carotid artery disease,

MDCTA is a useful adjunct to ultrasonography. It bears a negative predictive value of almost 100% for stenoses between 50% and 70% [29]. All the carotid trials have used ultrasonography as the "gold-standard" for imaging; MDCTA should be reserved for recurrent disease (re-stenosis), and plaques that have significant distal extension, as part of pre-operative assessment and planning.

Finally, coronary CTA has recently emerged as a promising non-invasive method for the detection and coronary artery disease (CAD). A recent randomized trial confirmed multidetector MDCTA as a modality that has equal clinical applicability as conventional DSA in diagnosing and planning treatment for CAD [30].

MAGNETIC RESONANCE IMAGING (MRI)

Angiography can be performed with or without contrast (intravenous) agents using MRI technology. MR-angiography (MRA) without contrast can be performed by imaging the intrinsic motion of protons in flowing blood using time-of-flight (TOF) sequences. However, the resolution is not optimal and the procedure is timely. Gadolinium can be administered intravenously to obtain better resolution pictures. Similar to MDCTA sequences, post-capture reconstruction can take place using maximum intensity projection (MIP), vessel density ratio (VDR), and multi-planar reconstruction (MPR). Gadolinium-enhanced MRA is mainly used to image peripheral arterial disease (PAD), renal artery disease (RAD) and carotid artery disease (CAD) in contemporary practice.

MRA and Peripheral Arterial Disease (PAD)

MRA is becoming an increasingly common modality in PAD to image, mainly, infrainguinal and infrapopliteral disease; MRA reconstructed images using MIP predicted have a sensitivity of 97%–100% and a specificity of 95%–99% compared to DSA in PAD. However, MRA may significantly over-estimate stenoses in the peripheral vasculature, more so than MDCTA, and is associated with increased cost. Interestingly, MRA for preoperative planning has been associated with a higher surgical re-intervention rate when compared with MDCTA.

MRA and Carotid Artery Stenosis (CAS)

Carotid disease is frequently assessed with MRA reconstructed images, mostly in lesions where a stenosis has already been shown using Duplex ultrasonography. Generally, in CAS MDCTA may underestimate clinically relevant grades of stenosis and is mostly helpful in assessing carotid occlusion as suggested by ultrasonography, whilst MRA is more comparable to conventional DSA, even though it may still give rise to a 5.0% overestimation of stenosis [31]. Overall, MRA is a useful, non-invasive modality for assessment of CAS with a more than 70% stenosis [31], even though it cannot be recommended as first line imaging modality in assessing patients with cerebral events, mostly due to cost (compared to

ultrasonography). Interestingly, a meta-analysis suggested that MRA has a better discriminatory power compared with ultrasonography in diagnosing 70% to 99% stenosis and is as sensitive and specific as DSA in the evaluation of CAS [32].

MRA and Renal Artery Disease (RAD)

MRA has been used extensively in evaluating patients with RAD. Previously, most patients had to undergo gadolinium enhanced MR imaging, which had a good diagnostic accuracy, but was limited due to cost and use of contrast, especially given that this population is more likely to present with renal dysfunction. More recent MR imaging protocols, such as non-contrast balanced steady-state free precession MRA have been assessed in patients with RAD, and a meta-analysis of 10 high-quality studies comparing this technique with gadolinium enhanced MRA or MDCTA has shown a pooled sensitivity of 0.88 (95% CI, 0.83-0.91) and a pooled specificity of 0.94 (95% CI, 0.93-0.95) [33]. Another type of MR imaging, time-spatial labeling inversion pulse (time-SLIP) MRA has also recently been assess in imaging of RAD without contrast, showing a specificity of 93% and accuracy of 90% compared to contrast-enhanced MDCTA [34]. Overall, MRA is becoming increasingly the study of choice in imaging the renal arteries, with or without gadolinium, depending on local availability and expertise.

DUPLEX ULTRASONOGRAPHY

Pulse-wave Doppler ultrasound and grey-scale ultrasound imaging are obtained and combined to provide cross-sectional imaging of the vasculature with real-time information regarding blood-flow in duplex ultrasonography (DU). Colour Doppler may be used as well to further augment assessment of blood flow. This non-invasive and dynamic method of imaging the vasculature has found several applications in vascular medicine and vascular surgery. DU is currently the imaging modality of choice in the initial assessment of patients with peripheral arterial disease (PAD), venous disease (VD), surveillance of both grafts and endovascular devices after endovascular aneurysm repair, as well as carotid artery stenosis (CAS). DU is also used more frequently in the assessment of abdominal vasculature as the experience of the operators and imaging capacity of the devices are expanding. Finally, DU is the imaging study of choice in screening the general population for abdominal aortic aneurysm. Clinical studies have shown that the quality of DU depends on the user's level of experience and that some arterial segments may be visualised more readily than others. However, it does not involve radiation or the use of contrast media and is relatively cheap, especially compared to modalities such as MDCTA and MRA. The main patient-associated limitations of DU include: heavily calcified vessels, very low flow (such as in the case of a low cardiac output), significant tissue oedema, obesity and presence of ulceration.

DU in Peripheral Arterial Disease

Ultrasound is now routinely used in the assessment of the vast majority of patients with peripheral arterial disease (PAD). It has been shown to be accurate in assessing stenoses of the vasculature in the upper and lower limbs [35, 36]. More specifically, several studies have looked at DU in isolation in planning peripheral bypass reconstruction in an emergency or semi-elective setting [37-40]. One year patency rates after bypass to the popliteal segment using DU as the sole pre-operative imaging modality are similar to those when using DSA or MDCTA reconstruction [37, 40]. Even infra-popliteal disease can be accurately assessed to allow planning for distal bypasses using DU, with similar patency rates compared to procedures planned with DSA [39, 41].

Besides baseline assessment and planning, DU is an acceptable imaging modality for surveillance of bypass conduits. Interestingly, a recent randomized controlled trial with 594 participants undergoing peripheral bypass demonstrated that intensive surveillance with DU did not show any additional benefit in terms of limb salvage rates for patients undergoing vein bypass graft operations, but it did incur additional costs [42]. If an imaging-guided surveillance programmed is in place, DU is usually the modality of choice, especially given that it performs very similarly to MDCTA or MRA [43, 44]. Testing frequency should be individualized to the patient, type of bypass, and degree of stenosis if one is indeed depicted. Graft surveillance should focus on the identification and repair of critical stenosis (peak systolic velocity exceeding 300 cm/s, and peak systolic velocity ratio across the stenosis exceeding 3.5) correlating with more than 70% diameter-reducing stenosis [43]. A graft surveillance program should result in a graft failure rate of less than 3% per year [43].

DU in Carotid Artery Disease

A large analysis of patients with carotid artery stenosis (CAS) who underwent DU imaging and DSA concluded that DU is similar to DSA in assessing high-grade CAS; however, it tends to lead to an overestimation of the degree of stenosis. Exclusion of 70%-99% angiographic stenosis with DU alone can be achieved with a sensitivity of 98% [45]. DU has been the procedure of choice in screening for CAS in the majority of the carotid trials to date [46]. Relevant diagnostic criteria and cut-offs for intervention have been reported by these trials with the NASCET and ECST criteria representing the most commonly used [47]. The recommended criteria, at least for the United Kingdom, are based on the NASCET method of grading carotid bulb disease. Key recommendations include recording peak systolic velocity (PSV) and end-diastolic velocity (EDV) in both internal and distal common carotid arteries; measuring all velocities at a Doppler angle of 45-60 degrees; the use of internal carotid PSV of >1.25 ms (-1) and >2.3 ms (-1) and a Peak Systolic Velocity Ratio of >2 and >4 to indicate >50% and >70% stenosis respectively; and the use of the St Mary's Ratio to grade >50% stenoses in deciles [47]. Regarding post-surgery or stenting stenoses, DU is also excellent in detecting recurrent disease with a sensitivity and specificity of greater than 95% compared to DSA [48]. The main advantage in using DU in assessing patients with CAS is the fact that it provides a dynamic image of the carotid plaque. High-risk plaques from symptomatic patients have been shown to demonstrate characteristics such as

intraplaque hemorrhage, higher lipid content, larger lipid core, less distance between lipid core and flow lumen, and less calcium compared to plaques from asymptomatic patients [49].

DU in Post-EVAR Surveillance and Endoleak Assessment

The role of DU in surveillance after endovascular aneurysm repair (EVAR) and the assessment of possible endoleak remains controversial [50]. EVAR offers the advantage of lower perioperative mortality and morbidity [51] but carries the cost of device-related complications such as endoleak, graft migration, graft thrombosis, and structural graft failure [52]. These mandate a lifelong surveillance. A low sensitivity of DU in detecting endoleak has previously been reported, in the range of 25% to 42% [53-56]. However, one study has reported that DU is better at determining the subsequent intervention strategy than CT alone in the case of endoleak [57]. Overall, studies comparing CDU with CT scan for investigation of post-EVAR complications have produced mixed results [25]. Newer DU imaging modalities aided by the administration of contrast may be more accurate at depicting endoleak, avoiding the need for radiation (MDCTA). A recent meta-analysis of plain and contrast enhanced DU including 25 studies (3,975 paired scans) compared DU with CT for all types of endoleak after EVAR. The pooled sensitivity was 74% and the pooled specificity was 94% for all endoleaks. Thirteen studies (2,650 paired scans) reported detection of types 1 and 3 endoleak by DU; the pooled sensitivity was 83% and the pooled specificity was 100%. The pooled sensitivity of contrast endhanced DU was 96% with a specificity of 85% (all endoleaks). For type 1 and 3 endoleaks the sensitivity and specificity of contrast enhanced DU were 99% and 100% respectively [25]. Current practices among centres vary; however, given the results of the aforementioned recent meta-analysis a surveillance programme using radiographs (serially) to assess for migration and DU with or without contrast can be considered as safe and is employed by several centres.

REFERENCES

[1] Perry JT, Statler JD. Advances in vascular imaging. *Surg. Clin. North Am*. 2007;87 (5):975-93, vii.

[2] Fitridge R, Quigley F, Vicaretti M. Should we develop a core international curriculum for Vascular and Endovascular Surgery? *Eur. J. Vasc. Endovasc. Surg*. 2010;39 Suppl 1:S10-4.

[3] Staub D, Partovi S, Imfeld S, Uthoff H, Baldi T, Aschwanden M, et al. Novel applications of contrast-enhanced ultrasound imaging in vascular medicine. *Vasa*. 2013;42 (1):17-31.

[4] Tepel M. Preventing nephropathy induced by contrast medium. *N. Engl. J. Med.* 2006;354 (17):1853-5; author reply -5.

[5] Saratzis AN, Goodyear S, Sur H, Saedon M, Imray C, Mahmood A. Acute kidney injury after endovascular repair of abdominal aortic aneurysm. *J. Endovasc. Ther*. 2013;20 (3):315-30.

[6] Walsh SR, Tang T, Gaunt ME, Boyle JR. Contrast-induced nephropathy. *J. Endovasc. Ther*. 2007;14 (1):92-100.

[7] Stacul F, van der Molen AJ, Reimer P, Webb JA, Thomsen HS, Morcos SK, et al. Contrast induced nephropathy: updated ESUR Contrast Media Safety Committee guidelines. *Eur. Radiol*. 2011;21 (12):2527-41.

[8] Saratzis A, Sarafidis P, Melas N, Saratzis N, Kitas G. Impaired renal function is associated with mortality and morbidity after endovascular abdominal aortic aneurysm repair. *J. Vasc. Surg.* 2013;58 (4):879-85.

[9] *Hypertension: The Clinical Management of Primary Hypertension in Adults: Update of Clinical Guidelines 18 and 34*. National Institute for Health and Clinical Excellence: Guidance. London2011.

[10] Eckardt KU, Kasiske BL. Kidney disease: improving global outcomes. *Nature reviews Nephrology*. 2009;5 (11):650-7.

[11] Prince MR, Arnoldus C, Frisoli JK. Nephrotoxicity of high-dose gadolinium compared with iodinated contrast. *J. Magn Reson Imaging.* 1996;6 (1):162-6.

[12] Ergun I, Keven K, Uruc I, Ekmekci Y, Canbakan B, Erden I, et al. The safety of gadolinium in patients with stage 3 and 4 renal failure. *Nephrol. Dial Transplant.* 2006;21 (3):697-700.

[13] Hellman RN. Gadolinium-induced nephrogenic systemic fibrosis. *Semin. Nephrol*. 2011;31 (3):310-6.

[14] Patel BN, Kapoor BS, Borghei P, Shah NA, Lockhart ME. Carbon dioxide as an intravascular imaging agent: review. *Curr. Probl. Diagn Radiol*. 2011;40 (5):208-17.

[15] Spinosa DJ, Angle JF, Hagspiel KD, Kern JA, Hartwell GD, Matsumoto AH. Lower extremity arteriography with use of iodinated contrast material or gadodiamide to supplement CO2 angiography in patients with renal insufficiency. *J. Vasc. Interv. Radiol*. 2000;11 (1):35-43.

[16] Lee AD, Hall RG. An evaluation of the use of carbon dioxide angiography in endovascular aortic aneurysm repair. *Vasc. Endovascular Surg.* 2010;44 (5):341-4.

[17] Criado E, Kabbani L, Cho K. Catheter-less angiography for endovascular aortic aneurysm repair: a new application of carbon dioxide as a contrast agent. *J. Vasc. Surg*. 2008;48 (3):527-34.

[18] Criado E, Upchurch GR, Jr., Young K, Rectenwald JE, Coleman DM, Eliason JL, et al. Endovascular aortic aneurysm repair with carbon dioxide-guided angiography in patients with renal insufficiency. *J. Vasc. Surg.* 2012;55 (6):1570-5.

[19] Cantisani V, Ricci P, Grazhdani H, Napoli A, Fanelli F, Catalano C, et al. Prospective comparative analysis of colour-Doppler ultrasound, contrast-enhanced ultrasound, computed tomography and magnetic resonance in detecting endoleak after endovascular abdominal aortic aneurysm repair. *Eur. J. Vasc. Endovasc. Surg*. 2011;41 (2):186-92.

[20] Giannoni MF, Citone M, Rossini M, Speziale F, David V. Role of contrast-enhanced ultrasound in the follow-up of endo-vascular aortic aneurysm repair: an effective and safe surveillance method. *Current pharmaceutical design.* 2012;18 (15):2214-22.

[21] Melas N, Saratzis A, Saratzis N, Kiskinis D. Endovascular repair of inadvertent subclavian artery perforation during cannulation for dialysis access: case report and review of the literature. *Eur. J. Emerg. Med.* 2009;16 (6):323-6.

[22] Heo YC, Lee HK, Yang HJ, Cho JH. Analysis of enlarged images using time-of-flight magnetic resonance angiography, computed tomography, and conventional angiography. *Journal of medical systems*. 2014;38 (12):146.

[23] Pua U, Tan K. Radiology of advanced EVAR techniques in complex abdominal aortic aneurysms. *Eur. Radiol*. 2012;22 (2):387-97.

[24] Ohana M, Georg Y, Lejay A, Girsowicz E, Gaertner S, Labani A, et al. Current optimal morphological evaluation of peripheral arterial diseases. *J. Cardiovasc. Surg.* (Torino). 2015;56 (2):287-97.

[25] Karthikesalingam A, Al-Jundi W, Jackson D, Boyle JR, Beard JD, Holt PJ, et al. Systematic review and meta-analysis of duplex ultrasonography, contrast-enhanced ultrasonography or computed tomography for surveillance after endovascular aneurysm repair. *Br. J. Surg*. 2012;99 (11):1514-23.

[26] Nordon IM, Karthikesalingam A, Hinchliffe RJ, Holt PJ, Loftus IM, Thompson MM. Secondary interventions following endovascular aneurysm repair (EVAR) and the enduring value of graft surveillance. *Eur. J. Vasc. Endovasc. Surg*. 2010;39 (5):547-54.

[27] Swanberg J, Nyman R, Magnusson A, Wanhainen A. Selective intra-arterial dual-energy CT angiography (s-CTA) in lower extremity arterial occlusive disease. *Eur. J. Vasc. Endovasc. Surg*. 2014;48 (3):325-9.

[28] Shareghi S, Gopal A, Gul K, Matchinson JC, Wong CB, Weinberg N, et al. Diagnostic accuracy of 64 multidetector computed tomographic angiography in peripheral vascular disease. *Catheter Cardiovasc Interv*. 2010;75 (1):23-31.

[29] Cinat ME, Casalme C, Wilson SE, Pham H, Anderson P. Computed tomography angiography validates duplex sonographic evaluation of carotid artery stenosis. *Am. Surg*. 2003;69 (10):842-7.

[30] Kock MC, Adriaensen ME, Pattynama PM, van Sambeek MR, van Urk H, Stijnen T, et al. DSA versus multi-detector row CT angiography in peripheral arterial disease: randomized controlled trial. *Radiology*. 2005;237 (2):727-37.

[31] Magarelli N, Scarabino T, Simeone AL, Florio F, Carriero A, Salvolini U, et al. Carotid stenosis: a comparison between MR and spiral CT angiography. *Neuroradiology*. 1998;40 (6):367-73.

[32] Nederkoorn PJ, van der Graaf Y, Hunink MG. Duplex ultrasound and magnetic resonance angiography compared with digital subtraction angiography in carotid artery stenosis: a systematic review. *Stroke*. 2003;34 (5):1324-32.

[33] Tao W, Shen Y, Guo L, Bo G. Role of non-contrast balanced steady-state free precession megnetic resonance angiography compared to contrast-enhanced megnetic resonance angiography in diagnosing renal artery stenosis: a meta-analysis. *Chin. Med. J. (Engl)*. 2014;127 (19):3483-90.

[34] Albert TS, Akahane M, Parienty I, Yellin N, Catala V, Alomar X, et al. An international multicenter comparison of time-SLIP unenhanced MR angiography and contrast-enhanced CT angiography for assessing renal artery stenosis: the renal artery contrast-free trial. *AJR Am. J. Roentgenol*. 2015;204 (1):182-8.

[35] Eiberg JP, Gronvall Rasmussen JB, Hansen MA, Schroeder TV. Duplex ultrasound scanning of peripheral arterial disease of the lower limb. *Eur. J. Vasc. Endovasc. Surg*. 2010;40 (4):507-12.

[36] Kakkos SK, Tsolakis IA. Is duplex ultrasound scanning for peripheral arterial disease of the lower limb a non-invasive alternative or an adjunct to angiography? *Eur. J. Vasc. Endovasc. Surg*. 2010;40 (4):513-4.

[37] Ascher E, Hingorani A, Markevich N, Costa T, Kallakuri S, Khanimoy Y. Lower extremity revascularization without preoperative contrast arteriography: experience with duplex ultrasound arterial mapping in 485 cases. *Ann. Vasc. Surg*. 2002;16 (1):108-14.

[38] Ascher E, Hingorani A, Markevich N, Schutzer R, Kallakuri S. Acute lower limb ischemia: the value of duplex ultrasound arterial mapping (DUAM) as the sole preoperative imaging technique. *Ann. Vasc. Surg.* 2003;17 (3):284-9.

[39] Ascher E, Mazzariol F, Hingorani A, Salles-Cunha S, Gade P. The use of duplex ultrasound arterial mapping as an alternative to conventional arteriography for primary and secondary infrapopliteal bypasses. *Am. J. Surg*. 1999;178 (2):162-5.

[40] Mazzariol F, Ascher E, Hingorani A, Gunduz Y, Yorkovich W, Salles-Cunha S. Lower-extremity revascularisation without preoperative contrast arteriography in 185 cases: lessons learned with duplex ultrasound arterial mapping. *Eur. J. Vasc. Endovasc. Surg*. 2000;19 (5):509-15.

[41] Grassbaugh JA, Nelson PR, Rzucidlo EM, Schermerhorn ML, Fillinger MF, Powell RJ, et al. Blinded comparison of preoperative duplex ultrasound scanning and contrast arteriography for planning revascularization at the level of the tibia. *J. Vasc. Surg*. 2003;37 (6):1186-90.

[42] Mills JL, Sr. Is duplex surveillance of value after leg vein bypass grafting? Principal results of the Vein Graft Surveillance Randomised Trial (VGST). *Perspect Vasc. Surg. Endovasc. Ther*. 2006;18 (2):194-6.

[43] Bandyk DF. Surveillance after lower extremity arterial bypass. *Perspect Vasc.Surg. Endovasc. Ther*. 2007;19 (4):376-83; discussion 84-5.

[44] Willmann JK, Mayer D, Banyai M, Desbiolles LM, Verdun FR, Seifert B, et al. Evaluation of peripheral arterial bypass grafts with multi-detector row CT angiography: comparison with duplex US and digital subtraction angiography. *Radiology*. 2003;229 (2):465-74.

[45] Sabeti S, Schillinger M, Mlekusch W, Willfort A, Haumer M, Nachtmann T, et al. Quantification of internal carotid artery stenosis with duplex US: comparative analysis of different flow velocity criteria. *Radiology*. 2004;232 (2):431-9.

[46] Yavin D, Roberts DJ, Tso M, Sutherland GR, Eliasziw M, Wong JH. Carotid endarterectomy versus stenting: a meta-analysis of randomized trials. *The Canadian journal of neurological sciences Le journal canadien des sciences neurologiques*. 2011;38 (2):230-5.

[47] Oates CP, Naylor AR, Hartshorne T, Charles SM, Fail T, Humphries K, et al. Joint recommendations for reporting carotid ultrasound investigations in the United Kingdom. *Eur. J. Vasc. Endovasc. Surg.* 2009;37 (3):251-61.

[48] Telman G, Kouperberg E, Sprecher E, Gruberg L, Beyar R, Hoffman A, et al. Duplex ultrasound verified by angiography in patients with severe primary and restenosis of internal carotid artery. *Ann. Vasc. Surg.* 2006;20 (4):478-81.

[49] Mayor I, Momjian S, Lalive P, Sztajzel R. Carotid plaque: comparison between visual and grey-scale median analysis. *Ultrasound Med. Biol.* 2003;29 (7):961-6.

[50] Karanikola E, Dalainas I, Karaolanis G, Zografos G, Filis K. Duplex Ultrasound versus Computed Tomography for the Postoperative Follow-Up of Endovascular Abdominal Aortic Aneurysm Repair. Where Do We Stand Now? *The International journal of angiology* : official publication of the International College of Angiology, Inc. 2014;23 (3):155-64.

[51] Sadat U, Boyle JR, Walsh SR, Tang T, Varty K, Hayes PD. Endovascular vs open repair of acute abdominal aortic aneurysms--a systematic review and meta-analysis. *J. Vasc. Surg*. 2008;48 (1):227-36.

[52] Melas N, Saratzis A, Saratzis N, Lazaridis J, Psaroulis D, Trygonis K, et al. Aortic and iliac fixation of seven endografts for abdominal-aortic aneurysm repair in an experimental model using human cadaveric aortas. *Eur. J. Vasc. Endovasc. Surg*. 2010;40 (4):429-35.

[53] Bakken AM, Illig KA. Long-term follow-up after endovascular aneurysm repair: is ultrasound alone enough? *Perspect Vasc. Surg. Endovasc. Ther.* 2010;22 (3):145-51.

[54] Clevert DA, Minaifar N, Weckbach S, Kopp R, Meimarakis G, Clevert DA, et al. Color duplex ultrasound and contrast-enhanced ultrasound in comparison to MS-CT in the detection of endoleak following endovascular aneurysm repair. *Clin. Hemorheol. Microcirc. 2008*;39 (1-4):121-32.

[55] Elkouri S, Panneton JM, Andrews JC, Lewis BD, McKusick MA, Noel AA, et al. Computed tomography and ultrasound in follow-up of patients after endovascular repair of abdominal aortic aneurysm. *Ann. Vasc. Surg.* 2004;18 (3):271-9.

[56] Sandford RM, Bown MJ, Fishwick G, Murphy F, Naylor M, Sensier Y, et al. Duplex ultrasound scanning is reliable in the detection of endoleak following endovascular aneurysm repair. *Eur. J. Vasc. Endovasc. Surg.* 2006;32 (5):537-41.

[57] Schmieder GC, Stout CL, Stokes GK, Parent FN, Panneton JM. Endoleak after endovascular aneurysm repair: duplex ultrasound imaging is better than computed tomography at determining the need for intervention. *J. Vasc. Surg*. 2009;50 (5):1012-7; discussion 7-8.

In: Encyclopedia of Surgery (22 Volume Set)
Editors: Andreas Lehrer and Kristin Mueller
ISBN: 978-1-53618-329-0
© 2020 Nova Science Publishers, Inc.

Chapter 82

THE ROLE OF IMAGING IN COLORECTAL SURGERY

M. G. Pramateftakis[1,*], A. Kalogera-Fountzila[2], K. Sapalidis[1] and E. Kotidis[1]

[1]3rd Surgical Department, AHEPA Hospital,
Aristotle University of Thessaloniki, Greece
[2]Department of Radiology, AHEPA Hospital,
Aristotle University of Thessaloniki, Greece

ABSTRACT

Colorectal surgery manages diseases of the small and large bowel, rectum, anal canal and pelvic floor. The colorectal surgeon undertakes a large array of minor and major, elective and emergency procedures. One of the main instruments in his quiver, aiding in the diagnostics of various diseases and conditions, are the radiological investigations. Plain radiographs have been used for many decades to assess patients with abdominal symptoms, but they have been replaced in the last years by more advanced techniques, such as computed topographies, magnetic resonance imaging and nuclear tests.

This chapter aims to introduce the reader to most of the radiological tests available to the colorectal surgeon today; some very specialized/specific tests will not be mentioned, as the authors believe that they are outside the aim of the book. Furthermore, we will look at specific diseases and pathologies and how radiological findings aid in their management and treatment.

ANATOMY OF THE COLON AND RECTUM

The colon frames the abdomen and is surrounded by fat. It has five distinguished portions: the cecum, the ascending, transverse, descending and sigmoid colon and the rectum, with a length of 1.5 m from the ileocecal valve to the distal rectum. Three longitudinal bands, the teniae, approximately 8 mm wide, run the length of the colon on its outer surface and merge in the appendicocecal and the rectosigmoid junction. Between the teniae, prominent

* Corresponding Author's Email: mpramateftakis@hotmail.com.

saculations are formed known as the haustrae. Along the teniae run epiploic appendices, which are small packets of fat. Their size depends on the nutritional status of the individual. The calibre of the colon varies from a 9 cm diameter in the cecum, to 6 cm in the transverse colon and with a slightly smaller diameter in the descending and sigmoid colon, with a large variation in the caliber of the rectum. The thickness of the wall is less than 3 mm; when the bowel is distended it is barely seen.

The rectum is bound by the sigmoid colon and the anus, extending 12 cm above the anal verge. Its proximal portion is located in the peritoneal cavity while the distal portion is extraperitoneal. The dentate line, extending for 5-10 mm in the anal canal, separates the rectal columnar epithelium from the anal squamous epithelium. At the rectosigmoid junction, the confluence of the taenia coli muscles form a surgically recognized line, at the level of the sacral promontory and the peritoneal reflection. The rectum is supplied by the inferior mesenteric and the superior and middle hemorrhoidal arteries. The proximal part is drained by the inferior mesenteric vein via the portal vein, while the distal part is drained by the internal ileac veins via the inferior vena cava. This venous drainage explains why cancers of the distal rectum usually form metastases in the lung, whereas proximal rectal cancers usually metastasize to the liver. Hemorrhoidal venous plexi, internal and external, are located on either side of the dentate line, causing hemorrhoids when dilated. Three valves of Houston project into the lumen, being normal folds in the mucosa, run up the length of the rectum in a spiral way. The internal anal sphincter is the thickening and continuation of the circular muscle layer of the rectum. The external sphincter is composed by the inferior portion of the levator ani muscle, the puborectalis muscle and the deep, superficial and subcutaneous external sphincter muscles. The wall of the rectum consists of five layers—the mucosa, the muscularis mucosa, the submucosa, the muscularis propria and the serosa—that are easily recognized in T2 weighted images at magnetic resonance imaging (MRI). On the MRI, one can also recognize the mesorectal fat and the fascia surrounding the rectum [1-4].

IMAGING

Plain Radiographs

Plain radiographs have always been a quick tool for assessment of bowel symptoms. 3 views are usually taken: The supine, which contrasts intra-abdominal organs and shows retroperitoneal air. The decubitus, which displays gas distribution in the bowel loops.

The erect chest radiograph, which detects extraluminal intra-abdominal air, presenting as free air under the diaphragm. Plain radiographs of the abdomen in these three positions can reveal signs of obstructive or paralytic ileus with air fluid levels and bowel distention (Figure 1), free peritoneal or retroperitoneal air (Figure 2), as well as stones (such as appendicoliths), calcifications and foreign bodies. Furthermore, it can aid in the diagnosis of pseudo-obstruction, volvulus or colitis.

The best indication for a plain abdominal x-ray is a patient with symptoms of bowel obstruction, and it aids in the differentiation between small and large bowel obstruction. As a rule of thumb, the more distal the obstruction, the more dilated loops of small bowel can be seen. In case of large bowel obstruction, the appearance and gas distribution may be similar to

the one of small bowel. Small bowel loops have plicae circulares, which traverse the whole lumen diameter, whereas colon shows haustral markings that do not reach the opposite wall.

Figure 1. Abdominal x-ray showing typical air-fluid levels of small bowel loops in the central and lower abdomen, suggestive of small bowel obstruction.

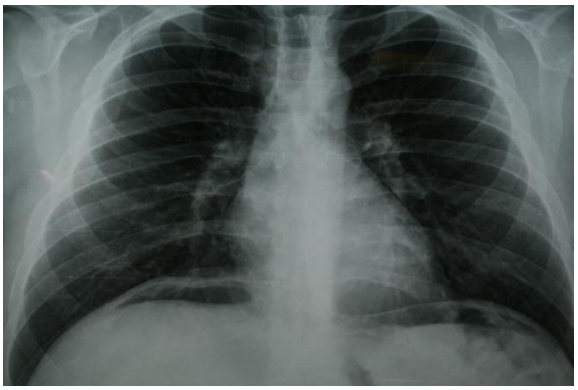

Figure 2. Erect chest radiograph, displaying free intraabdominal air under the diaphragm, suggestive of perforation of intraabdominal viscus.

Contrast Studies

Barium enema or air enema examination has acted as the gold standard examination in diagnosis of large bowel diseases for many years. In recent years, it has been replaced by more advanced techniques such as computed tomography (CT) and MRI. These tests allow a more precise evaluation of mucosal or submucosal, benign or neoplastic lesions, which is of course aided by the use of endoscopy. Cross sectional imaging can show the entire length of the large intestine and the thickness of the bowel wall, with the complementary evaluation of

the surrounding tissues, the extent of the disease, the origin and the internal composition of the lesion [3, 4].

Two different forms of contrast agents have been used to visualize colonic abnormalities: Barium studies and water-soluble contrast studies. Furthermore, one can differentiate between single and double contrast studies. Single contrast studies, using one medium to detect colonic lesions, are limited to only lesions of larger size. Double-contrast studies use gas as the second medium, which creates a thin coating on the mucosal surface allowing visualization of smaller lesions. Good bowel preparation is essential for any contrast study.

Double contrast barium enemas are simple and risk-free to perform and can rule out gross pathologies. They are obviously less accurate than endoscopy, as they can miss smaller lesions, there is no direct visualization and no biopsy possibility. Contrast enemas are, nevertheless, extremely useful in case of failed or incomplete colonoscopies, where the patient has undergone bowel preparation already.

In the case of a suspicion of perforation, barium as a contrast needs to be avoided. In this case, a water-soluble contrast such as Gastrografin® or Urografin® has to be used. When given orally, these agents also have a therapeutic effect on small bowel paralytic ileus. Contrast agents can also be used to visualize anastomotic integrity in colorectal or coloanal anastomoses and to visualize ileoanal pouches, giving information about the pouch's form, function and volume [5, 6].

Computed Tomography

Computed tomography (CT) is one of the commonest investigations undertaken by surgeons on a daily basis. CT takes cross-sectional images of the body and the computer software combines them to create tomographic images of the organ / body area of interest. Conventional CT scanning takes images at 1-cm intervals, whereas modern spiral CT scanners produce a continuous image as the camera rotates around the patient. Accurate CT imaging requires the opacification of the gastrointestinal tract and the vessels with the use of contrast medium, which is given as a bolus at the beginning of the investigation. CT is extremely useful in identifying postoperative complications but is also used in the investigation of non-specific abdominal symptoms and the staging of colorectal cancer. Images are obtained in two phases: the hepatic arterial and the portal venous phase. The radiologist analyzes the contrast behavior in various phases and concludes on the presenting pathology. Staging of colorectal cancer using CT includes assessment of the liver, grading of lymphadenopathy and assessment of possible intraperitoneal disease.

CT Colonography

CT colonography is also known as a virtual colonoscopy. Its accuracy is higher than that of the conventional CT, but the patients require full bowel preparation as for colonoscopy. Furthermore, they are exposed to radiation, even though there is no evidence that this radiation induces additional carcinogenesis. It is a good solution in patients too frail or unwell to undergo colonoscopy. The use of faecal tagging (with agents such as meglumine ioxithalamate) coats any residual bowel contents not cleared by the laxatives and allows the

radiologist to substract remaining faeces from the images, minimizing the risk of false positive results [7, 8].

Magnetic Resonance Imaging

MRI scanners use magnetic fields to acquire images of the body. Water molecules in tissues are used to create signals, translated into images. The radio-frequency emitted by the hydrogen atoms is measured by receiving coils. The contrast between various tissues is determined by the rate the hydrogen atoms return to their state of equilibrium. Contrast agents are given orally or intravenously.

Image contrast can be weighted to demonstrate different anatomical structures. Tissues return to their equilibrium states by the independent processes of T1 or T2 relaxation. T1-weighted images are better for assessing morphological information, whereas T2-weighted images are useful in detecting oedema and inflammation. MR Diffusion Weighted Imaging (DWI) measures the diffusivity of extracellular water. This is a very rapid acquisition which can identify active inflammation in inflammatory conditions of the colon and rectum, being equivalent to contrast enhanced MRI. [9-11].

MRI is a very important tool for the management of anorectal diseases, the two most important being low rectal cancers and perianal fistulas. MRI is used for the accurate staging of rectal cancer, leading to tailored case-guided treatment protocols. Similarly, the topography of complex perianal fistulas can be very well assessed by MRI, showing the exact location of tracts and abscesses, which can map the surgical exploration.

Scintigraphy (Radionuclide Imaging)

For scintigraphy, an isotope is administered within the body or a specific organ. A gamma-camera (also called a scintillation camera) picks up the radiation emitted by the isotope. Depending on the organ being scanned, the physician can choose a specific isotope. For example, thalium is preferred for cardiac stress tests, whereas technetium99m-sestamibi is used to detect parathyroid adenomas. In colorectal practice, GI bleeding can be detected by tagging red blood cells with Technetium99m and re-injecting them into the patient.

Positron Emission Tomography

Positron emission tomography (PET) produces a three-dimensional image of functional body processes. It studies metabolic activity in tissues. A low-dose radionuclide (tracer) is coupled with glucose and injected intravenously. The PET scanning system measures the photon emission of the tracer within the body and constructs a 3D-image. Because malignant tumors consume glucose faster than normal tissue, this can be displayed as a dynamic image. PET-CT is a hybrid technique utilizing the strengths of PET and CT. It is powerful in detecting disease recurrence and has become established in assessing response to oncological treatment [E].

Defecography

Defecography is a traditional imaging technique, evaluating the functional aspects of the anorectal region. Even though it can be used to define various pathologies, its main strength lies in the understanding of postoperative conditions. Following formation of an ileo-anal pouch, a low colo-anal anastomosis for a low rectal tumor or a stapled resection of a rectal doughnut during a STARR procedure, the defecogram can give answers to the new anatomical configuration and the efficiency of the pelvic floor work during defecation. After insertion of radiopaque contrast (most commonly paste) in the rectum, a patient is asked to defecate. This test will pick up poor emptying, poor contrast retention, rectal pockets and rectoceles, giving also the possibility of measuring their size. Furthermore, it can identify sinus tracts, strictures and ulcerations.

COLORECTAL DIAGNOSTICS

There are a number of mucosal and submucosal lesions, neoplastic or non-neoplastic, that can be identified and have to be differentiated in the wall of the colon and rectum. Neoplastic lesions include adenocarcinomas, dysplastic or carcinomatoid polyps, lipomas, carcinoid tumors, lymphomas, hemangiomas, gastrointestinal stromal tumors, metastases, as well as direct bowel invasion of extracolonic tumor and peritoneal carcinomatosis. Non-neoplastic lesions include lymphoid polyps and hyperplasia, vascular lesions, cystic lesions, hematomas, endometriosis, extrinsic impressions, and pre-sacral lesions. Imaging studies play an important role in differentiating neoplastic or non-neoplastic lesions, as well as in the evaluation of patients for screening and staging of colorectal cancer. Below we are mentioning the most common colorectal conditions a surgeon is faced with, and the radiological tests he has available, to aid him to the correct diagnosis.

INFECTIVE / INFLAMMATORY CONDITIONS OF THE COLON AND RECTUM

Appendicitis

Inflammation of the appendix vermiformis results in the commonest acute abdominal presentation in hospitals nowadays, namely appendicitis, which is expressed with right lower quadrant pain, fever and nausea/vomiting. Appendiceal lumen occlusion results in accumulation of fluid in the appendix with lumen dilatation (>6 mm), inflammation and ischemia with wall thickening of more than 2 mm. Furthermore, it can lead to stranding of the pericaecal fat, perforation and abscess formation (Figure 3). An appendicolith (a calcified deposit within the appendix) is detected in 25% to 40% of cases. CT is routinely used as the initial imaging modality in adults with suspicion of appendicitis, with high accuracy rates, while ultrasonography (US) is preferably used in children, young adults and pregnant women. At MRI, STIR (short tau inversion recovery) images and single shot T2 images can easily reveal fluid in the periappendicular fat and wall thickening respectively, whereas strong contrast enhancement and restricted diffusion is indicative of appendicitis. The latter can also provide information about abscess formation [2, 13-15].

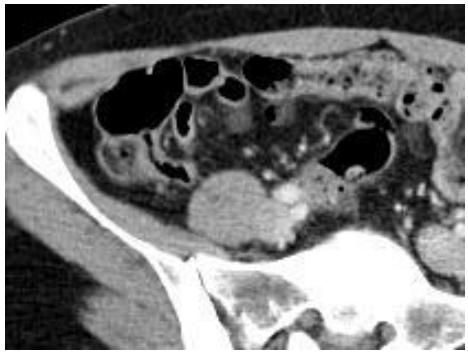

Figure 3. 38 year old female with right lower abdominal pain and leucocytosis. CT shows appendiceal wall thickening, lumen dilatation, inflammation and stranding of the pericecal fat, suggestive of appendicitis.

Epiploic Appendagitis

Torsion or venous thrombosis of one of the appendices epiploicae can result in inflammation or ischemia of the appendix, with sudden focal abdominal pain. An oval, up to 4 cm, fatty paracolic lesion accompanied by mesenteric inflammation is seen on CT, with a central dot corresponding to the thrombosed vein [2, 15].

Typhlitis

Typhlitis, also known as neutropenic enterocolitis, describes the inflammation and often necrosis of the cecum, ascending colon and terminal ileum. It can lead to edema, wall thickening and subsequent perforation. Clinical symptoms include fever, diarrhea and pain in the right lower quadrant. It is most often seen in neutropenic patients usually due to chemotherapy for leukemia or lymphoma, in patients with aplastic anemia, AIDS, or following kidney transplantation. Ischemia, cytomegalovirus infection and neoplastic infiltration are the probable mechanisms of the inflammation. In CT, hypodense wall thickening due to submural edema and sometimes intramural air is seen, as well as fat stranding and intraperitoneal free fluid or air [2, 15] (Figure 4).

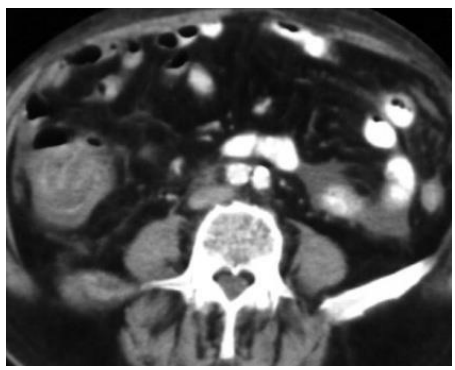

Figure 4. CT of a neutropenic patient following chemotherapy for leukemia. Ischemia of the cecum, hypodense wall thickening due to submural edema as well as fat stranding, suggestive of typhlitis.

Diverticulitis

Diverticulae represent small pouches of the colonic mucosa and submucosa through the muscular layers of the colonic wall, where the vessels pierce the muscularis, between the mesenteric and antimesenteric teniae. Diverticulosis corresponds to the presence of multiple diverticulae seen as air filled pouches, measuring from 2-3 mm to 2 cm. They are most commonly located in the sigmoid colon. Diverticulosis is a very common condition nowadays, mostly related to modern diet and lifestyle. Occlusion of the neck of the diverticulum results in inflammation, called diverticulitis. Findings of diverticulitis are very well seen in contrast enhanced CT, with or without oral contrast medium (Figures 5, 6a, 6b).

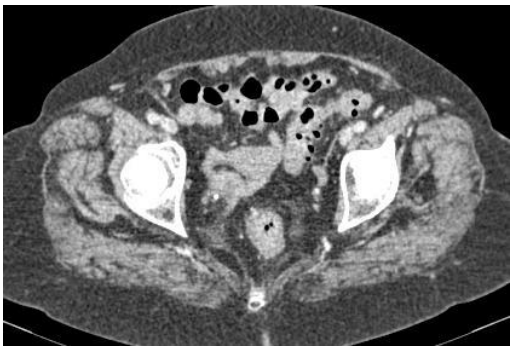

Figure 5. Diverticulosis. Non-inflammed pouches of the transverse and sigmoid colon.

(a)

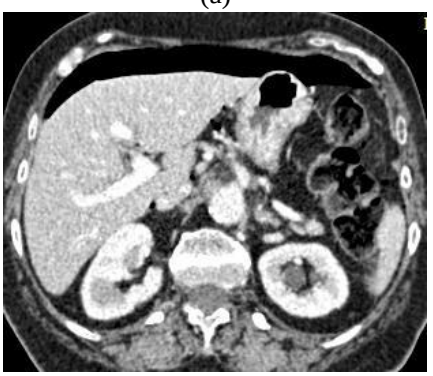

(b)

Figure 6. CT scan of a patient with diverticulitis. Inflammatory pericolic fat stranding and enhancement, with perforation and presence of free air locally in the peritoneal cavity (6a) with excessive air in the subphrenic space (6b).

Diverticulitis can lead to localised perforation, pericolic inflammation with fat stranding and presence of free air in the peritoneal cavity or retroperitoneum. Differential diagnosis of right colon diverticulitis, even though uncommon, can be made from appendicitis with careful analysis of CT images. In a study by Padidar et al, CT differentiation is made between acute diverticulitis and colonic cancer. Diverticulitis causes fluid in the root of the sigmoid mesentery as well as engorgement of mesenteric vasculature, whereas in colon cancer enlarged pericolic lymphnodes are found. Coronal STIR MRI and axial T2 images, as well as contrast enhanced and diffusion images, can also diagnose diverticulitis and its complications [2, 7, 15, 16-20].

Radiation Colitis

Following radiotherapy, any part of the colon can be affected, with acute findings of wall thickening and fat stranding. Chronic radiation injury causes strictures and fistulas, and can present with increased pelvic fat and thickening of perirectal fibrous tissue. All findings are best appreciated on CT images [2].

Ischemic Colitis

Ischemic Colitis is a cause of abdominal pain most commonly in the elderly. Causative factors can be colonic hypoperfusion, trauma, tumor invasion and mesenteric vascular occlusion by thrombus or embolus. When hypovolaemia is the etiologic factor, ischemic changes can be seen in the border of main vascular territories, such as in the splenic flexure and the rectosigmoid.

(a)

Figure 7. (Continued).

(b)

Figure 7. Axial (7a) and coronal (7b) reformation in a patient with hypovolemia and ischemic changes in the small and large bowel. Symmetric wall thickening, double halo or target sign (hypodense submural edema and hyperdense intramural hemorrhage) that can be seen in the thickened wall.

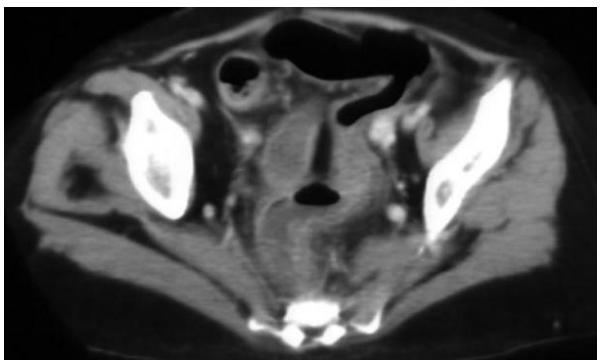

(a)

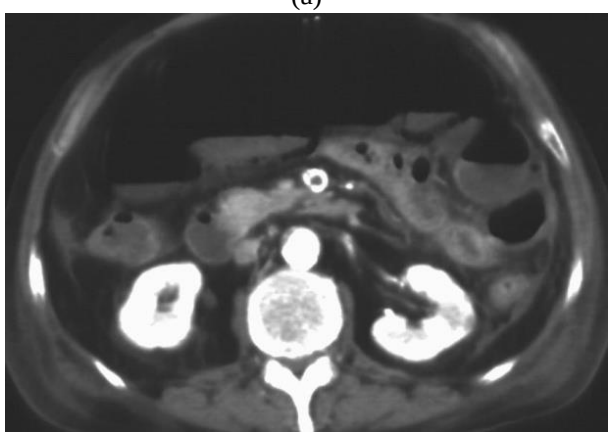

(b)

Figure 8. Necrosis of the rectum and the sigmoid colon (8a) in an 80 years old man due to embolic disease in IMA, that is shown non-enhanced with extensive wall calcifications in (8b).

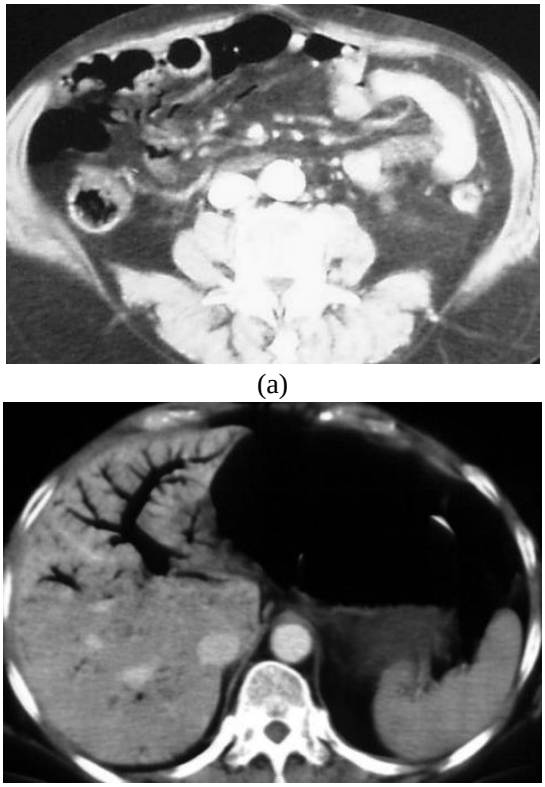

(a)

(b)

Figure 9. Presence of air in the mesenteric veins (9a) and portal vein (9b) due to bowel necrosis in a 79 years old patient.

When ischemia is suspected, CT evaluation of the colon can reveal diffuse or segmental circumferential, symmetric wall thickening with fold enlargement. The double halo or target sign, which can be seen in the thickened bowel wall, is due to hypodense submural edema and hyperdense intramural hemorrhage (Figures 7a, 7b). Thrombosis or embolic disease can easily be delineated by CT (Figures 8a, 8b), as well as the presence of intramular air or air in the mesenteric and portal veins (Figures 9a, 9b), a finding suggestive of bowel necrosis. Imaging of thrombosis or embolic disease, vasoconstriction, as well as aortic dissection relies mainly on CT or MRI angiographic techniques. MRI coronal STIR images can reveal the area of ischemic bowel with thickening of the wall and infiltration of the surrounding fat, while axial T2 images can be unremarkable. Patchy bowel enhancement in contrast enhanced MR images show the disturbed perfusion of the bowel wall. In conservatively treated patients, the colon can sometimes return to normal, with development of strictures of the involved segment [2, 16].

Infectious Colitis

Bacteria, fungi and viruses can cause infectious colitis that can affect any portion of the colon. The definitive diagnosis is given mainly by laboratory tests. CT, when utilized, reveals

bowel wall thickening with intramural diffuse or segmental edema, depending on the causative microorganism, with presence of pericolic inflammation and ascites [2].

Pseudomembranous Colitis

Antibiotic therapy, hypovolemia, chemotherapy or abdominal surgery can cause overgrowth of clostridium difficile, which results in pseudomembranous colitis (secondary to the production of toxins). Associated symptoms include diarrhea, fever and abdominal pain. On CT, the colon is dilated with wall thickening due to edema and a visible target sign. Significant haustral thickening with oral contrast entrapment can be seen, known as the accordion sign. The wall thickening is irregular and shaggy as well as greater than the thickness observed in other inflammatory bowel conditions. Only in Crohn's disease is the amount of wall thickness as great as it is in pseudomembranous colitis but it is symmetric and homogeneous [2].

INFLAMMATORY BOWEL DISEASES (IBD)

The incidence of inflammatory bowel disease in the Western World has increased in the past 50 years up to 8–14/100,000 patients for ulcerative colitis (UC) and up to 6–15/100,000 patients for Crohn's disease (CD). It is continuing to increase worldwide. The occurrence in the pediatric population is 4.56 per 100,000 children [21-23].

The principal tools for diagnosis and evaluation of suspected inflammatory bowel disease are CT and MRI, although classic barium studies are still used with sometimes equivocal results. CT and MRI have the advantage of visualization of the bowel wall, adjacent structures, extra luminal disease and complications in both diseases. The imaging modalities of choice are CT and/or MRI, with similar sensitivities in diagnosing IBD, with the latter being more sensitive in the detection of strictures and fistulas. MRI is the preferred modality in children and young adults because of lack of ionizing radiation and the potential in differentiation of chronic from acute disease, especially with the use of Diffusion Weighted Imaging. Restricted diffusion correlates with the severity of IBD, being an indicator of severe complications such as bowel perforation and abscess formation [11, 16, 21-23].

Ulcerative Colitis

Ulcerative colitis occurs more frequently in men and it is a typically left sided, diffuse disease (colon and rectum). It rarely involves the right colon only and it extends in a continuous retrograde mode. Wall thickening, with a mean of about 7.8 mm, may be diffuse and symmetric in thickness (Figure 10). A low attenuation ring, like a halo sign, can commonly be seen in the thickened bowel wall, due to deposition of submucosal fat [2, 11, 21].

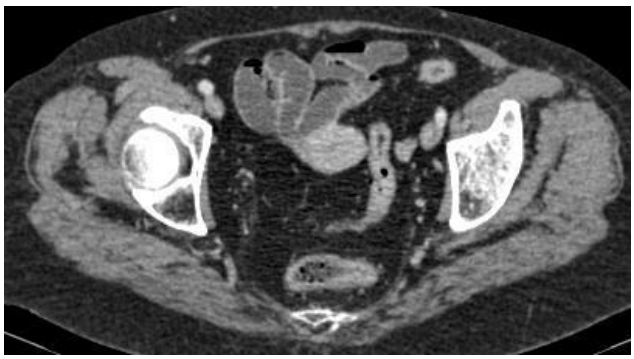

Figure 10. Ulcerative colitis: Diffuse and symmetric sigmoid wall thickening.

Crohn's Disease

CD occurs more frequently in women and it usually involves the right colon and small intestine with a mean wall thickening of about 11–13 mm that may be eccentric and segmental with skip regions. The thickened edematous bowel wall enhances strongly and homogeneously and it is accompanied by proliferation of mesenteric fat and mesenteric lymphadenopathy. (Figures 11, 12) Fibrofatty proliferation can also be seen in UC and in other inflammatory conditions of the bowel wall.

CT and MRI can visualize abscesses, strictures and fistulas as complications of CD. Abscesses can be confined to the bowel wall and pericolic fat, or can involve adjacent structures that can be drained under CT or US guidance. CD begins with apthous ulcers that develop into strictures and fistulas. Fistulas can be enteroenteric, enterocutaneous, enterovesical, rectovaginal or perianal. They can be evaluated with MRI, as well as with CT performed after oral or rectal contrast administration. Fistulas are more frequent in patients with terminal ileal disease. Large bowel Crohn's disease can remain uncomplicated for years. The diagnosis of terminal ileitis mainly relies on MRI, coronal STIR and axial T2 images. Lymphadenopathy is easily depicted with DWI. [2, 11, 15, 19-23].

Figure 11. Transverse CT image of a young patient with Crohn's disease. Thickened and edematous bowel wall at the ileocecal valve and terminal ileum.

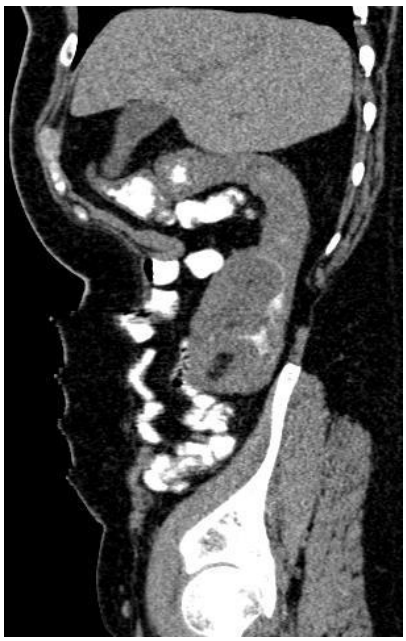

Figure 12. Saggital reformative CT image of a patient with Crohn's disease in the ileocecal valve, cecum and ascending colon with asymmetrically thickened wall.

COLORECTAL CANCER

Computed Tomography

CT enterography and CT colonography provides important information about TNM staging in preoperative assessment of colon cancer, as well as information about vascular anatomy. Standard colon window settings should be used, with a width of 1,500 Hounsfield Units (HU) and a level of -200 HU, as well as abdominal window settings with a width of 440 HU and a level of 20 HU.

The ability of CT colonography to demonstrate lesions >10 mm is very good. On the contrary small polyps, adenomas or lipomas < 5mm are impossible to be demonstrated, while lesions of 6-9 mm are demonstrated with less sensitivity compared to the larger ones. Colorectal carcinogenesis occurs after a series of mutations, as a polyp progresses from adenoma to adenocarcinoma. Larger polyps more likely harbor dysplasia or malignancy compared to sessile polyps, whereas pedunculated lesions do not usually harbor malignancies. An attempt should be made for lesions 6-9 mm to be removed colonoscopically. Larger polyps may be removed endoscopically but may require surgery, given the technical difficulties due to their size.

Flat colorectal lesions are difficult to identify at CT colonography, as are small or larger lesions that are hidden behind folds. Large carcinomas are either fungating masses or areas of mucosal irregularity homogeneously enhanced, that in a 5% of cases can be accompanied by a synchronous carcinoma elsewhere in the colon (Figure 13).

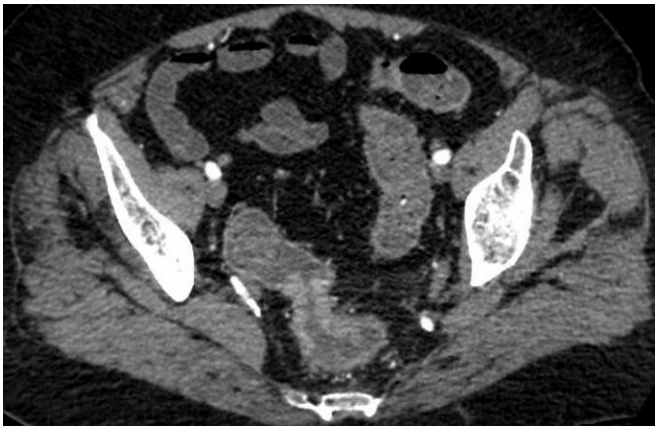

Figure 13. Sigmoid cancer: Mucosal irregular thickening of the sigmoid colon and stranding of the pericolic fat.

Lymphnode metastases from colorectal cancer often present with calcifications, as do liver metastases in about 10%-30% of cases.

Liver metastases are hypoattenuating lesions in non-enhanced CT scans, with rim enhancement in the arterial phase and heterogeneous enhancement in portal venous phase. Most of the lesions depicted in the lung are benign unless they are multiple and the primary tumor is located in the distal part of the rectum [3, 24, 25].

Magnetic Resonance Imaging

MRI, MR enterography and MR colonography with the use of DWI and T2 imaging can also give important information about TNM staging in colon but especially in rectal cancer. MRI has proven to be priceless in the analysis of rectal cancers, where one can evaluate intraluminal and extraluminal extent, mesorectal involvement, and assessment of tissues beyond the mesorectal fascia.

MRI can evaluate the integrity of rectal wall layers, as they are very well delineated on T2WI, with visualization of the rectal mucosa and muscularis propria by low signal intensity, the submucosa and mesorectum by high signal intensity and the mesorectal fascia by linear low signal intensity, with a high accuracy in T staging.

It is very important for the mesorectal fascia to be intact, as it determines the circumferential resection margin for a total mesorectal excision. The frequency of recurrence is 19%-22% in patients with positive circumferential resection margin, compared to 3%-5% in patients with negative circumferential resection margin. It is also frequently associated with distant metastatic disease.

Diffusion weighted imaging has high accuracy in depicting colorectal cancer, with a 90.9% sensitivity and 100% specificity. The cellularity of malignant tumors is greater than that of normal tissue and appears hyperintense in DWI with restricted diffusion, and hypointense in apparent diffusion coefficient (ADC) maps with low values (Figures 14a-14c). Possible fibrotic and desmoplastic tissue can be differentiated from tumor infiltration with low signal intensity in both DWI and ADC maps.

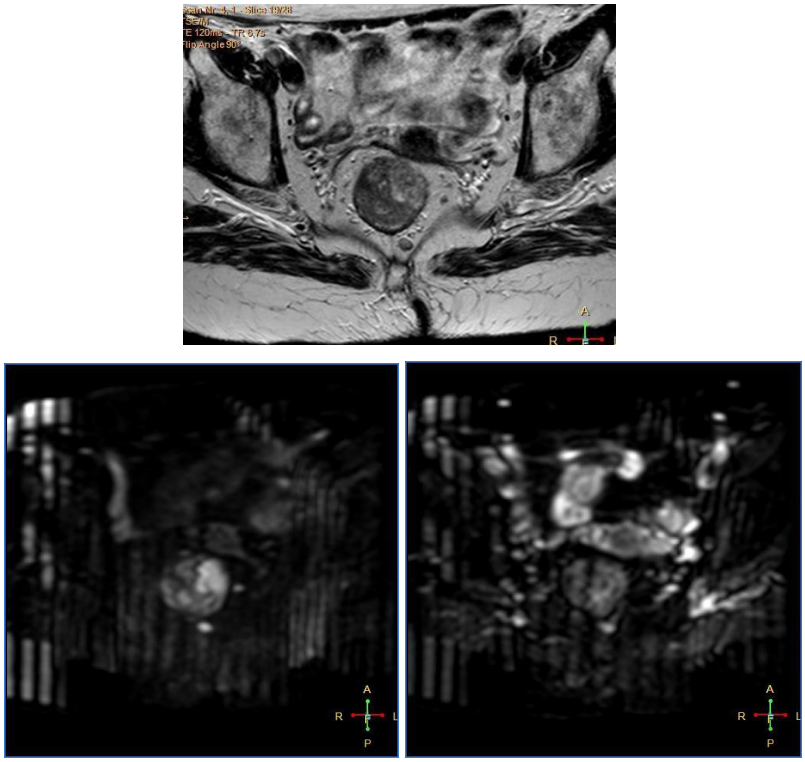

Figure 14. MRI of a rectal carcinoma shown in 14a with intermediate signal intensity on T2 weighted image, that infiltrates the mesorectal fat (shown with high signal) and its distance from mesorectal fascia (shown with low signal) is more than 5 mm. It is accompanied by two enlarged round lymphnodes with an intermediate signal intensity. The primary tumor and the metastatic lymphnodes show restricted diffusion on DWI with high signal intensity in image 14b with low apparent diffusion coefficient values and low signal intensity shown in image 14c (ADC values of the primary tumor and the metastatic lymphnodes of about 0.98 × 10-3 sec/mm2).

Criteria in predicting nodal involvement is a cutoff in size of 10 mm of a round lymphnode as well as the border irregularity, mixed signal intensity and T2* low signal of ultra-small iron particle uptake from the metastatic lymph node. Metastatic lymphnodes show restricted diffusion on MRI DWI with low ADC values (ADC values by using a threshold of 1.0-1.38 × 10^{-3} sec/mm^2), that is a good indicator of cancer cell viability and it is also used to show changes before and after chemo-radiation therapy in the assessment of the primary tumor and the lymphnodes [4, 25-28].

Recurrence of rectal cancer is best appreciated with MRI, being the modality of choice for follow up, evaluating recurrence patterns and findings of unresectability [27].

Positron Emission Tomography – Computed Tomography

PET-CT better delineates primary, lymphnode and metastatic disease in colorectal cancer for preoperative staging, and it is recommended for identification of recurrent disease. PET-CT colonography is recommended in patients with obstructive colorectal cancers [20].

Most of the times, a combination of CT, MRI and PET-CT is needed for accurate preoperative tumor staging.

REFERENCES

[1] Gray's Anatomy, 39th Edition, *Churchill Livingstone* 2005, Elsevier.

[2] Horton KM, Frank M, Elliot K et al. CT Evaluation of the Colon: Inflammatory Disease. *RadioGraphics* 2000; 20: 399–418.

[3] Silva AC et al. Evaluation of Benign and Malignant Rectal Lesions with CT Colonography and Endoscopic Correlation. *RadioGraphics* 2006; 26: 1085–1099.

[4] Kaur H, Choi H, You YN et al. MR Imaging for Preoperative Evaluation of Primary Rectal Cancer: Practical Considerations. *RadioGraphics* 2012; 32: 389–409.

[5] Branco BC, Barmparas G, Schnueriger B, et al. Systematic review and meta-analysis of the diagnostic and therapeutic role of water-soluble contrast agent in adhesive small bowel obstruction. *Br. J. Surg* 2010; 97: 470-478.

[6] Kalady MF, Mantyh CR, Petrofski J, et al. Routine contrast imaging of low pelvic anastomosis prior to closure of defunctioning ileostomy: is it necessary? *J. Gastrointest. Surg.* 2008; 12: 1227-1231.

[7] Veerappan GR, Ally MR, Choi JH, et al. Extracolonic findings on CT colonography increases yield of colorectal cancer screening. *AJR Am. J. Roentgenol.* 2010; 195: 677-686.

[8] Laghi A, Iafrate F, Rengo M, et al. Colorectal cancer screening: the role of CT colonography. *World J. Gastroenterol.* 2010; 16: 3987-3994.

[9] Pickhardt PJ, Kim DH, Menias CO, et al. Evaluation of submucosal lesions of the large intestine part 1. Neoplasms. *RadioGraphics* 2007; 27: 1681–1692.

[10] Pickhardt PJ, Kim DH, Menias CO, et al. Evaluation of submucosal lesions of the large intestine part 2. Non-neoplastic Causes. *RadioGraphics* 2007; 27: 1693–1703.

[11] Neubauer H, Pabst T, Dick A, et al. Small-bowel MRI in children and young adults with Crohn's disease: retrospective head-to-head comparison of contrast-enhanced and diffusion-weighted MRI. *Pediatr Radiol.* 2013; 43(1): 103–114.

[12] Chowdhury FU, Shah N, Scarsbrook Af, et al. [18F]FDG PET/CT imaging of colorectal cancer: a pictorial review. *Postgrad. Med. J.* 2010; 86: 174-82.

[13] Lee SS, Kim AY, Yang SK, et al. Crohn's disease of the small bowel: comparison of CT enterography, MR enterography, and small-bowel follow-through as diagnostic techniques. *Radiology* 2009; 251(3): 751–761.

[14] Balthazar EJ, Megibow AJ, Hulnick D, et al. CT of appendicitis. *AJR Am. J. Roentgenol.* 1986; 147: 705–710.

[15] Purysko AS, Remer EM, Filho HM, et al. Beyond Appendicitis: Common and Uncommon Gastrointestinal Causes of Right Lower Quadrant Abdominal Pain at Multidetector CT. *RadioGraphics* 2011; 31: 927- 947.

[16] Heverhagen JT, Klose KJ. MR Imaging for Acute Lower Abdominal and Pelvic Pain. *RadioGraphics* 2009; 29: 1781-1796.

[17] Labs JD, Sarr MG, Fishman EK, et al. Complications of acute diverticulitis of the colon: improved early diagnosis with computerized tomography. *Am. J. Surg.* 1988; 155: 331-336.

[18] Hulnick DH, Megibow AJ, Balthazar EJ, et al. Computed tomography in the evaluation of diverticulitis. *Radiology* 1984; 152: 491–495.

[19] Padidar AM, Jeffrey RB Jr, Mindelzun RE, Dolph JF. Differentiating sigmoid diverticulitis from carcinoma on CT scans: mesenteric inflammation suggests diverticulitis. *AJR Am. J. Roentgenol.* 1994; 163: 81–83.

[20] Chintapalli KN, Esola CC, Chopra S, et al. Pericolic mesenteric lymph nodes: an aid in distinguishing diverticulitis from cancer of the colon. *AJR Am. J. Roentgenol.* 1997; 169: 1253–1255.

[21] Tontini GE, Vecchi M, Pastorelli L, et al. Differential diagnosis in inflammatory bowel disease colitis: State of the art and future perspectives. *World J. Gastroenterol.* 2015 January 7; 21(1): 21-46.

[22] Cosnes J, Gower-Rousseau C, Seksik P, et al. Epidemiology and Natural History of Inflammatory Bowel Diseases. *Gastroenterology* 2011; 140: 1785–1794.

[23] Towbin AJ, Sullivan J, Denson LA, et al. CT and MR Enterography in Children and Adolescents with Inflammatory Bowel Disease. *RadioGraphics* 2013; 33: 1843–1860.

[24] Macari M, Bini EJ, Jacobs SL, et al. Filling defects at CT colonography: pseudo- and diminutive lesions (the good), polyps (the bad), flat lesions, masses and carcinomas (the ugly). *RadioGraphics* 2003; 23: 1073-1091.

[25] Kijima S, Sasaki T, Nagata K, et al. Preoperative evaluation of colorectal cancer using CT colonography, MRI and PET-CT. *World J. Gastoenterol.* 2014; 20(45): 16964-16975.

[26] Sinha R, Rajiah P, Ramachandran I, et al. Diffusion-weighted MR Imaging of the gastrointestinal tract: technique, indications and imaging findings. *RadioGraphics* 2013; 33: 655-676.

[27] Sinaei M, Swallow C, Moghaddam PA, et al. Patterns of signal intensity characteristics of pelvic recurrence of rectal cancer at MR Imaging. *RadioGraphics* 2013; 33: E171-E187.

[28] Nagtegaal ID, Quirke P. What is the role for circumferential margin in the modern treatment of rectal cancer? *J. Clin. Oncol.* 2008; 26: 303-312.

In: Encyclopedia of Surgery (22 Volume Set)
Editors: Andreas Lehrer and Kristin Mueller
ISBN: 978-1-53618-329-0
© 2020 Nova Science Publishers, Inc.

Chapter 83

THE ROLE OF IMAGING IN BREAST SURGERY

Vasileios N. Papadopoulos*, MD, PhD
1st Surgical Propedeutic Department
Medical School of Aristotle's University of Thessaloniki, Greece

ABSTRACT

During the past decades, there has been significant improvement in the equipment and image-recording systems for breast diseases and for investigation of the axilla. In addition to providing better images, these developments have resulted in a significant reduction in radiation dose. Screening mammography is used to detect unexpected breast cancer in asymptomatic women since the 1960s. Specific mammographic features that suggest a diagnosis of breast cancer include a solid mass with or without stellate features, clustered microcalcifications, and asymmetric thickening of breast tissues. Imaging of the breast has evolved from mammography alone to mammography with adjunctive modalities that primarily include ultrasound and magnetic resonance imaging (MRI scan). Until recently, ultrasound and MRI have functioned as problem-solving tools and have been used to help to diagnose a mammographically and/or clinically detected abnormality such as a breast mass or nipple discharge. As these modalities have improved technologically and immense clinical experience has been acquired, so have their roles expanded from diagnostic tools to potential screening tools as well. Ultrasound has many uses that relate to the evaluation of breast masses. Sonographic guidance is used frequently for the direction of percutaneous breast biopsies and to investigate the status of axillary lymph nodes in breast carcinoma. MRI was initially used for the evaluation of implants, but it now has a variety of roles associated with the evaluation of tumors. With a dedicated breast coil and contrast enhancement, MRI has been of great value in identifying the extent of breast carcinoma and contributing to better patient management plan. A breast positron emission tomography (PET) scan is another imaging modality of the breast that uses a radioactive substance (F-18-fluoro-2-deoxy-D-glucose - FDG). Whole-body FDG-PET can detect distant metastatic disease to the lymph nodes, the soft tissues, viscera, and bone. PET scan is also used to assess whether metastatic breast cancer is responding to treatment. After breast biopsy, scarring and distortion of breast tissue occur, making subsequent evaluation by mammography difficult. Thus,

* Corresponding Author's Email: bnpap@med.auth.gr.

other imaging techniques, such as MRI, and PET, are being increasingly used for characterizing lesions in the breast. All imaging techniques now used in breast surgery continue to be modified and improved to maintain optimum image quality that enhances interpretation skills of the clinicians and radiologists.

INTRODUCTION

Over the past decades the use of breast imaging has increased, with more emphasis being placed on ultrasound (US) and magnetic resonance imaging (MRI) than ever before. While mammography remains the front line in screening and first-time diagnosis, US and MRI allow a more accurate characterization of lesions and symptomatic findings. [1, 2] The number of breast cancer detections has increased, as have the instances of surgical breast interventions. In order to detect the abnormal changes in the breast, breast surgeons and breast imagers must be also familiar with the normal findings of the postsurgical breast. The techniques of biopsy, implantation, and reconstruction have also evolved, changing the breast imaging findings as well [1-4].

The progress of technology has enabled control of the status of breast and axillary lymph nodes with many imaging methods. The main methods currently used are:

1) Ultrasonography,
2) Mammography,
3) MRI,
4) CT scan,
5) Pet scan.
6) Scintimammography

1. ULTRASONOGRAPHY (US)

In breast US, sound waves are emitted into the breast, and an image is created by the returning sound waves received by the ultrasound detector. As there is no ionizing radiation, it is useful in young and pregnant women. Advantages of breast ultrasound include the ability to better characterize the composition of breast parenchyma, and to investigate the presence of lesions - nodules and easily recognize compact or cystic texture and the size, shape, perfusion, elements that distinguish and characterize a lesion as benign or malignant. In suspected lesions enable biopsy under the guidance of ultrasound. In axillary cavity status information of nodes there is substantial and ultrasound also checks outside of the lymph nodes status of vessels (arteries, veins) (Figure 1), nerves, connective tissue and sometimes ectopic mammary gland. The axillary lymph nodes are divided into three levels based on their anatomic relationship to the pectoralis minor muscle: level I nodes are inferior to the pectoralis minor muscle, level II nodes are posterior to the muscle, and level III nodes are medial to the muscle [5].

The main groups of axillary lymph nodes include: The group of axillary vein lymph nodes, the group of scapular, the central group, the lymph nodes of Rotter (between the pectoral muscles) the team of the pectoralis major muscle, and the group of subclavicular

lymph nodes. Skandalakis JE et al., [6], report that the axillary drainage of the breast includes an average number of 35.3 nodes in 6 groups.

Group 1. External mammary nodes (average number of 1.7 nodes), also called the anterior pectoral nodes. These lie along the lateral edge of the pectoralis minor, deep to the pectoralis major muscle, along the medial side of the axilla following the course of the lateral thoracic artery on the chest wall from the second to the sixth rib. Deep to the areola there is an extensive network of lymphatic vessels, the so-called subareolar plexus of Sappey. In the circumareolar region, large lateral and medial trunks receive much of the lymph from the breast parenchyma. The lateral trunk receives collaterals from the upper half of the breast and the internal trunk drains the lower part of the breast. These vessels pass around the lateral border of the pectoralis major muscle to reach the external mammary nodes.

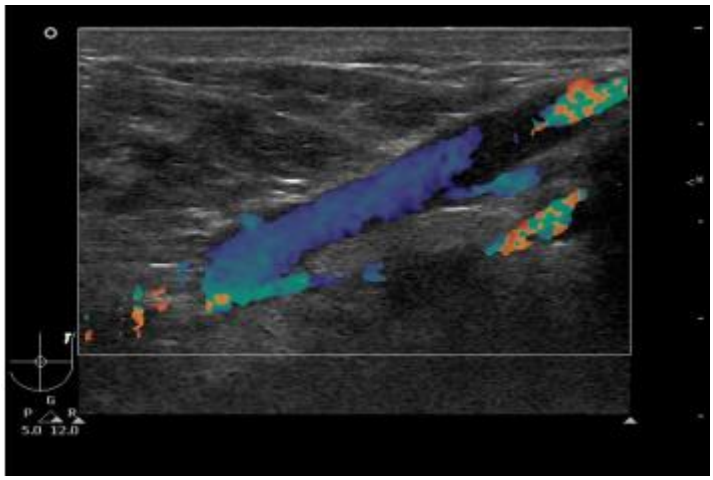

Figure 1. Axillary vessels in color US.

Group 2. Scapular nodes (average number of 5.8 nodes). These lie on the subscapular vessels and their thoracodorsal branches. Lymphatics from these intercommunicate with intercostal lymphatic vessels.

Group 3. Central nodes (average number of 12.1 nodes). This is the largest group of lymph nodes; they are the nodes most easily palpated in the axilla, because they are generally larger in size. They are embedded in fat in the center of the axilla. When these nodes enlarge, they can compress the intercostobrachial nerve, the lateral cutaneous branch of the second or third thoracic nerve, causing accompanying pain.

Group 4. Interpectoral nodes (Rotter's nodes) (average number of 1.4 nodes). These lie between the pectoralis major and minor muscles. Often there is a single node. They are the smallest group of axillary nodes and will not be found unless the pectoralis major is removed.

Group 5. Axillary vein nodes (average number of 10.7 nodes). This is the second largest group of lymph nodes in the axilla. They lie on the caudal and ventral surfaces of the lateral part of the axillary vein.

Group 6. Subclavicular nodes (average number of 3.5 nodes). These lie on the caudal and ventral surfaces of the medial part of the axillary vein [6].

Second only to mammography in frequency of use for breast imaging, ultrasonography is an important method of resolving equivocal mammographic findings, defining cystic masses,

demonstrating the echogenic qualities of specific solid abnormalities, and greatly facilitates the recommendations for follow-up or further evaluation of the patient [4].

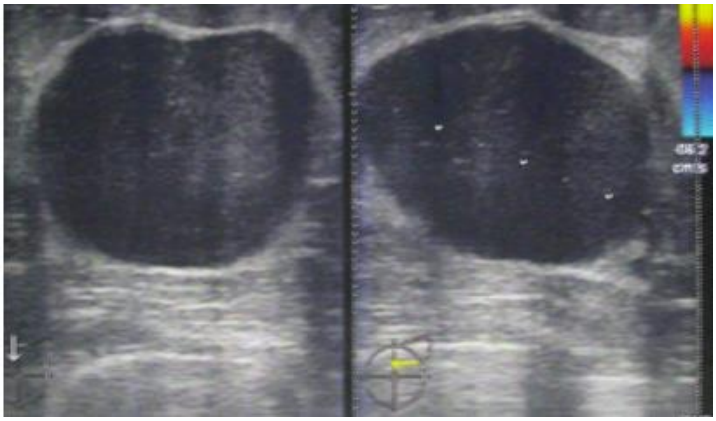

Figure 2. Breast cyst on ultrasound.

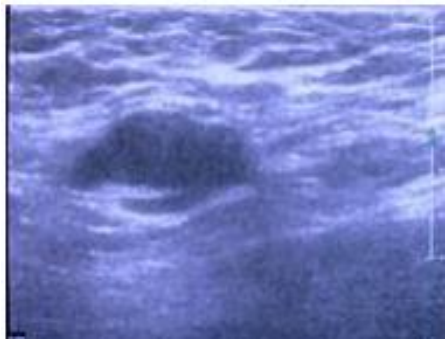

Figure 3. Solid tumor of left breast in US.

On ultrasound examination, breast cysts are well circumscribed, with smooth margins and an echo-free center (Figure 2). Benign breast masses usually show smooth contours, round or oval shapes, weak internal echoes, and well defined anterior and posterior margins. Breast cancer characteristically has irregular walls but may have smooth margins with acoustic enhancement (Figure 3,4).

Ultrasonography is used to guide fine-needle aspiration biopsy, core-needle biopsy, and needle localization of breast lesions (Figure 5). Its findings are highly reproducible and it has a high patient acceptance rate, but it does not reliably detect lesions that are less than one cm in diameter. In patients with breast cancer, evaluation of axillary lymph nodes (ALNs) is very important, as it is a powerful prognostic indicator and decisive factor for developing a breast cancer treatment plan. Traditionally, axillary lymph node dissection (ALND) has been used for nodal staging, but currently use of sentinel lymph node biopsy (SLNB) has increased in frequency as an alternative procedure for patients with early breast cancer. Importantly, while SLNB has decreased the morbidity of staging by avoiding unnecessary ALND, it is also an invasive method, and it may be an inconvenience for some patients to undergo a two-stage surgical procedure. Therefore, it would be of great clinical benefit if a reliable imaging method or minimally invasive procedure for determining ALN status were available. If there

were no evidence of ALN metastasis in preoperative staging, SLNB would be performed. On the other hand, patients with ALN metastasis found on preoperative staging would directly undergo ALND or neoadjuvant chemotherapy [7, 8].

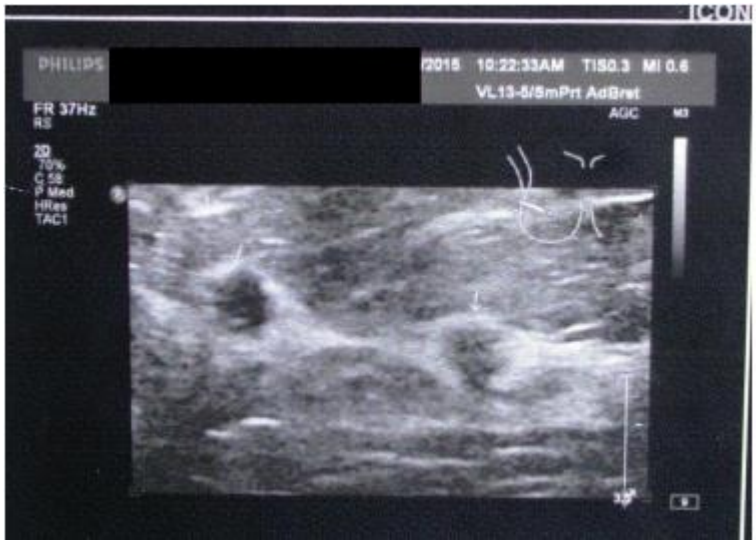

Figure 4. Right breast tumor (BIRADS 5) in US.

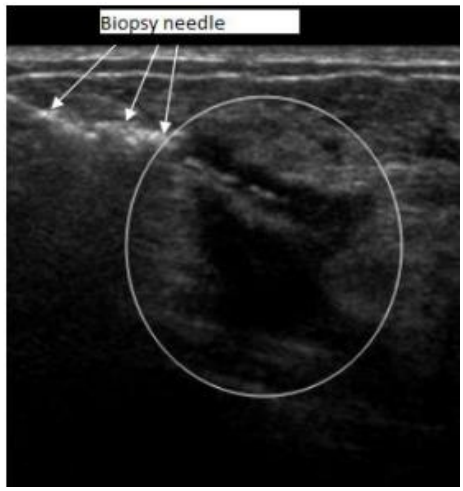

Figure 5. Needle biopsy with US guidance.

In terms of preoperative evaluation for ALN metastasis, physical examination has low sensitivity, between 35 and 82% and specificity ranges from 73% to 97%. Ultrasonography (US) of ALN has superior diagnostic accuracy in many studies when combined with US-guided fine-needle aspiration biopsy (US-FNA) of sonographically suspicious lymph nodes. The sensitivity and specificity of US examination in the evaluation of ALN metastasis have been reported to be 36–92 and 69–100%. Addition of US-FNA to axillary US may increase specificity to 93–100% [7-11].

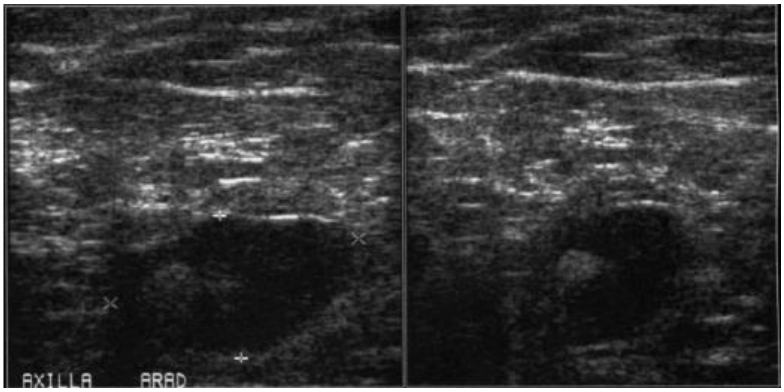

Figure 6. Metastatic axillary lymph node in US.

Figure 7. Metastatic axillary lymph node in US.

The combination of axillary US and US-FNA is useful in preoperative work-up of breast cancer patients and is valuable in planning proper management of breast cancer patients.

Ultrasonography can also be utilized to image the regional lymph nodes in patients with breast cancer (Figure 6, 7, 8). On ultrasound, lymph nodes have a characteristic appearance. They are very well defined and oval or lobular with mixed echogenicity (Figure 9). The cortex is hypoechoic, and the fatty hilum is hyperechoic. Abnormal nodes may lose this appearance and be more rounded and poorly marginated. Intramammary lymph nodes have an appearance similar to that of axillary nodes; namely, they are well defined, mixed density or medium to low density, round, ovoid, or reniform nodules with a fatty notch or center. Intramammary nodes can be found throughout the breast but most commonly are located in the middle- to upper-outer aspect of the breasts [12].

Ultrasound is an essential component in the workup of a palpable or mammographically evident lesion. It is also highly specific, relatively inexpensive, and widely available. Sonography can be used for a targeted region of the breast. Poor visualization of

microcalcifications, which are often a sign of malignancy, is the ultrasound's main disadvantage. Although sonography cannot definitely differentiate benign from malignant solid masses, the correlation of a circumscribed mass that has not enlarged on mammography and benign sonographic characteristics can be used to follow rather than biopsy a nonpalpable lesion. Malignant sonographic criteria include spiculation, a taller-than-wide shape, angular margins, shadowing, branching pattern, hypoechoicity, duct extension, and microlobulation. The presence of these features, even in the face of a relatively circumscribed mass on mammography, should prompt biopsy [4, 12].

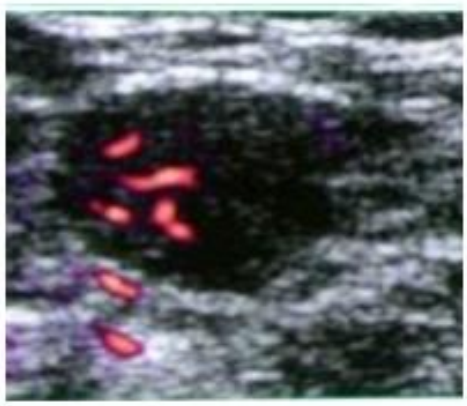

Figure 8. Multiple vessels in metastatic axillary lymph node in US.

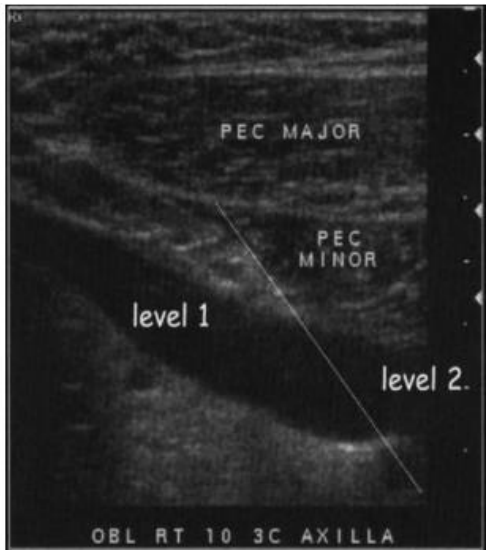

Figure 9. Normal axillary lymph node in US.

Pneumocystography also may be performed at the time of aspiration to outline the internal aspect of the cyst wall. When sonography demonstrates a complicated cyst (imperceptible wall, acoustic enhancement, and low-level echoes) or a cluster of microcysts, the likelihood of malignancy is very low. Cystic masses with thick walls, thick septae, or an

intracystic solid component or predominately solid masses with cystic foci are categorized as complex cysts. Complex cysts may be malignant, and biopsy is warranted. Papillomas and intracystic papillary carcinomas may develop within a cyst. Invasive papillary carcinomas tend to present as multiple, relatively well-defined masses. If a cyst contains an intracystic lesion, lobulation or slight irregularity of the wall may be seen on mammography. On pneumocystography, papillary lesions are seen as a polypoid filling defect within the cyst cavity [12, 13].

1.1. US Report Organization

According to the Guidelines of "The American College of Radiology (ACR)" in ACR BI-RADS® Atlas 5, the report should be concise and organized using a structure such as that provided in Table 1.

Table 1. Report organization

	Report Structure
1.	Indication for examination
2.	Statement of scope and technique of breast US examination
3.	Succinct description of the overall breast composition (screening only)
4.	Clear description of any important findings
5.	Comparison to previous examination(s), including correlation with physical, mammography, or MRI findings
6.	Composite reports
7.	Assessment
8.	Management

The indication for examination, relevant clinical history, and pertinent risk factor information should be clearly stated. If the study is performed for follow-up of a specific mass or area of concern, this should be described. The dates of any comparison examinations should be specified. When a specific sonographic finding is documented by recording a complete set of images, the longest horizontal dimension should be reported first, followed by the vertical measurement, and the orthogonal horizontal dimension last. Multiple simple cysts or a combination of multiple simple and complicated cysts need not be reported individually. If any lesions have been biopsied previously, this should be noted together with the prior biopsy results, if known. Correlation of any clinical, mammographic, and MRI findings with the sonographic findings should be specifically stated in the report. For diagnostic evaluations involving US characterization of mammographic abnormalities or confirmation of a mass suspected but not delineated mammographically, a single report integrating the two modalities will clearly communicate a final assessment based on the highest likelihood of malignancy and appropriate management recommendations. Consistent use of BI-RADS® descriptors for US, as for mammography and MRI, helps in lesion assessment and clarifies communication with physicians and patients. Also, structured, software-based reporting should be based on BI-RADS® terminology. For coding and reimbursement, it is considered the advisability of splitting the report combining the findings of two or more concurrently performed imaging modalities or procedures into specific sections or paragraphs, one for each

type of examination. However, a single assessment and recommendation for patient management should reflect integration of the findings from all of the imaging studies. It is important that an assessment based on specific findings needing most urgent attention will have the greatest clinical utility.

1.1.1. Indication for Examination

The reason for performing the examination should be stated briefly at the beginning of the report. The most common indications for breast US are confirmation and characterization of a palpable mass or mammographic or MRI abnormality, guidance of interventional procedures and as the initial imaging technique for young, pregnant, or lactating patients. Additional applications are listed in the ACR Practice Guideline for the Performance of the Breast Ultrasound Examination and include the extent of disease evaluation supplementing mammography in high-risk women who are not candidates for breast MRI or who have no easy access to MRI, and in breast imaging practices that provide the service, supplementary whole-breast screening in order to increase cancer detection in asymptomatic women with mammographically dense breasts.

1.1.2. Statement of Scope and Technique of Breast Us Examination

The scope of examination and technique used should be stated, for example, whether the examination was directed or targeted to a specific location, or whether it was performed for supplementary screening. It is important, since US is a real-time examination, to indicate who performed the examination (sonographer, sonographer and physician, physician alone) or whether an automated whole-breast scanning system was used. If a lesion was evaluated with color or power Doppler or with strain or shear-wave elastography, observations relevant to the interpretation should be reported. In certain situations, it may be beneficial to describe the position of the patient during the examination (e.g., “The breasts were imaged in both supine and lateral decubitus position.” or “The patient was imaged in seated position, the position in which she feels the left breast thickening best.”).

1.1.3. Succinct Description of the Overall Breast Composition (Screening Only)

Tissue composition patterns can be estimated more easily in the large field of view (FOV) of automated US scans but can also be discerned in the small FOV of a handheld US scan. The three US descriptors for tissue composition are “homogeneous background echotexture-fat,” “homogeneous background echotexture-fibroglandular,” and “heterogeneous background echotexture” (Table 2) correspond loosely to the four density descriptors of mammography and the four fibroglandular tissue descriptors of MRI. At US, breast tissue composition is determined by echogenicity. Subcutaneous fat, the tissue relative to which echogenicity is compared, is medium gray and darker than fibroglandular tissue, which is light gray. Heterogeneous breasts show an admixture of hypoechoic and more echogenic areas. Careful real-time scanning will help differentiate a small hypoechoic area of normal tissue from a mass.

Table 2. Breast tissue composition patterns

	Tissue composition
a.	Homogeneous background echotexture-fat
b.	Homogeneous background echotexture-fibroglandular
c.	Heterogenous background echotexture

1.1.4. Clear Description of Any Important Findings

The description of important findings should be made, in order of clinical relevance, using lexicon terminology, and should include:

a) Characterization of a mass using the morphological descriptors of shape, margin, and orientation. Note should be made of the lesion's effect on the surrounding tissue, such as architectural distortion. Feature categories, such as posterior features and echogenicity, and techniques, such as color or power Doppler and elastography, may contribute information to the analysis, but only pertinent positives need to be described. Recognition of special case findings, such as simple and complicated cysts, clustered microcysts, intramammary lymph nodes, and foreign bodies, should simplify interpretation. In reporting screening examinations in asymptomatic women, as in mammography, characteristically benign findings may be reported (assessment category 2), but it is not obligatory, and the appropriate assessment would then be negative (assessment category 1).
b) For important findings, lesion size should be given in at least two dimensions; three dimensions are preferable, especially if the volume of a mass is compared with one or more previous examinations. It is not necessary to report the measurements of every small simple cyst, and if numerous cysts are present, especially in both breasts; location and measurements of the largest cyst in each breast will suffice.

If a mass is measured, images should be recorded with and without calipers. Marginal characteristics are one of the most important criteria to be applied in assessing the likelihood of malignancy of a mass, and, particularly with small masses, caliper markings may obscure the margin, hindering analysis.

c) Location of the lesion(s) should be indicated using a consistent and reproducible system, such as clock-face location and distance from the nipple. When more than one mass or abnormality is located in the same scan frame or in the same locale, measurement of the distance from the skin to the center of the mass or its anterior aspect may help to differentiate one lesion from another. This measurement may be particularly useful when one mass is singled out for biopsy and others are depicted in the field.

1.1.5. Comparison to Previous Examination(s), Including Correlation with Physical, Mammography, or MRI Findings

Breast US should be correlated with physical findings, mammography, MRI, or other imaging studies, if performed. If no statement of comparison is included in the US report, it will be assumed that no comparison was made. Note that some report templates include a

"comparison" heading, in which the word "none" (if appropriate) may be entered. When correlating US findings with those seen at mammography and/or MRI, the operator performing handheld scanning should correlate the size and location of lesions and match the type and arrangement of tissues surrounding the lesion in order to reduce the likelihood of misregistration (identifying a different lesion or lesions at different imaging modalities). In doing this, allowance for positional changes should be made going from upright with mammography and prone with MRI to supine or supine-oblique with US. If it is determined that a sonographic finding corresponds to a palpable abnormality, or to a mammographic or MRI finding, this should be stated explicitly in the US report. If the US finding is new or has no correlate, this should also be stated in the report.

If the US examination was performed as part of a surveillance protocol to assess a previously identified finding, or if the finding was reported on a previous examination, the current report should describe any changes. An increase of 20% or more in the longest dimension of a probably benign solid mass within 6 months may prompt biopsy. An increase of only 1–2 mm in lesion size may be related to differences in scanning technique or patient positioning.

1.1.6. Composite Reports

When more than one type of examination is performed concurrently (on the same day), it is preferable that the examinations be reported together. The findings for each examination should be described in separate paragraphs with an overall assessment and management recommendations for the combined examinations.

In general, when the assessments for two examinations differ, the overall assessment (and concordant management recommendations) should reflect the more abnormal of the individual assessments (whatever management is expected to come first, supplemented by likelihood of malignancy), according to the following hierarchy of increasing abnormality: category 1, 2, 3, 6, 0, 4, 5 (Table 3.).

Table 3. Abnormality hierarchy

BI-RANDS Assessment category	Degree of Abnormality
1	Lowest
2	
3	
6	
0	
4	
5	Highest

Exceptions to this rule occur when the characteristically benign features of a given imaging finding on one examination supersede the less specifically benign features of the same finding on the other examination. An example is that of a partially circumscribed, non-calcified mass at mammography, superseded by simple cyst at US.

1.1.7. Assessment

The report should conclude with a concise summary of pertinent US findings with a final assessment using BI-RADS® US categories 1–6 and the phrases associated with them.

If report of a US examination is integrated with that of a concurrently performed mammography examination, the combined final assessment should reflect the highest likelihood of malignancy assessed at the two examinations. Clear and consistent communication is a goal that can be achieved for breast US by using the same assessment categories and similar wording described in the BI-RADS® Mammography section (Table 4).

In some cases, the interpreting physician may render an incomplete assessment (category 0) in order to request additional examination(s), such as mammography, comparison with previous but currently unavailable examinations, or additional physician-performed real-time scanning after either a sonographer-produced, real-time or automated whole-breast screening US examination.

Table 4. BI-RADS® classification

BI-RADS® Category Descriptive Recommendation

0	Incomplete - Needs further evaluation (Additional views, ultrasound, comparison with old films)
1	Negative - Routine annual screening
2	Benign - Routine annual screening
3	Probably benign - Short interval follow-up mammography
4	Suspicious - Biopsy should be considered
5	Highly suspicious - Appropriate action/biopsy
6	Proven malignancy - Appropriate action

1.1.8. Management

Management recommendations should be included in every report. Clear recommendations should be made as to the next course of action. Recommendations may include routine age-appropriate screening, surveillance imaging for a probably benign mass, annual follow-up after percutaneous or surgical biopsy, and clinical management. If an imaging-guided interventional procedure is recommended, the type of imaging for the procedure might also be suggested, for example, stereotactic, US, or MRI guidance.

2. MAMMOGRAPHY

During the last decades convincing evidence has emerged that mammographic screening has contributed to a significant reduction in breast cancer mortality. Mammographic screening is especially important in the diagnosis of early-stage breast cancer, which relies primarily on nonpalpable mammographic abnormalities for detection (Figure 10, 11, 12). Ductal carcinoma in situ (DCIS) now accounts for approximately 20–30% of mammographically detected cancers. Current US Preventive Services Task Force (USPSTF) guidelines recommend against routine screening mammography in women aged 40–49 years [14].

Mammography has evolved from more dedicated equipment and industrial film, through dedicated film-screen mammography, and now to full-field digital mammography. Factors that affect the image quality include equipment, image-recording system, processing, compression of the breast, and the technologist's skill in positioning the patient. Adherence to strict quality assurance guidelines is critical in mammography to maintain optimum image quality.

Once the mammographic images are presented to the radiologist for interpretation, an approach to the analysis and interpretation defines how lesions are identified and how they are described and managed. The assessment and description of the mammographic findings are defined in a standardized method known as the Breast Imaging Reporting and Data System (BI-RADS®) (Table 4).

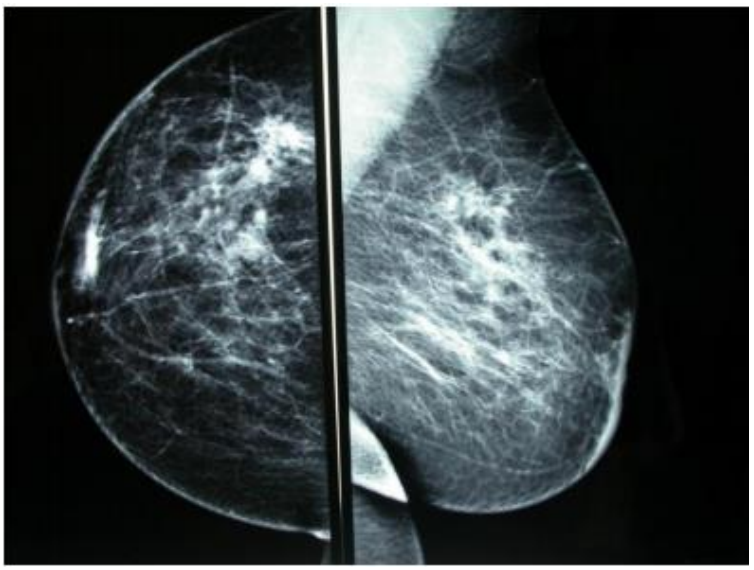

Figure 10. Right breast tumor in mammography.

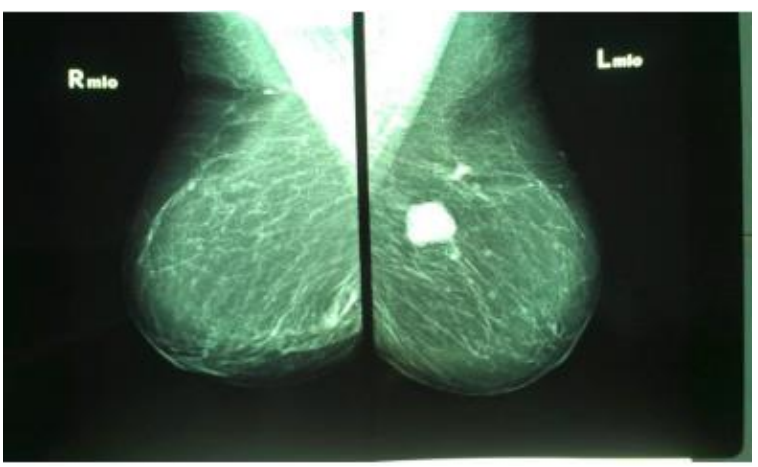

Figure 11. Left breast tumor in mammography.

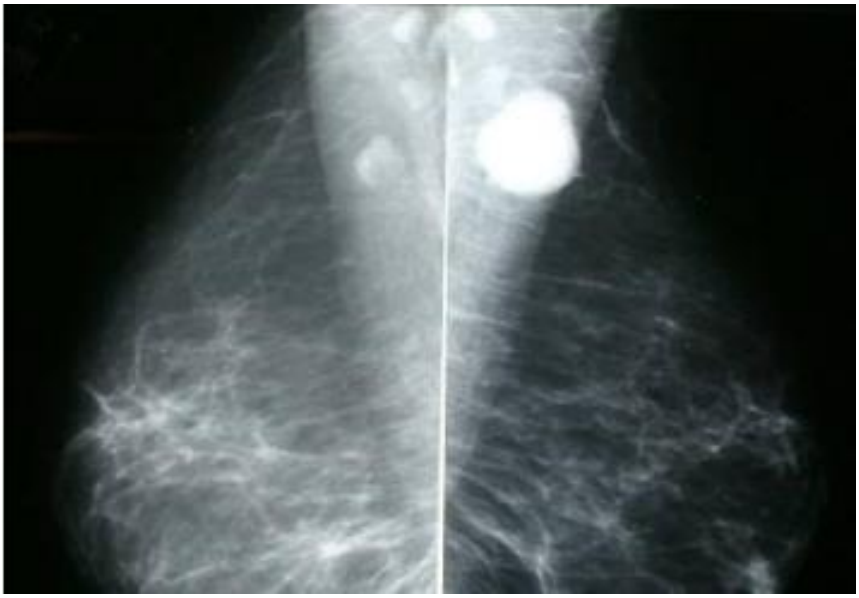

Figure 12. Metastatic axillary lymph nodes in mammography with no evidence of primary breast cancer.

BI-RADS® was developed by the American College of Radiology in the mid-1990s and includes a nomenclature for lesion description and overall assessment. BI-RADS® incorporates three basic components: (a) a description of the parenchymal density, (b) specific lesion descriptions for masses, calcifications, and other findings, and (c) an overall assessment or management recommendation for the patient. The use of this lexicon is ideal: The terms are standardized, and the correct use of the terms to describe an abnormality is helpful to the radiologist to correctly manage each case. The use of the standardized terminology and the requirement for an overall assessment are also very helpful for communication of the findings to the referring surgeon [12].

Mammogram reports will also include an assessment of breast density. BI-RADS® classify breast density into 4 groups:

1. The breasts are almost entirely fatty (Figure 13). The breasts contain little fibrous and glandular tissue, which means the mammogram would likely detect anything abnormal.
2. There are scattered areas of fibroglandular density (Figure 14). There are a few areas of fibrous and glandular tissue in the breast.
3. The breasts are heterogeneously dense, which may obscure small masses (Figure 15). The breast has more areas of fibrous and glandular tissue that are found throughout the breast. This can make it hard to see small masses.
4. The breasts are extremely dense, which lowers the sensitivity of mammography (Figure 16). The breast has a lot of fibrous and glandular tissue. This may make it harder to find a cancer that may be present, as it can blend in with normal breast tissue.

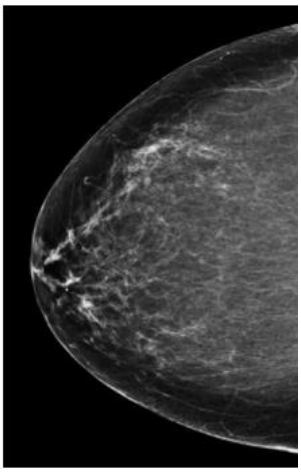

Figure 13. The breast is almost entirely fatty containing little fibrous and glandular tissue (Group 1).

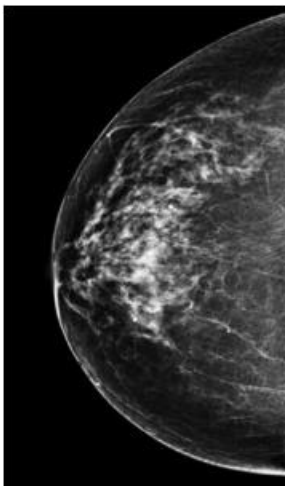

Figure 14. There are scattered areas of fibroglandular density (Group 2).

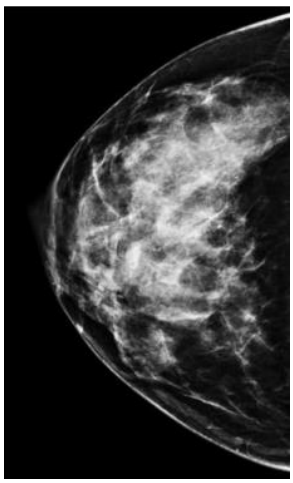

Figure 15. The breast is heterogeneously dense, which may obscure small masses (Group 3).

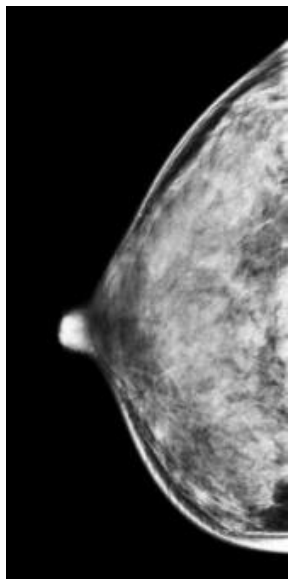

Figure 16. The breast is extremely dense, which lowers the sensitivity of mammography (Group 4).

The fourth edition of BI-RADS®, unlike previous editions, indicated quartile ranges of percentage dense tissue (increments of 25% density) for each of the four density categories, with the expectation that the assignment of breast density would be distributed more evenly across categories than the historical distribution of 10% fatty, 40% scattered, 40% heterogeneously, and 10% extremely dense. However, it has since been demonstrated in clinical practice that there has been essentially no change in this historical distribution across density categories, despite the 2003 guidance provided in the BI-RADS® Atlas. The absence of change in clinical practice of the assignment of breast density across categories may reflect the reality that a few coalescent areas of dense tissue may be present in breasts with as little as 10% dense tissue, whereas primarily fatty areas may be present in breasts with as much as 90% dense tissue. The fifth edition of BI-RADS® no longer indicates ranges of percentage dense tissue for the four density categories. This is done to emphasize the text descriptions of breast density, which reflect the masking effect of dense fibroglandular tissue on mammographic depiction of non-calcified lesions, because the Committee on BI-RADS® concludes that the association of subjectively estimated breast density with changes in the sensitivity of mammography is clinically more important than the relatively smaller effect of percentage breast density as an indicator for breast cancer risk.

The Committee on BI-RADS® indeed is aware of recent and continuing investigations of percent-age breast density as an indicator for breast cancer risk, and by eliminating percentage ranges they do not intend to compromise or impede any such research. They simply recognize the reality that interpreting physicians will continue to use density categories in mammography reports as they have done over the past years, independent of BI-RADS® guidance on percentage breast density. They further recognize that both subjective estimates and planimetry measurements of breast density based on area as depicted on (2-D) mammograms are imprecise indicators of the volume of dense tissue, which may be measured using (3-D) cross-sectional breast imaging modalities. They await publication of robust volume-based breast density data, using validated percentage cut points (not necessarily

quartiles) that are readily and reproducibly determined at imaging, before again indicating percentage ranges for BI-RADS® density categories. They also urge avoidance of numbers to classify breast density instead of BI-RADS® terminology in order to avoid confusion with BI-RADS® assessment categories, which are numbered. Some breasts may appear more or less dense when imaged using full-field digital mammography compared to screen-film mammography. Superior depiction of the skin line by digital mammography provides the observer with a more accurate (and usually larger) estimate of the extent of the subcutaneous fat. However, no change in the distribution across density categories has been observed when comparing full-field digital mammography with screen-film mammography.

Screening mammography is used to detect unexpected breast cancer in asymptomatic women, supplementing history taking and physical examination. Standard mammographic views include craniocaudal (CC) and mediolateral oblique (MLO) views. The MLO view images the greatest volume of breast tissue, including the upper outer quadrant and the axillary tail of Spence. Compared with the MLO view, the CC view provides better visualization of the medial aspect of the breast and permits greater breast compression. The 90-degree lateral view is used along with the CC view to triangulate the exact location of an abnormality. Spot compression may be done in any projection by using a small compression device, which is placed directly over a mammographic abnormality that is obscured by overlying tissues. The compression device minimizes motion artifact, improves definition, separates overlying tissues, and decreases the radiation dose needed to penetrate the breast. Magnification techniques (×1.5) often are combined with spot compression to better resolve calcifications and the margins of masses [12-18].

The most important findings on mammography (that are either of concern at screening, inherently suspicious, new, or seen to be larger or more extensive when compared to previous examination) are:

a. Mass: size, morphology (shape, margin), density, associated calcifications, associated features, location.
b. Calcifications: morphology, description of typically benign type or description of the shape of particles, distribution (may not be appropriate for typically benign calcifications), associated features, location.
c. Architectural distortion: associated calcifications, associated features, location.
d. Asymmetries (asymmetry, global asymmetry, focal asymmetry, developing asymmetry): associated calcifications, associated features, location.
e. Intramammary lymph node (rarely important): location.
f. Skin lesion: location.
g. Solitary dilated duct (rarely present): location.

Comparison to previous examination may assume importance if the finding of concern requires an evaluation of change or stability. Comparison is not important when a finding has unequivocally benign features. Comparison may be irrelevant when the finding is inherently suspicious for malignancy.

All final assessments (BI-RADS® categories 1, 2, 3, 4, 5, and 6 should be based on thorough evaluation of the mammographic features of concern or after determination that an examination is negative or benign.

An incomplete (category 0) assessment is usually given for screening examinations when additional imaging evaluation is recommended before it is appropriate to render a final assessment. There may be rare situations in the screening setting in which a category 4 or 5 assessment is used, but this practice is discouraged because it may compromise some aspects of outcome analysis. A recall (category 0) assessment should include specific suggestions for the next course of action (spot-compression magnification views, US, etc.)

In most circumstances and when feasible, if a mammography examination is not assessed as negative or benign, the current examination should be compared with prior examination(s). The interpreting physician should use judgment on how vigorously to attempt obtaining prior examinations, given the likelihood of success of such an endeavor and the likelihood that comparison will affect the final assessment. In this context, it is important to note that comparison with previous examination(s) may be irrelevant when a finding is inherently suspicious for malignancy.

Category 0 should be used for prior image comparison only when such comparison is required to make a final assessment. When category 0 is used in the context of awaiting prior examinations for comparison, there should be in place a tracking procedure guaranteeing with 100% reliability that a final assessment will be made within 30 days (preferably sooner) even if prior examinations do not become available. Some mammography practices may reasonably choose never to use category 0 in the context of awaiting prior examinations simply because they do not have a 100% reliable tracking procedure. If a mammography examination is assessed as category 0 in the context of awaiting prior examinations and then the prior examinations do become available, an addendum to the initial mammography report should be issued, including a revised assessment.

Category 1: Negative. This is a normal examination.

Category 2: Benign. Like category 1, this is a normal assessment, but here the interpreter chooses to describe a benign finding in the mammography report. Involuting calcified fibroadenomas, skin calcifications, metallic foreign bodies (such as core biopsy and surgical clips), and fat-containing lesions (such as oil cysts, lipomas, galactoceles, and mixed-density hamartomas) all have characteristically benign appearances and may be described with confidence. The interpreter may also choose to describe intramammary lymph nodes, vascular calcification, implants, or architectural distortion clearly related to prior surgery while still concluding that there is no mammographic evidence of malignancy. On the other hand, the interpreter may choose not to describe such findings, in which case the examination should be assessed as negative (category 1). Note that both category 1 and category 2 assessments indicate that there is no mammographic evidence of malignancy. Both should be followed by the management recommendation for routine mammography screening. The difference is that category 2 should be used when describing one or more specific benign mammographic findings in the report, whereas category 1 should be used when no such findings are described (even if such findings are present).

Category 3: Probably Benign. A finding assessed using this category should have a $\leq 2\%$ likelihood of malignancy, but greater than the essentially 0% likelihood of malignancy of a characteristically benign finding. A probably benign finding is not expected to change over the suggested period of imaging surveillance, but the interpreting physician prefers to establish stability of the finding before recommending management limited to routine mammography screening.

There are several prospective clinical studies demonstrating the safety and efficacy of periodic mammographic surveillance instead of biopsy for specific mammographic findings. Three specific findings are validated as being probably benign (non-calcified circumscribed solid mass, focal asymmetry, and solitary group of punctate calcifications). All the previously cited studies emphasize the need to conduct a complete diagnostic imaging evaluation before making a probably benign (category 3) assessment; hence, it is recommended not to render such an assessment in interpreting a screening mammography examination. The practice of rendering category 3 assessments directly from screening examination also has been shown to result in adverse outcomes: 1) unnecessary follow-up of many lesions that could have been promptly assessed as benign, and 2) delayed diagnosis of a small number of cancers that otherwise may have been smaller in size and less likely to be advanced in stage. Also, all the previously cited studies exclude palpable lesions, so the use of a probably benign assessment for a palpable lesion is not supported by robust scientific data, although there are two single-institution studies that do report successful outcomes for palpable lesions.

Finally, because evidence from previously cited studies indicates the need for biopsy rather than continued surveillance when a probably benign finding increases in size or extent, it is not prudent to render a category 3 assessment when a finding that otherwise meets "probably benign" imaging criteria is either new or has increased in size or extent.

Category 4: Suspicious. This category is reserved for findings that do not have the classic appearance of malignancy but are sufficiently suspicious to justify a recommendation for biopsy. The ceiling for category 3 assessment is a 2% likelihood of malignancy and the floor for category 5 assessment is 95%, so category 4 assessments cover the wide range of likelihood of malignancy in between. Thus, almost all recommendations for breast interventional procedures will come from assessments made using this category.

Category 5: Highly Suggestive of Malignancy. These assessments carry a very high probability ($\geq$ 95%) of malignancy. This category initially was established to involve lesions for which 1-stage surgical treatment was considered without preliminary biopsy, in an era when preoperative wire localization was the primary breast interventional procedure. Nowadays, given the widespread acceptance of imaging-guided percutaneous biopsy, 1-stage surgery is rarely, if ever, performed. Rather, current oncologic management almost always involves tissue diagnosis of malignancy via percutaneous tissue sampling to facilitate treatment options, such as when sentinel node biopsy is included in surgical management or when neoadjuvant chemotherapy is administered prior to surgery. Therefore, the current rationale for using a category 5 assessment is to identify lesions for which any non-malignant percutaneous tissue diagnosis is automatically considered discordant, resulting in the recommendation for repeat (usually surgical) biopsy.

Category 6: Known Biopsy-Proven Malignancy. This category is reserved for examinations performed after biopsy proof of malignancy (imaging performed after percutaneous biopsy but prior to complete surgical excision), in which there are no mammographic abnormalities other than the known cancer that might need additional evaluation.

Digital mammography was developed to allow the observer to manipulate the degree of contrast in the image. Digital mammography captures x-ray information after it passes through the breast in a digital format—without a film—that can be viewed, edited, and transferred electronically to viewing stations and picture archiving and communications systems viewers. This is especially useful in women with dense breasts and women less than

50 years of age. The use of digital breast tomosynthesis with 3D images has been introduced as an alternative to standard 2D mammography imaging that is limited by superimposition of breast parenchyma and breast density. The STORM trial reported that in 7,292 women screened, 3D mammography had a higher cancer detection rate and fewer false-positive recalls than the standard 2D imaging [19].

Specific mammographic features that suggest a diagnosis of breast cancer include a solid mass with or without stellate features, asymmetric thickening of breast tissues or architectural distortion, and clustered microcalcifications. The presence of fine, stippled calcium in and around a suspicious lesion is suggestive of breast cancer and occurs in as many as 50% of nonpalpable cancers. These microcalcifications are an especially important sign of cancer in younger women, in whom it may be the only mammographic abnormality.

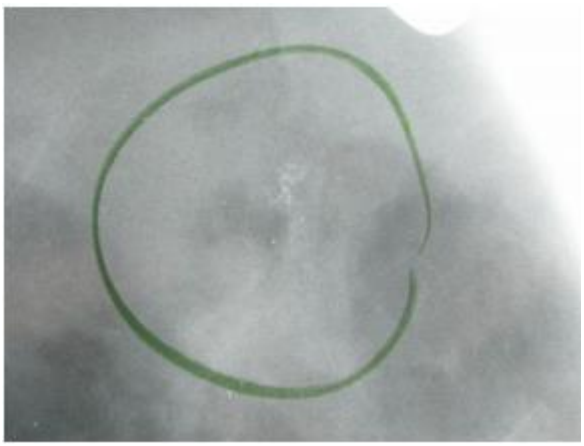

Figure 17. Microcalcifications in mammography.

The usual approach to the evaluation of a well-defined mass on mammography includes an assessment of the shape, size, margins, density, orientation, presence of a fatty halo, and presence of other findings (i.e., calcifications, Figure 17). Benign lesions tend to be isodense or less dense than the parenchyma and to have very circumscribed margins, whereas malignant masses are more often of greater density and have fine irregularity or micronodularity on their borders (Figure 18). A microlobulated margin appears as fine nodularity or undulation of the edge of the lesion and implies a more malignant nature.

The shapes of masses that are circumscribed may be oval, round, or lobular. The margination that is described as circumscribed allows one to visualize a fine, clear edge around the entire mass (i.e., cyst, Figure 19). Often masses that are circumscribed may be overlapped by parenchyma in some areas. These are described as obscured or partially circumscribed.

A basic division of well-circumscribed masses based on their density is of help in determining possible etiologies of and approach to such lesions. Masses that are fatty such as lipomas, oil cysts, and galactoceles and circumscribed masses that are mixed density are characteristically benign. Isodense circumscribed masses include benign and malignant lesions, and an evaluation of the borders is critical to help differentiate these etiologies. Masses that are of high density, particularly for their size, are of concern for malignancies. However, in a study of radiologists' interpretations of mass density, Jackson et al., [20] found

that the assessment of mammographic density of masses was quite variable among different readers; in addition, the density assessment was of limited value in the prediction of benign versus malignant for noncalcified breast masses.

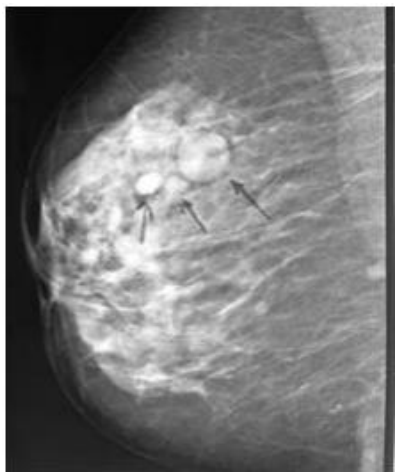

Figure 18. Fibroadenomas in mammography (arrows).

Figure 19. Breast cyst in mammography.

The mammographic feature of greatest importance in assessing a relatively circumscribed isodense mass is its margination. Any waviness, notching, or indistinctness of the margins of a mass should be regarded with suspicion. The presence of a halo sign, i.e., a fine radiolucent ring surrounding a well-defined mass, has long been considered to be a mammographic sign of benignancy. The halo may be due to compression of fat by the mass or to Mach effect. Swann et al. [21] have, however, described 25 malignant lesions from approximately 1,000 breast cancers in which a halo sign was present. The presence of a halo suggests but does not guarantee a benign process. Certainly, the presence of a partially circumscribed margin and a partially indistinct margin is suspicious, and biopsy is indicated in this situation.

Stability in size from prior mammography is an important factor that suggests that a circumscribed non-cystic mass is benign. The growth rates of breast cancers are quite variable. In two series, the mean doubling times for mammary carcinoma have been found to be 212 and 325 days, respectively [22, 23] The lack of interval change suggests that a well-defined lesion is more likely benign, but this is not confirmatory. Meyer and Kopans [24] reported five cases of occult cancers that did not change in size on follow-up mammography over a minimum of 2 years and a maximum of 4.5 years from the original study. Therefore, if a nodule is followed and there is no interval change in the size at 6 months or 1 year, continued follow-up is necessary. In addition, the other features of density and margination are used to decide whether to follow or biopsy a circumscribed mass.

Small solid breast lesions that are radiologically indeterminate sometimes yield an indeterminate histopathological assessment following a radiologically guided biopsy.

Although some centers may wish to just follow these lesions up, increasingly these are being treated using radiological wire localization followed by open surgery in the form of a wide local excision (Figure 20, 21, 22). However many of these are subsequently benign on final surgical pathology.

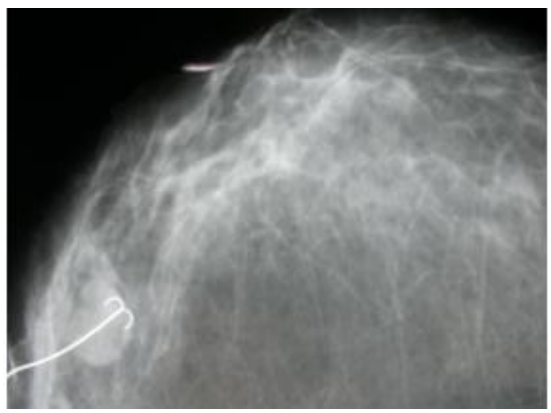

Figure 20. Radiological wire localization of breast lesion.

Figure 21. Radiological wire localization followed by open surgery in the form of a wide local excision.

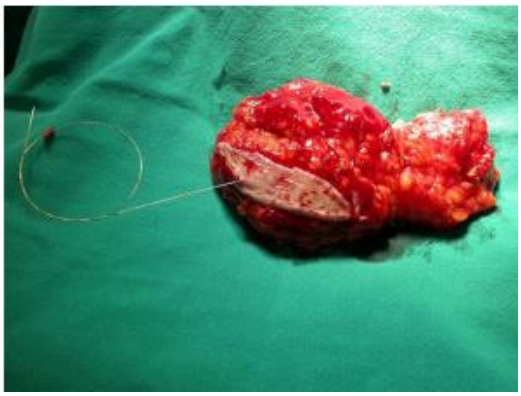

Figure 22. Specimen of open biopsy after Kopans wire used in needle localization.

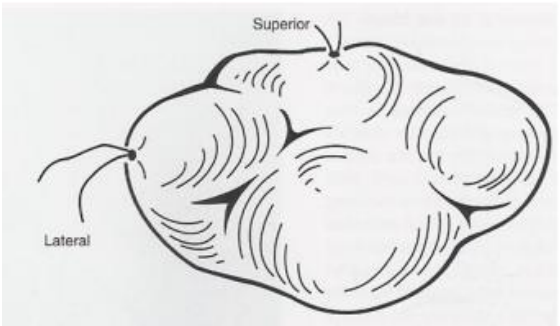

Figure 23. Important step is that of marking the specimen with two sutures (long suture for lateral, and short suture for superior).

Important step is the marking of the specimen with two sutures in order to assist the pathologist for better orientation on specimen findings (Figure 23). More recently there has been alternative radiological management to excise biopsy proven benign lesions, usually fibroadenomas, in women wishing to have them removed. This has been with vacuum assisted biopsy devices, such as the mammotome™ (Johnson and Johnson Ethicon Endo-Surgery Inc, Cincinnati, Ohio, USA), Encor™ (C.R. Bard, New York, USA) and Suros ATEC™(Suros Surgical Systems Inc, Indianapolis, USA). The advantages of these minimally invasive approaches to many women made this technique increasingly popular. They can be performed usually in less than 30 min, with only local anaesthetic and a minimal scar. Complication rates are very low, and the procedures are extremely well tolerated. These procedures are particularly suitable for young women where risk of the lesion being non benign is very low, and cosmesis is premium. The obvious limitation of this technique however, is that as it is only able to remove lesions in a "piecemeal" fashion. Such excisions are unable to provide an assessment of margins of the excision, thus there is no way of determining completeness of excision and whether any residual lesion is left behind. While this may not be particularly relevant if the lesions excised are fibroadenomas, or other such similar benign lesions, it will however obviate the vacuum assisted excision from being utilised for many other more "border- line" lesions where completeness of excision and a full margin status is desirable or essential [1, 4, 12].

Since 2001 the breast lesion excision system (BLES, Intact Medical, Framingham, USA), has been used as an alternative large biopsy device to other vacuum assisted biopsy devices in over 50,000 cases in the USA. It has been well validated as a safe and efficacious biopsy procedure. It however has the unique feature of using radiofrequency cautery to excise a small but whole sample in one piece with intact architecture and clear margins, as a swift local anaesthetic outpatient procedure.[25]

The BLES biopsy is an efficacious technique at excising small indeterminate breast lesions with a complete margin without the need for follow-up diagnostic surgery in the majority (Figures 24, 25, 26).

In cases with post biopsy parenchymal hemorrhage, a localized area of increased density corresponding to increased fluid and blood may be seen. Needle tracts may be noted as subtle, cylindrical mammographic densities in a projection parallel to the biopsy tract with 11-gauge needles. Fourteen gauge needles have not been shown to produce any detectable abnormality. Following vacuum-assisted core biopsy, gas pockets and hematomas are common, but they resolve within 2 to 4 weeks. [28] Overall, post–core biopsy changes should not be recognized on mammography after approximately 6 months; any density after this period likely represents an abnormality and should be further evaluated [29].

Figure 24. Breast lesion excision system.

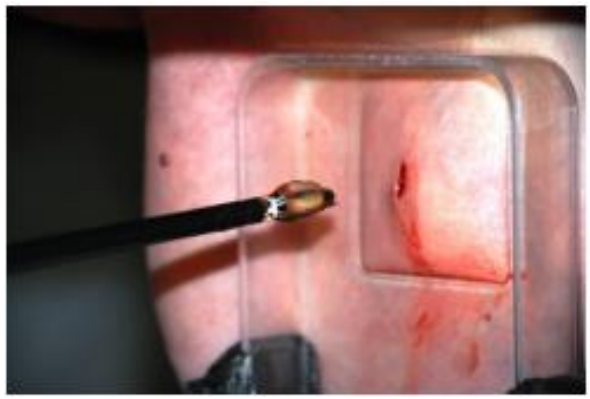

Figure 25. Removing suspicious breast area using BLES.

Post–core biopsy mammographic changes are few and very uncommon. In cases of clip placement, a small metallic clip should be visible at the biopsy site (Figure 27). Clips may demonstrate some migration from the area of initial placement [1, 26, 27].

Figure 26. Post excision trauma after BLES.

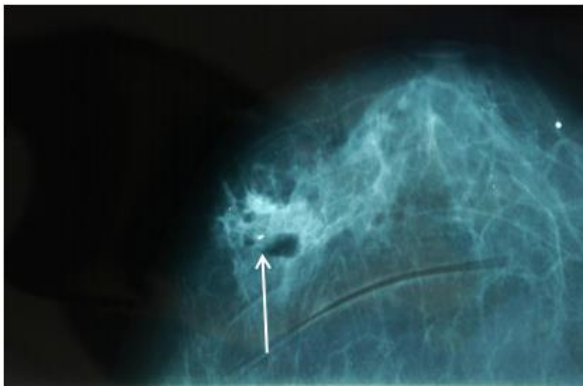

Figure 27. Clip placement after biopsy.

Post-excisional breast biopsies, which involve the removal of a larger amount of breast tissue, demonstrate significantly more imaging findings. Fifty percent of benign excisional breast biopsies show some mammographic change [30]/

Postsurgical mammograms are ideally performed at about 3 to 6 months after surgery and serve as new baseline views. Benign pathologies, however, may not prompt postsurgical imaging unless there is a need to confirm successful removal of a lesion or evaluate for postoperative complications.

In a postsurgical mammogram, a thin metallic marker is placed on the surgical skin scar to indicate its location on the images. The most commonly viewed post excisional change is architectural parenchymal distortion, followed by overlying focal skin thickening. These changes are seen mostly in the first 6 months after surgery. Other findings include calcifications or fat necrosis. Occasionally, 6 or more months after the procedure, calcifications form in the post excisional bed. Most are dystrophic in nature or associated with fat necrosis or oil cysts. Small irregular calcifications mimicking malignancy may also be seen and should be closely monitored for malignancy [31].

Ductography

Breast ductography (also known as galactography) is an imaging technique which is used to evaluate lesions causing nipple discharge. It helps in precisely locating the mass within breast tissue and gives useful information for surgical approach and planning.

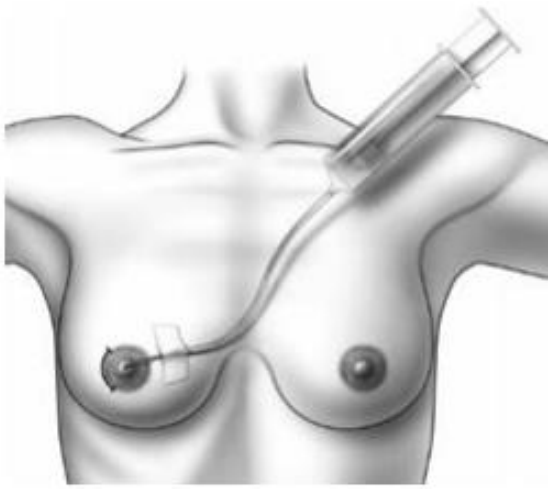

Figure 28. Ductography.

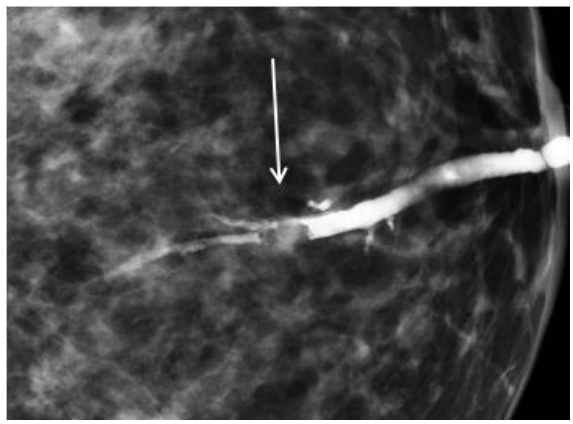

Figure 29. Intraductal papillomas are seen as small filling defects surrounded by contrast media.

The primary indication for ductography is nipple discharge, particularly when the fluid contains blood. Radiopaque contrast media is injected into one or more of the major ducts and mammography is performed (Figure 28). A duct is gently enlarged with a dilator and then a small, blunt cannula (sialogram needle of 30 gauge) is inserted under sterile conditions into the nipple ampulla. With the patient in a supine position, 0.1 to 0.2 mL of dilute contrast media is injected and a standard two view mammography (CC and MLO projections) are obtained without compression. Intraductal papillomas are seen as small filling defects surrounded by contrast media (Figure 29). Cancers may appear as irregular masses or as multiple intraluminal filling defects (Figure 30) [4, 12].

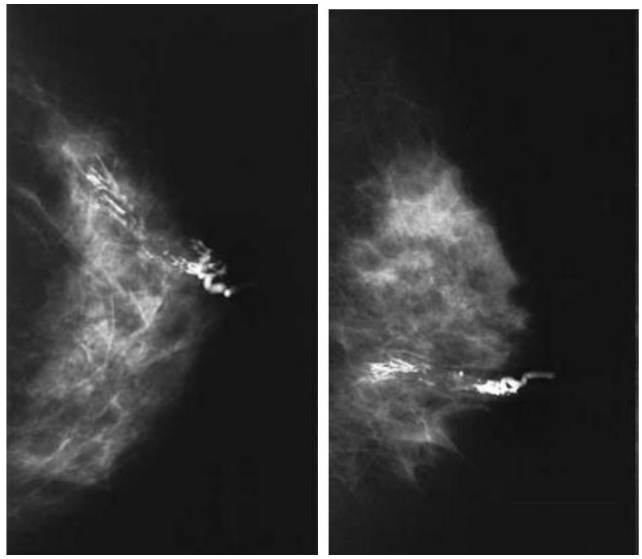

Figure 30. Cancers may appear as irregular masses or as multiple intraluminal filling defects.

The majority of the lesions found in ducts are duct papillomas. Current practice holds that these lesions should be excised to exclude a malignant lesion. If the duct lesion is large enough, ultrasound guided percutaneous biopsy can make the diagnosis of a papilloma quite successfully. The duct is excised after it is filled carefully with dye.

3. MAGNETIC RESONANCE IMAGING (MRI)

In the process of evaluating magnetic resonance imaging (MRI) as a means of characterizing mammographic abnormalities, additional breast lesions have been detected. However, in the circumstance of negative findings on both mammography and physical examination, the probability of a breast cancer being diagnosed by MRI is extremely low. Contrast enhanced breast MRI indications include (a) evaluation of the extension of known breast cancer, (b) detection of contralateral breast cancer in women with newly diagnosed breast cancer, (c) screening for women who are at high risk and/or positive for BRCA1 and BRCA2, (d) assessment of neoadjuvant chemotherapy response, (e) evaluation of chest wall invasion or mastectomy site for recurrence, and (f) detection of breast cancer in women with axillary metastases and a normal mammogram [1, 32, 33, 34].

The patient receives an intravenous line and is given gadolinium for contrast enhancement. Then 20 minutes of motionless scan time follows. [35] There are three different patterns of dynamic enhancement. The type 1 pattern (persistent) shows slow, progressive contrast uptake over time and is suggestive of benignity. The type II contrast pattern (plateau) shows a rapid uptake in contrast and then a leveling off of uptake. This pattern is suggestive of malignancy. The type III pattern (washout) is indicative of malignancy. [36] The diagnostic evaluation must also include the assessment of lesion morphology, which requires high-resolution imaging. The border of the lesion is the most important feature. Spiculated and irregular margins have a positive predictive value of malignancy ranging from 76% to

91%. Most benign masses have a smooth border with a negative predictive value for malignancy of 90%. [36, 37] DCIS is suggested by small, clumped foci that are within a segment or duct [38].

The use of dedicated breast coils is mandatory in the MRI imaging of the breast. A BIRADS lexicon is assigned to each examination and an abnormality noted on MRI that is not seen on mammography requires a focused ultrasound examination for further assessment. If the abnormality is not seen on corresponding mammogram or ultrasound then MRI guided biopsy is necessary. Some clinical scenarios where MRI may be useful include the evaluation of a patient who presents with nodal metastasis from breast cancer without an identifiable primary tumor; to assess response to therapy in the setting of neoadjuvant systemic treatment; to select patients for partial breast irradiation techniques; and evaluation of the treated breast for tumor recurrence.

There is current interest in the use of MRI to screen breasts of high-risk women and of women with a newly diagnosed breast cancer. In the first case, women who have a strong family history of breast cancer or who carry known genetic mutations require screening at an early age, because mammographic evaluation is limited due to the increased breast density in younger women [4].

In the second case, an MRI study of the contralateral breast in women with a known breast cancer has shown a contralateral breast cancer in 5.7% of these women. MRI can also detect additional tumors in the index breast (multifocal or multicentric disease) that may be missed on routine breast imaging and this may alter surgical decision making. In fact, MRI has been advocated by some for routine use in surgical treatment planning based on the fact that additional disease can be identified with this advanced imaging modality and the extent of disease may be more accurately assessed [4].

Preoperative imaging can change the case management approach in a significant number of cases: 18% using US and 11% to 30% using MRI. [8, 39, 40] US and MRI are generally more sensitive than mammography for invasive carcinomas, especially in dense and heterogeneous breasts. MRI is commonly used for the detection of multicentric and multifocal diseases once cancer is diagnosed [1].

A randomized trial performed in the United Kingdom (COMICE trial)[41] which enrolled 1,623 women did not show a decrease in rates of reoperation in those women randomized to undergo MRI in addition to mammography and ultrasonography (19%) compared to those undergoing standard breast imaging without MRI (19%). Houssami et al., [42] performed a meta-analysis including 2 randomized trials and 7 comparative cohort studies to examine the effect of preoperative MRI compared to standard preoperative evaluation on surgical outcomes. They reported that the use of MRI was associated with increased mastectomy rates. This is problematic since there is no evidence that the additional disease detected by MRI is of clinical or biologic significance, particularly in light of the low local-regional failure rates currently reported in patients undergoing breast conserving surgery who receive whole breast irradiation and systemic therapies [4, 42].

The manifestation of an isolated metastatic axillary lymph node without any clinical and radiologic evidence of primary breast cancer is uncommon, but this disease most commonly originates from breast cancer in women. For these cases, the traditional therapy has been upper outer quadrantectomy or blind mastectomy with axillary lymph node dissection, with or without radiation. However, 30 to 40% of the upper outer quadrantectomy or blind mastectomy specimens show no histologic evidence of carcinoma, and the survival rate of

patients who undergo blind mastectomy with axillary dissection is similar to those who undergo axillary dissection only [43]. Breast MRI techniques have improved significantly in recent years, and MRI with dynamic enhancement has been established as an important imaging modality for evaluating breast cancer with the highest sensitivity.

A Korean study [44] investigated the ability of breast MR imaging to identify the primary malignant focuses in patients with metastatic axillary lymph nodes and initially negative mammography and sonography, and correlated the results with the conventional imaging. The authors concluded that the high sensitivity of contrast-enhanced breast MRI played an essential role in evaluating occult breast cancer in patients who presented with a metastatic axillary lymph node with an unknown primary malignancy, and contrast-enhanced breast MRI also played an essential role for determining the therapeutic plan. In 90% of their cases, histologic work-up for the lesions detected on the breast MRI was practically feasible with successful localization being achieved under MR-guided, second-look US, or MR-correlated mammography.

With its recent technical advances, contrast-enhanced MRI plays an important role in identifying primary breast cancer, for defining the extent of tumor and for helping decide the therapeutic plans. While mammography is the primary imaging modality used to evaluate breast lesions, the false negative rate for mammography has been reported to be about 30%. [45, 46] The sensitivity of mammography is especially limited when the lesion is within dense breast parenchyma, and it is often as low as 45%. [8] Among mammography, US and MRI, MRI is the most sensitive method for evaluating breast cancer and it is well recognized that MRI can detect otherwise occult breast cancer [8, 32, 47].

A few previous reports that detailed the MR images of patients with axillary lymph node metastases, and the patients had prior negative clinical and mammography findings, demonstrated 36%, 75% and 86% rates of detecting cancer by breast MRI, respectively. [48, 49] In another previous study [50] on patients with axillary lymph node metastasis and negative clinical, mammographic and US findings, the investigators showed a lesion detection rate of 64% with breast MRI, and 67% of the detected lesions were found to be primary breast cancer [50].

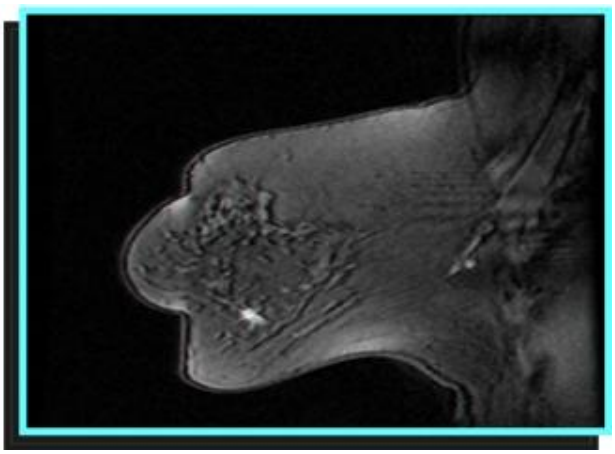

Figure 31. Small breast cancer in MRI.

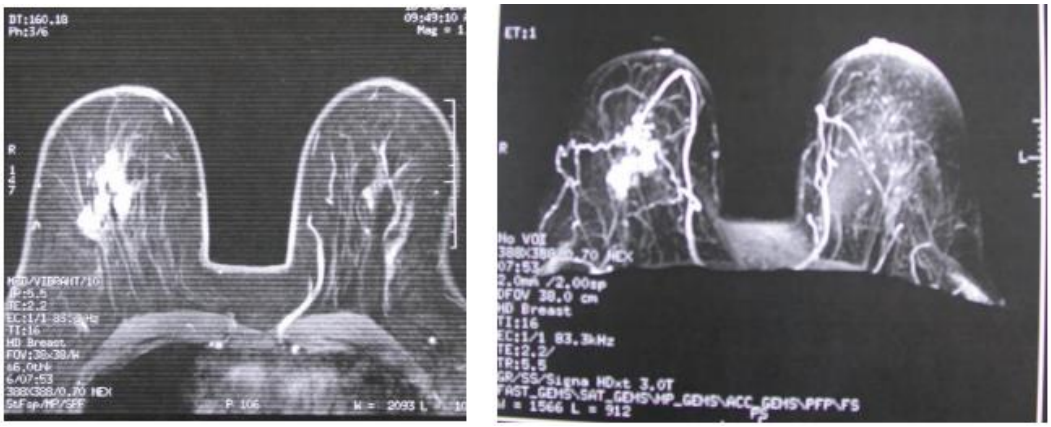

Figure 32. MRI Right breast tumor.

The reported mean size of the lesions visible by breast MRI alone was between 4.8 to 14.6 mm (Figure 31, 32) [44, 51].

Historically, the reported incidence of axillary metastasis in patients with DCIS is 1-2%, but the prevalence of positive lymph nodes in patients with pure DCIS is approximately 2-13% with performing immunohistochemical staining [52, 53].

Many authors suggest that before developing a therapeutic plan, breast MRI must be performed for those patients with axillary lymph node metastasis and who are without evidence of primary breast cancer. Although contrast-enhanced MRI has the highest sensitivity among the many imaging modalities for the breast, the specificity of breast MRI is low. [8, 47, 53] Therefore, preoperative biopsy or localization of the MRI-detected lesion is necessary. [54] Yet MR imaging-guided biopsy or localization requires commercially available MRI guiding equipment. Also, the cost-effectiveness of MRI-guided biopsy or localization has not yet been fully assessed. [55] Even when MRI guiding equipment is available, lesions in the medial breast are difficult to access and small enhancing lesions (around 5 mm) may be difficult to localize due to the transient nature of contrast enhancement and the obscuring that occurs when placing the biopsy needle. MR imaging-guided biopsy or localization is also a time-consuming procedure that lasts as long as 45 to 60 minutes [51, 54, 55].

A few studies have reported excellent performance of MR-guided second-look US localization. [48, 56] Therefore, localization with using MR-correlated mammography or MR-guided second-look US can be a cheaper, practical imaging alternative.

When BI-RADS category 2 or 3 lesions are detected on conventional images, but they do not correlate with the MR findings of the patients with suspicious occult breast cancer, then we should not neglect these lesions.

However, biopsy for all benign-looking lesions is not desirable or even necessarily meaningful [57]. When there is a benign or benign-looking lesion on the conventional images of the patients with metastatic axillary lymph node(s) and an unknown primary malignancy, then the conventional images should first be correlated with MR findings before performing a biopsy of the lesions [44].

3.1. MRI Report Organization

According to ACR BI-RADS® atlas the MRI reporting system should be concise and organized. Any pertinent clinical history that may affect scan interpretation, as well as any MRI acquisition techniques (including post-processing information) that may affect the scan interpretation, should be described (Table 5). The breast MRI report should first describe the amount of fibroglandular tissue and the background parenchymal enhancement (BPE -Table 6).

Abnormal enhancement (unique and separate from the BPE) is described based on morphology, distribution, and kinetics. Results from any physiologic or parametric imaging should be described.

An assessment is rendered that includes the degree of concern and any recommendation(s). Benign findings need not be reported, especially if the interpreting physician is concerned that the referring clinician or patient might infer anything other than absolute confidence in benignity.

Table 5. Report organization

	Report Structure
1.	Indication for examination
2.	MRI technique
3.	Succinct description of overall breast composition
4.	Clear description of any important findings
5.	Comparison to previous examination(s)
6.	Assessment
7.	Management

Table 6. Breast tissue: Background Parenchymal Enhancement (BPE)

	Background Parenchymal Enhancement
a.	Minimal
b.	Mild
c.	Moderate
d.	Marked

3.1.1. Indication for Examination

Provide a brief description of the indication for examination. For example, this may be high-risk screening, follow-up of a probably benign lesion, follow-up of cancer treated with neoadjuvant chemotherapy, or evaluation of the newly diagnosed cancer patient.

As background parenchymal enhancement can be affected by cyclical hormonal changes, it may be helpful to include menstrual history. If the patient is pre-menopausal, the week of the menstrual cycle may be important information to aid in interpretation. Current therapy (neoadjuvant, adjuvant, hormonal, or radiation therapy) for breast cancer treatment in the pre- or postsurgical setting may be important information and may inform exam interpretation.

The indication for examination should contain a concise description of the patient's clinical history, including:

a. Reason for performing the exam (e.g., screening, staging, problem solving)
b. Clinical abnormalities, including size, location, and duration
    i. Palpable finding
    ii. Nipple discharge
    iii. Other pertinent clinical findings or history
c. Previous biopsies
    i. Biopsy type
    ii. Biopsy location
    iii. Benign or malignant pathology (cytology or histology)
d. Hormonal status if applicable
    i. Pre- or post-menopausal
    ii. ii. Menstrual cycle phase (second week or other) or last menstrual period
    iii. Peripartum
    iv. Exogenous hormone therapy, tamoxifen, aromatase inhibitors, or other hormones or medications/herbs/vitamins that might influence MRI

3.1.2. MRI Technique

A detailed description of the technical factors of how the MRI examination was obtained must be given. At a minimum, a bright-fluid sequence of both breasts should be obtained. Pre- and post-gadolinium T1-weighted images should be obtained, preferably with fat suppression, simultaneously of both breasts. Subtraction imaging may be desired as well as other as processing techniques and parametric analysis. Elements of this description routinely include:

a. Right, left, or both breasts
b. Location of markers and their significance (scar, nipple, palpable lesion, etc.)
c. Weighting
    i. T1 weighted
    ii. ii. T2 weighted
    iii. Fat saturation
    iv. Scan orientation and plane
    v. Other pertinent pulse sequence features
d. Contrast dose
    i. Name of contrast agent
    ii. ii. Dosage (mmol/kg) and volume (in cc)
    iii. Injection type: bolus or infusion
    iv. Timing (relationship of bolus injection to scan start time and scan length)
    v. If multiple scans: number of post-contrast scans and acquisition techniques of each (how fast, how many slices, and slice thickness)
e. Post-processing techniques as applicable
    i. MPR/MIP (Multiplanar reconstruction / Maximum Intensity Projection)
    ii. ii. Time/signal intensity curves
    iii. Subtraction
    iv. Other techniques

3.1.3. Succinct Description of Overall Breast Composition

This should include an overall description of the breast composition, including:

a. The amount of FGT (FibroGlandular breast Tissue) that is present

The four categories of breast composition are defined by the visually estimated content of FGT within the breasts. If the breasts are not of apparently equal amounts of FGT the breast with the most FGT should be used to categorize breast composition. Although there may be considerable variation in visually estimating breast composition, categorizing based on percentages (and specifically into quartiles) is not recommended.

The BIRADS® committee recognizes that quantification of breast FGT volume on MRI may be feasible in the future, but they await publication of robust data before endorsing percentage recommendations. They urge the use of BI-RADS® terminology instead of numbers to classify breast FGT in order to eliminate any possible confusion with the BIRADS® assessment categories, which are numbered.

b. The amount of background parenchymal enhancement in the image

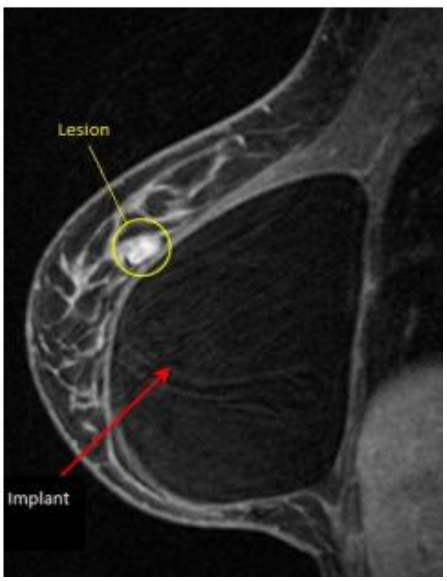

Figure 33. Breast MRI: Lesion over implant.

The four categories of BPE are defined by the visually estimated enhancement of the FGT of the breast(s). If the breasts are not of an apparently equal amount of BPE, the breast with the most BPE should be used to categorize BPE. In the event that treatment has altered BPE in one or both breasts, this can be reported. Although there may be considerable variation in visually estimating BPE, categorizing based on percentages (and specifically into quartiles) is not recommended.

Quantification of BPE volume and intensity on MRI may be feasible in the future, but the BIRADS® committee awaits publication of robust data on that topic before endorsing percentage recommendations.

The committee recognizes that there are variations in BPE distribution and morphology. However, committee defers on recommending descriptions of distribution or morphology until additional data are available. Currently, BPE refers to the volume of enhancement and the intensity of enhancement. On bilateral scans, describe whether the pattern is asymmetric or symmetric, if appropriate. Asymmetric denotes more enhancement in one breast than in the other. Symmetric enhancement is mirror image.

c. Whether implants are present (Figure 33)

If an implant is present, it should be so stated in the report. Information should include its composition (saline, silicone, or other) and the number of lumens (single or multiple).

3.1.4. Clear Description of Any Important Findings

Abnormal enhancement is unique and separate from BPE. Its description should indicate the breast in which the abnormal enhancement occurs, the lesion type, and modifiers. The clinical location of the abnormality as extrapolated from the MRI location (based on clock-face position and quadrant location) should be reported. It should be recognized that there may be variation in location of a clinically detected lesion (patient is upright or supine), a mammographically detected lesion (patient is upright and compressed), a sonographically detected lesion (patient is supine or supine oblique), and an MRI-detected lesion (patient is prone) based on positional differences.

A more consistent measurement is the distance from the nipple. It is encouraged that distance from the nipple for a lesion is reported in order to facilitate correlation between modalities, although it should be understood that one should expect some difference in distance from the nipple among the breast imaging modalities. For bilateral axial examinations, the breasts should be pointing up, following the cross-sectional imaging convention.

The descriptors should include techniques, all data, and any findings from MRI listed in Table 7.

Also, it is recognized that other techniques may be used in the evaluation of breast lesions. Newer and evolving techniques are constantly being introduced. Findings from other techniques, such as diffusion-weighted imaging or MR spectroscopy, should be reported if clinically important.

3.1.5. Comparison to Previous Examination(s)

Include a statement indicating that the current examination has been compared to previous examination(s) with specific date(s). If this is not included, it should be assumed that no comparison has been made; however, it is preferable to indicate explicitly that no comparison was made. Comparison to a previous examination may assume importance if the finding of concern requires an evaluation of change or stability. Comparison is less important when the finding has characteristically benign features. Comparison may be irrelevant if the finding is inherently suspicious for malignancy. Information in this area should include:

a. Previous MRI with the date of examination
b. Other imaging studies (mammogram, US, nuclear medicine examination, other) and date of examination (Figure 34, 35, 36).

Table 7. Description of all data and any important findings

a. Size
b. Location
i.Right or left
ii.Breast quadrant and clock-face position (or central, retroareolar, and axillary tail descriptors)
iii. Distance from nipple, skin, or chest wall in centimeters (if applicable)
Descriptors for abnormal enhancement:
c. Findings associated with abnormal enhancement include:
i. Artifacts that affect interpretation
ii. Focus: a tiny dot of enhancement that does not clearly represent a space-occupying lesion or mass and does not clearly show a mass on precontrast imaging
iii. Masses: space-occupying lesions, usually spherical or ball-like, may displace or retract surrounding breast tissue
Descriptors - modifiers describing a mass:
(a) Shape: describes the overall morphology of the enhancement
□Oval (includes lobulated)
□Round
□Irregular
(b) Margin: describes the borders
□Circumscribed
□Not circumscribed
- Irregular
- Spiculated
(c) Internal enhancement characteristics
Homogeneous
Heterogeneous
Rim enhancement
Dark internal septations

iv. Non-mass enhancement (NME): modifiers describing enhancement patterns with a specific MRI pattern
(a) Distribution
- Focal
- Linear
- Segmental
- Regional
- Multiple regions
- Diffuse

(b) Internal enhancement patterns (for all other types)
- Homogenous
- Heterogeneous
- Clumped
- Clustered ring

v. Intramammary lymph node (rarely important)
vi. Skin lesion
vii. Non-enhancing findings
a. Ductal precontrast high signal on T1W
b. Cyst
c. Postoperative collections (hematoma/seroma)
d. Post-therapy skin thickening and trabecular thickening
e. Non-enhancing mass
f. Architectural distortion
g. Signal void from foreign bodies, clips, etc.
viii. Associated features
a. Nipple retraction
b. Nipple invasion
c. Skin retraction
d. Skin thickening
e. Skin invasion (Direct invasion, Inflammatory cancer)
f. Axillary adenopathy
g. Pectoralis muscle invasion
h. Chest wall invasion
i. Architectural distortion

ix. Fat-containing lesions
(a) Lymph nodes
a. Normal
b. Abnormal
(b) Fat necrosis
(c) Hamartoma
(d) Postoperative seroma/hematoma with fat

x. Stability: describe how enhancement changed (if new, stable, or changed in size from previous examination)

xi. Kinetic curve assessment
(a) The fastest enhancing portion of the lesion or the most suspicious washout curve pattern in the lesion should be assessed
- Sample fast enhancing areas

Table 7. (Continued)

- Sample for and report on the worst looking curve shape

(b) Signal intensity/time curve
- Initial enhancement phase-describes the enhancement pattern within the first 2 minutes or when the curve starts to change
  - Slow
  - Medium
  - Fast
- Delayed phase – describe the enhancement pattern after 2 minutes or after the curve starts to change
  - Persistent
  - Plateau
  - Washout

xii. Implants

(a) Implant material and lumen type
- Saline
- Silicone
  - Intact
  - Ruptured
- Other implant material (such as soy oil, polypropylene, polyurethane, and sponges; includes direct injections)
- Lumen type

(b) Implant location
- Rectoglandular
- Retropectoral

(c) Abnormal implant contour
- Focal bulge

(d) Intracapsular silicone findings
- Radial folds
- Subcapsular line
- Keyhole design (teardrop, noose)
- Linguine sign

(e) Extracapsular silicone
- Breast
- Lymph nodes

(f) Water droplets

(g) Peri-impland fluid

3.1.6. Assessment

This is a description of an overall summary of MRI findings, including assessment.

Incorporating an assessment category in the overall summary of the breast MRI report is sound medical practice. All final impressions should be complete with each lesion fully categorized.

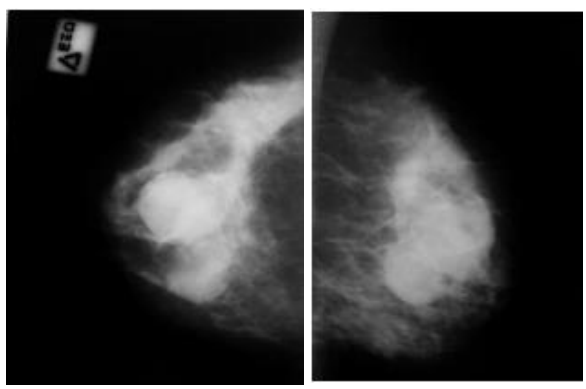

Figure 34. Mammography findings in a patient with cancer and large cysts in right breast.

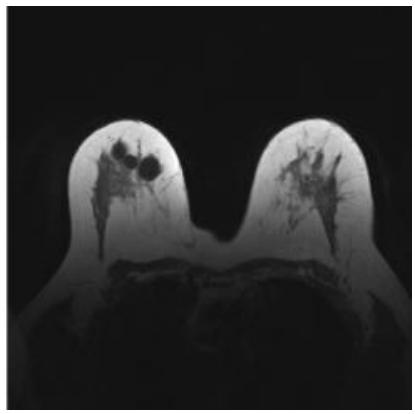

Figure 35. MRI of the same patient with breast cancer and cysts.

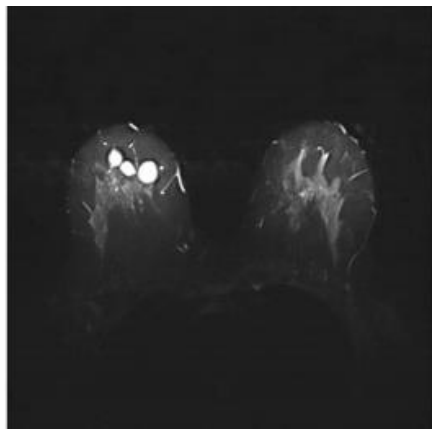

Figure 36. Abnormal enhancement on MRI.

An incomplete assessment (category 0) is used when full diagnostic imaging has not been performed and should be given only when additional imaging or clinical evaluation is recommended to establish the benignity of a finding (e.g., a possible intramammary lymph node or fat necrosis at MRI may require additional mammography and/or US examination).

3.1.7. Management

This is a description of patient management recommendations, as appropriate. If an incomplete assessment (category 0) is rendered, a specific suggestion for the next course of action should be given (physical examination, diagnostic mammography, targeted diagnostic US, etc.). Note that an incomplete assessment (category 0) should not be rendered when recommending targeted US in order to determine the feasibility of performing biopsy using sonographic guidance; such a scenario requires the use of a category 4 or 5 assessment (suspicious or highly suggestive of malignancy).

If a suspicious abnormality is detected, the report should indicate that a biopsy should be performed in the absence of clinical contraindication. This means that the radiologist has sufficient concern that a biopsy is warranted; the term “clinical contraindication” indicates that there may be reasons why the patient and her physician might wish to defer the biopsy.

Concordance between BIRADS® assessment categories and management recommendations is listed in Table 8.

MRI of the breast has evolved into an important tool in breast imaging with increasing indications for its use. MRI has plenty advantages such as increased contrast of tissues, multiple views, less ionizing radiation, use of contrast enhancement time course to differentiate benign from malignant lesions, detecting lesions close to chest wall and occult breast lesions, higher sensitivity but still poor specificity. The high sensitivity of MRI but it's not so high specificity creates many false-positive results and callbacks for further evaluation, including second-look ultrasound studies and biopsies. Another disadvantage is the newly recognized but rare side effect of MRI, nephrogenic sclerosing fibrosis that is related to intravenous administration of MRI contrast agents. Special attention is needed for women with impaired renal function or renal failure. [58] The limitations of MRI include its high cost, unsuitability for some patients (those who are obese, have pacemakers, or have renal failure), the potential for unnecessary biopsies, lack of portability and the length of time required for imaging.

Table 8. Concordance between BI-RADS® assessment categories and management recommendations

Assessment	Management	Likelihood of Cancer
Category 0: Incomplete – Need additional Imaging Evaluation	Recommend additional imaging: mammogram or targeted US	N/A
Category 1: Negative	Routine breast MRI screening if cumulative lifetime risk $\geq$ 20%	Essentially 0% likelihood of malignancy
Category 2: Benign	Routine breast MRI screening if cumulative lifetime risk $\geq$ 20%	Essentially 0% likelihood of malignancy
Category 3: Probably Benign	Short-interval (6-month) follow-up)	$\geq$ 0% but $\leq$ 2% likelihood of malignancy
Category 4: Suspicious	Tissue diagnosis	>2% but <95% likelihood of malignancy
Category 5: Highly Suggestive of Malignancy	Tissue diagnosis	> 95% likelihood of malignancy
Category 6: Known Biopsy-Proven Malignancy	Surgical excision when clinically appropriate	N/A

4. COMPUTERIZED TOMOGRAPHY SCAN (CT SCAN)

A computed tomography (CT or CAT) scan is not routinely used for breast cancer screening or diagnosis, but can be useful for contrast-enhancing lesions and lesions close to chest wall (contrast enhancing lesions suggest malignancy) (Figures 37, 38, 39). CT scan is routinely used to assess for chest, liver, pelvic and bony metastases and post-treatment follow-up.

Figure 37. Breast mass in CT scan.

Figure 38. Breast cancer in Pre contrast CT scan.

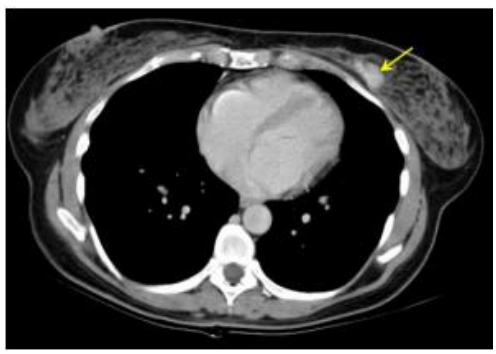

Figure 39. Post contrast CT scan enhancing lesion (yellow arrow), suggesting malignancy.

5. Positron Emission Tomography (PET) Scan

Most breast malignancies have greater metabolism than normal tissues and concentrate 18F-fluorodeoxyglucose (FDG), the agent most widely used in clinical positron emission tomography (PET) scanning. [59, 60] Whole-body PET does not have the spatial resolution needed for breast imaging. PET/computed tomography has been shown to be useful in the

restaging of breast cancer, in evaluation of response to therapy, and as a problem-solving method. [59, 61] Small, dedicated PET scanners have been developed for breast imaging, which use gentle compression.

The radiopharmaceutical that is primarily used in the clinical evaluation of most cancers, including breast cancer, is FDG. FDG is widely available from commercial radiopharmacies and provides clinically important information relevant to cancer. Other radiopharmaceuticals, such as F-18 fluoroestradiol and F-18 fluoro-L-thymidine, are now being evaluated in breast cancer patients, but these radiopharmaceuticals have not assumed a clinical role at this time.

The FDG is administered intravenously in the arm opposite a known or suspected breast lesion or through a foot vein, because extravasation can result in axillary lymph node accumulation. Accumulation in an axillary lymph node could be from either metastatic disease or extravasation, so it is important not to inject in the arm on the side of the lesion. The patient should be comfortable and warm after administration of the FDG. Movement of the head and neck should be minimized to avoid accumulation in neck and shoulder girdle muscles. Furthermore, some evidence suggests that keeping the patient comfortably warm at the time of administration decreases accumulation in brown fat that may be confused with supraclavicular and internal mammary lymph node accumulation. For the evaluation of primary breast lesions, some authors have suggested the use of prone imaging and 3-hour delayed imaging.

In most studies of FDG-PET imaging in breast cancer (Figure 40), investigators have administered 10-20 mCi of FDG, and imaging is started 45-60 minutes after injection. Whole-body scans have included the external auditory meatus through the proximal thighs. Attenuation corrected scans are performed. It is unclear at this time whether 3-dimensional acquisitions will have an advantage over the 2-dimensional acquisitions that have been used until now. Furthermore, the advantages of the combined PET and computed tomography over dedicated PET scanners alone have not been demonstrated at this time.

A pilot study of positron emission mammography (PEM) by Tafra et al. evaluated 44 images. PEM demonstrated 89% of the lesions. Multifocal disease was correctly ruled out in 17 of 17 cases. [62] Berg et al. found that PEM combined with mammography and sonography yielded 47 (98%) of 48 cancers. [8] Dense breasts do not appear to negatively affect PEM as they do mammography. Lower-grade tumors are more likely to be missed, which makes sense, as the technique employed in PEM is based on FDG concentration [59].

Positron emission tomography (PET) scans are one of the tests oncologists can use to establish a baseline of whether and to what extent your cancer may have spread to other parts of your body. The problem with PET scans is that they are not very accurate, because they are not very good at finding small cancer spots. In the past, tumor needs to be at least 2cm to be seen on the scan. There are now newer scans that are a bit better and they can detect virtually all 2 cm lesions. However, they can only detect about one-third of those that are smaller than 1 cm. This means they can result in a false negative result. In addition, they often give false positive results, indicating that something might be cancer when it is really an inflammation, infection, or cells that happen to be growing rapidly.

In a prospective study that evaluated the accuracy of PET in axillary nodal staging in 360 women with newly diagnosed breast cancer, PET had a 61% sensitivity and 80% specificity. [63] Patients with small nodal metastases and with only a few lymph nodes involved have their conditions missed on PET scans. PET is not accurate enough to replace the sentinel lymph node study. In a study that evaluated the impact of the site of the primary breast

cancer, patients having inner quadrant primary cancers had a much greater frequency of extra-axillary metastases than did patients having outer quadrant primaries and were twice as likely to have progression of their disease.

Several studies have evaluated the accuracy of FDG-PET in detecting primary breast cancer. A meta-analysis of the PET literature that included 606 patients demonstrated that PET had a sensitivity of 88% and a specificity of 79%. [64] The mean tumor size included in these studies ranged from 2-4 cm in diameter. Most false-negative results relate to small lesions (<1 cm), low-grade malignancy, and noninvasive cancers. False-positive results occur primarily from infectious or inflammatory lesions, such as mastitis and hemorrhagic inflammation after biopsy or surgery.

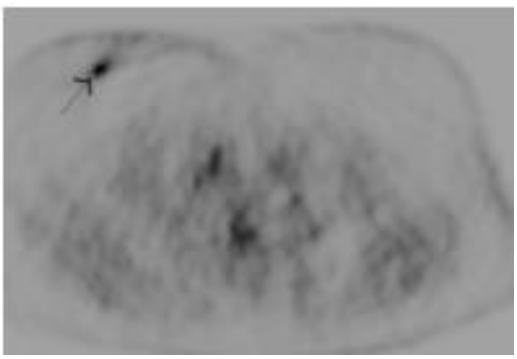

Figure 40. Invasive ductal carcinoma in PET scan (arrow).

PET in Lymph Node Staging

The evaluation of the axillary lymph nodes is important for determining prognosis (Figure 41). The 10-year survival of patients with negative axillary lymph nodes is 65% to 80% and is significantly greater than in patients with 1-3 nodes, who have a 38% to 63% 10-year survival, and in those patients with more than 3 axillary nodes, who have a 13% to 27% 10-year survival. [65] Axillary lymph node involvement influences the selection of treatment. Clinical evaluation, including conventional imaging, is not accurate in detecting axillary nodal disease. Sentinel lymph node localization is performed using Tc 99m-labeled colloids and/or blue dye in patients with invasive cancers that are 2 cm or less in diameter. Most of these patients (>80%) have negative axillary lymph nodes at surgery. Axillary nodal surgery has well-known risks, including lymphedema and diminished upper extremity motility and functioning. Metastases to the internal mammary lymph nodes have similar prognostic significance and occasionally are the only site of metastatic disease. The internal mammary lymph nodes are typically not assessed pathologically because of the extensive surgery required to sample these nodes. FDG-PET imaging has been used to evaluate whether it can replace or supplement the information available for lymphoscintigraphy and axillary lymph node staging. Several studies have evaluated FDG-PET for the detection of axillary metastatic disease. These studies have generally shown sensitivity between 50% and 100% and specificities between 67% and 100%. PET has minimal impact on patients with palpable axillary lymph nodes, because these patients will undergo axillary dissection. Thus, it is

important to consider the patients with nonpalpable lymph nodes. A meta-analysis of FDG-PET has demonstrated that it has a 95% sensitivity and an 88% specificity for palpable axillary lymph nodes compared with the 90% sensitivity and 94% specificity in patients having nonpalpable lymph nodes [64].

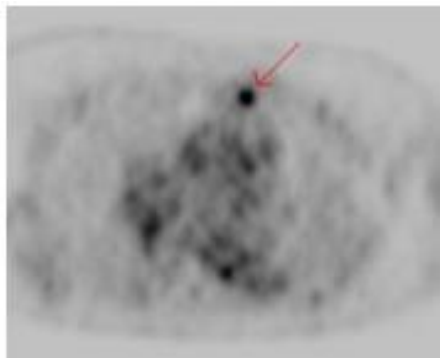

Figure 41. Breast cancer metastasis in internal mammary lymph node in PET scan (arrow).

Wahl et al., [66] performed a prospective study of axillary nodal staging. This study included 360 women with newly diagnosed breast cancer. The FDG-PET images of the draining nodal regions were interpreted qualitatively and qualitatively in a blinded manner by 3 experienced readers. The results from 308 assessable axillae were compared with axillary node pathology to determine the accuracy of the PET findings. The prevalence of axillary nodal metastases was 35%. The mean estimated area under the receiver operating characteristic curve for the 3 readers was 0.74. When at least 1 abnormal axillary focus was identified, the sensitivity was 61%, specificity was 80%, positive predictive value was 62%, and negative predictive value was 79%. False-negative results were obtained in patients who had smaller and fewer lymph nodes. The use of the standardized uptake value (SUV) normalized to lean body mass showed a positive predictive value of 90% and a sensitivity of 32% at an SUV of 1.8 or greater. If two or more foci of abnormal accumulation were noted, the predictive accuracy was 78% to 83%, but at a sensitivity of only 27%. The authors conclude that PET is not recommended for routine staging of the axilla in most patients with newly diagnosed breast cancer.

PET in Distant Metastatic Disease

In addition to detecting the primary breast cancer and loco-regional metastases, whole-body FDG-PET can detect distant metastatic disease to the soft tissues, viscera, and bone. FDG-PET imaging has been shown to be accurate for the detection of distant metastatic disease. In a study by Dehdashti and colleagues, [67] PET had a sensitivity of 89% and specificity of 100% for differentiating benign from malignant lesions. PET has been shown to identify metastatic disease that is not detected by conventional imaging. A study by Schirrmeister and colleagues [68] evaluated 89 patients with breast cancer undergoing initial staging. FDG-PET detected distant metastatic disease in 7 patients, 3 of whom had negative

conventional imaging study results. Four patients had false-positive bone scintigraphy and true-negative PET scan results.

Tran and colleagues [69] evaluated the frequency of extra-axillary metastases in the absence of axillary involvement in breast cancer patients with outer quadrant primary lesions and compared this frequency with that of inner quadrant breast cancers. Their study included 141 breast cancer patients, with 42 having inner quadrant lesions and 99 having outer quadrant lesions. The patients underwent a 3-year postscan and clinical follow-up. The patients with inner quadrant cancers had a 6-fold greater frequency of PET findings of extra-axillary metastasis compared with patients who had outer quadrant cancer. The patients with inner quadrant disease were twice as likely to experience progression of their disease as were patients with outer quadrant lesions.

Bone metastases are major contributors to the morbidity of breast cancer. The median survival of patients with metastatic disease to bone is 24 months. [70] Bone scintigraphy, the primary modality used for evaluating skeletal metastatic disease in breast cancer, has a low specificity and sensitivity for detecting osteolytic lesions. FDG-PET has been demonstrated to be more sensitive than bone scintigraphy. The FDG-PET scan is more accurate in detecting osteolytic lesions than osteoblastic lesions [71].

PET in Monitoring Therapeutic Response

The only cancer that Medicare has approved coverage for therapeutic monitoring is breast cancer. The assessment of response to therapy in patients with advanced breast cancer is important because preoperative therapy predicts outcome. Patients who respond to the chemotherapy or hormonal therapy have a better prognosis than patients who do not respond. Schelling and colleagues, [72] in a study of 22 patients with locally advanced breast cancer, demonstrated that PET correctly identified responders from nonresponders with a sensitivity of 100% and specificity of 85%. Response was defined as a decrease in the tumor SUV to less than 55% of the baseline value.

SPECT-CT Scan

SPECT-CT is where two different types of scans are taken and the images or pictures from each are fused or merged together. The fused scan can provide more precise information about how different parts of the body function and more clearly identify problems such as breast tumours. Single photon emission computed tomography (SPECT): SPECT images are obtained following an injection of a radiopharmaceutical that is used for nuclear medicine scans. The injected medication sticks to specific areas in the body, depending on what radiopharmaceutical is used and the type of scan being performed.

The radiopharmaceutical is detected by a nuclear medicine gamma camera. The camera or cameras rotate over a 360 degree arc around the patient, allowing for reconstruction of an image in three dimensions. CT scanner rotates much faster than the gamma camera, so the CT part of the study takes less time than the SPECT study.

The similarity between SPECT and CT in the method of image processing allows the images to be combined.

Preoperative imaging technologies such as scintigraphy or, recently, SPECT/CT may contribute to the precise localization of the SLN(s) and support surgical planning. [74, 75] Fluorescence imaging systems, mini gamma cameras and freehand SPECT (FhSPECT) have been suggested as alternatives that allow image-guided resection of the SLN. The first two technologies provide 2-D images of either fluorescent or radioactively labelled SLNs, [76-78] but none of the technologies has yet found its way into clinical routine. The FhSPECT technology was developed by a joint research group of the Faculty of Computer Science and the Faculty of Medicine at Technische Universität München and utilizes 3-D images, thus providing additional depth information and the possibility of image fusion with a live video of the operation sites (Figure 42) [79].

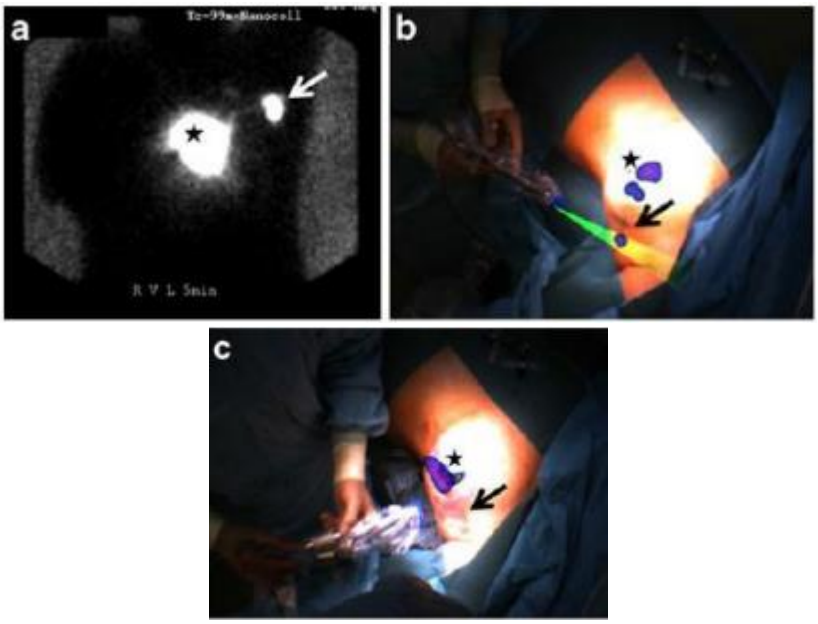

Figure 42. Patient with SLN (arrows) in the left axilla: a. preoperative scintigram; b. pre-incision FhSPECT image; c. postoperative FhSPECT image with no remaining activity (stars injection site).

FDG-PET plays an important role in the evaluation of patients with breast cancer. Its role in the detection of primary breast cancer is still under evaluation. FDG-PET is useful in the initial staging and restaging of patients with locally advanced breast cancer. FDG-PET scanning is not accurate enough to replace sentinel lymph node studies for the evaluation of axillary nodal involvement. FDG-PET scanning is rapidly becoming a critical method for monitoring response to therapy in patients with locally advanced breast cancer [73].

6. SCINTIMAMMOGRAPHY

Another form of breast imaging that involves the functional uptake of radiotracers is scintimammography. It uses 99Tcsestamibi, which is taken up by breast cancers. A dual-head machine was tested at the Mayo Clinic, which studied more than 900 patients in 6 years. [59] The machine functions independent of breast density. Heavy compression of the breast is not

required. They found a 97% concordance with mammography. Medicare charges are estimated at $1,029.69 for MRI and $292.12 for scintimammography. The final sensitivity is over 90%, making this a useful adjunct to mammography. [80] As these are emerging technologies that are not yet widely used, clinical data are still scarce.

Guidelines for Breast Cancer Screening

The American Cancer Society (ACS) guidelines for breast cancer screening currently recommend that for average-risk women mammographic screening begin at age 40 years and continuing for as long as a woman is in good health. Breast self-exam (BSE) is an option for women starting in their 20s. Women in their 20s and 30s should have a clinical breast exam every 3 years. Women over 40 years of age should have a clinical breast examination yearly. Women should be told about the benefits and limitations of breast self-examination and the importance of prompt reporting of any new breast symptoms. As long as a woman is in reasonably good health and would be a candidate for treatment, she should continue to be screened with mammography.

For women at high risk, earlier initiation of screening, shorter screening intervals, or the addition of other modalities may provide benefit. It recommended annual MRI screening in addition to mammography for BRCA mutation carriers; first-degree relatives of BRCA carriers who are untested and those patients with a calculated lifetime risk of 20% to 25% or greater as defined by BRCAPRO or other models that are largely dependent on family history. MRI is also recommended for patients who received radiation to their chest between age 10 and 30 years, patients with Li-Fraumeni syndrome and their first-degree relatives, and patients with Cowden and Bannayan-Riley-Ruvalcaba syndromes and their first-degree relatives.

Life expectancy continues to increase, and in developed countries women aged 75 years and older represent an increasing percentage of the population. Evidence-based guidelines for the regular screening of older women are lacking. Patients with life expectancies less than 5 years are not likely to derive any survival benefit from cancer screening. However, age in itself should not be a reason to stop screening but rather the patients overall health and ability to receive treatment and benefit from the screening.

REFERENCES

[1] Makariou E, Sayah A. Imaging of the surgically altered breast. In "*Surgery of the breast – Principles and Art*", 3rd ed, S. Spear et al, Lippincott 2011; 16-34.

[2] Berg WA. Rationale for a trial of screening breast ultrasound: American College of Radiology Imaging Network (ACRIN). *AJR Am. J. Roentgenol.* 2003;180:1225–1228.

[3] Mandelblatt JS, Cronin KA, Bailey S, et al. Effects of mammography screening under different screening schedules: model estimates of potential benefits and harms. *Ann. Intern. Med.* 2009;151(10):738–47.

[4] Hunt KK, Robertson JFR, Bland KI. The Breast. In *Schwartz's Principles of Surgery*, Editor-in-Chief F. Charles Brunicardi, by McGraw-Hill Education, 2015; 523-529.

[5] Crystal P, Strano SD, Shcharynski S, et al. Using sonography to screen women with mammographically dense breasts. *AJR Am. J. Roentgenol.* 2003;181:177–182.

[6] Skandalakis JE, Colburn GL, Weidman TA, Foster RS Jr, Kingsworth AN, Skandalakis LJ, Skandalakis PN, Mirilas PS. The breast. In *Skandalakis' Surgical Anatomy*, 2004; 185-203.

[7] Mustonen P, Farin P, Kosunen O. Ultrasonographic detection of metastatic axillary lymph nodes in breast cancer. *Ann. Chir. Gynaecol.* 1990;79:15–8.

[8] Berg WA, Gutierrez L, Ness Aiver MS, et al. Diagnostic accuracy of mammography, clinical examination, US, and MR imaging in preoperative assessment of breast cancer. *Radiology* 2004;233:830–849.

[9] Park SH, Kim MJ, Park BW, et al. Impact of Preoperative Ultrasonography and Fine-Needle Aspiration of Axillary Lymph Nodes on Surgical Management of Primary Breast Cancer. *Ann. Surg. Oncol.* 2011;18:738–744.

[10] Moore A, Hester M, Nam MW, et al. Distinct lymph nodal sonographic characteristics in breast cancer patients at high risk for axillary metastases correlate with the final axillary stage. *Br. J. Radiol.* 2008;81:630–6.

[11] Veronesi U, Paganelli G, Galimberti V, Viale G, Zurrida S, Bedoni M, et al. Sentinel-node biopsy to avoid axillary dissection in breast cancer with clinically negative lymph-nodes. *Lancet* 1997;349:1864–7.

[12] de Paredes, Ellen Shaw. *Atlas of Mammography*, 3rd Edition, Lippincott Williams & Wilkins, 2007;104-125.

[13] Krishnamurthy S, Sneige N, Bedi DG, et al. Role of ultrasound-guided fine-needle aspiration of indeterminate and suspicious axillary lymph nodes in the initial staging of breast carcinoma. *Cancer* 2002;95:982-988.

[14] Aragon R, Morgan J, Wong JH, Lum S. Potential Impact of USPSTF Recommendations on Early Diagnosis of Breast Cancer. *Ann. Surg. Oncol.* 2011; 18:3137–3142.

[15] Berry DA, Cronin KA, Plevritis SK, et al. Effect of screening and adjuvant therapy on mortality from breast cancer. *N. Engl. J. Med.* 2005;353(17):1784-92.

[16] Nystrom L, Andersson I, Bjurstam N, Frisell J, Nordenskjold B, Rutqvist LE. Long-term effects of mammography screening: updated overview of the Swedish randomised trials. *Lancet.* 2002;359(9310):909-19.

[17] Cady B, Michaelson JS, Chung MA. The ‘‘tipping point’’ for breast cancer mortality decline has resulted from size reductions due to mammographic screening. *Ann. Surg. Oncol*. 2011;18(4): 903–6.

[18] Virnig BA, Wang SY, Shamilyan T, Kane RL, Tuttle TM. Ductal carcinoma in situ: risk factors and impact of screening. *J Natl Cancer Inst Monogr.* 2010;(41):113-116.

[19] Ciatto S, Houssami N, Bernardi D, et al. Integration of 3D digital mammography with tomosynthesis for population breast cancer screening (STORM): a prospective comparison study. *Lancet Oncol.* 2013; 14:70134-70137.

[20] Jackson VP, Dines KA, Bassett LW, et al. Diagnostic importance of the radiographic density of noncalcified breast masses: analysis of 91 lesions. *AJR Am. J. Roentgenol.* 1991;157:25-28.

[21] Swann CA, Kopans DB, Koerner FC, et al. The halo sign and malignant breast tissues. *AJR Am. J. Roentgenol.* 1978;149: 1145-1147.

[22] Fournier DV, Weber W, Hoeffken M, et al. Growth rate of 147 mammary carcinomas. *Cancer* 1980;45:2198-2207.
[23] Heuser L, Spratt J, Polk H. Growth rates of primary breast cancer. *Cancer* 1979;43:1888-1894.
[24] Meyer JE, Kopans DB. Stability of a mammographic mass: a false sense of security. *AJR Am. J. Roentgenol.* 1981;137:595-598.
[25] Allen SD, Nerurkar A, Querci Della Rovere GU. The breast lesion excision system (BLES): a novel technique in the diagnostic and therapeutic management of small indeterminate breast lesions? *Eur. Radiol.* 2011;77(3):377-52.
[26] Kass R, Kumar G, Klimberg VS, et al. Clip migration in stereotactic biopsy. *Am. J. Surg.* 2002;184:325–331.
[27] Lamm RL, Jackman RJ. Mammographic abnormalities caused by percutaneous stereotactic biopsy of histologically benign lesions evident on follow-up mammograms. *AJR Am. J. Roentgenol.* 2000;174:753–756.
[28] Liberman L, Hann LE, Dershaw DD, et al. Mammographic findings after stereotactic 14-gauge vacuum biopsy. *Radiology* 1997;203:343–347.
[29] Kaye MD, Vicinanza-Adami CA, Sullivan ML. Mammographic findings after stereotaxic biopsy of the breast performed with large-core needles. *Radiology* 1994;192:149–151.
[30] Brenner RJ, Pfaff JM. Mammographic changes after excisional breast biopsy for benign disease. *AJR Am. J. Roentgenol.* 1996;167:1047–1052.
[31] Sickles EA, Herzog KA. Mammography of the postsurgical breast. *AJR Am. J. Roentgenol.* 1981;136:585–588.
[32] Orel SG, Schnall MD. MR imaging of the breast for the detection, diagnosis, and staging of breast cancer. *Radiology* 2001;220:13–30.
[33] Lehman CD. Role of MRI in screening women at high risk for breast cancer. *J. Magn. Reson. Imaging* 2006;24:964–970.
[34] Lee CH. Problem solving MR imaging of the breast. *Radiol. Clin. N. Am.* 2004;42:919–934.
[35] Rim A, Chellman-Jeffers M. Trends in breast cancer screening and diagnosis. *Cleve. Clin. J. Med.* 2008;75(suppl 1):S2–S9.
[36] Berman CG. Recent advances in breast-specific imaging. *Cancer Control* 2007;14(4):338–349.
[37] Buadu LD, Murakami J, Murayama S, et al. Breast lesions: correlation of contrast medium enhancement patterns on MR images with histopathologic findings and tumor angiogenesis. *Radiology* 1996;200(3):639–649.
[38] Nunes LW. Architectural-based interpretations of breast MR imaging. *Magn Reson Imaging Clin. N. Am.* 2001;9(2):303–320.
[39] Harms SE, Flamig DP, Hesley KL, et al. MR imaging of the breast with rotating delivery of excitation off resonance: clinical experience with pathologic correlation. *Radiology* 1993;187:493–501.
[40] Orel SG, Schnall MD, Powell CM, et al. Staging of suspected breast cancer: effect of MR imaging and MR-guided biopsy. *Radiology* 1995;196:115–122.
[41] Turnbull L, Brown S, Harvey I, et al. Comparative effectiveness of MRI in breast cancer (COMICE) trial: a randomized controlled trial. *Lancet.* 2010;375:563-571.

[42] Houssami N, Turner R, Morrow M. Preoperative magnetic resonance imaging in breast cancer: meta-analysis of surgical outcomes. *Ann. Surg.*. 2013; 257:249-255.

[43] Jackson B, Scott-Conner C, Moulder J. Axillary metastasis from occult breast carcinoma: diagnosis and management. *Am. J. Surg.* 1995;61:431-434.

[44] Ko EY, Han B-K, Shin JH, Kang SS. Breast MRI for Evaluating Patients with Metastatic Axillary Lymph Node and Initially Negative Mammography and Sonography. *Korean J. Radiol.* 2007;8:382-389.

[45] Harvey JA, Fajardo LL, Innis CA. Previous mammograms in patients with impalpable breast carcinoma: retrospective vs blinded interpretation. 1993 ARRS President's Award. *AJR Am. J. Roentgenol.* 1993;161:1167-1172.

[46] Majid AS, de Paredes ES, Doherty RD, Sharma NR, Salvador X. Missed breast carcinoma: pitfalls and pearls. *Radiographics* 2003;23:881-895

[47] Dershaw DD. Magnetic resonance imaging as a clinical tool. In: Morris EA, Liberman L, eds. *Breast MRI; Diagnosis and intervention*. New York, NY: Springer, 2004:256-264.

[48] Obdeijn IM, Brouwers-Kuyper EM, Tilanus-Linthorst MM, Wiggers T, Oudkerk M. MR imaging-guided sonography followed by fine-needle aspiration cytology in occult carcinoma of the breast. *AJR Am. J. Roentgenol.* 2000;174:1079-1084.

[49] Morris EA, Schwartz LH, Dershaw DD, van Zee KJ, Abramson AF, Liberman L. MR imaging of the breast in patients with occult primary breast carcinoma. *Radiology* 1997;205:437-440.

[50] Schorn C, Fischer U, Luftner-Nagel S, Westerhof JP, Grabbe E. MRI of the breast in patients with metastatic disease of unknown primary. *Eur. Radiol*. 1999;9:470-473.

[51] Kuhl CK, Morakkabati N, Leutner CC, Schmiedel A, Wardelmann E, Schild HH. MR imaging—guided large-core (14-gauge) needle biopsy of small lesions visible at breast MR imaging alone. *Radiology* 2001;220:31-39.

[52] Zujewski J, Eng-Wong J. Sentinel lymph node biopsy in the management of ductal carcinoma in situ. *Clin. Breast Cancer* 2005;6:216-222.

[53] Sakr R, Barranger E, Antoine M, Prugnolle H, Darai E, Uzan S. Ductal carcinoma in situ: value of sentinel lymph node biopsy. *J. Surg. Oncol.* 2006;94:426-430.

[54] Lara JF, Young SM, Velilla RE, Santoro EJ, Templeton SF. The relevance of occult axillary micrometastasis in ductal carcinoma in situ: a clinicopathologic study with long-term follow-up. *Cancer* 2003;98:2105-2113.

[55] Harms SE, Flamig DP, Hesley KL, Meiches MD, Jensen RA, Evans WP, et al. MR imaging of the breast with rotating delivery of excitation off resonance: clinical experience with pathologic correlation. *Radiology* 1993;187:493-501.

[56] Friedman P, Sanders L, Russo J, Sharo R, Swaminathan S, Smith R. Detection and localization of occult lesions using breast magnetic resonance imaging: initial experience in a community hospital. *Acad. Radiol.* 2005;12:728-738.

[57] American College of Radiology. BI-RADS: Breast Imaging Reporting and Data System Atlas(BI-RADS) atlas, 5th ed. *American College of Radiology,* 2013.

[58] Deo A, Fogel M, Cowper SE. Nephrogenic systemic fibrosis: a population study examining the relationship of disease development to gadolinium exposure. *Clin. J. Am. Soc. Nephrol.* 2007;2:264–267.

[59] Cocilovo C. Breast Cancer Screening and Diagnosis. In "*Surgery of the breast – Principles and Art*", 3rd ed, S. Spear et al, Lippincott 2011; 13.

[60] Ringash J. Preventive health care, 2001 update: screening mammography among women aged 40–49 years at average risk of breast cancer. *Can. Med. Assoc. J.* 2001;164(4):469–476.

[61] Rosen EL, Eubank WB, Mankoff DA, et al. FDG PET, PET/CT, and breast cancer imaging. *Radiographics* 2007;27(suppl 1):S215–S229.

[62] Tafra L, Cheng Z, Uddo J, et al. Pilot clinical trial of 18 F-fluorodeoxyglucose positronemission mammography in the surgical management of breast cancer. *Am. J. Surg.* 2005;190(4):628–632.

[63] Wahl RL, Siegel BA, Coleman RE, Gatsonis CG. Prospective multicenter study of axillary nodal staging by positron emission tomography in breast cancer: a report of the staging breast cancer with PET Study Group. *J. Clin. Oncol*. 2004: 15;22(2):277-85.

[64] Samson D, Flamm CR, Aronson N. *FDG Positron Emission Tomography for Evaluation of Breast Cancer*. Chicago, Illinois: Blue Shield and Blue Cross Association; 2001:1-93.

[65] Hellman S, Harris JR. Natural history of breast cancer. In: Harris JR, Lippman ME, Marrow M, Osborne CK, eds. *Diseases of the Breast*. 2nd ed. Philadelphia, Pa: Lippincott Williams & Wilkins; 2000:407-423.

[66] Wahl RL, Siegel BA, Coleman RE, Gatsonis CG. Prospective multi-center study of axillary nodal staging with FDG positron emission tomography in breast cancer. *J. Nucl. Med*. 2003;5(suppl):77P.

[67] Dehdashti F, Mortimer JE, Siegel BA, et al. Positron tomographic assessment of estrogen receptors in breast cancer: comparison with FDG-PET and in vitro receptor assays. *J. Nucl. Med*. 1995;36:1766-1774.

[68] Schirrmeister H, Kuhn T, Guhlmann A, et al. Fluorine-18 2-deoxy-2-fluoro-D-glucose PET in the preoperative staging of breast cancer: comparison with the standard staging procedures. *Eur. J. Nucl. Med.* 2001;28:351-358.

[69] Tran A, Khatibi B, Czernis J, Phelps ME, Silvermen DH. Prognostic value of FDG-PET in staging breast cancer patients with inner quadrant primary tumors: comparison with long-term outcomes. *J. Nucl. Med.* 2003;5(suppl):77P.

[70] Mundy GR, Guise TA, Yoneda T. Biology of bone metastases. In: Harris JR, Lippman ME, Marrow M, Osborne CK, eds. *Diseases of the Breast*. 2nd ed. Philadelphia, Pa: Lippincott Williams & Wilkins; 2000:911-920.

[71] Cook GJ, Houston S, Rubens R, et al. Detection of bone metastases in breast cancer by 18FDG PET: differing metabolic activity in osteoblastic and osteolytic lesions. *J. Clin. Oncol*. 1998;16:3375-3379.

[72] Schelling M, Avril N, Nahrig J, et al. Positron emission tomography using [18F]fluorodeoxyglucose for monitoring primary chemotherapy in breast cancer. *J. Clin. Oncol*. 2000;18:1689-1695

[73] R Edward Coleman. *PET Scanning of Breast Cancer: State-of-the-Art*. http://www.medscape.org/viewarticle/461316 2003.

[74] Bluemel C, Schnelzer A, Okur A, et al. Freehand SPECT for image-guided sentinel lymph node biopsy in breast cancer. *Eur. J. Nucl. Med. Mol. Imaging* (2013) 40:1656–1661.

[75] Ibusuki M, Yamamoto Y, Kawasoe T, et al. Potential advantage of preoperative three dimensional mapping of sentinel nodes in breast cancer by a hybrid single photon emission CT (SPECT)/CT system. *Surg. Oncol*. 2010;19:88–94.

[76] Troyan SL, Kianzad V, Gibbs-Strauss SL, et al. The FLARE intraoperative near-infrared fluorescence imaging system: a first-in-human clinical trial in breast cancer sentinel lymph node mapping. *Ann. Surg. Oncol.* 2009;16:2943–52.

[77] Scopinaro F, Tofani A, di Santo G, et al. High-resolution, hand-held camera for sentinel node detection. *Cancer Biother Radiopharm.* 2008;23:43–52.

[78] Kerrou K, Pitre S, Coutant C, et al. The usefulness of a preoperative compact imager, a hand-held gamma-camera for breast cancer sentinel node biopsy: final results of a prospective double-blind, clinical study. *J. Nucl. Med*. 2011;52:1346–53.

[79] Wendler T, Hartl A, Lasser T, et al. Towards intra-operative 3D nuclear imaging: reconstruction of 3D radioactive distributions using tracked gamma probes. *Med. Image Comput Comput Assist. Interv*. 2007;10:909–17.

[80] Hruska CB, Boughey JC, Phillips SW, et al. Scientific Impact Recognition Award: Molecular breast imaging: a review of the Mayo Clinic experience. *Am. J. Surg*. 2008;196(4):470–476.

In: Encyclopedia of Surgery (22 Volume Set)
Editors: Andreas Lehrer and Kristin Mueller
ISBN: 978-1-53618-329-0
© 2020 Nova Science Publishers, Inc.

Chapter 84

THE ROLE OF IMAGING IN NEUROSURGERY

Savvas Grigoriadis[1,*], Christine Karatziou[2], Maria Sidiropoulou[2], Athanasia Anastasiou[2], Eleni Tsatsali[3] and Georgios Giakoumettis[3]

[1]B' Neurosurgical Clinic, Aristotle University, Thessaloniki, Greece
[2]Department of Radiology, Hippokration Hospital, Thessaloniki, Greece
[3]Aristotle University, Thessaloniki, Greece

ABSTRACT

Sir Godfrey N. Hounsfield (28 August 1919 – 12 August 2004) was an electrical engineer who in 1979, together with Allan McLeod Cormack, received the Nobel Prize in Physiology or Medicine for developing the diagnostic technique of X-ray computed tomography (CT) [1]. The first CT scanners were designed exclusively for brain CT, and in 1972 a female with a suspected brain tumor was the first patient examined using CT scanning. In the next year, the first publication of brain CT imaging was true [2]. Early CT scans were of limited quality and demanded long scanning and processing times. Nevertheless, the following development of CT scanning provided neuroradiology with much better brain tumor images and revolutionized neurosurgical practice. A new era in modern neurosurgery had commenced [3]. The MRI, on the other hand, has literally transformed the status of neuroimaging by bringing most of the structural details of the brain and spinal cord in front of our eyes. The most important applications of the modern neuroimaging modalities in neurosurgical practice are presented in this chapter.

IMAGING IN NEUROSURGICAL ONCOLOGY

A. Brain Tumor Imaging

1. Computed Tomography

The decrease in number of the air studies, angiograms, and nuclear scans in detecting brain tumors is documented by an article from Mayo Clinic published in *Radiology* in 1975

* Corresponding Author's Email: grigo@auth.gr.

[4]. In the next article of the same *Radiology* issue, the application of contrast media administration in brain tumor imaging depicted that more than 80% of intracranial mass lesions enhanced [5]. *Enhancement* is a phenomenon caused by the disruption of the tumor vasculature's blood-brain barrier (Figure 1). Following the administration of contrast agent, there is an increased difference in an imaging characteristic between a lesion and the surrounding normal tissue due to the passage of contrast agent within the tumor's interstitium [6]. Correlation of contrast enhancement to astrocytoma grade was documented in 1978 [7]. CT has evolved over the years, with improvement of image quality, reduction of scan times and cost.

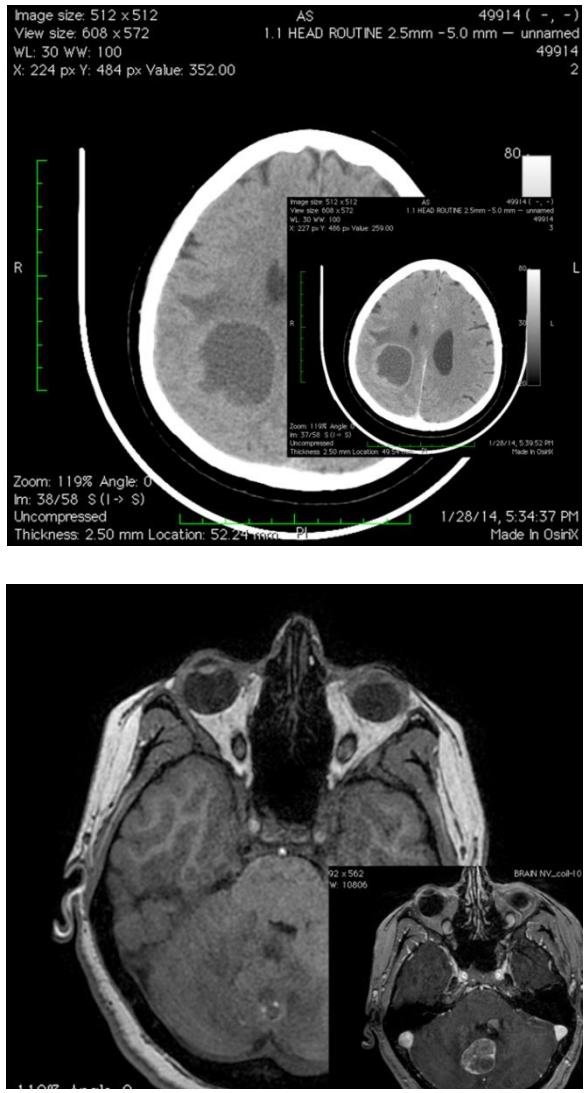

Figure 1. Enhancement of brain tumor after contrast agent administration.

Brain tumors may be *hypodense*, *isodense* or *hyperintense* to gray matter correlating to tumor histology and location. Small or isodense brain tumors may not be depicted on non-contrast CT scan, but they may be delineated after contrast media administration. Despite the

advent of Magnetic Resonance Imaging (MRI), CT is still not only appropriate, but also necessary for emergent imaging.

CT is superior to MRI in depiction of *calcification* within brain tumors. Oligodendrogliomas, ependymomas, gangliogliomas, choroid plexus papillomas, astrocytomas, central neurocytomas and metastases are the intra-axial brain tumors that more often present calcifications. Extra-axial tumors that have calcifications are craniopharyngiomas, meningiomas, chondrosarcomas and chordomas. Additionally, CT contributes to detection of *osseous changes* secondary to brain tumor.

Hemorrhage which is characteristic of oligodendroglioma, glioblastoma multiforme, and metastases from melanoma, breast and lung cancer, is readily evaluated on CT scans.

Fat presents characteristic negative HU values on CT and is encountered in lipomas, teratomas and dermoid cysts.

Last but not least, patients suffering from claustrophobia, with metallic devices or pacemakers, critically ill or unstable benefit from CT exams [6].

Perfusion CT

Perfusion CT (PCT) is an imaging technique that is usually applied in the evaluation of patients with acute brain infarct. Additionally, PCT has been used during the previous years as an imaging biomarker with parameters such as tumor blood volume, blood flow, vascularity permeability, and size of extravascular extracellular space that are applied to patients with brain tumor [8-10]. Data obtained by PCT is used for tumor grading and prognosis, as well as for estimation of the response to antiangiogenic agents.

Perfusion CT consists of acquiring sequential CT images during the wash-in and washout of an iodinated contrast agent through the brain tissue. Following the rapid administration of a contrast medium bolus and serial image scanning at short intervals, maps of perfusion parameters are obtained:

a) Cerebral blood volume (CBV)
b) Cerebral blood flow (CBF)
c) Mean transit time (MTT), and
d) Permeability surface-area product maps [11-13]

PCT is able to differentiate low- and high-grade gliomas presenting high sensitivity and specificity [11]. Additionally, PCT can distinguish enhancing grade III from grade IV astrocytic tumors and delineate heterogeneity of gliomas [10].

PCT can be useful in differentiating gliomas from tumefactive demyelinating lesions, mass-like lesions of vasculitis or angiopathy and lymphoma, as well as in distinguishing recurrent tumor from radiation necrosis [12].

It has also been demonstrated that metastases from different primaries can be distinguished from one another using CT perfusion in the majority of cases [14].

Finally, it is worth pointing out that PCT provides absolute quantification of perfusion parameters and has no susceptibility artifacts due to hemorrhage, which may be present in post-operative patients [13].

2. MRI Techniques

MR Perfusion

Perfusion imaging permits insight into angiogenesis, a process essential for neoplastic growth [15]. Angiogenesis leads to development of tumoral neovasculature that commonly exhibits increased endothelial permeability [16]. Neoplastic vessels are abnormally structured vessels that tend to be leaky, and thus neoplasms have *increased permeability parameters* [15].

Perfusion is the process by which nutrients and oxygen are delivered to tissue and metabolic products are removed by blood flow.

Perfusion MRI provides measurement of the parameters of cerebral microvascularisation:

a) Regional blood volume (RBV)
b) Mean transit time (MTT), and
c) Regional blood flow (RBF)

Measurement of tissue perfusion depends on the ability to serially measure concentration of a tracer agent in a target-organ of interest [17].

MR perfusion is based on the use of a tracer that may be *exogenous* or *endogenous* (spin labeling).

Imaging techniques acquired with exogenous contrast agents are dynamic susceptibility contrast (DSC) MRI and dynamic contrast enhanced (DCE) MRI.

Endogenous tracer MR perfusion takes advantage of signal loss resulting from magnetically labeled water protons flowing into the imaging plane and exchanging with tissue protons. Water protons within inflowing arterial blood are magnetically labeled ("tagged") by the application of a special radiofrequency pulse [17]. Arterial spin labeling (ASL) MRI is a routine endogenous tracer MR perfusion sequence.

CBV calculated by DSC-MRI is strongly correlated to tumor grade [18-20]. Areas of malignant transformation or tumor dedifferentiation in low-grade lesions at risk before they are visible on conventional MRI can be depicted, allowing accurate targeting of biopsies, and potentially more accurate estimation of tumor grade [23].

Astrocytoma rCBV is strongly correlated to astrocytoma grading but this should be limited to fibrillary astrocytomas because other gliomas (especially oligodendrogliomas) may present high rCBV despite grade [18, 22, 23]. Oligodendrogliomas are characterized by delicate neoangiogenic vessels ("chicken-wire" vasculature) and *even low-grade oligodendrogliomas present elevated rCBV that may be as high as in glioblastoma* [23].

Lymphoma can be differentiated from primary high-grade neoplasms and high-grade glial neoplasms on MRI perfusion parameter basis [24, 25].

Metastatic brain tumors contain capillaries that resemble the organ where the systemic cancer arose and not those of the brain [26].

Discrimination between high-grade glioma and metastatic brain lesion can be provided by examining the peritumoral lesion where the differences in mechanisms underlying peritumoral edema affect microvascularity [27]. Higher CBV values are documented around high-grade gliomas as compared to around metastases [24].

Regional changes in MR perfusion parameters that occur early during treatment can be used to construct a paramagnetic response map, which can predict overall survival in high-grade glioma, and may even distinguish pseudoprogression in temozolomide-treated glioblastoma multiforme [28, 29].

MRI perfusion techniques can differentiate between tumor recurrence (high CBV) and radiation necrosis (low CBV).

Diffusion Weighted Imaging

Diffusion weighted imaging is an MRI method that is sensitized to the random motion of water molecules in all directions ('Brownian motion"). Random water motion is not possible in various pathologies and this is called "restricted diffusion". Lesions are characterized according to the presence of unrestricted or restricted diffusion. Lesions with restricted diffusion present high signal on diffusion weighted images while they are hypointense on Apparent Diffusion Coefficient (ADC) maps [30].

ADC is inversely proportional to cellular density and reflects the intensity of diffusion of water molecules in a tissue and ADC maps quantify the degree of water molecule mobility.

Although initial reports between minimum ADC and glioma grade were promising, there is a significant overlap in ADC values among different grades of glioma [31].

Metastatic cerebral neoplasms present an elevated ADC. There is an overlap of ADC values between primary and secondary brain tumors. Measuring ADC values in peritumoral regions can differentiate primary (high ADC) from secondary (low ADC) brain tumors [32].

Medulloblastoma, lymphoma and meningioma present low ADC values. A necrotic tumor presents high ADC value whereas an abscess has low ADC value.

Also, an arachnoid cyst (low ADC) can be distinguished from an epidermoid (high ADC).

MR Spectroscopy

MRS is the only noninvasive technique that measures chemicals within the body. MRS distinguishes metabolites according to their slightly different chemical shifts or resonance frequencies [33]. Proton MR spectroscopic imaging (^{1}H-MRSI) incorporates spatial localization of MRI with biochemical data of ^{1}H-MRSI [34].

Brain tumors present different spectra from normal brain tissue. Choline (Cho, 3.24ppm) signal is elevated in nearly all tumor types due to alteration of membrane metabolism. Cho is a basic component of the cell membrane and contains contributions from Cho-containing compounds involved in membrane synthesis and degradation [35]. Cho also correlates with cellular density of the tumor [36], cell proliferation, and with degree of tumor infiltration into brain tissue [37]. *N*-acetyl-aspartate (NAA, 2.02 ppm) is a marker of neuronal activity.

NAA decreases due to loss, dysfunction, or displacement of normal neuronal tissue [38]. In almost all brain tumors, NAA signal is decreased and Cho signal often increased (increase of Cho/NAA ratio).

The Cr signal is the sum of Cr and phosphocreatine. Cr is associated with short-term energy storage and is decreased when there is rapid cell proliferation [34]. Lactate (Lac) is not normally encountered in the adult brain and is a marker of anaerobic glycolysis [39]. The presence of lipids has been correlated with necrosis where cellular death results in membrane breakdown [40]. Increased levels of myo-inositol (ml) reflect increase of glial cells. The most

useful parameters in MRS for the diagnosis and differential diagnosis of brain tumors are the following ratios: Cho/Cr, Cho/NAA, and NAA/Cr.

MRS, in combination with conventional MRI imaging, can aid to differentiate a tumor from a non-neoplastic lesion (Figure 2). Non-neoplastic lesions that mimic a tumor may be infectious (abscess), ischemic, or demyelinating (tumefactive demyelination) [35]. Some non-neoplastic lesions may present elevated Cho, making differential diagnosis difficult. For example, increased Cho, often increased lactate and decreased NAA can be found not only in brain tumors but also in acute demyelination lesions [41].

MRI is the most sensitive imaging modality for the detection of brain tumors. However, it lacks specificity as different lesions may share similar MR features.

Studies have suggested the correlation of tumor grade to Cho levels, implying that higher-grade tumors have greater Cho concentrations [42]. However, some high-grade tumors due to necrosis may present lower Cho levels than lower grade tumors. Heterogeneous tumors with central necrosis and proliferative rims, and invasion of surrounding brain tissue reflect metabolic heterogeneity also. ^{1}H-MRS is useful in studying changes in metabolic profile during the malignant transformation from diffuse to anaplastic astrocytoma [34].

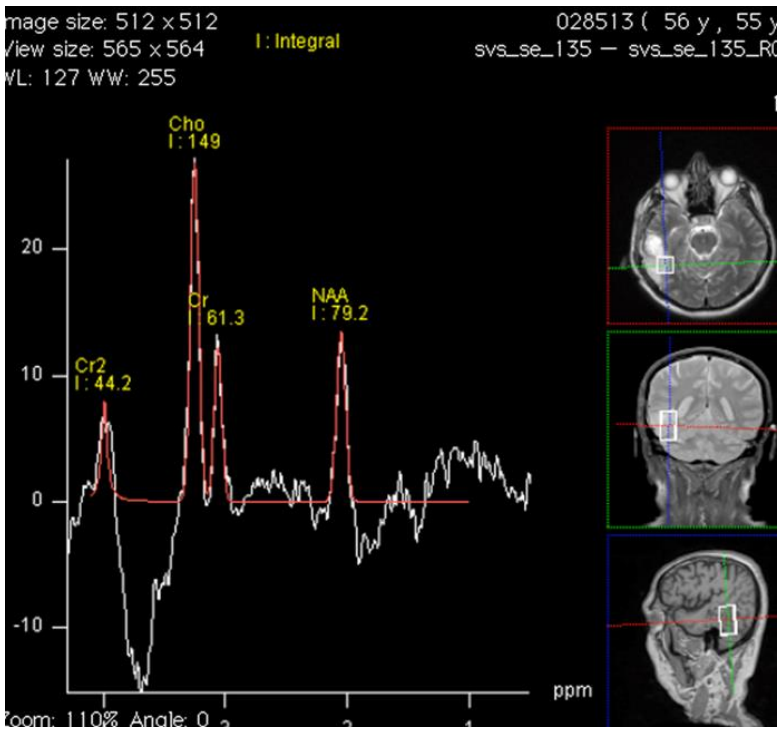

Figure 2. MR spectroscopy. The values of Cho, Cr and NAA are depicted.

MRS should be anticipated as an adjunct imaging modality that may aid to differential diagnosis rather than a modality diagnosing the exact type of a brain tumor on its own.

Investigation of peri-enhancing tumor regions can facilitate discrimination of solitary metastases from primary brain tumors. As gliomas are infiltrating lesions, Cho is elevated in surrounding tissue. On the contrary, as metastatic lesions tend to be more encapsulated, surrounding tissue does not demonstrate high Cho levels [43].

MPS can significantly aid the differential diagnosis between abscess and neoplasm. The acquisition of a single-voxel spectrum with short TE, besides the low Cho signal, will detect the presence of other minor peaks not encountered in neoplasia (e.g. succinate, acetate, leucine, alanine) [44].

In the study of Crawford et al. [45] GBM patient survival was studied in correlation to pre-surgical metabolic and physiological parameters. Survival was poor in patients with large areas of contrast enhancement, restricted diffusion, and abnormal metabolism. Survival time was also negatively associated with high lactate and lipid levels and the ADC in the enhancing area. Metabolic indices however have not always been proven to be prognostic in survival prediction in other brain tumors.

Total resection of the brain tumor is the basic goal in neuro-oncology. However, high-grade gliomas have indistinct boundaries and infiltration. MRS can aid proper tissue sampling at brain biopsy. Areas of increased angiogenesis, vascular permeability, and high metabolic activity should be sampled [46].

The dilemma between recurrent tumor and radiation necrosis, a focal reaction to radiation in patients undergoing radiation therapy, is common. Radiation necrosis demonstrates T2-hyperintense signal and enhancement after contrast medium administration, findings that are difficult to differentiate not only from tumor progression, but also from pseudo-progression (increase in edema, mass effect, and contrast enhancement that resolves over time) [47]. Increased Cho signal is indicative of recurrence whereas reduced Cho levels indicate radiation necrosis [48]. MRS cannot differentiate between tissue containing mixed tumor-radiation necrosis and either tumor or radiation necrosis, although it did achieve good separation between pure necrosis and pure tumor [49].

Functional MRI (fMRI)

The functional magnetic resonance imaging (fMRI imaging) is a non-invasive neuroimaging technique that can be used for studying the function of the human brain in vivo. The fMRI technique extends the use of classical MRI imaging beyond the anatomical information and provides information about the biological function. The study of the functional organization of the brain was the main interest of researchers since the late 19th century. In 1881 the Italian physiologist Angelo Mosso observed that the neural activity of a human is associated with the local brain cerebral blood flow (CBF). A few years later similar observations have been made by Charles Roy and Charles Sherrington in lab-animals. Unfortunately the objections of other researchers and the lack of sufficient experimental means led to a decrease in interest in this observation. It was not until half century passed that this observation came forth again, when researchers proved that the oxygenated hemoglobin is repelled, while the deoxyhemoglobin is attracted by magnetic fields. This phenomenon was used by Seiji Ogawa in order to prove that with the technique of imaging the oxygen level of blood [Blood Oxygenation Level Dependent imaging] (BOLD imaging), one can visualize the brain function. This is a standard technique used to create images in functional magnetic resonance imaging studies (fMRI) and is based on differences in cerebral blood flow in brain regions that show increased activity. The first successful attempt to elucidate the functional organization and mapping of the brain using magnetic resonance carried out in 1991 in the MRI center of the Massachusetts General Hospital in Boston. After that, identifying brain areas activated during a specific test offered a very satisfactory level of spatial resolution of 2 mm and a degree of temporal resolution of few seconds.

Blood flow to the brain is locally controlled and is in response to oxygen and carbon dioxide of the cortical tissue. When an area of the cortex increases its activity in response to a process, initially there is a fall of oxygenated hemoglobin (oxyHb) and an increase in deoxygenated hemoglobin (deoxyhemoglobin, deoxyHb). After a delay of 2-6 seconds, the cerebral blood flow (CBF) increases by providing an excess of oxygenated hemoglobin, replacing deoxyhemoglobin. This increase in local tissue oxygenation can be imaged. The reason that the fMRI is able to detect this change is due to a fundamental difference in the paramagnetic properties of oxyhemoglobin (oxyHb) and deoxyhemoglobin (deoxyHb), whereas the latter is paramagnetic, while the first is not. However, there are some limitations of BOLD imaging and other CBF imaging techniques. Therefore, i) cerebral blood flow is only an indirect indicator of activity, rather than direct visualization of cortical activation, ii) the smallest unit of the brain that is able to regulate its blood flow, it is measured in millimeters in diameter and finally iii) the increase in blood flow is in conjunction with the increase of the activity having a 2-6 seconds delay.

Statistical analysis of data obtained from BOLD technique is important and crucial for brain mapping with functional MRI. Thanks to wide range of experiments done with fMRI several statistical models and approaches can be applied in order to extract useful information. The simplest statistical model data analysis of BOLD technique is the t-test where the statistical parameter taken into consideration is the p-value, which reflects the level of confidence. The proposed p-value is $p < 0.05$ with a confidence level of 95%. Moreover, the selection of a certain threshold is equally important for the sensitivity of the signal that is to be received. The goal is not to identify the voxels that have a signal greater than the threshold, but to identify those voxels whose change of signal is much larger than expected and the level of statistical significance depends on the threshold applied according to predefined statistical parameters. Data analysis is done by software that processes the data of anatomical images and of fMRI. Before that, images of fMRI are aligned (alignment), normalized (normalization), smoothed and motion-corrected. Then statistical analysis is applied after using a threshold in signal sensitivity and the results of fMRI are displayed on high-definition three-dimensional anatomical images. The representation of functional areas is in accordance with a chromatic scale and the intensity of the signal is proportional to the threshold. The signal from brain activity is subtracted from the signal at rest. Changes in signal intensity are represented by the number Z, which is defined as:

$$Z = \frac{\text{average signal difference}}{\text{standard deviation}}$$

Low values of Z generate results of low resolution and specificity. High values of Z allow visualization of areas with high signal and have high resolution. Thus, setting this statistical parameter is depended on the signal intensity.

The idea of mapping functional areas of the brain for a safe navigation during a brain surgery is dated in the middle of 20th century. Although invasive techniques, such as transcortical stimulation, are a gold standard in functional neurosurgery, they do not allow the preoperative designing of the surgery, whilst neuropsychological tests do not offer precision. Thus, the need for an accurate preoperative technique in order to design and execute as safely as possible a brain surgery, has brought in the use of fMRI. Brain mapping is done in order to identify and surgically preserve eloquent areas such as motor speech area, sensorimotor

cortex, motor cortex and other brain areas that are responsible for writing, calculating, spatial perception, memory etc. Moreover brain mapping helps individualize an operation offering maximum surgical result. Consequently, fMRI contributes not only to the preoperatively design and to a safe neuronavigation during surgery, but it is also established as a decision-making examination for surgery. Finally, fMRI is widely used in neuroscience contributing to research, studying anatomy as well as brain diseases.

Diffusion Tensor Imaging

Diffusion tensor imaging (DTI) consists a rapidly growing area of research, as well as clinical application in intracranial tumors [50]. DTI is the only non-invasive *in vivo* method for mapping white matter tract in the human brain [51]. DTI is based on the concept of *anisotropic diffusion*. Water diffusion in the white matter is not equal in all 3 dimensions but tends to move along the long axis of the fiber bundle because myelin sheath allows less water diffusion perpendicularly [50, 51]. The portion of overall diffusion that is therefore directional is referred as fractional anisotropy (FA) [52] and permits visualization of white matter fiber direction. FA maps quantify changes in FA values as loss of brightness (gray scale) and direction of white matter tracts in color: fiber orientation is represented by different colors. Diffusion-based MRI tractography is an imaging tool that generates 3-D reconstructions of white matter fiber tracts as an aid to identifying safe margins of resection [53]. DTI can evaluate the relation of a brain tumor to the adjacent white matter tracts [54, 55]. White matter involvement by a tumor can be deviated, infiltrated, edematous and destroyed. DTI contributes to planning for brain tumor surgery as it indicates white matter tracts relative to the tumor.

B. Spinal Tumor Imaging

Tumors of the spine compose a vast group of lesions that are derived from diverse tissues: neoplasms from the spinal cord, the leptomeninges, extradural soft tissues, primary and metastatic bone lesions as well as paraspinal soft tissue tumors. This long list of tumors is usually categorized according to the site of origin [56].

CT consists the method of choice for delineating osseous involvement, calcifications and the degree of bone loss [57]. CT can demonstrate tumor destruction. Multidetector CT obtains axial, sagittal, and coronal reformatted images [57].

Bone metastases are the most common neoplasms of the spine. Spinal bone metastases consist the most common site of bone metastasis. Vertebral metastases are the cause of initial presentation of symptoms in a significant group of patients with cancer. Vertebral metastases are located at the lower thoracic, lumbar and, at a lesser degree, at the cervical spine.

Vertebral metastases originate from cancer of the breast, lung, prostate, gastrointestinal system and thyroid gland.

Osteolytic metastases present low signal on T1 and high signal on T2 images (Figure 3). Contrast media should be administrated at the end of basic sequences because the enhanced bone metastasis may be impossible to differentiate from the surrounding vertebra.

Osteosclerotic metastases are depicted with low signal on both T1 and T2 images.

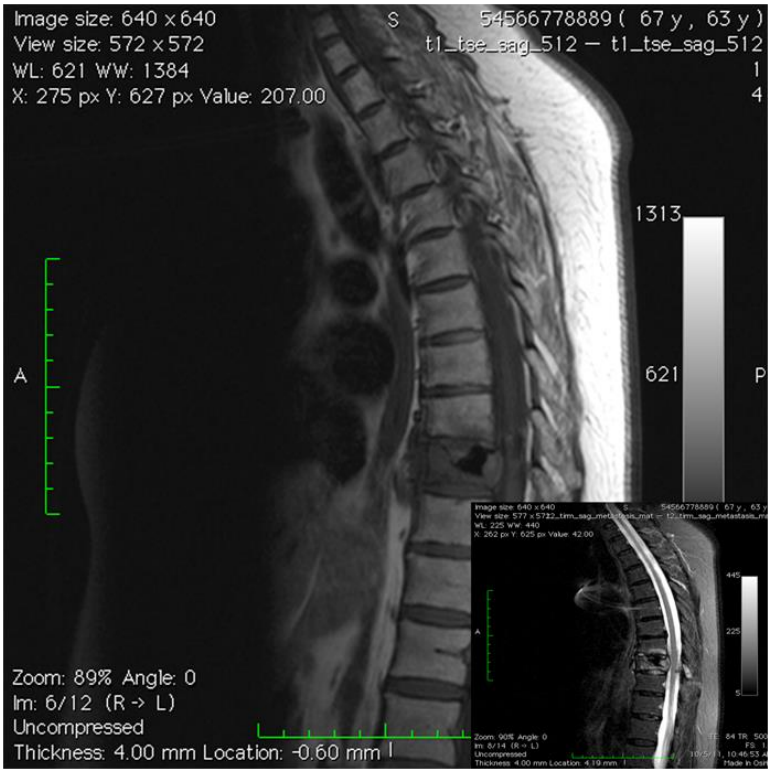

Figure 3. Metastatic spinal tumor with characteristic low signal on T1WI and high signal on T2WI.

In cases of spinal involvement in leukemia, bone marrow presents low T1 signal and intervertebral discs seem bright ("bright disk sign").

Hemangioma is the most common benign vertebral lesion. Hemangiomas are mainly located at the lower thoracic and lumbar spine. T1 signal is high or low according to ratio of vascular to fatty component of the lesion. Hemangiomas have saturation of high signal on STIR sequences.

Osteoid osteoma is a benign lesion with characteristic CT features.

MRI is the most sensitive imaging method for evaluation of the spinal cord. Infiltration of nerve roots, thecal sac, paraspinal soft-tissues as well as vertebral bone marrow is markedly revealed [58].

Spinal tumors are classified as intradural (intra-medullary and extra-medullary) and extradural (epidural and from the vertebral column) (Figure 4).

There are 3 significant features in MRI images while evaluating patients suspected of having an intramedullary spinal lesion: cord expansion, degree of enhancement, and the presence of a cyst [58].

Ependymoma is the most common intramedullary spinal tumor in adults [60]. Myxopapillary ependymoma consists a rare, variant type of ependymoma, usually without connection with the spinal cord. Cord ependymomas occur most commonly in the cervical spine. Most spinal cord ependymomas are iso- or hypo- intense on T1 images. Rarely, they may present hyperintensity on T1 due to hemorrhage. On T2 images, ependymomas may be hyperintense or isointense.

Astrocytoma has poorly defined margins and is iso- to hypointense on T2 and hyperintense on T2 images. A degree of contrast enhancement is depicted. Cyst is a common finding. In more than half cases, astrocytoma is eccentric within the spinal cord [59].

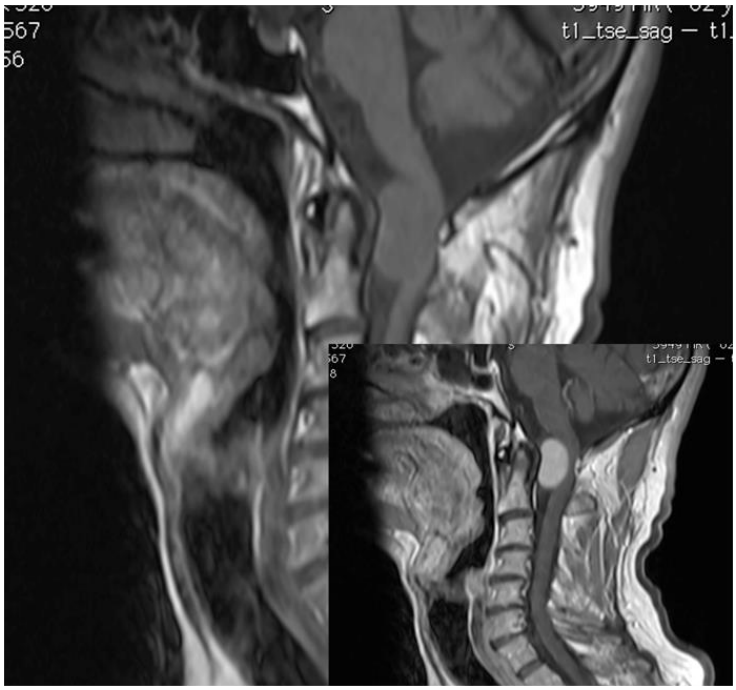

Figure 4. Cervical MRI showing an intradural extramedullary tumor (meningioma).

C. Intraoperative MRI

Ferenc Jolesz at the Brigham and Woman's Hospital in Boston in 1990 first conceived the idea of operating under real MRI guidance. Intraoperative MRI (ioMRI) can identify any residual tumor, delineate the degree of brain shift and update the neurosurgical navigation system [61].

Additionally, potential intracranial complications such as hemorrhage, hydrocephalus and cerebral edema could be depicted [62].

In the first reports of patients in which ioMRI data was used, the image quality was able to identify residual tumor in most cases [63].

Low-field ioMRI in the following years however was not able to efficiently depict residual tumor, especially low-grade glioma [64, 65].

High-field ioMRI enhances the extent of resection, even for non-enhancing gliomas [66].

In high-field ioMRI, operations are performed using conventional, non-MR compatible equipment. The disadvantage however is that more time is required to obtain a scan and real-time imaging is unavailable [61].

Other distinct advantages of ioMRI include the excellent soft tissue discrimination, the ability to view the surgical site in three dimensions, and the ability to "see" tumor beyond the surface visualization of the surgeon's eye. The enhanced ability to view the tumor being

biopsied or resected allows the surgeon to choose a safe surgical corridor that avoids critical structures, maximizes the extent of the tumor resection, and confirms that an intraoperative hemorrhage has not resulted from surgery [67].

CT AND MRI IN THE EMERGENCY DEPARTMENT

A. Craniocerebral Injuries

CT is the preferred method for evaluating patients after traumatic CNS traumatic injuries. The principal tool for imaging severe acute craniocerebral trauma is the Multidetector Computed Tomography (MDCT). It is used for the detection of:

a) Intracranial hemorrhage
b) Mass effect
c) Cerebral contusions
d) Cerebral edema and herniation
e) Skull fractures (Figure 5)
f) Displaced bone fragments
g) Foreign bodies
h) Intracranial air

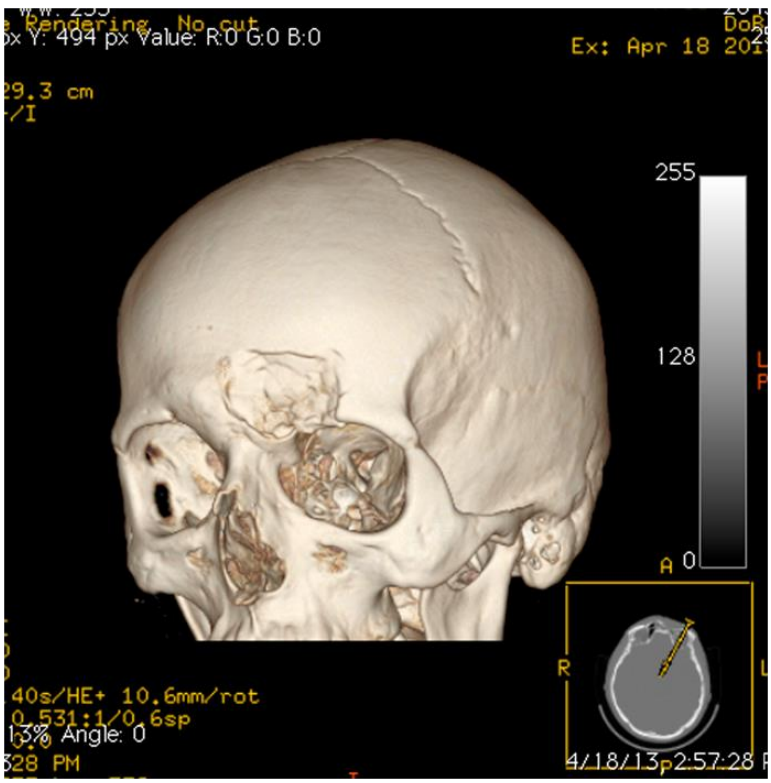

Figure 5. Cranial CT after 3-D reconstruction. Depressed skull fracture (frontal bone).

MRI is relatively insensitive for the detection of skull fractures and small bone fragments [68, 69]. However, the role of MRI is growing in the assessment of acute, subacute and chronic phase of craniocerebral trauma. MRI is more sensitive than CT to certain injuries like:

a) Diffuse axonal injury (DAI)
b) Small extra-axial fluid collections
c) Cortical contusions, and
d) Brainstem injuries [70]

In the acute or subacute phase of trauma:

FLAIR sequence presents high sensitivity for DAI, edema, subarachnoid and intraventricular hemorrhage [71].

Gradient echo T2* and SWI sequences are sensitive for detection of DAI, intracranial hemorrhage and blood degradation products with paramagnetic properties.

DWI-ADC map sequences are useful in the evaluation of DAI, cytotoxic edema and hypoxic-ischemic brain damage in cases of non-accidental head injury (e.g. child abuse) [72, 73].

Finally, MRI using a complex variety of sequences can provide data about the "age" of an intracranial hemorrhage.

As a general rule, MRI is indicated in stable patients in whom there is a significant discrepancy between the patient's clinical condition and CT findings [68, 74].

In the chronic phase of trauma:

MRI is superior to CT for the detection of chronic subdural hematomas (CSH), which are often isodense to CSF on non-contrast CT scans.

FLAIR and Gradient echo T2* sequences are superior to T2 sequence in the detection of small subdural hematomas, with different signals due to varying phases of the blood-breakdown process.

Gradient echo T2* and SWI sequences demonstrate hypointense hemosiderin deposits after DAI.

Post-traumatic encephalomalacia and gliosis are much better appreciated with FLAIR sequence. On FLAIR, the area of tissue loss is isointense to CSF and is surrounded by a rim of gliosis that is hyperintense.

B. Spine Injuries

MR imaging has supplanted CT as the modality of choice for the majority of CNS conditions including neoplasms and vascular lesions. However, in some instances, CT provides a diagnostic advantage for the evaluation of spinal pathology especially in evaluating spine-trauma patient. CT with multiplanar reformatted images and 3D-display remains the method of choice for the detection of fractures and their patterns, displacement or retro-pulsed bony fragments and narrowing of the spinal canal, information that is critical for the appropriate management of trauma victims (Figure 6).

The size, shape, integrity, as well as the degree of canal compromise are best assessed with CT. It is often the only modality to demonstrate subtle lesions especially small cortical

fractures, pars interarticularis defects, widening of the apophyseal joints, locked facets, occult fractures of the posterior elements and fractures of the occipital condyles [75, 76]. Evaluation also includes assessment of the disc, nerve root and paraspinous soft tissue including ligaments and evaluation of stability. When further evaluation of the cord and roots or an expanding extramedulary hematoma is indicated, MRI is preferable to CT, to reproduce the internal architecture of the spinal cord and the injured cord parenchyma.

Figure 6. Spine CT after 3-D reconstruction shows a traumatic vertebral fracture.

Except from the comprehensive display of spinal anatomy and pathology, CT can be performed with the same settings as CT for the other traumatic injuries of the body areas [77, 78]. In addition CT angiography is an accurate, rapid, noninvasive diagnostic alternative in the initial evaluation of patients who present to the emergency department with possible carotid and vertebral arterial injuries [79, 80].

IMAGING OF STROKE

Stroke can be defined as a sudden or rapid onset of a neurologic deficit due to a cerebrovascular lesion, lasting longer than 24 hours. If the neurologic deficit lasts <24 hours, it is called *transient ischemic attack* (TIA). There are four main etiologies for stroke:

a) Cerebral infarction (80%)
b) Intraparenchymal hemorrhage (ICH) (15%),
c) Non-traumatic subarachnoid hemorrhage (SAH) (5%)
d) Venous infarction (1%) [89]

Acute *ischemia* constitutes approximately 80% of all strokes and is an important cause of morbidity and mortality in the United States [81]. Stroke is the third leading cause of death in the USA, and cerebral infarction is the most common cause of disability among adult Americans [88].

Until recently, before effective therapies were introduced for acute ischemic stroke, imaging was used primarily to exclude "stroke mimickers". There is a long list of conditions that mimic the symptoms of acute ischemic stroke, such as intracranial hemorrhage, neoplasms, infection, migraine, seizures, functional and metabolic disorders and vasogenic edema syndromes [88]. It is therefore very important to confirm that the cause is an ischemic lesion, before therapy is started, as these non-ischemic stroke mimickers should not be treated with thrombolysis.

The development of new treatment options, such as intra-arterial and intravenous thrombolysis, have led to the evolution of imaging technology in order to decide which stroke victim will benefit from the new therapeutic modalities [81]. The new aggressive therapies are aimed to re-establish the blood flow in the infarcted area, to reduce the size of the infarcted tissue and to protect the surrounding brain at risk, which is called the *penumbra*. Brain tissue is exquisitely sensitive to ischemia. In the complete absence of blood flow, the available energy can maintain neuronal viability for approximately 2-3 minutes. However, in acute stroke, ischemia is more often incomplete, because uninjured arterial and leptomeningeal vessels supply blood to the injured area of the brain [81]. Therefore, acute cerebral ischemia may result in an infracted core, which is the ischemic region that is irreversibly injured, and the penumbra, which is defined as the brain tissue that is hypoperfused and is in danger of infarcting. Penumbra is the region that is potentially salvageable with early recanalization. Neuroimaging can provide excellent estimates of the core and penumbra in individual patients and help the clinicians to decide which stroke victim will benefit from thrombolysis.

The goals of neuroimaging in acute stroke ischemia are:

a) To assess brain parenchyma
b) To rule out hemorrhage and other stroke mimickers
c) To assess the intra- and extracranial circulation in order to depict endovascular thrombi
d) To assess the perfusion of the brain tissue, the size of the infarcted core, and the surrounding penumbra [81]

1. Non Contrast CT (NCCT)

The speed, widespread availability, low cost, and accuracy in detecting subarachnoid and intracranial hemorrhage have led conventional unenhanced computed tomography (NCCT) scanning to become the first-line diagnostic tool for the emergency evaluation of acute stroke.

CT findings that are useful in the detection of acute ischemia are focal parenchymal hypodensity, obscuration of the lenticular nuclei and the insular cortex, sulcal effacement due to brain edema, loss of gray-white matter differentiation, and the hyperdence MCA sign due to an acute thrombus in an intracranial vessel which has typically high attenuation [81, 87] (Figure 7).

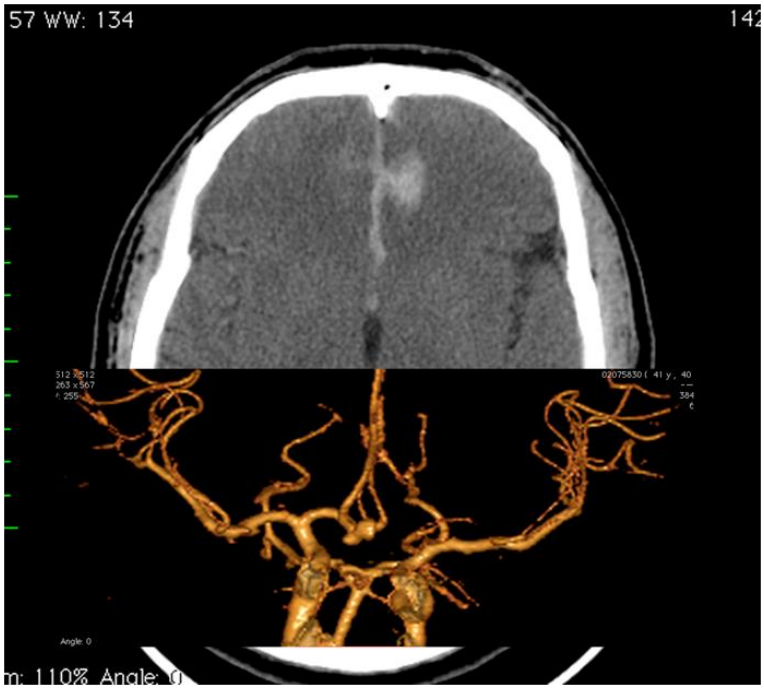

Figure 7. Non-contrast CT of the brain with evidence of subarachnoid hemorrhage and interhemispheric hematoma.

2. CT Angiography (CTA)

CT angiography is the next step in assessing intracranial and extracranial circulation. It is a widely available, fast and simple technique that is capable of detecting endovascular thrombi. CT angiography is performed after intravenous injection of contrast agent and it visualises vessels from the aortic arch to the circle of Willis. Multiplanar reformatted images and maximum intensity projection images are produced at a three-dimensional display workstation [81] (Figure 8).

CTA can detect endovascular thrombi and can define the level of intracranial vascular occlusion in patients presenting within 6 hours of embolic stroke onset [87]. It can detect large vessel occlusion but it can also provide information about collateral flow and lesion extent. Plaque burden at the origins of internal carotid arteries and arterial dissection can also be detected by CTA [87]. CTA plays a major role in the exclusion of unnecessary thrombolysis in patients presenting with acute embolic stroke, but who don't have large vessel occlusions amenable to thrombolysis [87]. CT angiographic demonstration of a significant thrombus burden, can guide appropriate therapy in the form of intra-arterial or mechanical thrombolysis, as it is known that intra-arterial thrombolysis may be more efficacious than intravenous therapy in patients with acute stroke and a significant thrombus burden [81]. Unlike MRA, CTA is an anatomic imaging technique and therefore it is not likely to yield false-positive results for occlusion due to slow flow or artefact [87].

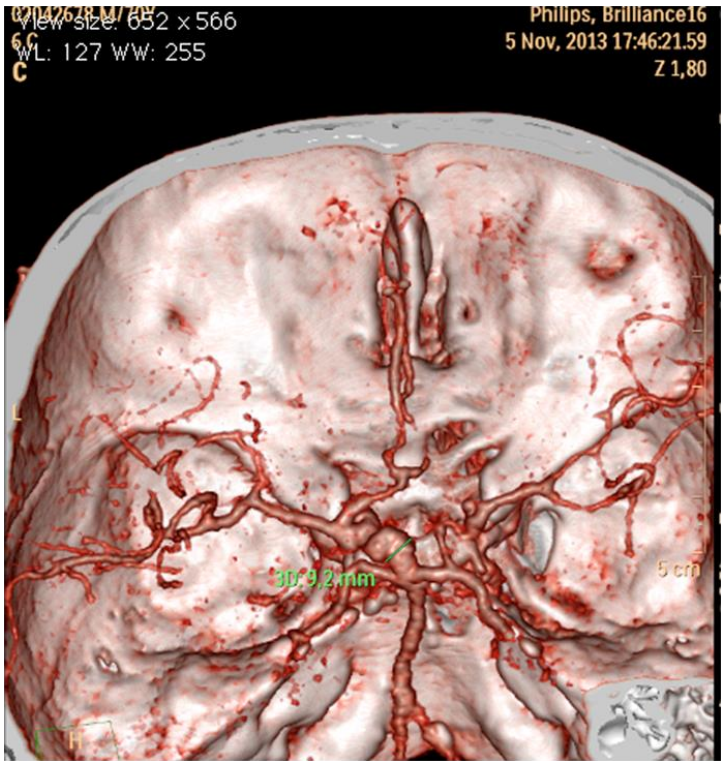

Figure 8. CT Angiography: a saccular aneurysm of the basilar tip is depicted.

3. CT Perfusion Imaging

CT perfusion imaging (CTP) in addition to CTA is fast, available and safe and adds no more than 10 minutes to the time required to perform a standard NCCT. CTP is based on dynamic i.v. administration of a contrast agent, which is tracked with serial imaging during its first pass circulation through the brain tissue capillary beds. Depending on the assumptions regarding the arterial inflow and venous outflow of the tracer, perfusion parameters can be estimated mathematically. CT perfusion maps then can be generated in a short time at an appropriate workstation.

CT perfusion imaging is used to estimate the following perfusion parameters:

- Cerebral blood volume (CBV), which is the volume of blood per unit of brain tissue (normal range, 4–5 mL/100g)
- Cerebral blood flow (CBF) defined as the volume of blood flow per unit of brain tissue per minute (normal range in gray matter, 50–60 mL/100 g/min)
- Mean transit time (MTT), defined as the time difference between the arterial inflow and venous outflow (MTT= CBV/CBF)
- Time to peak enhancement (TTP), which represents the time from the beginning of contrast material injection to the maximum concentration of contrast material within a region of interest (ROI) [81].

As mentioned before, the infarcted core is a region of brain tissue which is severely hypoperfused and irreversibly infarcted or is destined to infarct regardless of therapy. It is defined as an area with prolonged MTT, markedly decreased CBF and markedly reduced CBV.

The ischaemic penumbra, which in most cases surrounds the infarct core, also has prolonged MTT but in contrast has only moderately reduced CBF and importantly near normal or even increased CBV (due to autoregulatory vasodilatation) [83]. Hence, functional images can help differentiate between:

- A favourable pattern of ischemic stroke which consists of a small infarcted core and a large penumbra
- An unfavourable pattern with a large core and a small penumbra
- An intermediate pattern with relatively equal size of core and penumbra, and
- Malignant pattern with a very large core and small penumbra

This way the clinicians are guided in their decision-making process on whether to attempt revascularization or not [84].

4. MRI Imaging

Conventional MRI used in the evaluation of acute stroke, typically includes T1-weighted spin-echo, T2-weighted fast spin-echo, fluid-attenuated inversion recovery, T2*-weighted gradient-echo, and gadolinium-enhanced T1-weighted spin-echo sequences [81].

MRI can diagnose infarcts of all stages of evolution but it is most sensitive after the hyperacute stage. The basic findings during the hyperacute stage are loss of flow voids on T2-weighted images, FLAIR hyperintensity in the affected vessels and stasis of contrast material in the vessels of the affected territory [87]. Typical MR imaging findings in the acute phase include hyperintense signal in white matter on T2- weighted images and FLAIR images, with a resultant loss of grey-white matter differentiation. Sulcal effacement and mass effect can also be demonstrated. In the subacute phase, parenchymal swelling and enhancement after contrast administration may be seen [87].

T2*-weighted gradient-echo images and susceptibility-weighted imaging (SWI) depict an acute intracranial hemorrhage as an area of abnormal blooming. Compared with CT and other MR imaging methods, these techniques are superior in detecting very small cerebral hemorrhages in patients with acute stroke. However the impact of depicting these small hemorrhages in the infarcted area in deciding thrombolytic therapy is not strongly established yet [81, 92].

MR angiography (MRA) is divided into non-contrast (TOF MRA and Phase-contrast MRA) and contrast-enhanced techniques (Figure 9). TOF MRA is a gradient echo sequence that depicts vascular flow. Phase-contrast MRA is a gradient echo sequence that depicts blood flow by quantifying differences in the transverse magnetization between stationary and moving tissue. Contrast-enhanced MRA is usually obtained from the arch to the scull base. Three-dimensional TOF MRA is quite sensitive and specific for the evaluation of intracranial proximal stenoses and occlusions. Phase-contrast MRA can evaluate collateral flow patterns

in the circle of Willis. MR angiography is useful for detecting intravascular occlusion due to a thrombus and for evaluating the carotid bifurcation in patients with acute stroke. However MRA is relatively insensitive in depicting stenoses in distal intracranial vessels [87].

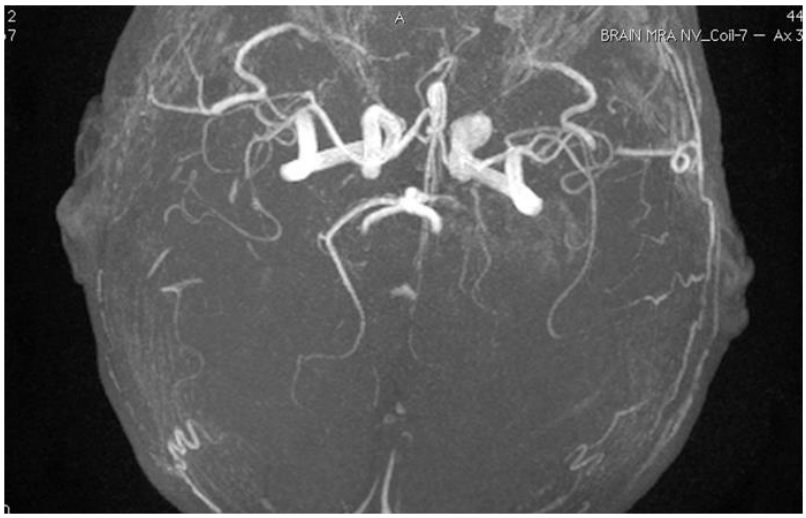

Figure 9. MR Angiography.

5. Diffusion Weighted Imaging

Diffusion weighted imaging (DWI) was introduced in the clinical setting in the mid-1990s and today is the most reliable method for detecting acute ischemia and it can be accomplished in less than 2 minutes [81]. The abnormal finding of infarction is an area of hyperintensity on DWI. This is likely caused by the cessation of ATP production and the dysfunction of Na^+-K^+ pump, which is unable to remove excess water from the cells, resulting in cytotoxic edema [88]. The actual diffusion coefficient cannot be measured by using diffusion-weighted MR imaging, for a number of reasons. Hence, the diffusion coefficient obtained from orthogonal diffusion-weighted MR images in all three planes is called the apparent diffusion coefficient (ADC) [81]. The ADC map is used to confirm that the signal abnormality on DWI is caused by restricted diffusion. Acute infarction is demonstrated as a hyperintence area on DWI and as an area of low signal intensity on ADC map and it corresponds to the irreversibly infarcted brain tissue. Diffusion restriction with reduced signal on ADC map has been observed as early as 30 minutes after the onset of ischemia. This information is critical as thrombolytic therapy can be started within the "golden period" of *3 hours from the onset of symptoms* resulting in early reperfusion of the hypoperfused tissue. In the hyperacute stage of infarction (<6 hours) the DW signal intensity is increased with a corresponding low ADC. In the acute phase (6 hours to 3 days) there is a further increase of the DW signal of the infarcted tissue and also a lower ADC. In the subacute phase (3 days to 3 weeks), there is a pseudonormalisation of the ADC. This is likely due to the development of vasogenic edema along with the persistence of cytotoxic edema. In the chronic stage (3 weeks to 3 months) there is an increase in ADC with a bright signal on ADC map [88]. In contrast to unenhanced CT or conventional MR imaging, which have low sensitivities (50%) for acute

ischemia detection within the first 6 hours after onset of symptoms, diffusion-weighted imaging was reported to have had high sensitivity and specificity, of 88%-100% and 86%-100%, respectively, in various studies [81].

6. Perfusion-Weighted MR Imaging (PWI)

While diffusion-weighted MR imaging is most useful for detecting irreversibly infarcted tissue, perfusion-weighted imaging may be used to identify areas of reversible ischemia as well. Perfusion-weighted MR Imaging describes techniques that study perfusion by visually depicting hemodynamic conditions at the microvascular level. Perfusion-weighted imaging techniques rely on measurement of the concentration within each voxel of a contrast agent that is dissolved in the blood. Multiple echo-planar images are made with a high temporal resolution.

Various post-processing algorithms are used to convert the sequence of dynamically acquired images into synthetic maps that depict any of perfusion parameters for each brain voxel [87].

What is the clinical role of PWI in conjunction with DWI? In the acute stroke setting, a region that shows both diffusion and perfusion abnormalities is thought to represent irreversibly infarcted tissue, while a region that shows only perfusion abnormalities and has normal diffusion likely represents viable ischemic tissue, or a penumbra. These are very helpful information in order to decide thrombolytic therapy [81, 85].

7. CT versus MR Imaging in Acute Stroke Evaluation

CT is widely available, and a stroke imaging protocol that consists of unenhanced CT, CT angiography, and CT perfusion imaging can be executed in 5 minutes for the comprehensive evaluation of the extra- and intracranial circulation, the amount of infarcted brain tissue, and the penumbra. The MR imaging protocol for evaluation of stroke, which includes conventional MR imaging, diffusion-weighted imaging, MR angiography, and perfusion-weighted imaging, may take a little longer (15 minutes) [81]. NCCT is a widely available tool and a very reliable one in detecting acute hemorrhage. Until recently, it is considered to be superior than MRI in depicting hemorrhage, however recent studies have shown that MRI, including T2*-weighted gradient-echo images or susceptibility-weighted imaging, can also depict hyperacute haemorrhage [91-93]. These new techniques, as mentioned before, are superior to CT in depicting old hemorrhages and hemorrhagic transformation in the infarcted area [92]. DWI is definitely superior to CT in evaluating the irreversibly infarcted tissue even in the hyperacute phase [87, 88]. CTA may be superior to MRA in depicting vessel occlusion because MRA is vulnerable to motion artifacts. The two modalities including CTP and PWI are equally useful for evaluating acute stroke and provide equivalent depiction of the penumbra. Some authors have pointed out that whereas CT is simple to perform, MR findings are simple to interpret [81]. Disadvantages of CT are ionizing radiation and higher risk for anaphylaxis and toxic effects on kidneys because of the administration of iodinated contrast material. On the other hand MRI is not so widely available as CT, it cannot be performed in patients with pacemakers, aneurysm clips, or other

ferromagnetic materials in their bodies and it may not be easy to perform in patients who need life support equipment [82]. Acute stroke imaging protocols vary among institutions, depending on the availability of imaging time, software, and expertise.

8. Intracranial Hemorrhage (ICH)

All hemorrhages, according to WHO classification are divided into cerebral, subarachnoid, subdural and intraventricular [90].

a. Etiologies of Intracranial Hemorrhage

Hypertension, hemorrhagic transformation of a previous cerebral infarction and cerebral amyloid angiopathy, are the most frequent causes of intraparenchymal hemorrhage in patients older than 60 years. In younger patients, we have to consider as possible causes of intraparenchymal hemorrhage, underlying cerebrovascular malformations such as arteriovenous malformations and cavernous angiomas, vasculopathy and venous infarctions due to venous thrombosis. Cerebral hemorrhage can also occur at any age in the case of an underlying tumor. Hemorrhage may be the first manifestation of a previously unknown tumor. Bleeding diathesis, coagulopathy due to anticoagulants and thrombolytic drugs administration should also be taken into account. Usage of illicit drugs and alcohol, endocarditis, congenital heart defects and long operations on heart should also be considered as possible causes of cerebral hemorrhage. Other more rare causes include eclampsia, encephalitis and brain abscess, Moyamoya disease, vasculitis, and hereditary hemorrhagic telangiectasia [86, 90, 94].

Non-traumatic subarachnoid hemorrhage (SAH) is usually related to an aneurysmal rupture (in 75% of cases) or a vascular malformation [89].

Subdural and epidural hematomas are most frequently caused by trauma. When there is no history of previous trauma we have to think of AVM rupture, dural arteriovenous fistulas, or coagulopathy [90].

The most frequent non-traumatic reasons for intraventricular hemorrhage are hypertonic hemorrhage in the basal ganglia, AVM rupture and deep cavernoma.

Dural sinus and cerebral vein thrombosis can lead to venous infarctions. Common causes of venous thrombosis are dehydration, pregnancy, infection, oral contraceptives, coagulopathies, malignancies, collagen vascular diseases and trauma [86, 90]. Detection of hemorrhage and identification of the etiology of non-traumatic intracranial hemorrhage is the major task of every neuroimaging method and it is crucial for the patient's therapeutic management.

b. What Are the Imaging Recommendations for Detecting a Spontaneous Nontraumatic Intracranial Hemorrhage?

Radiologists and clinicians should always take into consideration the patient's clinical history and physical examination's findings in order to decide which imaging modalities are suitable for each patient.

Non-contrast computed tomography (NCCT) is, in most hospitals, the first imaging modality used to investigate primary intraparechymal hemorrhage. CT scan is an excellent

tool for depicting acute hemorrhage. It can demonstrate the location and size of hemorrhage as well as the possible complications of it such as intraventricular hemorrhage, hydrocephalus, edema and herniations [82]. If the patient is old and suffers from hypertension and NCCT reveals an hematoma in the region of basal ganglia, which is typical for hypertensive intraparenchymal hemorrhage, there is no need for further radiological investigation. If there is no clear cause of hemorrhage or an atypical appearance on NCCT, MRI (including Diffusion-weighted imaging and T2*-weighted imaging or susceptibility-weighted imaging) should be performed [89].

T2*-weighted imaging or susceptibility-weighted imaging, are able to detect intracranial hemorrhage in the hyperacute stage and in chronic stage as well [91-93]. Multifocal black dots demonstrated on T2*-weighted imaging or susceptibility-weighted imaging, guide us to hypertensive or amyloid angiopathy [86, 90].

MRI with gadolinium administration contributes to investigate an underlying pathology such as tumors or vascular anomalies. CT angiography (CTA) and MR angiography (MRA) are the methods of choice for investigation of vascular anomalies such as aneurysms or AVMs, while CT venography (CTV) and MR venography (MRV) can reveal dural sinus and cerebral vein thrombosis. If the cause of intracerebral hemorrhage remains unclear we have to proceed to DSA. MRI can be used for the follow up [89].

c. What Is the Best Imaging Modality in Order to Investigate Spontaneous Intracranial Hemorrhage. CT or MRI?

Non-contrast computed tomography (NCCT) is in most hospitals the first imaging modality used to detect ICH. It is widely available, fast and can be performed in patients who are unable to tolerate an MRI examination or who have contraindications to MRI such as pacemakers, aneurysm clips, or other ferromagnetic materials in their bodies [82]. In addition, CT scan is more accessible to patients who need special equipment for life support. CT scan, as mentioned before, is an excellent tool for depicting acute hemorrhage and its potential complications. Contrast-enhanced CT scanning can be used easily for patients at risk for hematoma expansion [82]. NCCT in combination with contrast enhanced CT (CECT), CTA and CTV can reveal underlying abnormalities such as aneurysms, arteriovenous malformations, pre-existing tumors. However NCCT is less sensitive than MRI in depicting and visualizing ischemic changes in a very early stage, or small infarcts especially situated in the brainstem or posterior cranial fossa. Patient's exposure to ionizing radiation and possible allergic reactions to the iodinated contrast medium are also disadvantages of CT [81].

On the other hand, MRI is much more sensitive than CT in depicting ischemic changes in a very early stage. Diffusion-weighted imaging (DWI) is able to detect ischemic changes 30 minutes after vessel occlusion [81]. The usage of DWI and perfusion weighted imaging (PWI) can also detect the extent of the infarcted core and the penumbra. These are very significant elements for the decision of management and use of thrombolysis. In the past, MRI has been considered unable to detect hemorrhage in the hyperacute stage. In recent years there have been studies that support that MRI, including T2*-weighted imaging or susceptibility-weighted imaging, can be very sensitive in the detection of hyperacute cerebral hemorrhage [91, 93].

Some authors also noticed that MRI was more sensitive than CT in depicting hemorrhagic transformation of an ischemic infarction, which may play a role in deciding

thrombolytic therapy [81, 92]. MRI is also much more sensitive than CT in detecting hemorrhages in chronic phases and old microbleeds, which also contributes to the diagnosis and therapeutic management [92]. However, MRI is less sensitive than CT to differentiate small acute hemorrhages from chronic ones, because small acute hemorrhages, with minimal or no edema, may have similar characteristics to calcifications or endovascular clot [92]. MRI with gadolinium administration, MRA and MRV can help visualize the possible cause of cerebral hemorrhage. Some authors support that routine multimodal MRI adds diagnostic yield to NCCT and helps changing the therapeutic management [94]. Others have decided to examine patients with suspected cerebral ischemia only with MRI in order to save time and if there is no hemorrhage demonstrated on MRI, thrombolysis may be started [96]. However MRI is not so widely available as CT, some hospitals are supplied with low field strength equipment, with which the modern sequences cannot be performed and MRI is sometimes difficult to perform in critically ill patients who need life support equipment.

d. Radiological Findings of ICH on CT and MRI

Based on time, all hemorrhages can be divided in 5 stages, the huperacute (the first 24 hours), the acute (1-3 days), the early subacute (3-7 days), the late subacute (7-14 days), and the chronic stage (later than 14 days) [95].

Figure 10. Brain CT showing a mesencephalic hematoma.

The acute extravasated blood is hyperdense on CT scans. The hematoma's density in the first few hours can reach 60-80 HU [90]. On MRI, hyperacute hemorrhage containing oxyhemoglobin, appears to be made of three parts: a center, a periphery and a surrounding rim. The center is slightly hypointense or isointense relative to the brain on T1-weighted images. On T2-weighted images the center is heterogeneous and slightly hyperintense relative

to the brain. The periphery of the hematoma appears hypointense and the surrounding rim, which corresponds to perilesional edema, appears hyperintense. On T2*-weighted imaging or susceptibility-weighted imaging, the center appears heterogeneous iso- or hyperintense, but the peripherya appears hypointense. As time passes there is progressive enlargement of the periphery of the lesion towards the center [93]. Such lesions do not enhance after the administration of a gadolinium-based contrast agent.

During the acute stage, hematoma continues to appear hyperdense on CT (Figure 10). On MRI, the hematoma appears iso- to hypointense on T1 weighted images, markedly hypointense on T2 weighted images due to the formation of deoxyhemoglobin [89, 95]. In this phase perilesional edema increases [90].

In the subacute phase there is a progressive decrease in hematoma's density on CT. In the early subacute stage, hematoma appears hyperintense on T1 weighted images and hypointense on T2 weighted images due to the existence of intracellular methemoglobin [89, 90]. In the late subacute stage, the hematoma appears hyperintense on both T1 and T2 weighted images due to exracellular methemoglobin [89, 90].

In the chronic stage, at last, hematoma appears as a hypodense area on CT with density close to CSF. It may also appear as a slit-like lesion or calcinated areas [89, 90]. On MRI hematoma appears hypointense on both T1 and T2 weighted images because of the existence of hemosiderin and extracellular ferritin. In the subacute and chronic stage peripheral rim enhancement may be noticed after contrast administration either on CT and MRI [89, 95].

e. Radiological Appearances of Specific Causes of ICH

Hypertensive Hemorrhage

Hypertensive hemorrhage is the most common cause of intracranial hemorrhage and it most commonly involves the lenticulostriate arterial branches of the middle cerebral artery, leading to putaminal or caudate hemorrhage. It may also result from rupture of the small perforating branches, in which case it leads to pontine or thalamic bleeds. Large hematomas often dissect into the ventricles, causing intraventricular extension [95].

Hemorrhagic Transformation of Cerebral Infarction

Infarcted brain tissue has a propensity to bleed, particularly when reperfused in the acute phase. Infarcted brain tissue can be recognized on MRI and especially Diffusion -weighted images. Hemorrhagic transformation in the infracted area can be demonstrated on T2*-weighted imaging or susceptibility-weighted imaging. However, early massive bleeding may obscure the underlying infarct. The risk of bleeding in venous infarction is higher than arterial infarction [95].

Amyloid Angiopathy

Cerebral amyloid angiopathy (CAA), is caused by the deposition of beta-amyloid in the arterial media and/or adventitia of small arteries and arterioles in the meninges, cortex, and cerebellum [95]. Unlike the hemorrhages due to hypertension, which are usually located in the basal ganglia, the presense of multiple and small hemorrhages in the cortex and subcortical white matter of cerebral hemispheres, and rarely in the cerebellum, is typical for amyloid angiopathy [90]. MRI is the best imaging tool to depict old bleeds on T2*-weighted imaging or susceptibility-weighted imaging [92].

Intratumoral Hemorrhage

There is an increased risk for hemorrhage in brain tumors with significant neovascularity. High-grade tumors, such as glioblastoma multiforme, and certain metastases (e.g., melanoma, renal cell carcinoma, thyroid carcinoma, choriocarcinoma, lung cancer) are more likely to bleed than others. In the case of an intratumoral hemorrhage, blood of different ages may be present and admixed with abnormal neoplastic tissue. That explains why MRI appearances are often atypical and complex. There is usually delay of the evolution of changes in MRI signal intensity of hemorrhage inside the tumor. Vasogenic edema is greater with brain tumors than with primary ICH. The edema surrounding a primary ICH usually resolves after 4-8 weeks, while edema due to intratumoral hemorrhage persists even into the chronic phase of hematoma. Administration of contrast medium may reveal tumor enhancement [95].

Cerebrovascular Malformations (CVMs)

Cerebrovascular malformations are a heterogeneous group of disorders that represent lesions affecting arteries, veins, capillaries or various types of vessels. Arteriovenous malformations (AVMs) and cavernous malformations, may hemorrhage abruptly without any warning sign. Developmental venous anomalies and capillary telangiectasias are generally benign lesions and clinically silent [89]. MRI with gadolinium administration, including T2*-weighted imaging or susceptibility-weighted imaging and MRA, can reveal cerebrovascular malformations.

Catheter angiography is often needed to further evaluate AVMs and arteriovenous dural fistulaes. On MRI, AVM appears as a tightly packed honeycomb of flow voids like a “bag of worms” caused by high-velocity signal loss. Areas of hemorrhages in different stages can be seen [89].

Arteriovenous dural fistulaes are a network of tiny vessels in the wall of a thrombosed dural venous sinus [89].

Cavernous hemangiomas have a typical popcorn-like appearance with locules of variable size containing blood products of different ages [89]. Multiple lesions at different locations are seen in 50% of patients with cavernous hemangiomas [95].

Developmental venous anomalies, formerly known as venous angiomas, appear like an umbrella collection of enlarged medullary veins (Medusa head) [89].

Non-Traumatic Subarachnoid Hemorrhage (SAH)

Nontraumatic subarachnoid hemorrhage (SAH) accounts for 5% of all acute strokes. As mentioned before, the most common cause of SAH is a ruptured intracranial saccular (berry) aneurysm (aSAH). Saccular aneyrusms are focal sac or berry like arterial dilatations. They are most commonly located on the circle of Willis and the middle cerebral artery bi- or trifurcation. That is the reason why most aSAHs are located in the suprasellar cistern and the sylvian fissure. Other types of aneurysms are pseudoaneurysms, blood blister-like aneurysms and fusiform aneurysms [89]. The imaging modality recommended for investigating SAH is NCCT, which can demonstrate blood as hyperdense material in the sulci and cisterns. CTA with multiplanar reformation can be the next step as it can depict an aneurysm in 90-95% of cases, if the aneurysm is larger than 2mm [89]. If CTA is negative, we can proceed to DSA (Figure 11). On MRI, SAH may be demonstrated as high signal intensity material in sulci, compared with normally hypointense CSF spaces on Fluid-Attenuated Inversion Recovery (FLAIR) images. FLAIR MRI is similar to CT in terms of its findings in SAH [95]. It can be

more sensitive than CT in detection of small SAH but it is less specific as infectious material in the CSF spaces can present with the same signal intensity [89]. T2*-weighted images can potentially demonstrate SAH as an area of low signal intensity in normally hyperintense subarachnoid spaces. On T1-weighted images, acute SAH may appear as intermediate or high signal intensity in the subarachnoid space [95] and subacute SAH may appear as high signal intensity in CSF spaces [90]. Magnetic resonance angiography (MRA) may be useful in the evaluation of aneurysms and other vascular lesions that cause SAH. Factors that limit the utility of MRA in the diagnosis of acute SAH are its low sensitivity for aneurysms less than 5 mm, its inability to depict small aneurysm contour irregularities, and its difficulty in providing high-quality images in patients who are agitated or confused [95].

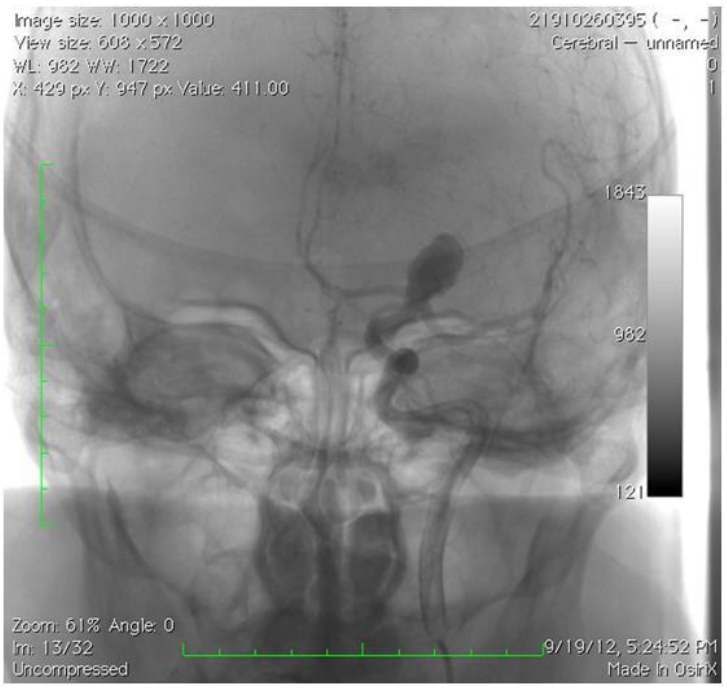

Figure 11. Digital Subtraction Angiography (DSA). A large saccular aneurysm of the left ICA bifurcation is shown.

Venous Infarction

Venous infarction can be a challenging diagnosis and it is caused by cerebral venous thrombosis, complicating both dural sinus thrombosis and deep cerebral vein thrombosis. Several conditions can lead to venous thrombosis, as mentioned before, like acute dehydration, hypercoaguable states, infection and malignancy [86]. The imaging modalities recommended are NCCT where thrombosed sinuses and cortical veins appear hyperdense and cortical/subcortical hemorrhages and edema can be demonstrated. The next step can be CECT. Empty delta sign is produced by enhancing the dura that surrounds the non-enhancing thrombus in a thrombosed sinus. CTV can demonstrate the thrombus as a filling defect in the sinus. If the CT exams are negative and there is a high clinical suspicion of venous thrombosis we can proceed to MRI including T2*-weighted imaging or susceptibility-weighted imaging and MRV (Figure 12) with gadolinium administration, in order to visualise

the thrombus [89]. MRI is superior to CT in detecting the complications of sinus thrombosis. Edema is easier to be detected on T2-weighted images and FLAIR images, while infarcted areas are best demonstrated on DWI. Hemorrhage may be detected on CT and MRI as well.

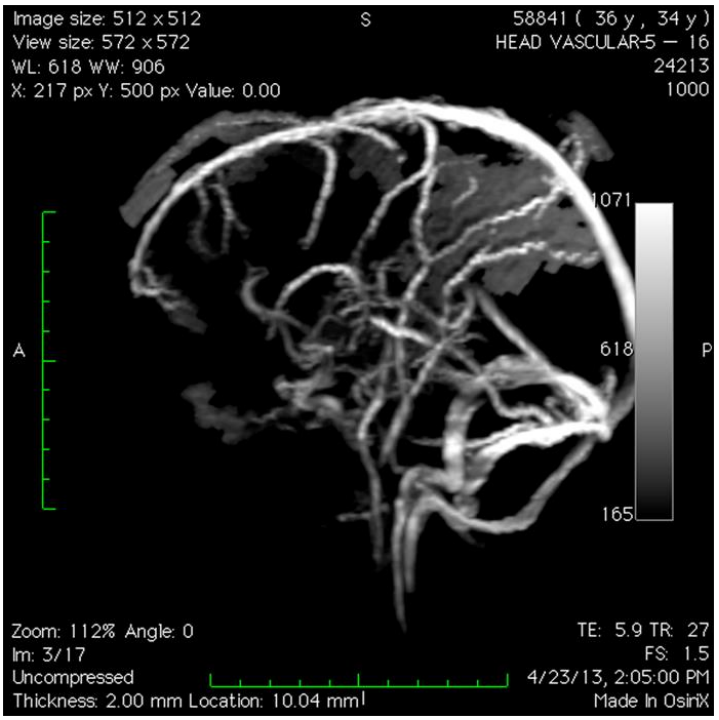

Figure 12. MR Venography with normal findings.

REFERENCES

[1] Castillo M. History and evolution of brain tumor imaging: insights through Radiology. *Radiology*: Volume 273: Number 2 (Suppl)-November 2014; S111-S125.

[2] Ambrose J, Hounsfield C. Computerized transverse axial tomography. *Br. J. Radiol* 1973; 46Q 148-9.

[3] Kirkman MA. The role of imaging in the development of neurosurgery. *Journal of Clinical Neuroscience* 2015; 22: 55-61.

[4] Baker HL Jr. The impact of computed tomography on neuroradiographic practice. *Radiology* 1975; 116(3): 637-640.

[5] Kramer RA, Janetos GP, Peristein G. An approach to contrast enhancement in computed tomography of the brain. *Radiology* 1975; 116(3): 641-647.

[6] Drevelegas A and Papanikolaou N. Imaging Modalities in brain tumors. In: A. Drevelegas (eds). *Imaging Brain Tumors with Histological Correlations*. Berlin Heidelberg, Germany: Springer-Verlag 2011.

[7] Burler AR, Horii SC, Kricheff II, Shammon MB, Budzilovich GN. Computed Tomography in astrocytomas. A statistical analysis of the parameters of malignancy and the positive contrast-enhanced CT scan. *Radiology* 1978; 129(2): 433-439.

[8] Law M, Young RJ, Babb JS, et al. Gliomas: predicting time to progression or survival with cerebral blood volume measurements at dynamic susceptibility- weighted contrast-enhanced perfusion MR imaging. *Radiology 2*008; 247: 490–98.

[9] Law M, Yang S, Babb JS, et al. Comparison of cerebral blood volume and vascular permeability from dynamic susceptibility contrast- enhanced perfusion MR imaging with glioma grade. *AJNR Am. J. Neuroradiol.* 2004; 25: 746–55.

[10] Jain R, Ellika SK, Scarpace L, et al. Quantitative estimation of permeability surface-area product in astroglial brain tumors using perfusion CT and correlation with histopathologic grade. *AJNR Am. J. Neuroradiol.* 2008; 29: 694–700.

[11] Ellika SK, Jain R, Patel SC, Scarpace L, Schultz LR, Rock JP, et al. Role of perfusion CT in glioma grading and comparison with conventional MR features. *AJNR Am. J. Neuroradiol.* 2007; 28: 1981-1987.

[12] Jain R. Perfusion CT imaging of brain tumors: an overview. *AJNR Am. J. Neuroradiol.* 2011; 32: 1570-1577.

[13] Huang APH, Tsai JC, Kuo LT, Lee CW, Lai HS, Tsai LK, et al. Clinical application of perfusion computed tomography in neurosurgery. Clinical article. *J. Neurosurg.* 2014; 120: 473-488.

[14] Dolgushin MB, Pronin IN, Holodny EA, Fadeeva LM, Holodny AI, Kornienko VN. Use of CT perfusion to discriminate between brain metastases from different primaries. *Clin. Imaging* 2015; 39: 9-14.

[15] Al-Okaili RN, Krejza J, Wang S, Woo JH, Melhem ER. Advanced MR Imaging techniques in the diagnosis of intraaxial tumors in adults. *RadioGraphics* 2006; 26: S173-S189.

[16] Jayson GC, Zweit J, Jackson A, et al. Molecular imaging and biological evaluation of HuMV833 anti-VEGF antibody: implications for trial design of antiangiogenic antibodies. *J. Natl. Cancer Inst.* 2002; 94(19): 1484-93.

[17] Patella JR and Provenzale JM. MR perfusion imaging of the brain: techniques and applications. *AJR* 2000; 175: 207-219.

[18] Aronen HJ, Gazit IE, Louis DN, et al. Cerebral blood volume maps of gliomas: comparison with tumor grade and histologic findings. *Radiology* 1994; 191(1): 41-51.

[19] Law M, Yang S, Wang H, et al. Glioma grading: sensitivity, specificity, and predictive values of perfusion MR imaging and proton MR spectroscopic imaging compared with conventional MR imaging. *AJNR Am. J. Neuroradiol.* 2003; 24(10): 1989-98.

[20] Ludemann L, Grieger W, Wurm R, et al. Comparison of dynamic contrast-enhanced MRI with WHO tumor grading for gliomas. *Eur. Radiol.* 2001; 11(7): 1231-41.

[21] Di Costanzo A, Scarabino T, Trojsi F, et al. Multiparametric 3T MR approach to the assessment of cerebral gliomas: tumor extent and malignancy. *Neuriradiology* 2006; 48(9): 622-31.

[22] Lev MH, Ozsunar Y, Henson JW, et al. Glial tumor grading and outcome prediction using dynamic spin-echo MR susceptibility mapping compared with conventional contrast-enhanced MR: confounding effect of elevated rCBV of oligodendrogliomas. *AJNR Am. J. Neuroradiol.* 2004; 25: 214-21.

[23] Cha S. Update on brain tumor imaging: from anatomy to physiology. *AJNR Am. J. Neuroradiol.* 2006; 27: 475-87.

[24] Cha S, Knopp EA, Johnson G, Wetzal SG, Litt AW, Zagzag D. Intracranial mass lesions: dynamic contrast-enhanced susceptibility-weighted echo-planar perfusion MR imaging. *Radiology* 2002; 223(1): 11-29.

[25] Hartmann M, Heiland S, Harting I, et al. Distinguishing of primary cerebral lymphomas from high-grade glioma with perfusion-weighted magnetic resonance imaging. *Neurosci.* 2003; 338(2): 119-122.

[26] Long DM. Capillary ultrastructure in human metastatic brain tumors. *J. Neurosurg.* 1979; 51:53-58.

[27] Thompson G, Mills SJ, Stivaros SM, Jackson A. Imaging of Brain Tumors: Perfusion/Permeability. In: *State of the Art Brain Tumor Diagnostic, Imaging, and Therapeutics. Neuroimaging Clinics of North America*. SK Mukherji (ed). August 2010; 20(3): 293-310.

[28] Galban CJ, Chenevert TL, Mayer CR, et al. The parametric response map is an imaging biomarker for early cancer treatment outcome. *Nat. Med.* 2009; 15(5): 572-6.

[29] Tsien C, Galban CJ, Chenevert TL, et al. Parametric response map as an imaging biomarker to distinguish progression from pseudoprogression in high-grade glioma. *J. Clin. Oncol.* 2010; 28(13): 2293-9.

[30] Sanghvi DA. Recent advances in imaging of brain tumors. *Indian Journal of Cancer* 2009; 46(2): 82-87.

[31] Cha S. Update on brain tumor imaging: from anatomy to physiology. *AJNR Am. J. Neuroradiol.* 2006; 27: 475-87.

[32] Al-Okaili RN, Krejza J, Wang S, Woo JH, Melhem ER. Advanced MR Imaging techniques in the diagnosis of intraaxial tumors in adults. *RadioGraphics* 2006; 26: S173-S189.

[33] Sanghvi DA. Recent advances in imaging of brain tumors. *Indian Journal of Cancer* 2009; 46(2): 82-87.

[34] Chapter 5. MRS in brain tumors. In: Barker PB, Bizzi A, De Stefano N, Gullapalli RP, Lin DDM. *Clinical MR Spectroscopy: Techniques and Applications*. New York, United States of America: Cambridge University Press 2011.

[35] Horská A, Barker PB. Imaging of Brain Tumors: MR Spectroscopy and Metabolic Imaging. In: *State of the Art Brain Tumor Diagnostic, Imaging, and Therapeutics*. Neuroimaging Clinics of North America. SK Mukherji (ed). August 2010; 20(3): 293-310.

[36] Gupta RK, Cloughesy TF, Sinha U, et al. Relationships between choline magnetic resonance spectroscopy, apparent diffusion coefficient and quantitive histopathology in human glioma. *J. Neurooncol.* 2000; 50(3): 215-226.

[37] Croteau D, Scarpace L, Hearshen D, et al. Correlation between magnetic resonance spectroscopy imaging and image-guided biopsies: semi-quantitative and qualitative histopathological analyses of patients with untreated glioma. *Neurosurgery* 2001; 49(4): 823-9.

[38] Barker PB. N- acetyl-aspartate-a neuronal marker? *Ann. Neurol.* 2001; 49(4): 423-4.

[39] Miller JC. Magnetic Resonance Spectroscopy in the brain. Radiology Rounds. *Massachusetts General Hospital Imaging*. July 2012; 10(7): 1-6.

[40] Remy C, Fouilhe N, Barba I, et al. Evidence that mobile lipids detected in rat brain glioma by 1H nuclear magnetic resonance correspond to lipid droplets. *Cancer Res.* 1997; 57: 407-414.

[41] Saindane AM, Cha S, Law M, et al. Proton MR spectroscopy of tumefactive demyelinating lesions. *AJNR Am. J. Neuroradiol.* 2002; 23(8) : 1378-1386.

[42] Hourani R, Horska A, Albayram S, et al. Proton magnetic resonance spectroscopic imaging to differentiate between nonneoplastic lesions and brain tumors in children. *J. Magn Reson Imaging* 2006; 23(2): 99-107.

[43] Fan G, Sun B, Wu Z, et al. In vivo single-voxel proton MR spectroscopy in the differentiation of high-grade gliomas and solitary metastases. *Clin. Radiol.* 2004; 59(1): 77-85.

[44] Law M, Hamburger M, Johnson G, et al. Differentiating surgical from non-surgical lesions using perfusion MR imaging and proton MR spectroscopy imaging. *Technol. Cancer Res. Treat* 2004; 3(6): 557-65.

[45] Crawford FW, Khayal IS, McGue C, et al. Relationship of pre-surgery metabolic and physiological MR imaging parameters to survival for patients with untreated GBM. *J. Neurooncol.* 2009; 91(3): 337-51.

[46] Klingebiel R, Bohner G. Neuroimaging. Recent results. *Cancer Res* 2009; 171: 175-190.

[47] Yang I, Aghi MK. New advances that enable identification of glioblastoma recurrence. *Nat. Rev. Clin. Oncol.* 2009; 6(11): 648-57.

[48] Taylor JS, Langston JW, Reddick WE, et al. Clinical value of proton magnetic resonance spectroscopy for differentiating recurrent or residual brain tumor from delayed cerebral necrosis. *Int. J. Radiat. Oncol. Biol. Phys.* 1996; 36(5): 1251-61.

[49] Rock JP, Hearshen D, Scarpace L, et al. Correlations between magnetic resonance spectroscopy and image-guided histopathology, with special attention to radiation necrosis. *Neurosurgery* 2002; 51(4): 912-9.

[50] Cha S. Update on brain tumor imaging: from anatomy to physiology. *AJNR Am. J. Neuroradiol.* 2006; 27: 475-87.

[51] Field AS, Wu YC, Alexander AL. Principal diffusion direction in peritumoral fiber tracts: Color map patterns and directional statistics. *Ann N Y Acad Sci* 2005; 1064: 193-201.

[52] Young RJ, Brennan N, Fraser JF, Brennan C. Advanced Imaging in Brain Tumor Surgery. In: *State of the Art Brain Tumor Diagnostic, Imaging, and Therapeutics*. Neuroimaging Clinics of North America. SK Mukherji (ed). August 2010; 20(3): 293-310.

[53] Farquharson S, Tournier JD, Calamante F, Fabinyi G, Schneider-Kolsky M, Jackson GD, Connelly A. White matter fiber tractography: why we need to move beyond DTI. *J. Neurosurg*. 2013; 118(6): 1367-77.

[54] Goebell E, Fiehler J, Ding XQ, Paustenbach S, Nietz S, Heese O, et al. Disarrangement of fiber tracts and decline of neuronal density correlate in glioma patients: A combined diffusion tensor imaging and ^{1}-H-MR Spectroscopy study. *AJNR Am. J. Neuroradiol.* 2006; 27: 1426-31.

[55] Field AS, Alexander AL, Wu YC, Hasan KM, Witwer B, Badie B. Diffusion Tensor Eigenvector Directional color imaging patterns in the evaluation of cerebral white matter tracts altered by tumor. *J. Magn Reson Imaging* 2004; 20: 555-562.

[56] Neoplastic disease of the spine. Maravilla KR, Cohen WA. In *MRI Atlas of the Spine*. Martin Dunitz London UK 1991.

[57] Rodallec MH, Feydy A, Larosserie F, Anract P, Campagna R, Babinet A, Zins M, Drape JL. Diagnostic imaging of solitary tumors of the spine: what to do and say. *Radiographics* 2008; 28: 1019-1041.

[58] Fuchs B, Boos N. Primary Tumors of the Spine. In: *Spinal Disorders: Fundamentals of diagnosis and treatment*. Boos N, Aebi M(eds). Springer-Verlag 2008; 951-976.

[59] Koeller KK, Rosenblum RS, Morrison AL. Neoplasms of the spinal cord and filum terminale. *Radiographics* 2000; 20: 1721-1749.

[60] Terrance L, Mastronardi L, Celli P, Lunardi P, Acqui M, Fortunately A. Intramedullary spinal cord ependymomas: a study of 45 cases with long-term follow-up. *Act Neurochir.* 1992; 119: 74-79.

[61] Young RJ, Brennan N, Fraser JF, Brennan C. Advanced Imaging in Brain Tumor Surgery. In: *State of the Art Brain Tumor Diagnostic, Imaging, and Therapeutics*. Neuroimaging Clinics of North America. SK Mukherji (ed). August 2010; 20(3): 293-310.

[62] Foroglou N and Black PM. Mid-Field Suite Design. In: *Intraoperative MRI-Guided Neurosurgery*. Hall WA, Nimsky C, Truwit CL (eds). First edition. Thieme 2010.

[63] Black PM, Moriarty T, Alexander E 3rd, et al. Development and implementation of intraoperative magnetic resonance imaging and its neurosurgical applications. *Neurosurgery.* 1997 Oct; 41(4): 831-42; discussion 842-5.

[64] Zimmermann M, Seifert V, Trantakis C, Raabe A. Open MRI-guided microsurgery of intracranial tumours in or near eloquent brain areas. *Acta Neurochir* (Wien). 2001; 143(4): 327-37.

[65] Nimsky C, Ganslandt O, Tomandl B, Buchfelder M, Fahlbusch R. Low-field magnetic resonance imaging for intraoperative use in neurosurgery: a 5-year experience. *Eur. Radiol*. 2002 Nov; 12(11): 2690-703.

[66] Mohammadi AM, Sullivan TB, Barnett GH, Recinos V, Angelov L, Kamian K, Vogelbaum MA. Use of high-field intraoperative magnetic resonance imaging to enhance the extent of resection of enhancing and nonenhancing gliomas. *Neurosurgery.* 2014 Apr; 74(4): 339-48; discussion 349; quiz 349-50.

[67] Hall WA, Truwit CL. Intraoperative magnetic resonance imaging. *Acta Neurochir. Suppl*. 2011; 109: 119-29.

[68] Lee B, Newborg A. Neuroimaging in Traumatic Brain Imaging. *Neuro* RX 2005 Apr;2(2): 372-383

[69] Haydel MJ, Preston CA, Mills TJ, Luber S, Blaudeau E, DeBlieux PM. Indications for Computed Tomography in patients with minor head injury. *N. Engl. J. Med.* 2000; 343: 100-105.

[70] Coles JP. Imaging after brain injury. *Br. J. Anaesth*, 2007;99(1):49-60.

[71] Ashikaga R, Araki Y, Ishida O. MRI of head injury using FLAIR. *Neuroradiology* 1997; 39: 239-242.

[72] Medana IM, Esiri MM. Axonal damage: a key predictor of outcome in human CNS diseases. *Brain.* 2003; 126(pt): 513-530.

[73] Dans PC. Head trauma. *AJNR Am. J. Neuroradiol*. 2007;28(8): 1619-1621

[74] Mittl RL, Grossman RI, Hiehle JE etal. Prevalence of MR evidence of diffuse axonal injury in patients with mild head injury and normal head CT findings. *AJNR Am. J. Neuroradiol*. 1994; 15(8): 1583-1589.

[75] Klanders AE, Croul SE. Spinal Trauma. In: Atlas S., ed. *Magnetic Resonance Imaging of the brain and spine*. Lippincott Williams and Wilkins, 2002 pp1769-1823.
[76] Olsen WL, Chakeres DW, Berry I, Richard J. Spine and Spinal Cord Trauma. In: Munelfe C., ed. *Imaging of the Spine and Spinal Cord*. Raven Press, New York, 1992 pp407-444.
[77] Munera F, Rivas LA, Nunez DB, Cluncer RM. Imaging evaluation of adult spinal injuries: Emphasis on Multidetector CT in Cervical Spine Trauma. *Radiology* 2012; 263(3): 645-660.
[78] Larson DB, Johnson LW, Schnell BM, Salisburg SR, Forman HP. National trends in CT use in the emergency department: 1995-2007. *Radiology* 2011: 258(1): 164-173.
[79] Chokshi FH, Munera F, Rivas LA, Henry RP, Cluencer PM. 64MDCT angiography of blunt vascular injuries of the neck. *AJR Am. J. Roentgenol.* 2011; 1966(3): w309-W315.
[80] Sliker CW, Shanmuganathan K, Mirvis SE. Diagnosis of blunt cerebrovascular injuries with 16-MDCT: accuracy of whole-body MDCT compared with neck MDCT angiography. *AJR Am. J. Roentgenol.* 2008; 190(3): 790-799.
[81] Ashok Srinivasan, Mayank Goyal, Faisal Al Azri, and Cheemun Lum. State-of-the-Art Imaging of Acute Stroke. *RadioGraphics* 2006 26: suppl_1, S75-S95.
[82] David S Liebeskind, J Stephen Huff, Howard S Kirshner, Richard S Krause, Helmi L Lutsep, Denise Nassisi, Jeffrey L Saver, Francisco Talavera, Chief Editor: Robert E O'Connor. *Hemorrhagic Stroke Workup*. Medscape Reference.
[83] Dr Tim Luijkx and Dr Frank Gaillard et al. *CT perfusion in ischaemic stroke* Radiopaedia.org.
[84] Josef Tacke. *Acute Stroke Imaging*. ECR Live 2014 (Video)
[85] Girish M. Fatterpekar, Thomas P. Naidich, Peter M. Som. *The Teaching Files: Brain and Spine*. Elsevier Health Sciences 2011.
[86] David M. Yousem, Robert I. Grossman. *Neuroradiology: The Requisites*, Third Edition. Elsevier Health Sciences, 2010.
[87] R. Gilberto González, Joshua A. Hirsch, Michael H. Lev, Pamela W. Schaefer, Lee H. Schwamm. *Acute Ischemic Stroke: Imaging and Intervention*. Springer Science & Business Media, 2010.
[88] Toshio Moritani, Sven Ekholm, Per-Lennart A. Westesson. *Diffusion-Weighted MR Imaging of the Brain*. Springer Science & Business Media, 2009.
[89] Anne G. Osborn, Karen L. Salzman, A. James Barkovich. *Diagnostic Imaging: Brain*. Amirsys, 2010.
[90] Valery N. Kornienko. *Diagnostic Neuroradiology*. Springer Science & Business Media, 2008.
[91] Montserrat Alemany Ripoll. *MRI Diagnosis of Intracranial Hemorrhage: Experimental and Clinical Studies*. Department of Oncology, Radiology and Clinical Immunology, 2003.
[92] Kidwell CS, Chalela JA, Saver JL, et al. Comparison of MRI and CT for Detection of Acute Intracerebral Hemorrhage. *JAMA.* 2004; 292(15): 1823-1830.
[93] Italo Linfante, MD; Rafael H. Llinas, MD; Louis R. Caplan, MD; Steven Warach, MD, PhD. MRI Features of Intracerebral Hemorrhage Within 2 Hours From Symptom Onset. *Stroke.* 1999 Nov; 30(11): 2263-7.
[94] Christine AC Wijman, Ryan Snider, Chitra Venkatasubramanian, Anna Finley-Caulfield, Marion Buckwalter, Irina Eyngorn, Nancy Fischbein, Alisa Gean, Daniel F

Hanley, Carlos S Kase, Jonathan T Kleinman, Neil ESchwartz, Maarten G Lansberg, Gregory W Albers, Michael Mlynash, Stephanie Kemp, Demi Thai, Rashmi Narayana, Michael Marks, Roland Bammer, and Mike Moseley. Diagnostic Accuracy of MRI in Spontaneous intra-cerebral Hemorrhage. *The DASH study – Final Results*. Stanford Neurocritical Care Program, Stanford Stroke Center Stanford University Medical Center.

[95] Jitendra L Ashtekar, Tufail Ahmed Patankar, David S Levey, C Douglas Phillips, Robert M Krasny, Chief Editor: L Gill Naul. *Intracranial Hemorrhage Evaluation with MRI*. Medscape Reference.

[96] Fiebach JB, Schellinger PD, Gass A, Kucinski T, Siebler M, Villringer A, Olkers P, Hirsch JG, Heiland S, Wilde P, Jansen O, Röther J, Hacke W, Sartor K; Kompetenznetzwerk Schlaganfall B5. Stroke magnetic resonance imaging is accurate in hyperacute intracerebral hemorrhage: a multicenter study on the validity of stroke imaging. *Stroke*. 2004 Feb; 35(2): 502-6.

In: Encyclopedia of Surgery (22 Volume Set)
Editors: Andreas Lehrer and Kristin Mueller
ISBN: 978-1-53618-329-0
© 2020 Nova Science Publishers, Inc.

Chapter 85

THE ROLE OF IMAGING IN PARATHYROID SURGERY

I. Koutelidakis*, A. Doundis, A. Ananiadis, S. Kalaitzis, T. Kaltsikis and V. Papaziogas
2nd Department of Surgery, Medical School,
Aristoteleio University of Thessaloniki, Greece

ABSTRACT

Primary hyperthyroidism (PHPT) is mainly caused by a parathyroid adenoma. The localization of this parathyroid lesion is essential for the surgical treatment of the disease. Various invasive and non-invasive localizing tests are available for evaluating PHPT. The traditional non-invasive imaging modalities include ultrasonography, scintigraphy, computed tomography and magnetic resonance imaging. In the era of minimally invasive parathyroidectomy (MIP), the utilization of SPECT and SPECT/CT in radioimaging, the 4D CT and various combinations of individual visualization techniques have established parathyroid imaging as an essential supplement to parathyroid surgery.

INTRODUCTION

There are typically two superior and two inferior parathyroid glands (PG) in humans. The superior PG develops from the dorsal wing of the third pharyngeal pouch and the inferior of the fourth. PG are composed mainly of chief cells, oxyphil cells and adipose tissue. The normal weight of each PG is about 40 to 50mg and measuring about 5 × 3 × 1 mm. The inferior thyroid artery is the predominant vascular supply to both superior and inferior PG in the majority of the cases [1].

The PG are located in the posterior surface, adjacent to the poles of the lobes of the thyroid gland. A nomenclature of possible locations of the PG is shown in figure 1 [2]. It should be mentioned that the inferior PG are consistently anterior (ventral) to the recurrent laryngeal nerve (RLN) and the superior PG posterior (dorsal) to the RLN [3].

* Corresponding Author's Email: iokoutel@gmail.com.

In approximately 10% of patients supernumerary glands and less than four glands have been reported. When the PG are situated above or below the level of the thyroid gland or they are distant from its posterior aspect, they are considered ectopic. Ectopic PG are usually intrathyroidal, in the carotid sheath, the trachealesophageal groove or in the thymus or the superior mediastinum [4].

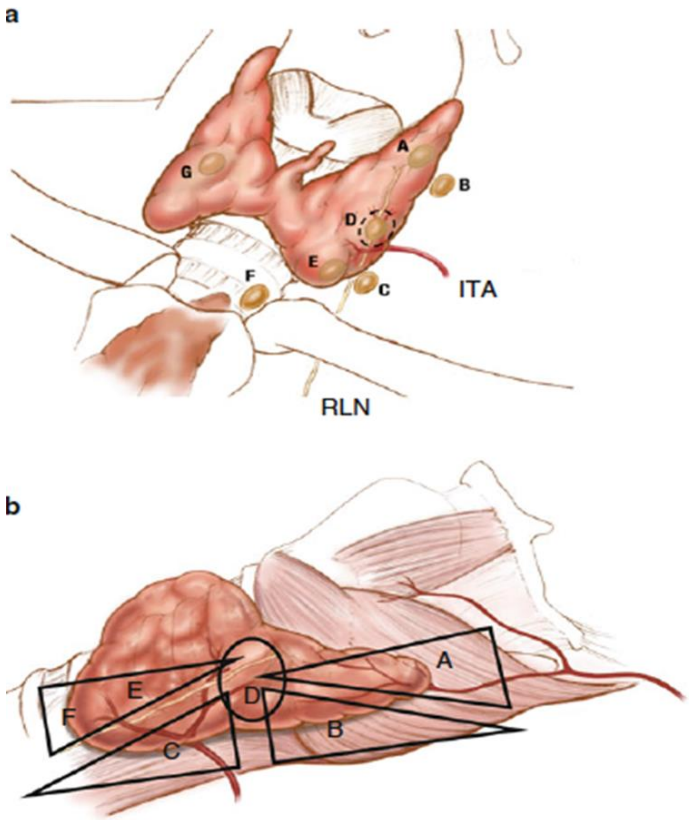

Figure 1. (a) Anterior view displaying nomenclature of possible locations of parathyroid adenomas. A: Superior gland, in proximity of posterior surface of thyroid parenchyma, may be intracapsular/ compressed. B: Superior gland, fallen posteriorly into tracheoesphageal groove, no contact with posterior surface of thyroid tissue in the cranio-caudal confines of thyroid lobe. C: Superior gland, fallen posteriorly into tracheoesphageal groove, no contact with posterior surface of thyroid tissue and is caudal/inferior to cranio-caudal confines of thyroid lobe. D: Superior or inferior gland, in mid region of posterior surface of thyroid parenchyma near junction of RLN and inferior thyroidal artery. E: Inferior gland, in region inferior to thyroid parenchyma, anterior to trachea. F: Inferior gland, descended into thyrothymic ligament or superior thymus and may appear in mediastinum. G: Intrathyroidal parathyroid. (b) Lateral view [2].

PG secrete parathyroid hormone (PTH) which is the key regulator of calcium homeostasis. Hyperfunction of the PG is leading to a condition known as primary hyperparathyroidism (PHPT). Secondary hyperparathyroidism is commonly due to chronic kidney disease, in which low serum calcium concentrations stimulate diffuse gland hyperplasia, In those patients PT glands may continue to grow and become overactive, resulting in typical asymmetric hypertrophy because of autonomous function (tertiary hyperparathyroidism) [5]. Most cases of PHPT are caused by a single parathyroid adenoma

(90%). Other causes include hyperplasia of all four glands (5%), double adenomas (5%), and, rarely, parathyroid carcinoma. There is an increased incidence of parathyroid hyperplasia in multiple endocrine neoplasia type I. Another rare cause of PHPT is familial hypocalciuric hypercalcemia [6].

PHPT is a common disease occurring in about 1% of the adults. It is 2-3 times more common in women than men and peaks around the fifth decade of life. Diagnosis of PHPT is accomplished by biochemical findings. The most common presenting symptoms of PHPT include fatigue, hypertension, bone pain, muscle weakness, and psychiatric illness. All symptomatic patients and asymptomatic patients younger than 50 years, as well as patients meeting specific criteria are candidates for surgical therapy [7].

The traditional approach to parathyroid surgery consists of bilateral neck exploration in order to identify and visually inspect all four parathyroid glands. The success of this approach exceeds to 90-95%. However, cervical exploration requires a larger incision, longer operating time and can have higher morbidity [1].

With the progress in parathyroid imaging a minimally invasive approach can be accomplished. The minimally invasive parathyroidectomy (MIP) includes small incision, out-patient parathyroidectomy, endoscopic or video assisted surgery and operation under local anesthesia. MIP is associated with significant reductions in operative time and hospital stay, provides a better cosmetic result while decreasing the potential complications of bilateral exploration [8].

Various invasive and non-invasive localizing tests are available for evaluating PHPT. The traditional non-invasive imaging modalities include ultrasonography, scintigraphy, computed tomography and magnetic resonance imaging.

In the era of MIP, the utilization of SPECT and SPECT/CT in radioimaging, the 4D CT and various combinations of individual visualization techniques have established parathyroid imaging as an essential supplement to parathyroid surgery.

ULTRASONOGRAPHY

Ultrasonography of the neck (US) is the most generally available and cheap examination in parathyroid imaging.

With the use of high-frequency 12- or 15-MHz transducers and the patient in supine position with his or her neck hyperextended, the neck is examined from the carotid bifurcation superiorly to the sternal notch inferiorly and the carotid artery/internal jugular vein laterally [9].

Normal PG are rarely visualized by US, because of their small size and insufficient acoustic difference compared to adjacent thyroid tissue. However, parathyroid adenomas, hyperplasia, and carcinomas exhibit a relatively hypoechogenic pattern, due to their compact cellularity relative to thyroid tissue [10].

Parathyroid adenomas are usually well-circumscribed ovoid, longitudinal in shape and tend to be solid and homogenously hypoechoic relative to echogenic thyroid tissue. An echogenic line that separates the thyroid gland from the enlarged parathyroid gland can usually be seen. Larger adenomas are more likely to have cystic change, lobulations, increased echogenicity due to fatty deposition, and occasional calcifications [11]. (Figure 2).

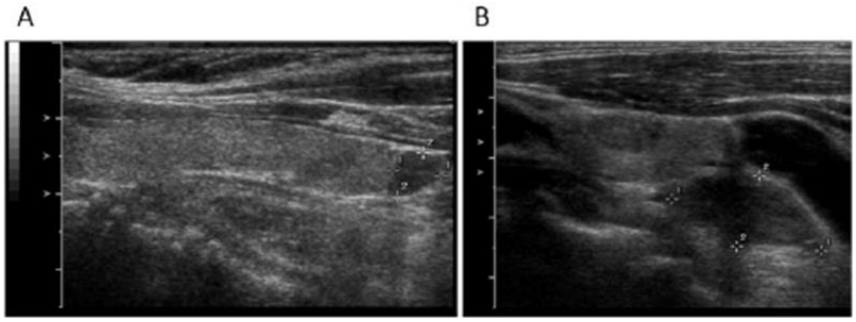

Figure 2. Hypoechoic left lower pole (A) and behind the left lower pole (B) parathyroid adenomas identified by ultrasound [1].

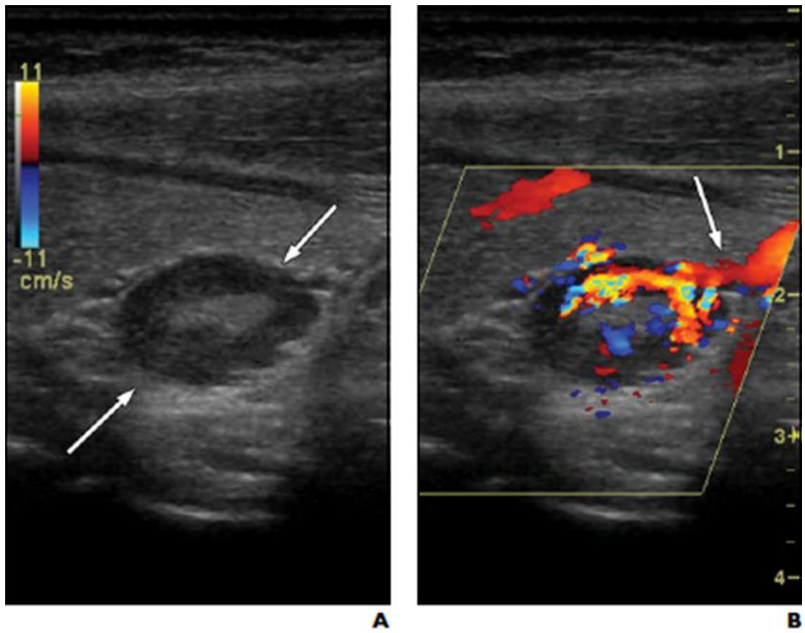

Figure 3. 44-year-old woman with hyperparathyroidism due to right inferior parathyroid adenoma. Resected gland weighed 629 mg, nearly 15 times weight of a normal gland (40–50 mg). A, Sonogram shows typical hypoechoic adenoma (arrows) deep in relation to lower pole of thyroid. B, Color Doppler sonogram shows peripheral feeding vessel (arrow) characteristic of parathyroid adenomas. Also note typical arc or rim vascularity [21].

Color Doppler US (CDUS) has also been used to localize enlarged parathyroid glands, while Contrast-Enhanced US (CEUS) has not yet shown a potential benefit. In CDUS, parathyroid adenomas tend to be hypervascular lesions. An extrathyroidal artery may lead to a parathyroid adenoma in the majority of patients. An extrathyroidal feeding vessel may provide a roadmap to an otherwise inconspicuous gland. Characteristically, the extrathyroidal artery enters at one pole of the gland (polar artery). However, color Doppler sonograms of parathyroid adenomas may not show increased vascularity until the lesions are 1 cm in size [12]. (Figure 3).

The sensitivity of US for detecting enlarged parathyroid glands ranges from 70% to 100% as it is, to a great degree, depended to the experience of the examiner, the size of the

PG lesion and the pathology of the adjacent thyroid tissue. An advantage of US is the fact that the identified concurrent thyroid disease can be addressed by fine needle aspiration (FNA) preoperatively or intraoperatively.

Additionally, even when US findings are atypical, US can be helpful leading to further investigation [10, 13-14].

False positive or negative sonographic diagnosis may be due to thyroid nodules, prominent blood vessels, cervical lymph nodes, esophagus and longus colli muscle and poor visualization of neck structures due to previous surgery. It must be stressed that US does not enable localisation of parathyroid glands placed in the mediastinum or in retrotracheal or retrooesophageal regions due to acoustic shadows from bones or air spaces [15].

RADIOIMAGING

The use of radionucleotid agents (radioimaging) is the most widely adopted method in parathyroid imaging.

Among several radiotracers that have been used in the past or are still in use, Hexakis-2-methoxy-isobutyl-isonitrile labeled with technetium- 99m (99mTc-sestamibi) holds a predominant place.

99mTc-sestamibi consists of monovalent cationic lipophilic molecules which after intravenous (i.v.) injection distribute according to blood flow. These molecules cross the cell membranes according to the electrochemical gradient and intracellularly accumulate in the mitochondria of the oxyphil cells. 99mTc-sestamibi is also taken up by the thyroid gland, but it washes out more rapidly from normal thyroid tissue than out of PT glands.99mTc-sestamibi is sequestered also in the myocardium, the salivary glands and in brown fat, which often is noted as a mild supraclavicular shade [16].

Two different protocols can be used in 99mTc sintigraphy.

The dual-phase protocol uses 99mTc-sestamibi alone. Early (10–30 min after injection) and delayed (1.5–2.5 h after injection) high-count images are obtained of the neck and chest. The concept of this technique is based on the different washout of the radiofactor between the thyroid and the abnormal parathyroid gland. Dual-phase imaging with 99mTc-tetrofosmin appears not to be useful because of rapid washout from parathyroid tissue. It should be mentioned that it is mainly a functional technique as it visualizes the difference in the wash out of the radiofactor between the thyroid and the parathyroid gland [17]. (Figure 4).

The dual-tracer protocol uses the coadministration of 99mTc-sestamibi as a substitute to Tl-201, 123I- or 99mTc pertechnetate. The thyroid images generated are then digitally subtracted from the 99mTc-sestamibi image and the residual signal after subtraction of the thyroid image is indicative of parathyroid uptake [17]. (Figure 5).

Two-dimensional planar PG scanning has been the standard technique for many years, the three-dimensional single photon emission tomography (SPET) was added later on and more recently the latter is combined with computed tomography (SPET/CT) leading to higher sensitivity rates [16]. (Figure 6).

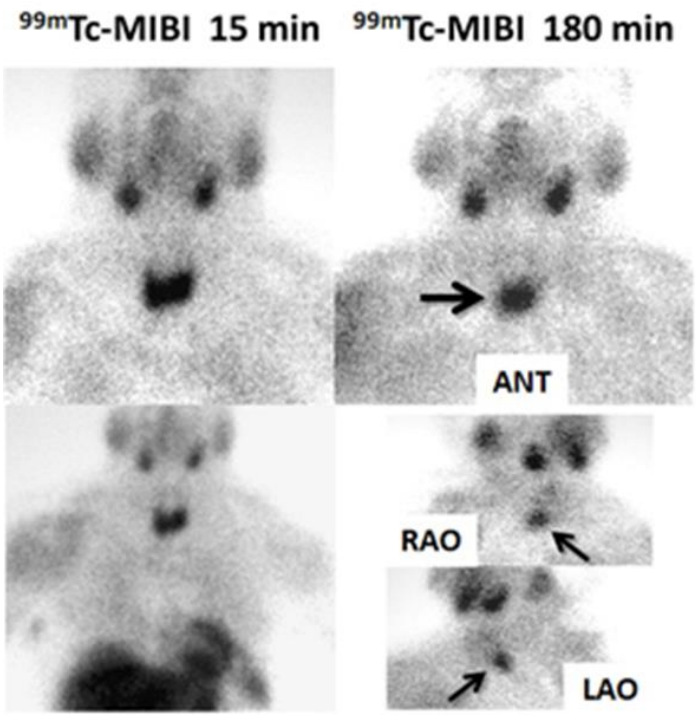

Figure 4. Double phase 99mTc-sestamibi (99mTc-MIBI) parathyroid scintigraphy. In delayed imaging focal tracer retention is seen in the lower part of the thyroid gland (arrow). In the right and left anterior oblique views (RAO and LAO, respectively) the abnormal focus "changes its position significantly" relative to the submandibular salivary glands, indicating that it is located in the thyroid area and not deep in the neck [16].

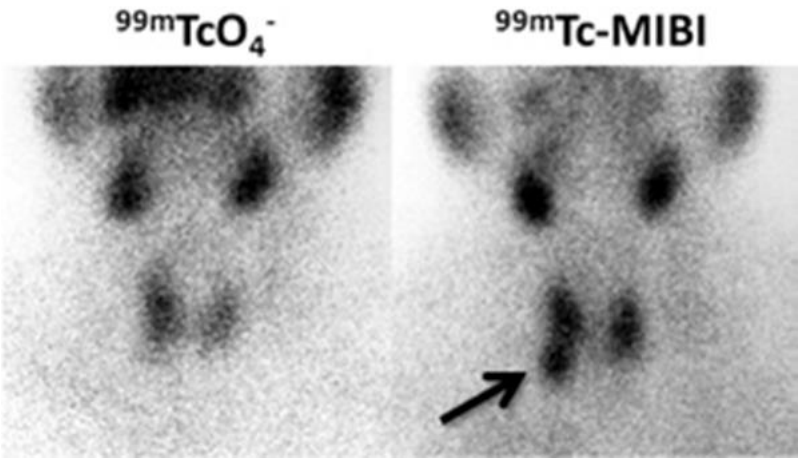

Figure 5. In a patient with primary hyperthyroidism double tracer parathyroid scintigraphy shows a solitary focus adjacent to the lower pole of the right thyroid lobe which takes up 99mTc-sestamibi but not 99mTcO4 -. It is very likely that this patient suffers from a single adenoma and he is suitable for a targeted surgical treatment [16].

If a dual-phase study is performed, then a high-resolution parallel-hole collimator or a pinhole or converging collimator can be used. Pinhole collimators are preferred if SPECT or SPECT/CT is not part of the imaging protocol. The range of intravenously administered radioactivity in adults is 740–1,110 MBq (20–30 mCi) [17].

In the double tracer subtraction technique the patient should remain immobile between the two successive scans and images should be carefully subtracted to avoid artifacts. In scanning in secondary HPT it is advised to withhold drugs refraining PG hyperfunction, namely calcimimetics for 2 weeks and vitamin D supplements for 1-4 weeks. If a subtraction technique is used, iodine-containing preparations should be avoided for >4 weeks and thyroxine for 3 weeks. If 123I is used for thyroid scanning, thyrostatic drugs should be stopped for 1 week [18].

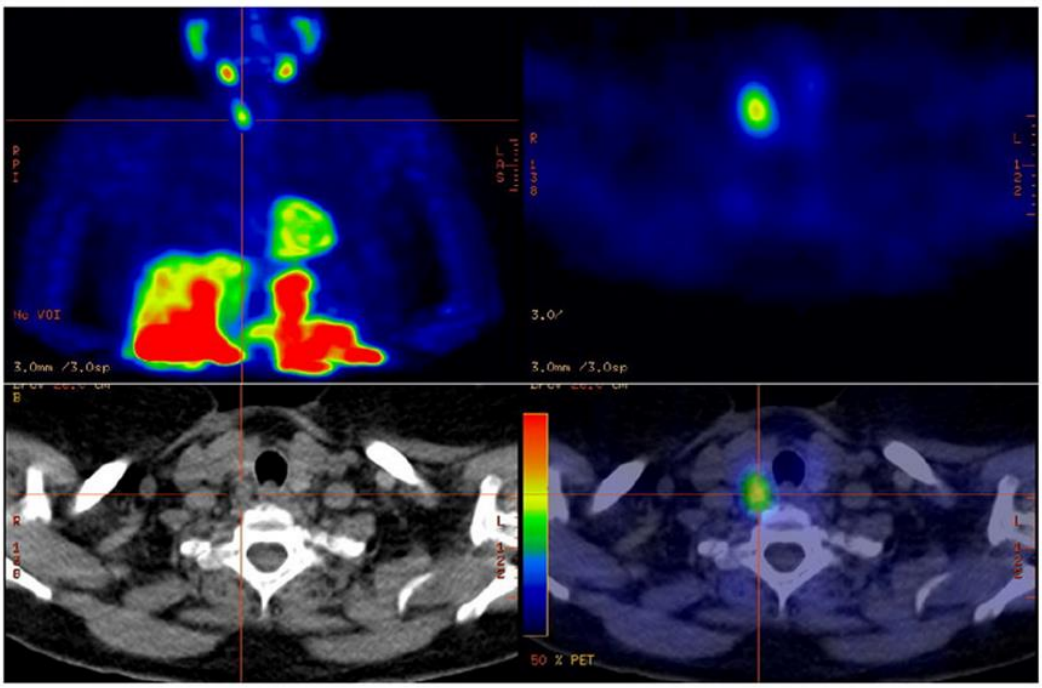

Figure 6. SPECT/CT demonstrating a right side parathyroid adenoma [1].

Sensitivity of 99mTc-sestamibi sintigraphy is reported to be about 80-100%.

Regional perfusion, gland size and functional activity, cell cycle phase, and prevalence of mitochondria-rich cells are some of the factors affecting the diagnostic accuracy of the method [19].

One further advantage of radioimaging is that the use of gamma probe intraoperatively can assist to the localization of the PG lesion and navigate the surgeon through challenging anatomies, especially in cases of ectopic PG [20].

COMPUTED TOMOGRAPHY

Computed tomography (CT) scanning was considered to be an effective adjunct to the conventional first line imaging techniques (US and radioimaging), reserved for cases of recurrent PHPT or cases of altered anatomy [21].

With the induction of 4D CT , therefore the addition of changes in the perfusion of contrast over time to the three dimensional anatomic CT images allowed for further functional information to the anatomic images due to the rapid uptake and washout of the contrast from the hyperfunctioning gland to the anatomic data and improved the sensitivity of the method [22,23].

Furthermore, 4D CT can be combined with US and this combination technique appears to be an excellent and cost effective preoperative localizing method for hyper-functioning parathyroid glands [24].

CT acquisition involves intravenous administration of nonionic iodinated contrast at a dose of 2 mL per kg patient weight. This technique relies on the vascularity of the parathyroid glands and their relative enhancement with contrast compared to the surrounding structures. A prominent feeding artery at the margin of a parathyroid adenoma (polar vessel), first described on ultrasound, may be seen in up to two thirds of parathyroid adenomas on high-quality 4D-CT studies. This finding can increase diagnostic confidence that a suspicious lesion is a parathyroid adenoma instead of a lymph node or thyroid nodule [25]. (Figure 7 and 8).

Figure 7. Computed tomography demonstrating a left sided parathyroid adenoma [1].

A 3-phase 4D-CT protocol with helical acquisition at 1.25-mm slice thickness from the bottom of the mandibular teeth down to the carina with noncontrast, early postcontrast, and delayed postcontrast imaging. The first noncontrast images can be helpful to distinguish adenomas from the intrinsically dense iodine-rich thyroid gland, while the early and delayed postcontrast imaging highlight the hypervascular nature of adenomas and their characteristic early washout [26].

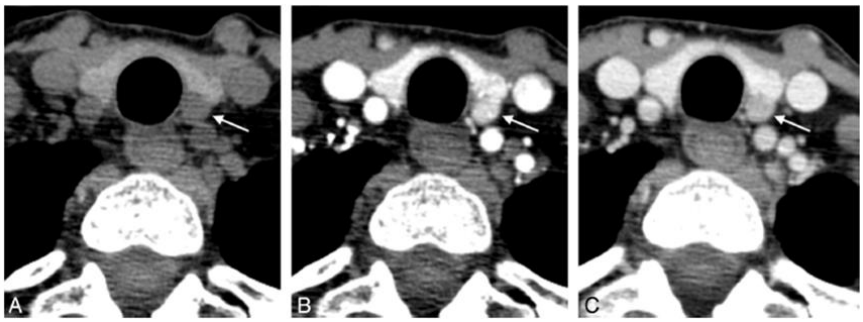

Figure 8. Axial noncontrast (A), axial early phase postcontrast (B), and axial delayed phase postcontrast (C) images show a hypoattenuated hypodense nodule contiguous with the left posterior thyroid gland, which demonstrates avid early contrast enhancement and washout. Pathology revealed a 600-mg parathyroid adenoma [23].

Most modern multiphase 4D-CT techniques report a sensitivity and specificity exceeding 90%. In a CT picture, a parathyroid adenoma can be difficult to differentiate from lymph nodes, normal vessel structures or an exophytic thyroid tuberculum, particularly in patients who have previously undergone an operation within the neck. PG can be difficult to identify by CT at the area of the sternal notch and mediastinum due to streak artifact or being mistaken with lymph nodes. CT is also not particularly useful in identifying the parathyroid glands in patients who are not able to receive IV contrast [22].

MAGNETIC RESONANCE IMAGING

Magnetic Resonance Imaging (MRI) is an expensive and not always available technique; therefore, like CT scanning, MRI is reserved for cases of recurrent PHPT and ectopic PG lesions, despite the advantage of lack of ionizing radiation.

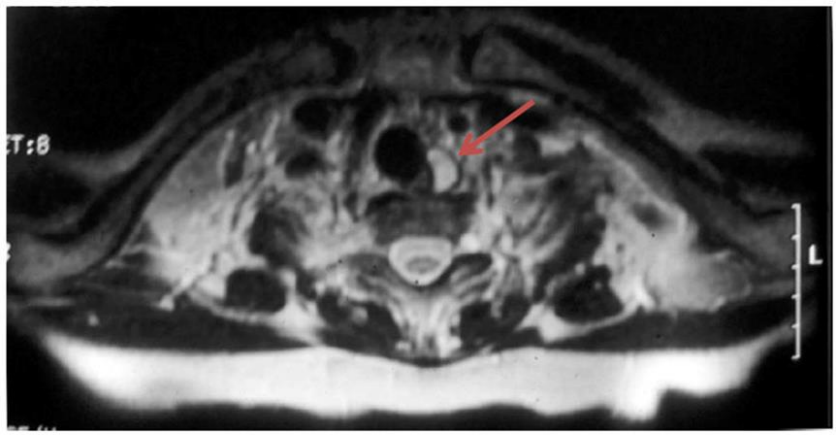

Figure 9. MRI demonstrating a left parathyroid adenoma [1].

Normal parathyroid glands usually are not seen on MRI. Parathyroid adenomas are isointense relative to the surrounding muscle and have low intensity on T1 weighted images.

They are generally hyper intense on T2 weighted images; however, hyper-functioning parathyroid glands show intense contrast enhancement on T1 weighted images [27]. (Figure 9).

The sensitivity of MRI in detecting abnormal parathyroid glands is reported from 70% to 90%. Factors resulting in false positive disease are concomitant thyroid disease and enlarged cervical lymph nodes that may mimic parathyroid adenomas. MRI is less sensitive and specific in identifying hyperplastic glands compared to parathyroid adenomas [28].

POSITRON EMISSION TOMOGRAPHY

Positron Emission Tomography/ Computed Tomography (PET/CT) with 18F-Fluorodeoxyglucose (18F-FDG) as an imaging tool in parathyroid cancer is not clearly reported in the literature, although there is a potential role of PET/CT in assessing the extent of disease and response to treatment which are the general principles used to correctly evaluate disease status. It has been proposed that FDG-PET can provided additional information related to the location and extent of parathyroid carcinoma, compared to CT, MRI and 99mTc-sestamibi [29,30]. (Figure 10).

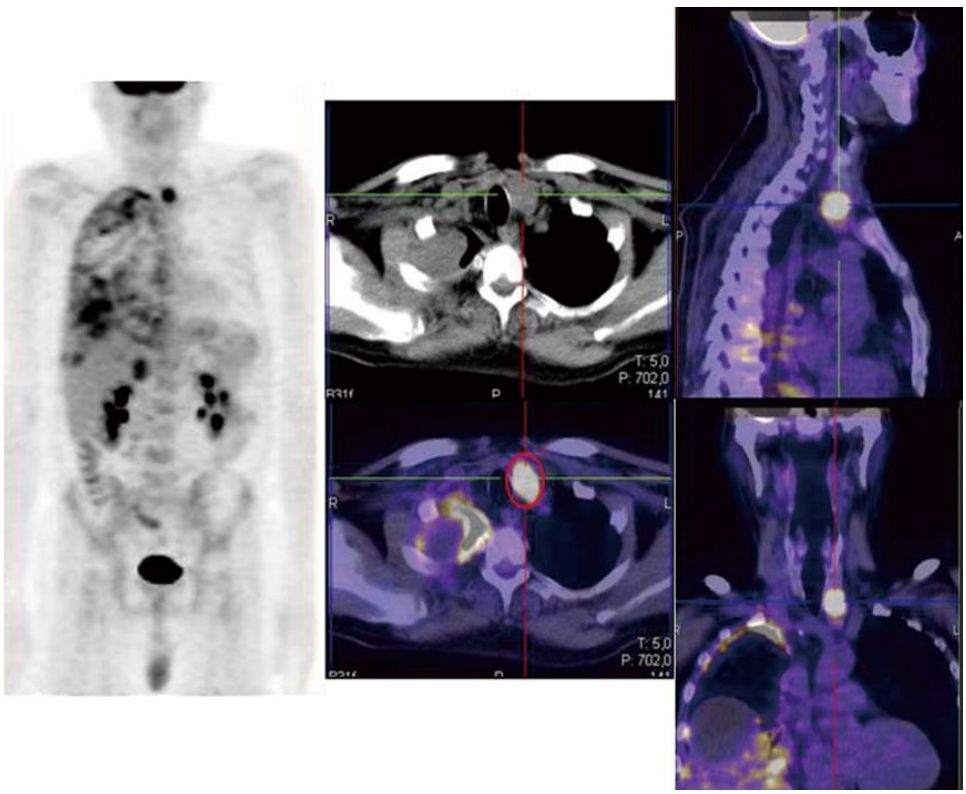

Figure 10. Staging. Right: At Maximum intensity projection the parathyroid and pleural involvements are visible; Central and left: High 18F-Fluorodeoxyglucose-uptake is clearly displayed corresponding to the left parathyroid gland and right pleura in coronal, transverse and sagittal planes [30].

INVASIVE METHODS

The invasive methods used for diagnosing primary hyperparathyroidism are quite sensitive. Selective angiography shows 60% sensitivity, and intra-operative determination of parathormone in venous blood 80%. If both examinations are used, the sensitivity will increase to as much as 91–95%. These examinations help to accurately localize an adenoma (angiography) and to identify further adenomas or hyperplasia (PTH in venous blood) . Unfortunately, the methods may involve dangerous complications, including neurological disorders, embolism or renal failure [31].

CONCLUSION

The role of imaging in parathyroid surgery is more than crucial as it is the factor that can alter the operative strategy and offer to the surgeon the ability for more precise, focused and minimally invasive techniques.

With US and 99mTc sestamibi sintigraphy SPECT or SPECT/CT as first line examinations and the implication of 4D CT and MRI for selected cases, the majority of PG lesions can be precisely visualized and surgically removed.

The combination of different methods has been showed to increase the sensitivity of parathyroid imaging and the intraoperative measurement of PTH can provide confidence to the surgeon and lead to safer parathyroid surgery for the patient.

REFERENCES

[1] Mohebati A, Shaha AR. Imaging techniques in parathyroid surgery for primary hyperparathyroidism. *Am. J. Otolaryngol*. 2012 Jul-Aug;33(4):457-68. doi: 10.1016/j.amjoto.2011.10.010. Epub 2011 Dec 7.

[2] Elizabeth G. Grubbs , Beth S. Edeiken , Maria K. Gule , Brett J. Monroe, Edmund Kim, Thinh Vu , and Nancy D. Perrier Chapter 2 *Preoperative Parathyroid Imaging for the Endocrine Surgeon Handbook of parathyroid diseases A case-based practical guide* Khan, MD ,AA; Clark O.H. (Eds.) 2012

[3] Wang C. The anatomic basis of parathyroid surgery. *Ann. Surg.* 1976;183(3):271–5.

[4] Thompson NW, Eckhauser FE, Haven JG. The anatomy of primary, *hyperparathyroldism Surgery* 1982:92:814-821.

[5] Gopinath P, Mihai R. Hyperparathyroidism. *Surgery* (Oxford) 2011; 29: 451-8.

[6] Ruda JM, Hollenbeak CS, Stack BC Jr. A systematic review of the diagnosis and treatment of primary hyperparathyroidism from 1995 to 2003. *Otolaryngol. Head Neck Surg* 2005; 132:359–372

[7] Eigelberger MS, Cheah WK, Ituarte PH, Streja L, Duh QY, Clark OH. The NIH criteria for parathyroidectomy in asymptomatic primary hyperparathyroidism: are they too limited?. *Ann. Surg. Apr* 2004;239(4):528-35.

[8] Norman J, Chheda H, Farrell C. Minimally invasive parathyroidectomy for primary hyperparathyroidism: decreasing operative time and potential complications while improving cosmetic results. *Am. Surg.* 1998 May;64(5):391-5; discussion 395-6.

[9] Leupe PK, Delaere PR, Vander Poorten VL, Debruyne F. Pre-operative imaging in primary hyperparathyroidism with ultrasonography and sestamibi scintigraphy. *B-ENT*. 2011;7(3):173-80.

[10] Gilat H, et al. Minimally invasive procedure for resection of a parathyroid adenoma: the role of preoperative high-resolution ultrasonography. *J. Clin. Ultrasound.* 2005; 33(6):283–7. [PubMed: 16134156]

[11] Solbiati L, et al. Ultrasound of thyroid, parathyroid glands and neck lymph nodes. *Eur Radiol*. 2001; 11(12):2411–24. [PubMed: 11734934]

[12] Lane MJ, Desser TS, Weigel RJ, Jeffrey RB Jr. Use of color and power Doppler sonography to identify feeding arteries associated with parathyroid adenomas. *AJR Am. J. Roentgenol*. Sep 1998;171(3):819-23.

[13] Boi F, Lombardo C, Cocco MC, Piga M, Serra A, Lai ML, Calò PG, Nicolosi A, Mariotti S. Thyroid diseases cause mismatch between MIBI scan and neck ultrasound in the diagnosis of hyperfunctioning parathyroids: usefulness of FNA-PTH assay. *Eur. J. Endocrinol*. 2012 Dec 10;168(1):49-58. doi: 10.1530/EJE-12-0742. Print 2013 Jan.

[14] Chandramohan A, Sathyakumar K, John RA, Manipadam MT, Abraham D, Paul TV, Thomas N, Paul MJ. Atypical ultrasound features of parathyroid tumours may bear a relationship to their clinical and biochemical presentation. *Insights Imaging*. 2014 Feb;5(1):103-11. doi: 10.1007/s13244-013-0297-x. Epub 2013 Nov 29.

[15] Barbaros U, et al. The characteristics of concomitant thyroid nodules cause false-positive ultrasonography results in primary hyperparathyroidism. *Am. J. Otolaryngol*. 2009; 30(4):239–43. [PubMed: 19563934]

[16] Moralidis E. Radionuclide parathyroid imaging: a concise, updated review. *Hell J. Nucl. Med*. 2013 May-Aug;16(2):125-33. doi: 10.1967/s002449910083. Epub 2013 May 20. Review. PMID: 23687643

[17] Greenspan BS, Dillehay G, Intenzo C, Lavely WC, O'Doherty M, Palestro CJ, Scheve W, Stabin MG, Sylvestros D, Tulchinsky M. SNM practice guideline for parathyroid scintigraphy 4.0. *J. Nucl. Med. Technol.* 2012 Jun;40(2):111-8. doi: 10.2967/ jnmt.112.105122. Epub 2012 Mar 27.

[18] Hindié E, Ugur Ö, Fuster D et al. 2009 EANM parathyroid guidelines. *Eur. J. Nucl. Med. Mol. Imaging* 2009; 36: 1201-16.

[19] Torregrosa JV, et al. (99m)Tc-sestamibi scintigraphy and cell cycle in parathyroid glands of secondary hyperparathyroidism. *World J. Surg.* 2000; 24(11):1386–90. [PubMed: 11038211]

[20] Daliakopoulos SI, Chatzoulis G, Lampridis S, Pantelidou V, Zografos O, Ioannidis K, Sapranidis M, Ploumis A. Gamma probe-assisted excision of an ectopic parathyroid adenoma located within the thymus: case report and review of the literature. *Cardiothorac Surg*. 2014 Mar 31;9:62. doi: 10.1186/1749-8090-9-62.

[21] Johnson NA, Tublin ME, Ogilvie JB Parathyroid imaging: technique and role in the preoperative evaluation of primary hyperparathyroidism. *AJR Am. J. Roentgenol*. 2007 Jun;188(6):1706-15. Review.

[22] Rodgers SE, et al. Improved preoperative planning for directed parathyroidectomy with 4- dimensional computed tomography. *Surgery.* 2006; 140(6):932–40. discussion 940-1. [PubMed: 17188140].

[23] Chazen JL, Gupta A, Dunning A, Phillips CD. Diagnostic accuracy of 4D-CT for parathyroid adenomas and hyperplasia. *AJNR Am. J. Neuroradiol.* 2012 Mar;33(3):429-33. doi: 10.3174/ajnr.A2805. Epub 2011 Dec 1.

[24] Kutler DI, et al. Parathyroid localization with modified 4D-computed tomography and ultrasonography for patients with primary hyperparathyroidism. *Laryngoscope*. 2011.

[25] Bahl M, Muzaffar M, Vij G, Sosa JA, Choudhury KR, Hoang JK. Prevalence of the Polar Vessel Sign in Parathyroid Adenomas on the Arterial Phase of 4D CT. *AJNR Am. J. Neuroradiol*. Aug 14 2013.

[26] Chazen JL, Gupta A, Dunning A, Phillips CD. Diagnostic accuracy of 4D-CT for parathyroid adenomas and hyperplasia. *AJNR Am. J. Neuroradiol.* Mar 2012;33(3):429-33.

[27] Abikhzer G, Levental M, Rush C. High resolution MRI in the detection of an intrathymic parathyroid adenoma. *Br. J. Radiol*. 2006; 79(945):e78–80. [PubMed: 16940365].

[28] McDermott VG, et al. Preoperative MR imaging in hyperparathyroidism: results and factors affecting parathyroid detection. *AJR Am. J. Roentgenol*. 1996; 166(3):705–10. [PubMed: 8623655].

[29] Neumann DR, Esselstyn CB, Kim EY. Recurrent postoperative parathyroid carcinoma: FDG-PET and sestamibi-SPECT findings. *J. Nucl. Med* 1996; 37: 2000-2001.

[30] Evangelista L, Sorgato N, Torresan F, Boschin IM, Pennelli G, Saladini G, Piotto A, Rubello D, Pelizzo MR. FDG-PET/CT and parathyroid carcinoma: Review of literature and illustrative case series. *World J. Clin. Oncol.* 2011 Oct 10;2(10):348-54. doi: 10.5306/wjco.v2.i10.348.

[31] Gawrychowski J, Buła G. Imaging diagnostics for primary hyperparathyroidism. *Endokrynol. Pol*. 2013;64(5):404-8. doi: 10.5603/EP.2013.0024. PMID: 24186598.

In: Encyclopedia of Surgery (22 Volume Set)
Editors: Andreas Lehrer and Kristin Mueller
ISBN: 978-1-53618-329-0
© 2020 Nova Science Publishers, Inc.

Chapter 86

THE ROLE OF IMAGING IN ADRENAL SURGERY

K. Sapalidis[1,*], I. Anastasiadis[1], E. Kotidis[1], M. G. Pramateftakis[2] and I. Chrysogonidis[3]

[1]3rd Surgery Department, AHEPA University Hospital, Thessaloniki, Greece
[2]Guy's and St Thomas' NHS Foundation Trust, London, United Kingdom
[3]Department of Radiology, AHEPA University Hospital, Thessaloniki, Greece

ABSTRACT

The adrenal glands constitute an indispensable part of human physiology and the diseases affecting them, ranging from benign to malignant ones, are often a challenge for the medical and surgical team. As a result, knowledge of the latest imaging technology is critical for the diagnosis and management of these diseases, in order to provide our patients with the best possible care. This chapter will present the various imaging modalities used for the adrenal glands, as well as discuss the advantages and disadvantages of each, in order to provide our readers with a practical decision-making guide.

INTRODUCTION

The adrenal glands constitute indispensable components of normal physiology. In terms of fundamental anatomy, the adrenal is divided in an outer layer, known as the cortex and in an inner layer, the medulla. [1-2] Each gland weighs approximately 2-4 grams. [1-2] Being of significant interest in surgical practice, their blood supply can arise from several different vessels including the aorta, the celiac trunk, the inferior phrenic or the renal arteries. [1-2]The adrenal cortex secretes glucocorticoids, mineralocorticoids and sex hormones, while the adrenal medulla secretes catecholamines (epinephrine and norepinephrine and dopamine). [3] From an embryology perspective, the adrenal cortex tissue stems from the intermediate mesoderm, whilst the medulla is derived from neural crest cells through a complex migration

* Corresponding Author's Email: sapalidis@med.auth.gr.

process. [4-5] Indeed, understanding the basis of embryonic adrenal development is a key aspect of deciphering certain pathology of this gland.

To begin with, lesions affecting the adrenal cortex have a higher prevalence than lesions located in the gland's medulla. [6] Further classification is focused on determining whether the lesion is primary or metastatic. Notably, primary adrenal lesions are metabolically functional in several cases leading to the clinical manifestations of hormone excess (e.g. Cushing syndrome, Conn syndrome, pheochromocytoma etc.). This is rare with metastatic adrenal tumors. [7] In respect with lege artis medicine, Radiologic Imaging proves to be indispensable in diagnosis and staging. Predominantly, adrenal imaging can be accomplished with Computed Tomography (CT), Magnetic Resonance Imaging (MRI), Ultrasonography (US), nuclear imaging and angiography which are implemented with regard to current guidelines and the surgical team's judgment [8].

METHODOLOGY

This chapter was composed after consulting with the PRISMA Statement (2009) [9]. A review of literature was conducted using PubMed (Medline). Inclusion criteria were: papers published in English which reported on humans. Both primary research (case reports, case series, clinical trials etc.) and secondary research (reviews and meta-analyses) were deemed eligible. Exclusion criteria were: papers published in a language other than English, experimental studies on animals, Editorials and commentaries or letters to the editor. Pre-decided keywords were applied to search the database and include the following: *adrenal lesion imaging, adrenal lesion CT, adrenal lesion MRI, adrenal lesion US, adrenal lesion nuclear imaging, adrenal lesion angiography, laparoscopic adrenalectomy, robotic adrenalectomy.*

MINIMALLY INVASIVE ADRENALECTOMY: NOVEL DIRECTIONS AND LIMITATIONS

1. The Role of Laparoscopy in Adrenal Surgery

Gagner introduced laparoscopy in the field of adrenal surgery in 1992. [10] Indisputably, in the 21st century, laparoscopic adrenalectomy has prevailed over conventional open surgery as the gold standard of care, mainly due to diminished ICU and hospital stay, fewer post-operative complications and higher cosmetic satisfaction expressed by patients. The fact that the adrenals are located in the retroperitoneal space ignited the genesis of several approaches such as: the lateral retroperitoneal, the transperitoneal, the posterior retroperitoneal and even the transthoracic technique [11].

Lateral Retroperitoneal Approach

The patient is subjected to general anaesthesia and placed in the lateral decubitus position. The ipsilateral, to the affected side, arm is suspended approximately 60°, whilst the contralateral arm safely rests on a special board protected with padding. Moreover, under the

contralateral axilla a soft cushion is applied. [11-12] Left adrenalectomies usually require four trocar portals. On the other hand, it is typical to utilize 5 portals when performing right adrenalectomies. [11-12] Trocars are inserted transversally along the posterior auxiliary and mid-clavicular line (just below the rib cage). During left adrenalectomy special care must be given out to the splenic flexure, the spleen and the tail of the pancreas. When working in close approximation to the right colonic flexure, the surgeon must be cautious in order to avoid inflicting injury to right lobe of the liver. Indeed, identification and clipping of the adrenal vein constitute priorities of paramount significance.

Transperitoneal Approach

This technique bears a most distinctive advantage. The surgeon has optimal visualization of the abdomen, which effectively decreases technical difficulties and leads to improved post-operative outcomes. [13] The transperitoneal approach constitutes a wise choice for pheochromocytomas and malignant tumours.

Posterior Retroperitoneal Approach

Walz et al introduced this approach in which the adrenal is resected from the superior pole of the kidney prior to adrenal vessel ligation. [14-15]Even though this technique has been questioned [11], Cleveland clinic series [16] and systematic reviews have revealed that the posterior retroperitoneal is similar in outcomes with the lateral retroperitoneal approach if not superior.[17] Limitations exist though, as these results can only be regenerated when the procedure is performed by experienced surgeons in carefully selected groups of patients.

Transthoracic Approach

This technique was initially described in 2001. Four ports were utilized without pneumo-insufflation. The diaphragm was incised under ultrasound guidance and the adrenal was visualized in the retroperitoneal space. Ultimately vessel ligation and specimen resection was successful. Gill et al. conclude that this approach is oriented towards patients with significant abdominal and retroperitoneal fibrosis from previous surgeries [18].

Indications and Contraindications to Laparoscopic Adrenalectomy

The usual scenario involves a benign, solitary, adrenal lesion with either cortical or medullary location. Specifically, non-secreting cortical adenomas represent the vast majority of cases, with secreting adenomas (e.g., aldosteronomas, glucorticoid secreting tumors), pheochromocytomas and metastases accounting for just a minor percentage of the total number of adrenal lesions. Other rare lesions regard neuroblastomas, myelolipomas, sex-hormone secreting tumors, ganglioneuromas and adrenal cysts. [19] As far as contraindications are concerned there is no widely-accepted consensus amongst Endocrine Surgeons. However, open adrenalectomy is preferable to the laparoscopic procedure in cases involving lesions larger than 8cm or malignant adrenal tumours; especially in the event of infiltration of adjacent structures [11], [17].

Chai et al. highlight that size criteria were less restrictive with laparoscopic lateral transperitoneal adrenalectomy. [17] Notably, a solitary metastatic adrenal lesion does not constitute an absolute contraindication for laparoscopic adrenalectomy [11].

2. The Role of Robotics in Adrenal Surgery

The first series of robotic adrenalectomy were described in 1999 by Piazza et al. and Hubbens et al. [20-21] The Da Vinci ® system is superior to its predecessor (AESOP 2000 ®) on account of the EndoWrist technique and the three-dimensional vision. [23] A 2014 meta-analysis comparing robotic to laparoscopic adrenalectomy confirmed that the transperitoneal approach is the most widely implemented method with both techniques (72.5 % of robotic adrenalectomies, 75.5 % of laparoscopic adrenalectomies, p=0.27). Conversion rates, OR time and incidence of post-operative complications did not differ statistically for the two techniques. However, laparoscopically treated patients did experience heavier intraoperative bleeding and required longer hospitalization than patients who underwent robotic adrenalectomy [24].

APPLICATIONS OF IMAGING IN ADRENAL SURGERY

Differential diagnosis between benign and malignant lesions is accomplished with the contribution of Radiology. With the progress of technology, current imaging equipment can offer highly detailed anatomical information and clues about a lesion's physiological behaviour. All of the above assist the Surgeon in implementing the most appropriate procedure for the patient.

1. Adrenal Cortical Adenoma

Adrenal cortical adenoma is usually a benign mass and in most cases nonfunctional. If the lesion is active it produces symptoms related to hypersecretion of cortisol or aldosterone, while its potential malignancy is increased with size (>3cm). Sex-hormone secreting tumors have commonly malignant behavior.

They produce androgens, estrogens or both. For androgen secreting tumors, high blood concentration of testosterone and DHEA-s levels combined with urine 17-ketosteroids forge the diagnosis. For estrogen secreting tumors, high blood concentration of estrogens and urine 17-ketosteroids serve the same cause.

Imaging is crucial in the evaluation of incidentalomas. It's also valuable to correlate current and previous imaging, as malignant lesions tend to change over time, unlike non-malignant ones. Adrenal lesions can be divided to typical and atypical according to their appearance. [25]

Typical adenomas: small: < 3 cm, homogeneous and with low density.

Atypical adenomas:

> 3 cm, may present: hemorrhage, calcification, necrosis, absence of adipose tissue

> 4 cm: 70% malignant (excluding adrenal myelolipomas which are easily recognized due to adipose tissue presence, and pheochromocytomas which are usually recognized with biochemical markers.

> 6 cm: 85% malignant potency [25]

Radiographic Approach

Computed Tomography (CT): Adrenal masses are usually first identified by CT scan. Most of adrenal adenomas (about 70%) contain significant intracellular fat and therefore CT presents with high sensitivity and specificity in their identification. Calculating the mean Hounsfield units (HU) of an adrenal lesion first at non-enhancing CT (between -10 Hounsfield units and 10 HU) and early and delayed enhanced CT using the region of interest. A washout rate, usually of 15-min-delayed CT, is most useful in the diagnosis of adrenal adenomas. CT is the most reliable test to differentiate between benign and malignant adrenal lesions. However, the diagnosis of lipid-poor adenomas is quite harder [26].

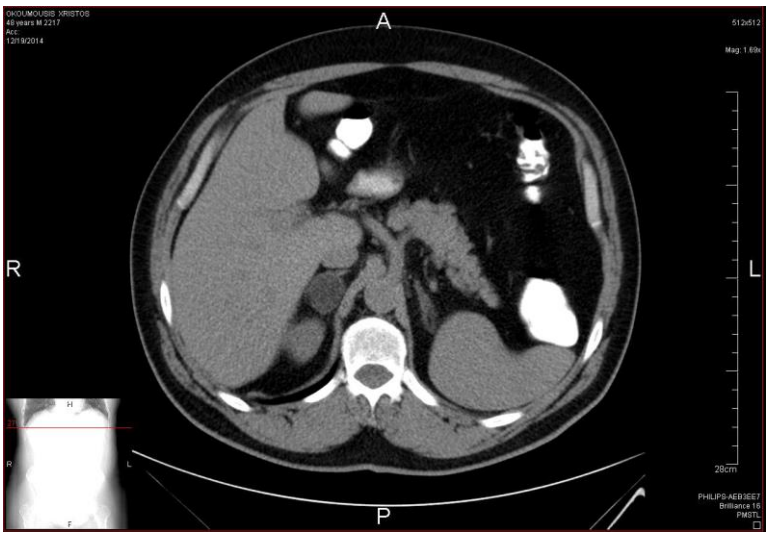

Figure 1. Right adrenal mass. Thin-section non-enhanced CT image, attenuation levels are at 15 HU, because of abundant intracytoplasmatic lipid in the cortex.

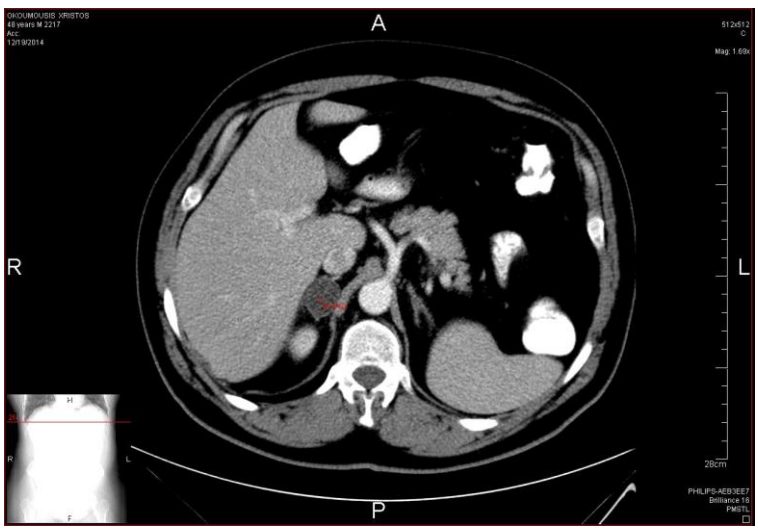

Figure 2. Right adrenal mass. Thin-section enhanced CT image. During the arterial phase of enhancement, density measurements reach 122 HU, dropping to 72 HU during the portal phase of enhancement.

Magnetic Resonance Imaging (MRI): MRI is mainly utilized when CT results are inconclusive. Chemical shift imaging demonstrates a high diagnostic reliability, as it is highly sensitive to little amounts of intracellular fat and therefore a signal intensity drop can be measured in the majority of adenomas. The adenoma can also be compared in and out of phase, using other adjacent tissues as reference (apart from the liver). Restricted diffusion is usually detected in malignant lesions [27] (Figures 3, 4).

Figure 3. Adrenal adenoma. A coronal T1-weighted out-of-phase MR image shows relative signal loss within the lesion, when compared with the signal loss of the spleen and paraspinal muscle. The signal loss on opposed-phase images related to intracellular lipid is based on phase cancellation of fat and water protons within the same voxel.

Figure 4. Adrenal adenoma. An axial T1-weighted in-phase MR image shows a large homogeneous mass in the left adrenal gland (arrow) with signal intensity similar to that of the paraspinal muscle or spleen.

2. Adrenal Myelolipoma

Adrenal myelolipoma is a rare non-malignant, non-secreting tumor usually appearing in the 5th-6th decade of life. In the majority of cases it is unilateral and represents 3-5% of all primary adrenal tumors [28].

Radiographic Approach

Ultrasound: Adipose tissue distribution in the lesion, determines its sonographic image. Most commonly they are depicted as a heterogeneous mass of both hyper- and hypoechoic components. [28].

Computed Tomography (CT): Myelolipomas typically appear as relatively well-circumscribed adrenal masses. They contain fatty components, the amount of which may vary. In many cases, small punctate calcifications can be seen, as well as regions of higher attenuation (in cases of present hemorrhage - seen in larger lesions) [28-29].

Magnetic Resonance Imaging (MRI): T1: typically hyper-intense due to fat contents, T1 (FS): typically shows fat suppression, T1 + (Gd): shows striking enhancement, T2: intermediate to hyperintense (varies depending of hemorrhage products), in and out of phase: out of phase imaging may demonstrate signal loss in mixed components masses [28], [30].

3. Adrenal Cortical Carcinoma

Adrenal cortical adenoma is a very rare but aggressive tumor (incidents 1-2 cases pes million). Clinical manifestations are present in around 50-60% of all cases and are attributed most commonly to cortisol excess (Cushing syndrome). Fewer cases are presented with symptoms of hyper secretion of the remaining cortical hormones (aldosterone, sex hormones). Usually at the time of the diagnosis local spread or distant metastasis are already present [31-32].

Radiographic Approach

Focal extensions can occur into the renal vein, as wells as in the IVC and liver [31-32].

Ultrasound: A well-defined adrenal mass is usually observed, with small lesions being homogeneous and larger ones rather heterogeneous, because of necrosis or hemorrhage [31-32].

Computed Tomography (CT): Adrenal carcinomas are usually large masses (> 6 cm), variably enhanced in CT, because of their irregular shape and central hemorrhagic and necrotic areas. Smaller carcinomas look much similar to adenomas [31-32].

Magnetic Resonance Imaging (MRI): It is usually used to determine the presence of metastases where CT may be inconclusive. The administration of gadolinium reveals the heterogeneity of the mass due to the presence of hemorrhagic components [31-32].

Angiography: Selective arteriography can distinguish renal from adrenal tumors by identifying the source of the primary vascular supply, when the organ of origin cannot be identified [31-32].

4. Pheochromocytoma

Pheochromocytoma is a neuroendocrine tumor of the adrenal medulla. Pathological origin can be traced to adrenal chromaffin cells which are derived from the neural crest. During embryological development, these cells migrate to the adrenal medulla (80-90%) and the rest can be found in the ganglia of the Autonomous Nervous System (ANS). [33] Usually pheos follow the ‘’rule of 10’’: 10% bilateral, 10% malignant, 10% are found in children 10% familial (associated with either MENII , Von Hippel-Lindau disease, Neurofibromatosis 1, familial types of pheochromocytomas), 10 % located in the ANS ganglia (paragangliomas), 10% are not associated with hypertension [33].

Cardinal clinical manifestations are headaches and blood pressure disorders: 1) typically paroxysmal type, 2) constant severe hypertension is more common in malignant pheos,3) even hypotension can occur in tumor necrosis when large quantities of epinephrine are released in the circulation leading to massive vasodilation by β- receptor activation. Other clinical symptoms include tachycardia, palpitations, anxiety, dyspnea, diaphoresis, vomiting, weight loss and hyperglycemia [33].

Diagnostics tests include 24 hour urine collection and measurement of metanephrine-VMA-catecholamine levels [33].

Radiographic Approach

Adrenal tumors are usually larger than 3cm (~5 cm) and therefore easy to identify. However, small extra-adrenal tumors are quite challenging to find. Malignancy can be evaluated from the image only when local tissue invasion or metastases are present [34-35] (Figure 5).

Ultrasound: The appearance is variable (solid/cystic/mixed) [34-35].

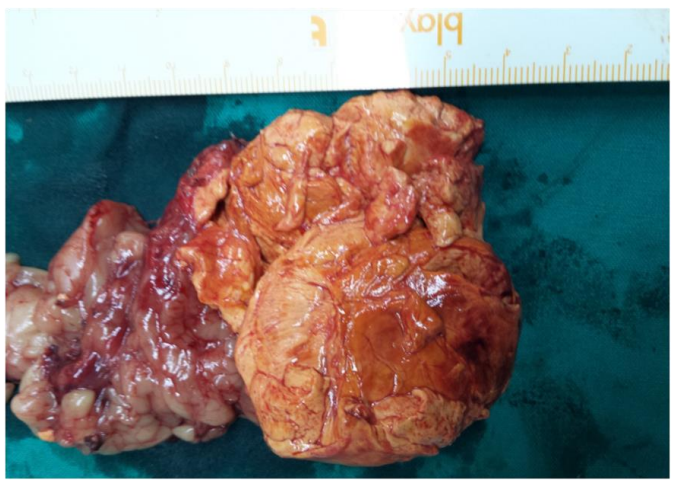

Figure 5. Pheochromocytoma. Surgical specimen.

Computed Tomography (CT): CT is highly sensitive and therefore the first imaging modality to be used. Pheochromocytomas are usually large and heterogeneous, with necrotic areas, cystic modifications and maybe calcifications. Rich enhancement is typically noted [34-35].

Magnetic Resonance Imaging (MRI): MRI demonstrates the highest sensitivity in identifying pheochromocytomas and most valuable in cases of extra-adrenal localization of tumors. T1 signal will be more heterogeneous in necrotic or hemorrhagic areas with the rest of the adrenal being slightly hypo-intense. T1 C+ (Gd): persistent heterogenous enhancement. T2 markedly hyper-intense: light bulb sign and areas of necrosis / haemorrhage /calcification would change the signal [34-35].

Nuclear medicine: Pheochromocytomas, even extra-adrenal ones, can be imaged using various agents. The specificity of this method is not very high though and its spatial resolution is limited [34].

Octreotide (somatostatin) scans: Somatostatin receptors are expressed in over 70% of pheochromocytomas. These method lacks specificity though as the same receptors can also be found in kidneys, areas of inflammation and other glands, making interpretation quite difficult. Imaging is executed 4 hours after intravenous infusion [34].

Positron Emission Tomography (PET): PET scan is considered to be highly sensitive [36].

5. Neuroblastoma

Neuroblastoma is the 4th most common malignancy in childhood. [6] Most children are diagnosed under the age of five. It's a malignancy that arises from nerves of the sympathetic system. [6]

They can be located anywhere along that path. Around 30% of these tumors are located in the adrenal glands. (Figures 6, 7) Other sites may include i) paraspinal ganglia, ii) thoracic cavity and pelvic cavity. [6] Symptoms and signs are usually restricted to a palpable abdominal mass which is only rarely accompanied with pain. [6] Less commonly, neuroblastomas are accompanied by: opsoclonus, Hutchinson syndrome due to bone metastases, Pepper syndrome which is in fact hepatomegaly due to extensive liver metastases, blueberry muffin syndrome presenting with multiple cutaneous lesions. [37-38] Diagnostic results include in 90% of cases elevated VMA, HVA in 24 hour urine collection sample [38].

Figure 6. Ganglioneuroma. Surgical specimen.

Figure 7. Ganglioneuroma. Surgical specimen (dissected).

Radiographic Approach

Ultrasound: Neuroblastoma is depicted as a heterogeneous mass with internal vascularity, necrotic areas and calcification. [37-38]

Nuclear medicine: Agents used for diagnosis and staging:

- pentetreotide labeled to Indium-In111 (somatostatin analog) – nonspecific
- MIBG (metaiodobenzylguanidine labeled to Iodine-123) – screening for metastatic recurrence.
- Tc-99m MDP-mostly used in evaluating metastases [37-38].

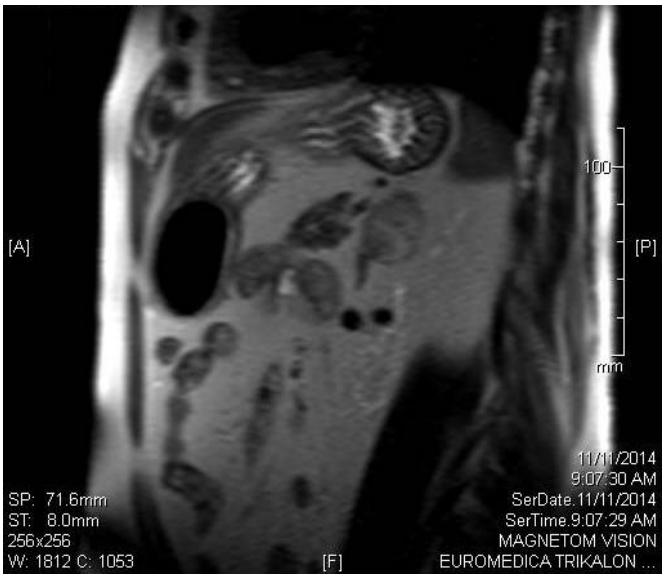

Figure 8. Ganglioneuroma. A coronal T1-weighted out-of-phase MR image shows no signal loss within the lesion, presence of intracellular lipid.

Figure 9. Ganglioneuroma. Axial T1weighted image heterogenously intermediate, distinguished mild capsule.

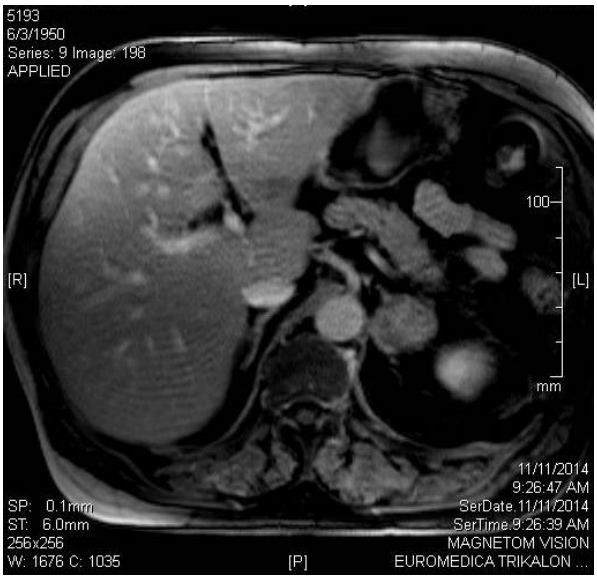

Figure 10. Ganglioneuroma. Axial T1 C+ (Gd) weighted image with heterogenous enhancement.

Computed Tomography (CT): A heterogeneous mass with calcifications is usually noticed. The tumor displaces, compresses or invades adjacent structures depending on its malignant potential [37-38].

Magnetic Resonance Imaging (MRI): MRI assesses CNS involvement, as well as determines the organ of origin.T1: heterogeneous and iso- to hypo- intense. T1+ (Gd): variable and heterogeneous enhancement. T2 heterogeneous and hyper-intense with cystic/necrotic areas of notably high intensity [37-38] (Figure 8, 9, 10).

6. Adrenal Metastases

Most common primary tumors which produce adrenal metastases are: lung cancer, colorectal cancer, breast cancer, pancreatic cancer and others like renal cell carcinoma, hepatocellular carcinoma, and malignant melanoma [39].

Radiographic Approach

Computed Tomography (CT): Metastases have variable appearance in a CT scan. The enhancement washout percentage is usually <50% and is similar to that of lipid-poor adrenal adenomas in cases of renal cell or hepatocellular carcinoma. [32], [39] *Magnetic Resonance Imaging (MRI):* Signal characteristics may vary; the most common ones include: T1: usually have a low signal intensity. T1 C+ (Gad): a progressive enhancement after administration of contrast material. T2: usually have a high signal intensity [32], [39].

7. Other Rare Adrenal Lesions

Ganglioneuromas

These constitute benign tumors of the Sympathetic Nervous System (SNS). They are extremely rare and usually asymptomatic. Majority of cases are diagnosed incidentally [37].

Radiographic Approach

Computed Tomography (CT): Findings are compatible with well circumscribed, solid, encapsulated masses. Lesions tend to be iso- to hypo-attenuating compared to muscle signals. May demonstrate calcifications (~ 20%) [37].

Magnetic Resonance Imaging (MRI): T1 - tends to have homogeneously low or intermediate signal. T2 - tends to have heterogeneously intermediate or high signal. T1 C+ (Gd) - variable ranging from none to heterogeneous enhancement. ADC - ADC values tend to be higher to that of a neuroblastoma [37].

Adrenal Cysts and Pseudocysts

Adrenal cysts constitute rare (incidence of 0.06% to 0.18% in autopsy studies), benign, and usually nonfunctional lesions. They tend to be large at presentation (> 6 cm), and at times hard to distinguish from renal upper-pole cysts. They are often the outcome of prior adrenal trauma or hemorrhage. Adrenal pseudocysts do not contain an epithelial wall but rather a fibrous sheath. They compromise about 40% of adrenal cysts and more likely than simple cysts to be asymptomatic [26-28].

Radiographic Approach

Symptoms may develop if the lesion is very large or in the event of hemorrhage, infection, or rupture. Simple endothelial-lined cysts are more often well-defined cysts with thin or imperceptible walls that show fluid density on CT and are homogeneously hypointense on T1weighted images and hyperintense on T2-weighted images. No enhancement occurs after the administration of intravenous (IV) contrast. Pseudocysts may have a more heterogeneous appearance because of the presence of blood products, septations, and

calcifications. On MRI, blood products present variable T1- and T2-weighted signal intensities, depending on the stage of degeneration. Calcifications are better appreciated on CT images [26-28].

Hemangiomas

Hemangiomas are benign lesions. Theoretically they can develop at any age in both sexes, but they do are more common in 40-70 year old female patients. As a rule these remain asymptomatic until and if they grow large.

Severe spontaneous bleeding is not a common phenomenon. Hemangiomas are predominantly solid tumors with cystic central areas and calcifications. Peripheral enhancement is noted after intravenous contrast administration [40].

CONCLUSION

In contemporary medicine, no one can function as a sole unit. Physicians need to cooperate, with each one offering their expertise for the benefit of the patient. In this spirit of holistic approach to healing, the surgeon acts a leading player of a team, which includes anaesthesiologists, internists, pathologists, surgical nurses and of course radiologists. It is with sophisticated imaging equipment and experienced diagnosticians that Surgeons acquire decisive information which help them understand the unique anatomical and physiological background of the patient's disease. Indeed, operating on adrenal lesions without detailed radiologic examinations could be catastrophic for a patient especially in cases of pheochromocytomas or malignancies. Indisputably, adrenal cysts and myelolipomas have characteristic imaging findings which lead to a safe diagnosis. Often, the specific diagnosis of adrenal adenoma can also be made based on CT attenuation measurements, CT washout criteria, or signal loss on opposed-phase MR imaging.

However, it is imperative to avoid blind adherence to imaging studies as they do have sensitivity and specificity limitations. Surgeons should embrace this endogenous flaw and invest in their training. In order to be considered an endocrine surgeon one is obliged to master at least open and laparoscopic techniques, whilst maintaining a high-volume patient load per year. Taking everything into account, the quality of care offered to patients with adrenal disease will boost exponentially with the combination of in-depth surgical training and sincere cooperation with other medical specialties.

CONFLICT OF INTEREST

The authors report no conflict of interest. Obtained funding: Not applicable.

REFERENCES

[1] Perrier, ND, Boger, MS. Surgical anatomy. In: *Adrenal Glands: Diagnostic Aspects and Surgical Therapy*, Linos, D, van Heerden, JA (Eds), Springer, New York 2005. p.7.

[2] Surgical embryology and anatomy of the adrenal glands. In: *Textbook of Endocrine Surgery*, 2nd edition, Clark, OH, Duh, QY, Kebebew, E (Eds), Elsevier Saunders, Philadelphia 2005. p.557.

[3] Hall JE, Guyton AC. *Guyton and Hall Textbook of Medical Physiology*, 12th edition. *Saunders*. ISBN 978-1416045748. 2010.

[4] Bland ML, Desclozeaux M, Ingraham HA. Tissue growth and remodeling of the embryonic and adult adrenal gland. *Ann. N. Y. Acad. Sci.* 2003; 995:59.

[5] Unsicker K, Huber K, Schober A, Kalcheim C. "Resolved and open issues in chromaffin cell development". *Mechanisms of Development* 130 (6–8): 324–329. 2013.

[6] Ramzi Cotran, Vinay Kumar, Tucker Collins (1999). *Robbins Pathologic Basis of Disease*, Sixth Edition. W.B. Saunders.

[7] Chaudhary V, Bano S. Anatomical and functional imaging in endocrine hypertension. *Indian J. Endocrinol. Metab.* 2012;16:713–21.

[8] Mayo-Smith WW, Boland GW, Noto RB, Lee MJ. State-of-the-art adrenal imaging. *Radiographics*. Jul-Aug 2001;21(4):995-1012.

[9] Liberati A, Altman DG, Tetzlaff J, Murlow C, Gøtzsche PC, et al. (2009) The PRISMA statement for reporting systematic reviews and meta-analyses of studies that evaluate health care interventions: explanation and elaboration. *Ital. J. Public Health* 4: 354–91.

[10] Gagner M, Lacroix A, Bolte E. Laparoscopic adrenalectomy in Cushing's syndrome and pheochromocytoma. *N. Engl. J. Med.* 1992;327:1033.

[11] M. Mellon, A. Sethi, C. Sundaram. Laparoscopic adrenalectomy: Surgical techniques. *Indian J. Urol*. 2008 Oct-Dec; 24(4): 583–589.

[12] Sung GT, Hsu THS, Gill IS. Retroperitoneoscopic adrenalectomy: Lateral approach. *J. Endourol*. 2001;15:505–11.

[13] Kiziloz H, Meraney A, Dorin R, Nip J, Kesler S, Shichman S. J .Prognostic indices of perioperative outcome following transperitoneal laparoscopic adrenalectomy. Laparoendosc *Adv. Surg. Tech. A*. 2014 Aug;24(8):528-33.

[14] Walz MK, Peitgen K, Walz MV, Hoermann R, Saller B, Giegler RM, et al. Posterior retroperitoneoscopic adrenalectomy: Lessons learned within five years. *World J. Surg*. 1998;20:769–74.

[15] Walz MK, Alesina PF, Wenger FA, Deligiannis A, Szuczik E, Petersenn S, Ommer A, Groeben H, Peitgen K, Janssen OE, Philipp T, Neumann HP, Schmid KW, Mann K. Posterior retroperitoneoscopic adrenalectomy--results of 560 procedures in 520 patients. *Surgery*. 2006 Dec;140(6):943-8.

[16] Berber E, Tellioglu G, Harvey A, Mitchell J, Milas M, Siperstein A. Comparison of laparoscopic transabdominal lateral versus posterior retroperitoneal adrenalectomy. *Surgery*. 2009 Oct;146(4):621-5.

[17] Chai YJ, Kwon H, Yu HW, Kim SJ, Choi JY, Lee KE, Youn YK. Systematic Review of Surgical Approaches for Adrenal Tumors: Lateral Transperitoneal versus Posterior Retroperitoneal and Laparoscopic versus Robotic Adrenalectomy. *Int. J. Endocrinol*. 2014;2014:918346.

[18] Gill IS, Meraney AM, Thomas JC, Sung GT, Novick AC, Lieberman I. Thoracoscopic transdiaphragmatic adrenalectomy: the initial experience. *The Journal of Urology*. 2001 Jun;165(6 Pt 1):1875-81.

[19] Lal G, Duh QY. Laparoscopic adrenalectomy--indications and technique. *Surg Oncol*. 2003 Aug;12(2):105-23.

[20] Piazza L, Caragliano P, Scardilli M, Sgroi AV, Marino G, Giannone G. *Laparoscopic robot-assisted right adrenalectomy and left ovariectomy (case reports)*. ChirItal 1999;51:465–6.

[21] Hubens G, Ysebaert D, Vaneerdeweg W, Chapelle T, Eyskens E. Laparoscopic adrenalectomy with the aid of the AESOP2000 robot. *Acta Chir Belg* 1999;99:125–7,discussion127–9.

[22] Hyams ES, Stifelman MD. The role of robotics for adrenal pathology. *Curr. Opin Urol.* 2009;19:89–96.

[23] Marescaux A., Leroy J., Gagner M., Rubino F., Mutter D., Vix M., Butner S., Smith M. Transatlantic robot-assisted telesurgery. *Nature* 413, 379-380 (27 September 2001).

[24] Brandao LF, Autorino R, Laydner H, Haber GP, Ouzaid I, De Sio M, Perdonà S, Stein RJ, Porpiglia F, Kaouk J. Robotic versus laparoscopic adrenalectomy: a systematic review and meta-analysis. *Eur. Urol*. 2014 Jun;65(6):1154-61.

[25] Boland GW, Blake MA, Hahn PF et-al. Incidental adrenal lesions: principles, techniques, and algorithms for imaging characterization. *Radiology*. 2008;249 (3): 756-75.

[26] Blake MA, Holalkere NS, Boland GW. Imaging techniques for adrenal lesion characterization. *Radiol. Clin. North Am*. 2008;46 (1): 65-78, vi.

[27] Elsayes KM, Mukundan G, Narra VR et-al. Adrenal masses: mr imaging features with pathologic correlation. *Radiographics.* 2004;24 Suppl 1 (suppl 1): S73-86.

[28] Brant WE, Helms CA. *Fundamentals of Diagnostic Radiology*. Lippincott Williams & Wilkins. (2007) ISBN:0781761352.

[29] Kenney PJ, Wagner BJ, Rao P et-al. Myelolipoma: CT and pathologic features. *Radiology*. 1998;208 (1): 87-95.

[30] Cyran KM, Kenney PJ, Memel DS et-al. Adrenal myelolipoma. *AJR Am. J. Roentgenol*. 1996;166 (2): 395-400.

[31] Fishman EK, Deutch BM, Hartman DS et-al. Primary adrenocortical carcinoma: CT evaluation with clinical correlation. *AJR Am. J. Roentgenol*. 1987;148 (3): 531-5.

[32] Mayo-smith WW, Boland GW, Noto RB et-al. State-of-the-art adrenal imaging. *Radiographics*. 21 (4): 995-1012.

[33] Tsirlin A, Oo Y, Sharma R et-al. Pheochromocytoma: a review. *Maturitas.* 2014;77 (3): 229-38.

[34] Leung K, Stamm M, Raja A et-al. Pheochromocytoma: the range of appearances on ultrasound, CT, MRI, and functional imaging. *AJR Am. J. Roentgenol.* 2013;200 (2): 370-8.

[35] Blake MA, Kalra MK, Maher MM et-al. Pheochromocytoma: an imaging chameleon. *Radiographics.* 2004;24 Suppl 1 (suppl_1): S87-99.

[36] Hoegerle S, Nitzsche E, Altehoefer C et-al. Pheochromocytomas: detection with 18F DOPA whole body PET--initial results. *Radiology.* 2002;222 (2): 507-12.

[37] Lonergan GJ, Schwab CM, Suarez ES et-al. Neuroblastoma, ganglioneuroblastoma, and ganglioneuroma: radiologic-pathologic correlation. *Radiographics*. 22 (4): 911-34.

[38] David R, Lamki N, Fan S et-al. The many faces of neuroblastoma. *Radiographics.* 1989;9 (5): 859-82.

[39] Choi YA, Kim CK, Park BK et-al. Evaluation of adrenal metastases from renal cell carcinoma and hepatocellular carcinoma: use of delayed contrast-enhanced CT. *Radiology*. 2013;266 (2): 514-20.

[40] Johnson PT, Horton KM, Fishman EK. Adrenal imaging with MDCT: Nonneoplastic disease. *AJR Am. J. Roentgenol*. 2009;193 (4): 1128-35.

In: Encyclopedia of Surgery (22 Volume Set)
Editors: Andreas Lehrer and Kristin Mueller
ISBN: 978-1-53618-329-0
© 2020 Nova Science Publishers, Inc.

Chapter 87

THE ROLE OF IMAGING IN HEPATOBILIARY SURGERY

Polyxeni Agorastou[1], MD, PhD, Andreas Tooulias[2], MD and Georgios Tsoulfas[2,*], MD, PhD

[1]Department of Gastroenterology, Aristoteleion University of Thessaloniki, Thessaloniki, Greece
[2]Department of Surgery, Aristoteleion University of Thessaloniki, Thessaloniki, Greece

ABSTRACT

The increasing complexity of hepatobiliary diseases, benign or malignant, that a surgeon is called to treat, has led to a deeper understanding of the importance of a multidisciplinary approach. Imaging, with its various modalities, plays a central role in the diagnosis and management of hepatobiliary malignancies. An integral part of this remains the communication between the surgeon and the radiologist regarding the exact findings, as well as the different types of management, ranging from surgery to interventional radiology. The goal remains to find the best treatment for the patient. This chapter will present the existing preferences regarding the diagnosis and management of one of the main primary hepatobiliary malignancies, which is hepatocellular carcinoma (HCC). Additionally, we will examine certain special cases (such as the imaging of the early lesion or standardization of imaging reporting), as well as report on the possibilities offered by newer imaging developments. Finally, we will also address the identification and management of a focal hepatic lesion. Overall, the goal is for this chapter to be part of the interplay and the dialogue between the surgeon and the radiologist, in terms of information that needs to be communicated and the best way to do that.

* Corresponding Author's Email: tsoulfasg@gmail.com; Fax: 302310342094.

THE ROLE OF IMAGING IN THE MANAGEMENT OF HEPATOCELLULAR CARCINOMA (HCC)

Introduction

Hepatocellular carcinoma (HCC) continues to increase in incidence, becoming the fifth most common cancer worldwide and responsible for slightly less than 10% of all cancers [1]. The major risk factor for HCC remains cirrhosis, irrespective of its etiology.

Specifically, a variety of causes, such as alcoholic liver disease, viral hepatitis, cholestatic liver diseases, autoimmune and metabolic disorders and the nonalcoholic steatohepatitis, all represent chronic liver insults, which in due time will change the liver architecture and physiology and lead to cirrhosis, if left untreated. Once cirrhosis occurs, irrespective of the causative factor, it is a risk factor for HCC. This process of carcinogenesis in the liver is a progressive one, and as such there would be great value in being able to recognize it at an early stage, something which is made harder by the presence of the cirrhotic nodules.

Additionally, these patients now have to face the dual threat of a hepatic malignancy, with the background of a declining liver function. The importance of HCC worldwide and the need for early diagnosis and successful treatment, have placed a heavy burden on the different imaging modalities. The role of hepatobiliary imaging is critical in the management of HCC, as it can make the difference when deciding whether a hepatic resection or an orthotopic liver transplantation (OLT) will be needed for treatment.

An example of the importance of accurate radiological diagnosis for HCC, is its role in deciding the need and the urgency for OLT for a patient. Specifically, currently in the United States and in many other countries, the place in the waiting list for a liver transplant is determined by the Model for End-Stage Liver Disease (MELD) score, which is basically an approximation of the patient's hepatic synthetic function by including the INR, serum bilirubin and serum creatinine into an equation. This will lead to a score of 6-40, with 6 representing normal liver function and anything over 30 representing an over 90% possibility of mortality in the next 3 months. Although this type of calculation is a relatively objective one, it does represent a problem for patients with cirrhosis and HCC. The reason is that in these patients, their hepatic function is usually well-preserved (and thus their MELD score is relatively low), whereas the more imminent danger for them is the HCC. If the disease progresses beyond certain criteria (usually the Milan criteria are the ones quoted most frequently with one lesion 5cm or less or 3 lesions none bigger than 3cm and no metastatic disease), then the patient cannot be transplanted and expect good results.

Based on this, the decision has been made in many countries using the MELD system to give extra points to patients with cirrhosis and HCC (if it is within criteria), in order to get them to an OLT sooner rather than later. However, in order to do that it is important to accurately diagnose the presence of HCC and liver biopsy is not an easy task for a small lesion in a cirrhotic patient. As a result, in over 95% of patients receiving these HCC exception points, the diagnosis of HCC was made using a good quality MDCT or MRI, thus underscoring the importance of radiological imaging for these patients. Additionally, advances in interventional radiology have added significant weapons (such as percutaneous radiofrequency or microwave ablation or chemoembolization) to the armamentarium of the hepatobiliary multidisciplinary management team.

As part of the overall progress, there are currently international guidelines, whereby dynamic cross-sectional hepatic imaging is considered diagnostic to the extent that a liver biopsy may not be needed [2]. Having said all that, we should stress that more questions have arisen, with the critical one being, what is the role of all this different radiologic modalities within the spectrum of therapeutic modalities for HCC. However, before answering this question, we need to review the existing radiological modalities, including their advantages and disadvantages and the future prospects.

THE ROLE OF DIFFERENT IMAGING MODALITIES IN THE DIAGNOSIS AND MANAGEMENT OF HCC

Ultrasound

The key to achieving long-term success in the management of HCC is early diagnosis. The majority of international societies have agreed that a major step towards this goal is the development of ultrasound surveillance programs, especially in patients who are at higher risk, such as cirrhotics [3, 4]. The major challenge is identifying a dysplastic lesion in the background of a cirrhotic liver, and then following it closely with serial exams, as approximately a third of them will develop into a malignancy [5]. Ultrasound offers the advantage of a practical, easily repeatable, cost-conscious method of being able to follow these patients, without the complications that can (rarely) arise in the other more complex methods. The disadvantage is the subjective nature of ultrasound, as it is very much dependent on the experience of the person performing it. One of the improvements has been the use of contrast-enhanced ultrasound, which used a variety of microbubble-based contrast agents to correctly diagnose HCC. These agents offer the advantage of being able to visualize and evaluate tumor hemodynamics, including the hypervascularity which is frequently associated with HCC in the arterial phase [6]. The increasing experience and aptitude with contrast-enhanced ultrasound may very soon challenge the primacy of dynamic CT for the diagnosis of HCC.

Multidetector Computed Tomography (MDCT)

One of the most frequent challenges in making the diagnosis of a liver lesion, is deciding between a primary HCC or a metastatic lesion. The way to make this differentiation is through the use of a triple-contrast CT, with an arterial, a portal venous and an equilibrium phase. The rationale is that HCC is characterized by hypervascularity during the arterial phase and contrast washout during the portal venous and equilibrium phases. On the other hand, hepatic metastatic disease will be more prominent during the portal venous phase, thus allowing the differentiation between HCC and liver metastatic disease. The significance of the hypervascularity of HCC is that for the majority of associations, such as the American Association for the Study of Liver Diseases (AASLD) and the European Association for the Study of the Liver (EASL), this pattern of contrast uptake (the arterial phase “wash in” and the portal venous phase “wash out”) is considered diagnostic for HCC, when the lesions are

2cm in diameter or bigger. The problem and the debate is for smaller lesions. Specifically, whereas for the AASLD the MDCT is sufficient for all lesions > 1cm, the EASL guidelines and for lesions 1-2cm require a second study for the confirmation, based on data from prospective studies [3, 4]. This is where Magnetic resonance imaging (MRI) comes into play, as it can offer a slightly improved accuracy or at least confirmation for lesions < 2cm. Adding to this problem is the fact that smaller lesions, such as early HCC or borderline ones, may not exhibit the typical HCC contrast uptake pattern and show isoattenuation or even low attenuation to the liver parenchyma in the arterial phase, thus making the MDCT less helpful.

Magnetic Resonance Imaging

Although there is a "typical" pattern for HCC in MRI, with lesions being hypointense on T1-weighted and hyperintense on T2-weighted images, this also depends on the degree of lesion differentiation, as early HCC may often exhibit hyperintensity on T-1 weighted images and iso- to hypointensity on T2-weighted images. Although it may seem counterintuitive, international guidelines do not support MRI over MDCT, as in most studies the diagnostic accuracy of both is similar [7]. The one area where there may be an advantage for the use of MRI, is for the smaller nodules (< 2cm) as it was mentioned before, as well as the fact that there are newer MRI techniques, such as the diffusion-weighted imaging (DWI) and newer hepatobiliary (HB) contrast agents, such as gadopentetate dimeglumine (Gd-EOB-DTPA), which allow for greater diagnostic capability [8-10].

These hepatobiliary agents use a delayed hepatobiliary phase, as they are transported into the hepatocytes. The use of Gd-EOB-DTPA, which is a T1-shortening, extracellular and hepatocyte contrast agent, with its increased accuracy have made it extremely useful in the case of lesions smaller than 2cm and for borderline lesions, such as those represented by hypovascular HCC [11, 12]. This increased sensitivity using the hepatobiliary contrast agents (such as Gd-EOB-DTPA) can be critical in patients with early HCC, as it was shown in a recent paper where treatment was modified in up to 12% of the included patients, based on information obtained by HB-enhanced MRI [13]. The value of MRI increases even more if we consider DWI MR sequences, which evaluate the random motion of water in biological tissues. This way, and because of the restriction of water molecules in the tumor, those areas appear brighter, and have made DWI a valuable resource for borderline and hypovascular lesions [14, 15]. Overall, the MRI is an excellent and safe study for HCC, and liver lesions in general. However, it remains an expensive imaging modality, and as such it is important to ensure that it is used wisely and that both the referring physician and the radiologist know what to ask for and what to look for, respectively.

Positron Emission Tomography

Positron Emission Tomography (PET) differs from CT and MRI, in the sense that it is more dependent on the molecular changes that occur in the tumor and normal tissue cells, versus anatomical changes.

The basis for the emphasis on these molecular changes has to do with the fact that tumors are metabolically different from normal tissue and, as such, the uptake and metabolism of certain molecules (glucose for example) can be used to identify cancerous changes.

Although PET is not an anatomic study, it is used in combination with CT (PET-CT), in order to locate "geographically" in the liver the area with the higher uptake. Despite its many promises, a recent review study of available literature, has shown that PET may not be ideal for identifying primary hepatic malignancies [16].

CHALLENGES IN THE ROLE OF IMAGING FOR HCC

The different imaging techniques that were described above represent the main ones involved in the diagnosis, staging and treatment of HCC. However, the deeper we delve into the variety of these imaging techniques, it becomes obvious that the more questions arise, which essentially point out the finer nuisances of these techniques, as well as the opportunities that they may offer. Next, we will discuss some of these challenges and opportunities that are presented by these current imaging methods.

Hepatocarcinogenesis

The presentation of a HCC is the result of the progression from a dysplastic nodule in a cirrhotic liver, to one with overt malignancy. This evolution is characterized by the development of new arteries, which are not accompanied by bile ducts, which allows the differentiation between a regenerative and a dysplastic nodule [17, 18]. It is interesting that there appears to be a correlation between the number of new arteries and the degree of HCC differentiation, especially in the case of smaller lesions. This, combined with the decrease in the number of Kupffer cells, has enabled current imaging techniques to observe and define the different phases and steps of hepatocarcinogenesis, thus playing a critical role in earlier detection [2].

Limitations of the Different Management Systems and the Need for Standardization

There are approximately a total of 19 diagnostic systems and guidelines published or presented between 2001 and 2013 for the diagnosis and management of HCC [19, 20]. The majority of these guidelines contain imaging-based diagnostic systems, which have become increasingly more detailed and sophisticated, given the corresponding progress and accuracy in imaging technology. In the earlier systems the hypervascular appearance of a lesion was sufficient, whereas in the more recent ones issues such as capsule appearance or contrast washout appearance play a more important role.

Some of the issues between the different systems have to do with terminology, whereas others have to do with more basic disagreements regarding the importance of different factors in the diagnosis and management.

These systems may reflect differences in clinical practice, contrast agents used, tumor biology, cultural preferences and geographical patterns. Additionally, these systems may not be detailed enough to help radiologists make the proper diagnosis, as they may place more emphasis on the classical appearance of HCC and not include the various subtypes, whose appearance may be more perplexing. Also, the European and the US systems, ask for a biopsy in cases of hypo- or iso-enhancing arterial phase lesions, given the fact that a 100% positive predictive value for these features does not exist. On the other hand, in 2008 the American College of Radiology came up with the Liver Imaging Reporting and Data System (LI-RADS), which would classify such lesions (hypo- or iso-enhancing) as LR 4, which is possible HCC [21]. Finally, most systems, with the exception of the Japan Society of Hepatology, do not include hepatobiliary phase MRI, thus making it harder, possibly, to diagnose smaller lesions. The reason is that HB phase MRI provides functional data on a lesion, such as water molecule motion and hepatobiliary cellular function, thus making the identification of hypovascular lesions possible.

No matter what these differences, the fact remains that we are lacking a common language to discuss the diagnosis, staging and management of HCC. This problem becomes an even bigger challenge, if we consider the continuous evolution of imaging techniques and the need to find the proper place for the newer methods by recognizing their advantages, as well as their limitations.

Assessing Response to Locoregional and Systemic Therapy for HCC

Locoregional treatments for HCC represent an important part of the armamentarium of the multidisciplinary team of physicians caring for the patient. The two main locoregional treatments include transarterial chemoembolization (TACE) and ablation methods, which include radiofrequency ablation or microwave ablation among others. TACE can be used in patients with hepatocellular carcinoma at various stages of the disease. Specifically, it can be used as first line treatment for unresectable intermediate stage HCC, or as a bridge to liver transplantation (avoid an increase in the tumor, while the patient is on the waiting list), or as a downstaging method. In the case of the latter, the goal is to reduce the tumor burden through the use of TACE, thus making the patient eligible for resection of liver transplantation [22-24]. Additionally, in patients with advanced disease, TACE can be used as a temporizing measure, in the sense that it can control the growth of the tumor or the symptoms caused by it and do that in a manner that does not affect hepatic function significantly (and thus quality of life for the patient) and can be repeated.

Radiofrequency ablation (RFA) is one of the main tumor ablation methods and can be done either percutaneously or surgically (open or laparoscopic surgery), depending on the size and location of the lesion. It is usually performed on patients with small HCCs, stage A1 to A3 by Barcelona Clinic Liver Cancer (BCLC), in order to avoid surgical resection [25]. It can also be used for resection of lesions, as well as in combination with other invasive techniques such as microwave ablation [26]. According to the American Association for the Study of Liver Diseases (AASLD) guidelines, RFA is a safe and effective method to treat patients with advanced liver tumors. For up to 4-5 hepatic lesions, less than 3cm in diameter, initial complete response rates of more than 90% and local tumor progression rates between 10-20% have been reported [27, 28].

Both of these types of locoregional treatment have proven to be a valuable tool for the management of patients at different stages of HCC and for different purposes. One of their most critical advantages, is the fact that they can be repeated with acceptable safety margins.

However, in order for this to be meaningful, it is essential to be able to evaluate the result of these treatments radiologically. The methods used most frequently are cross-sectional imaging with MRI and CT. The information needed in order to accurately assess the response to the therapy includes evaluation of the tumor size (including the margins involved and the areas of necrosis), the presence of any embolization agents used or not, and the detection either of remaining tumor (with the challenge being to identify whether it is active or not) or of tumor recurrence [29].

Portal Vein Embolization

Portal vein embolization (PVE) represents an extension of the role of embolization in the management of HCC. Specifically, there are patients where a hepatectomy to remove the HCC, may leave behind a liver remnant that is less than 40% (in a healthy liver) or 20-25% (in a cirrhotic liver), thus placing the patient's survival in jeopardy, as there is a significant risk of hepatic decompensation.

In order to improve on this predicament, one option is PVE, whereby interventional radiologists embolize the portal vein branch on the side of the tumor. In approximately 4-6 weeks, this leads to a hypertrophy of the healthy liver lobe, which will become the liver remnant after the resection, of about 10-30%, thus potentially allowing the liver resection to proceed [30]. Obviously, the overall process is significantly more complicated as it has to be performed with accuracy and there are several factors that play a role including the experience of the radiologist performing it, the type of embolization agent used, managing the complications that can occur and identifying the optimal timing to proceed with the resection.

Image-Guided Surgery

One of the challenges, which is more evident with the use of neoadjuvant treatment for hepatic metastatic disease, is the fact that although the lesions may disappear on the CT, cancer cells may still be present in approximately one third of the patients [31]. These patients may end up with recurrent disease, and as a result many favor a liver resection for the potentially involved segment. Another situation which may require delicate maneuvers, is that of a non-anatomic hepatectomy, where the involved part of the liver is resected, but not along the division of Quinaud, and essentially leaving behind as much parenchyma as possible. To be able to do this successfully, it is important to have accurate imaging of the liver "topography," which is not very easy with the routine cross-sectional methods, such as CT and MRI, given the complex 3-D anatomy of the liver with all its variations.

The answer to these problems could be the use of image-guided surgery, whereby preoperative medical images are registered with intraoperative landmarks, in order to provide a 3-D image of the liver that will allow the surgeon to proceed with the resection in an interactive manner, that is be aware at every point of the resection of the relation to the vascular and biliary structures that may be encountered [32].

The steps required include the preoperative processing of the CT or MRI images, obtaining information on the specific liver anatomy and matching the pre- and intra-operative data [33]. This last part, the matching or registration process, which essentially involves the linking of the preoperative imaging information with the real-time location of the resection plane during the surgery, is the hardest one to accomplish. There is significant interest in this endeavor, including several commercial programs, and so the hope is that there will continue to be improvements of the system. It is important to point out that the majority of the planning regarding the resection plane and strategy is done preoperatively using the 3-D imaging.

CONCLUSION

We have examined in this chapter the current techniques used for imaging of the liver, with special emphasis on the diagnosis, staging and treatment of hepatocellular carcinoma. Additionally, we have examined some of the developments in this field that represent significant achievements, as well as future challenges.

Obviously, the role of imaging techniques in hepatic surgery is critical and it continues to evolve as technology progresses. However, it is essential to identify for all the new techniques their proper place in the armamentarium of the multidisciplinary team dealing with this complex disease. The reason is that by knowing their advantages, as well as their limitations, only then can we offer our patients the best, all-around care and do that in a sensible manner.

REFERENCES

[1] Ferlay, J., Shin, H. R., Bray, F., Forman, D., Mathers, C., Parkin, D. M. Estimates of worldwide burden of cancer in 2008: GLOBOCAN 2008. *Int. J. Cancer* 2010; 127: 2893-2917.

[2] International Consensus Group for Hepatocellular Neoplasia. Pathologic diagnosis of early hepatocellular carcinoma: a report of the International Consensus Group for Hepatocellular Neoplasia. *Hepatology* 2009; 49: 658-664.

[3] European Association for the Study of the Liver, European Organisation for Research and Treatment of Cancer. EASL-EORTC clinical practice guidelines: management of hepatocellular carcinoma. *J. Hepatol*. 2012; 56:908-943.

[4] Bruix, J., Sherman, M. American Association for the Study of Liver Diseases. Management of hepatocellular carcinoma: an update. *Hepatology* 2011; 53: 1020-1022.

[5] Terasaki, S., Kaneko, S., Kobayashi, K., Nonomura, A., Nakanuma, Y. Histological features predicting malignant transformation of nonmalignant hepatocellular nodules: a prospective study. *Gastroenterology* 1998; 115: 1216-1222.

[6] Burns, P. N., Wilson, S. R. Microbubble contrast for radiological imaging: Principles. *Ultrasound Q*. 2006; 22: 5-13.

[7] Sangiovanni, A., Manini, M. A., Iavarone, M., et al., The diagnostic and economic impact of contrast imaging techniques in the diagnosis of small hepatocellular carcinoma in cirrhosis. *Gut* 2010; 59: 638-644.

[8] Noguchi, Y., Murakami, T., Kim, T., et al., Detection of hepatocellular carcinoma: comparison of dynamic MR imaging with dynamic double arterial phase helical CT. *AJR Am. J. Roentgenol*. 2003; 180: 455-460.

[9] Imai, Y., Murakami, T., Yoshida, S., et al., Superparamagnetic iron oxide-enhanced MR images of hepatocellular carcinoma: correlation with histological grading. *Hepatology* 2000; 32: 205-212.

[10] Saito, K., Kotake, F., Ito, N., et al., Gd-EOB-DTPA enhanced MRI for hepatocellular carcinoma: quantitative evaluation of tumor enhancement in hepatobiliary phase. *Magn. Reson. Med. Sci*. 2005; 4: 1-9.

[11] Di Martino, M., De Filippis, G., De Santis, A., et al., Hepatocellular carcinoma in cirrhotic patients: prospective comparison of US, CT, and MR imaging. *Eur. Radiol*. 2010; 23: 887-896.

[12] Inoue, T., Kudo, M., Komuta, M., et al., Assessment of Gd-EOB-DTPA-enhanced MRI for HCC and dysplastic nodules and comparison of detection sensitivity versus MDCT. *J. Gastroenterol*. 2012; 47: 1036-1047.

[13] Yoo, S. H., Choi, J. Y., Jang, J. W., et al., Gd-EOB-DTPA-enahnced MRI is better than MDCT in decision making of curative treatment for hepatocellular carcinoma. *Ann. Surg. Oncol*. 2013; 20: 2893-2900.

[14] Xu, P. J., Yan, F. H., Wang, J. H., Shan, Y., Ji, Y., Chen, C. Z. Contribution of diffusion-weighted magnetic resonance imaging in the characterization of hepatocellular carcinomas and dysplastic nodules in cirrhotic liver. *J. Comput. Assist. Tomogr*. 2010; 34: 506-512.

[15] Wu, L. M., Xu, J. R., Lu, Q., Hua, J., Chen, J., Hu, J. A pooled analysis of diffusion-weighted imaging in the diagnosis of hepatocellular carcinoma in chronic liver diseases. *J. Gastroenterol. Hepatol*. 2013; 28: 227-234.

[16] Lan, B. Y., Kwee, S. A., Wong, L. L. Positron emission tomography in hepatobiliary and pancreatic malignancies: a review. *Am. J. Surg*. 2012; 204: 232-241.

[17] Hiimeno, H., Enzan, H., Saibara, T., Onishi, S., Yamamoto, Y. Hitherto unrecognized arterioles within hepatocellular carcinoma. *J. Pathol*. 1994; 174: 217-222.

[18] Matsui, O. Analysis of intranodular hemodynamics of dysplastic nodules in cirrhotic livers. *Radiology* 2001; 218: 603-605.

[19] Song, P., Tobe, R. G., Inagaki, Y., et al., The management of hepatocellular carcinoma around the world: a comparison of guidelines from 2001 to 2011. *Liver Int*. 2012; 32: 1053-1063.

[20] Cruite, I., Tang, A., Sirlin, C. B. Imaging-based diagnostic systems for hepatocellular carcinoma. *Am. J. Roentgenol*. 2013; 201: 41-55.

[21] American College of Radiology. *Liver imaging reporting and fata system, version 1.0*. Amercian College of Radiology website. www.acr.org/Quality-Safety/Resources/LIRADS/Archive/. Published 2011. Accessed May 28, 2015.

[22] Yao, F. Y., Breitenstein, S., Broelsch, C. E., Dufour, J. F., Sherman, M. Does a patient qualify for liver transplantation after the down-staging of hepatocellular carcinoma? *Liver Transpl*. 2011;17: S109-S116.

[23] Majno, P., Lencioni, R., Mornex, F., Girard, N., Poon, R. T., Cherqui, D. Is the treatment of hepatocellular carcinoma on the waiting list necessary? *Liver Transpl*. 2011;17: S98-S108.

[24] Pomfret, E. A., Washburn, K., Wald, C., Nalesnik, M. A., Douglas, D., Russo, M., et al., Report of a national conference on liver allocation in patients with hepatocellular carcinoma in the United States. *Liver Transpl.* 2010;16: 262-78.

[25] Fontana, R. J., Hamidullah, H., Nghiem, H., et al., Percutaneous radiofrequency thermal ablation of hepatocellular carcinoma: a safe and effective bridge to liver transplantation. *Liver Transplant*. 2002;8:1165-74.

[26] Yin, X. Y., Xie, X. Y., Lu, M. D., Xu, H. X., Xu, Z. F., Kuang, M., Liu, G. J., Liang, J. Y., Lau, W. Y. Percutaneous thermal ablation of medium and large hepatocellular carcinoma: long-term outcome and prognostic factors. *Cancer* 2009; 115:1914-23.

[27] Cho, Y. K., Kim, Y., Rhim, H. Pitfalls in the radiological and pathological correlation of tumour response rates of hepatocellular carcinoma following radiofrequency ablation. *J. Clin. Pathol*. 2009; 62: 1071-3.

[28] Elias, D., Baton, O., Sideris, L., Matsuhisa, T., Pocard, M., Lasser, P. Local recurrence after intraoperative radiofrequency ablation of liver metastases: a comparative study with anatomic and wedge resections. *Ann. Surg. Oncol*. 2004;11: 500-5.

[29] Yaghmai, V., Besa, C., Kim, E., Gatlin, J. L., Siddiqui, N. A., Taouli, B. Imaging Assessment of hepatocellular carcinoma response to locoregional and systemic therapy. *Am. J. Roentgenol*. 2013; 201: 80-96.

[30] Madoff, D. C., Hicks, M. E., Vauthey, J. N., et al., Transhepatic portal vein embolization: anatomy, indications, and technical considerations. *Radiographics* 2002; 22: 1063-1076.

[31] Auer, R. C., White, R. R., Kemeny, N. E., Schwartz, L. H., et al., Predictors of a true complete response among disappearing liver metastases from colorectal cancer after chemotherapy. *Cancer* 2010; 116: 1502-1509.

[32] Kingham, T. P., Jayaraman, S., Clements, L. W., Scherer, M. A., Stefansic, J. D., Jarnagin, W. R. Evolution of image-guided liver surgery: transition from open to laparoscopic procedures. *J. Gastrointest. Surg*. 2013; 17: 1274-1282.

[33] Oldhafer, K. J., Stavrou, G. A., Prause, G., Peitgen, H. O., Lueth, T. C., Weber, S. How to operate a liver tumor you cannot see. *Langenbecks Arch. Surg*. 2009; 394: 489-494.

In: Encyclopedia of Surgery (22 Volume Set)
Editors: Andreas Lehrer and Kristin Mueller
ISBN: 978-1-53618-329-0
© 2020 Nova Science Publishers, Inc.

Chapter 88

THE ROLE OF IMAGING IN PANCREATIC SURGERY

A. Mastoraki[1], MD, N. Economopoulos[2], MD,
I. Papanikolaou[3], MD and N. Arkadopoulos[1,*], MD
[1]4th Department of Surgery, National and Kapodistrian University of Athens,
"Attikon" University Hospital, Athens, Greece
[2]2nd Department of Radiology, National and Kapodistrian University of Athens,
"Attikon" University Hospital, Athens, Greece
[3]2nd Department of Internal Medicine, National and Kapodistrian University of Athens,
"Attikon" University Hospital, Athens, Greece

ABSTRACT

The pancreas is an organ that has presented surgeons with significant challenges as both benign and malignant lesions, given the location and physiology of the organ, require significant expertise for both diagnosis and treatment. This chapter will present the most current imaging technology available for pancreatic disease and provide examples of how the surgeon and the medical team can choose the best one for each possible situation.

INTRODUCTION

The pancreas is a retroperitoneal organ that lies in an oblique position, sloping upward from the C-loop of the duodenum to the splenic hilum. In an adult, the pancreas weighs 75 to 100 g and is about 15 to 20cm long. The fact that the pancreas is situated so deeply in the abdomen and is sealed in the retroperitoneum explains the poorly localized and sometimes ill-defined nature with which pancreatic pathology presents.

In this chapter, we start with a brief overview of basic pancreatic anatomy and then we present thirteen common pancreatic conditions that may require surgical intervention and

* Corresponding Author's Email: narkado@ hotmail.com.

analyze the role of the various imaging modalities in the diagnosis and planning for surgery. All images used in this chapter originate from the authors' personal archives.

Pancreatic Anatomy

An understanding of embryology is required to appreciate the common variations in pancreatic duct anatomy. The pancreas is formed by the fusion of a ventral and dorsal bud. The duct from the smaller ventral bud connects directly to the common bile duct (CBD) while the duct from the larger dorsal bud drains directly into the duodenum. The duct of the ventral anlage becomes the duct of Wirsung, and the duct from the dorsal anlage becomes the duct of Santorini. With gut rotation, the ventral anlage rotates to the right and around the posterior side of the duodenum to fuse with the dorsal bud. The ventral anlage becomes the inferior portion of the pancreatic head and the uncinate process, while the dorsal anlage becomes the body and tail of the pancreas. The ducts from each anlage usually fuse together in the pancreatic head such that most of the pancreas drains through the duct of Wirsung, or main pancreatic duct (MPD), into the common channel formed from the bile duct and pancreatic duct. In 10% of patients, the ducts of Wirsung and Santorini fail to fuse. This results in the majority of the pancreas draining through the duct of Santorini and the lesser papilla, while the inferior portion of the pancreatic head and uncinate process drains through the duct of Wirsung and major papilla. This normal anatomic variant, which occurs in one out of 10 patients, is referred to as pancreas divisum. The MPD is usually only 2-3mm in diameter and runs midway between the superior and inferior borders of the pancreas. The MPD joins with the CBD and empties at the ampulla of Vater or major papilla, which is located on the medial aspect of the second portion of the duodenum. When the accessory pancreatic duct or lesser duct drains into the duodenum, a lesser papilla can be identified approximately 2cm proximal to the ampulla of Vater.

The blood supply to the pancreas comes from multiple branches from the celiac and superior mesenteric arteries (SMA). The common hepatic artery (CHA) gives rise to the gastroduodenal artery (GDA) before continuing toward the porta hepatis as the proper hepatic artery. The GDA becomes the superior pancreaticoduodenal artery as it passes behind the first portion of the duodenum and branches into the anterior and posterior superior pancreaticoduodenal arteries. As the SMA passes behind the neck of the pancreas, it gives off the inferior pancreaticoduodenal artery at the inferior margin of the neck of the pancreas. This vessel quickly divides into the anterior and posterior inferior pancreaticoduodenal arteries. The superior and inferior pancreaticoduodenal arteries join together within the parenchyma of the anterior and posterior sides of the head of the pancreas along the medial aspect of the C-loop of the duodenum to form arcades that give off numerous branches to the duodenum and head of the pancreas. Therefore, it is impossible to resect the head of the pancreas without devascularizing the duodenum, unless a rim of pancreas containing the pancreaticoduodenal arcade is preserved. Variations in the arterial anatomy occur in one out of five patients. The right hepatic artery, CHA, or gastroduodenal arteries can arise from the SMA. In 15 to 20% of patients, the right hepatic artery will arise from the SMA and travel upwards toward the liver along the posterior aspect of the head of the pancreas.

It is important to look for this variation on preoperative computed tomographic (CT) scans and in the operating room so the replaced hepatic artery is recognized and injury is

avoided. The body and tail of the pancreas are supplied by multiple branches of the splenic artery. The splenic artery arises from the celiac trunk and travels along the posterior-superior border of the body and tail of the pancreas toward the spleen. The inferior pancreatic artery usually arises from the SMA and runs to the left along the inferior border of the body and tail of the pancreas, parallel to the splenic artery.

Three vessels run perpendicular to the long axis of the pancreatic body and tail and connect the splenic artery and inferior pancreatic artery. They are, from medial to lateral, the dorsal, great, and caudal pancreatic arteries. These arteries form arcades within the body and tail of the pancreas, and account for the rich blood supply of the organ.

The venous drainage of the pancreas follows a pattern similar to that of the arterial supply. The veins are usually superficial to the arteries within the parenchyma of the gland. There is an anterior and posterior venous arcade within the head of the pancreas.

The superior veins drain directly into the portal vein (PV) just above the neck of the pancreas. The posterior inferior arcade drains directly into the inferior mesenteric vein (IMV) at the inferior border of the neck of the pancreas. The anterior inferior pancreaticoduodenal vein joins the right gastroepiploic vein and the middle colic vein to form a common venous trunk, which enters into the superior mesenteric vein (SMV).

1. ANNULAR PANCREAS

Definition

Annular pancreas refers to a ring of pancreatic tissue that encircles mainly the second part of the duodenum. This congenital anomaly of the pancreas usually manifests in neonates or remains asymptomatic until adulthood [1].

Associated congenital abnormalities consist of intestinal malrotation, imperforate anus, esophageal atresia, duodenal stenosis, Down syndrome and cardiovascular disorders.

Surgical Interventions

- ✓ Retrocolic duodenojejunostomy/gastrojejunostomy in pediatric population
- ✓ Surgical and interventional endoscopic procedures in adult population

Imaging Modalities

The role of imaging modalities in case of annular pancreas is to establish the diagnosis and differentiate other causes which can produce "narrow duodenal lumen."

Radiographic Findings

Plain x-ray of the abdomen reveals narrowing of descending duodenum. The classic "double-bubble" sign refers to a large proximal bubble describing the dilated stomach and a small distal one indicative of concomitant dilation of the duodenal bulb.

Fluoroscopic guided Barium Study depicts an extrinsic, eccentric defect on medial margin of the second part of the duodenum with concentric narrowing and dilation of the proximal duodenum [2]. Periampullary duodenal ulcer due to reverse peristalsis may be encountered in adults implying the presence of Zollinger-Ellison syndrome (ZES).

Ultrasonography

Real time U/S is only indicative of a nonspecific enlargement of pancreatic head.

Computed Tomography

CT findings are often non-specific suggesting pancreatic head enlargement along with central area of increased attenuation representing contrast within narrowed duodenal segments. Parallel gastric and duodenal dilatation with circumferential thickening of the wall as well as obstructing band of pancreatic tissue and dilated MPD, CBD and intrahepatic ductal system may be detected [3].

Magnetic Resonance Imaging

Fat-suppressed T1WI images describe normal pancreatic tissue encircling the duodenum. Subsequent MRCP depicts course and drainage pattern of pancreatic duct [4].

Angiography

Celiac angiography often reveals an anomalous branch from posterior pancreaticoduodenal artery that courses in a right and inferior direction supplying annular moiety.

Endoscopic Retrograde Cholangiopancreatography

ERCP describes a normal MPD in the body and tail of the pancreas communicating with small duct of pancreatic head encircling the duodenum.

On occasion, a small duct of the head originating on right anterior surface of duodenum, passing posteriorly around the organ and entering the MPD may be recognized.

Differential Diagnosis

- ✓ Duodenal carcinoma
- ✓ Postbulbar peptic ulcer
- ✓ Pancreatic carcinoma
- ✓ Duodenal hematoma

2. ACUTE PANCREATITIS

Definition

Acute pancreatitis is described as an acute inflammatory process of the pancreas with variable involvement of relevant regional tissues or remote organ systems. It can be initiated by several factors including biliary tract disease, alcohol, severe trauma, infectious disorders, ischemia, pancreatic duct obstruction and post-operative inflammation. Cases of hereditary pancreatitis have also been reported. Associated complications implicate fluid collection, extended edema, tissue destruction, fat necrosis and hemorrhage. Potential formation of pseudocyst, abscess or vascular pseudoaneurysm along with porto-splenic thrombosis or Disseminated Intravascular Coagulation (DIC) and sepsis has been suggested as major determinants of the outcome [5].

Surgical Interventions

- ✓ Drainage of infected pseudocyst
- ✓ Surgical debridement of infected necrosis

Imaging Modalities

The role of imaging modalities in case of acute pancreatitis is to establish the diagnosis and assess disease severity. Additional surgical intervention in case of necrotizing pancreatitis is also imaging dependent. If there is an indication of infection, then a CT- or US-guided fine-needle aspiration (FNA) should be performed for Gram's stain and culture of the fluid or tissue, and the indicated antibiotic therapy initiated.

Ultrasound

Abdominal U/S examination is the best imaging technique in confirming the presence of gallstones in suspected biliary pancreatitis. It may also determine extrapancreatic ductal dilations, pancreatic edema, swelling or fluid selection. Nevertheless, in the majority of affected patients U/S does not provide satisfactory results due to the presence of bowel gas which tends to obscure sonographic imaging of the pancreas.

Thus real time U/S could only reveal an enlarged hypoechoic gland or elucidate the formation of a pseudocyst or abscess. Therefore, additional CT is always implemented in order to distinguish milder categories of the disease from severe cases of necrotizing or infected pancreatitis and provide optimal care to the patient [6].

Computed Tomography

CT scanning with bolus intravenous contrast has become the gold standard for assessing the severity of acute pancreatitis. While clinically mild inflammation of the pancreas is correlated with interstitial edema with the microcirculation remaining intact and the gland presenting with uniform enhancement. In necrotizing pancreatitis, the microcirculation is disrupted. Therefore, the enhancement of the gland on contrast-enhanced CT (CECT) scan is considerably decreased (Figure 1). The presence of air bubbles is an indication of infected necrosis or abscess (Figure 2).

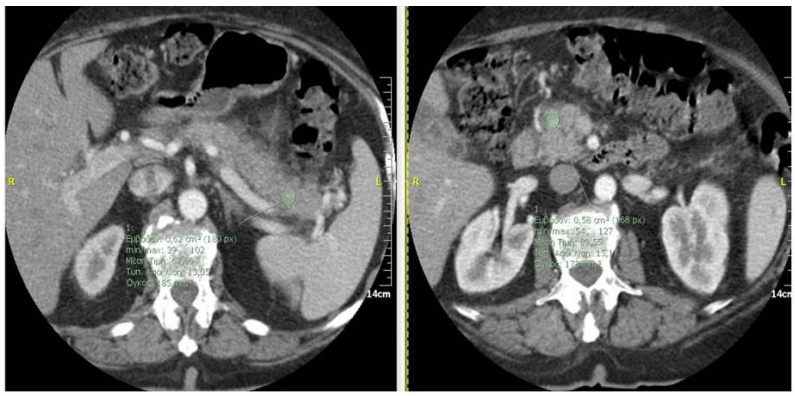

Figure 1. Abdominal CT in acute pancreatitis:-Pancreatic phase of enhancement: Decreased enhancement of the pancreas (less than 100HU) (green ROI).

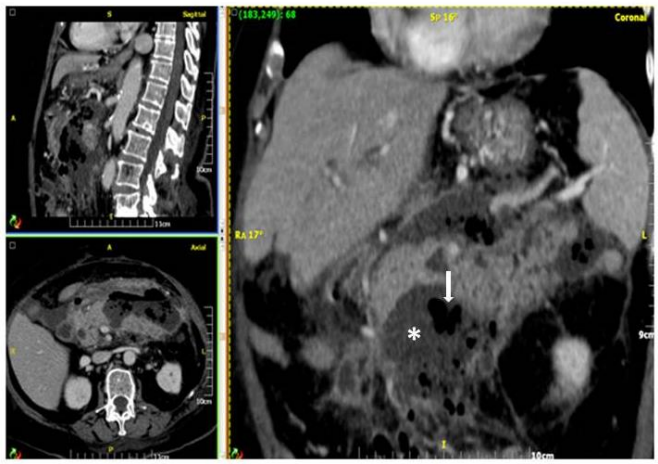

Figure 2. Abdominal CT in acute pancreatitis - Pancreatic phase of enhancement: Air containing (arrow) peripancreatic fluid collection (asterisk) in a septic patient.

In conclusion, focal or diffuse enlargement of the pancreas along with heterogenous enhancement and infiltration of peripancreatic fat are major CT findings indicative of acute pancreatitis [7, 8]. The formation of pseudoaneurysm may also be apparent (Figure 3). Chest CT may reveal concomitant pleural effusions and basal atelectasis. Currently, intravenous, contrast-enhanced CT scanning is routinely performed on patients who are suspected of harboring severe pancreatitis, regardless of Ranson's criteria or APACHE scores. Imaging of acute pancreatitis necessitates not only an understanding of the disease subtypes and the myriad of associated complications but also familiarity with the appropriate radiologic nomenclature as defined by the Atlanta symposium and recently revised by the Acute Pancreatitis Classification Working Group. The use of standardized terminology will hopefully improve the communication between radiologists, gastroenterologists and surgeons to facilitate treatment schedule and lead to favorable outcomes for patients with acute pancreatitis as well as create uniformity for enrollment into research surveys [9, 10].

CT revised Atlanta classification: Five grades based on severity

- Grade A: Normal pancreas
- Grade B
  - Focal or diffuse enlargement of the gland
  - Contour irregularities and heterogeneous attenuation (Figure 4)
  - Absence of peripancreatic inflammation
- Grade C: Intrinsic pancreatic abnormalities and associated inflammatory changes in peripancreatic fat (Figure 5)
- Grade D
  - Small and usually single, ill-defined fluid collection
- Grade E
  - Two or more large fluid collections
  - Presence of gas in pancreas or retroperitoneum
  - Most important criterion: Presence and extent of necrotizing pancreatitis (non-enhancing parenchyma) (Figure 6)

Figure 3. Abdominal CT in acute pancretitis: Pseudoaneurysm of the splenic artery (asterisk).

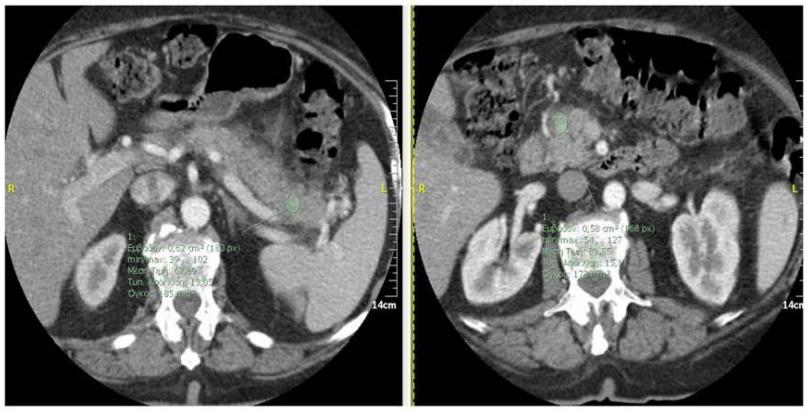

Figure 4. Abdominal CT in acute pancreatitis: Contour irregularity, heterogeneous attenuation of the pancreas.

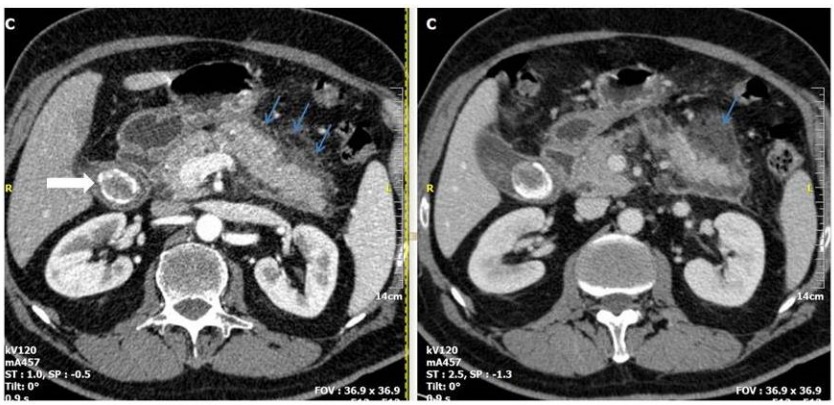

Figure 5. Abdominal CT in acute pancreatitis: Intrinsic pancreatic abnormalities and associated inflammatory changes in peripancreatic fat (blue arrows). Cholelithiasis (thick white arrow).

Magnetic Resonance Imaging – Magnetic Resonance Cholangiopancreatography

MR findings refer to variable decreased signal intensity and gland enlargement on T1WI images. A heterogenous enhancement pattern along with the detection of a pancreatic pseudocyst contiguous with the MPD and potential vascular occlusion may be easily demonstrated. On fat suppressed T2WI images fluid collections as well as pseudocysts and necrotic areas are depicted hyperintense contrary to hypointense lesions including gallstones or intraductal calculi [11].

Furthermore, MRCP provides evidence of a dilated MPD or an associated pseudocyst. Finally, it is important to differentiate between an acute pseudocyst and walled-off pancreatic necrosis (WOPN) by accurate definition and characterization of the solid necrotic debris. Patients presenting with WOPN require more aggressive endoscopic intervention, in contrast to simple transmural drainage, which may prove adequate for therapeutic approach of pseudocysts [12].

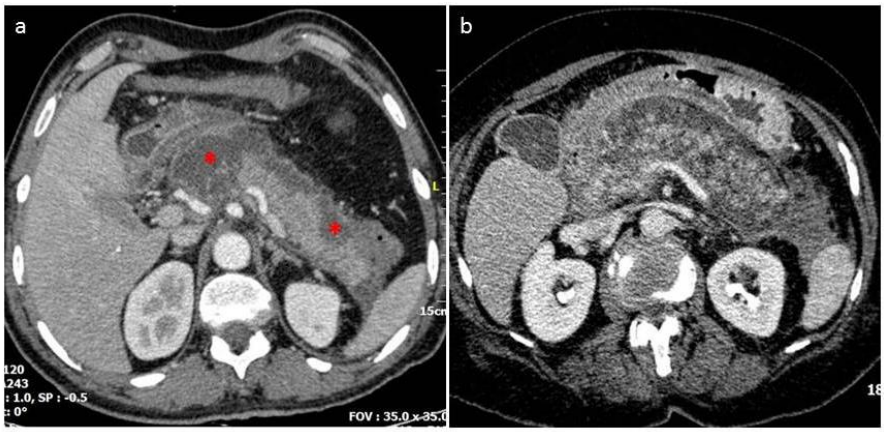

Figure 6. a) Abdominal CT in acute pancreatitis: Necrotizing pancreatitis (non enhancing parenchyma > 30%) (asterisks), b) More than 50%.

In addition, morphological features of WOPN determine treatment strategy since collections with greater amounts of solid necessitate direct endoscopic necrosectomy as well as aggressive surgical procedures for successful clinical outcome. WOPNs contain both liquid and solid necrotic debris and it is usually difficult to distinguish them from pure liquid collections on contrast-enhanced CT. MRI and endoscopic U/S (EUS) have been shown comparable sensitivity in the detection of the solid necrotic debris. Nevertheless, EUS is an invasive diagnostic modality that causes patient discomfort.

Angiography

Conventional angiography is performed when a pseudoaneurysm is suspected or for the detection of a vascular cause of pancreatitis with regard to polyartiritis nodosum, lupus or vasculitis.

Endoscopic Retrograde Cholangiopancreatography

ERCP is an invasive endoscopic technique which may be useful in the identification of a dilated or normal MPD. Additional communication with a pseudocyst could be acutely elucidated. Moreover, ERCP is warranted for the depiction of a narrowed or tapered distal CBD with prestenotic biliary dilatation.

Differential Diagnosis

- ✓ Infiltrating pancreatic carcinoma
- ✓ Perforated gastric ulcer
- ✓ Trauma
- ✓ Lymphoma and metastases

3. PANCREATIC PSEUDOCYST

Definition

The formation of a pseudocyst refers to a chronic collection of pancreatic fluid surrounded by a nonepithelialized wall of granulation tissue and fibrosis. Pseudocysts occur in up to 10% of patients presenting with acute pancreatitis and 20-38% of chronic pancreatitis affected patients. They may occur intrapancreatically or extend beyond the region of the pancreas into other cavities or compartments.

The lesions may become secondarily infected, in which case they behave as abscesses. They can compress or obstruct adjacent organs or structures, leading to superior mesenteric – portal vein or splenic vein thrombosis. In addition, they can erode into visceral arteries and provoke intracystic hemorrhage or pseudoaneurysm formation [13].

Surgical Interventions

- ✓ Percutaneous drainage of a symptomatic or increase in size pseudocyst
- ✓ Surgical internal (usually into the stomach) or external drainage of a pseudocyst

Imaging Modalities

The role of imaging modalities in case of pancreatic pseudocyst detection is to establish the diagnosis and assess potential necessitation of surgical intervention. Drainage of infected or obstructing pseudocysts is also based on imaging techniques.

If infection is suspected, the pseudocyst should be aspirated by CT- or US-guided FNA, and the contents examined for organisms by Gram's stain and culture. If infection is present, and the contents resemble pus, external drainage is employed, using either surgical or percutaneous techniques.

Finally, although pseudocysts comprise roughly two thirds of all pancreatic cystic lesions, they resemble cystadenomas and cystadenocarcinomas radiographically and therefore differential diagnosis is based on advanced imaging modalities and related diagnostic procedures.

Ultrasound

Real-time U/S usually depicts a solitary unilocular cystic mass at the body or the tail of the pancreas. Multilocular lesions are apparent in 6% of affected patients. Parallel description of fluid-debris level and internal echoes due to autolysis along with blood clots or cellular debris is common U/S finding.

Rarely, septations as well as signs of infection or hemorrhage are defined. Additional dilation of CBD and CPD and calcification of the gland in cases with chronic pancreatitis may be reported.

Computed Tomography

CT characteristic findings of a mature pseudocyst refer to a round or oval, homogeneous, hypodense lesion with a near water density. On the contrary, a hemorrhagic, infected pseudocyst appears as a lobulated, heterogeneous, mixed density lesion. Intense pancreatic calcification as well as MPD and CBD involvement are adequately detected. Enhancement of thin rim of fibrous capsule associated with absence of similar finding of pseudocyst contents is common in contrast-enhanced CT (Figure 7).

The presence of gas within pseudocyst suggests superimposed infection or decompression of pseudocyst into pancreatic duct, stomach or bowel.

Finally, pseudoaneurysms caused by or simulating a pseudocyst could be depicted [14]. Pitfalls in the management of pseudocysts result from the presumptive diagnosis of a cystic neoplasm masquerading as a pseudocyst, a failure to appreciate the solid or debris-filled contents of the lesion which appears fluid filled on CT scan and incompetence to document potential adherence with an adjacent portion of the stomach before attempting transgastric internal drainage. If infection is suspected, the pseudocyst should be aspirated (not drained) by CT- or U/S-guided Fine Needle Aspiration (FNA) and the content examined for organisms by Gram's stain and culture. If infection is identified and the content resembles pus, external drainage is employed using either surgical or percutaneous modalities [15, 16].

Magnetic Resonance Imaging – Magnetic Resonance Cholangiopancreatography

MR findings are indicative of a hypointense lesion with parallel enhancement of fibrous capsule on T1WI images. On the contrary on T2WI images the pseudocyst presents hyperintense or with mixed intensity containing both fluid and debris.

Figure 7. Abdominal CT: Smooth wall cystic lesions in the lesser sac and the transverse mesocolon (black asterisks). Splenic vein obstruction, gastrosplenic (thick white arrows) and gastric fundus varices.

Subsequent MRCP reveals a hyperintense cyst contiguous with dilated CPD. Similar findings are confirmed on ERCP with the communication of pseudocyst with CPD depicted in 70% of the cases.

Angiography

Conventional angiography is only performed in order to elucidate the diagnosis of pseudoaneurysm. Splenic artery is most frequently involved, followed by inferior and superior pancreatico-duodenal arteries.

Differential Diagnosis

- ✓ Serous microcystic cystadenoma
- ✓ Mucinous cystic tumor of pancreas
- ✓ Intraductal papillary mucinous tumor of the pancreas
- ✓ Cystic islet cell tumor
- ✓ Congenital cysts

4. CHRONIC PANCREATITIS

Definition

Chronic pancreatitis is an incurable, chronic inflammatory condition that is multifactorial in its etiology, highly variable in its presentation, and a challenge to treat successfully. Alcohol consumption and abuse is associated with chronic pancreatitis in up to 70% of cases.

Other major causes worldwide include tropical and idiopathic disease as well as metabolic disorders, hereditary cases and trauma. Radiologic imaging of chronic pancreatitis contributes in four areas including diagnosis, evaluation of severity of the disease, detection of complications and assistance in determining treatment options.

With the advent of cross-sectional imaging techniques such as CT and MRI, the contour, content, ductal pattern, calcifications, calculi and cystic disease of the pancreas are all readily discernible [17, 18].

Surgical Interventions

- ✓ Surgical internal or external drainage of a symptomatic or increase in size pseudocyst
- ✓ Pancreatic duct decompression for chronic obstructive pancreatitis
- ✓ Partial distal pancreatectomy for patients with focal inflammatory changes localized to the body and tail of the gland

- ✓ Radical distal pancreatectomy described by Fry and Child intended for patients with sclerotic small duct disease and preserving the rim of pancreas in the pancreaticoduodenal groove
- ✓ Pancreatoduodenectomy procedure with or without pylorus preservation for symptomatic chronic pancreatitis and pain relief
- ✓ Duodenum-preserving pancreatic head resection described by Beger for the treatment of chronic pancreatitis
- ✓ Extended lateral pancreaticojejunostomy with excavation of the pancreatic head for the complete decompression of the entire pancreatic ductal system described by Frey.

Imaging Modalities

The role of imaging modalities in case of chronic pancreatitis is to establish the diagnosis and differentiate from other conditions which may cause MPD dilatation and glandular atrophy. Additional assessment of potential necessitation of endoscopic or surgical intervention is also imaging dependent. Drainage of infected or obstructing pseudocysts is always based on imaging techniques.

Ultrasound

Transabdominal U/S is frequently employed as an initial imaging method in patients with abdominal symptoms and modifications consistent with pancreatic duct dilatation, intraductal filling defects, cystic changes and heterogeneous texture are encountered in chronic pancreatitis. The sensitivity of transabdominal U/S ranges from 48 to 96% and is operator dependent. Nevertheless, the contour, texture and ductal pattern are usually quite detectable and it is a reliable modality for periodic re-examination to determine the efficacy of therapeutic intervention.

Therefore, major U/S indications of chronic inflammation of the pancreas are the depiction of an atrophic gland along with a tubular anechoic structure consistent with a dilated MPD in up to 90% of the cases and the identification of calcifications appearing as echogenic foci with posterior acoustic shadowing and pseudocyst formation [19].

Computed Tomography

CT scanning has affected diagnostic approach of pancreatic disease more broadly than any other method. Prior to its widespread introduction, pancreatic imaging was largely a matter of detecting the displacement of adjacent, contrast-filled viscera by mass lesions of the pancreas. Since the application of cross-sectional techniques and with the advent of contrast-enhanced CT scanning and CT angiography, visualization of the nature, extent, location and relative relationships of pancreatic structures and lesions is accomplished with great clarity. CT scanning presents a false-negative rate of less than 10% for chronic pancreatitis, but early or mild chronic abnormalities may be undetected [20]. Another drawback of CT scanning is its lower sensitivity for identifying small neoplasms, which may be invisible to all modalities

apart from EUS. Nevertheless, major CT findings indicative of chronic pancreatitis are the presence of an atrophic gland along with an occasionally focal or diffuse enlargement of the pancreas, dilated MPD with ductal calculi, intra and peri-pancreatic cysts formation and extensive thickening of peri-pancreatic fascia (Figure 8).

Additional splenic vein thrombosis implied by splenomegaly and varices confirmation could be depicted. Moreover, a hypodense focal mass with fibrosis and fat necrosis usually in the pancreatic head may simulate neoplastic transformation.

Magnetic Resonance Imaging – Magnetic Resonance Cholangiopancreatography

MRI, in both the cross-sectional mode and the coronally-oriented heavily weighted T2 or high spin ratio imaging (MRCP) have added heavily to the imaging options of chronic pancreatitis. The resolution of MRI scanning is now approaching that of CT, although its availability and the complexity of the images produced have limited its large-scale use for routine imaging of the pancreas.

A heterogeneous enhancement pattern along with nonenhancing decreased signal areas implying necrosis, and pseudocyst formation usually contiguous with dilated MPD are well depicted. Vascular occlusions may also be demonstrated [21]. Moreover, MRCP has been shown to be an effective screening technique for disclosing ductal abnormalities possessing the advantage of noninvasive methodology and the ability to image obstructed ducts that are not opacified by ERCP injection. Parallel dilatation of MPD with radicles and CBD with smooth distal tapering is the pathognomonic MRCP finding of chronic pancreatitis (Figure 9). Therefore, MRCP remains a useful screening modality to determine duct abnormalities and confirm the need for interventional procedures. Oral, intravenous and intraductal contrast administration are not implemented. Thus, its lack of ionizing radiation makes this imaging technique the safest method to image the ductal system in high-risk patients [22, 23].

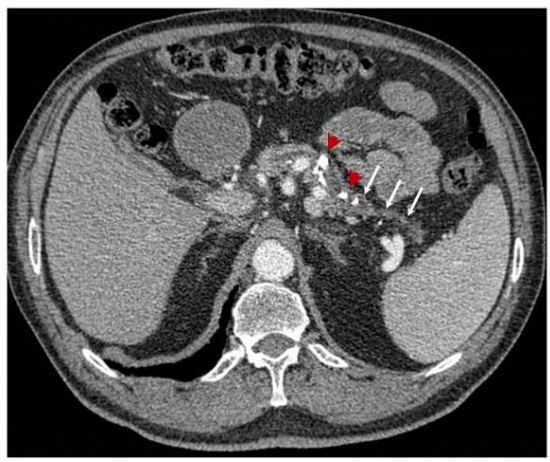

Figure 8. Abdominal CT in chronic pancreatitis: Calcification of the pancreatic parenchyma following the course of the main pancreatic duct and its branches (red arrowheads). Mild dilatation of main pancreatic duct and parenchymal atrophy (thick white arrows).

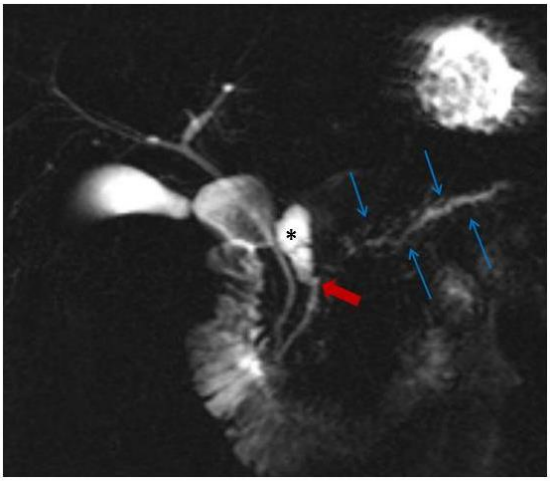

Figure 9. MRCP in chronic pancreatitis: Irregularly dilated main pancreatic duct and its branches (thin blue arrows), communicating (thick red arrow) with a pseudocyst (asterisk).

Endoscopic Ultrasonography

EUS has heavily impacted the evaluation and management of patients with chronic pancreatitis. Although it is more operator dependent and less widely available than transabdominal U/S, EUS provides not only imaging capability, but adds the capacity to obtain cytological and chemical samples of tissue and fluid aspirated with linear array monitor [24, 25]. EUS images obtained through a high-frequency transducer are to evaluate subtle changes in 2- to 3-mm structures within the pancreas, and detect indolent neoplasms in the setting of chronic inflammation. Small intraductal lesions and mucus as well as subtle ductular abnormalities and cystic disorders are also recognizable with EUS [26]. This allows ERCP to be reserved for these patients who require therapeutic maneuvers or for the identification of more problematic nosologic entities (Figure 10). EUS is comparable to ERCP in the detection of advanced changes in chronic pancreatitis and may be more sensitive in the confirmation of mild disease.

Endoscopic Retrograde Cholangiopanceatography (ERCP)

ERCP is considered to be the gold standard for the diagnosis and staging of chronic pancreatitis. It also serves as a vehicle that enables other diagnostic and therapeutic maneuvers such as brushing for cytology or the employment of stents to relieve obstruction or drain a pseudocyst. Dilated and beaded MPD with radicles along with MPD filling defects indicating the presence of intraductal calculi are common ERCP findings of chronic pancreatitis [27]. In addition, CBD may appear dilated with distal narrowing. Unfortunately, ERCP carries a risk of procedure-induced pancreatitis that occurs in approximately 5% of patients. Post-ERCP pancreatitis occurs after uncomplicated procedures as well as after those that require prolonged manipulation. Patients at increased risk include those with documented sphincter of Oddi dysfunction.

Figure 10. EUS in chronic pancreatitis identifying a dilated main pancreatic duct with filling defects indicative of the presence of intraductal calculi.

Therefore, this method should be reserved for patients with unclear diagnosis or in whom a diagnostic and therapeutic intervention is crucial [28].

Differential Diagnosis

- ✓ Pancreatic carcinoma
- ✓ Intraductal papillary mucinous tumor of the pancreas

5. TRAUMATIC PANCREATITIS

Definition

Blunt pancreatic transection at the neck of the pancreas can occur with a direct blow to the abdomen. As an isolated injury it is difficult to detect. Since the MPD is transected the patient will develop a pseudocyst or pancreatic ascites, but there is little inflammation since the pancreatic enzymes remain inactivated. Diagnostic approach can occasionally be accomplished with CT using fine cuts through the pancreas. Nevertheless, CT will not identify a significant number of transections if performed within 6 hours of injury. Optimal management of pancreatic trauma is determined by the location of the injury and whether or not the MPD is involved. In case of an intact MPD treatment may be accomplished only by drainage. In contrast, traumatic pancreatitis associated with a ductal injury always requires therapeutic intervention in order to prevent pancreatic ascites or a major external fistula. Direct exploration of perforations or lacerations will confirm the diagnosis in most instances [29, 30].

Surgical Interventions

- ✓ Surgical drainage in case of pancreatic trauma with an intact MPD
- ✓ Distal pancreatectomy with or without splenectomy for severe injury of the neck, body and tail of the pancreas with parallel MPD transection
- ✓ Limited resection from the site of the injury to the head of the pancreas with preservation of pancreaticoduodenal vessels and CBD in case of severe traumatic lesion of the head and MPD involvement

Imaging Modalities

The role of imaging modalities in case of traumatic pancreatitis is to establish the diagnosis and assess the pancreatic duct integrity. Conservative treatment can also be selected with imaging evaluation at regular intervals.

Ultrasound

Transabdominal U/S findings in traumatic pancreatitis may be similar to those of non-traumatic inflammation of the gland. In addition U/S depiction is not as sensitive and accurate as CT in diagnosing acute injury of the pancreas.

Computed Tomography

Focal or diffuse pancreatic enlargement with irregularity of pancreatic contour is always indicative of traumatic pancreatitis. The presence of edema as well as fluid collection in peri-pancreatic fat with concomitant heterogeneous parenchymal attenuation is often apparent. Thickening of anterior renal fascia may be an additional indirect CT finding. Nevertheless, peri-pancreatic soft tissue changes of traumatic pancreatitis are often subtle and become more evident within 24-48 hours. In case of laceration an area of low attenuation is usually revealed while its actual size is difficult to visualize.

Moreover, potential pancreatic fracture or transection is detected as an ill-defined low density area which results in clear separation of two ends of the gland and nearly always extends through pancreatic neck (Figure 11).

However, lacerations and fractures may produce non-specific changes in parenchymal density and become undetectable on CT scanning. Extra-pancreatic fluid collections around major vascular structures, transverse mesocolon, pararenal space, lesser sac, and the root of mesentery are usually well depicted along with concomitant injury to left lobe of the liver [31]. In conclusion, CT remains the most accurate method of detecting extra-pancreatic fluid collections, pancreatic lacerations or fractures taking into thorough consideration the protocol advice about performing 24-48 hours delayed scans that may uncover findings not present earlier.

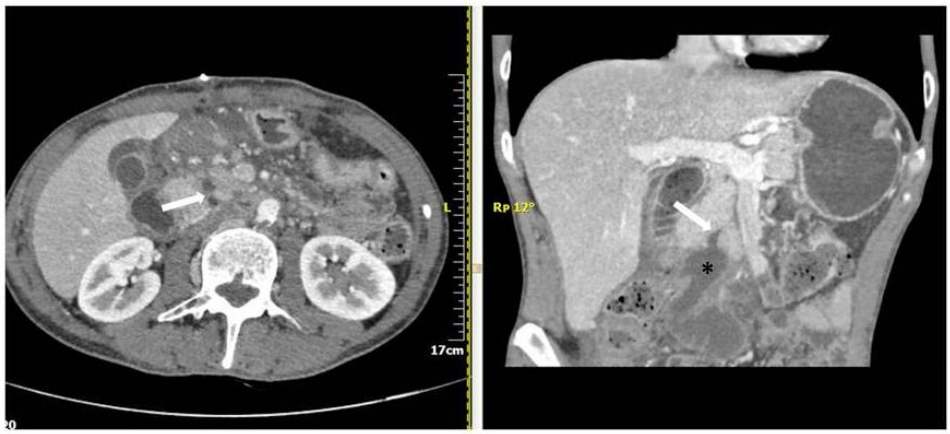

Figure 11. Abdominal CT in pancreatic trauma (axial and coronal reformation): Interruption of the pancreatic head (thick white arrow) associated with peripancreatic fluid collection (asterisk).

Magnetic Resonance Imaging – Magnetic Resonance Cholangiopancreatography

Variable decreased signal intensity with heterogeneous enhancement pattern and non-enhancing hypointense areas indicative of fluid collection, pseudocyst formation and necrosis are often defined in T1W1 images. On the other hand, on fat suppressed T2WI images liquid selections or pseudocysts are demonstrated as hyperintense lesions. Subsequent MRCP reveals possible rupture of MPD (23%) or potential communication with post-traumatic pseudocyst.

Endoscopic Retrograde Cholangiopanceatography (ERCP)

It is obvious based on the above options that no ideal method exists for identifying pancreatic ductal injuries that cannot be ruled out by direct exploration. Alternative method is the use of ERCP. Nevertheless, this modality is very helpful in the delayed diagnosis of a ductal pancreatic injury. Potential transection of MPD reveals an abrupt duct termination or contrast extravasation.

Additional communication of pseudocyst with pancreatic duct may be apparent. However, procedure-induced pancreatitis may also be invoked.

Differential Diagnosis

- ✓ “Shock” pancreas
- ✓ Intramural duodenal hematoma
- ✓ Duodenal rupture

6. SEROUS CYSTADENOMA OF THE PANCREAS

Definition

The term usually refers to a benign glycogen-rich pancreatic tumor that arises from acinar cells with mainly microcystic appearance. It is encountered most frequently incidentally in middle-aged women. Best diagnostic clue is the depiction of a honeycomb or sponge-like mass in pancreatic head with calcification and innumerable small cysts varying from 1-20mm within large cystic lesion.

Tumors show increased frequency in patients with von Hippel-Lindau disease. Based on WHO classification two types of serous cystadenoma are recognized including the microcystic adenoma and the less common oligocystic (macrocystic) variant [32].

Surgical Interventions

- ✓ Complete surgical excision of a symptomatic and large tumor

Imaging Modalities

The role of imaging modalities in cases of serous cystadenoma of the pancreas is to establish the diagnosis and assess whether surgical resection should be implemented.

Differential diagnosis of other cystic tumours categories and pseudocysts is only accomplished on the basis of specific imaging features as well as examination of fluid aspirated under imaging guidance.

Ultrasound

Real-time U/S usually depicts a hyperechoic mass with tiny cystic lesions. Less commonly, a tumor with large cysts defined as discrete anechoic areas with thin walls is described. Additional calcifications are detected as highly reflective echoes with acoustic shadowing.

Computed Tomography

Honeycomb pattern remains the pathognomonic CT finding indicative of a microcystic adenoma. Additional enhancement of septa delineating small cysts or calcification within central scar may be encountered (Figure 12). CBD and/or MPD dilatation as well as atrophy of pancreas distal to the tumor is common among cystic epithelial neoplastic lesions.

Furthermore, macrocystic (usually unilocular) serous cystadenoma is located in the pancreatic head and is depicted with one or few cystic components (locules) covered by thin

non enhancing imperceptible wall. Therefore, differential diagnosis from mucinous cystic lesions remains problematic [33, 34].

Magnetic Resonance Imaging – Magnetic Resonance Cholangiopancreatography

T1W1 MRI images usually elucidate the presence of a hypointense tumor with central scar enhancement on delayed scan and calcification while blood within cysts is often depicted with varied intensity (Figure 13). Capsular enhancement is also commonly observed. Relevant findings are detected on T2WI images. Subsequent MRCP confirms potential MPD and CBD dilatation. Displacement, narrowing and dilatation of adjacent MPD and/or CBD are also mentioned in ERCP.

Figure 12. Abdominal CT showing a multicystic lesion that contains tiny cysts and central calcification at the pancreatic tail (thick white arrow).

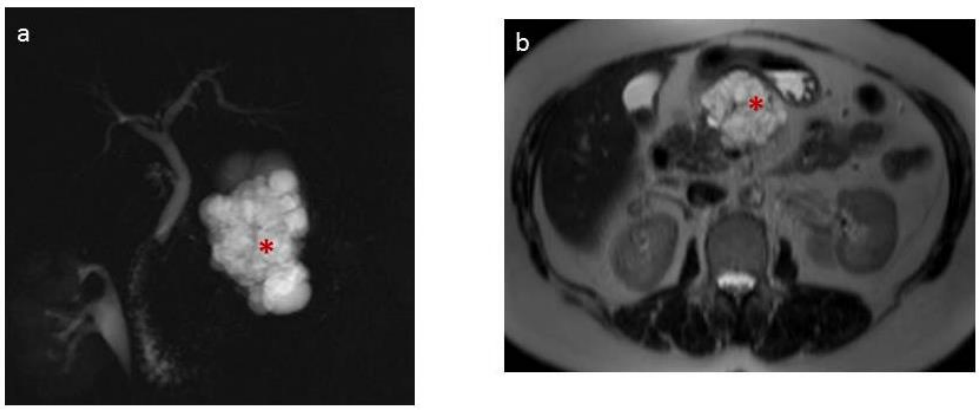

Figure 13. Abdominal MRI a) MRCP: Multicystic pancreatic lesion containing various sized cysts b) T2W image: Multicystic lesion with central scar (red asterisk).

Angiography

Conventional angiography reveals a highly vascular tumor due to extensive capillary network within septa with neovascularity and dense blush. Large cysts produce lucent regions with dilated feeding arteries and prominent draining veins.

Nevertheless, exclusive angiographic characteristics are absent.

Endoscopic Ultrasonography

The unequivocal diagnosis of a pancreatic cystic lesion without a clear association to acute or chronic pancreatitis should always raise a tumor suspicion, reinforced by other factors such as female gender, higher age and location in the gland. Among the tumors, the mucinous types have to be taken more seriously with surgery being considered in all of them, whereas the rate of malignancy in serous cystadenomas seems to be very low [35, 36]. Early papers suggested specific EUS image features to be more frequent among different types of cystic tumors, but this may not be helpful in the individual case (Figure 14).

Furthermore, agreement among endosonographers was only fair in this differential diagnosis. It is assumed that the risk of malignancy is very low for serous cystadenoma, which was confirmed recently in a series of 158 such cases undergoing surgery, with only two malignancies, one diagnosed initially, the other one on follow-up due to metastases after an initial benign diagnosis from the resection specimen.

Figure 14. EUS depiction of serous cystadenoma of the pancreas with multiple small compartments within a cystic mass (honeycomb appearance).

Studies evaluating EUS-FNA with different parameters to be assessed from the aspirated fluid (amylase, mucin, CEA, cytology) also reached contradictory conclusions [37]. EUS potentially with FNA in general contributes limited information to the management of patients with indeterminate cystic lesions.

Clinical parameters including absence of pancreatitis, gender and age add at least as much important information as morphology (EUS and/or CT) and FNA results do. Surgery should be considered in all operable patients with incidental cysts located at the head of the gland. Specific parameters with regard to morphology suggesting serous cystadenoma may lead to FNA in individual cases, if the results have an impact on the patient's management.

Differential Diagnosis

- ✓ Mucinous cystadenoma of pancreas
- ✓ Intraductal papillary mucinous tumor (IPMT)
- ✓ Pseudocyst
- ✓ Pancreatic carcinoma
- ✓ Congenital pancreatic cysts
- ✓ Cystic islet cell tumor

7. MUCINOUS CYSTIC PANCREATIC TUMOR (MCPT)

Definition

The terminology refers to an uncommon primary enhancing multiseptated mass in the body or tail of the pancreas. It is recognized as a large smooth encapsulated lesion with thick fibrous capsule and lobulated surface.

The presence of multi-/unilocular large cysts is obvious. Cystic cavity may be filled with thick mucoid material or clear, green blood-tinged fluid. Otherwise, solid papillary projections protrude into interior of the tumor indicating the malignant potential of the neoplasm which shares both clinical and pathologic characteristics of biliary and ovarian tumors.

Rarely MCPT may manifest with local invasion or distant metastases or symptoms of mass effect on adjacent structures. Laboratory data including increased levels of serum CEA and elevated cyst fluid levels of CA 19-9 and CA 72-4 present 80% sensitivity and 95% specificity for tumor identification [38].

Surgical Interventions

- ✓ Complete surgical excision

Imaging Modalities

The role of imaging modalities in case of mucinous cystic pancreatic tumor is to establish the diagnosis and confirm the need for subsequent complete surgical resection. Differential diagnosis of other cystic tumours categories and pseudocysts is only accomplished on the basis of specific imaging features as well as estimation of fluid aspirated with image-guided diagnostic procedures.

Ultrasound

Real Time U/S usually detects a multilocular cystic mass with echogenic internal septa. Alternatively, a unilocular anechoic lesion is frequently depicted with limited contribution to the differential diagnosis among cystic pancreatic neoplastic disorders.

Computed Tomography

NECT reveals a hypodense unilocular or multilocular cyst with focal calcifications.

Subsequent CECT describes a multilocular cystic lesion with enhancement of thin internal septa and cyst wall [39].

Magnetic Resonance Imaging – Magnetic Resonance Cholangiopancreatography

On T1W1 images variable signal intensity based on cyst content is documented. Fluid-like material as well as focal calcifications are characterized as hypointense while proteinaceous or hemorrhagic elements are hyperintense.

On the other hand, cystic lesions are depicted as hyperintense areas with hypointense internal septations and focal calcifications on T2WI images (Figure 15).

MRCP as well as ERCP is indicative of extensive displacement, narrowing and prestenotic dilatation of MPD adjacent to tumor [40].

Angiography

Conventional angiography often reveals a predominantly avascular cystic mass with solid components and small areas of vascular blush and neovascularity. Additional displacement of surrounding major vascular structures is identified.

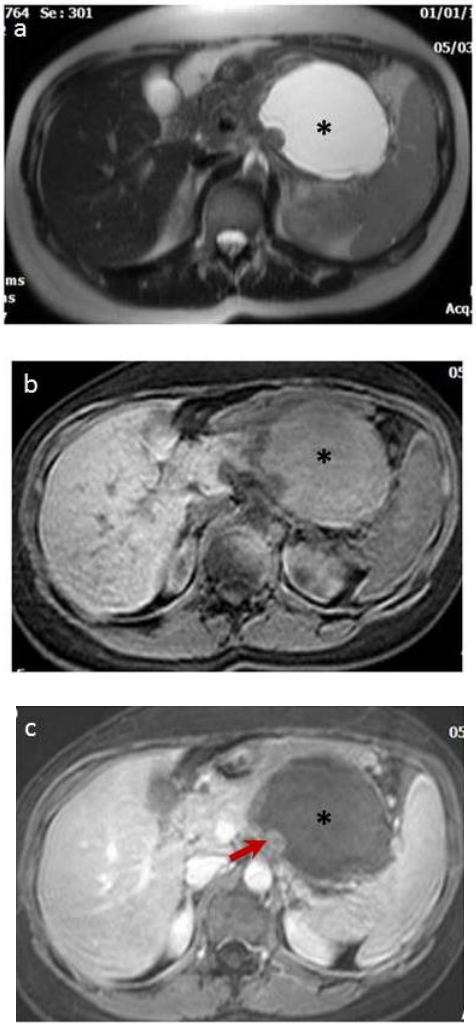

Figure 15. Abdominal MRI of a mucinous pancreatic tumor: a) T2W image: Unilocular cystic lesion with hypointense mural nodule (black asterisk) b) 3D T1 fat suppressed image: Hyperintensity of the cystic content indicating the presence of mucin (black asterisk) c) 3D T1 fat suppressed image after contrast medium administration: Enhancement of the mural nodule (red thick arrow).

Endoscopic Ultrasonography

Several EUS findings have been evaluated to diagnose pancreatic cystic lesions. Small cyst size does not exclude malignancy; one series reported 20% of lesions 2cm or smaller to be malignant and 45% possessed malignant potential.

However, only 3.5% among asymptomatic lesions with tumor size less than 2cm were malignant [41]. Certain features do appear to be more predictive in diagnosing particular types of cystic pancreatic lesions (Figure 16, 17). The finding of multiple small compartments within a cystic mass is suggestive of a serous cystadenoma, with an accuracy of 92% to 96%, and is not encountered in mucinous cystadenomas [42].

In addition, a cystic tumor without septations or solid components and detected within a pancreas having parenchymal abnormalities suggests a pseudocyst formation with a sensitivity of 94% and a specificity of 85%.

EUS findings may also help identify those patients with mucinous lesions with malignant potential who might benefit from surgical resection. One study reported that the presence of any one of the following had a sensitivity of 91% but a specificity of 60% for detecting a lesion with malignant potential: (1) cyst-wall thickness greater than 3mm, (2) intracystic compartments larger than 10mm ("macroseptations"), (3) intramural masses, or (4) cystic dilatation of the MPD [43]. Another study found the accuracy for detecting those lesions with malignant potential varied from 40% to 93%.

This suggests that, whereas EUS findings may add some diagnostic information, results may not be reliable enough for making management decisions [44].

Figure 16. EUS showing a mucinous cystic tumor of the tail of the pancreas with characteristic cyst-wall thickness.

Differential Diagnosis

- ✓ Serous cystadenoma of the pancreas
- ✓ Intraductal papillary mucinous tumor (IPMT)
- ✓ Pseudocyst
- ✓ Variant of ductal adenocarcinoma
- ✓ Congenital pancreatic cysts
- ✓ Cystic islet cell tumor
- ✓ Lymphangioma

8. INTRADUCTAL PAPILLARY MUCINOUS TUMOR

Definition

IPMT is a subdivision of mucin producing tumors along with mucinous macrocystic neoplasm and is classified into three types:

- Branch pancreatic duct (BPD) type with focal lobulated "multicystic" dilatation of branch ducts
- Main pancreatic duct (MPD) type with diffuse dilatation of MPD
- Combined type with parallel dilatation of both BPD and MPD which is the most common variety.

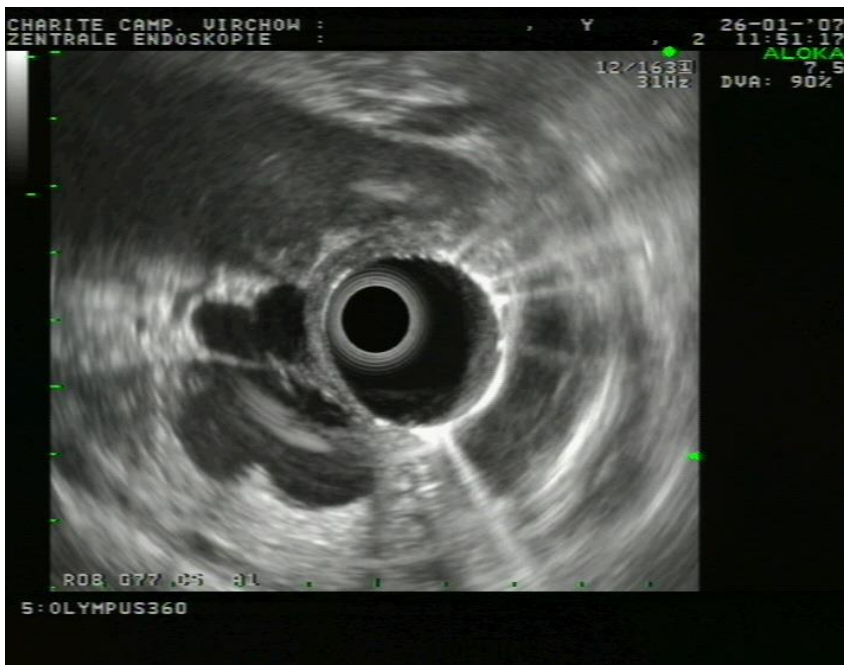

Figure 17. EUS showing a mucinous cystic tumor of the pancreas with intracystic compartments, intramural masses and associated cystic dilatation of the main pancreatic duct.

Tumors are typically papillary lesions ranging in size from a few millimeters to panductal with varying proportions of dysplasia and in situ cancer. Papillary projections protrude into and expand BPD and MPD as well. Excessive mucin production combined with obstruction and dilatation of BPD and MPD is also noted. Most specific predictive signs of malignant transformation refer to diabetes mellitus, detection of a solid mass on imaging or a dilated MPD more than 10mm, diffuse or multifocal involvement and presence of attenuating or calcified intraluminal content. Associated laboratory data refer to increased serum and urinary amylase and altered pancreatic function tests [45].

Surgical Interventions

- ✓ Laparoscopic distal pancreatectomy with or without splenic preservation may be employed for cystic lesions located in the tail of the pancreas
- ✓ Duodenum-preserving pancreatic head resection for isolated lesions in the head of the pancreas
- ✓ Total pancreatectomy in case of multi-focal disease

Imaging Modalities

The role of imaging modalities in case of intraductal papillary mucinous cystic tumor of the pancreas is to establish the diagnosis and confirm the necessity of concomitant complete surgical excision.

Differential diagnosis of other cystic tumours categories and pseudocysts is only accomplished on the basis of specific imaging features as well as estimation of fluid aspirated with advanced imaging guided diagnostic procedures.

Therefore, imaging methods potentially with FNA contributes significant information to the management of patients with indeterminate cystic lesions of the pancreas.

Ultrasound

Real-time U/S usually defines the presence of a septated cystic lesion along with a dilated MPD and occasionally punctate calcifications. Nevertheless, intra-operative or endoscopic sonography affords superior visualization of ductal system of the pancreas.

Computed Tomography

Differential diagnosis among pancreatic cystic lesions as well as specific types of IPMTs is always attempted with CECT scanning. BPD type is described as a thin, lobulated, irregular, peripheral ring-enhancing "multicystic" lesion.

A bulging ampulla at duodenal sweep with thin rim enhancement is often apparent [46]. On the contrary, MPD type is related to a markedly dilated tortuous MPD. Additional punctate calcifications along with polypoid lesions lining MPD may be visualized.

Magnetic Resonance Imaging – Magnetic Resonance Cholangiopancreatography

On axial TlWI images hypointense branch duct cysts associated with a dilated MPD are always revealed. In addition, clustered cystic lesions with thin septa are depicted on coronal T1W1 images. On T2WI depictions relevant disorders are hyperintense with parallel detection of papillary excrescence in cystic lesion of pancreatic head or along MPD.

Subsequent MRCP is mainly indicative of lobulated clustered cysts, dilated MPD and possible communication between cystic tumors and ductal system (Figure 18). Intraductal mucin and papillary lesions may be also described as nodular filling defects [47].

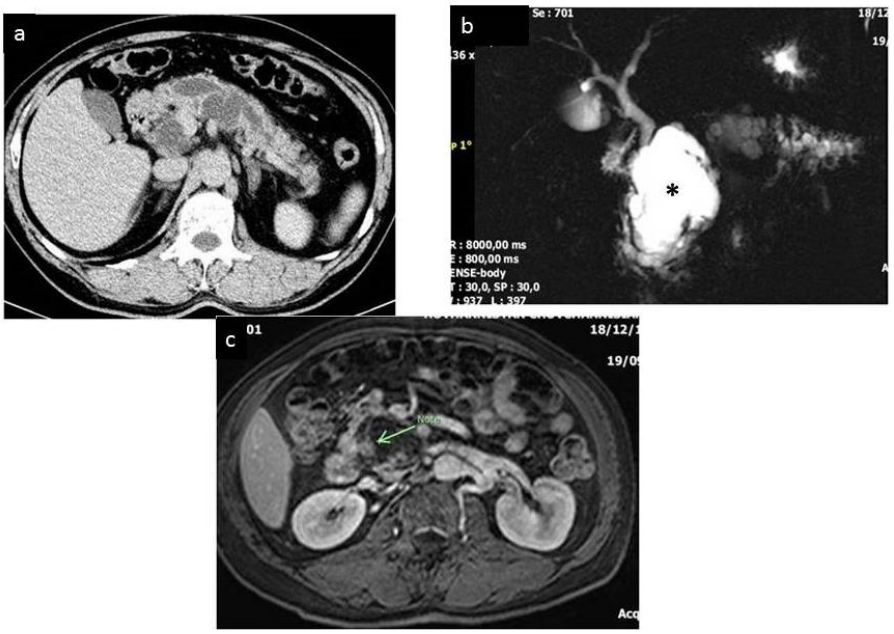

Figure 18. Intraductal papillary mucinous tumor of the pancreas a) Abdominal CT: Irregular dilatation of the main pancreatic duct with associated cystic branches dilatation b) MRCP: Large cystic lesion at the pancreatic head (black asterisk), cystic dilatation of main pancreatic duct and its branches c) 3D T1 Fat Suppressed image after contrast medium administration: Enhancement of the solid component of the cystic lesion, indicating malignant transformation (green arrow).

Endoscopic Retrograde Cholangiopanceatography

ERCP confirms the diagnosis of IPMT of pancreas contributing to the detection of a dilated MPD with thick intraductal mucinous secretions. Mucin and papillary tumors are clearly defined as elongated, nodular or band-like filling defects in MPD. Concomitant real-time visualization of patulous ampulla and increased mucus production is warranted.

Endoscopic Ultrasonography

EUS cannot accurately determine the extent of involvement of IPMT and is not reliable in distinguishing malignant from benign forms of this neoplasm (Figure 19).

Intraductal U/S may suggest malignant IPMT by the presence of protruding lesions ≥ 4 mm (Figure 20). Areas of uncertainty likely reflect the only fair to moderate agreement among experienced endosonographers about the presence or absence of particular EUS findings or specific diagnoses [48, 49]. EUS-guided FNA (EUS-FNA) of pancreatic cystic lesions yields fluid for cytological and chemical analyses.

Moreover, any solid components associated with a lesion or regional lymph nodes can be aspirated for cytology or histological evaluation. Dilated pancreatic ducts can be safely targeted for FNA when IPMT is suspected. Knowledge of patient's clinical history may help improve the accuracy of EUS for diagnosing IPMTs [50].

Differential Diagnosis

- ✓ Serous cystadenoma of the pancreas
- ✓ Mucinous cystic neoplasm
- ✓ Pancreatic pseudocyst
- ✓ Pancreatic carcinoma
- ✓ Chronic pancreatitis

Figure 19. EUS detection of double duct sign associated with main branch intraductal papillary mucinous tumor of the pancreas.

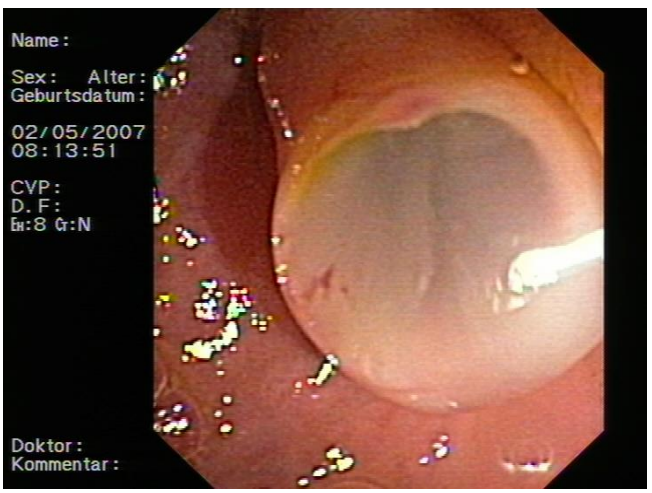

Figure 20. EUS detection of a dilated main pancreatic duct with thick intraductal mucinous secretions indicative of the presence of intraductal papillary mucinous tumor of the pancreas.

9. PANCREATIC DUCTAL CARCINOMA

Definition

Pancreatic adenocarcinoma is the most common type of pancreatic cancer accounting for more than 80% of all pancreatic malignancies. About two thirds of pancreatic adenocarcinomas arise within the head or uncinate process of the pancreas; 15% are located in the body, and 10% in the tail, with the remaining tumors demonstrating diffuse involvement of the gland [51]. Tumors in the pancreatic body and tail are generally larger at the time of diagnosis, and therefore, less commonly resectable.

Tumors in the head of the pancreas are typically diagnosed earlier because they cause obstructive jaundice. Ampullary carcinomas, carcinomas of the distal bile duct, and periampullary duodenal adenocarcinomas present in a similar fashion to pancreatic head cancer but possess a slightly better prognosis, probably because early obstruction of the bile duct and jaundice leads to the prompt diagnosis. Exact pathologic staging of pancreatic cancer is important because it allows accurate quantitative assessment of results and comparisons between institutions. Surgery with margin negative resection also known as R0 resection is the only potentially curative approach in pancreatic carcinoma.

However, only 15-20% of affected patients present with potentially resectable disease. Due to the high morbidity of the surgical procedure, accurate selection of patients in the preoperative setting who will proceed to operation is critical [52].

Surgical Interventions

- ✓ Distal pancreatectomy with splenectomy may be employed for pancreatic adenocarcinomas located in the body and the tail of the gland
- ✓ Pancreaticoduodenectomy, also called “Whipple operation,” for complete resection of isolated malignant lesions in the head of the pancreas
- ✓ Palliative endoscopic stenting for obstructive jaundice relief
- ✓ Palliative gastric by-pass in case of duodenal obstruction of unresectable tumor
- ✓ Palliative celiac nerve block for abdominal pain

Imaging Modalities

The role of imaging modalities in cases of pancreatic ductal carcinoma is to establish the diagnosis and assess tumor resectability. The accuracy of imaging techniques for predicting unresectable disease is about 90 to 95%.

Specific imaging findings that indicate a tumor is unresectable include invasion of the CHA or SMA, enlarged lymph nodes outside the boundaries of resection, ascites, and distant metastases mainly to the liver. Invasion of the SMV or PV remain relative contraindications to resection as long as the veins are patent.

Ultrasound

One of the common presentations of patients with pancreatic adenocarcinomas of the head of the pancreas is painless jaundice. The initial imaging modality is typically an ultrasound to evaluate the intrahepatic biliary system, the common duct and the gallbladder.

Presence of CBD dilatation along with intrahepatic and MPD involvement is a strong indication for further meticulous investigation with cross sectional imaging. Real-time U/S often reveals a hypoechoic mass combined with contour deformity of the gland. Due to overlying bowel gas and differences in operator scanning technique and experience, U/S in not typically used as the modality of choice in staging pancreatic adenocarcinoma.

Computed Tomography

CT is usually the cross sectional imaging modality of choice for staging in pancreatic cancer patients. Parallel administration of oral and iodinated contrast intravenously injected prior to the CT scan is implemented. Dual phase imaging is performed. The first phase refers to the pancreatic parenchymal process of enhancement while the second one describes the portal venous phase. The pancreatic tumor is best detected during the first phase of enhancement due to optimal depiction of the pancreas with greatest attenuation difference between the tumor and the normal gland (Figure 21).

Liver metastatic disease is best elucidated in the second portal phase of enhancement. The images are reconstructed at either 0.625 or 1.25mm slice thickness. These thin section images can help in multiplanar reconstructions and in improved detection of small tumors. Associated secondary signs of malignancy as well as potential vascular involvement are always assessed. Pancreatic adenocarcinomas are typically low attenuation, infiltrative masses on the pancreatic parenchymal phase of enhancement.

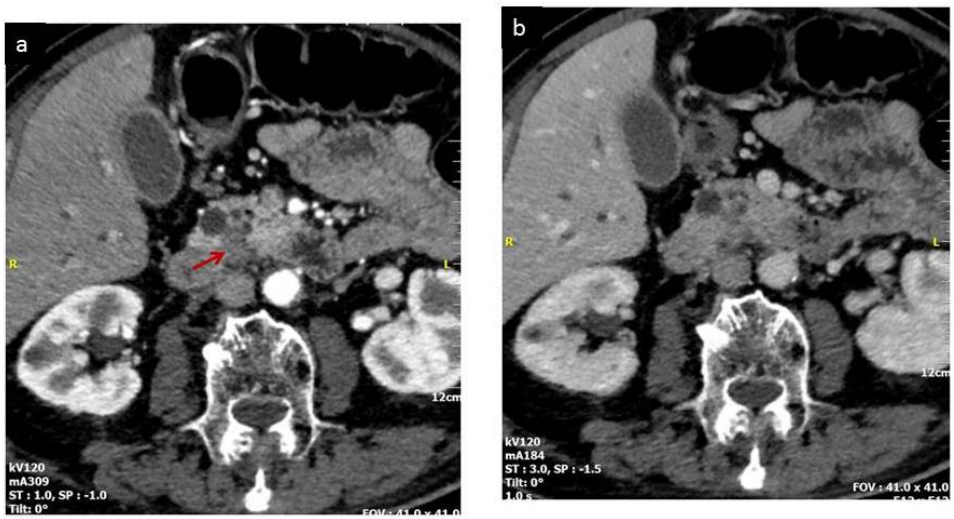

Figure 21. Abdominal CT in pancreatic ductal carcinoma: a) Pancreatic phase of enhancement: Small pancreatic cancer causing obstruction of the common bile duct and the main pancreatic duct (red arrow) b) Portal phase of enhancement: The pancreatic lesion is not visible.

Figure 22. Abdominal CT in pancreatic ductal carcinoma: Pancreatic phase of enhancement, curved reconstruction along the course of MPD: Hypoattenuating lesion (pancreatic cancer) obstructing the main pancreatic duct (white arrow), causing upstream dilatation and distal atrophic changes.

Secondary signs of malignancy include loss of normal lobulation of the pancreatic parenchyma along with CBD and MPD narrowing or obstruction with upstream dilatation and distal pancreatic atrophic changes (Figure 22) [53, 54].

Vascular involvement may be related to venous or arterial infiltration. The most commonly affected veins are the SMV, portal and splenic vein respectively depending on the primary tumor location (Figure 23). The most commonly involved arteries can include the GDA, SMA, inferior pancreaticoduodenal artery (IPDA), splenic artery, CHA and celiac trunk as well. The T3 stage refers to extension of the tumor outside the pancreas with respect to the celiac trunk or the SMA.

On the contrary, T4 stage suggests involvement of relevant vascular structures (Figure 24). The location of the pancreatic tumor determines its local spread and potential infiltration of major vessels. Gradual development of pancreatic tail lesions often involves the splenic vessels and the splenorenal ligament (Figure 25).

Moreover, a tumor that is located in the body of the pancreas may spread to involve the celiac trunk and its branches. A body tumor if large enough can extend caudally to involve the SMA. A tumor located in the anterior head and neck of the pancreas may spread to involve the GDA, CHA and the gastrocolic trunk respectively. A tumor of the posterior neck and head of the pancreas typically can involve the PV as well as the portal venous confluence, the SMV and the SMA.

Finally, an uncinate tumor tends to typically track along the IPDA and may secondarily involve the jejunal and the mesenteric vessels [55].

A relatively new category is emerging from pancreatic cancer staging called “borderline resectable” tumors. The amount of extension or involvement of the celiac artery or SMA can vary on CT evaluation [56]. The term “abutment or involvement” has been designated to correspond to extension of tumors that involve less than 180° of the circumference of the vessel while the term “encasement” has been proposed to refer to development of the tumor more than 180° of the circumference of the vessel.

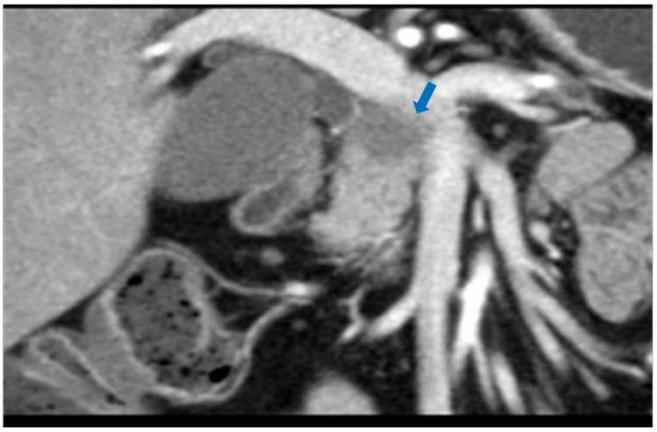

Figure 23. Abdominal CT in pancreatic ductal carcinoma: Portal phase of enhancement coronal reconstruction: Pancreatic neck cancer invading the splenomesenteric confluence and the proximal portal vein (thick blue arrow).

Figure 24. Abdominal CT in pancreatic ductal carcinoma: Pancreatic phase of enhancement: a) Pancreatic tumor encasing the superior mesenteric artery (white asterisk) b) Encasing of the superior mesenteric vein and the splenomesenteric confluence (black asterisk).

Figure 25. Abdominal CT in pancreatic ductal carcinoma: Pancreatic phase of enhancement: Inhomogeneous necrotic lesion at the pancreatic tail (blue circle), invading the perirenal fascia (white arrows).

Borderline resectable tumors are defined as lesions that abut or encase a short segment of the common hepatic artery without involvement of the celiac artery, abut the SMA or may cause short segment occlusion of the SMV, PV or the portal venous confluence with suitable veins above and below the level of the occlusion for venous reconstruction (Figure 26).

The importance of the borderline resectable category is that affected patients appear with CT findings that preclude immediate surgery due to high risk for a margin positive resection [57]. These patients are typically treated with neoadjuvant chemotherapy or combined chemoradiation therapy. Advantages of neoadjuvant chemoradiation include optimal patient selection for surgical intervention by excluding those patients with progressive disease on therapy and by initiating immediate treatment to prevent systemic spread.

Recently defined CT criteria for vascular involvement in pancreatic adenocarcinoma in comparison with surgical results confirm that identification of fat plane (type A) or normal pancreatic parenchyma (type B) separating the tumor from adjacent vessels predict tumor resectability in 95% of selected patients. When the tumor is inseparable from the vessels but the points of contact form a convexity against the vascular structure (type C), CT is not reliable in predicting vascular involvement.

When the tumor is partially encircling (type D) the vessel, the tumor is fixed against the vessels in the majority of the cases. Forty seven percent of these patients are resectable but relevant procedure usually involves venous resection as well.

When the tumor is completely encircling (type E) or occluding (type F) the vessel, 100% of the lesions could not be resected with a negative margin. This yielded a sensitivity of 84% and a specificity of 98% [55].

Detailed anatomy of the peripancreatic lymph nodes was originally described by the Japanese Pancreatic Society. The T, N, and M categories all independently influence survival of pancreatic carcinoma [58]. Nevertheless, nodal involvement has been reported the strongest predictor of poor survival after pancreatic resection for invasive pancreatic adenocarcinoma. The presence of GDA node positivity shares a poor prognosis similar to that of metastatic disease spread to the peritoneum or liver. The incidence of nodal involvement is 72-83% on autopsy series [59].

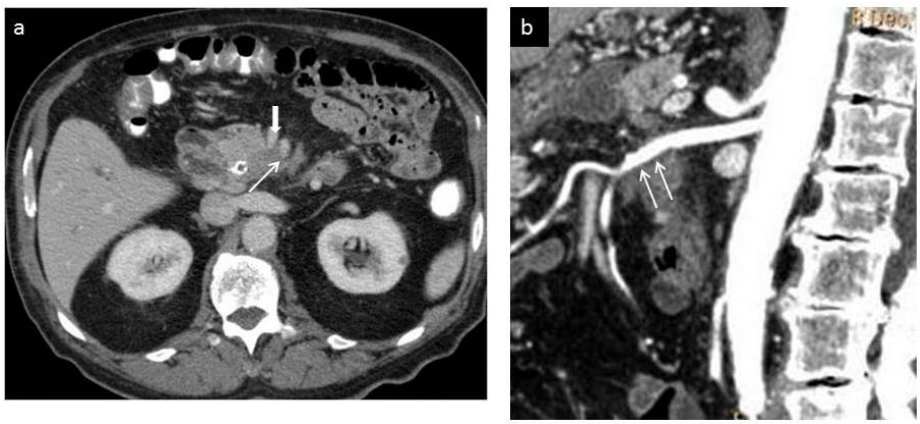

Figure 26. Abdominal CT in pancreatic ductal carcinoma: Abdominal CT: a) Portal phase of enhancement: Pancreatic tumor abutting the superior mesenteric artery, tear drop sign of the superior mesenteric vein (thick white arrow) b) Pancreatic phase of enhancement sagittal reformation: Pancreatic tumor abutting the superior mesenteric artery (thin white arrows).

CT accuracy for nodal staging is 44-47% after meticulous correlation of imaging findings with pathology results. In addition, detection of ovoid nodal shape, clustering of nodes and the absence of a fatty hilum are not useful predictors of malignancy on CT [60]. Moreover, the incidence of con-peritoneal involvement is between 40-55%. While the most common CT finding is that of peritoneal thickening, small nodules and ascites, larger peritoneal implants and omental caking may be encountered. Additional liver metastases are typically low attenuation lesions and may present perilesional enhancement on the pancreatic parenchymal phase, which fades on the portal phase of enhancement.

Nevertheless, detection of small volume liver metastases and peritoneal implants remains challenging despite the use of CT in the preoperative staging of pancreatic adenocarcinoma [61, 62]. Finally, the most common appearance of pulmonary metastases is lung nodules with irregular or speculated borders. However, lung metastases with a diffuse air space pattern or with lymphangitic carcinomatosis may be recognized [63].

Magnetic Resonance Imaging – Magnetic Resonance Cholangiopancreatography

Pancreatic ductal adenocarcinoma typically manifests as an infiltrating poorly defined mass, desmoplastic in nature, with sparse vascularity. This histology contrasts with that of normal pancreatic parenchyma. For this reason, small tumors are well seen as relatively low signal intensity poorly defined lesions on fat suppressed T1 weighted images against the normal high signal intensity of uninvolved pancreatic parenchyma (Figure 27) [64].

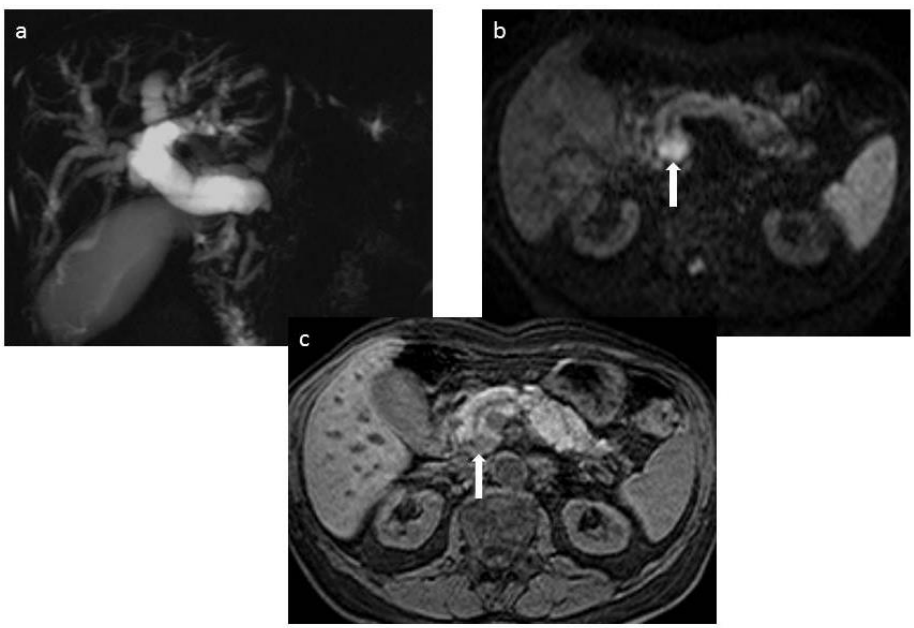

Figure 27. Abdominal MRI demonstrating a small pancreatic ductal carcinoma: a) MRCP: Obstruction of the common bile duct with proximal dilatation of the billiary ducts b) Diffusion Weighted Image: Hyperintense lesion (restricted diffusion pattern) at the pancreatic head (thick white arrow) c) 3D T1 Fat Suppressed image: Hypointense lesion at the pancreatic head (thick white arrow).

Pancreatic cancer is most conspicuous on the arterial phase of dynamic gadolinium imaging against the prominently enhancing capillary rich uninvolved surrounding pancreatic parenchyma. Close attention to technique, particularly timing, is vital [65].

On delayed, interstitial phase images, the appearance of pancreatic cancer can be very variable. Small pancreatic tumors can present a variable enhancement pattern, ranging from hypointense to slightly hyperintense on delayed images and may actually show rim enhancement. In contrast, large pancreatic ductal adenocarcinomas tend to remain low in signal intensity on delayed images [66].

Often pancreatic tissue proximal to pancreatic cancer may be lower in signal intensity than the normal gland. This typically occurs as a consequence of tumor associated pancreatitis secondary to the obstruction of the MPD. The greater the resultant progression to fibrosis and glandular atrophy from long standing pancreatic ductal obstruction, the less conspicuous the pancreatic carcinoma. For this reason, all sequences must be carefully evaluated to define the true extent of the tumor. The combined MRI features of a focal pancreatic mass, pancreatic duct dilatation and parenchymal atrophy are highly suggestive of ductal adenocarcinoma. However, it should be noted that it may be impossible to accurately differentiate pancreatic adenocarcinoma from focal chronic pancreatitis [67]. Comparing MR imaging with CT, several studies suggest that MRI is comparable to the detection and staging of pancreatic cancer. Recent meta-analysis of 68 studies revealed the sensitivity of MRI to be 84% versus 91% for helical CT in the evaluation of pancreatic adenocarcinoma. The sensitivity to resectability was equal for both MR and helical CT (82 and 81%). It has been suggested that due to MRI's inherently higher soft tissue contrast, the recognition of subtle pancreatic lesions could be potentially improved over CT [68].

Because of the heavily T2 weighted nature of MRCP imaging, what is visualized on this diagnostic modality is the effect of tumor on a fluid filled duct. The lesion itself is not commonly seen. For this reason, a comprehensive workup of a pancreatic mass typically includes additional sequences including dynamically enhanced imaging. The double duct sign indicating the obstruction of both the CBD and the MPD was described initially on ERCP, but this sign can also be identified with other modalities such as MRCP. More commonly depicted are ductal stenoses or associated obstruction. Nevertheless, although the double duct sign, when confirmed at MRCP, is highly suggestive of pancreatic head malignancy, it is not pathognomonic [69]. On MRCP, the "duct penetrating sign" has been suggested as a means to distinguish an inflammatory pancreatic mass from pancreatic carcinoma.

This sign is encountered in 85% of chronic pancreatitis and only 4% of patients with cancer and refers to the visualization of the MPD penetrating an inflammatory pancreatic mass rather than the complete obstruction seen commonly with pancreatic carcinoma (Figure 28) [64]. Some studies have reported the specificity of this sign being as high as 100% for benign stricture. Therefore, it has been suggested that MRCP may provide a benefit in differentiating benign lesions from malignancy [70]. Another important factor to consider is that seeing a normal sized pancreatic duct on MRCP in the setting of extrahepatic biliary obstruction should not be interpreted as excluding the possibility of pancreatic carcinoma. Indeed, it has been reported that the caliber of the MPD can be normal in up to 20% of patients with pancreatic malignancy causing bile duct obstruction. Finally, when MRCP is used in combination with a dynamic MR examination of the pancreas, comprehensive preoperative imaging can be accomplished to facilitate the detection and preoperative staging of a pancreatic cancer.

Meticulous evaluation of the combined use of MRI and MRCP in the diagnostic procedures of pancreatic neoplastic disease showed a sensitivity of 87%, a specificity of 97%, and an accuracy of 95% [71]. It is also important to note that the isolated obstruction of the pancreatic duct, even in the absence of a pancreatic mass, should be viewed with great suspicion for the possibility of an underlying tumor. Accurate staging is of particular importance for pancreatic cancer because of the aggressive nature of the disease.

Overstaging can prevent patients from potentially curative surgical intervention. On the contrary, understaging can subject patients to unnecessary morbidity from futile surgery. Complete surgical resection is only possible in the absence of metastatic disease and in those patients in whom the tumor can be removed in its entirety with negative surgical margins (R0 resection) [72]. Patients with locally advanced ductal adenocarcinoma of the pancreas subjected to surgery with macroscopic positive margins (R2 resection) have no survival benefit over those who receive palliative care.

Therefore, accurate pretreatment staging is crucial to correctly identify surgical candidates and differentiate them from patients with unresectable disease [73]. Recent advances in surgical technique with venous interposition grafts has impacted on patients previously considered with unresectable disease and moved them into the potentially resectable category. Advances in chemotherapy, surgery, and radiation, including protocols of combined preoperative therapeutic approach, can potentially result in downstaging of patients with previously unresectable tumors. The demand for accurate preoperative evaluation of treatment planning has placed added responsibility on radiology to precisely assess the local extent of disease. Furthermore, in those patients who are considered resectable, imaging is also expected to provide an accurate roadmap in order to facilitate surgical planning.

Accurate preoperative staging of pancreatic cancer requires a careful evaluation of tumor infiltration into the major peripancreatic arteries. The same principles and grading system have been applied in the literature to contrast enhanced CT and MRI [74].

Most studies have shown MRI to be comparable to CT regarding the accuracy of staging. Early investigations comparing MRI with helical CT showed MRI to be equal to, or even possibly slightly better than, helical CT.

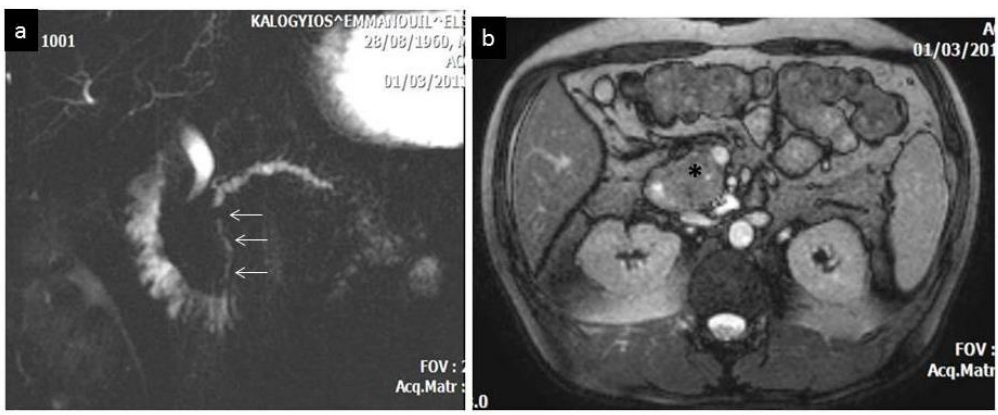

Figure 28. Abdominal MRI: a) MRCP, b) T2W image: Irregular dilatation with segmental stenoses of the main pancreatic duct, penetrating a solid lesion (black asterisk) at the pancreatic head with concomitant dilatation of the common bile duct (thin white arrows). This is a penetrating duct sign in a case of focal pancreatitis.

Recently, with the major advance of multidetector CT (MDCT) technology, which continues to evolve, the difference between MRI and CT has narrowed. In the past, the involvement of the PV or SMV was considered a contraindication to surgery. However, with the development of venous bypass grafts, venous involvement is no longer considered necessarily unresectable disease, but this is not necessarily the case at all institutions [75]. Careful description by radiologists of the extent of venous involvement is therefore necessary for surgical planning. The signs of venous vascular invasion are similar on both CT and MR imaging and refer to occlusion, deformity of the vascular contour including "beaking" and tumor vessel contiguity greater than half the circumference of the vessel.

With recent advances in surgical technique, particularly in venous resection and reconstruction with interposition venous grafts, tumor involvement limited to the PV or SMV can be considered for potentially curative resection. It is now possible in certain institutions to resect and reconstruct the SMV and PV as long as the vessel remains patent with normal flow and adequate distal (PV) and proximal (SMV) margins free of tumor can be obtained [76]. Vascular encasement is best demonstrated on MR imaging with contrast enhanced 3D spoiled gradient echo images with thin sections, which may be reviewed in the axial plane or reconstructed in the coronal or sagittal planes. Coronal and sagittal reconstructions may be of value to illustrate the length of tumor involvement of the vessel in question as this information has important implications for surgical planning [77].

In certain institutions, long segment (more than 2cm) encasement or occlusion of the SMV or PV is a relative contraindication to vascular reconstructive surgery, although the boundaries of resectable disease appear to be continually changing. In addition, attention to variant venous anatomy is now important, and certain anatomic variations may render venous reconstructions difficult or even impossible. As an illustration, multiple jejunal branches inserting high on the SMV near the PV may preclude an adequate proximal surgical margin for an interpositioned venous graft.

It is important to note that the location of the pancreatic tumor determines the primary route of spread and the regional nodal groups involved. The secondary drainage usually describes the nodal stations in the porta hepatis, celiac axis, and nodes along the root of the small bowel mesentery. The para-aortic nodal stations represent third order lymphatic drainage and are considered distant nodal metastases. Cross sectional imaging modalities such as CT and MRI traditionally rely on size to discriminate between normal and metastatic lymph nodes, and therefore both techniques suffer from poor sensitivity and specificity for the detection of nodal metastases. The high prevalence of nodal micrometastases in pancreatic cancer makes nodal enlargement a poor predictor of nodal involvement. Using a criterion of greater than 1cm in short axis diameter for metastatic nodes on helical CT yields a sensitivity of only 14%, specificity of 85%, positive predictive value (PPV) of 17%, and negative predictive value (NPV) of 82% [78]. Another confounding factor is that of superimposed inflammatory changes. Pancreatitis can complicate the diagnosis of pancreatic cancer, particularly, following invasive diagnostic procedures such as ERCP. The inflammatory changes may result in reactive peripancreatic lymphadenopathy, contributing to an overall low staging accuracy for CT and MRI.

On MRI, lymph nodes are well demonstrated on T2 weighted sequences with fat suppression and interstial phase gadolinium enhanced fat suppressed images. Lymph nodes appear as well defined moderately hyperintense oval masses against a background of low signal intensity with both techniques.

On T1 weighted images without fat saturation lymph nodes appear as low signal intensity oval masses in a background of high signal intensity fat. Imaging in the coronal plane may be helpful for the identification of mesenteric and peripancreatic nodes.

Pancreatic cancer frequently metastasizes to the liver and the detection and the characterization of hepatic lesions in the setting of pancreatic malignancy are of paramount importance and are achieved through differences in signal intensity between the metastatic implants and the adjacent liver parenchyma. High sensitivity for lesion assessment and specificity for lesion characterization are achieved by selecting the appropriate imaging protocol consisting of T2 weighted sequences, T1 weighted gradient echo images pre-contrast, and dynamic gadolinium enhanced gradient echo images with fat suppression. Most hepatic metastases are of lower signal than the surrounding hepatic parenchyma on T1 weighted sequences, which is in contradistinction to lesions of hepatocellular origin, such as focal nodular hyperplasia (FNH) or well differentiated hepatocellular carcinoma (HCC), which appear isointense to normal liver.

Furthermore, T1 weighted gradient echo in and out of phase sequences are very helpful to demonstrate focal fatty infiltration and sparing as well. These entities are known to decrease lesion conspicuity on CT, contributing to the lower sensitivity of this imaging modality for lesion detection in the setting of hepatic steatosis. T2 weighted sequences possess higher sensitivity to hepatic metastases than unenhanced T1 weighted images. Metastases usually appear as focal areas of moderately high signal on T2 weighted images in comparison with the remainder of the hepatic parenchyma.

Moreover, a broad range of MR imaging sequences and MR specific contrast agents is available to detect and characterize liver lesions. Finally, the appearance of peritoneal metastases on MR imaging ranges from small well demarcated nodules to diffuse thickening of the peritoneal lining, both of which usually show enhancement on T1 weighted fat suppressed sequences. The detection of small peritoneal nodules on cross sectional imaging involves a meticulous evaluation of the peritoneal cavity and its many recesses. Several studies have shown that dynamic contrast enhanced MR imaging is equal to or superior to contrast enhanced CT for the detection of peritoneal metastases [79].

Positron Emission Tomography

Currently CT is the modality of choice for diagnosing and staging pancreatic adenocarcinoma, because of its better spatial resolution and the ability to generate 3D images and multiplanar reformations. However, sometimes it is difficult to differentiate mass forming chronic pancreatitis, post treatment fibrosis from pancreatic adenocarcinoma and tumors less than 2cm in diameter [80].

Therefore, the utility of PET imaging is being explored to overcome some of these limitations. PET is an imaging technique that provides exclusive information about the molecular and metabolic changes associated with disease. The last years, remarkable improvements in technology, the routine availability of medical cyclotrons (to produce the necessary short lived positron emitters), and favorable reimbursement decisions have led to an increase in the use of this technology. The currently available agent for clinical use in published reports to evaluate pancreatic cancer with PET is the FDG. PET is a noninvasive method of tissue characterization based on specific tissue metabolism.

There are a few other investigational radiotracers available to image pancreatic cancer such as (18)F fluorothymidine (FLT) PET/CT, 11C harmine (a MAO A inhibitor) and (1 11C) acetate as well [81, 82].

In 1956, Warburg described that, malignant cells demonstrated increased glucose consumption. This high gylcolytic rate in malignant cells forms the basis of PET imaging. Several early comparative studies have shown FDG PET to be more accurate than conventional imaging techniques in diagnosing pancreatic carcinoma [83]. However, more recent surveys have shown that the role of FDGPET is still very controversial and suggest that there may be a complementary role of FDG PET to conventional CT imaging. A well-documented meta-analysis demonstrated that in the 387 patients studied, the weighted average sensitivity and specificity of FDG PET were 94 and 90% respectively compared with 82 and 75% for CT [84]. Nevertheless, a more recent investigation elucidates that FDG PET presents a lower sensitivity than CT and does not add additional information to the contrast enhanced CT. Therefore, FDG PET is helpful in the diagnostic approach of patients in whom CT does not identify a mass and in detection of metastatic disease [85].

Due to the high quality of cross sectional imaging, increasing number of patients are being diagnosed with cystic lesions the pancreas. However the conventional imaging techniques are limited in their ability to confidently distinguish benign from malignant cystic neoplasms. The presence of mural nodularity, internal septations, wall thickening and calcification is considered a predictor of malignancy on CT depiction. The presence of focal FDG activity within these lesions, irrespective of lesion morphology therefore provides a significant advantage to detect malignancy [86]. The importance of this finding lies in the fact that when FDG PET is used in the proper clinical setting of asymptomatic and high risk patients, lack of activity within a known cystic mass can reliably exclude malignancy and may help prevent unnecessary surgery.

Due to its low spatial resolution, FDG PET has a limited role in the T staging of pancreatic cancer. The extent of the tumor into the peripancreatic tissues and the adjacent vessels cannot be outlined. Therefore, conventional cross sectional imaging modalities, particularly multiphasic contrast enhanced multi detector helical CT and MRI can better demonstrate the relationship between the tumor, the adjacent organs, and the vascular structures. Currently no data supports the routine use of dual modality PET CTor FDG PET in the local T staging of pancreatic adenocarcinoma. In N staging of disease, both FDG PET and CT perform poorly. Reported sensitivities and specificities for FDG PET are 46% and 63% respectively [87]. The low sensitivity of FDG PET to detect locoregional adenopathy is attributed to the close proximity of the peripancreatic lymph nodes to the primary tumor, which can lead to a partial volume averaging effect and thereby obscure tumor in the nodal structures [88]. In addition, FDG uptake in the peripancreatic lymph nodes is nonspecific; particularly, reactive adenopathy can be avid or “hot” on FDG PET and may be encountered after biopsy of the primary pancreatic neoplasm.

FDG PET has the ability to identify distant metastases. In a large series of patients with pancreatic malignancies, reported sensitivity and specificity of FDG PET for detecting hepatic metastases > 1cm was respectively 68% and 95%. Smaller lesions could be detected with the same specificity but lower sensitivity of 43% [89].

The most important cause of false positives in these studies was intrahepatic cholestasis. FDG PET may detect occult peritoneal metastases, but only with difficulty. In approximately 25% of cases, however, poorly localized and microscopic disease may not be confirmed.

The utility of PET still remains controversial as some authors suggest that does not provide any additional information whereas other investigators support that it is complementary to conventional imaging in detecting distant metastases [90]. In conclusion, FDG PET has not yet been shown to be a valid population wide screening tool or to have a clear role in routine imaging related to the management of pancreatic cancer, including diagnosis, staging or prognostication.

As FDG PET has poor anatomical definition and spatial resolution capabilities, CT and EUS may be best suited to local staging of pancreatic disease to determine if the patient is a surgical candidate. To achieve this modality's full potential, combined PET CT should be performed, with the CT component optimized with intravenous contrast to provide full diagnostic information. However, the best use of PET CT must be further investigated to clearly define the criteria where the addition of FDG PET to CT would be additive. The existing evidence suggests that FDG PET has limited utility in initial staging. The strength of functional imaging lies in its ability to detect pathology, irrespective of lesion morphology.

This innate property gives FDG PET its strength in detecting small as well as cystic lesions and in differentiating benign from malignant disease. Thus, FDG PET may sometimes change the management strategy by providing a more precise diagnosis.

Endoscopic Ultrasonography

Pancreatic cancers are usually visualized on EUS as more or less well demarcated echo poor lesions, which depending on their exact morphology and size are homogeneous or inhomogeneous, with echo rich spots or even cystic spaces (Figure 29, 30) [91]. Nevertheless, small pancreatic carcinomas can also be recognized as echo poor and well demarcated lesions, thus resembling pancreatic tumors of the endocrine type, or display a pattern of focal inhomogeneity. With more advanced tumor stages, pancreatic cancers become more inhomogeneous and start to infiltrate into neighboring organs and major vascular structures [92]. Various criteria have been initiated to demonstrate vascular involvement in pancreatic cancer including lack of the hyperechoic interface between the vessel wall and the tumor, tumor infiltration in the vascular lumen, lack of visualization of a major vessel in the presence of collateral ones, or other indirect signs such as proximity of the tumor mass to vessels, or even mass size [93]. The accuracy and usefulness of these criteria remains under debate. In most cases of pancreatic cancer, some suspicion has already been raised by other imaging modalities before EUS is performed to visualize and stage the disease.

As previously mentioned, patients presenting with clinical evidence of a pancreatic neoplasm are initially imaged with transabdominal U/S. If the suspicion is further confirmed, a CT and/or EUS are usually suggested. Which examination should be performed first remains a topic of dispute. Despite attempts to gather objective data to answer the question, constant advancements in imaging technology render this a difficult task. Thus, despite existing reports (which are evolving and ambiguous anyway), the decision of the imaging procedure of choice for the management of pancreatic tumors is mostly dependent on test availability, local expertise, and referral patterns in everyday practice. Therefore, due to the wide access to helical CT scanners, CT is usually proposed prior to EUS in most centers. Combining clinical and laboratory data, together with initial imaging procedures in many cases is enough to confirm the diagnosis; further diagnostic evaluation is then unnecessary.

Figure 29. Radial EUS depiction of a relatively well demarcated echo poor lesion with inhomogeneous, echo rich spots indicative of a ductal adenocarcinoma of the pancreas.

Figure 30. Linear EUS detection of a less demarcated echo poor pancreatic adenocarcinoma with cystic spaces within.

There are cases, however, in which diagnosis of a pancreatic neoplasm may be less clear cut, especially when the original nature of a pancreatic mass remains vague. The frequent situation of questionable pancreatic head enlargement on routine CT remains an important indication for EUS [94].

Multiple imaging tests including EUS, CT, MRI, and perhaps PET compete as to which examination or combination of diagnostic modalities is the most preferable in these settings. Several studies have supported superiority of EUS in comparison with other imaging techniques, especially when small tumors are concerned, beginning from the method's initial steps [95]. The ability of performing FNA during the diagnostic procedure has to be regarded as an additional advantage of EUS (Figure 31). Tumor detection with EUS has remained consistently high throughout the years, as long as we are dealing with focal masses outside of full blown chronic pancreatitis [96]. On the other hand, the pancreas is screened stepwise from several stations in duodenum and stomach and there is no systematic study that has actually evaluated the real ability of EUS to fully cover the pancreas. Image quality probably also plays a pivotal role in the detection of subtle pancreatic malignancy. Additionally, electronic EUS scanning also provides the expanded diagnostic possibilities of modern U/S technologies. Pancreatic EUS images acquired by tissue harmonic imaging were assessed as significantly clearer compared with those obtained by standard imaging. In the difficult issue of differential diagnosis between benign and malignant pancreatic mass lesions, good sensitivity and specificity values were reported for the clinical use of power Doppler and contrast enhanced EUS. However, it is apparent that these results need to withstand the test of time and be further assessed by well-documented surveys [97].

The major advantage of EUS for pancreatic cancer detection even in the era of recent imaging advances seems to be its high negative predictive value. Recent data support that absence of a circumscript mass on EUS performed by an expert endosonographer can reliably exclude pancreatic cancer, especially when the pretest probability is low or indeterminate [98]. Comparisons of EUS with other imaging modalities show that, although it is not a 100% foolproof method, EUS still remains one of the best choices to detect a pancreatic neoplasm.

Figure 31. EUS FNA diagnostic procedure for pancreatic adenocarcinoma.

However, it should be emphasized that many of the studies comparing EUS and other cross sectional imaging techniques are characterized by the absence of blinding amongst examiners, and therefore, an objective evaluation of superiority of one test over another is inaccurate [99]. In everyday clinical practice, the role of CT, EUS, and the other imaging tests that might be available is rather complementary concerning the diagnosis and staging of pancreatic cancer.

EUS FNA is currently an established minimally invasive means of tissue acquisition, the implementation of which decisively broadened the spectrum of EUS by allowing direct transmural diagnosis (Figure 32). EUS FNA can therefore be extremely useful for various indications such as suspected pancreatic cancer, diagnosis of pancreatic carcinoma, or differential diagnosis of a pancreatic mass or smaller lesion [100]. Although criteria of EUS FNA remain rather controversial, the palliative setting where tissue confirmation is required prior to commencing chemotherapy or combined radiochemotherapy is a definitely undisputed indication of EUS FNA.

In contrast, in most cases of resectable tumors histological proof of pancreatic carcinoma it is not useful, since complete resection of the tumor is the only potentially curative approach [101]. The sensitivity, specificity, diagnostic accuracy, positive predictive value, and negative predictive value of EUS FNA, vary in published studies, but are generally high (e.g., 83%, 90%, 85%, 100% and 80% respectively in one multicenter study) [102]. Major complications after EUS FNA are rare. The rate of false positive diagnoses from EUS FNA is low in most papers.

Figure 32. EUS FNA procedure for histological confirmation of an advanced ductal adenocarcinoma with previous stenting of the common bile duct.

It has been reported that false positive diagnoses are attributed to interpretation errors. It is also evident that in most cases, only a positive diagnosis of malignancy counts.

It is obvious as with other puncture techniques that EUS guided FNP is mainly established to differentiate between benign and malignant conditions, or to allow parallel cytological and histological characterization of a lesion that is strongly suspected to be malignant, but in which different tissue diagnoses result in variable treatment approaches. In principle, clinical consequences must be clear and weighted against potential procedure associated risks before a EUS FNP is performed.

If a pancreatic mass is resectable and will also be operated on even if EUS guided FNP is negative, the procedure is not clinically implemented. EUS guided FNP is, however, also beneficial when other puncture methods have failed or when they are more invasive or risky. Pancreatic malignancy can be proved with a lower sensitivity, between 70% and 85%, and the influence on outcome is less clear.

In unresectable tumors, EUS FNA is obligatory when radiochemotherapy regimens are applied, and can be performed in one step with staging and perhaps celiac plexus blockade in case of severe pain [103]. In this occasion EUS is in competition with percutaneous puncture, but it seems that EUS FNA is preferable, not only because of its high diagnostic accuracy but also due to a possibly lower tumor seeding risk due to the shorter puncture canal.

Another interesting issue is to compare the value of EUS FNA with the other most available types of tissue sampling including CT guided and ERCP based. In order to address this question, recent prospective survey performed EUS FNA in 185 patients with known or suspected pancreatic masses.

Besides displaying the superiority of EUS in tumor detection (99% sensitivity to detect a mass for EUS vs. 57% for CT, $p < 0.0001$), EUS FNA proved superior compared with both CT and ERCP based tissue sampling, even in cases when the alternative acquisition methods were negative. Equally important, these results were achieved at a very low toll of complications [104]. Performance of EUS guided FNA of local lymph nodes in pancreatic cancer also makes sense only if a positive diagnosis would alter the management.

The role of EUS in locoregional staging of pancreatic cancer has been seen throughout the years both enthusiastically reaching levels of 93% for correct T staging and 88% for N staging, as well as more skeptically, even by groups which had previously published very optimistic results.

In a retrospective review of a cohort of 89 patients who were evaluated preoperatively with EUS for pancreatic adenocarcinoma, it was concluded that EUS was finally not as accurate as previously reported and not predictive for respectability [105]. This deterioration of results over time seems somewhat peculiar in view of the advances in EUS imaging.

However, it can partially be interpreted by carefully observing the populations examined in more recent studies. Patients with evidence of unresectable disease on high quality cross sectional imaging tests are increasingly not referred for EUS. This can be displayed when noticing the relative paucity of known T4, M1 lesions. Moreover, many patients with clearly resectable disease do not always undergo EUS.

In other words, the typical patients referred for EUS staging are cases with possibly marginal indications of curative surgery without clear cut evidence of irresectability [106].

Endoscopic Retrograde Cholangiopanceatography

ERCP indicates the presence of an irregular, nodular, rat-tailed eccentric ductal obstruction. Additional localized encasement with prestenotic dilatation may be depicted. Nevertheless, parallel obstruction of MPD and CBD at the same level referring to the "Double duct" sign remains the most common indication of the presence of a pancreatic tumor.

Angiography

Conventional angiography may be effective in detecting carcinomas of the body and tail of the pancreas indicating the presence of a hypovascular tumor with concomitant narrowing of major vascular structures as a result of displacement or occlusion by the malignant lesion.

Differential Diagnosis

- ✓ Islet cell carcinoma
- ✓ Chronic pancreatitis
- ✓ Metastases
- ✓ Lymphoma

10. PANCREATIC ISLET CELLS TUMORS

Definition

Neoplasms of the endocrine pancreas (neuroendocrine tumors-NETs) are relatively uncommon. Tumors arise from pancreatic endocrine cells including islet and Langerhans cells. Some NETs are functional, secreting peptide products that produce interesting clinical presentations.

NETs that are not associated with excess hormone levels and a recognizable clinical syndrome are considered nonfunctional. Multiple endocrine neoplasia (MEN) syndromes occur when related cells cause tumors in multiple sites.

Special immunohistochemical stains allow pathologists to confirm the peptide products being produced within the cells of a NET. However, the histologic characteristics of these neoplasms do not predict their clinical behavior, and malignancy is usually determined by the presence of local invasion and lymph node or hepatic metastases.

Unfortunately, most NETs are malignant, but the course of the disease is far more favorable than that encountered with pancreatic exocrine cancer.

The key to diagnosing these rare tumors is recognition of the classic clinical syndrome; confirmation is achieved by measuring serum levels of the elevated hormone. Localization of the tumor can be a challenging step, but once accomplished, the surgery is relatively straightforward [107, 108].

Surgical Interventions

- ✓ Complete surgical excision, often accomplished with insulinomas and in a minority of gastrinomas
- ✓ Complete surgical resection or embolization for nonfunctional NETs
- ✓ Debulking procedures to controlling symptoms
- ✓ Unresectable disease in the liver is often addressed with transarterial chemoembolization

Imaging Modalities

The role of imaging modalities in cases of pancreatic NETs is to establish the diagnosis and assess tumor resectability. Advanced imaging techniques are also recommended in localizing already diagnosed functioning pancreatic NETs for subsequent surgical removal.

In incidental lesions, imaging-guided FNA may be considered, depending on the possible influence on concomitant surgical management.

Computed Tomography

In Non-Enhanced CT (NECT) scanning functional tumors are depicted as lesions varying in size with cystic and necrotic areas. Additional calcifications may be obvious; whereas small tumors may not be identified. In Contrast-Enhanced CT (CECT) images relevant neoplasms are recognized as hyperdense lesions on the arterial phase due to their hypervascular appearance (Figure 33).

In case of functional insulinomas delayed scan presents a solid/ ring enhancement pattern. Enhancing metastases in the liver and lymph nodes are also detected in the same phase. Non-functional NETs are characterized with a similar depiction in NECT imaging.

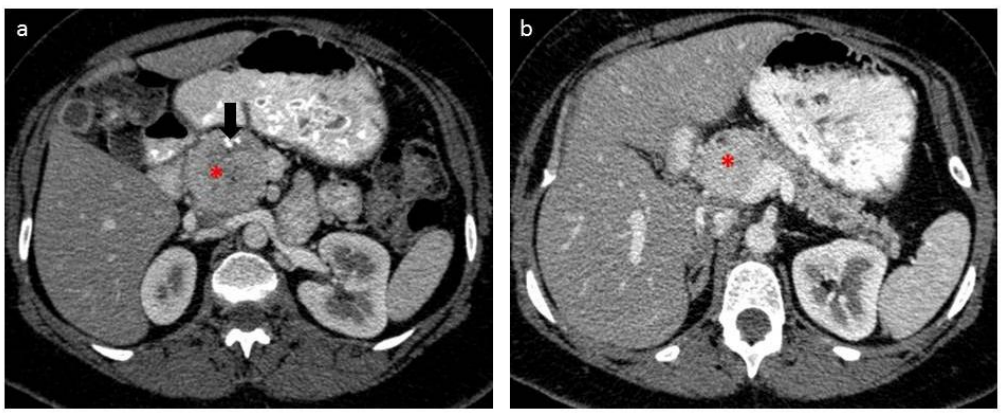

Figure 33. Abdominal CT of a non-functioning pancreatic neuroendocrine tumor: Pancreatic phase of enhancement: a, b) Hypervascular inhomogeneous pancreatic head lesion with calcifications (thick black arrow).

Nevertheless, in CECT depiction an enhancing hypervascular viable tumor as well as metastatic lesions is identified along with non-enhancing cystic or necrotic areas. Liver metastases are often extensive even in relatively healthy patients due to early invasion of PV. The presence of calcifications is indicative of local invasion and highly malignant behavior [109, 110].

Magnetic Resonance Imaging

Functional tumors behave as hypointense lesions on fat-saturated TlWI images with insulinomas presenting a solid or ring-enhancement pattern (Figure 34). Nevertheless, on delayed enhanced similar sequences NETs could be depicted as hyperintense solid enhancing lesions. On T2WI sequences both primary and secondary lesions are recognized as hyperintense areas. On the contrary, small non-functional NETs are usually isointense on T1WI images while large tumors appear heterogeneous with cystic and necrotic areas. On T2WI images increased size NETs often appear hyperintense. Finally, fat-saturated delayed enhanced TlWI sequences may reveal a small otherwise undetectable hyperintense NET [111, 112].

Endoscopic Ultrasonography

Another consistent indication for EUS is the localization of NETs, although specific limitations were recently analysed. The clinical scenario here is mostly quite different, since in functional endocrine tumors, the diagnosis is established on the basis of laboratory tests, and imaging is performed to identify the tumor for subsequent surgical removal. Problems can arise, if EUS is the only method to define the presence of the tumor, other preoperative tests are negative, palpation during surgery is doubtful and intraoperative imaging is inconclusive. Preoperative marking of the tumors has recently been suggested as a helpful adjunct but has not been extended beyond case report status [113].

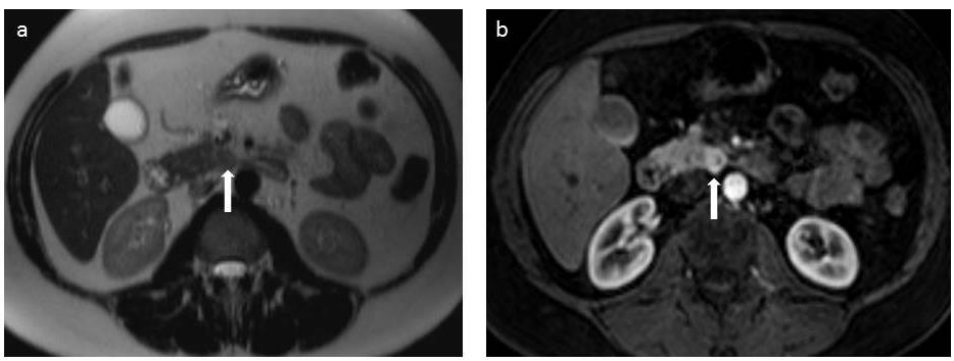

Figure 34. Abdominal MRI of an insulinoma: a) T2W image: Intermediate signal intensity lesion at the ucinate process of the pancreas (thick white arrow) b) 3D T1 Fat Suppression image: Arterial phase of enhancement: Homogeneously enhancing lesion at the ucinate process of the pancreas (thick white arrow).

The other setting are non-functional endocrine tumors which are mostly found incidentally even on transabdominal U/S [114]. They present as well demarcated, echo poor lesions in the pancreas (Figure 35, 36). FNA has been proposed to accomplish a tissue diagnosis, and further investigation from the specimens such as microsatellite loss analyses were recently performed and could be correlated to prognosis [115]. Therefore, EUS is still the diagnostic modality of choice in localizing NETs. In incidental lesions, FNA may be considered depending on the possible influence on subsequent management. Whether individual patients considered not being candidates for surgery can benefit from EUS-guided therapy using alcohol injection has to be evaluated [116].

Angiography

Conventional findings are indicative of hypervascular primary and secondary lesions. Subsequent hepatic venous sampling after intra-arterial stimulation of pancreas reveals elevated levels of hormones in case of functional NETs and decreased or absent elements for non-functional tumors.

Whole-Body Radionuclide Scanning

In contrast to pancreatic exocrine tumors, many of the NETs possess somatostatin receptors that allow them to be detected by a radiolabeled octreotide scan. A radioactive somatostatin analogue is injected intravenously, followed by whole-body radionuclide scanning.

Figure 35. EUS depiction of an islet cell tumor of the tail of the pancreas.

Figure 36. Power Doppler and contrast enhanced EUS findings indicative of advanced islet cell tumor of the pancreas and concomitant venous dilatation.

The success of this modality in localizing tumors and detecting metastases has decreased the use of older techniques such as angiography and selective venous sampling. Additional PET study with 68Ga (DFO)-octreotide may be complimentary in cases with disseminated disease.

Differential Diagnosis

- ✓ Pancreatic ductal adenocarcinoma
- ✓ Mucinous cystic tumor of the pancreas
- ✓ Metastases
- ✓ Serous cystadenoma of the pancreas

11. Solid and Papillary Neoplasm

Definition

The term refers to a pancreatic mass of low malignant potential with solid and cystic features. Areas of central hemorrhage and necrosis are surrounded by solid and pseudopapillary structure [117].

Surgical Interventions

- ✓ Complete surgical excision

Imaging Modalities

The role of imaging modalities in case of solid and papillary neoplasm of the pancreas is to establish the diagnosis and assess whether surgical resection can be implemented.

Differential diagnosis of other cystic tumours categories and pseudocysts is only accomplished on the basis of specific imaging features as well as estimation of fluid aspirated with advanced imaging guided diagnostic procedures.

Ultrasound

Transabdominal U/S could only recognize fluid-debris levels with posterior enhancement.

Computed Tomography

NECT usually reveals an encapsulated, hypodense mass with limited calcification. Metastatic liver disease or lymph node involvement could rarely be encountered. In addition, on CECT images a well-defined heterogenous large mass is usually depicted.

Further low density areas of variable size within the lesion depend on the degree of concomitant hemorrhage and necrosis [118].

Magnetic Resonance Imaging

On TlWI images a large well-demarcated mass with central areas of mixed low and high signal intensity secondary to hemorrhage may be detected. The presence of capsule appears as rim of low intensity (Figure 37).

Angiography

Conventional angiography defines the presence of an avascular or hypovascular lesion depending on the degree of co-existing necrosis.

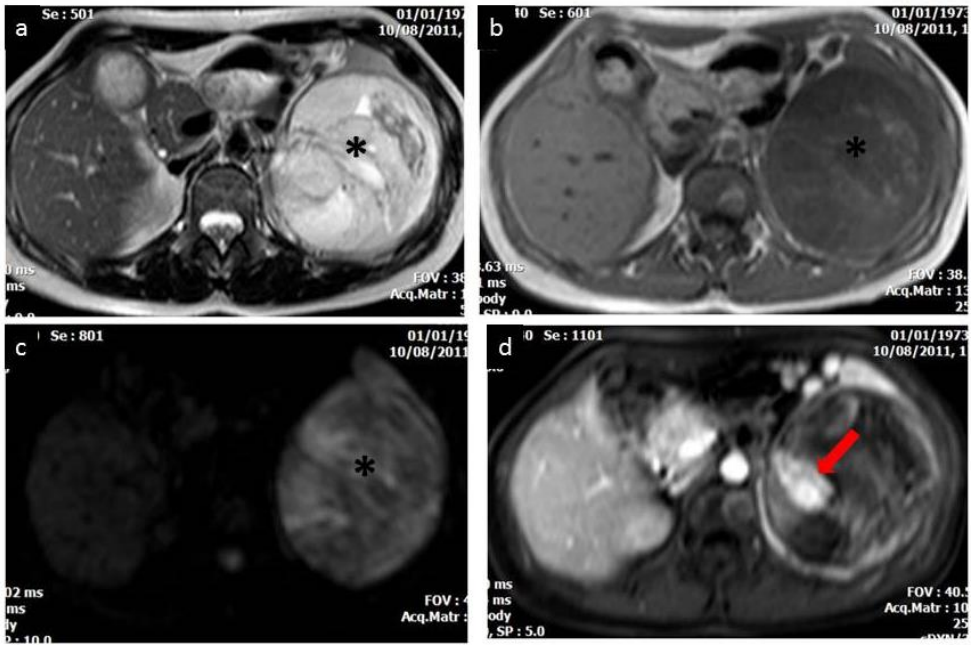

Figure 37. Abdominal MRI demonstrating a solitary pseudopapillary tumor of the pancreas: a) T2W image: Inhomogeneous predominantly high signal intensity lesion at the pancreatic tail (black asterisk), b) T1W image: Inhomogeneous predominantly low signal intensity, containing high intensity foci indicating hemorrhagic elements(black asterisk), c) Diffusion Weighted Image: Restricted diffusion pattern within the lesion (black asterisk), d) 3D T1 Fat Suppression image: Arterial phase of enhancement: Arterial enhancement of the solid portion of the lesion (thick red arrow).

Differential Diagnosis

- ✓ Pancreatic metastases
- ✓ Mucinous cystic tumor of the pancreas
- ✓ Exophytic gastric mass
- ✓ Serous cystadenoma of the pancreas
- ✓ Pseudocyst

12. PANCREATIC LYMPHOMA

Definition

Lymphoma can affect the pancreas. Primary involvement of the gland with no disease outside the pancreas also occurs. The clinical presentation often is similar to pancreatic adenocarcinoma, with vague abdominal pain and weight loss. Most common lymphoma is non-Hodgkin B cell subtype and is encountered usually in immunocompromised patients. Identification of a large mass often involving the head and body of the pancreas should raise suspicion. Percutaneous or EUS-guided biopsy will confirm the diagnosis in most cases.

If the diagnosis cannot be achieved preoperatively, laparoscopic exploration and biopsy are indicated [119].

Surgical Interventions

- ✓ There is no role for resection in the management of pancreatic lymphoma
- ✓ Endoscopic stenting to relieve jaundice followed by chemotherapy

Imaging Modalities

The role of imaging modalities in case of pancreatic lymphoma is to establish the diagnosis and achieve disease staging in order to avoid inadequate surgical interventions.

Differential diagnosis of other neoplastic disorders is only accomplished on the basis of specific imaging features as well as estimation of tissue aspirated with advanced imaging guided diagnostic procedures.

Computed Tomography

Pancreatic lymphoma is usually depicted as a homogeneous soft tissue mass with minimal enhancement. On occasion focal and circumscribed single or multiple masses may be encountered. Nevertheless, diffuse enlargement of pancreas with infiltrating tumor along with peri-pancreatic fat involvement could simulate acute pancreatitis (Figure 38).

Additional lymph node dissemination is often detected with lymphadenopathy below the level of renal veins consisting major determinant of the outcome. Dilatation of the pancreatic duct remains uncommon as well as encasement of the peri-pancreatic vessels [120, 121].

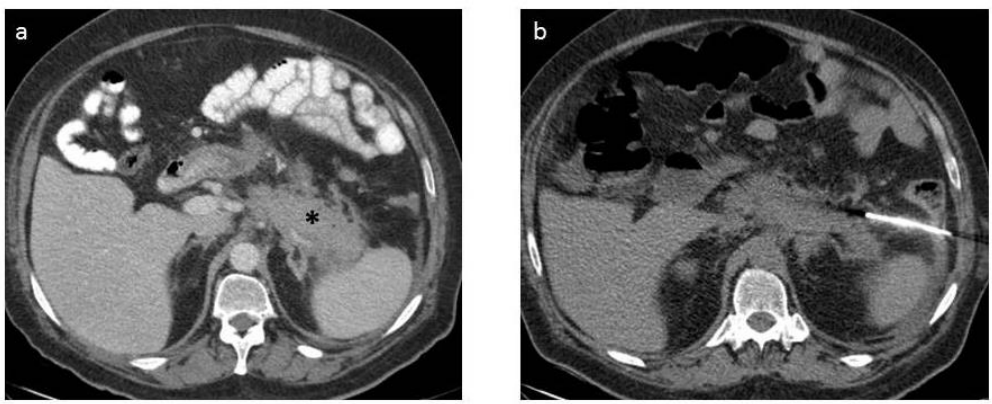

Figure 38. Abdominal CT in pancreatic lymphoma: Portal phase: a) Diffuse enlargement of the pancreatic tail in a patient with known Non Hodgkin lymphoma (black asterisk) b) Biopsy that revealed pancreatic involvement in lymphoma.

Differential Diagnosis

- ✓ Pancreatic ductal carcinoma
- ✓ Mucinous cystic tumor of the pancreas
- ✓ Pancreatic islet cell tumors

13. PANCREATIC METASTASES

Definition

The incidence of pancreatic metastases varies based on the primary malignant lesion. Solitary or multiple polypoid masses are usually recognized derived mainly from renal cell carcinoma (30%) and bronchogenic carcinoma (23%).

Cases of pancreatic secondary tumors due to advanced breast cancer, soft tissue sarcoma and primary tumors of the gastrointestinal track have also been described.

With regard to renal cell carcinoma it is common knowledge that may be isolated only to pancreas and detected occasionally several years or decades after initial diagnosis [122].

Surgical Interventions

- ✓ Surgical resection if metastasis is only isolated to the pancreas

Imaging Modalities

The role of imaging modalities in case of pancreatic metastases is to establish the diagnosis and achieve disease staging in order to avoid inadequate surgical interventions. Differential diagnosis of other neoplastic disorders is only accomplished on the basis of specific imaging features as well as estimation of tissue aspirated with advanced imaging guided diagnostic procedures.

Computed Tomography

Most common pancreatic metastases can be depicted as a discrete mass with variable enhancement pattern that usually mimics primary tumor.

Concomitant intra-abdominal metastases to the liver (36%), lymph nodes (30%) and adrenal glands (30%) may be recognized along with dilatation of the pancreatic duct or biliary tree and potential encasement of the major peri-pancreatic vascular structures [123].

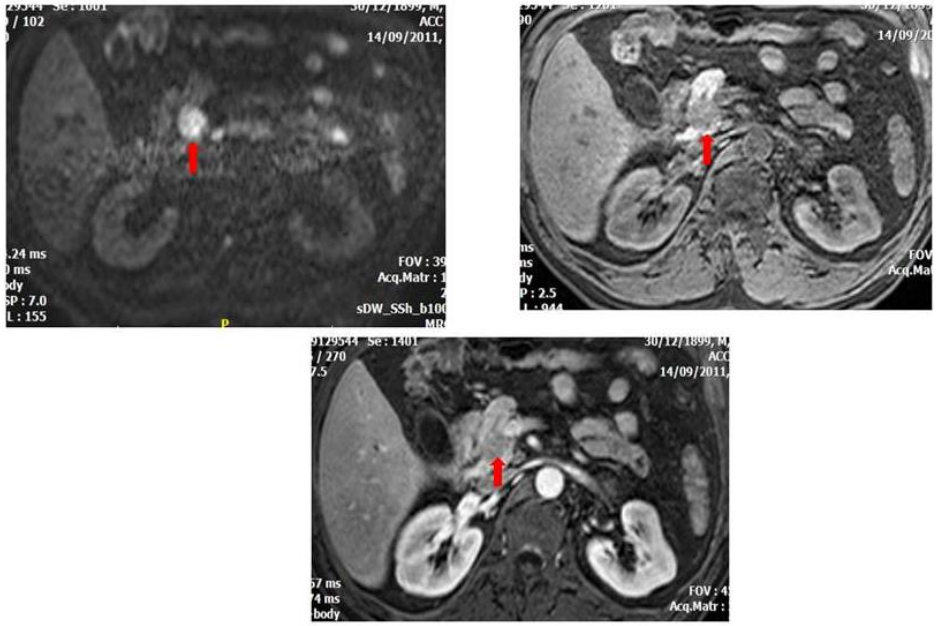

Figure 39. Abdominal MRI demonstrating metastasis to the pancreas from lung cancer. a) Diffusion Weighted image: Small hyperintense lesion (restricted diffusion pattern) at the pancreatic head (thick red arrow) b) T1 Fat Suppressed image: Hypointense lesion at the pancreatic head (thick red arrow) c) 3D T1 Fat Suppressed image after contrast medium administration: Hypovascular lesion at the pancreatic head (thick red arrow).

Magnetic Resonance Imaging

On TlWI images hypointense lesions with variable fat saturation are usually revealed. Smaller tumors present homogenous enhancement. On T2WI sequences slightly heterogenous and moderately hyperintense lesions as well as diffuse, enlarged metastases described as hypo-intense nodules may be recognized (Figure 39).

Differential Diagnosis

- ✓ Pancreatic ductal carcinoma
- ✓ Mucinous cystic tumor of the pancreas
- ✓ Pancreatic islet cell tumors

REFERENCES

[1] Kamisawa, T., Yuyanq, T., Eqawa, N., et al., A new embryologic hypothesis of annular pancreas. *Hepatogastroenterology*. 2001;48(37):277-8.

[2] Harthun, N. L., Morse, J. H., Shaffer, H. A. Jr, et al., Duodenal obstruction caused by intraluminal duodenal diverticulum and annular pancreas in an adult. *Gastrointest. Endosc*. 2002;55(7):940-3.
[3] Shan, Y. S., Sy, E. D., Lin, P. W. Annular pancreas with obstructive jaundice: beware of underlying neoplasm. *Pancreas*. 2002;25(3):314-6.
[4] Lecesne, R., Stein, L., Reinhold, C., et al., MR cholangiopancreatography of annular pancreas. *J. Comput. Assist. Tomogr*. 1998;22(1):85-6.
[5] Balthazar, E. J. Acute pancreatitis: assessment of severity with clinical and CT evaluation. *Radiology*. 2002;223(3):603-13.
[6] Balthazar, E. J. Complications of acute pancreatitis: clinical and CT evaluation. *Radiol. Clin. North Am*. 2002;40(6):1211-27.
[7] Vitellas, K. M., Paulson, E. K., Enns, R. A., et al., Pancreatitis complicated by gland necrosis: evolution of findings on contrast-enhanced CT. *J. Comput. Assist. Tomogr*. 1999;23(6):898-905.
[8] Balthazar, E. J. Staging of acute pancreatitis. *Radiol. Clin. North Am*. 2002;40(6):1199-209.
[9] Zaheer, A., Singh, V. K., Qureshi, R. O., et al., The revised Atlanta classification for acute pancreatitis: updates in imaging terminology and guidelines. Abdom. Imaging. 2013;38(1):125-36.
[10] Aydin, H., Tatar, I. G., Hekimoglu, B. The role of diffusion weighted MR imaging in the diagnosis of acute pancreatitis. *Int. J. Emerg. Ment. Health.* 2014;16(2):308-14.
[11] Rana, S. S., Chaudhary, V., Sharma, R., et al., Comparison of abdominal ultrasound, endoscopic ultrasound and magnetic resonance imaging in detection of necrotic debris in walled-off pancreatic necrosis. *Gastroenterol. Rep*. (Oxf.). 2015 [Epub. ahead of print].
[12] Pocard, M., Soyer, P. CT of acute pancreatitis: A matter of time. *Diagn. Interv. Imaging*. 2015;96(2):129-31.
[13] Morgan, D. E., Baron, T. H., Smith, J. K., et al., Pancreatic fluid collections prior to intervention: Evaluation with MR imaging compared with CT and US. *Radiology*. 1997;203:773-8.
[14] Sriram, P. V., Kaffes, A. J., Rao, G. V., et al., Endoscopic ultrasound-guided drainage of pancreatic pseudocysts complicated by portal hypertension or by intervening vessels. *Endoscopy*. 2005;37(3):231-5.
[15] Cahen, D., Rauws, E., Fockens, P., et al., Endoscopic drainage of pancreatic pseudocysts: long-term outcome and procedural factors associated with safe and successful treatment. *Endoscopy*. 2005;37(10):977-83.
[16] Kahaleh, M., Shami, V. M., Conaway, M. R., et al., Endoscopic ultrasound drainage of pancreatic pseudocyst: a prospective comparison with conventional endoscopic drainage. *Endoscopy*. 2006;38(4):355-9.
[17] Remer, E. M., Baker, M. E. Imaging of chronic pancreatitis. *Radiol. Clin. North Am*. 2002;40(6):1229-42.
[18] D'Onofrio, M., De Robertis, R., Demozzi, E., et al., *World J. Gastroenterol.* 2014;20 (45):16881-90.
[19] Jenssen, C., Dietrich, C. F. Endoscopic ultrasound in chronic pancreatitis. *Z. Gastroenterol*. 2005;43(8):737-49.

[20] Thuler, F. P., Costa, P. P., Paulo, G. A., et al., Endoscopic ultrasonography and alcoholic patients: can one predict early pancreatic tissue abnormalities? *JOP*. 2005;6 (6):568-74.

[21] Ichikawa, T., Sou, H., Araki, T., et al., Duct-penetrating sign at MRCP: usefulness for differentiating inflammatory pancreatic mass from pancreatic carcinomas. *Radiology*. 2001;221(1):107-16.

[22] Kim, T., Murakami, T., Takamura, M., et al., Pancreatic mass due to chronic pancreatitis: correlation of CT and MR imaging features with pathologic findings. *AJR Am. J. Roentgenol*. 2001;177(2):367-71.

[23] Manfredi, R., Costamagna, G., Brizi, M. G., et al., Severe chronic pancreatitis versus suspected pancreatic disease: dynamic MR cholangiopancreatography after secretin stimulation. *Radiology*. 2000;214(3):849-55.

[24] Kahl, S., Glasbrenner, B., Leodolter, A., et al., EUS in the diagnosis of early chronic pancreatitis: a prospective follow-up study. *Gastrointest. Endosc*. 2002;55(4):507-11.

[25] Ardengh, J. C., Lopes, C. V., Campos, A. D., et al., Endoscopic ultrasound and fine needle aspiration in chronic pancreatitis: differential diagnosis between pseudotumoral masses and pancreatic cancer. *JOP*. 2007;8(4):413-21.

[26] Norton, I. D., Zheng, Y., Wiersema, M. S., et al., Neural network analysis of EUS images to differentiate between pancreatic malignancy and pancreatitis. *Gastrointest. Endosc*. 2001;54(5):625-9.

[27] Catalano, M. F., Lahoti, S., Geenen, J. E., et al., Prospective evaluation of endoscopic ultrasonography, endoscopic retrograde pancreatography, and secretin test in the diagnosis of chronic pancreatitis. *Gastrointest. Endosc*. 1998;48(1):11-7.

[28] Chowdhury, R., Bhutani, M. S., Mishra, G., et al., Comparative analysis of direct pancreatic function testing versus morphological assessment by endoscopic ultrasonography for the evaluation of chronic unexplained abdominal pain of presumed pancreatic origin. *Pancreas*. 2005;31(1):63-8.

[29] Kao, L. S., Bulger, E. M., Parks, D. L., et al., Predictors of morbidity after traumatic pancreatic injury. *J. Trauma*. 2003;55(5):898-905.

[30] Mayer, J. M., Tomczak, R., Rau, B., et al., Pancreatic injury in severe trauma: early diagnosis and therapy improve the outcome. *Dig. Surg*. 2002;19(4):291-7.

[31] Akhrass, R., Yaffe, M. B., Brandt, C. P., et al., Pancreatic trauma: a ten-year multi-institutional experience. *Am. Surg*. 1997;63(7):598-604.

[32] Brandwein, S., Farrell, J. J., Centeno, B. A., et al., Detection and tumor staging of malignancy in cystic, intraductal, and solid tumor of the pancreas by EUS. *Gastrointest. Endosc*. 2001;53:722-7.

[33] Yeh, H. C., Stancato-Pasik, A., Shapiro, R. S. Microcystic features at US: a nonspecific sign for microcystic adenomas of the pancreas. *Radiographies*. 2001;21(6):1455-61.

[34] Curry, C. A., Enq, J., Horton, K. M., et al., CT of primary cystic pancreatic neoplasms: Can CT be used for patient triage and treatment? AJR. *Am. J. Roentgenol*. 2000;175:99-103.

[35] Song, M. H., Lee, S. K., Kim, M. H., et al., EUS in the evaluation of pancreatic cystic lesions. *Gastrointest. Endosc*. 2003;57(7):891-6.

[36] Ahmad, N. A., Kochman, M. L., Brensinger, C., et al., Interobserver agreement among endosonographers for the diagnosis of neoplastic versus non-neoplastic pancreatic cystic lesions. *Gastrointest. Endosc.* 2003;58(1):59-64.

[37] Galanis, C., Zamani, A., Cameron, J. L., et al., Resected serous cystic neoplasms of the pancreas: a review of 158 patients with recommendations for treatment. *J. Gastrointest. Surg*. 2007;11(7):820-6.

[38] Hara, T., Kawashima, H., Ishigooka, M., et al., Mucinous cystic tumors of the pancreas. *Surg. Today*. 2002;32(11):965-9.

[39] Friedman, A. C., Clifford, P., Wynn, G., et al., CT of primary cystic pancreatic neoplasms: nihilism may be unwarranted. *AJR Am. J. Roentgenol*. 2001;177(2):469-70.

[40] Megibow, A. J., Lombardo, F. P., Guarise, A., et al., Cystic pancreatic masses: cross-sectional imaging observations and serial follow-up. *Abdom. Imaging*. 2001;26(6):640-7.

[41] Fernandez-del Castillo, C., Targarona, J., Thayer, S. P., et al., Incidental pancreatic cysts: clinicopathologic characteristics and comparison with symptomatic patients. *Arch. Surg*. 2003;138:427-34.

[42] Le Borgne, J., de Calan, L., Partensky, C. Cystadenomas and cystadenocarcinomas of the pancreas: a multi-institutional retrospective study of 398 cases. *Ann. Surg*. 1999; 230:152-61.

[43] Sedlack, R., Affi, A., Vazquez-Sequeiros, E., et al., Utility of EUS in the evaluation of cystic pancreatic lesions. *Gastrointest. Endosc*. 2002;56: 543-7.

[44] Brandwein, S., Farrell, J. J., Centeno, B. A., et al., Detection and tumor staging of malignancy in cystic, intraductal, and solid tumor of the pancreas by EUS. *Gastrointest. Endosc*. 2001;53:722-7.

[45] Sugiyama, M., Izumisato, Y., Abe, N., et al., Predictive factors for malignancy in intraductal papillary-mucinous tumors of the pancreas. *Br. J. Surg*. 2003;90(10):1244-9.

[46] Prasad, S. R., Sahani, D., Nasser, S., et al., Intraductal papillary mucinous tumors of the pancreas. *Abdom. Imaging*. 2003;28(3):357-65.

[47] Peters, H. E., Vitellas, K. M. Magnetic resonance cholangiopancreatography (MRCP) of intraductal papillary-mucinous neoplasm (IPMN) of the pancreas: case report. *Magn. Reson. Imaging*. 2001;19(8):1139-43.

[48] Aithal, G. P., Chen, R. Y. M., Cunningham, J. T., et al., Accuracy of EUS for detection of intraductal papillary mucinous tumor of the pancreas. *Gastrointest. Endosc*. 2002;56: 701-7.

[49] Cellier, C., Cuillerier, E., Palazzo, L., et al., Intraductal papillary and mucinous tumors of the pancreas: accuracy of preoperative computed tomography, endoscopic retrograde pancreatography, and endoscopic ultrasonography, and long-term outcome in a large surgical series. *Gastrointest. Endosc*. 1998;47:42-9.

[50] Frossard, J. L., Amouyal, P., Amouyal, G., et al., Performance of endosonography-guided fine needle aspiration and biopsy in the diagnosis of pancreatic cystic lesions. *Am. J. Gastroenterol*. 2003;98:1516-24.

[51] Jemal, A., Siegel, R., Ward, E., et al., Cancer statistics, 2008. *CA Cancer J. Clin.* 2008; 58(2):71-96.

[52] Katz, M. H., Hwang, R., Fleming, J. B., et al., Tumornode-metastasis staging of pancreatic adenocarcinoma. *CA Cancer J. Clin*. 2008;58(2):111-25.

[53] Agarwal, B., Abu-Hamda, E., Molke, K. L., et al., Endoscopic ultrasound-guided fine needle aspiration and multidetector spiral CT in the diagnosis of pancreatic cancer. *Am. J. Gastroenterol*. 2004;99(5):844-50.

[54] Delbek, D., Pinson, C. W. Pancreatic tumors: role of imaging in the diagnosis, staging, and treatment. *J. Hepatobiliary Pancreat. Surg*. 2004;11:4-10.

[55] Loyer, E. M., David, C. L., Dubrow, R. A., et al., Vascular involvement in pancreatic adenocarcinoma: reassessment by thin-section CT. *Abdom. Imaging*. 1996;21(3):202-06.

[56] Varadhachary, G. R., Tamm, E. P., Abbruzzese, J. L., et al., Borderline resectable pancreatic cancer: definitions, management, and role of preoperative therapy. *Ann. Surg. Oncol*. 2006;13(8):1035-46.

[57] Katz, M. H., Pisters, P. W., Evans, D. B., et al., Borderline resectable pancreatic cancer: the importance of this emerging stage of disease. *J. Am. Coll. Surg.* 2008;206(5):833-46.

[58] Nakagohri, T., Kinoshita, T., Konishi, M., et al., Nodal involvement is strongest predictor of poor survival in patients with invasive adenocarcinoma of the head of the pancreas. *Hepatogastroenterology*. 2006;53(69):447-51.

[59] Maithel, S. K., Khalili, K., Dixon, E., et al., Impact of regional lymph node evaluation in staging patients with periampullary tumors. *Ann. Surg. Oncol*. 2007;14(1):202-10.

[60] DeWitt, J., Devereaux, B., Chriswell, M., et al., Comparison of endoscopic ultrasonography and multidetector computed tomography for detecting and staging pancreatic cancer. *Ann. Intern. Med*. 2004;141(10):753-63.

[61] Kamisawa, T., Isawa, T., Koike, M., et al., Hematogenous metastases of pancreatic ductal carcinoma. *Pancreas*. 1995;11(4):345-9.

[62] Hess, K. R., Varadhachary, G. R., Taylor, S. H., et al., Metastatic patterns in adenocarcinoma. *Cancer*. 2006;106(7):1624-33.

[63] Bluemke, D. A., Cameron, J. L., Hruban, R. H., et al., Potentially resectable pancreatic adenocarcinoma: spiral CT assessment with surgical and pathologic correlation. *Radiology*. 1995;197(2):381-5.

[64] Fayad, L. M., Mitchell, D. G. Magnetic resonance imaging of pancreatic adenocarcinoma. *Int. J. Gastrointest. Cancer*. 2001;30(1-2):19-25.

[65] Takehara, Y. Fast MR imaging for evaluating the pancreaticobiliary system. *Eur. J. Radiol*. 1999;29(3):211-32.

[66] Pamuklar, E., Semelka, R. C. MR imaging of the pancreas. *Magn. Reson. Imaging Clin. N. Am.* 2005;13(2):313-30.

[67] Sheridan, M. B., Ward, J., Guthrie, J. A., et al., Dynamic contrast-enhanced MR imaging and dual-phase helical CT in the preoperative assessment of suspected pancreatic cancer: a comparative study with receiver operating characteristic analysis. *AJR Am. J. Roentgenol*. 1999;173(3):583-90.

[68] Bipat, S., Phoa, S. S., van Delden, O. M., et al., Ultrasonography, computed tomography and magnetic resonance imaging for diagnosis and determining resectability of pancreatic adenocarcinoma: a meta-analysis. *J. Comput. Assist. Tomogr*. 2005;29(4):438-45.

[69] Ahualli, J. The double duct sign. *Radiology*. 2007;244(1):314-5.

[70] Johnson, P. T., Outwater, E. K. Pancreatic carcinoma versus chronic pancreatitis: dynamic MR imaging. *Radiology*. 1999;212(1):213-8.

[71] Gangi, S., Fletcher, J. G., et al., Time interval between abnormalities seen on CT and the clinical diagnosis of pancreatic cancer: retrospective review of CT scans obtained before diagnosis. *AJR Am. J. Roentgenol*. 2004;182(4):897-903.

[72] Lall, C. G., Howard, T. J., Skandarajah, A., et al., New concepts in staging and treatment of locally advanced pancreatic head cancer. *AJR Am. J. Roentgenol*. 2007; 189(5):1044-50.

[73] Tsiotos, G. G., Farnell, M. B., Sarr, M. G. Are the results of pancreatectomy for pancreatic cancer improving? *World J. Surg*. 1999;23(9):913-9.

[74] Bluemke, D. A., Fishman, E. K. CT and MR evaluation of pancreatic cancer. *Surg. Oncol. Clin. N. Am*. 1998;7(1):103-24.

[75] Tamm, E. P., Silverman, P. M., Charnsangavej, C., et al., Diagnosis, staging, and surveillance of pancreatic cancer. *AJR Am. J. Roentgenol*. 2003;180(5):1311-23.

[76] Lu, D. S., Reber, H. A., Krasny, R. M., et al., Local staging of pancreatic cancer: criteria for unresectability of major vessels as revealed by pancreatic-phase, thin-section helical CT. *AJR Am. J. Roentgenol*. 1997;168(6):1439-43.

[77] O'Malley, M. E., Boland, G. W., Wood, B. J., et al., Adenocarcinoma of the head of the pancreas: determination of surgical unresectability with thin-section pancreatic-phase helical CT. *AJR Am. J. Roentgenol*. 1999;173(6):1513-8.

[78] Zeman, R. K., Cooper, C., Zeiberg, A. S., et al., TNM staging of pancreatic carcinoma using helical CT. *AJR Am. J. Roentgenol*. 1997;169(2):459-64.

[79] Low, R. N. MR imaging of the peritoneal spread of malignancy. *Abdom. Imaging* 2007; 32(3):267-83.

[80] Pakzad, F., Groves, A. M., Ell, P. J. The role of positron emission tomography in the management of pancreatic cancer. *Semin. Nucl. Med*. 2006;36:248-56.

[81] Quon, A., Chang, S. T., Chin, F., et al., Initial evaluation of (18)F-fluorothymidine (FLT) PET/CT scanning for primary pancreatic cancer. *Eur. J. Nucl. Med. Mol. Imaging*. 2008;35:527-31.

[82] Herlin, G., Persson, B., Bergstrom, M., et al., 11C-harmine as a potential PET tracer for ductal pancreas cancer: in vitro studies. *Eur. Radiol*. 2003;13:729-33.

[83] Warburg, O. On the origin of cancer cells. *Science*. 1956;123:309-14.

[84] Gambhir, S. S., Czernin, J., Schwimmer, J., et al., A tabulated summary of the FDG PET literature. *J. Nucl. Med*. 2001;42:1S-93S.

[85] Lytras, D., Connor, S., Bosonnet, L., et al., Positron Emission Tomography does not add to Computed Tomography for the diagnosis and staging of pancreatic cancer. *Dig. Surg*. 2005;22(1-2):55-61.

[86] Sperti, C., Pasquali, C., Decet, G., et al., F-18-fluorodeoxyglucose positron emission tomography in differentiating malignant from benign pancreatic cysts: a prospective study. *J. Gastrointest. Surg*. 2005;9:22-8.

[87] Bares, R., Klever, P., Hauptmann, S., et al., F-18 fluorodeoxyglucose PET in vivo evaluation of pancreatic glucose metabolism for detection of pancreatic cancer. *Radiology*. 1994;192:79-86.

[88] Bares, R., Dohmen, B. M., Cremerius, U., et al., Results of positron emission tomography with fluorine-18 labeled fluorodeoxyglucose in differential diagnosis and staging of pancreatic carcinoma. *Radiologe*. 1996;36:435-40.

[89] Frohlich, A., Diederichs, C. G., Staib, L., et al., Detection of liver metastases from pancreatic cancer using FDG PET. *J. Nucl. Med*. 1999;40:250-5.

[90] Nishiyama, Y., Yamamoto, Y., Yokoe, K., et al., Contribution of whole body FDG-PET to the detection of distant metastasis in pancreatic cancer. *Ann. Nucl. Med*. 2005;19: 491-7.

[91] Fujita, N., Noda, Y., Kobayashi, G., et al., Endoscopic approach to early diagnosis of pancreatic cancer. *Pancreas*. 2004;28:279-81.

[92] Brugge, W. R., Lee, M. J., Kelsey, P. B., et al., The use of EUS to diagnose malignant portal venous system invasion by pancreatic cancer. *Gastrointest. Endosc*. 1996;43: 561-7.

[93] Ahmad, N. A., Kochman, M. L., Lewis, J. D., et al., Endosonography is superior to angiography in the preoperative assessment of vascular involvement among patients with pancreatic carcinoma. *J. Clin. Gastroenterol*. 2001;32:54-8.

[94] Horwhat, J. D., Gerke, H., Acosta, R. D., et al., Focal or diffuse "fullness" of the pancreas on CT. Usually benign, but EUS plus/minus FNA is warranted to identify malignancy. *JOP* 2009;10:37-42.

[95] Yasuda, K., Mukai, H., Fujimoto, S., et al., The diagnosis of pancreatic cancer by endoscopic ultrasonography. *Gastrointest. Endosc*. 1988;34:1-8.

[96] Varadarajulu, S., Eloubeidi, M. A. The role of endoscopic ultrasonography in the evaluation of pancreaticobiliary cancer. *Gastrointest. Endosc. Clin. N. Am*. 2005;15: 497-511.

[97] Saftoiu, A., Popescu, C., Cazacu, S., et al., Power Doppler endoscopic ultrasonography for the differential diagnosis between pancreatic cancer and pseudotumoral chronic pancreatitis. *J. Ultrasound Med*. 2006;25:363-72.

[98] Klapman, J. B., Chang, K. J., Lee, J. G., et al., Negative predictive value of endoscopic ultrasound in a large series of patients with a clinical suspicion of pancreatic cancer. *Am. J. Gastroenterol*. 2005;100:2658-2661.

[99] Bhutani, M. S., Gress, F. G., Giovannini, M., et al., The No endosonographic detection of tumor (NEST) study: a case series of pancreatic cancers missed on endoscopic ultrasonography. *Endoscopy*. 2004;36(5):385-9.

[100] Agarwal, B., Abu-Hamda, E., Molke, K. L., et al., Endoscopic ultrasound-guided fine needle aspiration and multidetector spiral CT in the diagnosis of pancreatic cancer. Am. *J. Gastroenterol*. 2004;99:844-50.

[101] Hartwig, W., Schneider, L., Diener, M. K., et al., Preoperative tissue diagnosis for tumors of the pancreas. *Br. J. Surg*. 2009;96:5-20.

[102] Eloubeidi, M. A., Jhala, D., Chhieng, D. C., et al., Yield of endoscopic ultrasound guided fine-needle aspiration biopsy in patients with suspected pancreatic carcinoma. *Cancer*. 2003;99:285-92.

[103] Fritscher-Ravens, A., Brand, L., Knofel, W. T., et al., Comparison of endoscopic ultrasound-guided fine needle aspiration for focal pancreatic lesions in patients with normal parenchyma and chronic pancreatitis. *Am. J. Gastroenterol*. 2002;97:2768-75.

[104] Harewood, G. C., Wiersema, M. J. Endosonography-guided fine needle aspiration biopsy in the evaluation of pancreatic masses. *Am. J. Gastroenterol*. 2002;97:1386-91.

[105] Ahmad, N. A., Lewis, J. D., Ginsberg, G. G., et al., EUS in preoperative staging of pancreatic cancer. *Gastrointest. Endosc*. 2000;52:463-8.

[106] Kochman, M. L. EUS in pancreatic cancer. *Gastrointest. Endosc*. 2002; 56:S6-S12.

[107] McLean, A. M., Fairclough, P. D. Endoscopic ultrasound in the localisation of pancreatic islet cell tumours. *Best Pract. Res. Clin. Endocrinol. Metab.* 2005;19(2):177-93.

[108] Anderson, M. A., Carpenter, S., Thompson, N. W., et al., Endoscopic ultrasound is highly accurate and directs management in patients with neuroendocrine tumors of the pancreas. *Am. J. Gastroenterol*. 2000;95(9):2271-7.

[109] Stafford Johnson, D. B., Francis, I. R., Eckhauser, F. E., et al., Dual-phase helical CT of nonfunctioning islet cell tumors. *J. Comput. Assist. Tomogr*. 1998;22(1):59-63.

[110] Sohaib, S. A., Reznek, R. H., Healy, J. C., et al., Cystic islet cell tumors of the pancreas. *AJR Am. J. Roentgenol*. 1998;170(1):217.

[111] Ichikawa, T., Peterson, M. S., Federle, M. P., et al., Islet cell tumor of the pancreas: biphasic CT versus MR imaging in tumor detection. *Radiology*. 2000;216(1):163-71.

[112] Thoeni, R. F., Mueller-Lisse, U. G., Chan, R., et al., Detection of small, functional islet cell tumors in the pancreas: selection of MR imaging sequences for optimal sensitivity. *Radiology*. 2000;214(2):483-90.

[113] Ashida, R., Yamao, K., Okubo, K., et al., Indocyanine green is an ideal dye for endoscopic ultrasound-guided fine-needle tattooing of pancreatic tumors. *Endoscopy*. 2006;38(2):190-2.

[114] Gines, A., Vazquez-Sequeiros, E., Soria, M. T., et al., Usefulness of EUS-guided fine needle aspiration (EUS-FNA) in the diagnosis of functioning neuroendocrine tumors. *Gastrointest. Endosc*. 2002;56(2):291-6.

[115] Chang, F., Chandra, A., Culora, G., et al., Cytologic diagnosis of pancreatic endocrine tumors by endoscopic ultrasound-guided fine-needle aspiration: a review. *Diagn. Cytopathol*. 2006;34(9):649-58.

[116] Jurgensen, C., Schuppan, D., Neser, F., et al., EUS-guided alcohol ablation of an insulinoma. *Gastrointest. Endosc*. 2006;63(7):1059-62.

[117] Madan, A. K., Weldon, C. B., Long, W. P., et al., Solid and papillary epithelial neoplasm of the pancreas. *J. Surg. Oncol*. 2004;85(4):193-8.

[118] Buetow, P. C., Buck, J. L., Pantongrag-Brown, L., et al., Solid and papillary epithelial neoplasm of the pancreas: imaging-pathologic correlation on 56 cases. *Radiology*. 1996;199(3):707-11.

[119] Behrns, K. E., Sarr, M. G., Strickler, J. G. Pancreatic lymphoma: is it a surgical disease? *Pancreas*. 1994;9(5):662-7.

[120] Shah, S., Mortele, K. J. Uncommon solid pancreatic neoplasms: ultrasound, computed tomography, and magnetic resonance imaging features. *Semin. Ultrasound CT MR*. 2007;28(5):357-70.

[121] Merkle, E. M., Bender, G. N., Brambs, H. J. Imaging findings in pancreatic lymphoma: differential aspects. *AJR Am. J. Roentgenol*. 2000;174(3):671-5.

[122] Kassabian, A., Stein, J., Jabbour, N., et al., Renal cell carcinoma metastatic to the pancreas: a single-institution series and review of the literature. *Urology*. 2000;56(2): 211-5.

[123] Ng, C. S., Loyer, E. M., Iyer, R. B., et al., Metastases to the pancreas from renal cell carcinoma: findings on three-phase contrast-enhanced helical CT. *AJR Am. J. Roentgenol*. 1999;172(6):1555-9.

In: Encyclopedia of Surgery (22 Volume Set)
Editors: Andreas Lehrer and Kristin Mueller
ISBN: 978-1-53618-329-0
© 2020 Nova Science Publishers, Inc.

Chapter 89

THE ROLE OF IMAGING IN ESOPHAGEAL SURGERY

Efstathios Kotidis*, Konstantinos Sapalidis and Manos-Georgios Pramateftakis
Department of Surgery, Aristotle University of Thessaloniki, Thessaloniki, Greece

ABSTRACT

The esophagus is a muscular tube connecting the pharynx with the stomach and represents an integral part of the digestive system. There is a wide range of diseases (congenital, functional, structural, trauma and neoplasia) affecting the esophagus. These combined with the fact that it is located in both the thoracic and the abdominal cavity, make the diagnosis and management of esophageal problems a significant challenge, even for the more experienced practitioners. Knowledge of the most current imaging technology can play a critical role in forming a successful strategy.

INTRODUCTION

The esophagus is a muscular tube connecting the pharynx with the stomach. It is 23-37 cm long with a diameter of 1-2 cm and is divided into three parts:

a) cervical: the cervical esophagus is in continuity with the oropharynx, commences at the lower border of cricoid cartilage (at level of C5/6) or cricopharyngeus muscle and continuous until the level of the thoracic aperture.
b) thoracic: extents from the thoracic aperture (T1) to the oesophageal hiatus (T11)
c) abdominal: from oesophageal hiatus and is continuous with the cardia of the stomach at the gastro-oesophageal junction.

It courses inferiorly to the left of the midline in the neck and superior mediastinum returning to the midline at T5 before coursing to the left again of the midline in the posterior

* Corresponding Author's Email: skotidis@gmail.com.

mediastinum and in its inferior aspect curving anteriorly to pass through the diaphragm into the abdominal cavity. The esophagus has three normal constrictions, due to its compression against the adjacent structures that should not be confused for pathological constrictions: The *cervical constriction* due to the cricoid cartilage at the level of C5/6, the *thoracic constriction* due to the aortic arch at the level of T4/5 and the abdominal constriction at the oesophageal hiatus (T10/11).

Its arterial blood supply comes from the thyroid artery (upper third), esophageal branches of the thoracic aorta (middle third) and esophageal branches of the left gastric artery (lower third. Regarding the venous drainage, the upper third drains to the brachiocephalic veins, the middle to the azygos and the lower third to the left gastric vein. The lymphatic drainage follows the arterial supply. The nerve supply is from the sympathetic trunk and the vagal plexus. Histologically, the oesophagus is characterised by the luck of serosal layer. It consists of the outer muscularis propria, the inner muscularis propria, the submucosa, the muscularis mucosae and the mucosa. It is covered by stratified squamous epithelium that abruptly changes to columnar epithelium in the lower oesophagus [1, 2]. The commonest pathologies of the esophagus include oesophageal cancer, benign oesophageal neoplasms, hiatus hernias, achalasia and other motility disorders, gastroesophageal reflux disease (GORD), esophageal rupture (Boerhaave syndrome), esophageal strictures (Schatzki ring or oesophageal web) and esophageal diverticula [2]. The radiographic imaging modalities of the esophagus include barium swallow, CT, endoscopic ultrasonography, MRI, and PET/CT. Barium swallow is the main radiological method of assessing the oesophagus. Endoscopic ultrasonography is used for evaluation of the depth of the oesophageal cancer. CT or MRI are used to diagnose hiatal hernias, diverticuli and tumors of the esophagus and to stage esophageal cancer. PET/CT is only use in staging esophageal malignancies [2].

CONGENITAL DISORDERS

Oesophageal atresia is the commonest of the congenital anomalies of the esophagus. It refers to an absence in contiguity of the oesophagus due to an inappropriate division of the primitive foregut into the trachea and oesophagus. It may be suspected on antenatal ultrasound or in the neonate due to inability to swallow saliva or milk, aspiration during early feedings, or failure to successfully pass a catheter into the stomach.

It is frequently associated with a tracheo-oesophageal fistula. As such, the types of oesophageal atresia / tracheo-oesophageal fistula can be divided into proximal atresia with distal fistula (85%) isolated oesophageal atresia (8-9%), isolated fistula (H-type) (4-6%), double fistula with intervening atresia (1-2%), proximal fistula with distal atresia [3, 4] (1%).

Radiographic Features

A plain chest x ray may show a dilated pharyngeal pouch, or the presence of air in the stomach and bowel in the setting of oesophageal with a distal tracheo-oesophageal fistula.

If an oesophago-gastric (feeding) tube insertion has been attempted this may show the tube blind looping and turning back at the upper thoracic part of the oesophagus or heading into the trachea and/or bronchial tree.

A contrast swallow fluoroscopy may show contrast blindly ending and pooling in an oesophageal stump and/or may show evidence of the tracheo-oesophageal fistula (Images 1, 2). CT scan with 3D detailed visualisation of anatomy has also been trialed but is not part of routine investigation.

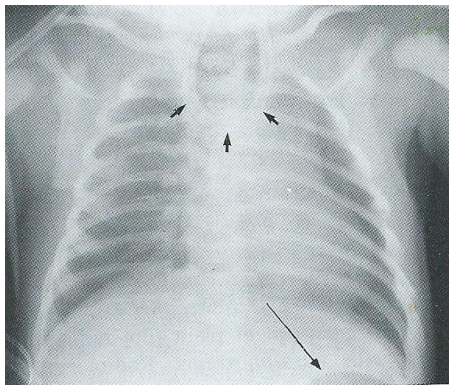

Image 1. Type I congenital atresia. The nasogastric tube folds at the level of the atresia.

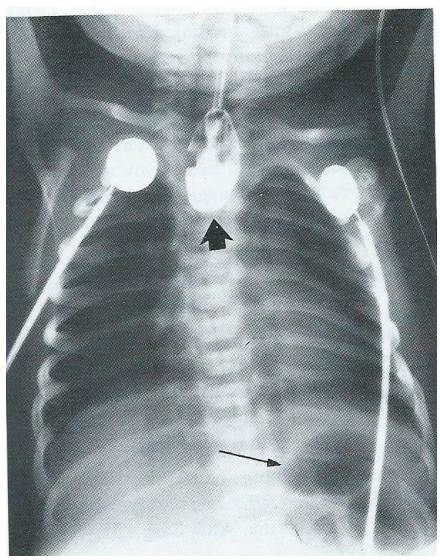

Image 2. The same patient after the administration of water soluble contrast.

FOREIGN BODIES

The presence of foreign bodies in the esophagus is more common in children. They are usually impacted in the first natural stricture of the esophagus at the level of the cricopharingeal muscle. In most cases the history along with a plain x ray are enough for the diagnosis [5, 6, 7] (Images 3, 4).

ESOPHAGEAL DIVERTICULA

Esophageal diverticulum is a pouch arising from the esophagus. It's lumen is in continuity with the esophageal lumen. They can occur in all ages but are more frequent in adults and elderly people. Based on their pathology, they are divided into *true* and *false* diverticula. True diverticula include all esophageal layers while false diverticula contain only mucosa and submucosa herniating through the muscular layer (e.g., Zenker's diverticulum).

Based on their pathophysiology they are divided into *traction diverticula* which occur secondary to pulling forces on the outer aspect of the oesophagus and *pulsion diverticula* which occur secondary to increased intraluminal pressure (e.g., Zenker diverticulum).

According to their location, they are divided into upper, middle and lower diverticula. Upper diverticula are generally pulsion diverticula and include Zenker's and Killian Jamieson diverticulum. Zenker's diverticulum is actually a pharyngeal pouch, located just proximal to the upper esophageal sphincter. Killian Jamieson diverticulum is infrequently encountered compared with the Zenker's and is located just below the cricopharyngeal muscle.

The middle esophageal diverticula can be both traction and pulsion diverticula (Image 5). Traction diverticula may occur secondary to scarring, fibrosis and inflammatory processes in the mediastinum pulling on the oesophageal wall.

They are more frequently located close to the tracheal bifurcation. They are usually small, rarely exceeding 2cm in diameter and in most cases asymptomatic.

Pulsion diverticula are usually false diverticula and occur secondary to abnormally increased intraluminal pressure against a weak esophageal segment.

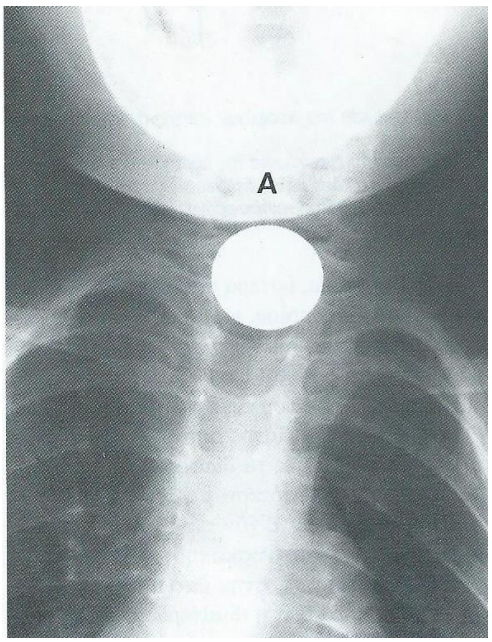

Image 3. Impacted foreign body (coin). Anteroposterior view.

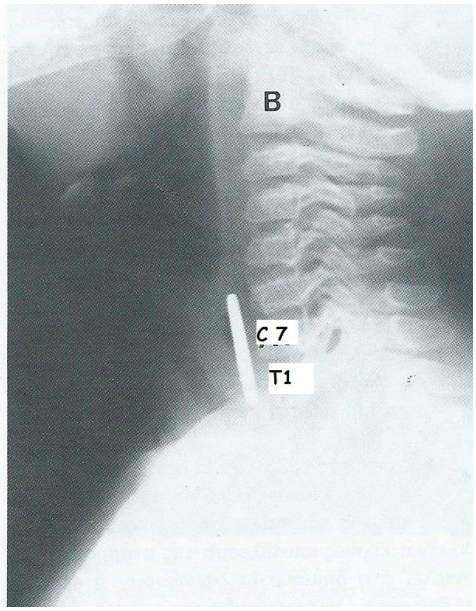

Image 4. Impacted foreign body (coin). Lateral view.

Image 5. Zenker's diverticulum.

Finally, lower or epiphrenic oesophageal diverticula are pulsion diverticula that occur through weak or defective sites of the muscular layer of the lower esophagus, usually in combination with achalasia or hiatus hernias. They are usually larger than middle esophageal diverticula and may be complicated with infection or perforation.

A rare condition mimicking diverticula is esophageal pseudodiverticulosis. It may occur in all age groups, but more commonly in the 6th and 7th decades. They represent dilated excretory ducts of the deep oesophageal mucosal glands [8, 9].

Radiographic Features

A barium swallow is the study of choice. *Zenker's diverticula* present as an outpouching arising from the midline of the posterior wall of the distal pharynx near the pharyngoesophageal junction. The pouch is best identified during swallowing and is best seen on the lateral view, on which the diverticulum is typically noted at the C5-6 level (Image 6). *Epiphrenic diverticula* present as outpouching of the distal esophagus, best seen in prone oblique views (Image 7).

Pseudodiverticula are best seen with a single contrast, rather than a double contrast, thin barium examination (Image 8). The findings are numerous tiny flask-shaped outpouchings usually diffusely distributed or clustered. CT scan may also be used to confirm the diagnosis and to provide more anatomic information that may facilitate the surgical treatment [9].

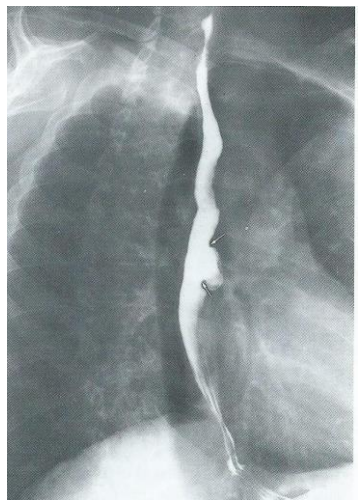

Image 6. Middle esophageal traction diverticulum.

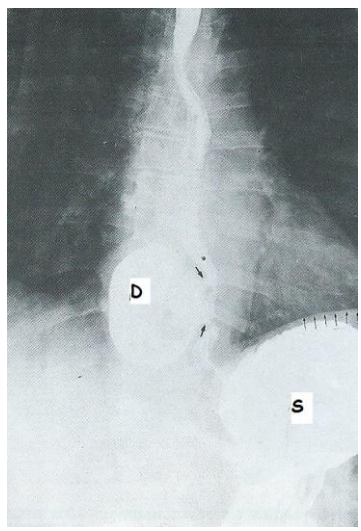

D = diverticulum, S = stomach.

Image 7. Epiphrenic diverticulum.

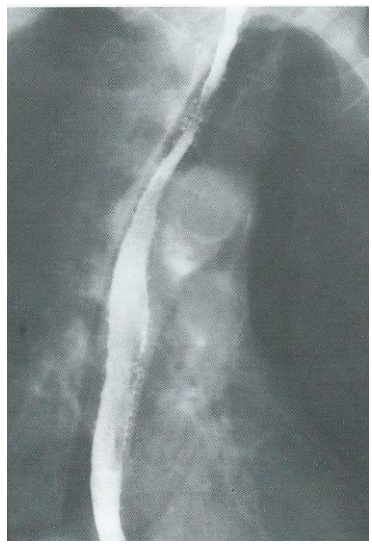

Image 8. Intramural pseudodiverticula.

ESOPHAGEAL VARICES

Esophageal varices are extremely dilated submucosal veins of the lower third of the esophagus. They are most often a consequence of portal hypertension, commonly due to cirrhosis; patients with esophageal varices have a strong tendency to develop bleeding.

The majority of blood from the esophagus is drained via the esophageal veins to the azygos vein, which in turn drains directly into the superior vena cava. These veins have no part in the development of esophageal varices. The remaining blood from the esophagus is drained into the superficial veins lining the esophageal mucosa, which drain into the left gastric vein (coronary vein), which in turn drains directly into the portal vein. These superficial veins (normally only approximately 1 mm in diameter) become distended up to 1-2 cm in diameter in case of portal hypertension. Normal portal pressure is approximately 9 mmHg compared to an inferior vena cava pressure of 2-6 mmHg.

This creates a normal pressure gradient of 3-7 mmHg. If the portal pressure rises above 12 mmHg, this gradient rises to 7-10 mmHg. A gradient greater than 5 mmHg is considered portal hypertension. At gradients greater than 10 mmHg, blood flow through the hepatic portal system is redirected from the liver into areas with lower venous pressures. This means that collateral circulation develops in the lower esophagus, abdominal wall, stomach, and rectum. The small blood vessels in these areas become distended, becoming more thin-walled, and appear as varicosities [10].

Radiographic Features

Lobulated masses in the posterior mediastinum or silhouetting of the aorta may be seen in plain x rays. Barium swallow with small amount of barium is the study of choice. Relaxation of the esophagus, in order not to compress the varices, is important.

Therefore, a sustained valsalva manoeuvre is important to preclude swallowing, since each swallow initiates a primary peristaltic wave that lasts for at least 10-30 seconds. The usual findings are thickened and interrupted mucosal folds, tortuous radiolucencies of variable size and location or "worm eaten" smooth lobulated filling defects (Images 9, 10).

A CT scan may also be useful to confirm the diagnosis. The commonest appearance is thickened esophageal wall with lobulatted outer contour, scalloped esophageal luminal masses and marked enhancement following dynamic CT. In case of paraesophageal varices right or left sided soft tissue masses may be seen [10, 11, 12] (Image 11).

ESOPHAGEAL STRICTURES

Oesophageal strictures refer to any persistent intrinsic narrowing of the oesophagus.

They are usually caused by inflammatory or neoplastic processes such as caustic ingestion, mediastinal radiation, esophagitis, scleroderma or congenital stenosis.

Radiographic Features

Benign strictures typically show smooth concentric narrowing. Malignant strictures are characteristically abrupt, asymmetric, eccentric narrowings with irregular, nodular mucosa (Image 12).

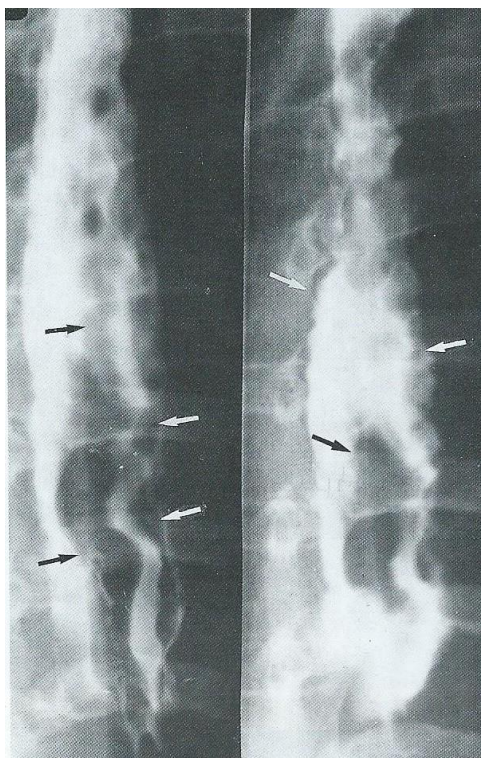

Image 9. Esophageal varices on barium swallow test.

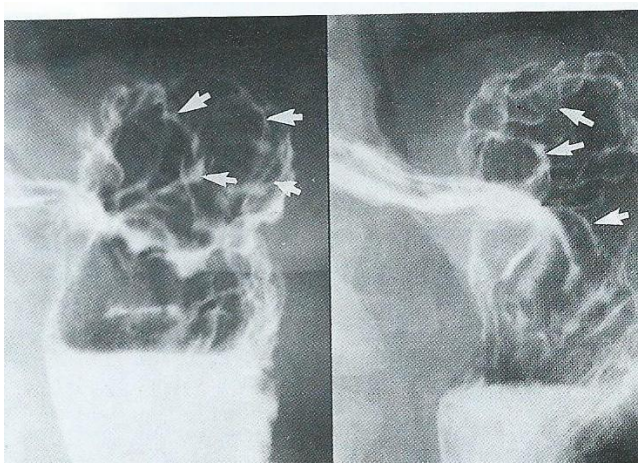

Image 10. Gastric varices.

Tapered margins may occur with malignant lesions because of the ease of submucosal spread of tumour. All esophageal strictures should be investigated with upper endoscopy to rule out malignancy [13, 14].

ESOPHAGEAL PERFORATION

Esophageal perforation is a rare but serious medical emergency with very high mortality rate, especially if the diagnosis is delayed.

Most perforations are iatrogenic, post dilatation or thoracic surgery. Other causes include trauma, foreign body ingestion, erosive material ingestion, esophageal cancer or spontaneous post vomiting rupture (Boerhaave syndrome). If perforation is not detected during the instrumentation, the patient will develop neck, chest or epigastric pain, dyspnoea, dysphagea and sepsis [15]. Subcutaneous emphysema may also be present.

Image 11. CT scan demonstrating esophageal varices.

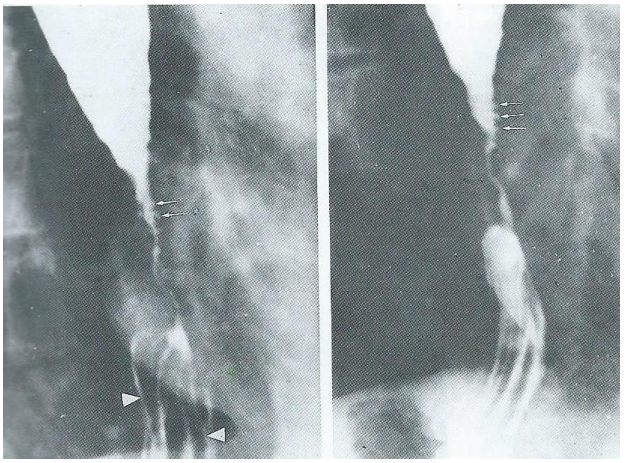

Image 12. Benign esophageal stricture secondary to esophagitis. A large sliding hiatus hernia is also seen.

Radiographic Features

Plain chest x-ray may show pneumomediastinum, pneumothorax and/or pleural effusion indicative of mediastinitis. Contrast swallow with water soluble agent is more sensitive, and should be done within 24 hours to confirm the diagnosis. CT scan may also be useful to evaluate the extent of pleural effusion and mediastinitis.

Once diagnosed, the esophageal perforation should immediately be treated either endoscopically or laparoscopically [15, 16].

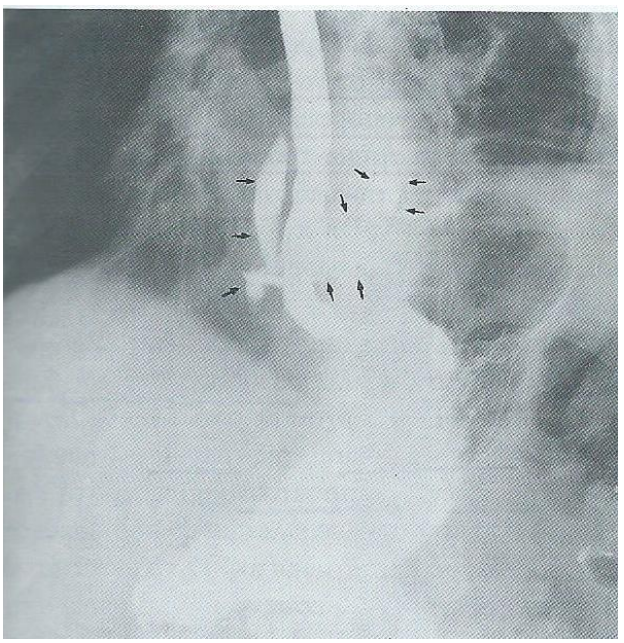

Image 13. Gastrographin swallow demonstrating iatrogenic perforation of the esopagus.

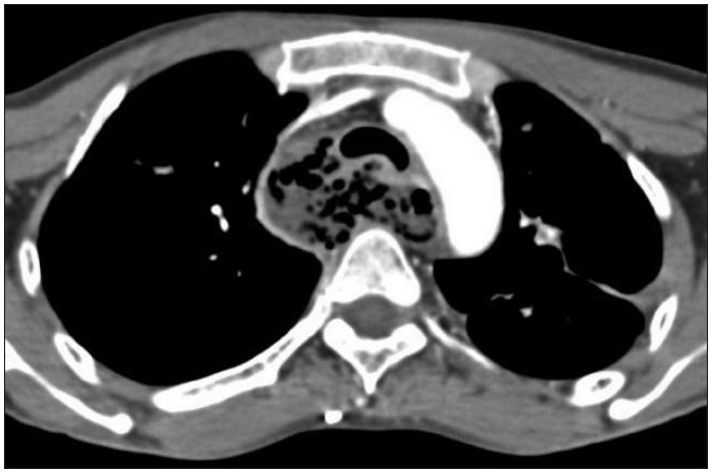

Image 14. CT scan after iatrogenic perforation of the esophagus. The scan shoes collection of fluid and air in the mediastinum.

SCHATZKI RING

Schatzki ring is a relatively common lower esophageal ring found in nearly 10% of barium swallows. It is located 2-3 cm above the hiatus and is thought to be a congenital anomaly formed by redundant pleats of mucosa. Its clinical presentation depends on its luminal diameter.

Most rings are asymptomatic unless the luminal diameter is < 13mm. In such cases they present with dysphagia especially to solid food. Interestingly, patients with Schatzki ring have lower incidence of Barret's esophagus. If they are symptomatic, boogie or balloon dilatation is the treatment of choice [17].

Radiographic Features

Single contrast barium swallow is the study of choice. Its sensitivity is even higher than endoscopy. A Valsalva manoeuvre may be useful to increase the sensitivity of the test.

A circumferential narrowing at the gastro-oesophageal junction, often a few centimeters above the diaphragmatic hiatus, is the commonest feature (15).

HIATUS HERNIA

Hiatus hernia (HH) is the herniation of abdominal viscera through the esophageal hiatus into the posterior mediastinum or the thoracic cavity. Depending on the location of the gastroesophageal junction, hiatus hernias are divided into sliding, where the junction is displaced up in the posterior mediastinum and paraesophageal hernias, where the junction is not displaced. Many patients with HH are asymptomatic and it is an incidental finding. However, symptoms may include epigastric or chest pain, post prandial fullness, nausea and

vomiting. Sometimes HH are considered synonymous with gastro-oesophageal reflux disease (GORD) but there is a poor correlation between the two conditions. The most common content of a HH is the stomach. Large HH containing stomach may result in gastric volvulus, which in turn presents as intestinal obstruction and may result in ischaemia or infarction [18].

There are two main types of hiatus hernia, although they may co-exist:

Sliding Hiatus Hernia

This is the most common type of hiatus hernia (95%). The gastro-oesophageal junction (GOJ) is usually displaced by more than 2 cm above the hiatus. The oesophageal hiatus is often abnormally widened to 3-4 cm (the upper limit of normal is 15 mm).

The gastric fundus may also be displaced above the diaphragm and present as aretrocardiac mass on a chest radiograph. The presence of an air-fluid level in the mass suggests the diagnosis. Small, sliding hiatus hernias commonly reduce in the upright position.

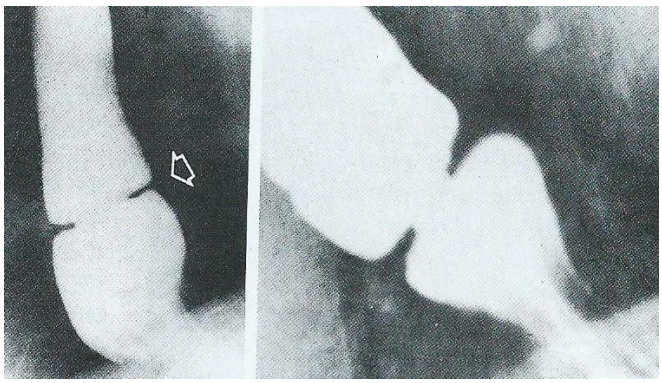

Image 15. Schatzki ring.

The mere presence of a sliding hiatus hernia is of limited clinical significance in most cases. The function of the lower oesophageal sphincter and the presence of gastro-esophageal reflux disease (GERD) are the crucial factors in producing symptoms and causing complications [18, 19].

Para-Oesophageal Hiatus Hernia

The para-oesophageal hiatus hernia is much less common than the sliding type (5%). The GOJ remains in its normal location while a portion of the stomach herniates above the diaphragm.

Mixed Hiatus Hernia

The two types of hiatus hernias may also coexist. The GOJ is displaced into the thorax with a large portion of the stomach, which is usually abnormally rotated.

Radiographic Features

A plain x ray may reveal retrocardiac opacity with air – fluid level. Single contrast barium swallow is diagnostic on most cases (Image 16, 17).

CT scan may be necessary to clarify in more detail the content and the relations of the hernia sack, especially in large paraesophageal hernias (Image 18). The differential diagnosis includes retrocardiac lung abscess or empyema and epiphrenic esophageal diverticulum [18].

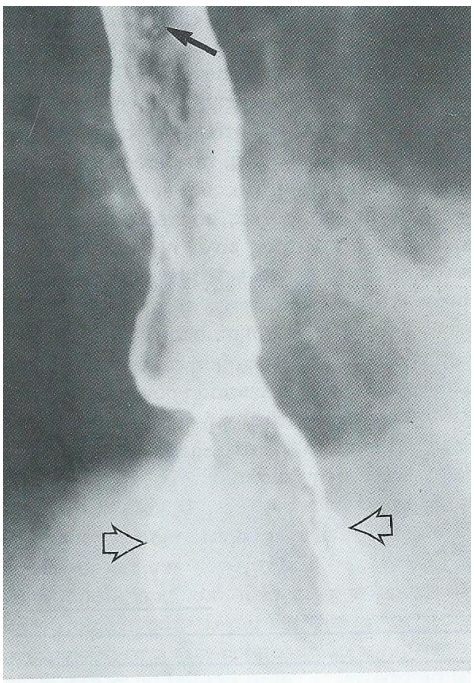

Image 16. Sliding hiatus hernia.

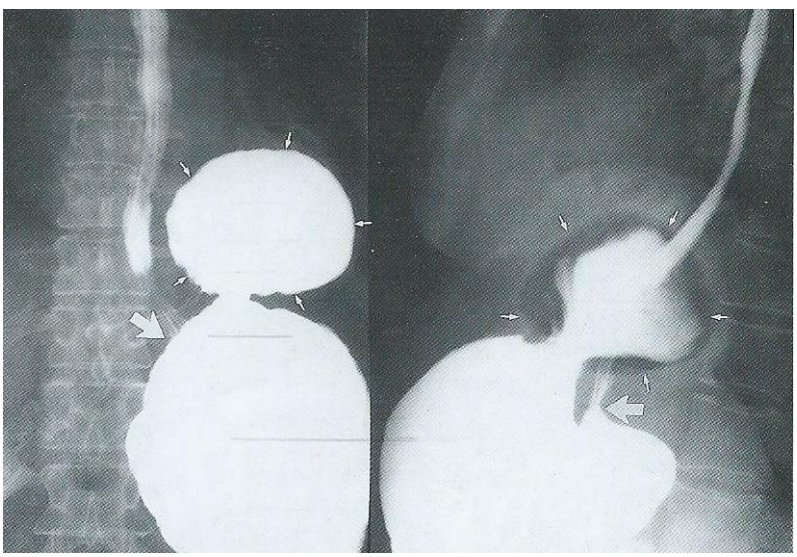

Image 17. Paraesophageal hiatus hernia.

Image 18. CT scan demonstrating sliding hiatus hernia.

GASTROESOPHAGEAL REFLUX DISEASE (GERD)

Gastroesophageal reflux disease occurs when the amount of gastric juice that refluxes into the esophagus exceeds the normal limit, causing symptoms with or without associated esophageal mucosal injury. Typical esophageal symptoms include heartburn, regurgitation and dysphagia.

Abnormal reflux can also cause atypical (extraesophageal) symptoms, such as coughing and/or wheezing, hoarseness, sore throat, otitis media, noncardiac chest pain, enamel erosion or other dental manifestations. A history of nausea, vomiting, or regurgitation should alert the physician to evaluate for delayed gastric emptying. Patients with suspected gastroesophageal reflux disease should be investigated with upper gastrointestinal endoscopy, esophageal manometry and ambulatory 24-hour pH monitoring. Ambulatory 24-hour pH monitoring is the criterion standard in establishing a diagnosis of gastroesophageal reflux disease [19].

Radiographic Features

Upper gastrointestinal contrast-enhanced studies are the initial radiologic procedure of choice in the workup gastroesophageal reflux disease. Plain chest radiographic findings are not useful in evaluating of this condition, but they are helpful in assessing pulmonary status and basic anatomy. Chest images may also demonstrate a large hiatal hernia, but small hernias can be easily missed. Currently, no role exists for computed tomography scanning, magnetic resonance imaging, or ultrasonography in the routine evaluation of patients with reflux disease [20].

Achalasia

Achalasia is a primary esophageal motility disorder characterized by the absence of esophageal peristalsis and impaired relaxation of the lower esophageal sphincter (LES) in response to swallowing. The LES is hypertensive in about 50% of patients. These abnormalities cause a functional obstruction at the gastroesophageal junction (GEJ).

It is most frequently seen in middle and late adulthood (30-70 years of age) with no gender predilection. In most cases achalasia is idiopathic, however an identical appearance is seen in patients with Chagas disease.

Authors differ as to whether they reserve the term achalasia for idiopathic cases, or whether they include Chagas disease. Symptoms of achalasia include dysphagia (most common), regurgitation, chest pain, heartburn and weight loss. Initially symptoms are intermittent. Patients may also present with a complication of long standing achalasia:

- oesophageal carcinoma: is the most dreaded complication and is seen in approximately 5%, and most often in the mid oesophagus. It is thought to relate to the chronic irritation of the mucosa by stasis of food and secretions.
- aspiration pneumonia and eventually abscess formation
- candida oesophagitis
- acute airway obstruction: this is a rare complication requiring immediate esophageal decompression with nasogastric tube

Esophageal manometry is the criterion standard in the diagnosis of achalasia. Findings include incomplete LES relaxation in response to swallowing, high resting LES pressure, absent esophageal peristalsis.

Ambulatory esophageal pH monitoring to rule out gastroesophageal reflux disease and determine if abnormal reflux is being caused by treatment may also be necessary. Esophagogastroduodenoscopy to rule out cancer of the GEJ or fundus is usually done in most cases. Concomitant endoscopic ultrasonography is necessary if a tumor is suspected [21].

Radiographic Features

Chest x-ray findings include:

- right convex opacity behind right cardiac border; occasionally left convex opacity if thoracic aorta tortuous
- air-fluid level due to stasis in thoracic esophagus filled with retained secretions and food
- small or absent gastric air bubble
- anterior displacement and bowing of trachea on the lateral view

The chronic presence of fluid debris in the esophagus makes patients very prone to aspiration and thus patchy bilateral alveolar opacities representing acute or chronic aspiration pneumonia may be seen.

Barium Swallow

A barium swallow is able to not only confirm that the esophagus is dilated but is also able to assess for mucosal abnormalities (Image 19).

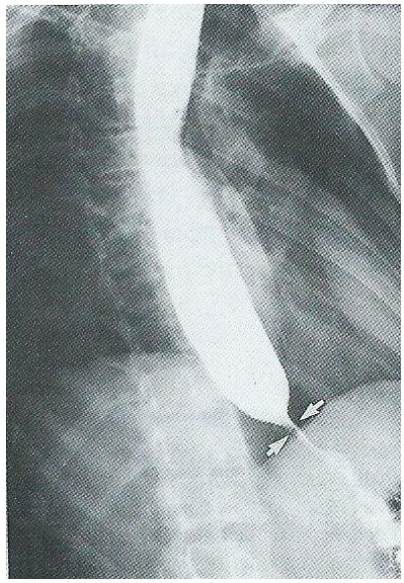

Image 19. Achalasia of the esophagus.

Findings include:

- failure of normal peristalsis to clear the esophagus of barium when the patient is in the recumbent position, with no primary waves identified
- uncoordinated, non-propulsive, tertiary contractions
- esophageal body dilatation, which is typically maximal in the distal esophagus
- pooling or stasis of barium in the esophagus when the esophagus has become atonic or non contractile (late feature in the disease)
- when barium column is high enough (patient standing) the hydrostatic pressure can overcome the LOS pressure allowing passage of esophageal content
- incomplete LOS relaxation that is not coordinated with esophageal contraction
- bird beak sign

CT

Patients with uncomplicated achalasia demonstrate a dilated thin walled esophagus filled with fluid/food debris. Overall CT has little role in directly assessing patients with achalasia, but is useful in assessing common complications. Careful assessment of the wall of the esophagus should be undertaken to identify any focal regions of thickening which may indicate malignancy. The lungs should be inspected for evidence of aspiration.

Differential Diagnosis

A number of entities may mimic achalasia, forming the so called 'achalasia pattern.' They include central and peripheral neuropathy, scleroderma, oesophageal malignancy or gastric carcinoma commonly referred as pseudoachalasia, oesophageal stricture, Chagas disease, non-specific oesophageal motility disorder and diffuse oesophageal spasm.

Treatment

The American College of Gastroenterology released new guidelines for the diagnosis and management of achalasia in July 2013. Treatment recommendations are as follows:

- Initial therapy should be either graded pneumatic dilation (PD) or laparoscopic surgical myotomy with a partial fundoplication in patients fit to undergo surgery
- Procedures should be performed in high-volume centers of excellence
- Initial therapy choice should be based on patient age, sex, preference, and local institutional expertise
- Botulinum toxin therapy is recommended for patients not suited to PD or surgery
- Pharmacologic therapy can be used for patients not undergoing PD or myotomy and who have failed botulinum toxin therapy (nitrates and calcium channel blockers most common) [20].

ESOPHAGEAL CYSTS

Esophageal cysts were initially described esophageal cysts as duplications. They can be divided into two categories. Simple epithelial-lined cysts and esophageal duplication, which is an embryologic duplication of a portion of the muscle and submucosa of the esophagus without epithelial duplication. Esophageal cysts are rare. Many patients with esophageal cysts are asymptomatic and never diagnosed. The true incidence of esophageal cysts is unknown, since no large study has defined it.

They are usually grouped with other benign lesions of the esophagus, comprising up to 20% of benign esophageal lesions. Up to 80% of them are diagnosed in childhood.

The diagnosis and treatment of esophageal cysts is still evolving. Diagnosis is aided by the relatively recent developments of CT scans and endoscopic ultrasonography. Treatment is currently moving from thoracotomy to less-invasive procedures, including video-assisted thoracoscopic surgery (VATS) and endoscopic treatment.

Symptoms are caused by compression of surrounding structures. Sixty percent of esophageal cysts occur in the lower third of the esophagus, where difficulty swallowing from compression is the most common symptom; 20% occur in the upper third of the esophagus, where respiratory difficulty from compression of the tracheobronchial tree is the most common symptom; and 20% occur in the middle third of the esophagus, where retrosternal chest pain and difficulty swallowing are the most common symptoms. Posterior cysts in the lower third of the esophagus can cause cardiac arrhythmias. The larger the cyst, the greater the chance of it causing symptoms [22].

Maldevelopment of the posterior division of the primitive foregut is the embryologic defect responsible for esophageal cysts. Esophageal cysts develop from aberrant elements of

the esophageal wall. Simple cysts are duplication of the epithelium, whereas true esophageal duplications are duplications of the submucosa and the muscle wall without duplication of the epithelium. The lining of the cyst can vary and can include squamous columnar, cuboidal, pseudostratified, ciliated, and gastric mucosae. Hemorrhage can be the presenting symptom if gastric mucosa is present in the cyst. The other types of mucosa are not specifically associated with particular symptoms [22].

Radiographic Features

Plain chest radiographs can reveal a cyst within the mediastinum.

Barium swallow studies reveal compression of the esophagus without ulceration.

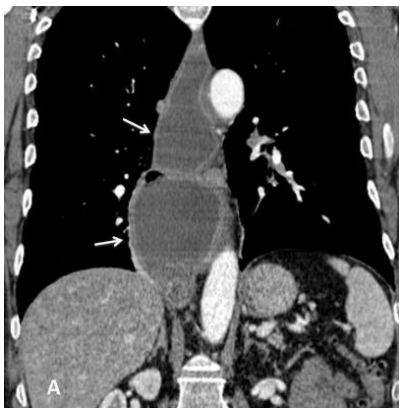

Image 20. CT scan. Achalasia of the esophagus.

CT scan reveals a fluid-filled cystic structure originating from the esophagus (Image 21).

Endoscopic ultrasonography reveals a cystic, filled structure in connection with the esophagus.

MRI scans can also help diagnose esophageal cysts.

All cysts should be resected unless the patient's other medical ailments prohibit operation.

BENIGN ESOPHAGEAL NEOPLASMS – LEIOMYOMA

Benign neoplasms of the esophagus are extremely rare that constitute less than 1% of esophageal neoplasms. A number of benign esophageal tumors have been recognized. They include leiomyoma, fibrovascular polyp of the esophagus, papilloma, fibroma, haemangioma, hamartoma and neurofibroma. Esophageal leiomyoma is the most common, representing nearly two thirds of benign esophageal tumors.

Leiomyomas represent a hyperproliferation of bundles of smooth muscle cells that are well-demarcated by adjacent tissue or by a smooth connective tissue capsule. They usually arise as intramural growths, most commonly along the distal two thirds of the esophagus. They are multiple in approximately 5% of patients. The majority is discovered incidentally or during investigation for dysphagia. The clinical presentation would often depend on the size

of tumour. Small tumours (< 5 cm) usually have no symptoms, while large tumours may cause dysphagia, regurgitation, oesophageal obstruction, chest pain, cough or bleeding. They typically involve the mid to distal oesophagus [23, 24].

Radiographic Features

Esophageal leiomyoma can be visualized using barium swallow. The classic appearance is a smooth concave mass underlying intact mucosa.

Distinct sharp angles are seen at the junction of the tumor and normal tissue. Encroachment onto the esophageal lumen usually is observed (Image 22).

Esophageal ultrasonography can be helpful in demonstrating a smooth, typically round, mass located in the muscularis without encroachment into the overlying mucosa or underlying adventitia.

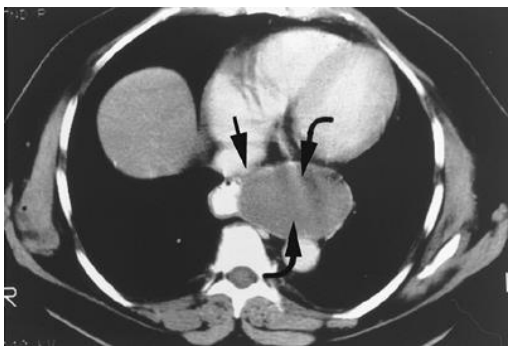

Image 21. Esophageal duplication cyst.

CT scan is even more accurate in diagnosing leiomyomas of the esophagus. Common findings include ovoid intramural solitary mass with a smooth surface, narrowing of oesophageal lumen, displacement of the esophagus, moderate diffuse contrast enhancement with no signs of invasion of adjacent tissues.

The presence of calcifications is almost pathognomonic. Imaging differential considerations include oesophageal carcinoma, leiomyosarcoma of the oesphagus, oesophageal hamartoma and other mediastinal tumours arising close to the oesophagus. The overall prognosis is excellent. If tumour is small (< 5 cm) and asymtomatic treatment is non necessary. Otherwise surgical enucleation is recommended [23].

ESOPHAGEAL CARCINOMA

Carcinoma of the esophagus remains a devastating disease because it is usually not detected until it has progressed to an advanced incurable stage. Oesophageal cancer is responsible for < 1% of all cancers and 4-10% of all gastrointestinal malignancies.

It represents a disease in epidemiologic transition. Until the 1970s, the most common type of esophageal cancer in the United States was squamous cell carcinoma, which has

smoking and alcohol consumption as risk factors; since then, there has been a progressive increase in the incidence of esophageal adenocarcinoma, for which the most common predisposing factor is gastroesophageal reflux disease (GERD) [25].

Presenting signs and symptoms of esophageal cancer include dysphagia, initially for solids and eventually progressing to include liquids, weight loss, bleeding epigastric or retrosternal pain, bone pain with metastatic disease, hoarseness, persistent cough. Clinical examination is typically normal unless the cancer has metastasized. In metastatic disease the commonest findings are hepatomegaly and lymphadenopathy in the laterocervical or supraclavicular areas. Diagnosis is based on esophagogastroduodenoscopy which allows direct visualisation and biopsy of the tumor [25, 26].

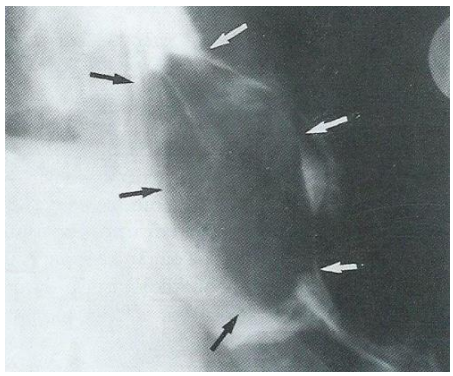

Image 22. Esophageal leiomyoma.

Radiographic Features

Barium esophagography is a useful initial examination in the evaluation of a patient with esophageal complaints. It is unique among esophageal studies for assessing both morphology and motility and therefore remains the study of choice for characterization of esophageal strictures. Esophageal carcinoma may demonstrate a variety of appearances on barium esophagram such as irregular stricture, pre-stricture dilatation with 'hold up' and shouldering of the stricture (Image 24, 25, 26).

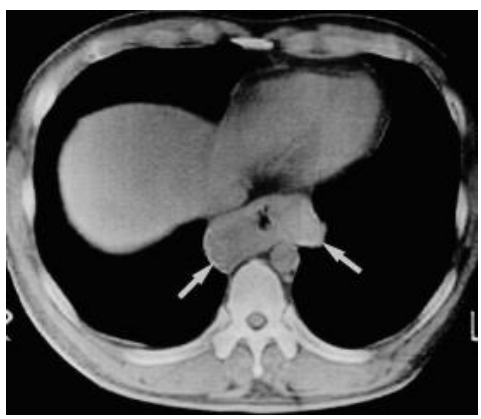

Image 23. CT scan. Esophageal leiomyoma.

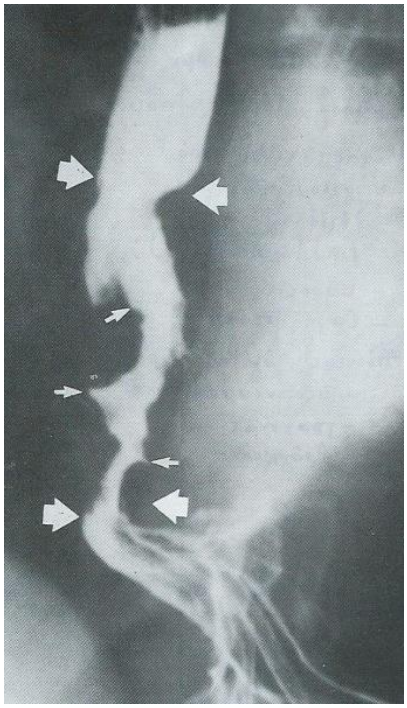

Image 24. Barium swallow illustrating carcinoma of the lower third of the esophagus in a patient with sliding hiatus hernia.

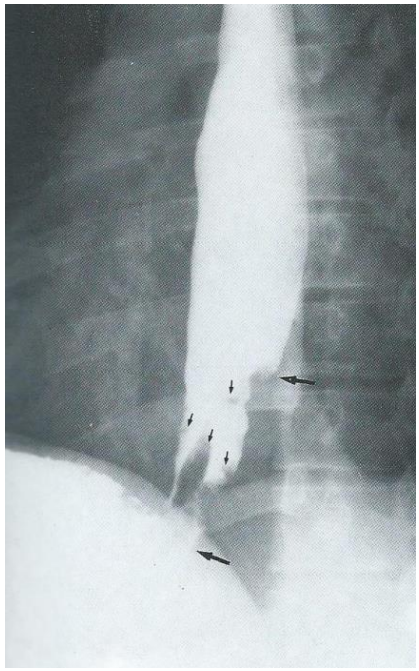

Image 25. Barium swallow illustrating esophageal carcinoma.

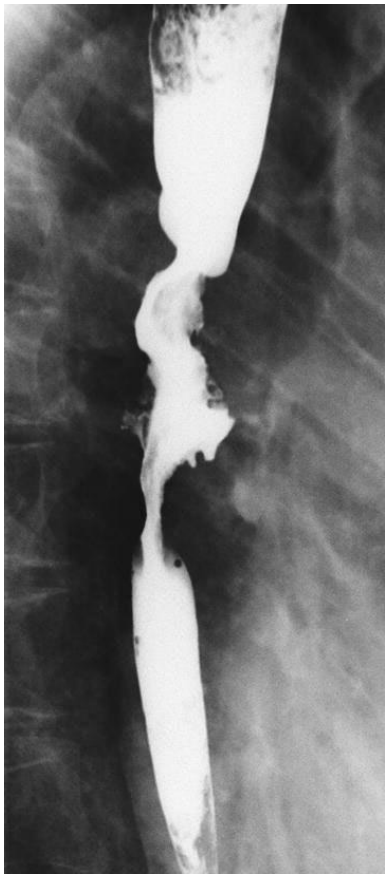

Image 26. Barium swallow illustrating carcinoma of the middle third of the esophagus.

Esophageal endoscopy permits direct inspection and biopsy of the esophageal mucosa for histologic diagnosis. For the purpose of staging esophageal carcinoma, EUS (Image 27), contrast-enhanced CT (Images 28, 29), and PET (Image 30) each offer unique information [26].



Image 27. EUS showing adenocarcinoma of the esophagus.

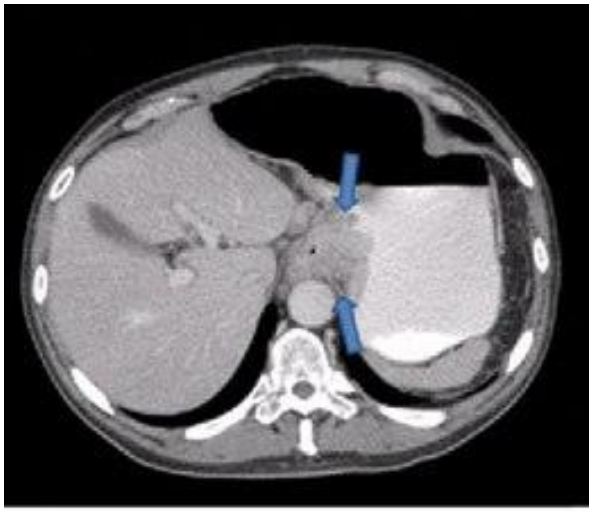

Image 28. CT scan in a patient with adenocarcinoma of the gastroesophageal junction.

Each of the diagnostic modalities has its limitations. Barium esophagography has optimal sensitivity for the detection of lesions when a double-contrast technique is used. Such technique requires that the patient be able to stand upright, which may not be possible with all patients. For bulkier obstructive lesions, an air-contrast technique may not be possible, and a detailed mucosal examination may not be achieved distal to the obstruction.

A notable limitation of CT in diagnosis involves the characterization of lymph nodes. With CT scans, size criteria are used to determine possible metastatic involvement; however, lymph nodes may be enlarged because of infectious or inflammatory aetiologies. Conversely, subcentimeter lymph nodes may harbour metastatic tumor.

Endoscopic ultrasonography (EUS) is highly operator dependent. Another limitation of EUS is its inability to pass the malignant stricture with the transducer. This limitation may result in an incomplete examination.

However, the use of a dedicated 8-mm-diameter esophagoprobe for EUS allows complete examination in most patients [25-27].

With PET, the resolution and cost remain the primary limitations. Subcentimeter foci of tumor metabolism may not be detected.

Staging of Esophageal Carcinima

Contrast-enhanced CT plays an important role in the staging of esophageal carcinoma. Attention is directed to determining the extent of the local tumor, invasion of mediastinal structures, involvement of supraclavicular mediastinal or upper abdominal lymph nodes and distant metastases. These observations are useful in distinguishing between T3 and T4 lesions and in determining the N and M status.

CT examination should extend from the thoracic inlet through the liver. Routine oral contrast material should be administered. It should be obtained during full inspiration when patients are evaluated for esophageal carcinoma since inward bowing or the trachea and mainstem bronchi during expiration may produce the false impression of tracheobronchial invasion. Common CT findings include eccentric or circumferential wall thickening > 5 mm,

perioesophageal soft tissue and fat stranding, dilated fluid- and debris-filled oesophageal lumen proximal to an obstructing lesion.

Tracheobronchial invasion appears as displacement of the airway (usually the trachea or left mainstem bronchus) as a result of mass effect by the oesophageal tumour. A careful search for lymph nodes is an essential component of the interpretation.

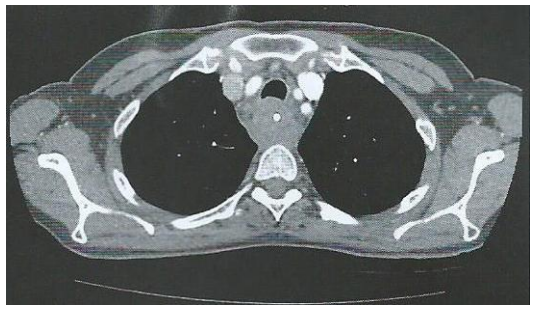

Image 29. CT scan illustrating scuamous cell carcinoma of the middle esophagus.

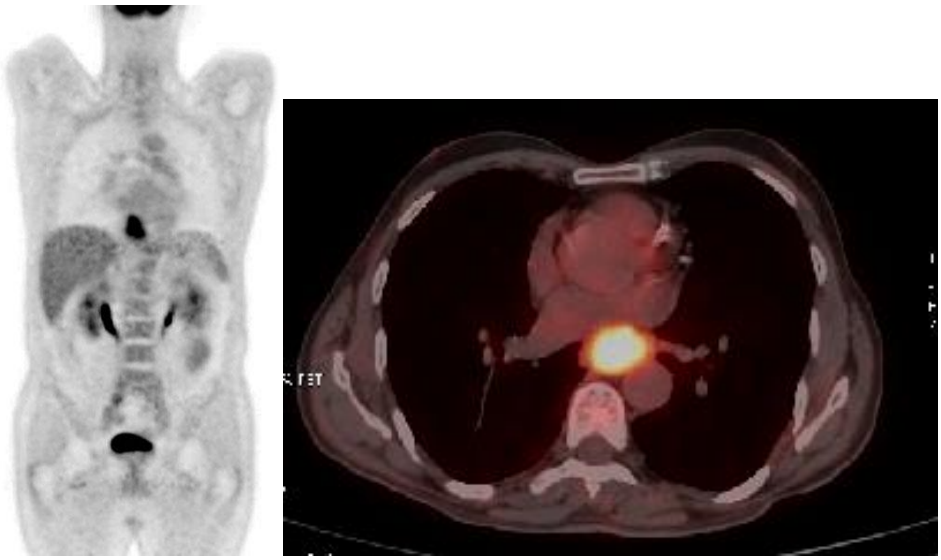

Image 30. PET scan and PET/CT in a patient with adenocarcinoma of the lower third of the esophagus.

A short-axis diameter exceeding 1 cm is considered abnormal for lymph nodes in all mediastinal locations except those in the subcarinal region, in which 1.4 cm is the upper limit of normal. Because lymph nodes may harbor metastases without being enlarged, noting the location of any identified lymph nodes is important. In addition, remembering that lymph nodes may be enlarged because of inflammatory or infectious aetiologies is important. Its sensitivity for the detection of lymph node metastases is in the range of 60-80%. Its specificity is higher, approximately 90%.

Magnetic resonance imaging (MRI) has the advantage of direct multiplanar imaging capabilities, which may be of particular use in assessing tracheobronchial, aortic, and pericardial invasion. Currently, MRI has not yielded other significant advantages compared

with CT in the staging of esophageal carcinoma. The sensitivity and specificity of MRI for the determination of tumor invasion are equivalent to those of CT.

EUS, unlike CT, allows visualization of the distinct layers within the esophageal wall. Alternating circumferential layers define the mucosal interface (hyperechoic), the mucosa (hypoechoic), the submucosa (hyperechoic), the muscularis propria (hypoechoic), and the adventitial interface (hyperechoic). Such resolution permits the distinction of T1, T2, T3, and T4 tumors. Esophageal carcinoma appears as a hypoechoic lesion disrupting the normal circumferential layers.

However, with standard EUS equipment, often only 3 layers are seen in the esophageal wall: the mucosa and submucosa (hyperechoic), the muscularis propria (hypoechoic), and the adventitial interface (hyperechoic). Local lymph nodes are also demonstrated by using EUS. Nodes are considered malignant if they are round, if they are hypoechoic, and if they have well-defined borders. Usually, benign nodes are hyperechoic and less well defined [27, 28].

T-stage accuracy with EUS is in the range of 79-94%. At this time, only EUS is useful in distinguishing T1 and T2 lesions. N-stage accuracy is in the range of 69-90%. Distant metastases cannot be reliably identified with EUS because of the limited field of view.

PET is quickly becoming a standard oncologic imaging modality. The technique is useful not only for the primary detection of tumor and metastases, but also for the further characterization of abnormalities discovered by using other imaging modalities.

The sensitivity of PET in assessing nodal metastasis is reportedly 33-83%, but studies have shown the superiority of PET to CT and EUS for determining the N status while PET is more sensitive than CT for the detection of distant metastases.

REFERENCES

[1] Buttler, P. *Applied radiological anatomy*. Cambridge University Press. (1999) ISBN: 0521481104.

[2] Ryan, S. *Anatomy for Diagnostic Imaging*. Saunders Ltd. ISBN:0702029718.

[3] Berrocal, T., Madrid, C., Novo, S., et al., Congenital anomalies of the tracheobronchial tree, lung, and mediastinum: embryology, radiology, and pathology. *Radiographics*. 24 (1): e17.

[4] Lam, W. W., Tam, P. K., Chan, F. L., et al., Esophageal atresia and tracheal stenosis: use of three-dimensional CT and virtual bronchoscopy in neonates, infants, and children. *AJR. Am. J. Roentgenol*. 2000;174(4): 1009-12.

[5] Emslander, H. C., Bonadio, W., Klatzo, M. Efficacy of esophageal bougienage by emergency physicians in pediatric coin ingestion. *Ann. Emerg. Med*. Jun. 1996;27(6): 726-9.

[6] Gilchrist, B. F., Valerie, E. P., Nguyen, M. Pearls and perils in the management of prolonged, peculiar, penetrating esophageal foreign bodies in children. *J. Pediatr. Surg.* Oct. 1997;32(10):1429-31.

[7] Jaramillo, D., Cleveland, R. N., Blickman, J. G. Radiologic management of esophageal foreign bodies. *Semin. Intervent. Radiol*. 8:198-203.

[8] Palanivelu, C., Rangarajan, M., Maheshkumaar, G. S., et al., Minimally invasive surgery combined with peroperative endoscopy for symptomatic middle and lower

esophageal diverticula: a single institute's experience. *Surg. Laparosc. Endosc. Percutan. Tech*. 2008;18(2): 133-8.

[9] Baker, M. E., Zuccaro, G., Achkar, E., et al., Esophageal diverticula: patient assessment. *Semin. Thorac. Cardiovasc. Surg*. 1999;11(4): 326-36.

[10] D'Journo, X. B., Ferraro, P., Martin, J., et al., Lower oesophageal sphincter dysfunction is part of the functional abnormality in epiphrenic diverticulum. *Br. J. Surg*. 2009;96 (8): 892-900.

[11] Luketic, V. A., Sanyal, A. J. Esophageal varices. I. Clinical presentation, medical therapy, and endoscopic therapy. *Gastroenterol. Clin. North Am*. Jun. 2000;29(2):337-85.

[12] Pieters, P. C., Miller, W. J., DeMeo, J. H. Evaluation of the portal venous system: complementary roles of invasive and noninvasive imaging strategies. *Radiographics*. Jul.-Aug. 1997;17(4):879-95.

[13] Kim, S. H., Kim, Y. J., Lee, J. M., Choi, K. D., Chung, Y. J., Han, J. K., et al., Esophageal varices in patients with cirrhosis: multidetector CT esophagography--comparison with endoscopy. *Radiology*. Mar. 2007; 242(3):759-68.

[14] Karasick, S., Lev-toaff, A. S. Esophageal strictures: findings on barium radiographs. *AJR Am. J. Roentgenol*. 1995;165(3): 561-5. *AJR Am. J. Roentgenol*.

[15] Hasimoto, C. N., Cataneo, C., Eldib, R., et al., Efficacy of surgical versus conservative treatment in esophageal perforation: a systematic review of case series studies. *Acta Cir. Bras*. 2013;28(4): 266-71.

[16] Søreide, J. A., Viste, A. Esophageal perforation: diagnostic work-up and clinical decision-making in the first 24 hours. *Scand. J. Trauma Resusc. Emerg. Med*. 2011;19 (1): 66.

[17] Müller, M., Gockel, I., Hedwig, P., et al., Is the Schatzki ring a unique esophageal entity?. *World J. Gastroenterol*. 2011;17(23): 2838-43.

[18] Kahrilas, P. J., Kim, H. C., Pandolfino, J. E. Approaches to the diagnosis and grading of hiatal hernia. *Best Pract. Res. Clin. Gastroenterol*. 2008; 22(4):601-16.

[19] Huang, X., Zhu, H. M., Deng, C. Z., et al., Gastroesophageal reflux: the features in elderly patients. *World J. Gastroenterol*. Oct. 1999;5(5):421-423.

[20] Lacy, B. E., Weiser, K. Esophageal motility disorders: medical therapy. *J. Clin. Gastroenterol*. May-Jun. 2008;42(5):652-8.

[21] Gonlachanvit, S., Fisher, R. S., Parkman, H. P. Diagnostic modalities for achalasia. *Gastrointest. Endosc. Clin. N. Am*. Apr. 2001;11(2):293-310.

[22] Jeung, M. Y., Gasser, B., Gangi, A., et al., Imaging of cystic masses of the mediastinum. *Radiographics*. 2002;22 Spec. No (suppl. 1): S79-93.

[23] Weissleder, R., Wittenberg, J., Harisinghani, M. G. *Primer of diagnostic imaging*. Mosby Inc. (2007) ISBN:0323040683.

[24] Gupta, V., Lal, A, Sinha, S. K., Nada, R., Gupta, N. M. Leiomyomatosis of the esophagus: experience over a decade. *J. Gastrointest. Surg*. Feb. 2009;13(2):206-11.

[25] Takashima, S., Takeuchi, N., Shiozaki, H., et al., Carcinoma of the esophagus: CT vs MR imaging in determining resectability. *AJR Am. J. Roentgenol*. Feb. 1991;156(2): 297-302.

[26] Levine, M. S., Chu, P., Furth, E. E., et al., Carcinoma of the esophagus and esophagogastric junction: sensitivity of radiographic diagnosis. *AJR Am. J. Roentgenol.* Jun. 1997;168(6):1423-6.

[27] Rankin, S. C., Taylor, H., Cook, G. J., Mason, R. Computed tomography and positron emission tomography in the pre- operative staging of oesophageal carcinoma. *Clin. Radiol*. Sep. 1998;53(9):659-65.

[28] Levine, M. S., Halvorsen, R. A. Esophageal carcinoma. In: Gore, R. M., Levine, M. S., Laufer, I., eds. *Textbook of Gastrointestinal Radiology*. Philadelphia: WB Saunders Co; 1994:446-78.

In: Encyclopedia of Surgery (22 Volume Set)
Editors: Andreas Lehrer and Kristin Mueller
ISBN: 978-1-53618-329-0
© 2020 Nova Science Publishers, Inc.

Chapter 90

THE ROLE OF IMAGING IN GASTRIC SURGERY

Efstathios Kotidis*, Manos-Georgios Pramateftakis and Nikolaos Michalopoulos
Department of Surgery, Aristotle University of Thessaloniki, Thessaloniki, Greece

ABSTRACT

The esophagus is an integral part of the digestive system. There is a wide range of diseases (congenital, functional, structural, trauma and neoplasia) affecting the stomach, and as a result knowledge of the most current imaging technology is critical for accurate diagnosis and a successful management. This chapter will present the various imaging modalities and discuss their advantages and disadvantages.

INTRODUCTION

The stomach lies between the oesophagus and the duodenum in the upper abdomen. It is divided into four distinct regions. The cardia, which is the area that receives the oesophagus (gastro-oesophageal junction); the fundus, which is formed by the upper curvature; the body, the main central region of the organ; and the pylorus (antrum), which represents the lower section of the stomach that facilitates emptying into the small intestine (Image 1).

Entry of food into the stomach is controlled by the lower esophageal sphincter and exit from the stomach by the pyloric sphincter. These are under the control of several mechanisms including stimulant (parasympathetic) and inhibitory (orthosympathetic) control from the anterior gastric, posterior, superior and inferior coeliac and myenteric nerve plexuses.

The inner mucosal surface has many rugal folds that act to increase the surface area of the stomach lining and increase its efficiency.

Its arterial supply is provided by the right gastric artery (inferior lesser curvature), the left gastric artery (superior lesser curvature and cardia), the right gastroepiploic artery (inferior greater curvature), the left gastroepiploic artery (superior greater curvature) and the short

* Corresponding Author's Email: skotidis@gmail.com.

gastric vessels (fundus). Regarding the venous drainage, the left and right gastric veins drain to portal vein, the short gastric vein and left gastroepiploic vein drain to splenic vein and the right gastroepiploic vein drain to superior mesenteric artery. Lymphatics drain with arteries to the coeliac lymph nodes.

The gastric wall is composed of four layers: the mucosa includes the internal layer of epithelium the lamina propria and the muscularis mucosae; the submucosa which is a fibrous layer of connective tissue under the mucosa; the muscularis externa which is composed of three muscular layers (inner oblique, middle circular and outer longitudinal); and the serosa, the outermost layer of the stomach wall consisting of connective tissue which is continuous with the peritoneum.

The stomach wall contains several different types of glandular tissue. The cardia, fundus and pylorus all have different types of glands and are composed of a variety of different cells:

- Mucous cells: secrete a mucus gell layer and are found throughout the stomach [1, 2]
- Parietal (oxyntic) cells: secrete gastric acid and intrinsic factor throughout the stomach
- Chief (zymogenic) cells: secrete pepsinogen and rennin in the fundus only
- Enteroendocrine (APUD) cells: secrete a variety of products and are found throughout the stomach

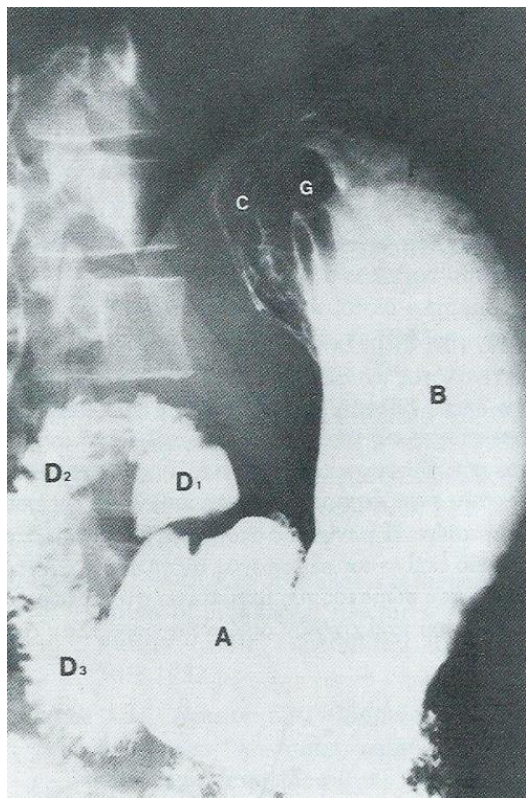

C = cardia, G = fundus, B = body, A = antrum, D = duodenum.

Image 1. Double contrast swallow.

GASTRIC DIVERTICULUM

The gastric diverticulum is a sac-like projection usually originated from the gastric fundus, located usually 1-2cm below the gastroesophageal junction.

It is the least common among gastrointestinal diverticula. The incidence varies from 0.01% to 0.11% at endoscopy studies. It is usually asymptomatic and, in some cases, could presents as a vague sensation of fullness immediately after meals or as gastric discomfort. Complications like ulceration, perforation, torsion, hemorrhage and malignancy are rare and an indication for surgical treatment [3].

Gastric diverticulum may be congenital (true diverticula that have all layers of the gastric wall) or acquired (false diverticula) and arise virtually anywhere along the stomach.

In imaging studies gastric diverticulum could mimic an adrenal mass. Surgical resection is recommended when the diverticulum is large, symptomatic or complicated [4].

Radiographic Features

A well defined saccular collection of barium protracting from the gastric wall is seen in barium swallow test (Image 2). CT scan may be needed and it shows a well defined saccular collection of fluid or gas, being filled by the iodinated oral contrast, demonstrating communication with the gastric cavity.

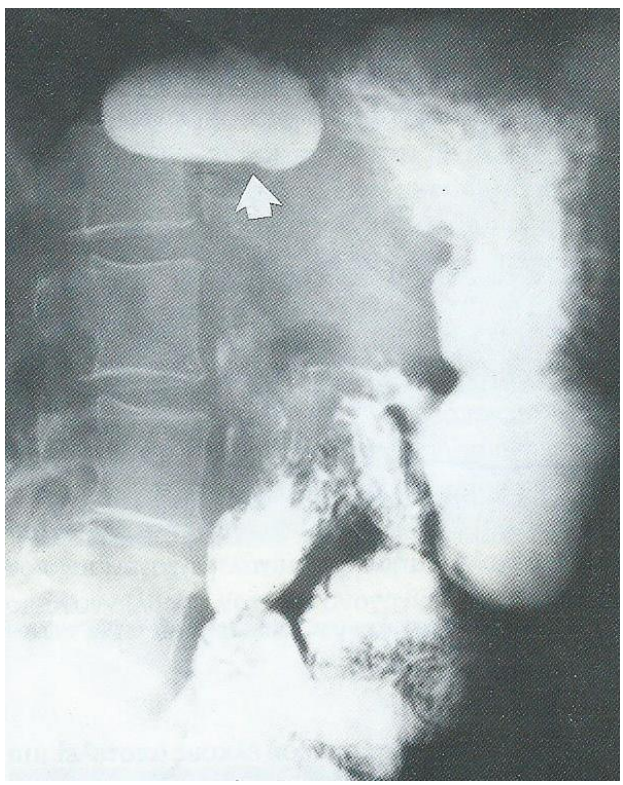

Image 2. Gastric diverticulum in the posterior wall of the cardia.

GASTRIC VOLVULUS

Gastric volvulus is a rare clinical entity defined as an abnormal rotation of the stomach of more than 180°, creating a closed-loop obstruction that can result in incarceration and strangulation. Borchardt described the classic triad associated with gastric volvulus: severe epigastric pain, retching without vomiting, and inability to pass a nasogastric tube [5].

Classification

The most frequently used classification system of gastric volvulus relates to the axis around which the stomach rotates, including organoaxial, mesentericoaxial, and combined.

Organoaxial type: In an organoaxial gastric volvulus, the stomach rotates around an axis that connects the gastroesophageal junction and the pylorus. The antrum rotates in opposite direction to the fundus of the stomach. This is the most common type of gastric volvulus and it is usually associated with diaphragmatic defects. Strangulation and necrosis commonly occur with organoaxial gastric volvulus.

Mesentericoaxial type: The mesentericoaxial axis bisects the lesser and greater curvatures. The antrum rotates anteriorly and superiorly so that the posterior surface of the stomach lies anteriorly. The rotation is usually incomplete and occurs intermittently. Vascular compromise is uncommon. Patients with mesentericoaxial gastric volvulus usually present without diaphragmatic defects and usually have chronic symptoms.

Combined type: The combined type of gastric volvulus is a rare form in which the stomach twists mesentericoaxially and organoaxially. This type of gastric volvulus makes up the remainder of cases and is usually observed in patients with chronic volvulus.

According to etiology, gastric volvulus can be classified as either type 1 (idiopathic) or type 2 (congenital or acquired).

Type 1: Idiopathic gastric volvulus comprises two thirds of cases and is presumably due to abnormal laxity of the gastrosplenic, gastroduodenal, gastrophrenic, and gastrohepatic ligaments. This allows approximation of the cardia and pylorus when the stomach is full, predisposing to volvulus. Type 1 gastric volvulus is more common in adults but has been reported in children.

Type 2: Type 2 gastric volvulus is found in one third of patients and is usually associated with congenital or acquired abnormalities that result in abnormal mobility of the stomach. The most common causes of gastric volvulus in adults are diaphragmatic defects.

Symptoms

Symptoms of gastric volvulus may range from mild abdominal pain and vomiting, when no or partial outlet obstruction is present, to severe pain and retching, when there is complete obstruction and ischemia.

Fiberoptic endoscopy has a limited role in the diagnosis of gastric volvulus because the twist precludes passage of the endoscope [6].

Radiographic Features

Typically, the first examination to be performed in the patient with symptoms referable to the chest and/or abdomen is a plain radiograph. Plain radiography may demonstrate findings that are indistinguishable from those that are produced by other causes of gastric atony or obstruction. In mesenteroaxial volvulus, the distended stomach appears spherical on supine images. Two air-fluid levels are visible on the upright film: 1 in the fundus, which is inferior, and 1 in the antrum, which is superior. Organoaxial volvulus is difficult to diagnose on plain images. The stomach lies horizontally and contains a single air-fluid level on upright views. No characteristic beak is observed. However, the modality is useful for excluding other causes of the patient's symptoms, such as pneumoperitoneum or pneumothorax.

Although this is a good examination to start with, the most definitive study is the upper GI barium study. Barium study is highly sensitive and specific. It is generally considered to be the criterion standard for diagnosis (Image 3). However, the diagnosis may be missed in cases of intermittent torsion. The upper GI series may show only a paraesophageal hernia during a symptom-free interval, leading to a false-negative diagnosis.

CT scanning and MRI are not typically considered to be the diagnostic examinations of choice in patients who are evaluated for gastric volvulus. However, the multiaxial reconstructions that are afforded by helical CT in particular may be preferred to the images obtained with conventional barium study, particularly in the acutely ill patient who is unable to tolerate a fluoroscopic examination. In addition, chronic gastric volvulus is often discovered incidentally in patients undergoing CT scanning for an unrelated condition.

Ultrasonography as a technique for the detection of gastric disease (and of gastric volvulus in particular) is still in its infancy. Angiography is often used in the evaluation of massive or refractory GI hemorrhage. Although it is a rare cause of such hemorrhage, gastric volvulus should be considered. The angiographic appearance is sensitive and specific during an acute episode.

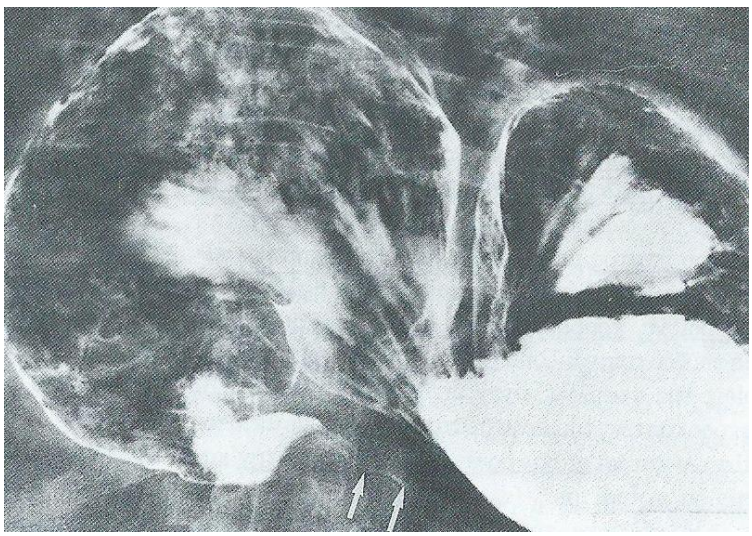

Image 3. Double contrast swallow test illustrating mesentericoaxial gastric volvulus.

MENETRIER DISEASE

Ménétrier disease (MD) is a form of rare idiopathic hypertrophic gastropathy. The exact aetiology is not well known. The juvenile form has been linked to cytomegaloviral infection and usually resolves spontaneously. The adult form tends to progress with time and TGF-A activation of the EGFR receptor has been implicated. The characteristic of the disease is gastric mucosal hypertrophy, which may cause the rugae to resemble convolutions of the brain. Rugal thickening is predominantly caused by the expansion of the epithelial cell compartment of the gastric mucosa.

It most commonly affects the gastric fundal region also any part of the stomach may be involved. Achlorhydria, hypoproteinaemia and oedema comprise the classic triad. It is thought to be caused by protein-loss in the digestive system, protein-losing enteropathy. Acid production may be compromised. Hypoproteinaemia may lead to ascites and pleural effusions. Imaging differential considerations for diffuse rugal thickening include gastric lymphoma, which may also occur as part of post transplant lymphoproliferative disorder affecting the stomach and other forms of gastritis (infective gastritis, radiation gastritis, eosinophilic gastritis). Treatment includes high protein diet to correct hypoproteinaemia, PPI to treat attendant gastritis, EGFR monocloncal antibody (Cetuximab) or gastrectomy.

Radiographic Features

On fluoroscopy MD is usually characterised by giant rugal folds (Images 3, 4). On contrast-enhanced CT images, the thickened rugae appear as areas of thickened mucosa that project into the gastric lumen to a degree that may resemble convolution of brain [7].

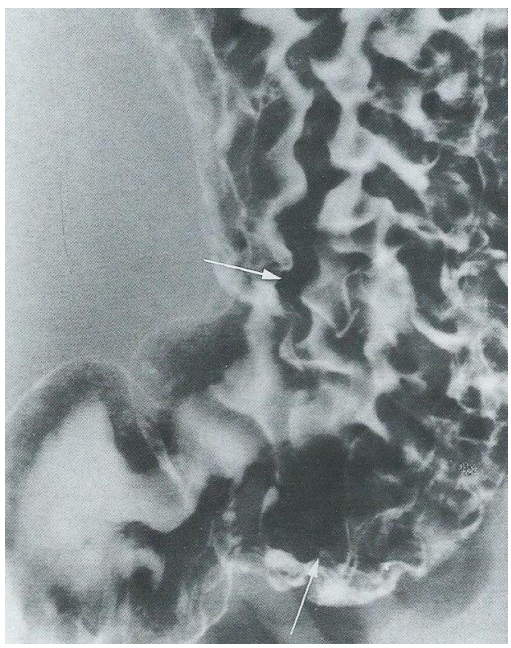

Image 4. Menetrier's disease. The arrows indicate the hypertrophic mucosal folds.

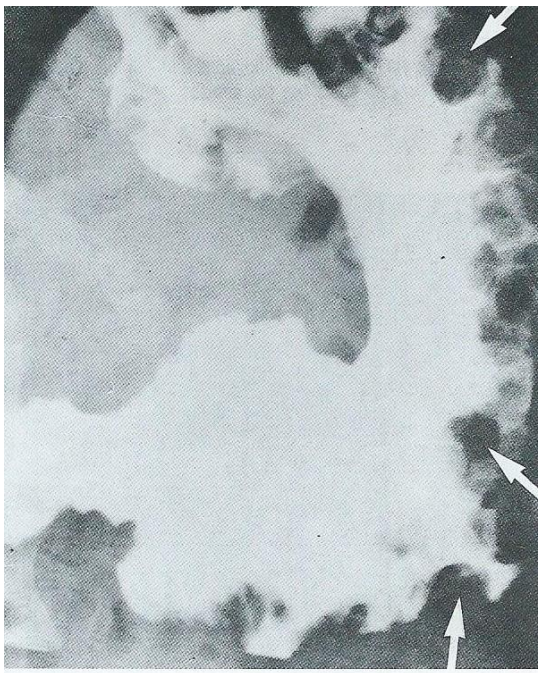

Image 5. Barium swallow test in a patient with Menetrier's disease.

PEPTIC ULCER DISEASE

Peptic ulcer disease (PUD) encompasses a number of entities, united by the presence of mucosal ulceration secondary to the effects of gastric acid. Since the recognition of *Helicobacter pylori* as a common causative agent, and the development of powerful anti-acid medications, peptic ulcer disease has become comparatively rare in western populations.

Generally peptic ulcer disease is encountered more frequently in males (M:F 3:1) and usually in the older population.

Risk factors include *Helicobacter pylori* infection, NSAIDs, corticosteroids, severe physiological stress/illness (e.g., admission to intensive care) and Zollinger-Ellison syndrome. The majority of cases are due to infection with *Helicobacter pylori*.

This can be confirmed with biopsies obtained at endoscopy and urea breath test, the combination of the two resulting in a detection rate of close to 100% [8]. Gastric and duodenal ulcers usually cannot be differentiated based on history alone, although some findings may be suggestive.

Epigastric pain is the most common symptom of both gastric and duodenal ulcers. It is characterized by a gnawing or burning sensation and occurs after meals—classically, shortly after meals with gastric ulcer and 2-3 hours afterward with duodenal ulcer. A peptic ulcer may present acutely as upper gastrointestinal bleeding (14%), perforation (6%) or gastric outlet obstruction (1%). Upper GI endoscopy is the preferred diagnostic test in the evaluation of patients with suspected PUD. Endoscopy provides an opportunity to visualize the ulcer, to determine the presence and degree of active bleeding, and to attempt hemostasis by direct measures, if required.

Endoscopy should be performed early in patients older than 45-50 years and in patients with associated so-called alarm features. When dyspeptic symptoms lead to identification of upper gastrointestinal ulceration (usually via endoscopy) patients are typically treated with acid lowering medications and tested for *Helicobacter pylori*, which if found is then eradicated.

This is important not only to prevent recurrence of peptic ulceration and reflux oesophagitis but also because it is associated with a number of malignancies including B-cell lymphoma and gastric adenocarcinoma [8].

Radiographic Features

Although historically barium studies were the mainstay of investigation for suspect peptic ulceration, endoscopy has in most centres largely replaced the barium meal. Many current younger radiologists have rarely if ever performed a full diagnostic barium meal, and the 'art' of this examination is gradually being lost. Barium meals are performed with liquid barium and an effervescent to distend the stomach with gas and allow a 'double contrast' image (Images 6, 7). Features of ulceration include pocket of barium filling the ulcer crater (85% round; 15% linear) and radiating folds of mucosa away from the ulcer. 10-15% of ulcers are multiple while postbulbar ulcers should raise the possibility of Zollinger-Ellison syndrome especially if ulcers are multiple and gastric folds are thickened.

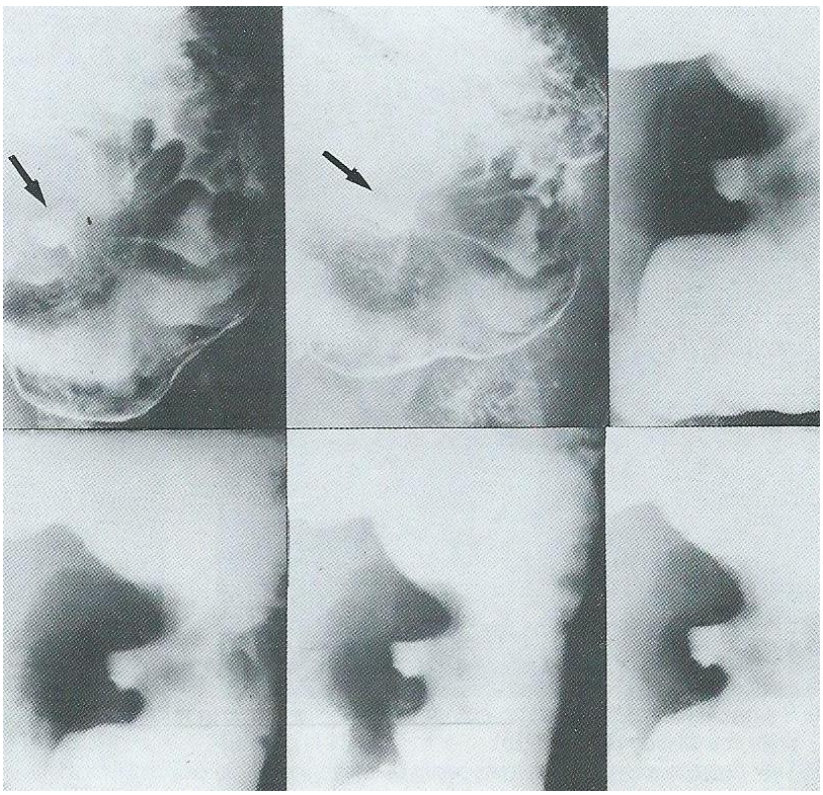

Image 6. Benign gastric ulcer.

Image 7. Benign gastric ulcer.

In patients presenting acutely, a chest radiograph may be useful to detect free abdominal air when perforation is suspected (Image 8). However, even in the acute setting CT is the modality of choice for assessing a patient with acute abdominal pain, especially in cases where plain chest x ray fails to demonstrate the presence of free intra-abdominal air. In some settings, CT scan may be able to identify the site of bleeding prior to endoscopy. Haemorrhage, though, is challenging to identify and requires a multi-phase scan without positive oral contrast (typically non-contrast, arterial and delayed phase scans are obtained) and the presence of active bleeding. Extravasation and pooling/accumulation of contrast into the lumen of the bowel may be seen. Angiography may be necessary in patients with a massive GI bleed in whom endoscopy cannot be performed. An ongoing bleeding rate of 0.5 mL/min or more is needed for the angiography to be able to accurately identify the bleeding source. Angiography can depict the source of the bleeding and can help provide needed therapy in the form of a direct injection of vasoconstrictive agents [6, 8].

BENIGN GASTRIC TUMORS

With the advent of modern techniques and the widespread use of gastric endoscopy, benign gastric wall lesions are now diagnosed more frequently and can be studied using the tissue obtained by biopsy or polypectomy.

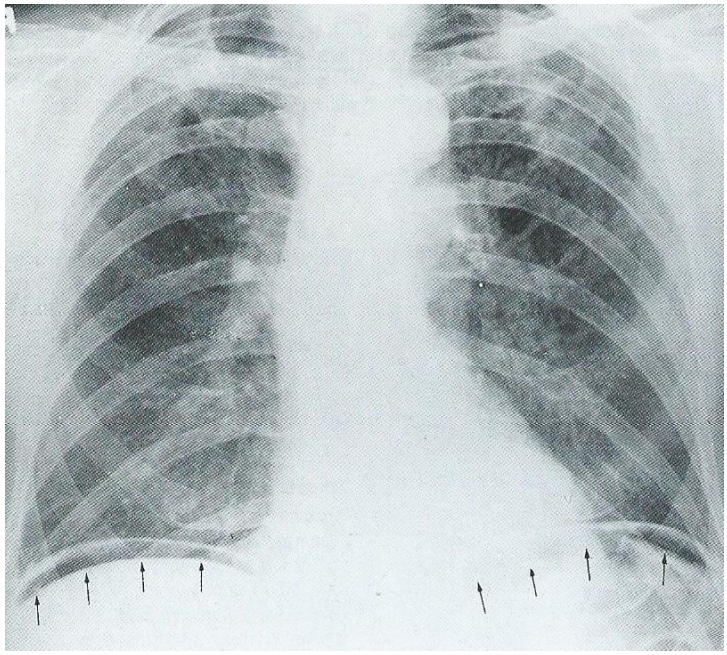

Image 8. Chest x-ray demonstrating free subphrenic air collection secondary to perforation of peptic ulcer.

All layers of the stomach wall have the potential to produce tumorous growths. In 40% of patients with benign gastric tumors, the lesions are mucosal tumors. Another 60% are nonmucosal based. Gastric polyps are defined as luminal lesions projecting above the plane of the mucosal surface and are relatively frequent in routine pathology practice.

Various subtypes of gastric polyps are recognized and divided into nonneoplastic and neoplastic and are also further classified by their association with polyposis syndromes [9].

Mucosal tumors are divided into nonneoplastic and neoplastic polyps.

Not neoplastic polyps include could either associated with polyposis syndrome (Peutz-Jeghers, juvenile polyps, Cowden disease, Cronkhite Canada syndrome, Gardner syndrome) or not associated with polyposis syndromes (hyperplastic polyps, inflammatory polyps, ectopic pancreas). Neoplastic polyps include fundic gland polyps, adenomatous polyps and gastric carcinoids [9, 10].

Nonmucosal tumors could be mesenchymal (GIST, lipoma, fibroma, glomus tumor) or vascular (hemangioma or lymphangioma). Many tumors are found incidentally on gastroscopy. Small tumors are usually asymptomatic, but larger tumors can ulcerate and cause occult bleeding and anemia. Large antral tumors cause intermittent gastric outlet obstruction. If ulcerated, these tumors may cause epigastric pain similar to a peptic ulcer.

Radiographic Features

Air-contrast studies of the stomach are sensitive in delineating mucosal details and lesions (Image 9). Lesions are often found incidentally by computerized tomography scan or other radiological evaluations of the upper gastrointestinal tract (Image 10).

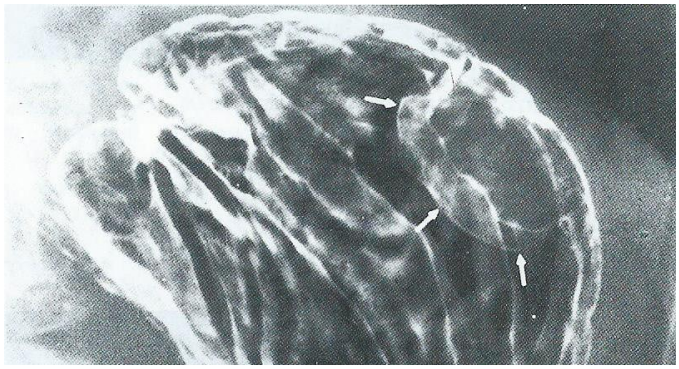

Image 9. Double contrasts swallow illustrating a leiomyoma of the stomach.

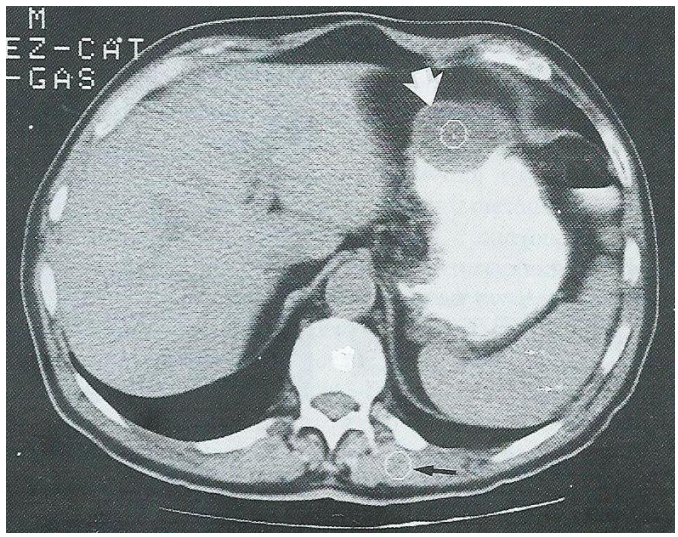

Image 10. CT scan in the same patient as in image 9.

Endoscopy however is the procedure of choice for both diagnostic and therapeutic purposes. If small superficial lesions are removed endoscopically, follow-up should include a regular annual endoscopy. Endoscopic biopsies are difficult to interpret and may be misleading because deep layers of the stomach wall or the tumor are not sampled. Snare biopsies that retrieve the whole specimen are preferred whenever technically possible. Endoscopic ultrasound (EUS) is helpful in broad-based lesions, where the relationship of the tumor to the layers of the stomach is important (Image 11). Disruption of the normal sonographic appearance of 5 layers on EUS may signify invasion [11].

GASTRIC CARCINOMA

Gastric cancer is the second most common cause of cancer-related death in the world, and it remains difficult to cure, primarily because most patients present with advanced disease. In most developed countries, however, rates of stomach cancer have declined dramatically over the past half century.

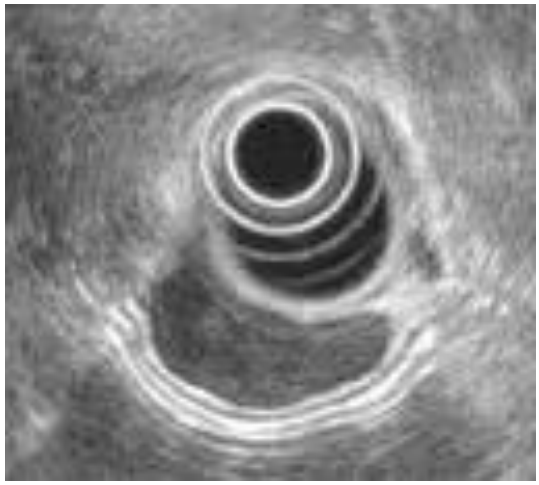

Image 11. EUS in a patient with gastric GIST.

Decreases in gastric cancer have been attributed in part to widespread use of refrigeration and therefore decreased contamination of food by carcinogenic compounds arising from the decay of unrefrigerated meat products as well as decreased intake of salt. Another reason is the lower rates of chronic *Helicobacter pylori* infection, thanks to improved sanitation and use of antibiotics, and increased screening in some countries [12].

Adenocarcinomas account for approximately 95% of all malignant gastric neoplasms. The remaining 5% of tumors are lymphomas, leiomyosarcomas, carcinoids, or sarcomas.

Early disease has no associated symptoms; however, some patients with incidental complaints are diagnosed with early gastric cancer. Most symptoms of gastric cancer reflect advanced disease. Patients may complain of indigestion, nausea or vomiting, dysphagia, postprandial fullness, loss of appetite, melena, hematemesis, and weight loss [13].

Late complications include pathologic peritoneal and pleural effusions; obstruction of the gastric outlet or the gastroesophageal junction. Other symptoms may include intrahepatic jaundice caused by hepatomegaly; extrahepatic jaundice; and inanition resulting from starvation or cachexia of tumor origin. The differential diagnosis can be broad and includes gastric lymphoma, gastric metastasis, gastric stromal tumour (GIST), gastritis, benign gastric (peptic) ulcer, Menetrier disease, secondary changes from pancreatitis (from extrinsic inflammatory change). Endoscopy and biopsy (at least 6 samples) of any gastric lesion is the cornerstone in the diagnosis of gastric cancer. Esophagogastroduodenoscopy has a diagnostic accuracy of 95%. In selected cases, endoscopic ultrasound may be helpful in assessing depth of penetration of the tumor or involvement of adjacent structures. Depending on the depth of tumor invasion into the gastric wall, gastric adenocarcinoma is divided into early, if the tumor invades no more deeply than the submucosa, irrespective of lymph node metastasis and advanced if the tumor invades deeper than the submucosa [14].

Radiographic Features

Radiological methods are often the initial examination that raises suspicion for gastric carcinoma, besides being used in the staging of the disease.

Single-contrast barium studies have an overall sensitivity of 75% in the detection of gastric cancer, but double-contrast barium examinations have a sensitivity of 90-95% in gastric cancer detection, comparable to that of endoscopy (Images 12, 13). Double-contrast upper GI series and barium swallows may be helpful in delineating the extent of disease when obstructive symptoms are present or when bulky proximal tumors prevent passage of the endoscope to examine the stomach distal to an obstruction.

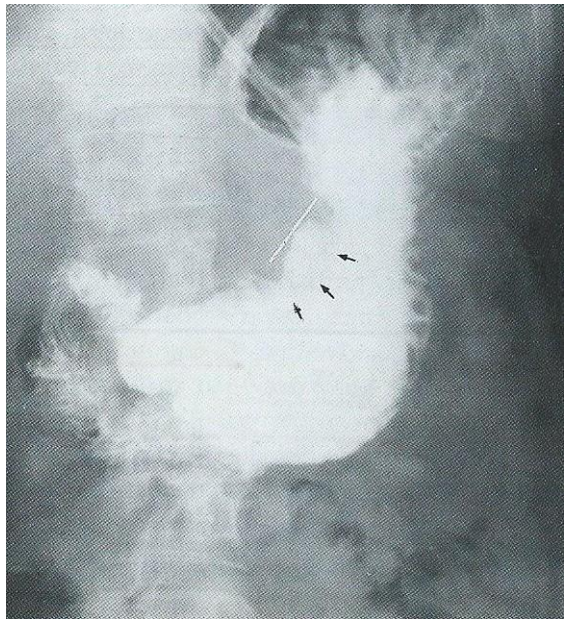

Image 12. Fluoroscopy test demonstrating gastric carcinoma.

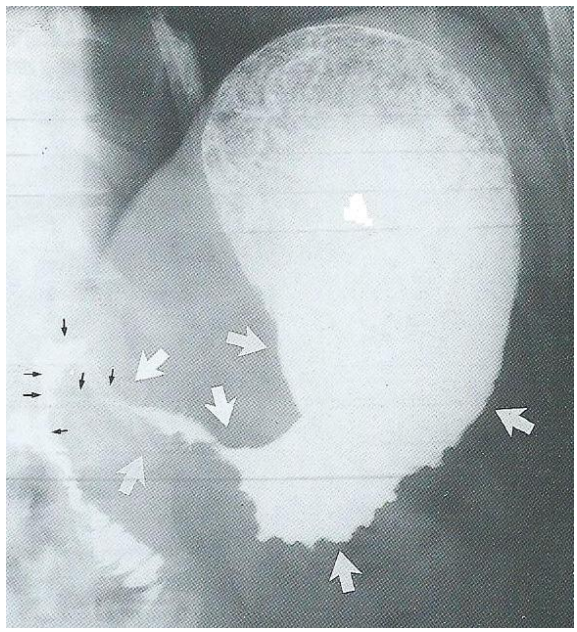

Image 13. Fluoroscopy test demonstrating linitis plastic.

Depending on the fluoroscopy findings, early gastric cancer is divided into three types.

type I: elevated lesion, protrudes > 5 mm into lumen (polypoid)
type II: superficial lesion (plaque-like, mucosal nodularity, ulceration)
type III: shallow, irregular ulcer crater with adjacent nodular mucosa and fusion or amputation of radiation folds.

Likewise, advanced gastric cancer may be polypoidal, ulcerative, or infiltrating lesions on barium studies.

With ulcerated carcinomas, an irregular crater is located in a rind of malignant tissue. Infiltrating carcinomas result in irregular narrowing of the stomach, with nodularity or spiculation of the mucosa Submucosal spread of tumors may result in pseudoachalasia or secondary achalasia with tapered, beaklike narrowing of the distal esophagus and infiltration of the gastric cardia. Ultrasound is not useful, unless a large epigastric mass is present or on endoscopic ultrasound study.

CT is currently the staging modality of choice because it can help identify the primary tumor, assess for local spread, and detect nodal involvement and distant metastases.

Additionally, CT is used to monitor a patient's response to treatment. Detection of gastric carcinoma is improved by using thin-section sequences and helical CT (14, 15). The early arterial phase is used to assess enhancement of the gastric wall; the later portal venous phase is used to assess the liver parenchyma for metastases. CT scans may show polypoidal mass with or without ulceration, focal wall thickening with mucosal irregularity or ulceration, wall thickening with the absence of normal mucosal folds (infiltrative lesions), focal infiltration of the gastric wall, variable thickening of the wall and marked contrast enhancement (typical of scirrhous lesions). Finally, mucinous carcinomas have low attenuation due to their high mucin content and which may contain calcification.

The depth of tumor invasion is not accurately assessed with CT. Tumor invasion of the perigastric fat is seen as soft-tissue stranding. Tiny 4- to 8-mm nodules may be observed. These may coalesce into sheets of tumor in advanced cases. Overall, the accuracy of determining the T-stage with CT is approximately 66%. CT depicts 75% of nodes larger than 5 mm in diameter, but it does not depict tumor in normal-sized nodes. CT is not useful in distinguishing between enlarged nodes due to reactive changes and those due to tumor. Because the portal vein drains the stomach, the liver is the most common site for hematogenous metastases (see the first image below).

Less common sites are the lungs (see the second image below), adrenal glands, and kidneys. Bony and cerebral metastases are uncommon. ntraperitoneal and omental metastases are common in advanced gastric cancer. They consist of nodules, localized fluid collections, and irregular thickening and stranding of the mesentery and omentum. Ascites and small-bowel obstruction may occur. Gastric carcinoma is the most common primary tumor to metastasize to the ovaries. These ovarian metastases are usually bilateral and are known as Krukenberg tumors. CT may fail to depict tiny omental and peritoneal deposits; small pelvic deposits may be overlooked as well [11-13].

MRI studies in which a breath-hold, fast-imaging technique and water were used showed accuracy rates comparable to those of helical, biphasic CT scanning. In T staging, the accuracy of MRI is 73%, compared with 67% for CT. In N staging, the accuracy of MRI is 55%, compared with 59% for CT. EUS has improved the accuracy of local staging of gastric

carcinomas. Unlike CT and MRI, EUS can depict individual layers of the gastric wall, with a rotating high-frequency probe inserted via an endoscope.

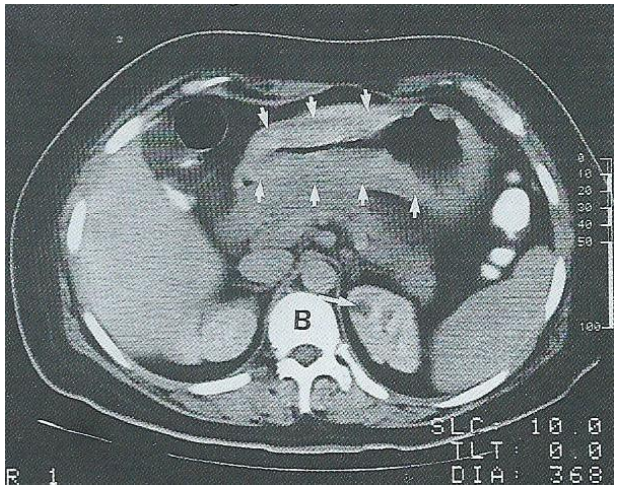

Image 14. CT scan illustrating thickening of the gastric wall because of adenocarcinoma of the antrum.

Image 15. CT scan in a patient with gastric outlet obstruction secondary to gastric cancer.

The gastric wall is visualized as 5 concentric bands: Mucosa – Echogenic, Muscularis mucosa – Hypoechoic, Submucosa – Echogenic, Muscularis propria – Hypoechoic andSerosa – Echogenic.

A gastric tumor is demonstrated as a hypoechoic mass with varying mural invasion. Regarding N staging, involved nodes are rounder and more hypoechoic than normal nodes. However, EUS is limited to an area 5 cm from the probe. It cannot be used to assess distant metastases or nodes more than 5 cm away from the probe. Intraoperative US and laparoscopy have an accuracy of 81% in T staging and an accuracy of 93% in N staging; however, the necessary equipment and expertise are not widely available.

PET scanning may be useful in the staging and postoperative assessment of gastric carcinomas. The only limitation of PET is that involved local lymph nodes cannot be separated from the primary tumor. Thus, its role in N staging is limited [15].

GASTRIC LYMPHOMA

Gastric lymphoma may either represent secondary involvement by systemic disease or primary malignancy confined to the stomach. Primary gastric lymphoma is an uncommon condition accounting for about 2% of all lymphomas. It is the most common source of lymphomas in the gastrointestinal tract. Typically primary gastric lymphoma occurs in adults in the 6th decade of life, without gender predilection. Secondary gastric lymphoma matches the demographics of the underlying lymphoma [16]. Patients usually present with long standing epigastric pain and/or dyspepsia which is attributable to *Helicobacter pylori* rather than the lymphoma *per se*. Three distinct types of gastric lymphoma are recognised:

- low-grade MALT lymphoma, accounting for 60% of all primary gastric lymphomas
- primary sporadic lymphoma, the vast majority of which are B-cell non-Hodgkins lymphoma
- secondary involvement of the stomach by systemic lymphoma

Mucosa-associated lymphoid tissue (MALT) lymphoma are strongly associated with *Helicobacter pylori* (85-98% of cases). These are low-grade lymphomas and may regress following treatment of *Helicobacter* infection. It is very important to differentiate gastric lymphoma from gastric adenocarcinoma and GIST since the treatment of lymphoma is primarily chemotherapy. Subtotal gastrectomy, with post-operative chemotherapy is undertaken in refractory cases, or in the setting of complications, including gastric outlet obstruction [17].

Radiographic Features

Appearances in barium swallow vary from normal, to grossly abnormal. Possible appearances include bull's eye appearance due to central ulceration, filling defects, thickened gastric rugae or linitis plastica. On CT scan, gastric lymphomas typically present with marked thickening of the gastric wall with extensive lateral extension of the tumour representing its submucosal spread. In some instances the submucosal spread involves nearly all the stomach, mimicking linitis plastica. In such cases, mural involvement may even extend across the pylorus into the duodenum or superiorly into the oesophagus. The mass is usually homogeneous in attenuation, but may contain focal areas of low density representing necrosis. Extensive retroperitoneal and local nodal enlargement is often seen.

Endoscopic ultrasound with EUS needle biopsy may be necessary to diagnose and to stage the disease. Hematological parameters are usually checked to assist with staging and to exclude concomitant leukemia [16, 17].

REFERENCES

[1] *Gray's Anatomy* 39th Edition, Elsevier.

[2] Butler, P., Mitchell, A., Healy, J. C. *Applied Radiological Anatomy*. Cambridge University Press. (2012) ISBN:0521766664.

[3] Mohan, P., Ananthavadivelu, M., Venkataraman, J. Gastric diverticulum. *CMAJ*. 2010; 182(5):E226.

[4] DuBois, B., Powell, B., Voeller, G. Gastric diverticulum: "a wayside house of ill fame" with a laparoscopic solution. *JSLS*. 2012;16(3): 473-7.

[5] Abbara, S., Kalan, M. M., Lewicki, A. M. Intrathoracic stomach revisited. *AJR Am. J. Roentgenol*. 2003;181(2): 403-14. AJR *Am. J. Roentgenol.*

[6] Underman, R. B. Essential radiology, clinical presentation, pathophysiology, imaging. *Thieme Medical Pub*. (2006) ISBN: 1588900827.

[7] De Sousa, L. C., Piza, M. R., Da Costa, S. S. Diagnosis of Meniere's disease: routine and extended tests. *Otolaryngol. Clin. North Am*. 2003; 35(3):547-64.

[8] Chey, W. D., Wong, B. C. American College of Gastroenterology guideline on the management of Helicobacter pylori infection. *Am. J. Gastroenterol.* Aug. 2007;102(8): 1808-25.

[9] Do Youn Park, MD; Gregory Y. Lauwers, MD. Gastric Polyps: Classification and Management. *Archives of Pathology and Laboratory Medicne*. Accepted October 2007; 132.

[10] Marcial, M. A., Villafana, M., Hernandez-Denton, J., et al., Fundic gland polyps: prevalence and clinicopathologic features. *Am. J. Gastroenterol*. Oct. 1993;88(10): 1711-3.

[11] Morais, D. J., Yamanaka, A., Zeitune, J. M., et al., Gastric polyps: a retrospective analysis of 26,000 digestive endoscopies. *Arq. Gastroenterol.* Jan-Mar 2007;44(1):14-7.

[12] Hallinan, J. T., Venkatesh, S. K. Gastric carcinoma: imaging diagnosis, staging and assessment of treatment response. *Cancer Imaging*. May 30 2013;13:212-27.

[13] Ge, M. Y., Yin, H. B., Wan, K. M., Ge, J. F., Jin, H. Computed tomography of gastrohepatic ligament involvement by gastric carcinoma. *Abdom. Imaging*. Aug. 2013; 38(4):697-704.

[14] Park, J. M., Jang, Y. J., Kim, J. H., Park, S. S., Park, S. H., Kim, S. J., et al., Gastric cancer histology: clinicopathologic characteristics and prognostic value. *J. Surg. Oncol*. Dec. 1 2008;98(7):520-5.

[15] Suzuki, H., Hasegawa, Y., Terada, A., Ogawa, T., Hyodo, I., Suzuki, M., et al., Limitations of FDG-PET and FDG-PET with computed tomography for detecting synchronous cancer in pharyngeal cancer. *Arch. Otolaryngol. Head Neck Surg*. Nov. 2008;134(11):1191-5.

[16] Buy, J. N., Moss, A. A. Computed tomography of gastric lymphoma. *AJR Am. J. Roentgenol*. 1982;138(5):859-65. *AJR Am. J. Roentgenol.*

[17] Yoo, C. C., Levine, M. S., Furth, E. E., et al., Gastric mucosa-associated lymphoid tissue lymphoma: radiographic findings in six patients. *Radiology*. 1998;208(1):239-43.

In: Encyclopedia of Surgery (22 Volume Set)
Editors: Andreas Lehrer and Kristin Mueller
ISBN: 978-1-53618-329-0
© 2020 Nova Science Publishers, Inc.

Chapter 91

THE ROLE OF IMAGING IN UROLOGY

Michelle Kim[1,*], MD, PhD, Douglas A. Mata[2], MD and Dicken S. C. Ko[1], MD

[1]Department of Urology, Massachusetts General Hospital, Harvard Medical School, Boston, MA, US

[2]Department of Pathology, Brigham and Women's Hospital, Harvard Medical School, Boston, MA, US

ABSTRACT

In this chapter, we examine the various imaging modalities used to evaluate the genitourinary (GU) tract. Advances in imaging technology have improved the clinical practice of urology and continue to be an active area of growth. Imaging modalities used by urologists include plain film radiography, ultrasonography (US), computed tomography (CT), magnetic resonance imaging (MRI), radionuclide studies, and positron emission tomography (PET). Each modality plays an important role in the diagnosis and management of urologic diseases and when used appropriately, provides cost-effective care. This chapter explores indications for these modalities and their optimal use.

Keywords: imaging, urology, uroradiology

PLAIN FILM RADIOGRAPHY

1. The Kidneys, Ureters, and Bladder (KUB) Film

Summary: Plain film abdominal radiographs are frontal, supine radiographs of the abdomen that capture the kidneys, ureters, and bladder and are often called KUBs. The KUB may be used as a primary study or as a scout film in anticipation of the use of contrast media [1]. In urology, KUBs are often used in the diagnosis of renal calculus disease and to assess

* Corresponding Author's Email: mkim27@partners.org; Fax: 617-726-6131.

the positioning of indwelling devices such as ureteral stents [1]. They are more commonly used to investigate the etiologies of non-GU processes such as bowel obstructions or bony fractures that may indicate the presence of urologic injuries. Because of the advent of the CT scan, use of the KUB has become limited. Nonetheless, it remains a cost-effective tool for monitoring residual stone burden after therapy for urolithiasis.

Technique: Placement of the patient is in the supine position [1]. The radiograph is obtained using an anterior-to-posterior (AP) exposure and should include the diaphragm superiorly and the pubic symphysis inferiorly. Oblique films may be used to aid in visualization and to clarify the location of peritoneal structures relative to the GU tract.

Limitations: The sensitivity of the KUB for the detection of uroliths can be adversely affected by overlying stool, bowel gas, or bony structures [1]. Non-GU calcifications in the pelvic veins or other vascular structures may also be confused with ureteral calculi. Poorly calcified, uric acid, or indinavir stones may be radiolucent and therefore not visualized. The KUB is also of limited use for evaluating soft tissue abnormalities.

Figure 1. Kidneys, ureters, and bladder (KUB) film.

2. Intravenous Urography (IVU)

Summary: IVU is used to demonstrate abnormalities of the renal collecting system, ureters, and bladder. IVU is widely considered obsolete and has now been replaced by US, CT, and MRI in most developed countries. In resource poor healthcare systems, an important indication for IVU is the investigation of renal and ureteral anatomy in the setting of suspected obstruction (i.e., secondary to nephrolithiasis or following surgery). IVU is also indicated for patients with unexplained hematuria to diagnose the presence of tumors or other anatomical abnormalities. IVU can also be used in the operating room to opacify the collecting system during extracorporeal shock wave lithotripsy (ESWL), to facilitate access during percutaneous nephrolithotomy (PCNL), or to assess renal trauma burden intraoperatively in trauma patients with suspected renal injuries who did not undergo preoperative imaging.

Technique: A bowel prep may be needed to facilitate the visualization of the ureters and upper collecting system [1]. Placement of the patient is in the supine position. A scout KUB

is taken to confirm correct positioning and exposure. A 50 to 100 mL bolus of contrast is injected. The nephrogenic phase radiograph is captured almost immediately after injection as the contrast is excreted from the bloodstream. Additional films are taken at five-minute intervals based on the clinical scenario. Abdominal compression and oblique views may be used to better visualize the ureters and to precisely differentiate ureteral stones from pelvic calcifications. Post-void films are obtained to evaluate for the presence of bladder outlet obstruction, or bladder-filling defects such as stones or malignancies.

Limitations: IVU has been largely replaced by CT and MRI for other diagnostic purposes given that they provide greater anatomic detail and three-dimensional reconstructions.

3. Retrograde Pyelography

Summary: Retrograde pyelography is a procedure in which contrast in injected into the upper urinary tract in a retrograde fashion to opacify the ureters and collecting system [1]. Retrograde pyelograms help identify filling defects (e.g., stones, tumors) and delineate renal anatomy in preparation for surgery. It is commonly used intraoperatively to opacify or to distend the collecting system to assist in percutaneous access of the kidney, ureteroscopy, or stent placement. Similar to an IVU, the retrograde pyelogram can also play a role in the workup of hematuria, in the surveillance of urothelial carcinoma, and in the evaluation of traumatic or iatrogenic injury to the ureter or collecting system. In children, retrograde pyelograms are indicated for evaluation of congenital or acquired ureteral obstruction and for elucidation of deformities of the ureters or intrarenal collecting system.

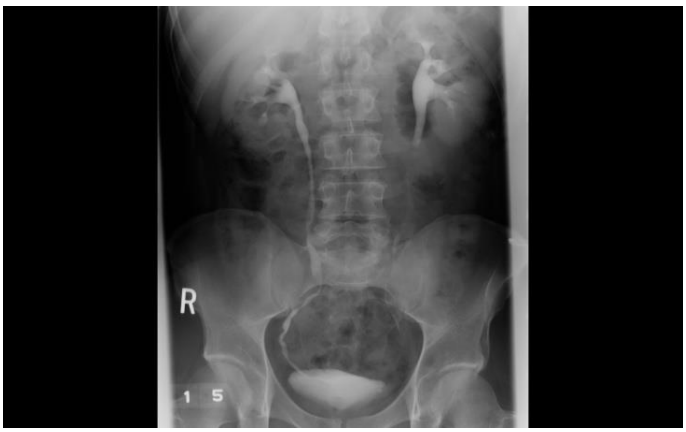

Figure 2. Retrograde pyelogram.

Technique: Retrograde pyelograms are performed with the patient under regional or general anesthesia [2]. The patient is placed in the dorsal lithotomy position. An abdominal plain film is initially obtained to ensure appropriate positioning. Cystoscopy is performed to visualize the ureteral orifice. A ureteral catheter or a cone tip catheter is inserted and contrast is injected into the upper urinary tract [1]. Contrast may be diluted to 50% with sterile saline to prevent subtle filling defects from being obscured. Care should be taken to prevent over-distension of the collecting system and contrast backflow, which can introduce infected urine

into the vascular system (by pyelolymphatic drainage) as well as systemic absorption of contrast media with resultant adverse systemic reactions. Retrograde pyelograms evaluate the upper urinary tract in real time and can be immediately interpreted as they are performed.

Limitations: Retrograde pyelography is difficult when the ureteral orifices cannot be properly identified or accessed [1]. Intravenous injection of methylene blue or indigo carmine (indigotindisulfonate sodium) can be used to identify the orifices. If trauma and extravasation of contrast occurs extraluminally, it is generally without serious complication. However, if large quantities of urine continue to extravasate, a stent may be indicated [2]. Retrograde pyelography should not be done in the setting of a urinary tract infection to avoid the risk of pyelonephritis and bacteremia.

4. Retrograde Urethrography

Summary: A retrograde urethrogram (RUG) is used to evaluate the integrity and anatomy of the anterior and posterior urethra [3]. It is essential for the diagnosis of urethral injury or stricture. RUGs are beneficial for demonstrating the length of a stricture when it cannot be determined by direct visualization. They can also show anatomy distal to a stricture that may not be readily visualized by voiding cystourethrogram. RUGs are also commonly used if there is suspicion of a foreign body or urethral trauma with additional clinical findings such as blood at the meatus, gross hematuria, scrotal hematoma, or high-riding prostate by digital rectal examination. If urethral injury is suspected, a RUG should be performed before placing a Foley catheter. If urethral disruption is observed, a suprapubic tube (SPT) would be preferred.

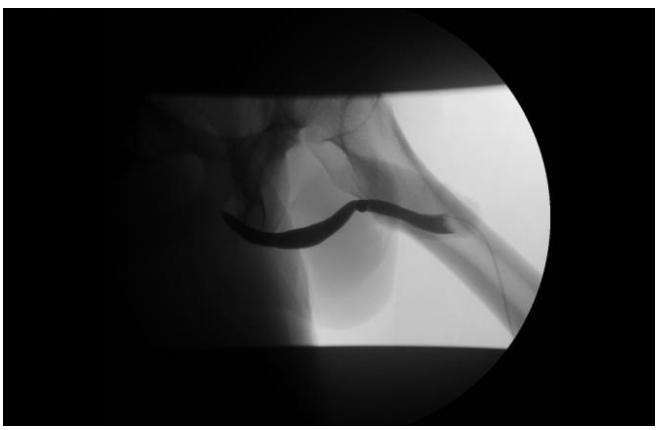

Figure 3. Retrograde urethrogram.

Technique: The patient is supine in a slightly oblique position with the penis on stretch [1]. A small Foley catheter is placed in the fossa navicularis, just past the urethral meatus, and inflated with 2 mL of sterile water. Thirty mL of contrast is injected into the catheter and a plain radiograph is obtained. A penile clamp can be used to keep the contrast in the urethra if desired. If contrast leakage is present, it suggests urethral injury and may help to determine whether surgery is indicated.

Limitations: RUGs provide limited information about surrounding soft tissue injury.

5. Cystogram

Summary: A cystogram evaluates the anatomy of the bladder and provides information about its size, shape, and contour [3]. Cystograms aid in the evaluation of intravesical pathology such as diverticula, fistulas, and trauma. Filling defects may provide information about stones or tumors. They are also indicated for evaluating inguinal hernias involving the bladder, colovesical or colovaginal fistulas, anastomotic integrity after surgery, and blunt or penetrating bladder trauma. Last, cystograms with contrast can be useful for studies of urodynamics.

Technique: The patient is placed in the supine position. A catheter is placed in the bladder and filled with 200 to 400 mL of contrast under gravity at 30-cm height. Adequate filling is necessary to ensure visualization of bladder extravasation or intravesical pathology [1]. AP and oblique films are taken to assess for lesions, including posterior lesions, which may be obscured. The patient is instructed to void three times, after which post-void images are taken to evaluate the quantity of urine left behind. A final radiograph of the kidneys may be performed to evaluate for occult vesicoureteral reflux not seen during the procedure itself.

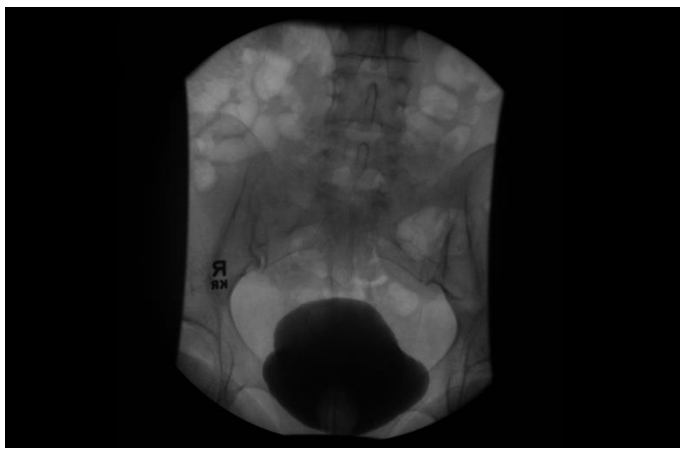

Figure 4. Cystogram.

Limitations: While the cystogram uses less radiation than a pelvic CT scan, it is less sensitive and specific for the diagnosis of most intravesical pathologies except the detection of bladder rupture [1].

6. Voiding Cystourethrogram (VCUG)

Summary: A VCUG is used to visualize the anatomy of the urethra and bladder during micturition [2]. The exam is most commonly used in children with UTIs to assess for the presence of vesicoureteral reflux. VCUG is indicated for all boys with recurrent UTIs, boys with abnormalities on US after their first UTI, girls less than three years of age with their first UTI, girls less than five years of age with their first febrile UTI, older girls and women with pyelonephritis or recurrent UTIs, and in the setting of suspected bladder obstruction, trauma,

or rupture. VCUGs should be avoided in patients with untreated UTIs, contrast media hypersensitivity, or fevers within the past day.

Technique: The patient is placed in the supine or semi-upright position using a table capable of reaching the full upright position [2]. A pelvic plain film is obtained. In children, a 5 to 8 French (F) feeding tube is used to fill the bladder with contrast using patient comfort as a guide to determine the appropriate volume [1]. In adults, a standard catheter is placed and the bladder is filled with 200 to 400 mL of contrast. The catheter is removed and an AP film is obtained. The patient is instructed to void while additional AP and oblique films are taken. The bladder neck and urethra may be evaluated by fluoroscopy during voiding. Oblique views may demonstrate low grade reflux that cannot be captured on an AP film. The exam ends when the patient voids while the radiologist is watching under fluoroscopy. Consumption of fluid promotes excretion of contrast media after the procedure. It is important to watch the contrast during voiding, as this is when the bladder has the most pressure and when reflux will most likely occur.

Figure 5. Voiding cystourethrogram.

Limitations: A VCUG requires filling the bladder with a catheter, which is difficult in children and in patients with anatomic abnormalities of the urethra or bladder neck [1]. Bladder filling may lead to autonomic dysreflexia in patients with spinal cord injuries and stimulate bladder spasms in some patients.

ULTRASONOGRAPHY

US uses the mechanical properties of sound to provide real-time images and is commonly used in urology for diagnosis, interventional management, and longitudinal follow up [3]. US is inexpensive, portable, and radiation-free. However, its specificity depends on the skill level of the operator and the body habitus of the patient.

1. Renal US

Summary: Renal US provides a cost-effective method of investigating renal lesions. A curved array transducer of 3.5 to 5.0 MHz is used in adults; higher frequencies can be used in children [1]. Intraoperative renal US during open or laparoscopic cases typically employs a linear transducer of 6 to 10 MHz given the physical proximity of the organ. Renal US is indicated for the assessment of renal and perirenal masses; upper GU tract dilation; flank pain during pregnancy; hematuria in patients who are not candidates for other imaging modalities; or impaired renal function. Renal US may also be used for interventional procedures such as renal biopsies, renal mass ablation, or nephrostomy tube placement. Vascular abnormalities including renal artery stenosis, renal vein thrombosis, arteriovenous fistulas, and pseudoaneurysms can also be detected by renal US with Doppler concurrent imaging.

Technique: US of the right kidney is performed with the patient supine. The kidney is located in the mid-clavicular line in the right upper quadrant [1]. The transducer is moved laterally until the mid-sagittal plane of the kidney to visualize the anterior and posterior kidney. The, probe is rotated 90 degrees counter clockwise and the kidney is imaged in the transverse plane which includes visualization of the renal hilum. Imaging of the left kidney is similar except that it is slightly more cephalad due to the absence of the liver. It is more difficult to image due to interference from bowel gas from the splenic flexure and because the liver does not provide an acoustic window. Echogenic renal lesions include renal stones, angiomyolipomas (AMLs), renal cortical neoplasms, abscesses, and hematomas.

Figure 6. Renal ultrasound.

Limitations: Obesity, intestinal gas, and physical deformity are limitations to adequate US imaging studies [1]. Renal US is excellent for diagnosing benign renal lesions such as cysts, but has poor sensitivity for renal masses less than 2 cm as well as for masses other than angiomyolipomas (AML). More complicated lesions require correlation with another imaging modality, most commonly a CT scan.

2. Transabdominal Pelvic US

Summary: Transabdominal pelvic US, commonly referred to as bladder US, is used to image the lower GU tract in men and women [3]. Common indications for transabdominal pelvic US include assessment of bladder volume, post-void residual, bladder wall configuration and thickness, prostate size and morphology, and catheter placement. A curved array transducer is used. Of note, handheld BladderScan™ devices used in the clinic and wards for measuring bladder volumes and post-void residuals are based on US technology.

Technique: The patient is positioned supine. The bladder is moderately distended to ensure appropriate visualization. The bladder is scanned in the sagittal and transverse planes angling the probe into the pelvis to visualize the bladder beneath the pubic bone [1]. To visualize the prostate, the transducer is fanned inferiorly until the largest transverse diameter of the prostate is identified. Measurements of the width and height are obtained. The transducer is rotated 90 degrees clockwise to produce a true sagittal image of the prostate, which is again measured. Detection of hypertrophy or an enlarged median lobe should be noted to provide additional information regarding the length, size, and configuration of the prostatic urethra and median lobe. These data may provide secondary information about the etiology of bladder outlet obstruction.

Limitations: An under-distended or empty bladder will interfere with the identification of distal ureteral or bladder obstructions, stones, or tumors, and with the assessment of prostatic morphology.

3. Scrotal US

Summary: Scrotal US is an excellent tool for investigating intratesticular and extratesticular disease including testicular neoplasms, torsion, infection, and inguinal hernias [3]. It is commonly used with Doppler sonography to evaluate blood flow to provide detailed anatomic and physiologic information. Indications include assessment of scrotal or testicular mass, pain, or trauma. It may also be used in the infertility workup.

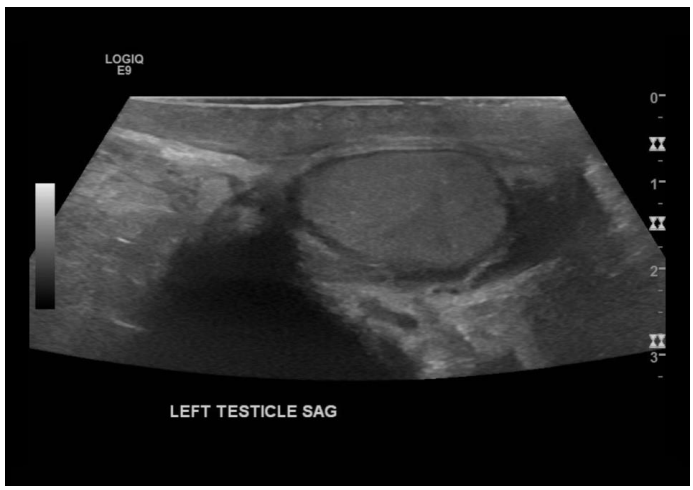

Figure 7. Scrotal ultrasound.

Technique: The patient is placed in the supine position with the scrotum supported on a towel. A high frequency linear array 6 to 12 MHz and 4 to 7.5 cm in width is used [1]. The sonographer starts with a sagittal view of testes from the midline medially and then laterally from the mid-transverse section to the upper and lower poles. The epididymis and scrotal contents are evaluated.

Limitations: The pathognomonic sign of torsion is the absence of intratesticular blood flow. Collateral blood flow may be preserved and it is important for the sonographer not to confuse its presence with that of intratesticular blood flow [1]. Imaging of the contralateral testis can be performed to confirm that the study is able to adequately detect intratesticular blood flow.

4. Penile US

Summary: Penile US is commonly used to assess the vascular supply of the penis for the diagnosis of erectile dysfunction secondary to arterial insufficiency and veno-occlusion etiologies. Moreover, penile US remains a mainstay for the diagnosis of traumatic injuries [1]. Penile US is also indicated for the evaluation corpora cavernosa fibrosis, urethral stricture or diverticulum, foreign body, priapism, and Peyronie's disease.

Technique: The patient is placed in the supine position. A 6 to 12 MHz linear array transducer is used to image the phallus in the longitudinal and transverse planes in a systematic fashion beginning at the base of the penis and proceeding distally to the glans [1]. Scanning the scrotum and perineum also allows for imaging of the proximal urethra and corporal bodies. Lubricating gels or intracavernosal injection of vasoactive substances may be useful for evaluating anatomy and vascular flow.

Limitations: Penile US has a limited sensitivity and specificity for the detection of penile arterial dysfunction. Pudendal arteriography may be needed to collect more definitive data prior to surgical intervention.

5. Transrectal US of the Prostate

Summary: Transrectal ultrasound (TRUS) allows for the visualization and evaluation of the prostate gland [3]. TRUS is used to guide prostate biopsy, to determine prostate volumes for brachytherapy and cryotherapy (e.g., by planimetry), and to evaluate benign prostatic hypertrophy (BPH). TRUS provides enough resolution to differentiate between the peripheral and transitional zones of the prostate so that the peripheral zone, in which cancers are more commonly located, can be targeted with the biopsy needle [1].

Technique: The patient is placed in left lateral decubitus position with the legs drawn inward [2]. A 6 to 10 MHz endorectal US probe is inserted into the rectum until it reaches the base of the prostate [1]. The probe is moved caudad to visualize the seminal vesicles, bladder neck, prostatic apex and proximal urethra. Complete evaluation of the prostate includes scanning in the sagittal and transverse planes, thoroughly inspecting the prostate for echogenic lesions, cysts, contour, and calcifications. The seminal vesicles and vas deferens should be fully visualized.

Limitations: The sensitivity and specificity of gray-scale TRUS is limited for the reliable detection of all cancers. Color and power Doppler imaging modes improve detection but biopsy remains the gold standard for diagnosis.

TOMOGRAPHY AND MAGNETIC RESONANCE IMAGING MODALITIES

1. X-Ray Computed Tomography

Summary: CT is often the imaging modality of choice for the diagnosis and management of urologic diseases and has largely replaced other types of imaging as the first-line imaging for nephrolithiasis, hematuria, and workup of renal or urothelial masses [1]. CT scans have advantages over plain film radiographs in that they eliminate superimposition of images of structures that obscure the organ of interest. CT scans of traumatic injuries of the bladder can be complemented by cystogram to better assess the location of the rupture.

Technique: The patient is placed in the supine position on a gantry that passes through the center of CT scanner [5]. The length of study depends on the indication.

Limitations: Although CT scans are generally associated with greater radiation exposure than IVUs, a low-dose CT stone protocol with minimal radiation exposure can be used to detect renal calculi. CT scans sometimes require radiocontrast agents, which often are not without side effects, for improved visualization. Contrast induced nephropathy, which is more prevalent in patients with preexisting renal insufficiency, diabetes, or hypovolemia, should be avoided. Metal implants may create radiographic artifacts.

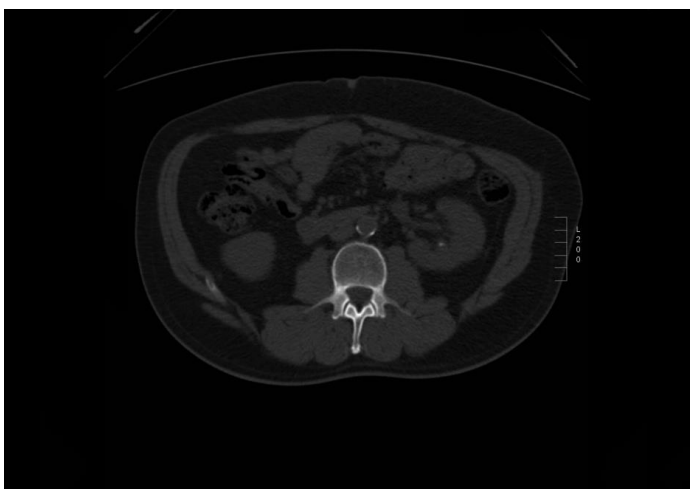

Figure 8. X-ray computed tomographic scan.

2. CT Urography

Summary: CT urography evaluates the entire GU tract using different phases of contrast enhancement [1, 3, 5]. Patients with hematuria and those presenting with flank or abdominal pain are often evaluated by CT urography.

1. The non-contrast phase scan provides an optimal set of images for detecting calcifications, and acts as a baseline for assessing the changes noted following contrast injection [5].
2. The arteriographic or early arterial phase scan is taken 20 seconds after contrast injection and evaluates arterial pathologies such as fibromuscular dysplasia or renal artery stenosis [3, 5].
3. The late arterial or corticomedullary phase is taken 40 seconds after contrast injection and allows for the detection of hypervascular renal masses [5]. This study should always be obtained when information about the renal vasculature is desired or if there may be an aneurysm, arteriovenous malformation, or fistula.
4. The nephrographic phase occurs 80 to 100 seconds after contrast injection and assesses the abdominal and pelvic viscera [5]. Non-hypervascular renal masses are best evaluated during this phase.
5. The excretory phase occurs two minutes after contrast injection and evaluates the collecting system [1, 5]. It is useful for evaluating hematuria and is more sensitive than retrograde pyelogram for detecting upper tract urothelial cancers.

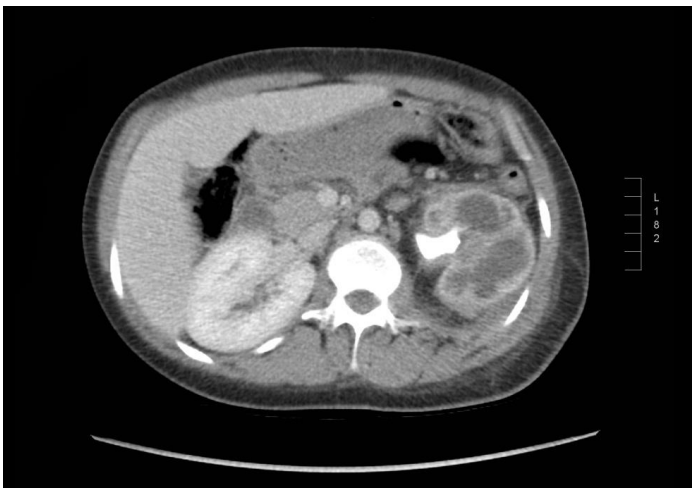

Figure 9. Computed tomographic urogram.

Technique: CT urography may be performed supine or prone [5]. Prone images help to precisely identify the locations of distal ureteral-vesical junction stones. If there is concern that the stone is in the distal ureter, other signs of obstruction helpfully differentiate it from pelvic calcifications. Non-contrast and excretory phase images should span the diaphragm to the pubic symphysis to visualize the entire GU tract.

Limitations: CT urography is not as sensitive as cystoscopy for the detection of intravesical tumors and should not be a substitute in the evaluation of hematuria. However, it can identify filling defects in the bladder caused by larger tumors. In patients with recurrent need for radiation exposure, low-dose CT protocols may be used with minimal sacrifice of diagnostic capabilities.

3. Magnetic Resonance Imaging

Summary: MRI uses magnetic fields and radio waves to provide excellent soft tissue resolution and can be used in patients who cannot be given iodinated contrast [1, 3, 5]. MRI images may be weighted to show different anatomical structures. Fluids such as urine have low signal and appear dark in T1-weighted images. Intravenous gadolinium contrast can be used to augment the relaxation of protons in T1-weighted images, making the kidneys brighter and increasing the chance of detecting renal masses. Fluids in T2-weighted images have higher signal and appear bright. In the kidney, this causes the cortex to appear brighter than the medulla. Urine in the bladder is also bright on T2-weighted images. MRI can differentiate among complex renal cysts, which may be filled with heterogeneous material, in ways that CT or US cannot. Blood breakdown products due to hemorrhage result in high signal on T1-weighted images, whereas they result in black rings around cyst walls on T2-weighted images. MRI is often used to evaluate renal masses, staging of renal malignancies, as well as aid in the planning of surgery for RCC, particularly in the setting of renal vein or inferior vena cava (IVC) invasion [1, 3, 5].Detectable lesions are assessed for increases in signal intensity by comparing non-enhanced to gadolinium-enhanced T1-weighted images. Adrenal evaluation by MRI is useful because of variations in tissue density among the various adrenal lesions.

Technique: The patient is placed in the supine position on a gantry that passes through the bore of the magnet [3]. More than 30 minutes are needed for the scanner and patients will need to hold their breath for 20 to 30 seconds during each imaging sequence. If the patient is noncompliant, the image will be compromised.

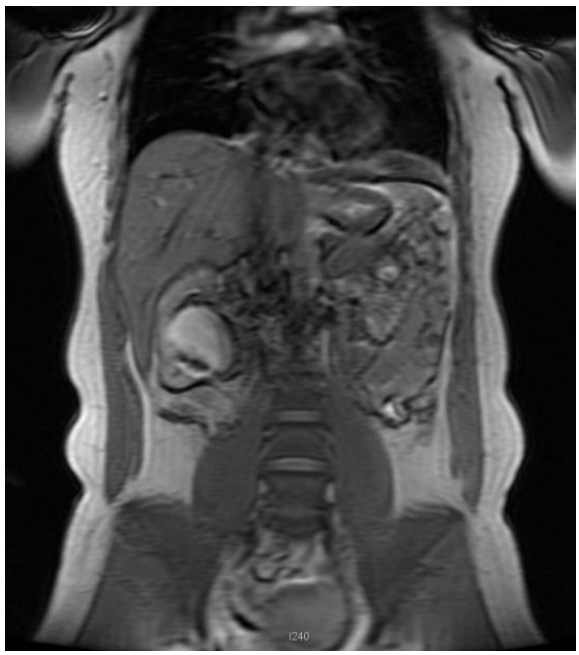

Figure 10. Magnetic resonance imaging scan.

Limitations: An important disadvantage of MRI is that patients must stay still for extended periods of time in enclosed environments [1]. If patients have difficulty with breath-holding, severe claustrophobia, pacemakers, sterile magnetic implants, retained magnetic foreign bodies, cochlear implants, neurovascular aneurysm clips, or cardiac defibrillators other imaging modalities are preferred. Gadolinium contrast agents should not be used in patients with renal insufficiency as it may lead to development of debilitating fibrosing dermopathy.

NUCLEAR MEDICINE

1. Positron Emission Tomography

Summary: PET allows for the detection of primary and metastatic cancers and for the determination of disease extent [4, 5]. PET is combined with high resolution CT to increase the detection of recurrent or metastatic cancers. For seminomas and nonseminomatous germ cell testicular tumors, PET/CT is more accurate than CT for staging of residual masses after chemotherapy [1]. PET/CT also has a promising role in clear cell RCC. The antibody cG250 recognizes carbonic anhydrase IX, which is related to unrestrained cancer growth, and positron-emitting radionuclide, iodine 124, has been successfully attached to it and injected into RCC patients. Other tracers are being developed for the detection of metastatic prostate cancer. Fewer studies have addressed the role of PET in bladder cancer.

Technique: Prior to the scan, a radioactive tracer isotope is injected into the blood [2]. After a waiting period during which the tracer becomes concentrated in the tissue of interest, the patient is scanned. Tissue concentrations are recorded as the tracer decays.

Limitations: The accuracy of PET can be compromised if it is performed within two weeks of completing chemotherapy due to decreased metabolism and increased macrophage activity.It is recommended that PET/CT be delayed for four to 12 weeks following chemotherapy [1].

2. Radioisotope Renography

Summary: Radioisotope renography plays an important role in providing information about kidney function[1, 5]. There are several commonly used agents in nuclear scintigraphy.

1. ^{99m}Tc-DTPA is used to evaluate obstruction and renal function. It is excreted through the kidney and requires a normal glomerular filtration rate (GFR) to provide accurate results.
2. ^{99m}Tc-DMSA, is cleared by filtration and secretion and localizes to the renal cortex. It is the standard test used to identify cortical defects and ectopic or aberrant kidneys, and can also differentiate between benign and malignant lesions.
3. ^{99m}Tc-MAG3, is cleared mainly through tubular secretion with approximately 10% cleared extra-renally. It is limited in its ability to measure GFR because it binds to plasma proteins. It is the study of choice to evaluate renal function and plasma flow

in individuals with impaired renal function and urinary obstruction and to evaluate anatomical abnormalities.

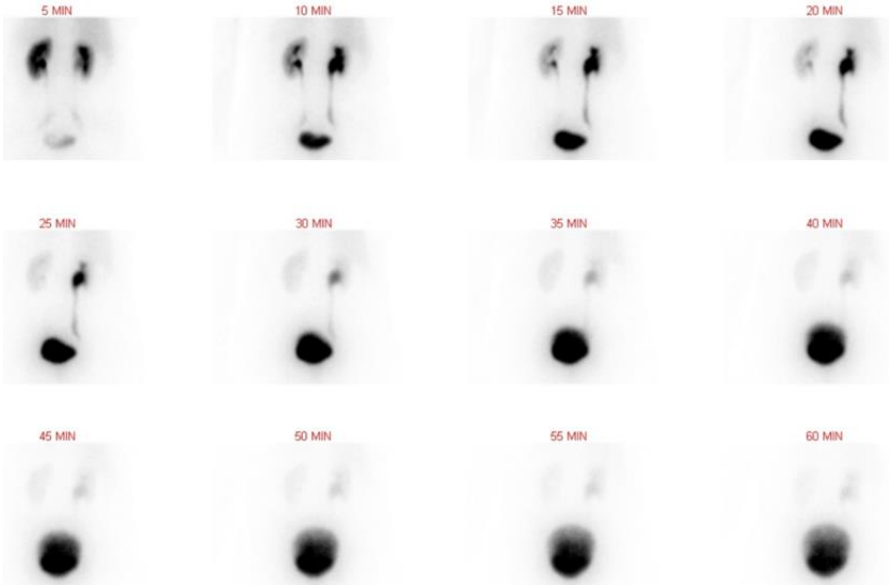

Figure 11. Radioisotope renogram.

Technique: The radioisotope is injected intravenously [1]. Gamma scintillation cameras measure radiation emitted from the radioisotope and digital workstations process and display the information. Of note, ^{99m}Tc-MAG3 works with diuretic scintigraphy to provide a differential of renal function and clearance time comparing the two kidneys. A diuretic, usually 0.5 mg/kg furosemide, is administered when maximum collecting system activity is visualized. The initial phase of the study is called the flow phase. Images are taken at 2-second intervals for two minutes. Images are taken at 1-second intervals for one minute. This phase demonstrates renal uptake, background clearance, and abnormal vascular lesions that may be due to AVM, tumors, or active bleeding. The second phase is called the renal phase. It is most useful for evaluating renal function. The time to peak uptake is typically between 2 and 4 minutes. During this phase, images are taken at 1-minute intervals for half an hour. In the last phase, the excretory phase, images are again taken at 1-minute intervals for half an hour. The half-life ($T_{1/2}$) is the time it takes for the collecting system activity to decrease by 50% from the time of diuretic administration. Transit time through the collecting system of less than 10 minutes is consistent with a normal, non-obstructed system [1]. A $T_{1/2}$ of 10 to 20 minutes represents a mild to moderate delay and may indicate the presence of a mechanical obstruction. A $T_{1/2}$ greater than 20 minutes is consistent with a high grade obstruction. If ureteral stents are in place, the patient should have an unclamped bladder catheter.

Limitations: For diuretic scintigraphy, the $T_{1/2}$ is highly technician dependent because the diuretic must be given when the collecting system displays maximum activity.

3. Whole-Body Bone Scintigraphy

Summary: Whole-body bone scans are the most sensitive method for detecting bone metastases from primary prostate and renal cancers [5].

Technique: The patient is injected with a radioactive tracer and then scanned with a gamma camera, a device that detects the radiation emitted [3].

Limitations: A positive bone scan is not specific for cancer and may prompt the use of other imaging modalities (e.g., plain film radiography, CT, or MRI) to confirm the findings and correlate them with any prior history of fracture, trauma, surgery, or arthritis. Bone scans can be mistaken as normal if there is uniformly increased uptake in the bony structures due to diffuse metastatic bony disease.

FINANCIAL DISCLOSURE

None.

REFERENCES

[1] Wein, A. J., Kavoussi, L. R., Novick, A. C., Partin, A. W., Peters, C. A. *Campbell-Walsh Urology: Expert Consult Premium Edition: Enhanced Online Features and Print*, 4-Volume Set, 10e. 10 edition. Philadelphia, PA: Saunders; 2011.

[2] Hanno, P. M., Guzzo, T. J., Malkowicz, S. B., Wein, A. J. *Penn Clinical Manual of Urology: Expert Consult - Online and Print*, 2e. 2 edition. Philadelphia, PA: Saunders; 2014.

[3] McAninch, J., Lue, T. F. *Smith and Tanagho's General Urology, Eighteenth Edition*. 18th edition. New York: McGraw-Hill Professional; 2012. Dunnick, R., Sandler, C., Newhouse, J. *Textbook of Uroradiology*. Fifth edition. Philadelphia: LWW; 2012.

[4] Kim, S. H., editor. *Radiology Illustrated: Uroradiology*. 2nd ed. 2012 edition. New York: Springer; 2012.

[5] Shoskes, D. A., Uzzo, R. G. *The American Urological Association Educational Review Manual in Urology*. 4th Ed. 2012. 4th edition. Castle Connolly Graduate Medical Publishing; 2012.

[6] Wang, L. J. *Key Diagnostic Features in Uroradiology: A Case-Based Guide*. 2015 edition. New York, NY: Springer; 2014.

In: Encyclopedia of Surgery (22 Volume Set)
Editors: Andreas Lehrer and Kristin Mueller
ISBN: 978-1-53618-329-0
© 2020 Nova Science Publishers, Inc.

Chapter 92

THE ROLE OF IMAGING IN PLASTIC SURGERY

Alexandros Mekras[1,*], MD, PhD
and Vasileios Kalles[2], MD, PhD
[1]Verbundkrankenhaus Bernkastel/Wittlich, Germany
[2]Naval and Veterans Hospital of Athens, Athens, Greece

ABSTRACT

From the era that Röntgen discovered X-rays, imaging studies have been a significant adjunct in the clinicians' armamentarium. The rapid development of modern imaging techniques, as well as the increased accessibility to sophisticated imaging techniques, has allowed physicians to have access to detailed anatomical and functional information. Plastic surgery, being one of the surgical specialties that uses the most up-to-date technologies in both diagnosis and treatment, is a field that modern imaging techniques have had a significant impact on. Current applications of imaging in plastic surgery range from staging of melanoma patients to preoperative submillimeter-scale planning of perforator flaps. Nearly all currently available imaging techniques, including X-rays, Ultrasound, Computed Tomography, Magnetic Resonance Imaging, and Positron Emission Tomography, are being used as adjuncts in the diagnosis and/or staging of plastic surgical conditions and diseases. Furthermore, as accurate preoperative planning of plastic and reconstructive surgical procedures has been shown to be of high importance for both the patient as well as the health system by improving the surgical outcomes, imaging techniques, and more specifically CT – and MRI – based studies, have emerged as the outstanding gold standard techniques.

INTRODUCTION

Over the past years, the field of imaging has seen continuous and increasingly rapid developments, regarding both the availability and the accessibility of imaging techniques. Imaging procedures nowadays integrate information strictly anatomical with high resolution

* Corresponding Author's Email: almekras @yahoo.gr.

images, and, in the case of molecular imaging, information on the functional nature of the tissue. All this detailed information allows plastic surgeons to have precise preoperative data that correlate with the clinical status of the patient.

As a result, imaging has become an essential part of preoperative planning for the patient undergoing a plastic surgical procedure, whether this should be reconstructive or aesthetic.

Apart from the classical applications of imaging in disease diagnosis and staging (such as skin melanoma), particular applications of preoperative imaging include perforator flap surgery and facial reconstruction, among others. It is now well established that accurate preoperative analysis can reduce the length of operations, enhancing the surgical design and minimizing unneeded dissections.

The modern imaging modalities that are now available can offer high–resolution, three–dimensional analysis of the vascular anatomy, and perfusion. Computed Tomography (CT) and magnetic resonance imaging (MRI) are the modalities that have lately been established as outstanding non–invasive techniques for the depiction of vascular and non–vascular systems.

This chapter will elaborate on the use and the importance of imaging techniques in plastic surgery, including the role of both CT and MR angiography, the techniques that are currently the state of the art in preoperative exploration of the vascular system.

1. DIAGNOSTIC IMAGING IN PLASTIC SURGERY

1.1. Skin Melanoma

Although skin melanoma accounts for only 5% of skin cancers, it represents nearly half of skin related deaths and globally, in 2012, melanoma occurred in 232,000 people and resulted in 55,000 deaths. Its prognosis is directly related to the clinical stage at presentation, and patients with metastatic disease survive for a median of 6-10 months (Table 1) [1, 2].

Melanoma can disseminate to virtually any organ of the human body, but has a predilection for the regional lymph nodes, liver, lung and brain [3]. Surgery remains the cornerstone of melanoma treatment, while imaging plays a key role in preoperative staging and postoperative follow – up. Although most imaging studies have a limited ability to diagnose melanoma, a variety of traditional or advanced imaging techniques are employed, in an attempt to detect occult metastases.

1.1.1. X – Rays

X – rays, the most classical imaging study, is a quick, inexpensive, and easy to perform technique, and can be applied in melanoma staging, especially since the lung is one of the most common metastatic sites. However, only a few lesions produce an appearance that can be correlated to a specific diagnosis. Investigating the use of chest X – ray in patients with localized melanoma, Terhune et al., [4] found that only 0.1% of the patients staged by this method were found to have occult metastatic lesions. In a more recent study, Hofmann et al., [5] reported that chest X - ray showed a yield of 0.2% and a false positive rate of 4.4%.

Still, a chest X – ray in a symptomatic patient remains of some use, and will also be useful as a routine preoperative screening exam.

1.1.2. Ultrasound

In melanoma, ultrasound has been used for both the diagnosis of skin lesions, and staging of regional nodes and abdominal organs. The ability of ultrasound to distinguish between basal cell papilloma and malignant melanoma has been investigated, and ultrasound has been reported to have sensitivity of up to 100%, but with low specificity rates [6, 7]. The addition of color Doppler in the investigation might also further improve accuracy [8].

Ultrasound has also been widely used in the evaluation of lymph node basins in melanoma staging. Compared to clinical examination, ultrasound has shown superior sensitivity rates, with comparable specificity, despite the fact that it is an operator – dependent technique [9-11]. However, in the era of the Sentinel Lymph Node Biopsy technique for lymph node staging of melanoma, ultrasound has limited utility, as its false negative rates remain high, especially in case of small metastatic deposits (2-4mm), and SLNB remains the golden standard for lymph node staging in clinically node – negative patients [12]. Finally, in distant metastases staging, ultrasound is not routinely used, but may be useful in the differential diagnosis of e.g. suspicious liver lesions.

1.1.3. Computed Tomography

Computed Tomography is the preferred imaging technique for the evaluation of abdominal metastases in melanoma patients. Liver metastases from melanoma are typically hypervascular lesions, and therefore the correct phase post contrast infusion is needed to be acquired. On the other hand, chest CT is also superior to chest radiography, more sensitive in detecting subcentimeter lesions and more capable to distinguish solitary from multiple pulmonary lesions [13]. In patients with normal chest radiography, the possibility of discovering additional metastasis in chest CT raises up to 19% in high – risk patients [14]. However, when the CT results in indeterminate findings, patients should undergo further imaging or diagnostic surgery.

1.1.4. Magnetic Resonance Imaging

Magnetic Resonance Imaging (MRI) is an excellent technique to delineate soft tissues, due to its high contrast resolution and multiplanar images.

Table 1. Expected survival of patients with melanoma

Stage	5 – year survival (%)
I	91 – 95
IIA	80
IIB	65
IIC	45
IIIA	65 – 70
IIIB	45 – 55
IIIC	25 – 30
IV	5 - 20

However, it still carries a lot of limitations, due to its high – cost, long examination times, and its patient – related contraindications (claustrophobia, pacemakers, certain surgical clips or metal prosthetic devices).

In melanoma patients, T1 – weighed images give a high signal density for melanoma deposits, consistent with the paramagnetic effect of melanin.

As a result of its increased soft – tissue contrast, MRI is more sensitive than CT in the detection of metastases that involve the brain, liver and musculoskeletal system [15], and results in alteration in the treatment plan in nearly one quarter of the patients. Still, MRI would not be a first – line investigation for staging of melanoma, and it is most useful as an adjunctive method of investigating indeterminate lesions found in previous imaging studies.

1.1.5. Sentinel Lymph Node Biopsy – Nuclear Medicine Imaging Modalities

The reference standard for the lymph node staging in melanoma patients with no clinical evidence of regional nodal metastasis, is sentinel lymph node biopsy (SLNB), a technique that was developed by Morton more than 20 years ago [16], typically performed following intraoperative lymphatic mapping. Formal regional lymphadenectomy is now reserved for patients with clinical suspicion of metastatic adenopathy, which is usually confirmed with ultrasound – guided fine needle aspiration (FNA).

In the event of a negative SLNB, patients are considered to have a clinical stage I/II disease, whereas patients with positive SLNB following a complete regional lymphadenectomy, will require further imaging in order to detect clinically occult metastases. Nuclear medicine imaging modalities, such as positron emission tomography (PET), with or without combination with computed tomography (PET/CT) are also becoming increasingly popular in the staging of melanoma. Their scientific basis lies on the fact that malignant cells have a higher metabolic rate, and this is detected by infusion of a radio-labeled glucose analogue, 18-fluoro-deoxy-D-gucose (18-FDG), which is taken up by tumor cells. However, a PET scan alone offers a limited spatial resolution, and small (< 1cm) or non-metabolically active lesions may be missed. Thus, PET alone is considered to be more accurate in stage III disease rather than stage I/II [17], while SLNB has been shown to have superior sensitivity in stage I/II melanoma patients (Table 2).

The addition of PET images to CT images acquired simultaneously has been the new revolution in Nuclear Medicine Imaging, and offers more accurate localization of 18-FDG uptake. The accuracy of PET/CT is increased compared to PET alone, even in patients with early stage melanoma [18, 19]. PET/CT has the potential of covering the whole body, which is not easy to accomplish with other imaging techniques, as well as an increased spatial resolution compared to PET alone (6mm vs 10mm).

Table 2. Selected studies comparing nodal status detection by SLNB and PET in Stage I/II melanoma patients

Author	No of patients	PET positive (%)	SLNB positive (%)
Wagner et al., 1999	70	3	16.7
Hafner et al., 2000	100	2	26
Wagner et al., 2005	144	9	43

However, some limitations still exist: its specificity is still low, as lesions with increased metabolic rate such as inflammatory on infectious can be falsely considered positive, and there are a small proportion of low – metabolic rate lesions that PET/CT will not detect.

Finally, its increased cost and limited availability pose another drawback to this technique, and its use is mostly reserved for patients with high risk of recurrence after successful resection or response to systemic treatment.

1.2. Assessment of Skin Burns

Burn wounds are a common clinical entity a plastic surgeon has to face in everyday clinical practice. Since burn wounds that heal within a short time (e.g. 2-3 weeks) have an acceptable aesthetic and functional outcome, it is critical that the burn depth is assessed accurately early, in order to better stratify patients that are deemed to undergo surgery that involves excision and grafting, in order to achieve healing within this 2-3 week timeframe.

The initial clinical assessment is usually effective when it comes to burns that are classified as superficial or full thickness, however, in partial thickness skin burns the depth is not well defined and the clinical estimation of the depth is often inaccurate. Studies have shown that in the case of an indeterminate depth burn, the clinical assessment has an accuracy ranging between 65-70%, even when the burn depth is assessed by experienced plastic surgeons [20, 21]. For this reason, much research has focused on potential imaging adjuncts that will assist the clinician in making a correct burn depth assessment.

The foremost among these techniques, that has met great approval among plastic surgeons, was the laser Doppler technique [22]. The laser Doppler technique utilizes the Doppler Effect in order to assess burn depth, as laser light is directed at the moving blood cells in the sampled tissue, and the frequency change of the waves of laser light is proportional to the amount of perfusion in the tissue.

The correlation between burn depth and perfusion has been documented since as early as 1984, when Micheels and colleagues showed that superficial or partial – thickness burns result in supranormal dermal perfusion, whereas deep or full – thickness burns display significantly reduced dermal blood flow [23, 24].

The current evidence in the evaluation of skin burns with laser Doppler is growing [22], and recent studies show that a new technique, the Laser Doppler Imaging is more efficient than LD flowmetry, superseding the latter one. The LDI is usually applied within 48 – 72 hours, and provides a significant aid to the clinical evaluation, predicting the possibility of healing within 21 days, and this has been validated in both adult and pediatric patients. Current limitations of the technique include its increased cost, the topographical artifacts when curved areas of the body are assessed, its difficulty in the assessment of tattooed areas of the body and possible ambiguous results in patients with concurrent infections, peripheral vascular disease or anemia.

Furthermore, there is no current consensus on the cut – off points of perfusion values, and burn centers still have to evaluate their devices independently and find the most suitable cut - off points and levels of burn wound depth stratification. However, the objective benefit of LDI, when used as an adjunct to clinical assessment, has now been well documented, and its use improves the prediction of burn healing and reduces ensures a timely decision to operate.

1.3. Scar Evaluation Using Modern Imaging

Skin scars are the end result of a cutaneous injury, iatrogenic or not, following a series of events that are involved in the wound healing process [25]. Cutaneous scarring is affected by a plethora of genetic, physiologic, environmental and biochemical factors, and all these produce a continuum of scar types (keloid, hypertrophic, atrophic, contracted, fine line, etc.), with up to 70% of the scars being symptomatic, aesthetically unsatisfactory, physiologically distressing or functionally restrictive to the individual [26].

The accurate assessment of the scar allows for better quantification of the scar inflammatory state, its morphology and evolution, as well as its response to interventional or conservative treatments [26]. In the quest of objective adjuncts in scar evaluation, a number of imaging techniques have been evaluated, such as laser Doppler and ultrasonography, along with a bunch of, mostly experimental, other techniques.

Laser Doppler Flowmetry is based on the fact that the blood perfusion in the cutaneous tissue correlates with the extent of the vascularization. Laser Doppler has been extensively used in burn assessment, and when applied to scars, it can act as a predictor during scar maturation, as hypertrophic scars tend to have increased blood flow [27]. The increased cost and low availability is currently the method's main drawback, but as this technology further disseminates, the cost is expected to decrease, increasing its clinical use.

Ultrasound is also a useful method in the assessment of cutaneous problems, and many devices have been used for scar depth quantification [28-30]. Ultrasound has been shown to be able to discriminate between hypertrophic scar and normal scar with good sensitivity and specificity, both in burn and surgical scars.

2. IMAGE – BASED PREOPERATIVE PLANNING IN PLASTIC AND RECONSTRUCTIVE SURGERY

Since the evolution and access to sophisticated imaging techniques has increased in the past decades, plastic surgery is one of the fields that has benefited most.

The detailed information that is acquired by modern imaging techniques allows plastic surgeons to have precise preoperative data related to the actual clinical status of the patient, allowing them to plan flaps in a refined and precise way, selecting the best option for the patient. In the current era of anatomically predefined flaps, preoperative imaging is now a routine method, not only to study the donor and recipient area, but also to improve the surgical outcome and ensure minimal morbidity.

Almost all kinds of available imaging modalities have been used in the preoperative evaluation of vessels in microvascular plastic surgery. These include Doppler ultrasound, angiography, computed tomographic angiography (CTA) and magnetic resonance imaging angiography (MRA) (Table 3). Although the latter two methods are nowadays being increasingly used, there is no consensus on which imaging modality should be used, and, as research in this field is ongoing, this chapter will focus on the use of CTA and MRA in preoperative planning of plastic surgery operations. CTA uses computer – analyzed x-ray images in combination with the infusion of a contrast agent, in order to produce highly accurate reconstruction images of the vasculature [31].

Table 3. Overview of pros and cons of imaging modalities in the preoperative evaluation of the vascular anatomy

Method	US Doppler	CTA	MRA
Pros	Low cost	High sensitivity and specificity	High sensitivity and specificity
	Easily accessible	Higher perforator detection rate	No exposure to ionizing radiation
	Simple use	Currently the gold standard	Better depiction of intramuscular vessels
	No contraindications		
Cons	Operator dependent	Exposure to ionizing radiation	Contraindications (severe obesity, metal or cochlear implants)
	Variable sensitivity and specificity	Medium – to –high cost	High cost
	May be time consuming	Contrast – related risks	Risk of nephrogenic systemic fibrosis
			Inferior to CTA (using 1.5T magnetic field)

CTA: Computed Tomographic Angiography, MRA: Magnetic Resonance Imaging Angiography.

CTA produces more accurate images than Doppler or color Doppler, providing detailed information regarding the intramuscular course of perforating vessels, and may give additional information on incidental findings or anatomic variations [32, 33], and has been used in the preoperative evaluation of both free and perforator flaps.

There is a plethora of studies that have demonstrated the effectiveness of CTA in accurately assessing perforating vessels, most of them in planning Deep Inferior Epigastric Perforator (DIEP) flaps [34-39].

While CTA is often criticized for the high radiation exposure, the benefits of its preoperative use include shortened dissection and operative times, reduced complication rates and, eventually, reduced overall cost. CTA can effectively depict perforators greater than 1mm in caliber and, in several international centers is considered as the gold standard in preoperative imaging of DIEP flaps.

On the other hand, Magnetic Resonance Imaging has also evolved from an initial use for solid organ study to an effective and feasible technique for vascular study.

Even small caliber vessels, including perforator vessels, can now be evaluated with MRA, without the need of exposure to radiation, maintaining high sensitivity and specificity in the evaluation of vessel course and size. Most studies available in the current literature report a sensitivity of 97-100% in the identification of perforators of the DIEA, which is similar to that of CTA [40-42].

However, in the study by Rozen et al., MRA is reported to have a lower perforator detection rate compared to CTA, particularly in perforators < 1mm [41]. These results are likely to be due to the fact that CTA has a better contrast in depicting the vessel course within fatty tissue, whereas, on the other hand, MRA can better depict the intramuscular vessel course.

Finally, a recent study by Hartung et al., suggests that the sensitivity of MRA can be improved when 3.0T magnetic fields are used, compared to 1.5T, offering increased spatial resolution, decreased acquisition time and better visibility of the vessels [42].

REFERENCES

[1] Balch, C. M., Soong, S. J., Murad, T. M., Smith, J. W., Maddox, W. A., Durant, J. R. A multifactorial analysis of melanoma. IV. Prognostic factors in 200 melanoma patients with distant metastases (stage III). *Journal of clinical oncology: official journal of the American Society of Clinical Oncology*. 1983;1(2):126-34.

[2] Lee, M. L., Tomsu, K., Von Eschen, K. B. Duration of survival for disseminated malignant melanoma: results of a meta-analysis. *Melanoma research*. 2000;10(1):81-92.

[3] Patel, J., Didolkar, M., Pickren, J., Moore, R. Metastatic pattern of malignant melanoma: a study of 216 autopsy cases. *The American Journal of Surgery*. 1978;135 (6):807-10.

[4] Terhune, M. H., Swanson, N., Johnson, T. M. Use of chest radiography in the initial evaluation of patients with localized melanoma. *Archives of dermatology*. 1998;134(5): 569-72.

[5] Hofmann, U., Szedlak, M., Rittgen, W., Jung, E. G., Schadendorf, D. Primary staging and follow-up in melanoma patients--monocenter evaluation of methods, costs and patient survival. *British journal of cancer*. 2002;87(2):151-7.

[6] Bessoud, B., Lassau, N., Koscielny, S., Longvert, C., Avril, M. F., Duvillard, P., et al., High-frequency sonography and color Doppler in the management of pigmented skin lesions. *Ultrasound in medicine and biology*. 2003;29(6):875-9.

[7] Harland, C. C., Kale, S. G., Jackson, P., Mortimer, P. S., Bamber, J. C. Differentiation of common benign pigmented skin lesions from melanoma by high-resolution ultrasound. *The British journal of dermatology*. 2000;143(2):281-9.

[8] Dancey, A. L., Mahon, B. S., Rayatt, S. S. A review of diagnostic imaging in melanoma. *Journal of plastic, reconstructive and aesthetic surgery: JPRAS*. 2008;61 (11):1275-83.

[9] Garbe, C., Schadendorf, D. Surveillance and follow-up examinations in cutaneous melanoma. *Onkologie*. 2003;26(3):241-6.

[10] Machet, L., Nemeth-Normand, F., Giraudeau, B., Perrinaud, A., Tiguemounine, J., Ayoub, J., et al., Is ultrasound lymph node examination superior to clinical examination in melanoma follow-up? A monocentre cohort study of 373 patients. *The British journal of dermatology*. 2005;152(1):66-70.

[11] Saiag, P., Bernard, M., Beauchet, A., Bafounta, M. L., Bourgault-Villada, I., Chagnon, S. Ultrasonography using simple diagnostic criteria vs palpation for the detection of regional lymph node metastases of melanoma. *Archives of dermatology*. 2005;141(2): 183-9.

[12] Chai, C. Y., Zager, J. S., Szabunio, M. M., Marzban, S. S., Chau, A., Rossi, R. M., et al., Preoperative ultrasound is not useful for identifying nodal metastasis in melanoma patients undergoing sentinel node biopsy: preoperative ultrasound in clinically node-negative melanoma. *Annals of surgical oncology*. 2012;19(4):1100-6.

[13] Halton, K. P. Radiological considerations in diagnosis of metastatic melanoma. *The Mount Sinai journal of medicine*, New York. 1992;59(3):211-6.

[14] Heaston, D. K., Putman, C. E., Rodan, B. A., Nicholson, E., Ravin, C. E., Korobkin, M., et al., Solitary pulmonary metastases in high-risk melanoma patients: a prospective

comparison of conventional and computed tomography. *AJR American journal of roentgenology*. 1983;141(1):169-74.

[15] Muller-Horvat, C., Radny, P., Eigentler, T. K., Schafer, J., Pfannenberg, C., Horger, M., et al., Prospective comparison of the impact on treatment decisions of whole-body magnetic resonance imaging and computed tomography in patients with metastatic malignant melanoma. *European journal of cancer* (Oxford, England: 1990). 2006;42 (3):342-50.

[16] Morton, D. L., Wen, D. R., Wong, J. H., Economou, J. S., Cagle, L. A., Storm, F. K., et al., Technical details of intraoperative lymphatic mapping for early stage melanoma. *Archives of surgery*. 1992;127(4):392-9.

[17] Prichard, R. S., Hill, A. D., Skehan, S. J., O'Higgins, N. J. Positron emission tomography for staging and management of malignant melanoma. *The British journal of surgery*. 2002;89(4):389-96.

[18] Reinhardt, M. J., Joe, A. Y., Jaeger, U., Huber, A., Matthies, A., Bucerius, J., et al., Diagnostic performance of whole body dual modality 18F-FDG PET/CT imaging for N- and M-staging of malignant melanoma: experience with 250 consecutive patients. *Journal of clinical oncology: official journal of the American Society of Clinical Oncology*. 2006;24(7):1178-87.

[19] Iagaru, A., Quon, A., Johnson, D., Gambhir, S. S., McDougall, I. R. 2-Deoxy-2-[F-18]fluoro-D-glucose positron emission tomography/computed tomography in the management of melanoma. *Molecular imaging and biology: MIB: the official publication of the Academy of Molecular Imaging*. 2007;9(1):50-7.

[20] Hoeksema, H., Van de Sijpe, K., Tondu, T., Hamdi, M., Van Landuyt, K., Blondeel, P., et al., Accuracy of early burn depth assessment by laser Doppler imaging on different days post burn. *Burns: journal of the International Society for Burn Injuries*. 2009;35 (1):36-45.

[21] Monstrey, S., Hoeksema, H., Verbelen, J., Pirayesh, A., Blondeel, P. Assessment of burn depth and burn wound healing potential. *Burns: journal of the International Society for Burn Injuries*. 2008;34(6):761-9.

[22] Khatib, M., Jabir, S., Fitzgerald O'Connor, E., Philp, B. A systematic review of the evolution of laser Doppler techniques in burn depth assessment. *Plastic surgery international*. 2014;2014:621792.

[23] Micheels, J., Alsbjorn, B., Sorensen, B. Laser doppler flowmetry. A new non-invasive measurement of microcirculation in intensive care? *Resuscitation*. 1984;12(1):31-9.

[24] Micheels, J., Alsbjorn, B., Sorensen, B. Clinical use of laser Doppler flowmetry in a burns unit. *Scandinavian journal of plastic and reconstructive surgery.* 1984;18(1):65-73.

[25] Bayat, A., McGrouther, D. A. Spectrum of abnormal skin scars and their clinical management. *British journal of hospital medicine*. 2006;67(10):527-32.

[26] Perry, D. M., McGrouther, D. A., Bayat, A. Current tools for noninvasive objective assessment of skin scars. *Plastic and reconstructive surgery*. 2010;126(3):912-23.

[27] Oliveira, G. V., Chinkes, D., Mitchell, C., Oliveras, G., Hawkins, H. K., Herndon, D. N. Objective assessment of burn scar vascularity, erythema, pliability, thickness, and planimetry. *Dermatologic surgery: official publication for American Society for Dermatologic Surgery* [et al.,]. 2005;31(1):48-58.

[28] Lau, J. C., Li-Tsang, C. W., Zheng, Y. P. Application of tissue ultrasound palpation system (TUPS) in objective scar evaluation. *Burns: journal of the International Society for Burn Injuries*. 2005;31(4):445-52.

[29] Nedelec, B., Correa, J. A., Rachelska, G., Armour, A., LaSalle, L. Quantitative measurement of hypertrophic scar: interrater reliability and concurrent validity. *Journal of burn care and research: official publication of the American Burn Association*. 2008; 29(3):501-11.

[30] Fong, S. S., Hung, L. K., Cheng, J. C. The cutometer and ultrasonography in the assessment of postburn hypertrophic scar--a preliminary study. *Burns: journal of the International Society for Burn Injuries*. 1997;23 Suppl. 1:S12-8.

[31] Pratt, G. F., Rozen, W. M., Chubb, D., Ashton, M. W., Alonso-Burgos, A., Whitaker, I. S. Preoperative imaging for perforator flaps in reconstructive surgery: a systematic review of the evidence for current techniques. *Annals of plastic surgery*. 2012;69(1):3-9.

[32] Rozen, W. M., Palmer, K. P., Suami, H., Pan, W. R., Ashton, M. W., Corlett, R. J., et al., The DIEA branching pattern and its relationship to perforators: the importance of preoperative computed tomographic angiography for DIEA perforator flaps. *Plastic and reconstructive surgery*. 2008;121(2):367-73.

[33] See, M. S., Pacifico, M. D., Harley, O. J., Francis, I., Smith, R. W., Jones, M. E. Incidence of 'Incidentalomas' in over 100 consecutive CT angiograms for preoperative DIEP flap planning. *Journal of plastic, reconstructive and aesthetic surgery: JPRAS*. 2010;63(1):106-10.

[34] Masia, J., Clavero, J. A., Larranaga, J. R., Alomar, X., Pons, G., Serret, P. Multidetector-row computed tomography in the planning of abdominal perforator flaps. *Journal of plastic, reconstructive and aesthetic surgery: JPRAS*. 2006;59(6):594-9.

[35] Masia, J., Kosutic, D., Cervelli, D., Clavero, J. A., Monill, J. M., Pons, G. In search of the ideal method in perforator mapping: noncontrast magnetic resonance imaging. *Journal of reconstructive microsurgery*. 2010;26(1):29-35.

[36] Masia, J., Kosutic, D., Clavero, J. A., Larranaga, J., Vives, L., Pons, G. Preoperative computed tomographic angiogram for deep inferior epigastric artery perforator flap breast reconstruction. *Journal of reconstructive microsurgery*. 2010;26(1):21-8.

[37] Alonso-Burgos, A., Garcia-Tutor, E., Bastarrika, G., Cano, D., Martinez-Cuesta, A., Pina, L. J. Preoperative planning of deep inferior epigastric artery perforator flap reconstruction with multislice-CT angiography: imaging findings and initial experience. *Journal of plastic, reconstructive and aesthetic surgery: JPRAS*. 2006;59(6):585-93.

[38] Rozen, W. M., Phillips, T. J., Ashton, M. W., Stella, D. L., Gibson, R. N., Taylor, G. I. Preoperative imaging for DIEA perforator flaps: a comparative study of computed tomographic angiography and doppler ultrasound. *Plastic and reconstructive surgery*. 2008;121(1 Suppl.):1-8.

[39] Pacifico, M. D., See, M. S., Cavale, N., Collyer, J., Francis, I., Jones, M. E., et al., Preoperative planning for DIEP breast reconstruction: early experience of the use of computerised tomography angiography with VoNavix 3D software for perforator navigation. *Journal of plastic, reconstructive and aesthetic surgery: JPRAS*. 2009;62 (11):1464-9.

[40] Newman, T. M., Vasile, J., Levine, J. L., Greenspun, D. T., Allen, R. J., Chao, M. T., et al., Perforator flap magnetic resonance angiography for reconstructive breast surgery: a

review of 25 deep inferior epigastric and gluteal perforator artery flap patients. *Journal of magnetic resonance imaging: JMRI*. 2010;31(5):1176-84.

[41] Rozen, W. M., Stella, D. L., Bowden, J., Taylor, G. I., Ashton, M. W. Advances in the pre-operative planning of deep inferior epigastric artery perforator flaps: magnetic resonance angiography. *Microsurgery*. 2009;29(2):119-23.

[42] Hartung, M. P., Grist, T. M., Francois, C. J. Magnetic resonance angiography: current status and future directions. *Journal of cardiovascular magnetic resonance: official journal of the Society for Cardiovascular Magnetic Resonance*. 2011;13:19.

In: Encyclopedia of Surgery (22 Volume Set)
Editors: Andreas Lehrer and Kristin Mueller
ISBN: 978-1-53618-329-0
© 2020 Nova Science Publishers, Inc.

Chapter 93

WRIST FRACTURES IN ADULTS: WHAT SHOULD A MEDICAL STUDENT KNOW?

Fares E. Sayegh*, MD, PhD
Aristotle University of Thessaloniki, Thessaloniki, Greece

ABSTRACT

Wrist fractures are common fractures and are seen frequently in the emergency department. They mainly occur in the elderly as a result of a fall on an outstretched hand. Wrist fractures are also seen in high-energy mechanism injuries such as road traffic accidents or a fall from a height. Those fractures are always accompanied with other injuries. The ability to detect the different types of wrist fractures requires an adequate understanding of the anatomy of the wrist, the mechanism that causes that type of injury, and the accurate interpretation of different imaging processes of the bony and articular structures of the wrist. Therefore, appropriate evaluation of the radiological x-rays is important for therapeutic intervention, surgical or conservative, and for the complete restoration of normal wrist function after an injury.

BONY ANATOMY

The wrist is composed of the distal parts of the radius, the ulna, the proximal and distal carpal rows, and the bases of five metacarpals. The distal extraarticular part of the radius is broadened 2-3 cm proximal to the radio-carpal joint and this small area of metaphyseal widening is characterized by a decrease of the amount of cortical bone and increase in the amount of cancellous bone that is weaker and easily predisposed to fracture if an injury of the wrist occurs [5, 6, 7]. On the lateral surface of the distal radius, one can also palpate the radial styloid, a strong cone shaped cortical projection. The Lister tubercle is a bony prominence that is found over the dorsal aspect of the distal radius.

* Corresponding Author's Email: fsayegh@auth.gr.

The intra-articular surface of the distal radius has a fossa for the scaphoid carpal bone where it sits, it is named scaphoid facet or fossa, and another fossa where the lunate carpal bone sits and it is named lunate facet or fossa [5, 6]. A narrow, concave, smooth depression is also found on the medial side of the distal radius. This is called the sigmoid notch and it acts as a seat for the distal ulna. The sigmoid notch facilitates the rotation and provide relative stability to the distal radio-ulnar joint [6] (Figure 1). The carpal bones of the wrist are eight in number and lie in two rows. From the radial to ulnar side, the proximal row consists of the scaphoid (navicular), lunate, triquetrum, and the pisiform carpal bones. Similarly, the distal row, from radial l to ulnar, includes the trapezium, trapezoid, capitate, and hamate carpal bones that normally articulate with the bases of the metacarpals. It is important to remember that the proximal carpal bone row is considered and named as intercalated segment as the forces acting on its proximal and distal articulations determine its position [5, 6, 7] (Figure 2). The collapse of this bony anatomy after a wrist injury is an indication of wrist instability. The surfaces of the distal and proximal rows carpal bones are joined together with intrinsic ligaments. As a result, the wrist is separated into different articular compartments; the radiocarpal compartment, the midcarpal, the pisiform-triquetal, the common carpometacarpal, intermetacarpal and the distal radioulnar compartments [6, 7].

IMAGING EVALUATION

In cases where a patient with a wrist injury is presented to the emergency room, a series of radiological views are to be requested. As a start, the standard x-rays; the postero-anterior (PA), and the lateral x-ray should be included. In many cases the detailed clinical examination of the injured wrist may require more radiological imaging in order to better describe the fracture. The therapeutic doctor should recognize (Figure 3, 4):

1) The location of the fracture. Is the fracture extra or intraarticular?
2) The configuration of the fracture. Is the fracture transverse, oblique, or comminuted?
3) The displacement. Is there a change in the radial tilt, length and angle
4) Are there any signs of joint instability? (radiocarpal, radioulnar, intercalated)
5) Is there any suspicious for an unrecognized underlying fracture of carpal bones? (scaphoid, hamate, triquetrum, …)

Postero-Anterior Wrist View

This is a standard view of the wrist and one can distinguish the many normal interosseous relationships [5, 6, 7].

In this poster-anterior view one should appreciate;

1) The three smooth arcs of the wrist
2) The scapholunate joint space
3) The ulnar length
4) The carpal height

1. Arcs of the Wrists

Three carpal arcs are distinguished along the radiocarpal and midcarpal joints. A line that follows the proximal articular surfaces of the scaphoid, lunate and the triquetrum carpal bones forms arc 1. A line drawn over the distal articular surfaces of the same carpal bones forms arc 2. The arc 3 is formed from a line that follows the proximal articular surfaces of the capitate and hamate carpal bones. In a normal x-ray of a wrist, the 3 carpal arcs are not disrupted and shown to be almost equal in size, smooth, and parallel to each other (Figure 5).

It is important to note that the interosseous carpal and intercarpal spaces are nearly equal in size. However, normal variants of step-off carpal arcs are described.

2. Scapholunate Joint Space

The normal size of scapholunate joint space does not differ from the size of the other joint spaces that lie between pairs of the other carpal bones.

There is a kind of parallelism between the carpal joint spaces. Normally the width of the intercarpal joint space at its midportion measures 2 mm or less and its width does not alter with the wrist in either radial or ulnar deviation.

3. Ulnar Variance (Known as Hulten Variance)

This refers to the change in the length of the ulna relative to the length of radius. This change in length can be found by drawing a line on the distal articular surface of the radius toward the ulna, and another line on the distal articular surface of the ulna. The distance measured between those 2 drawn lines is named the ulnar variance.

Normally both ulnar and radial articular surfaces are at the same level. If the ulna projects more distally than the radius the ulnar variance is considered to be positive. If the ulna projects more proximally, then the ulnar variance is negative.

4. Radial Inclination

It represents the angle formed between a line that connects the radial tip to the ulnar aspect of the distal radius and a second line drawn perpendicular to the long axis of the radius. This angle of radial inclination ranges from 13-30° (Figure 6).

5. Radial Length or Height

It can be measured along the longitudinal axis of the radius, and it is the distance between a line that passes through the distal tip of the radial styloid and a second line passing through the distal articular surface of the ulna. Normally, the radial length measures 11-13mm (Figure 7).

6. Carpal Height

This is a radiological concept that helps in the quantification of the carpal collapse in a patient over time. The height can be found by measuring the distance between the base of the 3rd metacarpal and the distal articular surface of the radius (Figure 8).

Lateral Wrist View

A true lateral x-ray of the wrist is considered when there is parallelism of the long axis of the 3rd metacarpal with the long axis of the radius, and the pisiform carpal bone overlie the distal pole of the scaphoid carpal bone [5, 6, 7].

1. The Longitudinal Axes of Radius, Lunate, Capitate

On a lateral x-ray of the wrist the longitudinal axes through the 3rd metacarpal, the capitate, the lunate, and the radius all fall on the same line.

2. The Capitolunate Angle

It is where the axes of the radius, lunate, and capitate should superimpose with 0-30° angle.

3. The Scapholunate Angle

It is the angle formed between the longitudinal axis of the scaphoid and the log axis of the radius, lunate, and the capitate carpal bones. Normally it ranges between 30-60°.

4. The Palmar or Volar Tilt of Distal Radius

This is the angle that is formed between a line that is drawn tangentially to the most distal articular surface and a perpendicular line to the midshaft of the radius. A normal wrist has a range of 11° of volar or palmar tilt to 4° of dorsal tilt.

Oblique Wrist View

In this view the fractures of the waist of the scaphoid and the tuberosity are better seen [5, 6, 7]. Fractures of the dorsal part of the triquetrum can be also detected.

Moreover, the scaphotrapezial, scaphotrapezoidal, trapezotrapezoidal, capitolunate, and the first carpometacarpal joints are well visualized [5, 6].

Radial and Ulnar Deviation Wrist Views

In both wrist projections, the scaphoid carpal bone is better visualized.

COMMON DISTAL WRIST FRACTURES

Fractures of the distal end of the radius are the most common fracture-injuries seen and treated by orthopaedic surgeons in the emergency room [2]. Looking at the x-ray of such fractures, the therapeutic doctor should be able to interpret and to describe the pattern and the characteristics of such fractures [1, 2, 3, 4]. Therefore, one should understand the location of the fracture; is the fracture line only located in the metaphysis of the radius and does not involve the radial articular surface? (extraarticular fracture).

Does the fracture line extend to the radiocarpal joint? (intraarticular fracture) [1, 2, 5].

It is also important to recognize the configuration of the fracture, is the fracture transverse, oblique, or comminuted? One should recognize if the fracture is unstable, and look for type of displacement of the fracture and if there is any change in the normal radial tilt, length or angle [5, 6].

Moreover, any signs of joint instability and the coexistence of other accompanied fractures of carpal bones or ulnar styloid should be interpreted and described.

1. Colles' Fracture

This is a fracture of the distal end of the wrist. It is one of the most common fractures seen at the emergency department. The incidence of this fracture is increased in the elderly due to osteoporosis. The mechanism of injury is usually a fall on an outstretched hand.

A colles' fracture is usually a transverse extraarticular fracture, but it could be comminuted and intraarticular. In this fracture, there is impaction and dorsal angulation of the distal fracture fragment (Figure 9).

Therefore beside the recognition of the presence of a transverse metaphyseal fracture of the distal radius, the doctor should look and describe the presence of other fracture features [3, 4, 5, 6]:

1. Extension of the fracture line to the radiocarpal joint
2. Extension of the fracture line medially to the distal radioulnar joint
3. Is there radial shortening due to fracture impaction?
4. Is there a loss of radial inclination?
5. Degree of dorsal angulation in relative to the proximal fracture fragment?

2. Smith Fracture

This is an extraarticular fracture of the metaphysis of the distal radius. It is also called the reverse colles, as the distal fracture fragment is displaced and angled volarly (palmar direction) relative to the proximal radial fracture fragment. This fractures mainly occurs in younger patients, and the mechanism of injury is a fall on a flexed wrist [2, 4, 5, 6] (Figure 10).

3. Barton Fracture

This is an intraarticular fracture of the distal radial articular surface. The intraarticular fracture fragment is displaced together with the carpus.

This translation or displacement of the distal fracture fragment with the carpus may be in a palmar (volar) or dorsal direction in relation to the shaft of the radius [1, 2] (Figure 11).

4. Hutchinson (Chauffeur) Fracture

This is an oblique intraarticular fracture of the radial styloid. It is rarely displaced and it is better distinguished on a PA view of the wrist [5, 6]. The fracture line may extend to the space between the scaphoid and the lunate fossae causing scapholunate ligamentous injuries that may lead to scapholunate instability or dissociation. The term "chauffeur" fracture was originally described in the early 20th century as an injury that occurred while using the starting automobile crank that suddenly reversed during an engine backfire (Figure 12).

5. Die-Punch Fracture

This is an intraarticular fracture of the distal radius. It is a depressed fracture of the lunate fossa of the articular radial surface as a result of a transverse load transmitted through the lunate carpal bone (Figure 13). Sometimes this type of fracture can be easily missed on a PA wrist view. A good understanding of the carpal arcs of a wrist as seen on a PA wrist view, will help in noticing the disturbance of the smooth carpal arc I that connects the outer proximal convexities of the scaphoid, lunate, triquetrum.

This finding should arouse suspicion of the existence of such a fracture [3, 5, 6].

COMMON CARPAL BONE FRACTURES

1. Scaphoid Fracture

It is the most common fractured carpal bone. It usually occurs in young males after a fall on an outstretched hand while the wrist is extended and radially deviated. If an injury to the scaphoid carpal bone is suspected, a PA, lateral and oblique views of the wrist are the routine x-rays that are required to visualize the scaphoid bone. Views with the wrist in an ulnar deviation (the scaphoid view) will better illustrate the waist of the scaphoid carpal bone [4, 5]. Anatomically, the scaphoid bone has a waist, a proximal and a distal pole. The most common fractures of the scaphoid occur through the waist. Early recognition of the scaphoid fracture is important, as early immobilization of the wrist with a cast is essential for achieving bone union. It should be emphasized that the blood supply of the scaphoid carpal bone is unique as the entire blood supply of this carpal bone enters from its distal pole. Therefore, fractures of the scaphoid and especially of the distal pole may predispose to avascular necrosis [3, 4, 5] (Figure 14 a, b).

2. Triquetrum Fracture

The triquetrum fracture is considered the 2nd most commonly injured carpal bone. The dorsal avulsion fracture of the triquetrum could be easily missed on conventional x-rays of the wrist. In cases where there is a clinical suspicion of such fracture, a CT tomography is the method of choice (Figure 15).

3. Hamate and Hook of the Hamate Fracture

Usually the fracture of the hamate may be detected on a plain x-ray. Fractures that involve the hook of the hamate are difficult to notice on standard views. Beside the use of using a carpal tunnel view, CT, or MRI to detect a clinically suspicion fracture of the hamate or hook of the hamate, a bone scan is another option to locate the fracture site [5, 6, 7] (Figure 16).

4. Pisiform Fracture

This fracture is usually the result of a direct blow to the pisiform carpal bone. Pisiform fractures occur in 1-3% of all the carpal bone fractures and are difficult to detect on standard x-rays. A carpal tunnel view, a lateral oblique, or a radial deviation view is sometimes necessary to show the fracture. MRI, and CT scan may also help in detecting the fracture [6] (Figure 17).

CONCLUSION

Fractures of the distal radius and the carpal bones are common and complex fractures that are seen routinely in the emergency room. This chapter provides the medical students with a concise and complete understanding of some of the common wrist fractures that they should know during their medical studies.

REFERENCES

[1] Catalano, L. W. III, Cole, R. J., Gelberman, R. H., Evanoff, B. A., Gilula, L. A., Borrelli, J. Jr. Displaced intra-articular fractures of the distal aspect of the radius. *J. Bone Joint Surg. Am*. 1997; 79:1290–1302.

[2] DePalma, A. F. Comminuted fractures of the distal end of the radius treated by ulnar pinning. *J. Bone Joint Surg. Am*. 1952; 34:651–662.

[3] Cohen, M. S. Fractures of the carpal bones. *Hand Clin*. 1997; 13:587–599.

[4] Dobyns, J. H., Linscheid, R. L. Fractures and dislocations of the wrist. In: Rockwood, C. A. Jr, Green, D. P., eds. *Fractures in adults*. 3rd ed. Philadelphia, Pa: Lippincott, 1984; 411–509.

[5] Goldfarb, C. A., Yin, Y., Gilula, L. A., Boyer, M. I. Wrist Fractures: What the Clinician Wants to Know. *Radiology* 2001; 219:11–28.

[6] Loredo, R. A., MD, Sorge, D. G., et al., Radiographic Evaluation of the Wrist: A Vanishing Art. *Semin. Roentgenol*. 2005 Jul;40(3):248-89.

[7] Scalcione, L. R., Gimber, L. H., A. M. Ho et al., Spectrum of Carpal Dislocations and Fracture-Dislocations: Imaging and Management. *AJR* 2014; 203:541–550.

In: Encyclopedia of Surgery (22 Volume Set)
Editors: Andreas Lehrer and Kristin Mueller
ISBN: 978-1-53618-329-0
© 2020 Nova Science Publishers, Inc.

Chapter 94

MINIMALLY INVASIVE MIDFACE LIFT USING ABSORBABLE SUTURES WITH CONES: A STEP BY STEP PROCEDURE

M. Goisis, A. Di Petrillo, L. Rosset, A. Kunderfranco, S. Mele, E. Stella and S. Khabouri

ABSTRACT

*Background***:** Since the invention of the first barbed (short) suture by Sulamanidze in the late 1990s, facial soft tissue lifting with subdermal sutures has a significant attraction for physician and patient alike. This study aimed to describe the authors' experience and the office techniques they have adopted to counteract the descent and laxity of facial soft tissues.

*Method***:** A retrospective chart review was performed during a period of 15 Months, from March 2013 to June 2014. The procedure was performed in 131 patients under local anesthesia using 2-0 absorbable polylactic sutures with 4 polylactic cones in their distal section (Silhouette Lift, Irvine, California).

The face was marked preoperatively to determine the appropriate vector of the thread and its two end exit points. The results were assessed objectively using serial photography with Canfield Camera System and subjectively according to patient assessment. Complications also were recorded.

*Result***:** All but two patients were satisfied with the outcomes after treatment. Consensus ratings by two independent surgeons found that objective outcomes were divided among "excellent," "good," and "fair." The postoperative course was uneventful except for two patients who presented with major hematoma and another patient who had minor skin dimpling. These three complicated cases were resolved spontaneously without any surgical interventions.

*Conclusion***:** The advantages of this technique are its simplicity, the fact that it produces no traumatic effects, and the fact that it can be performed with local anesthetic, reducing surgical time over current approaches.

INTRODUCTION

The process of facial aging involves all the layers of tissues. A general loss of volume is observed in the extracellular matrix of connective tissues, due to reduced synthesis of glicosaminoglicans and hyaluronic acid. Furthermore, alterations in the ultra structure of collagen and elastin lead to reduction of elasticity and increase of sagginess of soft tissues. The hypotrophy typical of the aging face and neck is then a process involving not only the skin but even fatty tissue and muscle.

The intermittent use of resorbable cone or barbed wires is aimed at preventing and treating the tissue sagginess and reinforcing the soft tissue of the face. The suture suspension technique falls in between the more aggressive and invasive procedures (for example, face lift) and the less invasive ones (such as fillers or Botox); the permanency of the results could measure up to 2 years. Coned and barbed wires allows accurate facial tissue repositioning by exerting immediate traction. Furthermore an even stronger force contrasting gravitational pull is provided by new collagen fibers formation. Starting around 2 months after the placement of the wires, the process of wire resorption leads to synthesis of collagen all around the wire, enhancing the traction over the tissues. The initial traction is produced by the presence of the slow-absorbing cones or barbs, which are reinforced by the buildup of new collagen formation. After the cones or barbs are reabsorbed the tissue traction is maintained by the collagen around and inside a series of knots interpolated along the wires. Further applications of wires on the same area are possible to enhance the support over soft tissue.

METHODS

A retrospective chart review was performed during a period of 15 Months, from March 2013 to June 2014. The procedure was performed in 131 patients under local anesthesia using 2-0 absorbable polylactic sutures with 4 polylactic cones in their distal section (Silhouette Lift, Irvine, California).

61 patients underwent coned wires lift on the cheeks for correction of medium and low facial sagginess; 12 patients underwent wire lift in the eyebrow and frontal region; 29 patients underwent lift of the cervical region; 29 patients underwent coned wires lift in both the facial and cervical area

The face was marked preoperatively to determine the appropriate vector of the thread and its two end exit points. The results were assessed objectively using serial photography with Canfield Camera System and subjectively according to patient assessment. Complications also were recorded.

The patients have been asked to give us an anonymous written feedback regarding the short term results with a simple scale by choosing among: very good, good, fair, bad, very bad.

For each patient pre and postoperative photos were sent to two independent surgeons to evaluate the aesthetic outcome. Results could be rated by a single scale marking among: very good, good, bad, very bad.

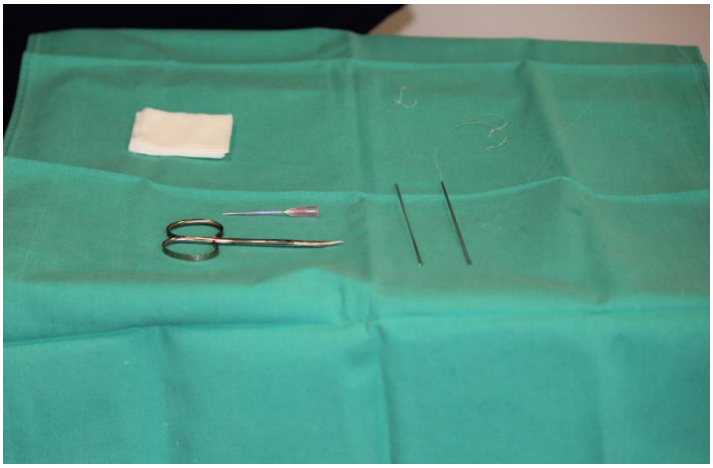

Figure 1. Materials (1): Coned wires, 18 G needle, scissors, bandages.

Figure 2. (Continued).

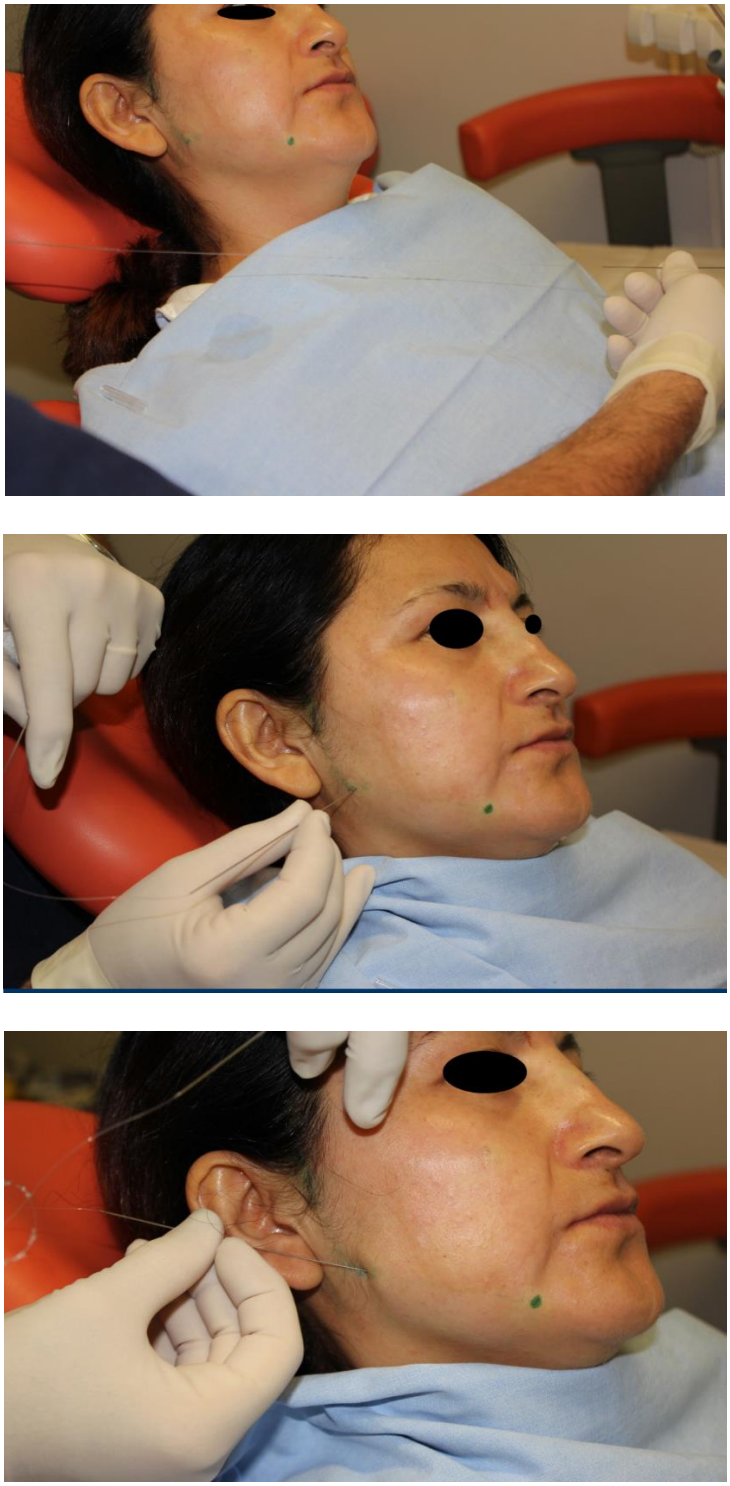

Figure 2. (Continued).

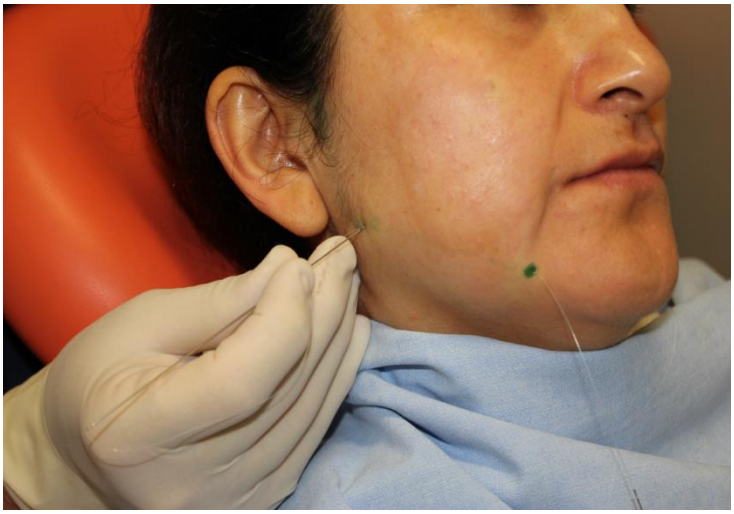

Figure 2. (Continued).

Figure 2. L shaped application of coned wire to lift the cheek: project (1); insertion of perforating needle (2); appropriate pre-surgical wire stripping (3); insertion of the guide needle (4); the needle is directed to the desired target point (5); complete insertion of the first half of the coned wire (6); wire stripping is used to be sure that all the cones are in the appropriate position (7); insertion of the guide needle for the second half of the wire (8); the second guide needle is directed to the desired target point (9); appliance of the appropriate tension on the wire provides the subcutaneous entrance of the cones (10); after the application the portion of the wire remaining out of the skin is removed by scissors (11).

Figure 3. (Continued).

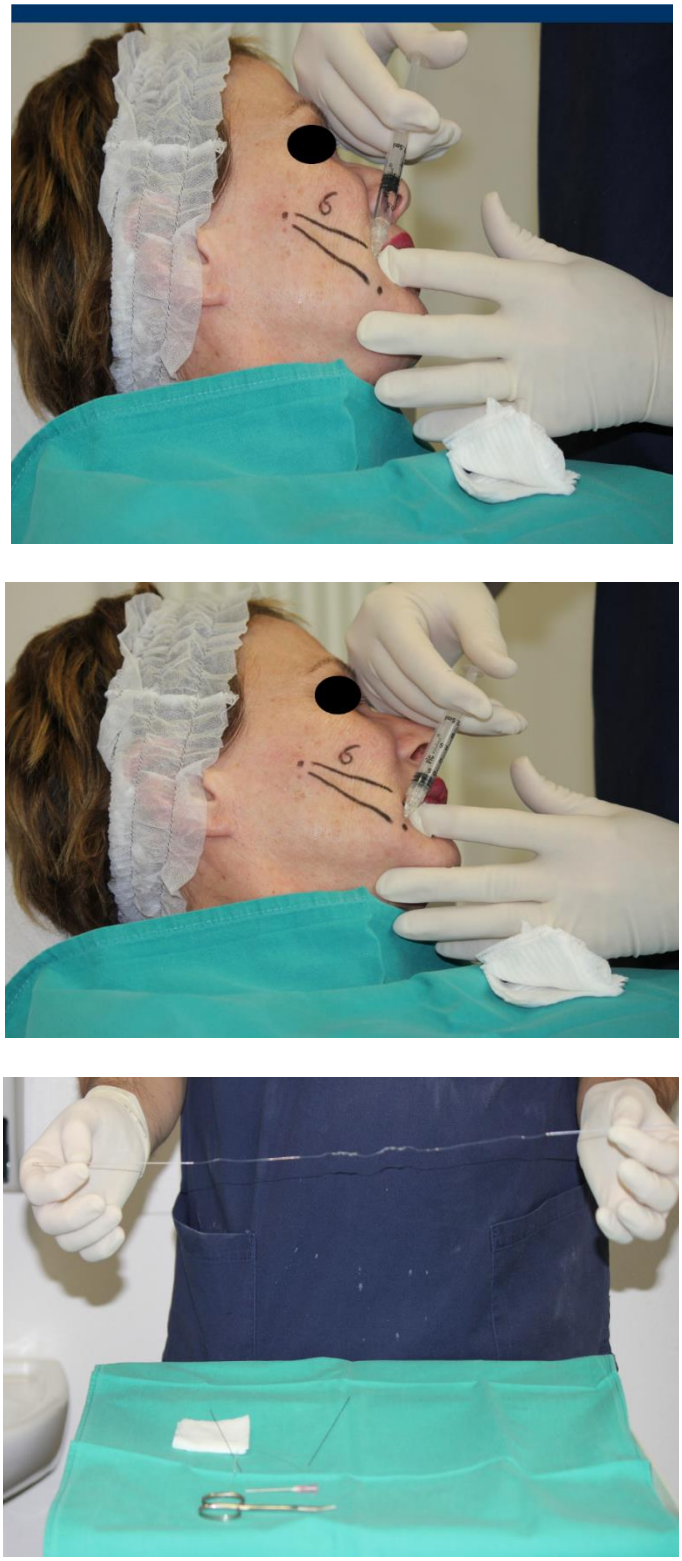

Figure 3. (Continued).

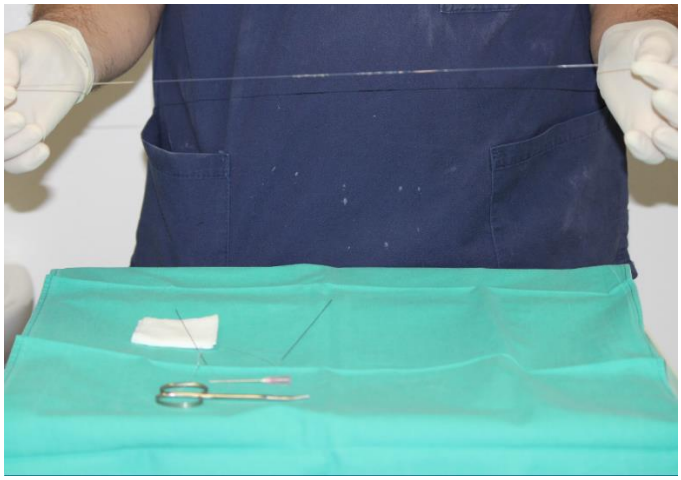

Figure 3. (Continued).

Figure 3. (Continued).

Figure 3. (Continued).

Figure 3. V shaped application of coned wire to lift the cheek: project (1,2); local anesthetic is injected on the cutaneous points in which the needle will enter (3) and exit (4,5) the skin; appropriate stripping of the wire (6,7) is needed before application; insertion of perforating 18 g needle (8); insertion of the guide needle of the first half of the wire (9); the needle is directed to the desired target point (10) and exits the skin (11,12); wire stripping is used to be sure that all the cones are in the appropriate position (13); insertion of the guide needle for the second half of the wire (14); once the two halves of the wire are inserted, appropriate tension (15) will lead to tissue remodeling (16); after the application the portion of the wire remaining out of the skin is removed by scissors (17); frontal pre and postsurgical photos (18).

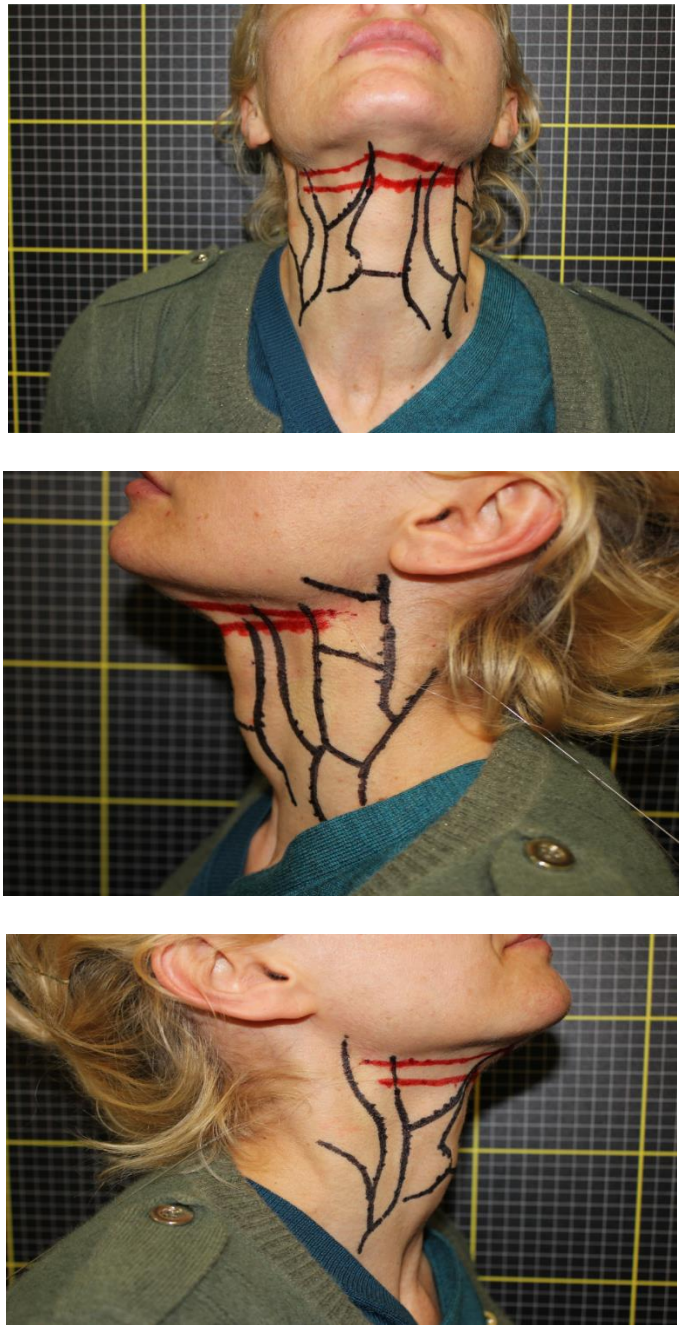

Figure 4. Topographical relationships between cervical applied coned wires and superficial vessels in cervical region on the frontal (1) and lateral (2,3) planes.

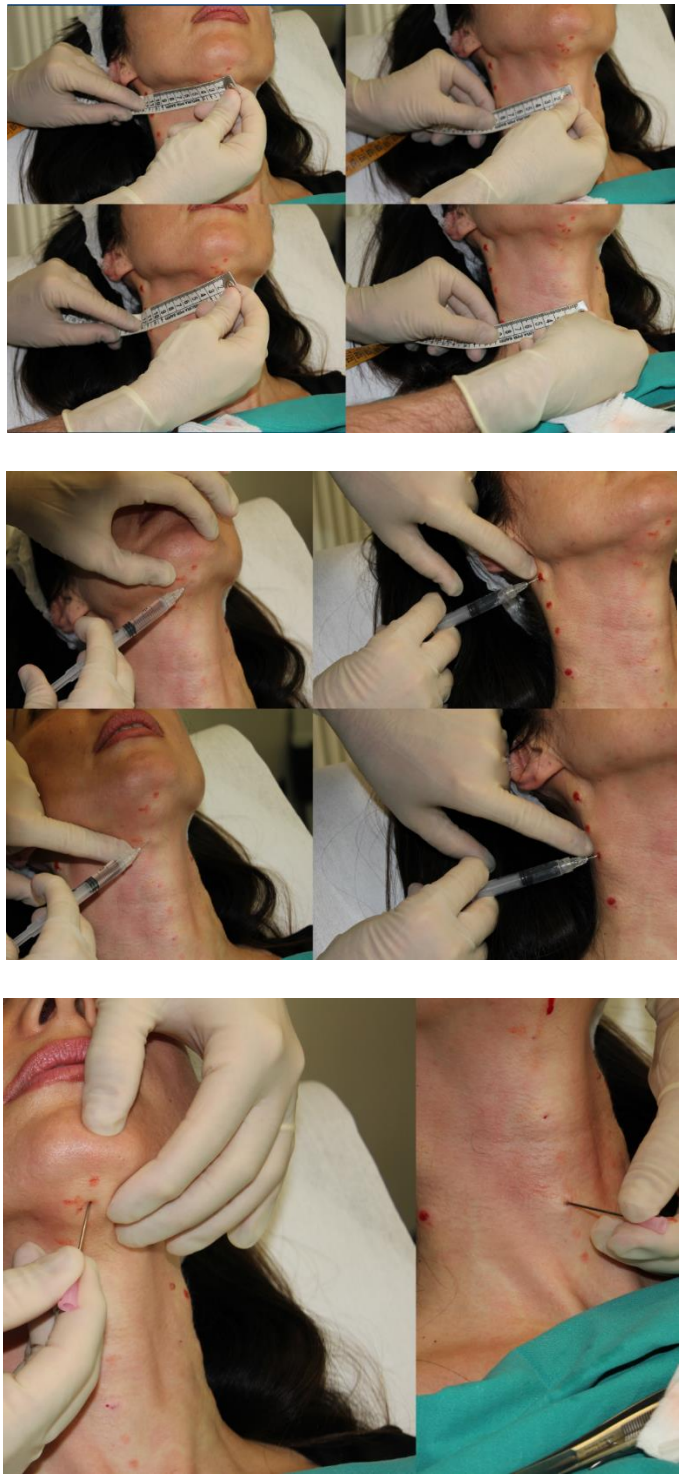

Figure 5. (Continued).

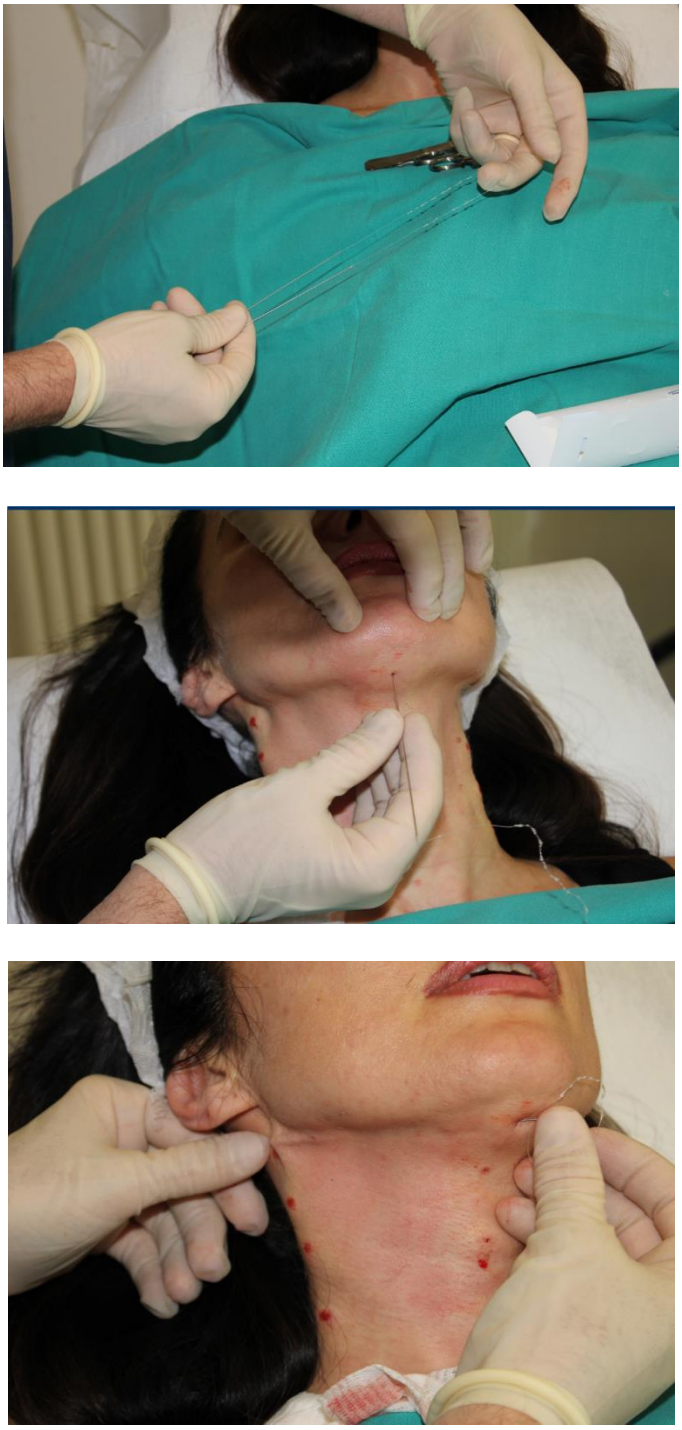

Figure 5. (Continued).

Figure 5. (Continued).

Figure 5. Multiple coned wires application to lift the cervical region: project (1); injection of local anesthetic (2); insertion of skin perforating 18 g needle (3) on the midline; appropriate stripping of the wire (4) is needed before application; insertion of the guide needle of the first half of the wire (5) on the midline; for cervical applications the guide needles of the two halves of the wired enter the skin on the midline and exit the cutaneous plane one for each side, allowing insertion of half of the wire on the right (6,7), and the other half on the left (8,9); this disposition is applied in order to provide optimal traction and maximize tissue repositioning (10); pre and postsurgical photos (11).

Figure 6. (Continued).

Figure 6. (Continued).

Figure 6. (Continued).

Figure 6. (Continued).

Figure 6. (Continued).

Figure 6. (Continued).

Figure 6. (Continued).

Figure 6. (Continued).

Figure 6. (Continued).

Figure 6. (Continued).

Figure 6. Multiple applications of coned wires to correct eyebrow asymmetry: project (1,2); injection of local anesthetic (3,4); the cutaneous plane is perforated by means of a 18 g needle (5); appropriate stripping of the wire (6) is needed before application; insertion of the guide needle for the first half of the first wire (7); the needle is the directed to the target point (8,9) and exits the cutaneous plane (10); insertion of the second half of the first wire (11-13); traction and tissue repositioning (14); for this very specific case we planned the central non coned part of the second wired to be hosted in a cutaneous tunnel to optimize traction: the tunnel is created by the usual 18 g needle (15-17), which is needed to allow precise insertion of the wire in the tunnel (18-21); guide needles are than used to insert the coned part of the wire in its two portions (22-24 and 25-27); traction and tissue repositioning (28); after the application the portion of the wires remaining out of the skin is removed by scissors (29); pre and postsurgical photos (30).

RESULTS

All but two patients were satisfied with the outcomes after treatment. Subjective marks provided by patients ranked among “very good” (51 cases), “good” (73 cases), “fair” (5 cases), “bad” (2 cases). Consensus ratings by two independent surgeons found that objective outcomes were divided among "excellent”(in 53 cases), "good” (in 49 cases), and "fair” (in 29 cases). The postoperative course was uneventful except for three patients. Among these, 2

patients presented with major hematoma and another patient had minor skin dimpling. The two case with hematoma resolved spontaneously without any surgical interventions. The patient presenting the skin rippling needed surgical intervention to remove the wire.

CONCLUSION

The coned wire lift offers several advantages over classical approaches like surgical facial lifting.

Because of its semplicity it can be executed under simple local anesthesia. Surgical time is dramatically reduced, with great advantage for the surgeon and for the patient. The absence of skin incisions leads to immediate recovery and absence of visible scars.

This technique can be associated with filler or botulin toxin injections in the same surgical time, to optimize the aesthetic enhancement and reduce patient stress.

In: Encyclopedia of Surgery (22 Volume Set)
Editors: Andreas Lehrer and Kristin Mueller
ISBN: 978-1-53618-329-0
© 2020 Nova Science Publishers, Inc.

Chapter 95

FREE FLAP BREAST RECONSTRUCTION: NEW UPDATES AND REFINEMENTS ON A WELL ESTABLISHED TECHNIQUE

Cedric L. Hunter, MD and Gordon K. Lee*, MD
Division of Plastic Surgery, Stanford University Medical Center,
Palo Alto, CA, US

ABSTRACT

The abdominal flap is the most common method of autologous breast reconstruction worldwide. Advocates argue the predictability and ability to create a more natural breast mound exceed that of implant based reconstruction. The transverse rectus abdominis (TRAM) flap has evolved from a pedicle flap to a free myocutaneous flap, and now to a deep inferior epigastric perforator (DIEP) flap as microsurgery technique and skill has improved. Multiple recipient vessels have been used historically including the thoracodorsal, lateral thoracic, thoracoacromial, transverse cervical, and internal mammary vessels. The internal mammary artery (IMA) and vein (IMV) are common recipient vessels in today's practice as the dissection can be done quickly and their medial position allows for medial placement of the reconstructed breast mound. During the oncologic portion of the case the axillary lymph nodes are often sampled with either sentinel lymph node biopsy or variations of axillary lymph node dissections. While the axilla is a major nodal basin for breast tissue drainage some studies report as much as 20% drainage to the internal mammary lymph node basin. The dissection of the internal mammary vessels also affords an opportunity to sample internal mammary lymph nodes that may significantly alter cancer staging and treatment. Traditionally the anastomosis from the free flap to the IMA and IMV is performed in an antegrade manner with a single artery and vein. However, when additional inflow or outflow is needed an additional anastomosis can be performed in the same zone with retrograde anastomosis to the IMA and IMV with success. While the free TRAM is currently the gold standard in autologous breast reconstruction, pre-existing abdominal scars are often a deterrent to the reconstructive surgeon given concern for potential ischemic complications. Techniques

* Corresponding Author's Email: glee@stanford.edu; Fax: 650-725-6605.

involving flap design modification and supercharging or turbocharging the flaps with additional anastomoses from contralateral deep inferior epigastric vessels or superficial inferior epigastric vessels provides the reconstructive surgeon with tools for successfully managing potential problems associated with abdominal scars.

Often clinical analysis of bleeding flap edges is sufficient for assessing flap viability intraoperatively; however, new imaging modalities involving intraoperative laser-assisted indocyanine green (ICG) angiography are also being used as an adjunct to assess tissue perfusion. Other vascular imaging studies such as computed tomography angiography (CTA) are increasingly being used preoperatively to assist with perforator identification and free flap planning. The techniques discussed within this chapter highlight recent advances in perforator based microsurgery, the reconstructive surgeon's potential contribution to breast cancer staging, strategies for managing abdominal scars in abdominal based free tissue breast reconstruction, and the use of vascular imaging for the reconstructive surgeon. These techniques and tips help the reconstructive surgeon to provide excellent and predictable results while limiting complications.

INTRODUCTION

Since the birth of breast reconstruction, the reconstructive plastic surgeon has focused on developing a reliable procedure and improving aesthetic results while limiting complications and donor site morbidity. In 1982, Hartrampf brought the transverse rectus abdominis musculocutaneous (TRAM) flap to the forefront of autologous tissue breast reconstruction following mastectomy.

This technique allowed the reconstructive surgeon to utilize a transverse island of abdominal skin, subcutaneous tissue, and its underlying musculature based upon the superior epigastric vessels to recreate a natural breast mound without the need for an implant [1].

While this was an improvement to previous techniques and allowed a single stage reconstruction, there was abdominal wall morbidity due to the sacrifice of the rectus abdominis muscle. The continued evolution of technology and skill provided substantial advances that have pushed the field of breast reconstruction towards the increased utilization of free flap techniques capable of sparing abdominal muscles. The realization that the dominant blood supply to the rectus abdominis musculature and overlying abdominal wall was through the deep inferior epigastric artery and the added benefit of preserving the medial and inferior inframammary fold by avoiding tunneling of the pedicled flap also encouraged use of the free TRAM flap [2].

Current microsurgery training involves both live in operating room training in an apprenticeship model and self-directed education through interactive alternative modalities such as practice models and web-based curricula. While microsurgery training is incredibly diverse the development of reliable tools for assessing microsurgeon development is key.

One such scale for evaluating microsurgeons in training is the Stanford Microsurgery and Resident Training (SMaRT) scale, which has been validated previously [3-6]. As microsurgery techniques and training improve, the field continues to strive for improving aesthetic results and limiting donor site morbidity, which has led to the transition from the primary utilization of the free TRAM flap to utilization of the free muscle-sparing TRAM flap, the deep inferior epigastric artery perforator (DIEP) flap, and the superficial inferior epigastric artery (SIEA) flap (Figure 1 and Figure 2).

Each of these flaps utilize the same lower abdominal skin and fat as a donor site but with varying degrees of abdominal wall donor site morbidity based upon the extent of muscle that is used. Despite the varying degree of abdominal wall violation these abdominal flaps are tolerated well by the patient and in some cases have been shown to have a lower incidence of complications when compared to implant based breast reconstructions [7].

In today's practice, for autologous breast reconstruction lower abdominal tissue remains a preferred option by most reconstructive surgeons and perforator flap transfer is quickly becoming the gold standard [8]. In addition alternative non-abdominal tissue flaps including the superior gluteal artery perforator (SGAP) flap, the latissimus dorsi flap, and the transverse gracilis myocutaneous (TUG) flap all help to provide the reconstructive surgeon with a large toolbox of options for creating an aesthetic breast with autologous tissue when lower abdominal tissue is unavailable or not preferred by the patient.

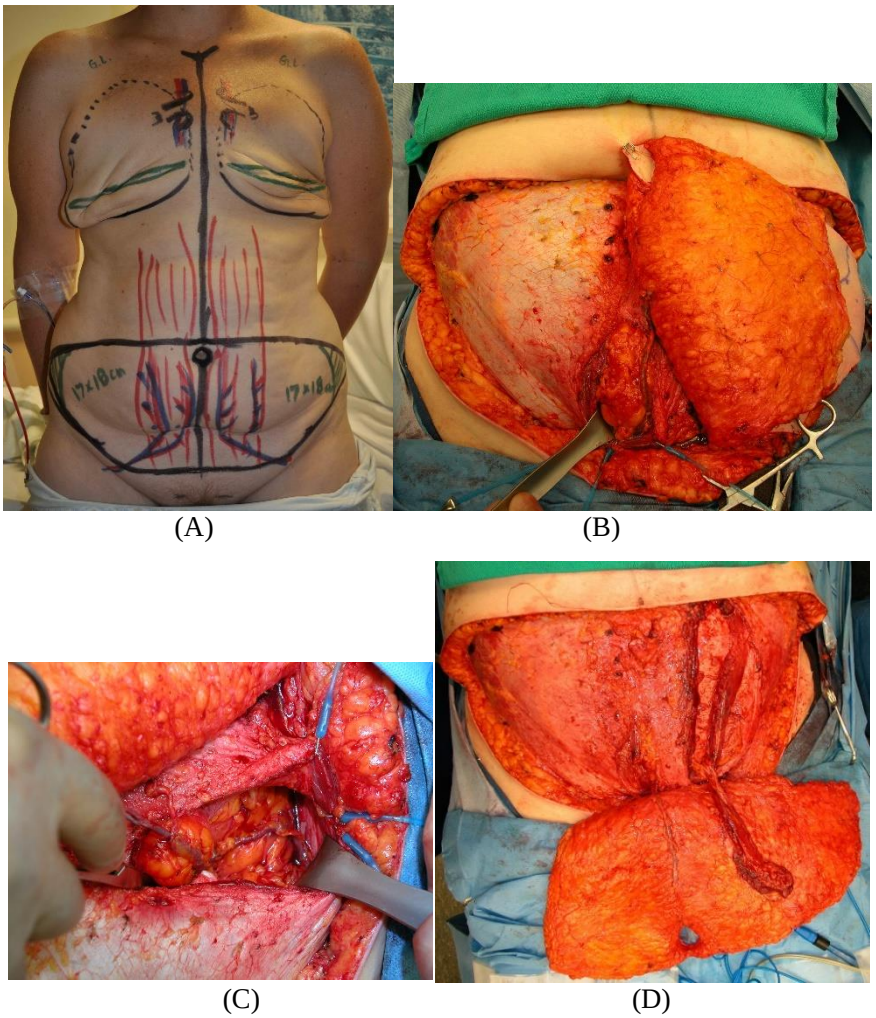

Figure 1. Free deep inferior epigastric artery flap. A) Markings used for a bilateral DIEP flap. B) After rectus sheath is opened the perforators are identified, preserved, and dissected free from the surrounding muscle back to the deep inferior epigastric artery. C) The pedicle is dissected distally. D) After flap elevation with a DIEP technique on the patient's right side and a muscle-sparing TRAM technique on the patients left side.

Figure 2. The final results. A) Preoperative photograph of patient with left mastectomy. B) Postoperative photograph following a left free DIEP flap and subsequent NAC reconstruction with tattooing for color. C) Preoperative photograph of patient with bilateral mastectomy defect. D) Postoperative photograph following bilateral free DIEP flap with subsequent NAC reconstruction and tattooing for color. Note significant natural ptosis consistent with patient body habitus.

RECIPIENT VESSELS

Historically, a variety of blood vessels have been used as potential recipient vessels for microvascular anastomosis in free flap breast reconstruction. Recipient arteries have included internal mammary, thoracodorsal, thoracoacromial, posterior humeral circumflex, circumflex scapular, and the axillary artery. Recipient veins have included internal mammary, thoracodorsal, cephalic vein of the arm, axillary vein branches, thoracoacromial vein, scapular circumflex, and the axillary vein [9]. While the use of the axillary, scapular

circumflex, and thoracoacromial vessels are infrequent; they can serve as lifeboats in the event of damage and unavailability of the primary planned vessels. The thoracoacromial vessels supply the pectoralis major muscle and can be found below the clavicle in the midclavicular region on the undersurface of the pectoralis major muscle. The circumflex scapular vessels are found where they join the thoracodorsal vessels to form the subscapular system. Tracing the subscapular system in a retrograde fashion into the axilla identifies the axillary vessels. Care must be taken to avoid traction injury to the brachial plexus during this dissection. Currently, the two most common recipient vessel sites for free tissue breast reconstruction are the thoracodorsal and internal mammary vessels.

In the case of immediate breast reconstruction following modified radical mastectomy in which axillary lymph node sampling is performed, the thoracodorsal vessels are either fully or partially exposed by the oncologic resection requiring minimal preparation by the reconstructive surgeon. Ideally, the reconstructed breast mound position should be medial enough to create medial fullness and cleavage for improved aesthetics. This is often difficult to achieve with anastomosis to the thoracodorsal vessels given their lateral location in the axilla. For improved results the thoracodorsal vessels must be dissected free not only from the surrounding tissue, but also freed from the branches to the serratus muscle to the level of the scapular circumflex vessels for sufficient length. In addition, for successful mound placement with use of the thoracodorsal vessels a long donor pedicle is needed.

Today, many surgeons prefer to use the internal mammary vessels as recipient vessels for breast reconstruction. This mirrors a change in the increased use of sentinel lymph node biopsy over axillary lymph node dissection for clinically uninvolved axillary lymph nodes. There are notable benefits to using the internal mammary vessels as primary recipients. In delayed reconstruction fresh tissue planes with lack of perivascular scarring from previous operations decreases the risk of damaging the recipient vessels during exposure. In delayed or immediate reconstruction the more medial position of the flap improves aesthetics and provides better positioning for vessel anastomosis [10, 11]. In cases of delayed axillary dissection after sentinel lymph node biopsy an internal mammary anastomosis circumvents possible damage to the pedicle, which would be at significant risk had the thoracodorsal vessels been used. Furthermore internal mammary vessel use as recipient vessels broadens the reconstructive surgeons flap options, as a shorter pedicle length can be accommodated and still allow medial placement of the flap while limiting lateral fullness [12].

The senior author prefers to use the internal mammary vessels as first-line recipient vessels for breast reconstruction when available (Figure 3). The internal mammary vessels are approached by elevating a flap of pectoralis major muscle overlying the third rib exposing the underlying rib and intercostal muscles. The perichondrium of the third rib is then incised along the anterior surface of the costal cartilage from the sternal junction to the costochondral junction. Blunt and sharp dissection is used to separate the perichondrium from the underlying cartilage on the anterior and posterior surface. The cartilage is then removed with a rongeur. The deep perichondrium is then incised and reflected from lateral to medial. Bipolar electrocautery and hemoclips are used to control small branches from the internal mammary vessels. Care must be taken to avoid injury to the underlying pleura and lung during the dissection. Once the internal mammary vessels are identified the exposure is increased by dividing the intercostal musculature from the second to the fourth rib. The internal mammary vein tends to be larger on the right side compared to the left. It is important to select the appropriate costal cartilage for removal as the internal mammary veins decrease

in size and bifurcate at or below the fourth interspace making venous anastomosis more difficult below this level [10]. After adequate exposure the vessels are generally divided at the level of the fourth rib for sufficient length during microscopic anastomosis (Figure 4). While the use of the internal mammary vessels in free flap breast reconstruction is becoming more widespread, it is not without its drawbacks. One particular drawback is that after the internal mammary vessels are used for breast reconstruction, they are no longer available for use as an arterial conduit in coronary revascularization. Studies have noted that the incidence of cardiovascular disease in women with breast cancer who have undergone free flap breast reconstruction is quite low as women with pre-existing coronary artery disease or significant comorbidities are likely to undergo a more simple operation such as implant based reconstruction.

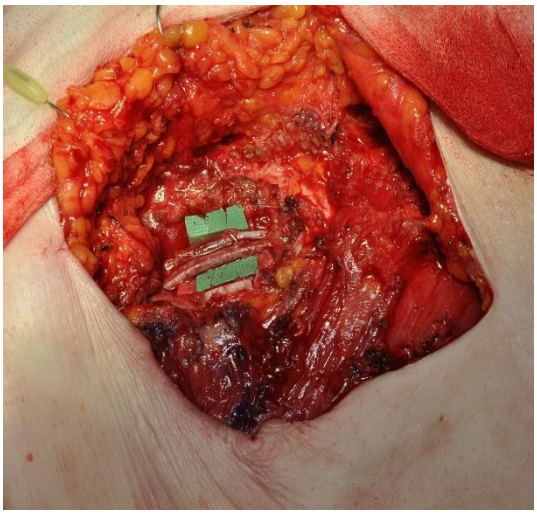

Figure 3. Exposed internal mammary artery and vein.

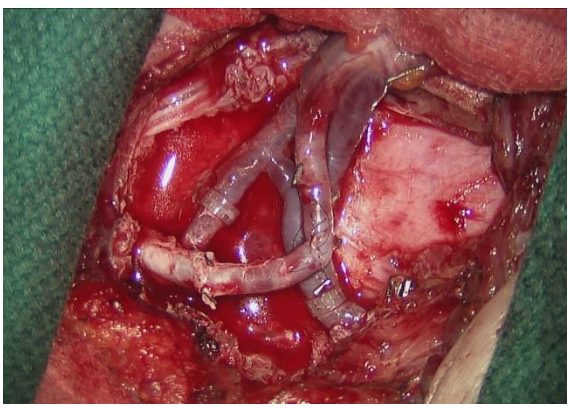

Figure 4. Free flap anastomosis to internal mammary artery and vein.

Additionally the increasing use of percutaneous angioplasty procedures decreases the need for mammary bridge in coronary revascularization. Overall, the use of internal mammary vessel use in breast reconstruction surgery is quite safe; however, this potential drawback should be discussed with the patient [13].

VASCULAR OPTIMIZATION

Venous Outflow

After vessel anastomosis and flap inset, one major complication that can be seen with free flap breast reconstruction is venous congestion. DIEP flap venous congestion is multifactorial and is influenced by patient factors (i.e., smoking history, obesity, etc.), technical expertise, and anatomy of the venous system. The reconstructive surgeon must be cognizant and capable of managing potential venous outflow complications that could comprise the reconstructed breast. In the past there were reports of managing venous congestion with cephalic vein harvest and transfer to augment venous drainage and reduce necrosis as either primary venous drainage or additional venous drainage [14]. Significant advances in the understanding of the venous drainage system of the lower abdominal tissues as well as the internal mammary vascular system has allowed for improved methods of augmenting and managing venous drainage after flap transfer.

Anatomic studies of abdominal based tissue flaps have noted that the superficial inferior epigastric vein (SIEV) or deep inferior epigastric vein (DIEV) alone may not be fully capable of supporting drainage of the entire flap leading to venous congestion if not appropriately addressed. If congestion is appreciated intra-operatively this is addressed with 1) separate anastomoses of the DIEV and the SIEV, or 2) if truly one system is dominant (superficial vs. deep) then single anastomosis of the dominant system with or without vein graft is justified. The senior author has reported harvesting the DIEV as a vein graft in cases of SIEV dominance when additional vein length is needed [15]. When needed there are several sources of additional drainage include the external jugular vein, external facial vein, thoracodorsal vein, etc. [14, 16, 17]. When performing primary anastomosis to the internal mammary vessels, one often appreciates that the internal mammary vein has already branched at the level of the anastomosis. In this case, the venous flow can be augmented by utilizing this paired system and performing additional venous anastomosis with SIEV or contralateral DIEV to this second internal mammary vein. In the absence of a branched or paired internal mammary vein another attractive option is to join the superficial and deep drainage systems by performing and additional anastomosis between the DIEV and the SIEV for venous augmentation. Yet another option, and that preferred by the senior author, in the absence of paired internal mammary veins is to perform independent antegrade and retrograde anastomosis to the internal mammary vein after division. We have experienced successful results with utilization of the distal internal mammary vein stump at our institution and there are a few series that have also reported positive results with this technique [18, 19]. Previous studies have noted or assumed that the lack of valves in the internal mammary veins contribute to the success of internal mammary vein use as a conduit in either an antegrade or retrograde fashion [20, 21]. On the contrary, Mackey et al. performed an anatomic study of the internal mammary veins and noted that 43% of cadavers had valves in at least one vein or major branch. They suggested that given the reported success it was likely that bulk of retrograde flow in the IMV occurs through collaterals and communicating side branches, or valve incompetence allowing regurgitant flow [22]. Options for antegrade and retrograde anastomosis include: 1) In the case of DIEP vena comitans, the larger can be anastomosed to the proximal limb in an antegrade fashion and the smaller can be anastomosed to the distal

limb in an retrograde fashion; 2) the deep inferior epigastric vein can be anastomosed to the proximal limb and the SIEV can be anastomosed to the distal limb in a retrograde fashion; and 3) for bipedicled DIEP flaps the internal mammary vein can again be used in an antegrade and retrograde fashion. By utilizing the internal mammary vein for retrograde flow, distal vein grafts and morbidity associated with additional dissection can be avoided. The retrograde use of the internal mammary vein provides another avenue for flap salvage, venous supercharging, and double pedicle reconstruction when appropriate. These all highlight the importance of preserving the SIEV on both sides and obtaining maximal length during the initial dissection. When no additional outflow can be established in venous congestion, leech therapy is considered for venous decompression to avoid venous stasis and thrombosis.

Arterial Inflow

While retrograde use of the internal mammary vein provides an additional option for venous drainage, retrograde anastomosis to the internal mammary artery provides the reconstructive surgeon with a means for augmenting vascular inflow to the flap. While the first choice for autogenous tissue breast reconstruction is the single pedicle flap, there are circumstances where similar to the need for increased venous drainage the reconstructive surgeon will be faced with a need for increased arterial in-flow. The increase in arterial inflow often comes in the form of a double pedicle flap. In 1990, Hartrampf et al. described the benefit of the double-pedicle TRAM: 1) in the presence of a midline scar when reconstruction requires greater tissue than that contained in the hemi-abdomen, 2) when the volume of the tissue needed for reconstruction was large and exceeded that which could reliably be carried on a single pedicle, and 3) those at high risk for partial flap necrosis [23]. The use of bilateral rectus muscles for bi-pedicled flaps resulted in significant abdominal wall morbidity [24]. Other techniques involving “supercharging” or “turbocharging” were developed to improve blood flow in the uni-pedicled flap. In the “supercharged” flap the deep inferior epigastric vessels or the superficial inferior epigastric vessels were anastomosed to independent and unrelated source vessels in the axilla such as the thoracodorsal vessels [25, 26]. Whereas, in the “turbocharged” flap the vascular augmentation was provided by a source vessel already intrinsic to the flap such as anastomosis of the deep inferior epigastric vessels to each other creating a loop [27]. As the use of free flaps increased techniques such as the bipedicled free TRAM flap with anastomosis to the thoracodorsal and serratus collateral vessels increased in popularity [28]. As changes in reconstructive surgery technique often mirrors change in technique of the extirpative surgeon, decreased axillary dissection resulted in an increase of internal mammary artery use for recipient vessels and a movement away from combining internal mammary vessels and axillary vessels for bipedicled free flaps to the use of internal mammary vessels alone with two sets of microvascular anastomosis to the proximal and distal ends of the transected internal mammary vessels [29, 30]. When vascular augmentation is needed for DIEP flap breast reconstruction the senior author prefers to utilize the proximal and distal cut ends of the internal mammary vessels for anastomoses to the deep inferior epigastric vessels or superficial inferior epigastric vessels in an end-to-end fashion. The retrograde flow through the distal cut end has been observed to provide sufficient flow for needed augmentation.

MANAGEMENT OF ABDOMINAL SCARS

The presence of pre-existing abdominal scars presents a challenge to the reconstructive surgeon as the scars can place the free flap or remaining abdominal wall tissues at risk for necrosis. The presence of an abdominal scar requires the reconstructive surgeon to recognize the potential challenge to tissue perfusion and make necessary modifications to flap design and/or harvest technique to mitigate complications. There are extreme cases where multiple abdominal scars may be a contraindication to surgery; however, abdominal scars in and of themselves are not absolute contraindications to abdominal tissue based autologous breast reconstruction. As mentioned, Hartrampf noted early on that patients with large tissue requirements and a midline abdominal scar benefited from double pedicle TRAM flaps [23]. This technique resulted in considerable abdominal wall weakness after the harvest of bilateral rectus abdominis muscles [31]. Other techniques for vascular augmentation were developed to prevent flap necrosis. Berrino originally described the "Parasite TRAM Flap" which involved harvesting a unilateral superiorly based pedicled TRAM flap and utilizing retrograde flow from the ipsilateral deep inferior epigastric vessels to supply the contralateral deep inferior epigastric vessels [32]. As free flap breast reconstruction became more prevalent others have compensated for the loss of volume by stacking free hemi-DIEP flaps with varying recipient vessels for antegrade and retrograde flow in the presence of a midline abdominal scar [33, 34]. There have been numerous modifications for in-flap vascular augmentation across midline scars that have included anastomosing a premuscular branch off the main deep inferior epigastric artery pedicle across the midline to the proximal end of the contralateral deep inferior epigastric vessels, or creating an anastomosis between the stump of the superior epigastric vessels to contralateral paraumbilical perforators [35-37].

The senior author prefers to use the DIEP flap as a first choice to create an aesthetic breast despite the presence of abdominal scars. With necessary adjustments in flap design and harvest the DIEP flap is safely done in patients with pre-existing abdominal scars. We routinely identify the superficial inferior epigastric vessels intraoperatively and dissect them for a minimum of 4-5 cm through the subcutaneous tissue for added length. These vessels are then preserved for possible later use. A recent anatomic study notes a 94% incidence of the SIEA on CTA; however, only 24% had a diameter > 1.5 mm. The SIEV was present in all cases [38]. The identification and preservation of these vessels when possible affords the reconstructive surgeon added flexibility for managing pre-existing abdominal wall scars. Each case is to be considered based on a number of factors including, the location of the abdominal scar, whether the reconstruction is unilateral or bilateral, and the volume of tissue needed for a symmetric reconstruction.

In the case of a midline infra-umbilical scar, a patient needing a unilateral reconstruction in the presence of a large and pendulous native breast, the reconstruction will require a large amount of tissue often crossing the midline and preventing the use of a hemi-DIEP flap. In this case a bipedicled DIEP flap is harvested to provide perfusion on both sides of the scar.

Other viable options include a DIEP pedicle on one side and an SIEA pedicle on the other side, or a bipedicled SIEA flap if a smaller volume is required (Figure 5). For bilateral reconstructions or small volume unilateral reconstructions the midline scar marks the medial edge of the flap. In cases of a midline supra-umbilical scar, there is no change in flap design; however, the scar can tether the skin to the fascia making donor site closure difficult.

Complete undermining of the skin and subcutaneous tissue flaps to the xiphoid past the scar should eliminate this problem.

The paramedian scar is encountered less frequently, yet can be a cause of significant morbidity if not addressed appropriately. For bilateral and unilateral cases one must ensure that there are perforators on each side of the scar. In unilateral breast reconstruction we preferentially harvest a bipedicled DIEP flap and proceed if the scar is medial to the lateral perforators. In bilateral cases or when the scar is located lateral to the deep inferior epigastric perforators we utilize the superficial inferior epigastric vessels to supercharge or turbocharge the flap for blood supply across the scar [39]. In these cases we prefer to perform two independent anastomoses to the proximal and distal cut ends of the internal mammary artery and vein limiting the need for further dissection into the axilla to access the thoracodorsal vessels [34] (Figure 6).

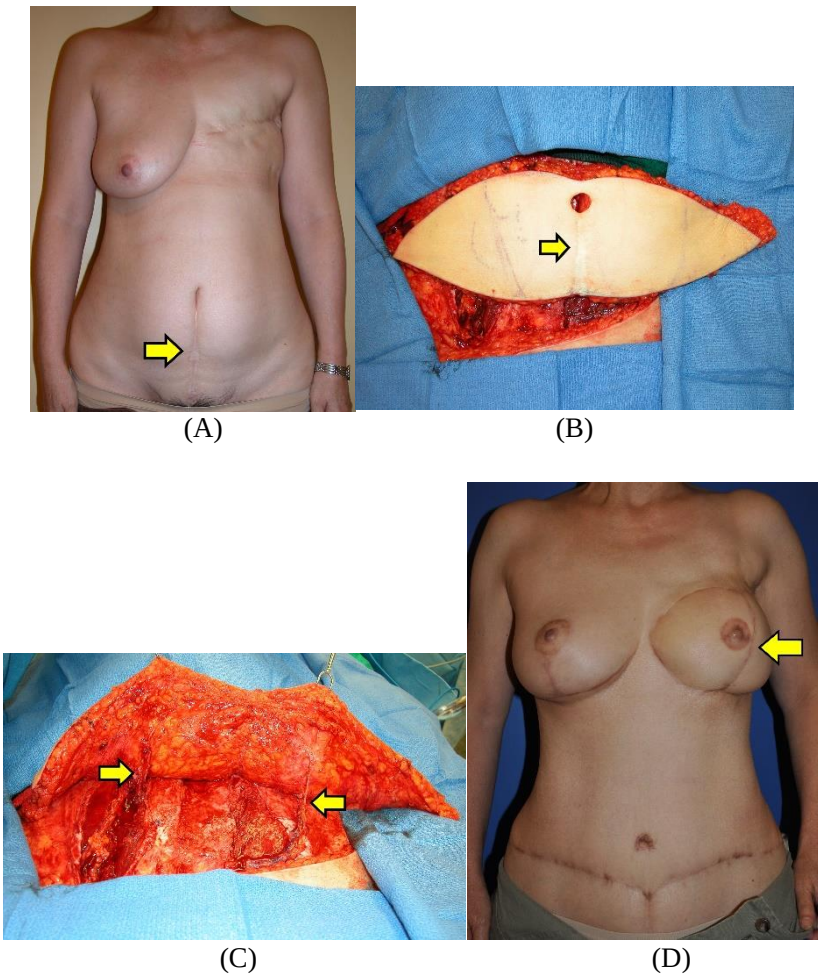

Figure 5. Midline infraumbilical scar. A) Preoperative photograph of a patient with midline infraumbilical scar and left mastectomy defect. B) Intraoperative photograph of harvested abdominal tissue flap. C) Intraoperative photograph of bipedicled DIEP flap, pedicles marked with arrows. D) Postoperative photograph of patient with a bipedicled DIEP flap for left breast reconstruction and right breast mastopexy for symmetry.

With a pre-existing low transverse or pfannenstiel incision scar the flap is positioned more inferiorly so that the scar becomes the inferior border of the flap. Flap dissection and vessel selection may then usually proceed as planned. In theory the perforators and deep inferior epigastric vessels are preserved as Pfannenstiel's original description describes a transverse skin incision with vertical splitting of the rectus muscles through the linea alba to access the pelvis [40, 41]. Despite this description it is prudent to fully evaluate for intact source vessels prior to completing flap harvest, as it is not uncommon to encounter transected muscle and source vessels or an undermined flap with damage to abdominal wall perforators jeopardizing the ability to safely harvest an abdominal flap. If there is any question of perforator viability the flap should be harvested as either an MS-TRAM or free TRAM flap.

The subcostal scar, often used for open cholecystectomy, if low enough can be incorporated as a superior edge of the flap. When the scar is too high to incorporate into the incision modifications are made to both flap design and harvest. While the deep inferior epigastric vessels are remote from the scar, they play a key role in providing perfusion to the abdominal tissue below the scar as often the rectus muscle and superior epigastric arteries have been transected. Harvest of the deep inferior epigastric artery places the remaining abdominal wall at risk for ischemic complications.

In this case the designed peaks of the abdominal flap are lower than normal and the flap is smaller to preserve a broad base of tissue beneath the scar to perfuse the remaining skin flap. Undermining of the skin and subcutaneous flap near the scar is limited to only that what is needed for tension free closure in an effort to preserve nearby perforators to the skin (Figure 7).

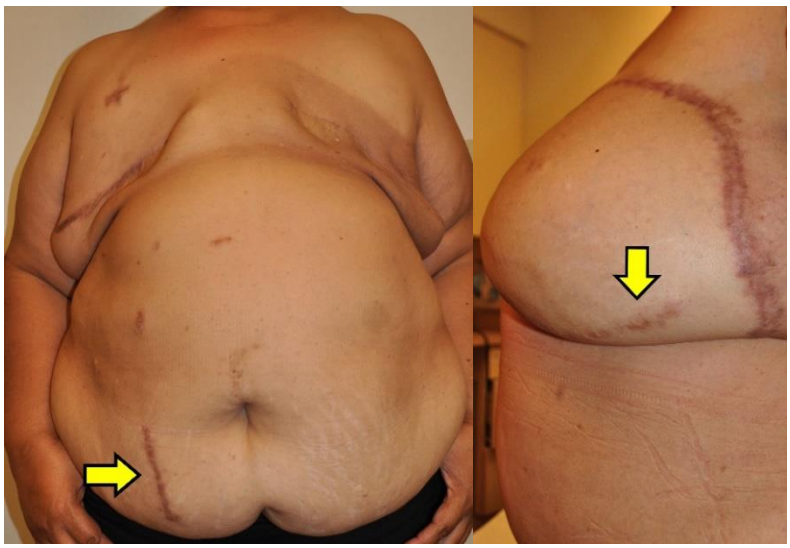

(A) (B)

Figure 6. Paramedian scar. A) Preoperative photograph of a patient with a right paramedian scar and bilateral mastectomy defects. B) Postoperative photograph of patient with bilateral DIEP flap breast reconstruction. The left breast is reconstructed with a bipedicled DIEP and SIEA flap to preserve as much volume as possible.

Right lower quadrant or McBurney's incisions for open appendectomy result in abdominal scars that could compromise the lateral edges of the DIEP flap. In these cases if the orientation and location of the scar is amenable, it is best served to shift the flap so that the scar marks the inferolateral edge of the flap. When this is not possible and the scar has to be included to increase flap volume the SIEA and SIEV are available to supercharge or turbocharge the flap and perfuse the area across the scar (Figure 8).

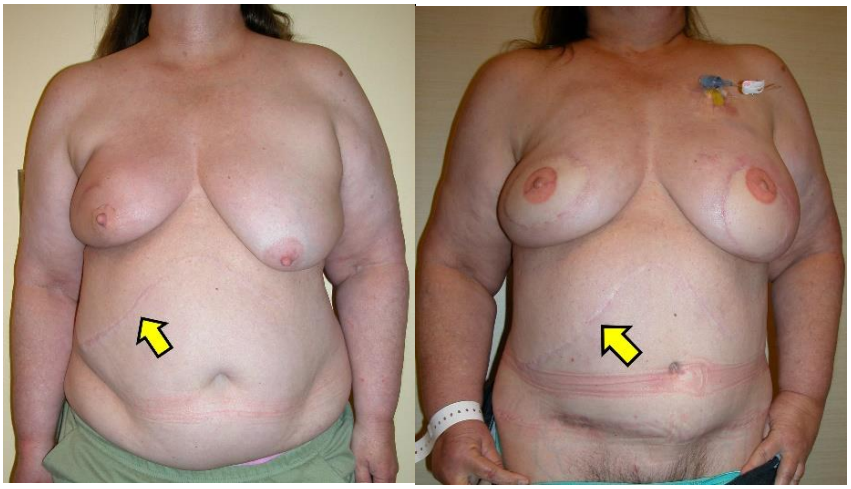

(A) (B)

Figure 7. Subcostal scar. A) Preoperative photograph of a patient with a right subcostal scar and right breast cancer. B) Postoperative photograph after patient has undergone bilateral mastectomy and bilateral DIEP flap breast reconstruction with subsequent NAC reconstruction and tattooing for color.

(A) (B)

Figure 8. Right lower quadrant scar. A) Preoperative photograph of a patient with a right lower quadrant scar from a McBurney's incision and bilateral mastectomy defects. B) Postoperative photograph after bilateral DIEP flap breast reconstruction. She has yet to undergo NAC reconstruction.

If the SIEA and SIEV are unavailable and there are ischemic concerns beyond the scar excision of the ischemic portion of the flap is recommended. Although there has been no demonstrated increase of flap or donor site complications for DIEP flaps in the presence of abdominal scars from laparoscopic port placement, port scars in the vicinity of the vascular pedicle and perforators can increase the technical difficulty of the dissection [42].

The key when performing autologous breast reconstruction with abdominal tissue in the presence of pre-existing abdominal scars is providing independent perfusion on both sides of the scar.

Tissue perfusion should be assessed intraoperatively for final decision-making and any evidence of venous or arterial insufficiency should prompt vascular supplementation.

IMAGING

There has been a growing popularity for the use of preoperative and intraoperative imaging amongst breast reconstructive surgeons. The most critical aspect of designing and harvesting the DIEP flap is determining the amount of viable tissue that can safely be harvested on a particular perforator. Doppler sonography with or without color duplex imaging has been used to localize cutaneous perforators with high sensitivity allowing preoperative identification. Qualitative assessments based on the harshness of the sound provided a subjective comparison for perforator dominance within a certain skin territory [43, 44]. However, Doppler sonography has its drawbacks including detecting vessels that may be too small to support a given skin flap, inability to identify location of perforator take off, and operator dependence [45]. Due to increased detail and reproducibility, preoperative imaging in the form of computed tomography angiography (CTA) has largely supplanted previously used color duplex sonography in assisting with the planning and selection of perforators for flap harvest. Multidetector-row computed tomography (MDCT) is a recent innovation that allows rapid simultaneous acquisition of multiple thin collimated slices with high spatial resolution and low artifact. The time of acquisition is 10-12 seconds and the total procedure time takes about 10 minutes to perform. The data is then used to reconstruct 1 mm slices and reformatted images in multiple planes (coronal, axial, sagittal, and oblique) as well as a three-dimensional volume reconstruction [46]. Reports suggest that with CTA perforator mapping operative times and postoperative complications associated with partial necrosis of the flap are decreased [47, 48]. In addition to its utility in evaluating free flap donor site anatomy, CTA can also be used to evaluate recipient site anatomy and detect vascular anomalies that can alter the surgical plan, particularly in the cases of traumatic injury reconstructive procedures [49]. While there is acknowledgement that CTA can indeed accurately identify perforators and provide a roadmap for the surgeon there are drawbacks with regard to radiation exposure, need for intravenous contrast media, and increased cost. In a recent study by Mathes et al., they noted that 44% of abdominal perforator flaps involved intraoperative changes due to features not seen on preoperative CT imaging that resulted in the use of additional perforators that were not a part of the initial preoperative plan or the abandonment of initially planned perforators. They noted that while CTA does provide an excellent roadmap for surgical planning and can facilitate flap dissection, it is not a panacea for free flap breast reconstruction. The surgeon must consider not only the anatomical aspects, but

also the functional aspects such as location, intramuscular course, and intervening muscle between perforators [50].

More recently, magnetic resonance angiography (MRA) has shown promise in perforator imaging. High field 3-Tesla MRA is capable of producing detailed, multiplanar images, and three-dimensional reconstruction without the associated radiation exposure seen in CT imaging.

Some have utilized blood-pool contrast agents such as gadofosveset trisodium for contrast-enhanced MRA. Reportedly, gadofosveset trisodium is retained in the intravascular space resulting in higher spatial resolution, in contrast to the conventional gadolinium-based contrast [51]. This technology is in its early stages and still requires further investigation. In general, preoperative imaging when used should not replace or supersede clinical judgment, but can be used as an adjunct for the reconstructive surgeon in preoperative planning. At this time the necessity of and clinical utility of preoperative imaging remains a topic of debate. Currently, we do not routinely obtain preoperative imaging studies.

(A)

(B)

Figure 9. Ischemic complications. A) Flap ischemia of the right reconstructed breast that will require debridement and alternative reconstruction. B) Ischemia of lower breast skin flaps in breast reconstruction.

With regard to intraoperative imaging, there are new imaging modalities such as intraoperative laser-assisted indocyanine green (ICG) angiography that are being used as an adjunct to help assess tissue perfusion. Inadequate tissue perfusion is one of the known key causes to early complications in free flap surgery [52] (Figure 9). To identify areas of decreased perfusion, laser assisted ICG angiography begins with intravenous injection of ICG fluorescent dye, which binds to plasma proteins confining the dye to the intravascular compartment as it travels rapidly through the vascular system. The dye fluoresces at 806 nm. Following stimulation with laser energy the fluorescence pattern can be captured on a charge-coupled device camera or monitor for dynamic and real time images in the operating room [53, 54]. Similarly, fluorescein has been used in the past as a perfusion marker; however, capillary leakage, and prolonged clearance of 12-18 hours limited its utility as a useful intraoperative tool [55, 56]. In contrast, ICG is not as susceptible to capillary leakage and with increased clearance repetitive dye administration may occur after 9 minutes for perfusion re-evaluation [54]. The infrared laser and ICG are capable of demonstrating dermal and superficial soft tissue perfusion to a depth of approximately 3.6 mm [57].

This technology has wide applicability to the plastic surgeon for evaluation of all components of the flap including, skin, fat, fascia, muscle, and nipples in breast reconstruction, and arterial and venous flow in microsurgery [58] (Figure 10).

A major drawback with any form of vascular imaging is that the observed imaging only produces a single snapshot of perfusion at a given time. For ICG angiography in particular, while the surgeon may obtain real-time qualitative data with regards to flap perfusion at time point zero, ICG angiography cannot account for resolved vasospasm or the opening of "choke vessels" at a later time point. Blindly accepting that areas of decreased perfusion on ICG angiography are and will remain ischemic and later necrotic could result in resection of tissue that may have survived with more time. While this modality has been correlated with clinical outcomes and has been used for surgical decision-making, at this time there are no quantitative perfusion thresholds above which tissue survival can be anticipated. Interestingly, in the rat model, skin necrosis has been appreciated when perfusion was less than 25% of reference skin and delayed wound healing was seen in a human study with a signal of less than 60% of normal skin [56, 59]. This technology remains in its initial phases and more basic work is needed in defining the correlation between tissue perfusion and necrosis to develop predictive guidelines and strategies for clinical use. At this time while clinical judgment of the flap based on tissue color, capillary refill, flap temperature, and dermal bleeding may inaccurately assess the adequacy of tissue perfusion; it remains the most common method of flap blood supply evaluation [60].

Reconstructive surgeons are constantly looking for ways to improve free flap outcomes, as free flap loss can be catastrophic. Ideally, the surgeon could identify simple, reliable, and accurate adjunctive modalities that allow early intervention and limit postoperative complications. At this time no imaging modality has satisfied all of these criteria; however, as the use of promising innovative technologies such as intraoperative ICG angiography continue to grow and improve they could ultimately prove invaluable in decreasing complications due to ischemic causes.



(A)

(B)

(C)

Figure 10. Laser-assisted indocyanine green angiography. A) An initial low intensity signal is seen in the artery. B) A stronger intensity signal is seen in the artery to the flap as the ICG continues to be distributed throughout the vascular system. C) As blood containing ICG perfuses and exits the flap a signal is now seen in the vein.

Internal Mammary Lymph Nodes

Historically, the extended radical mastectomy involved axillary and internal mammary (IM) lymph node dissection with studies demonstrating a 20-30% incidence of IM nodal disease in breast cancer [61]. A randomized trial comparing radical mastectomy with

extended radical mastectomy demonstrated no significant survival benefit of an extended procedure that was associated with significant morbidity. They did however note the prognostic value of the IM nodes as mortality rates of IM nodal involvement alone was similar to that of axillary nodal involvement alone, while involvement of both locations was associated with a significantly higher mortality [62]. The dissection of IM nodes has since been largely abandoned. On the other hand, axillary lymph node disease is a well-established prognostic indicator and predictor of survival in breast cancer. Reports suggest that 20-30% of node negative patients will develop recurrence within 10 years compared to approximately 70% of those with axillary nodal disease [63]. Traditionally axillary nodal status was established by axillary lymph node dissections [64]. However, development of sentinel lymph node (SLN) biopsy, where the first lymph nodes receiving lymphatic drainage from the primary tumor are selectively sampled with radioactive or blue dye, has rapidly emerged as a less morbid alternative to axillary dissection. In fact, sentinel lymph node biopsy is now regarded as the standard of care in patients without clinical or radiographic evidence of nodal disease in early-stage breast cancer [64, 65].

As Halstedian mastectomies have now fallen out of favor for modified radical and total mastectomies, and imaging technologies have improved allowing for sentinel lymph node biopsies the question of IM nodal management has again presented itself. A recent study evaluating the rate of metastasis to the IM nodal basin and the clinical implications noted a visualization of IM SLNs in 22% of patients using preoperative lymphoscintigraphy. Of those nodes that were surgically removed, they noted that 25% were positive for metastatic disease. Clinically, based on tumor-positive IM SLNs, 7% of those patients that underwent IM SLN biopsy had a change in their treatment regimen of radiation or chemotherapy [66]. Internal mammary lymph node biopsy can be done through a parasternal incision at a selected intercostal space with or without partial rib removal. Given the low numbers of patients that require changes to their systemic or radiation therapy regimen, some consider the biopsy unnecessary [67]. As mentioned above, with decreasing axillary dissections the reconstructive surgeon has transitioned from use of axillary vessels to primary use of internal mammary vessels as recipient vessels for free flap breast reconstruction. During this procedure a partial rib resection is routine and IM lymph nodes are often immediately accessible. The senior author routinely samples these lymph nodes with no time added to the case and no additional morbidity. We contend that biopsy of these nodes is important and should not be overlooked. Ideally, the biopsied nodes provide more accurate staging of breast cancer. Particularly those patients with involvement of the IM nodes with no disease in the axillary nodes and no high-risk features that would indicate the need for systemic therapy or those without metastases to the IM nodes that would lead to sparing the potential toxicity of parasternal IM node irradiation would benefit the most [68]. In this manner the reconstructive surgeon not only contributes to the breast reconstruction, but to the oncologic treatment as well as the information obtained from the IM lymph node biopsy taken in the context of other clinical factors such as axillary node status, age, tumor features, etc. will help guide further adjuvant therapies needed beyond breast reconstruction.

REFERENCES

[1] Scheflan, M., Hartrampf, C. R., Black, P. W. Breast reconstruction with a transverse abdominal island flap. *Plastic and reconstructive surgery*. 1982;69(5):908-9. Epub. 1982/05/01. PubMed PMID: 7071252.

[2] Scheflan, M., Dinner, M. I. The transverse abdominal island flap: part I. Indications, contraindications, results, and complications. *Annals of plastic surgery*. 1983;10(1):24-35. Epub. 1983/01/01. PubMed PMID: 6219607.

[3] Satterwhite, T., Son, J., Carey, J., Echo, A., Spurling, T., Paro, J., et al. The Stanford Microsurgery and Resident Training (SMaRT) Scale: validation of an on-line global rating scale for technical assessment. *Annals of plastic surgery*. 2014;72 Suppl. 1:S84-8. Epub. 2014/04/03. doi: 10.1097/SAP.0000000000000139. PubMed PMID: 24691332.

[4] Satterwhite, T., Son, J., Carey, J., Zeidler, K., Bari, S., Gurtner, G., et al. Microsurgery education in residency training: validating an online curriculum. *Annals of plastic surgery*. 2012;68(4):410-4. Epub. 2012/03/ 17. doi: 10.1097/SAP.0b013e31823b6a1a. PubMed PMID: 22421490.

[5] Nykiel, M., Wong, R., Lee, G. An economical training model to teach and practice deep inferior epigastric artery perforator dissection. *Annals of plastic surgery*. 2014;72 Suppl. 1:S66-70. Epub 2014/04/18. doi: 10.1097/SAP.0000000000000176. PubMed PMID: 24740027.

[6] Son, J., Zeidler, K. R., Echo, A., Otake, L., Ahdoot, M., Lee, G. K. Teaching Core Competencies of Reconstructive Microsurgery With the Use of Standardized Patients. *Annals of plastic surgery*. 2013. Epub. 2013/03/15. doi: 10.1097/SAP.0b013e 3182853f2c. PubMed PMID: 234 86137.

[7] Liu, C., Momeni, A., Zhuang, Y., Luan, J., Chung, M. T., Wright, E., et al. Outcome analysis of expander/implant versus microsurgical abdominal flap breast reconstruction: a critical study of 254 cases. *Annals of surgical oncology*. 2014;21(6):2074-82. Epub. 2014/02/22. doi: 10.1245/s10434-014-3521-0. PubMed PMID: 24558063.

[8] Yu, S. C., Kleiber, G. M., Song, D. H. An algorithmic approach to total breast reconstruction with free tissue transfer. *Archives of plastic surgery*. 2013;40(3):173-80. Epub. 2013/06/05. doi: 10.5999/aps.2013. 40.3.173. PubMed PMID: 23730589; PubMed Central PMCID: PMC 3665857.

[9] Shaw, W. W. Breast reconstruction by superior gluteal microvascular free flaps without silicone implants. *Plastic and reconstructive surgery*. 1983;72(4):490-501. Epub. 1983/10/01. PubMed PMID: 6611775.

[10] Clark, C. P., 3rd, Rohrich, R. J., Copit, S., Pittman, C. E., Robinson, J. An anatomic study of the internal mammary veins: clinical implications for free-tissue-transfer breast reconstruction. *Plastic and reconstructive surgery*. 1997;99(2):400-4. Epub. 1997/02/01. PubMed PMID: 9030147.

[11] Feller, A. M., Galla, T. J. The deep inferior epigastric artery perforator flap. *Clinics in plastic surgery*. 1998;25(2):197-206. Epub. 1998/06/17. PubMed PMID: 9627777.

[12] Dupin, C. L., Allen, R. J., Glass, C. A., Bunch, R. The internal mammary artery and vein as a recipient site for free-flap breast reconstruction: a report of 110 consecutive

cases. *Plastic and reconstructive surgery*. 1996;98(4):685-9; discussion 90-2. Epub. 1996/ 09/01. PubMed PMID: 8773691.

[13] Nahabedian, M. Y. The internal mammary artery and vein as recipient vessels for microvascular breast reconstruction: are we burning a future bridge? *Annals of plastic surgery*. 2004;53(4):311-6. Epub. 2004/09/24. PubMed PMID: 15385762.

[14] Barnett, G. R., Carlisle, I. R., Gianoutsos, M. P. The cephalic vein: an aid in free TRAM flap breast reconstruction. Report of 12 cases. *Plastic and reconstructive surgery*. 1996;97(1):71-6; discussion 7-8. Epub. 1996/01/01. PubMed PMID: 8532808.

[15] Momeni, A., Lee, G. K. A case of intraoperative venous congestion of the entire DIEP-flap--a novel salvage technique and review of the literature. *Microsurgery*. 2010;30(6):443-6. Epub. 2010/09/30. doi: 10. 1002/micr.20774. PubMed PMID: 20878727.

[16] Pennington, D. G., Hassall, M. The free transverse rectus abdominis myocutaneous flap in breast reconstruction after mastectomy. *The Australian and New Zealand journal of surgery*. 1991;61(6):446-51. Epub. 1991/06/01. PubMed PMID: 1829352.

[17] Serafin, D., Voci, V. E., Georgiade, N. G. Microsurgical composite tissue transplantation: indications and technical considerations in breast reconstruction following mastectomy. *Plastic and reconstructive surgery*. 1982;70(1):24-36. Epub. 1982/07/01. PubMed PMID: 7089105.

[18] Kerr-Valentic, M. A., Gottlieb, L. J., Agarwal, J. P. The retrograde limb of the internal mammary vein: an additional outflow option in DIEP flap breast reconstruction. *Plastic and reconstructive surgery*. 2009;124(3): 717-21. Epub. 2009/09/05. doi: 10.1097/PRS.0b013e3181b179fc. Pub Med PMID: 19730291.

[19] Galanis, C., Nguyen, P., Koh, J., Roostaeian, J., Festekjian, J., Crisera, C. Microvascular lifeboats: a stepwise approach to intraoperative venous congestion in DIEP flap breast reconstruction. *Plastic and reconstructive surgery*. 2014;134(1):20-7. Epub. 2014/07/17. doi: 10.1097/PRS. 0000000000000271. PubMed PMID: 25028816.

[20] Li, S., Mu, L., Li, Y., Xu, J., Yang, M., Zhao, Z., et al. Breast reconstruction with the free bipedicled inferior TRAM flap by anastomosis to the proximal and distal ends of the internal mammary vessels. *Journal of reconstructive microsurgery*. 2002;18(3):161-8. Epub. 2002/05/15. doi: 10.1055/s-2002-28498. PubMed PMID: 120070 53.

[21] Schwabegger, A. H., Ninkovic, M. M., Moriggl, B., Waldenberger, P., Brenner, E., Wechselberger, G., et al. Internal mammary veins: classification and surgical use in free-tissue transfer. *Journal of reconstructive microsurgery*. 1997;13(1):17-23. Epub. 1997/01/01. doi: 10.1055/s-2008-1063936. PubMed PMID: 9120838.

[22] Mackey, S. P., Ramsey, K. W. Exploring the myth of the valveless internal mammary vein--a cadaveric study. *Journal of plastic, reconstructive and aesthetic surgery: JPRAS*. 2011;64(9):1174-9. Epub 2011/05/07. doi: 10.1016/j.bjps.2011.03.045. PubMed PMID: 21546327.

[23] Wagner, D. S., Michelow, B. J., Hartrampf, C. R., Jr. Double-pedicle TRAM flap for unilateral breast reconstruction. *Plastic and reconstructive surgery*. 1991;88(6):987-97. Epub. 1991/12/11. PubMed PMID: 1835103.

[24] Kroll, S. S., Schusterman, M. A., Reece, G. P., Miller, M. J., Robb, G., Evans, G. Abdominal wall strength, bulging, and hernia after TRAM flap breast reconstruction. *Plastic and reconstructive surgery*. 1995; 96 (3):616-9. Epub. 1995/09/01. PubMed PMID: 7638285.

[25] Harashina, T., Sone, K., Inoue, T., Fukuzumi, S., Enomoto, K. Augmentation of circulation of pedicled transverse rectus abdominis musculocutaneous flaps by microvascular surgery. *British journal of plastic surgery*. 1987;40(4):367-70. Epub. 1987/07/01. PubMed PMID: 2957016.

[26] Takayanagi, S. Extended transverse rectus abdominis musculocutaneous flap. *Plastic and reconstructive surgery*. 1993;92(4):757-8. Epub. 1993/ 09/01. PubMed PMID: 8356140.

[27] Semple, J. L. Retrograde microvascular augmentation (turbocharging) of a single-pedicle TRAM flap through a deep inferior epigastric arterial and venous loop. *Plastic and reconstructive surgery*. 1994;93(1):109-17. Epub. 1994/01/01. PubMed PMID: 8278465.

[28] Arnez, Z. M., Scamp, T. The bipedicled free TRAM flap. *British journal of plastic surgery*. 1992;45(3):214-8. Epub. 1992/04/01. PubMed PMID: 1596662.

[29] Blondeel, P. N., Boeckx, W. D. Refinements in free flap breast reconstruction: the free bilateral deep inferior epigastric perforator flap anastomosed to the internal mammary artery. *British journal of plastic surgery*. 1994;47(7):495-501. Epub. 1994/10/01. PubMed PMID: 79528 20.

[30] Ng, R. L., Youssef, A., Kronowitz, S. J., Lipa, J. E., Potochny, J., Reece, G. P. Technical variations of the bipedicled TRAM flap in unilateral breast reconstruction: effects of conventional versus microsurgical techniques of pedicle transfer on complications rates. *Plastic and reconstructive surgery*. 2004;114(2):374-84; discussion 85-8. Epub. 2004/07/28. PubMed PMID: 15277802.

[31] Lejour, M., Dome, M. Abdominal wall function after rectus abdominis transfer. *Plastic and reconstructive surgery*. 1991;87(6):1054-68. Epub. 1991/06/01. PubMed PMID: 1827922.

[32] Berrino, P., Casabona, F., Adami, M., Muggianu, M. The "parasite" TRAM flap for autogenous tissue breast reconstruction in patients with vertical midabdominal scars. *Annals of plastic surgery*. 1999;43(2):119-26. Epub. 1999/08/24. PubMed PMID: 10454315.

[33] Ali, R. S., Garrido, A., Ramakrishnan, V. Stacked free hemi-DIEP flaps: a method of autologous breast reconstruction in a patient with midline abdominal scarring. *British journal of plastic surgery*. 2002;55(4):351-3. Epub. 2002/08/06. PubMed PMID: 12160543.

[34] Das-Gupta, R., Busic, V., Begic, A. Deep inferior epigastric perforator flap (DIEP) breast reconstruction in the presence of a midline vertical scar. *Journal of plastic, reconstructive and aesthetic surgery: JPRAS*. 2006;59(6):675-6. Epub. 2006/07/05. PubMed PMID: 16817262.

[35] Schoeller, T., Wechselberger, G., Roger, J., Hussl, H., Huemer, G. M. Management of infraumbilical vertical scars in DIEP-flaps by crossover anastomosis. *Journal of plastic, reconstructive and aesthetic surgery: JPRAS*. 2007;60(5):524-8. Epub. 2007/04/03. doi: 10.1016/j.bjps.2006. 11.008. PubMed PMID: 17399662.

[36] Pennington, D. G., Nettle, W. J., Lam, P. Microvascular augmentation of the blood supply of the contralateral side of the free transverse rectus abdominis musculocutaneous flap. *Annals of plastic surgery*. 1993;31 (2):123-6; discussion 6-7. Epub. 1993/08/01. PubMed PMID: 8215126.

[37] Lam, T. C., Sellars, G. D. Free perforator crossover TRAM flap for breast reconstruction. *Annals of plastic surgery*. 2003;50(2):126-31. Epub. 2003/02/05. doi: 10.1097/01.SAP.0000032307.61429.9E. Pub Med PMID: 12567047.

[38] Rozen, W. M., Chubb, D., Grinsell, D., Ashton, M. W. The variability of the Superficial Inferior Epigastric Artery (SIEA) and its angiosome: A clinical anatomical study. *Microsurgery*. 2010;30(5):386-91. Epub. 2010/01/09. doi: 10.1002/micr.20750. PubMed PMID: 20058298.

[39] Hallock, G. G. Further clarification of the nomenclature for compound flaps. *Plastic and reconstructive surgery*. 2006;117(7):151e-60e. Epub. 2006/06/15. doi: 10.1097/01.prs.0000219178.20541.7f. PubMed PMID: 16772903.

[40] Rahn, D. D., Phelan, J. N., Roshanravan, S. M., White, A. B., Corton, M. M. Anterior abdominal wall nerve and vessel anatomy: clinical implications for gynecologic surgery. *American journal of obstetrics and gynecology*. 2010;202(3):234 e1-5. Epub. 2009/12/22. doi: 10.1016/j. ajog.2009.10.878. PubMed PMID: 20022582.

[41] Kisielinski, K., Conze, J., Murken, A. H., Lenzen, N. N., Klinge, U., Schumpelick, V. The Pfannenstiel or so called "bikini cut": still effective more than 100 years after first description. *Hernia: the journal of hernias and abdominal wall surgery*. 2004;8(3):177-81. Epub. 2004/03/ 05. doi: 10.1007/s10029-004-0210-0. PubMed PMID: 14997364.

[42] Parrett, B. M., Caterson, S. A., Tobias, A. M., Lee, B. T. DIEP flaps in women with abdominal scars: are complication rates affected? *Plastic and reconstructive surgery*. 2008;121(5):1527-31. Epub. 2008/05/06. doi: 10.1097/PRS.0b013e31816b14a5. PubMed PMID: 18453974.

[43] Taylor, G. I., Doyle, M., McCarten, G. The Doppler probe for planning flaps: anatomical study and clinical applications. *British journal of plastic surgery*. 1990;43(1):1-16. Epub. 1990/01/01. PubMed PMID: 2178717.

[44] Giunta, R. E., Geisweid, A., Feller, A. M. The value of preoperative Doppler sonography for planning free perforator flaps. *Plastic and reconstructive surgery*. 2000;105(7):2381-6. Epub. 2000/06/09. PubMed PMID: 10845290.

[45] Hallock, G. G. Doppler sonography and color duplex imaging for planning a perforator flap. *Clinics in plastic surgery*. 2003;30(3):347-57, v-vi. Epub. 2003/08/15. PubMed PMID: 12916592.

[46] Masia, J., Clavero, J. A., Larranaga, J. R., Alomar, X., Pons, G., Serret, P. Multidetector-row computed tomography in the planning of abdominal perforator flaps. *Journal of plastic, reconstructive and aesthetic surgery: JPRAS*. 2006;59(6):594-9. Epub. 2006/05/24. doi: 10. 1016/j.bjps.2005.10.024. PubMed PMID: 16716952.

[47] Masia, J., Larranaga, J., Clavero, J. A., Vives, L., Pons, G., Pons, J. M. The value of the multidetector row computed tomography for the preoperative planning of deep inferior epigastric artery perforator flap: our experience in 162 cases. *Annals of plastic surgery*. 2008;60(1):29-36. Epub. 2008/02/19. doi: 10.1097/SAP.0b013e31805003c2. PubMed PMID: 18281792.

[48] Uppal, R. S., Casaer, B., Van Landuyt, K., Blondeel, P. The efficacy of preoperative mapping of perforators in reducing operative times and complications in perforator flap breast reconstruction. *Journal of plastic, reconstructive and aesthetic surgery: JPRAS*. 2009;62(7):859-64. Epub. 2008/05/21. doi: 10.1016/j.bjps.2008.04.015. PubMed PMID: 18490207.

[49] Lee, G. K., Fox, P. M., Riboh, J., Hsu, C., Saber, S., Rubin, G. D., et al. Computed tomography angiography in microsurgery: indications, clinical utility, and pitfalls. *Eplasty*. 2013;13:e42. Epub. 2013/09/12. PubMed PMID: 24023972; PubMed Central PMCID: PMC3742152.

[50] Keys, K. A., Louie, O., Said, H. K., Neligan, P. C., Mathes, D. W. Clinical utility of CT angiography in DIEP breast reconstruction. *Journal of plastic, reconstructive and aesthetic surgery: JPRAS*. 2013;66 (3):e61-5. Epub. 2012/10/23. doi: 10.1016/j.bjps. 2012.09.025. PubMed PMID: 23084649.

[51] Alonso-Burgos, A., Garcia-Tutor, E., Bastarrika, G., Benito, A., Dominguez, P. D., Zubieta, J. L. Preoperative planning of DIEP and SGAP flaps: preliminary experience with magnetic resonance angiography using 3-tesla equipment and blood-pool contrast medium. *Journal of plastic, reconstructive and aesthetic surgery: JPRAS*. 2010;63 (2):298-304. Epub. 2009/01/06. doi: 10.1016/j.bjps.2008.11.009. Pub Med PMID: 19121986.

[52] Newman, M. I., Samson, M. C., Tamburrino, J. F., Swartz, K. A., Brunworth, L. An investigation of the application of laser-assisted indocyanine green fluorescent dye angiography in pedicle transverse rectus abdominus myocutaneous breast reconstruction. *The Canadian journal of plastic surgery = Journal canadien de chirurgie plastique*. 2011;19(1):e1-5. Epub. 2012/03/02. PubMed PMID: 22379372; PubMed Central PMCID: PMC3086506.

[53] Desai, N. D., Miwa, S., Kodama, D., Koyama, T., Cohen, G., Pelletier, M. P., et al. A randomized comparison of intraoperative indocyanine green angiography and transit-time flow measurement to detect technical errors in coronary bypass grafts. *The Journal of thoracic and cardiovascular surgery*. 2006;132(3):585-94. Epub. 2006/08/29. doi: 10. 1016/j.jtcvs.2005.09.061. PubMed PMID: 16935114.

[54] Komorowska-Timek, E., Gurtner, G. C. Intraoperative perfusion mapping with laser-assisted indocyanine green imaging can predict and prevent complications in immediate breast reconstruction. *Plastic and reconstructive surgery*. 2010;125(4):1065-73. Epub. 2010/03/26. doi: 10.1097/PRS.0b013e3181d17f80. PubMed PMID: 20335859.

[55] Rubben, A., Eren, S., Krein, R., Younossi, H., Bohler, U., Wienert, V. Infrared videoangiofluorography of the skin with indocyanine green--rat random cutaneous flap model and results in man. *Microvascular research.* 1994;47(2):240-51. Epub. 1994/03/01. doi: 10.1006/mvre. 1994.1018. PubMed PMID: 8022322.

[56] Holm, C., Mayr, M., Hofter, E., Becker, A., Pfeiffer, U. J., Muhlbauer, W. Intraoperative evaluation of skin-flap viability using laser-induced fluorescence of indocyanine green. *British journal of plastic surgery*. 2002;55(8):635-44. Epub. 2003/01/29. PubMed PMID: 12550116.

[57] Holm, C., Tegeler, J., Mayr, M., Becker, A., Pfeiffer, U. J., Muhlbauer, W. Monitoring free flaps using laser-induced fluorescence of indocyanine green: a preliminary experience. *Microsurgery*. 2002;22(7): 278-87. Epub. 2002/10/31. doi: 10.1002/micr.10052. PubMed PMID: 12404345.

[58] Gurtner, G. C., Jones, G. E., Neligan, P. C., Newman, M. I., Phillips, B. T., Sacks, J. M., et al. Intraoperative laser angiography using the SPY system: review of the literature and recommendations for use. *Annals of surgical innovation and research.* 2013;7(1):1. Epub. 2013/01/08. doi: 10.1186/1750-1164-7-1. PubMed PMID: 23289664; PubMed Central PMCID: PMC3558356.

[59] Giunta, R. E., Holzbach, T., Taskov, C., Holm, P. S., Brill, T., Busch, R., et al. Prediction of flap necrosis with laser induced indocyanine green fluorescence in a rat model. *British journal of plastic surgery*. 2005;58(5):695-701. Epub. 2005/06/01. doi: 10.1016/j.bjps.2005.02.018. PubMed PMID: 15925341.

[60] Jallali, N., Ridha, H., Butler, P. E. Postoperative monitoring of free flaps in UK plastic surgery units. *Microsurgery*. 2005;25(6):469-72. Epub. 2005/09/01. doi: 10.1002/micr. 20148. PubMed PMID: 16134095.

[61] Cody, H. S., 3rd, Urban, J. A. Internal mammary node status: a major prognosticator in axillary node-negative breast cancer. *Annals of surgical oncology*. 1995;2(1):32-7. Epub. 1995/01/01. PubMed PMID: 7834452.

[62] Veronesi, U., Marubini, E., Mariani, L., Valagussa, P., Zucali, R. The dissection of internal mammary nodes does not improve the survival of breast cancer patients. 30-year results of a randomised trial. *European journal of cancer*. 1999;35(9):1320-5. Epub. 2000/02/05. PubMed PMID: 10658521.

[63] Fitzgibbons, P. L., Page, D. L., Weaver, D., Thor, A. D., Allred, D. C., Clark, G. M., et al. Prognostic factors in breast cancer. College of American Pathologists Consensus Statement 1999. *Archives of pathology and laboratory medicine*. 2000;124(7):966-78. Epub. 2000/ 07/11. doi: 10.1043/0003-9985(2000)124<0966:PFIBC>2.0.CO;2. Pub Med PMID: 10888772.

[64] Ahmed, M., Purushotham, A. D., Douek, M. Novel techniques for sentinel lymph node biopsy in breast cancer: a systematic review. *The Lancet Oncology*. 2014;15(8):e351-62. Epub. 2014/07/06. doi: 10.1016/ S1470-2045(13)70590-4. PubMed PMID: 24988938.

[65] Veronesi, U., Paganelli, G., Viale, G., Luini, A., Zurrida, S., Galimberti, V., et al. A randomized comparison of sentinel-node biopsy with routine axillary dissection in breast cancer. *The New England journal of medicine*. 2003;349(6):546-53. Epub. 2003/08/09. doi: 10.1056/NEJMoa 012782. PubMed PMID: 12904519.

[66] Madsen, E., Gobardhan, P., Bongers, V., Albregts, M., Burgmans, J., De Hooge, P., et al. The impact on post-surgical treatment of sentinel lymph node biopsy of internal mammary lymph nodes in patients with breast cancer. *Annals of surgical oncology*. 2007;14(4):1486-92. Epub. 2007/ 01/27. doi: 10.1245/s10434-006-9230-6. PubMed PMID: 17253106; PubMed Central PMCID: PMC1914262.

[67] Leidenius, M. H., Krogerus, L. A., Toivonen, T. S., Leppanen, E. A., von Smitten, K. A. The clinical value of parasternal sentinel node biopsy in breast cancer. *Annals of surgical oncology*. 2006;13(3):321-6. Epub. 2006/02/18. doi: 10.1245/ASO.2006. 02.022. PubMed PMID: 16485152.

[68] Kong, A. L., Tereffe, W., Hunt, K. K., Yi, M., Kang, T., Weatherspoon, K., et al. Impact of internal mammary lymph node drainage identified by preoperative lymphoscintigraphy on outcomes in patients with stage I to III breast cancer. *Cancer*. 2012;118(24):6287-96. Epub. 2012/06/01. doi: 10.1002/cncr.27564. PubMed PMID: 22648744; PubMed Central PMCID: PMC3913471.

In: Encyclopedia of Surgery (22 Volume Set)
Editors: Andreas Lehrer and Kristin Mueller
ISBN: 978-1-53618-329-0
© 2020 Nova Science Publishers, Inc.

Chapter 96

NEW MATERIALS AND TECHNIQUES IN GENERAL AND DIGESTIVE AMBULATORY SURGERY

J. M. Suárez Grau[1,2], MD, Dra. S. García Ruiz[2], Dra. C. Mendez García[3], C. Rubio Chaves[4] and F. Docobo Durántez[4]

[1]General Hospital of Riotinto, Huelva, Spain
[2]Clinic Quirón Bilbao and Sagrado Corazón Seville, Spain
[3]University Hospital of Jerez, Spain
[4]University Hospital Virgen del Rocío, Seville, Spain

ABSTRACT

Ambulatory surgery is constantly being updated, and is becoming more numerous interventions in this one day regime.

New materials and technological advances will certainly provide a large field of advantages for further proceedings in regimen of short-stay surgery.

New materials:

- Active Sutures: able to release substances at the site where they are applied. For example you sutures with antibiotics.
- Barbed Sutures (self-fixation): no need knotting, facilitating surgery and reducing surgical time.
- Self-gripping Meshes: no need of sutures or glues. This mesh improves the pain results. It reduces the surgical time.
- Biological synthetics meshes: useful in hernia repair and in perianal fistulae.
- Laser: useful in hemorrhoids and perianal fistulae.

New techniques:

- Laparoscopy and Open surgery in inguinal hernia repair: TEP, TAPP, using new meshes and barbed sutures, traumatic (absorbable and metallic tackers) and non-traumatic fixation (glues).
- Hernioplasty using new meshes: self-gripping, biological meshes
- Proctology interventions with laser: FILAC, HELP, LHP

All these advances in the surgery field, could improves the results in the ambulatory surgery in our centers. The main reasons are: minor surgical time, the rate of pain is very low, the discharge is in 6-8 hours after the intervention, the quick recovery and functional capacity to work, and the big satisfaction of the patients with these techniques.

Keywords: ambulatory, surgery, materials, devices, innovations, sutures, mesh, laparoscopy

NEW MATERIALS

1) Active Sutures

The sutures are the ones who have advanced in recent years, as the research focuses on finding new components that allow better absorption, less foreign body reaction and better integration with tissue. In addition to the synthesis of new products for sutures, they are trying to improve existing ones by adding substances to provide more resistance to the sutures.

It was well known to add antimicrobials such as triclosan to absorbable sutures polymer to increase the strength of sutures to infections. These active sutures prevented bacterial colonization and healing favored in an antiseptic environment. However, being described microbial resistance to triclosan, which new antiseptics are being investigated for covering sutures, such as chlorhexidine or short chain fatty acids. Both have proven effective in vitro for inhibition of bacterial growth and are harmless under biological conditions.

The short chain fatty acids are harmless substances used as preservatives in food and cosmetics. Their presence inhibits bacterial growth by creating a hostile environment for reproduction, yet is harmless to the native cell growth. Its low cost and absence of complications make it an ideal for creating active sutures to combat infection item.

Besides the addition of substances, it is improving in creating surfaces that hinder the development of infections. The discoveries of the ability of biofilm formation by pathogenic bacteria increased aggressiveness have put us on track for infection prevention can be done by preventing the formation of biofilm.

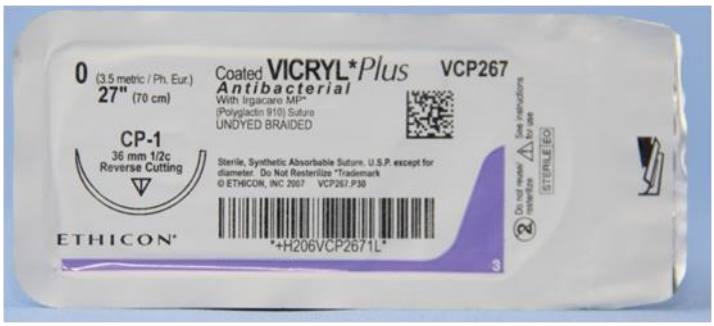

Figure 1. Active antibacterial suture: Vicryl Plus.

The last line of research is based on generating changes in the molecular structure of sutures to prevent bacterial growth. Nanotechnology, continuous development in other areas such as aerospace engineering or tele-communications, is allowing the appearance of

materials that change under certain physiological conditions, resulting in a nano-porous structure.

With high surface area for protein binding. Then biologically active molecules are bound to the surface of the suture for subsequent release in vivo. Protein binding can be Achieved Rapidly in the operating room, and the process can be ready to enable the incorporation of a wide range of other therapeutic molecules.

2) Self-Adhesions Sutures

The suture materials have been evolving throughout the years so that at the present time we have great amount of non-absorbable synthetic sutures as much absorbable, these last biopolymers with different times from absorption according to each necessity, as well as elastic sutures, impregnated in antiseptic substances, sutures that incorporate needles less and less traumatic and more and more and resistant… etc… in this epigraph we make mention to a special type of suture threads, the bearded sutures whose three-dimensional conformation presents a species of teeth or beards throughout its route (Figure 1) that once applied to the weave leaves the suture anchored preventing that the thread moves. Of this form they obtain that the approach of the edges is perfect and mainly, the benefit that seem to contribute is that they distribute the tension of the suture to length of all its extension.

Figure 2. Schedule of bearded suture.

This bearded self-fixing system allowing the suture material for tissue approximation, which eliminates a long and tedious step in wound closure, the making of knots to attach and secure the connection.



Figure 3.

The helically barbs distributes tension across the entire length of the wound or tissue being approximated and eliminate the need for interrupted suture or tying knots. In this way some new opportunities appears above all in that cases of stitches are more difficult allowing

surgeons to do things they could previously not do with traditional sutures, and, undoubtedly, making operating time shorter.

There are two main brands of bearded suture nowadays in the market: Quill ™ Knotless Tissue-Closure Device and V-Loc ™ Wound Closure Device.

- Quill ™ Knotless Tissue-Closure Device represents a revolutionary technology in wound closure made possible by bidirectional fixation within the wound. Its patented design

The Quill™ device is available in sizes 4/0 to 2. The bidirectional Quill ™ device is available in absorbable and non-absorbable materials and configurations including Monoderm ™, PDO, Nylon and Polypropylene. The unidirectional Quill ™ loop device is available in absorbable Monoderm ™ and PDO configurations.

- V-Loc ™ Wound Closure Device: it incorporates a double angle to the line marked by the base of the suture and the beard that, theoretically contributes takes more trustworthy and lasting anchorage.

The different types from sutures Pad ™ are mentioned in the following table:



Figure 4. V-Loc (incorporate an eyelet to toughen the suture).

	V-Loc™ 90 device	V-Loc™ 180 device	V-Loc™ PBT Non-Absorbable Wound Closure Device
Tensile Strength	7 days, 90%; 14 days, 75%	7 days, 80%; 14 days, 75%; 21 days, 65%	Permanent
Absorption Profile	90-110 days	180 days	Permanent
Procedural Applications	Soft tissue approximation where support is required consistent with the absorption profile	Soft tissue approximation where support is required consistent with the absorption profile	Soft tissue approximation
Color	Undyed, violet	Clear, green	Blue
Composition	Glycolide, dioxanone and trimethylene carbonate	Copolymer of glycolic acid and trimethylene carbonate	Polybutester

3) Self-Gripping Meshes

In the last years we are attending to the birth of new prothesis devices for surgical treatment of abdominal wall pathology, that incorporate some measures like a three-dimensional conformation and a combination of biomaterials that confer an auto-adhesion capacity to them that makes unnecessary the use of fixation methods added.

They are in his majority, prothesis composed, elaborated from a base of polypropylene or polyester, both materials whose effectiveness is very well verified, and a biopolymer which is the one that support, of a way or another one, the anchorage capacity, without necessity to fix the prothesis with metallic tackers, stitches or biological glues, this reduces costs, operating time and risk of grabbing the nerve, with the consequent effect on the diminution of the postoperative pain.

In this sense, the mesh *Adhesix®, (Laboratoires Cousin Biotech, Wervicq Sud, France)* one is made up of a layer of polypropylene and on her a mixture of two biopolymers, polyethylene glycol (PEG) and polyvinylpyrrolidone (PVP) that to the contact with the humidity and the corporal heat forms an hydrogel with adherent characteristics, the mesh has not adhesiveness in dry environment.

Equally, the mesh *Hi-Tex Contact®, (Laboratoires Bioser, Montpellier, France)* made from a polyester base impregnated with alifatic polyurethane as a rough appendix is provided of a porous structure in 3D it accelerates its integration and colonization by the fibroblasts.

The Mesh *Parietene ™ Progrip ™ (Sofradim, Group Covidien® Trévoux, France)* is a partially absorbable mesh, of low molecular weight, composed of polypropylene monofilament and Polylactic Acid, this last as a shape of hooks which are inserted between the muscle fibers, allowing secure attachment from its inner surface, with less risk of mobilization of the hernia sac under the prosthesis.



Figure 5. Progrip mesh (self gripping mesh) in open surgery and for laparoscopic surgery.

4) Biological-Synthetics Meshes: Hernia Repair and in Perianal Fistulae

Hernia Repair

Biologic mesh development resulted from a search for a biomaterial that could address the problems associated with permanent synthetic mesh, including chronic inflammation and foreign body reaction, stiffness and fibrosis, and mesh infection. New biological or synthetics

absorbable meshes can be use in ambulatory surgery in order to decrease the pain, surgical time and infection associated with the surgery procedure.

Hernia Plug BIO-A polymer (Gore Bio-A; W. L. Gore and Associates, Flagstaff, Ariz): Hernia Plug is a porous fibrous structure composed of synthetic copolymer that is bioabsorbed in approximately six months. It is both biocompatible and nonantigenic. The GORE® BIO-A® Hernia Plug repairs hernia defects by promoting a well-organized tissue response, while markedly reducing chronic complications associated with permanent implants. The unique design of the plug serves as a scaffold to facilitate tissue generation, and is highly adaptable and easily tailored to create an optimal fit for the defect. Results in an experience multicentric for two years of follow-up show the GORE Bioabsorbable Hernia Plug with onlay mesh is effective with minimal short-term complications (3.6%) and minimal long-term pain (3% incidence of pain at two years).

Biologic Meshes: Given the high cost of most of these materials and the limited available data, biologic mesh should be used judiciously and only when permanent synthetic mesh is inappropriate, such as in the contaminated field.

Figure 6. Gore BioA- inguinal hernia plug.

Fistulae Repair

The anal fistula plug is a noncutting, sphincter-sparing technique. It has low morbidity and can be repeated if necessary. We can use this procedure in patients who has had prior drainage with a seton before placement of the plug. The anal fistula Plugs are in this moment: 1)treated porcine submucosa (Cook Biodesign; Cook Medical, Bloomington, Ind) 2) synthetic bioabsorbable polymer (Gore Bio-A; W. L. Gore and Associates, Flagstaff, Ariz)

The fistula tract should be curetted, and the external opening débrided deeply. The plug should be advanced in one direction (inside to outside)from the internal opening to the external opening.

The base of the plug is seated at the internal opening. We sutured the base to the internal opening with absorbable suture to close the internal opening over the plug. The excess plug at the external opening is removed with shears, and the external opening left open (such a natural drainage). Success rates have been reported in a range from 43% to 87%. In our

experience, around the 50% of the patients had good results with total resolution of the fistula.

Figure 7. Fistuale Plug Bio-A.

5) Laser in Proctology Procedures

Ambulatory surgery is in a constant development because, by its nature, requires that operating times are reduced and recovery occurs most easily, without postoperative complications and without hospital cares for the patient. In this sense, any innovation to perform safe surgery in less time and with a rapid recovery, is particularly susceptible to being included in outpatient surgery programs.

In proctology, the increased difficulty in performing ambulatory techniques is postoperative pain, since it is an extremely sensitive area. Most proctologic interventions also include a complete removal of tissue, which greatly increases the discomfort during recovery. In this sense, the use of proctologic laser allows first performing an occlusion to treat the pathology without removing it.

The laser proceeds very selectively to the lesion, minimally damaging adjacent tissues. It produces minimal tissue damage, so pain is drastically reduced or it even completely disappears after surgery. So has fewer side effects needless destruction of healthy tissue and inflammation.

Laser devices used in proctology are made of glass fiber optic, transmitting the pulse of laser light right in the area you need. Its minimum size prevents extensive manipulations on the surrounding tissues, allowing addressing areas inaccessible to conventional surgery, with greater assurance of results. The console device allows you to adjust the dose of energy transmitted in each incision and in total intervention, so that the desired results are calibrated exactly. The laser also produces the sealing of nerve terminals that conduct the sensation of pain, by which the patient suffers at all during the procedure.

The procedure is ambulatory and requires a minimum hospital stay, blood loss and anesthesia needed is reduced. After surgery, the individual who has gone through she should just stay a couple of hours in the hospital before going home.

The fiber system used is different according to the pathology. For perianal fistula is required of an optical fiber blunt and flexible, that does not generate false paths during surgery. To address an intermittent pulse laser and prolonged periodic moderate frequency. The fiber should be blunt to produce a circumferential burn to close the fistula tract and promotes the healing thereof, since the objective of this intervention is the sealing of the duct and eliminate chronic granulation tissue which remains active infection.

For the treatment of hemorrhoids, an optical fiber with change angular tip, higher precision is used and is capable of moving as a needle, with minimal trauma, within solid tissue. The laser pulse used should be intermittent, short period, with high frequency and high energy. These high-energy short pulses allow vascular occlusion by the hemorrhoid vessels blood clotting inside, with a solid seal that prevents vessel patency. If the pulses were of long duration, the heat transfer to the surroundings of the vessel could cause a painful and burn recovery worse.

NEW TECHNIQUES

1) Inguinal Hernia Repair

Surgical pathology of abdominal wall is one of the most frequent pathology operated by ambulatory surgery system.

Traditionally, main issue that surgeons keeping in mind had been the hernia relapse. A long time ago, this concern is relatively well managed, because of the new prothesis made of different biomaterials and tridimensional conformations which get a free-tension repair.

Once this objective could be considered obtained, the interest of surgical community all over the world has been deposited in other clinical aspects of quality assistance. For this reason, the most of actual researches are going deeply in new techniques that besides of being safe and effective could provide the maximum comfort, with less postoperative pain, in an efficient way from an economic point of view.

In that sense, new methods of fixation, self-fixation prosthesis and minimal invasive surgery play an important role.

a) Inguinal Hernioplasty Without Sutures

The new availability of prosthetics and biomaterials has allowed to invent ever more anatomical surgical repair techniques and concurrently, the fact of eliminating, or at least reducing, the need of additional fixation has had a big impact in improving the efficiency of major outpatient surgery units: on the one hand making shorter operative times in order to optimizing the operating room occupation, and on the other hand, minimizing the risk of nerve damage, reducing in that way the chances of postoperative pain, essential issue in cases where discharges of patients have to be established at an early stage.

Fixation with Biological Glues

We have disposable two kinds of biomaterials derivatives of cyanoacrylate and fibrin sealants.

The cyanocrylate have shown a high adhesive capacity with minimal inflammatory response, which added to the simplicity of management, its low cost and its so-called antibacterial properties, placed it at the head of the biological glues used for the fixation of prostheses in hernia surgery. They do not require a special conservation or a complex processing. Its mode of employment is limited to pour a few drops of product in strategic places where traditional suture stitches would be situated and allow to dry for few seconds.

Fibrin sealants are chemical compounds containing among other products: fibrinogen, fibronectin, factor XIII, and as VEGF, TGF-B, EGF and FGF growth factors. They produce a fibroblastic proliferation in the first moments after the placement of the mesh, which helps correct integration and an optimal final result. It has a cost significantly higher than the previous, and processing prior to their use which requires a deep knowledge of the product. In the case of heterologous fibrin sealants *(Tissucol®)* this means a correct conservation in cold, removing several minutes before use and follow the instructions in the commercial kit that involves a transfer of product to different syringes and continuous agitation. Its application above the mesh is not done directly, but through a propeller device that sprayed product.

In the case of autologous fibrin sealants *(Vivostat®)* the cost is even higher. This system involves the removal of a sample of blood from the patient, prior to surgery and its treatment in a special container that extracted from the patient's own fibrin. Its main advantage is the elimination of possible immunological reactions.

Self Fixating Prosthesis

Self fixating meshes more utilized in One–day surgery are the previously commented, Adhesix® and Parietene™ Progrip™.

The mesh Parietene™ Progrip™ (Covidien®) appears in three modalities, two of them of elliptical form, specially designed to adapt to the anatomy of the inguinal region, with an adjustable auto-adhesive lapel around the cord, either towards the left, or towards right. The third variant is a flat plate of 15x9 cm2.

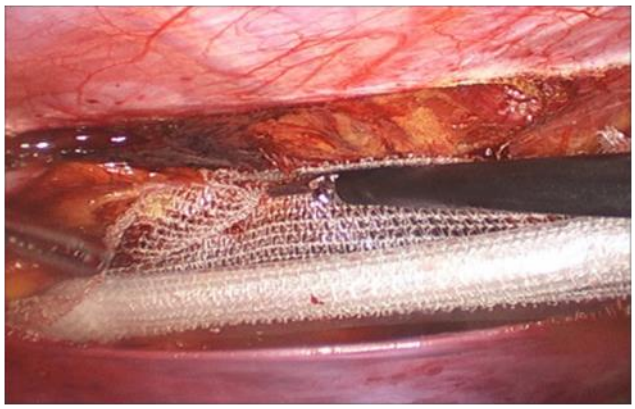

Figure 8. Progrip in laparoscopic TAPP.

It’s easy to use, surgeons only have to complete the dissection of the anatomical area and put the mesh in correct orientation, making sure the spermatic cord is suitably rounded by the lapel, once done this, last step is make a soft pressure pushing down for a few seconds in

order to PLA grips taking place on the surface. After that, only rest closing muscular fascia, cellular subcutaneous tissue and skin above it.

Adhesix® mesh has four varieties about size and shape: one oval shape, and three specially designed for inguinal region, one of them completely plate and the other two types with an aperture for the spermatic cord placement.

Its use is similar to the one before described for Progrip®, but in this case the adhesiveness of the mesh depends in great measure of the humidity of the surface. It is so important checking the correct position of the mesh before starting the closure for avoiding undesirable movements of it.

b) Laparoscopy Surgery In Inguinal Hernia Repair: TEP, TAPP

The advantages of this method include less pain, smaller scars, and an ability to visualize both sides of the abdomen through a single approach. That being said, this is the preferred technique when there are hernias present on both sides. It is also preferred when a hernia has recurred following a prior repair, as the surgeon is able to dissect through non-scarred tissues in order to fix the defect.

The laparoscopic approach is ideal for patients who are obese, have recurrence from a prior open approach, have bilateral hernias, or require an operation that may result in a shorter convalescence (ambulatory surgery). All laparoscopic inguinal hernia repairs require placing mesh in the preperitoneal space to reinforce the myopectineal orifice. This was initially performed with a TAPP approach requiring initial entry into the abdominal cavity followed by division of the peritoneum and subsequent entry into the preperitoneal space. TAPP is preferred for patients with a large hernia or a prior infraumbilical abdominal incision because the contents of a large hernia can be assessed and reduced from the abdominal cavity, and scar tissue from a prior midline incision makes TEP entry more difficult due to adhesions.

TEP is the most cost-efficient technique in terms of outcome, and recovery / reinsertion in work. Although TEP is a demanding technique, with a longer learning curve than TAPP, the results in ambulatory surgery make it the most appropriate laparoscopic technique for a discharge on the same day (with high rates of security against TAPP, because there is no access to the intra-abdominal cavity).

Indications in the Table:

TEP versus TAPP		
Attributes	**TAPP**	**TEP**
Indications	Bilateral inguinal hernia	Bilateral inguinal hernia
	Recurrence from prior open inguinal hernia surgery with Mesh or TEP Surgery.	Reucurrence from prior open inguinal hernia surgery without Mesh.
	Prior Midline abdominal or preperitoneal surgery.	Smaller or normal unilateral hernia (fully reductible defect).
	Large, partially reductible hernias	
	Obese patient	
Common Complications	Bowel injury	Bleeding from injured epigastric vessels or corona mortis.
	Port site hernia	Incomplete hernia reduction
	Mesh exposure to bowel due to incomplete peritoneal closure or peritoneal tears (causing obstructions)	Small peritoneal tears (undetectable) with pneumoperitoneum (causing pain and avoiding ambulatory surgery)

2) Proctology Interventions with Laser

FILAC (FIstula LAser Closure)

The perianal fistula is mostly mild pathology of chronic tendency, so although most cases are not serious or present complications, the high recurrence rate and the difficulty of finding a definitive solution make it a condition that requires a careful treatment.

The usual treatment of perianal fistula has been performed in ambulatory surgical programs for years, because they are usually not painful or complicated treatments. Fistulotomy and traditional fistulectomy involve significant discomfort in the late postoperative period, because the healing of these wounds usually requires time, but not usually cause pain in the immediate postoperative period, since the effect of anesthesia adequately control these symptoms.

FILAC technique involves occlusion of the fistula energy emitted by a blunt laser fiber. The energy transmitted to the tissue inside the path causes scarring that is immediately after the emission of energy and which is produced by the coagulation of proteins usually granulation tissue filled the duct. For proper sealing, it is necessary to treat all abscesses that may exist and completely remove the remains of the fistulous tract infection. The recommended method to eliminate the infection is the placement of a drain placed between the internal and the external fistulous opening fistula orifice to cease issuing pus. This drain help us following placement of the fiber laser through the hole.

When the path is clean, you can proceed to sealing by laser, to be held from the internal fistula opening retreating toward the outer and never backwards, to prevent the formation of abscessed cavity and false ways to annul the effect of occlusion. If the internal fistulous chronic signs of granulation, the production of a small mucosal flap to reinforce the effect of the laser on the mucosa is recommended.

The laser pulses must be programmed into the device to be moderate, intermittent frequency and maintained timing. Fiber is slowly removed from inner hub to the outer, we left the checking successively closed by a soft tip reintroduction fiber path.

In the external fistulous opening any action may not be necessary, although some authors recommend excision circumferential external fistulous opening with monopolar scalpel, favoring the creation of a stronger and without chronic granulation tissue scar. The removal of surrounding tissue has not been shown to cause better results, but a slight increase postoperative pain, so it is only recommended in patients with fistulas very long evolution in which the external fistulous opening is large.

The FILAC has no contraindication size of the fistula or by location, since not require excision of tissue damage or cross brings many fewer complications than other more aggressive techniques. Can be used in e intersphinterics extrasphinterics fistulas, provided the path is well defined.

The main limitation of this technique are multiple perianal fistulas involving the difficulty in occluding fistulas branched, especially if you have not managed to track properly. In these cases, you can make partial occlusions localized paths to progressively decrease the size of the fistula and the roads that form, to meet with a single journey.

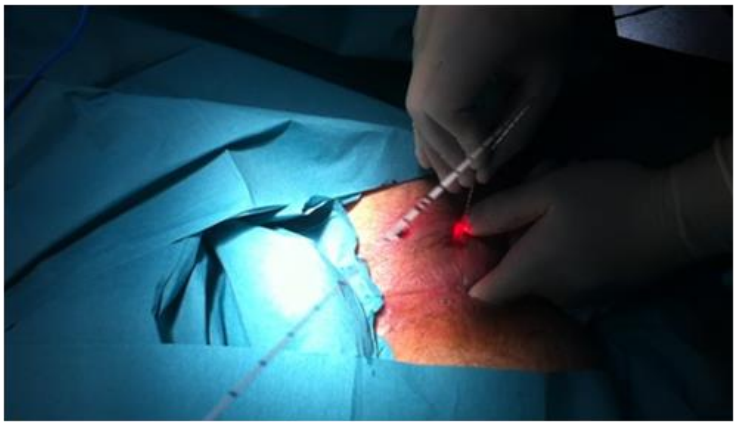

Figure 9. FILAC: in an extrasphinteric anal fistulae.

LHP

Venous occlusion hemorrhoid laser is effective for the treatment of this disease that prevents the main postoperative complication option: the pain of excision of tissue. In performing this technique, the hemorrhoidal package is not removed, leaving a wound, but it is coagulated and occluded under the mucosa as a solid callus prevents venous dilatation and consequent hemorrhoidal prolapse.

By leaving scar tissue included under the mucosa, is not indicated in patients with grade IV hemorrhoids bulky, since the excess tissue of these patients makes their removal is necessary to obtain a satisfactory result. The best indication of hemorrhoidal laser occlusion are patients with grade II-III hemorrhoids, especially those who have presented episodes of rectal bleeding not associated with prolapse or those who complain of pruritus ani.

The technique is performed in the operating room under general or spinal anesthesia, as it requires an anal dilation anuscope that allows control the process of hemorrhoidal occlusion. You can place the patient in a position to Seville knife or lithotomy. Postoperative not exceed the length of anesthetic recovery as surgical discomfort is minimal.

To occlusion, three or four small incisions are made in the base of each hemorrhoid pedicle going to try (usually in the anterior pedicle right, rear right and left side). These incisions are made in the mucocutaneous junction, on the anoderm, before you begin to glimpse the hemorrhoidal package. It is not necessary that the incisions maximum of 2 mm in length, and we only need the caliber of the laser fiber. The fiber should be introduced parallel to the anal canal, without going through the anal mucosa to prevent bleeding and even exceed the length of the hemorrhoidal plexus. From that point, the laser pulses which have previously been programmed into the console to be short, high-energy start.

The laser pulses are applied repetitively removing the fiber over the hemorrhoidal package and through the anoscope watching a hemorrhoid lie clotting integrity of the anal mucosa and the internal anal sphincter is maintained is performed.

If the technique is performed well, after occlusion must observe a discrete skin retraction anus into the anal canal and the absence of bleeding through surgical wounds. If you notice any bleeding, can coagulate using long laser pulses, assuming the burn could cause pain.

After recovery from anesthesia, the patient can be discharged. The most frequent postoperative discomfort usually appear after 48 hours after surgery, when the occlusion is more established and has triggered inflammatory response in the area.

Long term results are unknown for this technique and the real rate of recurrence as well. Detractors argue that the results are poor, considering that hemorrhoids treated are in moderate degrees, they should have final results regardless of the treatment applied. The reality is that no treatment has been shown definitively described to eradicate hemorrhoids, you always have a recurrence rate, and laser results has been no worse than other painful techniques.

HeLP

Besides hemorrhoidal vein occlusion we have described, the laser can be used to generate a selective hemorrhoidal artery occlusion, which devascularice hemorrhoids by cutting the blood flow. By high energy pulses coagulation arterial dilation hemorrhoidal limiting is achieved. It can be used as the sole method or associated with LHP.

To perform this technique, you must first locate the artery going to flirt. Devices that are marketed include ecodoppler system coupled to Anoscope to find the arterial pulse before I coagulate. The administration of laser energy will also be incorporated into the anoscope, which is much simpler power management at the required point.

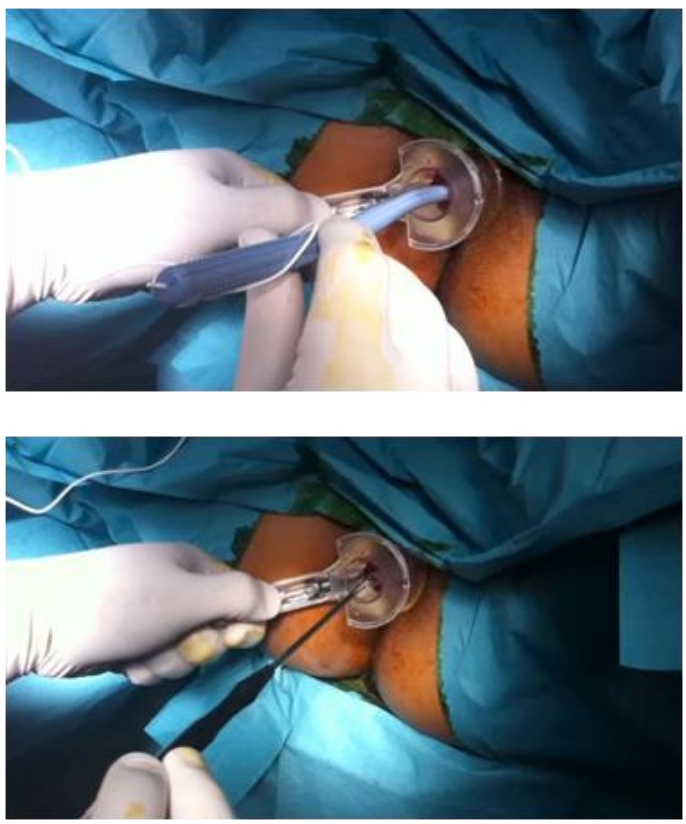

Figure 10. Doppler detection of hemorroidals artery and devacularization with laser.

It is important to locate 3-4 hemorrhoidal arteries occlude want because if the treatment is performed in part, recurrence is more likely to be a fine vascular network connected to each other. Given the difficulty of finding all packages (in patients with previous vascular problems, for example), a LHP proccedure associated is a simple technique that does not require selective localization of blood vessels.

The recovery is in 3-4 hours after intervention, with no pain and major complications in follow-up. Total recovery (work and normal life) is usually complete within 24 hours.

In: Encyclopedia of Surgery (22 Volume Set)
Editors: Andreas Lehrer and Kristin Mueller
ISBN: 978-1-53618-329-0
© 2020 Nova Science Publishers, Inc.

Chapter 97

AMBULATORY SURGERY: ANESTHETIC MANAGEMENT AND COMPLICATIONS

***Monica del-Rio-Vellosillo*[1,*] *and Jose Javier Garcia-Medina*[2,†]**
[1]Department of Anesthesia, University Hospital Virgen de la Arrixaca,
El Palmar, Murcia, Spain
[2]Department of Ophthalmology, University Hospital Reina Sofia, Murcia, Spain
and Department of Ophthalmology and Optometry, University School of Medicine,
University of Murcia, Murcia, Spain

ABSTRACT

Many surgical procedures are performed by ambulatory surgery and account for around 60-70% of all surgical procedures.

The ideal anesthesia in an outpatient setting should offer a smooth, rapid onset of action, produce intraoperative amnesia and analgesia, provide optima surgical conditions with short recovery times, and have no adverse effects.

One of the factors determining the speed of anesthesia recovery is the anesthetic technique used.

Although local and regional anesthesias are anesthetic techniques that are increasingly used for ambulatory surgery because they allow fast recovery, general anesthesia continues to be the most widely employed anesthetic technique.

Inhalation anesthesia is the cornerstone of modern anesthetic practice. New short-acting inhalation anesthetics (e.g., desflurane and sevoflurane) offer fast recovery from anesthesia. However, with the introduction of propofol and new supply systems (e.g., target-controlled infusion), interest in total intravenous anesthesia is growing.

Postoperative pain and vomiting are two factors that usually delay patient recovery and hospital discharge. Identifying those patients at greater risk of postoperative nausea and vomiting may help modify the anesthetic technique used and to use a suitable perioperative prophylaxis.

Older patients and those with a higher classification according to the American Society of Anesthesiologists are at increased risk of perioperative complications.

* Corresponding Author's Email: monicadelriov@hotmail.com.
† Corresponding Author's Email: josegarciam@yahoo.com.

However, deaths related to ambulatory surgery or anesthesia are extremely rare. Some studies have described several complications, but only in 0.08% of cases: e.g., myocardial infarction, stroke, pulmonary embolism and respiratory failure.

The most frequent intraoperative complications are cardiovascular events, especially hypotension and hypertension. Other less frequent complications include bradycardia, tachycardia and arrhythmia.

Respiratory events are the second most frequent intraoperative complication, as the commonest are laryngospasm and bronchospasm. Other more unusual complications include apnea episodes, aspiration, pneumothorax and pulmonary edema.

The complexity of ambulatory surgical procedures is increasing, as is the morbidity of those patients operated as in an outpatient setting. So while selecting patients for ambulatory surgery, it is very important to minimize perioperative complications as much as possible.

INTRODUCTION

Ambulatory surgery is one of the main areas of anesthesia and surgical practice, and comprises between 60-70% of all procedures [1, 2]. The result of increased limited resources, together with a bigger older population, mean having to place much more emphasis on seeking efficiency and less economic expenditure in medical resources [1].

This type of surgery offers certain benefits for patients, besides monetary saving. It lowers the risk of nosocomial infections and allows patients to recover in a comfortable environment with their family without disrupting their daily routine, which facilitates the cure process and reduces postoperative discomfort [3]. As some authors have demonstrated, this situation is remarkable for the elderly as they suffer cognitive dysfunctions and stress events more often during the first weeks of the postoperative period [4].

Careful patient selection is important to avoid adverse perioperative events. The selection criteria are surgical-, anesthetic- based, and are related to each patient´s characteristics and social environment [5, 6]. Surgical criteria include those patients who do not need any complex preoperative preparations, with no major anatomic or blood volume loss (< 500 mL), require simple postoperative care and no subsequent parenteral treatment, and whose postoperative pain is managed by oral pain medication. Anesthetic criteria include the surgical procedures lasting less than 90 minutes. Patients are catalogued according to the American Society of Anesthesiologists (ASA) I, II and stable III, and can also be considered ASA IV for surgical procedures with local anesthesia. As regards patient characteristics, they need to be cooperative, responsible and have the capacity to understand oral and written orders. Furthermore, the possibility of disposing of responsible adult care when allowed home and during the first 24 h of the postoperative period is also necessary.

One of the important factors that determines patient recovery speed is the anesthetic technique used [2]. Although the use of local and regional anesthesia is increasing in ambulatory surgery as they allow quick patient recovery [7], general anesthesia is still the most widely used anesthetic technique [8, 9]. With the development of new anesthetics drugs, the impulse of multimodal analgesia and antiemetic therapy has extended the ambulatory surgery field [1].

ANESTHETIC MANAGEMENT

The main goal of ambulatory surgery is to provide smooth surgical anesthesia with rapid onset of action that produces suitable analgesia and intraoperative amnesia. It should also provide quick emergence and recovery, rapid patient rotation at low cost to finally end in a safe hospital discharge with few adverse effects [10].

The quality of anesthetic management includes measures that do not cause further damage to patients, facilitates the best working conditions for surgeons, provides an optimal perioperative care and helps process algorithms to achieve the best clinical results [11].

New anesthetic techniques, short-term anesthetic drugs and analgesics, as well as the development of new anesthetic monitoring equipment, have contributed to make patient recovery quicker [1]. However, all these factors have combined to increase patient costs. Even so, the cost of anesthetic drugs is below 6% of perioperative costs [11]. These costs lower as they also follow economic benefits such as: being able to perform several surgical procedures in the same operative time; a shorter recovery process; fewer staffing requirements.

The choice of the anesthetic technique to be undertaken must be adapted to patient needs, and also to the kind of ambulatory surgery. Premedication, anesthetic, analgesic and antiemetic drugs, and the cardiovascular, hormonal and fluid therapy therapies used will influence the quick recovery of those patients who have undergone ambulatory surgery [12].

PREOPERATIVE MEDICATION

Premedication is administered to produce sedation, reduce anxiety, optimize intraoperative hemodynamic stability and cut postoperative side effects without prolonging recovery from anesthesia [13].

Benzodiazepines are the most frequently used drugs for this purpose since small doses improve the perioperative fast-tracking process by reducing anxiety and its complications, as well as improving patient comfort and satisfaction [14]. However, small doses of midazolam which provide anxiolysis and anterograde amnesia, could delay patients from being discharged [15]. Other drugs like β-blockers and α2-agonists, are becoming more popular due to their anesthetic and analgesic-sparing effects [16, 17].

Premedication with α2-agonists, clonidine and dexmedetomidine has been associated with a reduced use of opioid analgesics, postoperative nausea and vomiting (PONV), and intraoperative blood loss [17-19]. The inhibitory effects of these α2-agonists in the sympatho-adrenergic and hypothalamo-pituitary stress response provide glucose control in patients with type 2 diabetes and cut the incidence of ischemic heart disease after surgery [20-22].

β-blockers (e.g. atenolol and esmolol) suppress the increase in circulating catecholamines induced by surgery and prevent cardiovascular events in elderly patients. The anesthetic and analgesic-sparing effects of β-blockers in ambulatory surgery allow quick recovery from anesthesia and cut postoperative side effects (e.g. PONV) [23].

PERIPHERAL NERVE BLOCKADE

A peripheral nerve block (PNB) shares many features of an ideal anesthesia for ambulatory surgery, and provides surgical anesthesia and analgesia at the specific surgical intervention site with few side effects. Administration of long-term local anesthetics is an appealing anesthetic alternative for outpatients [24, 25], and provides a suitable anesthesia and prolonged postoperative analgesia [1].

Placement of perineural catheters with ultrasound guidance as opposed to neurostimulation has proved more effective for treating pain during the first 24 h [26]. Furthermore, ultrasound guidance cuts the number of punctures in patients, makes inserting the catheter much quicker, diminishes vascular punctures, and reduces failing blocks and patient discomfort [27, 28]. It is unclear and has not been scientifically determined whether ultrasound techniques minimize the volume of local anesthetic required besides other non ultrasound block techniques [29].

Determining the concentration of the local anesthetic to be used with this technique is important to strike a balance between pain relief and maintaining appropriate mobility of the operated limb since local anesthetics can affect motor function [30]. Yet for the time being, the optimal regime of the local anesthetic used remains unclear. It would appear that continuous perfusion of local anesthetic combined with on-demand patient-controlled boluses could maximize pain control, and there is some evidence that it improves safety of patients and improves side effects. However, the use of low local anesthetic concentrations does not always correlate with a lower degree of motor block [31-35].

Other drugs have been combined with local anesthetics to increase the speed with which the block begins, to prolong its duration, and to increase intensity and success, while the possibility of toxicity from local also lowers at the same time. Evidence-based studies support the combined use of epinephrine or clonidine together with local anesthetics to delay the systemic absorption of local anesthetics [36-38].

This anesthetic technique acts in a specific place, has few side effects, provides excellent surgical conditions, and a superior analgesia compared with systemic opioids. PNB also lowers the surgical stress response, consumption of opioids, and cuts the duration of stays in postanesthesia care units (PACU), and also the incidence of PONV. It can be used in patients with anticoagulant treatment, increases patient satisfaction and facilitates early patient discharge, besides cutting costs [39-48].

Although this anesthetic technique provides a high degree of satisfaction among the patients undergoing ambulatory surgery [25], the advantages of a single puncture of PNB are limited given the duration of long-term local anesthetics (10-24 h) [24-25]. After the resolution of PNB, postoperative pain management is often difficult and unsuitable in an ambulatory setting. In fact a high proportion of patients (22%) continue to suffer pain and require oral opioids for 7 days of the postoperative period.

This anesthetic technique also offers the possibility of placing perineural catheters for the home pump infusion of local anesthetics by providing patients with continuous analgesia to avoid side effects of oral opioids and to offer greater efficiency than these do [49]. So a continuous peripheral nerve block (CPNB) is a technique that prolongs the effect of local anesthetics at the specific site thanks to the possibility of continuing with the administration of local anesthetics, employing analgesia more profoundly, and avoiding the use of opioids

and the early regression of the analgesic block [24]. This technique is well-tolerated by patients as side effects, such as toxicity of local anesthetic, infection or permanent nerve damage [50], are infrequent. On occasion, catheters are difficult to remove due to knotting or looping around nervous structures [51, 52]. It is possible to perform this anesthetic technique in a wide range of surgical procedures for both upper and lower limbs: an interscalene block for shoulder surgery; a supraclavicular and infraclavicular block for surgery of the upper arm to the hand; a lumbar plexus block for hip surgery; a femoral nerve block for surgery of the femur and knee; a sciatic nerve block for the posterior thigh, lower leg and foot [41-44, 53].

However, the clear benefits of this technique to manage pain after ambulatory surgery must be balanced against the cost of the equipment and the resources required to manage these systems safety beyond a medical environment.

CENTRAL NEURAXIAL BLOCK

The introduction of atraumatic pencil-point needles with a small gauge has become an appropriate anesthetic technique with outpatients as it provides a quick, safe and profound surgical block, along with the single injection of small doses of local anesthetics [54].

Choice of local anesthetic type is unclear. Bupivacaine can delay the recovery of the motor function and cause urinary retention by delaying patients from being discharged. Nonetheless, some studies have used low doses of bupivacaine to achieve motor block recovery more quickly, which makes it suitable anesthesia [55]. Nowadays, selective spinal anesthesia is often carried out using minimum doses of intrathecal local anesthetic to anesthetize a specific area. In fact some studies have compared this technique with the use of desflurane, and have reported better postoperative pain control and cost effectiveness with spinal anesthesia [56].

Ropivacaine offers the advantage of producing a reduced motor block by allowing patients to start walking about faster than bupivacaine. However, introperative analgesia and muscle relaxation are suboptimal [57].

Short-acting local anesthetics, such as lidocaine, are associated with a higher incidence of transient neurological symptoms (TNSs), and their use in ambulatory surgery has declined [58].

Other short-acting local anesthetics, such as articaine, chloroprocaine, mepivacaine and prilocaine, have been used in ambulatory surgery successfully [59-63]. These local anesthetics are potentially beneficial because they [64]: 1) produce a motor block of shorter duration and less urinary retention compared with long-acting local anesthetics; 2) offer quick recovery; 3) provide a predictable hospital discharge time; 4) entail a reduced risk of transient neurologic symptoms (TNS) compared with lidocaine. Even so, more urinary retention has been described after administering prilocaine and the block is longer than with articaine, which delays patients from being discharged [65]. However, articaine produces faster recovery than prilocaine, although this does not seem to offer significant advantages compared to 2-chloroprocaine [66, 67]. Several studies have also suggested that the recovery time with 2-chloroprocaine is similar to general anesthesia. However, the use of this drug is not approved in all countries [68-72].

It is possible to add an opioid (e.g. fentanyl or sufentanyl) to the spinal anesthesia solution to reduce the side effects of local anesthetics, shorten patient recovery time and prolong analgesia [73]. This produces increased incidence of postoperative nausea and itching [74]. Another adjuvant used in spinal anesthesia is clonidine, but this combination can produce hypotension and prolong patient recovery [75, 76].

The use of epidural anesthesia with a continuous catheter might help control neuraxial block length in ambulatory surgery [1]. Some studies have suggested that epidural anesthesia is associated with less pain during the postoperative period, fewer interventions by nursing staff in the PACU, lower anesthesia costs and more hemodynamic stability [77]. Nonetheless, it has also been associated with prolonged anesthetic time, delays in discharging patients in short-acting surgeries and potential postoperative urinary retention, particularly in the elderly [3].

Although recovery after a central neuroaxial blockade has improved due to the use of low doses of local anesthetic combined with opioids (fentanyl), patient discharge is often unpredictable and prolonged by approximately 2-4 h after its administration in comparison to general or local anesthesia with sedation [1, 78-79].

A central neuroaxial block offers the benefits of being a simple, safe technique which provides suitable surgical anesthesia. Although it has been associated with prolonged induction times for surgery, they are shorter than with PNB. It has advantages over general anesthesia in terms of cutting the incidence of PONV and sedation [1]. Levels of pain are lower and the need to use opioids in PACU is smaller [80]. It does not cut long-term morbidity, but reduces neurological, cardiac and endocrine complications [81]. Spinal anesthesia as an epidural anesthesia may also lead to perioperative hypotension, postoperative urinary retention, postdural puncture headache, dizziness and delay in onset of walking [3, 82, 47].

GENERAL ANESTHESIA

An ideal general anesthesia technique should provide smooth, quick induction, optimum surgical intervention conditions and a quick recovery with minimum or null side effects [2].

Compared to other anesthetics or inhalations drugs, propofol, sevoflurane, desflurane and short-acting opioids, such as remifentanyl and fentanyl, produce an excellent anesthesia with quick recovery, and also reduce postoperative complications (e.g. respiratory complications, such as airway obstruction and hypoxemia) [83]. Discharge times after using these drugs are comparable with regional anesthesia [77]. Nevertheless, general anesthesia has a higher incidence of PONV and implies more costs [84, 85].

Given its unique recovery profile, propofol is considered the hypnotic of choice to anesthetic induction, although it is more expensive than inhalation anesthetics. Other potential benefits of this drug are antiemetic properties and lower incidence of euphoria and tremors on awakening from anesthesia [86]. However, the non irritant properties of sevoflurane also allow a smooth, quick inhalation anesthesia induction [87-89]. Inhalation anesthesia can be used as an alternative to intravenous induction with propofol and neuromuscular blocking agents if access to an intravenous line is difficult, patients fear needles or it is preferable to keep patients in spontaneous ventilation (e.g. patients with a difficult airway).

Inhalation anesthetics allow faster awakening, probably due to its easy titratibility, and has some neuromuscular blocking effects, which could reduce the requirements of neuromuscular blocking agents [90]. Avoiding neuromuscular blocking agents helps good patient recovery. This is because a residual block may cause uncomfortable symptoms (visual disturbances, inability to sit down without support, facial or generalized weakness) which could delay patient discharge [91], and are usually noticed clinically. Furthermore, the use of sevoflurane can prove more economic than propofol infusion [85, 89, 92]. Even so, with the introduction of new delivery systems (e.g. target-controlled infusion), interest in total IV anesthesia (TIVA) is increasing [93]. When sevoflurane is used, the risk of postoperative emesis and worse patient satisfaction increases. This increase in PONV can delay patient discharge and generate an indirect increase in costs [94, 2].

In clinical terms, there are very few differences between desflurane and sevoflurane. Nonetheless, desflurane allows faster awakening from anesthesia, especially among the elderly and the obese [86]. Desflurane is not often used in ambulatory surgery because it causes cough and irritation in airways [95]. Desflurane is also associated with an increase in PONV compared with propofol. Combinations of antiemetic drugs, such as droperidol, metoclopramide and ondansetron, can lower the incidence of PONV when desflurane is employed [96].

Nitrous oxide is widely utilized in ambulatory surgery. It provides analgesia, reduces inhalation and intravenous anesthetic requirements, which are more expensive, and shortens recovery time. Its higher incidence in PONV has been recently challenged. So there is no convincing reason to avoid its use [86]. New technologies also contribute to fast anesthesia recovery, such as electroencephalographic bispectral index monitoring, which allows the titration of general anesthesia and reduces the amount of hypnotic (propofol or volatile) anesthetic used to maintain anesthesia, thereby facilitating early patient awakening [97-100]. Another monitor to measure anesthesia depth is middle latency auditory evoked potential response amplitudes and latency [101, 102]. It may speed up patient discharge, but has no effect on the amount of anesthetic used or emergence time when inhalation anesthesia is employed.

Remifentanyl has a short-acting duration that is independent of infusion duration. It offers improvement over preoperative analgesia and hemodynamic stability with no harmful effects on the patient awakening time, and this drug even shortens this time because it lowers the concentrations of other drugs used. Neither does it increase PONV as other long-acting opioids do. Providing postoperative rescue analgesia due to the absence of a residual analgesia must also be anticipated [86].

Neuromuscular blocking agents are used to ease endotracheal intubation and the surgical field. In ambulatory surgery, short-acting neuromuscular blocking agents (e.g. succinylcholine) or intermediate-acting neuromuscular blocking agents (e.g. rocuronium) should be considered [103, 104]. The use of sugammadex, a synthetic γ cyclodextrin, allows fast recovery from neuromuscular block after administering rocuronium by avoiding the anticholinergics side effects produced with atropine and neostigmine, or with glycopyrrolate and neostigmine. The latter combination is associated with less nausea and vomiting [105]. It also allows faster tracheal extubation and reduces the postoperative respiratory complications caused by residual muscle paralysis [106].

A laryngeal mask airway (LMA) is a useful, effective alternative to endotracheal intubation for airway management in general anesthesia for ambulatory surgery. Its use

reduces the incidence of postoperative sore throat, although no differences have been observed in anesthetic requirements, hospital discharge and the incidence of general side effects [107]. However, LMA is inadvisable in patients at risk of regurgitation (gastroesophageal reflux disease, hiatal hernia, prior gastric surgery, obesity), with pharyngeal or laryngeal pathology, or who present failing lung compliance.

SEDATION

The objective of sedation is to achieve hypnosis, anxiolysis and amnesia. Furthermore, we must maintain spontaneous patient breathing and avoid emesis. This requires a striking balance between comfort and patient safety, while preventing cardiovascular and respiratory commitment or delaying patient discharge [108].

Although sedation is often offered as a safer anesthetic technique than general anesthesia, this is not often the case as numerous articles on cardiovascular and respiratory adverse events after the sedation technique have been published [109].

It is accepted that the characteristics of an ideal agent for moderate sedation include rapid onset of action, quick recovery of cognitive and physical faculties following the procedure, and a predictable pharmacokinetic and pharmacodynamic profile.

IV sedatives include short-acting drugs such as propofol, benzodiazepines, ketamine, barbiturates, etomidate and dexmedetomidine. Inhalational agents include sevoflurane and nitrous oxide. Common opioids analgesics comprise fentanyl, remifentanyl and alfentanyl [108, 109].

Many anesthesiologists use a combination of several drugs, and it is difficult to decide between an opioid and a hypnotic as the main drug components of sedation to perform painless sedation.

Sedation is used on many occasions as an adjuvant during the infiltration of local anesthesia or regional anesthesia. However, central nervous system, cardiovascular, and respiratory monitoring is necessary to ensure patient safety.

The success of sedation techniques depends on careful patient and procedure selection, patient preparation, appropriate monitoring, and attention to recovery and discharge.

COMPLICATIONS

Unanticipated hospital admissions after ambulatory surgery reflect intraoperative and postoperative complications, with frequency at around 0.3-1.4% [110]. The reason for higher frequency is for surgical complications (38±79%) [111]. In 10±26% of cases, it is due to anesthetic complications, and more frequently to PONV, somnolence or dizziness, and less commonly to aspiration. In 6-17% of cases, it is due to medial causes, a worsened basal clinic situation, like diabetes, angina and sleep apnea, or to postoperative complications, such as dysrhythmias, myocardial infarction or bronchospasm [111].

Patients who have been subjected to general anesthesia are at a 2-7-fold higher risk of hospital readmission. This is related to length of surgery and perioperative complications [1].

The more frequent causes of hospital readmission are bleeding, fever, infection, wound disruption, and urinary retention [1].

Deaths associated with ambulatory surgery or anesthesia are extremely rare [1]. Studies like that carried out by Warner et al. with 38 598 patients, found two deaths caused by myocardial infarction and two others owing to traffic accidents, at 30 days of ambulatory surgery [112]. Thirty-one cases (0.08%) suffered myocardial infarction, stroke, pulmonary embolism and respiratory failure [112].

With increased complexity in surgical procedures and greater patient comorbidity, the selection of patients for ambulatory surgery is a very important step because patients with cardiovascular and respiratory disease, obesity or smoking history are at increased risk of perioperative complications [113]. Old patients and a higher ASA stage are at risk of intraoperative side effects. Cardiovacular events are the commonest intraoperative side effect in ambulatory surgery [114], these being hypotension and hypertension with rhythm disturbances, such as bradycardia, tachycardia and arrhythmias, and they happen in approximately 1-2% of outpatients [114].

Respiratory disturbances are the second most frequent intraoperative side effect and occur in less than 1% of cases. Laryngospasm and bronchospasm, with or without desaturation, are the more frequent respiratory events. However, apnea episodes, aspiration, pneumothorax and pulmonary edema have also been described. Development relating to intubation (e.g. tooth damage or esophageal intubation) present a low incidence (0.2±0.5%) [1].

Obese patients can have associated comorbidity with difficult venous access and airway maintenance, thus they present more postoperative complications [115].

Old patients are associated with an overall ‘stiffening’ of the heart and vascular system, as well as autonomic nervous system dysfunction, and are at higher risk of hypothermia. Lung compliance and vital capacity decline are important predictors of postoperative lung complications. The number of neurons and reduced cerebral perfusion with age predispose old patients to greater postoperative cognitive dysfunction. Such patients are more sensitive to the central depressant effects of anesthetic drugs. Deterioration of kidney and liver functions affects the metabolism and excretion of lots of drugs. Old people are also more vulnerable to suffer hypoglycemia episodes during the perioperative period [116].

Other complications might come into play, such as a prolonged hospital stay for several reasons. Postoperative pain, together with nausea and vomiting, are important factors that may prolong hospital stays or produce hospital readmission by 3-4 times [117]. Other side effects include cardiovascular events, dizziness or drowsiness, which also prolong hospital stays [1]. The best predictors of a prolonged hospital stay are intraoperative hemoglobin concentration and blood loss [118].

Postoperative stay duration correlates with the frequency of minor or moderately severe complications. These complications do not tend to require hospital admission, but frequently delay patient discharge. Hospital discharge criteria include stable vital signs, orientation, no pain, no nausea or vomiting, and a responsible attendant being available. In addition patients should be able to start walking about, diuresis should commence, and they should tolerate oral fluids. The use of scoring systems can help standardize care and minimize the risk of unanticipated admission. Several scoring systems are available for postanesthetic discharge, such as the Aldrete Scoring System, or the system designed by Chung and Chung in Toronto,

similar to Aldrete´s system, which scores patients from 0 to 2 for the five main criteria prior to discharge [119].

General anesthesia is associated with a major incidence of nausea and vomiting (PONV) (10±50%), and certain more painful surgeries (nose, ear, throat, orthopedic and urological surgeries) will require a longer hospital stay [118, 120]. Several factors have been identified for PONV: female sex, history of PONV or motion sickness, nonsmoking status and use of postoperative opioids [121]. Other predictors include type of anesthesia, surgery lasting more than 60 min, major and laparoscopic gynecological surgery, laparoscopic cholecystectomy, intra-abdominal surgery, and middle-ear surgery [123-125]. Hypotension due to inadequate hydration, early walking and movement, and force fluid intake can increase the risk of PONV [126]. Strategies to cut the incidence of PONV include: 1) use of TIVA with propofol which reduces PONV by around 19% [12, 86, 127-131]; 2) use of nitrous oxide is a questioned risk factor of PONV, although it is not as significant as volatile anesthetic agents. Both propofol and inhalation anesthetic agent produce more emesis when they are used with nitrous oxide. No differences among isoflurane, desflurane and sevoflurane have been found for emesis. A drop in PONV by up to 12% has been described when nitrous oxide; 3) minimizing opioids lowers the risk of PONV. Infiltration of local anesthetics, and use of alternative non narcotic analgesics and multimodal anesthetic techniques will reduce the employment of opioid; 4) regional anesthesia is associated with a marked cut in the risk of PONV compared to inhalation-based general anesthesia, thus avoiding exposure to volatile anesthetics and narcotics; 5) minimizing the use of reversal drugs; 6) maintaining adequate patient hydration; 7) multimodal individualized antiemetic treatment

Therefore, identifying these patients will help achieve successful PONV control through a change in the anesthetic technique used, a lower basal risk and a suitable prophylaxis technique.

A wide variety of antiemetic drugs are available for treating PONV, including serotonin antagonists, steroids, dopamine antagonists. Other drugs include antihistamines, anticholinergics, sympathomimetics drugs and neurokinin-1 antagonists [132]. Use of sympatholytic drugs (e.g. esmolol, labetalol), agonist/antagonists, and even ketamine, to control transient autonomic responses during surgery, can reduce PONV because of their anesthetic and opioid-sparing effects [17, 133, 134].

Serotonin antagonists are drugs such as ondansetron, dolasetron, granisetron, and palonosetron. Ondansetron was the first to appear and is the most broadly studied one, whose most frequent side effects include headache, constipation and diarrhea. Doses of 4 mg administered 20-30 min before surgery and finishing the supply of a PONV prophylaxis between 4-6 h post-surgery are recommended [135].

Other drugs used to prevent PONV are steroids, such as dexamethasone. This drug has a slower onset of action, so its administration is recommended immediately after inducing anesthesia. Its exact mechanism is not completely known, although it is thought that steroids inhibit prostaglandin synthesis at the central level and allow endorphin release. It is recommended in doses of 4-8 mg [136, 137].

Among dopamine antagonists, droperidol and haloperidol produce an alpha blockade, so they could produce sedation and extrapyramidal symptoms. However, these side effects do not usually appear with small the doses administered to prevent PONV (0.625/1.25 mg) [135].

Of all these drugs that prevent PONV, the three most commonly used ones are ondansetron 4 mg, dexamethasone 4 mg, and droperidol 1.25 mg, which all have a similar effectiveness on preventing PONV, and the risk is cut up to 26% when any of them is used [127]. The use, or not, of these drugs, and their combination, depend on the risk factors presented by each patient. Hence treatment must be individualized since performing antiemetic prophylaxis in all patients may not be indicated due to the expense and side effects involved [127, 138, 139].

Managing pain with a multimodal approach will allow the better control of postoperative pain and will involve fewer side effects, such as those observed with certain drugs like opioids [140]. We must ensure that patients are discharged from hospital with good pain control.

The drugs used in multimodal analgesia tend to be non steroidal anti-inflammatory drugs (NSAIDs), beta-blockers, N-methyl D-aspartate (NMDA) inhibitors, steroids and alpha-2 agonists, or local anesthetics. Other techniques have also been used: non pharmacological techniques like transcutaneous electrical stimulation and transcutaneous acupoint electrical stimulation [1, 128, 141].

Regarding the use of morphine or fentanyl in ambulatory surgery, fentanyl offers a faster onset of action, but according to some published studies, it does not seem to be associated with faster patient discharge. Most patients required additional analgesia to control pain. However, morphine has been reported to produce better quality analgesia, but has been associated with a higher incidence of nausea and vomiting, especially after discharge [142].

Other factors that can delay patients from being discharged include: sore throat, headache, dizziness and drowsiness [143]. The incidence of sore throat is 12.1%, and this becomes higher with the use of an endotracheal tube compared to LMA (45.4% *vs.* 17.5%, respectively) [144]. Perioperative hydration with 20 mL/kg^1 of IV isotonic fluid produces fewer postoperative symptoms, like thirst, nausea, dizziness and drowsiness, for the first 24 h of the postoperative time [126].

REFERENCES

[1] Troy AM, Cunningham AJ. Ambulatory surgery: an overview. *Curr Opin Anaesthesiol*. 2002;15:647-57.

[2] Joshi GP. Inhalational techniques in ambulatory anesthesia. *Anesthesiol Clin North America*. 2003;21:263-72.

[3] White PF, White LM, Monk T, Jakobsson J, Raeder J, Mulroy MF, Bertini L, Torri G, Solca M, Pittoni G, Bettelli G. Perioperative care for the older outpatient undergoing ambulatory surgery. *Anesth Analg*. 2012;114:1190-215.

[4] Canet J, Raeder J, Rasmussen LS, Enlund M, Kuipers HM, Hanning CD, Jolles J, Korttila K, Siersma VD, Dodds C, Abildstrom H, Sneyd JR, Vila P, Johnson T, Munoz CL, Silverstein JH, Nielsen IK, Moller JT. Cognitive dysfunction after minor surgery in the elderly. *Acta Anaesthesiol Scand*. 2003;47:1204-10.

[5] Ministerio de Sanidad y Consumo. Dirección General de Aseguramiento y Planificación Sanitaria. Cirugía Mayor Ambulatoria. *Guía de Organización y Funcionamiento*. Madrid; Ministerio de Sanidad y Consumo, 1993.

[6] Royal Australasian College of Surgeons, Australian and New Zealand College of Anaesthetists, The Australian Society of Anaesthetists. Day Surgery in Australia. *Report and Recommendations of the Australian Day Surgery Council*. 2004.

[7] Joshi GP. Recent developments in regional anesthesia for ambulatory surgery. *Curr Opin Anaesthesiol*. 1999;12:643-7.

[8] Joshi GP. Fast tracking in outpatient surgery. *Curr Opin Anaesthesiol*. 2001;14:635-9.

[9] Joshi GP, Twersky RS. Fast tracking in ambulatory surgery. *Ambulatory Surgery*. 2000;8:185-90.

[10] Chikungwa M, Smith I. Controversial issues in ambulatory anesthesia. *Anesthesiol Clin North America*. 2003;21:313-27.

[11] White PF, Watcha MF. Pharmacoeconomics in anaesthesia: what are the issues? *Eur J Anaesthesiol Suppl.* 2001;23:10-5.

[12] White PF, Eng M. Fast-track anesthetic techniques for ambulatory surgery. *Curr Opin Anaesthesiol*. 2007;20:545-57.

[13] White PF. Pharmacologic and clinical aspects of preoperative medication. *Anesth Analg*. 1986;65:963-74.

[14] van Vlymen JM, Sa Rego MM, White PF. Benzodiazepine premedication: can it improve outcome in patients undergoing breast biopsy procedures? *Anesthesiology*. 1999;90:740-7.

[15] Taylor E, Ghouri AF, White PF. Midazolam in combination with propofol for sedation during local anesthesia. *J Clin Anesth*. 1992;4:213-6.

[16] Chia YY, Chan MH, Ko NH, Liu K. Role of beta-blockade in anaesthesia and postoperative pain management after hysterectomy. *Br J Anaesth*. 2004;93:799-805.

[17] Segal IS, Jarvis DJ, Duncan SR, White PF, Maze M. Clinical efficacy of oral-transdermal clonidine combinations during the perioperative period. *Anesthesiology*. 1991;74:220-5.

[18] Aho MS, Erkola OA, Scheinin H. Effect of intravenously administered dexmedetomidine on pain after laparoscopic tubal ligation. *Anesth Analg*. 1991;73:112-8.

[19] Okuyama K, Inomata S, Toyooka H. The effects of prostaglandin E1 or oral clonidine premedication on blood loss during paranasal sinus surgery. *Can J Anesth.* 2005;52:546-7.

[20] Mertes N, Goetters C, Kuhlmann M, Zander JF. Postoperative alpha-2 adrenergic stimulation attenuates protein catabolism. *Anesth Analg*. 1996;82:258-63.

[21] Belhoula M, Ciebiera JP, De La Chapelle A, Boisseau N, Coeurveille D, Raucoules-Aimé M.. Clonidine premedication improves metabolic control in type 2 diabetic patients during ophthalmic surgery. *Br J Anaesth*. 2003;90:434-9.

[22] Wallace AW, Galindez D, Salahieh A, Layug EL, Lazo EA, Haratonik KA, Boisvert DM, Kardatzke D.. Effect of clonidine on cardiovascular morbidity after noncardiac surgery. *Anesthesiology*. 2004;101:284-93.

[23] Zaugg M, Tagliente T, Lucchinetti E, Jacobs E, Krol M, Bodian C, Reich DL, Silverstein JH. Beneficial effects from betaadrenergic blockade in elderly patients undergoing noncardiac surgery. *Anesthesiology*. 1999;91:1674-86.

[24] Klein S. M, Pietrobon R, Nielsen K. C, Warner D. S, Greengrass R. A. Peripheral nerve blockade with longacting local anesthetics, of the Society for Ambulatory Anesthesia. *Anesth Analg*. 2002;94:71-6.

[25] Klein SM, Nielson KC, Greengrass RA, Warner DS, Martin A, Steele SM. Ambulatory discharge after longacting peripheral nerve blockade: 2382 blocks with ropivacaine. *Anesth Analg*. 2002;94:65-70.

[26] Fredrickson M, Ball C, Dalgleish A. A prospective randomized comparison of ultrasound guidance versus neurostimulation for interscalene catheter placement. *Regional Anesth Pain Med*. 2009;34:590-4.

[27] Abrahams M, Aziz M, Fu R, Horn J. Ultrasound guidance compared with electrical stimulation for peripheral nerve block: a systemic review and metaanalysis of randomized controlled trials. *BJA*. 2009;102:408-17.

[28] Mariano E, Loland V, Bellars R, Sandhu NS, Bishop ML, Abrams RA, Meunier MJ, Maldonado RC, Ferguson EJ, Ilfeld BM. Ultrasound guidance versus electrical stimulation for infraclavicular brachial plexus perineural catheter insertion. *J Ultrasound Med*. 2009;28:1211-8.

[29] Duggan E, Beheiry H, Perlas A, Lupu M, Nuica A, Chan VW, Brull R. Minimum effective volume of local anesthetic for ultrasound-guided supraclavicular brachial plexus block. *Regional Anesth Pain Med*. 2009;34:215-8.

[30] Axley M, Horn JL. Indications and management of continuous infusion of local anesthetics at home. *Curr Opin Anaesthesiol*. 2010;23:650-5.

[31] Fisher H, Simanski C, Sharp C, Bonnet F, Camu F, Neugebauer EA, Rawal N, Joshi GP, Schug SA, Kehlet H. A procedure-specific systematic review and consensus recommendations for postoperative analgesia following total knee arthroplasty. *Anaesthesia*. 2008;63:1105-23.

[32] Ilfeld B, Loland V, Gerancher J, Wadhwa AN, Renehan EM, Sessler DI, Shuster JJ, Theriaque DW, Maldonado RC, Mariano ER. The effects of varying local anesthetic concentration and volume on continuous popliteal sciatic nerve blocks: a dual center, randomized, controlled study. *Anesth Analg*. 2008;107:701-7.

[33] Brodner G, Buerkle H, Van Aken H, Lambert R, Schweppe-Hartenauer ML, Wempe C, Gogarten W. Postoperative analgesia after knee surgery: a comparison of three different concentrations of ropivacaine for continuous femoral nerve blockade. *Anesth Analg*. 2007;105:256-62.

[34] Paauwe J, Thomassen B, Weterings J, van Rossum E, Ausems ME. Femoral nerve block using ropivacaine 0.025%, 0.05% and 0.1% effects on the rehabilitation programme following total knee arthroplasty: a pilot study. *Anaesthesia*. 2008;63:948-53.

[35] Ilfeld B, Le LT, Ramjohn J, Loland V, Wadhwa AN, Gerancher JC, Renehan EM, Sessler DI, Shuster JJ, Theriaque DW, Maldonado RC, Mariano ER. The effects of local anesthetic concentration and dose on continuous infraclavicular nerve blocks: a multicenter, randomized, observer-masked, controlled study. *Anesth Analg*. 2009; 108:345-50.

[36] Thornton PC, Grant SA, Breslin DS. Adjuncts to local anesthetics in peripheral nerve blockade. *Int Anesthesiol Clin*. 2010;48:59-70.

[37] Bernards CM, Kopacz DJ. Effect of epinephrine on lidocaine clearance in vivo: a microdialysis study in humans. *Anesthesiology*. 1999;91:962-8.

[38] Eisenach JC, DeKock M, Klimscha W. Alpha(2)-adrengic agonists for regional anesthesia. A clinical review of clonidine (1984 to 1995). *Anesthesiology*. 1996;85:655-74.

[39] Rawal N, Axelsson K, Hylander J, Allvin R, Amilon A, Lidegran G, Hallén J. Postoperative patient-controlled local anesthetic administration at home. *Anesth Analg.* 1998;86:86-9.

[40] Ilfeld B, Morey T, Enneking K. Continuous infraclavicular brachial plexus block for postoperative pain control at home. a randomized, double-blinded, placebo-controlled study. *Anesthesiology*. 2002;96:1297-304.

[41] Ilfeld B, Vandenborne K, Duncan P, Sessler DI, Enneking FK, Shuster JJ, Theriaque DW, Chmielewski TL, Spadoni EH, Wright TW. Ambulatory continuous interscalene nerve blocks decrease the time to discharge readiness after total shoulder arthroplasty: a randomized, triple-masked, placebo-controlled study. *Anesthesiology*. 2006;105:999-1007.

[42] Ilfeld B, Morey T, Enneking F. Infraclavicular perineural local anesthetic infusion. *Anesthesiology.* 2004;100:395-402.

[43] 43. Ilfeld B, Morey T, Wang D. Continuous popliteal sciatic nerve block for postoperative pain control at home. *Anesthesiology*. 2002;97:959-65.

[44] Ilfeld B, Ball S, Gearen P. Ambulatory continuous posterior lumbar plexus nerve blocks after hip arthroplasty. *Anesthesiology*. 2008;109:491-501.

[45] Ilfeld B, Le L, Meyer S. Ambulatory continuous femoral nerve blocks decrease time to discharge readiness after tricompartmental total knee arthroplasty. *Anesthesiology.* 2008;108:703-13.

[46] Ilfeld B, Mariano E, Williams B, Woodard JN, Macario A. Hospitalization costs of total knee arthroplasty with a continuous femoral nerve block provided only in the hospital versus on an ambulatory basis: a retrospective, case-control, cost-minimization analysis. *Reg Anesth Pain Med*. 2007;32:46-54.

[47] Capdevila X, Dadure C. Perioperative management for one day hospital admission: regional anesthesia is better than general anesthesia. *Acta Anaesthesiol Belg*. 2004;55 Suppl:33-6.

[48] Hadzic A, Williams BA, Karaca PE, Hobeika P, Unis G, Dermksian J, Yufa M, Thys DM, Santos AC. For outpatient rotator cuff surgery nerve block anesthesia provides superior same-day recovery over general anesthesia. *Anesthesiology*. 2005;102:1001-7.

[49] Apfelbaum J, Chen C, Mehta S, Gan TJ. Postoperative pain experience: results from a national survey suggest postoperative pain continues to be undermanaged. *Anesth Analg*. 2003;97:534-40.

[50] Swenson J, Bay N, Loose E, Bankhead B, Davis J, Beals TC, Bryan NA, Burks RT, Greis PE. Outpatient management of continuous peripheral nerve catheters placed using ultrasound guidance: an experience in 620 patients. *Anesth Analg*. 2006;103:1436-43.

[51] Offerdahl MR, Lennon RL, Horlocker TT. Successful removal of a knotted fascia iliaca catheter: principles of patient positioning for peripheral nerve catheter extraction. *Anesth Analg*. 2004;99:1550-2.

[52] MacLeod D. Knotted peripheral nerve catheter. *Reg Anesth Pain Med*. 2003;28:487-8.

[53] Ilfeld B, Wright T, Enneking K, Vandenborne K. Total elbow arthroplasty as an outpatient procedure using a continuous infraclavicular nerve block at home: a prospective case report. *Regional Anesth Pain Med.* 2006;31:172-6.

[54] Casati A, Cappelleri G, Fanelli G, Borghi B, Anelati D, Berti M, Torri G. Regional anaesthesia for outpatient knee arthroscopy: a randomized clinical comparison of two different anaesthetic techniques. *Acta Anaesthesiol Scand*. 2000;44:543-7.

[55] Valanne JV, Korhonen AM, Jokela RM, Ravaska P, Korttila KK. Selective spinal anesthesia: a comparison of hyperbaric bupivicaine 4 mg versus 6 mg for outpatient knee arthroscopy. *Anesth Analg*. 2001;93:1377-9.

[56] Lennox PH, Chilvers C, Vaghadia H. Selective spinal anesthesia versus desflurane anesthesia in short duration outpatient gynecological laparoscopy: a pharmacoeconomic comparison. *Anesth Analg*. 2002;94:565-8.

[57] Gautier P, De Kock M, Van Steenberge A, Poth N, Lahaye-Goffart B, Fanard L, Hody JL. Intrathecal ropivicaine for ambulatory surgery: a comparison between intrathecal bupivicaine and intrathecal ropivicaine for knee arthroscopy. *Anesthesiology*. 1999;91:1239-45.

[58] Keld DB, Hein L, Dalgaard M, Krogh L, Rodt SA. The incidence of transient neurologicsymptoms (TNS) after spinal anesthesia in patients undergoing surgery in the supine position: hyperbaric lidocaine 5% versus hyperbaric bupivacaine 0.5%. *Acta Anesthesiol Scand*. 2000;44:285-90.

[59] Watson B, Howell V. Spinal anaesthesia: the saviour of day surgery? *Curr Anaesth Crit Care*. 2007;80:96-112.

[60] Förster JG, Rosenberg PH. Revival of old local anesthetics for spinal anesthesia in ambulatory surgery. *Curr Opin Anaesthesiol*. 2011;24:633-7.

[61] Wulf H, Hampl K, Steinfeldt T. Speed spinal anesthesia revisited: new drugs and their clinical effects. *Curr Opin Anaesthesiol*. 2013;26:613-20.

[62] del-Rio-Vellosillo M, Garcia-Medina JJ, Abengochea-Cotaina A, Pinazo-Duran MD. Intrathecal local anaesthetics in ambulatory surgery. *Acta Anaesthesiol Scand*. 2014;58:906.

[63] Camponovo C, Wulf H, Ghisi D, Fanelli A, Riva T, Cristina D, Vassiliou T, Leschka K, Fanelli G. Intrathecal 1% 2-chloroprocaine vs. 0.5% bupivacaine in ambulatory surgery: a prospective, observer-blinded, randomised, controlled trial. *Acta Anaesthesiol Scand*. 2014;58:560-6.

[64] Förster JG. Short-acting spinal anesthesia in the ambulatory setting. *Curr Opin Anaesthesiol*. 2014;27:597-604.

[65] Kreutziger J, Frankenberger B, Luger TJ, Richard S, Zbinden S. Urinary retention after spinal anaesthesia with hyperbaric prilocaine 2% in an ambulatory setting. *Br J Anaesth*. 2010;104:582-6.

[66] Hendriks MP, de Weert CJ, Snoeck MM, Hu HP, Pluim MA, Gielen MJ. Plain articaine or prilocaine for spinal anaesthesia in day-case knee arthroscopy: a double-blind randomized trial. *Br J Anaesth*. 2009;102:259-63.

[67] Förster JG, Kallio H, Rosenberg PH, Harilainen A, Sandelin J, Pitkänen MT. Chloroprocaine vs. articaine as spinal anaesthetics for day-case knee arthroscopy. *Acta Anaesthesiol Scand*. 2011;55:273-81.

[68] Casati A, Fanelli G, Danelli G, Berti M, Ghisi D, Brivio M, Putzu M, Barbagallo A. Spinal anesthesia with lidocaine or preservative-free 2-chlorprocaine for outpatient knee arthroscopy: a prospective, randomized, double-blind comparison. *Anesth Analg*. 2007;104:959-64.

[69] Sell A, Tein T, Pitkänen M. Spinal 2-chloroprocaine: effective dose for ambulatory surgery. *Acta Anaesthesiol Scand*. 2008;52:695-9.

[70] Yoos JR, Kopacz DJ. Spinal 2-chloroprocaine for surgery: an initial 10-month experience. *Anesth Analg*. 2005;100:553-8.

[71] Kouri ME, Kopacz DJ. Spinal 2-chloroprocaine: a comparison with lidocaine in volunteers. *Anesth Analg*. 2004;98:75-80.

[72] Hejtmanek MR, Pollock JE. Chloroprocaine for spinal anesthesia: a retrospective analysis. *Acta Anaesthesiol Scand*. 2011;55:267-72.

[73] Akcaboy ZN, Akcaboy EY, Mutlu NM, Serger N, Aksu C, Gogus N. Spinal anesthesia with low-dose bupivacaine–fentanyl combination: a good alternative for day case transurethral resection of prostrate surgery in geriatric patients. *Rev Bras Anesthesiol*. 2012;6:753-61.

[74] Ben-David B, DeMeo PJ, Lucyk C, Solosko D. A comparison of minidose lidocaine-fentanyl spinal anesthesia and local anesthesia/propofol infusion for outpatient knee arthroscopy. *Anesth Analg*. 2001;93:319-25.

[75] Singh H, Liu J, Gaines GY, White PF. Effect of oral clonidine and intrathecal fentanyl on tetracaine spinal block. *Anesth Analg*. 1994;79:1113-6.

[76] van Tuijl I, Giezeman MJ, Braithwaite SA, Hennis PJ, Kalkman CJ, van Klei WA. Intrathecal low-dose hyperbaric bupivacaine-clonidine combination in outpatient knee arthroscopy: a randomized controlled trial. *Acta Anaesthesiol Scand*. 2008;52:343-9.

[77] Mulroy MF, Larkin KL, Hodgson PS, Helman JD, Pollock JE, Liu SS. A comparison of spinal, epidural, and general anesthesia for outpatient knee arthroscopy. *Anesth Analg*. 2000;91:860-4.

[78] Nair GS, Abrishami A, Lermitte J, Chung F. Systematic review of spinal anaesthesia using bupivacaine for ambulatory knee arthroscopy. *Br J Anaesth*. 2009;102:307-15.

[79] O'Donnell D, Manickam B, Perlas A, Karkhanis R, Chan VW, Syed K, Brull R. Spinal mepivacaine with fentanyl for outpatient knee arthroscopy surgery: a randomized controlled trial. *Can J Anaesth*. 2010;57:32-8.

[80] Liu SS, Strodtbeck WM, Richman JM, Wu CL. A comparison of regional versus general anesthesia for ambulatory anesthesia: a meta-analysis of randomized controlled trials. *Anesth Analg*. 2005;101:1634-42.

[81] Nordquist D, Halaszynski TM. Perioperative multimodal anesthesia using regional techniques in the aging surgical patient. *Pain Res Treat*. 2014;2014:902174.

[82] Auroy Y, Benhamou D, Bargues L, Eccoey C, Falissard B, Mercier FJ, Bouaziz H, Samii K. Major complications of regional anesthesia in France: the SOS Regional Anesthesia Hotline Service. *Anesthesiology*. 2002;97:1274-80.

[83] Georgiou LG, Vourlioti AN, Kremastinou FI, Stefanou PS, Tsiotou AG, Kokkinou MD. Influence of anesthetic technique on early postoperative hypoxemia. *Acta Anaesthesiol Scand*. 1996;40:75-80.

[84] Tang J, Chen L, White PF, Watcha MF, Wender RH, Naruse R, Kariger R, Sloninsky A. Recover profile, costs, and patient satisfaction with propofol and sevoflurane for fast-track office-based anesthesia. *Anesthesiology*. 1999; 91:253-61.

[85] Smith I, Terhoeve PA, Hennart D, Feiss P, Harmer M, Pourriat JL, Johnson IA. A multicentre comparison of the costs of anaesthesia with sevoflurane or propofol. *Br J Anaesth*. 1999;83:564-70.

[86] Dewandre PY. Peroperative management for ambulatory anaesthesia: does the choice of drug matter? *Acta Anaesthesiol Belg*. 2004;55 Suppl:39-40.

[87] Joo HS, Perks WJ. Sevoflurane versus propofol for anesthetic induction: a meta-analysis. *Anesth Analg*. 2000;91:213-9.

[88] Philip BK, Lombard LL, Roaf ER, Drager LR, Calalang I, Philip JH.. Comparison of vital capacity induction with sevoflurane to intravenous induction with propofol for adult ambulatory anesthesia. *Analg Anesth*. 1999; 89:623-7.

[89] Watson KR, Shah MV. Clinical comparison of 'single agent' anaesthesia with sevoflurane versus target controlled infusion of propofol. *Br J Anaesth*. 2000;85:541-6.

[90] Eriksson LI. The effects of residual neuromuscular blockade and volatile anesthetics on control of ventilation. *Anesth Analg*. 1999;89:243-51.

[91] Kopman AF, Yee PS, Neuman GG. Relationship of the train-of-four fade ratio to clinical signs and symptoms of residual paralysis in awake volunteers. *Anesthesiology*. 1997;86:765-71.

[92] Thwaites A, Edmends S, Smith I. Inhalation induction with sevoflurane: a double-blind comparison with propofol. *Br J Anaesth*. 1997;78:356-61.

[93] Tonner PH, Scholz J. Total intravenous or balanced anaesthesia in ambulatory surgery? *Curr Opin Anaesthesiol*. 2000;13:631-6.

[94] Smith I, Thwaites AJ. Target-controlled propofol vs. sevoflurane: a double-blind, randomised comparison in day-case anaesthesia. *Anaesthesia*. 1999;8:745-52.

[95] Mahmoud NA, Rose DJA, Laurence AS. Desflurane or sevoflurane for gynaecological day-case anaesthesia with spontaneous respiration? *Anaesthesia*. 2001; 56:171-4.

[96] Tang J, White PF, Wender RH, Naruse R, Kariger R, Sloninsky A, Karlan MS, Uyeda RY, Karlan SR, Reichman C, Whetstone B. Fast-track office-based anesthesia: a comparison of propofol versus desflurane with antiemetic prophylaxis in spontaneously breathing patients. *Anesth Analg*. 2001;92:95-9.

[97] Nelskyla KA, Yli-Hankala AM, Puro PH, Korttila KT. Sevoflurane titration using bispectral index decreases postoperative vomiting in phase II recovery after ambulatory surgery. *Anesth Analg*. 2001;93:1165-9.

[98] Pavlin DJ, Hong JY, Freund PR, Koerschgen ME, Bower JO, Bowdle TA. The effect of bispectral index monitoring on end-tidal gas concentration and recovery duration after outpatient anesthesia. *Anesth Analg*. 2001;93:613-9.

[99] Gan TJ, Glass PS, Windsor A, Payne F, Rosow C, Sebel P, Manberg P. Bispectral index monitoring allows faster emergence and improved recovery from propofol, alfentanil, and nitrous oxide anesthesia. BIS Utility Study Group. *Anesthesiology*. 1997;87:808-15

[100] Song D, Joshi GP, White PF. Titration of volatile anesthetics using bispectral index facilitates recovery after ambulatory anesthesia. *Anesthesiology*. 1997;87:842-8.

[101] Assareh H, Anderson RE, Uusijarvi J, Jakobsson J. Sevoflurane requirements during ambulatory surgery: a clinical study with and without AEP-index guidance. *Acta Anaesthesiol Scand*. 2002;46:495-9.

[102] Assare H, Anderson RE, Jakobsson J. Sevoflurane requirements during ambulatory surgery: a clinical study of bispectral index and auditory evoked potential guided anaesthesia. *Amb Surg*. 2002;9:207-11.

[103] Schlaich N, Mertzlufft F, Soltesz S, Fuchs-Buder T. Remifentanil and propofol without muscle relaxants or with different doses of rocuronium for tracheal intubation in outpatient anaesthesia. *Acta Anaesthesiol Scand*. 2000;44:720-6.

[104] Murphy GS, Szokol JW, Marymont JH, Avram MJ, Vender JS, Rosengart TK. Impact of shorter-acting neuromuscular blocking agents on fast-track recovery of the cardiac surgery patient. *Anesthesiology*. 2002;96:600-6.

[105] Chhibber AK, Lustik SJ, Thakur R, Francisco DR, Fickling KB. Effects of anticholinergics on postoperative vomiting, recovery and hospital stay in children undergoing tonsillectomy with or without adenoidectomy. *Anesthesiology*. 1999;90:697-700.

[106] Sacan O, White PF, Tufanogullari B, Klein K. Sugammadex reversal of rocuronium-induced neuromuscular blockade: a comparison with neostigmine-glycopyrrolate and edroponium–atrophine. *Anesth Analg*. 2007;104:569-74.

[107] Joshi GP, Inagaki Y, White PF, Taylor-Kennedy L, Wat LI, Gevirtz C, McCraney JM, McCulloch DA. Use of the laryngeal mask as an alternative to the tracheal tube during ambulatory anesthesia. *Anesth Analg*. 1997;85:573-7.

[108] Greenberg CP, De Soto H. Sedation techniques. In: Twersky RS, ed: *The Ambulatory Anesthesia Handbook.* St Louis, MO: Mosby; 1995:301-59.

[109] Philip BK, Minzter BH. Intravenous sedation and monitored anesthesia care. In: White PF, ed. *Ambulatory Anesthesia and Surgery*. Philadelphia, PA: W.B. Saunders; 1997:349-67.

[110] Fortier J, Chung F, Su J. Unanticipated admission after ambulatory surgery: a prospective study. *Can J Anaesth*. 1998;45:612-9.

[111] Twersky R, Fishman D, Homel P. What happens after discharge? Return hospital visits after ambulatory surgery. *Anesth Analg*. 1997;84:319-24.

[112] Warner MA, Shields SE, Shute CG. Major morbidity and mortality within one month of ambulatory surgery and anesthesia. *JAMA*. 1993;270:1437-41.

[113] Chung F, Mezei G, Tong D. Pre-existing medical conditions as predictors of adverse events in day-case surgery. *Br J Anaesth*. 1999;83:262-70.

[114] Duncan PD, Reccan PG, Cohen MM, Tweed WA. The Canadian Four Centre Study of anaesthetic outcomes: are anesthetic complications predictable in day surgical practice? *Can J Anesth*. 1992;39:440-8.

[115] Atkins M, White J, Ahmed K. Day surgery and body mass index: results of a national survey. *Anaesthesia*. 2002;57:180-2.

[116] Aurini L, White PF. Anesthesia for the elderly outpatient. *Curr Opin Anaesthesiol*. 2014;27:563-75.

[117] Chung F, Ritchie E, Su J. Post-operative pain in ambulatory surgery. *Anesth Analg*. 1997;85:808-16.

[118] Junger A, Klasen J, Benson M, Sciuk G, Hartmann B, Sticher J, Hempelmann G. Factors determining length of stay of surgical day-case patients. *Eur J Anaesthesiol*. 2001;18:314-21.

[119] Marshall SI, Chung F. Discharge criteria and complications after ambulatory surgery. *Anesth Analg*. 1999;88:508-17.

[120] Golembiewski J, Chernin E, Chopra T. Prevention and treatment of postoperative nausea and vomiting. *Am J Health Syst Pharm*. 2005;62:1247-60.

[121] Apfel CC, Laara E, Koivuranta M, Greim CA, Roewer N. A simplified risk score for predicting postoperative nausea and vomiting: conclusions from cross-validations between two centers. *Anesthesiology*. 1999;91:693-700.

[122] Watcha MF, White PF. Post-operative nausea and vomiting: its etiology, treatment and prevention. *Anesthesiology*. 1992;77:162-84.

[123] Apfel CC, Kranke P, Eberhart LH, Roos A, Roewer N. Comparison of predictive models for postoperative nausea and vomiting. *Br J Anaesth*. 2002;88:234-40.

[124] Koivuranta M, Laara E, Snare L, Alahuhta S. A survey of postoperative nausea and vomiting. *Anaesthesia*. 1997;52:443-9.

[125] Chinnappa V, Chung F. Postdischarge nausea and vomiting: an overlooked aspect of ambulatory anesthesia? *Can J Anaesth*. 2008;55:565-71.

[126] Yogendran S, Asokumar B, Cheng DC, Chung F. A prospective randomized double-blinded study of the effect of intravenous fluid therapy on adverse outcomes on outpatient surgery. *Anesth Analg*. 1995;80:682-6.

[127] Apfel CC, Korttila K, Abdalla M, Kerger H, Turan A, Vedder I, Zernak C, Danner K, Jokela R, Pocock SJ, Trenkler S, Kredel M, Biedler A, Sessler DI, Roewer N. A factorial trial of six interventions for the prevention of postoperative nausea and vomiting. *N Engl J Med*. 2004;350:2441-51.

[128] Elvir-Lazo OL, White PF. The role of multimodal analgesia in pain management after ambulatory surgery. *Curr Opin Anaesthesiol*. 2010;28:697-703.

[129] White PF. The role of non-opioid analgesic techniques in the management of pain after ambulatory surgery. *Anesth Analg*. 2002;94:577-85.

[130] Apfel CC, Kranke P, Katz MH, Goepfert C, Papenfuss T, Rauch S, Heineck R, Greim CA, Roewer N. Volatile anaesthetics may be the main cause of early but not delayed postoperative vomiting: a randomized controlled trial of factorial design. *Br J Anaesth*. 2002;88:659-68.

[131] Leslie K, Myles PS, Chan MT, Paech MJ, Peyton P, Forbes A, McKenzie D. ENIGMA Trial group. Risk factors for severe postoperative nausea and vomiting in a randomized trial of nitrous oxide-based vs nitrous oxide-free anaesthesia. *Br J Anaesth*. 2008;101:498-505.

[132] Le TP, Gan TJ. Update on the management of postoperative nausea and vomiting and postdischarge nausea and vomiting in ambulatory surgery. *Anesthesiol Clin*. 2010;28:225-49.

[133] White PF, Wang B, Tang J, Wender RH, Naruse R, Sloninsky A. The effect of intraoperative use of esmolol and nicardipine on recovery after ambulatory surgery. *Anesth Analg*. 2003;97:1633-8.

[134] Bell RF, Dahl JB, Moore RA, Kalso E. Peri-operative ketamine for acute post-operative pain: a quantitative and qualitative systematic review (Cochrane review). *Acta Anaesthesiol Scand*. 2005;49:1405-28.

[135] Keyes M. Management of postoperative nausea and vomiting in ambulatory surgery: the big little problem. *Clin Plast Surg*. 2013;40:447-52.

[136] Gan TJ, Meyer T, Apfel CC, Chung F, Davis PJ, Habib AS, Hooper VD, Kovac AL, Kranke P, Myles P, Philip BK, Samsa G, Sessler DI, Temo J, Tramèr MR, Vander Kolk C, Watcha M. Society for ambulatory anesthesia guidelines for the management of postoperative nausea and vomiting. *Anesth Analg*. 2007;105:1615-28.

[137] Elhakim M, Nafie M, Mahmoud K, Atef A. Dexamethasone 8 mg in combination with ondansetron 4 mg appears to be the optimal dose for the prevention of nausea and vomiting after laparoscopic cholecystectomy. *Can J Anaesth*. 2002;49:922-6.

[138] Mc Kenzie R, Lim Uy NT, Riley TJ, Hamilton DL. Droperidol/ ondansetron combination controls nausea and vomiting after tubal banding. *Anesth Analg*. 1996; 83:1218-22.

[139] Grimsehl K, Whiteside JB, MacKenzie N. Comparison of cyclizine and ondansetron for the prevention of postoperative nausea and vomiting in laparoscopic day-case gynaecological surgery. *Anaesthesia*. 2002;57:61-5.

[140] Rawal N. Analgesia for day-case surgery. *Br J Anaesth*. 2001;87:73-87.

[141] Pavlin JD, Kent CD. Recovery after ambulatory anesthesia. *Curr Opin Anaesthesiol*. 2008;21:729-35.

[142] Claxton AR, McGuire G, Chung F, Cruise C. Evaluation of morphine versus fentanyl for postoperative analgesia after ambulatory surgical procedures. *Anesth Analg*. 1997;84:509-14.

[143] Awad IT, Chung F. Factors affecting recovery and discharge following ambulatory surgery. *Can J Anaesth*. 2006;53:858-72.

[144] Higgins PP, Chung F, Mezei G. Postoperative sore throat after ambulatory surgery. *Br J Anaesth*. 2002;88:582-4.

In: Encyclopedia of Surgery (22 Volume Set)
Editors: Andreas Lehrer and Kristin Mueller
ISBN: 978-1-53618-329-0
© 2020 Nova Science Publishers, Inc.

Chapter 98

AMBULATORY SURGERY IN ORTHOPAEDICS: PREVALENCE, COMPLICATIONS AND LONG-TERM OUTCOMES

Omar Faour Martín[1,*] and Miguel Ángel Martín Ferrero[2]
[1]Service of Traumatology and Orthopaedic Surgery,
Hospital of Ávila- Sacyl, Spain
[2]Service of Traumatology and Orthopaedic Surgery,
Clinic Universitary Hospital of Valladolid, Spain

ABSTRACT

The concept of day surgery is becoming an increasingly important part of elective surgery worldwide. Relentless pressures to cut costs may constrain clinical judgments regarding the most appropriate location for a patient's surgical care. Ambulatory surgery in Orthopaedics has shown in our institution to be able to provide good-quality service. There still seems to be potential to increase the proportion of these procedures. Therefore, surgeons and anaesthesiologists must strongly adhere to strict patient selection criteria in order to reduce complications in the immediate postoperative term. We expose a revision of more than 10.000 patients during the last twenty years following the protocols of our Ambulatory Surgery Unit. Major complications recorded in our revision were minimal without any mortal case. Unplanned overnight admission rate of 0.14 % was achieved and a high rate of ambulatory substitution in procedures studied was registered.

Keywords: Ambulatory, orthopaedics, surgery, procedures

[*] Corresponding Author's Email: ofmartin@msn.com.

1. INTRODUCTION

Orthopaedic surgery is the branch of surgery concerned with conditions involving the musculoskeletal system. In recent years, the prevalence of musculoskeletal procedures has drastically increased around the world. In this context, the notion of day surgery is becoming an increasingly important part of elective surgery worldwide [1]. Decreased healthcare costs, efficacy of operative care, patient's satisfaction, and dedicated staff are important factors that have led to an increase in its popularity.

Public health policies have promoted ambulatory surgery. This has been one of the most important and dynamic changes in medical care during the last decades. Many managers consider it as a way to increase and enhance access and control costs [2]. At this respect, it has been estimated that the costs for day-surgery procedures are 25–68% lower compared with inpatient care [3,4].

However, this large diffusion has occurred without the outcome assessments that are usually associated with such an important change in health care practices and policies [5]. The potential advantages of day-surgery practice disappear when patients require emergency care due to adverse events. In this respect, the data provided by Matilla et al. [6], after a thorough study of day surgery of all specialties in Finland, revealed rates of admission of 5.9% and readmission within 24 hours postoperatively of 0.1%. In other studies, unplanned admissions after ambulatory surgery were thought to occur in approximately 0.5% to 1.5% of cases [7,8]. Direct admissions from a day surgical unit during a five-year study [9] varied by service: 0.80% for gynecologic, 0.79% for orthopaedic and 0.57% for general surgery departments. The main reported risk factors for hospital admission were duration of the surgical procedure, general anesthesia, bleeding and uncontrolled pain.

2. OUR EXPERIENCE IN ORTHOPAEDICS DAY-SURGERY

In many centers, ambulatory procedures are considered the norm for programmed surgical treatments. Local structural and functional differences may explain the variation in outpatient surgery activity still seen between hospitals together with different patient and procedure-related selection criteria [10].

We have performed an updated of data registered previously of our experience in orthopaedic day surgery [11]. The centre is a teaching university hospital with a referral population of up to 300,000 people. It belongs to the National Health System, which provides free universal coverage and is financed through the resources of the Spanish Public Administration. The Orthopedic Academic Department has an Ambulatory Surgery Unit, composed of three consultants with independent functionality. Four to six surgical sessions are held each week. The upgrade comprises the incorporation of recent years so that the data of patients operated in this regime from June 1993 to November 2014 are collected.

Inclusion Criteria for Orthopaedic Day-Surgery

As in the previous years, the patient inclusion criteria for orthopaedic ambulatory surgery in our institution are considered as follows [12]:

a) Patient comorbidities: the patients could not have any uncontrolled metabolic or psychiatric illness, drug addiction, coagulopathy, epilepsy, history of severe anesthetic complications, symptomatic cardiac disease six months previous to surgery, body mass index exceeding 30, or be undergoing anticoagulant treatment. We considered patients that were I and II or controlled III and IV status, according to the preoperative risk criteria established by the American Society of Anesthesiologists (ASA). Controlled arterial hypertension, stable chronic obstructive pulmonary disease and diabetes treated with oral agents were not considered as exclusion criteria.
b) Social status of the patient**:** the patient needed an adequate family environment with an available telephone, no architectural obstacles, a responsible caregiver for the 24-48 hour postoperative period, easy land communication with a hospital, and needed to be over 18 months of age.
c) Surgical technique: patients with no complex preoperative preparation, with little bleeding and mild physiological aggression were included. The postoperative period should have been managed without invasive procedures.
d) Anesthesia: possibility of using a safe method that allowed for a fast recovery profile.

Discharge after Ambulatory Orthopaedic Surgery

Patients were discharged according to Korttila's criteria for day surgery [13]:

- Vital signs stable for at least 1 hour.
- Patient oriented to person, place, and time
- Able to tolerate orally administered fluids
- Able to void, to dress and to walk without assistance
- No more than minimal nausea or vomiting
- Absence of excessive pain and bleeding
- The patient must be discharged by both anesthetist and surgeon
- Written instructions for the postoperative period at home, including a contact place and a person who may be telephoned, need to be reinforced; presence of a responsible adult to escort patient.

The patient had to be able to swallow and cough as well, and explicit consent from the patient or the adult caregiver was necessary for discharge.

Preoperative and Immediate Postoperative Management

The day before surgery all patients were personally given detailed oral and written instructions to follow for the ambulatory procedure. Hospital contact phone numbers for any eventuality were given.

During the immediate postoperative period, patients were transferred to a recovery room and discharged whenever they met the criteria described above. In most of the cases, all drainages (if placed) were removed the day after the surgical procedure.

Checks were done by a home-hospital unit during the first 48 hours after discharge. This unit used a public phone to ask all the questions about the process. All patients were reviewed in the surgeon's office within 7 days of discharge.

A clinical evaluation, both in the preoperative period and one week after surgery, was performed using the SF36 questionnaire [14]. It contains 36 items in nine separate domains. Eight of these comprise two or more items and the final one has only one item. Each domain is computed to give a scaled score of 0-100. It was adapted for use in our country and is widely recommended as a tool for health status assessments in care settings [14]. Subjective satisfaction, scored from 0-10, was registered, as well as an actual comparative satisfaction study with a subgroup of patients operated on in an inpatient regime of the main processes. This latter group comprised patients operated on by orthopedic surgeons from our institution that work outside our ambulatory surgery unit. Patients that would not fulfill the inclusion criteria for outpatient surgery because of clinical reasons were excluded.

Updated Results

The sex distribution of the 11,355 patients evaluated was 4,326 males (38.2%) and 7029 females (61.8%). The mean age was 42.3 years (range 2-81). The age distribution was as follows: 69 patients younger than 15 years old (0.60%), 1,340 aged between 15 and 30 years (11.9%), 2135 between 30 to 45 years (18.7%), 3,997 between 45 and 60 years (35.1%), between 60 and 75 years 3213 (28.4%) and 601 patients (5.6%) over 75 years.

The number of patients that were living in rural areas was 1,851 (16.3%), compared to 9504 (83.7%) patients that inhabited urban areas.

ASA scores were distributed as follows: ASA I in 6132 cases (54.0 %), ASA II in 4,962 cases (43.7%), ASA III in 261 cases (2.3%) and no patients with ASA IV.

Intervened diseases represented a wide range of pathologies: knee arthroscopy for meniscus resection, meniscus suture, and anterior cruciate ligament (ACL) reconstruction, shoulder arthroscopy for rotator cuff repair, acromioplasty and instability treatment joint mobilization, removal of osteosynthesis material, excision of synovial cysts, opening of pulleys for trigger fingers, tenotomies, removal of external fixators, arthrodesis and arthroplasty of the fingers, osteosynthesis of hand fractures, fasciectomy for Dupuytren´s disease, removal of foreign bodies, nerve decompression (carpal tunnel syndrome, Guyon's syndrome, cubital algoparesia in the elbow); excision of neuromas, amputation of fingers, correction of toe deformities (hallux valgus, hammer toes) fingernail operations, skin grafting, neurorrhaphy, nerve grafting, palliative surgery of peripheral nerve paralysis, tenorrhaphy and tenolysis.

Regional anesthesia was used in 8289 cases (73%), local anesthesia was used in 2,964 cases of (26.1%), and general anesthesia was used in 102 cases (0.9 %).

The average time of the intraoperative period, from patient entry to the theater until exit to the recovery postsurgical area, was 28 minutes (range 10-117). The average time the patient spent in the unit, from arrival to discharge, was 184 minutes (range 24-322).

No major complications were recorded. Only 16 patients (0.14 %) required overnight admission after surgery. The reasons for admission were suspected pneumothorax (two patients), lack of a responsible adult to accompany the patient (four patients), non-acceptance of discharge due to general discomfort (four patients), monitoring the vascular status of the toes where slow revascularization persisted two hours after surgery (four patients), and vomiting (four patients). The main characteristics of these 16 patients were: mean age of 70.4 years (range: 61-78); ASA grade III in 12 cases (75%) and grade II in four cases (25%); regional anesthesia had been administered in eight cases (50%) and general anesthesia in seven patients (42.9%). The mean surgical mean duration was 67 minutes (range 35-119).

59 patients (0.52%) left the hospital by ambulance due to the postoperative indication of not being able to bear weight on a lower limb. 147 patients needed attention at the emergency department during the first 24 hours after discharged (1.3%) because of pain (108 patients) or bleeding (39 patients), with four subsequent hospitalizations after shoulder arthroscopy, six because of knee pain and swelling after ACL reconstruction and one after arthroscopic knee arthrolysis.

During the first 48 hours after surgery, a medical consultation by phone was needed by 2124 patients (18.7%) due to discomfort (1020 patients), concerns regarding postoperative prescriptions (224 patients), or bleeding (880 patients). Most of these queries were sorted out by phone.

Painkillers were needed during a mean postoperative period of 5.2 days (range 1 -29). The following complications were recorded during the first clinical revision that took place seven days after surgery: superficial infections were found in seven patients, which resolved with outpatient care; a metacarpophalangeal prosthesis infection in a rheumatoid patient that required surgical revision; two deep infections in diabetic patients operated on for Dupuytren's disease, one of which needed amputation of the fifth finger; suture dehiscence in five patients, one of whom was diabetic; intra-articular hematoma due to suction drainage malfunction in seven patients. The number of patients requiring admission between postoperative 24 hours and 28 days after surgery was eight (0.06%).

Subjective outcomes made reference to those patients capable of understanding and answering the items of the SF-36 questionnaire (11299 patients, 99.5%). The results of the questionnaire revealed a significant improvement in the quality of life index in postoperative values as compared to the preoperative values *(p* <0.0001), in all the items: *general health, limitation of activities, physical health problems, emotional health problems, social activities, pain, energy and emotions*

The mean satisfaction value for the management of all surgical procedures was of 8.64 / 10 (range 4-10). The results for satisfaction between in Day and inpatient surgery during the last five years did not show significant differences overall, so the ambulatory management of the procedure did not mean a decrease in patient satisfaction.

Quality Indicators

To sum up, our experience in Ambulatory Orthopedic Surgery has presented the following quality indicators:

- Unplanned overnight admission: 0.14 %
- Readmission rate within 24 hours: 0.09 %
- Readmission rate 1-28 days after discharge: 0.06 %
- Emergency room visits rate: 1.3%
- Cancellation of booked procedures: 1.51%
- Ambulatory Orthopedic Surgery / All elective surgeries of the orthopedic department for the period studied: 39.2 %.

Reasons of cancellation of booked procedures (164) were: acute illness in 114 cases (73.8%), decision by the patient in 18 cases (10.3%), and lack of surgical material in 32 cases (15.9%).

The substitution rate for different surgical interventions, defined as the number of ambulatory surgeries divided by all surgeries performed for a specific procedure [7], was as follows:

- *Carpal tunnel decompression: 97.2%*
- *Arthroscopic meniscectomy: 77,5%*
- *Acromioplasty / bursectomy:83.4%*
- *Hallux valgus correction:96.2%*
- *Rhizarthrosis surgery: 87.2%*
- *Osteosynthesis of hand and wrist bones: 87.3%*
- *Anterior cruciate ligament reconstruction: 36.4%*
- *Dupuytren disease:88.4%*
- *Arthroscopical Shoulder inestability repair: 42.7%*
- *Tenolysis of trigger fingers:98.9%*

The number of total ambulatory procedures without unplanned admission was of 11,320. The mean direct cost of day-admission in our institution during the last twenty years was of 375.4 Euros. The economic global results coming from the data registered in our revision indicate that the saving has been at least of 4, 2495,627 Euros.

3. PRESENT AND FUTURE

The aim of our actualization was to determine the clinical and quality indicators of our experience in Orthopedic Day Surgery in a revision of more than 11,000 patients during the last twenty years, mainly in relation to the unplanned overnight admission and readmission rates. Also we consider that the description of the main characteristics of the patients that experimented complications and the patient comparative satisfaction rate between the

ambulatory and non-ambulatory procedures is a fundamental issue. As such, our revision may provide a benchmark to evaluate future outpatient orthopedic surgery disposition rates. Clinical indicators from the SF-36 score revealed favorable outcomes in the immediate postoperative term. The results for satisfaction between in Day and inpatient surgery did not show significant differences, so the ambulatory management did not lead to a decrease in patient satisfaction.

Ambulatory surgery in Orthopedics has shown in our institution to be able to provide good-quality service, with high patient satisfaction. There still seems to be potential to increase the proportion of these procedures, and best practices should be sought. The efficacy and quality of the process itself requires further study. Figures for clinical indicators and the proportion of day surgery of all elective surgeries at individual hospitals, and nationally, should be made easily accessible for benchmarking and quality control with an automated reporting system. In future, day surgery should be the norm for elective surgery.

Assessment of quality of care is not only important for health control, but fundamental for the development of the expanding day-surgery service. Relentless pressures to cut costs and to provide services in the least costly setting may, in the absence of contrary evidence, constrain clinical judgments regarding the most appropriate location for a patient's surgical care [2].

Our patient selection criteria were rather uniform and in line with present-day recommendations [15]. In the future, the demand for day surgery in the increasing elderly population and in patients with notable comorbidities will undoubtedly increase. Therefore, surgeons and anesthesiologists must strongly adhere to those criteria in order to reduce complications in the immediate postoperative time [16]. Some of these risk factors may be proxies for surgical and/or case complexity; however, there is currently no generally accepted measure of procedure complexity.

Major complications in our review were minimal, and there were no deaths. Despite a controlled IV ASA risk was not considered as an exclusion criteria, no patient with this condition were registered due to a concomitant disease, such as coagulopathy or cardiopathy that excluded them from our study. Quality of care was measured by rates regarding with unplanned overnight admission, patient returns to hospital within 24 hours, admission within 24 hours and during the first month after surgery, and cancellation of booked procedures. Those outcomes have been lower than data shown by other studies about ambulatory surgery overall [16-19].

Efforts must be carrying out in the management of Ambulatory Surgery in Orthopedics in order to reduce the unplanned admission rates. In this way, a deep preoperative specific clinical evaluation must be performed closed in time to the intervention in order to detect conditions that contraindicate an ambulatory procedure. Operations must be performed as minimally invasive as possible and clear indications must be given to the patients during the first hours with a tight ambulatory follow-up.

As in other articles [17-19], pain and bleeding still continue being the most common reason of adverse events after ambulatory surgical procedures. In our experience, most of the patients needing unexpected overnight admission or readmission during the first 24 hours after surgery, presented an advanced age, ASA condition of III, or a considerable surgical duration.

In order to minimize complications in ambulatory surgery, we consider essential to act on factors influencing on immediate recovery, such as postoperative analgesia and anti-emetic

prophylaxis [20]. In the same way, dressing of the limbs after surgery is critical. An inappropriate choice or placement could cause important and serious adverse events, and it is necessary to avoid bandages that could create compression and vascular problems, such as a full plaster.

In addition, we have recorded a high replacement rate for procedures such as knee arthroscopy, osteosynthesis of the hand, or carpal tunnel decompression, when compared with other published studies that report these rates up to 83.1%, 70.7%, and 64.3% respectively [21].

Ambulatory surgery in Orthopaedics may be consider a present and future essential part of the management of the specialty. Units Ambulatory Surgery have, within the National Health System as well as in the private sector, a considerable development over the past fifteen years That lead to an increasing efficiency in the care of patients eligible for orthopaedic surgical procedures that previously were admitted in conventional hospital units. The relative novelty of this healthcare modality, its important dissemination, the diversity of organizational, structural and functional configurations must be taken into account. Its significant impact in terms of quality and patient safety, make this kind of Unit, as one of the elements of priority in health politics. Standard criteria of quality and safety should be developed and established, as well as its continuous evaluation. Support and management of ambulatory orthopaedic surgery in the framework of the objectives and quality plan of any National System of Health must be consolidated.

From the perspective of the quality and efficiency there is widespread consensus on the quality, safety and efficiency of ambulatory surgery as healthcare modality. There have been indicators to know the exact value of this type of healthcare service and its quality control. The most used ones are: cancellation of procedure, Adverse events (Same-day unplanned repeated surgery, Unplanned overnight stay, Emergency consultation, Readmission to hospital, Risk-adjusted complications index), Substitution Index, Ambulatory surgery index and Satisfaction Index and postoperative pain assessment.

Disadvantages of this type of surgery, such as failure to follow perioperative instructions, inability to be served by another competent person during convalescence, the impossibility to dispose of transportation to be connected to hospital or the worry and lack of patient trust, is significantly attenuated with good patient selection.

Advantages offered by ambulatory surgery are many because of it allows more individual attention and according to the needs of the patient, altering the minimum lifestyle and allowing less disability and return to work as quickly as possible in lot of cases. Besides, it avoids all the complications of hospitalization and reduce healthcare costs.

To ensure the proper functioning and quality of this surgical modality is essential a multidisciplinary coordination and training in the techniques and requirements of day surgery in staff to be practice it communication of all professionals who are part of it. The training of practice leaders in principles of root-cause analysis, quality improvement, and process redesign is also essential so that when they receive reports of safety concerns, they are able to analyze them and enact change. Provider organizations that recognize these challenges and respond to them will be ahead of the game as the spotlight is increasingly focused on care delivered not just by hospitals but by truly accountable care organizations in all settings of care.

The complications described are rare and mild, with a low rate of unexpected admissions, without any mortal case, and good satisfaction results and overall outcome with an optimal acceptance by all those involved.

Units of ambulatory surgery require a number of structural resources and equipment, which are mainly in relation to the characteristics of the scheduled clinical activity and the degree of autonomy with regard to existing resources of each hospital centre.

Given the consolidation and advancement of ambulatory surgery in Orthopaedics, it is considered that the structural conditions of the units should be targeted to meet the requirements in good standards and recommendations, giving priority to Autonomous Units over other designs. It should be noted that the design recommendations at this respect must include functional aspects and be adapted to each specific reality. Decisions regarding the practical structure of the ambulatory units must be dependent on the organizational form and specific management of each one, and adopted, in particular, taking into account the organization and management of human resources.

Day case surgery in Orthopaedics is a very important concept which can be used to reduce the waiting time for elective operations, and help clinicians and managers to prioritize and plan patient's treatments. It needs to be incorporated in healthcare policies designs in order to minimize the hospital stay and cost, and ultimately to increase productivity.

REFERENCES

[1] National Center for Health Statistics. Hospital admissions, average length of stay, and outpatient visits, according to type of ownership and size of hospital, and percent outpatient surgery: United States, selected years 1975-2000 [Table 96]. In: *Health*, United States, 2002, With Chartbook on Trends in the Health of Americans. Hyattsville, Md: NCHS; 2002.

[2] Fleisher LA, Pasternak LR, Lyles A. A novel index of elevated risk of inpatient hospital admission immediately following outpatient surgery. *Arch Surg* 2007;142:263-8.

[3] National Research and Development Centre for Welfare and Health. *Care periods in 2006 and trends of care periods in the years 1997–2006*. Finnish official statistics. 2007.

[4] Wu CL, Berenholtz SM, Pronovost PJ, Fleisher LA. Systematic review and analysis of postdischarge symptoms after outpatient surgery. *Anesthesiology* 2002; 96:994-1003.

[5] Punnonen H. January–December 2007 *at hospitals and hospital districts – a summary of demand, production and finance.* Helsinki: Finnish Local and Regional Authorities 34–9 2008.

[6] Mattila K, Hynynen M. Day surgery in Finland: a prospective cohort study of 14 day-surgery units. *Acta Anaesthesiol Scand* 2009; 53: 455-63.

[7] Mezei G, Chung F. Return hospital visits and hospital readmissions after ambulatory surgery. *Ann Surg* 1999; 230:721-727.

[8] Twersky R, Fishman D, Homel P. What happens after discharge? return hospital visits after ambulatory surgery. *Anesth Analg* 1997;84:319-324.

[9] Johnson CD, Jarrett PE. Admission to hospital after day case surgery. *Ann R Coll Surg Engl* 1990;72:225-228.

[10] NHS Modernisation Agency. *10 high impact changes for service improvement and delivery: a guide for NHS leaders*. London: NHS Modernisation Agency 15–84 2004.

[11] Martin Ferrero MA, Faour Martin O. Ambulatory surgery in orthopedics: experience of over 10,000 patients. *J orthopaedic science* 2014; 19:332-8.

[12] American Society of Anesthesiologists Task Force on Preoperative Fasting. Practice guidelines for preoperative fasting and the use of pharmacologic agents to reduce the risk of pulmonary aspiration: application to healthy patients undergoing elective procedures. *Anesthesiology* 1999; 90: 896–905.

[13] Korttila K. Anaesthesia for ambulatory surgery: firm definitions of "home readiness" needed. *Ann Med* 1991;23:635-6.

[14] Herrera FJ, Wong J, Chung MB. A Systematic Review of Postoperative Recovery Outcomes Measurements After Ambulatory Surgery. *Anesth Analg* 2007: 105: 1: 63-69.

[15] Smith I. Day surgery for all: updated selection criteria. *Current Anaesth & Critical* Care 2007; 18: 181–7.

[16] Aldwinckle RJ, Montgomery JE. Unplanned admission rates and postdischarge complications in patients over the age of 70 following day case surgery. *Anaesthesia* 2004; 59: 57–9.

[17] Ansell GL, Montgomery JE. Outcome of ASA III patients undergoing day case surgery. *Br J Anaesth* 2004; 92: 71–4.

[18] Fortier J, Chung F, Su J. Unanticipated admission after ambulatory surgery – a prospective study. *Can J Anaesth* 1998; 45: 612–9.

[19] Coley KC, Williams BA, DaPos SV, Chen C, Smith RB. Retrospective evaluation of unanticipated admissions and readmissions after same day surgery and associated costs. *J Clin Anesth* 2002; 14: 349–53.

[20] Lindh A, Andersson AS, Westman L. Is transient lumbar pain after spinal anaesthesia with lidocaine influenced by early mobilisation? *Acta Anaesthesiol Scand* 2001: 45: 290–3.

[21] Colomer J, Ondategui S, Esteban E. Substitution indexes in ambulatory surgery: measure, count and compare. *Gac Sanit* 2001; 15:523-6.

In: Encyclopedia of Surgery (22 Volume Set)
Editors: Andreas Lehrer and Kristin Mueller
ISBN: 978-1-53618-329-0
© 2020 Nova Science Publishers, Inc.

Chapter 99

ADVANCES IN SURGICAL PROCEDURES THYROID GOITRES: SURGERY FOR LARGE AND DIFFICULT GOITRES

Yassar A. Qureshi and Fiona McClenaghan
The Royal London Hospital, London, UK

ABSTRACT

Thyroidectomy for goitres can often be challenging, but this is especially apparent for large and difficult goitres. These can often reach very large sizes prior to surgical intervention, and may also extend into, and adhere to, surrounding structures. This makes the surgery more exigent, and increases the risk of damaging major structures inadvertently, including the recurrent laryngeal nerve and parathyroid glands. In this chapter, we describe the optimal pre-operative management, including essential imaging to assess the thyroid, and investigations necessary for careful operative planning. We describe the operation for such glands in a logical manner, and incorporate techniques and advances which make the surgery more straightforward, and allow the surgeon to carefully identify and preserve vital structures. Further, we describe how to approach specific complications resulting from surgery for large goitres, including both intra-operative techniques and post-operative care.

INTRODUCTION

"Can the thyroid in the state of enlargement be removed? Emphatically, experience answers no… every stroke of the knife will be followed by a torrent of blood and lucky if his victims lived long enough for him to finish his horrid butchery! No honest and sensible surgeon would ever engage in it."

Samuel Gross, 1866

This famous quote by Samuel Gross, a US surgeon is, thankfully, rarely the case in contemporary thyroid surgery. However, the thyroid surgeon can certainly appreciate his exasperation at this form of surgery, owing to the very high risk and demanding nature of the operation. His particular reference to an enlarged thyroid gland, or goitre, makes it a more remarkable observation, as thyroid surgery for such a diseased thyroid is much more challenging and carries its own peculiar and significant risks.

The ancient Chinese first described large goitres as early as 2700 BC, but it was not until much later that the disease was understood. The Romans coined the term goitre, from the Latin 'gutter' or throat, and indeed, it was Julius Caesar who observed that goitres tended to be endemic in his conquered Gauls- a fact owing to the low iodine concentration in the local water.

Although herbal remedies, incantations and exorcisms were used not uncommonly for the treatment of goitres, surgery was first described in 952 AD. Ali Ibn Abbas, an Arab Physician, performed a successful excision of a goitre under opium sedation. In the 12th Century in Italy, surgeons continued to perform this operation, albeit with an incredibly high mortality rate. It was not until 1791 that a French Surgeon, Pierre Joseph Desault, refined the surgery, with some success, but mortality remained so high that the French Academy of Medicine took the drastic action of banning the operation in 1850. With future developments in the field of anaesthesia, antisepsis and surgical technology, the operation resumed, with improved outcomes. Although the words of Samuel Gross held true at the time, it should not be forgotten that the first Surgeon to achieve a Nobel Prize was Theodore Kocher, for his work on thyroid physiology and refinement of surgical technique for the goitre.

Surgery for large goitres can be challenging. Goitres may reach very large sizes, and will invariably, to some degree, distort anatomy, thus making dissection in correct tissue planes problematic. Vital structures may be more difficult to identify, making the risk of complications more pronounced. Furthermore, the sheer size of the goitre often means the surgery is longer, with more dissection than anticipated, and the goitres may encroach into seldom visited body cavities, such as the chest.

Careful operative planning and investigation is most useful in ensuring that an optimal operation is performed. Exposure is key to good dissection, and thus certain intra-operative techniques may allow better access to tissue planes. After such operations, the patient is, perhaps, more likely to suffer post-operative complications and protracted recovery, and so must be carefully monitored and reassessed, to ensure their good recovery and early discharge.

PRE-OPERATIVE PLANNING

Examination

A thorough examination of the patient should be performed by the operating surgeon. This is to ascertain the size of the goitre, and plan for the site of the incision to give optimal access. Large thyroid glands may be due to benign or malignant disease. This needs to be ascertained pre-operatively, often by a combination of radiological and histopathological investigations. The importance of delineating the diagnosis prior to the operation is because

malignant disease may require more extensive surgery to obtain clear margins, and may be associated with extended lymph node dissection. Although true for inflammatory disease too, malignant disease is often invasive into surrounding structures. Tissue planes may be disrupted and dissection more difficult. Indeed, if a sub-total or debulking operation is envisaged, for example to relieve compression of the airway, this should be determined pre-operatively, rather than in the midst of the operation.

On examination, local lymphadenopathy should be assessed for, and previous scars should be specifically looked for. In some cases, a re-do operation will need to be performed, which are typically more challenging, and previous scars will need to be incorporated into the new incision. This is to ensure both good access, but also a reasonable cosmetic outcome for the patient.

Ideally, if possible, it is better to operate on euthyroid patients, and hence a pre-operative review by an endocrinologist is beneficial. This will minimise peri-operative erratic thyroid function, and avoid a potential 'thyroid storm' during the operation. Calcium levels should also be checked to ensure normal parathyroid function. The vocal cords and voice quality should be checked independently, and the results documented. This is especially important given that 1% of the population will have a unilateral asymptomatic paralysis of the cord. Medical co-morbidity should be assessed and optimised, to ensure minimal peri-operative risk, and to enhance healing and recovery.

Radiological Investigation

Most patients presenting with thyroid problems will undergo an ultrasound scan as an initial radiological investigation. This will give an indication as to the size of the thyroid goitre, and its relationship to surrounding structures. However, if dealing with large goitres, a contrast enhanced computerised tomography (CT) scan is especially useful, as it will give significantly more detailed information regarding the dimensions of the thyroid. In, particular, it will also clearly show the proximity to surrounding vital structures, and show extension of the thyroid gland into the retrosternal space or the thoracic cavity. These factors will allow the surgeon to carefully plan for the operation, not only in terms of the incision, but also the best method to approach the dissection of the gland. Consistent landmarks such as the trachea and carotid sheath can be helpful to convey the radiological findings to the actual dissection. However, more slender structures such as the recurrent laryngeal nerve and parathyroid glands will not be seen radiologically; in the case of the latter, unless there is a concurrent parathyroid adenoma. A magnetic resonance imaging (MRI) scan provides similar detail to the CT scanning, and is preferred in some units.

Previous radiotherapy to the neck can cause tissue damage by inflammation and necrosis and even if surgery is many years later, tissue planes will be compromised, anatomy may be distorted, and healing may be protracted.

Anaesthetic Review

The anaesthetist should be familiar with difficult and shared airways, and review the patient prior to the operation. This is to familiarise oneself with the patient's medical history,

biochemical thyroid status and to perform an examination. Particular history of airway and respiratory disease should be elucidated, and any possibility of airway encroachment explored. The patient's oropharynx should be thoroughly assessed: this will allow better planning for anaesthesia and intubation. Any potential disease involvement of the trachea must be fully explored, as it should be borne in mind that longstanding involvement of the trachea by a goitre may be associated with tracheomalacia. Positional breathlessness, dysphagia, and stridor should be evaluated, if present. Rarely, a very large or retrosternal goitre may compress the superior vena cava.

For thyroid surgery, owing to the ever-present risks to the airway, a definitive airway for the extent of surgery should be performed. This would normally involve a cuffed endotracheal tube. Fibre-optic intubation may be useful in cases where there is some degree of airway obstruction. Indeed, a pre-operative tracheostomy may be required where complete airway obstruction is imminent. There is no specific guideline on the use of paralytic agents, but it may help in reducing laryngeal reflexes. A strong analgesic, such as remifentanyl, is often used, as apart from its analgesic effect, it contributes to a mild hypotension, thus aiding the minimisation of blood loss. Dexamethasone at induction may also contribute to reduced inflammation and oedema around the airway and dissection field.

INTRAOPERATIVE TECHNIQUE FOR GOITRE SURGERY

The normal thyroid gland lies at the anterior aspect of the neck. It has two lobes, normally about 5cm each in size, connected by a central isthmus overlying the trachea. Generally, the superior aspects of the lobes are narrow, and become broader inferiorly. Medially, the relations of each lobe are the larynx, trachea and oesophagus, anterolaterally the strap muscles and the sternocleidomastoid and posteriorly the carotid sheath. These relations are important to bear in mind when approaching a large thyroid. The gland itself is surrounded by a thin fibrous capsule, which extends over the trachea (the pre-trachea fascia) and laterally onto the carotid sheath. When a large goitre is encountered, it often extends laterally, displacing the carotid sheath, but if the goitre is secondary to an invasive disease, it may infiltrate into any surrounding structure.

Initial Operative Approach

The patient is positioned supine on the operative table, with the head in extension, which can be achieved by placing sand bags beneath the shoulders. The head is placed on a circular head ring, and the anaesthetist should ensure that they are content with the endotracheal tube positioning prior to the preparation and draping of the patient. Once an unencumbered sterile field is set up, the surgeon can mark the skin incision. This usually lies 2-3cms above the sternal notch, ideally in a skin crease. However, the exact site and extent of the skin incision may vary dependent on the size of the thyroid. Indeed, if a re-do operation is being performed, the old scar should be incorporated into the contemporary incision.

Once the skin and platysma is breached, the anterior jugular veins will be encountered, and if they are obscuring the operative field, can be ligated. Once flaps are raised, the

infrahyoid muscles are delineated, separated in the midline and the central portion of the thyroid gland exposed. The strap muscles are dissected off the thyroid lobes. This will expose the superior pole of the thyroid, which should be dissected off surrounding structures in the correct plane beneath its capsule. The dissection is within the sterno-laryngeal (or Joll's) triangle, constituting the midline, infrahyoid muscles and the superior thyroid pedicle. Once the superior pole and its vascular pedicle are secured, the remainder of the thyroid can be mobilised, and the inferior thyroid pole approached. The middle thyroid vein, draining into the internal jugular vein, should be identified and ligated, prior to inadvertent avulsion.

ANTEROLATERAL DISSECTION

The strap muscles form this relationship with the thyroid, and the surgeon will encounter first the sternothyroid, then the sternohyoid and the superior belly of the omohyoid. The pairs of strap muscles converge in the midline and separated to gain access to the thyroid gland. Division of these muscles may ease access in dissecting the superior lobe of the thyroid. It can be safely performed by dividing the sternothyroid and sternohyoid muscles transversely as close to their origin in the midline as possible, as the specific branches of the ansa cervicalis which innervate these muscles approach from inferiorly. The divided muscles can then be retracted superior-laterally to expose the large superior pole of the thyroid. After excision of the gland, continuity of the muscle edges can be restored using interrupted sutures.

Often, between the sternothyroid and sternohyoid muscles, there lies an avascular plane, dissection through which will enable the surgeon to reach the carotid sheath. Development of this plane may be sufficient to allow the superior pole to be safely mobilised. Indeed, the deeper sternothyroid may still be transected, but division of the sternohyoid can be altogether avoided.

When approaching the superior lobe where there is clear invasion into or toward the muscles, the surgeon can employ the 'back door to thyoid' approach. This involves dissection of the sternocleidomastoid off the strap muscles. A plane between the carotid sheath and the lateral aspect of the sternohyoid is then developed, which allows access to the thyroid gland. If required, the inferior belly of the omohyoid may be transected to allow further access. This technique allows access to the lateral aspect of the thyroid for dissection, and can aid the avoidance of a protracted and bloody dissection if there is thyroid invasion or encroachment laterally, as may be found in very large goitres, goitres secondary to malignancy or in recurrent multinodular goitre.

POSTERIOR DISSECTION AND THE PARATHYROID GLANDS

The large goitre tends to enlarge in this direction, and can push the carotid sheath from a posterior to a lateral relation. The carotid sheath transmits the common carotid artery, and laterally the internal jugular vein, with the vagus nerve lying in between. The ansa cervicalis, motor nerves which innervate ipsilateral strap muscles, lie anteriorly on the sheath.

As mentioned, dissection of the plane between the medial sheath and the thyroid aids the mobilisation of the large thyroid. Owing to the potential catastrophe of injury to the carotid sheath structures, dissection around this relation should be slow and careful. If thyroid disease is invading onto the sheath, then the sheath can be carefully dissected off immediately above the underlying vessels.

The parathyroid glands, two superior and two inferior, will also be encountered during posterior dissection of the thyroid. The position of the parathyroid glands is not always consistent, and they may be located either outside or within the thyroid capsule, or in 0.2% of cases deep within the thyroid parenchyma. [1] The superior parathyroid glands, which arise from the fourth branchial pouch, are more consistently located, with most posterior to the superior thyroid pole. The inferior glands, arising from the third pouch, are often more variably located, but generally should lie around the lower thyroid pole. Normal parathyroid glands are only 5mm in size and often difficult to identify, particularly in a bloody dissection field. However, their identification and preservation is of utmost importance in good surgical practise. Interestingly, even with very large goitres, the non-ectopic parathyroid glands are consistently located within the expected field of variation. Pre-operatively, parathyroid glands, unless aberrantly large, will seldom be seen on ultrasonography or cross-sectional imaging.

The superior parathyroid glands lie superior to the inferior thyroid artery, on the posterolateral aspect of the thyroid gland. When dissecting the pre-tracheal fascia off the thyroid from a lateral to medial direction, the superior parathyroids will become apparent, and will most often lie deep to the recurrent laryngeal nerve.

The inferior parathyroid glands lie below the inferior thyroid artery, and are generally more anterior than the recurrent laryngeal nerve. Again, when dissecting the inferior pole of the thyroid, these will become apparent as the surgeon comes from lateral to medial, whilst the thyroid is lifted to visualise its posterior aspect. [1, 2]

Rather than inadvertent excision, the more common cause of parathyroid function failure after thyroid surgery is the devascularisation of the parathyroid glands. This can easily be caused by rough dissection, inadequate field of vision, or mass ligature of vessels. In 80% of cases, the parathyroids will receive an arterial blood supply from branches originating from the inferior thyroid artery. Regardless of the size of the goitre, this pivotal vessel and its immediate surroundings should be clearly visualised. To avoid devascularisation of the parathyroids, rather than ligate the main trunk of the inferior thyroid artery, only its terminal branches on the pre-tracheal fascia of the thyroid capsule should be ligated. This will ensure reasonable blood supply to the parathyroid glands and avoid post-operative hypocalcaemia. In the circumstance where the parathyroid glands are embedded within the thyroid parenchyma, a peri-capsular dissection can be performed, whereby a cuff of thyroid tissue is left attached to parathyroid to avoid vascular injury to the parathyroid gland.

In absolutely unavoidable situations, if the parathyroids are not all accounted for prior to excision of the thyroid gland, then the specimen must be examined.

The parathyroid glands, if salvageable, can be cut into small pieces and implanted into a small pocket fashioned in the sternocleidomastoid muscle. This scenario may be encountered, for example, when performing a curative resection for malignant disease which is infiltrating into or around the parathyroid glands.

MEDIAL DISSECTION AND THE RECURRENT LARYNGEAL NERVE

Medially, the surgeon will encounter the larynx and trachea. The thyroid goitre which is applied to these structures can be gently dissected off. If there is invasion into the trachea, then a small cuff may be excised with a primary suture repair performed, but dissecting into the larynx is more haphazard owing to the presence of the vocal cords and their nerves. Dissection must remain on the thyroid capsule at this border, and must only be conducted once the recurrent laryngeal nerves and the parathyroid glands have been clearly identified: this is perhaps the most crucial part of a thyroidectomy.

The external laryngeal nerve is a branch of the superior laryngeal nerve, which in turns originates from the vagus. It innervates the cricothyroid muscle, damage to which affects the quality and tonality of phonation. It lies anterior and medial to the superior thyroid artery, although in 20% of people it is intertwined within branches of the artery. [3] It is thus necessary that the superior pole of the thyroid is dissected completely free and the superior thyroid vascular pedicle appropriately visualised. For large goitres, as mentioned previously, transection of the strap muscles, particularly the sternothyroid, would aid in obtaining access to the superior pole of the thyroid. Further, the ligation of the superior thyroid artery should be precise, to ensure that the nerve is not inadvertently divided.

The most critical aspect of a thyroidectomy, made more difficult by large goitres, is the identification and preservation of the recurrent laryngeal nerve. Its inadvertent iatrogenic injury will have significant impact on the patient's quality of life; indeed, bilateral injury to the nerve can be life-threatening. Knowledge of the anatomy of the nerve is paramount, including its aberrations: indeed, the right and left recurrent laryngeal nerves run a different course. At the root of the neck, the right vagus gives off its right recurrent laryngeal branch. It winds around the subclavian artery and emerges behind the common carotid artery. Here, it takes a medial course and enters the right trachea-oesophageal groove. The left recurrent laryngeal nerve originates from the left vagus just lateral to the aortic arch, which it winds around to emerge medially into the left trachea-oesophageal groove. Once in the groove, the nerves ascend and pass either through or behind the ligament of Berry and into the larynx. This ligament is where the pre-tracheal fascia condenses between the thyroid and the anteromedial trachea. [3, 4] Division or ligation of the ligament here will undoubtedly injure the nerves. Care must be taken when dissecting the superior pole of the thyroid around the cricothyroid muscle, where either inadvertent damage to the ligament of Berry, nerve, or the muscle itself, can affect vocal cord function.

The inferior thyroid artery provides a most useful landmark when identifying the nerve. Although the exact relationship between the two is not always consistent, they can be identified in the same vicinity. The nerve can run superficial to the artery (25% of patients), deep (50%) or intertwined between branches of the artery (25%). [4] The inferior pole of the thyroid is usually approached after the superior pole: anterior displacement of the superior lobe should give a clear view of the inferior pole, and dissection approached carefully from lateral to medial. Gentle lateral retraction of the carotid sheath will aid in exposure of the tissue planes where the nerve is located. Once the artery has been identified, with its pulsation, careful examination will reveal the nerve. This should be traced along its length all the way into the larynx. It should be dissected free with as minimal contact as possible in

order to avoid neuropraxia. Ligation of the inferior thyroid artery should be of its terminal branches, precisely and one at a time.

The incidence of a right non-recurrent laryngeal nerve is up to 0.7% of the population. Here, the nerve directly enters the larynx coming from behind the common carotid artery. Non-recurrent laryngeal nerves are much rarer on the left, affecting 0.04% of patients. Of further note, although the nerves lie in the trachea-oesophageal groove in 80% of patients, they may traverse in and out of the groove, or may be lying outside of it. [4] Hence, medial dissection of the thyroid off the trachea must be deferred until the nerve is elucidated for its entire course.

Very rarely, when performing surgery for large goitres, malignant disease, or where a re-operation is performed, there may be an anticipation of disease involving the recurrent laryngeal nerve. For example, the nerve may be infiltrated by disease, making it impossible to dissect. This needs to be carefully discussed with the patient pre-operatively; the consideration of sacrifice of the nerve for disease control is a decision to be made jointly by the surgeon and the patient. The latter should be made fully aware of the possible implications on their quality of life following such an intervention.

Intra-operative nerve monitoring is not yet mandatory, but many surgeons do utilise it. If used, it must be borne in mind that it is not a substitute for actual visualisation of the nerve in its anticipated anatomical location. Further, false readings may be apparent if there is an effect on the nerve from local anaesthesia or from a neuromuscular blockade from an agent administered by the anaesthetist. Indeed, the tracheal-laryngeal electrode may become displaced, giving a false-negative reading. However, if used appropriately, it can audibly confirm gross nerve continuity, but should still be used in conjunction with correct anatomical correlation.

Although the recurrent laryngeal nerve provides the surgeon with some degree of anxiety, careful dissection, avoidance of mass ligature, and a detailed knowledge of nerve anatomy is sufficient to avoid inadvertent injury. Surgery for large goitres can make anatomical identification more challenging, but if key principles are carefully adhered to, the nerve should not be at risk. Meticulous dissection of the thyroid lobes, in a bloodless field and in the correct planes, will allow the surgeon to encounter the nerves, and the parathyroid glands, with a clear view.

Retrosternal Goitre

Although first described in 1749 by Albrecht von Haller, the famous Swiss anatomist, the precise definition of a retrosternal goitre remains debated. Generally, however, it is taken to mean where greater than 50% of the thyroid mass lay in the mediastinum, or below the thoracic inlet. This may be an extension from a normally located cervical goitre, or more rarely an ectopically sited thyroid gland which grows *de novo*. The incidence varies geographically, ranging from between 2-19% of all thyroidectomies. [5, 6] The treatment for retrosternal goitre is extremely challenging, fraught with risk, and controversial; it most certainly is a distinct operation to a cervical thyroidectomy. We will briefly highlight some important points for this type of goitre.

The main clinical implications of retrosternal goitre are related to the pressure they exert on mediastinal structures. This can be primarily by the thyroid parenchyma itself, or from secondary events such as haemorrhage or malignant growth.

The common structures that are affected include the trachea and bronchus, oesophagus, the aortic arch, carotid artery and superior vena cava. In some instances, the goitre may extend over the pericardium and below the right atrium. Pre-operative planning with cross-sectional imaging is mandatory. The structures affected by the goitre need to be known prior to an operation, and if necessary, the aid of a cardiothoracic surgeon enlisted.

The approach to such goitres is mostly through a cervical incision, especially if they are relatively small, or only enter the very proximal mediastinum. If more extensive, then a partial or total median sternotomy (to the 4th intercostal space) is required. [6] This is particularly true if the goitre is abutting major vascular structures where there is a high risk of haemorrhage, if the goitre is largely positioned in the posterior mediastinum, or if the goitre is secondary to malignant disease.

The key phases of the operation, once the thyroid is exposed, is to ensure vascular control. This is true for the superior thyroid vessels, which can be safely ligated, but principally for larger vessels, such as the carotids or those around the aortic arch: proximal and distal control is advocated. This ensures that, in case of vascular injury, haemorrhage can be curtailed swiftly, and it also allows more confident dissection of the thyroid off these major vessels. The inferior thyroid vessels will still be located cervically, and the same principles as a standard thyroidectomy apply: care to avoid inadvertent injury to the recurrent laryngeal nerve, the careful ligation of its distal branches to avoid parathyroid gland devascularisation, and to carefully identify these structures prior to pursuing medial dissection. Where airway structures are involved by goitre, the anaesthetist must be kept fully alerted: if necessary, endobronchial ventilation instituted. Dissection of the gland is performed from superior to lateral to inferior, all the while applying gentle traction to help deliver the retrosternal portion of the gland into the wound.

The risks of a standard thyroidectomy, particularly parathyroid or recurrent laryngeal nerve injury, are magnified. This is sometimes because these structures are stretched or splayed into aberrant positions. Thus, the surgeon must very clearly identify these structures, moving to more normal anatomy and tracing them if necessary. It should be borne in mind that a torrential haemorrhage from the chest will unlikely be controlled by a cervical incision, and a sternotomy would thence be required. Patients, therefore, should be appropriately consented and fully informed of such risks. [6]

Lymph Node Dissection

For goitre secondary to malignancy, a lymph node harvest is advocated for both therapeutic and prognostic and staging purposes. Pre-operative assessment with MRI or Ultrasound Scanning is essential to be able to ascertain the degree of lymph node excision required.

Level VI neck dissection is most often performed for malignant disease, and such a harvest is aided by finding the recurrent laryngeal nerve in the low or mid-level of neck. It can then be traced superiorly, and the lymph nodes excised without jeopardising it. The thymus is included in the excision specimen, if possible. Lateral neck dissection tends to be

more straightforward, unless there is invasion into the carotid sheath. Level IV dissection should be performed with care, as the thoracic duct may be injured, particularly if the nodes are affected by disease, and thus will be adherent. [7]

In some centres, sentinel lymph node biopsy has been performed for some thyroid cancers, but as yet there is no suggestion of enhanced outcome or improved staging information gleaned from this procedure. Indeed, misplacement of blue dye may cause spread of the stain across the whole operating field, making dissection trickier!

POST-OPERATIVE CARE

The post-operative patient should, ideally, be nursed in area of direct observation, such as a high dependency unit at a 45 degree angle. Owing to the anatomical location of the thyroid and the field of dissection, airway compromise is an ever present threat, and should be specifically assessed for periodically.

Once the thyroid goitre is excised, prior to layered closure of the wound, a check and then re-check should be made to ensure haemostasis. A large expanding haematoma collecting in the wound can definitely cause airway compromise and is a surgical emergency. The thyroid is a very vascular organ, and bleeding should be controlled during the operation with precise suture ligation, clips or diathermy. At the end, the entire bed should be thoroughly assessed, using warm saline wash, to review and address any bleeding. Positioning the patient in the head-down position will aid in this. Furthermore, the anaesthetist can be asked to induce several val salva manoeuvres, which may highlight further bleeding. If there is a tear in the thyroid capsule during dissection of the goitre, then this should be repaired with a fine suture, to control bleeding and also to stop the dissemination of thyroid cells. A bloody operative field makes thyroid surgery far more difficult, especially around the nerves and parathyroid glands, in this quintessential plane based operation. Larger vessels, such as the common carotid or internal jugular very rarely are involved with disease. If encountered, dissection must be performed with great care, to avoid a potentially catastrophic haemorrhage, and to avoid post-operative neurological complications. The assistance of a vascular surgeon should be enlisted if there is any concern. Finally, prior to closure, a vacuum based drain (such as a Redivac®) may be left *in situ*, both to stop compression of the airway from a potential haematoma or inflammatory fluid, but also in order to monitor blood output in case of a large bleed. If a haematoma does develop post-operatively, with airway compromise, then the wound and deeper sutures should be immediately removed to allow the haematoma to escape. Re-bleeding should warrant an early re-exploration of the wound, and any bleeding points addressed. Often, there is no active bleeding found, but rather generalised ooze. In this instance, a haemostatic adjunct, such as Surgicel®, may be used. A vacuum based drain should be left in the wound after a re-operation for bleeding.

It is mandatory for the surgeon and his or her equipment to remain sterile until the patient is successfully extubated. This is in case of immediate airway compromise where an emergency tracheostomy may be required. Bilateral injury to the recurrent laryngeal nerve will cause such an airway compromise, but thankfully, this is very rare indeed. More common is a neuropraxia, and this would be diagnosed if the surgeon had clearly delineated and ensured continuity of the nerves at the time of the operation. An elective tracheostomy is

rarely required, unless there is very significant stenosis of the trachea. In the authors' experience, tracheomalacia is very rare, even after surgery for very large and longstanding goitres, and can be treated with a tracheal stent, rather than with a tracheostomy.

Unilateral recurrent laryngeal nerve injury or neuropraxia will cause a change or hoarseness in voice. A naso-endoscope should be performed to assess the vocal cords; neuropraxia will generally settle within a few weeks. If dysfunction persists, then early referral to a speech and language therapist may be of benefit. Of course, the patient should be fully counselled about the likely long-term effects of such an injury.

In the post-operative period, metabolic imbalances should be assessed for regularly, both clinically and by serum biochemical analysis. If a total thyroidectomy has been performed, then oral thyroxine is commenced, and serum concentrations monitored to ascertain the optimal dose. Serum calcium should be monitored regularly in the post-operative setting, as levels can fluctuate. At its worst, an imbalance in calcium homeostasis can cause cardiac dysfunction and arrest. Hypocalcaemia may be due to inadvertent excision of the parathyroid gland(s) or desvalcularisation. For the latter cause, levels may improve over time. There is no set guideline on replacing calcium; rather this is based on local or even surgeon specific practise. Some centres place patients on calcium supplements pre-operatively. Most, however, will discharge patients after the operation on a short course of oral calcium supplements, regardless of the serum calcium or parathyroid hormone concentration. These serum analyses are continued in the outpatient setting until there is a consistent return to normal readings. If this is not achieved, then it may indicate permanent injury (after 6 months from surgery) to the parathyroid glands, and long-term replacement therapy is instituted. Intravenous calcium replacement is rarely required, and should be reserved for patients who either have a drastic drop in serum calcium concentration, or those who are symptomatic of hypocalcaemia.

CONCLUSION

Thyroid surgery for large goitres can be challenging, difficult and fraught with an increased risk of complications. However, it is this group of patients with thyroid disease-benign or malignant – who have large goitres that cause the most symptoms. Thus, they stand to benefit the most from surgical intervention. Detailed anatomical knowledge and adherence to safe dissection principles, along with some specific manoeuvres to improve access and visibility of the operative field, can render such operations a safe undertaking. Indeed, the surgeon, if competent and safe, may begin to enjoy these stimulating operations and the benefit the patient derives from them.

REFERENCES

[1] Bailey B J, Calhoun K H, Friedman N R: *Thyroid and Parathyroid. Atlas of Head and Neck Surgery – Otolaryngology*, Bailey B J, Calhoun K H (Eds) 2nd Edition. Lippincott Williams and Wilkins (2001)

[2] Bliss R D, Gauger P C & Delbridge L W: Surgeon's approach to the Thyroid gland: surgical anatomy and the importance of technique. *World J. Surg.*, 2000; 24(8): 891 – 897.

[3] Randolph G.W.: *Surgical anatomy of the recurrent laryngeal nerve*. *Surgery of the thyroid and parathyroid glands*; Randolph G W (Ed). Saunders, Philadelphia (2003)

[4] Gavilan J, Gavilan C. Recurrent laryngeal Nerve: Identification during thyroid and parathyroid surgery. *Arch Otolaryngol Head Neck Surg*., 1986; 112: 1286 – 1288.

[5] Wheeler MH. Clinical Dilemma: Retrosternal Goitre. *Br. J. Surg.,* 1999; 87(4): 1235-6.

[6] Wheeler MH. The Surgical management of Retrosternal (Intrathorcic) Goiter. *World J. Endooc. Surg.,* 2013; 5(1): 28-30.

[7] Upile T, Jerjes W, Mahil J, *et al*. How to do it: The Difficult Thyroid. *Head Neck Oncol.,* 2011; 3: 54.

In: Encyclopedia of Surgery (22 Volume Set)
Editors: Andreas Lehrer and Kristin Mueller
ISBN: 978-1-53618-329-0
© 2020 Nova Science Publishers, Inc.

Chapter 100

ELECTRICAL STIMULATION FOR IMPROVING PHYSICAL FITNESS PRE- AND POSTOPERATIVELY AFTER ABDOMINAL SURGERY

Artur Marc Hernández*
Laboratory of Training Analysis and Optimization,
Sports Research Center, Miguel Hernández University,
Elche, Alicante, Spain

ABSTRACT

In the last few decades, surgical techniques have been developed in terms of safety and efficacy, however, abdominal surgery continues to present some disadvantages. On one hand, is not unusual that patients develope perioperative complications, wich can lead to longer hospital stay, higher costs to health system or even the death of the patient. On the other hand, it achieves bed rest after surgery, which causes a decrease in muscle mass and muscle strength, and reduces cardiorespiratory fitness. As a consequence, the functional capacity of the patient decreases, so the patient's recovery is delayed.

At present there are numerous studies showing that physical fitness at the time of surgery is a significant factor that relates to postoperative complications, indicating that poor physical fitness is associated with these complications and slower recovery after surgery. Consecuently, in order to prevent these disadvantages, patients need to improve their physical fitness prior to surgery. Although exercise is an effective method for achieving these improvements, in clinical setting, electrical stimulation has several advantages. In sedentary subjects or patients with a poor or impaired physical fitness, it allows strength levels and muscular mass to be increased in a short period of time. In addition, due to its application, d no voluntary physical movement of the patient is required, it can be applied in bed rest conditions. In this case, it has been proven to maintain levels of strength, muscular mass and funtional capacity, resulting in earlier postoperative recovery.

Keywords: NMES, postoperative complications, prehabilitation, muscle strength

* Corresponding Author's Email: arturmarc.hernandez@gmail.com.

INTRODUCTION

Abdominal Surgery

Actually, the number of surgeries is increasing all over the world, especially in developed countries. It has been estimated that between 2004 and 2012, the number of surgeries performed has raised in a 33.6%, and becoming 312.9 million of surgeries performed in 2012 [1]. Among all these surgical procedures, abdominal surgery is one of the most frequently performed surgery, so that it represents 32.5% of the total surgeries [2]. Abdominal surgery refers to any procedure that implies the surgical management of the abdomen or any of the abdominal organs [3]. Abdominal surgery includes colorectal surgery, hepatic and renal transplant, gastrectomy, esophagectomy or bariatric surgery, among other procedures.

Traditionally, this procedure required opening the abdomen through a large incision, however, at present, technological advances have allowed new techniques to emerge, such as laparoscopy, which are less invasive. Compared to open surgery, the use of this approach has shown, among other benefits, a lower mortality rate [4–6], a decreasing number of perioperative complications [5, 7, 8] and an earlier postoperative recovery [9].

Despite the benefits obtained by laparoscopy, abdominal surgery might still present complications. It has been reported that nearly 35.6% of patients suffer from any type of complication after major abdominal surgery, with 20.8% of major complications, which require invasive treatment or admission to intensive care [10]. Another study that was conducted with approximately 466,000 patients, strengthen the latter percentage, concluding that the risk of suffering from one major postoperative complication after intra-abdominal surgery was 18.6% [11]. These complications may provoke great disadvantages. On one hand, it may raise the mortality rate after surgery [12], which in abdominal surgery ranges between 2.73 and 3.5% [2, 10]. For instance, Sabaté et al. established in their study that, among patients who presented postoperative pulmonary complications, mortality rate was around 24.4%, while patients who did not present this type of complication, mortality rate was only 1.2% [13]. On the other hand, these complications may lead to a higher hospital stay [12, 14–16] and the admission to intensive care [12]. Altogether, this lead to an increase in healthcare costs. Some studies have reported that, after major abdominal surgery, myocardial infarction increases the costs in approximately $20,000 per patient [14], while pulmonary complications raise it in around $28,000 [17].

Due to these reasons, it is necessary to detect, determine and understand factors that influence the perioperative complications, in order to decrease the risks of suffering them.

Abdominal Surgery Complications

As previously mentioned, it is not unusual that certain complications may occur after abdominal surgery. Among all of them, the most frequent are infections with 13.3% of cases [18], pulmonary complications with 5.8% of the total patients [19] and cardiac complications, which cause 1.4% of the mortality after major abdominal surgery [14].

There are certain factors that are going to influence on the possibility of developing postoperative complications. Some of them can not be modified, such as age [4, 16, 20], male

gender [4, 21] or history of cancer [20]. Nevertheless, there are some other factors, such as the presence of different comorbidities (hypertension, cardio-pathology or diabetes mellitus) [16, 22, 23], smoking [16, 20, 24], body mass index [20, 25], sarcopenia [26–28] and poor physical fitness [21, 22, 24, 29], which are modifiable factors.

Currently, factors related to physical fitness are becoming important on surgery, since they are highly associated with postoperative complications. In fact, some studies determine that these factors are the most strongly related to postoperative complications [21]. Therefore, the improvement of physical fitness may lead to a reduction of these complications and an earlier recovery after surgery.

PHYSICAL FITNESS

Physical fitness has been defined as "a state characterized by (a) an ability to perform daily activities with vigor, and (b) demonstration of traits and capacities that are associated with low risk of premature development of the hypokinetic diseases (i.e., those associated with physical inactivity)" [30]. In general, physical fitness is defined by different components. On one hand, the skill-related components refer to athletic capacities, as agility, power or coordination [31]. On the other hand, the health-related components, are integrated by cardiorespiratory and muscular endurance, muscle strength, body composition and flexibility [31]. Health-related components have a greater incidence on public health, since they are related to the health of individuals. For instance, cardiorespiratory fitness is inversely proportional to mortality [32], while a low muscular strength is directly proportional to premature death [33].

At this point, it is necessary to define several concepts referred to health-related components which are proved to influence on the results of abdominal surgery. In respect of body composition, it is highly remarkable its significant impact on health, since a high weight, especially a high body mass index, is related to different cardio metabolic pathologies [34], and the reduction of life expectancy. In fact, body mass index is associated with mortality risk [35]. Nonetheless, apart from the total weight, it is also important the body composition. Our organism is composed of different tissues (Figure 1), which have an influence on individuals' health status, emphasizing two of them: fat mass and skeletal muscle. The former affects to health status, because an excess of it is related to health risks [36]. The latter, skeletal muscle, presents great benefits for health, since it is associated to an optimal functional capacity and is considered as a secretory organ. In this sense, skeletal muscle has different functions, such as absorbing 75% of the postprandial glucose [37] or releasing of myokines [38].

Here sarcopenia becomes particularly important. Sarcopenia is a syndrome that is characterized by a loss of skeletal muscle in addition to a decrease of muscle strength or performance, that developes into adverse results as poor quality of life or physical disability [40]. Although, both low muscle mass and low strength levels are independently associated with postoperative complications, when both conditions appear together, as sarcopenia's case, the risk of suffering from any complication increases [26].

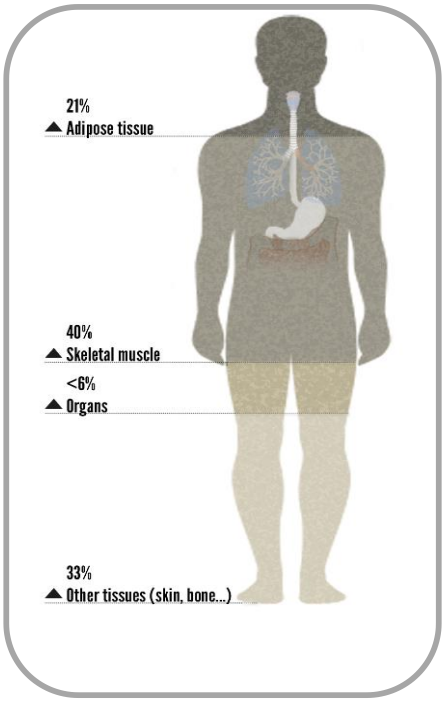

Data obtained from Dullo et al. [39].

Figure 1. Distribution of body tissues.

On the other hand, cardiorespiratory fitness makes reference to the capacity of circulatory and respiratory systems in order to provide fuel during physical activity [31]. Determining the cardiorespiratory fitness in patients undergoing abdominal surgery is really important, since it indicates the cardiorespiratory reserve that every patients disposes, and thus, it can be recognized the risk of suffering from any complication [41]. Cardiopulmonary exercise testing is a suitable method for determining this capacity [42]. This test allows numerous variables to be obtained, however, maximum oxygen uptake (VO_{2max}), peak oxygen uptake (VO_{2peak}) and anaerobic threshold are the most frequent variables for establishing relationships between cardiorespiratory fitness and postoperative complications. The VO_{2max} and VO_{2peak} define the maximum amount of oxygen that the patient is able to use, however it must be noticed that for being considered as VO_{2max}, it must have been produced a plateau in oxygen uptake [43]. In turn, when the oxygen provided to the muscles is not enough to cover the energy demands, anaerobic glycolysis intervenes transcendentally to provide ATP, accumulating lactate exponentially, process known as anaerobic threshold [44].

Although cardiopulmonary exercise testing is the "gold standard" to determine cardiorespiratory fitness, sometimes, the necessary tools to perform this test are not available. Nevertheless, there are other type of measurements, as six-minute walk test, that can be used, since they establish functional capacity of the patients [43] and are also related to postoperative complications [45].

Role of Physical Fitness in Abdominal Surgery Complications

At present, physical fitness is considered itself as a factor of great importance in patients awaiting for abdominal surgery, since it may contribute to reduce perioperative complications.

First of all, there are factors related to muscular function. Sarcopenia has been proved to be really relevant, since it increases between 3.12 and 4.5 times the risk of suffering from postoperative complication [26, 27], so it is shown as an independent predictor of infection (odds ratio: 4.6) [46]. In fact, it has been reported that after colorectal cancer surgery, 23.1% of the patients with sarcopenia suffered from infections, while this data was reduced to 12.6% in patients without sarcopenia [46]. Furthermore, both the incidence of medical and total complications increase according to the level of sarcopenia (Figure 2) [47]. Nevertheless, components, that define sarcopenia (muscle mass and strength), are also related to postoperative complications. Patients with low muscle mass have 3.8 times more chances of suffering from postoperative complications, while patients with low strength levels have proved to have 2.1-2.5 more times of suffering from complications [21, 47].

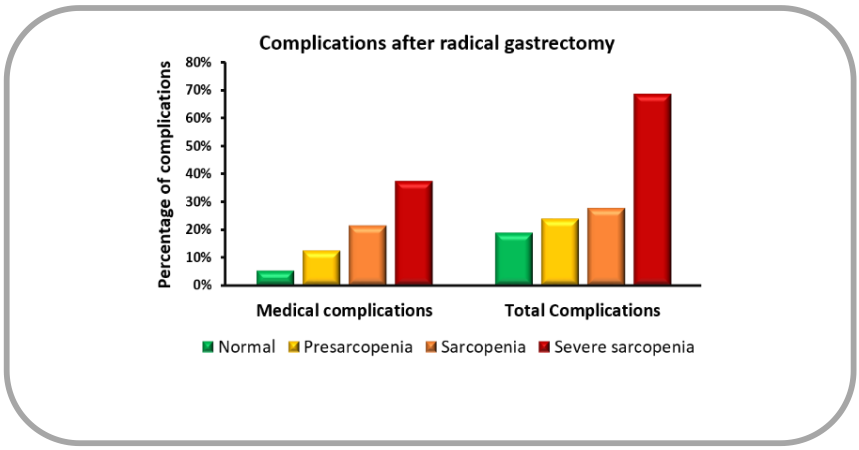

Data obtained from Huang et al. [47].

Figure 2. Percentage of medical and total complications according to sarcopenia level.

On the other hand, cardiorespiratory fitness has proved to be especially significant in postoperative complications. Recent systematic reviews have shown that cardiorespiratory fitness predicts postoperative complications after different major abdominal surgeries, like hepatic transplant, abdominal aortic aneurysm repair, bariatric, upper gastrointestinal and colorectal surgery [12, 48, 49]. Furthermore studies have showed how anaerobic threshold and VO_{2peak} are powerful predictors for different disadvantages, as infections and pulmonary and cardiovascular complications [50]. For example, a VO_{2peak} lower than 15.8 for bariatric surgery and 16,7 $ml \cdot kg^{-1} \cdot min^{-1}$ for major colonic surgery [51, 52] is related to a higher number of complications and a longer hospital stay after bariatric surgery and major colonic surgery [51, 52]. Likewise, a $VO_{2peak} < 15$ $ml \cdot kg^{-1} \cdot min^{-1}$ predicts mortality after abdominal aortic aneurysm repair [53]. Equally, anaerobic threshold range lower than 9,2-11,4 $ml \cdot kg^{-1} \cdot min^{-1}$ predicts postoperative mortality and morbidity , as well as hospital stay and admission

to intensive care unit [54–57]. In addition, poor cardiorespiratory fitness affects to different complications. West et al. showed in their study that 16% and 23% of patients with an anaerobic threshold < 10.1 $ml \cdot kg^{-1} \cdot min^{-1}$ presented pneumonia and infections after surgery, while in patients with a higher anaerobic threshold, these percentages decreased to 3% and 8%, respectively [52].

Besides, the risk of suffering from complications varies depending on different aspects. On one hand, a lower of cardiorespiratory fitness is associated with postoperative complications. It has been found that after major surgery, patients with a VO_{2peak} > 20 $ml \cdot kg^{-1} \cdot min^{-1}$ have a low risk of suffering from complications, while patients with a VO_{2peak} < 15 $ml \cdot kg^{-1} \cdot min^{-1}$ and VO_{2peak} < 10 $ml \cdot kg^{-1} \cdot min^{-1}$ have a moderate and high risk, respectively [58]. On the other hand, these postoperative complications can aggravate if they are accompanied by comorbidities. A study conducted in "elderly patients" shows that, after major abdominal surgery, patients who presented an anaerobic threshold < 11 $ml \cdot kg^{-1} \cdot min^{-1}$ showed a mortality of 18%, but patients who also presented preoperative ischemia, the mortality increased to 42%. In contrast, patients who presented the same morbidity, but with an anaerobic threshold > 11 $ml \cdot kg^{-1} \cdot min^{-1}$, the mortality rate was 0.8% and 4%, respectively [59].

After the data provided, it can be concluded that a poor physical fitness has a close relationship with postoperative complications. Both body composition and muscular and cardiorespiratory fitness are associated with postoperative complications, finding fewer complications in patients with greater fitness.

SURGICAL STRESS

In order to understand these associations between physical fitness and postoperative complications, it is necessary to know that surgery leads the human body to a state of stress that compromises the organism (surgical stress) [60].

The human body responds to the surgical process through different physiological pathways to maintain homeostasis,, allowing cardiovascular, respiratory and metabolic changes. These changes are, among others, increases in cardiac output, heart rate, blood pressure, oxygen demand, and respiratory rate, as well as a mobilization of energy reserves to provide substrates as fuel to the repair processes of tissue and protein synthesis for the immune response [61, 62]. This will increase the risk of complications [61], therefore, it is necessary that the organism is prepared to deal with these physiological variations.

Surgical Stress and Physical Fitness

Physical fitness will determine the impact of surgical stress on the patient in different ways. After major surgery, there is an increase of 50% in oxygen consumption at rest, (from 110 $ml \cdot min^{-1} \cdot m^{-2}$ to 170 $ml \cdot min^{-1} \cdot m^{-2}$), which can be maintained for several days [63], and it is not strange that some patients reach an oxygen consumption of 240 $ml \cdot min^{-1} \cdot m^{-2}$ [59]. Consequently, these increases in oxygen demand will generate a deficit of it [45]. If the human body is not able to provide the oxygen necessary to respond to this O_2 deficit, different postoperative complications can be developed [45]. For example, one study showed that

patients who died after surgery had an oxygen deficit averaged at its maximum of 33.2_$L \cdot m^{-2}$, while this deficit was 21.6 $L \cdot m^{-2}$ in those who only had complications (without mortality) and 9.2 $L \cdot m^{-2}$ in patients who did not suffer any complications [64].

Therefore, it is likely that patients with an adequate cardiorespiratory reserve are able to resist this additional oxygen demand without exceeding their physiological parameters [49], thus reducing the probabilities of suffering from complications. This can be of great importance, especially in surgeries, such as liver transplants, in which there is a high mortality rate, around 10% [2]. In this regard, the cardiorespiratory capacity is so important, that only the increase in 1_$ml \cdot kg^{-1} \cdot min^{-1}$ of oxygen consumption at anaerobic threshold decreases the odds ratio of postoperative complications by 20%, while the increase of 2_$ml \cdot kg^{-1} \cdot min^{-1}$ decreases it by 40% [52].

Likewise, skeletal muscle and muscle strength also seem to be important factors to resist successfully surgical stress. In patients with sarcopenia, a reduction in the expression of myocins is observed, which may decrease the activity of NK cells [65], increasing the risk of infection [21]. In fact, both sarcopenia and low levels of fat free mass are associated with the risk of infection after major surgery [46, 66]. For instance, after cardiac surgery, 18.5% of subjects with a low fat free mass index suffer from infectious complications, compared to 4.7% of subjects with a normal fat free mass index [66]. A reason could be that the amount of muscle mass is associated with the reserves of proteins available to the human body. Patients with low protein reserves have been associated with an increased risk of complications (especially pneumonia) and mortality after major abdominal surgery [67]. Thus, a larger amount of skeletal muscle indicates a greater reserve of muscle proteins, which are necessary to respond appropriately to surgical stress [68].

In addition, skeletal muscle could also play a relevant role in different metabolic aspects. Due to surgical stress, after surgery there is a large increase in blood glucose levels [69], which can be maintained for a few days. This can represent a drawback, since impaired fasting glucose is associated with perioperative cardiovascular events in patients undergoing major surgery [70]. Skeletal muscle is considered the largest store of glucose in the body, storing approximately 80% of glucose (around 500 grams) [71]. Therefore, it can be hypothesized that increasing muscle mass before surgery may provide a larger body's ability to store glycogen. This could prevent or reduce postoperative hyperglycemia, thus decreasing the problems associated with it.

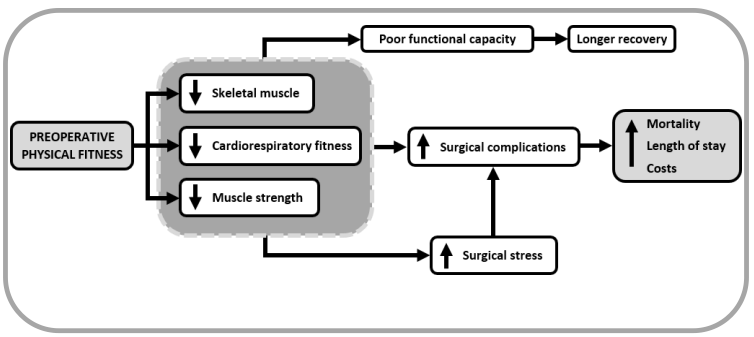

Figure 3. Effects of preoperative fitness on surgical complications.

Relationship between Surgical Stress, Fitness and Recovery

Physical fitness plays a fundamental role in patient's recovery. After a major surgery, human body takes some time to recover functional capacity prior to surgery. After 3 weeks of colon resection surgery, only 41% of the patients showed equal or higher values of functional capacity compared to the preoperative levels [72]. However, patients who increase their functional capacity prior to surgery show an earlier recovery of walking capacity (Figure 4) [72]. For example, at two months of colorectal surgery, 81% of the patients who performed a prehabilitation program that included a part of exercise, recovered their functional capacity levels prior to surgery, compared to 40% of patients who did not perform this program [73].

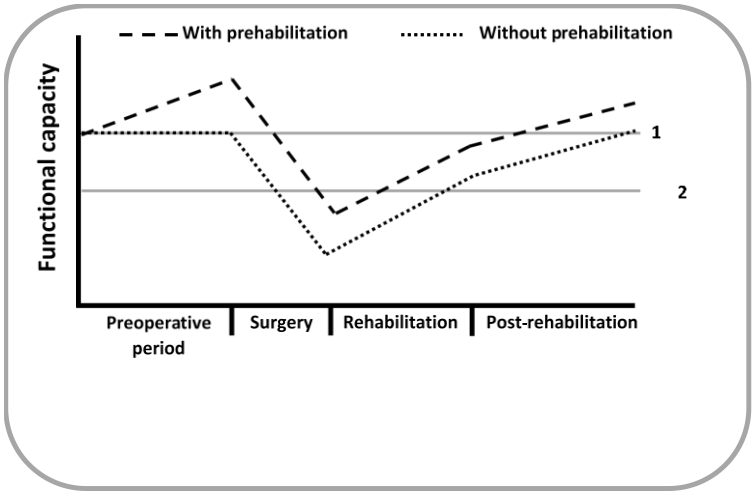

Adapted from Santa Mina et al. [77]. 1, initial functional capacity; 2, functional threshold.

Figure 4. Effects of increase functional capacity prior to surgery on the functional recovery after surgery, theoretical model.

Both low levels of strength and muscle mass have been associated with a longer hospital stay after major surgery [66], therefore, it is necessary to reach surgery with these variables in an optimal state. Due to surgical stress, protein degradation is accelerated, in turn protein synthesis is low, which leads to a negative protein balance, causing the degradation of muscle tissue [62]. Moreover, abdominal surgery is followed by a period of inactivity, which causes losses of muscle mass and muscle function, and as a consequence, recovery after surgery would be delayed.

A study showed how, after only 10 days of bed rest, there was a reduction of 1.5 kg of lean mass, reducing by 6.3% lean body mass and by 15.6% muscle strength of lower extremity [74]. These values can be aggravated with admission to intensive care, since it has been reported that after 10 days, there have been reductions in rectus femoris cross-sectional area of 17.7%, observing that this loss increases proportionally with days of admission in intensive care [75]. Unfortunately, bed rest also causes decreases in cardiorespiratory fitness. In fact, it has been reported decreases of 7.6% and 15.3% of VO_{2peak} in young and older people, in just 2 weeks of bed rest [76].[

ELECTRICAL STIMULATION AND PHYSICAL FITNESS

As has been observed, physical fitness is of great importance in abdominal surgeries. Improving physical fitness prior to surgery has two well-defined objectives. On one hand, to provide the organism with an adequate physiological reserve so it is able to cope with the stress induced by surgery. On the other hand, the improvement of physical fitness favors an earlier recovery. In turn, after surgery, a period of bed rest will occur, which will lead to muscle wasting and decrease the functional capacity of the patients.

Electrical stimulation has been shown as an optimal method to achieve improvements in physical fitness, especially in the clinical setting, where it is common to find sedentary or with a poor or impaired physical fitness patients. In addition, it is an effective treatment in bed rest conditions and in intensive care admissions, when voluntary exercise is not able to be applied.

Electrical stimulation is a non-invasive treatment that consists on the delivery of stimuli using electrodes that are placed on the skin [78]. There are different types of electrical stimulation, which vary according to their objectives: a) transcutaneous electrical nerve stimulation, which is used for treating acute and chronic pain conditions [79]; b) functional electrical stimulation, which aim is to help patients to perform a certain function, such as getting out of a chair [80]; c) neuromuscular electrical stimulation (NMES), which is used mainly during rehabilitation periods [81], being a useful tool to improve and maintain physical condition. Therefore, this chapter will focus on this last modality of electrical stimulation, due to the benefits that presents on physical fitness.

Effects of Neuromuscular Electrical Stimulation on Physical Fitness

Body Composition

The main advantage of NMES over body composition lies in its effects on skeletal muscle. To achieve increases in muscle mass by means of conventional resistance training, it is necessary to train with high loads around 60 - 80% of the maximum repetition [82]. However, many of the patients who are undergoing major surgery are sedentary subjects, which means that their body is not prepared to train at high intensities. To reduce the risk of injury, a period of anatomical adaptation before hypertrophy training should be carried out. However, NMES generates increases in muscle mass, especially in sedentary individuals [83], with the advantages that brings as a safe treatment, and therefore does not require such a long adaptation period. These characteristics make this method an effective alternative to use prior to surgery.

Regarding the intervention time that is necessary to achieve hypertrophy by NMES, although some studies have reported that it is possible to obtain hypertrophy in 4 weeks [84], most show that it takes around 8 weeks. Gondin et al. reported that after 4 weeks of NMES there were no significant increases in quadriceps cross-sectional area, finding significant gains after 8 weeks of training [85]. Likewise, other studies have shown increases of approximately 10% cross-sectional areal of the quadriceps femoris after 9 weeks of electrical stimulation in sedentary subjects [83].

One of the most remarkable advantages of NMES are its safety and effectiveness in patients with weakened muscles or under special situations, such as bed rest after surgery or admission in intensive care, where patients' physical fitness is reduced. At this point, NMES assumes particular relevance, since it avoids reductions in muscle mass [86]. For instance, it has been reported that after a period of 6-7 weeks of immobilization of the leg, the group that received treatment with NMES had a reduction of only 4.5% of quardriceps cross-sectional area, compared to a reduction of 17% of the group without treatment [87].

Unfortunately, some surgical complications result in a patient's admission to intensive care. In this situation, patients may have a reduction of up to 21.5% of sectional diameter of the vastus intermedius, however, in those who receive treatment through NMES, this loss is reduced by almost half, being 12.5% [88]. In addition, this is achieved safely, since the intervention by NMES in patients in intensive care does not cause increases in heart rate, blood pressure or O_2 saturation [89], indicating that it does not suppose a stressful treatment for the organism. Apart from that, NMES is considered a useful method to recover muscle mass during rehabilitation periods. In patients who have decreased their muscle mass, NMES has generated raises in the total area of the quadriceps (from 129.2 cm^2 to 142.2 cm^2) after 12 weeks of intervention [90].

Although treating aspects focused on nutrition is not the objective of this chapter, it must be emphasized that in order to achieve the desired effects on muscle architecture (gain and maintenance of muscle mass), it is essential to have an adequate protein intake. To achieve increases in muscle mass it will be necessary to intake about 1.8 grams of protein per kilogram of weight, while the intake of 1.4 and 1.8 grams per kilograms of weight can prevent muscle protein catabolism, and therefore avoid the loss of muscle mass [91]. In fact, some studies recommend to take 25-30 grams of high-quality protein at each meal in order to minimize the loss of muscle mass during bed rest [92].

Muscle Strength and Functional Capacity

At present, it is widely accepted that NMES improves strength levels. The studies show increases of between 7.7% and 60% of the maximum dynamic force [83, 93], although it should be noted that the treatment must be carried out dynamically. Regarding isometric strength, these increases can reach up to 47.5% for the brachial biceps [94], 44% for the quadriceps [95], or 58% in abdominal strength [96]. Equally, NMES is effective for improving muscular endurance, showing increases of up to 243% after treatment [97]. Furthermore, these increases can be obtained in a short period of time. Although most studies last for 8 weeks or longer, shorter studies or intermediate evaluations also show positive effects on strength levels. For example, in only 2 weeks of treatment with NMES, there is 64% increase in muscular endurance [97], while after 5 weeks of treatment 33% increase in maximal isometric strength is achieved [93].

These benefits can be transferred to the clinical setting. Patients who are in a period of immobilization show a muscle strength loss of approximately 1.8% per day [86]. However, it has been widely accepted that NMES avoids or reduces the loss of strength in these situations, and also contributes to the recovery of strength levels during the rehabilitation period [98, 99]. Similarly, treatment with NMES avoids strength reductions in patients in intensive care [100], enabling a recovery of force 4.5 times faster compared to subjects who are not on treatment [101].

The loss of strength that will be generated after surgery will cause reductions in functional capacity [86], which is of vital importance to perform day-to-day activities. But NMES has also proved to be an adequate method to prevent these reductions. In adults with advanced disease, through 6 weeks of NMES the results in the six-minute walk test (+ 35 m), incremental shuttle walk test (+ 9 m) and endurance shuttle walk test (+ 64 m) are improved [102]. Likewise, patients in the rehabilitation period, where NMES was applied for 12 weeks, achieved a reduction in the time to perform the "sit to stand to sit" test and an improvement of approximately 10% of the six-minute walk test [103].

Cardiorespiratory Fitness

Many of the studies in which electrical stimulation is used for improving cardiorespiratory fitness are performed in combination with exercise, obtaining enhancements in VO_{2peak} [104, 105]. However, when electrical stimulation is applied in isolation, this technique does not seem to be so effective. Currently, this topic has been addressed by several meta-analyses. In one of them, it was determined that subjects who received NMES, achieved improvements in VO_{2peak}, but these were trivial (+ 0.10 $L \cdot min^{-1}$) [106], while another meta-analysis showed that NMES did not produce increases in VO_{2peak} [102]. However, two important factors must be considered On one hand, it is possible that parameters of NMES have not been correctly handled, and because of it, improvements have not been achieved. On the other hand, it should be noted that these analyzes were performed in patients who were clinically stable [106]. Possibly, NMES is effective in patients with poor or impaired cardiorespiratory fitness. As has been reported, after the application of NMES, healthy subjects only improved their functional endurance by 4%, however, clinical populations had improvements of 35% [107].

NMES presents different advantages in the clinical setting. First, it can be used for patients who are unable to exercise voluntarily. Apart from that, the movement caused by NMES is minimal, [108], in that way, it is unlikely to affect tissues that have been damaged during surgical intervention. Therefore, the use of NMES may be relevant to maintaining or increasing VO_{2peak} under clinical conditions, like bed rest or rehabilitation phase. For example, after cardiac transplant, through 8 weeks of NMES, VO_{2peak} was increased from 17.1 to 18.7_$ml \cdot kg^{-1} \cdot min^{-1}$ [109].

Limitations of Neuromuscular Electrical Stimulation

Nevertheless, treatment with NMES to improve physical fitness has some limitations, especially when compared to conventional exercise. First, the order of fiber recruitment. When a voluntary contraction occurs, small motor units (composed of slow fibers) are recruited in first place, and progressively larger motor units (composed of fast fibers) are recruited too [110]. This theory is known as "size principle" [110]. This order differs when electrical stimulation is used [98], presenting a disordered recruitment, stimulating both large and small motor units from the beginning [111]. This behaviour presents a great disadvantage. As large motor units are composed of fast fibers, that are more fatigable [112], NMES presents an earliest emergence of the fatigue compared to voluntary contraction [111].

Unfortunately, NMES has more drawbacks. This method is not able to activate all muscle fibers, activating those that are closest to the electrodes, that is to say, the superficial fibers, and not reaching the deepest ones [113]. In addition, by NMES, the same motor units are

always recruited, which will contribute to the emergence of early fatigue and therefore a decrease in torque [114]. Finally, when a voluntary contraction of a certain duration occurs, other muscle fibers are activated to replace those which are fatigued. This effect does not occur in NMES, in which the same muscle fibers are activated throughout the contraction (simultaneous recruitment), causing a greater fatigue [115].

All these factors will provoke that NMES causes great fatigue. On the other hand, for NMES to be effective, it is necessary to work at high intensities, reaching the threshold of pain, which will generate discomfort, reducing tolerance and adherence to treatment [116].

Maximal Voluntary Contraction

A fundamental concept in the NMES treatment is the maximal voluntary contraction (*MVC*), which is the maximum force that an individual is able to perform in a specific isometric exercise [117]. MVC is useful both to evaluate strength improvements after treatment with NMES and determine the intensity training. Therefore, NMES intensity training is the ratio between MVC force and NMES evoked force, expressed in percentage [118]. For example, if a subject has a maximum force of 200 Newton, and the treatment with NMES reaches 100 Newton, this means that subject is training at 50% of the MVC. An important aspect is that muscle activation increases linearly to the MVC percentage. In fact, even a formula has been proposed to determine quadriceps muscle cross-sectional area activated by NMES:

$$\text{Activated area (\%)} = 0.70 \cdot \text{\% MVC} + 0.77 \text{ [119].}$$

The effectiveness of the NMES treatment depends on the MVC percentage at which training is carried out. It has been observed that if high muscle tension is achieved [120], the effects on hypertrophy improve. Equally, strength gains are associated with the intensity of treatment [121]. For instance, in one study it was reported that subjects who performed the treatment of NMES at 25% of the MVC, increased their strength levels by 24%, while subjects who reached 50% in the treatment had gains of 48% [122].

Parameters of Neuromuscular Electrical Stimulation

To optimize the treatment through NMES, several aspects must be considered. On one hand, high percentages of the MVC must be reached, trying to stimulate as many muscle fibers as possible. On the other hand, the appearance of fatigue must be minimized and the sensation of discomfort must be reduced. This will increase the torque during the sessions and let a greater tolerance and adherence to the treatment. In order to maximize the benefits of NMES, the different parameters that constitute this method must be manipulated correctly. In the following paragraphs, the most important parameters will be described (Figure 5).

Frequency

The frequency is expressed in Hertz (Hz), and refers to the “pulses” that are repeated in a second. As previously seen, to be effective, the treatment with NMES must cause a high percentage of the MVC, and this will increase with the frequency used. Unfortunately, the frequency is directly associated with the fatigue caused, observing that the higher the frequency used, the greater the fatigue obtained [123]. In fact, the frequency has been more

decisive in the appearance of fatigue compared to other parameters, such as current amplitude or pulse duration [124]. This will decrease the torque that is reached during the session, and therefore, the effectiveness of the treatment. It was observed that by applying a frequency of 100 Hz, the maximum torque was reduced by 76% at the end of the session, while by using a frequency of 25 Hz, the reduction was by 39% [124]. However, some authors have reported that working with frequencies lower than 50 Hz, tetanic contractions are not achieved, which is essential to generate benefits in muscle strength and muscle architecture [125]. In turn, too high frequencies will generate great fatigue, reducing the effectiveness of the treatment.

Nevertheless, when using high frequencies and occurring tetanic contractions, cardiovascular response is minimal, according to some authors, is approximately of 2 metabolic equivalents [126]. However, low frequencies produce sub-tetanic isometric muscle contractions, which generate a greater oxygen demand in the tissues [127]. Thereby, oxygen consumption raises and is able to reach into 53% of the VO_{2max} [128] or requires a cardiovascular response between 4 - 7 metabolic equivalents [127].

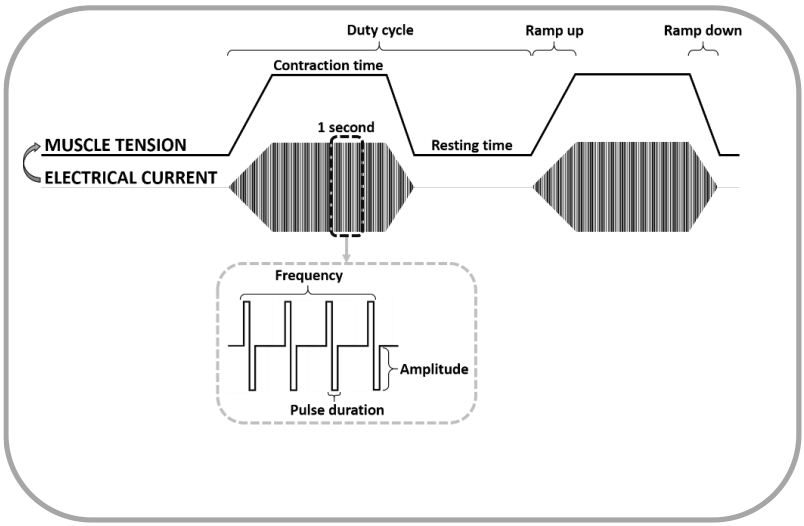

Adapted from Vivodtzev et al. [125].

Figure 5. Electrical current parameters and theoretical model of muscle tension evoked by electrical current.

Therefore, the frequency used will depend on the objective of the intervention. In order to maintain or recover skeletal muscle mass and muscle strength, it is recommended to apply frequencies between 50-120 Hz [98, 125, 129, 130]. On the contrary, to improve cardiorespiratory fitness, it is recommended to use low frequencies, between 4-10 Hz [108, 127, 128, 131], where 4 Hz frequencies has been proved to be especially effective [126].

Pulse Duration

Pulse duration, also known as pulse width is the duration of each current pulse, which is usually expressed in microseconds (μs). This parameter will influence directly the results of the treatment by electrical stimulation, since the higher the pulse duration applied, the greater the torque obtained [1]. For example, increasing the pulse duration from 150 to 450 μs

generates an increase of 40% of the muscle activation and enlarges torque by 55% [2]. In addition, a longer pulse duration will allow to recruit more fibers and reach deeper tissues, and it will be also useful when it is pursued to treat layers of secondary tissue [3]. However, too high pulse duration (> 500 μs) should not be used, since sensory nerve fibers will be recruited, which causes a large discomfort. On the contrary, too short pulse duration (< 100 μs) will not generate benefits [4]. This parameter manifests a great advantage. As long as it is within the appropriate ranges (between 150 - 500 μs), the increases in pulse duration do not increase fatigue [5] and are well tolerated by subjects [6]. Thus, it allows more efficient interventions.

Lastly, some authors have reported that pulse duration will depend on the size of the muscles to be treated. For larger muscle groups, greater pulse duration (> 300 μs) should be used, whereas lower pulse duration (100 - 300 μs) are recommended for smaller muscle groups [7]. In summary, with the aim of achieving high muscular tension, with a low fatigue index, it has been recommended to use pulse duration between 100 and 500 μs [8, 9].

Duty Cycle

Duty cycle is the relation that exists between the time in which the stimulation is activated, that is, when muscle contraction is provoked, and the period in which it is deactivated. In the literature it is usually expressed in two different ways: a) as a ratio, for example 1:5, which means that muscle contraction is 1 second-long and resting time is 5 second-long; b) in percentage, for example 20% indicates that the stimulation is activated for 20% of a complete cycle. This parameter affects directly fatigue, and therefore, could reduce the effectiveness of the treatment. As the study by McLoda et al. showed, when using a duty cycle of 10%, the average of forced evoked was 132.9 Newton, while using a duty cycle of 90%, this average decreased to 41.3 Newton [132]. Equally, it can be observed how 72% of the subjects who used a duty cycle with a ratio of 1:1, decreased their initial force output by 50% in the first 10 minutes of electrical stimulation, while using a ratio of 1:5, only 6% of sample showed this fatigue [133]. Therefore, to reduce the fatigue caused by NMES within the same session, an effective strategy would be to extend the resting time in the duty cycle [134].

Nevertheless, duty cycle will be different depending on the desired objectives: a) to achieve increases in muscle mass, some authors recommend to use high duty cycles (1:1 or 1:2), with contractions of at least 2 seconds [120]; b) to obtain an increase in force, it must be used lower duty cycles, such as 1:5 [135]; c) concerning cardiorespiratory fitness, it is required high duty cycles, with ratios between 1:1 and 9:2 in order to obtain improvements [131, 136].

Amplitude

The amplitude is the intensity with which current is applied. It is usually expressed in milliamperes (mA), although sometimes it also appears in millivolts (mV). It is one of the most important parameters of electrical stimulation, since the torque produced increases linearly with amplitude [137]. In fact, according to some authors, muscle tension generated by amplitude is the greatest determinant of the effectiveness of NMES [138].

Treatment with high amplitudes has concrete advantages. NMES treatment stimulates the superficial muscle fibers, which are closer to the electrodes, observing how the recruitment of

fibers decreases when distanced from the electrodes [113]. However, when using higher amplitudes, apart from superficial fibers, deeper muscle fibers are depolarized, which are further from the electrodes [139]. As a result, a greater amplitude provokes a greater activation of the muscle and, therefore, a greater resulting torque [140], reaching higher percentages of the MVC [141]. In addition to obtaining a greater torque, the application of a higher amplitude will let the organism to enlarge the VO_{2max}. For instance, using an ~86 mA amplitude allows to reach 40% of the VO_{2max}, however, when rising amplitude to ~ 104 mA, it is achieved 53% of the VO_{2max} [108]. This intensity training has proved to be effective in improving cardiorespiratory fitness [128].

Furthermore, the amplitude has not been proved as a decisive parameter in the development of fatigue. For example, one study showed that frequency influences more than amplitude in fatigue [142], while it has been reported that increasing the amplitude enlarges the torque produced without increasing fatigue during NMES [124]. The major drawback of using high amplitudes resides in patient tolerance, since high amplitudes generate discomfort [143]. Therefore, the amplitude used depends on the tolerance of the patient [144], where it is recommended to apply the maximum amplitude that is tolerated in order to optimize the treatment [116].

There are different strategies that will help to increase tolerance and allow to train at higher amplitudes. In first place, training should not start using the highest amplitudes that the patient is able to bear, since this produces a certain degree of pain and discomfort, generating reticence of the patient to use electrical stimulation and, therefore, a low adherence [95]. Secondly, it must be considered that, at the beginning of NMES, the maximum amplitude that is tolerated increases rapidly during the first 10 days of treatment, after which a plateau occurs [145]. Therefore, before beginning a treatment with NMES, a period of 8-10 days of familiarization should be carried out. Thirdly, in order to maximize the effects of NMES, it is advisable to increase the intensity within the same session, since superficial muscle fibers (closer to the electrodes) can be fatigued [119]. As shown, increasing the amplitude allows stimulate deeper fibers, thus maintaining MCV levels [119].

Electrodes: Size and Location

Both size and location of the electrodes will determine the effectiveness of an NMES treatment. Firstly, the size of the electrodes is relevant in different aspects. Very small-sized electrodes will have a higher current density, which will increase the sensation of pain, generating discomfort [146]. On the contrary, large-sized electrodes are more comfortable, at the same time produce a greater torque [146]. However, the use of electrodes with an excessively large size should be avoided, since they could stimulate other muscles, which would lead to a loss of efficacy of the treatment [145].

Although there has been some debate about the location of the electrodes, it has already been reported that placing the electrodes on the motor point generates a greater torque, in addition to decreasing discomfort sensation [147]. The motor point is the region that covers the peripheral neuromuscular junctions, so it represents the closest area of the skin to the motor end-plates of the cross-sectional area of the muscle, which are highly excitable [98]. When placing the electrode on motor point, a less intense current is required in order to excite the motor axons and generate muscular contraction [148]. On the contrary, when placing the electrode in a point different from motor point, the intensity to reach the motor branch must

be greater, increasing the possibility of exciting sensory fibers, which transmit the pain (Figure 6) [148].

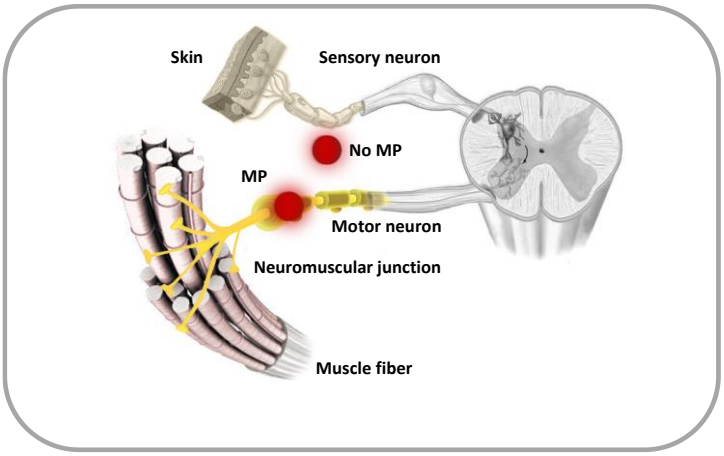

Adapted from Gobbo et al. [148]. MP, motor point.

Figure 6. Location of motor point.

Although currently there are atlas that indicate where the motor points of each muscle are located, the situation of these points is different for each subject [149], so it is necessary to locate them individually, which is quite simple. Only one pen-electrode is needed, with which the surface of the muscle is mapped until one concrete point is found. This point is the one that generates a contraction with the minimum possible current intensity [149]. In turn, the electrodes should be placed longitudinally with respect to the muscle fibers, because this position will generate a greater torque compared to transverse position [150].

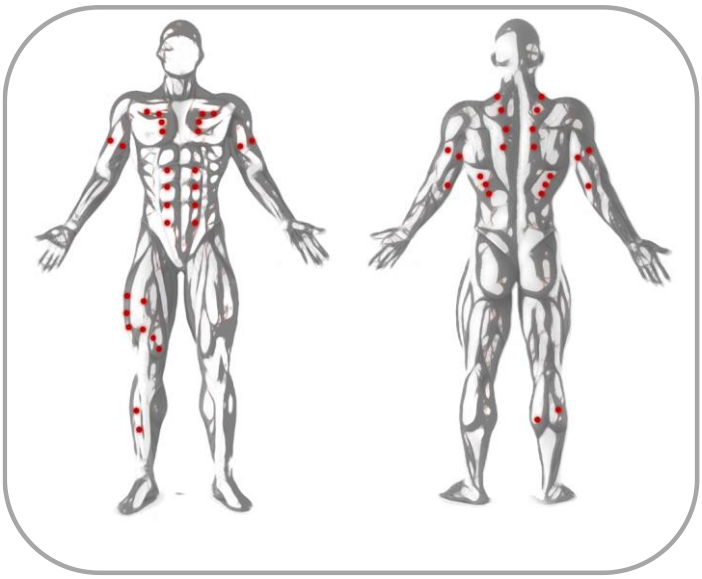

Data obtained from Franz et al. [151] and Botter et al. [149].

Figure 7. Motor points for the upper and lower body.

Finally, some authors recommend, with the aim of activating other muscle fibers and minimizing fatigue, to change the electrodes of position, both in the same session and between different sessions [118]. Furthermore, as can be seen in Figure 7, a muscle may have several motor points that are going to activate different muscle portions [152]. This fact strengthens the usefulness of changing the position of the electrodes. While other authors have determined that using a greater number of electrodes will allow more motor fibers to be recruited, reducing fatigue [134].

Treatment Frequency

The frequency of the treatment trough NMES also has an influence on the results. Although it seems that, 2-3 sessions per week are effective in order to achieve strength improvements, several studies have proved how gains increase with volume of treatment. For instance, 3 session training generated greater benefits compared to one of 2 times per week, while 5 session training caused higher gains of strength compared to one of 3 times per week.

In turn, to rise cardiorespiratory fitness, 5 sessions per week (1 hour/session) have proved to be especially effective [81, 127]. Furthermore, enhancements of the VO_{2peak} are significantly associated with training hours [128]. Then, it seems that a higher volume of training will increase the effectiveness of NMES.

CONCLUSION

Electrical stimulation is a method that offers great advantages in the clinical setting. It is a safe and effective treatment, especially for sedentary subjects. Within the types of electrical stimulation, NMES may be very useful in abdominal surgery, since it includes the following benefits: a) improves the physical fitness of patients prior to surgery, reducing the risk of postoperative complications; b) maintains physical fitness in bed rest conditions; c) allows the patient to increase the level of physical fitness faster, obtaining a patient's early recovery.

However, in order to obtain the highest effectiveness of the treatment, several aspects must be considered. First, the intended aim has to be defined. Second, electrical stimulation is composed of parameters that must be properly manipulated. The most relevant issues to maximize the benefits of the NMES treatment are:

- Training at high percentages of maximal voluntary contraction will generate a greater muscle activation, which provides larger benefits.
- To allow the patient to tolerate high intensities, it is necessary a familiarization period of approximately 10 days.
- In order to improve muscle strength and muscle mass, high frequencies (50 - 120 Hz) must be used, while low frequencies (4 - 10 Hz) just increase the cardiorespiratory fitness.
- Pulse duration must be applied in ranges of values between 100 - 500 μs, which is shorter for small muscle groups (100 - 300 μs) and longer for larger muscle groups (> 300 μs).

- High duty cycles must be used in order to increase muscle mass (1:1 or 1:2) and cardiorespiratory fitness (1:1, 2:9). On the contrary, low duty cycles (1:5) must be applied to achieve strength improvements.
- The maximum voluntary contraction increases linearly with amplitude. Similarly, the increase in this last parameter does not lead to significant increases of fatigue.
- Electrical stimulation effectiveness increases when the electrodes are placed in motor points.
- Fatigue increases with frequency, while modifying pulse duration or amplitude has not a significant effect on the fatigue.
- Regarding the frequency of treatment, 2 - 3 sessions per week develop strength gains and 5 sessions per week is especially effective in order to improve cardiorespiratory fitness.

REFERENCES

[1] Weiser, TG; Haynes, AB; Molina, G; Lipsitz, SR; Esquivel, MM; Uribe-Leitz, T; et al. Estimate of the global volume of surgery in 2012: an assessment supporting improved health outcomes. *Lancet*, 2015, 385, S11.

[2] Noordzij, PG; Poldermans, D; Schouten, O; Bax, JJ; Schreiner, FAG; Boersma, E. Postoperative Mortality in The Netherlands. *Anesthesiology*, 2010, 112, 1105–15.

[3] Mosby. *Mosby's Medical Dictionary*, 10th Edition., 2016.

[4] Masoomi, H; Kang, CY; Chen, A; Mills, S; Dolich, MO; Carmichael, JC; et al. Predictive factors of in-hospital mortality in colon and rectal surgery. *J Am Coll Surg*, 2012, 215, 255–61.

[5] Wang, CL; Qu, G; Xu, HW. The short- and long-term outcomes of laparoscopic versus open surgery for colorectal cancer: a meta-analysis. *Int J Colorectal Dis*, 2014, 29, 309–20.

[6] Rausa, E; Bonavina, L; Asti, E; Gaeta, M; Ricci, C. Rate of Death and Complications in Laparoscopic and Open Roux-en-Y Gastric Bypass. A Meta-analysis and Meta-regression Analysis on 69, 494 Patients. *Obes Surg*, 2016, 26, 1956–63.

[7] Inokuchi, M; Otsuki, S; Ogawa, N; Tanioka, T; Okuno, K; Gokita, K; et al. Postoperative Complications of Laparoscopic Total Gastrectomy versus Open Total Gastrectomy for Gastric Cancer in a Meta-Analysis of High-Quality Case-Controlled Studies. *Gastroenterol Res Pract*, 2016, 2016.

[8] Haverkamp, L; Weijs, TJ; Van Der Sluis, PC; Van Der Tweel, I; Ruurda, JP; Van Hillegersberg, R. Laparoscopic total gastrectomy versus open total gastrectomy for cancer: A systematic review and meta-analysis. *Surg Endosc Other Interv Tech*, 2013, 27, 1509–20.

[9] Aziz, O; Constantinides, V; Tekkis, PP; Athanasiou, T; Purkayastha, S; Paraskeva, P; et al. Laparoscopic versus open surgery for rectal cancer: A meta-analysis. *Ann Surg Oncol*, 2006, 13, 413–24.

[10] Straatman, J; Cuesta, MA; Gisbertz, SS; van der Peet, DL. Value of a step-up diagnosis plan: CRP and CT-scan to diagnose and manage postoperative complications after major abdominal surgery. *Rev Esp Enfermedades Dig*, 2014, 106, 515–21.

[11] Kim, M; Wall, MM; Li, G. Risk Stratification for Major Postoperative Complications in Patients Undergoing Intra-abdominal General Surgery Using Latent Class Analysis. *Anesth Analg*, 2018, 126, 848–57.

[12] Levett, D; Grocott, M. Cardiopulmonary Exercise Testing for Risk Prediction in Major Abdominal Surgery. *Anesth Clin*, 2015, 33, 1–16.

[13] Sabaté, S; Mazo, V; Canet, J. Predicting postoperative pulmonary complications: Implications for outcomes and costs. *Curr Opin Anaesthesiol*, 2014, 27, 201–9.

[14] Sanaiha, Y; Juo, YY; Aguayo, E; Seo, YJ; Dobaria, V; Ziaeian, B; et al. Incidence and trends of cardiac complications in major abdominal surgery. *Surg* (United States), 2018.

[15] Lawrence, VA; Hilsenbeck, SG; Mulrow, CD; Dhanda, R; Sapp, J; Page, CP. Incidence and hospital stay for cardiac and pulmonary complications after abdominal surgery. *J Gen Intern Med*, 1995, 10, 671–8.

[16] Pereira, EDB; Fernandes, ALG; Anção, M da S; Peres C de, A; Atallah, ÁN; Faresin, SM. Prospective assessment of the risk of postoperative pulmonary complications in patients submitted to upper abdominal surgery. *Sao Paulo Med J*, 1999, 117, 151–60.

[17] Thompson, DA; Makary, MA; Dorman, T; Pronovost, PJ. Clinical and economic outcomes of hospital acquired pneumonia in intra-abdominal surgery patients. *Ann Surg*, 2006, 243, 547–52.

[18] Pessaux, P; Msika, S; Atalla, D; Hay, J; Flamant, Y. Risk Factors for Postoperative Infectious Complications in Noncolorectal Abdominal Surgery. *Arch Surg*, 2003, 138, 314–24.

[19] Yang, CK; Teng, A; Lee, DY; Rose, K. Pulmonary complications after major abdominal surgery: National Surgical Quality Improvement Program analysis. *J Surg Res*, 2015, 198, 441–9.

[20] Brooks-Brunn, JA. Predictors of postoperative pulmonary complications following abdominal surgery. *Chest*, 1997, 111, 564–71.

[21] Sato, T; Aoyama, T; Hayashi, T; Segami, K; Kawabe, T; Fujikawa, H; et al. Impact of preoperative hand grip strength on morbidity following gastric cancer surgery. *Gastric Cancer*, 2016, 19, 1008–15.

[22] Wang, SL; Zhuang, CLe; Huang, DD; Pang, WY; Lou, N; Chen, FF; et al. Sarcopenia Adversely Impacts Postoperative Clinical Outcomes Following Gastrectomy in Patients with Gastric Cancer: A Prospective Study. *Ann Surg Oncol*, 2016, 23, 556–64.

[23] Choudhuri, A; Chandra, S; Aggarwal, G; Uppal, R. Predictors of postoperative pulmonary complications after liver resection: Results from a tertiary care intensive care unit. *Indian J Crit Care Med*, 2014, 18, 358.

[24] Scholes, RL; Browning, L; Sztendur, EM; Denehy, L. Duration of anaesthesia, type of surgery, respiratory co-morbidity, predicted VO2max and smoking predict postoperative pulmonary complications after upper abdominal surgery: An observational study. *Aust J Physiother*, 2009, 55, 191–8.

[25] Benotti, P; Wood, GC; Winegar, DA; Petrick, AT; Still, CD; Argyropoulos, G; et al. Risk Factors Associated With Mortality After Roux-en-Y Gastric Bypass Surgery. *Ann Surg*, 2014, 259, 123–30.

[26] Huang, DD; Wang, SL; Zhuang, CL; Zheng, BS; Lu, JX; Chen, FF; et al. Sarcopenia, as defined by low muscle mass, strength and physical performance, predicts complications after surgery for colorectal cancer. *Color Dis*, 2015, 17, O256–64.

[27] Peng, PD; Van Vledder, MG; Tsai, S; De Jong, MC; Makary, M; Ng, J; et al. Sarcopenia negatively impacts short-term outcomes in patients undergoing hepatic resection for colorectal liver metastasis. *HPB*, 2011, 13, 439–46.

[28] Jones, K; Gordon-Weeks, A; Coleman, C; Silva, M. Radiologically Determined Sarcopenia Predicts Morbidity and Mortality Following Abdominal Surgery: A Systematic Review and Meta-Analysis. *World J Surg*, 2017, 41, 2266–79.

[29] Reddy, S; Contreras, CM; Singletary, B; Bradford, TM; Waldrop, MG; Mims, AH; et al. Timed Stair Climbing is the Single Strongest Predictor of Perioperative Complications in Patients Undergoing Abdominal Surgery. *J Am Coll Surg*, 2016, 222, 559–66.

[30] Pate, RR. The evolving definition of physical fitness. *Quest*, 1988, 40, 174–9.

[31] Caspersen, CJ; Powell, KE; Christenson, GM. Physical Activity, Exercise, and Physical Fitness: Definitions and Distinctions for Health-Related Research. *Public Heal Rep*, 1985, 100, 126–31.

[32] Lee, DC; Sui, X; Ortega, FB; Kim, YS; Church, TS; Winett, RA; et al. Comparisons of leisure-time physical activity and cardiorespiratory fitness as predictors of all-cause mortality in men and women. *Br J Sports Med*, 2011, 45, 504–10.

[33] Ortega, FB; Silventoinen, K; Tynelius, P; Rasmussen, F. Muscular strength in male adolescents and premature death: Cohort study of one million participants. *BMJ*, 2012, 345, 1–12.

[34] Savva, SC; Lamnisos, D; Kafatos, AG. Predicting cardiometabolic risk: Waist-to-height ratio or BMI. A meta-analysis. *Diabetes, Metab Syndr Obes Targets Ther*, 2013, 6, 403–19.

[35] Kitahara, CM; Flint, AJ; Berrington de Gonzalez, A; Bernstein, L; Brotzman, M; MacInnis, RJ; et al. Association between Class III Obesity (BMI of 40-59 kg/m2) and Mortality: A Pooled Analysis of 20 Prospective Studies. *PLoS Med*, 2014, 11.

[36] Sellen, D. Physical status: the use and interpretation of anthropometry. Report of a WHO Expert Committee. *WHO Tech Rep*, 1995, 854, 1–452.

[37] Houmard, JA; Pories, WJ; Dohm, GL. Severe obesity: evidence for a deranged metabolic program in skeletal muscle? *Exerc Sport Sci Rev*, 2013, 40, 204–10.

[38] Pedersen, BK; Febbraio, MA. Muscles, exercise and obesity: Skeletal muscle as a secretory organ. *Nat Rev Endocrinol*, 2012, 8, 457–65.

[39] Dulloo, AG; Jacquet, J; Solinas, G; Montani, J; Schutz, Y. Body composition phenotypes in pathways to obesity and the metabolic syndrome. *Int J Obes*, 2010, 34, S4–17.

[40] Cruz-Jentoft, AJ; Baeyens, JP; Bauer, JM; Boirie, Y; Cederholm, T; Landi, F; et al. Sarcopenia: European consensus on definition and diagnosis. *Age Ageing*, 2010, 39, 412–23.

[41] Moran, J; Wilson, F; Guinan, E; McCormick, P; Hussey, J; Moriarty, J. Role of cardiopulmonary exercise testing as a risk-assessment method in patients undergoing intra-abdominal surgery: A systematic review. *Br J Anaesth*, 2016, 116, 177–91.

[42] Hennis, PJ; Meale, PM; Grocott, MPW. Cardiopulmonary exercise testing for the evaluation of perioperative risk in non-cardiopulmonary surgery. *Postgr Med J*, 2011, 87, 550–7.

[43] Weisman, IM. Clinical Exercise Testing. *Clin Chest Med*, 2001, 22, 366–78.

[44] Pallarés, J; Morán-Navarro, R. Methodological approach to the Cardiorespiratory Endurance Training. *J Sport Heal Res*, 2012, 4, 119–36.

[45] Piazza, O; Miccichè, V; Esposito, C; Romano, G; De Robertis, E. Individualised prediction of postoperative cardiorespiratory complications after upper abdominal surgery. *Trends Anaesth Crit Care*, 2016, 6, 11–9.

[46] Lieffers, JR; Bathe, OF; Fassbender, K; Winget, M; Baracos, VE. Sarcopenia is associated with postoperative infection and delayed recovery from colorectal cancer resection surgery. *Br J Cancer*, 2012, 107, 931–6.

[47] Huang, DD; Zhou, CJ; Wang, SL; Mao, ST; Zhou, XY; Lou, N; et al. Impact of different sarcopenia stages on the postoperative outcomes after radical gastrectomy for gastric cancer. *Surg (United States)*, 2017, 161, 680–93.

[48] Moran, J; Wilson, F; Guinan, E; McCormick, P; Hussey, J; Moriarty, J. Role of cardiopulmonary exercise testing as a risk-assessment method in patients undergoing intra-abdominal surgery: A systematic review. *Br J Anaesth*, 2016, 116, 177–91.

[49] Smith, TB; Stonell, C; Purkayastha, S; Paraskevas, P. Cardiopulmonary exercise testing as a risk assessment method in non cardio-pulmonary surgery: a systematic review. *Anaesthesia*, 2009, 64, 883–93.

[50] Lee, CHA; Kong, JC; Ismail, H; Riedel, B; Heriot, A. Systematic Review and Meta-analysis of Objective Assessment of Physical Fitness in Patients Undergoing Colorectal Cancer Surgery. *Dis Colon Rectum*, 2018, 61, 400–9.

[51] McCullough, PA; Gallagher, MJ; DeJong, AT; Sandberg, KR; Trivax, JE; Alexander, D; et al. Cardiorespiratory fitness and short-term complications after bariatric surgery. *Chest*, 2006, 130, 517–25.

[52] West, MA; Lythgoe, D; Barben, CP; Noble, L; Kemp, GJ; Jack, S; et al. Cardiopulmonary exercise variables are associated with postoperative morbidity after major colonic surgery: A prospective blinded observational study. *Br J Anaesth*, 2014, 112, 665–71.

[53] Hartley, RA; Pichel, AC; Grant, SW; Hickey, GL; Lancaster, PS; Wisely, NA; et al. Preoperative cardiopulmonary exercise testing and risk of early mortality following abdominal aortic aneurysm repair. *Br J Surg*, 2012, 99, 1539–46.

[54] Bernal, W; Martin-Mateos, R; Lipcsey, M; Tallis, C; Woodsford, K; McPhail, M; et al. Aerobic capacity during cardiopulmonary exercise testing and survival with and without liver transplantation for patients with chronic liver disease. *Liver Transplant*, 2014, 20, 54–62.

[55] Junejo, MA; Mason, JM; Sheen, AJ; Moore, J; Foster, P; Atkinson, D; et al. Cardiopulmonary exercise testing for preoperative risk assessment before hepatic resection. *Br J Surg*, 2012, 99, 1097–104.

[56] Lai, CW; Minto, G; Challand, CP; Hosie, KB; Sneyd, JR; Creanor, S; et al. Patients' inability to perform a preoperative cardiopulmonary exercise test or demonstrate an anaerobic threshold is associated with inferior outcomes after major colorectal surgery. *Br J Anaesth*, 2013, 111, 607–11.

[57] Hennis, PJ; Meale, PM; Hurst, RA; Doherty, AFO; Otto, J; Kuper, M; et al. Cardiopulmonary exercise testing predicts postoperative outcome in patients undergoing gastric bypass surgery. *Br J Anaesth*, 2012, 109, 566–71.

[58] Brunelli, A; Kim, AW; Berger, KI; Addrizzo-Harris, DJ. Physiologic evaluation of the patient with lung cancer being considered for resectional surgery: Diagnosis and

management of lung cancer, 3rd ed: American college of chest physicians evidence-based clinical practice guidelines. *Chest*, 2013, 143, e166S–e190S.

[59] Older, P; Smith, R; Courtney, P; Hone, R. Preoperative evaluation of cardiac failure and ischemia in elderly patients by cardiopulmonary exercise testing. *Chest*, 1993, 104, 701–4.

[60] Giannoudis, PV; Dinopoulos, H; Chalidis, B; Hall, GM. Surgical stress response. *Injury*, 2006, 37, S3–9.

[61] Singh, M; Anaesthesiology, H; Singh, MM. Stress Response and Anaesthesia Altering the Peri and Post-Operative Management. *Indian J Anaesth*, 2003, 47, 427–34.

[62] Gillis, C; Carli, F. Promoting Perioperative Metabolic and Nutritional Care. *Anesthesiology*, 2015, 123, 1455–72.

[63] Agnew, N. Preoperative cardiopulmonary exercise testing. *Contin Educ Anaesthesia, Crit Care Pain*, 2010, 10, 33–7.

[64] Shoemaker, W; Appel, P; Kram, H. Role of oxygen debt in the development of organ failure sepsis, and death in high-risk surgical patients. *Chest*, 1992, 102, 208–15.

[65] Lutz, CT; Quinn, LBS. Sarcopenia, obesity, and natural killer cell immune senescence in aging: Altered cytokine levels as a common mechanism. *Aging (Albany NY)*, 2012, 4, 535–46.

[66] Van Venrooij, LMW; De Vos, R; Zijlstra, E; Borgmeijer-Hoelen, MMMJ; Van Leeuwen, PAM; De Mol, BAJM. The impact of low preoperative fat-free body mass on infections and length of stay after cardiac surgery: A prospective cohort study. *J Thorac Cardiovasc Surg*, 2011, 142, 1263–9.

[67] Windsor, JA; Hill, GL. Protein Depletion and Surgical Risk. *Aust N Z J Surg*, 1988, 58, 711–5.

[68] Van Venrooij, LMW; Verberne, HJ; de Vos, R; Borgmeijer-Hoelen, MMMJ; van Leeuwen, PAM; de Mol, BAJM. Postoperative loss of skeletal muscle mass, complications and quality of life in patients undergoing cardiac surgery. *Nutrition*, 2012, 28, 40–5.

[69] Nygren, J; Thorell, A; Efendic, S; Nair, KS; Ljungqvist, O. Site of insulin resistance after surgery: the contribution of hypocaloric nutrition and bed rest. *Clin Sci (Lond)*, 1997, 93, 137–46.

[70] Biteker, M; Dayan, A; Can, MM; Ilhan, E; Biteker, FS; Tekkeşin, A; et al. Impaired fasting glucose is associated with increased perioperative cardiovascular event rates in patients undergoing major non-cardiothoracic surgery. *Cardiovasc Diabetol*, 2011, 10, 1–7.

[71] Jensen, J; Rustad, PI; Kolnes, AJ; Lai, YC. The role of skeletal muscle glycogen breakdown for regulation of insulin sensitivity by exercise. *Front Physiol*, 2011, 2, 1–11.

[72] Moriello, C; Mayo, NE; Feldman, L; Carli, F. Validating the Six-Minute Walk Test as a Measure of Recovery After Elective Colon Resection Surgery. *Arch Phys Med Rehabil*, 2008, 89, 1083–9.

[73] Li, C; Carli, F; Lee, L; Charlebois, P; Stein, B; Liberman, AS; et al. Impact of a trimodal prehabilitation program on functional recovery after colorectal cancer surgery: A pilot study. *Surg Endosc Other Interv Tech*, 2013, 27, 1072–82.

[74] Kortebein, P; Ferrando, A; Lombeida, J; Wolfe, R; Evans, WJ. Effect of 10 Days of Bed Rest on Skeletal Muscle in Healthy Older Adults. *JAMA*, 2007, 297, 1772–4.

[75] Puthucheary, ZA; Rawal, J; McPhail, M; Connolly, B; Ratnayake, G; Chan, P; et al. Acute skeletal muscle wasting in critical illness. *JAMA - J Am Med Assoc*, 2013, 310, 1591–600.

[76] Pišot, R; Marusic, U; Biolo, G; Mazzucco, S; Lazzer, S; Grassi, B; et al. Greater loss in muscle mass and function but smaller metabolic alterations in older compared with younger men following 2 wk of bed rest and recovery. *J Appl Physiol*, 2016, 120, 922–9.

[77] Santa Mina, D; Scheede-Bergdahl, C; Gillis, C; Carli, F. Optimization of surgical outcomes with prehabilitation. *Appl Physiol Nutr Metab*, 2015, 40, 966–9.

[78] Zeng, C; li, H; Yang, T; Deng, ZH; Yang, Y; Zhang, Y; et al. Electrical stimulation for pain relief in knee osteoarthritis: Systematic review and network meta-analysis. *Osteoarthr Cartil*, 2015, 23, 189–202.

[79] Vance, CGT; Dailey, DL; Rakel, BA; Sluka, KA. Using TENS for pain control: the state of the evidence. *Pain Manag*, 2014, 4, 197–209.

[80] Peckham, PH; Knutson, JS. Functional Electrical Stimulation for Neuromuscular Applications. *Annu Rev Biomed Eng*, 2005, 7, 327–60.

[81] O'Connor, D; Brennan, L; Caulfield, B. The use of neuromuscular electrical stimulation (NMES) for managing the complications of ageing related to reduced exercise participation. *Maturitas*, 2018, 113, 13–20.

[82] Wernbom, M; Augustsson, J; Thomeé, R. The influence of frequency, intensity, volume and mode of strength training on whole muscle cross-sectional area in humans. *Sports Med*, 2007, 37, 225–64.

[83] Ruther, CL; Golden, CL; Harris, RT; Dudley, GA. Hypertrophy, resistance training, and the nature of skeletal muscle activation. *J Strength Cond Res*, 1995, 9, 155–9.

[84] Cabric, M; Appell, HJ. Effect of electrical stimulation of high and low frequency on maximum isometric force and some morphological characteristics in men. *Int J Sport Med*, 1987, 8, 256–60.

[85] Gondin, J; Guette, M; Ballay, Y; Martin, A. Electromyostimulation training effects on neural drive and muscle architecture. *Med Sci Sports Exerc*, 2005, 37, 1291–9.

[86] Dirks, ML; Wall, BT; Snijders, T; Ottenbros, CLP; Verdijk, LB; Van Loon, LJC. Neuromuscular electrical stimulation prevents muscle disuse atrophy during leg immobilization in humans. *Acta Physiol*, 2014, 210, 628–41.

[87] Gibson, JNA; Smith, K; Rennie, MJ. Prevention of Disuse Muscle Atrophy By Means of Electrical Stimulation: Maintenance of Protein Synthesis. *Lancet*, 1988, 332, 767–70.

[88] Gerovasili, V; Stefanidis, K; Vitzilaios, K; Karatzanos, E; Politis, P; Koroneos, A; et al. Electrical muscle stimulation preserves the muscle mass of critically ill patients: A randomized study. *Crit Care*, 2009, 13, 1–8.

[89] Segers, J; Hermans, G; Bruyninckx, F; Meyfroidt, G; Langer, D; Gosselink, R. Feasibility of neuromuscular electrical stimulation in critically ill patients. *J Crit Care*, 2014, 29, 1082–8.

[90] Esteve, V; Carneiro, J; Moreno, F; Fulquet, M; Garriga, S; Pou, M; et al. The effect of neuromuscular electrical stimulation on muscle strength; functional capacity and body composition in haemodialysis patients. *Nefrologia*, 2017, 37, 68–77.

[91] Urdampilleta, A; Vicente-Salar, N; Martínez-Sanz, J. Necesidades proteicas de los deportistas y pautas diétetico-nutricionales para la ganancia de masa muscular. *Rev Española Nutr Humana y Dietética …*, 2012, 16, 25–35.

[92] English, KL; Paddon-Jones, D. Protecting muscle mass and function in older adults during bed rest. *Curr Opin Clin Nutr Metab Care*, 2010, 13, 34–9.

[93] Kubiak, RJ; Whitman, KM; Johnston, RM. Changes in quadriceps femoris muscle strength using isometric exercise versus electrical stimulation. *J Orthop Sports Phys Ther*, 1987, 8, 537–41.

[94] Colson, S; Martin, A; Van Hoecke, J. Re-examination of training effects by electrostimulation in the human elbow musculoskeletal system. *Int J Sports Med*, 2000, 21, 281–8.

[95] Selkowitz, DM. Improvement in isometric strength of the quadriceps femoris muscle after training with electrical stimulation. *Phys Ther*, 1985, 65, 186–96.

[96] Porcari, JP; Miller, J; Cornwell, K; Foster, C; Gibson, M; McLean, K; et al. The effects of neuromuscular electrical stimulation training on abdominal strength, endurance, and selected anthropometric measures. *J Sport Sci Med*, 2005, 4, 66–75.

[97] Porcari, J; Ryskey, A; Foster, C. The Effects of High Intensity Neuromuscular Electrical Stimulation on Abdominal Strength and Endurance, Core Strength, Abdominal Girth, and Perceived Body Shape and Satisfaction. *Int J Kinesiol Sport Sci*, 2018, 6, 19.

[98] Hainaut, K; Duchateau, J. Neuromuscular electrical stimulation and voluntary exercise. *Sport Med*, 1992, 14, 100–13.

[99] Bax, L; Staes, F; Verhagen, A. Does neuromuscular electrical stimulation strengthen the quadriceps femoris? A systematic review of randomised controlled trials. *Sport Med*, 2005, 35, 191–212.

[100] Wageck, B; Nunes, GS; Silva, FL; Damasceno, MCP; de Noronha, M. Application and effects of neuromuscular electrical stimulation in critically ill patients: Systematic review. *Med Intensiva*, 2014, 38, 444–54.

[101] Fischer, A; Spiegl, M; Altmann, K; Winkler, A; Salamon, A; Themessl-Huber, M; et al. Muscle mass, strength and functional outcomes in critically ill patients after cardiothoracic surgery: Does neuromuscular electrical stimulation help? The Catastim 2 randomized controlled trial. *Crit Care*, 2016, 20, 1–13.

[102] Jones, S; Wdc, M; Gao, W; Ij, H; Wilcock, A; Maddocks, M. Neuromuscular electrical stimulation for muscle weakness in adults with advanced disease (Review). *Cochrane Libr*, 2016.

[103] Esteve, V; Carneiro, J; Moreno, F; Fulquet, M; Garriga, S; Pou, M; et al. The effect of neuromuscular electrical stimulation on muscle strength, functional capacity and body composition in haemodialysis patients. *Nefrologia*, 2017, 37, 68–77.

[104] Banerjee, P; Caulfield, B; Crowe, L; Clark, AL. Prolonged Electrical Muscle Stimulation Exercise Improves Strength, Peak VO2, and Exercise Capacity in Patients With Stable Chronic Heart Failure. *J Card Fail*, 2009, 15, 319–26.

[105] Deley, G; Eicher, JC; Verges, B; Wolf, JE; Casillas, JM. Do low-frequency electrical myostimulation and aerobic training similarly improve performance in chronic heart failure patients with different exercise capacities? *J Rehabil Med*, 2008, 40, 219–24.

[106] Hill, K; Cavalheri, V; Mathur, S; Roig, M; Robles, P; Te, D; et al. Neuromuscular electrostimulation for adults with chronic obstructive pulmonary disease (Review). *Send to Cochrane Database Syst Rev*, 2018.

[107] Veldman, MP; Gondin, J; Place, N; Maffiuletti, NA. Effects of neuromuscular electrical stimulation training on endurance performance. *Front Physiol*, 2016, 7, 544.

[108] Banerjee, P; Clark, A; Witte, K; Crowe, L; Caulfield, B. Electrical stimulation of unloaded muscles causes cardiovascular exercise by increasing oxygen demand. *Eur J Cardiovasc Prev Rehabil*, 2005, 12, 503–8.

[109] Vaquero, AF; Chicharro, JL; Gil, L; Ruiz, MP; Sanchez, V; Lucia, A; et al. Effects of muscle electrical stimulation on peak VO2 in cardiac transplant patients. *Int J Sports Med*, 1998, 19, 317–22.

[110] Henneman, E. Relation between size of neuron and their susceptibility to discharge. *Science*, (80-), 1957, 126, 1345–7.

[111] Gregory, CM; Bickel, CS. Recruitment patterns in human skeletal muscle during electrical stimulation. *Phys Ther*, 2005, 85, 358–64.

[112] Bickel, CS; Gregory, CM; Dean, JC. Motor unit recruitment during neuromuscular electrical stimulation: A critical appraisal. *Eur J Appl Physiol*, 2011, 111, 2399–407.

[113] Vanderthommen, M; Depresseux, J; Dauchat, L; Degueldre, C; Croisier, J; Crielaard, J. Spatial distribution of blood flow in electrically stimulated human muscle: a positron emission tomography study. *Muscle Nerve*, 2000, 23, 482–9.

[114] Boerio, D; Jubeau, M; Zory, R; Maffiuletti, NA. Central and peripheral fatigue after electrostimulation-induced resistance exercise. *Med Sci Sports Exerc*, 2005, 37, 973–8.

[115] Jubeau, M; Sartorio, A; Marinone, PG; Agosti, F; Hoecke, JV; Nosaka, K; et al. Comparison between voluntary and stimulated contractions of the quadriceps femoris for growth hormone response and muscle damage. *J Appl Physiol*, 2007, 104, 75–81.

[116] Lake, DA. Neuromuscular electrical stimulation. An overview and its application in the treatment of sports injuries. *Sports Med*, 1992, 13, 320–36.

[117] Jennett, S. *Churchill Livingstone's dictionary of sport and exercise science and medicine*. Churchill Livingstone Elsevier, 2008.

[118] Maffiuletti, NA. Physiological and methodological considerations for the use of neuromuscular electrical stimulation. *Eur J Appl Physiol*, 2010, 110, 223–34.

[119] Adams, GR; Harris, RT; Woodard, D; Dudley, GA. Mapping of electrical muscle stimulation using MRI. *J Appl Physiol*, 1993, 74, 532–7.

[120] Herzig, D; Maffiuletti, NA; Eser, P. The Application of Neuromuscular Electrical Stimulation Training in Various Non-neurologic Patient Populations: A Narrative Review. *PMR*, 2015, 7, 1167–78.

[121] Selkowitz, DM. High frequency electrical stimulation in muscle strengthening. A review and discussion. *Am J Sport Med*, 1989, 17, 103–11.

[122] Strauss, GR. The Effect of Different Electro-Motor Stimulation Training Intensities on Strength Improvement. *Aust J Physiother*, 1988, 34, 151–64.

[123] Gregory, CM; Dixon, W; Bickel, CS. Impact of varying pulse frequency and duration on muscle torque production and fatigue. *Muscle and Nerve*, 2007, 35, 504–9.

[124] Gorgey, AS; Black, CD; Elder, CP; Dudley, GA. Effects of Electrical Stimulation Parameters on Fatigue in Skeletal Muscle. *J Orthop Sport Phys Ther*, 2009, 39, 684–92.

[125] Vivodtzev, I; Lacasse, Y; Maltais, F. Neuromuscular electrical stimulation of the lower limbs in patients with chronic obstructive pulmonary disease. *J Cardiopulm …*, 2008, 28, 79–91.

[126] Minogue, CM; Caulfield, BM; Reilly, RB. What are the electrical stimulation design parameters for maximum VO2 aimed aimed at Cardio-Pulmonary rehabilitation? *Annu Int Conf IEEE Eng Med Biol – Proc*, 2007, 2007, 2428–31.

[127] Carty, A; McCormack, K; Coughlan, GF; Crowe, L; Caulfield, B. Increased aerobic fitness after neuromuscular electrical stimulation training in adults with spinal cord injury. *Arch Phys Med Rehabil*, 2012, 93, 790–5.

[128] Crognale, D; De Vito, G; Grosset, JF; Crowe, L; Minogue, C; Caulfield, B. Neuromuscular electrical stimulation can elicit aerobic exercise response without undue discomfort in healthy physically active adults. *J Strength Cond Res*, 2013, 27, 208–15.

[129] Vanderthommen, M; Duchateau, J. In contrast, tetanic contractions induced by pulses of low intensity and long duration favor the normal recruitment of motor units (size principle) (25) and neural adaptations through reflex inputs to the spinal cord and supraspinal centers. *Exerc Sport Sci Rev*, 2007, 35, 180–5.

[130] Enoka, RM. Muscle strength and its development: New perspectives. *Sport Med*, 1988, 6, 146–68.

[131] Deley, G; Babault, N. Could low-frequency electromyostimulation training be an effective alternative to endurance training? An overview in one adult. *J Sport Sci Med*, 2014, 13, 444–50.

[132] McLoda, TA; Carmack, JA. Optimal Burst Duration during a Facilitated Quadriceps Femoris Contraction. *J Athl Train*, 2000, 35, 145–50.

[133] Packman-Braun, R. Relationship between functional electrical stimulation duty cycle and fatigue in wrist extensor muscles of patients with hemiparesis. *Phys Ther*, 1988, 68, 51–6.

[134] Glaviano, NR; Saliba, S. Can the Use of Neuromuscular Electrical Stimulation Be Improved to Optimize Quadriceps Strengthening? *Sports Health*, 2016, 8, 79–85.

[135] Matheson, GO; Dunlop, RJ; McKenzie, DC; Smith, CF; Allen, PS. Force output and energy metabolism during neuromuscular electrical stimulation: a 31P-NMR study. *Scand J Rehabil Med*, 1997, 29, 175–80.

[136] Hamada, T; Sasaki, H; Hayashi, T; Moritani, T; Nakao, K. Enhancement of whole body glucose uptake during and after human skeletal muscle low-frequency electrical stimulation. *J Appl Physiol*, 2003, 94, 2107–12.

[137] Binder-Macleod, Sa; Halden, EE; Jungles, Ka. Effects of stimulation intensity on the physiological responses of human motor units. *Med Sci Sports Exerc*, 1995, 27, 556–65.

[138] Maffiuletti, NA; Gondin, J; Place, N; Stevens-Lapsley, J; Vivodtzev, I; Minetto, MA. Clinical Use of Neuromuscular Electrical Stimulation for Neuromuscular Rehabilitation: What Are We Overlooking? *Arch Phys Med Rehabil*, 2018, 99, 806–12.

[139] Theurel, J; Lepers, R; Pardon, L; Maffiuletti, NA. Differences in cardiorespiratory and neuromuscular responses between voluntary and stimulated contractions of the quadriceps femoris muscle. *Respir Physiol Neurobiol*, 2007, 157, 341–7.

[140] Gorgey, AS; Mahoney, E; Kendall, T; Dudley, GA. Effects of neuromuscular electrical stimulation parameters on specific tension. *Eur J Appl Physiol*, 2006, 97, 737–44.

[141] Doucet, BM; Lam, A; Griffin, L. Neuromuscular electrical stimulation for skeletal muscle function. *Yale J Biol Med*, 2012, 85, 201–15.

[142] Bickel, CS; Gregory, CM; Azuero, A. Matching initial torque with different stimulation parameters influences skeletal muscle fatigue. *J Rehabil Res Dev*, 2012, 49, 323.

[143] Broderick, BJ; Kennedy, C; Breen, PP; Kearns, SR; Ólaighin, G. Patient tolerance of neuromuscular electrical stimulation (NMES) in the presence of orthopaedic implants. *Med Eng Phys*, 2011, 33, 56–61.

[144] Delito, A; Shulman, A; Strube, MSMS. A study of discomfort with electrical stimulation. *Phys Ther*, 1992, 72, 410–24.

[145] Gondin, J; Cozzone, PJ; Bendahan, D. Is high-frequency neuromuscular electrical stimulation a suitable tool for muscle performance improvement in both healthy humans and athletes? *Eur J Appl Physiol*, 2011, 111, 2473–87.

[146] Alon, C; Kantor, G; Ho, HS. Effects of Electrode Size on Basic Excitatory Responses and on Selected Stimulus Parameters. *J Orthop Sport Phys Ther*, 1994, 20, 29–35.

[147] Gobbo, M; Gaffurini, P; Bissolotti, L; Esposito, F; Orizio, C. Transcutaneous neuromuscular electrical stimulation, Influence of electrode positioning and stimulus amplitude settings on muscle response. *Eur J Appl Physiol*, 2011, 111, 2451–9.

[148] Gobbo, M; Maffiuletti, NA; Orizio, C; Minetto, MA. Muscle motor point identification is essential for optimizing neuromuscular electrical stimulation use. *J Neuroeng Rehabil*, 2014, 11, 1–6.

[149] Botter, A; Oprandi, G; Lanfranco, F; Allasia, S; Maffiuletti, NA; Minetto, MA. Atlas of the muscle motor points for the lower limb: Implications for electrical stimulation procedures and electrode positioning. *Eur J Appl Physiol*, 2011, 111, 2461–71.

[150] Brooks, ME; Smith, EM; Currier, D. Effect of Longitudinal Versus Transverse Electrode Placement on Torque Production by the Quadriceps Femoris Muscle during Neuromuscular Electrical Stimulation. *J Orthop Sports Phys Ther*, 1990, 11, 530–4.

[151] Franz, A; Klaas, J; Schumann, M; Frankewitsch, T; Filler, TJ; Behringer, M. Anatomical versus functional motor points of selected upper body muscles. *Muscle and Nerve*, 2018, 57, 460–5.

[152] Behringer, M; Franz, A; McCourt, M; Mester, J. Motor point map of upper body muscles. *Eur J Appl Physiol*, 2014, 114, 1605–17.

In: Encyclopedia of Surgery (22 Volume Set)
Editors: Andreas Lehrer and Kristin Mueller
ISBN: 978-1-53618-329-0
© 2020 Nova Science Publishers, Inc.

Chapter 101

SCENARIO BASED MCQS IN ORAL SURGERY

Arun Priya Srinivasan, Namdeo Prabhu and Mohammed Kassab
Oral Surgery, College of Dentistry, Jouf University, Saudi Arabia

Oral and Maxillofacial surgery is a branch of dentistry, under the broad specialty of Oral-Maxillofacial surgery and diagnostic sciences, which deals with the complex treatment of the face, jaws and the oral cavity which primarily includes the surgical management, but also involves complex medical regimes which sometimes extend in the neck region. Oral and Maxillofacial surgery also deals with the diseases and defects that affect the Head and Neck region. Numbers of sub-specialties have evolved over the period of time which can be broadly classified as Oncosurgery, Plastic Reconstructive and Orthognathic surgery, TMJ surgery and Head and Neck Trauma. Apart from the surgical treatment, Pain management and Anesthesia also forms an important part of this field of dentistry, which amounts to medical and surgical management to treat any amount of pain which also sometimes includes those of neuronal origin like Neuralgias. At the simplest methods like Dental extraction and Disimpaction of the teeth and alike tissue, along with cyst enucleation and debridement of the infection, it extends till the surgical resection of the cancer tissue and reconstruction of the missing parts of the Oral cavity and the face. A truly complex field, this branch of the dentistry is rightly addressed as a bridging link between the Surgery, Dentistry and Medicine which also encompasses the Anesthetic part.

The MCQs aid the student's and the practitioners to understand the subject effectively and to assess the knowledge acquired.

1. A 60-year-old patient suffered injuries to his lower half of face that suggested mandibular body fracture on examination. What is the most appropriate way of management of such a Patient where there is no presence of teeth?
   A. Gunning splint
   B. Cap splint
   C. Ribbon splint
   D. All of the above

2. Long term effect of radiotherapy to oral mucosa is characterized by:
   A. Epithelium becomes more keratinized
   B. Sub mucosa becomes highly vascular
   C. Break down & delayed healing, submucosa less vascular
   D. No sub mucosal fibrosis

3. A 20-year-old patient met with a bike accident and CT scan revealed a displaced, unfavorable fracture in the mandibular angle region. During surgery it was seen that it was a fairly difficult fracture to treat? This might be because of,
   A. Injury to neurovascular bundle
   B. Malocclusion secondary to injury
   C. Distraction of fracture segments by muscle pull
   D. Increased density of bone in this region of mandible

4. Any trauma sustained by a jaw bone and communicating with the teeth bearing section of the alveolus should be considered as a
   A. Simple
   B. Open
   C. Greenstick
   D. Comminuted

5. An 8-year-old child was diagnosed with fracture in twin jaws and it was further noticed it was just a single fracture line. What is the best way of treating such a fracture?
   A. Cap splint fixation
   B. Intermaxillary fixation
   C. Risdon wiring
   D. Transosseous wiring

6. A patient came with history of sharp, lancinating pain on right side of face, not relieved by analgesics. On progressive symptoms carbamazepine was found to be effective in this patient. What is the most probable diagnosis?
   A. Acute pulpitis.
   B. Trigeminal neuralgia
   C. Acute dental abscess
   D. Dry socket

7. Any patient being instilled with cancer chemotherapy is candidate of myelosuppression, what is the most common manifestation of this?
   A. Anemia& thrombocytopenia
   B. Thrombocytosis
   C. Leukocytosis
   D. Lymphocytosis

8. All patients sustaining mandibular fracture will show one or all of the symptoms except:
   A. Malocclusion
   B. Paresthesia of lower lip
   C. Fractured ends are prevented from dislocation by masticatory muscles
   D. Are usually compound

9. A 47-year-old patient was suffering from severe headache and heaviness of face since 4 days. On further evaluation it was noticed that there was inflammation of most or all of the paranasal sinuses simultaneously. This condition is best described as,
   A. Pan sinusitis
   B. Sinusitis
   C. Paranasal sinusitis
   D. Parasinusitis

10. Most common culprit for Maxillary sinus infection of odontogenic origin is due to,
    A. Aerobic bacteria
    B. Anaerobic bacteria
    C. Fungal
    D. Viral

11. During a peripheral posting in a hospital it was found out that there were only basic instruments available for treatment and no means of open reduction for treating facial skeleton was available. In such a scenario all of the following are the techniques can be of help except,
    A. Risdon's wiring technique
    B. Eyelet wiring technique
    C. Erich's arch bar fixation
    D. Champy miniplates osteosynthesis

12. On doing a CT scan it was seen that mandible of a patient was badly comminuted and all fragments were grossly displaced due to muscle pull. Each of the muscle mentioned will cause displacement of the muscles except one. Which is that muscle?
    A. Lateral Pterygoid
    B. Medial Pterygoid
    C. Masseter
    D. Buccinator

13. During extraction of 16 and 17 root stump was broken and surgical procedure was instilled to remove the roots, but as soon as the root was retrieved, bubbling for the socket was seen and communication with the maxillary sinus was inferred. What is the best treatment for the accidental Oro-antral communication like this one during extraction which is around 0.5 mm in size?
    A. Buccal flap technique
    B. Palatal flap technique
    C. Periodic observation and follow up
    D. Caldwell-luc approach

14. In WINTER'S classification, white line tells us:
    A. Depth of the impacted tooth
    B. Angulation of the impacted tooth
    C. Point of application for elevator
    D. Used to classify fracture of the tooth

15. Various anatomical structures can involve in various levels of the facial trauma. In which of the following maxillary sinus is usually involved in fractures
    A. Lefort 1
    B. Zygomatic arch fracture
    C. Lefort 3
    D. Nasoethmiodal fracture

16. Which of the following methods of sterilization is not as effective as other techniques?
    A. Ethylene oxide gas
    B. Gamma radiation
    C. UV radiation
    D. Autoclaving

17. If a patient comes with a history of cardiac problem taking aspirin what will be the possible complication if you do extraction:
    A. Increases bleeding time
    B. Increases prothrombin time
    C. Increases clotting time
    D. Increases partial thrombin time

18. Cross bar elevator and winter-cryer works on mechanical principle of:
    A. Wedge
    B. Lever
    C. Wheel & axle
    D. Pulley

19. While removing an impacted wisdom tooth, if we have to do the apicoectomy of 2nd molar also, which type of incision should be given?
    A. Semilunar
    B. Ward's
    C. Extended ward's
    D. Envelop

20. Which is the most commonly used size of suture in oral cavity:
    A. 1/0
    B. 2/0
    C. 3/0
    D. 4/0

21. Which of the following can be said to have occurred if the patient develops severe pain on second postoperative day of mandibular 3rd molar disimpaction
    A. Hemorrhage
    B. Infection
    C. Dry socket
    D. Fracture of cortical plate

22. A 58-year-old man is attending surgery for extraction of his upper right canine and lateral incisor and his upper left second premolar and first molar, with insertion of an immediate partial denture. After extracting the teeth, you attempt to insert the denture but are unable to seat it. Which one of the following is the most likely cause of this problem?
    A. Bony undercut not blocked out
    B. Distortion of tissues by local anesthetic
    C. Failure to use a soft lining material
    D. Porosity introduced during processing of acrylic E Post-extraction swelling

23. A 45-year-old patient woke up with swollen face, puffiness around the eyes, and edema of the upper lip with redness and dryness. When he went to bed he had the swelling, pain or dental complaints. Examination shows several deep silicate restorations in the anterior teeth but examination is negative for caries, thermal tests, percussion, palpation, pain, and periapical area of rarefaction. The patient's temperature is normal. The day before he had a series of gastrointestinal x-rays at the local hospital and was given a clean bill of health. The condition is:
    A. Acute periapical abscess
    B. Angioneurotic oedema
    C. Infectious mononucleosis
    D. Acute maxillary sinusitis

24. A 65-year-old woman arrived for dental therapy. The answered questionnaire shows that she is suffering from severe cirrhosis. The problem that can be anticipated in the routine dental therapy is:
    A. Extreme susceptibility to pain
    B. Tendency towards prolonged hemorrhage
    C. Recurring oral infection
    D. Increased tendency to syncope

25. Patient received heavy blow to the right body of the mandible sustaining a fracture there. You should suspect a second fracture is most likely to be present in,
    A. Symphysis region
    B. Left body of the mandible
    C. Left sub-condylar region
    D. Right sub-condylar region

26. Cardiac patient came to dental office which signs and symptoms that commonly suggest Cardiac failure in him being assessed for oral surgery are,
    A. Elevated temperature and nausea
    B. Palpitations and malaise
    C. Ankle edema and dyspnea
    D. Erythema and pain

27. Patient with a cyst at the apex of an upper central incisor measuring 1 cm in diameter is visualized in radiograph and confirmed by aspiration biopsy; which method of treatment would you consider?
    A. Extraction of the central incisor and retrieving the cyst through the socket
    B. Exteriorizing the cyst through the buccal bone and mucosa
    C. Making a mucoperiosteal flap and removing the cyst through an opening made in the alveolar bone, followed by tooth removal
    D. Making a mucoperiosteal flap and removing the cyst through an opening made in the alveolar bone, followed by endodontic treatment

28. A 40 year aged patient with a persistent oro-antral fistula for a 12 weeks period following the extraction of a maxillary first permanent molar is best treated by
    A. Further review and reassurance since it will most probably heal spontaneously
    B. Antibiotic therapy and nasal decongestants
    C. Curettage and dressing of the defect
    D. Excision of the fistula and surgical closure

29. A patient complains of a stomach upset 48 hours after starting a course of antibiotic for severe pericoronitis of lower right impacted wisdom tooth, this is an example of,
    A. Type I allergic reaction
    B. Nervous disorder
    C. Side effect of the drug
    D. Type IV hypersensitivity reaction

30. A patient who is on long term aspirin therapy might show increased post-operative bleeding because aspirin inhibits:
    A. Synthesis of thromboxane A_2 and prevents platelet aggregation
    B. Synthesis of prostacyclin and prevents platelet aggregation
    C. Synthesis of prostaglandin and prevents production of blood platelets
    D. Thrombin and prevents formation of the fibrin network

31. A patient who has been taking warfarin came to oral surgery for a procedure, which of the following is not true about warfarin,
    A. INR of 3 is enough to start any extraction
    B. Affects extrinsic system and increases prothrombin time
    C. Heparin can be given subcutaneously and acts rapidly
    D. It takes at least 12 hours for Vitamin K to reverse the effects of coumarin

32. A 35 years old male patient came to oral surgery clinic with trigeminal neuralgia which of the following is NOT CHARACTERISTIC of trigeminal neuralgia?
    A. The pain usually last for few seconds up to a minute in the early stages of the disease
    B. The pain is usually unilateral
    C. Patient characteristically have sites on the skin that when stimulated precipitate an attack of pain
    D. An attack of pain is usually preceded by sweating in the region of the forehead

33. In a patient with impacted maxillary canine; by moving the X ray tube distally the canine moves distally too; where do you expect the impacted canine to be:
    A. Labially impacted
    B. Palatally impacted
    C. Lingually impacted
    D. In the maxillary sinus

34. An 8-year-old child presents with all permanent incisors erupted, but yet only three permanent first molars are erupted. Oral examination revealed a large gingival bulge in the unerupted permanent molar area. A panoramic radiograph showed the alveolar emergence of the unerupted permanent first molar crown and three fourth root developments, there are no other radiographic abnormalities. The most appropriate diagnosis and treatment plan in such situation would be:
    A. Dentigerous cyst; surgical enucleation
    B. Idiopathic failure of eruption, surgical soft tissues exposure
    C. Ankylosis of the molar, removal of the first molar to allow the second one to erupt into its place.
    D. Ankylosis of the molar, surgical soft tissues exposure and luxation of the molar

35. A young patient of 24 years came with alveolar abscess related to upper right central incisor. What is the best treatment for alveolar abscess?
    A. Endodontic treatment or extraction
    B. Incision and drainage
    C. Extraction
    D. Endodontic treatment

36. A patient 58 years old came to oral surgeon with rheumatoid arthritis the most common complication of TMJ
    A. Ankylosis
    B. MPDS
    C. Internal derangement
    D. Osteoma of condyle

37. A patient came to hospital following an accident with bilateral parasymphyseal fractures of the mandible the segment is displaced posterior under influence of
    A. Anterior belly of Digastric muscle, Geniohyoid and Mylohyoid muscles
    B. Masseter, Lateral Pterygoid and Medial Pterygoid muscles
    C. Buccinator, anterior and posterior belly of Digastric muscle
    D. Geniohyoid, posterior belly of Digastric muscle and Genioglossus

38. Patient with lupus erythematosus and on cortisone needs a surgical extraction of a tooth. What should the surgeon instruct the patient?
    A. Take half of the cortisone dose at the day of operation
    B. Double the cortisone dose at the day of operation
    C. Take half of the cortisone dose day before and at the day of operation and day after
    D. Double the cortisone dose day before and at the day of operation and day after

39. Patient presents with lateral sub-conjunctival hemorrhage, infraorbital step & diplopia on right side with inability to open mouth. It could be:
    A. Fracture subcondylar right side
    B. Fracture zygomatic right side
    C. Fracture Lefort II right side
    D. Fracture of the floor of the orbit

40. A patient presents bilateral infraorbital step, paraesthesia on left cheek region, with posterior gagging and mobility of maxillary complex at nasal bones. It indicates
    A. Bilateral fracture Zygomatic
    B. Bilateral fracture Lefort II
    C. Fracture Zygomatic left side with bilateral Lefort II
    D. Fracture bilateral sub condoyle & fracture Zygomatic left side

41. A 24-year- old patient presented with sub-conjunctival hemorrhage on medial & lateral side of eye & history of bleeding from nose and mouth with disturbed occlusion. On moving the maxilla, mobility was palpable at infraorbital margins only. It can be suspected to be fracture
    A. Lefort I
    B. Lefort II
    C. Lefort III
    D. Lefort II & fracture zygoma

42. A 58-year-old male patient complained of pain on right side of tongue, inability to protrude tongue, dysphagia, increased salivation & alteration in voice, one should suspect;
    A. Carcinoma of anterior tongue
    B. Carcinoma of posterior tongue
    C. Carcinoma larynx
    D. Carcinoma epiglottis

43. A hypertension patient having café-au-lait spots, hypoplastic maxilla & signs of mental deficiency presented with soft tissue mass on buccal mucosa, this should incite surgeon to investigate for:
    A. Neurofibromatosis
    B. Neurilemmoma
    C. Down syndrome
    D. Pierre Robion syndrome

44. If after extracting a mandibular tooth, one encounters bleeding due to an underlying haemangioma, the first step in treatment would be:
    A. Carotid artery ligation
    B. Inferior alveolar artery ligation
    C. Replacing the tooth in the socket
    D. Pressure packing

45. A 12-year-old patient had episodes of haemarthrosis but characteristically petechiae & ecchymosis were not seen. His BT & platelet count was normal. It is hematological picture of:
    A. Hemophilia A
    B. Thrombocytopenic purpura
    C. von Willebrand's disease
    D. Scurvy

46. A 12-year-old patient of thrombocytopenic purpura has to undergo minor oral surgery procedure; he should first be given:
    A. Packed red cells to improve oxygen carrying capacity of blood
    B. Fresh frozen plasma to provide coagulation factors
    C. Platelet-rich plasma to allow normal clotting
    D. None of above since his BT/CT should be normal

47. Following roadside accident, a patient presented with bleeding from ear and impaired hearing with sign of head injury, there could be a fracture of:
    A. Anterior cranial fossa
    B. Middle cranial fossa
    C. Posterior cranial fossa
    D. Mandibular fracture

48. A 15-Year-old otherwise healthy female patient presents at 1pm with a large, firm, brawny submandibular swelling on the right side. The patient has severe trismus, pyrexia and radiographs show a grossly carious lower right 6, the patient has some dysphagia but the tongue is not elevated, which of the following is/are indicated?
    A. Start antibiotics intramuscularly and drain the abscess under local anesthesia following admission a ward and medical care
    B. Start antibiotics intramuscularly and drain the abscess under general anesthesia following admission a ward and medical care
    C. Aspirate swelling and send to culture and sensitivity test to begin antibiotic therapy
    D. Give corticosteroids

49. A 29-year old patient taking 60mg hydrocortisone for the last one month, requires periodontal surgery:
    A. It should not be carried out.
    B. The dose should be halved and then surgery carried out.
    C. The dose should be doubled and then surgery performed
    D. NO change in dose should be made and surgery should be carried out

50. Patient with iron deficiency anemia came for extraction of impacted wisdom tooth. Which of the following would be a contraindication for such a procedure?
    A. HB = 7 mg/dl
    B. HB = 11 mg/dl
    C. HB = 12 mg/dl
    D. HB = 13 mg/dl

51. Healthy pregnant woman came for extraction of lower wisdom tooth and she went into syncope. Which of the following is the most common cause?
    A. Hypotension
    B. Hypertension
    C. High blood sugar
    D. Low blood sugar

52. A 60-year-old patient suffered injuries to his lower half of face that suggested mandibular body fracture on examination. What is the most appropriate way of management of such a patient where there is no presence of teeth?
    A. Gunning splint
    B. Cap splint
    C. Ribbon splint
    D. All of the above

53. Long term effect of radiotherapy to oral mucosa is characterized by:
    A. Epithelium becomes more keratinized
    B. Sub mucosa becomes highly vascular
    C. Break down & delayed healing, submucosa less vascular
    D. No sub mucosal fibrosis

54. Trauma to lower third of face is characterized by all of the following except.
    A. Fractures of the mandible are common at the angle of the mandible
    B. Fractures of the mandible are affected by the muscle pull
    C. Fractures of the mandible are usually characterized by sublingual hematoma
    D. CSF Rhinorrhea is a common finding

55. A decision was made to treat a mandibular body fracture with closed reduction using ivy-eyelet wiring technique. Such a fracture mandible should be immobilized for an average of
    A. 3 weeks
    B. 6 weeks
    C. 9 weeks
    D. 12 weeks

56. In a worldwide consideration which part of the mandible can be considered to be suffering traumatic fractures the most?
    A. Body
    B. Angle
    C. Symphysis
    D. Condyle

57. A six-year-old child fell from a height and it was noticed on CT scan that one of the cortices of his mandible was fractured while other one was almost intact. What kind of fracture can be said to have occurred in him?
    A. Displaced fracture
    B. Telescopic fracture
    C. Greenstick fracture
    D. Overlapping fracture

58. An 8-year-old child fell on his chin while playing football and mid-symphysis fracture of lower jaw was noticed. What is the treatment of choice in such a patient?
    A. Intermaxillary fixation
    B. Cap splint with circumferential wiring
    C. Open reduction
    D. No treatment indicated

59. Submandibular gland is known to open in floor of the mouth by various openings but one of them forms a major duct to carry out secretions, which one of the following is that?
    A. Bartholin's duct
    B. Minor salivary gland's duct
    C. Stenson's duct
    D. Wharton's duct

60. Which of the following complication may result from injury to auriculotemporal nerve during removal of parotid tumor is:
    A. Facial palsy
    B. Gustatory sweating
    C. Oro lingual paresthesia
    D. Anorexia

61. Duct for the parotid gland opens commonly in which region
    A. Upper 2nd molar
    B. Upper 3rd molar
    C. Lower 2nd molar
    D. Lower 3rd molar

62. Cross bar elevator which works on the wheel and axle principle has a mechanical advantage of
    A. 1.5 times the force applied
    B. 3 times the force applied
    C. 4.5 times the force applied
    D. 5.5 times the force applied

63. Which is the most preferred size of suture for skin sutures of face:
    A. 1/0
    B. 2/0
    C. 3/0
    D. 4/0

64. Person with known history of diabetes mellitus has been on medications for past 10 years and needs a surgical extraction of 38. What is the best way of managing such a patient on the day of surgery?
    A. Double the dose of Insulin
    B. Double the quantity of breakfast
    C. Usual dose of insulin and Breakfast
    D. To not take insulin and come nil per oral

65. A 23-year-old male patient started having epileptic attack following overdose administration of local anesthesia and was not subsiding. The agent of choice to reverse status epilepticus induced by local anesthetic overdose is?
    A. Phenobarbital
    B. Epinephrine
    C. Oxygen
    D. Diazepam

66. A 40-year-old patient with severe maxillofacial injuries presented to the emergency in an unconscious state, he has to be
    A. Immediately treated for maxillofacial injuries
    B. Immediately Glasgow coma scale should be assessed
    C. Immediately airway should be secured
    D. Immediately examine for any associated fractures

67. A young female patient presented with a history of trauma to the face following a road traffic accident. On examination flattening of cheek on the left side was observed suggesting zygomatic arch fracture. The suggested radiograph will be
    A. Occlusal view
    B. Facial Profile Survey
    C. Reverse - Towne Projection
    D. Submentovertex Projection

68. A patient with continuity defect of mandible due to segmental resection of mandible is reconstructed using anterior iliac crest graft. This graft is an example for
    A. Autogenous Corticocancellous bone graft
    B. Autogenous Cancellous bone graft
    C. Xenograft
    D. Alloplastic bone graft

69. A 60-year-old patient with mandibular fracture was admitted post operatively in the ICU following open reduction and internal fixation. He suffered from nosocomial pneumonia. The most commonly involved organisms are
    A. Gram positive organisms
    B. Gram negative organisms
    C. Mycoplasma
    D. Virus infections

70. A female patient with a huge swelling on the face is diagnosed with buccal space infection. The method of treatment is
    A. William's method of abscess drainage
    B. Hilton's method of abscess drainage
    C. Hilton's method of enucleation
    D. William's method of decompression

71. A child was diagnosed with cleft of lip and palate upon birth, the initial step in management is
    A. Nasoalveolar moulding
    B. Surgery for cleft lip
    C. Surgery for cleft palate
    D. No treatment till adulthood

72. A patient with deep soft tissue laceration on the right mandibular region of the face associated with displaced parasymphysis of the right side walked into the emergency.
    A. The soft tissue is closed with layered sutures, and the patient is posted for fracture reduction the next day.
    B. **The soft tissue debridement is done and stay sutures are placed. The patient is posted for fracture reduction the next day.**
    C. The patient is posted for surgery immediately for both soft and hard tissue management.
    D. The patient is treated with closed reduction for parasymphysis fracture and stay sutures are placed for soft tissue.

73. A 50-year-old patient with history of chronic alcoholism requires multiple extractions. Which of the following conditions will he be more prone for?
    A. Increased PTT
    B. Increased blood sugar levels
    C. Decreased PTT
    D. Decreased INR

74. A 30-year-old patient had a severe cardiac arrest on the dental chair. After how much time of total oxygen obstruction to brain, permanent neurologic damage can occur?
    A. 1 min
    B. 2mins
    C. 3mins
    D. 4mins

75. A patient with mild gnawing pain radiating around the right TMJ reported to our unit requesting extraction of upper and lower third molars of the right side. On examination, the muscles on the affected side were tender and the pain was radiating. Intraoral examination revealed fully erupted, non-carious upper and lower third molars in occlusion. The most probable diagnosis is
    A. MPDS
    B. Pericoronitis
    C. TMJ Dislocation
    D. Periapical disease of lower third molar

76. A 25-year-old patient with upper canine impaction gave a radiographic picture of canine placed horizontally in the palate. How do we classify this position?
    A. WHO Class I
    B. WHO Class II
    C. WHO Class III
    D. WHO Class IV

77. A 30-year-old patient had a hard swelling on the palate in the midline measuring around0.5 cm to 1cm. The swelling was painless on palpation and non-mobile. What is the most probable diagnosis?
    A. Lipoma
    B. Torus palatinus
    C. Fibroma
    D. Osteosarcoma

78. A 40-year-old female patient presented with a swelling on the right side of the forehead since many years, and is gradually growing in size. On examination, it was well circumscribed, soft, and not attached to the underlining structure. Slip sign was positive. What is your diagnosis and management?
    A. Sebaceous cyst, Aspiration of the contents
    B. Infected follicle, Antibiotics
    C. Lipoma, excision
    D. Hyperplastic frontalis muscle shaving

79. An 18-year-old female patient was diagnosed with a radicular cyst extending from left canine to right canine of the mandible. The preferred treatment is
    A. Segmental resection of mandible
    B. Marsupialization
    C. Electrocautery
    D. Cryotherapy

80. A 60-year-old female patient, who was on long term bisphosphonate therapy for multiple myeloma, underwent extraction of 34 and 35. Postoperatively the mandibular bone was exposed and painful, with halitosis, swelling, and oro-cutaneous fistula. This condition is
    A. Dry socket
    B. Osteonecrosis
    C. Osteoradionecrosis
    D. Osteomyelitis

81. A 34-year-old patient presented with nasal bone fracture and deviated nasal septum with a history of trauma during boxing. It can be reduced using
    A. Ashleys and Walshams forceps
    B. Ashleys and Rowes disimpaction forceps
    C. Walshams and Rowes disimpaction forceps
    D. Index finger and thumb

82. A 40-year-old male patient with multiple facial fractures (PAN FACIAL TRAUMA) reported to the emergency unit with respiratory distress. The best way to secure airway is
    A. Blind nasal intubation
    B. Oral airway
    C. Emergency tracheostomy
    D. Mouth to mouth breathing

83. A 21-year-old female patient complained of large swelling on the right side of the face extending to neck, following the access opening of right lower second molar the previous day. Most likely she developed
    A. Abscess of submandibular space
    B. Cellulitis
    C. Chemical burn
    D. Allergic condition

84. A 25-year-old female patient presented with drooping of upper eyelid, drooling of saliva and inability to close the eye on the left side of the face following parotidectomy of the left side. The reason could be
    A. Injury to facial nerve
    B. Injury to trigeminal nerve
    C. Injury to parotid gland
    D. Injury to optic nerve

85. Following road traffic accident, a 50-year male patient presented with disturbed occlusion, ecchymosis in the greater palatine foramen region, ecchymosis in the buccal sulcus and mild mobility of the maxillary segment. And no tenderness over the nasal bridge or frontozygomatic suture region. The clinical diagnosis will be
    A. Dentoalveolar fracture
    B. Lefort I fracture
    C. Lefort II fracture
    D. Lefort III fracture

86. A 35-year-old female patient required extraction of left upper molars, but since she presented with exophthalmos, tremors and increased blood pressure the operating surgeon suspected
    A. Hypertension
    B. Hyperthyroidism
    C. Hypothyroidism
    D. Adrenal crisis

87. A 45-year-old male patient was ambulated to the emergency in a semiconscious state. He was diagnosed with mandibular, zygomatic and femoral fracture. Which of the fracture should be addressed first?
    A. Mandibular fracture
    B. Zygomatic fracture
    C. Femoral fracture
    D. Treatment should be postponed till he gains consciousness

88. A female with maxillofacial injuries was ambulated to the emergency following road traffic accident. She had feeble pulse, fall in blood pressure and tachycardia indicating hypovolemia. The circulatory volume should be immediately compensated with
    A. Blood of the same group
    B. Crystalloids
    C. Colloids
    D. Universal blood group

89. A patient with bilateral parasymphysis fracture of the mandible presenting with respiratory distress. The most likely cause will be
    A. Blood clot in the mouth
    B. Tongue falls back and obstructs the airway
    C. Soft palate obstructs the airway
    D. Hyoid bone is compressed

90. In a patient with bilateral parasymphysis fracture of the mandible presenting with respiratory distress the immediate measure taken to maintain airway is
    A. Pull the tongue with suture or towel clip
    B. Emergency tracheostomy
    C. Emergency cricothyroidectomy
    D. Jaw thrust method

91. While extracting a maxillary premolar the buccal root of the tooth got fractured, while trying to retrieve the root, it vanished from the socket. On radiograph the maxillary sinus was clear. Which is the next possible location for the root to escape
    A. Palatal space
    B. Buccal space
    C. Nasal cavity
    D. Orbital cavity

92. A young male patient was diagnosed with communited fracture of mandible. The ideal method of fixation is
    A. 2.5 mm plate
    B. 1.5 mm plate
    C. Dynamic compression plates with eccentric holes
    D. Reconstruction plates with central holes

93. A young female patient complained of painless swelling on the right side of the mandible which gradually increased in size. Histology revealed abnormal fibrous connective proliferation in which new non-maturing bone is seen, replacing the normal bone. The treatment is
    A. Enucleation of the lesion
    B. Bone shaving
    C. Mandibulectomy
    D. Radiation

94. A patient with suspected central giant cell granuloma was advised to check his levels of parathyroid hormone to rule out
    A. Primary hyperparathyroidism
    B. Primary hypoparathyroidism
    C. Primary hyperthyroidism
    D. Primary hypothyroidism

95. Which of the following is false?
    A. Gingival and palatal cyst of newborn is derived from dental lamina
    B. Epstein's pearl is found along the mid palatine suture
    C. Bohn's nodules are found along the mid palatine suture
    D. Palatal cyst of newborn persists into adult life

96. Which of the following glands is both endocrine and exocrine in nature?
    A. Pancreas
    B. Thyroid gland
    C. Sweat gland
    D. Pituitary gland

97. Which of the following GA agent is contraindicated in severe coronary artery disease
    A. Ketamine
    B. Fentanyl
    C. Thiopentanyl
    D. Xylocaine

98. Glenoid fossa is found in:
    A. Orbital cavity
    B. Nasal cavity
    C. Middle cranial fossa
    D. **Temporal bone**

99. After you inject LA for maxillary 2nd molar, the patient's face becomes colorless with an extraoral swelling. Its due to:
    A. Facial artery
    B. Plexus of vein
    C. Posterior alveolar nerve
    D. Maxillary artery

100. Patient reports to the clinic with the history multiple lesions of the Head and neck manifested as nevi with is the most probable diagnosis?
    A. Peterson Kelly syndrome
    B. vander Woude syndrome
    C. Eagle syndrome
    D. Albright syndrome

101. All the following are examples of diseases causing aplastic anemia, EXCEPT:
    A. Hepatitis
    B. Pregnancy
    C. Cold hemoglobinuria
    D. PNH

102. A 5-year-old child came to the set up with an avulsed tooth. What is the most important factor that affects reimplantation of avulsed tooth
    A. Time since the avulsion
    B. Skill of dentist
    C. Contaminated roots
    D. Patient age

103. An increase in shear stress in a blood vessel results in which of the following changes?
    A. Decreased endothelin production
    B. Increased nitric oxide
    C. Increased rennin production
    D. Decreased prostacyclin production

104. Which of the following patterns is the characteristic of the response to nerve stimulation produced by a depolarizing neuromuscular agent
    A. A Lack of fade in response to train of four
    B. Increase in post-tetanic stimulation
    C. Tetanus is associated with fade in muscle response
    D. Fourth twitch of TOF disappears with 60-70% receptor occupancy

105. Drainage of tip of the tongue:
    A. Sub lingual lymph nodes
    B. Submental lymph nodes
    C. Submandibular lymph nodes
    D. Parotid lymph nodes

106. Base of the flap should be wide for:
    A. Healing
    B. For better suture placement
    C. Better blood supply to the wound.
    D. Nothing relevant

REFERENCES

Bagheri, S. C. (2014). *Clinical review of oral and maxillofacial surgery: A case-based approach*.

Balaji s. M. (2018). *Textbook of oral & maxillofacial surgery*. S.l.: Elsevier India.

Birn, H., & Winther, J. E. (1982). *Manual of minor oral surgery: A step by step atlas*. Copenhagen: Munksgaard.

Contemporary Oral and Maxillofacial Surgery. James R, Myron R, Edward Ellis. 6th Edition. Mosby; 2014.

Fonseca, R. J., Marciani, R. D., Turvey, T. A. (2009). *Oral and maxillofacial surgery*. St. Louis, Mo: Saunders/Elsevier.

Hupp J. (2019). *Contemporary oral and maxillofacial surgery*. S.l.: Mosby.

Kruger, G. O. (1984). *Textbook of oral and maxillo-facial surgery*. Saint-Louis: Mosby.

Laskin, D. M. (2009). *Oral and maxillofacial surgery*. Delhi, India: A.I.T.B.S. Pub.

Malik, N. A. (2012). *Textbook of oral and maxillofacial surgery*.

Medical Emergencies in the Dental Office. Stanley Malamed. 7th Edition. Mosby. 2014.

Scully, C. (2014). *Scully; medical problems in dentistry*.

Textbook of Oral and Maxillofacial Surgery. B Srinivasan. 2nd Edn. Elsevier Science. 2015.

In: Encyclopedia of Surgery (22 Volume Set)
Editors: Andreas Lehrer and Kristin Mueller
ISBN: 978-1-53618-329-0
© 2020 Nova Science Publishers, Inc.

Chapter 102

THE ROLE OF SURGERY IN THE TREATMENT OF OSAS

F. Lorusso*, MD, A. Battaglia, MD,
A. Mistretta, MD and S. Gallina
Unit of Otolaringology, Department of Experimental Biomedicine and Clinical Neurosciences, Polyclinic University Hospital "Paolo Giaccone", University of Palermo, Via del Vespro, Palermo, Italy

ABSTRACT

The American Academy of Sleep Medicine [1] and the American Academy of Otolaryngology–Head and Neck Surgery [2] recommend surgery as an option for the treatment of OSAS, when non-invasive treatments such as CPAP or oral appliances have not been successful or are not tolerated. Surgical treatment is more effective when there is an evident anatomical deformity that can be corrected to alleviate the respiratory obstruction.

According to the American Sleep Apnea Association, a gradual and logical approach must be taken into account when a patient seeks a surgical solution, and it is a fundamental requirement that the patient find a surgeon who understands both the pathophysiology of sleep apnea and anatomy of the upper airways (UA) to guarantee the best chances of success [3].

The surgical options aim to solve the obstructive problem according to two ways, the first is the reduction of the content, and then acts through the volumetric reduction of soft tissues at the level of UA, most often at the level of palate, uvula, tonsils, adenoids and tongue. The second option aims at enlarging the container, and therefore on more complex interventions to adapt the bony structures of the skull.

Surgical interventions can be schematically divided into nasal surgery, oropharyngeal surgery, hypopharyngeal surgery, laryngeal surgery, multilevel surgery and upper airway by-pass.

The soft palate in the snore-surgery is the anatomical site on which most of the attention has always been concentrated since it is responsible for most of the phenomena of snoring and most of the obstructive ones and has undergone the greatest innovations.

* Corresponding Author's Email: dott.francescolorusso@gmail.com.

The rationale for palatal surgery is to reduce volume and stiffen a structure that vibrating with the passage of air causes snoring and collapsing causes an obstruction of the UA.

In general, interventions on the palate can be broadly divided into two groups, the first is represented by interventions that have the aim of reduce snoring, and in this case are less invasive surgeries, as the goal is that of stiffening the palate and reducing the excess mucosa that vibrating causes snoring.

The second group consists of interventions that have the aim of reducing above the snoring especially the apnoic episodes, so they are interventions that have a greater invasiveness, since they must stiffen and reconstitute the functionality of a segment of the UA.

In this context, in the last few years great importance has been placed in the surgeon of the oropharynx side wall starting from the Cahali techniques [4], followed by the Exphansion Sphincter Pharingoplasty by Pang and Woodson [5] up to the innovative techniques such as the Barbed Reposition Pharingoplasty of Vicini and Mantovani [6].

SURGICAL TREATMENT

The American Academy of Sleep Medicine [1] and the American Academy of Otolaryngology–Head and Neck Surgery [2] recommend surgery as an option for the treatment of OSAS, when non-invasive treatments such as CPAP or oral appliances have not been successful or are not tolerated. Surgical treatment is more effective when there is an evident anatomical deformity that can be corrected to alleviate the respiratory obstruction.

According to the American Sleep Apnea Association, a gradual and logical approach must be taken into account when a patient seeks a surgical solution, and it is a fundamental requirement that the patient find a surgeon who understands both the pathophysiology of sleep apnea and anatomy of the upper airways (UA) to guarantee the best chances of success [3].

The surgical options aim to solve the obstructive problem according to two ways, the first is the reduction of the content, and then acts through the volumetric reduction of soft tissues at the level of UA, most often at the level of palate, uvula, tonsils, adenoids and tongue. The second option aims at enlarging the container, and therefore on more complex interventions to adapt the bony structures of the skull.

Fundamental assumptions are:

- the patient must be highly motivated and must express the desire to carry out the treatment,
- treatment should not damage the patient and after any treatment nasal ventilatory therapy should remain possible,
- surgical treatment must be planned according to the patient's specific anatomical characteristics and the severity of the syndrome.
- As with all other treatment modalities, there is no surgical intervention that can guarantee a certainty of a stable result over time.
- More serious is the OHSAS, more complex and challenging it is the effective intervention.

- In any case we will try to opt for the minimum effective solution able to manage the severity of the complained disorder.

Nasal surgery
- Septoplasty
- Functional rhinoplasty, nasal valve surgery
- Turbinate surgery
- Adenoidectomy
- Nasal polypectomy
- Endoscopic procedure

Oropharyngeal surgery
- Tonsillectomy
- Palatal surgery (uvulectomy and pharyngoplasty)
- Minimally invasive surgery (RF, pillar, sclerotherapy)

Hypopharyngeal surgery
- Hyoid suspension
- Lingual surgery (tongue reductions, glossectomies and TORS)
- Advancement of genioglossus
- Mandibular advancement

Laryngeal surgery
- Epiglottectomy
- Supraglottoplasty

UA by-pass
- Tracheostomy

Global procedures
- Bi-maxillary advancement
- Multilevel surgery
- Bariatric surgery

NASAL SURGERY

The relationship between sleep disorder breathing (SDB) and nasal function is complex, in fact the nose is not only an obstructive site, but it also has considerable influence on the most downstream sites because a difficult nasal breathing creates an increase in negative pressure at the level of the pharyngeal tract it is more collapsible. If the obstruction is such that it does not allow an adequate air flow, it causes the necessary passage to oral breathing, with consequent worsening of the obstruction linked to the lingual and hypopharyngeal component.

There are many interventions aimed at improving nasal breathing, but none of these is considered alone as osas surgery, as the improvement of nasal breathing can also drastically reduce the signs and symptoms associated with SDB, but in most cases the benefit is partial.

- Septoplasty
- Decongestion of inferior turbinates
- Turbinoplasty
- Polypectomy or endoscopic surgery
- Functional rhinoplasty, nasal valve surgery

The results on snoring are often controversial and are also difficult to interpret because often there is an improvement of the noise, since they reduce the constrictions and the vortical flows at the nasal level responsible for the nasal snoring. But in other cases there may be a worsening of the symptomatology due to the greater vibration of the soft tissues of the most downstream sites linked to the greater air flow established thanks to the surgery.

Usually the improvement of nasal breathing is associated with an improvement in the quality of sleep and daytime vigilance. The results on the OSAS are however partial and aleatory.

Only Rubin and coll. [7] in their study achieved a significant improvement in OSAS severity only with nasal surgery, while remaining far from the parameters of surgical success. In subjects with mild OSAS, nasal tamponade is usually not a problem. But in patients with moderate to severe OSAS, nasal tamponade can precipitate respiratory failure in post-surgery. Therefore, in these cases it would be appropriate to use medications that allow nasal breathing through appropriate channels. The most risky period is represented by the first 6 hours post-surgery [7], therefore in this period the patient should be constantly monitored. In subjects with severe OSAS who have already undergone CPAP therapy and who must necessarily receive post-operative nasal tamponade, it is recommended to resume post-operative CPAP therapy immediately, either with a facial mask or an oral mask.

The importance of nasal surgery in improving nCPAP compliance should not be forgotten [8].

Friedman et al. [9] in a group of patients undergoing septoplasty and lower turbinoplasty reported a reduction in CPAP pressure required to resolve OSAS from 9.3 mbar to 6.7 mbar. Dorn and coll. [10] showed a reduction in CPAP of 3.2 mbar, 6 weeks after nasal surgery.

Rhinopharyngeal Surgery

If an obstacle is detected, its ablation is indicated here, but assumptions and expectations are similar to those of nasal surgery. The most frequent causes are adenoid hypertrophy and rarely antrocoanal polyps in children, while in adults there are rarely obstructions at this level. Should this occur, attention must be paid to the risks of scarring stenosis in case of a contemporary adenoidectomy to palatal surgery, in fact it is not recommended by many authors to make it in a single time.

In children, adenoid hypertrophy contributes to the determinism of childhood SDB. But adenoidectomy is not sufficient to solve the OSAS problem, but together with tonsillectomy it

is considered the primary therapy for the resolution of infant SDB. [11] Adenoidectomy is to be considered only in simple snoring in fact it is known in children a strong relationship between the adenoid dimension and snoring [12, 13]. Nieminen et al. [14] in a prospective non-randomized controlled trial evaluated with PSG a group of children subjected to adenoidectomy before and after surgery, 73% of these did not resolve the obstructive problem or symptoms started after adenoidectomy, probably due to compensatory tonsil hypertrophy.

Oropharyngeal Surgery

The oropharynx is the anatomical site with the most important role in the ronco-surgery as it is located at the carrefour between the oral and nasal respiratory tract, and it is mostly at this level that due to the considerable presence of loose structures there is the greatest influence on the obstruction of the UA.

Therefore, the objectives of the ronco-surgery at this level are two [15]:

1. Reduction/abolition of vibrating tissue responsible for snoring;
2. Reduction/abolition of the obstructing tissue responsible for RERAs, hypopneas and apnea.

Tonsil Surgery

Child's Tonsillar Ronco-Surgery

Tonsillar hypertrophy is the main cause of OSAS and snoring in the pediatric population [16-18]. The age of less than three years, neurological and maxillofacial comorbidity are to be assessed with care and caution for an increased post-operative risk and for a greater share of failures. The opportunity for post-operative monitoring in pediatric intensive care units should be considered in this group of patients.

Various techniques have been developed that can be basically divided into two basic types of intervention:

- *Tonsillotomy or tonsillar volumetric reduction:* which consists in reducing the volume of the tonsils, with preservation of their capsule, which can be performed with various instruments such as coblator, microdebrider, radiofrequency. This technique appears to be burdened with a lower risk of post-operative bleeding [19]. But it presents the risk of recurrence of hypertrophy.
- *Tonsillectomy*: which consists in the complete removal of the tonsil with its capsule, it can be performed with cold techniques or with hot techniques [20]. These latter techniques are burdened from a slightly higher risk of post-operative late hemorrhage 2-4%, compared to 1-2% of cold techniques [21].

The almost total disappearance of night snoring after adenotonsillectomy in children is widely known, but there are only a few studies to prove it.

The work of Hultcranz et al. Is interesting in this regard [22] that in a randomized study compared the effectiveness on tonsillectomy and tonsillotomy snoring after one year, showing

a 9.5% recurrence of snoring in the group of patients undergoing tonsillotomy, suggesting a possible relapse hypertrophy.

Adenotonsillectomy is considered the first line treatment in the treatment of pediatric OSAS [2, 15, 24-27].

Brietzke [28] in his meta-analysis has shown how obesity is a fundamental factor in the determinism of the presence of post-surgical OSAS residue. Finding an AHI> 5 sleep events/hour in 59% of obese children subjected to adenotonsillectomy. And highlighting as predisposing factors in the maintenance of a post-operative high AHI age> 7 aa, the presence of asthma and a severe preoperative OSAS, in all these cases the child must undergo post-operative polysomnography, to evaluate the possible presence of residual OSAS.

In an attempt to reduce post-operative pain, various devices have been developed, which in most cases aim to achieve the simplicity of a tonsillectomy with hot instruments while maintaining contained temperatures of use. From this point of view we conducted a comparative study between tonsillectomy for cold dissection and tonsillectomy with Molecular Quantum Resonance, results showed a saving in surgical time and a significant reduction in intra-operative bleeding, although not having significant results with regard to post-operative pain that was substantially overlapping [20].

Adult's Tonsillar Surgery

The hypertrophic palatine tonsil is a significant obstacle at the VAS level, easily eliminated with relatively rudimentary surgery, but usually this is not sufficient to completely solve the snoring and OSAS problem. As evidenced by Tzifa and coll. [29] tonsillectomy in children does not reduce the risk of becoming snoring adults. Rarely in the surgical treatment of snoring and OSAS is it limited only to tonsillectomy, but when this procedure is performed within a multisite procedure the contribution of tonsillar time to overall success appears to be relevant. This is also due to the fact that an important tonsillar hypertrophy is rare in the adult subject, but when this happens the tonsillectomy has a success rate similar to that of the pediatric age.

Tonsillar Volumetric Reduction Radio-Frequencies

The principle consists in the submucosal application of low frequency radio waves. It is used as an interstitial treatment, with an electrode that is inserted into the soft tissue of the tonsil creating a thermal lesion that causes necrosis and is followed by successive cicarizial processes. As a consequence, the soft tissue shrinks and stiffens. [19, 30].

Palatal Surgery

The soft palate in otolaryngology surgery is the anatomical site on which most of the attention has always been concentrated since it is responsible for most of the snoring phenomena and a good part of the obstructive ones.

The rationale of palatal surgery is to reduce volume and stiffen a structure that vibrates with the passage of air causing snoring and collapsing causes an obstruction of the UA.

Generally, interventions on the palate can be broadly divided into two groups, the first is represented by treatments that aim to reduce snoring, and in this case they are less invasive surgical interventions, as the goal is that of stiffening the palate and reducing the excess mucosa that vibrates, causeing snoring. The second group is made up of the treatments that

aim to reduce the apnoic episodes above snoring, therefore they are surgical interventions that have a greater invasiveness, since they must stiffen and rebuild the functionality of a segment of the UA.

- Treatment of Snoring

Uvulectomy

In literature there are few results regarding the uvulectomy as a single surgical treatment for the treatment of snoring. It is a very painful procedure and is not recommended, except for removing the exuberant mucosa, especially if you are going to resect the muscular component of the uvula. As demonstrated by Mortimore [31], mere resection of the uvula increases oral bleeding in patients undergoing CPAP.

Radiofrequency (RF) Snoreplasty

In 1995 Whinney et al. suggested a procedure considered to be a precursor to soft palatal RF, using diathermocoagulation of the palatal muscles by infixion [23]. The use of RF has made it possible to considerably reduce thermal damage. The procedure is usually performed under local anesthesia with the patient in a sitting position. But it can also be associated with other nasal procedures or tonsillectomy and is therefore performed in the context of a general anesthesia.

There are numerous studies on the effectiveness of RF on snoring with an average improvement of about 82.4%. The most frequent complications are burn, erosion and ulceration of the lining mucosa. This phenomenon, however, besides causing a greater post-operative pain, usually does not affect the final result since, if the lesion is only on the ventral side of the palate, it creates a greater scarring reaction that makes the palate more rigid. On the other hand, excessively deep thermal lesions that cause damage to the mucous membrane of the dorsal side of the palate are to be avoided, causing an alteration of the healing dynamics.

Certainly effective on simple snoring, it can also be effective in mild OSAS, both as a single technique on the palate and in a minimally invasive multilevel surgery.

Injection Snoreplasty

The rational is similar to that of the RF, only that instead of the thermal stimulus, sclerosing substances are used to induce the formation of scars on the palate. Introduced for the first time in 2001 by Brietzke [33], initially using a 3% solution of sodium tetradecyl sulfate (STS). Provided after local anesthesia at sub-mucosal level, and within a few weeks the mucosa undergoes healing. Transient improvement in snoring has been reported.

Palatal Implants

They consist of small polyethylene splints (PET) similar to that used for vascular endoprostheses or gastric meshes. Three of these are applied under local anesthesia thanks to a special applicator in the context of the palatal musculature, stimulating a fibrotic reaction that creates a capsule around the implant with the aim of stiffening the palate reducing its vibration.

The technique has been virtually abandoned in the light of poor clinical results encountered and of the rare, but still detected episodes of implant expulsion with a percentage from 0 to 25% [34].

Velo-Uvulo-Pharyngeal Lift (VUPL)

In 2008 Hur [35] proposed a technique of snoreplasty based on the stiffening of the redundant soft tissues of the soft palate through the trans-mucosa introduction of permanent sutures through the fibro-muscular plane of the palate. This study achieved poor results on the OSAS, but highlighted the perfect tolerability of these sutures, already widely used in plastic surgery, at the palatal level, allowing to obtain the desired modifications in the fibro-muscular tissues surrounded by the sutures. In 2012 Mantovani and coll. [36], have developed a new palatal lifting technique using non-resorbable sutures, the so-called "Roman blinds" technique. This has the aim not only to make the veil-uvular complex rise and stiffen, but also making it advance also widens the mesopharyngeal space to eliminate the noisy vibrations or occlusions. The technique involves the use of non-absorbable 2-0 sutures that are anchored with different passages to three bony structures (the two pterygoid hamuli, and the posterior nasal spine), through a small mucosal incision and then in a loop inside the palatopharyngeal fibro-muscular tissues. The side effects of the technique were limited to post-operative pain that disappears rapidly within a few days. Subsequently the technique has been further implemented [37] with the use of barbed wires (QUill ® Knotless Tissue Closure Device, Angiotech Pharmaceutical inc., Vancouver, CA), normally used in vascular surgery, which do not require knots, as they are self-locking and allow you to get new geometries.

- Treatment of Apnea

The first plastic coded intervention of the soft palate was described for the first time by Ikematsu in 1963, since then numerous interventions have been proposed that aim to reduce the excess components of the soft palate tissue, without compromising the swallowing and phonatory functions. In fact the palatoglossus muscle (anterior palatal pillar) contains within it neuro-muscular spindles, playing an important role in swallowing and therefore must be preserved together with the muscle of the uvula.

While the glossopharyngeal muscle (posterior palatal pillar) has no neuro-muscular spindles, therefore, it can be partially dissected without hindering swallowing or the possibility of a future nasal ventilatory therapy (nCPAP). In fact, an excessive resection of the palatal musculature creates serious difficulties in the application of nCPAP due to oral venting. A fundamental prerequisite of palatal surgery is the implementation of techniques that make it possible to maintain CPAP in any case as a therapeutic alternative in the event of failure.

Indications and contraindications are similar for all palatal interventions to reduce apnea.

Indications for exclusive palatal intervention:

- Hypertrophic and elongated uvula (dolico-mega-uvula)
- Palatine Ptosis
- Thick palate
- Tonsillar hypertrophy

- Restricted oropharyngeal isthmus
- Plication of the pharyngeal walls
- BMI <30
- AHI <20 or simple snoring

Absolute contraindications of palatal surgery

- Cleft palate
- Short palate
- Insufficient oral opening, interdental distance <3 cm (small operating field)
- Chronic cardiac or pulmonary disorders
- Neurological or psychiatric disorders requiring pharmacological treatment
- High anesthetic risk
- Alcoholism
- Sedative abuse
- Skull facial anomalies

Contraindications to treatment with palatal surgery only

- Obesity: generally represents a negative selection criterion. But only palatal intervention with BMI> 30 is contraindicated
- severe OSAS, AHI> 30 also 20 according to some authors
- Retrognathia or micrognathia (usually lingual back obstruction)
- Severe occlusal or temporomandibular joint dysfunction (oral opening <3cm)
- High distance between the hyoid and lower edge of the jaw

Relative contraindications of palatal surgery

- Professional use of the voice
- Wind instrument players
- Scuba diving activities (possible problems of tubal compensation)
- Professional use of taste

Uvulo Palato Pharyngoplasty (UPP or UP3)

The original technique was first described by Ikematsu in 1963, since then numerous variants have been proposed, as long as UPPP is to be considered as a group of procedures.

The first UPPs included a very aggressive resection of the soft palate with frequent complications such as velo-farinea insufficiency 24% [38], 4% nasopharyngeal stenosis [39] and frequent failure to use nCPAP due to oral venting [40]. Therefore these techniques have been globally abandoned.

UPP is effective in the resolution of snoring of velar origin.

Hassid et al. [41] have recently described a decrease in success rates with increasing follow-up periods.

A polysomnographic follow-up is recommended after 1-3 aa. From the data it is clear that the effectiveness of UPPP decreases over the years. Using the Sher success criteria as a parameter (AHI reduction> 50% and values <20) [42], a long-term success rate of 49.5% is achieved.

According to the AASM in patients with moderate-severe OSAS, UPPP with or without tonsillectomy does not allow a normalization of the AHI therefore should be proposed only after a manifest refusal of treatment with CPAP or oral appliances [43].

The effectiveness of the surgery is not proportional to the size of the resection while the side effects and risks are directly proportional to the size of the resection [15].

Mortimore [31] has shown that an aggressive resection of the velar muscles during UPPP does not allow the application of nCPAP at pressures greater than 13 cm of H2O.

Excessive aggression on the side walls and post-operative infections are the main cause of nasopharyngeal strictures.

Uvulo-Palatal Flaps

Palatal flaps are generally an interesting alternative to UPPP and are indicated for primary snoring and mild to moderate OSAS. Post-operative pain is less than UP3. The operation is always preceded by tonsillectomy, in the case of tonsillectomized patients unlike UPPP the scar tissue should not be removed to highlight the pharyngeal palate muscle that should not be dissected here. The tip of the uvula must be pulled down and an incision is made about 2 cm away from the contact point represented by the junction between the hard palate and the soft palate. At this point part of the redundant mucosa is removed at the level of the anterior aspect of the soft palate together with the distal part of the muscle of the uvula, making a posterior mucous flap which, depending on the techniques, may have a rectangular or triangular shape.

This is in turn tipped forward and sutured to the edges of the incision. Depending on the techniques, more or less abundant resections of the uvula or incisions of the soft palate can also be performed. Then the two palatine pillars are sutured together if tonsillectomy was performed. This flap must have an adequate thickness in so as to avoid that the new palate is excessively thick. A possible dehiscence of the sutures creates functional and subjective difficulties. The duplication of the flap on a palate is often not without functional and subjective problems.

There are few data in the literature regarding the treatment of snoring, while there is some study about the treatment of OSAS, but from the limited data available and the extreme similarity of the technique to the more conservative UPPP is possible to assume that they have comparable results.

Laser Uvulopalatoplasty (LUPP) and Laser Assisted Uvulopalatoplasty (LAUP)

The LUPP introduced by Carenfelt [44] in the late 1980s was similar to classical UPPP under general anesthesia, but used the CO2 laser for incisions. In 1990 Kamami [45] completely modified the technique, developing a procedure under local anesthesia in several sessions called LAUP. This technique in the 90s due to its simplicity of application has quickly taken off in Europe and the USA, with the appearance of innumerable variants. In general, the technique involves two paramedian incisions of the palate, at full thickness, from both sides of the uvula with a height of 1-2 cm. And a total or partial uvulectomy. The technical variants include variants in which the intervention was performed in a single step and variants performed in different sessions. Subsequently some authors, given the scarce results obtained and the frequent complications, started to develop more conservative techniques on the palatal musculature, removing only the mucosa at the palatoglossus muscle

level, while the uvula and the posterior pillar were treated as in the LUPP or LAUP [46]. From the results obtained, the LAUP was less effective than UPPP in the reduction of snoring, nocturnal awakenings, daytime sleepiness and apneas. It is also a very painful technique and in multi-step procedures about 20% of patients refused to undergo another session because of pain [22]. Furthermore the complications were very frequent.

Therefore, due to poor results and frequent side effects from the early 2000s, LUPP and LAUP are not recommended as surgical procedures. In 2001, the Standards of Practice Committee of the American Academy of Sleep Medicine issued some guidelines regarding the LAUP advising against its use [23].

Lateral Pharingoplasty (LP)

It is the first technique to pay significant attention to the role of the lateral wall of the pharynx in the determinism of the OSAS. Developed by Cahali [32] in 2003 it has as a fundamental premise the stiffening of the lateral wall of the pharynx. In fact the obstruction linked to the lateral walls of the pharynx is the only risk factor, besides BMI and neck circumference, which acts independently in the determinism of the OSAS in man [48].

Cahali in the indications inserted the presence of at least two of the following characteristics:

- Lateral peritonsillar narrowing (defined as the size of peritonsillar tissues greater than 25% of the pharyngeal space, calculated as the internal distance of the mandible measured in the middle of the tonsillar fossa);
- tonsillar hypertrophy (defined as lateral bulkiness of the tonsils greater than 50% of the distance between the posterior tonsillar pillars);
- ptosic soft palate (which does not allow visualization of the posterior pharyngeal wall).

In addition to these assumptions, the subjects had to present to the fiber optic pharyngoscopy a narrowing or collapse in the retropalatal region without narrowing in the hypopharynx, both at rest and during the Müller maneuver.

The first step of the surgical procedure is tonsillectomy with identification of the palatoglossus and palatofaingeo muscle. Then they identify and raise the fibers of the upper constrictor muscle of the pharynx at the level of the tonsillar fossa, as far as possible from the glossopharyngeal. Once detached from the lateropharyngeal space, the upper pharynx constrictor is sectioned in a cranio-caudal direction obtaining two muscular flaps. The medial flap is left in situ, while the lateral flap is sutured anterior to the palatoglossus muscle. Then a Z-plastic is made between the mucosa of the anterior aspect of the soft palate and the upper portion of the palate-pharyngeal muscle, covering the upper part of the tonsillar fossa, while the lower part of the loggia is closed by suturing the remaining part of the pharyngeal palate muscle to the anterior pillar.

With the suspension to the palatoglossus muscle Cahali tries to give support to the oropharynx and the tongue. While with the Z plastic, he tries to orient the scar retraction laterally.

The technique has several side effects such as persistent pain, reflux of fluids from the nose. But the main complication due to the section of the upper pharyngeal constrictor is lasting dysphagia especially for solids.

In a subsequent article Cahali [48] reports the improvement of post-operative swallowing recovery with the preservation of the stylopharyngeal muscle that was frequently sacrificed. But the main risk is related to the section of the upper pharynx constrictor is the exposure of the parapharyngeal space with its important neuro-vascular structures.

Expansion Sphincter Pharyngoplasty (ESP)

Even ESP is based on the fundamental concept that at pharyngeal level the obstruction linked to the collapse of the lateral walls of the pharynx plays a fundamental role. This technique was developed by Pang and Woodson in 2007 [49], and is currently one of the most applied pharyngoplasty, even by our group [50], since it is effective and less invasive than lateral pharyngoplasty.

The main indications are:

- Predominantly lateral pharyngeal collapse
- Wide and thick posterior pillars
- Thick soft palate

It has specific contraindications, in addition to the general ones for palatal surgery, in the event of:

- Absence of lateral pharyngeal collapse
- Tonsillary pillars fused together
- Very thin soft palate
- Scar palate

The first step of the surgery consists in bilateral tonsillectomy with identification of the palato-glosso and palato-pharyngeal muscle and preservation of the covering mucosa. The palato-pharyngeal muscle is then isolated from the surrounding tissues, preserving the fibers of the upper pharyngeal constrictor. At this point, two ligatures are placed at the level of the distal margin of the muscle, to keep the muscle fibers together and to ensure better hemostasis, since the muscle is sectioned downwards creating a superior hinged muscle flap, in part connected to the upper constrictor of the pharynx.

At this point, the original technique involves an incision of the palato-glossus muscle fibers at the palatine arch plane and the suture of the distal portion of the flap at this level, and the subsequent suturing of the superficial mucous planes. In our experience this passage was modified by creating a tunnel with a klemmer forceps in the context of the soft palate with a 45° angle in the direction of the pterigoid hamulus, tipping the muscular flap inside the tunnel and fixing it with two resorbable stitches in position, obtaining an antero-lateral palate stretching [50]. At this point the palatine pillars are joined with a resorbable suture. A partial uvulectomy is performed depending on the laxity of the uvular mucosa.

Patients are monitored post-operatively for a few hours with pulso-oximetry and an adequate pain therapy is administered, since for the first post-operative week there is pain on swallowing.

Pang et al. do not report complications such as reflux of fluids from the nose or palatal insufficiency, palatal fistulas or oral infections. Which did not even occur in our experience. But unlike the author we reported 2 cases of post-operative haemorrhage, occurring in the first operations, probably linked to the inevitable learning curve.

The key points of the surgery are:

- The increased space at the transverse level at the level of the pharynx both for the removal of the tonsils and for the dislocation of the palato-pharyngeal muscle
- The incomplete isolation of the palato-pharyngeal muscle from the upper pharyngeal constrictor thanks to which it creates sufficient tension on the side walls
- ESP also tends to widen further, in the anterolateral sense, the space at the level of the oropharyngeal vestibule during the healing phases, since the cicatricial retraction of the palate-pharyngeal muscle flap stretches the palate and the lateral walls of the pharynx even more in this sense by creating centrifugal healing vectors. Contrary to UPPP where the healing vectors were centripetal with a progressive worsening of the results obtained.

Pang et al. [49] showed a significant improvement in AHI compared to UPPP, with a percentage of surgical success according to the Sher criteria of 82.6% for ESP against 68.1% for UPPP, with a significant difference in oropharyngeal transverse diameters post-operative where after ESP the residual transverse collapse with Muller maneuver was modest, while after UPPP it was still very evident.

In our experience ESP has proved to be an effective weapon in the management of palatal obstruction. In fact in patients subjected exclusively to ESP due to the presence of a predominantly palatal obstructive site, an improvement in AHI was obtained, which on average was reduced by 63.4% with a success rate according to the Sher criteria of 65% [50]. We have also shown in all patients subjected to ESP a notable improvement as regards the anatomical parameters at the oropharyngeal level. In fact, a notable dilatation of the transverse diameters and a progression of the palate considerably higher than the UPPP, with a reduction of the oropharyngeal collapse to the Müller maneuver equal to 64.7%.

Relocation Pharyngoplasty

This technique introduced in 2009 by Li and coll. [51], based on the increase in the volume of the pharyngeal vestibule acting on the lateral walls of the pharynx, with a technique similar to that of Cahali [32]. After tonsillectomy with careful conservation of the mucosa of the palatine pillars. The pharyngeal palate muscle is taken near the uvula and rotated upwards and sideways making it approach the remaining part of the soft palate.

The full-thickness tissue of two elliptical zones at the level of the soft palate is removed, including mucosa, submucosa, adipose tissue and muscle. The upper pharyngeal constrictor is sutured to the homolateral palatoglossus muscle with a cranio-caudal direction. The palatal-pharyngeal muscle is separated from the upper constrictor of the pharynx to facilitate tension-

free approximation. The pharyngeal palate muscle with its mucous flap is then anteriorized and also sutured on the palatoglossus muscle. Finally, a partial uvulectomy is planned.

With this technique a single, rigid and anterior newly formed palatine is created, which puts the lateral walls of the pharynx in tension and increases the posterior space because the advancement of the posterior pillar also brings with it the dorsal portion of the palate.

The results show a significant reduction in snoring of daytime sleepiness and AHI. No post-operative bleeding, reflux of liquids from the nose or alterations of the voice were found.

This technique, unlike that of Cahali, does not involve a dissection of the upper pharyngeal constrictor with consequent opening of the lateropharyngeal space and the risk of damaging the important neuro-vascular structures contained in it.

Anterior Pharyngoplasty

It consists of a technique of palatal tightening introduced for the first time by Pang in 2008 [52], indicated in the treatment of snoring and mild-moderate OSAS associated with tonsillectomy. Pang performed the procedure under local anesthesia if it was not associated with tonsillectomy in the case of absent or small tonsils (grade 0-2) or in general anesthesia when associated with tonsillectomy (grade 3-4 tonsils). In our experience we have always preferred to carry out surgery under general anesthesia.

The technique consists in practicing a partial uvulectomy, removing only the mucosa. Followed by the removal of a rectangle of anterior mucosa of the palate about 40-50 mm long and 7-10 mm high, until the underlying musculature is uncovered. And then after haemostasis, the two upper and lower flaps are gathered together with absorbable sutures anchored at full thickness in the musculature of the palate, creating an elevation and anteriorization of the palate. Pang reported no major complications and showed improvement in snoring and sleepiness in all patients, with an improvement in the IHI according to Sher's criteria of 71.8%. The only negative effect reported is a modest post-operative pain, greater in the case of tonsillectomy.

In 2014 Salamanca and coll. [53] proposed a modification of the technique, the Barbed anterior pharyngoplasty, introducing the use of self-locking "hooked" wires (QUill ® knotless tissue closure device, angiotech Pharmaceutical inc., Vancouver, canada). The technique involves a rectangular incision like that made by Pang, the closest possible to the pterygoid hamulus where the muscle suture is anchored to be fixed to bone structures. Then with a continuous suture the muscular part of the palate is sutured. And then the same procedure is repeated on a submucosal level.

At this point, to further stabilize the palate, a suture is made by anchoring the palate to the posterior nasal spine and bilaterally to the pterygoid hamulus and to the mandibular raphe creating a suspension of the edge of the soft palate and the posterior palatine pillars.

Obtaining at the end of the procedure a palate shortened and projected forward. The only reported side effect was a modest uvular edema and moderate pain for about ten days. Within 4-6 weeks the final fibrosis and consequent stiffening of the palate was obtained.

Barbed Reposition Pharyngoplasty (BRP)

This new technique developed by Vicini et al. [54], arises from the idea of using self-locking wires applied to a technique similar to relocation faringoplasty [51]. It is based on the principle that the palatine pillars and the palate are considered as a tripod and weakening the

posterior palatine pillar and moving it forward tends to unbalance the whole system forward increasing the mesopharynx space. The first step consists in tonsillectomy with careful preservation of the mucosa of the anterior and posterior pillars, therefore the lower portion of the palate-pharyngeal muscle is partially incised weakening it. Then a full-thickness mucosa and muscle triangle is removed at the upper lateral edge of the tonsillar loggia to obtain a wider and more squared space at the level of the pharyngeal vestibule. The needle is then introduced at the level of the posterior palatal spine, made to pass completely through the palate in a lateral direction, then around the pterigo-mandibular raphe and is taken out of the bed of the tonsillectomy and then passed through the upper part of the palate muscle pharyngeal making it come out near the mucosa of the posterior pillar, but not crossing it. Then the needle is passed again through the palatopharyngeal muscle and through the raphe by suspending the posterior pillar. By allowing the posterior pillar to be positioned in a more lateral and anterior position, this passage is repeated several times up to the most distal part of the palate-pharyngeal muscle and therefore the thread is passed through the soft palate blocking it.

This technique is currently the most used in our group with excellent results both for snoring and apnea. The only side effect was the pain and the sense of foreign body, which is reduced within a couple of weeks.

Hypopharyngeal Surgery

Hypopharyngeal surgery is basically divided into hyoid surgery and tongue surgery.

Hyoid Surgery

The hyoid surgery consists mainly of the thyro-thyroid disease or suspension of the hyoid. Represents the most reviewed and most documented mode of management of hypopharyngeal collapse, especially on the side walls. The modern surgical procedure, according to Ryley [55] is not very complex, rapid and relatively effective, especially in the range of moderate OSAS even if it is undergoing a progressive decline in recent years as it is considered no longer valid in the management of hypopharyngeal collapses and therefore used only in some selected cases in association with the plastic of the palate.

The indications are:

- Moderate OSAS
- Presence of obstruction at the retrolingual level

A horizontal skin incision of about 3-4 cm is made at an intermediate distance between the inferior edge of the hyoid and upper edge of the thyroid cartilage, possibly at the level of a skin fold. Once the hyoid is identified, a myotomy of the muscles inserted on it is performed, this varies according to the authors. According to the original technique the infraioid muscles are completely detached and the hyoid ligaments are dissected from the lesser cornu, while the suprahyoid musculature is left intact.

In our experience we prefer to dissect both the suprahyoid and subioid muscles, up to the level of the lesser cornu, leaving the stylohyoid ligament intact. In this way we obtain a better

mobilization of the hyoid that allows us to overtake the anterior margin of the thyroid cartilage in pexia, but still maintains a good traction on the musculature of the lateral walls of the pharynx which is largely adherent to the great cornu of the Hyoid. This allows the side walls of the pharynx to be in tension and the base of the tongue to advance. At this point the pre-thyroid muscles are separated medially, to allow the identification of the thyroid notch, and the thyroid pexia is performed by 2 points per side with Vicryl n° 1, while in the meantime trying to gently draw forward the iode in the attempt to make them overtake the upper edge of the thyroid cartilage. If the traction is excessive can happen that fractures the hyoid, in these cases it is sufficient to proceed with pexia correctly and usually has no influence on the outcome of the surgery. Normally a small drainage is placed, the muscles above and below the hyoid and all the subcutaneous planes are recovered and then the skin is closed with an intradermal suture.

The surgery does not present any particular post-operative pain, there may be a transient dysphagia which usually resolves in a few days [71]. Rarely, other post-operative complications may occur, such as the most frequent hematoma, seroma, scarring and transient joint distortion. Only Riley assessed the efficacy of the ioidea suspension as a single intervention in the treatment of OSAS, with a 53% success rate.

Tongue Surgery

The tongue surgery is a field that over the years has become increasingly wider, because it is adding numerous techniques ranging from minimally invasive radiofrequency surgery to partial glossectomies. The procedures can be roughly grouped into three categories: tongue reductions, glossopexy and glossectomies.

Tongue Reductions

Most authors perform this procedure by applying radiofrequencies, which represent the single least invasive procedure on hypopharyngeal obstruction and vibration.

The indications are represented by:

- Predominantly lymphatic lingual base hypertrophy
- Simple non-palatal snoring
- Mild to moderate OSAS with predominant retro-lingual obstruc-tive component

It is the only hypopharyngeal procedure that can be performed under local and outpatient anesthesia. Depending on the device used, 8 to 16 applications are used, the application pattern is variable. The main precautions are to avoid repeating the infixion in the same spot and to avoid an excessive duration of the application such as to cause thermal damage to the mucosal level, which creates an important pain and consequent dysphagia for a few days. It is however preferable to have one night of observation after the treatment.

The most severe complication, although not frequent, is the abscess of the base of the tongue [56]. The ulceration of the lingual base mucosa is much more frequent, usually due to too superficial or prolonged application of the electrode.

Glossopexy

The glossopexy are techniques based on the application of devices for containing and anchoring the base of the tongue, aimed at preventing its posterior collapse.

In fact various kits have been developed including the best known is the Repose system (Influ-ENT, USA). It consists of a non-resorbable suture that is passed with two loops around the base of the tongue and then fixed thanks to a screw at the inner edge of the chin [57].

The technique was almost completely abandoned due to the partial results, average success rate of 32.6%, comparable to the less invasive RF.

Another technique is the one developed by Woodson [58] with the ADVANCE system which consists in the surgical positioning of an anchorage system of the midline tissue of the posterior portion of the tongue connected to an anchorage at the level of the adjustable mandibular bone with a flexible tether. But the high failure rate from anchoring in the tissue of the device precluded its clinical use.

Glossectomy

A factor to be carefully evaluated in tongue base surgery is the rich vascular network provided by the lingual artery. According to Vicini et al. [59] the base of the tongue does not offer safe and reproducible landmarks, except for a rich arterial network that approaches the constantly present midline. And theoretically this can be used as an anatomical plane above which there are no large nerves or vessels.

Trans-cervical resection of the base of the tongue was developed in the 1990s by Chabolle et al. [60] when even minimally invasive volumetric reduction techniques were not available. For these reasons this technique has been totally abandoned.

Subsequently, several techniques of transverse oral lingual resection have been proposed.

Woodson and Fujita [61] recommend the excision of the front corner of the resection of a 3 cm side wedge in order to create a defect.

Because of their invasiveness and post-operative morbidity these techniques are considered reserved for patients with severe OSAS who are not compliant with nCPAP therapy. It can be considered an alternative therapeutic option in severe apnea in overweight subjects as an alternative to bimascillary advancement.

Thanks to the emergence of new technologies, some authors have tried to overcome the highly invasive technique. The former were Maturo and Mair [62] using the plasma-mediated bipolar radiofrequency technology (coblator) and then Friedman et al. [63] who developed the submucosal minimally invasive lingual excision (SMILE). This technique involves the prior identification of the course of the lingual arteries with doppler. He then proceeds to a medial incision with a cold blade scalpel, then proceeds with tissue removal with coblator with movements from the top down, paying attention to stay within 1 cm from the median line and medial to the previously marked arteries.

The advent of trans oral robotic surgery (TORS) has allowed the emergence of a further alternative in the management of the lingual base, similar to what happens with oncological surgery.

Lee et al. [64] achieved a 45% success rate in the treatment of severe OSAS with lingual tonsillectomy with TORS and UPPP, with an average AHI reduction from 55.6 to 24.1.

Friedman et al. [65] compared the efficacy of TORS in the management of obstruction of the base of the tongue with that of the coblator and the RF. In none of the 3 groups were major bleeding reported, with similar post-operative pain. The average AHI reductions were

60.5% ± 24.9% for TORS, 37.0% ± 51.6% for the Coblator and 32.0% ± 43.3% for radiofrequency, respectively. Furthermore the authors affirmed the possibility and safety of performing the TORS for the lingual base without the need for tracheotomy.

Vicini et al. [66] with lingual tonsillectomy with TORS obtained a reduction of AHI from 38.3 +/- 23.5 to 20.6 +/- 17.3 with no particular pain-related disorders, difficulty swallowing and no particular complications. Therefore he claims that in case of important hypertrophy of the base of the tongue, minimally invasive techniques are absolutely insufficient and only an adequate removal of tissue can effectively increase the space. Therefore the TORS can be considered in some cases a valid alternative also to the bimascillary advancement in the management of obstructions at the base of the tongue, with a more easily acceptable post-operative course.

HYPOGLOSSAL NERVE STIMULATION

In recent years, thanks to technological progress, the neurostimulation of the lingual musculature during the night is being re-evaluated. In the past the major limitation of these stimulation techniques was the continuous induction of arousals that equally compromised the architecture of sleep [67, 68]. The solution to this problem has been found through selective stimulation of the hypoglossal nerve, which mainly contains efferent motor fibers that give a minimum sensitive afferent feedback.

The musculature of the tongue consists of extrinsic muscles and intrinsic muscles, both groups innervated by the hypoglossal nerve, except the palatoglossus which is innervated by the pharyngeal plexus.

It is above all the stimulation of the genioglossus that has the greatest role, as it represents the major dilator of the VAS, allows the protrusion of the tongue and the tension of the anterior pillars.

The neurostimulator is implanted under general anesthesia, through a small submandibular incision. Then the hypoglossus is exposed inferiorly to the submandibular and above the tendon of the digastric. Once the nerve is isolated, the cuff with the electrodes is placed on the main nerve trunk distal to the branch that innervates the retrusor muscles. This is done thanks to the intraoperative nerve stimulation which allows to identify the correct level to which the neuro-stimulator can be applied based on the muscular response obtained. In the case of neuro stimulators with thoracic sensor, the sensor is tunneled subcutaneously in the ipsilateral infraclavicular space. After 30 days the device is activated and the patient is subjected to a night polysomnography for titration, in order to find the difficult balance between stimulation and tolerance without arousals.

Certal and coll. [69] in a recent review they compared the effectiveness of existing systems, highlighting an improvement in the AHI, the overall reduction in the AHI was 54% at 3 months, 57% at 6 months, and 50% at 12 months.

None of the analyzed studies reported serious side effects, but in 4.5% of patients it was necessary to resort to explanting the device. The defined indications were BMI $\leq$ 32 kg/m2, AHI between 20 and 50 without complete concentric collapse at the level of the soft palate, patients with bulky tongues reported better results. They noted some technical differences in particular with regard to the multi-electrode system that only targets the desired parts of the

hypoglossal nerve, allowing a high degree of specificity. The targeted activation of the genioglossus muscle avoids the need to synchronize stimulation with the respiratory cycle and can reduce some of the costs related to surgical time.

Laringeal Surgery

Although the most frequent obstruction sites are those in the retropalatal and retrolingual level, the larynx can also contribute to the genesis of OSAS. It is essential to distinguish pediatric forms from those of adults, as in the former the main causes of obstruction are laryngomalacia, malformations and only rarely from neoformations, neoplasms or laryngeal paralysis. While in the adult the causes are specularly opposite.

Laryngeal obstruction plays a minor role in the adult compared to the child in the determinism of the OSAS.

Possible anatomo-functional conditions to be treated:

1. laryngeal diplegia;
2. laryngeal monoplegia;
3. floppy epiglottis;
4. tumors;
5. post radiotherapy larynx;
6. post-reconstructive neolaringe;
7. acquired laryngomalacia (laryngeal trauma, sarcoidosis, acromegaly, etc.);
8. stridor from MSA;

In the case of floppy epiglottis, a partial resection is indicated, usually V or horizontal in the free part associated with a shortening of the glosso-epiglottic ligament [70].

It is essential to use sleep-endoscopy in cases with suspected laryngeal obstruction, since CPAP therapy is not possible in the case of floppy epiglottis because positive pressure air presses the epiglottis against the laryngeal vestibule as if it were a lid, worsening the situation [72]. In these cases, there is no alternative to surgery. The decisive criterion is not the size of the epiglottis but its rigidity. In the case of very flaccid epiglottids, a partial resection should be considered, but if the cause of the prolapse is related to the posterior thrust operated by the base of the tongue, it is on this that one must act with a volumetric reduction or with hyoid advancement.

FACIAL SKELETON SURGERY

Unlike the interventions described above, it acts on the container and not on the content, allowing an extension of the UA. It is very effective being comparable to CPAP but it is also very invasive and has relevant anatomical and aesthetic modifications.

There are numerous groups of different procedures reviewed on the facial skeleton:

1. Advancement of the isolated genioglossus muscle or integrated with other procedures: This procedure is practiced entirely orally through an incision on the gingival mucosa, creating an advancement of the base of the tongue.

   It represents an invasive technique, with a high risk of complications, it has been replaced by most groups by less invasive techniques such as RF of the base of the tongue.
2. Isolated mandibular advancements.
3. Maxillo-mandibular advancements: Designed by Kuo et al. [73], today it is surgery with the greatest success rate after tracheotomy. But it is a complex and invasive intervention with high morbidity and complications, and considerable aesthetic consequences. It allows the simultaneous dilation of all the rhino-hypo-pharyngeal structures thanks to the increase of the volumes of the UA with tensioning of the lateral walls of the pharynx and advancement of the soft palate and the base of the tongue. It is one of the few surgical procedures that does not require an oropharyngeal time on the palate. Many studies have shown the effectiveness of maxillo-mandibular progress compared with CPAP. In a meta-analysis and systematic review of the literature Holty et al. [74] showed an average reduction in the AHI from 63.9/h to 9.5/h.
4. Rapid expansions of the upper jaw.
5. Anterior and transverse maxillary osteodistraction procedures: It is used when the advance must be greater than 10 mm or in children, as progressive progression reduces the risk of alveolar nerve injury. The procedure involves osteotomies similar to AMM, but these are mobilized only progressively (usually 1 mm per day) after a few days under the guidance of distractors. Thus non-mineralized tissue fills the osteotomy gap which is slowly lengthening and after the end of distraction it will turn into bone during the consolidation period. Since there are multidirectional distractors, it is possible to correct the distraction vector during treatment.

TRACHEAL SURGERY

Tracheotomy was the first effective treatment on OSAS and still remains the last but most certain resource [75].

It is indicated in some cases

1. In urgency: in case of newborns with severe respiratory distress, also due to VAS malformations, following surgical complications.
2. Pending: in the presence of laryngomalacia with severe OSAS, or in children with facial cranial anomalies awaiting surgery
3. Alternatively; to CPAP or other types of surgery especially in the case of patients with morbid obesity.
4. In recovery of techniques, however indicated in the most serious cases (advancement of bilaxel or Chabolle) did not go well.

The success rate is close to 100%, but in patients with cardiopulmonary decompensation the trachestomy reduces drastically but does not eliminate the OSAS problem probably due to the persistence of central events, and in some cases due to the occlusion of the ostomy by the tissue exuberant fat.

In adult patients in the rare cases in which the tracheotomy is a procedure of choice in our experience, it is preferable to perform a so-called "skin lined" technique [76] in which the edges of the tracheostoma are covered laterally and upper-inferiorly by two flaps of tracheal mucosa. This technique allows to obtain a more stable tracheostoma, which does not undergo the formation of granulation tissue and allows the eventual daily occlusion.

BARIATRIC SURGERY

Bariatric surgery is indicated for significant weight loss in patients with BMI> 40 kg/m2 or in those with BMI ≥ 35 kg/m2 but with important comorbidities and where dietary recommendations were not successful. This therapy should be implemented in conjunction with ventilatory therapy, and the severity of the OSAS should be re-evaluated following weight loss. A reduction in OSAS has been reported, following weight loss after two years of bariatric surgery of 40% [77].

REFERENCES

[1] American Academy of Sleep Medicine. *Obstructive Sleep Apnea.* 2008.

[2] *AAO-HNS Treatment of Obstructive Sleep Apnea* http://www.entnet.org/content/treatment-obstructive-sleep-apnea#

[3] American Sleep Apnea Association website. *OSA treatment options.* 2012.

[4] Cahali MB. Lateral pharyngoplasty: A new treatment for obstructive sleep apnea hypopnea syndrome. *Laryngoscope.* 2003 Nov;113(11):1961-8.

[5] Pang KP, Woodson BT. Expansion sphincter pharyngoplasty: a new technique for the treatment of obstructive sleep apnea. *Otolaryngol Head Neck Surg.* 2007 Jul;137(1):110-4.

[6] Vicini C, Hendawy E, Campanini A, Eesa M, Bahgat A, AlGhamdi S, Meccariello G, DeVito A, Montevecchi F, Mantovani M. Barbed reposition pharyngoplasty (BRP) for OSAHS: a feasibility, safety, efficacy and teachability pilot study. "We are on the giant's shoulders". *Eur Arch Otorhinolaryngol.* 2015 Apr 12.

[7] Rubin AH, Eliaschar I, Joachim Z, Alroy G, Lavie P. Effects of nasal surgery and tonsillectomy on sleep apnea. *Bull Eur Physiopathol Respir* 1983; 19: 612–615.

[8] Modica DM, Marchese D, Lorusso F, Speciale R, Saraniti C, Gallina S. Functional Nasal Surgery and Use of CPAP in OSAS Patients: Our Experience. *Indian J Otolaryngol Head Neck Surg.* 2018 Dec;70(4):559-565.

[9] Friedman M, Tanyeri H, Lim JW, Landsberg R, Vaidyanathan K, Caldarelli D. Effect of improved nasal breathing on obstructive sleep apnea. *Otolaryngol Head Neck Surg* 2000; 122: 71–74.

[10] Dorn M, Pirsig W, Verse T. Management of patients with severe obstructive sleep apnea following rhinosurgical interventions. A pilot study [in German]. *HNO* 2001; 49: 642–645.

[11] Lorusso F, Martines F, Mistretta A, Alagna E, Modica Dm, Dispenza F, Gallina S. Effects of adenotonsillectomy on neurocognitive and behavioural function in pediatric obstructive sleep apnea syndrome. *B-ENT*, 2018, 14, 113-118.

[12] Hibbert J, Stell P. Adenoidectomy. An evaluation of the indications. *Arch Dis Child* 1978; 53: 910–911.

[13] Maw AR, Jeans WD, Cable HR. Adenoidectomy. A prospective study to show clinical and radiological changes two years after operation. *J Laryngol Otol* 1983; 97: 511–518.

[14] Nieminen P, Tolonen U, Löppönen H. Snoring and obstructive sleep apnea in children. A 6-month follow-up study. *Arch Otolaryngol Head Neck Surg* 2000; 126: 481–486.

[15] Guidelines in roncosurgery ENT - Italian Society of Otorhinolaryngology and Head and Neck Surgery – *Topics of Acta Otorhinolaryngologica Italica* 2007.

[16] Arens R, McDonough JM, Costarino AT, et al. Magnetic resonance imaging of the upper airway structure of children with obstructive sleep apnea syndrome. *Am J Respir Crit Care Med.* 2001;164:698–703.

[17] Shintani T, Asakura K, Kataura A. Adenotonsillar hypertrophy and skeletal morphology of children with obstructive sleep apnea syndrome. *Acta Otolaryngol Suppl.* 1996;523:222–4.

[18] Kara CO, Ergin H, Kocak G, Kilic I, Yurdakul M. Prevalence of tonsillar hypertrophy and associated oropharyngeal symptoms in primary school children in Denizli, Turkey. *Int J Pediatr Otorhinolaryngol.* 2002;66:175–9.

[19] Hörmann K, Verse T. *Surgery for Sleep-Disordered Breathing*. Springer-Verlag Berlin Heidelberg 2005.

[20] Lorusso F, Gallina S, Modica DM, Di Salvo N, Riggio F. Bipolar Quantum Molecular Resonance versus Blunt Dissection tonsillectomy. *B-ENT*. 2015;11(2):101-8.

[21] Hilton M. Tonsillectomy technique-tradition versus technology. *Lancet.* 2004;364:642-3.

[22] Hultcrantz E, Linder A, Markström A. Tonsillectomy or tonsillotomy? A randomized study comparing postoperative pain and long-term effects. *Int J Pediatr Otorhinolaryngol* 1999; 51: 171–176.

[23] Whinney DJ, Williamson PA, Bicknell PG. Punctate diathermy of the soft palate: a new approach in the surgical management of snoring. *J Laryngol Otol* 1995; 109: 849–852.

[24] Sundaram S, Bridgman SA, Lim J, Lasserson TJ. Surgery for obstructive sleep apnoea. *Cochrane Database Syst Rev.* 2005 Oct 19;(4):CD001004. Review.

[25] *SNLG Appropriatezza e sicurezza degli interventi di tonsillectomia e/o adenoidectomia.* 2008.http://www.snlg-iss.it/lgn.

[26] Baugh RF, Archer SM, Mitchell RB, Rosenfeld RM, Amin R, Burns JJ, Darrow DH, Giordano T, Litman RS, Li KK, Mannix ME, Schwartz RH, Setzen G, Wald ER, Wall E, Sandberg G, Patel MM; American Academy of Otolaryngology-Head and Neck Surgery Foundation. Clinical practice guideline: Tonsillectomy in children. *Otolaryngol Head Neck Surg.* 2011 Jan;144(1 Suppl):S1-30.

[27] Lescanne E, Chiron B, Constant I, Couloigner V, Fauroux B, Hassani Y, Jouffroy L, Lesage V, Mondain M, Nowak C, Orliaguet G, Viot A; French Society of ENT (SFORL); French Association for Ambulatory Surgery (AFCA); French Society for

Anaesthesia, Intensive Care (SFAR). Pediatric tonsillectomy: clinical practice guidelines. *Eur Ann Otorhinolaryngol Head Neck Dis.* 2012 Oct;129(5):264-71.

[28] Brietzke S, Gallagher D, The effectiveness of tonsillectomy and adenoidectomy in the treatment of pediatric obstructive sleep apnea/hypopnea syndrome: A meta-analysis. *Otolaryngol Head Neck Surg,* 134(6), 979-984, 2006.

[29] Tzifa KT, Shehab ZP, Robin PE. The relation between tonsillectomy and snoring. *Clin Otolaryngol* 1998; 23: 148–151.

[30] Nelson LM. Radiofrequency treatment for obstructive tonsillar hypertrophy. *Arch Otolaryngol Head Neck Surg* 2000; 126: 736–740.

[31] Mortimore IL, Bradley PA, Murray JA, Douglas NJ. Uvulopala-topharyngoplasty may compromise nasal CPAP therapy in sleep apnea syndrome. *Am J Respir Crit Care Med* 1996; 154:1759–1762.

[32] Cahali MB. Lateral pharyngoplasty: a new treatment for obstructive sleep apnea hypopnea syndrome. *Laryngoscope.* 2003 Nov;113(11):1961-8.

[33] Brietzke SE, Mair EA. Injection snoreplasty: how to treat snoring without all the pain and expense. *Otolaryngol Head Neck Surg* 2001; 124: 503–510.

[34] Choi JH, Kim SN, Cho JH. Efficacy of the Pillar implant in the treatment of snoring and mild-to-moderate obstructive sleep apnea: a meta-analysis. *Laryngoscope.* 2013 Jan; 123(1):269-76.

[35] Hur J. A new treatment for snoring: sling snoreplasty with a permanent thread. *Acta otolaryngol* 2008;128:1381-4.

[36] Mantovani M, Minetti A, Torretta S, Pincherle A, Tassone G, Pignataro L. The velo-uvulo-pharyngeal lift or "roman blinds" technique for treatment of snoring: A preliminary report. *Acta Otorhinolaryngol Ital.* 2012 Feb;32(1):48-53.

[37] Mantovani M, Minetti A, Torretta S, Pincherle A, Tassone G, Pignataro L. The "Barbed Roman Blinds" technique: a step forward. *Acta Otorhinolaryngol Ital.* 2013 Apr;33(2):128.

[38] Haavisto L, Suonpaa J. Complications of uvulopalatoplasty. *Clin Otolaryngol* 1994; 19: 243–247.

[39] Katsantonis GP, Friedman WH, Krebs FJ, Walsh JK. Nasopharyngeal complications following uvulopalatopharyn-goplasty. *Laryngoscope* 1987; 97: 309–314.

[40] Mortimore IL, Bradley PA, Murray JA, Douglas NJ. Uvulopalatopharyngoplasty may compromise nasal CPAP therapy in sleep apnea syndrome. *Am J Respir Crit Care Med* 1996; 154:1759–1762.

[41] Hassid S, Afrapoli AH, Decaaestecker C, Cho- ufani G. UPPP for snoring: long-term results and patient satisfaction. *Acta Otorhinolaryngol Belg* 2002; 56: 157–162.

[42] Sher AE, Schechtman KB, Piccirillo JF. The efficacy of surgical modifications of the upper airway in adults with obstructive sleep apnea syndrome. *Sleep* 1996; 19: 156–177.

[43] Aurora RN, Casey KR, Kristo D, et al. Practice parameters for the surgical modifications of the upper airway for obstructive sleep apnea in adults. *Sleep.* 2010a;33(10):1408-1413.

[44] Carenfelt C. Laser uvulopalatopharyngoplasty in treatment of habitual snoring. *Ann Otol Rhinol Laryngol* 1991; 100: 451–454.

[45] Kamami YV. Laser CO2 for snoring: preliminary results. *Acta Otorhinolaryngol Belg* 1990; 44:451–456.

[46] Morar P, Nandapalan V, Lesser THJ, Swift AC. Mucosal-strip/uvulectomy by the CO2 laser as a method of treating simple snoring. *Clin Oto-laryngol* 1995; 20: 308–311.

[47] Astor FC, Hanft KL, Benson C, Amaranath A. Analysis of short-term outcome after office-based laser-assisted uvulopalatoplasty. *Otolaryngol Head Neck Surg* 1998; 118: 478–480.

[48] Mesti JJ, Cahali MB. Evolution of swallowing in lateral pharyngoplasty with stylopharyngeal muscle preservation. *Braz J Otorhinolaryngol.* 2012 Dec;78(6):51-5.

[49] Pang KP, Woodson BT. Expansion sphincter pharyngoplasty: a new technique for the treatment of obstructive sleep apnea. *Otolaryngol Head Neck Surg.* 2007 Jul;137(1):110-4.

[50] Lorusso F, Dispenza F, Modica DM, Gallina S. The Role of Modified Expansion Sphincter Pharyngoplasty in Multilevel Obstructive Sleep Apnea Syndrome Surgery. *Int Arch Otorhinolaryngol.* 2018 Oct;22(4):432-436.

[51] Li HY, Lee LA (2009) Relocation pharyngoplasty for obstructive sleep apnea. *Laryngoscope* 119:2472–2477.

[52] Pang KP, Tan R, Puraviappan P, Terris DJ. Anterior palatoplasty for the treatment of OSA: three-year results. *Otolaryngol Head Neck Surg.* 2009 Aug;141(2):253-6.

[53] Salamanca F, Costantini F, Mantovani M, Bianchi A, Amaina T, Colombo E, Zibordi F. Barbed anterior pharyngoplasty: an evolution of anterior palatoplasty. *Acta Otorhinolaryngol Ital.* 2014 Dec;34(6):434-438. Review.

[54] Vicini C, Hendawy E, Campanini A, Eesa M, Bahgat A, AlGhamdi S, Meccariello G, DeVito A, Montevecchi F, Mantovani M. Barbed reposition pharyngoplasty (BRP) for OSAHS: a feasibility, safety, efficacy and teachability pilot study. "We are onthe giant's shoulders". *Eur Arch Otorhinolaryngol.* 2015 Apr 12.

[55] Riley RW, Powell NB, Guilleminault C. Obstructive sleep apnea and the hyoid: a revised surgical procedure. *Otolaryngol Head Neck Surg* 1994; 111: 717–721.

[56] Pazos G, Mair EA. Complications of radiofrequency ablation in the treatment of sleep-disordered breathing. *Otolaryngol Head Neck Surg* 2001; 125: 462–466.

[57] DeRowe A, Günther E, Fibbi A, Lehtimaki K, Vahatalo K, Maurer J, Ophir D. Tongue-base suspension with a soft tissue-to-bone anchor for obstructive sleep apnea: preliminary clinical results of a new minimally invasive technique. *Otolaryngol Head Neck Surg* 2000; 122; 100–103.

[58] Multicenter study of a novel adjustable tongue-advancement device for obstructive sleep apnea. Woodson BT, Steward DL, Mickelson S, Huntley T, Goldberg A. *Otolaryngol Head Neck Surg.* 2010 Oct;143(4):585-90. doi: 10.1016/j.otohns. 2010.06.902.

[59] *Transoral robotic surgery of the tongue base in obstructive sleep Apnea Hypopnea syndrome Anatomic considerations and clinical experience*.

[60] Chabolle F, Wagner I, Blumen M, Séquert C, Fleury B, de Dieuleveult T. Tongue base reduction with hyoepiglottoplasty: a treatment for severe obstructive sleep apnea. *Laryngoscope* 1999; 109:1273–1280

[61] Woodson BT, Fujita S. Clinical experience with lingualplasty as part of the treatment of severe obstructive sleep apnea. *Otolaryngol Head Neck Surg* 1992; 107: 40–48.

[62] Maturo SC, Mair EA. Submucosal minimally invasive lingual excision: An effective, novel surgery for pediatric tongue base reduction. *Ann Otol Rhinol Laryngol* 2006; 115:624–30.

[63] Friedman M, Soans R, Gurpinar B, Lin HC, Joseph N. Evaluation of submucosal minimally invasive lingual excision technique for treatment of obstructive sleep apnea/hypopnea syndrome. *Otolaryngol Head Neck Surg.* 2008 Sep;139(3):378-84.

[64] Lee JM, Weinstein GS, O'Malley BW Jr, Thaler ER. Transoral robot-assisted lingual tonsillectomy and uvulopalatopharyngoplasty for obstructive sleep apnea. *Ann Otol Rhinol Laryngol.* 2012 Oct;121(10):635-9.

[65] Friedman M, Hamilton C, Samuelson CG, et al. Transoral robotic glossectomy for the treatment of obstructive sleep apnea-hypopnea syndrome. *Otolaryngol Head Neck Surg.* 2012 May;146(5):854-62.

[66] Vicini C, Dallan I, Canzi P, et al. Transoral robotic tongue base resection in obstructive sleep apnoea-hypopnoea syndrome: a preliminary report. *ORL J Otorhinolaryngol Relat Spec.* 2010;72(1):22-7. Epub 2010 Feb 18.

[67] REDLINE S. Genetics of obstructive sleep apnea. In: KRYGER MH, ROTH T, DEMENT WC, eds. *Principles and Practice of Sleep Medicine.* Philadelphia: Elsevier Saunders, 2005:1013–1022.

[68] Smith PL, Eisele DW, Podszus T, et al. Electrical stimulation of upper airway musculature. *Sleep* 1996;19:S284-7.

[69] Certal VF, Zaghi S, Riaz M, Vieira AS, Pinheiro CT, Kushida C, Capasso R, Camacho M. Hypoglossal nerve stimulation in the treatment of obstructive sleep apnea: A systematic review and meta-analysis. *Laryngoscope.* 2014 Nov 12.

[70] Golz A, Goldenberg D, Netzer A, Westerman ST, Joachims HZ. Epiglottic carcinoma presenting as obstructive sleep apnea. *J Otolaryngol* 2001; 30: 58–59.

[71] Lorusso F, Dispenza F, Martinciglio G, Messina A, Battaglia A, Gallina S. Postural changes in patients undergoing hyoid surgery for osas. *Euromediterranean biomedical journal* 2017, 12 (29) 140–143 (formerly: capsula eburnea).

[72] Verse T, Pirsig W. Age-related changes in the epiglottis causing failure of nasal continuous positive airway pressure therapy. *J Laryngol Otol* 1999; 113: 1022–1025.

[73] Kuo PC, West RA, Bloomquist DS, McNeil RW. The effect of mandibular osteotomy in three patients with hypersomnia sleep apnea. *Oral Surg Oral Med Oral Path* 1979; 48: 385–392.

[74] Holty JE, Guilleminault C. Maxillomandibular advancement for the treatment of obstructive sleep apnea: a systematic review and meta-analysis. *Sleep Med Rev.* 2010 Oct; 14(5):287-97.

[75] Kuhlo W, Doll E, Franck MC. Successful management of Pickwickian syndrome using long-term tracheostomy [in German]. *Dtsch Med Wschr* 1969; 94: 1286–1290.

[76] Fee WE Jr, Ward PH. Permanent tracheostomy: A new surgical technique. *Ann Otol Rhinol Laryngol.* 1977 Sep-Oct;86(5 Pt 1):635-8.

[77] Mechanick JI, Kushner RF, Sugerman HJ, Gonzalez-Campoy JM, Collazo-Clavell ML, Guven S, Spitz AF, Apovian CM, Livingston EH, Brolin R, Sarwer DB, Anderson WA, Dixon J. American Association of Clinical Endocrinologists, The Obesity Society, and American Society for Metabolic & Bariatric Surgery Medical guidelines for clinical practice for the perioperative nutritional, metabolic, and nonsurgical support of the bariatric surgery patient. *Endocr Pract.* 2008 Jul-Aug; 14.

In: Encyclopedia of Surgery (22 Volume Set)
Editors: Andreas Lehrer and Kristin Mueller
ISBN: 978-1-53618-329-0
© 2020 Nova Science Publishers, Inc.

Chapter 103

LAPAROSCOPIC SURGERY IN SITUS INVERSUS

Pankaj Kumar*, Tushar S. Mishra and Siddhant Sarthak
Department of General Surgery, AIIMS Bhubaneswar, Odisha, India

ABSTRACT

Laparoscopic surgery have certain undisputed advantages over open surgeries. Less pain, early recovery, better cosmesis, early return to work and increasing expertise have prompted surgeons to offer the minimal access surgery for wider spectrum of indications.

Situs inversus is a condition where the anatomy is saggitally reversed like a mirror image. With better understanding of the anatomy, ergonomics and availability of robotic surgery, numerous minimally invasive surgical procedures has been reported in patients with situs inversus. This chapter will provide insight about laparoscopic surgeries done for various indications in patients with situs inversus along with the various difficulties and methods to address them.

Keywords: situs inversus, laparoscopy

INTRODUCTION

The first laparoscopic cholecystectomy in a patient with situs inversus was attempted by Camos and Sipes, in 1991 [1]. Since then various surgical procedures like splenectomy, gastrectomy, hepatectomy, esophagectomy, colonic resection and others have been successfully performed laparoscopically.The major challenge faced by most surgeons is adapting to the mirror image anatomy. Diagnosis of situs inversus preoperatively and adapting to the changed anatomy for better ergonomics is the key to safe and successful completion of surgery. Most surgeon still prefer open procedures in patients with situs inversus, because of technical difficulties like position of monitor, site of port placement, difficult dissection and long operative time. Reports of successful surgical procedures in many parts of the world have helped in better understanding of laparoscopic anatomy and

* Corresponding Author's Email: drpkushwaha@gmail.com.

technical difficulties encountered. But a comprehensive review of these challenges and various modifications is lacking. This chapter will discuss the ergonomics and challenges of laparoscopic surgeries in patients with situs inversus.

LAPAROSCOPIC CHOLECYSTECTOMY

Nearly seventy cases have been reported by now ever since it was first described in 1991. Most of the surgeons have used mirror image of conventional four ports of laparoscopic cholecystectomy. With experience and expertise single incision multiport cholecystectomy has also been performed recently[2].

The identification and orientation to the mirror image position of the biliary tree is the first step for successful completion of the surgery. The left-handed surgeons may actually benefit in a scenario of laparoscopic cholecystectomy in situs inversus. The right-handed surgeons however are more likely to face difficulty in dissection and delineation of Calot's triangle. Proper preoperative planning to adapt to the changed anatomy, including the port placement, position of the surgeon, assistant and the monitor would help in performing a safe cholecystectomy laparoscopically.

A mirror image strategy of the OR set up is recommended. The operating surgeon and camera assistant will benefit standing on the right side and the monitor to be above the patients left shoulder. Two 10 mm ports should be placed, one in the sub umbilical and the other epigastric, and two 5mm ports in the left midclavicular and in the left anterior axillary line. The suggested position of port, monitor and surgeon is shown in Figure 1. A 30-degree scope is recommended for the procedure. Although dissection of the Calot's triangle can be done by a right handed surgeon using epigastric port and left midclavicular port, the dissection is usually difficult, due to use of less used left hand. Hence the movements should be smooth and adequate time must be spent while performing the Calot's dissection. Most of the surgeons have reported major difficulty clip application, which requires both precision and power[3]. Surgeon may stand between the legs during dissection for better ergonomics. The assistant should hold the Hartmann's pouch, rather than fundus to prevent crossing of hands while retracting. The dissection should be carried out from lateral side of Hartmann's pouch remaining close to the gallbladder. The possibility of associated biliary tract and vascular anomalies is higher in patients with situs inversus partialis and they may require intraoperative cholangiography and conversion to open cholecystectomy[4]. Successful laparoscopic exploration of common bile duct for choledocholithiasis in a patient with situs inversus has also been reported[5].

Laparoscopic Gastrectomy

Laparoscopic radical gastrectomy is increasingly being performed these days with the standardization of the surgical technique, improved instrumentation, high definition imaging systems and advanced energy sources. Alteration of the anatomy makes laparoscopic gastrectomy in presence of situs inversus more difficult.

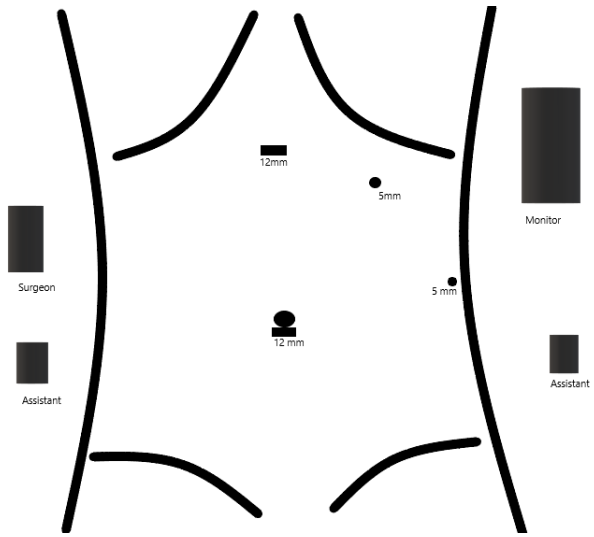

Figure 1. Suggested port placement for laparoscopic cholecystectomy.

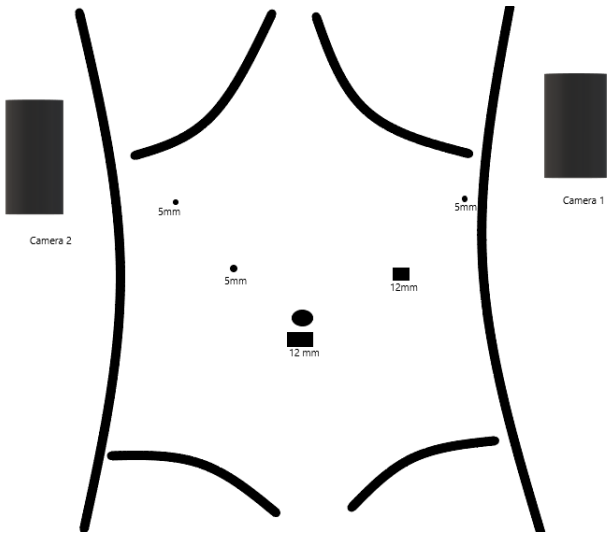

Figure 2. Suggested port placement for laparoscopic gastrectomy.

The first case of laparoscopic distal gastrectomies (LADG)+ in situs inversus was performed in Japan, in 2003[6]. Since then more than thirty cases of laparoscopic gastrectomies have been performed for gastric carcinoma in patients with situs inversus. Most of these cases done are laparoscopic distal gastrectomies. The esophagojejunal anastomosis and the lymphadenectomy make laparoscopic total gastrectomy (LATG) technically more demanding and hence less frequently attempted. The first case of LATG with extended (D1+) lymphadenectomy was done by Morimoto et al. [7]. They took 359 minutes as against the average time of 267 minutes for LADG in the other reported cases.

Laparoscopic radical gastrectomy requires frequent change of position of the operating surgeon The port positions also need to be altered for better ergonomics for doing this

procedure in patients of situs inversus. However there have been four cases where successful completion of the procedure has been reported without the surgeon changing the sides.

The mirroring of the images in situs inversus may confuse the surgeon during the surgery, which can potentially be hazardous. Hence only surgeons reasonably experienced with laparoscopic gastrectomy should attempt doing it. However, robot-assisted distal gastrectomy (RADG) is an exception to this, as the surgeon does not need to change his position during surgery because of the centered robotic view of the field with easy changing of the instruments between hands.

After creation of pneumoperitoneum, a 12 mm optical trocar should be placed at the umbilicus for the telescope. The working ports are placed in the left and right subcostal positions with additional 5 mm trocars laterally (Figure 2). The lymph nodal stations 5, 6, 7, 8a, and 9 are usually dissected with the surgeon standing on the right side of the patient and those in the stations1, 2, 3, 4sa, 4sb, 4d, and 11p from the left side.

Laparoscopic Colon Resection

Laparoscopic colectomy has been reported only in 16 patients with SIT. It is a common belief that laparoscopic colonic surgeries with situs inversus are the same operations as without situs inversus, except for the mirror images. But the cases reported in literature have highlighted the difficulties related to the use of non-dominant hand during some critical steps. Various modifications have been suggested to improve the ergonomics during colonic surgery, to improve the outcome.

Right Hemicolectomy

The first laparoscopic right hemicolectomy was reported by Fuziwara Y et al. in 2007[8]. Since than three more cases have been done. Right hemicolectomy in SIT is relatively easier than the other colonic surgery. The major emphasis is to understand the mirror image anatomy by proper radiological investigation. The most important step in preoperative workup is identification of superior mesenteric artery on the left side. Under general anesthesia, the patient should be placed in the low lithotomy position with leg separated, head end and right side down to displace the small bowel away from the operating field. The operating surgeon and camera assistant are suggested to stand on the right side of the patient while the first assistant on the left. The suggested port position is similar to the sigmoidectomy in normal patient, i.e., 12 mm camera port either umbilical or 1 cm cranial and right to the umbilicus, working 12 mm port in right iliac fossa, another 5 mm working port in right flank, two 5 mm ports for the assistant on left flank and left iliac fossa (Figure 3). Mirror image anatomy must be visualized after creating the pneumoperitoneum. Medial to lateral dissection is preferred. The mesentery should be opened just caudal to the ileocolic vessel. Dissection should be continued cranially till anterior surface of duodenum is seen. The ileocolic vessels should be secured and divided near its insertion in superior mesenteric vein. Caecum and ascending colon is mobilized next with precaution to safe guard the ureter from injury. Division of colon and further anastomosis is similar to that of orthotopic hemicolectomy.

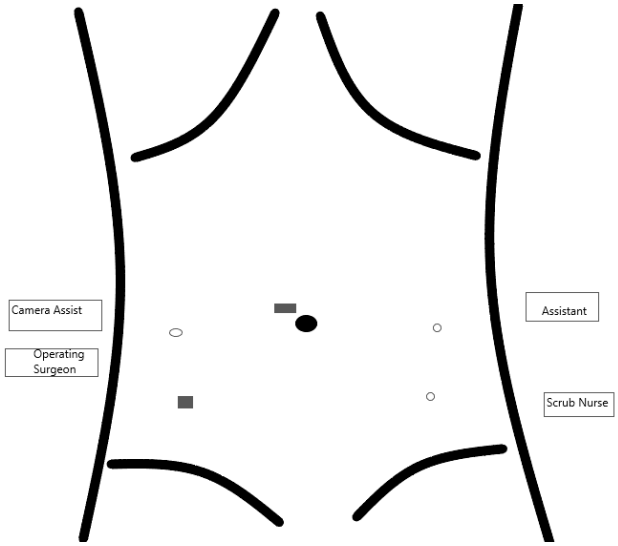

Figure 3. Suggested port placement for laparoscopic right hemicolectomy.

Sigmoidectomy

The laparoscopic sigmoidectomy has been attempted for diverticulitis and malignancy. In SIT, sigmoid colon is positioned on the right side instead of left. Laparoscopic sigmoidectomy in SIT should be operated in low lithotomy with leg separated or the position, according to the surgeon's comfort. The position of operating surgeon, camera assistant and first assistant should be mirror image of orthotopic patient. Hence operating surgeon and camera assistant should stand on the left side, while first assistant will stand on the right. The patient should be placed in the Trendelenburg position at 30 degree and right side up to displace the small bowel. Trocar positions used by various surgeons differ. The trocar placement used by Yaegashi et al. was similar to the standard laparoscopic colon resection with one additional 5-mm trocar in left lower quadrant[9]. While, Davies et al., Kobus et al and Karabay et al. changed the position of right iliac fossa 12 mm port to the left iliac fossa for insertion of stapler and camera[10]–[12].

We suggest 12-mm supra-umbilical trocar for the camera; 12-mm trocars in the left and right iliac fossae as working ports and for the introduction of the laparoscopic stapler, which can be used interchangibly; a 5-mm trocar in the right flank for traction and a 5-mm trocar in the left flank (Figure 4). After creating the pneumoperitoneum the anatomy must be revisited. Sigmoid colon will be seen on right side, liver on left and spleen on right. The next step would be the mobilization of sigmoid and descending colon using energy devices. The dissection should begin at the sacral promontory. Putting the traction on sigmoid colon by the first assistant using the right flank port will help in identification of inferior mesenteric artery. The right ureter must be identified during medial mobilization. The inferior mesenteric artery should be ligated distal to the origin of left colic artery. The inferior mesenteric vein should be dissected till its insertion, secured and divided. Since the position of rectum remain same in both the normal and situs inversus patients, we suggest to change the position of the team as in normal laparoscopic sigmoid colon resection i.e., surgeon and camera assistant on right

and assistant on the left side for the rectosigmoid division. The rectosigmoid junction can be divided using an articulating endoscopic linear stapler. Further surgery can be continued as in patients with normal anatomy.

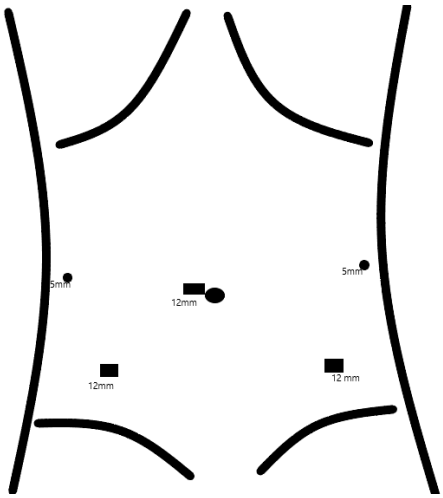

Figure 4. Suggested port placement for laparoscopic sigmoidectomy, anterior resection and abdominoperineal resection.

Anterior Resection and Abdominoperineal Resection

The first laparoscopic total mesorectal excision and abdominoperineal resection (APR) in a patients with situs inversus was reported by Huh et al, in 2010 and Choi et al. in 2011 respectively[13], [14]. Cui et al. have recently reported a robotic anterior resection with natural orifice specimen retrieval in SIT patient [15]. Most part of the surgery including the patient and port positions is similar to the sigmoidectomy as discussed earlier. A five-port method is preferred. The surgeon and camera assistant should stay on the left during initial part of surgery. The procedure starts with incising the peritoneum at the root of inferior mesenteric artery. The inferior mesenteric vessels should be defined, clipped, and divided. The peritoneum of the sigmoid mesentery is next incised over the sacral promontory. An avascular plane between the mesentery and the retroperitoneum is developed. Descending colon and splenic flexure which would be present on right side of the patient should be mobilized in the same position. After the complete mobilization of colon, mesorectal excision is performed with surgeons and camera assistant changing the side on the right side of the patient. The further procedure is same as in the standard laparoscopic anterior resection or APR.

Laparoscopic Splenectomy

There is only one report of laparoscopic splenectomy in a patient with situs inversus [16]. It was successfully performed in 185 minutes with just 35 ml blood loss. The mirror image

anatomy made the procedure difficult for the right-handed surgeon, so they used the anterior approach through the subxiphoid area. Patient was kept in the left semilateral position, with the operating surgeon on the left side, camera assistant between the leg and the assistant on the right. Three 12 mm ports were inserted in supraumbilical area, subxiphoid region, and in the right axillary line and one 5mm port in the right subcoastal region. The dissection in this case was started with mobilisation of the lower pole by dividing the splenocolic ligament. Ultrasonic dissector was used to take down the adhesion and expose the anterior aspect of the hilum. It was followed with division of short gastric vessels using harmonic scalpel. The upper pole division of gastrosplenic and splenophrenic attachments was next done. The spleen was then lifted and an endoscopic stapling device was inserted from the subxiphoid port to divide the splenic vessels at the hilum. Finally, the last attachments to the retroperitoneum were divided to complete the procedure. We suggest proper preoperative planning and involvement of an experienced surgeon to perform splenectomy in these patients.

Laparoscopic Bariatric Surgery

Laparoscopic bariatric surgery has become the standard of care for patients with morbid obesity. Situs inversus in a patient undergoing laparoscopic Roux-en-Y gastric bypass (LRYGB) was first performed by Wittgrove, in 1998[17]. Since then 27 laparoscopic bariatric surgery have been reported in patients of situs inversus, in whom the entire range of bariatric series including Laparoscopic Roux-en-Y gastric bypass (LRYGB), banded Roux-en-Y gastric bypass (LBRYGB), laparoscopic adjustable gastric banding (LAGB), Laparoscopic sleeve gastrectomy (LSG), modified duodenal switch, Omega loop gastric bypass or mini gastric bypass, laparoscopic bilopancreatic diversion and Robotic assisted RYGB (RRYGB) have been performed.

A higher complication rate and a longer operating time has been reported in laparoscopic bariatric surgery in patients of Situs inversus, which could be due the unfamiliar anatomy caused by the visceral transposition of organs in the sagittal plane. The technical difficulty of this procedure multiplies as does the complication rates, especially when the diagnosis of Situs inversus in missed preoperatively.

Several technical challenges and ways to overcome have been reported. The mirror imaging technique, where the operating surgeon stands on the left side and alteration in the port positions are the only suggestion which has some consensus. Wittgrove described using the opposite hands and foot for handling instruments and operating the foot pedal respectively and needed double the usual time. Ahmed et al however could finish the entire procedure from the left side of the patient without the need for changing hands for the instruments unlike Whitgrove [18]. Wall et al described the first robot assisted RYGB in 2013[19]. The dexterity of the robotic arms obviated the need to change the position of the ports or of the surgeon during the surgery. Kassir et al. (2017), reported a mini gastric bypass with the patient in modified lithotomy and the surgeon standing in between the legs[20]. This position caused minimal confusion and the procedure was completed within the standard operating time. There was no need for any change in their port positions or in the position of the operating surgeon.

CONCLUSION

Laparoscopic surgeries can safely be performed in situs inversus patients with proper preoperative planning and with modifications in port placement and position of the surgeons and monitor and some amount of ambidexterity. Better understanding of ergonomics will definitely help in successful completion of laparoscopic surgeries in such patients. The experience in advanced laparoscopic surgery is an important factor to safely complete the procedure.

REFERENCES

[1] Ahmed, Ahmed R. & William, O'malley. (October 2006). "Laparoscopic Roux-En-Y Gastric Bypass in a Patient with Situs Inversus." *Obesity Surgery*, *16*, no. 10, 1392–94. https://doi.org/10.1381/096089206778663670.

[2] Campos, Luis.& Earl Sipes. (January 1, 1991). "Laparoscopic Cholecystectomy in a 39-Year-Old Female with Situs Inversus." *Journal of Laparoendoscopic Surgery*, *1*, no. 2, 123–26. https://doi.org/10.1089/lps.1991.1.123.

[3] Choi, Sung Il., Sun Jin, Park., Byung Mo, Kang., Kil Yeon, Lee., Haeng Chul, Lee.& Suk-Hwan, Lee.(April 2011). "Laparoscopic Abdominoperineal Resection for Rectal Cancer in a Patient with Situs Inversus Totalis." *Surgical Laparoscopy, Endoscopy & Percutaneous Techniques*, *21*, no. 2, e87-90. https://doi.org/10.1097/SLE.0b013e31820b0258.

[4] Cui, Beibei., Sanlin, Lei., Kuijie, Liu.& Hongliang, Yao. (August 20, 2018)."Robotic Low Anterior Resection plus Transanal Natural Orifice Specimen Extraction in a Patient with Situs Inversus Totalis." *BMC Surgery*, *18*, no. 1, 64. https://doi.org/10.1186/s12893-018-0394-3.

[5] Davies, H., Slater,G. H.& Bailey, M.(January 1, 2003). "Laparascopic Sigmoid Colectomy for Diverticular Disease in a Patient with Situs Inversus." *Surgical Endoscopy And Other Interventional Techniques*, *17*, no. 1, 160–61. https://doi.org/10.1007/s00464-002-4231-4.

[6] Fujiwara, Yushi., Yosuke, Fukunaga., Masayuki, Higashino., Shinya, Tanimura., Masashi, Takemura., Yoshinori, Tanaka. & Harushi, Osugi. (October 7, 2007). "Laparoscopic Hemicolectomy in a Patient with Situs Inversus Totalis." *World Journal of Gastroenterology: WJG*, *13*, no. 37, 5035–37. https://doi.org/10.3748/wjg.v13.i37.5035.

[7] Huh, Jung Wook., Hyeong, Rok Kim., Sang Hyuk, Cho., Choong Young, Kim., Hoon Jin, Kim., Jae Kyoon, Joo.& Young, Jin Kim.(May 2010). "Laparoscopic Total Mesorectal Excision in a Rectal Cancer Patient with Situs Inversus Totalis." *Journal of Korean Medical Science*, *25*, no. 5, 790–93. https://doi.org/10.3346/jkms.2010.25.5.790.

[8] Kang, Sung-Bum.& Ho-Seong, Han.(April 2004). "Laparoscopic Exploration of the Common Bile Duct in a Patient with Situs Inversus Totalis." *Journal of Laparoendoscopic & Advanced Surgical Techniques. Part A*, *14*, no. 2, 103–6. https://doi.org/10.1089/109264204322973880.

[9] Karabay, Onder., Bulent, Gurbuz., Serkan, Zenger., Emre, Balik.& Dursun, Bugra. (2019). "Laparoscopic Colon Resection in Patients with Situs Inversus Totalis: Is It the Same Operation as in Patients without Situs Inversus Totalis?" *Journal of Minimal Access Surgery*, *15*, no. 1, 68–70. https://doi.org/10.4103/jmas.JMAS_13_18.

[10] Kassir, Radwan., Farouk, Mourthadhoi., Olivier, Tiffet.& Patrice, Lointier. (2017). "How Do I Do a Laparoscopic One-Anastomosis Gastric Bypass in a Patient with Situs Inversus Totalis." *Obesity Surgery*, *27*, no. 8, 2218–19. https://doi.org/10.1007/s11695-017-2761-z.

[11] Kobus, Christian., Eduardo M., Targarona., Galit, Even Bendahan., Verónica, Alonso., Carmen, Balagué., Sandra, Vela., Jordi, Garriga., & Manuel, Trias. (October 1, 2004). "Laparoscopic Surgery in Situs Inversus: A Literature Review and a Report of Laparoscopic Sigmoidectomy for Diverticulitis in Situs Inversus." *Langenbeck's Archives of Surgery*, *389*, no. 5, 396–99. https://doi.org/10.1007/s00423-004-0500-0.

[12] Morimoto, Mamoru., Tetsushi, Hayakawa., Hidehiko, Kitagami., Moritsugu, Tanaka., Yoichi, Matsuo.& Hiromitsu, Takeyama.(June 19, 2015). "Laparoscopic-Assisted Total Gastrectomy for Early Gastric Cancer with Situs Inversus Totalis: Report of a First Case." *BMC Surgery*, *15*, https://doi.org/10.1186/s12893-015-0059-4.

[13] Salama, Ibrahim Abdelkader., Mohammed, Hussein Abdullah.& Mohammed, Houseni. (May 6, 2013). "Laparoscopic Cholecystectomy in Situs Inversus Totalis: Feasibility and Review of Literature." *International Journal of Surgery Case Reports*, *4*, no. 8,711–15. https://doi.org/10.1016/j.ijscr.2013.02.030.

[14] Uludag, Mehmet., Gurkan, Yetkin.& Abdulcabbar, Kartal. (June 2011). "Single-Incision Laparoscopic Cholecystectomy in Situs Inversus Totalis." *JSLS: Journal of the Society of Laparoendoscopic Surgeons*, *15*, no. 2, 239–43. https://doi.org/10.4293/108680811X13071180407032.

[15] Wall, Anji., Zuliang, Feng.& Willie, Melvin. (June 2014). "Robotic-Assisted Roux-En-Y Gastric Bypass in a Patient with Situs Inversus." *Journal of Robotic Surgery*, 8, no. 2, 169–71. https://doi.org/10.1007/s11701-013-0402-7.

[16] Wittgrove, A. C. & Clark, G. W.(February 1998). "Laparoscopic Gastric Bypass for Morbid Obesity in a Patient with Situs Inversus." *Journal of Laparoendoscopic & Advanced Surgical Techniques. Part A*,*8*, no. 1, 53–55. https://doi.org/10.1089/lap.1998.8.53.

[17] Yaegashi, Mizunori., Toshimoto, Kimura., Takashi, Sakamoto., Tadao, Sato., Yuichiro, Kawasaki., Koki, Otsuka.& Go, Wakabayashi. (April 2015). "Laparoscopic Sigmoidectomy for a Patient With Situs Inversus Totalis: Effect of Changing Operator Position." *International Surgery*, *100*, no. 4, 638–42. https://doi.org/10.9738/INTSURG-D-14-00217.1.

[18] Yaghan, R. J., Gharaibeh, K. I. & Hammori, S.(August 2001). "Feasibility of Laparoscopic Cholecystectomy in Situs Inversus." *Journal of Laparoendoscopic & Advanced Surgical Techniques. Part A*,*11*, no. 4, 233–37. https://doi.org/10.1089/109264201750539763.

[19] Yamaguchi, S., Orita, H.Yamaoka, T.Mii, S.Sakata,H.& Hashizume, M.(February 1, 2003). "Laparoscope-Assisted Distal Gastrectomy for Early Gastric Cancer in a 76-Year-Old Man with Situs Inversus Totalis." *Surgical Endoscopy And Other Interventional Techniques*, *17*, no. 2, 352–53. https://doi.org/10.1007/s00464-002-4504-y.

[20] Yodonawa, Satoshi., Yukinobu, Goto., Isao, Ogawa., Susumu, Yoshida., Hiromichi, Itoh., Reiji, Nozaki., Akinori, Kato.& Masahiko, Takahashi. (December 2010). "Laparoscopic Splenectomy for Idiopathic Thrombocytopenic Purpura in a Woman with Situs Inversus: Report of a Case." *Surgery Today*, *40*, no. 12, 1176–78. https://doi.org/10.1007/s00595-009-4183-6.

In: Encyclopedia of Surgery (22 Volume Set)
Editors: Andreas Lehrer and Kristin Mueller
ISBN: 978-1-53618-329-0
© 2020 Nova Science Publishers, Inc.

Chapter 104

MANAGEMENT OF SURGICAL WOUNDS INFECTIONS IN SPINE SURGERY

M. Dobran[1], D. Nasi[1], S. Veccia[2] and A. Giacometti[2]
[1]Neurosurgery Clinic, Polytechnic University of Marche, Ancona, Italy
[2]Infectious Diseases Clinic, Polytechnic University of Marche, Ancona, Italy

ABSTRACT

Postoperative surgical wound infection (SWI) in the lumbar spine is unfortunately a common and potentially devastating complication. It is associated with increasing morbidity and the need for further surgery.

The rate of spinal wound infection in literature ranges from 0.7 to 11.9% . The type of surgery is perhaps the most significant variable affecting the rate of infection. When instrumentation is used for lumbar fusions, the infection rate increases and Staphylococcus aureus is the most common organism causing SWI. Other reported causative organisms include Staphylococcus epidermidis, Enterococcus faecalis, Pseudomonas spp., Enterobacter cloacae and Proteus mirabilis. Gram-negative bacteria are more common in trauma patients. White blood cell count is an unreliable indicator of infection. Erythrocyte sedimentation rate (ESR) may remain elevated for up to six weeks after surgery and C-reactive protein (CRP) levels normalize within two weeks. In regard to the potential role of Procalcitonine (PCT), recent trials demonstrated that PCT may be useful to diagnose neurosurgical patients with SWI.

Magnetic resonance imaging (MRI) is the most useful study to diagnose SWI. Gadolinium enhancement improves the diagnostic accuracy of MRI and it should be used whenever an infection is suspected. Rim enhancing fluid collections, ascending epidural collections, the evidence of bone destruction and progressive marrow signal changes are suggestive of infection. The nonoperative treatment of postoperative spinal wound infections is rarely indicated and it is generally limited to significantly immuno-compromised patients.

Treatment of SWI is centered on the surgical debridement of all necrotic tissue and the obtainment of intra-operative cultures to guide antibiotic therapy. We recommend the involvement of an infectious disease specialist to adjust and monitor the efficacy of the antibiotic treatment. In most cases, SWI can be adequately treated while leaving spinal instrumentation in place. For severe SWI, repeat debridements, delayer closure and the

involvement of a plastic surgeon may be necessary. In some patients the use of the VAC therapy may be useful for the wound closure. Proven methods to prevent wound infection include prophylactic antibiotics, meticulous adherence to aseptic technique, frequent release of retractors to prevent myonecrosis and shorter operative time.

Keywords: surgical wound infections; spine surgery; antibiotic; surgical debridement

INTRODUCTION

Postoperative surgical wound infection (SWI) in the lumbar spine is unfortunately a common and potentially devastating complication [1]. It is associated with increased morbidity and the need for further surgery [2]. Additionally, the increasing prevalence of antibiotic-resistant organisms such as methicillin-resistant Staphylococcus aureus (MRSA) presents new challenges for both prevention and treatment of SWI, especially in patients with spinal instrumentation [3]. In this chapter, we review the epidemiology, the clinical presentation, the diagnosis and management of SWI.

EPIDEMIOLOGY

The rate of spinal wound infection in literature ranges from 0.7 to 11.9% [4]. The type of surgery is perhaps the most significant variable affecting the rate of infection. Simple lumbar discectomy carries a risk of infection of less than 1% thanks to shorter operative times, minor muscle trauma and generally healthier patients than those requiring more extensive spinal procedures [5]. When more extensive decompression is performed, with no fusion, the risk of infection increases from 1.5 to 2% [5]. With the addition of fusion to the procedure, operative time becomes longer, blood loss is greater and a separate operative site is usually required to harvest bone graft. The overall complication rate associated with a separate bone graft site is nearly 20%, some of them due to infection [6]. When instrumentation is used for lumbar fusions, the infection rate escalates from 2 to 6% [7].

Koutsoumbelis et al. [8] recently reviewed a consecutive series of 3,218 patients who underwent posterior lumbar instrumented arthrodesis. The surgery-related risk factors identified by their study included: (1) the presence of more than ten people in the operating room (OR), specifically cautioning against the presence of extraneous staff; (2) the long duration of surgery; (3) great intra-operative blood loss, the need for transfusion and (4) incidental durotomy.

Regarding patient-related risk factors for SWI, several studies reported the following factors: smoking, diabetes mellitus, alcohol abuse, obesity, malnutrition, advanced age, pre-operative hospitalization longer than one week and corticosteroid use. Smoking and diabetes have been shown to predispose patients to infection by inducing tissue ischemia and microvascular damage [9-11]. The thick layer of adipose tissue in obese patients provides a large potential space following surgical wound closure, which has poor vascular perfusion and may become necrotic.

Staphylococcus aureus is the most common organism causing SWI [12]. Recently, however, MRSA has become increasingly prevalent with 34% of SWIs according to the

positive cultures in the series by Koutsoumbelis et al [8]. Other reported causative organisms include Staphylococcus epidermidis, Enterococcus faecalis, Pseudomonas spp., Enterobacter cloacae and Proteus mirabilis. Gram-negative bacteria are more common in trauma patients.

PREVENTION

The meticulous adherence to aseptic technique is the single most important component of SWI prevention [13]. The use of prophylactic antibiotic therapy has significantly decreased the rate of SWI after spinal surgery. Finally, frequent release of retractors to prevent myonecrosis, debridement of any necrotic appearing muscle and irrigation at the end of the procedure are recommended [14].

CLINICAL PRESENTATION

The overall diagnosis of SWI must be made using clinical judgment and taking into account any available information. SWI can be defined according to his anatomic relationship to the fascia (superficial or deep). In the early postoperative period, the most common signs of infection are increasing pain at the surgical site, open wound, metal protruding through skin, prominent metal ware, abscess and fluctuant wound. Objective findings on examination include peri-incisional erythema, tenderness to palpation, induration and drainage. Constitutional symptoms such as fever or chills are especially concerning revealing clues.

DIAGNOSIS

White blood cell count is an unreliable indicator of infection. The acute phase reactants are more useful to diagnose infection, but they must be interpreted. Erythrocyte sedimentation rate (ESR) may remain elevated for up to six weeks after surgery. C-reactive protein (CRP) levels normalize within two weeks. Consequently, CRP has been shown to be a more sensitive indicator of the presence of SWI [15].

In regard to the potential role of Procalcitonine (PCT), recent trials demonstrated that PCT may be useful in the diagnosis of neurosurgical patients with post-operative fever. Nevertheless other authors showed that CRP is more sensitive compared to PCT in patients with SWI [16].

Plain radiographs of the spine are rarely useful for the diagnosis of early infection. In the setting of discitis, there may be evidence of disc height loss and end plate erosion. In latent infections, lucencies may be present around the hardware. Magnetic resonance imaging (MRI) is the most useful study to diagnose SSI. Gadolinium enhancement improves the diagnostic accuracy of MRI and it should be used whenever an infection is suspected. Rim enhancing fluid collections, ascending epidural collections, evidence of bony destruction and progressive marrow signal changes are all suggestive of infection.

MANAGEMENT

Today titanium instrumentation in spine surgery grants an advantage: titanium alloy is less prone to colonization than stainless steel. Titanium is handy and widely used in spinal stabilization in traumatic and degeneratives pathologies of the column. In vitro studies suggest that the biofilm can block antibiotics, phagocytes and other humoral immune responders, making the infection relatively resistant to host defensive mechanisms and antibiotics. When a wound infection occurs in stabilized patients, the nonoperative treatment is rarely indicated and it is generally limited to significantly immunocompromised patients following an initial procedure involving irrigation and debridement to allow open-wound healing by means of secondary intention, dressing changes and wound packing.

Eradication of infection, however, nearly always requires careful debridement. Debate continues in literature about the need of serial debridements and their correct technique, if any, to close the skin and the fascial defect.

Debridement should consist of aggressive removal of all necrotic tissue and foreign materials such as sutures. Once the superficial layer has been debrided and irrigated copiously, the fascial layer must be inspected. This may be left unopened only if the surgeon is totally sure that the infection is only superficial. Once the deep layer is opened, debridement of necrotic muscle and significantly necrotic bone graft should be performed. In our experience and in literature, the leading philosophy is not to remove consolidating bone graft and instrumentation unless the infection is not healing in spite of debridements [1-5;16,17]. Instrumentation serves to stabilize the motion segment, theoretically decreasing inflammation and promoting bone healing. Some authors do not agree with leaving instrumentation in a contaminated wound. Non-essential spinal instrumentation such as loose pedicle screws should be removed. Anyway infection increases the risk of developing a pseudarthorosis and these patients must be closely monitored with serial imaging studies [18]. In cases of late infection with a solid fusion, instrumentation can be removed at the time of surgical debridement to facilitate the clearance of the infection.

Intra-operative tissue culture is essential to tailor antibiotic therapy before giving any. Close blood sugar control in diabetic patients and a nutrition consult in patients at risk for malnutrition are recommended [19-25].

It is a standard practice at our Institution to involve infectious disease specialists in the selection and serial monitoring of antibiotic therapy for SWI or other post-operative infections [26-28]. The antibiotic regimen is designed and monitored by an infectious disease specialist and based on the type of infectious organism and its drug sensitivity profile.

Intravenous antibiotic therapy is continued for at least six weeks postoperatively. In case of resistant organisms, such as MRSA, recent recommendations suggest extending intravenous antibiotic therapy for eight weeks [25]. At the end of the intravenous antibiotic therapy, we routinely maintain patients on oral suppressive antibiotics tailored to the infectious organism. The decision regarding the removal of the instrumentation versus life-time oral antibiotic suppression is based on the causative pathogen, the patient's health status and the presence of a fusion mass. Recently, vacuum-assisted closure of postoperative spinal wounds after infection has gained in popularity, although only isolated reports have appeared in literature. This technique consist of an occlusive dressing over a suction drainage system. The vacuum effect draws the edges of the wound together removing any purulent tissue.

Success has been reported on a limited basis, but further trials need to be performed to determine any potential benefit compared with repeated debridement and tertiary closure or flap closures.

The necessary debridement of necrotic tissue following SWI may result in a significant soft tissue defect repaired with a muscle flap. This allows for high local antibiotic concentrations despite poor tissue vascularity. Multiple debridements are usually necessary and we recommend involvement of a plastic surgeon at early stage to grant an optimal wound management. Until today multiple techniques have been used for delayed wound closure. Negative pressure wound therapy (vacuum-assisted closure VAC) has been widely used for many years to treat complicated wounds and in case of failure of any surgical procedure. In many patients VAC therapy, also in presence of a wound infection, allowed the healing of the wound without removing the hardware. This is in line with the current trend to maintain the hardware in infected patients too.

In a recent study [28] we reviewed retrospectively 550 patients who underwent spinal fusion surgery from 2011 to 2015; 16 developed SSI after spinal instrumentation. The diagnosis of SWI was established according to positive wound swab or blood cultures and several clinical, laboratory and radiological findings. Additional pre-operative and intraoperative risk factors were analyzed. The incidence of SWI after spinal instrumentation surgery was 2.9%. Obesity was a statistically significant parameter ($p = 0{,}013$) that contributed to SWI along with alcoholism and/or drug abuse ($p = 0.034$).

The second study [27] on our patients documented that ESR and CRP values were statistically significant parameters to diagnose SWI after spinal implant. The leukocyte count, the number of lymphocytes and fever integrates the data of ESR and CRP with no statistical significance. MRI with contrast is the exam of choice, but FDG PET/CT may be useful in patients with a suspicion of SWI. Some pathogens have proved to be particularly hard to treat conservatively such as staphylococcus-MRSA. However some patients with SWI gain clinical healing with favorable outcome by means of target antibiotic therapy with no hardware removal.

In regard to the potential role of Procalcitonine (PCT), recent trials demonstrated that PCT may be useful to diagnose neurosurgical patients with post-operative fever. Nevertheless other authors showed that CRP is more sensitive than PCT in patients with SWI [15,16].

Plain radiographs of the spine are rarely useful to the diagnosis of early infection. In the setting of discitis there may be evidence of disc height loss and end plate erosion. In latent infections, lucencies may be present around the hardware. Magnetic resonance imaging (MRI) is the most useful study to diagnose SWI. Gadolinium enhancement improves the diagnostic accuracy of MRI and it should be used whenever an infection is suspected. Rim enhancing fluid collections, ascending epidural collections, the evidence of bony destruction and the progressive marrow signal changes are all suggestive of infection.

CONCLUSION

The treatment of SWI is centered on the surgical debridement of all necrotic tissue and the obtainment of intra-operative cultures to guide antibiotic therapy. We recommend the involvement of an infectious disease specialist to adjust and monitor the efficacy of antibiotic

treatment. In most cases, SWI can be adequately treated while leaving spinal instrumentation in place. For severe SWI, repeated debridements, delayed closure and the involvement of a plastic surgeon are necessary. Proven methods to prevent wound infection include prophylactic antibiotics, meticulous adherence to aseptic technique, frequent release of retractors to prevent myonecrosis and shorter operative time. To prevent myonecrosis, debridement of any necrotic appearing muscle and the irrigation at the end of the procedure are recommended [14].

REFERENCES

[1] Weinstein MA, McCabe JP, Cammisa FP Jr (2000) Postoperative spinal wound infection: a review of 2,391 consecutive index procedures. *J. Spinal Disord.* 13:422–426.

[2] Bassewitz HL, Fischgrund JS, Herkowitz HN (2000) Postoperative spine infections. *Semin. Spine Surg.* 12:203–211.

[3] Weiner BK, Kilgore WB (2007) Bacterial shedding in common spine surgical procedures. *Spine* 32:918–920.

[4] National Nosocomial Infections Surveillance System (2004) National nosocomial infections surveillance (NNIS) system report, data summary from January 1992 through June 2004, issued October 2004. *Am. J. Infect. Control.* 32:470–485.

[5] Fang A, Hu SS, Endres N, Bradford DS (2005) Risk factors for infection after spinal surgery. *Spine* 30:1460–1465.

[6] Olsen MA, Mayfield J, Lauryssen C, Polish LB, Jones M, Vest J, Fraser VJ (2003) Risk factors for surgical site infection in spinal surgery. *J. Neurosurg.* 98(2 Suppl):149–155.

[7] Olsen MA, Nepple JJ, Riew KD, Lenke LG, Bridwell KH, Mayfield J, Fraser VJ (2008) Risk factors for surgical site infection following orthopaedic spinal operations. *J. Bone Joint Surg. Am.* 90:62–69.

[8] Koutsoumbelis S, Hughes AP, Girardi FP, Cammisa FP, Finerty EA, Nguyen JT, Gausden E, Sama AA (2011) Risk factors for postoperative infection following posterior lumbar instrumented arthrodesis. *J. Bone Joint Surg. Am.* 93:1627–1633.

[9] Carreon LY, Puno RM, Dimar JR 2nd, Glassman SD, Johnson JR (2003) Perioperative complications of posterior lumbar decompression and arthrodesis in older adults. *J. Bone Joint Surg. Am.* 85:2089–2092.

[10] Cassinelli EH, Eubanks J, Vogt M, Furey C, Yoo J, Bohlman HH (2007) Risk factors for the development of perioperative complications in elderly patients undergoing lumbar decompression and arthrodesis for spinal stenosis: an analysis of 166 patients. *Spine* 32:230–235.

[11] Patel N, Bagan B, Vadera S, Maltenfort MG, Deutsch H, Vaccaro AR, Harrop J, Sharan A, Ratliff JK (2007) Obesity and spine surgery: relation to perioperative complications. *J. Neurosurg. Spine* 6:291–297.

[12] Levi AD, Dickman CA, Sonntag VK (1997) Management of postoperative infections after spinal instrumentation. *J. Neurosurg.* 86:975–980.

[13] Barker FG II (2002) Efficacy of prophylactic antibiotic therapy in spinal surgery: A meta-analysis. *Neurosurgery* 51:391–400.

[14] Transfeldt EE, Lonstein JE (1985) Wound infections in elective reconstructive spinal surgery. *Orthopaedic Transactions* 9:128–129.
[15] Silber JS, Anderson DG, Vaccaro AR, Anderson PA, McCormick P (2002) Management of post procedural discitis. *Spine J.* 2:279– 287.
[16] Sierra-Hoffman M, Jinadatha C, Carpenter JL, Rahm M (2010) Postoperative instrumented spine infections: a retrospective review. *South Med. J.* 103:25–30.
[17] Pappou IP, Papadopoulos EC, Sama AA, Girardi FP, Cammisa FP (2006) Postoperative infections in interbody fusion for degenerative spinal disease. *Clin. Orthop. Relat. Res.* 444:120–128.
[18] Viola RW, King HA, Adler SA, Wilson CB (1997) Delayed infection after elective spinal instrumentation and fusion. A retrospective analysis of eight cases. *Spine* 22:2444–2450.
[19] Toulson C, Walcott-Sapp S, Hur J, Salvati E, Bostrom M, Brause B, Westrich GH (2009) Treatment of infected total hip arthroplasty with a 2-stage reimplantation protocol. *J. Arthroplasty* 24:1051–1060.
[20] Westrich GH, Walcott-Sapp S, Bornstein LJ, Bostrom MP, Windsor RE, Brause BD (2010) Modern treatment of infected total knee arthroplasty with a 2-stage reimplantation protocol. *J. Arthroplasty* 25:1015–1021.
[21] Volin SJ, Hinrichs Sh, Garvin KL (2004) Two-stage reimplantation of total joint infections: a comparison of resistant and non-resistant organisms. *Clin. Orthop. Relat. Res.* 427:94–100.
[22] Weinstein MP, Stratton CW, Hawley HB, Ackley A, Reller LB (1987) Multicenter collaborative evaluation of a standardized se- rum bactericidal test as a predictor of therapeutic efficacy in acute and chronic osteomyelitis. *Am. J. Med.* 83:218–222.
[23] Liu C, Bayer A, Cosgrove SE et al (2011) Clinical practice guidelines by the infectious diseases society of America for the treatment of methicillin-resistant Staphylococcus aureus infections in adults and children. *Clin. Infect. Dis.* 52:285–292.
[24] Mitra A, Mitra A, Harlin S (2004) Treatment of massive thoracolumbar wounds and vertebral osteomyelitis following scoliosis surgery. *Plast Reconstr. Surg.* 113:206–213.
[25] Dumanian GA, Ondra SL, Liu J, Schafer MF, Chao JD (2003) Muscle flap salvage of spine wounds with soft tissue defects or infection. *Spine* 28:1203–1211.
[26] Dobran M, Mancini F, Nasi D, Scerrati M (2017) A case of deep infection after instrumentation in dorsal spinal surgery: the management with antibiotics and negative wound pressure without removal of fixation. *BMJ Case Rep.* 28;2017.
[27] Dobran M, Marini A, Gladi M, Nasi D, Colasanti R, Benigni R, et al. (2017) Deep spinal infection in instrumented spinal surgery: diagnostic factors and therapy. *G Chir.* 38(3):124-129.
[28] Dobran M, Marini A, Nasi D, Gladi M, Liverotti V, Costanza MD et al. (2017) Risk factors of surgical site infections in instrumented spine surgery. *Surg. Neurol. Int.* 6;8:212.

In: Encyclopedia of Surgery (22 Volume Set)
Editors: Andreas Lehrer and Kristin Mueller
ISBN: 978-1-53618-329-0
© 2020 Nova Science Publishers, Inc.

Chapter 105

HISTORICAL EVOLUTION OF CONSERVATIVE SURGERY OF BREAST CANCER

Maria Antonia Vaquero-Pérez[1,*], MD, PhD,
Jesus S. Torres-Jimenez[1], MD, PhD
and José Manuel Ramia-Ángel[2], MD, PhD
[1]Department of Surgery, Hospital Infanta Sofia,
San Sebastián de los Reyes, Madrid, Spain
[2]Department of Surgery, Hospital Universitario de Guadalajara,
Guadalajara, Spain

ABSTRACT

In the 70s, B. Fisher described breast cancer as a systemic disease (biological determinism). This hypothesis suggested that results of the treatment of breast cancer depend exclusively on the extent of systemic dissemination produced before the disease was detected. This biological model determined a huge change in the treatment of breast cancer, considering that a less radical breast surgery could get a survival equivalent to that obtained with radical surgery but with less physical and psychological morbidity. Furthermore, administration of systemic therapy (chemotherapy and/or hormone therapy), whose action would be directed to the treatment of systemic disease at diagnosis, should improve survival and increase disease-free period.

Changes to less radical surgical techniques were progressive and began with conservative radical mastectomy (Patey-Dyson). No differences in survival and local recurrence among patients treated with conservative radical mastectomy and traditional mastectomy was observed. In 1972, the use of modified radical mastectomy (Madden-Auchincloss) without compromising the oncological outcome was published.

Next step was performing conservative surgery for breast cancer (lumpectomy with axillary lymph node dissection followed by radiation therapy to the breast). Oncological results of this technique were confirmed with the NSABP 06 study. Pioneers of this technique are Fisher in America and Veronesi in Italy. The National Institutes of Health Consensus Conference in 1991, affirm that: "the conservative treatment of the breast is an

* Corresponding Author's Email: mantonia.vaquero@salud.madrid.org.

appropriate method for breast cancer patients with stage I and II and is preferable because breast conserving further provides equivalent survival to mastectomy ".

In 1992, Morton gave another step to a less radical approach to breast cancer with implementation of axillary sentinel node biopsy. Morton followed the hypothesis of Cabañas of sentinel node concept (1976), Cabañas affirmed that migration of tumor cells from the primary tumor targets a group of loco-regional lymph nodes (sentinel node) before spreading to the following lymph nodes areas, so if the sentinel node is free of tumor no other nodes would be affected. So if we confirm that axillary sentinel node is free of tumor, we could avoid axillary systematic lymphadenectomy. Selective sentinel node biopsy is now used routinely to stage the axilla.

In this chapter, we would perform a historical review from radical surgical techniques to lumpectomy and sentinel node biopsy and how surgeons have tried to evolve searching the best oncological results trying to offer also the best cosmesis to our patients.

HISTORICAL EVOLUTION OF BREAST CANCER CONSERVATIVE SURGERY

The surgical treatment of breast cancer has evolved dramatically since the early twentieth century, when techniques of radical resection were the norm. Today, it is accepted that breast cancer is a systemic disease, and so radical surgery does not offer longer survival than conservative surgery techniques. The aim of this chapter is to trace the evolution of breast cancer surgery over the past hundred years.

Halsted: From Radical Mastectomy to Modified Radical Mastectomy

During the first half of the twentieth century, Halsted radical mastectomy was the treatment of choice for breast cancer. This approach was supported by the mechanistic theory which considered breast cancer as a disease of loco-regional spread. The tumor was believed to disseminate gradually from its site of origin to the lymphatic vessels, then to regional lymph nodes, and finally to the bloodstream [1]. William Stewart Halsted (1852-1922), who subscribed to the theory of centrifugal spread, believed that local resection could cure cancer and that cancer recurrence seen in another location represented a new disease. In 1894 he described the technique of radical mastectomy, with which he managed to reduce the incidence of local recurrence from between 56-81% to 6%; unfortunately, 10-year survival was only 25%. The technique involves en bloc resection of the breast and of the major and minor pectoral muscles, and complete lymphadenectomy of the axilla and the supra- and infraclavicular fossa [2].

In the 1920s, Lane-Claypon carried out the first comparative studies of breast cancer survival, in relation to the surgical treatment performed. He observed that survival at three years was 29% after a non-radical mastectomy and improved to 43% after a radical mastectomy. Prognosis was related to the stage of disease at the time of surgery. This opinion was shared by Ewing, who found that survival was associated more with early diagnosis than with the surgical technique performed [3].

In the second half of the twentieth century, the improvements in health policy and medical care meant that breast cancers were diagnosed at earlier stages. In 1948, Patey and Dyson introduced a less aggressive form of mastectomy, called conservative radical mastectomy [4]. The Patey-Dyson technique preserved the pectoralis major muscle and achieved results for survival and local recurrence which were as good as those obtained with traditional mastectomy. In 1965, Madden and Auchincloss described the use of modified radical mastectomy with preservation of the major and minor pectoral muscles, without compromising the oncological outcome [5]. However, the first attempts at breast conservation are attributed to Mustakalio in Finland (1954), who proposed surgical tumor excision with free margins and adjuvant radiotherapy in patients with breast carcinoma without palpable lymph node, and obtained 5- and 10-year overall survival rates of 80.9% and 67.3% respectively [6]

In the 1950s and 1960s, less aggressive surgery for breast cancer gained growing support. It seemed reasonable to assume that tumor removal could be as effective as mastectomy. However, in 1978 Tagart et al [7] reported excessively high rates of local recurrence (37%) in stage I and II breast cancers three years after conservative surgery; therefore, modified mastectomy remained the standard of care.



Figure 1. Umberto Veronesi.

Fisher and Veronesi (Figure 1 and 2). In the 1980s, radical changes were introduced in the surgical management of breast cancer as a result of several factors.

The first of these factors was a change in the conception of the natural history of breast cancer. The mechanistic concept of illness was abandoned and breast cancer was now considered a systemic disease from the beginning. In this theory, first proposed by McDonald and reactivated by Fisher et al, tumor biology (cell kinetics, the host/ tumor relationship and degree of differentiation) determined the progression of the disease; this meant that regional lymph nodes were not a barrier against tumor progression, but an indicator of biological behavior [8].



Figure 2. Bernard Fisher.

This theory holds that tumor cells invade lymph nodes by embolization rather than by permeation, and that there is no ordered pattern of spread. Furthermore, the spread from the primary cancer occurs simultaneously via hematogenous and lymphatic pathways [8]. According to this new conception of the disease, the extent of local resection does not determine survival.

The second factor was the huge increase in the percentage of patients diagnosed with tumors less than 2 cm in size. This group now accounts for 30-50% of patients in industrialized countries. This is due to improved health education (media campaigns, assessment of the importance of early diagnosis and practice of breast self-examination), the application of non-selective screening programs including clinical, radiological and

laboratory tests, the development of better radiological techniques (mammography, ultrasound, xerography, thermography, breast CT), and the emergence of Breast Units [9].

The third factor was the confirmation that the survival rates achieved with conservative surgical treatment were similar to those obtained in the 1960s with more aggressive surgical and radiotherapeutic procedures [10]. Last but not least, the fourth factor was the active participation of patients in decisions regarding the treatment of their disease [10].

In 1973, Veronesi and colleagues began the first controlled clinical study at the Instituto Nazionale di Tumori in Milan, including 701 patients, which compared a group undergoing Halsted radical mastectomy versus another managed with an approach the authors termed QUART: lumpectomy (removal of the breast quadrant where the tumor is located) and axillary dissection and radiotherapy. They found no differences between the two groups regarding rates of overall survival (80% at 10 years) and achieved a 10-year local recurrence rate of 4.3% [11].

In the surgical technique described by Veronesi et al, quadrantectomy is defined by removing an entire breast quadrant including skin and fascia pectoralis. The breast nodule is identified and removed through a small skin incision, and sent to intraoperative study for histological confirmation. Once malignancy is confirmed, a lozenge incision is made whose major axis has a radial orientation relative to the nipple and the center is the scar made previously to perform the biopsy. En bloc exeresis, including skin, subcutaneous adipose tissue, mammary gland and the fascia of the *pectoralis major*, is performed. The mammary gland is then reconstructed in two planes (deep and superficial), with interrupted sutures of absorbable material, followed by suturing of the skin. The latter procedure requires special care, in view of the cosmetic purpose of conservative surgery [12].

Fisher et al published the results of the National Surgical Adjuvant Breast Project (NSABP), a multicenter controlled trial conducted at 34 hospitals in the US and Canada. In this study 1843 patients with stage I and II tumors up to 4 cm in diameter were randomly assigned to three groups: modified radical mastectomy, segmental mastectomy and axillary dissection without radiotherapy, and segmental mastectomy with axillary dissection and radiotherapy. At eight years, overall survival rates were similar for the three groups [13]. The results obtained with NSABP protocol confirm the role of conservative surgery plus radiotherapy for breast cancer [14].

Fisher et al describes lumpectomy as a tumor excision with 1-2 cm of surrounding healthy tissue. To achieve optimal aesthetic results these authors recommend using curved incisions rather than radial ones, and that these incisions must be located above the tumor. A small oval of the skin may be resected next to the underlying tumor to enable the pathologist to locate the anterior margin of the specimen, but skin resection does not increase the efficiency of the operation. The tumor is resected including the surrounding normal breast or adipose tissue and is immediately sent to the pathologist to confirm the diagnosis of cancer and to determine the macroscopic margin status. If the margin is positive, a re-resection is performed until a tumor-free margin is obtained. In the interests of improving the aesthetic results, it is not recommended to obliterate the "dead space" by bringing the breast tissue nearer, or to create thin skin flaps; nor are drains used. It is advisable to approximate subcutaneous fat with absorbable suture. The skin is closed with an intradermal suture [15].

At the Marseille Cancer Institute in France, between 1960 and 1981, Spitalier and Amalric treated more than 3,000 consecutive patients presenting operable infiltrating breast carcinoma with radiotherapy with or without primary limited surgery, which usually consisted

of local excision. Overall survival rates at 5, 10, 15 years were 85%, 75% and 55% respectively. They concluded that: "This conservative approach offers most women with operable breast cancer an excellent chance at breast preservation with the same chance for ten-year survival as with radical mastectomy" [16].

The National Institutes of Health Consensus Conference in 1990 stated that "Among their findings, the panel recommended that: (1) breast conservation treatment is an appropriate method of primary therapy for the majority of women with Stage I and II breast cancer and is preferable because it provides survival equivalent to total mastectomy and axillary dissection while preserving the breast; (2) the majority of patients with node negative breast cancer are cured by surgery or by surgery and radiation without further therapy; (3) there is clear evidence that rate of local and distant recurrence is decreased by both adjuvant combination cytotoxic chemotherapy and by adjuvant tamoxifen; (4) the decision to use adjuvant treatment should follow a thorough discussion with the patient regarding the possible risks and toxicities of therapy and its impact on quality of life; and (5) patients with tumors less than or equal to 1 centimeter have an excellent prognosis and do not require adjuvant therapy outside the clinical trials" [17].

After 20 years of follow up of previously cited randomized control trials, Veronesi's results confirmed that: "The rate of long-term survival among women who undergo breast-conserving surgery is the same as among women undergo a radical mastectomy. Therefore, conservative breast surgery is the treatment of choice for women with relatively small breast cancers" [18] and Fisher remarked that "lumpectomy followed by breast irradiation therapy remains appropriate for women with breast cancer, if margins of resected specimens are free of tumor and an acceptable aesthetic result can be obtained"[19].

According to the National Cancer Institute (Breast Cancer Database, 2007) conservative surgery is performed in more than 60% of patients with breast cancer, and conservative treatment should be considered the treatment of choice. It is indicated in all patients with a single, small tumor in the breast which can be excised with tumor-free margins, and achieves good cosmetic results. The patient must be able to receive postoperative external radiotherapy. If not all these conditions are met, mastectomy should be offered [20].

SENTINEL NODE LYMPHADENECTOMY (FIGURE 3)

Histological axillary node status is considered one of the most important prognostic factors. For many years, lymphadenectomy was crucial in the loco-regional surgical management of breast cancer.

In 1977, Ramón Cabañas established the concept of sentinel node (SN). Tumor cells migrate from the primary tumor to a group of loco-regional lymph nodes before spreading to the following lymph node "stations"; therefore, if the sentinel node is tumor-free, the other nodes will be tumor-free as well [21]. Based on Busch et al's studies of testicular lymphatic drainage with radiological contrast, Cabañas performed lymphangiography to locate the SN in patients with penile cancer. He established that this node was the first location of lymph node metastasis and may be the only one affected [22]. Therefore, he concluded that if the SN biopsy was negative, inguinal lymphadenectomy could be avoided.

In the 1980s, Morton et al applied the concept of SN to malignant melanoma by injecting dyes around the injury and subsequently inspecting the dyed lymphatic route and SN. Morton defined the concept of "intraoperative lymphatic mapping" and indicated the need for a learning curve of at least 30 patients to achieve good results [23]. In 1993, Alex and Krag [24, 25] used a gamma-ray probe after peritumoral injection of 99mTc-sulfur colloid to locate SN in patients with melanoma and breast cancer. In 1994 Giuliano used vital blue dye intraoperatively in the treatment of breast cancer [26], and Albertini combined the two methods in melanoma and breast cancer [27]. Turner validated the SN hypothesis [28] in a study of the first 103 patients with early breast cancer operated on by Giuliano. In these patients, the SN was located using dye, and subsequently lymphadenectomy was performed. The histopathological study of the SN was carried out staining with hematoxylin eosin (HE) and immunohistochemistry (IHC) was made using cytokeratins. In patients with disease-free SN, all non-sentinel lymph nodes were studied, finding metastases in only one. Turner concluded that if the GC is free from metastasis, the likelihood of disease in non-SN lymph nodes is <0.1%. Therefore, identification of SN and histopathology study using HE and IHC techniques is a reliable indicator of axillary node status in patients with breast cancer.

Figure 3. Searching sentinel node with gamma probe.

Nowadays, selective sentinel node biopsy is the diagnostic technique of choice for axillary staging of breast cancer, since it avoids axillary lymphadenectomy. Being a less invasive technique, it is associated with lower rates of wound complication, as well as a lower risk of lymphedema and nerve involvement. It is indicated in all patients with breast cancer with clinically negative axilla, although it may be waived in cases in which the information on nodal status will not change the therapeutic decision [29]. Currently, most centers perform lymphadenectomy of Berg levels I and II in patients with positive sentinel node, though recently this practice has been questioned.

ONCOPLASTIC SURGERY

Conservative surgery of breast cancer has two objectives: local control of the disease, and a satisfactory cosmetic outcome. However, it is sometimes difficult to achieve both. The attempt to achieve adequate control of disease may require large resections that negatively affect the aesthetic results; alternatively, an attempt to improve the cosmetic results may mean that the resections made are too small and there is an increased risk of local relapse. Up to 30% of women operated on with conservative techniques present cosmetic defects such as breast asymmetry or deformity.

The word “oncoplastic” derives from the Greek: "onco" (tumor) and "plastic" (modeling). In 1998, the term was used by Werner Audretsch to define the concept of “tumor-specific immediate reconstruction” [30]. Its aim is to preserve the breast shape and contour, and symmetry with the healthy breast, by combining oncologic and reconstructive techniques. These techniques comprise four elements: a proper oncological technique for tumor removal and control, immediate remodeling of the defect, the re-placement of the nipple-areola complex (NAC) after remodeling, and correction of asymmetry in the contralateral breast [31]. Oncoplastic techniques have successfully expanded the indications for conservative surgery for bigger tumors.

CONCLUSION

In the twenty-first century, there is no doubt about the efficiency of breast conservative techniques. The management of the breast cancer patient should combine the best cancer treatment with minimal cosmetic damage. Breast cancer surgery should be individualized to each woman, to her tumor, and to her personal expectations.

REFERENCES

[1] Díe Goyanes A. Breve relato de la evolución histórica del tratamiento quirúrgico del cáncer de mama. *Cir. Esp* 1993; 54:61-68.

[2] Halsted WS. *The results of operations for the cure of cancer of the breast performed at the Johns Hopkins Hospital from June 1889 to January 1894. Ann Surg*, 1894; 20(5):497-555.

[3] Robinson JO. Treatment of breast cancer through the ages. *Am. J. Surg.* 1986; 151:317-333.

[4] Patey DH, Dyson WH. The prognosis of carcinoma of the breast in relation to the type of operation performed. *Br. J. Cancer* 1948; 2:7-13.

[5] Madden JL. Modified radical mastectomy. *Surg. Gynecol. Obstet.* 1965; 121:1221-1230.

[6] Mustakalio S. Treatment of breast cancer by tumor extirpation and roentgen therapy in sead of radical operation. *J. Fac. Radiol.* 1954; 6:23.

[7] Tagart REB: Partial mastectomy for breast cancer. *Br. Med. J.* 1978; 2:1268.

[8] Fisher B, Redmond C, Fisher ER et al. The contribution of recent NSABP clinical trials of primary breast cancer therapy to an understanding of tumor biology. An overview of findings. *Cance*r 1980; 46:1009-1025.

[9] Sierra García A: Cirugía del cáncer de mama. *Madrid Médico* 1989; 9:5-14.

[10] Veronesi U. Cirugía conservadora y radioterapia en el cáncer de mama en los estadios I y II en el Istituto Nazionali Tumori (Milan). In Bland KI, Copeland EM III eds. La mama. *Manejo multidisciplinario de las enfermedades benignas y malignas*. Philadelphia. WB Saunders Co 1991; 970-974.

[11] Veronesi U, Banfi A, Del Vecchio M, et al. Comparison of Halsted mastectomy with quadrantectomy, axillary dissection and radiotherapy in early breast cancer: long term results. *Eur. J. Cancer Clin. Oncol.* 1986; 22:1085-1089).

[12] Veronesi U. Cuadrantectomía. In Bland KI, Copeland III EM eds. La mama. *Manejo multidisciplinario de las enfermedades benignas y malignas*. Philadelphia. WB Saunders Co 1991; 776-780.

[13] Fisher B, Redmond C, et al. Eight-year results of randomized clinical trial comparing total mastectomy and lumpectomy with or without irradiation in the treatment of the breast cancer. *N. Engl. J. Med* 1989; 320:822-828.

[14] Fisher B, Bauer M, Margolese R. Five year results of a randomized clinical trial comparing total mastectomy and segmental mastectomy with or without radiation in the treatment of breast cancer. *N. Engl. J. Med.* 1985; 312:665-673.

[15] Fisher B. Nodulectomía. In Bland KI, Copeland III EM eds. La mama. *Manejo multidisciplinario de las enfermedades benignas y malignas*. Philadelphia. WB Saunders Co 1991; 780-802.

[16] Amalric R, Santamaria F, Robert J, Seigle J, Altschuler C, Kurtz, Spitalier J, et al. *Radiation therapy with or without primary limited surgery for operable breast cancer: a 20 year experience at the Marseilles Cancer Institute*.

[17] Treatment of Early-Stage Breast Cancer. *NIH Consensus Statement* 1990 Jun 18-21;8(6)1-19.

[18] Veronesi U, Cascinelli N, Mariani L, Greco M, Saccozzi R, Luini A, et al. Twenty-year follow-up of a randomized study comparing breast-conserving surgery with radical mastectomy for early breast cancer. *N. Engl. J. Med.* 2002; 347(16):1227-32.

[19] Fisher B, Anderson S, Bryant J, Margolese RG, Deutsch M, Fisher ER, et al. Twenty-year follow-up of a randomized trial comparing total mastectomy, lumpectomy and lumpectomy plus irradiation for the treatment of invasive breast cancer. *N. Engl. J. Med.* 2002; 347(16):1233-41.

[20] NCCN. Breast Cancer. *Practice guidelines in Oncology*-v.2.2007. www.nccn.org.

[21] Cabañas R. An approach for the treatment of penile carcinoma. *Cancer* 1977; 39: 456-466.

[22] Buch FM, Sayeggh ES. Roentgenographic visualization of human testicular lymphatics: a preliminary reports. *J. Urology* 1963; 89 (1): 106-110.

[23] Morton DL, Wen DR, Wong JH, Economou JS, Cagle LA, Storm FK et al: Technical details of intraoperative lymphatic mapping for early stage melanoma. *Arch. Surg.* 1.992; 127: 392-399.

[24] Alex JC, Krag DN. Gamma-probe-guided localization of lymph nodes. *Surg. Oncol.*1.993; 2: 137-144.

[25] Krag DN, Meijer SJ, Weaver DL: Minimal-access surgery for staging of malignant melanoma. *Arch. Surg*. 1995; 130: 654-658.
[26] Giuliano AE, Kirgan DM, Guenther JM and Morton DL. Lymphatic mapping and sentinel lymphadenectomy for breast cancer. *Ann. Surg.*; 1.994, 220: 391-401.
[27] Albertini JJ, Lyman GH, Cox C, Yeatman T, Balducci L, Ku N et al. Lymphatic mapping and sentinel node biopsy in the patient with breast cancer. *JAMA.* 1996; 276: 1818-1822.
[28] Turner RR, Ollila DW, Krasne DL, Giuliano AE. Histopathologic validation of the sentinel lymph node hypothesis for breast cancer. *Ann. Surg.* 1997; 226 (3): 271-278.
[29] Harlow SP & Weaver DL. *Sentinel lymph node biopsy for breast cancer: indications and outcomes*, in UpToDate, Duda RB (Ed), UpToDate, Waltham MA 2013.
[30] Audretsch WP, Rezai M, Kolotas C, et.al. *Tumor-specific immediate reconstruction in breast cancer patients. Perspectives in Plastic Surgery*, 1998.11(1):71-100.58.
[31] Acea-Nebril B. Cirugía oncoplástica conservadora en el cáncer de mama. Indicaciones y límites en su aplicación quirúrgica. *Cir. Esp.* 2005;78(1):12-8.

In: Encyclopedia of Surgery (22 Volume Set)
Editors: Andreas Lehrer and Kristin Mueller
ISBN: 978-1-53618-329-0
© 2020 Nova Science Publishers, Inc.

Chapter 106

SURGERY OF COLORRECTAL LIVER METASTASES INVOLVING THE INFERIOR VENA CAVA

Mario Serradilla-Martín[1,*], MD, Pablo Ruíz-Quijano[1], MD, Ana Palomares-Cano[1], MD and José M. Ramia-Ángel[2], MD, PhD
[1]Department of Surgery, Miguel Servet University Hospital, Zaragoza, Spain
[2]Department of Surgery, Guadalajara University Hospital, Guadalajara, Spain

ABSTRACT

Liver resection remains the only potentially curative treatment for primary and metastatic tumours of the liver. Nowadays, chemotherapy as the only treatment is not considered to be a curative option. In the past, suspected involvement of the hepatocaval confluence or inferior vena cava was long considered a contraindication for liver resection as a result of the risks for intraoperative air embolism or massive haemorrhage. The development of surgical technical innovations have made it possible to perform combined liver and inferior vena cava resections and expand the population of patients who may be considered for hepatic resection, and favourable clinical outcomes have been reported. However, the numbers of both related articles published and patients involved are limited so that it is difficult to provide sufficient evidence to draw a conclusion about the value of this procedure. Most of the data available consist of case reports or small series that emphasize the technical aspects of the procedures. In this chapter, a systematic review of the literature is performed to pool data from all individually documented patients to evaluate the safety and efficacy of combined liver and inferior vena cava resection in patients with colorrectal liver metastases involving inferior vena cava. Perioperative mortality rate is acceptable. The 5-year survival rate is also acceptable, given the lack of alternative nonsurgical curative therapies at present. Survival is comparable with corresponding survival data in previously described reports for such tumors. In the absence of prospective randomized studies, which are difficult to perform on the other hand, we can affirm the inferior vena cava resection is safe and feasible in high-volume centers with proven experience.

[*] Corresponding Author's Email: marioserradilla@hotmail.com.

Keywords: colorectal liver metastases, inferior vena cava, liver resection, and hepatic resection

1. INTRODUCTION

Liver resection remains the only potentially curative treatment for primary and metastatic tumours of the liver. 5-year survival rates are reported to range from 30% to 50% after liver resection for metastatic colorectal cancer [1-4]. Nowadays, chemotherapy as the only treatment is not considered to be a curative option and, if left untreated, these patients usually have a median survival of considerably lower than 12 months [5].

In the past, patients with colorrectal liver metastases involving the inferior vena cava (IVC) were considered poor candidates for surgical management and included few 5-year survivors. Suspected involvement of the hepatocaval confluence or IVC was long considered a contraindication for liver resection as a result of the risks for intraoperative air embolism or massive haemorrhage [6, 7].

The development of surgical technical innovations such as portal vein embolization, two-stage hepatectomies, re-do hepatectomies, total hepatic vascular exclusion (THVE), venovenous bypass, and ex vivo hepatic resection combined with new chemotherapy regimens have made it possible to perform combined liver and IVC resections and expand the population of patients who may be considered for hepatic resection, and favourable clinical outcomes have been reported [8, 9]. Liver resection in patients with IVC involvement is becoming more common with the adoption of these techniques and, when necessary, with the replacement of the IVC using several materials [10-13].

However, the number of both related articles published and patients involved are limited so that it is difficult to provide sufficient evidence to draw a conclusion about the value of this procedure. Most of the data available consist of case reports or small series that emphasize the technical aspects of the procedures [14-23]. The longterm outcomes and oncological integrity of such procedures remain unclear.

In this chapter, a systematic review of the literature is performed to pool data from all individually documented patients to evaluate the safety and efficacy of combined liver and IVC resection in patients with colorrectal liver metastases involving IVC.

2. METHODS

This study was performed by following the recommendations of the Preferred Reporting Items for Systematic Reviews and Meta-Analyses (PRISMA) Statement [24]. The level of evidence of each study was classified according to the Oxford Centre for Evidence-Based Medicine levels of evidence [25].

2.1. Literature Review

A systematic literature search was conducted using PubMed, Embase and the Cochrane Library, to identify articles published from January 1980 to July 2018. Search terms were: "colorectal liver metastases," "inferior vena cava," "liver resection," and "hepatic resection." Bibliographies of the retrieved studies were checked manually for additional studies.

2.2. Inclusion Criteria

a) Papers presenting data on combined liver and IVC resection for colorrectal metastases; b) original data published; c) long-term outcomes available.

2.3. Exclusion Criteria

a) Non-English language studies; b) papers without original data; c) animal studies; d) the absence of individual patient data; e) IVC resection for any type of tumor other than colorectal cancer metastasis, and f) the absence of longterm data.

Three authors independently reviewed all the retrieved studies that met the inclusion and exclusion criteria. Discrepancies between the three authors were resolved by discussion and consensus.

The following data were collected for each patient: age, sex, number of resected metastases, type of hepatic resection, type of vascular control, type of reconstruction of the IVC, morbidity, mortality, 3 and 5-years survival, mean follow up, and disease-free survival. As the IVC resection is still a rare type of surgery, in several studies there are series of this type of surgeries for different tumors as cholangiocarcinoma, hepatocellular carcinoma, or renal or adrenal tumors with IVC infiltration. Sometimes it is difficult to extrapolate data from patients operated only for colorectal liver metastases. A descriptive analysis of all the data collected is shown.

3. RESULTS

3.1. Characteristics of the Study Population

Search of the literature yielded 73 articles (Figure 1). After screening, a total of 151 patients were described in 16 articles eligible for inclusion [26-41]. All these studies were observational in nature and classified as level-4 evidence. The characteristics of the studies populations are outlined in Table 1.

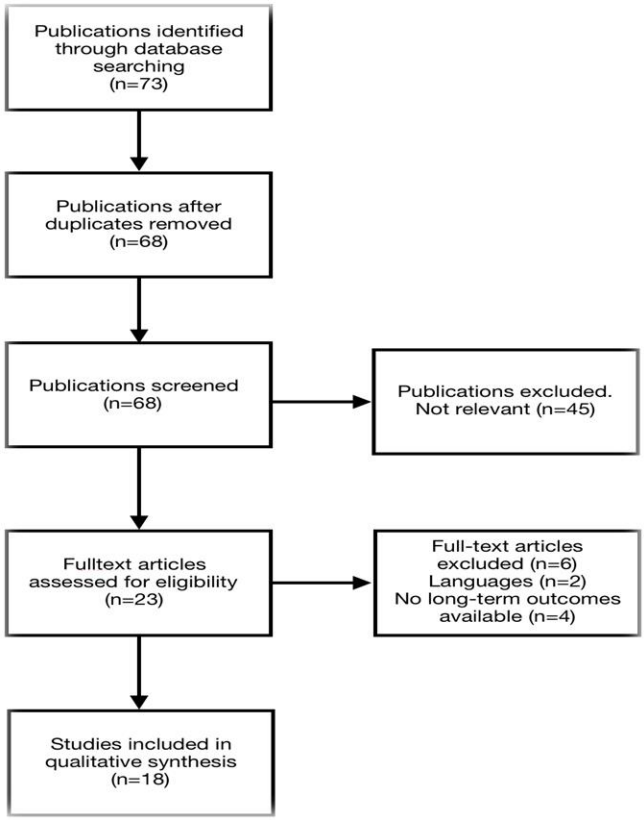

Figure 1. Flowchart of study selection.

3.2. Surgical Outcomes

A total of 151 patients with resection of liver metastases and ICV were included. The mean age was 58 years (range 35-84 years). We included 66 men and 53 women (2 studies did not include the sex of the patients). The mean number of resected metastases was 2.2 (range 1-27). The most frequent hepatic resections were: 36 right hepatectomies, 21 right trisectionectomies, 21 segmentectomies, 10 left hepatectomies, 8 extended right hepatectomies, 7 extended left hepatectomies, 6 left trisectionectomies, and 3 wedge resections. In 3 cases diaphragm was resected, in 3 the right adrenal gland and in 1 the right kidney. The most performed types of vascular control were: THVE in 63 cases, lateral clamping in 42 cases, total vascular exclusion with hepatic hypothermic perfusion in 6 cases, partial vascular exclusion in 3 cases, intermittent pedicular clamping in 4 cases, and IVC clamping in 2 cases (in 2 papers, it was not possible to extrapolate the type of clamping because was not specified according to the type of tumor). Postoperative morbidity was 45.6%, and mortality was 4.5%. Survival at 3 and 5 years was 55.6% and 32%, respectively. The mean follow-up was 22.7 months and the median disease-free time was 10.5 months. No conclusive data can be extracted from the average survival in these subgroup patients in the studies shown.

Table 1. Characteristics of documented patients

Year	Author	Nº pat.	Mean age	M/F	MMN	Type of hepatectomy	Vascular control	IVC repair	MB	MT	3YS	5YS	MFU	MDFS
1999	Miyazaki	14	58	8/6	2.4	4 RT 6 RH 2 LH 2 segmentectomy	8 THVE 3 HIHP 3 LC	11 PC 2 patches 1 PTFE graft	25%	16%	33%	22%	NA	NA
2000	Tono	3	62.3	2/1	1.3	2 extended LH 1 S1 resection	3 LC	3 PC	0%	0%	0%	0%	18	10.3
2004	Aoki	4	54.8	2/2	4.0	2 extended RH 1 extended LH 1 wedge resection	4 LC	4 AVG	75%	0%	75%	50%	25.8	8.1
2005	Johnson	11	60.5	4/7	1.1	3 RT 3 RH 2 LH 1 RH + adrenalectomy + diaphragm 1 RT + diaphragm 1 LT+ diaphragm	10 THVE 1 LC	8 PTFE patches 2 PC 1 PTFE graft	36%	0%	91%	27.3%	33	9
2005	Nardo	11	55.3	8/3	2.2	4 extended LH 4 extended RH 1 RH 1 LH 1 S7 resection	6 THVE 1 IVC clamp 2 IHPC 2 IHPC/LC	7 PC 3 PTFE grafts 1 PBP	57.9%	5.9%	NA	51.9%	24	NA
2005	Yamamoto	4	61.2	3/1	NA	2 S1 resection 2 RH + S1 resection	3 LC 1 IVC clamp	3 PC 1 AVG	50%	0%	NA	NA	19	13.5
2007	Delis	6	46.2	3/3	NA	4 RH 2 LT	3 THVE 3 PHVE	6 PTFE grafts	41.2%	0%	83%	NA	24	NA
2009	Kim	1	56	1/0	1	1 S1-4-8 partial resection	1THVE	1 AVG	0%	0%	NA	NA	12	NA
2009	Tanaka	20	63.4	10/10	3.7	NA	17 LC 3 THVE	17 PC 2 PTFE grafts 1 patch	16%	0%	58.6 %	24.9%	NA	9
2011	Malde	21	57.9	11/10	NA	5 RH 4 RT 4 RT + S1 3 LH 1 LH + adrenalectomy 1 LT + S1 1 S1 + nephrectomy 1 RH + S1 1 segmentectomy	15 THVE 4 THVE + HIHP + ex vivo 1 THVE + HIHP, + ante situm 1 THVE + HIHP	14 PC 3 Dacron grafts 2 PTFE grafts 2 PBP	40%	5.7%	NA	19.6%	30	NA

Table 1. (Continued)

Year	Author	Nº pat.	Mean age	M/F	MMN	Type of hepatectomy	Vascular control	IVC repair	MB	MT	3YS	5YS	MFU	MDFS
2013	Ie	9	55	4/5	NA	6 RH 2 segmentectomy 1 wedge resection	9 LC	9 PC	44.4%	0%	60%	40%	NA	13
2013	Azoulay	26	56.9	NA	NA	NA	NA	NA	62%	14%	44%	26%	37.3	NA
2013	Hemming	13	53	9/4		5 RT 5 RH 2 LT 1 LH	NA	9 PTFE grafts 2 patches 2 PC	NA	8%	NA	35%	31	NA
2014	Guerrini	1	67	1/0	1	1 S4	1 THVE	1 PTFE graft	100%	0%	NA	NA	6	NA
2016	Ko	6	69	NA	6.3	2 extended RH 1 S8 resection 1 RH 1 RH + S2-3 1 wedge resection	6 THVE	3 PC 3 AVG	46.6%	0%	NA	54.6%	NA	NA

MMN: mean metastasic nodules; MB: morbidity; MT: mortality; 3YS: 3-year survival; 5YS: 5-year survival; MFU: mean follow up; MDFS: mean disease free survival; NA: not available; RH: right hepatectomy; LH: left hepatectomy; RT: right trisectionectomy; LT: left trisectionectomy; THVE: total hepatic vascular exclusion; PHVE: partial hepatic vein exclusion; HIHP: hypothermic isolated hepatic perfusion; IHPC: intermittent hepatic pedicle clamping; LC: lateral clamping; PBP: pericardium bovine patch; PC: primary closure; AVG: autologous vein graft.

4. DISCUSSION

Hepatic malignancies involving the IVC are generally associated with poor clinical outcomes. The principles of curative-intent surgical oncology demand an en-bloc resection of organs potentially invaded by cancer. Limited availability of organs and poor survival resulting from the high rate of tumor relapse after liver transplantation for advanced hepatic malignancies with macroscopic vascular invasion have made liver transplantation unsuitable for these types of malignancies. Since the first description of combined liver and IVC resection by Starzl in 1980 [19], an increasing number of papers have been published in recent years, but robust evaluation of the literature is limited. All these studies are single patient reports or series including only a small number of patients [26-41], and the majority are studies that include IVC resections for different types of tumor, with analysis of the results together, without being able to extract reliable results in the subgroup of patients with hepatic metastases of colorectal cancer. The present study is based on individual patient data and includes the largest number of patients who underwent combined liver and IVC resection for colorrectal liver metastases, thus providing clear evidence to support this surgical approach as a safe and effective intervention for liver metastases involving the IVC. Considering the technical complexity of combined liver and IVC resection as compared with standard liver resection, the perioperative mortality rate of 4.5% is acceptable. Long-term survival is the most conclusive parameter in the assessment of therapeutic strategies for malignant tumors. The 32% 5-year survival rate is also acceptable, given the lack of alternative nonsurgical curative therapies at present. Survival is comparable with corresponding survival data in previously described reports for such tumors [42, 43].

Histopathological examination of the resected specimens in different papers showed that almost 40% of hepatic malignancies with suspected IVC involvement had only fibrous adhesion without true tumor invasion. Precise distinction between vascular invasion and inflammatory adhesions is difficult by preoperative imaging modalities or intraoperative exploration. Malde *et al.* [35] proposed that the surgeon should endeavor to peel the tumor from the IVC as this is possible more often than not. However, such procedure may cause tumor rupture, massive bleeding and dissemination of tumor cells. In addition, it is almost impossible to dissect from the IVC wall without producing a caval vein defect even in the setting of inflammatory adhesions. More importantly, data showed that long-term survival of patients with true invasion of the IVC was comparable to that of patients without vascular invasion, indicating that true invasion of the IVC per se is not a surrogate of aggressive tumor biology; rather it is a reflection of tumor location.

The vascular control was adapted in all the cases during surgery with the aims of minimizing the need for transfusion, shortening the ischaemia time of the remaining liver, maintaining stable systemic haemodynamics, and improving the tolerance of the remnant liver to ischaemia–reperfusion injury.

Several types of vascular control were used in this series. The first of these was hemiliver clamping, whereby no clamping was applied to the remaining liver and the clamp time was considered to be zero. Similarly, when only the portal vein or the hepatic artery was clamped, maintaining the flow of the other vessel (the artery or the portal vein respectively), the clamp time was considered to be zero as well. The second option was intermittent Pringle manouver, consisting of alternating periods of clamping of 15 min for and 5 min declamping, repeated

until the end of the hepatectomy; the total clamp time was taken as the sum of the periods of clamping. Third, vascular exclusion without caval clamping (preserving retrohepatic caval flow) was used for liver tumours compressing or involving at least one of the three main hepatic veins away from their roots at the vena cava. Resection was then performed via an anterior approach is most of the patients. Finally, standard THVE of the liver was used for tumours of the hepatocaval confluence. This method involved mobilization of the liver and isolation of the suprahepatic and infrahepatic vena cava and the hilum. A venovenous bypass was used in the event of haemodynamic intolerance to caval clamping. Vascular resections were carried out only when the vessels could not be freed safely from the tumour, irrespective of the preoperative plan [35-37].

Reconstruction of the IVC depends on the extent of IVC involvement. In general, direct suture of the IVC is indicated if a <2 cm wall is excised without involving the major hepatic veins. A patch or a synthetic/autologous graft can be used in the presence of extended infiltration of the wall (>2 cm) to prevent lumen stenosis. Finally, in patients with infiltration of at least one half of the IVC circumference, total replacement of the IVC with a vascular conduit is often required [35]. Although the autogenous or homologous vein is the preferred material for venous replacement due to its nonthrombogenic and infection-resistant advantages, it may not be technically feasible, particularly if a relatively long segment of the IVC is to be replaced. Thus, reconstructions using synthetic grafts are most frequently performed. A major concern with the use of synthetic grafts is infection, however, which was not documented in any patients included in current analysis of the literature. In patients where tumor involvement of the IVC is small, control of the IVC can be achieved simply by placing the vascular clamps tangential to the vena cava to preserve the IVC flow.

In patients where tumor involvement requires resection of a greater portion of the IVC, THVE including continuous clamping of the portal triad and the suprahepatic and infrahepatic IVC with or without veno-venous bypass is the standard technique. If involvement of the IVC is below the level of the hepatic veins and there is sufficient room to place a vascular clamp above the tumor but below the hepatic veins, caval occlusion should be performed below the hepatic vein after hepatic transection to maintain perfusion of the liver and minimize the hepatic ischemic time [38]. If extensive involvement of the IVC at the hepatic vein confluence exists, ex situ hypothermic liver resection is indicated. However, this technique is associated with a significant mortality rate, as high as 28%, with some patients needing salvage liver transplantation [44]. An alternative technique is the ante situm procedure, which was first introduced by Hannoun *et al.* in 1991 [45]. In this technique, after completely dividing the liver together with the IVC from the retroperitoneum, the liver can be anteriorly mobilized out of the abdomen. Then, the liver is perfused with a cold preservation solution via portal vein and the parenchymal resection is performed. After completion of the parenchymal resection, the IVC and venous outflow reconstruction is performed with or without the use of grafts. The major advantage of the ante situm procedure over an ex situ resection is the preservation of the hepatic pedicle without division, which can reduce the morbidity and mortality significantly [44]. Given the extensive nature of the ante situm procedure, it is usually performed in highly selected patients in experienced high-volume hepatobiliary centers.

This present analysis has several limitations. First, all of the included studies were retrospective with an inherent risk of bias. Differences in some variables including the institution's experience, perioperative management, study populations, surgical procedures,

IVC resections, and reconstructions may have influenced survival results. Secondly, the favorable survival rate achieved with combined resection of the liver and IVC could be due in part to the highly selected patients who may have had a good prognosis. Third, considering the included studies over three decades, it is important to consider that outcomes may have been influenced by the era in which the surgery was performed. Fourth, the survival of patients with hepatic metastases from colorectal cancer has increased in recent decades not only because of technically more aggressive surgeries, but also because of the development of new lines of chemotherapy that allow a better control of the disease. In fact, in most studies, the percentage of patients receiving adjuvant chemotherapy is greater than 50%, in some cases even reaching 80% [37].

CONCLUSION

Despite the difficulty of resection of the IVC, in recent decades there have been numerous technical advances that allow the increasing resection of patients with liver metastases of colorectal cancer involving IVC. The studies published so far are retrospective and many of them include resection of IVC for tumors other than colorectal liver metastases. However, published perioperative morbidity and mortality are comparable to the data published for this type of tumor without involvement of IVC. In the absence of prospective randomized studies, which are difficult to perform, we can affirm the IVC resection is safe and feasible in high-volume centers with proven experience.

REFERENCES

[1] Lévi F, Zidani R, Brienza S, Dogliotti L, Perpoint B, Rotarski M et al. 1999. “A multicenter evaluation of intensified, ambulatory, chronomodulated chemotherapy with oxaliplatin, 5-fluorouracil, and leucovorin as initial treatment of patients with metastatic colorectal carcinoma: International Organization for Cancer Chronotherapy.” *Cancer* 85:2532–2540.

[2] De Gramont A, Figer A, Seymour M, Homerin M, Hmissi A, Cassidy J et al. 2000. “Leucovorin and fluorouracil with or without oxaliplatin as firstline treatment in advanced colorectal cancer.” *J Clin Oncol* 18:2938–2947.

[3] Fong Y. 1999. “Surgical therapy of hepatic colorectal metastases.” *CA Cancer J Clin* 49:231–255.

[4] Bismuth H, Adam R, Lévi F, Farabos C, Waechter F, Castaing D et al. 1996. “Resection of non-resectable liver metastases from colorectal cancer after neoadjuvant chemotherapy.” *Ann Surg* 224:509–522.

[5] Giacchetti S, Perpointl B, Zidani R, Le Bail N, Faggiuolo R, Focan C et al. 2000. “Phase III multicenter randomized trial of oxaliplatin added to chronomodulated fluorouracil-leucovorin as first-line treatment of metastatic colorectal cancer.” *J Clin Oncol* 18:136–147.

[6] Verma D, Ogata S, Belghiti J. 2007. "Isolated total caval clamping with 'preserved remnant liver perfusion' for combined hepatic and venacaval resection in tumours involving vena cava." *Surgery* 141:112–116.

[7] Abu Hilal M, Lodge JPA. 2008. "Pushing back the frontiers of resectability in liver cancer surgery." *Eur J Surg Oncol* 34:272–280.

[8] Hemming AW, Reed AI, Langham MR Jr, Fujita S, Howard RJ. 2004. "Combined resection of the liver and inferior vena cava for hepatic malignancy." *Ann Surg* 239:712–721.

[9] Belghiti J, Noun R, Zante E, Ballet T, Sauvanet A. 1996. "Portal triad clamping or hepatic vascular exclusion for major liver resection. A controlled study." *Ann Surg* 224:155–161.

[10] Malassagne B, Cherqui D, Alon R, Brunetti F, Humeres R, Fagniez PL. 1998. "Safety of selective vascular clamping for major hepatectomies." *J Am Coll Surg* 187:482–486.

[11] Smyrniotis VE, Kostopanagiotou GG, Gamaletsos EL, Vassiliou JG, Voros DC, Fotopoulos AC et al. 2002. "Total versus selective vascular exclusion in major liver resections." *Am J Surg* 183:173–178.

[12] Torzilli G, Makuuchi M, Midorikawa Y, Sano K, Inoue K, Takayama T et al. 2001. "Liver resection without total vascular exclusion: hazardous or beneficial? An analysis of our experience." *Ann Surg* 233:167–175.

[13] Grazi GL, Mazziotti A, Jovine E, Pierangeli F, Ercolani G, Gallucci A et al. 1997. "Total vascular exclusion of the liver during hepatic surgery: selective use, extensive use or abuse?" *Arch Surg* 132:1104–1109.

[14] Yagyu T, Shimizu R, Nishida M, Nakashima K, Uchiyama T, Suzuki T. 1994. "Reconstruction of the hepatic vein to the prosthetic inferior vena cava in right extended hemihepatectomy with ex situ procedure." *Surgery* 115:740–744.

[15] Ohwada S, Kawashima Y, Ogawa T. 1999. "Extended hepatectomy with ePTFE graft vena caval replacement and hepatic vein reconstruction: a case report." *Hepatogastroenterology* 46:1151–1155.

[16] Yamamoto Y, Terajima H, Ishikawa Y, Uchinami H, Taura K, Nakajima A. 2001. "In situ pedicle resection in left trisegmentectomy of the liver combined with reconstruction of the right hepatic vein to an inferior vena caval segment transpositioned from the infrahepatic portion." *J Am Coll Surg* 192:137–141.

[17] Lechaux D, Megevand JM, Raoul JL, Boudjema K. 2002. "Ex vivo right trisegmentectomy with reconstruction of inferior vena cava and 'flop' reimplantation." *J Am Coll Surg* 194:842–845.

[18] Del Campo C, Konok GP. 1994. "Use of a pericardial xenograft patch in repair of resected retrohepatic vena cava." *Can J Surg* 37:59–61.

[19] Starzl TE, Koep LJ, Weil R 3rd, Lilly JR, Putnam CW, Aldrete JA. 1980. "Right trisegmentectomy for hepatic neoplasms." *Surg Gynecol Obstet* 150:208–214.

[20] Iwatsuki S, Todo S, Starzl TE. 1988. "Right trisegmentectomy with a synthetic vena cava graft." *Arch Surg* 123:1021–1022.

[21] Kumada K, Shimahara Y, Fukui K, Itoh K, Morikawa S, Ozawa K. 1988. "Extended right hepatic lobectomy: combined resection of inferior vena cava and its reconstruction by PTFE graft (Goretex). Case report." *Acta Chir Scand* 254:481–483.

[22] Risher WH, Arensman RM, Ochsner JL, Hollier LH. 1990. "Retrohepatic vena cava reconstruction with polyfluoroethylene graft." *J Vasc Surg* 12:367–370.

[23] Miller CM, Schwartz ME, Nishizaki T. 1991. "Combined hepatic and vena caval resection with autogenous caval graft replacement." *Arch Surg* 126:106–108.

[24] Moher D, Liberati A, Tetzlaff J Altman DG, &, PRISMA Group. 2009. "Preferred reporting items for systematic reviews and meta-analyses: the PRISMA statement." *BMJ* 339, b2535.

[25] https://www.cebm.net/2009/06/oxford-centre-evidence-based-medicine-levels-evidence-march-2009/. Accessed December 28, 2018.

[26] Miyazaki M, Ito H, Nakagawa K, Ambiru S, Shimizu H, Okuno A, Nukui Y, Yoshitomi H, Kusashio K, Furuya S, Nakajima N. 1999. "Aggressive surgical resection for hepatic metastases involving the inferior vena cava." *Ann Surg* 177(4):294-8.

[27] Tono T, Ohzato H, Fukunaga M, Hasuike Y, Nakagawa H, Monden T, Okamura J, Kikkawa N, Takatsuka Y. 2000. "Surgical treatment of hepatic caudate lobe metastases originating from colorectal primaries." *Int Surg* 85(3):237-42.

[28] Aoki T, Sugawara Y, Imamura H, Seyama Y, Minagawa M, Hasegawa K, Kokudo N, Makuuchi M. 2004. "Hepatic resection with reconstruction of the inferior vena cava or hepatic venous confluence for metastatic liver tumor from colorectal cancer." *J AM Coll Surg* 98(3):366-72.

[29] Johnson ST, Blitz M, Kneteman N, Bidam D. 2006. "Combined hepatic and inferior vena cava resection for colorectal metastases." *J Gastrointest Surg* 10(2):220-6.

[30] Nardo B, Ercolani G, Montalti R, Bertelli R, Gardini A, Beltempo P, Puviani L, Pacilè V, Vivarelli M, Cavallari A. 2005. "Hepatic resection for primary or secondary malignancies with involvement of the inferior vena cava: is this operation safe or hazardous?" *J AM Coll Surg* 201(5):671-9.

[31] Yamamoto H, Nagino M, Kamiya J, Hayakawa N, Nimura Y. 2005. "Surgical treatment for colorectal liver metastases involving the paracaval portion of the caudate lobe." *Surgery* 137(1):26-32.

[32] Delis SG, Madariaga J, Ciancio G. 2007. "Combined liver and inferior vena cava resection for hepatic malignancy." *J Surg Oncol* 96(3):258-64.

[33] Kim Z, Jeong GA, Chung JC, Chu CW, Shin EJ, Kim HC. 2009. "Ante-situm liver resection in recurrent liver metastasis from colorectal cancer." *Hepatogastroenterology* 56(90):508-11.

[34] Tanaka K, Matsuyama R, Takeda K, Matsuo K, Nagano Y, Endo I. 2009. "Aggressive liver resection including major vessel resection for colorectal liver metastases." *World J Hepatol* 1(1):79-89. Accessed December 17, 2018. doi: 10.4254/wjh.v1.i1.79.

[35] Malde DJ, Khan A, Prasad KR, Toogood GJ, Lodge JP. 2011. "Inferior vena cava resection with hepatectomy: challenging but justified." *HPB* 13(11):802-10.

[36] Masafumi Ie, Hideyuki Kanemoto, Yukiyasu Okamura, Takashi Mizuno, Teiichi Sugiura, Katsuhiko Uesaka, Yusuke Kinugasa, Etsuro Bando, Masanori Terashima. 2013. "Surgical outcome of the hepatectomy with combined resection of the inferior vena cava for colorectal liver metastases." *Hepatol Int* 7(Suppl 1): 713.

[37] Azoulay D, Pascal G, Salloum C, Adam R, Castaing D, Tranecol N. 2013. "Vascular reconstruction combined with liver resection for malignant tumours." *Br J Surg* 100(13):1764-75.

[38] Hemming AW, Mekeel KL, Zendejas I, Kim RD, Sicklick JK, Reed AI. 2013. "Resection of the liver and inferior vena cava for hepatic malignancy." *J Am Coll Surg* 217(1):115-24.

[39] Guerrini JP, Soliani P. 2015. “Repeated hepatic resection combined with inferior vena cava replacement: Case report and review of literature.” *Int J Surg Case Rep* 6C:114-7.

[40] Marangoni G, Hakeem A, Khan A, Rotimi O, Lodge JP. 2015. “Repeat hepatectomy with inferior vena cava re-resection for colorectal liver metastases: case report and review of the literature.” *Surg Today* 45(11):1450-6.

[41] Ko S, Kirihataya Y, Matsusaka M, Mukogawa T, Ishikawa H, Watanabe A. 2016. “Parenchyma-Sparing Hepatectomy with Vascular Reconstruction Techniques for Resection of Colorectal Liver Metastases with Major Vascular Invasion.” *Ann Surg Oncol* 23(Suppl 4):501-507.

[42] Mohammad WM, Balaa FK. 2009. “Surgical management of colorectal liver metastases.” *Clin Colon Rectal Surg* 22:225–232.

[43] Yanming Zhou, Lupeng Wu, Dong Xu, Tao Wan & Xiaoying Si. 2017. “A pooled analysis of combined liver and inferior vena cava resection for hepatic malignancy.” *HPB* 19, 768–774.

[44] Mehrabi A, Ito H, Nakagawa K, Ambiru S, Shimizu H, Okuno A et al. 2011. “Hypothermic ante situm resection in tumors of the hepatocaval confluence.” *Dig Surg* 28:100–108.

[45] Hannoun L, Delriviere L, Gibbs P, Borie D, Vaillant JC, Delva E. 1996. “Major extended hepatic resections in diseased livers using hypothermic protection: preliminary results from the first 12 patients treated with this new technique.” *J Am Coll Surg* 183:597–605.

In: Encyclopedia of Surgery (22 Volume Set)
Editors: Andreas Lehrer and Kristin Mueller
ISBN: 978-1-53618-329-0
© 2020 Nova Science Publishers, Inc.

Chapter 107

MULTIDISCIPLINARY APPROACH TO GENDER REASSIGNMENT SURGERY IN A DSD 46XX PATIENT WITH DELAYED DIAGNOSIS OF CONGENITAL ADRENAL HYPERPLASIA: A CASE REPORT

K. Sumapradja[1,*], R. A. Putri [4], A. K. Harzif [1], C. L. Sukasah[2] and S. D. Elvira [3]

[1]Department of Obstetrics and Gynecology, Faculty of Medicine, Universitas Indonesia, Dr. Cipto Mangunkusumo Hospital, Jakarta, Indonesia
[2]Department of Surgery, Faculty of Medicine, Universitas Indonesia, Dr. Cipto Mangunkusumo Hospital, Jakarta, Indonesia
[3]Department of Mental Health, Faculty of Medicine, Universitas Indonesia, Dr. Cipto Mangunkusumo Hospital, Jakarta, Indonesia
[4]Department of Obstetrics and Gynecology, Faculty of Medicine, Universitas Indonesia, Dr. Cipto Mangunkusumo Hospital, Jakarta, Indonesia

ABSTRACT

The disorder of sex development (DSD) is defined as the congenital conditions in which the development of the chromosomal, gonadal, or anatomical sex is atypical. Congenital adrenal hyperplasia (CAH) consists of a family of disorders caused by reduced activity of enzymes required for the biosynthesis of cortisol in the adrenal cortex, resulting in increased levels of dehydroepiandrosterone sulfate and testosterone. The masculinization of a DSD 46XX patient with CAH is caused by excessive levels of male hormones. During adolescence, the diagnosis of DSD is often an alarming and traumatic event for both the adolescent and the family, considering that this a rare disorder and absolutely foreign to the majority of non-medical individuals. The management of DSD is extraordinarily heterogeneous across centers, and pre- and post-treatment evaluations are mostly subjective, examiner-dependent, and influenced by cultural norms.

* Corresponding Author's E-mail: kanadisuma@yahoo.com.

In this article, we report a rare case of delayed diagnosis of DSD 46XX in a 23-year-old patient with CAH. The patient exhibiting genital ambiguity and primary amenorrhea, desired to be a male person. The levels of hormones were as follows: high dehydroepiandrosterone sulfate, 937.8µg/dL); high testosterone, 27.3nmL/L; and low estradiol, 45pg/mL, corresponding to the normal levels of a male. A multidisciplinary team, consisting of a reproductive endocrinologist, plastic surgeon, metabolic endocrinologist, psychiatrist, and the hospital ethics committee, collaborated to address the patient's desire regarding her gender condition. Prolonged exposure to androgens results in masculinization of the brain.

Therefore, she preferred to become a male instead of a female. She underwent total laparoscopy hysterectomy and masculinizing reconstructive surgery on her external genitalia.

In addition, prior to and following surgery, the patient received psycho-adaptive therapy.

Keywords: disorder of sex development 46XX, congenital adrenal hyperplasia, gender reassignment surgery, multidisciplinary approach

INTRODUCTION

The disorder of sex development (DSD) is defined as congenital conditions in which the development of the chromosomal, gonadal, or anatomical sex is atypical. This broad category is divided into three primary groups based on karyotype, namely 46XY; 46XX, and sex chromosome DSD. Secondary groups are formed based on hormonal assessment and imaging [1, 2].

Congenital adrenal hyperplasia (CAH) consists of a family of disorders caused by reduced activity of enzymes required for the biosynthesis of cortisol in the adrenal cortex. The most common defect is 21-hydroxylase (21-OH) deficiency, occurring in 90% of all cases [3]. The disorder appears to be more common in individuals of Hispanic, Slavic, Italian, and European Jewish ancestry. The incidence of genital ambiguity is 1 per 4,500 individuals, though some degree of male under-virilization or female virilization may be present in 2% of live births [4]. In Indonesia, only a limited number of hospitals have a team dedicated for the management of DSD. Thus, currently, data related to DSD remains scarce.

Typically, the management of a DSD patient with CAH depends on the time of diagnosis. In cases in whom CAH is recognized immediately after birth, medical treatment is the treatment of choice. However, in those diagnosed at a later stage of life, it has been suggested to offer the following option to the patients/family: raise the child as a male, postpone the surgery, and suppress puberty until a definitive choice is reached by the patient. Genital surgery continues to be controversial regarding its indications, timing, and technical aspects [5].

During adolescence years, the diagnosis of DSD is often an alarming and traumatic event both for the adolescent and the family, considering that this is a rare disorder and absolutely foreign to the majority of non-medical individuals [6]. The goal of gender reassignment is to improve the quality of life of the patient. The development of the reproductive system, sexual identity, sexual function, and fertility are important factors to be considered in this process [7]. The management of DSD is extraordinarily heterogeneous across centers, and pre- and

post-treatment evaluations are mostly subjective, examiner-dependent, and influenced by cultural norms [5].

In this article, we report a rare case of delayed diagnosis of DSD 46XX in a patient with CAH. A multidisciplinary approach was used to address the gender condition of this patient.

CASE REPORT

A 23-year-old patient was referred to our hospital from the Public Hospital in Riau Province due to DSD 46XX. She was delivered by a traditional birth attendant. Initially she was pointed out as a female. During her childhood, she was nurtured as a female.

However, after the age of 12 years, her behavior changed dramatically. She began to identify herself as a male individual. Furthermore, her genitals did not resemble those of a normal female. Since she was unable to accept the response from the surrounding, she finally decided to discontinue her education. Initially, her parents recognized a discrepancy in the appearance of her genitals. Unfortunately, they did not have sufficient information to explain the phenomenon, and considered it to be a normal variation. In 2012, the patient was examined by a local urologist and was referred to the Dr. Cipto Mangunkusumo Tertiary Hospital, Jakarta, Indonesia. Unfortunately, her parents postponed this plan due to financial challenges.

The patient is the youngest in a family of seven children who live with their parents. Daily activities include assisting her parents with their work. She performs household chores similar to a male person (i.e., lifts the bucket, fixes the electricity, and paints the wall). Sometimes she is confused regarding her gender, sex, and social identity. Currently, individuals who live in the surrounding call her “Ucok” (a nickname for a young boy). Lately, she began to be attracted to a female, but was unsure how to express her feelings to a woman.

The patient has not experienced menstruation or breast development, and did not report a history of cyclic lower abdominal pain. However, she demonstrates growth of pubic and axillary hair.

Following physical examination, she appeared in good condition and hemodynamically stable. The body mass index of the patient was 27.30kg/m2 (i.e., overweight), while the body height and weight were 148cm and 60kg, respectively. The general status was within normal limits (i.e., no galactorrhea, the Ferriman Galleway score was >7, and the Tanner stage was M1P4).

Gynecological evaluation revealed ambiguous genitalia (i.e., a vagina and phallus of 5cm were observed, without scrotum). Rectovaginal touch showed non-palpable uterus and adnexal mass.

Transrectal ultrasound was performed, and the results were as follows: uterine size 29 × 16 × 26mm, volume 6.72mL, and endometrium 3.7mm, with a regular basal layer.

Both ovaries were small (volume of right and left ovaries: 1.32mL and 0.62mL, respectively) with a total number of follicles <6. Computed tomography, previously performed at a different hospital, confirmed the presence of a uterus and absence of testes.

Figure 1. 1) M1 of breast maturity, 2–4 and 7) Ferriman Galleway score >7, 5) male appearance and short stature, 6 and 7) genital ambiguity.

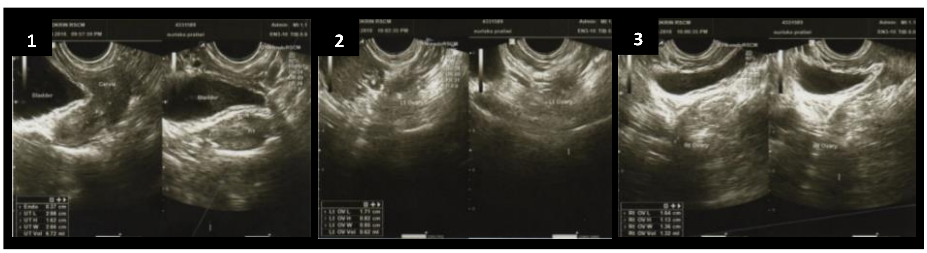

Figure 2. Transrectal ultrasound shows: 1) small uterine size, 2) and 3) small ovaries.

The results of the chromosomal analysis revealed DSD 46XX. Laboratory findings were as follows: normal morning cortisol 8.8µg/dL (normal range, 3.7 – 19.4µg/mL), high dehydroepiandrosterone sulfate (DHEAS) 937.8µg/dL (normal range, 134.2 – 407.4µg/dL), normal anti-mullerian hormone 2.32ng/mL (normal range, 0 – 14.8ng/mL), high testosterone 27.3nmL/L (normal range for male, 4.94 – 32nmol/L), low luteinizing hormone <0.5mIU/mL (normal range for male, 0.57 – 12.07mIU/L), follicle stimulating hormone 2.62mIU/mL (normal range for male, 0.95 – 11.95mIU/mL), estradiol 45pg/mL (normal range for male, 11 – 44pg/mL). The glucose profile was normal in terms of fasting blood glucose, and 1h and 2h glucose tolerance test (89mg/dL, 183mg/dL, and 148mg/dL, respectively). Kidney function was normal in terms of urea and creatinine. The levels of electrolytes were also within normal limits (natrium 138mEq/L, kalium 4.3mEq/L, and chlorine 101.3mEq/L).

The patient was diagnosed with primary amenorrhea, DSD 46XX, ambiguous genitalia, and CAH. A multidisciplinary team, consisting of a reproductive endocrinologist, plastic

surgeon, metabolic endocrinologist, psychiatrist, and the ethics committee of the hospital, was formed. An immediate consultation was arranged to assess the case based on every discipline involved in the team.

Examination using abdominal ultrasound did not detect the presence of an adrenal tumor or abnormalities in the abdominal organs. No specific therapy from Metabolic-Endocrine of Internal Medicine. The patient was evaluated by a psychiatrist and diagnosed as follows: axis I, mood adaptation disturbance; axis II, avoidance of personality; axis III, DSD 46XX; axis IV, this medical condition; axis V: current Global Assessment of Functioning score was 80 and the highest level past year was 85. Supportive psychotherapy and psychoeducation for the patient and her family were planned. The plastic surgeon concurred with the initial diagnosis, and planned to perform reconstructive surgery (i.e., radial free forearm flap and implant to enlarge the phallus) to support the gender preference of the patient.

According to a meeting of the multidisciplinary team, the patient identified (i.e., self and gender concept) with the male gender. For preparatory purposes related to the reconstructive surgery, the plastic surgeon reexamined her external genitalia during erection. Considering that the level of testosterone at the time of consultation was already sufficiently high to support her gender identity, the reproductive endocrinologist decided not to administer hormonal support. A member of the ethics committee proposed that the gender reassignment should also proceed legally after the surgery.

She underwent total laparoscopic hysterectomy, performed by a reproductive endocrinologist. The management was continued with the release of cordae and urethroplasty, performed by a plastic surgeon. The decision regarding the hysterectomy was reached based on the patient's request.

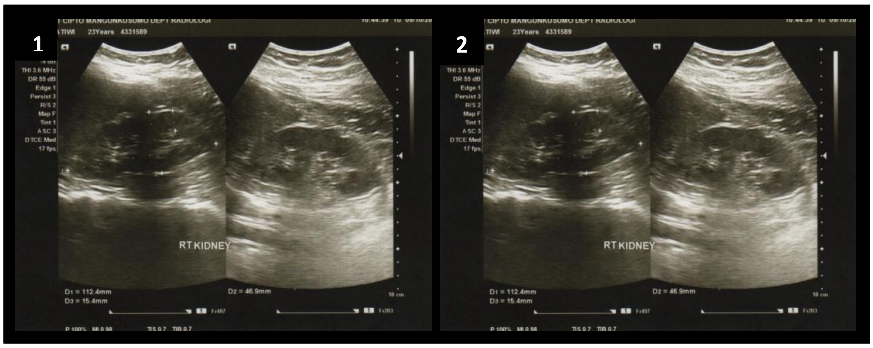

Figure 3. Abdominal ultrasound: Absence of a suprarenal mass.

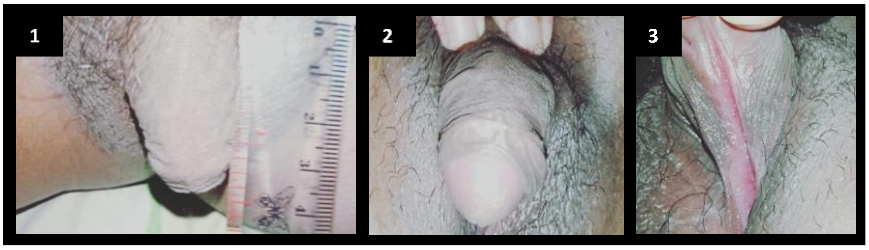

Figure 4. External genitalia in erection condition: 1) penile shaft 4–5 cm, 2) erection position, and 3) cordae.

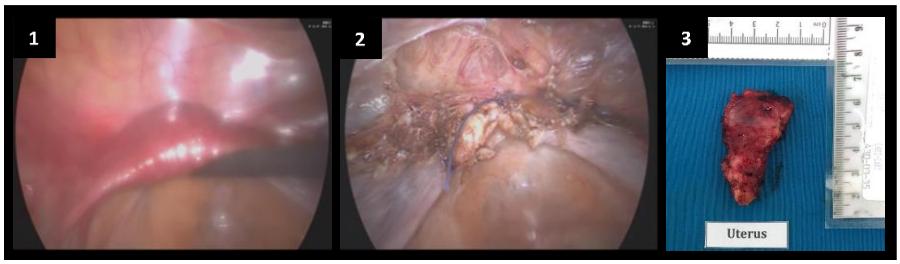

Figure 5. 1 and 2) total laparoscopic hysterectomy, 3) uterus specimen.

Figure 6. Release of cordae and urethroplasty (step 1), performed by a plastic surgeon.

The psychiatrist administered anti-depressant agents and psycho-supportive therapy. Moreover, the plastic surgeon planned to perform a second procedure (i.e., reconstruction surgery to form the scrotum and phallus) 6 months later.

DISCUSSION

In patients with DSD 46XX, classic CAH represents the most common diagnosis. Usually, there are no gender issues in this group of patients, except in cases of late diagnosis and severe masculinization [5]. In the present case, gender was the main issue due to the delayed diagnosis. The lack of knowledge by the parents and traditional birth attendant regarding genital ambiguity, the minimal information regarding DSD among the community, and financial challenges contributed to this delay. In settings of limited resources, especially in the absence of neonatal screening, examination of the genitalia is crucial for the detection of CAH. Virilization of the external genitalia without palpable gonads should arouse suspicion of CAH, and is an indication for the urgent referral of the patient to an endocrine specialist [8].

Genital ambiguity can be caused by high exposure to androgens in a 46XX individual, or under-masculinization in a 46XY individual. In 46XX genital ambiguity, the source of high exposure to androgen may be external or internal. Internally, there are two organs responsible for the production of androgens, namely the ovary and adrenal gland [5, 6].

CAH results in increased production of androgens from the adrenal gland due to an enzyme deficiency. The most common defect in CAH is 21-OH deficiency, caused by mutations in the cytochrome CYP21A2 gene. This leads to failure in the synthesis of cortisol due to the impaired conversion of 17α-hydroxyprogesterone to 11-deoxycortisol [9]. Clinical

consequences of 21-OH deficiency arise primarily from the overproduction and accumulation of precursors proximal to the blocked enzymatic step. These precursors are shunted into the androgen biosynthesis pathway and further converted to testosterone and dihydrotestosterone [3, 10]. These hormones affect multiple somatic systems that may have psychological implications, including glucose household (at any ages), differentiation of the reproductive tract and presumably the brain (during prenatal development), and growth of primary sex characteristics, development of secondary sex characteristics, further differentiation of the brain, and activation of previously organized brain circuits (during puberty) [11].

Masculinization of patients is observed since childhood. The brain organization theory suggests that, during fetal development, steroid hormones permanently organize the brain in terms of gender, including patterns of sexuality, cognition, temperament, interests, and mental health that are considered "masculine" or "feminine" [12]. In DSD 46XX patients with CAH, prenatal exposure to androgens (the high prenatal levels of male sex hormones to which the genetically female brain is exposed) may shift some, but not all, personality characteristics in the male-typical direction in females [8, 10, 11].

The three components of sexual psychosexual development (i.e., gender identity, gender role, and sexual orientation) may not always be concordant and aligned in individuals with DSD. However, in those with DSD, the primary goal is for gender identity to be consistent with gender assignment [7]. In cases of late diagnosis, it has been suggested to offer the option of raising the child as a boy, and postpone surgery until a definitive choice is reached by the individual. The majority of DSD 46XX patients with CAH are raised as males (usually with a marked degree of genital masculinization) and do not develop gender dysphoria. The cultural environment of the child is of utmost importance in this decision process [5].

As suggested by different studies, the multidisciplinary approach should be established for the management of DSD cases [4]. Such a multidisciplinary team consists of a reproductive endocrinologist, plastic surgeon, psychiatrist, urologist, and ethic-medicolegal consultant. This approach satisfies the requirement to assess and manage DSD patients from different medical perspectives, prior to reaching a consensus based on the preferences of the individual.

As the child develops and reaches adolescence, the gynecologist is again uniquely positioned to assist the family with discussions regarding sexuality and reproductive issues. In addition, many of these conditions are not diagnosed until adolescence when lack of menstruation, pubertal development, or virilization elicits a referral to the gynecologist. Thus, the first physician to diagnose many of these conditions during adolescence may be the gynecologist [2]. The initial evaluation involves assessment of the patient's medical history of familial disorders, a physical examination with particular attention to the genitalia, determination of the karyotype, and (if findings are consistent with CAH) a rapid evaluation of 17-hydroxyprogesterone. However, in Indonesia, finding a laboratory which provides an evaluation of the level of 17-hydroxyprogesterone is challenging. Therefore, initially, the level of total testosterone should be measured to confirm the increased presence of androgens. In cases with high levels of total testosterone, the primary source of androgens should be determined either in the ovary or the adrenal gland by measuring the DHEAS. A high level of DHEAS indicates that the primary source of androgens is the adrenal gland.

Gender is determined by the chromosome, social environment, social role, and sexual orientation. Although the chromosome of this patient was 46XX, the patient's gender identity tended to develop as a male individuals based on the social role, social environment, and

sexual orientation [11, 13]. It is truly a great challenge to deal with gender issues in DSD cases. Such research lays the groundwork for additional investigation regarding the contribution of genetic risk, pubertal timing, and sociocultural experience of gender to neural changes underlying mood and anxiety symptoms [14]. Mood conditions, especially depression, anxiety and affective distress, are frequently reported in males and females with CAH. Such conditions may be traced to imbalances of steroid hormones, including cortisol, and the cortisol precursors adrenocorticotropic hormone and corticotropin releasing hormone, a neurotransmitter centrally involved in endocrine, autonomic, immune, and behavioral responses to stress [12]. Psychiatric treatment includes the use of psychopharmacologic agents and supportive psychotherapy techniques [13].

The aims of surgery in DSD patients are as follows: to restore functional genital anatomy allowing future penetrative intercourse (as a male or a female), facilitate future reproduction (as a male or a female) when possible, and reduce urological hazards related to abnormal genitourinary anatomy [5]. For the reconstruction of the genital tubercle in males, surgery is based on the principles of hypospadias surgery, which involves three main steps: (1) degloving of the genital tubercle to assess the severity of the hypospadias based on the level of division of the corpus spongiosum, the degree of hypoplasia of the ventral tissues and the subsequent ventral curvature, the position of the urethral meatus, the length of the urethra to be reconstructed, the size of the genital tubercle, the size and shape of the glans, and the availability of foreskin tissue; (2) refashioning of the missing urethra (i.e., urethroplasty), and (3) refashioning of the penile skin shaft [5].

Although the relevant legislation varies between countries, it is usually allowed to delay a child's gender registration until the medical situation is clarified. Genital surgery continues to be controversial regarding its indications and ethical aspects. The management is extraordinarily heterogeneous across centers, and pre- and post-treatment evaluations are mostly subjective, examiner-dependent, and influenced by cultural norms [5]. The ethical-medicolegal aspect was included in this multidisciplinary team to support the family in processing the legal aspect of gender registration in this patient.

It is important to note that the formation of a multidisciplinary team is more than bringing together different specialists. These specialists create a process for clinical care and decision-making. This process is continuously evaluated and adjusted to optimally serve the patients and the community. It is important that the members of the team communicate with each other on a regular basis to ensure optimal care for the patient and family. Currently, there are many areas for which there are no clear guidelines regarding management. In such cases, the team must reach decisions together with the patient and parents, taking into account a variety of factors (i.e., genetic, endocrine, and anatomic findings) along with the preferences of the individual and the values of the family. Among these decisions, gender reassignment and surgical management are among the most difficult. Thus, communication between the team members regarding their unique perspective, based on their field of expertise, is essential. It has been noted that parents reach different decisions depending on the individual who counsels them regarding surgery. Therefore, it is important for the team members to communicate with the families regarding their different perspectives in an open and caring manner. In addition, the members of the team can discuss all pertinent medical and psychosocial issues prior to the consultation with the family (to ensure a clear understanding of the medical condition), as well as after the consultation (to reach a consensus regarding management) [2].

CONCLUSION

DSD is a clinical condition which requires attention from a clinical perspective, as well as beyond the clinic. Lack of knowledge may significantly contribute to a delayed diagnosis. DSD is a condition that should be managed individually, based on the main needs and values of the patients and their families. Masculinization of the brain and genitalia in patients with delayed diagnosis of DSD 46XX requires a multidisciplinary approach. Raising awareness and advancing knowledge related to genital ambiguity is crucial for the prevention of delayed diagnosis.

REFERENCES

[1] Listyasari, N. A., Santosa, A., Juniarto, A. Z., Faradz, S. M. (2017). Multidisciplinary management of disorders of sex development in indonesia, a prototype for developing country. *Journal of Biomedical and Translational Research*, 01:17 - 22.

[2] Gomez-Lobo, V. (2014). Multidisciplinary care for individuals with disorders of sex development. *Current Opinion in Obstetrics Gynecology*, 26: 366 - 71.

[3] Pang, S., Silverstein, J. (2000). Technical report: congenital adrenal hyperplasia. *Pediatrics*, 106: 1511 - 6.

[4] Chowdhury, M. A. K., Anwar, R.; Saha, A. (2018). Ambiguous genitalia-A social dilemma in Bangladesh: A case report. *International Journal of Surgery Case Reports*, 42: 98 - 101.

[5] Mouriquand, P. D.; Gorduza, D. B.; Gay, C. L.; Meyer-Bahlburg, H. F.; Baker, L.; Baskin, L. S. et al. (2016). Surgery in disorders of sex development (DSD) with a gender issue: If (why), when, and how? *Journal of Pediatric Urology*, 12:139 - 49.

[6] Auchus, R. J., Quint, E. H. (2015). Adolescents with disorders of sex development (DSD)--lost in transition? *Hormone and Metabolic Research*, 47: 367 - 74.

[7] Houk, C. P.; Lee, P. A. (2010). Approach to assigning gender in 46,XX congenital adrenal hyperplasia with male external genitalia: replacing dogmatism with pragmatism. *The Journal of Clinical Endocrinology and Metabolism*, 95: 4501 - 8.

[8] Ganie, Y., Aldous, C., Balakrishna, Y., Wiersma, R. (2018). Congenital adrenal hyperplasia due to 21-hydroxylase deficiency in South Africa. *South African Medical Journal*:108.

[9] Mussig, K.; Kaltenbach, S.; Maser-Gluth, C.; Hartmann, M. F.; Wudy, S. A.; Horger, M. et al. (2006). Late diagnosis of congenital adrenal hyperplasia due to 21-hydroxylase deficiency. *Experimental and Clinical Endocrinology and Diabetes*, 114: 208 - 14.

[10] Speiser, P. W.; Arlt, W.; Auchus, R. J.; Baskin, L. S.; Conway, G. S.; Merke, D. P. et al. (2018). Congenital adrenal hyperplasia due to steroid 21-hydroxylase deficiency: an endocrine society clinical practice guideline. *The Journal of Clinical Endocrinology and Metabolism*, 103: 4043 - 88.

[11] Meyer- Bahlburg, H. F. (2011). Brain Development and cognitive, psychosocial, and psychiatric functioning in classical 21- hydroxylase deficiency. *Endocr. Dev. Basel Karger*, 20:88 - 95.

[12] Jordan-Young, R. M. (2012). Hormones, context, and "brain gender": a review of evidence from congenital adrenal hyperplasia. *Social Science and Medicine,* 74:1738 - 44.

[13] Ozbaran, B., Ozen, S., Goksen, D., Korkmaz, O., Onay, H., Cogulu, O. et al. (2013) Psychiatric approaches for disorders of sex development: experience of a multidisciplinary team. *Journal of Clinical Research in Pediatric Endocrinology,* 5: 229 - 35.

[14] Eckstrand, K. L., Travis, M. J., Forbes, E. E., Phillips, M. L. (2016). Sex differences and personalized psychiatric care. *Biological Psychiatry,* 80: e81 - e3.

In: Encyclopedia of Surgery (22 Volume Set)
Editors: Andreas Lehrer and Kristin Mueller
ISBN: 978-1-53618-329-0
© 2020 Nova Science Publishers, Inc.

Chapter 108

CEREBROVASCULAR BYPASS SURGERY IN THE TREATMENT OF BRAIN ANEURYSMS

Goran Mrak, Jakob Nemir*, MD, PhD and Hrvoje Barić
Department of Neurosurgery, Clinical Hospital Center Zagreb,
Zagreb University Medical School, Zagreb, Croatia

ABSTRACT

Background: Nontraumatic subarachnoid hemorrhage (SAH) occurs secondary to a ruptured brain aneurysm or an arteriovenous malformation (AVM) or, rarely, the underlying etiology remains uncertain. The vast majority of aneurysm cases are treated by open surgery (clipping), using the endovascular approach (coiling), or a combination of both. However, complex aneurysms, such as giant and fusiform aneurysms, are not amenable to treatment using the conventional techniques. Rather, in such cases a cerebrovascular bypass procedure is used to enable sacrifice of the parental vessel and preserve distal blood flow. Different techniques and approaches have been described in the literature for various types of aneurysms. Given the relative scarcity of cases and technical differences between neurovascular centers, defining robust diagnostic criteria, indications, surgical techniques and outcome measures to assess efficacy and safety, remains a challenge.

Aim: The aim of this chapter is to provide a summary of techniques and indications related to cerebrovascular bypass surgery for aneurysmal SAH cases and to provide a review of published series.

Methods: First, a historical perspective is outlined, followed by preoperative assessment, summary of techniques, postoperative evaluation, and complications associated with the procedure. A review of the literature is reported next: relevant electronic databases and scholarly journal archives were searched, ending March 2019, and complemented by a hand-search of lists of references, to identify publications which: i) described a surgical revascularization technique; ii) reported patients are brain aneurysm cases (with or without SAH); iii) reported safety and efficacy outcomes; iv) were published in English or German; and v) were published in a peer-reviewed journal. Two illustrative cases operated at our Department are presented at the end.

* Corresponding Author's Email: jakob.nemir@kbc-zagreb.hr.

Conclusion: Despite its technical challenges and lack of data from clinical trials, cerebral revascularization procedures should be further developed by neurosurgeons, as they remain the only option of treatment for a significant number of patients.

HISTORICAL PERSPECTIVE

The Ebers Papyrus, dating back to 3000 BC, contains what is considered the first description of cerebrovascular anatomy. Among the ailments and remedies reported in the Papyrus is the case of a brain aneurysm treated by a "fireglazed instrument" (Lippi 1990, Engelhardt 2017)). The influence of ancient Greek medical practices had a profound impact on the overall medical sciences, including surgery. Hippocrates (460-370 BC) was the first to recognize the clinical syndrome of sudden onset headache and co-occurring neural deficits - the "apoplexy" - and, what is more, he realized it to be a direct consequence of a cerebrovascular event. Herophilus of Chalcedon (335–280 BC), the "father of anatomy" is credited with the first description of the circulatory system, including the "wonderful net" (lat. *rete mirabile*) of the brain vessels and the confluence of dural sinuses, the *torcular herophili* (Soldozy et al. 2019). Galen of Pergamon (AD 129–199) further enriched the anatomical corpus and coined the term "aneurysm" (Polevaya et al. 2006). In the Dark Ages that followed, Western medical knowledge largely remained dormant as dissections were banned by the religious authorities. During the period that spanned 1500 years, advances were made by Islamic scholars, most notable of which are Rhazes (865–925) and Avicenna (980–1037). However, it was not until the 16th century that the Galenic anatomical dogmas were challenged and corrected by Andreas Vesalius in his revolutionary 1543 *De humani corpris fabrica* (Lo and Ellis 2010). Over a century later, a major breakthrough in the understanding of anatomy and physiology of the brain circulation occurred, when in 1684 Thomas Willis described the bypass properties of the cerebral vascular supply.

Despite these anatomical advancements, the guiding philosophy in treatment of vascular pathology remained unchanged for hundreds of years - the aim of treatment was to exclude the impaired vessel from the circulation. Until the early 19th century the main treatment option was cauterization, which was then replaced by the technique popularized by John Hunter, who showed that peripheral arteries could be safely and efficiently ligated (Cooper 1837). This technique was introduced into the neurosurgical armamentarium by Victor Horsley, who, in 1885, ligated the internal carotid artery of a patient suffering from an aneurysm encountered after craniotomy for removal of a presumed middle fossa tumor (Drake 1985). A quarter of century later, Alexis Carell developed the triangulation suturing technique which enabled the means to achieve vessel anastomosis and was the first to describe venous patch grafts (Rickard and Hudson 2014). In the meanwhile, proximal ligation remained the primary treatment option for aneurysms and was used by the great Harvey Cushing himself, in spite of its unpredictable outcomes (Polevaya et al. 2006). Interestingly, Cushing invented the first surgical clip to place on inaccessible vessels during tumor resections. However, he did not use the device to clip an aneurysm – the first surgeon to use this device in this indication was Walter Dandy in 1937. In the years that followed, the field witnessed technical refinements in surgical instruments and advancements in understanding of properties of cerebral blood flow, but two achievements completed the setting from which

modern neurovascular surgical procedures would evolve – angiography by Egas Moniz in 1927, and use of the operating microscope in neurosurgery in 1957 (Kurze 1964).

In 1967, Mahmut Gazi Yaşargil performed the first extracranial-intracranial (EC-IC) bypass (superficial temporal artery – middle cerebral artery (STA-MCA)) on a patient with occlusion of the MCA (Vilela and Newell 2008). In 1972, he performed the first EC-IC bypass for moyamoya disease and was the first to report the use of a EC-IC bypass in the management of an aneurysm (Thanapal et al. 2018, Spetzler, Schuster and Roski 1980). In 1971 Lougheed performed a EC-IC bypass using a venous graft, in 1974 Spetzler described the use of the occipital artery for the EC-IC bypass, and in 1978 Ausman anastomized the vertebral artery (VA) to the posterior inferior cerebellar artery (PICA) using a radial artery (RA) graft (Soldozy et al. 2019). Other innovative techniques in the field were subsequently reported and are today considered standard (Tamargo 2008).

To evaluate efficacy and safety of the possibilities that the EC-IC bypass procedure provided, three landmark studies were performed. First was the 1977-1985 EC/IC bypass study to investigate the procedure in symptomatic carotid artery occlusion and it failed to show benefits of the procedure. Second was the 2002-2010 Carotid Occlusion Surgery Study (COSS) which was terminated early for futility and showed that EC-IC bypass plus medical therapy was not superior to medical therapy alone in reducing the risk of recurrent ipsilateral ischemic stroke in patients with symptomatic atherosclerotic internal carotid artery occlusion (AICAO) and hemodynamic cerebral ischemia (The EC/IC Bypass Study Group 1985, Powers et al. 2011). Finally, the 2001-2013 Japan Adult Moyamoya (JAM) trial showed that bilateral EC-IC bypass surgery was superior to conservative care in preventing rebleeding at five years in patients with hemorrhagic moyamoya disease (Miyamoto et al. 2014).

Owing to the results of the mentioned studies, as well as advances in medical treatment and renaissance of endovascular techniques, the indications for the EC-IC bypass have narrowed and the numbers of patients undergoing the procedure declined. Nevertheless, it remains the primary treatment option for certain groups of patients (Mrak et al. 2018).

INDICATIONS

Despite the lack of robust evidence, the EC-IC bypass continues to be used in the treatment of complex intracranial aneurysms not treatable by endovascular coiling or surgical clipping, skull base tumors encasing arteries, moyamoya disease, and vascular occlusive disease refractory to conservative management.

As reported by Kalani et al, complex aneurysms are the single largest indication for direct EC-IC bypass (Kalani et al. 2015). The complexity of an aneurysm may be due to its shape, broad neck or its absence, calcified or atherosclerotic neck, extensive aneurysm thrombosis, or incorporated origin of important vessels (Tamargo 2008). In any such case, treating the aneurysm by clipping or coiling would require sacrificing a major vessel (Soldozy et al. 2019). Other indications include inaccessible sites, such as intracavernous aneurysms (Tamargo 2008).

Surgery of certain skull base tumor encasing the internal carotid artery (ICA), or the vertebral artery (VA) poses a challenging task which sometimes demands sacrificing a major artery and, subsequently, a bypass procedure of the resected segment. The most common

tumors in this group are meningiomas, although the procedure is used in treatment of other entities. Due to the advances in radiosurgery, the procedure has witnessed a dramatic decline in popularity, since tumor remnants encasing arteries are amenable to this non-operative modality (Natarajan et al. 2007, Sekhar et al. 1999).

Cerebral arteries appearing as a "puff of smoke" on cerebral angiography are landmark feature of the moyamoya disease (Scott and Smith 2009). The finding is due to collateral vessels surrounding the constricted brain arteries. If the constriction is primary the condition is called the moyamoya disease; if, on the other hand, the constriction is secondary, it is called the moyamoya syndrome (Scott and Smith 2009). It is a progressive occlusive disease which has a wide presentation – from asymptomatic to transient or persistent neurologic events, or intracerebral, subarachnoid, and intraventricular hemorrhage (Kim 2016). Medical treatment is used to manage complications and active treatment lies with various surgical procedures that have been developed with the aim to revascularize the ischemic parenchyma. Revascularization procedures are either direct or indirect and include: i) STA-MCA anastomosis; ii) encephaloduroarteriosynangiosis (EDAS); iii) encephaloduroarterio-myosynangiosis (EDAMS); iv) pial synangiosis; v) omental transplantation (Kim et al. 2016). Despite lack of robust evidence from randomized controlled trials moyamoya is considered the largest indication for EC-IC bypass procedures (Kalani et al. 2015).

Results of the EC-IC bypass and the COSS study failed to show benefits from the EC-IC procedure for revascularization of occlusive cerebrovascular disease. However, the results of the trials are to be interpreted with caution, due to design issues, in particular that of the EC-IC bypass (Kalani et al. 2015). The procedure is nevertheless offered to patients with proven reduced blood flow and who remain symptomatic despite medical treatment, since it was shown that the bypass procedure helps to restore cerebral hemodynamics (Leblanc 1987, Kawamura et al. 1994).

PREOPERATIVE EVALUATION

Before even considering surgery, all patients should undergo a thorough general medical examination to rule out comorbiditites that are known to be associated with a less than optimal outcome. Patients who are not candidates for surgery are directed to alternative treatments or no treatment at all, if such decision confers a lower risk. To definitively establish whether or not a patient has an indication to undergo a cerebrovascular bypass procedure, imaging studies are a *sine qua non* and include brain computerized tomography (CT) and CT-angiography, or, alternatively, magnetic resonance imaging (MRI) and MR angiography and digital subtraction angiography (DSA), which are followed by blood flow assessment studies. In general, the decision to perform a revascularization is done based on preoperative data; however, in some cases the decision is made intraoperatively. When assessing blood vessel morphology in aneurysm cases, particular aspects which are evaluated include the features of the aneurysm itself (presence of calcification or thrombi, size and shape), status of the vessels surrounding and arising from the aneurysm, and status of the donor, graft, and recipient vessels. Vessel grafts, both the SVG and the RAIG, are assessed by ultrasonographic imaging. Additionally, the Allen test is performed when the RA is harvested as a graft, to assess arterial blood flow to the hand, i.e., to screen for patients at risk of

ischemic damage to the hand in case the RA is sacrificed. Intraoperatively, blood flow and graft patency are assesed using indocyanine green (ICG) angiography and Doppler sonography. Preoperatively, patients undergoing a revascularization procedure are administered acetylsalicylic acid to improve graft patency. As with other types of surgical procedures, prophylactic intravenous antibiotics are also administered. If a RA or SV grafts are harvested, intravenous heparin is administered. Anesthesia is tailored to enable intraoperative neurophysiologic monitoring (somatosensory, motor, and brainstem evoked potentials) for intraoperative ischemia and minimize possible secondary injury during temporary arterial occlusion; the latter measures include inducing burst suppression and elevating blood pressure in non-ruptured aneurysm cases and maintaining normotension in ruptured cases.

TECHNIQUES

Brain revascularization procedures are divided into two categories, according to the aim of the procedure: i) flow augmentation bypasses (to treat cerebral ischemia); and ii) flow replacement bypasses (to replace a sacrificed vessel in complex aneurysm and tumor cases). This can be achieved using different approaches and techniques, donor and recipient vessels and interposition grafts. With regard to the donor artery, bypasses are divided into the EC-IC and IC-IC category. Intracranial-to-intracranial techniques include "local" procedures (in situ, reimplantation, reanastomosis, and interpositional bypass) and circle of Willis reconstructions (e.g., interpositioning grafts to restore flow between the MCA and ACA/PCA). The most common EC-IC procedures are the STA-MCA bypass and the ECA-MCA bypass and their respective variations. The spectrum of the reported revascularization procedures and technical nuances is wide (Table 3) and it is beyond the scope of this chapter to describe all of them; instead, the technical aspects of the STA-MCA bypass, the most common revascularization procedure, are summarized and serve as a representative example of the EC-IC bypass in general.

In most cases, the recipient artery is the insular (M2) or the opercular (M3) segment of the MCA, although other segments can be used. At the beginning of the procedure, before the craniotomy, the donor vessel (usually the STA) is dissected for a minimum length of 5 cm and mobilized. If grafting is planned, a segment of the SV or RA is harvested, bearing in mind to mark the proximal end of the venous graft. Next, a craniotomy (usually a pterional craniotomy) is performed, allowing an exposure of the Slyvian fissure and the recipient vessel. After dural incision, the M3 branches are identified and traced back inside the Sylvian fissure. The aneurysm is exposed and the arterial segment proximal to the aneurysm is exposed for proximal control. The distal end of the STA is clamped proximally, transected elliptically and flushed with 1% diluted heparin to prevent thrombosis. The donor vessel stump is fish-mouthed to fit the recipient vessel opening. The recipient vessel is trapped and the recipient site is prepared between two temporary clips by means of a longitudinal arteriotomy approximately 2.5 times as long as the diameter of the vessel, and then irrigated with the heparin solution. Under temporary occlusion, an end-to-side anastomosis is performed using interrupted and continuous 10-0 nylon sutures. First the heel of the mouth of the donor artery is sutured to the recipient arteriotomy site; then the apex of the mouth is

sutured, followed by a continuous suturing of first the posterior and then the anterior wall of the recipient vessel. After suturing the anastomosis, the temporary clips are removed and the aneurysm is either clipped or trapped. The patency of the anastomosis and successfulness of aneurysm exclusion is assessed intraoperatively using ICG angiography and Doppler ultrasonography.

Finally, the dura is sutured, bearing in mind not to damage or occlude the donor vessel. Caution is also exercised when fixing the craniotomy and a burr hole is enlarged to prevent compression on the donor vessel. A suction drain is placed onto the exposed cranium and soft tissues carefully approximated.

POSTOPERATIVE EVALUATION

Standard postoperative evaluation includes a DSA or, alternatively, CTA/MRA on the first postoperative day and routine bedside assessment – donor artery palpation to check pulsations and ultrasonographic evaluation. All patients are administered aspirin and blood pressure is regulated during the first week not to exceed 140 mmHg. Patients are discharged at 7-10 postoperatively and clinical and radiologic follow-up is scheduled at latest three months postoperatively.

COMPLICATIONS

Peri- and postoperative complications can be grouped into two categories: i) general neurosurgical complications; and ii) bypass-related specific complications. The former include postoperative hemorrhage and cerebral ischemia, brain edema, elevated intracranial pressure, seizures, cerebrospinal fluid leaks, septic and aseptic meningitis, wound infections and dehiscence, among others. The latter include bypass occlusion (with or without graft) due to thrombosis or vasospasm. To lower the risk of graft thrombosis in revascularization cases, antiagreggation and anticoagulation regimes have been tailored and usually include clopidogrel, aspirin, and heparin. At our institution, the first case was reported of a successful off-label eptifibatide use in a patient who underwent an urgent STA-MCA bypass procedure for treatment of an MCA (M2) aneurysm (Stambolija et al. 2017).

REVIEW OF PUBLISHED SERIES

For the purpose of this chapter, we performed a systematic review of the literature with the aim of identifying published series of aneurysm cases treated by revascularization techniques. We performed a Medline search (via PubMed) using the search terms “aneurysm,” “bypass,” and “revascularization” No other limitations were imposed. References of the included studies were hand-searched for additional relevant items. Series published in publication types other than peer-reviewed journal articles were not included. Overall, 52 studies were included (Table 1).

Most of the studies were published in the last decade (27, 51.9%) and the majority were from the United States (27, 51.9%) and Japan (9, 17.3%), three from China (5.8%), two from the Netherlands, Taiwan, India, Italy and South Korea (3.8% each), and one study (1.9%) from Canada, Switzerland, and United Kingdom (Table 1). There were 1397 cases of aneurysms treated by revascularization procedures, among the 2634 identified cases; other were either cases in which revascularization procedures used for indications other than aneurysms (e.g., skull base tumors or vascular diseases), or aneurysm cases treated by techniques other than revascularization (different endovascular or open surgical techniques). Overall, the largest series were from the USA (*n*=430), India (*n*=177), and two from the same author from Canada (*n*=171; *n*=160). Two of the studies report exclusively pediatric cases; in the remaining studies patients were most commonly in sixth decade of life and women were predominant in all but three studies. The majority of series were reports of giant aneurysm cases (15 studies), followed by, complex aneurysms (9 studies), blood blister-like aneurysm cases (7 studies), and very large aneurysms (3 studies); others were reports of mixed cases (i.e., aneurysms and tumors or vascular diseases) (Table 1). Aneurysm locations included the cervical CA, petrous CA, cavernous CA, bifurcation of the CA, PCoA, OphA, ACoA, ACA (different segments), MCA (different segments), PCA (different segments), PCA, PICA, BA, and VA (Table 1). The proportion of patients presenting with SAH ranged from 0% to 100%; in general, studies reporting lower incidence of SAH were those on very large and giant aneurysms of the anterior circulation, while studies that reported the highest incidence were small cohorts of patients with ICA BBL aneurysms. Other presentations included headache, cranial nerve deficits, seizures, hydrocephalus, mass effect, cerebrovascular accidents, transitory ischemic attacks, thromboembolism, carotid-cavernous fistula symptoms, hemiparesis, intracerebral hematoma, and finally, a significant proportion of patients was asymptomatic (Table 2). Most commonly reported types of revascularization procedures were EC-IC bypass (40 studies, 76.9%), followed by reports of both EC-IC and IC-IC bypass procedures (9 studies, 17.3%), and only two studies (3.8%) reported of exclusively IC-IC bypass procedures (Table 1). Among the most common techniques was the high flow EC-IC bypass, using either the saphenous vein or the radial artery as the interposition graft. However, numerous other techniques were used for different indications: this is delineated in Table 3. Graft patency rates ranged from 66-100% and aneurysm obliteration rates were over 90% in most reports (Table 1). Morbidity ranged from 0-60% and was highest in the BBL ICA cohorts, which also we the most likely aneurysms to rupture; however, there were also reports on BBL ICA aneurysms which reported 0% morbidity (Table 1). Mortality ranged from 0-44.5% and was highest in a report from 1986, on giant aneurysms of the anterior circulation (Table 1). In general, BBL ICA aneurysms cases had high mortality, which is not surprising, given their complexity and thus high rate of rupture and morbidity.

Table 1. Review of published series of aneurysm cases treated by revascularization techniques

First Author	Year	Country	Cases*	Indication/Location	Type	Age**	%F	PR (%)	Morb.	Mort.
Drake	1979	Canada	7 (171)	3 ICA bifurcation; 3 MCA; 1 BA	EC-IC	24-66	71.4	-	0	14.3
Sundt	1979	USA	11 (80)	GA ICA	EC-IC	-	-	-	14 ov.	4 ov.
Spetzler	1985	USA	34	GA ICA	EC-IC	-	-	100	14	0
Sundt	1986	USA	29 (132)	GA: 20 ant.; 9 post.	EC-IC	-	-	84	25; 15.8	44.4; 5
de Jong	1989	Netherlands	26	GA ICA	EC-IC	50	46.2	92.3	13.3	0
Ausman	1990	USA	16 (62)	GA ant.: 15 CCA; 1 OphA	EC-IC	23-82	76	-	6	6
Drake	1994	USA	61 (160)	16 GA ICA; 11 OphA; 3 PCoA; 16 ICA bifurcation; 15 MCA	EC-IC	-	-	66.6-81.8	10.5 ov.	4.3 ov.
Lawton	1996	USA	61	33 ICA; 17 MCA; 4 ACA; 5 VA/PICA; 4 BA	IC-IC/EC-IC	-	-	92	8	2
Hacein-Bey	1998	USA	12	ICA	EC-IC	49.9	58.3	89	11	0
Abe	1998	Japan	1 (6)	BBL ICA	EC-IC	56 (43-74)	66.7	-	25	33.3 ov.
Sano	1998	Japan	2 (18)	GA: 3 VA; 4 BA; 4 ICA; 5 MCA; 2 ACoA	-	-	-	-	-	27.8 ov.
Houkin	1999	Japan	43	ICA	EC-IC	56.5	65.1	95	4	0
Sekhar	1999	USA	23 (101)	20 ICA; 1 MCA; 2 VA; 1 BA	EC-IC	-	64.4 ov.	98	13.6	4.3
Sekhar	2001	USA	17	14 ant.; 3 post.	EC-IC	33-74	76.5	94.1		11.8
Jaffar	2002	USA	29	25 ICA; 2 MCA; 2 BA	EC-IC	57	62.1	93.3	7.1	3
van Doormaal	2002	Netherlands	34	ICA	EC-IC	53 (13-76)	74	100	21	6
Amin-Hanjani	2005	USA	143	population-based study	EC-IC	53 (11-85)	62	-	-	7.7; 21
Cantore	2008	Italy	42	GA	EC-IC	46	65.9	92.7 ov.	16.6	9.8
Park	2008	South Korea	15	CPX: 11 ICA; 2 MCA; 1 PCA; 1 PICA	EC-IC	48.7 (14-76)	60	86.7	20	0
Baskaya	2008	USA	4	BBL ICA	EC-IC	23-57	25	50	33.3	25
Hauck	2008	USA	9 (62)	VLA ant.	EC-IC	55.5 (15-75)	64.5	-	20	15
Sharma	2008	India	11 (177)	GA	EC-IC	3-76	60	-	4.5	9 ov.; 27.3
Sanai	2009	USA	82	19 ICA; 16 MCA; 10 PICA; 15 multiple; 46 GA; 67 FF	IC-IC/EC-IC	53 (12-78)	61	94; 89	4.9	3.7
Ishikawa	2009	Japan	4	BBL ICA	EC-IC	33-64	100	100	25	0
Kamijo	2010	Japan	7	BBL ICA	EC-IC	61 (51-77)	100	100	0	0
Patel	2010	UK	9	CPX ICA	EC-IC	57	-	88	11.1	0
Gobble	2011	USA	37	GA: 30 ICA; 4 MCA; 3 BA	EC-IC	57 (IQR 49-66)	61.1	100	89.2	5.6

Table 1. (Continued)

First Author	Year	Country	Cases*	Indication/Location	Type	Age**	%F	PR (%)	Morb.	Mort.
Roh	2011	South Korea	10 (13)	6 GA ICA; 1 ICA psA; 1 GA BA; 2 BBL ICA	EC-IC	44-76	80	90	10	0
Yonekawa	2011	Switzerland	3 (20)	PCA via SAHEA and SCTTA	EC-IC	46.6±13.6	75	-	18.8	20
Zhu	2011	China	39 (49)	CPX ICA	EC-IC	46	53.8	-	90.7	14.3
Kalani	2013	USA	16	GA MCA: 5 M1; 9 M2; 2 M1 and M2	EC-IC	36.3	31.3	93.8	18.8	0
Kim	2013	USA	10 (17)	pediatric: 6 MCA, 1 PCA, 1 ACoA, and 2 BA; 7 VLA	IC-IC/EC-IC	12 (4-17)	58.8	100	0	0
Zhu, Liu	2013	China	21 (59)	CPX MCA	IC-IC/EC-IC	47 (19-66)	48.3	95.2	5.1 ov.	6.8 ov.; 0
Abla	2014	USA	10	ACA	IC-IC	56 (18-86)	70	80	2	0
Ishishita	2014	Japan	38	GA ICA	EC-IC	56.3	81.6	94.7	2.6	0
Kalani	2014	USA	27	pediatric	EC-IC	11.5 (1-17)	28.6	82.1	25	0
Menon	2014	India	12	11 CCA; 1 FF cervical CA aneurysm	EC-IC	45.8 (21-67)	75	81.8	10	8.3
Kazumata	2014	Japan	14 (20)	BBL ICA	EC-IC	51 (29-73)	75	-	10	0
Abla	2015	USA	35	PICA	IC-IC	54.8 ± 13.5	45.7	94	24	2
Gazyakan, Lee	2015	Taiwan	6	mixed	EC-IC	60.8	83.3	100	16.7	0
Song	2015	China	6 (11)	GA ICA	EC-IC	44 (24-60)	72.7	100	100	16.7
Hara	2016	Japan	26	7 MCA; 10 ICA; 5 ACA; 10 VA-BA; 1 PCA	IC-IC/EC-IC	59.2	61.5	96.2	26.9	3.8
Owen	2017	USA	3 (17)	BBL ICA	IC-IC/EC-IC	46 (27-63)	64.7	-	60 ov.	17.6
Matsukawa	2017	Japan	75	CPX ICA	EC-IC	59±15	83	-	94.7	4
Meybodi	2017	USA	30	CPX MCA	IC-IC/EC-IC	47 (7-80)	57	90	10	0
Lee	2018	Taiwan	6	CPX MCA	EC-IC	49 (27-59)	50	100	16.7	0
Luzzi	2018	Italy	15 (75)	GA/VLA	EC-IC	53 (14-80) ov.	57.7 ov.	86	23.9 ov.	8.5 ov.
Strickland	2018	USA	4 (17)	BBL ICA	EC-IC	-	-	-	25	0
Yoon	2018	USA	175 (430)	CPX	IC-IC/EC-IC	47.8 ± 19.9	59.3	-	100	-
Zeeshan	2018	USA	63 (73)	VLA/GA: 35 ICA; 17 MCA; 8 ACoA; 2 ACA; 3 VA; 8 BA; 3 PCA	IC-IC/EC-IC	-	-	99	13.4	8.2
Wang	2019	China	12	CPX MCA	EC-IC	32 (21-56)	25	83.3	16.7	0

* number outside the bracekts is cases treated by revascularization, number in brackets is the total number of cases in the published series; ** numbers are mean, mean±SD, range, or median (range); %F – proportion of female patients; PR (%) – bypass patency rate; morb. – morbidity; mort. – mortality; ICA – Internal Carotid Artery; MCA – Medial Cerebral Artery; BA – Basilar Artery; EC – extracranial; IC – intracranial; GA – Giant Aneurysm; ov. – overall; ant. – anterior circulation; post. – posterior circulation; CCA – Cavernous Carotid Artery; PCoA – Posterior Communicating Artery; ACA – Anterior Cerebral Artery; VA – Vertebral Artery; PICA – Posterior Inferior Cerebellar Artery; BBL – Blood Blister-Like; ACoA – Anterior Communicating Artery; CPX – Complex Aneurysm; FF – fusiform; PCA – Posterior Cerebral Artery; VLA – Very Large Aneurysm; IQR – interquartile range; SAHEA – selective amygdalohippocampectomy approach; SCTTA – supracerebellar transtentorial approach.

Table 2. Initial presentation of patients in the identified studies

First Author	Year	Presentation
Drake	1979	2 SAH; 3 HA; 1 SE; 1 HCP
Sundt	1979	-
Spetzler	1985	-
Sundt	1986	posterior: 2 SAH; 7 ME; anterior: 1 SAH; 4 CVA; 15 ME
de Jong	1989	10 SAH; 13 ME; 3 TIA/CVA;
Ausman	1990	32 ME; 26 SAH; 3 TIA; 3 SE
Drake	1994	-
Lawton	1996	12 SAH; 21 ME; 8 AS 9 TE; 4 CVA; 3 SE; 3 other
Hacein-Bey	1998	7 SAH; 5 AS
Abe	1998	6 SAH
Sano	1998	-
Houkin	1999	36 CND
Sekhar	1999	-
Sekhar	2001	7 ME; 2 TIA; 6 CVA; 1 CCF; 1 AS
Jaffar	2002	4 SAH; 15 ME; 7 HA; 2 TIA; 1 SE
van Doormaal	2002	9 SAH; 22 CND; 3 AS
Amin-Hanjani	2005	18.9% SAH
Cantore	2008	10 SAH; 20 ME; 5 TIA; 4 SE; 2 HA
Park	2008	6 SAH; 2 TIA; 1 CVA; 1 prior coiling
Baskaya	2008	4 SAH
Hauck	2008	27 CND; 20 HA; 11 memory loss; 10 TIA; 12 other
Sharma	2008	overall 110 SAH; 57 ME
Sanai	2009	21 SAH; HA 22; CND 29; 9 HP; 3 SE; 8 TIA/CVA; 4 HCP; 7 recurrent aneurysm
Ishikawa	2009	4 SAH
Kamijo	2010	7 SAH
Patel	2010	4 SAH; 3 CND; 2 CSS
Gobble	2011	-
Roh	2011	1 epistaxis; other -
Yonekawa	2011	15 ICH/IVH
Zhu	2011	-
Kalani	2013	2 SAH; other ME or AS
Kim	2013	3 SAH
Zhu, Liu	2013	27 SAH/ICH; 8 multiple; 2 prior coiling; 1 prior clipping
Abla	2014	4 SAH; 3 ME; 1 mycotic A; 1 iatrogenic A; 1 AS
Ishishita	2014	4 SAH; 23 AS
Kalani	2014	11 ME; 5 SAH; 2 TIA; 3 SE; 6 AS
Menon	2014	11 visual disturbances; 1 neck swelling
Kazumata	2014	20 SAH
Abla	2015	24 SAH
Gazyakan, Lee	2015	4 SAH
Song	2015	7 HA/vertigo; 6 visual disturbances; 1 tremor; 2 SAH
Hara	2016	13 SAH; 2 ME; 5 AS; 3 CND; 2 CVA
Owen	2017	15 SAH
Matsukawa	2017	30 HA; 23 visual disturbances; 5 aneurysm regrowth; 4 SAH; 3 CVA
Meybodi	2017	8 SAH; 12 FD; 7 HA; 2 SE; 1 AS
Lee	2018	3 SAH
Luzzi	2018	38 SAH; 33 MME/CVA
Strickland	2018	overall 15 SAH
Yoon	2018	-
Zeeshan	2018	24 SAH
Wang	2019	3 SAH; 1 CND; 6 HA; 1 SE; 1 vertigo

SAH – Subarachnoid Hemorrhage; HA – Headache; SE – Seizures; HCP – Hydrocephalus; ME – Mass Effect; CVA – Cerebrovascular Accident; TIA – Transitory Ischemic Attack; AS – Asymptomatic; TE – Thromobembolism; CND – Cranial Nerve Deficit; CCF – Carotid-Cavernous Fistula; HP – Hemiparesis; ICH – Intracerebral Hematoma; FD – Focal Deficit.

Table 3. Revascularization techniques used in the identified studies

First Author	Year	Revascularization Technique
Drake	1979	4 EC-SVG-IC; 1 OA-MCA; 1 STA-MCA; 1 STA-OA-MCA
Sundt	1979	STA-MCA
Spetzler	1985	-
Sundt	1986	ECA-SVG-PCA/MCA(M2)
de Jong	1989	STA-MCA
Ausman	1990	9 STA-MCA; 1 ECA-SVG-MCA; 6 STA-MCA
Drake	1994	STA-MCA or STA-SVG-MCA
Lawton	1996	12 ICA-ICA; 15 STA-MCA; 5 STA-SVG-MCA; 4 STA-SCA; 11 long SVG; 3 in situ; 13 primary anastomosis
Hacein-Bey	1998	HF/LF (SVG and STA)
Abe	1998	1 STA-MCA
Sano	1998	-
Houkin	1999	HF ECA-RAG-M2
Sekhar	1999	HF (SVG/RAG)
Sekhar	2001	HF (RAG) ECA-MCA
Jaffar	2002	HF ECA-SVG-M2
van Doormaal	2002	HF ECA-SVG-ICA
AminHanjani	2005	-
Cantore	2008	HF EC-IC (SVG)
Park	2008	6 HF (5 RAG; 1 SVG); 9 LF: 1 STA-M2; 6 STA-M4; 1 STA-PCA; 1 OA-PICA
Baskaya	2008	EC-RAG-M2
Hauck	2008	HF ECA-MCA
Sharma	2008	-
Sanai	2009	47 EC-IC: 16 LF (15 STA, 1 OA); 31 HF (SVG 27; RAG 54); 35 IC-IC: 9 in situ; 6 reimplantation; 11 reanastomosis; 9 IC bypass graft
Ishikawa	2009	EC-RAG-M2
Kamijo	2010	7 ECA-RAG-M2
Patel	2010	9 HF ECA-SVG-M2
Gobble	2011	HF EC-IC: 34 GSV; 3 RAG
Roh	2011	ECA/STA-RAG-MCA
Yonekawa	2011	2 STA-PCA; 1 OA-PCA
Zhu	2011	21 STA-RAG-MCA; 18 ECA-RAG-MCA
Kalani	2013	13 STA-MCA; 1 STA-SVG-MCA; 2 STA-RAG-MCA
Kim	2013	4 STA-SVG-MCA; 1 S2S, 2 intracranial reimplantation; 3 interposition (2 RAGs; 1 LAG)
Zhu, Liu	2013	2 STA-RAG-M3; 1 STA-M3; other -
Abla	2014	4 in-situ; 4 interposition; 1 reimplantation; 1 reanastomosis
Ishishita	2014	17 ECA-RAG-M2; 21 ECA-SVG-M2
Kalani	2014	6 STA-MCA; 1 STA-PCA; 3 STA onlay; 7 ECA-SVG-ICA; 3 ECA-RAG-ICA; 1 OA-PCA; 1 E2E; 6 in situ
Menon	2014	STA-MCA
Kazumata	2014	12 EC-RAIG-MCA; 2 STA-MCA
Abla	2015	11 in situ p3-p3; 9 reimplantation; 14 reanastomosis; 1 V3 VA-to-PICA with interposition
Gazyakan, Lee	2015	1 ECA-SVG-M3; 1 STA-ACA; 1 ECA-SVG-P2; 1 STA-M3; 1 STA-SVG-M3; 1 STA-M4; 1 OA-PICA
Song	2015	3 ECA-RAG-MCA; 2 STA-RAG-MCA; 1 STA-MCA DB

Table 3. (Continued)

First Author	Year	Revascularization Technique
Hara	2016	7 STA-MCA; 9 HF STA-MCA; 3 HF OA-PCA; 1 STA-SCA; 4 A3-A3; 1 A3-STA-A3
Owen	2017	1 STA-MCA; 1 ECA-RAG-MCA; 1 ICA-RAG-MCA
Matsukawa	2017	55 STA-RAG-MCA; 20 STA-SVG-MCA
Meybodi	2017	EC-IC: 8 STA-MCA; 4 HF EC-IC; IC-IC: 6 reanastomosis; 3 reimplantation; 1 M3-M3 in situ; 3 interposition; 5 combined
Lee	2018	6 STA-MCA
Luzzi	2018	1 OA-RAG-VA; 1 OA-RAG-PCA; 1 STA-RAG-SVG-MCA; 8 STA-RAG/SVG-MCA
Strickland	2018	3 ECA-RAIG-M2; 1 STA-M2
Yoon	2018	361 EC-IC (majority STA-MCA); 67 IC-IC
Zeeshan	2018	-
Wang	2019	IMA-RAG-MCA

EC – extracranial; SVG – Saphenous Vein Graft; IC – intracranial; OA – Occipital Artery; MCA – Middle Cerebral Artery; STA – Superficial Temporal Artery; PCA – Posterior Cerebral Artery; HF – High Flow; LF – Low Flow; RAG – Radial Artery Graft; PICA – Posterior Inferior Cerebellar Artery; S2S – side-to-side; LAG – Lingual Artery Graft; E2E – end-to-end; VA – Vertebral Artery; ACA – Anterior Cerebral Artery; DB – Double Barrel.

ILLUSTRATIVE CASES

Case 1

A 67-year-old Caucasian woman presented with an acute onset right-sided limb weakness, altered state of consciousness, and frontal headache to an Emergency Department at an external hospital. At index examination she was drowsy, confused, obeyed motor commands and had neck stiffness. An urgent brain CT was performed which showed an intracerebral hematoma and SAH in the left frontotemporal region. CT angiography showed an aneurysm of the left MCA. The patient had a Hunt and Hess grade III and the hemorrhage was graded as being Fisher grade 4. Telemedicine consultation was referred to our Department and the decision was made to immediately transport and operate on the patient.

Upon admission, a follow-up CT/CT angiography was performed which showed a giant irregular-shaped dissecting aneurysm on the parietal branch of the cranial M2 trunk of the left MCA (Figure 1). The patient underwent surgery under total intravenous anesthesia (TIVA); eptifibatide 1 mcg/kg/min was administered intraoperatively and 72 hours postoperatively. After inserting an external ventricular drain through the right Kocher point, a left frontotemporal craniectomy was performed, the dura incised and the Sylvian fissure dissected. A large aneurysm was identified on the MCA bifurcation; M1, temporal (tM2) and frontal M2 (fM2) were incorporated into the aneurysm, while the aneurysm itself was thrombosed and surrounded by a hematoma. First the neck of the aneurysm was clipped and then temporary clips were placed on the M1, tM2 and fM2 and then the aneurysm was resected. To reconstruct the vascular architecture, an end-to-end M1 to tM2 and STA to fM2 bypasses were performed (Figure 2). Intraoperative ICG angiography showed patency of the revascularized segments. The dura and bone were reconstructed in a fashion to accommodate the traversing STA. Postoperative angiography showed patency of the M1 to tM2 bypass and

no flow in the STA to fM2 bypass (Figure 3). The patient was weaned from the ventilator on the third postoperative day; upon emerging from sedation he was found to have a mild right-sided limb weakness and difficulties with spatio-temporal orientation. Both deficits gradually improved and she was discharged three weeks postoperatively. The patient recovered well and was readmitted six months postoperatively for a cranioplasty procedure with a discrete aphasia and an otherwise normal neurological status.

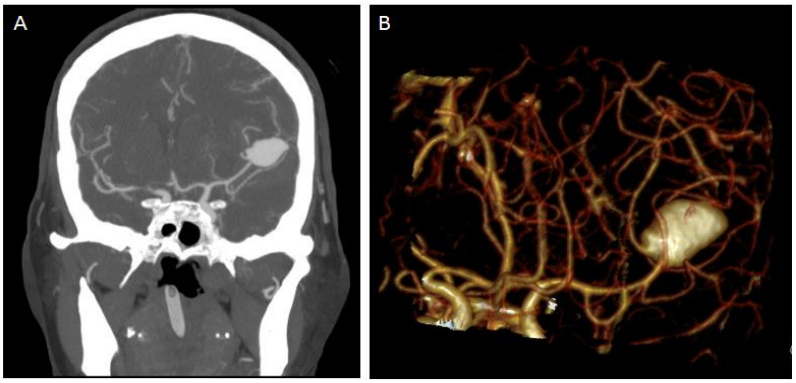

Figure 1. CT angiography showing a giant aneurysm on the parietal branch of the left MCA (A); reconstructed image (B).

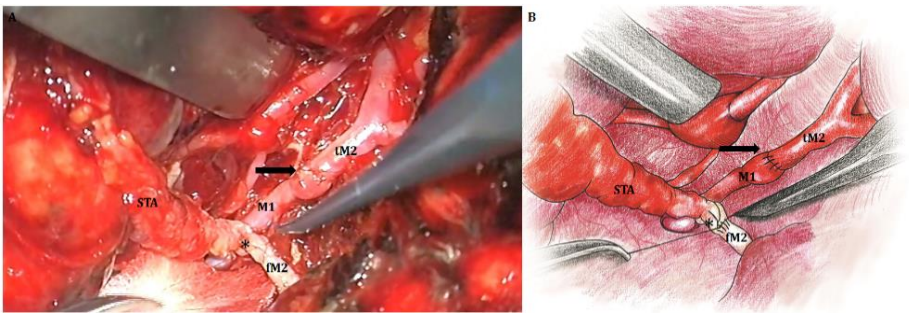

Figure 2. Intraoperative image (A) showing the end M1 to tM2 (arrow) and STA to fM2 bypass (asterisk); schematic drawing (B).

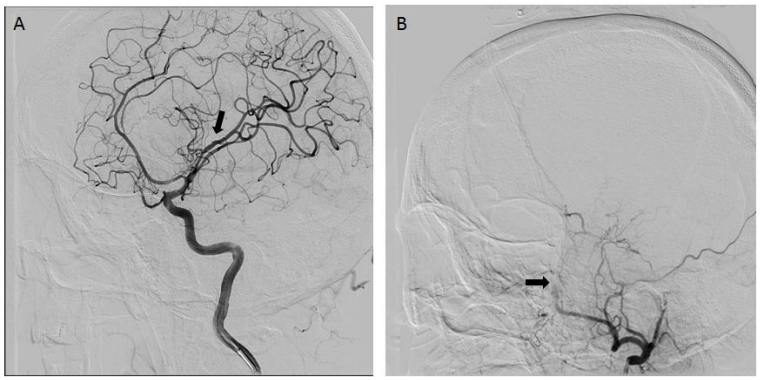

Figure 3. Pigital subtraction angiography showing patency of the M1 to tM2 bypass (A) and no flow in the STA to fM2 bypass (B).

Case 2

A 28-year-old Caucasian man presented with a grand-mal epileptic seizure to an Emergency Department at an external hospital. At initial examination he complained of a headache and had no neurological deficits. Urgent nonenhanced brain CT showed SAH in the left Sylvian fissure and an M1 aneurysm, which was confirmed on the DSA (Figure 4). The patient had a Hunt and Hess grade I and was transferred to our Clinic for an angiography and treatment. The angiography showed a giant aneurysm on the bifurcation of the left MCA and the patient was scheduled for surgery on the following day. During the night the patient became unresponsive, bradycardic and hypotensive and an urgent CT showed progression of the SAH.

An urgent surgery was performed during which a ruptured MCA bifurcation aneurysm was identified as the source of bleeding. The neck of the aneurysm was clipped as, well as an M2 branch arising from the dome of the aneurysm (Figure 5). To revascularize the parenchyma supplied by the sacrificed vessel, an STA-M2 bypass was performed; intraoperative ICG angiography showed bypass flow patency. Postoperative angiography showed occlusion of the bifurcation of the left MCA and a patent STA-MCA bypass (Figure 6). Postoperative stay in the ICU was complicated by a respiratory insufficiency which prolonged ventilator weaning. Eventually, the patient was extubated 13 days postoperatively and transferred to a hospital at his place of residence with a right-sided limb weakness and sensory dysphasia.

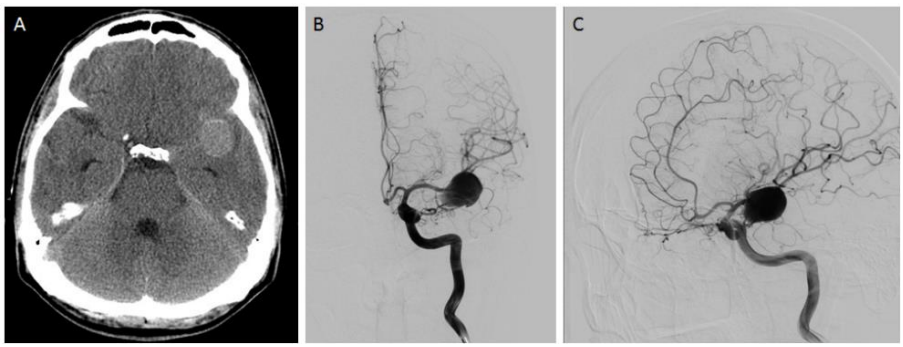

Figure 4. CT showing SAH in the left Sylvian fissure and an aneurysm of the left MCA (A); the finding is confirmed by digital subtraction angiography, on the anterior-posterior view (B) and lateral-lateral view (C).

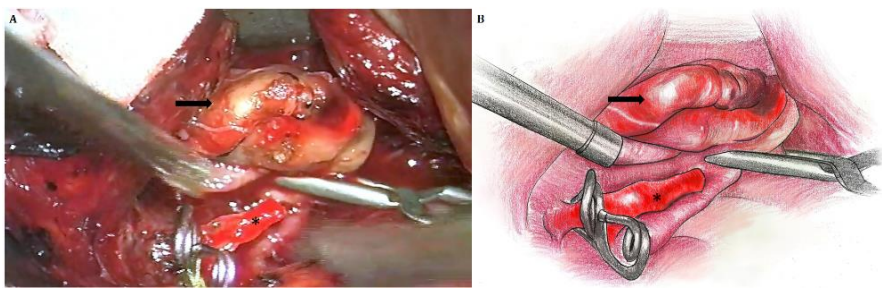

Figure 5. Intraoperative image (A) showing the clipped and resected aneurysm (arrow) and the M2 branch arising from the dome of the aneurysm (asterisk); schematic drawing (B).

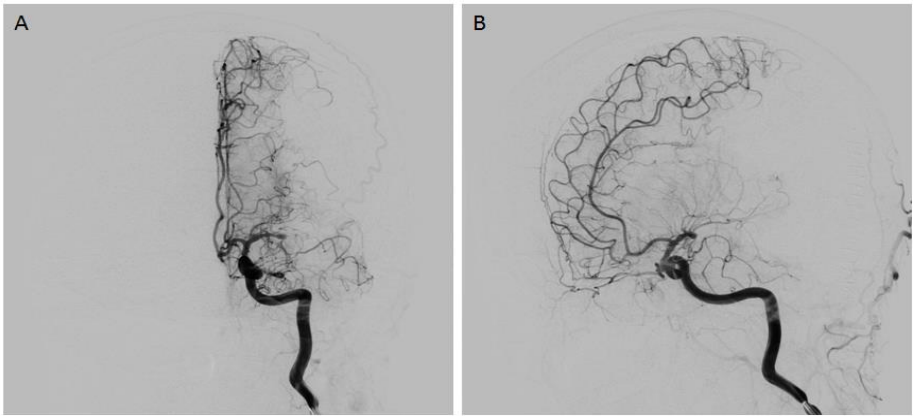

Figure 6. Postoperative angiography (A – anterior-posterior, and B – lateral-lateral view) showing occlusion of the bifurcation of the left MCA and a patent STA-MCA bypass.

CONCLUSION

Despite lack of robust evidence from quality clinical trials, cerebral revascularization techniques are indispensable in modern neurosurgical settings. The review of cohorts presented in this chapter supports this view and shows a progressive growth in numbers of reported cases worldwide, which is likely associated with a growth in the number of performed procedures. It is our firm belief that these techniques will not go extinct in the years to follow. On the contrary, they remain the only hope for a significant subset of patients suffering from cerebrovascular diseases. What is needed to further strengthen their use are high-quality data from well-designed studies.

REFERENCES

[1] Abe, Masamitsu, Kazuo Tabuchi, Hiroaki Yokoyama, and Akira Uchino. 1998. "Blood Blisterlike Aneurysms Of The Internal Carotid Artery." *Journal Of Neurosurgery* 89 (3): 419-424. doi:10.3171/jns.1998.89.3.0419.

[2] Abla, Adib A., Cameron M. McDougall, Jonathan D. Breshears, and Michael T. Lawton. 2016. "Intracranial-To-Intracranial Bypass For Posterior Inferior Cerebellar Artery Aneurysms: Options, Technical Challenges, And Results In 35 Patients." *Journal Of Neurosurgery* 124 (5): 1275-1286. doi:10.3171/2015.5.jns15368.

[3] Abla, Adib A., and Michael T. Lawton. 2014. "Anterior Cerebral Artery Bypass For Complex Aneurysms: An Experience With Intracranial-Intracranial Reconstruction And Review Of Bypass Options." *Journal Of Neurosurgery* 120 (6): 1364-1377. doi:10.3171/2014.3.jns132219.

[4] Amin-Hanjani, Sepideh, William E. Butler, Christopher S. Ogilvy, Bob S. Carter, and Fred G. Barker. 2005. "Extracranial—Intracranial Bypass In The Treatment Of Occlusive Cerebrovascular Disease And Intracranial Aneurysms In The United States

Between 1992 And 2001: A Population-Based Study." *Journal Of Neurosurgery* 103 (5): 794-804. doi:10.3171/jns.2005.103.5.0794.

[5] Ausman, James I., Fernando G. Diaz, Balaji Sadasivan, Marco Gonzeles-Portillo, Ghaus M. Malik, and Chandrashekhar E. Deopujari. 1990. "Giant Intracranial Aneurysm Surgery: The Role Of Microvascular Reconstruction." *Surgical Neurology* 34 (1): 8-15. doi:10.1016/0090-3019(90)90166-m.

[6] Başkaya, Mustafa K., Azam S. Ahmed, Özkan Ateş, and David Niemann. 2008. "Surgical Treatment Of Blood Blister–Like Aneurysms Of The Supraclinoid Internal Carotid Artery With Extracranial–Intracranial Bypass And Trapping." *Neurosurgical Focus* 24 (2): E13. doi:10.3171/foc/2008/24/2/e13.

[7] Cantore, Giampaolo, Antonio Santoro, Giulio Guidetti, Catia P. Delfinis, Claudio Colonnese, and Emiliano Passacantilli. 2008. "Surgical Treatment Of Giant Intracranial Aneurysms." *Operative Neurosurgery* 63: 279-290. doi:10.1227/01.neu.0000313122.58694.91.

[8] Chiu, Tsung-Lang, Chien-Hui Lee, and Sheng-Tzung Tsai. 2018. "Superficial Temporal Artery-Middle Cerebral Artery Bypass For The Treatment Of Complex Middle Cerebral Artery Aneurysms." *Tzu Chi Medical Journal* 30 (2): 110. doi:10.4103/tcmj.tcmj_193_17.

[9] Cooper, Astley. 1837. *Lectures On The Principles And Practice Of Surgery*. London: Published for the proprietor by Henry Rebshaw, medical Bookseller.

[10] de Jong, T.H.R., C.A.F. Tulleken, and L. Ramos. 1989. "Place Of The Extra-Intra-Cranial-Bypass In Aneurysmsurgery." *Clinical Neurology And Neurosurgery* 91 (3): 221-228. doi:10.1016/0303-8467(89)90115-7.

[11] Drake, Charles G. 1979. "Giant Intracranial Aneurysms: Experience With Surgical Treatment In 174 Patients." *Neurosurgery* 26 (CN_suppl_1): 12-95. doi:10.1093/neurosurgery/26.cn_suppl_1.12.

[12] Drake, Charles G. 1985. "Earlier Times In Aneurysm Surgery." *Clinical Neurosurgery* 32: 41-50.

[13] Drake, Charles G., Sydney J. Peerless, and Gary G. Ferguson. 1994. "Hunterian Proximal Arterial Occlusion For Giant Aneurysms Of The Carotid Circulation." *Journal Of Neurosurgery* 81 (5): 656-665. doi:10.3171/jns.1994.81.5.0656.

[14] Engelhardt, Eliasz. 2017. "Apoplexy, Cerebrovascular Disease, And Stroke: Historical Evolution Of Terms And Definitions." *Dementia & Neuropsychologia* 11 (4): 449-453. doi:10.1590/1980-57642016dn11-040016.

[15] Gazyakan, Emre, Ching-Yi Lee, Chieh-Tsai Wu, Chung-Kan Tsao, Randall Craft, Steven L. Henry, Ming-Huei Cheng, and Shih-Tseng Lee. 2015. "Indications And Outcomes Of Prophylactic And Therapeutic Extracranial-To-Intracranial Arterial Bypass For Cerebral Revascularization." *Plastic And Reconstructive Surgery - Global Open* 3 (4): e372. doi:10.1097/gox.0000000000000339.

[16] Gobble, Ryan M., Han Hoang, Jafar Jafar, and Mark Adelman. 2012. "Extracranial-Intracranial Bypass: Resurrection Of A Nearly Extinct Operation." *Journal Of Vascular Surgery* 56 (5): 1303-1307. doi:10.1016/j.jvs.2012.03.281.

[17] Hacein-Bey, Lotfi, E. Sander Connolly, Stephan A. Mayer, William L. Young, John Pile-Spellman, and Robert A. Solomon. 1998. "Complex Intracranial Aneurysms: Combined Operative And Endovascular Approaches." *Neurosurgery* 43 (6): 1304-1312. doi:10.1097/00006123-199812000-00020.

[18] Hara, Takayuki, Shintaro Arai, Yoshiaki Goto, Tsuguhito Takizawa, and Tatsuya Uchida. 2016. "Bypass Surgeries In The Treatment Of Cerebral Aneurysms." *Acta Neurochirurgica Supplement*, 57-64. doi:10.1007/978-3-319-29887-0_8.

[19] Hauck, Erik F., Bryan Wohlfeld, Babu Guai Welch, Jonathan A. White, and Duke Samson. 2008. "Clipping Of Very Large Or Giant Unruptured Intracranial Aneurysms In The Anterior Circulation: An Outcome Study." *Journal Of Neurosurgery* 109 (6): 1012-1018. doi:10.3171/jns.2008.109.12.1012.

[20] Houkin, Kiyohiro, Hiroyasu Kamiyama, Satoshi Kuroda, Tatsuya Ishikawa, Akihiro Takahashi, and Hiroshi Abe. 1999. "Long-Term Patency Of Radial Artery Graft Bypass For Reconstruction Of The Internal Carotid Artery." *Journal Of Neurosurgery* 90 (4): 786-790. doi:10.3171/jns.1999.90.4.0786.

[21] ISHIKAWA, Tatsuya, Tatsushi MUTOH, Naoki NAKAYAMA, Hiroshi YASUDA, Mikio NOMURA, Ken KAZUMATA, Junta MOROI, and Nobuyuki YASUI. 2009. "Universal External Carotid Artery To Proximal Middle Cerebral Artery Bypass With Interposed Radial Artery Graft Prior To Approaching Ruptured Blood Blister-Like Aneurysm Of The Internal Carotid Artery." *Neurologia Medico-Chirurgica* 49 (11): 553-558. doi:10.2176/nmc.49.553.

[22] Ishishita, Yohei, Rokuya Tanikawa, Kosumo Noda, Hisashi Kubota, Naoto Izumi, Makoto Katsuno, and Nakao Ota et al. 2014. "Universal Extracranial-Intracranial Graft Bypass For Large Or Giant Internal Carotid Aneurysms: Techniques And Results In 38 Consecutive Patients." *World Neurosurgery* 82 (1-2): 130-139. doi:10.1016/j.wneu. 2013.02.063.

[23] Jafar, Jafar J., Stephen M. Russell, and Henry H. Woo. 2002. "Treatment Of Giant Intracranial Aneurysms With Saphenous Vein Extracranial-To-Intracranial Bypass Grafting: Indications, Operative Technique, And Results In 29 Patients." *Neurosurgery* 51 (1): 138-146. doi:10.1097/00006123-200207000-00021.

[24] Kalani, M. Yashar S., Ali M. Elhadi, Wyatt Ramey, Peter Nakaji, Felipe C. Albuquerque, Cameron G. McDougall, Joseph M. Zabramski, and Robert F. Spetzler. 2014. "Revascularization And Pediatric Aneurysm Surgery." *Journal Of Neurosurgery: Pediatrics* 13 (6): 641-646. doi:10.3171/2014.3.peds13444.

[25] Kalani, M. Yashar S., Joseph M. Zabramski, Yin C. Hu, and Robert F. Spetzler. 2013. "Extracranial-Intracranial Bypass And Vessel Occlusion For The Treatment Of Unclippable Giant Middle Cerebral Artery Aneurysms." *Neurosurgery* 72 (3): 428-436. doi:10.1227/neu.0b013e3182804381.

[26] Kalani, M. Yashar S., Leonardo Rangel-Castilla, Wyatt Ramey, Peter Nakaji, Felipe C. Albuquerque, Cameron G. McDougall, Robert F. Spetzler, and Joseph M. Zabramski. 2015. "Indications And Results Of Direct Cerebral Revascularization In The Modern Era." *World Neurosurgery* 83 (3): 345-350. doi:10.1016/j.wneu.2014.10.013.

[27] Kamijo, Koji, and Toru Matsui. 2010. "Acute Extracranial-Intracranial Bypass Using A Radial Artery Graft Along With Trapping Of A Ruptured Blood Blister–Like Aneurysm Of The Internal Carotid Artery." *Journal Of Neurosurgery* 113 (4): 781-785. doi:10.3171/2009.10.jns09970.

[28] Kawamura, Sh., I. Sayama, N. Yasui, and K. Uemura. 1994. "Haemodynamic And Metabolic Changes Following Extra-Intracranial Bypass Surgery." *Acta Neurochirurgica* 126 (2-4): 135-139. doi:10.1007/bf01476423.

[29] Kazumata, Ken, Naoki Nakayama, Toshitaka Nakamura, Hiroyasu Kamiyama, Shunsuke Terasaka, and Kiyohiro Houkin. 2014. "Changing Treatment Strategy From Clipping To Radial Artery Graft Bypass And Parent Artery Sacrifice In Patients With Ruptured Blister-Like Internal Carotid Artery Aneurysms." *Operative Neurosurgery* 10 (1): 66-73. doi:10.1227/neu.0000000000000076.

[30] Kim, Jong S. 2016. "Moyamoya Disease: Epidemiology, Clinical Features, And Diagnosis." *Journal Of Stroke* 18 (1): 2-11. doi:10.5853/jos.2015.01627.

[31] Kim, Tackeun, Chang Wan Oh, Jae Seung Bang, Jeong Eun Kim, and Won-Sang Cho. 2016. "Moyamoya Disease: Treatment And Outcomes." *Journal Of Stroke* 18 (1): 21-30. doi:10.5853/jos.2015.01739.

[32] Kim, Louis J., Farzana Tariq, and Laligam N. Sekhar. 2013. "Pediatric Bypasses For Aneurysms And Skull Base Tumors: Short- And Long-Term Outcomes." *Journal Of Neurosurgery: Pediatrics* 11 (5): 533-542. doi:10.3171/2013.1.peds12444.

[33] Kurze, T. 1964. "Microtechniques In Neurological Surgery." *Clinical Neurosurgery*2: 128-137.

[34] Lawton, Michael T., Mark G. Hamilton, Jacques J. Morcos, and Robert F. Spetzler. 1996. "Revascularization And Aneurysm Surgery: Current Techniques, Indications, And Outcome." *Neurosurgery* 38 (1): 83-94. doi:10.1097/00006123-199601000-00020.

[35] Leblanc, Richard. 1987. "Hemodynamic And Metabolic Effects Of Cerebral Revascularization: Correction." *Journal Of Neurosurgery* 67 (3): 474. doi:10.3171/jns.1987.67.3.0474a.

[36] Lippi, D. 1990. "An Aneurysm In The Papyrus Of Ebers." *Med Secoli* 2 (1): 1-4.

[37] Lo, William B., and Harold Ellis. 2010. "The Circle Before Willis." *Neurosurgery* 66 (1): 7-18. doi:10.1227/01.neu.0000362002.63241.a5.

[38] Luzzi, Sabino, Massimo Gallieni, Mattia Del Maestro, Donatella Trovarelli, Alessandro Ricci, and Renato Galzio. 2018. "Giant And Very Large Intracranial Aneurysms: Surgical Strategies And Special Issues." *Acta Neurochirurgica Supplement*, 25-31. doi:10.1007/978-3-319-73739-3_4.

[39] Matsukawa, Hidetoshi, Rokuya Tanikawa, Hiroyasu Kamiyama, Toshiyuki Tsuboi, Kosumo Noda, Nakao Ota, Shiro Miyata, Rihei Takeda, and Sadahisa Tokuda. 2017. "Graft Occlusion And Graft Size Changes In Complex Internal Carotid Artery Aneurysm Treated By Extracranial To Intracranial Bypass Using High-Flow Grafts With Therapeutic Internal Carotid Artery Occlusion." *Neurosurgery*. doi:10.1093/neuros/nyx075.

[40] Menon, G, Sudhir Jayanand, K Krishnakumar, and S Nair. 2014. "EC-IC Bypass For Cavernous Carotid Aneurysms: An Initial Experience With Twelve Patients." *Asian Journal Of Neurosurgery* 9 (2): 82. doi:10.4103/1793-5482.136718.

[41] Miyamoto, Susumu, Takashi Yoshimoto, Nobuo Hashimoto, Yasushi Okada, Ichiro Tsuji, Teiji Tominaga, and Jyoji Nakagawara et al. 2014. "Effects Of Extracranial–Intracranial Bypass For Patients With Hemorrhagic Moyamoya Disease." *Stroke* 45 (5): 1415-1421. doi:10.1161/strokeaha.113.004386.

[42] Mrak, Goran, Jakob Nemir, Klara Brgic, Hrvoje Baric, Josip Paladino, and Vasilije Stambolija. 2018. "Cerebral Bypass Surgery For Internal Carotid Artery Occlusion, Complex Supraclinoid Carotid Artery Aneurysm, And Tumors: A Report Of Four Cases." *Asian Journal Of Neurosurgery* 13 (3): 938-942. doi:10.4103/ajns.AJNS_26_18.

[43] Natarajan, Sabareesh K., Laligam N. Sekhar, David Schessel, and Akio Morita. 2007. "Petroclival Meningiomas." *Neurosurgery* 60 (6): 965-981. doi:10.1227/01.neu.0000255472.52882.d6.

[44] Owen, Christopher M., Nicola Montemurro, and Michael T. Lawton. 2016. "Blister Aneurysms Of The Internal Carotid Artery." *Neurosurgery*, 1. doi:10.1227/neu.0000000000001259.

[45] Park, Eun Kyung, Jae Sung Ahn, Do Hoon Kwon, and Byung Duk Kwun. 2008. "Result Of Extracranial-Intracranial Bypass Surgery In The Treatment Of Complex Intracranial Aneurysms: Outcomes In 15 Cases." *Journal Of Korean Neurosurgical Society* 44 (4): 228. doi:10.3340/jkns.2008.44.4.228.

[46] Patel, H. C., M. Teo, N. Higgins, and P. J. Kirkpatrick. 2010. "High Flow Extra-Cranial To Intra-Cranial Bypass For Complex Internal Carotid Aneurysms." *British Journal Of Neurosurgery* 24 (2): 173-178. doi:10.3109/02688690903531075.

[47] Polevaya, Nika V., M. Yashar S. Kalani, Gary K. Steinberg, and Victor C. K. Tse. 2006. "The Transition From Hunterian Ligation To Intracranial Aneurysm Clips: A Historical Perspective." *Neurosurgical Focus* 20 (6): 1-7. doi:10.3171/foc.2006.20.6.3.

[48] Powers, William J., William R. Clarke, Robert L. Grubb, Tom O. Videen, Harold P. Adams, Colin P. Derdeyn, and for the COSS Investigators. 2011. "Extracranial-Intracranial Bypass Surgery For Stroke Prevention In Hemodynamic Cerebral Ischemia." *JAMA* 306 (18): 1983. doi:10.1001/jama.2011.1610.

[49] Rickard, Rory F., and Donald A. Hudson. 2014. "A History Of Vascular And Microvascular Surgery." *Annals Of Plastic Surgery* 73 (4): 465-472. doi:10.1097/sap.0b013e3182710027.

[50] Roh, Sung Woo, Jae Sung Ahn, Han Yoo Sung, Young Jin Jung, Byung Duk Kwun, and Chang Jin Kim. 2011. "Extracranial-Intracranial Bypass Surgery Using A Radial Artery Interposition Graft For Cerebrovascular Diseases." *Journal Of Korean Neurosurgical Society* 50 (3): 185. doi:10.3340/jkns.2011.50.3.185.

[51] SANO, Hirotoshi, Yoko KATO, Krupa SHANKAR, Narimasu KANAOKA, Motoharu HAYAKAWA, Kazuhiro KATADA, and Tetsuo KANNO. 1998. "Treatment And Results Of Partially Thrombosed Giant Aneurysms." *Neurologia Medico-Chirurgica* 38 (suppl): 58-61. doi:10.2176/nmc.38.suppl_58.

[52] Sanai, Nader, Zsolt Zador, and Michael T. Lawton. 2009. "Bypass Surgery For Complex Brain Aneurysms." *Neurosurgery* 65 (4): 670-683. doi:10.1227/01.neu.0000348557.11968.f1.

[53] Scott, R. Michael, and Edward R. Smith. 2009. "Moyamoya Disease And Moyamoya Syndrome." *New England Journal Of Medicine* 360 (12): 1226-1237. doi:10.1056/nejmra0804622.

[54] Sekhar, Laligam N., John M. Duff, Chandrasekar Kalavakonda, and Michael Olding. 2001. "Cerebral Revascularization Using Radial Artery Grafts For The Treatment Of Complex Intracranial Aneurysms: Techniques And Outcomes For 17 Patients." *Neurosurgery* 49 (3): 646-659. doi:10.1097/00006123-200109000-00023.

[55] Sekhar, Laligam N., Sorin D. Bucur, William O. Bank, and Donald C. Wright. 1999. "Venous And Arterial Bypass Grafts For Difficult Tumors, Aneurysms, And Occlusive Vascular Lesions: Evolution Of Surgical Treatment And Improved Graft Results." *Neurosurgery* 44 (6): 1207-1224. doi:10.1097/00006123-199906000-00028.

[56] Sharma, Bhawani Shankar, Aditya Gupta, Faiz Uddin Ahmad, Ashish Suri, and Veer Singh Mehta. 2008. "Surgical Management Of Giant Intracranial Aneurysms." *Clinical Neurology and Neurosurgery* 110 (7): 674-681. doi:10.1016/j.clineuro.2008.04.001.

[57] Soldozy, Sauson, John S. Costello, Pedro Norat, Jennifer D. Sokolowski, Kamron Soldozy, Min S. Park, Petr Tvrdik, and M. Yashar S. Kalani. 2019. "Extracranial-Intracranial Bypass Approach To Cerebral Revascularization: A Historical Perspective." *Neurosurgical Focus* 46 (2): E2. doi:10.3171/2018.11.focus18527.

[58] Song, Jianping, Liqin Lang, Wei Zhu, Yuxiang Gu, Bin Xu, Jiajun Cai, Qi Yue, Geng Xu, Liang Chen, and Ying Mao. 2015. "Application Of Intraoperative Motor Evoked Potential Monitoring During Giant Internal Carotid Artery Aneurysm Surgery Using Prolonged Temporary Occlusion." *Acta Neurochirurgica* 157 (11): 1833-1840. doi:10.1007/s00701-015-2568-4.

[59] Spetzler, Robert F., Herbert Schuster, and Richard A. Roski. 1980. "Elective Extracranial-Intracranial Arterial Bypass In The Treatment Of Inoperable Giant Aneurysms Of The Internal Carotid Artery." *Journal Of Neurosurgery* 53 (1): 22-27. doi:10.3171/jns.1980.53.1.0022.

[60] Spetzler, Robert F., and Philip L. Carter. 1985. "Revascularization And Aneurysm Surgery: Current Status." *Neurosurgery* 16 (1): 111-116. doi:10.1227/00006123-198501000-00026.

[61] Stambolija, Vasilije, Goran Mrak, Marin Lozic, Josip Ljevak, Martina Miklic Bublic, and Miroslav Scap. 2017. "Intraoperative Eptifibatide Administration During Urgent Arterial Bypass In Neurosurgery." *World Neurosurgery* 103: 952.e5-952.e9. doi:10.1016/j.wneu.2017.04.083.

[62] Strickland, Ben A., Robert C. Rennert, Josh Bakhsheshian, Kristine Ravina, Vance Fredrickson, Steven L. Giannotta, and Jonathan J. Russin. 2018. "Extracranial-Intracranial Bypass For Treatment Of Blister Aneurysms: Efficacy And Analysis Of Complications Compared With Alternative Treatment Strategies." *World Neurosurgery* 117: e417-e424. doi:10.1016/j.wneu.2018.06.046.

[63] Sundt, Thoralf M., and David G. Piepgras. 1979. "Surgical Approach To Giant Intracranial Aneurysms." *Journal Of Neurosurgery* 51 (6): 731-742. doi:10.3171/jns.1979.51.6.0731.

[64] Sundt, Thoralf M., David G. Piepgras, W. Richard Marsh, and Nicolee C. Fode. 1986. "Saphenous Vein Bypass Grafts For Giant Aneurysms And Intracranial Occlusive Disease." *Journal Of Neurosurgery* 65 (4): 439-450. doi:10.3171/jns.1986.65.4.0439.

[65] Tayebi Meybodi, Ali, Wendy Huang, Arnau Benet, Olivia Kola, and Michael T. Lawton. 2017. "Bypass Surgery For Complex Middle Cerebral Artery Aneurysms: An Algorithmic Approach To Revascularization." *Journal Of Neurosurgery* 127 (3): 463-479. doi:10.3171/2016.7.jns16772.

[66] Tamargo, R. J. 2008. "Cerebral Revascularization For Ischemia, Aneurysms, And Cranial Base Tumors." *Neurosurgery*. doi:10.1227/01.neu.0000315873.41953.74.

[67] Thanapal, Sengottuvel, Shyam Duvuru, Treepob Sae-Ngow, Yoko Kato, and Katsumi Takizawa. 2018. "Direct Cerebral Revascularization: Extracranial-Intracranial Bypass." *Asian Journal Of Neurosurgery* 13 (1): 9. doi:10.4103/ajns.ajns_76_17.

[68] The EC/IC Bypass Study Group. 1985. "Failure Of Extracranial–Intracranial Arterial Bypass To Reduce The Risk Of Ischemic Stroke." *New England Journal Of Medicine* 313 (19): 1191-1200. doi:10.1056/nejm198511073131904.

[69] van Doormaal, Tristan P.C., Albert van der Zwan, Bon H. Verweij, David J. Langer, and Cornelis A.F. Tulleken. 2008. "Treatment Of Giant And Large Internal Carotid Artery Aneurysms With A High-Flow Replacement Bypass Using The Excimer Laser-Assisted Nonocclusive Anastomosis Technique." *Neurosurgery* 62 (suppl_3): ONS-328-ONS-335. doi:10.1227/01.neu.0000333804.74832.e5.

[70] Vilela, Marcelo D., and David W. Newell. 2008. "Superficial Temporal Artery To Middle Cerebral Artery Bypass: Past, Present, And Future." *Neurosurgical Focus* 24 (2): E2. doi:10.3171/foc/2008/24/2/e2.

[71] Wang, Long, Shuaibin Lu, Li Cai, Hai Qian, Rokuya Tanikawa, and Xiang'en Shi. 2019. "Internal Maxillary Artery Bypass For The Treatment Of Complex Middle Cerebral Artery Aneurysms." *Neurosurgical Focus* 46 (2): E10. doi:10.3171/2018.11.focus18457.

[72] Yoon, Seungwon, Jan-Karl Burkhardt, and Michael T. Lawton. 2018. "Long-Term Patency In Cerebral Revascularization Surgery: An Analysis Of A Consecutive Series Of 430 Bypasses." *Journal Of Neurosurgery*, 1-8. doi:10.3171/2018.3.jns172158.

[73] Yonekawa, Yasuhiro, P. Roth, J. Fandino, and H. Landolt. 2011. "Aneurysms Of The Posterior Cerebral Artery And Approach Selection In Their Microsurgical Treatment: Emphasis On The Approaches: SAHEA And SCTTA." *Trends In Neurovascular Surgery*, 85-92. doi:10.1007/978-3-7091-0661-7_15.

[74] Zeeshan Qazi, Laligam N Sekhar, Basavaraj V Ghodke, Gordana Juric-Sekhar, Jason K Barber, and LouisJ Kim. 2018. "Surgery For Very Large And Giant Intracranial Aneurysms: Results And Complications." *Neurology India* 66 (6): 1741. doi:10.4103/0028-3886.246291.

[75] Zhu, Wei, Peixi Liu, Yanlong Tian, Yuxiang Gu, Bin Xu, Liang Chen, Liangfu Zhou, and Ying Mao. 2013. "Complex Middle Cerebral Artery Aneurysms: A New Classification Based On The Angioarchitecture And Surgical Strategies." *Acta Neurochirurgica* 155 (8): 1481-1491. doi:10.1007/s00701-013-1751-8.

[76] Zhu, Wei, Yan-Long Tian, Liang-Fu Zhou, Dong-Lei Song, Bin Xu, and Ying Mao. 2011. "Treatment Strategies For Complex Internal Carotid Artery (ICA) Aneurysms: Direct ICA Sacrifice Or Combined With Extracranial-To-Intracranial Bypass." *World Neurosurgery* 75 (3-4): 476-484. doi:10.1016/j.wneu.2010.07.043.

In: Encyclopedia of Surgery (22 Volume Set)
Editors: Andreas Lehrer and Kristin Mueller
ISBN: 978-1-53618-329-0
© 2020 Nova Science Publishers, Inc.

Chapter 109

INDOCYANINE GREEN VIDEO-ANGIOGRAPHY WITH FLOW 800 ANALYSIS: APPLICATIONS IN NEURO-ONCOLOGICAL SURGERY

Morgan Broggi*[*,†], MD, PhD, Jacopo Falco*[*], MD, Costanza M. Zattra, MD, Marco Schiariti, MD, Ignazio G. Vetrano, MD, Giovanni Tringali, MD, Giovanni Broggi, MD, Paolo Ferroli, MD and Francesco Acerbi, MD, PhD
Department of Neurosurgery, Fondazione IRCCS Istituto Neurologico Carlo Besta, Milan, Italy

ABSTRACT

Vascular pathophysiology in central nervous system (CNS) tumors and its management during surgical procedures are complex issues, sparking to this date a heated debate. Brain tumors can, in fact, distort the already variable vascular anatomy, posing a significant challenge during tumor removal. Furthermore, although venous sacrifice can cause devasting consequences, under specific circumstances, it can be desirable to help creating/widening a surgical corridor in order to increase the extent of tumor resection. It is therefore mandatory to develop intraoperative tools which allow to outline, both before and during tumor resection, the patient's unique CNS circulation and the relationships between the tumor and the surrounding brain vessels. Finally, in the possible event of an unexpected artery or vein damage, the neurosurgeon would surely benefit from a tool able to predict the consequences of this injury in real-time in order to reverse the situation, when possible.

Indocyanine green video-angiography (ICG-VA) is an intraoperative technique designed to highlight superficial vessels during neurosurgical procedures; the FLOW 800

[*] Both co-authors equally contributed to the manuscript.
[†] Corresponding Author's Email: morganbroggi@hotmail.com.

analysis software (*Carl Zeiss Meditec*), which is able to provide a semiquantitative evaluation of cerebral blood flow, has further expanded the usefulness of ICG-VA, especially in neuro-oncological surgery.

In this chapter, the authors present their extensive experience with ICG-VA and FLOW 800 analysis software during surgical removal of CNS tumors; in particular, they identified 5 possible applications of ICG-VA and FLOW 800 in this field: a) extradural analysis to explore sinuses patency and bridging veins anatomy before dural opening; b) ICG temporary clipping test to verify the feasibility of venous sacrifice in deeply located tumors; c) pre-resection analysis to identify pathological vascularization (arterialized veins, neo-angiogenesis and distorted regional venous outflow); d) analysis during and after tumor resection to identify the effects of an unintended/compelled venous sacrifice or of an unintentional arterial damage in real-time and to evaluate vessels patency and parenchymal perfusion after tumor removal; e) pre-myelotomy analysis during intramedullary tumors excision to highlight the posterior median sulcus.

In conclusion, ICG-VA with FLOW 800 analysis can be considered a useful method to provide reliable and real-time intraoperative information regarding the patient's unique vascular anatomy during microsurgical removal of CNS tumors. In particular, this technique can help the decision-making process concerning vascular management during neuro-oncological procedures, thus minimizing the risk of surgical complications.

Keywords: CNS tumors, FLOW 800, indocyanine green, neuro-oncological surgery, vascular pathophysiology, video-angiography

ABBREVIATIONS

AI	Arbitrary Intensity Unit
CNS	Central Nervous System
ICG-VA	Indocyanine Green Video-Angiography
ROI	Region of Interest

INTRODUCTION

The best strategy to handle blood vessels during a neurosurgical procedure, either purely neurovascular or even neuro-oncological, is sometimes still a matter of debate and often a univocal approach does not exist.

For instance, one of the main issues in brain vessels management concerns planned venous sacrifice, which can lead to devastating consequences but, at the same time, under certain circumstances, it may actually be desirable to enlarge surgical exposure of the target site or to increase the extent of resection in brain tumor surgery (Broggi et al. 2016; Jang et al. 2012; Kiya et al. 2001; Liebelt et al. 2017; Masuoka et al. 2009; Mathiesen et al. 2014; McNatt et al. 2011; Nakase et al. 2005; Schaller and Graf 2004; Sindou, Auque, and Jouanneau 2005; Sughrue et al. 2011; Suzuki et al. 2003). Furthermore, during neuro-oncological procedures, an unexpected arterial damage can occur: in this dramatic event, neurosurgeons would benefit from a fast real-time tool able to identify regions of parenchymal hypoperfusion in order to predict the effects of this inadvertent occlusion and, if

possible, to reverse the situation (Acerbi, Cavallo, and Ferroli 2016; Kamp et al. 2012; Takagi et al. 2007; Ye et al. 2013; Ng et al. 2013; Kobayashi et al. 2014; Uchino et al. 2014).

Microscope-integrated indocyanine green video-angiography (ICG-VA) has been employed in the last decades in vascular neurosurgery to better visualize cerebral vessels during aneurysm clipping, bypass surgery or arterovenous malformation resection (Hettige and Walsh 2010; Dashti et al. 2009; Ferroli et al. 2010; Ferroli, Acerbi, Tringali, et al. 2011; Ferroli, Nakaji, et al. 2011; Ferroli et al. 2008; Hao et al. 2013; De Oliveira et al. 2008; Hide et al. 2015; Imizu et al. 2008; Li et al. 2009; Raabe et al. 2003; Raabe, Beck, and Seifert 2005; Raabe et al. 2009). But, ICG-VA is also a useful adjunct in almost any kind of neurosurgical procedure, since it allows to study venous flow dynamics intraoperatively, both in pathological (Raabe et al. 2003; Schebesch et al. 2015) and in normal vessels (Takagi et al. 2012), and to predict the consequences of venous sacrifice during different surgical procedures (Uchino et al. 2014).

In 2011, our group was the first to propose that ICG-VA be used regularly to evaluate vascular anatomy in central nervous system (CNS) tumors and its role in shaping the surgical strategy (Ferroli, Acerbi, Tringali, et al. 2011): in particular, we analyzed venous flow dynamics, taking into account flow velocity, flow direction and uniform/nonuniform filling, and we proposed a classification with the aim of predicting the effects of venous sacrifice. Since then, very few reports on the application of ICG-VA in the context of CNS tumors resection have been published (D'Avella et al. 2013; Endo et al. 2013; Hojo et al. 2014; Hwang et al. 2010; Kamp et al. 2012; Takami et al. 2017; Takeshima et al. 2015).

Lately, the integration of the new FLOW 800 software (*FLOW 800 Software Analysis Tool, Pentero and Kinevo microscopes, Carl Zeiss Co., Oberkochen, Germany*) in the operating microscope, has allowed to perform, with the data derived from the standard ICG-VA, a post-processing semi-quantitative analysis of blood flow in the arteries, brain parenchyma (capillary phase) and veins, thus expanding our knowledge on the pathophysiology of the different vascular phases in neurosurgical procedures (Acerbi, Cavallo, and Ferroli 2016).

In this chapter, the authors present their extensive experience with ICG-VA and FLOW 800 analysis in a decennial retrospective series of patients undergoing surgical removal of cerebral and spinal tumors.

METHODS

Patients

In the period between January 2009 and December 2018, 2173 patients underwent surgical removal of a CNS tumor at the Department of Neurosurgery of the Fondazione IRCCS Istituto Neurologico Carlo Besta, Milano (Italy). All patients affected by CNS neoplasms and scheduled for surgical removal, gave their informed consent to the utilization of ICG-VA. In 204 out of 2173 (9.4%) cases, ICG-VA and FLOW 800 analysis were used at least once during surgical resection; all surgical videos and images were reviewed with the aim of categorizing the different specific applications of this technique. All data were obtained from an institutional, prospectively collected database, containing all patients'

demographic data, type of pathology, surgical management and clinical outcome. The present study has been approved by the Istituto Neurologico Carlo Besta Ethical Committee.

Surgical Management

All patients underwent standard preoperative evaluation including blood tests, general and neurological clinical assessment and preoperative MRI, including standard volumetric sequences (T1-weighted with intravenous contrast administration and T2-weighted) for brain and spinal tumors. The surgical approach was tailored to each individual patient according to the location and features of the tumor itself. All the patients were operated with the best available tools at the moment of the surgery, such as neuronavigation, fluorescent-guided techniques, contrast-enhanced ultrasound, neurophysiological and clinical monitoring according to the surgeon's preference. Tumors were histologically classified based on the 2007 WHO CNS tumors classification (Louis et al. 2007) before May 2016, and on the current WHO 2016 revision, after May 2016 (Louis et al. 2016).

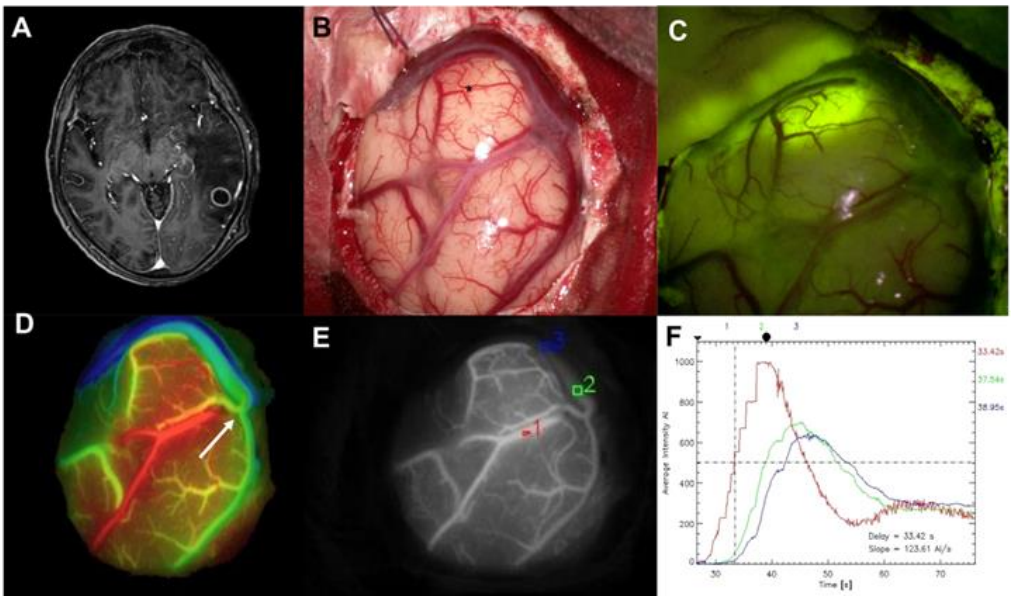

Figure 1. Example of ICG-VA and FLOW 800 analysis in a case of left temporal adenocarcinoma metastasis (A: T1-weighted axial with i.v. contrast administration pre-operative MRI). Under standard white-light microscopy view (B), the superficial projection of the tumor is identified by neuronavigation, as depicted by the asterisk; the same superficial region is explored under YELLOW 560 filter (C), specific for SF, to highlight the superficial component of the tumor as bright yellow-green. The FLOW 800 algorithm is able to reconstruct the map of delay time (D) based on the time to half-maximal fluorescence in the area exposed by the craniotomy and the map of fluorescence intensity (E) based on intensity detected by the camera and graded by the average AIs. In the map of delay time, arteries are represented in red, veins in blue, and the arterialized portion of the veins in green/yellow (arrow). The software also makes it possible to study different ROIs in the map of gray intensity, with automatic reconstruction of flow curves over time, as depicted in F. In the graph of this case, the arterial curve is shown in red; the venous curve in blue; and the arterialized part of the vein, with faster flow than normal veins, in green.

ICG Video-Angiography with FLOW 800 Analysis

The ICG-VA technique has already been extensively described (Ferroli, Nakaji, et al. 2011; Ferroli, Acerbi, Tringali, et al. 2011; Acerbi, Vetrano, Sattin, de Laurentis, et al. 2018; Acerbi, Vetrano, Sattin, Falco, et al. 2018); briefly, intravenous ICG administration with a standard dose of 12.5 mg in single bolus, was administered every time, upon surgeon's request, never exceeding the maximum daily dose of 5 mg/kg (Hope-Ross et al. 1994). Flow analysis was performed by means of the FLOW 800 software, integrated in the surgical microscope. The algorithm calculated fluorescence intensities in the exposed areas based on arbitrary intensity units (AIs) detected by the camera and it reconstructed maps of maximal fluorescence intensities and of delay times (time interval until 50% of maximum fluorescence). Specifically, the maps were showed as grey-scale of maximal fluorescence intensities, and as color-scale based on the time to half-maximal fluorescence, respectively. In addition, the course of fluorescence could be further analyzed in any area of the exposed brain, including parenchyma, by using freely definable regions of interest (ROIs) (Figure 1).

RESULTS

Patients and CNS Tumors

In the 204 cases included, there were 183 intracranial (51 meningiomas, 36 high-grade gliomas, 28 hemangioblastomas, 19 cerebral metastases, 7 chordomas, 5 tumors of the pineal region and 37 other neoplasms) and 21 spinal tumors (10 ependymomas, 5 hemangioblastomas, 3 pilocytic astrocytomas, 2 astrocytomas [WHO II] and 1 schwannoma). Additionally, in 126 cases, sodium fluorescein was used to better visualize and remove intra-axial tumors enhancing after contrast medium injection on the preoperative MRI: tumors were visualized using a fluorescein-guided technique (YELLOW 560 filter on the same surgical microscope), with the dose of 5 mg/kg, according to the recommendations of the FLUOCERTUM study, approved by our Institutional Ethics Committee in 2016 (Acerbi, Broggi, et al. 2018; Acerbi et al. 2017; Acerbi et al. 2016; Acerbi et al. 2015).

ICG-VA allowed us to optimally visualize arterial, capillary-parenchymal and venous phases of exposed vessels and brain regions, whenever it was considered necessary by the first surgeon. Even in the cases in which fluorescein was used, ICG-VA could provide useful information and depict vascular anatomy; no interactions due to the contemporary use of sodium fluorescein and ICG-VA, making tumor visualization difficult, were registered. In selected cases, ICG injections could be repeated, after a wash-out period of at least 10 minutes. No adverse reactions to ICG injections, even repeated ones, or to the combined use of fluorescein and ICG, were observed. Depending on the pathology, the following 5 main applications of ICG-VA and FLOW 800 in neuro-oncological surgery were employed (Table 1).

Table 1. Field of application and number of ICG-VA procedures, related to number of cases and tumor histological types

Application	No of ICG-VAs	No of Cases	Tumor Histological Type
Extradural	14	14	
		11	Meningiomas
		2	Cerebral Metastases
		1	Oligodendroglioma
Temporary Clipping Test	28	28	
		10	Meningiomas
		6	High-Grade Gliomas
		4	Cerebral Metastases
		4	Tumors of the Pineal Region
		2	Spinal Ependymomas
		1	Chordoma
		1	Pleomorphic Xanthoastrocytoma
Pre-resection	84	59	
		18	High-Grade Gliomas
		14	Meningiomas
		10	Cerebral Metastases
		8	Hemangioblastomas
		3	Chordomas
		6	Others
During and After Resection	123	87	
		31	Meningiomas
		22	High-Grade Gliomas
		17	Hemangioblastomas
		14	Cerebral Metastases
		3	Others
Pre-myelotomy	11	11	
		7	Ependymomas
		2	Pilocytic Astrocytomas
		2	Astrocytomas (WHO II)

EXTRADURAL ANALYSIS BEFORE DURAL OPENING

ICG video-angiography was used extradurally in order to identify the course of bridging cortical veins, before dural opening, in sovratentorial lesions, especially for parasagittal meningiomas involving the superior sagittal sinus but also for every kind of tumor in which an interhemispheric approach was deemed necessary (Vetrano, Ferroli, and Acerbi 2018).

ICG-VA showed an advantage also during posterior fossa surgery: in case of brainstem lesions, extradural analysis could prove the feasibility of sigmoid sinus sacrifice (that is, if the presence of retrograde flow could be documented) when performing a petro-occipital trans-sigmoid surgical route to approach deep-seated tumors. Finally, for meningiomas involving the torcular/transverse sinus, ICG-VA showed both the position and the patency of afferent and efferent sinuses before dural opening (Figure 2).

In this field of application, a specific advantage related to the use of FLOW 800 analysis was not found, since all the information could be retrieved with maps of grey intensity as in classic ICG-VA.

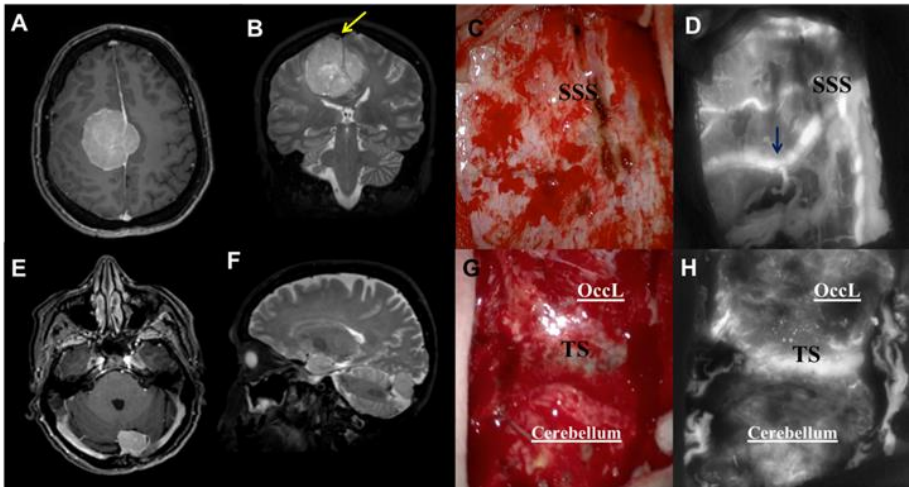

Figure 2. Example of extradural analysis in a case of a left parasagittal meningioma (preoperative MRI, axial T1-weighted post i.v. contrast administration in A and coronal T2-weighted in B) involving the superior sagittal sinus (SSS) in which, with the aid of ICG-VA (D), it was possible to identify the sinus and a patent cortical vein (arrow) draining into the SSS, that was not clearly identifiable under white light (C). A case of a right side infra- and supra-tentorial meningioma involving the torcular (preoperative MRI, axial T1-weighted post i.v. contrast administration in E and sagittal T2-weighted in F), approached in semisitting position, in which the extradural examination (white light in G, ICG-VA in H) revealed the patent transverse sinus (TS) below the occipital lobe (OccL) and above the cerebellar parenchyma.

MANAGEMENT OF VENOUS SACRIFICE BY ICG TEMPORARY CLIPPING TEST

ICG temporary clipping test was developed by our group much like a provocative occlusion test for those occasions in which planned venous sacrifice was considered necessary to create/enlarge a surgical corridor and to maximize the extent of resection (Ferroli, Acerbi, Tringali, et al. 2011; Ferroli, Nakaji, et al. 2011).

Briefly, the test was performed as follows: after a baseline ICG videoangiogram was obtained, a temporary clip (or more simply, the closed tips of a bipolar forcep) was placed on the vein to be tested and flow direction and dynamics were again analyzed by ICG video-angiography; flow stagnation was considered to be a sign of lack of collateral circulation whereas flow reversal was interpreted as a sign of the presence of collateral circulation, suggesting compliance to sacrifice.

A positive temporary clipping test, indicating venous sacrifice feasibility, was found to be correlated with a baseline ICG-VA pattern of slow-draining veins (slow and nonuniform filling, with multiple tributaries and one large collector, and a time to half-maximal fluorescence greater than 5 seconds of the arterial phase), whereas fast-draining veins (fast and homogenous filling and a time to half-maximal fluorescence that was within 5 seconds of

the arterial phase) usually exhibited stagnation when clipped, suggesting their non-compliance to sacrifice due to the assumed absence of collateral venous circulation (Figure 3). Although we reported this association, we did not systematically study the effects of venous sacrifice on the basis of ICG-VA assessment of venous flow characteristics; furthermore, an arterovenous 5-second gap mark as a criterion to distinguish the 2 groups was arbitraly chosen.

Nevertheless, since it is safe and easy to use, an ICG temporary clipping test is performed in every case in which the authors want to examine the effect of venous sacrifice and to determine its tolerability. In particular, the test is routinely performed on different bridging veins, draining to the superior sagittal, sphenoparietal, and superior petrosal sinuses, to the tentorium, and also on posterior median sulcus veins in the spinal cord.

The use of FLOW 800 analysis in association to ICG-VA helps to evaluate venous flow and flow reversal during the temporary clipping, especially in borderline cases.

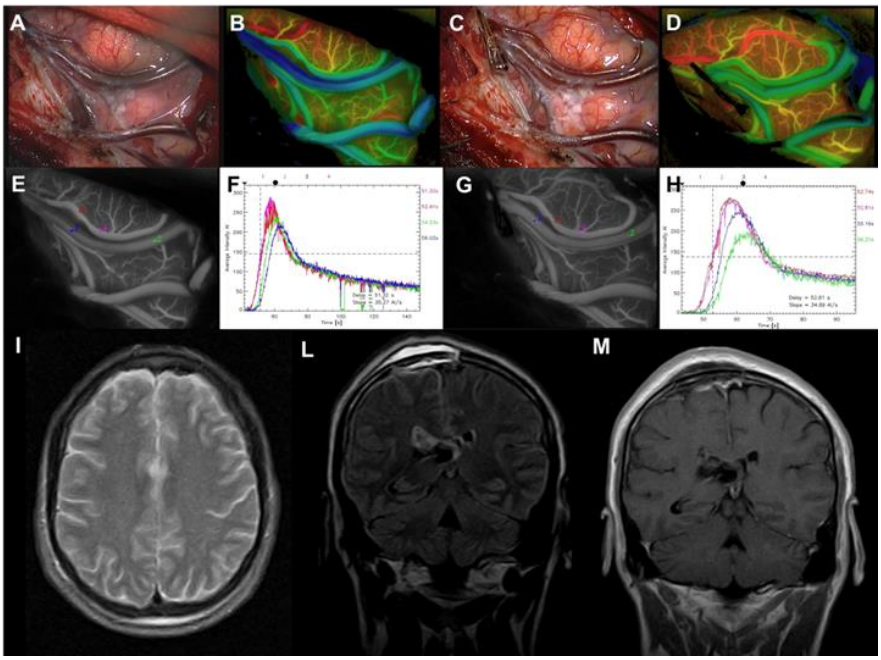

Figure 3. Example of a clipping test to evaluate the possibility to sacrifice a group of bridging veins to the superior sagittal sinus (SSS) during a right transcallosal approach for removal of an intraventricular lesion (subependymal giant cell astrocytoma). Under microscopic view (A), two main bridging vein complexes draining into the SSS are clearly identified. After intravenous administration of ICG, the FLOW 800 software view shows the temporal fluorescence projection in the exposed vessels under physiological conditions (B). ROIs are identified on a classic ICG-VA map: the red and violet ROIs are positioned on the fast vein, while the green and blue ROIs are on the slow vein (E). The graph clearly confirms the difference in flow speed between a fast vein and a slow vein, both of them with an anterograde flow (F). The clipping test is shown in microscopic view (C). The FLOW 800 software identifies the changes in temporal fluorescence projection in the exposed vessels during the clipping test, demonstrating that the fast vein is now draining through a common chamber into the slow one (D). The same ROIs are positioned as in E, during the clipping test (G). The graph shows that the flow speed in the two veins is now very similar, with an inversion of the flow (retrograde) in the previous slow vein (H). Postoperative MRI, axial T2-weighted (I), coronal FLAIR sequence (L) and coronal T1-weighted (M), excluding ischemia, edema or hemorrhage in the territory drained by the clipped vein complex.

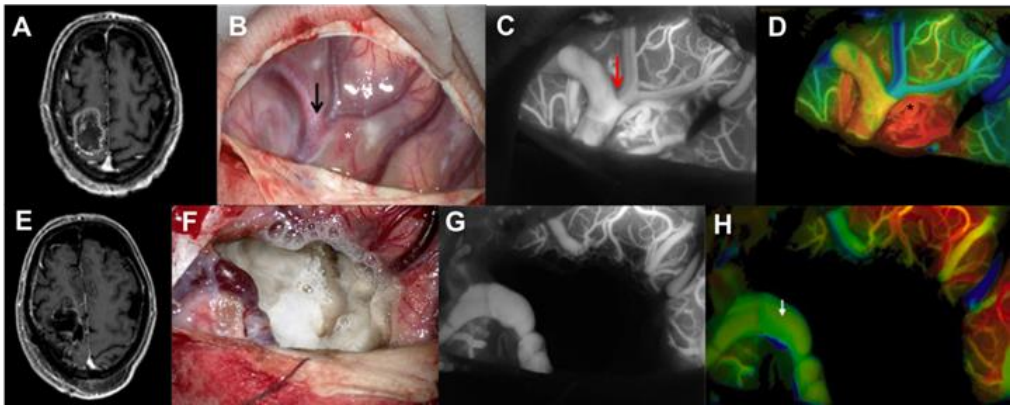

Figure 4. Exemplificative use of ICG-VA during the resection of a right rolandic glioblastoma. A: Preoperative T1-weighted with i.v. contrast administration MRI. B: After dural opening, the standard white-light microscopic view shows the superficial part of the tumor with a pathological vessel (asterisk), and an arterialized red flow (arrow) in the context of a cortical vein draining toward the superior sagittal sinus. C: The classic ICG-VA confirms the point where the fistula and the large cortical vein meet (arrow) and other pathological vessels in the tumoral area. D: The map of delay time after FLOW 800 analysis better depicts the arterialized flow into the vein (in red-yellow), compared to normal venous flow in blue in the more proximal venous compartment; in addition, it clearly identifies the superficial component of the glioblastoma as a red nodule (asterisk). E–H: ICG-VA and FLOW 800 analysis are repeated after tumor removal (F), showing the flow normalization in the cortical vein and normal perfusion in the brain parenchyma close to the surgical cavity, both on the map of gray intensity (G) and on the delay time one (H). In E, a postoperative T1-weighted with i.v. contrast administration MRI scan confirms total tumor resection.

PRE-RESECTION ANALYSIS

ICG-VA was often performed before tumor resection. For parenchymal tumors abutting the brain/spinal cord surface, a superficial vascular analysis was used to demonstrate areas of pathological neo-angiogenesis within the tumor, or the presence of arterovenous fistulas with vein flow disturbances especially in high-grade gliomas or in hemangioblastomas. Moreover, in this specific case, FLOW 800 analysis allowed to better discriminate the margins of the tumor based on maps of delay time and on the analysis of flow curves showing pathological neo-angiogenesis and vessels or the presence of arterovenous fistulae (Figure 4). In the oncological cases undergoing fluorescein-guided removal (high-grade gliomas, metastases and pylocitic astrocytomas) (Cavallo et al. 2018), the neo-angiogenesis areas shown on maps of delay times, corresponded to the areas highlighted by fluorescein (Figure 1C).

In few cases, ICG video-angiography showed brain congestion with a delayed flow, particularly in the parenchymal phase, due to tumor mass effect. The use of FLOW 800 analysis, even if not essential to show this finding, allowed to identify a slower time to peak in post-processing analysis due to cerebral congestion; if repeated post-resection, the same analysis could show a steeper flow curve, indicating an improvement of cortical flow.

ANALYSIS DURING AND AFTER TUMOR RESECTION

ICG-VA and FLOW 800 analysis performed during and after tumor resection currently represent the most frequent indication.

While in the other cases, we predominatly addressed the venous system, in this field of application, arterial evaluation was the main focus, especially when an inadvertent injury occured.

The authors often perform ICG video-angiography to evaluate the patency of arteries directly encased by skull base tumors, such as meningiomas, cranial nerve schwannomas, craniopharyngiomas or chordomas, especially for recurrent lesions. In this context, damage of an artery, likely one of the Willis polygon, is a dramatic situation which the neurosurgeon has to manage within the shortest possile time and with the best available technologies. In case of arterial fissuration, after bleeding stabilization and/or arterial direct reparir, ICG video-angiography was routinely performed: standard ICG-VA survey was useful to depict flow disturbances whereas FLOW 800 post hoc analysis resulted fundamental in order to visualize cerebral regions of hypoperfusion and to evaluate the delay time in arterial perfusion. In selected cases, a rescue extracranial-intracranial (superficial temporal artery to middle cerebral artery) end to side bypass was performed to reverse the situation and ICG-VA with FLOW 800 analysis was repeated after the anastomosis showing bypass patency with no ischemic insults in brain cortical areas exposed by the craniotomy.

Regarding subcortical lesions, predominantly gliomas and metastases, in case of arterial injury, ICG-VA and FLOW 800 analysis helped the surgeon to identify brain regions vascularized by the specific damaged branch: in case of an eloquent artery, i.e., vessels that feeds brain eloquent parenchyma, such as the rolandic branch of the middle cerebral artery, a rescue intracranial-intracranial end to side or side to side or end to end bypass, using another cortical branch as donor artery, was executed, in order to revert the hypoperfusion, avoiding postoperative ischemic complications (Acerbi, Cavallo, and Ferroli 2016). Also in this context, ICG-VA with FLOW 800 analysis was repeated after the anastomosis to assess bypass patency (Figure 5).

Within the series, there was also a case of a left temporal glioblastoma with an associated unruptured posterior communicating artery aneurysm. In this case, ICG-VA was used to characterize the aneurysm and to check arterial patency, both posterior communicating and choroidal, after its clipping (Acerbi et al. 2016).

On the other hand, the identification, during tumor removal, of a thrombosed vein encased by the lesion, as detectable by ICG-VA, allowed the surgeon to remove it, preserving the point of reverse flow to a collateral vessel, which is identified with the video-angiographic study (Figure 6).

In several cases, which were also studied with a temporary clipping test or a pre-resection analysis, ICG-VA with FLOW 800 analysis was performed post-tumor resection to directly assess brain or spinal cord perfusion, even when arterial manipulation was not performed during surgical maneuvers. The same ICG video-angiographic study and, more precisely, the use of maps of delay times and flow curve analysis based on FLOW 800 software allowed to evaluate the patency and flow characteristics of the veins manipulated during surgical resection and to assess the effect of unintended or necessary venous sacrifice.

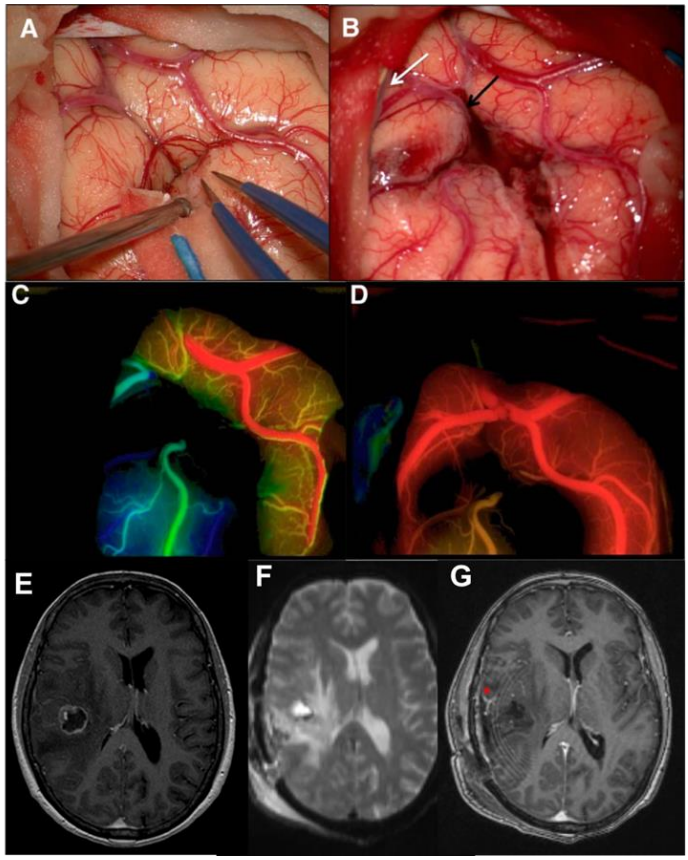

Figure 5. A: Intraoperative image under white-light microscopic magnification of the brain parenchyma during a trans-sulcus approach to reach a temporo-parietal subcortical metastasis (preoperative T1-weighted axial with i.v. contrast administration MRI is shown in E). B: Same area at the end of tumor removal after coagulation and section of the encased middle cerebral artery branch (black arrow). No difference in macroscopic appearance of the brain surface can be highlighted. The subcortical strip electrode toward the rolandic area is shown by a white arrow. C: Color map of delay time of ICG-VA with FLOW 800 software suggests a reduced blood flow in the rolandic area vascularized by the coagulated middle cerebral artery branch. D: Color map of delay time of ICG-VA with FLOW 800 software after intracranial-intracranial bypass shows the revascularization of the rolandic area. Postoperative MRI shows no ischemic region (axial DWI sequence in F) and the patency of the bypass (asterisk in T1-weighted axial with i.v. contrast administration MRI in G).

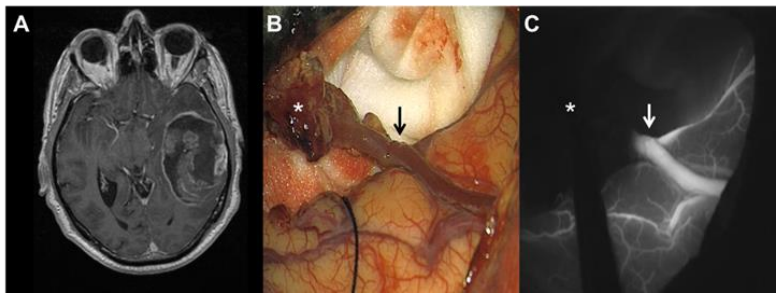

Figure 6. B: After resection of a left temporal glioblastoma (preoperative T1-weighted axial with i.v. contrast administration MRI in A), the left vein of Labbé is found to be encased by residual neoplastic tissues (asterisk). C: ICG-VA shows that the proximal segment of the vein closer to the transverse sinus is already thrombosed (asterisk), with a collateral circulation that developed in the distal segment of the vein, draining toward the sylvian venous system (black arrow in B, white arrow in C). Therefore, it was possible to sacrifice the vein of Labbé without clinical consequences, achieving a gross total resection.

In cases in which the pre-resection analysis documented the presence of an arterovenous fistula, ICG video-angiography with FLOW 800 analysis was performed postoperatively to evaluate involved veins, usually confirming the normalization of venous flow after tumor removal (Figure 4F-H).

PRE-MYELOTOMY ANALYSIS

ICG-VA was used in selected cases of spinal cord lesions not abutting the spinal cord surface to highlight the posterior median sulcus based on the position of posterior veins exiting the sulcus itself (Figure 7). During pre-myelotomy analysis, the use of FLOW 800 with maps of delay time did not represent a specific advantage.

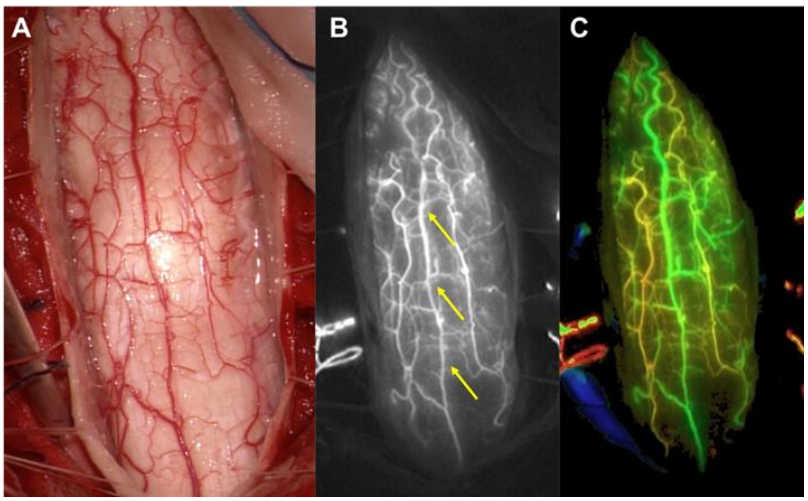

Figure 7. Intramedullary C2–C6 ependymoma not abutting the spinal cord surface: the spinal cord appears edematous and the median sulcus is not easily recognizable (A). The ICG-VA study (B) highlights a posterior vein (arrows) exiting the median sulcus, improving its identification. The map of delay times is shown in a corresponding image (C).

DISCUSSION

Indocyanine green video-angiography is an intraoperative technique designed to highlight superficial vessels during neurosurgical procedures; the FLOW 800 analysis software (*Carl Zeiss Meditec*) has further expanded the usefulness of ICG-VA, especially in neuro-oncological surgery.

In the last 10 years the authors gained a wide experience with these techniques, applying them to various fields of neurosurgery (Acerbi, Vetrano, Sattin, de Laurentis, et al. 2018; Acerbi, Vetrano, Sattin, Falco, et al. 2018; Ferroli, Acerbi, Tringali, et al. 2011). In particular, from the series here presented, five possible applications of ICG-VA and FLOW 800 during surgical removal of CNS tumors have emerged: a) extradural analysis to explore sinuses patency and bridging veins anatomy before dural opening; b) ICG temporary clipping test to

verify the feasibility of venous sacrifice in deeply located tumors; c) pre-resection analysis to identify pathological vascularization (arterialized veins, neo-angiogenesis and distorted regional venous outflow); d) analysis during and after tumor resection to identify the effects of an unintended/compelled venous sacrifice or of an unintentional arterial damage in real-time and to evaluate vessels patency and parenchymal perfusion after tumor removal; e) pre-myelotomy analysis during intramedullary tumors excision to highlight the posterior median sulcus.

In 2011, our group was the first to propose the use of classic ICG-VA during the resection of CNS tumors, based on a retrospective series of patients treated between 2006–2008 (Ferroli, Acerbi, Tringali, et al. 2011). That study focused mainly on two aspects: the evaluation of pre-resection video-angiography, which provided useful information on the tumoral circulation and the pathology-induced alterations in surrounding brain circulation, and post-resection examination, which allowed for a quick, real-time check of the patency of those vessels that were closely related to the tumor mass and that the surgeon aimed to preserve. However, at that time, the FLOW 800 software was not available yet, while, nowadays, a semiquantitative analysis of blood flow in the brain area exposed by the craniotomy can be performed. In particular, the algorithm integrated in the surgical microscope is able to reconstruct maps of gray intensity based on the average AIs of infrared fluorescence detected by the microscope camera, and maps of delay time based on the time needed to reach 50% of the maximal fluorescence intensity. In addition, it is possible to study the curves of fluorescence detected by the camera over the time of ICG-VA registration for multiple ROIs.

The first authors to explore the use of microscope-integrated quantitative analysis of ICG-VA for blood flow assessment were Kamp et al. (Kamp et al. 2012), who studied 30 patients with neuro-vascular pathologies, and were the first to hypothesize the possibility of using the different parameters derived from FLOW 800 analysis in clinical applications. In particular they showed that the maps of delay time could be of great value in giving an immediate representation of blood flow perturbation in cortical areas, either as an effect of the disease itself, or due to iatrogenic damage to arteries manipulated in the surgical approach.

Despite several applications of ICG-VA have been described so far (Dashti et al. 2009; De Oliveira et al. 2008; Ferroli et al. 2008; Imizu et al. 2008; Killory et al. 2009; Li et al. 2009; Woitzik et al. 2009; Xu et al. 2010), it is remarkable to note the paucity of articles reporting its use along with quantitative analysis to explore cerebral perfusion in the intraoperative setting (Ye et al. 2013; Uchino et al. 2014). Even less interest could be found in the context of surgery for brain tumors, where only cerebral and spinal hemangioblastomas have been studied (Hojo et al. 2014; Takeshima et al. 2015; Benedetto, Aquila, and Vannozzi 2013).

In 2009, when we acquired the technology to use the FLOW 800 algorithm for flow analysis, we started to sistematically use ICG-VA with the new software, not only in vascular cases, but also during CNS tumor removal. Our population consisted of a heterogeneous group of cerebral and spinal tumors, represented mainly by meningiomas and high-grade gliomas. The most frequent application was an analysis of the arterial and venous patency, and brain perfusion, during or after tumor resection. In most cases, this evaluation confirmed arterial and venous patency and the absence of local hypoperfusion, thus reassuring us on the low risk of postoperative complications related to vessel manipulation. On the contrary, in few situations, the postoperative analysis showed local hypoperfusion directly related to

vessels manipulation. The intraoperative recognition of this complication allowed the surgeon to perform compensatory surgical maneuvers to immediately revert the local hypoperfusion and reduce the risk of postoperative complications (Acerbi, Cavallo, and Ferroli 2016; Ng et al. 2013; Kobayashi et al. 2014). Even though this task could be performed also with classic ICG-VA, as already reported in our previous experience and in a similar study by other authors (Ferroli, Acerbi, Albanese, et al. 2011; Kim, Cho, Chang, et al. 2011), the analysis of blood flow by FLOW 800 software allowed to better interpret brain perfusion, particularly with maps of delay times, as reported also in the vascular field (Kamp et al. 2012).

The preoperative analysis was used to identify both specific tumor-related pathophysiologic vascular changes and non-specific mass-effect changes. This was particularly important in glioblastomas and hemangioblastomas, where the superficial vascular pattern and the presence of arterovenous fistulae could be clearly shown. When dealing with arterialized veins, we tried to selectively sacrifice only arterovenous fistulas directly causing venous arterialization, always checking at the end of the procedure the normalization of venous flow.

The possibility to identify feeding arteries and the tumor nodule in hemangioblastomas was reported also by Hojo et al. in 2014 (Hojo et al. 2014), but mainly with classic ICG-VA. However, we believe that also for this application the use of semiquantitative flow analysis can improve and simplify the interpretation of videoangiographic data. Furthermore, preoperative analysis and long recording time allowed to concentrate the attention on the venous flow and, when needed, to perform a temporary clipping test to decide whether or not a vein could be sacrificed to enlarge the surgical corridor and/or completely resect the tumor, as shown by our group in a preliminary experience in 8 cases (Ferroli, Nakaji, et al. 2011). As underlined by Morcos and Munich in 2018 (Morcos and Munich 2018), the temporary clipping test can be thought of as a "provocative" test – the venous equivalent of the "balloon test occlusion" – to determine if a given vein can be sacrificed.

In our experience, although in the minority of cases, we also dealt with tumors approached with the patient in a semisitting position. Also in these cases, we could recognize the different flow patterns of draining veins (predominanlty supracerebellar veins) and temporary clipping test could be performed as in the supratentorial district. Theoretically, there should have been a difference in flow characteristics for veins exposed in the posterior fossa when the patient is in the semisitting position, due to the position of the head in relation to the heart and the reduced central venous pressure. Nonetheless, in all patients in whom surgery was performed in this position, we tried to maintain a positive central venous pressure in order to reduce the risk of venous air embolism; thus, this could be one of the reasons why there was no clear difference in venous flow characteristics. We never performed an arterial clipping test for arterial sacrifice, as proposed by Kim and Cohen-Gadol in 2013 (Kim and Cohen-Gadol 2013), but we believe that this application is worth expanding in the future.

An innovation compared to previous experiences was also the utilization of ICG video-angiography in spinal tumors as a way to help in posterior median sulcus identification when the tumor was not abutting the spinal cord surface, or when, due to edema and congestion, the normal anatomy was distorted and the sulcus was difficult to find with white light illumination.

Finally, we were also able to show, in very selected cases, that an extradural analysis was feasible and it allowed the identification of dural sinuses and cortical veins, thus helping in

dural opening, as already shown by Nussbaum et al. (Nussbaum, Defillo, and Nussbaum 2012).

ICG-VA presents some technical limitations, indipendently from which field of neurosurgery it is applied to (vascular, oncological, spinal, etcetera). Most authors agree that the major drawback of ICG-VA is that it captures only what is visible within the field of the surgical microscope (Acerbi et al. 2019) and, as a consequence, it requires that the vessels must be cleared of any overlying tissue, such as blood clots or cottonoids (Killory et al. 2009; Hänggi, Etminan, and Steiger 2010); in addition, also calcifications within the vessels could impede a correct evaluation of blood flow. The meticulous and sometimes difficult dissection of tumor-related vessels, which is a precondition to use ICG videoangiography, can be a time-consuming process.

Secondly, experience demonstrated that ICG-VA usefulness is decreased in deep-seated lesions that must be approached through a long, narrow surgical corridor. In this setting, the signal and illumination can be low and the limited depth of field can make interpretation difficult (Killory et al. 2009; Hänggi, Etminan, and Steiger 2010).

Furthermore, the classic ICG method is purely qualitative and its interpretation is based on the judgement of the operating neurosurgeon without any objective measures. Only with the introduction of the software FLOW 800, ICG video-angiography became a reliable method to evaluate vascular and regional cerebral cortical blood flow during surgical procedures (Kamp et al. 2012); however, again, it requires more time to be performed and interpreted (in our series a mean of 7.9 minutes longer than classic ICG total time).

Finally, even though both classic ICG-VA and FLOW 800 software, do not have a steep learning curve, some training is still necessary to acquire the skills to use them and to interpret the results; in neuro-oncological surgery, we suggest starting with superfical analysis on veins flow in order to familiarize oneself with the technique and thereafter proceed to the clipping tests and to the intra-resection and post-resection evaluation of arterial flow.

Of course, we are aware of the fact that, in this chapter, we are presenting a retrospective evaluation of the different applications of ICG video-angiography with FLOW 800 analysis, based on the specific experience of our group. In addition, we did not perform any comparison with other techniques of blood flow monitoring, thus we could not provide any information about sensitivity and specificity.

Nonetheless, we believe that the results of this work underline the concept that surgery of brain tumors is also a surgery of brain vessels, and that understanding the pathophysiologic changes of brain circulation, due to the tumor presence and sometimes to the surgical manipulation, as derived by flow analysis provided by ICG video-angiography with FLOW 800 analysis, can be associated with better surgical results in selected cases.

CONCLUSION

Complete and real-time data on vascular pathophysiology represent a key point in modern neurosurgery that should be undoubtedly evaluated not only in neurovascular cases. We found ICG-VA with FLOW 800 analysis to be a useful technique to monitor blood flow in the exposed vessels and parenchyma during microsurgical removal of CNS tumors in selected cases and to guide the decision-making process regarding planned venous sacrifice or

unintended arterial damage, with a possible impact on the reduction of surgical complications. In particular, a pre-resection analysis provides useful information about pathophysiological changes of brain vasculature related to the tumor and individuates helpful landmarks for the surgical approach, while a post-resection analysis may help to prevent potential complications associated with the resection (such as local hypoperfusion or venous infarction). Future systematic studies comparing also other methodologies of blood flow monitoring are warranted to confirm all the potential advantages of this technique in the surgical management of CNS tumors.

REFERENCES

Acerbi, Francesco, Claudio Cavallo, Karl-Michael Schebesch, Mehmet Osman Akçakaya, Camilla de Laurentis, Mustafa Kemal Hamamcioglu, Morgan Broggi, et al. 2017. "Fluorescein-Guided Resection of Intramedullary Spinal Cord Tumors: Results from a Preliminary, Multicentric, Retrospective Study." *World Neurosurgery*. https://doi.org/10.1016/j.wneu.2017.09.061.

Acerbi, Francesco, Claudio Cavallo, and Paolo Ferroli. 2016. "Letter: Intraoperative Assessment of Blood Flow With Quantitative Indocyanine Green Videoangiography: The Role for Diagnosis of Regional Cerebral Hypoperfusion." *Neurosurgery* 78 (2): E310-2. https://doi.org/10.1227/NEU.0000000000001053.

Acerbi, Francesco, Francesco Prada, Ignazio G. Vetrano, Jacopo Falco, Giuseppe Faragò, Paolo Ferroli, and Francesco DiMeco. 2019. "Indocyanine Green and Contrast-Enhanced Ultrasound Videoangiography: A Synergistic Approach for Real-Time Verification of Distal Revascularization and Aneurysm Occlusion in a Complex Distal Middle Cerebral Artery Aneurysm." *World Neurosurgery*. https://doi.org/10.1016/j.wneu.2019.01.241.

Acerbi, Francesco, Francesco Restelli, Morgan Broggi, Marco Schiariti, and Paolo Ferroli. 2016. "Feasibility of Simultaneous Sodium Fluorescein and Indocyanine Green Injection in Neurosurgical Procedures." *Clinical Neurology and Neurosurgery*. https://doi.org/10.1016/j.clineuro.2016.05.003.

Acerbi, Francesco, Ignazio G Vetrano, Tommaso Sattin, Camilla de Laurentis, Lorenzo Bosio, Zefferino Rossini, Morgan Broggi, Marco Schiariti, and Paolo Ferroli. 2018. "The Role of Indocyanine Green Videoangiography with FLOW 800 Analysis for the Surgical Management of Central Nervous System Tumors: An Update." *Neurosurgical Focus*. https://doi.org/10.3171/2018.3.FOCUS1862.

Acerbi, Francesco, Ignazio G. Vetrano, Tommaso Sattin, Jacopo Falco, Camilla de Laurentis, Costanza M. Zattra, Lorenzo Bosio, et al. 2018. "Use of ICG Videoangiography and FLOW 800 Analysis to Identify the Patient-Specific Venous Circulation and Predict the Effect of Venous Sacrifice: A Retrospective Study of 172 Patients." *Neurosurgical Focus* 45 (1): E7. https://doi.org/10.3171/2018.4.FOCUS18120.

Acerbi, Francesco, Morgan Broggi, Giovanni Broggi, and Paolo Ferroli. 2015. "What Is the Best Timing for Fluorescein Injection during Surgical Removal of High-Grade Gliomas?" *Acta Neurochirurgica*. https://doi.org/10.1007/s00701-015-2455-z.

Acerbi, Francesco, Morgan Broggi, Karl-Michael Schebesch, Julius Höhne, Claudio Cavallo, Camilla De Laurentis, Marica Eoli, et al. 2018. "Fluorescein-Guided Surgery for

Resection of High-Grade Gliomas: A Multicentric Prospective Phase II Study (FLUOGLIO)." *Clinical Cancer Research* 24 (1): 52–61. https://doi.org/10.1158/1078-0432.CCR-17-1184.

Benedetto, Nicola, Filippo Aquila, and Riccardo Vannozzi. 2013. "Use of Near-Infrared Indocyanine Videoangiography and Flow 800 in the Resectioning of a Spinal Cord Haemangioblastoma." *British Journal of Neurosurgery*. https://doi.org/10.3109/02688697.2013.798863.

Broggi, Morgan, Francesco Restelli, Francesco Acerbi, and Paolo Ferroli. 2016. "Postoperative Acute Cerebellar Swelling after Pineal Surgery: Pathogenesis and Treatment." *Acta Neurochirurgica*. https://doi.org/10.1007/s00701-015-2622-2.

Cavallo, Claudio, Camilla De Laurentis, Ignazio G Vetrano, Jacopo Falco, Morgan Broggi, Marco Schiariti, Paolo Ferroli, and Francesco Acerbi. 2018. "The Utilization of Fluorescein in Brain Tumor Surgery: A Systematic Review." *Journal of Neurosurgical Sciences*, May. https://doi.org/10.23736/S0390-5616.18.04480-6.

D'Avella, Elena, Francesco Volpin, Renzo Manara, Renato Scienza, and Alessandro Della Puppa. 2013. "Indocyanine Green Videoangiography (ICGV)-Guided Surgery of Parasagittal Meningiomas Occluding the Superior Sagittal Sinus (SSS)." *Acta Neurochirurgica*. https://doi.org/10.1007/s00701-012-1617-5.

Dashti, Reza, Aki Laakso, Mika Niemelä, Matti Porras, and Juha Hernesniemi. 2009. "Microscope-Integrated near-Infrared Indocyanine Green Videoangiography during Surgery of Intracranial Aneurysms: The Helsinki Experience." *Surgical Neurology*. https://doi.org/10.1016/j.surneu.2009.01.027.

Endo, Toshiki, Misaki Aizawa-Kohama, Kenichi Nagamatsu, Kensuke Murakami, Akira Takahashi, and Teiji Tominaga. 2013. "Use of Microscope-Integrated near-Infrared Indocyanine Green Videoangiography in the Surgical Treatment of Intramedullary Cavernous Malformations: Report of 8 Cases." *Journal of Neurosurgery: Spine*. https://doi.org/10.3171/2013.1.spine12482.

Ferroli, Paolo, Francesco Acerbi, Erminia Albanese, Giovanni Tringali, Morgan Broggi, Angelo Franzini, and Giovanni Broggi. 2011. "Application of Intraoperative Indocyanine Green Angiography for CNS Tumors: Results on the First 100 Cases." In *Acta Neurochirurgica. Supplement*. https://doi.org/10.1007/978-3-211-99651-5_40.

Ferroli, Paolo, Francesco Acerbi, Giovanni Tringali, Erminia Albanese, Morgan Broggi, Angelo Franzini, and Giovanni Broggi. 2011. "Venous Sacrifice in Neurosurgery: New Insights from Venous Indocyanine Green Videoangiography." *Journal of Neurosurgery*. https://doi.org/10.3171/2011.3.JNS10620.

Ferroli, Paolo, Francesco Acerbi, Morgan Broggi, and Giovanni Broggi. 2010. "Arteriovenous Micromalformation of the Trigeminal Root: Intraoperative Diagnosis with Indocyanine Green Videoangiography: Case Report." *Neurosurgery*. https://doi.org/10.1227/01.NEU.0000381769.15291.4C.

Ferroli, Paolo, Francesco Acerbi, Morgan Broggi, and Giovanni Broggi. 2013. "The Role of Indocyanine Green Videoangiography (ICGV) in Surgery of Parasagittal Meningiomas." *Acta Neurochirurgica* 155 (6): 1035. https://doi.org/10.1007/s00701-013-1722-0.

Ferroli, Paolo, Giovanni Tringali, Erminia Albanese, and Giovanni Broggi. 2008. "Developmental Venous Anomaly of Petrous Veins: Intraoperative Findings and Indocyanine Green Video Angiographic Study." *Neurosurgery*. https://doi.org/10.1227/01.neu.0000326029.47090.16 [doi]\r00006123-200805002-00022 [pii].

Ferroli, Paolo, Peter Nakaji, Francesco Acerbi, Erminia Albanese, and Giovanni Broggi. 2011. "Indocyanine Green (ICG) Temporary Clipping Test to Assess Collateral Circulation before Venous Sacrifice." *World Neurosurgery*. https://doi.org/10.1016/j.wneu.2010.09.011.

Hänggi, Daniel, Nima Etminan, and Hans Jakob Steiger. 2010. "The Impact of Microscope-Integrated Intraoperative near-Infrared Indocyanine Green Videoangiography on Surgery of Arteriovenous Malformations and Dural Arteriovenous Fistulae." *Neurosurgery*. https://doi.org/10.1227/NEU.0b013e3181eb5049.

Hao, Shuyu, Dezhi Li, Guangshuo Ma, Jun Yang, and Guihuai Wang. 2013. "Application of Intraoperative Indocyanine Green Videoangiography for Resection of Spinal Cord Hemangioblastoma: Advantages and Limitations." *Journal of Clinical Neuroscience*. https://doi.org/10.1016/j.jocn.2012.12.008.

Hettige, Samantha, and Daniel Walsh. 2010. "Indocyanine Green Video-Angiography as an Aid to Surgical Treatment of Spinal Dural Arteriovenous Fistulae." *Acta Neurochirurgica*. https://doi.org/10.1007/s00701-009-0445-8.

Hide, Takuichiro, Shigetoshi Yano, Naoki Shinojima, and Jun-ichi Kuratsu. 2015. "Usefulness of the Indocyanine Green Fluorescence Endoscope in Endonasal Transsphenoidal Surgery." *Journal of Neurosurgery*. https://doi.org/10.3171/2014.9.jns14599.

Hojo, Masato, Yoshiki Arakawa, Takeshi Funaki, Kazumichi Yoshida, Takayuki Kikuchi, Yasushi Takagi, Yoshio Araki, et al. 2014. "Usefulness of Tumor Blood Flow Imaging by Intraoperative Indocyanine Green Videoangiography in Hemangioblastoma Surgery." *World Neurosurgery*. https://doi.org/10.1016/j.wneu.2013.02.009.

Hope-Ross, Monique, Lawrence A. Yannuzzi, Evangelos S. Gragoudas, David R. Guyer, Jason S. Slakter, John A. Sorenson, Sara Krupsky, Dennis A. Orlock, and Carmen A. Puliafito. 1994. "Adverse Reactions Due to Indocyanine Green." *Ophthalmology*. https://doi.org/10.1016/S0161-6420(94)31303-0.

Hwang, Steven W., Adel M. Malek, Robert Schapiro, and Julian K. Wu. 2010. "Intraoperative Use of Indocyanine Green Fluorescence Videography for Resection of a Spinal Cord Hemangioblastoma." *Neurosurgery*. https://doi.org/10.1227/01.NEU.0000383876.72704.7B.

Imizu, S., Yoko Kato, A. Sangli, D. Oguri, and H. Sano. 2008. "Assessment of Incomplete Clipping of Aneurysms Intraoperatively by a Near-Infrared Indocyanine Green-Video Angiography (Niicg-Va) Integrated Microscope." *Minimally Invasive Neurosurgery*. https://doi.org/10.1055/s-2008-1080916.

Jang, Woo Youl, Shin Jung, Tae Young Jung, Kyung Sub Moon, and In Young Kim. 2012. "Predictive Factors Related to Symptomatic Venous Infarction after Meningioma Surgery." *British Journal of Neurosurgery*. https://doi.org/10.3109/02688697.2012.690914.

Kamp, Marcel A., Philipp Slotty, Bernd Turowski, Nima Etminan, Hans-Jakob Steiger, Daniel Hänggi, and Walter Stummer. 2012. "Microscope-Integrated Quantitative Analysis of Intraoperative Indocyanine Green Fluorescence Angiography for Blood Flow Assessment." *Operative Neurosurgery*. https://doi.org/10.1227/neu.0b013e31822f7d7c.

Killory, Brendan D., Peter Nakaji, L. Fernando Gonzales, Francisco A. Ponce, Scott D. Wait, and Robert F. Spetzler. 2009. "Prospective Evaluation of Surgical Microscope-Integrated Intraoperative near-Infrared Indocyanine Green Angiography during Cerebral

Arteriovenous Malformation Surgery." *Neurosurgery*. https://doi.org/10.1227/01.NEU.0000346649.48114.3A.

Kim, Daniel L., and Aaron A. Cohen-Gadol. 2013. "Indocyanine-Green Videoangiogram to Assess Collateral Circulation before Arterial Sacrifice for Management of Complex Vascular and Neoplastic Lesions: Technical Note." *World Neurosurgery*. https://doi.org/10.1016/j.wneu.2012.07.028.

Kiya, Katsuzo, Hideki Satoh, Tatsuya Mizoue, and Yasuyuki Kinoshita. 2001. "Postoperative Cortical Venous Infarction in Tumours Firmly Adherent to the Cortex." *Journal of Clinical Neuroscience*. https://doi.org/10.1054/jocn.2001.0889.

Kobayashi, Shinya, Tatsuya Ishikawa, Jun Tanabe, Junta Moroi, and Akifumi Suzuki. 2014. "Quantitative Cerebral Perfusion Assessment Using Microscope-Integrated Analysis of Intraoperative Indocyanine Green Fluorescence Angiography versus Positron Emission Tomography in Superficial Temporal Artery to Middle Cerebral Artery Anastomosis." *Surgical Neurology International*. https://doi.org/10.4103/2152-7806.140705.

Li, Jin, ZhiGang Lan, Min He, and Chao You. 2009. "Assessment of Microscope-Integrated Indocyanine Green Angiography during Intracranial Aneurysm Surgery: A Retrospective Study of 120 Patients." *Neurology India*. https://doi.org/10.4103/0028-3886.55607.

Liebelt, Brandon D., Sean M. Barber, Viren R. Desai, Richard Harper, Jonathan Zhang, Rob Parrish, David S. Baskin, Todd Trask, and Gavin W. Britz. 2017. "Superior Petrosal Vein Sacrifice During Microvascular Decompression: Perioperative Complication Rates and Comparison with Venous Preservation." In *World Neurosurgery*. https://doi.org/10.1016/j.wneu.2017.05.098.

Louis, David N., Hiroko Ohgaki, Otmar D. Wiestler, Webster K. Cavenee, Peter C. Burger, Anne Jouvet, Bernd W. Scheithauer, and Paul Kleihues. 2007. "The 2007 WHO Classification of Tumours of the Central Nervous System." *Acta Neuropathologica*. https://doi.org/10.1007/s00401-007-0243-4.

Louis, David N., Arie Perry, Guido Reifenberger, Andreas von Deimling, Dominique Figarella-Branger, Webster K. Cavenee, Hiroko Ohgaki, Otmar D. Wiestler, Paul Kleihues, and David W. Ellison. 2016. "The 2016 World Health Organization Classification of Tumors of the Central Nervous System: A Summary." *Acta Neuropathologica*. https://doi.org/10.1007/s00401-016-1545-1.

Masuoka, Jun, Toshio Matsushima, Takashi Hikita, and Eiko Inoue. 2009. "Cerebellar Swelling after Sacrifice of the Superior Petrosal Vein during Microvascular Decompression for Trigeminal Neuralgia." *Journal of Clinical Neuroscience*. https://doi.org/10.1016/j.jocn.2008.12.024.

Mathiesen, Tiit, Jenny Pettersson-Segerlind, Lars Kihlström, and Elfar Ulfarsson. 2014. "Meningiomas Engaging Major Venous Sinuses." *World Neurosurgery*. https://doi.org/10.1016/j.wneu.2013.01.095.

McNatt, Sean A., Ivan J. Sosa, Mark D. Krieger, and J. Gordon McComb. 2011. "Incidence of Venous Infarction after Sacrificing Middle-Third Superior Sagittal Sinus Cortical Bridging Veins in a Pediatric Population." *Journal of Neurosurgery: Pediatrics*. https://doi.org/10.3171/2010.11.peds09261.

Morcos, Jacques J., and Stephan A. Munich. 2018. "Editorial. The Use of ICG Videoangiography and FLOW 800 Analysis." *Neurosurgical Focus*. https://doi.org/10.3171/2018.4.focus18207.

Nakase, H., Y. Shin, I. Nakagawa, R. Kimura, and T. Sakaki. 2005. "Clinical Features of Postoperative Cerebral Venous Infarction." *Acta Neurochirurgica*. https://doi.org/10.1007/s00701-005-0501-y.

Ng, Yew Poh, Nicolas Kk King, Kai Rui Wan, Ernest Wang, and Ivan Ng. 2013. "Uses and Limitations of Indocyanine Green Videoangiography for Flow Analysis in Arteriovenous Malformation Surgery." *Journal of Clinical Neuroscience*. https://doi.org/10.1016/j.jocn.2011.12.038.

Nussbaum, Eric S., Archie Defillo, and Leslie Nussbaum. 2012. "The Use of Indocyanine Green Videoangiography to Optimize the Dural Opening for Intracranial Parasagittal Lesions." *Operative Neurosurgery*. https://doi.org/10.1227/neu.0b013e31822ecfeb.

Oliveira, Jean G. De, Jürgen Beck, Volker Seifert, Manoel J. Teixeira, and Andreas Raabe. 2008. "Assessment of Flow in Perforating Arteries during Intracranial Aneurysm Surgery Using Intraoperative Near-Infrared Indocyanine Green Videoangiography." *Neurosurgery*. https://doi.org/10.1227/01.NEU.0000279982.48426.A1.

Raabe, Andreas, Jürgen Beck, Rüdiger Gerlach, Michael Zimmermann, and Volker Seifert. 2003. "Near-Infrared Indocyanine Green Video Angiography: A New Method for Intraoperative Assessment of Vascular Flow." *Neurosurgery* 52 (1): 132–9; discussion 139.

Raabe, Andreas, Jürgen Beck, and Volker Seifert. 2005. "Technique and Image Quality of Intraoperative Indocyanine Green Angiography during Aneurysm Surgery Using Surgical Microscope Integrated Near-Infrared Video Technology." *Zentralblatt Fur Neurochirurgie*. https://doi.org/10.1055/s-2004-836223.

Raabe, Andreas, Peter Nakaji, Jürgen Beck, Louis J. Kim, Frank P. K. Hsu, Jonathan D. Kamerman, Volker Seifert, and Robert F. Spetzler. 2009. "Prospective Evaluation of Surgical Microscope—Integrated Intraoperative near-Infrared Indocyanine Green Videoangiography during Aneurysm Surgery." *Journal of Neurosurgery*. https://doi.org/10.3171/jns.2005.103.6.0982.

Schaller, Bernhard, and Rudolf Graf. 2004. "Cerebral Venous Infarction: The Pathophysiological Concept." *Cerebrovascular Diseases*. https://doi.org/10.1159/000079939.

Schebesch, Karl Michael, Julius Hoehne, Christoph Hohenberger, Francesco Acerbi, Morgan Broggi, Martin Proescholdt, Christina Wendl, Markus J. Riemenschneider, and Alexander Brawanski. 2015. "Fluorescein Sodium-Guided Surgery in Cerebral Lymphoma." *Clinical Neurology and Neurosurgery*. https://doi.org/10.1016/j.clineuro.2015.09.015.

Sindou, Marc P., Jean Auque, and Emmanuel Jouanneau. 2005. "Neurosurgery and the Intracranial Venous System." *Acta Neurochirurgica, Supplementum*. https://doi.org/10.1007/3-211-27911-3_27.

Sughrue, Michael E., Martin J. Rutkowski, Gopal Shangari, Shanna Fang, Andrew T. Parsa, Mitchel S. Berger, and Michael W. McDermott. 2011. "Incidence, Risk Factors, and Outcome of Venous Infarction after Meningioma Surgery in 705 Patients." *Journal of Clinical Neuroscience*. https://doi.org/10.1016/j.jocn.2010.10.001.

Suzuki, Yasuhiro, Takahiro Endo, Hisato Ikeda, Yukio Ikeda, and Kiyoshi Matsumoto. 2003. "Venous Infarction Resulting from Sacrifice of a Bridging Vein during Clipping of a Cerebral Aneurysm: Preoperative Evaluation Using Three-Dimensional Computed Tomography Angiography--Case Report." *Neurologia Medico-Chirurgica*.

Takagi, Yasushi, Ken-ichiro Kikuta, Kazuhiko Nozaki, Keiko Sawamura, and Nobuo Hashimoto. 2007. "Detection of a Residual Nidus by Surgical Microscope-Integrated Intraoperative near-Infrared Indocyanine Green Videoangiography in a Child with a Cerebral Arteriovenous Malformation." *Journal of Neurosurgery: Pediatrics*. https://doi.org/10.3171/ped-07/11/416.

Takagi, Yasushi, Keiko Sawamura, Nobuo Hashimoto, and Susumu Miyamoto. 2012. "Evaluation of Serial Intraoperative Surgical Microscope-Integrated Intraoperative Near-Infrared Indocyanine Green Videoangiography in Patients With Cerebral Arteriovenous Malformations." *Operative Neurosurgery*. https://doi.org/10.1227/neu.0b013e31822d9749.

Takami, Toshihiro, Kentaro Naito, Toru Yamagata, Nobuyuki Shimokawa, and Kenji Ohata. 2017. "Benefits and Limitations of Indocyanine Green Fluorescent Image-Guided Surgery for Spinal Intramedullary Tumors." *Operative Neurosurgery*. https://doi.org/10.1093/ons/opx057.

Takeshima, Yasuhiro, Yoshitaka Tanaka, Yasuo Hironaka, Yoichi Shida, and Hiroyuki Nakase. 2015. "Visualization of Vascular Structure of Spinal Hemangioblastoma Using Intraoperative Indocyanine Green Videoangiography and Temporary Feeder Occlusion." *European Spine Journal*. https://doi.org/10.1007/s00586-014-3755-3.

Uchino, Haruto, Ken Kazumata, Masaki Ito, Naoki Nakayama, Satoshi Kuroda, and Kiyohiro Houkin. 2014. "Intraoperative Assessment of Cortical Perfusion by Indocyanine Green Videoangiography in Surgical Revascularization for Moyamoya Disease." *Acta Neurochirurgica*. https://doi.org/10.1007/s00701-014-2161-2.

Vetrano, Ignazio G., Paolo Ferroli, and Francesco Acerbi. 2018. "Dynamic Intraoperative Assessment of Draining Veins in Parasagittal Meningiomas: Changing the Paradigm?" *World Neurosurgery*. https://doi.org/10.1016/j.wneu.2018.07.094.

Woitzik, Johannes, Peter Horn, Peter Vajkoczy, and Peter Schmiedek. 2009. "Intraoperative Control of Extracranial—Intracranial Bypass Patency by near-Infrared Indocyanine Green Videoangiography." *Journal of Neurosurgery*. https://doi.org/10.3171/jns.2005.102.4.0692.

Xu, Bai nan, Zheng hui Sun, Rossana Romani, Jin li Jiang, Chen Wu, Ding biao Zhou, Xin guang Yu, Juha Hernesniemi, and Bao min Li. 2010. "Microsurgical Management of Large and Giant Paraclinoid Aneurysms." *World Neurosurgery*. https://doi.org/10.1016/j.surneu.2009.07.042.

Ye, Xun, Xing Ju Liu, Li Ma, Ling Tong Liu, Wen Lei Wang, Shuo Wang, Yong Cao, et al. 2013. "Clinical Values of Intraoperative Indocyanine Green Fluorescence Video Angiography with Flow 800 Software in Cerebrovascular Surgery." *Chinese Medical Journal*. https://doi.org/10.3760/cma.j.issn.0366-6999.20131649.

In: Encyclopedia of Surgery (22 Volume Set)
Editors: Andreas Lehrer and Kristin Mueller
ISBN: 978-1-53618-329-0
© 2020 Nova Science Publishers, Inc.

Chapter 110

THE APPLICATION OF INDOCYANINE GREEN VIDEOANGIOGRAPHY AS AN ADJUNCT FOR ARTERIOVENOUS MALFORMATION SURGERY

Ann Knoll[1], MD, Dara Sam Farhadi[1], MD, Megan Cadigan[1], MD, Joseph Georges[3,4], MD and Peter Nakaji[1,2,*], MD

[1]Department of Neurosurgery, University of Arizona College of Medicine Phoenix, Phoenix, AZ, US
[2]Department of Neurosurgery, Banner University Medical Center Phoenix, Phoenix, AZ, US
[3]Department of Neurosurgery, Philadelphia College of Osteopathic Medicine, Philadelphia, PA, US
[4]Department of Neurosurgery, Cooper University Healthcare, Philadelphia, PA, US

ABSTRACT

Visualizing the anatomy and angioarchitecture of an arteriovenous malformation is important for their successful microsurgical removal. Resection ideally proceeds with pruning of arteries first, then the nidus, and finally the veins, while preserving normal en passage arteries Indocyanine green has particular properties as fluorophore and pharmacodynamics that make it useful as an intravascular contrast agent that can be visualize vessels and their flow under the view of the operating microscope. Indocyanine green videoangiography can provide additional information that correlates anatomy and flow which the surgeon can use to assist in resection. This chapter describes the key attributes of indocyanine green angiography and contrasts it with digital subtraction angiography. Herein we also review the studies that have been published detailing the available experience with this technique in the surgery of arteriovenous malformations.

Keywords: arteriovenous malformation, indocyanine green, videoangiography, microsurgery, angiography

[*] Corresponding Author's Email: nakaji@email.arizona.edu.

INTRODUCTION

Visualizing anatomical relationships and angioarchitecture is crucial during surgery for the resection of arteriovenous malformation (AVM)s. Magnetic resonance imaging (MRI), doppler sonography, computer-assisted navigation, digital subtraction angiography (DSA), and indocyanine green (ICG) videoangiography have all been used to improve intraoperative visualization of the vascular networks and structures of AVMs. While DSA is the gold standard for interrogating neurovascular structures, intraoperative ICG imaging has become widely adopted for its speed, safety, and superior capability for identifying vessels by their flow timing and for resolving very small vessels in the operative field with a surgical microscope. This chapter will examine the pharmacology, history, methodology, and use of ICG as an adjunct for AVM resection surgery.

PHARMACOLOGY

Indocyanine green (C43H47N2NaO6S2) is a sterile, water-soluble tricarbocyanine dye that contains less than 5.0% sodium iodide. ICG is an infrared fluorophore, with a peak spectral absorption and emission of approximately 800 and 850 nm, respectively. Globulins are the major carriers of ICG in human plasma, specifically alpha-1 lipoproteins. There is negligible renal, peripheral, pulmonary, and cerebrospinal fluid (CSF) uptake, and ICG is not absorbed by the intestines or excreted by the kidneys. Excretion occurs hepatically by biliary secretion after uptake via hepatic parenchymal cells. The half-life is 3-4 minutes [1]. Doses can be given 5-10 minutes apart and visualized in real-time using a near-infrared (NIR) camera [2]. The recommended dose is 0.2-0.5 mg/kg, with a maximum daily dose of 5 mg/kg [1]. The most common clinical dose is 25 mg.

Adverse reactions to ICG are comparable to other contrast materials with a severe reaction rate of 0.05% and mild to moderate reaction rate of 0.15%-0.2% [3, 4]. Because of the small sodium iodide content, it should be administered with caution in patients with a history of sodium iodide allergy. Mild and moderate adverse reactions are classified as transient and pseudo-allergic, possibly due to non-immunologic release of histamine or other inflammatory mediators. Common non-life-threatening reactions include nausea, vomiting, sneezing, urticaria rashes, nerve palsy and localized tissue necrosis with complete resolution of symptoms after appropriate medical treatment [4]. No adverse sequelae were observed after resolution of mild to moderate reactions [4]. Severe reactions are classified as allergic-like, possibly due to a hapten-protein complex recognized by IgE, leading to mast cell degranulation and manifesting as anaphylactic shock with associated cardiopulmonary arrest or seizures [4]. Severe reactions do not appear to be dose-dependent and should be treated with appropriate medical protocol corresponding to the nature of the reaction [4]. Adverse reactions can be observed in patients without any history of iodine allergies [4]. Table 1 is a summary of ICG's pharmacological profile.

Table 1. Characteristics of ICG for neurosurgical use

Route of Administration	Intravenous
Excitation/Emission wavelengths	800 nm excitation, 850 nm emission
Dose	0.2-0.5 mg/kg
Maximum Dose in 24 hours	5 mg/kg
Clearance	5-10 minutes
Carrier protein in blood	Alpha-1 lipoproteins
Clearance System	Hepatic
Half Life	3-4 minutes
Rate of Adverse Events - mild/moderate	0.15-0.20%
Types of Adverse Events - mild/moderate	Nausea, vomiting, sneezing, urticaria, rashes, nerve palsy, localized tissue necrosis
Treatment Adverse Events - mild/moderate	Appropriate medical management of symptoms
Rate of Adverse Events - Severe	0.05%
Types of Adverse Events - Severe	Anaphylaxis, cardiopulmonary arrest, seizures
Treatment of Adverse Events - Severe	Appropriate medical management of symptoms
Recommended use	Superficial, complex vascular abnormalities
No evidence for use	Deep vascular abnormalities out of surgical microscopic visual field
Contraindications	Known allergy to ICG

HISTORY OF INDOCYANINE GREEN DYE USE IN AVMS

Neurosurgical intraoperative fluorescent vascular imaging began with the use of fluorescein, a fluorescent dye similar to ICG, in 1967 by W. Feindel [5]. Four years later, the same group would publish their results from implementing fluorescein in an AVM surgery [6]. It was the first recorded application of fluorescein in vascular neurosurgery [7]. Fluorescein was used with fluoroscopy and provided sharper contrast and finer detail compared to a subtraction angiogram alone, especially of the capillary and venous phases, demarcation of tumors, and visualization of vessels of all sizes of the epicerebral vessels (surface vessels including the pial arteries and veins, perforating branches, and superficial cortical capillary beds). The first human cases with fluorescein use included an occipital lobe angioma, atrophic cortex causing severe electrographic epileptogenic abnormalities, and a malignant glioma [5]. The usefulness of intraoperative fluorescein motivated neurosurgeons to identify additional fluorophores with intraoperative utilities. One option they turned to was ICG, which was originally approved by the Food and Drug Administration (FDA) in 1956 for cardiovascular applications. Recent studies show ICG produces similar information to fluorescein, with some differences based on differences in the chemistry. In general, ICH is more useful for elucidating hemodynamic information and benefits from being repeatable, whereas fluorescein has extended uses in tumoral applications [8]. The half-life of fluorescein is much longer than ICG and at usual doses is used only once per procedure. ICG's rapid clearance allows for multiple injections during a procedure [8].

ICG has been predominantly used in ophthalmology to assess retinal microcirculation [9]. ICG has also been used in plastic surgery to evaluate intraoperative flap perfusion and in gastrointestinal surgery to assess blood flow during anastomosis procedures [2]. In

neurosurgery, ICG is recognized for its use in identifying residual aneurysm perfusion, AVM nidi, spinal dural arteriovenous fistulae, arteriovenous shunting, patency of arteries, and for confirming the adequacy of collateral blood flow and patency after cerebrovascular bypass [2, 9]. ICG is useful in distinguishing AVM vessels (early arteries and veins) in real-time, therefore providing intraoperative guidance. However, ICG is restricted to the field of view through the microscope, making it less useful for deep AVMs that must be accessed through a narrow corridor or vessels outside the surgeon's direct visual field [10]. A cerebral ICG videoangiography run can be completed in less than one minute, and the results are available for review within 2 minutes, allowing for immediate action or correction of a procedure, such as temporary clip re-positioning in a time frame that should precede ischemia. The high spatial resolution from ICG allows for observation of patency of all vessels within the surgeon's view [10].

METHODOLOGY/INTRAOPERATIVE APPLICATION

As noted previously, the recommended range for individual doses is between 0.2 to 0.5 mg/kg, with a maximum dose of 5 mg/kg/day. ICG can be administered multiple times at the surgeon's discretion, with an average of 5-10 minutes between injections. The microscope can be switched back to near-infrared visualization mode to check if it has cleared. Note that is not necessary for the ICG from a prior dose to have cleared completely, as the brightness of the new dose overwhelms the partially metabolized one. Typically, ICG is administered once to visualize the arteriovenous malformation prior to resection, at least once while the pathology is being addressed, and then once after what is presumed to be complete surgical treatment and before closing to ensure complete resolution of vascular pathology [1]. While lack of AVM on ICG does not obviate the need for an angiogram, the presence of early draining vessels should prompt further surgical exploration prior to the angiogram.

During an ICG videoangiographic run, near-infrared light from a modified microscope light source is passed onto the surgical field, then ICG fluorescence is passed back from the surgical field into the optical path of the surgical microscope. The light illuminating the field has a wavelength covering part of the ICG absorption band (700-850 nm, absorption peak 805 nm) and the returning fluorescence is recorded by a nonintensified charged coupled device (CCD) camera (780-950 nm, emission peak 835 nm) [1, 10, 11]. The microscope has an optical filter that blocks ambient and excitation light allowing only ICG-induced fluorescence to be collected. ICG's integration into NIR imaging allows for speed adjustment of the video feedback, allowing the surgeon to watch a slowed version of ICG angiography as well as real-time feedback [1]. Angiographic images are displayed on a video screen in real-time and recorded for later review [11]. One disadvantage of NIR-imaging is the inability to visualize fluorescence directly through the microscope ocular lens, but rather on a monitor. Some newer commercial systems allow the ICG signal to be displayed in the oculars as a ghosted overlay (Figure 1).

Figure 1. A microscopic view of a small pial AVM shows the ICG videoangiogram as a superimposed yellow overlay on the microscope image.

INDOCYANINE GREEN DYE AND ARTERIOVENOUS MALFORMATIONS

AVMs can be anatomically complex, making incomplete resection one of the most common complications of AVM surgery [12]. AVM resection requires dissection of intricate structures to control feeding arteries and isolation and resection of the nidus, necessitating the use of high-power imaging studies, such as DSA and ICG [12]. To better estimate the risks of operating on an AVM and to determine operative morbidity and mortality, R. Spetzler and N. Martin created the Spetzler-Martin (SM) grading system [13]. A Grade I AVM has the lowest grade with relatively minor technical difficulty and low risk of morbidity or mortality. A Grade V AVM has the highest grade, indicating significant risk of morbidity and mortality, due to the large size, the close proximity to important/eloquent brain regions, and the presence of deep draining veins. There is a further grade, Grade VI or "inoperable," that are very large, diffuse and dispersed through critical areas, or encompassing critical structures that would be associated with disabling deficit or death upon injury [13].

As the Spetzler-Martin Grading System suggests, there is a great need for accurate visualization of AVMs of varying complexity. Intraoperative supplementation of DSA with ICG can be used to temporally distinguish AVM vessels based on fluorescence. Arteries fluoresce first within 3-12 seconds following intravenous injection, followed by arterialized veins, and finally cortical (non-arterialized) veins [1]. ICG can also be helpful in identifying small, ruptured AVMs in hematoma cavities once the hematoma has been evacuated to allow for visualization of the cavity walls. In a study by Killory et al. [1] of 10 patients with AVMs ranging from Grades I to IV, ICG angiography was performed before resection, at least once during, and after the resection. The surgeon was able to clearly distinguish vessels and arteriovenous shunting, discern AVM arteries, draining veins, and cortical veins. ICG was helpful in 9 out of the 10 cases; one AVM was located deep, and approached through a narrow corridor, only allowing for portions of the lesion to be visualized. In 3 procedures, the surgeon was confident enough with the ICG results to forgo intraoperative DSA results and only conduct postoperative DSA [1].

During AVM resection, ICG can be utilized at three stages: first, a primary superficial survey can be performed prior to resection to obtain identify the AVM and to provide information about superficial angioarchitecture and flow dynamics (Figure 2). It can also be used as resection progressed during resection with as-needed repeated boluses to obtain hemodynamic information on en passage feeders, and terminal assessment at the end of the resection to identify residual AVM. Hanggi et al. [12] studied 46 AVM and dural arteriovenous fistula procedures with ICG and found that 41 ICGs were rated excellent, 2 intraoperative ICG injections provided information that changed the surgical procedure, and 16 out of the 17 AVM postoperative DSA results corresponded to the postoperative ICG results. In one procedure, the terminal assessment was inconclusive due to insufficient illumination of a deep thalamic AVM. The primary superficial ICG survey that was conducted in 12 cases (excluding deep AVM cases) provided additional information and orientation of the nidus, terminal and en passage feeders. In 14 of the 18 intraoperative injections, ICG provided information on the localization of en passage feeders, the integrity of adjacent arteries, and the location of AVM compartments. Eleven postoperative injections observed early filing of the major draining vein and allowed for detection or exclusion of residual nidus [12].

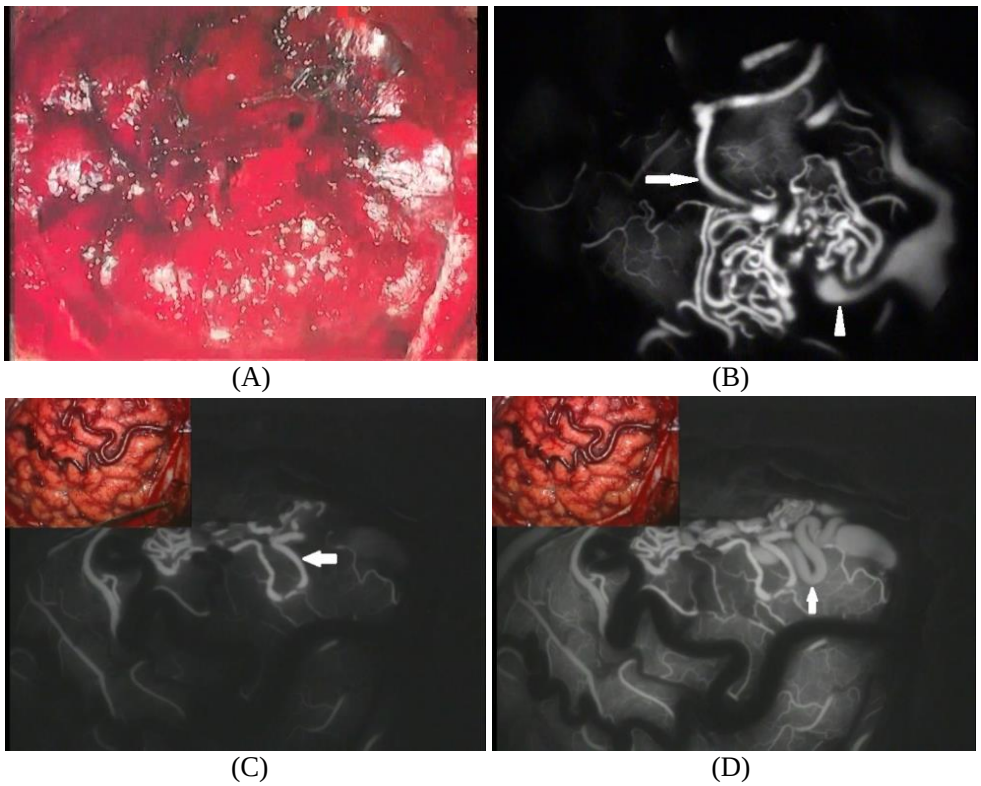

Figure 2. (Continued).

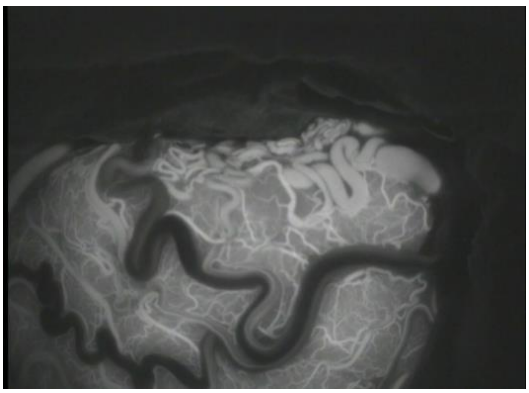

(E)

Figure 2. A. A close-up view of the pial surface in a patient with subarachnoid hemorrhage from the underlying AVM. Blood obscures much of the AVM. B. The ICG run clearly shows the AVM through the blood and identifies both a feeding artery (arrow) and draining vein (arrowhead). C. A view of the cortex showing a different patient with a left frontal AVM in early phase. The arrow indicates an early-filling loop which can therefore be identified as an artery which feeds the AVM. D. A middle-phase run shows arterialized veins filling next (arrow). E. The late phase shows all of the AVM vessels filling, and in the normal draining veins there is some early drainage from the AVM in these veins seen as a slipstream (arrow).

In a retrospective review of 130 AVM resection cases (56 ICG and 74 non-ICG), Zaidi et al. [14] determined that ICG was used more frequently in lobar and cortical surface AVM resections, and less frequently in cases with deep arterial supply to the nidus and posterior fossa. The SM Grade between the ICG and non-ICG groups were similar (2.2 vs 2.4), with the same AVM diameter (2.7 cm) in both groups. There was no statistical decrease in the incidence of residual disease with ICG use or statistical differences in modified Rankin Scale scores preoperatively, postoperatively, or at last follow up. There were no complications attributed to ICG use [14].

ICG can also be used in atypical AVM resections. In one case, a patient presented with a small cerebellar AVM resembling a posterior fossa cavernous hemangioma on preoperative imaging. MRI results were equivocal, and angiography confirmed a Grade I AVM. ICG was used pre-, intra-, and post-resection [15]. Pre-resection ICG infusion displayed a “blackberry-like” appearance with tiny surrounding vessels lacking the basement membranes and astrocyte foot processes of the blood-brain barrier. ICG videoangiography was noted to be helpful in guiding surgical approach, especially prior to dissection where video playback was used to distinguish venous and arterial phases and allowed for real-time analysis and understanding of the unique AVM features.

ALTERNATIVE USES AND METHODS OF INDOCYANINE GREEN DYE

ICG can be used with FLOW 800 (Carl Zeiss Co) microscopic analysis to provide increased information about blood flow dynamics. Without FLOW 800, recognition of feeders from draining vessels can be determined based on the chronological order after injection, but FLOW 800 provides additional pseudocoloring to map blood flow dynamics and distinguish between feeding arteries, draining veins, and normal arteries along with

intensity diagrams to document blood flow. Temporal fluorescence maps can be used to visualize the direction and sequence of blood flow with color coding based on velocity to allow for temporary clip placement and observation. Comparative analysis of curves showing variations in blood flow over time in a certain region can be utilized to determine the completeness of surgical resection. As with ICG alone, this method is limited in deeply located lesions [16].

Acerbi et al. examined venous flow intraoperatively in pathological and normal veins over a variety of procedures, including 16 AVMs, and were able to characterize five different venous patterns: 1. arterialized veins with flow characteristics similar to arteries (observed in all 16 AVMs), 2. thrombosed veins with retrograde flow (observed in a left temporal glioblastoma), 3. fast and homogeneously filling fast bridging veins and anterograde flow towards the usual draining sinus, 4. slow and non-uniform filling slow bridging veins with anterograde flow with multiple tributaries and one large collector close to the sinus with multiple velocities, 5. and slow bridging veins with retrograde flow in the direction opposite the sinus (observed in parasagittal meningiomas). After the procedure, they were able to use ICG to confirm the normalization of venous flow in arterialized veins or only retrograde flow from normal continuous veins, including in all 16 of the AVMs, as well as confirm good collateral circulation in select cases [17].

DIGITAL SUBTRACTION ANGIOGRAPHY AND ARTERIOVENOUS MALFORMATIONS

From the 1960s to the 1980s, the value of intraoperative angiography became more widely acknowledged as beneficial for avoiding errors and for tracking procedure progress. Previous techniques were known for being expensive, cumbersome, requiring large amounts of contrast medium, and excessive time for film development. The development of DSA simplified this process [18]. In DSA, x-rays are passed through the patient's body to a photoelectric receiver that then converts the x-rays into electrical signals. When these digital impulses are amplified, they can be assembled into real-time images allowing immediate review at normal, slow, and frame-by-frame speeds [18, 19]. There are three types of DSA: temporal subtraction, energy subtraction, and hybrid subtraction [20]. Temporal subtracted is constructed by subtracting single or integrated images (a "mask") from images with contrast medium obtained at different times and may contain artifactual changes resulting from incomplete subtraction due to movement. Energy subtraction results from images produced by high and low energy x-ray pulses that are digitized and may be more useful in the abdomen or regions with more overlying bony structures. Hybrid subtraction utilizes energy subtracted images as a sequence for temporal subtraction and reduces movement artifacts.

Modern DSA through femoral or radial artery access allows for macroscopic resolution with reduced amount of contrast medium and radiation doses for both the patient and the surgeon compared to carotid or vertebral angiography and traditional intraoperative x-ray, as well as elimination of direct puncture of the carotid artery [19]. In a study to examine intraoperative angiography in the management of several different neurovascular disorders, D Barrow et al. noted that out of 39 AVM resections, DSA revealed some residual malformation during 6 of the procedures. While DSA provided the ability to recognize and correct technical

defects and reduce the risk of another operation and post-operative complications, they did note that DSA added 30-60 minutes to each procedure [18]. The rate of complications with DSA use is 1 to 3%, and can include permanent neurological deficits including embolism and carotid dissection [21].

COMPARISON OF INDOCYANINE GREEN DYE AND DIGITAL SUBTRACTION ANGIOGRAPHY

DSA has been shown to be useful in the detection of AVMs in a patient undergoing emergent hematoma evacuation, and in distinguishing AVMs from normal nutrient carrying, or "en passage" vessels [1]. It also remains the most accurate for large, complex aneurysms [11] or deep AVMs, and is the gold standard for confirming AVM resection. Despite this, DSA use is expensive, technically demanding, and requires major logistical support. Administration of the contrast medium and acquisition of the images is an invasive and time-consuming process [1]. There is risk of potential vascular or neurological injury along with complications due to increased operating time [1].

With the development of technological advancements, ICG has become more prominently used due to the ability to quickly integrate vital information about vessel patency and flow during an operation, low cost of use and absence of additional equipment required other than microscope software modifications, and low to no morbidity [22]. ICG can be used to determine immediate action for correction of aneurysm clip position and is easily repeatable before, during, and after a procedure. While results for DSA can take upwards of 20 minutes, ICG results are available within 2 minutes. Since most surgery-related complications result from injury to arterial branches of the normal tissues or incomplete resection [12], use of ICG could theoretically contribute to a reduction in morbidity. ICG is best utilized with smaller, low grade and superficial AVMs where the integrity of the AVM and the resection cavity is readily observable. The surgeon is unable to see ICG fluorescence through blood clots, aneurysms, brain tissues, or outside of the field of view of the microscope, leaving the possibility of a nonvisualized remnant. Calcification, thick-walled atherosclerotic vessels, or partially or completely thrombosed aneurysms can also obstruct fluorescence [11, 14].

In a study comparing DSA to ICG, Bilbao et al. reported that ICG was useful for distinguishing AVMs in 26 out of the 32 patients with AVM Grades I to IV. In 9 of the 16 patients, ICG allowed for differentiation of en passage vessels from malformation-based pathological vessels. ICG missed three out of four residual AVMs, compared to intraoperative DSA that only missed one, confirming ICG's use in small, superficial AVMs but decreased efficacy with deep, high grade AVMs [14, 22].

Given this data, reasonable applications of ICG in AVM surgery are 1) as an initial tool to distinguish feeding arteries from draining veins, so as to guide the order of resection, 2) to identify en passage arteries and distinguish them from primary AVM vessels, and 3) as a screening tool to look for residual AVM and track the progress of resection, recognizing that a negative result does not exclude residual AVM.

CONCLUSION

Indocyanine green videoangiography has been shown to provide safe, fast, and vital information that can be used intraoperatively to identify en passage and pathological vessels, measure vessel patency, and determine complete AVM resection. As a water-soluble infrared fluorophore, ICG dye has limited renal or intestinal excretion and has a high safety profile with an allergic reaction rate under 0.2% and a severe allergic reaction rate of 0.05%. The recommended injection dose is 0.2-0.5 mg/kg and with a maximum daily dose of 5 mg/kg. ICG is a formidable video angiographic technology with a capacity for multiple injections during procedures and decreased time to results. The integration of ICG fluorescence information into the surgical microscope revolutionized the ease of use of ICG at all stages of a procedure, and additional technological advances, such as FLOW 800 software, continue to expand ICG applications. However, the use of ICG is limited to the surgeon's visual field, making it less useful for deep AVMs but adequate for superficial vascular pathologies. Although it cannot replace DSA in certain cases, the advantages of ICG can possibly be used to complement DSA angiography. In the scope of ICG videoangiography in AVM resection, further research is needed to establish protocols for combined IGA and DSA use. As ICG use becomes more prevalent and surgeons become more accustomed to using ICG videoangiography in AVM resection and other procedures, ICG will become more prominent both as a stand-alone technique and in conjuncture with DSA.

REFERENCES

[1] Killory, B. D., et al. 2009. "Prospective evaluation of surgical microscope-integrated intraoperative near-infrared indocyanine green angiography during cerebral arteriovenous malformation surgery." *Neurosurgery*, 65(3): p. 456-62; discussion 462.

[2] Raabe, A., et al. 2003. "Near-infrared indocyanine green video angiography: a new method for intraoperative assessment of vascular flow." *Neurosurgery*, 52(1): p. 132-9; discussion 139.

[3] Cochran, S. T., K. Bomyea, and J. W. Sayre. 2001. "Trends in adverse events after IV administration of contrast media." *AJR Am. J. Roentgenol.*, 176(6): p. 1385-8.

[4] Hope-Ross, M., et al. 1994. "Adverse reactions due to indocyanine green." *Ophthalmology*, 101(3): p. 529-33.

[5] Feindel, W., Y. L. Yamamoto, and C. P. Hodge. 1967. "Intracarotid fluorescein angiography: a new method for examination of the epicerebral circulation in man." *Can. Med. Assoc. J.*, 96(1): p. 1-7.

[6] Feindel, W., Y. L. Yamamoto, and C. P. Hodge. 1971. "Red cerebral veins and the cerebral steal syndrome. Evidence from fluorescein angiography and microregional blood flow by radioisotopes during excision of an angioma." *J. Neurosurg.*, 35(2): p. 167-79.

[7] Zhao, X., et al. 2019. "Application of Fluorescein Fluorescence in Vascular Neurosurgery." *Front. Surg.*, 6: p. 52.

[8] Bretonnier, M., et al. 2018. "Fluorescein-guided resection of brain arteriovenous malformations: A short series." *J. Clin. Neurosci.*, 52: p. 37-40.

[9] Hanel, R. A., P. Nakaji, and R. F. Spetzler. 2010. "Use of microscope-integrated near-infrared indocyanine green videoangiography in the surgical treatment of spinal dural arteriovenous fistulae." *Neurosurgery*, 66(5): p. 978-84; discussion 984-5.

[10] Raabe, A., et al. 2005. "Prospective evaluation of surgical microscope-integrated intraoperative near-infrared indocyanine green videoangiography during aneurysm surgery." *J. Neurosurg.*, 103(6): p. 982-9.

[11] Raabe, A., J. Beck, and V. 2005. "Seifert, Technique and image quality of intraoperative indocyanine green angiography during aneurysm surgery using surgical microscope integrated near-infrared video technology." *Zentralbl. Neurochir.*, 66(1): p. 1-6; discussion 7-8.

[12] Hanggi, D., N. Etminan, and H. J. Steiger. 2010. "The impact of microscope-integrated intraoperative near-infrared indocyanine green videoangiography on surgery of arteriovenous malformations and dural arteriovenous fistulae." *Neurosurgery*, 67(4): p. 1094-103; discussion 1103-4.

[13] Spetzler, R. F. and N. A. Martin.1986. "A proposed grading system for arteriovenous malformations." *J. Neurosurg.*, 65(4): p. 476-83.

[14] Zaidi, H. A., et al. 2014. "Indocyanine green angiography in the surgical management of cerebral arteriovenous malformations: lessons learned in 130 consecutive cases." *Neurosurgery*, 10 Suppl. 2: p. 246-51; discussion 251.

[15] Barbagallo, G. M., et al. 2015. "Role of intraoperative indocyanine green video-angiography to identify small, posterior fossa arteriovenous malformations mimicking cavernous angiomas. Technical report and review of the literature on common features of these cerebral vascular malformations." *Clin. Neurol. Neurosurg.*, 138: p. 45-51.

[16] Kato, Y., et al. 2017. "Intraoperative Anatomical and Hemodynamic Analysis of Intracerebral Arteriovenous Malformations by Semi-quantitative Color-coded Indocyanine Green Videoangiography." *Asian J. Neurosurg.*, 12(4): p. 638-643.

[17] Acerbi, F., et al. 2018. "Use of ICG videoangiography and FLOW 800 analysis to identify the patient-specific venous circulation and predict the effect of venous sacrifice: a retrospective study of 172 patients." *Neurosurg. Focus*, 45(1): p. E7.

[18] Barrow, D. L., K. L. Boyer, and G. J. Joseph. 1992. "Intraoperative angiography in the management of neurovascular disorders." *Neurosurgery*, 30(2): p. 153-9.

[19] Bauer, B. L. 1984. "Intraoperative angiography in cerebral aneurysm and AV-malformation." *Neurosurg. Rev.*, 7(2-3): p. 209-17.

[20] Jeans, W. D. 1990. "The development and use of digital subtraction angiography." *Br. J. Radiol.*, 63(747): p. 161-8.

[21] Derdeyn, C. P., et al. 1995. "Intraoperative digital subtraction angiography: a review of 112 consecutive examinations." *AJNR Am. J. Neuroradiol.*, 16(2): p. 307-18.

[22] Bilbao, C. J., et al. 2015. "Comparison of indocyanine green fluorescent angiography to digital subtraction angiography in brain arteriovenous malformation surgery." *Acta Neurochir.* (Wien), 157(3): p. 351-9.

In: Encyclopedia of Surgery (22 Volume Set)
Editors: Andreas Lehrer and Kristin Mueller
ISBN: 978-1-53618-329-0
© 2020 Nova Science Publishers, Inc.

Chapter 111

CURRENT TRENDS IN FUNCTIONAL MUSCLE TRANSFER TO IMPROVE OUTCOMES IN FACIAL REANIMATION SURGERY

Ioana Lese [*] ***and Adriaan O. Grobbelaar***
Department of Plastic, Aesthetic and Reconstructive Surgery
Inselspital, Bern University, Bern, Switzerland

ABSTRACT

A spontaneous and symmetrical smile is the goal of long-lasting facial paralysis surgery. Even though two-stage free functional muscle transfers are considered the gold standard treatment, only about 60% of patients get a perfect symmetrical smile in response to emotion. Under or overactivity of the transplanted muscle is an unpredictable surgical phenomenon contributing to inferior surgical outcomes. Surgeons and researchers attempt through continuing research and the development of novel surgical strategies to improve the reliability of functional muscle transfers. Terzis first popularized the babysitting procedure of the damaged facial nerve by a partial hypoglossal transfer to protect the muscle end plates until the facial nerve can recover or a cross-facial nerve can innervate the facial muscles. Various supercharging procedures with sensory nerves have been suggested as a protection mechanism for the muscle and also for the nerve graft while the motoneurons reach their final target. The dual-innervation concept relies on a second neural input to serve the cross-facial nerve graft until the new motor axons from the contralateral facial nerve reach the recent paretic facial musculature. In this chapter, we will attempt to discuss current trends in re-innervating functional muscle transfers and the neurophysiological basis for these various techniques.

1. INTRODUCTION

Reconstruction of the middle and lower face in long-lasting facial paralysis implies restoration of spontaneous and symmetrical smile, as well as symmetry at rest. The gold

[*] Corresponding Author's Email: ioana.lese@gmail.com.

standard treatment is considered a two-stage free functional muscle transfer [1], but lack of a consistent, reproducible result still eludes the surgeon and patients. It is generally accepted that only 60% of patients get a perfect symmetrical smile in response to emotion [2]. Under or over activity of the transplanted muscle are the most common presentation in patients that do not achieve excellence [3]. Basic knowledge and understanding of nerve physiology is still lacking. Is there an ideal nerve size/muscle ratio for the transplanted muscle to function optimally? Organization patterns of the motor axons pre and post neurorrhaphy can now be examined with the concept of connectomics [4].

Baby-sitting of the damaged facial nerve is a novel technique employed in the surgeons' armamentarium to improve ultimate results [5]. The partial hypoglossal nerve is connected in an end-to-side technique to the damaged facial nerve, while multiple cross-facial nerve grafts are connected to the contralateral healthy facial nerve. The distal ends of these grafts are later, in a second stage, connected to the distal branches of the damaged facial nerve. The partial hypoglossal nerve is thought to provide endogenous growth support to the denervated distal nerve stump.

Surgeons try to enhance facial reanimation outcomes by supercharging the cross facial nerve graft with sensory nerves postulating that it has a protective capability [6]. These sensory-to-motor innervations exerted trophic effects on the muscle and also maintain the architecture of the distal nerve stump until the reinnervated axons are able to reach their target.

Dual-innervation is yet another method explored in order to produce a more repeatable result every time [7]. Through this technique, the spontaneous neural input provided by the contralateral facial nerve is combined with the great axonal load of the masseteric nerve, ensuring therefore a shorter reinnervation time, as well as a stronger muscle contraction.

The history of free muscle transfer for facial reanimation began in 1971, when Thompson described the first free muscle transfer for facial palsy [8]. He used the extensor digitorum brevis muscle, however without performing any vascular anastomoses or neurorrhaphies. Subsequently, the muscle cells were replaced by fibrous tissue due to the lack of vascular inflow and neural input. Inspired by his and Tamai's work [9], Harii described in 1976 the first microvascular transfer of the gracilis muscle for facial reanimation [10]. He used the superficial temporal vessels and the deep temporal nerve as the recipient neurovascular pedicle. Later, he recommended the now standard two-stage procedure with a contralateral cross-face nerve followed by a functional free gracilis muscle transfer 9-12 months later [11]. In order to address the bulkiness of the gracilis muscle and the lack of sufficient contractile force of the extensor digitorum brevis muscle, Manktelow and Zuker developed the concept of 'functional anatomy' by separating the gracilis muscle into territories based on the individual fascicular nerve stimulation [12]. They proposed this technique as a way of trimming the muscle and therefore avoiding the postoperative bulkiness, as well as a way of achieving separate contractions within a single muscle. The same principle was applied by MacKinnon for the latissimus dorsi muscle [13]. The major problem of these trimming techniques is the risk of postoperative hematoma. In order to overcome this, an alternative muscle was described by Harrison [14] and Terzis [15]: the pectoralis minor muscle, which seems to offer just enough bulk, while also being able to provide good excursion.

When looking at recipient nerves, a spontaneous smile can only be achieved by the 7th nerve and is the desired choice of motor nerve for facial reanimation, especially in children. Other recipient nerves have been described, such as the accessory [16] and the hypoglossal

nerve [17]. The former, even though it offers a good neural input, the morbidity of sacrificing the nerve, as well as the lack of ability to respond to emotion has made its use fairly rare [18]. The latter also presents disadvantages such as hemiglossal atrophy and difficulty with speech. In order to overcome these shortcomings, Terzis introduced the minihypoglossal procedure in combination with a cross-face nerve, where only 40% of the hypoglossal nerve circumference was used, with little side effects [19, 20]. The masseteric nerve seems to be the most frequently employed nerve in one-stage procedures in adults or children with Moebius syndrome where bilateral facial palsy is present. The biggest problem with alternative motors nerves is the question of brain plasticity and whether patients ever develop a spontaneous smile. Manktelow et al. showed that spontaneous smile occurred in 59% of the patients undergoing facial reanimation surgery with gracilis muscle innervated by the masseter motor nerve, which was attributed to cerebral plasticity [21].

2. PARADIGM SHIFT IN FACIAL REANIMATION SURGERY

2.1. Baby-Sitting of the Damaged Facial Nerve

The baby-sitter procedure was first introduced by Terzis in 1984 [22] as a way of assisting the cross-facial nerve graft until the new motor axons from the contralateral facial nerve reach the recent paretic facial musculature. It entails a 40% neurectomy of the hypoglossal nerve, with end-to-side neurorrhaphy to the ipsilateral damaged facial nerve trunk, performed at the same time with the first stage of a cross-facial nerve graft. The second stage of the procedure has to be performed 8 to 12 months later, when the distal ends of the cross-facial nerve grafts are connected distally to the branches of the affected facial nerve.

Patients with recent complete clinical paralysis of the facial muscles and unusable proximal facial nerve are candidates for the baby-sitter procedure. Needle electromyography has to show signs of denervation, like fibrillations, in order for the patients to qualify for such a procedure. These translates in muscles that still have the potential to be resuscitated.

The standard treatment of patients where the proximal part of the facial nerve cannot be used to reanimate the facial musculature are nerve transfers, such as accessory, hypoglossal, trigeminal and phrenic nerve. All these transfers are associated with loss of function at the donor side ranging from minimal to significant, as well as uncoordinated mass movement

- accessory nerve – limited active shoulder abduction, severe shoulder pain and stiffness, shoulder girdle depression [23, 24];
- hypoglossal nerve – hemi-tongue atrophy with mastication problems, difficulty in swallowing and speech impairment [19, 25]
- trigeminal nerve – rare reports of temporary limited mouth opening, cheek thinning
- phrenic nerve - diaphragm dysfunction with dyspnea and sleep disturbances [26]

Moreover, these donor nerves are not capable of providing spontaneous emotional expression, apart from the masseteric nerve, where spontaneous smile could be recorded in some of the patients [21, 27]. These results are attributed to the cerebral cortical reorganization, a concept still not entirely understood. Nonetheless, latent pre-existing

horizontal connections between facial nerve and fifth nerve centers are believed to become active through learning exercises.

Since its first description by Sacramella in 1970 [28], the cross-facial nerve graft represents the first choice when it comes to reanimation of coordinated and spontaneous smile. The neural input provided by the healthy facial nerve cortical center enables the spontaneity and synchronicity of facial expression. However, this important breakthrough in the field of facial nerve paralysis still has a major shortcoming: the long distance for axon regeneration might take too long for the target muscles and reach them after atrophy has occurred [29], on the one hand, while there are theories stating that the chronic denervation of Schwann cells in the distal stump of the nerve has more impact on poor functional recovery than the irreversible denervation atrophy of the muscle [30]. Compared to the ideal situation were a direct immediate repair of a nerve takes places in close proximity of the target muscle and in the time window when the Schwann cells' neurotrophic support for axonal regeneration is optimal (1-8 weeks in animal studies [31]), only 10% of these regenerating axons crossing the suture line are present in a chronically denervated distal nerve stump. Moreover, Sulaiman et al. showed not only that this reduced number of regenerated motorneurons reinnervated the denervated muscle fibers, but they were able to reinnervate up to 3 times the number of muscle fibers that they normally do. Therefore, this enlargement of the reinnervated motor units made them conclude that it is not the inability of the denervated muscle fibers to be reinnervated that leads to poor functional recovery, but the chronic denervation of the Schwann cells that limits the number of regenerated axons.

In order to surpass this obstacle, Terzis envisioned the babysitter procedure using part of the hypoglossal nerve as described at the beginning of the section in order to provide endogenous growth support by adding motor donor axons into the denervated distal nerve stump. Depending on the need for additional procedures, she divided the patients in 3 groups [5]:

A. Short denervation time (6-9 months denervation tima) – the two-stage procedure should provide sufficient symmetrical animation, without the need for additional interventions
B. Later cases (denervation > 9 months) – even though there are some fibrillations on needle electromyography, the patient should be warned that the need for additional muscle transfer is frequent
C. Late cases (denervation > 24 months) – the baby-sitter procedure is still recommended, provided that sparse fibrillation potentials can be evoked; however, in this group, a free muscle transfer will certainly be needed in order to achieve satisfactory results

In the late cases, the baby-sitting procedure is believed to make the secondary procedures more successful, even if just minimal function of the autologous facial musculature returns.

In one study [20], 20 patients underwent the original baby-sitter procedure. Overall, all the patients achieved a degree of emotional and coordinated movement, with 10% recording an excellent result (symmetrical smile and full contraction), 16% a good result (nearly symmetrical smile and nearly full contraction) and 25% a moderate result. Postoperative eye closure and lower lip depression also recorded a significant improvement.

In another study pertaining to the same group [5], 18 patients underwent the baby-sitter procedure together with a free muscle flap (gracilis muscle or pectoralis minor muscle) or a regional muscle transfer (frontalis, platysma muscle). While all the free muscle flaps where performed during the second stage of the baby-sitter procedure, only part of the regional muscle transfers were performed at the same time. 10 patients needed an additional third stage for the regional muscle transfer. Eyelid closure, smile and lower lip depression seemed to record statistically significant improvement.

Since sacrificing the entire hypoglossal nerve, as in the classic hypoglossal transfer, leads to tongue atrophy with subsequent dysarthria and dysphagia [32, 33], Kalantarian et al. [19] investigated the number of fibers sufficient enough to restore eye sphincter function in a rat model of facial paralysis and blink reflex, but without sacrificing the vital function of the tongue. Nerve conduction studies and axonal counts in the hypoglossal nerve and motor end-plates showed a minimal atrophy of the tongue in the 40% group, while warranting sufficient reinnervation of the zygomatic branch. Since the 80% group lead to an excessive tongue atrophy, the group concluded that 40% neurectomy of the hypoglossal nerve ensures preservation of the tongue and adequate target function.

Apart from the mini-hypoglossal nerve, Bianchi et al. [34] described a modification of the baby-sitter procedure, where the masseteric nerve is coopted to the principal inferior branch of the facial nerve on the affected side, while 2 cross-facial nerve grafts are connected both on the healthy and the paralyzed side to distal zygomatico-ocular and zygomatico-buccal branches, therefore having just a one-stage procedure. All 8 patients achieved spontaneous and emotional smile, without biting, between 7 and 13 months postoperatively.

2.2. Supercharging the Cross Facial Nerve Graft with Sensory Nerves

Distal nerve stumps undergo Wallerian degeneration and Schwann cells play an important role in this process [35]. At the beginning, they are involved in the degeneration and phagocytosis of debris, such as axons and myelin. In a more advanced phase, the loss of axonal contact induces the Schwann cells to proliferate and change in phenotype from that of myelinating to a nonmyelinating, growth-supportive phenotype. Therefore, the myelin-associated genes are downregulated, while the regeneration-associated genes are upregulated [36]. This process is also known as chronic denervation. The same happens to a cross-facial nerve graft that can be over 20 cm long. The time needed for the axons to regenerate through them is several months, since axon growth rate was appreciated at around 1 mm/day [37].

Frey et al. [38] showed in an animal study on sheep that a high number of regenerated fibres, closer to the number of the fibre input by the motor donor nerve was present at the distal end of the sensory donor graft. Moreover, the median diameter of the healthy nerve fibers in the sensory nerve graft in the distal end, at 9 months, is around one quarter of the normal supplying motor nerve. However, this finding was not supported by their clinical study, where only 10 - 20% of the original sural nerve fibers were identified on the distal end.

Jacobs et al. [39] recorded a mean number of 426 myelinated fibers at the distal end of the sural nerve graft, compared to a mean of 1736 of the normal buccal branch of the healthy side used as donor. Even though only a small portion of the myelinated nerve fibers reach the distal end of the sural graft, very large numbers of unmyelinated axons regenerate (mean of 3853 in the buccal branch, compared to 11043 in the distal end of the sural graft). The authors

suggest that the functional free muscle transfer connected to the sural nerve graft in the second stage is evidence that these unmyelinated fibers have the potential to become myelinated once the target muscle is present.

Since results of free functional muscle transfer with cross-facial nerve graft are partial at best, Placheta et al. [6] envisioned a study where they could help with the chronic degeneration that takes place at the end of the cross-facial nerve graft due to the long distance and therefore duration of axonal regeneration. Their idea came from the babysitting [22] and sensory protection [40, 41] of chronically denervated nerves, both of the procedures providing endogenous trophic support, therefore improving regeneration. The sensory protection theory has been further investigated by Bain and collaborators [40, 41], based on previous studies which showed that sensory-to-motor innervation are incapable of forming excitable neuromuscular junctions, but they surprisingly exerted trophic effects on the muscle [42, 43]. In a rat model, they cut the tibial nerve before entering the gastrocnemius and soleus muscles and delayed the peroneal-tibial nerve transfer for 4-6 months. In one group, no sensory nerve was used, while in the second group ('sensory-protected'), the saphenous nerve was sutured in an end-to-end technique to the distal stump of the tibial nerve for these 4-6 months. In the end, the mean weights, twitch and tetanic tensions, as well as the histological appearance of the gastrocnemius and soleus muscles in the sensory-protected rats were always superior to the other group. Their assumption was that neurotrophins, produced by motor and possibly sensory nerves, might have effects on skeletal muscle fibers and maintain the architecture of the distal nerve stump. The same group further published the first clinical case of sensory protection in a patient with complete sciatic nerve palsy following hip arthroplasty. The patients underwent neurolysis of the sciatic nerve after neuroma formation and saphenous nerve transfers to the motor branches of the medial and lateral gastrocnemius muscles, as well as to the motor branch of the deep peroneal nerve to the tibialis anterior muscle. After 3 months, electromyography studies showed amelioration of denervation potentials and improved motor recovery only in these specific muscles.

Ladak et al. [44] tried to protect the distally denervated nerve stump with 1 to 3 side-to-side nerve grafts between an intact donor tibial nerve and the distal stump of the severed common peroneal nerve. The grafts were taken from the common peroneal nerve and the delayed surgical repair of the distal stump of the common peroneal nerve to the proximal stump took place several months after the initial procedure. After allowing the delayed surgical repairs to regenerate for 5 months, the common peroneal motoneurons had more regenerating axons in the denervated nerve stumps of the 'protected group' and the weight of the reinnervated muscles also registered higher values.

Since all of these experiments are hard to translate in the clinical setting, Placheta et al. [6] used regional sensory nerves in an end-to-side technique for the cross-facial nerve grafts in a rat model in order to enhance facial reanimation outcomes. The right common peroneal nerve was used as the cross-facial nerve graft. The right side of the face was considered the healthy one and the buccal branch of the facial nerve was used as the donor motor nerve for the cross-facial nerve graft. After passing the graft on the other side of the face, the distal end was sutured to the buccal and marginal mandibular branches of the facial nerve. In the sensory protection group, the 2 occipital nerves were dissected and sutured in an end-to-side technique to the cross-facial nerve graft in an epineural window at 10 and 20 mm from the proximal suture of the graft. The *in vivo* imaging of regenerating axons demonstrated that axons reached the left side of the face (recipient) earlier than the group where no occipital

nerves were used. At 16 weeks, the right facial nucleus showed more retrograde labelled motoneurons in the protected group. The same group registered higher amplitudes and higher velocity during retraction of the whisker movement analysis. These results were also supported by the histomorphometric analysis of the buccal and marginal branches on the left side, 10 mm distal to the branching. The mean number of myelinated axons was 1873 in the unprotected group, while the protected group with occipital nerves recorded a mean number of 2458 myelinated axons. Both of these values are higher than the mean of 1685 myelinated axons of the donor buccal branch on the right side, indicating axonal sprouting in these groups. Through this model, the authors intended to avoid a motor nerve deficit and also the overpower of the facial nerve impulses from the contralateral side through the introduction of another motor donor nerve. The end-to-side technique used is a modification of the supercharge nerve transfer already described in the literature [45-47]: the end of the donor nerve is coapted in an end-to-side manner to the injured recipient nerve in order to maintain the partially regenerated function of the recipient nerve and further augment it.

For example, Farber et al. [45] employed this principle in an incomplete rodent sciatic nerve injury model. The group where supercharging was performed in combination with normal grafting of the severed nerve showed more intense labelling of motoneurons in the ventral horn and also a higher number of myelinated fiber counts in the distal nerve. Therefore, this higher number of myelinated fibers cannot only be attributed to sprouting, since the more intense ventral horn motoneuron labelling indicated that the supercharged end-to-site transfer provided additional motoneurons to the target muscles. Moreover, this higher number of myelinated fibers correlated with a greater muscle specific force. On specific muscle force analysis, the supercharged end-to-site transfer group didn't drop to the values of the control group with normal grafts after sectioning of the supercharging donor. One possible explanation might be that even if both groups would have the same number of prime donor regenerated to the muscle, the supercharged group showed a better performance of the muscle due to protection from atrophy conferred by the transfer. Altogether, the supercharging procedure seems to preserve muscle function apart from motor neurons' delivery.

In another study, Isaacs et al. [47] compared muscle force in the gastrocnemius muscle after transection with primary repair (group 1) and transection with primary repair and supercharged end-to-side transfer of the peroneal nerve (group 2). After elimination of potential regenerative pathways in the second group, proximal stimulation showed that both axonal pathways determined notable reinnervation. Another study of the same group concluded that a supercharged end-to-side transfer to a non-injured, non-transected recipient nerve didn't account for any part of the muscle force recorded in the recipient's target muscle [48].

2.3. Dual-Innervation

Since first described by Harii in 1976 [10], free functional muscle transfer is considered the gold standard treatment of long-standing facial paralysis. However, when used in conjunction with a nerve other than the facial nerve, like for example the masseteric nerve, the voluntary clenching of the teeth needed as stimulus and the inability to achieve coordinated movement with the healthy side of the face led to the development of the nowadays standard procedure: two-stage cross-facial nerve graft (first stage), followed by the

transfer of a free functional muscle (second stage) as described by O'Brien [49] and Vedung [50]. The main advantage of the cross-facial nerve graft is the ability to provide synchronous and spontaneous activity of the free muscle transfer, while its unpredictability and lack of consistency in muscle contraction degree are considered its main drawbacks [51]. An explanation for the latter might be the lower number of axons reaching the target muscle due to the fact that they have to cross two neurorrhaphy sites [52]. Moreover, the long time required for the two-stage procedure was also seen as a disadvantage. In order to reduce this time, but still maintain the spontaneous and synchronous impulses coming through the non-paralyzed 7th cranial nerve, Koshima [53] and Harii [54] envisioned a one-stage free functional muscle transfer with a long nerve, connected directly to a branch of the healthy facial nerve. While the rectus femoris muscle used by Koshima achieved adequate contraction, the bulk of the flap was seen as an impediment of this technique. To overcome this aspect, Harii used the segmental latisimuss dorsi muscle. Even though the aesthetic results were better, the predictability of the amount of contraction couldn't be guaranteed.

Another well-established technique is the free gracilis muscle flap anastomosed to the masseteric nerve [55]. The main advantage of this procedure is the short period of time needed for the reinnervation of the flap, apart for the single-stage aspect. Moreover, the reliability of the masseteric nerve and its contractibility in 100% of the cases was also reported by Manktelow et al. [21]. In the same study, the authors reported the presence of spontaneous smile in 59% of the patients, as described by the ability of the patients to smile involuntarily in over half the time or more. This finding was attributed to cerebral cortical reorganization (a process also known as cortical adaptation) through the activation of dormant horizontal connections [56] or the appearance of new synaptic connection [57] between the fifth nerve center and the facial nerve center. However, identification of these connections with functional magnetic resonance imaging wasn't possible due to the close proximity of these two centers in the cortex.

The first description of a dual-innervation technique was provided by Watanabe et al. [58]. The authors transferred a free functional latissimus dorsi muscle with a long thoracodorsal nerve (15 cm) to the paralyzed face, while the nerve was tunneled through the upper lip to reach the healthy, contralateral side where it was coapted to a buccal branch of the facial nerve. Additionally, they removed the soft-tissue of the hilum where the thoracodorsal nerve entered the latissimus dorsi muscle, as well as the soft tissue present over the masseter muscle. The two 'raw' surfaces were then placed in contact. Voluntary movement was recorded at 3.4 months, while spontaneous smiling was achieved 5.9 months postoperatively. The benefits of their technique consisted, among others, in a faster reinnervation of the latissimus dorsi muscle than a standard one-stage technique and the augmentation of the neural input to the muscle for the symmetrical smile.

Based on the aforementioned techniques, Biglioli et al. [7] developed a one-stage facial reanimation procedure with dual innervation, where the gracilis muscle was used as a free functional muscle flap innervated by the masseteric nerve, together with a cross-facial sural nerve graft. More exactly, the anterior branch of the obturator nerve is connected to the masseteric nerve. For the cross-facial sural nerve graft, a branch of the facial nerve from the healthy side is used for the proximal neurorrhaphy, while the distal end of the sural nerve is connected end-to-side to the anterior obturator branch, after excising an epineural window. The end-to-side anastomosis of the cross-facial nerve graft is a neurotization techqinue that doesn't disrupt any regenerated axons from the masseteric nerve. Therefore, these regenerated

axons remain intact, even if the cross-facial nerve graft would fail to bring reinnervated axons to the gracilis muscle. In their cohort of 4 patients, all the patients were able to contract the muscle voluntary at around 3.8 months postoperatively, while spontaneous flap activity was recorded around 7.2 months after the operation. The fact that the muscle also received reinnervated axons through the cross-facial nerve graft was confirmed by the motor potentials recorded with electromyography during stimulation of the contralateral facial nerve. The authors hypothesize that the axons passing through the cross-facial nerve graft also activate the masseteric nerve fibers, leading therefore to a favorable quantity of contraction during spontaneous smiling.

The masseter nerve is thought to provide a more powerful smile than the cross-facial nerve graft [59, 60]. The great axonal load, as well as the crossing of only one nerve connection support this statement. Even though this technique guarantees a shorter reinnervation time and a stronger muscle contraction, there is doubt that by the time the cross-facial nerve graft axons reach the muscle they still have free motor units to connect to. Based on this theory, Cardenas-Mejia et al. [52] described a variation of the double-innervation proposed by Biglioli [7]. The authors envisioned a two-stage reanimation procedure where a cross-facial nerve graft was connected to a branch of the healthy facial nerve and tunnelled to the paralyzed side in the first stage. In the second stage, the obturator nerve of the gracilis muscle was coapted in an end-to-end technique to the cross-facial nerve graft, while the masseteric nerve was connected end-to-side to the obturator nerve, about 1 cm away from the muscle. Their results showed an average of 70% motor unit recruitment, while clinically, all 9 patients achieved voluntary and spontaneous smile.

CONCLUSION

The strive for perfection will continue in facial reanimation surgery. Better understanding of the mechanisms and physiology of nerve regeneration will hopefully in the future enable the surgeon to produce an excellent surgical result in almost every case. The influence of proprioception of the transplanted muscle on functional outcomes is yet to be determined. Afferent sensory feed-back may also prove to be more important than previously thought in producing the required complex movement to enable the transplanted muscle to mimic the three-dimensional function of the normal facial musculature.

REFERENCES

[1] Gousheh, J. & Arasteh, E. (2011). Treatment of facial paralysis: dynamic reanimation of spontaneous facial expression-apropos of 655 patients. *Plastic and reconstructive surgery*., *128*(6), 693e-703e.

[2] Leckenby, J. & Grobbelaar, A. (2013). Smile restoration for permanent facial paralysis. *Archives of plastic surgery*., *40*(5), 633-8.

[3] Terzis, J. K. & Olivares, F. S. (2009). Secondary surgery in adult facial paralysis reanimation. *Plastic and reconstructive surgery*., *124*(6), 1916-31.

[4] Leckenby, J. I. (2018). *Nerve regeneration through autologous grafts: exploring the "Bottleneck" theory further*: UCL.

[5] Terzis, J. K. & Tzafetta, K. (2009). "Babysitter" procedure with concomitant muscle transfer in facial paralysis. *Plastic and reconstructive surgery.*, *124*(4), 1142-56.

[6] Placheta, E., Wood, M. D., Lafontaine, C., Liu, E. H., Hendry, J. M., Angelov, D. N., et al. (2015). Enhancement of facial nerve motoneuron regeneration through cross-face nerve grafts by adding end-to-side sensory axons. *Plastic and reconstructive surgery.*, *135*(2), 460-71.

[7] Biglioli, F., Colombo, V., Tarabbia, F., Pedrazzoli, M., Battista, V., Giovanditto, F., et al. (2012). Double innervation in free-flap surgery for long-standing facial paralysis. *Journal of plastic, reconstructive & aesthetic surgery: JPRAS.*, *65*(10), 1343-9.

[8] Thompson, N. (1971). Autogenous free grafts of skeletal muscle. A preliminary experimental and clinical study. *Plastic and reconstructive surgery.*, *48*(1), 11-27.

[9] Tamai, S., Komatsu, S., Sakamoto, H., Sano, S. & Sasauchi, N. (1970). Free muscle transplants in dogs, with microsurgical neurovascular anastomoses. *Plastic and reconstructive surgery.*, *46*(3), 219-25.

[10] Harii, K., Ohmori, K. & Torii, S. (1976). Free gracilis muscle transplantation, with microneurovascular anastomoses for the treatment of facial paralysis. A preliminary report. *Plastic and reconstructive surgery.*, *57*(2), 133-43.

[11] Harii, K. (1979). Microneurovascular free muscle transplantation for reanimation of facial paralysis. *Clinics in plastic surgery.*, *6*(3), 361-75.

[12] Manktelow, R. T. & Zuker, R. M. (1984). Muscle transplantation by fascicular territory. *Plastic and reconstructive surgery.*, *73*(5), 751-7.

[13] Dellon, A. L. & Mackinnon, S. E. (1985). Segmentally innervated latissimus dorsi muscle. Microsurgical transfer for facial reanimation. *Journal of reconstructive microsurgery.*, *2*(1), 7-12.

[14] Harrison, D. H. (1985). The pectoralis minor vascularized muscle graft for the treatment of unilateral facial palsy. *Plastic and reconstructive surgery.*, *75*(2), 206-16.

[15] Terzis, J. K. (1989). Pectoralis minor: a unique muscle for correction of facial palsy. *Plastic and reconstructive surgery.*, *83*(5), 767-76.

[16] Balance, C. A., Balance, H. A. & Stewart, P. (1903). Remarks on the operative treatment of chronic facial palsy of peripheral origin. *British medical journal.*, *1*(2209), 1009-13.

[17] Körte, W. (1903). Ein fall Nervenpfropfung der nervus facialis auf der Nervus hypoglossus. *Deutsch Medic Woch.*, (39), 293-5.

[18] Harrison, D. H. (2002). The treatment of unilateral and bilateral facial palsy using free muscle transfers. *Clinics in plastic surgery.*, *29*(4), 539-49, vi.

[19] Kalantarian, B., Rice, D. C., Tiangco, D. A. & Terzis, J. K. (1998). Gains and losses of the XII-VII component of the "baby-sitter" procedure: a morphometric analysis. *Journal of reconstructive microsurgery.*, *14*(7), 459-71.

[20] Terzis, J. K. & Tzafetta, K. (2009). The "babysitter" procedure: minihypoglossal to facial nerve transfer and cross-facial nerve grafting. *Plastic and reconstructive surgery.*, *123*(3), 865-76.

[21] Manktelow, R. T., Tomat, L. R., Zuker, R. M. & Chang, M. (2006). Smile reconstruction in adults with free muscle transfer innervated by the masseter motor

nerve: effectiveness and cerebral adaptation. *Plastic and reconstructive surgery*., *118*(4), 885-99.

[22] Terzis, J. K. editor 'Babysitters': An exciting new concept in facial reanimation. The facial nerve. *Proceedings of the Sixth International Symposium on the Facial Nerve*, 1988 October 2-5, Rio de Janeiro, Brazil: Berkley, Calif: Kugler & Ghedini.

[23] Kelley, M. J., Kane, T. E. & Leggin, B. G. (2008). Spinal accessory nerve palsy: associated signs and symptoms. *The Journal of orthopaedic and sports physical therapy*., *38*(2), 78-86.

[24] Poe, D. S., Scher, N. & Panje, W. R. (1989). Facial reanimation by XI-VII anastomosis without shoulder paralysis. *The Laryngoscope*., *99*(10 Pt 1), 1040-7.

[25] Biglioli, F., Frigerio, A., Colombo, V., Colletti, G., Rabbiosi, D., Mortini, P., et al. (2012). Masseteric-facial nerve anastomosis for early facial reanimation. *Journal of cranio-maxillo-facial surgery : official publication of the European Association for Cranio-Maxillo-Facial Surgery*., *40*(2), 149-55.

[26] Ricoy, J., Rodriguez-Nunez, N., Alvarez-Dobano, J. M., Toubes, M. E., Riveiro, V. & Valdes, L. (2018). Diaphragmatic dysfunction. *Pulmonology*.

[27] Lifchez, S. D., Matloub, H. S. & Gosain, A. K. (2005). Cortical adaptation to restoration of smiling after free muscle transfer innervated by the nerve to the masseter. *Plastic and reconstructive surgery*., *115*(6), 1472-9, discussion 80-2.

[28] Scaramella, L. F. editor Preliminary report on facial nerve anastomosis. *Proceedings of the 2nd International Symposyum on Facial Nerve Surgery*, 1970, Osaka, Japan.

[29] Gutmann, E. & Young, J. Z. (1944). The re-innervation of muscle after various periods of atrophy. *Journal of anatomy*., *78*(Pt 1-2), 15-43.

[30] Sulaiman, O. A. & Gordon, T. (2009). Role of chronic Schwann cell denervation in poor functional recovery after nerve injuries and experimental strategies to combat it. *Neurosurgery*., *65*(4 Suppl), A105-14.

[31] Sulaiman, O. A., Midha, R., Munro, C. A., Matsuyama, T., Al-Majed, A. & Gordon, T. (2002). Chronic Schwann cell denervation and the presence of a sensory nerve reduce motor axonal regeneration. *Experimental neurology*., *176*(2), 342-54.

[32] Hammerschlag, P. E. (1999). Facial reanimation with jump interpositional graft hypoglossal facial anastomosis and hypoglossal facial anastomosis: evolution in management of facial paralysis. *The Laryngoscope*., *109*(2 Pt 2 Suppl 90), 1-23.

[33] Pensak, M. L., Jackson, C. G., Glasscock, M. E. 3rd. & Gulya, A. J. (1986). Facial reanimation with the VII-XII anastomosis: analysis of the functional and psychologic results. *Otolaryngology--head and neck surgery: official journal of American Academy of Otolaryngology-Head and Neck Surgery*., *94*(3), 305-10.

[34] Bianchi, B., Ferri, A., Ferrari, S., Copelli, C., Magri, A., Ferri, T., et al. (2014). Cross-facial nerve graft and masseteric nerve cooptation for one-stage facial reanimation: principles, indications, and surgical procedure. *Head & neck*., *36*(2), 235-40.

[35] Ide, C. (1996). Peripheral nerve regeneration. *Neuroscience research*., *25*(2), 101-21.

[36] Mirsky, R. & Jessen, K. R. (1999). The neurobiology of Schwann cells. *Brain pathology (Zurich, Switzerland)*., *9*(2), 293-311.

[37] Braam, M. J. & Nicolai, J. P. (1993). Axonal regeneration rate through cross-face nerve grafts. *Microsurgery*., *14*(9), 589-91.

[38] Frey, M., Koller, R., Liegl, C., Happak, W. & Gruber, H. (1996). Role of a muscle target organ on the regeneration of motor nerve fibres in long nerve grafts: a synopsis of experimental and clinical data. *Microsurgery*., *17*(2), 80-8.

[39] Jacobs, J. M., Laing, J. H. & Harrison, D. H. (1996). Regeneration through a long nerve graft used in the correction of facial palsy. A qualitative and quantitative study. *Brain: a journal of neurology*., *119* (Pt 1), 271-9.

[40] Bain, J. R., Veltri, K. L., Chamberlain, D. & Fahnestock, M. (2001). Improved functional recovery of denervated skeletal muscle after temporary sensory nerve innervation. *Neuroscience*., *103*(2), 503-10.

[41] Bain, J. R., Hason, Y., Veltri, K., Fahnestock, M. & Quartly, C. (2008). Clinical application of sensory protection of denervated muscle. *Journal of neurosurgery*., *109*(5), 955-61.

[42] Gutmann, E. (1945). The reinnervation of muscle by sensory nerve fibres. *Journal of anatomy*., *79*(Pt 1), 1-8, 4.

[43] Karpati, G., Carpenter, S. & Charron, L. (1981). Experimental reinnervation attempts of skeletal muscle cells by non-motor nerves. In: Gorio A, Millesi H, Mingrino S, editors. *Posttraumatic Peripheral Nerve Regeneration: Experimental Basis and Clinical Implications*. Raven, New York.

[44] Ladak, A., Schembri, P., Olson, J., Udina, E., Tyreman, N. & Gordon, T. (2011). Side-to-side nerve grafts sustain chronically denervated peripheral nerve pathways during axon regeneration and result in improved functional reinnervation. *Neurosurgery*., *68*(6), 1654-65, discussion 65-6.

[45] Farber, S. J., Glaus, S. W., Moore, A. M., Hunter, D. A., Mackinnon, S. E. & Johnson, P. J. (2013). Supercharge nerve transfer to enhance motor recovery: a laboratory study. *The Journal of hand surgery*., *38*(3), 466-77.

[46] Frey, M., Giovanoli, P. & Michaelidou, M. (2006). Functional upgrading of partially recovered facial palsy by cross-face nerve grafting with distal end-to-side neurorrhaphy. *Plastic and reconstructive surgery*., *117*(2), 597-608.

[47] Isaacs, J. E., Cheatham, S., Gagnon, E. B., Razavi, A. & McDowell, C. L. (2008). Reverse end-to-side neurotization in a regenerating nerve. *Journal of reconstructive microsurgery*., *24*(7), 489-96.

[48] Isaacs, J., Allen, D., Chen, L. E. & Nunley, J. 2nd. (2005). Reverse end-to-side neurotization. *Journal of reconstructive microsurgery*., *21*(1), 43-8, discussion 9-50.

[49] O'Brien, B. M., Franklin, J. D. & Morrison, W. A. (1980). Cross-facial nerve grafts and microneurovascular free muscle transfer for long established facial palsy. *British journal of plastic surgery*., *33*(2), 202-15.

[50] Vedung, S., Hakelius, L. & Stalberg, E. (1984). Cross-face nerve grafting followed by free muscle transplantation in young patients with long-standing facial paralysis. Reanimation of the cheek and the angle of the mouth. *Scandinavian journal of plastic and reconstructive surgery*., *18*(2), 201-8.

[51] Faria, J. C., Scopel, G. P., Busnardo, F. F. & Ferreira, M. C. (2007). Nerve sources for facial reanimation with muscle transplant in patients with unilateral facial palsy: clinical analysis of 3 techniques. *Annals of plastic surgery*., *59*(1), 87-91.

[52] Cardenas-Mejia, A., Covarrubias-Ramirez, J. V., Bello-Margolis, A. & Rozen, S. (2015). Double innervated free functional muscle transfer for facial reanimation. *Journal of plastic surgery and hand surgery*., *49*(3), 183-8.

[53] Koshima, I., Moriguchi, T., Soeda, S., Hamanaka, T., Tanaka, H. & Ohta, S. (1994). Free rectus femoris muscle transfer for one-stage reconstruction of established facial paralysis. *Plastic and reconstructive surgery*., *94*(3), 421-30.

[54] Harii, K., Asato, H., Yoshimura, K., Sugawara, Y., Nakatsuka, T. & Ueda, K. (1998). One-stage transfer of the latissimus dorsi muscle for reanimation of a paralyzed face: a new alternative. *Plastic and reconstructive surgery*., *102*(4), 941-51.

[55] Zuker, R. M., Goldberg, C. S. & Manktelow, R. T. (2000). Facial animation in children with Mobius syndrome after segmental gracilis muscle transplant. *Plastic and reconstructive surgery*., *106*(1), 1-8, discussion 9.

[56] Ziemann, U., Muellbacher, W., Hallett, M. & Cohen, L. G. (2001). Modulation of practice-dependent plasticity in human motor cortex. *Brain: a journal of neurology*., *124*(Pt 6), 1171-81.

[57] Hess, G. & Donoghue, J. P. (1996). Long-term potentiation and long-term depression of horizontal connections in rat motor cortex. *Acta neurobiologiae experimentalis*., *56*(1), 397-405.

[58] Watanabe, Y., Akizuki, T., Ozawa, T., Yoshimura, K., Agawa, K. & Ota, T. (2009). Dual innervation method using one-stage reconstruction with free latissimus dorsi muscle transfer for re-animation of established facial paralysis: simultaneous reinnervation of the ipsilateral masseter motor nerve and the contralateral facial nerve to improve the quality of smile and emotional facial expressions. *Journal of plastic, reconstructive & aesthetic surgery: JPRAS*., *62*(12), 1589-97.

[59] Bae, Y. C., Zuker, R. M., Manktelow, R. T. & Wade, S. (2006). A comparison of commissure excursion following gracilis muscle transplantation for facial paralysis using a cross-face nerve graft versus the motor nerve to the masseter nerve. *Plastic and reconstructive surgery*., *117*(7), 2407-13.

[60] Hontanilla, B., Marre, D. & Cabello, A. (2013). Facial reanimation with gracilis muscle transfer neurotized to cross-facial nerve graft versus masseteric nerve: a comparative study using the FACIAL CLIMA evaluating system. *Plastic and reconstructive surgery*., *131*(6), 1241-52.

In: Encyclopedia of Surgery (22 Volume Set)
Editors: Andreas Lehrer and Kristin Mueller
ISBN: 978-1-53618-329-0
© 2020 Nova Science Publishers, Inc.

Chapter 112

THE ROLE OF ENDOSCOPIC SINUS SURGERY IN PEDIATRIC PATIENTS

Marco Berlucchi[1,*], MD and Michele Tomasoni[2], MD
[1]Department of Pediatric Otorhinolaryngology,
Spedali Civili di Brescia, Brescia, Italy
[2]Department of Otorhinolaryngology, University of Brescia,
Brescia, Italy

ABSTRACT

Introduction of pediatric endoscopic sinus surgery (PESS) is relatively recent. Owing to the excellent outcomes of functional endoscopic sinus surgery observed in the adult population, in 1990s the development of suitable pediatric instruments and optics was encouraged. Moreover, improvements in technology and surgical techniques enabled pediatric otolaryngologists to progressively expand the surgical indications of endoscopic nasal approaches. Nowadays, PESS is routinely performed in children affected by sinonasal inflammation pathologies, anatomic malformations, benign expansible lesions, and lacrimal stenosis. Furthermore, this surgical management is favoring PESS over open approaches for CSF leak repair and other skull base disorders, including some neoplastic masses. However, specific considerations in PESS must be addressed. The major issues regard reduced nostril aperture and nasal fossae volume, and degree of sinus pneumatization. Herein, the authors describe this surgical technique and its main use in pediatric patients. Finally, the advantages of this less invasive surgery are described compared to traditional surgical treatments.

PEDIATRIC NASAL EMBRYOLOGY AND DEVELOPMENT

Thorough knowledge of nasal and paranasal sinuses anatomy is mandatory to achieve familiarity in endo-nasal endoscopic surgery. A major issue in the pediatric population concerning sinonasal anatomy is the variability according to age, stage of development, and

* Corresponding Author's Email: marco.berlucchi@tin.it; Fax: +390303996009.

pathology treated [1]. A key point in paranasal sinuses consists in the development of the maxillo- and ethmoido-turbinals by the 10th week of gestation from the lateral wall of the nasal capsule. Each of these ridges contribute to the formation of important anatomical structures and key landmarks in endoscopic surgery. The inferior turbinate develops from the inferior ridge, called maxillo-turbinal; 5 to 6 ridges develop superiorly and form the ethmoido-turbinals. The first ethmoido-turbinal forms the agger-nasi and uncinated process, and the second through fourth participate in the formation of portions of the bulla, middle and superior turbinate. The fifth and sixth ethmoido-turbinals degenerate or contribute to the supreme turbinate [1-3].

Two types of sinus pneumatization are recognized: "intramural" when confined to the nasal capsule (ethmoid primary pneumatization) and "extramural" when extended to the surrounding bones (ethmoid secondary pneumatization and other sinus development) [4]. In fact, whereas the maxillary, frontal, and sphenoid sinuses develop as extensions of the ethmoid (extra-nasal capsule development), ethmoid pneumatization starts within the nasal capsule as intra-capsular diverticular spaces (primary pneumatization) and progressively expanding beyond nasal capsule borders within the contiguous structures. Ethmoidal air cells develop by the 12th week of gestation and continue to grow up to early adolescence (generally around 12 years) [3-4].

The maxillary sinus is the first paranasal sinus to develop (by the 10th week) as a lateral bud from the ethmoidal infundibulum, between the first and second ethmoido-turbinals; at birth the sinus volume is small, but its diameter increases greatly in the first 8 years of life. During childhood and adolescence, the maxillary sinus continues to grow and, reaches an adult size by 16-18 years [5]. Frontal sinus development starts with migration of extramural anterior ethmoidal cells within the inferior aspect of the frontal bone during the 13th week of gestation. Thereafter, the anterior ethmoidal outpouching proceeds further between the frontal bone until about 20 years of age (can generally be seen on X-rays between 2 and 6 years). According to Terracol and Ardouin, the variable drainage pathway of the frontal sinus depends mostly on which ethmoidal cell the sinus developed (nasal, orbital or bullar groups) [4,6]. During the 4th month of gestation, the sphenoid sinus develops as an "extramural" extension of posterior ethmoidal cells from the sphenoethmoidal recess, with a posterior directed gradual extension starting from the antero-inferior wall, proceeding to the floor and then to the planum sphenoidale and anterior sellar wall. A varying degree of sellar floor pneumatization is reached in the majority of patients by age 7; extension beyond the posterior sellar wall, when present, rarely occurs before age 12 [7]. Absence or underdevelopment of the frontal and sphenoid sinuses is typical of Down and Apert's syndromes. The skull base derives almost entirely from the chondrocranium (cartilagineous neurocranium) and starts its development at the 4th week of gestation. The basicranium grows slower than the cranial vault. The anterior skull base is cartilaginous at birth, with a progressive ossification process that becomes evident by 4 months of age. Between the ages of 2 and 4 the anterior cranial fossa reaches an adult conformation, with the definitive closure of the spheno-ethmoidal and ethmoido-frontal sutures by adolescence. Anterior displacement of the anterior skull base, frontal bone, and sinus occur during the first years of life secondary to development of the frontal lobe and nasomaxillary complex [8].

Pediatric ENT surgeons must always keep in mind that any surgical procedure in this anatomical region can potentially affect normal development of the craniofacial complex. Extensive procedures on the skull base demands a thorough knowledge of sinonasal and skull base growth centers in order to avoid a major impact on their key role.

NASAL ENDOSCOPY AND PEDIATRIC NASAL ENDOSCOPIC ANATOMY

In-office diagnostic nasal endoscopy is generally performed with patients placed in either a sitting position or kept in the arms of a nurse or parent. The application of cottons soaked with decongestants and local anesthetics in the nasal cavity is generally preferable to increase compliance and space of the nasal cavity. When the use of cottons is not tolerated or in patients younger than 36 months, a local anesthetic can be sprayed in the nasal cavity. In neonates, topical drugs are not generally utilized. Before starting the endoscopy, the child should be informed about the procedure in the attempt to get better collaboration. Four-mm rigid endoscopes are generally reserved for compliant patients older than 8 years; 2.7 and 3 mm rigid endoscopes ensure the same visual quality with better performance in small nasal fossae. Flexible endoscopes, despite the lower visual quality, must be used in non-compliant patients because of their nearly neglible traumatic potential. After removal of cottons and application of anti-fog products on the endoscopic lens, the endoscope is delicately inserted into the nasal fossa. Endoscopic access through the nostril in the first 6 years of life can be difficult because of the significantly narrower aperture, and can pose a major issue during surgical procedures that require the simultaneous use of two instruments. Diagnostic endoscopy is a standardized procedure that is generally performed as follows. First, it starts with the inspection of the nasal fossa floor, nasal septum, inferior nasal turbinate, and inferior meatus; it then proceeds along the floor of the nasal cavity to observe the choanal aperture, nasopharynx, Eustachian tube orifices, and torus tubarius. At this point, the endoscope is directed superiorly and proceeding backwards to assess the sphenoethmoidal recess, middle turbinate, and middle meatus. The uncinate process, bulla ethmoidalis, and iatus semilunaris are generally easily assessable. Finally, anterior to the middle turbinate, the endoscope is rotated superiorly to evaluate the olfactory fossa. Complications are rare, and the most common is nasal bleeding, which is often self-limiting. Parents should be informed to not let their children drink or eat for 20 minutes after the procedure because of partial laryngeal anesthesia from nasal local anesthesia.

Endoscopy plays a major role as a diagnostic tool in the evaluation of the nasal anatomy and functional status by assessing the mucosa, presence of pathologic secretions and their origin, inspection of adenoid hypertrophy, and diagnosis of nasal masses (polyps, congenital malformations, tumors, etc.). In addition, thanks to its high benefit/cost ratio, it is commonly used to evaluate response to medical treatment and for surgical follow-up.

Figure 1. Classic position of the main surgeon (arrow) during pediatric endoscopic sinus surgery. Surgeon operates holding in his hands surgical instrumentations and nasal rigid endoscope connected to camera. The surgeon can check the surgical procedure on the monitor sited in front of him (A). Close up view of nasal endoscope (arrow) and surgical instrumentation (white arrowhead), both inserted into nasal fossa.

PEDIATRIC ENDOSCOPIC SINUS SURGERY

Pediatric endoscopic sinus surgery (PESS) (Figure 1A, B) is performed for several sinonasal disorders ranging from inflammatory diseases to malignant tumors. Herein, the main sinonasal pathologies treated by nasal endoscopic surgical approaches are presented.

Inferior Turbinate Hypertrophy

Inferior turbinate hypertrophy can be either congenital or acquired. The former is rare, whereas the latter is usually due to septal deviation, allergic rhinitis, or gastroesophageal reflux disease [9-10]. The primary presenting symptom is nasal obstruction occasionally associated with seromucosal rhinorrhea, itching, and sneezing. Moreover, chronic nasal obstruction can modify the normal function of the Eustachian tube causing effusion in the middle ear [11]. Diagnosis is made by nasal endoscopy. Rhinomanometry in basal conditions and after nasal decongestion can be useful in selected cases. Medical therapy is usually effective and consists of regular saline irrigations and the application of topical steroids for at least 3 weeks. Association of topical steroids with an anti-histamine is a valid alternative for patients with allergies. Surgery is reserved for hypertrophy resistant to medical therapy and, in pediatric patients, is generally performed under general anesthesia.

Adenoid Hypertrophy

Adenoid hypertrophy represents the most common cause of nasal obstruction in the pediatric population, and is generally diagnosed in the first 6 years of life. The most commonly observed manifestations are bilateral nasal obstruction, snoring, mouth breathing,

rhinorrhea, hyponasal speech, and cough. Clinical history commonly shows recurrent episodes of acute otitis media, persistent effusive otitis and/or chronic or recurrent rhinosinusitis [12]. Adenoid hypertrophy may play a major role in pediatric chronic rhinosinusitis, working as a reservoir for pathological bacteria [13-15]. For this reason, adenoidectomy with or without antral irrigation and balloon sinus dilation can be considered as first-line treatment when maximal medical therapy fails. Adenoid hypertrophy may also present with episodes of sleep apnea and, albeit rarely, affect the cardiovascular system (cor pulmonale in extreme cases). Nasal endoscopy is the gold standard diagnostic procedure for adenoid hypertrophy, evaluating size, intrachoanal extension, residual choanal lumen, and anatomical relationships with the Eustachian tube orifice. Adenoids (Figure 2) appear as a lobulated, pinkish, pyramid-like shaped aggregations of lymphoid tissue with the apex pointed toward the nasal septum and the base at the level of the superior and posterior nasopharyngeal walls. Many surgical options have been developed for treatment of adenoid hypertrophy. In our opinion, the use of adenotome or microdebrider under endoscopic control with a 70° angle optic rigid scope represents the best surgical option for removal of adenoids.

Sinonasal Polyposis

Except for antrochoanal polys, polyposis is quite rare in the pediatric population [16] and when bilateral should raise concern for a potential diagnosis of cystic fibrosis or fungal allergic rhinosinusitis. Even if some predisposing factors are well known (i.e., hereditary, allergies, asthma and aspirin sensitivity), the etiology of sinonasal polyposis is still debated. Sinonasal polyposis can be classified into 5 categories [17]: 1. antrochoanal polyps; 2. choanal polyps; 3. polyposis associated with chronic rhinosinusitis (non-eosinophilic dominated); 4. polyposis associated with chronic rhinosinusitis (eosinophilic dominated); 5. polyposis associated with specific illnesses (asthma, cystic fibrosis, primary ciliary dyskinesia, etc.)

Figure 2. At nasal endoscopy, adenoid hypertrophy (asterisk) obstructing totally the posterior choanae.

Children affected by this disorder report hypo/anosmia, nasal obstruction, rhinorrhea, and sometimes headache or facial pressure [16]. Diagnosis is easily confirmed by nasal endoscopy. Polyps (Figure 3) show a characteristic edematous and translucid appearance

(closely resembling a grape) and generally originate from the middle meatus or the olfactory region. Computed tomography (CT) scan is the gold standard diagnostic technique, defining the exact extension of disease and allowing for detailed study of sinonasal anatomy in the preoperative setting [16].

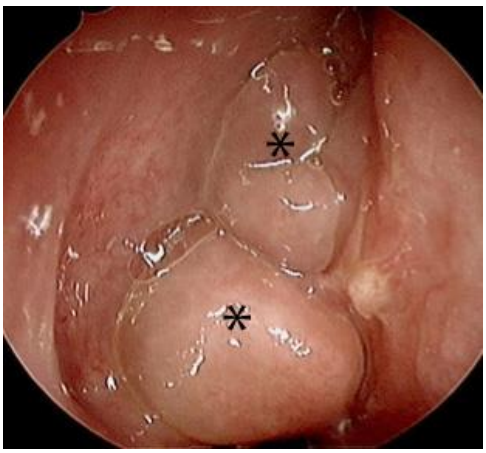

Figure 3. Nasal polyps obstructing completely right nasal fossa.

Medical therapy is usually effective and is managed through saline irrigations and the application of topical steroids for at least 4 weeks. Allergic patients may benefit more from a combination of topical steroids and anti-histamine drugs. When symptoms are not tolerated and polyposis proves to be resistant to medical therapy, surgery is offered to the patient. In the pediatric population, polypectomy is usually performed under general anesthesia. After the application of cottons soaked with decongestants into the nasal cavity 10 minutes before starting surgery, a solution of local anesthetic and epinephrine is injected at the level of the polyp pedicle, which is then stripped with Weil forceps, or more commonly removed by micro-debrider. When planning a polypectomy, it is recommended to define the surgical strategy according to the necessity to correct anatomic anomalies that have might favored the formation of polyps.

Antrochoanal polyp (ACP) is a peculiar form of sinonasal polypoid formation, more frequently observed in infants, where it is observed in almost one-third of cases of polyposis [18-21]. ACP are usually unilateral and has a male prevalence (M:F = 2.1:1). They originate inside the maxillary sinus, from one of the intramural Tonrwaldt's cysts within sinus walls [22-23]. As it grows, it first occupies the maxillary sinus volume, and then protrudes through the natural or accessory maxillary ostium into the nasal cavity towards the choanal aperture. ACP generally shows a cystic composition in its intra-maxillary portion and a solid composition in the emerging portion within the nasal fossa. Clinical presentation depends on local extension. Patients generally complain of unilateral nasal obstruction, occasional bleeding, rhinorrhea, and foreign body sensation [24-25]. Bilateral symptoms are typical of ACPs with large involvement of the nasopharyngeal lumen or when ACP is bilateral. Dysphagia, dyspnea, and pharyngeal sensation of foreign bodies may be reported by extremely advanced cases. Diagnosis can be easily confirmed by endoscopy. A bright-white mass protruding from the middle meatus and occupies the nasal cavity with a variable

posterior extension toward the nasopharynx. CT (Figure 4) offers details of sinonasal anatomy and disease extension. MRI is not routinely performed.

Acute and Chronic Rhinosinusitis

Rhinosinusitis is defined as an inflammatory condition of the sinonasal tract, characterized by the presence of at least two of the following symptoms: nasal obstruction, hypo/anosmia, cough, pain on pressure of tender spots, facial pain and/or headache, rhinorrhea, and postnasal drip [26]. Diagnosis is generally confirmed by endoscopy, demonstrating diffuse mucosal inflammation, turbinate congestion, and pathologic nasal discharge (more commonly coming from the middle meatus).

Based on duration of symptoms, rhinosinusitis can be distinguished as:

1. acute rhinosinusitis, when symptoms lasts less than 12 weeks;
2. chronic rhinosinusitis, when symptoms lasts continuously at least 12 weeks; and
3. recurrent chronic rhinosinusitis, when multiple acute episodes occur with complete resolution of each within 12 weeks.

The association of chronic rhinosinusitis with nasal polyposis is far less common in the pediatric age compared to adult population. Recurrent/chronic rhinosinusitis and the concomitant presence of bilateral polyposis should raise concern for immunodeficiency and primary ciliary disorders. CT scan is usually reserved for chronic rhinosinusitis when endoscopy is not sufficient to make differential diagnosis and/or surgical treatment is necessary. Because of the underdevelopment of frontal and sphenoid sinuses in the first years of life, CT scan often shows involvement of maxillary and ethmoid sinuses. The Lund-Mackay score is a reliable and highly predictive model used for diagnosis of chronic rhinosinusitis based on CT findings [27]. MRI is mandatory when clinical presentation raises suspicion for severe forms or orbital (Figure 5) or intracranial complications.

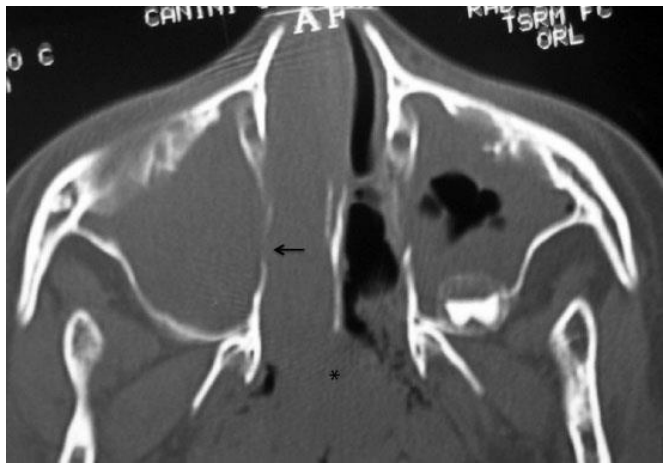

Figure 4. At CT scan, Antrochoanal polyp fills the right maxillary sinus growing the natural ostium (arrow) into the middle meatus to the choana (asterisk).

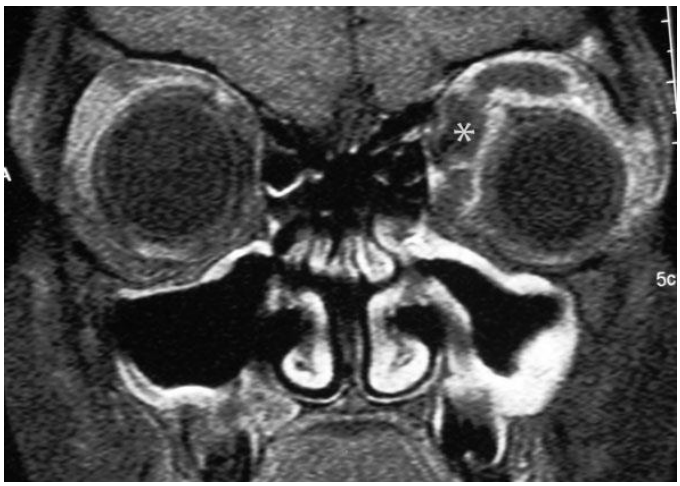

Figure 5. Coronal MRI view of the left extraconal orbital lesion (asterisk) associated with displacement of the orbital globe.

Differential diagnosis should exclude viral or allergic rhinitis and adenoid infection or hypertrophy. Once diagnosis is made, the ENT specialist must always take into account concurrent disorders that may coexist with chronic rhinosinusitis: adenoid hypertrophy, immunodeficiency, asthma, cystic fibrosis, allergy, ciliary dyskinesia, and gastroesophageal reflux disease. Accurate anamnesis and close collaboration with pediatrics, pulmonologists, and immunologists is therefore recommended.

Pathogens most commonly isolated in acute rhinosinusitis are those generally responsible for acute bacterial upper airway infections such as *Streptococcus pneumoniae*, *Haemophilus influenzae*, and *Moraxella catharralis*. However, *Staphylococcus aureus* and anaerobes can be occasionally found [28]. Origin of purulent discharge can be assessed through endoscopy, and nasal samples for cultures can be easily taken directly from the involved meatus. At first presentation, microbiological cultures are not mandatory since the success rate of empiric antibiotic therapy is satisfactory. When patients fail to improve despite medical therapy within 72 hours or a second episode recurs within 2 weeks, cultures are necessary to guide antibiotic therapy. Cultures are also mandatory in any case of rhinosinusitis with severe presentation or in immunocompromised patients [29-30].

Medical therapy is the first treatment of choice for chronic rhinosinusitis. The European Position Paper on Rhinosinusitis and Nasal Polyps [26] suggests an algorithm for treatment of pediatric chronic rhinosinusitis based on presentation. Mild symptoms may be managed with nasal saline irrigation and application of nasal topical steroid puff. The use of oral antibiotics is reserved for persistent symptoms or moderate to severe symptoms. Antibiotic therapy is generally empiric (e.g., amoxicillin/clavulanate) and requires one or two courses. When medical therapy fails to control symptoms of chronic rhinosinusitis and acute infection exacerbates, intranasal samples of nasal discharge should be taken and antibiotic chosen according to the pathogens isolated. When maximal medical therapy fails, surgical therapy must be considered: adenoidectomy with or without antral irrigation and balloon sinus dilation, and PESS are the most commonly performed surgical procedures.

PESS represents the surgical treatment of choice for complicated rhinosinusitis or when associated with systemic conditions (i.e., cystic fibrosis). Because of potential harm to

sinonasal and facial growth centers, it is recommended to adopt a conservative approach aimed to restore nasal fossa patency by polypectomy, correction of turbinate hypertrophy or concha bullosa, anterior ethmoidectomy, and maxillary antrostomy. PESS is always performed under general anesthesia and requires the use of rigid endoscopes of different angles (0°, 30°, 45°, 70°) and size (4 mm, 3 mm, 2.7 mm diameter). Generally, the application of cottons soaked with decongestants in the nasal cavity 10 minutes before starting surgery increases nasal fossae volume. A solution of 1% mepivacaine chlorohydrate and 1:200,000 epinephrine is then injected in the submucosa at the roof of the middle turbinate and uncinated process. With a small seeker, the posterior aspect of uncinated process and main ostium of maxillary sinus are probed before proceeding with uncinectomy. In order to be as conservative as possible, the uncinectomy is partial and the upper third is conserved. Natural ostium of maxillary sinus is then widened both inferiorly and posteriorly. Once the uncinate process has been removed, the anterior wall of the bulla ethmoidalis is visible and is opened using a debrider or a Weil forceps. Following this, the opening of basal lamella medially and inferiorly is performed to give access for posterior ethmoidectomy. The aperture of the sphenoid sinus is achieved at an infero-medial angle because of the close relationship on the lateral side with optic nerve and internal carotid artery. Just below the sphenoid sinus aperture runs the posterior septal branch of sphenopalatine artery, which should be preserved if a Hadad-Bassagasteguy flap [31] for skull base reconstruction is planned. Sphenoid sinusotomy can also be effectively performed through a trans-nasal or a trans-septal corridor. Frontal sinusotomy is rarely required as the frontal sinuses are usually underdeveloped until late childhood. When necessary, this procedure should be performed by pediatric ENT surgeons with expertise in sinonasal and skull base surgery, even if it is generally sufficient to remove agger nasi cells after anterior ethmoidectomy in order to expose the frontal recess, where a sinusotomy can be easily performed using angle circular-biting forceps.

Adenoidectomy with intranasal irrigation and balloon sinuplasty represent a surgical alternative to PESS, especially for children without complicated rhinosinusitis [32-33]. The role of adenoids in chronic rhinosinusitis in children is under debate. The long-term benefit some patients with chronic rhinosinusitis gain from adenoidectomy may suggest a major role of adenoids in maintaining sinonasal chronic infection [13], [14-15] although a definitive conclusion cannot be established with current evidence. In chronic rhinosinusitis, adenoidectomy is generally performed along with maxillary antral irrigation. Balloon sinuplasty may be performed to increase the definitive outcome. However, its real impact on sinonasal restoration is yet to be determined.

Complications and Quality of Life

PESS is considered a safe and effective treatment for pediatric chronic rhinosinusitis. The success rate, defined as increased quality of life, reduced symptoms and/or willingness to suggest PESS to other patients, varies from 76% to 89% [27,34-35]. Patients affected by chronic rhinosinusitis with or without cystic fibrosis, eligible for PESS, reported an impaired general quality of life prior to surgery. Dedicated questionnaires were submitted to analyze specific quality of life after PESS for these patients, showing a net improvement after 1-3 months [36].

Reported complications from PESS range between 0.6% - 1.4% [27,34,37] Although rare, PESS may result in major complications, including orbital damage, skull base lesion with subsequent CSF leak, and meningitis, requiring prompt intervention. Minor complications (i.e., minor bleeding, synechiae, local infection) are usually treated conservatively. The low overall risk of readmission, reoperation and complication rates were also confirmed by a recent study, with reported rates of 4.5%, 2.6%, and 3.0%, respectively. In this study, independent factors associated with an increased risk of postoperative adverse events were urgent/emergent procedures and presence of bleeding disorders. Age < 3 years was an independent risk factor only for bleeding requiring transfusion [38].

Mucocele

Mucocele is a benign, cyst-like, locally expansive paranasal sinus mass consisting of a collection of aseptic mucus, and products of mucosal debris, lined by respiratory mucosa, that develops within a paranasal sinus [39,40]. A mucocele grows slowly and expands by eroding the surrounding bony walls as a consequence of ostium blockage. The obstruction can result from congenital anomalies, adherences from chronic rhinosinusitis, previous radiotherapy and/or surgical treatment, trauma, and sinonasal neoplasms [41]. Recognized predisposing factors are congenital illnesses such as cystic fibrosis and primary ciliary dyskinesia. Mucoceles occur rarely in the pediatric age, and most cases described were associated with the abovementioned congenital conditions [42-44]. The most common site of origin is the frontal sinus, where it occurs in 60% of cases, followed by the ethmoid labyrinth and maxillary sinus with 30% and less than 10% of cases, respectively. Few cases are localized in the sphenoid sinus [45]. The higher incidence of mucoceles in the frontal sinus seems to be related to anatomical complexity of the frontal recessal [46]. Mucoceles are almost always monolateral, and no gender prevalence has been observed. Clinical presentation is dependent on localization, but is generally characterized by nasal obstruction, headache or facial pain, rhinorrhea, check swelling, allodynia or dental pain, and local hypo/anesthesia. When a frontal mucocele grows enough to involve the orbital content, periorbital pain, edema, proptosis, diplopia, blurred vision, and sudden vision loss can occur [40,47]. Whenever erosion of the anterior or posterior wall of the frontal sinus is present, a Pott's puffy tumor or neurological symptoms may be evident. Diagnosis is based on signs and symptoms, nasal endoscopic evaluation, and imaging. Nasal endoscopy is generally silent during the intra-sinusal phase, whereas, during subsequent expansion of the mucocele, alterations of the bony walls of the paranasal sinus may be evident. Advanced maxillary mucocele may cause medialization of the middle turbinate, anterior dislocation of the uncinate process (Figure 6), and bulging of the agger nasi cells. Submucosal remodeling or bulging of the sphenoethmoid recess or posterior ethmoid, on the other hand, is more typical of high-volume sphenoidal mucoceles. In frontal mucoceles, endoscopic examination is usually negative, since the lesion expands inferiorly to involve the agger nasi [48]. CT scan shows an homogenous lesion that completely occupies the involved sinus with smooth clear-cut margins of bone erosion of its walls, giving details on the origin, extension of disease, entity of bony erosion, and hyperostotic changes (Figure 7). MRI is usually reserved for mucoceles secondary to sinonasal expansive tumors.

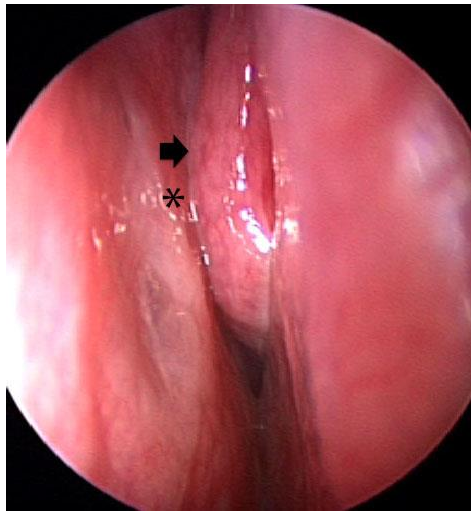

Figure 6. Endoscopic view of the anterior dislocation of the uncinate process (asterisk) and medialization of the middle turbinate (arrow).

Figure 7. At CT scan, lesion involves completely the maxillary sinus bilaterally and erosion of the medial bone walls (arrows) is evident.

Naso-Lacrimal Duct Congenital Disorders

Naso-lacrimal duct obstruction (NLDO) in the newborn and infants is usually congenital, secondary to a defect of its canalization during embryogenesis. This defect typically presents at the level of Hasner valve. Causes of this disorder include persistence of a membranous diaphragm, bony stricture, or ab-extrinseco closure from edematous nasal mucosa. At birth, the persistence of a membrane at the Hasner valve can be found in 20 -30% of newborns. However, in many cases canalization occurs spontaneously hereafter [53]. Children affected by NLDO show persistent epiphora and an increased risk of lacrimal system infection. Crusting of the ipsilateral medial canthus is commonly observed. Diagnostic work-up generally includes nasal endoscopy and ophthalmologic evaluation. Dacryocystography (Figure 8) is commonly performed to confirm diagnosis and localize the site of obstruction [54]. When dacryocystorhinostomy (DCR) is planned, presurgical CT scan of the sinus is mandatory to evaluate sinus anatomy.

Treatment of this disorder includes conservative and non-conservative procedures. When conservative approaches such as lacrimal massage, probing and irrigation of lacrimal system, balloon dacryoplasty, and nasolacrimal duct intubation fail, DCR is mandatory. Despite the optimal success rate and diffusion of external approaches, endoscopic-DCR is encouraged because of the far lower incidence of complications and recovery time and because it is less invasive than external surgerry. Use of a nasolacrimal stent is debated, since it might elicit local inflammatory response and granulation, increasing the risk of re-stenosis [57,58]. Known risk factors for surgical failure are pre-saccal obstruction and presence of craniofacial anomalies. Major complications following endoscopic DCR are exceedingly rare [52,54-56]. Minor complications include bleeding, synechiae, and eye itchiness. A new promising and more conservative endoscopic-assisted procedure has been reported. After inspection of the inferior meatus, the valve of Hasner is incised and the nasolacrimal duct is irrigated [59].

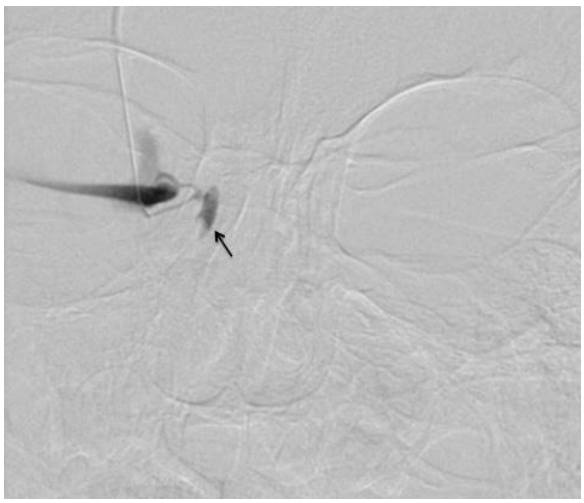

Figure 8. Dacryocystography shows obstruction of the lacrimal system at inferior third of the lacrimal sac (arrow).

Naso-lacrimal duct cysts (NLDC) (Figure 9) are congenital cystic dilation of the distal portion of the nasolacrimal duct secondary to failure of the Hasner membrane to canalize. It is a rare condition, most commonly symptomatic at birth or within few weeks of age [60]. It is more commonly observed in females. Clinical presentation depends on extension and laterality. Monolateral NLDCs typically present as ipsilateral persistent epiphora, recurrent dacryocystitis, and nasal obstruction, whereas bilateral NLDCs may cause acute respiratory distress at birth because of bilateral nasal obstruction. Susceptibility to aspiration and feeding difficulties may accompany bilateral NLDCs [61]. The evidence of a grayish-blue cystic mass in the inferior meatus on nasal endoscopy confirms diagnosis. CT scan can further confirm diagnosis showing a cystic formation at the level of Hasner's valve in the lateral wall of the inferior meatus, with progressive dilation of nasolacrimal duct and lacrimal sac. Surgical intervention is indicated for symptomatic patients, since spontaneous canalization occurs in most patients within 9 months after birth. Under general anesthesia, the cyst is endoscopically incised, drained, and marsupialized into the inferior meatus [62-63].

Congenital Choanal Atresia

Congenital choanal atresia (CCA) is defined as the congenital pathological closure of the posterior choanae, either mono- or bilateral, by a diaphragm of membranous, bony, or mixed tissue. CCA is the most common congenital malformation in the sinonasal tract, with an incidence of 1 in 5000-9000 live births, with a prevalence for the female gender and the right side (both with a ratio of 2:1) [64,65]. The pathogenesis of CCA is still debated. Persistence of the bucco-pharyngeal membrane, naso-buccal membrane of Hochstetter, misdirection of neural crest cell migration, and abnormal location of mesoderm are the most accepted theories [66,67]. CCA is an isolated finding in 50% of cases, while in the remaining is due to syndromic conditions. CHARGE (Coloboma, Heart disease, Atresia choanae, Retarded growth, Genital anomalies, Ear anomalies), Di George, Treacher Collins syndromes and Blackfan-Diamond anemia are the most important in this regard [67]. Choanal narrowing is caused by the presence of a pathologic diaphragm, extended from the floor of the sphenoid bone to the horizontal process of the palatine bone, and from the vomer to the medial pterygoid plate. Since the condition is mainly secondary to bony malformation of vomer and sphenoid bone, in almost all cases the diaphragm has a mixed (70%) or bony (30%) structure, while a pure membranous occlusion is extremely rare [68-70].

CCA is unilateral in two-thirds of cases and bilateral in the remaining. Bilateral CCA usually presents at birth as an airway emergency, since newborns show an obligate nasal ventilation. Severe respiratory distress, paradoxical cyanosis and stridor are the most commonly observed symptoms [64]. Differential diagnosis includes other sinonasal congenital malformations (midnasal or pyriform aperture stenosis), bilateral nasolacrimal duct cysts, septal deviation, nasopharyngeal wall collapse and reflux, and congenital sinonasal lesions (e.g., teratoma) [71]. In these cases, prompt intervention to secure airway is mandatory, and pediatric ENT surgeons must be prepared for tracheostomy in selected cases. Unilateral CCA usually shows a delayed presentation (5-24 months or even after), with symptoms of unilateral nasal obstruction and ipsilateral otitis media on occasion. Differential diagnosis includes septal deviation, nasal foreign bodies, inferior turbinate hypertrophy, antrochoanal polyp, and expansive sinonasal benign of malignant lesions [64].

Diagnosis can be easily confirmed by observing fogging on a cold metal speculum positioned at the nasal pyriform aperture [64]. For differential diagnosis with pyriform aperture stenosis, a catheter is inserted into the nasal cavity: if it passes through the nasal cavity, but is blocked more posteriorly, CCA is confirmed. Nasal endoscopy and CT (Figure 10) represent the gold standard for definitive diagnosis. Nasal endoscopy shows a complete uni- or bilateral choanal occlusion, usually associated with abundant mucous secretions. CT allows evaluation of the bony details of the CCA and other craniofacial malformations that can accompany choanal atresia in syndromic cases. In order to exclude CCA as part of a syndromic condition, thorough diagnostic work-up, including evaluation of craniofacial malformations, muscle tone, and airway assessment, is usually recommended [64].

Therapeutic strategies are planned based on type, grade of stenosis, and associated conditions. While bilateral CCA requires prompt intervention aimed to secure the airway and stabilize ventilation, surgical planning for unilateral atresia might be postponed after the first years of life in order to increase the rate of success. The first surgical approaches introduced were transnasal puncture and transpalatal repair, but were progressively abandoned in favor of transnasal endoscopic choanal plasty [72,73]. In order to maximize the chance of success

and reduce the rate of restenosis, medial choanal enlargement over lateral extensive drilling, and protection of exposed bone with local mucosal flap are encouraged [74].

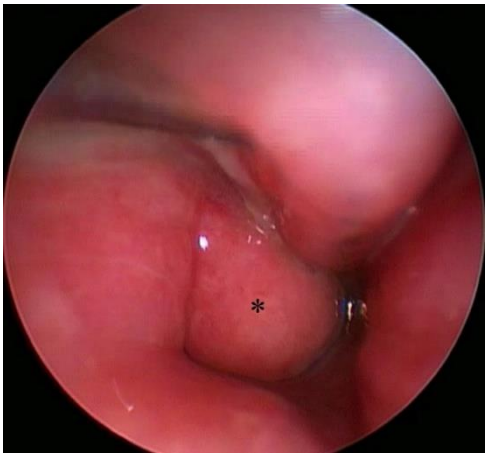

Figure 9. At endoscopic evaluation, a naso-lacrimal duct cyst (asterisk) is observed.

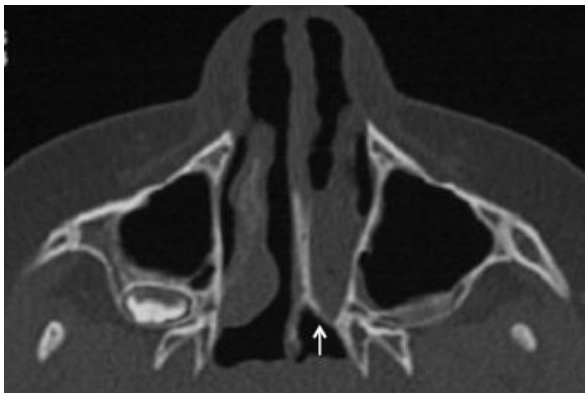

Figure 10. CT-scan shows left choanal atresia (white arrow).

A metanalysis published in 2008 reported that endoscopic choanal plasty had a success rate of 85.3%, although criteria for definition of failure varied widely among the individual studies considered [72]. Risk of restenosis is mainly associated with bilateral CCA, CHARGE syndrome, and age and weight at the time of surgery [75]. Recent data show a higher risk of failure with the employment of choanal stents, secondary to granulation and inflammatory reactions that may locally cause [76,77]. For this reason, their use is discouraged. Application of topical steroids and accurate endoscopic toilette of the nasal cavities have been reported as fundamental precautions in reducing the risk of re-intervention.

Nasal Dermoids

Nasal congenital midline lesions, consisting of nasal dermoids, gliomas, and encephaloceles, are rare developmental malformations with and estimated incidence of

1:3000 - 1:40,000 births [78,79]. Nasal dermoids (ND) are defined as frontonasal inclusion cystic masses, sometimes associated with sinus opening. Males are slightly more affected. NDs may associate with other congenital malformations (5 - 41%), such as external ear anomalies, cleft lip and palate, hypertelorism [80]. Foramen caecum plays a key role in the pathogenesis of these congenital anomalies. It is a transient skull base corridor, anterior to the crista galli, that forms from the third week of gestation. Through the foramen caecum, the dura protrudes towards the prenasal space, located posteriorly to the nasal bone, where the ectoderm is apposed. As the foramen caecum regresses spontaneously during the eighth week of gestation, the dura retracts back into the intracranial space. Nasal dermoids typically form from ectodermal and mesodermal tissues entrapped along the dural descent pathway towards the prenasal space [81].

Histologic examination confirms the presence of ectodermal and mesodermal elements (i.e., hair, keratin, sweat, and sebaceous glands). Lack of the endodermal component differentiates them from teratoma. Unlike encephaloceles and gliomas, NDs do not present glial elements. Generally, clinical presentation is peculiar. A dimple, fistula or cystic lesion can present anywhere along the embryologic midline line, from the nasal tip into the skull base, with the rhinion as the most common location. Although a rare finding, hair protruding through the midline lesion is pathognomonic for nasal dermoid. When a midline external lesion presents protruding hair, this is pathognomonic for nasal dermoids. A widened nasal bridge, intermittent sebaceous discharge, and recurrent infections are commonly observed. Unlike encephaloceles, NDs do not transilluminate and do not expand with crying. NDs may have an intracranial extension in 4% 45% of cases, with a potential for recurrent meningitis (caused by skin flora bacteria) [80].

Diagnostic work-up includes nasal endoscopy and radiological imaging, and should be aimed at identifying the location and size of ND, indirect or direct signs of intracranial extension, nasal anatomy, and associated malformations. Indirect signs of intracranial extension are well-established with CT and include bifid crista galli, enlarged foramen caecum, and cribriform plate anomalies [82]. If intracranial tract is suspected, contrast-enhanced MRI is recommended.

Surgical treatment is mandatory since progressive enlargement of NDs can cause craniofacial deformities, recurrent infections, meningitis, and brain abscess. The surgical strategy should obtain radical removal, allow proper skull base reconstruction, with optimal cosmetic outcomes [83].

Conservative treatment, such as curettage, drainage, and aspiration are not recommended, because of the high risk of recurrence [83]. Different surgical strategies have been proposed according to the type of ND and its extension, with external rhinoplasty incision as the most widely adopted. When NDs show intracranial extension, coronal incision and frontal craniotomy are generally required. Although external approaches are considered safe and effective [84-87], efforts have been made to introduce endoscopic-assisted transnasal excision for intracranial NDs [88-89].

Encephalocele

Encephaloceles are sac-like herniations of intracranial content caused by a skull base defect [90]. They are called meningoceles when formed only by meningeal linings and CSF,

and meningo-encephaloceles when brain tissue is also included. Encephaloceles form secondary to failure of proper neural tube closure. No gender predominance has been reported. The incidence is higher in Asia, with a reported incidence of 1 in 6000 births [91]. Low levels of maternal folic acid during first weeks of development may be a major risk factor. Encephaloceles typically present as smooth, white-bluish, pulsatile lesions, increasing in volume with crying or on jugular vein compression (Furstenberg sign) [90]. If left untreated, encephaloceles can cause recurrent meningitis and epilepsy. Depending on their localization, encephaloceles are classified into 3 major classes: sincipital, basal, occipital.

Sincipital encephaloceles are further classified as naso-frontal, naso-ethmoidal, and naso-orbital. *Nasofrontal* encephaloceles develop through a defect between nasal and frontal bones, presenting as a protruding mass in the glabellar region and causing inferior displacement of nasal pyramid and lateral displacement of the eyes (telecanthus). *Nasoethmoidal* encephaloceles protrude through a patent foramen caecum towards the prenasal space, where junction of nasal cartilages and bones is located (rhinion). Typical presentation is a mass on the nasal dorsum causing a superior displacement of nasal bones and inferior displacement of alar cartilages. If an encephalocele protrudes through a patent foramen caecum and laterally extends through a defect in the medial orbital wall, then a *naso-orbital* encephalocele forms, causing ipsilateral proptosis, visual impairment, epiphora, and recurrent dacryocystitis. *Basal* encephaloceles originate more posteriorly, between the cribriform plate and the middle skull base. They are further classified as *transethmoidal*, *sphenoethmoidal*, *transsphenoidal*, and *sphenorobital. Transethmoidal* and *sphenoethmoidal* encephaloceles present as an endo-nasal protruding mass, causing nasal obstruction and orbital displacement (hypertelorism). They occur secondary to a defect in the cribriform plate or at sphenoethmoidal junction, respectively. *Trans-sphenoidal* encephaloceles develop secondary to a persistent craniopharyngeal canal, protruding into nasopharynx, causing nasal obstruction and affecting swallowing. Trans-sphenoidal encephaloceles are typically associated with cleft palate defects. *Spheno-orbital* encephaloceles expand toward the spheno-palatine fossa, passing through the superior and inferior orbital fissures. Ipsilateral proptosis and visual impairment with no visible masses is the typical presentation. Finally, *occipital* encephaloceles occur secondary to a defect in the posterior cranial fossa.

The neural tissue in meningo-encephaloceles was initially considered dysplastic and non-functioning, but since functioning brain has been found in some occipital and trans-sphenoidal encephaloceles, this concept has been recently revised [90]. The presence of ependymal tissue on histologic examination is pathognomonic [92]. Diagnosis of an endo-nasal protruding encephalocele is made by nasal endoscopy and CT and/or MRI. Contrast-enhanced MR allows to identify the composition of the encephalocele (meninges with or without brain tissue), and also provides details on skull base defects and possible associated malformations. In order to obtain the best outcomes, prompt surgical intervention within the first months of life is advisable. Traditionally, small lesions could be managed endoscopically, while external craniotomic approaches were reserved for larger lesions.

Gliomas

Nasal gliomas (NG) are a rare benign developmental disorder, composed by heterotopic glial tissue, sequestered outside the cranium secondary to premature and abnormal skull base

closure (e.g., foramen caecum) [94-96]. For this reason, gliomas lack a patent communication with the brain (in contrast to encephalocele), and therefore do not transilluminate and do not show a change in size with straining, crying, or jugular vein compression (negative Furstenberg sign) [90]. However, a fibrous attachment to the dura can be identified in a minority of cases. NGs are classified into *extranasal* (60% of cases), *intranasal* (30% of cases), and *mixed* (10% of cases). *Extranasal* NGs present as a firm, smooth mass, external to the nasal bones and cavities (more commonly at the glabella). *Intranasal* NGs lie within the nasal cavity (more commonly from nasal lateral wall close to the middle turbinate) and can protrude through the ipsilateral nostril, causing nasal obstruction. Further extension to adjacent sinuses is not common. *Mixed* NGs show a typical dumbbell shape with a connecting band between the extra- and intra-nasal components. NGs are present at birth, although clinical presentation occurs typically between 5 and 10 years of age and may include: nasal obstruction, epistaxis, CSF rhinorrhea, broadening of the nasal bridge, hypertelorism, and epiphora secondary to nasolacrimal duct stenosis [96-98]. The intranasal components present as a non-pulsatile polypoid mass with a gray-reddish-purple color on nasal endoscopy. CT and contrast-enhanced MR are mandatory for diagnosis, in order to study nasal anatomy, bony structures, skull base attachment, and possible associated malformations. Extranasal gliomas generally require external surgical access that allows possible exploration of the skull base, with external rhinoplasty as the most commonly adopted approach. Intranasal gliomas are generally successfully treated with an endoscopic approach. In patients with fibrous attachment to dural layer, it is recommended to follow its entire course, in order to be radical and exclude intracranial extension. If required, endoscopic skull base reconstruction can be performed with synthetic, allogeneic, autologous tissue and/or local flaps [93].

Cerebrospinal Fluid Leak

Cerebrospinal fluid (CSF) leak occurs when there is an abnormal communication between the subarachnoid space and the sinonasal tract and/or the ear cavity, through a breach of the skull base and underlying meninges [90]. CSF leaks are classified as *non-traumatic* (with high or normal CSF pressure) and *traumatic* (accidental and iatrogenic) [99]. Traumatic skull base lesions are the most common cause of CSK leak: 80% secondary to craniofacial trauma and 16% secondary to sinonasal or skull base surgery [100]. Spontaneous CSF leak may be caused by congenital defects (potentially associated with encephaloceles, large arachnoid granulation cysts), skull base erosion by malignant tumors, or indirectly by increasing CSF pressure (i.e., aqueductal stenosis). The most common locations for spontaneous CSF fistula are the cribriform plate, sphenoid sinus, and pterygoid recess. Unilateral or bilateral watery rhinorrhea (rhinoliquorrea), which is exacerbated when the patient bends forward, is the most typical presentation. Clinical manifestation of CSF leak may also include salty or sweet taste, recurrent meningitis, and signs of CSF hypertension such as headache, vomit, and papilla edema [90]. The “reservoir sign” is suggestive for sphenoid CSF fistula. In a recumbent position, CSF accumulates within the sphenoid sinus, until the patient resumes an erect position and sudden abundant watery rhinorrhea occurs [101].

Laboratory test on watery rhinorrhea can confirm the CSF leak by demonstrating the presence of beta-2 transferrin or beta-trace protein, polypeptides exclusively produced by the

CNS. Fluorescein test consists in the intra-techal administration of fluorescent dye solution, allowing the surgeon to localize the specific site of the leak. Fluorescein test can be used for pre-operative diagnosis, have a pre-operative diagnostic role, or an intra-operative role in guiding surgery. Contrast-enhanced CT and MR are recommended to study skull base anatomy, extension of the CSF leak, and possible associated disorders [90,102-103].

Reconstruction of Pediatric Skull Base Defects

Endoscopic skull base reconstruction can be performed with synthetic, allogeneic, autologous tissue and/or vascularized pedicled flaps. For large skull base defects, especially with moderate-high CSF pressure (as in the middle cranial fossa), vascularized pedicled flaps are generally preferred. Vascularized pedicled flaps are divided into sinonasal and scalp flaps [1,106].

The most commonly used vascularized sinonasal vascularized flaps are all based on branches of the sphenopalatine artery: *nasoseptal flap* [31] (Hadad-Bassagasteguy flap), *inferior turbinate flap*, and *middle turbinate flap*. Recently, some authors [104-105] have advocated the *naso-septal flap* as a safe and effective reconstruction for anterior skull base defects in the pediatric population, showing a success rate similar to open reconstructions. It is a robust mucoperiosteal-mucoperichondrial flap, potentially eligible for most skull base defects. The Hadad-Bassagasteguy flap is pedicled on the posterior septal artery, a branch of the sphenopalatine artery that runs along the inferior surface of the sphenoid ostium bilaterally. Therefore, if skull base reconstruction is planned, this artery must be preserved during sphenoidotomy. After the age of 13 years, the width and length of this flap have the same dimension of adults, whereas between 24 months and 10 years the length may be insufficient for repair of larger defects, thus requiring accurate pre-operatory surgical planning. Under 24 months of age the nasoseptal flap is not recommended because of its limited overall dimensions [105]. Traditional scalp pedicled flaps are the *pericranial flap*, based on the supraorbital and supratrochlear arteries, the *temporoparietal fascial flap*, based on the superficial temporal artery, and the *temporalis muscle flap*, based on deep temporal arteries. For reconstruction of smaller anterior skull base defects, free grafts of iliotibial tract fascia and fat is a safe option, with high rate of success [1,106-107].

Juvenile Nasopharyngel Angiofibroma

Juvenile nasopharyngeal angiofibroma (JNA) is a rare, benign, highly vascularized expansive lesion that typically affects male adolescents [108]. JNA has a controversial etio-pathogenesis, sharing features of both vascular malformations (origin from incomplete regression of the first branchial artery along its course) and tumors (chromosomal alterations, relentless growth) [109-112]. These lesions typically increase their growth rate following hormonal changes during puberty and can potentially regress when sexual hormonal levels decrease [113]. JNAs originate at the level of the sphenopalatine foramen, from where it extends typically to adjacent structures, widening skull base foramina and displacing fat, muscles, nerves, and vessels. This disorder has a peculiar propensity to expand infiltrating the

cancellous bone of the sphenoid, especially at the level of the vidian canal, pterygoid process, and middle cranial fossa floor [114].

Patients complain of recurrent spontaneous epistaxis with persistent monolateral nasal obstruction usually occurring in a young male adolescent. Less frequently, advanced JNAs can present with visual and ocular motility impairment, headache, conductive hearing loss, or facial pain/swelling and remodeling [114-115]. Nasal endoscopy shows a lobulated, rubbery, red-pink to gray mass covered by vascular structures, occupying the nasopharynx and nasal cavity. When JNA is suspected on nasal endoscopy, biopsy is strongly discouraged because of the high risk of high-flow bleeding [108,114]. MRI (Figure 11) is necessary to confirm diagnosis and for surgical planning. MRI is considered the gold standard diagnostic procedure, thanks to its optimal evaluation of sphenoid cancellous bone infiltration, involvement of cavernous sinus, orbital apex, and potential close relationship with the dura [108,114,116]. JNA is traditionally classified according to Andrews classification, as reported in Table 1 [117].

Transarterial embolization of the lesion, followed by its endoscopic transnasal resection is considered the mainstay of treatment [108,114].

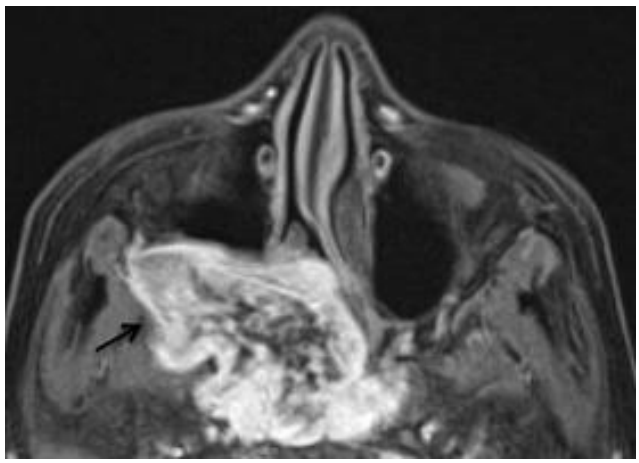

Figure 11. At axial MRI, juvenile nasopharyngeal angiofibroma involves infratemporal fossa (arrow).

Table 1. Classification of juvenile nasopharyngeal angiofibroma according to Andrews [117]

Type I	Tumor limited to the nasopharynx and nasal cavity. No bone destruction or limited to the sphenopalatine foramen.
Type II	Tumor invading the pterygopalatine fossa or the maxillary, ethmoid or sphenoid sinus with bone destruction
Type III	Tumor invading the infratemporal fossa or orbital region: • IIIa: without intracranial extension • IIIb: with intracranial (parasellar) extradural involvement
Type IV	Intracranial intradural tumor: • IVa: without infiltration of the cavernous sinus, pituitary fossa or optic chiasm • IVb: with infiltration of the cavernous sinus, pituitary fossa or optic chiasm.

When present, postsurgical JNA residuals generally show an indolent course and can be effectively managed with a "wait-and-see" strategy, especially if located in critical areas. Revision surgery is usually reserved for symptomatic growing residuals [118].

Infantile Intranasal Hemangioma

Infantile hemangiomas are benign, painless, easily-bleeding, solitary lesions most commonly present in the skin and in the mucosa of the upper aerodigestive tract [119]. They are typically not observable at birth, but rapidly grow in the first months of life. Head and neck hemangiomas localize in the sinonasal tract in 7% - 29% of cases, typically involving the anterior portion of the nasal septum or head of the turbinates [48]. Sinonasal hemangiomas present with recurrent epistaxis and nasal obstruction. Local pain, headache, and hyposmia are rarely observed. Nasal endoscopy shows a reddish-purple, hypervascularized, easy-to-bleed, polypoid mass. MRI is generally required, especially when the actual extension of larger hemangiomas is not assessable with endoscopy [44,48]. Medical treatment of hemangiomas include propranolol, which reduces their size significantly [120-121]. Surgical intervention is generally reserved for symptomatic lesions with critical relationships with the orbit or skull base and/or non-response to medical therapy [93]. Wide endoscopic excision is generally sufficient. Pre-operative angio-embolization has been reported for large hemangiomas as an efficient strategy to reduce intra-operative bleeding [122].

Ameloblastoma

Ameloblastoma is a benign epithelial tumor that is derived from the dental lamina remnants or from the developing enamel organ. It is the most common odontogenic tumor, generally arising in the mandible or less frequently in the maxilla [123]. Primary sinonasal ameloblastoma is a rare condition [124]. No gender predilection has been reported. The peak of incidence is between the third and fifth decade, although ameloblastoma can occur in the pediatric population. Primary sinonasal and maxillary ameloblastoma with secondary extension in the sinonasal tract can be both
asymptomatic or present as unilateral nasal obstruction, chronic/recurrent rhinosinusitis, bleeding, facial swelling, headache, and dizziness [124]. Radiographically, sinonasal ameloblastoma present as more commonly opacification of the nasal fossae and/or paranasal sinuses [125]. Imaging (CT and/or MRI) (Figure 12) is mandatory to identify the origin and extension of the lesion, and to plan its surgical removal Children are more commonly affected by the unicystic subtype, with a lower rate of recurrence and better response to conservative treatment [123]. Trans-nasal endoscopic-assisted resection may be considered in primary sinonasal ameloblastoma and in combination with more traditional, open approaches for lesions arising in the maxilla and extending within the sinonasal tract [125,126].

Teratoma

Teratomas are rare neoplasms, with a reported incidence of 1 in 20,000-40,000 live births; however, they represent the most common type of germ cell tumor in the pediatric age [127]. They are formed by a heterogeneous mixture of tissues from each of the 3 embryonic germ layers (ectodermal, mesodermal, endodermal), such as hair follicles, teeth, bony, and muscular structures. They are rarely malignant. Up to 5% of pediatric teratomas occur in the head and neck region (nasopharynx, oropharynx, nasal cavities, orbit, cervical region, etc.). Larger teratomas are generally detected on prenatal ultrasound, allowing for prompt management at birth to secure the airway. Smaller lesions may present later as respiratory difficulties, dysmorphic features, or dysphagia, depending on their location [128]. Sinonasal and nasopharyngeal teratomas can be successfully treated endoscopically, avoiding palate splitting or resection with transoral approaches. Abnormal levels of serum alpha-fetoprotein during follow-up raise suspicion for recurrence.

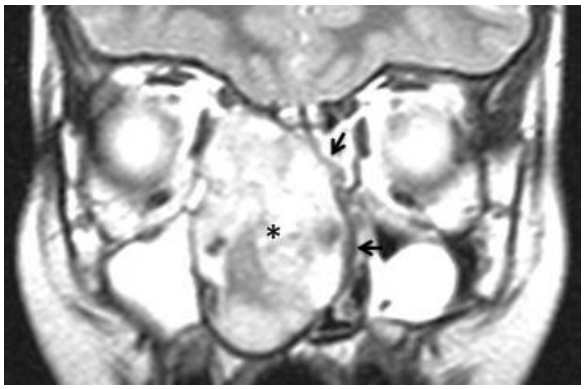

Figure 12. Giant lesion (asterisk) occupies totally the right nasal fossa with displacement of the nasal septum (arrows).

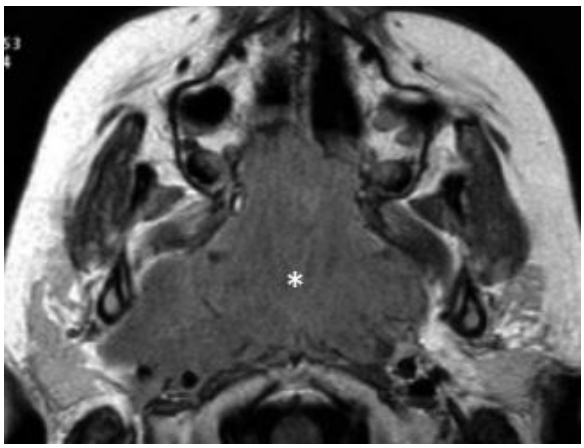

Figure 13. Large lesion (white asterisk) involves rinopharynx and it expands anteriorly and laterally.

Sinonasal Malignancies

Pediatric sinonasal malignancies represent an extremely rare form of cancer, with a reported incidence of 0.036 per 100,000 individuals [129]. Although more commonly associated with male gender, a clear gender predominance has not been demonstrated in the pediatric population [129], [130]. These diseases commonly present with non-specific symptoms, such as monolateral nasal obstruction, epistaxis, facial pain/swelling, headache, ipsilateral visual acuity or ocular motility impairment, thus frequently delaying diagnosis to an advanced stage [129]. The most commonly affected sites are the nasal cavity, followed by the maxillary sinus, ethmoidal complex, and sphenoid sinus [131]. Diagnosis is based on biopsy of the lesion performed by a transnasal endoscopic approach and imaging (Figure 13), which allows to identify the origin and extension of the mass, involvement of nearby structures, and to hypothesize a histological diagnosis. Rhabdomyosarcoma is the most frequently observed histology, followed by NK-T cell lymphoma, olfactory neuroblastoma, and sarcoma. Mesenchymal tumors are more common in the first years of life, while the incidence of olfactory neuroblastoma increases during adolescence. When indicated, naso-ethmoidal malignancies can be treated through an endoscopic assisted wide removal with or without trans-nasal craniectomy and anterior skull base reconstruction. Prognosis is generally extremely poor and mostly depends on high grading and advanced staging at presentation. Both distant and local recurrences and failures are frequent [129-132]. Non-lymphoma sinonasal malignancies show a 5-year overall survival of 37.2% - 60.2% and a 20-year overall survival of 20.6% [129-130].

CONCLUSION

The use of transnasal endoscopic approach for the treatment of several sinonasal disorders in the pediatric age has radically modified long-term results. Endonasal optic fibers permit to identify and assess sinonasal sites that are not easily evaluated by traditional surgical procedures and to better evaluate relationships with adjacent anatomical structures. These advantages make PESS more precise and resolute. PESS is usually performed with good results for sinonasal inflammatory diseases, anatomical malformations, benign expansible lesions, benign tumors, and CFS-leak. The role of this surgical technique for malignant neoplasms is above all diagnostic. The therapeutic utility of PESS for these latter pathologies is limited to highly selected cases and to treatment of tumor residues.

REFERENCES

[1] Rastatter, JC; Snyderman, CH; Gardner, PA; Alden, TD; Tyler-kabara, E. Endoscopic endonasal surgery for sinonasal and skull base lesions in the pediatric population. *Otolaryngol Clin North Am.*, 2015, 48(1), 79-99.

[2] Bailey, B. editor. *Head and Neck Surgery-Otolaryngology*. Philapdelphia: Lippincott Willimas and Wilkins, 2009.

[3] Márquez, S; Tessema, B; Clement, PA; Schaefer, SD. Development of the ethmoid sinus and extramural migration: the anatomical basis of this paranasal sinus. *Anat Rec (Hoboken)*., 2008, 291(11), 1535-53.

[4] Ferrari, M; Schreiber, A; Mattavelli, D; et al. The Terracol and Ardouin developmental model of frontal sinus drainage pathway and surrounding spaces: a radiologic validation. *Int Forum Allergy Rhinol.*, 2018, 8(5), 624-630.

[5] Lorkiewicz-muszyńska, D; Kociemba, W; Rewekant, A; et al. Development of the maxillary sinus from birth to age 18. Postnatal growth pattern. *Int J Pediatr Otorhinolaryngol.*, 2015, 79(9), 1393-400.

[6] Terracol, J; Ardouin, P. *Anatomy of the Nasal Fossae and Associated Cavities*. Paris: Maloine, 1965, French.

[7] Tatreau, JR; Patel, MR; Shah, RN; et al. Anatomical considerations for endoscopic endonasal skull base surgery in pediatric patients. *Laryngoscope*., 2010, 120(9), 1730-7.

[8] Gruber, DP; Brockmeyer, D. Pediatric skull base surgery. 1. Embryology and developmental anatomy. *Pediatr Neurosurg*., 2003, 38(1), 2-8.

[9] Cingi, C; Ure, B; Cakli, H; Ozudogru, E. Microdebrider-assisted versus radio-frequency-assisted inferior turbinoplasty: a prospective study with objective and subjective outcome measures. *Acta Otorhinolaryngol Ital*., 2010, 30(3), 138-43.

[10] Kwok, J; Leung, MK; Koltai, P. Congenital inferior turbinate hypertrophy, an unusual cause of neonatal nasal obstruction. *Int J Pediatr Otorhinolaryngol Extra*, (2007), Vol. 2, No. 1, (March 2007), pp. 26-30.

[11] Pelikan, Z. Role of nasal allergy in chronic secretory otitis media. *Curr Allergy Asthma Rep*., 2009, 9(2), 107-13.

[12] Berlucchi, M; Salsi, D; Valetti, L; Parrinello, G; Nicolai, P. The role of mometasone furoate aqueous nasal spray in the treatment of adenoidal hypertrophy in the pediatric age group: preliminary results of a prospective, randomized study. *Pediatrics*., 2007, 119(6), e1392-7.

[13] Hsin, CH; Tsao, CH; Su, MC; Chou, MC; Liu, CM. Comparison of maxillary sinus puncture with endoscopic middle meatal culture in pediatric rhinosinusitis. *American journal of rhinology.*, 2008, May-Jun, 22(3), 280-4.

[14] Hsin, CH; Su, MC; Tsao, CH; Chuang, CY; Liu, CM. Bacteriology and antimicrobial susceptibility of pediatric chronic rhinosinusitis: a 6-year result of maxillary sinus punctures. *Am J Otolaryngol.*, 2010, May-Jun, 31(3), 145-9.

[15] Orobello, PW; Jr. Park, RI; Belcher, LJ; Eggleston, P; Lederman, HM; Banks, JR; et al. Microbiology of chronic sinusitis in children. *Archives of otolaryngology-head & neck surgery.*, 1991 Sep, 117(9), 980-3.

[16] Triglia, JM; Nicollas, R. Nasal and sinus polyposis in children. *Laryngoscope*., 1997, 107(7), 963-6.

[17] Stammberger, H. Surgical treatment of nasal polyps: past, present, and future. *Allergy*., 1999, 54 Suppl, 53, 7-11.

[18] Schramm, VL; Effron, MZ. Nasal polyps in children. *Laryngoscope*., 1980, 90(9), 1488-95.

[19] Başak, S; Karaman, CZ; Akdilli, A; Metin, KK. Surgical approaches to antrochoanal polyps in children. *Int J Pediatr Otorhinolaryngol*., 1998, 46(3), 197-205.

[20] Ozdek, A; Samim, E; Bayiz, U; Meral, I; Safak, MA; Oğuz, H. Antrochoanal polyps in children. *Int J Pediatr Otorhinolaryngol*., 2002, 65(3), 213-8.

[21] Yaman, H; Yilmaz, S; Karali, E; Guclu, E; Ozturk, O. Evaluation and management of antrochoanal polyps. *Clin Exp Otorhinolaryngol*., 2010, 3(2), 110-4.

[22] Berg, O; Carenfelt, C; Silfverswärd, C; Sobin, A. Origin of the choanal polyp. *Arch Otolaryngol Head Neck Surg*., 1988, 114(11), 1270-1.

[23] Składzień, J; Litwin, JA; Nowogrodzka-zagórska, M; Wierzchowski, W. Morphological and clinical characteristics of antrochoanal polyps: comparison with chronic inflammation-associated polyps of the maxillary sinus. *Auris Nasus Larynx*., 2001, 28(2), 137-41.

[24] Orvidas, LJ; Beatty, CW; Weaver, AL. Antrochoanal polyps in children. *Am J Rhinol.*, 2001, 15(5), 321-5.

[25] Aydil, U; Karadeniz, H; Sahin, C. Choanal polyp originated from the inferior nasal concha. *Eur Arch Otorhinolaryngol*., 2008, 265(4), 477-9.

[26] Fokkens, WJ; Lund, VJ; Mullol, J; et al. European Position Paper on Rhinosinusitis and Nasal Polyps 2012. *Rhinol Suppl*., 2012, 23, 3 p preceding table of contents, 1-298.

[27] Lund, VJ; Mackay, IS. *Staging in rhinosinusitis Rhinology*, 1993, 107, 183–4.

[28] Lieser, JD; Derkay, CS. Pediatric sinusitis: when do we operate? *Curr Opin Otolaryngol Head Neck Surg*., 2005, 13(1), 60-6.

[29] Lusk, RP; Stankiewicz, JA. Pediatric rhinosinusitis. *Otolaryngol Head Neck Surg.*, 1997, 117(3 Pt 2), S53-7.

[30] Clement, PAR. Rhinosinusitis in children. In: *Pediatric ENT*, J. M. Graham; G. K. Scadding & P. D. Bull, (Eds.), 307-25, Springer, Berlin, Germany., (2008).

[31] Hadad, G; Bassagasteguy, L; Carrau, RL; et al. A novel reconstructive technique after endoscopic expanded endonasal approaches: vascular pedicle nasoseptal flap. *Laryngoscope*., 2006, 116(10), 1882-6.

[32] Brietzke, SE; Brigger, MT. Adenoidectomy outcomes in pediatric rhinosinusitis: a meta-analysis. *Int J Pediatr Otorhinolaryngol.*, 2008, 72(10), 1541-5.

[33] Ramadan, HH; Cost, JL. Outcome of adenoidectomy versus adenoidectomy with maxillary sinus wash for chronic rhinosinusitis in children. *Laryngoscope*., 2008, 118(5), 871-3.

[34] Cunningham, MJ; Cunningham, JM; Chiu, EJ; Landgraf, JM; Gliklich, RE. The health impact of chronic recurrent rhinosinusitis in children. *Arch Otolaryngol Head Neck Surg.*, 2000, 126(11), 1363-8.

[35] Hebert, RL; Bent, JP. Meta-analysis of outcomes of pediatric functional endoscopic sinus surgery. *Laryngoscope*., 1998, 108(6), 796-9.

[36] Taylor, RJ; Miller, JD; Rose, AS; et al. Comprehensive quality of life outcomes for pediatric patients undergoing endoscopic sinus surgery. *Rhinology*., 2014, 52(4), 327-33.

[37] Siedek, V; Stelter, K; Betz, CS; Berghaus, A; Leunig, A. Functional endoscopic sinus surgery--a retrospective analysis of 115 children and adolescents with chronic rhinosinusitis. *Int J Pediatr Otorhinolaryngol*., 2009, 73(5), 741-5.

[38] Roxbury, CR; Li, L; Rhee, D; Jatana, KR; Shah, RK; Boss, EF. Safety and Perioperative Adverse Events in Pediatric Endoscopic Sinus Surgery: An ACS-NSQIP-P Analysis. *Int Forum Allergy Rhinol.*, 2017, 7(8), 827-836.

[39] Marks, SC; Latoni, JD; Mathog, RH. Mucoceles of the maxillary sinus. *Otolaryngol Head Neck Surg.*, 1997, 117(1), 18-21.

[40] Busaba, NY; Salman, SD. Maxillary sinus mucoceles: clinical presentation and long-term results of endoscopic surgical treatment. *Laryngoscope*., 1999, 109(9), 1446-9.

[41] Johnson, JT; Ferguson, BJ. Infection. In: *Otolaryngology, Head and Neck Surgery*, 3rd edition, C. W. Cummings; J. M. Fredrickson, L. A. Harker; C. J. Krause; D. E. Schuller; M. A. Richardson, (Eds.), 1115-6, Mosby, St. Louis, U.S.A.

[42] Guttenplan, MD; Wetmore, RF. Paranasal sinus mucocele in cystic fibrosis. *Clin Pediatr (Phila)*., 1989, 28(9), 429-30.

[43] Olze, H; Matthias, C; Degenhardt, P. Paediatric paranasal sinus mucoceles. *Eur J Pediatr Surg*., 2006, 16(3), 192-6.

[44] Berlucchi, M; Maroldi, R; Aga, A; Grazzani, L; Padoan, R. Ethmoid mucocele: a new feature of primary ciliary dyskinesia. *Pediatr Pulmonol.*, 2010, 45(2), 197-201.

[45] Lloyd, G; Lund, VJ; Savy, L; Howard, D. Optimum imaging for mucoceles. *J Laryngol Otol.*, 2000, 114(3), 233-6.

[46] Arrué, P; Kany, MT; Serrano, E; et al. Mucoceles of the paranasal sinuses: uncommon location. *J Laryngol Otol.*, 1998, 112(9), 840-4.

[47] Tseng, CC; Ho, CY; Kao, SC. Ophthalmic manifestations of paranasal sinus mucoceles. *J Chin Med Assoc.*, 2005, 68(6), 260-4.

[48] Maroldi, R; Berlucchi, M; Farina, D; Tomenzoli, D; Borghesi, A; Pianta, L. Benign neoplasms and tumor-like lesions. In: *Imaging in treatment planning for sinonasal diseases*, R. Maroldi & P. Nicolai, (Eds.), 107-158, Springer, Berlin, Germany.

[49] Baxter, DJ; Shroff, MM. Developmental maxillofacial anomalies. *Semin Ultrasound CT MR.*, 2011, 32(6), 555-68.

[50] Van den abbeele, T; Triglia, JM; François, M; Narcy, P. Congenital nasal pyriform aperture stenosis: diagnosis and management of 20 cases. *Ann Otol Rhinol Laryngol.*, 2001, 110(1), 70-5.

[51] Demyer, W; Zeman, W; Palmer, CD. Familial alobar holoprosencephaly (arhinencephaly) with median cleft lip and palate. report of patient with 46 chromosomes. *Neurology*., 1963, 13, 913-8.

[52] Saniasiaya, J; Abdullah, B; Husain, S; Wang, Y; Wan mohammad, Z. Primary endoscopic endonasal dacryocystorhinostomy for pediatric nasolacrimal duct obstruction: A systematic review. *Am J Rhinol Allergy.*, 2017, 31(5), 328-333.

[53] Gupta, AK; Bansal, S. Primary endoscopic dacryocystorhinostomy in children -- analysis of 18 patients. *Int J Pediatr Otorhinolaryngol.*, 2006, 70(7), 1213-7.

[54] Berlucchi, M; Staurenghi, G; Rossi Brunori, P; Tomenzoli, D; Nicolai, P. Transnasal endoscopic dacryocystorhinostomy for the treatment of lacrimal pathway stenoses in pediatric patients. *Int J Pediatr Otorhinolaryngol.*, 2003, 67(10), 1069-74.

[55] Woog, JJ; Kennedy, RH; Custer, PL; Kaltreider, SA; Meyer, DR; Camara, JG. Endonasal dacryocystorhinostomy: a report by the American Academy of Ophthalmology. *Ophthalmology*., 2001, 108(12), 2369-77.

[56] Hartikainen, J; Antila, J; Varpula, M; Puukka, P; Seppä, H; Grénman, R. Prospective randomized comparison of endonasal endoscopic dacryocystorhinostomy and external dacryocystorhinostomy. *Laryngoscope*., 1998, 108(12), 1861-6.

[57] Saeed, BM; Tawalbeh, M. Pediatric Endoscopic DCR: The Outcome in 50 Patients. *Indian J Otolaryngol Head Neck Surg.*, 2014, 66(3), 276-80.

[58] Allen, K; Berlin, AJ. Dacryocystorhinostomy failure: association with nasolacrimal silicone intubation. *Ophthalmic Surg.*, 1989, 20(7), 486-9.

[59] Korkmaz, H; Korkmaz, M; Karakahya, RH; Serhatlı, M. Endoscopic intranasal surgery for congenital nasolacrimal duct obstruction--a new approach. *Int J Pediatr Otorhinolaryngol.*, 2013, 77(6), 918-21.

[60] Paoli, C; François, M; Triglia, JM; Frydman, E; Polonovski, JM; Narcy, P. Nasal obstruction in the neonate secondary to nasolacrimal duct cysts. *Laryngoscope*., 1995, 105(1), 86-9.

[61] Fishman, G; Dollberg, S; Ben-sira, L; Derowe, A. Bilateral congenital nasolacrimal duct cyst: an unusual cause of respiratory distress in the neonate. *Isr Med Assoc J.*, 2002, 4(10), 831-2.

[62] Roy, D; Guevara, N; Santini, J; Castillo, L. Endoscopic marsupialization of congenital nasolacrimal duct cyst with dacryocoele. *Clin Otolaryngol Allied Sci.*, 2002, 27(3), 167-70.

[63] Cunningham, MJ. Endoscopic management of pediatric nasolacrimal anomalies. *Otolaryngol Clin North Am.*, 2006, 39(5), 1059-74, viii-ix.

[64] Ramsden, JD; Campisi, P; Forte, V. Choanal atresia and choanal stenosis. *Otolaryngol Clin North Am.*, 2009, 42(2), 339-52, x.

[65] Silverman, FN; Kuhn, JP. *Caffey's Pediatric X-Ray Diagnosis: an integrated imaging approach*. Mosby Year Book, 9th edition., (1993).

[66] Hengerer, AS; Brickman, TM; Jeyakumar, A. Choanal atresia: embryologic analysis and evolution of treatment, a 30-year experience. *Laryngoscope*., 2008, 118(5), 862-6.

[67] Kurosaka, H. Choanal atresia and stenosis: Development and diseases of the nasal cavity. *Wiley Interdiscip Rev Dev Biol.*, 2019, 8(1), e336.

[68] Corrales, CE; Koltai, PJ. Choanal atresia: current concepts and controversies. *Curr Opin Otolaryngol Head Neck Surg.*, 2009, 17(6), 466-70.

[69] Rajan, R; Tunkel, DE. Choanal Atresia and Other Neonatal Nasal Anomalies. *Clin Perinatol.*, 2018, 45(4), 751-767.

[70] Shirkhoda, A; Biggers, WP. Choanal atresia: a case report illustrating the use of computed tomography. *Radiology*., 1982, 142(1), 93-4.

[71] Patel, VA; Carr, MM. Congenital nasal obstruction in infants: A retrospective study and literature review. *Int J Pediatr Otorhinolaryngol*., 2017, 99, 78-84.

[72] Brihaye, P; Delpierre, I; De villé, A; Johansson, AB; Biarent, D; Mansbach, AL. Comprehensive management of congenital choanal atresia. *Int J Pediatr Otorhinolaryngol.*, 2017, 98, 9-18.

[73] Verwoerd, CD; Verwoerd-verhoef, HL. Rhinosurgery in children: developmental and surgical aspects of the growing nose. *Laryngorhinootologie*., 2010, 89, Suppl 1, S46-71.

[74] Karligkiotis, A; Farneti, P; Gallo, S; et al. An Italian multicentre experience in endoscopic endonasal treatment of congenital choanal atresia: Proposal for a novel classification system of surgical outcomes. *J Craniomaxillofac Surg*., 2017, 45(6), 1018-1025.

[75] Teissier, N; Kaguelidou, F; Couloigner, V; François, M; Van den abbeele, T. Predictive factors for success after transnasal endoscopic treatment of choanal atresia. *Arch Otolaryngol Head Neck Surg.*, 2008, 134(1), 57-61.

[76] Velegrakis, S; Mantsopoulos, K; Iro, H; Zenk, J. Long-term outcomes of endonasal surgery for choanal atresia: 28 years experience in an academic medical centre. *Eur Arch Otorhinolaryngol.*, 2013, 270(1), 113-6.

[77] Carter, JM; Lawlor, C; Guarisco, JL. The efficacy of mitomycin and stenting in choanal atresia repair: a 20 year experience. *Int J Pediatr Otorhinolaryngol.*, 2014, 78(2), 307-11.

[78] Harley, EH. Pediatric congenital nasal masses. *Ear Nose Throat J.*, 1991, 70(1), 28-32.

[79] Re, M; Tarchini, P; Macrì, G; Pasquini, E. Endonasal endoscopic approach for intracranial nasal dermoid sinus cysts in children. *Int J Pediatr Otorhinolaryngol.*, 2012, 76(8), 1217-22.

[80] Rahbar, R; Shah, P; Mulliken, JB; et al. The presentation and management of nasal dermoid: a 30-year experience. *Arch Otolaryngol Head Neck Surg.*, 2003, 129(4), 464-71.

[81] Di ieva, A; Bruner, E; Haider, T; et al. Skull base embryology: a multidisciplinary review. *Childs Nerv Syst*., 2014, 30(6), 991-1000.

[82] Pensler, JM; Bauer, BS; Naidich, TP. Craniofacial dermoids. *Plast Reconstr Surg.*, 1988, 82(6), 953-8.

[83] Zapata, S; Kearns, DB. *Nasal dermoids*, *Curr. Opin. Otolaryngol. Head Neck Surg.*, 14, (2006), 406–411.

[84] Denoyelle, F; Ducroz, V; Roger, G; Garabedian, EN. Nasal dermoid sinus cysts in children, *Laryngoscope*, 107, (1997), 795–800.

[85] Rohrich, RJ; Lowe, JB; Schwartz, MR. The role of open rhinoplasty in the management of nasal dermoid cysts, *Plast. Reconstr. Surg.*, 104, (1999), 1459–1468.

[86] Locke, R; Kubba, H. The external rhinoplasty approach for congenital nasal lesions in children, *Int. J. Pediar. Otorhinolaryngol.*, 75 (3), (2011), 337–341.

[87] Morrissey, MS; Bailey, CM. External rhinoplasty approach for nasal dermoids in children, *Ear Nose Throat J.*, 70, (1991), 445–449.

[88] Duz, B; Secer, HI; Tosun, F; Gonul, E. Endoscopic endonasal resection of a midline intradural frontobasal dermoid tumor, *Minim. Invas. Neurosurg.*, 50, (2007), 363–366.

[89] Schuster, D; Riley, KO; Cure, JK; Woodworth, BA. Endoscopic resection of intracranial dermoid cysts, *J. Laryngol. Otol.*, 125, (2011), 423–427.

[90] Pianta, L; Pinelli, L; Nicolai, P; Maroldi, R. Cerebrospinal fluid leak, meningocele and meningoencephalocele. In: *Imaging in treatment planning for sinonasal diseases*, R. Maroldi & P. Nicolai, (Eds.), 93-106, Springer, Berlin, German

[91] Mahapatra, AK; Suri, A. Anterior encephaloceles: a study of 92 cases. *Pediatr Neurosurg.*, 2002, 36(3), 113-8.

[92] Rahbar, R; Resto, VA; Robson, CD; et al. Nasal glioma and encephalocele: diagnosis and management. *Laryngoscope*., 2003, 113(12), 2069-77.

[93] Wilson, M; Snyderman, C. Endoscopic Management of Developmental Anomalies of the Skull Base. *J Neurol Surg B Skull Base.*, 2018, 79(1), 13-20.

[94] Bradley, PJ; Singh, SD. Nasal glioma. *J Laryngol Otol.*, 1985, 99(3), 247-52.

[95] Hanikeri, M; Waterhouse, N; Kirkpatrick, N; Peterson, D; Macleod, I. The management of midline transcranial nasal dermoid sinus cysts. *Br J Plast Surg.*, 2005, 58(8), 1043-50.

[96] Vuckovic, N; Vuckovic, D; Dankuc, D. Jovancevic, L. *Nasal glioma. Arch Oncol*, Vol. 14, No. 1-2, (June 2006), pp. 57-9.

[97] Bradley, PJ; Singh, SD. Congenital nasal masses: diagnosis and management. *Clin Otolaryngol Allied Sci.*, 1982, 7(2), 87-97.
[98] Fitzpatrick, E; Miller, RH. Congenital midline nasal masses: dermoids, gliomas, and encephaloceles. *J La State Med Soc.*, 1996, 148(3), 93-6.
[99] Ommaya, AK. Spinal fluid fistulae. *Clin Neurosurg.*, 1976, 23, 363-92.
[100] Beckhardt, RN; Setzen, M; Carras, R. Primary spontaneous cerebrospinal fluid rhinorrhea. *Otolaryngol Head Neck Surg*., 1991, 104(4), 425-32.
[101] Nuss, DW; Costantino, PD. Diagnosis and Management of Cerebrospinal Fluid Leaks. In: *Highlights of the Instructional Courses of the American Academy of Otolaryngology-Head and Neck Surgery.*, (1995).
[102] Lloyd, KM; Delgaudio, JM; Hudgins, PA. Imaging of skull base cerebrospinal fluid leaks in adults. *Radiology*., 2008, 248(3), 725-36.
[103] Bachmann, G; Nekic, M; Michel, O. Clinical experience with beta-trace protein as a marker for cerebrospinal fluid. *Ann Otol Rhinol Laryngol.*, 2000, 109(12 Pt 1), 1099-102.
[104] Reardon, EJ. The impact of image-guidance systems on sinus surgery. *Otolaryngol Clin North Am.*, 2005, 38(3), 515-25.
[105] Shah, RN; Surowitz, JB; Patel, MR; et al. Endoscopic pedicled nasoseptal flap reconstruction for pediatric skull base defects. *Laryngoscope*., 2009, 119(6), 1067-75.
[106] Khalili, S; Palmer, JN; Adappa, ND. The expanded endonasal approach for the treatment of intracranial skull base disease in the pediatric population. *Curr Opin Otolaryngol Head Neck Surg.*, 2015, 23(1), 65-70.
[107] Keshri, AK; Shah, SR; Patadia, SD; Sahu, RN; Behari, S. Transnasal endoscopic repair of pediatric meningoencephalocele. *J Pediatr Neurosci.*, 2016, 11(1), 42-5.
[108] Bertazzoni, G; Schreiber, A; Ferrari, M; Nicolai, P. Contemporary management of juvenile angiofibroma. *Curr Opin Otolaryngol Head Neck Surg.*, 2019, 27(1), 47-53.
[109] Kulas, P; Willnecker, V; Dlugaiczyk, J; et al. Mesenchymal-endothelial transition in juvenile angiofibroma? *Acta Otolaryngol*, 2015, 135, 955–961.
[110] Coutinho-Camillo, CM; Brentani, MM; Nagai, MA. Genetic alterations in juvenile nasopharyngeal angiofibromas. *Head Neck*, 2008, 30, 390–400.
[111] Zhang, M; Sun, X; Yu, H; et al. Biological distinctions between juvenile nasopharyngeal angiofibroma and vascular malformation: an immunohistochemical study. *Acta Histochem*, 2011, 113, 626–630.
[112] Schuon, R; Brieger, J; Heinrich, UR; et al. Immunohistochemical analysis of growth mechanisms in juvenile nasopharyngeal angiofibroma. *Eur Arch Otorhinolaryngol*, 2007, 264, 389–394.
[113] Rowan, NR; Stapleton, AL; Heft-Neal, ME; et al. The natural growth rate of residual juvenile angiofibroma. *J Neurol Surg B Skull Base*, 2018, 79, 257–261.
[114] Safadi, A; Schreiber, A; Fliss, DM; Nicolai, P. Juvenile angiofibroma: current management strategies. *J Neurol Surg B Skull Base*, 2018, 79, 21–30.
[115] Lopez, F; Triantafyllou, A; Snyderman, CH; et al. Nasal juvenile angiofibroma: current perspectives with emphasis on management. *Head Neck*, 2017, 39, 1033–1045.
[116] Lloyd, G; Howard, D; Phelps, P; Cheesman, A. Juvenile angiofibroma: the lessons of 20 years of modern imaging. *J Laryngol Otol*, 1999, 113, 127–134.

[117] Andrews, JC; Fisch, U; Valavanis, A; et al. The surgical management of extensive nasopharyngeal angiofibromas with the infratemporal fossa approach. *Laryngoscope*, 1989, 99, 429–437.

[118] Schreiber, A; Bertazzoni, G; Ferrari, M; et al. Management of persistent juvenile angiofibroma after endoscopic resection: Analysis of a single institution series of 74 patients. *Head Neck.*, 2019, 41(5), 1297-1303.

[119] Puxeddu, R; Berlucchi, M; Ledda, GP; Parodo, G; Farina, D; Nicolai, P. Lobular capillary hemangioma of the nasal cavity: A retrospective study on 40 patients. *Am J Rhinol.*, 2006, 20(4), 480-4.

[120] Léauté-Labrèze, C; Dumas de la Roque, E; Hubiche, T; Boralevi, F; Thambo, JB; Taïeb, A. Propranolol for severe hemangiomas of infancy. *N Engl J Med*, 2008, 358(24), 2649–2651.

[121] Léauté-Labrèze, C; Hoeger, P; Mazereeuw-Hautier, J; et al. A randomized, controlled trial of oral propranolol in infantile hemangioma. *N Engl J Med*, 2015, 372(08), 735–746.

[122] Andronikou, S; Mandelstam, S; Fasulakis, S. MRI and preoperative embolization of a nasal cavity haemangioma in a child. *Australas Radiol.*, 2003, 47(4), 386-8.

[123] Ord, RA; Blanchaert, RH; Nikitakis, NG; Sauk, JJ. Ameloblastoma in children. *J Oral Maxillofac Surg.*, 2002, 60(7), 762-70.

[124] Schafer, DR; Thompson, LD; Smith, BC; Wenig, BM. Primary ameloblastoma of the sinonasal tract: a clinicopathologic study of 24 cases. *Cancer*., 1998, 82(4), 667-74.

[125] Tranchina, MG; Amico, P; Galia, A; Emmanuele, C; Saita, V; Fraggetta, F. Ameloblastoma of the sinonasal tract: report of a case with clinicopathologic considerations. *Case Rep Pathol.*, 2012, 2012, 218156.

[126] Temporale, H; Zatoński, T; Roszkowska, A; Kręcicki, T. Ameloblastoma of the nasal septum origin: a case report. *Case Rep Otolaryngol.*, 2013, 2013, 280509.

[127] Azizkhan, RG; Caty, MG. Teratomas in childhood. *Curr Opin Pediatr*., 1996, 8(3), 287-92.

[128] April, MM; Ward, RF; Garelick, JM. Diagnosis, management, and follow-up of congenital head and neck teratomas. *Laryngoscope*., 1998, 108(9), 1398-401.

[129] Chung, SY; Unsal, AA; Kılıç, S; Baredes, S; Liu, JK; Eloy, JA. Pediatric sinonasal malignancies: A population-based analysis. *Int J Pediatr Otorhinolaryngol.*, 2017, 98, 97-102.

[130] Yi, JS; Cho, GS; Shim, MJ; Min, JY; Chung, YS; Lee, BJ. Malignant tumors of the sinonasal tract in the pediatric population. *Acta Otolaryngol*., 2012, 132, Suppl 1, S21-6.

[131] Shapiro, NL; Bhattacharyya, N. Staging and survival for sinus cancer in the pediatric population. *Int J Pediatr Otorhinolaryngol.*, 2009, 73(11), 1568-71.

[132] Benoit, MM; Bhattacharyya, N; Faquin, W; Cunningham, M. Cancer of the nasal cavity in the pediatric population. *Pediatrics*., 2008, 121(1), e141-5.

In: Encyclopedia of Surgery (22 Volume Set)
Editors: Andreas Lehrer and Kristin Mueller
ISBN: 978-1-53618-329-0
© 2020 Nova Science Publishers, Inc.

Chapter 113

FEMTOSECOND LASER-ASSISTED REFRACTIVE SURGERY

Hui Sun*
Aerospace Information Research Institute, Chinese Academy of Sciences,
Beijing, China
University of Chinese Academy of Sciences, Beijing, China

ABSTRACT

A femtosecond is the SI unit of time equal to 10^{-15} of a second. The term "femtosecond laser" refers to a laser in which the pulse duration is in femtosecond range. Femtosecond laser has the advantage of combined high ablation precision and minimized collateral tissue effects, when creating photodisruption at corneal tissue. The accuracy and predictability of femtosecond lasers not only provides new treatment options, but also increases clinical outcomes in refractive procedures and corneal transplantations. The most important advantage of femtosecond laser technology is the ability to create vertical and lamellar corneal incisions with a limitless variety of shapes and angulations at a precise depth. The femtosecond laser technology has allowed a new era in the field of corneal transplantation surgery and it is now being used in a wide variety of corneal surgeries including customized trephination penetrating keratoplasty, anterior and posterior lamellar keratoplasty, tunnel creation for intrastromal ring segments, and astigmatic keratotomy. One of the most popular applications for femtosecond laser eye surgery has been laser in situ keratomileusis (LASIK) surgery, where the creating a corneal flap is a key step. Flap creation was originally performed by a mechanical microkeratome. Over the past two decades, femtosecond lasers have replaced the mechanical microkeratome as the dominant tool for LASIK flap creation in the United States, primarily due to its ability to create a thinner, flatter, and more even corneal flap. After a thin flap is created on the anterior surface of the cornea and lifted, the underlying corneal stroma is ablated by an excimer laser using direct photoablation. Today the entire procedure of LASIK can be accomplished independently with a femtosecond laser. At present, two approaches are used: one method is small incision lenticule extraction, which initial creates a corneal lenticule using the femtosecond laser, makes a cut around,

* Corresponding Author's Email: sunhui@aircas.ac.n.

and performs the lenticule extraction. The other approach is femtosecond lenticule extraction, which utilizes a femtosecond laser to create the corneal flap, separates and extracts the lenticule from the corneal bed using a forceps, and manually restores the corneal flap. Because the application of femtosecond lasers in LASIK surgery is so successful and near-infrared wavelengths are almost not absorbed by optically clear tissue in the human eye, it is of no surprise that the application of these lasers to cut deeper eye tissues will be explored. The newest application of femtosecond lasers in ophthalmology is cataract surgery. Currently, there are a few lasers at or near the point of commercial release, including LenSx (Alcon Laboratories Inc., Fort Worth, Texas), Catalys (Abbott Medical Optics, Santa Ana, California), LensAR (LensARInc, Orlando, Florida), Victus (Technolas Perfect Vision and Bausch & Lomb, Rochester, New York), and Femto LDV (Ziemer Ophthalmic Systems AG, Port, Switzerland). All laser systems share a common platform, which includes an anterior-segment imaging system, patient interface, and femtosecond laser to image, to calculate and deliver the laser pulses. Some part of this chapter explains the principle of OCT-guided femtosecond laser cataract surgery. The combination of femtosecond laser surgery and OCT imaging simultaneously guides the development of next-generation femtosecond surgical lasers in cataract surgery and explores femtosecond-laser surgical strategies.

1. CONCEPTS RELATED TO FEMTOSECOND LASER-ASSISTED REFRACTIVE SURGERY

1.1. Femtosecond Laser

The name LASER is an acronym for “Light Amplification by the Stimulated Emission of Radiation.” A laser is a device that generates or amplifies coherent radiation at frequencies in the infrared, visible, or ultraviolet regions of the electromagnetic spectrum, which emits light through a process of optical amplification based on the stimulated emission of electromagnetic radiation [1]. A laser differs from other sources of light in that it emits light coherently. Spatial coherence allows a laser to be focused to a tight spot, enabling application such as laser cutting. Temporal coherence can be used to produce pulses of light as short as a femtosecond. A femtosecond is the SI unit of time equal to 10^{-15} of a second. The term “femtosecond laser” refers to a laser in which the pulse duration is in femtosecond range. Different types of lasers can produce femtosecond pulse like as dye lasers, solid state lasers, and fiber lasers. Solid state lasers are typically optically pumped, using either a flash lamp or laser diodes. Diode pumped solid state lasers tend to be much more efficient, and have become much more common as the cost of high-power semiconductor lasers has decreased. Single femtosecond laser pulse is employed to ablate eye tissue in femtosecond laser-assisted refractive surgery. The single laser pulse energy from oscillator cannot satisfy the threshold requirement even though the laser beam focused very well. A technique called chirped pulse amplification (CPA) is used for amplifying a femtosecond laser pulse to satisfy this intensity requirement was invented by G Mourou in the 1980s [2]. In order to keep the intensity of a femtosecond laser pulse below the threshold of the nonlinear effects inside the amplifier, this femtosecond laser pulse is stretched out in time prior to introducing it to the amplifier using a pair of gratings that are arranged so that the low-frequency component of the laser pulse travels a shorter path than the high-frequency component does. After going through the grating pair, the laser pulse becomes positively chirped, namely, the high-frequency

component lags behind the low-frequency component, and has longer pulse duration than the original one by a factor of 10^3 to 10^5. Then the stretched pulse, whose intensity is sufficiently low, is safely introduced to the amplifier and amplified by a factor 10^3 or more. Finally, the amplified laser pulse is recompressed back to the femtosecond range through the reversal process of stretching, achieving orders of magnitude higher peak power than laser systems could generate before the invention of chirped pulse amplification technique.

1.2. Laser Tissue Interactions

We obtain more than 80% of our information from the external world by means of visual function. Good vision depends on the cornea and lens as refractive components. The cornea serves as the gateway into the eye for external images. The cornea accounts for more than two-thirds of the total refractive power of the eye. Maintenance of corneal shape and transparency is critical for refraction. Femtosecond laser has the advantage of combined high ablation precision and minimized collateral tissue effects, when creating laser induced ablation at corneal tissue. Numerous studies investigated the interaction of pulsed laser radiation with bulk material. A common finding is that the short pulse damage is deterministic in nature and the threshold is lower with shorter laser pulses. There are five types of laser tissue interaction: photochemical interactions, thermal interactions, photoablation, plasma-induced ablation, and photodisruption [3]. There are two types of laser tissue interactions which related to femtosecond laser-assisted refractive surgery: plasma-induced ablation, and photodisruption. A phenomenon called laser induced optical breakdown (LIOB) will occur when the power densities exceed 10^{11} W/cm^2 in solids and fluids or 10^{14} W/cm^2 in air. A bright plasma spark is clearly visible with this effect [3]. Without thermal or mechanical damage, the tissue is well defined and can be removed very cleanly. This kind of ablation is primarily caused by plasma ionization itself. Puliafito and Steinert describe the initiation of plasma generation as a two-fold process [4]. Either Q-switched pulses in the nanosecond range or mode locked laser pulses in the picosecond or femtosecond range can induce the microplasma. The first step is that a free electron absorbs a photon and accelerates. The second step is that the accelerated electron collides with another atom and ionizes it. The result is two free electrons, both having less individual kinetic energy than the initial electron. The third step is that these free electrons absorb photons, accelerate, strike other atoms, and release two more electrons. These steps will continue, and more and more free electrons will be induced. In order to achieve optical breakdown, the irradiance must be intense enough to cause rapid ionization so that the losses do not quench the electron avalanche. Due to the increased absorption coefficient of the induced plasma, an important feature of optical breakdown is that it renders an energy deposition in nominally weakly absorbing media. Therefore, transparent tissue like cornea or lens can become a target of medical laser application. Plasma formation and shock wave generation are physical effects associated with optical breakdown. Cavitation and jet formation may additionally take place if breakdown occurs inside soft tissues or fluids. Different from the plasma induced ablation, secondary effects of the plasma at higher pulse energies like shock waves become more significant. In the breakdown region the effect is plasma induced ablation while in the adjacent region the effects are shock wave and cavitation. Since adjacent tissue can be damaged by disruptive forces, the presence of these effects is often an undesired but associated symptom. The

difference between the plasma induced ablation and photodisruption is the different power energy during the process. Photodisruption is a multi-cause mechanical effect starting with optical breakdown. Shock wave generation and cavitation are the primary mechanisms, completed by jet formation if cavitation's collapse in fluids and near a solid boundary.

2. FEMTOSECOND LASER ASSISTED LASIK SURGERY

2.1. LASIK Surgery Procedure

An extension of wave front measurement technology to ophthalmology has quantitatively characterized the quality of the human eye. An exact measurement of aberrations induced by the eye opens the door for refractive surgery in the pursuit of perfect vision by a sophisticated surgical approach. The use of the excimer laser to directly alter the cornea curvature was made in photorefractive keratectomy (PRK) surgery. In 1995 the U.S. Food and Drug Administration (FDA) issued approval of the Summit (Waltham, MA) laser for PRK. In 1996 FDA approved the VISX (Santa Clara, CA) laser for PRK. At PRK surgery, the ablation starts from the front surface of the cornea. The excimer lasers direct split of molecular bonds with minimal adjacent heating. Because of the nerval cells in epithelium, patients will feel pain during and after PRK surgery. New solution is to introduce a method which ablate the stroma after a flap is lifted. At this point, the excimer laser story joins the keratomileusis story to become Laser In-situ Keratomileusis (LASIK) [5]. This procedure consists of two steps. In the first step, a thin flap is created on the anterior surface of the cornea and lifted. This step involves cutting a thin flap in the cornea with a microkeratome in order to expose the stromal bed for excimer laser ablation. When flap is achieved, a hinge is left at one end of this flap. The flap is folded back, revealing the corneal stroma. In the second step, the underlying corneal stroma is ablated and then the corneal flap is replaced. The curvature of the cornea is altered by removing corneal tissue using direct photo ablation with ultraviolet light from the excimer laser. The excimer laser vaporizes the tissue in a finely controlled manner without damaging the adjacent stroma. No burning with heat or actual cutting is required to ablate the tissue. The layers of tissue removed are tens of micrometers thick. Performing the laser ablation in the deeper corneal stroma provides for more rapid visual recovery and less pain. The creating a corneal flap is a key step in LASIK. Flap creation was originally performed by a mechanical microkeratome. Over the past two decades, femtosecond lasers have replaced the mechanical microkeratome as the dominant tool for LASIK flap creation in the United States, primarily due to its ability to create a thinner, flatter, and more even corneal flap. Today the entire procedure of LASIK can be accomplished independently with a femtosecond laser. At present, two approaches are used: one method is small incision lenticule extraction, which initial creates a corneal lenticule using the femtosecond laser, makes a cut around, and performs the lenticule extraction. The other approach is femtosecond lenticule extraction, which utilizes a femtosecond laser to create the corneal flap, separates and extracts the lenticule from the corneal bed using a forceps, and manually restores the corneal flap.

2.2. Femtosecond Laser Assisted Flap Creation

Flap creation, a crucial step in LASIK procedure, was originally performed using a mechanical microkeratome. However, factors such as blade quality, gap width of the microkeratome head, and translation speed can affect the quality of the flap [6, 7]. Over the past two decades, femtosecond lasers have displaced the mechanical microkeratome as the dominant tool for LASIK flap creation in the United States, primarily due to enhanced precision and minimized collateral tissue effects [8-15]. Diode pumped all-solid-state femtosecond lasers are now commonly used to perform flap creation in LASIK. Yb-doped fiber lasers or solid-state lasers, which emit around 1 μm wavelength, are currently the most reliable systems and also the cheapest way to produce femtosecond lasers. Their pulse duration is typically around 200 to 800 femtoseconds. In 2000 the flap created by a femtosecond laser along with a refractive error corrected by the excimer laser was conducted on a patient for the first time. This procedure is called IntraLASIK, also known as Femto-LASIK or All-laser LASIK. The term IntraLASIK is derived from IntraLase, the name of the first manufacturer to achieve Food and Drug Administration approval of a femtosecond laser for use in the United States for the surgical procedure LASIK. For femtosecond laser flap creation, the patient's eye is fixed with disposable patient interface and the femtosecond laser focus first is scanned along a certain pattern inside the corneal stroma at a predetermined depth. The intrastromal cut is followed by several semicircular shaped cuts at decreasing depth in the cornea to connect this intrastromal cut to the corneal surface, with a hinge present to maintain connection to the cornea surface. After removal of patient interface then the flap is lifted to give the excimer laser access to deeper corneal stroma. A LASIK flap created with a femtosecond laser is regarded by many ophthalmologists as an improvement over traditional one created with a mechanical microkeratome because of a greater accuracy in flap size, shape, and thickness. Although the final long-term clinical outcome of LASIK with a mechanical micorkeratome and with a femtosecond laser may be similar, the increased accuracy of the flap with the femtosecond laser provides an added margin of safety [16]. The femtosecond lasers have displaced the mechanical microkeratome as the dominant tool for LASIK flap creation in the United States today. Multiple commercial femtosecond lasers have now been cleared for use by the U.S. Food and Drug Administration for ophthalmic surgery, including for the creation of corneal flaps in LASIK surgery. Femtosecond laser systems have successfully entered the refractive surgery market since IntraLase (Irvine, California, USA), which was founded at Irvine, introduced its first commercial system in 2001 as a replacement for the mechanical microkeratome. Shortly after the market launch of the IntraLase laser, a company which is called 20/10 Perfect Vision (Heidelberg, Germany) introduced its FEMTEC system. Then, four years later, the Ziemer Ophthalmic Systems Group (Port, Switzerland) launched its DaVinci system (FEMTO LDV) in the late 2005, and exactly one year later, Zeiss introduced VisuMax (Carl Zeiss Meditec, Jena, Germany) in fall 2006. From 2008 to 2011, one more company enters this market. It is Alcon and the laser name is wavelight. At 2012, LenSx laser got the FDA approval for flap creation in LASIK surgery. It belongs to Alcon company (Fort Worth, Texas). Because Alcon was acquired by Novartis (Basel, Switzerland), now wavelight and LenSx are products of Novartis. The commercial systems on the market can be classified into two groups: one group is characterized by high pulse energy and low pulse frequency, Amplified laser systems are used to deliver pulse energy in the order of μJ to the cornea. The typical laser repetition rate is on

the order of kHz. Every CPA system belongs to this group. The other group is characterized by low pulse energy and high pulse frequency, which delivers energy on the order of nJ to the cornea. The typical laser repetition rate is on the order of MHz. DaVinci system belongs to this group. The nature of the ablating processes of the two groups is different. In the high pulse energy laser group, the cutting process is driven by mechanical forces, which are applied by the expanding bubbles and which disrupt the tissue. This is an efficient process because the radius of disrupted tissue is larger than the laser spot itself. In the low pulse energy laser group, the cutting process is confined by the focal spot size of the laser pulse so that more laser pulses are needed to cut the same spot size. The surface quality of the LASIK stromal bed seems to be of the same quality for these two groups.

3. FEMTOSECOND LASER ASSISTED CORNEAL TRANSPLANTATION SURGERY

The invention of the femtosecond laser technology has allowed great advances in the field of corneal surgery. The initial application of this technology is the flap creation in LASIK surgery. Further advances in this technology enabled the full thickness corneal cuts in a variety of patterns to be made. As a result, the femtosecond laser is now being used in corneal transplantation surgery [17]. The accuracy and predictability of femtosecond lasers not only provides new treatment options, but also increases clinical outcomes in refractive procedures and corneal transplantations. The most important advantage of femtosecond laser technology is the ability to create vertical and lamellar corneal incisions with a limitless variety of shapes and angulations at a precise depth. The femtosecond laser technology has allowed a new era in the field of corneal transplantation surgery and it is now being used in a wide variety of corneal surgeries including customized trephination penetrating keratoplasty, anterior and posterior lamellar keratoplasty, tunnel creation for intrastromal ring segments, and astigmatic keratotomy. The first machine to accomplish the full thickness corneal cuts for penetrating keratoplasty (PKP) was the Intralase. The second femtosecond laser platform to finish this work was FEMTEC. Results using femtosecond laser assisted PKP have generally shown a better fit between donor and host, larger surface area between the donor and host resulting in faster and improved wound healing, and less suture induced astigmatism. Femtosecond laser also used to treat the deep anterior lamellar keratoplasty (DALK). At this surgery, a technique that can maintain the patient's own healthy endothelial layer and replace the entire anterior stromal layer with the addition of superior wound edge healing and minimal induced astigmatism is ideal. The combination of the femtosecond laser-assisted custom shaped cut with the DALK big bubble technique achieves such a goal [17].

4. FEMTOSECOND LASER ASSISTED CATARACT SURGERY

4.1. Physical Concepts of Femtosecond-Laser-Assisted Cataract Surgery

The most prevalent ocular disease and the major cause of blindness in the world is cataract. Either clumps of protein or yellow brown pigment may be deposited in the lens reducing the transmission of light to the retina. Such opacity of the lens, whether it is a small

local opacity or a diffuse general loss of transparency is a cataract. The extent of people's visual disability decides the treatment decision for the patient with cataract. If the cataract is not seriously, the surgery maybe not need. But in most circumstances, there is no alternative to cataract surgery for correcting visual impairment. Under most circumstances, the standard of care in cataract surgery is removal of the cataract by two main types of surgical procedures throughout the world. The first procedure is phacoemulsification (PE or Phaco) and the second procedure is extracapsular cataract extraction (ECCE). PE is the most common technique used in United States today for cataract surgery. It involves the use of a machine with an ultrasonic to remove cataract. After the opening incision and anterior capsulotomy, an ultrasonic probe emulsifies the hard nucleus, enabling the ophthalmologist to remove the lens material using a suction device. The normal depth of the anterior chamber is maintained during this procedure. The wound is then enlarged to allow insertion of a posterior chamber intraocular lens (IOL) into the capsular bag. An IOL is usually implanted into the eye by two ways, either through a small incision using a foldable one, or through an enlarged incision using polymethylmethacrylate (PMMA) lens.

The state of the art of optical coherence tomography (OCT) is an interferometric imaging instrument. The basic principle of hardware of OCT is Michelson Interferometer. Today OCT is a clinical imaging technique that uses light to capture micrometer resolution and three-dimensional images from optical scattering within biological tissue. OCT is particularly suited to ophthalmic applications since it has micrometer resolution and millimeter penetration depth [18]. Like in Michelson Interferometer, light in an OCT system is split into two arms—a sample arm and a reference arm. When the light from both arms have traveled an optical distance which a difference of less than a coherence length of light, the combination of reflected light from the sample arm and reference light from the reference arm gives rises to an interference pattern. A reflectivity profile of the sample can be obtained through scanning the mirror in the reference arm. Interference will not happen when light is outside the short coherence length. Greater interference will create at areas of the sample that reflect back a lot of light. From the analysis of the such data the imaging of tissue will be achieved. An OCT system for ophthalmic use must have good image resolution, deep tissue penetration, and high scan speed. Anterior segment imaging and retinal imaging of the human eye are most common clinical application of OCT.

4.2. OCT Guided Femtosecond Laser Cataract Surgery Procedure

Because the application of femtosecond lasers in LASIK surgery is so successful and near-infrared wavelengths are almost not absorbed by optically clear tissue in the human eye, it is of no surprise that the application of these lasers to cut deeper eye tissues will be explored. Anterior segment femtosecond laser applications were investigated in many methods. To achieve this goal, an imaging technique for anterior segment need to be developed to assist the femtosecond laser ablation. The advent of all solid-state femtosecond lasers, coupled with computer-controlled beam delivery system, enables the new applications of high precision femtosecond laser ablation for ophthalmology. Combining with a precision imaging technique for anterior segment, such as an OCT system, can make it possible to accurate target of tissue in crystalline lens by femtosecond laser. It opened the door for femtosecond laser cataract surgery. Femtosecond laser systems have successfully entered the

cataract surgery market since LenSx (Alcon Laboratories Inc., Ft Worth, TX, USA), which was founded at Aliso Viejo in 2007, introduced its first commercial system in 2008 as a promising new technological advance which plays an ever increasing role in cataract surgery where it automates the three main surgical steps: corneal incision, capsulotomy and lens fragmentation. It is an innovative growing new technology for cataract surgery because the enhanced precision and minimized collateral tissue effects from femtosecond laser ablation. This attribute of femtosecond lasers is especially important for femtosecond laser cataract surgery, wherein preservation of ocular structures like capsular bag is critical for good visual outcomes [19]. The first clinical report of human eye treated by femtosecond laser cataract surgery was in Hungary in 2008 [20]. There has been increasing interest in the use of femtosecond laser in cataract surgery after the first report. The U.S. Food and Drug Administration approved the usage of femtosecond laser for cataract surgery in 2010. The application of femtosecond laser in cataract surgery increased dramatically after LenSx system was cleared for use by FDA. Just in a few years, femtosecond lasers have become relevant in cataract surgery in clinic as an opportunity to improve the quality of the surgical procedure. Currently, there are a few lasers at or near the point of commercial release, including LenSx (Alcon Laboratories Inc., Fort Worth, Texas), Catalys (Abbott Medical Optics, Santa Ana, California), LensAR (LensARInc, Orlando, Florida), Victus (Technolas Perfect Vision and Bausch & Lomb, Rochester, New York), and Femto LDV (Ziemer Ophthalmic Systems AG, Port, Switzerland). All laser systems share a common platform, which includes an anterior-segment imaging system, patient interface, and femtosecond laser to image, to calculate and deliver the laser pulses. They are solid state femtosecond lasers integrated with imaging subsystem. The principles are same but they differ in versatility, docking, and speed of action and so on. Although the steps for each laser platform very, they share four primary steps for the femtosecond laser cataract surgery procedure: planning, engagement, visualization and customization, and treatment [19]. A series of parameters, such as pupil dilation, lens thickness, and corneal thickness, will need to be measured before cataract surgery. Then surgical plan will be made. Normally the planning parameters include the size, shape, and desired center of laser ablation for capsulotomy. The planning parameters also include diameter, depth, and patterns of cut for lens fragmentation. The planning parameters will include location, depth, and architecture of incisions for corneal incisions. Adjustments still can be performed in real time guiding by cross sectional imaging during cataract surgery. The patient interface optically couples the eye to the optical delivery system to prevent eye movement is the first clinical step for femtosecond-laser-assisted cataract surgery (FLACS). The docking system, namely patient interface, is comprised of a curved applanation lens and suction ring normally. Both parts are integrated into a single piece and mounted on the laser delivery system. Patient interface serves as a sterile barrier between the patient's eye and the femtosecond laser. All commercially available femtosecond lasers have appeared to be effective in stabilizing the patient' eye, however, the methods and devices for docking are an area of differentiation for these femtosecond lasers. The image guidance subsystem gives the instruction about the dimensions and location of ocular structures. It is a critical part of femtosecond laser cataract surgery because it guides the surgeon in lens fragmentation zones and placement of incisions. This subsystem must be able to detect the iris boundaries so that the surgery can be made safely without cutting iris. For the reason to maintain a safety zone and not cut in posterior capsule, this subsystem must be able to detect the posterior surface of the lens. The corneal thickness should be measured in order to

customize corneal incisions for each patient. The non-contact, fast method of high-resolution image acquisition with Fourier domain optical coherence tomography (FD-OCT) enables detailed cross-sectional imaging of the anterior segment useful in various clinical settings. Some important parameters for cataract, such as iris boundaries, corneal thickness, lens position, and iridocorneal angle can be measured by FD-OCT in real time. The platforms that using FD-OCT for three-dimensional, high resolution viewing of ocular structures in cataract surgery include LenSx, Catalys, Victus, and Femto LDV, while LensAR utilizes Scheimpflug imaging technology. The treatment is the final step of femtosecond laser cataract surgery. The femtosecond laser creates incisions through tightly focused femtosecond laser pulses that cut eye tissue with micron scale precision. The incision is achieved by contiguously placed femtosecond laser focus scanned by a computer-controlled delivery system through the laser spot pattern from posterior to anterior which will reduce the amount of radiation reaching the retina. The femtosecond laser beam creates individual photodisruption sites in a contiguous pattern to form continuous incisions. The spacing between each spot is programmed by the surgeon who programs the size, shape and location of the scanning pattern before the treatment. The treatment includes four parts, namely clear corneal incisions, creation of the capsulotomy, fragmentation of the lens nucleus, and correction of astigmatism through corresponding arcuate incisions.

The first clinical report of human eye treated by femtosecond laser cataract surgery was in Hungary in 2008 [20]. It is a promising new technological advance which plays an ever-increasing role in cataract surgery. The accumulating clinical experience to date with FLACS indicates that it offers several potential advantages over manual surgery are: a better quality of incision with reduced induced astigmatism; increased reliability and reproducibility of the capsulotomy with increased stability of the implanted lens; a reduction in the use of ultrasound [21]. Clear corneal self-sealing incision architecture is of paramount importance. Previous study shows the corneal incision with internal wound gape will increase the risk of leakage and thus postoperative endophthalmitis. Manual corneal incisions are difficult to control in terms of length and architecture. One of the benefits from FLACS is that corneal wounds and arcuate incisions in the desired position and depth make the control of postoperative astigmatism much more effective [22]. If FLACS can produce a reproducibly round, centered and intact anterior capsule, this alone would improve the safety of cataract surgery in a way that could possible justify the introduction of this new technology [23]. The anterior capsular tears in the hands of experienced surgeons have a high incidence. There was a high ease of removal of the capsular button which created by femtosecond lasers. It is well known the importance of a precisely sized capsulorhexis to optimize intraocular lens (IOL) position and performance. FLACS can create capsulotomy more precise, rounder, more regularly shaped and greater centration than with a manual technique. This allowed for better intraocular lens and capsule overlap. The improved overlap of the anterior capsule by the IOL has been shown to produce less IOL tilt and decentration compared with manual continuous curvilinear capsulorhexis (CCC) [24]. A lot of similar results were obtained from commercially available femtosecond lasers in cataract surgery [25]. Femtosecond lasers are powerful tool to segment the crystalline lens, allowing the difficult chop steps in regular cataract surgery that most frequently lead to complications much easier. Femtosecond laser cuts on the crystalline lens soften the harder cataracts with a result of decrease the amount of ultrasound energy from the phachmulsification probe, thereby diminishing the risk of capsule complications and corneal endothelial injury. To date, the clinical reports showed the

percentage reduction of FLACS phachemulsification varied by company and grade of cataract, but was 33% at least [26, 27]. Other benefits of FLACS include it has the ability to correct of astigmatism through corresponding arcuate incisions, reduction of infection possibility, decreased endothelial cell loss and maybe better visual and refractive outcomes.

CONCLUSION

Femtosecond laser has the advantage of combined high ablation precision and minimized collateral tissue effects, when creating photodisruption at corneal tissue. The accuracy and predictability of femtosecond lasers not only provides new treatment options, but also increases clinical outcomes in refractive procedures and corneal transplantations. One of the most popular applications for femtosecond laser eye surgery has been laser in situ keratomileusis surgery, where the creating a corneal flap is a key step. Flap creation was originally performed by a mechanical microkeratome. Over the past two decades, femtosecond lasers have replaced the mechanical microkeratome as the dominant tool for LASIK flap creation in the United States, primarily due to its ability to create a thinner, flatter, and more even corneal flap. Today the entire procedure of LASIK can be accomplished independently with a femtosecond laser. Femtosecond laser-assisted corneal surgery is improving traditional outcomes in transplantation. The femtosecond laser technology has allowed a new era in the field of corneal transplantation surgery and it is now being used in a wide variety of corneal surgeries including customized trephination penetrating keratoplasty, anterior and posterior lamellar keratoplasty, tunnel creation for intrastromal ring segments, and astigmatic keratotomy. The advent of all solid-state femtosecond lasers, coupled with computer-controlled beam delivery system, enables the new applications of high precision femtosecond laser ablation for ophthalmology. Combining with a precision imaging technique for anterior segment, such as an OCT system, can make it possible to accurate target of tissue in crystalline lens by femtosecond laser. Femtosecond laser systems have successfully entered the cataract surgery market as a promising new technological advance. The clinical experiences so far indicate that this new technology is promising for the field of cataract surgery. FLACS appears safe and efficacious, and may eventually be proven superior to conventional cataract surgery.

REFERENCES

[1] Anthony E. Siegman "*Lasers*" University Science Books Mill Valley, California, 1990.

[2] D Strickland, and G Mourou, "Compression of amplified chirped optical pulses," *Opt. Commun*, 56, 219-225, 1985.

[3] Niemz MH, "*Laser Tissue Interactions: Fundamentals and Applications 3rd ed*.," Berlin, Germany, Springer Verlag, 2004.

[4] Puliafito C. A and Steinert R. F, "Short-pulsed Nd:YAG laser microsurgery of the eye: biophycisal considerations." *IEEE J. Qu. Electron. QE-20*, 1442-1448, 1984.

[5] Pallikaris, I. G., Papatzanaki, M. E., Siganos, D. S., and Tsilimbaris, M. K. (1991). A corneal flap technique for laser in situ keratomileusis: human studies. *Arch Ophthalmol*, 109: 1699-1702.

[6] Liu K-Y, Lam DSC, "Direct measurement of microkeratome gap width by electron microscope," *J Cataract Refract Surg*, 27, 924-927, 2001.

[7] Javaloy J, Vidal MT, Ruiz-Moreno JM, Alio JL, "Confocal microscopy of disposable and nondisposable heads for the Moria M2 microkeratome," *J Refract Surg*, 22, 28-33, 2006.

[8] Juhasz T, Loesel FH, Kurtz RM, Horvath C, Bille JF, Mourou G, "Corneal refractive surgery with femtosecond lasers," *IEEE J Sel Top Quant Electron*, 5, 902-910, 1999.

[9] Sun H, Han M, Niemz MH, Bille JF, "Femtosecond laser corneal ablation threshold: dependence on tissue depth and laser pulse width," *Lasers Surg Med*, 39, 654-658, 2007.

[10] Juhasz T, Djoyan G, Loesel FH, Kurtz RM, Horvath C, Bille JF, Mourou G, "Applications of femtosecond lasers in corneal surgery," *Laser Physics*, 10, 495-500, 2000.

[11] Hui S, Ronald K, Tibor J, "Evaluation of human sclera after femtosecond laser ablation using two photon and confocal microscopy," *J Biomed Opt*, 17(8), 081411, 2012.

[12] H Sun, E Mikula, RM Kurtz, T Juhasz, "Temperature increase in human cadaver retina during direct illumination by femtosecond laser pulses," *J Refract Surg*, 26(4), 272-277, 2010.

[13] H Sun, E Mikula, RM Kurtz, Tibor Juhasz, "Temperature increase in the porcine cadaver iris during direct illumination by femtosecond laser pulses," *J Cataract Refract Surg*, 37(2), 386-391, 2011.

[14] H Sun, RM Kurtz, Tibor Juhasz, "Simulation of the temperature increase in human cadaver retina during direct illumination by 150-kHz femtosecond laser pulses," *J Biomed Opt*, 16(10), 108001, 2011.

[15] H Sun, RM Kurtz, Tibor Juhasz, "Finite element model of the temperature increase in excised porcine cadaver iris during direct illumination by femtosecond laser pulses," *J Biomed Opt*, 17(7), 078001, 2012.

[16] Jon G Dishler, "All laser LASIK: is it what patients have been waiting for," *Refractive Eyecare for Ophthalmologists*, 6(1), 120-124, 2002.

[17] Marjan Farid and Roger F. Steinert, "Femtosecond laser-assisted corneal surgery," *Curr Opin Ophthalmol*, 21, 288-292, 2010.

[18] Zysk AM, Nguyen FT, Oldenburg AL et al., "Optical coherence tomography: a review of clinical development from bench to bedside," *Journal of Biomedical Optics*, 12(5), 051403, 2007.

[19] Lingmin He, Katrina Sheehy, William Culbertson, "Femtosecond laser assisted cataract surgery," *Current Opinion in Ophthalmology*, 22, 43-52, 2011.

[20] Nagy Z, Takacs A, Filkorn T et al., "Initial clinical evaluation of an intraocular femtosecond laser in cataract surgery," *J Refract Surg*, 25, 1053-1060, 2009.

[21] Abouzeid H, Ferrini W, "Femtosecond laser assisted cataract surgery: a review," *Acta Ophthalmologica*, 92, 597-603, 2014.

[22] Nagy ZZ, Takacs AI, Filkorn T et al., "Complications of femtosecond laser assisted cataract surgery," *J Cataract Refract Surg*, 40, 20-28, 2014.

[23] Chris H, Shveta JB, Michael L et al., "Femtosecond cataract surgery a review of current literature and the experience from an initial installation," *Saudi Journal of Ophthalmology*, 26, 73-78, 2012.

[24] Abouzeid H, Ferrini W, "Femtosecond laser assisted cataract surgery: a review," *Acta Ophthalmologica*, 92, 597-603, 2014.

[25] Alio JL, Abdou AA, Puente AA et al., "Femtosecond laser cataract surgery updates on technologies and outcomes," *J Refract Surg, 30*(6), 420-427, 2014.

[26] Abell RG, Kerr NM, Vote BJ, "Femtosecond laser assisted cataract surgery compared with conventional cataract surgery," *Clin Experiment Ophthalmol*, 41, 455-462, 2013.

[27] Reddy KP, Kandulla J, Auffarth GU, "Effectiveness and safety of femtosecond laser assisted lens fragmentation and anterior capsulotomy versus the manual technique in cataract surgery," *J Cataract Refract Surg*, 39, 1297-1306, 2013.

In: Encyclopedia of Surgery (22 Volume Set)
Editors: Andreas Lehrer and Kristin Mueller
ISBN: 978-1-53618-329-0
© 2020 Nova Science Publishers, Inc.

Chapter 114

SURGERY IN MALIGNANT PLEURAL MESOTHELIOMA: EXTRA-PLEURAL PNEUMONECTOMY – A CRITICAL APPRAISAL

Luca Bertolaccini*[1,*]*, MD, PhD
and Lorenzo Spaggiari*[1,2]*, MD, PhD
[1]Division of Thoracic Surgery, IEO,
European Institute of Oncology IRCCS, Milan, Italy
[2]Department of Oncology and Hemato-Oncology,
University of Milan, Milan, Italy

ABSTRACT

Surgical intervention plays a crucial role in the diagnosis, staging, and treatment of malignant pleural mesothelioma (MPM) and can apply with curative intent using extended pleurectomy/decortication or extrapleural pneumonectomy (EPP).

EPP is defined as the en-bloc resection of the pleura, lung, diaphragm, and pericardium, excision of previous biopsy and chest tube sites, and radical mediastinal lymphadenectomy and other lymph nodes such as found in the mammary chain, along the intercostal structure and in the costodiaphragmatic region, as well as reconstruction of the diaphragm and pericardium with prosthetic patches to prevent herniation. It was shown that EPP could be performed with acceptable morbidity and mortality. One of the most complex decisions is the surgical indication. Laparoscopy or contralateral pleuroscopy should be performed in case of suspicion of intra-abdominal or contralateral disease in staging imaging. Mediastinal staging is performed via endobronchial ultrasound or mediastinoscopy to exclude N3 disease. The analysis of prognostic factors to identify patient groups benefitting from multimodality therapy led to the development of different prognostic scores, such as the Multimodality Prognostic Score Technical experience has led to decreased operative times and surgical adaptations that include the reconstruction of the diaphragm and pericardium with mesh in all patients regardless of side, buttressing of the bronchial stump with well-vascularized tissue, and advanced methods of

* Corresponding Author's Email: luca.bertolaccini@gmail.com.

haemostasis including argon beam coagulation and topical haemostatic agents for chest wall bleeding.

Keywords: extrapleural pneumonectomy, malignant pleural mesothelioma, thoracic surgery

INTRODUCTION

The technique of tumour resection for malignant pleural mesothelioma (MPM) is one of the most debated topics in thoracic surgery, mainly as more significant analyses confirm that even the most aggressive surgical approaches rarely result in cure or long-term survival. Butchart first applied pleuro-pneumonectomy in 1976; on the other hands, en bloc diaphragm and pericardial resection were performed in most cases. To date, the evidence has still significant deficiencies due to the lack of prospective comparative analyses. Despite this, surgery continues to play a significant role in the management of MPM, with the achievement of macroscopic resection of tumour [1].

Table 1. IASLC definitions of surgical procedures for malignant pleural mesothelioma [12]

Extrapleural pneumonectomy	En bloc resection of the visceral and parietal pleura, pericardium, ipsilateral hemidiaphragm, and lung
Pleurectomy/Decortication	Resection of the parietal and visceral pleura, to remove all gross tumours, without removing diaphragm and pericardium
Extended Pleurectomy/Decortication	Pleurectomy/Decortication with the resection of ipsilateral diaphragm and pericardium
Partial pleurectomy	Partial removal of the parietal and/or visceral pleura for diagnostic or palliative intentions

TECHNICAL DEFINITION

The chaos of surgical terminology in MPM was standardised and refined by the International Association for Study of Lung Cancer (IASLC) in 2011. Extrapleural pneumonectomy (EPP) was defined as en bloc resection of the parietal and visceral pleura with the ipsilateral lung, pericardium, and diaphragm. Extended pleurectomy/decortication (P/D) was defined as parietal and visceral pleurectomy to remove all gross tumour with resection of the diaphragm and/or pericardium (Table 1) [1].

OBJECTIVES OF SURGICAL TREATMENT

Surgery can help to achieve an correct diagnosis of MPM (open or VATS pleural biopsies) or to palliate symptoms caused by malignant pleural effusions (VATS talc pleurodesis, pleurectomy, placement of indwelling pleural drainage). In very selected patients (early-stage disease and satisfactory performance status), radical surgical procedures have

been offered in the past, with or without different neoadjuvant or adjuvant treatments. Whenever aggressive surgery is planned, it aims to remove all gross disease, lengthening survival by reducing the intrathoracic tumour burden to microscopic levels. Due to biological characteristics of MPM, the intrathoracic anatomical structures may be rapidly invaded by the tumour, generally without the development of distant metastases. This loco-regional tumour invasiveness should be considered when a surgical approach is planned. MPM surgery is a maximal cytoreductive procedure and usually results in an R1 resection. An R0 resection with surgery alone is theoretically unobtainable, regardless of the type of aggressive procedure is chosen. Consequently, the first goal of surgery is to achieve a complete macroscopic resection; other treatment modalities have been combined with surgery, to control the residual microscopic disease. Patients should undergo this treatment in the setting of a multidisciplinary tumour board, where the single clinical cases are carefully discussed. Ideally, all candidates for surgery should be operated in Thoracic Surgery Units whit recognised broad experience in MPM management, commonly connected with Medical and Radiation Oncology Divisions also involved in clinical trials for MPM. The secondary goal for surgery is to achieve a local tumour control (evacuate pleural effusions, palliate chest pain and ameliorate ventilation/perfusion mismatch) [2].

PROGNOSTIC FACTORS AND PATIENT SELECTION

This risk factors significantly impact on survival in patients undergoing surgery:

- T stage (most apparent in patients undergoing surgery with curative intent);
- Nodal status;
- Tumour histology (epithelial with better outcomes);
- Gender and age;
- Curative intent.

Such factors are critical in the determination as to whether an individual patient may benefit from surgical resection where removal of the macroscopic tumour is the goal. Surgical resection with the goal of removal of the macroscopic tumour can be considered in only a small percentage of patients with MPM. That distant and/or local recurrences are inevitable after aggressive surgical approaches, unfortunately, emphasise that these procedures are not curative. Therefore, the demonstration of a meaningful impact of surgery in the form of prolongation of overall survival without significant morbidity or detrimental impact on the quality of life is needed but is currently lacking. Multidisciplinary management and treatment planning at centres that are experienced in MPM management should be the norm for patients with this disease, given the relatively small number of cases that present every year. Institutional bias and practice will continue to have a significant influence on the surgical approaches used, and the selection that occurs in the accrual and reporting of small multimodality trials makes it difficult to incorporate neoadjuvant or adjuvant therapies with confidence. However, one current randomised trial should provide valuable data in the future [3].

SURGICAL TECHNIQUE

EPP was always performed via double lateral thoracotomy (first thoracotomy through IV-V intercostal space and second thoracotomy through VII-VIII intercostal space) with en bloc excision of the parietal pleura with the entire lung, ipsilateral hemidiaphragm and pericardium. The diaphragm was reconstructed with a synthetic dual mesh placed in the anatomic position of the resected diaphragm or with the bovine pericardium. The pericardium was reconstructed both on the right and on the left sides to prevent cardiac torsion using a synthetic mesh or bovine pericardium. Lymph node dissection should be performed in all patients. Surgery was always performed within four weeks after the last cycle of induction chemotherapy [4].

PERIOPERATIVE MANAGEMENT

Preparation for EPP by the anesthesiologist includes placement of routine monitors, lines, and an epidural catheter for perioperative regional pain control. An arterial line is needed owing to rapid hemodynamic changes and large-bore intravenous access, including a central line, is recommended. If there is any concern regarding pulmonary hypertension, a Swan-Ganz catheter is floated with caution to pull this back before pulmonary artery division. Central lines should be placed on the operative side to avoid pneumothorax on the side of the ventilated (and postoperatively, only) lung. Lung isolation may be obtained with a double-lumen endotracheal tube (preferred) or bronchial blocker, with the latter to be pulled back before the division of the bronchus. Finally, a nasogastric tube is inserted to aid in identifying the oesophagus intraoperatively and to decompress the stomach postoperatively. The disruption of vagal fibres to the bronchus often causes mild postoperative oesophageal dysmotility, and nasogastric decompression may prevent life-threatening aspiration after pneumonectomy in the early postoperative period [5].

PREOPERATIVE EVALUATION

Patients diagnosed with MPM who are considered for EPP are staged with Positron Emission Tomography/Computed Tomography (PET/CT) to evaluate for nodal or distant metastases. The level of PET avidity of the pleural tumour has been shown to correlate with survival, with higher avidity associated with lesser survival. Enlarged and/or PET-positive mediastinal lymph nodes are evaluated with endobronchial ultrasonography or cervical mediastinoscopy. Although some centres perform routine staging mediastinoscopy in all patients, others have abandoned this because of the variable nodal drainage of the pleura with an unpredictable pattern of nodal metastases and the lack of sensitivity of cervical mediastinoscopy for detecting extrapleural nodal spread in MPM. Chest Magnetic Resonance is often performed to evaluate for thin chest wall, transdiaphragmatic, or transmediastinal invasion of the tumour. The presence of a transdiaphragmatic extension of the tumour and/or ascites warrants further evaluation with staging laparoscopy because intraabdominal tumour would preclude surgical resection. The remaining preoperative evaluation is to determine the

patient's ability to tolerate EPP. Pulmonary function tests, including spirometry and diffusion lung capacity, should be performed. Quantitative ventilation/perfusion scan is routinely done to assess perfusion to the affected lung. The product of the proportion of perfusion to the contralateral lung (which will remain after pneumonectomy) and the forced expiratory volume in 1 second (FEV1) is the predicted postoperative FEV1. Although many clinicians recommend a value of at least 800 mL for pneumonectomy, the added morbidity of extrapleural, diaphragmatic, and pericardial resection have led most surgeons to consider a higher level, such as 1.2 L, for all but the smallest patients. Both a stress test to rule out inducible myocardial ischemia from coronary artery disease and an echocardiogram with Doppler estimation of pulmonary artery pressure based on tricuspid regurgitation should also be performed. A patient with pre-existing pulmonary hypertension may not survive the added right ventricular strain of pneumonectomy. Finally, duplex ultrasound of the lower extremity veins to rule out deep vein thrombosis, particularly in patients who have undergone neoadjuvant therapy, is performed. MPM patients have a high incidence of occult deep vein thrombosis and preoperative treatment with anticoagulation (and possibly inferior vena cava filter) may reduce the risk of fatal pulmonary embolus after pneumonectomy [6].

COMMENTS

Nevertheless, current literature favours P/D to EPP for several reasons. As P/D is a procedure with lower morbidity and mortality, it seems to be the most logical and preferred choice in the treatment of MPM. Others suggest that EPP should one day become of historical interest only due to repeated analyses of historical datasets that fail to show a benefit to EPP over P/D. So, P/D is indicated in most cases, except those with extensive tumour invasion into the pulmonary parenchyma. Resection of the diaphragm, pericardium, and lung parenchyma is performed if required. Conversion to EPP is decided based on intraoperative findings. This concept is supported by other paper in the literature who state that patients who are scheduled for P/D should be prepared to undergo EPP in case of extensive lung infiltration discovered during surgery as one surgical procedure does not fit for all patients with MPM. Lung preservation should be achieved whenever possible, but EPP may be a valuable solution in selected cases. The Clinical Practice Guidelines of the European Society of Medical Oncology (ESMO) on MPM do not advocate a specific procedure to perform a complete macroscopic resection [7]. The NCCN guidelines on MPM suggest P/D may be safer than EPP in early-stage disease with favourable histology but does not conclude on which procedure is oncologically superior because of the lack of adequately designed well-performed randomised controlled trials. In more advanced disease, P/D reduces the risk for perioperative mortality and may be acceptable in terms of achieving complete macroscopic resection [8]. However, the decision about whether to do P/D or EPP may not be made until surgical exploration [9]. Literature reports yield evidence that the success of EPP in skilled referral centres, when part of multimodality treatment, depends on a good selection of patients with appropriate variables and technically favourable conditions to reduce the usually high perioperative morbidity and mortality rates and improve the overall survival. Younger women with epithelial histology type of disease and undergoing induction chemotherapy could be considered the best group of patients to propose EPP, as a part of multimodality

treatment, with an estimated 2-year survival up to 68% [10]. For many years, EPP was the only surgical procedure which achieves a complete macroscopic resection, and it was applied in treatable patients independent of stage and histology. In some individuals with very early disease, a P/D was performed to preserve the lungs. Since the OS of patients after P/D is not different compared to EPP, most groups started a transition from EPP to P/D in most patients over the last years. However, as in other malignancies, one procedure does not fit for all, and there are situations, in which a patient may require an EPP in order to obtain a complete mesothelioma resection and still have a "functioning" lung left behind. This can be anticipated from the CT scan, but the final decision is sometimes made during surgery only. This is typically the case in tumours with relevant lung parenchyma infiltration and preferentially on the left side was an EPP is usually better tolerated. Therefore, patients foreseen for a P/D should be prepared to undergo EPP in case of extensive lung infiltration discovered during surgery. Not only during patients informed consent discussion, the patient should be informed about EPP, but also preoperative functional assessments must be performed accordingly [11].

CONCLUSION

The surgical technique in MPM aims to achieve a complete macroscopic resection. The best technique to achieve this was with EPP in the beginning. The technique of EPP, a morbid and risky procedure, has been refined over time and became a procedure with acceptable morbidity and mortality. In several large patient series of EPP and P/D, there was no difference in terms of long-term survival. The main prognostic factors were epithelioid histology, extrapleural lymph node metastasis and completion of multimodality treatment.

REFERENCES

[1] Batirel HF. Extrapleural pneumonectomy (EPP) vs. pleurectomy decortication (P/D). *Ann. Transl. Med*. 2017;5(11):232.

[2] Filosso PL, Guerrera F, Lausi PO, Giobbe R, Lyberis P, Ruffini E, et al. Pleurectomy/decortication versus extrapleural pneumonectomy: a critical choice. *J. Thorac. Dis*. 2018;10(Suppl. 2):S390-S4.

[3] Azzouqa AG, Stevenson J. The evolution of the diminishing role of extrapleural pneumonectomy in the surgical management of malignant pleural mesothelioma. *OncoTargets and Therapy*. 2016;Volume 9:7247-52.

[4] Casiraghi M, Maisonneuve P, Brambilla D, Solli P, Galetta D, Petrella F, et al. Induction chemotherapy, extrapleural pneumonectomy and adjuvant radiotherapy for malignant pleural mesothelioma. *European Journal of Cardio-Thoracic Surgery*. 2017;52(5):975-81.

[5] Wolf AS, Flores RM. Extrapleural pneumonectomy for pleural malignancies. *Thorac. Surg. Clin*. 2014;24(4):471-5.

[6] Schwartz RM, Lieberman-Cribbin W, Wolf A, Flores RM, Taioli E. Systematic review of quality of life following pleurectomy decortication and extrapleural pneumonectomy for malignant pleural mesothelioma. *BMC Cancer*. 2018;18(1):1188.

[7] Baas P, Committee obotEG, Fennell D, Committee obotEG, Kerr KM, Committee obotEG, et al. Malignant pleural mesothelioma: ESMO Clinical Practice Guidelines for diagnosis, treatment and follow-up†. *Annals of Oncology*. 2015;26(suppl. 5):v31-v9.

[8] Ettinger DS, Wood DE, Akerley W, Bazhenova LA, Borghaei H, Camidge DR, et al. NCCN Guidelines Insights: Malignant Pleural Mesothelioma, Version 3.2016. *J. Natl. Compr. Canc. Netw.* 2016;14(7):825-36.

[9] Domen A, Berzenji L, Hendriks JMH, Yogeswaran SK, Lauwers P, Van Meerbeeck JP, et al. Extrapleural pneumonectomy: still indicated? *Transl. Lung Cancer Res*. 2018;7(5):550-5.

[10] Spaggiari L, Marulli G, Bovolato P, Alloisio M, Pagan V, Oliaro A, et al. Extrapleural pneumonectomy for malignant mesothelioma: an Italian multicenter retrospective study. *Ann. Thorac. Surg*. 2014;97(6):1859-65.

[11] Opitz I, Weder W. A nuanced view of extrapleural pneumonectomy for malignant pleural mesothelioma. *Ann. Transl. Med*. 2017;5(11):237.

[12] Rice D, Rusch V, Pass H, Asamura H, Nakano T, Edwards J, et al. Recommendations for Uniform Definitions of Surgical Techniques for Malignant Pleural Mesothelioma: A Consensus Report of the International Association for the Study of Lung Cancer International Staging Committee and the International Mesothelioma Interest Group. *Journal of Thoracic Oncology*. 2011;6(8):1304-12.

In: Encyclopedia of Surgery (22 Volume Set)
Editors: Andreas Lehrer and Kristin Mueller
ISBN: 978-1-53618-329-0
© 2020 Nova Science Publishers, Inc.

Chapter 115

GUIDED TISSUE REGENERATION IN MAXILLOFACIAL SURGERY

Francine Benetti*[*], João E. Gomes-Filho, Gustavo Sivieri-Araújo, Rogério de C. Jacinto, Elói Dezan-Júnior and Luciano T. A. Cintra
Department of Endodontics, São Paulo State University (Unesp), School of Dentistry, Araçatuba, São Paulo, Brazil

ABSTRACT

The regeneration of oral tissues depends on the body's natural capacity and the materials and techniques currently available. Bone loss in the cranio-maxillo-facial region because of trauma, anatomical or congenital causes, cancer, and bone disease requires surgical intervention. The proposed techniques include treatment with bone grafts, bone substitutes, distraction osteogenesis and guided tissue regeneration (GTR), as well as their combinations. Research in this area has been advancing. The most recent developments in tissue engineering and stem cell and gene therapy have been used in the maxillofacial surgery with good results. Tissue engineering can be divided into conductive, inductive, and cell transplantation modes. GTR is a conductive technique. This procedure, which uses biomaterials to facilitate the growth or regeneration of already existing tissue, entails using a resorbable or non-resorbable membrane that excludes undesirable types of tissue growth and permits only bone cells to populate the surgically treated site, thus guiding the whole regeneration process. Among the indications for the use of GTR technique in maxillofacial surgery are oronasal fissures requiring surgical treatment, oro-antral communication, maxillary sinus lift, increasing the height and thickness of insufficient alveolar ridge for the placement of endosseous implants and prosthetic rehabilitation, and maxillary and mandibular bone changes that require appropriate aesthetic and functional reconstruction. Depending on the size and location of the defect, various surgical techniques for bone regeneration have been described in the literature. The choice of appropriate treatment is a difficult and complex process. The technique of GTR is feasible with good prognosis, when used properly

[*] Corresponding Author's Email: francine_benetti@hotmail.com.

following the basic requirements for the correct application of the membranes. Over the past several years, new concepts and materials have been developed with the aim of increasing the therapeutic arsenal of professionals employing tissue regeneration therapies. This chapter will describe the use of GTR techniques in maxillofacial surgery, as well as the materials used in this procedure and different experimental models studied.

Keywords: guided tissue regeneration, guided bone regeneration, maxillofacial surgery

UNIT 1 – TISSUE ENGINEERING IN THE MAXILLOFACIAL SURGERIES

Tissue loss resulting from trauma, anatomical reasons or congenital abnormalities, cancer, and bone disease, is a major health concern. Besides being impaired physiologically, many of these patients are affected psychologically, especially when the damage occurs in the craniofacial region [1]. Craniofacial deformities have an enormous impact on psychosocial interactions in the lives of these patients [2]. Functional and aesthetic requirements in the management of facial surgeries have steadily increased in the last decade [3]. It is necessary to restore not only the structure and function, but also the aesthetics, to restore the self-esteem of these patients.

The regeneration in the oral maxillofacial area depends on the systemic health status of the patients, in addition to the materials and techniques currently available.

Although tissues of the oral complex exhibit regenerative capacity in response to disease or trauma, damage to these tissues can at many times be irreversible [4]. Researchers in this area have focused their efforts on developing methods based on tissue engineering and gene therapy for oro-facial reconstruction [5]. The attempts to regenerate fully functional tissue will result in multiple solutions that are beneficial for the future of craniofacial medicine [6].

Using mechanical devices, with little consideration to the effects on local cells and tissues [1], has given way to today's regenerative medicine using the techniques of tissue engineering as well as bioactive materials in combination with cells and/or biological molecules capable of inducing cell proliferation, to regenerate a functional replacement tissue at a diseased or damaged site [1].

There has been a shift from the use of materials that simply replace tissue in a non-functional manner, to that of utilizing specific materials, which will regenerate fully functional and structurally acceptable tissue.

Disfigurement and extension of a defect seen in clefts and long-lasting defects after trauma or tumor surgery, affecting speech, mastication, deglutition, and respiration, demand a restoration that is as close to normal physiological functionality as possible [3]. Synthetic materials cannot replicate the physiological properties of the original tissue [4].

Thus, the simple replacement of fully functioning sets with metal prostheses in the 60s, when the materials were thought to be 'inert', has made room to materials that are physically, chemically, and biologically capable of effectively replacing the damaged or diseased tissue with repaired or regenerated tissue [1].

The discovery of stem cells and developments in cellular and molecular biology have led to new therapeutic strategies for the regeneration of tissues that were injured by disease [3].

Tissue engineering is a multidisciplinary field that involves the principles of engineering and life sciences, biology and clinical medicine, for the development of biological substitutes

that restore or improve tissue function [3, 7]. It is based on the fundamental principles of identifying appropriate cells, developing scaffolds and identifying the morphogenic signals required to stimulate cells to regenerate a tissue [3]. There are 3 major classes of tissue engineering techniques: conductive, inductive, and cell transplantation [4, 7].

Cell substitutes allow the replacement of only those cells that supply the needed function [7] and involve direct introduction of tissue that has been manipulated earlier *in vitro*. An example is cell transplantation, which involves taking existing tissue from the patient, isolating and multiplying the desired cells, and inserting them back into the patient at the defect site, to bring about tissue regeneration [4]. Limitations of this method include failure of the infused cells to maintain their function at the transplantation site [7].

The approach of using inductive substances depends on the purification and large-scale production of appropriate signaling molecules, such as bone morphogenetic proteins and platelet-derived growth factor [4], and the development of methods to deliver these molecules to the target sites [7], to stimulate surviving cells and promote regeneration [4].

The conductive technique, such as guided tissue regeneration (GTR), uses biomaterials to facilitate the growth of existing tissue or regeneration of new tissue [4]. In closed systems, a cell occlusive membrane that is permeable to nutrients and wastes but keeps out large entities such as antibodies or immune cells that destroy the transplant, is used. In open systems, cells attached to matrices are implanted and get incorporated into the body [7].

The choice of the method for regenerating lost tissue depends on factors such as the size of the defect, supply of cells from adjacent areas, cell migration rate, and presence of vasculature in the surrounding areas [6].

When the clinical need is the regeneration of a small amount of tissue, conductive and inductive techniques are utilized to recruit cells from host tissue into a scaffold, whereas regeneration in large defects often requires the direct transplantation of cells. If cells are not present in the surrounding tissue in sufficient quantities to populate the defect, depending solely on cell migration would require an unacceptably long healing time [6].

As early as in 1993, Langer & Vacanti [7] discussed the future of tissue engineering research. Researchers need to continuously explore various aspects of cell biology, regarding the causes of cellular differentiation and growth, and the relationship of the extracellular matrix with cell function. The study of molecular genetics will lead to the design of cells and materials that are not rejected by the immune system.

The ultimate goal of tissue engineering is to engineer virtually every type of tissue, including nervous tissue, cornea, skin, liver, pancreas, tubular structures, cartilage, bone, muscle, and vascular tissue [7].

UNIT 2 – INTRODUCTION TO GTR IN MAXILLOFACIAL SURGERY

GTR, based on the principle of in situ tissue regeneration, also termed “endogenous regeneration,” stimulates the intrinsic potential of a tissue to heal or regenerate [8]. GTR, a conductive approach uses a natural or synthetic matrix that acts as a scaffold or barrier on which cells can attach, proliferate, migrate, and differentiate [6]. The ultimate aim of the regenerative therapy is the restoration of lost tissue form and function.

In 1980, Nyman et al. [9] developed the concept of GTR based on the principle that specific cells would contribute to the formation of specific tissues. Melcher [10] described in 1976, the concept of repopulation of defects by specific cell types to enhance healing. Exclusion from the defect site of tissues that grow faster than bone tissue, such as epithelium and connective tissue, facilitates the growth of desired tissues such as bone, into the defect site [11].

In GTR, a resorbable or nonresorbable barrier membrane is used to prevent the invasion of the defect site by undesirable cells [4]. Non-resorbable membranes require a re-entry procedure to remove them, and are prone to exposure and infection. In contrast, resorbable membranes do not require re-entry. However, these are frequently used in combination with grafts that provide support to the membrane [4].

Thus, GTR, a conductive technique, uses membranes alone or a combination of membranes and bone grafts, to guide the formation of new tissue. It can also employ inductive methods and bioactive scaffolds, which stimulate cell migration and proliferation [6, 12]. Various growth factors can also be used in this procedure.

The scaffold supports the proliferation of cells in the remaining tissue while it breaks down over time. The membrane allows the proliferation of desired cells in the defect site, and excludes undesirable cells. The growth factors, if used, their rate of release at the defect site as well as the quantity should be controlled. It is also necessary to control the rate of membrane degradation to ensure space maintenance long enough for new tissue formation.

Bone graft scaffolds represent the extracellular matrix (ECM), and the membrane isolates the necessary cells to proliferate and regenerate lost tissue.

Understanding of the development of tissues and organs during embryogenesis and the mechanism by which they remodel and maintain their functionalities are the prime sources of information for designing synthetic ECM used in tissue engineering and regeneration [13].

The synthetic ECMs provide structural support to tissues and play role in controlling cell adhesion, migration, growth, and differentiation via intracellular signaling pathways [13].

In the conductive technique, synthetic ECMs maintain space to allow host cell infiltration into the tissue defect site [13]. The synthetic ECMs are often used as depots of growth factors and control their release at the defect site. Similar to native ECM molecules, adhesive signals can be incorporated into the matrix to control cell migration from the surrounding tissue into the defect site [13].

Types of Membranes Used in GTR

Many factors contribute to a successful GTR outcome, including adequate barrier properties, biocompatibility, space maintenance, cell-occlusiveness, tissue integration, and clinical manageability [14].

Biomembranes are used as barriers to prevent the invasion of the defect site by undesirable cells and allow the slow migration of cells to restock the area [15]. Numerous barrier membranes have been developed, and can be grouped into resorbable or non-resorbable varieties.

Resorbable membranes are natural or synthetic polymers. Most popular ones are collagen and aliphatic polyester membranes [13, 14].

Among the non-resorbable membranes, expanded polytetrafluoroethylene (e-PTFE) and titanium mesh are the most widely used barriers [14].

Membrane e-PTFE is a practically inert substance that exhibits a low coefficient of friction, impermeability, and low adherence [15]. These membranes provide an effective barrier function in terms of biocompatibility and can maintain the space beneath the membrane for a sufficient period, beyond which they have a reduced risk of long-term complications [14]. All these advantages overcome the major disadvantage of the necessity for removal using a second surgical procedure [14].

Another nonresorbable material applicable for dental bone repair is titanium mesh, which was previously studied by Boyne et al. in 1969 [16], for the reconstruction of large discontinuous osseous defects [14, 16].

Titanium has been used extensively because of its high strength and rigidity, low density and weight, ability to withstand high temperatures, and resistance to corrosion [14]. According with Degidi et al. [17], titanium mesh is helpful for maintaining space in large mandibular and maxillary defects [17, 18].

However, to eliminate the need for a second surgery to remove the membrane, resorbable membranes, which should be fully absorbed, must be used without causing major damage during the healing process.

In principle, stiff resorbable membranes promote a similar degree of bone regeneration and bone formation as nonresorbable membranes [14].

Collagen is the main structural macromolecule of the human body and can be used for membrane fabrication via multiple methods. However, native collagen is degraded within a few days, and untreated collagen membranes lack stability to maintain space if a bony support is missing. To overcome these problems, various crosslinking techniques have been developed, leading to the development of stiffer collagen membranes and slowing enzymatic degradation [19].

Polyglycolide or polylactide (aliphatic polyesters) can be prepared in large quantities and allows for the creation of a wide spectrum of membranes with different physical, chemical, and mechanical properties [14, 20].

UNIT 3 – GTR IN OSSEOUS OR GUIDED BONE REGENERATION

The shape and contour of the head region depends on the mechanical integrity of bone tissue and functions to protect the soft tissues of the cranial cavity [6, 21]. Approximately 800,000 bone grafting procedures are completed each year in the United States of America [22], and restoring or enhancing the repair of bone is a crucial problem in orthopedics and dentistry [13].

Advanced atrophy or jaw defects, cleft palates, bony nasal pyramid defects following removal of a fistulous tract or cyst, extreme deficiency of the chin, scoliosis of the mandibular arch, mandibular asymmetry, and defects following removal of sinus and mandibular tumors all require the generation of novel bone tissue [23]. Car accidents, sporting activities, and gunshot wounds can also result in blowout fractures of the orbital floor, orbital rim fractures, craniocerebral trauma, malunited fractures, major fractures of the maxilla or mandible, osteoradionecrosis, and dento-alveolar trauma [6, 23].

Various attempts have been made to reconstruct craniofacial tissues, including application of bone or bone substitutes as autogenous grafts, allogeneic grafts, xenografts [4], demineralized bone matrices, synthetic bone pastes, semisynthetic scaffolds, and various alloplastic materials.

Although each method can achieve the objective of tissue restoration, these methods all have limitations, such as donor site morbidity, graft resorption, contour irregularities, insufficient autogenous resources, disease transmission, major histoincompatibility, graft-versus-host disease, immunosuppression, structural failure, stress shielding, and infection by foreign material [2].

Among the graft materials used for bone regeneration, autogenous bone is considered an ideal material because it shows increased capacity for bone formation, osteoconduction, and osteoinduction; it does not induce immunological rejection; and heals rapidly [24, 25]. Additionally, autogenous bone grafts are limited by the inability to harvest large amounts of tissue [24], significant bone resorption, harvesting difficulties, donor site pain, and poor contouring [6, 23]. Several types of allografts and xenografts are available; however, disease transmission and immunorejection remain substantial obstacles to their implementation [6]. Synthetic bone replacements are also utilized; however, these materials generally fail over time and may show problems with biocompatibility [6, 13].

Thus, engineering tissue with the ideal features may allow formation new bone tissue through osteoconduction, osteoinduction, and cell transplantation strategies [6, 13].

In extensive reconstruction, transfer techniques for vascularized osseous bone are often used and include osseo- and cutaneous-free flaps, which are primarily applied in oncologic surgery of the head and neck region [3]. Additionally, bone block transplantation is used in cases of advanced atrophy or jaw defects before application of surgical preprosthetics to enable patients to be fitted with implants [3]. This is a necessary surgical step in the extra-oral region because of need for large-volume grafts, such as grafts in the fibula, scapula, and iliac crest, causing donor-site morbidity [26, 27]. To achieve adequate bone regeneration, adequate scaffolds and appropriate cells of the annex are needed, showing adequate proliferation and differentiation [3].

Osteoconductive approaches using engineering tissue may allow infiltration of osteoprogenitors from the bone marrow into local defects while providing temporary mechanical support; this is called guided bone regeneration (GBR) [13].

Through a combination of transplanted biomaterials, stem cells, an appropriate mixture of regulatory factors that stimulate cellular growth and proliferation, and extracellular matrix components to allow the growth and specialization of the cells, important clinical applications in alveolar bone surgery and facial skull surgery may be achieved [3, 28].

Anatomical sealing has been employed in periodontics to allow regeneration of materials providing tooth support, i.e., the GTR. By covering the tooth roots of monkeys with membranes, Gottlow et al. [29] observed that the membrane and root were involved in bone regeneration and concluded that the principles of GTR can be used in GBR.

In addition to the membranes, scaffolds can also be used for GBR. For example, scaffolds of synthetic extracellular matrix can promote osteoconduction according to the distribution of pore diameters. Thus, the surface in contact with the bone tissue requires the largest pores, allowing cell conduction to occur more easily. In contrast, the surface in contact with fibroblasts requires smaller pores to inhibit cell proliferation. Therefore, the material blocks

undesired cells types, while allowing cell types that can form bone to migrate into the site [13].

Utilization of growth factors may enhance the utilization of grafts. Urist demonstrated the capabilities of demineralized bone matrixes to form bone using rat muscle, proposing that growth factors can induce bone formation independently of the bone tissue condition [18].

To date, researchers have identified many growth factors, including bone morphogenetic protein (BMP) and growth factor beta (TGF-β). BMP is an osteoinductive growth factor that reduces the need for autogenous bone grafts [18] and has an essential role in the regulation of bone formation, maintenance, and repair [4]. Among these roles, recombinant human BMP-2 has been approved for use in sinus augmentation [4] and for localized alveolar ridge augmentation for defects associated with extraction sockets [18].

Platelet-rich plasma (PRP) is a platelet concentrate that contains a number of growth factors, including TGF-β. PRP can be prepared chair side with minimal complications because PRP is an autologous material. Utilization of PRP has been shown to have varying effects, ranging from no effect to significant enhancement of clinical attachment. However, most studies have consistently shown that PRP results in more rapid healing, less postoperative pain, and less membrane exposure [4].

Growth factors and PRP will be described in greater detail in later chapters.

GBR in Maxillary Sinus Floor Elevation Surgery

Therapy through implantology has provided an alternative to edentulous patients. Alveolar bone loss associated with periodontitis and alveolar atrophy after tooth extraction in adults, which can result in pneumatization of the maxillary sinus, causes severe vertical and horizontal bone loss in the posterior maxilla [30]. Thus, the placement of dental implants in partially or totally edentulous posterior maxilla remains a challenging procedure owing to the small amount and poor quality of bone.

Although the use of short or tilted implants has been demonstrated to be a suitable therapeutic option, showing long-term biomechanical stability of prostheses, sinus grafting has emerged as a good option for facilitate implant placement. Maxillary sinus floor augmentation is the most frequently used method to increase the alveolar bone height of the posterior part of the maxilla. Several types of bone grafts have been studied and used for maxillary sinus floor augmentation.

Different grafting techniques have also been proposed; the lateral approach is the most commonly used technique [31]. Introduced by Tatum [32] and later modified [33,34], this approach accesses the maxillary sinus through the creation of a bone window in the lateral sinus with a round bur and maintains the sinus membrane intact; this structure is then elevated and mobilized with placement of the grafting materials [31].

Alternative techniques have also emerged, including elevation of the sinus membrane with a crestal approach using osteotomes, and the position is maintained by implants [32, 35, 36]. Lundgren et al. [37] showed that mere lifting of the sinus membrane without graft placement created a void space, allowing the formation of blood clots, resulting in late formation of new bone in accordance with the principles of GTR [31, 38, 39].

Based on these findings, Cricchio et al. [31] performed a study in 2011 in which they elevated the maxillary sinus membrane and realized the simultaneous insertion of titanium

implants without the use of any grafting material, as described by Lundgren et al. [37]. Thus, a bone window was created in the lateral wall of the sinus, and the bone flap was removed into saline solution. The sinus membrane was elevated in order to create a secluded compartment for the implants. After elevation of the membrane, the implant was positioned, and a twist drill was used for the final preparation of residual bone. The removed bone window was then repositioned and, if necessary, secured with the aid of cyanoacrylate tissue glue. Finally, the mucoperiosteal flap was reattached.

Of the 239 implants inserted, 50 were inserted entirely in residual bone, and the remaining 189 protruded into the maxillary sinus. Of these 189 implants, 179 protruded at least 4 mm in the created sinus compartment (mean: 8 mm, range: 4–13 mm). After 96 sinus membrane elevations, the authors suggested that mere elevation of the maxillary sinus membrane at the time of implant insertion may be a successful approach for bone reformation and implant survival, consistent with other studies [37, 40, 41-43].

Thus, Cricchio et al. [31] utilized the principles of GTR and GBR without utilization of the membrane. However, the bone flap, which was removed from the bone window, was used in a protective role.

When teeth are adjacent to the edentulous area, bone augmentation is required, and the procedure becomes more difficult. The antral membrane balloon elevation (AMBE) technique is useful in this area. This technique is realized with a limited incision, minimal mucoperiosteal flap reflection, and a small window, in which the membrane is elevated to the medial wall of the sinus cavity, avoiding sharp dissection around the roots of the adjacent teeth [44]. Thus, complications, such as morbidity, blood loss, long operative time, and postoperative pain, are reduced [44].

Solta and Smiler [45] described the AMBE technique. A crestal incision is made, extending the length of the edentulous area. Osteotomy of the buccal bone is performed, and the sinus membrane must be preserved. The resulting bony fenestration is gently pressed inward, carrying the underlying membrane along with it. The dissection should progress all the way to the medial wall of the sinus. A balloon of latex material is placed against the sinus floor midway between the lateral and medial walls and is gently inflated with 2–4 mL sterile saline. As it expands, the membrane is elevated. Thus, the fragile epithelium will be subjected to minimal trauma. The balloon is then deflated and removed. A resorbable collagen membrane is soaked with PRP and placed under the elevated sinus membrane. A grafting material can then be utilized and mixed with PRP. A second guided bone regenerative membrane is trimmed, moistened with PRP or aqueous antibiotic, and placed over the lateral wall window. The mucoperiosteal flap is repositioned and sutured [45].

Among the advantages already cited, such as elevation of the sinus membrane with minimal risk of tearing and reducing postoperative pain, bleeding, and infection, this technique can be completed within 30 min, as reported by Soltan and Smiler [45]. Thus, this technique, which uses elevation of the sinus membrane, placement of the grafting material with PRP, and membranes to guide regeneration, has become a highly successful and reliable procedure [45].

As described above, application of growth and differentiation factors can be used to enhance the wound healing process. Platelets produce and release PDGF, which enhances osteogenic differentiation and bone repair in fracture models and critical-sized calvaria defects [46-48]. Additionally, PDGF has a significant role in the wound healing process with the capacity to stimulate chemotaxis, cellular activation, and proliferation in fibroblasts and

osteoblast-like cells. Therefore, considerable interest has emerged because of the potential benefits of using PRP, a highly concentrated form of platelets.

In a case-series report, Kassolis et al. [48] described the use of PRP in combination with freeze-dried bone allografts (FDBAs) for alveolar ridge and maxillary sinus GBR procedures. The authors created full-partial thickness flaps that were elevated at both the sinus and the ridge augmentation sites, and the sinus cavity was exposed for graft insertion. Maxillary sinus grafting was accomplished using the Caldwell-Luc approach. The composite graft was a mixture of FDBA and PRP, saturated with an autologous thrombin-rich extract. After the placement of the graft, coagulated PRP gel was used to cover the graft. Ridge augmentation sites required added flap mobilization and repositioning of the facial mucoperiosteum to permit passive primary closure over the FDBA/PRP.

In all three cases, the authors observed new bone formation, where FDBA particles were amalgamated with the newly forming bone. Consistent with previous studies [49], these data suggested that the use of PRP may allow for earlier implant placement and/or loading by stimulating and enhancing the wound healing process, including osseous regeneration. Bovine thrombin has been used to activate coagulation and precipitate gel formation.

One of the problems with the utilization of allografts is that osseous wound repair occurs more slowly than that with autogenous bone grafts. The degree of revascularization of bone allografts also appears to be slower than that with autogenous grafts. Utilization of these materials that may improve osseous wound repair following regenerative procedures using allografts, similar to the use of PRP. Thus, an alternative to autogenous bone grafting, which would require a second surgery for graft removal, would be allografts and PRP.

The use of bone inductive growth factors may enhance the development of mature lamellar bone, which could support dental implants sooner and more predictably. Recombinant human PDGF (rhPDGF-BB) has been shown to improve regeneration, as previously described in this chapter.

Urban et al. [50] demonstrated the successful use of rhPDGF-BB in conjunction with autogenous bone, anorganic bone mineral, and barrier membranes to reconstruct severe alveolar bone defects in the posterior maxilla. A patient with a history of dentoalveolar infection, several fistulous tracts, and advanced mobility showed advanced periodontal bone loss with associated periapical lesions upon radiographic examination. In this case, the teeth were extracted, and a severe vertical ridge defect was noted 2 months later.

After adequate incision, a rectangular antrostomy with rounded corners was created at the lateral wall of the maxillary sinus. The sinus window was infractured, and the sinus membrane was elevated with care to prevent perforations. The recipient bony bed was prepared with multiple decortical holes to expose the medullary space. Autogenous bone was harvested from the right ascending ramus, mixed with anorganic bone mineral, and hydrolyzed in rhPDGF-BB. The e-PTFE membrane was fixed on the palatal side, and the bone graft then was placed within the subantral space and appositionally on the vertical alveolar defect. The membrane was folded over onto the buccal alveolus and fixed with additional titanium pins.

The mesial border of the e-PTFE membrane was placed 4 mm from the distal surface of tooth and was unfilled for about 2 mm supracrestally. This area was filled with additional bone graft material, connecting the denuded root surface to the open end of the membrane. A resorbable collagen membrane was applied to protect and contain this area. An additional

collagen membrane was applied to cover the sinus window. Suturing was performed for tension-free primary closure.

Bone growth was evident over the membrane in the area where the resorbable collagen membrane was utilized. After removal of the titanium pins and the e-PTFE membrane, the authors observed complete vertical bone regeneration [50].

In another study [51], a 100% success rate was observed when placement surface implants were realized after vertical GBR. Thus, this treatment modality may allow bone harvesting to be avoided altogether.

GBR in Oro-Antral Communication (OAC)

The large volume of the maxillary sinus, which can be in close proximity with some tooth apexes under certain circumstances, facilitates pathological communication between the oral cavity and the maxillary sinus, i.e., OAC, and this clinical complication is often encountered by oral surgeons [52]. The condition mostly follows dental extraction or endodontic treatment, and the intra-operative diagnosis of OAC is usually based on the Valsalva maneuver [53] or penetration of a blunt-edged Bowman probe to assess perforations of the maxillary sinus floor [54-56]. This can be contaminated by bacteria, resulting in infection, impaired healing, and chronic sinusitis. OAC may progress to the formation of oro-antral fistula (OAF), when the epithelium is involved [57]. Small fistulae tend to heal spontaneously after formation of blood clots and secondary healing [56], whereas larger fistulae rarely heal. Surgery is indicated if a fistula does not heal within 3 weeks [57], in order to avoid infection and fistula formation [56].

Many techniques have been proposed to resolve this condition. However, the selected technique should achieve both hard and soft tissue closure, repair OAC, and facilitate prosthetic rehabilitation through the placement of an endosseous implant [56]. Ogunsalu described this technique for the first time in 2005 [52].

The techniques described above have some limitations, including reduction in the depth of the vestibular sulcus, achievement of soft tissue closure only, requirement of bone grafting, and induction of severe pain and scarring in the palatal flaps.

Notably, the Bio-Oss-Bio-Gide Sandwich technique described by Ogunsalu [52] excludes all of the above limitations and has additional advantages of concurrent bone tissue regeneration, which will enable the later placement of an endosseous implant. Bio-Gide is a pure collagen membrane extracted from pigs and has a porous surface facing the bone, which allows the in-growth of bone-forming cells and the formation of a dense surface facing the soft tissue, which will prevent the in-growth of fibrous tissue into the bony defects. The membrane is made of type I and type III collagen and will resorb within 24 weeks. Additionally, Bio-Oss is a safe bone graft material processed from bovine sources with high similarity to human bone.

The technique utilizes sandwiches of Bio-Oss granules in Bio-Gide, which is sutured together at three sides. After insertion of the Bio-Oss, the fourth side is adequately closed using resorbable sutures, creating a closed sandwich. The sandwich has a smooth side oriented upwards and a rough side positioned to face the alveolar bone. The mucoperiosteal flap is raised, and the prepared sandwich is tucked into the OAC in such a way that it forms a convexity towards the sinus and a concavity towards the alveolar bone. Bio-Oss is added to

fill the concavity. The height of the alveolar ridge is substantially reduced at the site of the opening. Edges of the soft tissue to be approximated are prepared such that raw surfaces will be in contact with each other, and suturing is carried out without tension [52, 56].

In a case presented by Ogunsalu [52], after 8 months, a new maxillary sinus and subantral bone of good quality and height were created, permitting the placement of an endosseous implant. This sandwich technique at the closure of OAC is new and promising, without the need for donor site surgery, providing advantages in terms of time and cost. By using the membrane to isolate the bone tissue, this technique allows the formation of new bone tissue and achieves soft tissue closure [52].

After reporting of the Ogunsalu technique [52], Sandhya et al. [56] performed a study with 10 patients and a 6-month follow-up to investigate both soft and hard tissue closure of OACs with the use of resorbable GTR membranes and bone substitutes and application of human freeze-dried mineralized bone as grafting material. The authors did not observe significant immediate complications. Pain was present only in three patients, and swelling was present in four patients; these side effects gradually subsided by the end of day 7. Epistaxis was observed in one patient on day 1 postoperation. Delayed complications were not observed, and there was no evidence of infection, wound gaping, fistula formation, loss of graft, or sinusitis. An average bone formation of 11.84 mm was observed after 6 months, and the average width was 6.9 mm. In relation to the quality of bone formation, by the end of the 6-month follow-up, seven patients showed trabaculae indistinguishable from the adjacent bone [56].

Ogunsalu et al. first used this technique in 2000 [58], and in their classic papers, the authors suggested other possible applications of this technique to include reconstruction of the orbital floor, closure of oro-antral fistula, reconstruction of bony cleft defects, and mastoid ablation [56, 58].

GBR in Treatment for Alveolar Cleft

One of the most common congenital anomalies is orofacial clefts, with a prevalence of 1:1000 and 0.4:1000 for complete unilateral and bilateral cleft lip and palate, respectively [59]. Patients with this deformity require multiple surgical procedures over long periods by multiple specialists in various fields [60]. The patients must undergo surgery to balance functional and esthetic outcomes against the potential increased restriction of normal maxillary growth and development [61].

The final aim is to rehabilitate these patients with missing teeth using dental endosseous implants, which requires adequate alveolar bone volume at the appropriate anatomic position [60].

Currently, the standard treatment for alveolar cleft repair is grafting with autogenous bone [60]. Although other sources of autogenous bone have been attempted, autogenous bone grafting from the ilium is considered the gold standard [59] owing to its abundance andease of access [61].

However, this site can produce a considerable degree of postoperative morbidity, including persistent pain, prolonged recovery time, hemorrhage, scarring, and lesions of the lateral femoral cutaneous nerve [59]. In addition, iliac crest bone grafting has been shown to result in total mean volume losses of 43.1% [62] and 49.5% [63] at approximately 1 year after

the secondary alveolar cleft repair. This resorption may prevent successful placement of endosseous implants without further grafting [60].

Thus, Le and Woo [60] reported the successful utilization of mineralized human allografts to treat two adult patients with severe alveolar cleft defects using a GBR technique. The treatment consisted of completely exposing the cleft defect. In case 1, in which the patients had a congenital unilateral cleft palate and large fistula on the buccal vestibule of the area around the alveolar cleft site extending into her right nostril, the nasal layer was closed primarily by suturing, and a resorbable collagen membrane was placed to reinforce the recreated nasal lining; mineralized human allograft material mixed with the patient's blood was then placed into the cleft defect.

In case 2, a patient with a congenital cleft lip underwent multiple previous surgeries, including alveolar cleft repair with iliac crest bone grafting. Panoramic radiographs and computed tomography scanning showed a large alveolar defect at the site of the missing incisor, making it unsuitable for implant placement. Mineralized human allograft material mixed with a BMP-soaked collagen sponge and the patient's blood was then placed into the cleft defect. A resorbable collagen membrane was placed over the graft material, and in both cases, the oral mucosal layer was closed in a tension-free manner. Re-entry at 5 months was realized and showed dense bone where the graft was placed, with later placement of the endosteal implant. After 3 months, good osseointegration was noted, and the alveolar bone height and width remained stable.

Thus, the repairs were accomplished with a GBR technique without the use of autogenous bone, suggesting potential applications in the treatment of patients with alveolar clefts defects, without the need for iliac crest bone grafting and associated morbidities.

Bone grafting of the residual alveolar cleft is now a well-established technique. However, Kawata et al. [64] reported the closure of an alveolar bony defect without bone grafting, using a nonabsorbable membrane.

A patient with unilateral and nonsyndromic cleft lip or palate on the left side had late mixed dentition with good soft tissue closure. The upper left permanent canine was present, adjacent to a narrow bony cleft at the height of the apex of the neighboring central incisor. The oronasal fistula was excised, and the alveolar cleft was completely exposed. Subsequently, the nasal mucosa was carefully dissected from the oral mucosa, sutured, and pushed upwards into the nasal cavity. An e-PTFE nonabsorbable membrane barrier was placed to cover the bony defect. The membrane was pushed under the periosteum and secured passively at the base of the flaps. The flaps were then repositioned and sutured to cover totally the membrane. Four months after surgery, radiographs showed a bony bridge and closure of the alveolar cleft. This was the first study to evaluate the use of GBR with a nonabsorbable membrane to close the alveolar cleft when the bony cleft was large and lacked bone support, indicating the requirement for the supporting membrane [64].

GBR in Reconstruction of Defects after Tumor Resection

GBR can also be used to reconstruct bone defects after tumor resection. Reconstruction of these defects represents a challenge in head and neck reconstructive surgery.

Vitkus and Meltzer [65] described a patient with adenomatoid odontogenic tumor (AOT) combined with calcifying epithelial odontogenic tumor (CEOT); this presentation was

referred to as combined epithelial odontogenic tumor. Approximately 1 year after surgery for removal of an impacted canine, the patient presented with an erupted maxillary left canine with an asymptomatic firm, red swelling circumscribing the buccal and palatal aspects of the tooth and extending from the keratinized tissue to the mucosa. Intra-oral radiographs revealed a well-circumscribed radiolucency superimposed on the entire root. Buccal and palatal flaps were raised, exposing a cystic-type lesion that was easily removed and leaving a large cavity exposing the root just short of the apex. A thin layer of bone covering the root surface was found, with large vertical defects interproximally. To prevent the ultimate destruction of the tooth, a graft of demineralized freeze-dried bone was placed in the cavity and covered with a nonresorbable barrier membrane made of e-PTFE. Eight weeks later, the membrane was removed, and an intra-oral radiograph showed trabecular bone.

The literature suggests that only the lesion should be surgically excised, with little mention of whether this will result in complete regeneration of the bone and how long this process will take. However, it is unclear whether complete regeneration will occur given the large bone loss, and it is expected that even partial regeneration will take considerable time. Despite this, the choice of GTR with freeze-dried bone grafting was made in an attempt to increase the predictability of the result.

Thus, the results showed that GTR combined with bone grafting could be used to aid in the rapid filling of large defects surrounding the teeth, created after surgical removal of the odontogenic tumors.

The quantity of bone available for harvesting may be insufficient for larger defects. rhBMP-2 is an osteoinductive growth factor that reduces the need for autogenous bone grafts. To date, studies of the use of rhBMP-2 for maxillofacial reconstruction have been promising [18].

Cicciu et al. [18] investigated the clinical and radiographic long-term results of a hemimandibular reconstruction using rhBMP-2, an absorbable collagen sponge, and titanium mesh. The patient in this case presented a large tissue mass and extension in the left mandibular region, with ominous growth; this lesion was diagnosed as a dentinogenic ghost cell tumor. The decision was made to manage the local tumor with en bloc resection and immediate reconstruction using an inferior titanium plate in order to maintain the mandibular soft tissue space. This process was carried out using an incision that extended into the bone and subperiosteal dissection to expose the entire defect. Subsequently, a mesh was placed to correct the defect. The underlying ridge was pierced to stimulate bleeding, allowing faster integration of the graft and supplying stem cells to the area. The rhBMP-2 was added to the absorbable collagen sponge, and a portion of the sponge was then cut into small pieces, mixed with the bone allograft, and placed into the titanium mesh. The titanium plate was subjected to maxillomandibular fixation and locked with the inferior plate for mandibular reconstruction.

After 3 or 4 months, the patient exhibited radiographic evidence of bone formation, and mandibular continuity was regained, as demonstrated both clinically and radiographically. After 9 months, the titanium mesh was removed, and dental implants were placed in position. Despite the extent of bone formation, the titanium remained inside the defect. The process of induced bone formation is a controlled response to highly concentrated levels of rhBMP-2.

Thus, the use of rhBMP-2, an osteoinductive agent, and allografts, which are osteoconductive, can enhance the amount and rate of bone formation [18].

GBR in Ridge Augmentation in Defects after Tooth Extraction

Vertical and horizontal alveolar ridge augmentation utilizing GBR has become a significant treatment option to provide optimal bone support for placement of osseointegrated dental implants. Vertical bone defects are more complicated to handle because of their high technical sensitivity [66].

In 1994, Simion et al. [67] performed a study in which the patients received conical Brånemark-type implants in sites requiring vertical augmentation. The implants protruded 4–7 mm from the bone crest, and titanium miniscrews were positioned distally to the implants, protruding 3–4 mm from the bone level. Both were covered with a titanium-reinforced membrane, and the flaps were sutured. After 9 months, the membranes were removed. There was a gain in bone height from 3–4 mm, and the implants were in direct contact with bone.

In a retrospective study in 1998, Tinti and Benfenati [68] evaluated the predictability of obtaining a vertical ridge augmentation around dental implants following GTR principles. The authors observed that when the clinical protocol was accurately followed, the possibility of clinical complications was reduced, and the results for achieving vertical ridge augmentation around implants were predictable.

Implants are often removed due to placement in unfavorable positions. Incorrect positioning of implants may result in biomechanical problems, loosening, and/or fracturing of the cover screws, implants, or implant collars in addition to occlusal discrepancies and compromised aesthetics and speech [69].

An ideal bone tissue volume is required for proper implant placement. Bone resorption will occur secondary to tooth extraction, mainly when multiple teeth are extracted at the same time. Among various ridge expansion techniques, GTR for the treatment of ridge deficiencies is considered a safe and predictable treatment modality [70, 71].

Using this method, Toscano et al. [69] analyzed 73 consecutively treated lateral ridge augmentations that used composite material of demineralized freeze-dried allografts, mineralized cortical cancellous chips, and a biologically degradable thermoplastic carrier combined with a resorbable membrane for GBR in partial or completely edentate patients. An incision was made to the palate or lingual of the treatment site and was extended at least one tooth beyond in the mesial and distal directions. The periosteal was then released to allow for tension-free closure of the flap over the membrane and graft. Measurements of the pre-augmentation ridge width were made, and the bone defect was frayed to enhance revascularization of the site. The membrane was trimmed to fit the site and was applied to the thermoplastic composite graft. The graft was covered with the pretrimmed resorbable collagen membrane, and tension-free closure was performed. All cases were allowed to heal for a minimum of 6 months before implants were placed, and a second measurement was performed close to where the first measurement was made.

Researchers observed that the average presurgical ridge width was 4 mm. During stage I implant placement, an average ridge width postaugmentation of 7.5 mm was achieved, and the average gain in horizontal ridge width was 3.5 mm (range, 3–6 mm).

In 2012, Kao et al. [66] used a GBR technique and obtained satisfactory results for the edentulous area with severe bone loss. The patient suffered from advanced periodontitis of teeth 36, 37, and 47. Periapical radiographs revealed severe alveolar bone loss around teeth 36 and 37, which were subsequently extracted.

The GBR procedure was then performed. The flaps were elevated to expose the atrophic ridge and the immature healing sockets, and evident vertical and horizontal bone defects were found. The bleeding process was promoted, and two tenting screws were positioned. Autogenous bone was harvested from the mandibular ramus and mixed with FDBA particles. The Ti-reinforced e-PTFE membrane (TR6Y) was shaped for perfect adaptation and fixed to the lingual and buccal regions. The soft tissue was secured with nonresorbable horizontal mattress sutures and interrupted sutures. Six months later, the second surgery was performed to remove the nonresorbable membrane, and the site revealed regenerated hard tissue covering the surface of the tenting screws.

The authors concluded that GBR with the Ti-reinforced e-PTFE membrane, tenting screws, and bone grafts offered predictable functional reconstruction of large vertical defects [66].

Studies in Animals

Kostopoulos et al. [72] conducted an interesting study in rats that has had a major clinical impact on cranial and maxillofacial surgery. They created bone increases equivalent to 5–6 times the original width of the mandibular ramus. The study involved exposure of the mandibular ramus; on the test side, the periosteum was left covering the lateral surface of the ramus, and on the other side (control), the periosteum was elevated together with the flap. A Teflon capsule was then placed to face the periosteum or the bone surface with the open part before the closure of the wound. At 120 days, the mean amount of bone obtained in the test specimens was 56%, reaching up to 52% in controls. These findings indicated that a secluded space created by an occlusive barrier adjacent to existing bone or periosteum may be filled with bone tissue.

This enabled GBR to be performed as an alternative method when it was necessary to obtain bone autografts from patients without sites having adequate amounts of donor bone.

In 1995, Bosch et al. [73] aimed to investigate the amount of bone formed in defects created experimentally in bone parietal. They protected the bone with one or two e-PTFE membranes in 29 Wistar rats, which were divided into two groups. In the double membrane group, the left experimental bone defect was protected by an outer e-PTFE membrane under the periosteum and parietal muscles and an inner membrane between the dura mater and the parietal bone. In the single membrane group, only the outer membrane was placed.

From this analysis, the authors observed that in the majority of specimens in the group in which only one membrane was used, the experimental site did not regenerate. In contrast, in the group with the double membrane, the majority of experimental defects had complete closure of the bone. These data demonstrated the importance of the separation of bone tissue and muscle tissue to obtain correct regeneration.

In 1997, Hurzeler et al. [74] extracted the maxillary canines and lateral incisors from eight rhesus monkeys. After a healing period and soft tissue expansion, implants were placed in the atrophic ridge on each side in such a way that its coronal 4–5 mm remained circumferentially exposed above the bone level. Two types of membranes were tested for implantation: 1) a bioresorbable barrier made of D,L-lactid-co-trimethylencarbonate (poly membrane) and 2) a nonresorbable e-PTFE barrier.

The results showed that the mean bone-to-implant contact length fraction was 32% of the total implant length with the polymembrane and 58% with e-PTFE, which exhibited significantly greater bone filling capacity than the polymembrane. Histologic observations of polymembrane specimens demonstrated a moderate inflammatory reaction related to the degradation and resorption products of the barrier. In conclusion, the nonresorbable e-PTFE GBR barrier was found to be superior to the bioresorbable barriers tested in the present investigation.

Li et al. [75] investigated the effects of guided bony regeneration using collagen membranes for sinus augmentation in the first maxillary molars of 18 adult female beagle dogs. After extraction of teeth, the sinus floors were lifted, and the implants were placed. A combination of autografts and Bio-Oss was used as a grafting material. The collagen membrane was folded at the lateral osteotomy window, at the apex of the implants, and at a certain part of the palatal bone. As a control group, the opposite site received a collagen membrane covering the osteotomy window. From the results, the authors observed grafted materials without resorption or subsidence on the experimental side, with new bone formation at the apex of the implants. On the control side, the grafted materials were shifted and absorbed. Histological examination showed increased formation of new bone in the experimental group, and this new bone matured over time. This study showed that the presence of the membrane facilitated bone regeneration on the apical surface of the implants and that the only sinus membrane could not effectively stimulate formation of new bone in sinus augmentation.

Many materials have been studied for bone regeneration. The best results are found with utilization fresh autogenous materials due to its capacity for osteoinduction and osteoconduction. However, there are some disadvantages, as already discussed, such as pain and edema caused by additional injury to the donor site, the limited volume of bone tissue that can be harvested, and high graft-fragment resorption [76, 77]. Thus, other materials, such as allogeneic bone graft materials, which do not have bone regenerative capacity but do not require an additional donor site, have been used for bone grafting.

Using this method, Ahn et al. [78] evaluated bone formation after the use of allogeneic bone, with or without utilization of a membrane, in rats. The materials used in the experiment were the allograft Tutoplast Spongiosa Microchip, mineralized cancellous bone allografts (MCBAs), and absorbable membranes made from human pericardium and collagen. A 2-cm incision was made from the occipital bone to the frontal bone, and subcutaneous tissues were elevated together with the periosteum. A full-thickness defect area approximately 8 mm in diameter was then created. The control group was sutured without addition of graft material or the membrane. In group 1, the Tutoplast was transplanted into the area and sutured in place by closing the periosteum. In experimental group 2, the Tutoplast was transplanted into the defect area, covered with pericardium attached tightly to graft materials, and sutured by closing the periosteum.

In the control group, most areas were filled with loose connective tissue. In group 1 (allogeneic bone), bone from new bony spurs and host bone were observed on the edge of the defect area, with abundant proliferation of blood vessels and features of active bone formation. All animals showed immature bone formation in the center of the defect area and exhibited delayed bone fusion. In group 2 (allogeneic bone and absorbable barrier membrane graft), within 6 weeks, the membranes were partially absorbed, and numerous inflammatory cells were present. At week 12, the membrane boundary had disappeared in several areas, indicating that membrane absorption had progressed substantially, and the center defect area

was connected with the rim area and proliferated continuously. A bone-filling pattern was observed at the center of the defect area, and connective tissues were hardly detected.

Utilization of membranes is essential for osteoinductive regeneration. Membranes that are not degradable require a second surgery, which can be harmful to growing granular tissue. Thus, the use of absorbable membranes is recommended. As described by Ahn et al. [78], membranes inhibit connective tissue invasion, thereby facilitating new bone formation. Inflammation that occurs around the absorbable collagen barrier membrane is associated with degradation, as observed by Ahn et al. [78], and inflammatory cell infiltration was found to be restricted to the membrane rim and to not significantly affect bone regeneration [78].

Theoretically, the ideal bone substitute should have osteoconductive characteristics by acting as an intermediate-phase scaffold to give support during bone healing and osteoinductive characteristics by working as a guide to stimulate bone growth before being gradually replaced by the newly formed bone [79].

Deproteinized bovine bone mineral (DBBM) is an inorganic bovine bone derivative with a mineral content comparable to that of human bone, allowing integration of the material into bone. In addition to osteoconductive mechanisms, studies have suggested that this material may also trigger osteoinductive mechanisms [79].

Bioactive ions can also have favorable effects on the bone response during healing. Calcium sulfate (CaS) is a common bone substitute that is highly biocompatible and osteoconductive and undergoes virtually complete resorption *in vivo* [79, 80].

Turri and Danlin [79] evaluated the potential biological differences of a synthetic bone substitute material characterized by a high dissolution rate and release of high concentrations of ions in the wound area (CaS) with an osteoconductive material (DBBM) with a barrier membrane acting as control, in the GBR setting.

The CaS and DBBM particles were placed in defects created in the edentulous space between the incisors and molars in the maxilla of rabbits, with or without placement of a membrane. After 2 weeks, total resorption of the CaS material was observed, regardless of the presence of a barrier membrane, and minor resorption was observed for the DBBM particles. Because of deproteinization, bone resorption was blocked by osteoclasts [81]. The CaS group showed more bone regeneration that the DBBM group. Moreover, the addition of an ECM membrane had substantial effects on bone regeneration owing to stimulation of angiogenesis in the early healing process [79].

UNIT 4 - GTR IN ORAL SOFT TISSUE

Oral mucosal defects are often an inevitable consequence of tumor excision. Recently, great progress has been made in reconstructive surgery for large soft-tissue defects in the oral cavity, resulting in increased survival rates in patients [82].

In small oral tissue defects, the use of palatal or buccal mucosal autografts or muscle may be appropriate [82, 83]. However, for reconstruction of large soft-tissue defects, cutaneous or myocutaneous flaps are needed [82].

Autologous skin grafts have been employed in animal and human studies; however, these grafts seem to maintain their original characteristics, such as hair growth, and are associated with donor-site morbidity [83]. Moreover, skin flaps are less flexible than the mucosa of the

oral cavity and are inadequate for restoration of oral functions, such as speech, mastication, or swallowing [82]. Additionally, the use of skin flaps is associated with problems of cosmetic appearance. For example, the color and texture of the skin are not completely consistent with the tissues of the oral cavity [84]. Scar formation at the donor site may also occur, often necessitating secondary operations [82]. Thus, it is advisable to reconstruct intra-oral soft-tissue defects with soft tissues from the mucosa.

Wada et al. [82] described a procedure called biological-guided mucosa regeneration (BGMR). Based on the results of animal experiments and epithelialization of the grafted myofascia in the oral cavity, various myofascial graft materials have been applied for reconstruction of intra-oral soft-tissue defects, thereby restoring nearly normal mucosa. This mucosal tissue shows good mobility of the intra-oral organs, as opposed to the more rigid and less flexible skin tissue.

The authors grafted myofascial flaps without skin in patients with oral defects caused by tumor resection in the tongue, buccal mucosal, lower gingival, floor of the mouth, and/or oropharynx.

The myofascial flap was tunneled up and inserted into defect in such a way that the fascial surface was oriented to face the oral cavity, and the myofascial flap was tightly sutured to the surrounding incised mucosal margin, resulting in a yellowish fibrin membrane on the surface.

Based on this clinical experience, using platysma myofascial flaps or pectoralis major myofascial flaps, the authors observed favorable progression of mucosal regeneration, with gradual epithelialization along the immature granulated myofascial and without clinical evidence of infection on the bare granulated myofascial. This method was useful for reconstruction of the inferior half of the oral cavity, including the oropharynx.

In summary, the authors presented a procedure for myofascial grafting that served as an alternative for the reconstruction of intra-oral soft tissue defects based on GTR principles.

Among the biomaterials employed by maxillofacial surgeons, those derived from animals are widely used; for example, catgut tissues are still popular. Collagen materials are also commonly used and are available in various forms, including laminates, sheets, fabrics, gels, and powders, and have been used as dressings for ulcers and burns and for induction of bone formation [84].

Rastogi et al. [84] utilized xenogenous, crosslinked collagen sheets as a cover for wounds in the oral cavity after excision of premalignant lesions, benign lesions, reactive proliferation, and incisional biopsy wounds in 60 patients. The collagen membrane showed good conformability, granulation, and epithelialization in most cases.

Wounds that are left uncovered in the oral cavity are prone to infection. Grafted wounds are known to heal faster than open wounds. The best solution may be mucosal grafts; however, materials for these grafts are not sufficiently abundant. Although skin grafts may be the next-best solution, the disadvantages of these grafts have already been discussed.

In the study by Rastogi et al. [84], the collagen membranes slowly underwent collagenolysis and were sloughed off over time, allowing changes to occur in granulation tissues, which appeared to be clinically healthy and uniform. The adherence of the collagen membrane may be a result of the interaction between fibrin and collagen, but was most likely a result of fibrovascular ingrowth into the collagen membrane.

The collagen membrane exhibited minimal growth of granulation tissue and no major infection, thus supporting its use as a temporary biological dressing material in the oral cavity

devoid of the mucous membrane. Accordingly, this material is an alternative to autologous grafts and a satisfactory addition to the armamentarium of oral surgeons as an excellent wound graft material [84].

UNIT 5 – FINAL CONSIDERATIONS

Based on the limited capacity of current strategies to reproduce tissues damaged by trauma, disease, anatomical or congenital defects, or tumors, surgeons have attempted to identify alternatives to tissue engineering approaches. Thus, tissue engineering strategies have been developed to facilitate reproduction of various body tissues.

However, when considering the craniofacial region, these approaches are more complex and challenging.

Today, GTR, a subfield within tissue engineering, is a reality and has been shown to be a very promising approach. The use of barriers to protect the tissue and select desirable cells to facilitate tissue regeneration, the presence of scaffolds, the use of growth factors, and the biocompatibility of tissue grafts have made the development of effective grafts that can restore lost tissue more achievable.

In dentistry, the utilization of GTR has been reported in surgery for maxillary sinus floor elevation, ridge augmentation for implant planning, correction of OAC, reconstruction of defects after tumor resection, and treatment of alveolar cleft, among other applications.

Although GTR still needs to be more established in osseous tissues, this method, similar to GBR, should also be applicable in other tissues, including the oral mucosa, thereby contributing to successful tissue engineering.

Advances in GTR have expanded the range of treatment possibilities, allowing us to achieve the regeneration of ideal, well-formed, functional tissues; this approach should be studied in great detail in order to improve the potential success and applications of GTR-based therapies.

REFERENCES

[1] Neel EAA, Chrzanowskid W, Salihc VM, Kim HW, Knowlesc JC. Tissue engineering in dentistry. *J Dent.* 2014 Aug ;42(8) :915-928.

[2] Warren SM, Fong KD, Chen CM, Loboa EG, Cowan CM, Lorenz HP, Longaker MT. Tools and techniques for craniofacial tissue engineering. *Tissue Eng*. 2003 Apr;9(2):187-200.

[3] Grimm WD, Dannan A, Giesenhagen B, Schau I, Varga G, Vukovic MA, Sirak, SV. Translational Research : Palatal-derived Ecto-mesenchymal Stem Cells from Human Palate: A New Hope for Alveolar Bone and Cranio-Facial Bone Reconstruction. *Int J Stem Cell.* 2014;7(1) :23-29.

[4] Nguyen TT, Mui B, Mehrabzadeh M, Chea Y, Chaudhry Z, Chaudhry K, Tran SD. Regeneration of tissues of the oral complex: current clinical trends and research advances. *J Can Dent Assoc.* 2013;79 :d1.

[5] Herford AS, Akin L, Cicciu M, Maiorana C, Boyne PJ. Use of a porcine collagen matrix as an alternative to autogenous tissue for grafting oral soft tissue defects. *J Oral Maxillofac Surg*. 2010 Jul; 68(7):1463-1470.

[6] Alsberg E, Hill EE, Mooney DJ. Craniofacial tissue engineering. *Crit Rev Oral Biol Med.* 2001;12(1) :64-75.

[7] Langer R, Vacanti JP. Tissue engineering. *Science* 1993;260:920-926.

[8] Uebersax L, Merkle HP, Meinel L. Biopolymer-based growth factor delivery for tissue repair: from natural concepts to engineered systems. *Tissue Eng Part B Rev.* 2009;15:263–289.

[9] Nyman S, Karring T, Lindhe J, Planten S. Healing following implantation of periodontitis-affected roots into gingival connective tissue. *J Clin Periodontol.* 1980;7(5):394-401.

[10] Melcher AH. On the repair potential of periodontal tissues. *J Periodontol.* 1976 ;47(5) :256-260.

[11] Farzad M, Mohammadi M. Guided bone regeneration : A literature review. *J Oral Health Oral Epidemiol*. 2012;1(1):3-18.

[12] Cochran DL, Wozney JM. Biological mediators for periodontal regeneration. *Periodontol*. 2000;19:40-58.

[13] Silva EA, Mooney DJ. Synthetic Extracellular Matrices for Tissue Engineering and Regeneration. *Curr Top Dev Biol*. 2004;64:181-205.

[14] Rakhmatia YD1, Ayukawa Y, Furuhashi A, Koyano K. Current barrier membranes : Titanium mesh and other membranes for guided bone regeneration in dental applications. *J Prosthodont Res*. 2013 Jan; 57(1) :3-14.

[15] Martins R, Kinoshita AMO, Carvalho NTA, Guimarães SAC. Estudo comparativo da resposta do tecido ósseo em técnica de regeneração tecidual guiada – avaliação macroscópica. *Parte 1. Full Dent Sci.* 2010;1(3).

[16] Boyne PJ, Cole MD, Stringer D, Shafqat JP. A technique for osseous restoration of deficient edentulous maxillary ridges. *J Oral Maxillofac Surg*. 1985;43:87–91.

[17] Degidi M, Scarano A, Piattelli A. Regeneration of the alveolar crest using titanium micromesh with autologous bone and a resorbable membrane. *J Oral Implantol.* 2003;29:86-90.

[18] Cicciù M, Herford AS, Stoffella E, Cervino G, Cicciù D. Protein-Signaled Guided Bone Regeneration Using Titanium Mesh and Rh-BMP2 in Oral Surgery : A Case Report Involving Left Mandibular Reconstruction after Tumor Resection. *Open Dent J*. 2012;6:51-55.

[19] Behring J, Junker R, Walboomers XF, Chessnut B, Jansen JA. Toward guided tissue and bone regeneration: morphology, attachment, proliferation, and migration of cells cultured on collagen barrier membranes. *A systematic review*. *Odontology*. 2008 Jul;96(1):1-11.

[20] Fields T. Guided bone regeneration : focus on resorbable membranes. In: *Baylor oral surgery*. Thursday morning conference. 2001.

[21] Jee WSS. The skeletal tissues. In: *Histology: cell and tissue biology*. Weiss L, editor. New York, NY: Elsevier Biomedical. 1987. P. 212-54.

[22] Laurencin C T, Ambrosio AM, Borden MD, Cooper-Jr JA. Tissue engineering: Orthopedic applications. *Annu Rev Biomed Eng*. 1999;1:19–46.

[23] Tardy MEJ, Kastenbauer ER. *Head and neck surgery*, Vol. I. 2nd rev. Ed. New York, NY: Thieme Medical Publishers, Inc. 1995.

[24] Kim YK, Kim SG, Bae JH, Um IW, Oh JS, Jeong KI. Guided bone regeneration using autogenous tooth bone graft in implant therapy: case series. *Implant Dent.* 2014 Apr;23(2):138-143.

[25] Cunha MJ, Esper LA, Sbrana MC, de Oliveira PG, do Valle AL, de Almeida AL. Effect of Low-Level Laser on Bone Defects Treated with Bovine or Autogenous Bone Grafts: *In Vivo* Study *in Rat Calvaria. Biomed Res Int*. 2014;1-9.

[26] Grimm WD, Dittmar T, Varga G, Giesenhagen B. Use of stem-cell induced allogenic bonerings for pre-implantological vertical augmentations of alveolar bone defects in humans- a clinical controlled study. *Proceedings, BIT's 5h Annual World Congress of Regenerative Medicine & Stem Cells*. Guangzhou, China. Dec 2-4. 2012.

[27] Grimm WD, Varga G, Dittmar T. Palate-derived ecto-mesenchymal stem cells in Periodontology and Implant Dentistry. Does The Chronically Inflamed Periodontium Harbour Cancer Stem Cells? Proceedings, *BIT' 5th Annual World Congress of Regenerative Medicine & Stem Cell*. Guangzhou, China. Dec 2-4. 2012a.

[28] Bartold PM, McCulloch CA, Narayanan AS, Pitaru S. Tissue engineering: a new paradigm for periodontal regeneration based on molecular and cell biology. *Periodontol* 2000. 2000;24:253-69.

[29] Gottlow J, Nyman S, Karring T, Lindhe J. New attachment formation as the result of controlled tissue regeneration. *J Clin Periodontol*. 1984;11:494-503.

[30] Harrison K, Iskandar I, Chien HH. Fixation tack penetration into the maxillary sinus: A case report of a guided bone regeneration procedure complication. *Am J Case Rep*. 2013;14:43-47.

[31] Cricchio G, Sennerby L, Lundgren S. Sinus bone formation and implant survival after sinus membrane elevation and implant placement: a 1- to 6-year follow-up study. *Clin Oral Implants Res.* 2011 Oct;22(10):1200-1212.

[32] Tatum-Jr H. *Maxillary sinus elevation and subantral augmentation*. Lecture Alabama Implant Study Group, Birmingham, AL. 1977.

[33] Boyne PJ, James RA. Grafting of the maxillary sinus floor with autogenous marrow and bone. *J Oral Surg.* 1980;38:613–616.

[34] Wood RM, Moore DL. Grafting of the maxillary sinus with intraorally harvested autogenous bone prior to implant placement. *Int J Oral Maxillofac Implants*. 1988;3:209–213.

[35] Summers RB. The osteotome technique: part 3- less invasive methods of elevating the sinus floor. *Compend Cont Educ Dent*. 1994;15:698–708.

[36] Bruschi GB, Scipioni A, Calesini G, Bruschi E. Localized management of sinus floor with simultaneous implant placement: a clinical report. *Int J Oral Maxillof Implants*. 1998;3:219–226.

[37] Lundgren S, Andersson S, Gualini F, Sennerby L. Bone reformation with sinus membrane elevation: a new surgical technique for maxillary sinus floor augmentation. *Clin Implant Dent Relat Res.* 2004;6:165–173.

[38] Dahlin C, Linde A, Gottlow J, Nyman S. Healing of bone defects by guided tissue regeneration. *Plast Reconstr Surg*. 1988;81:672–676.

[39] Nyman S. Bone regeneration using the principle of guided tissue regeneration. *J Clin Periodontol.* 1991;18:494–498.

[40] Ellegaard B, Kolsen-Petersen J, Baelum V. Implant therapy involving maxillary sinus lift in periodontally compromised patients. *Clin Oral Implants Res*. 1997;8:305–315.

[41] Ellegaard B, Baelum V, Kolsen-Petersen J. Non-grafted sinus implants in periodontally compromised patients: a time-to-event analysis. *Clin Oral Implants Res.* 2006;17:156–164.

[42] Hatano N, Sennerby L, Lundgren S. Maxillary sinus augmentation using sinus membrane elevation and peripheral venous blood for implantsupported rehabilitation of the atrophic posteriormaxilla : case series. *Clin Implant Dent Relat Res.*2007;9:150–155.

[43] Thor A, Sennerby L, Hirsch JM, Rasmusson L. Bone formation at maxillary sinus floor following simultaneous elevation of the mucosal lining and implant installation without graft material: an evaluation of 20 patients treated with 44 Astra Teach implants. *J Oral Maxillofac Surg*. 2007;65:64–72.

[44] Ballini A, Scivetti M, Cantore S, Rapone B, Favia G, Grassi FR. *Tissue Engineering in Maxillary Sinus Lifting: A Comparison of Different Grafts and Confocal Laser Scanning Microscopic Evaluation: Bone Regeneration* Edited by Prof. Haim Tal April, 2012; 95-108.

[45] Soltan M, Smiler DG. Antral membrane balloon elevation. *J Oral Implantol.* 2005;31(2):85-90.

[46] Nash TJ, Howlett CR, Martin C, Steele J, Johnson KA, Hicklin DJ. Effect of platelet-derived growth factor on tibial osteotomies in rabbits. *Bone.* 1994;15:203-208.

[47] Vikjaer D, Blom S, Hjorting-Hansen E, Pinholt EM. Effect of platelet-derived growth factor-BB on bone formation in calvarial defects: An experimental study in rabbits. *Eur J Oral Sci.* 1997;105:59-66.

[48] Kassolis JD, Rosen PS, Reynolds MA. Alveolar ridge and sinus augmentation utilizing platelet-rich plasma in combination with freeze-dried bone allograft: case series. *J Periodontol*. 2000 Oct;71(10):1654-1661.

[49] Marx RE, Carlson ER, Eichstaedt RM, Schimmele SR, Strauss JE, Georgeff KR. Platelet-rich plasma: Growth factor enhancement for bone grafts. *Oral Surg Oral Med Oral Pathol Oral Radiol Endod.* 1998;85:638-646.

[50] Urban I, Caplanis N, Lozada JL. Simultaneous vertical guided bone regeneration and guided tissue regeneration in the posterior maxilla using recombinant human platelet-derived growth factor: a case report. *J Oral Implantol.* 2009;35(5):251-256.

[51] Urban IA, Jovanovic SA, Lozada JL. Vertical ridge augmentation using guided bone regeneration (GBR) in 3 clinical scenarios: a retrospective study of 35 patients 12 to 72 months after loading. *Int J Oral Maxillofac Implants.* 2009a;24:502–510.

[52] Ogunsalu C. A New Surgical Management for Oro-antral Communication. *West Indian Med J*. 2005;54(4):261.

[53] Kretzschmar DP, Kretzschmar CJL, Salem W. Rhinosinusitis: review from a dental perspective. *Oral Surg Oral Med Oral Pathol Oral Radiol Endod.* 2003;96:128–135.

[54] Horch HH. *Cirugia Odontoestomatológica.* Barcelona: Ed. Masson-Salvat. 1992. P. 167-189. [*Odontoestomatologic Surgery*. Barcelona: Ed. Masson-Salvat. 1992. P. 167-189].

[55] Vericat-Queralt A, Aytes LB, Escoda CG. Tratamiento quirurgico de las comunicaciones bucosinusales. *Ver Vasca Odontoestomatol*. 2000;2:10–23. [Surgical treatment of bucosinusal communications. *Ver Vasca Odontoestomatol*. 2000;2:10–23].

[56] Sandhya G, Reddy PB, Kumar KA, Sridhar Reddy B, Prasad N, Kiran G. Surgical Management of Oro-Antral Communications Using Resorbable GTR Membrane and FDMB Sandwich Technique: A Clinical Study. *J Maxillofac Oral Surg.* 2013 Sep;12(3):254-259.

[57] Meirelles RC, Neves-Pinto RM. Fístula oroantral e retalho mucoso geniano – revisão de 25 casos. *Rev Bras Otorrinolaringol*. 2008;74(1):85-90.

[58] Ogunsalu C, Jadusign W, Lewis A. Sinus floor and alveolar floor reconstruction using synthetic bioactive glass (Biogran) Sandwich—an innovation in bone regeneration and pre-implant reconstructive surgery. *J Oral Maxillofac Surg*. 2000;38:645–655.

[59] Eichhorn W, Blessmann M, Pohlenz P, Blake FA, Gehrke G, Schmelzle R, Heiland M. Primary osteoplasty using calvarian bone in patients with cleft lip, alveolus and palate. *J Craniomaxillofac Surg.* 2009 Dec;37(8):429-433.

[60] Le BT, Woo I. Alveolar cleft repair in adults using guided bone regeneration with mineralized allograft for dental implant site development: a report of 2 cases. *J Oral Maxillofac Surg*. 2009 Aug;67(8) :1716-1722.

[61] Miller LL, Kauffmann D, St John D, Wang D, Grant JH 3rd, Waite PD. Retrospective review of 99 patients with secondary alveolar cleft repair. *J Oral Maxillofac Surg*. 2010 Jun;68(6):1283-1289.

[62] Tai CC, Sutherland IS, McFadden L. Prospective analysis of secondary alveolar bone grafting using computed tomography. *J Oral Maxillofac Surg.* 2000;58:1241.

[63] Feichtinger M, Mossböck R, Kärcher H: Assessment of bone resorption after secondary alveolar bone grafting using three dimensional computed tomography: A three-year study. *Cleft Palate Craniofac J.* 2007;44:142.

[64] Kawata T, Yuki M, Miyamoto Y, Fujita T, Kaku M, Kohno S, Tsutsui K, Ohtani J, Tenjo K, Motokawa M, Shigekawa M, Tohma Y, Kamada H, Tanne K. Guided bone regeneration to repair an alveolar bone defect in a girl whose cleft lip and palate had been repaired. *Br J Oral Maxillofac Surg*. 2005 Oct;43(5):420-422.

[65] Vitkus R, Meltzer JA. Repair of a defect following the removal of a maxillary adenomatoid odontogenic tumor using guided tissue regeneration. A case report. *J Periodontol.* 1996 Jan;67(1):46-50.

[66] Kao PC, Huang MS, Shiau YY. Vertical Ridge Augmentation with a Titanium-Reinforced ePTFE Membrane And Tenting Screws: A Case Report. *J Prosthod Implantol*. 2012;1(1):12-18.

[67] Simion M, Trisi P, Piattelli A. Vertical ridge augmentation using a membrane technique associated with osseointegrated implants. *Int J Periodontics Restorative Dent*. 1994;14:497–512.

[68] Tinti C, Benfenati SP. Vertical ridge augmentation: surgical protocol and retrospective evaluation of 48 consecutively inserted implants. *Int J Periodontics Restorative Dent*. 1998;18:435–443.

[69] Toscano N, Holtzclaw D, Mazor Z, Rosen P, Horowitz R, Toffler M. Horizontal ridge augmentation utilizing a composite graft of demineralized freeze-dried allograft, mineralized cortical cancellous chips, and a biologically degradable thermoplastic carrier combined with a resorbable membrane: a retrospective evaluation of 73 consecutively treated cases from private practices. *J Oral Implantol.* 2010;36(6):467-474.

[70] Konstantinidis I, Kumar T, Kher U, Stanitsas PD, Hinrichs JE, Kotsakis GA. Clinical results of implant placement in resorbed ridges using simultaneous guided bone regeneration: a multicenter case series. *Clin Oral Investig.* 2014 Jun.

[71] Tomlin EM, Nelson SJ, Rossmann JA. Ridge Preservation for Implant Therapy: a Review of the Literature. *Open Dent J*. 2014; 8: 66–76.

[72] Kostopoulos L, Karring T, Uraguchi R. Formation of jawbone tuberosities by guided tissue regeneration. An experimental study in the rat. *Clin Oral Implants Res.* 1994 Dec;5(4):245-253.

[73] Bosch C, Melsen B, Vargervik K. Guided bone regeneration in calvarial bone defects using polytetrafluoroethylene membranes. *Cleft Palate Craniofac J.* 1995 Jul;32(4):311-317.

[74] Hürzeler MB, Quiñones CR, Schüpbach P. Guided bone regeneration around dental implants in the atrophic alveolar ridge using a bioresorbable barrier. An experimental study in the monkey. *Clin Oral Implants Res.* 1997 Aug;8(4):323-331.

[75] Li X, Chen SL, Zhu SX, Zha GQ. Guided bone regeneration using collagen membranes for sinus augmentation. *Br J Oral Maxillofac Surg.* 2012 Jan;50(1):69-73.

[76] Alberius P, Dahlin C, Linde A. Role of osteopromotion in experimental bone grafting to the skull: a study in adult rats using a membrane technique. *J Oral Maxillofac Surg.* 1992;50:829-834.

[77] Linde A, Alberius P, Dahlin C, Bjurstam K, Sundin Y. Osteopromotion: a soft-tissue exclusion principle using a membrane for bone healing and bone neogenesis. *J Periodontol.* 1993;64:1116-1128.

[78] Ahn YS, Kim SG, Kim CS, Oh JS, Lim SC. Effect of guided bone regeneration with or without pericardium bioabsorbable membrane on bone formation. *Oral Surg Oral Med Oral Pathol Oral Radiol.* 2012 Nov;114(5 Suppl):S126-131.

[79] Turri A, Dahlin C. Comparative maxillary bone-defect healing by calcium-sulphate or deproteinized bovine bone particles and extra cellular matrix membranes in a guided bone regeneration setting: an experimental study in rabbits. *Clin Oral Implants Res*. 2015 May;26(5):501-6.

[80] Thomas MV, Puleo DA. Calcium sulfate : properties and clinical applications. *Journal of Biomedical Materials Research. Part B, J Biomed Mater Res B Appl Biomater.* 2009 Feb;88(2):597-610.

[81] Schwartz Z, Weesner T, van Dijk S, Cochran DI, Mellonig JT, Lohman CH, Carnes DL, Goldstein M, Dean DD, Boyan B. Ability of deproteinized cancellous bovine bone to induce new bone formation. *J Periodontol.* 2000;71:1258–69.

[82] Wada T, Okamoto K, Nakanishi Y, Nakano H, Iwagami Y, Morita N. Myofascial flap without skin for intra-oral reconstruction. 2: Clinical studies. *Int J Clin Oncol.* 2001 Jun;6(3):143-148.

[83] Ophof R, Maltha JC, Kuijpers-Jagtman AM, Von den Hoff JW. Implantation of tissue-engineered mucosal substitutes in the dog palate. *Eur J Orthod*. 2008 Feb ;30(1) :1-9.

[84] Rastogi S, Modi M, Sathian B. The efficacy of collagen membrane as a biodegradable wound dressing material for surgical defects of oral mucosa: a prospective study. *J Oral Maxillofac Surg*. 2009 Aug;67(8) :1600-1606.

In: Encyclopedia of Surgery (22 Volume Set)
Editors: Andreas Lehrer and Kristin Mueller
ISBN: 978-1-53618-329-0
© 2020 Nova Science Publishers, Inc.

Chapter 116

HOW TO PREVENT ORTHOPEDIC COMPLICATIONS AND EARLY SURGERY IN CP CHILDREN: ROLE OF BOTULINUM TOXIN THERAPY

Vera Zmanovskaya[1,*], MD, PhD, Elena Levitina[2], MD, PhD and Svetlana Ushakova[2], MD, PhD

[1]Children's psychoneurological medical rehabilitation center "Nadezhda", Tyumen, Russia
[2]Tyumen state medical university, Tyumen, Russia

ABSTRACT

Short-term effects of multilevel Botulinum Toxin therapy allow to reduce muscle spasticity and thereby ensure optimal conditions for motor functions recovery in children with cerebral palsy (CP), delay the onset of secondary orthopedic complications and postpone orthopedic surgery. Multiple injections of botulinum toxin type A in combination with rehabilitation measures reduce the need in surgery comparing to rehabilitation without Botulinum Toxin therapy. Multilevel Botulinum Toxin therapy provides control postoperative pain syndrome, reduces the time to start functional rehabilitation in postoperative period, including standing with weight-bearing and encourages CP patients to recover the activity temporarily reduced after surgery.

Keywords: cerebral palsy, spasticity, botulinum toxin type A, multilevel Botulinum Toxin therapy

1. Role of Long-Term Botulinum Toxin Therapy in Prevention of Secondary Orthopedic Complications in Cerebral Palsy

Introduction

Despite a great variety of methods of non-surgical treatment in cerebral palsy, the occurrence of contractures and skeletal deformities is significant in CP children. Disproportional length of the tendomuscular complex relative to the growth of the corresponding bone segments as well as muscle retraction caused by long-term existing spasticity are considered important elements for pathogenesis of articular contractures, limb deformities, joint dislocations and other secondary orthopedic complications [1-5]. Botulinum neurotoxin type A (BoNT-A) is used as part of the basic therapy in CP patients for over 25 years. In literature, temporary improvements following Botulinum Toxin therapy such as increased range of motion at joints, muscle tone reduction, muscle lengthening and improved gait pattern have been reported [6-9]. Although short-term effects of Botulinum Toxin therapy are recognized, data about sustained functional disease-modifying effects of the therapy and role of Botulinum Toxin therapy in term of prevention of orthopedic complications still remain controversial and insufficient [4, 10, 11].

Objective of our prospective study was to assess the efficacy of multiple injections of BoNT-A (Dysport®) as part of the complex rehabilitation program of children with spastic cerebral palsy in prevention of secondary orthopedic disorders.

Material and Methods

This prospective study included 86 children with spastic CP aged from 2 to 13 years at the beginning of treatment followed during the period from 2001 to 2012. All children were ambulant, classified as level I-III according to the Gross Motor Function Classification System (GMFCS). Criteria of inclusion were muscular spasticity of (1+) or more measured by Ashworth scale; no previous injections of botulinum neurotoxin A (Dysport®). Patients should not have fixed contractures.

Patients were divided into two groups. The group 1 included 45 children (21 girls and 24 boys, mean age of 4.8 ± 1.8 years) who received 8 consecutive injections of Dysport® a part of the complex rehabilitation program. The group 2 included 41 CP children (19 girls and 22 boys, mean age of 5.1 ± 2.2 years) who underwent a similar complex treatment but without BoNT-A injections due to parents' refusal. There were no statistically significant differences between the groups in gender, age and motor development according to the GMFCS.

In group 1, the children received multilevel injections of Dysport® at least in 24-week intervals. Dysport® was administered with calculated dose of 14 to 30 U/kg, the average dose being 26 ± 4 U/kg. Follow-up controls after injections were performed in 2, 6, 10, 16 and 24 weeks.

Physical and neurological examinations including Modified Ashworth Scale for Grading Spasticity, goniometric measurements of the active and passive range of motion in adjacent joints, assessment of active ROM with the selective motor control scale, and assessment of

the gait pattern (using initial foot contact subscale of the Physican's Rating Scale) were carried out on all subjects in both groups every 6 months during two following years.

The statistical values described the mean and standard deviation. The Modified Ashworth Scale data were compared by using Wilcoxon signed–ranks test for independent samples. The test was two-tailed with a 0.05 level of significance. The chi-square test determined the significance of differences in the cases with indications for surgical treatment. This research was approved by the Review Board of our institution. The study complies with the Declaration of Helsinki statement on medical protocol and ethics. Representatives of all patients enrolled in the study provided oral and written informed consent.

Results

In group 1, the significantly reduced muscle tone assessed by Ashworth scale was revealed in follow-up period after multilevel Dysport® injections. The muscle spasticity didn't return to initial values during 24 weeks after the first four multilevel procedures. The difference remained statistically significant. The decrease of spasticity after following multilevel injections (the 5th-8th procedures) were also noticed but the difference was no more significant in comparison to the initial values.

Follow-up of the subjects from both treatment groups over a 24 months' period revealed a tendency to a fewer number of cases who required surgical treatment of orthopedic complications after 4 consecutive injections of Dysport® in the BoNT-A group (Table 1).

In 48 months after beginning of treatment, the difference in occurrence of orthopedic complications requiring surgical intervention became significant between the groups (Table 2). In group 1 only 21 patients (47%) developed orthopedic complications justifying surgery, the occurrence of secondary orthopedic disorders surgery was significantly higher in group 2 (without BoNT-A injections): 29 patients (71%).

Table 1. Number of children with orthopedic complications required surgery in 24 months after beginning of the study

	Group 1	Group 2	P
Numbers of children with indications for orthopedic surgery, n (%)	18 (40)	18 (45)	p = 0.883

Table 2. Number of children with orthopedic complications required surgery in 48 months after beginning of study

	Group 1	Group 2	P
Numbers of children with indications for orthopedic surgery, n (%)	21 (47)	29 (71)	p = 0.041

Thus, our findings demonstrated that repeated BoNT-A injections in association with complex rehabilitation program ensure a reduced occurrence of the secondary orthopedic complications requiring surgery in long-term follow-up.

2. Role of Botulinum Toxin Therapy in Prevention of Early-Age and Repeated Surgeries in CP Children

Introduction

Actual evidence-based approaches emphasize that the surgical interventions to address orthopedic complications and to correct the gait pattern should be delayed till secondary orthopedic problems occur. Generally. the age of the first orthopedic surgery varies from 7 to 14 years in patients with GMFCS I-III [12-14]. The modern concept of surgical orthopedic treatment in CP children implies a single-event multilevel surgery (SEMLS) aimed to manage all orthopedic issues and followed with a rehabilitation period for both lower limbs [1, 5]. Surgeries performed at early age have high risk of failure and relapses with less predictable final outcomes [15].

The objective of this comparative study was to evaluate effectiveness of multilevel Botulinum Toxin therapy on age of the first orthopedic surgery and on the recurrence rate of orthopedic disorders in postoperative period.

Material and Methods

The study has been performed during the period 2001 to 2017. It involved 149 CP children (78 boys and 71 girls aged from 2 to 14 years). All patients were classified as level II-IV according to the GMFCS.

The group 1 included 108 children with spastic CP who received injections of Dysport® as a part of their rehabilitation treatment. The group 2 included 41 children without BoNT-A treatment. Patients of both groups followed kinesiotherapy, complex physiotherapy and orthotics.

The multilevel surgeries when indicated have been performed in the Russian Ilizarov Scientific Center for Restorative Traumatology and Orthopedics. Postoperative follow-up with rehabilitation was ensured in Tyumen Children Psychoneurological Rehabilitation Center “Nadezhda”. Extensive rehabilitation treatment was performed during 1.5 months with interval of 6 to 8 weeks between courses for all children.

We assessed the age of the first surgical intervention and the incidence of repeated orthopedic operations in children included in the study.

Results

In group 1 (BoNT-A) the mean age, when indications for orthopedic surgery were revealed, was 10.5 ± 2.8 years (range: 8 years 4 months to 13 years). Only 5 children (4.6%) from this group had orthopedic disorder recurrence and underwent repeated surgery required a reoperation after the age of 14 years.

In the group 2 (without BoNT-A) the first surgery was done much earlier with mean age of 6.7 ± 2.1 years (range: 5 years 8 months to 9 years 2 months). The worsening of the gait parameters was observed in 95% (39 children) in the group 2 throughout pubertal growth

spurt. Thus, the recurrence of orthopedic complications resulted in repeated surgery in these children.

Finally, multilevel injections of BoNT-A in combination with complex rehabilitation and orthotics can postpone an orthopedic surgery avoiding high risks of orthopedic disorder recurrence during pubertal growth spurt. This strategy resulted in 4.6% orthopedic complication recurrence in patients following Botulinum Toxin therapy in contrast to 95% recurrence in children without BoNT-A injections.

3. MULTILEVEL BOTULINUM TOXIN THERAPY IN THE PAIN MANAGEMENT IN POSTOPERATIVE PERIOD IN CP CHILDREN

Introduction

The success of any surgical intervention depends on how early rehabilitation is started and how extensive it is. An active participation of a CP patient in the rehabilitation program for motor function recovery is crucial [16, 17]. But pain syndrome can interfere with comprehensive rehabilitation [18, 19]. Our study aimed to assess the effects of multilevel Botulinum Toxin therapy for pain management in early postoperative period following multilevel orthopedic surgery in CP children.

Material and Methods

We followed 55 GMFCS II-IV level CP children (29 boys and 26 girls) who underwent a single-event multilevel surgery. The children were aged from 5 to 17 years (mean age: 11.9 ± 2.5 years). The surgery was done in the Russian Ilizarov Scientific Center for Restorative Traumatology and Orthopedics. The rehabilitation program that included multilevel Botulinum Toxin therapy in all patients was performed in Children's psychoneurological medical rehabilitation center "Nadezhda" (Tyumen, Russia) during 1.5 months with interval of 6 to 8 weeks between courses for all children.

The early rehabilitation techniques included verticalization with total weight-bearing since the 14th-21st postoperative day, passive and active mobilization of joints since the 7th-14th postoperative day. After plaster cast removal, rehabilitation consisted of massage, strengthening exercises, posture management, muscle stretching, bracing, electric stimulation of weakened or impaired muscle groups.

In addition, injections of Dysport® were done in period of 2-3 months postoperatively depending on the muscle strength recovery, degree of spasticity and pain syndrome. In particular, after varus derotation femoral osteotomy, distal extension femoral osteotomy, various soft-tissue releases, distal rectus tendon transfer, children could complain on the pain syndrome in related anatomic zones during passive joint mobilization. The targets of Botulinum Toxin therapy were medial hamstring muscles, m.gracilis, m. adductor brevis, m. adductor longus, m. adductor magnus, m.rectus femoris.

After Grice procedure, calf-lengthening procedures, foot arthrodeses, tibial tendon transfers transplantation the pain was caused by passive motion such as knee extension and

ankle plantarflexion and dorsiflexion. The pain was localized in the popliteal region and along the posterior surface of lower leg. Thus, the targets of Botulinum Toxin therapy were caput mediale m.gastrocnemii, mm. tibialis posterior et anterior.

The pain severity in pre- and postoperative period was assessed using an adapted for children visual scale. A child was asked to point out the face whose expression was most closely corresponding to severity of the pain in particular moment of passive motion.

Results

In total, 74 surgical multilevel interventions were performed. There were 36 simultaneous bilateral surgeries and 19 consecutive interventions with mean interval of 29.4 days.

In mid-postoperative period CP patients received injections of botulinum neurotoxin type A (Dysport®) with total dose varied from 100 to 380 U (from 4 to 15 U/kg). The dose was calculated on base of body weight, then calculated dose was distributed between target-muscles. In details, 48 injections were done in adductors, 12 injections - in the rectus muscle, 14 injections - in m.iliopsoas, 48 injections – in muscles of medial hamstring group, and 18 injection in the ankle flexors and extensors (Table 3).

Table 3. Total and calculated Dysport® doses given to operated ICP children

Study group, n = 55	
Body weight, kg, M ± SD	31.5 ± 7.1
Dysport® total dose, U	
M ± SD	270 ± 100
Me (25; 75)	270 (100; 380)
Dysport® calculated dose, U/kg bw	
M ± SD	10 ± 4
Me (25; 75)	10 (4;15)
Dysport® calculated dose – hip adductors, U/kg bw, n = 48	
M±SD	6.8 ± 2.3
Me (25; 75)	7 (6; 9)
min ÷ max	4 ÷ 10
Dysport® calculated dose – rectus muscle, U/kg bw, n = 12	
M ± SD	2.8 ± 1.8
Me (25; 75)	2.8 (2; 3)
min ÷ max	1 ÷ 5
Dysport® calculated dose – iliopsoas muscle, U/kg bw, n = 14	
M ± SD	2.5 ± 1.8
Me (25; 75)	2.5 (2; 3)
min ÷ max	2 ÷ 4
Dysport® calculated dose– lower leg flexors, U/kg bw, n = 48	
M ± SD	4.5 ± 1.2
Me (25; 75)	4.5 (3; 5)
Min ÷ max	1 ÷ 8
Dysport® calculated dose – foot flexors and extensors, U/kg bw, n = 18	
M ± SD	5.8 ± 4
Me (25; 75)	6 (3; 11)
min ÷ max	1 ÷ 12

The postoperative Botulinum Toxin therapy ensured reduction of pain score from 8.6 ± 1.2 to 4.3 ± 1.1 ($p < 0.001$) and provided favorable conditions for complex rehabilitation program.

So, SEMLS implies the use of appropriate techniques permitting early passive and active joint mobilization for ROM recovery. But the pain syndrome can interfere with rehabilitation program. Our approach with low dose injections of BoNT-A allows to reduce muscle pain significantly and thereby to improve conditions for rehabilitation program fulfillment.

DISCUSSION

Long-lasting spasticity in CP children results in muscle contractures, impaired motor abilities, pathologic gait patterns, posture disorders, and other secondary orthopedic issues [6, 20]. The injections of BoNT-A in spastic muscles have important role in spasticity reduction and orthopedic complication prevention [11, 21-24]. Therefore, Botulinum Toxin therapy ensures a double advantage to CP patients: 1) reduction of increased muscle tone and improvement of motor control; 2) stretching of muscle due to reduced spasticity that allows their longitudinal growth along the spontaneous growth of bones [6, 10]. The use of botulinum neurotoxin A in clinical practice has been ever increased over the last years and currently Botulinum Toxin therapy is recognized obligatory technique in management of CP [6, 11, 22, 25-28].

Previously published studies demonstrated an increase in ankle ROM after BoNT-A injections and normalization of ankle dorsiflexion at mid-stance of the gait cycle. Injections into hamstring group resulted in improved knee extension angle throughout the stance phase [6, 18, 29, 30].

According to the European consensus on the use of BoNT-A, the percentage of patients with spastic CP who can benefit from this treatment varies from 50 to 75% depending on the age and GMFCS level [22].

Nevertheless, only an appropriate approach to Botulinum Toxin therapy can provide required results. In most cases, complex treatment should associate Botulinum Toxin therapy to facilitate the use of orthotics, kinesiotherapy and physical methods of rehabilitation [23, 30]. Botulinum toxin is not intended to serve as replacement of physical therapy but should be considered as add-on to the modern therapeutic strategies instead. Indeed, an advanced use of physical therapy and optimal splinting following Botulinum Toxin therapy is substantiated for increasing the effect of muscle relaxation which facilitates muscle stretch exercises. An intensive physical therapy delays a subsequent injection of botulinum toxin, which favors the muscular growth and, therefore, improves long-term outcomes [11, 29]. By combining botulinum toxin administration with rehabilitation measures, an improvement can be achieved even in severe CP cases associated with pronounced spastic disorders [29, 31].

According to the modern concept, Botulinum Toxin therapy should be done as single-event multilevel intramuscular injections aimed to correct pathologic motor stereotypes and to stimulate motor development of a child with CP [6].

Numerous clinical series demonstrated beneficial effects of botulinum toxin type A on painful muscular spasms, use of bracing devices and prevention of fixed muscular contractures. There are data suggesting that the treatment of the lower limb spasticity with

botulinum toxin type A decreases the energy requirements when moving and increases exercise tolerance in walking children with spastic cerebral palsy [3, 6, 30, 32]. All this leads to improvements in physical health parameters, especially, in the case of early treatment (before the age of 6 years) [18, 29].

Surgery is indicated in case of secondary orthopedic complications in CP [5, 10, 33]. A SEMLS is defined as a surgical intervention on the tendomuscular system and/or bones of two and more anatomical regions performed in a single session during one hospitalization followed by a single rehabilitation period [17]. Despite the consensus achieved in relation to single-event multilevel surgeries, there are different points of view as to the optimal age for the surgery: some authors advocate for intervention in young children aged 4 to 6 years [14, 34] while other authors consider the age of 8 to 12 years optimal [5, 13, 27].

In our study, age of patients varied from 5 to 17 years. We suggest the time for surgical intervention to be determined by occurrence of orthopedic complications. On the other hand, our study revealed that operated on at an earlier age develop recurrent orthopedic complications during pubertal growth spurt and require reoperation in 95% of cases. If orthopedic surgery was postponed by appropriate complex rehabilitation program including BoNT-A, the reoperation rate decreases significantly down to 4.6% of cases.

The outcome of multilevel surgery largely depends on early start of rehabilitation. Our findings showed that low doses of BoNT-A in postoperative short-term allow to control pain syndrome and maintain motivation of children to develop specific motor skills and functions. Our results conform with previously published studied [16, 17, 19, 32]. Botulinum toxin type A provides antinociceptive effect improving quality of life of patients and increase his/her motivation to moving [29, 31].

CONCLUSION

Our studies demonstrated that BoNT-A injections resulted in reduced rate of orthopedic complications requiring surgery in early age, postponed the surgeries in majority of patients and reduced orthopedic issues recurrence after SEMLS. We found a favorable effect of low doses of BoNT-A for postoperative rehabilitation. It should be highlighted that Botulinum Toxin therapy is a part of complex management of CP ensuring effectiveness of postural management, orthotics and kinesiotherapy.

REFERENCES

[1] Aiona, M. D. & Sussman, M. D. (2004). Treatment of spastic diplegia in patients with cerebral palsy: part II. *J Pediatr Orthop*, *13*, 1–38.

[2] Blackmore, A. M., Boettcher-Hunt, E., Jordan, M. & Chan, M. D. Y. (2007). A systematic review of the effect of casting on eguinus in children with cerebral palsy: an evidence report of the AACPDM. *Dev Med and Child Neurology*, *49*, 781-790.

[3] Hunt, A., Wisbeach, A., Seers, K., Goldman, A., Crichton, N., Perry, L. & Mastroyannopoulou K. (2007). Development of the paediatric pain profile: role of

video analysis and saliva cortisol in validating a tool to assess pain in children with severe neurological disability. *J Pain Symptom Manage*, *33*(3), 276–289.

[4] Yang, E. J., Rha, D. W., Kim, H. W. & Park, E. S. (2008). Comparison of Botulinum Toxin Type A Injection and Soft-Tissue Surgery to Treat Hip Subluxation in Children with Cerebral Palsy. *Arch Phys Med Rehabil*, *89*(11), 2108-2113.

[5] Saraph, V., Zwick, M., Zwick, G., Steinwender, C., Steinwender, G. & Linhart, W. (2002). Multilevel surgery in spastic diplegia: evaluation by physical examination and gait analysis in 25 children. *J Pediatr Orthop*, *22*, 150-157.

[6] Delgado, M. R., Bonikowski, M., Carranza, J., Dabrowski, E., Matthews, D., Russman, B., Tilton, A., Velez, J. C., Grandoulier, A. S. & Picaut, P. (2017). Safety and efficacy of repeat open-label Abobotulinumtoxin A treatment in pediatric cerebral palsy. *J Child Neurol*, *32*(13), 1058-1064.

[7] Kurenkov, A. L., Klochkova, O. A., Zmanovskaya, V. A., Falkovskiy, I. V., Kenis, V. M., Vladykina, L. N., Krasavina, D. A., Nosko, A. S., Rychkova, L. V., Karimova, K. M., Bursagova, B. I., Namazova-Baranova, L. S., Mamedyarov, A. M., Kuzenkova, L. M., Dontzov, O. G., Ryzhenkov, M. A., Butorina, M. N., Pavlova, O. L., Harlamova, N. N., Dankov, D. M., Levitina, E. V., Popkov, D. A., Ryabykh, S. O., Medvedeva, S. N., Gubina, E. B., Agranovich, O. V., Kiseleva, T. I., Vasileva, O. N., Zykov, V. P., Mihnovich, V. I. & Belogorova, T. A. (2016). [The First Russian Consensus on the Multilevel Abobotulinumtoxin A Injections in Spastic Forms of Cerebral Palsy]. *Zh Nevrol Psikhiatr Im S S Korsakova*, *116*(11), 121-130. Russian.

[8] Ryll, U., Bastiaenen, C., De Bie, R. & Staal, B. (2011). Effects of leg muscle botulinum toxin A injections on walking in children with spasticity-related cerebral palsy: a systematic review. *Dev Med Child Neurol*, *53*(3), 210-216.

[9] Sutherland, D. H., Kaufman, K. R., Wyatt, M. P., Chambers, H. G. & Mubarak, S. J. (1999). Double-blind study of botulinum A toxin injections into the gastrocnemius muscle in patients with cerebral palsy. *Gait Posture*, *10*, 1-9.

[10] Damiano, D. L., Alter, K. E. & Chambers, H. (2009). New Clinical and Research Trends in Lower Extremity Management for Ambulatory Children with cerebral Palsy. *Phys Med Rehabil Clin N Am*, *20*(3), 469–491.

[11] Novak, I., McIntyre, S., Morgan, C., et al. (2013). A systematic review of interventions for children with cerebral palsy: state of the evidence. *Develop Med & Child Neurol*, *55*(10), 885–910.

[12] Novacheck, T. F., Stout, J. L., Gage, J. R. & Schwartz, M. H. (2009). Distal femoral extension osteotomy and patellar tendon advancement to treat persistent crouch gait in cerebral palsy. Surgical technique. *J Bone Joint Surg (Am)*, *91*(2), 271-286.

[13] Rodda, J. M., Graham, H. K., Nattrass, G. R., Galea, M. P., Baker, R. & Wolfe, R. (2006). Correction of severe crouch gait in patients with spastic diplegia with use of multilevel orthopaedic surgery. *J Bone Joint Surg (Am)*, *88*(12), 2653-2664.

[14] Wohlfarth, K., Sycha, T., Ranoux, D., Naver, H. & Caird, D. (2009). Dose equivalence of two commercial preparations of botulinum neurotoxin type A: time for a reassessment? *Curr Med Res Opin*, *25*(7), 1573-1584.

[15] Svehlík, M., Steinwender, G., Kraus, T., Saraph, V., Lehmann, T., Linhart, W. E. & Zwick, E. B. (2011). The influence of age at single-event multilevel surgery on outcome in children with cerebral palsy who walk with flexed knee gait. *Dev Med Child Neurol*, *53*(8), 730-735.

[16] Gage, J. R. (2004). *The treatment of Gait Problems in cerebral palsy*. London: Mac Keith Press, 1-3.

[17] McGinley, J. L., Dobson, F., Ganeshalingam, R., Shore, B. J., Rutz, E. & Graham, H. K. (2012). Single-event multilevel surgery for children with cerebral palsy: a systematic review. *Dev Med Child Neurol*, *54*(2), 117-128.

[18] Hadden, K. L., LeFort, S., O'Brien, M., Coyte, P. C. & Guerriere, D. N. (2015). A comparison of observers' and self-report pain ratings for children with cerebral palsy. *J Dev Behav Pediatr*, *36*(1), 14-23.

[19] Zhao, X., Chen, M., Du, S., Li, H. & Li, X. (2015). Evaluation of Stress and Pain in Young Children with Cerebral Palsy During Early Developmental Intervention Programs: A Descriptive Study. *Am J Phys Med Rehabil*, *94*(3), 169-175.

[20] Papavasiliou, A. S., Nikaina, I., Foska, K., Bouros, P., Mitsou, G. & Filiopoulos, C. (2013). Safety of botulinum toxin A in children and adolescents with cerebral palsy in a pragmatic setting. *Toxins (Basel)*, *5*(3), 524-536.

[21] Alhusaini, A. A., Dean, C. M., Crosbie, J., Shepherd, R. B. & Lewis, J. (2010). Evaluation of spasticity in children with cerebral palsy using Ashworth and Tardieu Scales compared with laboratory measures. *Dev Med and Child Neurology*, *52*(6), 101–106.

[22] Heinen, F., Desloovere, K., Schroeder, A. S., et. al. (2010). The updated European Consensus 2009 on the use of Botulinum toxin for children with cerebral palsy. *Eur J Paediatr Neurol*, *14*(1), 45-66.

[23] Lebarbier, P. & Penneçot, G. (2006). L'infirmité motrice d'origine cérébrale (IMOC). *Rev Chir Orthop*, *92*, 393–395.

[24] Penneçot, C. F. (2009). *Marche pathologique de l'enfant paralysé cérébral* [*Pathological gait of a child with cerebral palsy*]. Montpellier: Sauramps.

[25] Thorley, M., Donaghey, S., Edwards, P., Copeland, L., Kentish, M., McLennan, K., Lindsley, J., Gascoigne-Pees, L., Sakzewski, L. & Boyd, R. N. (2012). Evaluation of the effects of botulinum toxin A injections when used to improve ease of care and comfort in children with cerebral palsy whom are non-ambulant: a double blind randomized controlled trial. *BMC Pediatr*, *12*, 120.

[26] Tilton, A. (2017). Abobotulinumtoxin A (Dysport®) improves function according to goal attainment in children with dynamic equinus due to cerebral palsy. *J Child Neurol*, *32*(5), 482-487.

[27] Tolo, T., Vernon, T., Scaggs, D. L. & David L. (2008). *Master techniques in orthopaedic surgery: pediatrics*. Lippincott Williams and Wilkins, 485p.

[28] Viehweger, E., Robitail, S., Rohon, M. A, Jacquemier, M., Jouve, J. L., Bollini, G. & Simeoni, M. C. (2008). Measuring quality of life in cerebral palsy children. *Ann Readapt Med Phys*, *51*(2), 119-137.

[29] Lowing, K., Thews, K., Haglund-Akerlind, Y. & Gutierrez-Farewik, E. M. (2017). Effects of botulinum toxin-A and goal-directed physiotherapy in children with cerebral palsy GMFCS levels I & II. *Phys Occup Ther Pediatr*, *37*(3), 268-282.

[30] Marco, E., Duarte, E., Vila, J., Tejero, M., Guillen, A., Boza, R., Escalada, F. & Espadaler, J. M. (2007) Is botulinum toxin type A effective in the treatment of spastic shoulder pain in patients after stroke? A double-blind randomized clinical trial. *J Rehabil Med*, *39*(6), 440–447.

[31] Lowe, K., Novak, I. & Cusick, A. (2006). Low-dose/high-concentration localized botulinum toxin A improves upper limb movement and function in children with hemiplegic cerebral palsy. *Dev Med Child Neurol*, *48*(3), 170–175.

[32] Yelnik, A. P., Colle, F. M., Bonan, I. V. & Vicaut, E. (2007). Treatment of shoulder pain in spastic hemiplegia by reducing spasticity of the subscapular muscle: a randomised, double blind, placebo-controlled study of botulinum toxin A. *J Neurol Neurosurg Psychiatry*, *78*(8), 845–848.

[33] Westbom, L., Hagglund, G. & Nordmark, E. (2007). Cerebral palsy in a total population of 4–11-year olds in southern Sweden. Prevalence and distribution according to different CP classification systems. *BMC Pediatrics*, *7*, 41-48.

[34] Dequeker, G., Van Campenhout, A., Feys, H. & Molenaers, G. (2018). Evolution of self-care and functional mobility after single-event multilevel surgery in children and adolescents with spastic diplegic cerebral palsy. *Dev Med Child Neurol*, *60*(5), 505-512.

In: Encyclopedia of Surgery (22 Volume Set)
Editors: Andreas Lehrer and Kristin Mueller
ISBN: 978-1-53618-329-0
© 2020 Nova Science Publishers, Inc.

Chapter 117

NUTRITIONAL CARE IN CHILDREN WITH CEREBRAL PALSY. PERIOPERATIVE MANAGEMENT OF PATIENTS WITH CEREBRAL PALSY UNDERGOING ORTHOPEDIC SURGERY

Anna Shaitarova*, MD, PhD, Olga Perfilova, MD, PhD and Elena Khramova, MD, DSc
Tyumen State Medical University of the Ministry of Healthcare of the Russian Federation, Tyumen, Russia

ABSTRACT

Nutritional status malformations are frequently associated with neurological and orthopedic disorders of patients with cerebral palsy (CP). At that, both weight and height excess and deficit can be observed, however, the deficiency of weight and height factors is more clinically significant, that most CP patients demonstrate. According to the recent epidemiological studies, up to 70% of children with cerebral palsy are malnourished [1, 2, 3]. Nutritional disorders in children with cerebral palsy were also reported by Studenikin V.M. and Buksh A.A. (2016), Aydin K. et al. (2018), Scarpato E. et al. (2017), García Íñiguez J.A. et al. (2018) [4, 5, 6]. Nutritional disorders in children with CP include weight loss of varying degrees, growth disturbance, micronutrient inefficiency, osteopenia, and obesity [7]. Nutritional disorders in children with cerebral palsy are associated with growth inhibition, subpar growth curve, impaired peripheral circulation, immune system failure, impaired wound healing, breathing muscles weakness, and an increased risk of pathologic fractures [8, 9]. The functional effect of such concomitant disorders can be so strong that its negative impact on everyday activity and participation can be much more significant than from motor problems caused by CP, and depending on the disease severity. Typically, nutritional status disorders occur in children with severe motor impairment (GMFCS levels III-V) and cognitive deficiency [10]. This category of children demonstrates significant orthopedic complications, which often require a multi-stage surgical correction causing a long hospital stay of the child.

1. Weight Deficit and Malnourishment in Cerebral Palsy

The nutritional deficiency in children with CP increases the risk of developing intercurrent diseases (cardiovascular, endocrine, immune systems, respiratory failure) [11, 12, 13, 14, 9, 15], impaired tissue tropism (pressure sores nascency, impaired wound healing, muscle atrophy, decreased bone mineralization) [16, 17, 18], the decrease in the efficiency of specialized medical care [19], the development of side effects from a specific (anticonvulsant, hormonal, etc.) therapy [20]. As a result, children with cerebral palsy have a relatively high frequency and duration of hospital stays and the related increase of 20-30% in the costs of managing each patient [21, 22].

Malnutrition in CP is the result of the following causes and factors: 1) feeding difficulties as a result of chewing and swallowing disorders (the incoordination of lips, tongue, palate, and pharynx muscle movements); 2) a slow development caused by the damage of the brain centers that provide nutrition and growth (hypothalamic centers); 3) tooth decay/enamel hypoplasia and other dental problems; 4) the discrepancy of food habits to individual energy needs; 5) mineral deficiency caused by a chronic use of anticonvulsants or lack of active movements; 6) underlying diseases of the gastro-intestinal tract [23].

Oral-motor disorders are one of the main factors that determine difficulties during eating and drinking in patients with CP. The uncoordinated work of tongue and pharynx muscles, disruptions in the jaw functioning lead to slow chewing, difficulties with swallowing, the need to eat a certain food consistency, a high risk of aspiration during eating and drinking, which leads to a decrease in the amount of food consumed and, as a result, malnutrition. According to the study by S. Reilly et al. [24], every third child with oral-motor problems had a restriction on the texture and consistency of food and liquid taken. 60% of children were completely dependent on their parents during feeding and could not eat on their own, 57 % of children choked on food and had episodes of aspiration in infancy. The authors of the study found a connection between the severity of dysphagia and motor disorders: a severe oral motor dysfunction was reported in children with more significant motor disorders. Further studies also confirm a direct correlation between the severity of motor disorders and the severity of dysphagia [25, 26, 27].

Dental problems such as ulcers, oral candidacies, tooth decay, gingivitis caused by a poor oral hygiene worsen eating disorders [8] and, according to Jan B.M. and Jan M.M. (2016), may have a harmful effect on health and a negative impact on the quality of life [28]. Cardoso A. M. R. et al. (2018) conducted a study of 149 CP patients (age 2-18) who were assessed by the factors affecting the quality of life related to health (Health-Related Quality of Life - HRQoL) and the quality of life related to oral health (Oral Health-Related Quality of Life – OHRQoL) [29]. Consequently, it proved that patients with cerebral palsy had lower HRQoL and OHRQoL indices than healthy peers. It was shown that the average OHRQoL index of 78.0 ± 24.6 in the study group was 12.1% associated with the age, presence of gastroesophageal reflux disease, tooth decay, and periodontics [16]. Rodriguez J. P. L. et al. (2018) examined 120 children and adolescents with various CP forms (spastic - 62.5%, mixed - 18.3%, atactic - 10%, athetoid - 9.1%) [7]. Tooth decay was most frequently detected in children with a mixed form of cerebral palsy compared to other patients ($p < 0.05$). Among other types of dental pathologies, the researchers identified erosion and traumatic injuries of

the teeth, pathological occlusion (dental bite), regular oral muscle actions, Gum Hyperplasia, and dental fluorosis. The detection rate of pathological occlusion was 87.5% [7].

Children with CP often find it difficult to maintain oral hygiene at an acceptable level due to a variety of factors. In particular, children with nasal breathing problems and hypersalivation are particularly prone to have difficulties with maintaining oral hygiene [8]. The presence of GERD can also increase the risk of tooth decay as constant acid reflux destroys the tooth enamel [30]. Motor disorders can contribute to difficulties in maintaining a proper oral hygiene. For example, Sedky N.A. (2018) evaluated the teeth and oral cavity health in 62 patients with cerebral palsy aged 3-12, correlating them with the type of disease and the GMFCS scale [31]. 84% of the examined children had spastic tetraparesis, 41.9% of them were sitting with support, 32.3% of the patients matched GMFCS level IV, and 29% matched GMFCS level V. Tooth decay was detected in 54.8% of the cases, and 43.6% of the patients had severe gum inflammation. Children, who used a support while sitting, did not hold their head, and stood with a support were more likely to have tooth decay than those who had the skill of sitting and walking independently. Accordingly, tooth decay was indicated more frequently in patients with GMFCS levels IV/V. In older children, significant gingivitis was more often detected [31].

Among the gastroenterological problems that often lead to nutritional disorders in children with cerebral palsy, the list should include as follows: decreased appetite, dysphagia (oral, pharyngeal, esophageal), nutritional dysfunction, hypersalivation, chronic constipation, gastroesophageal reflux disease, etc. [32]. GERD is one of the concomitant conditions occurring frequently in children with cerebral palsy and complicating significantly their feeding [30]. Risk factors for GERD in children with CP and severe motor function restriction are the disruption of the gastrointestinal tract smooth muscle cells innervation, which leads to a decrease in the lower esophageal sphincter tonus, gastric emptying rate, esophagus dysmotility; general spasticity; inability to sustain a pose, short duration of verticalization; convulsive disorder; taking antiepilepsy drugs; postural disorder, etc. [33]. Aspiration pneumonia and refusal to eat, which often occur in GERD, can be a serious obstacle to an efficient nutritional support for children with CP and are prognostically unfavorable signs [34].

Constipation is a serious comorbid condition in children with cerebral palsy. Campanozzi A. et al. (2007) described a high prevalence rate of constipation in children with severe cerebral palsy in more than 50% of the cases [35], which may be associated with difficulties in the inguinal and perineal zone care in patients with hip joints adduction contracture and a high risk of the urinary tract and skin infection development.

2. MICRONUTRIENT STATUS IN CHILDREN WITH CEREBRAL PALSY

Micronutrients, which barely provide food energy intake, perform many important roles that are of particular importance in CP.

Bone fractures associated with diminished bone mineralization pose a major problem in children with spastic tetraparesis. Some children with CP take anticonvulsants (to control epileptic seizures); their use is associated with Calcium and vitamin D metabolism imbalance. Some antiepileptic drugs stimulate the hepatic microsomal enzyme system, increasing the 25-

hydroxyvitamin D conversion to active metabolites, thereby reducing the availability of vitamin D for the body. This increases the risk of bone fractures in the given group of children. Folic acid deficiency has also been reported among people taking antiepileptic drugs [32]. Hillesund E. et al. (2007), when examining the group of children with CP, determined that these patients had a deficiency in a range of micronutrients (minerals and vitamins): iron, calcium, folic acid, niacin, vitamin E and vitamin D. Significantly, the lack of these micronutrients occurred in children even when using special nutritional supplements [16]. According to King W. et al. (2003), in children with spastic tetraparesis, there is often a decrease in bone mass due to insufficient intake of calcium and vitamin D, as well as the use of anticonvulsants (as a result, patients experience a greater risk of non-traumatic bone fractures) [36]. When examining the patients with this form of cerebral palsy, American researchers found a significant decrease in the mineral density of vertebral spine bones compared to healthy individuals, and in 58% of the cases, z-number was less than -2. The history of limb fractures was observed in 39% of the patients; in these cases, z-number values for the density of vertebral spine bones were significantly lower than in patients without any indications of previous fractures [36]. Papadopoulos A. et al. (2008) note a high degree of incidence of iron-deficient anemia among patients with CP, which, in their opinion, is a direct consequence of insufficient consumption of nutritional iron [37]. Hypochromic anemia was detected in 33% of the patients, and in 38% of the children due to iron deficiency. There were no statistical differences in the iron deficiency degree of incidence depending on age; the tests aimed at detecting occult blood and/or intestinal parasites in the fecal matter were negative; the levels of folic acid and vitamin B12 in blood corresponded to the age norm. The researchers established that anemia and iron deficiency were observed in 95.6% of the patients who received liquid nutrition, and among the children who received a regular diet, anemia and iron deficiency were much less common – 18.8% and 22.3% of the patients, respectively. The authors conclude that a high degree of anemia incidence in patients with CP is the result of inadequate intake of iron with food and its delayed absorption, which suggests the need for appropriate supplementation [37]. In their review, Schoendorfer N. et al. (2010) address publications on the availability of vitamins and minerals for children with cerebral palsy and the impact of various micronutrient deficiencies on various aspects of their health [38]. The authors emphasize that it is common for children with cerebral palsy to have difficulties with eating that impact negatively on their development indicators, overall health and life expectancy. In their opinion, unreasonably few studies and publications are related to the micronutrient status in cerebral palsy, while the main part of the scientific search is aimed primarily at the problem of energy consumption in this group of patients. Meanwhile, a recognized role of micronutrients in maintaining cellular homeostasis of the entire body determines the necessity to focus attention and efforts of researchers on this specific area [38].

3. NUTRITIONAL STATUS ASSESSMENT IN CP CHILDREN

The nutritional status assessment in children with CP is a difficult task for clinicians. Features of physical development, metabolism, and numerous neurological disorders in children with CP determine the need to use several non-invasive techniques for an objective

nutrition assessment (Table 1). However, it should be noted that only a comprehensive multidisciplinary approach to the CP child rehabilitation, when the nutritional status assessment and nutritional correction are significant, will increase the efficiency of rehabilitation measures, reduce the number of complications and improve the life quality of patients with CP. The algorithm of nutritional status assessment includes several stages. The first stage involves a physical examination of the patient, study of the dietary history; the second stage is assessing the gross body composition using modern non-invasive methods: anthropometry, bioimpedansometry, osteodensimetry; the third stage is based on the study of energy production using direct and indirect calorimetry; the fourth stage includes the study of biochemical markers of nutritional status. A comprehensive assessment is both necessary to identify problems in development and nutrition, and it allows choosing the right treatment or intervention tactics.

A thorough physical examination can help to determine a deficiency of calories and nutrients. Subcutaneous edema indicates protein malnutrition and may be a sign of heart failure. Paleness or heart murmurs are often present in iron-deficient, folic-deficient, and B12-deficient anemia. Due to chronic aspiration, broncho-obstructive syndrome may occur. The skin, nails and tunica mucosa of the mouth also need to be examined for pathological changes associated with hypovitaminosis D. Wounds can heal poorly if the food does not contain enough calories, vitamins C, E, and zinc [39]. Rachitic rosary, thickening of wrist bones and bowleg, found in the musculoskeletal examination, are signs of vitamin D deficiency. An ophthalmological examination also helps to identify vitamin A deficiency (corneal clouding, conjunctival xerosis) and B1 deficiency (nystagmus, ophthalmoplegia).

Table 1. Evaluation of clinical symptoms related to nutritional disorders

Signs	Possible reasons related to nutrition
Hair	
Dull, dry; no natural gloss; uncombable hair syndrome in the morning	Protein deficiency
Thin, sparse; without curls	Zinc deficiency
Eyes	
Pale, injected sclera	Iron deficiency
Dry sclera; triangular grey spots on the sclera	Vitamin A deficiency
Hyperemia of the eyelids	Riboflavin deficiency
Lips	
Redness and puffiness of the lips; angular stomatitis	Niacin, riboflavin and/or pyridoxine deficiency
Gums	
Spongy, swollen, bleeding	Vitamin C deficiency
Teeth	
Enamel erosion	GER
Face	
Round, edematous	Protein malnutrition, thiamine deficiency
Peeling skin around the nostrils	Vitamin A, zinc, and essential aliphatic acids deficiency

The assessment of the physical development of a child with cerebral palsy involves certain difficulties because such patients have multiple skeletal bone deformities, joint

contractures, involuntary muscle spasm, cognitive and behavioral disorders, therefore, it is impossible to interpret obtained data on the physical development of children with CP according to the generally accepted scores. In 2011 Brooks J. et al. developed the Life Expectancy Project scores that take into account not only physical development, gender and age of the child, but also the level of restriction of global motor skills [40]. The evaluation of physical development indicators on the Life Expectancy Project scores is of great importance in clinical practice, as it also allows assessing the risks of mortality. It is known that in children with GMFCS levels III – V and body weight <20 percentile, the risk of death is 1.5 times higher than in children with normal rates of physical development [41].

To assess the risks of nutritional status malformations, methods for body composition assessment are used along with anthropometric methods [34]. The concept of "body composition" provides an assessment of the water, fat and non-fat solids content (bone and muscle tissue) - lean body mass. The body composition is affected by the ratio of the amount of fat and muscle tissue, changes in the volume of total, extracellular and intracellular fluids [4, 42]. Various methods are used to assess the body composition (caliperometry, bioelectric bioimpedance analysis, X-ray absorptiometry, etc.). Caliperometry helps to assess the state of the fat depot in the body. The thickness of subcutaneous-fat folds indicates the value of the total fat depot in the body and can be measured with a caliper, providing standard pressure on the folds (10 g/mm^2). The most common practice is to measure the thickness of the skin fold in the triceps and biceps muscles of the arm, in the infrascapular region, above the crest of the iliac crest, along the anterior axillary line. Yakut A. et al. (2006) demonstrated that the thickness of the skin fold above the triceps is an optimum indicator for nutritional status assessment in CP [43]. The bioimpedance analysis of the body composition allows assessing the status of protein, fat, and water metabolism, the intensity of metabolic processes, and assessing the body's reserve capacity and disease risks based on the electrical resistance (impedance) of the human body and anthropometric data. According to ESPGHNG recommendations, this method of functional diagnostics enables us to determine absolute and relative values of the body composition individual components and metabolic correlates and to assess objectively the patient's nutritional status [34]. The research conducted by Oeffinger D.J. et al. [44] proves a high assessment accuracy of the body composition components using bioimpedansometry and estimating the skin fold thickness using Gurka equations in CP children with mild motor disorders.

Dual energy X-ray absorptiometry is the most common and preferred method for bone status assessment [45]**.** Dual energy X-ray absorptiometry works on a three-component model (muscle, fat, and bone). The method is based on measuring the attenuation of the X-ray flux when passing through bone, fat, and muscle tissues of the body. The exposure to radiation is extremely low in comparison with fluoroscopy and computerized tomography. As a rule, in children with CP, the distal segment of the femoral bone is chosen for BMD scanning because this area is most likely to fracture, and it is easily accessible. Current guidelines, based on the expert opinion, recommend prescribing dual energy X-ray absorptiometry only in case of a pathologic fracture. Performing the procedure at the treatment beginning and after the intervention helps to analyze changes in the BMD. The results of the bone density study should be compared to reference standards and presented as Z-scores, adjusted to the child's age, gender, and height [46]. Using the most advanced X-ray densitometers and installed "Total Body" software, it is possible to accurately determine both the bone strength and total body fat percentage, and to assess the content of soft lean mass and fatty tissue in various

body segments. Given the minimum error of the measurement (no more than 1-3%), this method can be used as the "gold standard" for accessing the body composition components.

Determining the intake of actual calories and micronutrients in relation to the body's desirable physiological need for them is an integral part of the nutritional status assessment. For example, knowing whether a child intakes enough calories can reveal the etiology of malnutrition. There are several different ways to evaluate the required child's energy intake. The most accurate method is indirect calorimetry, which allows the patient to determine the number of calories, proteins, fats and carbohydrates needed based on the expired air analysis. Indirect calorimetry is performed with a fase mask metabolimeter or a mask for patients with spontaneous breathing. The study is carried out at rest with passive and active loads. Currently, various equations are available to assess energy consumption in children with CP. In 2011, Rieken et al. proposed a method for estimating the basal metabolism rate using well-known Schofield equation [47]. The Schofield-based method became widely used in determining energy needs in children with CP because of its simplicity. The Rieken daily energy need calculation method is used to determine the basic energy requirements, which are then used to calculate the total energy consumption, corrected for physical activity levels, GMFCS level, and the overall energy consumption correction based on the cerebral palsy presence. The Rieken daily energy need calculation formulas using the Schofield equation are shown in Table 2.

Table 2. Calculating daily energy need in children with cerebral palsy [47]

	Schofield Equation Method
3-9 years old Boys Girls	 BMR = (0.095 x weight, kg) + 2.110 BMR = (0.085 x weight, kg) + 2.033
10-18 years old Boys Girls	 BMR = (0.074 x weight, kg) + 2.754 BMR = (0.056 x weight, kg) + 2.898
Total energy consumption, kcal	1.1 x BMR x 238.8
Additional correction:	
General correction physical activity energy costs GMFCS level IV	– 280 kcal + 222 kcal + 431 kcal

Note: BMR - basic metabolism rate, kJ; TBW - total body water; DLV-double labeled water.

Laboratory tests can be extremely useful in assessing the nutritional status of a CP patient. Mostly, preliminary studies include a general blood test, counting absolute lymphocytes, biochemical analysis and determining the indicators of protein metabolism, lipid pattern, hepatic and renal function indicators, serum iron, and 25 (OH) D - major metabolite of vitamin D. Further blood tests for folic acid and vitamin B12 levels may be prescribed, depending on the presence and type of anemia. Regular testing of 25-OH vitamin D level and, if possible, alkaline phosphatase, calcium and phosphorus are advised for children with CP, and the motor activity should be restricted for those who take anticonvulsants [19]. Low levels of prealbumin, retinol-binding protein, and transferrin may indicate a protein deficiency, although, due to a longer half-life, albumin is still the best indicator of chronic malnutrition. Depending on the physical examination results and

anamnesis, additional laboratory tests are necessary to exclude other causes of physical development delay, including hypothyroidism or hyperthyroidism (free thyroxine, thyroid-stimulating hormone), growth hormone hunger (IGF-1, STH-stimulating tests with glucagon), delayed puberty (follicle-stimulating hormone, luteinizing hormone, estradiol, testosterone), inflammatory diseases (C-reactive protein, ferritin), celiac syndrome (IgA to tTG and deamidated gliadin peptides, total IgA level), and chronic infections of the urinary organs (common urine test, urine culture test). To interpret the skill of taking solid and liquid food in children with CP, Seiiers D., Anne Mandi et al. (2014) validated the Eating Drinking Assessment Classification System (EDACS). The scale can be used to assort the ability of taking food and liquids in terms of efficiency and safety, and to determine the amount of help needed for levels I - V in this scale. Starting from level II, a physician must evaluate the associated clinical pattern: 1) frequent (possibly of aspirating nature) bronchitis and pneumonia; 2) negative weight changes; 3) the capability of a child to consume a sufficient amount of food; 4) the duration of existing changes (during an acute condition, for several months). Videofluoroscopy is a necessary tool to determine the degree of meal safety. This study remains the "gold standard" for diagnosing dysphagia and selecting the food bolus consistency. The method includes a dynamic fluoroscopic assessment of oral, oral-transfer, pharyngeal, and partially esophageal stages of swallowing. It allows detecting aspiration before, during, and after swallowing, determining dysphagia location, and its possible cause (a muscle spasm of the esophagus). It can also help to choose the best feeding position, appropriate consistency, and feeding speed [8].

4. NUTRITIONAL SUPPORT IN THE PERIOPERATIVE PERIOD

Nutritional status normalization is an important component of the preoperative preparation in patients with CP as the incidence rate of postoperative complications increases with malnutrition, which affects the course and duration of the postoperative period, and the efficiency of treatment in general. Thus, Baranek E.S. et al. (2019) published the results of the study demonstrating a high correlation between the preoperative BMI percentile in stratified GMFCS growth charts and SSI (Surgical Site Infection) after spinal surgery [48].

The general principles of approaches to the nutritional status correction in patients with CP are as follows:

- involvement of specialized professionals: gastroenterologist, dietitian-nutritionist;
- correction of comorbidity affecting food consumption and digestion processes;
- calculation of the daily caloric value taking into account the basic metabolism, cerebral palsy form, severity of motor disorders, perioperative energy consumption compensation;
- selection of the food type (natural nutrition or specialized supplements), the consistency of food, diet, ways of nutrients intake.

A surgical intervention, like any other injurious exposure on the body, causes a number of reactions, including the catecholamine and pro-inflammatory cytokine discharge, which inevitably contributes to the development of hypermetabolism and catabolism with excessive

surgical release of energy substances [39, 49]. In the setting of already existing nutritional inefficiency, hypermetabolism, as a result of surgical stress, leads to a further decrease of growth process, an increase in cognitive deficiency, an increased risk of infectious complications, a delayed soft tissue regeneration and bone union. The occurrence of these disorders results in a delayed commencement of postoperative rehabilitation and its increased duration, which ultimately reduces the efficiency of treatment and rehabilitation measures. ERAS (enhanced recovery after surgery) rehabilitation programs include preoperative preparation and drug therapy, fluid balance, anesthesia and postoperative analgesia regimens, perioperative nutrition, and surgical release. The ERAS concept is aimed at reducing the time of treatment and recovery after surgery and involves, along with the widespread use of field block anesthesia and minimizing the use of opioids, the earliest possible recovery of vital functions, and, if possible, patient's motor activity. The perioperative nutritional support in this approach is considered an integral part of early activization of a patient.

In addition to a faster recovery through accelerated rehabilitation programs after surgery, more and more publications indicate that these programs reduce the risks of postoperative complications.

The ERAS concept involves reducing the time of preoperative fasting and anhydrous periods and starting postoperative nutrition as early as possible as a way of reducing postoperative hypermetabolism and catabolism. In the preoperative period, despite the tendency of reducing the duration of preoperative fasting, it remains mandatory for patients with CP to refuse food no later than 6 hours before anesthesia. This measure is associated with the gastro-intestinal tract dysmotility, especially in the upper parts, in children with cerebral palsy. The consequences of forced fasting in patients with malnourishment are obvious: oligemia, further glycogen depletion in the muscles, hypoglycemia, and metabolic stress. However, preoperative fasting is associated with significant metabolic shifts and negatively affects the course of the postoperative period. To reduce the preoperative fasting period, it is possible to prescribe special nutritional care medicine – high-caloric carbohydrate maltodextrin-based drinks with hydrolyzed vegetable protein and additional ingredients. These medications do not contain any fat and dietary fiber, and this induces fast gastric emptying in less than two hours. Taking carbohydrate drinks two hours before surgery reduces metabolic stress and improves perioperative metabolism, reduces hunger and thirst, and makes the preoperative period more comfortable for the patient [50]. These medications can be used in the preoperative period in children from 1 year old.

Due to frequent problems with food consumption and digestion, which are initially present in patients with CP, as well as a higher rate of postoperative nausea and vomiting, and a decrease in appetite in the early postoperative period, it is extremely difficult to achieve a proper nutritional support with only natural nutrition in the next few days after surgery. Current ESPEN guidelines (European Society for Clinical Nutrition and Metabolism) give priority to enteral nutrition in patients who cannot meet at least 50% of their energy needs orally for more than 7 days. For these purposes, nutritional care medications are designed, they allow both providing CP patients with all the necessary energy and flexible substances, and solving a number of specific problems with feeding these patients. In addition to macro- and micronutrients, nutritional care medications usually contain additives that improve food digestion and gastro-intestinal tract motility, such as dietary fibers, probiotics, and certain pharmaconutrients designed to reduce the inflammatory reaction and oxidative stress. It is possible to use standard isocaloric mixtures during the postoperative period in patients with

CP without severe dysphagia and nutritional status malformations. Usually, such patients can also eat traditional food, and nutritional care can be prescribed additionally.

Patients with nutritional deficiency, dysphagia, difficulties in digesting large amounts of food, but capable of oral alimentation, use medications with increased energy density (1.5–2 kcal/ml) and high protein content (5–10 g/100 ml), which reduces the amount of nutrition. The ratio of macro-and micronutrients in such medications meets the specific needs of children. These medications meet all the nutritional requirements for children with malformed nutritional status; they use medium chain fat as sources of fat – the most easily digestible type of fat that is digested independently from pancreatic lipase. To correct the immune status and metabolism of postoperative patients, it is possible to use nutritional care medications containing omega-3 aliphatic acid, L-carnitine and individual amino acids (arginine, glutamine). For patients with dysphagia, special medications with higher viscosity of different consistency have been developed. It is also possible to create an optimum consistency of nutrition for swallowing by adding thickeners to any liquid, including nutrition therapy medications.

Patients with gastro-intestinal tract dysmotility and GERD are prescribed anti-reflux mixtures based on partially or completely hydrolyzed milk whey protein. Thanks to the hydrolyzed milk protein, the medicine is quickly excreted from the stomach, and it fully absorbs, even in cases of severe digestive disorders and intestinal absorption. These products can be either standard or high-protein. It is possible to use them both for oral and enteral feeding in children older than 1 year. For patients suffering from constipation, dietary fiber mixtures are prescribed to improve gastro-intestinal tract motility.

If oral feeding is not possible or difficult in the postoperative period, tube feeding is used in patients with CP. Modern probe enteral nutrition is carried out by using enteromats with a controlled speed, which reduces the risk of regurgitation and contributes to a better food absorption. Depending on the degree of nutritional disorders, both standard and hypercaloric high protein mixtures can be used for enteral nutrition. Mixtures for enteral nutrition fully cover the daily need for macro- and micronutrients, and they can be used for GERD and malabsorption syndrome. These mixtures can be used for PEG feeding.

CONCLUSION

Nutrition disorders in children with CP are a largely underestimated problem, including the preparation process for surgical treatment. Numerous research data indicate that malnutrition affects health and life quality of patients with CP, and worsens the prognosis for the underlying disease. Meanwhile, different degrees of motor disorders cause difficulties in standardizing approaches to determine the nutritional status and correct it in such patients. The severity of nutritional disorders usually increases with a decrease in the ability of patients to move independently, and it correlates with a decrease in intellectual abilities. The assessment, correction and support of nutritional status should be an integral part of management and rehabilitation measures and of the perioperative period as they generally influence the efficiency of treatment.

REFERENCES

[1] Aydin, K., Turkish Cerebral Palsy Study Group. (2018). A multicenter cross-sectional study to evaluate the clinical characteristics and nutritional status of children with cerebral palsy. *Clin Nutr ESPEN*, 26: 27-34.

[2] Ljungqvist, O., Scott, M., Fearon, K.C. (2017). Enhanced Recovery After Surgery: A Review. *JAMA Surg*, 152 (3): 292-298.

[3] Marchand, V., Motil, K.J. (2006). NASPGHAN Committee on Nutrition. Nutrition support for neurologically impaired children: a clinical report of the North American Society for Pediatric Gastroenterology, Hepatology, and Nutrition. *J Pediatr Gastroenterol Nutr*, 43 (1): 123-135.

[4] Studenikin, V.M., Buksh, A.A. (2016). Nutritional Status Malformations in Children with Cerebral Palsy (Part 1). *The treating doctor*, 9: 56-59.

[5] Scarpato, E., Staiano, A., Molteni, M., Terrone, G., Mazzocchi, A., Agostoni, C. (2017). Nutritional assessment and intervention in children with cerebral palsy: a practical approach. *Int J Food Sci Nutr*, 68(6): 763-770.

[6] García Íñiguez, J.A., Vásquez Garibay, E.M., García Contreras, A.A., Romero Velarde, E., Troyo Sanromán, R., Hernández Rocha, J., Rea Rosas, A., Rodríguez León M., Uribe Martínez E. (2018). Energy expenditure is associated with age, anthropometric indicators and body composition in children with spastic cerebral palsy. *Nutr Hosp*, 35(4): 909-913.

[7] Rodríguez, J.P.L., Ayala-Herrera, J.L., Muñoz-Gomez, N., Martínez, R.E., Santos-Díaz, M.A., Olvera-Delgado, J.H., Loyola-Leyva, A. (2018). Dental decay and oral findings in children and adolescents affected by different types of cerebral palsy: a comparative study. *J Clin Pediatr Dent*, 42(1): 62-66.

[8] Strudwick, W. (2009). Oral motor impairment and swallowing dysfunction: assessment and management. In: Sullivan PB, editor. *Feeding and Nutrition in Children with Neuro developmental Disabilities*. London: Mac Keith Press, chapter 3.

[9] Katona, P., Katona-Apte, J. (2008). The interaction between nutrition and infection. *Clin Infect Dis*, 46: 1582-1588.

[10] Penagini, F., Mameli, C., Fabiano, V., Brunetti, D., Dilillo, D., Zuccotti, G.V. (2015). Dietary Intakes and Nutritional Issues in Neurologically Impaired Children. *Nutrients*, 7(11): 9400-9415.

[11] Day, S.M., Brooks, J., Shumway, S., et al. (2012). Growth charts for children with cerebral palsy: weight and stature percentiles by age, gender, and level of disability. In: Preedy VR, editor. *Handbook of growth and growth monitoring in health and disease*. NY, USA: Springer-Verlag: pp. 1675-1706.

[12] Kuperminc, M.N., Gottrand, F., Samson-Fang, L., et al. (2013). Nutritional management of children with cerebral palsy: a practical guide. *Eur J Clin Nutr*, 67 (2): 21-23.

[13] Arvedson, J.C. (2013). Feeding children with cerebral palsy and swallowing difficulties. *Eur J Clin Nutr*, 67 (2): 9-12.

[14] Bell, K.L., Davies P.S. (2003). Body composition of ambulatory children with mild cerebral palsy. *Asia Pac J Clin. Nutr*, 12 (2): 57.

[15] Sullivan, P.B. (2013). Nutrition and growth in children with cerebral palsy: setting the scene. *Eur J Clin Nutr*, 67(2):S3–S4.

[16] Hillesund, E., Skranes, J., Trygg, K.U. et al. (2007). Micronutrient status in children with cerebral palsy. *Acta Paediatr*, 96 (8): 1195-1198.

[17] Alvarez Zaragoza, C., Vasquez Garibay, E.M., Garcia Contreras, A.A., et al. (2018). Bone mineral density and nutritional status in children with quadriplegic cerebral palsy. *Arch Osteoporos*, 13(1):17.

[18] Henderson, R.C., Lark, R.K., Gurka, M.J., et al. (2002). Bone density and metabolism in children and adolescents with moderate to severe cerebral palsy. *Pediatrics*, 110(1): 5.

[19] Trabacca, A., Vespino, T., Di Liddo, A., Russo, L. (2016). Multidisciplinary rehabilitation for patients with cerebral palsy: improving long-term care. *J Multidiscip Health*, 9:455-462.

[20] Sangermano, M., D'Aniello, R., Massa, G., et al. (2014). Nutritional problems in children with neuromotor disabilities: an Italian case series. *Ital J Pediatr*, 40:61.

[21] Moeeni, V., Walls, T., Day, A. (2014). The STRONGkids nutritional risk screening tool can be used by paediatric nurses to identify hospitalised children at risk. *Acta Paediatrica*, 103(12):528- 531.

[22] Barker, L.A., Gout, B.S., Crowe, T.C. (2011). Hospital malnutrition: prevalence, identification and impact on patients and the healthcare system. *Int J Environ Res Public Health*, 8(2):514-527.

[23] Asgarshirazi, M., Farokhzadeh-Soltani, M., Keihanidost, Z., Shariat, M. (2017). Evaluation of Feeding Disorders Including Gastro-Esophageal Reflux and Oropharyngeal *Dysfunction in Children With Cerebral Palsy*, 11(4):197-201.

[24] Reilly, S., Skuse, D., Poblete, X. (1996). Prevention of feeding problems and oral motor dysfunction in children with cerebral palsy: A community survey. *J Pediatr*, 129: 877-882.

[25] Erkin, G., Culha, C., Ozel, S., Kirbiyik E. G. (2010). Feeding and gastrointestinal problems in children with cerebral palsy. *J Rehabil Res*, 33:218-224.

[26] Santoro, A., Lang, M.B., Moretti, E., Sellari-Franceschin, I., Orazini, L., Cipriani, P., Cioni, G., Battini, R. (2012). A proposed multidisciplinary approach for identifying feeding abnormalities in children with cerebral palsy. *J Child Neurol*, 27:708-712.

[27] Benfer, K.A., Weir, K.A., Bell, K.L., Ware, R.S., Davies, P.S.W., Boyd, R.N. (2013). Oropharyngeal dysphagia and gross motor skills in children with cerebral palsy. *Pediatrics*, 131: 1553-1562.

[28] Jan, B.M., Jan, M.M. (2016). Dental health of children with cerebral palsy. *Neurosciences (Riyadh*), 21(4): 314-318.

[29] Cardoso, A.M.R., de Medeiros, M.M.D., Gomes, L.N., Martins, M.L., Padilha, W.W.N., Cavalcanti, A.L. (2018). Factors associated with health and oral health-related quality of life of children and adolescents with cerebral palsy. *Spec Care Dentist*, 38(4): 216-226.

[30] Sullivan, P.B. (2009). Gastrointestinal disorders: assessment and management. In: Sullivan PB, editor. *Feeding and Nutrition in Children with Neurodevelopmental Disabilities*. London: Mac Keith Press, chapter 6.

[31] Sedky, N.A. (2018). Assessment of oral and dental health status in children with cerebral palsy: An exploratory study. *Int J Health Sci (Qassim)*, 12(1): 4-14.

[32] Studenikin V.M. Cerebral palsy (CP). *Chapter 16. In Pediatric Neurodietology (Joint Monograph)*. M.: Dinastiya, 2012. P. 242-251.

[33] Kim, S., Koh, H., Lee, J.S. (2017). Gastroesophageal Reflux in Neurologically Impaired Children: What Are the Risk Factors? *Gut Liv*, 11(2):232-236.

[34] Romano, C., van Wynckel, M., Hulst, J., Broekaert, I., Bronsky, J., Dall'Oglio, L.F., Mis, N., Hojsak, I., Orel, R., Papadopoulou, A., Schaeppi, M., Thapar, N., Wilschanski, M., Sullivan, P., Gottrand, F. (2017). European Society for Paediatric Gastroenterology, Hepatology and Nutrition Guidelines for the Evaluation and Treatment of Gastrointestinal and Nutritional Complications in Children with Neurological Impairment. *J Pediatr Gastroenterol Nutr*, 65:242-264.

[35] Campanozzi, A, Capano, G, Miele, E, et al. (2007). Impact of malnutrition on gastrointestinal disorders and gross motor abilities in children with cerebral palsy. *Brain Dev.*, 29: 25-29.

[36] King, W., Levin, R., Schmidt, R. et al. (2003). Prevalence of reduced bone mass in children and adults with spastic quadriplegia. *Dev Med Child Neurol*, 45 (1): 12-16.

[37] Papadopoulos, A., Ntaios, G., Kaiafa, G. et al. (2008). Increased incidence of iron deficiency anemia secondary to inadequate iron intake in institutionalized, young patients with cerebral palsy. *Int J Hematol*, 88 (5): 495-497.

[38] Schoendorfer, N., Boyd, R., Davies, P.S. (2010). Micronutrient adequacy and morbidity: paucity of information in children with cerebral palsy. *Nutr Rev*, 68 (12): 739–748.

[39] Langermo, D., Anderson, J., Hanson, D., Hunter, S., Thompson, P., Posthauer, M.E. (2006). Nutritional considerations in wound care. *Adv Skin Wound Care*. 19: 297-300.

[40] Brooks, J., Day, S.M., Shavelle, R.M., Strauss, D.J. (2011). Low weight, morbidity, and mortality in children with cerebral palsy: new clinical growth charts. *Pediatrics*, 128: 299-307.

[41] Brooks, J.C., Strauss, D.J., Shavelle, R.M., Tran, L.M., Rosenbloom, L., Wu Y.W. (2014). Recent trends in cerebral palsy survival. Part II: individual survival prognosis. *Dev Med Child Neurol*, 56:1065-1071.

[42] Studenikin, V.M., Buksh, A.A. (2016). Nutritional Status Malformations in Children with Cerebral Palsy (Part 2). *Lechashchij vrach*, 11: 68-71.

[43] Yakut, A., Dinleyici, E.C., Idem S. et al. (2006). Serum leptin levels in children with cerebral palsy: relationship with growth and nutritional status. *Neuro Endocrinol Lett*, 27 (4): 507–512.

[44] Oeffinger, D.J., Gurka, M.J., Kuperminc, M., Hassani, S., Buhr, N., Tylkowski, C. (2014). Accuracy of skinfold and bioelectrical impedance assessments of body fat percentage in ambulatory individuals with cerebral palsy. *Dev Med Child Neurol*, 56: 475-481.

[45] Fehlings, D., Switzer, L., Agarwal, P., et al. (2012). Informing evidence-based clinical practice guidelines for children with cerebral palsy at risk of osteoporosis: a systematic review. *Dev Med Child Neurol*, 54: 106-116.

[46] Aronson, E., Stevenson, S.B. (2012). Bone health in children with cerebral palsy and epilepsy. *J Pediatr Health Care*, 26: 193-199.

[47] Rieken, R., van Goudoever, J.B., Schierbeek, H., Willemsen, S.P., Calis, E.A.C., Tibboel, D., Evenhuis, H.M., Penning, C. (2011). Measuring body composition and

energy expenditure in children with severe neurological impairment and intellectual disability. *Am J Clin Nutr*, 94: 759-766.

[48] Baranek, E.S., Maier, S.P. 2nd, Matsumoto, H., Hyman, J.E., Vitale, M.G., Roye, D.P. Jr, Roye, B.D. (2019). Gross Motor Function Classification System Specific Growth Charts-Utility as a Risk Stratification Tool for Surgical Site Infection Following Spine Surgery. *J Pediatr Orthop*, 39(4): 298-302.

[49] Ljungqvist, O., Jonathan, E. (2012). Rhoads lecture 2011: Insulin resistance and enhanced recovery after surgery. *J Parenter Enteral Nutr*, 36: 389-398.

[50] Gawecka, A., Mierzewska-Schmidt, M. (2014). Tolerance of, and metabolic effects of, preoperative oral carbohydrate administration in children – a preliminary report. *Anaesthesiol Intensive Ther*., 46 (2): 61-64.

In: Encyclopedia of Surgery (22 Volume Set)
Editors: Andreas Lehrer and Kristin Mueller
ISBN: 978-1-53618-329-0
© 2020 Nova Science Publishers, Inc.

Chapter 118

SINGLE-EVENT MULTILEVEL ORTHOPEDIC SURGERY IN CHILDREN WITH TRUE EQUINUS GAIT AND JUMP KNEE GAIT

Sergey Leonchuk*, MD, PhD, Georgy Chibirov, MD, PhD, Tamara Dolganova, MD, PhD, Dmitry Dolganov, PhD and Dmitry Popkov, MD, PhD

Ilizarov National Medical Research Center for Traumatology and Orthopedics, Kurgan, Russia

ABSTRACT

Introduction. Single-event multilevel surgery is the gold standard of care to treat gait problems in children with cerebral palsy. SEMLS is not a uniform procedure but is tailored to the patient's needs and includes realigning bony levers, lengthening or transferring muscle-tendon units. A key element for planning surgical treatment is comprehensive assessment of gait disorders.

The *purpose* of this study was to evaluate the results of surgical orthopedic management in patients with true equinus gait and jump gait using Gillette Functional Assessment Questionnaire, Edinburgh gait score and three-dimensional gait analysis in a sample of subjects with cerebral palsy.

Material and methods. This study was a retrospective review of all patients (56 children, mean age 8.8 ± 2.6 years) diagnosed with CP having true equinus or jump knee gait who were treated with SEMLS at a single institution. The other inclusion criteria used for patient selection were medical history for more 1.5 year of follow-up; spastic diplegia and tetraplegia corresponding to level I or II GMFCS.

The Edinburgh score and three-dimensional gait analysis were performed before surgery and at a minimum of 1.5 years after surgery. The subjects were also scored using the Gillette Functional Assessment Questionnaire.

Results. The Edinburgh visual gait score revealed significant improvement in the kinematic parameters at latest follow-up examination. The mean total score was reduced

* Corresponding Author's Email: leon4yk@mail.ru.

from 42.7 to 15.3. This strongest of the rank correlation coefficient between total Edinburgh score and FAQ was at r = -0.825 (before surgery) and r = -0.845 (2-3 years follow-up control). The correlation was negative for the both period of clinical examination. It was preoperatively revealed that the maximum deviations in the parameters "knee progression angle" and "trunk maximal lateral shift" of the Edinburgh scale correlates with clinically significant torsional femoral deformities requiring surgical correction.

In long-term, three-dimensional gait analysis revealed improved ankle joints kinematics and normal values of foot progression angle. Knee joint flexion decreased significantly during the stance phase. We observed decrease in the magnitude of maximum swing-phase knee flexion. The hip decreased its flexion at initial contact, peak hip extension achieved physiological values. Kinetic data showed that timing of maximum at ankle moment had improved significantly as well as generated ankle power representing the increased push-off ability of the foot during walking. The knee joint reduced its moment.

Conclusion. Multilevel orthopedic surgery in CP children with true equinus and jump knee gait significantly improve kinematic and kinetic parameters of gait cycle, both directly related to muscular contractions, foot deformities and rotational abnormalities and due to incorrect compensating biomechanical position of the distant segments. Rotational abnormalities should be revealed and quantified considering kinematic data. Correction of rotational abnormalities and surgical improvement of gait disorders in the sagittal plane should be performed simultaneously. Intramuscular aponeurotic recession associated with other elements of multi-level surgical event does not impair maximum power generation at the ankle representing the increased push-off ability.

Keywords: cerebral palsy, true equinus gait, jump gait, torsion deformities, orthopedic surgical treatment, gait analysis

INTRODUCTION

Cerebral palsy (CP) is the most common motor disorder in children with an incidence from two to five cases per 1,000 newborns [1–4]. In Russia, the reported incidence of cerebral palsy varies from 2.2 to 3.8 per 1,000 births. Spastic cerebral palsy types represent over 80 % of CP population [5, 6].

Despite the CP is a stable encephalopathy, progressive orthopedic secondary complications are the principle cause of motor activity impairment in CP children [7-9]. The etiology of true equinus gait and jump knee gait is multi-factorial. The factors include abnormal motor control, spasticity, muscle weakness and imbalance, torsional deformities resulting in progressive muscle contractures, foot deformities and lever arm disfunction. These two patterns are characterized by similar parameters; thus, the cases with those gait abnormalities may be united for analysis of treatment outcomes [10, 11].

Single-event multilevel surgery (SEMLS) is the actual standard of care to treat gait problems in children with cerebral palsy. SEMLS is not a uniform procedure but is tailored to the patient's needs and includes realigning bony levers, lengthening or transferring muscle-tendon units [12-15]. A key element for planning surgical treatment is comprehensive assessment of gait disorders. Based on computer gait analysis, the main pathological patterns in spastic diplegia have been identified [16-20]. Lofterød et al. [21] and Simon et al. [22] emphasize the role of the three-dimensional gait analysis both for understanding the

pathology of motions and planning surgical events, for control of gait development and its modifications in the long-term follow-up. If three-dimensional gait analysis is unavailable, observation scales based on goniometric data on video recordings in orthogonal planes are recommended [23-25]. Novacheck [24] and Read [26] showed that the Edinburgh visual gait score, developed specifically for the gait analysis of patients with CP, correlates with the Gillette Gait Index and the Gillette Functional Assessment Questionnaire (FAQ).

The purpose of this study was to evaluate the results of surgical orthopedic management in patients with true equinus gait and jump gait using FAQ, Edinburgh gait score and three-dimensional gait analysis in a sample of subjects with cerebral palsy.

MATERIAL AND METHODS

This study was a retrospective review of all patients diagnosed with CP having true equinus or jump knee gait who were treated with SEMLS at a single institution. The other inclusion criteria used for patient selection were medical history for more 1.5 year of follow-up; spastic diplegia and tetraplegia corresponding to level I or II GMFCS.

Gait analysis using the Edinburgh score was performed before surgery and at a minimum of 1.5 years after surgery. The subjects were also scored using the Gillette Functional Assessment Questionnaire (FAQ) [27] before first surgery and in 1,5-2 years after single event multilevel orthopedic surgery.

Three-dimensional gait analysis was also carried out on all subjects walking barefoot. Kinematic and kinetic variables were evaluated before surgery and at last follow-up. We used 6-camerax Qualisys Oqus system and one AMTI force plate (Advanced Mechanical Technology Inc., Watertown, MA) to collect motion analysis data. In the Ilizarov Gait Analysis Laboratory the IOR model was used for markers [28], which is optimal for minimal system configuration and for appropriate kinematic analysis to decrease artefacts of skin motion. The Delphi consensus was applied to classify observed pathologic gait patterns [29]. Preoperative values were compared with those at the last follow-up.

AtteStat 12.0.5 software was used for the statistical analyses. The statistical values described the mean and standard deviation. The Edinburgh score data were compared by using Wilcoxon signed–ranks test for matched pairs. The test was two-tailed with a 0.05 level of significance. Spearman's rank correlation score was used to assess correlation between Edinburgh score and FAQ. The chi-square test determined the significance of differences in the Edinburgh scale in patients with or without clinically significant torsion femoral deformities. The specificity and sensitivity of associated Edinburgh score maximum deviations of the “knee progression angle” and “trunk maximal lateral shift” were determined as criterium justifying surgical intervention.

This research was approved by the Ilizarov Center Review Board. The study complies with the Declaration of Helsinki statement on medical protocol and ethics. Representatives of all patients enrolled in the study provided oral and written informed consent.

RESULTS

Initially, 117 charts were reviewed from children with spastic diplegia level I, II GMFCS who underwent SEMLS and clinical gait analysis. There were 56 children with spastic CP meeting our criteria for true equinus and jump knee gait.

Not all measures were available for every subject, resulting in a total of 56 subjects (26 girls and 30 boys) being scored for the Edinburgh score, 56 also being scored for FAQ, and 15 being scored for three-dimensional gait analysis. Mean age at surgery was 8.8 ± 2.6 years. Fourteen patients had level I of GMFCS, 52 patients were of level II GMFCS. One surgical event included an average of 7.7 elements (Table 1).

Furthermore, in 12 patients (24 femurs) torsional femoral deformities were underestimated before initial surgery. At 1-year FU control, revealed rotational abnormalities of the gait were recognized clinically significant. Thus, 12 patients underwent correction of torsion deformities in 12 to 15 months after the initial SEMLS.

The Edinburgh visual gait score revealed significant improvement in the kinematic parameters in 1-year follow-up period. The mean total score was reduced from 42.7 to 15.3. The most significant ameliorations were observed in stance regarding initial contact, heel lift, maximum ankle dorsiflexion, peak knee extension, peak hip extension, trunk maximum lateral shift, foot progression angle, knee progression angle (Figures 1-4; Table 2). The decrease of some swing parameter values was also observed: maximum ankle dorsiflexion, peak knee flexion, clearance, knee terminal swing position. Further amelioration of the gait parameters was progressive and observed at latest follow up control in 2-3 tears after surgery.

Table 1. Elements of initial SEMLS

Surgery element	Number
Hamstring lengthening	112
Lengthening of adductors, m. gracilis	44
Strayer or Vulpius procedure	112
Grice procedure	48
Evans procedure	14
Shortening of m. tibialis posterior tendon	86
Detorsion osteotomy of the femur	10
Detorsion osteotomy of the tibia	6
Total	432



Figure 1. Patient B, 6 y.o. girl, II GMFCS, equinus gait, before surgery: Knee and ankle terminal swing position (a), initial contact (b), plantar flexion in middle stance (c), heel lift (d), toe-off (e), clearance (f), knee and ankle terminal swing position (h).

Table 2. Mean values of Edinburgh visual gait score

Parameter	Before surgery	12 months FU	2-3 years FU
Initial contact	2.0	0.83	0.75
Heel lift	1.93	0.7	0.5
Maximum ankle dorsiflexion	1.73	0.3	0.21
Hind-foot varus/valgus	1.2	0.1	0.13
Foot progression angle	1.43	0.77	0.54
Knee progression angle	1.2	0.7	0.46
Peak knee extension	1	0.13	0.13
Peak hip extension	0.8	0.13	0.13
Pelvic obliquity at Mid-Stance	0.93	0.63	0.5
Pelvic rotation at Mid-Stance	0.73	0.5	0.3
Trunk Peak Sagittal Position	1.07	0.6	0.58
Trunk maximum lateral shift	1.53	1.23	0.75
Clearance	0.9	0.27	0.13
Maximum ankle dorsiflexion	1.47	0.4	0.33
Peak knee flexion	1.1	0.37	0.125
Knee terminal swing position	1.46	0.1	0.04
Peak hip flexion	1.2	0.13	0.08
Total	42.7	15.3	11.3

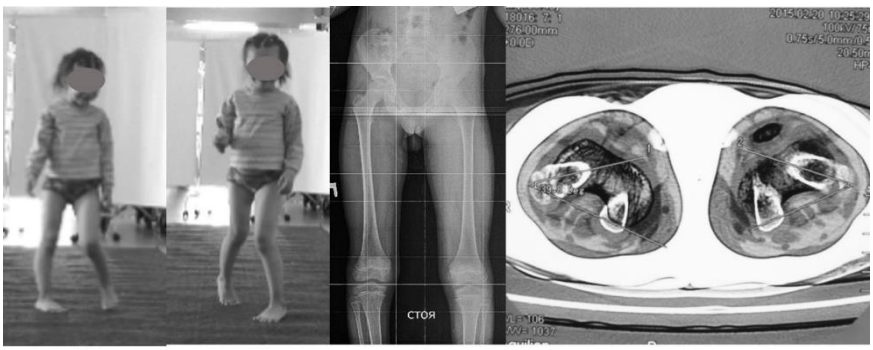

Figure 2. Patient B, before surgery: internal knee and ankle progression angle in middle stance for right leg (a) and left leg (b); radiograph of both femurs, AP view (c); CT scan, femoral neck anteversion 39.8° in right hip, 40.5° in left hip (d).

Figure 3. Patient B, 8.5 y.o. girl, II GMFCS, 2 years after surgery: Knee and ankle terminal swing position (a), initial contact (b), plantar flexion in middle stance (c,d), heel lift (e), clearance (f), knee and ankle terminal swing position (g).

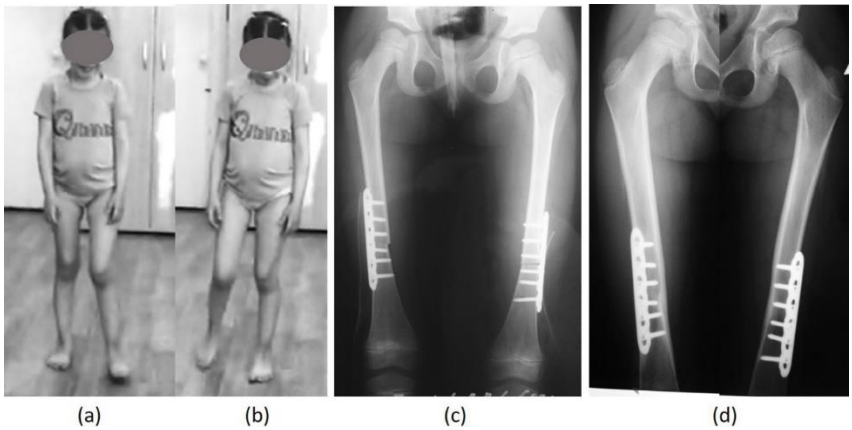

Figure 4. Patient B, 8.5 y.o. girl, II GMFCS, 2 years after surgery: normal knee and ankle progression angle in middle stance for right leg (a) and left leg (b); radiograph of both femurs on the day of bilateral surgery, AP view (c); radiograph of both femurs in 2 years after surgery, AP view (d).

Table 3. Correlation of Edinburgh scores and FAQ

Period	Edinburgh score	FAQ	Spearman
Before surgery	42.7	3.8	-0.825
In 12 months	15.3	6.3	-0.491
In 2-3 years	11.3	7.7	-0.845

Table 3 demonstrates correlation between total Edinburgh score and FAQ. This strongest of the rank correlation coefficient was with the Gillette FAQ at r = -0.825 (before surgery) and r = -0.845 (2-3 years follow-up control). The correlation was negative for the both periods of clinical examination.

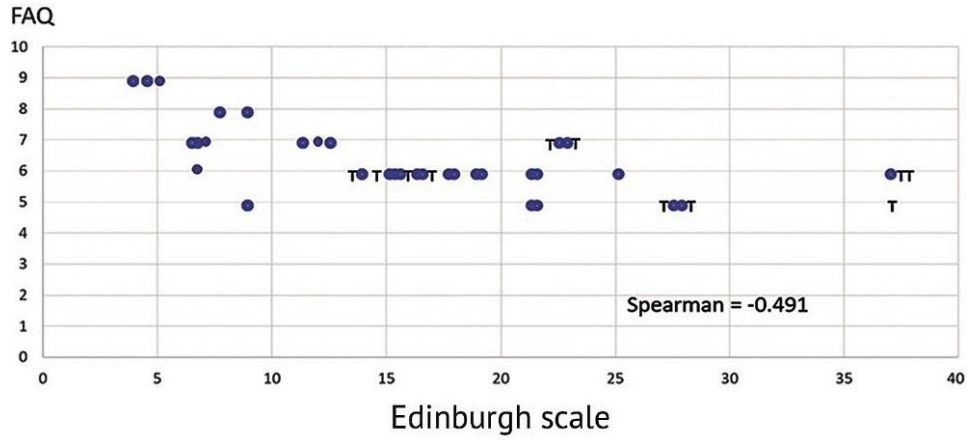

Figure 5. Scatterplot of Gillette FAQ against Edinburgh Gait score in 12 months after the initial surgery. Cases with clinically significant torsion deformities are marked with “T”.

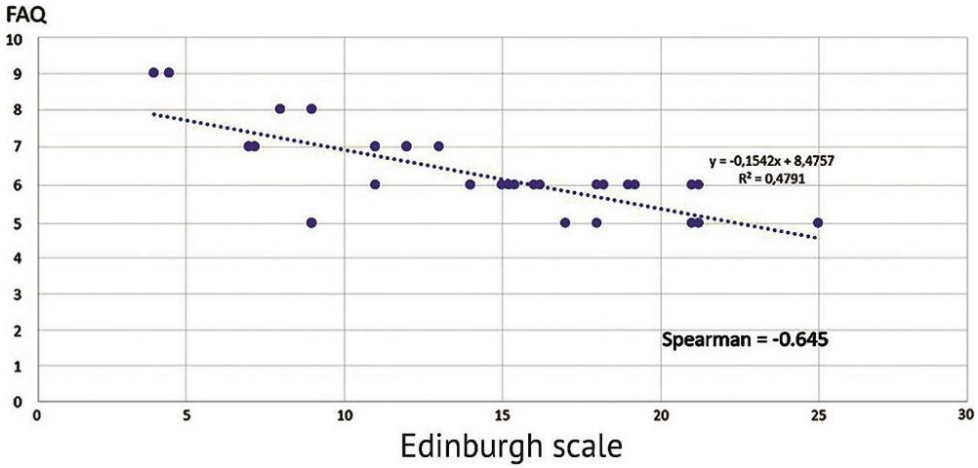

Figure 6. Scatterplot of Gillette FAQ against Edinburgh Gait score in 12 months after the initial surgery representing only cases without torsional abnormalities. Negative correlation values become significant.

In 12 patients, pathological kinematic values of foot and knee progression angles related to underestimated torsional deformity allowed to reveal and justified additional surgeries in 12-15 months after initial interventions. Figures 5 and 6 present scatterplots of Gillette FAQ against Edinburgh Gait score for a period of 12 months after the initial operation. If only cases without torsional deformities have been taken into consideration (Figure 6), the negative correlation becomes significant with stronger Spearman correlation coefficient. The correlation becomes the weakest if all cases are included in the analysis regardless presence or not of torsional abnormalities.

An analysis of correlation between data of Gillette FAQ and Edinburgh visual gait score are presented separately for the both group without torsional deformity and group with clinically significant torsional deformity (Table 4). We believe that the loss of correlation between Gillette score and FAQ in 12 months after surgery for group with uncorrected torsional deformity is due to gait disorders related to torsional abnormalities. The additional surgery for torsional deformity allowed to achieve strong correlation between these measures at latest follow-up control.

Table 4. Spearman's rank correlation score for Edinburgh scale and FAQ represented separately for group without torsinal deformities and for group with internal torsion of femur

	Before treatment		12 months FU		2–3 years FU	
	no torsional deformity	Torsional deformity	no torsional deformity	Torsional deformity	no torsional deformity	Torsional deformity
Edinburgh score	42.5	43.2	13.4	23.2	9.75	14.6
FAQ	3.7	4.1	6.5	6.0	7.9	7.2
Spearman	-0.836 (p = 0.9999)	-0.873 (p = 0.9995)	-0.645 (p = 0.9989)	-0.194 (p = 0.7043)	-0.842 (p = 0.999)	-0.776 (p = 0.9958)

Table 5. Correlation of maximal deviations in parameters "knee progression angle" and "trunk maximal lateral shift" of the Edinburgh scale in the initial gait analysis with clinically significant torsion deformities, prognostic significance

	KPA	TMLS	Incidence of association of KPA and TMLS of maximal deviation	chi-square test	Sensitivity	Specificity
No torsional deformity	0.9 ± 0.44	1.25 ± 0.43	7.3%	$p < 0.001$	0.772	0.921
Internal torsional deformity of femur	1.8 ± 0.41	2.0 ± 0.0	84.7%			

It was preoperatively revealed that the maximum deviations in the parameters "knee progression angle" (KPA) and "trunk maximal lateral shift" (TMLS) of the Edinburgh scale correlates with clinically significant torsion deformities. Those rotational gait abnormalities were corrected as part of the first intervention or in 1 year. We should emphasize the high sensitivity and specificity of this finding justifying indication for detorsion osteotomy of femur as an element of SEMLS (Table 5).

The mean values (standard deviation) of kinematic and kinetic parameters revealed by three-dimensional gait analysis are detailed in Tables 6 and 7, in preoperative session and in long term follow-up. The mean value of Gait Profile Score has been improved from 18,1 ± 3,6 (preoperative value) to 12,3 ± 1,9 (at latest FU control).

In preoperative session, excessive ankle plantarflexion was observed during the whole gait cycle as well as low ankle range of motion. Foot progression was internally orientated. The knee was characterized by excessive flexion during stance and slightly increased and delayed maximum swing-phase knee flexion, which was estimated as compensating. The hip flex-extension graph revealed a increase mean hip flexion angle at initial contact and high flexion during midstance. A limited extension in hip joint in midstance was observed. Pelvic tilt was characterized by normal values while slightly high pelvis excursion was present on transversal plane. Sagittal plane kinetic evaluation showed lack of the first rocker and a unphysiological and early maximum of ankle moment. A lack of power generation at the push-off for the ankle occurred. The knee joint kinematics were characterized by high flexor moment in stance phase of gait cycle.

In long-term FU, ankle joints improved significantly, passing from the previous plantarflexed position to dorsiflexion during stance phase. Three-dimensional gait analysis revealed normal values of foot progression angle. Knee joint flexion decreased significantly during the stance phase, showing the position close to physiological one. We observed decrease in the magnitude of maximum swing-phase knee flexion. The hip decreased its flexion at initial contact, peak hip extension achieved physiological values. After surgery pelvic tilt was in a more physiological position. No changes for pelvis kinematics were displayed in the frontal and transversal planes. Kinetic data showed that timing of maximum at ankle moment had improved significantly as well as generated ankle power representing the increased push-off ability of the foot during walking. The knee joint reduced its moment. No significant changes of knee generated power occurred.

Table 6. Summary of kinematic parameters (mean and standard deviation)

	Preoperative values	2-3 yrs FU
Ankle joint angle at the initial contact (on sagittal plane);	-19,6 ± 10,34	2,1 ± 4,41*
Maximum of ankle dorsiflexion (on sagittal plane) during stance phase;	-14,7 ± 14,83	14,4 ± 5,66*
Range of motion at ankle joint on the sagittal plane during stance phase;	5,6 ± 11,04	17,7 ± 4,58*
Maximum of ankle dorsiflexion (on sagittal plane) during swing phase;	-34,3 ± 15,65	-3,9 ± 7,51*
Foot Progression (foot position on the transversal plane);	-15,1 ± 21,3	6,0 ± 12,7*
Stance Time, %	62,9 ± 6,48	64,1 ± 4,28
Stance peak knee extension; °	21,4 ± 18,63	12,9 ± 6,55
Swing peak knee flexion; °	62,3 ± 12,75	56,1 ± 12,75
Timing of peak knee flexion; %	81,1 ± 4,31	77,5 ± 4,65
Gait Profile Score	18,1 ± 3,59	12,3 ± 1,94
Hip joint angle at the initial contact (on sagittal plane);	37,9 ± 8,31	31,3 ± 12,76
Stance peak hip extension;	5,85 ± 9,95	-4,5 ± 12,38*
Stance Hip range of motion; °	40,1 ± 11,66	39,0 ± 9,84
Mean Hip Rotation during all the gait cycle;	16,2 ± 17,3	13,9 ± 9,61
Pelvic Tilt during the gait cycle;	9,4 ± 12,26	9,0 ± 15,36

*Significant difference in comparison to initial mean value ($p < 0.05$).

Table 7. Summary of kinetic parameters (mean and standard deviation)

	Preoperative values	2-3 yrs FU
Timing of maximum of ankle moment; %	23,5 ± 16,4	50,4 ± 3,83*
Maximum value of plantarflexion ankle moment during terminal stance; N∗m/Kg	0,70 ± 0,27	0,98 ± 0,24*
Maximum value of generated ankle power during terminal stance; W/Kg	1,17 ± 0,84	1,91 ± 0,85*
Maximum knee flexion moment in stance phase; N∗m/Kg	0,37 ± 0,42	0,22 ± 0,19
Knee Power generation; W/kg	0,42 ± 0,30	0,58 ± 0,45
Knee Power relaxation; W/kg	1,24 ± 1,62	1,0 ± 0,60

*Significant difference in comparison to initial mean value ($p < 0.05$).

DISCUSSION

The SEMLS was recognized as gold standard in neuroorthopedic surgery in CP children [12, 13, 15]. The true equinus gait and jump knee gait are most common gait disorders in young CP children. These patterns are caused by spasticity and/or retraction of the plantar flexors of the feet and flexors of the knee joint [19]. If this is associated with critical deterioration of goniometric parameters, surgical orthopedic treatment becomes indicated [30-32]. However, in addition to muscle lengthening procedures, foot deformity and rotational gait abnormality corrections are often included in the program [33-43].

The main surgeon's objectives regarding true equinus gait and jump gait are contractures of the knee and ankle joints of both limbs [25, 44]. On the other hand, it is crucial to avoid unreasonable surgical interventions in diplegia (lengthening of spastic muscles, Achilles tendon lengthening, surgery in young aged under 5 years) [45-47]. Surgery performed in early age leads to the weakness of sural triceps, loss of strength for its eccentric contraction in stance phase. This functional failure results in early excessive knee flexion and progressive knee extensor failure evolving into severe crouch gait and loss of walking ability in the medium-long term [48-50]. The method of choice for triceps lengthening in cerebral palsy is fasciotomy of the calf muscles, which provides an improvement in the kinematic parameters

of the ankle joint without development of crouch gait in the long term [44, 48, 50, 51]. We observed these outcomes in our study: gait parameters and foot kinematics improved in all patients without iatrogenic crouch gait in the long-term follow-up.

According to Gorton et al. [47] and Terjesen et al. [52], the improvement or normalization of ankle joint motion was not associated with compensatory changes in the hip and knee kinematics observed preoperatively. In our study, we noted an improvement in kinematics of the hip and knee joints, estimating this effect as a remote indirect effect of SEMLS. Normalization of knee terminal swing position contributes to appropriate orientation of the foot at the beginning of the stance. That was also reported in the study of Adolfsen [10].

Among other positive effects of multilevel surgery, we found a decrease of compensating flexed position in knee and hip joints in swing phase associated with clearance increase.

It was highlighted that achievement of dorsiflexed position of the foot during stance reduces lever arm disfunction in the sagittal plane [26, 53] and improves the timing of maximum of ankle moment shifting it to the end of stance phase [25, 44, 52]. In our study, simultaneously applied techniques of gastrocnemius fascia lengthening, foot deformity and torsional deformity correction provided increase of ankle power generation during terminal stance in long-term follow up. Dreher et al suggest that gastrocnemius intramuscular aponeurotic recession in cases of spastic diplegic CP sufficiently corrects equinus deformity without risks of overlengthening [54]. Rose et al reported that lengthening of gastrocnemius fascia does not result in weakening of the triceps surae for push-off over the long term [51].

Ounpuu [18] and Theologis [53] pointed out the necessity to simultaneously correct deformities on the transversal plane to eliminate lever arm disfunction and decrease energy consumption during gait. Clinically significant rotational deformities causing every-day functional disabilities require correction in childhood even if there is weak correlation between radiological and gait analysis data of rotational deviation [41]. Our study demonstrated that in CP children with clinically significant rotational abnormalities of the gait, torsional deformity correction is indicated as an element of SEMLS. The association of maximal deviations in knee progression angle and trunk maximum lateral shift of the Edinburgh scale justifies that element of SEMLS. This evaluation criterion has high specificity and sensitivity.

CONCLUSION

This study demonstrated that multilevel orthopedic surgery in CP children with true equinus and jump knee gait significantly improve kinematic and kinetic parameters of gait cycle, both directly related to muscular contractions, foot deformities and rotational abnormalities and due to incorrect compensating biomechanical position of the distant segments. Rotational abnormalities should be revealed and quantified considering kinematic data. Correction of rotational abnormalities and surgical improvement of gait disorders in the sagittal plane should be performed simultaneously. Intramuscular aponeurotic recession associated with other elements of multi-level surgical event does not impair maximum power generation at the ankle representing the increased push-off ability.

REFERENCES

[1] Alriksson-Schmidt, A., Hägglund, G. (2016). Pain in children and adolescents with cerebral palsy: a population-based registry study. *Acta paediatrica (Oslo, Norway: 1992)*, 105(6): 665–670.

[2] Bottos, M., Granato, T., Allibrio, G., Gioachin, C., Puato M. L. (1999). Prevalence of cerebral palsy in north-east Italy from 1965 to 1989. *Dev Med Child Neurol,* 41(1): 26-39.

[3] Cans, C. (2006). Comprendre la paralysie cérébrale: Qui sommes nous? Combien sommes-nous? La recherche sur l'infirmité motrice cérébrale en Europe. *Paris, Fondation Motrice.*

[4] Stavsky, M., Mor, O., Mastrolia, S. A., Greenbaum, S., Than, N. G., Erez, O. (2017). Cerebral Palsy – Trends in Epidemiology and Recent Development in Prenatal Mechanisms of Disease, Treatment, and Prevention. *Front Pediatr*, 5: 21.

[5] Zmanovskvaia, V. A., Levitina, E. V., Popkov, D. A., Butorina, M. N., Pavlova, O. L. (2014). [Long use of Type A Botulinum Toxin: disport in complex rehabilitation of children with spastic forms of cerebral palsy]. *Zhurnal Nevrologii i Psikhiatrii im S. S. Korsakova*, 114(7): 33-36. (in Russian).

[6] Nemkova, S. A., Namazova-Baranova, L. S., Maslova, O. I., Zavadenko, N. N., Kholin, A. A., Karkashadze, G. A., Mamediarov, A. M., Nesterovskii, Iu. E., Govorun, S. V. (2012). [Cerebral Palsy: Diagnosis and Correction of Cognitive Disorders: technique manual]. *GBOU VPO Ros. Nats. Issled. Med. Un-t im. N. I. Pirogova. M., Soiuz Pediatrov Rossii,* 60 p. (in Russian)

[7] Horstmann, H. M., Bleck, E. E. (2007). Orthopaedic management in cerebral palsy. *2nd Ed. London, Mac Keith Press*, 412 p.

[8] Hurley, D. S., Sukal-Moulton, T., Msall, M. E., Gaebler-Spira, D., Krosschell, K. J., Dewald, J. P. (2011). The cerebral palsy research registry: development and progress toward national collaboration in the United States. *J Child Neurol*, 26(12): 1534-1541.

[9] Rosenbaum, P. L., Palisano, R. J., Bartlett, D. J., Galuppi, B. E., Russell D. J. (2008). Development of the Gross Motor Function Classification System for cerebral palsy. *Dev Med Child Neurol*, 50(4): 249-253.

[10] Adolfsen, S .E., Ounpuu, S., Bell, K.J., DeLuca, P. A. (2007). Kinematic and kinetic outcomes after identical multilevel soft tissue surgery in children with cerebral palsy. *J Pediatr Orthop*., 27(6): 658-667.

[11] Lofterød, B., Terjesen, T. (2008) Local and distant effects of isolated calf muscle lengthening in children with cerebral palsy and equinus gait. *J Child Orthop*, 2(1): 55-61.

[12] Aiona, M. D., Sussman, M. D. (2004) Treatment of spastic diplegia in patients with cerebral palsy: Part II. *J Pediatr Orthop B*, 13(3): 13-38.

[13] Damiano, D. L., Alter, K. E., Chambers H. (2009) New clinical and research trends in lower extremity management for ambulatory children with cerebral palsy. *Phys Med Rehabil Clin N Am*, 20(30): 469-491.

[14] Novacheck, T. F., Stout, J. L., Gage, J. R., Schwartz, M. H. (2009) Distal femoral extension osteotomy and patellar tendon advancement to treat persistent crouch gait in cerebral palsy. Surgical technique. *J Bone Joint Surg Am*, 91(2): 271-286.

[15] Popkov, D. A., Zmanovskaia, V. A., Gubina, E. B., Leonchuk, S. S., Butorina, M. N., Pavlova, O. L. (2015) [Results of multilevel orthopedic surgeries and early rehabilitation in combination with Botulinum therapy in patients with spastic cerebral palsy]. *Zhurnal Nevrologii i Psikhiatrii im. S. S. Korsakova*, 115 (4): 41-48. (in Russian)

[16] DeLuca, P. A., Davis, R. B. 3rd, Ounpuu, S., Rose, S., Sirkin, R. (1997) Alterations in surgical decision making in patients with cerebral palsy based on three-dimensional gait analysis. *J Pediatr Orthop*, 17(5): 608-614.

[17] Gage, J. R. (2004) The treatment of gait problems in cerebral palsy. *Series: Clinics in developmental medicine*. London, Mac Keith Press, 164-165.

[18] Ounpuu, S., DeLuca, P., Davis, R., Romness, M. (2002) Long-term effects of femoral derotation osteotomies: an evaluation using three-dimensional gait analysis. *J Pediatr Orthop*, 22(2): 139-145.

[19] Rodda, J., Graham, H. K. (2001) Classification of gait patterns in spastic hemiplegia and spastic diplegia: a basis for a management algorithm. *Eur J Neuro*l, 8 (5): 98-108.

[20] Sutherland, D. H., Davids, J. R. (1993) Common gait abnormalities of the knee in cerebral palsy. *Clin Orthop Relat Res*, 288: 139-147.

[21] Lofterød, B., Terjesen, T., Skaaret, I., Huse, A. B., Jahnsen, R. (2007) Preoperative gait analysis has a substantial effect on orthopedic decision making in children with cerebral palsy: comparison between clinical evaluation and gait analysis in 60 patients. *Acta Orthop*, 78(1): 74-80.

[22] Simon, S. R. (2004) Quantification of human motion: gait analysis-benefits and limitations to its application to clinical problems. *J Biomech*, 37(12): 1869-1880.

[23] Hillman, S. J., Hazlewood, M. E., Schwartz, M. H., Van der Linden, M. L., Robb, J. E. (2007) Correlation of the Edinburgh Gait Score with the Gillette Gait Index, the Gillette Functional Assessment Questionnaire, and dimensionless speed. *J Pediatr Orthop*, 27(1): 7-11.

[24] Novacheck, T. F., Stout, J. L., Tervo, R. (2000) Reliability and validity of the Gillette Functional Assessment Questionnaire as an outcome measure in children with walking disabilities. *J Pediatr Orthop*, 20(1): 75-81.

[25] Schwartz, M. H., Viehweger, E., Stout, J., Novacheck, T. F., Gage, J. R. (2004) Comprehensive treatment of ambulatory children with cerebral palsy: an outcome assessment. *J Pediatr Orthop*, 24(1): 45-53.

[26] Read, H. S., Hazlewood, M. E., Hillman, S. J., Prescott, R. J., Robb, J. E. (2003) Edinburgh visual gait score for use in cerebral palsy. *J Pediatr Orthop*, 23(3): 296-301.

[27] Gorton, G. E. 3rd, Stout, J. L., Bagley, A. M., Bevans, K., Novacheck, T. F., Tucker, C. A. (2011) Gillette Functional Assessment Questionnaire 22-item skill set: factor and Rasch analyses. *Dev Med Child Neurol*, 53(3): 250-255.

[28] Leardini, A., Sawacha, Z., Paolini, G., Ingrosso, S., Nativo, R., Benedetti, M. G. (2007) A new anatomically based protocol for gait analysis in children. *Gait Posture*, 26(4): 560-571.

[29] Nieuwenhuys, A., Õunpuu, S., Van Campenhout, A., Theologis, T., De Cat, J., Stout, J., Molenaers, G., De Laet, T., Desloovere, K. (2016) Identification of joint patterns during gait in children with cerebral palsy: a Delphi consensus study. *Dev Med Child Neurol*, 58(3): 306-313.

[30] Craig, J. J., van Vuren, J. (1976) The importance of gastrocnemius recession in the correction of equinus deformity in cerebral palsy. *J Bone Joint Surg Br*, 58(1): 84-87.

[31] Karamitopoulos, M. S., Nirenstein, L. (2015) Neuromuscular Foot: Spastic Cerebral Palsy. *Foot Ankle Clin*, 20(4): 657-668.

[32] Nordmark, E., Hägglund, G., Lauge-Pedersen, H., Wagner, P., Westbom, L. (2009) Development of lower limb range of motion from early childhood to adolescence in cerebral palsy: a population-based study. *BMC Med*, 7: 65.

[33] Bennet, G. C., Rang, M., Jones, D. (1982) Varus and valgus deformities of the foot in cerebral palsy. *Dev Med Child Neurol*, 24(4): 499-503.

[34] De Coulon, G., Turcot, K., Canavese, F., Dayer, R., Kaelin, A., Ceroni, D. (2011) Talonavicular arthrodesis for the treatment of neurological flat foot deformity in pediatric patients: clinical and radiographic evaluation of 29 feet. *J Pediatr Orthop*, 31(5): 557-563.

[35] Frost, N. L., Grassbaugh, J. A., Baird, G., Caskey, P. (2011) Triple arthrodesis with lateral column lengthening for the treatment of planovalgus deformity. *J Pediatr Orthop*, 31(7): 773-782.

[36] Fulford, G. E. (1990) Surgical management of ankle and foot deformities in cerebral palsy. *Clin. Orthop Relat Res*, 253: 55-61.

[37] Grice, D. S. (1952) An extra-articular arthrodesis of the subastragalar joint for correction of paralytic flat feet in children. *J Bone Joint Surg Am*, 34-A (4): 927-940.

[38] Kołodziej, Ł., Dobiecki, K., Sadlik, B. (2013) Surgical treatment of advanced, stiff neurologic cavovarus foot in adults. *Ortop Traumatol Rehabil*, 15(4): 325-333.

[39] Ławniczak, D., Jóźwiak, M., Manikowska, F. (2010) Assessment of absolute knee joint linear and angular velocity in patients with spastic cerebral palsy after operative treatment of lever arm disfunction deformities – prospective study. *Chir Narzadow Ruchu Ortop Pol*, 75(2): 92-97.

[40] Mosca, V. S. (1995) Calcaneal lengthening for valgus deformity of the hind foot. Results in children who had severe, symptomatic flatfoot and skewfoot. *J. Bone Joint Surg Am*, 77(4): 500-512.

[41] Radler, C., Kranzl, A., Manner, H. M., Höglinger, M., Ganger, R., Grill, F. (2010) Torsional profile versus gait analysis: consistency between the anatomic torsion and the resulting gait pattern in patients with rotational malalignment of the lower extremity. *Gait Posture*, 32(3): 405-410.

[42] Sees, J. P., Miller, F. (2013) Overview of foot deformity management in children with cerebral palsy. *J Child Orthop*, 7(5): 373-377.

[43] Yoo, W. J., Chung, C. Y., Choi, I. H., Cho, T. J., Kim, D. H. (2005) Calcaneal lengthening for the planovalgus foot deformity in children with cerebral palsy. *J Pediatr Orthop*, 25(6): 781-785.

[44] Kay, R. M., Rethlefsen, S. A., Ryan, J. A., Wren, T. A. (2004) Outcome of gastrocnemius recession and tendo-achilles lengthening in ambulatory children with cerebral palsy. *J Pediatr Orthop B*, 13(2): 92-98.

[45] Baddar, A., Granata, K., Damiano, D. L., Carmines, D. V., Blanco, J. S., Abel, M. F. (2002) Ankle and knee coupling in patients with spastic diplegia: effects of gastrocnemius-soleus lengthening. *J Bone Joint Surg (Am)*, 84(5): 736-744.

[46] Dietz, F. R., Albright, J. C., Dolan, L. (2006) Medium-term follow-up of Achilles tendon lengthening in the treatment of ankle equinus in cerebral palsy. *Iowa Orthop J*, 26: 27-32.

[47] Gorton, G. E. 3rd, Abel, M. F., Oeffinger, D. J., Bagley, A., Rogers, S. P., Damiano, D., Romness, M., Tylkowski, C. (2009) A prospective cohort study of the effects of lower extremity orthopaedic surgery on outcome measures in ambulatory children with cerebral palsy. *J Pediatr Orthop*, 29(8): 903-909.

[48] Borton, D. C., Walker, K., Pirpiris, M., Nattrass, G. R., Graham, H. K. (2001) Isolated calf lengthening in cerebral palsy. Outcome analysis of risk factors. *J Bone Joint Surg Br*, 83(3): 364-370.

[49] Segal, L .S., Thomas, S. E., Mazur, J. M., Mauterer, M. (1989) Calcaneal gait in spastic diplegia after heel cord lengthening: a study with gait analysis. *J Pediatr Orthop*, 9(6): 697-701.

[50] Galli, M, Cimolin, V, Crivellini, M, Albertini, G. (2005) Gait analysis before and after gastrocnemius fascia lengthening in children with cerebral palsy. *J Appl Biomater Biomech*, 3: 98-105.

[51] Rose, S. A., DeLuca, P. A., Davis, R. B. 3rd, Ounpuu, S., Gage, J. R. (1993) Kinematic and kinetic evaluation of the ankle after lengthening of the gastrocnemius fascia in children with cerebral palsy. *J Pediatr Orthop*, 13(6): 727-732.

[52] Terjesen, T., Lofterød, B., Skaaret, I. (2015) Gait improvement surgery in ambulatory children with diplegic cerebral palsy. *Acta Orthop*, 86(4): 511-517.

[53] Theologis, T. (2013) Lever arm dysfunction in cerebral palsy gait. *J Child Orthop*, 7(5): 379-382.

[54] Dreher, R, Buccoliero, T, Wolf, SI, Heitzmann, D, Gantz, S, Braatz, F, Wenz, W (2012) Long-term results after gastrocnemius–soleus intramuscular aponeurotic recession as a part of multilevel surgery in spastic diplegic cerebral palsy. *J Bone Joint Surg*, 94: 627–637.

In: Encyclopedia of Surgery (22 Volume Set)
Editors: Andreas Lehrer and Kristin Mueller
ISBN: 978-1-53618-329-0
© 2020 Nova Science Publishers, Inc.

Chapter 119

DISTAL RECTUS FEMORIS TRANSFER AS A PART OF SINGLE-EVENT MULTILEVEL ORTHOPEDIC SURGERY

Georgy Chibirov*, MD, PhD, Orhan Gatamov, MD, Tamara Dolganova, MD, PhD, Dmitry Dolganov, PhD and Arnold Popkov, MD, PhD
Ilizarov National Medical Research Center for Traumatology and Orthopedics, Kurgan, Russia

ABSTRACT

Stiff knee gait is relatively common specific knee pattern in ambulatory children with cerebral palsy. The *objective* of the study was assessment of results of single-event multilevel orthopedic surgery in patients with cerebral palsy with stiff knee gait.

Material and methods. A total of 20 patients (F/M = 8/12) with a mean age 17.1 ± 12.9 years who presented with stiff knee gait were operated on with single-event multilevel orthopedic surgery (SEMLS). The mean follow-up period was 17 months (range 14-26 months). The distal rectus femoris transfer represented primary treatment in all subjects. Sixteen 16 patients were classified as GMFCS II, 4 patients were GMFCS III. Patients were scored with Edinburgh visual gait score and 3D computed gait analysis (4 patients) before and, at least, 12 months after surgery. Analysis included Gait Profile Score, peak knee flexion in swing, knee range of motion throughout the gait cycle, timing of peak knee flexion in swing.

Results. Edinburgh gait score and 3D gait analysis revealed that SEMLS improved peak knee flexion in swing and related foot clearance. Improved terminal knee angle resulted in more physiological ankle initial contact angle. In several patients with crouch gait, simultaneous surgical correction of excessive dorsiflexion in stance and improvement of peak knee extension contributed to increased knee range of motion as well.

* Corresponding Author's Email: georgii_chibirov@mail.ru.

Conclusion. The distal rectus femoris transfer allows to correct the knee kinematics in patients with stiff knee gait. We recommend performing this procedure in association with other surgical methods to manage multilevel orthopedic disorders in CP patients. In patients previously undergone triceps lengthening, rectus femoris transfer should be combined with correction of excessive ankle dorsiflexion in stance to avoid iatrogenic crouch gait.

Keywords: cerebral palsy, single-event multilevel orthopedic surgery, stiff knee gait

INTRODUCTION

Stiff knee gait (SKG) is common in ambulatory children with cerebral palsy (CP) classified as GMFCS I and II [1]. This specific pattern results from permanent activity of the rectus femoris muscle during gait cycle or increased activity of the muscle in the swing phase [2]. It is associated with reduced peak knee flexion (PKF) and delayed time of PKF as well as limited knee range of motion (KROM) throughout gait cycle [3, 4].

The 3D-gait analysis permitted to detect and define this pattern, and to justify the procedure of distal rectus femoris transfer to knee flexors (m. semimembranosus, m. sartorius or m. biceps femoris). This surgery increases knee flexion during the swing phase and improves foot clearance. Distal rectus femoris transfer (DRFT) removes the action of this biarticular muscle from knee extension shifting its action posterior to knee joint axis and preserves its function as a hip flexor [4, 5].

The 3D gait analysis is recognized crucial in diagnosis of the stiff knee gait. It is mandatory in planning for this kind of orthopedic surgery [2, 6]. In literature, the results of this procedure are studied separately from other aspects often surgical and functional outcomes [7-10]. There are few publications reporting results of DRFT performed in association with other surgical procedures [11-13]. Surgical approaches in stiff knee gait associated with excessive ankle dorsiflexion in stance remain controversial.

Objective of the study was assessing the results of single-event multilevel orthopedic surgery in patients with cerebral palsy with stiff knee gait when the distal rectus femoris transfer was primary but the not only surgical element.

MATERIAL AND METHODS

This study was a retrospective review of ambulatory patients diagnosed with spastic CP having stiff knee gait who were operated on with SEMLS. The other inclusion criteria used for patient selection were medical history for 1 and more year of follow-up; spastic diplegia classified as level I, II or III of the GMFCS. Exclusion criteria were baclofen pomp, botulinotherapy within the preceding 6 months, orthopedic lower limb surgery within the preceding 12 months, patients having other gait patterns.

In total, studied cohort included 20 patients (F/M = 8/12) with mean age 17.1 ± 2.94 years. Their gait was characterized by reduced foot clearance, toe drag, excessive abduction in swing. The Duncan-Ely test was positive or extremely positive (++/+++). Sixteen 16 patients were classified as GMFCS II, 4 patients were GMFCS III.

Ten patients previously underwent overlengthening of triceps by Achillis tendon lengthening (6 patients) or by percutaneous Ulzibat fibromyotomies (4 patients). Strayer procedure associated with medial hamstring release was done in the remaining 10 patients. The time period between previous surgeries and our interventions was, at least, 4 years 3 months.

Generally, one surgical event included an average of 5.5 elements (Table 1). It reflects multiple orthopedic disorders observed in older children and young adults having stiff knee gait and bilateral surgical approach.

Table 1. Elements of SEMLS

Element	Number
Medial hamstring lengthening, gracilis release	12
Adductor tenotomy	4
Strayer, Vulpius procedure or Achillis tendon lengthening	2
Shortening of tibialis posterior tendon	6
DRFT	40
Patellar advancement	29
Detorsion osteotomy of tibia	4
Bunion correction/I metatarsophalangeal arthrodesis	2
Achillis tendon shortening	8
Talonavicular arthrodesis	8
Evans procedure	4
Subtalar arthrodesis	2
Total	121

Table 2. Mean values of Edinburgh scale preoperative parameters in comparison to values in long-term follow-up

Parameter	Preoperative	At latest FU
Initial contact	1.0 ± 0.51	0.5 ± 0.51
Heel lift	0.94 ± 0.25	0.93 ± 0.26
Maximum ankle dorsiflexion	0.19 ± 0.39	0.09 ± 0.17
Hind-foot varus/valgus	0.38 ± 0.49	0.36 ± 0.49
Foot progression angle	0.75 ± 0.84	0.07 ± 0.26*
Knee progression angle	0.13 ± 0.34	0.0 ± 0.0
Peak knee extension	0.06 ± 0.25	0.0 ± 0.0
Peak hip extension	0.13 ± 0.34	0.14 ± 0.36
Pelvic obliquity at Mid-Stance	0.75 ± 0.67	0.43 ± 0.50
Pelvic rotation at Mid-Stance	0.31 ± 0.59	0.21 ± 0.42
Trunk Peak Sagittal Position	0.63 ± 0.49	0.29 ± 0.46
Trunk maximum lateral shift	1.5 ± 0.72	1.43 ± 0.50
Clearance	1.2 ± 0.51	0.21 ± 0.42*
Maximum ankle dorsiflexion	0.61 ± 0.59	0.13 ± 0.19
Peak knee flexion	1.4 ± 0.65	0.14 ± 0.35*
Knee terminal swing position	1.19 ± 0.74	0.18 ± 0.39*
Peak hip flexion	0.25 ± 0.44	0.0 ± 0.0
Total	22.0 ± 5.48	9.79 ± 2.83*

* significant difference in comparison to preoperative value by Wilcoxon signed-ranks test for matched samples ($p < 0,05$).

Gait analysis using the Edinburgh score [14] was performed before surgery and at a minimum of 1.5 years after surgery. Three-dimensional gait analysis was also carried out on all subjects walking barefoot. Kinematic and kinetic variables were evaluated before surgery and at the last follow-up control. We used 6-camerax Qualisys Oqus system and one AMTI force plate (Advanced Mechanical Technology Inc., Watertown, MA) to collect motion analysis data. In the Ilizarov Gait Analysis Laboratory the IOR model was used for markers [15], which is optimal for minimal system configuration and for appropriate kinematic analysis decreasing artefacts of skin motion. Preoperative values were compared with those measured at the last follow-up.

AtteStat 12.0.5 software was used for the statistical analyses. The statistical values described the mean and standard deviation. The Edinburgh score data and 3D gait analysis values were compared by using Wilcoxon signed-ranks test for matched or independent samples. The test was two-tailed with a 0.05 level of significance. This research was approved by the Ilizarov Center Review Board. The study complies with the Declaration of Helsinki statement on medical protocol and ethics. Representatives of all patients enrolled in the study provided oral and written informed consent.

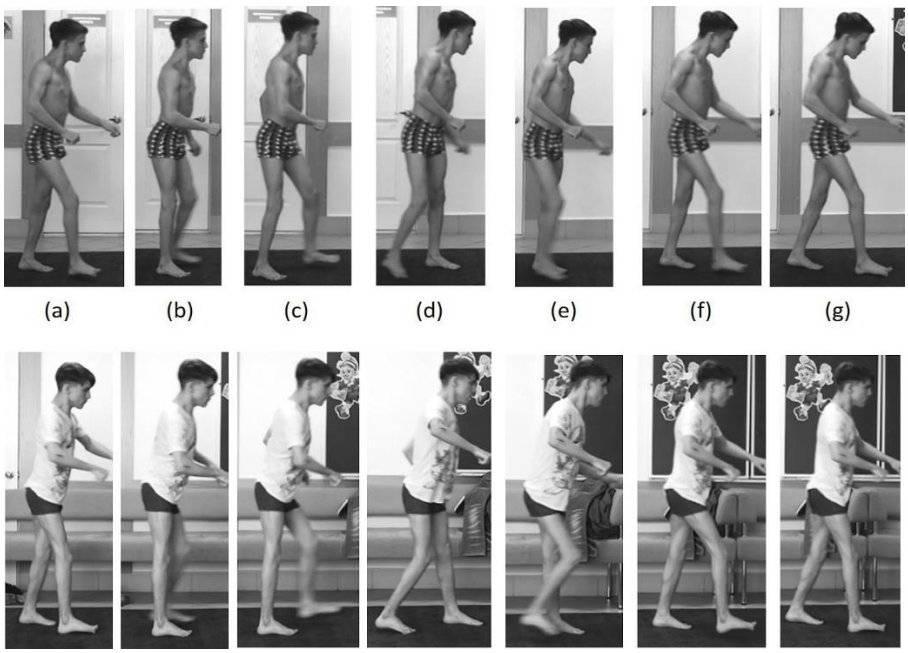

Figure 1. Patient R., 15-year-old boy, level II GMFCS, photographs before surgery (upper row), photographs in 1.5 years after surgery (lower row): initial contact (a); midstance (b); terminal stance (c); toe off (d); midswing (e); terminal swing (f); initial contact (g).

RESULTS

Mean values of Edinburgh scale in preoperative period and at the final follow-up visit are shown in Table 2. Generally, the SEMLS allowed an overall improvement of gait parameters. The mean total score was reduced from 22.0 to 9.8. The most significant ameliorations were

observed in swing, namely, improvement of peak knee flexion, foot clearance and knee terminal swing position, and foot progression in stance (Figure 1). On the other hand, delayed heel lift related to previous triceps lengthening procedures did not improve in postoperative period. We found no significant changes in pelvis and trunk kinematics in postoperative follow-up as well.

Table 3. Kinematics and kinetics of ankle joint, percentage of stance phase of gait cycle

Gait Profile Score		PKF; °		Timing of PKF; %		KROM; °	
Before surgery	In long-term FU	Before surgery	In long-term FU	Before surgery	In long-term FU	Before surgery	In long-term FU
14.2 ± 2.8	12.3 ± 1.3	44.2 ± 6.7	54.8 ± 5.7	91.4 ± 4.5	81.6 ± 3.1	21.3 ± 10.4	42.8 ± 7.2*

* significant difference in comparison to preoperative value by Wilcoxon signed-ranks test for matched samples ($p < 0,05$).

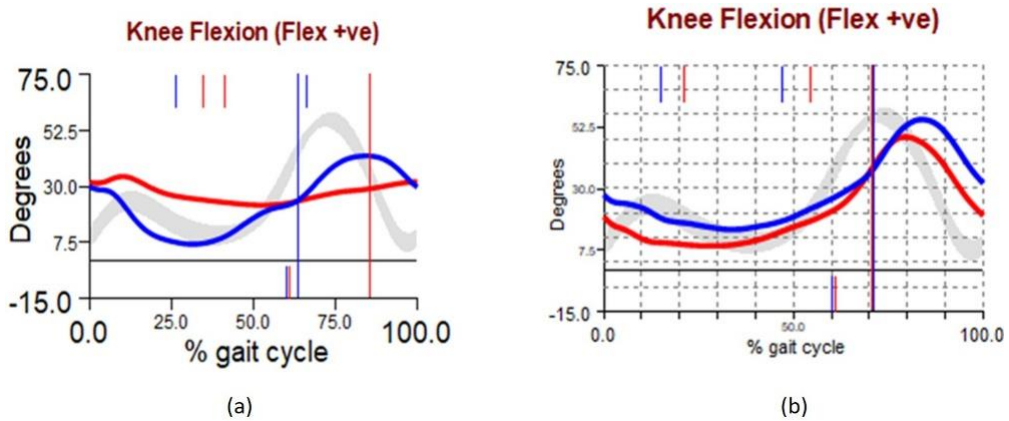

Figure 2. Knee kinematics of a 17-year-old boy undergone bilateral DRFT, Evans procedure and shortening of tibialis posterior tendon to achieve normal foot progression angle: reduced and delayed PKF in swing and excessive left knee flexion in stance before treatment (a); normal knee flexion instance, physiological KROM, but slightly delayed PKF in swing after surgery (b).

The changes in spatio-temporal parameters, kinetics and kinematics revealed by 3D gait analysis are shown in Table 3.

Statistically significant improvement in KROM after surgery was due to increased PKF in swing but also to reduced or even normalized knee flexion in stance (Figure 2). We explain the last amelioration by correction of excessive ankle dorsiflexion in stance. Physiological angle of stance dorsiflexion did not require compensatory knee flexion in stance phase.

DISCUSSION

Instrumented three-dimensional analysis of gait helped in the understanding of pathological patterns and the lever arm dysfunction in patients with CP [1, 11, 16]. This analysis demonstrated objective and quantifiable information regarding permanent or inappropriate rectus muscle spasticity and its detrimental effect at the knee kinematics in stiff knee gait pattern patients causing reduced foot clearance, toe drag, circumduction, and impaired limb advancement [3-5].

Rectus femoris transfer in patients with stiff knee gait increases knee flexion and decreases time to PKF during the swing phase, thereby foot clearance is improved [4, 9, 18]. On the other hand, this procedure preserves its function as a hip flexor which is needed during the first 20% of the swing phase [4, 17].

In literature, the DRFT ensures an increase PKF varying from 1.2° to 17° [2, 4, 9, 12, 19]. In our series, mean elevation of PKF was slightly over 10°, that conforms to reported results. The outcomes in PKF are controversial in long term follow-up. Saw et al. [19] reported that increased PKF remained stable within mean follow-up of 4.6 years. In contrast to that, Saraph et al. [20] reported loss of 5° during 3 postoperative years. Thawrani et al. [2] demonstrated 6° loss of PKF in 10-year follow-up in comparison to the short follow-up time.

The selection of patients for DRFT should be rigorous. The patients classified as level I or II demonstrates better outcomes in comparison to patients with GMFCS level III [6, 12]. Thawrani et al. [2] suggest that the patients who will benefit the most from surgery are those with PKF less than 64° and time to PKF more than 80% [2].

The place of DRFT in multilevel surgery should be discussed as well. It was highlighted that rectus transfer performed in association with medial hamstring lengthening improves PKF in swing phase and prevents progressing of crouch gait [4, 5]. Results of our series demonstrated both amelioration of PKF and improvement of knee extension in stance if DRFT was associated with hamstring lengthening and correction of lever arm dysfunction.

Be Morais et al. [6] discuss the risk of quadriceps weakness due to DRFT and related flexed knee walking. Their study revealed increased knee flexion angle in stance after multilevel surgery in both patients undergone RFDT and patients without rectus transfer. The patients with GMFCS III were more prone to increased knee flexion in stance after DRFT [6]. Carney et al. [21] reported higher risk of crouch gait after rectus transfer in children who used walker or crutches (GMFCS III). For Gage et al. [5], lever arm dysfunction caused by torsional deformities resulted in poor outcomes in DRFT procedures. Thus, we find mandatory to perform rectus transfer in conjunction with hamstring lengthening, excessive dorsiflexion correction and torsional deformity alignment to avoid secondary crouch gait [12, 13].

In patients of our series, excessive dorsiflexion in stance due to weakness of triceps was caused by previously performed Achilles tendon lengthening or percutaneous fibromyotomies (Ulzibat method) [22]. The correction of excessive dorsiflexion, excessive external foot progression angle in combination with stabilization of the foot shape resulted in preservation of the knee-extension plantar-flexion coupling. We combined the DRFT with shortening of Achilles tendon, shortening of tibialis posterior tendon, talo-navicular arthrodesis, Evans procedure, detorsion osteotomies [23, 24]. This strategy has been showed justified. We found no patient with flexed knee gait after distal rectus transfer in the series.

CONCLUSION

1. Rectus femoris transfer in children with CP with stiff knee gait ensures increasing of knee flexon during the swing phase, knee range of motion throughout gait cycle, and improving foot clearance.
2. We recommend performing DRFT as a part of single-event multilevel surgery.

3. If stiff knee gait is associated with iatrogenic excessive ankle dorsiflexion, the surgery must include rectus transfer and simultaneous correction of excessive passive dorsiflexion, lever arm dysfunction and weakness of triceps. This strategy is intended to avoid secondary crouch gait.

REFERENCES

[1] Wren, T. A., Rethlefsen, S., Kay, R. M. (2005). Prevalence of specific gait abnormalities in children with cerebral palsy: influence of cerebral palsy subtype, age, and previous surgery. *J. Pediatr. Orthop.*, 25:79-83.

[2] Thawrani, D., Haumont, T., Church, C., Holmes, L. Jr, Dabney, K. W., Miller, F. (2012). Rectus femoris transfer improves stiff knee gait in children with spastic cerebral palsy. *Clin. Orthop. Relat. Res.*, 470(5):1303-1311.

[3] Miller, F., Cardoso, D. R., Lipton, G. E., Albarracin, J. P., Dabney, K. W., Castagno, P. (1997). The effect of rectus EMG patterns on the outcome of rectus femoris transfers. *J. Pediatr. Orthop*. 17:603-607.

[4] Sutherland, D. H., Santi, M., Abel, M. F. (1990). Treatment of stiff-knee gait in cerebral palsy: a comparison by gait analysis of distal rectus femoris transfer versus proximal rectus release. *J. Pediatr. Orthop*. 10:433-441.

[5] Gage, J. R., Perry, J., Hicks, R. R., Koop, S., Werntz, J. R. (1987). Rectus femoris transfer to improve knee function of children with cerebral palsy. *Dev. Med. Child Neurol*. 29(2):159-166.

[6] de Morais, M. C., Blumetti, F. C., Kawamura, C. M., Lopes, J. A., Neves, D. L., Cardoso, Mde, O. (2016). Does rectus femoris transfer increase knee flexion during stance phase in cerebral palsy? (2016). *Acta Ortop. Bras*. 24(1):27-31.

[7] Asakawa, D. S., Blemker, S. S., Gold, G. E., Delp, S. L. (2002). In vivo motion of the rectus femoris muscle after tendon transfer surgery. *J. Biomech*. 35:1029-1037.

[8] Goldberg, S. R., Ounpuu, S., Arnold, A. S., Gage, J. R., Delp, S. L. (2006). Kinematic and kinetic factors that correlate with improved knee flexion following treatment for stiff-knee gait. *J. Biomech*. 39:689-698.

[9] Ounpuu, S., Muik, E., Davis, R. B. III, Gage, J. R., DeLuca, P. A. (1993). Rectus femoris surgery in children with cerebral palsy. Part I: the effect of rectus femoris transfer location on knee motion. *J. Pediatr. Orthop*. 13:325-330.

[10] Ounpuu, S., Muik, E., Davis, R. B. III, Gage, J. R., DeLuca, P. A. (1993). Rectus femoris surgery in children with cerebral palsy. Part II: a comparison between the effect of transfer and release of the distal rectus femoris on knee motion. *J. Pediatr. Orthop*. 13: 331-335.

[11] Nene, A. V., Evans, G. A., Patrick, J. H. (1993). Simultaneous multiple operations for spastic diplegia. Outcome and functional assessment of walking in 18 patients. *J. Bone Joint Surg. Br*. 75:488-494.

[12] Lee, S. Y., Kwon, S. S., Chung, C. Y., Lee, K. M., Choi, Y., Kim, T. G., Shin, W. C., Choi, I. H., Cho, T. J., Yoo, W. J., Park, M. S. (2014). Rectus femoris transfer in cerebral palsy patients with stiff knee gait. *Gait Posture*. 40(1):76-81.

[13] Ławniczak, D., Jóźwiak, M., Manikowska, F. (2010). [Assessment of absolute knee joint linear and angular velocity in patients with spastic cerebral palsy after operative treatment of lever arm disfunction deformities--prospective study]. *Chir. Narzadow Ruchu Ortop. Pol*. 75(2):92-97. Polish.

[14] Read, H., Hazlewood, M., Hillman, S., Prescott, R., Robb, J. (2003). Edinburgh visual gait score for use in cerebral palsy. *J. Pediatr. Orthop*. 23(3):296-301.

[15] Leardini, A., Sawacha, Z., Paolini, G., Ingrosso, S., Nativo, R., Benedetti, M. G. (2007). A new anatomically based protocol for gait analysis in children. *Gait Posture*, 26(4):560-571.

[16] Bell, K. J., Ounpuu, S., DeLuca, P. A., Romness, M. J. (2002). Natural progression of gait in children with cerebral palsy. *J. Pediatr. Orthop.*, 22:677-682.

[17] Perry, J. (1987). Distal rectus femoris transfer. *Dev. Med. Child Neurol*. 29: 153-158.

[18] Moreau, N., Tinsley, S., Li, L. (2005). Progression of knee joint kinematics in children with cerebral palsy with and without rectus femoris transfers: a long-term follow up. *Gait Posture*. 22:132-137.

[19] Saw, A., Smith, P. A., Sirirungruangsarn, Y., Chen, S., Hassani, S., Harris, G., Kuo, K. N. (2003). Rectus femoris transfer for children with cerebral palsy: long-term outcome. *J. Pediatr. Orthop.* 23: 672-678.

[20] Saraph, V., Zwick, E. B., Auner, C., Schneider, F., Steinwender, G., Linhart, W. (2005). Gait improvement surgery in diplegic children: how long do the improvements last? *J. Pediatr. Orthop.* 25: 263-267.

[21] Carney, B. T., Oeffinger, D., Gove, N. K. (2006). Saggital knee kinematics after rectus femoris transfer without hamstring lengthening. *J. Pediatr. Orthop*. 26(2): 265-267.

[22] Shishov, S. V., Ivshin, V. G. (2016). Minimalno invazivnye operatsii na myshtsakh u detei s DTsP. Opyt piatiletnego primeneniia [Minimally invasive surgery of muscles in children with cerebral palsy. The experience of five-year use]. *Vestnik Novykh Meditsinskikh Tekhnologii* (Electronic Edition), 2: 137-141 (in Russian) doi: 10.12737/20085.

[23] Popkov. D. A., Zmanovskaya, V. A., Gubina, E. B., Leonchuk, S. S., Butorina, M. N., Pavlova, O. L. (2015). [The results of single-event multilevel orthopedic surgeries and the early rehabilitation used in complex with botulinum toxin treatment in patients with spastic forms of cerebral palsy]. *Zh. Nevrol. Psikhiatr. Im. S. S. Korsakova*. 115(4):41-48. Russian.

[24] Leonchuk, S. S., Chibirov, G. M., Popkov, D. A. (2016). Foot deformity correction according to Evans technique in a child with cerebral palsy within performing the acute multilevel orthopedic intervention. A case report. *Genij Ortopedii*, 3: 77-83 (In Russian).

In: Encyclopedia of Surgery (22 Volume Set)
Editors: Andreas Lehrer and Kristin Mueller
ISBN: 978-1-53618-329-0
© 2020 Nova Science Publishers, Inc.

Chapter 120

SINGLE-EVENT MULTILEVEL ORTHOPEDIC SURGERY IN CP PATIENTS WITH NATURAL AND IATROGENIC CROUCH GAIT

Tamara Dolganova*, MD, PhD, Georgy Chibirov, MD, PhD, Orhan Gatamov, MD, Dmitry Dolganov, PhD and Dmitry Popkov, MD, PhD
Ilizarov National Medical Research Center for Traumatology and Orthopedics, Kurgan, Russia

ABSTRACT

Introduction. Crouch gait in cerebral palsy is characterized by excessive knee and hip flexion as well as excessively dorsiflexed ankle throughout stance. We report the results of single-event multilevel orthopedic surgery in natural and iatrogenic crouch gait.

Material and methods. A total of 39 patients (F/M = 10/29) with a mean age 16.3 years (range 7.1 to 26 years) who presented with crouch gait were operated on with single-event multilevel orthopedic surgery (SEMLS). The mean follow-up period was 21 months (range 14-36 months). According to the GMFCS, 4 patients were GMFCS I, 16 patients were GMFCS II, 19 patients were GMFCS III.

Cases were analyzed in two groups: group 1 (15 patients, no previous surgery, naturally developed crouch gait) and group 2 (24 patients with previously overlengthened triceps by illimited Achillis tendon lengthening or by percutaneous Ulzibat fibromyotomies, condition resulted in iatrogenic crouch gait). Participants underwent Edinburgh visual gait score and 3D computed gait analysis before and approximately 20 months after surgery.

Results. Edinburgh gait score revealed that SEMLS improved ankle and knee kinematics in stance and swing phases for both groups, namely, decrease of excessive dorsiflexion in stance, improvement of peak knee extension and foot progression angle as well as knee terminal swing position. The 3D gait analysis displayed an improvement in various gait outcome measures postoperatively. The mean gait profile score reduced from

* Corresponding Author's Email: dti025fd@mail.ru.

17,1 to 13,4 in natural crouch gait, and from 15,9 to 14,8 – in iatrogenic gait group. This significant improvement was due to elimination of lever arm disfunction in sagittal and transverse planes. On the other hand, there was no elevation of ankle power generation during terminal stance in both groups at the latest follow-up control.

Conclusion. Crouch gait pattern is multifaceted and associates various orthopedic disorders requiring a reconstructive surgery. There is significant difference between natural and iatrogenic crouch gait. The iatrogenic caused by surgical over-lengthening of triceps is not necessarily associated with lever arm dysfunction on the transverse plane. Given that cause of crouch gait is multiple and difficult to identify, instrumented 3D gait analysis has an important role in clinical decision-making.

Keywords: cerebral palsy, single-event multilevel orthopedic surgery, iatrogenic crouch gait

INTRODUCTION

Cerebral palsy (CP) is a major source of motor disability in childhood globally [1, 2]. While the primary neural impairment is stable, the secondary orthopedic manifestations are progressive. Crouch gait is one of the most common gait deviations observed in CP. The prevalence of crouch gait is higher in older children, adolescents and adults with levels I-III of the GMFCS [3-7]. Rodda et al. described the pattern of crouch gait as an abnormality of gait (group IV) with permanent ankle dorsiflexion and excessively flexed knee joint in stance phase [8]. Being prevalent gait pattern in CP children, the crouch gait is characterized by excessive knee flexion (knee flexion is over 20° at initial contact and over 30° throughout the stance phase) and permanent ankle dorsiflexion during stance phase [4, 8-10]. Lever arm dysfunction caused by skeletal deformities contributes crouch gait a lot. There include increased femoral neck anteversion, patella alta, planovalgus foot deformities, external tibial torsion [11-13].

The progressive knee flexion over the time is part of the natural history of this gait disorder. It results in the ground direction force to move a lot to posterior to knee joint [8]. Then, the plantar flexion/knee extension coupling fails resulting in severe walking impairment, furthermore, adolescents refuse standing and walking Once crouch gait established, progressive knee and hip contractures, breaching of the mid-foot, valgus hind-foot, patella alta, pain syndrome in anterior knee and foot due to early onset arthritis, torsional deformity causing lever arm dysfunction, weakness and poor selective motor control combined with deleterious effects of the adolescent growth spurt result in refuse to stand and loss of walking ability [9, 14-21].

The single-event multilevel orthopedic surgery becomes mandatory to correct secondary orthopedic issues of CP. It addresses contractures and level arm dysfunction simultaneously ensuring only one prime period of rehabilitation and reducing number of hospital admissions, surgeries and general anesthetic procedures [5, 22-28]. Planning of multi-level surgery requires preoperative 3D Gait Analysis) and considering its results with clinical and radiological findings [23, 29].

Presence and degree of orthopedic disorders vary in CP patients with crouch gait [5, 8, 22, 30, 31]. Furthermore, the natural and iatrogenic (surgeon-induced) crouch gait patterns have been distinguished. The first one occurs as an element of natural history of gain progression in CP children and onsets around puberty. The iatrogenic crouch gait is caused by

excessive calf-lengthening procedures, lengthening of spastic muscles without fixed contractures (e.g., Ulzibat percutaneous fibromyotomies) [10, 22, 32, 33]. Iatrogenic crouch gait represents a serious issue due to the limited possibilities to manage this condition including excessive dorsiflexion.

The first aim of this prospective study was to evaluate the effectiveness of SEMLS on the walking outcomes in CP patients with crouch gait. The second aim was to reveal the differences between natural and iatrogenic crouch gait patterns in preoperative period and compare outcomes in those two groups.

MATERIAL AND METHODS

This study was a retrospective review of ambulatory patients diagnosed with spastic CP having crouch gait who were operated on with SEMLS at a single institution in the period 2015-2018. The other inclusion criteria used for patient selection were medical history for 1.5 and more year of follow-up; spastic diplegia classified as level I, II or III of the GMFCS. GMFCS level was determined by physical examinations and medical records. Exclusion criteria were baclofen pomp, botulinotherapy within the preceding 6 months, orthopedic lower limb surgery within the preceding 12 months, patients having other gait patterns.

In total, studied cohort included 39 patients (F/M=10/29) with mean age 16.3 years (range 7.1 to 26 years). Patients were divided into two groups. Group 1 (15 patients) included patients never operated with naturally developed crouch gait. Patients who previously underwent overlengthening of triceps by Achillis tendon lengthening or by percutaneous Ulzibat fibromyotomies formed Group 2. That group 2 of iatrogenic crouch gait consisted of 24 patients.

Gait analysis using the Edinburgh score [34] was performed before surgery and at a minimum of 1.5 years after surgery. Three-dimensional gait analysis was also carried out on all subjects walking barefoot. Kinematic and kinetic variables were evaluated before surgery and at the last follow-up control. We used 6-camerax Qualisys Oqus system and one AMTI force plate (Advanced Mechanical Technology Inc., Watertown, MA) to collect motion analysis data. In the Ilizarov Gait Analysis Laboratory the IOR model was used for markers [35], which is optimal for minimal system configuration and for appropriate kinematic analysis decreasing artefacts of skin motion. The Delphi consensus was applied to classify observed pathologic gait patterns [50]. Preoperative values were compared with those measured at the last follow-up.

AtteStat 12.0.5 software was used for the statistical analyses. The statistical values described the mean and standard deviation. The Edinburgh score data and 3D gait analysis values were compared by using Wilcoxon signed-ranks test for matched or independent samples. The test was two-tailed with a 0.05 level of significance. A chi-squared test was used to assess the difference in prevalence of the GMFCS level III cases in compared groups.

This research was approved by the Ilizarov Center Review Board. The study complies with the Declaration of Helsinki statement on medical protocol and ethics. Representatives of all patients enrolled in the study provided oral and written informed consent.

RESULTS

The Table 1 represents distribution of cases between groups depending on age, GMFCS level and gender.

Table 1. Age, gender and GMFCS level of patients

Group	n	F/M	age; years	GMFCS level; n		
				I	II	III
1	15	4/11	18.9 ± 4.75	-	4	11
2	24	6/18	14.8 ± 3.07*	4	13	7#

*- significant difference between groups (p = 0.013).
#- significant difference in distribution of GMFCS level III between groups (p = 0.0301).

Comparison of groups revealed that in group 2 (iatrogenic crouch gait) the patients were indicated for SEMLS and surgeries have been done in earlier age than in group 1. Furthermore, the prevalence of patients using crutches or walker for ambulating (GMFCS level III) was significatively higher in naturally developed crouch gait. We may speculate that the previously done triceps lengthening contributes to progression to crouch gait pattern even in mild and moderate forms of CP.

Generally, one surgical event included an average of 7.7 elements (Table 2). It reflects multiple orthopedic disorders observed in older children and young adults having crouch gait.

Table 2. Elements of SEMLS in groups

Surgery element	Group 1	Group 2 (iatrogenic crouch)
Medial hamstring lengthening	30	48
Adductor tenotomy	8	4
Strayer, Vulpius procedure or Achillis tendon lengthening	28	7
Shortening of the m.tibialis post. Tendon	18	28
Distal femoral extension osteotomy	8	18
Patellar advancement	22	42
Detorsion osteotomy of femur	6	8
Distal transfer of m.rectus femoris	2	8
Psoas release	4	-
Detorsion osteotomy of tibia	2	1
Talo-navicular arthrodesis	8	8
Evans procedure	4	12
Triple foot arthrodesis	6	16
Transfer of m.peroneus longus to calcaneus	-	7
Shortening of Achillis tendon	-	12
Release of m.tibialis ant./lengthening of m.tibialis anterior	-	2
Bunion correction/ I metatarsophalangeal arthrodesisC	11	20
Total	155	241

There was an evident difference between groups in prevalence of some specific surgical elements. In particular, the shortening of Achillis tendon and transfer of m.peroneus longus to calcaneus have been performed only in group of iatrogenic crouch in order to try restoration power for plantar flexion and to resist to excessive ankle dorsiflexion in stance. In contrast to that, in group 1, the Strayer or Vulpius procedures were done to correct equinus in 28 cases,

in group 2 those elements were encountered only in 7 patients. The distal femoral extension osteotomy, different foot arthrodesis, detorsion osteotomies and patellar advancement were noticed as common in both groups.

Mean values of Edinburgh scale in preoperative period and at the final follow-up visit are shown in Table 3. Generally, the SEMLS allowed an overall improvement of gait parameters in groups 1 and 2. The mean total score was reduced from 43.7 to 20.9 in group 1 and from 40.8 to 19.2 in group 2. The most significant ameliorations were observed in stance, namely, reduction of excessive ankle dorsiflexion, normalization of foot progression angle and knee terminal swing position (Figure 1, Figure 2). On the other hand, we found no significant changes in pelvis and trunk kinematics assessed by Edinburgh gait scale.

Table 3. Mean values of Edinburgh scale preoperative parameters in comparison to values of long-term follow-up

Parameters	Group 1		Group 2	
	preoperative	At latest FU	preoperative	At latest FU
Initial contact	1,4 ± 0,50	0,7 ± 0,52	1,2 ± 0,51	0,67 ± 0,50
Heel lift	1,3 ± 0,53	0,9 ± 0,25	1,02 ± 0,5	0,75 ± 0,38
Maximum ankle dorsiflexion	1,4 ± 0,50	0,3 ± 0,53*	1,5 ± 0,54	0,21 ± 0,42*
Hind-foot varus/valgus	1,5 ± 0,68	0,27 ± 0,45*	1,35 ± 0,73	0,2 ± 0,32*
Foot progression angle	1,7 ± 0,58	0,23 ± 0,50*	1,44 ± 0,69	0,3 ± 0,55*
Knee progression angle	1,1 ± 0,63	0,53 ± 0,51	0,88 ± 0,69	0,4 ± 0,48
Peak knee extension	1,8 ± 0,38	0,47 ± 0,57*	1,7 ± 0,47	0,27 ± 0,49*
Peak hip extension	1,5 ± 0,57	0,8 ± 0,81	1,17 ± 0,79	0,58 ± 0,51
Pelvic obliquity at Mid-Stance	0,97 ± 0,41	1,03 ± 0,32	1,13 ± 0,74	0,96 ± 0,48
Pelvic rotation at Mid-Stance	0,6 ± 0,72	0,33 ± 0,48	0,71 ± 0,73	0,46 ± 0,55
Trunk Peak Sagittal Position	1,1 ± 0,48	1,17 ± 0,83	1,2 ± 0,68	1,04 ± 0,67
Trunk maximum lateral shift	1,5 ± 0,51	1,4 ± 0,5	1,9 ± 0,23	1,6 ± 0,54
Clearance	1,1 ± 0,45	0,43 ± 0,50	0,78 ± 0,62	0,5 ± 0,51
Maximum ankle dorsiflexion	0,77 ± 0,68	0,1 ± 0,31	0,94 ± 0,87	0,19 ± 0,40
Peak knee flexion	1,2 ± 0,75	0,7 ± 0,58	1,1 ± 0,71	0,63 ± 0,59
Knee terminal swing position	1,7 ± 0,47	0,47 ± 0,63*	1,6 ± 0,49	0,52 ± 0,50*
Peak hip flexion	1,1 ± 0,78	0,5 ± 0,51	0,79 ± 0,88	0,33 ± 0,48
Total	43,7 ± 7,54	20,9 ± 8,98*	40,8 ± 10,91	19,2 ± 6,05*

*- significant difference in comparison to preoperative value by Wilcoxon signed-ranks test for matched samples, ($p < 0,05$).

The changes in spatio-temporal parameters, kinetics and kinematics revealed by 3D gait analysis are shown in Tables 4, 5, 6.

Preoperative assessment demonstrated specific elements of crouch gait including excessive ankle dorsiflexion, flexed knee in stance and the lack of power generation at the push-off. It should be pointed out that external foot progression angle was less excessive in group of iatrogenic crouch. Statistical analysis revealed a significant effect of SEMLS on ankle position at initial contact and on peak ankle dorsiflexion (mean decrease up to 39% in group 1 and 32% in group 2). The foot progression angle has been improved or even normalized in both groups as well. On the other hand, we found no significant elevation in the parameter of maximum ankle power generation over the time.

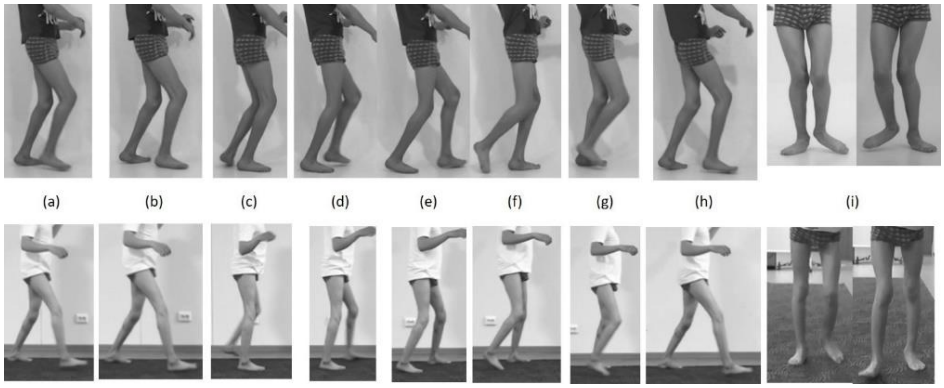

Figure 1. Patient Kh, 16-year-old boy, level II GMFCS, group 1, photographs before surgery (upper row), photographs in 2 years after surgery (lower row): terminal swing position (a); initial contact (b); midstance (c); terminal stance (d); preswing (e); toe off (f); midswing (g); terminal swing (h); monopodial stance (i), AP view, excessive external foot angle progression (before surgery), normal foot angle progression (after treatment).



Figure 2. Patient Z, 7-year-old boy, level II GMFCS, group 2, photographs before surgery (upper row), photographs in 2 years after surgery (lower row): terminal swing position (a); initial contact (b); midstance (c); terminal stance (d); preswing (e); toe off (f); midswing (g); terminal swing (h); monopodial stance (i), AP view, excessive external foot angle progression (before surgery), normal foot angle progression (after treatment).

Table 4. Kinematics and kinetics of ankle joint, percentage of stance phase of gait cycle

Parameter	Group 1, naturally developed crouch gait		Group 2, iatrogenic crouch gait	
	Before surgery	In 18-24 months after surgery	Before surgery	In 18-24 months after surgery
Ankle position at initial contact; °	14.8 ± 2.99	3.50 ± 0.36*	12.7 ± 6.03	6.1 ± 5.70*
Peak ankle dorsiflexion in stance; °	27.3 ± 5.33	16.8 ± 8.03*	26.5 ± 10.3	18.2 ± 10.33*
Ankle at toe off; °	-1.35 ± 6.30	-0.23 ± 6.60	-0.8 ± 7.49	-1,88 ± 6,50
Stance phase, %	68.7 ± 7.86	65.9 ± 5.72	66.1 ± 8.80	68.6 ± 7.67
Foot progression angle; °	-33.5 ± 27.2	-18.8 ± 22.7	-25.1 ± 18.2	-11.9 ± 19.2
Ankle plantar flexion moment; N*m/kg	0.95 ± 0.26	0.92 ± 0.14	0.88 ± 0.37	0.86 ± 0.26
Maximum ankle power generation; W/kg	1.27 ± 0.72	1.35 ± 0.44	1.21 ± 0.57	1.31 ± 0,99

*- significant difference in comparison to preoperative values by Wilcoxon signed-ranks test for matched samples, ($p < 0,05$).

Table 5. Kinematics and kinetics of knee joint

Parameter	Group 1, naturally developed crouch gait		Group 2, iatrogenic crouch gait	
	Before surgery	In 18-24 months after surgery	Before surgery	In 18-24 months after surgery
Knee flexion at initial contact; °	45,7 ± 3,92	27,0 ± 6,78*	39,2 ± 12,28	26,1 ± 14,9*
Minimum of knee flexion in midstance; °	38,4 ± 11,38	20,1 ± 8,98*	28,3 ± 18,7	13,4 ± 18,8*
Peak knee flexion in swing; °	66,0 ± 14,7	47,8 ± 5,64	56,5 ± 13,5	49,1 ± 15,83
Timing of Peak knee flexion in swing; %	81,3 ± 6,25	78,8 ± 7,87	82,9 ± 4,96	80,9 ± 5,05
Knee extension moment; N*m/kg	1,08 ± 0,55	0,77 ± 0,22	0,96 ± 0,50	0,61 ± 0,42*
Knee flexion moment; N*m/kg	0,03 ± 0,08	0,15 ± 0,07*	0,12 ± 0,17	0,36 ± 0,28*
Maximum knee extension power generation; W/kg	0,65 ± 0,43	0,66 ± 0,43	0,68 ± 0,42	0,61 ± 0,55

*- significant difference in comparison to preoperative values by Wilcoxon signed-ranks test for matched samples, ($p < 0,05$).

Table 6. Pelvis and hip kinematics and kinetics, Gait Profile Score

Parameter	Group 1, naturally developed crouch gait		Group 2, iatrogenic crouch gait	
	Before surgery	In 18-24 months after surgery	Before surgery	In 18-24 months after surgery
GPS	17,1 ± 3,01	13,4 ± 3,19	15,9 ± 6,16	14,8 ± 4,6
Hip position at initial contact;°	43,6 ± 12,1	37,1 ± 4,45	39,5 ± 10,8	41,1 ± 14,7
Maximum hip extension in stance; °	-14,6 ± 12,8	-9,1 ± 9,74	-10,0 ± 10,1	-10,8 ± 16,6
Hip rotation in stance; °	26,3 ± 11,48	14,1 ± 18,2	19,2 ± 16,7	17,3 ± 14,87
Pelvic tilt; °	14,4 ± 9,53	20,8 ± 5,18	17,8 ± 10,6	22,4 ± 12,7

Knee joint improved significantly passing from the preoperatively excessive flexed position to a more physiological position during the stance phase (Table 5). Kinetic data showed reduction of knee joint extensor moments and power maximum values, approaching the normal values. The knee joint flexor moments increased significantly reflecting the correction of lever arm dysfunction in sagittal plane.

After surgery the hip femur was in a more physiological position, but the pelvic tilt increased slightly in both groups. No changes were displayed in assessment of maximum femur extension in stance. Detorsion osteotomy of femur allowed to improve the average of knee progression angle in group 1 (Table 6). In group 2, the values of that parameter were more physiological and required to correct them rarely. The reduction of GPS in both groups corresponded to overall improvement of gait parameters over times.

DISCUSSION

The widely recognized classification of gait patterns based on sagittal plane kinematics defines crouch gait as a symmetric gait with excessively dorsiflexed ankle throughout stance phase and excessively flexed knee and hip [8]. The crouch gait represents a part of a large group of flexed-knee gaits encompassing jump gait, apparent equinus gait and crouch gait when the knee flexion at initial contact is 15° more (it corresponds to 1SD above the mean value of the parameter in a healthy 6-year-old child [Haumont, 5, 9, 22]. But excessive ankle

dorsiflexion and excessive knee flexion throughout stance phase are specific qualitative criteria of the crouch pattern [5, 8].

Abnormalities observed in crouch gait are well-known and include spasticity or contracture of knee and hip flexors, increased femoral anteversion, planovalgus foot deformities, patella alta, quadriceps weakness, and external tibial torsion [8, 11, 36]. Skeletal abnormalities result in lever arm dysfunction with ground reaction vector progressing from anterior to the knee to posterior to the knee [11, 12, 20, 37]. The biomechanics of this pathologic gait pattern is more complex in that sagittal plane deformities interact with transverse and coronal plane deformities in addition to muscle weakness and impaired selective motor control [19].

The crouch gait pattern may be considered as a part of the natural history of pathologic gait progression in spastic diplegia. This pattern is specific in children older than 12 years and related to the imbalance between body mass and muscle strength during puberty [14, 21]. Crouch gait can appear as a shift from equinus or jump gait due to the development of foot deformities associated with deleterious effects of pubertal growth spurt [8]. In crouch gait, the 3D gait analysis can reveal the presence of stiff knees [8]. Furthermore, quadriceps muscles are often weak in flexed-knee gait pattern [6, 8, 17, 18].

The iatrogenic crouch gait occurs after the lengthening of the triceps surae, especially the soleus by Achillis tendon surgery, without addressing of the proximal limb issues. Because after excessive isolated calf-lengthening the knee becomes overloaded and the extensor mechanism fails [22, 33]. That results in incompetence of the plantar-flexion knee-extension coupling over time [8, 20, 33, 39, 40]. From the point of view of biomechanics, the weakened soleus fails to absorb kinetic energy by eccentric contracture in midstance and to prevent early excessive knee flexion. Rose et al. reported that only lengthening of gastrocnemius fascia provides physiological ankle power generation at push-off over the long term [39].

In literature, the prevalence of crouch gait, orthopedic and surgical management aspects, operative techniques and outcomes are reported together without separating naturally developed crouch gait cases from iatrogenic crouch gait ones [14, 31, 36, 44, 45]. Our study demonstrated that patients with iatrogenic crouch gait had got indications for SEMLS and were referred to hospital at earlier age than patients with naturally developed crouch gait. Furthermore, the GMFCS level II was dominant in group of crouch gait while prevalence of patients with level III was significantly higher in group without previous calf lengthening. Thereby our findings conform to the observations of the previous authors that isolated and/or excessive calf-lengthening predispose for crouch gait in long-term follow-up even in children with moderate walking disability [25, 32, 33].

Given that the etiology of crouch gait is multifactorial, the surgical treatment is still controversial. The multiplanar and multilevel deformities and the variability in patients' clinical profiles cause decision-making difficulties regarding the choice and timing of the surgery [4, 5, 10, 15]. The actual standard of management of crouch gait is SEMLS allowing correction of primary and secondary deformities and related to them lever arm dysfunction. SEMLS minimizes the number of surgical events and hospitalizations for children and adults with crouch gait, reduces overall recovery and rehabilitation time [23, 30, 31, 46-48].

The use of instrumented 3D gait analysis in this population allows to determine elements for orthopedic surgery, to quantify the amount of correction and to decrease the incidence of deformity recurrences after SEMLS [7, 47].

Our study revealed the features of iatrogenic crouch gait distinguishing it from naturally developed one. Postoperative weakness of plantar flexors persisting in long-term follow-up was rarely associated with torsional abnormalities and excessive knee or ankle progression angle in stance. We conclude that rotational malalignments and fixed foot deformities have no important influence for progression of the iatrogenic crouch gait.

The mean peak knee flexion in swing was more evidently decreased in group of iatrogenic crouch gait. We suppose that the presence of stiff knee represented a compensating biomechanical element in patients with mild and moderate motor disorders (GMFCS level I, II). On the other hand, there were no significant differences between groups regarding kinematics in sagittal plane in stance phase. There was a significant reduction in the maximum ankle power generation at toe-off in both groups.

So, results of gait assessment in our series demonstrate the deleterious long-term effect of the early-age interventions for triceps lengthening (percutaneous Achillis tendon lengthening, mini-invasive Ulzibat fibromyotomies) [32, 33, 43, 49]. That strategy results in permanent weakness of plantar flexors and predisposes for early onset crouch gait in ambulatory children regardless the GMFCS level.

In our series, the combination of serial history, physical examination, visual gait assessment and three-dimensional gait analysis provided quantitative measurements of the biomechanics of the pathologic gait pattern and allowed to customize a treatment algorithm.

As it has been shown in the study, the SEMLS addressing primary and secondary etiologies of crouch gait improved kinematics and some kinetic parameters in sagittal and transverse planes. There was no significant difference in final outcomes of compared groups. The reduction of GPS reflected overall gait improvement.

In previously published studies, surgical techniques, results and outcomes of the SEMLS have been reported without separated analysis of iatrogenic or naturally developed crouch gait treatment [15, 30, 37, 48]. Our approach in correction of iatrogenic crouch gait included procedures aimed to restore the plantar flexion force by shortening of Achillis tendon, transfer of peroneus longus tendon to calcaneus and foot arthrodesis in combination with correction of flexed knee contracture and detorsion osteotomy if rotational abnormalities were revealed preoperatively. This combination allowed to remove lever arm dysfunction in both sagittal and transverse planes.

However, the ankle power generation at toe-off in long-term follow-up remained still low and largely inferior to mean physiological values. Nevertheless, the correction of fixed flexed knee position, excessive external foot progression angle in combination with stabilization of the foot shape by arthrodesis resulted in restoration of the knee-extension plantar-flexion coupling and reduction of walking energy consumption. This strategy allowed to preserve ankle movement without excessive dorsiflexion. The stabilization of the foot position in sagittal and transverse planes, full knee extension with patellar advancement for increasing active knee extension force should be objectives of SEMLS in iatrogenic crouch gait management. The elevation of ankle power generation at toe-off should not be expected in older children, adolescent and adults with crouch gait, especially in iatrogenic one.

CONCLUSION

The pattern of crouch gait is multifaceted. It may be a part of natural progression in gait disorders in children with spastic diplegia. The early-age triceps lengthening predisposes to and even causes iatrogenic crouch gait. Iatrogenic crouch gait can progress without torsional abnormalities. In our study, this disorder was observed in younger population with mild and moderate motor disorders. The multilevel orthopedic surgery should be justified by 3D gait analysis and has as objective to address primary and secondary abnormalities in order to restore walking ability with lower energy consumption and without flexed-knee in stance.

REFERENCES

[1] Quinby, J. M., Abraham, A. (2005). Musculoskeletal problems in cerebral palsy. *Curr Paediatr,* 15: 9–14.

[2] Temelli, Y., Akalan, N. E. (2009). Treatment approaches to flexion contractures of the knee. *Acta Orthop Traumatol Turc,* 43: 113–120.

[3] El-Sobky., T. A., Fayyad, T. A., Kotb, A. M., Kaldas, B. (2018). Bony reconstruction of hip in cerebral palsy children gross motor function classification system levels III to V: A systematic review. *J Pediatr Orthop B,* 27: 221-230.

[4] Galey, S. A., Lerner, Z. F., Bulea, T. C., Zimbler, S., Damiano, D. L. (2017) Effectiveness of surgical and non-surgical management of crouch gait in cerebral palsy: a systematic review. *Gait Posture,* 54: 93-105.

[5] Haumont, T., Church, C., Hager, S., Cornes, M. J., Poljak, D., Lennon, D., Henley, J., Taylor, D., Niller, T., Miller, F. (2013). Flexed-knee gait in children with cerebral palsy: a 10-year follow-up study. *J Child Orthop,* 7(5):435-443.

[6] Sutherland, D. H., Davids, J. R. (1993). Common gait abnormalities of the knee in cerebral palsy. *Clin Orthop Relat Res,* 288:139–147.

[7] Wren, T. A., Rethlefsen, S., Kay, R. M. (2005). Prevalence of specific gait abnormalities in children with cerebral palsy: influence of cerebral palsy subtype, age, and previous surgery. *J Pediatr Orthop,* 25: 79–83.

[8] Rodda, J. M., Graham, H. K., Carson, L., Galea, M. P., Wolfe, R. (2004). Sagittal gait patterns in spastic diplegia. *J Bone Joint Surg (Br),* 86: 251–258.

[9] Kedem, P., Scher, D. M. (2016). Evaluation and management of crouch gait. *Curr Opin Pediatr,* 28: 55-59.

[10] Vuillermin, C., Rodda, J., Rutz, E., Shore, B. J., Smith, K., Graham, H. K., et al. (2011). Severe crouch gait in spastic diplegia can be prevented: A population-based study. *J Bone Joint Surg (Br),* 93: 1670-1675.

[11] Arnold, A. S., Anderson, F. C., Pandy, M. G., Delp, S. L. (2005). Muscular contributions to hip and knee extension during the single limb stance phase of normal gait: a framework for investigating the causes of crouch gait. *J Biomech,* 38: 2181–2189.

[12] Hicks, J. L., Schwartz, M. H., Arnold, A. S., Delp, S. L. (2008). Crouched postures reduce the capacity of muscles to extend the hip and knee during the single-limb stance phase of gait. *J Biomech,* 41: 960–967.

[13] Sutherland, D. H., Olshen, R., Cooper, L., Woo, S. L. (1980). The development of mature gait. *J Bone Joint Surg (Am)*, 62: 336–353.

[14] Bell, K. J., Ounpuu, S., DeLuca, P. A., Romness, M. J. (2002). Natural progression of gait in children with cerebral palsy. *J Pediatr Orthop*, 22: 677–682.

[15] Rodda, J. M., Graham, H. K., Nattrass, G. R., Galea, M. P., Baker, R., Wolfe, R. (2006). Correction of severe crouch gait in patients with spastic diplegia with use of multilevel orthopaedic surgery. *J Bone Joint Surg (Am)*, 88: 2653-2664.

[16] Rose, G. E., Lightbody, K. A., Ferguson, R. G., Walsh, J. C., Robb, J.E. (2010). Natural history of flexed knee gait in diplegic cerebral palsy evaluated by gait analysis in children who have not had surgery. *Gait Posture*, 31: 351–354.

[17] Sutherland, D. H., Cooper, L. (1978). The pathomechanics of progressive crouch gait in spastic diplegia. *Orthop Clin North Am*, 9: 143–154.

[18] Murphy, K. P. (2009). Cerebral palsy lifetime care - four musculoskeletal conditions. *Dev Med Child Neurol*, 51, Suppl 4: 30-37.

[19] Theologis, T. (2013). Lever arm dysfunction in cerebral palsy gait. *J Child Orthop*, 7(5): 379-382.

[20] Miller, F., Browne, E. (2005) *Cerebral palsy*. Springer, New York.

[21] Opheim, A., Jahnsen, R., Olsson, E., Stanghelle, J. K. (2012). Balance in relation to walking deterioration in adults with spastic bilateral cerebral palsy. *Phys Ther*, 92: 279-288.

[22] Amen, J., El-Gebeily, M., El-Mikkawy, D. M., Yousry, A. H., El-Sobky, T. A. (2018). Single-event multilevel surgery for crouching cerebral palsy children: Correlations with quality of life and functional mobility. *J Musculoskelet Surg Res*, 2: 148-155.

[23] Lamberts, R. P., Burger, M., du Toit, J., Langerak, N. G. (2016). A Systematic Review of the Effects of Single-Event Multilevel Surgery on Gait Parameters in Children with Spastic Cerebral Palsy. *PLoS ONE* 11(10): e0164686.

[24] Popkov, D. A., Zmanovskaya, V. A., Gubina, E. B., Leonchuk, S. S., Butorina, M. N., Pavlova, O. L. (2015). [The results of single-event multilevel orthopedic surgeries and the early rehabilitation used in complex with botulinum toxin treatment in patients with spastic forms of cerebral palsy]. *Zh Nevrol Psikhiatr Im S S Korsakova*, 115(4):41-48. doi: 10.17116/jnevro20151154141-48. Russian.

[25] Gatamov, O. I., Chibirov, G. M., Borzunov, D. Yu., Popkov, D. A. (2018). Surgical orthopaedic management of cerebral palsy in adults: literature review and preliminary analysis of our treatment experience. *Genij Ortopedii*, 24(4): 538-547. doi 10.18019/1028-44272018-24-4-538-547. (In Russian).

[26] Rang, M., Silver, R., de la Garza, J. (1986). Cerebral palsy. In: Lovell WW, Winter RB (eds) *Pediatric orthopaedics*, 2nd edn, vol. 1. JB Lippincott, Philadelphia, pp 345–396.

[27] van den Hecke, A., Malghem, C., Renders, A., Detrembleur, C., Palumbo, S., Lejeune, T. M. (2007). Mechanical work, energetic cost, and gait efficiency in children with cerebral palsy. *J Pediatr Orthop*, 27: 643–647.

[28] Graham, H. K., Baker, R., Dobson, F., Morris, M. E. (2005). Multilevel orthopaedic surgery in group IV spastic hemiplegia. *J Bone Joint Surg (Br)*, 87: 548–555.

[29] Chibirov, G. M., Dolganova, T. I., Dolganov, D. V., Popkov, D. A. (2019). Analysis of the causes of pathological patterns of the kinematic locomotor profile based on the findings of computer gait analysis in children with spastic CP types. *Genij Ortopedii*, 25(4): 493-500. doi 10.18019/1028-4427-2019-25-4-493-500. (In Russian).

[30] Aroojis, A., Patel, M., Shah, A., Sarathy, K., Vaidya, S., Mehta, R. (2019). Distal femoral extension osteotomy with 90° pediatric condylar locking compression plate and patellar tendon advancement for the correction of crouch gait in cerebral palsy. *Indian J Orthop,* 53: 45-52.

[31] Dreher, T., Thomason, P., Švehlík, M., Döderlein, L., Wolf, S. I., Putz, C., Uehlein, O., Chia, K., Steinwender, G., Sangeux, M., Graham, H. K. (2018). Long-term development of gait after multilevel surgery in children with cerebral palsy: a multicentre cohort study. *Dev Med Child Neurol*, 60(1): 88-93.

[32] Gomez-Andres, D., Pulido-Valdeolivas, I., Martin-Gonzalo, J. A., Lopez-Lopez, J., Martinez-Caballero, I., Gomez-Barrena, E., Rausell, E. (2014). External evaluation of gait and functional changes after a single-session multiple myofibrotenotomy in school-aged children with spastic diplegia. *Rev Neurol*, 58(6):247-254.

[33] *Pilloni, G., Pau, M., Costici, F., Condoluci, C., Galli, M. (2018). Use of 3D gait analysis as predictor of Achilles tendon lengthening surgery outcomes in children with cerebral palsy. Eur J Phys Rehabil Med, 55(2): 250-257.*

[34] Read, H., Hazlewood, M., Hillman, S., Prescott, R., Robb, J. (2003). Edinburgh visual gait score for use in cerebral palsy. *J Pediatr Orthop*, 23(3): 296-301.

[35] Leardini, A., Sawacha, Z., Paolini, G., Ingrosso, S., Nativo, R., Benedetti, M. G. (2007). A new anatomically based protocol for gait analysis in children. *Gait Posture*, 26(4) :560-571.

[36] Svehlik, M., Steinwender, G., Kraus, T., et al. (2011). The influence of age at single-event multilevel surgery on outcome in children with cerebral palsy who walk with flexed knee gait. *Dev Med Child Neurol*, 53: 730–735.

[37] Arnold, A. S., Liu, M. Q., Schwartz, M. H., Ounpuu, S., Dias, L. S., Delp, S. L. (2006). Do the hamstrings operate at increased muscle-tendon lengths and velocities after surgical lengthening? *J Biomech*, 39: 1498–1506.

[38] Wren, T. A., Gorton, G. E., Ounpuu, S., Tucker, C. A. (2011). Efficacy of clinical gait analysis: A systematic review. *J Gait Post,* 34: 149-153. doi: 10.1016/j.gaitpost.2011. 03.027.

[39] Rose, S. A., DeLuca, P. A., Davis, R. B. 3rd, Ounpuu, S., Gage, J. R. (1993). Kinematic and kinetic evaluation of the ankle after lengthening of the gastrocnemius fascia in children with cerebral palsy. *J Pediatr Orthop,* 13: 727–732.

[40] Shore, B. J., White, N., Graham, H. K. (2010). Surgical correction of equinus deformity in children with cerebral palsy: a systematic review. *J Child Orthop,* 4:277–290.

[41] Borton, D. C., Walker, K., Pirpiris, M., Nattrass, G. R., Graham, H. K. (2001). Isolated calf lengthening in cerebral palsy. Outcome analysis of risk factors. *J Bone Joint Surg (Br)*, 83: 364–370.

[42] Dietz, F. R., Albright, J. C., Dolan, L. (2006). Medium-term follow-up of Achilles tendon lengthening in the treatment of ankle equinus in cerebral palsy. *Iowa Orthop J,* 26: 27–32.

[43] Segal, L. S., Thomas, S. E., Mazur, J. M., Mauterer, M. (1989). Calcaneal gait in spastic diplegia after heel cord lengthening: a study with gait analysis. *J Pediatr Orthop*, 9: 697–701.

[44] McGinley, J., Dobson, F., Ganeshalingam, R., Shore, B. J., Rutz, E., Graham, H. K. (2012). Single-event multilevel surgery for children with cerebral palsy: a systematic review. *Dev Med Child Neurol*, 54: 117–128.

[45] Wilson, N. C., Chong, J., Mackey, A. H., Stott, N. S. (2014). Reported outcomes of lower limb orthopaedic surgery in children and adolescents with cerebral palsy: a mapping review. *Dev Med Child Neurol*, 56: 808–814.

[46] Chang, F. M., Rhodes, J. T., Flynn, K. M., Carollo, J. J. (2010). The role of gait analysis in treating gait abnormalities in cerebral palsy. *Orthop Clin North Am*, 41: 489-506. doi: 10.1016/j.ocl.2010.06.009.

[47] Ławniczak, D., Jóźwiak, M., Manikowska, F. (2010). [Assessment of absolute knee joint linear and angular velocity in patients with spastic cerebral palsy after operative treatment of lever arm disfunction deformities - prospective study]. *Chir Narzadow Ruchu Ortop Pol*, 75(2): 92-97.

[48] Novacheck, T. F., Stout, J. L., Gage, J. R., Schwartz, M. H. (2009). Distal femoral extension osteotomy and patellar tendon advancement to treat persistent crouch gait in cerebral palsy. Surgical technique. *J Bone Joint Surg (Am)*, 91(Suppl 2):271–286.

[49] Shishov, S. V., Ivshin, V. G. (2016). Minimalno invazivnye operatsii na myshtsakh u detei s DTsP. Opyt piatiletnego primeneniia [Minimally invasive surgery of muscles in children with cerebral palsy. The experience of five-year use]. *Vestnik Novykh Meditsinskikh Tekhnologii (Electronic Edition)*, 2: 137-141. (in Russian) doi: 10.12737/20085.

[50] Nieuwenhuys, A., Õunpuu, S., Van Campenhout, A., Theologis, T., De Cat, J., Stout, J., Molenaers, G., De Laet, T., Desloovere, K. (2016) Identification of joint patterns during gait in children with cerebral palsy: a Delphi consensus study. *Dev Med Child Neurol*, 58(3), 306-313.

In: Encyclopedia of Surgery (22 Volume Set)
Editors: Andreas Lehrer and Kristin Mueller
ISBN: 978-1-53618-329-0
© 2020 Nova Science Publishers, Inc.

Chapter 121

RECONSTRUCTIVE HIP SURGERY AS A PART OF MULTILEVEL SURGERY IN NON-AMBULANT CP CHILDREN. HIP DEVELOPMENT AFTER RECONSTRUCTIVE SURGERY

Ahmed Tomov[1] *, Georgy Chibirov[1], Sinisa Ducic[2], Arnold Popkov[1] and Anna Aranovich[1]

[1]Ilizarov National Medical Research Center for Traumatology and Orthopedics, Kurgan, Russia

[2]Children's University Hospital, Belgrade, Serbia

ABSTRACT

Purpose of the study was to assess radiological parameters of the hip joint in patients with cerebral palsy who underwent single-event multilevel orthopedic surgery including hip reconstruction. The treatment outcomes (proximal femoral and acetabular growth) were studied depending on the age of surgery and time period between interventions in bilateral hip dislocation. The hip development after varus derotation osteotomy osteotomy associated with acetabuloplasty were assessed as well as development of contralateral uninvolved hip in cases of unilateral hip displacement.

Material and methods. This study included 124 children with spastic types of cerebral palsy who underwent hip reconstructive treatment at the Ilizarov Scientific Center between 2012 and 2016. Mean age at index surgery was 7.01 ± 2.47 years (range: 3 years 7 months to 11 years 2months). Assessment of outcomes was based on AP pelvic radiographs and CT scans.

Results. Multilevel surgeries including hip reconstructions, foot reconstructions, hamstring lengthening and gastrocnemius fascia lengthening provided favorable hip development in long-term follow-up in patients with bilateral or unilateral hip subluxation. Mean increase of migration index was 3% per year after varus derotation femoral osteotomy and 2% per year after varus derotation osteotomy associated with acetabuloplasty. Progressive slow increase of Wiberg angle was observed only during 2

* Corresponding Author's Email: ahmed-tomov@mail.ru.

years after surgery. In unilateral hip disorders the contralateral release of the adductors (in case of diminished hip abduction), rigorous postural management and passive verticalization with weight-bearing ensured favorable growth and development of undislocated hip joint in long-term follow-up. The risk of hip subluxation (Reimers index over 40% or progression of Reimers index over 7% per year) increased up to 11.8% (in children younger 8 y.o.) and up to 14.3% (age over 8 y.o.) if release of the adductors of contralateral hip was not performed in unilateral hip dislocation.

Conclusion. Hip dislocation in CP children requires reconstructive surgery combining hip procedures of foot reconstructions and knee and ankle soft-tissue release in order to gain soft-tissue balance and facility to appropriate postural management.

Keywords: cerebral palsy, hip reconstruction, multilevel orthopedic surgery, outcomes

INTRODUCTION

Hip dislocation in children with severe forms of cerebral palsy is quite common pathology. This orthopedic complication occurs in 60–90% in patients with level IV-V of GMFCS levels IV–V [1]. Hip dislocation results in restriction of the ability to stand and walk, sitting imbalance, diminished hip motion, difficulty with perineal care, pain, pelvic obliquity and early onset coxarthrosis [1–3]. Moreover, unilateral dislocations attribute to scoliosis [4, 5]. Hip disorders are often associated to knee and ankle contractures, deformities of the feet. And this complex severe problem impairs quality of [6–8].

It is known that correct postural management including passive weight-bearing verticalization is favorable for development of the hip joints [9]. It has also been reported that the neck shaft angle (NSA) increases over time after a varus derotation osteotomy (VDRO) and re-dislocations must be expected in 6–7% of cases [3]. Therefore, some authors suggest that higher GMFCS levels require a higher degrees of NSA correction associated with extensive soft-tissue release [3, 10-13]. Regarding development of the operated hip in long-term follow-up, few radiological parameters have studied: NSA (°), Wiberg angle (°), acetabular angle (°) and Reimers index (migration percentage; %) [11, 14-16].

However, in reported series, the hip reconstruction procedures were performed without surgeries for associated orthopedic disorders. The authors of above-mentioned publications do not consider the role of simultaneous corrections of knee and ankle contractures and foot deformities. Whereas only realignment of the whole leg allows to apply longitudinal charge during the passive verticalization in postural management.

The aim of the study was to assess radiological parameters of the hip joint in patients with severe spastic cerebral palsy who underwent single-event multilevel orthopedic surgery including hip reconstruction. The treatment outcomes (proximal femoral and acetabular growth) were studied depending on the age of surgery and time interval between operations in bilateral hip subluxation/dislocation.

MATERIAL AND METHODS

In the present study, we included 124 children with spastic CP who underwent hip reconstruction during the period 2012-2016 in the Russian Ilizarov scientific center.

Inclusion criteria in the study were as follows: children affected with spastic CP, manifesting subluxated or dislocated hip and who underwent hip reconstructive procedure (VDRO added with acetabuloplasty if needed) in combination with simultaneously performed single-event multilevel surgery for knee and ankle contractures and foot deformities. The other inclusion criteria were clinical and radiological follow-up at least 3 years, level III, IV and V of GMFCS.

Exclusion criteria in the study were as follows: varus osteotomy in patient without CP, valgus osteotomy in CP. In total, four patients were excluded from the study.

Pre-, post-operative and the latest follow-up radiographs were analyzed for Reimers index, Acetabular index, NSA by a consultant orthopedic surgeon. Wiberg angle was measured only on post-operative and latest follow-up radiographs.

Considering the influence of the age of surgery on the prognosis for further hip joint development, radiological findings were assessed separately for the group of patients under 8 y.o. (Group I) and for the group of children aged 8 and more years (Group II). In patients with bilateral surgery, each hip was reviewed independently, except for age analysis.

Within these two big groups we distinguish subgroups for fine radiological analysis:

- Bilateral subluxation and/or dislocation who underwent bilateral consecutive hip reconstruction within period less 6 months – subgroups Ia and IIa. Each hip was reviewed independently, except for age analysis.
- Unilateral subluxation or dislocation – subgroups Ib and IIb - radiological analysis for operated hip;
- Unilateral subluxation or dislocation – subgroups Ic and IIc - radiological analysis for uninvolved hip (Reimers index less 40%);
- Bilateral subluxation and/or dislocation where the second hip was operated in 1 year more after index surgery because of a somatic disorder – subgroup Id;

No cases corresponding the criteria for subgroups IId were found in the cohort.

Prior to surgical intervention, computed tomography (CT) scans with 3D reconstructions were acquired at a thickness of 1 mm to visualize the direction of migration, sphericity of the femoral head and to determine the sector of the maximal acetabular dysplasia. In 15 patients the lack of acetabular cover was measured comparing pathological findings to normal values of a given age [17]. Thus, the required amount of correction by acetabuloplasty was determined prior to surgery (Figure 1).

During surgery the height of bone graft after femoral shortening was tailored depending on the needed size for inter-position on the pelvic osteotomy side. Our approach ensured the amount of correction adjusted to the individual situation.

All the surgeries were performed by the same senior surgeon, an author of this chapter, who has regularly practiced these procedures with these two types of plates during the previous 5 years. He was always assisted by full staff member surgeons. The technique femoral and pelvic osteotomies, soft tissue procedures were standard [18-20].

Postoperatively, bilateral short leg plasters with a connecting bar were applied for six to eight weeks. All patients were passively verticalized in standers in 14 to 21 days after the intervention. At discharge, recommendations were given on orthosis fitting, postural management, joint mobilization. Consultations were scheduled at regular basis.

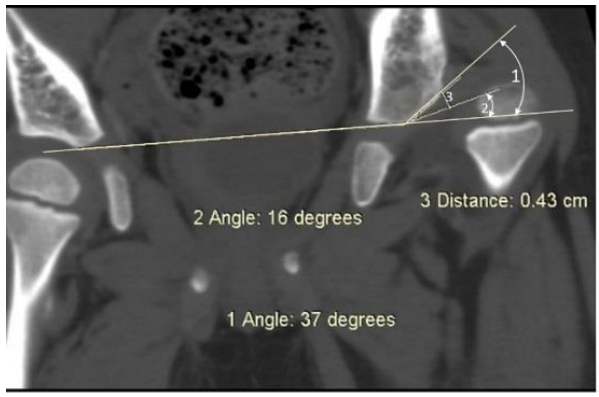

(a)

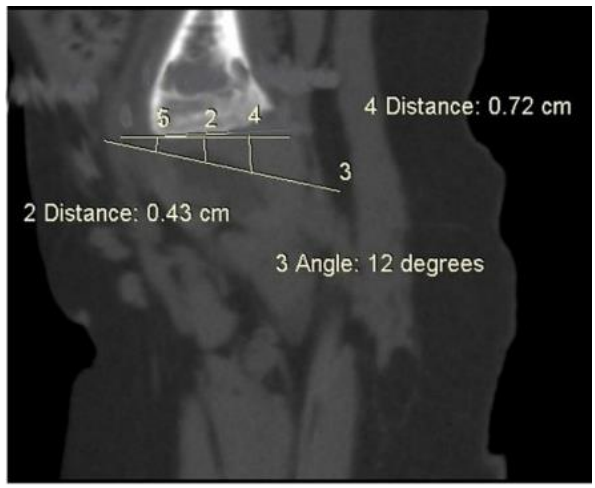

(b)

Figure 1. CT scan showing the measurement of the lack of acetabular cover: measurement in coronal plane , dysplastic acetabular angle (1), normal virtual acetabular angle (2), distance between two oblique lines measured from the acetabular edge represents the lack of acetabulum in coronal plane (3) (a); measurements in sagittal plane, the virtual line (3) making normal angle obliquity (12°) of acetabulum edge in sagittal plan and taking into consideration amount of acetabulum correction (line 2, distance of 0.43 mm in middle sector of acetabulum) representing the most important acetabular dysplasia of 0.72 mm in posterior sector of acetabulum (b).

Statistical assessment was performed with AtteStat® software. Mean values of indices and their errors were defined for descriptive statistics. The comparisons between the groups in the quantitative study were carried out using Wilcoxon signed-ranks test for matched or independent samples. The test was two-tailed with a 0.05 level of significance.

This research was approved by the Ilizarov Center Review Board. The study complies with the Declaration of Helsinki statement on medical protocol and ethics and the "Rules of Clinical Practice in the Russian Federation" approved by Order of the Ministry of Health of the Russian Federation of June 19, 2003 No. 266. Representatives of all patients enrolled in the study provided oral and written informed consent.

RESULTS

Two hundred seventy-three pediatric patients were treated operatively for neurologic reconstructable hip dysplasia at our institution between 2012 and 2015. Out of 273 patients with cerebral palsy, 149 did not meet our inclusion criteria.

One hundred twenty-four patients (81 males and 43 females) were included in our study. One hundred nineteen patients (95.97%) were non-ambulatory (GMFCS IV or V) and 5 patients (4.03%) were walkers (GMFCS III) (Table 1). The mean age at the index surgery was 7.01 ± 2.47 years (range: 3 years 7 months to 11 years 2months). According to GMFCS levels, the distribution was as follows: level III – five patients, level IV – 70 patients, level V – 49 patients.

All radiographic parameters were significantly improved compared with pre-operative values in subgroups Ia and IIa (Table 2, Figure 2).

In the long-term follow-up, in subgroups Ia and IIa, the centered position of the femoral head was maintained. The values of Wiberg angle corresponded to the normal development of acetabulum. Slight elevation of the NSA was 1° to 2° per year. Mean Reimers index remained within normal range except 2 cases (two hips, 1.9%) in group 1a where this parameter exceeded 30% in 3 years after surgery with annual progression of more than 10%. In both fair cases, there was not any postural management and orthosis fitting.

Table 1. Patient distribution across GMFCS levels, elements of surgery

		Group I (age under 8 years)		Group II (age of 8 years and older)	
		Bilateral subluxation/ dislocation	Unilateral subluxation/ dislocation	Bilateral subluxation/ dislocation	Unilateral subluxation/ dislocation
Number of patients		52	31	20	21
Mean age at index surgery; years		5.8 ± 1.03	5.3 ± 1.17	9.6 ± 1.67	10.0 ± 2.41
GMFCS, n	III	-	2	1	2
	IV	33	13	12	13
	V	19	17	7	6
Surgical elements; n					
VDRO		104	31	40	21
Acetabuloplasty		40	15	14	12
Open hip reduction		3	-	4	-
Adductotomy		92	31	34	22
Hamstring lengthening		60	24	28	12
Triceps or gastrocnemius lengthening		36	25	4	6
Shortening of m.tibialis post.		32	6	10	6
Foot osteotomy\ arthrodesis Grice		29	2	12	4

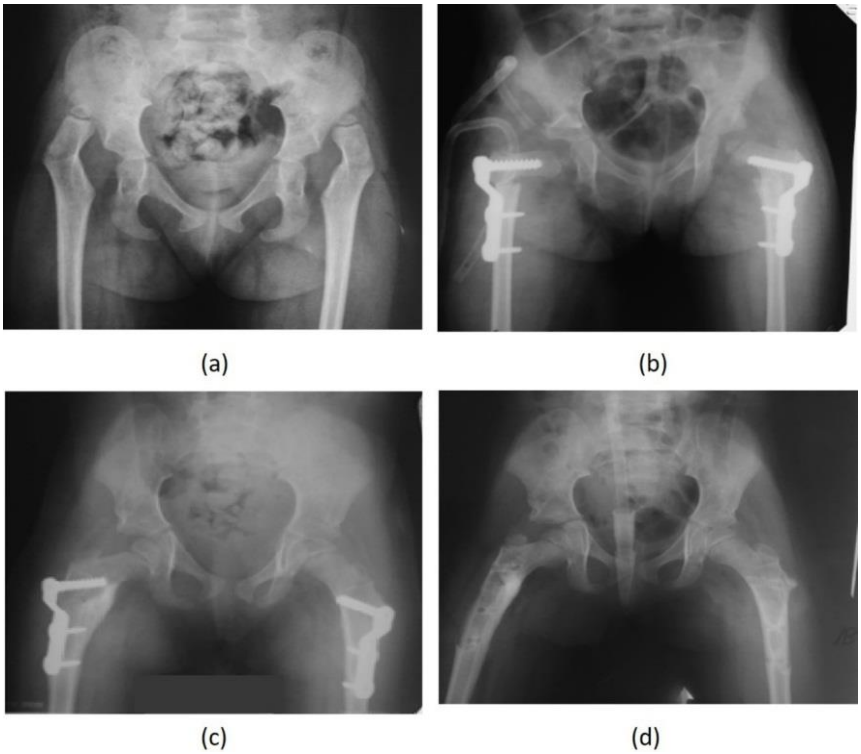

Figure 2. Bilateral hip dislocation, 5 y.o. girl, GMFCS V: before surgery, Reimers index 100% (right hip), 100% (left hip), acetabular index 29° (right hip), 30˚ (left hip) (a); after surgery Reimers index 0% (right hip), 0% (left hip), acetabular index 12° (right hip), 13˚ (left hip), Wiberg angle 37° (right hip), 36° (left hip) (b); in 1 year after surgery Reimers index 0% (right hip), 0% (left hip), acetabular index 12° (right hip), 12˚ (left hip), Wiberg angle 34° (right hip), 32° (left hip) (c); in 3 years after surgery Reimers index 0% (right hip), 0% (left hip), acetabular index 11° (right hip), 12˚ (left hip), Wiberg angle 30° (right hip), 30° (left hip) (d).

Table 2. Pre-operative, post-operative and long-term FU radiographic parameters in subgroups Ia and IIa

	Subgroup	Preoperative	Early postoperative	1-year FU	2.5 to 3 years FU
Reimers index; %	Ia	61,2 ± 25,8	2,0 ± 10,6*	3,3 ± 6,6*	6,1 ± 9,6*
	IIa	62,4 ± 22,7	0,4 ± 1,7*	3,2 ± 5,7*	3,7 ± 4,6*
Acetabular index; °	Ia	30,8 ± 8,1	23,1 ± 6,8	22,6 ± 7,3	22,4 ± 15,8
	IIa	29,4 ± 6,1	20,4 ± 7,7	18,9 ± 6,9	20,0 ± 4,6
NSA; °	Ia	161,1 ± 10,1	119,8 ± 8,2*	120,2 ± 15,1*	122,8 ± 15,3*
	IIa	158,1 ± 12,4	118,6 ± 6,9*	117,7 ± 9,6*	121,2 ± 9,0*
Wiberg angle; °	Ia		25,8 ± 6,8	27,0 ± 7,9	30,3 ± 7,9
	IIa		32,8 ± 6,7	37,6 ± 16,0	34,9 ± 7,0

*- significant difference in comparison to initial value, Wilcoxon signed-rank test ($p < 0.05$).

In unilateral subluxation, the final outcomes were good, with stable centered hips (Reimers index less 30%) in all operated hips (Table 3, Figure 3). The mean Wiberg angle corresponded to the favorable development of the hip. Slight elevation of the NSA did not exceed 7% per year and remained within normal values.

Table 3. Pre-operative, post-operative and long-term FU radiographic parameters in subgroups Ib and IIb

	Subgroup	Preoperative	Early postoperative	1-year FU	2.5 to 3 years FU
Reimers index; %	Ib	72,3 ± 23,7	1,5 ± 8,6*	2,9 ± 6,2*	5,3 ± 7,7*
	IIb	57,6 ± 23,5	0,4 ± 1,7*	2,2 ± 4,5*	5,2 ± 4,9*
Acetabular index; °	Ib	31,7 ± 7,2	21,5 ± 7,3	23,4 ± 7,0	19,3 ± 5,0
	IIb	33,9 ± 8,9	22,6 ± 9,3	24,7 ± 7,3	20,2 ± 8,8
NSA; °	Ib	165,0 ± 11,1	122 ± 11,9*	126,3 ± 22,1*	130,6 ± 17,9*
	IIb	156,1 ± 12,9	120,1 ± 11,0*	122,7 ± 13,0*	128,2 ± 10,1*
Wiberg angle; °	Ib		27,7 ± 7,11	28,1 ± 6,9	32,0 ± 9,1
	IIb		32,6 ± 7,9	27,8 ± 8,6	29,2 ± 7,7

*- significant difference in comparison to initial value, Wilcoxon signed-rank test ($p < 0.05$)

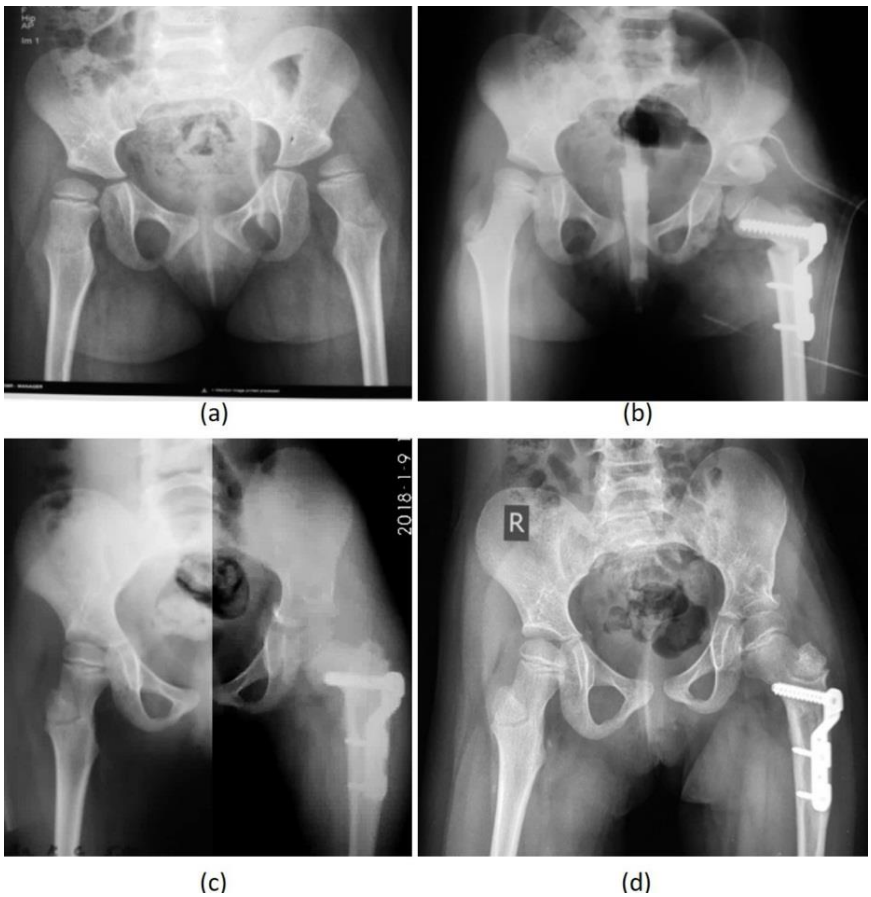

Figure 3. Unilateral left hip subluxation, 6 y.o. boy, GMFCS IV: before surgery, Reimers index 26% (right hip), 64% (left hip), acetabular index 28° (right hip), 32° (left hip) (a); after surgery Reimers index 26% (right hip), 2% (left hip), acetabular index 28° (right hip), 14° (left hip), Wiberg angle 16° (right hip), 40° (left hip) (b); in 1 year after surgery Reimers index 18% (right hip), 0% (left hip), acetabular index 26° (right hip), 16° (left hip), Wiberg angle 23° (right hip), 31° (left hip) (c); in 3 years after surgery Reimers index 13% (right hip), 5% (left hip), acetabular index 19° (right hip), 18° (left hip), Wiberg angle 28° (right hip), 30° (left hip) (d).

In unilateral hip subluxation cases, among the contralateral hips, 48 hips had Reimers index of less than 20% at the 3-year follow-up (Table 4). Four of the contralateral hips (7.7% of unilateral forms) showed fast progressive increase of 12 to 23% per year at follow-up in subgroup Ic (Figure 4).

Table 4. Pre-operative, post-operative and long-term FU radiographic parameters in subgroups Ic and IIc

	Subgroup	At the index surgery	1 year FU	2.5 to 3 years FU
Reimers index;%	Ic	19,8 ± 12,2	14,9 ± 10,1	9,0 ± 6,7
	IIc	17,8 ± 10,7	21,5 ± 12,5	14,2 ± 10,9
Acetabular index; °	Ic	17,5 ± 5,3	19,5 ± 54	23,3 ± 6,1
	IIc	18,9 ± 6,2	18,9 ± 7,2	19,8 ± 2,9
NSA; °	Ic	162,1 ± 8,6	160,2 ± 12,9	159 ± 16,5
	IIc	158,9 ± 8,9	154,6 ± 12,2	157 ± 11,5
Wiberg angle; °	Ic	22,5 ± 8,6	31,0 ± 8,8	29,3 ± 7,1
	IIc	28,9 ± 6,6	30,9 ± 10,5	25,5 ± 2,6

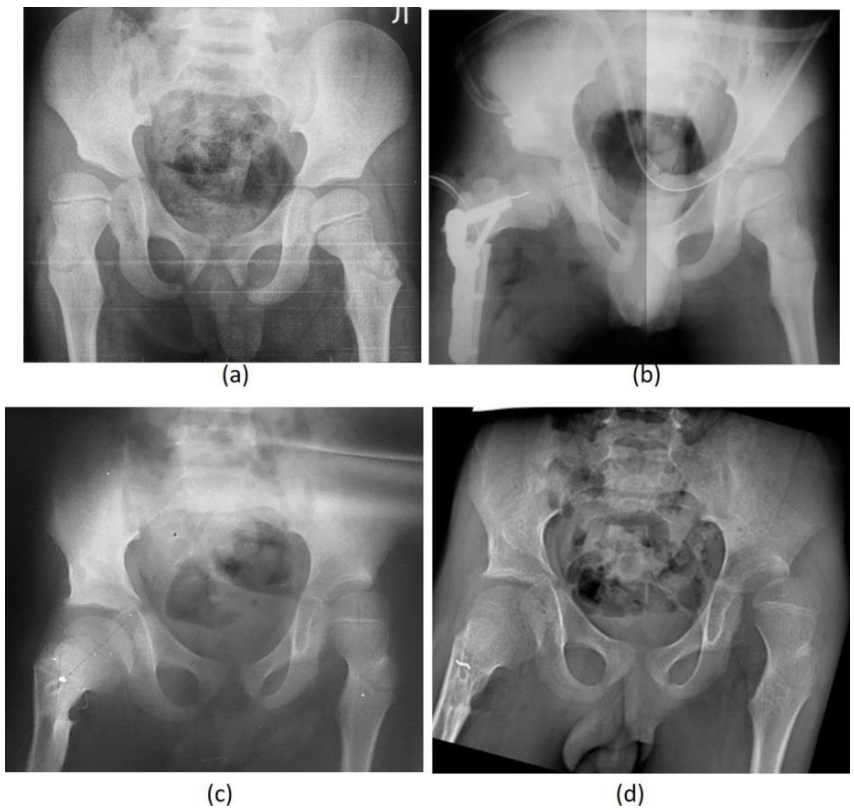

Figure 4. Unilateral right hip subluxation, 6 y.o. boy, GMFCS IV: before surgery, Reimers index 52% (right hip), 12% (left hip), acetabular index 32° (right hip), 27˚ (left hip) (a); after surgery Reimers index 0% (right hip), 12% (left hip), acetabular index 18° (right hip), 25˚ (left hip), Wiberg angle 32° (right hip), 23° (left hip) (b); in 1 year after surgery Reimers index 0% (right hip), 25% (left hip), acetabular index 9° (right hip), 25˚ (left hip), Wiberg angle 32° (right hip), 19° (left hip) (c); in 3 years after surgery Reimers index 11% (right hip), 52% (left hip), acetabular index 9° (right hip), 31˚ (left hip), Wiberg angle 30° (right hip), 3° (left hip) (d).

Reconstructive surgery for contralateral hip was required in two cases. In all these 4 cases with high annual elevation of migration index, the limited abduction ROM has been preoperatively noted but the adductor-psoas tenotomy was not performed on the contralateral site during the index surgery. It should be noted that adductor tenotomy on contralateral hip was never required in windswept deformity.

Table 5 demonstrates radiographic parameters for hips operated on in more than 1 year after index surgery in cases of bilateral hip subluxation/dislocations. It is obvious that unilateral reconstructive surgery doesn't improve or even stabilize the radiographic parameters of the contralateral hip joint already having the Reimers index over 40% at index surgery. On the other hand, even postponed surgery provided satisfactory outcomes in long term.

Table 5. Pre-operative, post-operative and long-term FU radiographic parameters in subgroups Id

	Before index surgery	In a year (before the second surgery)	Early postoperative	In 12 months	In 2 years
Reimers index;%	60,8 ± 20,2	64,7 ± 24,0	1,02 ± 2,13*	1,2 ± 2,7*	2,8 ± 5,5*
Acetabular index; °	30,6 ± 4,7	30,5 ± 6,3	23,5 ± 5,8	20,4 ± 5,3*	19,5 ± 1,7*
NSA; °	163,8 ± 9,9	162,7 ± 10,9	121,7 ± 4,2*	120,2 ± 9,7*	120,5 ± 12,7*
Wiberg angle; °			26,9 ± 7,4	30,2 ± 9,5	28,8 ± 1,7

*- significant difference in comparison to initial value, Wilcoxon signed-rank test ($p < 0.05$)

Comparing radiographic outcomes of hip reconstructions in patients aged less 8 years and patients with age of 8 and more years, we found no difference in development of operated hip joints. Furthermore, the outpatient records revealed that none of the patients suffered from hip pain at the latest follow-up. We may speculate that simultaneous realignment of the whole leg provide favorable conditions for postural management and ensure improved hip development even after the age of 8 years in reconstructable cases.

CT morphometric analysis (Table 6) revealed amelioration of the operated hip anatomy (Table 6, Figure 5). Our approach provided a quantitative basis to calculate the amount of acetabular correction. Acetabular cover studied in a year after surgery had improved significantly towards the normal values in all 15 cases.

Table 6. CT morphometric measurements

	Acetabular anteversion	Axial acetabular index	Coronal acetabular index	Femoral neck anteversion	NSA	Sagittal acetabular inclination
Preoperative	15,86° ± 4,5°	125,2° ± 9,5°	30,9° ± 9,4°	47,3° ± 6,9°	152,1° ± 7,4°	4,9° ± 3,5°
In 10 to 14 months after surgery	14,43° ± 3,48°	120,8° ± 18,9°	20,8° ± 6,3°	22,8° ± 10,2°	118,5° ± 17,8°	12,2° ± 2,8°

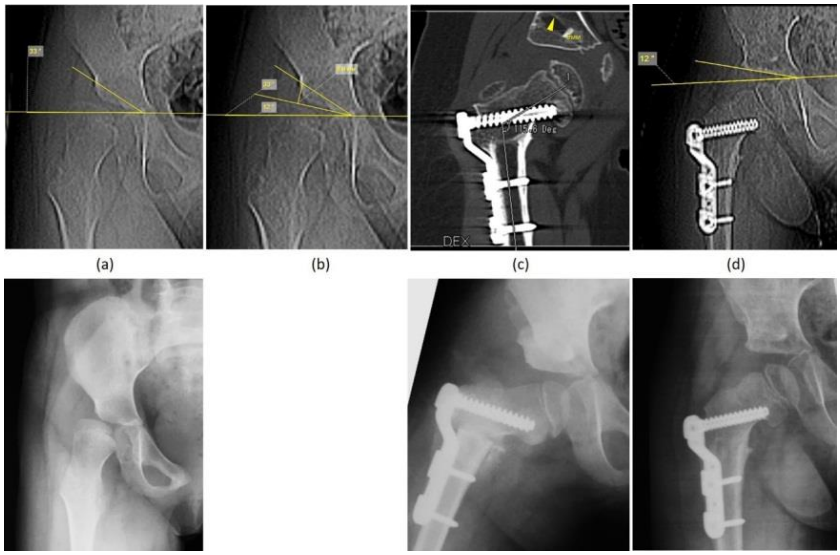

Figure 5. CT scans of hip reconstruction with previously calculated amount of acetabular correction, upper row – CT scans, lower row – corresponded radiographs of the reconstructed hip: preoperative scan and radiograph (a); measurement of amount of acetabular correction – length of perpendicular line between real and virtual lines connecting Y-cartilage and acetabular edge (b); immediate postoperative scan and radiograph (c); outcome in 2 years (d).

DISCUSSION

Spastic hip subluxation or dislocation is a frequent problem in children with cerebral palsy [12-14, 16, 19]. Optimal clinical decision making and surgical management of hip disorders in children with cerebral palsy requires an understanding of the pathogenesis and natural history [21-23]. The incidence of subluxation and dislocation of the hip in children with cerebral palsy correlates with the severity of motor impairment and is accompanied by a serious deterioration in the quality of life for both the child and his family or caregivers [6, 15, 23–25].

The hip problems management in CP children surveillance should include following a surveillance program, counteracting the effects of the muscle imbalance, proper positioning with the hips in abduction and extension, botulinum therapy, surgical treatments consisting of adductor-psoas release, VDRO of the proximal femur and pelvic osteotomy [16, 26-28]. This program allows, in most cases, to prevent unreconstructable hip dislocation requiring palliative surgery.

Among the radiological parameters in assessment of the hip joint, the Reimers index is the major criterion of indication for the surgery along with the acetabular index [12, 14, 18, 21, 29, 30]. The NSA and the Wiberg index have less importance in preoperative period, but in combination with above-mentioned parameters ensure a reliable assessment of morphometric changes of the hip in long-term follow-up after surgery [11, 31].

Currently, there is a consensus on the indications for reconstructive hip surgery in CP children: the Reimers index 40% or more or the rate of its increase ≥7% a year [21, 22, 29]. Regarding the acetabular index, its threshold values for reconstructive surgery (pelvic

osteotomy) are controversial. It is recognized, that the lateralisation of the femoral head precedes the acetabular dysplasia [1, 2, 10, 13]. Hägglund et al. reported that hip centration by non-operative treatment in patients with Reimers index 30-39% resulted in decrease of acetabular index below the threshold values of operative treatment [29].

Most commonly, combinations of adductor-psoas release, VDRO and pelvic osteotomies are used for hip reconstruction [11, 12, 18, 19, 30, 32]. The optimal age for reconstructive procedures is up to 5–7 years old as during the residual growth the favorable remodeling of the hip occurs on conditions of appropriate postural management [15, 22, 33-35].

McNerney et al. demonstrated immediate and long-term (average FU 6.9 years) results of hip reconstruction in CP children analyzing changes in Reimers index: mean postoperative decrease from 66% to 5% followed by slight elevation of 11% by the latest follow-up control [32]. Moreover, the average acetabular index decreased from 26° to 13° in the short term and continue to decrease up to 11° in the long-term FU. Karlen et al. in a series with an average follow-up of 56 months showed an evident improvement in the migration index from 84 to 8% in the short term and up to 14% in the long-term observation period [30]. Jozwiak et al. in a series of 25 patients (30 hips) achieved required hip correction. In lonr-term follow-up they observe a slight increase of radiographic parameters: acetabular index from postoperative 22° to 23° in the long term, Reimers index from 11% to 23%, Wiberg angle from 16° to 23°, NSA from 133° to 140° [19]. Reidy et al. also reported improvement of Reimers index from 63.6% to 2.7% by surgery followed. Slow increase of mean Reimers index up to 9.7% occurred in the long-term period [12]. A review of the current literature shows that there is not clear understanding what postoperative increase of Reimers index corresponds to favorable development of operated hip. Bayusentono et al. [36] found a statistically significant increase of the Reimers index of 2.0% per year in GMFCS level IV and 3.5% in level V, which corresponds to increase of 4.0% in walkers and 7.7% in non-walkers in long-term follow up of 5 years in the article of Reidy et al. [12]. In both series final outcomes were classified as good. Regarding non operated hip in CP children, the risks of subluxation are not negligible if annual increase of migration index is 4% or more for Terjesen [37], 6-7% or more for Soo et al. [38] and Connelly et al. [39]. In our series, in majority of cases elevation of Reimers index remained less than 3% a year in long-term follow-up. In 98.1% of surgeries outcomes were classified good. Thus, the progressive elevation of Reimers index less than 4% per year in post-operative period should be recognized reflecting favorable development of operated hip.

It has been shown that the NSA increases over time after a VDRO [11, 12, 19]. Davids et al. [40] reported a 29%-loss of correction in 5 years and 6 months after surgery. Miller et al. [13] recommend correcting the NSA down to 100° in non-ambulatory patients and 120° in ambulatory patients. Mazur et al. suggests a correction to a post-operative NSA down to 100°–110° at the age of 4–12 years in non-walking children with GMFCS levels IV–V considering a spontaneous increase of 20° during residual growth, for older children NSA of 110°–120° should be recommended [11].

In our series, mean change of NSA was 1°-2° per year in bilateral dislocations and 7.7° per year in monoliteral hip dislocation. However, these changes were accompanied by improvement of mean Wiberg angle, that reflects harmonious development of the proximal femur and acetabulum. Progressive slow increase of Wiberg angle until normal values was observed during 2 years after surgery.

There remains controversy about the rate of re-dislocations after hip procedures. Sankar et al. reported one hip dislocation recurrence out of 14 reconstructive interventions [33].

Jozwiak et al. showed one dislocation and 6 subluxations (23%) after 30 reconstructive interventions in the long-term period [19]. Rutz et al. [41] found two hip re-dislocations in the long-term period after 168 interventions. Reidy et al. [12] stated that only 96.5% of operated hip joints were considered stable in the long-term period with a Reimers index of less than 33%. The authors explain recurrences with surgical errors. On the other hand, none of the above series of patients had SEMLS performed on knee and ankle joint, feet. Postural management, standing, orthosis fitting applied in post-operative period were not mentioned. However, postural correction using standing frames and proper positioning when sitting and lying is crucial for further hip development [9, 15, 21, 42]. Simultaneous correction of associated contractures and foot deformities seems to be necessary in order to facilitate postural management, shoes-wearing. On the short series, we showed previously the benefice of multilevel surgical approach in CP children with hip dislocation [18]. The present large series evaluating outcomes in long-term period is concordant with earlier study. Hip subluxation recurrence with rate of Reimers index of over 10% per year occurred only in two cases (2 hips, 1.9%). In both cases there was failure of postural management and lack of orthosis fitting.

Another controversial issue is unilateral hip dislocation. In literature, there is not consensus regarding contralateral hip. Carr et Gage observed lateralization of femoral head on contralateral site only in 0.9% of cases [43]. Gordon et al. did not find any critical elevation of Reimers index in the long-term follow-up [44]. Settecerri et al. had to perform VDRO of the contralateral hip only in two out of 48 children who had previously undergone unilateral hip reconstruction [45]. On the other hand, Noonan et al. operated on the contralateral hip in 15 out of 35 children in the long term after the index surgery [46]. Canavese et al. performed 12 hip surgeries on the contralateral hip in 27 children [47].

Owers et al. demonstrated more appropriate approach combining unilateral VDRO with bilateral soft tissue release to restore muscle balance [48]. Larsson et al. suggest VDRO only of dislocated hip with soft-tissue release carried out bilaterally followed with intensive non-operative treatment [16].

In our series, lateralization of contralateral hip and elevation the Reimers index were never observed on condition of bilateral adductor-psoas release. On the other hand, unilateral soft-tissue release resulted in significant deterioration of Reimers index in 7.7% in the contralateral hip. Thus, we share the opinion that children operated on with unilateral soft-tissue release have a high risk of displacement of the contralateral hip. And bilateral release of soft tissues to restore muscle balance should be mandatory in unilateral hip dislocation.

Using three-dimensional CT, Chung et al. [49] have shown the improved acetabular cover improved following a Dega osteotomy in hip reconstruction. Our approach to calculate a required acetabular edge advancement in acetabuloplasty demonstrated its reliability. Surgery with predetermined size of autograft resulted in precise correction angular acetabular parameters and improved acetabular cover.

Our long-term results show that reconstructive hip surgery in combination with SEMLS is a safe way to generate stable, pain free hips. Muscle balance, postoperative postural management, passive verticalization have crucial role for long-term normal development of operated hip. In our series this rule was not followed in 4 cases and it resulted in recurrent subluxation.

CONCLUSION

Reconstructive surgery in hip subluxation or dislocation in CP children should be combined with restoration of bilateral muscle balance, especially adductors, as well as correction of contractures of the knee and ankle joints, foot deformities in order to ensure favorable conditions for postural management in early and late postoperative period.

The rate of migration index elevation less than 4% per year corresponds to favorable development of operated hip. Combination of hip reconstruction and SEMLS ensures good outcomes even in children aged more 8 years. Bilateral release of soft tissues to restore muscle balance should be mandatory in unilateral hip dislocation.

REFERENCES

[1] Pritchett, J. W. (1983). The untreated unstable hip in severe cerebral palsy. *Clin Orthop Relat Res, 173*, 169-172.

[2] Bagg, M. R., Farber, J. & Miller, F. (1993). Long-term follow-up of hip subluxation in cerebral palsy patients. *J Pediatr Orthop, 13*(1), 32-36.

[3] Brunner, R. & Baumann, J. U. (1994). Clinical benefit of reconstruction of dislocated or subluxated hip joints in patients with spastic cerebral palsy. *J Pediatr Orthop, 14*(3), 290-294.

[4] Cooperman, D. R., Bartucci, E., Dietrick, E. & Millar, E. A. (1987). Hip dislocation in spastic cerebral palsy: long-term consequences. *J Pediatr Orthop, 7*(3), 268-276.

[5] Heidt, C., Hollander, K., Wawrzuta, J., et al. (2015). The radiological assessment of pelvic obliquity in cerebral palsy and the impact on hip development. *Bone Joint J, 97-B*, 1435–1440.

[6] Viehweger, E. (2013). Importance of hip problems in daily activities for cerebral palsy patients. *J Child Orthop., 7*(5),401-406.

[7] Karamitopoulos, M. S. & Nirenstein, L. (2015). Neuromuscular Foot: Spastic Cerebral Palsy. *Foot Ankle Clin., 20*(4), 657-668.

[8] Jozwiak, M., Walczak, M. & Idzior, M. (2005). Appearance of spastic hip pain in cerebral palsy children. *Chir Narzadow Ruchu Ortop., 70*,101–104.

[9] Paleg, G. & Livingstone, R. (2015). Outcomes of gait trainer use in home and school settings for children with motor impairments: a systematic review. *Clin Rehabil., 29*(11), 1177-1191.

[10] Brunner, R. & Baumann, J. U. (1997). Long-term effects of intertrochanteric varus-derotation osteotomy on femur and acetabulum in spastic cerebral palsy: an 11- to 18-year follow-up study. *J Pediatr Orthop, 17*(5), 585-591.

[11] Mazur, J. M., Danko, A. M., Standard, S. C., Loveless, E. A. & Cummings, R. J. (2004). Remodeling of proximal femur after varus osteotomy in children with cerebral palsy. *Dev Med Child Neurol, 46*(6), 412-415.

[12] Reidy, K., Heidt, C., Dierauer, S. & Huber, H. (2016). A balanced approach for stable hips in children with cerebral palsy: a combination of moderate VDRO and pelvic osteotomy. *J Child Orthop, 10*(4), 281-288.

[13] Miller, F., Girardi, H., Lipton, G., Ponzio, R., Klaumann, M. & Dabney, K. W. (1997). Reconstruction of the dysplastic spastic hip with peri-ilial pelvic and femoral osteotomy followed by immediate mobilization. *J Pediatr Orthop*, *17*(5), 592-602.

[14] Reimers, J. (1980). The stability of the hip in children. A radiological study of the results of muscle surgery in cerebral palsy. *Acta Orthop Scand*, Suppl, *184*, 1-100.

[15] Krebs, A., Strobl, W. M. & Grill, F. (2008). Neurogenic hip dislocation in cerebral palsy: quality of life and results after hip reconstruction. *J Child Orthop*, *2*(2), 125-131.

[16] Larsson, M., Hägglund, G. & Wagner, P. (2012). Unilateral varus osteotomy of the proximal femur in children with cerebral palsy: a five-year follow-up of the development of both hips. *J Child Orthop*, *6*(2), 145-151.

[17] Akel, I., Songür, M., Karahan, S., Yilmaz, G., Demirkıran, H. G. & Tümer, Y. (2013). Acetabular index values in healthy Turkish children between 6 months and 8 years of age: a cross-sectional radiological study. *Acta Orthop Traumatol Turc*, *47*(1), 38-42.

[18] Popkov, D., Journeau, P. & Popkov, A. (2014). Comparative study on results of reconstructive surgery in 45 hip joints of 25 children with cerebral palsy. *Eur Orthop Traumatol*, *5*(1), 57-63.

[19] Jóźwiak, M., Marciniak, W., Piontek, T. & Pietrzak, S. (2000). Dega's transiliac osteotomy in the treatment of spastic hip subluxation and dislocation in cerebral palsy. *J Pediatr Orthop B*, *9*(4), 257-264.

[20] Miller, F. (2005). *Cerebral Palsy*. New York, Springer-Verlag.

[21] Pountney, T. & Green, E. M. (2006). Hip dislocation in cerebral palsy. *BMJ*, *332*(7544), 772-775.

[22] Scrutton, D. & Baird, G. (1997). Surveillance measures of the hips of children with bilateral cerebral palsy. *Arch Dis Child*, *76*(4), 381-384.

[23] Davids, J. R. (2018). Management of Neuromuscular Hip Dysplasia in Children with Cerebral Palsy: Lessons and Challenges. *J Pediatr Orthop*, *38*(Suppl 1), S21-S27.

[24] Jung, N. H., Pereira, B., Nehring, I., Brix, O., Bernius, P., Schroeder, S. A., Kluger, G. J., Koehler, T., Beyerlein, A., Weir, S., Von Kries, R., Narayanan, U. G., Berweck, S. & Mall, V. (2014). Does hip displacement influence health-related quality of life in children with cerebral palsy? *Dev Neurorehabil*, *17*(6), 420-425.

[25] Narayanan, U. G., Fehlings, D., Weir, S., Knights, S., Kiran, S. & Campbell, K. (2006). Initial development and validation of the Caregiver Priorities and Child Health Index of Life with Disabilities (CPCHILD). *Dev Med Child Neurol*, *48*(10), 804-812.

[26] Damiano, D. L., Alter, K. E. & Chambers, H. (2009). New clinical and research trends in lower extremity management for ambulatory children with cerebral palsy. *Phys Med Rehabil Clin N Am*, *20*(3), 469-491.

[27] Dobson, F., Boyd, R. N., Parrott, J., Nattrass, G. R. & Graham, H. K. (2002). Hip surveillance in children with cerebral palsy. Impact on the surgical management of spastic hip disease. *J Bone Joint Surg (Br)*, *84*(5), 720-726.

[28] Elkamil, A. I., Andersen, G. L., Hägglund, G., Lamvik, T., Skranes, J. & Vik, T. (2011). Prevalence of hip dislocation among children with cerebral palsy in regions with and without a surveillance programme: a cross sectional study in Sweden and Norway. *BMC Musculoskelet Disord*, *12*, 284.

[29] Hägglund, G., Lauge-Pedersen, H. & Persson, M. (2007). Radiographic threshold values for hip screening in cerebral palsy. *J Child Orthop*, *1*(1), 43-47.

[30] Karlen, J. W., Skaggs, D. L., Ramachandran, M. & Kay, R. M. (2009). The Dega osteotomy: a versatile osteotomy in the treatment of developmental and neuromuscular hip pathology. *J Pediatr Orthop*, *29*(7), 676-682.

[31] Chougule, S., Dabis, J., Petrie, A., Daly, K. & Gelfer, Y. (2016). Is head-shaft angle a valuable continuous risk factor for hip migration in cerebral palsy? *J Child Orthop*, *10*(6), 651-656.

[32] McNerney, N. P., Mubarak, S. J. & Wenger, D. R. (2000). One-stage correction of the dysplastic hip in cerebral palsy with the San Diego acetabuloplasty: results and complications in 104 hips. *J Pediatr Orthop*, *20*(1), 93-103.

[33] Sankar, W. N., Spiegel, D. A., Gregg, J. R. & Sennett, B. J. (2006). Long-term follow-up after one-stage reconstruction of dislocated hips in patients with cerebral palsy. *J Pediatr Orthop*, *26*(1), 1-7.

[34] Reichel, H. & Hein, W. (1996). Dega acetabuloplasty combined with intertrochanteric osteotomies. *Clin Orthop Relat Res*, *323*, 234-242.

[35] Harris, N. H. (1976). Acetabular growth potential in congenital dislocation of the hip and some factors upon which it may depend. *Clin Orthop Relat Res*, *119*, 99-106.

[36] Bayusentono, S., Choi, Y., Chung, C. Y., Kwon, S. S., Lee, K. M. & Park, M. S. (2014). Recurrence of hip instability after reconstructive surgery in patients with cerebral palsy. *J Bone Joint Surg*, *96*, 1527–1534.

[37] Terjesen, T. (2012). The natural history of hip development in cerebral palsy. *Dev Med Child Neurol*, *54*(10), 951-957.

[38] Soo, B., Howard, J. J., Boyd, R. N., Lanigan, A., Wolfe, R., Reddihough, D. & Graham, H. K. (2006). Hip displacement in cerebral palsy. *J Bone Joint Surg (Am)*, *88*(1), 121-129.

[39] Connelly, A., Flett, P., Graham, H. K. & Oates, J. (2009). Hip surveillance in Tasmanian children with cerebral palsy. *J Paediatr Child Health*, *45*, 437-443.

[40] Davids, J. R., Gibson, T. W., Pugh, L. I. & Hardin, J. W. (2013). Proximal femoral geometry before and after varus rotational osteotomy in children with cerebral palsy and neuromuscular hip dysplasia. *J Pediatr Orthop*, *33*(2), 182-189.

[41] Rutz, E. & Brunner, R. (2010). The pediatric LCP hip plate for fixation of proximal femoral osteotomy in cerebral palsy and severe osteoporosis. *J Pediatr Orthop*, *30*(7), 726-731.

[42] Glickman, L. B., Geigle, P. R. & Paleg, G. S. (2010). A systematic review of supported standing programs. *J Pediatr Rehabil Med*, *3*(3), 197-213.

[43] Carr, C. & Gage, J. R. (1987). The fate of the nonoperated hip in cerebral palsy. *J Pediatr Orthop*, 7(3), 262-267.

[44] Gordon, J. E., Parry, S. A., Capelli, A. M. & Schoenecker, P. L. (1998). The effect of unilateral varus rotational osteotomy with or without pelvic osteotomy on the contralateral hip in patients with perinatal static encephalopathy. *J Pediatr Orthop*, *18*(6), 734-737.

[45] Settecerri, J. J. & Karol, L. A. (2000). Effectiveness of femoral varus osteotomy in patients with cerebral palsy. *J Pediatr Orthop*, 20(6), 776-780.

[46] Noonan, K. J., Walker, T. L., Kayes, K. J. & Feinberg, J. (2000). Effect of surgery on the nontreated hip in severe cerebral palsy. *J Pediatr Orthop*, *20*(6), 771-775.

[47] Canavese, F., Emara, K., Sembrano, J. N., Bialik, V., Aiona, M. D. & Sussman, M. D. (2010). Varus derotation osteotomy for the treatment of hip subluxation and dislocation

in GMFCS level III to V patients with unilateral hip involvement. Follow-up at skeletal maturity. *J Pediatr Orthop*, *30*(4), 357-364.

[48] Owers, K. L., Pyman, J., Gargan, M. F., Witherow, P. J. & Portinaro, N. M. (2001). Bilateral hip surgery in severe cerebral palsy: a preliminary review. *J Bone Joint Surg (Br)*, *83*, 1161-1167.

[49] Chung, C. Y., Choi, I. H., Cho, T. J., et al. (2007). Morphometric changes in acetabulum after Dega osteotomy in patients with cerebral palsy. *J Bone Joint Surg*, *90*(B), 88-91.

In: Encyclopedia of Surgery (22 Volume Set)
Editors: Andreas Lehrer and Kristin Mueller
ISBN: 978-1-53618-329-0
© 2020 Nova Science Publishers, Inc.

Chapter 122

PERCUTANEOUS ENDOSCOPIC GASTROSTOMY: HISTORICAL PERSPECTIVE

Jeffrey L. Ponsky*, MD
Cleveland Clinic, Cleveland, OH, US

INTRODUCTION

It has been nearly four decades since Michael Gauderer and I had the opportunity to first perform an endoscopically guided percutaneous gastrostomy (PEG) [1]. Prior to that time, gastrostomy was performed by means of a laparotomy in order to access the stomach. The indication for the gastrostomy usually involved the need for long term enteral feeding in patients with neurological impairment or for long term gastric decompression.

The techniques of open gastrostomy were varied but the most common was the Stamm gastrostomy. This method involved placing two concentric purse string sutures in the anterior wall of the stomach and performing a gastrotomy in the center of the sutures (Figure 1). A mushroom type catheter was then placed in the gastrotomy, the purse strings tied and the tube brought out through a small incision in the abdominal wall. Typically, the anterior gastric wall was also sutured to the parietal peritoneum to hold the stomach to the anterior abdominal wall. Other methods, such as the Janeway gastrostomy, created a tube out of the anterior gastric wall which was brought out of a small incision in the abdominal wall to create a permanent gastric stoma (Figure 2).

These methods were effective, yet the use of gastrostomy for feeding was not commonly employed as the laparotomy and anesthesia required were viewed as significant interventions in these severely debilitated patients. Moreover, the patient faced risks associated not only with the gastrostomy creation itself but also those of a midline laparotomy, including hernia formation, surgical site infection and pain.

Dr. Gauderer, a pediatric surgeon at Rainbow Babies and Children's Hospital in Cleveland, Ohio, had dealt with many children requiring long term enteral feedings and had pondered whether less invasive access to the stomach might be achieved. I was a general

* Corresponding Author's Email: ponskyj@ccf.org.

surgeon and endoscopist also at the Case Western Reserve University School of Medicine and brought both endoscopic skills and technology to the clinical problem.

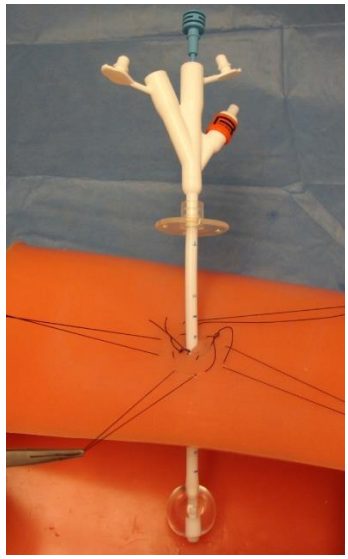

Figure 1. Stamm gastrostomy model demonstrating two concentric purse-string sutures around a balloon tip catheter and four gastropexy sutures used to secure the stomach to the posterior layers of the anterior abdominal wall.

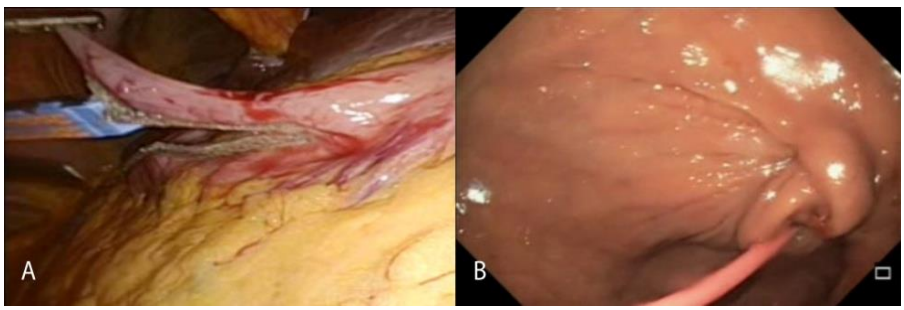

Figure 2. Janeway gastrostomy. A) Laparoscopic view of the stapled creation of a tubularized portion of stomach that is delivered to the skin surface and surgically matured. B) Endoscopic view of the anti-reflux valve and non-ballooned catheter.

Together, we conceived of the idea of using the endoscope to guide a percutaneous needle puncture of the stomach and passage of a suture. The suture would be grasped by the endoscope and pulled out of the patient's mouth. Then, a modified de Pezzar (mushroom type) catheter could be affixed to the suture and pulled through the mouth, down esophagus, into the stomach, and out of the abdominal wall. In order to provide a dilating function to the leading end of the flexible rubber catheter, a tapered plastic intravenous catheter (Medicut) was placed over the end of the tube (Figure 3) [1].

This procedure was first performed in five children by Drs. Gauderer and myself in the spring of 1979. All of the children did well and the procedure was reported in 12 children and 19 adults shortly thereafter in the *Journal of Pediatric Surgery* [1]. Modifications in the tube,

suture and the technique have followed, but the key steps of the method have remained essentially unchanged.

Initially, we placed much emphasis upon the use of trans-illumination of the abdominal wall by the light of the endoscope in order to select the best site for gastric puncture. Most practitioners have switched to the use of the "safe tract" technique which uses a finder needle to aspirate, looking for air, as the needle is advanced through the abdominal wall into the stomach. This method, described by Gregory Foutch in 1988, aimed to reduce the incidence of inadvertent puncture of adjacent viscera [2].



Figure 3. Modified de Pezzar catheter with dilating tip and pull suture as originally described for percutaneous endoscopy gastrostomy.

Figure 4. Russell introducer method of gastrostomy. Following dilation, a foley catheter is passed into the body of the stomach through a peel-away sheath.

Figure 5. Endoscopic view of a PEG with jejunal feeding extension. The extension curves in the stomach and passes post-pyloric.

Shortly after the initial description of PEG, a number of other approaches to placement of a percutaneous gastrostomy were described. These included the method published by Saks and Vine which localized the planned gastrostomy site as Dr Gauderer and I initially described, but passed a semi-stiff guidewire instead of a suture and pushed the tube down over the wire instead of pulling it [3]. Results of the 'Pull' and 'Push' methods of have been equivalent [4].

Another technique, described by Russell and Brotman, involved puncturing the stomach under endoscopic guidance, then dilating the needle tract and placing a Foley catheter into the stomach through a peel away sheath (Figure 4) [5]. This technique suffered from kinking of the dilating catheter and enjoyed only limited popularity. More recent substitution of laparoscopic type trocars to perform the puncture have somewhat revitalized the method.

Once the principle of endoscopically guided enteral access was established, numerous modifications and variations of the method were developed. Jejunal extensions of the gastrostomy tube for use in patients with gastroparesis were described by Dr Aszodi and myself. They are still used in spite of the frequent frustration with extension migration or dysfunction (Figure 5) [6]. Shike described and popularized direct percutaneous endoscopic jejunostomy (PEJ) which is performed by the same method as the PEG, but in the small bowel [7].

The development of percutaneous endoscopic gastrostomy was a small innovation using the methods of surgery and endoscopy to facilitate patient care. Perhaps more significant is the fact that this innovation heralded the beginning of the era of minimally invasive therapeutics.

EDITOR'S COMMENT

The 'small innovation' that Dr Ponsky quite humbly describes in this chapter was another revolutionary leap forward in the combination of surgical knowledge and endoscopic skill, similar to the development of methods for endoscopic polypectomy and control of gastrointestinal (GI) hemorrhage [8]. It stands apart from these other innovations, however, in

that he and Dr Gauderer developed an endoscopic therapy that intentionally created a full thickness GI tract defect. This not only permitted hundreds of thousands of patients to receive necessary enteral nutrition in a safe fashion each year, but was the basis upon which numerous other endoscopic and surgical therapies have been based. (EMP and JMM)

REFERENCES

[1] Gauderer MWL, Ponsky JL, Izant RJ Jr. Gastrostomy without laparotomy: A percutaneous endoscopic technique. *J Pediatr Surg* 1980;15:872-875.

[2] Foutch PG, Talbert GA, Waring JP, Sanowski RA. Percutaneous endoscopic gastrostomy with prior abdominal surgery: virtues of the safe tract. *Am J Gastroenterol* 1988;83:147.

[3] Sacks BA, Vine HS, Palestrant AM, et al. A non-operative technique for establishment of gastrostomy in the dog. *Invest Radiol* 1983;18:485-87.

[4] Lynch C, Fang J. Prevention and management of complications of percutaneous endoscopic gastrostomy tubes. *Pract Gastroenterol* 2004; 28: 66-76.

[5] Russell TR, Brotman M, Norris F. Percutaneous gastrostomy: A new simplified and cost-effective technique. *Am J Surg* 1984;148:132-37.

[6] Ponsky JL, Aszodi A: Percutaneous endoscopic jejunostomy. *Am J Gastroenterol* 1984; 79(2):113-6.

[7] Shike M, Wallsch C, Likier H. Direct percutaneous endoscopic jejunostomies. *Gastrointest Endosc* 1991;37(1): 62-65.

[8] Pauli EM and Ponsky JL. A Modern History of the Surgeon-Endoscopist. *Techniques in Gastrointestinal Endoscopy* 2013; 15(4):166-172.

In: Encyclopedia of Surgery (22 Volume Set)
Editors: Andreas Lehrer and Kristin Mueller
ISBN: 978-1-53618-329-0
© 2020 Nova Science Publishers, Inc.

Chapter 123

INDICATIONS, CONTRAINDICATIONS, DECISION MAKING AND INFORMED CONSENT

***Robert D. Fanelli*[*], MD and Josephine A. Fanelli*[†]**
The Guthrie Clinic, Sayre, PA, US

INTRODUCTION

Enteral hyperalimentation is the preferred method of nutritional support for patients with an intact, functional gastrointestinal tract who are unable to ingest adequate calories to meet metabolic requirements [1]. Enteral nutrition has several advantages over parenteral hyperalimentation, including reduced risks of phlebitis, bacteremia, thromboembolism, and it provides continued stimulation of the gastrointestinal tract, important for maintaining physiologic function. The costs associated with enteral hyperalimentation are reduced compared with other routes of nutritional support as well [2].

Nasogastric and nasojejunal hyperalimentation has been recommended for patients who will require 30 or fewer days of enteral feeding, reserving direct enteral access for patients expected to require longer term solutions [1]. However, nasoenteric feeding devices are uncomfortable, and most typically require continued hospitalization while in use because their tendencies toward clogging and inadvertent removal make them generally unsuitable for long-term care settings and home use. Given current emphasis on the Institute for Healthcare Improvement Triple Aim of improved patient experience, reduced per capita cost, and overall improvement in population health, nasoenteric feeding falls short [3, 4]. Therefore, percutaneous feeding tubes typically are advocated for in those with all but very short-term needs.

Percutaneous endoscopic gastrostomy (PEG) has become the preferred method for providing moderate to long-term enteral feedings since its introduction more than 35 years ago [5-7]. Owing to its cost-effectiveness, ease of placement, and relative safety as compared to surgical methods, PEG is a minimally-invasive procedure that typically can be performed

[*] Corresponding Author's Email: surgical.presentations@gmail.com.
[†] Josephine A. Fanelli, RN.

without the need for general anesthesia, making it a suitable choice for a variety of clinical conditions. In addition to enteral feeding, the PEG tube commonly is utilized as a means for hydration, medication administration, and gastrointestinal decompression for benign and malignant conditions [8, 9].

Percutaneous endoscopic gastrostomy tube placement is associated with improvements in nutritional status, maintenance of body weight, and improved quality of life for patients unable to sustain adequate oral nutrition [10]. Percutaneous endoscopic gastrostomy has been accepted widely into use in both pediatric and adult populations and has been associated with improvement in generalized failure to thrive as well as numerous specific conditions such as neurologic, malignant, and traumatic conditions among others [11, 12]. Although PEG is useful in many patients, there are specific patient populations that may not realize benefit from feeding tube placement; therefore, the decision to proceed with PEG should be individualized according to patient characteristics and clinical scenarios, and carefully considered. Several studies have reported no improvement in survival, nutritional status, or resolution of pressure wounds after PEG placement for adult patients with advanced dementia, particularly those over 80 years of age [13-15]. In these scenarios, the decision to proceed with PEG should be based on holistic appraisal of patient circumstance.

INDICATIONS

Before consideration is given to providing permanent gastrointestinal access for enteral support, individual patient characteristics and circumstances should be evaluated. These include the natural history of the underlying disease, associated diagnoses, patient comfort and quality of life, and the likelihood for meaningful clinical improvement if nutritional support is initiated and maintained [16].

Generally speaking, PEG is used to accomplish two rather broad goals in the clinical setting: Provide enteral nutrition support for patients with inadequate oral intake and a functional gastrointestinal tract; and provide gastric decompression for patients with chronic benign and malignant partial or complete obstructions of the gastrointestinal tract who are not considered candidates for operative remedy at the time of planned PEG placement [17]. These and other general indications for PEG are summarized in Table 1.

For patients with short-term nutritional or decompressive needs, a nasoenteric approach often is more suitable than PEG due to ease of placement, use, and removal. Prolonged use of transnasal access, however, is associated with mucosal erosions, gastroesophageal reflux, bleeding, aspiration pneumonitis, and chronic sinusitis [2, 18]. Therefore, while a brief trial of transnasal access is reasonable as a means of assessing feeding tolerance and short-term survival, when the likelihood of longer term need is suspected, PEG placement should be considered early in the decision-making process.

Nutritional support through PEG placement most often becomes necessary as the result of dysphagia caused by neurodegenerative disease, whether of acute onset like with stroke, or more insidious and chronic, as with amyotrophic lateral sclerosis, for example. Dysphagia secondary to neurodegenerative diseases accounts for as many as 90% of PEG placements in adults [19]. Obstructive dysphagia related to esophageal neoplasia, and recurrent pulmonary aspiration with oral feeding are other common indications for PEG placement [20]. Chapters 7-14 of this text outline specific PEG techniques and their associated results.

Table 1. General indications and common diagnoses for percutaneous endoscopic gastrostomy tube placement

Indications for PEG for enteral nutrition
Neurological diseases resulting in dysphagia, increased aspiration risk
Cerebrovascular disease (e.g. stroke)
Motor neuron diseases (e.g. Amyotrophic Lateral Sclerosis)
Multiple Sclerosis
Pseudobulbar Palsy
Cerebral palsy
Parkinson's disease
Psychomotor retardation
Traumatic Brain Injury
Coma
Malignant conditions resulting in dysphagia
Head and neck malignancy
Dysfunction resulting from prior treatment of head and neck malignancy
Esophageal malignancy
Chemotherapy-induced anorexia
Miscellaneous conditions necessitating enteral access
Failure to thrive, generalized inanition
Burn injury
Significant trauma not precluding oropharyngeal access
Cystic fibrosis
Prolonged intensive care
Congenital anomalies (e.g. tracheoesophageal fistula)
Facial or oral surgery
Chronic renal failure
Esophageal injury (perforation, caustic injury, etc.)
Superior mesenteric artery syndrome
Indications for PEG for enteral decompression
Benign obstruction (not amenable to stenting or operative therapy)
Gastric outlet obstruction
Chronic small bowel obstruction, partial or complete
Persistent idiopathic or cyclical nausea and vomiting
Refractory gastroparesis
Malignant obstruction (not amenable to stenting or operative therapy)
Gastrointestinal neoplasia
Malignant bowel obstruction
Metastatic
Locally advanced, infiltrative or compressive
Widely spread visceral involvement (carcinomatosis)

PEG increasingly is utilized for gastric decompression in patients with intractable nausea and vomiting resulting from a variety of benign and malignant conditions. Table 1 offers a listing of common indications for decompressive PEG. Chapter 15 (Alternative Uses of Percutaneous Endoscopic Gastrostomy) discusses decompressive PEG in greater detail.

CONTRAINDICATIONS

While PEG has demonstrated proven benefit for a variety of indications, each consultation must be evaluated on an individual basis for medical necessity and risk, since

some patient populations have not realized demonstrable improvements from PEG placement. In one study of patients with advanced dementia undergoing PEG placement, increased mortality rates were observed both at one-month (54%) and at twelve-months post-PEG placement (90%) [21]. Based on these data, advanced or irreversible dementia is no longer considered by these authors to be an indication for PEG. The leading potential contraindication to PEG that must be evaluated is the patient's overall clinical scenario; is there a reasonable likelihood for benefit through enhanced delivery of enteral nutrition and not be harmed during the surgical procedure? Generally accepted absolute and relative contraindications to PEG are listed in Table 2.

Since PEG was first introduced, many of its initial absolute contraindications have become relative contraindications, e.g., coagulopathy that routinely is reversed rapidly prior to PEG placement. Some of the initial contraindications to PEG are no longer considered even relative contraindications in some scenarios, because techniques have evolved that address the underlying concern; T-anchors can be used to aid in opposing the gastric and abdominal walls, and drainage and improved medical management of ascites allows safe PEG placement in some patients. These and other relative contraindications remain in Table 2 to provoke thoughtful planning as physicians consider PEG placement for complex patients. Specific technique modifications and management strategies will be highlighted in subsequent chapters of this text.

Table 2. Contraindications to PEG placement

Absolute	Relative
No opportunity for patient benefit	Limited opportunity for patient benefit
Diffuse peritonitis	Coagulopathy
Complete pharyngeal obstruction	Clinical instability, extremis, shock
Complete esophageal obstruction	Altered anatomy
Altered anatomy*	*Gastric resection, minor*
Gastric bypass	Regionalized peritonitis
Gastric resection, major	Ascites
Advanced dementia	Peritoneal dialysis
Lack of informed consent	Hiatus hernia
IV anesthetic contraindication**	Immunosuppression
	Head and neck malignancy
	Oral maxillofacial trauma
	High mortality patient group
	Inability to oppose gastric and abdominal wall
	Despite use of T-fasteners, other techniques
	Hepatomegaly
	Splenomegaly
	Portal hypertension with gastric varices
	Cirrhosis
	Conditions affecting the epigastric abdominal wall
	Inflammatory, malignant, infiltrative disease, hernia, open wound
	Obesity with extreme BMI > 60 kg/m^2
	Pregnancy

* May be a candidate for percutaneous endoscopic jejunostomy (PEJ) tube (see Chapters 10 and 14)

** May be a candidate for PEG under local/topical anesthesia only (see Chapter 5)

The patient with altered anatomy presents unique challenges in PEG placement. Partial gastrectomy may not preclude safe PEG placement, but more extensive gastric resection likely will make PEG impossible. Patients requiring feeding or decompressive access to the remnant stomach following Roux en Y gastric bypass generally are not candidates for PEG placement, although retrograde access to the remnant stomach using enteroscopy may be feasible in some circumstances [22]. In both of these circumstances, the endoscopist may have to consider placement of a percutaneous jejunal feeding tube (PEJ). Oral maxillofacial trauma treated with intermaxillary fixation has long been considered at least a relative contraindication to PEG because transoral gastric access is restricted by this therapy. Transnasal PEG placement, reported recently in this patient population, may provide feeding access for carefully selected patients [23-25]. When medically indicated, there is no age or weight limit that absolutely contraindicates PEG [2].

Assessing the impact that absolute and relative contraindications will have on PEG placement remains an important part of procedure planning. Physicians must continue to evaluate the needs and circumstances of patients in context with a critical evaluation of their own skill set and level of experience as they seek to provide solutions for patient needs.

DECISION MAKING

While PEG holds many advantages over other techniques, the decision for placement must be considered carefully on a case-by-case basis to assure that necessity, risk, and overall prognosis with and without enteral access are consistent with each patient's goals for their care and their likelihood for improvement [26, 27]. In many settings, PEG placement has become automated; a consult is placed by the primary care, internal medicine, hospitalist or trauma service and the procedure is scheduled after brief evaluation, primarily of procedure-related risk factors.

Table 3. Predictive indices of increased 30-day mortality following PEG

Patient clinical factors
Age > 75 years
ASA class IV
CCI > 4
BMI < 18.5 kg/m^2
Prolonged antibiotic needs

ASA – American Society of Anesthesiologists; CCI – Charlson Comorbidity Index; BMI – body mass index

Predictive modeling science has been applied to the decision-making process for PEG placement. Increased 30-day mortality rates after PEG long have been noted in patients with age >75 years, continued need for hospitalization after PEG, low serum albumin, persistent leukocytosis, chronic obstructive lung disease (COLD), diabetes, Glasgow coma score <10, advanced American Society of Anesthesiologists (ASA) risk score, Charlson Comorbidity

Index (CCI) >4, advanced malignancy, severe malnutrition, low albumin, and elevated C-reactive protein [28, 29]. Multivariate analysis demonstrates that age >75 years, ASA class IV, CCI > 4, BMI < 18.5 kg/m^2, and prolonged antibiotic needs predict increased 30-day mortality after PEG [30]. Patients with these factors should be evaluated carefully for PEG and their mortality risk realistically assessed prior to placement (Table 3). Acute and chronic PEG related complications are discussed in more detail in Chapters 17 and 18.

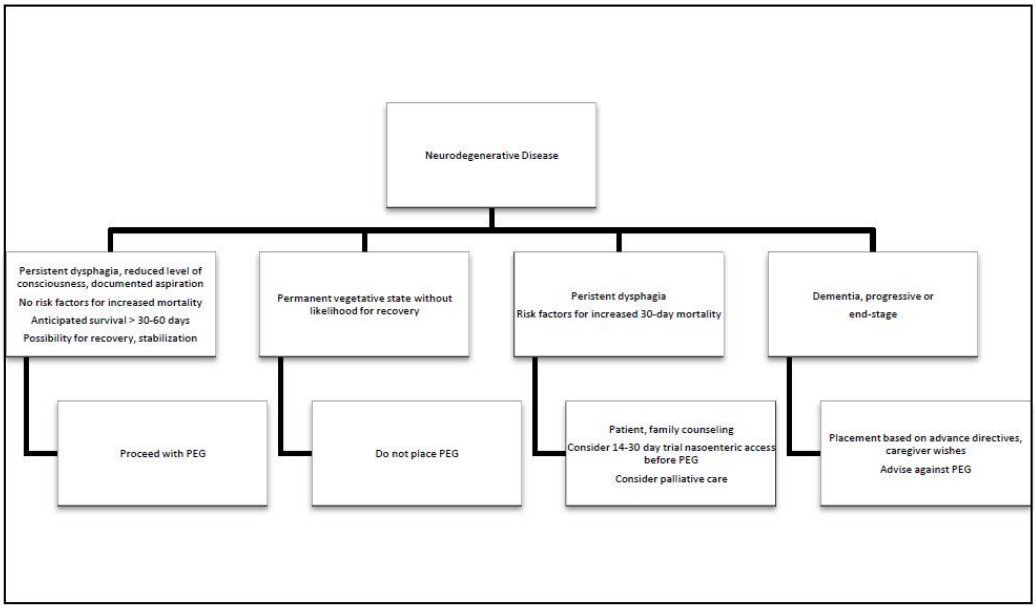

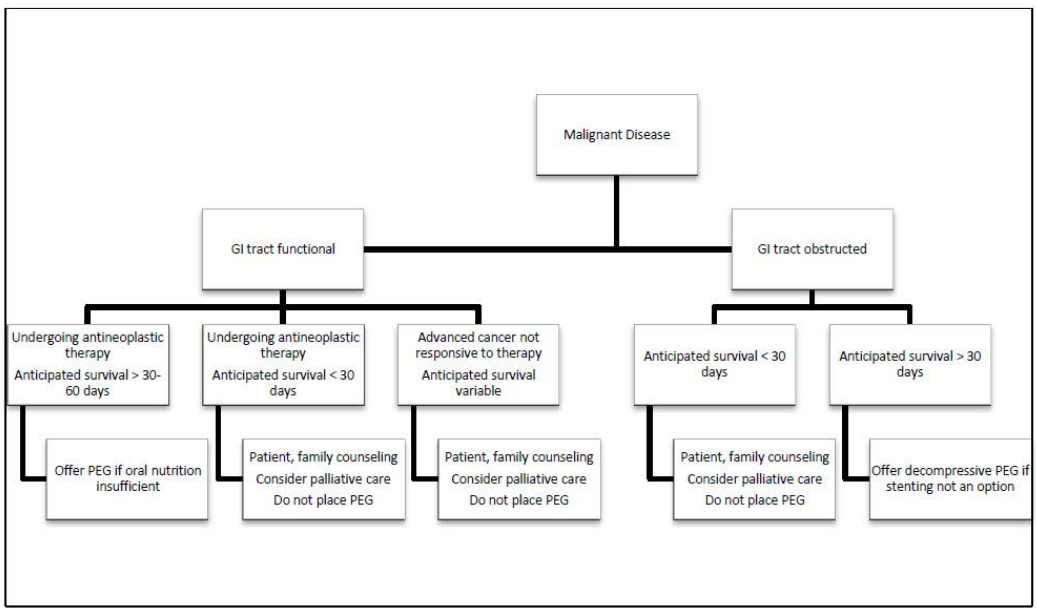

Figure 1. Decision algorithms for PEG placement in neurodegenerative or malignant disease states.

In order to support appropriate decision-making, an algorithmic approach to PEG is suggested (Figure 1) [27]. Patients with neurodegenerative disorders that are stable, or not rapidly progressing, typically benefit from PEG, whereas those in persistent vegetative states and those with end-stage dementia are not considered candidates for PEG because of their overall poor prognosis [21]. Cancer patients with dysphagia, aspiration, malnutrition, and other reversible factors, with reasonable risk profiles, anticipated survival greater than 30 – 60 days, and an opportunity for remission or cure, make excellent candidates for PEG when indicated for nutritional support [31, 32]. Those with diminished anticipated survival, or tumors that are or have become non-responsive to therapy generally are not considered suitable candidates for PEG. Finally, cancer patients with an obstructed gastrointestinal tract who are not suitable candidates for surgical remedy or in whom GI stenting has failed or is not possible may benefit from decompressive PEG [27].

INFORMED CONSENT

Despite its relative ease in scheduling and placement, the decision to proceed with PEG requires significant consideration and discussion with all involved parties and must take into account patient, family, guardian, and caregiver wishes, goals, expectations, and advance directives in order to establish a cohesive treatment plan. Although much of the discussion in the surgical care of patients involves an assessment of risk and development of risk mitigation strategies, PEG introduces considerations far in excess of those routinely considered in anticipation of an equivalently minor procedure. The risks are high with significant mortality rates associated with PEG at 30 days and 12 months. This life extending therapy, often provided in the wake of significant life-altering occurrences, might be inconsistent with patient wishes and desires. Given that the patient often has sustained a degenerative neurological event, stroke, or trauma, they may not be able to contribute meaningfully to the discussion or express their viewpoint adequately.

Patient autonomy and self-determination both are important doctrines central to the granting of informed consent for medical treatments and procedures. Patients have a right to make life choices, and are entitled to receive health care free of control by others, including family, staff, and providers. Patients are entitled to determine which recommended treatments and procedures they will avail themselves of without retribution, and without decisions being made by others that override their own. For patients to make these choices, they must be informed of facts and likelihoods related to treatments, procedures, and the refusal of treatments and procedures. The consent discussion for PEG often is a proxy for a more detailed discussion involving end of life issues that may or may not have been considered previously by the patient and their network. Robust palliative care support is an essential ingredient to efficient and appropriate use of PEG. Chapter 3 discusses the nuances in a more complete fashion.

Although it is well accepted that informed consent requires patient autonomy, in the case of determining acceptance of PEG, the patient may be all but autonomous, and there may be little or no indication of their pre-conceived decisions or thoughts relating to enteral access. Furthermore, there might be strong dispute among family members about what their relative would choose if they were capable of making that choice independently. PEG placement may

invoke the need for Ethics Committee consultation, and might strain family members and caregivers, all interested in protecting the patient despite their often polarizing views.

CONCLUSION

The introduction of percutaneous endoscopic gastrostomy revolutionized patient care, and for many years, PEG has provided a means of minimally invasive nutritional support for patients with a functional GI tract, and a means of decompression for patients with obstruction not amenable to stenting or surgery. Although the indications for PEG had been expanded over the decades following its introduction, including use in patients with dementia and those in persistent vegetative states, current thinking has evolved. PEG should be considered in patients with benign and malignant conditions in whom clinical improvement or stabilization is likely, and counseling against this invasive measure should be advocated for those with limited life expectancy and little chance for improvement, or at high risk for early procedure-related mortality. An algorithmic approach to decision-making is advocated, although the most important determinant in PEG placement is a holistic approach to patient evaluation and care, one that takes into account clinical needs, risks, and social factors.

EDITOR'S COMMENT

The speed and relative simplicity with which PEG can be accomplished frequently hides the complex decision making processes that happen behind the scenes when a request for an endoscopic gastrostomy is placed. There are increasingly fewer absolute contraindications to PEG placement, but the absence of a contraindication does not imply that the procedure should be performed. As the authors point out, the risk benefit ratio for each patient (as well as the endoscopists comfort level with relative contraindications) needs to be examined for each patient in each circumstance. (EMP)

REFERENCES

[1] Committee ASoP, Jain R, Maple JT, Anderson MA, Appalaneni V, Ben-Menachem T, et al. The role of endoscopy in enteral feeding. *Gastrointest Endosc*. 2011; 74(1):7-12.

[2] Rahnemai-Azar AA, Rahnemaiazar AA, Naghshizadian R, Kurtz A, Farkas DT. Percutaneous endoscopic gastrostomy: indications, technique, complications and management. *World J Gastroenterol*. 2014;20(24):7739-51.

[3] Institute for Healthcare I. The Triple Aim. Optimizing health, care and cost. *Healthc Exec*. 2009;24(1):64-6.

[4] Berwick DM, Nolan TW, Whittington J. The triple aim: care, health, and cost. *Health Aff* (Millwood). 2008;27(3):759-69.

[5] Gauderer MW, Ponsky JL, Izant RJ, Jr. Gastrostomy without laparotomy: a percutaneous endoscopic technique. 1980. *Nutrition*. 1998;14(9):736-8.

[6] Ponsky JL, Gauderer MW. Percutaneous endoscopic gastrostomy: indications, limitations, techniques, and results. *World J Surg*. 1989;13(2):165-70.

[7] Gauderer MW, Ponsky JL, Izant RJ, Jr. Gastrostomy without laparotomy: a percutaneous endoscopic technique. *J Pediatr Surg*. 1980;15(6):872-5.

[8] Daigle CR, Boules M, Corcelles R, McMichael J, Kroh M, El-Hayek K, et al. Percutaneous Endoscopic Gastrostomy for Decompression of Nonmalignant Gastrointestinal Disease. *J Laparoendosc Adv Surg Tech A*. 2015;25(10):804-7.

[9] Kawata N, Kakushima N, Tanaka M, Sawai H, Imai K, Hagiwara T, et al. Percutaneous endoscopic gastrostomy for decompression of malignant bowel obstruction. *Dig Endosc*. 2014;26(2):208-13.

[10] DiLorenzo J, Dalton B, Miskovitz P. Percutaneous endoscopic gastrostomy. What are the benefits, what are the risks? *Postgrad Med*. 1992;91(1):277-81.

[11] Kaur S, Ceballos C, Bao R, Pittman N, Benkov K. Percutaneous endoscopic gastrostomy tubes in pediatric bone marrow transplant patients. *J Pediatr Gastroenterol Nutr*. 2013;56(3):300-3.

[12] Nataraja RM, Fishman JR, Naseer A, Dodge J, Walters SM, Clarke SA, et al. Percutaneous endoscopic gastrostomy placement in a human immunodeficiency virus-positive pediatric population leads to an increase in minor complications. *J Laparoendosc Adv Surg Tech A*. 2011;21(2):171-5.

[13] Teno JM, Gozalo PL, Mitchell SL, Kuo S, Rhodes RL, Bynum JP, et al. Does feeding tube insertion and its timing improve survival? *Journal of the American Geriatrics Society*. 2012;60(10):1918-21.

[14] Teno JM, Gozalo P, Mitchell SL, Kuo S, Fulton AT, Mor V. Feeding tubes and the prevention or healing of pressure ulcers. *Arch Intern Med*. 2012;172(9):697-701.

[15] Teno JM, Mitchell SL, Kuo SK, Gozalo PL, Rhodes RL, Lima JC, et al. Decision-making and outcomes of feeding tube insertion: a five-state study. *Journal of the American Geriatrics Society*. 2011;59(5):881-6.

[16] Kruse A, Misiewicz JJ, Rokkas T, Hammer H, Niv Y, Allison M, et al. Recommendations of the ESGE workshop on the Ethics of Percutaneous Endoscopic Gastrostomy (PEG) Placement for Nutritional Support. First European Symposium on Ethics in Gastroenterology and Digestive Endoscopy, Kos, Greece, June 2003. *Endoscopy*. 2003;35(9):778-80.

[17] Scheidbach H, Horbach T, Groitl H, Hohenberger W. Percutaneous endoscopic gastrostomy/jejunostomy (PEG/PEJ) for decompression in the upper gastrointestinal tract. Initial experience with palliative treatment of gastrointestinal obstruction in terminally ill patients with advanced carcinomas. *Surg Endosc*. 1999;13(11):1103-5.

[18] Gomes CA, Jr., Andriolo RB, Bennett C, Lustosa SA, Matos D, Waisberg DR, et al. Percutaneous endoscopic gastrostomy versus nasogastric tube feeding for adults with swallowing disturbances. *Cochrane Database Syst Rev*. 2015;5:CD008096.

[19] Lucendo AJ, Friginal-Ruiz AB. Percutaneous endoscopic gastrostomy: An update on its indications, management, complications, and care. *Rev Esp Enferm Dig*. 2014;106(8):529-39.

[20] Friginal-Ruiz AB, Lucendo AJ. Percutaneous Endoscopic Gastrostomy: A Practical Overview on Its Indications, Placement Conditions, Management, and Nursing Care. *Gastroenterol Nurs*. 2015;38(5):354-66.

[21] Sanders DS, Carter MJ, D'Silva J, James G, Bolton RP, Bardhan KD. Survival analysis in percutaneous endoscopic gastrostomy feeding: a worse outcome in patients with dementia. *Am J Gastroenterol*. 2000;95(6):1472-5.

[22] Rueth N, Ikramuddin S, Andrade R. Endoscopic gastrostomy after bariatric surgery: a unique approach. *Obes Surg*. 2010;20(4):509-11.

[23] Lin LF, Shen HC. Unsedated transnasal percutaneous endoscopic gastrostomy carried out by a single physician. *Dig Endosc*. 2013;25(2):130-5.

[24] Seth AK, Puri P, Chandra A. Transnasal percutaneous endoscopic gastrostomy. *Tropical Gastroenterology*. 2010;31(1):54-5.

[25] Desai D, Joshi A, Abraham P, Chawla M, Sonsale A. Transnasal percutaneous endoscopic gastrostomy using a standard-diameter gastroscope (9.8 mm). *Endoscopy*. 2005;37(10):1035.

[26] Breier-Mackie SJ. PEGs and ethics revisited: a timely reflection in the wake of the Terri Schiavo case. *Gastroenterol Nurs*. 2005;28(4):292-7.

[27] Angus F, Burakoff R. The percutaneous endoscopic gastrostomy tube. medical and ethical issues in placement. *Am J Gastroenterol*. 2003;98(2):272-7.

[28] Zopf Y, Maiss J, Konturek P, Rabe C, Hahn EG, Schwab D. Predictive factors of mortality after PEG insertion: guidance for clinical practice. *Journal of Parenteral and Enteral Nutrition*. 2011;35(1):50-5.

[29] Lang A, Bardan E, Chowers Y, Sakhnini E, Fidder HH, Bar-Meir S, et al. Risk factors for mortality in patients undergoing percutaneous endoscopic gastrostomy. *Endoscopy*. 2004;36(6):522-6.

[30] Udd M, Lindstrom O, Mustonen H, Back L, Halttunen J, Kylanpaa L. Assessment of indications for percutaneous endoscopic gastrostomy--development of a predictive model. *Scand J Gastroenterol*. 2015;50(2):245-52.

[31] Mobily M, Patel JA. Palliative percutaneous endoscopic gastrostomy placement for gastrointestinal cancer: Roles, goals, and complications. *World Journal of Gastrointestinal Endoscopy*. 2015;7(4):364-9.

[32] Mansoor H, Masood MA, Yusuf MA. Complications of percutaneous endoscopic gastrostomy tube insertion in cancer patients: a retrospective study. *Journal of Gastrointestinal Cancer*. 2014;45(4):452-9.

In: Encyclopedia of Surgery (22 Volume Set)
Editors: Andreas Lehrer and Kristin Mueller
ISBN: 978-1-53618-329-0
© 2020 Nova Science Publishers, Inc.

Chapter 124

PALLIATIVE CONSIDERATIONS OF GASTROSTOMY

Julie L. Mitchell, DO and Susan A. Glod*, MD
Penn State Hershey Medical Center, Hershey, PA, US

INTRODUCTION

Palliative Care is a rapidly-growing and increasingly available medical subspecialty that focuses on maximizing quality of life for patients with serious illness, regardless of the stage of illness and current treatment plan [1, 2]. Specialty Palliative Care provides management of complex or refractory symptoms, including pain, nausea, dyspnea, and anxiety, as well as assistance in establishing goals of care in the setting of complex illness, and managing challenging communication [3]. Timely consultation has been shown to improve quality of life and decrease healthcare costs, and in some instances has been associated with lengthened lifespan [4, 5, 6]. As population needs outstrip the supply of available specialists, and in order to avoid the unintentional undermining of existing relationships between patients and current providers, the role of the Palliative Care consultant has become increasingly more well-defined [3].

It should be noted that for a variety of reasons, including the relatively short life expectancy of patients who are seen by palliative care specialists, ethical challenges in enrolling members of this vulnerable patient population, and difficulties with trial design inherent to studies that test the efficacy of what are often directions of care rather than specific interventions, there are relatively few published randomized prospective clinical trials within the palliative care literature in comparison to other specialties [7]. This landscape is changing as the evidence base of high-quality, specialty-specific literature expands, but current published randomized studies to address the use of gastrostomy tubes are still a rarity. But despite this lack of data, it is likely that discussions around procedurally-based interventions, including gastrostomy tube placement, will occur between the patient and the proceduralist. This chapter will review the available literature and make recommendations about the palliative considerations of gastrostomy tube placement.

* Corresponding Author's Email: sglod@hmc.psu.edu.

GENERAL CONSIDERATIONS

The minimally invasive nature of percutaneous endoscopic gastrostomy (PEG) makes it a viable consideration in patients with life-threatening progressive illness [8]. The two populations of patients in whom this therapy is most utilized for palliation include those with progressive neurologic disorders, such as amyotrophic lateral sclerosis (ALS) and Parkinson disease, and those with malignancy, often of the gastrointestinal tract or oropharynx. Gastrostomy is most commonly used as a means to establish enteral access for feeding and to enable GI decompression [8]. Weight loss, decreasing BMI, and deteriorating nutritional status as a result of nausea, vomiting, or dysphagia secondary to the underlying disease process are considerations when determining the appropriateness of PEG placement in these patients [8]. Although medication administration alone is usually not a sufficient cause for PEG insertion, this can play a role in decision-making, particularly when medications needed for symptom management are not available for administration through buccal, rectal, or transdermal routes.

Each individual patient's goals and values should be taken into account when considering PEG placement. A provider should consider end-of-life decision making and lead a basic discussion of harm versus benefit analysis when making decisions regarding PEG insertion in these patients [8]. Careful discussion of and agreement upon the expected goals of placement, (e.g., medication administration, relief of nausea or abdominal distention through venting, etc.) versus the limitations (e.g., whether or not patients should expect improvement in weight or functional status when PEG is placed in the setting of advanced malignancy) and potential burdens (e.g., procedural complications, dislodgement, abdominal symptoms related to enteral nutrition) should occur and be documented in the medical record. In this patient population, ongoing discussions of goals of care are vital, and careful documentation of the goals of gastrostomy placement can provide a basis for future providers to continue this discussion. In a review of 154 consecutive adults undergoing PEG for palliative purposes, only one medical record documented a procedure-specific discussion of benefits and burdens and alternatives to tube feeding [8].

CONSIDERATIONS PRIOR TO PLACEMENT

If PEG placement is for the purposes of hydration or nutritional support, the reason(s) behind the patient's dehydration and or/malnutrition should be considered. As a general rule of thumb, patients who are experiencing hunger but are unable to eat because of anatomic or neurologic reasons are most likely to benefit from placement. If patients do not have a physiologic barrier that prevents oral intake, but they either do not have a desire to eat or are experiencing decreased consciousness as a result of disease progression, they may gain less benefit from enteral nutrition.

From a legal and ethical standpoint, artificial nutrition is no different from any other life-sustaining therapy, such as antibiotics, hemodialysis, or ventilatory support [8]. That having been said, the decision to withhold or withdraw artificial nutrition and/or hydration can be incredibly emotionally charged for patients, their caregivers, and clinicians as well. Decisions to withhold or withdraw nutrition, and thus often decisions to pursue gastrostomy, must take

into account a patient's individual cultural and spiritual beliefs as well as goals of care. Patients and families may often express concerns that by not pursuing artificial nutrition they are hastening death through starvation. In addition to empathic listening and emotional support, general discussion points under these circumstances may include the following: in the absence of hunger, patients do not experience the symptoms typically associated with starvation; artificial nutrition in the terminal stages of illness can be associated with an increased symptom burden; artificial nutrition in the last stages of terminal illness does not prolong life and may in fact confer an increased risk of mortality (see below).

If there is uncertainty as to whether a patient will benefit from PEG placement, a trial period of enteral feeding and/or hydration through nasogastric or nasojejunal feeding may be helpful in clarifying expected outcomes. Similarly, if the tube is to be used for decompression, a trial of nasogastric decompression is helpful in clarifying the degree of symptom (e.g., nausea, abdominal pain) relief. Prior to insertion, patients, families, and clinicians should agree on a set goal (for example, improved delirium, improved functional status, time for rehabilitation to improve swallowing ability) as well as a reasonable time period over which these improvements can be expected. We suggest a period of 2-4 weeks. A plan of care in the event that the agreed-upon goal is not met after the trial period, or if patients experience increased symptom burden related to artificial nutrition, such as worsening anasarca, pulmonary edema, or ascites, should be established prior to initiation of artificial nutrition. No ethical or legal distinction exists between withdrawing artificial nutrition and choosing not to initiate it in the first place, and this consideration should not impact decision-making.

POPULATIONS FOR WHICH PEG MAY NOT BE BENEFICIAL

Patients in the Last Days to Weeks of Life

Adequate nutritional support is a well-accepted facet of supportive care in patients with good functional status, regardless of disease type. Cachexia, which includes decreased appetite, weight loss, diminished functional status, and sarcopenia, is a common condition in many terminal illnesses, and is often a predictor of limited prognosis [9-12]. Data to support the use of enteral nutrition in patients with relatively good functional status but an anticipated life expectancy in the range of several months is mixed. An individualized choice, after discussion of the potential benefits as well as potential burdens (disruption to activities of living, caregiver fatigue, and complications associated with line/device placement) is warranted [13].

For patients in the last days to weeks of life, no compelling evidence for improvement in symptom control or quality of life with artificial nutrition has been demonstrated [13, 14]. Early evidence suggested that dying patients with poor oral intake and delirium may experience improvement in mental status with hydration, but this has not been demonstrated in subsequent studies [15, 16].

Patients with Advanced Dementia

Patients with advanced dementia may experience prolonged periods of diminished functional status, including decreased oral intake and difficulty swallowing prior to death. This is often complicated by weight loss, malnutrition, decubitus ulcers, and recurrent episodes of aspiration [17, 18]. A 2009 Cochrane Review found no benefit of artificial nutrition on survival, risk of aspiration, development or healing of decubitus ulcers, or functional status in patients with advanced dementia [19]. Furthermore, mounting evidence suggests that alternative means of nutritional support may be detrimental to this population, as evidenced by an observational trial that demonstrated higher mortality rates in patients after initiation of alternative means of nutritional support versus patients who were provided with oral feeding alone [20].

It is important that discussions around nutrition in patients with advanced dementia or other neurodegenerative diseases are not limited to binary options of artificial nutrition versus no feeding. An individualized feeding plan, focused on the patient's comfort and usually managed through careful hand feeding and strategies to minimize aspiration, is appropriate in these circumstances [21]. In such cases, the goal of the intervention is not to obtain sufficient caloric intake, but to maintain social engagement, support cultural, ritual, and personal significance to patients, and to involve family members and other loved ones in the patient's care [22].

POPULATIONS FOR WHICH INSERTION SHOULD BE CONSIDERED

Proximal Obstruction – Head and Neck Cancers

Patients with proximal obstructing lesions may develop swallowing difficulties long before their malignancy impacts their functional status or other aspects of quality of life, making long-term enteral feeding an appropriate choice for this population. The most common indication for PEG insertion in patients with known or impending proximal obstruction remains long term enteral feeding for nutritional support in those who are unable to swallow or maintain sufficient oral intake [23, 24]. Patients who undergo gastrostomy under these circumstances experience improvement in nutritional status and quality of life [24]. PEG placement for nutritional gains may allow for more aggressive or effective disease-modifying therapy with enteral access for a finite period [24]. Though it does not impact long-term survival at 4 years, studies have shown that PEG allowed for better attainment of full-dose chemotherapeutic regimens by minimizing weight loss throughout therapy and improved short-term survival at 12 months [8]. The improvements in quality of life gained with PEG appear to outweigh survival benefits.

In this population, PEG placement is most beneficial intraoperatively or after tumor resection rather than preoperatively [25]. Patients who had PEG placed before resection of their proximal cancer had the highest complication rate of 57%, while those who underwent PEG intraoperatively or postoperatively had a much lower complication rate between 11% and 7% [8, 25]. The authors noted that intraoperative placement also conveyed the benefit of

minimizing anesthesia and operative time, and suggested intraoperative placement as being the safest and most efficient timing of PEG placement.

Neuromuscular Disease – ALS

Malnutrition is associated with reduced survival in ALS patients, as it contributes to muscle atrophy and diaphragmatic weakness [26]. The American Academy of Neurology (AAN) recommends gastrostomy placement for nutritional management when weight loss of more than 10% over baseline occurs and/or before functional vital capacity (FVC) falls below 50% of predicted [26]. Gastrostomy placement in patients who have ALS with dysphagia may confer a survival benefit of approximately six months [26]. Results of studies investigating the impact of FVC on the success of gastrostomy placement are mixed. In one trial, patients with mean FVC of 36% who underwent gastrostomy experienced a 30-day mortality rate of 9.6%, while those with FVC of >50% had a 30-day mortality of 0%, suggesting that the timing of insertion may impact survival. Gastrostomy placement prior to the development of respiratory insufficiency may be most effective [8, 26, 27]. Another trial demonstrated comparable mortality between patients with ALS and dysphagia with FVC above and below 50% [26]. More data is needed in order to establish the best timing for gastrostomy placement in this patient population.

Variables such as culture, site of onset of disease, and rate of disease progression may confound survival data. Patients with spinal-onset ALS receiving a PEG have been observed to have a significantly longer survival (8 months) than those who did not. For bulbar-onset patients, there was a 3 month survival advantage in favor of PEG placement, although here the difference was not significant [26]. Factors that may improve quality of life should be considered, as well. For example, the social interactive role of eating by mouth along with the PEG feedings for nutritional supplementation may improve quality of life, though is a largely understudied variable [26].

Gastric Outlet or Malignant Bowel Obstruction

A recently-proposed specific definition of malignant bowel obstruction by an international consensus group includes the following criteria: a) clinical evidence of bowel obstruction, b) obstruction distal to the ligament of Treitz, c) intra-abdominal primary cancer with incurable disease, or d) non-intra-abdominal primary cancer with clear intraperitoneal disease [28]. Symptoms of malignant obstruction may be secondary to mechanical impedance, motility dysfunction, aggregation of secretions, diminished intestinal absorption, and inflammation [29]. Refractory symptoms can lead to a significantly diminished quality of life, such as increased hospital admissions and poor oral intake [23]. Obstruction is common in advanced malignancies, most frequently colorectal, pancreatic, and gynecological cancers, with a global prevalence of occurrence in 3-15% of all individuals with cancer [23, 30]. Abdominal carcinomatosis, ascites, and gastric disease are frequent complications within this patient population, in whom prognosis is often poor and associated with considerable suffering [31].

Gastric outlet obstruction secondary to unresectable primary or metastatic malignancy complicates 20-30% of periampullary malignancies, leading to a variety of symptoms such as nausea, vomiting, abdominal pain, and dysphagia, often leading to oral restrictions [32]. Survival outcomes in patients with malignant gastric outlet obstruction are poor, therefore effective palliation of symptoms is an important goal [32]. While focal obstruction is often best managed by surgical bypass or endoscopic stenting, the risk of surgical intervention may outweigh the benefit in patients with very limited prognoses [29]. In this population, gastrostomy placement for symptom management through decompression may be a viable option [33].

Parameters for and Timing of Insertion for Decompression

Nasogastric (NG) decompression, along with hydration, electrolyte management, and the administration of analgesics and anti-emetics is often included in the initial management plan for malignant obstruction [23]. This allows for immediate symptom relief in most patients and affords time for patients and their loved ones to engage in discussions of goals of care. A patient's symptomatic response to nasogastric decompression can be used to help predict the effectiveness of PEG for symptom control through decompression. Seventy-three percent of patients who underwent gastrostomy had experienced good symptomatic response to NG decompression [23]. Ninety-three percent of those patients with documented improvement in their symptoms with an NG tube in place had no readmissions for obstructive symptoms after gastrostomy [23]. If relief is obtained from NG decompression, venting gastrostomy is a reasonable next step in order to allow for less nasogastric discomfort and minimize cosmetic factors associated with NG drainage [31].

The best timing for conversion of NG decompression to gastrostomy has not been established, and no formal guidelines for gastrostomy placement for symptomatic gastrointestinal obstruction are in place [23]. This is an important clinical decision, as up to one-third of patients with inoperable obstruction will experience spontaneous resolution with conservative management [30]. In a meta-analysis of the use of corticosteroids in malignant obstruction, a trend towards improved rates of resolution was observed with the addition of intravenous dexamethasone [34]. It is reasonable to suppose, then, that very early gastrostomy placement in patients who are undergoing active medical management for obstruction may place a subset of patients at unnecessary procedural risk. More than half of these patients, however, will experience recurrence of the obstruction [30]. If it is felt that the patient is at high risk for recurrence, and if gastrostomy for symptom management is consistent with the patient's overall goals, we typically recommend gastrostomy placement for venting in the future, lest the patient be too debilitated at the time of recurrence to tolerate the procedure.

Functional Outcomes of Decompressive PEG

The presence of a malignant bowel obstruction is in-and-of itself a poor prognostic indicator, and prolonged survival is usually a secondary consideration after effective management of symptoms. Functional status at the time the obstruction occurs tends to be most predictive of survival in this population; in one study the most significant factor related

to the patient's survival was his or her Eastern Cooperative Oncology Group (ECOG) status prior to gastrostomy [31]. Even in patients with poor performance status, gastrostomy can provide substantial relief; therefore limited functionality should not preclude gastrostomy but should be factored into continued discussion with patients and families regarding decision-making and goal setting [31]. Patients with poor performance status, rapidly progressive disease, carcinomatosis, malignant ascites, very short (<30 days) life expectancy, or failure of previous surgical intervention or stenting are often best served by observation or palliative gastrostomy rather than other surgical interventions [32].

Complete relief of obstructive symptoms was found in a high proportion of patients (84-97% in multiple studies [23, 29, 31, 33, 35]. Resolution of symptoms occurred quickly, with a mean number of days to relief of 1.7 [31, 33]. Only 8% of patients were considered treatment failures due to continued symptoms with functioning PEG in place [23].

Following decompressive PEG, many patients are able to resume oral intake of fluids and softer foods [31]. There is a large range of oral tolerability after PEG, from sips to full meals, primarily dependent upon the patient's disease process [29]. Sometimes oral intake is still limited due to the location of obstruction, though overall, intake improved from pre-PEG diet [29]. Patients should be instructed on proper techniques for clamping and draining the gastrostomy. Symptom relief with the resolution of nausea and vomiting and the ability to take in soft foods and liquids within 7 days of the procedure was observed in 84% to 91% of patients [8, 35]. In one study, after an initial period of rest, patients were able to have liquids or pureed solids with the drainage tube to gravity with complete resolution of their symptoms (nausea and vomiting) in 91% of patients [33]. Eating for social interaction rather than nutritive benefits significantly improves quality of life, as well [31]. It has been our experience that after a few days, many individuals are able to self-regulate a schedule for venting the gastrostomy that results in good symptom control and minimizes disruptions to the patient's desired routine.

Improvements in quality of life are an important goal surrounding PEG placement. Although most hospice agencies are able to provide fairly intensive levels of home care, including nasogastric drainage if necessary, this can prove burdensome to patients and their loved ones. Gastrostomy placement may allow for the development of a pragmatic plan for palliation at home, thereby decreasing hospital readmissions and time spent in the hospital, for patients and families who otherwise may have been overwhelmed with the symptom burden associated with bowel obstruction [23]. PEG dysfunction requiring readmission for symptoms is infrequent, and in all cases of readmission due to PEG dysfunction, PEG was successfully replaced [23]. The average length of time spent at home prior to readmission for in-hospital palliation after PEG placement was 126 days, and these readmissions were not necessarily related to symptoms that would have been relieved by PEG [29]. Even at the end of life, gastrostomy can be successfully managed either at home or in an inpatient hospice setting, rather than in the hospital [33]. In one study of patients with gynecologic malignancy who had underwent gastrostomy, all patients died at home without recurrent symptoms of bowel obstruction with only very minimal abdominal symptoms up to 210 days [35].

Complications of Decompressive PEG

PEG placement is highly effective, not technically difficult, and is accompanied by a low complication rate [35]. Reported complications of palliative PEG are low, with an incidence of minor complications around 5% to 13% [8]. These include pain at the insertion site, skin excoriation, leakage of ascites and gastric contents, peristomal infections, skin excoriation, ileus, PEG tube migration, and tube blockage [31, 33]. Major complications, defined as those often requiring repeat endoscopic procedures, occur in only 1.3% to 3% of cases, and include peritonitis, inadvertent removal of the tube, fasciitis, and tumor implantation at the PEG site [8]. Infectious complications are higher in those with ascites, though this was decreased when ascites was drained prior to insertion of the PEG [23].

Overall, the morbidity rate related to PEG placement for decompression is only slightly higher than the same technique used for nutritional purposes [8]. Overall mortality is low at 0.2% to 1%. The median overall survival was worse in those who underwent initial palliation with PEG versus those who underwent endoscopic stent placement or surgical bypass (median 49 days versus median 64 days, respectively), though the patients were not offered bypass or stenting as a therapeutic option, indicating very advanced disease and short life expectancy in itself [32]. In the advanced cancer population, multifocal obstruction and/or poor surgical candidacy makes these aforementioned interventions rarely viable [23]. Overall morbidity and mortality rates relate to the underlying disease process rather than the PEG itself, which does not seem to hasten the patient's demise. Advanced tumor stage was an independent predictor of 30-day mortality [24].

Patients with high illness severity are more likely to have complications and are at increased risk of mortality after PEG insertion, as previously discussed. In patients undergoing venting PEG for palliation however, the benefits of improved symptomatic control may outweigh the mortality risk, particularly given already shortened life expectancy post-PEG [24]. In general, we advocate for earlier gastrostomy placement in order to maximize time spent with good symptom control.

Decision-Making for Decompressive PEG

The most important factors in decision-making regarding palliative PEG placement were physician's recommendations and the desire to eat and drink normally [32]. Patient and family goals and values play a large role here, as they often do in discussions surrounding palliative interventions. Fears of surgery or anesthesia were not reported to influence decision making [32].

Technical Considerations to Decompressive PEG

An unsuccessful attempt to place a decompressive PEG usually occurs because of malignant ascites, multiple previous surgeries, or tumor involvement of the abdominal wall, as these preclude transillumination. Fluoroscopy, computed tomography and transcutaneous US can be used to localize the best site when transillumination is not possible (see Chapter 13 for more information on the use of assistive techniques for PEG placement). Ascites and

abdominal carcinomatosis are not absolute contraindications to palliative PEG placement, though may make the procedure technically more difficult [23]. Ascites should be drained as much as possible before the procedure, which improves ability to transilluminate and decreases infectious complications [23]. A peritoneal catheter can be left in place for several days to allow healing at the gastrostomy site. Although hyperthermic intraperitoneal chemotherapy with attempted cytoreduction has been shown to be effective in management of malignant ascites, recovery time from this procedure can be as long as six months, making concomitant therapy for bowel obstruction and ascites less feasible [36]. Adding a gastropexy to the procedure may help to promote maturation of the tract and prevent leakage after PEG placement in patients that have ascites (see Chapter 9 for a discussion of gastropexy technique).

PEG placement is feasible even in patients with tumor encasing the stomach, diffuse carcinomatosis, and ascites [33]. These patients still quickly obtain significant symptomatic relief. When decompression with NG does not relieve symptoms, however, it is possible that patients will not respond well to PEG for decompression.

There is no standardized technique for insertion of palliative PEG. Only very minor modifications to the technique used for PEG insertion for nutritional purposes are required to adapt the technique to a wide variety of palliative indications. “Pull” method was used in most cases with good results [23, 24]. In most studies, tube size was not standardized [23]. One study showed that increased tube size did not reduce incident of tube blockage [29]. In one study, majority of patients had a 28 Fr tube with good results; however, prior studies have shown that 15-20 Fr tubes are large enough to provide adequate decompression [33]. Another recommends 20 Fr tube in comparison to 15 Fr, as it has good decompressive effects, causes minimal abdominal wound, and allows introduction of smaller jejunostomy tube if necessary for better air decompression [35].

Medical Management

Medical management is the cornerstone of treatment for malignant bowel obstruction and pharmacologic intervention should be continued along with venting PEG [31]. For patients who do have recurrent nausea and vomiting despite PEG, octreotide has been shown to help symptoms by decreasing GI secretions and bowel distention [35].

Quality of Life Outcomes Following PEG

Studies evaluating overall quality of life (QOL) after PEG placement are significantly disparate [8]. The severity of the underlying disease may preclude significant improvements in QOL, so this must not be the sole reason for PEG insertion. One study showed no significant improvement in any measure of QOL including functional status, cancer-related symptoms, or gastric-specific symptoms after PEG [32]. Another study showed similar results, though one third of this population included dementia patients [8]. Improvements in QOL are more likely to be observed when PEG is inserted for patients who have neurological disease or abnormalities in the GI tract than for those with dementia.

The perception of improved QOL for patients with palliative PEG seems to be different among caregivers and patients themselves. Improvements in QOL of family members of those receiving PEG have been evaluated. In one study, only 55% of patients said their QOL improved with PEG, while 80% of their family members reported improvements in their own QOL [8]. Another similar study showed no change in overall quality of life for patients, but 68% of their relatives reported that the patient's quality of life had improved [8]. Some of this disparity may be explained by differing expectations between families, caregivers, and clinicians after gastrostomy placement. Aside from relief of symptoms associated from the gastrostomy, patients are unlikely to feel better since nutritional parameters are not affected. Loved ones, on the other hand, may witness increased oral intake and interpret this as improved nutrition and QOL. Particularly in the setting of malignant obstruction, a frank discussion with patients and families outlining the anatomic role of the gastrostomy, and the high likelihood that despite increased oral intake, overall nutritional parameters are unlikely to improve, should take place prior to placement.

Supplemental Information

The Center to Advance Palliative Care website (www.getpalliativecare.org) provides general information on Palliative Care for patients, caregivers, and clinicians as well as links to sites dedicated to disease-specific management and support. The American Academy of Hospice and Palliative Medicine site, (www.palliativedoctors.org) provides answers to frequently asked questions about both palliative care and hospice as well as a description of palliative care services for patients.

EDITOR'S COMMENT

Appropriate patient selection for enteral access can be challenging as it is difficult to predict life expectancy in many of the patients that we are asked to place PEGs. This chapter succinctly describes the important issues that must be addressed in patients undergoing palliative PEG placement. Family involvement as well as careful assessment of underlying co-morbid diseases will allow the safest approach to this complex end of life issue. (JMM)

REFERENCES

[1] Strand JJ, Kamdar MM, Carey EC. Top 10 things palliative care clinicians wished everyone knew about palliative care. *Mayo Clinic Proceedings*. 2013;88(8):859-65.

[2] Morrison RS, Augustin R, Souvanna P, Meier DE. America's care of serious illness: a state-by-state report card on access to palliative care in our nation's hospitals. *J Palliat Med.* 2011; 14:1094-1096.

[3] Quill TE, Abernethy AP. "Generalist plus specialist palliative care—creating a more sustainable model." *New England Journal of Medicine*. 2013;368(13):1173-1175.

[4] Temel JS, Greer JA, Muzikansky A, et al. Early palliative care for patients with metastatic non–small-cell lung cancer. *New England Journal of Medicine*. 2010;363 (8):733-742.

[5] Morrison RS, Dietrich J, Ladwig S, et al. Palliative care consultation teams cut hospital costs for Medicaid beneficiaries. *Health Affairs.* 2011;30(3):454-463.

[6] Zimmermann C, Swami N, Krzyzanowska M, et al. Early palliative care for patients with advanced cancer: a cluster-randomized controlled trial. *The Lancet*. 2014;383 (9930):1721-1730.

[7] Grande GE, Todd CJ. Why are trials in palliative care so difficult?. *Palliative Medicine*. 2000;14(1):69-74.

[8] McClave SA, Ritchie CS. The Role of Endoscopically Placed Feeding or Decompression Tubes. *Gastroenterol Clin N Am*. 2006;35:83-100.

[9] Fearon K, Strasser F, Anker SD, et al. Definition and classification of cancer cachexia: an international consensus. *The Lancet Oncology*. 2011;12(5):489-495.

[10] Christensen HM, Kistorp C, Schou M, et al. Prevalence of cachexia in chronic heart failure and characteristics of body composition and metabolic status. *Endocrine*. 2013;43(3):626-634.

[11] Evans WJ, Morley JA, Argiles, et al. Cachexia: a new definition. *Clin Nutr*. 2008;27:793–799.

[12] Remels AH, Gosker HR, Langen RC, Schols AM. The mechanisms of cachexia underlying muscle dysfunction in COPD. *Journal of Applied Physiology*. 2013;114 (9):1253-1262.

[13] Dy SM. Enteral and parenteral nutrition in terminally ill cancer patients: a review of the literature. *American Journal of Hospice and Palliative Medicine*. 2006;23(5):369-377.

[14] Dev R, Dalal S, Bruera E. Is there a role for parenteral nutrition or hydration at the end of life? *Current Opinion in Supportive and Palliative Care*. 20126(3):365-370.

[15] Bruera E, Hui D, Dalal S, et a. Parenteral hydration in patients with advanced cancer: a multicenter, double-blind, placebo-controlled randomized trial. *Journal of Clinical Oncology*. 2013;31(1):111-8.

[16] Bruera E, Sala R, Rico MA, et al. Effects of parenteral hydration in terminally ill cancer patients: a preliminary study. *Journal of Clinical Oncology*. 2005;23(10):2366-2371.

[17] Sachs GA, Shega JW, Cox-Hayley D. Barriers to excellent end-of-life care for patients with dementia. *Journal of General Internal Medicine*. 2004;19(10):1057-1063.

[18] Kalia M. Dysphagia and aspiration pneumonia in patients with Alzheimer's disease. *Metabolism*. 2003;52:36-38.

[19] Sampson EL, Candy B, Jones L. "Enteral tube feeding for older people with advanced dementia." *Cochrane Database Syst Rev*. 2009 Apr 15;(2):CD007209.

[20] Cintra MTG, De Rezende NA, De Morales EN, et al. A comparison of survival, pneumonia, and hospitalization in patients with advanced dementia and dysphagia receiving either oral or enteral nutrition. *The Journal of Nutrition, Health & Aging*. 2014;18(10):894-899.

[21] Palecek EJ, Teno JM, Casarett DJ, et al. Comfort Feeding Only: A Proposal to Bring Clarity to Decision-Making Regarding Difficulty with Eating for Persons with Advanced Dementia. *Journal of the American Geriatrics Society*. 2010;58(3):580-584.

[22] Schwartz DB, Barrocas A, Wesley JR, et al. Gastrostomy tube placement in patients with advanced dementia or near end of life. *Nutrition in Clinical Practice*. 2014;29(6):829-840.

[23] Issaka RB, Shapiro DM, Parikh ND, et al. Palliative venting percutaneous endoscopic gastrostomy tube is safe and effective in patients with malignant obstruction. *Surg Endosc*. 2014;28(5):1668-1673.

[24] Richards DM, Tanikella R, Arora G, et al. Percutaneous Endoscopic Gastrostomy in Cancer Patients: Predictors of 30-Day Complications, 30-Day Mortality, and Overall Mortality. *Dig Dis Sci*. 2013;58(3):768-776.

[25] Raynor EM, Williams MF, Martindale RG, et al. Timing of percutaneous endoscopic gastrostomy tube placement in head and neck cancer patients. *Otolaryngology - Head and Neck Surgery*. 1999;120(4):479-482.

[26] Spataro R, Ficano L, Piccoli F, La Bella V. Percutaneous endoscopic gastrostomy in amyotrophic lateral sclerosis: Effect on survival. *Journal of the Neurological Sciences*. 2011;304:44-48.

[27] Andersen PM, Abraham S, Borasio GD, et al. EFNS guidelines on the clinical management of amyotrophic lateral sclerosis (ALS) - revised report of an EFNS task force. *Eur J Neurol*. 2012;19(3):360-375.

[28] Anthony T, Baron T, Mercadante S, et al. Report of the clinical protocol committee: development of randomized trials for malignant bowel obstruction. *Journal of Pain and Symptom Management*. 2007; 34(1):S49-S59.

[29] Teriaky A, Gregor J, Chande N. Percutaneous Endoscopic Gastrostomy Tube Placement for End-stage Palliation of Malignant Gastrointestinal Obstructions. *Saudi J Gastroenterol. 2012;*18(2):95-98.

[30] Tuca A, Guell E, Martinez-Losada E, Codorniu N. Malignant bowel obstruction in advanced cancer patients: epidemiology, management, and factors influencing spontaneous resolution. *Cancer Management and Research*. 2012;42:159-69.

[31] Dolan EA. Malignant Bowel Obstruction: A Review of Current Treatment Strategies. *American Journal of Hospice & Palliative Medicine*. 2011;28(8):576-582.

[32] Schmidt C, Gerdes H, Hawkins W, et al. A prospective observational study examining quality of life in patients with malignant gastric outlet obstruction. *The American Journal of Surgery*. 2009;198(1):92-99.

[33] Pothuri B, Montemarano M, Gerardi M. et al. Percutaneous endoscopic gastrostomy tube placement in patients with malignant bowel obstruction due to ovarian carcinoma. *Gynecologic Oncology. 2005;*96(2):330-334.

[34] Feuer DDJ, Broadley KE. Corticosteroids for the resolution of malignant bowel obstruction in advanced gynaecological and gastrointestinal cancer. *Cochrane Database Syst Rev*. 2008; CD001219.

[35] Campagunatta E, Cannizzaro R, Gallo A, et al. Palliative Treatment of Upper Intestinal Obstruction by Gynecological Malignancy: The Usefulness of Percutaneous Endoscopic Gastrostomy. *Gynecologic Oncology*. 1996;62(1):103-105.

[36] Randle RW, Swett KR, Swords DS, et al. Efficacy of cytoreductive surgery with hyperthermic intraperitoneal chemotherapy in the management of malignant ascites. *Annals of Surgical Oncology*. 2014;21(5):1474-1479.

[37] Shaw C, Bassett RL, Fox PS, et al. Palliative Venting Gastrostomy in Patients with Malignant Bowel Obstruction and Ascites. *Annals of Surgical Oncology*. 2012;20(2):497-505.

In: Encyclopedia of Surgery (22 Volume Set)
Editors: Andreas Lehrer and Kristin Mueller
ISBN: 978-1-53618-329-0
© 2020 Nova Science Publishers, Inc.

Chapter 125

PREOPERATIVE MANAGEMENT

Valerie Wu Chao Ying, MD and Jose M. Martinez*, MD
University of Miami, Miller School of Medicine, Miami, FL, US

INTRODUCTION

Percutaneous endoscopic gastrostomy (PEG) tube placement is a safe procedure that can be undertaken with minimal risks after adequate preoperative assessment. In addition to reviewing indications and contraindications of the procedure, potential complications can be reduced by taking specific steps such as ensuring appropriate antimicrobial coverage, managing antithrombotic therapy, ordering preoperative laboratory tests and imaging when necessary, as well as considering the needs of special populations such as those with implantable cardiac devices and on chemotherapy treatment. This chapter gives a brief overview and summarizes the latest evidence for each of these topics as well as our own personal approach.

ANTIBIOTIC PROPHYLAXIS

Patients undergoing PEG or percutaneous endoscopic jejunostomy (PEJ) tube placement are vulnerable to infections because of old age, compromised nutritional intake, immunosuppression, and underlying medical comorbidities, such as malignancy [1]. Peristomal infection represents one of the most common complications after PEG tube insertion with an incidence rate of 3 to 30% [2]. Infection involves the skin or subcutaneous tissue and typically presents with purulent discharge, erythema, tenderness, induration or warmth around the feeding tube insertion site. Positive bacterial culture site and systemic leukocytosis can also be present.

The use of broad-spectrum prophylactic antibiotics has been shown to be effective in decreasing peristomal infections following PEG tube placement. A 2013 Cochrane systematic review which included 12 trials, with a total of 1271 patients, comparing the use of antibiotics

* Corresponding Author's Email: jmartinez4@med.miami.edu.

vs. placebo, as well as different antibiotic regimens, showed a consistently beneficial effect for antibiotics (OR 0.36, 95% CI 0.26 to 0.50). The antibiotics selection included intravenous (IV) cephalosporins and penicillins. The timing of administration varied but mainly ranged from 30 minutes to immediately prior the procedure [3].

Rates of methicillin-resistant *Staphylococcus aureus* (MRSA) infections have been rising in many hospitals and concerns have been raised regarding high rates of MRSA peristomal wound colonization and subsequent increasing rates of MRSA PEG site infections [4]. A 2007 retrospective analysis by Thomas, demonstrated that screening for MRSA, subsequent decontamination and antibiotic prophylaxis statistically reduces peristomal MRSA infection rates [5].

In accordance to 2015 American Society of Gastrointestinal Endoscopy (ASGE) guidelines, we recommend the use of an appropriate IV antibiotic (such as weight based dosed cefazolin) 30 minutes prior to skin incision. In areas where MRSA is endemic, we recommend screening, decontamination and targeted antibiotic prophylaxis to reduce MRSA peristomal infection (e.g., IV vancomycin) [6]. This is in addition to standard surgical skin prep with chlorhexidine prior to skin incision. Chapter 17 reviews additional preventative measure to reduce the risk of wound infections associated with PEG placement.

ANTITHROMBOTIC THERAPY

While managing patients on antithrombotic therapy, one should balance the bleeding risk of the procedure with the thromboembolic event risk associated with interruption of the therapy. One must keep in mind the numerous types of current antithrombotic therapy, their half-life and mechanism of therapy as all these play a crucial role on appropriate interruption of management.

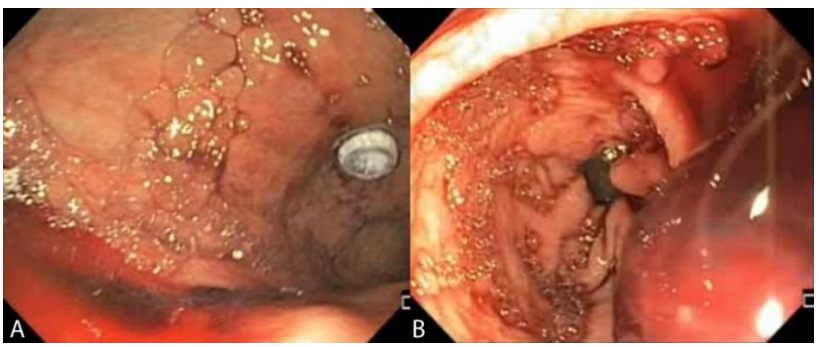

Figure 1. Post PEG bleeding. A) Endoscopic evaluation demonstrated blood in the body of the stomach and no active bleeding from the gastrostomy. B) Blood clot was found in the pre-pyloric region.

Assessing Risk for Bleeding

Elective endoscopic procedures can be divided into high risk and low risk bleeding procedures. Low risk procedures which are associated with a bleeding risk of <1%, include diagnostic EGD, colonoscopy and flexible sigmoidoscopy with or without biopsy, endoscopic

retrograde cholangiopancreatography (ERCP) without sphincterotomy, endoscopic ultrasound (EUS) without fine needle aspiration (FNA) and enteral stent deployment. Examples of high-risk procedures which have a >1% bleeding risk, include polypectomy, EMR, biliary sphincterotomy, EUS with FNA and pneumatic dilation. PEG placement is considered a higher risk procedure with an overall bleeding complication rate of 2.5% (Figure 1) [7, 8].

Assessing Risk for Thromboembolism

The American College of Chest Physicians (ACCP) published guidelines in 2012 for the perioperative management of antithrombotic therapy. In this article, they suggest a risk stratification model for perioperative thromboembolism risk. High-risk conditions are associated with >10% annual risk for thromboembolism and include patients with:

1) mechanical heart valve with a prosthetic valve in the mitral position; caged-ball or tilting disc aortic valve prosthesis; or a recent history stroke or TIA within 6 months;
2) atrial fibrillation with a "Congestive heart failure, Hypertension, Age, Diabetes, prior Stroke" (CHADs) score of 5 or 6; or with a recent history of stroke or TIA within 3 months;
3) recent venous thromboembolism (VTE) within 3 months or severe thrombophilia (protein C/S and antithrombin deficiency; antiphospholipid antibodies).

Moderate risk diseases are associated with a 5-10% annual risk of thrombotic events and low risk conditions have a <5% annual risk of thromboembolism [9].

Antithrombotic Management

In accordance to the most recent guidelines published by ACCP (2012) and ASGE (2016), we have summarized the periprocedural management of antithrombotic therapy [9, 10]. Of note, these guidelines are supported by few prospective randomized trials and are primarily based on observational studies, expert opinion and extrapolation from studies on other surgical procedures. These recommendations do not stem from studies specifically evaluating PEG tube placement.

Warfarin

For elective endoscopic procedures in patients on temporary anticoagulation therapy (e.g., deep venous thrombosis), we suggest delaying the procedure until anticoagulation is no longer needed if possible. In patients with a high thromboembolic risk, we recommend stopping vitamin K antagonist (VKA) such as warfarin, 5 days prior to PEG placement. In these patients, bridging anticoagulation is also recommended with either unfractionated heparin (UFH) or low molecular weight heparin (LMWH). In low risk patients, we suggest stopping and resuming VKA with no bridging anticoagulation. In moderate risk patients, individualized risk assessment is suggested. International normalizing ratio (INR) testing the day before surgery is also recommended to ensure timely identification of patients with

elevated INRs requiring additional reversal agents such as vitamin K (1.0-2.5mg). Warfarin can be restarted the same day as the procedure in all patients with adequate hemostasis.

Heparin

In patients receiving therapeutic dose of IV unfractionated heparin, we recommend stopping UFH 4 to 6 hours prior to the procedure. In patients receiving therapeutic dose of sub cutaneous (SC) LMWH, we suggest administrating the last dose of LMWH 24 hours prior to the procedure and resuming therapy 48 to 72 hours after.

Antiplatelet Therapy

There is limited data on the bleeding risk associated with the use of antiplatelet agents in patients undergoing PEG placement [11-16]. A recent systematic review of eleven studies with a total of 6,233 patients (among whom 3,665 were undergoing antiplatelet treatment) showed that antiplatelet therapy did not increase the risk of bleeding during PEG tube insertion. Pooled relative risk (RR) for bleeding in patients taking aspirin, when compared to controls, was 1.43 (95% CI 0.89, 2.29; I2 = 0%); pooled RR for clopidogrel was 1.21 (95% CI 0.48, 3.04; I2 = 0%) and for dual antiplatelet therapy, 2.13; (95% CI 0.77, 5.91; I2 = 47%) [17].

The most recent ACCP guidelines suggest that aspirin should be continued in patients at moderate to high risk for cardiovascular events [9]. In patients with a coronary stent who are receiving dual antiplatelet therapy, they recommend deferring the procedure for at least 6 weeks after placement of a bare-metal stent and for at least 6 months after placement of a drug-eluting stent instead of proceeding with the procedure within these periods. If the procedure is deemed necessary during this time-frame, they recommend continuing the antiplatelet therapy perioperatively instead of stopping them. For procedures scheduled after these intervals, thienopyridine can be stopped 5-7 days before the PEG tube insertion and aspirin should be continued. Specifically, clopidogrel should be stopped 5 days prior to the procedure and prasugel 7 days prior to procedure. Both can be resumed once hemostasis has been achieved, usually within 24 hours, with or without an initial oral loading dose, depending on the anticipated risk of thrombosis and bleeding [9, 10, 16].

Novel Oral Anticoagulants

There is a paucity of data regarding the management of novel oral anticoagulants (NOAC), such as dabigatran, rivaroxaban and apixaban, in the elective endoscopy setting. The current guidelines reflect expert opinion and suggest that NOAC are held for 2-3 half-lives, which corresponds to 24-72 hours in patients with normal drug elimination. In patients with impaired kidney function, cessation duration needs to be adjusted accordingly. After hemostasis is secure, NOAC can typically be resumed 24-48 hours after the procedure. Of note, the peak plasma concentrations occur within 2 to 3 hours of the first dose, which differs from warfarin which full anticoagulation effect is achieved days after [10, 18].

In light of the complexity of antithrombotic management and the lack of strong randomized data, we recommend evaluation of each patient on a case-by-case basis in coordination with a cardiologist and/or hematologist Tables 1 and 2 summarize the basic recommendations for the management of anticoagulation and antiplatelet agents in patients with cardiovascular risk undergoing PEG [10].

Table 1. Summary recommendations for the management of oral anticoagulation in patients with cardiovascular risk

Patient Cardiovascular Risk	
Low Risk	**High Risk**
1. Discontinue anticoagulation 2. Resume warfarin on the same day as the procedure 3. Delay resuming NOAC until hemostasis has been achieved	1. Discontinue anticoagulation 2. Bridge with UFH or LMWH 3. Resume warfarin on the same day as the procedure 4. Delay resuming NOAC until hemostasis has been achieved

NOAC – novel oral anticoagulants; UFH – unfractionated heparin; LMWH – low molecular weight heparin

Table 2. Summary recommendations for the management of oral antiplatelet agents in patients with cardiovascular risk

Patient Cardiovascular Risk	
Low Risk	**High Risk**
1. Continue standard dose of ASA or NSAID 2. Discontinue thienopyridines* 5 days before or switch to ASA 3. If on dual therapy: stop the thienopyridine 5 days before, continue ASA	1. Continue standard dose of ASA or NSAID 2. Discontinue thienopyridines* 5 days before or switch to ASA 3. If on dual therapy: stop the thienopyridine 5 days before, continue ASA

ASA – aspirin; NSAID – nonsteroidal anti-inflammatory drug
** thienopyridines include: clopidrogrel (Plavix), ticlodipine (Ticlid), prasugrel (Effient) and ticagrelor (Brillinta)*

LABORATORY TESTING

Routine laboratory testing before PEG placement is generally not indicated [19]. Rather, pre-endoscopy laboratory tests should be performed selectively guided by history, physical examination, and patient's risk factors [20]. With that being said, patients undergoing PEG placement often have some degree of malnutrition and other risk factors, and it is reasonable to obtain a complete blood count, as well as an INR and aPTT preoperatively [21].

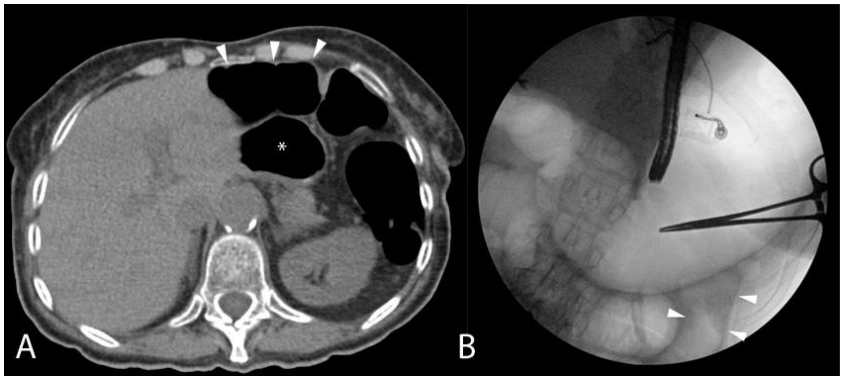

Figure 2. Patient with dysphagia secondary to amyotrophic lateral sclerosis who was initially refused a PEG based on A) CT scan demonstrating transverse colon (arrowheads) to be interposed between the stomach (*) and the anterior abdominal wall. B) Endoscopic findings were favorable for the placement of a PEG and fluoroscopic images showed inferior displacement of the colon (arrowheads) with gastric insufflation. A PEG was subsequently placed.

IMAGING

Routine imaging before PEG placement is not indicated. In certain scenarios, further delineation of the patient's anatomy may warrant additional imaging such as an abdominal computed tomography (CT) scan or upper GI series. Prior relevant surgery such as foregut surgery, bariatric, colectomy or abdominal wall hernia repair with mesh placement are likely to increase complexity of PEG placement and pre-procedure imaging should be considered in these populations. As discussed in Chapter 14, for example, CT scan can elucidate complex bariatric anatomy (such as the anatomical location of the alimentary limb following Roux-en-Y gastric bypass) to provide information about the ability to safely perform a direct percutaneous endoscopic jejunostomy tube. Known significant anatomical variants such as large hiatal hernia, or medical conditions such as ascites and hepatosplenomegaly may also alter the feasibility or the approach to the procedure and should be further investigated [21].

Even in cases where radiologic investigation may demonstrate non-favorable anatomy, we often proceed with upper endoscopy to evaluate feasibility of PEG as demonstrated by good one-to-one finger indentation motion, transillumination and safe-tract technique (Figure 2). In cases where imaging appeared non-favorable but endoscopic techniques proves favorable, we will proceed with placement of the gastrostomy tube.

IMPLANTABLE CARDIAC DEVICES

Patients with implanted electronic devices undergoing PEG placement should undergo the same precautions as when undertaking other endoscopic procedures. Electromagnetic interference may result from the use of electrocautery, causing inadvertent inhibition or triggering of cardiac devices. In 2007, ASGE published guidelines for patients with implanted cardiac devices undergoing endoscopic procedures, which can be summarize as follows:

1) Determine the type of cardiac device, indication and underlying patient's cardiac rhythm. This may be done in conjunction with the patient cardiologist or heart rhythm specialist.
2) Continually monitor the patient's cardiac rhythm throughout the procedure.
3) Have adequate resuscitation equipment available, in case the need for defibrillation or cardioversion arises.
4) Limit the use of electrosurgery, using the lowest effective power output for the shortest amount of time possible.

Most patients with cardiac pacemakers may undergo PEG placement including the use of electrocautery for hemostasis with no alterations in management. For patients with an implantable cardiac defibrillator (ICD) in whom the use of any electrosurgery is anticipated, it is recommended to have a consultation with the cardiologist or heart rhythm specialist ahead of the procedure to evaluate for the need of deactivation of the ICD function and reprogrammation after the procedure with the help of a magnet [23]. Most PEG procedures do not require the use of electrosurgery. Minor bleeding can usually be controlled with temporary manual pressure, tightening of the bumper over the skin or by placing a suture.

IMMUNOSUPPRESSION

Endoscopic procedures in immunocompromised patients, particularly patients with severe neutropenia (absolute neutrophil count <500 cells/mL) and advanced hematologic malignancies carry a higher risk of bacteremia and sepsis [24]. Prophylactic antibiotics are recommended for these patients, as with any other patient undergoing PEG placement [10]. For patients undergoing active chemotherapy treatment, there are no specific guidelines regarding the management of chemotherapeutic agents before PEG tube placement. Certain agents, particularly those who impair angiogenesis by inhibiting vascular endothelial growth factor (e.g., bevacizumab) are known to affect wound healing and it is generally recommended that at least a month elapse between the last dose and major surgery [25]. A multidisciplinary approach to determine the risk and benefit ratio of continuing or stopping chemotherapy at time of procedure, or delaying the procedure until the systemic effects of these agents are minimized is recommended.

MALNUTRITION

Patients undergoing endoscopic feeding tube insertion often suffer from malnutrition, which also has been associated with an increased risk of complication after PEG placement [26, 27]. A retrospective review of 232 patients demonstrated that a low body mass index and advanced malignancies were poor predictors for complications [28]. As the patient's malnutrition worsens, the balance between the need for appropriate nutritional support compared to patient's increased post procedure morbidity must be carefully evaluated. To date, no clear guidelines are available to guide this decision making process.

EDITOR'S COMMENT

The preoperative management of a PEG patient is not to be under estimated. Bleeding after the procedure can be clinically significant and appropriate management of anticoagulation around the procedure is necessary. Similarly, the administration of antibiotics should be appropriately timed to reduce the risk of infection (See Chapter 17 for more details) which can be difficult to diagnose early in the PEG patient for a variety of reasons. Among these are the possible altered sensorium and inability to communicate symptoms related to infection. Doctors Wu Chao Ying and Martinez smartly note that unfavorable pre-operative imaging commonly does not equate to 'un-PEGable' and consideration should be given to an endoscopic evaluation prior to seeking alternative means of enteral access (EMP).

REFERENCES

[1] Lee JH, Kim JJ, Kim Y-H, et al. Increased risk of peristomal wound infection after percutaneous endoscopic gastrostomy in patients with diabetes mellitus. *Digestive and Liver Disease.* 2002;34(12): 857-861.

[2] Panigrahi H, Shreeve DR, Tan WC, et al. Role of antibiotic prophylaxis for wound infection in percutaneous endoscopic gastrostomy (PEG): result of a prospective double-blind randomized trial. *Journal of Hospital Infection.* 2002;50(4): 312-315.

[3] Lipp A, Lusardi G. Systemic antimicrobial prophylaxis for percutaneous endoscopic gastrostomy. *The Cochrane Database Syst Rev*. 2013 Nov 14;11:CD005571.

[4] Mainie I, Loughrey A, Watson J, Tham TC. Percutaneous endoscopic gastrostomy sites infected by methicillin-resistant Staphylococcus aureus: impact on outcome. *Journal of Clinical Gastroenterology.* 2006;40(4): 297-300.

[5] Thomas S, Cantrill S, Waghorn DJ, McIntyre A. The role of screening and antibiotic prophylaxis in the prevention of percutaneous gastrostomy site infection caused by methicillin-resistant Staphylococcus aureus. *Alimentary Pharmacology & Therapeutics* 2007;25(5): 593-597.

[6] Khashab A, Chithadi KV, Acosta RD, et al for the ASGE Standards of Practice Committee. Antibiotic prophylaxis for GI endoscopy. *Gastrointestinal Endoscopy*. 2015;81(1):81-89.

[7] Luman W, Kwek KR, Loi KL, et al. Percutaneous endoscopic gastrostomy--indications and outcome of our experience at the Singapore General Hospital." *Singapore Medical Journal* 2001;42(10):460-465.

[8] Schapiro GD, Edmundowicz SA. Complications of percutaneous endoscopic gastrostomy. *Gastrointestinal Endoscopy Clinics of North America*. 1996;6(2):409-422.

[9] Douketis JD, Spyropoulos AC, Spencer FA, et al. Perioperative management of antithrombotic therapy: Antithrombotic Therapy and Prevention of Thrombosis, 9th ed: American College of Chest Physicians Evidence-Based Clinical Practice Guidelines. *Chest.* 2012;141(2 Suppl): e326S-e350S.

[10] Acosta RD, Abraham NS, Chandrasekhara V, et al. for the for the ASGE Standards of Practice Committee. The management of antithrombotic agents for patients undergoing GI endoscopy. *Gastrointestinal Endoscopy*. 2016;83(1);3-16.

[11] Richter JA, Patrie JT, Richter RP, et al. Use of High-Dose Aspirin or Clopidogrel Before or After Percutaneous Endoscopic Gastrostomy Is Not Associated With Post-Procedural Bleeding. *Gastrointestinal Endoscopy* 2010;71(5):AB114.

[12] Becker RC, Scheiman J, Dauerman HL, et al. Management of platelet-directed pharmacotherapy in patients with atherosclerotic coronary artery disease undergoing elective endoscopic gastrointestinal procedures. *Journal of the American College of Cardiology*. 2009;54(24):2261-2276.

[13] Bhatt DL, Scheiman J, Abraham NS, et al. ACCF/ACG/AHA 2008 expert consensus document on reducing the gastrointestinal risks of antiplatelet therapy and NSAID use: a report of the American College of Cardiology Foundation Task Force on Clinical Expert Consensus Documents. *Journal of the American College of Cardiology*. 2008; 52(18): 1502-1517.

[14] Coronel MF, Banner K, Nannegari V, et al. Does Aspirin Increase the Risk of Bleeding for Percutaneous Endoscopic Gastrostomy Procedure? *Gastrointestinal Endoscopy*. 2006;63. 5: AB113.

[15] Kwok A, Faigel DO. Management of anticoagulation before and after gastrointestinal endoscopy. *The American Journal of Gastroenterology*. 2009;104(12): 3085-3097.

[16] Boustière C, Veitch A, Vanbiervliet G, et al. Endoscopy and antiplatelet agents. European Society of Gastrointestinal Endoscopy (ESGE) guideline. *Endoscopy*. 2011;43(5): 445.

[17] Lucendo AJ, Sánchez-Casanueva T, Redondo O, et al. Risk of bleeding in patients undergoing percutaneous endoscopic gastrotrostomy (PEG) tube insertion under antiplatelet therapy: A systematic review with a meta-analysis. *Revista Espanola de Enfermedades Digestivas*. 2015;107(3):128-136.

[18] Desai J, Granger CB, Weitz JA, Aisenberg J. Novel oral anticoagulants in gastroenterology practice. *Gastrointestinal Endoscopy*. 2013;78(2):227-239.

[19] Levy MJ, Anderson MA, Baron TH, et al for the ASGE Standards of Practice Committee. Position statement on routine laboratory testing before endoscopic procedures. *Gastrointestinal Endoscopy*. 2008;68(5):827-832.

[20] Pasha SF, Acosta R, Chandrasekhara V, et al for the ASGE Standards of Practice Committee . Routine laboratory testing before endoscopic procedures. *Gastrointestinal Endoscopy* 2014;80(1):28-33.

[21] Itkin M, DeLegge MH, Fang JC, et al. "Multidisciplinary practical guidelines for gastrointestinal access for enteral nutrition and decompression from the Society of Interventional Radiology and American Gastroenterological Association (AGA) Institute, with endorsement by Canadian Interventional Radiological Association (CIRA) and Cardiovascular and Interventional Radiological Society of Europe (CIRSE)." *Journal of Vascular and Interventional Radiology*. 2011;22(8):1089-1106.

[22] Jain R, Maple JT, Anderson MA, et al. for the ASGE Standards of Practice Committee. The role of endoscopy in enteral feeding. *Gastrointestinal Endoscopy*. 2011;74(1):7-12.

[23] Petersen BT, Hussain N, Marine JE, et al. for the ASGE Technology Assessment Committee. Endoscopy in patients with implanted electronic devices. *Gastrointestinal Endoscopy*. 2007;65(4):561-568.

[24] Bianco JA, Pepe MS, Higano C, et al. Prevalence of clinically relevant bacteremia after upper gastrointestinal endoscopy in bone marrow transplant recipients. *The American Journal of Medicine*. 1990;89(2):134-136.

[25] Manzullo EF, Sahai SK, Weed HG. Preoperative evaluation and management of patients with cancer. In: *UpToDat*e, Post TW (Ed), UpToDate, Waltham, MA. (Accessed December 19, 2015).

[26] Zopf Y, Maiss J, Konturek P,et al. Predictive factors of mortality after PEG insertion: guidance for clinical practice. *Journal of Parenteral and Enteral Nutrition*. 2011;35(1):50-5.

[27] Lang A, Bardan E, Chowers Y, et al. Risk factors for mortality in patients undergoing percutaneous endoscopic gastrostomy. *Endoscopy*. 2004;36(6):522-6.

[28] Amann W, Mischinger HJ, Berger A, et al. Percutaneous endoscopic gastrostomy (PEG) 8 years of clinical experience in 232 patients. *Surgical Endoscopy*. 1997;11(7):741-744.

In: Encyclopedia of Surgery (22 Volume Set)
Editors: Andreas Lehrer and Kristin Mueller
ISBN: 978-1-53618-329-0
© 2020 Nova Science Publishers, Inc.

Chapter 126

ANESTHESIA FOR PEG TUBE PLACEMENT

S. William Hazard*, III, MD
Penn State Hershey Medical Center, Hershey, PA, US

INTRODUCTION

Patients present for PEG tube placement for a variety of anatomic or physiologic derangement ranging from neurologic diseases such as amyotrophic lateral sclerosis (ALS), traumatic brain injury (TBI) and stroke to aerodigestive dysfunction or surgical resection. As such, no single anesthetic protocol can meet the needs of all patients. The success of any anesthetic relies on a comprehensive assessment of each of the patient's comorbidities, careful patient preparation and a thorough understanding of the proceduralist's expectations. This is done in an attempt to minimize the risks associated with procedural analgesia and sedation. Guidelines from the American Society of Anesthesiology and the American College of Cardiology aid practitioners in achieving this goal. The purpose of this chapter is to provide recommendations for the pre-procedure evaluation of patients scheduled for a percutaneous endoscopic gastrostomy (PEG) tube placement. Anesthetic technique definitions (sedation, monitored anesthesia care (MAC), general anesthesia, or a combination of techniques), indications, commonly used anesthetic agents as well as immediate and long-term sequela of related to anesthesia will be discussed. This information aims to aid practitioner's decision making related to both the timing and anesthetic plan for this procedure.

CARDIAC RISK ASSESSMENT

Regardless of the specific indication for PEG placement a careful cardiopulmonary assessment should be performed. The most recent guidelines for the Perioperative Cardiovascular Evaluation and Management of Patients Undergoing Non-cardiac Surgery were published jointly by The American College of Cardiology and the American Heart

* Corresponding Author's Email: shazard@hmc.psu.edu.

Association in 2014. The focus of these guidelines is to provide tools to aid the clinician in assessing preoperative cardiac risk and to recommend the necessity, and timing of cardiovascular testing [1]. These guidelines begin with a description of cardiac risk factors including coronary artery and valvular heart disease, congestive heart failure, rhythm and conduction disturbances, pulmonary vascular disease, implantable electronic devices, and cardiomyopathy. Individual recommendations are beyond the scope of this chapter however, knowledge of the patients existing comorbidities will allow practitioners to utilize risk indices and calculators to help predict perioperative cardiac morbidity.

There are a number of validated risk-assessment tools including; the Revised (Lee) Cardiac Risk Index (RCRI), the American College of Surgeons National Surgical Quality Improvement Program (NSQIP) risk prediction calculator, the Gupta myocardial infarction/ cardiac arrest (MICA), and the Bilimoria ACS surgical risk calculator. All are simple to use and readily available. The RCRI is particularly easy to use and has been validated many times over in the past 15 years [2]. It consists of six independent predictors of major cardiac complications: high risk surgery, history of ischemic heart disease, heart failure, cerebrovascular disease, diabetes (requiring insulin) and creatinine greater than 2 mg/dL. These risk factors are additive and are used to predict the rate of cardiac death, nonfatal myocardial infarction and cardiac arrest. The likelihood of a cardiac event occurring ranges from 0.4% (with no risk factors) to 5.4% (if three or more risk factors are present) [3]. According to the guidelines, if the patient is at "low risk" (less than 1%), no further testing is recommended prior to the procedure [4].

When approaching perioperative cardiac testing, one of the simplest and most reliable predictor of perioperative cardiac events is the patient's functional capacity. The functional status of the patient can be determined simply by evaluating activities of daily living [5]. Functional capacity is most often reported as Metabolic EquivalenTs (METs): 1 MET - dressing one's self, 4 METs- climbing a flight of stairs, 10 METs - swimming or running quickly. Perioperative cardiac risk is increased in patients unable to perform 4 metabolic equivalents [1]. In fact, a study published in 1999 examined self-reported exercise tolerance in an effort to predict in-hospital perioperative risk. The authors found that the likelihood of a serious complication was inversely related to the number of blocks that could be walked or flights of stairs that could be climbed [5].

CARDIAC EVALUATION

Supplemental preoperative testing can be helpful when indicated Indiscriminate testing, however, can lead to procedural delays, unnecessary evaluations, and increased healthcare costs and potential morbidity. Observational studies have demonstrated that abnormal electrocardiogram (ECG) findings occur in 4.6 to 44.9% of asymptomatic patients [6-9]. These abnormal findings led to cancellation of surgery or changes in management in only 0.46-2.6% of cases [6, 10]. Preoperative ECG is recommended, however, for patients with known coronary heart disease, significant arrhythmia, cerebrovascular or peripheral arterial disease, and for patients with significant structural heart disease [11, 12]. A stipulation to this recommendation is that an ECG may not be necessary if the surgery is *low risk* (such as PEG tube placement) [1].

Preoperative transthoracic echocardiogram (TTE) has the potential to modify both patient management and timing of a procedure. An association between low ejection fraction and postoperative complications has been clearly demonstrated, however, screening asymptomatic patients can lead to resource overutilization and added expensive [13]. Determining which patients should be screened was made more difficult by a study of 1000 patients undergoing vascular surgery (both open and endovascular) published in 2010. Of the patients screened, nearly 40% had asymptomatic left ventricular failure. The presence of LV failure doubled the risk of 30-day cardiovascular morbidity and quadrupled the risk of long-term mortality [14]. Despite these findings, the American Heart Association and American Society of Echocardiography states there is no benefit to *routine* TTE screening. There are, however, situations in which TTE can be helpful [15]. Patients with dyspnea of unknown origin or worsening dyspnea as well as those with previously documented LV dysfunction (not assessed within one year) should undergo testing [1].

CARDIAC RISK MANAGEMENT STRATEGY

Following a stepwise approach to perioperative cardiac risk assessment, patients with CAD and poor (<4 METS) or unknown functional capacity should undergo stress testing only if further testing will impact medical decision in their perioperative care [16, 17]. The proportion of abnormal findings during stress testing, in appropriately selected patients, was noted to be as high as 61.9% (variability between studies was high: 15.2-61.9%). These findings lead to additional invasive cardiac testing in almost 40 percent of these patients [18, 19]. Patients with an elevated risk of perioperative cardiac events and excellent functional capacity (>10 METs) or elevated risk and moderate to good functional capacity (>4 METs to 10 METs) should proceed to PEG without further exercise testing with cardiac imaging [1]. Similar to other perioperative cardiac tests, there is no utility in routine screening of low risk patients before a non-cardiac surgery.

Recent myocardial infarction (MI), defined as occurring within 6 months, is an independent risk factor for perioperative stroke and is associated with an 8-fold increase in mortality [20]. Postoperative MI rates decrease substantially the further out from a prior MI the patient is, if the procedure is non-cardiac (e.g., PEG) [21]. This risk changes if the patient undergoes coronary revascularization (coronary artery bypass grafting or percutaneous coronary interventions) [22]. Many percutaneous coronary interventions are accompanied with coronary stent placement. Elective non-cardiac surgery should not be performed within 30 days after placement of bare metal stents or 12 months after the placement of drug eluding stents due to the risk of stent thrombosis. This recommendation is specific to patients in which dual antiplatelet therapy (DAPT) will need to be discontinued perioperatively [23, 24]. As reviewed in Chapters 4 and 16, current guidelines permit the continuation of aspirin in high-risk patients (such as those how received a stent within the last 12 months) undergoing PEG. If a patient does not undergo a coronary intervention (stenting) following an MI, it is recommended waiting ≥60 days before performing non-cardiac surgery [1].

NON-CARDIAC TESTING

In observational studies of asymptomatic patients, routine hemoglobin testing was found to be abnormal in 0.5% to 65.4% of patients [9, 10]. These findings led to cancellation of procedures and changes in management in 2.4-28.6% of cases [25-27]. Routine screening of asymptomatic patients is not recommended however, patients with liver disease, a history of anemia, bleeding, or other hematologic disorders should be screened [10]. The majority of transfusions in the perioperative period are due to either preoperative anemia, blood loss, or the result of liberal transfusion thresholds [28].

Recent studies have raised concerns that red blood cell (RBC) transfusions may be associated with higher mortality, increased hospital length of stay, and a higher incidence of organ dysfunction. As such Patient Blood Management (PBM) programs have attempted to reduce unnecessary RBC transfusions [29-33]. These programs attempt to optimize preoperative hematopoiesis by first determining the etiology of the anemia and then treating the underlying cause and to transfuse only when absolutely necessary. The AABB (formerly the American Association of Blood Banks) endorses a restrictive transfusion strategy (7 to 8 g/dL) in stable, hospitalized patients [34].

Coagulation testing (e.g., platelet count, aPTT and PT), to predict bleeding risk, is commonly performed in patients even when there is no known risk factors or history of excessive bleeding [35, 36]. This occurs despite the fact that coagulation testing of unselected patients *has not* been demonstrated to have *any* significant positive predictive value for bleeding risk [37-39]. Prothrombin and and partial thromboplastin time screening has both high false positive and false negative rates that can lead to unnecessary surgical delays and more costly testing [40]. In 2008, the British Committee for Standards in Haematology concluded that no further coagulation testing is indicated if a patients bleeding history is negative [37].

Serum chemistries, including glucose, sodium, potassium, renal and liver function studies are often ordered indiscriminately or as a part of protocol. They should only be obtained as indicated by patients with comorbidities affecting the endocrine, renal, or hepatic systems or those taking certain medications (such as diuretics or alternative therapies) [10].

SEDATION/ANALGESIA/ANESTHESIA

An understanding of accepted definitions will help a practitioner ensure that the type and doses of medications will produce the desired effect and will be unlikely to place the patient at risk (cause airway obstruction or create a situation requiring hemodynamic support). In an effort to eliminate ambiguity surrounding procedural sedation, the American Society of Anesthesiologists (ASA) has created a series of position statements defining levels of sedation (minimal and deep sedation, monitored anesthesia care, and general anesthesia) along with the associated physiologic derangements that can be expect at each particular level[1].

[1] Continuum Of Depth Of Sedation: Definition Of General Anesthesia And Levels Of Sedation/Analgesia Approved by the ASA House of Delegates on October 13, 1999, and last amended on October 15, 2014 and accessed December 2015 www.asahq.org.

Minimal Sedation/Anxiolysis is defined as a drug-induced state in which the patient can respond normally to verbal commands. Although patients are typically cognitively impaired, it is important to note that airway reflexes remain intact and both pulmonary and cardiovascular function remains normal.

Moderate Sedation/Analgesia, also known as "Conscious Sedation," retains the patient's ability to respond purposefully, but not normally, to verbal commands. During conscious sedation, a patient will respond to verbal commands alone or accompanied by light tactile stimulation. Without intervention, the patient must be able to maintain a patent airway and ventilate spontaneously. Cardiovascular function is usually unaffected at this level of sedation.

Deep Sedation/Analgesia patients cannot be easily aroused but will respond purposefully following repeated or painful stimulation. The key difference between deep and conscious sedation is that patients may not be able to maintain either the patency of their airway or sustain adequate ventilation without assistance from the practitioner.

Monitored Anesthesia Care ("MAC") is a term used to describe *a specific anesthesia service* in which an anesthesiologist has been requested to participate in the care of a patient undergoing a diagnostic or therapeutic procedure. It is not meant to describe a particular depth of sedation.* Monitored Anesthesia Care will often include the same medications used for moderate/deep sedation, however the provider must maintain the ability to convert to general anesthesia should the need arise. The provider must also be able to rescue a patient's airway should the patient develop airway obstruction as a result of the medications administered.

General Anesthesia is defined as a state of medically induced loss of consciousness that renders a patient unarousable, even by painful stimulation. The ability of the patient to *independently* maintain ventilatory function is often impaired. Patients typically require assistance maintaining airway patency and in some cases may require mechanical ventilation. Also included in the definition is the possibly that cardiovascular performance may be altered by the medications administered.

MEDICATION ADMINISTRATION

Medications used for sedation and analgesia are titrated to effect and it is often not possible to predict how individual patients will respond to either the medications themselves or the stimuli of the procedure. The ASA recommends that practitioners, when attempting to provide a particular level of sedation[2], be able to treat the consequences of a patient entering a deeper level of sedation (i.e., hypoventilation, hypoxia and hypotension). If deep sedation is planned, the practitioner should be proficient in both airway management and advanced life support. Whenever propofol is being administered, the ASA recommends it be done so by *practitioners trained in the administration of general anesthesia* and that he or she not be *simultaneously* involved in performing the procedure itself due to the likelihood of respiratory and/or cardiovascular instability.

[2] Standards For Basic Anesthetic Monitoring (Approved by the ASA House of Delegates on October 21, 1986, last amended on October 20, 2010, and last affirmed on October 28, 2015 accessed December 2015 www.asahq.org).

PATIENT MONITORING DURING PEG

Because of the rapid changes in patient physiology during sedation/anesthesia, the ASA has made recommendation regarding the type of monitoring during procedural sedation. Recommendations are specific to monitoring under general anesthesia however; more invasive monitoring should be considered if patient's condition dictates even if minimal sedation is being utilized. For example, if a patient has severe pulmonary hypertension where hypercarbia may lead to elevated right heart pressures, an arterial line for sampling of arterial carbon-dioxide (CO_2) level and/or capnography may be warranted.

With any level of sedation during placement of a PEG tube, some combination of oxygenation, ventilation, circulation and temperature monitoring should be performed. Oxygenation can be assessed by means of a pulse oximetry. To date, pulse oximetry remains the most widely used monitor during procedural sedation [41] [42]. Although the value of pulse oximetry during sedation/anesthesia cannot be overstated it is an inadequate monitor of ventilation. Oxygen saturation (SpO_2) rarely demonstrates significant changes during deep sedation even with significant hypercarbia particularly when supplemental oxygen is being delivered. This was nicely illustrated in a study examining the ability of end tidal CO2 monitoring (during procedural sedation with propofol) to decrease the incidence of hypoxic events. The authors found that hypoxia was more likely (42% vs 25%) in patients without capnography. Furthermore, capnography predicted all cases of hypoxia (SpO2 less than 93%) before its onset. The median time from capnographic evidence of respiratory depression (end tidal CO2 greater than 50 mm Hg, ETCO2 change from baseline of 10%, or loss of the waveform) to hypoxia was 60 seconds (range 5 to 240 seconds). (43) In addition to pulse oximetry and expired carbon dioxide; continuous electrocardiogram (ECG), heart rate and non-invasive blood pressure should be measured at least every five minutes during the procedure.

SEDATIVES AND ANESTHETIC MEDICATIONS

A wide variety of hypnotic, sedative and opioid medications are used for procedural sedation and or general anesthesia.

Benzodiazepines

Benzodiazepines activate γ-aminobutyric acid A (GABA-A) receptors within the brain producing anxiolysis, amnesia, sedation, and hypnosis, but without analgesia [44]. The sedative effects of benzodiazepines can vary widely especially in extremes of ages. In children, paradoxical excitement occurs in up to 10-15% of patients whereas the elderly are more sensitive to their sedative and respiratory depressant effects [45, 46]. Respiratory and cardiovascular depression is more likely to occur in critically ill patients with preexisting respiratory or cardiovascular instability [47].

Midazolam is the most commonly used benzodiazepine for procedural sedation in endoscopy [48]. Adverse effects of benzodiazepine use extend beyond the cardiopulmonary

system. Some studies have reported a relationship between benzodiazepine use and the development of delirium [49, 50]. Numerous prospective studies have demonstrated that patients who develop delirium after either general anesthesia or sedation, have an increased risk of mortality. This risk is independent of preexisting comorbidities [51, 52]. The author recommends that caution should be used when administering benzodiazepines for sedation or anesthesia in critically ill or hospitalized patients due to differences in the outcomes of patients treated with benzodiazepine-based versus non-benzodiazepine sedation (i.e., Propofol or Dexmedetomidine). These studies included a meta-analysis demonstrating that benzodiazepine sedation is associated with an increased ICU length of stay as well as an increase in the duration of mechanical ventilation [53].

Opioids

Opioids bind to receptors distributed throughout the central (CNS) and peripheral nervous system. Respiratory depression occurs with all opioids in a dose-dependent manner (related to their potency). Opioids interact with respiratory centers in the medulla and pons; areas of the brain that regulate rhythmicity of breathing [54]. Opioids are frequently co-administered with other sedative drugs leading to additive effects on respiratory depression, increasing the risk of hypoventilation and apnea [55]. Synthetic opioids, particularly fentanyl, can cause chest wall rigidity. This occurs more commonly with large doses, with rapid administration, and with co-administration of other induction agents such as propofol [56]. Synthetic opioids decrease the release of endogenous catecholamines during stimulating procedures. Patients who are hypovolemic or dependent on high sympathetic tone (heart/liver failure) are predisposed to hypotension [57]. Morphine, uniquely, can cause venodilation as well as histamine release, compounding this problem [58].

Propofol

Propofol (2,6-di-isoprophylphenol) is one of the most (if not the most) frequently used induction agent in the world [42]. The current formulation of propofol is insoluble in water. As a result, it is prepared in an emulsion of oil, glycerol, and lecithin. Propofol has no intrinsic analgesic properties and its sedative/amnestic effects are mediated by activating the GABA receptor system [42]. Propofol is rapidly cleared from the central compartment, undergoes hepatic metabolism, and cleared by the kidney. Since it is so rapidly redistributed, and has no active metabolites, propofol is particularly useful for procedural sedation [59]. Propofol's respiratory depressant effects include hypoventilation, upper airway obstruction, and apnea. As with other sedatives, these effects are exacerbated with the co-administration of other hypnotic-sedatives or opioids [41]. Propofol decreases mean arterial pressure through peripheral vasodilation and negative inotropic effects [60]. Due to the frequency of adverse respiratory and hemodynamic events with the use of propofol, practitioners should have the skill, medications and equipment immediately available to deal with these problems should they arise.

Ketamine

The mechanism of action of ketamine is thought to be the inhibition of N-methyl-D-aspartate (NMDA) receptors within the limbic and thalamic systems of the central nervous system. This inhibition creates what has been described as "dissociative anesthesia." It is characterized by having an unresponsive, spontaneously ventilating patient with his or her eyes open demonstrating a low frequency nystagmic gaze. It is also accompanied with increased lacrimation and salivation. This lacrimation and salivation, in combination with ketamine's tendency to produce an unpleasant emergence (which includes vivid dreams and hallucinations), has limited its use [42]. Ketamine is frequently administered with a benzodiazepine in an attempt to prevent the psychotropic effects. This relatively simple solution is not entirely effective in decreasing the incidence of the ketamine emergence phenomena [61]. Despite these untoward side effects, ketamine's unique ability to preserve cardiovascular function and maintain respiratory mechanics makes it unique among induction agents. These characteristics make it useful in patients with cardiopulmonary instability requiring procedural sedation that would otherwise poorly tolerate the administration of other medications.

Dexmedetomidine

Dexmedetomidine is an alpha-2 (α2) agonist similar to clonidine. It exhibits a much higher specificity for the α2 versus the α1 receptor. It works by activation of transmembrane α2 adrenergic receptors within the CNS, which results in sedation, anxiolysis, and analgesia. It does so with minimal effect on respiratory function and as such, end-tidal CO_2, oxygen saturation, and respiratory rate are maintained [62]. Adverse hemodynamic effects with dexmedetomidine include hypotension and bradycardia, which are both dose related. In one study of adult patients undergoing vascular surgery who were given dexmedetomidine, 27% experienced a mean arterial pressure ≤60 mmHg (or a 30% decrease from baseline) or heart rate ≤50 beats/minute [63]. Dexmedetomidine has been used for procedural sedation for upper endoscopy although much less so than the other agents described. In one prospective, randomized study, the use of dexmedetomidine was found to have a similar incidence of gagging, patient satisfaction, patient discomfort, anxiety scores, and recovery time compared to midazolam. Its use had, however, higher endoscopist satisfaction and fewer episodes of retching [64]. In another study, sixty patients were randomized to receive either a loading dose of dexmedetomidine followed by a maintenance infusion, or midazolam during upper endoscopy. The authors concluded that dexmedetomidine was as safe and effective as midazolam [65]. Dexmedetomidine has also been found to be useful for procedural sedation in patients with obstructive sleep apnea or pulmonary hypertension in which depression of respiratory function can rapidly lead to cardiopulmonary collapse.

Topical Pharyngeal Anesthesia

There are conflicting reports regarding the efficacy of the use of pharyngeal anesthesia to facilitate upper endoscopy. In one study the effects of topical lidocaine on the ability of

patients to tolerate upper endoscopy (as assessed by the endoscopist) was examined. The authors concluded there was significantly greater acceptance/tolerance in patients receiving topicalization of the pharynx [66]. A meta-analysis including 53 studies and 5 RCTs concluded that pharyngeal anesthesia with local anesthesia before upper endoscopy improved both the ease of endoscopy and patient tolerance [67]. This is in contrast to a randomized, double-blind, placebo-controlled trial in which propofol sedation alone was compared to propofol in combination with pharyngeal lidocaine in patients undergoing upper GI endoscopy. The authors concluded that topical pharyngeal anesthesia reduced the gag reflex in patients and did not influence patient satisfaction or ease of the procedure as determined by the endoscopist [68].

Choice of Anesthetic

A number of factors, outside of patient tolerance and comorbidities, play a role in the choice of anesthetic technique for PEG tube placement. Anticipated technical difficulty (and therefore length of the procedure), the possibility for conversion to a laparoscopic or open procedure, and procedures occurring simultaneously during PEG placement must be taken into consideration.

Where the procedure will be performed will also play a role in the choice of anesthetic: If the patient's hemodynamics or respiratory function were to change unexpectedly, is the procedure taking place in a location with access to all the equipment and or assistance needed? If the procedure will be performed under general anesthesia, will there be appropriate nursing staff to safely recover the patient?

A safe anesthetic not only seeks to minimize cardiovascular events, in a location with adequate support and equipment, but also to anticipate any number of complications that can result from sedation and anesthesia. For example, dysphagia is common following stroke with frequencies reported as high as 81% [69, 70]. Cerebral, cerebellar, or brain stem strokes all can impair swallowing physiology [71]. Delivering a safe anesthetic to patients who have recently suffered from a stroke is likely to involve endotracheal intubation due to high aspiration risk at baseline. Seemingly mild physiologic derangements can be the determining factor performing the procedure safely with sedation or general anesthesia with spontaneous ventilation versus general anesthesia with mechanical ventilation via an endotracheal tube.

Choosing an anesthetic for PEG tube placement can only be made after all patient factors, proceduralist's expectations, and environmental factors have been accounted for. Careful preparation will lead to better patient and proceduralist satisfaction and will ensure that management of the patient's pain and anxiety will occur in a safe and controlled manner.

EDITOR'S COMMENT

This chapter provides a comprehensive overview of the peri-procedural issues in terms of risk stratification, anesthetic selection, and post-procedural management. Even the most efficient and safely placed PEG can be easily affected by an anesthetic complication. With all endoscopic procedures, risks beyond the actual endoscopic therapy will exist and it is

imperative that the endoscopist is astutely aware of techniques to identify and manage these scenarios (JMM).

REFERENCES

[1] Fleisher LA, Fleischmann KE, Auerbach AD, Barnason SA, Beckman JA, Bozkurt B et al. 2014 ACC/AHA guideline on perioperative cardiovascular evaluation and management of patients undergoing noncardiac surgery: a report of the American College of Cardiology/American Heart Association Task Force on Practice Guidelines. *Circulation*. 2014;130(24):e278-333.

[2] Lee TH, Marcantonio ER, Mangione CM, Thomas EJ, Polanczyk CA, Cook EF et al. Derivation and prospective validation of a simple index for prediction of cardiac risk of major noncardiac surgery. *Circulation*. 1999;100(10):1043-9.

[3] Devereaux PJ, Goldman L, Cook DJ, Gilbert K, Leslie K, Guyatt GH. Perioperative cardiac events in patients undergoing noncardiac surgery: a review of the magnitude of the problem, the pathophysiology of the events and methods to estimate and communicate risk. *Canadian Medical Association Journal*. 2005;173(6):627-34.

[4] Schein OD, Katz J, Bass EB, Tielsch JM, Lubomski LH, Feldman MA et al. The value of routine preoperative medical testing before cataract surgery. Study of Medical Testing for Cataract Surgery. *The New England Journal Of Medicine*. 2000;342(3):168-75.

[5] Reilly DF, McNeely MJ, Doerner D, Greenberg DL, Staiger TO, Geist MJ et al. Self-reported exercise tolerance and the risk of serious perioperative complications. *Archives Of Internal Medicine*. 1999;159(18):2185-92.

[6] Perez A, Planell J, Bacardaz C, Hounie A, Franci J, Brotons C et al. Value of routine preoperative tests: a multicentre study in four general hospitals. *Br J Anaesth*. 1995;74 (3):250-6.

[7] Noordzij PG, Boersma E, Bax JJ, Feringa HH, Schreiner F, Schouten O et al. Prognostic value of routine preoperative electrocardiography in patients undergoing noncardiac surgery. *The American Journal Of Cardiology*. 2006;97(7):1103-6.

[8] Tait AR, Parr HG, Tremper KK. Evaluation of the efficacy of routine preoperative electrocardiograms. *Journal Of Cardiothoracic And Vascular Anesthesia*. 1997;11(6): 752-5.

[9] Turnbull JM, Buck C. The value of preoperative screening investigations in otherwise healthy individuals. *Archives of internal medicine*. 1987;147(6):1101-5.

[10] Apfelbaum JL, Connis RT, Nickinovich DG et al. for the American Society of Anesthesiologists Task Force on Preanesthesia Evaluation. Practice advisory for preanesthesia evaluation: an updated report by the American Society of Anesthesiologists Task Force on Preanesthesia Evaluation. *Anesthesiology*. 2012;116 (3):522-38.

[11] Jeger RV, Probst C, Arsenic R, Lippuner T, Pfisterer ME, Seeberger MD et al. Long-term prognostic value of the preoperative 12-lead electrocardiogram before major noncardiac surgery in coronary artery disease. *American Heart Journal*. 2006;151(2): 508-13.

[12] Payne CJ, Payne AR, Gibson SC, Jardine AG, Berry C, Kingsmore DB. Is there still a role for preoperative 12-lead electrocardiography? *World Journal Of Surgery*. 2011;35 (12):2611-6.

[13] Wong CM, Hawkins NM, Petrie MC, Jhund PS, Gardner RS, Ariti CA et al. Heart failure in younger patients: the Meta-analysis Global Group in Chronic Heart Failure (MAGGIC). *European Heart Journal*. 2014;35(39):2714-21.

[14] Flu WJ, van Kuijk JP, Hoeks SE, Kuiper R, Schouten O, Goei D et al. Prognostic implications of asymptomatic left ventricular dysfunction in patients undergoing vascular surgery. *Anesthesiology*. 2010;112(6):1316-24.

[15] American College of Cardiology Foundation Appropriate Use Criteria Task F, American Society of E, American Heart A, American Society of Nuclear C, Heart Failure Society of A, Heart Rhythm S et al. ACCF/ASE/AHA/ASNC/HFSA/HRS/ SCAI/SCCM/SCCT/SCMR 2011 Appropriate Use Criteria for Echocardiography. A Report of the American College of Cardiology Foundation Appropriate Use Criteria Task Force, American Society of Echocardiography, American Heart Association, American Society of Nuclear Cardiology, Heart Failure Society of America, Heart Rhythm Society, Society for Cardiovascular Angiography and Interventions, Society of Critical Care Medicine, Society of Cardiovascular Computed Tomography, and Society for Cardiovascular Magnetic Resonance Endorsed by the American College of Chest Physicians. *Journal of the American College of Cardiology*. 2011;57(9):1126-66.

[16] Carliner NH, Fisher ML, Plotnick GD, Garbart H, Rapoport A, Kelemen MH et al. Routine preoperative exercise testing in patients undergoing major noncardiac surgery. *The American Journal Of Cardiology*. 1985;56(1):51-8.

[17] Sgura FA, Kopecky SL, Grill JP, Gibbons RJ. Supine exercise capacity identifies patients at low risk for perioperative cardiovascular events and predicts long-term survival. *The American Journal Of Medicine*. 2000;108(4):334-6.

[18] Troisi N, Dorigo W, Lo Sapio P, Pratesi G, Pulli R, Gensini GF et al. Preoperative cardiac assessment in patients undergoing aortic surgery: analysis of factors affecting the cardiac outcomes. *Annals Of Vascular Surgery*. 2010;24(6):733-40.

[19] Therre T, Ribal JP, Motreff P, Lusson JR, Espeut JB, Cassagnes J et al. Assessment of cardiac risk before aortic reconstruction: noninvasive work-up using clinical examination, exercise testing, and dobutamine stress echocardiography versus routine coronary arteriography. *Annals Of Vascular Surgery*. 1999;13(5):501-8.

[20] Mashour GA, Shanks AM, Kheterpal S. Perioperative stroke and associated mortality after noncardiac, nonneurologic surgery. *Anesthesiology*. 2011;114(6):1289-96.

[21] Livhits M, Ko CY, Leonardi MJ, Zingmond DS, Gibbons MM, de Virgilio C. Risk of surgery following recent myocardial infarction. *Annals Of Surgery*. 2011;253(5):857-64.

[22] Livhits M, Gibbons MM, de Virgilio C, O'Connell JB, Leonardi MJ, Ko CY et al. Coronary revascularization after myocardial infarction can reduce risks of noncardiac surgery. *Journal of the American College of Surgeons*. 2011;212(6):1018-26.

[23] Nuttall GA, Brown MJ, Stombaugh JW, Michon PB, Hathaway MF, Lindeen KC et al. Time and cardiac risk of surgery after bare-metal stent percutaneous coronary intervention. *Anesthesiology*. 2008;109(4):588-95.

[24] Wijeysundera DN, Wijeysundera HC, Yun L, Wasowicz M, Beattie WS, Velianou JL et al. Risk of elective major noncardiac surgery after coronary stent insertion: a population-based study. *Circulation*. 2012;126(11):1355-62.
[25] Keating EM, Meding JB, Faris PM, Ritter MA. Predictors of transfusion risk in elective knee surgery. *Clin Orthop Relat Res*. 1998(357):50-9.
[26] Narr BJ, Hansen TR, Warner MA. Preoperative laboratory screening in healthy Mayo patients: cost-effective elimination of tests and unchanged outcomes. *Mayo Clinic Proceedings*. 1991;66(2):155-9.
[27] Kaplan EB, Sheiner LB, Boeckmann AJ, Roizen MF, Beal SL, Cohen SN et al. The usefulness of preoperative laboratory screening. *JAMA*. 1985;253(24):3576-81.
[28] Gombotz H, Rehak PH, Shander A, Hofmann A. Blood use in elective surgery: the Austrian benchmark study. *Transfusion*. 2007;47(8):1468-80.
[29] Karkouti K, Wijeysundera DN, Beattie WS, Reducing Bleeding in Cardiac Surgery I. Risk associated with preoperative anemia in cardiac surgery: a multicenter cohort study. *Circulation*. 2008;117(4):478-84.
[30] Reeves BC, Murphy GJ. Increased mortality, morbidity, and cost associated with red blood cell transfusion after cardiac surgery. *Current Opinion In Anaesthesiology*. 2008; 21(5):669-73.
[31] Goodnough LT, Maggio P, Hadhazy E, Shieh L, Hernandez-Boussard T, Khari P et al. Restrictive blood transfusion practices are associated with improved patient outcomes. *Transfusion.* 2014;54(10):2753-9.
[32] Koch CG, Li L, Sessler DI, Figueroa P, Hoeltge GA, Mihaljevic T et al. Duration of red-cell storage and complications after cardiac surgery. *The New England Journal Of Medicine*. 2008;358(12):1229-39.
[33] Shander A, Javidroozi M, Perelman S, Puzio T, Lobel G. From bloodless surgery to patient blood management. T*he Mount Sinai Journal Of Medicine, New York*. 2012; 79(1):56-65.
[34] Carson JL, Grossman BJ, Kleinman S, Tinmouth AT, Marques MB, Fung MK et al. Red blood cell transfusion: a clinical practice guideline from the AABB*. *Annals Of Internal Medicine*. 2012;157(1):49-58.
[35] Amukele TK, Baird GS, Chandler WL. Reducing the use of coagulation test panels. *Blood Coagulation and Fibrinolysis*. 2011;22(8):688-95.
[36] Kruse-Jarres R, Singleton TC, Leissinger CA. Identification and basic management of bleeding disorders in adults. *Journal of the American Board of Family Medicine* . 2014;27(4):549-64.
[37] Chee YL, Crawford JC, Watson HG, Greaves M. Guidelines on the assessment of bleeding risk prior to surgery or invasive procedures. British Committee for Standards in Haematology. *Br J Haematol*. 2008;140(5):496-504.
[38] Eckman MH, Erban JK, Singh SK, Kao GS. Screening for the risk for bleeding or thrombosis. *Annals Of Internal Medicine*. 2003;138(3):W15-24.
[39] Dzik WH. Predicting hemorrhage using preoperative coagulation screening assays. *Current Hematology Reports*. 2004;3(5):324-30.
[40] Chee YL, Greaves M. Role of coagulation testing in predicting bleeding risk. *The Hematology Journal*. 2003;4(6):373-8.
[41] Tobias JD, Leder M. Procedural sedation: A review of sedative agents, monitoring, and management of complications. *Saudi Journal Of Anaesthesia*. 2011;5(4):395-410.

[42] Miller RD, Pardo M, *Stoelting RK. Basics of anesthesia*. 6th ed. Philadelphia, PA: Elsevier/Saunders; 2011. xii, 817 p. p.

[43] Deitch K, Miner J, Chudnofsky CR, Dominici P, Latta D. Does end tidal CO2 monitoring during emergency department procedural sedation and analgesia with propofol decrease the incidence of hypoxic events? A randomized, controlled trial. *Annals Of Emergency Medicine*. 2010;55(3):258-64.

[44] Young CC, Prielipp RC. Benzodiazepines in the intensive care unit. *Critical Care Clinics*. 2001;17(4):843-62.

[45] Doyle WL, Perrin L. Emergence delirium in a child given oral midazolam for conscious sedation. *Annals Of Emergency Medicine*. 1994;24(6):1173-5.

[46] Barr J, Zomorodi K, Bertaccini EJ, Shafer SL, Geller E. A double-blind, randomized comparison of i.v. lorazepam versus midazolam for sedation of ICU patients via a pharmacologic model. *Anesthesiology*. 2001;95(2):286-98.

[47] Shafer A. Complications of sedation with midazolam in the intensive care unit and a comparison with other sedative regimens. *Crit Care Med*. 1998;26(5):947-56.

[48] Triantafillidis JK, Merikas E, Nikolakis D, Papalois AE. Sedation in gastrointestinal endoscopy: current issues. *World Journal Of Gastroenterology*. 2013;19(4):463-81.

[49] Pandharipande P, Cotton BA, Shintani A, Thompson J, Pun BT, Morris JA, Jr. et al. Prevalence and risk factors for development of delirium in surgical and trauma intensive care unit patients. *J Trauma*. 2008;65(1):34-41.

[50] Pandharipande PP, Sanders RD, Girard TD, McGrane S, Thompson JL, Shintani AK et al. Effect of dexmedetomidine versus lorazepam on outcome in patients with sepsis: an a priori-designed analysis of the MENDS randomized controlled trial. *Critical Care*. 2010;14(2):R38.

[51] Shehabi Y, Riker RR, Bokesch PM, Wisemandle W, Shintani A, Ely EW et al. Delirium duration and mortality in lightly sedated, mechanically ventilated intensive care patients. *Crit Care Med*. 2010;38(12):2311-8.

[52] Pisani MA, Kong SY, Kasl SV, Murphy TE, Araujo KL, Van Ness PH. Days of delirium are associated with 1-year mortality in an older intensive care unit population. *American Journal Of Respiratory And Critical Care Medicine*. 2009;180(11):1092-7.

[53] Barr J, Fraser GL, Puntillo K, Ely EW, Gelinas C, Dasta JF et al. Clinical practice guidelines for the management of pain, agitation, and delirium in adult patients in the Intensive Care Unit: executive summary. *American Journal Of Health-System Pharmacy*. 2013;70(1):53-8.

[54] Satoh M, Minami M. Molecular pharmacology of the opioid receptors. *Pharmacology and Therapeutics*. 1995;68(3):343-64.

[55] Bailey PL, Pace NL, Ashburn MA, Moll JW, East KA, Stanley TH. Frequent hypoxemia and apnea after sedation with midazolam and fentanyl. *Anesthesiology*. 1990;73(5):826-30.

[56] Fahnenstich H, Steffan J, Kau N, Bartmann P. Fentanyl-induced chest wall rigidity and laryngospasm in preterm and term infants. *Crit Care Med*. 2000;28(3):836-9.

[57] Sato A, Sato Y, Schmidt RF. Modulation of somatocardiac sympathetic reflexes mediated by opioid receptors at the spinal and brainstem level. *Experimental Brain Research*. 1995;105(1):1-6.

[58] Grossmann M, Abiose A, Tangphao O, Blaschke TF, Hoffman BB. Morphine-induced venodilation in humans. *Clinical Pharmacology And Therapeutics*. 1996;60(5):554-60.

[59] Beller JP, Pottecher T, Lugnier A, Mangin P, Otteni JC. Prolonged sedation with propofol in ICU patients: recovery and blood concentration changes during periodic interruptions in infusion. *Br J Anaesth*. 1988;61(5):583-8.

[60] Kassam SI, Lu C, Buckley N, Lee RM. The mechanisms of propofol-induced vascular relaxation and modulation by perivascular adipose tissue and endothelium. *Anesth Analg*. 2011;112(6):1339-45.

[61] Wathen JE, Roback MG, Mackenzie T, Bothner JP. Does midazolam alter the clinical effects of intravenous ketamine sedation in children? A double-blind, randomized, controlled, emergency department trial. *Annals Of Emergency Medicine*. 2000;36(6): 579-88.

[62] Hall JE, Uhrich TD, Barney JA, Arain SR, Ebert TJ. Sedative, amnestic, and analgesic properties of small-dose dexmedetomidine infusions. *Anesth Analg*. 2000;90(3):699-705.

[63] Venn RM, Bradshaw CJ, Spencer R, Brealey D, Caudwell E, Naughton C et al. Preliminary UK experience of dexmedetomidine, a novel agent for postoperative sedation in the intensive care unit. *Anaesthesia*. 1999;54(12):1136-42.

[64] Demiraran Y, Korkut E, Tamer A et al. The comparison of dexmedetomidine and midazolam used for sedation of patients during upper endoscopy: A prospective, randomized study. *Can J Gastroenterol*. 2007; 21(1): 25-29.

[65] Wu W, Chen Q, Zhang LC, Chen WH. Dexmedetomidine versus midazolam for sedation in upper gastrointestinal endoscopy. *J Int Med Res*. 2014;42(2):516-22.

[66] Leitch DG, Wicks J, el Beshir OA, Ali SA, Chaudhury BK. Topical anesthesia with 50 mg of lidocaine spray facilitates upper gastrointestinal endoscopy. *Gastrointestinal Endoscopy*. 1993;39(3):384-7.

[67] Evans LT, Saberi S, Kim HM, Elta GH, Schoenfeld P. Pharyngeal anesthesia during sedated EGDs: is "the spray" beneficial? A meta-analysis and systematic review. *Gastrointestinal Endoscopy*. 2006;63(6):761-6.

[68] Heuss LT, Hanhart A, Dell-Kuster S, Zdrnja K, Ortmann M, Beglinger C et al. Propofol sedation alone or in combination with pharyngeal lidocaine anesthesia for routine upper GI endoscopy: a randomized, double-blind, placebo-controlled, non-inferiority trial. *Gastrointestinal Endoscopy*. 2011;74(6):1207-14.

[69] Martino R, Foley N, Bhogal S, Diamant N, Speechley M, Teasell R. Dysphagia after stroke: incidence, diagnosis, and pulmonary complications. *Stroke*. 2005;36(12):2756-63.

[70] Meng NH, Wang TG, Lien IN. Dysphagia in patients with brainstem stroke: incidence and outcome. *American Journal Of Physical Medicine and Rehabilitation*. 2000;79(2): 170-5.

[71] Zald DH, Pardo JV. The functional neuroanatomy of voluntary swallowing. *Annals of Neurology*. 1999;46(3):281-6.

In: Encyclopedia of Surgery (22 Volume Set)
Editors: Andreas Lehrer and Kristin Mueller
ISBN: 978-1-53618-329-0
© 2020 Nova Science Publishers, Inc.

Chapter 127

DIAGNOSTIC ENDOSCOPY DURING PEG

Susan M. Wetzel, MD, Mei Chris Huang, MD, PhD and John D. Mellinger*, MD
Southern Illinois Univeristy, Springfield, IL, US

INTRODUCTION

Percutaneous endoscopic gastrostomy (PEG) tube placement has done much to minimize the risk associated with surgically placed gastrostomy tubes by obviating the need for open operation and general anesthesia. In comparison to other modes of gastrostomy formation, including radiologically placed gastrostomy, PEG has the added advantage of providing simultaneous evaluation of the mucosal surface of the upper gastrointestinal (GI) tract. For this potential advantage to be realized, the practitioner of PEG must be familiar with common foregut pathologies and their management. This chapter reviews common esophageal, gastric and duodenal pathology that may be encountered during PEG tube placement, and will succinctly summarize their current management, and any impact on PEG placement.

BARRETT'S ESOPHAGUS

Barrett's esophagus is a recognized premalignant change of the esophagus from stratified squamous epithelium to columnar epithelium with intestinal metaplasia including gastric surface cells, goblet cells and absorptive cells [1]. It is found in 6-15% of patients with symptomatic gastroesophageal reflux disease (GERD) undergoing esophago-gastroduodenoscopy (EGD), and 4% of all patients undergoing EGD [2, 3]. Barrett's esophagus is known to arise in the setting of GERD; additional risk factors include male gender, white race, obesity and obstructive sleep apnea [4, 5]. It represents a risk factor for the development of esophageal adenocarcinoma.

* Corresponding Author's Email: jmellinger@siumed.edu.

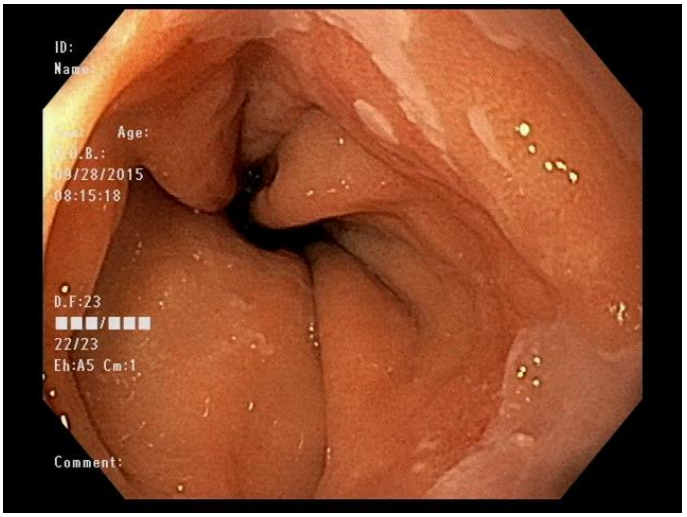

Figure 1. Barrett's esophagus. Note the irregular Z-line with islands of gastric epithelium interspersed with squamous esophageal mucosa.

Identification of Barrett's esophagus is often possible by visual inspection, characterized by salmon colored gastric-type mucosa arising from the gastric folds with extension into the distal esophagus (Figure 1) [6, 7]. Once identified, biopsies are required to confirm the diagnosis, histologically confirmed by the presence of intestinal goblet cells, and to assess for the degree of any associated dysplasia. It is suggested that biopsies be taken of all suspicious lesions as well as four quadrant random biopsies, which may show intestinal metaplasia even in the abscess of visual endoscopic findings [8]. This allows the pathologist to distinguish between nondysplastic Barrett's esophagus, low-grade dysplasia and high-grade dysplasia. This classification has ramifications on further treatment and surveillance.

For nondysplastic Barrett's esophagus, the risk of esophageal adenocarcinoma is only 0.12% to 0.38% per year [9]. Although there has been increasing interest in endoscopic intervention in this population, the mainstay of treatment has been acid suppression with proton-pump inhibitors (PPIs) and serial endoscopic surveillance with biopsy [7]. Surveillance recommendations include EGD with biopsy at one year and follow-up every three years onward [9, 10]. It is felt that aggressive acid suppression with PPIs significantly reduces the risk of progression to dysplasia [11]. Anti-reflux surgery may also be considered in certain patients, and while regression of Barrett's changes may be observed after such interventions, several studies have shown no significant difference in progression of Barrett's esophagus or symptom management between surgical intervention and medical management [12-14].

Low-grade dysplasia is also most commonly treated with medical management and increased surveillance with EGD with biopsy at 6 months and every year thereafter as long as dysplasia is identified [7, 9, 10]. In high-grade dysplasia, the risk of progression to adenocarcinoma is 6% per year, therefore more aggressive therapy is often employed [15, 16]. Management options include intense surveillance with EGD with biopsy every three months, endoscopic management and surgery [7]. Endoscopic options include electrocoagulation, various forms of ablation such as laser ablation, radiofrequency ablation and cryoablation, and endoscopic mucosal resection [5]. Given the risk of associated occult

malignancy, reported as high as 35-41% in some series, some advocate for esophagectomy in those with high-grade dysplasia [17, 18]. One advantage of esophagectomy is the lack of need for further surveillance; however, mortalities rates range from 4.9%-12.1% with long-term complications that may affect quality of life for years to come [19]. Ablation of dysplasia and long-term reduction in malignant risk are well documented through the use of such techniques, and in particular, radiofrequency ablation in the recent literature [20]. Given the success of such treatments, some also advocate for treatment of patients with low grade dysplasia or even nondysplastic Barrett's with high risk profiles, such as long segment disease in obese males or those with a family history of esophageal adenocarcinoma [21, 22].

Although Barrett's esophagus is not a contraindication for PEG placement, it does necessitate placement of patients with prolonged life expectancy to be placed in a surveillance program.

HIATAL HERNIA

Hiatal hernias occur when non-esophageal contents prolapse into the thorax via the esophageal hiatus, most commonly the proximal stomach. There are four types of hiatal hernia: a type I, or sliding hernia, occurs when the gastroesophageal junction (GEJ) migrates cranially as a result of weakening of the phrenoesophageal ligament; a type II is a pure paraesophageal hernia where the GEJ remains in place and proximal stomach herniates through a weakness of the phrenoesophageal-esophageal membrane; a type III is a combination of one and two; and a type IV is characterized by the presence of abdominal organs other than stomach in the thorax. Type one hernias are the most common, followed by type three and type two, respectively [23, 24].

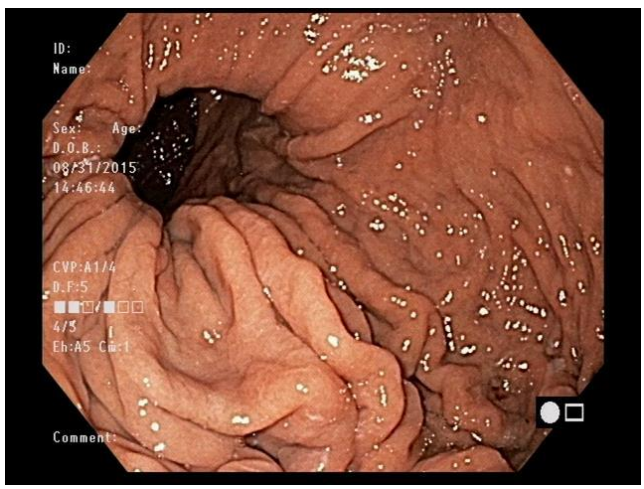

Figure 2. Large hiatal hernia viewed antegrade from the gastroesophageal junction. Narrowing of the lumen corresponds to location of esophageal hiatus of the diaphragm.

Hiatal hernias can be diagnosed both endoscopically and radiographically. Endoscopically, a hiatal hernia is identified as the presence of the Z-line more than 2 cm above the hiatus (Figure 2) [6, 24]. Recognition of the hiatus endoscopically can be facilitated

by watching for the diaphragmatic 'pinch' with inspiration (Figure 3). Radiographically, a hiatal hernia may be seen as a soft tissue mass on chest x-ray and confirmed with a contrast study, or may be seen on CT as the presence of stomach in the thorax [23].

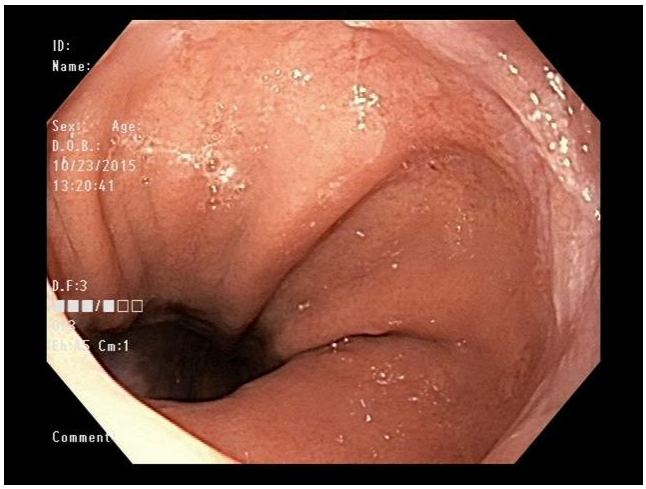

Figure 3. Diaphragmatic 'pinch' seen below the squamocolumnar junction.

If discovered, an asymptomatic type I hiatal hernia requires no intervention. Reduction of the hernia and an antireflux procedure is indicated in those with GERD symptoms, particularly if the patient's symptoms are not readily controlled with lifestyle modifications and pharmacologic therapy. Asymptomatic paraesophageal hernias may also be safely observed, as the rate of progression of symptoms appears to be approximately 14% per year [25, 26]. In patients with symptoms in association with paraesophageal component to their hiatal defect, it is recommended that they undergo surgical repair due to the risk of progression to severe symptoms requiring emergent surgery such as volvulus [23]. These recommendations must be weighed against the risk of surgery in an already high risk population in need of a PEG.

Paraesophageal hernias can complicate PEG placement due to the intrathoracic position of the stomach and inability to identify a portion of gastric lumen below the costal margin to allow placement of the PEG. With endoscopic reduction of the herniated stomach, PEG can sometimes be performed. If neither transillumination nor finger depression on the gastric lumen can be appreciated, alternative techniques including surgical or radiographic guidance may be required to obtain gastrostomy placement. Additionally, consideration should be given to the addition of a jejunal extension to the PEG or a direct percutaneous endoscopic jejunostomy (PEJ) if concern exists that the hiatal hernia could result in reflux and aspiration of gastric enteral nutrition.

ESOPHAGITIS AND GASTRITIS

Inflammation of the esophagus and/or stomach is one of the most common findings on routine EGD. There are many causes of upper gastrointestional inflammation such as reflux,

nonsteroidal anti-inflammatory drugs (NSAIDs), physiologic stress, drugs and viruses being relatively common.

Reflux Esophagitis

Reflux esophagitis is characterized by mucosal edema and increased vascularity (Figure 4) [6]. Several classification systems have been published to aid in defining the severity of reflux esophagitis, the most popular of which is the Los Angeles classification system that relies on the degree of mucosal breaks as identified on EGD. Class A esophagitis is disease in which there are one or more mucosal breaks not longer than 5mm and does not extend between the tops of two mucosal folds; class B involves breaks greater than 5mm but still not extending between the tops of two mucosal folds; class C mucosal breaks are continuous between two or more mucosal folds but less than 75% of the esophageal circumference; and class D involves more than 75% of the luminal circumference [27, 28]. The degree of reflux may be further characterized by pH monitoring. Biopsies are not required in the setting of typical reflux esophagitis, but should be taken if the diagnosis is questioned, or if there is concern for associated Barrett's esophagus. The mainstay of treatment remains medical treatment with proton pump inhibitors (PPIs). For those that fail medical management, antireflux procedures may be performed, but the risks of surgery must again be placed in the context of patients with comorbidities and potentially limited lifespans. Without treatment, continued exposure to gastric acid can result in esophageal structures, the treatment of which is discussed later in this chapter.

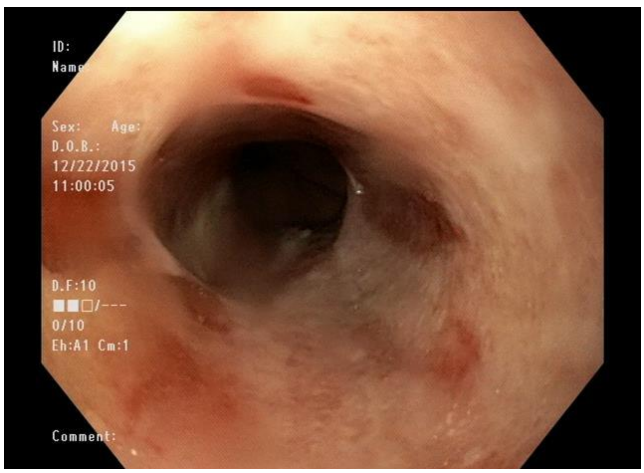

Figure 4. Reflux esophagitis.

Eosinophilic Esophagitis

Eosinophilic esophagitis is a chronic immune-mediated entity often found in children, but also increasingly in the adult population, and occurs predominantly in males. It is characterized by mucosal edema, longitudinal furrows, mucosal fragility, whitish exudates, esophageal rings (also sometimes referred to as "trachealization") and diffuse luminal

narrowing (Figure 5). It is felt to be caused largely by food allergens, but there appears to be a genetic component as well. Symptoms usually include dysphagia, food impaction and GERD like symptoms. Biopsy is required for diagnosis and it is recommended that biopsies be taken throughout the esophagus as at least three biopsies are required to confirm the diagnosis. On histology, at least 15 eosinophils per high-power field are consistent with the diagnosis of eosinophilic esophagitis in the appropriate clinical setting. Topical steroids and dietary modification represent the first line treatment, along with symptom management with esophageal dilation [29-32].

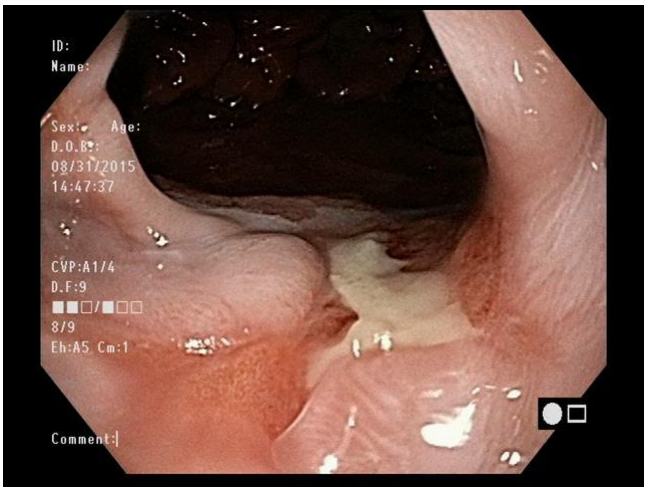

Figure 5. Eosinophilic esophagitis.

The presence of diffuse luminal narrowing may alter the method of PEG placement if the endoscopist has concerns about the ability to pull or push a gastrostomy tube through the diseased esophagus. In such cases, and introducer method of PEG may be considered.

NSAID Gastritis

NSAID-related gastric effects are present in 50-90% of patients after regular use. Findings include subepithelial hemorrhages, erosions and/or ulcers (Figure 6). These pathologic findings are thought to be caused by the inhibition of prostaglandin synthesis by this class of drugs, undermining their mucosal protective effects, as synthetic prostaglandins such as misoprostol have been found to reduce the incidence of NSAID induced damage. Treatment includes cessation of NSAID therapy, if possible, and the addition of a PPI or histamine 2 (H_2) antagonist [33, 34]. The endoscopist performing PEG should communicate these findings to the primary care team to ensure that proper therapy is administered.

Stress Gastritis

Stress related gastritis occurs in the vast majority, 75-100%, of critically ill patients when endoscopic examination is undertaken. This is typically seen as erosions and ulcerations that

begin in the proximal stomach and progress distally. Fortunately, clinically significant bleeding secondary to stress gastritis is uncommon, occurring with an incidence of approximately 3-4%. Stress gastritis is thought to occur when gastric defensive mechanisms such as mucous production, prostaglandin synthesis and mucosal blood flow are impaired by mucosal ischemia causing cell death and free radical production. Mechanical ventilation greater than 48 hours and coagulopathy are two well- recognized risk factors that predict the development of clinically significant bleeding. PPIs or H_2 antagonists should be used in the critically ill to prevent clinically significant bleeding, with the former showing greater clinical and cost effectiveness [35-39].

If the degree of gastritis is severe (most notably with the loss of mucosal integrity) postponement of PEG placement might be considered.

Figure 6. Distal gastritis related to NSAID use. Note the patchy erythema and mucosal edema.

VARICES

Esophageal and gastric varices are seen endoscopically as enlarged submucosal veins underlying normal mucosa within the distal esophagus and gastric cardia and fundus, respectively, of patients with cirrhosis and associated portal hypertension [6]. Varices have been found in 30% of compensated and 60% of decompensated cirrhotics at time of diagnosis [40]. They are known to have a hemorrhage rate of 5-15% per year [41]. In 10% of patients, isolated gastric varices can be caused by splenic vein thrombosis and associated isolated splenic compartment portal hypertension, usually secondary to pancreatitis or cancer. Varices develop as the portal pressure increases such that blood flow is redirected to lower pressure collateral systems such as the abdominal wall (resulting in *caput medusa*), the stomach and esophagus (resulting in varices) and the rectum (resulting in hemorrhoids) [42]. Features as seen on endoscopy that predict a higher incidence of hemorrhage include larger size, red wale signs (a longitudinal red streak on a varix suggestive of recent bleeding) and varix on varix. Non-endoscopic predictors include alcoholic origin of cirrhosis, Child class B or C, and a hepatic venous portal gradient of greater than 12mmHg [43, 44].

Esophageal Varices

Patients with esophageal varices usually present in two ways, either by routine screening after the diagnosis of cirrhosis has been made, or with acute hemorrhage. Once detected, it is recommended that measures be taken to prevent hemorrhage. In patients with no varices on initial endoscopy, surveillance should be performed every 2-3 years, while those with low-grade varices should have yearly surveillance. Primary prophylaxis consists of oral non-selective beta-blockers, such as propranolol, and regular endoscopic surveillance. Endoscopic rubber band ligation may also be used as primary prophylaxis in those found to have varies on surveillance endoscopy. Rubber band ligation is performed by placing rubber bands at the base of the varix causing thrombosis and mucosal necrosis. Repeat ligations are performed every 1-2 weeks until complete resolution is seen. In patients who present with gastrointestinal bleeding secondary to esophageal varices endoscopic methods such as rubber band ligation or injection sclerotherapy may be used to control bleeding. Once the hemorrhage has been controlled it is recommended that a non-selective beta-blocker be added to prevent future bleeding. Additional procedures such as transjugular intrahepatic portosystemic shunt (TIPS), in which a stent is placed from the portal vein to the hepatic vein by a radiologist to reduce portal vein pressure, or surgical shunting may be performed [45, 46].

Gastric Varices

Gastric varices are categorized into four separate entities based on their location by the Sarin classification [41, 47]. Gastroesophageal varices are esophageal varices that extend below the GEJ and onto the lesser curve of the stomach or onto the fundus, GOV1 and GOV2 respectively. Isolated gastric varices can occur on the fundus or sporadically throughout the stomach (IVG1 and IVG2). Although hemorrhage from isolated gastric varices occurs less frequently, higher mortality rates are seen, as are higher rates of rebleeding.

Non-selective beta-blockers are similarly used for primary prophylaxis in gastric varices. Endoscopic cyanoacrylate glue injection is another option for primary prevention of hemorrhage. Once hemorrhage has occurred, rubber band ligation, injection of cyanoacrylate glue and TIPS are again therapeutic options. Balloon-occluded retrograde transvenous obliteration (BRTO) is a technique used in Japan, and gaining greater acceptance in the US, in which a balloon-inflated catheter is used to access the shunt contributing to the varix. A sclerosing agent is then introduced through the catheter; after 30-50 minutes the catheter is withdrawn. In those with gastric varices caused by isolated splenic vein thrombosis, splenectomy or partial splenic embolization represents definitive management [43, 46-49].

Bleeding esophageal or gastric varices should be appropriately managed before attempting PEG placement. Non-bleeding varices (and other portal hypertensive gastropathies) should be approached carefully. They are considered a relative contraindication to PEG due to the risk of trauma with gastrostomy placement as well as the risk of post-PEG bleeding from the portal hypertension they herald.

GASTRIC OUTLET OBSTRUCTION

Gastric outlet obstruction (GOO) usually presents with nausea, vomiting and inability to tolerate oral intake. Both benign and malignant pathology can result in GOO, either by causing stricture or compression of the pylorus or proximal duodenum. Traditionally, benign causes, most commonly stricture secondary to peptic ulcer disease, have been the most prominent form of GOO, however, in the era of PPIs, malignancy has predominated [50, 51].

Benign gastric ulcer disease has become less frequent since it has been recognized that *H. pylori* and NSAIDs cause the majority of peptic ulcer disease. *H. pylori* can be eradicated with a regimen of antibiotics and acid suppressing medication, while NSAIDs can be stopped entirely in many patients [52]. Benign obstructions can often be treated endoscopically with balloon dilatation (Figure 7). This treatment may require several sessions for therapeutic benefit to become apparent and enduring, but it offers a minimally invasive alternative for those patients with comorbidities who may not tolerate a surgical approach [53, 54]. For those who fail endoscopic management or who wish for a more aggressive approach, surgical bypass may be performed (most often by gastrojejunostomy) either in an open or laparoscopic fashion.

In the Western world, malignant gastric outlet obstructions are most often caused by pancreatic cancer, followed by periampullary cancer, gastric cancer and cholangiocarcinoma. By the time malignant obstruction is discovered, the prognosis is usually quite poor with a short life expectancy. There are several options for palliation including endoscopic stenting and surgical bypass [55, 56]. Several studies have shown that endoscopic stenting is a safe and effective means of palliation that is associated with lower morbidities compared with surgical gastrojejunostomy, however the reintervention rate is higher [57, 58].

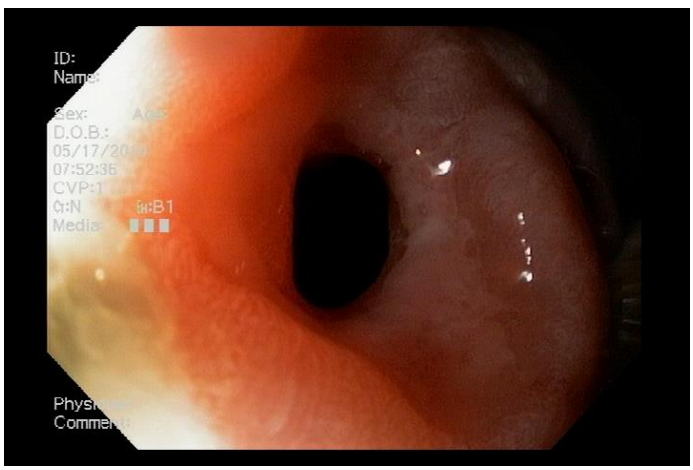

Figure 7. A) Gastric outlet obstruction (GOO) with associated ulceration..

Decompressive PEG for palliation can be considered if there is a portion of gastric wall uninvolved in tumor burden for safe positioning of gastrostomy. If the PEG is being used for enteral feeding, consideration should be given to placing a jejunal extension beyond the GOO as many patients with chronic GOO do not tolerate intra-gastric feeding as a result of gastric dysfunction from chronic obstruction.

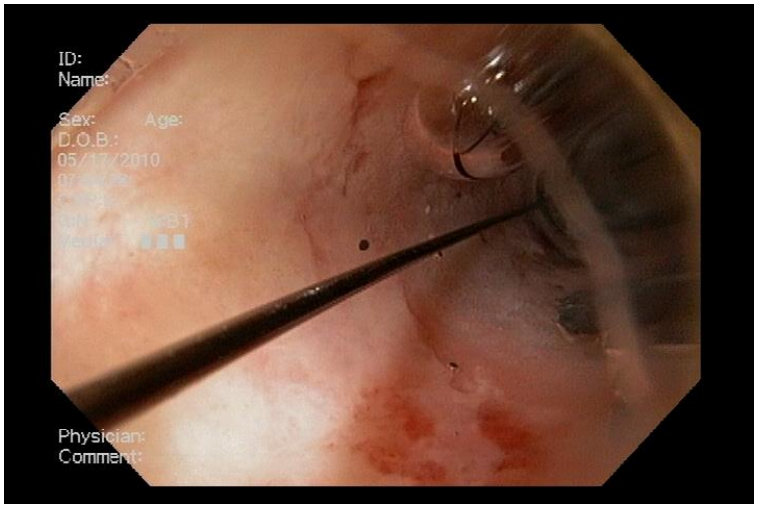

Figure 7B. Balloon dilation of GOO with endoscopic visualization through balloon.

POLYPS

Fundic Gland Polyps

Gastric polyps come in many different forms, the most common of which are fundic gland polyps. Fundic gland polyps are found in 1-25% of EGDs and most often represent sporadic polyps or those associated with PPIs. They are similar in appearance to normal gastric mucosa, have a broad base and frequently are found in multiple (i.e., not singular) (Figure 8). These have a low chance of malignancy and do not require biopsy unless they exceed 1 cm in diameter. Those associated with PPIs can improve with discontinuation of the PPI.

Hyperplastic Polyps

Hyperplastic polyps, found most frequently within the antrum of the stomach, are caused by an inflammatory condition such as chronic gastritis, H. pylori and pernicious anemia. They can be sessile or pedunculated, are usually less than 2 cm and can be associated with ulceration and bleeding. It is recommended that biopsies of the surround tissue be taken to identify the underlying cause. Although the incidence of malignant change within these polyps is low, they are associated with increased risk of cancer within the stomach. Those that are greater than 1 cm should be excised completely. These can resolve with treatment of the underlying disorder.

Figure 8. Gastric fundic gland polyps.

Adenomatous Polyps

Adenomatous polyps represent a similar pathologic process to that seen in colon polyps and are precancerous. They are usually flat and found within the gastric antrum or duodenum (Figure 9). Those that are greater than 2 cm and those with villous histology have a greater chance of harboring malignancy. It is recommended that these polyps be fully excised and a surveillance program initiated. [59, 60] Patients with known polyposis syndromes, such as familial adenomatous polyposis (FAP), should have foregut screening included in their long term surveillance, and use of a side viewing duodenoscope to optimize periampullary visualization may be helpful in such settings. Polyps are not a contraindication to PEG placement.

GASTROESOPHAGEAL REFLUX DISEASE

Gastroesophageal reflux disease (GERD) is an increasingly common condition in the United States with up to 25% of adults experiencing symptoms weekly [61]. GERD results from abnormal relaxation of the lower esophageal sphincter (LES) outside of swallow initiation or from an incompetent LES. This causes abnormal exposure of the esophagus to gastric acid which manifests as pyrosis, regurgitation and dysphagia.

GERD is frequently treated empirically, most often with PPIs, H_2 antagonists or antacids. In many this leads to resolution of symptoms. Weight loss and other lifestyle changes such as avoiding nighttime meals, elevating the head of bed and avoiding chocolate, coffee, carbonated beverages, tobacco and alcohol, can also aid in alleviating symptoms. For those who do not respond to empiric treatment, it is recommended that EGD be performed to evaluate for complications, such as esophageal erosion or Barrett's esophagus (discussed

previously), or for an alternative diagnosis. Diagnosis of GERD can be confirmed with ambulatory pH monitoring [61-63].

Ambulatory pH monitoring is performed by placing a probe 5 cm proximal to the LES either transnasally or by endoscopy. Episodes of esophageal pH < 4 are recorded and categorized as reflux episodes. This data can be used to calculate a DeMeester score, which factors in the amount of time (frequency and duration) or acid exposure, with a score of more than 14.72 indicating pathologic reflux. The DeMeester score is specifically obtained by taking into account the number of reflux episodes, the duration of those episodes, the total time with a pH < 4, and the upright versus supine time with a pH < 4 [64].

For patients with chronic symptoms who do not wish to commit to lifelong medical therapy despite successful medical management, for those who fail medical therapy, for those with complications of GERD or for those with extraesophageal symptoms, there are surgical options for the treatment of GERD. Fundoplication has a cure rate up to 90% or greater, with esophageal acid exposure proven to be less than those successfully controlled with medical management [65, 66]. Prior to surgical therapy, there must be objective evidence of GERD, whether through EGD findings such as erosion, Barrett's esophagus or peptic stricture or through pH monitoring. Many patients will also undergo esophageal manometry, employed to rule out esophageal dysmotility disorders that may be a contraindication for surgery or define an impaired clearance component to the reflux diathesis, and barium swallow, to further delineate anatomy. Surgery is then individualized for each patient as these procedures can include several different types of fundoplication, and can be performed in either an open, laparoscopic or even robotic fashion [67].

Intragastric feedings via PEG in patients with GERD can lead to aspiration. Transpyloric PEG feedings with a jejunal extension tube do not eliminate the risk of aspiration, and either direct PEJ or surgical jejunostomy can be considered.

Peptic Ulcer Disease

Peptic ulcer disease (PUD) once represented one of the most common causes of presentation of the acute abdomen. As mentioned previously, with the discovery of *H. pylori* and the widespread use of PPIs, complications such as perforation, hemorrhage and stricture are increasingly less common. Gastric ulcers are associated with post-prandial pain with resulting in weight loss, whereas the pain of duodenal ulcers are often relieved with ingestion of food leading to weight gain. They can be seen throughout the stomach and in the duodenum as depressions of the mucosal surface and may extend into the submucosal tissue layers or beyond (Figure 10).

Gastric ulcers are classified based on their location. The type of ulcer suggests the underlying cause and, therefore, guides treatment. Type I ulcers are the most common making up 60% of gastric ulcers and are found on the lesser curvature. They are not associated with acid hypersecretion and most are caused by *H. pylori* infection. *H. pylori* is treated by a 14 day regimen of antibiotics and acid suppression, with subsequent documentation of eradication. Type II ulcers are comprised of both ulcers on the lesser curvature and within the duodenum. They are associated with acid hypersecretion as are type III ulcers. Type III ulcers are pre-pyloric. Types II and II are both treated with acid suppression. Those ulcers refractory to acid suppressing medication should be evaluated for Zollinger-Ellison syndrome. Type IV

ulcers are near the GEJ and are specifically classified because of the anatomic challenges of their surgical management; and type V are associated with NSAIDs and can be located throughout the stomach. Type V ulcers are treated by cessation of the offending medication and the addition of an acid suppression medication. Patients with ulcers refractory to medical management may be candidates for partial gastrectomy (including excision of the ulcer) with reconstruction, with or without vagotomy, with the latter generally being reserved for settings with acid hypersecretion.

Duodenal ulcers are also caused by *H. pylori* and acid hypersecretion. Similar treatment regimens exist for duodenal ulcers [68, 69].

All ulcer patients should undergo gastric biopsy to establish whether *H. pylori* infection is present. Gastric ulcers should themselves be biopsied to rule out malignant changes. Ulcers associated with *H. pylori* do not require reevaluation by endoscopy unless; the biopsy demonstrates dysplastic changes, symptoms are not resolving with medical treatment or, the patient has complications of the ulcer such as bleeding, perforation or stricture. Successful *H. pylori* eradication can be confirmed non-invasively via the urea breath test [70].

PUD is not a contraindication to PEG placement but the presence of disease should be documented in the endoscopy note in case the patient develops bleeding following PEG placement which may not be secondary to the gastrostomy puncture.

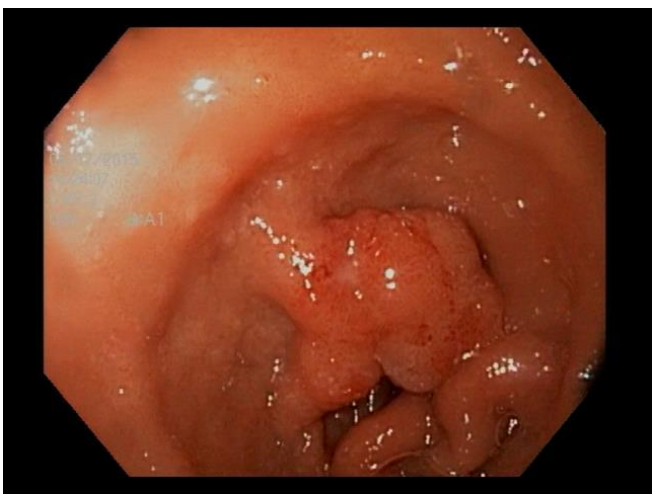

Figure 9. Duodenal adenomatous polyp.

GASTROINTESTINAL STROMAL TUMORS

Submucosal pathology is not uncommonly seen during EGD. Gastrointestinal stromal tumors (GISTs) are the most common neoplasm of mesenchymal origin within the GI tract. These tumors arise from the interstitial cells of Cajal, which serve as pacemaker cells within the bowel. They are predominantly found within the stomach and small intestine, but can be found elsewhere within the GI tract. Many are asymptomatic and are found on routine imaging; others present with bleeding, early satiety or pain. On endoscopy they are seen as submucosal masses that are often exophytic in nature (Figure 11). GISTs have malignant

potential but rarely metastasize. Diagnosis is often based on clinical characteristics and biopsy is not required [71]. Mucosal biopsies alone are often nondiagnostic, and biopsy under endoscopic ultrasound guidance may be performed where tissue sampling will affect treatment.

The mainstay of treatment remains complete surgical excision. In elderly patients that are poor operative candidates, small GISTs (<2 cm) may be kept under surveillance. There have been recent reports of endoscopic enucleation and resection via endoscopic submucosal dissection (ESD) with good results [72]. Pathological examination is needed to determine whether adjuvant therapy is required. Risk factors for malignant GIST include mitotic index, size and location. Most GISTs are *KIT* positive and respond favorably to tyrosine kinase inhibitors, the most commonly used of which is imatinib.

The presence of a GIST on endoscopy is not a contraindication to PEG, but appropriate diagnostic and therapeutic follow-up must be arranged. Surveillance following successful excision (if performed) consists of annual imaging for five years [73, 74].

Figure 10. Non-bleeding gastric ulcer.

GASTROPARESIS

Gastroparesis represents delayed gastric emptying in the absence of mechanical obstruction, with symptoms including abdominal pain, postprandial fullness, early satiety, nausea, vomiting and weight loss. As a sensorimotor disorder, its exact etiology is unknown but related disease processes include long-standing, poorly controlled diabetes, medications (such as narcotics and anticholinergics), connective tissue disorders, prior upper gastrointestinal surgery, specifically in association with vagotomy, and others. Gastroparesis is found more predominantly in female patients, and a depletion of the interstitial cells of Cajal have been implicated. Diagnosis is confirmed by gastric-emptying scintigraphy with delayed emptying seen at four hours. Endoscopic findings of retained food bezoar within the stomach after an overnight fast are also pathognomonic for gastroparesis (Figure 12) [75, 76].

Several treatment options exist for gastroparesis. Management begins with dietary changes by adopting smaller, more frequent meals that are low in fat. Medications such as promotility agents (metaclopromide or erythromycin) and psychotropic medications may then be added. Surgical and endoscopic options also exist. Gastric neurostimulation utilizes electrical impulses to stimulate the stomach. Temporary wires are placed endoscopically and the wires exteriorized either through a PEG tube or transnasal. If neurostimulation improves symptoms during a temporary trial, a neurostimulator may be surgically implanted. Endoscopic or surgical pyloroplasty reduces the resistance of gastric drainage and can be a useful adjunct in refractory disease. Transpyloric stenting and injection of botulinum toxin into the pylorus have also been described, but are associated with the potentials for stent migration and need for repeat treatments, respectively. Radical treatment includes subtotal or total gastrectomy with reconstruction, but is reserved for truly refractory cases [75-78].

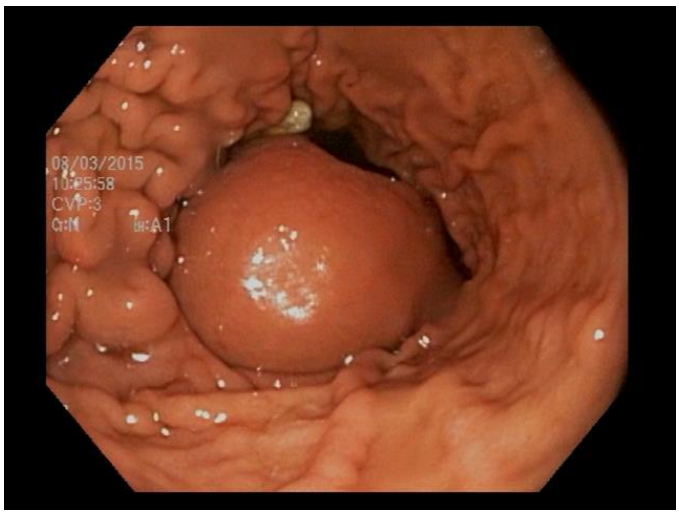

Figure 11. Large gastric GIST.

Figure 12. Retained gastric food bezoar in a patient with gastroparesis.

If significant weight loss occurs as a result of gastroparesis, it may be necessary to place an enteral feeding tube. In this clinical situation, PEG (alone) is contraindicated and direct percutaneous endoscopic jejunostomy (PEJ) or percutaneous endoscopic gastrostomy with jejunal extension tube (PEG-JET) may provide more benefit as these procedures bypass the nonfunctional stomach and allow for distal feeding. The PEG-JET allows for feeding via the J-limb as well as providing ventilation through the G-limb. They are associated with a need for more frequent hardware changes as they become clogged more frequently than the traditional PEG. If these procedures are unsuccessful percutaneously, they may be performed surgically. An additional option includes traditional PEG with the placement of an extension into the jejunum by interventional radiology [79-80].

CONCLUSION

The endoscopist performing PEG will encounter potentially unexpected upper gastrointestinal pathologies in a not-insignificant number of cases. A complete endoscopic examination of the esophagus, stomach, and duodenum is vital. Identifying such pathology is an important potential advantage of PEG compared to other gastrostomy techniques. It may not only guide the need for further intervention, but affect the decision making regarding PEG placement. Recognition of the common pathologies described, along with a working knowledge of their appropriate management, is an important skill for the endoscopist performing PEG placement.

EDITOR'S COMMENT

This chapter details the importance of performing a complete endoscopic exam at the time of enteral access placement. The implications of identified anatomical/pathological abnormalities need to be well understood by the endoscopist, as well as the need for subsequent surveillance of pathology. Although many abnormalities identified will have minimal impact on patients with limited life expectancy, it is also very important to fully document these findings in the procedural report. (JMM)

REFERENCES

[1] Maish MS. "Chapter 43: Esophagus." Townsend CM, Beauchamp RD, et al. Sabiston *Textbook of Surgery: The Biological Basis of Modern Surgical Practice*. 19th Edition. Philadelphia: Elsevier Saunders, 2012. 1012-1066.

[2] Teran MD, Brock MV. "Management of Barrett's Esophagus." Cameron JL, Cameron AM. *Current Surgical Therapy*. 11th Edition. Philadelphia: Elsevier Saunders, 2014. 19-23.

[3] Ford AC, Forman D, Reynolds PD, et al. Ethnicity, gender and socioeconomic status as risk factors for esophagitis and Barrett's esophagus. *American Journal of Epidemiology*. 2005;162:454-460.

[4] Halland M, Katzka D, Iyer PG. Recent developments in pathogenesis, diagnosis and therapy of Barrett's esophagus. *World Journal of Gastroenterology*. 2015;21(21):6479-6490.

[5] Estores D, Velanovich V. Barrett esophagus: epidemiology, pathogenesis, diagnosis, and management. *Current Problems in Surgery*. 2013;50:192-226.

[6] Haycock A, Cohen J, Saunders BP, et al. Cotton and Williams' *Practical Gastrointestinal Endoscopy: The Fundamentals*. 7th Edition. West Sussex: Wiley Blackwell, 2014.

[7] Garud SS, Keilin S, Cai Q, et al. Diagnosis and management of Barrett's esophagus for the endoscopist. *Therapeutic Advances in Gastroenterology*. 2010;3(4):227-238.

[8] Bennett C, Vakil N, Bergman J, et al. Consensus statements for management of Barrett's dysplasia and early-stage esophageal adenocarcinoma based on a Delphi process. *Gastroenterology*. 2012;143:336-346.

[9] Wang KK, Sampliner RE. Updated guidelines 2008 for the diagnosis, surveillance and therapy of Barrett's esophagus. *American Journal of Gastroenterology*. 2008;103:788-797.

[10] Hirota WK, Zuckerman MJ, Adler DG, et al. ASGE guideline: the role of endoscopy in the surveillance of premalignant conditions of the upper GI tract. *Gastrointestinal Endoscopy*. 2006;63:570-580.

[11] El-Serag HD, Aguirre TV, Davis S, et al. Proton pump inhibitors are associated with reduced incidence of dysplasia in Barrett's esophagus. *American Journal of Gastroenterology*. 2004;99(10):1877-1883.

[12] Attwood SE, Lundell L, Hatlebakk JG, et al. Medical or surgical management of GERD patients with Barrett's esophagus: the LOTUS trial 3-year experience. *Journal of Gastrointestinal Surgery*. 2008;12(10):1646-1654.

[13] Fiocca R, Mastracci L, Engstrom C, et al. Long-term outcome of microscopic esophagitis in chronic GERD patients treated with esomeprazole or laparoscopic antireflux surgery in the LOTUS trial. *American Journal of Gastroenterology*. 2010;105(5):1015-1023.

[14] Galmiche JP, Hatlebakk JG, Attwood S, et al. Laparoscopic antireflux surgery vs esomeprazole treatment for chronic GERD: the LOTUS randomized clinical trial. *JAMA*. 2011;305(19):1969-1977.

[15] Dunbar KB, Spechler SJ. Controversies in Barrett Esophagus. *Mayo Clinic Proceedings*. 2014;89(7):973-984.

[16] Spechler SJ. Barrett Esophagus and Risk of Esophageal Cancer: A Clinical Review. *JAMA*. 2013;310(6):627-636.

[17] Mirnezami R, Rohatgi A, Sutcliffe RP, et al. Transhiatal oesphogectomy: treatment of choice for high-grade dysplasia. *European Journal of Cardiothoracic Surgery*. 2009;36:364-367.

[18] Edwards MJ, Gable DR, Lentsch AB, et al. The rationale for esphoagectomy as the optimal therapy for Barrett's esophagus with high-grade dysplasia. *Annuals of Surgery*. 1996;223:585-589.

[19] Viklund P, Wengstrom Y, Rouvelas I, et al. Quality of life and persisting symptoms after oesophageal cancer surgery. *European Journal of Cancer*. 2006;42:1407-1414.

[20] Shaheen NJ, Sharma P, Overholt BF, et al. Radiofrequency Albation in Barrett's Esophagus with Dysplasia. *NEJM*. 2009;360(22):2277-2288.

[21] Belghazi K, Cipollone I, Bergman JJ, et al. Current Controversies in Radiofrequency Ablation Therapy for Barrett's Esophagus. *Current Treatment Options in Gastroenterology*. 2016;14(1):1-18.

[22] Shaheen NJ, Falk GW, Iyer PG, et al. ACG Clinical Guideline: Diagnosis and Management of Barrett's Esophagus. *American Journal of Gastroenterology*. 2016;111(1):30-50.

[23] Kohn GP, Price RR, DeMeester SR, et al. Guidelines for the management of hiatal hernia. *Surgical Endoscopy*. 2013;27:4409-4428.

[24] Johnson DA, Ruffin WK. "Hiatal Hernia." Sivak MV, Fennerty MB. *Gastrointestinal Endoscopy Clinics of North America: The Stomach*. Volume 6, Number 3. Philadelphia: WB Saunders Company, 1996. 641-666.

[25] Stylopoulous N, Gazelle GS, Rattner DW. Paraesophageal Hernias: Operation or Observation? *Annals of Surgery*. 2002;236(4):492-501.

[26] Treacy PJ, Jamieson GG. An approach to the management of paroesophageal hiatus hernias. *The Australian and New Zealand Journal of Surgery*. 1987;57(11):813-817.

[27] Lundell LR, Dent J, Bennett JR, et al. Endoscopic assessment of oesophagitis: clinical and functional correlates and further validation of the Los Angeles classification. *Gut*. 1999;45(2):172-180.

[28] Krugmann J, Neumann H, Vieth, et al. What is the role of endoscopy and oesophageal biopsies in the management of GERD? *Best Practice & Research Clinical Gastroenterology*. 2013;27:373-385.

[29] D'Alessandro A, Esposito D, Pesce M, et al. Eosinophilic esophagitis: From pathophysiology to treatment. *World Journal of Gastrointestinal Pathophysiology*. 2015;6(4):150-158.

[30] Muir AB, Merves J, Liacouras CA. Role of Endoscopy in Diagnosis and Management of Pediatric Eosinophilic Esophagitis. *Gastrointestinal Endoscopy Clinics of North America*. 2016;26(1):187-200.

[31] Miehlke S. Clinical features of Eosinophilic esophagitis in children and adults. *Best Practice & Research Clinical Gastroenterology*. 2015;29:739-748.

[32] Sodikoff J, Hirano I. Therapeutic strategies in eosinophilic esophagitis: Induction, maintenance and refractory disease. *Best Practice & Research Clinical Gastroenterology*. 2015;29:829-839.

[33] Laine L. Nonsteroidal Anti-Inflammatory Drug Gastropathy. *Gastroenterology Clinics of North America*. 1996;6(3):489-504.

[34] Scarpignato C, Lanas A, Blandizzi C, et al. Safe prescribing of non-steroidal anti-inflammatory drugs in patients with osteoarthritis—an expert consensus addressing benefits as well as gastrointestinal and cardiovascular risks. *BMC Medicine*. 2015;15:55.

[35] Yang Yx, Lewis JD. Prevention and treatment of stress ulcers in critically ill patients. *Seminars in Gastrointestinal Disease*. 2003;14(1):11-19.

[36] Constantin VD, Paun S, Ciofoaia VV, et al. Multimodal management of upper gastrointestinal bleeding caused by stress gastropathy. *Journal of Gastrointestinal and Liver Diseases*. 2009;18(3):279-284.

[37] Goldin GF, Peura DA. Stress-Related Mucosal Damage. What to do or not to do. *Gastroenterology Clinics of North America*. 1996;6(3):505-526.

[38] Bardou M, Quenot JP, Barkun A. Stress-related mucosal disease in the critically ill patient. *Nature Reviews: Gastroenterology and Hepatology*. 2015;12(2):98-107.
[39] Ali T, Harty RF. Stress-induced ulcer bleeding in critically ill patients. *Gastroenterology Clinics of North America*. 2009;38(2):245-265.
[40] Abraldes JG, Tandon P. Therapies: Drugs, Scopes and Transjugular Intrahepatic Portosystemic Shunt—When and How? *Digestive Diseases*. 2015;33(4):524-533.
[41] Sarin SK, Kumar A. Endoscopic treatment of gastric varices. *Clinics in Liver Disease*. 2014;18(4):809-827.
[42] Tripathi D, Stanley AJ, Hayes PC, et al. U.K. guidelines on the management of variceal haemorrhage in cirrhotic patients. *Gut*. 2015;64(11):1680-1704.
[43] Cordon JP, Torres CF, Garcia AB, et al. Endoscopic management of esophageal varices. *World Journal of Gastrointestinal Endoscopy*. 2012;4(7):312-322.
[44] Merli M, Nicolini G, Angeloni S, et al. Incidence and natural history of small esophageal varices in cirrhotic patients. *Journal of Hepatology*. 2003;38(3):266-272.
[45] Caldwell SH. Management of Cardio-Fundal Gastric Varices. *Gastroenterology & Hepatology*. 2008;4(7):477-479.
[46] Luigiano C, Iabichino G, Judica A, et al. Role of endoscopy in management of gastrointestinal complications of portal hypertension. *World Journal of Gastrointestinal Endoscopy*. 2015;7(1):1-12.
[47] Sarin SK, Kumar A. Gastric varices: profile, classification, and management. *American Journal of Gastroenterology*. 1989;84(10):1244-1249.
[48] Garcia-Pagan JC, Barrufet M, Cardenas A, et al. Management of gastric varices. *Clinical Gastroenterology and Hepatology*. 2014;12(6):919-928.
[49] Al-Osaimi AM, Caldwell SH. Medical and endoscopic management of gastric varices. *Seminars in Interventional Radiology*. 2011;28(3):273-282.
[50] Khullar SK, DiSario JA. Gastric Outlet Obstruction. *Gastrointestinal Endoscopy Clinics of North America*. 1996;6(3):585-603.
[51] Appasani S, Kochhar S, Nagi B, et al. Benign gastric outlet obstruction—spectrum and management. *Tropical Gastroenterology*. 2011;32(4):359-366.
[52] Sontag SJ. Guilty as charged: bugs and drugs in gastric ulcer. *American Journal of Gastroenterology*. 1997;92(8):1255-1261.
[53] Craig PI, Gillespie PE. Through the endoscope balloon dilation of benign gastric outlet obstruction. *BMJ*. 1988;297(6645):396.
[54] Yusuf TE, Brugge WR. Endoscopic therapy of benign pyloric stenosis and gastric outlet obstruction. *Current Opinions in Gastroenterology*. 2006;22(5):570-573.
[55] van Halsema EE, Rauws EA, Fockens P, et al. Self-expandable metal stents for malignant gastric outlet obstruction: A pooled analysis of prospective literature. *World Journal of Gastroenterology*. 2015;21(43):12468-12481.
[56] Oh SY, Edwards A, Mandelson M, et al. Survival and clinical outcome after endoscopic duodenal stent placement for malignant gastric outlet obstruction: comparison of pancreatic cancer and nonpancreatic cancer. *Gastrointestinal Endoscopy*. 2015;82(3):460-468.
[57] Khashab M, Alawad AS, Shin EJ, et al. Enteral stenting versus gastrojejunostomy for palliation of malignant gastric outlet obstruction. *Surgical Endoscopy*. 2013;27(6):2068-2075.

[58] Endoscopic stenting versus operative gastrojejunostomy for malignant gastric outlet obstruction--a systematic review and meta-analysis of randomized and non-randomized trials. *Journal of Gastrointestinal Oncology*. 2014;5(2):92-98.

[59] Shaib YH, Rugge M, Graham DY, et al. Management of gastric polyps: an endoscopy-based approach. *Clinical Gastroenterology and Hepatology*. 2013;11(11):1374-1384.

[60] Islam RS, Patel NC, Lam-Himlin D, et al. Gastric polyps: a review of clinical, endoscopic, and histopathologic features and management decisions. *Gastroenterology and Hepatology*. 2013;9(10):640-651.

[61] Moore M, Afaneh C, Benhuri D, et al. Gastroesophageal reflux disease: A review of surgical decision making. *World Journal of Gastrointestinal Surgery*. 2016;8(1):77-83.

[62] Badillo R, Francis D. Diagnosis and treatment of gastroesophageal reflux disease. *World Journal of Gastrointestinal Pharmacology and Therapeutics*. 2014;5(3):105-112.

[63] Patti MG. An Evidence-Based Approach to the Treatment of Gastroesophageal Reflux Disease. *JAMA Surgery*. 2016;151(1):73-78.

[64] Johnson LF, DeMeester TR. Development of the 24-hour intraesophageal pH monitoring composite scoring system. *Journal of Clinical Gastroenterology*. 1986;8 Suppl 1:52-58.

[65] Lundell L, Attwood S, Ell C, et al. Comparing laparoscopic antireflux surgery with esopmeprazole in the management of patients with chronic gastro-oesophageal reflux disease: a 3-year interim analysis of the LOTUS trial. *Gut*. 2008;57(9):1207-1213.

[66] Hatlebakk JG, Zerbib F, Bruley des Varannes S, et al. Gastroesophageal Acid Reflux Control 5 Years After Antireflux Surgery, Compared with Long-Term Esomeprazole Therapy. *Clinical Gastroenterology and Hepatology*. 2016;14(5):678-685.

[67] Stefanidis D, Hope WW, Kohn GP, et al. Guidelines for surgical treatment of gastroesophageal reflux disease. *Surgical Endoscopy*. 2010;24:2647-2669.

[68] Abdel-Misih RZ, Larson JD, Abdel-Misih SR. "The Management of Benign Gastric Ulcer" Cameron JL, Cameron AM. *Current Surgical Therapy*. 11th Edition. Philadelphia: Elsevier Saunders, 2014. 69-76.

[69] Beaulieu RJ, Eckhauser FE. "The Management of Duodenal Ulcers" Cameron JL, Cameron AM. *Current Surgical Therapy*. 11th Edition. Philadelphia: Elsevier Saunders, 2014. 76-80.

[70] Kuiper EJ. When Is Endoscopic Follow-up Appropriate After Helicobacter pylori Eradication Therapy? *Gastroenterology Clinics of North America*. 2015;44(3):597-608.

[71] Miettinen M, Lasota J. Gastrointestinal stromal tumors: review on morphology, molecular pathology, prognosis and differential diagnosis. *Archives of Pathology and Laboratory Medicine*. 2006;130(10):1466-1478.

[72] Mino JS, Guerron AD, Monteiro R, et al. Long-term outcomes of combined endoscopic/laparoscopic intragastric enucleation of presumed gastric stromal tumors. *Surgical Endoscopy*. 2015. [Epub ahead of print]

[73] Nishida T, Blay JY, Hirota S, et al. The standard diagnosis, treatment and follow-up of gastrointestinal stromal tumors based on guidelines. *Gastric Cancer*. 2016;19(1):3-14.

[74] Blay JY, Casali PG, Dei Tos AP, et al. Management of Gastrointestinal Stromal Tumour: Current Practices and Visions for the Future. *Oncology*. 2015;89(1):1-13.

[75] Tack J, Carbone F, Rotondo A. Gastroparesis. *Current Opinions in Gastroenterology*. 2015;31(6):499-505.

[76] Stein B, Everhart KK, Lacy BE. Gastroparesis: A Review of Current Diagnosis and Treatment Options. *Journal of Clinical Gastroenterology*. 2015;49(7):550-558.
[77] Soares RV, Swanstrom LL. Endoscopic approaches to gastroparesis. *Current Opinions in Gastroenterology*. 2015;31(5):368-373.
[78] McCarty TR, Rustaqi T. Endoscopic treatments of gastroparesis. *World Journal of Gastroenterology*. 2015;21(22):6842-6849.
[79] Del Piano M, Ballare M, Carmagnola S, et al. DPEJ placement in cases of PEG insertion failure. *Digestive and Liver Disease*. 2008;40(2):140-143.
[80] Shike M, Latkany L, Gerdes H, et al. Direct percutaneous endoscopic jejunostomies for enteral feeding. *Gastrointestinal Endoscopy*. 1996;44(5):536-540.

In: Encyclopedia of Surgery (22 Volume Set)
Editors: Andreas Lehrer and Kristin Mueller
ISBN: 978-1-53618-329-0
© 2020 Nova Science Publishers, Inc.

Chapter 128

PERCUTANEOUS ENDOSCOPIC GASTROSTOMY: THE 'PULL' TECHNIQUE

Kyle L. Kleppe, MD and Melissa Phillips LaPinska*, MD
University of Tenessee Graduate School of Medicine, Knoxville, TN, US

INTRODUCTION

Medical providers have long recognized the importance of nutritional support in patients who are critically ill or undergoing medical or surgical interventions. Enteral access has been shown to be superior when compared to parenteral access for this purpose with reduced infectious complications, cost benefit, and immune-related advantages. The percutaneous gastrostomy tube (PEG) is the most common form of enteral access performed. There are two main methods for PEG tube placement: the 'pull' technique which will be described in this chapter and the 'push' technique which will be described in Chapter 8. Together, these two approaches for oral insertion represent the most common approach for endoscopic gastrostomy tube placement.

Originally, all patients needing enteral access required a laparotomy for gastrostomy tube placement. Endoscopic gastrostomy tube placement radically transformed the approach for gastrostomy tube placement, transitioning it from a surgical to an endoscopic approach. The pull technique was the original method first described by Drs. Ponsky and Gauderer in 1980 [1]. Although the technique has subsequently undergone refinement, the core features remain the same [1, 2]. Experience with the pull technique has been well documented in the literature with excellent safety record and outcomes.

* Corresponding Author's Email: MSPhillips1@utmck.edu.

PATIENT PREPARATION AND SEDATION

The patient is prepared by fasting for 8 hours prior to the planned endoscopic procedure to decrease the risk of aspiration. This fasting period should include discontinuation of enteral feeds as well as oral intake. Prophylactic antibiotics should be routinely administered within one hour of the procedure in all patients undergoing PEG tube insertion using the 'pull' method. Antibiotic administration is associated with a significant reduction in peristomal and abdominal wall infections [3]. Coverage should be focused on coverage of skin flora and it is the authors' practice to administer cefazolin unless contradicted by patient allergy or established antibacterial resistance. Patients must also have intravenous access for the administration of sedation and systemic analgesics. The patient is placed in the supine position on the endoscopy table. The upper abdomen is clipped of hair and prepped using chlorhexidine or another antimicrobial agent.

The endoscopy suite should be prepared with all necessary supplies for either sedation with monitoring or, under select circumstances, general anesthesia. All patients must have heart rate, blood pressure monitoring, and pulse oximetry throughout the entire procedure. Capnography may be available in many endoscopy units and can be utilized at the provider's preference. A dedicated member of the team should monitor for adverse sedation-related events and be able to provide rescue measures if required. Step-wise titration of medication is performed until the patient has reached the desired level of sedation. This most commonly involves a narcotic and a benzodiazepine, although many endoscopy areas are now strictly using propofol with the assistance of an anesthetic provider. General endotracheal anesthesia is considered for patients who cannot maintain airway safety and in patients at increased risk for aspiration. More details regarding patient preparation and sedation are available in Chapters 2 and Chapters 5 respectively.

STEP-BY-STEP TECHNIQUE FOR THE PULL TECHNIQUE

1. Perform a Full Upper Endoscopy

After adequate sedation, the endoscopist should introduce the gastroscope though the mouth and advance it into the stomach. If difficulty is encountered with passing the gastroscope in the supine position, rolling the patient into a modified left lateral decubitus position by elevating the right shoulder should help with this. Other considerations for difficult passage include upper airway obstruction which can be relieved by a jaw lift or obstructing oral pathology, as may be the case when enteral access is needed for oropharyngeal cancer. If malignant obstruction is present and the endoscope is unable to pass, one must consider either an introducer technique or a laparoscopic assisted gastrostomy. See Chapter 9 for additional details on these methods.

Once access to the esophagus has been intubated, care should be taken to evaluate the esophagus and esophageal hiatus for pathology, specifically for a paraesophageal hernia or for signs of esophageal stricture. The most important part of the complete upper endoscopy is to evaluate for and rule out gastric outlet obstruction by passing the gastroscope through the pylorus and into the second portion of the duodenum (see Chapter 6 for additional details).

Following this, the gastroscope is withdrawn into the stomach to insufflate. Full gastric insufflation allows the anterior wall of the stomach to be in direct contact with the anterior abdominal wall without intervening viscera between the two structures.

2. Identify the Site for PEG Placement

The anterior abdominal wall is examined for the site of maximal transillumination where the light of the gastroscope is most strongly seen through the anterior abdominal wall (Figure 1). This site represents where the inflated stomach is most closely approximated to the anterior abdominal wall without intervening viscera. It may be necessary to turn off the room lights to see this, particularly in patients with morbid obesity. Multiple sites may be evaluated with transillumination before selecting the best site using this technique in combination with direct palpation. It should be noted that transillumination may be identified at non-ideal locations or in a concerning pattern suggesting that PEG should not be performed (Figure 2).

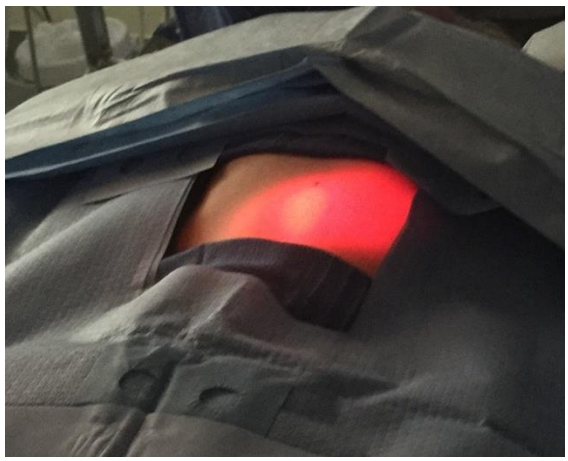

Figure 1. Abdominal wall transillumination at the site of planned PEG.

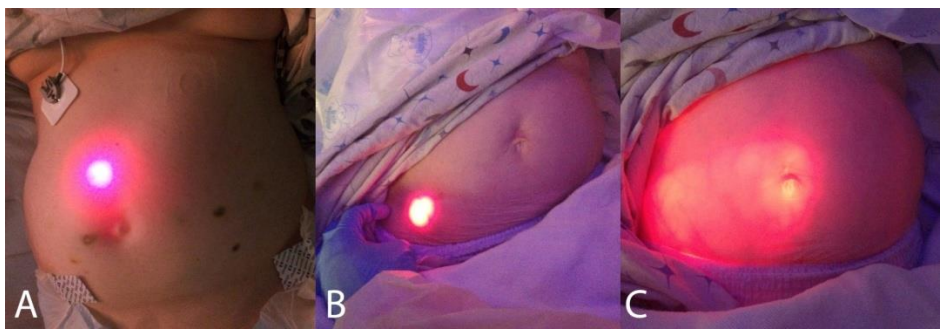

Figure 2. Abnormal transillumination patterns during PEG endoscopy. A) Peri-umbilical. B) Right lower quadrant. C) Diffuse abdominal illumination (including illumination of colonic haustral folds).

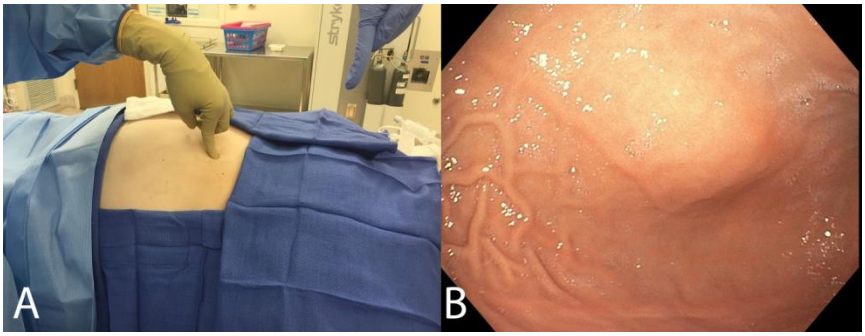

Figure 3. Sight selection for PEG. A) A finger is used to indent the abdominal wall at the location of best transillumination. B) The endoscopist observes for clear one-to-one motion of the gastric wall with abdominal palpation.

To assess for this, the assistant should gently depress the abdominal wall with one finger, beginning 2 cm below the costal margin near midline. The endoscopist should see the gastric wall indent simultaneously in a one-to-one fashion with palpation of the abdominal wall (Figure 3). The initial site chosen should be between the greater and the lesser curve of the stomach (to avoid major vasculature). Ideally, placement of the PEG should be located distally in the body of the stomach or in the proximal antrum as this location allow for easier insertion of the jejunal extension through the gastrostomy tube, also known as a PEG-J feeding tube, if indicated for poor gastric motility. Care should be taken to avoid selecting a site within one centimeter of the costal margin as this area is typically more uncomfortable for the patient.

3. Perform the "Safe Tract" Technique

Once the ideal location has been selected using the transillumination and one-to-one palpation detailed above, the "safe-tract" method is then used to confirm that no intervening viscera, specifically loops of bowel, are between the stomach and the anterior abdominal wall. This is performed by slowly advancing a small-caliber needle, such as the local anesthesia needle included in most PEG kits, attached to a syringe filled with fluid through the abdominal wall while negative pressure (aspiration) is applied to the plunger (Figure 4A). The endoscopist, using the gastroscope, should visualize the needle entering the stomach at the same instance the assistant sees air within the syringe outside the abdominal wall (Figure 4B). If air is seen in the syringe before the needle is visualized in the gastric lumen, the needle has passed through another hollow viscus, likely the colon or small bowel, rather than entered directly into the stomach. If blood is visualized, it is presumed that the needle has encountered the left lobe of the liver interposed between the stomach and abdominal wall, the epigastric vessel behind the rectus muscle one of the named vessels supplying the stomach (e.g., gastroepiploic). In either of these settings, the location choice should be reevaluated and a repeat safe tract performed before proceeding. Once the safe tract technique confirms an appropriate location for the PEG, the selected site is infiltrated with local anesthesia. The authors believe the "safe-tract" technique, above transillumination and direct palpation, to be the most reliable method for identifying the best site for PEG introduction.

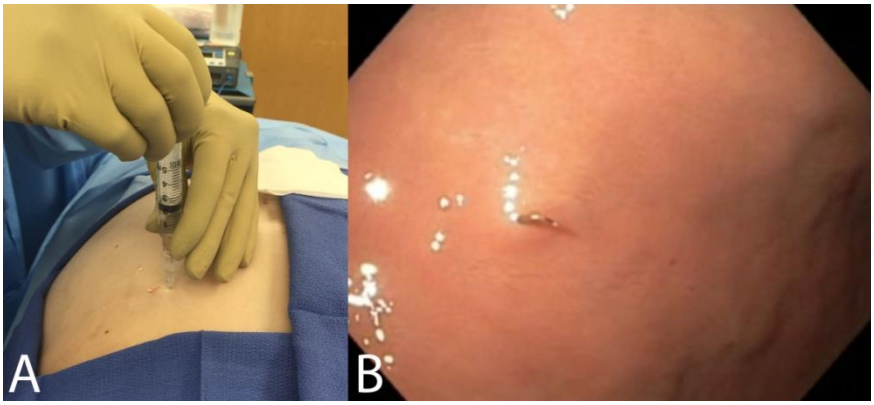

Figure 4. Safe tract technique. A) Finder needle is advanced through the abdominal wall while aspirating with the syringe. B) Endoscopic view of the finder needle entering the gastric lumen. The needle tip should be visualized at the same time as bubbles are seen in the syringe to confirm a safe tract.

4. Gain Access to the Gastric Lumen

After preparing the area with antiseptic prep, a skin incision should be made in the transverse direction using a #11-blade through the area where local anesthetic was infiltrated. An incision that is larger than the PEG tube, leaving space around the tube, decreases the incidence of peri-tubal infections by allowing efflux of bacteria that are introduced during the passage of the gastrostomy through the oropharynx. For a standard 20-French tube, the external diameter is 6.7 mm and the calculated length of the required incision to allow for adequate drainage is 10.5 mm in length. The stomach should be kept insufflated throughout the procedure to ensure contact of the gastric and abdominal walls. The endoscopist should position an open snare through the working channel of the gastroscope against the anterior stomach wall at the anticipated entry site (Figure 5A). The needle/cannula assembly is then introduced through the anterior abdominal wall incision (Figure 6) and into the gastric lumen under the direct visualization of the gastroscope. If performed correctly, the snare should be in an appropriate location to immediately secure the cannula (Figure 5B). The snare is closed, securing the cannula and the introducer needle is removed (Figure 5C).

5. Placement of the Guidewire

The looped guide wire is passed by the assistant through the cannula on the abdominal wall and the endoscopist uses the snare to grasp the wire (Figure 5D). The endoscopist then withdraws the endoscope, snare, and guide wire through the patient's mouth. Care must be taken to avoid pulling the guide wire through the abdominal wall, and losing access to the stomach.

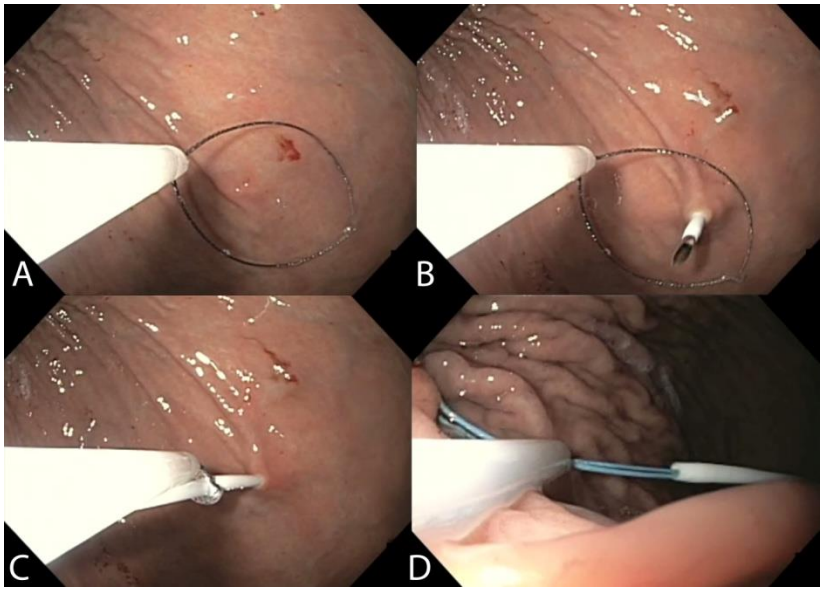

Figure 5. A) Endoscopic snare is opened and placed against the gastric wall at the site of planned PEG (note the small blood spot from the safe tract needle). B) Needle and cannula are passed through the gastric wall and through the appropriately placed snare loop. C) The snare is subsequently closed to secure the cannula. D) Guidewire is passed through the cannula. The snare is opened, releasing the cannula, is repositioned, and subsequently closed around the guidewire.

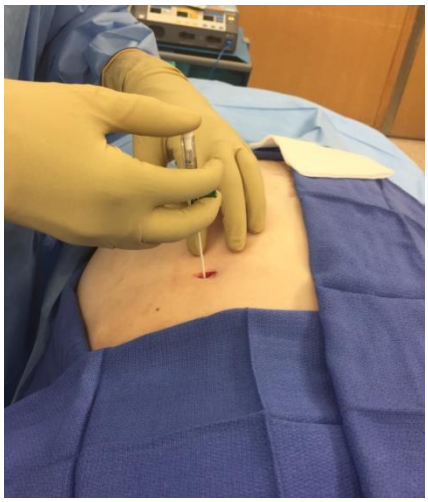

Figure 6. Introduction of the needle/cannula assembly through the abdominal wall.

6. Assembly of the 'Pull' PEG

The PEG tube contains an all-in-one apparatus that has a long flexible tube with internal bumper and a short stiff dilating end attached to a small pre-looped wire (Figure 7). To secure the PEG tube to the guidewire, pass both strands of the guidewire through the wire loop dilator end of the feeding tube, then pass the internal retention-bumper of the feeding tube

between the strands of the insertion guidewire. Pulling tightly forms a knot (Figure 8). Water-soluble lubricant is applied to the stiff short dilating end to facilitate passage.

The endoscopist may use the snare to hold the internal retention-bumper of the PEG, allowing the endoscope to be pulled into the esophagus as the PEG is pulled into the stomach (Figure 9). Reinsertion of the endoscope allows one to assess the gastrostomy site for hemostasis and ideal length of the tube in relationship to the subcutaneous tissue; however, studies have not shown this to be an absolute requirement when performing the procedure. The easiest way to grasp the PEG with the snare is around the internal retention bumper rather than around the tubing itself (Figure 10). This configuration not only folds the bumper into a lower-profile configuration, but permits the tube to be easily released from the snare within the esophagus. It also places the endoscope, snare and tube in an in-line configuration rather than forcing the tube to be at a right angle to the scope and snare.

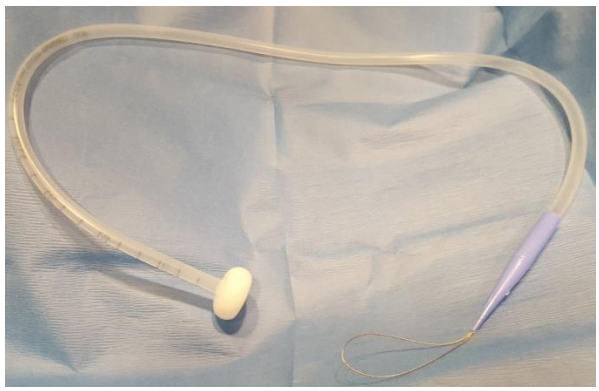

Figure 7. Pull PEG tube.

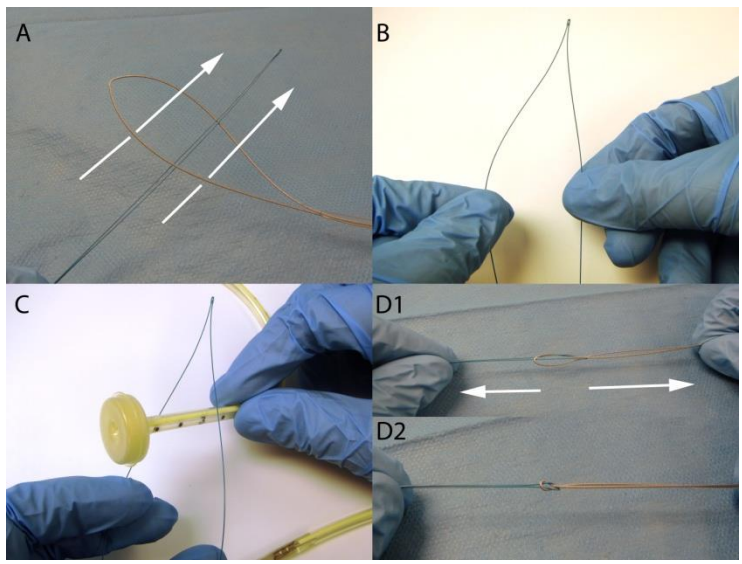

Figure 8. Joining a 'pull' PEG to the guidewire. A) Both strands of the guidewire are passed through the wire loop at the end of the PEG dilator. B) The strands of the guidewire are separated. C) The internal retention bumper of the PEG is passed between the guidewire strands. D) The guidewire and wire loop are pulled opposite one another (1) to form a tight knot (2).

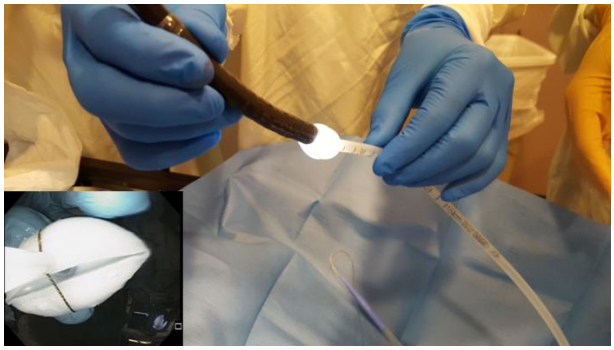

Figure 9. Endoscopic snare is used to grasp the internal-retention bumper of the PEG allowing the gastroscope to be pulled into the esophagus along with the tube thus facilitating esophageal reintubation. Inset shows the endoscopic view.

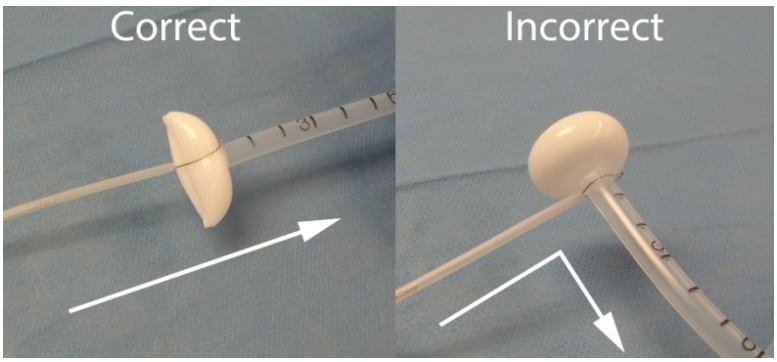

Figure 10. Correct positioning of the snare on the PEG bumper folds the retention dome and places the tube and snare in a straight line. Incorrect positioning places the snare around the tubing itself creating a 90° angle.

7. Insertion of the 'Pull' PEG

Apply gentle pressure to the abdominal side of the guide wire, advancing the tapered PEG tube and endoscope to enter the mouth and then the esophagus. If the endoscope is being reintroduced to reassess PEG placement, when the endoscope reaches the 30-cm mark the endoscopist should open the snare to release the bumper. The endoscopist should then remove the snare from the working channel of the gastroscope. The assistant will continue to apply gentle traction on the guidewire to advance the PEG into the body of the stomach under direct endoscopic visualization. After the tapered portion has exited the anterior abdominal wall, the flexible portion of PEG will be seen (Figure 11).

8. Confirm Position of the PEG Tube

The assistant will apply gentle pressure to confirm that the internal bumper of the PEG tube is engaged on the stomach wall (Figure 12A). Care should be taken to avoid overt traction of the tube (and more importantly the bumper) against the anterior portion of the

abdominal stomach to prevent a "buried bumper" syndrome. The endoscopist, having followed the PEG into the stomach, visualizes the entry site and confirms hemostasis. The external portion of the PEG is then assembled per manufacturer's recommendations. Visual confirmation of adequate position of the external bumper (which should be snug but not tight against the gastric wall) is the final maneuver prior to securing the catheter before removal of the gastroscope (Figure 12B). The endoscopist should note the centimeter marking at the level of the skin and record it in the patients chart for future reference if tube migration is ever questioned. The external tube clamp (if included in the kit) can be applied as well as the feeding adapter (Figure 13).

TECHNICAL VARIATIONS

Second-Look Gastroscopy

After placement of the PEG tube, the gastroscope is often returned to the stomach to confirm adequate position of the internal bumper and assess for other complications such as bleeding. Some practitioners have challenged the need for this as changes in tube position are required in a minority of patents. One study demonstrated adjustments in tube position was made to only 7% of patients and felt that repeat endoscopy is not routinely required [4].

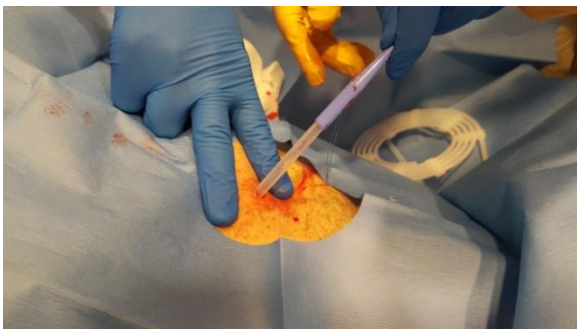

Figure 11. Rigid dilating portion of the PEG has traversed the abdominal wall and the flexible portion of the tube is visible. Note the two-finger counter-traction being applied to the abdominal wall.

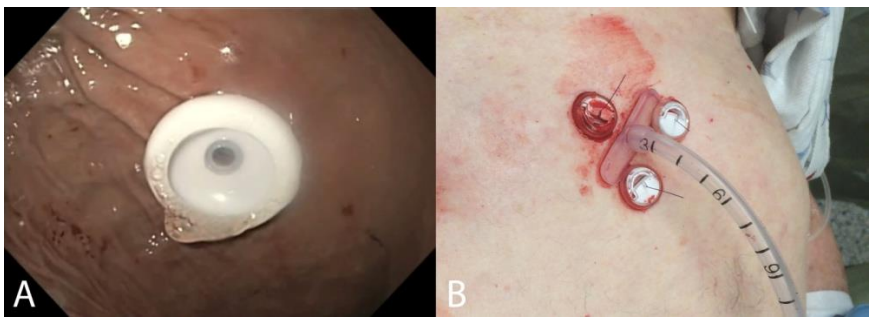

Figure 12. Final PEG bumper position. A) Endoscopic view of the internal bumper shows it is lightly touching the gastric mucosa. B) External bumper is lightly touching the skin surface and easily turns when spun.

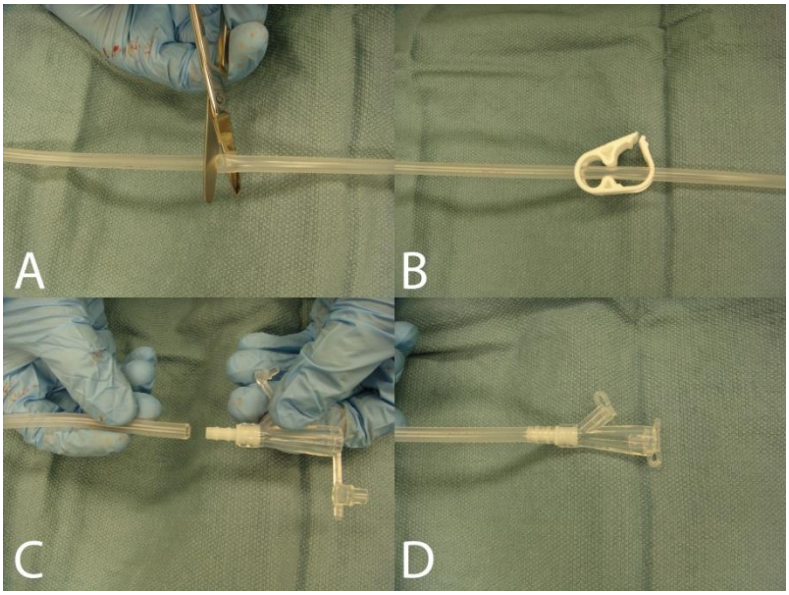

Figure 13. Final PEG assembly. A) The soft portion of the tubing is cut to desired length. B) The tubing clamp (if provided) is applied. C) The feeding adapter is applied. D) The caps are closed.

A technique for rapid re-insertion has been described utilizing a rat tooth forceps through the biopsy channel of the endoscope grasping the center hub of the mushroom catheter allowing the endoscope to be drawn into the esophagus and stomach as the tube is pulled into the mouth [5]. It is the authors' practice to perform repeat endoscopy to confirm placement. We utilize the included snare within the kit placed around the mushroom to allow for rapid re-introduction of the scope into the stomach to confirm visualization as described above.

Gastrointestinal T-Anchors

If the endoscopist desires to use gastrointestinal T-anchors, they can be placed at this time (Figure 12B). It is not routine in the authors' practice to use these for a routine pull PEG although they are commonly used in other techniques for PEG such as the introducer technique or in high-risk patients.

Low Profile Tubes

Newer devices allow for delivery of low profile tubes utilizing the pull technique. The tube is a one piece device that has several predefined lengths. The introducer needle had external markings to measure the thickness of the anterior abdominal wall. An appropriately sized tube can then be selected. The external flange is housed within the dilator portion of the device and is deployed once it has been pulled externally (Figure 14). The authors frequently utilize this type of tube in the pediatric population to prevent larger external aspects on the feeding device.

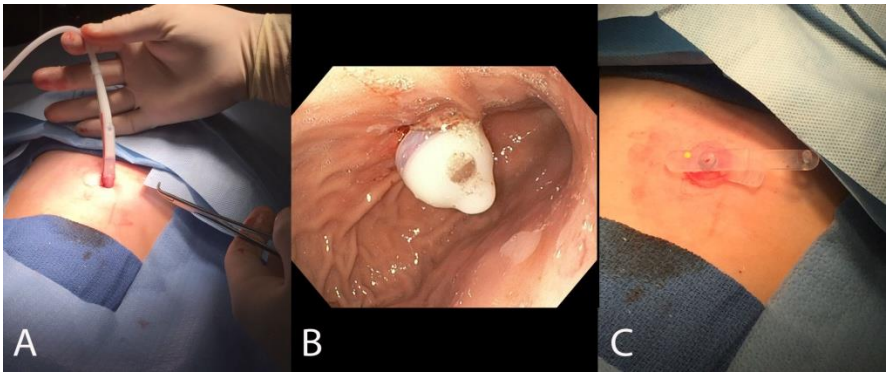

Figure 14. Low profile pull type PEG. A) Dilating portion of the tube houses the collapsed external bumper and cap. B) Endoscopic view of the internal bumper. C) View of the external bumper after completion of the procedure.

GASTROSTOMY USE

There is considerable variability in the timing of utilization of the tube for nutrition and medications in the literature and by individual practitioners. Several manufacturers recommend the patient to remain without enteral feeding for 24 hours. PEG feeding can safely begin 3 hours after tube placement if there are no problems with placement [6]. Post-operative fasting length was found to be shortest in the pull technique when compared to other technique [7]. It is authors' practice to utilize the tube immediately after the procedure for medications and to begin enteral feeding at three hours post PEG placement in the medically stable patient.

CONTRAINDICATIONS AND COMPLICATIONS

A general list of contraindications for orally introduced PEG placement are listed in Table 1. These are additionally detailed in Chapter 2. Specifically with the pull technique, one must pay special attention to head and neck cancers as gastrostomy site metastasis, although rare, has been reported. The oral insertion technique may also be difficult or impossible if there is stricture in the oral cavity or esophagus due to inflammatory process, radiation, or cancer. The endoscope may not be able to pass or the PEG tube itself may not pass. Alternative methods, such as the introducer methods and radiologically or surgically placed gastrostomy tubes, may be required in this situation.

CONCLUSION

The 'pull' technique is a commonly used standard method for placing endoscopic feeding tubes. Careful selection of the appropriate patient and the use of additional steps such as the "safe tract" technique, has created an excellent safety profile for this method has allowed for its wide adoption.

Table 1. Absolute and relative contraindications to PEG

Contraindications and considerations	
Absolute	Relative and Special Considerations
Nonfunctioning or obstructed upper GI tract *(exception of use for decompression)*	Upper aerodigestive tract malignancy *(head and neck vs esophageal)*
Presence of peritonitis	Massive ascites
Sepsis	Severe malnutrition
	Infectious processes of stomach and abdominal wall
	Proximal small bowel fistulae
	Portal hypertension
	Coagulopathy
	Morbid obesity
	Previous abdominal surgeries
	Hiatal hernia
	History of peritoneal dialysis
	Peritoneal carcinomatosis
	General decompensation

EDITOR'S COMMENT

This chapter describes the indications and techniques for one of the commonly used approaches to gaining enteral access. The choice for one technique over the others should be based on patient indications rather than merely personal experience. Although physicians may surely have personal preferences, endoscopists should become familiar and skilled in all alternatives for placement of enteral access tubes (JMM).

REFERENCES

[1] Gauderer M, Ponsky J, Izant R. Gastrostomy without laparotomy: a percutaneous endoscopic technique. *J. Pediatr. Surg*. 1980;15:872-5.

[2] Ponsky J. The Development of PEG: How it was. *J. Interv. Gastroenterol*. 2011;1(2): 88-89.

[3] Lipp A, Lusardi G. Systemic antimicrobial prophylaxis for percutaneous endoscopic gastrostomy. *Cochrane Database Syst. Rev.* 2013;Nov. 14;11:CD005571.

[4] Odelowo OO, Dasaree L, Hamilton Y et al. Is repeat endoscopy necessary after percutaneous endoscopic gastrostomy? *J. Assoc. Acad. Minor. Phsy*. 2002;13(2):57-8.

[5] Fanelli R and Ponsky J. A simplified technique for percutaneous edoscopic gastrostomy. *Surg. Endosc*. 1992;6:261-262.

[6] Choudhry U, Barde CJ, Markert R, Gopalswamy N. Percutaneous endoscopic gastrostomy: a randomized prospective comparison of early and delayed feeding. *Gastrointest. Endosc*. 1996;44:164-7.

[7] Gang M, Kim J. Short-Term Complications of Percutaneous Endoscopic Gastrostomy according to the Type of Technique. *Pediatr. Gastroenterol. Hepatol. Nutr*. 2014;17(4): 214-222.

In: Encyclopedia of Surgery (22 Volume Set)
Editors: Andreas Lehrer and Kristin Mueller
ISBN: 978-1-53618-329-0
© 2020 Nova Science Publishers, Inc.

Chapter 129

PERCUTANEOUS ENDOSCOPIC GASTROSTOMY: THE 'PUSH' TECHNIQUE

Keyur Parikh[1], MD and Richard C. K. Wong[1,*], MD
[1]University Hospitals Case Medical Center, Cleveland, OH, US

ABSTRACT

Since the development of the PEG over 3 decades ago by Gauderer, Ponsky and Izant in 1980, it has been a widely adapted technique to help establish long-term enteral feeding for patients worldwide [1]. As a result, there have also been several different endoscopic methods to perform the procedure including: the 'Pull', the 'Push', the 'Introducer', and the 'Single-step button'. There are surgical and radiological methods as well. The two most commonly used techniques in the placement of PEG's are the 'Push', which is described in this chapter, and the 'Pull', which is described in detail in Chapter 7.

TECHNIQUE OVERVIEW

While the original PEG technique described in 1980 was 'Pull', the 'Push' technique was later described by Sacks, et al., in 1983 [2]. Essentially, this technique is very similar to the 'Pull' method for PEG except that a more durable single guidewire is passed into the stomach instead of a more flexible looped guidewire (or suture). Since the development of PEG, there have been several comparative studies to help determine which technique is superior as judged by means of complication rates, dislocation rates, and ease of use.

A recent retrospective study in 2015 by Kohler, et al., compared 231 patients who underwent PEG via either Push (100) or Pull (131) technique and found that there was a significantly increased incidence of complications with the 'Push' technique 33% vs 21.4% (p=0.047) [3]. It is important to note that a vast majority of these were considered minor, Clavien-Dindo grade 1 (97.8%), complications meaning that no additional intervention was

[*] Corresponding Author's Email: Richard.wong@uhhospitals.org.

necessary. Additionally they found that rates of tube dislocation and occlusion were significantly higher with the 'Push' technique in comparison to the 'Pull'. Older retrospective studies have also suggested similar findings [4].

One of two prospective randomized-controlled trial was performed by Hogan, et al., in 1986. In that study, 40 patients were randomized to either technique. Difficulty of technique was considered similar as per endoscopist reports. The 'Pull' technique had a 40% minor complication rate, including 4 patients with peristomal inflammation, 2 with purulent drainage and 2 with an easily replaced tube dislodgement. The 'Push' technique had a 10% minor complication rate with 1 patient with purulent drainage and 1 with an easily replaced tube dislodgement. Reported major complications were similar for both groups and were 20% for the 'Pull' and 15% for the 'Push' techniques. In the 'Pull' group, 1 patient developed a subcutaneous abscess, 2 patients developed aspiration, with 1 passing away, and 1 patient developed peristomal leakage. In the 'Push' group, 1 patient had a tube dislodgement requiring a repeat procedure, 1 patient died from aspiration, and 1 had peristomal leakage. Overall, they concluded that although there was a high number of patients with minor complications, 25% of the group, these were reported for the purposes of a study and overall those were not truly clinically significant. They found that complication rates between both groups were similar [5].

A second prospective randomized-controlled trial was performed in Spain by Fernandez, et al., in 1995. In this study, 44 patients were randomized to either technique. No differences were found between the two procedures in terms of technical difficulty or complications. Minor site infections occurred in 3 patients from each group, which resolved with topical antibiotic therapy. No procedure-related mortality was reported in either technique. Three tube dislodgements were observed in the 'Pull' technique group [6].

For patients with advanced head and neck cancer, the author's practice is to preferentially use the 'Push' technique. A retrospective study by Tucker, et al., in 2003 found a statistically significant increase in complications with the 'Pull' technique compared to the 'Push' technique (30 vs. 0%; $p = 0.006$). The majority of complications, again, were minor and required no additional invasive intervention; however, there were no reported major or minor complications with the 'Push' technique [7].

Based on the results of these studies, at the present time, use of 'Pull' or 'Push' technique for gastrostomy rests upon the endoscopist's preference.

PRE-PROCEDURE PREPARATION

As for any non-urgent endoscopic procedure, the patient is prepared by withholding gastric feedings for generally 6-8 hours before the procedure. A thorough assessment of the patient should be performed prior to scheduling the procedure. This includes a review for the indication of the procedure. The patient's anatomy should be understood and any altered gastroesophageal anatomy should be known prior to PEG placement. Small bowel feeding should be considered in patients with known gastroparesis (eg. PEG with jejunal extension (PEG-J) or direct percutaneous endoscopic jejunostomy (D-PEJ)). A careful review of medications should be performed, specifically, to evaluate for agents that would place the patient at increased risk of bleeding.

As noted in Chapter 4, recent updated guidelines by the American Society for Gastrointestinal Endoscopy (ASGE) indicate that monotherapy with aspirin/NSAIDS or clopidogrel are considered low risk for bleeding in patients undergoing PEG placement and do not need to be held prior to the procedure (this does not apply to dual antiplatelet therapy, which is considered high risk for bleeding) [8]. For patients on warfarin or the newer anticoagulants (anti-thrombin inhibitors, anti-Xa inhibitors), we generally bridge with heparin if they are on longer-acting agents, but for medications with shorter half-lives, these are held for the appropriate time interval prior to the procedure [8]. In addition, it is important that the endoscopist discuss peri-procedure management of antiplatelet and anticoagulant medications with the prescribing medical provider.

Finally, and often most importantly, the ethical considerations of PEG should be considered. Placement of a feeding gastrostomy is certainly appropriate when it is anticipated to improve a patient's quality of life. It is clear that nasoenteric tube feedings may be equally effective (using dedicated small caliber nasoenteric tubes), are less invasive, and more appropriate in patients with limited potential for survival. As such, it is important to approximate what period of time enteral feedings may be required. If a PEG is being performed simply for the purpose of prolonging life in an otherwise unsalvageable situation, the authors strongly advocate for a careful consultation with family members and the managing medical provider, and an evaluation of overall goals of care prior to deciding whether or not a PEG should be performed. See Chapter 3 for a more detailed discussion of this topic.

Within 30 minutes of PEG placement, a single prophylactic dose of an antibiotic is given. The authors use a first generation cephalosporin and begin to administer the dose immediately prior to the start of the procedure. A 2002 study found that infectious complications without the use of routine pre-procedure antibiotics were as high as 38% and current ASGE guidelines recommend the use of intravenous cefazolin (or an antibiotic with equivalent coverage) within 30 minutes of the start of the procedure [9-11]. Patients who are allergic to penicillin should receive a single one-time IV dose of vancomycin for prophylaxis. In addition to providing adequate prophylaxis against local or systemic infection, this step is an important metric in measurement of procedure quality. In the age of value-based medicine, meeting these metrics is an important part in delivering high-quality medical care to patients.

'PUSH' TECHNIQUE

The patient is placed in supine position on the bed in the procedure room and the abdomen is exposed. Some endoscopists use a topical anesthetic agent for the throat; however, we do not use this in all patients. Sedative drugs are administered intravenously under appropriate anesthesia monitoring. Once adequately sedated a complete and careful esophagogastroduodenoscopy (EGD) is performed to evaluate for any endoscopic findings that would change patient management and/or prevent safe placement of PEG (See Chapter 6). It is important to mention that introduction of the endoscope may occasionally be difficult with the patient in the supine position and may be facilitated, if necessary, by rolling the patient to his or her side or by using a chin-lift maneuver to straighten passage. After the EGD, the first step in PEG is to find the appropriate location for placement.

When the endoscope is positioned in the body of the stomach, it should be fully inflated. During this time, the lights in room should be dimmed, if not done previously. The authors prefer the use of carbon dioxide rather than air for insufflation during endoscopy as this is easily reabsorbed with improved patient comfort. Full distension of the stomach is an important step for several reasons. First, it displaces the liver in a cephalad direction and the colon towards the pelvis. Second, full gastric distention brings the anterior gastric wall in contact with the peritoneal surface. Third, it allows for trans-illumination of light from inside the stomach to the external surface. All of these measures help prevent risk of traumatic solid organ injury and inadvertent puncture of the colon or small bowel during this procedure by helping to ensure there is no intervening viscera.

Endoscopically, it is important to choose a location for PEG placement that is proximal to the gastric angularis because puncture of the antrum may damage the gastric pacemaker and could result in gastroparesis. The external location of the PEG should generally be in the left upper quadrant of the abdomen, approximately two fingerbreadths distance from bony structures such as the xiphoid process and costal margin.

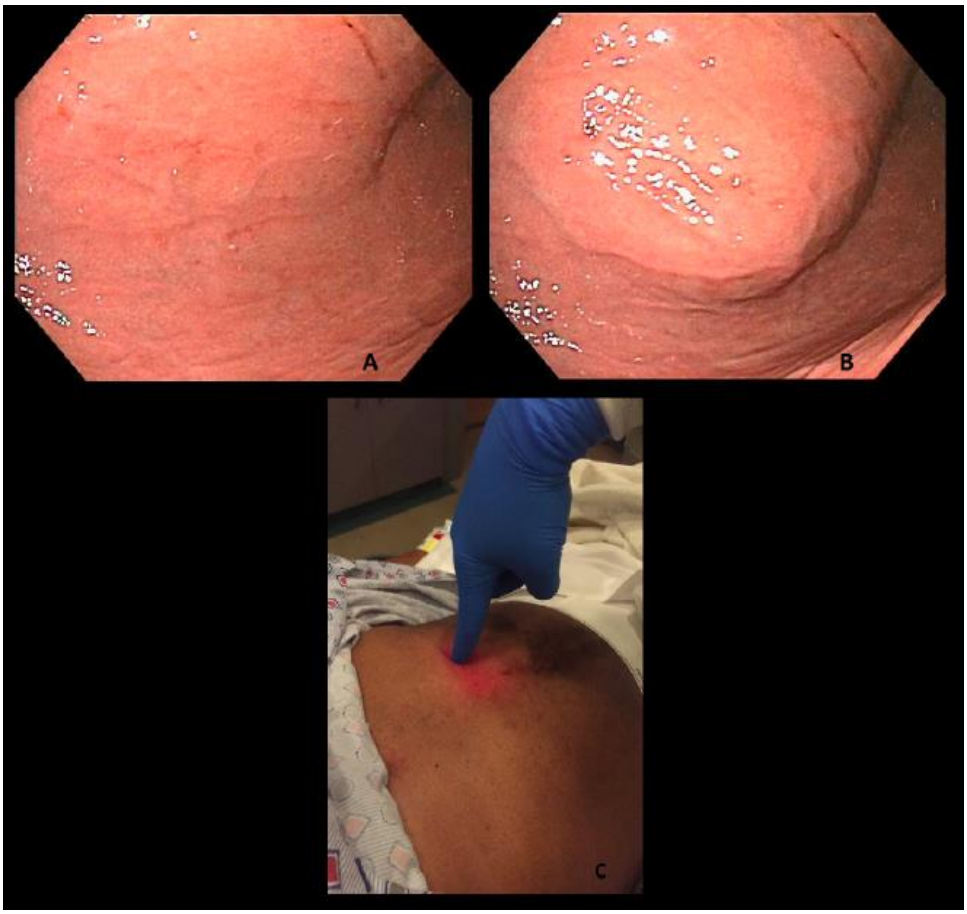

Figure 1. Localization of the gastrostomy site. It is important to choose a site proximal to the angularis approximately 2 fingerbreadths distance from bony structures. A) Endoscopic view of the gastric body before and B) after pressing down with one finger on the abdominal wall. C) External view and internal view should show good one-to one finger indentation.

Figure 2. Transillumination will help guide direct puncture of the abdominal wall at the selected location for PEG placement.

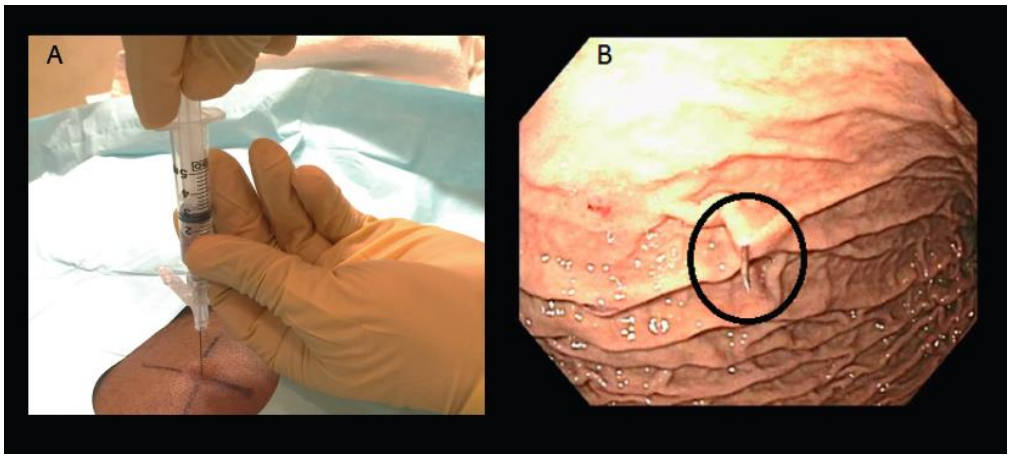

Figure 3. Safe-Tract Technique. A) The external anesthetic needle is B) visualized endoscopically. Bubbles should not be seen in the syringe until the needle is seen in the stomach breaching the mucosa.

The chosen location should be the site where there is the best one-to-one finger indentation of the stomach (Figure 1), where trans-illumination (Figure 2) can be readily visualized, and where there are no intervening air bubbles between the skin and the site of gastric puncture using the 'safe-tract' needle aspiration technique [12]. This will be the site for the PEG and it should be marked on the skin with a sterile pen. The skin may need to be shaved if there is excessive surface hair.

Once the site is selected, all subsequent steps are performed using standard aseptic technique. The skin is then aseptically cleaned using an appropriate agent. The patient's skin should be anesthetized with local anesthetic. Then, with constant negative pressure on the syringe after the anesthetic needle enters the skin, the needle is inserted into the stomach until the needle is visualized endoscopically with air bubbles only being seen in the syringe when the needle breaches the gastric mucosa (Figure 3). This so-called, 'safe-tract' technique, once again, ensures that there are no intervening gas-containing viscera between the abdominal wall and the stomach. If air bubbles are seen before the needle enters the stomach, then a different site should be chosen.

Next, approximately a 1cm incision is made at the site and blunt dissection performed with a hemostat (Figure 4). Then, the puncturing cannula (needle) within a plastic catheter is inserted into the stomach through the incision and visualized endoscopically (Figure 5A). At this time, a snare loop should be used to seize the cannula (Figure 5B). After this, the inner stylet is removed, and a sturdy 0.035' guidewire is passed through the cannula (Figure 5C).

The snare loop is tightly closed around this wire (Figure 5D) and the wire is carefully withdrawn along with the gastroscope from the patient's mouth while continuously maintaining a tight grasp of the snare loop around the wire.

It is very important that the assistant is tightly holding the other end of the wire outside the skin so that full control is maintained of both ends of the wire at all times during the procedure.

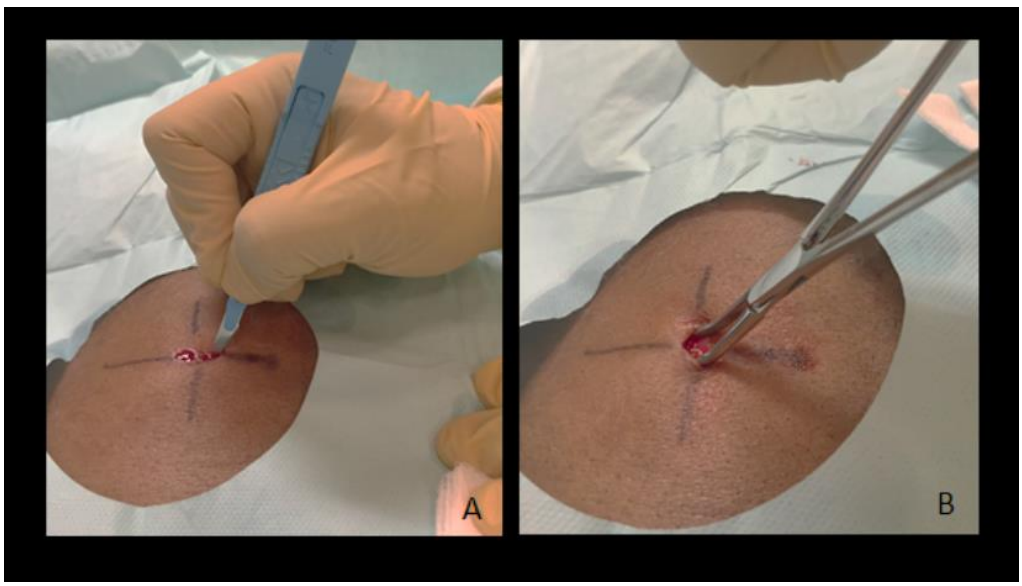

Figure 4. A) An approximately 1-cm horizontal skin incision is made at the site of planned puncture. B) Blunt dissection of the subcutaneous tissues is performed with a hemostat.

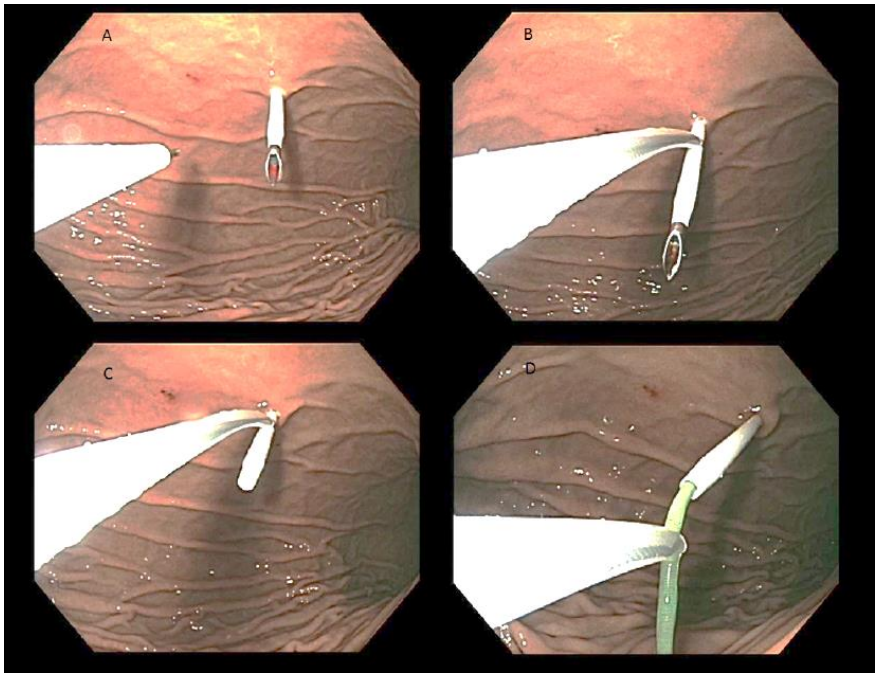

Figure 5. Guidewire access of the stomach. A) The puncturing needle with a plastic cannula is inserted in to the stomach through the incision site and visualized endoscopically. B) At this time, the snare loop should be used to seize the cannula. C)The puncturing needle is removed. D) A sturdy guidewire is passed through the cannula and the snare loop is then tightly closed around the wire. Following this, the wire is carefully withdrawn along with the endoscope *per os*.

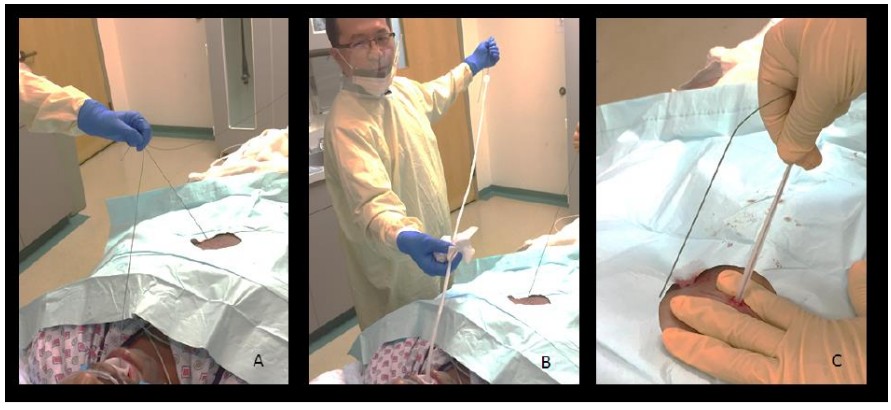

Figure 6. Push gastrostomy insertion. A) Once the wire is out of the patient's mouth, it is released from the snare and grasped by the endoscopist. In this figure, both ends of the wire are held by the endoscopist for demonstration purposes. B) A Push-type gastrotomy tube with a rigid dilator end is threaded over the mouth-end of the wire. Both ends of the wire are held taught (one by the endoscopist one by the assistant) so that the wire is relatively straight and not bent. The lubricated gastrostomy tube is then carefully pushed over the mouth-end of the wire and into the stomach. C) As the dilator end of the gastrostomy tube emerges from the abdominal wall, the wire is released and the tube is grasped and carefully pulled the rest of the way to its final position. Note that constant counter-pressure is being applied to the abdominal wall with two fingers on either side of the tube.

Once the wire is out of the patient's mouth, it is released from the snare, and the mouth-end of the wire is grasped by the endoscopist (Figure 6A). A 'Push'-type gastrostomy tube is threaded over it with a rigid dilator end towards the patient.

It is very important that both ends of the wire are held taut (so that the wire is relatively straight and not bent) as the lubricated gastrostomy tube is carefully pushed over the wire and into the stomach (Figure 6B).

As the dilator end of the gastrostomy tube emerges from the abdominal wall, the wire is released, and the tube is grasped and carefully pulled the rest of the way to its final position while maintaining constant counter-pressure on the abdominal wall with two fingers on either side of the tube to reduces risk of abdominal wall injury (Figure 6C). The connection between the rigid dilator and the softer gastrostomy tube is the widest portion of the tube and thus it is important that the initial incision has been wide enough and that blunt dissection has been adequately performed to prevent significant resistance during passage of the tube (Figure 7).

An external plastic bumper is placed over the PEG tube and the final anchoring position is adjusted so that the external bumper is only lightly touching the skin (there should be about a 1cm gap in-between the skin and the external bumper). The authors prefer a plastic "T" bar as the external bumper as it is more comfortable for the patient (Figure 8).

In addition, although not mandatory, the authors prefer to re-intubate the stomach in order to provide photo-documentation of the final position of the intra-gastric PEG bumper (Figure 9). The tube can then be cut to length and have the external clamp and feeding adaptor placed.

Figure 7. The connection between the rigid dilator and the softer gastrostomy tube is the widest portion of the tube. It is important that the initial skin incision has been made wide enough and that blunt dissection has been adequately performed to prevent resistance during passage of the tube through the skin and subcutaneous tissues.

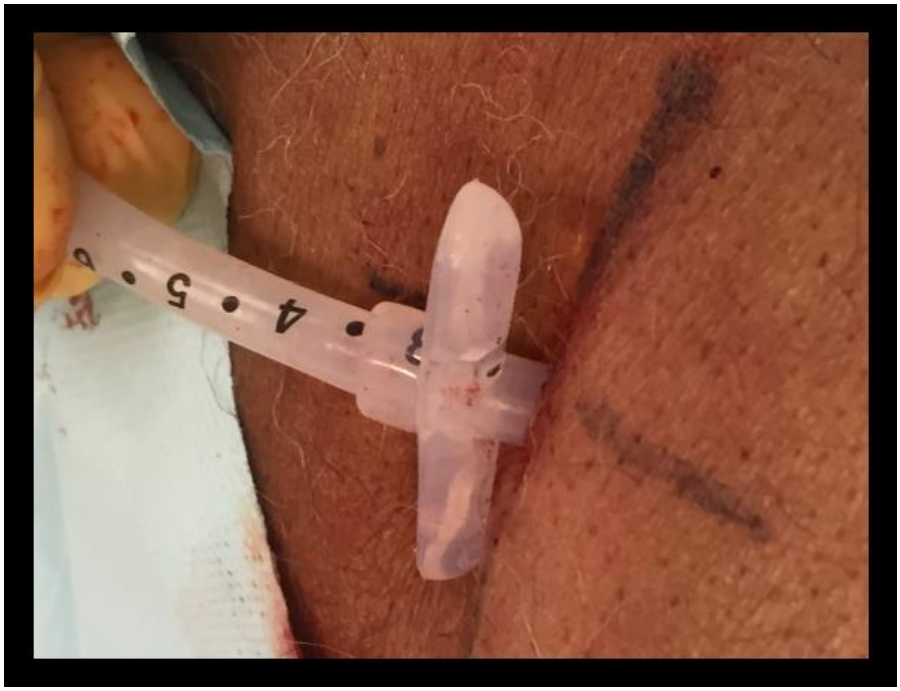

Figure 8. The external plastic bumper is placed over the PEG tube and the final anchoring position is adjusted so that the external bumper is only lightly touching the skin. There should be about a 1-cm gap between the skin and the external bumper.

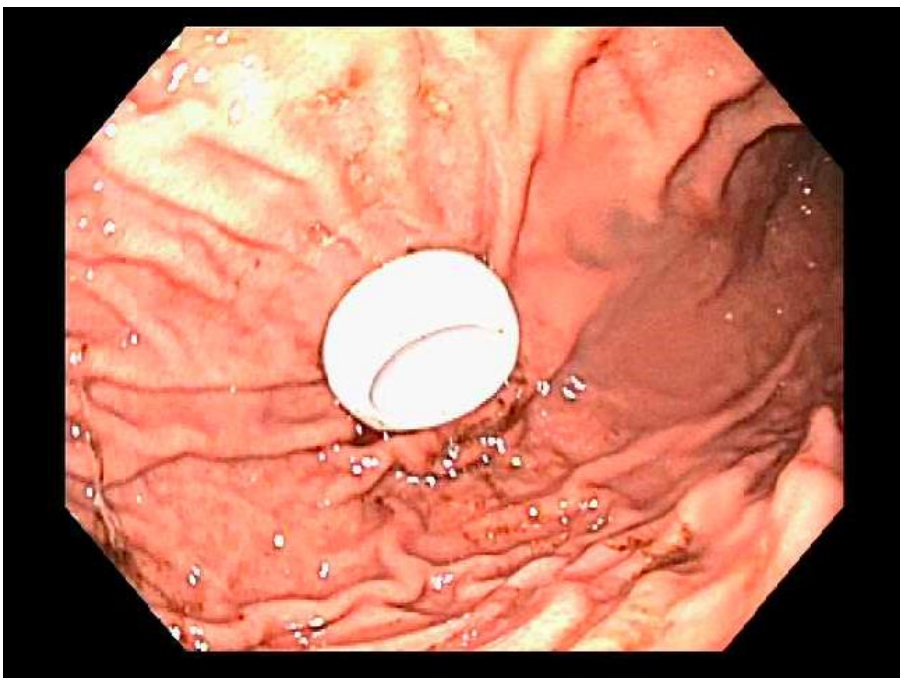

Figure 9. Endoscopic view after re-intubation of the stomach in order to provide photo documentation of the final position of the internal PEG bumper.

EDITOR'S COMMENT

The authors describe one of the commonly utilized techniques for gaining access during percutaneous endoscopic gastrostomy tube placement. The components of the procedure are well delineated and endoscopists must pay attention to these details to allow for safe and effective PEG placement. The use of safe tract technique and appropriate indications should be utilized for all PEG placements (JMM).

REFERENCES

[1] Gauderer M. W., Ponsky J. L., Izant R. J. Gastrostomy without laparotomy: a percutaneous endoscopic technique. *J. Pediatr. Surg.,* 1980; 15(6):872-5.

[2] Sacks B. A., Vine H. S., Palestrant A. M., et al. A nonoperative technique for establishment of a gastrostomy in the dog. *Invest. Radiol.,* 1983; 18(5):485-7.

[3] Kohler G., Kalcher V., Koch O. O., et al. Comparison of 231 patients receiving either "pull-through" or "push" percutaneous endoscopic gastrostomy. *Surg. Endosc.,* 2015; 29(1):170-5.

[4] Kozarek R. A., Ball T. J., Ryan J. A. Jr. When push comes to shove: a comparison between two methods of percutaneous endoscopic gastrostomy. *Am. J. Gastroenterol.,* 1986; 81(8):642-6.

[5] Hogan R. B., DeMarco D. C., Hamilton J. K., et al. Percutaneous endoscopic gastrostomy—to push or pull. A prospective randomized trial. *Gastrointest. Endosc.,* 1986; 32(4):253-8.

[6] Fernandez I., Rodriguez S., Gonzales A., et al. A comparative study of 2 technics of percutaneous endoscopic gastrostomy. *Rev. Esp. Enferm. Dig.,* 1995; 87(5):357-61.

[7] Tucker A. T., Gourin C. G., Ghegan M. D., et al. 'Push' vs 'pull' percutaneous endoscopic gastrostomy tube placement in patients with advanced head and neck cancer. *Laryngoscope,* 2003; 113(11):1898-1902.

[8] ASGE Standards of Practice Committee, Acosta RD, Abraham NS, et al. The management of antithrombotic agents for patients undergoing GI endoscopy. *Gastrointest. Endosc.,* 2016; 83(1):3-16.

[9] Lockett M. A., Templeton M. L., Byrne T. K., et al. Percutaneous endoscopic gastrostomy complications in a tertiary-care center. *Am. Surg.,* 2002; 68:117-20.

[10] ASGE Standards of Practice Committee, Banerjee S., Shen B., et al. Antibiotic prophylaxis for GI endoscopy. *Gastrointest. Endosc*., 2008; 67:791-8.

[11] ASGE Standards of Practice Committee, Jain R., Maple J. T., et al. The role of endoscopy in enteral feeding. *Gastrointest. Endosc*., 2011; 74(1):7-12.

[12] Foutch P. G., Talbert G. A., Waring J. P., Sanowski R. A. Percutaneous endoscopic gastrostomy in patients with prior abdominal surgery: Virtues of the safe tract. *Am. J. Gastroenterol*., 1988; 83:147-50.

In: Encyclopedia of Surgery (22 Volume Set)
Editors: Andreas Lehrer and Kristin Mueller
ISBN: 978-1-53618-329-0
© 2020 Nova Science Publishers, Inc.

Chapter 130

PERCUTANEOUS ENDOSCOPIC GASTROSTOMY: INTRODUCER TECHNIQUE

Sean B. Orenstein*, MD
Oregon Health & Science University, Portland, OR, US

INTRODUCTION

Since its inception by Drs. Ponsky and Gauderer in 1980, percutaneous endoscopic gastrostomy (PEG) tube placement has revolutionized and simplified gastric feeding access [1]. The ability to place a gastrostomy tube in a minimally invasive fashion has allowed surgeons, gastroenterologists, and other clinicians to provide safe and efficient enteral nutrition to innumerable patients in need. While little has changed in the overall design and procedural flow of PEG tube placement, several technique modifications have been developed to provide enteral access to a wider variety of patients. One such modification is the "Introducer Technique," first described in 1980 by Hashibal, but popularized by Russell et al. in 1984 [2, 3]. Using endoscopic guidance, the gastrostomy tube (G-tube) is inserted directly through the abdominal wall via the Seldinger technique into the gastric lumen utilizing a peel-away sheath, akin to placing a central venous catheter over a wire with a sheath. Radiographic techniques without the use of endoscopy have also been described for direct percutaneous gastrostomy tube placement, and are routinely used among radiologists [4-7]. This chapter provides an overview of the introducer technique, including applicable patient population, advantages and disadvantages and technical considerations of the method.

ADVANTAGES, DISADVANTAGES AND INDICATIONS

There are several advantages of using the introducer technique. While endoscopic guidance during G-tube placement is desirable, the introducer technique can be employed without the need for endoscopy as long as there is either sufficient extraluminal visualization during tube placement (e.g., laparoscopic or open) or controlled radiographic guidance (e.g.,

* Corresponding Author's Email: orenstei@ohsu.edu.

computed tomography or fluoroscopy). A major advantage with introducer techniques described in the literature is reduced infection rates when compared to the pull and push techniques, likely as a result of oral cavity flora being dragged through the abdominal wound with the latter. This is supported by a small handful of prospective randomized trials that have demonstrated significantly lower peristomal infection rates with the direct introducer technique. A meta-analysis of 16 studies likewise favored the introducer technique, with significantly higher wound infection rates reported when using the pull technique (OR 13.0; $p < 0.0001$) [7-10].

Another benefit is the ability to place multiple types of G-tubes using the introducer technique (e.g., traditional PEG tubes, balloon-based tubes, Foley or Malecot catheter, and others), giving both the endoscopist and patient numerous options to choose from for appropriate tube sizing and selection. The introducer technique also permits the placement of low-profile button-type G-tube without the need for exchanges in clinic. Last, several case series exist that demonstrate malignant metastases at PEG tube sites when using the pull technique in patients with active oropharyngeal or esophageal malignancies [11-14]. While it is unclear if this is due to direct exfoliation and dragging of malignant cells into the PEG site or other forms of dissemination, the series' authors recommend utilizing the push or introducer technique when faced with oropharyngeal or esophageal malignancies.

The introducer technique is not without disadvantages; it tends to be more technically challenging given the need to safely pass multiple objects (needle, wire, dilators, sheath, tube) through the insertion site. There is also, theoretically, a greater risk of injuring or perforating the posterior gastric wall with the wire and dilators during sequential dilations. Compared to the introducer technique, the traditional pull technique simplifies this by requiring only a single pass of the needle and wire, with auto-dilation of the tract during external withdrawal of the tube.

Indications for using the introducer technique can be general or population-specific. Many endoscopists routinely utilize this technique when electively placing a G-tube, though certain pathologic conditions may warrant the need for an introducer technique over the pull or push techniques. If there are contraindications to oropharyngeal or esophageal manipulation such as after traumatic injury, perforation, recent instrumentation, obstruction, or high risk for iatrogenic injury with G-tube placement, the introducer technique should be considered. Having a history of head and neck malignancy, radiation or recent resection may make oropharyngeal manipulation challenging [15]. Likewise, a history of esophageal diseases such as malignant masses, stricture or obstruction, history of radiation therapy, recent resection with friable and edematous tissue, as well as other pathologies may make tube placement difficult and potentially dangerous if the internal retention portion of the G-tube is to be pulled through the esophageal lumen. In these situations, the ability to completely bypass the oropharynx and esophagus with tube placement reduces iatrogenic risks to the areas of concern.

Supplies

While it is possible to obtain the items separately, manufactures produce convenient all-in-one kits that contain the majority of the necessary instruments and supplies including (Figure 1);

- Gastrostomy tube: 18 and 20 French (Fr) are common sizes though there exist are a wide variety of sizes for various body habitus' and uses. Tube type is based on endoscopist and patient preferences. The introducer technique allows placement of a wide variety of tubes. Tube types include traditional Ponsky® PEG tubes (balloon-less with protruding tubing), MIC-KEY™ (low profile tubes that stay relatively flush to skin; require attachment of an external tube during feeding; internal balloon), other balloon-based tubes, Foley catheter or Malecot tube, and others.

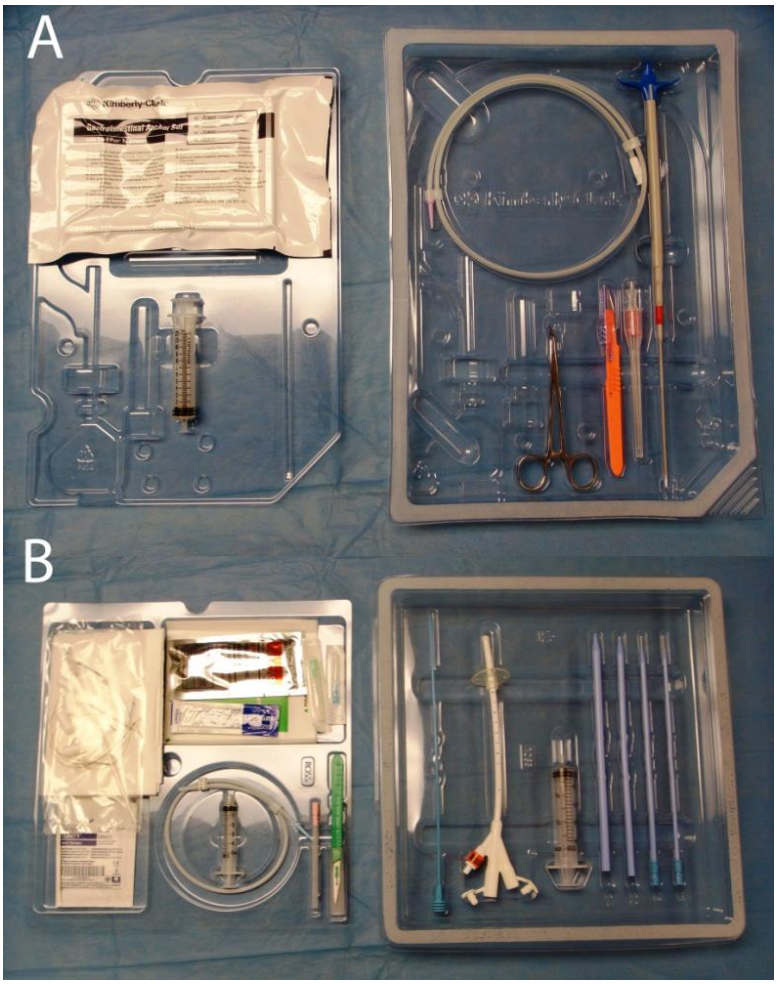

Figure 1. Introducer PEG kits. A) Kimberly Clark 20 Fr introducer kit with SAF-T-PEXY™ T-fasteners and all in one dilator and peel-away sheath. B) Ross18 Fr introducer gastrostomy kit with Brown/Mueller T-Fastener™ and serial (12, 16, 20, 24 Fr dilators).

- Guidewire: flexible 0.035" guidewire with a J-shaped tip
- Dilators: serial dilators or all-in-one telescoping dilator (Figure 2).
- Peel-away sheath: it is critical to ensure that the sheath lumen size will accommodate the chosen G-tube size (Figure 3). Some kits do not include a peel away sheath but rather include a stylet that fits into the gastrostomy permitting it to pass over the wire (Figure 4)

- Lubricating jelly
- Gastropexy supplies: most kits will include gastrointestinal T-anchors (Figure 5). Alternative methods include laparoscopically placed size 2-0 slowly resorbable sutures (3-4) sewn as seromuscular bites. Alternatively, laparoscopic suture passer can be use under endoscopic or laparoscopic (or both) to deliver trans-abdominal, transgastric sutures.

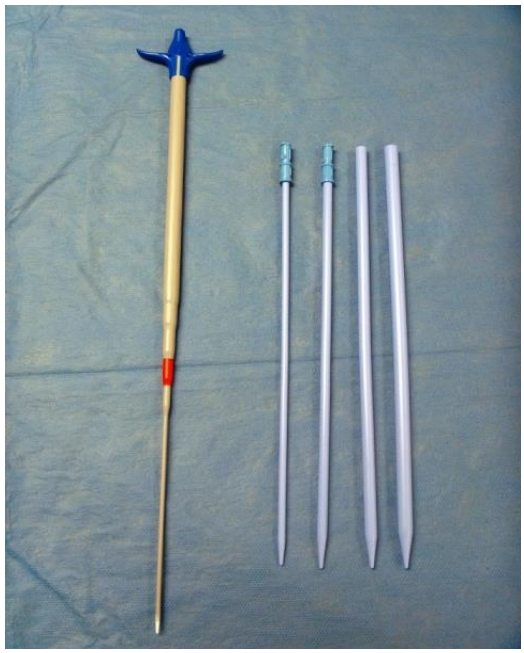

Figure 2. Introducer gastrostomy dilators; all-in-one dilator and peel-away sheath (left) and serially enlarging dilators (right).

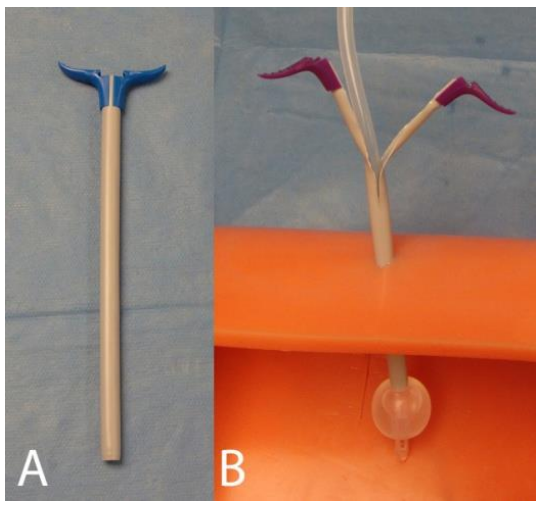

Figure 3. A) Peel-away introducer sheath. B) With the gastrostomy tube balloon inflated within the stomach, the sheath is cracked and peeled away.

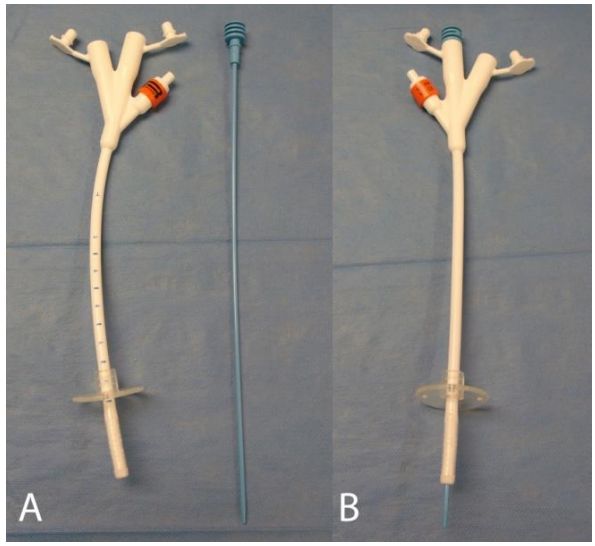

Figure 4. A) 18 Fr gastrostomy tube and stylet B) Stylet and gastrostomy assembled and ready to be passed over the wire through the already dilated tract.

For a narrowed oropharyngeal or esophageal lumen, slim gastroscopes are available that have outer diameters less than 5 mm. Such modern ultraslim gastroscopes contain 2 mm working channels to allow for instrumentation. If instruments will be utilized (e.g., snare, grasper), ensure the size is compatible with the working channel diameter. A standard-sized gastroscope may be used if no obstructing pathology present.

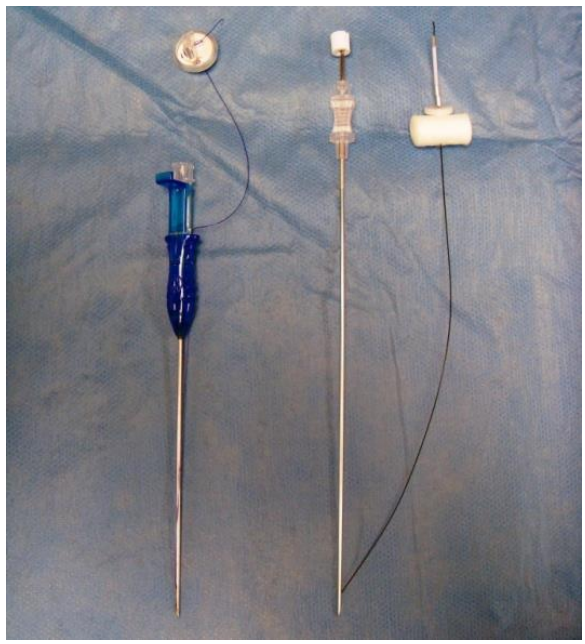

Figure 5. Gastrointestinal T-anchors; SAF-T-PEXY™ T-fasteners (left) and Brown/Mueller T-Fastener™ (right).

Technique

Setup

The patient is positioned supine and slight reverse-Trendelenburg if they are a high aspiration risk. Having the left arm tucked is helpful for transitioning to/from endoscopy. The endoscope should be easily accessible near patient's head on working side, with monitor(s) in clear view by all team members. If the patient is intubated, tape the endotracheal tube to right side of the mouth, adjacent to or though the side of the bite-block.

The abdomen can be prepped locally for an endoscopic only method while wide prepping and draping of the entire abdomen is required for a laparoscopic approach. This ensures adequate exposure of the epigastrium and lower chest.

If laparoscopy is used, typically 3 trocars are required, with one camera port and two working ports for gastropexy suture placements. Five mm trocars can be routinely used for two of the ports, however, a 10-12 mm trocar is typically necessary for needle/suture insertion. Alternatively, three 5 mm ports can be used with a ski needle or if a laparoscopic suture passer is being employed for the gastropexy stitches. An additional right upper quadrant port may be necessary for liver retraction.

Endoscopy-Only Approach

Endoscopic guidance allows for assistance with tube placement as well as confirmation of intraluminal placement. If there is no oropharyngeal or esophageal pathology, a standard gastroscope is advanced into the gastric body. A slim or ultraslim gastroscope should be used if there is a question of intraluminal narrowing from a mass, stricture, swelling, etc. This slim scope can be passed transnasal in the event of significant oral pathology. A gastroscope with a working channel is advisable in case the need arises for grasping or snaring.

Insufflating the stomach with gas, preferably carbon dioxide (CO_2) due to its rapid post-procedure resorption, allows for easier identification of optimal tube location as well as adds a layer of safety by providing more working space for suture placement and wire/dilator/tube manipulation. The expanded stomach should abut the epigastrium with external finger pressure, thus providing an optimal target for tube location.

A site on the anterior gastric wall should be chosen for tube placement. The central gastric body is an ideal location, however, the patient's anatomy may necessitate a different location for tube placement. A high-riding stomach may require a more inferior and distal tube placement. If the tube is placed distally in the stomach, be sure tubes with balloons do not obstruct the gastric outlet. The skin is marked with a skin marker to identify the proposed site of gastrostomy placement and a safe-tract method performed to confirm the safety of the proposed location.

Gastrointestinal T-anchors (typically 3-4) are then placed surrounding the proposed location in a triangle or square configuration and secured (Figure 6A). These gastropexy sutures will permit the dilators to be more easily pushed through the gastric wall without the tissue catching on the dilators and causing collapse of the gastric lumen. The remainder of the procedure then proceeds as described below in *Tube Placement*.

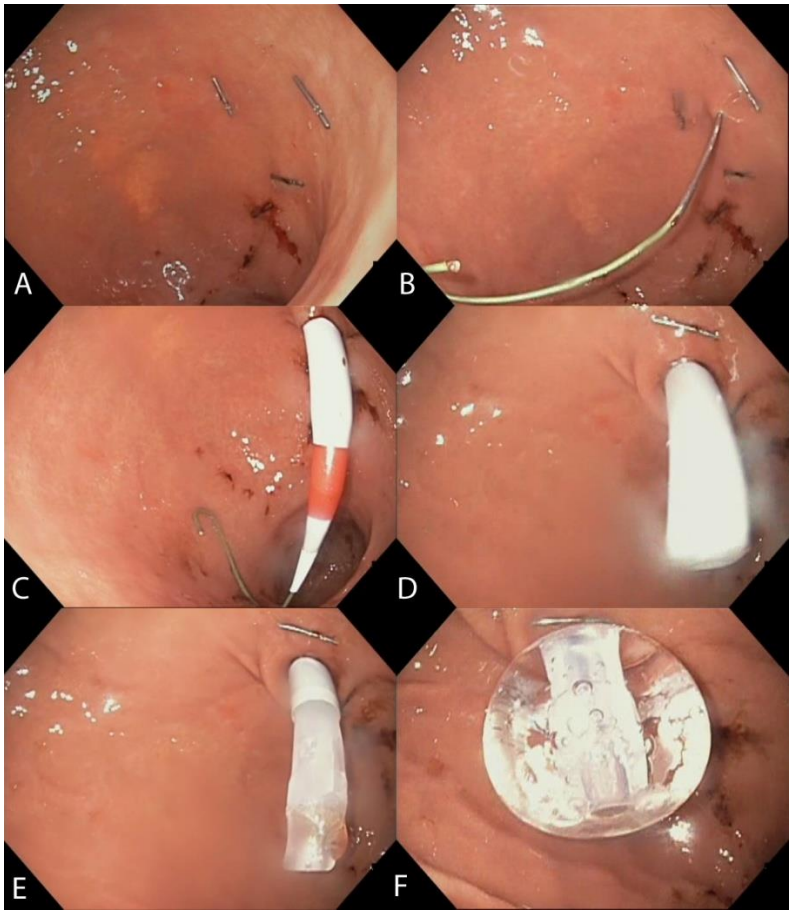

Figure 6. Endoscopic view of introducer method of PEG placement. A) Gastrointestinal T-anchors are placed to perform a gastropexy. B) Introducer needle and J-tipped guidewire are passed. C) Over the wire, dilators are introduced to sequentially dilate the tube tract. D) Peel-away sheath remains across the gastrotomy. E) Gastrostomy tube is introduced through the sheath, which is subsequently cracked and peeled away. F) Gastrostomy balloon is inflated, securing the tube within the gastric lumen.

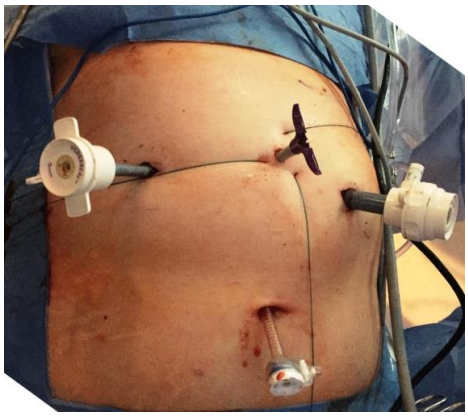

Figure 7. Trocar placement for laparoscopic-assisted approach to introducer gastrostomy. Peel-away sheath shown in center of three transfascial gastropexy sutures.

Laparoscopic-Assisted Approach

If laparoscopic access is being used, obtain desired abdominal access (optical vs Veress vs Hassan) at or near the umbilicus with a 5-mm trocar, utilizing a 5-mm laparoscope for versatility in camera port placement. This should be performed before any endoscopic gastric insufflation is performed to reduce the risk of an access-related injury. Subsequently, one 5-mm trocar is placed to the right of mid-epigastrium and one 12-mm trocar is placed in the left upper quadrant (Figure 7). This 12-mm trocar permits easy passage of needles for the placement of gastropexy stitches. Alternatively, a 5-mm trocar can be used to pass ski needles or assist a suture passer-only method of gastropexy described below in *Endoscopic-Assisted Gastropexy*. Gentle atraumatic clamping of the distal stomach will assist with maintaining gastric insufflation. If no upper endoscopy is available or feasible (e.g., complete obstruction) the procedure can proceed with trans-abdominal-only approach. However, confirmation of proper intraluminal placement should be performed with a contrast radiographic study via the feeding tube following case completion.

After performing any necessary adhesiolysis, the stomach is mobilized enough to provide wide access to the anterior gastric wall. Using gentle atraumatic grasping, the anterior gastric wall is retracted anteriorly towards the abdominal wall in the epigastrium to test for sufficient reach to the abdominal wall. The abdomen may require partial release of CO_2 insufflation along with setting a lower insufflation pressure to allow retraction without tearing the stomach. Endoscopic insufflation of the stomach aids in identifying proper tube location by pushing the gastric wall anteriorly. If no endoscope is used, the guidewire introducer needle can be used to insufflate the stomach. A site on the anterior gastric wall should be chosen for tube placement. The central gastric body is an ideal location, however, the patient's anatomy may necessitate a different location for tube placement. A high-riding stomach may require a more inferior and distal tube placement. If the tube is placed distally in the stomach be sure tubes with balloons do not obstruct the pyloric channel. The skin is marked with a skin marker to identify the proposed site of gastrostomy placement.

Laparoscopic gastropexy provides a useful way to "tripod," or suspend, the stomach in order allow streamlined tube placement as well as subsequently fixate the stomach to the abdominal wall. Three or four separate gastropexy sutures are placed laparoscopically using size 2-0 slowly-resorbable sutures, with good seromuscular tissue purchase (Figure 8). After each suture is placed, a stab incision is made in the skin, and a laparoscopic suture passer is used for trans-fascial retrieval of the suture. A surgical clamp is used to secure both suture tails externally. To maximize visualization of the gastric wall it is helpful to place one suture superiorly around 12 o'clock and two separate sutures inferiorly at approximately 4 and 8 o'clock. The sutures are typically suspended just enough to permit visualization of the space between the anterior abdominal wall and the anterior gastric wall and are not tied until after complete placement of the g-tube (Figure 8). The sutures can be loosened somewhat in order to manipulate the stomach into position, providing a "tripod" effect thus allowing direct visualization of the gastric wall during tube placement. Because trans-fascial sutures can be painful, it is advisable to inject local anesthetic into the fascia and peritoneum prior to pulling the stomach up all the way with the sutures. Alternatively, pre-packaged T-fasteners can be used for this step under direct endoscopic visualization. Some surgeons prefer to place the T-fasteners following completion of tube insertion.

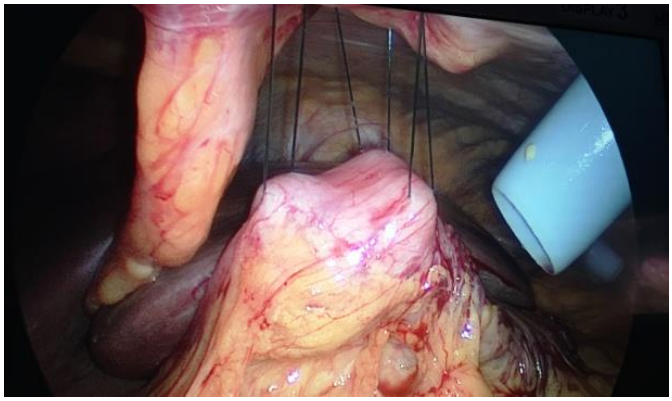

Figure 8. Laparoscopic view of three transfascial gastropexy sutures adjacent to the falciform ligament and a 12 mm laparoscopic trocar.

Endoscopic-Assisted Gastropexy

If gastrointestinal T-anchors or laparoscopic suturing methods are not available or not desired, gastropexy can be performed with endoscopic assistance. There are two primary methods by which this technique can be performed.

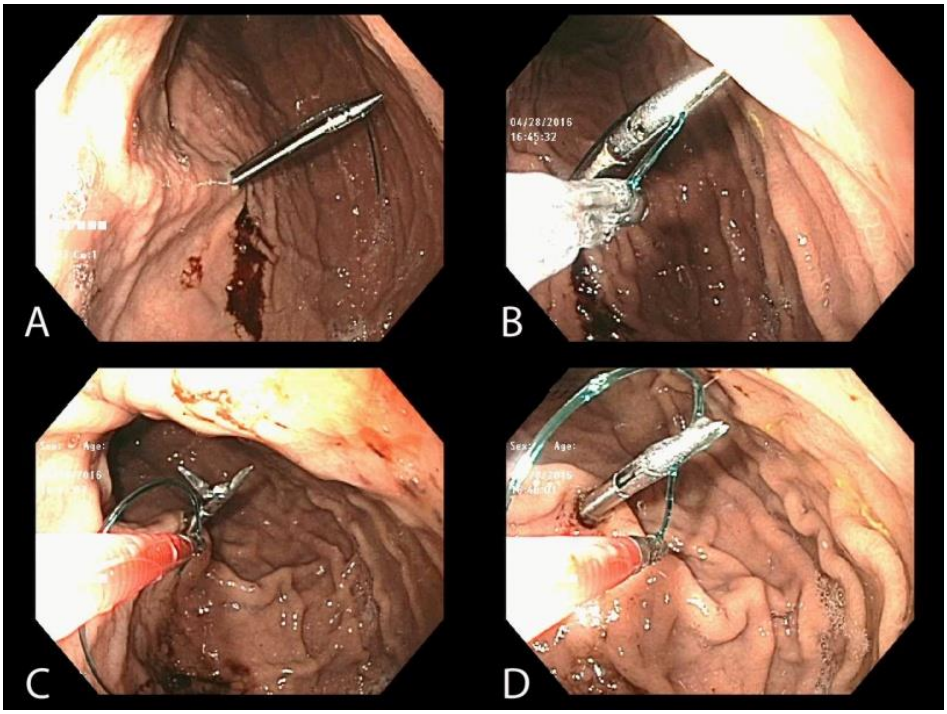

Figure 9. Laparoscopic suture passer method of gastropexy. A) Suture passer and suture are delivered through the abdominal and gastric wall. B) The suture is grasped with an endoscopic grasping forceps and the empty suture passer is withdrawn. C) The empty suture passer is delivered at a new location. D) The endoscopic forceps returns the suture to the suture passer for removal, completing the gastropexy stitch.

After making a small stab incision with a #11 blade, a laparoscopic suture passer is delivered through the abdominal and gastric walls pulling a suture with it. The suture is secured within in the gastric lumen with an endoscopic snare or grasping forceps passed through the gastroscope. The empty suture passer is withdrawn and delivered at a new fascial/gastric location but through the same skin incision. The endoscope is used to pass the tail of the suture to the empty passer and the suture is withdrawn, completing the gastropexy (Figure 9). This is repeated until 2-4 gastropexy sutures have been placed around the planned location for the gastrostomy.

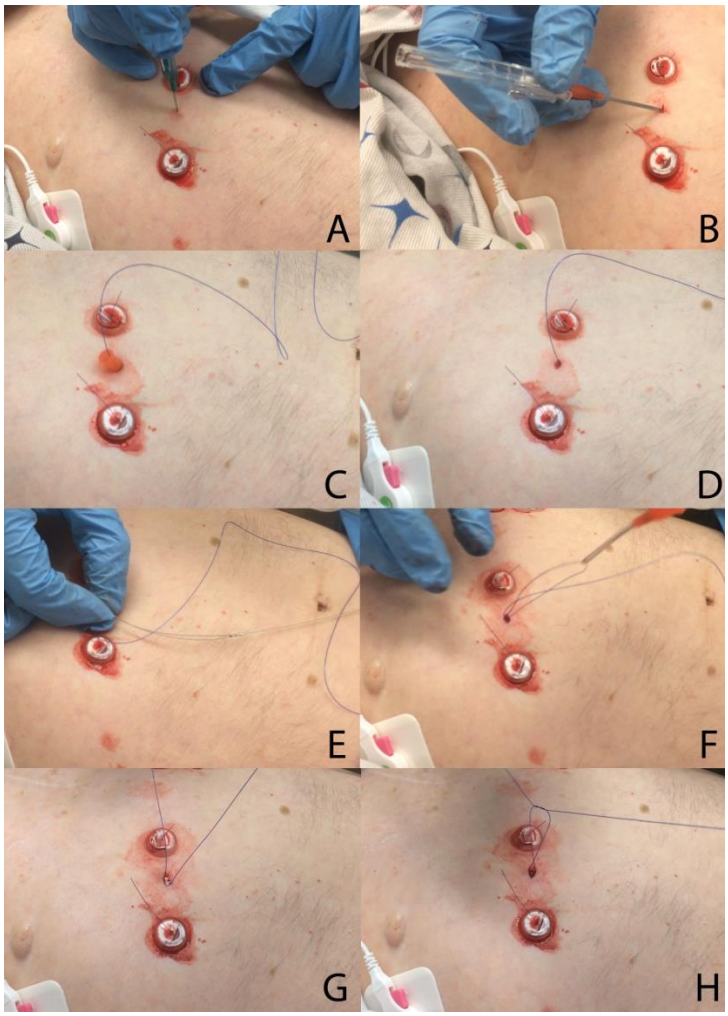

Figure 10. Angiocatheter method of transfascial gastropexy. In this case, a permanent suture is being placed in between two temporary gastrointestinal T-anchors A) A skin nick is made with a #11 blade. B) An 18 gauge angiocatheter is passed transfascial and transgastric under endoscopic visualization. C) Suture is passed through the catheter after the needle is removed. D) The catheter is removed as the suture is held by an endoscopic accessory passed through the gastroscope working channel. E) The angiocatheter is reintroduced and the needle removed. Through the angiocatheter, an unsheathed endoscopic snare is passed into the gastric lumen. The endoscope passes the suture through the loop of the snare. F) The snare is withdrawn, pulling the intragastric tail of the suture back to the skin surface. G) The two tales are untangled. H) Knots are tied to complete the gastropexy.

As an alternative, an angiocatheter can be used to deliver and retrieve the suture for gastropexy (Figure 10). After a skin nick has been made in the desired location with a #11 blade, an 18-gauge angiocatheter is passed through the abdominal and gastric walls under endoscopic visualization. The desired suture is passed through the catheter and is grasped with an endoscopic accessory (e.g., snare or biopsy forceps) within the gastric lumen. The catheter is removed over the suture, reloaded with the needle and passed through the abdominal and gastric wall a second time. The loop end of an unsheathed polypectomy snare (or a simple suture loop) is passed through the catheter. The endoscope accessory is then used to deliver the intragastric end of the suture through the snare loop. The snare is withdrawn, capturing the suture and pulling it back to the skin surface. This is repeated until 2-4 gastropexy sutures have been placed around the planned location for the gastrostomy. Knots are tied, completing the gastropexy.

Tube Placement

Guidewire Placement

With retraction of the anterior gastric wall, the large bore (e.g., 18G) introducer needle is inserted full thickness into the gastric lumen under endoscopic visualization. The flexible J-tip guidewire is inserted into the introducer needle (Figure 6B). Any resistance should prompt repositioning and replacement. Take great care to observe for gastric wall perforation, as even flexible tip wires can perforate or dissect through the gastric wall.

If no endoscope is available to verify intraluminal placement (laparoscopic or radiology only approach), the stomach should be insufflated with either air boluses or by attaching the needle to the laparoscopic CO_2 tubing for insufflation (Figure 11). The stomach should rapidly enlarge; any resistance to flow should prompt needle replacement as it likely within the gastric wall (submucosal) or has traversed the posterior gastric wall. Gentle atraumatic clamping of the distal stomach will assist with maintaining gastric insufflation. Once insufflation has occurred, the guidewire can be advanced and the needle removed (Figure 12).

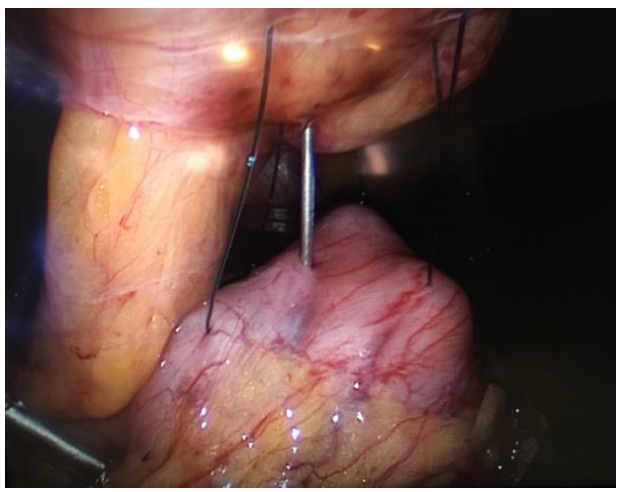

Figure 11. Laparoscopic view of introducer needle entering the gastric body. The stomach is subsequently insufflated via this needle, confirming intraluminal position.

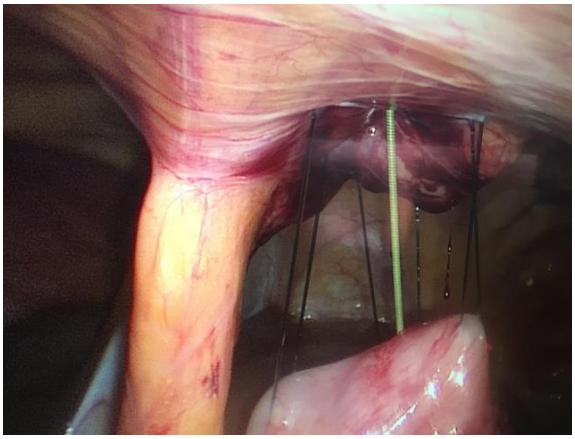

Figure 12. Laparoscopic view of J-tipped guidewire entering the gastric body.

Dilator and Sheath Placement

Introducer kits come with either separate serial dilators or all-in-one systems with sequential dilators that telescope over themselves. These are used to sequentially dilate the tract to the size of the peel-away sheath (Figure 6C). After insertion of the sheath the other dilators and wire are removed for tube placement (Figure 6D and Figure 13). Because of their rigidity and length, great care must be taken to avoid gastric wall injury or perforation with the dilators. Carefully observe the entire dilator and surrounding area during each passing of the dilator & sheath. While some resistance will be met when traversing the abdominal and gastric walls, any further resistance or difficulty with insertion should prompt retraction of the dilator. If no endoscope is being used (laparoscopic or radiology only method), measuring the abdominal wall thickness with either the needle, wire, or first dilator can help with judging the approximate length that resistance through the wall should be encountered.

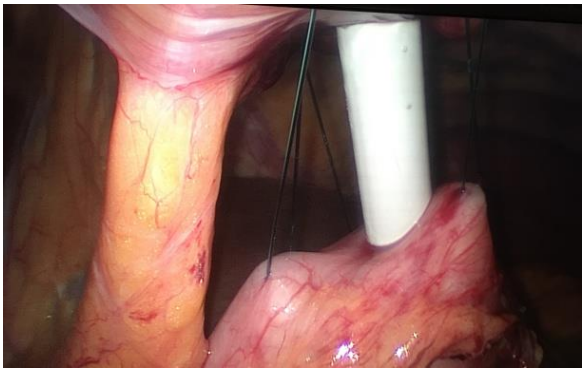

Figure 13. Laparoscopic view of the peel-away sheath entering the gastric body.

Tube Insertion

Tube choice is based on surgeon and patient preference. With adequate lubrication on the distal end of the tube, including any inner flange or balloon, the tube is inserted thought the sheath (Figure 6E). The use of a PEG-style tube, with internal plastic bumper, may require “taco” folding of the tip/bumper during insertion. The peel-away sheath is carefully broken

and slowly torn while the tube is inserted into the stomach (Figure 14). Care is taken to not inadvertently pull the tube out during final sheath removal. If using a balloon-type tube fill the balloon to the manufacturer's recommended volume with sterile water, as saline can crystallize over time. The balloon should be inflated as soon as the entire balloon is clear of the sheath tip to help prevent inadvertent tube pull during sheath removal (Figure 6F).

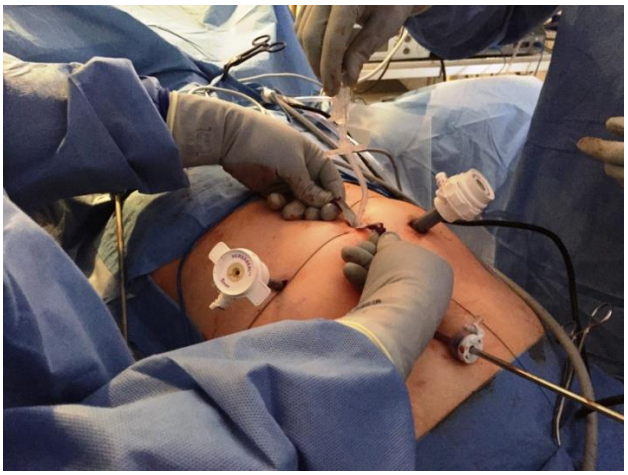

Figure 14. Peel-away sheath being removed from around a gastrostomy tube during a laparoscopic assisted introducer method PEG.

Gastropexy Completion

At this time the previously-placed gastropexy sutures can be tied down to the abdominal wall. Care should be taken to not apply excessive tension when tying as this can lead to tearing, ischemia or necrosis of the gastric wall.

Post-Procedure Care

Document the volume of fluid instilled into the balloon for later reference. The tube should be flushed with water to assess patency and ensure no kinking or tube malfunction. If endoscopy was not used during placement, a water-soluble contrast study can be obtained on the table with fluoroscopy, if available, or post-procedure in a radiology unit.

The tube should be able to spin freely without catching tissue internally or externally. Excess tension on the external bumper can lead to superficial pressure necrosis. Allow a small amount (0.5-1 cm) of excess tubing between skin and external bumper. To test this, gently bend tube near the skin level. Document the depth of the G-tube at level of skin, not at level of external bumper. Any post-procedural adjustments to the tube or external bumper should be documented for later reference. In general, it is not recommended to suture the external bumper to the skin as this can lead to superficial pressure necrosis as well as pain. However, certain circumstances may warrant suturing, such as if the patient is high risk for early tube withdrawal. Other options to reduce accidental tube dislodgement include taping the tube to the skin, loosely covering the abdomen with a binder, patient distraction, or restraints (if other options have been exhausted).

CONCLUSION

The introducer technique has emerged as an important minimally invasive gastrostomy technique. While endoscopic guidance is ideal in this procedure, it can be performed without an endoscope, thus allowing enteral access when upper endoscopy is either not feasible or available. Because the introducer technique relies on multiple passes through the gastric wall including serial dilation posteriorly into the stomach prior to sheath placement this method can be technically more challenging than other G-tube techniques. If performed in a safe and controlled manner, however, it is a highly useful technique in the armamentarium of minimally invasive gastrostomy procedures.

EDITOR'S COMMENT

This chapter very succinctly describes the introducer method of gastrostomy insertion, which can be performed under fluoroscopic, ultrasonographic, computed tomographic, laparoscopic or pure endoscopic guidance. This versatility has made the method a favorite among radiologists. As noted by Dr. Orenstein, the method has clear advantages when performed clinically for patients with cancers of the head and neck or esophagus (regardless of the degree of luminal obstruction). Familiarity with the technique will also permit surgeons to easily access the stomach and small bowel laparoscopically. (EMP)

REFERENCES

[1] Gauderer MW, Ponsky JR, Izant RJ. Gastrostomy without laparotomy: a percutaneous endoscopic technique. *J Pediatr Surg*. 1980;15(6):872-5.

[2] Hashiba K. Technic for opening a gastrostomy under endoscopic control and manipulation. *Rev Paul Med*. 1980;95(1-2):37-8.

[3] Russell TR, Brotman M, Norris F. Percutaneous gastrostomy. A new simplified and cost-effective technique. *Am J Surg*. 1984;148(1):132-7.

[4] Ho CS. Percutaneous gastrostomy for jejunal feeding. *Radiology*. 1983;149(2):595-6.

[5] Tao HH, Gillies RR. Percutaneous feeding gastrostomy. *Am J Roentgenol* 1983;141(4):793-4.

[6] Wills JS, Oglesby JT. Percutaneous gastrostomy. *Radiology*. 1983;149(2):449-53.

[7] Campoli PM, de Paula AA, Alves LG, Turchi MD. Effect of the introducer technique compared with the pull technique on the peristomal infection rate in PEG: a meta-analysis. *Gastrointest Endosc*. 2012;75(5):988-96.

[8] Maetani I, Tada T, Ukita T, et al. PEG with introducer or pull method: a prospective randomized comparison. *Gastrointest Endosc* 200; 57(7):837-41.

[9] Horiuchi A, Nakayama Y, Tanaka N, et al. Prospective randomized trial comparing the direct method using a 24 Fr bumper-button-type device with the pull method for percutaneous endoscopic gastrostomy. *Endoscopy*. 2008;40(9):722-6.

[10] Shigoka H, Maetani I, Tominaga K, et al. Comparison of modified introducer method with pull method for percutaneous endoscopic gastrostomy: prospective randomized study. *Dig Endosc*. 2012.24(6):426-31.

[11] Adelson RT, Ducic Y. Metastatic head and neck carcinoma to a percutaneous endoscopic gastrostomy site. *Head Neck*. 2005;27(4):339-43.

[12] Cappell MS. Risk factors and risk reduction of malignant seeding of the percutaneous endoscopic gastrostomy track from pharyngoesophageal malignancy: a review of all 44 known reported cases. *Am J Gastroenterol*. 2007;102(6):1307-11.

[13] Huang AT, Georgolious A, Espino S, et al. Percutaneous endoscopic gastrostomy site metastasis from head and neck squamous cell carcinoma: case series and literature review. *J Otolaryngol Head Neck Surg*. 2013;42:20.

[14] Ellrichmann M, Sergeev P, Bethge J, et al. Prospective evaluation of malignant cell seeding after percutaneous endoscopic gastrostomy in patients with oropharyngeal/ esophageal cancers. *Endoscopy*. 2013;45(7):526-31.

[15] Foster JM, Filocamo P, Nava H, et al. The introducer technique is the optimal method for placing percutaneous endoscopic gastrostomy tubes in head and neck cancer patients. *Surg Endosc*. 2007;21(6):897-901.

In: Encyclopedia of Surgery (22 Volume Set)
Editors: Andreas Lehrer and Kristin Mueller
ISBN: 978-1-53618-329-0
© 2020 Nova Science Publishers, Inc.

Chapter 131

DIRECT PERCUTANEOUS ENDOSCOPIC JEJUNOSTOMY

Mena Boules, MD, Andrew Strong, MD and Matthew Kroh*, MD
Cleveland Clinic, Cleveland, OH, US

INTRODUCTION

Establishing durable enteral access for medication administration and delivery of nutrition is a common indication for upper therapeutic endoscopy. Since 1980, when it was first reported, the percutaneous endoscopic gastrostomy (PEG) tube has been a mainstay of enteral access [1-3]. In most clinical settings the PEG has replaced open gastrostomy tubes as the preferred method for enteral access. However, the PEG is not a panacea for enteral access. In certain patient populations, post-pyloric feeding has been demonstrated to be more appropriate, with corresponding better clinical outcomes [4, 5]. Furthermore, directed gastric feeding may be inadvisable, or contraindicated in patients with gastric outlet obstruction, post-vagotomy syndrome, gastroparesis, or pancreatitis. In these clinical scenarios, establishment of enteral access in the jejunum is preferable [3, 6].

In the short term, nasojejunal feeding can be established with or without endoscopic assistance. However, over longer periods of time and in the outpatient setting, trans-abdominal enteral access is preferred. Traditionally, open jejunostomy tube was surgically placed, later adapted as a laparoscopic technique; but both of these require general anesthesia. The first endoscopic technique for durable small bowel enteral access across the abdominal wall, was by means of introducing a small bore (8-10 Fr) jejunal extension tube (PEG-J) through a previously existing gastrostomy tube [7]. Successful in certain circumstances, PEG-Js may result in more frequent clogging and proximal migration of the jejunal extension retrograde into the stomach. Both scenarios result in the need for repeat endoscopy for revision or replacement [8, 9].

Direct percutaneous endoscopic jejunostomy tube (DPEJ) was first published by Shike et al. in 1987, as an adaptation of the pull PEG procedure, in 9 patients with prior partial- or

* Corresponding Author's Email: krohm@ccf.org.

total- gastrectomies [10]. In these patients, the surgically absent or surgically reduced gastric length, allowed access to the jejunum through an esophago-jejunostomy or gastro-jejunostomy with a standard upper endoscope. Since this initial description, applications of the technique have expanded, including placement in native and post-surgical settings (Figure 1 and Figure 2, respectively) [11, 12]. DPEJ placement is typically more technically challenging to perform, but when compared to the PEG-J, DPEJ tubes are less apt to kink or migrate back into the stomach [4, 13-16]. There is also the ability to place larger bore tubes, with decreased propensity to clog. [6] Due to this, rates of endoscopic re-intervention after successful initial placement of DPEJ tubes are less than PEG-J [17].

PATIENT SELECTION AND INDICATIONS

Patients should be considered for DPEJ if they meet two initial clinical criteria. First, that they are unable to maintain oral nutrition, but have a functional intestine suitable for enteral feeding. Second, a gastrostomy tube must be inadvisable, typically based on surgically altered anatomy, or functional gastric impairment. Generally accepted indications are patients with a need for enteral access with:

1. Documented gastroparesis and nutritional compromise
2. Prior bariatric operations with inadequate nutritional intake, and/or anastomotic complications
3. Prior total or subtotal gastrectomy where PEG is technically difficult or impossible
4. Esophageal or gastric malignancies, either for nutritional support during neoadjuvant therapy, or for palliation
5. High aspiration risk or severe GERD
6. Chronic pancreatitis
7. Need for administration of certain medications into the jejunum, such as L-dopa in the treatment of Parkinson’s disease

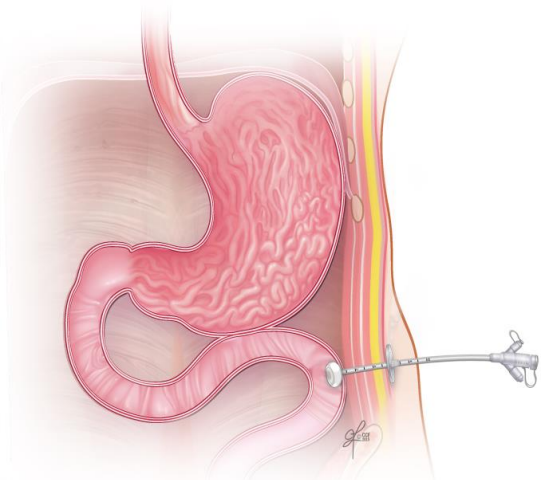

Figure 1. Schematic of DPEJ tube in a patient with native anatomy.

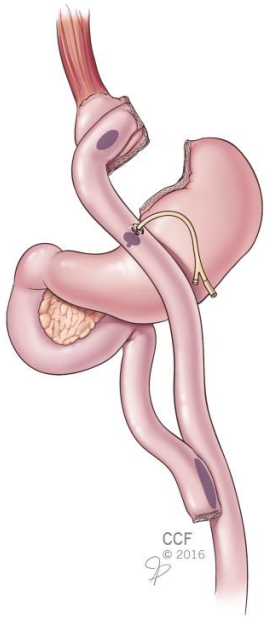

Figure 2. DPEJ location following Roux-en-Y gastric bypass.

Contraindications to DPEJ include inability for the patient or a proxy to provide consent, large volume ascites, uncorrected coagulopathy, severe malnutrition where they are unlikely to heal, intestinal perforation or inability to undergo procedural sedation or general anesthesia. Patients with only short-term need for enteral feeds may be better served with naso-jejunal feeding. In our practice, the need for naso-jejunal feeding for greater than several weeks prompts consideration of DPEJ or laparoscopic jejunostomy. Moreover, in patients with a life expectancy of less than 30 days, this procedure may put the patient at risk for undue morbidity, and are better served with non-invasive or palliative measures.

TECHNIQUE

The initial report of successful DPEJ placement by Shike et al. was a modification of the pull technique for the PEG [10]. Since this description, technical modifications and alternatives have been published, including image-assisted techniques. We prefer to use a standard pediatric colonoscope or front-viewing diagnostic gastroscope, depending on the length needed to reach an appropriate segment of jejunum. Rumalla et al. detailed the technique well [18]. A number of commercial kits are available specifically for DPEJ; however, smaller diameter PEG tube kits (14-20 Fr) can typically be adapted as well.

DPEJ may be performed in an endoscopy suite, operative suite, or at the bedside with appropriate monitoring, as in the Intensive Care Unit. The patient is positioned supine on the procedure table. Conscious sedation may used, and is typically accomplished using an opioid analgesic in combination with a benzodiazepine. General anesthesia may also be utilized, depending on setting, and facility capabilities.

Endoscope selection is based upon the patient's anatomy. If native anatomy exists, the use of a pediatric colonoscope provides sufficient length to reach a loop of jejunum distal to the ligament of Treitz. A standard upper endoscope may be used in patients with prior surgical resections and esophago-enteric or gastro-enteric anastomoses, wherein the jejunum is positioned more proximally [3, 19].

Advancement of the endoscope is continued until reaching the most proximal loop of jejunum that can be easily opposed to the abdominal wall. A discrete area of trans-illumination is identified on the abdominal wall. This candidate site is secondarily confirmed by finger indentation on the abdominal wall to create intra-jejunal localization by application of external pressure. The site is prepped and a finder needle is advanced while aspirating [20-22]. This safe tract technique is designed to identify the needle in the jejunal lumen simultaneously with aspiration of air in the finder needle. This helps confirm that no other air filled organ, e.g., colon, or adjacent small bowel, are inadvertently cannulated. After the finder needle localizes the appropriate location, a skin incision is made, and the needle with hollow cannula is inserted along the same trajectory. There are reports claiming that usage of a 21G needle is safer, due to a small potential iatrogenic puncture wound to other intra-abdominal structures, including interposed or adjacent loops of bowel [21, 22].

Upon successful endoscopic visualization of the cannula in the jejunum, an endoscopic snare grasps the cannula and stabilizes the jejunal loop to the anterior abdominal wall. Once this is successfully completed, the procedure is carried out in a similar fashion to a pull-type PEG, with advancement of a guidewire and tube placement (see Chapter 7 for additional technical description) [18]. Repeat upper endoscopy immediately after placement confirms correct position of the tube and evaluates the jejunotomy site for bleeding. Additionally, the position of the external bumper, and appropriate tension can be adjusted based on the endoscopic view. In most cases enteral feeding can begin within 24 hours.

There are published alternative methods for DPEJ placement. Some groups prefer a hybrid approach, utilizing endoscopy with the assistance of fluoroscopic guidance [23, 24]. Endoscopic insufflation provides air contrast on fluoroscopy and can simultaneously confirm the location of the endoscope, the bowel lumen, and guide needle trajectory. This advantage, however, requires additional personnel, training, and proper shielding [25]. There are additional reports utilizing double balloon endoscopy for DPEJ placement [26, 27]. This advanced endoscopic technique is likely best reserved as a rescue technique, when an orally passed colonoscope fails to reach a suitable jejunal loop for DPEJ placement.

SPECIAL CONSIDERATIONS IN PATIENTS WITH PRIOR FOREGUT SURGERY

In our practice, a large proportion of our referrals have had prior foregut surgery, which merits special consideration in terms of both specific nutritional complications and anatomy prior to placement of a jejunostomy tube. Patients with altered foregut anatomy may have a spectrum of macro- and micronutrient deficiencies, which can develop both early and late. Specific nutritional analysis is important, as deficiencies in calcium, vitamins D and B12, iron, and overall protein-calorie malnourishment are not uncommon. Post-foregut operative complications, such as marginal ulceration, stricture, and leak, all can also adversely affect a

patient's ability to tolerate oral intake. DPEJ can provide nutritional support, and bypass the affected anastomosis to better allow healing and promote enteral nutrition [14, 28, 29].

In general, patients who have previously undergone near-total or total- gastrectomy, Ivor-Lewis esophagectomy, pancreatoduodenectomy, Roux-en-Y reconstruction (for gastric bypass or other reason) or Billroth II, have a straighter and shorter course to reach the jejunum. In these circumstances, the site for DPEJ can typically be reached with a standard upper endoscope. Additionally, the reconstruction used, such as a Roux- or loop-jejunal limb, may be placed in an ante- or retro-colic position. Ante-colic position of the jejunal limb makes DPEJ technically easier and increases the overall successful placement rate.

Studies have shown improved DPEJ placement rates in patients with previous surgery when compared to those with native anatomy [19]. However, the endoscopist must understand the patients' current anatomy and the possible presence of both efferent and afferent jejunal limbs. In the case of Billroth II anatomy, the ampulla can serve as indicator of the incorrect, afferent limb. A consideration in post-Roux en-Y surgical anatomy is the possible presence of a "candy-cane" or "Bakers pouch" which exists when the anastomosis was formed in an end to side fashion. If the blind end of this anastomosis is particularly long, the endoscopist may errantly place a DPEJ in this limb. In post-surgical patients, consideration must be also given to the presence of post-operative adhesions, which may be an additional impediment or beneficial.

In some circumstances, adhesions may tether jejunal loops posteriorly, and make trans-illumination difficult, or fix intervening intra-abdominal structures between a target loop of jejunum and the abdominal wall. In other circumstances, adhesions may fix a desirable jejunal loop to the anterior abdominal wall. For this reason, patients that previously had a surgical jejunostomy tube can be excellent candidates for DPEJ, utilizing the same site, and the secured jejunal limb likely still adherent to the abdominal wall.

OUTCOMES

Reported success rates of DPEJ range from 68% to 100% [4, 11, 13-16]. One hundred percent success was reported by studies conducted by Barrera et al. and Shetzline and colleagues [4, 23]. The largest published study to date was conducted by Maple et al. which included 307 consecutive DPEJ attempts in 286 patients, and reports success in 68% of patients [11]. Several factors are speculated to contribute to this variable success rate, including technique variation amongst endoscopists, technique modification over time, and patient selection. Examination of patient selection criteria in this large study reveals a heterogeneous group, including patients with cancer (n = 80, 28%), gastroparesis (n = 61, 21%), history of previous upper GI surgery (n = 55, 19%), high risk of aspiration (n = 37, 13%), and other causes (n = 53, 19%) [11]. The highest success rate was achieved in patients with previous history of upper gastrointestinal tract surgery. This is similar to other reported studies [3]. The higher completion rate is accounted for by the gastro-enteric anastomoses, which functionally moves the small intestine more proximally. The more accessible position of the jejunum reduces difficulty in intubating the small intestine and may also provide additional fixation. Poor trans-illumination or difficulty intubating the jejunum accounts for most failures [3, 23].

COMPLICATIONS

Unsuccessful placement is the most common complication of DPEJ. Most often, unsuccessful placement is the result of inadequate or absent trans-illumination or failure to identify an appropriate safe tract for access. While interposed intra-abdominal structures or adhesive disease preventing apposition to the anterior abdominal wall contribute to failure rates; increased BMI also correlates with decreased likelihood of successful DPEJ placement [30]. One study queried pre-procedural abdominal computed tomography scans for factors predictive of DPEJ placement success and failure [31]. Both the skin to jejunum distance, and more so the abdominal wall thickness, predicted failure of DPEJ placement [31]. While cross sectional imaging would not be indicated for the sole purpose of predicting ease of DPEJ placement, in general, abdominal wall thickness should be considered prior to attempting percutaneous endoscopic access.

Complications in the immediate peri-procedural period include anesthesia-related complications such as aspiration, hypotension, and hypoxemia. Rarely bleeding from the insertion site can occur, and this is usually self-limited. The most feared, and most common major complication is tube dislodgement prior to maturation of the tract. The resultant peritonitis often requires operative intervention to close the enterotomy site and to control peritoneal contamination. The intraluminal location of the balloon or bumper of the tube, in a relatively small caliber jejunal lumen, lends to a greater likelihood of intraluminal mechanical intestinal obstruction. Overall, studies report complications ranging between 0% to 15% [3, 11].

Minor complications at the insertion site, including superficial infection, insertion site irritation or maceration, and peri-tube leakage may occur at early and late time periods. Rates for these complications are similar to that of PEG, and make up the majority of published complication rates [11]. Typically these can be solved with improvements to the local site and tube care. Pain at the insertion site can be a frustrating problem for both the patient and proceduralist, as both the etiology and a successful treatment regimen can be elusive. In these circumstances, physical exam or imaging should be used to identify any signs of localized abscess or tube dislodgement. Without findings of abnormality, intolerable pain at the insertion site may best solved by removal of the tube, assuming there is a mature tract and another method for feeding or medication administration has been established.

Long-term complications are similar to other enteral access devices. Traction injuries on tube removal, although rare, can result in bowel perforation [32, 33]. Mechanical bowel obstruction and volvulus may be more common and unique to DPEJ tubes, when compared to surgically placed jejunostomy tubes. As DPEJ tubes lack secondary fixation points, the tube itself may act as the fulcrum for jejunal volvulus, which is minimized in surgically placed tubes by suture fixation at several sites on the abdominal wall [11]. Similar to other enteral access devices, DPEJ tubes are subject to the risk of fracture and degradation, estimated around 3% for PEG tubes, and similar for DPEJ [34].

Maple et al. also confirms an adverse events rate of 22.5% post-DPEJ placement. In a large (n = 286) series of patients, DPEJ resulted in a 10% overall complication rate (bowel perforation, bleeding, volvulus, chronic enterocutaneous fistula, and aspiration) [11].

Despite these drawbacks, DPEJ placement offers advantages over PEG-J and surgically placed jejunostomy tubes. DPEJ circumvents the proximal migration inherent to the jejunal

extension of PEG-J. Additionally, tube dysfunction is also reduced given the usage of a larger caliber tubes (16-20 French). Overall, DPEJ shows greater durability and reduction for re-intervention when compared to PEG-J [13, 17, 35]. When compared to surgically placed jejunostomy tubes, DPEJ avoids the need for general anesthesia, and morbidity of an open or laparoscopic surgical incision.

CONCLUSION

DPEJ is an effective technique with relatively low complications to provide durable enteral access directly into the small bowel for nutritional support and medication administration. This technique is particularly useful in patients with surgically altered foregut anatomy.

EDITOR'S COMMENT

Direct percutaneous endoscopic jejunosotmy, particularly in the patient with native foregut anatomy, is a technically challenging procedure, requiring prior mastery of pull type PEG technique but also an understanding and acceptance by the endoscopist that it will have a higher primary failure rate. Knowing when it is not a technically feasible procedure is as important as being able to complete the task. Despite these limitations, it offers clear advantages over surgically placed jejunostomy tubes and PEG tubes with jejunal extension and should be considered in patients requiring durable post-pyloric feeding (EMP).

REFERENCES

[1] Gauderer MW, Ponsky JL, Izant RJ. Gastrostomy without laparotomy: a percutaneous endoscopic technique. *J Pediatr Surg.* 1980;15:872-875.

[2] Ponsky JL, Gauderer MW. Percutaneous endoscopic gastrostomy: a nonoperative technique for feeding gastrostomy. *Gastrointest Endosc.* 1981;27:9-11.

[3] Zhu Y, Shi L, Tang H, Tao G. Current considerations of direct percutaneous endoscopic jejunostomy. *Can J Gastroenterol.* 2012;26:92-96.

[4] Barrera R, Schattner M, Nygard S, Ahdoot M, Ahdoot A, Adeyeye S, Groeger J, Shike M. Outcome of direct percutaneous endoscopic jejunostomy tube placement for nutritional support in critically ill, mechanically ventilated patients. *J Crit Care.* 2011; 16:178-181.

[5] Panagiotakis PH, DiSario JA, Hilden K, Ogara M, Fang JC. DPEJ tube placement prevents aspiration pneumonia in high-risk patients. *Nutr Clin Pract.* 2008;23:172-175.

[6] Schirmer BD. Chapter 29: Laparoscopic Placement of Jejunostomy Tube. *SAGES Manual Volume 1: Basic laparoscopy and Endoscopy*. Springer, 2012.

[7] Ponsky JL, Aszodi A. Percutaneous endoscopic jejunostomy. *Am J Gastroenterol.* 1984.79:113-116.

[8] DiSario JA, Foutch PG, Sanowski RA. Poor results with percutaneous endoscopic jejunostomy. *Gastrointest Endosc.* 1990;36:257-260.
[9] Wolfsen HC, Kozarek RA, Ball TJ, Patterson DJ, Botoman VA, Ryan JA. Long-term survival in patients undergoing percutaneous endoscopic gastrostomy and jejunostomy. *Am J Gastroenterol.* 1990;85:1120-1122.
[10] Shike M, Schroy P, Ritchie MA, Lightdale CJ, Morse R. Percutaneous endoscopic jejunostomy in cancer patients with previous gastric resection. *Gastrointest Endosc.* 1987;33:372-374.
[11] Maple JT, Petersen BT, Baron TH, Gostout CJ, Wong Kee Song LM, Buttar NS. Direct percutaneous endoscopic jejunostomy: outcomes in 307 consecutive attempts. *Am J Gastroenterol.* 2005;100:2681-2688.
[12] Shike M, Latkany L. Direct percutaneous endoscopic jejunostomy. *Gastrointest Endosc Clin N Am.* 1998;8:569-580.
[13] Fan AC, Baron TH, Rumalla A, Harewood GC. Comparison of direct percutaneous endoscopic jejunostomy and PEG with jejunal extension. *Gastrointest Endosc.* 2002;56: 890-894.
[14] Bueno JT, Schattner MA, Barrera R, Gerdes H, Bains M, Shike M. Endoscopic placement of direct percutaneous jejunostomy tubes in patients with complications after esophagectomy. *Gastrointest Endosc.* 2003;57:536-540.
[15] Del Piano M, Ballarè M, Carmagnola S, Orsello M, Garello E, Pagliarulo M, Sartori M, Montino F. DPEJ placement in cases of PEG insertion failure. *Dig Liver Dis.* 2008;40: 140-143.
[16] Zopf Y, Rabe C, Bruckmoser T, Maiss J, Hahn EG, Schwab D. Percutaneous endoscopic jejunostomy and jejunal extension tube through percutaneous endoscopic gastrostomy: a retrospective analysis of success, complications and outcome. *Digestion.* 2009;79:92-97.
[17] Singh A, Gelrud A. Adverse Events Associated with Percutaneous Enteral Access. *Gastrointestinal Endoscopy Clinics of North America.* 2015;25:71-82.
[18] Rumalla A, Baron TH. Results of direct percutaneous endoscopic jejunostomy, an alternative method for providing jejunal feeding. *Mayo Clin Proc.* 2000;75:807-810.
[19] Baron TH. Direct percutaneous endoscopic jejunostomy. *Am J Gastroenterol.* 2006; 101:1407-1409.
[20] Varadarajulu S, Delegge MH. Use of a 19-gauge injection needle as a guide for direct percutaneous endoscopic jejunostomy tube placement. *Gastrointest Endosc.* 2003;57: 942-945.
[21] Karhadkar AS, Rengen MR, Dubin EH, Schwartz HJ, Dutta SK. Direct percutaneous endoscopic jejunostomy tube placement using a fine needle for jejunal anchoring. *Endoscopy.* 2006;38:952.
[22] Moran GW, Fisher NC. Direct Percutaneous Endoscopic Jejunostomy: High Completion Rates with Selective Use of a Long Drainage Access Needle. *Diagn Ther Endosc.* 2009:520879.
[23] Shetzline MA, Suhocki PV, Workman MJ. Direct percutaneous endoscopic jejunostomy with small bowel enteroscopy and fluoroscopy. *Gastrointest Endosc.* 2001; 53:633-638.
[24] Velázquez-Aviña J, Beyer R, Díaz-Tobar CP, Peter S, Kyanam Kabir Baig KR, Wilcox CM, Mönkemüller K. New method of direct percutaneous endoscopic jejunostomy tube

placement using balloon-assisted enteroscopy with fluoroscopy. *Dig Endosc.* 2015;27: 317-322.

[25] Shetzline MA, Suhocki PV, Agrawal N. Direct percutaneous endoscopic jejunal feeding tube placement. *Am J Gastroenterol.* 2005;100:1627-1628; author reply 1628.

[26] Despott EJ, Gabe S, Tripoli E, Konieczko K, Fraser C. Enteral access by double-balloon enteroscopy: an alternative method of direct percutaneous endoscopic jejunostomy placement. *Dig Dis Sci*. 2011;56:494-498.

[27] Song LMWK, Baron TH, Saleem A, Bruining DH, Alexander JA, Rajan E. Double-balloon enteroscopy as a rescue technique for failed direct percutaneous endoscopic jejunostomy when using conventional push enteroscopy (with video). *Gastrointest Endosc.* 2012;76:675-679.

[28] Baigrie RJ, Devitt PG, Watkin DS. Enteral versus parenteral nutrition after oesophagogastric surgery: a prospective randomized comparison. *Aust N Z J Surg*. 1996;66:668-670.

[29] Gerndt SJ, Orringer MB. Tube jejunostomy as an adjunct to esophagectomy. *Surgery.* 1994;115:164-169.

[30] Mackenzie SH, Haslem D, Hilden K, Thomas KL, Fang JC. Success rate of direct percutaneous endoscopic jejunostomy in patients who are obese. *Gastrointest Endosc.* 2008;67:265-269.

[31] Maple JT, Petersen BT, Baron TH, Harewood GC, Johnson CD, Schmit GD. Abdominal CT as a predictor of outcome before attempted direct percutaneous endoscopic jejunostomy. *Gastrointest Endosc.* 2006;63:424-430.

[32] Zschau N, Nguyen N, Tam W, Schoeman M. Intestinal perforation: a rare complication of percutaneous endoscopic jejunostomy removal. *Endoscopy.* 2008;40 Suppl. 2:E178.

[33] Hoyer RJ, Arora AS, Baron TH. Complications after traction removal of direct percutaneous endoscopic jejunostomy: three case reports. *Gastrointest Endosc.* 2005; 62:802-805.

[34] Wolfsen HC, Kozarek RA, Ball TJ, Patterson DJ, Botoman VA. Tube dysfunction following percutaneous endoscopic gastrostomy and jejunostomy. *Gastrointest Endosc.* 1990;36:261-263.

[35] Simon T, Fink AS. Recent experience with percutaneous endoscopic gastrostomy/ jejunostomy (PEG/J) for enteral nutrition. *Surg Endosc.* 2000;14:436-438.

In: Encyclopedia of Surgery (22 Volume Set)
Editors: Andreas Lehrer and Kristin Mueller
ISBN: 978-1-53618-329-0
© 2020 Nova Science Publishers, Inc.

Chapter 132

PEG WITH JEJUNAL EXTENSION TUBE

Ryan R. Gaffney, DO and Matthew T. Moyer*, MD
Penn State Hershey Medical Center, Hershey, PA, US

INTRODUCTION

The delivery of enteral nutrition and medications to patients who have in an intact and functional gastrointestinal tract but cannot sustain their caloric needs orally is essential to both acute, critical care and long-term care of patients [1]. The literature consistently demonstrates that enteral nutrition is preferred to parenteral nutrition for preservation of gut integrity, prevention of bacterial translocation, and downregulation of inflammation [2-3]. These effects ultimately translate into better clinical outcomes for patients including decreased incidence of infections, reduced chance for organ failure, and decreased hospital length of stay [4]. The ability to place gastric feeding tubes endoscopically in a percutaneous fashion has therefore become a major advancement in the delivery of nutrition therapy.

There are several clinical situations in which PEG alone is insufficient and placement of a more distal feeding tube to provide post-pyloric nutrition is advantageous. Jejunal feeding tubes are frequently used to minimize aspiration of gastric contents when gastric outlet obstruction or motility disorders preclude gastric feeding or when such feedings have resulted in tube feed-related aspiration [5]. In patients with severe gastroparesis, for example, percutaneous endoscopic techniques may provide two essential purposes: gastrostomy tube placement for decompression and jejunostomy tube insertion for facilitating enteral feeding [6].

Randomized trials and meta-analyses have evaluated the role of post-pyloric tube feeding compared with intra-gastric feeding in critically ill patients. Although heterogeneity exists among these studies, there is a trend towards reduced incidence of aspiration pneumonia with post-pyloric feeding [7-8]. In patients with recurrent episodes of chronic pancreatitis and nutritional compromise, placement of an endoscopic jejunostomy tube has been shown to reduce yearly hospitalizations and need for opiate analgesia [9]. For patients with altered surgical anatomy and/or non-operable luminal obstruction, enteral tubes directed distally past

* Corresponding Author's Email: mmoyer@hmc.psu.edu.

the lesion can be used for hydration and medication administration while providing decompression capabilities if a simultaneous gastrostomy tube is placed [10]. Table 1 summarizes patients who may benefit from the placement of a jejunal feeding extension via PEG.

Table 1. Indications for the placement of jejunal extension via a PEG

Clinical and Endoscopic Findings That Favor PEGJ Placement
Gastric outlet obstruction
Gastroparesis
Intolerance to gastric enteral feeding (high residual volumes, aspiration)
Pancreatitis
Gastro-enteric anastomotic issue (stricture, leak, fistula, etc)
Large hiatal hernia or findings suggestive of gastro-esophageal reflux on endoscopy
Proximal enteric fistula (distal esophagus, stomach, duodenum)
Superior mesenteric artery syndrome

CURRENT DEVICES

Once a careful clinical evaluation has identified the need for a jejunal feeding tube, awareness of patient-specific and technical factors becomes essential for proper tube choice and method of placement. A variety of percutaneous options for jejunal access are currently available from several manufacturers [5]. The initial choice of tube is often dependent upon a patient's anatomy and the presence or absence of a pre-existing percutaneous gastrostomy (PEG). For patients who have already undergone PEG tube placement, conversion of the PEG into a percutaneous endoscopic gastrojejunostomy (PEGJ) can be performed endoscopically with or without the aid of fluoroscopy [11]. These PEGJ devices are manufactured as a single-piece gastrojejunostomy tube with the jejunal portion permanently molded within a gastrostomy portion to allow one ostomy to perform venting through the gastric port and feeding through the jejunal extension (Figure 1). These devices are commercially available and are familiar to most gastroenterologists and surgeons are trained in the basics of PEG tube placement [12].

The PEGJ tube has an internal retention balloon that is inflated after placement to keep the tube positioned against the gastric wall. If a PEG tube has previously been placed, and a single single-piece gastrojejunostomy tube is desirable, conversion should wait a recommended 1 to 3 weeks following initial PEG placement to allow maturation of the new ostomy tract [10]. If gastropexy fasteners (gastrointestinal T-anchors) are available, however, this conversion can generally take place sooner, at the discretion of the endoscopist. The conversion is accomplished as follows; the existing PEG is removed and the single-piece PEGJ device is carefully advanced through the gastrostomy tract into the small bowel over a

guidewire (with or without fluoroscopic guidance). Alternatively, it can be endoscopically dragged into a post-pyloric position with a snare, forceps or endoclip.

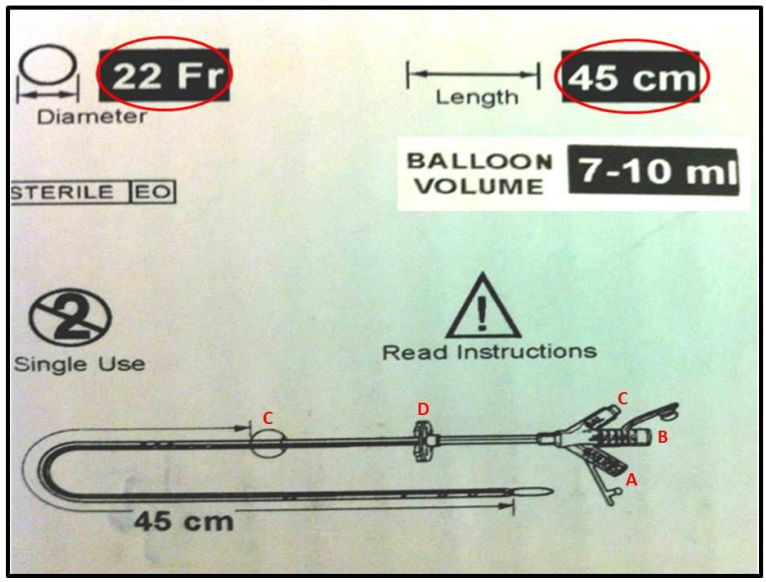

Figure 1. Components of a single-piece percutaneous endoscopic gastrojejunostomy (PEGJ) tube. A) Gastric port for venting and decompression. B) Jejunal extension for administration of enteral feeds and medications. C) Internal retention balloon and balloon port. D) External appliance bolster. The length of the jejunal arm in this particular example is 45 cm, which sufficiently provides capabilities for deep enteral access beyond the ligament of Treitz.

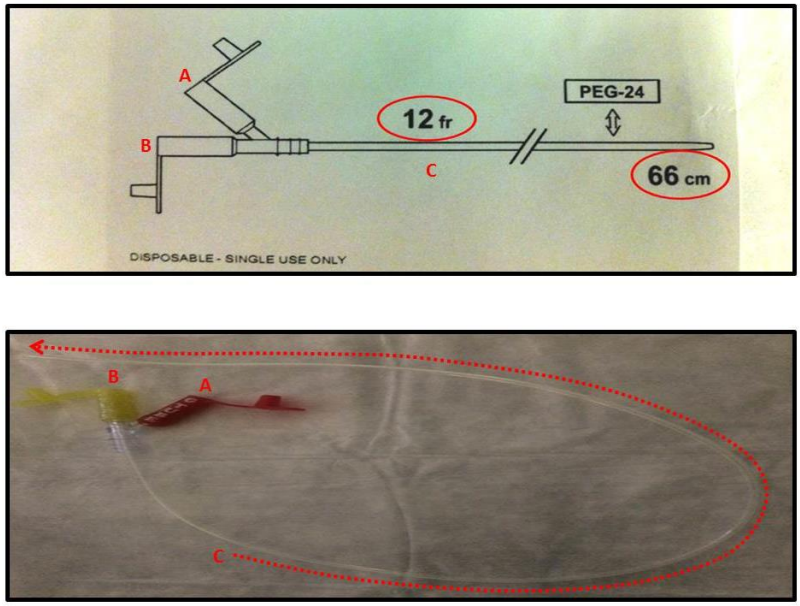

Figure 2. Components of a jejunal extension tube. A) Gastric port. B) Jejunal port. C) Jejunal extension arm. The jejunal extension can be inserted simultaneously at the time of PEG tube insertion or at a subsequent endoscopy.

A second method for jejunal access in patients who have a PEG involves placement of a jejunal extension through the PEG tube (Figure 2). These extension tubes are commercially available kits that measure 8 Fr to 12 Fr in diameter and up to 90 cm in length to facilitate deep access beyond the ligament of Treitz [5]. Successful insertion of the extension tube is most commonly done endoscopically at the time of initial PEG tube placement as there is minimal to no further manipulation of the gastrostomy tract by placing this device. A variety of endoscopic methods have been described for successful placement of jejunal extension tubes and will be elaborated below. It is important to know that the jejunal adaptor is designed to fit the type of PEG tube being used, as there are proprietary differences between manufacturers that can result in tube incompatibility. This can result in inability to complete the procedure, tube malfunction and leak.

Following successful insertion, the jejunal extension tube is then fitted with a Y-adapter that is used for tube feeding and flushing. The final tube position is usually confirmed with abdominal radiographs under fluoroscopy (Figure 3) and enteral feeding can be started immediately. While simultaneous placement of a jejunal extension tube during the same procedure as PEG insertion is convenient for patients and physicians, it has been our experience that the smaller caliber size and shorter length of jejunal extension tubes more commonly results in tube dysfunction (clogging and retrograde displacement into the stomach) as compared to the single-piece PEGJ devices (Figure 4). These complications unfortunately require re-intervention with another endoscopic procedure and can be very frustrating for patients, caregivers and clinicians.

For patients with abnormal anatomy precluding initial PEG placement into the stomach, direct percutaneous endoscopic jejunostomy (DPEJ) provides an endoscopic alternative for jejunal access (see Chapter 10) [13]. Direct PEJ tubes demonstrate greater longevity and decreased need for repeat intervention compared with PEGJ tubes but do so at a higher complication rate primarily because of difficulty identifying a safe access site for placement [14-15].

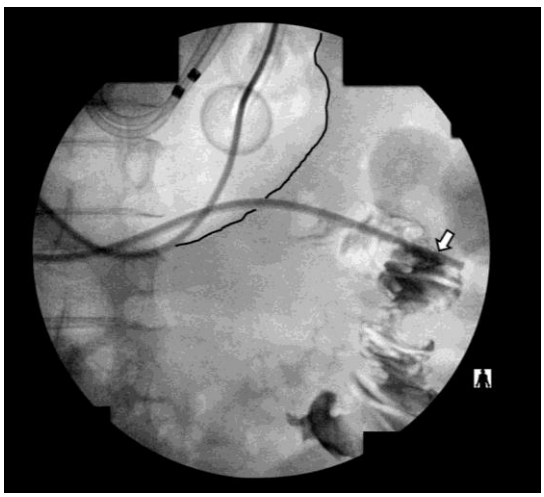

Figure 3. Spot radiograph demonstrating placement of a jejunal extension tube with injection of contrast through the jejunal limb opacifying loops of small bowel (arrowhead). The air signature of the greater curvature of the stomach is also apparent (black solid line).

Figure 4. Retrograde displacement of jejunal extension tubes into the stomach. A) Endoscopic view demonstrating gastrojejunostomy tube loop formation in the stomach body. B) Abdominal radiograph showing migration of a jejunal extension tube proximally into the stomach. Contrast injected into the jejunal limb opacifies the stomach. C) Computed tomography showing a PEGJ appliance that has coiled completely in the stomach.

TECHNICAL CONSIDERATIONS OF PEGJ

While significant progress has been made with both endoscopic insertion techniques and devices for deep jejunal access, PEGJ procedures remain technically difficult. Often they can be very trying and time consuming, and advanced training for their insertion may be variable depending on staff experience and available resources. The role of experience and interventional endoscopy training is therefore vital to consistent tube placement. Procedural success is also aided by adhering to important principles of PEG placement, with a few modifications.

Localization of the PEG in the antrum and not the body of the stomach is important to shorten the distance to the pylorus and straighten the insertion angle of the jejunal tube as it coarses from the stomach into the small intestine [16]. A site on the patient's anterior abdominal wall to the right of the midline at or above the umbilicus is usually preferable to achieve this [16]. In the event that the initial PEG was placed above the level of the antrum thereby creating a longer distance through the stomach for jejunal tube passage, we recommend insertion of the longest available jejunal extension tube through the PEG or preferably conversion of the PEG to a single-piece PEGJ. Our experience is that single-piece PEGJ devices have a larger diameter jejunal portion that affords higher reliability for keeping it post-pyloric, even if coiling occurs in the stomach.

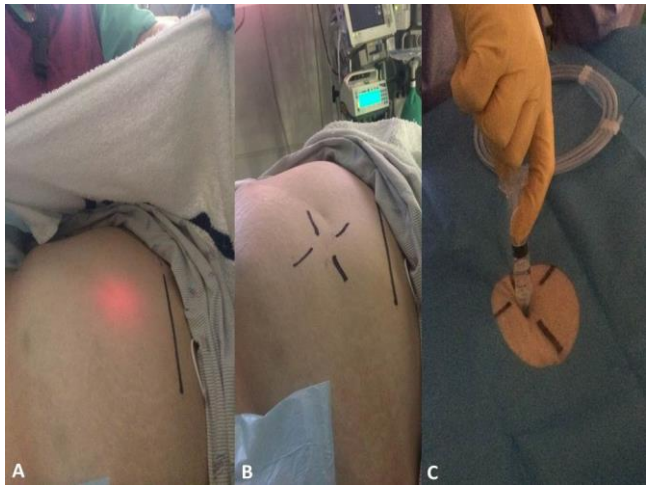

Figure 5. Initial gastrostomy tube insertion for PEGJ. A and B, Outlining the costal margins and confirming "one to one" finger palpation with transillumination prior to PEGJ tube placement will help identify the appropriate site for enteric access. C, Safe tract technique is performed to avoid inadvertent tracking through an adjacent loop of bowel.

It is helpful to outline the relationships of the costal margins and the midline of the abdomen with an indelible marker just prior to PEGJ insertion. The optimal site should be localized by confirming endoscopic evidence of "one to one" finger palpation and transillumination of the endoscope light through the anterior abdominal wall if possible (Figure 5A, B). Intervening loops of bowel can be avoided by confirming a 'safe tract' for the guide sheath through the anterior abdominal wall directly into the stomach [17]. As a 10 ml syringe filled with saline is pushed inward, steady aspiration is performed to ensure that no bubbles or blood are seen in the syringe prior to entering the stomach (Figure 5C). If air bubbles appear in the syringe before the needle is visualized in the stomach, it is likely that there has been penetration through another part of the intestine and the position of the site should be re-evaluated.

Coiling of the jejunal tube in the stomach is a potential hindrance to successful placement. To help avoid this, use of a stiff endoscope is recommended. While many texts advocate use of a pediatric colonoscope, we typically have success using shorter, standard adult upper gastroscopes with an 8.8 mm outer diameter and 2.3 mm working channel as long as intubation into the third portion of the duodenal is possible [12, 16]. A longer endoscope (such as a pediatric colonoscope) may become necessary if patients with significant gastric distension (e.g., gastroparesis or gastric outlet obstruction patients) where much of the scope length is utilized simply by traversing the distended gastric body.

For wire-guided methods, the use of stiff 0.035-inch guidewires measuring 450-480 cm in length can also help reduce the tendency for coiling of the jejunal tube as it is passed over the wire. Wire and device handling should be facilitated by copious lubrication with a mineral oil or silicone-based oil. We typically flush the working channel of the endoscope with mineral oil prior to wire advancement and also lubricate the jejunal extension tube extensively before inserting it through the PEG. Several authorities also stress the importance of using an air retention valve or plug during jejunal extension tube placement to allow passage of a wire or snare through the gastrostomy without losing air insufflation [12, 16].

While air valves are available commercially in some PEGJ kits, one can be custom-made by cutting the cap off the port of a spare enteric feeding tube. The modified cap is then directly placed into the pre-existing PEG and the wire or snare inserted through the valve created in the cap and into the stomach. By serving as a barrier to ongoing air loss from the stomach during endoscopy, the air retention valve facilitates direct visualization of the stomach thereby preventing potential frustration for the endoscopist.

THROUGH-THE-SNARE TECHNIQUE

In our experience, the through-the-snare technique is the most reliable and least frustrating method for successfully placing a 9 or 12 Fr jejunal extension tube. As mentioned previously, this technique requires a pre-existing PEG tube (a 20 Fr PEG for a 9 Fr jejunal tube and a 24 Fr PEG for a 12 Fr jejunal tube), however the PEG can be placed during the same procedure. After cutting the PEG down to approximately 10 cm from the skin (Figure 6A), an endoscopic snare is passed through the PEG into the stomach (Figure 6B) and opened (Figure 6C). The esophagus is intubated with a standard upper endoscope or pediatric colonoscope. Upon reaching the stomach, the endoscope is navigated through the open snare and then is maneuvered post-pyloric and into the small bowel. Once the endoscope has reached the small bowel, the snare can be closed and opened once to ensure that it contains the endoscope. The position of the endoscope in the small bowel can be confirmed with fluoroscopic guidance, but this is not absolutely necessary. Once the scope has reach its deepest site of penetration into the small bowel, a long guidewire (at least 450 cm in length) is passed through the working channel of the endoscope into the jejunum (Figure 6D). The location of the wire can also be confirmed fluoroscopically. Using standard wire exchange techniques, the endoscope is then slowly withdrawn from the small bowel, leaving the guidewire distally.

Once the endoscope has been withdrawn into the proximal stomach (Figure 7A) above the level of the snare, the snare is closed on the guidewire to capture it and then pulled back through the PEG to the outside of the patient (Figure 7B). The loop in the guidewire is manually separated by the endoscopist. The proximal and distal aspects of the guidewire are then identified by gently pulling on the wire to visualize the end exiting the patient via the working channel of the endoscope. Once this proximal end of the wire is confirmed, it is pulled out completely through the PEG, resulting in a single, straightened guidewire grasped by the snare and passing through the PEG into the small bowel (Figure 7C). With the endoscope still positioned in the proximal part of the stomach, a lubricated jejunal extension tube is passed in position over the wire, through the PEG, and into the small bowel (Figure 7D). During this step, care should be taken to avoid putting substantial resistance on the guidewire as this could result in its displacement. Once successful placement is achieved (Figure 8A), the tube is secured by attaching an external bumper or bolster appliance over the PEG tubing next to the skin. At this point, additional components such as a C-clamp to keep the external tube closed and a Y-adapter for tube feeding, flushing, and gastric aspiration can be attached (Figure 8B). Radiopaque contrast can be injected through the jejunal port of the Y-adapter to confirm the location of the jejunal extension tube in the small bowel, but this is not absolutely necessary.

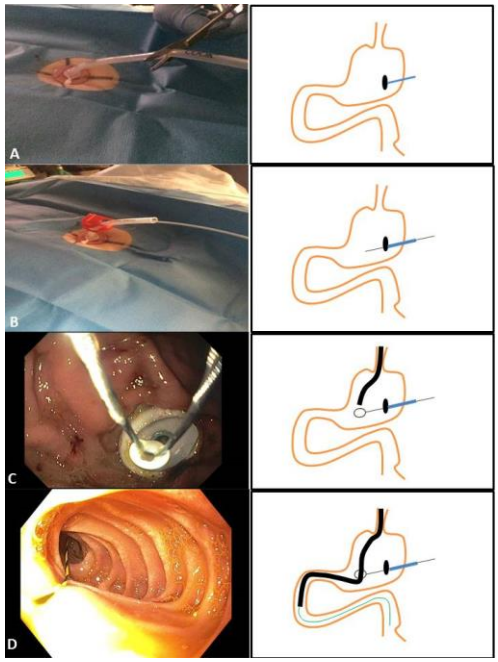

Figure 6. Through-the-snare technique for jejunal extension tube placement. A) PEG tube is cut down to approximately 10 cm from the skin surface. B) Endoscopic snare is passed through the PEG. C) Snare is opened to capture the endoscope which subsequently advances into the small bowel. D) A guidewire is passed through the working channel and extended beyond the scope (ideally beyond the ligament of Treitz).

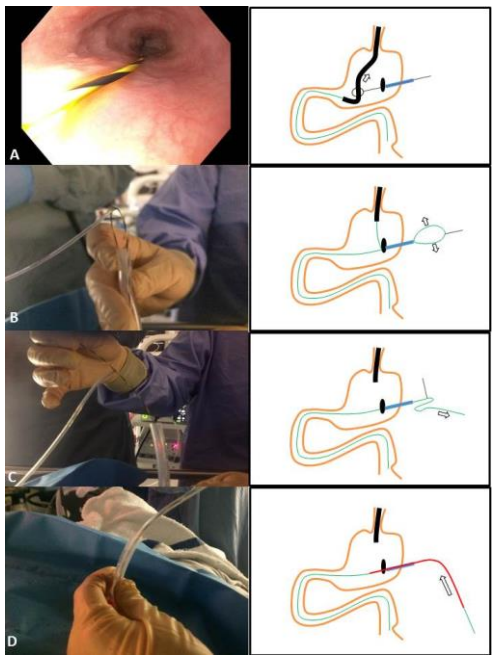

Figure 7. Through-the-snare technique for jejunal extension tube placement (continued). A) The endoscope is brought back into the stomach while maintaining position of the guidewire in the small intestine. B) The snare is then closed on the guidewire to capture it and sequentially pulled back through the PEG, creating an external loop in the guidewire. C) The proximal loop carefully pulled through the PEG tube, leaving only a straightened guidewire that extends from across the PEG and into the small intestine. D) A well lubricated jejunal extension tube is advanced over the guidewire slowly and passed through the PEG and into position in the small bowel.

Figure 8. Through-the-snare technique for jejunal extension tube placement (continued). A) Endoscopic view showing the internal bumper of a gastrostomy tube placed at the level of the incisura with a 12 Fr jejunal extension inserted through the PEG and extending beyond the pylorus. Note the relative short angle that the jejunal extension tube makes as it coarses from the antrum towards the small bowel which is ideal for maintaining deep enteral access and avoiding retrograde migration. B) Newly placed PEG tube with jejunal extension and associated adapters.

OVER-THE-GUIDEWIRE TECHNIQUE

The fundamentals for the over-the-guidewire technique are based primarily upon carefully pushing a jejunal extension tube over a guidewire that has been successfully advanced into the small bowel and is held there manually. Similar to the through-the-snare technique, the over-the-guidewire technique involves placing a jejunal extension tube through an already created gastrostomy, therefore necessitating the need for PEG tube placement prior to or during the same procedure as jejunal extension tube insertion. This technique is made successful with endoscopic grasping devices that offer a secure grasp including those with distal teeth (rat-tooth forceps) or longer jaws (alligator-jaw clamp). Biopsy forceps are generally not as helpful for this procedure because they have jaws with limited capacity that cannot take hold of longer objects with a harder texture than tissue.

For this technique, a long guidewire with a length of at least 450 cm is passed through the PEG into the stomach. The esophagus is then intubated with a standard upper endoscope. Upon reaching the stomach, a rat-tooth forceps or similar grasping device is passed through the working channel of the scope to grasp the guidewire in the stomach and drag it into the jejunum (Figure 9A).

If a pediatric colonoscope or longer endoscope is used, longer grasping forceps will be necessary to maintain a sufficient working length beyond the tip of the endoscope. While maintaining a secure hold on the guidewire with the grasping device, the endoscope is advanced as far distally as possible to a depth at or beyond the ligament of Treitz. Once the endoscope has been inserted as far as possible into the small bowel, the guidewire is held in place in the small bowel by slowly advancing the biopsy forceps forward as the scope is backed out into the proximal stomach (Figure 9B). Once the endoscope is in the stomach, the jejunal extension tube is lubricated, and under direct endoscopic visualization, advanced over the wire, through the PEG, and beyond the stomach until it encounters the grasping forceps holding the guidewire in position in the small bowel (Figure 9C).

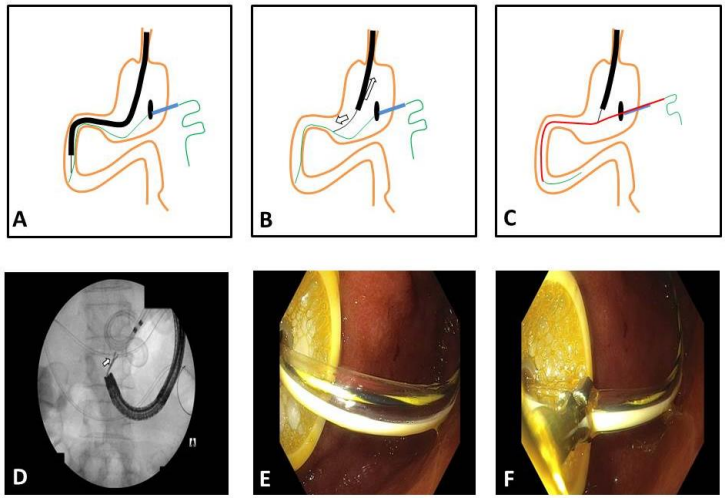

Figure 9. Over-the-guidewire technique for jejunal extension tube placement. A) A long guidewire is passed through a pre-existing gastrostomy tube and pulled into the small bowel with a grasping device. B) The endoscope is withdrawn into the stomach while maintaining guidewire position with the grasper. C) A well-lubricated jejunal extension tube is advanced over the guidewire and through the gastrostomy tube into the stomach and beyond the pylorus. D) Fluoroscopic image showing distal advancement of the jejunal extension tube made possible by forward traction with a rat tooth forceps (arrow). E) Endoscopic view of the jejunal extension tube as it is gently pushed distally into the small bowel with forceps. F) Appropriate positioning of the jejunal extension tube using the over-the-wire technique.

At this point, the forceps are released from the wire and used to facilitate passage of the jejunal extension tube along the tract of the guidewire into the small bowel, if necessary (Figure 9D, E). Once the jejunal extension tube has been successfully placed into the small bowel, the guidewire may be completely withdrawn and removed. The final endoscopic view before releasing the wire should be direct passage of the feeding tube down through the pylorus without a loop formed in the stomach (Figure 9F).

While the over-the-guidewire technique may seem more straightforward and simplistic compared to the through-the-snare technique, it can be a more tiring and frustrating process because of the potential for tube displacement and/or loop formation within the stomach. Poor placement is generally indicated by formation of a loop which arches towards the fundus of the stomach. If the tube is not completely withdrawn as this occurs and insertion reattempted, the natural tendency of this loop is to promote proximal displacement of the tube back into the stomach. Fluoroscopy can be very helpful to guide advancement of the jejunal extension tube over the guidewire and detect loop formation if it occurs. Use of an air retention valve as previously described can help maintain air insufflation and visualization while endoscopically advancing the tube into the small bowel.

ENDOCLIP TECHNIQUE

This technique relies on several of the principles outlined above in the over-the guidewire technique, namely the use of an endoscopy accessory being held distally in the small bowel while the endoscope is functioning in the body of the stomach. Withdraw of the accessory

after the tube has been successfully positioned creates minimal drag on the jejunal extension at the level of the pylorus which reduces the risk of retrograde tube migration.

Through an established PEG, a jejunal extension containing a suture loop is passed (Figure 10A). Many commercially available kits come with a suture pre-loaded, but this can be added to almost any jejunal extension. The suture loop is grasped with an endoscopic clip which functions as a grasper. The clip is withdrawn into the endoscope to prevent inadvertent mucosal damage and the endoscope is advanced to the desired level in the small bowel. The clip is advanced out of the working channel of the scope, and is deployed, affixing the suture to the mucosa (Figure 10B). Additional clips can be added as desired by the endoscopist. The final clip is positioned and closed but not fired (Figure 10C). As described above, the clip is held distally in the small bowel as the endoscope is withdrawn over the accessory shaft and back into the stomach (Figure 10D). Fluoroscopy can be utilized to aid in this maneuver and to confirm that the tube remains in the desired position. The clip is fired, and the instrument shaft is withdrawn into the endoscope under direct visualization of the pylorus.

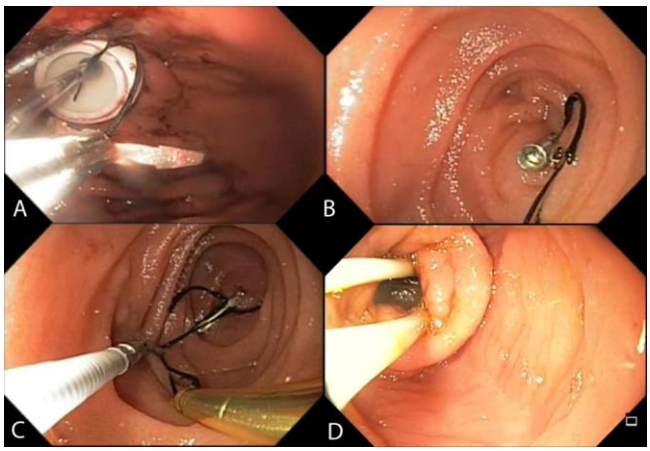

Figure 10. Endoclip technique for jejunal extension tube placement. A) A jejunal extension tube with suture loop is advanced through the PEG and grasped with an endoclip. B) After the endoscope has passed deep into the small bowel, the clip is used to secure the suture loop to the mucosa. C) An additional clip is used to grasp the mucosa, but is not fired, as the scope is withdrawn into the stomach. D) Endoscopic view of the pylorus demonstrating the jejunal extension (superior) and endoclip (inferior) immediately prior to withdrawal of the accessory.

TRANS-PERCUTANEOUS ENDOSCOPIC GASTROSTOMY TECHNIQUE

At our institution, the trans-PEG technique is reserved for patients who have already undergone PEG tube placement during a separate procedure and therefore have a mature gastrostomy (typically at least 2-3 weeks old). Additionally, we recommend a single-piece PEGJ for patients who have required repeated endoscopic procedures to replace their jejunal extension tubes for various reasons, the most common including tube malfunction from clogging or retrograde migration into the stomach.

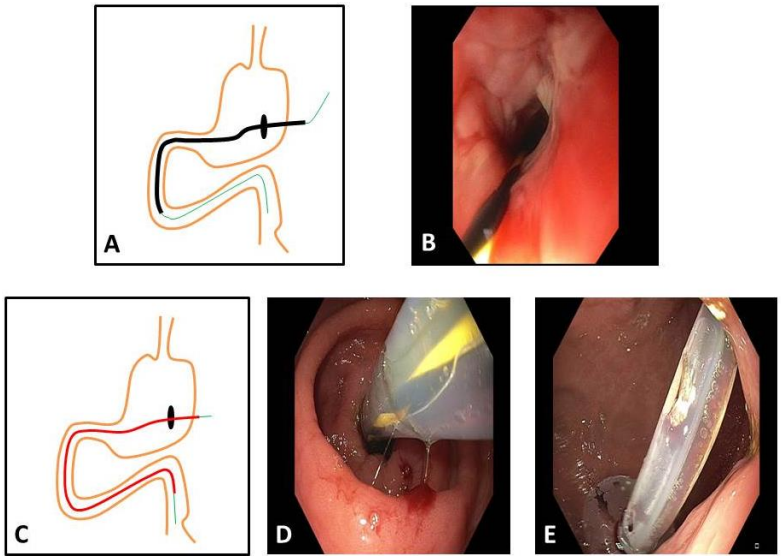

Figure 11. Trans-percutaneous endoscopic gastrostomy technique for PEGJ placement. A) A small caliber endoscope is passed percutaneously through a mature gastrostomy tract, beyond the stomach, and into the small bowel. A guidewire is then advanced beyond the distal tip of the endoscope and into the small bowel. B) Endoscopic view showing advancement of a stiff 0.035 guidewire through a gastrostomy tract. C) A lubricated single-piece PEGJ device is passed over the guidewire and into the small bowel. D) Endoscopic view of tube advancement over the wire and across the pylorus. E) Endoscopic view demonstrating adequate positioning of the PEGJ in the distal body of the stomach with the jejunal extension arching towards the pylorus. The internal retention balloon is filled with saline to secure the PEGJ in place against the wall of the stomach.

This technique is simple and involves passing a small caliber endoscope percutaneously through a mature gastrostomy tract into the stomach, through the pylorus, and into the small bowel. Our preference is to use an ultrathin endoscope with a 5-6 mm outer diameter and a working channel capable of accommodating a stiff 0.035-inch guidewire. In some cases, the gastrostomy tract may need to be carefully dilated to facilitate passage of the endoscope and instruments. Once the maximum depth of insertion of the endoscope has been reached, a stiff, long guidewire is passed either endoscopically or under fluoroscopic guidance through the working channel of the endoscope and into the small bowel, ideally beyond the ligament of Treitz (Figure 11A). The endoscope is then withdrawn slowly to the exterior of the patient and off of the wire (Figure 11B). Then a single-piece PEGJ is passed over the wire and directed into the small bowel (Figure 11C, D). The guidewire is subsequently removed. Similar to the previously described techniques for jejunal extension tube placement, avoiding loop formation in the stomach is critical. Once appropriate positioning of the PEGJ has been confirmed, the internal retention balloon is filled to capacity with saline to secure the device in place and tube feeds can be immediately delivered (Figure 11E).

POST-PEGJ CARE AND COMPLICATIONS

Management principles are generally similar for most patients who have undergone percutaneous endoscopic deep enteral access procedures. Patients are typically observed for 4

hours after initial PEG with jejunal extension tube placement, after which enteral feeds may be started if there are no contraindications. Patients undergoing PEG to PEGJ conversion who already have a mature gastrostomy tract can often be administered tube feeds immediately. For patients with significant gastric outlet obstruction type symptoms, it is important to maintain aspiration precautions before and after jejunal extension tube placement, especially when enteral feeds are initiated. If nausea, abdominal pain, and/or significant vomiting persist, the G-tube can be placed to gravity with the output closely monitored. When administering feedings, all enteric medications and tube feeds should be given via the jejunal port and followed with a flush of least 15 mL of saline or sterile water. It is critically important that only liquids are given through the jejunal port. Administration of pills or crushed pill fragments will undoubtedly lead to clogging of the tube and the potential need for repeat procedures for tube replacement.

Other post-procedure instructions include those common to patients who have undergone PEG tube insertion. The gastrostomy site should be kept clean with mild soap and water for the first 7 to 10 days after placement. Use of hydrogen peroxide should be avoided during that timeframe as it can irritate the skin and contribute to stomal leaks. Occlusive dressings at the enteric site should also be avoided as they can lead to skin maceration and breakdown. We do not routinely apply a dressing to the enteric site after placement. However, if a dressing is applied, it should be placed over rather than under the external bumper, and a cut dry sponge is preferable. To prevent buried bumper syndrome, the external bumper of the gastrostomy or PEGJ should be positioned so that the tube is moveable and can be pushed in and out of the tract at least 1-2 cm. We customarily have patients return in one to two weeks to evaluate the enteral access site and confirm that the external tube and adapters remain intact and are appropriately functioning.

Complications of PEGJ tubes include those described elsewhere for PEG tube placement as well as those unique to insertion of the jejunal extension including tube migration into the stomach and tube dysfunction from clogging, kinking, or occlusion. One note to be made is that while free intra-peritoneal air likely occurs universally after PEG, if the placement of the jejunal extension requires significantly more endoscopy time, the amount of air that leaks around the newly created gastrotomy can be significant and may be more likely to be detected clinically or radiographically. Use of carbon dioxide during PEGJ placement can increase the rate at which the intra-abdominal air is reabsorbed.

Retrograde dislodgement of the jejunal extension tube is common and has been reported in up to 33% of cases [18]. This is often a source of frustration for patients and providers and usually results in repeated procedures to obtain proper positioning. Occlusion of the smaller caliber 8-12 Fr jejunal extension tubes can also be problematic with rates as high as 35% when crushed medications are administered through the jejunal port [19]. The functional longevity of the jejunal arm varies in each clinical situation, but we typically have patients return for tube changes every 3-6 months or as needed.

EDITOR'S COMMENT

As Drs Gaffney and Moyer point out in this chapter, the simplistic concept of placing the distal end of a PEGJ tube beyond the pylorus and ensuring that it remains there is often not so

simplistic in its execution. The fact that there are multiple viable techniques to accomplish this task speaks to the true complexity of this endeavor and to the ingenuity of endoscopists who have been faced with the problem of a tube that simply will not go or will not stay post-pyloric. Experience, training and patience are a must when attempting PEGJ. (EMP).

REFERENCES

[1] Stapleton RD, Jones N, Heyland DK. Feeding critically ill patients: what is the optimal amount of energy? *Crit Care Med*. 2007;35(suppl 9):S535-40.

[2] Runyon BA, Squier S, Borzio M. Translocation of gut bacteria in rats with cirrhosis to mesenteric lymph nodes partially explains the pathogenesis of spontaneous bacterial peritonitis. *J Hepatol.* 1994;21(5):792-96.

[3] Windsor AC, Kanwar S, Li AG, et al. Compared with parenteral nutrition, enteral feeding attenuates the acute phase response and improves disease severity in acute pancreatitis. *Gut.* 1998;42(3):431-35.

[4] Moore FA, Feliciano DV, Andrassy RJ, et al. Early enteral feeding, compared with parenteral, reduces postoperative septic complications. The results of a meta-analysis. *Ann Surg*. 1992;216(2):172-83.

[5] Kwon RS, Banerjee S, Desilets D, et al. Enteral nutrition access devices. *Gastrointest Endosc.* 2010;72(2):236-48.

[6] Camilleri M. Clinical practice. Diabetic gastroparesis. *N Engl J Med*. 2007;356:820-29.

[7] Drover JW. Gastric versus postpyloric feeding. *Gastroenterol Clin N*. 2007;17(4):765-775.

[8] Heyland DK, Drover JW, Dhaliwal R, et al. Optimizing the benefits and minimizing the risks of internal nutrition in the critically ill: Role of small bowel feeding. *J Parenter Enteral Nutr*. 2002;26(Suppl 6):S51-55.

[9] Stanga Z, Giger U, Marx A, et al. Effect of jejunal long-term feeding in chronic pancreatitis. *J Parenter Enteral Nutr*. 2005;29:12-20.

[10] Herman LL, Hoskins WJ, Shike M. Percutaneous endoscopic gastrostomy for decompression of the stomach and small bowel. *Gastrointest Endosc*. 1992;38:314-8.

[11] Shih JH, Park AW. Updates on percutaneous radiologic gastrostomy/ gastrojejunostomy and jejunostomy. *Gut Liver*. 2010;4(Suppl 1):S25-31.

[12] Palmer LB, McClave SA, Bechtold ML, et al. Tips and tricks for deep jejunal enteral access: Modifying techniques to maximize success. *Curr Gastroenterol Rep*. 2014;16:409-16.

[13] Shike M, Latkany L. Direct percutaneous endoscopic jejunostomy. *Gastrointest Endosc Clin N Am*. 1998;8:569-80.

[14] Fan A, Baron T, Rumalla A, et al. Comparison of direct percutaneous endoscopic jejunostomy and PEG with jejunal extension. *Gastrointest Endosc*. 2002;56:890-94.

[15] Maple J, Petersen B, Baron T, et al. Direct percutaneous endoscopic jejunostomy: outcomes in 307 consecutive attempts. *Am J Gastroentol*. 2005;100:2681-8.

[16] McClave SA, Chang WK. Techniques in enteral access. In: Ginsberg G, editor. *Clinical Gastrointestinal Endoscopy*. Philadelphia: Saunders; 2011. 279-96.

[17] Foutch PG, Talbert GA, Waring JP, et al. Percutaneous endoscopic gastrostomy in patients with prior abdominal surgery: virtues of the safe tract. *Am J Gastroenterol*. 1988;83:147-50.

[18] Zopf F, Rabe C, Bruckmoser T, et al. Percutaneous endoscopic jejunostomy and jejunal extension tube through percutaneous endoscopic gastrostomy: a retrospective analysis of success, complications and outcome. *Digestion*. 2009;79:92-7.

[19] DeLegge M. Enteral access in home care. *J Parenter Enteral Nutr*. 2006;30(1):S13-20.

In: Encyclopedia of Surgery (22 Volume Set)
Editors: Andreas Lehrer and Kristin Mueller
ISBN: 978-1-53618-329-0
© 2020 Nova Science Publishers, Inc.

Chapter 133

ALTERNATIVE GASTRIC ACCESS METHODS: SLiC AND PTEG

Adrian B. Dobrowolsky, MD and Bipan Chand*, MD
Loyola Univeristy Medical Center, Marywood, IL, US

INTRODUCTION

While percutaneous endoscopic gastrostomy (PEG) placement is generally easy to perform with an overall low morbidity to patients, not all patients have favorable anatomy to allow for its use. For example, those with large nearly-obstructing oropharyngeal masses bring challenges that may be difficult to overcome with many surgeons opting for an open approach instead of endoscopically placed feeding catheters. Additionally, seeding of the abdominal wall has been reported from PEG placement in those with head and neck cancers. Alternatively, patients with ascites secondary to hepatic failure or malignancy are at a higher risk and the dangers of potentially developing infected ascites and its sequelae greatly outweigh the benefits in many. In this chapter we will focus on two alternative methods of enteral access; the Sabnis, Liu and Chand (SLiC) technique and the percutaneous transesophageal gastrostomy (PTEG) technique.

SLiC Indications

The SLiC technique was first described in 2005 by Sabnis et al. [1]. In this method, a gastroscope is used to visualize a dilating laparoscopic trocar enter the stomach. A Malecot catheter is then placed through the trocar and secured. Reasons to utilize this technique include strictures of the aerodigestive tract from radiation, inflammation, or obstructive cancers that may preclude a large mushroom tipped catheter from traversing the lesion in a traditional PEG procedure. Because this method permits the immediate placement of a 20 French (Fr) tube, the technique is less prone to clogging by medication and tube feed

* Corresponding Author's Email: bchand@lumc.edu.

administration associated with radiologically placed 12 Fr gastrostomy tubes and does not require the tube to be upsized at a subsequent clinical encounter [1].

In a prospective review by Ellrichmann et al. 26 patients with head and neck cancers, 13 with esophageal cancers, and one with esophageal invasion by a lung cancer underwent traditional pull-type PEG and cytologic analysis of tubing and incision sites. They demonstrated malignant cells in 22.5% of tube samples and a metastatic seeding rate of 9.4% in those whose PEG sites were tested again at a later date [2]. Metastatic seeding of the PEG sites has been well documented in case reports with an overall prevalence of about 1-2 cases per year, most commonly from squamous cell cancers [2, 3]. The SLiC method eliminates pulling the tube through the location of any oral-pharyngeal-esophageal cancer.

SLiC Technique

This method requires the following equipment: gastroscope, local anesthetic, number 11 blade scalpel, Step™ insufflation needle and 7-8 mm MiniStep™ trocar (Medtronic, USA) 20 Fr Malecot catheter, stiff metal stylet, nonabsorbable suture (Figure 1). The Malecot is prepared by placing the stylet inside and elongating the mushroom tip for easy placement. A slim pediatric (6 mm) or ultra-slim (<5 mm) gastroscope (possibly passed transnasal) may be necessary in order to traverse a large or partly-obstructing mass lesion or stricture (Figure 2).

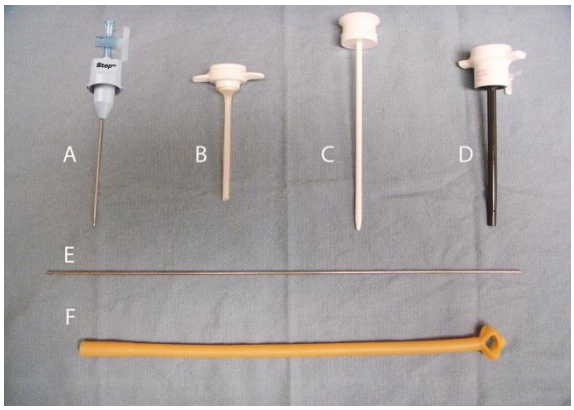

Figure 1. Instrumentation for SLiC procedure. A) Access Needle B) 7-8 mm trocar sleeve C) Dilator D) 7/8 MiniStep™ cannula E) Stylet F) 20Fr Malecot catheter.

Procedure specifics are adapted from Sabnis et al. [1]. The patient is placed supine on the procedure table and the upper abdomen prepped and draped in the usual sterile fashion. Under direct visualization the gastroscope is passed into the stomach and then the stomach is insufflated. Using transillumination, gastric indentation by a second individual and a safe-tract technique, the location of gastrostomy is safely confirmed. Local anesthetic is then used to infiltrate the site and a 7 mm skin incision is made using the 11-blade scalpel. The trocar sleeve and access needle are quickly driven through the incision, abdominal wall, and stomach under visualization with the gastroscope (Figure 3). A swift, controlled motion is necessary here because the outer diameter of the dilating sleeve is larger than that of the 14 gauge Veress-type access needle. The access needle is subsequently removed and the 7-8 mm

dilator along with its cannula is then passed through the sleeve to dilate the tract and place the cannula. The dilator is then removed leaving the sleeve and cannula in place (Figure 4). The one way valve on the laparoscopic trocar prevents air leak, allowing gastric inflation to be maintained. The Malecot catheter is then placed through the trocar approximately 5-6 cm into the gastric lumen using the stylet and lubricant (Figure 5). The stylet is removed. The StepTM trocar is then carefully withdrawn over the tube leaving the Malecot in place (Figure 6). The Malecot is sutured to the skin. The Malecot tip can be directed into the fundus if decompression of the stomach is the desired affect.

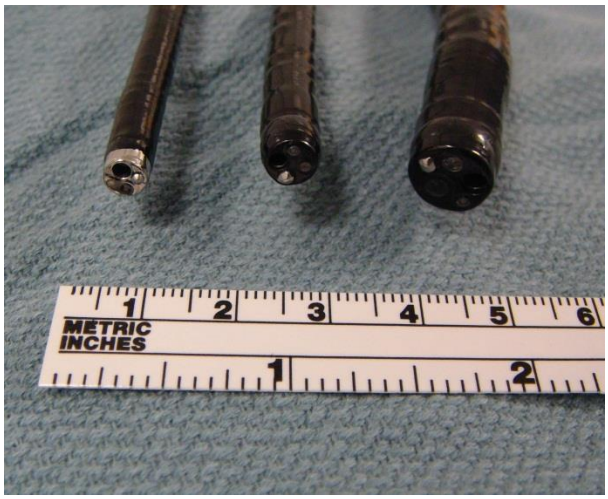

Figure 2. Contrasting diameters of a ultraslim (4.9 mm), slim pediatric (6 mm) and standard diagnostic (9.8 mm) gastroscope (left to right).

Figure 3. The access needle and sleeve are quickly thrust through the abdominal and gastric walls under direct endoscopic visualization.

Figure 4. The dilator is removed, leaving the cannula within the sleeve.

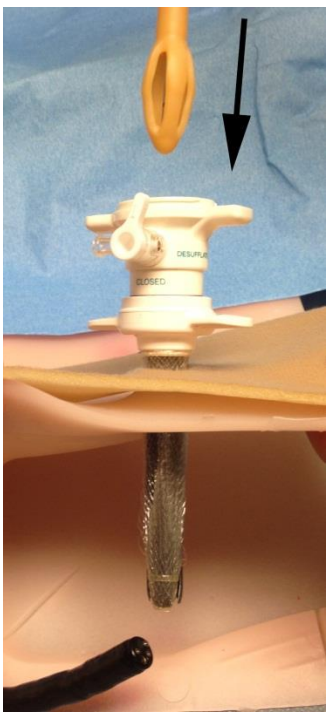

Figure 5. The 20Fr Malecot catheter is prepared with a metal stylet inside its tip and inserted into the stomach through the cannula. The stylet is then removed.

Figure 6. The cannula is removed while holding the Malecot catheter in place.

PTEG Indications

In 1994, Oishi et al in Japan developed the percutaneous transesophageal gastrostomy (PTEG) technique as a novel way to provide a gastric tube for decompression or feeding by means of direct access to the esophagus [4]. In patients with hostile abdominal cavities from bulky malignancies, adhesive disease, or ascites secondary to hepatic dysfunction or intraabdominal neoplasm, PTEG is an alternative to the traditional transabdominal gastrostomy tube. During PEG placement, patients with ascites are at a much higher risk of secondary bacterial contamination and subsequent peritonitis from poor apposition of the gastric and abdominal walls from the ascites or malnutrition leading to poor tract formation [5]. Like the nasogastric tube, PTEG is suitable for gastric decompression as the tube lays in the most dependent portion of the stomach. This is in contrast to the PEG tube that lies anteriorly and is only able to decompress the stomach when it is filled to its most anterior portion providing a far inferior decompression of the stomach. Also, inadvertent removal of a PEG may necessitate laparotomy when the tract has not matured whereas, due to its location, inadvertent removal of a PTEG is less concerning as the site will likely heal without major consequence if not expeditiously replaced with another catheter.

PTEG Technique

This method requires the following equipment: a rupture free balloon (RFB) and catheter, straight and angled guidewires, contrast, needle with sheath, 16 Fr dilator with peel-away sheath, PTEG catheter, scalpel, nylon suture, ultrasound, and fluoroscopy (Figure 7). The

current “kit” is not readily available in the United States. However, the majority of the equipment can be pieced together from existing hospital inventory. The RFB balloon is composed of chloroethylene, a material that permits it to not burst when punctured with a needle and be readily visible on ultrasound.

Procedure specifics are adapted from Oishi et al. and Mackey et al. [4, 6]. The patient is placed supine on the procedure table and sedated. A straight guidewire is passed transnasal into the esophagus and confirmed on fluoroscopy. Using Seldinger technique, the RFB is placed over the wire and advanced distal to the cricopharyngeus muscle where it is filled with dilute contrast media. When confirmed in the esophagus, it is advanced to just above the clavicles and using an ultrasound probe on the patients left neck, the common carotid artery, internal jugular vein, and thyroid are visualized. Due to the distention of the RFB, the trachea and thyroid become displaced medially and the vessels laterally. At the proposed entry site, local anesthetic is used and using ultrasound guidance, the needle and its sheath are used to puncture into the RFB (Figure 8). Confirmation of successful RFB puncture is established by resistance when the RFB is punctured, visualization of the tip of the needle entering the RFB under ultrasound guidance, and visualized contrast media outside the balloon into the sheath upon withdrawing the needle on fluoroscopy (Figure 9). When confirmed, the needle is carefully removed while holding its sheath within the RFB. Then, an angled guidewire is introduced through the sheath into the RFB. Under fluoroscopic guidance, both the cervical guidewire and the RFB are advanced approximately 20 cm distally where the guidewire will fall out of the RFB but remain in the esophagus (Figure 10).

The RFB and nasal wire are removed leaving only the trans-cervical guidewire. At the skin level, a 1 cm incision is made and the 16 Fr dilator and peel-away sheath are inserted over the guidewire under fluoroscopy using a twisting motion (Figure 11). Once fully inserted, the guidewire and dilator are removed leaving the peel-away sheath. The PTEG catheter is then introduced into the sheath and advanced into the stomach with its location confirmed with injection of contrast under fluoroscopy. The sheath is then peeled away and the PTEG tube is secured with nylon suture (Figure 12).

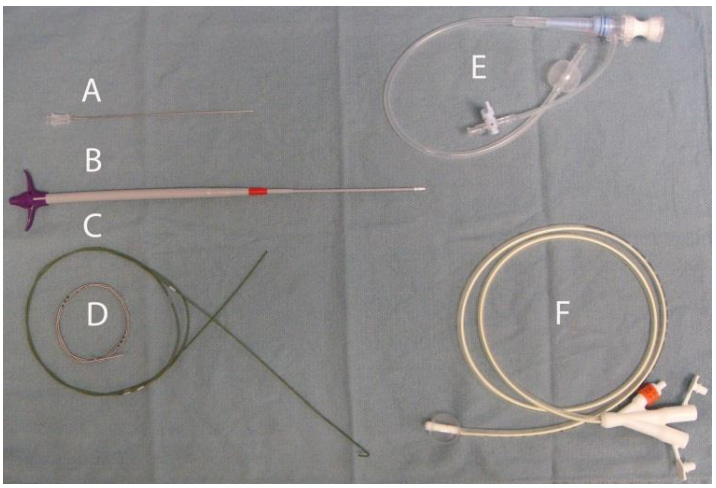

Figure 7. PTEG kit. A) Needle with sheath B) Dilator with peel-away sheath, C) Angle-tip guidewire passed trans-cervical D) Straight guidewire passed trans nasally E) Rupture-free balloon F) PTEG catheter.

Figure 8. Needle puncture of rupture-free balloon under ultrasound guidance.

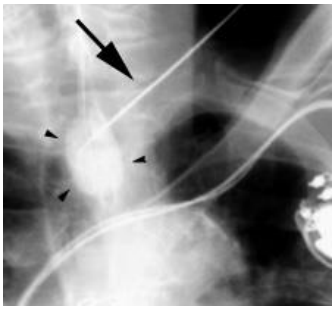

Figure 9. Fluoroscopy confirms successful percutaneous access of rupture-free balloon (arrowheads) with contrast back flowing into the needle sheath (arrow).

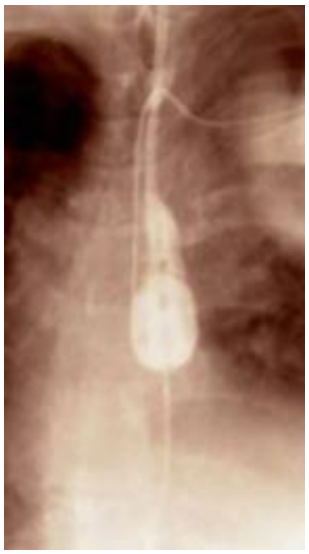

Figure 10. The balloon and guidewire advancing into the distal esophagus under fluoroscopic guidance.

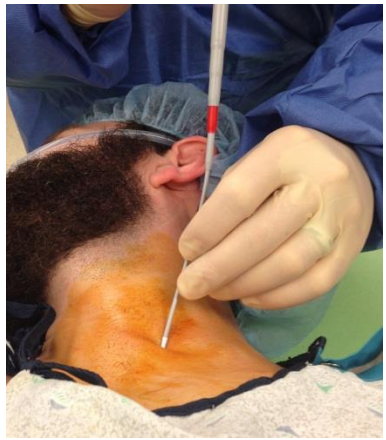

Figure 11. Dilator and peel-away sheath are passed over the trans-cervical guidewire. The dilator is removed and the PTEG catheter passed through the peel away sheath.

Figure 12. Percutaneous transesophageal gastrostomy site after the tube is secured and dressed.

PTEG Limitations

Not all patients are suitable for PTEG placement. Specifically, those patients with head and neck lesions, coagulopathy, and right recurrent laryngeal nerve paralysis are contraindicated to undergo PTEG placement [6]. PTEG carries an overall 23.5% risk of minor complications seminal to PEG placement, including tube dislodgement, blockage, leakage, bleeding and wound infections [4]. Procedural limitations to performing successful PTEG placement are the ability to interpret not only ultrasonography, but also fluoroscopy [6].

CONCLUSION

While most patients are suitable for PEG placement, special situations call for alternative therapies to provide similar results. The SLiC technique is useful in the setting of aerodigestive obstruction that makes a traditional PEG difficult or impossible to place without undue trauma to the offending lesion. Also, this prevents the small possibility of PEG site seeding of malignant cells when the pull or push PEG mechanism is utilized. PTEG provides a means for feeding or gastric decompression in patients with advanced malignancies or ascites from secondary causes which preclude them from other transabdominal approaches.

EDITOR'S COMMENT

The techniques outlined here not only require specialized equipment, but they required advanced surgical and/or imaging interpretation capabilities. Despite these two limitations, they remain very useful methods for those patients who are not candidates for more traditional methods of gastric access. Practitioners who can master these adjunct PEG methods are capable of providing advanced gastric access to patients who might otherwise be deemed not candidates for a more permanent gastrostomy tube (EMP).

REFERENCES

[1] Sabnis A, Liu R, Chand B, Ponsky J. SLiC technique. A novel approach to percutaneous gastrostomy. *Surg Endosc*. 2006;20(2):256-262.

[2] Ellrichmann M, Sergeev P, Bethge J, et al. Prospective evaluation of malignant cell seeding after percutaneous endoscopic gastrostomy in patients with oropharyngeal/ esophageal cancers. *Endoscopy*. 2013;45(7):526-531.

[3] Sinapi I, Navez B, Hamoir M, et al. Seeding of the percutaneous endoscopic gastrostomy site from head and neck carcinoma: Case report and review of the literature. *Head Neck*. 2013;35(7):E209-12.

[4] Oishi H, Shindo H, Shirotani N, Kameoka S. A nonsurgical technique to create an esophagostomy for difficult cases of percutaneous endoscopic gastrostomy. *Surg Endosc*. 2003;17(8):1224-1227.

[5] Udomsawaengsup S, Brethauer S, Kroh M, Chand B. Percutaneous transesophageal gastrostomy (PTEG): A safe and effective technique for gastrointestinal decompression in malignant obstruction and massive ascites. *Surg Endosc*. 2008;22(10):2314-2318.

[6] Mackey R, Chand B, Oishi H, Kameoka S, Ponsky JL. Percutaneous transesophageal gastrostomy tube for decompression of malignant obstruction: Report of the first case and our series in the US. *J Am Coll Surg*. 2005;201(5):695-700.

In: Encyclopedia of Surgery (22 Volume Set)
Editors: Andreas Lehrer and Kristin Mueller
ISBN: 978-1-53618-329-0
© 2020 Nova Science Publishers, Inc.

Chapter 134

'ASSISTED' PEG PLACEMENT

Salvatore Docimo, Jr., DO and Eric M. Pauli*, MD
Penn State Hershey Medical Center, Hershey, PA, US

INTRODUCTION

As outlined in previous chapters, percutaneous endoscopic gastrostomy (PEG) placement requires anatomical landmarks and technical maneuvers (such as gastroscopic transillumination and external manual palpation of the abdominal wall with visualized confirmation endoscopically) in order to ensure safe and appropriate placement [1]. However, certain patient characteristics (e.g., difficulty passing a gastroscope, previous gastric surgery, failure of transillumination of the abdominal wall, colon interposition) make PEG placement both difficult and potentially unsafe. In many of these scenarios, laparoscopic or open gastrostomy tube placement may be preferable. However, the use of upper endoscopy in conjunction with advanced imaging such as computerized tomography (CT) scans, fluoroscopy, or ultrasound can also help overcome the difficulties outlined above. Simultaneous upper and lower endoscopy has also been utilized to ensure safe PEG placement. This chapter focuses on the use of an adjunct modality (upper endoscopy plus a secondary modality) to assist in the performance of PEG.

LAPAROSCOPIC-ASSISTED PERCUTANEOUS ENDOSCOPIC GASTROSTOMY

Laparoscopic-assisted PEG (LA-PEG) is likely the most common utilized method of muti-modal therapy and it represents the fusion of two minimally invasive techniques into one laparo-endoscopic procedure. Raaf et al. first described LA-PEG in 1993 in a patient requiring a gastrostomy tube where the colon lay on the greater curvature of the stomach [2]. This technique can be utilized in patients where viscera (left lateral segment of the liver,

* Corresponding Author's Email: epauli@hmc.psu.edu.

colon, small bowel) are known to overlay the stomach and in patients where there is absence of transillumination of the abdominal wall and/or a 'safe-tract' during a standard PEG. In a series published by Hermanowicz et al. twelve patients underwent laparoscopic assisted PEG placement. In a supine position, a 5-mm trocar was inserted under the umbilicus using Hasson's open technique and pneumoperitoneum was obtained. A gastroscope was then introduced and a gastrostomy site was selected under laparoscopic and endoscopic visualization. The PEG was completed utilizing the 'pull' technique. All twelve patients successfully received a PEG with no major intraoperative complications [3].

Typically, laparoscopic-assisted PEG requires the placement of just one 5-mm trocar for insertion of a laparoscope which is utilized for selection of a safe gastrostomy site. A second working port can be placed if needed for retraction of intraperitoneal viscera in order to create a clear gastrostomy site (Figure 1). Once laparoscopic visualization has confirmed that there is a safe location for the gastrostomy with no intervening abdominal viscera, the PEG can be completed using pull, push or introducer methods based on surgeon preference (Figure 2). As outlined in Chapter 9, the procedure can be conducted with additional working ports and laparoscopic suturing methods but at this point the procedure essentially becomes a laparoscopic gastrostomy tube with endoscopic guidance.

FLUOROSCOPY-ASSISTED PERCUTANEOUS ENDOSCOPIC GASTROSTOMY

While fluoroscopy is routinely utilized by therapeutic endoscopists for more complex interventions (e.g., bilio-pancreatic procedures, management of leaks and fistulae) the use of fluoroscopy to assist in PEG placement (FA-PEG) is not common. Grant utilized intra-operative fluoroscopy in only 0.33% (2/598) of patients undergoing PEG [4]. Fluoroscopically placed gastrostomy tubes (without the use of endoscopy) can be safely performed with the introducer method, although the initial tube size is generally smaller that with other methods of PEG [5]. There are several circumstances in which the combined use of endoscopy and fluoroscopy for PEG placement are advisable.

We occasionally use fluoroscopy in patients who have been deemed to be not candidates for PEG based on pre-operative imaging studies, or who have failed a previous attempt at PEG by another provider (typically due to no transillumination or inability to find a 'safe-tract') (Figure 3). FA-PEG may also be beneficial in patients that have medical-surgical hardware (e.g., ventricular-peritoneal (VP) shunt, diaphragm or gastric pacemaker, temporary cardiac pacemaker wires, ventricular assist device drive lines) that traverses the epigastrium [4]. In these circumstances the real-time imaging allows the endoscopist to avoid puncture of the device with the PEG and to place the PEG remotely from the devise to reduce the risk of post-procedure infection (Figure 4).

We routinely utilize fluoroscopy during PEG when we are also performing simultaneous colonoscopy (see Colonoscopic-Assisted Percutaneous Endoscopic Gastrostomy section below) as an adjunct to ensure adequate colonic decompression prior to performing a 'safe-tract' maneuver. Similarly, as better outlined in Chapter 15, fluoroscopy during hiatal hernia reduction and double-PEG gastropexy is a useful adjunct to ensure the safety of the procedure.

Figure 1. Laparoscopic-assisted PEG in a patient with colon distension that prohibited a 'safe-tract' to be found during the initial PEG attempt. A 5 mm trocar was placed at the umbilicus for visualization. A second 5 mm left sided working port was necessary to permit retraction of the transverse colon that could not be sufficiently moved by reverse Trendelenburg position. Gastrointestinal T-anchors were subsequently placed and an introducer PEG method was used to place a primary button gastrostomy tube under endoscopic visualization.

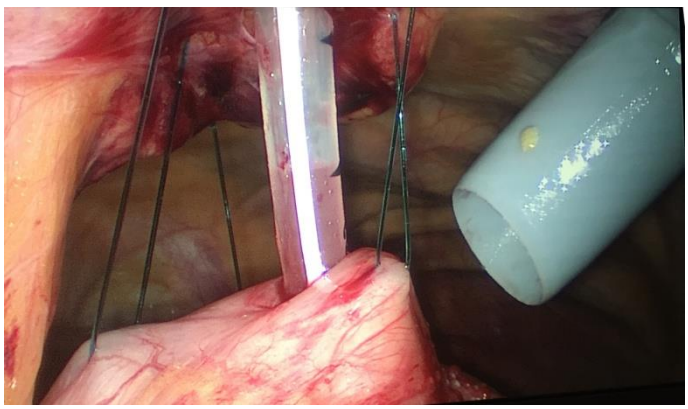

Figure 2. Laparoscopic view of a gastrostomy tube safely traversing the abdominal and gastric wall during a laparoscopic-assisted PEG.

COMPUTED TOMOGRAPHY-ASSISTED PERCUTANEOUS ENDOSCOPIC GASTROSTOMY

Although PEG has become more widely used than percutaneous radiologic gastrostomy (PRG), PRG remains a better option in some circumstances including; inability to transilluminate endoscopically, obstructing head and neck cancer (HNC) or esophageal cancers, obesity, previous gastric surgery, or patients with a hostile abdomen, either due to malignancy or severe adhesive disease secondary to multiple surgeries. During the procedure, the stomach is often inflated via a nasogastric tube and a CT scan is performed in order to ascertain a clear path to the stomach, ideally, one in which the stomach is in close proximity

to the anterior abdominal wall without any anterior organs in between (Figure 5). This includes radiologic guided insertion of intercostal pigtail tubes. Utilizing CT imaging, an introducer needle is visualized entering the air filled stomach. A guidewire is then placed. At this point, dilation and placement of the gastrostomy tube can occur in either the radiology or endoscopy suite.

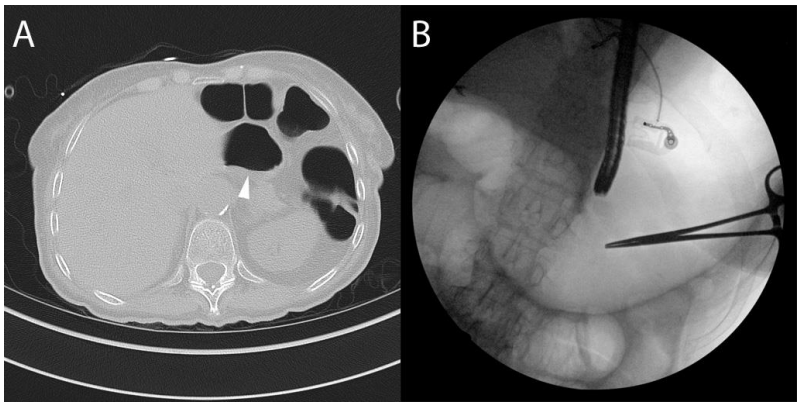

Figure 3. Imaging from a patient who had failed routine PEG tube placement due to inability to find a 'safe-tract.' A) The patient was deemed not a candidate for a CT-guided gastrostomy based on the distended colon overlying the stomach (arrowhead). B) FA-PEG was performed which safely identified a location below the costal margin with no intervening colon (at instrument tip) where a PEG tube was ultimately placed utilizing a routine 'pull' method.

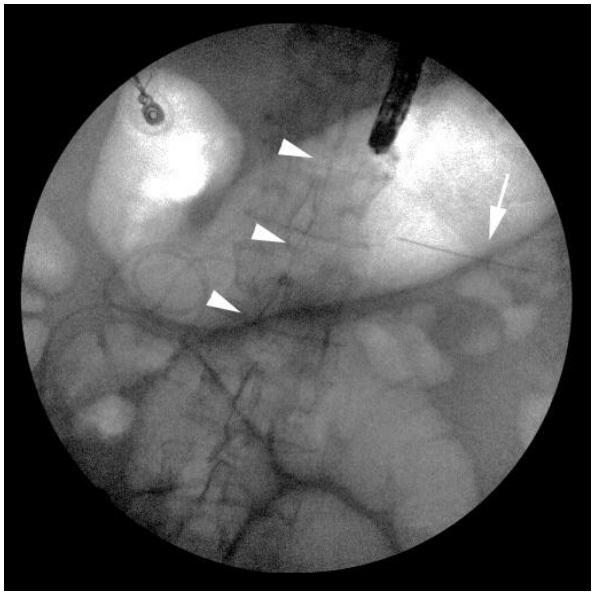

Figure 4. Image obtained during FA-PEG on a patient with a 4-day-old VP shunt that traverses the epigastrium (arrowheads). A finder needle (arrow) is used to mark the planned location for a 'safe-tract' attempt at a location remote from the shunt. The endoscope can be seen in the body of the stomach providing insufflation.

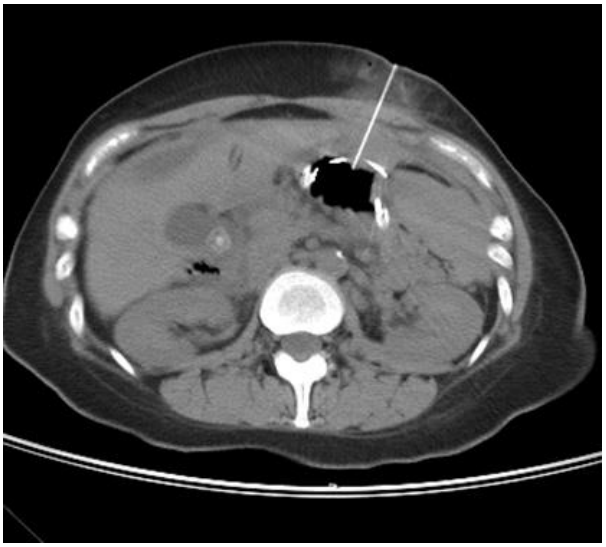

Figure 5. CT-guided access to the stomach in a patient with ovarian carcinomatosis and bowel obstruction symptoms who failed PEG due to the inability to distend the stomach.

Computed Tomography-Assisted Percutaneous Endoscopic Gastrostomy (CTA-PEG) was first described by Vogt et al. in 1996. In 7 or 124 patients, PEG was not possible due to failure to transilluminate the abdominal wall; 3 from prior Billroth gastrectomy, 2 from hepatosplenomegaly, and 1 each from obesity and Chilaiditi syndrome (colonic interposition). Utilizing real-time CT guidance, they were successful in PEG placement in 6 of the 7 patients with no major complications [6].

Spelsberg et al. published a series of patient undergoing CT guidance with or without endoscopy for the placement of gastrostomy tubes. Gastrostomy was success in 89 of 101 patients with CTA-PEG being employed in 61 of the 89. Forty-five of the 61 patients (74%) were noted to have previously unknown pathological findings and twenty-nine (48%) were found to have pathological findings, such as peptic ulcer disease or suspicious tumor manifestations, which altered the management plan [7].

There are three methods by which CTA-PEG can occur; immediate, same-day rendezvous or delayed rendezvous. In immediate CTA-PEG, both the endoscopy team and radiology team are present in the interventional radiology (IR) suite (Figure 6). Following the administration of anesthesia, an upper endoscopy is performed with the patient on the CT table. Standard maneuvers to localize the PEG site (transillumination, 'safe-tract') are augmented by the use of real-time CT images as well as the placement of radiopaque skin markers (Figure 6E). Once a location is identified, standard PEG methods (pull, push or introducer) can be performed. This procedure has the advantage of permitting a large caliber (20-24 Fr) gastrostomy to be placed in a safe and immediate fashion, but it requires careful coordination of 2-3 (radiology, endoscopy and possible anesthesiology) services in a limited procedure space.

Same-day rendezvous CTA-PEG begins as with a percutaneous radiologic gastric access. CT images are obtained and a safe location for the tube is identified. Needle and wire access to the stomach are obtained. The wire is robustly-secured to the skin, and the patient is transported to an endoscopy or procedural suite where endoscopy is used to retrieve the wire

per os. A PEG is completed using standard methods. While there is potential for wire dislodgement during transport, this procedure has the advantage of permitting both involved services (radiology and endoscopy) to function independently of one another and to both perform their portion of the procedure in familiar, well-equipped environments.

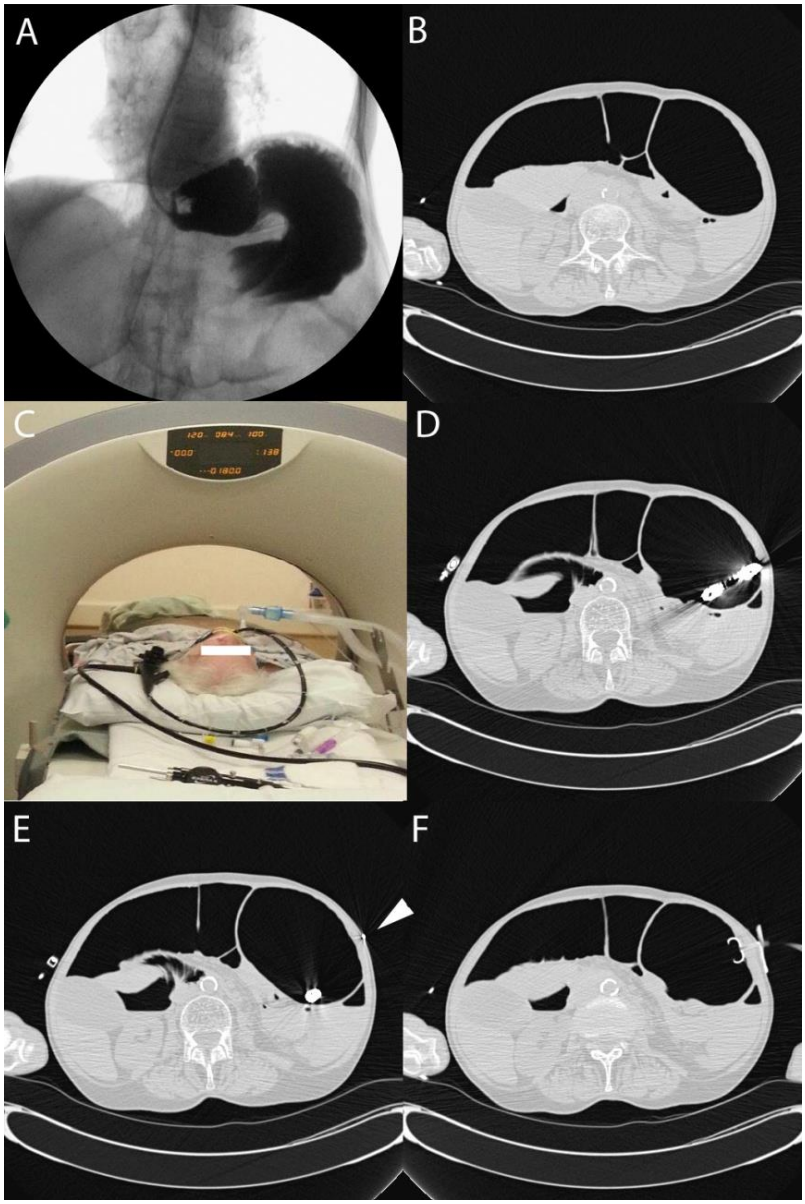

Figure 6. Immediate CT-Assisted PEG in a patient with obstructive symptoms from a small bowel motility disorder. A) Upper GI study demonstrates abnormal gastric positioning in the left upper quadrant (entirely subcostal) and severe small bowel dilation. B) Scout CT image demonstrates similar bowel distension. C) On-table upper endoscopy is performed in the IR suite. D) Repeat CT scan shows the endoscopic within the body of the stomach. E) Radiopaque skin marker (arrowhead) identifies the proposed site for PEG. F) Completed 'pull' method PEG position is confirmed via completion CT.

Delayed rendezvous CTA-PEG begins as with a percutaneous radiologic gastrostomy. CT images are obtained and a safe location for the tube is identified. Needle and wire access to the stomach are obtained and a small caliber pigtail catheter is placed over the wire into the lumen of the stomach. Several weeks after this procedure (i.e., in a delayed fashion), endoscopy is used to rendezvous with the well-established drain tract and replace the small caliber tube with a larger caliber standard PEG gastrostomy (Figure 7).

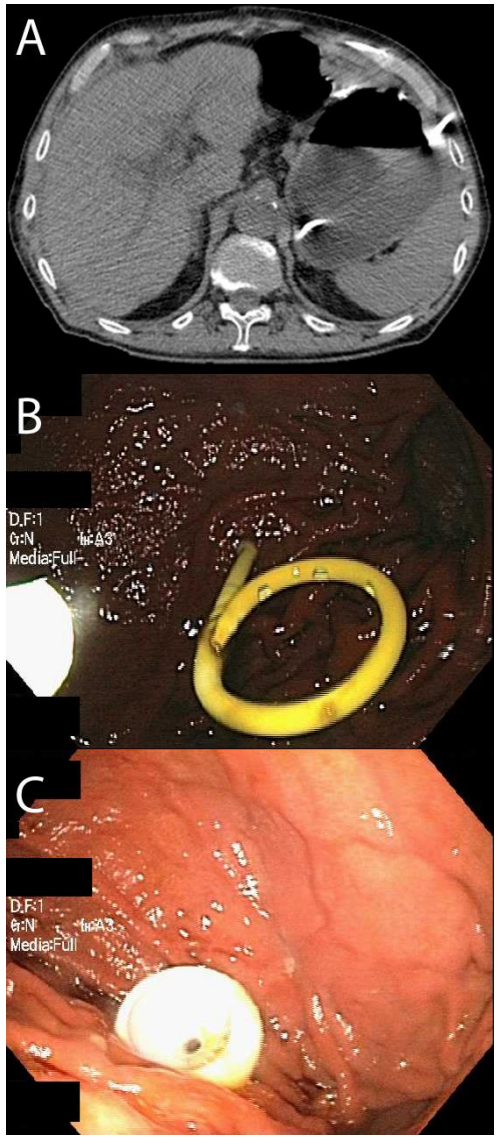

Figure 7. Delayed CT-Assisted PEG for decompression of malignant bowel obstruction. A) CT guided pigtail tube is placed through the intercostal space due to carcinomatosis limiting safe PEG placement. B) Several weeks after placement, endoscopy is performed to identify the intercostal pigtail tube in the lumen of the stomach. C) The small caliber pigtail is exchanged for a larger caliber standard PEG tube for more effective gastric decompression.

It should be noted that while both utilize CT and endoscopy technology, CTA-PEG differs from Endoscopic Ultrasound Assisted/Computed Tomography-Guided enteral access described in detail in Chapter 13. In CTA-PEG, the gastrostomy placement is primarily being performed endoscopically with CT providing imaging data to assure safety, or providing a wire/tube over which the PEG can be performed. During Endoscopic Ultrasound Assisted/ Computed Tomography-guided gastrostomy, endoscopy techniques are used to assist in gastric insufflation for what is ultimately a percutaneous radiologic gastrostomy.

ULTRASOUND-ASSISTED PERCUTANEOUS ENDOSCOPIC GASTROSTOMY

Similar to CT and fluoroscopy, ultrasound (US) can be utilized as a sole or adjunct modality for gastrostomy placement. Hoffer first described the use of US alone to perform 17 percutaneous gastrostomies in patients warranting enteral access [8]. Klek et al. utilized a thin nasogastric tube passed into the stomach to fill it with 1000 ml of water. US was then performed with a 7.5 MHz probe. The stomach was located and contact between abdominal and gastric walls was confirmed. An additional 500 ml water bolus was used to improve contact between the gastric and abdominal walls. Gastropexy sutures were then placed, the abdominal wall was punctured and a gastrostomy tube was passed. Once water began to flow through the gastrostomy tube, placement in the stomach lumen was confirmed and the balloon was filled with 10 ml of water. Correct placement of the gastrostomy tube in the stomach could then be confirmed with ultrasonography. Eleven patients obtained successful placement of a gastrostomy tube via this method described. Two patients (18%) experienced minor complications which included postoperative pain requiring removal of one to the gastropexy sutures after 3 days and re-insertion of a new balloon catheter [9].

Ultrasound-Assisted Percutaneous Endoscopic Gastrostomy (USA-PEG) has been described in the literature. In circumstances where transillumination has failed, US can be utilized to identify a safe location for the gastrostomy. In 1993, Vargo described the use of US to assist endoscopic gastrostomy placement in a patient with ovarian carcinomatosis. Transcutaneous US assisted in localizing the site for PEG, allowing a tract to be identified that avoided abdominal viscera and metastatic foci [10]. In a larger series, Schlottmann et al. successfully performed USA-PEG in 14/15 patients who failed to transilluminate during endoscopy alone thereby eliminating the need for a surgical gastrostomy in 93% of their patients [11]. USA-PEG has also been performed successfully on patients with abdominal wall varices, with US images being utilized to help identify a safe location for gastrostomy placement around the dilated veins [12].

COLONOSCOPY-ASSISTED PERCUTANEOUS ENDOSCOPIC GASTROSTOMY

In order to safely perform a PEG, transillumination of the abdominal wall via the gastroscope is necessary. One cause of failed transillumination is the interposition of the colon between the stomach and abdominal wall. Penetration of the colon, with development

of a gastro-colo-cutaneous fistula, is a complication of failure to recognize overlying colon. Lax mesentery, motility disorders, and previous abdominal surgery can predispose other segments of the colon to lay anterior to the stomach. Fortunately, misplacement of a PEG tube into the colon is a rare occurrence. Over a five year period, only six cases out of 2384 PEGs resulted in colonic injury and formation of colocutaneous fistulae [13].

Attempts at minimizing injury to the colon during a PEG are focused upon mobilizing the colon away from the anterior stomach wall. Generally, gastric insufflation and reverse Trendelenburg positioning are sufficient to move the colon to a safe position, but in situations where the colon still prevents direct access to the stomach, a colonoscopy-assisted percutaneous endoscopic gastrostomy can be performed. The patient is placed in a supine, frog-leg (or low lithotomy) position to permit simultaneous access to both mouth and anus for endoscopy. Our preference is to perform the procedures in an operative suite under general anesthesia.

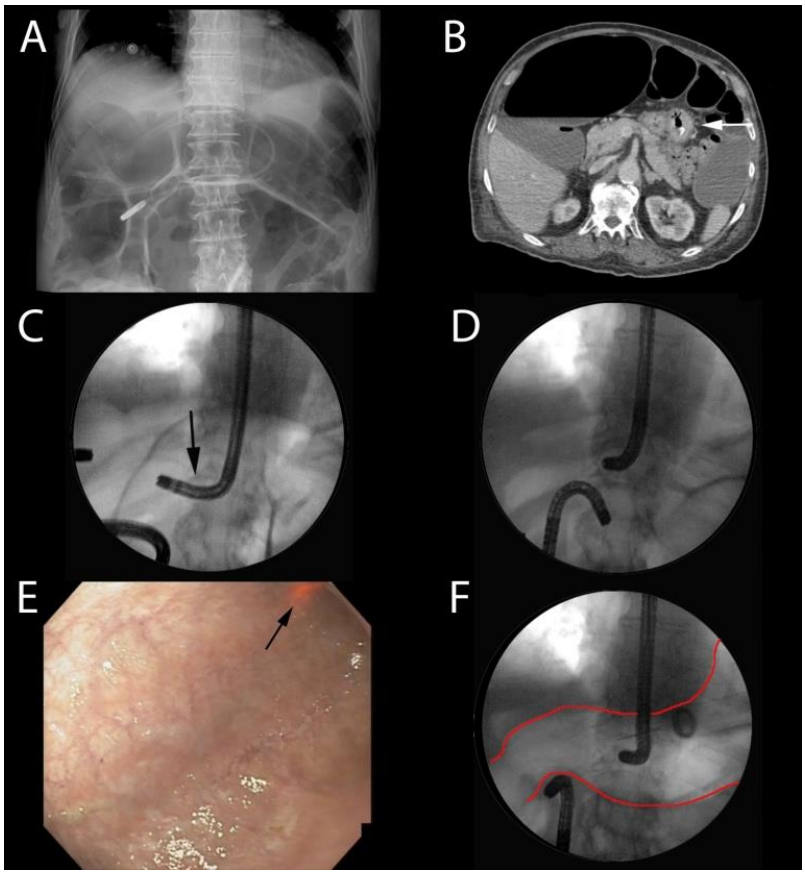

Figure 8. Colonoscopic-assisted PEG. A) Distended transverse and sigmoid colon overlay the stomach (outlined by post-pyloric feeding tube) in a patient with a colonic motility disorder post-operative day 7 after a blowhole transverse colostomy. B) CT scan demonstrating the body of the stomach (white arrow) and interposed colon. C) Despite decompression of the transverse colon via the stoma, the sigmoid colon is still seen anterior to the stomach and gastroscope (black arrow). D) Decompression of the sigmoid colon is performed by passing the colonoscope per rectum. E) Endoscopic view from the stomach demonstrates the colonoscopic light source within the sigmoid colon. F) Fluoroscopy is used to localize a safe location to place the PEG within the distended gastric body (outlined in red).

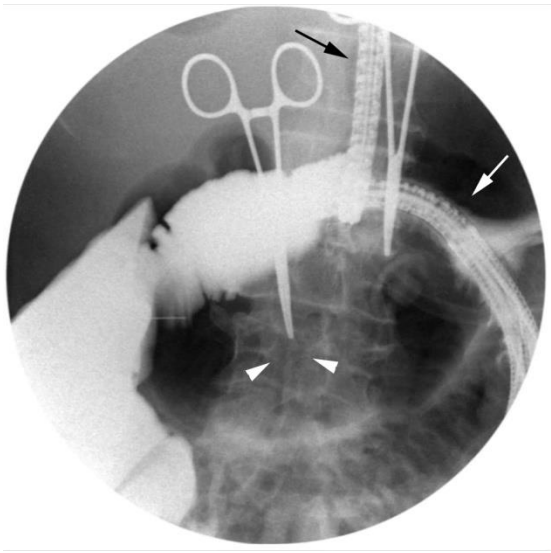

Figure 9. Colonoscopic-assisted PEG. A colonoscope (white arrow) is being use to manually distract a contrast filled transverse colon to permit an upper endoscope (black arrow) to place a gastrostomy tube in the body of the stomach in a safe location (arrowheads).

The use of the colonoscope (simultaneously with upper endoscopy and generally fluoroscopy) has several rolls. In cases of colonic distension, the colonoscope can be used to decompress the colon and permit a safe window for PEG (Figure 8) [14]. If simple decompression alone is insufficient, standard colonoscopy maneuvers can be utilized to manually shift the position of the colon under fluoroscopic guidance (Figure 9) [15, 16]. Once the guidewire access has been placed, it is our preference to visually inspect the colon lumen for any endoscopic evidence of injury prior to completing the gastrostomy and dilating the tract with a 20 Fr gastrostomy tube (Figure 10).

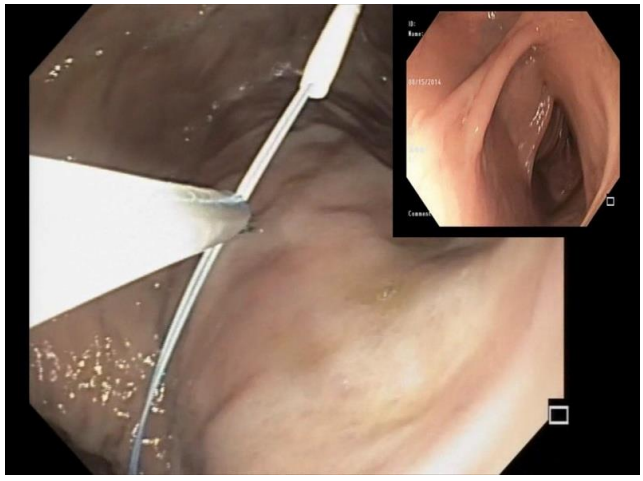

Figure 10. Gastroscope view of the retrieval of a PEG guidewire with a snare and simultaneous colonoscopic view (inset) demonstrating no evidence of wire perforation of the colon.

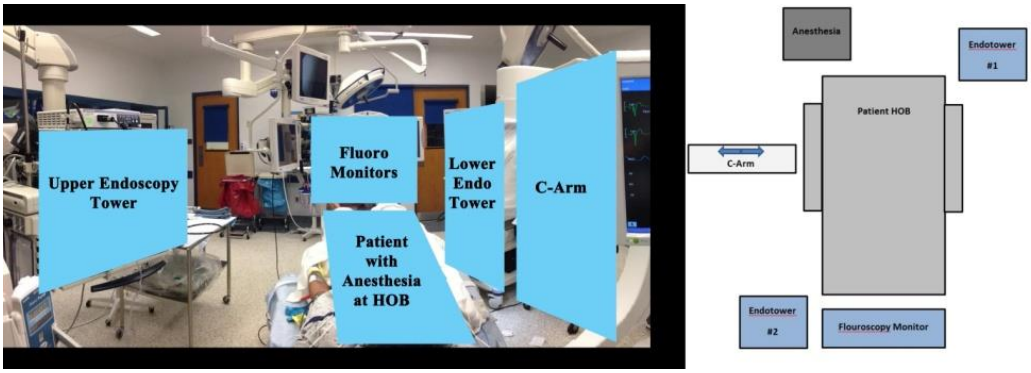

Figure 11. Room setup for colonoscopic-assisted PEG. Left image taken from the head of bed (HOB), right image represents an overhead view.

While safely reported in the literature, colonoscopic-assisted PEG is a highly complex procedure requiring two skilled endoscopists and an elaborate room set-up (Figure 11). The endoscopists must be able to interpret simultaneous upper and lower endoscopy images as well as fluoroscopy. It should only be performed by practitioners skilled in all three modalities and only after careful patient selection and appropriate pre-operative counseling.

CONCLUSION

These 'assist' modalities for PEG have broadened its reach to include even those who would otherwise require a surgical gastrostomy. While demonstrated to be safe, they all require high levels of procedural skill, adaptability and coordination of teams and should be approached with caution and careful consideration.

EDITOR'S COMMENT

This chapter reviews the many techniques needed to gain enteral access in patients who are unable to undergo routine endoscopic placement. The endoscopist must be aware of the roles of the surgeon and radiologist in assuring safe placement of feeding tubes. A collaborative, multidisciplinary approach will allow for the most efficient and safe performance of eternal access (JMM).

REFERENCES

[1] Gauderer MWL, Ponsky JL, Izant RJ. Gastrostomy without laparotomy: a percutaneous endoscopic technique. *J Pediatr Surg*. 1980;15:872-875.

[2] Raaf JH, Manney M, Okafor E et al. Laparoscopic placement of a percutaneous endoscopic gastrostomy (PEG) feeding tube. *Laparoendosc. Surg*. 1993;3(4):411-414.

[3] Hermanowicz A, Matuszczak E, Komarowska M et al. Laparoscopy-assisted percutaneous endoscopic gastrostomy enables enteral nutrition even in patients with distorted anatomy. *World J Gastroenterol*. 2013;19(43):7696-700.

[4] Grant JP. Percutaneous endoscopic gastrostomy. Initial placement by single endoscopic technique and long-term follow up. *Annals of Surgery*. 1993;217(2):168-174.

[5] de Baere T, Chapot R, Kuoch V et al. Percutaneous gastrostomy with fluoroscopic guidance: Single–center experience with 500 consecutive cancer patients. *Vascular and Interventional Radiology*. 1999;210(3):651-654.

[6] Vogt W, Messmann H, Loch G et al. CT-guided PEG in patients with unsuccessful endoscopic transillumination. *Gastrointestinal Endoscopy*. 1996;43(2):138-140.

[7] Spelsberg FW, Hoffman RT, Lang RA et al. CT fluoroscopy guided percutaneous gastrostomy or jejunostomy without (CT-PG/PJ) or with simultaneous endoscopy (CT-PEG/PEJ) in otherwise untreatable patients. *Surgical Endoscopy*. 2013;27(4):1186-1195.

[8] Hoffer EK. US-guided percutaneous gastrostomy: A portable technique. *Journal of Vascular and Interventional Radiology*. 1996;7(3):431-434.

[9] Klek S, Hermanowicz A, Salowka J et al. Ultrasound-guided percutaneous 'push-introducer' gastrostomy is a valuable method for accessing the gastrointestinal tract. *Nutr Hosp*. 2014;1;29(2):365-9.

[10] Vargo JJ, Germain MM, Swenson JA, Harrison CR. Ultrasound-assisted percutaneous endoscopic gastrostomy in a patient with advanced ovarian carcinoma and recurrent intestinal obstruction. *Am J Gastroenterol*. 1993;88(11):1946-8.

[11] Schlottman K, Klebel L, Wiest R et al. Ultrasound-guided percutaneous endoscopic gastrostomy in patients with negative diaphanoscopy. *Endoscopy*. 2007;39(8):686-691.

[12] Horoldt BS, Lee FKT, Gleeson D et al. Ultrasound guidance in the placement of a percutaneous endoscopic gastrostomy (PEG): An adjuvant technique in patients with abdominal wall varices? *Digestive and Liver Disease*. 2005;37(9):709-712.

[13] Friedmann R, Feldman H, Sonnenblick M. Misplacement of percutaneously inserted gastrostomy tube into the colon: report of 6 cases and review of the literature. *J Parenter Enteral Nutr*. 2007; 31:469-476.

[14] Juza RM, Winder JS, Pauli EM. Colonoscopic-Assisted Percutaneous Endoscopic Gastrostomy Tube Placement. *Surgical Endoscopy* 2016 in press DOI 10.1007/s00464-016-5000-0.

[15] Winder JS, Staszak RM, Pauli EM. Multimodal Endoscopic Management of Iatrogenic Transverse Colon Injuries from a Percutaneous Endoscopic Gastrostomy Tube. *Gastrointestinal Endoscopy* 2016 [Epub. ahead of print].

[16] Fukita Y, Katakura Y, Adachi S et al. Colonoscopy-assisted percutaneous endoscopic gastrostomy to avoid a gastrocolocutaneous fistula of the transverse colon. *Endoscopy*. 2014;46 Suppl. 1. Epub. 2014 Feb. 12.

In: Encyclopedia of Surgery (22 Volume Set)
Editors: Andreas Lehrer and Kristin Mueller
ISBN: 978-1-53618-329-0
© 2020 Nova Science Publishers, Inc.

Chapter 135

PEG AND PEJ IN THE POST-BARIATRIC SURGERY PATIENT

Ryan M. Juza and Ann M. Rogers*
Penn State Hershey Medical Center, Hershey, PA, US

INTRODUCTION

Weight loss surgery comprises one of the most common group of elective general surgical procedures performed in academic medical centers in the United States, with over 200,000 operations performed annually in the United States (US) alone [1, 2]. The two most common bariatric surgical operations performed in the US are vertical sleeve gastrectomy (VSG) and Roux-en-Y gastric bypass (RYGB) respectively [2, 3]. Roux-en-Y gastric bypass, for years the gold standard operation for obesity, was replaced in 2013 by VSG as the most frequently performed weight loss operation [4, 5]. Bariatric surgery is the most durable and effective treatment for severe obesity and demonstrates a significant improvement in obesity-related conditions such as Type II diabetes, hypertension, and heart disease [6-8]. While surgical outcomes are excellent, postoperative complications and other pathology may require the establishment of durable enteral access for the purpose of diagnosis and treatment [9-12].

Indications for durable enteral access in post-bariatric surgical patients include primary access for the treatment of postoperative complications such as refractory anastomotic strictures, recalcitrant nausea, chronic distention, dehydration, and failure to thrive. Secondary causes include providing access to the biliary tree for endoscopic therapy in RYGB patients [13]. Patients who have undergone a bariatric surgical procedure remain susceptible to the same disease states that may warrant enteral feeding access in the general population (intra-cranial pathology, neuromuscular disorders, traumatic injuries, etc.) and as such, endoscopists need to be familiar with methods of obtaining enteral feeding access in post-bariatric surgery patients.

Established enteric access can be used for decompression, delivery of medications or nutrition, and as an access point for endoluminal therapies. Open and laparoscopic surgery

* Corresponding Author's Email: arogers@hmc.psu.edu.

remain the pillars of clinical management for these conditions but often previous surgeries, postoperative adhesions, and the need for general anesthesia make these options less desirable. Endoscopy is already widely used for diagnostic and therapeutic purposes in bariatric patients. With the addition of advanced instrumentation and balloon-assisted endoscopy (BAE), several methods of endoscopically establishing enteral access in post-bariatric patients are now described in the literature and widely used in practice [14]. In this chapter we describe options for establishing enteral access in the post-bariatric surgical patient based on the postoperative anatomy and the medical indication for placement.

TECHNIQUES: PERCUTANEOUS ENDOSCOPIC GASTROSTOMY (PEG) TUBE PLACEMENT

Roux-en-Y Gastric Bypass (RYGB) Excluded Stomach

Accessing the excluded stomach following RYGB is often challenging because of postoperative adhesions, altered surgical anatomy, and the native location of the transverse colon. Previously, some advocated creating a prophylactic surgical gastrostomy in the bypassed stomach at the time of surgery for challenging cases to aide in access should complications arise postoperatively [15]. This practice has fallen out of favor because of the low complication rates of laparoscopic bariatric surgery as well the increasing number of options available to gain percutaneous access to the excluded stomach. Indications for durable tube access through the bypassed stomach following RYGB include chronic distention of this viscus and in the instance of biliary pathology to provide access to the biliary tree for therapies such as endoscopic retrograde cholangiopancreatography (ERCP). Other indications include GI bleeding, anemia, and abnormal imaging suggestive of gastric neoplasm. When open or laparoscopically placed gastric access is not desirable, endoscopically placed and radiographically-guided access are suitable options.

Balloon-Assisted Endoscopy (BAE)

The combined length of the alimentary and biliopancreatic limbs following RYGB makes endoscopic access to the bypassed stomach challenging. BAE was first described by Yamamoto et al. in 2001 as a method of providing deep endoscopic access to the entire small bowel [16]. BAE has since been adapted and utilized in post-bariatric surgical patients to provide retrograde endoscopic access to the bypassed foregut structures for diagnostic and therapeutic uses [17-20]. In BAE, the endoscope is introduced *per os* and advanced into the gastric pouch and through the gastrojejunal anastomosis. Typically the entire alimentary limb can be traversed by directly advancing the endoscope until the confluence of the alimentary and biliopancreatic limbs is reached. At this point, the distance and anatomy often prevent further forward motion of the endoscope. From the jejunojejunostomy, a balloon attached to the end of the endoscope can be advanced and inflated to contact the bowel wall. The friction between the balloon and the bowel wall is used to pull the endoscope forward a short distance and the steps repeated. This push-and-pull technique can be used to telescope the bowel over the endoscope as it advances, to shorten the distance between the mouth and bypassed stomach. The BAE endoscopy is continued retrograde up the biliopancreatic limb until the

excluded stomach is reached. Once the pylorus is intubated, the excluded stomach is insufflated to create apposition between the anterior gastric wall and the abdominal wall. With the remnant insufflated, options for tube placement include a Pull method (see Chapter 7) or an Introducer method (see Chapter 9) utilizing standard PEG kits. Fluoroscopy is a useful adjunct for both methods.

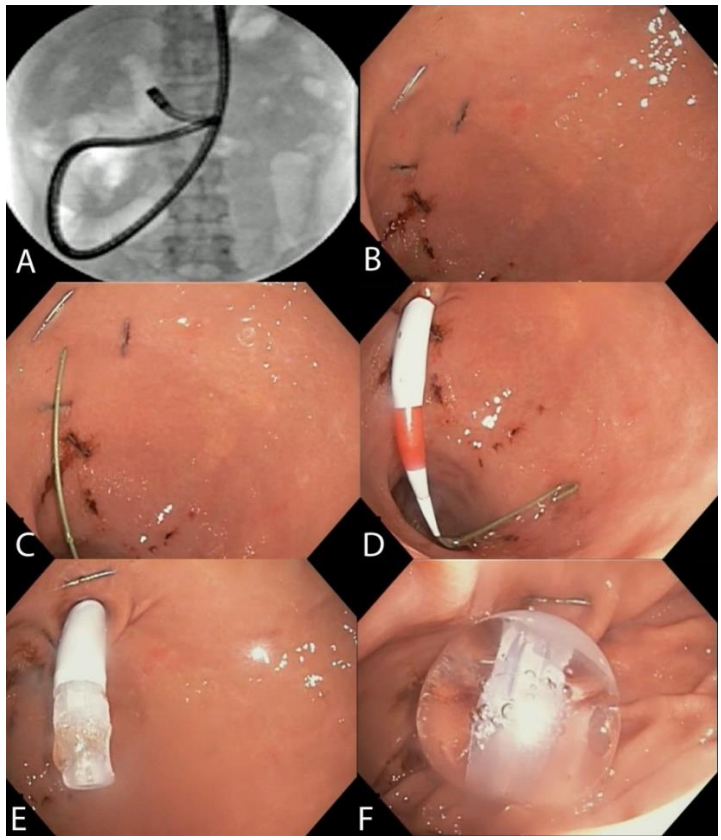

Figure 1. Introducer method of PEG via Balloon Assisted Endoscopy. A) Endoscope is inserted per-os, and then advanced to the remnant stomach using standard balloon enteroscopy maneuvers B) Following the identification of a safe tract for PEG, gastrointestinal T-anchors are placed into the remnant stomach for gastropexy. C) A guidewire is positioned centrally to the T-anchors and D) The tract is serially dilated to the desired diameter. E) Through a peel away sheath a balloon gastrostomy tube is introduced F) As the sheath is removed the balloon is inflated, securing the gastrostomy tube within the gastric lumen.

For the Ponsky-Gauderer “pull” technique, the endoscope is directed toward the anterior wall of the stomach and transillumination used for localization on the abdominal wall. The endoscope is left in place and a snare is advanced through the instrument channel. A hollow bore localizing needle is then passed transabdominally and escape of air bubbles through the needle confirms appropriate placement. Through the needle a looped wire is passed, and the snare is used to grasp and secure the wire. The endoscope and wire are drawn toward the pylorus. With the endoscope removed, the end of the snare is opened to release the wire. The appropriate sized PEG tube is secured to the wire and the endoscopic snare cinched to the

PEG bumper to permit the endoscopist to directly follow the gastrostomy tube back into the bypassed stomach [21]. The size of gastrostomy tube used is determined based on the pathology being treated. If the patient has chronic dilatation of the bypassed stomach, a small caliber (14F) gastrostomy tube can be placed to allow intermittent decompression.

If the patient requires access to permit endoscopic therapy of the biliary tree, a larger gastrostomy tube can be placed, or serially upsized once the tract is established, to accommodate a duodenoscope. In these situations, because of the complexity of reaching and subsequently placing the gastrostomy tube, we choose to pexy the stomach using gastrointestinal T-anchors to prevent disruption of the gastrostomy tract in the event of inadvertent tube dislodgement.

For the Russell "introducer" technique, the endoscope is directed toward the anterior wall of the stomach and transillumination used for localization on the abdominal wall (Figure 1A). A safe tract is established in a standard fashion and gastrointestinal T-anchors (typically 3-4) are placed surrounding the anticipated location for the gastrostomy (Figure 1B). With upward traction on the anchors, and under direct endoscopic visualization, a wire is positioned in the stomach (Figure 1C) and the gastrostomy tract is serially dilated over the wire to the desired size (Figure 1D). A peel away sheath (typically included as part of the last dilator) is positioned across the tract, and the tube is advanced intraluminally (Figure 1E). The peel away sheath is removed, the gastrostomy balloon is inflated (Figure 1F).

Despite advances in BAE, this technique remains challenging. Success rates in the literature range from 60-70% of cases and it is not practiced by all endoscopists because it carries a steep learning curve [17-19, 22]. BAE requires general endotracheal anesthesia and operative times to reach the excluded stomach can be 2-3 hours. Despite these challenges, BAE provides an option for endoscopically accessing the bypassed stomach for PEG.

Endoscopic Ultrasound Assisted/Computed Tomography-Guided Enteral Access

Computed Tomography (CT)-guided percutaneous enteral access have a high rate of success in post-RYGB surgical patients but are contraindicated when bowel is interposed or in the absence of a clear window into to the lumen [23-27]. Endoscopic assistance for radiographically-placed enteral access is an alternative to open or laparoscopic surgical options when image guided (ultrasound, fluoroscopy, CT) percutaneous gastrostomy tube placement is unsuccessful in itself. As described in several small series, echoendoscopic-assistance for a radiographic guided gastrostomy tube placement is used in cases where a clear window cannot initially be seen [28-30]. In this technique an echoendoscope is passed *per os* into the gastric pouch and endoscopic ultrasound (EUS) used to identify the decompressed lumen of the adjacent bypassed stomach (Figure 2A). A large gauge biopsy needle is used to puncture through the gastric pouch and into the juxtaposed wall of the remnant stomach (Figure 2B). Contrast is injected and fluoroscopy is used to confirm accurate puncture of the viscus (Figure 2C). The remnant stomach is then insufflated through the needle to create apposition between the gastric body and the anterior abdominal wall (Figure 2D) thus facilitating radiographically-guided gastrostomy tube placement using a percutaneous introducer technique (Figure 2E and F). Successful EUS-assisted radiologic gastrostomy tube placement was accomplished in 10/11 patients in two small series [28-29]. This option provides a less-invasive treatment alternative to open or laparoscopic gastrostomy

tube placement when BAE is not feasible, but requires expertise in EUS as well as potential coordination of two teams (EUS team and radiology team).

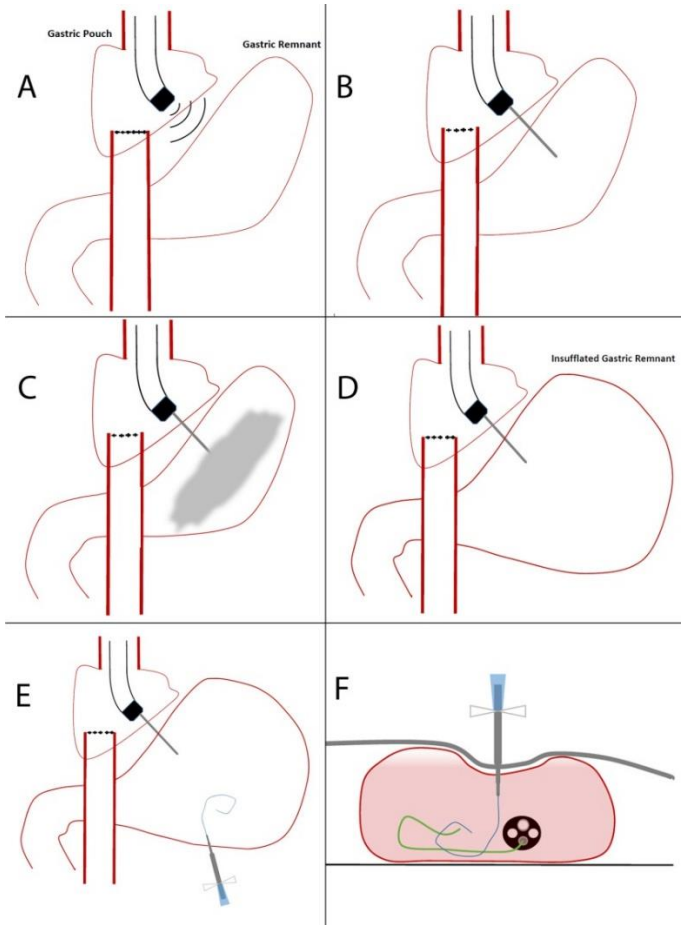

Figure 2. Endoscopic Ultrasound (EUS) assisted access to the gastric remnant. A) The Echoendoscope is passed *per os* into the gastric pouch and ultrasound used to identify the decompressed lumen of the adjacent remnant stomach. B) A biopsy needle is used to puncture through the pouch and into the adjacent lumen of the remnant stomach. C) Contrast is injected to confirm intraluminal positioning of the biopsy needle. D) Carbon dioxide insufflation is used to distend the gastric remnant creating apposition between the anterior abdominal wall and the gastrostomy. E) Anterior and F) Lateral view of the gastric access to the remnant stomach utilizing the introducer method (see Chapter 9 for more detailed description of this method).

Roux-en-Y Gastric Bypass (RYGB) Gastric Pouch

Establishing enteral access into the gastric pouch may be required in post-RYGB patients who present with refractory marginal ulcer and/or gastric outlet obstruction at the gastrojejunal anastomosis. PEG tube placement into the gastric pouch may be challenging for a number of reasons. A standard restrictive gastric pouch measures 30cc, at least in the early postoperative period, allowing little room for placing a gastrostomy tube with bumper or

balloon. In addition, the gastric cardia sits anatomically above the costal margin, making it inaccessible to percutaneous access methods in most cases. However, attempts at endoscopically placing enteral access tubes are warranted in appropriate clinical settings with acceptable patient anatomy. In the setting of a chronic obstruction, for example, the gastric pouch may be substantially dilated and therefore be accessible below the costal margin. In addition, if outlet obstruction was the indication for enteral access, a gastrostomy tube with jejunal extension should be considered if possible, to provide gastric decompression through the gastric port and enteral nutrition through the jejunal extension.

A radiographically placed G-tube may be required in these cases due to inability to safely access the gastric pouch by endoscopy alone, due to its pocation above the costal margin. See Chapters 12 and 15 for additional details about radiographic assisted PEG tube placement.

Adjustable Gastric Band (AGB)

Indications for PEG following AGB are the same as for those in the non-bariatric patient (see Chapter 2). The presence of the band itself may be the sole or contributing factor to the patient's dysphagia. Deflating the band should be in the treatment algorithm for any AGB band with dysphagia or odynophagia.

The method of PEG placement in an AGB patient does not differ substantially from the methods described in Chapters 7 and 8. We find the Pull method technically easier to perform in the post-AGB patient as the dilating tip and/or the silicone retention dome of the gastrostomy tube itself can get hung up at the level of the band, resulting in resistance to forward tube advancement with the Push method. Complete deflation of the AGB facilitates both methods of PEG.

TECHNIQUES: DIRECT PERCUTANEOUS ENDOSCOPIC JEJUNOSTOMY (DPEJ) TUBE

Roux-en-Y-Gastric Bypass

Direct Percutaneous Endoscopic Jejunostomy (DPEJ) was originally described as an option for establishing enteral feeding in total and subtotal gastrectomy cancer patients to treat chronic malnutrition, dehydration, and failure to thrive [31-34]. DPEJ has since been utilized in post-RYGB patients who suffer from intractable nausea, gastric outlet obstruction, refractory ulcerations, malnutrition and dehydration. In patients with unaltered anatomy, deep jejunal access requires balloon-assisted endoscopy to traverse beyond the ligament of Treitz. In RYGB patients, however, deep jejunal access is simplified by the gastrojejunal anastomosis, which permits easy intubation of the jejunum. Despite rapid access to the anatomically more distal small bowel, determination of the post-surgical anatomy is important prior to proceeding with establishing enteral access in RYGB patients.

Special attention must be paid to whether the gastrojejunostomy was created in a retrogastric or antegastric fashion as well as whether the alimentary limb was placed in a retrocolic or antecolic position. This information can be obtained from the prior operative

note or by obtaining a CT with enteric contrast (or while a naso-jejunal tube is in place) to better delineate the anatomy. Patients who have had their RYGB created with an antegastric, antecolic configuration provide a better opportunity for successful DPEJ as the proximal jejunum is affixed in a more anterior position that will likely be more easily accessible for percutaneous puncture (Figure 3). Patients with a retrocolic RYGB construction will require more care taken to avoid injury to the colon as it passes over the alimentary limb. If there is concern for harm to overlying bowel, simultaneous colonoscopy and fluoroscopy with intraluminal contrast injection can be used to help identify the colon prior to passing a needle.

DPEJ placement is more challenging than standard PEG or percutaneous endoscopic gastrojejunal (PEGJ) placement due to the smaller target, difficult transillumination, and continuous peristaltic waves of the small bowel [35-6]. To improve successful endoscopic placement some advocate the use of glucagon or another antiperistaltic agent to decrease motility during key portions of the procedure [37]. Alternatively, gastrointestinal T-anchors can be used to rapidly affix the appropriate segment of bowel once the desired location has been selected. Although the native jejunum typically lies within the left upper quadrant, the surgically-altered anatomy means that the most anterior segment of bowel could lie anywhere within the abdominal cavity. Again, knowing the anatomy preoperatively is key to success in this operation, and liberal use of fluoroscopy is a useful adjunct. Owing to this variability, the entire abdominal wall should be sterilely prepared to avoid any delay once the site of maximum transillumination is identified.

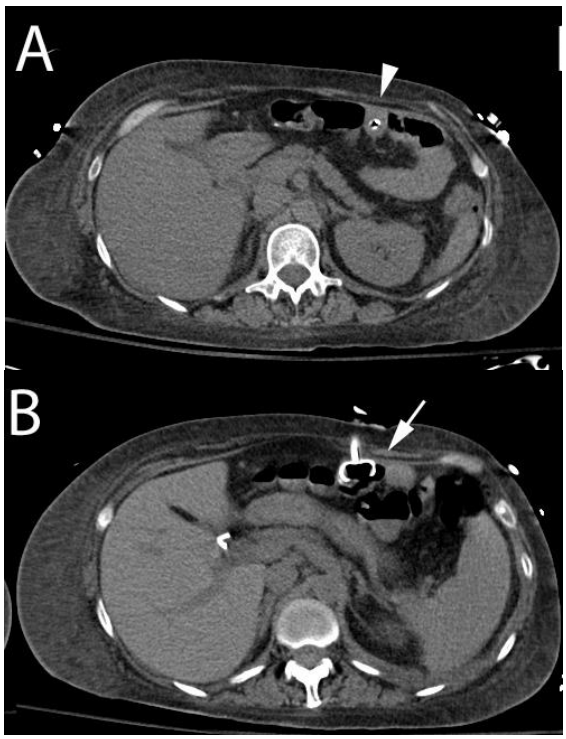

Figure 3. Post RYGB patient in need of durable enteral access following an intra-cerebral hemorrhage. A) CT scan obtained with NJ tube in position demonstrates an antecolic, antegastric bypass and a safe window for DPEJ directly beneath the left rectus muscle (arrowhead) B) CT scan obtained after DPEJ demonstrates the tube to be in an anticipated position.

Figure 4 demonstrates the steps of DPEJ in a post-RYGB patient. After adequate preparation, the endoscope is then passed orally and advanced to the gastric pouch. A scout fluoroscopy film prior to introduction of the endoscopy can help identify the location of the colon (Figure 4A). After traversing the gastrojejunal anastomosis the endoscope is advanced 10-20cm into the jejunum. Transillumination and finger palpation are used to localize a segment of bowel against the anterior abdominal wall. Fluoroscopy can be used to confirm this location (Figure 4B). Once an appropriate segment is identified, standard steps for PEJ tube placement are employed beginning with a safe tract method (Figure 4C). Surrounding this safe tract, gastrointestinal T-anchors can be placed as desired (Figure 4D) [38]. The lumen is accessed with a core needle (Figure 4E), a wire is passed, and a snare is used to grasp and extract the wire into the lumen (Figure 4F). Because of the narrow caliber of the intestine, a Ponsky-pull technique is used to place a smaller, such as 20F, gastrostomy tube to minimize the risk of intestinal obstruction caused by the tube bumper (Figure 4G) [21]. If desired, a jejunal feeding extension can be passed distally into the small bowel and secured with endoclips (Figure 4H and I). This feeding extension has two roles, the first is to ensure that feeds do not reflux into the small gastric pouch and result in aspiration, the second is to reduce confusion about the presence of a 20 Fr tube in the left abdomen which may be incorrectly assumed to be a gastrostomy. The jejunal extension may therefore reduce the risk of inadvertent administration of bolus feeds to the small bowel. Contrast fluoroscopy can also be used to confirm correct placement of the tube at the completion of the DPEJ (Figure 4J) [39].

A modification to this technique has been described in an animal model utilizing intraluminal and extracorporeal magnetics to improve jejunal apposition to the abdominal wall prior to DPEJ placement [40]. The authors report a 100% success rate in establishing enteral access using this device; however such devices are not yet approved for human use.

Sleeve Gastrectomy

Sleeve gastrectomy has much less malabsorption compared to RYGB, as it only involves removing the distensible gastric fundus and does not alter intestinal continuity. DPEJ in post-VSG patients therefore follows the same steps of DPEJ in native anatomy. However, because of the small gastric body, BAE (with or without the use of endoscopic overtubes) or the use of a colonoscope *per os* are frequently not required [41]. DPEJ placement for VSG patients should only be considered in the setting of a well-healed, intact sleeve, as the large diameter of the working devices or the forces needed to advance the endoscope could lacerate or risk perforating a tenuous staple line [42].

To begin the procedure, again the entire abdominal wall is prepared to avoid delay once a suitable loop of bowel is identified. Endoscopy is performed and the endoscope is advanced until an appropriate loop of bowel, approximately 20cm beyond the ligament of Treitz is selected. The intraluminal location is approximated to the abdominal wall using a combination of transillumination and palpation. A hollow bore needle is used to puncture the jejunal loop under endoscopic visualization, and return of bubbles confirms placement. A wire is passed through the needle and an endoscopic snare is used to draw the wire retrograde. The remainder of the DPEJ tube placement is performed using standard PEJ technique. Because of the narrow caliber of the intestine, a 20F tube is again used to minimize the risk of

intestinal obstruction. Gastrointestinal T-anchors are always placed longitudinally to affix the bowel to the abdominal wall and prevent inadvertent tube dislodgement and free perforation. Chapter 10 covers the steps of DPEJ in greater detail.

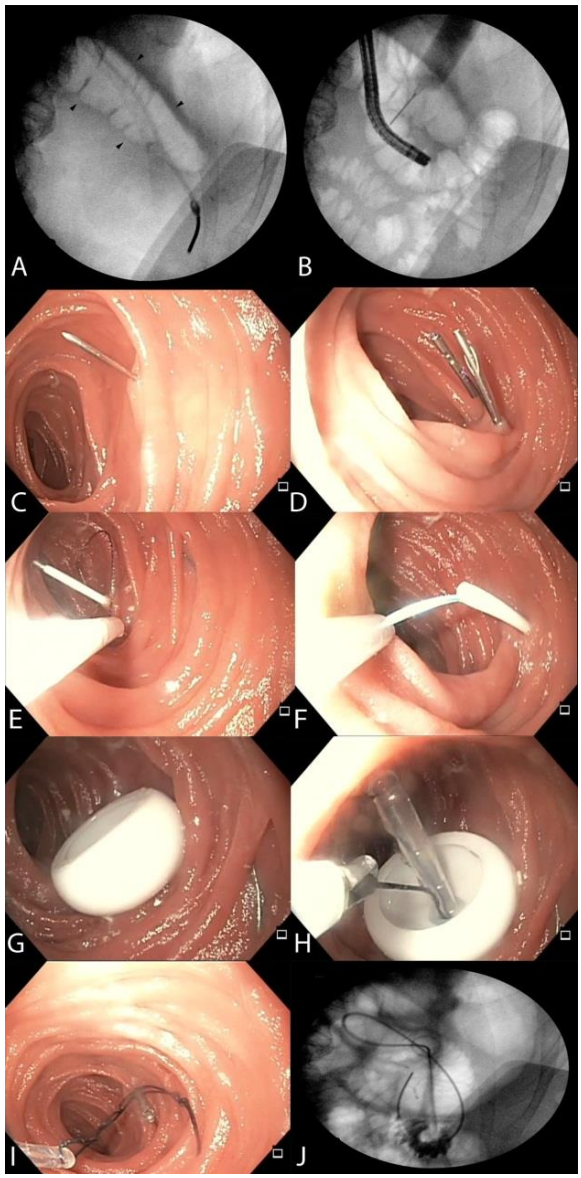

Figure 4. Direct PEJ in an antecolic antegastric RYGB patient. A) Scout fluoroscopy film identifies air within the transverse colon (arrowheads) B) The endoscope if visualized within the alimentary limb and the location of maximal transillumination is marked with the blunt tip needle C) A safe tract method is used to confirm the correct location before D) Gastrointestinal T-Anchors are placed E) A guide sheath and needle are passed into the jejunum and F) A guidewire is grasped with a snare and withdrawn *per os* G) A 20 Fr gastrostomy is positioned (note that it is not obstructing the lumen) H) A jejunal extension is introduced via the 20 Fr tube I) The jejunal extension is advanced distally and clipped to the mucosa J) Completion contrast study demonstrates the 20 Fr DPEJ, jejunal extension, endoclips and contrast filling the distal alimentary limb.

CONCLUSION

Endoscopy plays a crucial role in the diagnosis and treatment of many post-bariatric surgical complications. Management can include closure of leaks, establishing feeding access, and creating enteral access to permit endoscopic therapy in the post-surgical anatomy. Anatomy can vary substantially and an accurate understanding and recognition of this variability is essential prior to performing such procedures. The method and type of access may be guided by which bariatric operation was performed and the exact indication for access. Despite an overall low complication rate, the number of weight loss surgical procedures performed annually mandates that endoscopists be well-versed in the options for establishing endoluminal enteral access to assist in management and treatment of the unique pathology that can arise in post-bariatric surgical patients.

REFERENCES

[1] Maggard, MA; Shugarman, LR; Suttorp, M; et al. Meta-analysis: surgical treatment of obesity. *Ann Intern Med*., 2005, 142(7), 547–5.

[2] Buchwald, H; Oien, DM. Metabolic/bariatric surgery worldwide 2011. *Obes Surg*., 2013, 23(4), 427-36.

[3] Young, MT; Gebhart, A; Phelan, MJ; Nguyen, NT. Use and Outcomes of Laparoscopic Sleeve Gastrectomy vs Laparoscopic Gastric Bypass: Analysis of the American College of Surgeons NSQIP. *J Am Coll Surg*., 2015, 220(5), 880-5.

[4] Esteban Varela, J; Nguyen, NT. Laparoscopic sleeve gastrectomy leads the U.S. utilization of bariatric surgery at academic medical centers. *Surg Obes Relat Dis*., 2015, 11(5), 987-90.

[5] Nguyen, NT; Nguyen, B; Gebhart, A; Hohmann, S. Changes in the makeup of bariatric surgery: a national increase in use of laparoscopic sleeve gastrectomy. *J Am Coll Surg*., 2013, 216(2), 252-7.

[6] Karamanakos, SN; Vagenas, K; Kalfarentzos, F; Alexandrides, TK. Weight loss, appetite suppression, and changes in fasting and postprandial ghrelin and peptide-YY levels after Roux-en-Y gastric bypass and sleeve gastrectomy: prospective, double blind study. *Ann Surg*., 2008, 247(3), 401-7.

[7] Colquitt, JL; Pickett, K; Loveman, E; Frampton, GK. Surgery for weight loss in adults. *Cochrane Database Syst Rev*., 2014, 8, CD003641.

[8] Peterli, R; Wölnerhanssen, B; Peters, T; Devaux, N; Kern, B; Christoffel-Courtin, C; Drewe, J; von Flüe, M; Beglinger, C. Improvement in glucose metabolism after bariatric surgery: comparison of laparoscopic Roux-en-Y gastric bypass and laparoscopic sleeve gastrectomy: a prospective randomized trial. *Ann Surg*., 2009, 250(2), 234-41.

[9] Fobi, MA; Chicola, K; Lee, H. Access to the bypassed stomach after gastric bypass. *Obes Surg*., 1998, 8(3), 289-95.

[10] McNeely, G; Stork, J; Macgregor, A; Burns, E. Percutaneous Examination of the Bypassed Stomach. *Obes Surg*., 1991, 1(4), 427-430.

[11] Ceppa, FA; Gagné, DJ; Papasavas, PK; Caushaj, PF. Laparoscopic transgastric endoscopy after Roux-en-Y gastric bypass. *Surg Obes Relat Dis*., 2007, 3(1), 21-4.

[12] Roberts, KE; Duffy, AJ; Bell, RL. Laparoscopic transgastric repair of a gastrogastric fistula after gastric bypass: a novel technique. *Surg Innov*., 2007, 14(1), 18-23.

[13] ASGE Standards of Practice Committee, Evans, JA; Muthusamy, VR; Acosta, RD; Bruining, DH; Chandrasekhara, V; Chathadi, KV; Eloubeidi, MA; Fanelli, RD; Faulx, AL; Fonkalsrud, L; Khashab, MA; Lightdale, JR; Pasha, SF; Saltzman, JR; Shaukat, A; Wang, A; Stefanidis, D; Richardson, WS; Khothari, SN; Cash, BD. The role of endoscopy in the bariatric surgery patient. *Surg Obes Relat Dis*., 2015, 11(3), 507-17.

[14] Moreels, TG. Altered anatomy: enteroscopy and ERCP procedure. *Best Pract Res Clin Gastroenterol*., 2012, 26(3), 347-57.

[15] Wood, MF; Sapala, JA; Sapala, MA; Schuhknecht, MP; Flake, TM. Micropouch gastric bypass: indications for gastrostomy tube placement in the bypassed stomach. *Obes Surg*., 2000, 10(5), 413-9.

[16] Yamamoto, H; Sekine, Y; Sato, Y; Higashizawa, T; Miyata, T; Iino, S; Ido, K; Sugano, K. Total enteroscopy with a nonsurgical steerable double-balloon method. *Gastrointestinal Endoscopy*., 2001, 53(2), 216–20.

[17] Baron, TH. Double-balloon enteroscopy to facilitate retrograde PEG placement as access for therapeutic ERCP in patients with long-limb gastric bypass. *Gastrointest Endosc.*, 2006, 64, 973-4.

[18] Ross, AS; Semrad, C; Alverdy, J; et al. Use of double-balloon enteroscopy to perform PEG in the excluded stomach after Roux-en-Y gastric bypass. *Gastrointest Endosc*., 2006, 64, 797-800.

[19] Ross, AS; Dye, C. Double-balloon enteroscopy to facilitate retrograde PEG placement as access for therapeutic ERCP in patients with long-limb gastric bypass. *Gastrointest Endosc*., 2007, 66(2), 419.

[20] Sakai, P; Kuga, R; Safatle-Ribeiro, AV; Faintuch, J; Gama-Rodrigues, JJ; Ishida, RK; Furuya, CK; Jr. Yamamoto, H; Ishioka, S. Is it feasible to reach the bypassed stomach after Roux-en-Y gastric bypass for morbid obesity? The use of the double-balloon enteroscope. *Endoscopy*., 2005, 37(6), 566-9.

[21] Ponsky, JL. The Development of PEG: How it was. *J Interv Gastroenterol*., 2011, 1(2), 88-89.

[22] Palmer, LB; McClave, SA; Bechtold, ML; Nguyen, DL; Martindale, RG; Evans, DC. Tips and tricks for deep jejunal enteral access: modifying techniques to maximize success. *Curr Gastroenterol Rep*., 2014, 16(10), 409.

[23] Goitein, D; Gagné, DJ; Papasavas, PK; McLean, G; Foster, RG; Beasley, HS; Caushaj, PF. Percutaneous computed tomography-guided gastric remnant access after laparoscopic Roux-en-Y gastric bypass. *Surg Obes Relat Dis*., 2006, 2(6), 651-5.

[24] Singh, A; Gelrud, A. Adverse events associated with percutaneous enteral access. *Gastrointest Endosc Clin N Am*., 2015, 25(1), 71-82.

[25] Spelsberg, FW; Hoffmann, RT; Lang, RA; Winter, H; Weidenhagen, R; Reiser, M; Jauch, KW; Trumm, C. CT fluoroscopy guided percutaneous gastrostomy or jejunostomy without (CT-PG/PJ) or with simultaneous endoscopy (CT-PEG/PEJ) in otherwise untreatable patients. *Surg Endosc*., 2013, 27(4), 1186-95.

[26] Stein, EG; Cynamon, J; Katzman, MJ; Goodman, E; Rozenblit, A; Wolf, EL; Jagust, MB. Percutaneous gastrostomy of the excluded gastric segment after Roux-en-Y gastric bypass surgery. *J Vasc Interv Radiol*., 2007, 18(7), 914-9.

[27] Sundbom, M; Nyman, R; Hedenström, H; Gustavsson, S. Investigation of the excluded stomach after Roux-en-Y gastric bypass. *Obes Surg*., 200, 11(1), 25-7.

[28] Rueth, N; Ikramuddin, S; Andrade, R. Endoscopic gastrostomy after bariatric surgery: a unique approach. *Obes Surg*., 2010, 20(4), 509-11.

[29] Attam, R; Leslie, D; Arain, MA; Freeman, ML; Ikramuddin, S. EUS-guided sutured gastropexy for transgastric ERCP (ESTER) in patients with Roux-en-Y gastric bypass: a novel, single-session, minimally invasive approach. *Endoscopy*., 2015, 47(7), 646-9.

[30] Iqbal, S; Bessler, M; Stevens, PD; Sethi, A. Endoscopic neogastrogastrostomy in a postgastric bypass patient by application of an endoscopic antegrade-retrograde rendezvous technique. *Surg Obes Relat Dis*., 2012, 8(5), 651-3.

[31] Panagiotakis, PH; DiSario, JA; Hilden, K; et al. DPEJ tube placement prevents aspiration pneumonia in high-risk patients. *Nutr Clin Pract*., 2008, 23, 172-175.

[32] Shike, M; Berner, YN; Gerdes, H; Gerold, FP; Bloch, A; Sessions, R; Strong, E. Percutaneous endoscopic gastrostomy and jejunostomy for long-term feeding in patients with cancer of the head and neck. *Otolaryngol Head Neck Surg*., 1989, 101(5), 549-54.

[33] Shike, M; Latkany, L. Direct percutaneous endoscopic jejunostomy. *Gastrointest Endosc Clin N Am*., 1998, 8(3), 569–80.

[34] Bueno, JT; Schattner, MA; Barrera, R; Gerdes, H; Bains, M; Shike, M. Endoscopic placement of direct percutaneous jejunostomy tubes in patients with complications after esophagectomy. *Gastrointest Endosc*., 2003, 57(4), 536-40.

[35] Fan, AC; Baron, TH; Rumalla, A; et al. Comparison of direct percutaneous endoscopic jejunostomy and PEG with jejunal extension. *Gastrointest Endosc*., 2002, 56, 890-894.

[36] Maple, JT; Petersen, BT; Baron, TH; Gostout, CJ; Wong Kee Song, LM; Buttar, NS. Direct percutaneous endoscopic jejunostomy: outcomes in 307 consecutive attempts. *Am J Gastroenterol*., 2005, 100(12), 2681-8.

[37] Baron, TH. Direct percutaneous endoscopic jejunostomy. *Am J Gastroenterol*., 2006, 101(7), 1407-9.

[38] Alberca-de-Las-Parras, F; Navalón-Rubio, M; Egea-Valenzuela, J; Álvarez-Higueras, FJ; Antón-Ródenas, G; Alajarín-Cervera, M; Serrano-Giménez, A; Gil-Ortega, D; Muñoz-Tornero, M; Ono-Ono, A; Carballo-Álvarez, LF. Direct percutaneous endoscopic jejunostomy in pediatric age with a pexies triangulation system: report of a case and literature review. *Rev Esp Enferm Dig*., 2015, 107(4), 240-2.

[39] Velázquez-Aviña, J; Beyer, R; Díaz-Tobar, CP; Peter, S; Kyanam Kabir Baig, KR; Wilcox, CM; Mönkemüller, K. New method of direct percutaneous endoscopic jejunostomy tube placement using balloon-assisted enteroscopy with fluoroscopy. *Dig Endosc*., 2015, 27(3), 317-22.

[40] Yano, T; Yamamoto, H; Sunada, K; Miura, Y; Taguchi, H; Arashiro, M; Yoshizawa, M; Hayashi, Y; Miyata, T; Tanaka, H; Kobayashi, E; Sugano, K. New technique for direct percutaneous endoscopic jejunostomy using double-balloon endoscopy and magnetic anchors in a porcine model. *Dig Endosc*., 2011, 23(2), 206.

[41] Pinho, RT; Rodrigues, MA; Proença, ML. Overtubes and fluoroscopy for direct percutaneous endoscopic jejunostomy: useful, although not always needful and sometimes harmful. *Dig Endosc*., 2015, 27(3), 399-400.

[42] Balmadrid, B; Andrew Ross, A. Severe laceration in a percutaneous endoscopic jejunostomy placement resolved with over-the-scope clips *Gastrointestinal Endoscopy*., 2013, 78(5), 783-785.

In: Encyclopedia of Surgery (22 Volume Set)
Editors: Andreas Lehrer and Kristin Mueller
ISBN: 978-1-53618-329-0
© 2020 Nova Science Publishers, Inc.

Chapter 136

ALTERNATIVE USES OF PERCUTANEOUS ENDOSCOPIC GASTROSTOMY

Heidi J. Miller, MD and Jeffrey M. Marks*, MD
University Hospitals Case Medical Center, Cleveland, OH, US

INTRODUCTION

Since its introduction in 1980 in Cleveland, PEG technique has been performed and studied for a wide array of uses. The most common indications (as described elsewhere in this book) are impaired swallowing due to a number of causes, catabolic conditions requiring supplemental nutrition, and delivery of hydrating fluids or medications [1]. Other uses that have been described include decompression of benign and malignant gastrointestinal (GI) tract obstruction, refeeding of biliary and GI tract losses, colonic access, gastropexy, GI access for procedural intervention, esophagostomy, management of leaks and fistulas and natural orifice transluminal endoscopic surgery (NOTES) [1, 2]. This chapter provides an overview of the alternative uses of PEG technique beyond affording a route for enteral nutrition.

DECOMPRESSION

The most commonly recognized "alternative" use of the PEG described in the literature and among gastroenterological societies is the "venting" gastrostomy for decompression of the GI tract. This is primarily utilized in the setting of bowel obstruction, both benign and malignant. Other indications for decompressive PEG that have been studied include gastroparesis and prolonged ileus.

The use of PEG tubes for decompression of patients with malignant bowel obstructions has been found to be both safe (with a minor complication profile) and successful at eliminating the need of nasal tubes in most patients [3]. Decompression via venting

* Corresponding Author's Email: jeffrey.marks@uhhospitals.org.

gastrostomy is utilized similarly to stenting and surgical interventions in the presence of malignant bowel obstruction to treat intractable nausea and vomiting. The venting PEG has a 92% success rate and serves to permit removal of nasal tubes, treat symptoms and increase quality of life by allowing resumption of oral fluids and soft food intake for comfort and social reasons. The complications are few and mild including pain, leakage, skin excoriation and tube blockage. If a PEG is not possible or adequate, percutaneous endoscopic jejunostomy (PEJ) or percutaneous transesophageal gastrostomy (PTEG) have also been found to be successful [4]. See Chapters 10 and 12, respectively, for further discussion on PEJ and PTEG.

Venting gastrostomy tubes should be used in combination with well managed medical and pharmacologic interventions [5]. Kawata et al. placed PEG tubes in 76 patients with malignant obstructions over the course of 10 years using either the pull or modified introducer method, and placed gastrojejunostomy tubes where indicated [3]. They showed a 93% success rate for placement, 96% reduction in the need for nasal tubes and a 21% complication rate (mostly leakage or infection around the gastrostomy). The median survival was 63 days (range 8-444 days) with no procedure related mortality. Outcomes in malignant bowel obstruction seem to be related more to the patient's functional status and disease-free time than intervention type, and the average median survival following decompressive PEG is around 80 days [5].

Decompressive PEG has also been found to be safe and effective in the management of obstructive symptoms in benign disease in patients who cannot be easily managed with surgery, ultimately allowing removal of the nasogastric tube and discharge from the hospital [6]. Such conditions include non-malignant obstruction, motility disorders, need for diversion of gastric contents, and prolonged ileus. The literature is limited to a few small case series and retrospective reviews of subgroup outcomes within larger series of obstructed patients, evaluating nonmalignant indications for decompression. There is a high success rate of placement of PEGs with a low complication profile and they can play three ultimate roles: bridge to surgical therapy, intermediate therapy allowing for resolution of obstructive/paralytic pathology, and permanent venting gastrostomy in a small number of patients [7-9].

Daigle et al. report a retrospective review of 72 patients over 5 years who underwent decompressive PEG for nonmalignant indications including postoperative ileus, dysmotility, chronic or subacute small bowel obstruction (SBO), benign gastric outlet obstruction, superior mesenteric artery syndrome, and complicated SBO with contraindications for immediate surgical intervention. Only one procedural complication of PEG-associated bleeding was reported and there were no procedure related mortalities. Fifty-two patients were followed long term and PEG was kept in place for a median of 69.5 days (range 17-316 days). Sixty-three patients were discharged on total parenteral nutrition (TPN). The 36 patients that were followed long-term received TPN for a median of 51 days but ultimately achieved resolution of their obstructive problems and were able to resume enteral nutrition. Three patients became chronically TPN-dependent and their PEG tubes remained in place [7].

In a small series of PEG use for prolonged ileus, Takayama showed that patients tolerated PEG better than nasogastric tubes, and PEG decompression provided better outcomes. PEG tubes allowed 4 of 5 patients to improve without surgical intervention and one patient to improve functional and nutritional status preoperatively. All five of these patients eventually had their tubes clamped, tolerated oral feeds and tubes removed in succession [9].

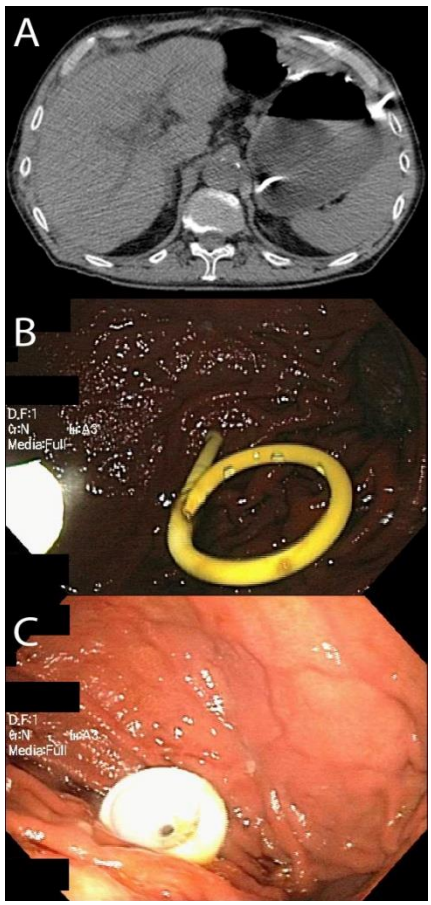

Figure 1. Endoscopic rendezvous technique for intercostal PEG placement. A) CT guided placement of pigtail tube through the intercostal space due to carcinomatosis limiting safe PEG placement for decompression of malignant bowel obstruction. B) Endoscopic view of intercostal pigtail tube in the lumen of the stomach. C) Endoscopic view of decompressive PEG following exchange of the intercostal pigtail catheter.

The European Society for Pediatric Gastroenterology Hepatology and Nutrition recognizes gastric stasis as an indication for PEG placement in pediatric patients. The use of PEG in gastroparesis in pediatric patients can be for venting via gastrostomy alone but also allows for transpyloric feeding with the use of a jejunal feeding extension tube (PEG-J) [10]. The clinical guidelines for management of gastroparesis by the American College of Gastroenterology also discuss the use of a gastrostomy. Gastrostomy for venting and jejunostomy for enteral feeding in the management of gastroparesis is a conditional recommendation due to the lack of evidence [11]. However, the PEG-J provides benefits over a simple jejunostomy and gastrostomy by allowing venting of the stomach to decrease or prevent emesis, as well as providing post-pyloric feeds through distal J-tube ports. This also comes with potential complications such as J-tube migration into the stomach, obstruction at the pylorus and potential interference with gastric stimulator placement, but reduces the potential complications compared to two separate access sites [11].

Finally, PEG and direct percutaneous tube enterostomies have been described for decompression of afferent loop obstruction following surgical gastrojejunostomy [12].

Technical Pearls

Safe percutaneous access to the stomach can be difficult in the patient with a hostile abdomen, either due to malignancy or severe adhesive disease secondary to multiple surgeries. Radiologic guidance for pigtail catheter placement into the stomach can be used in these cases as well as in patients where safe tract or transillumination below the costal margin cannot be achieved. An endoscopic rendezvous technique can be used for intercostal placement of PEG for palliative uses. This includes radiologic guided insertion of intercostal pigtail tube and the PEG is then placed endoscopically through the created track (Figure 1). PEG technique may also be utilized to aid in difficult open gastrostomy cases, such as a frozen abdomen, to safely identify and place a decompressive tube.

GASTROPEXY

Paraesophageal hernia (PEH) can often be asymptomatic in elderly patients but large PEH hold a 30-45% risk of incarceration, volvulus or strangulation. These complications can have up to a 50% risk of mortality which leads surgeons to be more aggressive in definitive repair at early stages. Laparoscopic repair with recreation of normal anatomy, intraabdominal esophagus, and closure of the crural defect is the standard of care. However, as the population ages and incidence of large PEH increases, so do the comorbid conditions with which patients present. Open repair of PEH has been shown to have up to 27% morbidity rates and 1-2% mortality and elective laparoscopic repair has been reported to have up to 28% morbidity with a 16% major complication rate. Endoscopy is the most logical approach for a less invasive but effective palliative and preventive procedure [13]. The second most common alternative use of the PEG is gastropexy in the setting of PEH or gastric volvulus.

Endoscopic reduction of large PEH was described in the literature in the 1990s, starting with a small series where this was used as a bridge for optimization for definitive surgery. This then led to the use of the dual PEG technique for gastropexy (Figure 2). There have been single cases and case series that describe both laparoscopic and endoscopic gastropexy for the treatment of large PEH, but these report a higher recurrence rate compared to the use of PEG [13]. Kercher et al. describe a series of 11 high risk elderly patients with symptomatic large PEH that were treated with either endoscopic reduction and dual PEG placement or laparoscopic-assisted endoscopic reduction and dual PEG placement [13]. Pull-PEGs were placed in the mid body and antrum with at least a 12 inch interval between the tubes to allow for definitive gastropexy. Tubes were left in place for 2 months. Lap-assisted cases also had laparoscopic gastropexy sutures placed to reinforce the PEG gastropexy. Of these 11 patients, three had mild reflux symptoms and one had evidence of an asymptomatic recurrent sliding hiatal hernia at 2 months [13]. More recently, multiple case reports for the treatment of gastric volvulus, obstruction or incarcerated PEH have been published. These techniques can include laparoscopic repair and reduction with PEG gastropexy, endoscopic reduction with PEG gastropexy or endoscopic reduction with percutaneous gastropexy devices (Figure 3) [14-18]. See Chapter 9 for a more indepth discussion of methods of endoscopic and laparoscopic gastropexy.

There are reports of recurrent volvulus and herniation with the use of single PEG gastropexy and suture gastropexy alone, as both of these create another potential axis for rotation [13, 19]. Therefore, a dual PEG or multiple gastropexy site technique is recommended.

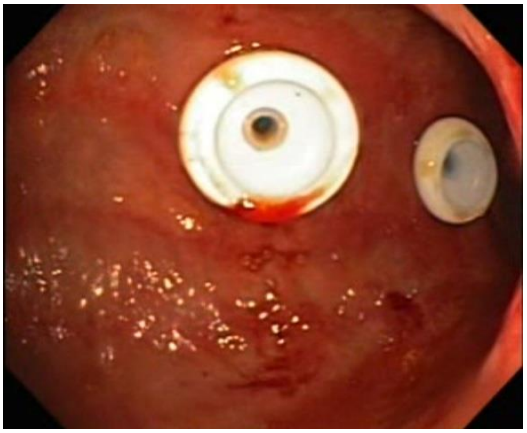

Figure 2. Endoscopic view of dual PEG technique for gastropexy.

Figure 3. Abdominal view following endoscopic reduction and gastropexy with PEG, gastrointestinal T-anchors (*) and a permanent gastropexy stitch (arrowhead) placed with a transfascial suture passer.

Technical Pearls

It is prudent to perform these procedures in the operating suite with the option to provide airway protection, sedation or general anesthesia as needed and for laparoscopic assistance in some cases. Fluoroscopy is also helpful in some cases for external visualization of anatomy

and scope placement (Figure 4). Endoscopic reduction of gastric herniation or volvulus may be accomplished with slow advancement and insufflation of the endoscope, being careful to maintain a view of the gastric lumen. A pediatric colonoscope may be used as its added length may be necessary to fully traverse the gastric volvulus and resultant gastric distension. Aggressive use of suction is beneficial to decompress the incarcerated stomach prior to endoscopic reduction below the diaphragm.

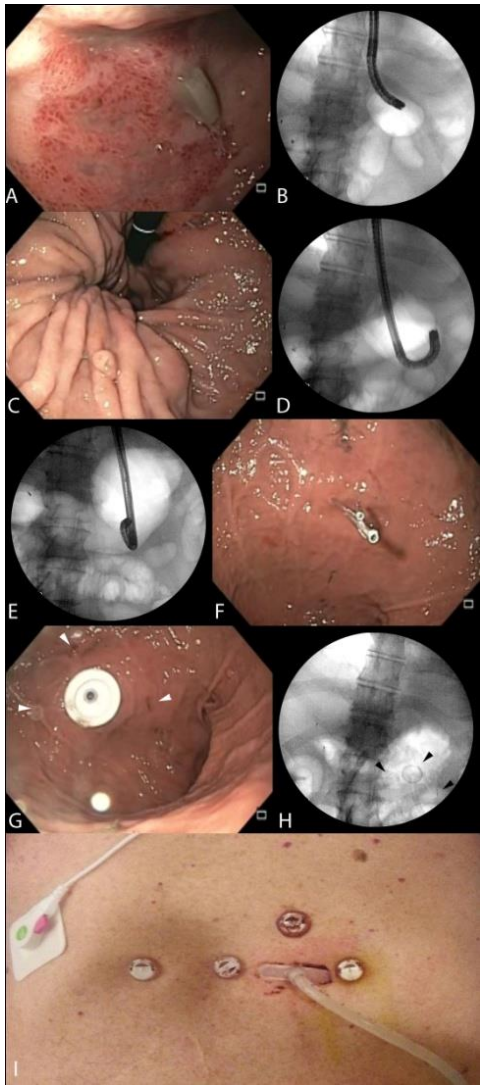

Figure 4. Endoscopic and fluoroscopic reduction, PEG and gastropexy of incarcerated hiatal hernia. A) Endoscopic view of the obstructed cardia. B) Fluoroscopic view of the air filled cardia above the diaphragm. C) Endoscopic and D) fluoroscopic view of partly reduced stomach with the gastroscope in retroflex. E) Fluoroscopic view of the completely reduced stomach with the gastroscope holding the stomach in an intraabdominal position while F) gastrointestinal T-anchors are placed. G) PEG bumper and surrounding T-anchors (arrowheads) on endoscopy and H) fluoroscopy. I) View of the abdomen shows PEG and T-anchors.

In the dual gastroscope technique, one gastroscope may be left in place along the greater curvature, weighing the stomach down in a reduced anatomical position while another is placed alongside for PEG placement. Alternatively, a first PEG may be placed in the antrum to hold the stomach in position and a second in the body of the stomach for dual PEG gastropexy. A standard colonoscope passed per rectum under fluoroscopy may be used to move the transverse colon into the pelvis and out of the path of the PEG gastropexy [13, 14, 16].

COLONIC INTERVENTION

The percutaneous endoscopic colostomy (PEC), which can be placed with the same techniques described for PEG has seen some fluctuations in indication and breadth of use since the 1980s when PEG was first becoming popular. The PEC is generally used as an alternative to surgical intervention in patients with many comorbidities or contraindications for surgery. Indications for PEC described in the literature are acute colonic pseudo-obstruction, recurrent sigmoid volvulus, constipation, and neurogenic bowel. Complications that have accompanied these uses include, self-limited bleeding, stercoral peritonitis, sepsis, and seizures. Most published cases have resulted in the resolution of the underlying problem and eventual removal of the PEC [20].

Multiple percutaneous endoscopic approaches to recurrent or chronic sigmoid volvulus have been described, including a singular PEC, multiple gastrointestinal T-fasteners and percutaneous endoscopic sigmoidopexy with buried sutures. Each comes with advantages such as potential use of decompressive tube, nonpermanent sutures, and multipoint permanent fixation respectively [21]. Bruzzi et al. described the management of acute sigmoid volvulus in 65 patients over 10 years. As first line treatment 95% underwent nonsurgical reduction, and two-thirds of patients had recurrence. Thirty-three patients underwent prophylactic surgical resection and six patients underwent percutaneous endoscopic colostomy. These patients were elderly (84-99 years-old) with median ASA 4 and all were neuropsychiatric inpatients. There was a 67% complication rate, mostly local site infections, pain and bleeding and 50% mortality rate from causes unrelated to volvulus. There was only one recurrence amongst the PEC treated patients after the tube was removed. The procedure does not require general anesthesia and is quicker and easier than a colon resection. Post procedure, patients should be placed on antibiotics and observed after the procedure [22].

Indications have been expanded to PEC for fecal incontinence and chronic constipation using a PEG kit and technique in the cecum. One reported case in an adult had four months of follow up with resolution of fecal incontinence using the PEC with daily saline irrigation [23]. PEC button placement for antegrade enemas in chronic constipation and incontinence in children has been described. Twenty-six cecostomy and three sigmoidostomy trap door buttons were place by Becmeur et al. without complication and this reversible procedure improved quality of life for patients and caregivers [24].

National Institutes for Health and Clinical Excellence published guidelines for PEC in 2006 and found evidence that supported PEC as an adequate procedure in elderly or frail patients with recurrent sigmoid volvulus and colonic motility problems. However, for the use of PEC in children with chronic constipation further evidence is needed. Good patient

selection and a multidisciplinary team approach (include a pediatric gastroenterologist and colorectal surgeon) should be employed. The guidelines also emphasize that true informed consent should be discussed with the patient and information about the risk of peritonitis should be made clear [25].

Advantages of PEC are the ability to safely be performed without general anesthesia and they can be removed when the underlying pathology has resolved. Considerations are post procedure antibiotics and observation, avoiding traction, and rapid replacement to skin level button type tubes. The complication profile of PEC has been describe above, but care should be taken and patients followed as multiple cases of peritonitis have been described as far as 6-8 weeks out from the procedure [20, 26].

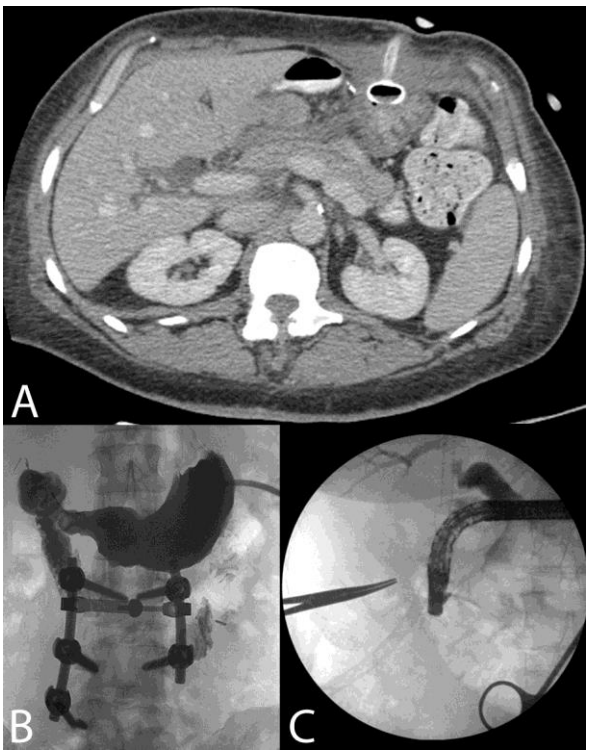

Figure 5. PEG assisted ERCP following Roux-en-Y gastric bypass. A) CT scan demonstrating percutaneously placed PEG in the remnant stomach. B) Fluoroscopic image of UGI via PEG tube. C) Fluoroscopic image of transgastric ERCP being performed via the gastrostomy tract in the remnant stomach.

GASTROINTESTINAL TRACT ACCESS FOR PROCEDURES

With increasingly successful surgical treatments of complex disease and improved survival, more patients present an unusual challenge of accessing the GI tract for otherwise commonplace procedures. PEGs may be useful in such situations especially in cases of esophageal stricture or obstruction or due to altered anatomy such as in post gastric bypass patients. With the obesity epidemic reaching 35% of the US population, the rates of weight-loss surgery continue to increase and Roux-en-Y Gastric Bypass (RYGB) is a common

procedure. As 50% of RYGB patients develop gallstone disease and many require pancreaticobiliary intervention, the challenge of endoscopic retrograde cholangiopancreatography (ERCP) in gastric bypass patients is real.

Transgastric ERCP can be done surgically or percutaneously with laparoscopic and/or radiographic assist, both of which require the collaboration of two teams and are fraught with complications, high costs and significant failure rates. Thus laparoscopic-assisted ERCP with the use of PEGs have become increasingly more common (Figure 5) [27]. This is commonly done in multiple stages and often requires postponement of the ERCP for 4 weeks to allow the PEG tract to mature. However, Law et al. have shown the efficacy and safety of a single session transgastric ERCP. The gastric remnant was reached using balloon enteroscopy and a retrograde PEG was created and maintained using a self-expanding metal stent (SEMS) (Figure 6), through which the duodenoscope was advanced. Once the ERCP was completed a PEG tube was placed to maintain the stoma if needed for further access [28]. Endoscopic ultrasound has also been employed for creation of a PEG into the remnant stomach for ERCP access [27]. Fluoroscopy and SEMS are used in both cases to increase the success and safety of the procedure.

Figure 6. Percutaneous self-expanding metal stent and gastrointestinal T-anchors within the gastric remnant in a patient following Roux-en-Y gastric bypass. The gastrostomy tract created by the stent was subsequently used to perform a transgastric ERCP.

PEGs are used to access the GI tract for endoscopy for other purposes as well and an ultrathin endoscope may be used through the PEG stoma site for access. This is especially useful in patients with esophageal stricture or obstruction and can be used for retrograde identification of the esophageal lumen for dilation or transillumination of short segment strictures. Complete obstruction of the esophagus may be treated with retrograde submucosal tunneling via a previously placed PEG [29]. Stent placement is another possible use of PEGs either in patients with esophageal stricture or to improve angulation of the stiff stent deployment devices. Some of these uses include: drainage of a malignant biliary stricture with a transgastric biliary stent, placement of direct percutaneous jejunostomy feeding tube via a

PEG, endoscopic treatment of marginal ulcer following trauma requiring esophageal discontinuity, and intraluminal surgery for multiply recurrent hiatal hernia with gastric herniation [29-32].

Although PEG tubes with J extensions have been used for palliation of malignant gastric outlet obstruction, gastroduodenal stents have been found to have better patency and survival [33]. These stents may be placed either through in-situ PEGs or via a PEG-like pathway using a sheath catheter for insertion which may ease the angulation of the deployment device as well as allow for PEG tube placement for ease of access as further stenting is required [34].

MANAGEMENT OF LEAKS AND FISTULAE

PEG tubes and stomas have been used for the management of gastrointestinal leaks and fistulas in many ways. PEG as a drainage tube to decompress the stomach and divert gastric contents has been shown to help with healing of GI fistulous disease and can be used to bridge patients to surgery over the course of a few months and allow for improved nutritional status [8]. PEG tubes with jejunal extension tubes have been used in this method for the management of colo-duodenal fistula in the setting of Crohn's disease. A double lumen gastrojejunostomy tube placed past the fistula site along with ileostomy for treatment of the colonic stricture was used to bridge to surgery after two months where the gastrocolonic fistula was found to be nearly healed [35].

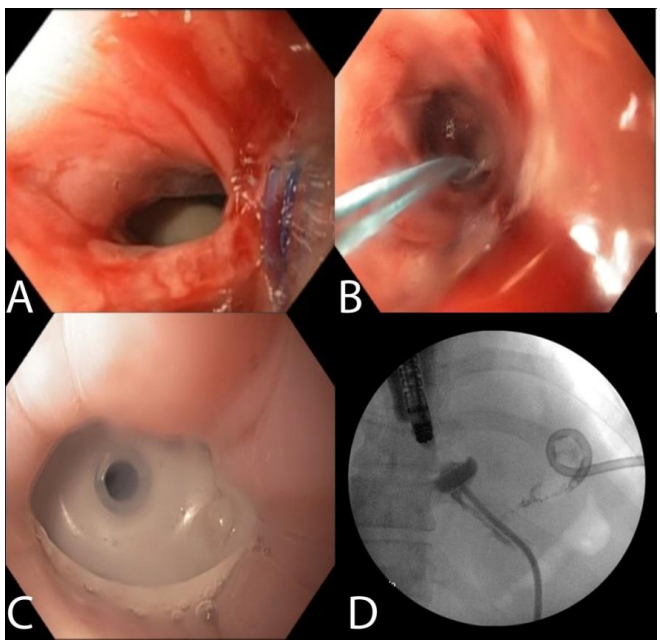

Figure 7. Decompressive esophagostomy tube replacement. A) Endoscopic view of the distal esophagus demonstrates free intraperitoneal communication and a purse string suture that previously secured the surgically placed tube. B) Rendezvous with a percutaneous guidewire within the old tube tract establishes communication from skin level to distal esophagus. C) PEG bumper in position in the distal esophagus D) Fluoroscopic image demonstrates contrast in the distal esophagus decompressing via the PEG. The small amount of leak around the tube is adequately controlled with the percutaneous drain.

Gastric perforation after chemotherapy for diffuse large B-cell lymphoma has been treated in a similar manner [36]. Negative pressure sponge therapy has been shown to be effective in treating esophageal anastomotic breakdowns or perforations and these therapies have had their indications expanded to include other areas of the GI tract [37]. Glatz et al. used negative pressure to heal an iatrogenic duodenal perforation and employed the PEG tube to hold the sponge and tubing in place to prevent migration and to allow ease of changing the sponge. They showed closure of the perforation at 20 days and were able to remove the PEG one week later [38].

PEG tubes can be used to help manage fistulas, leaks or perforations either through decompression and diversion of GI contents, bypassing the problem for enteral feeding, or aiding in the placement or use of other devices. Juza et al. described a modified PEG rescue technique to replace a dislodged decompression tube in a patient with a blind ending abdominal esophagus following an emergency total gastrectomy without reconstruction (See Chapter 20 for more information on PEG Rescue) [39]. The patient presented with an intra-abdominal leak from the distal esophagus. Once wire access was achieved between the old tube tract and the distal esophagus, a pull-type PEG method was used to position the bumper in the distal esophagus under fluoroscopic guidance to decompress the esophagus and eliminate leak (Figure 7).

NATURAL ORIFICE TRANSLUMINAL ENDOSCOPIC SURGERY (NOTES)

As NOTES is being explored to further reduce the invasiveness of surgical procedures and allow for intervention on even the sickest of patients, it has emerged as a potentially valuable tool for urgent intervention of intra-abdominal emergencies [40]. PEG is being studied in animal models as an access point for expansion of possible NOTES procedures including repair of ventral hernia with mesh [41-43].

CONCLUSION

As the population ages and minimally invasive surgical techniques evolve, the indications and uses for percutaneous endoscopic gastrostomy will continue to expand. Endoscopists must be aware of the expanding indications for PEG to employ them for the benefit and safety of patients.

EDITOR'S COMMENT

As Dr. Marks clearly knows from his training with Dr. Ponsky, the utility of a percutaneously placed gastrostomy and PEG technique extends well beyond enteral feeding access. The ability to place a PEG under sedation to alleviate symptoms of a bowel obstruction, reduce an incarcerated hiatal hernia or as part of the management strategy for a fistula means that patients with highly morbid conditions can be managed in as minimally

invasive a fashion as possible. The coming years are likely to see even more techniques based on PEG technique. (EMP)

REFERENCES

[1] Delis KC. Percutaneous endoscopic gastrostomy. Twenty four years after, still space for debate. *Ann Gastroenterol*. 2004;17(1):19-22.

[2] Ponsky JL. Percutaneous endoscopic stomas. *Surg Clin North Am*. 1989;69(6):1227-1236.

[3] Kawata N, Kakushima N, Tanaka M, et al. Percutaneous endoscopic gastrostomy for decompression of malignant bowel obstruction. *Dig Endosc*. 2014;26(2):208-213.

[4] Oishi H, Shindo H, Shirotani N, Kameoka S. A nonsurgical technique to create an esophagostomy for difficult cases of percutaneous endoscopic gastrostomy. *Surg Endosc Other Interv Tech*. 2003;17(8):1224-1227.

[5] Dolan EA. Malignant Bowel Obstruction: A Review of Current Treatment Strategies. *Am J Hosp Palliat Med*. 2011;28(8):576-582.

[6] Daigle R, Boules M, Corcelles R, et al. Percutaneous Endoscopic Gastrostomy for Decompression of Nonmalignant Gastrointestinal Disease. *J Laparoendosc Adv Surg Tech A*. 2015;25(10):804.

[7] Daigle R, Boules M, Corcelles R, et al. Percutaneous Endoscopic Gastrostomy for Decompression of Nonmalignant Gastrointestinal Disease. *J Laparoendosc Adv Surg Tech A*. 2015;25(10):804.

[8] Felsher J, Chand B, Ponsky J. Decompressive percutaneous endoscopic gastrostomy in nonmalignant disease. *Am J Surg*. 2004;187(2):254-256.

[9] Takayama S, Sakamoto M, Wakasugi T, Takeyama H. Temporary transgastrostomy tube for ileus. *Clin J Gastroenterol*. 2011;4(5):298-301.

[10] Heuschkel RB, Gottrand F, Devarajan K, et al. ESPGHAN Position Paper on Management of Percutaneous Endoscopic Gastrostomy in Children and Adolescents. *J Pediatr Gastroenterol Nutr*. 2015;60(1):131-141.

[11] Camilleri M, Parkman HP, Shafi MA, et al. Clinical guideline: Management of gastroparesis. *Am J Gastroenterol*. 2013;108(1):18-37.

[12] Blouhos K. Management of afferent loop obstruction: Reoperation or endoscopic and percutaneous interventions. *World J Gastrointest Surg*. 2015;7(9):190.

[13] Kercher KW, Matthews BD, Ponsky JL, et al. Minimally invasive management of paraesophageal herniation in the high-risk surgical patient. *Am J Surg*. 2001;182 (5):510-514..

[14] Fukita Y, Ishibashi H, Yasuda I, et al. Upside-down stomach repositioned and fixed by colonoscopy-assisted percutaneous endoscopic gastrostomy. *Endoscopy*. 2014;46(Suppl 1):E388-E389.

[15] Hamai Y, Hihara J, Tanabe K, et al. Laparoscopic Repair and Percutaneous Endoscopic Gastrostomy to Treat Giant Esophageal Hiatal Hernia with Gastric Obstruction: A Case Report. *Hiroshima J Med Sci*. 2015;64(1-2):27-30.

[16] Jamil LH, Huang BL, Kunkel DC, et al. Successful Gastric Volvulus Reduction and Gastropexy Using a Dual Endoscope Technique. *Case Rep Med*. 2014;2014:1-3.

[17] Jeong SH, Ha CY, Lee YJ, et al. Acute gastric volvulus treated with laparoscopic reduction and percutaneous endoscopic gastrostomy. *J Korean Surg Soc*. 2013;85(1):47-50.

[18] Nikaido M, Miyamoto S, Iinuma S. Prevention of Gastric Volvulus-induced Recurrent Acute Pancreatitis by Percutaneous Endoscopic Gastropexy. *Clin Gastroenterol Hepatol*. 2015;13(2):e11-e12.

[19] Tanaka H, Hiramatsu K, Iida T, et al. Recurrent gastric volvulus resolved surgically after therapeutic percutaneous endoscopic gastrostomy in Duchenne muscular dystrophy. *J Japanese Soc Gastroenterol*. 2012;109(3):418-424..

[20] Bertolini D, De Saussure P, Chilcott M, et al. Severe delayed complication after percutaneous endoscopic colostomy for chronic intestinal pseudo-obstruction: A case report and review of the literature. *World J Gastroenterol*. 2007;13(15):2255-2257.

[21] Ito E, Ohdaira H, Suzuki N, et al. Percutaneous endoscopic sigmoidopexy for sigmoid volvulus: A case report. *Int J Surg Case Rep*. 2015;17:19-22.

[22] Bruzzi M, Lefevre JH, Desaint B, et al. Management of acute sigmoid volvulus: Short- and long-term results. *Color Dis*. 2015;17(10):922-928.

[23] Lykke J, Hansen M, Meisner S. Fecal incontinence treated with percutaneous endoscopic cecostomy. Endoscopy. 2006;38(9):950.

[24] Becmeur F, Demarche M, Lacreuse I, et al. Cecostomy button for antegrade enemas: survey of 29 patients. *J Pediatr Surg*. 2008;43(10):1853-1857.

[25] Nice. IPG161 *Percutaneous endoscopic colostomy - information for the public*; IPG161 Percutaneous endoscopic colostomy - information for the public.

[26] Molina-Infante J, Fernandez-Bermejo M, Mateos-Rodriguez JM. Recurrent rectosigmoid volvulus and fatal peritonitis after percutaneous endoscopic sigmoidostomy. *Endoscopy*. 2012;44(2):E331-E332.

[27] Kedia P, Kumta NA, Widmer J, et al. Endoscopic ultrasound-directed transgastric ERCP (EDGE) for Roux-en-Y anatomy: A novel technique. *Endoscopy*. 2015;307(1):491-497.

[28] Law R, Petersen BT, Wong Kee Song LM, Baron TH. Single-session ercp utilizing patent technique: A case series in patients with previous roux-en-y gastric bypass. *Gastrointest Endosc*. 2013;77(5):AB300.

[29] Babich JP, Diehl DL, Entrup MH. Retrograde submucosal tunneling technique for management of complete esophageal obstruction. *Surg Laparosc Endosc Percutan Tech*. 2012;22(4):e232-e235.

[30] Nishiwaki S, Araki H, Shirakami Y, et al. Direct percutaneous endoscopic jejunostomy using a transgastrostomic endoscope in patients with previous endoscopic gastrostomy. *Endoscopy*. 2009;41:E36-E37.

[31] Baron TH, Wong Kee Song LM. Placement of an esophageal self-expandable metal stent through a percutaneous endoscopic gastrostomy tract, for endoscopic therapy of upper gastrointestinal bleeding. *Endoscopy*. 2012;44(2):E319-E320.

[32] Conaglen P, Emery G, Wright G. Percutaneous intra-luminal gastroscope-assisted surgery. *ANZ J Surg*. 2012;82(9):659-660.

[33] Strand DS, Thlick J-EC, Patrie JT, et al. Gastroduodenal stents are associated with more durable patency as compared to percutaneous endoscopic gastrojejunostomy in the palliation of malignant gastric outlet obstruction. *J Interv Gastroenterol*. 2012;2(4):150-154.

[34] Niu HX, Zhang XK, Wang B, et al. Stent implantation technique through PEG-like pathway for treatment of malignant gastroduodenal obstruction. *Int J Clin Exp Med*. 2015;8(8):14236-14241.

[35] Zuiki T, Meguro Y, Kumano H, et al. Successful management of a colo-duodenal fistula in a patient with Crohn's disease using a double lumen gastro-jejunostomy tube. *Case Rep Gastroenterol*. 2014;8(2):162-168.

[36] Khadraoui H, Feigin KN, Fox JJ, et al. Successful management of gastric perforation in stage IV diffuse large B-cell lymphoma with chemoradiation therapy, percutaneous endoscopy gastrostomy for gastric drainage, and percutaneous endoscopy jejunostomy for Nutrition. *Clin Lymphoma, Myeloma Leuk*. 2013;13(3):327-330.

[37] Loske G, Schorsch T, Muller C. Endoscopic vacuum sponge therapy for esophageal defects. *Surg Endosc Other Interv Tech*. 2010;24(10):2531-2535.

[38] Glatz T, Fischer A, Hoeppner J, et al. Vacuum sponge therapy using the pull-through technique via a percutaneous endoscopic gastrostomy to treat iatrogenic duodenal perforation. *Endoscopy*. 2015;47(S 01):E567-E568.

[39] Juza RM, Tran TT, Pauli EM. Endoscopic rescue of a dislodged transabdominal decompressive esophagostomy tube. *Gastrointest Endosc*. 2015;81(4);1001.

[40] Bingener J, Ibrahim-Zada I. Natural orifice transluminal endoscopic surgery for intra-abdominal emergency conditions. *Br J Surg*. 2014;101(1):e80-e89.

[41] Earle DB, Desilets DJ, Romanelli JR. NOTES transgastric abdominal wall hernia repair in a porcine model. *Hernia*. 2010;14(5):517-522.

[42] Miedema BW, Bachman SL, Sporn E, et al. Transgastric placement of biologic mesh to the anterior abdominal wall. *Surg Endosc Other Interv Tech*. 2009;23(6):1212-1218.

[43] Hyder Q, Li W, Yang Y, et al. NOTES: "pre-dilatation" as a remedy for technical issues during transgastric access. *J Pak Med Assoc*. 2012;62(2):111-115.

In: Encyclopedia of Surgery (22 Volume Set)
Editors: Andreas Lehrer and Kristin Mueller
ISBN: 978-1-53618-329-0
© 2020 Nova Science Publishers, Inc.

Chapter 137

POSTOPERATIVE MANAGEMENT

Fazia A. Mir, MD, Douglas L. Nguyen, MD and Matthew L. Bechtold*, MD
University of Missouri, Columbia, MO, US

INTRODUCTION

Percutaneous endoscopic gastrostomy (PEG) is the most commonly performed enteral feeding procedure for long-term enteral nutrition in patients with dysphagia due to a variety of causes (especially neurologic and neoplastic). PEG tubes are placed if enteral feeding is required beyond four weeks of hospitalization with life expectancy greater than two months [1]. PEG tubes can also be placed for gastric decompression in patients with gastroparesis or malignant obstruction [2].

Although PEG placement is done by a wide array of practitioners (gastroenterologists, general surgeons, neurosurgeons, medical and surgical intensivists, otolaryngologists, interventional pulmonologists and thoracic surgeons), once the PEG is placed, post-gastrostomy care is pivotal and should be standardized. PEG care is focused on feeding (or decompression), maintaining a functional gastrostomy, and early recognition and treatment of potential complications. In this chapter, we focus on post-operative management of PEG with emphasis on the clinicians' perspective with suggestions on when to initiate feeding and how to handle potential major and minor complications associated with PEGs.

ENTERAL FEEDING AFTER PEG PLACEMENT

Delays in feeding after PEG placement can result in prolonged hospital stays, malnutrition, and increased health care expenditures. Based on surgical dogma regarding intra-abdominal surgery, it has been common practice to wait 24-48 hours before initiation of tube feeds after PEG placement. This practice was based primarily on clinical experience with

* Corresponding Author's Email: bechtoldm@health.missouri.edu.

the reasoning being a possible increase in gastric residual volume after surgical manipulation of the gut [3].

A meta-analysis by Bechtold et al. demonstrated no difference in complication rate or short-term mortality in patients who received early PEG feeding (defined as ≤4 hours post procedure) compared with delayed or next day feeding (Table 1) [3]. Furthermore, a large retrospective 5-year study in an institution that practiced early feeding (within 4 hours post procedure) demonstrated no differences in complications between early and delayed feeding [4]. Data is changing the dogmatic practice of delayed feeding and more centers are initiating tube feeds 3-6 hours after PEG placement without any noted increase in adverse events or complications. Emerging data demonstrates the safety and feasibility of initiating tube feeds as early as 3-4 hours after PEG placement [5-6]. Anecdotally, some practitioners begin or resume tube feedings immediately after PEG placement in the absence of another clinical contraindication. It should be noted, however, that there is no large study to support this practice.

It is recommended that tube feeds should be started in conjunction with dietician and the use of an appropriate enteral feeding supplement. During feeding, the patient must be positioned at a 45 degrees head-up angle while being fed to prevent reflux and aspiration [7]. After feeding through the tube, the tube should be flushed with 50 mL of water and the tube rotated clockwise to prevent injury and pressure ulcer formation at the abdominal wall. Rotating the tube in conjunction with routine feedings is not mandatory, but since the tube is being accessed at this time it is a convenient way to coordinate two nursing care events.

Prevention of aspiration is important as aspiration pneumonia is fatal in 17-62% of cases [8]. Risk factors for aspiration pneumonia include a previous history of aspiration, vomiting, gastro-esophageal reflux, anatomic abnormalities (hiatal hernia, gastric outlet obstruction), and prolonged supine position [9]. Many of these conditions can be identified on the diagnostic endoscopy performed during PEG (see Chapter 6), highlighting the importance of the endoscopist communicating these findings to the patients primary management team.

A prospective study done recently noted that re-aspiration within 6 months of PEG placement was lower when compared to oral feeding and nasogastric tube feeding. However, PEG placement did predispose to aspiration risk and was not 100% protective against it [10].

Table 1. Meta-analysis outcomes of early (≤4 hours) versus delayed/next day feeding after PEG placement [3]

OUTCOME	ODDS RATIO	95% CONFIDENCE INTERVAL	p-VALUE
All Complications	0.86	0.47-1.58	0.63
Mortality ≤ 72 hours	0.56	0.18-1.74	0.31

Aspiration risk can be reduced by proper posture when administering feeds, control of esophageal reflux, and avoidance of over-feeding the patient [7, 11].

Early feeding (as defined as feeding ≤3 hours after PEG placement) also did not have any association with increased gastric residual volumes during the first 24 hours [12]. A great deal of debate has occurred over the use of gastric residuals as a guide for aspiration risk. In critically ill patients, gastric residual volumes are also no longer a guide for enteral nutrition as the risk of ventilator-associated pneumonia was not associated with an increase if gastric residual volumes were not checked [13]. In the future, constant checking of gastric residual volumes may be significant diminished.

ENTERAL DECOMPRESSION AFTER PEG PLACEMENT

If the tube has been placed for decompression of the GI tract, then the tube can be left open to gravity drainage by connecting it to a biliary or urinary collection bag. If the volume of output is anticipated to be high, some practitioners leave a nasogastric tube in for decompression for the first 48 hours to reduce the risk of early intra-peritoneal leak from high gastric volumes. If the volume of output is anticipated to be low, the tube can be clamped and opened intermittently (either on a scheduled basis or when symptoms arise) by either the caregiver or the patient. The addition of tubing and a collecting bag to the PEG can add traction to the device and present an additional risk for early tube dislodgement. Care should be taken when the patient is transitioning (e.g., into or out of bed, etc.).

MECHANICAL MANAGEMENT OF THE GASTROSTOMY

Preventing Premature Removal of PEG

In an agitated or combative patient, or occasionally with routing patient care or activities of daily living, PEGs can become accidently dislodged within the first 7 days of placement. Within this time frame, the PEG tract has not had time to mature and lack of adherence of the gastric wall to the abdominal wall can result in the contamination of the peritoneal cavity with gastric contents, resulting in peritonitis. If peritonitis occurs, treatment should be initiated with antibiotics and surgical consult should be initiated See Chapters 18 and 20 for more information about the management of early PEG dislodgement.

To prevent this complication, post-PEG placement abdominal binders may be used for patients who are at high risk for pulling out the tube inadvertently [14]. Abdominal binders have been deemed safe in most cases; however, they do pose a risk for gastric and/or skin breakdown by mechanical pressure caused by torsion [15, 16]. To prevent this complication, the binder should be oversized to the patient and/or placed loosely around the abdomen (Figure 1). The primary function of the binder is to provide a mechanical barrier to the tube to prevent a patient with altered sensorium from easily grasping the tube.

Figure 1. Abdominal binder placed loosely to protect a newly-placed PEG.

Figure 2. PEG secured to the skin with a tape ‘mesentery.’

Figure 3. Gastrointestinal T-anchors positioned in around a PEG tube in a patient at high risk for early tube dislodgement.

Other potential anchoring devices have been used to secure the PEG, most commonly tape (Figure 2). Some practitioners elect to suture the external PEG bumper to the skin while others avoid this practice due to concerns of skin ulceration/necrosis; there is limited data to support either of these practices. Gastrointestinal T-anchors, inserted through the abdominal wall into the stomach around the PEG (Figure 3), do not prevent early tube removal. They do, however, prevent an immature gastrostomy from falling away from the abdominal wall thereby minimizing the risk of peritoneal leak as a result of early tube dislodgement (Figure 4). Also, a safety break device has been developed by Rosenberger and colleagues to prevent accidental dislodgement of PEG tubes. In a trial, this device was noted to reduce accidental dislodgement by 51% [17]. If repeated dislodgement occurs, a low-profile PEG tube or permanent surgical gastrostomy (Janeway gastrostomy) should be considered (Figure 5).

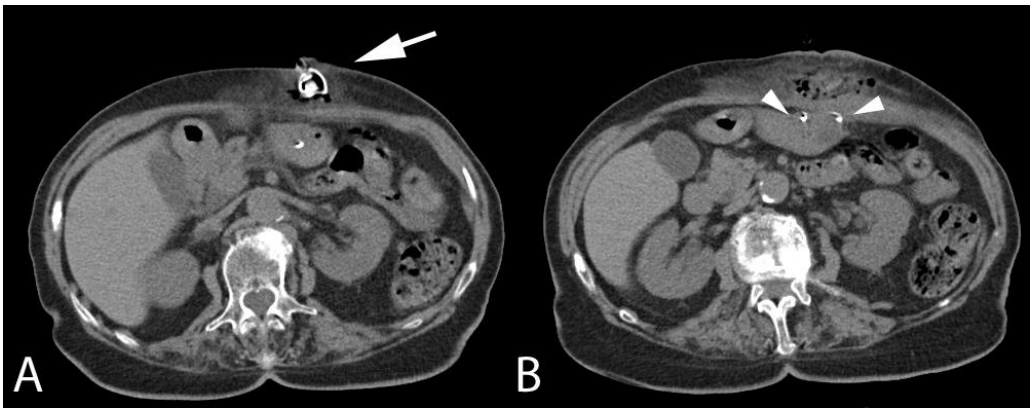

Figure 4. CT scan of a patient following early PEG dislodgement. A) PEG bumper is located in a subcutaneous position with surrounding soft tissue stranding and air (arrow). B) Gastrointestinal T-anchors (arrowheads) prevented the gastrotomy from falling away from the abdominal wall preventing free intraperitoneal leak.

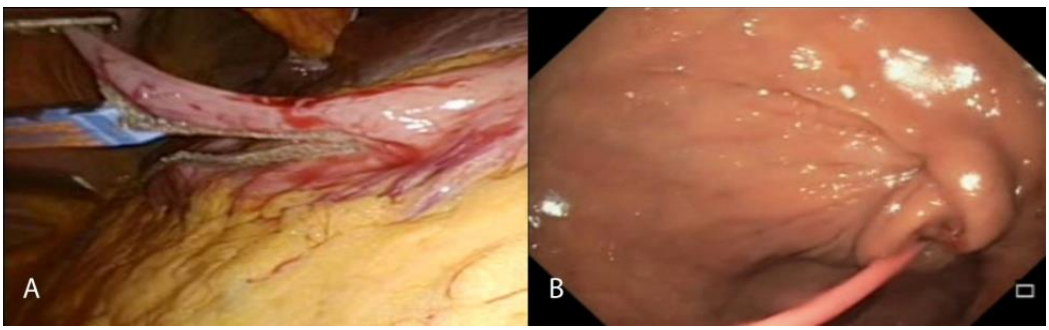

Figure 5. Janeway gastrostomy. A) Laparoscopic stapler creating a tubularized portion of stomach that is delivered to the skin surface and surgically matured. B) Endoscopic view of the anti-reflux valve and non-ballooned catheter placed via the gastrostomy.

Managing PEG Bumper Tension

Excessive force on the PEG bumpers can result in both gastric and abdominal wall erosions from tension induced ischemia. In the best case scenario, such ulceration is asymptomatic. In the worst case, significant bleeding (from erosion in to gastric or abdominal wall blood supply) or infection (including necrotizing soft tissue infections) can result (Figure 6). Such major complication may be prevented by multiple ways.

First, the skin incision made for the gastrostomy should be approximately 1 cm (Figure 7). If the incision is less than 1 cm, added pressure is applied on the tissue around the inserted PEG which may lead to decrease blood flow to the area and subsequent tissue necrosis. Second, the external bolster should be fastened no less than 2 cm (Figure 8).

Figure 6. Pressure induced full thickness abdominal wall erosion and superimposed infection as a result of excessive gastrostomy tension. This defect measures 3 x 3 cm.

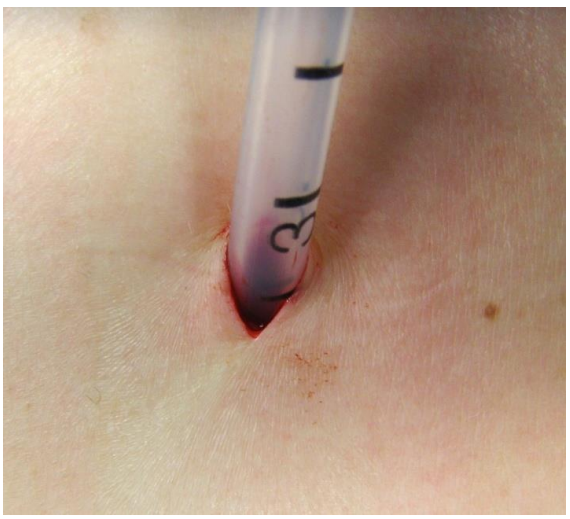

Figure 7. Skin incision for PEG is slightly oversized for the diameter of the tube to prevent undo pressure on the skin. For a 20 Fr tube, 8 mm is appropriate, for 24 Fr, 1 cm is appropriate.

In many institutions, PEGs are tightly fastened for the first 24 hours after placement to ensure apposition of stomach and the abdominal wall. On the next day, the external bolster is loosened to the standard distance for the patient. Although a popular practice, it subjects the patient to potential complications without benefit. Given that the PEG tract takes weeks to fully mature, tightening the external bolster in the first 24 hours does little to ensure a secure PEG tract.

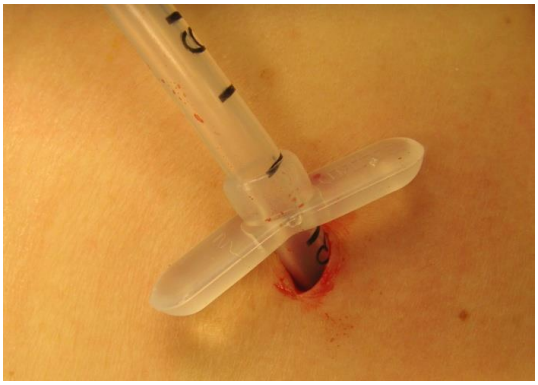

Figure 8. External PEG bumper sits above the level of the skin when tensioned correctly.

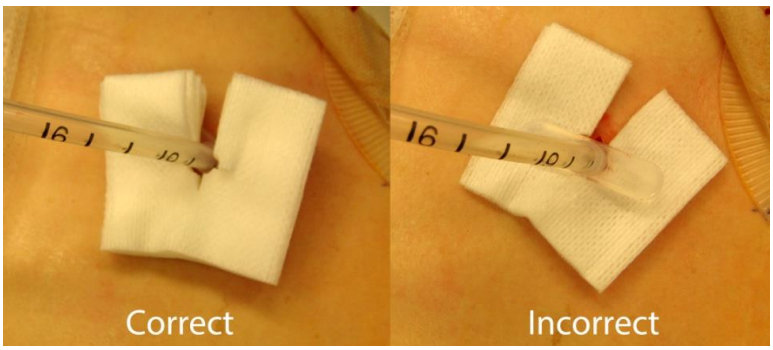

Figure 9. Correctly dressed PEG site has gauze over the top of the external bumper. Incorrectly positioning the gauze under the bumper adds tension to the internal retention dome placing the patient at risk for buried bumper syndrome.

Therefore, we recommend setting the external bolster at a preferred long-term distance at time of procedure, approximately 3 cm in most patients (depending on body habitus). In a respective study over 5 years where this management plan was employed, no major complications were identified (Table 2) [4]. In addition, many caregivers like to place gauze between the skin and external bolster. This also may be problematic as the distance between the external bolster and internal bolster is a fixed distance. By placing gauze in between the two bolsters, added pressure is applied to the tissue which may lead to erosion and/or buried bumper syndrome (BBS) (Figure 9).

BBS is a long-term complication of PEG placement and occurs at a rate of 1.5-2.0% [18]. In children with PEGJ tubes (PEG with jejunal extensions) the risk of developing BBS is increased, approaching 32% [18]. It can happen anywhere from months to up to years after PEG placement. BBS occurs when the internal bumper of the PEG tube erodes through the

gastric wall and into the abdominal wall. The gastric mucosa eventually covers the gastrostomy tube bumper.

Table 2. Post-procedure complications over a 5-year period where PEG (n = 444) was placed at ~3 cm mark [4]

Complication	Patients n (%)
Leakage	4 (0.9%)
Infection	5 (1.1%)
Bleeding	1 (0.2%)
Vomiting	15 (3.4%)
Stomatitis	4 (0.9%)
Mortality ≤ 72 hours	11 (2.5%)

Several risk factors have been implicated in the development of BBS and include increase tension on the tube with suboptimal PEG tube care [19]. Patients present with inability of tube feeds to normally pass thru the tube and inability to rotate the PEG tube [20]. Diagnosis can be confirmed endoscopically by failure to visualize the PEG tube bumper internally [21]. BBS can lead to further severe clinical complications such as wound infection, peritonitis, and necrotizing fasciitis [22]. Definitive treatment for BBS includes removal of the PEG tube by external traction, endoscopically, or surgically [23].

To prevent BBS, the external bumper should be loose and the PEG should rotate freely; however, the external bumper cannot be too loose as it can lead to PEG site leakage and peritonitis [24]. Avoidance of gauze between the external bolster and skin, having the external bolster slightly loose (~3-4 cm mark), and proper skin care are essential in preventing this complication.

Prevention of Tube Clogging

Feeding tubes get clogged with feeds or medications at a rate of 23-35% [25]. Feeding tubes need to be flushed with 30-60 mL of water after every tube feed and medication administration. Despite taking good care of the PEG, clogging can still occur at a rate of 15% [26]. If the PEG becomes clogged, common practice is to use pancreatic enzymes and carbonated beverages to unclog the tube with variable efficacy [17, 27]. A study in 1989 compared nine substances (pancreatic enzymes, pork pancreatin, bromelain, papain, cranberry juice, chymotrypsin, Coca-Cola, and distilled water) for effective unclogging of the PEG tube. It found that papain (commonly found in meat tenderizers) and chymotrypsin were most effective at de-clogging PEGs [28]. Commercially available medical devices such as PEG cleaning brush and 'Clog Zapper' are available but no trials are available to compare efficacy with other agents [29]. Furthermore, some commonly used substances, may results in damage

to the PEG itself. Novel devices, such as flexible motor-operated brushes, offer promise as a more effective method of tube clearance (Figure 10).

Managing PEG Site Leakage

PEG tube site leakage is reported in 1-2% of patients [30]. Factors that lead to PEG tube site leakage include bacterial or fungal infection of the stomal site, development of granulation tissue, use of excessive chemical cauterization with hydrogen peroxide or silver nitrate, inadequate acid suppression, and buried bumper syndrome [31].

Excessive leakage around a PEG may also happen with intolerance to tube feeds. If this is the case, cessation of tube feeds and placement of the PEG tube to gravity drainage may be helpful [32]. Patients should be started on a proton pump inhibitor to decrease acid production. Zinc oxide paste or nystatin powder can be used for local healing of PEG site. The cause of PEG site leakage should be sought and treated rather than changing the PEG tube to a larger size. Contrary to popular belief and practice, placement of a larger tube in the leaking PEG site, increasing the tension on the PEG bumpers, or overinflating a gastrostomy balloon will not help leakage and likely worsen the problem by creating a larger hole. Minimizing both tube movement and tension at the external bumper will help solve this problem. Conversion to a low profile button can sometimes meet fulfill both of these needs and allow for resolution of excessive leakage.

Figure 10. Electromechanical motor-operated device that can be utilized to unclog PEG tubes (TubeClear® System, Actuated Medical, Bellefonte, PA). The system is comprised of a re-usable control box and a single use ‘Clearing Stem.’ One end of the Clearing Stem is attached to the control box and the other end is inserted into the feeding tube. The mechanical motion of the control box actuates the Clearing Stem Wire Brush Tip as it is advanced through the tube to actively work on and remove the clog.

PEG Dysfunction and Replacement

PEGs may be removed once the condition requiring placement has resolved. This can be accomplished at 2-3 weeks after placement, with most clinicians preferring to wait 4-6 weeks. The delay in removal permits the tract to mature so that when it is removed there is not spillage of gastric contents into the peritoneal cavity. Once a PEG is removed, the gastrocutaneous fistula usually closes within 24-72 hours [2]. If the fistula does not close and leakage is a problem, the fistula may be treated with chemical cautery, managed endoscopically with special over-the-scope clips or endoscopic suturing, or surgically (See Chapters 19 and 20) [33].

Chronic conditions requiring PEG will need care and replacement every 6-12 months (See Chapter 19). PEG tubes can be changed at the bedside or in clinic by the percutaneous method which involves a strong and sustained pull until the internal bumper goes thru the stoma. For a balloon PEG, deflation of the balloon and gentle traction will remove the tube. A retrospective study compared the complication rate of PEG removal via traction method versus endoscopy removal and reported that the percutaneous method is safer to employ when removing the tube [34]. The tube can be replaced with a balloon gastrostomy or with a non-balloon PEG tube utilizing a rigid introducer to elongate the replacement PEG (Figure 11).

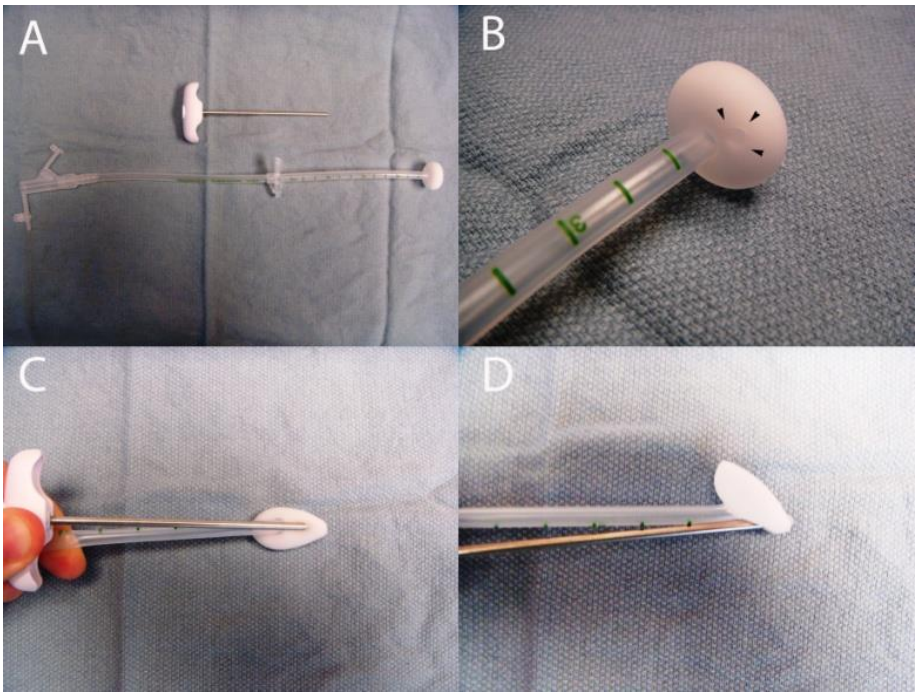

Figure 11. A) Replacement PEG tube with introducer. B) Internal PEG bumper has a dimple (arrowheads) into which the introducer is placed. C and D) Traction on the PEG against the introducer elongates and folds the bumper, allowing it to be pushed through the mature gastrotomy tract and into the stomach.

Anticoagulant/Antiplatelet Management

Reports of bleeding after placement of PEGs are rare but range from approximately 0-2.8% [35-37]. Bleeding can occur as a result of injury to the gastric or other mesenteric vessels, from the rectus sheath, from PEG tube site tumor metastasis, or from the retroperitoneum [38-41]. In regards to bleeding, the main concern of clinicians is the use peri-procedural anticoagulant or antiplatelet medications.

The American Society of Gastrointestinal Endoscopy (ASGE) 2015 consensus statement recommends that aspirin and clopidogrel/ticlopidine be held peri-procedurally for 5 days in an effort to prevent post-procedure bleeding but non-steroidal anti-inflammatory agents can be continued if there is no pre-existing coagulation disorder [42]. Large retrospective cohort studies have shown that the use of aspirin or clopidogrel did not appear to be associated with procedure-related bleeding in after placement of the PEG [36, 37, 43-45]. An observational study by Singh et al. did not find an increased risk of bleeding with the use of low molecular weight heparin (LMWH) [44]. Coumadin will need to be held, and the risks and benefits of doing this must be assessed (see Chapter 4).

If patient needs to be on therapeutic anticoagulation immediately, they it may be started [44, 46]. ASGE guidelines recommend that warfarin should be held 3-5 days prior to PEG tube placement and if the patient is high risk for thromboembolism, then LMWH or unfractionated heparin (UFH) may be instituted. LMWH should be held at least 8 hours before the PEG procedure; UFH infusion should be discontinued 4-6 hours before PEG and can be restarted after 6 hours of PEG tube placement [42]. Another observational study by Richter-Schrag et al. reported that patients with INR values greater than 2 on therapeutic anticoagulation have no elevated risk of bleeding during PEG placement but a cut-off value for supra-therapeutic INR was not mentioned [47].

Therefore, in summary, NSAIDs do not need to be withheld prior to PEG placement and may continue immediately after. Similarly, based on the literature, aspirin does not require cessation prior to PEG and may continue after. Clopidogrel should be held before the procedure, but can be resumed immediately after. Lastly, anticoagulation with heparin, LMWH, and coumadin can be managed as suggested above. Following PEG, coumadin can be resumed the evening of the procedure.

Management of Antibiotics

PEG placement is a interventional endoscopic procedure practiced under clean-contaminated conditions and may result in wound infections due to prior colonization of the skin or bacterial colonization from the upper aero-digestive tract [48]. Administration of antibiotics prior to PEG placement is safe and decreases vulnerability to infections even in high risk populations (e.g., old age, compromised nutritional intake, immunosuppression, and diabetes) [49]. Although pre-PEG antibiotic prophylaxis is highly recommended, continuing any antibiotics after placement of the PEG tube is not necessary and generally not practiced unless the patient requires the antibiotic for another etiology (pneumonia, sepsis).

CONCLUSION

PEG placement is a safe procedure with post-procedure mortality being less than 1% [50]. It has become the preferred method for enteral feeding in patients who need nutritional support with an intact gastrointestinal tract. Many complications that arise after placement can be prevented with appropriate post-procedure care and if they occur, appropriate care can permit effective management. All providers should be trained on post-PEG care to enable safe enteral nutrition support for the patient with long-term PEG placement.

EDITOR'S COMMENT

This chapter provides the necessary information for safe management of patients following enteral access. Without appropriate care of the tube and feedings, patient morbidity and mortality can be greatly increased. It is routine that PEG patients have limited follow-up with the endoscopist after the procedure so appropriate instructions for the nursing staff is vital including the cues requiring immediate physician evaluation. (JMM)

REFERENCES

[1] Gomes CA, Andriolo RB, Bennett C, Lustosa SA, Matos D, Waisberg DR, Waisberg J. Percutaneous endoscopic gastrostomy versus nasogastric tube feeding for adults with swallowing disturbances. *Cochrane Database Syst Rev*. 2015;5:CD008096.

[2] Lucendo AJ, Friginal-Ruiz AB. Percutaneous endoscopic gastrostomy: An update on its indications, management, complications, and care. *Rev Esp Enferm Dig*. 2014;106(8): 529-539.

[3] Bechtold ML, Matteson ML, Choudhary A, Puli SR, Jiang PP, Roy PK. Early versus delayed feeding after placement of a percutaneous endoscopic gastrostomy: a meta-analysis. *Am J Gastroenterol*. 2008;103(11):2919-2924.

[4] Cobell WJ, Hinds AM, Nayani R, Akbar S, Lim RG, Theivanayagam S, Matteson-Kome ML, Choudhary A, Puli SR, Bechtold ML. Feeding after percutaneous endoscopic gastrostomy: experience of early versus delayed feeding. *South Med J*. 2014;107(5):308-311.

[5] Srinivasan R, Fisher RS. Early initiation of post-PEG feeding: do published recommendations affect clinical practice? *Dig Dis Sci*. 2000;45(10):2065-2068.

[6] Choudhry U, Barde CJ, Markert R, Gopalswamy N. Percutaneous endoscopic gastrostomy: a randomized prospective comparison of early and delayed feeding. *Gastrointest Endosc*. 1996;44(2):164-167.

[7] Friginal-Ruiz AB, Lucendo AJ. Percutaneous Endoscopic Gastrostomy: A Practical Overview on Its Indications, Placement Conditions, Management, and Nursing Care. *Gastroenterol Nurs*. 2015;38(5):354-366.

[8] Jung SH, Dong SH, Lee JY, Kim NH, Jang JY, Kim HJ, Kim BH, Chang YW, Chang R. Percutaneous Endoscopic Gastrostomy Prevents Gastroesophageal Reflux in Patients

with Nasogastric Tube Feeding: A Prospective Study with 24-Hour pH Monitoring. *Gut Liver*. 2011;5(3):288-292.

[9] Kitamura T, Nakase H, Iizuka H. Risk factors for aspiration pneumonia after percutaneous endoscopic gastrostomy. *Gerontology*. 2007;53(4):224-227.

[10] Onur OE, Onur E, Guneysel O, Akoglu H, Denizbasi A, Demir H. Endoscopic gastrostomy, nasojejunal and oral feeding comparison in aspiration pneumonia patients. *J Res Med Sci*. 2013;18(12):1097-1102.

[11] Singh A, Gelrud A. Adverse events associated with percutaneous enteral access. *Gastrointest Endosc Clin N Am*. 2015;25(1):71-82.

[12] Szary NM, Arif M, Matteson ML, Choudhary A, Puli SR, Bechtold ML. Enteral feeding within three hours after percutaneous endoscopic gastrostomy placement: a meta-analysis. *J Clin Gastroenterol*. 2011;45(4):e34-38.

[13] Reignier J, Mercier E, Le Gouge A, Boulain, T, Desachy A, Bellec F, Clavel M, Frat JP, Plantefeve G, Quenot JP, Lascarrou JB. Effect of not monitoring residual gastric volume on risk of ventilator-associated pneumonia in adults receiving mechanical ventilation and early enteral feeding: a randomized controlled trial. *JAMA*. 2013;309(3):249-256.

[14] Larson DE, Burton DD, Schroeder KW, DiMagno EP. Percutaneous endoscopic gastrostomy. Indications, success, complications, and mortality in 314 consecutive patients. *Gastroenterology*. 1987;93(1):48-52.

[15] Hall AB, Northern D. Effect of abdominal binders on pulmonary mechanics with implications for the military surgical population. *J Surg Educ*. 2012;69(1):34-36.

[16] Fang JC. Minimizing endoscopic complications in enteral access. *Gastrointest Endosc Clin Nam*. 2007;17(1):179-196.

[17] Rosenberger LH, Guidry CA, Davis JP, et al. Reducing Accidental Dislodgement of the Percutaneous Endoscopic Gastrostomy: A Prospective Trial of the "SafetyBreak" Device. *Surg Innov*. 2016;23(1):62-9.

[18] Goring J, Lawson A, Godse A. Are PEGJs a Risk Factor for the Buried Bumper Syndrome? *JPediatr Surg*. 2016;51(2):257-9.

[19] Behrle KM, Dekovich AA, Ammon HV. Spontaneous tube extrusion following percutaneousendoscopic gastrostomy. *Gastrointest Endosc*. 1989;35(1):56-58.

[20] Geer W, Jeanmonod R. Early presentation of buried bumper syndrome. *West J Emerg Med*. 2013;14(5):421-423.

[21] Baskin WN. Acute complications associated with bedside placement of feeding tubes. *NutrClin Pract*. 2006;21(1):40-55.

[22] 22. Khalil Q, Kibria R, Akram S. Acute buried bumper syndrome. *South Med J*.2010;103(12):1256-1258.

[23] Lee TH, Lin JT. Clinical manifestations and management of buried bumper syndrome in patients with percutaneous endoscopic gastrostomy. *Gastrointest Endosc*. 2008;68(3):580-584.

[24] McClave SA, Jafri NS. Spectrum of morbidity related to bolster placement at time of percutaneous endoscopic gastrostomy: buried bumper syndrome to leakage and peritonitis. *Gastrointest Endosc Clin Nam*. 2007;17(4):731-746.

[25] Bourgault AM, Heyland DK, Drover JW, Keefe L, Newman P, Day AG. Prophylactic pancreatic enzymes to reduce feeding tube occlusions. *Nutr Clin Pract*. 2003;18(5):398-401.

[26] Pancorbo-Hidalgo PL, Garcia-Fernandez FP, Ramirez-Perez C. Complications associated with enteral nutrition by nasogastric tube in an internal medicine unit. *J Clin Nurs*.2001;10(4):482-490.

[27] Pearce CB, Duncan HD. Enteral feeding. Nasogastric, nasojejunal, percutaneous endoscopic gastrostomy, or jejunostomy: its indications and limitations. *Postgrad Med J*. 2002;78(918):198-204.

[28] Nicholson LJ. Declogging small-bore feeding tubes. *J Parenter Enteral Nutr*. 1987;11(6):594-597.

[29] Heinzelmann EJ, Wong S. Obstructed PEG tubes. *Gastrointest Endosc*. 1993;39(4):600-601.

[30] Committee ASoP, Jain R, Maple JT, Anderson, et al. The role of endoscopy in enteral feeding. *Gastrointest Endosc*. 2011;74(1):7-12.

[31] Iyer KR, Crawley TC. Complications of enteral access. *Gastrointest Endosc Clin N Am*. 2007;17(4):717-729.

[32] McClave SA, Chang WK. Complications of enteral access. *Gastrointest Endosc* 2003;58(5):739-751.

[33] Shen SS, Zhang XQ, Li ZL, Zou XP, Ling TS. Over-the-scope clip to close a gastrocutaneous fistula after esophagectomy. *World J Gastroenterol*. 2015;21(47): 13396-13399.

[34] Lee CG, Kang HW, Lim YJ, Lee JK, Koh MS, Lee JH, Yang CH, Kim JH. Comparison of complications between endoscopic and percutaneous replacement of percutaneous endoscopic gastrostomy tubes. *J Korean Med Sci*. 2013;28(12):1781-1787.

[35] Luman W, Kwek KR, Loi KL, Chiam MA, Cheung WK, Ng HS. Percutaneous endoscopic gastrostomy--indications and outcome of our experience at the Singapore General Hospital. *Singapore Med J*. 2001;42(10):460-465.

[36] Ruthmann O, Seitz A, Richter S, Marjanovic G, Olschewski M, Hopt UT, Fischer A, Schrag HJ. [Percutaneous endoscopic gastrostomy. Complications with and without anticoagulation]. *Chirurg*. 2010;81(3):247-254.

[37] Lee C, Im JP, Kim JW, Kim SE, Ryu DY, Cha JM, Kim EY, Kim ER, Chang DK. Risk factors for complications and mortality of percutaneous endoscopic gastrostomy: a multicenter, retrospective study. *Surg Endosc*. 2013;27(10):3806-3815.

[38] Ranney N, Hoffman B. A Rare Cause of Upper GI Bleeding: Metastatic Implantation at a Percutaneous Endoscopic Gastrostomy Site Presenting as a Bleeding Gastric Mass. *Am J Gastroenterol*. 2015;110(12):1652.

[39] Schurink CA, Tuynman H, Scholten P, et al. Percutaneous endoscopic gastrostomy: complications and suggestions to avoid them. *Eur J Gastroenterol Hepatol*. 2001;13(7):819-823.

[40] Ubogu EE, Zaidat OO. Rectus sheath hematoma complicating percutaneous endoscopic gastrostomy. *Surg Laparosc Endosc Percutan Tech*. 2002;12(6):430-432.

[41] Lau G, Lai SH. Fatal retroperitoneal haemorrhage: an unusual complication of percutaneous endoscopic gastrostomy. *Forensic Sci Int*. 2001;116(1):69-75.

[42] Khashab A, Chithadi KV, Acosta RD, et al. for the ASGE Standards of Practice Committee. Antibiotic prophylaxis for GI endoscopy. *Gastrointestinal Endoscopy*. 2015;81(1):81-89.

[43] Richter JA, Patrie JT, Richter RP, Henry ZH, Pop GH, Regan KA, Peura DA, Sawyer RG, Northup PG, Wang AY. Bleeding after percutaneous endoscopic gastrostomy is

linked to serotonin reuptake inhibitors, not aspirin or clopidogrel. *Gastrointest Endosc*. 2011;74(1):22-34 e21.

[44] Singh D, Laya AS, Vaidya OU, Ahmed SA, Bonham AJ, Clarkston WK. Risk of bleeding after percutaneous endoscopic gastrostomy (PEG). *Dig Dis Sci*. 2012;57(4): 973-980.

[45] Lucendo AJ, Sanchez-Casanueva T, Redondo O, Tenias JM, Arias A. Risk of bleeding in patients undergoing percutaneous endoscopic gastrotrostomy (PEG) tube insertion under antiplatelet therapy: a systematic review with a meta-analysis. *Rev Esp Enferm Dig*. 2015;107(3):128-136.

[46] Barton CA, McMillian WD, Osler T, Charash WE, Igneri PA, Brenny NC, Aloi JJ, Fortune JB. Anticoagulation management around percutaneous bedside procedures: is adjustment required? *J Trauma Acute Care Surg*. 2012;72(4):815- 820.

[47] Richter-Schrag HJ, Richter S, Ruthmann O, Olschewski M, Hopt UT, Fischer A. Risk factors and complications following percutaneous endoscopic gastrostomy: a case series of 1041patients. *Can J Gastroenterol*. 2011;25(4):201-206.

[48] Hull M, Beane A, Bowen J, Settle C. Methicillin-resistant Staphylococcus aureus infection of percutaneous endoscopic gastrostomy sites. *Aliment Pharmacol Ther*. 2001;15(12):1883-1888.

[49] Lee JH, Kim JJ, Kim YH, Jang JK, Son HJ, Peck KR, Rhee PL, Paik SW, Rhee JC, Choi KW. Increased risk of peristomal wound infection after percutaneous endoscopic gastrostomy in patients with diabetes mellitus. *Dig Liver Dis*. 2002;34(12):857-861.

[50] Vanis N, Saray A, Gornjakovic S, Mesihovic R. Percutaneous endoscopic gastrostomy(PEG): retrospective analysis of a 7-year clinical experience. *Acta Inform Med*. 2012;20(4):235-237.

In: Encyclopedia of Surgery (22 Volume Set)
Editors: Andreas Lehrer and Kristin Mueller
ISBN: 978-1-53618-329-0
© 2020 Nova Science Publishers, Inc.

Chapter 138

PREVENTION OF PERISTOMAL PEG INFECTION

Iruru Maetani**, MD
Toho University Ohashi Medical Center, Tokyo, Japan

INTRODUCTION

Since its clinical introduction by Ponsky and Gauderer, percutaneous endoscopic gastrostomy (PEG) has become a widely used method of maintaining enteral nutrition, particularly for patients with swallowing disturbances [1, 2]. PEG plays an important role in creating a nutritional access route, especially for patients who require enteral nutrition for long periods of time. A meta-analysis of randomized comparative studies showed that PEG has a lower probability of intervention failure than conventional nasogastric tube feeding, and is therefore considered the preferable method [3]. Compared with operative gastrostomy, PEG is associated with fewer major complications and decreased procedure-related mortality [4]. Nevertheless, other complications remain a problem, particularly local and systemic infection, of which peristomal wound infection is the most common with an occurrence rate of 3%–30%. [5, 6].

Gottlieb et al reported that gastrostomy tubes are colonized by *Candida* species, probably of oral origin, that have made their way into the stomach [8]. There is also concern that introduction of a gastrostomy tube that is pulled out through the abdominal wall to the outside carries a great deal of potentially infectious organisms with it. Thus, PEG stomas are assumed to have the potential to be contaminated by oropharyngeal bacteria. In aged and/or frail patients indicated for this procedure, peristomal infection may pose critical, sometimes life-threatening problems, such as abscess formation (Figure 1), necrotizing fasciitis (Figure 2), and peritonitis. Measures to prevent peristomal infection are critical. This chapter provides a broad overview of preventive measures for peristomal wound infection associated with PEG tubes.

* Corresponding Author's Email: mtnir50637@med.toho-u.ac.jp.

Figure 1. Localized subcutaneous abscess following primary button PEG placement via the introducer method [7].

Figure 2. Necrotizing soft tissue infection following PEG and gastrointestinal T-anchor placement.

ROUTINE ANTIBIOTIC PROPHYLAXIS

The role of antibiotics in the prevention of peristomal infection has been extensively investigated [9-19]. Most studies have claimed that antibiotic prophylaxis is significantly effective in preventing peristomal infection after PEG placement, although a few reports have failed to show efficacy [9, 12]. Prophylactic antibiotics may be helpful in reducing peristomal infection in patients undergoing percutaneous radiologic gastrostomy [20]. Several meta-analyses and systematic reviews of randomized controlled trials evaluating the use of prophylactic antimicrobials during PEG-tube placement also support the benefits of antibiotic prophylaxis in preventing peristomal infection [21-24]. A pooled analysis of 12 trials (1271 cases) of prophylactic antibiotics demonstrated a statistically significant reduction in the incidence of peristomal infection (9.4% vs. 24.2%, odds ratio [OR] 0.36, 95% CI 0.26–0.50). Subgroup analysis of studies which compared intravenous antibiotics with placebo (eight trials; 586 cases) also found significantly fewer infections in patients treated with antibiotics (11.6% vs. 27.3%, OR 0.34, 95% CI 0.22–0.53). Another subgroup analysis assessing only studies comparing systemic antibiotics with no intervention (three trials; 613 cases) also

showed significantly fewer infections in patients treated with antibiotics (5.2% vs. 20%, OR 0.30, 95% CI 0.17–0.53) [24].

A meta-analysis of costs in seven published prospective randomized placebo-controlled trials showed that antibiotic prophylaxis led to an expected cost savings of 76.72 US dollars per PEG procedure [25].

At present, the American Society for Gastrointestinal Endoscopy (ASGE), the European Society of Gastrointestinal Endoscopy (ESGE) and the British Society of Gastroenterology (BSG) recommend the use of antibiotic prophylaxis prior to PEG placement in all patients [26-28]. ASGE guidelines state that parenteral cefazolin should be administered 30 minutes before PEG tube placement, while BSG guidelines mention that patients should receive a single dose of intravenous (IV) co-amoxiclav (amoxicillin-clavulanic acid) during the hour before the PEG placement procedure [26, 28]. Cefuroxime is an alternative, but should be avoided in regions with a high incidence of *C. difficile* infection or infections due to extended-spectrum β-lactamase-producing organisms.

A Taiwanese group evaluated the relationship between respiratory infection and peristomal infection. Patients with respiratory infections had an increased risk of peristomal infection after PEG placement. They found that patients with PEG-site infection were more likely to have a positive sputum culture than those without (63.3% vs. 14.6%, $P < 0.001$). The authors concluded that appropriate prophylactic antibiotics should be selected to cover the microorganisms isolated from the sputum of each patient [29].

A randomized study indicated that 20 mL of co-trimoxazole solution deposited in a newly-inserted PEG catheter is at least as effective as intravenous cefuroxime prophylaxis before PEG in preventing wound infection [30].

METHICILLIN-RESISTANT *STAPHYLOCOCCUS AUREUS* PATIENTS

With its increasing prevalence of colonization in hospitalized patients, methicillin-resistant *Staphylococcus aureus* (MRSA) is emerging as a major pathogen in PEG site infections [31-33]. Those patients who are colonized may require MRSA-specific adjuncts to prevent PEG site infections. Currently recommended antibiotic prophylaxis regimens using cephalosporins may have diminishing effectiveness against MRSA. Patients with prior MRSA colonization are at a significantly higher risk of developing symptomatic MRSA infection of the PEG site [34, 35].

Rao et al reported that decontamination and glycopeptide prophylaxis are effective in preventing PEG-site infections with MRSA [36]. Horiuchi et al reported that oropharyngeal decolonization of MRSA with intranasal application of mupirocin, inhalation of arbekacin, and oral trimethoprim/sulfamethoxazole can reduce peristomal infection from pull-through PEG insertion [37]. A similar study from the United Kingdom showed that MRSA screening before PEG placement and subsequent decontamination and prophylactic IV teicoplanin in patients testing positive can decrease the incidence of MRSA wound infection [37]. The decontamination procedure involved daily skin decontamination with 2% triclosan shampoo washes for 5 days and nasal treatment with mupirocin ointment 8 hours prior to PEG insertion.

In a study evaluating the overall efficacy of antimicrobial prophylaxis, none of 51 patients receiving co-amoxiclav or cefotaxime (if penicillin-allergic) were found to have MRSA on wound swabs, whereas MRSA was found in nine of 48 patients receiving placebo [18]. This result may imply that co-amoxiclav has a prophylactic effect against MRSA. However, baseline MRSA status was not identified in this study. Further, although co-amoxiclav has significant *in vitro* activity against some strains of MRSA, there is no evidence of significant clinical activity against MRSA, and it is not among the antibiotics recommended for MRSA infection [39-41].

In general, standard antibiotic prophylaxis according to guidelines may not be appropriate due to the increased prevalence of resistant organisms [42]. Prevention of peristomal infection may require procedures such as decontamination of resistant organisms before PEG placement [36].

LOCAL STERILIZATION OF THE OROPHARYNX

Reducing nasopharyngeal flora using antiseptic agents prior to PEG placement appears to be an effective means of reducing the risk of infection associated with the procedure [6]. Grant et al used antibiotic-impregnated lubricating ointment before pulling the tube through the mouth to prevent PEG-site infection [43]. To avoid peristomal infection, Deitel et al suggested an antiseptic gargle where possible, or preparation of the oral cavity with povidone-iodine-moistened packing before introducing the gastroscope [44]. Other authors have recommended that in addition to antibiotic prophylaxis, patients should gargle with povidone-iodine, and have their faces painted with povidone-iodine and fully draped prior to PEG placement [45]. The efficacy of these methods, however, has not been proven in prospective trials, moreover the maneuvers may be impractical in patients who are at a high risk of aspiration. Oral surgeons have known for many years that topical antimicrobials applied to the oral cavity and pharynx prior to dental procedures reduce the number of bacteria, the incidence of bacteremia, and related infectious complications [46-48]. However, these measures need to be tested in a prospective randomized trial for PEG placement.

Bypassing the Oropharynx (PRG/PEG with the Introducer Method)

The introducer technique may carry a lower risk of peristomal infection compared with pull-through or push-over wire techniques, since the PEG catheter does not pass through the oropharyngeal cavity during placement. Based on their study of fungal organisms from the oral cavity, stomach, and gastrostomy tubes, Gottlieb et al suggested that gastrostomy tubes are probably colonized by oral organisms that have migrated to the stomach [8].

A review article assessing over 5000 cases revealed that percutaneous radiologic gastrostomy (PRG) was associated with significantly fewer major complications (e.g. wound-related problems, aspiration, and peritonitis) than PEG (mostly pull-through technique) [49]. Presumably, the lower risk of peristomal infections with PRG is attributable to the direct insertion of the feeding catheter into the opacified stomach under sterile conditions without the need for passage of a catheter or other instrument and its accompanying flora from the

oropharynx to the stomach and through the abdominal wall and skin. In a prospective but nonrandomized study, local wound infection was more common in PEG than with PRG (18% vs. 2%, P = 0.008) [7]. No randomized comparison of PEG and PRG has yet been published. Two articles suggested that peristomal infection was more frequent with PRG than with PEG; however, these studies appear to have been subject to selection bias, as the PRG group included more cancer patients, who are often at higher risk of infection from immunosuppression [50, 51].

In 1984, Russell and colleagues reported a percutaneous endoscopic gastrostomy performed by pushing an introducer contained in a pacemaker lead peel-away sheath over a guidewire directly into the stomach [52]. A study comparing the pull-through technique with introducer-PEG placement using Russell's technique reported that no peristomal infections occurred in the introducer group (0% for introducer vs. 21% for pull) [44]. Later, an introducer technique which used a large-caliber trocar became available, allowing larger-bore gastrostomy tubes to be inserted. Several reports on this procedure have also indicated a low rate of peristomal infection (0–3.7%), as the gastrostomy tube does not pull oropharyngeal flora across the abdominal wall [53-56].

Many studies have compared the introducer technique with the pull and push techniques, with varying results. A randomized controlled trial assessing the occurrence of peristomal infection following introducer PEG placement with or without prophylactic antibiotics revealed that this technique can be safely performed without them, even in patients who are at high risk of peristomal infectious complications (e.g., those with advanced oropharyngeal malignancies) [19].

Several other reports have compared various PEG-with-introducer methods with the conventional pull or push methods. A retrospective comparison of the push and introducer methods for PEG placement found no difference in the occurrence of peristomal infection [57]. A previously mentioned study suggested that the introducer method was faster and was associated with fewer peristomal infections than the pull method (0% vs. 21%, respectively). Another comparative study revealed similar results (1.9% vs. 36.5%, P = 0.001) [58]. A prospective randomized trial comparing the Russell method with the pull method found that the rate of peristomal infection was significantly lower with the introducer method than the pull method (0% vs. 31%, respectively; P = 0.00094) [59]. A recent retrospective study found no significant difference between pull-type and introducer-type PEG insertion with respect to acute wound infection rate (≤ 7 days after PEG insertion) [60]. A significantly low rate of peristomal infection (2.6%) was found for the pull technique, while the rate of peristomal infection for the introducer group was 1.7%, which is comparable to previous studies.

One of the drawbacks of PRG or introducer PEG, including the trocar method, is that they are restricted to the use of only small caliber catheters. To make up for this shortcoming, a modified introducer technique which allows direct placement of a larger catheter has been developed. For this technique, two prospective randomized studies and two retrospective studies comparing the modified introducer with the pull technique showed a lower incidence of peristomal infection in the modified introducer group, with the exception of one randomized study, in which peristomal infection was less likely in the modified introducer group although not to a statistically significant extent (12.9% vs 23.3%, P = 0.3354) [61-64].

A meta-analysis which included both standard introducer and modified introducer techniques analyzing six comparative and 10 observational studies (2336 cases) concluded

that the pull technique appears to be associated with a significantly higher risk of infection than the introducer technique [65]. In the comparative studies, the risk of infection was significantly higher with the pull technique (OR 13.0; 95% CI, 4.6–36.8; $P < 0.0001$). The observational studies also reported higher infection rates with the pull technique (10.7%; 95% CI, 4.9–21.8 for the pull technique vs 0.9%; 95% CI, 0.2–4.5 for the introducer technique).

As stated above, the introducer technique, which avoids passage of the PEG tube through the oropharyngeal cavity before crossing the abdominal wall, appears reasonably effective in reducing the occurrence of peristomal infection. However, the pull method has long been the gold standard of PEG placement, and most endoscopists are familiar with the technique. In Japan, in contrast, standard and modified introducer techniques together accounted for more than half of all PEG placement procedures in 2013 [66].

OVERTUBE USE

Sharma et al advocated the use of an overtube (Figure 3) during the PEG procedure in head-and-neck cancer patients to prevent implantation of cancer cells at the PEG site [67]. Takahashi et al first reported the clinical application of an overtube during PEG placement [68]. They showed that use of an overtube such as that used for endoscopic variceal ligation (EVL) helps to simplify the second insertion of the endoscope to confirm positioning of the internal bumper. The authors assumed that this procedure can lower the risk of peristomal infection, as it avoided contact of the catheter with the oropharyngeal cavity [68].

To confirm this assumption, Maetani et al conducted a randomized controlled trial to compare the occurrence of PEG-site infection between PEG placement with and without an overtube, and found that the use of an overtube lowered the risk of peristomal infection (5% vs. 33%, respectively; $P = 0.0029$) [69]. This procedure has the additional advantage of allowing the use of many different sizes and models of PEG tube. Although no overtube-related complication were encountered in the study, complications associated with overtube-related pinch injury during EVL have been reported, indicating the need for caution in overtube insertion [70]. A recent study evaluated the feasibility and safety of the overtube method for PEG placement in patients with head and neck cancer, employing a new overtube featuring a tapered tip designed to protect against mucosal damage [71]. In this study, peristomal infection occurred in only 5.7%, which is comparable to the aforementioned study using standard overtubes [69]. There also were no cases of overtube-related adverse events such as implantation of cutaneous metastases during a median follow-up period of 16 months [67].

Figure 3. Gastric length esophageal overtube.

Thus, use of an overtube appears to be beneficial in reducing the transmission of bacteria or tumor cells from the oropharyngeal area to the PEG site. These results suggest that the use of an overtube may be beneficial in reducing the risk of PEG-associated peristomal infection when using a peroral route. Overtubes can be placed in patients receiving conscious sedation only, but occasionally the discomfort associated with placement may require general anesthesia. The risk/benefit ratio of their use in this circumstance should be considered by the endoscopist.

COVERED PEG

Suzuki et al evaluated the efficacy of a covered PEG kit in preventing peristomal infection [72]. The kit (Nutrex Gastrostomy Tube, Nippon Sherwood Medical, Tokyo, Japan) contains a 20 Fr PEG catheter preloaded in a narrow overtube. The overtube is easily passed through the oropharynx to the stomach using the pull technique and once there the overtube is pulled retrograde off of the PEG and removed from the mouth (Figure 4). They reported that use of this kit was associated with significantly fewer peristomal infections than uncovered PEG insertion with the same pull technique (2% vs. 33%, OR 0.05; 95% CI 0.02–0.13) [72]. The overtube group also had significantly lower body temperature, white blood cell counts, and C-reactive protein levels. Although the entire pathway from the mouth to the stomach was completely covered by the overtube using this device, this method is disadvantaged by its incompatibility with other PEG catheters.

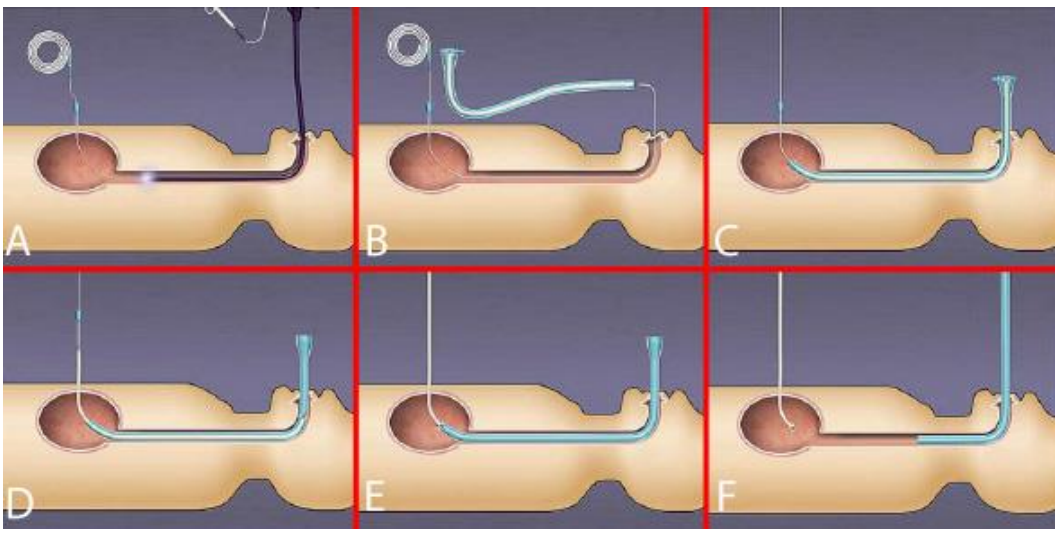

Figure 4, Inserting a covered percutaneous endoscopic gastrostomy (PEG). A) Needle and sheath are inserted through the abdominal wall and grasped with a snare in the stomach. B) Needle is removed from sheath. C) Guidewire is inserted through the sheath. D) Endoscope is removed, bringing the guidewire with it. E) Covered PEG is connected to the guidewire. F) Inserting covered PEG tube along with guide wire. G) PEG and overtube are pulled into the stomach. H) PEG tube is pulled through the abdominal wall. I) PEG tube now free from the covering sheath. J) The covering sheath is removed via the oral cavity. K) Confirm the position of PEG by endoscopy.

ANTISEPTIC USE AT THE PEG SITE

Radhakrishnan and colleagues showed that a single application of povidone-iodine local antiseptic spray combined with systemic antibiotic prophylaxis at the time of PEG insertion reduces the incidence of PEG site infection [73]. Among three groups, an antibiotic group (A), antiseptic spray group (B), and combined group (C) (n = 34, 28 and 34, respectively), MRSA was not isolated in any patient in group (C), but was isolated in four patients from group (A) and two from group (B).

GASTROPEXY

Gastropexy is often performed during PEG insertion, particularly in skin-to-stomach PEG placement methods such as the standard and modified introducer techniques [7, 19, 63, 74]. Campoli et al assessed the rate of peristomal infection between two different gastropexy techniques [75]. All patients underwent the introducer technique without use of antibiotic prophylaxis. One group underwent gastropexy with two straight needles, one having a strand of nylon suture and the second having a loop made with another nylon suture. A polypectomy snare is introduced through the endoscope and used to bring the loose suture through the loop. After capture, the whole set is taken out so as to obtain a U-shaped suture. The other group underwent gastropexy using a long curved needle to place two suture stitches, which transfixed the abdominal and gastric walls. Gastropexy performed with a curved needle was associated with a lower rate of infection than gastropexy with two straight needles (0.2% vs. 2.8%, P = 0.03). The higher rate of peristomal infection in the latter group is presumably due to contact of the endoscopic accessories with the sterile suture, and the complexity of the procedure. However, a gastropexy device which enables suture stitching without the use of an endoscopic accessory device is now commercially available [19].

A retrospective study in Japan indicated that PEG with gastropexy markedly reduced peristomal inflammation compared with PEG without gastropexy [76]. When evaluation was confined to patients who underwent pull-type PEG placement, however, no statistically significant difference between procedures with or without gastropexy was seen.

MISCELLANEOUS ADJUNCTS

Kuo and colleagues conducted a randomized study to determine whether 14-day discharge before PEG placement reduced the rate of peristomal infection, following previous findings that outcomes after PEG placement were better in ambulatory than hospitalized patients [77-79]. The study concluded that a 14-day grace period after discharge, before PEG placement, may decrease peristomal infection, length of hospital stay after PEG, and the need for antibiotics.

Fagundes et al retrospectively analyzed the association of peristomal infection with the extent of the skin incision and use of prophylactic antibiotics. Peristomal infection was less common in patients with 5 mm incisions than those with 10 mm incisions (2.2% vs. 12.4%, P = 0.01), while there was no association with prophylactic antibiotics (P = 0.3) [80].

Blumenstein and colleagues evaluated the efficacy of glycerin hydrogel (GHG) wound dressing, which possesses more effective antimicrobial properties than dry dressings [81]. Their randomized study revealed a significantly reduced rate of peristomal infection at 7 days in the GHG group (14.7% vs. 47.05%, $P < 0.005$). In addition, dressing changes with the GHG wound dressing were five times less frequent than with the traditional dressing. Cost-effectiveness analysis for the first month revealed a net cost saving of about 425 US dollars (310 €) per patient in favor of the GHG dressing.

Another study found that an activated charcoal dressing with silver (ACTISORB® Silver 220, Johnson & Johnson Medical, New Brunswick, NJ, USA) used for post procedural wound care may be helpful in reducing peristomal infection [82]. These results are preliminary, although the dressing's antimicrobial effect was demonstrated in a previous *in vitro* study [83].

Japanese researchers evaluated the relationship between gastric acidity and the occurrence of PEG site infection [84]. Results showed a trend toward a higher pH level in the infected group (4.05 ± 2.61 vs. 3.09 ± 1.86, $P = 0.07$). In patients negative for MRSA in the oropharynx, the pH level was significantly higher in the infected group (5.05 ± 2.55 vs. 3.06 ± 1.83, $P = 0.0019$). In this study, the median pH of ten patients with peristomal infections caused by MRSA was 2.96. MRSA might be unaffected by gastric acidity, presumably due to acquired resistance to low pH. On the basis of these results, the authors suggested that an H2-receptor antagonist or proton pump inhibitor should not be administered during the course of PEG placement to reduce the risk of PEG site infection.

Aside from said procedures, basic tube management procedure is quite important, despite the empirical manners. The external bumper should be 1-2 cm away from the abdominal wall to avoid excessive tension between internal and external bumpers which may cause impaired vascular perfusion of peristomal site and gastric ulceration. These may be associated with occurrence of peristomal infection and/or buried bumper syndrome. In one or two days after PEG placement, possible significant tissue edema at PEG-stoma may lead to excessive tension between both bumpers. In such case, external bumper should be moved in keeping away from the abdominal wall.

CONCLUSION

Peristomal wound infection is the most common complication associated with PEG procedures. Preventing wound infection is important, as many PEG patients will have poor healing due to associated malnutrition. Prophylactic antibiotics are effective in reducing the risk of peristomal infection, as has been suggested in some guidelines. However, MRSA and other resistant organisms have emerged as major pathogens in peristomal infection, and alternative procedures other than standard prophylactic antibiotics may be necessary. Possible effective measures include decontamination of the oropharynx and skin prior to PEG placement, but these remain uncertain. A standardized procedure to prevent MRSA-related infection needs to be established. In addition, PEG with an introducer method, use of the pull method with an overtube, or antiseptic use at the PEG site appear to be beneficial in reducing the risk of PEG site infection.

EDITOR'S COMMENT

As eloquently outlined in this chapter, infection prevention during PEG extends well beyond the prophylactic dose of antibiotics. There are a wide array of maneuvers applicable to PEG placement that have been shown in small studies to reduce the risk of infection. What is not always delineated in these studies, however, is the cost/benefit ratio of the intervention. The number needed to treat and the relative risk reduction of these interventions is not always clear. Consideration must be given by the endoscopist to the added cost and added risk associated with these adjunct maneuvers before widespread implementation should be considered. (EMP)

REFERENCES

[1] Gauderer MW, Ponsky JL, Izant RJ, Jr. Gastrostomy without laparotomy: a percutaneous endoscopic technique. *J Pediatr Surg*. 1980;15:872-875.

[2] Ponsky JL, Gauderer MW. Percutaneous endoscopic gastrostomy: a nonoperative technique for feeding gastrostomy. *Gastrointestinal Endoscopy*. 1981;27:9-11.

[3] Gomes CA, Jr., Lustosa SA, Matos D, et al. Percutaneous endoscopic gastrostomy versus nasogastric tube feeding for adults with swallowing disturbances. *Cochrane Database Syst Rev* 2012; 3: CD008096.

[4] Grant JP. Comparison of percutaneous endoscopic gastrostomy with Stamm gastrostomy. *Ann Surg*. 1988;207:598-603.

[5] Mamel JJ. Percutaneous endoscopic gastrostomy. *The American Journal of Gastroenterology*. 1989;84:703-710.

[6] Safadi BY, Marks JM, Ponsky JL. Percutaneous endoscopic gastrostomy. *Gastrointestinal Endoscopy Clinics of North America*. 1998;8:551-568.

[7] Laasch HU, Wilbraham L, Bullen K, et al. Gastrostomy insertion: comparing the options--PEG, RIG or PIG? *Clin Radiol*. 2003;58:398-405.

[8] Gottlieb K, Iber FL, Livak A, et al. Oral Candida colonizes the stomach and gastrostomy feeding tubes. *JPEN*. 1994;18:264-267.

[9] Jonas SK, Neimark S, Panwalker AP. Effect of antibiotic prophylaxis in percutaneous endoscopic gastrostomy. *The American Journal of Gastroenterology*. 1985;80:438-441.

[10] Jain NK, Larson DE, Schroeder KW, et al. Antibiotic prophylaxis for percutaneous endoscopic gastrostomy. A prospective, randomized, double-blind clinical trial. *Annals of Internal Medicine*. 1987;107:824-828.

[11] Akkersdijk WL, van Bergeijk JD, van Egmond T, et al. Percutaneous endoscopic gastrostomy (PEG): comparison of push and pull methods and evaluation of antibiotic prophylaxis. *Endoscopy*. 1995;27:313-316.

[12] Sturgis TM, Yancy W, Cole JC, et al. Antibiotic prophylaxis in percutaneous endoscopic gastrostomy. *The American Journal of Gastroenterology*. 1996;91:2301-2304.

[13] Gossner L, Keymling J, Hahn EG, et al. Antibiotic prophylaxis in percutaneous endoscopic gastrostomy (PEG): a prospective randomized clinical trial. *Endoscopy*. 1999;31:119-124.

[14] Dormann AJ, Wigginghaus B, Risius H, et al. A single dose of ceftriaxone administered 30 minutes before percutaneous endoscopic gastrostomy significantly reduces local and systemic infective complications. *The American Journal of Gastroenterology*. 1999;94:3220-3224.

[15] Preclik G, Grune S, Leser HG, et al. Prospective, randomised, double blind trial of prophylaxis with single dose of co-amoxiclav before percutaneous endoscopic gastrostomy. *BMJ*. 1999;319:881-884.

[16] Panigrahi H, Shreeve DR, Tan WC, et al. Role of antibiotic prophylaxis for wound infection in percutaneous endoscopic gastrostomy (PEG): result of a prospective double-blind randomized trial. *J Hosp Infect*. 2002;50:312-315.

[17] Ahmad I, Mouncher A, Abdoolah A, et al. Antibiotic prophylaxis for percutaneous endoscopic gastrostomy--a prospective, randomised, double-blind trial. *Aliment Pharmacol Ther*. 2003;18:209-215.

[18] Saadeddin A, Freshwater DA, Fisher NC, et al. Antibiotic prophylaxis for percutaneous endoscopic gastrostomy for non-malignant conditions: a double-blind prospective randomized controlled trial. *Aliment Pharmacol Ther*. 2005;22:565-570.

[19] Shastri YM, Hoepffner N, Tessmer A, et al. New introducer PEG gastropexy does not require prophylactic antibiotics: multicenter prospective randomized double-blind placebo-controlled study. *Gastrointestinal Endoscopy*. 2008;67:620-628.

[20] Cantwell CP, Perumpillichira JJ, Maher MM, et al. Antibiotic prophylaxis for percutaneous radiologic gastrostomy and gastrojejunostomy insertion in outpatients with head and neck cancer. *J Vasc Interv Radiol*. 2008;19:571-575.

[21] Sharma VK, Howden CW. Meta-analysis of randomized, controlled trials of antibiotic prophylaxis before percutaneous endoscopic gastrostomy. *The American Journal of Gastroenterology*. 2000;95:3133-3136.

[22] Jafri NS, Mahid SS, Minor KS, et al. Meta-analysis: antibiotic prophylaxis to prevent peristomal infection following percutaneous endoscopic gastrostomy. *Aliment Pharmacol Ther*. 2007;25:647-656.

[23] Lipp A, Lusardi G. A systematic review of prophylactic antimicrobials in PEG placement. *Journal of Clinical Nursing*. 2009;18:938-948.

[24] Lipp A, Lusardi G. Systemic antimicrobial prophylaxis for percutaneous endoscopic gastrostomy. *Cochrane Database Syst Rev*. 2013;11:CD005571.

[25] Kulling D, Sonnenberg A, Fried M, et al. Cost analysis of antibiotic prophylaxis for PEG. *Gastrointestinal Endoscopy*. 2000;51:152-156.

[26] AAGE Standards Of Practice Committee, Banerjee S, Shen B, et al. Antibiotic prophylaxis for GI endoscopy. *Gastrointestinal Endoscopy*. 2008;67:791-798.

[27] Barthet M, Napoleon B, Gay G, et al. Antibiotic prophylaxis for digestive endoscopy. *Endoscopy*. 2004;36:1123-1125.

[28] Allison MC, Sandoe JA, Tighe R, et al. Antibiotic prophylaxis in gastrointestinal endoscopy. *Gut*. 2009;58:869-880.

[29] Chuang CH, Hung KH, Chen JR, et al. Airway infection predisposes to peristomal infection after percutaneous endoscopic gastrostomy with high concordance between sputum and wound isolates. *J Gastrointest Surg*. 2010;14:45-51.

[30] Blomberg J, Lagergren P, Martin L, et al. Novel approach to antibiotic prophylaxis in percutaneous endoscopic gastrostomy (PEG): randomised controlled trial. *BMJ*. 2010;341:c3115.

[31] Chaudhary KA, Smith OJ, Cuddy PG, et al. PEG site infections: the emergence of methicillin resistant Staphylococcus aureus as a major pathogen. *The American Journal of Gastroenterology*. 2002;97:1713-1716.

[32] Ogundipe OA, Kar-Purkayastha S. An audit of antibiotics usage and their effect on MRSA infection or colonisation following percutaneous endoscopic gastrostomy in a district general hospital. *Int J Clin Pract*. 2004;58:632-634.

[33] Thomas S, Cantrill S, Waghorn DJ, et al. The role of screening and antibiotic prophylaxis in the prevention of percutaneous gastrostomy site infection caused by methicillin-resistant Staphylococcus aureus. *Aliment Pharmacol Ther*. 2007;25:593-597.

[34] Mainie I, Loughrey A, Watson J, et al. Percutaneous endoscopic gastrostomy sites infected by methicillin-resistant Staphylococcus aureus: impact on outcome. *J Clin Gastroenterol*. 2006;40:297-300.

[35] Kroupa R, Jurankova J, Dastych M, et al. Different clinical utility of oropharyngeal bacterial screening prior to percutaneous endoscopic gastrostomy in oncological and neurological patients. *Biomed Res Int*. 2014;2014:590891.

[36] Rao GG, Osman M, Johnson L, et al. Prevention of percutaneous endoscopic gastrostomy site infections caused by methicillin-resistant Staphylococcus aureus. *J Hosp Infect*. 2004;58:81-83.

[37] Horiuchi A, Nakayama Y, Kajiyama M, et al. Nasopharyngeal decolonization of methicillin-resistant Staphylococcus aureus can reduce PEG peristomal wound infection. *The American Journal of Gastroenterology*. 2006;101:274-277.

[38] Cantoni L, Wenger A, Glauser MP, et al. Comparative efficacy of amoxicillin-clavulanate, cloxacillin, and vancomycin against methicillin-sensitive and methicillin-resistant Staphylococcus aureus endocarditis in rats. *The Journal of Infectious Diseases*. 1989;159:989-993.

[39] Prieto J, Aguilar L, Gimenez MJ, et al. In vitro activities of co-amoxiclav at concentrations achieved in human serum against the resistant subpopulation of heteroresistant Staphylococcus aureus: a controlled study with vancomycin. *Antimicrobial Agents and Chemotherapy*. 1998;42:1574-1577.

[40] Gurusamy KS, Koti R, Wilson P, et al. Antibiotic prophylaxis for the prevention of methicillin-resistant Staphylococcus aureus (MRSA) related complications in surgical patients. *Cochrane Database Syst Rev*. 2013;8:CD010268.

[41] Liu C, Bayer A, Cosgrove SE, et al. Clinical practice guidelines by the infectious diseases society of america for the treatment of methicillin-resistant Staphylococcus aureus infections in adults and children: executive summary. *Clin Infect Dis*. 2011;52:285-292.

[42] Mahadeva S, Khoo BL, Khoo PS, et al. Clinical impact and risk factors for percutaneous gastrostomy wound infections due to resistant organisms. *Int J Infect Dis*. 2008;12:e149-150.

[43] Grant JP. Percutaneous endoscopic gastrostomy. Initial placement by single endoscopic technique and long-term follow-up. *Ann Surg*. 1993;217:168-174.

[44] Deitel M, Bendago M, Spratt EH, et al. Percutaneous endoscopic gastrostomy by the "pull" and "introducer" methods. *Canadian Journal of Surgery*. 1988;31:102-104.

[45] Greif JM, Ragland JJ, Ochsner MG, et al. Fatal necrotizing fasciitis complicating percutaneous endoscopic gastrostomy. *Gastrointestinal Endoscopy*. 1986;32:292-294.

[46] Scopp IW, Orvieto LD. Gingival degerming by povidone-iodine irrigation: bacteremia reduction in extraction procedures. *J Am Dent Assoc*. 1971;83:1294-1296.
[47] Brenman HS, Randall E. Local degerming with povidone-iodine, II. Prior to gingivectomy. *J Periodontol*. 1974;45:870-872.
[48] Aguada E, Olona IL, Salazar MB. Gingival degerming by povidone-iodine irrigation: bacteremia reduction in extraction procedures. *J Philipp Dent Assoc*. 1997;49:42-50.
[49] Wollman B, D'Agostino HB, Walus-Wigle JR, et al. Radiologic, endoscopic, and surgical gastrostomy: an institutional evaluation and meta-analysis of the literature. *Radiology*. 1995;197:699-704.
[50] Galletti R, Finocchiaro E, Repici A, et al. Comparison of complication rates between endoscopic and fluoroscopic percutaneous gastrostomies. *Nutrition*. 2001;17:967-968.
[51] Silas AM, Pearce LF, Lestina LS, et al. Percutaneous radiologic gastrostomy versus percutaneous endoscopic gastrostomy: a comparison of indications, complications and outcomes in 370 patients. *Eur J Radiol*. 2005;56:84-90.
[52] Russell TR, Brotman M, Norris F. Percutaneous gastrostomy. A new simplified and cost-effective technique. *Am J Surg*. 1984;148:132-137.
[53] Giordano-Nappi JH, Maluf-Filho F, Ishioka S, et al. A new large-caliber trocar for percutaneous endoscopic gastrostomy by the introducer technique in head and neck cancer patients. *Endoscopy*. 2011;43:752-758.
[54] Lee HS, Lim CH, Park EY, et al. Usefulness of the introducer method for percutaneous endoscopic gastrostomy using ultrathin transnasal endoscopy. *Surg Endosc*. 2014;28:603-606.
[55] Dormann AJ, Glosemeyer R, Leistner U, et al. Modified percutaneous endoscopic gastrostomy (PEG) with gastropexy--early experience with a new introducer technique. *Z Gastroenterol*. 2000;38:933-938.
[56] Foster JM, Filocamo P, Nava H, et al. The introducer technique is the optimal method for placing percutaneous endoscopic gastrostomy tubes in head and neck cancer patients. *Surg Endosc*. 2007;21:897-901.
[57] Kozarek RA, Ball TJ, Ryan JA, Jr. When push comes to shove: a comparison between two methods of percutaneous endoscopic gastrostomy. *The American Journal of Gastroenterology*. 1986;81:642-646.
[58] Lim CH, Park JM, Cho YK, et al. Successful control of peristomal infection by introducer-type percutaneous endoscopic gastrostomy: a retrospective historical control study. *Digestive Diseases and Sciences*. 2011;56:2024-2029.
[59] Maetani I, Tada T, Ukita T, et al. PEG with introducer or pull method: a prospective randomized comparison. *Gastrointestinal Endoscopy*. 2003;57:837-841.
[60] Lee SW, Lee JH, Cho H, et al. Comparison of clinical outcomes associated with pull-type and introducer-type percutaneous endoscopic gastrostomies. *Clinical Endoscopy*. 2014;47:530-537.
[61] Horiuchi A, Nakayama Y, Tanaka N, et al. Prospective randomized trial comparing the direct method using a 24 Fr bumper-button-type device with the pull method for percutaneous endoscopic gastrostomy. *Endoscopy*. 2008;40:722-726.
[62] Shigoka H, Maetani I, Tominaga K, et al. Comparison of modified introducer method with pull method for percutaneous endoscopic gastrostomy: Prospective randomized study. *Digestive Endoscopy*. 2012;24:426-431.

[63] Hiki N, Maetani I, Suzuki Y, et al. Reduced risk of peristomal infection of direct percutaneous endoscopic gastrostomy in cancer patients: comparison with the pull percutaneous endoscopic gastrostomy procedure. *J Am Coll Surg*. 2008;207:737-744.

[64] Ohno T, Ogawa A, Yanai M, et al. The usefulness and safety of the introducer technique using a bumper-button-type device as compared with the pull method for percutaneous endoscopic gastrostomy. *Surg Laparosc Endosc Percutan Tech*. 2015;25:e1-4.

[65] Campoli PM, de Paula AA, Alves LG, et al. Effect of the introducer technique compared with the pull technique on the peristomal infection rate in PEG: a meta-analysis. *Gastrointestinal Endoscopy*. 2012;75:988-996.

[66] [Anonymous]. Total Market of PEG devices. In, *Yearbook of Medical Devices* 2014, Market Analysis Edition. Aichi, Japan: R & D Co. Ltd.; 2014:320-325.

[67] Sharma P, Berry SM, Wilson K, et al. Metastatic implantation of an oral squamous-cell carcinoma at a percutaneous endoscopic gastrostomy site. *Surg Endosc*. 1994;8:1232-1235.

[68] Takahashi M, Horiuchi R. Percutaneous endoscopic gastrostomy. *Endoscopia Digestiva*. 1999;11:932-937.

[69] Maetani I, Yasuda M, Seike M, et al. Efficacy of an overtube for reducing the risk of peristomal infection after PEG placement: a prospective, randomized comparison study. *Gastrointestinal Endoscopy*. 2005;61:522-527.

[70] Dennert B, Ramirez FC, Sanowski RA. A prospective evaluation of the endoscopic spectrum of overtube-related esophageal mucosal injury. *Gastrointestinal Endoscopy*. 1997;45:134-137.

[71] Musumba CO, Hsu J, Ahlenstiel G, et al. Feasibility and Safety of Overtubes for PEG-Tube Placement in Patients with Head and Neck Cancer. *Gastroenterology Research and Practice*. 2015;2015:612610.

[72] Suzuki Y, Urashima M, Ishibashi Y, et al. Covering the percutaneous endoscopic gastrostomy (PEG) tube prevents peristomal infection. *World J Surg*. 2006;30:1450-1458.

[73] Radhakrishnan NV, Shenoy AH, Cartmill I, et al. Addition of local antiseptic spray to parenteral antibiotic regimen reduces the incidence of stomal infection following percutaneous endoscopic gastrostomy: A randomized controlled trial. *European Journal of Gastroenterology & Hepatology*. 2006;18:1279-1284.

[74] Shigoka H, Maetani I, Tominaga K, et al. Comparison of modified introducer method with pull method for percutaneous endoscopic gastrostomy: prospective randomized study. *Digestive Endoscopy*. 2012;24:426-431.

[75] Campoli PM, Cardoso DM, Turchi MD, et al. Peristomal infection in percutaneous endoscopic gastrostomy (PEG): a comparative study of two gastropexy techniques in a before-and-after design. *Acta Gastroenterol Latinoam*. 2011;41:296-301.

[76] Okumura N, Tsuji N, Ozaki N, et al. Percutaneous endoscopic gastrostomy with Funada-style gastropexy greatly reduces the risk of peristomal infection. *Gastroenterology Report*. 2015;3:69-74.

[77] Kuo CH, Hu HM, Tsai PY, et al. A better method for preventing infection of percutaneous endoscopic gastrostomy. *J Gastrointest Surg*. 2008;12:358-363.

[78] Abuksis G, Mor M, Plaut S, et al. Outcome of percutaneous endoscopic gastrostomy (PEG): comparison of two policies in a 4-year experience. *Clin Nutr*. 2004;23:341-346.

[79] Abuksis G, Mor M, Segal N, et al. Percutaneous endoscopic gastrostomy: high mortality rates in hospitalized patients. *The American Journal of Gastroenterology*. 2000;95:128-132.

[80] Fagundes RB, Cantarelli JC, Jr., Fontana K, et al. Percutaneous endoscopic gastrostomy and peristomal infection: an avoidable complication with the use of a minimum skin incision. *Surg Laparosc Endosc Percutan Tech*. 2011;21:275-277.

[81] Blumenstein I, Borger D, Loitsch S, et al. A glycerin hydrogel-based wound dressing prevents peristomal infections after percutaneous endoscopic gastrostomy (PEG): a prospective, randomized study. *Nutr Clin Pract*. 2012;27:422-425.

[82] Leak K. PEG site infections: a novel use for Actisorb Silver 220. *Br J Community Nurs*. 2002;7:321-325.

[83] Muller G, Winkler Y, Kramer A. Antibacterial activity and endotoxin-binding capacity of Actisorb Silver 220. *J Hosp Infect*. 2003;53:211-214.

[84] Ono H, Ito S, Yamazaki Y, et al. Effects of gastric acidity on peristomal infection after percutaneous endoscopic gastrostomy placement. *J Hosp Infect*. 2010;76:42-45.

In: Encyclopedia of Surgery (22 Volume Set)
Editors: Andreas Lehrer and Kristin Mueller
ISBN: 978-1-53618-329-0
© 2020 Nova Science Publishers, Inc.

Chapter 139

ACUTE COMPLICATIONS OF PEG

Lava Y. Patel, MD and Michael B. Ujiki*, MD
North Shore University HealthSystem, Evanston, IL, US

INTRODUCTION

Advancements in laparo-endoscopic techniques over the past 30 years have led to significant improvements in enteral access with regards to procedure-related morbidity and cost when compared to previous open techniques [1, 2]. Percutaneous endoscopic gastrostomy (PEG) is now of the most commonly performed upper endoscopic procedures. It has been shown to be safe, cost-effective, and with continued high rates of success (>95%), PEG is the preferred method of gastrostomy insertion [2-7].

Recent studies show that overall complication rates following PEG range from 6.5-39.0% [8-13]. This wide range is due to differences in study populations, techniques, and outcomes reported. Minor complications, which account for 4.6-23% of all complications following PEG, can broadly be thought of as self-limiting, include local wound infection, tube malfunction, leakage, peristomal pain, and fever [12, 14]. Major or severe complications vary in definition, but include potentially life-threatening ones which require further intervention. These complications include aspiration, perforation, peritonitis, thromboembolic events, sepsis, necrotizing fasciitis, hemorrhage, and both solid organ and hollow viscus injury. The incidence of major PEG complications has typically been reported at 1%-4%, but can be as high as 7%-10% [3, 12-17].

Table 1 summarizes reported complications associated with PEG. Minimizing complications begins with prevention. Appropriate initial assessment with proper patient selection (see Chapter 2), preoperative management (see Chapter 3) and sound technique (see Chapters 7-11), are well recognized ways to minimize complications]. In this chapter we discuss commonly described acute complications associated with PEG tube placement and provide diagnostic and therapeutic management options.

* Corresponding Author's Email: MUjiki@northshore.org.

Table 1. Reported complications of PEG

Minor
Tube site pain
Wound Infection
Pneumoperitoneum
Tube malfunction
Gastric outlet obstruction
Inadvertent tube removal
Major
Aspiration
Esophageal perforation
Leak and Peritonitis
Necrotizing fasciitis
Hemorrhage
Hollow viscus injury
Liver/Spleen Injury
Buried Bumper Syndrome
Tumor tract seeding
Thromboembolic Events

DEATH

Regardless of technique type, procedure-related mortality for PEG is low (0%-3%) [8, 12, 18-21]. However, most major complications can be attributed to technical errors during initial insertion and PEG-related complications themselves have been shown to be independent predictors of hospital mortality [22, 23]. Thirty-day mortality rates range from 0%-18.4% [12, 15, 17, 21, 24-26]. Multicenter data has shown low albumin and high C-reactive protein (CRP) levels to be predictive of 30-day mortality [27, 28]. Certain populations have been shown to be at higher risk of PEG-related mortality, including cancer patients and geriatrics [3, 17, 29]. In a systematic review and meta-analysis of 2379 head and neck cancer patients undergoing percutaneous gastrostomy, Grant et al. observed overall mortality of 2.2%, but the mortality rate in head and neck cancer patients was found to be higher than that in mixed patient populations [3]. Overall mortality has been reported as high as 51% in PEG patients and is usually due to associated comorbidities [30]. Early diagnosis and management of post-PEG complications is of utmost importance and can reduce the already high mortality seen in this vulnerable population [31, 32]. Table 2 summarizes reported risk factors for morbidity and mortality following PEG.

Table 2. Risk factors for major complication or mortality following PEG

	Major complications	30-day Mortality	Overall Mortality
Age			
Age >75[21]		X	
Age >65	X		
Nutritional Status			
BMI <20[21,30]		X	
BMI >30	X		
Albumin		X	X
Co morbidity Profile			
Diabetes Mellitus	X		
ASA 4/5		X	
Charleston Co-morbidity index[25]		X	X
Infection/ Inflammation			
Elevated WBC	X		
Elevated CRP[25]		X	
Indication for PEG			
Neurologic Disorder	X		
Head and Neck Cancer		X	X
Disposition			
In-patient	X	X	
Technical Aspects			
Endoscopist Experience	X		
Bolster Location	X		
Bolster Height	X		

Pneumoperitoneum

Routine chest or abdominal radiographs after uncomplicated PEG procedures is not common practice at many institutions, although some authors have recommended that it should be [33]. However, because the many PEG patients are critically ill, imaging may frequently be indicated for other reasons (i.e., respiratory distress, fever work-up, daily chest X-ray for intubated patients) and often leads to findings of free intra-peritoneal air [34]. Possible etiologies of PEG-associated pneumoperitoneum include the introduction of air during gastric insufflation, needle puncture and tube placement, tube malposition (dislodgement or intra-peritoneal placement) or hollow viscus injury. Hollow viscus injury (including colon, small bowel or stomach) is uncommon although several reports and case-series have described injuries to each. Inadvertent esophageal injury has also been reported

[8. 35]. These injuries, along with tube mal-position, are discussed later throughout the chapter.

Pneumoperitoneum following PEG is frequently encountered (Figure 1), with earlier reported rates ranging from 23.3 -55.6% and can last up to 4 weeks after the procedure [36, 37]. This initial high rate may be explained by the use of room air insufflation in these earlier studies. Carbon dioxide (CO_2) insufflation, long used in laparoscopic surgery, has been shown to decrease post-procedural pain, flatus, and bowel distention and is now commonly used for endoscopic procedures [38]. CO_2 is a highly diffusible, non-combustible gas that is rapidly absorbed and excreted and can be expected to be fully reabsorbed within the first 24 hours [39]. A recent randomized trial compared pneumoperitoneum rates between CO_2 and air insufflation using computed tomography (CT) imaging at 24 hours post-PEG, and found that pneumoperitoneum was only present in patients in the room air group [24]. Literature over the last decade has shown the rate of CO_2 pneumoperitoneum to be closer to 0-16% [34, 40-42].

In the general population, free air is indicative of hollow viscus injury and has typically warranted exploratory laparotomy. However, interpreting the clinical significance of such findings in PEG patients can be challenging. In the vast majority of cases, benign pneumoperitoneum will be encountered [34]. Unless accompanied by peritonitis, sepsis, or hemodynamic instability, no further work-up is typically necessary in these situations. Clinically significant pneumoperitoneum can be found in up to 15% of cases [34]. Free air may sometimes be the only clinical sign of perforation (misplaced tube; organ injury) as peritoneal irritation may go unnoticed in diabetics, patients receiving antibiotics, steroids, or those with altered consciousness. A “silent perforation” may also occur if retroperitoneal organs (i.e., descending colon) are injured and can lead to a delay in diagnosis.

The presence of free-air within 24 hours of PEG should not be unexpected. Patients found to have free-air on plain radiographs 24-48 hours after PEG without signs of peritonitis or clinical decline can generally be observed and plain films repeated in 24 hours. When repeating plain films, we recommend obtaining at least two views. The combination of upright lateral chest and lateral decubitus imaging increases the sensitivity of detecting pneumoperitoneum to 98% [43]. If free-air is again seen, then additional evaluation may be warranted (see below). If at any point pneumoperitoneum is encountered in a patient with signs of peritonitis and/or hemodynamic instability, time should not be wasted obtaining further imaging and the patient should be surgically explored.

Free-air encountered 72hr or more after PEG, should raise clinical suspicion in the typically debilitated patients undergoing this procedure as a missed hollow viscous injury which can be devastating. Even for clinically stable patients, further evaluation with a CT scan is a prudent decision is most cases. CT is considered the gold standard and more sensitive for identifying pneumoperitoneum than plain radiographs [24]. In a study describing PEG-induced pneumoperitoneum, CT revealed the presence of free air in 6 out of 10 patients who had no evidence of pneumoperitoneum on previous chest x-ray [44].

In a retrospective review of over 700 PEG cases, Blum et al. found pneumoperitoneum on imaging in 5/6 patients who had undergone exploratory laparotomy for a PEG-related complication [34]. They recommended that any patient with free air on plain radiograph, even those without peritonitis, undergo CT evaluation and if free fluid is seen (Figure 2) surgical exploration be performed. With the lack of published guidelines, it is important to approach each patient with free-air on an individual basis. Knowledge of insufflation gases, timing of

pneumoperitoneum, relevant clinical findings, and when to obtain further imaging can better equip clinicians to handle this diagnostic dilemma.

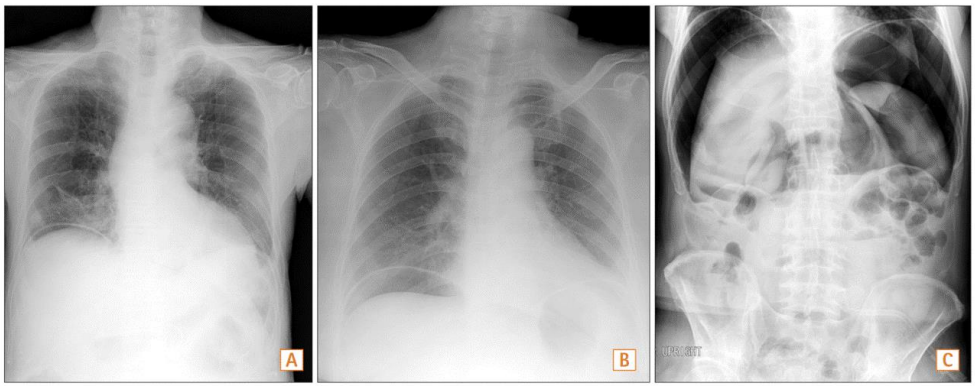

Figure 1. Pneumoperitoneum grades following PEG A) Small grade pneumoperitoneum (<2 cm tall column of air under the diaphragm). B) Moderate grade pneumoperitoneum (2-4 cm tall column of air under the diaphragm). C) Large grade pneumoperitoneum (>4 cm tall column of air under the diaphragm). Reproduced from Park et al with permission [40].

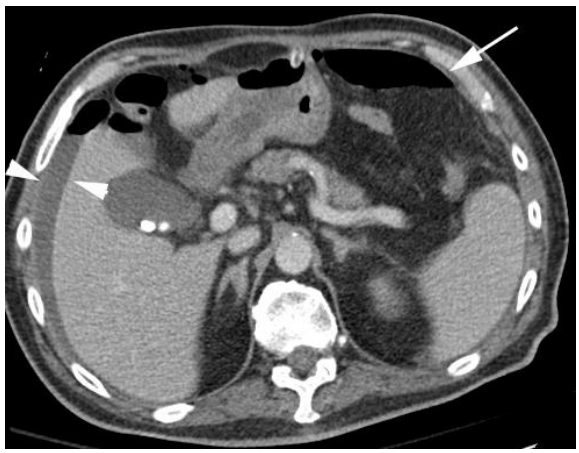

Figure 2. Post-PEG intraperitoneal leak. Free air (arrow) and an air fluid level (arrowheads) are noted on a CT obtained for moderate grade pneumoperitoneum 48 hours after a PEG was performed with CO_2 insufflation. The patient subsequently underwent a laparotomy and Stamm gastrostomy.

Leak and Early PEG Dislodgement

Accidental tube dislodgement is a well published and frequently encountered complication following PEG, occurring in up to 32% of cases [10]. The gastro-cutaneous tube tract begins to mature at 1-2 weeks and is well developed by 4-6 weeks [33]. Inadvertent tube removal can occur either early (before the fistula tract has fully matured) or late (several weeks to years following initial placement), and the timing of such has different implications. Here we will discuss diagnostic and management strategies for early tube dislodgement. Late dislodgement after tract maturity will be discussed in the Chapter 19.

Figure 3. Post-PEG transabdominal leak. Flow of fluid (arrowheads) and air bubble (arrow) were noted on postoperative day 2.

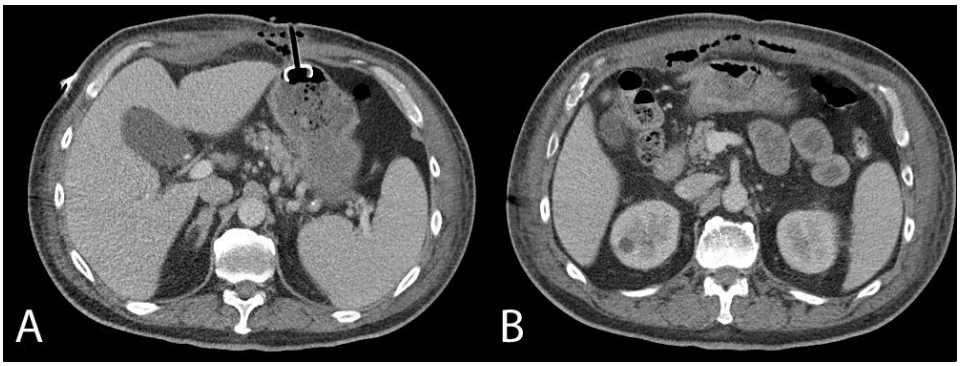

Figure 4. Post-PEG leak into the pre-peritoneal space in a patient with clinical signs of abdominal wall erythema and fluctuance. A) Gastrostomy bumper correctly positioned in the body of the stomach with air surrounding the tract. B) Air and fluid contained within the abdominal wall.

Differences in techniques, catheters, and fastening devices may explain the wide range of rates reported. The most commonly used PEG tubes are designed with collapsible inner bumpers or balloons to facilitate easy removal with external traction. This design also carries with it the risk of inadvertant removal especially in the confused, mentally-altered patients who often require them. Other causes of leakage include excessive tension leading to gastric necrosis, excessive movement of the tube and malnutrition. Loss of stomach opposition to the anterior abdominal wall then leads to leakage of gastric contents from the gastrostomy site into the peritoneal cavity or externally around the tube (Figure 3). Clinical findings along with degree of dislodgement should dictate further work-up and management.

Clinical signs of tube leak or dislodgement include erythema, induration, and fluctuance (Figure 4). The tube itself should be interrogated, looking for peri-tubal leakage, difficulty flushing/aspirating, or difficulty manipulating tube position. If there is any evidence of the above, enteral feeding should be discontinued, a decompressive naso-gastric tube (NGT) inserted, and broad-spectrum antibiotics initiated [1]. Cases of *Candida* peritonitis have been reported and empiric anti-fungal coverage should also be considered [45]. Peritonitis should

be suspected in patients with abdominal pain, tenderness (more than just insertion site discomfort), fever, or leukocytosis and immediate surgical consultation obtained.

Some patients may have clinical findings but no evidence of peritoneal irritation. In these situations, a tube or tract fistulogram may be useful. Water-soluble contrast can be injected into the PEG catheter of patients with partial tube dislodgement or into the stoma site of patients with complete removal. Subsequent abdominal radiographs can delineate tract anatomy and display gross or contained leakage within the peritoneal cavity. For partially removed tubes, tract continuity with the gastric lumen, without contrast extravasation, means that the tube has been slightly pulled out. If complete removal is encountered and the stoma site is patent, contrast injection into the tract itself can be performed. The contrast injection may reveal partial disruption of the tract (Figure 5). In patients with healed stomas sites, avoid attempts at dilation. In this case, a CT abdomen/pelvis with oral contrast should replace the fistulogram. CT will provide similar information with regards to extravasation and more details regarding tube location and potential organ injury. Some authors have reported the presence of hepatic portal venous gas on CT imaging obtained in patients who were found to have gastrostomy leak [46, 47]. A recommended management algorithm is shown in Figure 6.

Replacing tubes after removal can potentially lead to further complications. Best practice should be to never blindly re-insert a PEG tube if it has been completely pulled out within 7 days of placement as the fistula tract may not have fully matured. Endoscopic replacement with direct visualization is the safest means for replacing a tube during this period. Diagnostic endoscopy should be performed to visualize gastrostomy site and other potential pathology. A new PEG can be inserted distally and the original site can be closed using endoscopic clips or an endolumenal suturing device (Figure 7) [48]. See Chapter 20 for further discussion on endoscopic management of early tube dislodgement.

Early tube pull can also be managed with basic laparoscopy. Laparoscopy obviates the need for a potentially time-consuming fistulogram in patients who may need surgical exploration anyway, as it provides direct visualization of entire intra-peritoneal cavity. The ability to assess the posterior gastric wall, duodenum, small bowel and colon adds the benefit of ruling out inadvertent injury to them. The gastrostomy can either be repaired primarily with intracorporeal suturing or can be converted to a Stamm gastrostomy (Figure 8) [1].

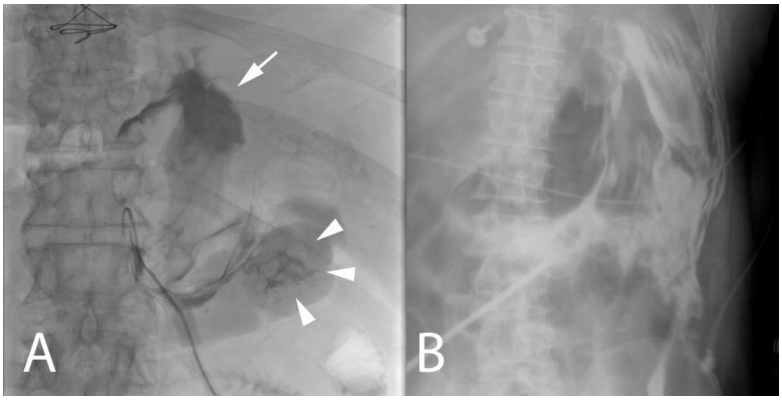

Figure 5. Gastrostomy track disruption after early PEG dislodgement. A) Partial Disruption – injection via the PEG tract demonstrates contrast within the body of the stomach (arrow), but also free leak of contrast into the peritoneal cavity (arrowheads). B) Complete Disruption – injection via PEG demonstrates only free intraperitoneal contrast with no filling of the gastric body.

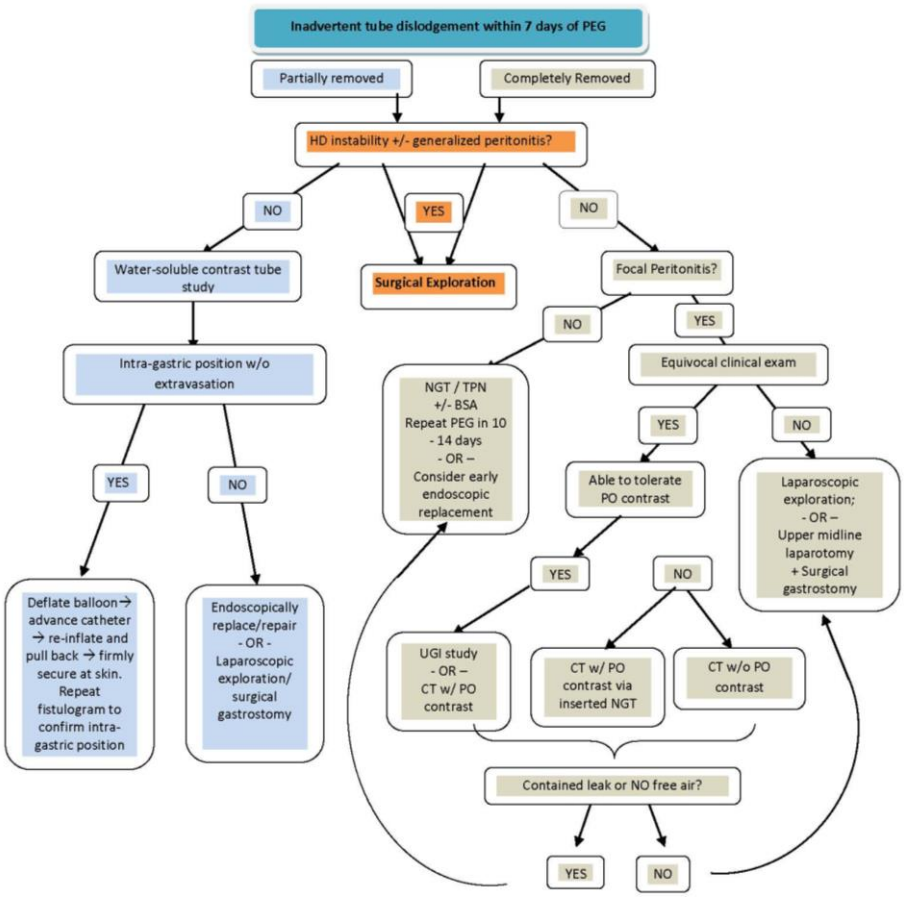

Figure 6. Proposed algorithm for the management of early PEG dislodgement.

Tube dislodgement, occurring at any time, increases patient morbidity and mortality and management of these complications is associated with significant healthcare costs (readmissions, length of stay and resource utilization) (Figure 9). Educating patients, care-givers, and nursing staff about the potential complications can help reduce early tube pull and leakage. As clinicians, being able to identify at risk patients and using certain preventive strategies can minimize these occurrences and healthcare burden (Table 3).

Table 3. Measures to prevent early tube dislodgement in high risk patients

Procedural	
Additional gastropexy	Maintains gastric apposition even if pre-mature removal occurs
Use mushroom tip or button catheters	Not as easily removable
Post-Procedural	
Confirm integrity of external fixation	Address security of sutures or appliances daily
Daily tube check	Ensure original position maintained and no undue tension
Ensure comfort with appropriate narcotic use and tube hygiene	Minimize pain/skin irritation that may cause patients to tamper with tube
Physical barriers	Use of soft restraints or abdominal binder

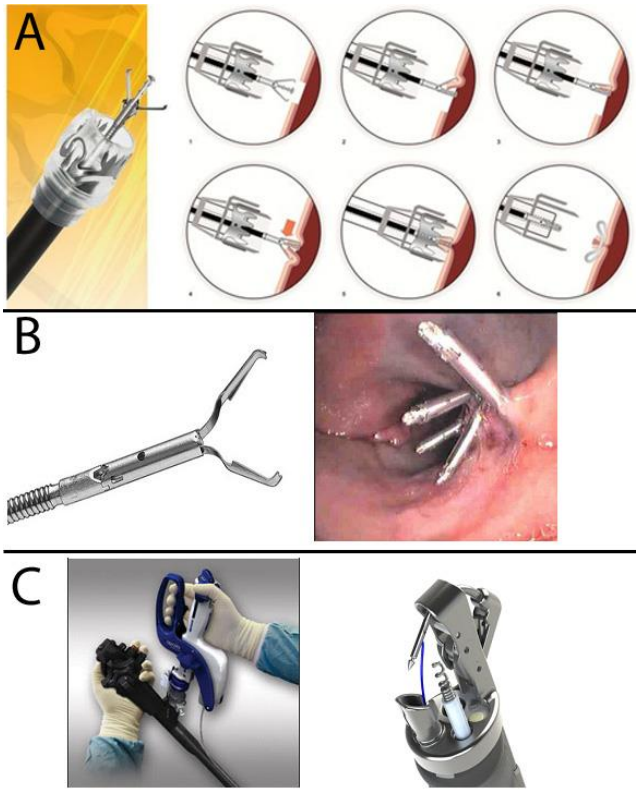

Figure 7. Endoscopic mucosal closure devices. A) Over the scope clip (OVESCO OTSC ™). B) Through the scope clip (Boston Scientific Resolution Clip). C) Endoscopic suturing device (Apollo Overstictch ™).

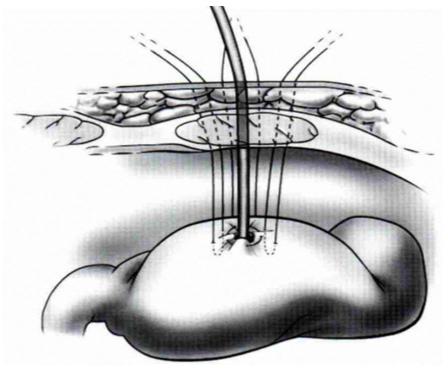

Figure 8. Leaking PEG converted to Stamm gastrostomy with the use of 4 trans-abdominal sutures [1]. Reprinted with permission from B. Todd Heniford, MD.

Hollow Viscus Injury

Inadvertent bowel injury is typically rare and therefore its true incidence is difficult to define. Based on several case reports, inadvertent injury to bowel occurs in approximately

1.3% of cases. Free perforation or enterocutaneous fistula formation (including gastro-enterocutaneous) can manifest in the early post-operative period (up to 2 weeks) [49]. Injury to small bowel also very rare but may occur for many of the same reasons as colonic injury. Causes may include inadvertent initial placement, compression necrosis and migration of catheter tip and retained flange with subsequent perforation [50]. Through and through penetrating injury to the mesentery during initial placement resulting in small bowel volvulus and obstruction has also been described [51].

Colonic perforation is one of the most serious complications and can be fatal if missed. The transverse colon typically lays antero-superior to the stomach, placing it in harm's way during peg (Figure 10). The sigmoid colon may loop anterior to the stomach in patients with colon motility disorders, colonic distention or altered body habitus (Figure 11).

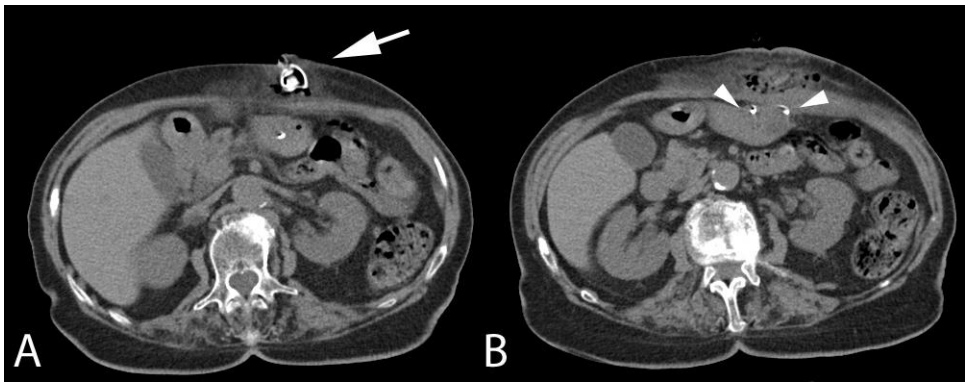

Figure 9. CT scan of a patient following her third early PEG dislodgement. A) PEG bumper is located in a subcutaneous position with surrounding soft tissue stranding and air. B) Gastrointestinal T-Anchors prevented the gastrotomy from falling away from the abdominal wall preventing free intraperitoneal leak.

Figure 10. Transverse colon injury from PEG placement. Flat plate X-ray demonstrates contrast filling the transverse colon. Reproduced from Friedmann et al with permission [59].

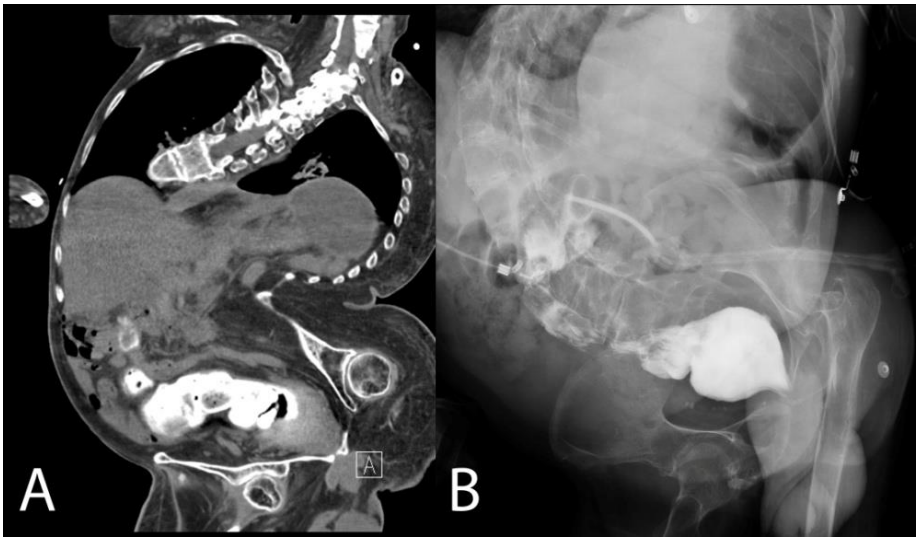

Figure 11. Sigmoid colon injury from PEG placement. A) CT scan demonstrates severe abdominal distortion from scoliosis. B) Flat plate X-ray demonstrates contrast filling the sigmoid colon and rectum when injected into the gastrostomy tube.

Geriatric patients may be at higher risk due to lax peritoneal attachments or redundant segments of colon. Adequate insufflation allows gastric opposition to the abdominal wall while displacing the overlying colon inferiorly. Adherence to sound technique with subsequent trans-illumination and visual finger indentation minimizes the possibility of injury to colon or small bowel [53].

Although PEG has been shown to be safe in patients with previous abdominal surgery, additional preventative strategies may be necessary. Strodel described inserting a small-gauge needle from through the abdominal wall into the insufflated stomach while aspirating on the needle syringe. If air is aspirated into the syringe before the needle seen in the stomach, then there is air-filled bowel, small or large, interposed between the stomach and the abdominal wall [54]. A similar "safe-tract method" with a fluid filled syringe has also been shown decrease inadvertent bowel injury in patients with previous abdominal surgery, with misplacement being assumed if air bubbles appear in the syringe before needle visualization in the gastric lumen [55]. A second-look, with either upper endoscopy or placement of a laryngofiberscope through the inserted feeding tube can be used to confirm intra-gastric tube placement [56].

The use of image guidance to prevent complications and facilitate safe PEG placement should be considered in certain situations. CT-guidance for patients with unsuccessful endoscopic trans-illumination has been shown to be effective for PEG placement without bowel injury [57]. Sasaki et al. described the use of pre-PEG abdominal CT to identify high risk patients based on colon anatomy relative to the stomach who then underwent PEG with the use of contrast radiography of the colon and no injuries occurred in these patients [58]. Colonic compromise can occur during initial placement or at any time re-insertion or exchange is performed. Misplacement of PEG through or into the colon has been reported and the time to diagnose the injury can range from 1 day to 6months [19, 59, 60]. PEG patients are often critically ill, sedated or have altered levels of consciousness at baseline, making it is easy to miss clinical signs of perforation and peritonitis (i.e., pain, tenderness,

rebound/guarding), making early diagnosis difficult [14, 61]. There should be a low threshold of clinical concern in these high risk patients. Severe diarrhea, fecal presence within the PEG tube, or feculent drainage around the tube have all been identified as clinical signs of colonic injury and should warrant further investigation [19, 59, 60].

If a colonic injury is suspected, assess the patient for hemodynamic stability and perform a focused abdominal exam to include interrogation of the PEG tube. If the patient is hemodynamically stable, obtaining an upright CXR or lateral decubitus abdominal film can quickly identify pneumoperitoneum or changes in tube position, which may expedite surgical exploration (See pneumoperitoneum section above for further details and management algorithm). However, if clinical concern is high and findings equivocal, abdominal CT is more specific for identifying organ injury and can provide a more definitive diagnosis (Figure 12) [61]. Fistulograms are also helpful as they can be performed rather quickly at the bedside. Water soluble contrast can be injected into insertion site and portable abdominal film obtained which can show if there is intra-peritoneal extravasation, controlled leak, or inadvertent placement into bowel.

Controlled perforations in hemodynamically stable patients can be managed non-operatively. The PEG tube should be removed and a NGT placed while allowing the tract to heal. A new PEG can be attempted at a new site 7-10 days thereafter. If the patient is unstable or has signs of peritonitis or sepsis, urgent surgical exploration is warranted and exploratory laparotomy may be the most conservative approach proving quick access and full exposure. However, if the patient is able to tolerate it, laparoscopy can be performed to evaluate the extent of injury and foregoes the morbidity associated with a laparotomy incision. Surgeon experience and patient status should dictate whether or not to proceed with laparoscopic or open management. The goal of exploration, open or laparoscopic, should be to efficiently identify the injury, repair or resect injured bowel (with or without the formation of a colostomy), and perform adequate abdominal washout of enteric content [19].

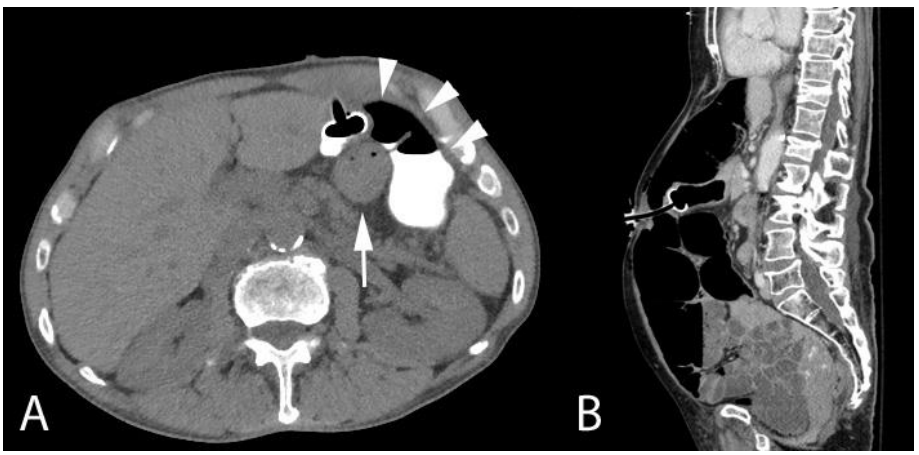

Figure 12. CT scans of patients with colon injury following PEG. A) Patient 1 – contrast injected into the gastrostomy is identified in the colon (arrowheads) as is the PEG bumper. The decompressed stomach is seen posterior to the colon (arrow). B) Patient 2 – Sagittal view demonstrates PEG bumper within the body of the stomach but traversing the transverse colon as it leaves the abdominal cavity.

The need for on-going enteral nutrition should be re-assessed at this point, taking into account the patient's initial indication and current overall prognosis. When feasible, enteral nutrition is preferable because it is safer, less costly, and offers several physiologic benefits: it maintains gut flora, helps to preserve the enteral immune system, decreases mucosal atrophy, and avoids the risk of bacterial translocation into the bloodstream [62]. For patients found to have intra-colonic or trans-colonic misplacement at exploration, the original tube should be removed and NGT can be placed for gastric decompression and parenteral nutrition started post-operatively. A nasojejunal tube may be placed intra-operatively and can provide enteral nutrition for up to 4 weeks. If longer term feeding or gastric decompression is necessary, a surgical gastrostomy tube can be placed at that time. Broad spectrum antibiotics should be continued post-operatively until the patient shows resolution of sepsis or infection (hemodynamically stable, afebrile, normal WBC count).

Bleeding

Recent literature from large series in the United States shows the overall incidence of bleeding following a PEG to be 2.8-3.3% [63, 64]. The American Society for Gastrointestinal Endoscopy has defined PEG to be a high-risk endoscopic procedure with a 2-2.5% risk of clinically significant bleeding [65, 66]. Patients on anti-platelet or anti-thrombotic therapy may be at increased risk of bleeding but the risk may outweigh the potential complications of stopping such medications in patients with cardiovascular or cerebrovascular diseases. See Chapter 4 for guidelines for antiplatelet and anticoagulation management. Some evidence suggests that selective serotonin re-uptake inhibitors and not anti-platelet agents increase the risk of bleeding following PEG [64].

Upper gastrointestinal bleeding (UGIB) following PEG can be due to gastric ulcers, or gastritis/esophagitis caused by iatrogenic mucosal injury [67]. Mucosal injury to upper GI tract can occur while pulling the catheter into the stomach from the oropharynx over a string or guidewire [68]. Signs of such injuries may include hematemesis, melena, positive fecal occult blood test, blood in or around PEG tube, or unexplained drop in hemoglobin.

Use of an overtube may help prevent inadvertent injury to the GI mucosa. An overtube is a sleeve-like semi-rigid plastic tube, with an inner diameter large enough to accommodate endoscopes for various procedures (Figure 13). It is intended to protect the UGI mucosa from trauma and can also reduce the risk of aspiration [69]. If suspected, patients should be stabilized, transfused with blood products as necessary and transferred to an intensive care unit for closer monitoring if necessary. Once stable, an upper endoscopy can be performed to identify the source of bleeding and hemostasis achieved with injection, topical cautery, or hemostatic clips [67]. See Chapter 20 for more information on the endoscopic management of post-PEG bleeding. For patients that have complex anatomy or obstructing upper aero-digestive cancers, endoscopic access may be obtained through the PEG tract itself [70]. All patients should be started on acid suppression therapy before the procedure, and maintained on such after it.

Bleeding from the skin incision made to accommodate the PEG tube is common and usually self-limiting or controlled with direct pressure or topical cautery. Abdominal wall and gastric wall vessels may be at risk during percutaneous needle stick. Abdominal wall vessel injury typically presents with hematoma formation [71]. Patients with portal hypertension and

coagulopathy may be at increased risk. Abdominal vessel injury may be controlled with direct pressure over the area in some cases or may require suturing of the vessel in others. Early gastric bleeding after PEG should raise concern for possible injury to the gastric arteries or their branches, which occurs in <1% of cases [72-74]. Some cases may be managed simply by pulling the tube more tightly at the skin in an attempt to increase direct pressure between the stomach and abdominal wall, causing a tamponade effect. If successful, it is important to release that tension within 48 hours to prevent compression necrosis of the gastric wall. In other cases, the bleeding may not be controlled but such maneuvers, and further intervention is needed. Successful angio-embolization of injured gastric and gastro-epiploic arteries has been described and may be the least invasive option [75]. If resources are not available or any signs of hemodynamic instability present at any time, operative exploration is warranted and can be done either laparoscopically or via laparotomy (Figure 14).

Figure 13. Overtube devices. A) Apollo OverTube™ (Apollo Endosurgery). B) Guardus™ overtube (US Endoscopy).

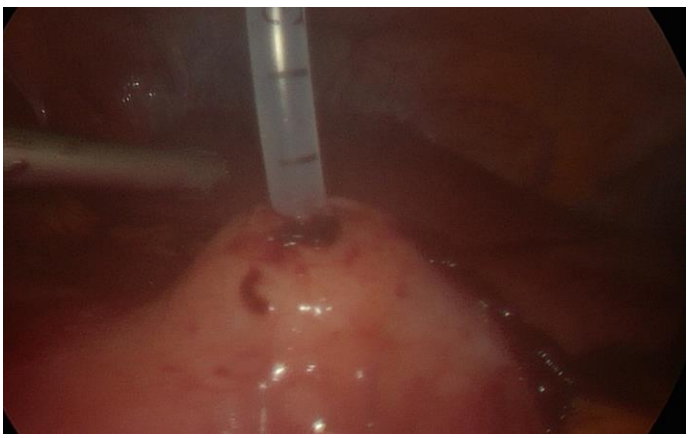

Figure 14. Laparoscopic view of acute bleeding from a gastric submucosal vessel following PEG placement.

Solid Organ Injury

Splenic or hepatic injury during PEG is exceedingly rare, but cases of each have been reported. Patients with hepatosplenomegaly may be at increased risk [76]. In these patients, image-guided PEG may be prudent or simply ultrasound guidance to confirm proper needle insertion into the stomach can prevent inadvertent injury.

The anatomic location of the left hepatic lobe may place it in harm's way during percutaneous insertion (Figure 15). Most inadvertent liver injuries occur during needle stick and are self-limiting. In those cases, conservative measures with serial hemoglobin checks to assess for on-going bleeding can be used. If there is any concern for ongoing blood loss, the patient should be stabilized with fluid resuscitation and/or blood transfusion and monitored in the intensive care unit. A contrast enhanced CT of the abdominal and pelvis can then be performed to further evaluate the extent of injury and for active extravasation of intravenous contrast agent. For cases in which the catheter itself is inserted and the balloon inflated within the hepatic parenchyma, significant hemorrhage can occur [77]. If the patient remains hemodynamically stable but with ongoing blood loss, angio-embolization may be appropriate. Any unstable patients should undergo rapid transfusion and emergent laparotomy for hemostasis.

Iatrogenic splenic injury during endoscopy in general is quite uncommon. However, about a dozen or more cases of splenic avulsion been reported in both patients undergoing endoscopic retrograde cholangiography or colonoscopy [78]. The mechanism is thought to be from torsional stress on the short gastric vessels or excessive tension placed on the lateral spleno-peritoneal attachments leading to capsular avulsion. Excessive bowing of the endoscope in the stomach can produce enough stress to cause similar injuries during PEG [79]. Patients with hiatal hernia and intra-thoracic stomach who undergo therapeutic upper endoscopy with insufflation may be at increased risk of undo tension on the short-gastric vessels or lateral splenic attachments [80].

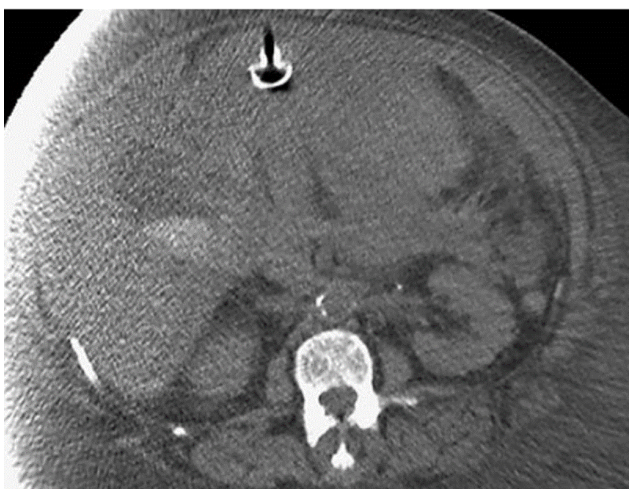

Figure 15. Intrahepatic PEG placement. CT image demonstrates intra-hepatic placement in a patient who presented with acute hemodynamic instability and drop in hemoglobin 8 hours following PEG. Reproduced from Wiggins et al. with permission [77].

Table 4. Potential sources of bleeding following PEG placement

Sources of Bleeding
GI Tract Lumen
Iatrogenic mucosal Injury
Gastritis/Esophagitis
PEG ulcer (tight bumper)
Submucosal vessel
Abdominal Wall
Skin
Abdominal wall vessels
Tumor tract seeding
Intra-Peritoneal
Named gastric vessels
Submucosal gastric vessels
Liver
Spleen
Retroperitoneal
Splenic / Mesenteric veins

Direct needle laceration of the splenic and superior mesenteric veins during percutaneous needle insertion has also been described as a complication of PEG, leading to fatal hemorrhage [81]. Although rare, splenic injury should be considered in patients presenting with acute hemodynamic instability and abdominal or flank pain immediately following a PEG. In a stable patient, a contrast enhanced CT of the abdomen pelvis may provide useful information. Rapid diagnosis, aggressive resuscitation, and surgical exploration with hemorrhage control can be life-saving.

CONCLUSION

Recognizing that PEG is an invasive procedure with potentially serious complications, endoscopists must be knowledgeable about the complications described here and experienced with the diagnosis and management of them. Appropriate patient selection, sound technique, use of preventative measures, and early diagnosis can minimize procedure related complications and further morbidity in a patient population already at risk.

EDITOR'S COMMENT

The endoscopist who has not experienced the complications described by Drs. Patel and Ujiki in this chapter simply has not put in enough PEGs yet. Even in the most skilled hands, PEG-related complications happen. A high clinical suspicion, early imaging and a low threshold for therapeutic intervention (whether radiologic, endoscopic, laparoscopic or open) are critical to prevent a devastating outcomes from happening after a PEG related complication. (EMP)

REFERENCES

[1] Backus CL, Muscoriel SJ, Iannitti DA, Heniford BT. Laparoscopic repair of the leaking percutaneous endoscopic gastrostomy. *J Laparoendosc Adv Surg Tech A.* 2000;10(2):105-109.

[2] Dwyer KM, Watts DD, Thurber JS, et al. Percutaneous endoscopic gastrostomy: the preferred method of elective feeding tube placement in trauma patients. *J Trauma.* 2002;52(1):26-32.

[3] Grant DG, Bradley PT, Pothier DD, et al. Complications following gastrostomy tube insertion in patients with head and neck cancer: a prospective multi-institution study, systematic review and meta-analysis. *Clin Otolaryngol.* 2009;34(2):103-112.

[4] Keung EZ, Liu X, Nuzhad A, et al. In-hospital and long-term outcomes after percutaneous endoscopic gastrostomy in patients with malignancy. *J Am Coll Surg.* 2012;215(6):777-786.

[5] Shastri YM, Shirodkar M, Mallath MK. Endoscopic feeding tube placement in patients with cancer: a prospective clinical audit of 2055 procedures in 1866 patients. *Aliment Pharmacol Ther.* 2008;27(8):649-658.

[6] Rustom IK, Jebreel A, Tayyab M, et al. Percutaneous endoscopic, radiological and surgical gastrostomy tubes: a comparison study in head and neck cancer patients. *J Laryngol Otol.* 2006;120(6):463-466.

[7] Triantafyllou K, Papanikolaou IS, Stasinos I, et al. Percutaneous endoscopic gastrostomy tube replacement unexpected serious events. *Nutr Clin Pract.* 2014;29(1):142-145.

[8] Mansoor H, Masood MA, Yusuf MA. Complications of percutaneous endoscopic gastrostomy tube insertion in cancer patients: a retrospective study. *J Gastrointest Cancer.* 2014;45(4):452-459.

[9] Glazer ES, Kulvatunyou N, Green DJ, et al. Contemporary acute care surgery percutaneous endoscopic gastrostomy tube placement: an extreme bumper height and complications. *J Trauma Acute Care Surg.* 2013;75(5):859-863.

[10] MacLean AA, Alvarez NR, Davies JD, et al. Complications of percutaneous endoscopic and fluoroscopic gastrostomy tube insertion procedures in 378 patients. *Gastroenterol Nurs.* 2007;30(5):337-341.

[11] Blomberg J, Lagergren J, Martin L, et al. Complications after percutaneous endoscopic gastrostomy in a prospective study. *Scand J Gastroenterol.* 2012;47(6):737-742.

[12] Birgisson S. [Percutaneous endoscopic gastrostomy in Iceland over 10 year period: a retrospective study of indications, complications and ethical issues]. *Laeknabladid.* 2012;98(2):97-102.

[13] Zuercher BF, Grosjean P, Monnier P. Percutaneous endoscopic gastrostomy in head and neck cancer patients: indications, techniques, complications and results. *Eur Arch Otorhinolaryngol.* 2011;268(4):623-629.

[14] Ahmad J, Thomson S, McFall B, et al. Colonic injury following percutaneous endoscopic-guided gastrostomy insertion. *BMJ case reports.* 2010;2010.

[15] Richter-Schrag HJ, Richter S, Ruthmann O, et al. Risk factors and complications following percutaneous endoscopic gastrostomy: a case series of 1041 patients. *Can J Gastroenterol.* 2011;25(4):201-206.

[16] Taheri MR, Singh H, Duerksen DR. Peritonitis after gastrostomy tube replacement: a case series and review of literature. *JPEN J Parenter Enteral Nutr.* 2011;35(1):56-60.
[17] Wirth R, Voss C, Smoliner C, et al. Complications and mortality after percutaneous endoscopic gastrostomy in geriatrics: a prospective multicenter observational trial. *J Am Med Dir Assoc.* 2012;13(3):228-233.
[18] Schrag SP, Sharma R, Jaik NP, et al. Complications related to percutaneous endoscopic gastrostomy (PEG) tubes. A comprehensive clinical review. *J Gastrointestin Liver Dis.* 2007;16(4):407-418.
[19] Guloglu R, Taviloglu K, Alimoglu O. Colon injury following percutaneous endoscopic gastrostomy tube insertion. *J Laparoendosc Adv Surg Tech A.* 2003;13(1):69-72.
[20] Ruthmann O, Seitz A, Richter S, et al. [Percutaneous endoscopic gastrostomy. Complications with and without anticoagulation]. *Chirurg.* 2010;81(3):247-254.
[21] Udd M, Lindstrom O, Mustonen H, et al. Assessment of indications for percutaneous endoscopic gastrostomy--development of a predictive model. *Scand J Gastroenterol.* 2015;50(2):245-252.
[22] Stayner JL, Bhatnagar A, McGinn AN, Fang JC. Feeding tube placement: errors and complications. *Nutr Clin Pract.* 2012;27(6):738-748.
[23] Schulenberg E, Schule S, Lehnert T. Emergency surgery for complications related to percutaneous endoscopic gastrostomy. *Endoscopy.* 2010;42(10):872-874.
[24] Nishiwaki S, Araki H, Hayashi M, et al. Inhibitory effects of carbon dioxide insufflation on pneumoperitoneum and bowel distension after percutaneous endoscopic gastrostomy. *World J Gastroenterol.* 2012;18(27):3565-3570.
[25] Figueiredo FA, da Costa MC, Pelosi AD, et al. Predicting outcomes and complications of percutaneous endoscopic gastrostomy. *Endoscopy.* 2007;39(4):333-338.
[26] Koc D, Gercek A, Gencosmanoglu R, Tozun N. Percutaneous endoscopic gastrostomy in the neurosurgical intensive care unit: complications and outcome. *JPEN J Parenter Enteral Nutr.* 2007;31(6):517-520.
[27] Lee C, Im JP, Kim JW, et al. Risk factors for complications and mortality of percutaneous endoscopic gastrostomy: a multicenter, retrospective study. *Surg Endosc.* 2013;27(10):3806-3815.
[28] Beau P, Kull E, Kaffy F, et al. [Malnutrition is an independent risk factor of early complications following percutaneous endoscopic gastrostomy]. *Gastroenterol Clin Biol.* 2001;25(10):891-895.
[29] Richards DM, Tanikella R, Arora G, et al. Percutaneous endoscopic gastrostomy in cancer patients: predictors of 30-day complications, 30-day mortality, and overall mortality. *Dig Dis Sci.* 2013;58(3):768-776.
[30] Rimon E KN, Levy S. Percutaneous endoscopic gastrostomy; evidence of different prognosis in various patient subgroups. *Age Ageing* 2005;34:353-357.
[31] Fang JC. Minimizing endoscopic complications in enteral access. *Gastrointest Endosc Clin N Am.* 2007;17(1):179-196.
[32] Kanie J, Akatsu H, Suzuki Y, et al. Mechanism of the development of gastric ulcer after percutaneous endoscopic gastrostomy. *Endoscopy.* 2002;34(6):480-482.
[33] Milanchi S, Allins A. Early pneumoperitoneum after percutaneous endoscopic gastrostomy in intensive care patients: sign of possible bowel injury. *Am J Crit Care.* 2007;16(2):132-136.

[34] Blum CA, Selander C, Ruddy JM, Leon S. The incidence and clinical significance of pneumoperitoneum after percutaneous endoscopic gastrostomy: a review of 722 cases. *Am Surg.* 2009;75(1):39-43.

[35] Guvenc BH, Rasa K, Guvenc S. The presence of percutaneous endoscopic gastrostomy (PEG)-related postprocedural pneumoperitoneum. *Endoscopy.* 2009;41 Suppl 2:E269-270.

[36] Pidala MJ, Slezak FA, Porter JA. Pneumoperitoneum following percutaneous endoscopic gastrostomy. Does the timing of panendoscopy matter? *Surg Endosc.* 1992;6(3):128-129.

[37] Gottfried EB, Plumser AB, Clair MR. Pneumoperitoneum following percutaneous endoscopic gastrostomy. A prospective study. *Gastrointest Endosc.* 1986;32(6):397-399.

[38] Dellon ES, Hawk JS, Grimm IS, Shaheen NJ. The use of carbon dioxide for insufflation during GI endoscopy: a systematic review. *Gastrointest Endosc.* 2009;69(4):843-849.

[39] Wang WL, Wu ZH, Sun Q, et al. Meta-analysis: the use of carbon dioxide insufflation vs. room air insufflation for gastrointestinal endoscopy. *Aliment Pharmacol Ther.* 2012;35(10):1145-1154.

[40] Park WY, Lee TH, Lee JS, et al. Reappraisal of Pneumoperitoneum After Percutaneous Endoscopic Gastrostomy. *Intest Res.* 2015;13(4):313-317.

[41] Alley JB, Corneille MG, Stewart RM, Dent DL. Pneumoperitoneum after percutaneous endoscopic gastrostomy in patients in the intensive care unit. *Am Surg.* 2007;73(8):765-767; discussion 768.

[42] Nazarian A, Cross W, Kowdley GC. Pneumoperitoneum after percutaneous endoscopic gastrostomy among adults in the intensive care unit: incidence, predictive factors, and clinical significance. *Am Surg.* 2012;78(5):591-594.

[43] Woodring JH, Heiser MJ. Detection of pneumoperitoneum on chest radiographs: comparison of upright lateral and posteroanterior projections. *AJR Am J Roentgenol.* 1995;165(1):45-47.

[44] Dulabon GR, Abrams JE, Rutherford EJ. The incidence and significance of free air after percutaneous endoscopic gastrostomy. *Am Surg.* 2002;68(6):590-593.

[45] Sridhar AV, Nichani S, Luyt D, Nour S. Candida peritonitis: a rare complication following early dislodgement of percutaneous endoscopic gastrostomy tube. *J Paediatr Child Health.* 2006;42(3):145-146.

[46] Bobba RK, Arsura EL. Hepatic portal and mesenteric vein gas as a late complication of percutaneous endoscopic gastrostomy tube placement in an elderly patient. *Dig Dis Sci.* 2005;50(2):411-414.

[47] Kadomatsu Y, Kojima T, Kohara M, Inamori M. Hepatic portal venous gas development following percutaneous endoscopic gastrostomy. *Intern Med.* 2013;52(1):153.

[48] Singhal S, Changela K, Culliford A, Duddempudi S, Krishnaiah M, Anand S. Endoscopic closure of persistent gastrocutaneous fistulae, after percutaneous endoscopic gastrostomy (PEG) tube placement, using the over-the-scope-clip system. *Therap Adv Gastroenterol.* 2015;8(4):182-188.

[49] Scapa E, Broide E, Slutzki S, Halevy A. Colocutaneous fistula--a rare complication of percutaneous endoscopic gastrostomy. *Surg Laparosc Endosc.* 1993;3(5):430-432.

[50] Brown JN, Borrowdale RC. Small bowel perforation caused by a retained percutaneous endoscopic gastrostomy tube flange. *Nutr Clin Pract.* 2011;26(3):227-229.
[51] Roos J. A case of small-bowel obstruction after insertion of a percutaneous endoscopic gastrostomy tube due to mesenteric penetration. *Annals of the Royal College of Surgeons of England.* 2015;97(5):e79-80.
[52] Moriwaki Y, Arata S, Tahara Y, et al. Duodenal perforation due to compression necrosis by the tip of percutaneous endoscopic gastrostomy tube. *Nutrition.* 2011;27(9):979-981.
[53] Ponsky JL, Gauderer MW. Percutaneous endoscopic gastrostomy: indications, limitations, techniques, and results. *World J Surg.* 1989;13(2):165-170.
[54] Strodel WE, Lemmer J, Eckhauser F, et al. Early experience with endoscopic percutaneous gastrostomy. *Arch Surg.* 1983;118(4):449-453.
[55] Foutch PG, Talbert GA, Waring JP, Sanowski RA. Percutaneous endoscopic gastrostomy in patients with prior abdominal surgery: virtues of the safe tract. *Am J Gastroenterol.* 1988;83(2):147-150.
[56] Lujber L, Pytel J. Second-look endoscopy during percutaneous endoscopic gastrostomy by passing a laryngofiberscope through the inserted feeding tube. *Endoscopy.* 2003;35(10):885.
[57] Vogt W, Messmann H, Lock G, et al. [CT-guided percutaneous endoscopic gastrostomy: a successful method if transillumination is not possible]. *Dtsch Med Wochenschr.* 1996;121(12):359-363.
[58] Sasaki T, Fukumori D, Sakai K, et al. The safety and feasibility of percutaneous endoscopic gastrostomy placement. *Hepatogastroenterology.* 2004;51(58):1062-1065.
[59] Friedmann R, Feldman H, Sonnenblick M. Misplacement of percutaneously inserted gastrostomy tube into the colon: report of 6 cases and review of the literature. *J Parenter Enteral Nutr*. 2007;31(6):469-476.
[60] Liu SY, Ng SS, Yip HC, et al. Migration of a percutaneous endoscopic gastrostomy tube into the transverse colon: a forgotten cause of refractory diarrhea. *Endoscopy.* 2010;42 Suppl 2:E324-325.
[61] Maccabee DL, Dominitz JA, Lee SW, Billingsley KG. Acute presentation of transverse colon injury following percutaneous endoscopic gastrostomy tube placement: case report and review of current management. *Surg Endosc.* 2000;14(3):296.
[62] Safadi BY, Marks JM, Ponsky JL. Percutaneous endoscopic gastrostomy. *Gastrointest Endosc Clin N Am.* 1998;8(3):551-568.
[63] Singh D, Laya AS, Vaidya OU, et al. Risk of bleeding after percutaneous endoscopic gastrostomy (PEG). *Dig Dis Sci.* 2012;57(4):973-980.
[64] Richter JA, Patrie JT, Richter RP, et al. Bleeding after percutaneous endoscopic gastrostomy is linked to serotonin reuptake inhibitors, not aspirin or clopidogrel. *Gastrointest Endosc.* 2011;74(1):22-34 e21.
[65] Committee ASoP, Jain R, Maple JT, et al. The role of endoscopy in enteral feeding. *Gastrointest Endosc.* 2011;74(1):7-12.
[66] Committee ASoP, Anderson MA, Ben-Menachem T, et al. Management of antithrombotic agents for endoscopic procedures. *Gastrointest Endosc.* 2009;70(6): 1060-1070.

[67] Hsu YC, Tsai JJ, Perng CL, Lin HJ. Massive gastrointestinal bleeding associated with contralateral mucosal abrasion by percutaneous endoscopic gastrostomy tube. *Endoscopy.* 2009;41 Suppl 2:E144.

[68] Cappell MS. Esophageal bleeding after percutaneous endoscopic gastrostomy. *J Clin Gastroenterol.* 1988;10(4):383-385.

[69] Committee AT, Tierney WM, Adler DG, et al. Overtube use in gastrointestinal endoscopy. *Gastrointest Endosc.* 2009;70(5):828-834.

[70] Baron TH, Wong Kee Song LM. Placement of an esophageal self-expandable metal stent through a percutaneous endoscopic gastrostomy tract, for endoscopic therapy of upper gastrointestinal bleeding. *Endoscopy.* 2012;44 Suppl 2 UCTN:E319-320.

[71] Aschl G, Kirchgatterer A, Allinger S, et al. [Indications and complications of percutaneous endoscopic gastrostomy]. *Wien Klin Wochenschr.* 2003;115(3-4):115-120.

[72] Bunai Y, Akaza K, Nagai A, et al. Iatrogenic rupture of the left gastric artery during percutaneous endoscopic gastrostomy. *Leg Med (Tokyo).* 2009;11 Suppl 1:S538-540.

[73] Schurink CA, Tuynman H, Scholten P, et al. Percutaneous endoscopic gastrostomy: complications and suggestions to avoid them. *Eur J Gastroenterol Hepatol.* 2001;13(7):819-823.

[74] Bordes J, Hornez E, Kenane N, et al. The complications of percutaneous endoscopic gastrostomy. *Crit Care.* 2008;12(4):422.

[75] Lewis MB, Lewis JH, Marshall H, Lossef SV. Massive hemorrhage complicating percutaneous endoscopic gastrostomy: treatment by means of transcatheter embolization of the right and left gastroepiploic arteries. *J Vasc Interv Radiol.* 1999;10(3):319-323.

[76] Moreno JM, Galiano MJ, Urruzuno P, et al. [A patient with visceromegaly: risk factor for performing percutaneous endoscopic gastrostomy. A clinical case]. *Nutr Hosp.* 1999;14(6):237-239.

[77] Wiggins TF, Kaplan R, DeLegge MH. Acute hemorrhage following transhepatic PEG tube placement. *Dig Dis Sci.* 2007;52(1):167-169.

[78] Weaver JL, Jones W, Miller KR. Life-threatening splenic rupture after endoscopic retrograde cholangiopancreatography. *Am Surg.* 2014;80(8):E230-231.

[79] Patel BB, Andrade C, Doraiswamy V, Amodeo D. Splenic Avulsion Following PEG Tube Placement: A Rare but Serious Complication. *ACG Case Rep J.* 2014;2(1):21-23.

[80] Jabr F, Skeik N. Spleen rupture complicating upper endoscopy. *Endoscopy.* 2012;44 Suppl 2 UCTN:E206.

[81] Lau G, Lai SH. Fatal retroperitoneal haemorrhage: an unusual complication of percutaneous endoscopic gastrostomy. *Forensic Sci Int.* 2001;116(1):69-75.

In: Encyclopedia of Surgery (22 Volume Set)
Editors: Andreas Lehrer and Kristin Mueller
ISBN: 978-1-53618-329-0
© 2020 Nova Science Publishers, Inc.

Chapter 140

CHRONIC COMPLICATIONS OF PEG

Faris M. Murad, MD and Jeffrey A. Blatnik*, MD
Washington University School of Medicine, St. Louis, MO, US

INTRODUCTION

Complications from placement of PEG and enteral feeding tubes can be classified as acute and chronic. Acute complications typically occur within a 2-week timeframe from the initial placement and were reviewed in Chapter 18. Chronic complications come from long-term placement of PEG (or other enteral feeding tubes) and can be broken down into major and minor complications (Table 1). Chronic complications from gastrostomy or jejunostomy tubes can be difficult to manage both endoscopically and surgically. This chapter reviews chronic complications of PEG tube placement and offers management strategies to deal with each.

Table 1. Chronic complications of PEG / PEJ Tubes

Major Complications	Minor Complications
Aspiration	Peristomal wound infections
Peritonitis	Tube obstruction or tube breaks
Gastrocutaneous fistula	Leakage around feeding tubes
Tube migration	Internal or external migration
Tube dislodgement	Granulation Tissue Formation
Hemorrhage	Mucosal Prolapse
Necrotizing fasciitis	
Tumor implantation at PEG site	
Hernia at PEG site	

* Corresponding Author's Email: blatnikj@wudosis.wustl.edu.

TUBE REPLACEMENTS

PEG tubes may require replacement either due to PEG tube dislodgement or malfunction/cracking of the PEG tube. Inadvertent PEG tube removal occurs in 1.6 to 4.4% of patients [1, 2]. Before removal or replacement of any percutaneous enteral tube, it is important to ask a few questions: 1. Is the tract thought to be mature? 2. Will the patient require continued enteral nutrition support through a percutaneous enteral tube? 3. What type of replacement tube is required? 4. Can the tube be removed without endoscopy? Of these, the most important point to keep in mind is whether there is a mature tract. The tract maturity is dependent on a variety of factors including the patient's general nutritional status and the use of immunosuppressive agents or steroids. In general, gastrostomy/jejunostomy tract maturity is complete between 2-6 weeks. It is imperative that the PEG tube is not removed before the tube tract has matured or the patient may develop a leak and peritonitis.

Prior to removing a PEG, it is critical to ensure that the patient will no longer require the tube. Such assurance would include documentation of safe swallowing capabilities, ability to meet caloric and hydration needs, resolution of obstruction (if the tube is being used for decompression), or patient/family desired withdrawal of tube (if being removed as part of a comprehensive palliative care plan; see Chapter 3). PEG tubes can be removed manually or endoscopically. Replacement tube placement (if indicated) may be performed with or without endoscopic guidance depending on the complexity of the case or other patient factors.

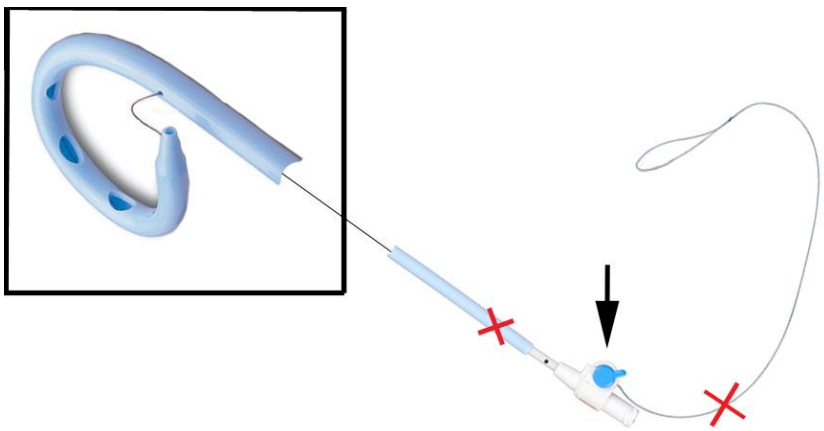

Figure 1. Pigtail type catheter commonly used as a gastrostomy. To remove the tube, the locking mechanism (arrow) should be released and the suture cut. As an alternative, the entire tube can be cut (inducing the suture) between the locking mechanism and the patient's skin. Unlocking and/or dividing the suture permits the Cope loop to come undone during traction withdrawal of the tube.

If a PEG tube needs to be removed due to malfunction, crack, or partial dislodgement, most can be manually removed in the office or GI lab without the use of anesthesia. It will be important to understand which type of PEG tube was placed previously (button, inflated balloon, pigtail catheter). Different types of tubes are removed in slightly different fashions. Endoscopy should be readily available in case there is a complication during manual removal (tube breaks and only a portion of the PEG is removed) although this capability does not need to be on-site of the removal location.

If the patient has a PEG tube with a pigtail, this generally requires that the PEG tube be cut to release the locking string that maintains the Cope loop (Figure 1). Once the tube is cut, the PEG tube is easily removed with manual traction. The pigtail uncurls as it passes through the PEG tube tract.

If the patient has a balloon tube to anchor the PEG, then an appropriate syringe size should be used to remove all the water within the balloon (i.e., 20 ml syringe to remove a balloon inflated with 20 ml). It is advisable to ensure that the balloon is completely empty before removing the tube, remembering that occasionally the tube may have been overinflated beyond manufacturer recommendations.

PEG tubes that were placed with an inner bolster/button require a more physical effort to remove them. The patients are typically placed in a supine position. One hand is used to secure the PEG tube and the other hand is placed over the abdomen with the thumb and index finger used to cradle the PEG tube. Constant manual traction is needed to pull on the tube while the other hands supports the abdomen and puts counter traction on the abdomen. This will result in gradual deformity and collapse of the inner bolster/button so that it can be extracted from the PEG tube tract. Such manual withdrawal can require substantial force (often novices may report that the tube is 'stuck'). The patient will experience pain as the inner bolster traverses the fascia and the skin. Often, gastric content will flow through the tract and onto the skin. Minor bleeding can be managed with pressure or silver nitrate application to the tract.

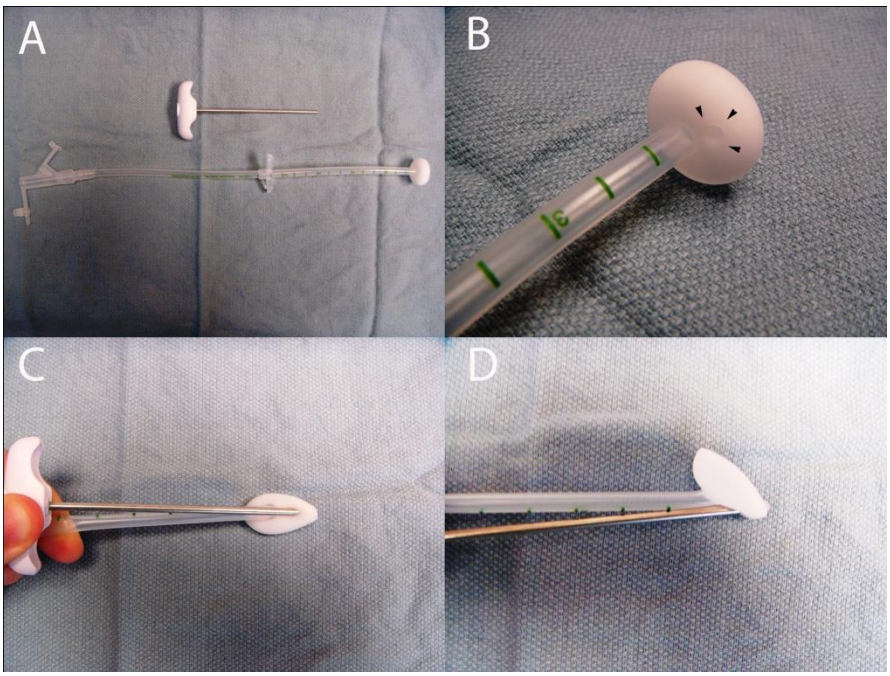

Figure 2. A) Replacement PEG tube with introducer. B) Internal PEG bumper has a dimple (arrowheads) into which the introducer is placed. C and D) Traction on the PEG against the introducer elongates and folds the bumper, allowing it to be pushed through the mature gastrostomy tract and into the stomach.

The PEG tube tract will rapidly close over the next several hours if not replaced by another tube or secured with a Foley catheter. The PEG tube tracts shrink rapidly over several hours and typically close completely in a few days. Replacement tubes typically have a balloon that is inflated once it is across the PEG tube tract and into the gastric lumen. The balloon is then inflated with the appropriate amount of sterile water to secure the gastric side of the PEG tube. Some replacement tubes have a mushroom configuration that must be straightened before passing across the PEG tube tract. Once into the stomach, the stiffening device is removed and the mushroom configuration reforms securing the tube in place (Figure 2). In both types of replacement tubes, the internal bolster/balloon prevents external migration and an external bolster might need to be applied to prevent internal migration of the tube. If there is any difficulty in placing the replacement tube, a water soluble contrast X-ray study may be useful to ensure correct placement or an endoscopy can be performed. Another option is to place a guidewire either through the PEG tube before removal or through the PEG tube tract (with or without fluoroscopy) and then replace the PEG tube over the guidewire. In the clinic setting, flushing the tube to assure easy use (the patient should experience no pain) and aspirating fluid to assess for gastric content are adjuncts to confirm placement.

TUBE CLOGS AND BREAKS

PEG tube occlusion occurs commonly for patients receiving enteral nutrition and medications through the PEG tube. The diameter of the PEG tube utilized is an important factor in patency of the tubes; the larger the diameter, the longer the patency. When the PEG tube becomes clogged, this can interrupt the patient's enteral nutrition and medications necessitating urgent intervention. Several issues must be considered with concurrent administration of medications and enteral formulas via the gastrostomy. Incorrect administration methods may result in clogged feeding tubes, decreased drug efficacy, increased adverse effects, or drug-formula incompatibilities. Liquid medications, particularly elixirs and suspensions, are preferred for enteral administration; however, these formulations may be hypertonic or contain large amounts of sorbitol, and these properties increase the potential for adverse effects. Before solid dosage forms are administered through the feeding tube, it should be determined if the medications are suitable for manipulation, such as crushing a tablet or opening a capsule. Medications should not be added directly to the enteral formula, and feeding tubes should be properly flushed with water before and after each medication is administered. Most nursing policies recommend flushing the PEG tubes with 20-30 mLs of water every 4-6 hours. This also needs to be performed before and after administration of medications and/or enteral nutrition through the PEG tube. Despite this flushing, PEG tubes still can become clogged.

Many solutions have been attempted to clear clogs including flushing water, Coca-Cola based liquids, and even pancreatic enzyme replacement therapy. One study used Creon (12,000 units lipase delayed-release capsule) dissolved in a solution of sodium bicarbonate 650 mg and sterile water. This had efficacy in clearing fewer than 50% of clogged Dobhoff feeding tubes, much less than Viokase which was taken off the market at one point [3, 4]. Another method used to clear a clogged tube is passing a tiny brush into the lumen of the PEG tube. Bard makes a manual PEG Tube Cleaning Brush (Figure 3, Bard Peripheral

Vascular, Inc. Tempe, AZ). Brushes like this can be used to help dislodge or clear a clog. One problem with some of the brushes or mechanical devices that are used to help clear a clog is that they might compress the matter within the tube and make it even more difficult to clear. Novel devices, such as flexible motor-operated brushes, offer promise as a more effective method of tube clearance (Figure 4).

PEG tubes that have broken typically need to be replaced. If the PEG tube break occurs near or within the universal/bolus adapter, then the PEG tube can be cut a few centimeters distal to the break and a replacement bolus adapter can be placed (Figure 5). This will avoid having to completely remove and replace the PEG tube. If the break is near the external bolster, then the PEG tube will need to be removed. If the break is near the external bolster, manual traction on the tube to remove it may completely break the tube leaving the internal bolster in the stomach. In this circumstance, options for management include endoscopic retrieval of the bumper or expectant observation (i.e., treat the situation as a 'cut-and-push' method; see below). Some patient-factors favor endoscopic retrieval, such as a known stricture of the GI tract or an individual who would be at extraordinarily high risk should the bumper result in an obstruction. If endoscopy is to be performed, a new PEG tube can be placed and its location visually confirmed.

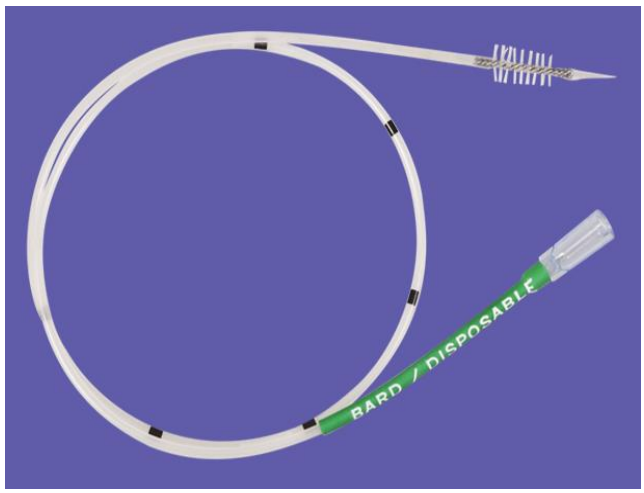

Figure 3. Bard PEG Tube Cleaning Brush (Bard Peripheral Vascular, Inc. Tempe, AZ).

Another method of PEG removal (called the 'cut-and-push' method) has been described, in which the tube is cut at the skin level and the internal bumper allowed it to pass through the GI tract via peristalsis. The original and follow up reports described the safety of leaving 15 Fr PEG bumpers within the gastric body [5, 6]. More recent reports have evaluated the technique in 20-24 Fr tubes as well with the authors reporting retrieval of the bumper from the stool within 48 hours in 80% of patients [7]. While larger patient series suggest the method is safe for small and large sized tubes, reports of complications (including death) have emerged when this technique is employed leading some experts to question its utility [8-11]. There are no prospective trials comparing the cut-and-push method with the traction removal method, and it logically carries some inherent risk (similar to an ingested foreign body. Unless there is a compelling reason why the tube cannot be removed by traction or endoscopically retrieved after being cut, we generally do not utilize this method.

Figure 4. Electromechanical motor-operated device that can be utilized to unclog PEG tubes (TubeClear® System, Actuated Medical, Bellefonte, PA). The system is comprised of a re-usable control box and a single use 'Clearing Stem.' One end of the Clearing Stem is attached to the control box and the other end is inserted into the feeding tube. The mechanical motion of the control box actuates the Clearing Stem Wire Brush Tip as it is advanced through the tube to actively work on and remove the clog.

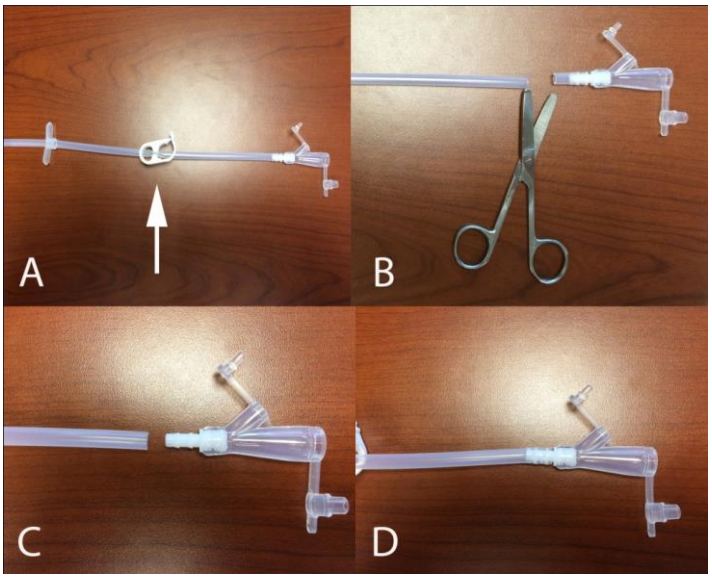

Figure 5. Replacing the feeding adapter on a PEG. A) The tube clamp should be placed in the locked position to prevent leak. B) The feeding adapter is cut free of the tubing. C and D) The new feeding adapter is pushed into the tubing until the ends are flush.

BURIED BUMPER SYNDROME

One of the least described, but more common complications with long-term PEG tube use is the buried bumper syndrome (BBS). Over time, and with increased tension on the bumper, it can erode through the gastric wall and become buried somewhere below the skin. First described in the literature in 1988, the reported incidence is anywhere from 1.5-8.8% [1, 12]. In children with PEGJ tubes (PEG with jejunal extensions) the risk of developing BBS is increased, approaching 32% [13]. The etiology of BBS is related to excessive compression between the internal and external bumpers [6]. This ultimately leads to tissue ischemia and necrosis. Over time BBS can result in GI bleeding, perforation or peritonitis and abdominal wall abscess [14-16].

The typical presentation of buried bumper syndrome is tube malfunction associated with local abdominal discomfort. In general, the time to diagnosis is somewhat dependent on the functional status of the patient as those who are unable to complain about pain in the area often have a delay. In most cases, a simple history and physical exam are sufficient to diagnose a patient with BBS. A tube that does not spin on physical exam will help make the diagnosis of BBS. The addition of a CT scan or EGD can help confirm the diagnosis and is also useful for estimate the depth of bumper migration within the abdominal or gastric wall [1]. EGD will demonstrate an ulcer below the intra-gastric bumper or tissue growing over the edge of the disk (Figure 6).

Figure 6. Endoscopic view of a BBS demonstrating a partly visible internal PEG bumper with inflamed gastric mucosa overgrowing the tube.

The management of BBS depends initially on the depth of tube migration. In most cases one can simply pull the internal retention device through, often times pulling a new tube into place at the same time [17]. If there is significant tissue that has grown over the bumper, some endoscopists have described using a needle knife to expose the buried bumper [18, 19].

Caution should be taken as several authors have reported episodes of bleeding following such dissection. Local surgical interventions are reserved for those patients where the bumper has migrated into the subcutaneous tissue and requires surgical excision [20]. In those patients presenting with perforation or peritonitis laparoscopic or open abdominal exploration can facilitate removal of the bumper or control of subsequent gastric leakage or infection [21].

Prevention of BBS relies primarily on appropriate position and tension on the external bolster. When placing or evaluating a PEG tube it is imperative to ensure that the bumper is slightly loose with approximately 10 mm between the skin and the external bumper [22]. In addition it should be able to spin without difficulty. In addition it is important to frequently evaluate the PEG tube after placement to ensure that the tension on the bumper does not change as the patient may gain weight or spend additional time sitting or standing [23].

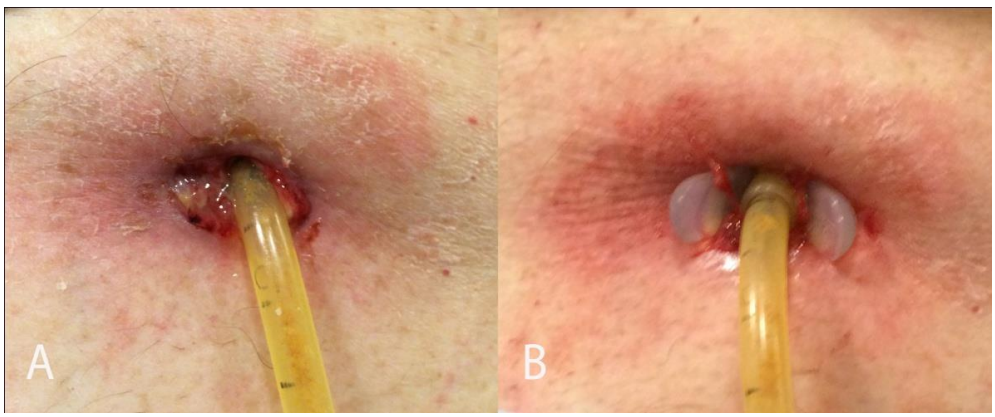

Figure 7. "Reverse" Buried bumper syndrome in a patient who presented to clinic with pain and erythema around the PEG tube. A) Before and B) after manual retrieval of the bumper.

Another related entity that is poorly described in the literature is 'reverse' BBS. Here, the external bumper of the PEG tube erodes through the skin and into the subcutaneous tissue while the internal bumper remains in a functional, intra-gastric position. Patients generally present with pain and erythema around the tube and physical exam reveals absence of the external bumper of the PEG tube (Figure 7). If possible, the bumper can be retrieved in the clinic or operating room (if necessary) and reset to have significantly less tension.

PERISTOMAL LEAKAGE AND SKIN IRRITATION

The reported incidence of peristomal leakage is 1-2% [24]. There are multiple factors that must be considered when evaluating a patient with peristomal leakage (Table 2). A small amount of mucoid discharge from the tract is normal. Similarly, mild oozing of fluid around the PEG tube is normal in the short term after placement. This typically goes away after a few weeks. If there is persistent output of fluid, then it must be determined if this is due to an infection or persistent leak. A persistent leak may occur due to the skin incision being too large at time of placement. It is important that during placement, the skin incision is kept to a minimum. This will allow the subcutaneous tissue to be closely approximated to the PEG tube.

Table 2. Potential causes of gastrostomy tube leak

Potential Causes of Leak Around a PEG Tube
1. Tube displacement
2. Recent weight loss
3. Inadequate tube stabilization (internal/external bumpers loose)
4. Failure of tract closure/approximation around tube (inadequate wound healing)
5. Too large an incision at time of PEG tube placement
6. Increased intraabdominal or intragastric pressure:
a. Cough, constipation, straining
b. Inability to decompress gastric contents (high residual volumes)
c. Delayed gastric motility

The first thing to determine with persistent leaking of a PEG tube is whether the tube in the correct place. If the tube is correctly positioned the tension on the bumpers should be checked (to ensure that it is neither too loose nor too tight). Balloon gastrostomy should be checked for appropriate balloon inflation. The PEG tube and skin site should be kept clean and dry by washing it with soap and water. Excessive tension of the external bolster should be avoided to prevent the complication of skin ulceration and development of buried bumper syndrome.

Treatment should begin with optimizing the patient's nutritional status and glycemic control. Barrier creams and other types of skin protectants with zinc oxide may reduce the irritation around the skin being exposed to leaking gastric contents. Using acid suppression such as proton pump inhibitors or Histamine 2-blockers may also help reduce irritation by raising the pH of the leaking fluid. Other principles of managing leakage around tubes is to minimize tension and movement. Conversion of PEG tubes to low profile tube (button) may help in minimizing movement of the tube, as can tube stabilizing devices.

If leaking persists and there are associated complications, this can be managed in several ways. The tube can be upsized to see if this helps reduce the amount of leakage around the tube. Upsizing the tube should not be the first step in managing a leak as it can potentially worsen the situation if the original reason for leak (for example tube motion) was not addressed. In such circumstances the larger tube will eventually leak as well and the resultant PEG tract will now be even larger. Another option would be to remove the PEG tube altogether for several days to allow the PEG tube tract to partially close. The tract will need to be secured with something smaller (guidewire or smaller catheter) so that a new PEG tube can then be placed in the same site [25].

PERSISTENT GASTROCUTANEOUS FISTULA

PEG tubes that have been in place for an extended time (> 6 months) develop a mature tract. Typically after the PEG tube is removed, the PEG tube tract closes on its own. Persistent gastrocutaneous (GC) fistulae are rare and account for approximately 0.5-3.9% of patients who have had long term PEG tubes. Several factors (mentioned earlier) hamper healing and closure of the PEG tube tract. The crucial element thought to influence

persistence of a chronic GC fistula is epithelialization of the PEG tube tract. Such fistulae can be problematic for patients due to persistent skin irritation, superimposed bacterial and fungal infections as well as issues with cleanliness and soilage of dressings and clothes (Figure 8).

Conservative management includes dietary modification (avoiding oral liquids without solid food to thicken gastric contents), topical therapy to protect the skin and treat any infections and local therapy with silver nitrate to chemically cauterize the epithelial tract. The majority of fistulae can be managed in this fashion. Fistulae failing conservative therapy can be managed endoscopically. See Chapter 20 for a complete discussion of endoscopic management of persistent GC fistulae. Fistulae failing both conservative and endoscopic management should be considered for laparoscopic or open surgical takedown.

Figure 8. Persistent GC fistula 1.5 years after PEG removal in a patient who underwent surgery for a head and neck malignancy. Patient wore an ostomy appliance to collect gastric effluent and had a superimposed area of fungal infection that responded to topical therapy. His fistula was closed endoscopically.

PEG SITE HERNIA

The occurrence of a hernia at the PEG site is a rare, but documented complication (Figure 9). The literature on hernia following PEG tube removal is limited primarily to case reports. Bolbo-Roda et al. described a 43 year old male who underwent PEG tube placement for oral malignancy [26]. Following removal the patient presented with gastric leak and 4 months following tube removal the patient returned with an abdominal wall defect in the area of his previous PEG tube. Kaplan and Delegge described a 66 year old female who underwent a 24 Fr PEG tube placement for squamous cell carcinoma of the vocal cords [27]. In the initial period following tube placement she had some issues with local superficial cellulitis. The tube was eventually removed after 7 months of use and the patient returned to the clinic 2 months later with complaint of a bulge at the former PEG site. CT scan on the patient demonstrated a Richter's style hernia. McElrath et al. described the even more rare combination of a persistent GC fistula and a PEG site hernia in a 69 year old male who ultimately required a laparoscopic fistula takedown and herniorrhaphy 4 months following PEG removal [28].

One reason for the relatively rare presentation of a hernia at a former PEG site is the survival of most PEG patients is typically limited by their underlying illness that necessitated the PEG tube in the first place. In general, patients do not survive long-enough to form a hernia or never have their tube removed. The same considerations for tube placement should be reevaluated when deciding if surgical repair of the hernia is necessary. If the patients expected survival is limited, and the hernia is asymptomatic, then a non-operative approach to repair can be undertaken. Risk factors for hernia formation likely follow the same as those for any incisional hernia; midline placement, obesity, history of wound infection, larger diameter PEG tube.

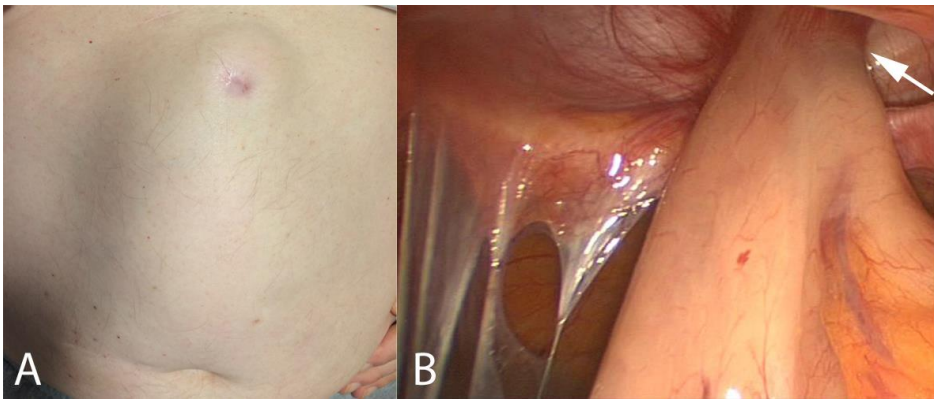

Figure 9. PEG site hernias. A) PEG site hernia from midline placement of a PEG in a patient with preexisting diastasis of the rectus muscles. B) Laparoscopic view of a PEG site hernia with the old gastrostomy site (arrow) present in the hernia.

GRANULOMA FORMATION

Hypergranulation tissue formation is a common complication of PEG placement with reported occurrences above 50% [29]. Risk factors include trauma, friction, ill-fitting low profile tube, and moisture [30]. Many treatments for granulation tissue exist. First, a clinician must identify and treat any possible infection, minimizing external irritation, prevent excessive moisture. Topical application of 0.5% triamcinolone application or polyurethane foam has been described [31]. In addition, many clinicians use silver nitrate or cryotherapy on the tissue. Surgical excision of the tissue can also be performed [32]. All of these treatments are equally efficacious with none being reported to be superior to the other [30].

MANAGEMENT OF PEG DURING SUBSEQUENT PROCEDURES

Management of previously placed PEG tube at the time of an additional procedure depends primarily on the type of procedure to be performed and the location of any necessary incision. For patients who are undergoing a procedure that does not require an abdominal incision, the PEG tube can simply be secured to the abdomen to minimize accidental dislodgement. In those patients who require an abdominal wall incision, the PEG tube should

be prepped out of the field when possible, or excluded by using a sterile drape after the abdomen is prepped. If the tube itself is in a location interfering with the procedure, it can be removed before and replaced at the conclusion of the procedure For patients undergoing upper endoscopy, it is crucial to ensure that the PEG tube is appropriately capped when insufflating the stomach as this can lead to difficulty with appropriate visualization, as well as spillage of gastric contents through the PEG tube itself.

CONCLUSION

Long term complications of PEG tube are well described, and most can be successfully managed while maintaining a functioning tube. Occasionally, such problems cannot be managed conservatively and endoscopic or surgical therapy may be indicated, including removal and replacement of the PEG.

EDITOR'S COMMENT

This chapter describes many of the commonly identified chronic complications associated with PEG tube placement. Most of these issues are not life threatening but can dramatically alter quality of life. Understanding how to manage these postoperative problems is as vital as the comprehension of safe PEG tube placement. (JMM)

REFERENCES

[1] Larson DE, Burton DD, Schroeder KW, DiMagno EP. Percutaneous endoscopic gastrostomy. Indications, success, complications, and mortality in 314 consecutive patients. *Gastroenterology*. 1987;93(1):48-52.

[2] Dwyer KM, Watts DD, Thurber JS, Benoit RS, Fakhry SM. Percutaneous endoscopic gastrostomy: the preferred method of elective feeding tube placement in trauma patients. *J Trauma*. 2002;52(1):26-32.

[3] Stumpf JL, Kurian RM, Vuong J, Dang K, Kraft MD. Efficacy of a Creon delayed-release pancreatic enzyme protocol for clearing occluded enteral feeding tubes. *Ann Pharmacother*. 2014;48(4):483-487.

[4] Williams NT. Medication administration through enteral feeding tubes. *Am J Health Syst Pharm*. 2008;65(24):2347-2357.

[5] Merrick S, Harnden S, Shetty S, Choppa P, Clamp P, Kapadia S. An evaluation of the "cut and push" method of percutaneous endoscopic gastrostomy (PEG) removal. *JPEN J Parenter Enteral Nutr*. 2008;32(1):78-80.

[6] Kejariwal D, Bromley D, Milao Y. The "cut and push" method of percutaneous endoscopic gastrostomy tube removal in adult patients: the Ipswich experience. *Nutr Clin Pract*. 2009;24(2):281-3.

[7] Agha A, AlSaudi D, Furnari M, Abdulhadi Ali MM, Morched Chakik R, Alsaudi I, Savarino V, Giannini EG. Feasibility of the cut-and-push method for removing large-

caliber soft percutaneous endoscopic gastrostomy devices. *Nutr Clin Pract*. 2013;28(4): 490-2.

[8] Harrison E, Dillon J, Leslie FC. Complications of the cut-and-push technique for percutaneous endoscopic gastrostomy tube removal. *Nutr Clin Pract*. 2011;26(3):230-1.

[9] Peacock, O, Singh Rajeev, Cole A, Speake W. The 'cut and push' technique: is it really safe? *MJ Case Reports* 2012; doi:10.1136/bcr-2012-006607.

[10] Brown JN, Borrowdale RC. Small bowel perforation caused by a retained percutaneous endoscopic gastrostomy tube flange. *Nutr Clin Pract*. 2011;26(3):227-9.

[11] Kirby, Donald F. "Never Say Never Again." *Nutrition in Clinical Practice*. 2011;26(3):225-226.

[12] Lee T-H, Lin J-T. Clinical manifestations and management of buried bumper syndrome in patients with percutaneous endoscopic gastrostomy. *Gastrointest Endosc*. 2008;68(3):580-584.

[13] Goring J, Lawson A, Godse A. Are PEGJs a Risk Factor for the Buried Bumper Syndrome? *J Pediatr Surg*. 2016;51(2);257-9.

[14] McClave SA, Jafri NS. Spectrum of morbidity related to bolster placement at time of percutaneous endoscopic gastrostomy: buried bumper syndrome to leakage and peritonitis. *Gastrointest Endosc Clin N Am*. 2007;17(4):731-746.

[15] Van Weyenberg SJ, Lely RJ. Arterial hemorrhage due to a buried percutaneous endoscopic gastrostomy catheter. *Endoscopy*. 2013;45 Suppl 2:E261-E262.

[16] Finocchiaro C, Galletti R, Rovera G, et al. Percutaneous endoscopic gastrostomy: a long-term follow-up. *Nutrition*. 1997;13(6):520-523.

[17] Venu RP, Brown RD, Pastika BJ, Erikson LW. The buried bumper syndrome: a simple management approach in two patients. *Gastrointest Endosc*. 2002;56(4):582-584.

[18] Rieder B, Pfeiffer A. Treatment of the Buried Bumper Syndrome using a Savary Dilator. *Endoscopy*. 2008;40 Suppl 2:E115.

[19] El AZ, Arvanitakis M, Ballarin A, Devière J, Le Moine O, Van Gossum A. Buried bumper syndrome: low incidence and safe endoscopic management. *Acta Gastroenterol Belg*. 2011;74(2):312-316.

[20] Frascio F, Giacosa A, Piero P, Sukkar SG, Pugliese V, Munizzi F. Another approach to the buried bumper syndrome. *Gastrointest Endosc*. 1996;43(3):263.

[21] Boreham B, Ammori BJ. Laparoscopic percutaneous endoscopic gastrostomy removal in a patient with buried-bumper syndrome: a new approach. *Surg Laparosc Endosc Percutan Tech*. 2002;12(5):356-358.

[22] Itkin M, DeLegge MH, Fang JC, et al. Multidisciplinary practical guidelines for gastrointestinal access for enteral nutrition and decompression from the Society of Interventional Radiology and American Gastroenterological Association (AGA) Institute, with endorsement by Canadian Intervention. *Gastroenterology*. 2011;141(2):742-765.

[23] Steenblik M, Hilden K, Fang JC. A retrospective correlation of percutaneous feeding tube stoma length in sitting and supine positions compared with body mass index. *Nutr Clin Pract*. 2012;27(3):406-409.

[24] Lin HS, Ibrahim HZ, Kheng JW, Fee WE, Terris DJ. Percutaneous endoscopic gastrostomy: strategies for prevention and management of complications. *Laryngoscope*. 2001;111(10):1847-1852.

[25] Schrag SP, Sharma R, Jaik NP, et al. Complications related to percutaneous endoscopic gastrostomy (PEG) tubes. A comprehensive clinical review. *J Gastrointestin Liver Dis*. 2007;16(4):407-418.
[26] Boldo-Roda E, Peris-Trias A, de Lucia-Peñalver GP, Martinez-Ramos D, Miralles-Tena JM. Reflections in front of a case of ventral hernia after PEG tube removal. *Gastrointest Endosc*. 2005;62(2):323-324.
[27] Kaplan R, Delegge M. An unusual case of a ventral Richter's hernia at the site of a previous PEG tube. *Dig Dis Sci*. 2006;51(12):2389-2392.
[28] McElrath L, Pauli EM, Marks JM. Hernia formation and persistent fistula after percutaneous endoscopy gastrostomy: unusual complications of a common procedure. *Am Surg*. 2012;78(4):E200-1.
[29] Goldberg E, Barton S, Xanthopoulos MS, Stettler N, Liacouras CA. A descriptive study of complications of gastrostomy tubes in children. *J Pediatr Nurs*. 2010;25(2):72-80.
[30] Warriner L, Spruce P. Managing overgranulation tissue around gastrostomy sites. *Br J Nurs*. 2012;21(5):S14-16, S18, S20 passim.
[31] Borkowski S. G tube care: managing hypergranulation tissue. *Nursing*. 2005;35(8):24.
[32] Gal-or N, Gil T, Metanes I, et al. Intralesional cryosurgery for the treatment of severe stoma hypergranulation following percutaneous endoscopic gastrostomy. *Isr Med Assoc J*. 2015;17(4):251-252.

In: Encyclopedia of Surgery (22 Volume Set)
Editors: Andreas Lehrer and Kristin Mueller
ISBN: 978-1-53618-329-0
© 2020 Nova Science Publishers, Inc.

Chapter 141

ENDOSCOPIC MANAGEMENT OF PEG RELATED COMPLICATIONS

Joshua S. Winder, MD and Eric M. Pauli*, MD
Penn State Hershey Medical Center, Hershey, PA, US

INTRODUCTION

As outlined in the previous two chapters, PEG tube placement has a set of well-defined risks and potential complications. Familiarity with proper technique and relevant anatomy is key to minimizing the risk of undesired outcomes. However, even with technical expertise and appropriate peri-procedural management, complications may still occur. In this chapter we will examine endoscopic management of a variety of adverse events following PEG placement. It should be emphasized that any patient presenting with hemodynamic instability, sepsis, or peritonitis as a result of any of a PEG complication is not a candidate for endoscopic therapy and should be managed by a traditional surgical approach.

ACUTE GI BLEEDING

PEG placement is considered a higher risk procedure with an overall bleeding complication rate of 2.5% [1]. Management of bleeding is dictated by the nature and severity of the hemorrhage. Most bleeding from the abdominal wall puncture site can be controlled with direct pressure. Should the patient present with frank blood aspirated from the PEG tube, hematemesis, hematochezia, melena, drop in hemoglobin (acute blood loss anemia), or hemodynamic instability, an upper endoscopy should be performed to assess and potentially treat the source (Figure 1). Often in these cases, bleeding can be seen from the gastrostomy tract, or from gastric ulceration (often occurring in the setting where the PEG bumper is pulled too tightly against the gastric mucosa). Local endoscopic management of the hemorrhage can be achieved with traditional endoscopic techniques including electrocautery,

* Corresponding Author's Email: epauli@hmc.psu.edu.

clipping, and injection therapy. While a recent meta-analysis concluded that endoscopic clipping was superior to injection alone (but comparable to thermocoaguation) in the setting of non-variceal upper gastrointestinal (GI) hemorrhage, we prefer to utilize multimodal therapy to manage this problem [2]. Additional consideration should be given to the possibility that traditional endoclips may be dislodged by the motion of the internal PEG bumper against the clip itself, which can lead to re-bleeding.

COLON INJURIES

Perforation of the transverse or sigmoid colon may occur when the colon in located between the abdominal wall and the anterior wall of the stomach. Although techniques such as using a pilot needle or utilizing the safe-tract were developed to prevent such perforations, this injury continues to occur. Patients may be completely asymptomatic or present with abdominal pain, diarrhea (from the administration of tube feeds to the colon), tenderness, peritonitis, or sepsis. Patients who present in extremis merit a formal operation with repair of the perforation (or perforations, as the anterior and posterior wall of the colon are typically both involved) while simultaneously establishing enteral feeding access.

Misplacement of a PEG through the colon is often an unrecognized event. Even with a through-and-through colon injury, the endoscopic view of stomach will show the PEG bumper in what appears to be a proper position. Utilizing a finder needle may not be sufficient if the same tract is not followed with the angiocatheter needle or trocar. When aspirating with a small gauge finder needle, there may be insufficient air in the colon or the enteric content may be too thick to pass into the syringe with aspiration to signal the endoscopist that colonic puncture has occurred.

Trans-colonic PEG placement results in both gastrocolic and colocutaneous fistulae. In asymptomatic patients or those with vague abdominal complaints, the injury may be identified on routine colonoscopy.

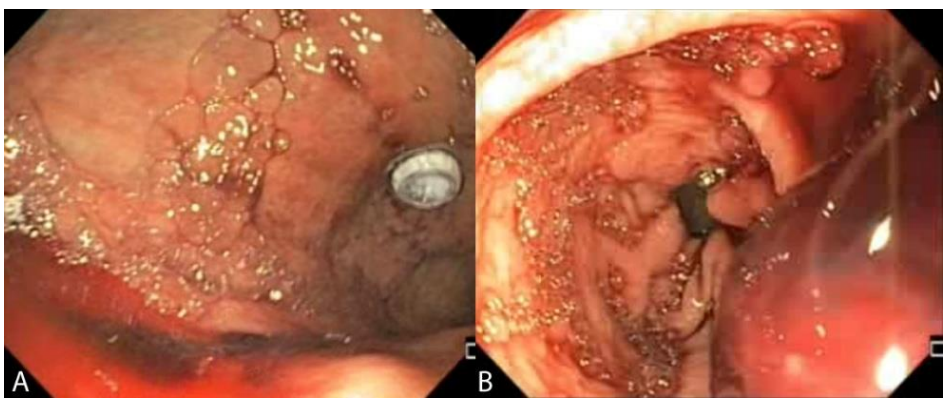

Figure 1. Post-PEG bleeding due to ulceration of the gastric mucosa at the PEG tube site from excessive traction. A) Endoscopic evaluation demonstrated blood in the body of the stomach and no active bleeding from the gastrostomy. B) Blood clot was found in the pre-pyloric region.

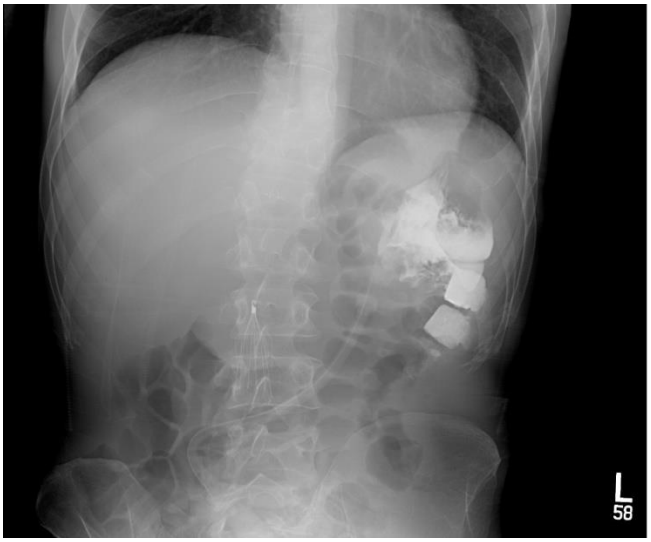

Figure 2. Colon injury after PEG placement; Plain abdominal film following contrast injection via gastrostomy demonstrates contrast outlining the haustral folds of the splenic flexure and descending colon.

Other patients may not have the injury identified until months later when the PEG tube bumper migrates into the colon or is positioned intra-colonic during PEG tube replacement [3]. Such patients may present with copious diarrhea immediately after initiation of tube feeds, but may otherwise be stable. Diagnosis is made by injecting contrast through the PEG tube and identifying haustral folds outlined by contrast on plain x-ray, or identifying the bumper and injected contrast within the lumen of the colon on computed tomography (Figure 2).

Conservative management includes removing the PEG at the bedside and allowing spontaneous closure of the fistulae [3]. A localized abscess or generalized peritonitis may develop depending on the age of the tract and whether or not a fully epithelialized fistula has developed. A small percentage of these fistulae persist which may not be acceptable based on the patients' comorbid conditions, life expectancy, and preference.

Endoscopic management has the potential to simultaneously address the three problems created by this scenario: repair of the gastrocolic fistula, repair of the colocutaneous fistula, and reestablishment of enteral feeding access. Prior to intervention and once intra-colonic location has been verified by imaging, colon prep can be administered through the PEG tube to facilitate colonoscopy. Our preference has been to first address the gastrocolic fistula [4]. During upper endoscopy the fistula can be readily identified on the anterior wall of the stomach (Figure 3A). We advocate for superficial ablation of the tract with an argon plasma coagulation catheter to disrupt the epithelialized superficial layer and induce inflammation that will further obliterate the tract [5]. An over-the-scope clip (OTSC) or other endoscopic closure device can then be placed at the opening of the tract (Figure 3B). We routinely verify closure fluoroscopically by instilling contrast within the lumen at the location of clip placement.

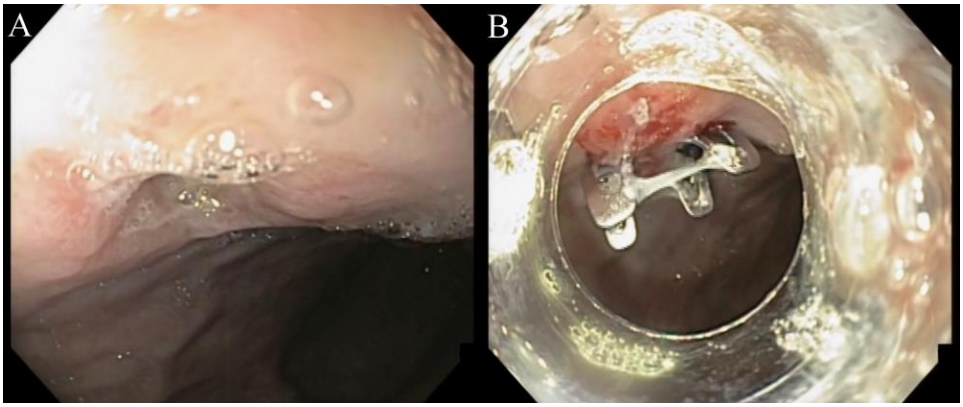

Figure 3. A) Endoscopic view of a gastrocolic fistula on the anterior wall of the stomach. B) Closure of fistula utilizing an OTSC.

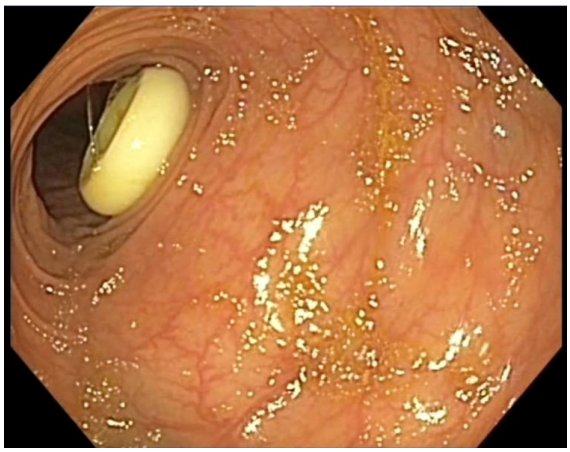

Figure 4. Colonoscopic view of a gastrostomy bumper within the transverse colon resulting from a transcolonic PEG tube placement.

With the gastrocolic fistula closed, a colonoscopy is then performed to identify the location of the colocutaneous fistula. The PEG bumper should be easily visualized within the lumen of the colon (Figure 4). We prefer to utilize a 'cut and push' method of tube removal rather than a simple removal under traction to prevent any further dilation/enlargement of the colocutaneous fistula tract. The PEG is cut close to the level of the skin and a flexible guidewire is passed through the cut lumen of the PEG. Using a Roth net the PEG bumper and flexible wire are secured endoscopically and removed per rectum. This results in a flexible guidewire that traverses the colocutaneous fistula, travels distally through the colon, and traverses the anus. Backloading this guidewire through the working channel of the colonoscope serves two main purposes: it facilitates identification of the fistula in what may be a difficult location such as the splenic flexure, and assists in OTSC placement by allowing the colonoscope to be pulled into position (i.e., pull colonoscopy) by applying gentle traction on the externalized wire at the fistula site. A Foley catheter can be placed into the tract to enable insufflation during the remainder of the colonoscopy. Alternatively, petroleum impregnated gauze can be placed over the cutaneous opening to eliminate air leak. Once the colonoscope has reached the fistula, the Foley is deflated and removed and an OTSC (or other

endoscopic closure device) is applied and closure verified fluoroscopically. The wire can then be removed.

If the patient's underlying condition requires continued enteral feeding access, it can be addressed at this time. The new PEG tube is placed following traditional techniques described in earlier chapters, but with the following modifications: In order to find an appropriate tract that will not traverse the colon once again, fluoroscopy is used with intra-colonic contrast, in addition to transillumination, external depression of the abdominal wall, and a safe-tract technique. Additionally, once the guidewire has been passed into the stomach, colonoscopic visualization should be utilized to ensure that the wire does not traverse the colon. Colonoscopic maneuvers may be required to obtain a safe window (decompressing the colon, rotating the transverse colon, etc.), which may be facilitated by the presence of an additional endoscopist [4, 6].

GASTROSTOMY SITE LEAK

The incidence of leak around the PEG tube has been reported at 1-4% though this number is likely much higher due to underreporting [7, 8]. Risk factors contributing to leakage including diabetes, malnutrition, immunosuppression, infection, gastric hypersecretion, side torsion on the PEG tube, excessive cleansing of the site, absence of an external bolster, or if the bolster is too tight. Modification of these factors should be attempted whenever possible.

There are a number of endoscopic techniques that can slow and even stop leakage. The aperture of the gastrostomy can be decreased by applying an OTSC on the luminal surface at the edge of the PEG tube (Figure 5). Plication can also be performed with endoscopic suturing or a combination of suturing and clips (Figure 6). Alternatively, a detachable ligating device can be placed around the PEG tube and sequentially secured to the mucosa with endoclips. Once the ligation loop is tightened, the result is a cinching of the gastric mucosa around the PEG similar to a purse string suture (Figure 7).

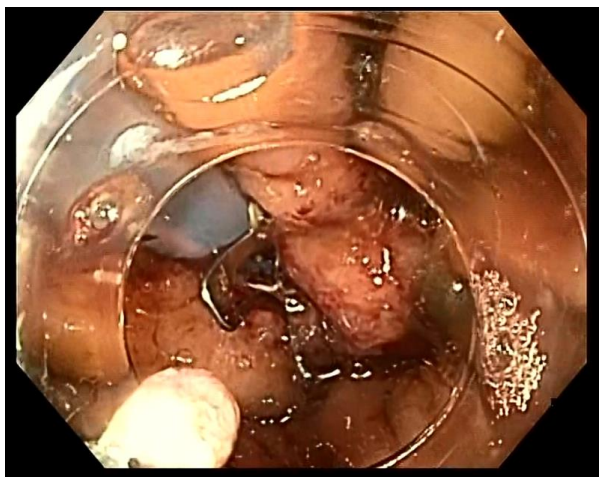

Figure 5. Over-the-scope clip applied adjacent to an existing PEG tube to close the aperture around the leaking PEG.

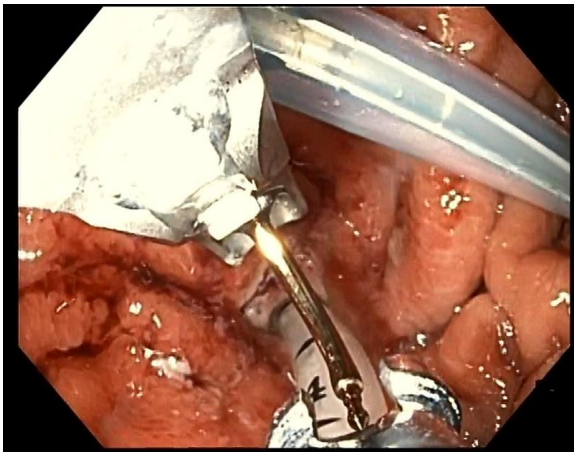

Figure 6. Endoscopic suturing device being used to plicate the adjacent mucosa surrounding the PEG tube in the setting of a leaking PEG.

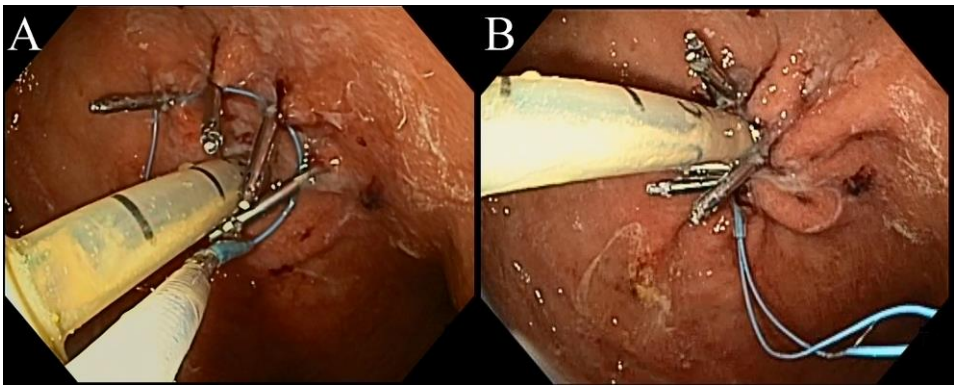

Figure 7. A) Detachable ligating device placed around PEG tube with endoclips placed sequentially around PEG securing the loop to the gastric mucosa. B) Closure of the ligation loop creates a cinch of gastric mucosa around the PEG resulting in smaller aperture of the gastrostomy similar to purse string suture.

If leakage persists or is exacerbated when tube feeds are given, conversion to a gastrojejunal tube should be considered. Advantages of this approach include continued enteral access via the jejunal extension, post-pyloric feeds which should decrease the total amount of gastric contents and subsequently reduce the amount of leakage, and persistent access to the stomach through the gastric port which can be used both for infusion and drainage (venting). In the patient with a well-established gastrostomy tract, the PEG tube can be removed and a flexible wire placed through the gastrostomy. The wire can then be endoscopically directed through the pylorus and past the ligament of Treitz. The gastrojejunostomy tube can then be placed over the wire. Final position can then be assessed using fluoroscopy and injection of contrast through the jejunostomy tube. Some PEG tube brands allow placement of a jejunostomy extension through the existing PEG tube. In these cases the jejunostomy extension can be dragged into position endoscopically. See Chapter 11 for a more detailed description of the technical steps of placing a gastrojejunal tube.

Figure 8. Laparoscopic view of a 7 day-old PEG tube in a severely malnourished patient presenting with intraperitoneal leakage of tube feeds. The anterior wall of the stomach has yet to fuse with the anterior abdominal wall and there is no omentum surrounding the gastrotomy site.

Figure 9. Gastrointestinal T-anchors (arrows) placed in triangle pattern around a leaking PEG tube to afford gastropexy.

Gastrointestinal T-anchors can be used in cases were leakage is occurring around the tube and into the peritoneal cavity. In these patients the serosa of the anterior stomach has not become adherent to the peritoneum of the anterior abdominal wall (Figure 8). Ideally 3-4 anchors (forming either a triangle or a square) would be placed sequentially around the existing PEG tube to pexy the stomach to the anterior abdominal wall (Figure 9). Care should be taken when placing T-anchors around a balloon-type gastrostomy as the introducer needle can easily rupture the balloon, necessitating tube exchange.

PERSISTENT GASTROCUTANEOUS FISTULA

Gastrocutaneous (GC) fistulae occur when PEG tubes are removed and a persistent tract results. While the overwhelming majority of these fistulae close spontaneously, approximately 1.1% persist and require further treatment [9]. Traditional therapies include application of silver nitrate to the external opening, limiting oral intake and providing post-

pyloric feeding access such as nasojejunal feeds, or in some cases laparoscopic or open fistula takedown.

Our experience with endoscopic closure of persistent GC fistula closure with OTSC's has been positive with a long-term success rate of 100% in 5 cases (Figure 10) [5]. Fistulae up to 2 cm in diameter have been successfully closed using OTSC's [10]. Alternatively, endoscopic suturing devices can be used for GC fistulae, including those larger than 2 cm [11].

Fistula formation and persistence are multifactorial and must be addressed as such in order to achieve long-term closure. We advocate removal of any foreign material that may be present in the tract (typically suture material), treatment of any associated infection (adjacent abscess or overlying cellulitis) with drainage and/or appropriate antibiotics, optimization of nutrition with enteral feeding whenever possible (which may require alternate access such as nasojejunal feeds as mentioned previously), optimization of medical comorbidities including diabetes, cessation or tapering of steroids if possible, relieving downstream obstructions or strictures (including pyloric injection with botulinum toxin in select cases), and ablation of the epithelialized tract with argon plasma coagulation or mechanical debridement [12].

EARLY PEG-TUBE DISLODGMENT

Inadvertent removal of the PEG tube is a relatively uncommon, but well-known occurrence. Previous authors have reported a dislodgment rate of 2-28% [13, 14]. Dislodgment in the patient with a well-established gastrostomy tract becomes a minor issue and can be replaced at the bedside with a new gastrostomy tube, verifying intra-gastric positioning with contrast injection through the newly placed tube as indicated. However, in patients where the gastric serosa has not yet fused to the peritoneum of the abdominal wall and the tract has not yet fully matured (1-2 weeks) a dislodged PEG tube may result in a free spillage of gastric contents into the abdominal cavity [15]. The period from placement to tract maturation can vary based on the patient's baseline comorbidities and nutritional status, further prolonging tract-maturation time. The patient's presentation will dictate the management; patients displaying signs of peritonitis, sepsis, or hemodynamic instability require emergent operative intervention with abdominal washout, closure of the previous gastrostomy, and creation of a new gastrostomy at a separate site.

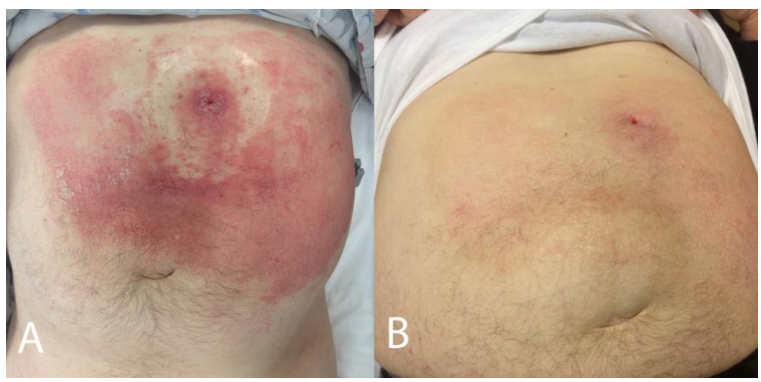

Figure 10. Abdominal wall of a patient with a persistent gastrocutaneous fistula following PEG removal. A) Before and B) Three weeks after closure with an over-the-scope clip.

Figure 11. Endoscopic snare awaiting passage of a guidewire through a recently removed gastrostomy tract. Newly placed T-anchor is visible lateral to the former PEG tube site.

In the stable patient there are various management options. Historically, the gastrostomy tube could be blindly placed through the immature tract. Water-soluble contrast was then injected to verify placement. Misplacement could result in dire consequences with the patient developing peritonitis from a misplaced gastrostomy tube. Conservative management was also acceptable, consisting of nasogastric tube decompression and antibiotics with repeated PEG tube placement 7-10 days afterwards [16].

There are a number of endoscopic options for early PEG tube dislodgment in the stable patient. The first is semi-urgent upper endoscopy, percutaneous insertion of a flexible wire or silk suture under direct endoscopic visualization, and then replacement of the PEG tube through the original gastrostomy. Galat and colleagues used this technique in 5 consecutive patients with PEG dislodgement with good results [13]. Another option is to place a new PEG tube at an alternate site, pulling the anterior wall of the stomach to the abdominal wall and occluding the previous gastrostomy. The endoscopist can additionally use T-anchors to achieve a more definitive gastropexy, especially in patients at risk for repeated PEG tube dislodgements (Figure 11). Alternatively, the previous gastrostomy can be closed using OTSC's as described previously and a new PEG placed at an alternate site.

PEG Rescue

Marks et al. first described rescue of a dislodged PEG using a method based on natural orifice transluminal endoscopic surgery (NOTES) principles [17]. The technique, a so-called PEG Rescue, proceeds as follows: an upper endoscopy utilizing carbon dioxide insufflation is performed and the gastrostomy identified (Figure 12A). If it is patent, the gastrostomy is dilated pneumatically with balloon dilation to allow passage of the endoscope into the peritoneal cavity (Figure 12B). A systematic examination of the abdominal cavity is then performed to inspect the abdominal viscera for injury or compromise. Any identified abscess, succus, or free fluid can be aspirated at this point. The abdominal wall defect can be used to pass a 5 mm laparoscopic suction/irrigation device to aid in peritoneal lavage, with the trans-gastric endoscope being used for visualization.

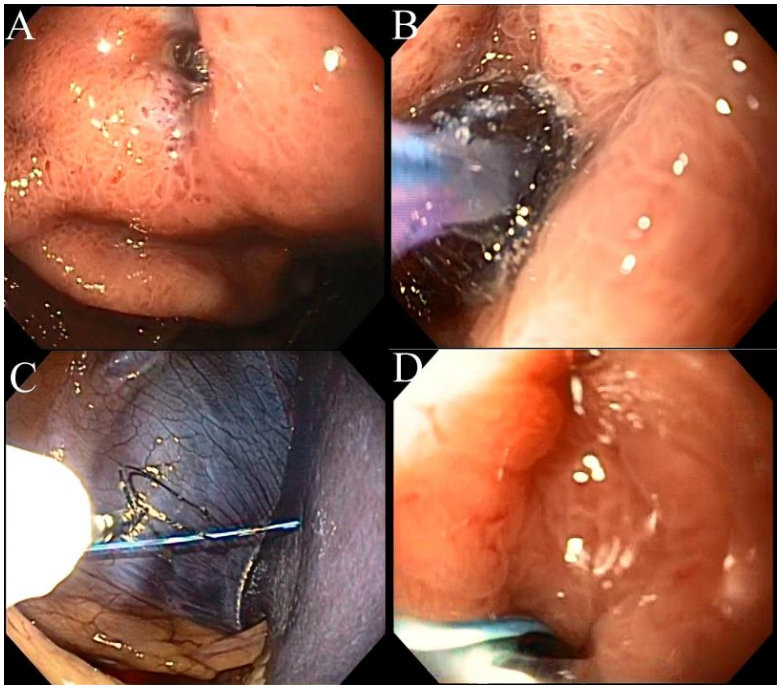

Figure 12. PEG Rescue technique. A) Endoscopic view of a gastrotomy following early PEG dislodgement. B) Balloon dilation of the gastrostomy utilizing a 10 mm radially expanding balloon. C) Endoscopic view of the liver and falciform ligament. A transabdominal guidewire is being passed through a snare. D) The guidewire withdrawn into the stomach and is ultimately retrieved per os to permit a new PEG tube to be placed.

After a determination has been made that no formal surgical intervention is necessary, the PEG guidewire is then passed through the abdominal wall defect and grasped with a snare (Figure 11C). The guidewire is then pulled back to an intra-gastric position and ultimately retrieved per os (Figure 11D). The remainder of the procedure proceeds similar to a standard pull-method PEG placement. As the gastrostomy tube is pulled into position, the anterior wall of the stomach is drawn up against the anterior abdominal wall as it was prior to dislodgement. Gastrointestinal T-anchors should be placed to further secure the gastrostomy. Tube feeds can be restarted once the patient is clinically stable, at the provider's discretion. We have performed PEG rescue in multiple cases of stable patients and the results have been very positive.

CONCLUSION

Endoscopic therapies are appropriate in many settings where PEG tube related complications have occurred. The guiding principle for endoscopic management is the clinical stability of the patient. In the stable patient, we recommend all of the above interventions when appropriate with the understanding that endoscopic therapies should only be offered by those who are experienced in their respective applications.

EDITOR'S COMMENT

This chapter gives a comprehensive description of the many complications associated with PEG placement and the associated management options. The majority of these issues revolve around troublesome post-procedure scenarios such as PEG site leakage or gastrostomy site enlargement. Life threatening complications can also develop and endoscopists must be aware of these and the appropriate evaluation and management techniques (JMM).

REFERENCES

[1] Schapiro GD, Edmundowicz SA. Complications of percutaneous endoscopic gastrostomy. *Gastrointest Endosc Clin N Am*. 1996;6(2):409-22.

[2] Sung JJ, Tsoi KK, Lai LH et al. Endoscopic clipping versus injection and thermocoagulation in the treatment of non-variceal upper gastrointestinal bleeding: a meta-analysis. *Gut*. 2007;56(10):1364-73.

[3] Berger SA, Zarling EJ. Colocutaneous fistula following migration of PEG tube. *Gastrointest Endosc*. 1991;37(1):86-8.

[4] Winder JS, Staszak RM, Pauli EM. Multimodal endoscopic management of iatrogenic transverse colon injuries from a percutaneous endoscopic gastrostomy tube. *Gastrointest Endosc*. 2016 [epub. ahead of print].

[5] Winder JS, Kulaylat AN, Schubart JR et al. Management of non-acute gastrointestinal defects using the over-the-scope clips (OTSCs): a retrospective single-institution experience. *Surg Endosc*. 2015 [epub. ahead of print].

[6] Tominaga K, Saigusa Y, Ito S et al. Percutaneous endoscopic gastrostomy with the aid of a colonoscope to avoid gastrocolic fistula formation. *Endoscopy*. 2007;39 Suppl. 1:E 112-3.

[7] Lin HS, Ibrahim HZ, Kheng JW et al. Percutaneous endoscopic gastrostomy: strategies for prevention and management of complications. *Laryngoscope*. 2001;111(10):1847-52.

[8] Grant DG, Bradley PT, Pothier DD et al. Complications following gastrostomy tube insertion in patients with head and neck cancer: a prospective multi-institution study, systematic review and meta-analysis. *Clin Otolaryngol*. 2009;34(2):103-12.

[9] Shellito PC, Malt RA. Tube gastrostomy. Techniques and complications. *Ann Surg*. 1985;201(2):180-5.

[10] Al Ghossaini N, Lucidarme D, Bulois P. Endoscopic treatment of iatrogenic gastrointestinal perforations: an overview. *Dig Liver Dis*. 2014;46(3):195-203.

[11] Kantsevoy SV, Thuluvath PJ. Successful closure of a chronic refractory gastrocutaneous fistula with a new endoscopic suturing device (with video). *Gastrointest Endosc*. 2012;75(3):688-90.

[12] Winder JS, Pauli EM. Comprehensive management of full-thickness luminal defects: The next frontier of gastrointestinal endoscopy. *World J Gastrointest Endosc.* 2015;7 (8):758-68.

[13] Galat SA, Gerig KD, Porter JA, Slezak FA. Management of premature removal of the percutaneous gastrostomy. *Am Surg*. 1990;56(11):733-6.
[14] Koulentaki M, Reynolds N, Steinke D et al. Eight years' experience of gastrostomy tube management. *Endoscopy*. 2002;34(12):941-5.
[15] Mellinger JD, Simon IB, Schlechter B et al. Tract formation following percutaneous endoscopic gastrostomy in an animal model. *Surg Endosc*. 1991;5(4):189-91.
[16] Marshall JB, Bodnarchuk G, Barthel JS. Early accidental dislodgement of PEG tubes. *J Clin Gastroenterol*. 1994;18(3):210-2.
[17] Marks JM, Ponsky JL, Pearl JP, McGee MF. PEG "Rescue": a practical NOTES technique. *Surg Endosc*. 2007;21(5):816-9.

In: Encyclopedia of Surgery (22 Volume Set)
Editors: Andreas Lehrer and Kristin Mueller
ISBN: 978-1-53618-329-0
© 2020 Nova Science Publishers, Inc.

Chapter 142

GASTRIC BYPASS SURGERY AND THE SKIN

Katherine Fiala, MD and Ryan Batson
Scott and White Hospital, Texas A&M Health Science Center College of Medicine, Temple, TX, US

ABSTRACT

Gastric bypass surgery can affect the skin in both positive and negative ways. Recently, the positive outcomes have been demonstrated with psoriasis, necrobiosis lipoidica, acanthosis nigricans, and hidradenitis suppurativa. In this chapter, we will discuss the recent findings of the relationship between gastric bypass and these four skin disorders. On the other hand, with aims to achieve radical weight reduction, bariatric surgery can be accompanied by nutrient insufficiencies and metabolic imbalances that affect the skin. Such deficiencies can lead to changes in the skin's micro-architecture which can, in turn, affect processes such as wound healing. Changes in the skin's immunity and defense mechanisms can result from vitamin and nutrient deficiency. The nutrient deficiencies are thought to be a result of a combination of decreased food intake, changes in the digestive system's anatomy, and high levels of oxidative stress that interfere with the absorptive process. This chapter will explore the most prominent metabolic and nutritional deficiencies that have dermatologic manifestations including: iron, biotin, zinc, copper, and vitamins B3, A, C, and K. Interestingly, patients may be compliant with their oral nutritional supplements, but the absorption is decreased resulting in low circulating levels. This can, moreover, result in skin and systemic manifestations. Recognizing various skin changes secondary to nutrient deficiency in post bariatric surgery patients is a valuable asset in providing comprehensive care.

BENEFITS TO THE SKIN

Psoriasis

Psoriasis is a common chronic inflammatory condition characterized by high epithelial cell turnover. The classic cutaneous manifestation includes red patches with overlying thick, silvery scales, which may be itchy. The distribution is often symmetrical and shows

predilection for the elbows, knees, scalp, and nails (Farias, 2012). Obesity is noted to be a major risk factor for psoriasis. Perhaps one of the greatest contributions to the increased incidence of psoriasis in the obese patient population is the chronic inflammatory state imposed on the body. Psoriasis is regarded as a systemic autoimmune disease in which leukocytes, inflammatory cytokines, and dendritic cells play a role (Faurschou 2011). Pro-inflammatory cytokines such as tumor necrosis factor (TNF) alpha, interleukin (IL)-1, IL-6, IL-8 and leptin synthesized by adipose tissue are over expressed in obesity (Hector, 2014). Furthermore, the severity of psoriasis is associated with the degree of obesity observed. Hossler et al. noted that almost two-thirds of their 24 patients with psoriasis self-reported postoperative improvement after undergoing weight loss surgery. In addition, this study demonstrated an improved response to psoriasis treatment after surgery (Hossler 2013).

Interestingly, while it is no surprise that drastic weight loss after the surgery reduces symptoms of psoriasis, marked clinical improvement may be noted immediately following the procedure even before significant weight loss is achieved. The suspected mechanism involves the glucose lowering gut incretin hormone, glucagon-like peptide-1 (GLP-1). After gastric bypass, the levels of postprandial GLP-1 may increase up to 20 fold (Faurschou 2011). This hormone is not, however, increased in the purely restrictive surgeries, including gastric band or sleeve. GLP-1 is found in the epithelium of the intestinal tract with the greatest density located in the ileum. It is secreted in response to the presence of nutrients in the intestinal lumen (Holst 2007). The GLP-1 receptors on pancreatic beta cells have been shown to enhance all steps of insulin biosynthesis and insulin gene transcription as well as beta cell mass (in cell and animal studies). GLP-1 also inhibits the secretion of glucagon from alpha cells. It is the cumulative effects on insulin and glucagon that ultimately inhibit hepatic glucose production (Faurschou 2011). Lastly, GLP-1 reduces appetite, gastrointestinal motility, and empting. These effects ultimately lead to decreased food intake.

In addition to contributing to glucose homeostasis, gut motility, and satiety, GLP-1 has been shown to have some anti-inflammatory effects. It is this implication as an immunological modulator that provides an additional contribution to the improvement of psoriasis postoperatively (Faurshcou 2011). Its anti-inflammatory actions include decreased expression of cytokines induced by TNF-alpha. This is of special interest when understanding the mechanism of psoriasis resolution. TNF-alpha promotes inflammation through the pro-survival transcription factor NF-kB (Pasparakis 2009). Although data on immunological effects of GLP-1 are still primarily based on *in vitro* and animal models, new and exciting data are emerging. The potential immunological effects pose a link between bariatric surgery, GLP-1 and psoriasis.

Ultimately, it is the additive effects of improved glucose homeostasis, increased weight loss, and reduced inflammation that result in improved psoriasis. Farias et al. reported that seven of the 10 patients in their study remained in remission six months after surgery. Seventy-five percent of these patients were previously taking systemic medications including: acitretin, methotrexate, and cyclosporine. By achieving resolution of psoriasis with a bariatric procedure, serious side effects of these systemic medications may be avoided (Farias 2012). Despite the fact that psoriasis is not considered a life-threatening illness, it is associated with stigmatizing chronic lesions that affect a patient's physical and psychological morbidity. Gastric bypass, therefore, may provide an effective means of treating patients with refractory psoriasis and, ultimately, significantly contribute to an improved quality of life.

Necrobiosis Lipoidica

Necrobiosis lipoidica (NL), a granulomatous skin disease, is commonly associated with diabetes mellitus. It is typically observed bilaterally on patients' shins, but may also be seen on the forearms, hands and trunk. In the initial stages, the lesions are typically asymptomatic but may become tender and ulcerate over time or when injured. The initial presenting symptom is the appearance of an "erythematous ecchymosis." The lesions are red-brown and indurated with smooth, atrophic central portions. Over time, the chronic disease may lead to ulceration which can then cause dysethesia, pain, secondary infection and cosmetically sensitive scarring (Weismann 2004).

While the etiology of NL is still largely unknown, some of the proposed mechanisms implicated include: T cell involvement, microangiopathy, and immune complex vasculitis resulting in a release of pro-inflammatory cytokines and abnormal collagen production (Sehgal 2011).

The diagnosis is made by punch biopsy demonstrating superficial and deep perivascular and interstitial mixed inflammatory cell infiltrates including: lymphocytes, plasma cells, multinucleated histiocytes, and eosinophils in the dermis and subcutis. Necrotic areas with collagen degeneration in the deep dermis, peripheral fibrosis, and subcutaneous tissue panniculitis may also be diagnostic (Patsatsi 2011).

A very poor response to treatments, including topical and systemic steroids, nicotinamide, pentoxifylline, tretinoin, TNF alpha inhibitors, mycophenolate mofetil, thalidomide, cyclosporine, tacrolimus, and antimalarials, is typically observed in most patients with this condition (Bozkurt 2013; Patsatsi, 2011). Case reports, however, have detected symptomatic, morphologic, and histopathologic remission of NL after bariatric surgery (Bozkurt 2013). It is believed that the significant improvement of a patient's NL is secondary to type 2 diabetes mellitus remission (Bozkurt 2013). This provides a promising therapeutic option for morbidly obese patients with NL who failed medical therapy.

Acanthosis Nigricans

Acanthosis nigricans is a common dermatologic manifestation of obesity, insulin resistance, and consequent hyperinsulinemia. It is classically a symmetrical hyperpigmented, velvety plaque that may occur in almost any location. The most common regions affected include the posterior neck, axilla, and groin. Additionally, less common regions include the knuckles, elbows, and face (Atwa 2014). The skin has abundant insulin-like growth factor-1 (IGF-1) receptors on the keratinocyte surface membrane. Acanthosis nigricans is a common feature in severe insulin resistance, in patients with insulin receptor disorders, and hyperinsulinemia (Babieri 1983; Pugeat 2000; Cruz 1992; Stuart 1986). Large amounts of unbound insulin are free to bind IGF-1 receptors on keratinocytes or fibroblasts, leading to proliferation of the epidermis (Barbieri 1983). Reduced fasting insulin and C-peptide levels suggest that daily insulin levels status post gastric bypass surgery are likely secondary to reduced free fatty acids, leptin, or gut incretins. Moreover, the dramatic decrease of circulating leptin occurring after gastric bypass may contribute to reduced acanthosis nigricans and hyperandrogenism. Androgens target the skin and lead to hair growth and sebum secretion. Increased secretion of testosterone, the main active androgen, can lead to

dermatologic manifestations including hirsutism, acne, alopecia, and acanthosis nigricans. A decrease in androgens by the aforementioned mechanism, in addition to decreased active androgen synthesis in human adipose tissue, leads to improvement of acanthosis nigricans. In summary, the combined effects of decreased insulin resistance in addition to reduced levels of systemic androgens results in the improvement of acanthosis nigricans.

Hidradenitis Suppurativa

Hidradenitis suppurativa (HS) and acne inversa are chronic relapsing, scarring skin conditions involving the follicular and pilosebaceous units, which have a damaging impact on patients' quality of life. Diagnostic criteria for HS is clinical and must meet the following three criteria: typical lesions (deep-seated painful nodules, abscesses, draining sinuses, bridged scars, and open comedones within secondary lesions); typical topography in one or more of the predilected areas (intertrigionus skin of the axillary, inguinal, genital, perineal, or infra-mammary regions); and chronicity and recurrence (Revuz 2016; Margesson 2014). The myriad of complications that may result include anal and perianal fistulae, arthropathy, lymphedema, and, even, squamous cell carcinoma of the buttocks and perineum.

Lack of early detection, accurate diagnosis, and proper therapy resulting in relapsing and severe HS is a common occurrence. The influence of endogenous reproductive hormones, exogenous hormones and androgens lead to keratin plugging and distention of the follicular unit. Shearing forces, friction, and pressure ultimately lead to rupture and leakage of the ductal contents, resulting in an inflammatory reaction that is mediated by the innate immune system (Margesson 2014). Given this pathophysiology, the chronic state of inflammation observed in obesity makes it an obvious risk factor for this condition. Additionally, in obesity, the hyperandrogenism, elevated insulin, and elevated IGF-1 activate androgen receptors that control growth. As a result, there is uncontrolled cellular proliferation and subsequent follicular duct plugging. The role of obesity in the pathophysiology of HS was further supported by Thomas et al. in a case report of a man who experienced rapid improvement of long-standing, treatment-resistant HS after bariatric surgical intervention (gastric sleeve) and subsequent drastic weight loss. The improvement was noted within weeks of the surgical intervention, and the patient remained in remission for over a year following the procedure (Thomas 2014). This highlights the rationale that weight loss plays an important role in the intervention of HS and, ultimately, the prevention of the more severe complications that may follow. Standard therapy includes lifestyle modifications such as dietary compliance and weight loss, avoidance of trauma that leads to follicular rupture and active multimodal anti-inflammatory therapy. Given the importance of weight loss in the aims to resolve HS, bariatric intervention (both restrictive and malabsorptive) may be viewed as a means to achieve the drastic reduction in weight needed in patients who struggle to accomplish this without surgical intervention.

RISKS TO THE SKIN

While the aforementioned are examples of the positive effects of gastric bypass surgery on the skin, achieving radical weight reduction via an invasive bariatric procedure is not

without inherent risks and complications. Bariatric surgery includes restrictive procedures such as laparoscopic banding, sleeves, and malabsorptive procedures including Roux-en-Y-gastric bypass (RYGB) and biliopancreatic diversion. The most common method is RYGB where an isolated portion of the stomach is directly connected to the small intestine, resulting in decreased gastric capacity, decreased acid secretion and diminished nutrient absorption. Bariatric surgery can be accompanied by micronutrient insufficiencies and metabolic imbalances that affect the skin. Such deficiencies can lead to changes in the skin's micro-architecture, which can, in turn, affect processes including wound healing. Changes in the skin's immune defense mechanisms can also result from vitamin and nutrient deficiency, increasing susceptibility to pathogens (Zouridaki 2014). The nutrient insufficiencies are presumed to be a result of a combination of decreased food intake, changes in the digestive system's anatomy, and high levels of oxidative stress that interfere with the absorptive process (Halawi 2013). The specific nutrition-related complications that will be detailed in this chapter include vitamin A, vitamin B3, biotin, vitamin C, iron, copper, vitamin K, and zinc. In attempt to prevent the dermatologic complications, post-bariatric patients are routinely prescribed dietary supplements to compensate for future insufficiencies. Interestingly, while patients may be compliant with their oral nutritional supplements, low circulating levels can still persist since the absorption is decreased. Recognizing various skin changes secondary to nutrient deficiency in post bariatric surgery patients is a valuable asset in providing comprehensive care.

Vitamin A

Vitamin A or retinol is a liposoluble vitamin found in foods derived from sources including cow's milk, liver, eggs, fish oils, mangos, tomatoes, and beta-carotene containing vegetables. Vitamin A is vital for optimum immune system function (Zalesin 2011; Jen 2010). Deficiency in retinol may be due to inadequate intake in patients with restricted diets or various metabolic alterations observed after gastric bypass procedures. These alterations include fat malabsorption, diminished protein absorption, and higher levels of oxidative stress. Interestingly, in developing countries, vitamin A-deficient children who were treated with augmented dietary protein intake demonstrated an increase in serum retinol levels (Zalesin 2011). This supports the intimate interaction between serum retinol and the carrier proteins that determine the bioavailability of serum retinol concentration. As such, total body stores of vitamin A may not truly be deficient but, rather, low levels of nutritional protein binding transport capacity may underlie these serum retinol findings.

Cutaneous findings classically observed include follicular and keratotic papules that usually affect the anterolateral surface of thighs and arms. This condition is known as phrynoderma and may also be associated with other vitamin deficiencies. The lesions may overtake the extensor surface of upper and lower limbs, shoulder, abdomen, dorsal area, buttocks and neck. Other dermatologic signs of vitamin A deficiency include: xeroderma, brittle or corkscrew hair, and thinning of the skin (Jen 2010). A correlation between low plasma vitamin A and E and the subsequent development of acne has also been speculated (El-Akawi 2006).

Diagnosis is made based on serum retinol levels, clinical evaluation, and positive response to treatment. Normal serum retinol levels range from 28 to 86 μg/dL (1 to 3

µmol/L). Levels, however, decrease only after the deficiency is advanced because the liver contains large stores of vitamin A. Therefore, when a deficiency is clinically suspected, a therapeutic trial of vitamin A may help establish the definitive diagnosis. Supplementation alone or in combination with other fat-soluble vitamins (D, E, and K) may be indicated in this setting. Current treatment recommendations are as follows: vitamin A palmitate in oil 60,000 international units (IU) orally once per day for two days, followed by 4500 IU orally once per day.

In summary, vitamin A deficiency remains an underreported postoperative complication of bariatric surgery. It is of paramount importance in the ongoing medical management of these patients that clinicians are aware of the cutaneous signs of retinol insufficiency. Furthermore, vitamin A deficiency should be suspected in those with protein-calorie malnutrition.

Vitamin B3

Vitamin B3 is converted to nicotinamide, a cofactor essential for cellular metabolism. In the intestine, the gut flora converts nicotinamide into nicotinic acid that is subsequently transported to the liver, kidneys and intestines. Sources of B3 include meat, poultry, nuts, eggs, fish, coffee and beans. Vitamin B3 is also synthesized in humans from the essential amino acid tryptophan. Pellagra, the classic triad of dementia, dermatitis and diarrhea, is the typical manifestation of vitamin B3 insufficiency. The dermatologic signs resemble a sunburn on the affected areas. A symmetrical eruption of scaling and skin thickening, with a clear margin between the unaffected and affected skin, is classically observed. The dorsal aspect of the hands is the most affected site and may present in a glove-like distribution. Additionally, the skin lesions may also be noted around the neck; this is denoted as Casal's necklace (Jen 2010) (Figure 1). Other skin manifestations linked to niacin deficiency include glossitis and angular cheilitis, sulfur flakes over the nose, and a copper hue to affected skin (Burke 2013). The patient may report that the rash burns or is intensely itchy. Histopathological changes in the acute phase include subepidermal vesicle formation as a result of spongiosis, ballooning degeneration, and vacuolar alteration of the basal layer (Hegyi 2004).

It is critical for clinicians to remain vigilant in assessing for vitamin B3 deficiency in patients that have undergone gastric bypass. The diagnosis can be made by measuring urinary N-methyl-nicotinamide concentration. Alternatively, low 5-hydroxyindoleacetic acid (5-HIAA), a metabolite of serotonin, may also be an indication of niacin insufficiency. Pellagra can be devastating to the patient but is, fortunately, easily reversed with replacement therapy. Complications such as delirium, depression, dilated cardiomyopathy, and, ultimately, death can be prevented by prompt recognition and implementation of vitamin B3 replacement. Dietary niacin, however, may not be sufficient to maintain the body's needs over an extended period of time (Leklem 1991). The recommended daily allowance is around 16mg per day for adult males and 14mg per day for females. Treatment is usually oral nicotinoamide (100-200mg three times daily) until signs and symptoms resolve after several weeks of therapy (Crook 2014).

Figure 1. Casal's necklace of pellagra. Courtesy of Ron Grimwood, MD.

Biotin

Biotin, a cofactor for carboxylase synthetase enzymes, is absorbed in the small intestine. It is essential in the metabolism of carbohydrates, fats, and select amino acids. Furthermore, it is critical for proper cellular function, growth, and development. Additional studies have also suggested that biotin may play a role in glucose metabolism at the level of gene expression (Rodriguez 2003). Likewise, biotin is crucial in immune function and cell proliferation. Humans cannot synthesize biotin and, therefore, must obtain this vitamin from exogenous sources (i.e., nutrition and intestinal bacterial synthesis). Dietary sources of biotin include egg yolks, liver, nuts, peanuts, mushrooms, cow's milk, and soy (Mock 2000; Lanska 2012). Deficiency occurs in patients with a short gut or malabsorption. The classic cutaneous finding associated with biotin deficiency is an erythematous, scaling, crusting dermatitis present around the eyes, nose, mouth, and perineal region. The tongue may also be red and sore, and the hair is commonly fine and thinned (Balint 1998). Diagnosis is made on clinical grounds based on the presenting dermatologic findings, as well as response to replacement therapy. If left untreated, acquired biotin deficiency may ultimately result in hyperaesthesia, paraesthesia, depression, and muscle pain. It is important for physicians to be astute in initiating a trial of biotin if clinical suspicion of insufficiency is high and the patient has a known risk factor such as a history of gastric bypass. A dose of 10-40mg per day orally, or intramuscularly, is the current recommendation for therapeutic replacement.

Vitamin C

In addition to serving as a cofactor in the synthesis of carnitine and catecholamines (dopamine and norepinephrine), ascorbic acid has anti-oxidant properties, stabilizes vitamin E and folic acid, and, also, acts as a cofactor for the enzyme that catalyzes the formation of hydroxylysine and hydroxyproline. Flaws in the synthesis of hydroxylysine and hydroxyproline secondary to vitamin C insufficiency interfere with collagen synthesis, thus, impairing wound healing. Additionally, ascorbic acid is part of the metabolism of prostaglandins and prostacyclins which, when inadequately produced, can generate decreased inflammatory response and increased immunological susceptibility (Jen 2010).

Dietary sources include citrus fruits, strawberries, tomatoes, vegetables and potatoes. Absorption occurs in the upper third of the intestine. Scurvy is the most classic consequence of vitamin C deficiency. This insufficiency, therefore, is often diagnosed by dermatologists. The clinical manifestations tend to occur one to three months after the start of a vitamin-deficient diet. The first signs are fatigue, malaise, and lethargy. The "four Hs" are characteristic of scurvy: hemorrhagic signs, hyperkeratosis of hair follicles (on the lateral and posterior areas of the arms buttocks, and thighs), hypochondriasis, and hematologic abnormalities. Perifollicular petechiae are also a characteristic finding (Fossitt 2009). The main changes in the oral cavity are the presence of edematous, erythematous, and friable gingiva with tendency to bleeding (Li 2008). Hansen et al. report a case of a woman following gastric bypass who presented with painful swelling, bruising, and small ulcers on her lower extremities (Hansen 2012). Within 24 hours, she developed confluent purpuric plaques on the lower extremities and a sepsis-like condition. The diagnosis of vitamin C deficiency was based on the clinical picture in conjunction with a positive response to supplementation. The daily recommended supplementation is ascorbic acid, 800-1000mg per day given orally for a few days to one week and maintenance of 100mg per day. In cases where the diagnosis is uncertain, serum ascorbic acid levels may be confirmatory.

In summary, following bariatric surgery, patients are at risk of developing vitamin C deficiency, especially if the operation is combined with a poor diet. When spontaneous ecchymosis or petechiae are observed in at-risk patients, scurvy must be included in the differential. While untreated scurvy may be fatal, the symptoms of scurvy rapidly improve when the patient is treated with adequate doses of vitamin C.

Iron

Iron is a mineral found in all cells of the human body. Dietary sources include dried beans, fruits, egg yolks, liver, beef, oysters, salmon, whole grains, broccoli, spinach, and kale. The majority of iron absorption is carried out in the duodenal epithelium. Acidity and the presence of solubilizing agents like sugars facilitate the intestinal absorption. Reduced gastric acid secretion after a gastric bypass, therefore, can impair the absorption of iron in the duodenum. Additionally, after Laparoscopic Roux-en-Y Gastric Bypass (LRYGB) the duodenum is excluded from digestive continuity, further impairing iron absorption (Ruz 2009).

Iron is essential for a multitude of functions including oxygen transport, DNA synthesis, energy metabolism, and metabolism of collagen (Richardson 1996; Polefka 2012). Iron plays

a critical role in the structure and function of skin. It aids in wound healing and protection against cellular damage secondary to reactive oxygen species. Exposure of skin fibroblasts to UVA can generate reactive oxygen species that promote oxidative damage in lysosomal, mitochondrial, nuclear, and plasma membranes. Ultimately, necrotic cell death will result due to the loss of plasma membrane integrity (Aroun 2012). As a transition metal which exists in two stable states, Fe^{2+} (electron donor) and Fe3+ (electron acceptor), iron plays a key role in preventing oxidative stress processes (Pelle 2011). Dermatologic manifestations of these effects are pallor, glossitis, koilonychia, angular cheilitis, and brittle hair and nails. Additionally, the tongue may become swollen and smooth and develop a burning sensation. Iron deficiency may also predispose one to bacterial and fungal infections, such as impetigo, boils and candidiasis (Jen 2010).

Obinwanne et al. performed a 10-year analysis of iron deficiency after laparoscopic Roux-en-Y Gastric Bypass (LRYGB) and reported an incidence of 53.1% (492 of 959 patients) (Obinwanne 2013). Furthermore, iron deficiency was more common in women, particularly those who were premenopausal or who had a history of abnormal uterine bleeding. According to the American College of Surgeons, female patients should be counseled that there is a 50% chance they will become iron deficient after LRYGB. Serum ferritin levels are assayed at three and six months postoperatively and then annually after the second postoperative year for those with initially low ferritin levels. Oral replacement is indicated if the patient has a postoperative ferritin less than 50 ng/mL and is administered in the following forms: ferrous gluconate, ferrous sulfate, ferrous fumarate, and ferrous bisglycinate. Oral iron therapy is limited after surgery due to decreased intestinal absorption (Mizon 2007). Another limitation of oral iron is that it is associated with significant gastrointestinal side effects that may ultimately lead to poor compliance. Common side effects include nausea, abdominal pain, diarrhea, and constipation. After a 3-month period of oral iron therapy, the ferritin level is assayed again. If it remains less than 50 ng/mL, the patient should be referred to the hematology clinic.

Indications for initiating intravenous (IV) iron therapy are poor tolerance of oral iron and poor response to oral iron treatment. IV iron treatment was required in 64 (6.7%) of the patients in the Obinwanne et al. study. The most commonly used form of IV iron was iron dextran (81.3%). This is largely because, unlike other forms, it is typically given as a single dose and does not require frequent visits to the hematology clinic. It is, therefore, the most cost-effective form of IV iron therapy. However, due to its association with rare, but serious, anaphylaxis, a test dose with premedication is recommended before infusion begins (Quinibi 2010; Defilipp 2013).

Iron deficiency is a problem that continues to cause complications in patients who have had gastric bypass. The aforementioned longitudinal study highlights the importance of strict postoperative follow-up of patients, with particular attention to those who may be at a higher risk for developing iron deficiency. Early detection of iron deficiency is key to the successful management of patients after gastric bypass.

Copper

Copper, a metal found in plasma, erythrocytes, cerebrospinal fluid, saliva, and gastric secretions, is obtained from the ingestion of meat, seafood, vegetables, grains, and nuts.

Copper is an essential cofactor in many enzymatic reactions vital to the normal function of hematologic and vascular systems. Additionally, copper has a crucial role in direct and indirect antibacterial mechanisms as well as early wound healing (Griffith 2009; Mirastschijski 2013). Many patients with an acquired copper deficiency have a history of gastric surgery, even in the distant past (Prodan 2009). The proposed mechanism of copper deficiency is likely due to the decreased absorption in the stomach and proximal duodenum. Consequences of copper deficiency may manifest clinically dermatologically as poor wound healing, depigmented and thinning hair, and alopecia (Palint 1998). Copper deficiency does not manifest as dramatically on the skin as other micronutrient deficiencies, but a high level of suspicion should remain because it may accompany other deficiencies. Approximately 70% of women may experience some level of copper deficiency after gastric bypass. Early detection and treatment can prevent the hematologic and neurologic symptoms such as pancytopenia and myeloneuropathy, respectively.

Diagnosis is based on low levels of cerulopasmin and copper. These laboratory values, however, are not always accurate. Therefore, a positive response to supplementation may be the key in diagnosing the insufficiency. Treatment is usually in the form of copper sulfate 1.5-3mg per day given orally, but severe deficiencies may need to be replaced intravenously (Griffith, 2009).

Vitamin K

Dietary deficiency of vitamin K, a fat-soluble vitamin, is rare in adults because 50% of daily needs are synthesized by bacteria. Low vitamin K, however, may be seen in patients after undergoing malabsorptive procedures. Vitamin K is essential for the synthesis of several coagulation factors such as II, VII, IX, X, protein C, and protein S. Dietary vitamin K (phylloquinone) is found in green leafy vegetables, liver, brussel sprouts, lentils, plant oils, and soybeans. It is absorbed through active transport in the upper small intestine. The classic cutaneous findings secondary to vitamin K deficiency are related to the extravasation of blood into the skin manifested as purpura, petechiae, ecchymoses, and bruising (Jen 2010; Palint 1998). Clinically, it is important for physicians to be vigilant in investigating evidence of bleeding and bruising on the skin so as to prevent more severe and devastating hemorrhages.

Diagnosis is suspected based on routine coagulation study findings (prolonged prothrombin time or elevated international normalized ratio) and confirmed by a positive response to vitamin K administration. Some institutions may detect vitamin K deficiency more directly by measuring serum vitamin K levels (normal: 0.2-1.0 ng/ml). Vitamin K deficiency is typically treated orally, but, in the instance of fat malabsorption seen after bariatric interventions, intramuscular phytonadione 5-10 mg per day may be required.

Zinc

Bariatric surgery is a risk factor for developing a zinc deficiency. Zinc absorption occurs in the duodenum and proximal jejunum. It is these portions of the intestine that are bypassed in the RYGB procedure. Zinc is a primordial element essential to the structural and regulatory functions of over 200 enzymes. It can be found in most meat, legumes, whole grains, and

dairy products. Its key role is in metabolic pathways, mediating immune function, cell replication, and DNA synthesis. Overall, zinc allows for the proper function of T-cells, neutrophils, natural killer cells, and proper wound healing (Kumar 2012; Vick 2015).

Due to this mineral's extensive roles in a multitude of biological processes, many systemic and dermatologic complications may manifest in the setting of moderate to severe deficiency. The classic clinical triad is comprised of diarrhea, alopecia, and acral and periorifacial rashes. This rash tends to be symmetrical, erosive, and eczematous. Other cutaneous features include vitiligo-like lesions, delayed wound healing, paronychia, stomatitis, psoriasiform dermatitis, angular cheilitis, and blepharitis (Kumar 2012).

Diagnosis is generally made by serum zinc levels below 50-70 μg/dL paired with recognition of the classic cutaneous findings (Krebs 2013). In cases of protein malnutrition experienced after surgery, there are changes in the intestinal structure and function with decrease in villi surface area culminating in a reduced capacity of zinc absorption. Moreover, it is likely that the decline in gastric secretion and the oxidative stress resulting from surgery also contribute to this diminished absorption of zinc. Ruz et al. studied the effects of zinc absorption in 56 morbidly obese women status post RYGB surgery. They measured mean plasma zinc, erythrocyte membrane alkaline phosphatase activity, and absorptive capacity of zinc. The percentage of absorption decreased significantly from 32.3% to 21% 18 months post-operation (Ruz 2011).

Figure 2. Perineal dermatitis of zinc deficiency. *Reprinted with permission* (Vick G, Mahmoudizad R, Fiala K. Intravenous therapy for acquired zinc deficiency secondary to gastric bypass surgery: a case report. Dermatologic Therapy; 2015. Wiley publisher).

If left untreated, zinc deficiency has the potential to be lethal. Typical treatment of acquired zinc deficiency consists of elemental zinc 1-3mg/kg orally once daily until symptoms and signs resolve. Serum or plasma levels of zinc should be monitored during administration of oral replacement. Cutaneous findings will clinically improve prior to a

significant change in serum levels. Additionally, copper levels should be monitored as high levels of zinc may lead to a reciprocal decrease in serum copper. Interestingly, Vick et al. reported a case of a woman who presented with a painful, pruritic vulvar rash despite 35mg of oral zinc replacement (Figure 2). The patient eventually had complete resolution of symptoms after two infusions of 2mg/kg per day of IV zinc. This highlights the fact that patients receiving malabsorptive procedures may not respond to traditional oral supplementation. Clinicians must be mindful of the fact that patients who have undergone structurally altering, malabsorptive surgeries may not respond to oral dietary supplementation, but rather require IV supplementation to resolve the consequences of the dietary insufficiency.

CONCLUSION

In summary, bariatric surgery has significant value in aiding patients who are unable to lose weight without surgical intervention to achieve drastic weight loss. Additionally, the literature provides ample evidence that this weight loss, combined with alteration of hormones and inflammatory mediators, results in reduced comorbidities of obesity including chronic, refractory dermatologic conditions such as psoriasis, necrobiosis lipoidica, acanthosis nigricans, and hidradenitis suppurativa. Along with the various benefits, risks and the potential for serious complications are inherent as well. Patients who have a recent or remote history of gastric bypass surgery are prone to a myriad of dermatological manifestations related to skin inflammation or impaired ability to promote proper wound healing. Even after vitamin and nutrient replacement therapy, however, clinical improvement may not be completely sustained. This highlights the dynamic nature of nutrient insufficiencies and the clinical manifestations that follow. Given the current obesity epidemic and steadily rising number of bariatric procedures performed each year, knowledge of these dermatologic complications secondary to micronutrient deficiency is essential to the clinician's ability to provide comprehensive care, and, subsequently, improve the patient's quality of life.

REFERENCES

Aroun, A., Zhong, J. L., Tyrrel, R. M. et al. Iron, Oxidative stress and the example of solar ultraviolet a radiation. *Photochemical and Photobiological Sciences*, 2012 11, 118-134.

Atwa, M., Emara, A., Balata, M., et al. Serum leptin adiponectin and resistin among adult patients with acanthosis nigricans: correlations with insulin resistance and risk factors for cardiovascular disease. *International Journal of Dermatology*, 2014 53, 410-420.

Balint, J. Physical findings in nutritional deficiencies. *Pediatric clinics of North America*, 1998 45, 245-260.

Barbieri, R., Ryan, K. Hyperandrogenism, insulin resistance, and acanthosis nigricans syndrome: a common endocrinopahy with distinct pathophysiologic features. *American Journal of Obstetrics and Gynecology*, 1983 147, 90-101.

Bozkurt, S., Coskun, H., Kadioglu, H. et al. Remission of Ulcerated Necrobiosis Lipoidica Diabeticorum after Bariatric Surgery. *Case Reports in Dermatologic Medicine*, 2013, 352579-352579.

Burke, K., Adams, E. Nutritional Deficiency. *Directions in residency*, 2013, 1-2.

Crook M. The importance of recognizing pellagra (niacin deficiency) as it still occurs. *Nutrition, 2014* 30, 729-730.

Cruz, P., Hud, J. Excess insulin binding to insulin-like growth factor receptors: proposed mechanism for acanthosis nigricans. *Journal of Investigative Dermatology*, 1992 98, 82-85.

Defilipp, Z., Lister, J., Gagne, D. et al. Intravenous iron replacement for persistent iron deficiency anemia after Roux-en-Ygastric bypass. *Surgery for Obesity and Related Diseases*, 2013 9, 129-132.

El-Akawi, Z., Abdel-Latif, N., Abdul-Razzak, K. Does the plasma level of vitamins A and E affect acne condition. *Clinical and Experimental Dermatology*, 2006 31, 430-434.

Farias, M. M., Achurra, P., Boza, C. et al. Psoriasis following bariatric surgery: clinical evolution and impact on quality of life on 10 patients. *Obesity Surgery*, 2012 *22*, 877-80.

Faurschou, A., Zachariae, C. Gastric Bypass Surgery: Improving psoriasis through a GLP-1 dependent mechanism. *Medical hypotheses*, 2011 77, 098-1101.

Fossitt, D., Kowalski T. Classic skin findings of scurvy. *Mayo Clinic Proceedings*, 2014 89, 61.

Griffith, D. P., Liff, D. A., Ziegler, T. R. et al. Acquired copper deficiency: a potentially serious and preventable complication following gastric bypass surgery. *Obesity* (Silver Spring), 2009 17, 827-831.

Halawi, A., Abiad, F., Abbas, O. Bariatric surgery and its effects on the skin and skin diseases. *Obesity Surgery*, 2013 23, 408-413.

Hansen, E. P., Metzxche, C., Henningsen, E. et al. Severe scurvy after gastric bypass surgery and a poor postoperative diet. *Journal of Clinical Medical Research*, 2012 4, 135-137.

Hector, R. T., Aminian, A., Corcelles, R. Psoriasis Improvement After Bariatric Surgery. *Surgery for obesity and related diseases*, 2014 10, 1155-1160.

Hegyi, J., Schwartz, R., Hegyi, V. Pellagra: dermatitis, dementia, and diarrhea. *International Journal of Dermatology*, 2004 43, 1-5.

Holst, J. J. The Physiology of Glucagon-like Peptide 1. *Physiological Reviews*, 2007 87, 1409-1439.

Hossler, E. W., Wood, G. C., Still, C. D. et al. The effect of weight loss surgery on the severity of psoriasis. *British Journal of Dermatology*, 2013 168, 660-661.

Jen, M., Yan, A. Syndromes associated with nutritional deficiency and excess. *Clinics in dermatology*, 2010 28, 669-685.

Krebs, N. F. Update on zinc deficiency and excess in clinical pediatric practice. *Annals of Nutrition and Metabolism*, 2013 62, 19-29.

Kumar, P., Lal, N. R., Mondal, A. K. et al. Zinc and skin: a brief summary. *Dermatology Online Journal [eScholarship]*, 2012 8.

Lanska, D. The discovery of niacin, biotin, and pantothenic acid. *Annals of Nutrition and Metabalism*, 2012 61, 246-253.

Leklem, J., Machlin, L. *Handbook of Vitamins*. 2nd ed. New York: Marcel Dekker., 1991.

Li, R., Byers, K., Walvekar, R. R. Gingival hypertrophy: a solitary manifestation of scurvy. *American Journal of Otolaryngology*, 2008 29, 426.

Margesson, L., Danby, F. Hidradenitis suppurativa. *Best Practice and Research Clinical obstetrics and Gynocology*, 2014 28, 1013-1027.

Mirastschijski, U., Martin, A., Jorgensen, L. N. et al. Zinc, copper, and selenium tissue levels and their relation to subcutaneous abscess, minor surgery, and wound healing in humans. *Biological Trace Element Research*, 2013 153, 76-83.

Mizon, C., Ruz, M., Csendes, A. et al. Persistent anemia after Roux-en-Y gastric bypass. *Nutrition*, 2007 23, 277-280.

Mock, D., Shils, M. *Modern Nutrition in Health and Disease*. 9th ed. Philadelphia: Lippincott Williams and Wilkins., 2000 459-459.

Obinwanne, K. M., Fredrickson, K. A., Mathiason, M. A. et al. Incidence, Treatment, and Outcomes of Iron Deficiency after Laproscopic Roux-en-Y Gastric Bypass: A 10-Year Analysis. *Journal of American College of Surgeons*, 2013 218, 246-252.

Palint, J. P. Physical Finding in Nutritional Deficiency. *Pediatric Clinics of North America*, 1998, 245-260.

Pasparakis, M. Regulation of tissue homeostasis by NF-kB signaling: implications for inflammatory diseases. *Nature Reviews Immunology*, 2009 9, 778-788.

Patsatsi, A., Kyriakou, A., Sotiriadis, D. Necrobiosis lipoidica: early diagnosis and treatment with tacrolimus. *Case Reports in Dermatology*, 2011 *3*, 89-93.

Pelle, E., Jian, J., Eclercq, L. et al. Protection against ultraviolet A-induced oxidative damage in normal human epidermal keratinocytes under post-menapausal conditions by an ultraviolet A-activated caged-iron chelator: a pilot study. *Photodermatology, Photoimmunology and Photomedicine*, 2011 27, 231-235.

Polefka, T. G., Bianchini, R. J., Shapiro, S. Interaction of mineral salts with the skin: a literature survey. *International Journal of Cosmetic Science*, 2012 34, 416-423.

Prodan, C. I., Bottomley, S. S., Vincent, A. S. Copper deficiency after gastric surgery: a reason for caution. *American Journal of the Medical Sciences*, 2009 337, 256-258.

Pugeat, M., Ducluzeau, P. H., Mallion-Donadieu, M. Association of insulin resistance with hyperandrogenia in women. *Hormone Research in Paediatrics*, 2000 54, 322-6.

Qunibi, W. Y. The efficacy and safety of current intravenous iron preparations for the management of iron-deficiency anemia: a review. *Arzneimittel-forschung*, 2010 60, 399-412.

Revuz, J. E., Gregor, B. E. Diagnosing hidradenitis suppurativa. *Dermatologic Clinics, 2016 34, 1-5.*

Richardson, D. R., Dickson, L., Baker, E. Intermediate steps in cellular iron uptake from transferrin II. A cytoplasmic pool of iron is released from cultured cells via temperature-dependent mechanical wounding. *In Vitro Cellular and Developmental Biology - Animal*, 1996 32, 486-495.

Rodriguez-Melendez, R., Zempleni, J. Regulation of gene expression by biotin. *Journal of Nutritional Biochemisty*, 2003 14, 680-90.

Ruz, M., Carrasco, F., Rojas, P. et al. Iron absorption and iron status are reduced after Roux-en-Y gastric bypass. *American Journal of Clinical Nutrition*, 2009 90, 527-532.

Ruz, M., Carrasco, F., Rojas, P. et at. Zinc absorption and zinc status are reduced after Roux-en-Y gastric bypass: a randomized study using 2 supplements. *American Journal of Clinical Nutrition*, 2011 94, 1004-1011.

Sehgal, V., Bhattacharya., S., Verma, P. Juvenile, insulin-dependent diabetes mellitus, type 1-related dermatoses. *Journal of the European Academy of Dermatology and Venereology*, 2011 *25*, 625-636.

Stuart, C., Peters, E., Prince, M. et al. Insulin resistance with acanthosis nigricans: the roles of obesity and androgen excess. *Metabolism*, 1986 35, 197-205.

Thomas, C., Gordon, K., Mortimer, P. Rapid resolution of hidradenitis suppurativa after bariatric surgical intervention. *Clinical Experimental Dermatology*, 2014 39, 315-317.

Vick, G., Mahmoudizad, R., Fiala, K. Intravenous Zinc Therapy for Acquired Zinc Deficiency Secondary to Gastric Bypass Surgery: A Case Report. *Dermatologic Therapy*, *2015* 28, 222-225.

Weismann, K., Burns, D. Skin disorders in diabetes mellitus. *Rook's Textbook of Dermatology*, 2004, 106-157.

Zalesin, K., Miller, W., Franklin, B. et al. Vitamin A Deficiency after Gastric Bypass Surgery: An Underreported Postoperative Complication. *Journal of Obesity*, 2011 2011, 760-764.

Zouridaki, E., Papafragkaki D. K., Papafragkaki H. et al. Dermatological Complications after Bariatric Surgery: Report of Two Cases and Review of the Literature. *Dermatology*, 2014 228, 5-9.

In: Encyclopedia of Surgery (22 Volume Set)
Editors: Andreas Lehrer and Kristin Mueller
ISBN: 978-1-53618-329-0
© 2020 Nova Science Publishers, Inc.

Chapter 143

TREATING THE OBESE PATIENT WITH TYPE 2 DIABETES POST-BARIATRIC SURGERY

Steven K. Malin[1,2,*], PhD, Jennifer L. Kirby[2], MD, PhD and Peter T. Hallowell[3], MD

[1]Department of Kinesiology
[2]Division of Endocrinology and Metabolism, Department of Medicine
[3]Department of Surgery, University of Virginia, Charlottesville, VA, US

ABSTRACT

Bariatric surgery is currently the most effective and durable weight loss treatment for morbidly obese individuals with type 2 diabetes (T2D). In fact, up to 85% of individuals experience remission within days to weeks post-surgery, suggesting that the improvement in glycemia is independent of weight loss. Moreover, many individuals see improvements/resolution of their hypertension and hyperlipidemia in the months following surgery. Clinical trials indicate that the resolution of T2D in particular is maintained in approximately 40% of individuals 3-15 years post-surgery and highlights that over half of the people undergoing bariatric surgery may not meet diabetes remission criteria and/or redevelop the disease. Pre-operative clinical factors (e.g., age, fasting C-peptides, medication numbers, etc.) and gluco-regulatory mechanisms (e.g., insulin resistance, β-cell dysfunction) have emerged as clinically meaningful predictors of those who are likely to experience resistance to bariatric-induced diabetes remission. The management of individuals with T2D following surgery requires a personalized approach. Attention to lifestyle (i.e., diet plus exercise) should be the mainstay of therapy while attending to the risks of protein malnutrition and micronutrient and fat-soluble vitamin deficiencies. If these interventions are ineffective, pharmacological treatment in these patients will be an important consideration and should balance the need to control hyperglycemia with the risk of weight gain. A pharmacological approach may also include weight loss agents to combat obesity related insulin resistance and β-cell dysfunction. Collectively, these efforts are recommended to optimize clinical strategies that treat hyperglycemia following bariatric surgery.

* Corresponding Author's Email: skm6n@virginia.edu; Fax: (434) 924-1389.

Keywords: obesity, insulin resistance, β-cell function, pharmacology, exercise, nutrition

INTRODUCTION

An estimated 347 million adults live with Type 2 diabetes (T2D) worldwide, about half of whom are undiagnosed [1]. Although the etiology of T2D is likely multi-factorial, nearly 80% of all people with T2D are obese, positioning obesity as a key modifiable factor in the development of hyperglycemia. The exact mechanism by which obesity, or excess body fat, induces T2D is an area of intense research. However, inadequate compensation of the β-cells in response to an increasingly insulin resistant skeletal muscle and liver characterize T2D and this is likely the principle cause. Indeed, patients with prediabetes have approximately 20% normal β-cell function remaining and have comparable degrees of insulin resistance to people with T2D [2]. In addition, adipose tissue is considered a chief culprit in the development of multi-organ insulin resistance and β-cell dysfunction through increased circulatory factors (free fatty acids, leptin, etc.) that promote hyperglycemia [3]. Newer understandings of T2D pathophysiology acknowledge that the gastrointestinal tract (e.g., small intestine), kidney, and central nervous system in addition to the aforementioned organs collectively play an important role in the progression to T2D. Thus, identification of end-organ targets that induce hyperglycemia is critical to the advancement of successful treatments strategies, as it seems focus on one tissue alone will not suffice in combating the rise in the diabetes epidemic.

Although controversial, the majority of health organizations consider obesity as a disease [4]. In either case, it is reasonable that current focus be placed on intensifying efforts to improve both weight management and glycemic control to combat the increased incidence of cardiovascular disease (CVD) in people with T2D. Here, we discuss studies relevant to addressing anti-obesity therapeutic options for the T2D individual as well as dual actions to improve glycemic control. To date the most effective treatment for obese people with T2D that induces substantial and durable weight loss as well as improved glycemic control is bariatric surgery. We refer readers to prior work for discussion on the Rouen-Y gastric bypass (RYGB) and sleeve gastrectomy (SG) procedures [5, 6] as here we summarize studies relevant to bariatric surgery as a gastrointestinal procedure that promotes favorable changes in β-cell function and insulin sensitivity for glycemic control. In addition, we present evidence suggesting that lifestyle modification directly and successfully induces meaningful weight loss and increase overall cardiorespiratory fitness, thereby highlighting exercise as a first-line therapy for the post-surgical patient. The present chapter also highlights recent advances in our understanding of pharmacological interventions that may in conjunction with lifestyle medicine drive weight loss and improve insulin sensitivity and β-cell function to maintain/improve diabetes care and obesity management. Lastly, we discuss potential role of these aforementioned treatments in an algorithm for the post-bariatric surgery patient to be considered in the optimization of health care and wellbeing.

TREATING T2D WITH BARIATRIC SURGERY

Several randomized trials confirm that bariatric surgery is an effective treatment that promotes T2D remission [7, 8] and contributes to durable weight loss in part by alternating gut hormones that regulate insulin metabolism (e.g., GLP-1 and ghrelin) [9, 10]. Subsequently, bariatric surgery has highlighted the gastrointestinal system as a key pathophysiologic mediator in the development of T2D. This is of particular clinical relevance given that bariatric surgery (in particular RYGB) improves survival when compared with matched controls [11]. While the literature is inconsistent with the definition of T2D remission, Ribaric and colleagues recently utilized the individual remission criteria of each study to report an overall remission rate of patients with T2D was 63.5% who underwent bariatric surgery compared to a rate of 15.6% with conventional therapy at a mean follow-up time of 17.3 months [12]. The results of this work indicate that people undergoing bariatric surgery are 9.8-15.8 times more likely to reach diabetes remission compared with conventional therapy. As a result of the collective impact of these studies and the literature, both the American Diabetes Association (ADA) and the International Diabetes Federation have identified bariatric surgery as an effective treatment for T2D [13, 14]. Indeed, data support the use of bariatric surgery as not only a weight loss treatment option, but also a "metabolic surgery" that restores glucose homeostasis in people with T2D. However, it is worth recognizing that not all people remain in T2D remission following bariatric surgery and insulin resistance as well as be β-cell dysfunction appear to be key factors explaining the increased glucose levels [15-17]. It is not entirely clear why some people relapse to T2D post-surgery, but some work suggests a direct relationship between T2D relapse and years after surgery [7]. Most recently, a follow-up report to the Swedish Obese Subjects (SOS) study showed T2D remission rates decreased from 72.3% at 2 years to 30.4% at 15 years after surgery [18]. Moreover, long pre-operative T2D duration, insulin use, poor glycemic control despite oral hypoglycemic agents, inflammation, and microvascular complications are all additional indicators of inadequate β-cell function [16, 19]. Moreover, given the importance of sustained weight loss and prevention of weight regain in maintaining durable T2D remission, clinicians must be aware of the various factors that influence weight changes after surgery. Inadequate weight loss and weight regain is associated with non-adherence to lifestyle and dietary recommendations, pre-surgical weight variations, and surgical failure [20, 21]. Additional evidence suggests that surgery type may be associated with T2D re-emergence. Gastric restrictive procedures (e.g., SG) appear to be associated with higher weight regain and lower diabetes resolution rates than RYGB surgery, which may provide a basis for the differential T2D remission and re-emergence rates observed between bypass and restrictive surgeries [18, 22, 23]. Optimal weight loss therefore likely requires greater evaluation of each candidate with regard to their psychological history, as untreated depression, alcohol use, history of sexual abuse and eating disorders have been related to suboptimal weight loss [24, 25]. Indeed, a careful consideration of the benefits and risks of bariatric surgery should occur between clinician and patient prior to surgery such that lifestyle (e.g., exercise, nutrition, support groups, etc.) and/or pharmacology interventions may also be helpful in sustaining glycemic improvements. Thus, while bariatric surgery is a highly effective tool for promoting the reversal of T2D, it does not appear to be a treatment that "cures" T2D in all people. Additional work is required to determine appropriate treatment

plans with lifestyle modification or pharmacological therapy for preventing the relapse in T2D and weight regain [26].

POST-SURGERY CARE OF T2D: LIFESTYLE MODIFICATION

A central goal of obesity and diabetes care is to aid individuals in making better lifestyle decisions that lead to healthier body weights. Sedentary behavior and increased caloric intake are two key factors known to trigger insulin resistance and force the β-cell to secrete more insulin thereby over time leading to pancreatic exhaustion and hyperglycemia. In contrast, lifestyle intervention consisting of increased physical activity and low-fat diet inducing approximately 5 kg for 2 years or beyond lowers diabetes risk by 30-60% [27]. Interestingly, weight loss of 2-5% over 1 to 4 years decreases Hb_{A1c} by 0.2 to 0.3%. Moreover, losses of 5-10% at 1 year are associated with reductions in Hb_{A1c} of 0.6-1.0%. The Finnish Diabetes Prevention Study provided advice for subjects to lose >5% weight loss by decreasing total fat under 30% (with <10% coming from saturated fat), increased fiber consumption (i.e., 15g per 1000 kcal) and increased physical activity (30 min/d). This lifestyle prescription lowered the cumulative incidence of diabetes by 58% in people with prediabetes compared with controls [28]. In another landmark trial, the U.S. Diabetes Prevention Program (DPP) Study recommended adults with prediabetes to perform 150 min/wk and lose 7% weight loss. The DPP demonstrated that new diabetes cases were lowered by 58% with lifestyle treatment [29], although subjects who lost the most weight and met physical activity/diet targets had >90% risk reductions of T2D. These reports are consistent with recent work showing that the combination of a well-balanced diet (e.g., low fat and high fiber diet) promoting nearly 5-8% weight loss with increased physical activity is a well-established strategy for managing T2D as higher doses of physical activity generally increase insulin sensitivity [30, 31] and pancreatic function [32]. While caloric restriction is arguably the most important factor driving weight loss, it remains possible that low carbohydrate intake per se may yield greater reductions in circulating blood glucose and body fat, particularly during the first few months during the start of a lifestyle program [33, 34]. Nevertheless, increased physical activity is a primary determinant of maintaining the lost weight. As such, structured exercise interventions in particular have been shown to significantly improve Hb_{A1c} levels [35, 36]. But, whether exercise is effective at improving glycemic control in the post-surgical patient remains unclear, as some evidence suggests that not all people with hyperglycemia respond favorably to standard lifestyle interventions [37, 38] and additional work is needed to define the optimal exercise prescription that sustains lifestyle modification benefits in bariatric patients over time [39].

Although patients undergoing bariatric surgery report being highly motivated for future engagements in physical activities [40], few prospective exercise trials have been conducted following bariatric surgery to provide evidenced based medical practice. In fact, physical capacity and activity following bariatric surgery have been primarily investigated by questionnaire [41-45], pedometer [46], accelerometer [47, 48], or by a short physical performance battery test [44]. In general, the collective evidence suggests that increased physical function to perform daily activities occur with weight loss in bariatric patients [41, 44, 46, 49] as well as disease risk reduction (e.g., hypertension, T2D, etc.) [45]. However,

few studies exist objectively measuring cardiorespiratory fitness via whole-body maximal oxygen uptake (VO_2max). Interestingly, in the few studies reporting VO_2max, it was demonstrated that higher fitness levels prior to surgery were associated with decreases in short-term complication and hospitalization stay after surgery [50, 51] as well as increased physical activity post-surgery, which is linked to greater weight loss [20, 21]. Additionally, individuals with reduced physical limitations prior to surgery (defined as an inability to climb two flights of stairs) were associated with greater weight loss after surgery [52]. Thus, it seems clear that pre- and post-operative physical fitness of bariatric patients is clinically important, despite some reporting increased fitness is driven solely by weight loss [53].

Recently, a number of randomized controlled trials have been conducted to investigate the effects of exercise imposed on bariatric surgery to determine whether exercise can effectively promote greater weight loss, fitness, and cardiometabolic health when compared to a standard of care health education group. Shah and colleagues [54] demonstrated that a 12-week exercise program following bariatric surgery improved glucose tolerance. These findings are consistent with work by Coen and colleagues [55] highlighting that moderate intensity aerobic exercise increases insulin sensitivity and glucose effectiveness (i.e., the ability of glucose to facilitate glucose disposal), along with increased VO_2max and mitochondrial adaptation for fat oxidation during bariatric induced weight loss [56]. Indeed, others suggest that supervised endurance exercise or educational based programs with resistance exercise can facilitate greater weight loss, improved muscle strength and increased fitness capacity [54, 55, 57-59]. However, a limitation of the existing body of work is whether these effects of exercise on cardiometabolic health are maintained overtime, and whether exercise is an effective tool for the prevention of weight regain. These are important clinical questions that are likely to improve medical practice. Further randomized controlled trials are needed to define the optimal exercise prescriptions that provide additional health benefit as well as to elucidate mechanisms by which these improvements occur.

POST-SURGERY CARE OF T2D: PHARMACOLOGY

Despite randomized clinical trials showing the efficacy of lifestyle modification on weight loss and fitness, long-term adherence to diet and exercise remains difficult. While meeting glycemic goal with lifestyle interventions alone may be challenging for some post-bariatric patients, it is important to acknowledge there are no studies or guidelines to direct therapy in the post-bariatric surgery patient. However, if conventional approaches to improve glycemic control and weight with lifestyle do not work well, then pharmacological agents that target specific pathological defects contributing to insulin resistance, β-cell dysfunction and obesity may be necessary for T2D management in the post-surgical patient. As such, a reasonable pharmacological approach would the one proposed by the ADA/European Association for the Study of Diabetes (EASD) [60].

Insulin Sensitizers

Metformin is the most widely prescribed drug to treat hyperglycemia in people with T2D [61]. In fact, metformin is the first-line oral anti-diabetic medication recommended by the ADA [62]. Current evidence suggests that metformin increases whole-body insulin sensitivity through the suppression of hepatic gluconeogenesis and stimulation of peripheral (mainly skeletal muscle) glucose uptake through activation of adenosine monophosphate-kinase (AMPK) [61]. Although considered weight neutral in most patients, for some patients with T2D and obesity, the use of metformin is of low cost and can promote weight loss [63]. To date, the longest and best study of metformin on body weight comes from the U.S. DPP. Within the first 3 years of this double-blind randomized trial, the metformin group lost approximately 2.9 kg vs. 0.42 kg in the control group [29]. Impressively, this weight loss effect has persisted up to 15 years [64]. Thus, metformin is a logical first-line pharmacotherapy for T2D to manage blood glucose and reduce body weight, although it is worth noting that interactions of metformin with lifestyle are an area of needed research. Studies report that metformin enhances, blunts or has no effect on exercise-induced improvements in insulin sensitivity and glucose homeostasis [61]. Whether there is an optimal combination of metformin with exercise and/or diet remains to be determined.

Of note, metformin is considered contraindicated by the FDA in the setting of renal disease due to a risk of metformin accumulation leading to lactic acidosis. The recommendations indicate that metformin should not be used when serum creatinine is 1.4 mg/dl or higher in women or 1.5 mg/dl or higher in men. In a review, Lipska and colleagues have nicely clarified the many issues raised by these recommendations and have made proposed adjustments to dosing based on estimated glomerular filtration rate, which is likely a better indicator of renal function [65]. Thus, caution should be used in patients at risk for acute kidney injury or significant fluctuations in renal status (e.g., potent diuretic use), based on prior history, comorbidities or drug interactions.

Thiazolidinediones (TZDs)

TZDs act on peroxisome proliferator-activated receptor (PPAR)γ, and are effective at improving both insulin sensitivity (e.g., adipose, liver and muscle) and increasing/restoring pancreatic β-cell function [2]. Despite these gluco-regulatory benefits, many physicians have concern about prescribing TZDs because they promote weight gain of approximately 2-5 kg. However, it is worth acknowledging that this fat storage is in part the mechanism by which TZDs increase insulin sensitivity and β-cell function. In fact, TZDs are known to lower circulating free fatty acid concentrations thereby lowering ectopic lipids (e.g., intramuscular fat) and visceral fat while distributing circulating free fatty acids to subcutaneous fat [66]. In addition, TZDs also have potent anti-atherogenic effects that may lower overall risk for CVD as well as delay the progression from prediabetes to T2D [67]. Thus, given the modest weight gain with this agent, TZDs should be considered as a second-line therapy for individuals who do not achieve glycemic control with metformin plus lifestyle modification.

A concerning side effect of TZDs include the increased risk of fracture, which was found to be increased in women in both the ACCORD trial [68] and in the

PROACTIVE trial [69] Given that more recent data has suggested a negative impact of bariatric surgery on bone metabolism [70] it may be prudent to avoid TZDs, particularly those known to be a high fracture risk (i.e., with osteopenia/osteoporosis).

Sulfonylureas (SUs)

SUs increase pancreatic insulin secretion through the binding of receptors related to potassium channels on β-cells [71]. Sulfonylureas are relatively inexpensive and easy to administer making them a popular choice for many patients. Utilization of SUs along with metformin may be prudent for those patients who experience T2D to prevent further β-cell failure. However, it was shown in the UK Prospective Diabetes Study (UKPDS) that SUs had no protective effect on the pancreatic β-cell in newly diagnosed T2D patients over the 15-year study [72]. In fact, blood glucose concentrations showed a continuous rise regardless of SU treatment when compared with control, and this decline in glycemic control was paralleled by a loss in β-cell function (estimated by HOMA-β). This is clinically concerning because by approximately 3 years of treatment, nearly 50% of people required additional pharmacological treatment to maintain Hb_{A1c} less than 7.0% [72]. Given that SU usage carries a risk of inducing hypoglycemia, does not preserve pancreatic function, has conflicting and potentially harmful cardiovascular risk and promotes weight gain compared with usage of oral insulin-sensitizing agents, SUs should be used with caution [71, 73].

Incretin Mimetics

GLP-1 (glucagon-like polypeptide 1) and GIP (glucose-dependent insulinotropic peptide) are incretin hormones that account for approximately 60% of the meal-stimulated insulin secretion, and are important for delaying gastric emptying and reducing post-prandial glucose levels by stimulating pancreatic function [74]. Some, but not all studies, suggest that a GLP-1 partial deficiency occurs in impaired glucose tolerance and in T2D, but there is no resistance to its action. There are two classes of medications- DPP-IV inhibitors that restore low GLP-1 to more normal levels and GLP-1 receptor agonists that directly bind to GLP-1 receptors with agonistic activity that is supra-physiological. As a therapy, GLP-1 targeted therapies have a degree of built-in safety because the insulin secretagogue effect is reduced when eu- or hypoglycemia is present. GLP-1 receptor agonists have two actions that are missing from the DPP-IV inhibitors- substantial appetite suppression with resultant weight loss of moderate degree in most patients and an ability to delay gastric emptying. GLP-1 receptor agonists are more effective in Hb_{A1c} reduction than DPP-4 inhibitors and they are not used in combination.

GLP-1 Receptor Agonists

There are 5 GLP-1 receptor agonists approved for the treatment of T2DM, including exenatide, exenatide extended-release, liraglutide, dulaglutide and albiglutide. Each has been modified to prolong the half-life of the molecule compared to native GLP-1, which has a half-life of minutes [75]. Given the capacity of GLP-1 to promote pancreatic β-cell function and

promote significant weight loss, many studies have highlighted the GLP-1 therapy as a novel approach to promote glycemic control and weight loss [76-78]. In addition, a recent meta-analysis suggests that GLP-1 receptor agonists provide more benefit to glycemic control than other anti-diabetic drugs added to existing metformin regimens [79]. Interestingly, studies looking at GLP-1 receptor agonist use with basal insulin suggest that the combination may provide greater glycemic efficacy than either component alone. In addition, the common side effects of nausea (GLP-1 receptor agonist) and weight gain (insulin) may be ameliorated by the combination [80, 81]. Cardiovascular safety trials are ongoing with these agents. Lixisenatide, not currently approved for use in the U.S., was found to be neutral in the ELIXA trial [82], but early reports from the LEADER trial with liraglutide suggest that there may be cardiovascular benefit. It should be noted that GLP-1 receptor agonists have been associated with an increased risk of pancreatitis and pancreatic cancer [83], although this has not been bourn out in the published trials to date.

Dipeptidyl Peptidase-IV (DPP-IV) Inhibitors

DPP-IV is an enzyme that cleaves GLP-1, thereby limiting the gluco-regulatory benefits of this incretin hormones action. Inhibitors of DPP-IV act by increasing GLP-1 concentrations, and are dependent of endogenous GLP-1 secretion [84, 85]. This is physiologically relevant as DPP-IV not only attenuates β-cell function but also decreases insulin sensitivity in adults with metabolic syndrome [86]. While there is limited data on the long-term utility of DPP-IV inhibitors, several studies show that this class of pharmacological agents improve post-prandial glucose metabolism while maintaining insulin levels. Interestingly, this point is consistent with work demonstrating that lifestyle modifications lowers DPP-IV in relation to lowered CVD risk [86]. Nevertheless, DPP-IV inhibitors have no effect on weight loss, so this treatment regimen appears unique to glycemia per se and may not be appropriate for combating the obesity often associated with T2D during the post-surgery period. Currently, there are four DPP-IV inhibitors approved for use in the U.S. (alogliptin, linagliptin, saxagliptin and sitagliptin). Cardiovascular safety trials in high risk patients have been carried out with alogliptin, saxagliptin and sitagliptin in the EXAMINE, TIMI-SAVOR and TECOS trials, respectively [87-89]. All three agents were found to be safe in patients, but saxagliptin showed a signal for increased risk of hospitalization for heart failure (a secondary end point). The cardiovascular safety trial for currently in progress.

Insulin

Patients with less than adequate responses to oral or non-insulin injectable medications should be considered for treatment with basal and/or prandial insulin as necessary. Although insulin use carries risk of hypoglycemia and weight gain [90], evidence suggests that individualizing insulin titration in conjunction with oral pharmacological agents promotes better glycemic benefit compared to patients who do not respond to other oral agents. For instance, obese patients with insulin-requiring T2D after gastric bypass showed higher rates of complete remission at 1 year post-surgery with personalized insulin titration schedules and metformin compared with patients whose post-surgical medical care did not involve protocol-

driven pharmacological treatment [91]. Thus, the few studies that do exist suggest that combinations of existing T2D therapeutics can provide adequate glycemic control during the post-surgical period despite the tendency of insulin use to cause weight gain of 2-9 kg within 6-12 months of treatment [2]. It is important to keep in mind those patients with longer duration of T2D and/or insulin use prior to surgery may have relative insulin deficiency due to reduced pancreatic function. In these patients, initiation of insulin therapy should not be delayed.

Sodium-Glucose Co-Transporter 2 (SGLT2) Inhibitors

The kidney plays an important role in filtering approximately 160 g of glucose each day, and nearly 90% of all glucose is reabsorbed in the body by SGLT2 transporters located in the proximal tubule [2]. Novel data suggest that SGLT2 inhibitors, or gliflozins, are an additional anti-diabetes option that block glucose reabsorption in the renal tubules that in turn promotes loss of glucose in the urine. Canagliflozin, dapaglifozin and empagliflozin are the currently approved SGLT2 inhibitors approved for use in the U.S. for treatment of T2D. A meta-analysis of 25 randomized trials concluded that use of SGLT2 inhibitors for T2D is associated with significant improvements in glycemic control and blood pressure as well as reductions in body weight [92]. This is consistent with other work in patients with poorly controlled T2D showing that SGLT2 treatment as an add-on therapy to metformin improves many of these CVD risk factors [93]. A recent study of the use of empagliflozin in patients with T2D and high cardiovascular risk showed improved cardiovascular outcomes, driven mostly by reduced death due to cardiovascular causes [94]. Not surprisingly, a common side effect of the use of SGLT2 inhibitors includes risk of genital mycotic infections and lower urinary tract infections [95]. In addition, volume depletion and orthostatic hypotension can occur likely due to the osmotic diuresis induced with glucosuria. Finally, the FDA recently updated the labeling of canagliflozin to include a warning about an increase in fracture risk (seen as early as 12 weeks after initiation of the drug) and reduced bone density. The FDA is continuing to evaluate the fracture risk in the other medications in this class. Like TZDs, the use of SGLT2 inhibitors (especially canagliflozin) in the post-bariatric surgery patient should be approached with caution balancing the risks and benefits for each patient. Nevertheless, given the favorable effects of SGLT2 inhibitors on glycemic control, weight loss, and blood pressure, SGLT2 inhibitors constitute an attractive treatment modality to approach management of T2D, especially for obese patients suffering from hypertension.

Weight Loss Agents with Glycemic Benefit

Four new therapies have been approved for weight loss since 2012 and join orlistat for the long-term management of overweight and obesity. These therapies are generally recommended for obese (BMI $\geq$ 30 kg/m^2) individuals or overweight (BMI $\geq$ 27 kg/m^2) people who suffer from at least one weight-related complication, such as hypertension, T2D, or dyslipidemia. With the exception of orlistat, these medications act in the central nervous system to reduce appetite and increase. These agents have been recommended as important adjuncts to lifestyle modification [96] and may benefit those individuals with weight re-gain

after bariatric surgery. Many of these therapies have shown benefit in improving glycemic control.

Orlistat

Orlistat is a gastric and pancreatic lipase inhibitor that blocks dietary fat absorption from the gastrointestinal system by approximately 30%. Both randomized trials and meta-analyses have demonstrated that orlistat treatment can produce weight loss and reduce the incidence of T2D in people with impaired glucose tolerance [97]. A recent randomized controlled trial over 1 year reported greater weight loss and improvements in insulin sensitivity in patients treated with orlistat as compared with those treated with placebo [98]. Several mechanisms have been proposed to account for the anti-diabetic effect of orlistat, such as improved insulin sensitivity, incomplete dietary fat digestion, partial stimulation of GLP-1 release, and decreases in visceral adiposity [99]. However, orlistat intake is subject to fecal urgency, mild steatorrhea, and flatus with discharge, and the drug may interfere with absorption of fat-soluble vitamins [90]. As such, orlistat should be used with caution to ensure healthy nutrient intake for the patient.

Phentermine-Extended Release (ER) Topiramate

Phentermine is a sympathomimetic that reduces appetite by stimulating norepinephrine action in the hypothalamus. Topiramate is a carbonic anhydrase inhibitor and a monosaccharide that lowers food cravings, decreases lipogenesis, and increases energy expenditure. In the SEQUEL trial, which is an extension of the CONQUER trial, phentermine- combined with ER topiramate induced greater weight loss and HbA_{1c} improvements in patients with T2D with compared to patients treated with placebo alone [100]. In fact, study participants with prediabetes, metabolic syndrome, or both who underwent treatment with phentermine-topiramate had significant weight loss and lowered the progression to T2D [101]. Therefore, because phentermine-ER topiramate appears to induce beneficial effects on weight loss and glycemic control, it warrants consideration as a potential obesity related therapy for T2D.

Lorcaserin

Lorcaserin is a selective agonist of the serotonin 2C receptor. It activates central serotonin 2C receptors with a functional selectivity of approximately 15 and 100 times over that for serotonin receptors 2A and 2B, respectively. It reduces appetite and food intake thereby reducing body weight in men and women [102]. In a randomized trial called BLOOM-DM, 604 patients with T2D were randomly assigned to Lorcaserin (10 mg once daily or twice daily) or placebo, and the majority of patients were treated with metformin, a sulfonylurea, or both. After one year, more patients lost ≥5% of their body weight with Lorcaserin compared with placebo (44.7, 37.5, and 16.1%, respectively). There was also a significant reduction in HbA_{1c} (-1.0, -0.9, and -0.4% points, respectively) and fasting blood

glucose (-28.4, -27.4, and -11.9 mg/dL) in the Lorcaserin compared with placebo group [103]. Since Lorcaserin appears to affect both body weight and glycemic control, it appears to be an agent for promoting or maintaining weight loss in individuals. However, future studies are needed to clarify the efficacy of Lorcaserin in maintaining weight loss over time as well as blocking weight gain due to aging or other pharmacological agents (e.g., TZDs, insulin, etc.).

Naltrexone-Bupropion

The combination of naltrexone and bupropion (e.g., Contrave) is designed to target the mesolimbic dopamine reward system and the hypothalamic melanocortin system to reduce food intake. Naltrexone-bupropion induces significant weight loss as well as proportional reductions in fat mass and visceral adiposity [104]. In addition, Hollander and colleagues demonstrated that overweight/obese patients with T2D randomized to naltrexone-bupropion experienced significantly greater weight loss and improvements in HbA_{1c} levels following treatment when compared with placebo [105]. Although these results appear promising for combating both obesity and hyperglycemia in the T2D patient, caution at this time should be considered since attrition rates have been approximately 50% in current trials with the most common side effect reported being constipation, headache, vomiting and dizziness. As a result, further clinical research is warranted to understand the long-term safety and utility of this agent.

POTENTIAL RISKS OF BARIATRIC SURGERY AND CONSIDERATIONS

It is worth acknowledging that serve hypoglycemia has been documented after RYGB and is associated with post-prandial hyperinsulinemia due to elevated GLP-1 levels [106]. This hypoglycemia is classified as neuroglycopenia and seizures have been reported in are rare circumstances. The conventional treatment of hypoglycemia in these patients involves carbohydrate restriction to minimize hypoglycemic related episodes and at times, requires reversal of the surgical procedure [107]. To that end, nutritional deficiencies also may occur in 30-70% of patients. Patients at high risk of developing severe nutritional deficiencies include those who have lost more than 10% of their body weight by 1 month, and those with: anastomotic stenosis, surgical revision requirements, and persistent vomiting [108]. Protein calorie malnutrition is also a concern and can be recognized by signs such as edema, hypoalbumineia, anemia, and hair loss. To minimize these effects, it is generally recommended that patients consume between 60-80 g/d of protein and approximately 800 kcal/d. Vitamin deficiencies can lead to peripheral neuropathy (B_{12}), Wernicke encephalopathy (B_1), and metabolic bone disease (Vitamin D). Subsequently, in addition to multi-vitamin supplementation, monitoring nutrient and vitamin levels after bariatric surgery is recommended at least every 6 months [108-110].

CLINICAL APPROACHES AND CONCLUSION

The re-emergence of T2D and cardiometabolic disease post-bariatric surgery occurs in approximately 30-70% of individuals. Optimal evidenced based treatment strategies for the obese person with T2D following bariatric surgery is currently lacking, but is likely going to relate to the underlying pathophysiology. In fact, the complicated etiology of T2D highlights that a number of therapeutic options will likely be required in order to correct varying disturbances with tissues (e.g., skeletal muscle, liver, adipose, gut, kidney, etc.) based on the persons age and pre-existing weight status. In this sense, it is prudent to select therapies based on the underlying cause of T2D re-emergence rather than purely on blood glucose concentrations. Moreover, monitoring earlier on in post-surgical process of the disease is likely to preserve β-cell function and restore insulin sensitivity for ultimate reductions in blood glucose and CVD risk over time. In fact, the available evidence and our clinical experience suggest that T2D is related to weight gain combined with the exhaustion of insulin-secreting pancreatic β-cells due to skeletal muscle, liver and adipose insulin resistance. While it is often reported that maintenance of this lower weight following exercise and diet is difficult due to strong compensatory mechanisms that promote feeding to restore energy balance, we propose that exercise and diet is successful at maintaining long-term weight loss and improves glycemic control in hyperglycemic individuals when performed at adequate "doses." Thus, lifestyle modification should remain the first-line therapy for treatment of T2D. However, not all people are able to perform the necessary levels of physical activity needed to maintain metabolic health. As a result, we believe that pharmacologic intervention aimed at reducing weight and increasing insulin sensitivity (such as metformin, TZDs or canagliflozin), followed by treatments that promote insulin secretion if this initial treatment proves unsuccessful, are appropriate treatment strategies. In addition, several of these pharmacological agents (metformin, GLP-1 agonists, SLGT2, etc.) are a viable pharmacological agent for promoting modest weight loss in the obese individuals with T2D. Importantly though, it should be recognized that the quantity of weight loss following these pharmacological treatment plans are modest (1-5 kg) relative to the amount needed for most obese people to achieve healthy weight status and/or optimal glycemic control and CVD risk reduction. Thus, any one pharmacological agent is unlikely to be a sole anti-obesity agent, and these drugs should only be considered as an adjunctive therapy to exercise plus diet. As more patients may redevelop T2D following bariatric procedures, we will need improved understanding of ideal treatment modalities (i.e., metabolic fitness programs via lifestyle and/or pharmacology) to manage these individuals.

REFERENCES

[1] Maruthur NM. The growing prevalence of type 2 diabetes: increased incidence or improved survival? *Curr Diab Rep* 2013;13(6):786-794.

[2] Defronzo RA. Banting Lecture. From the triumvirate to the ominous octet: a new paradigm for the treatment of type 2 diabetes mellitus. *Diabetes* 2009;58(4):773-795.

[3] Malin SK, Kashyap SR, Hammel J, Miyazaki Y, DeFronzo RA, Kirwan JP. Adjusting Glucose-Stimulated Insulin Secretion for Adipose Insulin Resistance: An Index of β-Cell Function in Obese Adults. *Diabetes Care* 2014;37(11):2940-2946.

[4] Hurt RT, Edakkanambeth Varayil J, Mundi MS, Martindale RG, Ebbert JO. Designation of obesity as a disease: lessons learned from alcohol and tobacco. *Curr Gastroenterol Rep* 2014;16(11):415-014-0415-z.

[5] Rubino F. Bariatric surgery: effects on glucose homeostasis. *Curr Opin Clin Nutr Metab Care* 2006;9(4):497-507.

[6] Steinbrook R. Surgery for severe obesity. *N Engl J Med* 2004;350(11):1075-1079.

[7] Brethauer S, Aminian A, Romero Talamás H, et al. Can diabetes be surgically cured? Long-term metabolic effects of bariatric surgery in obese patients with type 2 diabetes mellitus. *Ann Surg* 2013;258(4):628-36.

[8] Courcoulas AP, Belle SH, Neiberg RH, et al. Three-Year Outcomes of Bariatric Surgery vs. Lifestyle Intervention for Type 2 Diabetes Mellitus Treatment: A Randomized Clinical Trial. *JAMA Surg* 2015;150(10):931-940.

[9] Malin SK, Samat A, Wolski K, et al. Improved acylated ghrelin suppression at 2 years in obese patients with type 2 diabetes: effects of bariatric surgery vs. standard medical therapy. *Int J Obes* 2014; 38(3)364-370.

[10] Kashayp SR, Bhatt DL, Wolski K, et al. Metabolic Effects of Bariatric Surgery in Patients with Moderate Obesity and Type 2 Diabetes: Analysis of a Randomized Control Trial Comparing Surgery vs. Intensive Medical Treatment. *Diabetes Care* 2013; 36(8):2175-2182.

[11] Hunter Mehaffey J, Turrentine FE, Miller MS, Schirmer BD, Hallowell PT. Roux-en-Y gastric bypass 10-year follow-up: the found population. *Surg Obes Relat Dis* 2015.

[12] Ribaric G, Buchwald JN, McGlennon TW. Diabetes and weight in comparative studies of bariatric surgery vs conventional medical therapy: a systematic review and meta-analysis. *Obes Surg* 2014 Mar;24(3):437-455.

[13] Dixon, J B Zimmet, P Alberti, K G Rubino, F. Bariatric surgery: an IDF statement for obese Type 2 diabetes. *Surg Obes Relat Dis* 2011;7(4):433-447.

[14] Standards of medical care in diabetes-2015: summary of revisions. *Diabetes Care* 2015;38 Suppl:S4.

[15] Khanna V, Malin SK, Bena J, et al. Adults with long-duration type 2 diabetes have blunted glycemic and ß-cell function improvements after bariatric surgery. *Obesity* 2015;23(3):523-6.

[16] Malin SK, Bena J, Abood B, et al. Attenuated improvements in adiponectin and fat loss characterize type 2 diabetes non-remission status after bariatric surgery. *Diabetes Obes Metab* 2014; 16(12):1230-1238.

[17] Wang GF, Yan YX, Xu N, et al. Predictive factors of type 2 diabetes mellitus remission following bariatric surgery: a meta-analysis. *Obes Surg* 2015 Feb;25(2):199-208.

[18] Sjostrom L, Peltonen M, Jacobson P, et al. Association of bariatric surgery with long-term remission of type 2 diabetes and with microvascular and macrovascular complications. *JAMA* 2014;311 (22):2297-2304.

[19] Lee WJ, Hur KY, Lakadawala M, Kasama K, Wong SK, Lee YC. Gastrointestinal metabolic surgery for the treatment of diabetic patients: a multi-institutional international study. *J Gastrointest Surg* 2012 Jan;16(1):45-51; discussion 51-2.

[20] Welch G, Wesolowski C, Piepul B, Kuhn J, Romanelli J, Garb J. Physical activity predicts weight loss following gastric bypass surgery: findings from a support group survey. *Obes Surg* 2008;18(5):517-524.

[21] Evans RK, Bond DS, Wolfe LG, Meador JG, Herrick JE, Kellum JM, et al. Participation in 150 min/wk of moderate or higher intensity physical activity yields greater weight loss after gastric bypass surgery. *Surg Obes Relat Dis* 2007;3(5):526-530.

[22] Heber D, Greenway FL, Kaplan LM, et al. Endocrine and nutritional management of the post-bariatric surgery patient: an Endocrine Society Clinical Practice Guideline. *J Clin Endocrinol Metab* 2010;95(11):4823-4843.

[23] Schauer PR, Bhatt D, Kirwan JP, et al. Bariatric surgery versus intensive medical therapy for diabetes--3-year outcomes. *N Engl J Med* 2014;370(21):2002-13.

[24] Odom J, Zalesin KC, Washington TL, et al. Behavioral predictors of weight regain after bariatric surgery. *Obes Surg* 2010 Mar;20(3):349-356.

[25] Karmali S, Brar B, Shi X, Sharma AM, de Gara C, Birch DW. Weight recidivism post-bariatric surgery: a systematic review. *Obes Surg* 2013 Nov;23(11):1922-1933.

[26] Robinson AH, Adler S, Stevens HB, Darcy AM, Morton JM, Safer DL. What variables are associated with successful weight loss outcomes for bariatric surgery after 1 year? *Surg Obes Relat* Dis 2014;10(4):697-704.

[27] Ebbert JO, Elrashidi MY, Jensen MD. Managing overweight and obesity in adults to reduce cardiovascular disease risk. *Curr Atheroscler Rep* 2014;16(10):445-014-0445-x.

[28] Tuomilehto J, Lindström J, Eriksson JG, et al. Prevention of type 2 diabetes mellitus by changes in lifestyle among subjects with impaired glucose tolerance. *N Engl J Med* 2001;344(18):1343-1350.

[29] Knowler WC, Barrett-Connor E, et al. Reduction in the incidence of type 2 diabetes with lifestyle intervention or metformin. *N Engl J Med* 2002;346(6):393-403.

[30] Malin SK, Niemi N, Solomon TPJ, et al. Exercise Training with Weight Loss and either a High- or Low-Glycemic Index Diet Reduces Metabolic Syndrome Severity in Older Adults. *Ann Nut Metabol* 2012;61(2):135-141.

[31] Houmard JA, Tanner CJ, Slentz CA, Duscha BD, McCartney JS, Kraus WE. Effect of the volume and intensity of exercise training on insulin sensitivity. *J Appl Physiol* 2004;96(1):101.

[32] Malin SK, Solomon TPJ, Blaszczak A, Finnegan S, Filion J, Kirwan JP. Pancreatic beta cell function increases in a linear dose-response manner following exercise training in adults with prediabetes. *Am J Physiol Endocrinol Metab* 2013; 305(10):E1248-1254.

[33] Rock CL, Flatt SW, Pakiz B, et al. Weight loss, glycemic control, and cardiovascular disease risk factors in response to differential diet composition in a weight loss program in type 2 diabetes: a randomized controlled trial. *Diabetes Care* 2014;37(6):1573-1580.

[34] Tay J, Luscombe-Marsh ND, Thompson CH, et al. A very low-carbohydrate, low-saturated fat diet for type 2 diabetes management: a randomized trial. *Diabetes Care* 2014;37(11):2909-2918.

[35] Solomon TPJ, Malin SK, Karstoft K, Kashyap SR, Haus JM, Kirwan JP. Pancreatic β-cell Function Is a Stronger Predictor of Changes in Glycemic Control After an Aerobic

Exercise Intervention Than Insulin Sensitivity. *J Clin Endocrinol Metab* 2013;98(10): 4176-4186.

[36] Umpierre D, Ribeiro PA, Kramer CK, et al. Physical activity advice only or structured exercise training and association with HbA1c levels in type 2 diabetes: a systematic review and meta-analysis. *JAMA* 2011;305(17):1790-1799.

[37] Malin SK, Haus JM, Solomon TPJ, Blaszczak A, Kashyap SR, Kirwan JP. Insulin sensitivity and metabolic flexibility following exercise training among different obese insulin resistant phenotypes. *Am J Physiol Endocrinol Metab* 2013; 305(10):E1292-1298.

[38] Solomon TPJ, Malin SK, Karstoft K, Haus JM, Kirwan JP. The Influence of Hyperglycemia on the Therapeutic Effect of Exercise on Glycemic Control in Patients With Type 2 Diabetes Mellitus. *JAMA internal medicine* 2013; 173(19):1834-1836.

[39] Wing RR, Goldstein MG, Acton KJ, Birch LL, Jakicic JM, Sallis JF,Jr, et al. Behavioral science research in diabetes: lifestyle changes related to obesity, eating behavior, and physical activity. *Diabetes Care* 2001;24(1):117-123.

[40] Bond DS, Evans RK, DeMaria EJ, et al. Physical activity stage of readiness predicts moderate-vigorous physical activity participation among morbidly obese gastric bypass surgery candidates. *Surg Obes Relat Dis* 2006;2(2):128-132.

[41] Silver HJ, Torquati A, Jensen GL, Richards WO. Weight, dietary and physical activity behaviors two years after gastric bypass. *Obes Surg* 2006;16(7):859-864.

[42] Bond DS, Evans RK, DeMaria E, et al. Physical activity and quality of life improvements before obesity surgery. *Am J Health Behav* 2006;30(4):422-434.

[43] Bond D, Thomas JG, King W, et al. Exercise improves quality of life in bariatric surgery candidates: results from the Bari-Active trial. *Obesity* 2015;23(3):536-42.

[44] Miller GD, Nicklas BJ, You T, Fernandez A. Physical function improvements after laparoscopic Roux-en-Y gastric bypass surgery. *Surg Obes Relat Dis* 2009;5(5):530-537.

[45] Shada AL, Hallowell PT, Schirmer BD, Smith PW. Aerobic exercise is associated with improved weight loss after laparoscopic adjustable gastric banding. *Obes Surg* 2013;23(5):608-12.

[46] Josbeno DA, Jakicic JM, Hergenroeder A, Eid GM. Physical activity and physical function changes in obese individuals after gastric bypass surgery. *Surg Obes Relat Dis* 2010;6(4):361-366.

[47] Bond DS, Jakicic JM, Unick JL, et al. Pre- to postoperative physical activity changes in bariatric surgery patients: self report vs. objective measures. *Obesity* 2010 Dec;18(12):2395-2397.

[48] Berglind D, Willmer M, Tynelius P, Ghaderi A, Naslund E, Rasmussen F. Accelerometer-Measured Versus Self-Reported Physical Activity Levels and Sedentary Behavior in Women Before and 9 Months After Roux-en-Y Gastric Bypass. *Obes Surg* 2015.

[49] Elkins G, Whitfield P, Marcus J, Symmonds R, Rodriguez J, Cook T. Noncompliance with behavioral recommendations following bariatric surgery. *Obes Surg* 2005;15(4):546-551.

[50] McCullough PA, Gallagher MJ, Dejong AT, Sandberg KR, Trivax JE, Alexander D, et al. Cardiorespiratory fitness and short-term complications after bariatric surgery. *Chest* 2006 Aug;130(2):517-525.

[51] Hennis PJ, Meale PM, Hurst RA, et al. Cardiopulmonary exercise testing predicts postoperative outcome in patients undergoing gastric bypass surgery. *Br J Anaesth* 2012 Oct;109(4):566-571.

[52] Hatoum IJ, Stein HK, Merrifield BF, Kaplan LM. Capacity for physical activity predicts weight loss after Roux-en-Y gastric bypass. *Obesity* 2009;17(1):92-99.

[53] Lund MT, Hansen M, Wimmelmann CL, et al. Increased post-operative cardiopulmonary fitness in gastric bypass patients is explained by weight loss. *Scand J Med Sci Sports* 2015 Dec 4.

[54] Shah M, Snell PG, Rao S, et al. High-volume exercise program in obese bariatric surgery patients: a randomized, controlled trial. *Obesity* 2011;19(9):1826-1834.

[55] Coen P, Tanner C, Helbling N, Dubis G, Hames K, Xie H, et al. Clinical trial demonstrates exercise following bariatric surgery improves insulin sensitivity. *J Clin Invest* 2015;125(1):248-57.

[56] Coen PM, Menshikova EV, Distefano G, et al. Exercise and Weight Loss Improve Muscle Mitochondrial Respiration, Lipid Partitioning, and Insulin Sensitivity After Gastric Bypass Surgery. *Diabetes* 2015;64(11):3737-3750.

[57] Stegen S, Derave W, Calders P, Van Laethem C, Pattyn P. Physical fitness in morbidly obese patients: effect of gastric bypass surgery and exercise training. *Obes Surg* 2011;21(1):61-70.

[58] Rothwell L, Kow L, Toouli J. Effect of a post-operative structured exercise programme on short-term weight loss after obesity surgery using adjustable gastric bands. *Obes Surg* 2015;25(1):126-128.

[59] Huck CJ. Effects of supervised resistance training on fitness and functional strength in patients succeeding bariatric surgery. *J Strength Cond Res* 2015;29(3):589-595.

[60] Inzucchi SE, Bergenstal RM, Buse JB, et al. Management of hyperglycemia in type 2 diabetes, 2015: a patient-centered approach: update to a position statement of the American Diabetes Association and the European Association for the Study of Diabetes. *Diabetes Care* 2015 Jan;38(1):140-149.

[61] Malin SK, Braun B. Impact of Metformin on Exercise-Induced Metabolic Adaptations to Lower Type 2 Diabetes Risk. *Exerc Sport Sci Rev* 2016; 44(1):4-11.

[62] Rhee M, Herrick K, Ziemer D, et al. Many Americans have pre-diabetes and should be considered for metformin therapy. *Diabetes Care* 2010;33(1):49-54.

[63] Malin SK, Kashyap SR. Effects of metformin on weight loss: potential mechanisms. *Curr Opin Endocrinol Diabetes Obes* 2014;21(5):323-9.

[64] Diabetes Prevention Program Research Group. Long-term effects of lifestyle intervention or metformin on diabetes development and microvascular complications over 15-year follow-up: the Diabetes Prevention Program Outcomes Study. *Lancet Diabetes Endocrinol* 2015;3(11):866-875.

[65] Lipska KJ, Bailey CJ, Inzucchi SE. Use of metformin in the setting of mild-to-moderate renal insufficiency. *Diabetes Care* 2011;34(6):1431-1437.

[66] Punthakee Z, Almeras N, Despres JP, et al. Impact of rosiglitazone on body composition, hepatic fat, fatty acids, adipokines and glucose in persons with impaired fasting glucose or impaired glucose tolerance: a sub-study of the DREAM trial. *Diabet Med* 2014;31(9):1086-1092.

[67] DeFronzo RA, Tripathy D, Schwenke DC, et al. Pioglitazone for diabetes prevention in impaired glucose tolerance. *N Engl J Med* 2011;364(12):1104-1115.

[68] Schwartz AV, Chen H, Ambrosius WT, et al. Effects of TZD Use and Discontinuation on Fracture Rates in ACCORD Bone Study. *J Clin Endocrinol Metab* 2015;100(11): 4059-4066.

[69] Dormandy J, Bhattacharya M, van Troostenburg de Bruyn AR, PROactive investigators. Safety and tolerability of pioglitazone in high-risk patients with type 2 diabetes: an overview of data from PROactive. *Drug Saf 2*009;32(3):187-202.

[70] Yu EW. Bone metabolism after bariatric surgery. *J Bone Miner Res* 2014;29(7):1507-1518.

[71] Kahn SE, Cooper ME, Del Prato S. Pathophysiology and treatment of type 2 diabetes: perspectives on the past, present, and future. *Lancet* 2014;383(9922):1068-1083.

[72] Matthews DR, Cull CA, Stratton IM, Holman RR, Turner RC. UKPDS 26: Sulphonylurea failure in non-insulin-dependent diabetic patients over six years. UK Prospective Diabetes Study (UKPDS) Group. *Diabet Med* 1998;15(4):297-303.

[73] Bennett WL, Maruthur NM, Singh S, et al. Comparative effectiveness and safety of medications for type 2 diabetes: an update including new drugs and 2-drug combinations. *Ann Intern Med* 2011;154(9):602-613.

[74] Holst J, Vilsbll T, Deacon C. The incretin system and its role in type 2 diabetes mellitus. *Mol Cell Endocrinol* 2009;297(1-2):127-136.

[75] Gil-Lozano M, Mingomataj EL, Wu WK, Ridout SA, Brubaker PL. Circadian secretion of the intestinal hormone GLP-1 by the rodent L cell. *Diabetes* 2014;63(11):3674-3685.

[76] Pi Sunyer X, Blackburn G, Brancati F, et al. Reduction in weight and cardiovascular disease risk factors in individuals with type 2 diabetes: one-year results of the look AHEAD trial. *Diabetes Care* 2007;30(6):1374-1383.

[77] Davies MJ, Bergenstal R, Bode B, Kushner RF, Lewin A, Skjoth TV, et al. Efficacy of Liraglutide for Weight Loss Among Patients With Type 2 Diabetes: The SCALE Diabetes Randomized Clinical Trial. *JAMA* 2015;314(7):687-699.

[78] Wadden TA, Hollander P, Klein S, et al. Weight maintenance and additional weight loss with liraglutide after low-calorie-diet-induced weight loss: the SCALE Maintenance randomized study. *Int J Obes* (Lond) 2013;37(11):1443-1451.

[79] Liu SC, Tu YK, Chien MN, Chien KL. Effect of antidiabetic agents added to metformin on glycaemic control, hypoglycaemia and weight change in patients with type 2 diabetes: a network meta-analysis. *Diabetes Obes Metab* 2012;14(9):810-820.

[80] Buse JB, Bergenstal RM, Glass LC, et al. Use of twice-daily exenatide in Basal insulin-treated patients with type 2 diabetes: a randomized, controlled trial. *Ann Intern Med* 201118;154(2):103-112.

[81] Gough SC, Bode B, Woo V, et al. Efficacy and safety of a fixed-ratio combination of insulin degludec and liraglutide (IDegLira) compared with its components given alone: results of a phase 3, open-label, randomised, 26-week, treat-to-target trial in insulin-naive patients with type 2 diabetes. *Lancet Diabetes Endocrinol* 2014;2(11):885-893.

[82] Pfeffer MA, Claggett B, Diaz R, et al. Lixisenatide in Patients with Type 2 Diabetes and Acute Coronary Syndrome. *N Engl J Med* 2015;373(23):2247-2257.

[83] Ryder RE. The potential risks of pancreatitis and pancreatic cancer with GLP-1-based therapies are far outweighed by the proven and potential (cardiovascular) benefits. *Diabet Med* 2013;30(10):1148-1155.

[84] Shah Z, Kampfrath T, Deiuliis J, et al. Long-term dipeptidyl-peptidase 4 inhibition reduces atherosclerosis and inflammation via effects on monocyte recruitment and chemotaxis. *Circulation* 2011;124(21):2338-2349.

[85] Shah P, Ardestani A, Dharmadhikari G, et al. The DPP-4 inhibitor linagliptin restores beta-cell function and survival in human isolated islets through GLP-1 stabilization. *J Clin Endocrinol Metab* 2013;98(7):E1163-72.

[86] Malin SK, Huang H, Mulya A, Kashyap SR, Kirwan JP. Lower dipeptidyl peptidase-4 following exercise training plus weight loss is related to increased insulin sensitivity in adults with metabolic syndrome. *Peptides* 2013;47:142-147.

[87] White WB, Cannon CP, Heller SR, Nissen SE, Bergenstal RM, Bakris GL, et al. Alogliptin after acute coronary syndrome in patients with type 2 diabetes. *N Engl J Med* 2013;369(14):1327-1335.

[88] Scirica BM, Bhatt DL, Braunwald E, et al. Saxagliptin and cardiovascular outcomes in patients with type 2 diabetes mellitus. *N Engl J Med* 2013;369(14):1317-1326.

[89] Green JB, Bethel MA, Armstrong PW, et al. Effect of Sitagliptin on Cardiovascular Outcomes in Type 2 Diabetes. *N Engl J Med* 2015;373(3):232-242.

[90] Yanovski SZ, Yanovski JA. Long-term drug treatment for obesity: a systematic and clinical review. *JAMA* 2014;311(1):74-86.

[91] Fenske WK, Pournaras DJ, Aasheim ET, Miras AD, Scopinaro N, Scholtz S, et al. Can a protocol for glycaemic control improve type 2 diabetes outcomes after gastric bypass? *Obes Surg* 2012;22(1):90-96.

[92] Monami M, Nardini C, Mannucci E. Efficacy and safety of sodium glucose co-transport-2 inhibitors in type 2 diabetes: a meta-analysis of randomized clinical trials. *Diabetes Obes Metab* 2014;16(5):457-466.

[93] Bailey CJ, Gross JL, Pieters A, Bastien A, List JF. Effect of dapagliflozin in patients with type 2 diabetes who have inadequate glycaemic control with metformin: a randomised, double-blind, placebo-controlled trial. *Lancet* 2010;375(9733):2223-2233.

[94] Zinman B, Wanner C, Lachin JM, et al. Empagliflozin, Cardiovascular Outcomes, and Mortality in Type 2 Diabetes. *N Engl J Med* 2015;373(22):2117-2128.

[95] Vasilakou D, Karagiannis T, Athanasiadou E, et al. Sodium-glucose cotransporter 2 inhibitors for type 2 diabetes: a systematic review and meta-analysis. *Ann Intern Med* 2013;159(4):262-274.

[96] Apovian CM, Aronne LJ, Bessesen DH, et al. Pharmacological management of obesity: an endocrine Society clinical practice guideline. *J Clin Endocrinol Metab* 2015;100(2): 342-362.

[97] Torgerson JS, Hauptman J, Boldrin MN, Sjostrom L. XENical in the prevention of diabetes in obese subjects (XENDOS) study: a randomized study of orlistat as an adjunct to lifestyle changes for the prevention of type 2 diabetes in obese patients. *Diabetes Care* 2004;27(1):155-161.

[98] Derosa G, Cicero AF, D'Angelo A, Fogari E, Maffioli P. Effects of 1-year orlistat treatment compared to placebo on insulin resistance parameters in patients with type 2 diabetes. *J Clin Pharm Ther* 2012;37(2):187-195.

[99] Scheen AJ, Van Gaal LF. Combating the dual burden: therapeutic targeting of common pathways in obesity and type 2 diabetes. *Lancet Diabetes Endocrinol* 2014;2(11):911-922.

[100] Garvey WT, Ryan DH, Look M, et al. Two-year sustained weight loss and metabolic benefits with controlled-release phentermine/topiramate in obese and overweight adults (SEQUEL): a randomized, placebo-controlled, phase 3 extension study. *Am J Clin Nutr* 2012;95(2):297-308.

[101] Garvey WT, Ryan DH, Henry R, et al. Prevention of type 2 diabetes in subjects with prediabetes and metabolic syndrome treated with phentermine and topiramate extended release. *Diabetes Care* 2014;37(4):912-921.

[102] Martin CK, Redman LM, Zhang J, et al. Lorcaserin, a 5-HT(2C) receptor agonist, reduces body weight by decreasing energy intake without influencing energy expenditure. *J Clin Endocrinol Metab* 2011;96(3):837-845.

[103] O'Neil PM, Smith SR, Weissman NJ, et al. Randomized placebo-controlled clinical trial of lorcaserin for weight loss in type 2 diabetes mellitus: the BLOOM-DM study. *Obesity* 2012;20(7):1426-1436.

[104] Smith SR, Fujioka K, Gupta AK, et al. Combination therapy with naltrexone and bupropion for obesity reduces total and visceral adiposity. *Diabetes Obes Metab* 2013;15(9):863-866.

[105] Hollander P, Gupta AK, Plodkowski R, et al. Effects of naltrexone sustained-release/bupropion sustained-release combination therapy on body weight and glycemic parameters in overweight and obese patients with type 2 diabetes. *Diabetes Care* 2013;36(12):4022-4029.

[106] Service G, Thompson G, Service FJ, Andrews J, Collazo Clavell M, Lloyd R. Hyperinsulinemic hypoglycemia with nesidioblastosis after gastric-bypass surgery. *N Engl J Med* 2005;353(3):249-254.

[107] Goldfine AB, Mun EC, Devine E, et al. Patients with neuroglycopenia after gastric bypass surgery have exaggerated incretin and insulin secretory responses to a mixed meal. *J Clin Endocrinol Metab* 2007;92(12):4678-4685.

[108] Davies DJ, Baxter JM. Nutritional deficiencies after bariatric surgery. *Obesity Surg* 2007;17(9):1150-1158.

[109] Ritz P, Becouarn G, Douay O, Salle A, Topart P, Rohmer V. Gastric bypass is not associated with protein malnutrition in morbidly obese patients. *Obesity Surg* 2009;19(7):840-844.

[110] Angstadt J, Bodziner R. Peripheral polyneuropathy from thiamine deficiency following laparoscopic Roux-en-Y gastric bypass. *Obesity Surg* 2005;15(6):890-892.

In: Encyclopedia of Surgery (22 Volume Set)
Editors: Andreas Lehrer and Kristin Mueller
ISBN: 978-1-53618-329-0
© 2020 Nova Science Publishers, Inc.

Chapter 144

GASTROINTESTINAL HORMONES AND ROUX-EN-Y GASTRIC BYPASS

Deniz Atalayer, PhD
Sabanci University, Istanbul, Turkey

ABSTRACT

Obesity is a multifactorial global epidemic with associated risk factors for an array of vascular, metabolic, psychological and economical consequences. Bariatric surgery offers the most effective results and Roux-en-Y gastric bypass (RYGB) is the most commonly performed bariatric surgery worldwide. The effective weight loss achieved by RYGB is thought to be caused by the re-arrangement of the gastrointestinal tract leading malabsorption and restriction of the ingested nutrients, and consequently resulting in alterations in the gut hormone levels. This review briefly summarizes the current literature on the changes in the gastrointestinal hormones following RYGB. Understanding these post-operative alterations may provide insights on the efficacy of RYGB that may help developing superior surgical techniques, novel pharmacological and psychological interventions, as well as prevention strategies against obesity.

INTRODUCTION

Obesity is a global pandemic however; weight loss achieved by pharmacological and behavioral treatments are generally ineffective in maintaining a healthy body weight over a longer period of time and thus usually followed by weight regain. Bariatric surgery is currently the most effective anti-obesity intervention (Sjostrom et al., 2004, 2007) in comparison with the non-surgical treatments (Gloyet al., 2013; Buchwald et al., 2004) inducing a negative energy balance by reducing food intake (Rubino et al., 2010) and increasing energy expenditure (Stylopoulos et al., 2009). It also has been shown to improve glucose homeostasis and resolve type-2-diabetes (T2D) (Sala et al., 2014). Roux-en-Y gastric bypass (RYGB) has been the most commonly performed procedure in the world and although there had been a marked decrease in the number of RYGB performed from 2003 to 2008 with

the co-morbid increase in the preference for sleeve gastrectomy, another bariatric surgery procedure, RYGB still remains the most commonly performed bariatric procedure worldwide in 2013 (Buchwald et al., 2009b, Angrisani et al., 2015).

During RYGB, a small proximal pouch (typically < 30 ml) is created from the stomach, which is attached to a segment of the jejunum that has been brought rostrally after being transected. The large gastric remnant is joined to the mid- to distal jejunum, creating the Roux-en-Y limb. RYGB causes restriction by reducing stomach capacity by ~95%, and re-directs the flow of nutrients, which results in ingested foods bypassing the 95% of the stomach, entire duodenum, and a small portion (15–20 cm) of the proximal jejunum (Cummings et al., 2004), passing the small re-sectioned stomach pouch directly being shunted into the mid- to distal jejunum. It has been reported that patients, after RYGB, often experience significant reductions in appetite, as well as greater satiety following the ingestion of smaller meals (Ashrafian et al., 2009). Several studies in humans and animals have shown that physiological changes in, i.e., intragastric pressure (Raybould 1991) and emptying rate (rats) (Kalogeris et al., 1983), as well as pyloric motility (Treacy et al., 1992), following nutrient delivery to different parts of the gastrointestinal (GI) tract. Moreover, the mechanoreceptors and chemoreceptors embedded in the lining of the GI tract respond to specific amount and type of macronutrients (Mei 1985). In RYGB, a re-arrangement of the GI tract is achieved; the nutrients bypass the duodenum and proximal jejunum and are being shunted directly into the mid jejunum. It is assumed that this re-arrangement causes alterations in the gut hormone responses, which may be contributing to the efficacy of RYGB on effective weight loss (Cummings et al., 2004). However, the specific mechanisms underlying the efficacy of RYGB are still under investigation. It has been reported that RYGB produces changes in the gut-brain communication regulating energy balance which then leads to reductions in subjective appetite and food intake causing weight loss of approximately 25–30% of total body weight (Sjostrom et al., 2007). The weight loss following RYGB has been shown to plateau after 1-1.5 years and to be maintained in most patients for at least 10 years following the surgery (Sjostrom et al., 2007). However, the degree of successful weight loss after RYGB varies considerably along with the remission rates. Thus, understanding the hormonal changes following RYGB may help elucidating the mechanisms underlying its success and lead to the development of novel preventative strategies and treatments with or without the surgical interventions.

GASTRIC SIGNALS

Gastrin, ghrelin and obestatin that are secreted by the stomach will be reviewed in this section.

Gastrin

Gastrin, a peptide of 34 amino acids, is secreted by G-cells that are located in the pyloric antrum and duodenum. It leads to the production of pepsinogen (an enzyme that breaks down the proteins) and stimulation of acid secretion in response to the expansion of the stomach or

ingestion of protein, caffeine, and alcohol (Posovszky and Wabitsch 2015). A direct anorectic or orexigenic effect of gastrin is not established so far. Earlier studies showed significantly reduced gastrin release postprandially at 3 and 12 months following RYGB (Schrumpf et al., 1981). Recent data also indicated lower postprandial incremental area under the curve (iAUC) with no changes for fasting levels of gastrin at 2 weeks post-RYGB (Jacobsen et al., 2012). Postprandial reductions in gastrin levels were also reported following a protein-rich meal in RYGB patients after 3 ≥ months post-operatively (Grong et al., 2015). Moreover significant reductions in gastrin cells in the excluded portion of the stomach in RYGB patients compared to the obese controls (Safatle-Ribeiro et al., 2013) have been reported at ≥3 years of follow-up. Taken together, these reports, along with similar findings from animal studies (Stenstrom et al., 2006), suggest a reduction in gastrin levels following RYGB.

Ghrelin

Ghrelin has been shown to be a major orexigenic hormone, mainly produced by the endocrine X/A-cells of the oxyntic glands of the stomach mucosa and released to the blood stream (Choi et al., 2003; Sakata et al., 2009; Thompson et al., 2004). Studies have also shown that its expression is highest in the stomach (Kojima et al., 1999) and to a lesser degree, in the pituitary gland (Howard et al., 1996) and the hypothalamus (Wren et al., 2000). Ghrelin rises prior to meals and declines rapidly postprandially (Carlson et al., 2009; English et al., 2002; Zwirska-Korczala et al., 2007), suggesting a role in preprandial hunger and meal initiation (Cummings et al., 2001). Moreover, ghrelin has been shown to have a circadian fluctuation in both animals and humans; it increases in the morning and decreases later in the day. Conditions of positive energy balance (e.g., hyperglycemia, insulin resistance, obesity) are associated with lower ghrelin concentrations (Shiiya et al., 2002; Tschop et al., 2001). Obese individuals have lower fasting plasma ghrelin levels compared to lean people (Shiiya et al., 2002; Tschop et al., 2001). However, the reduced levels of ghrelin in obese individuals do not appear to prevent further weight gain. The lower fasting ghrelin levels in obesity suggest a possible down-regulation of ghrelin in response to overeating or excess body weight. Higher ghrelin levels, on the other hand, have been observed during periods of fasting, hunger, or other conditions associated with negative energy balance, such as short-term starvation, cancer cachexia, as well as anorexia nervosa (Bloomgarden, 2007).

The major hypothesis regarding the success behind the RYGB had been the suppression of the secretion of the main orexigenic hormone ghrelin (ghrelin hypothesis) (Cummings et al., 2002). This was supported by the majority of the studies showing decreases in ghrelin levels following the surgery (Foschi et al., 2008; Frühbeck et al., 2004; Garcia de la Torre et al., 2008; Lin et al., 2004; Morinigo et al., 2004; Rodieux et al., 2008). However, results have been inconsistent; increases (Pardina et al., 2009; Holdstock et al., 2003; Vendrell et al., 2004, , Garcia-Fuentes et al 2008) as well asno change (Korner et al., 2009; Whitson et al., 2007a) in ghrelin levels have also been reported.

It is important to note that there are two major molecular forms of ghrelin; *octanoylated* (acyl) which comprises <10% of circulating ghrelin, and des-n-octanoyl (des-acyl) ghrelin, which have different, and perhaps opposing functions in relation to energy homeostasis (Toshinai et al., 2006; Zhang et al., 2005). Although the des-acyl form of ghrelin comprises more than 90% of the total ghrelin released (Hosoda et al., 2000; Leite-Moreira and Soares,

2007), the acyl (active ghrelin) is the portion that binds to the growth hormone secretagogue receptor-1A (Kojima et al., 1999) to regulate several metabolic processes and to promote food intake. Thus, it had become crucial to analyze the total, acyl and des-acyl ghrelin separately and therefore the assays distinguishing between acyl and des-acyl ghrelin moieties have been developed recently (Prudom et al., 2010). The reports using such assays support the initial ghrelin hypothesis showing significant reductions in the fasting levels of total and active ghrelin as well as postprandial (AUC) levels of active ghrelin at 2 weeks following RYGB (Jacobsen et al., 2012). Fasting and postprandial (AUC) des-acyl ghrelin levels were also shown to decrease in RYGB patients at 1-year follow-up (Nannipieri et al., 2013). Interestingly, studies indicated that both fasting and postprandial (AUC) total ghrelin levels following 1 and 3 months returned to pre-surgery levels at 1-year post-surgery follow-up (Peterliet al., 2012). Increases at 1-year post-op following an initial decrease have been consistently reported for total, active and des-acyl ghrelin during fasting and postprandially (Sundbom et al., 2007; Samat et al., 2013; Yang et al., 2014). It is possible that ghrelin decreases are transient after RYGB; and that ghrelin subsequently increases as weight loss continues due to lower food intake.

Obestatin

Obestatin is a 23-amino acid peptide hormone and is derived from posttranslational cleavage of preproghrelin, and released from the stomach (Zhang et al., 2005; Zhao et al., 2008). Although ghrelin is an orexigenic hormone, obestatin has been shown to have anorexigenic effects such as reducing food intake, delaying gastric emptying, and reducing body weight in rodents therefore antagonizing the orexigenic effect of ghrelin (Zhang et al., 2005). However, later, controversial findings have been reported on the effects of obestatin on food intake (Gourcerol et al., 2007; Lacquaniti et al., 2011). In humans, the common finding was that the fasting plasma obestatin was to be reduced in obese individuals compared to the normal-weight persons (Lippl et al., 2008; Huda et al., 2008; Guo et al., 2007) along with the findings showing lower ghrelin-to-obestatin ratio in obese vs. normal weight women (Vicennati et al., 2007).

A study reported a significant decrease in obestatin levels after a gastrectomy surgery (Huda et al., 2008) and studies investigating the changes in obestatin levels following RYGB have mostly been contraversial reporting increases at 1-year (Yang et al., 2014) and 3-year (Martins et al., 2011), as well as no change at 2-year follow-ups (Roth et al., 2009).

FOREGUT SIGNALS

In this section, cholecystokinin (CCK) and glucose-dependent insulinotropic peptide (GIP) that are secreted by the duodenum and jejunum will be reviewed.

Cholecystokinin (CCK)

CCK was the first gut hormone found to be implicated in appetite control (Gibbs et al., 1973). It regulates gut motility, pancreatic secretion, and gall bladder contractions. It is secreted predominately from the I-cells in the duodenum and jejunum in response to the presence of nutrients in the intestinal lumen (Lieverse et al., 1994, Parker et al., 2005, Liddle et al., 1985). CCK regulates the digestive enzymes from the pancreas, stimulates gall bladder contraction, increases intestinal motility and inhibits gastric emptying (Liddle et al., 1985, Moran et al., 1994). Higher concentrations are associated with a reduction in meal size and meal duration. CCK has a short plasma half-life of a few minutes, plasma levels of CCK rise within 15 minutes after meal ingestion (Liddle et al., 1985) and enhance perceptions of fullness and reduce hunger during the course of a meal in both humans and animals (Kissilef et al., 1981; 2003; Gibbs et al., 1973). Fatty acids (with chain lengths of 12 or more carbons) and proteins stimulate CCK secretion (Holzer et al., 1994; Lal et al., 2004; Corp et al., 2003). It has been suggested that CCK signaling is a vagally mediated process between the gut and the brain. Supporting this, studies with animals showed that vagotomised rats do not show the lipid induced delay in gastric emptying or suppression in subsequent food intake (Moriarty et al., 1997). Moreover it has been shown that there is CCK-1 receptor expression in human vagal afferent neurons (Feinle et al., 2003).

Although CCK is involved in meal-termination, it does not appear to have an independent role in the long-term regulation of energy balance and body weight, but rather a primary role in short term control of appetite and satiety (Moran, 2000; Tadross and le Roux 2009). Thus, there had not been much interest in investigating CCK regarding a possible role in the efficacy of RYGB and are only few studies to date reporting on the changes in CCK levels following RYGB. Earlier studies compared postprandial CCK levels following RYBG showed that the CCK response was not affected (Rubino et al., 2004; Kellum et al., 1990). In addition, animal studies also lead similar findings: CCK was not significantly altered after RYGB-induced weight loss in rats, (Suzuki et al., 2005). However recent studies suggested some effects, at 1-week (Peterli et al., 2012) and 2-weeks (Jacobsen et al., 2012) following the surgery: the patients with RYGB had elevated postprandial maximum peak CCK levels with no difference for AUC concentrations. Thus postprandial CCK peak was increased, but the effect was short-lasting. Post-operative fasting CCK levels were also shown to be unchanged (Jacobsen et al., 2012). Although a reduction in CCK following RYGB might be expected due to the diversion of the ingested food away from it secretion site -the upper part of the small intestine (the duodenum), the jejunum also was shown to release CCK (Katsusuke et al., 2008), which may explain the unchanged AUC levels of CCK following surgery. However, the role of CCK in the efficiency of RYGB warrants further investigations.

Glucose-Dependent Insulinotropic Peptide (GIP)

Glucose-dependent insulinotropic polypeptide (GIP) is a 42 amino acid peptide and is proposed to have a role in the pathophysiology of obesity and type-2-diabetes (T2D). It is one of two well-known incretins (along with glucagon-like peptide-1; GLP-1) and synthesized in the enteroendocrine cells (K-cells) primarily in the proximal small intestine (duodenum and jejunum) and its secretion is induced by food intake, especially carbohydrate and lipid intake

(Nauck, 1986). Once released, GIP stimulates β-cells of the Islets of Langerhans to cause GIP secretion which gives it the property of an incretin. It also inhibits gastric acid secretion, suppresses lipolysis in adipose tissue, induces appetite and reduces energy expenditure in the brain (Paschetta et al., 2011). It promotes glucose absorption in the small intestine by increasing the number of GLUT1 glucose receptors (Creutzfeldt et al., 2001; Cheeseman 1996, 1998) and based on its effects on insulin secretion, GIP has been offered as a critical target for T2D treatments and etiology. Several studies have found that GIP (both basal and simulated) was elevated in obese compared to lean persons (Vilsboll et al., 2003) and severely blunted in patients with T2D (Saxena et al., 2010; Gautier et al., 2008).

In an RYGB procedure, the duodenum and a part of the jejunum are bypassed resulting in a lack of nutrient exposure (Rao and Kini, 2011). This rationale was agreed with the proponents of the foregut theory explaining the efficacy of RYGB, whereby bypass of the proximal small intestine leads to decreased anti-incretin effects. Thus, less GIP secretion was predicted following RYGB (Pories and Albrecht, 2001; Rubino 2008). However, results have been less consistent, with studies showing elevated (Lafarrere et al., 2007; 2008; Goldfine et al., 2007) or reduced (Rodieux et al., 2008; Korner et al., 2007), as well as unchanged GIP levels independent of weight loss (Cohen et al., 2007). Fasting GIP levels were reduced in diabetics but no change in non-diabetics who underwent RYGB at a 3-week (Rubino et al., 2004) as well as at 6- and 12-week (Clements et al., 2004) follow-ups. Furthermore, no change in non-fasting plasma GIP levels at 6-month follow-up in diabetic and non-diabetic RYGB patients have also been reported (Whitson et al., 2007a). Similarly, total postprandial iAUC GIP levels over a 4-hour period were significantly reduced in the non-diabetic RYGB patients compared to the gastric banding and non-operated controls (Rodieux et al., 2008) ≥ 9-48 months after the surgery. The most recent study by Xiong et al. (2015) showed that fasting and postprandial (at the 2-hour point) GIP decreased following RYGB at the 1-week and 1, 3, and 6-month follow-up periods gradually. However one limitation of this study is that in their sample they used a group of gastric cancer patients with T2D and or simple T2D. Thus their report may not be representative of non-diabetic obese nor T2D patients. However, in diabetic RYGB patients at a 1-month follow-up, postprandial GIP was found to increase 1.5 fold in response to 50 g glucose load (Laferrere et al., 2007; 2008). Another study also reported plasma GIP increases in hypoglycemic vs. non-hypoglycemic RYGB patients in response to a standard test meal (Rabiee et al., 2011). A possible explanation for the inconsistencies in the literature may stem from the nature of the GIP action. During this peak, the major insulinotropic effect of GIP is achieved at approximately 60 min after an oral glucose bolus and serum levels return to basal levels in approximately 120–180 min (Nauck, 1986). The short half life of GIP (Nauck, 1986) as well as the fast degradation following its peak after a bolus with only a small percentage left in the circulation however makes the detection and analyses of GIP in serum extremely difficult as well as unreliable. One group used whole blood GIP mRNA as a marker for systemic GIP gene expression to avoid the unreliability issues of measuring serum GIP (Moran-Atkin et al., 2013). In agreement with Lafarere et al.'s (2007; 2008) findings, they showed significant increases in GIP gene expression in correlation with the clinical amelioration of T2D following RYGB (Moran-Atkin et al., 2013). To summarize, the current literature suggest that GIP levels are elevated in persons with obesity and T2D which may contribute to insulin resistance and defective glucose-stimulated insulin secretion that are sympromatic in these conditions. Along with this, majority of the findings seem to agree with the notion that GIP decreases following

RYGB. Thus, GIP antagonism may be considered a target action for the therapeutic agents as decrease in GIP or a blockade in its action seem to be theoretically and preliminarily useful for obese persons and T2D patients. However, inconsistencies warrant further investigation.

HIND GUT SIGNALS

L cell-derived factors (peptide tyrosine tyrosine (PYY), glucagon like peptide-1 (GLP-1), GLP- 2, oxyntomodulin (OXM)), pancreatic signals (pancreatic polypeptide (PP), glucagon, insulin, amylin, somatostatin), and adipokines (leptin, adiponectin, resistin) will be reviewed in this section. GLP-1, GLP-2, OXM along with the pancreatic glucagon are products of proglucagon gene and known as proglucagon-derived peptides. However post-translational processing of proglucagon-derived peptides differs in a tissue-specific manner: glucagon is the main product in the pancreas, whereas GLP-1, GLP-2, OXM are the major products in the intestine and the brain (Posovszky and Wabitsch, 2015a; 2015b). PYY ($PYY_{1\text{-}36}$ and $PYY_{3\text{-}36}$) and PP almost exclusively expressed at the level of the digestive system (Cox, 2007; Holzer et al., 2012).

L Cell-Derived Factors

Intestinal L cells are open-type cells predominantly located in the distal ileum and colon and express fatty acid receptors (Pozowski and Wabitsch, 2015a). GLP-1, GLP-2, and OXM are cleaved from the precursor preproglucagon that is synthesized from the intestinal L cells along with PYY. Together, the L cell-derived factors are thought to meadiate an ileal brake effect by reducing gastric acid secretion, gastric emptying and decelerating mouth-to-cecum transit time, and thus reduce food intake and prevent malabsorption and postprandial metabolic disturbances.

Peptide Tyrosine Tyrosine ($PYY_{3\text{-}36}$)

PYY is a 36-amino-acid peptide that has two circulating endogenous forms ($PYY_{1–36}$ and $PYY_{3–36}$) and one of the Neuropeptide Y peptide family, along with Y (NPY), and pancreatic polypeptide (PP) (Michel, 1998; Cox, 2007). $PYY_{3\text{-}36}$ is the biologically active form (Batterham et al., 2003a) and *originally isolated* from porcoine intestine (Tatemoto, 1982). It is produced mostly in the small intestine and colon, released from the L-cells of the distal small bowel postprandially in proportion to the consumed calories. It is co-localized with pro-glucagon products, glicentin and glucagon-like peptide 1 (GLP-1) and GLP-2 (Ekblad and Sunder, 2002). It inhibits food intake (Batterham et al., 2002), increases energy expenditure (Guo et al., 2006) and delays gastric emptying (Sloth et al., 2007). PYY immunoreactivity is also found in the central nervous system regions such as the hypothalamus, medulla, pons, and spinal cord (Ekblad and Sundler, 2002; Kara et al., 2009). G-protein coupled Y receptor superfamily (Y1, Y2, Y4, Y5 and Y6) has specific affinities for each member of the peptide family; NPY and PYY do not grossly differ in their affinities for the Y1, Y2 and Y5 receptors

subtypes and $PYY_{3–36}$ prefrentially binds to Y2 receptors (Cox, 2007). Endogenous $PYY_{3–36}$ levels were found to be low (Batterham et al., 2003a; Cummings et al., 2004; le Roux et al., 2006; Peterli et al., 2012) and blunted in obese individuals (Ashby and Bloom 2007), and increased in patients with anorexia nervosa (Misra et al., 2006).

Postprandial (AUC) PYY_{3-36} levels were persistently elevated post-operatively at 2 weeks (Evans et al., 2012), at 1-month (Jacobsen et al., 2012), and 3- and 12-month post- follow-ups (Korner et al., 2009; Bose et al., 2010). At a 12-month follow-up, it has been reported that fasting and 3-meal 9-hour postprandial PYY_{3-36} (AUC) levels did not differ between patients who lost 85% of their initial weight comparec to the patients who only lost 35% of their initial weight (Dirksen et al., 2013a). However both group of patients had higher levels of AUC PYY_{3-36} than the normal weight individuals showing that the increased levels of PYY_{3-36} did not correlate with weight loss following surgery (Dirksen et al., 2013a). Similarly, postprandial peak for PYY_{3-36} and AUC analysis for postprandial (OGTT) PYY_{3-36} were found to increase significantly in RYGB patients at 1 month follow-up at 10% weight loss compared to the dieting group with the equivalent weight loss (approx. at 8 weeks) (Lafarrere et al., 2010). Regarding the fasting levels of PYY_{3-36} several studies reported no change following RYGB at 2-week (Evans et al., 2012), 1-year (Bose et al., 2010) follow-ups, and with7-10% weight loss levels (Plum et al., 2011). These implicate that the effect of RYGB on PYY_{3-36} is not weight loss dependent and possibly related to the re-arrangement of the GI tract.

Glucagon Like Peptide-1 (GLP-1)

GLP-1 is mainly released by the L-cells of the small bowel following meal ingestion (Naslund et al., 2004; Feinle et al., 2003; Hermann et al., 1995; Doyle and Egan, 2007; Jang et al., 2007).) There are multiple circulating moieties of GLP-1: the biologically active forms, $GLP\text{-}1_{7–37}$ (comprising the 80% of the circulating GLP-1) and $GLP\text{-}1_{7–36}$ and the inactive forms $GLP\text{-}1_{1–37}$ and $GLP\text{-}1_{1–36}$. The active forms are powerful insulinotropics (i.e., they induce insulin secretion) (Schmidt et al., 1985). They act on the pancreas to secrete insulin (incretin effect) and also slow gastric emptying, inhibit glucagon release (Komatsu et al., 1989; Willms et al., 1996, Russell-Jones and Gough, 2012). GLP-1 is secreted in two phases; the first short rapid release occurs 5-10 minutes following a meal, and the later delayed and extended release occurs 30 to 60 minutes postprandially (Hermann et al., 1995; Ghatei et al., 1983). Thus, it is hypothesized that there are two distinct mechanisms of GLP-1 secretion. The initial phase, occurs when L-cells and K/L cells in the upper small intestine are in contact with the nutrients whereas the prolonged second phase occurs when L-cells in the distal bowel are activated (Rocca and Brubaker, 1999; De León et al., 2006). Thus, GLP-1 along with PYY may contribute to the “ileal brake” (Wen et al., 1995), an inhibitory feedback process of nutrients (specifically lipids) in the colon inhibiting motility and transit of further nutrients within the upper GI tract to optimize the meal digestion and absorption (Spiller et al., 1984).

Post-operatively, enhanced amounts of postprandial circulating GLP-1(both maximum peak and AUC) with no change in the fasting levels, have been repeatedly shown, even when there is no significant weight loss (Peterli et al., 2009; Karamanakos et al., 2012; Bose et al.,

2010; Borg et al., 2006; Morinigo et al., 2006; 2008; le Roux et al., 2007; Korner et al., 2006; 2007; 2009; Laferrère et al., 2008; 2010; de Carvalho et al., 2009; Goldfine et al., 2007; Dirksen et al., 2010; Holdstock et al., 2008; Ochner et al., 2011). Furthermore, increased GLP-1 receptor signaling and GLP-1 secretion from the L-cells have also been shown (Mason, 1999; Gaitonde et al., 2012). The reduced size of the stomach and exclusion of the foregut, together allow for a faster delivery of food contents through the gut which may add to the dramatic increase in GLP-1 levels following RYGB. This is the 'hindgut' mechanism that has been proposed in explaining the efficacy of RYGB, whereby a direct flow nutrients to the distal small bowel causing an increase in the incretin effect. Thus the elevated levels of GLP-1 may contribute to the successful weight loss following RYGB in addition to the glucose homeostasis-related effects (i.e.T2D improvements and resolution) (Laferrère et al., 2008; Bose et al., 2009; Peterli et al., 2009). Based on these reports, it is likely that an earlier and enhanced increase in postprandial GLP-1 (and PYY_{3-36}) levels after RYGB may contribute to an early sense of satiety and reduced meal size (Santoro et al., 2008; Borg et al., 2006; le Roux et al., 2006; Rodieux et al., 2008) regardless of the reported unchanged fasting levels in both hormones.

Glucagon-Like Peptide-2 (GLP-2)

The 33-amino-acid peptide GLP-2, along with GLP-1, is also cleaved from the precursor proglucagon by intestinal endocrine L-cells (Rothenberg et al., 1995). However, unlike GLP-1, GLP-2 is not insulinotropic; does not inhibit insulin, but it is co-secreted with GLP-1 into the bloodstream in response to ingestion of lipids and proteins (Doyle and Egan, 2007; Jang et al., 2007; Matikainen et al., 2016). GLP-2 reduces gastric motility and acid secretion (Burrin et al., 2001), increases hexose transport, and in animals is shown to inhibit feeding (Tang-Christensen et al., 2000; Rotondo et al., 2011). However, there are only few studies to date that examined the changes in GLP-2 following bariatric surgery. In a study with obese persons with T2D, GLP-2 was shown to significantly increase postprandially (AUC) 6-weeks after RYGB (Romero et al., 2012). Another study comparing RYGB patients who are weight loss resistant and surgery patients achieving successful weight loss showed no changes in the fasting and postprandial (AUC) levels of GLP-2 at 1-year follow up (de Hollanda et al., 2014). However, although a statistical significance was not reached, an increasing trend for postprandial (AUC) GLP-2 was noted for the successful weight loss group (1354 ± 256 ng/mL) vs. weight loss resistant patients (658 ± 341 ng/mL, marginal means ± SD) (de Hollanda et al., 2014). Increased plasma GLP-2 was also shown following RYGB operation in rats (Le Roux et al., 2010). Based on its role in initiating intestinal epithelial barrier function and mucosal growth (Burrin et al., 2001; Holst 2010) GLP-2 may play a role in gut adaptation following RYGB to prevent malabsorption (Rhee et al., 2015).

Oxyntomodulin (OXM)

OXM is a 37-amino acid peptide originally isolated from porcine jejunoileal cells (Bataille et al., 1981). It is released from the gut in post-prandial state thus has anorectic effects. OXM is another product of the preproglucagon gene and is co-secreted with GLP-1

and PYY by the L-cells of the distal intestines, in response to nutrient ingestion proportionally to the calorie intake (Ghatei et al., 1983). Laferrere and colleagues (2010) also showed that the increase of OXM was strongly correlated with total GLP-1 and PYY_{3-36} after gastric bypass surgery. It was found that OXM shows glucagon-like activity in the liver (Bataille et al., 1982) and has a much lower potency when compared with GLP-1 (Schjoldager et al., 1988). OXM also inhibits gastric acid secretion and delays gastric emptying (Schjoldager et al., 1989). Administration of OXM is associated with decreased food intake and increased energy expenditure in both rodents and humans (Dakin et al., 2001; Cohen et al., 2003; Wynne et al.; 2006, Maida et al., 2008).

Recently, few groups have investigated OXM levels following RYGB. Laferrere and colleagues (2010) reported enhanced levels of OXM (AUC and maximum peak) in response to oral glucose tolerance test (OGTT; 50g glucose load) 1-month following RYGB in morbidly obese women with T2D, which was not found in patients who achieved an equivalent weight loss by dieting. (Laferrere et al., 2010). A similar result was also reported by Le Roux and colleagues showing OXM increases following a standard breakfast postprandially (AUC) 6 months after RYGB (Werling et al., 2015). Another group have also reported slight OXM increases at 2-and 4-months following RYGB for postprandial levels (AUC) in response to OGTT and during fasting, however the effects were not statistically significant (Wu et al., 2013).

The proglucagon gene is also expressed in the intestines L-cells where it is cleaved into a number of peptides other than glucagon (i.e., GLP-1, GLP-2, OXM, glicentin) which were originally termed "enteroglucagon," and are collectively known as "proglucagon-derived peptides." Previous studies indicate that OXM makes up 30–40% of the plasma concentration of enteroglucagon in humans (Holst et al., 1983). Glicentin is a product of the proglucagon gene, and part of it is cleaved to generate OXM similar to GLP-1 (Sinclair and Drucker, 2005; Sala et al., 2014) and some researchers consider glicentin only a remnant metabolite of proglucagon after the cleavage of GLP-1 and GLP-2 (Sinclair and Drucker, 2005). Falken et al. (2011) reported a progressive rise in enteroglucagon at 3 days, 2 months, and 1 year following RYGB. Thus Falken et al. (2011) suggested that OXM may play an indirect role in the consequent weight loss.

PANCREATIC SIGNALS

The pancreatic endocrine cells are located in islets of Langerhans that contain four principal cell types, and are defined by the hormones they secrete. These include insulin and amylin-secreting β-cells (70%), glucagon-secreting α-cells (20%), somatostatin-secreting δ-cells, and pancreatic polypeptide–secreting PP-cells (originally termed F cells) (Fiocca et al., 1983).

Glucagon

Glucagon is produced by α-cells in the pancreatic islets of Langerhans and once released, binds to glucagon receptors in the liver initiating its critical role in glucose homeostasis by

increasing glycogenolysis and gluconeogenesis (Dunning et al., 2007). Glucagon, along with the intestinal GLP-1, GLP-2, OXM, glicentin, is synthesized initially as the protein proglucagon, which, in mammals, is encoded by a single gene. Decreases in food intake have been shown following glucagon administration both in animals (Martin and Novin, 1977) and humans (Penick and Hinkle 1961; Grossman 1986; Geary et al., 1992). It has been used as a therapeutic agent to treat severe hypoglycemia due to excess exogenous insulin administration, neonatal hyperinsulinism (Aynsley-Green et al., 2000), tumor-induced hypoglycemia (Chung et al., 1996), and severe post-RYGB hypoglycemia (Halperin et al., 2010). Elevated fasting plasma glucagon concentrations have been reported in severely obese individuals (Swarbrick et al., 2008).

Although the role of glucagon in glucose homeostasis is well established, so far the relationship between gut hormone responses and glucagon level changes following RYGB has not been extensively studied. Following RYGB (1-4 weeks post-surgery), fasting glucagon was reported to slightly increase (Swarbrick et al., 2008; Jacobsen et al., 2012; Jorgensen et al., 2012). Postprandial (with mixed meal text) glucagon has been found to be significantly higher 2 weeks following RYGB compared to the preoperative levels (Jacobsen et al., 2012) whereas this difference has not been found for glucose tolerance tests (25g and 50g). Lafarere et al. (2010) however found significant increases for AUC analysis of postprandial (OGTT; 50g glucose) glucagon at 1-month follow-up in RYGB patients compared to the dieting group with the equivalent weight loss (8 weeks). Using a mixed meal test, Campos et al. (2013) also reported that postprandial (AUC) glucagon increased at 2 weeks post-operatively however this did not persist and returned to the preoperative baseline levels at 6 months following RYGB. Similar results came from Jorgensen et al. (2012) showing postprandial (mixed meal) increases at 1 week after RYGB which declined and returned to baseline levels at 3 and 12 month follow-ups. Another study in obese patients with T2D also confirmed these findings that, fasting and postprandial (AUC) glucagon increased 2-4 weeks following RYGB which returned to the baseline levels at 3-, 6-, and 12-month follow-ups (Swarbrick et al., 2008; Nannipieri et al., 2013). However, in an earlier study, glucagon values were still found to be higher during mixed meal test in RYGB patients after 2-4 years following the surgery compared to the obese controls (Goldfine et al., 2007). It should be noted that Goldfine et al. (2007) used a cross-sectional study design study that may affect the results based on a possible lower baseline glucagon levels of the obese controls at the time of the study compared to the preoperative baseline glucagon levels in RYGB patients. Thus, based on the previous longitudinal studies, it is a stronger assumption that glucagon has an excursion at short-term after RYGB and a long-term decrease after a substantial weight loss.

Insulin

Insulin is one of the principal hormones involved in glucose metabolism and is synthesized in the ß-cells of the pancreas and rises rapidly after a meal, with well characterized optimization of glycaemic index (Polonsky et al., 1988). Insulin resistance –a key feature of T2D (along with the subsequent hypoinsulinemia followed by hyperglycemia) is defined as the reduced sensitivity to the metabolic actions of insulin on glucose

homeostasis in the muscles and fat tissue or the suppressed hepatic glucose production in the liver (Rask-Madsen et al., 2012; Kahn et al., 2014). Insulin concentrations vary directly with body fat and insulin sensitivity is negatively correlated with body adiposity (Despres and Lemieux, 2006) and reductions of fasting insulin have been well documented following weight loss (Schwartz and Seeley, 1997).

RYGB has been suggested as a potential treatment for T2D as an alternative to pharmacological agents and meta-analyses and longitudinal studies report that that 60-80% of the RYGB patients show a complete resolution of T2D markers such as lower insulin sensitivity and resistance as well as blood glucose levels (Ferrannini et al., 2009; Buchwald et al., 2009a; Adams et al., 2012; Edholm et al., 2013; Yip et al., 2013). Fasting insulin and insulin resistance have been found to lower following RYGB in obese adults (Rodieux et al., 2008; Plum et al., 2011; Jacobsen et al., 2012; Peterli et al., 2009; 2012; Nannipieri et al., 2013) and adolescents (Oberbach et al., 2014). Postprandial (AUC) insulin following a mixed meal was shown to significantly decrease at 1-year follow-up whereas this was not shown at 2 weeks following the surgery (Nannipieri et al., 2013). However, Korner and colleagues reported greater insulin sensitivity and lower insulin resistance (HOMA-IR) following a intravenous glucose tolerance tests (IGTT) and fasting insulin levels in patients who underwent RYGB compared to persons who lost equal amount (7-10% weight loss) of weight by dieting (Plum et al., 2011). Campos et al. (2013) used a more accurate technique (Borai et al., 2011) of hyperinsulinemic euglycemic clamp to measure insulin sensitivity. They found that the average steady-state insulin concentration during the final hour of the euglycemic–hyperinsulinemic clamp decreased significantly in the morbidly obese non-diabetic RYGB patients 2-weeks after surgery, but was unchanged in the dieting group. Moreover, at the 6-month follow-up, when substantial weight loss has been reached, the decrease in steady-state insulin concentrations during clamp persisted, relative to pre-operative values (Campos et al., 2013). In agreement with this,1-year changes in insulin sensitivity were shown to correlate with the corresponding changes in body mass index (BMI) following RYGB (Nannipieri et al., 2013). Thus, the early changes seem to be weight loss-independent.

Pancreatic Polypeptide (PP)

PP, the other member of the Neuropeptide Y Fold Family, is synthesized by endocrine PP cells in the pancreatic islets of Langerhans. It is secreted in response to a meal (Ekblad and Sundler, 2002), exerting anorexic effects in humans (Batterham et al., 2003b) by a mechanism through the parasympathetic vagus nerve (Asakawa et al., 2003; Cox, 2007; Field et al., 2010). The anorectic effects of PP are abolished by vagotomy in rodents (Asakawa et al., 2003). Its role in inhibits gastric emptying which may in part account for its ability to reduce appetite (Murphy and Bloom, 2006; Field et al., 2010).

In RYGB patients, fasting PP was shown to have a strong tendency to decrease at 2 weeks (Jacobsen et al., 2012; Campos et al., 2013), which was found to be significant at 1-month and 1-year follow-ups (Swarbrick et al., 2008). One study with T2D patients who underwent RYGB showed significant increases in fasting PP at 2-week which persisted at 1-year follow-up independent of the T2D remission (Nannipieri et al., 2013). However, the same study also showed marked reductions in postprandial (AUC) PP levels at both 2-week and 1-year follow-ups (Nannipieri et al., 2013). Others reported similar findings for non-T2D

RYGB patients 2 weeks after the surgery (Swarbrick 2008; Campos et al., 2013) and at the 12-month follow-up (Dirksen et al., 2013a).

Amylin

Islet/insulinoma amyloid polypeptide (IAPP, amylin) is a 37-aminoacid secreted hormone that was discovered (Westermark et al., 1986) to be co-secreted with insulin from the in the β-cells within the pancreatic islets of Langerhans with a molar ratio of approximately 15:1 (insulin:amylin) (Hay et al., 2015) in response to blood glucose levels (Kahn et al., 1990). Amylin has been shown to inhibit insulin-stimulated glucose metabolism and muscle glycogen synthesis, and to slow gastric emptying (Hay et al., 2015). It is considered a satiety hormone (Lutz 2005) based on its short-term effects lowering food intake mainly via reducing meal sizes that is possibly through the central mechanisms within the hypothalamus and brain stem (Rowland et al., 1997; Lutz and Meyer 2015). Similar to leptin and insulin, number of experiments suggests a role for amylin as an adiposity signal affecting eating behavior by enhancing the anorectic effects of CCK (Mollet et al., 2003) and obesity was shown to be associated with high levels of amylin (Nannipieri et al., 2013). Administration of pramlintide, a synthetic analogue of human amylin, has been shown to improve glycaemic control and decrease body weight in T2D patients (Thompson et al., 1998; Schorr and Ofan, 2012; Weinzimer et al., 2012) suggesting a role for amylin in glucose mechanism and body weight regulation in humans.

Several studies reported decreased fasting and postprandial amylin (AUC) levels following RYGB at 1-year follow-up (Bose et al., 2010; Nannipieri et al., 2013). However reports on the 2-week follow-up have shown no change in amlyin levels (Nannipieri et al., 2013; Jacobsen et al., 2015). Bose et al., (2010) reported significantly reduced fasting and postprandial amlyin levels at the time when patients reached at least a weight loss of 12kg. These results seem to be in line with the notion that amylim may be considered an adiposity signal. Consistent with this, a recent study showed an association between BMI decreases and lower levels of total amylin in adolescents (Jensen et al., 2015). However most of the studies investigating amylin had been on preclinical models and further investigation is needed to fully understand its mechanism of action in humans.

Somatostatin

Somatostatin is mainly produced in the pancreas but also in the hypothalamus and in the D-cells of the GI tract exerting inhibitory functions and thus decreases the release of GI hormones and appetite (Barkan et al., 2003). Somatostatin analogs were shown to significantly reduce postprandial sensations of fullness in obese humans after a satiating meal without altering the tolerated maximum meal volume or postprandial gastric volume, suggesting an effect on the upper gut sensation but not directly on satiety regulation (Cremonini et al., 2005). Few studies assessing somatostatin showed no change following RYGB during a fasted state (Falken et al., 2011; Jacobsen et al., 2012) and postprandially (AUC) following an OGTT (50g glucose) or a mixed meal (Jacobsen et al., 2012). Statistical

significance was reached for AUC levels in response to 25g glucose load for the same study (Jacobsen et al., 2012).

ADIPOKINES

The adipokines are cytokines that are secreted by adipose tissue. Leptinwas the first adipokine that was discovered (Zhang et al., 1994) and is released by the white adipose tissue (WAT).

Leptin

Leptin is an anorexigenic hormone and involved in long-term energy balance primarily by acting on the hypothalamus to decrease food intake and to increase energy expenditure (Beckman et al., 2011). It is secreted predominantly by the adipocytes with circulating levels proportionally to the fat mass in the body (Considine et al., 1996) and was observed to be higher in obese (vs. lean) persons during fasting and postprandially (Carlson et al., 2009; Carroll et al., 2007). Thus, perhaps it is not surprising that decreased leptin levels have consistently been reported following RYGB (Molina et al., 2003; Nijhuis et al., 2004; DePaula et al., 2009; Korner et al., 2009; Stoeckli et al., 2004; Kotidis et al., 2006; Shak et al., 2008; Faraj et al., 2003; Rubino et al., 2004; Lafarrere et al., 2010; Woelnerhanssen et al., 2011; Terra et al., 2013; Yousseif et al., 2014), and all bariatric surgeries irrespective of the surgery type (Frühbeck et al., 2002; Cigdem et al., 201; Knerr et al., 2006; Garcia de la Torre et al., 2008).

Adiponectin

Adiponectin or adipocyte complement–related protein of 30 kDa is a circulating protein and like leptin, secreted predominantly from the adipose tissue and is highly abundant in the plasma. However, unlike leptin, adiponectin levels remain relatively constant throughout the day and are not affected by food intake (Arora et al., 2006) and inversely correlated with body fat percentage in adults (Ukkola and Santaniemi, 2002) and BMI (Vendrell et al., 2004). Lower plasma levels of adiponectin have been reported in obese individuals with T2D compared to the non-diabetic obese individuals (Vendrell et al., 2004; Garcia de la Torre et al., 2008), suggesting a role in insulin resistance.

Following RYGB, adiponectin has been consistently shown to increase (Holdstock et al., 2003; Vendrell et al., 2004; Garcia de la Torre et al., 2008; Faraj et al., 2003; Whitson et al., 2007b; de Carvalho et al., 2009). To date, many clinical and, preclinical studies, as well as in vitro analyses indicated an involvement of adiponectin in glucose regulation and fatty acid oxidation, thus an association between insulin sensitivity and circulating levels of adiponectin (Fruebis et al., 2001; Diez and Iglesias, 2003; Scherer et al., 2013; Yamauchi et al., 2013; Kadowaki et al., 2014). This suggests adiponection as a potential biomarker for insulin resistance (Scherer et al., 2013; Yamauchi et al., 2013; Kadowaki et al., 2014, Li et al., 2012).

Resistin

Resistin is a one of the family of cysteinerich resistin-like molecules (RELMs) produced by adipocytes and immune competent cells (Steppan et al., 2001a; Holcomb et al., 2000). It was discovered as a secreted product of murine adipose tissue and shown to positively correlate with body weight in animals and to be suppressed by antidiabetic drugs (i.e., thiazoledinedione) (Steppan et al., 2001b). Upon its discovery and regarding its link with inflammation, resistin also was termed FIZZ3 (found in inflammatory zone 3) related to a protein induced during lung inflammation known as 'found in inflammatory zone 1' (Holcomb et al., 2000). Resistin has been mostly studied in animals (Rabe et al., 2008; Won et al., 2009; Rajala et al., 2004; Singhal et al., 2007; Osawa et al., 2008) and is commonly associated with insulin mechanism: higher resistin was speculated to contribute to insulin resistance (Vendrell et al., 2004) and administration of exogenous resistin was found to result in impaired glucose tolerance and insulin resistance in mice (Steppan et al., 2001a).

Numerous studies suggested an association between increased serum resistin levels and obesity, as well as visceral fat (Degawa-Yamauchi et al., 2003; Matsuda et al., 2004; Vendrell et al., 2004; Pagano et al., 2005), insulin resistance (Malo et al., 2011) and inflammatory markers (Vendrell et al., 2004; Luis et al., 2010) in humans. In astudy with children, significantly elevated resistin levels have been reported in children with metabolic syndrome compared to obese children without the metabolic syndrome or the healthy controls(Makni et al., 2013). However inconsistent results exist reporting lack of such correlations between resistin and body weight (Chen et al., 2005; Utzschneider et al., 2005; Won et al.,2009; Rabe et al.,2008; Koc et al., 2011) or insulin sensitivity (Pagano et al., 2005; Utzschneider et al., 2005).

The highest levels of murine resistin have been shown to be expressed in white adipose tissue (i.e., highest in the gonadal adipose tissue) (Steppan and Lazar, 2002). However, human resistin in adipose tissue is significantly lower and almost undetectable. It was shown to be expressed at the highest level in the bone marrow followed by the lung (Patel et al., 2003) with mRNA found in the nonfat cells of adipose depots (Fain et al., 2003) as well as in human placenta (Yura et al., 2003). The discrepancies between the reports may be due to the molecular and genetic diversity between human resistin with its murine counterpart (Steppan and Lazar, 2004). Thus, whether the physiology of mouse resistin is pertinent to humans needs to be determined.

Although there had been implications suggesting a possible role for resistin in the mechanism for the resolution of T2D following bariatric surgery, few studies investigated the alterations in resistin following RYGB in humans (Vendrell et al., 2004; Whitson et al., 2007b; Lee et al., 2011). One study showed no change in resistin levels in morbidly obese patients following gastric bypass at 6-month follow-up (Vendrell et al., 2004). However, they found that preoperative resistin levels were predictive of the extent of weight loss following RYGB (Vendrell et al., 2004). A study in nondiabetic RYGB patients showed a significant increase in resistin after 6 months following the surgery compared to the preoperative levels (Whitson et al., 2007b). However, the small sample size (n =4) weakens the results of this study. Furthermore, Lee et al. (2011) reported lower fasting plasma and postprandial (AUC following a 3-hour mixed meal tolerance test) resistin levels after 2 years following RYGB. Although there was not a preoperative baseline comparison, the intriguing aspect of this study was that they reported that the weight loss at the 2-year follow-up was similar between

RYGB and sleeve gastrectomy patients however there was a significant difference in T2D remission in RYGB compared to the sleeve gastrectomy (81% vs. 19%). Thus the investigators suggested that resistin played a role in T2D resolution (Lee et al., 2011). Taken together, although a link between resistin and T2D has been reported, the normal physiologic role of resistin is still unclear, and the target tissues and molecular mechanisms by which resistin modulates glucose homeostasis require further investigation.

OTHER FACTORS RELATED TO GI TRACT

The alterations in the gut hormones caused by the rearrangement of the gut leading restriction and malabsorption of the nutrients following RYGB have been long suggested to be the major factor behind the success of RYGB leading weight loss and T2D resolution (i.e., the BRAVE effects of RYGB (Bile flow alterations, due to exclusion of the biliary limb, Reduced gastric size, Anatomic gut rearrangement, Vagal alterations secondary to the gut rearrangement, and Enteric (gut) hormone alterations). In addition to the BRAVE effects, recently, it has been suggested that the altered nutrient flux in the GI tract after RYGB might have different effects on the gut microbiota profile along the intestine. Accordingly, numerous studies have been conducted suggesting that the modulation of the gut microbial physiology to be responsible for the outcomes on energy homeostasis and metabolic function following RYGB (Erim et al., 2008, Papasavas et al., 2008). A few studies have examined the post-operative morphological changes following RYGB. Increased cell proliferation and downregulated apoptosis have been shown in the excluded gastric mucosa of the RYGB patents post-operatively compared to the non-operated obese controls (Safatle-Ribeiro et al., 2013). Such morphological and cellular alterations may be linked to changes in the number and function of enteroendocrine cells leading to increased plasma hormone levels after bariatric surgery.

CONCLUSION

Obesity is an epidemic and bariatric surgery is currently the most effective anti-obesity intervention and although the preference rate has been decreased, RYGB is still the most commonly performed bariatric surgery worldwide. However, the complete understanding of the mechanics behind the operation is still under investigation. It has been proposed that the anatomical re-arrangement alters food passage dynamics, evoking changes in gut hormone secretion to food that plays a major role in the efficacy of RYGB. During RYGB, a shortcut to the distal small intestine is created causing the bulk of foods passing into the small intestine without hindrance and a prolonged transit in the small intestine is achieved (Dirksen et al., 2013b); the stomach and chyme are restricted, and excluded from the foregut making the operation both restrictive and malabsorptive in nature. Overall, anorexigenic GLP-1, PYY_{3-36} (Ochner et al., 2011) and orexigenic ghrelin (Ybarra et al., 2009; Sundbom et al., 2007) have been the most intensively studied gut hormones following RYGB and are considered to be the best candidates for explaining the reductions in food intake and a consequent extensive weight loss. Caution must be always applied regarding the factors such

as sample size, ethnicity, methodology (i.e., assay type, test meal load etc.), and obesity category, when interpreting the inconsistencies in findings regarding the gut hormone changes. Thus, contributions of reviews on the subject would prove to be very crucial for the field to have meaningful comparisons. Moreover, the physiological changes after RYGB are unlikely to be due to a single hormone, or single mechanism, but are more likely to due to the complex interplay between the gut hormones as well as the gut-brain communication that has not been reviewed here. Thus, new information is needed on the contribution of the different GI sites in reducing appetite and food intake in addition to its interactions with central systems on energy homeostasis and eating behavior. This will provide better understanding of the efficacy of RYGB on weight loss and may help to develop novel anti-obesity interventions to stimulate GI tract regions without surgery.

REFERENCES

Adams TD, Davidson LE, Litwin SE, et al. Health benefits of gastric bypass surgery after 6 years. *JAMA.* 2012;308(11):1122-1131.

Álvarez-Blasco F, Luque-Ramírez M, Escobar-Morreale HF. Obesity impairs general health-related quality of life (HR-QoL) in premenopausal women to a greater extent than polycystic ovary syndrome (PCOS). *Clinical endocrinology.* 2010;73(5):595-601.

Angrisani L, Santonicola A, Iovino P, Formisano G, Buchwald H, Scopinaro N. Bariatric surgery worldwide 2013. *Obesity surgery.* 2015 1;25(10):1822-32.

Arora S, Anubhuti. Role of neuropeptides in appetite regulation and obesity—review. *Neuropeptides.* 2006; 40:375–401.

Asakawa A, Inui A, Yuzuriha H, Ueno N, Katsuura G, Fujimiya M, Fujino MA, Niijima A, Meguid MM, Kasuga M. Characterization of the effects of pancreatic polypeptide in the regulation of energy balance. *Gastroenterology.* 2003;124(5):1325-36.

Ashby D, Bloom SR. Recent progress in PYY research—an update report for 8th NPY meeting. *Peptides.* 2007;28(2):198-202.

Ashrafian H, le Roux CW. Metabolic surgery and gut hormones–a review of bariatric entero-humoral modulation. *Physiology & behavior.* 2009;97(5):620-31.

Aynsley-Green A, Hussain K, Hall J, Saudubray JM, Nihoul-Fekete C, De Lonlay-Debeney P, Brunelle F, Otonkoski T, Thornton P, Lindley KJ. Practical management of hyperinsulinism in infancy. *Archives of Disease in Childhood-Fetal and Neonatal Edition.* 2000;82(2):F98-107.

Barkan AL, Dimaraki EV, Jessup SK, Symons KV, Ermolenko M, Jaffe CA. Ghrelin secretion in humans is sexually dimorphic, suppressed by somatostatin, and not affected by the ambient growth hormone levels. *The Journal of Clinical Endocrinology & Metabolism.* 2003;88(5):2180-4.

Bataille D, Gespach C, Tatemoto K, Marie JC, Coudray AM, Rosselin G, Mutt V. Bioactive enteroglucagon (oxyntomodulin): present knowledge on its chemical structure and its biological activities. *Peptides.* 1981 Dec 31;2:41-4.

Batterham RL, Cowley MA, Small CJ, Herzog H, Cohen MA, Dakin CL, Wren AM, Brynes AE, Low MJ, Ghatei MA, Cone RD and Bloom SR. Gut hormone PYY(3-36) physiologically inhibits food intake. *Nature,* 2002;418: 650-654.

Batterham RL, Cohen MA, Ellis SM, Le Roux CW, Withers DJ, Frost GS, Ghatei MA, Bloom SR. Inhibition of food intake in obese subjects by peptide YY3–36. *New England Journal of Medicine*. 2003a;349(10):941-8.

Batterham RL, Le Roux CW, Cohen MA, Park AJ, Ellis SM, Patterson M, Frost GS, Ghatei MA, Bloom SR. Pancreatic polypeptide reduces appetite and food intake in humans. *The Journal of Clinical Endocrinology & Metabolism*. 2003b; Aug 1;88(8):3989-92.

Beckman LM, Beckman TR, Sibley SD, Thomas W, Ikramuddin S, Kellogg TA, Ghatei MA, Bloom SR, le Roux CW, Earthman CP. Changes in gastrointestinal hormones and leptin after Roux-en-Y gastric bypass surgery. *Journal of Parenteral and Enteral Nutrition.* 2011 Mar 1;35(2):169-80.

Borai A, Livingstone C, Kaddam I, Ferns G. Selection of the appropriate method for the assessment of insulin resistance. *BMC medical research methodology*. 2011;11(1):1.

Borg CM, le Roux CW, Ghatei MA, Bloom SR, Patel AG, Aylwin SJ. Progressive rise in gut hormone levels after Roux-en-Y gastric bypass suggests gut adaptation and explains altered satiety. *Br J Surg*. 2006 Feb;93(2):210-5.

Bose M, Olivan B, Teixeira J, Pi-Sunyer FX, Laferrère B. Do Incretins play a role in the remission of type 2 diabetes after gastric bypass surgery: What are the evidence? *Obes Surg*. 2009; 19:217–229.

Bose M, Machineni S, Olivan B, Teixeira J, McGinty JJ, Bawa B, et al. Superior appetite hormone profile after equivalent weight loss by gastric bypass compared to gastric banding. *Obesity (Silver Spring).* 2010; 18:1085–1091.

Bryden MP, Ley RG, Sugarman JH. A left-ear advantage for identifying the emotional quality of tonal sequences. *Neuropsychologia.* 1982;20(1):83-7.

Buchwald H, Avidor Y, Braunwald E, Jensen MD, Pories W, Fahrbach K, Schoelles K. Bariatric surgery: a systematic review and meta-analysis. *JAMA* 2004;292(14):1724-37.

Buchwald H, Estok R, Fahrbach K et al. Weight and type 2 diabetes after bariatric surgery: systematic review and meta-analysis. *Am J Med* 2009a;122:248–256.e5.

Buchwald H, Oien DM. Metabolic/bariatric surgery worldwide 2008. *Obesity surgery.* 2009b;19(12):1605-11.

Burrin DG, Petersen Y, Stoll B, Sangild P. Glucagon-like peptide 2: a nutrient-responsive gut growth factor. *The Journal of nutrition.* 2001;131(3):709-12.

Campos GM, Rabl C, Havel PJ, Rao M, Schwarz JM, Schambelan M, Mulligan K. Changes in post-prandial glucose and pancreatic hormones, and steady-state insulin and free fatty acids after gastric bypass surgery. *Surgery for Obesity and Related Diseases.* 2014 Feb 28;10(1):1-8.

Carlson JJ, Turpin AA, Wiebke G, Hunt SC, Adams TD. Pre- and post- prandial appetite hormone levels in normal weight and severely obese women. *Nutr Metab (Lond).* 2009;6:32.

Carrasco, F., Rojas, P., Csendes, A. et al., "Changes in ghrelin concentrations one year after resective and non-resective gastric bypass: associations with weight loss and energy and macronutrient intakes," *Nutrition*, 8(7)757–761, 2012.

Carroll JF, Kaiser KA, Franks SF, Deere C, Caffrey JL. Influence of BMI and gender on postprandial hormone responses. *Obesity* (Silver Spring). 2007 Dec;15(12):2974-83.

Carlson JJ, Turpin AA, Wiebke G, Hunt SC, Adams TD. Pre- and post-prandial appetite hormone levels in normal weight and severely obese women. *Nutr Metab (Lond)* 2009;6:32.

Carrasco F, Rojas P, Csendes A, Codoceo J, Inostroza J, Basfi-fer K, Papapietro K, Watkins G, Rojas J, Ruz M. Changes in ghrelin concentrations one year after resective and non-resective gastric bypass: associations with weight loss and energy and macronutrient intakes. *Nutrition*. 2012;28(7):757-61.

Carter ME, Soden ME, Zweifel LS, Palmiter RD. Genetic identification of a neural circuit that suppresses appetite. *Nature.* 2013;503(7474):111-4.

Cecil JE, Francis J, Read NW. Relative contributions of intestinal, gastric, oro-sensory influences and information to changes in appetite induced by the same liquid meal. *Appetite.* 1998;31(3):377-90.

Cheeseman CI, O'Neill D. Basolateral D-glucose transport activity along the crypt–villus axis in rat jejunum and upregulation induced by gastric inhibitory peptide and glucagon-like peptide-2. *Exp Physiol.* 1998;83:605–16.

Cheeseman CI, Tsang R. The effect of GIP and glucagon-like peptides on intestinal basolateral membrane hexose transport. *Am J Physiol.* 1996;271:G477–82.

Chen CC, Li TC, Li CI, Liu CS, Wang HJ, Lin CC. Serum resistin level among healthy subjects: relationship to anthropometric and metabolic parameters. *Metabolism.* 2005;54(4):471-5.

Choi K, Roh SG, Hong YH, Shrestha YB, Hishikawa D, Chen C, et al. The role of ghrelin and growth hormone secretagogues receptor on rat adipogenesis. *Endocrinology* 2003;144:754–9.

Chung J, Henry RR. Mechanisms of tumor-induced hypoglycemia with intra abdominal hemangiopericytoma. *J Clin Endocrinol Metab* 1996; 81: 919–925.

Cigdem Arica P, Kocael A, Tabak O, Taskin M, Zengin K, Uzun H. Plasma ghrelin, leptin, and orexin-A levels and insulin resistance after laparoscopic gastric band applications in morbidly obese patients. *Minerva Med* 2013;104(3):309e16.

Clements RH, Gonzalez QH, Long CI, et al. Hormonal changes after Roux-en Y gastric bypass for morbid obesity and the control of type-II diabetes mellitus. *Am Surg*. 2004;70:1–4.

Cohen MA, Ellis SM, Le Roux CW, Batterham RL, Park A, Patterson M, Frost GS, Ghatei MA, Bloom SR. Oxyntomodulin suppresses appetite and reduces food intake in humans. *J Clin Endocrinol Metab* 2003; 88:4696–4701.

Cohen RV, Schiavon CA, Pinheiro JS, Correa JL, Rubino F. Duodenal-jejunal bypass for the treatment of type 2 diabetes in patients with body mass index of 22–34 kg/m2: a report of 2 cases. *Surg Obes Relat Dis* 2007; 3(2): 195–197.

Considine RV, Sinha MK, Heiman ML, Kriauciunas A, Stephens TW, Nyce MR, Ohannesian JP, Marco CC, McKee LJ, Bauer TL, Caro JF. Serum immunoreactive-leptin concentrations in normal-weight and obese humans. *New England Journal of Medicine.* 1996;334(5):292-5.

Corp ES, Woods SC, Porte D, Dorsa DM, Figlewicz DP, Baskin DG. Localization of 125I-insulin binding sites in the rat hypothalamus by quantitative autoradiography. *Neuroscience letters.* 1986;70(1):17-22.

Corp ES, McQuade J, Moran TH and Smith GP. Characterization of type A and type B CCK receptor binding sites in rat vagus nerve. *Brain Res*, 1993; 623: 161-166.

Cox HM. Neuropeptide Y receptors; antisecretory control of intestinal epithelial function. *Auton. Neurosci.* 2007;133, 76–85.

Cremonini F, Camilleri M, Gonenne J, Stephens D, Oenning L, Baxter K, Foxx-Orenstein A, Burton D. Effect of somatostatin analog on postprandial satiation in obesity. *Obesity research.* 2005;13(9):1572-9.

Cummings DE, Purnell JQ, Frayo RS, Schmidova K, Wisse BE, Weigle DS. A preprandial rise in plasma ghrelin levels suggests a role in meal initiation in humans. *Diabetes* 2001;50:1714–9.

Cummings DE, Weigle DS, Frayo RS, et al. Plasma ghrelin levels after diet-induced weight loss or gastric bypass surgery. *N Engl J Med*. 2002;346:1623–30.

Creutzfeldt W. The entero-insular axis in type 2 diabetes— incretins as therapeutic agents. *Exp Clin Endocrinol Diabetes*. 2001;109(2):288–303.

Cummings DE, Overduin J, Foster-Schubert KE. Gastric bypass for obesity: mechanisms of weight loss and diabetes resolution. *The journal of clinical endocrinology & metabolism.* 2004;89(6):2608-15.

Dakin CL, Gunn I, Small CJ, Edwards CM, Hay DL, Smith DM, Ghatei MA, Bloom SR. Oxyntomodulin inhibits food intake in the rat. *Endocrinology.* 2001;142(10):4244-50.

de Carvalho CP, Marin DM, de Souza AL, Pareja JC, Chaim EA, de Barros Mazon S, et al. GLP-1 and adiponectin: effect of weight loss after dietary restriction and gastric bypass in morbidly obese patients with normal and abnormal glucose metabolism. *Obes Surg.* 2009;19:313–320.

Degawa-Yamauchi M, Bovenkerk JE, Juliar BE, Watson W, Kerr K, Jones R, Zhu Q, Considine RV Serum resistin (FIZZ3) protein is increased in obese humans. *J Clin Endocrinol Metab* 2003; 88:5452–5455.

de Hollanda A, Jiménez A, Corcelles R, Lacy AM, Patrascioiu I, Vidal J. Gastrointestinal hormones and weight loss response after Roux-en-Y gastric bypass. *Surgery for Obesity and Related Diseases*. 2014;10(5):814-9.

De León DD, Crutchlow MF, Ham JY, Stoffers DA. Role of glucagon-like peptide-1 in the pathogenesis and treatment of diabetes mellitus. *Int J Biochem Cell Biol* 2006;38:845–859.

De Luis DA, Gonzalez Sagrado M, Conde R, Aller R, Izaola O. Resistin levels and inflammatory markers in patients with morbid obesity. *Nutr Hosp.* 2010;25(4):630-4.

DePaula AL, Macedo AL, Schraibman V, Mota BR, Vencio S. Hormonal evaluation following laparoscopic treatment of type 2 diabetes mellitus patients with BMI 20-34. *Surg Endosc.* 2009 Aug;23(8):1724-32.

Despres JP, Lemieux I. Abdominal obesity and metabolic syndrome. *Nature* 2006;444:881–887.

Diez JJ and Iglesias P. The role of the novel adipocyte-derived hormone adiponectin in human disease. *Eur J Endocrinol*, 2003; 148: 293-300.

Dirksen C, Hansen DL, Madsbad S, Hvolris LE, Naver LS, Holst JJ, Worm D. Postprandial diabetic glucose tolerance is normalized by gastric bypass feeding as opposed to gastric feeding and is associated with exaggerated GLP-1 secretion: a case report. *Diabetes Care* 2010; 33(2): 375–377.

Dirksen C, Jørgensen NB, Bojsen-Møller, KN, Kielgast U, Jacobsen SH, Clausen TR, et al. Gut hormones, early dumping and resting energy expenditure in patients with good and poor weight loss response after Roux-en-Y gastric bypass. *International journal of obesity* 2013a, 37(11),1452-9.

Dirksen C, Damgaard M, Bojsen-Møller KN, Jørgensen NB, Kielgast U, Jacobsen SH, Naver LS, Worm D, Holst JJ, Madsbad S, Hansen DL. Fast pouch emptying, delayed small intestinal transit, and exaggerated gut hormone responses after Roux-en-Y gastric bypass. *Neurogastroenterology & Motility*. 2013b;25(4):346-e255.

Doyle ME, Egan JM. Mechanisms of action of glucagon-like peptide 1 in the pancreas. *Pharmacol Ther* 2007;113:546–593.

Dunning BE, Gerich JE. The role of alpha-cell dysregulation in fasting and postprandial hyperglycemia in type 2 diabetes and therapeutic implications. *Endocr Rev* 2007; 28:253–283.

Edholm D, Svensson F, Naslund I, Karlsson FA, Rask E, Sundbom M. Long-term results 11 years after primary gastric bypass in 384 patients. *Surg Obes Relat Dis* 2013;9:708.

Edwards C, Hindle AK, Fu S, Brody F. Downregulation of leptin and resistin expression in blood following bariatric surgery. *Surg Endosc* 2011; 25:1962–1968.

Ekblad E, Sundler F, Distribution of pancreatic polypeptide and peptide YY. *Peptides* 2002; 23, 251–261.

English PJ, Ghatei MA, Malik IA, Bloom SR, Wilding JP. Food fails to suppress ghrelin levels in obese humans. *J Clin Endocrinol Metab* 2002;87:2984.

Erim T, Cruz-Correa MR, Szomstein S, Velis E, & Rosenthal R. Prevalence of Helicobacter pylori seropositivity among patients undergoing bariatric surgery: a preliminary study. *World journal of surgery*. 2008; 32(9): 2021-2025.

Fain JN, Cheema PS, Bahouth SW, Lloyd Hiler M. Resistin release by human adipose tissue explants in primary culture. *Biochem Biophys Res Commun* 2003; 300: 674–8.

Falkén Y, Hellström PM, Holst JJ, Nälund E. Changes in glucose homeostasis after Roux-en-Y gastric bypass surgery for obesity at day three, two months, and one year after surgery: role of gut peptides. *J Clin Endocrinol Metab* 2011;96:2227-2235.

Faraj M, Havel PJ, Phelis S, Blank D, Sniderman AD, Cianflone K. Plasma acylation-stimulating protein, adiponectin, leptin, and ghrelin before and after weight loss induced by gastric bypass surgery in morbidly obese subjects. *J Clin Endocrinol Metab*. 2003; 88:1594–1602.

Feinle C, O'Donovan D, Doran S, Andrews JM, Wishart J, Chapman I and Horowitz M. Effects of fat digestion on appetite, APD motility, and gut hormones in response to duodenal fat infusion in humans. *Am J Physiol Gastrointest Liver Physiol*, 2003; 284: G798-807.

Ferrannini E, Mingrone G. Impact of different bariatric surgical procedures on insulin action and beta-cell function in type 2 diabetes. *Diabetes Care* 2009;32:514-20.

Field BC, Chaudhri OB, Bloom SR. Bowels control brain: gut hormones and obesity. *Nature reviews endocrinology*. 2010;6(8):444-53.

Fiocca R, Sessa F, Tenti P, Usellini L, Capella C, O'Hare M.M, Solcia E. Pancreatic Polypeptide (PP) cells in the PP-rich lobe of the human pancreas are indentified ultrastructurally and immunocytochemically as F cells. *Histochemistry* 1983; 77: 511-523.

Flegal, K.M. and D.F. Williamson, Incident CHD and excess body weight in the US population. *Obesity (Silver Spring)*, 2010. 18(6): 1069; author reply 1069-70.

Foschi D, Corsi F, Colombo F, Vago T, Bevilaqua M, Rizzi A, et al. Different effects of vertical banded gastroplasty and Roux-en-Y gastric bypass on meal inhibition of ghrelin secretion in morbidly obese patients. *J Invest Surg* 2008;21:77–81.

Fruebis J, Tsao TS, Javorschi S, Ebbets-Reed D, Erickson MR, Yen FT, Bihain BE, Lodish HF. Proteolytic cleavage product of 30-kDa adipocyte complement-related protein increases fatty acid oxidation in muscle and causes weight loss in mice. P*roceedings of the national academy of sciences.* 2001;98(4):2005-10.

Frühbeck G, Diez-Caballero A, G_omez-Ambrosi J, Gil MJ, Monreal I, Salvador J, et al. Disruption of the leptin-insulin relationship in obesemen24 hours after laparoscopic adjustable silicone gastric banding. *Obes Surg* 2002;12(3):366e71.

Frühbeck G, Rotellar F, Hernandez-Lizoain JL, Gil MJ, Gomez-Ambrosi J, Salvador J, et al. Fasting plasma ghrelin concentrations 6 months after gastric bypass are not determined by weight loss or changes in insulinemia. *Obes Surg* 2004;14:1208–15.

Gaitonde S, Kohli R, Seeley R. The role of the gut hormone GLP-1 in the metabolic improvements caused by ileal transposition. *J Surg Res* 2012; 178(1): 33–39.

Garcia de la Torre N, Rubio MA, Bordiu E, Cabrerizo L, Aparicio E, Hernandez C, et al. Effects of weight loss after bariatric surgery for morbid obesity on vascular endothelial growth factor-A, adipocytokines, and insulin. *J Clin Endocrinol Metab* 2008;93: 4276–81.

Garcia-Fuentes E, Garrido-Sanchez L, Garcia-Almeida JM, Garcia-Arnes J, Gallego-Perales JL, Rivas-Marin J, Morcillo S, Cardona I, Soriguer F. Different effect of laparoscopic Roux-en-Y gastric bypass and open biliopancreatic diversion of Scopinaro on serum PYY and ghrelin levels. *Obesity surgery*. 2008;18(11):1424-9.

Gautier JF, Choukem SP, Girard J. Physiology of incretins (GIP and GLP-1) and abnormalities in type 2 diabetes. *Diabetes Metab* 2008;34(2):S65–S72.

Geary N, Kissileff HR, Pi-Sunyer FX, Hinton VE. Individual, but not simultaneous, glucagon and cholecystokinin infusions inhibit feeding in men. *American journal of physiology-regulatory, integrative and comparative physiology.* 1992;262(6):R975-80.

Ghatei MA, Uttenthal LO, Christofides ND, Bryant MG, Bloom SR. Molecular Forms of Human Enteroglucagon in Tissue and Plasma: Plasma Responses to Nutrient Stimuli in Health and in Disorders of the Upper Gastrointestinal Tract*. *The journal of clinical endocrinology & metabolism. 1983*;57(3):488-95.

Gibbs J, Young RC and Smith GP. Cholecystokinin decreases food intake in rats. *J Comp Physiol Psychol*, 1973;84: 488-495.

Gloy VL, Briel M, Bhatt DL, Kashyap SR, Schauer PR, Mingrone G, et al. Bariatric surgery versus non-surgical treatment for obesity: a systematic review and meta-analysis of randomised controlled trials. *British Medical Journal*, 2013;347, f5934.

Goldfine AB, Mun EC, Devine E, Bernier R, Baz-Hecht M, Jones DB, et al. Patients with neuroglycopenia after gastric bypass surgery have exaggerated incretin and insulin secretory responses to a mixed meal. *J Clin Endocrinol Metab* 2007; 92(12): 4678–4685.

Goldstein JM, Jerram M, Poldrack R, Ahern T, Kennedy DN, Seidman LJ, et al. Hormonal cycle modulates arousal circuitry in women using functional magnetic resonance imaging. *J Neurosci*. 2005;25(40):9309-16.

Gortmaker, S.L., et al., Social and economic consequences of overweight in adolescence and young adulthood. *N Engl J Med*, 1993. 329(14): p. 1008-12.

Gourcerol G, Coskun T, Craft LS, Mayer JP, Heiman ML, Wang L, Million M, St-Pierre DH, Taché Y. Preproghrelin-derived peptide, obestatin, fails to influence food intake in lean or obese rodents. *Obesity.* 2007;15(11):2643-52.

Grong E, Græslie H, Munkvold B, Arbo IB, Kulseng BE, Waldum HL, Mårvik R. Gastrin secretion after bariatric surgery—response to a protein-rich mixed meal following Roux-En-Y gastric bypass and sleeve gastrectomy: a pilot study in normoglycemic women. *Obesity surgery.* 2015;27:1-9.

Gunstad J, Strain G, Devlin MJ, Wing R, Cohen RA, Paul RH et al. Improved memory function 12 weeks after bariatric surgery. *Surg Obes Relat Dis* 2011; 7: 465–472.

Guo Y, Ma L, Enriori PJ, Koska J, Franks PW, Brookshire T, Cowley MA, Salbe AD, DelParigi A, Tataranni PA. Physiological evidence for the involvement of peptide YY in the regulation of energy homeostasis in humans. *Obesity*. 2006;14(9):1562-70.

Guo ZF, Zheng X, Qin Y-W, et al. Circulating preprandial ghrelin to obestatin ratio is increased in human obesity. *J Clin Endocrinol Metab.* 2007;92:1875–80.

Herrmann, C., et al., Glucagon-like peptide-1 and glucose-dependent insulin-releasing polypeptide plasma levels in response to nutrients. *Digestion,* 1995;56(2):117-26.

Holcomb IN, Kabakoff RC, Chan B et al. FIZZ1, a novel cysteine- rich secreted protein associated with pulmonary inflammation, defines a new gene family. *EMBO J* 2000; 19: 4046–55.

Holdstock C, Engstrom BE, Ohrvall M, Lind L, Sundbom M, Karlsson FA. Ghrelin and adipose tissue regulatory peptides: effect of gastric bypass surgery in obese humans. *J Clin Endocrinol Metab*. 2003;88:3177–83.

Holdstock C, Zethelius B, Sundbom M, Karlsson FA, Edén Engström B. Postprandial changes in gut regulatory peptides in gastric bypass patients. *Int J Obes (Lond)* 2008; 32(11): 1640–1646.

Holst JJ, Pedersen JH, Baldissera F, Stadil F. Circulating glucagon after total pancreatectomy in man. *Diabetologia* 1983; 25:396–399.

Holst JJ. Glucagon and glucagon-like peptides 1 and 2. *Cellular Peptide Hormone Synthesis and Secretory Pathways.* Berlin Heidelberg. Springer. 2009.

Holzer HH, Turkelson CM, Solomon TE and Raybould HE. Intestinal lipid inhibits gastric emptying via CCK and a vagal capsaicin-sensitive afferent pathway in rats. *Am J Physiol,* 1994;267: G625-629.

Howard AD, Feighner SD, Cully DF, Arena JP, Liberator PA, Rosenblum CI, et al. A receptor in pituitary and hypothalamus that functions in growth hormone release. *Science* 1996;273:974–7.

Huda MS, Durham BH, Wong SP, Deepak D, Kerrigan D, McCulloch P, Ranganath L, Pinkney J, Wilding JP. Plasma obestatin levels are lower in obese and post-gastrectomy subjects, but do not change in response to a meal. *International journal of obesity.* 2008;32(1):129-35.

Itoh H, Takei K. Immunohistochemical and statistical studies on the islets of Langerhans pancreas in autopsied patients after gastrectomy. *Human pathology.* 2000;31(11):1368-76.

Jacobsen SH, Olesen SC, Dirksen C, Jørgensen NB, Bojsen-Møller KN, Kielgast U, Worm D, Almdal T, Naver LS, Hvolris LE, Rehfeld JF. Changes in gastrointestinal hormone responses, insulin sensitivity, and beta-cell function within 2 weeks after gastric bypass in non-diabetic subjects. *Obesity surgery.* 2012;22(7):1084-96.

Jang HJ, Kokrashvili Z, Theodorakis MJ, Carlson OD, Kim BJ, Zhou J, Kim HH, Xu X, Chan SL, Juhaszova M, et al. Gut-expressed gustducin and taste receptors regulate secretion of glucagon-like peptide-1. *Proc Natl Acad Sci USA* 2007;104:15069–15074.

Jensen DE, Nguo K, Baxter KA, Cardinal JW, King NA, Ware RS, Truby H, Batch JA. Fasting gut hormone levels change with modest weight loss in obese adolescents. *Pediatric obesity.* 2015;10(5):380-7.

Kadowaki T, Yamauchi T, Okada-Iwabu M, Iwabu M. Adiponectin and its receptors: implications for obesity-associated diseases and longevity. *Lancet Diabetes Endocrinol.* 2014;2(1):8-9.

Kahn SE, D'Alessio DA, Schwartz MW, Fujimoto WY, Ensinck JW, Taborsky GJ, Porte D. Evidence of cosecretion of islet amyloid polypeptide and insulin by β-cells. *Diabetes.* 1990;39(5):634-8.

Kahn SE, Cooper ME, Del Prato S. Pathophysiology and treatment of type 2 diabetes: perspectives on the past, present, and future. *Lancet.* 2014;383(9922):1068-83.

Kalogeris TJ, Reidelberger RD, Mendel VE. Effect of nutrient density and composition of liquid meals on gastric emptying in feeding rats. *American journal of physiology-regulatory, integrative and comparative physiology.* 1983;244(6):R865-71.

Karra E, Chandarana K, Batterham RL. The role of peptide YY in appetite regulation and obesity. *The journal of physiology.* 2009;587(1):19-25.

Karamanakos SN, Vagenas K, Kalfarentzos F, Alexandrides TK. Weight loss, appetite suppression, and changes in fasting and postprandial ghrelin and peptide-YY levels after Roux-en- Y gastric bypass and sleeve gastrectomy: a prospective, double blind study. *Ann Surg.* 2008;247:401–407.

Katsusuke S, Takeuchi T, Watanabe S, Nishiwaki H. Postprandial plasma cholecystokinin response in patients after gastrectomy and pancreatoduodenectomy. *Am J Gastroenterol.* 2008; 81:1038–1042.

Kellum JM, Kuemmerle JF, O'Dorisio TM, Rayford P, Martin D, Engle K, et al. Gastrointestinal hormone responses to meals before and after gastric bypass and vertical banded gastroplasty. *Ann Surg.*1990;211:763–770.

Kissileff HR, Pi-Sunyer FX, Thornton J and Smith GP. C-terminal octapeptide of cholecystokinin decreases food intake in man. *Am J Clin Nutr,* 1981;34: 154-160.

Kissileff HR, Carretta JC, Geliebter A and Pi-Sunyer FX. Cholecystokinin and stomach distension combine to reduce food intake in humans. *Am j physiol regul integr comp physiol*, 2003; 285: R992-998.

Kloting N, Graham TE, Berndt J, et al. Serum retinol-binding protein is more high-ly expressed in visceral than in subcutaneous adipose tissue and is a marker of intra-abdominal obesity fat mass. *Cell Metab* 2007;6:79–87.

Knerr I, Herzog D, Rauh M, RascherW, Horbach T. Leptin and ghrelin expression in adipose tissues and serum levels in gastric banding patients. *Eur J Clin Invest* 2006;36(6):389e94.

Koç F, Tokaç M, Kocabas V, Kaya C, Buyukbas S, Erdem S, Karabag T, Demir K, Alihanoglu Y, Kaya A. Ghrelin, resistin and leptin levels in patients with metabolic syndrome. *European Journal of General Medicine. Eur J Gen Med*, 2011;8 (2) 92–97.

Kojima M, Hosoda H, Date Y, Nakazato M, Matsuo H, Kangawa K. Ghrelin is a growth-hormone-releasing acylated peptide from stomach. *Nature* 1999;402: 656–60.

Komatsu R, Matsuyama T, Namba M, Watanabe N, Itoh H, Kono N, Tarui S. Glucagonostatic and insulinotropic action of glucagonlike peptide I-(7–36)-amide. *Diabetes* 1989;38:902–905.

Korner J, Inabnet W, Conwell IM, Taveras C, Daud A, Olivero- Rivera L, Restuccia NL, Bessler M. Differential effects of gastric bypass and banding on circulating gut hormone and leptin levels. *Obesity (Silver Spring)* 2006; 14(9): 1553–1561.

Korner J, Bessler M, Inabnet W, Taveras C, Holst JJ. Exaggerated glucagon-like peptide-1 and blunted glucose-dependent insulinotropic peptide secretion are associated with Roux-en-Y gastric bypass but not adjustable gastric banding. *Surg Obes Relat Dis* 2007; 3(6): 597–601.

Korner J, Inabnet W, Febres G, Conwell IM, McMahon DJ, Salas R, et al. Prospective study of gut hormone and metabolic changes after adjustable gastric banding and Roux-en-Y gastric bypass. *Int J Obes (Lond).* 2009 Jul;33(7):786-95.

Kotidis EV, Koliakos GG, Baltzopoulos VG, Ioannidis KN, Yovos JG, Papavramidis ST. Serum ghrelin, leptin and adiponectin levels before and after weight loss: comparison of three methods of treatment—prospective study. *Obes Surg.* 2006; 16:1425–1432.

Lacquaniti A, Donato V, Chirico V, Buemi A, Buemi M. Obestatin: an interesting but controversial gut hormone. *Annals of nutrition and metabolism.* 2011;59(2-4):193-9.

Laferrere B, Heshka S, Wang K, et al. Incretin levels and effect are markedly enhanced 1 month after Roux-en-Y gastric bypass surgery in obese patients with type 2 diabetes. *Diabetes Care* 2007; 30:1709–16.

Laferrère B, Teixeira J, McGinty J, Tran H, Egger JR, Colarusso A, et al. Effect of weight loss by gastric bypass surgery versus hypocaloric diet on glucose and incretin levels in patients with type 2 diabetes. *J Clin Endocrinol Metab* 2008; 93(7): 2479–2485.

Laferrere B, Swerdlow N, Bawa B, Arias S, Bose M, Olivan B, Teixeira J, McGinty J, Rother KI. Rise of oxyntomodulin in response to oral glucose after gastric bypass surgery in patients with type 2 diabetes. *The journal of clinical endocrinology & metabolism.* 2010;95(8):4072-6.

Lal S, McLaughlin J, Barlow J, D'Amato M, Giacovelli G, Varro A, Dockray GJ and Thompson DG. Cholecystokinin pathways modulate sensations induced by gastric distension in humans. *Am j physiol gastrointest liver physiol,* 2004; 287: G72-79.

Lee WJ, Chen CY, Chong K, et al. Changes in postprandial gut hormones after metabolic surgery: a comparison of gastric bypass and sleeve gastrectomy. *Surg Obes Relat Dis.* 2011;7(6):683–90.

le Roux CW, Aylwin SJ, Batterham RL, Borg CM, Coyle F, Prasad V, et al. Gut hormone profiles following bariatric surgery favor an anorectic state, facilitate weight loss, and improve metabolic parameters. *Ann Surg.* 2006;243(1):108-14.

le Roux CW, Welbourn R, Werling M, Osborne A, Kokkinos A, Laurenius A, et al. Gut hormones as mediators of appetite and weight loss after Roux-en-Y gastric bypass. *Ann Surg.* 2007; 246:780–785.

le Roux CW, Borg C, Wallis K, Vincent RP, Bueter M, Goodlad R, Ghatei MA, Patel A, Bloom SR, Aylwin SJ. Gut hypertrophy after gastric bypass is associated with increased glucagon-like peptide 2 and intestinal crypt cell proliferation. *Annals of surgery.* 2010;252(1):50-6.

Li FY, Lam KS, Xu A. Therapeutic perspectives for adiponectin: an update. *Current medicinal chemistry*. 2012;19(32):5513-23.

Liddle RA, Goldfine ID, Rosen MS, Taplitz RA and Williams JA. Cholecystokinin bioactivity in human plasma. Molecular forms, responses to feeding, and relationship to gallbladder contraction. *J Clin Invest,* 1985;75: 1144-1152.

Lieverse RJ, Jansen JB, Masclee AM and Lamers CB. Satiety effects of cholecystokinin in humans. *Gastroenterology*, 1994;106: 1451-1454.

Lin E, Gletsu N, Fugate K, McClusky D, Gu LH, Zhu JL, et al. The effects of gastric surgery on systemic ghrelin levels in the morbidly obese. *Arch Surg* 2004;139:780–4.

Lippl F, Erdmann J, Lichter N, et al. Relation of plasma obestatin levels to BMI, gender, age and insulin. *Horm Metab Res.* 2008;40:806–12.

Lutter M and Nestler EJ. Homeostatic and hedonic signals interact in the regulation of food intake. *J Nutr,* 2009;139(3):629-32.

Lutz TA. Pancreatic amylin as a centrally acting satiating hormone. *Curr Drug Targets* 2005; 6: 181–189.

Lutz TA, Meyer U. Amylin at the interface between metabolic and neurodegenerative disorders. *Frontiers in neuroscience.* 2015; 9:216.

Maida A, Lovshin JA, Baggio LL, Drucker DJ. The glucagon-like peptide-1 receptor agonist oxyntomodulin enhances β-cell function but does not inhibit gastric emptying in mice. *Endocrinology* 2008;149:5670–5678.

Makni E, Moalla W, Benezzeddine-Boussaidi L, Lac G, Tabka Z, Elloumi M. Correlation of resistin with inflammatory and cardiometabolic markers in obese adolescents with and without metabolic syndrome. *Obes Facts* 2013;6(4):393–404.

Malo E, Ukkola O, Jokela M, et al: Resistin is an indicator of the metabolic syndrome according to five different definitions in the Finnish health 2000 survey. *Metab Syndr Relat Disord* 2011;9:203-210.

Martin JR, Novin D. Decreased feeding in rats following hepatic-portal infusion of glucagon. *Physiology & behavior.* 1977;19(4):461-6.

Martins C, Kjelstrup L, Mostad IL, Kulseng B. Impact of sustained weight loss achieved through Roux-en-Y gastric bypass or a lifestyle intervention on ghrelin, obestatin, and ghrelin/obestatin ratio in morbidly obese patients. *Obesity surgery.* 2011;21(6):751-8.

Mason EE. Ilial transposition and enteroglucagon/GLP-1 in obesity (and diabetic?) surgery. *Obes Surg* 1999; 9(3): 223–228.

Matikainen N, Björnson E, Söderlund S, Borén C, Eliasson B, Pietiläinen KH, Bogl LH, Hakkarainen A, Lundbom N, Rivellese A, Riccardi G. Minor Contribution of Endogenous GLP-1 and GLP-2 to Postprandial Lipemia in Obese Men. *PloS one.* 2016;11(1).

Matsuda M, Kawasaki F, Yamada K, Kanda Y, Saito M, Eto M, et al. Impact of adiposity and plasma adipocytokines on diabetic angiopathies in Japanese type 2 diabetic subjects. *Diabet Med* 2004;21(8):881–8.

McIntosh CH, Widenmaier S, Kim SJ. Glucose-dependent insulinotropic polypeptide (gastric inhibitory polypeptide; GIP). *Horm.* 2009;80:409–71.

McLaughlin J, Lucà MG, Jones MN, D'Amato M, Dockray GJ, Thompson DG. Fatty acid chain length determines cholecystokinin secretion and effect on human gastric motility. *Gastroenterology.* 1999;116(1):46-53.

Meguid MM, Glade MJ, Middleton FA. Weight regain after Roux-en-Y: a significant 20% complication related to PYY. *Nutrition.* 2008;24(9):832-42.

Mei N, Intestinal chemosensitivity. *Physiol Rev,* 1985;65(2):211-37.

Menéndez J, Atrens DM. Insulin and the paraventricular hypothalamus: modulation of energy balance. *Brain research.* 1991;555(2):193-201.

Michel MC, Beck-Sickinger A, Cox H, Doods HN, Herzog H, Larhammar D, Quirion R, Schwartz T, Westfall T. XVI. International Union of Pharmacology recommendations for the nomenclature of neuropeptide Y, peptide YY, and pancreatic polypeptide receptors. *Pharmacological reviews*. 1998;50(1):143-50.

Misra M, Miller KK, Tsai P, Gallagher K, Lin A, Lee N, Herzog DB, Klibanski A. Elevated peptide YY levels in adolescent girls with anorexia nervosa. *The journal of clinical endocrinology & metabolism*. 2006;91(3):1027-33.

Molina A, Vendrell J, Gutiérrez C, Simón I, Masdevall C, Soler J, Gómez JM. Insulin resistance, leptin and TNF-α system in morbidly obese women after gastric bypass. *Obesity surgery.* 2003;13(4):615-21.

Mollet A, Meier S, Grabler V, Gilg S, Scharrer E, and Lutz TA. Endogenous amylin contributes to the anorectic effects of cholecystokinin and bombesin. *Peptides* 2003a; 24:91–98.

Moran TH, Kornbluh R, Moore K and Schwartz GJ. Cholecystokinin inhibits gastric emptying and contracts the pyloric sphincter in rats by interacting with low affinity CCK receptor sites. 1994; *Regul Pept*, 52: 165-172.

Moran TH. Cholecystokinin and satiety: current perspectives. *Nutrition.* 2000;16:858–65.

Moran-Atkin E, Brody F, Fu SW, Rojkind M. Changes in GIP gene expression following bariatric surgery. *Surg Endosc*, 2013;27:2492–2497.

Moriarty P, Dimaline R, Thompson DG and Dockray GJ. Characterization of cholecystokinin A and cholecystokinin B receptors expressed by vagal afferent neurons. *Neuroscience*, 1997;79: 905-913.

Morinigo R, Casamitjana R, Moize V, Lacy AM, Delgado S, Gomis R, et al. Short-term effects of gastric bypass surgery on circulating ghrelin levels. *Obes Res* 2004;12: 1108–16.

Morinigo R, Moize V, Musri M, Lacy AM, Navarro S, Marin JL, et al. Glucagon-like peptide-1, peptide YY, hunger, and satiety after gastric bypass surgery in morbidly obese subjects. *J Clin Endocrinol Metab.* 2006; 91:1735–1740.

Morinigo R, Vidal J, Lacy AM, Delgado S, Casamitjana R, Gomis R. Circulating peptide YY, weight loss, and glucose homeostasis after gastric bypass surgery in morbidly obese subjects. *Ann Surg.* 2008; 247:270–275.

Nannipieri M, Baldi S, Mari A, Colligiani D, Guarino D, Camastra S, Barsotti E, Berta R, Moriconi D, Bellini R, Anselmino M. Roux-en-Y gastric bypass and sleeve gastrectomy: mechanisms of diabetes remission and role of gut hormones. *The journal of clinical endocrinology & metabolism.* 2013;98(11):4391-9.

Näslund E, King N, Mansten S, Adner N, Holst JJ, Gutniak M, Hellström PM. Prandial subcutaneous injections of glucagon-like peptide-1 cause weight loss in obese human subjects. *British journal of nutrition.* 2004;91(03):439-46.

Naslund E, Hellstrom PM. Appetite signaling: from gut peptides and enteric nerves to brain. *Physiol Behav.* 2007;92(1-2):256-62.

Nauck MA, Homberger E, Siegel EG, Allen RC, Eaton RP, Ebert R, Creutzfeldt W. Incretin effects of increasing glucose loads in man calculated from venous insulin and C-peptide responses. *J Clin Endocrinol Metab* 1986; 63:492–498.

Nijhuis J, van Dielen FM, Buurman WA, Greve JW. Ghrelin, leptin and insulin levels after restrictive surgery: a 2-year follow-up study. *Obes Surg.* 2004;14(6):783-7.

Ochner CN, Stice E, Hutchins E, Afifi L, Geliebter A, Hirsch J, Teixeira J. Relation between changes in neural responsivity and reductions in desire to eat high-calorie foods following gastric bypass surgery. *Neuroscience*. 2012;209:128-35.

Osawa H, Ochi M, Tabara Y, Kato K, Yamauchi J, Takata Y, et al. Serum resistin is positively correlated with the accumulation of metabolic syndrome factors in type 2 diabetes. *Clin Endocrinol (Oxf).* 2008; 69:74–80.

Pagano C, Marin O, Calcagno A, Schiappelli P, Pilon C, Milan G, et al. Increased serum resistin in adults with Prader-Willi syndrome is related to obesity and not to insulin resistance. *J Clin Endocrinol Metab 2005*;90(7):4335–40.

Papasavas PK, Gagné DJ, Donnelly PE, Salgado J, Urbandt JE, Burton KK, et al. Prevalence of Helicobacter pylori infection and value of preoperative testing and treatment in patients undergoing laparoscopic Roux-en-Y gastric bypass. *Surgery for obesity and related diseases*. 2008; 4(3): 383-388.

Pardina E, Lopez-Tejero MD, Llamas R, Catalan R, Galard R, Allende H, et al. Ghrelin and apolipoprotein AIV levels show opposite trends to leptin levels during weight loss in morbidly obese patients. *Obes Surg* 2009;19:1414–23.

Parker BA, Doran S, Wishart J, Horowitz M and Chapman IM. Effects of small intestinal and gastric glucose administration on the suppression of plasma ghrelin concentrations in healthy older men and women. *Clin Endocrinol (Oxf),* 2005; 62: 539-546.

Paschetta E, Hvalryg M, Musso G. Glucose-dependent insulinotropic polypeptide: from pathophysiology to therapeutic opportunities in obesity-associated disorders. *Obesity Reviews.* 2011;12(10):813-28.

Patel L, Buckels AC, Kinghorn IJ, Murdock PR, Holbrook JD, Plumpton C, Macphee CH, Smith SA. Resistin is expressed in human macrophages and directly regulated by PPARγ activators. *Biochemical and biophysical research communications.* 2003;300(2):472-6.

Penick SB, Hinkle Jr LE, Paulsen EG. Depression of food intake induced in healthy subjects by glucagon. *New England journal of medicine*. 1961;264(18):893-7.

Peterli R, Wolnerhanssen B, Peters T, Devaux N, Kern B, Christoffel-Courtin C, et al. Improvement in glucose metabolism after bariatric surgery: comparison of laparoscopic Roux-en-Y gastric bypass and laparoscopic sleeve gastrectomy: a prospective randomized trial. *Ann Surg*. 2009; 250:234–241.

Peterli R, Steinert RE, Woelnerhanssen B, Peters T, Christoffel-Courtin C, Gass M, Kern B, von Fluee M, Beglinger C. Metabolic and hormonal changes after laparoscopic Roux-en-Y gastric bypass and sleeve gastrectomy: a randomized, prospective trial. *Obes Surg.* 2012;22(5):740-8.

Poirier P, Giles TD, Bray GA, Hong Y, Stern JS, Pi-Sunyer FX, Eckel RH. Obesity and cardiovascular disease: pathophysiology, evaluation, and effect of weight loss an update of the 1997 American Heart Association Scientific statement on obesity and heart disease from the obesity committee of the council on nutrition, physical activity, and metabolism. *Circulation* 2006;113(6):898-918.

Polednak AP. Estimating the number of U.S. incident cancers attributable to obesity and the impact on temporal trends in incidence rates for obesity-related cancers. *Cancer Detect Prev*, 2008. 32(3):190-9.

Polonsky KS, Given BD, Van Cauter E. Twenty-four-hour profiles and pulsatile patterns of insulin secretion in normal and obese subjects. *Journal of clinical investigation.* 1988;81(2):442.

Porte Jr D, Woods SC. Regulation of food intake and body weight by insulin. *Diabetologia.* 1981;20(3):274-80.

Posovszky C, Wabitsch M. Regulation of appetite, satiation, and body weight by enteroendocrine cells. Part 1: characteristics of enteroendocrine cells and their capability of weight regulation. *Hormone Research in Paediatrics.* 2015;83(1):1-10.

Posovszky C, Wabitsch M. Regulation of Appetite, Satiation, and Body Weight by Enteroendocrine Cells. Part 2: Therapeutic Potential of Enteroendocrine Cells in the Treatment of Obesity. *Hormone Research in Paediatrics.* 2015;83(1):11-18.

Prudom C, Liu J, Patrie J, Gaylinn BD, Foster-Schubert KE, Cummings DE, et al. Comparison of competitive radioimmunoassays and two-site sandwich assays for the measurement and interpretation of plasma ghrelin levels. *J Clin Endocrinol Metab*. 2010;95:2351-8.

Rabe K, Lehrke M, Parhofer KG, Broedl UC (2008) Adipokines and insulin resistance. *Mol Med* 14:741–751.

Rabiee A, Magruder JT, Salas-Carrillo R, Carlson O, Egan JM, Askin FB, Elahi D, Andersen DK. Hyperinsulinemic hypoglycemia after Roux-en-Y gastric bypass: unraveling the role of gut hormonal and pancreatic endocrine dysfunction. *Journal of Surgical Research.* 2011;167(2):199-205.

Rajala MW, Qi Y, Patel HR, Takahashi N, Banerjee R, Pajvani UB, et al. Regulation of resistin expression and circulating levels in obesity, diabetes, and fasting. *Diabetes.* 2004; 53:1671–1679.

Rao RS, Kini S. GIP and bariatric surgery. *Obesity surgery.* 2011;21(2):244-52.

Rask-Madsen C, Kahn CR. Tissue-specific insulin signaling, metabolic syndrome, and cardiovascular disease. *Arterioscler Thromb Vasc Biol*. 2012;32(9):2052-9.

Raybould, H.E., Capsaicin-sensitive vagal afferents and CCK in inhibition of gastric motor function induced by intestinal nutrients. *Peptides* 1991;12(6):1279-83.

Rhee NA, Wahlgren CD, Pedersen J, Mortensen B, Langholz E, Wandall EP, Friis SU, Vilmann P, Paulsen SJ, Kristiansen VB, Jelsing J. Effect of Roux-en-Y gastric bypass on the distribution and hormone expression of small-intestinal enteroendocrine cells in obese patients with type 2 diabetes. *Diabetologia.* 2015;58(10):2254-8.

Rocca AS, Brubaker PL. Role of the vagus nerve in mediating proximal nutrient-induced glucagon-like peptide-1 secretion. *Endocrinology* 1999;140:1687–1694.

Rodieux F, Giusti V, D'Alessio DA, Suter M, Tappy L. Effects of gastric bypass and gastric banding on glucose kinetics and gut hormone release. *Obesity (Silver Spring)* 2008;16: 298-305.

Romero F, Nicolau J, Flores L, Casamitjana R, Ibarzabal A, Lacy A, Vidal J. Comparable early changes in gastrointestinal hormones after sleeve gastrectomy and Roux-En-Y gastric bypass surgery for morbidly obese type 2 diabetic subjects. *Surgical endoscopy.* 2012;26(8):2231-9.

Rosmond, R., et al., Mental distress, obesity and body fat distribution in middle-aged men. *Obes Res* 1996;4(3):245-52.

Roth CL, Reinehr T, Schernthaner GH, Kopp HP, Kriwanek S, Schernthaner G. Ghrelin and obestatin levels in severely obese women before and after weight loss after Roux-en-Y gastric bypass surgery. *Obesity surgery.* 2009;19(1):29-35.

Rothenberg ME, Eilertson CD, Klein K, Zhou Y, Lindberg I, McDonald JK, Mackin RB, Noe BD. Processing of mouse proglucagon by recombinant prohormone convertase 1 and immunopurified prohormone convertase 2 in vitro. *J Biol Chem* 1995;270:10136-10146.

Rotondo A, Amato A, Baldassano S, Lentini L, Mulè F. Gastric relaxation induced by glucagon-like peptide-2 in mice fed a high-fat diet or fasted. *Peptides.* 2011;32(8):1587-92.

Rowland NE, Crews EC, Gentry RM. Comparison of Fos induced in rat brain by GLP-1 and amylin. *Regul Pept* 1997;71:171–174.

Rubino F, Gagner M, Gentileschi P, Kini S, Fukuyama S, Feng J, et al. The early effect of the Roux-en-Y gastric bypass on hormones involved in body weight regulation and glucose metabolism. *Ann Surg.* 2004;240:236–242.

Rubino F. Is type 2 diabetes an operable intestinal disease? A provocative yet reasonable hypothesis. *Diabetes Care.* 2008;31(2):S290–6.

Rubino F, Schauer PR, Kaplan LM, Cummings DE. Metabolic surgery to treat type 2 diabetes: clinical outcomes and mechanisms of action. *Annu Rev Med.* 2010;61:393-411.

Russell-Jones D, Gough S. Recent advances in incretin-based therapies. *Clinical endocrinology.* 2012;77(4):489-99.

Safatle-Ribeiro AV, Petersen PA, Pereira Filho DS, Corbett CE, Faintuch J, Ishida R, Sakai P, Cecconello I, Ribeiro Jr U. Epithelial cell turnover is increased in the excluded stomach mucosa after Roux-en-Y gastric bypass for morbid obesity. *Obesity surgery.* 2013;23(10):1616-23.

Sakata I, Yang J, Lee CE, Osborne-Lawrence S, Rovinsky SA, Elmquist JK, et al. Colocalization of ghrelin O-acyltransferase and ghrelin in gastric mucosal cells. *Am J Physiol Endocrinol Metab* 2009;297:E134–41.

Sala PC, Torrinhas RS, Giannella-Neto D, Waitzberg DL. Relationship between gut hormones and glucose homeostasis after bariatric surgery. *Diabetology & metabolic syndrome.* 2014;6(1):1.

Samat A, Malin SK, Huang H, Schauer PR, Kirwan JP, Kashyap SR. Ghrelin suppression is associated with weight loss and insulin action following gastric bypass surgery at 12 months in obese adults with type 2 diabetes. *Diabetes, Obesity and Metabolism.* 2013;15(10):963-6.

Santoro S, Milleo FQ, Malzoni CE, Klajner S, Borges PC, Santo MA, et al. Enterohormonal changes after digestive adaptation: five-year results of a surgical proposal to treat obesity and associated diseases. *Obes Surg.* 2008;18(1):17-26.

Saxena R, Hivert MF, Langenberg C, Tanaka T, Pankow JS, Vollenweider P, Lyssenko V, et al. Genetic variation in GIPR influences the glucose and insulin responses to an oral glucose challenge. *Nat Genet* 2010;42:142–148.

Schjoldager BT, Baldissera FG, Mortensen PE, Holst JJ, Christiansen J. Oxyntomodulin: a potential hormone from the distal gut. Pharmacokinetics and effects on gastric acid and insulin secretion in man. *European journal of clinical investigation.* 1988;18(5):499-503.

Schjoldager B, Mortensen PE, Myhre J, Christiansen J, Holst JJ. Oxyntomodulin from distal gut. *Digestive diseases and sciences.* 1989;34(9):1411-9.

Schmidt WE, Siegel EG, Creutzfeldt W. Glucagon-like peptide-1 but not glucagon-like peptide-2 stimulates insulin release from isolated rat pancreatic islets. *Diabetologia* 1985;28:704–707.

Schorr AB, Ofan R. Simultaneous use of two external subcutaneous pumps delivering insulin and SYMLIN: use of a double-pump system. *J. Diabetes Sci. Technol*. 2012;6:1507-8.

Schrumpf E, Giercksky KE, Nygaard K, Fausa O. Gastrin secretion before and after gastric bypass surgery for morbid obesity. *Scandinavian journal of gastroenterology.* 1981;16(6):721-5.

Schwartz MW, Seeley RJ. Seminars in medicine of the Beth Israel Deaconess Medical Center. Neuroendocrine responses to starvation and weight loss. *N Engl J Med* 1997;336:1802-11.

Shak JR, Roper J, Perez-Perez GI, Tseng CH, Francois F, Gamagaris Z, et al. The effect of laparoscopic gastric banding surgery on plasma levels of appetite-control, insulinotropic, and digestive hormones. *Obes Surg.* 2008; 18:1089–1096.

Shiiya T, Nakazato M, Mizuta M, Date Y, Mondal MS, Tanaka M, et al. Plasma ghrelin levels in lean and obese humans and the effect of glucose on ghrelin secretion. *J Clin Endocrinol Metab* 2002;87:240–4.

Silver AJ, Flood JF and Morley JE. Effect of gastrointestinal peptides on ingestion in old and young mice. *Peptides*, 1988;9: 221-225.

Sinclair EM, Drucker DJ: Proglucagon-derived peptides: mechanisms of action and therapeutic potential. *Physiology (Bethesda)* 2005, 20:357–365.

Singhal NS, Lazar MA and Ahima RS. Central resistin induces hepatic insulin resistance via neuropeptide Y. *J Neurosci*, 2007;27: 12924-12932.

Sjöström L, Lindroos AK, Peltonen M, Torgerson J, Bouchard C, Carlsson B, et al. Lifestyle, diabetes, and cardiovascular risk factors 10 years after bariatric surgery. *New England Journal of Medicine.* 2004;351(26):2683-93.

Sjöström L, Narbro K, Sjöström CD, Karason K, Larsson B, Wedel H, et al. Effects of bariatric surgery on mortality in Swedish obese subjects. *New England journal of medicine.* 2007; 357:741–752.

Sloth B, Holst JJ, Flint A, Gregersen NT, Astrup A. Effects of PYY1–36 and PYY3–36 on appetite, energy intake, energy expenditure, glucose and fat metabolism in obese and lean subjects. *American Journal of Physiology-Endocrinology and Metabolism.* 2007;292(4):E1062-8.

Spiller RC, Trotman IF, Higgins BE, Ghatei MA, Grimble GK, Lee YC, Bloom SR, Misiewicz JJ, Silk DB. The ileal brake--inhibition of jejunal motility after ileal fat perfusion in man. *Gut*. 1984;25(4):365-74.

Stenstrom B, Zhao CM, Tommeras K, Arum CJ, Chen D. Is gastrin partially responsible for body weight reduction after gastric bypass? *Eur Surg Res.* 2006; 38:94–101.

Steppan CM, Brown EJ, Wright CM, Bhat S, Banerjee RR, Dai CY, et al. A family of tissue-specific resistin-like molecules. *Proceedings of the national academy of sciences.* 2001;98(2):502-6.

Steppan CM, Bailey ST, Bhat S, Brown EJ, Banerjee RR, Wright CM, Patel HR, Ahima RS, Lazar MA (2001b) The hormone resistin links obesity to diabetes. *Nature* 409:307–312.

Steppan CM and Lazar MA. The current biology of resistin. *J Intern Med* 2004;255: 439-447.

Stoeckli R, Chanda R, Langer I, Keller U. Changes of body weight and plasma ghrelin levels after gastric banding and gastric bypass. *Obes Res* 2004; 12:346–350.

Stylopoulos N, Hoppin AG, Kaplan LM. Roux-en-Y gastric bypass enhances energy expenditure and extends lifespan in diet-induced obese rats. *Obesity (Silver Spring).* 2009;17(10):1839-47.

Sundbom M, Holdstock C, Engstrom BE, Karlsson FA. Early changes in ghrelin following Roux-en-Y gastric bypass: influence of vagal nerve functionality? *Obes Surg* 2007;17:304–10.

Suzuki S, Ramos EJ, Goncalves CG, Chen C, Meguid MM. Changes in GI hormones and their effect on gastric emptying and transit times after Roux-en-Y gastric bypass in rat model. *Surgery* 2005;138:283–290.

Suzuki K, Jayasena CN, Bloom SR. Obesity and appetite control. *Experimental diabetes research.* 2012; doi:10.1155/2012/824305.

Swarbrick MM, Stanhope KL, Austrheim-Smith IT, Van Loan MD, Ali MR, Wolfe BM, Havel PJ. Longitudinal changes in pancreatic and adipocyte hormones following Roux-en-Y gastric bypass surgery. *Diabetologia*. 2008;51(10):1901-11.

Tadross JA, le Roux CW. The mechanisms of weight loss after bariatric surgery. *Int J Obes (Lond).* 2009;33(1):S28–32.

Tang-Christensen M, Larsen PJ, Thulesen J, Romer J, Vrang N. The proglucagon-derived peptide, glucagon-like peptide-2, is a neurotransmitter involved in the regulation of food intake. *Nat Med* 2000; 6: 802–807.

Tatemoto K. Isolation and characterization of peptide YY (PYY), a candidate gut hormone that inhibits pancreatic exocrine secretion. *Proceedings of the national academy of sciences.* 1982;79(8):2514-8.

Terra X, Auguet T, Guiu-Jurado E, Berlanga A, Orellana-Gavaldà JM, Hernández M, Sabench F, Porras JA, Llutart J, Martinez S, Aguilar C. Long-term changes in leptin, chemerin and ghrelin levels following different bariatric surgery procedures: Roux-en-Y gastric bypass and sleeve gastrectomy. *Obesity surgery.* 2013;23(11):1790-8.

Theodorakis MJ, Carlson O, Muller DC, Egan JM. Elevated plasma glucose–dependent insulinotropic polypeptide associates with hyperinsulinemia in impaired glucose tolerance. *Diabetes care* 2004;27:1692–1698.

Thompson RG, Pearson L, Schoenfeld SL, Kolterman OG. Pramlintide, a synthetic analog of human amylin, improves the metabolic profile of patients with type 2 diabetes using insulin. *Diabetes Care.* 1998;21(6):987-93.

Thompson NM, Gill DA, Davies R, Loveridge N, Houston PA, Robinson IC, et al. Ghrelin and des-octanoyl ghrelin promote adipogenesis directly in vivo by a mechanism independent of the type 1a growth hormone secretagogue receptor. *Endocrinology* 2004;145:234–42.

Treacy PJ, Jamieson GG, Dent J, Devitt PG, Heddle R. Duodenal intramural nerves in control of pyloric motility and gastric emptying. *American journal of physiology-gastrointestinal and liver physiology.* 1992;263(1):G1-5.

Tschop M, Weyer C, Tataranni PA, Devanarayan V, Ravussin E, Heiman ML. Circulating ghrelin levels are decreased in human obesity. *Diabetes* 2001;50:707–9.

Ukkola O, Santaniemi M. Adiponectin: a link between excess adiposity and associated comorbidities?. *Journal of molecular medicine.* 2002;80(11):696-702.

Utzschneider K, Carr D, Tong J, Wallace T, Hull R, Zraika S, et al. Resistin is not associated with insulin sensitivity or the metabolic syndrome in humans. *Diabetologia* 2005;48(11):2330–3.

Vendrell J, Broch M, Vilarrasa N, Molina A, Gomez JM, Gutierrez C, et al. Resistin, adiponectin, ghrelin, leptin, and proinflammatory cytokines: relationships in obesity. *Obes Res* 2004;12:962–71.

Vicennati V, Genghini S, De Iasio R, et al. Circulating obestatin levels and the ghrelin/obestatin ratio in obese women. *Eur J Endocrinol*. 2007;157:295–301.

Vilsboll T, Krarup T, Sonne J, et al. Incretin secretion in relation to meal size and body weight in healthy subjects and people with type 1 and type 2 diabetes mellitus. *J Clin Endocrinol Metab* 2003;88:2706–13.

Weinzimer SA, Sherr JL, Cengiz E, Kim G, Ruiz JL, Carria L, Voskanyan G, Roy A, and Tamborlane WV. Effect of pramlintide on prandial glycemic excursions during closed-loop control in adolescents and young adults with type 1 diabetes. *Diabetes care* 2012; 35:1994–9.

Wen J, Phillips SF, Sarr MG, Kost LJ, Holst JJ. PYY and GLP-1 contribute to feedback inhibition from the canine ileum and colon. *American journal of physiology-gastrointestinal and liver physiology*. 1995;269(6):G945-52.

Westermark P, Wernstedt C, Wilander E, and Sletten K. A novel peptide in the calcitonin gene related peptide family as an amyloid fibril protein in the endocrine pancreas. *Biochem Biophys Res Commun* 1986;140:827–831.

Whitson BA, Leslie DB, Kellogg TA, Maddaus MA, Buchwald H, Billington CJ, Ikramuddin S. Entero-endocrine changes after gastric bypass in diabetic and nondiabetic patients: a preliminary study. *Journal of surgical research* 2007a;141(1):31-9.

Whitson BA, Leslie DB, Kellogg TA, Maddaus MA, Buchwald H, Billington CJ, et al. Adipokine response in diabetics and nondiabetics following the Roux-en-Y gastric bypass: a preliminary study. *Journal of surgical research* 2007b; 142:295–300.

Willms BE, Werner JE, Holst JJ, Orskov C, Creutzfeldt WE, Nauck MA. Gastric emptying, glucose responses, and insulin secretion after a liquid test meal: effects of exogenous glucagon-like peptide-1 (GLP-1)-(7-36) amide in type 2 (noninsulin-dependent) diabetic patients. *The journal of clinical endocrinology & metabolism.* 1996;81(1):327-32.

Woelnerhanssen B, Peterli R, Steinert RE, Peters T, Borbely Y, Beglinger C. Effects of postbariatric surgery weight loss on adipokines and metabolic parameters: comparison of laparoscopic Roux-en-Y gastric bypass and laparoscopic sleeve gastrectomyea prospective randomized trial. *Surg Obes Relat Dis* 2011;7(5):561e8.

Won JC, Park CY, Lee WY, Lee ES, Oh SW, Park SW. Association of plasma levels of resistin with subcutaneous fat mass and markers of inflammation but not with metabolic determinants or insulin resistance. *J Korean Med Sci* 2009; 24:695–700.

Wren AM, Small CJ, Ward HL, Murphy KG, Dakin CL, Taheri S, Kennedy AR, Roberts GH, Morgan DG, Ghatei MA, Bloom SR. The novel hypothalamic peptide ghrelin stimulates food intake and growth hormone secretion. *Endocrinology* 2000;141(11):4325-8.

Wu Q, Xiao Z, Cheng Z, Tian H. Changes of blood glucose and gastrointestinal hormones 4 months after Roux-en-Y gastric bypass surgery in Chinese obese type 2 diabetes patients with lower body mass index. *Journal of diabetes investigation*. 2013;4(2):214-21.

Wynne K, Park AJ, Small CJ, Meeran K, Ghatei MA, Frost GS, Bloom SR. Oxyntomodulin increases energy expenditure in addition to decreasing energy intake in overweight and obese humans: a randomised controlled trial. *International journal of obesity*. 2006;30(12):1729-36.

Yamauchi T, Kadowaki T. Adiponectin receptor as a key player in healthy longevity and obesity-related diseases. *Cell metabolism.* 2013;17(2):185-96.

Yang J, Feng X, Zhong S, Wang Y, Liu J. Gastric bypass surgery may improve beta cell apoptosis with ghrelin overexpression in patients with BMI≥ 32.5 kg/m2. *Obesity surgery.* 2014;24(4):561-71.

Ybarra J, Bobbioni-Harsch E, Chassot G, Huber O, Morel P, Assimacopoulos-Jeannet F et al. Persistent correlation of ghrelin plasma levels with body mass index both in stable weight conditions and during gastric-bypass-induced weight loss. *Obes Surg* 2009; 19: 327–331.

Ye R, Scherer PE. Adiponectin, driver or passenger on the road to insulin sensitivity? *Molecular metabolism.* 2013;2(3):133-41.

Yip S, Plank LD, Murphy R. Gastric bypass and sleeve gastrectomy for type 2 diabetes: a systematic review and meta-analysis of outcomes. *Obesity surgery.* 2013;23(12):1994-2003.

Yousseif A, Emmanuel J, Karra E, Millet Q, Elkalaawy M, Jenkinson AD, et al. Differential effects of laparoscopic sleeve gastrectomy and laparoscopic gastric bypass on appetite, circulating acyl-ghrelin, peptide YY3-36 and active GLP-1 levels in non-diabetic humans. *Obes Surg* 2014;24(2):241e52.

Yura S, Sagawa N, Itoh H, Kakui K, Nuamah MA, Korita D, Takemura M, Fujii S. Resistin is expressed in the human placenta. *The journal of clinical endocrinology & metabolism.* 2003;88(3):1394-7.

Zahorska-Markiewicz B, Olszanecka-Glinianowicz M, Janowska J, et al. Serum concentration of visfatin in obese women. *Metabolism* 2007;56:3095–100.

Zhang Y, Proenca R, MaffeiM, BaroneM, Leopold L, Friedman JM. Positional cloning of the mouse obese gene and its human homologue. *Nature* 1994;372:425–32.

Zhang JV, Ren P-G, Avsian-Kretchmer O, et al. Obestatin, a peptide encoded by the ghrelin gene, opposes ghrelin's effects on food intake. *Science* 2005;310:996–9.

Zhao CM, Furnes MW, Stenström B, Kulseng B, Chen D. Characterization of obestatin-and ghrelin-producing cells in the gastrointestinal tract and pancreas of rats: an immunohistochemical and electron-microscopic study. *Cell and tissue research.* 2008;331(3):575-87.

Zwirska-Korczala K, Konturek SJ, Sodowski M, Wylezol M, Kuka D, Sowa P, et al. Basal and postprandial plasma levels of PYY, ghrelin, cholecystokinin, gastrin and insulin in women with moderate and morbid obesity and metabolic syndrome. *J Physiol Pharmacol* 2007;58(1):13–35.

In: Encyclopedia of Surgery (22 Volume Set)
Editors: Andreas Lehrer and Kristin Mueller
ISBN: 978-1-53618-329-0
© 2020 Nova Science Publishers, Inc.

Chapter 145

BARIATRIC SURGERY ALTERS GUT METABOLISM: ROLE IN OBESITY AND TYPE 2 DIABETES RESOLUTION

Steven K. Malin, PhD
Department of Kinesiology, Division of Endocrinology and Metabolism,
Department of Medicine, University of Virginia, Charlottesville, VA, US

ABSTRACT

Bariatric surgery has revealed a significant link between gastrointestinal metabolism and obesity that extends to resolution of many metabolic diseases including type 2 diabetes and cardiovascular disease risk. Much of this beneficial metabolic health effect of bariatric surgery can be ascribed to weight loss. However, type 2 diabetes remission occurs within days post-surgery, such that it is likely independent of weight loss. This clinical observation has raised the possibility that altering gastrointestinal anatomy creates rapid metabolic responses that confer normalization of glucose tolerance. The exact mechanism by which bariatric surgery elicits favorable glucose changes remains unclear, but a leading hypothesis is that re-routed nutrient flow to the gut alters entero-endocrine (e.g., GLP-1, PYY, ghrelin, etc.) hormone production, circulating bile acid levels, and gut microbiome metabolites (e.g., LPS, SCFA, etc.) that favor appetite suppression, metabolic rate, and insulin sensitivity as well as β-cell function. While there is little work in the post-operative period describing the impact of lifestyle modification and/or pharmacology on gut metabolism post-bariatric surgery in men and women, the collective evidence provides strong support for an essential role for the gastrointestinal tract as a modulator of obesity-related disease. Thus, the gut is now considered a novel endocrine organ and a therapeutic target for prevention and medical approaches that favorably prevent and treat obesity related metabolic disorders.

Keywords: incretins, appetite-hormones, gut microbiome, bile acids, insulin resistance and secretion

INTRODUCTION

Lifestyle modification, consisting of exercise and diet, is the primary medical treatment for inducing weight loss and preventing the progression to type 2 diabetes. However, the magnitude and long-term adherence of this weight loss remains low, and with development of hyperglycemia, many people turn to exogenous compounds (e.g., pharmacological/dietary supplement tools) to manage their health. Unfortunately, the durability of these approaches does not typically work well over time in most individuals, and β-cell function declines such that glycemic control worsens. To date, the most effective treatment for obesity that induces substantial and durable weight loss is bariatric surgery. We refer readers to prior work for a summary on the Rouen-Y gastric bypass (RYGB) and sleeve gastrectomy (SG) procedure itself [1, 2], as here we summarize studies relevant to bariatric surgery as a gastrointestinal procedure that promotes favorable changes in insulin sensitivity and β-cell function for glycemic control. Because preservation of pancreatic insulin secretion is a primary determinant of glucose tolerance, we also discuss the mechanisms by which surgery improves β-cell function, and present evidence for the role of gut metabolism in a weight loss-independent way. In particular, we pay attention to surgery-induced changes in insulin secretion that may be influenced by hormones, bile acids and gut microbiota as these represent novel mechanisms potentially governing the rise in pancreatic function.

EFFECT OF BARIATRIC SURGERY ON BLOOD GLUCOSE

Obesity is a strong risk factor for type 2 diabetes. Excess body fat contributes to diabetes development by inducing insulin resistance and inflammation, which in turn, exacerbate β-cell function [3-5]. The notion that bariatric surgery "cures" diabetes has been recognized for over 20 years. In fact, Pories and colleagues [6] demonstrated in 141 patients with type 2 diabetes or impaired glucose tolerance that all but 2 individuals had normalized glucose tolerance within 10 days after RYGB. At 7.6 years after surgery, 83% of the patients with diabetes were off their anti-diabetic drugs, and 99% of those with impaired glucose tolerance were normoglycemic with a normal fasting glucose and HbA1c [7]. In the Swedish Obesity Study, at 2 years post-surgery with an average weight loss of nearly 28 kg, 72% of patients had complete resolution of type 2 diabetes compared with 21% of controls [8]. Many of these patients had been able to stop taking oral hypoglycemic drugs or insulin, which is in contrast to the control group who had an increased need for these agents. These results are similar to those of Scopinaro and colleagues [9, 10] who reported long-term follow up data on 312 patients with type 2 diabetes undergoing biliopancreatic diversion surgery. Their results indicated that 99% of patients achieved normal glucose concentrations by 1 year after surgery. At 10 years after surgery, 98% of the patients were still in complete remission of diabetes (i.e., normal blood glucose without anti-diabetic medication use). However, not all surgical approaches induce comparable glycemic benefit. Diabetes resolution was observed in approximately 98% of patients who underwent biliopancreatic diversion (with or without duodenal switch), 84% who underwent RYGB, 72% who underwent vertical banded gastroplasty surgery and 48% who underwent adjustable gastric banding [11]. In addition, it is also worth considering that more recent guidelines for diabetes remission have been

established, and current work suggests that approximately 50-70% of individuals undergoing RYGB or SG may not meet remission criteria at 5 years post-operation [12]. This would suggest that biological factors, such as weight regain or insulin resistance, may contribute diabetes relapse. Indeed, resolution of type 2 diabetes is likely to occur in those with the shortest duration of diabetes (<5 years) or milder forms of diabetes (diet-controlled), lower central obesity, and/or the greatest weight loss after surgery [13]. Conversely, patients that do not resolve diabetes post-surgery are usually older or have a more prolonged surgical disease course [7, 14, 15]. Thus, further work understanding how to optimize diabetes remission rates are needed following surgery. Nevertheless, the majority of these observational studies have been supported by randomized control trials (RCTs) in obese cohorts with type 2 diabetes [16-18]. For instance, the Surgical Treatment and Medications Potentially Eradicate Diabetes Efficiently (STAMPEDE) trial recently demonstrated the effects of bariatric surgery on controlling glycaemia in obese individuals with type 2 diabetes. In the STAMPEDE trial, Schauer and colleagues [19] compared the effects of RYGB and SG vs. intensive medical therapy in 150 obese patients with uncontrolled type 2 diabetes at 1 year post-operation. People were randomly assigned to surgical or medical therapy groups, and the primary end-point was a HbA1c < 6.0%. The results indicated that RYGB and SG each produced significant improvements in HbA1c in 42% and 37% of patients, respectively, meeting glycemic control criteria. Taken together, bariatric surgery appears to result in dramatic glycemic control and weight loss improvements in obese patients with type 2 diabetes.

LINKING GUT METABOLISM TO OBESITY RELATED DISEASE POST-SURGERY

Although weight loss is likely important for gains in insulin sensitivity and β-cell function following bariatric surgery [20], restrictive procedures do not induce comparable diabetes resolution rates as compared to biliopancreatic diversion or RYGB. Moreover, despite malabsorption explaining to some extent reductions in reactive oxygen species and inflammation derived from excess glucose and lipid digestion in obese individuals, nutrient malabsorption does not occur after standard RYGB [21], implying that additional factors likely drive the improvements in glycemic control post bariatric surgery [22]. Altered gut metabolism is currently the leading candidate as the major mechanism following bariatric surgery explaining improved weight regulation and decreased type 2 diabetes and cardiovascular disease risk.

Rubino and colleagues have hypothesized that overstimulation of the gastrointestinal tract by overeating leads to metabolic disturbances that promote blood glucose elevations, whereas restricting food contact with the intestine improves these conditions [20]. A possible mean for improving insulin sensitivity and/or β-cell function is related to the secretion of various hormones released by the gut in response to the re-routing of food intake [23]. Surgical exclusion of the duodenum in the RYGB procedure and exclusion of the duodenum and jejunum in biliopancreatic diversion result in altered sites – or at least altered relative distribution – of carbohydrate and fat absorption. This in turn has been related to increased anorectic hormones that induce satiety (e.g., glucagon-like polypeptide 1 (GLP-1), polypeptide tyrosine-tyrosine (PYY), oxyntomodulin (OXM)) and decreased levels of the

orexigneic hormone ghrelin that promote hunger. Based on these observations, the "hindgut," "midgut," and "foregut" hypotheses have been raised. The hindgut hypothesis suggests that diabetes control is due to accelerated delivery of nutrients to the distal intestine, which augments an insulinotropic signal (e.g., GLP-1) that improves glucose homeostasis via enhanced insulin action [24]. Indeed, augmented GLP-1 secretion increases the insulin response to nutrient intake, and at least in animal models, induces β-cell proliferation [25], which together reduces blood glucose levels. In addition to a rapid delivery of nutrients to the distal intestine for GLP-1 secretion, the "midgut" hypothesis suggests that nutrient delivery to the distal intestine increases intestinal gluconeogenesis and activates a heptao-portal sensor that leads to neural signal for reduced food intake and lower hepatic glucose output (26). In contrast, the "foregut hypothesis," suggests that nutrient interactions in the duodenum and proximal jejunum are diabetogenic and, hence, bypassing the duodenum alleviates this intestinal factor that induces insulin resistance and β-cell dysfunction [27, 28]. However, this later hypothesis has been controversial since the diabetic intestinal factor has not been identified and SG, which does not bypass the duodenum, improves glycemic control. It is important to note that although the "hindgut," "midgut," and "foregut" hypotheses are often explained in terms of hormonal changes, they are not exclusive of altered nutrient flow that affects neural signaling. Interestingly, patients following surgery often report a reduction in snack numbers and/or portion size as well as food preference. In fact, these individuals often have reduced preference for sweet and fat tasting foods [29]. In addition, although the gut hypotheses are often presented as mutually exclusive theories, no data actually exist excluding portions of the upper or lower intestine. Moreover, the exact molecular mechanism underlying the improvement in metabolism following RYGB is unknown, and it is likely that as a number of gut hormones and neural signals produced at various sites of the gastrointestinal tract elicit unique mechanisms of action. Indeed, RYGB was reported to enhance intestinal glucose uptake and utilization, leading to overall improvements in systemic glucose control [30].

GUT HORMONES POST-SURGERY: ROLE ON β-CELL FUNCTION

The enteroendocrine cells of gastrointestinal tract are comprised of cells that secrete hormonal factors that modulate not only food intake, but also the upregulation of insulin synthesis and secretion. For instance, L cells are located throughout the small intestine and colon, but are found in highest density within the lower portion of the small intestine. These L-cells are responsible for secreting GLP-1, OXM, and PYY. The release of these hormones, are well characterized, and considered major factors related to β-cell function. Laferrere and colleagues (31) reported increased post-prandial levels of GLP-1 within 4 weeks following RYGB, whereas levels of GLP-1 did not rise with comparable weight loss induced by diet. These findings are consistent with data in patients with type 2 diabetes at 1 year following RYGB in which elevated GLP-1 was significantly associated with insulin action and weight loss [32]. In fact, enhanced β-cell glucose sensitivity (i.e., the relationship between circulating glucose and insulin secretion rates) increase independent of weight loss following RYGB in adults with and without type 2 diabetes [33], although β-cell glucose sensitivity is not observed following gastric band surgery despite comparable weight loss to that of RYGB

[34]. Bojsen-Moller and colleagues expanded on this prior work and characterized the longitudinal assessment of insulin secretion and multi-organ sensitivity at 1 week, 3 months and 1 year following RYGB in obese adults with and without type 2 diabetes [35]. Interestingly, at 1 week fasting glucose had significantly declined in patients with type 2 diabetes and this change in glycemia corresponded with improvements in hepatic glucose production since tests of skeletal muscle glucose disposal via the euglycemic clamp, free fatty acid suppression (measure of adipose insulin sensitivity), and pancreatic insulin secretion assessed by intravenous glucose tolerance tests revealed no change. However, at 3 months, while the improvement in the disposition index (i.e., insulin secretion x insulin sensitivity) indicated that insulin sensitivity is a key driver of systemic glucose control, insulin secretion in response to oral glucose was improved in people with type 2 diabetes and directly associated with GLP-1. These latter results highlight that the gastrointestinal tract per se plays a key role in the amelioration of type 2 diabetes. This notion is strengthened by evidence of the GLP-1 receptor inhibitor exendin$_{9\text{-}39}$ nearly eliminating the improved β-cell insulin secretion response to bariatric surgery [36]. In line with these observations, more recent work reports that SG produce similar rises in GLP-1 to RYGB surgery at 1 year in both obese non-diabetic and diabetic individuals [33, 37]. These findings are intriguing given that increased exposure of nutrients to the distal part of the intestine is a leading hypothesis for robust increases in GLP-1 post-RYGB surgery. It remains possible that SG accelerates gastric emptying compared to pre-surgery, and this contributes to greater nutrient exposure. Alternatively, other factors in the proximal region of the intestine may play a role. Indeed, it has been reported that both RYGB and SG surgery also increase GLP-1 and insulin secretion compared to intensive medical therapy 2 years post-surgery, although RYGB may provide some additional benefit [38]. However, unlike oral glucose ingestion, use of the intravenous glucose tolerance test suggests that insulin secretion does not change post-bariatric surgery despite improvements in glycemic control [35]. Subsequently, the collective work in the literature suggests that the intestinal system is a key mechanism increasing insulin secretion, and that improvements in post-prandial hyperglycemia occur in conjunction with the disposition index mainly due to rises in insulin sensitivity. Therefore, factors other than GLP-1 alone likely play a role in improved glucose homeostasis after bariatric surgery.

GIP is secreted in the K-cells located mainly in the duodenum and proximal jejunum and released in response to nutrients (mainly lipid). Unlike, GLP-1, GIP is more involved in lipid metabolism (storage) and is thus thought to play a more direct role in the pathogenesis of obesity. While some report similar improvements in GIP between RYGB and SG surgery [39], others have documented GIP levels to be unchanged following surgery [38]. Subsequently, the effect of bariatric surgery on GIP is more controversial than the findings of GLP-1, and the role of GIP is less clear on the regulation of lower fat mass and/or insulin secretion following surgery. Nevertheless, like GLP-1, PYY and OXM are co-secreted by the L-cells of the distal small intestine and are responsible for reducing hunger, decreasing food intake and delaying gastric emptying after meals. Several studies have documented increases in postprandial PYY and GLP-1 after RYGB [40-42], with some also reporting enhanced OXM [43]. Although no published study to date has determined the role of SG on OXM, SG has been reported to elevate PYY and GLP-1 [33, 37, 44]. Ghrelin is a gastric hormone produced primarily in the stomach with secondary secretion emanating from the proximal small intestine, and ghrelin has been documented to play a role in both appetite stimulation as well as impairing insulin sensitivity and reducing glucose-stimulated insulin secretion [45].

Ghrelin suppression is usually improved following RYGB or SG, suggesting that suppression of hunger signals helps sustain weight loss. However, it is worth considering that these surgery types may exert different mechanisms to lower ghrelin. Indeed, prior work by Malin and colleagues suggested that RYGB is effective at suppressing post-prandial ghrelin levels, while SG surgery primarily lowers fasting ghrelin [46]. This phenomenon of ghrelin suppression vs. lower fasting ghrelin may contribute to changes in GLP-1 and β-cell function, although further work is needed. In either case, both surgery types appear effective at reducing ghrelin levels, and this likely contributes to some extent on the beneficial weight regulation and insulin secretion changes post-surgery.

ROLE OF BILE ACIDS ON β-CELL FUNCTION

Bile acids are traditionally known for their role in micelle formation and processing/digestion of dietary fat. However, it is now clear that bile acids contribute to energy metabolism and glucose regulation before and after bariatric surgery. Patti and colleagues demonstrated that total plasma bile acids were significantly elevated compared with weight matched controls in post-RYGB patients [47]. Interestingly, Pournaras and colleagues [48] showed that fasting total serum bile acids are elevated within days following RYGB, but not LAGB, suggesting that bile acids may contribute to weight-independent improvements in glucose homeostasis. Indeed, fasting total bile acids are inversely correlated with post-prandial glucose and positively correlated with peak GLP-1 levels [49] and 2-hour blood glucose levels [47]. In line with these observations, bile acids are known to act on TGR5 receptors located on enteroendocrine cells and promote the secretion of GLP-1 release [50], which may contribute to satiety and β-cell insulin secretion. In fact, farnesoid X receptor (FXR) in pancreatic β-cells may directly respond to the rise in bile acids, thereby increasing insulin release [51]. However, not all studies support the theory that bile acids play an important role in GLP-1 induced pancreatic β-cell function. In fact, recent work showed that bile acids do not rise within the first week post-RYGB and SG despite improved glycemic control [52, 53]. These latter results suggest that while bile acids may contribute to improved gut hormone secretion over longer periods of time, bile acids may not explain the early effects of bariatric surgery on glucose tolerance and GLP-1. Thus, further work is required to understand independent and dependent mechanisms by which bile acids affect β-cell function post-bariatric surgery.

RELATIONSHIP OF GUT MICROBIOTA AND OBESITY RELATED DISEASE RISK

The gut microbiome has emerged as an important regulator of obesity, metabolism and inflammation. In human intestine, approximately 400 bacterial species are present and together resemble a multicellular organ that has evolved to provide complex nutrient signaling and metabolic functions [54]. The vast majority of these microorganisms belong to 3 main groups: *Firmicutes*, *Bacteriodetes*, and *Actinobacteria* (comprising of 95% of total intestinal bacteria) and reside in the distal portions of the intestine. The gut microbiome is a

dynamic organ that changes in response to the environment. In animals provided a high-fat diet, the gut microbiota resulted in increased levels of *Firmicutes* prior to the development of obesity [55]. This renders the microbiota to be more obesogenic and may result in increased energy harvest from the diet. In line with this observation, Ley and colleagues demonstrated that food restriction, not macronutrient content per se (low-carbohydrate vs. low-fat), was linked to decreased levels of *Firmicutes* and elevated levels of *Bacteroidetes* [56], suggesting that nutrient overload is important for gut bacteria modifications. For instance, this altered gut microbiome has been associated with intestinal inflammation and systemic insulin resistance [57]. Further evidence for a role of gut microbiome on metabolic health is evident from germ-free rodents, which are protected from developing diet-induced obesity. In fact, germ-free mice have lower adiposity and have higher food consumption when compared with control mice. But when germ-free mice are colonized with cecal content from control mice, weight is rapidly gained and food consumption decreases, suggesting that gut microbiome regulates fat mass and energy store [58]. Further, genetically identical mice fed high-fat diets differed in their metabolic phenotype due to differences in gut microbiota composition [54], indicating that the cause of metabolic disease may be due to a complex interaction of environmental factors as well as gut microbiota profiles. In either event, germ-free mice have reduced expression of CD36 and SGLT-1, which are important for fatty acid and glucose transport in the intestine [59]. Together, these data highlight gut bacteria as important modulators of nutrient absorption, and suggest that two mechanisms are likely involved in explaining the link between obesity and gut microbiome. First, increased capacity to process otherwise indigestible polysaccharides, leading to subsequent rises in nutrients, and second, increased gene expression promoting fat storage in adipose tissue [58]. Thus, a current working hypothesis is that obese animals are better able to extract energy from dietary intake and store those calories as fat. Indeed, obese humans have fewer calories from the diet in feces [60].

EFFECT OF BARIATRIC SURGERY ON GUT MICROBIOTA

Bariatric surgery changes gut microbiota to reflect more of a lean phenotype. Zhang and colleagues [61] showed that microbiota functional differences occurred in obese individuals post-RYGB surgery. In fact, RYGB markedly altered *Gammaproteobacteria* (member of *Enterobacteriacease*), decreased *Firmicutes*, and lowered methanogens (key for energy harvest). Similarly, Furet and colleagues [62] reported that gut micobiota adapted to RYGB surgery by increasing the *Bacteroides/Prevotella* ratio, which was correlated with reduced body fat. Moreover, *Escherichia coli* species also increased in individuals undergoing RYGB, and this change was significantly correlated with fat mass and leptin independent of caloric intake restriction. Changes in adipose tissue mass is strongly linked to systemic inflammation, and consistent with weight loss following RYGB, the rise in *Faecalibacterium prausnitzil* species in people with type 2 diabetes was related to lower inflammation (hs-CRP and IL-6). Together, these findings strengthen the view that obesity and gut microbiota are intimately involved in the regulation of metabolic health. In fact, Kong and colleagues [63] demonstrated that RYGB increased gut microbiota richness, and this change in gut microbiota was directly correlated with genes encoding white adipose tissue mass, metabolism and inflammation. Interestingly, approximately 50% of these relationships were independent of

caloric intake, suggesting that RYGB uniquely alters gut metabolism in favor of weight reduction maintenance. Although distal portions of the small intestine contribute to the majority of nutrient absorption and gut microbiome in humans, the upper portions include gut bacteria that have metabolic function. Indeed, when microbiota from lean individuals are administered into the duodenum of humans with metabolic syndrome, insulin resistance declines independent of weight loss [64], suggesting that exclusion of the duodenum contributes to the regulation of glucose metabolism.

The cause for this altered gut flora milieu is presently an area of intense research, but several proposed mechanisms are currently being investigated. First, the surgical induced restriction in food intake and/or change in food preference, including lower sugary foods and dietary fat, may explain modifications in the gut microbiome composition because of the smaller stomach size and shorter intestinal length [58]. Next, by diverting nutrients away from the proximal intestine, gut microbiota are exposed to more rapid food delivery and adapt accordingly. For instance, intestinal cells are exposed to more oxygen than usual due to the shorter intestinal lengths and facultative anaerobes occurs. Lastly, from an anatomical perspective, pH levels rise after RYGB surgery in the stomach and upper intestine. Although a pH < 4 is potentially "deadly" for many microorganisms, some reports suggest that pH modification affects the overall gut microbiota composition. Further, modification of acid secretion following RYGB not only lowers distal small intestine pH and influences the production of decongjugated primary bile acids, but also increases acidification in the distal small intestine thereby increasing secondary bile acid levels via gut bacteria. Indeed, elevated secondary bile acid levels are reported to decrease hepatic fatty acid uptake, which may contribute to improvements in hepatic triglyceride metabolism and hepatic steatosis [80]. Alterations in gut microbiome in the colon have also been linked to lower pH, and this altered gut bacteria favors the rise in short-chain fatty acid production, which may have lipid metabolism regulatory effects [65]. Taken together, these findings following RYGB surgery support the gut microbiome as being a key physiologic player involved in fostering nutrient sensing for both weight regulation and glucose homeostasis [63].

EFFECT OF GUT DERIVED INFLAMMATORY METABOLITES ON METABOLIC HEALTH

Low-grade inflammation in humans is a common co-morbidity of type 2 diabetes and cardiovascular disease. Locally, the gut microbiome is directly linked to intestinal inflammation via changes in bacterial fragments and/or metabolites known to increase innate immune system responses. Interestingly, these bacterial components and metabolites have implicated the gut microbiome as a key factor in the development of obesity and metabolic disease [66]. The innate immune system has the capacity to sense various bacterial components (e.g., via toll-like receptors (TLRs)) and while several gut derived materials have been documented to play a role in chronic disease, endoxemia by means of lipopolysaccharides (LPS) as well as short chain fatty acids (SFCAs) have received much recent attention as it specifically pertains to inflammatory related mechanisms of glucose regulation.

ROLE OF LIPOPOLYSACCARIDES

LPS originating from Gram-negative bacteria in the gut induces low-grade inflammation and insulin resistance, thereby contributing to disturbances in energy metabolism that promote metabolic disease. LPS is sensed by TLR4, and is elevated in the circulation following high fat diets via a "leaky gut" phenomena (or chylomicron transport mechanism) [67]. This may be of particular relevance for humans, as obesity is associated with elevated circulating LPS levels compared with healthy controls [68]. Human work also supports the LPS linkage to hyperglycemia, as treatment with insulin-sensitizing agents in patients with type 2 diabetes lowered LPS in line with greater rises in insulin action [69]. Further, elevated LPS in type 1 diabetic and kidney vascular disease were highly associated with serum triglycerides, diastolic blood pressure and inflammation markers (e.g., MCP-1) [70], suggesting that metabolic LPS is linked to cardiovascular disease. Given that bariatric surgery alters the gut microbiome composition, it would seem reasonable to suspect changes in LPS. The limited evidence suggests that not only does bariatric surgery reduce LPS, but also this reduction in LPS is directly linked to lower adipose mass and improved HbA1c levels [68]. Taken together, it appears LPS is related to obesity-induced disease risk, but additional work is required to determine if LPS has direct roles on insulin sensitivity and/or pancreatic function.

ROLE OF SHORT CHAIN FATTY ACIDS

SCFAs on the other hand are produced in the colon by gut microbes that ferment non-digestible polysaccharides (e.g., inulin) [71]. The rise in SCFA (i.e., acetate, butyrate, and propionate) levels are important for weight regulation as they are implicated in satiety and decreased food intake, although SCFAs may act as substrate for lipogenesis. As mentioned previously**,** improved β-cell function following bariatric surgery is in part related to elevated GLP-1 as well as lower ghrelin. The effects of bariatric surgery on gut hormones and gut microbiome would suggest that the changes in SCFA could contribute to the overall regulation of insulin secretion. Interestingly, SCFA have been shown to influence gut peptides, appetite and energy expenditure [67]. Although studies in humans are limited, Arora and colleagues [72] suggested that propionate may reduce appetite. In addition to the effects on gut peptides, butyrate and propionate may increase leptin secretion from adipocytes [73]. This later mechanism may provide an alternative mechanism by which the gut directly communicates with adipose tissue to regulate body weight and feeding behavior. While SCFAs may play important roles in body weight regulation through increases in total energy expenditure [74], SCFAs also act on GPR43 receptors in L cells of the small intestine. Since L cells are also responsible for GLP-1 secretion, it is reasonable that SCFA may influence insulin secretion [75]. Recent work by McNeilis and colleagues [76] supports this hypothesis and identified GPR43 as a modulator of microbiota-pancreatic cross-talk. Interestingly, high fat diet feeding increased the expression of GPR43 and serum levels of acetate. Knockout mice of the GPR43 receptor developed glucose intolerance in part due to inadequate insulin secretion. Treatment of islets with the GPR43 receptor agonist, however, demonstrated that insulin secretion could be restored, thereby providing evidence that activation of GPR43 by

SCFA may initiate insulin responses post-feeding. Overall, these data highlight SCFA as an important factor that reduces appetite and/or increases energy metabolism to promote insulin secretion and action following bariatric surgery.

ROLE OF TRIMETHYLAMINE-N-OXIDE

Gut microbiota release choline from dietary phosphatidylcholine where it gets metabolized to trimethylamine (TMA). TMA is transported to the liver via the portal vein and is oxidized to trimethylamine-N-oxide (TMAO). Elevated levels of plasma TMAO, choline, and betaine have dose-dependent associations with the presence of cardiovascular disease independent of conventional risk factors (e.g., blood pressure, triglycerides, etc.) and medication use [77]. Rats fed high choline diets or TMAO diets develop elevated circulating TMAO levels and greater aortic root atherosclerotic plaque without alterations in plasma glucose or blood lipids. Although obesity may influence circulating TMAO levels, dietary manipulation appears important for modulating TMAO, such that high fat and increased meat consumption lead to greater elevated TMAO compared with low fat and vegetarian style meals. Gut micrbiota production of TMAO following bariatric surgery is sparse, as some urinary data suggest that TMA is elevated in rodents following bariatric surgery [78]. Increased TMAO levels have also been demonstrated in humans with and without diabetes following bariatric surgery, although lifestyle modification had no effect [79]. While a rise in TMAO post-surgery would be unexpected given the relationship to cardiovascular disease, future prospective work is needed to determine the impact TMAO has on metabolic health. Additional work is also warranted to determine if gut microbiota therapies influence TMAO since this metabolite appears to be independently associated with cardiovascular disease risk [80].

IMPLICATIONS AND CONCLUSION

Bariatric surgery is a proven treatment option for weight loss and glycemic control. However, much of the metabolic benefit derived from surgery occurs within days following the operation. The resulting weight loss from bariatric surgery is persistent in most patients, and this durability in weight loss is considered an underlying mechanism responsible for the majority of glycemic control benefit and cardiovascular disease risk reduction. However, it is clear that gut metabolism has distinct effects on not only appetite, but also on insulin sensitivity, β-cell function, and blood glucose. Specifically, GLP-1, PYY and ghrelin not only impacts satiety but also modulates whole body insulin secretion and sensitivity. In addition to alterations of the stomach, proximal to distal small intestine re-routing of nutrient delivery to the jejunium may contribute to increased bile acids, intestinal remodeling, and changes in the gut microbiome that collectively contribute to improved glucose and insulin metabolism. In fact, identification of novel gut derived metabolites related to inflammation suggests that the gastrointestinal tract “cross-talks” with several tissues (e.g., skeletal muscle, liver, adipose, pancreas) to impact blood glucose regulation. Thus, additional work is required to determine the exact mechanism by which gastrointestinal, neuronal, and endocrine systems contribute to

diabetes remission and β-cell function. Taken together, the interaction between the gastrointestinal tract and obesity related metabolic improvements seen following bariatric surgery warrant referral to chronic disease, such as type 2 diabetes, as a "gastrointestinal related disease." Further understanding of mechanisms related to gut metabolism following bariatric surgery, with or without lifestyle modification, will likely promote innovative medical strategies that improve rates of obesity, type 2 diabetes and cardiovascular resolution.

REFERENCES

[1] Rubino F. Bariatric surgery: effects on glucose homeostasis. *Curr Opin Clin Nutr Metab Care* 2006; 9: 497-507.

[2] Steinbrook R. Surgery for severe obesity. *N Engl J Med* 2004; 350: 1075-1079.

[3] Despres JP, Lemieux I and Prud'homme D. Treatment of obesity: need to focus on high risk abdominally obese patients. *BMJ* 2001; 322: 716-720.

[4] DeFronzo RA and Abdul Ghani MA. Preservation of ß-cell function: the key to diabetes prevention. *J Clin Endocrinol Metab* 2011; 96: 2354-2366.

[5] Samuel VT and Shulman GI. Mechanisms for insulin resistance: common threads and missing links. *Cell* 2012; 148: 852-871.

[6] Pories WJ, Caro JF, Flickinger EG, Meelheim HD and Swanson MS. The control of diabetes mellitus (NIDDM) in the morbidly obese with the Greenville Gastric Bypass. *Ann Surg* 1987; 206: 316-323.

[7] Pories WJ, Swanson MS, MacDonald KG, Long SB, Morris PG, Brown BM et al. Who would have thought it? An operation proves to be the most effective therapy for adult-onset diabetes mellitus. *Ann Surg* 1995; 222: 339-50.

[8] Sjostrom L. Lifestyle, Diabetes, and Cardiovascular Risk Factors 10 Years after Bariatric Surgery. *N Engl J Med* 2004; 351: 2683-93.

[9] Scopinaro N, Marinari GM, Camerini GB, Papadia FS and Adami GF. Specific effects of biliopancreatic diversion on the major components of metabolic syndrome: a long-term follow-up study. *Diabetes Care* 2005; 28: 2406-2411.

[10] Scopinaro N, Papadia F, Marinari G, Camerini G and Adami G. Long-term control of type 2 diabetes mellitus and the other major components of the metabolic syndrome after biliopancreatic diversion in patients with BMI < 35 kg/m2. *Obesity Surg* 2007; 17: 185-192.

[11] Buchwald H, Avidor Y, Braunwald E, Jensen M, Pories W, Fahrbach K et al. Bariatric surgery: a systematic review and meta-analysis. *JAMA* 2004; 292: 1724-1737.

[12] Brethauer SA, Aminian A, Romero Talamás H, et al. Can diabetes be surgically cured? Long-term metabolic effects of bariatric surgery in obese patients with type 2 diabetes mellitus. *Ann Surg* 2013; 258: 628-36.

[13] Torquati A, Lutfi R, Abumrad N and Richards W. Is Roux-en-Y gastric bypass surgery the most effective treatment for type 2 diabetes mellitus in morbidly obese patients? *J Gastroint Surg* 2005; 9: 1112-6.

[14] Pories WJ, MacDonald KG, Flickinger EG, Dohm GL, Sinha MK, Barakat HA et al. Is type II diabetes mellitus (NIDDM) a surgical disease? *Ann Surg* 1992; 215: 633-42.

[15] Sugerman H, Wolfe L, Sica D and Clore J. Diabetes and hypertension in severe obesity and effects of gastric bypass-induced weight loss. *Ann Surg* 2003; 237: 751-6.
[16] Dixon J, O'Brien P, Playfair J, et al. Adjustable gastric banding and conventional therapy for type 2 diabetes: a randomized controlled trial. *JAMA* 2008; 299: 316-323.
[17] Mingrone G, Panunzi S, De Gaetano A, Guidone C, Iaconelli A, Leccesi L et al. Bariatric surgery versus conventional medical therapy for type 2 diabetes. *N Engl J Med* 2012; 366: 1577-1585.
[18] Ikramuddin S, Korner J, Lee WJ, et al. Roux-en-Y gastric bypass vs intensive medical management for the control of type 2 diabetes, hypertension, and hyperlipidemia: the Diabetes Surgery Study randomized clinical trial. *JAMA* 2013; 309: 2240-2249.
[19] Schauer PR, Kashyap SR, Wolski K, et al. Bariatric surgery versus intensive medical therapy in obese patients with diabetes. *N Engl J Med* 2012; 366: 1567-1576.
[20] Rubino F, R'bibo SL, del Genio F, Mazumdar M and McGraw T. Metabolic surgery: the role of the gastrointestinal tract in diabetes mellitus. *Nat Rev Endocrinol* 2010; 6: 102-109.
[21] Marceau P, Hould FS, Simard S, et al. Biliopancreatic diversion with duodenal switch. *World J Surg* 1998; 22: 947-954.
[22] Brolin RE, LaMarca LB, Kenler HA and Cody RP. Malabsorptive gastric bypass in patients with superobesity. *J Gastrointest Surg* 2002; 6: 195-203.
[23] Kashyap SR, Gatmaitan P, Brethauer SA and Schauer PR. Bariatric surgery for type 2 diabetes: weighing the impact for obese patients. *Cleve Clin J Med* 2010; 77: 468-476.
[24] Cummings DE. Endocrine mechanisms mediating remission of diabetes after gastric bypass surgery. *Int J Obes* 2009; 33 Suppl 1: S33-S40.
[25] Pournaras DJ and le Roux CW. Obesity, gut hormones, and bariatric surgery. *World J Surg* 2009; 33: 1983-1988.
[26] Mithieux G. A novel function of intestinal gluconeogenesis: central signaling in glucose and energy homeostasis. *Nutrition* 2009; 25: 881-884.
[27] Rubino F. The Early Effect of the Roux-en-Y Gastric Bypass on Hormones Involved in Body Weight Regulation and Glucose Metabolism. *Ann Surg* 2004; 240: 236-242.
[28] Salinari S, Debard C, Bertuzzi A, et al. Jejunal proteins secreted by db/db mice or insulin-resistant humans impair the insulin signaling and determine insulin resistance. *PLoS ONE* 2013; 8: e56258-e56258.
[29] Ionut V and Bergman RN. Mechanisms responsible for excess weight loss after bariatric surgery. *J Diabetes Sci Tech* 2011; 5: 1263-1282.
[30] Saeidi N, Meoli L, Nestoridi E, et al. Reprogramming of intestinal glucose metabolism and glycemic control in rats after gastric bypass. *Science* 2013; 341: 406-410.
[31] Laferrere B, Teixeira J, McGinty J, Tran H, Egger J, Colarusso A et al. Effect of weight loss by gastric bypass surgery versus hypocaloric diet on glucose and incretin levels in patients with type 2 diabetes. *J Clin Endocrinol Metab* 2008; 93: 2479-2485.
[32] Samat A, Malin SK, Huang H, Schauer PR, Kirwan JP and Kashyap SR. Ghrelin suppression is associated with weight loss and insulin action following gastric bypass surgery at 12-months in obese adults with type 2 diabetes. *Diabetes Obes Metab.* 2013; 15: 963-6
[33] Nannipieri M, Mari A, Anselmino M, et al. The role of beta-cell function and insulin sensitivity in the remission of type 2 diabetes after gastric bypass surgery. *J Clin Endocrinol Metab* 2011; 96: E1372-9.

[34] Kashyap SR, Daud S, Kelly KR, et al. Acute effects of gastric bypass versus gastric restrictive surgery on beta-cell function and insulinotropic hormones in severely obese patients with type 2 diabetes. *Int J Obes* 2010; 34: 462-471.

[35] Bojsen Møller KN, Dirksen C, Jørgensen NB, et al. Early enhancements of hepatic and later of peripheral insulin sensitivity combined with increased postprandial insulin secretion contribute to improved glycemic control after Roux-en-Y gastric bypass. *Diabetes* 2014; 63: 1725-37.

[36] Salehi M, Prigeon RL and D'Alessio DA. Gastric bypass surgery enhances glucagon-like peptide 1-stimulated postprandial insulin secretion in humans. *Diabetes* 2011; 60: 2308-14.

[37] Peterli R, Steinert RE, Woelnerhanssen B, et al. Metabolic and hormonal changes after laparoscopic Roux-en-Y gastric bypass and sleeve gastrectomy: a randomized, prospective trial. *Obesity Surg* 2012; 22: 740-748.

[38] Kashayp SR, Bhatt DL, Wolski K, et al. Metabolic effects of bariatric surgery in patients with moderate obesity and type 2 diabetes: analysis of a randomized control trial comparing surgery with intensive medical treatment. *Diabetes Care.* 2013; 36: 2175-82.

[39] Romero F, Nicolau J, Flores L, et al. Comparable early changes in gastrointestinal hormones after sleeve gastrectomy and Roux-En-Y gastric bypass surgery for morbidly obese type 2 diabetic subjects. *Surg Endosc* 2012; 26: 2231-9.

[40] Korner J, Bessler M, Inabnet W, Taveras C and Holst JJ. Exaggerated glucagon-like peptide-1 and blunted glucose-dependent insulinotropic peptide secretion are associated with Roux-en-Y gastric bypass but not adjustable gastric banding. *Surg Obesity Relat Dis* 2007; 3: 597-601.

[41] Hanusch Enserer U, Ghatei MA, Cauza E, Bloom SR, Prager R and Roden M. Relation of fasting plasma peptide YY to glucose metabolism and cardiovascular risk factors after restrictive bariatric surgery. *Wien Klin Wochenschr* 2007; 119: 291-296.

[42] le Roux CW, Aylwin SJ, Batterham RL, et al. Gut hormone profiles following bariatric surgery favor an anorectic state, facilitate weight loss, and improve metabolic parameters. *Ann Surg* 2006; 243: 108-114.

[43] Laferrere B, Swerdlow N, Bawa B, et al. Rise of oxyntomodulin in response to oral glucose after gastric bypass surgery in patients with type 2 diabetes. *J Clin Endocrinol Metab* 2010; 95: 4072-4076.

[44] Quercia I, Dutia R, Kotler DP, Belsley S, Laferrere B. Gastrointestinal changes after bariatric surgery. *Diabetes Metab* 2014; 40(2):87-94.

[45] Tong J, Prigeon RL, Davis HW, et al. Ghrelin suppresses glucose-stimulated insulin secretion and deteriorates glucose tolerance in healthy humans. *Diabetes* 2010; 59: 2145-2151.

[46] Malin SK, Samat A, Wolski K, et al. Improved acylated ghrelin suppression at 2 years in obese patients with type 2 diabetes: effects of bariatric surgery vs standard medical therapy. *Int J Obes* 2014; 38(3):364-70.

[47] Patti ME, Houten S, Bianco AC, et al. Serum bile acids are higher in humans with prior gastric bypass: potential contribution to improved glucose and lipid metabolism. *Obesity* 2009; 17: 1671-1677.

[48] Pournaras DJ, Glicksman C, Vincent R, et al. The role of bile after Roux-en-Y gastric bypass in promoting weight loss and improving glycaemic control. *Endocrinology* 2012; 153: 3613-3619.

[49] Katsuma S, Hirasawa A, Tsujimoto G. Bile acids promote glucagon-like peptide-1 secretion through TGR5 in a murine enteroendocrine cell line STC-1. *Biochem Biophys Res Commun* 2005; 329: 386-390.

[50] Thomas C, Gioiello A, Noriega L, et al. TGR5-mediated bile acid sensing controls glucose homeostasis. *Cell metabolism* 2009; 10: 167-177.

[51] Dufer M, Horth K, Wagner R, et al. Bile acids acutely stimulate insulin secretion of mouse β-cells via farnesoid X receptor activation and K(ATP) channel inhibition. *Diabetes* 2012; 61: 1479-1489.

[52] Jørgensen N, Dirksen C, Bojsen Møller K, et al. Improvements in glucose metabolism early after gastric bypass surgery are not explained by increases in total bile acids and fibroblast growth factor 19 concentrations. *J Clin Endocrinol Metab* 2015; 100: E396-406.

[53] Steinert RE, Peterli R, Keller S, et al. Bile acids and gut peptide secretion after bariatric surgery: a 1-year prospective randomized pilot trial. *Obesity (Silver Spring)* 2013; 21: E660-8.

[54] Breen DM, Rasmussen BA, Cote DA, Jackson VM, Lam TK. Nutrient-sensing mechanisms in the gut as therapeutic targets for diabetes. *Diabetes* 2013; 62: 3005-3013.

[55] Hildebrandt MA, Hoffmann C, Sherrill Mix SA, et al. High-fat diet determines the composition of the murine gut microbiome independently of obesity. *Gastroenterology* 2009; 137: 1716-24.e1.

[56] Ley RE, Turnbaugh PL, Klein S, Gordon JI. Microbial ecology: human gut microbes associated with obesity. *Nature* 2006; 444: 1022-1023.

[57] Ding S, Chi MM, Scull B, et al. High-fat diet: bacteria interactions promote intestinal inflammation which precedes and correlates with obesity and insulin resistance in mouse. *PLoS ONE* 2010; 5: e12191-e12191.

[58] Aron-Wisnewsky J, Dore J, Clement K. The importance of the gut microbiota after bariatric surgery. *Nat Rev Gastroenterol Hepatol* 2012; 9: 590-598.

[59] Swartz TD, Duca FA, de Wouters T, Sakar Y, Covasa, M. Up-regulation of intestinal type 1 taste receptor 3 and sodium glucose luminal transporter-1 expression and increased sucrose intake in mice lacking gut microbiota. *Br J Nutr* 2012; 107: 621-630.

[60] Schwiertz A, Taras D, Schafer K, Beijer S, Bos NA, Donus C, Hard PD. Microbiota and SCFA in lean and overweight healthy subjects. *Obesity* 2010; 18: 190-195.

[61] Zhang H, DiBaise JK, Zuccolo A, et al. Human gut microbiota in obesity and after gastric bypass. *Proc Natl Acad Sci U S A* 2009; 106: 2365-2370.

[62] Furet JP, Kong LC, Tap J, et al. Differential adaptation of human gut microbiota to bariatric surgery-induced weight loss: links with metabolic and low-grade inflammation markers. *Diabetes* 2010; 59: 3049-3057.

[63] Kong LC, Tap J, Aron-Wisnewsky J, et al. Gut microbiota after gastric bypass in human obesity: increased richness and associations of bacterial genera with adipose tissue genes. *Am J Clin Nutr* 2013; 98: 16-24.

[64] Vrieze A, Van Nood E, Holleman F, et al. Transfer of intestinal microbiota from lean donors increases insulin sensitivity in individuals with metabolic syndrome. *Gastroenterology* 2012; 143: 913-6.e7.

[65] Walker AW, Duncan SH, McWilliam Leitch EC, Child MW, Flint HJ. pH and peptide supply can radically alter bacterial populations and short-chain fatty acid ratios within microbial communities from the human colon. *Appl Environ Microbiol* 2005; 71: 3692-3700.

[66] Laferrere B. Gut feelings about diabetes. *Endocrinol Nutr* 2012; 59: 254-260.

[67] Tilg H, Kaser A. Gut microbiome, obesity, and metabolic dysfunction. *J Clin Invest* 2011; 121: 2126-2132.

[68] Trøseid M, Nestvold TK, Rudi K, Thoresen H, Nielsen EW, Lappegård KT. Plasma lipopolysaccharide is closely associated with glycemic control and abdominal obesity: evidence from bariatric surgery. *Diabetes Care* 2013; 36: 3627-3632.

[69] Creely SJ, McTernan PG, Kusminski CM. Lipopolysaccharide activates an innate immune system response in human adipose tissue in obesity and type 2 diabetes. *Am J Physiol Endocrinol Metabol* 2007; 292: E740-E747.

[70] Lassenius MI, Pietiläinen KH, Kaartinen K, et al. Bacterial endotoxin activity in human serum is associated with dyslipidemia, insulin resistance, obesity, and chronic inflammation. *Diabetes Care* 2011; 34: 1809-1815.

[71] Cani PD, Neyrinck AM, Fava F, et al. Selective increases of bifidobacteria in gut microflora improve high-fat-diet-induced diabetes in mice through a mechanism associated with endotoxaemia. *Diabetologia* 2007; 50: 2374-2383.

[72] Arora T, Sharma R, Frost G. Propionate. Anti-obesity and satiety enhancing factor? *Appetite* 2011; 56: 511-515.

[73] Soliman MM, Ahmed MM, Salah-Eldin AE, Abdel-Aal AA. Butyrate regulates leptin expression through different signaling pathways in adipocytes. *J Vet Sci* 2011; 12: 319-323.

[74] Liou AP, Paziuk M, Luevano JM Jr, Machineni S, Turnbaugh PJ, Kaplan LM. Conserved shifts in the gut microbiota due to gastric bypass reduce host weight and adiposity. *Sci Transl Med* 2013; 5: 178ra41-178ra41.

[75] Bjursell M, Admyre T, Göransson M, Marley AE, Smith DM, Oscarsson J, Bohlooly-Y M Improved glucose control and reduced body fat mass in free fatty acid receptor 2-deficient mice fed a high-fat diet. *Am J Physiol Endocrinol Metab* 2011; 300: E211-E220.

[76] McNelis J, Lee Y, Mayoral R, van der Kant R, Johnson AMF, Wollam J et al. GPR43 Potentiates ß-Cell Function in Obesity. *Diabetes* 2015; 64: 3203-17.

[77] Wang Z, Klipfell E, Bennett BJ, et al. Gut flora metabolism of phosphatidylcholine promotes cardiovascular disease. *Nature* 2011; 472: 57-63.

[78] Seyfried F, Li JV, Miras AD, et al. Urinary phenotyping indicates weight loss-independent metabolic effects of Roux-en-Y gastric bypass in mice. *J Proteome Res* 2013; 12: 1245-1253.

[79] Troseid M, Hov JR, Nestvold TK, et al. Major Increase in Microbiota-Dependent Proatherogenic Metabolite TMAO One Year After Bariatric Surgery. *Metab Syndr Relat Disord* 2016; 14: 197-201.

[80] Tang WH, Wang Z, Levison BS, et al. Intestinal microbial metabolism of phosphatidylcholine and cardiovascular risk. *N Engl J Med* 2013; 368: 1575-1584.

In: Encyclopedia of Surgery (22 Volume Set)
Editors: Andreas Lehrer and Kristin Mueller
ISBN: 978-1-53618-329-0
© 2020 Nova Science Publishers, Inc.

Chapter 146

CT SCAN AND 3D APPLICATIONS FOR HIP SURGERY

T. Robba*, D. Molino, D. Martorano and A. Borre'
Radiology Department, Città della Salute e della Scienza di Torino –
C.T.O. Hospital, Torino, Italy

ABSTRACT

Since its introduction in the seventies, Computed Tomography has evolved into an essential diagnostic imaging tool for an ever-increasing variety of clinical applications. CT was the first technology to combine a computer with a medical imaging machine, the first to display X-ray images as cross sections and the modality that marked the beginning of a new era in digital imaging. It has quickly become the choice examination in the diagnosis of traumatic and musculoskeletal lesions. Indeed, in hip diseases, anthropometric measurements of acetabular geometry and orientation determine the decision-making process regarding surgical treatment and also affect outcome. Improvements in MPR and 3D imaging have given clinicians the opportunity to find practical tools for qualitative and quantitative evaluation of acetabular pathology. It is now also used in interventional imaging (injection guidance, bone and soft tissue biopsies, vertebroplasty, etc.). CT has helped with surgical decision in fractures (fractured neck of femur for example is a serious consequence of falls in the elderly, and is associated with high morbidity and mortality); it is also important in the assessment of avascular necrosis. CT defines the entire surface of the femoral head better than axial radiographs in the osteoarthritis, helping in the choice of total hip replacement over osteotomy and allowing more precise preoperative planning. CT allows for the evaluation of the femoroacetabular impingement parameters independently from the position of the patient and the pelvic tilt and, for this reason, should be used in pelvic pre-operatory evaluation. CT is also important in total hip replacement because it can depict peri-implant fluid and soft-tissue masses that may be completely hidden on radiography.

Keywords: CT scan, hip surgery, 3d reconstruction

* Corresponding Author's Email: tizianarobba@yahoo.it.

1. INTRODUCTION

1.1. Principles of Physics and Technical Considerations

Since its introduction in the seventies, Computed Tomography has evolved into an essential diagnostic imaging tool for an ever-increasing variety of clinical applications. The word tomography derives from the Greek word "*tomos*" meaning section, so the process of tomography involves the generation of narrow sections through an object. CT was the first technology to combine a computer with a medical imaging machine, the first to display X-ray images as cross sections and the modality that marked the beginning of a new era in digital imaging. Between 1957 and 1963, a South African physicist, A. Cormick, independently developed a method of calculating radiation absorption distributions in the human body, based on transmission measurements. He postulated that CT would be able to display very small differences in the absorption through the body, but never applied his research. In the early 1970s, CT scanning was conceived, yet again, by William Oldendorf and developed by Godfrey Hounsfield (Nobel prize winner in 1979 for Physiology and Medicine). CT was introduced into clinical practice in 1971 with a scan of a cystic frontal lobe tumour in a patient at Atkinson Morley Hospital in Wimbledon (United Kingdom). After this, CT was immediately welcomed by the medical community and has often been referred to as the most important invention in radiological diagnosis, since the discovery of X-rays [1].

A CT system consists of an X-ray source, a sliding table, an X-ray detector and a data processing unit for computation, visualisation and data analysis of measurement results. CT creates cross-section images by projecting a beam of emitted photons through one plane of an object from defined angle positions performing one revolution.

X-rays are electromagnetic waves with a wavelength smaller than approximately 10 nm. The energy of each photon is proportional to its frequency and the X-ray energy is usually expressed in eV (1eV = 1.602 × 10−19J). X-rays are produced when an accelerated beam of electrons is delayed by a metal object (target material, usually corresponding to the anode), with emission of X-ray photons. An X-ray source consists of a hot cathode (tungsten filament) and an anode inside a vacuum tube, between which an electrical potential is applied. Electrons ejected from the cathode surface are accelerated towards the anode. When these electrons impinge on the target, they interact with these atoms and transfer their kinetic energy to the anode. These interactions occur within a very small penetration depth into the target. As they occur, the electrons slow down and finally almost come to rest, at which time they can be conducted through the anode and out into the associated electronic circuit. The electron interacts with either the orbital electrons or the nuclei of the metal atoms. The interactions result in a conversion of kinetic energy into thermal energy and electromagnetic energy in the form of X-rays.

As the X-rays (emitted photons) pass through the patient, some of them are absorbed, some are scattered and some are transmitted. The process of X-ray intensity reduction, involving only X-rays that are scattered or absorbed, is called attenuation. X-rays that are attenuated due to interactions with the tissues do not reach the X- ray detector. Photons transmitted through the patient at each angle are collected on the detector, measured as a local attenuation coefficient in "Hounsfield units" and coded in grey value. Each image ("slice") of the body scanned is divided in a matrix of voxels (volume picture element), whilst the

corresponding CT image of the slice is divided into pixels (picture element): a voxel of CT image corresponds to each voxel of the slice.

For each voxel, the attenuation coefficient in calculated and coded in a grey value attributed to the corresponding pixel. In other words, each voxel is assigned with a grey value of the corresponding pixel, representing a local X-ray absorption density. The quality of the image depends on several parameters that have to be set before the CT scan is performed, bearing in mind that the absorbed dose depends on them. These parameters refer to the energy of the X-ray source (mAs, KV), the slice thickness, the dimensions of the voxel and the depth of matrix (256x256, 512x512, etc.), the dimension of the FOV (field of view: 40x40 cm, 24x24 cm), depending on the anatomic district and other more in depth parameters.

In the evolution of CT, further types of scanners have followed. The *first two generations* of CT scanners (or single-slice CT scanners) didnot provide volumetric studies and were superseded in the late 1970s by third- and fourth-generation scanners, which are still in use today as well as fifth-generation CT.

First-generation CT systems are characterised by a single X-ray source (pencil beam) directing across the object and a single detector. Both the source and the detector, translate simultaneously in a scan plane. This process is repeated for a given number of angular rotations. The most important disadvantage of first-generation CT was a longer scanning time.

Second-generation CT systems use the same translate/rotate scan geometry as the first generation. The difference here is that a pencil beam is replaced by a fan beam and a single detector by multiple detectors, so that a series of views can be acquired during each translation, which leads to correspondingly shorter scanning times. So, objects of wide range sizes can be easily scanned with the second-generation scanners.

Third-generation scanners, tube and detector arrays rotate synchronously around the patient. The detector array covers the full width of the fan beam.

The introduction of spiral CT in the early 1990s (*third-generation*) constituted a fundamental evolutionary step in the development and ongoing refinement of CT imaging techniques. For the first time, volume data could be acquired without misreporting of anatomic detail.

Fourth-generation CT systems also use a rotate-only scan motion. The detector elements cover a full circle around the scanner opening and remain stationary during the scan, while only the x-ray tube rotates around the patient. The number of views is equal to the number of detectors. These scanners are more susceptible to scattered radiation.

Fifth-generation CT systems are different from the previous systems, in that there is no mechanical motion involved. The scanner uses a circular array of X-ray sources, which are electronically switched on and off. The sources project onto a curved fluorescent screen, so that when an X-ray source is switched on, a large volume of the part is imaged simultaneously, providing projection data for a cone beam of rays diverging from the source. Here, a series of two-dimensional projections of a three-dimensional object is collected.

The ability to acquire volume data also paved the way for the development of three-dimensional (3D) image processing techniques such as multiplanar reformation (MPR), maximum intensity projection, surface-shaded display, and volume-rendering techniques, which have become a vital component of medical imaging today.

1.2. Post-Processing Reconstruction

The creation of new and customised visual representations by applying mathematical algorithms to the original data is called a reconstruction technique. Many techniques have been developed to post-process CT volumetric data. The simplest techniques extract one single parameter of the volumetric data and produce two-dimensional reconstructions highlighting a desired structure. These reconstructions are two-dimensional MPRs (multiplanar reconstructions) and can also be performed on curved planes (along vessels, lordosis or kyphosis of the spine, etc.). They generally provide superior anatomic detail, whereas surgeons tend to prefer three-dimensional images for surgical planning. Multi-planar reconstruction is the reformatting of data, typically along the sagittal and coronal plane, although any off-axis slice can also be obtained.

1.3. 3D Reconstruction

When the acquisition process of the scanned object is completed, reconstruction algorithms are used to reconstruct the 3D volume [2]. These reconstructed 3D images are made of voxels. There are several 3D post-processing techniques available. Volume rendering reconstruction (VR) takes the entire volume of data, calculates the contributions of each voxel (volume pixel) along a line from the viewer's eye through the data set, and displays the resulting composite for each pixel of the display. Threshold value is a critical parameter in CT and is used for accurate image segmentation and surface data determination, which influence the resulting reconstructed geometry of the scanned object. Threshold converts a grey value image into a binary one. The resulting image then comprises two sets: one represents the background (e.g., black), the other the object (e.g., white). In principal, a threshold determines where the boundaries lie between the object and the air, so that a surface can be assigned to the scanned object.

Except for cases with secondary vascular imaging, the key reconstruction algorithms used in pelvic bone imaging are shaded-surface display and volume rendering. The correct acquisition and reconstruction of axial image data is the base for a multi-planar two-dimensional reformatted image or a 3D CT image. The 3D rendering software algorithms attempt to display 3D spatial relationships in a two-dimensional image [3]. Both shaded surface rendering and volume rendering have been advocated as reconstruction algorithms for 3D musculoskeletal imaging, but certain advantages of volume rendering make it our preferred algorithm for all 3D musculoskeletal imaging applications. Volume algorithms show 3D relationships with varying degrees of success depending on the degree of surface shading and opacity. Volume-rendered images may be viewed in any plane or projection and in a range of opacities, from transparent to opaque.

1.4. Dose and Noise

Noise is caused by the variation in attenuation coefficients between individual voxels. In CT, we are measuring the attenuation coefficients of the individual tissue voxels. If we have two voxels with identical tissue, we would expect to measure identical attenuation coefficient

values and, when these are translated into CT numbers, we would expect to obtain similar numbers. In reality, we do not due to the noise, which is the random variation of density and which can be quantified. The amount of this variation can be evaluated by determining the standard deviation, which is the easiest and an excellent way of quantifying the amount of noise in CT images. All CT systems have the software capability of defining a region of interest (ROI) and measuring and calculating the standard deviation of this ROI. To decrease noise, we must increase the number of X-ray photons absorbed in each voxel during the imaging process. The quantity of radiation photons in each voxel can be controlled in two ways: adjusting the size of the voxel or modifying the exposure. Obviously, a large voxel will intercept and absorb more photons than a small voxel and will result in decreased noise in the image. The other way of controlling the quantity of absorbed radiation photons per voxel is by increasing the total radiation imparted to the patient. This is controlled through the number of photons emitted per second by the X-ray source, which depends on the current intensity applied on the cathodic tube (mAsecond or mAs). By increasing the milliampere seconds, we deposit more photons in each voxel of tissue, which results in less statistical variation (less standard deviation), therefore, less noise in the image. We must bear in mind that increasing the milliampere seconds leads to an increased absorbed dose. This is why many technological innovations have tended to reduce the dose delivered over the last few years. The best example is the recent appearance of iterative reconstructions that reduce the dose by half with an equivalent image quality [4]. With these technological innovations and better control of the optimisation of the acquisition parameters, it is now possible to obtain CT imaging with a dose almost equal that of the standard X-ray assessment while the diagnostic performance of CT is much higher than that of X-rays. Moreover, one of the benefits of iterative reconstructions is the possibility of reducing the artefacts, in particular, the beam hardening artefacts. This is of particular interest in the analysis of the soft tissue and bone structures in contact with osteosynthesis material [5].

1.5. Contrast Media in CT: CT and Perfusion-CT

Intravenous contrast is used in CT to help highlight blood vessels and to enhance the tissue structure of various organs. Contrast-enhanced CT is used to find pathologies by enhancing the contrast between a lesion and normal surrounding structures. Therefore, it is important to know in which phase a CT should be performed, depending on the pathology that you are looking for.

The major families of contrast agents are ionic and nonionic. Contrast agents can be further classified as high or low osmolality, based on the iodine concentration. Most centres use nonionic contrast agents (which are generally low osmolality) for IV contrast studies. The rate of major reactions (e.g., anaphylaxis, death) is the same for ionic and nonionic IV contrast agents - an estimated one in 170,000 administrations - but nonionic contrast agents have a lower rate of minor reactions. Approximately 5% to 12% of patients who receive high-osmolality contrast have adverse reactions, most of which are mild or moderate. Use of low-osmolality contrast has been associated with a reduction in adverse effects. Children have a lower incidence of reactions to IV contrast agents and most of these are mild (0.18% for low-osmolality agents).

The CT with contrast study comprises different phases:

- non-enhanced CT. Helpful in detecting calcifications, fat in tumours, fat-stranding as seen in inflammation such as diverticulitis, omental infarction, etc.
- early arterial phase - 15-20 sec. This is the phase when the contrast is still in the arteries and has not enhanced the organs and other soft tissues.
- late arterial phase - 35-40 sec. Sometimes also called “arterial phase” or “early venous portal phase”, as some enhancement of the portal vein can be seen. All structures that receive their blood supply from the arteries will show optimal enhancement.
- hepatic or late portal phase - 70-80 sec. Although hepatic phase is the most accurate term, most people use the term “late portal phase”. In this phase, the liver parenchyma enhances through blood supply by the portal vein and you should see the enhancement of the veins.
- nephrogenic phase - 100 sec. This is when all of the renal parenchyma, including the medulla, is enhanced.
- delayed phase - 6-10 minutes. Sometimes called “wash-out phase” or “equilibrium phase”. There is wash-out of contrast in all abdominal structures except for fibrotic tissue, since fibrotic tissue has a poor late wash-out and will become relatively dense compared to normal tissue.

The use of intravenous contrast material is not usually necessary for the pelvic bone study, but is usually used in combination with abdominal CT scans during initial high-energy blunt trauma evaluation. When pelvic CT scans are obtained alone for the detection of subtle fractures and displacements not appreciated on radiographs, intravenous contrast can be used to create vascular maps to rule out vascular injury. In pelvic trauma, if vascular injury is suspected, a spiral CT using CT angiographic technique would ideally be used. In this process, we can evaluate the lower abdominal aorta, iliac vessels and their branching as well as the bony pelvis in a single examination. Rapid-acquisition spiral CT allows the entire dataset to be acquired at the peak of contrast enhancement. In these cases, a delay of 30–40 in scanning is ideal. Three-dimensional images produced with maximum intensity projection or volume-rendering techniques require an optimal administration of contrast material if vascular images are to be generated. Injection rates are typically 2–4 ml/s.

The use of CT with contrast in the hip and musculoskeletal system is important in trauma to assess bleeding.

Perfusion CT was first described many years ago [6]. Like with dynamic examinations, the CT perfusion of musculoskeletal tumours is possible due to an improvement in the temporal resolution of multislice CT imaging and the development of multidetector CT. The study of perfusion by CT combines the advantages of perfusion imaging, providing data similar to that provided by the MRI but with better visualisation of bone invasion (periosteal reaction, cortical break, osteolysis), femoral necrosis and neovascularisation. The quantification of perfusion curves by CT is as easy as with MRI [7].

1.6. Dual Energy Computed Tomography

Dual energy CT is based on the acquisition of two superimposable images with two different kilovoltages. Based on these native images, it is possible to reconstruct a virtual image corresponding to any voltage of the X-ray tube [8]. Each manufacturer proposes dual energy acquisitions on their CT. However, the techniques used often differ. This accounts for differences in terms of performance and clinical applications between these techniques. Several applications of the dual energy CT in the osteoarticular domain are now clinically available although still in the assessment phase: improvement in tissue characterisation, bone subtraction, differentiation of bone and iodine contrast product or even reduction of metallic artefacts. The improvement in tissue characterisation was first used for the detection and characterisation of urate deposits in gout [9]. An initial study by Nicolaou et al. [10]demonstrated that the dual energy acquisition of all peripheral joints (elbows, wrists, hands, knees, ankles and feet) provides good sensitivity and good specificity in the detection of locations of topaceous gout, while the total effective dose ranged from only 2 to 3 mSv. Another dual energy application is the possibility of obtaining reconstructions in bone subtraction. It is then possible to detect bone marrow oedema. Pache et al. [11] demonstrated that it was possible to detect post-traumatic bone marrow oedema in knee CT imaging, with an increase in irradiation of about 28% compared with a conventional CT. The dual energy bone CT may also become an alternative in case of contraindication for MRI or if this is unavailable. However, clinical studies are required to specify the role of this technique compared with MRI [12]. Finally, with a dose equivalent to that of a standard single energy acquisition, Bamberg et al. [13] demonstrated that the use of dual energy allowed for a reduction in prosthesis-related metallic artefacts.

2. CT IN MUSCULOSKELETAL RADIOLOGY

Since its introduction in the 1970s, computer tomography has played a major role in the diagnosis of many osteoarticular diseases. It has quickly become the choice examination in the diagnosis of traumatic and malformative lesions. Indeed, in hip diseases, anthropometric measurements of acetabular geometry and orientation determine the decision-making process regarding surgical treatment and also affect outcome. Improvements in 3D imaging have given clinicians the opportunity to find practical tools for qualitative and quantitative evaluation of acetabular pathology. It is now also used in interventional imaging (injection guidance, bone and soft tissue biopsies, vertebroplasty, etc.) [14]. However, the performance of CT is limited by the less contrast resolution for soft tissues compared with Magnetic Resonance Imaging (MRI) and, above all, CT is X-ray-related imaging. For all of these reasons, MRI has taken a preponderant role in musculoskeletal imaging. Nevertheless, in recent years, the speed of acquisition and spatial resolution with submillimetric isotropic acquisitions of CT have considerably improved and, as mentioned before, recent technological evolutions reduce the dose the patient is exposed to. As opposed to MRI, the other advantages of CT include its lower cost, improved availability, the possibility of use on postsurgical or unstable patients and the absence of contraindications related to prosthetic materials or pacemakers. Therefore, the scanner still plays an important role in osteoarticular disease [15].

3. CT of the Hip and Pelvic Anatomy

The osseous anatomy of the pelvis is a complex union of the sacrum and two hemipelvic bones, each derived from three smaller bones: the ilium, ischium and pubis. Each of these bones is of a variable thickness and they are spatially oriented at a different angle with respect to each other and to the different axes of the human body. The pelvis is firmly fixed at the sacroiliac joint and its moves as a unit. This means it is impossible to project, in traditional radiology, some areas free of overlying osseous structures. Thus, the deeper and more central structures such as the posterior iliac spines, the sacroiliac joints and most of the sacrum are particularly difficult to image. Overlying faecal matter and bowel gas further compromise conventional radiologic evaluation of the sacrum. Computed tomography overcomes these anatomical difficulties and graphically displays both the anatomic location and intraosseous extent of osteolytic lesion of the pelvis.

The hip is a ball socket joint with a complex origin of the socket, due to the contribution of three bones joined at the triradiate cartilage. These separate contributions to the acetabulum are seen in paediatric patients. At this age, it is apparent that the acetabular roof is contributed by the ilium, the small antero-medial portion by the pubic bone and the major postero-medial portion by the ischium. CT has been shown to have a role in solving selected problems related to congenital hip dislocation, trauma and infection.

In adults, CT scans of the hip have been useful due their display of cross-sectional anatomy. Computed Tomography shows that the acetabulum is not merely a socket, but rather a focal concavity supported at the apex of an arch derived from two substantial columns of bone. The posterior, or ileo-ischial, column is large and descends from the sciatic notch to the ischial tuberosity. The anterior, or ileopubic, column runs downwards, inwards and forwards from the iliac crest to the pubic symphysis. The periphery of the acetabulum narrows into a labrum that is complete except inferiorly, where it meets the acetabular fossa. The posterior acetabular rim is more substantial and extends further laterally than the anterior rim. The femoral head is seated centrally in the acetabulum, but may not be shown with an equal width of cartilage space around it. When supine and relaxed, the patient, assisted by gravity, permits the leg to rotate externally. This causes minimal subluxation of the femoral head so that the anterior joint space is slightly wider than the posterior.

4. CT in Hip Trauma

Computed tomography of the hip has made its greatest contribution in the evaluation of hip fracture-dislocations. CT has few of the disadvantages of conventional radiography. Computer tomography is simple and accurate, whereas radiography now seems cumbersome and less accurate. Standard radiography requires moving the patient into various positions, which can be painful and there is always concern that further displacement may occur. When optimal radiographs are obtained, they still provide only two-dimensional information. Computed tomography is accomplished without moving the patient's leg or pelvis into various positions and provides three-dimensional information.

The fracture-dislocation pattern and the complications associated with each determine whether or not the specific injury will be treated or subjected to surgery. Computer

tomography has helped with this surgical decision. For a hip to do well following an acetabular fracture, there must be no major intra-articular fragments. The posterior acetabular labrum must be stable and the fragments must be anatomically reduced so that there is minimal incongruity between the femur and acetabulum. Computer tomography readily confirms and accurately localises intra-articular osseous fragments not clinically suspected and not shown on radiographs. Furthermore, CT following a reduction in posterior hip dislocation should be used to investigate the relationship of fracture fragments and help estimate their stability and congruity.

Computed tomography can show the anatomic orientation of post-traumatic hips prior to total hip replacement. Such information helps surgeons plan hip replacement procedures by showing the amount of bone stock present in order to seat the acetabular component. Following gunshot wounds, CT may show the radial spread of bullet fragments better than radiographs. The information derived from CT may help the surgeon decide whether or not to examine the hip.

Fractured neck of femur is a serious consequence of falls in the elderly, and is associated with high morbidity and mortality [16].

Delay in surgical treatment has been shown to significantly increase mortality [17], whilst undisplaced fractures may become displaced if unrecognised and untreated, requiring surgery associated with much higher risk [18].

The sensitivity of plain X-rays in detecting hip fracture is believed to be 90-98%, based on multiple studies [19][20]. More recent studies suggest that approximately 4% of patients with symptoms suggesting of a hip fracture but with a normal initial hip X-ray in the Emergency Department, in fact have an occult hip fracture [21][22]. As a result, where there is high clinical suspicion of hip fracture despite a negative X-ray (patients with significant pain or non-weight bearing after effective analgesia), alternative forms of imaging must be considered and a CT scan must be performed. Nevertheless, there are theoretical limitations (i.e., the potential to miss some fractures in patients with severely osteoporotic bone, owing to the resolution of the trabecular structure and where the cuts are taken in a coincident plane).

5. CT IN AVASCULAR NECROSIS OF THE FEMORAL HEAD

In the assessment of avascular necrosis, therapeutic decisions are based on staging and subsequent surgical decision is based on anatomy. Early diagnosis is based on MRI and eventually nuclear medicine. In stage II, avascular necrosis may become radiologically detectable thanks to bone sclerosis and cystic changes, with preservation of the articular surface of the femoral head. Stage III disease indicates loss of structural integrity of the articular surface and requires aggressive surgery such as a varus osteotomy. In stage IV, there is a loss of the structural integrity of the femoral head, requiring total hip replacement.

The contribution of CT with multiplanar projection in pre-surgical planning are the definition of the arc and area of the sclerotic bone in the femoral head with the extent of the remaining intact femoral head, the detailed assessment of the weight-bearing acetabular dome and, especially, along the posterior acetabular rim, frequently defining radiographically unsuspected involvement. This may help in defining repositioning osteotomies in a more precise pre-operative planning.

6. CT IN OSTEOARTHRITIS

A progressive deterioration and loss of articular cartilage characterise osteoarthritis at the beginning. Afterward, the spherical femoral head starts flattening in the anterocranial and lateral zones. This migration can increase, even over a long time. Subsequently, the spherical head becomes more ellipsoid, biomechanical forces are impaired and the rate of joint destruction accelerates. Clinically, this phase is characterised by pain, increasing in duration and intensity, and by decreasing range of motion. Osteotomy can be considered the best procedure to treat moderate disease, until total hip replacement in the case of severe pathology. Computed tomography with sagittal and coronal MPR helps to evaluate the major weight bearing surfaces with higher resolution detail than radiographs and freely from superimposed anatomical structures, allowing the detection of subtle narrowing of the rim. Furthermore, CT defines the entire surface of the femoral head better than axial radiographs, helping in the choice of total hip replacement over osteotomy and allowing more precise preoperative planning (femoral neck angulation, portion of head best suited to become a new weight-bearing surface).

7. CT IN HIP INSTABILITY AND FEMOROACETABULAR IMPINGEMENT

On the basis of radiographic assessment of femoral-acetabular joint, various surgical options can be taken, as not all parameters may change to a clinically relevant degree, with differences in pelvic orientation (Tannast parameters) [23]. Nevertheless, many pelvic radiographic measurements such as anterior and posterior acetabular coverage, the crossover sign, retroversion index and posterior wall sign can vary depending on pelvic orientation due to orthostatic/clinostatic acquisition of radiographs and due to X-rays tube inclination. This is why radiographic limits in evaluating pelvic abnormalities are mandatory, to avoid mistakes in decision-making and in the execution of joint-preserving surgery of the acetabulum. On the contrary, CT allows for the evaluation of these parameters independently from the position of the patient and the pelvic tilt and, for this reason CT, should be used in pelvic pre-operatory evaluation.

Similarly, focal anterior over-coverage, or “cephalad retroversion,” can be difficult to distinguish from true acetabular retroversion on radiographs. CT also allows for defining the location of focal pincer along all the acetabulum. Distinguishing these lesions is critical, since the treatment plans and approaches for these two conditions are different.

In CT images, the alpha-angle and beta-angle measurements are more accurate than in the axial-view radiographs, as you can correctly choose the plane on which the cam lesion is more prominent. Mostly, the alpha-angle can be measured in radial reconstruction. The beta-angle is formed by the line connecting the centre of the head to the point at which sphericity is lost (same line as that used for the alpha-angle) and the line connecting the centre of the head to the edge of the acetabulum. It provides a rough assessment of the interaction between the cam lesion and acetabular over-coverage on a single plane.

Cam deformity is an osseous prominence that lacks epiphyseal sphericity and a decreased head–neck offset, sometimes also with epiphyseal retroversion (pistol grip deformity). Cam deformity may be depicted on the Dunn lateral radiograph, but the true topography and, above

all, the extension of cam along the head–neck junction may be only fully appreciated and measured with CT imaging. Furthermore, CT scanning helps to identify cam's variants (accessory face, reactive plate) that represent entities with clinical relevance even if not fully understood. This information of the size, site and extent of the cam morphology is critical, as an osteoplasty must restore sphericity and offset in all planes and may affect the selection of an open versus arthroscopic approach. Milone et al. [24] demonstrated that an automated 3D CT-based imaging software was even more accurate than conventional CT, in identifying the location and magnitude of cam lesions in order to plan the surgical approach. Bedi et al. [25] applied similar 3D CT-based imaging software technology to quantify the location and topography of the cam lesion and demonstrate predictable improvements in range of motion with surgical treatment of the deformity.

An area of increasing interest has been the application of novel 3D CT-based imaging software, not only to quantify femoral and acetabular deformity, but also to perform a dynamic analysis to determine the location of mechanical conflict that reproduce symptoms. The beta-angle was an attempt to investigate the additive relationship of cam deformities and acetabular over-coverage on a single spatial plane. Hips with impingement should tend toward negative beta-angles, where the edge of the acetabulum overlies the cam deformity, while hips without impingement lesions should have values ranging between 20° and 40°. The 3D evaluation of the impingement surface, corresponding to the beta-angle in the space, has led to design the omega-e and omega-surface. Patients with high alpha proximal femur angle may not have symptoms when coupled with an acetabulum with low central-edge angles or viceversa. Nevertheless, the true clinical reliability of these spatial evaluations should be still assessed.

For all these reasons, CT is very precise for defining the dynamic and static abnormalities in a young patient with hip pain and should be used in joint-preserving surgery of the acetabulum.

8. CT IN HIP ARTHROPLASTY AND METAL ARTEFACTS

Following total hip replacements, patients may develop painful prosthetic joints. CT is important in evaluating hip replacements despite the presence of metal artefacts. Since the inception of CT, numerous methods have been proposed to suppress metal artefacts with varying degrees of success.

The presence of high atomic number materials (e.g., prosthetics, dental fillings) in CT images may cause severe artefacts. These artefacts present as streaks and dark areas in the image and are due to beam hardening and scatter. As the X-ray passes through the body, low energy X-ray photons are attenuated more easily and the remaining high energy photons are not attenuated as easily. Compared with low atomic number materials such as water, metals have a dramatically increased attenuation at lower energies. For low energy X-rays, attenuation is primarily due to the photoelectric effect. At high energies, attenuation is primarily due to Compton scatter and is inversionally proportional to the beam energy. Compton scatter causes X-ray photons to change direction (and energy) and thus end up in a different detector. This creates the greatest error when the scattered photons end up in a detector that otherwise would have very few photons. In particular, if a metal implant blocks all photons, the corresponding detector element will only detect scattered photons. Scatter

also becomes more significant with an increased number of detector rows, as a larger volume of tissue is irradiated. Now, there are many kinds of algorithms of reconstruction to reduce these metal artefacts. The crucial point of these algorithms is an iterative loop where the output correction image is subtracted from the original input image. The resulting image can then become the new input image and the process can be repeated. The first step is to threshold the input image to create a metal-only image. The metal-only image consists of all pixels set to zero, except for those pixels categorised as metal. This image is be used to identify the projections within the sinogram data that have contributions from metal. If no large clusters of metal pixels are present in the image, no further processing is performed. Recently, novel imaging techniques have been introduced that are capable of reducing the effects of artefacts on scans and improving image quality. In addition, several companies have developed dedicated software packages for 3D image analysis (e. g. Mimics Innovation Suite, Materialise N.V., Leuven, Belgium or AQ implants, Ahrensburg, Germany) making it possible to further enhance the quality of the images and to incorporate novel analytic tools for characterising the defect and the remaining bone stock. These companies provide a specified scanning protocol that can be used byradiologists for data acquisition using metal artefact reduction modes. Consequently, the data are sent to the company for virtual reconstruction of the diseased pelvis by means of segmentation. Once the initial segmentation is performed, various algorithms help the user make adjustments, including edge detection, smart separation of bones from other structures and closing gaps. Despite this advanced technology, the process of segmentation still requires stringent quality control and manual corrections by an experienced user. This can be done through projecting the segmented bone contours onto the original images and editing them where required. Eventually, a detailed protocol is sent to the surgeon, including a proposal for an endoprosthetic reconstruction where required.

CT is superior to radiography in detecting, localising, and quantifying osteolysis around the acetabulum, which is especially helpful in patients who are being considered for revision arthroplasty.

Its particular importance to orthopaedic surgeons includes:

- whether there are cavitary or segmental defects (i.e., holes surrounded by bone or extending through the bone), especially posteriorly and superiorly;
- whether there is pelvic discontinuity (i.e., the superior and inferior portions of the socket are discontinuous).

On the femoral side, fractures, bone loss at the proximal femur (i.e., the calcar) and loss of the normal diaphyseal tapering are important for surgical planning.

CT can depict peri-implant fluid and soft-tissue masses that may be completely hidden on radiography. Ossified masses are usually well visualised on radiographs, but multidetector CT allows more precise localisation of these masses, definition of their extent and determination of whether they bridge the joint.

Surgeons preparing for acetabular component revision should be aware of the limitations associated with plain radiographic acetabular defect analysis. Nevertheless, currently-used acetabular bone defect classifications are mainly based on the interpretation of antero-posterior radiographs of the pelvis. However, multiple studies have demonstrated that a simplified analysis based on a single radiograph is not suitable to reliably detect

periprosthetic osteolysis and measure its dimensions, even with the additional use of iliac and obturator oblique views to better visualise bone defects. In particular, small periprosthetic defects located in the ischium or the acetabular rim were hard to detect on a single radiograph with a sensitivity of approximately 15% only [26]. Inter-observer reliability in the radiographic assessment of periacetabular bone defects has been demonstrated to be low with different surgeons not agreeing on what constitutes an osteolysis and what does not [27]. This is why surgeons preparing for acetabular component revision should be aware of the limitations associated with plain radiographic acetabular defect analysis.

Therefore, computed tomography has been advocated as an appropriate tool for acetabular defect analysis. Several research groups were able to demonstrate that CT analyses are capable of adequately detecting osteolysis and reliably measuring the dimensions of periprosthetic defects. Depending on the analysis technique and the artefact reduction mode used, a sensitivity of 74–98% has been described for both the detection of large and small defects [28][29]. Using CT as the gold standard, several authors were able to show that, in many cases, plain radiographic analysis was not sufficient in detecting periprosthetic acetabular osteolysis with an overall sensitivity of just 58–78% [30][31].

In literature, the Paprosky classification is the most widely used system for reporting outcomes after acetabular component revision and osteolysis [32][33]. It distinguishes six different defect types depending on the defect size and location and the capability of the acetabular walls and anterior and posterior columns to support a cementless hemispherical press-fit cup. Three-dimensional CT or MRI based image analysis might potentially be able to deliver the desired information, but their use in patients with metallic implants has so far been limited due to the presence of artefacts. The volume of the acetabular defect can be measured in cm^3 (ml) allowing the surgeon to determine the size of acetabular augments or amount of bone graft needed for reconstruction. Furthermore, radial acetabular bone loss (in mm or %) can be estimated, helping the surgeon to determine if the remaining bone stock of the acetabulum is supportive of a pressfit implant and whether the anterior and posterior columns are intact. Finally, an analysis of overall bone thickness and cortical thickness can be provided, which makes it possible to anticipate what osseous structures are supportive of implants or screws. Novel software tools not only provide the possibility of anticipating the intraoperative reality in more detail, but may also make the development of defect-specific monoblock acetabular implants possible in case the remaining bone stock does not support a standard implant. However, even these novel software tools do not provide the possibility of an automated defect analysis. The process of segmentation has to be manually controlled and adjusted, if necessary. Consequently, the quality of the final 3D reconstruction and the deduced defect analysis are highly dependent on user experience. Therefore, the final steps in evaluating the quality of the provided analysis and integrating it into a medical treatment plan have to be carried out by the surgeon himself. Despite all these advantages, routine CT-based defect analysis has still not gained wide popularity, mainly due to higher costs and higher radiation doses compared with conventional radiographic examination. In addition, further studies have to confirm whether these novel analytical tools are capable of improving the reliability and validity of currently used defect classification schemes.

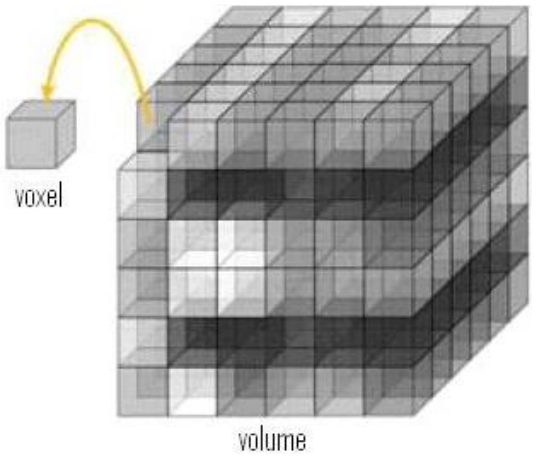

Figure 1. Voxel representation.

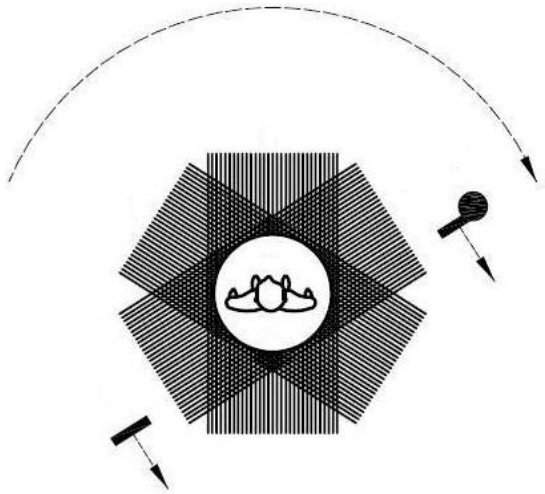

Figure 2. 1st generation single pencil beam translate/rotate scanner.

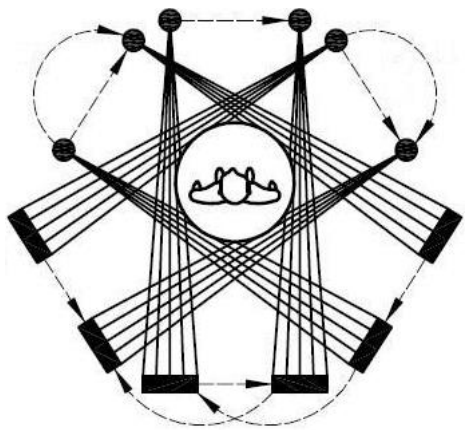

Figure 3. 2nd multiple pencil beam translate/rotate scanner.

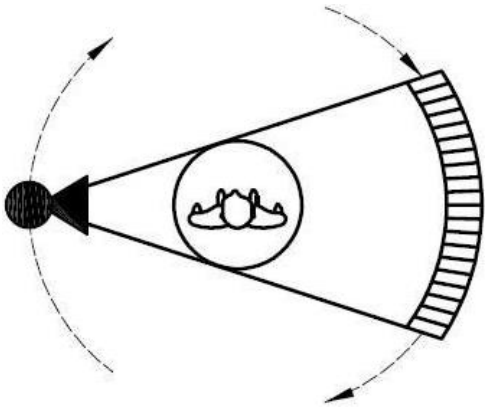

Figure 4. 3rd generation rotate/rotate fan beam scanner.

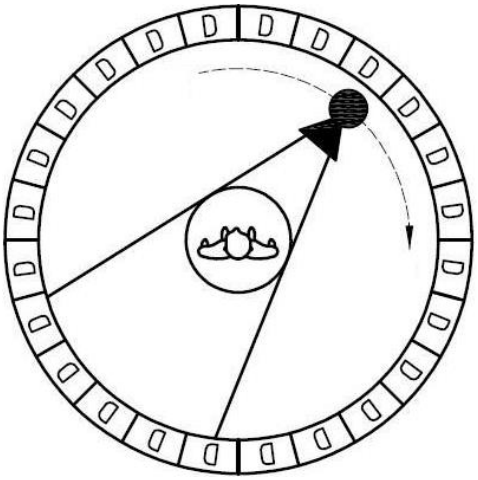

Figure 5. 4th generation rotate/stationary scanner. inverted fan beam scanner.

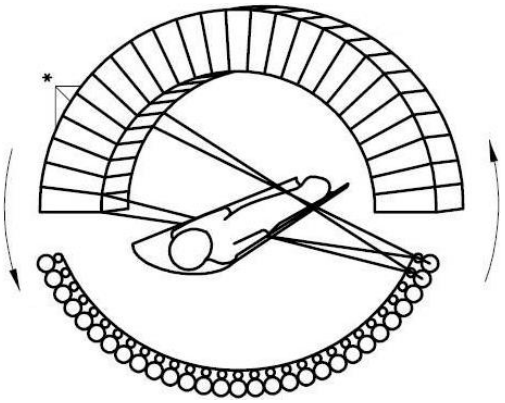

Figure 6. 5th generation cone beam ’cylindrical’ scanner.

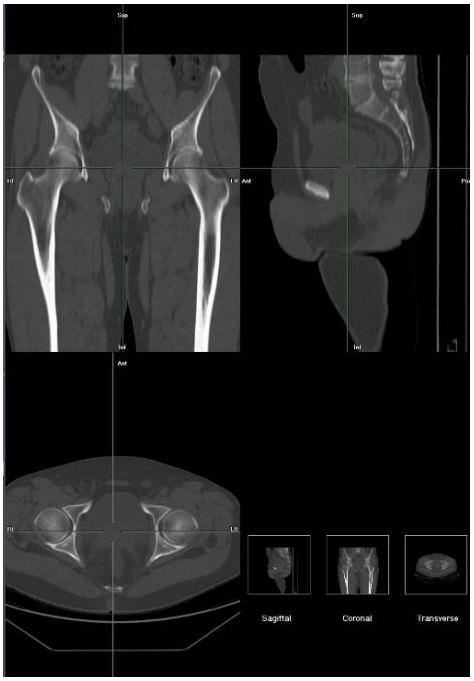

Figure 7. Multiplanar reconstruction.

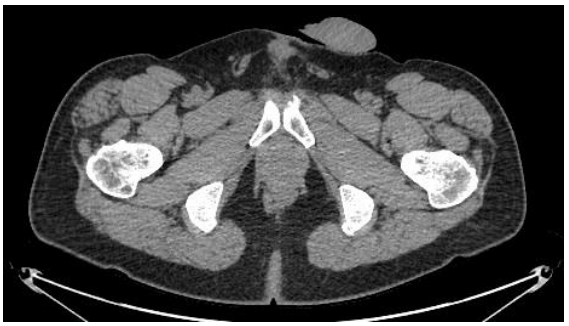

Figure 8a. CT (axial) without intravenous contrast.

Figure 8b. CT (axial) with intravenous contrast.

(a) (b)

Figure 9a,b. CT (3D Volume Rendering) with intravenous contrast.

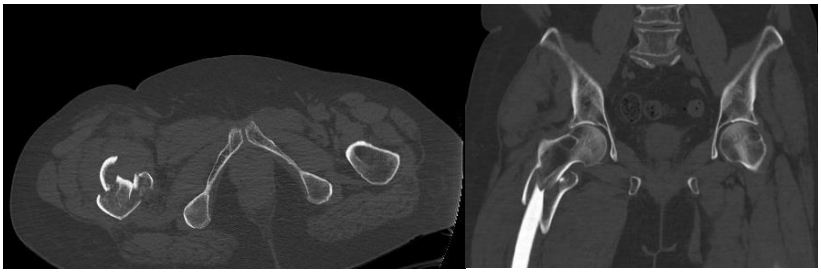

(a) (b)

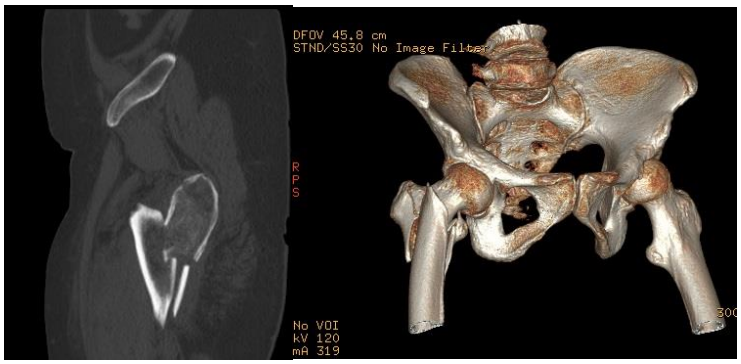

(c) (d)

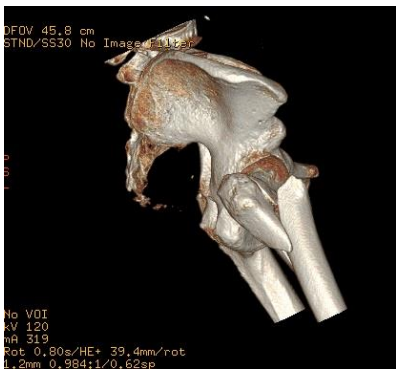

(e)

Figure 10. An example of fracture of the trochanteric region. Axial (10a), coronal (10b), sagittal (10c) and 3D volume rendering reconstruction (10d, 10e).

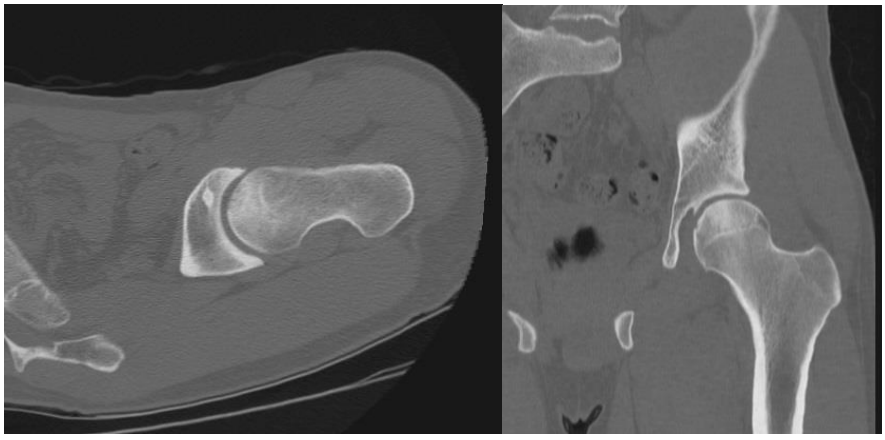

(a) (b)

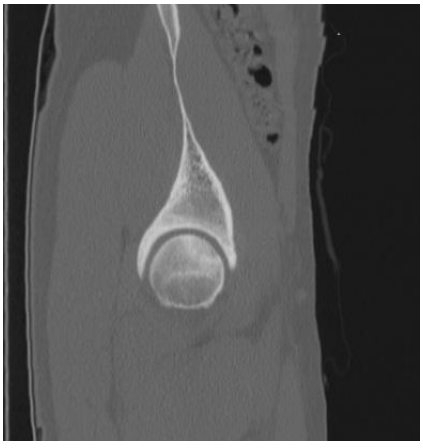

(c)

Figure 11. Axial (11a), coronal (11b) and sagittal (11c) multi planar reconstructions (MPR) show an osteochondral lesion of femoral head with sclerotic halo.

(a) (b)

Figure 12. A post-Perthes femoral deformity is seen at coronal MRP (2a) and 3D volume rendering reconstruction (2b).

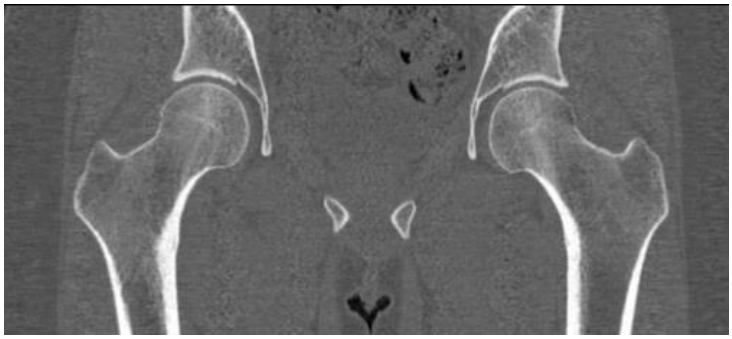

(a)

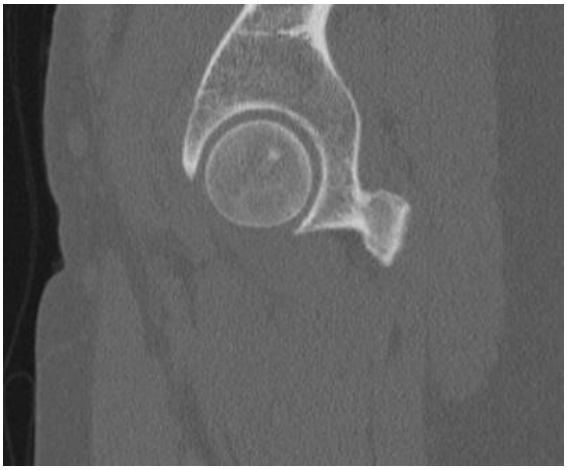

(b)

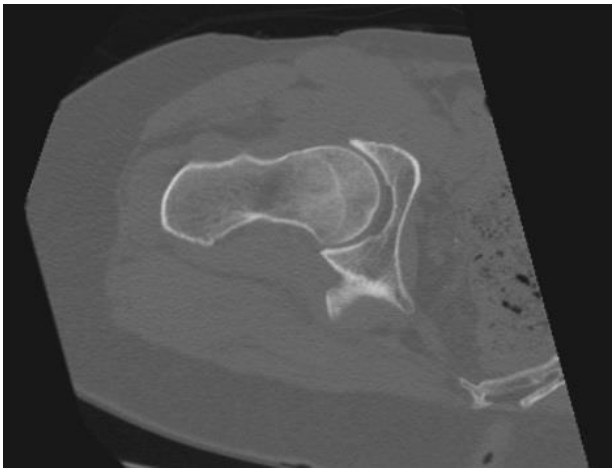

(c)

Figure 13. A small bump femural deformity, not seen in standard coronal (13a) and sagittal (13b) MPR, is clearly depicted in axial oblique MPR (13c).

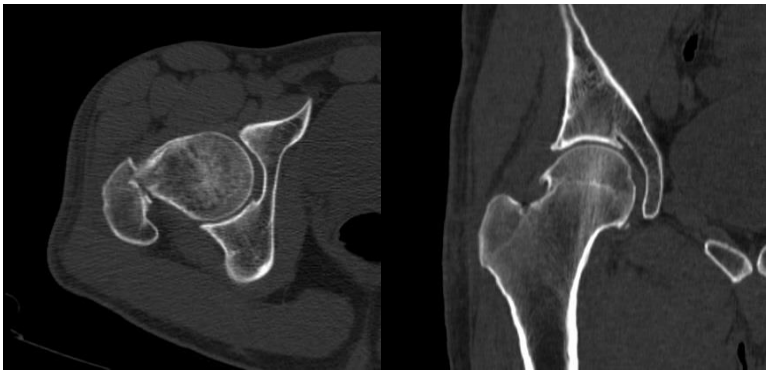

(a) (b)

(c) (d)

Figure 14. In this patient there are bump (14a) and osteophytosis (14b), both seen in 3D volume rendering reconstructions (14c, 14d).

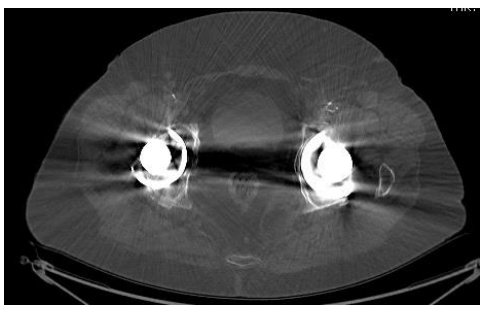

(a)

(b) (c)

Figure 15. Total hip replacement. Normal acquisition (15a) Iterative reconstruction for the reduction of the metal artifacts (15b, 15c).

REFERENCES

[1] Kalender, WA. X-ray computed tomography, *Physics in Medicine & Biology*,51**,**2006, 29–43.

[2] Flohr, TG; Schaller, S; et al. Multi-detector row CT systems and image reconstruction techniques. *Radiology*, 2005, 235, 756–773.

[3] Calhoun, P; Kuszyk, B; et al. *Three-dimensional Volume Rendering of Spiral CT Data: Theory and Method Radiographics.*, 1999, 19, 745–764.

[4] Gervaise, A;Osemont, B;Lecocq, S; Noel, A;Micard, E;Fel- blinger, J; et al. CT image quality improvement using adaptive iterative dose reduction with wide-volume acquisition on 320- detector CT. *Eur Radiol*, 2012, 22, 295–301.

[5] Boas, FE; Fleischmann, D. Evaluation of two iterative techniques for reducing metal artifacts in computed tomography. *Radiology*, 2011, 259, 894–90.

[6] Levine, E; Neff, JR. Dynamic computed tomography scanning of benign bone lesions: preliminary results. *Skeletal Radiol*, 1983, 9, 238–45.

[7] Miles, KA;Charnsangavej, C; Lee, F; Fishman, E; Horton, K; Lee, TY. Application of CT in the investigation of angiogenesis in oncology. *Acad Radiol*, 2001, 7, 840–50.

[8] Karcaaltincaba, M;Aktas, A. Dual energy CT revisited with mul- tidetector CT: review of principles and clinical applications. *Diagn Interv Radiol*, 2011, 17, 181–94.

[9] Flohr, TG;McCollough, CH;Bruder, H;Petersilka, M; Gruber, K;Süss, C; et al. First performance evaluation of a dual-source CT (DSCT) system. *Eur Radiol*, 2006, 16, 256–68.

[10] Nicolaou, S; Yong-Hing, CJ;Galea-Soler, S;Hou, DJ; Louis, L;Munk, P. Dual energy CT as a potential new diagnostic tool in the management of gout in the acute setting. *AJR Am J Roentgenol*, 2010, 194, 1072–8.

[11] Pache, G; Krauss, B;Strohm, P;Saueressig, U;Blanke, P; Bulla, S; et al. Dual energy CT virtual non-calcium technique: detecting post-traumatic bone marrow lesions-feasibility study. *Radiology*, 2010, 256, 617–24.

[12] Subhas, N; Freire, M;Primak, AN;Polster, JM;Recht, MP;Davros, WJ; et al. CT arthrography: *in vitro* evaluation of single and dual energy for optimization of technique. *Skeletal Radiol*, 2010, 39, 1025–31.

[13] Bamberg, F;Dierks, A; Nikolaou, K;Reiser, MF; Becker, CR; Johnson, TRC. Metal artifact reduction by dual energy computed tomography using mono energetic extrapolation. *Eur Radiol*, 2011, 21, 1424–9.

[14] West, ATH; Marshall, TJ;Bearcroft, PW. CT of the musculoskeletal system: what is left is the days of MRI? *Eur Radiol*, 2009, 19, 152–64.

[15] Lochum, S;Ludig, T; Walter, F; Fuchs, A;Henrot, P; Blum, A. Intérêt de la technique de renduvolumiqueenpathologieostéoarticulaire. *J Radiol*, 2001, 82, 221–30.

[16] Reimers, A; Laflamme, L. Hip fractures among the elderly: personal and contextual social factors that matter. *J Trauma*, 2007,62, 365–369.

[17] Zuckerman, JD; Skovron, ML; Koval, KJ;et al. Post operative complications and mortality associated with operative delay in older patients who have a fracture of the hip. *J Bone Joint Surg Am*, 1995,77, 1,551–1,556.

[18] Kim, KC; Ha, YC; Kim, TY;et al. Initially missed occult fractures of the proximal femur in elderly patients: implications for need of operation and their morbidity. *Arch Orthop Trauma Surg*, 2010,130, 915–920.

[19] Parker, MJ. Missed hip fractures. *Arch Emerg Med*, 1992,**9**, 23–27.

[20] Lubovsky, O; Liebergall, M; Mattan, Y;et al. Early diagnosis of occult hip fractures MRI versus CT scan. *Injury*, 2005,36, 788–792.

[21] Cannon, J;Silvestri, S; Munro, M. Imaging choices in occult hip fracture. *J Emerg Med*, 2009,37, 144–15.

[22] Dominguez, S; Liu, P; Roberts, C;et al. Prevalence of traumatic hip and pelvic fractures in patients with suspected hip fracture and negative initial standard radiographs – a study of emergency department patients. *Acad Emerg Med*, 2005,12, 366–369.

[23] Tannast, M; Siebenrock, KA; Anderson, SE. Femoroacetabular impingement: radiographic diagnosis—what the radiologist should know. *Am J Radiol*, 2007, 188, 1540–52.

[24] Milone, MT; Bedi, A;Poultsides, L; et al. Novel CT-based three-dimensional software improves the characterization of cam morphology. *Clin Orthop Relat Res.* Epub, 31 Jan 2013.

[25] Bedi, A; Dolan, M;Magennis, E;Lipman, J;Buly, R; Kelly, BT. Computer-assisted modeling of osseous impingement and resection in femoroacetabular impingement. *Arthroscopy*., 2012, 28(2), 204–210.

[26] Claus, AM;Engh, CA; Jr.Sychterz, CJ;Xenos, JS;Orishimo, KF;Engh, CA. Sr. (2003). Radio- graphic definition of pelvic osteolysis following total hip arthroplasty. *J Bone Joint Surg Am*, 85–A(8), 1519–1526.

[27] Engh, CA; Jr.Sychterz, CJ; Young, AM; Pollock, DC; Toomey, SD;Engh, CA. Sr. (2002) Interobserver and intraobserver variability in radiographic assessment of osteolysis. *J Arthroplasty*,17(6), 752–759.

[28] Stamenkov, R; Howie, D; Taylor, J; Findlay, D; McGee, M;Kourlis, G; Carbone, A; Burwell, M. (2003). Measurement of bone defects adjacent toacetabular components of hip replacement. *Clin Orthop Relat Res*, 412, 117–124.

[29] Walde, TA; Weiland, DE; Leung, SB; Kitamura, N;Sychterz, CJ;Engh, CA; Jr. Claus, AM; Potter, HG;Engh, CA. Sr. (2005). Comparison of CT, MRI, and radiographs in assessing pelvic osteolysis: a cadaveric study. *Clin Orthop Relat Res*, 437, 138–144.

[30] Wenz, JF; Hauser, DL; Scott, WW; Robertson, DD;Tsapakos, MJ; Kearney, DK;Bluemke, DA;Naiman, DO; Brooker, AF; Chao, EY. (1997). Observer variation in the detection of acetabular bone deficiencies. *Skeletal Radiol*, 26(5), 272–278.

[31] Walde, TA; Mohan, V; Leung, S;Engh, CA. Sr. (2005). Sensitivity and specificity of plain radiographs for detection of medial-wall perforation secondary to osteolysis. *J Arthroplasty*, 20(1), 20–24.

[32] Telleria, JJ; Gee, AO. (2013). Classifications in brief: Paprosky classification of acetabular bone loss. *Clin Orthop Relat Res*, 471(11), 3725–3730.

[33] Paprosky, WG;Perona, PG; Lawrence, JM. Acetabular defect classification and surgical reconstruction in revision arthroplasty: a 6-year follow-up evaluation. *J Arthroplasty*., 1994, 9, 33–44.

In: Encyclopedia of Surgery (22 Volume Set)
Editors: Andreas Lehrer and Kristin Mueller
ISBN: 978-1-53618-329-0
© 2020 Nova Science Publishers, Inc.

Chapter 147

3D FLUOROSCOPY AND ITS APPLICATIONS IN HIP SURGERY

Matteo Giachino[1], Alessandro Aprato[1], Claudio Degiorgis[2], Luigi Conforti[1], Giuseppe Massazza[1] and Alessandro Massè[1]
[1]University of Turin, Turin, Italy
[2]Radiology Department, Città della Salute e della Scienza di Torino – C.T.O. Hospital, Torino, Italy

ABSTRACT

The introduction of the three-dimensional (3D) fluoroscopy brought new intra-operative imaging possibilities for the orthopedic surgeons, aiming at the improvement of the conventional fluoroscopy. Different authors demonstrated a high reliability of this technique for the evaluation of articular fracture reduction, for the presence of articular gaps and for implant positioning. The performances of 3D-fluoroscopy were estimated to be comparable to CT-scan and significantly superior to 2D fluoroscopy. The most favorable indications in pelvic and hip surgery comprehend both traumatic and elective surgery. Pelvic ring and acetabular fractures along with femoro-acetabular impingement are the fields where 3D-fluoroscopy more satisfactorily operates at the moment. For best performing this procedure it's essential a special care for patient's positioning, as any radio-opaque disturbance unfavorably influences the result. Moreover, further developments of 3D fluoroscopy with the support of secondary modeling softwares will be introduced in the next years, expanding its utilization.

Keywords: 3d fluoroscopy, intraoperative imaging, hip surgery

INTRODUCTION

Three-dimensional (3D) fluoroscopy has been developed in the last two decades to improve surgeons' intraoperative capability of understanding complex anatomy [1, 2]. The aim of this technology is to fill the gap between the highly accurate pre-operative imaging

regularly available with a CT scan, and the intra-operative low quality images of conventional fluoroscopy. Main concerns of 2D-fluoroscopy are well perceived by clinicians and mainly consist in the difficult assessment of articular fractures displacement and implants positioning [3]. Irregular anatomy, bone overlapping and soft tissues interposition are the principal bewildering factors for the conventional fluoroscopy. For those reasons and for their scarce maneuverability, pelvis and spine are considered the most problematic areas to examine. However, it's supposed that conventional devices can properly afford most of the cases.

Before the introduction of 3D-fluoroscopy the only way to detect sub-optimal reductions or minimally protruding intra-articular implants was the post-operative radiographic or CT control, leading to complications or an even more undesirably secondary surgery [4]. Thus, intra-operative diagnostic accuracy has gained more attentions among the development of new technologies. The best possible approach would be the setting of intra-operative CT scan as it happens in some very advanced trauma centers, though this solution still remains hypothetical for the greatest majority of hospitals. Moreover the radiation exposure for a CT scan is considerably higher compared to fluoroscopy. Navigation systems also provide surgeons further assistance for orientation in complex anatomy, but generally they consist in sophisticated devices, needing accurate pre-operative settings, eventually resulting less functional for daily practice.

3D-Fluoroscopy Technical Aspects

Conventional radiography produces a single-plane image of the anatomic segment positioned through the electron beam. To obtain different projections the operator can either rotate the patient or the instrument; following this concept the worldwide standard in intra-operative hip imaging has been represented by the C-arm, an efficient device that can easily rotate for 180° or more around the patient, maximizing the possibilities of radiographic projections. Along with that, the fluoroscopic intensifier efficiently limits the radiation exposure for the patient and the operators. Despite the optimal mechanism, it's a common feeling for the orthopedic surgeons that conventional fluoroscopy still have relevant limitations in clearly depicting structures in complex situations. The limits for the diagnostic accuracy are unfortunately intrinsic of the technique.

The first issue is dealing with the artifacts that often emerge from conventional scans, when the combination of soft tissues and air tend confuse the field. For this reason, pelvic or spinal surgery are chronically affected by the phenomenon and very little can be done for dealing with it. Furthermore, another limit is the bi-dimensional representations that cannot accurately reproduce articular surfaces. Since this problem becomes more significant as the joint space gets hollow and irregular, it's clear that for segments like talus, hip and spine is frequently achieved a sub-optimal intra-operative imaging.

The development of the 3D C-arm aimed at the resolution of these limitations, while maintaining an acceptable radiation dose for the patient. The principle on which the 3D-fluoroscopy lays is a software-based multiplanar reconstruction obtained by rotation of the arm. During the rotation an established number of images are acquired, each one at a slightly different orientation.

Figure 1. A modern 3D C-arm.

Then, an on-board software combines the data and provides a three planar scan of the analyzed volume, mocking a CT scan. Moreover, the devices usually show an animated clip of the rotating analyzed volume (Figure 1). Manufacturers follow two principal construction philosophies, so that 3D C-arms are classified into isocentric and non-isocentric devices. Simplifying, an isocentric device rotates around the subject in a perfectly circular movement, while the non-isocentric follows an elliptical path. For a C-arm to be classified as isocentric all the x-ray beams collimate through the same center all along the rotation, so the distance between the source and the intensifier is maintained constant. The minimization of distortions and a constant image size are the main goal of this solution. For non–isocentric C-arms the combination of rotation and elliptical orbit requires more elaborated software calculations, whereas the main advantage is the reduction in the amount of rotation needed. Up to date, there isn't any absolute supremacy among the available devices on the market, as each one offers the highest standards. The present excellences generally provide fully digital 1024x1024 resolution, time of scan less than 60s, variable 3D reconstruction modes on screen, full data export and many others [2, 5].

LITERATURE

Since the introduction of 3D-fluoroscopy, several efforts have been made to prove its advantages in surgical theatre; yet, it's still challenging to demonstrate the subjective additional diagnostic value commonly perceived. Outcomes heterogeneity, different scoring protocols and different examined variables are the main limits for a bright scientific support from the review of the existing literature.

In order to assess the level of 3D-fluoroscopy accuracy, most of the authors compared its preciseness to conventional techniques as 2D-fluoroscopy, X-ray and CT-scan. Analyses were made both on cadaver and in clinical studies. Condensing the available cadaver studies, it emerges that usually authors produced various articular fractures artificially or by applying forces resembling major traumas. Fractures reductions were performed under conventional 2D-fluoroscopy, then the achieved results evaluated with 3D-fluoroscopy. At the end of the

process the specimens were dissected and the discrepancies between the two imaging methods were observed. Moreover, a CT-scan was frequently performed prior to dissection and added for comparison. Modifications from this ideal scheme can be found in literature. When in-vivo studies were conducted, a combination of 2D and 3D-fluoroscopy was employed during the operations. Some authors performed 3D-fluoroscopy as final control for detecting any defect in reduction or fixation, some other ones during the procedure. One of the most interesting information obtained by these last studies is the rate of corrections needed after the 3D-fluoroscopy check, once that controls with conventional fluoroscopy were considered acceptable. Therefore, these corrections were performed after inaccuracies detected only by 3D-fluoroscopy and not perceivable on 2D-fluoroscopy, which is indeed the real worth of this technology. The main causes for resetting a finished fixation were implants suboptimal position and excessive step-offs or gaps in articular surface. In several studies, 3D-fluoroscopy showed to provide a clearer visualization of those defects when compared to 2D fluoroscopy and to X-ray, producing a higher rate of intra-operative corrections [1, 5-7].

Some authors also tested the diagnostic accuracy of 3D-fluoroscopy compared to conventional fluoroscopy, X-ray and CT scan. Summarizing the protocols adopted, 3D-fluoroscopy seems to have better, or at least equal, performances relatively to the first two techniques. Furthermore, diagnostic accuracy was found similar to CT-scan in most of the cases, which attests a considerable level of performance. Direct consequence of this reliability is the chance of sparing post-operative CT controls when doubts about reduction or implants positioning still exist after surgery. Advantages in diagnostic accuracy seems greater in bigger and more complex joints, when anatomy gets more irregular and articular surfaces intersect on plain radiographs [5, 8, 9]. As previously stated, existing studies comparing efficacy of conventional X-rays against 3D-fluoroscopy give to the latter a slight advantage, although scoring systems and adopted protocols were not homogeneous [5]. As supported by statistics, opinion leaders concluded that the most valuable field of 3-D fluoroscopy versus X-ray was in detecting articular gaps [10].

A significant contributing factor for choosing 3D-fluoroscopy for complex surgeries consists in the “spatial awareness” that can be obtained from reconstructions, not only for the poli-axial views that mirror the CT, but also for the immediate virtual 3D view available. Every surgeon approaching this technology appraises this feeling, though it is simultaneously hard to communicate or estimate it.

APPLICATION FIELDS

3D fluoroscopy best performs where anatomy gets more complex. Typically the most demanding segments are irregular anatomical districts as spine or pelvis and highly displaced and comminuted fractures (Figure 2).

These two extremes represent the perfect examples for an ideal use of 3D-fluoroscopy, though there isn’t any black or white situation for its employment.

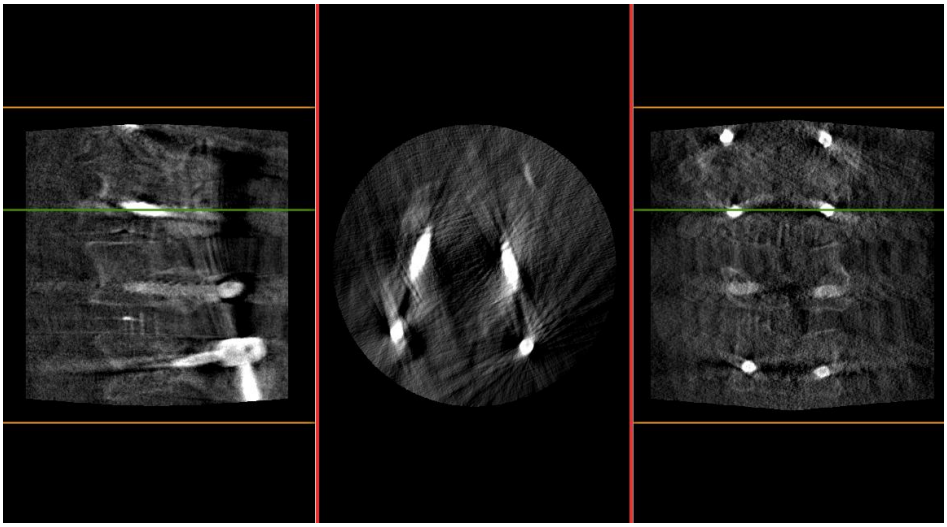

Figure 2. Pedicle screws of a lumbar stabilization.

Focusing on hip and pelvis, an increased spatial awareness could be a valuable support both for traumatic and elective surgery. For instance, the pelvic ring is a common site of fracture in major traumas whereas surgical treatment still remains demanding. If anterior stabilization is generally achieved by external fixation or plating without any remarkable difficulties, posterior fixation could hide some delicacies due to the abundance of critical structures surrounding the bone. The main threats to avoid for posterior synthesis are the lumbosacral plexus, the major vessels of the iliac fossa, and the intra-peritoneal organs. A well-established method for posterior fixation consists in percutaneous placement of sacroiliac screws under fluoroscopic guidance, which allow for a rapid and effective stabilization without the invasiveness of open surgery. Some criticisms still exist about this technique, as for achieving a good result both optimal patient positioning and fluoroscopy maneuvering is mandatory. Moreover, fulfilling these conditions does not always guarantee a satisfying result in terms of imaging quality, due to soft tissues or internal air. For safe practicing sacral foramina have to be identified in outlet view, in order to avoid the plexus during screws placement; then, the antero-posterior positioning has to be repeatedly checked in inlet view during the procedure. Nevertheless, the view of sacral foramina is often confused, especially in displaced fractures and/or obese patients, increasing the risk of iatrogenic lesions, incorrect placement of hardware and sub-optimal fracture reduction. Considering this background, a significant support should come out from the employment of 3D-fluoroscopy (Figure 3, Figure 4).

Really, if there's the chance of performing a 3D scan in order to clear up any uncertainty in reduction or in implants position, it should be done, as it is demonstrated that the diagnostic power is similar to the one of the CT-scan [11-13].

Following the same principles of safety and accuracy, also acetabular fractures could considerably benefit from 3D-fluoroscopy, as this anatomical district meet all the characteristics for a difficult imaging.

Figure 3. Irregular sacral anatomy is difficult to depict on conventional 2D radiograms.

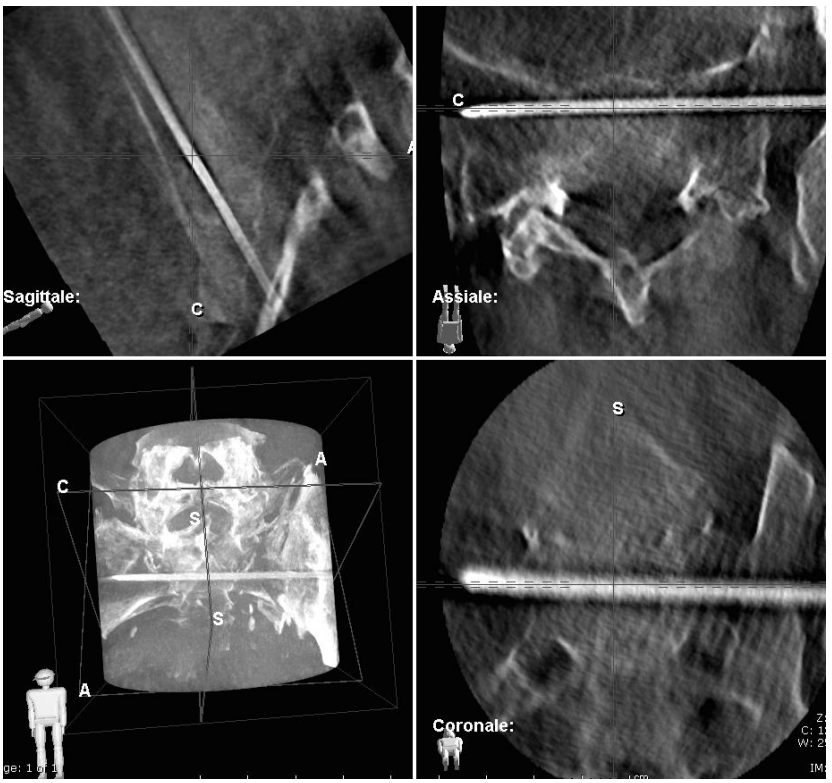

Figure 4. The 3D-fluoroscopic scan helps in detecting dangerous structures.

Since the reduction and fixation of every articular fracture has the goal of reducing the risk of post-traumatic osteoarthritis, achieving a perfect congruence of the articular surface is mandatory. When a direct visualization of the entire joint is not available as it frequently happens in acetabular fractures, the role of the imaging become primary. In such cases a big help can be obtained by the multiplanar reconstructions produced by the 3D fluoroscopy scan, for detecting step-offs, gaps and dangerous misplaced screws (Figure 5, Figure 6) [14, 15].

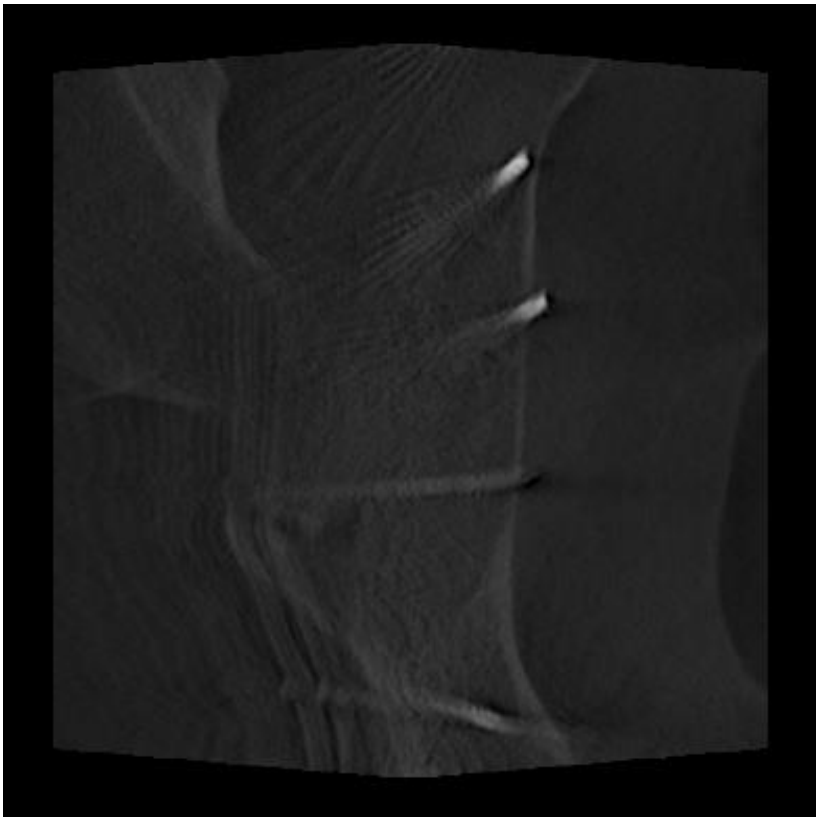

Figure 5. Checking of intra-pelvic screw protrusion in posterior acetabular wall plating.

On the other side, the applications in elective surgery of hip and pelvis are less common, since pre-operative imaging is often fulfilling and the techniques more standardized. However, some exceptions could be found in the developing field of mini-invasive surgery; it is easily understood that a big exposure should rarely profit from accurate intra-operative imaging, as the structures are generally under direct view. On the contrary, since tissue sparing techniques often produce hollow cavities where orientation becomes complicated, an additional aid is frequently requested. In prosthetic surgery this is variously achieved, having in navigation systems probably its most effective example. In this case 3D-fluoroscopy could hardly become competitive. Conversely, the other branch of interest where a 3D intra-operative imaging can produce tangible advantages is the treatment of femoro-acetabular impingement. We know that the clinical entity of hip impingement can be produced by multiple factors, although two main types are scholastically described: cam and pincer.

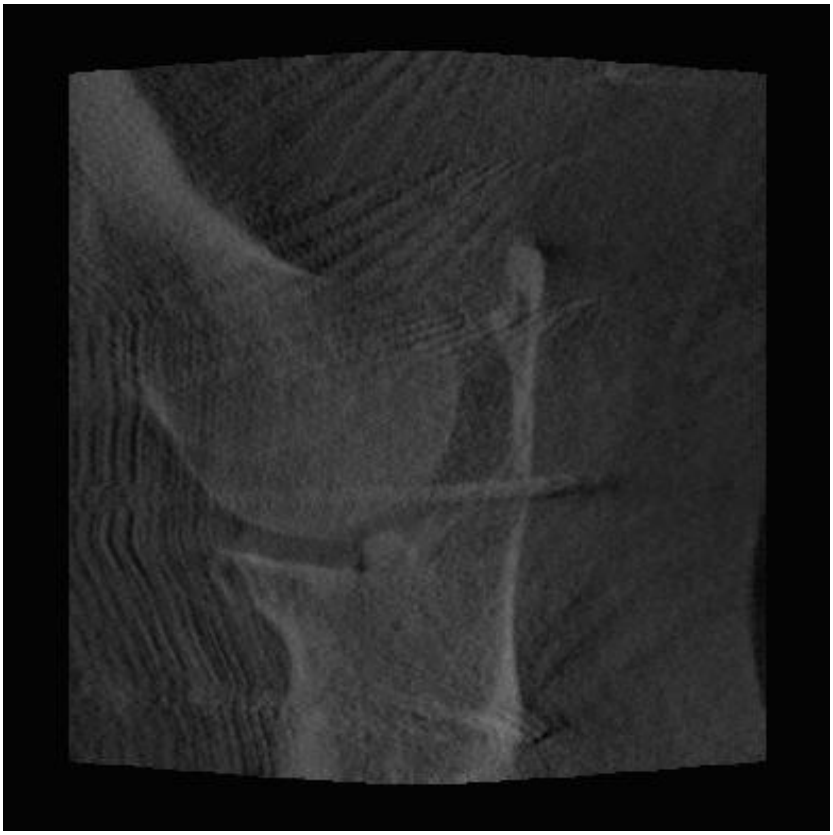

Figure 6. Acetabular fracture with an unexpected intra-articular fragment.

For both of them the pathophysiologic mechanism that produces pain, functional limitations and articular damages takes place in prolonged collisions between bony excesses from acetabular side (pincer), femoral side (cam) or a combination of the two. Surgical treatments have the aim of reducing the redundant bone from each side, while minimizing the procedure invasiveness. This strategy let the development of the two most diffused approaches, which are hip arthroscopy and "mini-open" technique. In both techniques, a common critical aspect is represented by the decision of the amount of bone tissue to be removed, because no direct control of impingement can be accurately made, even under conventional fluoroscopy. An insufficient correction won't resolve the symptoms, while in the worst of the cases an excessive bone removal could produce a serious hip instability [16-18]. With this background, the application of intra-operative 3D-fluoroscopy may help the surgeon to detect more precisely the areas of impingement and to better evaluate the amount of correction performed. Moreover, in a hypothetic protocol a pre-operative scan could be made for planning the resection, while at the end of the procedure a new 3D-scan could verify if an adequate result has been achieved.

As mentioned, there are no actual limitations for 3d-fluoroscopy employment and this statement is valid for hip and pelvis as well; other possible applications could comprehend bone deformities, other conservative surgeries, complications of routine operations and so on.

PATIENT'S POSITIONING

For best performing a 3D-fluoroscopy, great importance is given to the patient's optimal position and even more to the surrounding hardware. Commonly surgeons pay lot of attentions for the appropriate setting of the operative room, in order to reduce the risks of fluoroscopy dysfunctions due to interposed radio-opaque objects.

There's a strong association between the amount of tissues or dense material that the electron beam has to cross and the quality of the final image. If this statement regards traditional 2D fluoroscopy, it becomes even firmer for 3D fluoroscopy. The principal reason is the necessity of a rotation around the target between 120° and 180°, which unfortunately tends to include undesired objects in the field. In extremities' surgery the problem is easily overcome by radio-transparent supports and isolation of the limb, while the scarcity of soft tissues contributes to perform good quality imaging (Figure 7).

The issue is actually to deal with central segments, as it happens in spine or hip and pelvis surgery. In these areas the problems occurring for a complete and clear scansion frequently cohabit, as soft tissues among with abdominal gases use to create artifacts, while surgical table is not often entirely radiolucent.

Figure 7. Scarcity of soft tissues provides high-quality imaging.

Even minor metal parts like sustaining lateral bars, gelatins or cables have the power to alter the quality of the 3D-fluoroscopy scan (Figure 8, Figure 9).

In hip and pelvic surgery an excellent solution is the employment of a carbon fiber table, completely radiolucent and without metal sidebars (Figure 10). Moreover, the table should be offset as much as possible from the central sustaining column, in order to create an empty space right below the pelvis, permitting the C-arm to freely rotate around the patient. Although this setting provides the best results in reducing external disturbs, it's hard to employ it for all the cases, as it works for supine or prone positions only. For lateral approaches the ideal use of radiolucent sustains should be pursued, even if rarely available at present time.

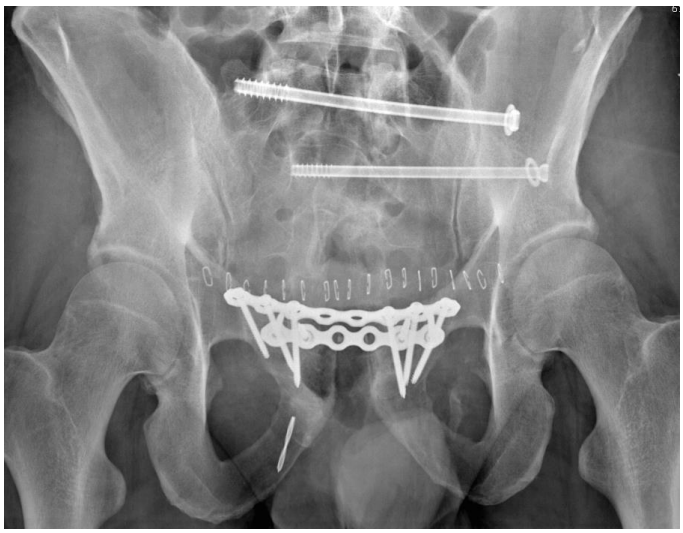

Figure 8. Other metallic objects can affect image quality.

Figure 9. Severe disturb from several surrounding metal parts, causing a useless scansion.

Figure 10. An example of completely radiolucent carbon-fiber surgical table.

An interesting field of application for 3D-fluoroscopy is hip arthroscopy, which is gaining popularity; beside the potential advantages in detecting bone corrections, there's a troublesome difficulty in avoiding external disturbs.

The obstacle comes from patient's position and the necessity of traction of the lower limbs, as traction table frequently includes metal braces and joints that lay into the C-arm scan. The ideal solution would be a completely radiolucent traction table or, at least, a big reduction of disturbing dense parts around the pelvis.

Once more, the two main aspects to be pursued for optimal patient's positioning before performing a 3D-scan are the reduction of interposed material and the chance for the C-arm to rotate around the subject without collisions.

The accurate setting of the surgical theatre is then of utter importance, as it is demonstrated that the presence of artifacts lowers both specificity and sensibility of 3D-fluoroscopy, until causing it to be useless [5].

CRITICAL ISSUES

The technology for intra-operative 3D-fluoroscopic scans has significantly advanced in the last twenty years, up to the last released systems that are highly optimized in terms of efficacy and versatility. Although good performances are relatively easy to obtain and advantages are clear, there are still some issues that limit the widespread diffusion of the technique.

For instance, the acquirement of high quality images is a proper example of tricky practice, as it appears reasonably simple for everyone in most of the cases.

However, even if the C-arm works automatically once started, the role of the radiologic technologist is still central for the success of obtaining a true diagnostic scan without

confounding factors. Optimized machinery settings along with accurate patient's positioning produce substantial modifications in imaging quality, often making the difference over the millimeter involved in crucial clinical decisions. Therefore, for a convincing experience with 3D-fluoroscopy it is recommended to enroll trained personnel with adequate experience (Figure 11).

Figure 11. Confounding factors can be many in an ordinary operating room.

Some concerns exist about the amount of time employed to perform the entire scan process in the utilization of the 3D-fluoroscopy. Even if the true operative time of the machineries is less than a couple of minutes, the whole positioning of the C-arm and its semi-automatic verification motions it's somewhat time-consuming.

Actually, most of the time spent for obtaining a scansion is wasted for the correct setting of the environment. Again, for the optimization of the process and to limit this dissipation is recommended to engage properly trained staff, used to regularly practice.

At the moment, the main practical difficulties in the utilization of the 3D fluoroscopy are related to the equipment encumbrance, along with the necessity of circling the involved anatomical region, and to the requisite of radiolucent hardware.

FUTURE IMPROVEMENTS

Since the introduction of the 3D-fluoroscopy it has been immediately clear the additional support given to the surgeon for better comprehend complex intra-operative imaging. This was surely the initial aim successfully achieved by the creators, and the following improvements brought this technology to the standards we currently know. However, the massive digital evolution we are experiencing could really expand its limits of application, opening for new and fascinating possibilities in the immediate future.

For example, the output files generated by the device could be collected and manipulated for obtaining additional information more than simple observation.

The potentiality of modern softwares allows in fact a quick secondary processing of the raw data, in order to generate virtual models to work on (Figure 12).

Applications of this process are sensibly growing because of the increasing awareness of the digital world by the orthopedic community, and because researchers are getting more confident with informatics.

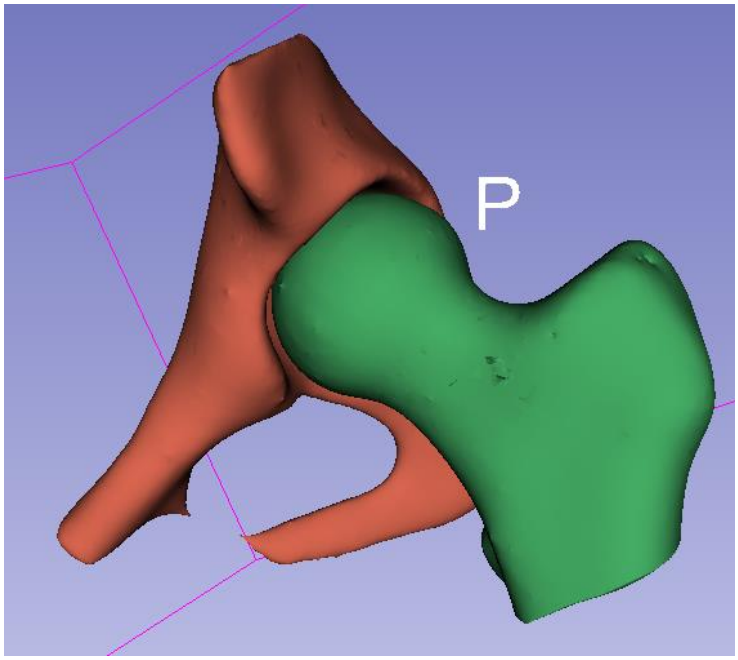

Figure 12. Example of a virtual model of the hip.

When a virtual model is imported into a CAD (computer assisted design) software, a great amount of operations could be run on it to produce animations, cuts, sections, virtual explorations and so on. Moreover, a recent idea of creating collision models for the intra-operative control during hip impingement treatment is now on course of development. However, it is of utmost importance that all the secondarily revised data can be live-processed in order to guarantee the chance of adjustments during operations. The live action is indeed the real added value that makes the difference between 3D-fluoroscopy and the other diagnostic procedures now available. Thinking about the future, it cannot be excluded the opportunity to apply the concepts of virtual rendering also in the pre-operative phase, in order to increase diagnostic capability with tolerable radiation exposure. These hypotheses could bring the 3D-fluoroscopy to new experimental employments, until leading to possible overlapping with CT-scan. A further attractive topic in orthopedic surgery regards 3D printing, a branch in remarkable expansion with great potentiality. Until now, the creation of printed models has passed through the segmentation of a CT-scan, frequently bringing out the question of risk-benefit assessment when not strictly necessary for diagnostic purpose. If sufficiently implemented and optimized, there would be the concrete possibility for 3D-fluoroscopy to supply adequate imaging destined to 3D printing; along with that, even the indications of printing could be extended to the cases that wouldn’t have beneficiated of CT scan.

CONCLUSION

The last couple of decades has seen the introduction of 3D-fluoroscopy and its following evolutions to nowadays' standards. Even if several authors proved the effectiveness of this technology along with the consequent advantages, there is not yet the broad diffusion that can be reasonably expected. A first explanation could be found in the additional costs related to the machinery acquisition, which are considerably higher than conventional fluoroscopy. However, if put aside the investment issue, it could be supposed that 3D-fluoroscopy hasn't spread so far into the surgeons practice for a lack of familiarity and insufficient awareness of its potential. Definitely the wish is to encourage the production of lot more studies on the topic, both for strengthen the scientific validation of known benefits, and for investigate new applications in the computer era.

REFERENCES

[1] Euler E., Wirth S., Linsenmaier U., et al. Comparative study of the quality of C-arm based 3D imaging of the talus. *Unfallchirurg,* 2001; 104:839–46.

[2] Rock C., Linsenmaier U., Brandl R., et al. Introduction of a new mobile C-arm/CT combination equipment (ISO-C-3D). Initial results of 3D sectional imaging. *Unfallchirurg,* 2001; 104:827–33.

[3] Carelsen B., Haverlag R., Ubbink D. T., et al. Does intraoperative fluoroscopic 3D imaging provide extra information for fracture surgery. *Archives of Orthopaedic and Trauma Surgery,* 2008; 128: 1419–24.

[4] Beerekamp M. S. H., et al. Accuracy and consequences of 3D-fluoroscopy in upper and lower extremity fracture treatment: A systematic review. *Eur. J. Radiol.,* 2012.

[5] Linsenmaier U., Rock C., Euler E., et al. Three-dimensional CT with a modified C-arm image intensifier: feasibility. *Radiology,* 2002; 224:286–92.

[6] Rock C., Kotsianos D., Linsenmaier U., et al. Studies on image quality, high contrast resolution and dose for the axial skeleton and limbs with a new, dedicated CT system (ISO-C-3D). *Rofo,* 2002; 174:170–6.

[7] Kendoff D., Citak M., Gardner M., et al. Three-dimensional fluoroscopy for evaluation of articular reduction and screw placement in calcaneal fractures. *Foot and Ankle International,* 2007; 28:1165–71.

[8] Wirth S., Euler E., Linsenmaier U., et al. C-arm-based mobile computed tomography: a comparison with established imaging on the basis of simulated treatments of talus neck fractures in a cadaveric study. *Computer Aided Surgery,* 2004; 9:27–38.

[9] Wirth S., Euler E., Kotsianos-Hermle D., et al. Comparison of C-arm CT and standard imaging in osteosyntheses of fractured distal radius specimens. *Unfallchirurg,* 2007; 110:41–8.

[10] Rübberdt A., Feil R., Stengel D., et al. The clinical use of the ISO-C(3D) imaging system in calcaneus fracture surgery. *Unfallchirurg,* 2006; 109:112–8.

[11] Ochs B. G. 1., Gonser C., Shiozawa T., et al. Computer-assisted periacetabular screw placement: Comparison of different fluoroscopy-based navigation procedures with conventional technique. *Injury,* 2010 Dec.; 41(12):1297-305.

[12] Xu P. 1., Wang H., Liu Z. Y., et al. An evaluation of three-dimensional image-guided technologies in percutaneous pelvic and acetabular lag screw placement. *J. Surg. Res.,* 2013 Nov.; 185(1): 338-46.

[13] Thakkar S. C., Thakkar R. S., Sirisreetreerux N., et al. 2D versus 3D fluoroscopy-based navigation in posterior pelvic fixation: review of the literature on current technology. *Int. J. Comput. Assist. Radiol. Surg.,* 2017 Jan.; 12(1):69-76.

[14] Oberst M., Hauschild O., Konstantinidis L., et al. Effects of three-dimensional navigation on intraoperative management and early postoperative outcome after open reduction and internal fixation of displaced acetabular fractures. *J. Trauma Acute Care Surg.,* 2012 Oct.; 73(4):950-6.

[15] Kendoff D., Gardner M. J., Citak M., et al. Value of 3D fluoroscopic imaging of acetabular fractures comparison to 2D fluoroscopy and CT imaging. *Arch. Orthop. Trauma Surg.,* 2008 Jun.; 128(6):599-605.

[16] Aprato A., Jayasekera N., Villar R. N. Revision hip arthroscopic surgery: outcome at three years. *Knee Surg. Sports Traumatol. Arthrosc.,* 2014 Apr.; 22(4):932-7.

[17] Sardana V., Philippon M. J., de Sa D., et al. Revision Hip Arthroscopy Indications and Outcomes: A Systematic Review. *Arthroscopy,* 2015 Oct.; 31(10):2047-55.

[18] Harris J. D., McCormick F. M., Abrams G. D., et al. Complications and reoperations during and after hip arthroscopy: a systematic review of 92 studies and more than 6,000 patients. *Arthroscopy,* 2013 Mar.; 29(3):589-95.

In: Encyclopedia of Surgery (22 Volume Set)
Editors: Andreas Lehrer and Kristin Mueller
ISBN: 978-1-53618-329-0
© 2020 Nova Science Publishers, Inc.

Chapter 148

MRI AND 3D APPLICATIONS FOR HIP SURGERY

M. Busso[1,*], M. Falco[2], E. Shaipi[1], G. Gallo[1], P. Arnoffi[1] and A. Veltri[1]
[1]University of Turin, Turin, Italy
[2]Koelliker Hospital, Turin, Italy

ABSTRACT

Hip pain has different etiologies in adults and children. In adults hip pain may be caused by intra-articular disorders (such as avascular necrosis, arthritis, loose bodies, labral tears), periarticular disorders (such as tendonitis and bursitis) or extrarticular pathology (such as referred pain from lumbar spine, sacroiliac joints and nerve entrapment syndromes). Imaging of the hip needs to be complementary to the clinical history and physical examination because it is well known that imaging findings do not always correlate with the presence of pain and vice versa.

MRI is the imaging modality of choice for evaluation of hip joint pain, due to its contrast and resolution for soft tissues, for the absence of operator dependence and for not needing ionizing radiation. It offers information regarding occult bony and cartilage injury such as stress fracture, avascular necrosis and osteoarthritis, as well as soft tissue abnormalities such as muscle tear and bursitis.

MRI provide a useful assessment of patients in whom a femoro-acetabular impingement (FAI, Cam and Pincer types) is clinically suspected. A high resolution, non arthrographic technique can provide preoperative information regarding the presence and anatomic site of labral and cartilage abnormalities.

The MRI arthrography is superior to conventional MRI for detecting labral tears and acetabular cartilage defects; it also shows higher interobserver agreement. Both modalities (with and without artrography) have comparable results for femoral cartilage lesions.

MRI helps also surgeon to decide which patients may require an arthroscopic versus an open surgical technique.

Keywords: hip imaging, MRI, MRA, 3D

[*] Corresponding Author's Email: busso.marco@gmail.com.

INTRODUCTION

The hip is a stable, major weight-bearing join with significant mobility.

Hip pain has different etiologies in adults and children. In adults hip pain may be caused by intra-articular disorders (such as avascular necrosis, arthritis, loose bodies, labral tears), periarticular disorders (such as tendonitis and bursitis) or extrarticular pathology (such as referred pain from lumbar spine, sacroiliac joints and nerve entrapment syndromes). Imaging of the hip needs to be complementary to the clinical history and physical examination because it is well known that imaging findings do not always correlate with the presence of pain and vice versa.

MRI is the imaging modality of choice for evaluation of hip joint pain, due to its contrast and resolution for soft tissues, for the absence of operator dependence and for not needing ionizing radiation [1]. It offers information regarding occult bony and cartilage injury such as stress fracture, avascular necrosis and osteoarthritis, as well as soft tissue abnormalities such as muscle tear and bursitis.

MRI provide a useful assessment of patients in whom a femoro-acetabular impingement is clinically suspected. A high resolution, non arthrographic technique can provide preoperative information regarding the presence and anatomic site of labral and cartilage abnormalities. MRI helps surgeon to decide which patients may require an arthroscopic versus an open surgical technique.

HIP ANATOMY

The hip joint is a ball-and-socket type joint and is formed where the femur meets the three bones that make up the pelvis: the ilium at the rear, the ischium at the lower front and the pubis above it. At the age of 15-17, the tree parts begin to fuse. Their fusion forms a cup-shaped socket knows as the acetabulum, which becomes complete at 20-25 years of age. This involves the stability of the hip. The depth of the acetabulum is further increased by a fibrocartilagenous labrum attached to the acetabulum. Additional stability is provided by the strong joint capsule and its surrounding muscles and ligaments. The hip joint capsule is a dense, fibrous structure which includes the iliofemoral, pubofemoral, and ischiofemoral ligaments. These ligaments along with the ligamentum teres and the labrum help give stability of the hip. The fibrous capsule of the hip joint is covered internally by the synovial membrane, while the hyaline cartilage covering the articular surface of the femoral head acetabulum several important intra-articular structures can be identified by MRI. The acetabular margin is surrounded by a fibrocartilaginous labrum which is identified through better arthro-MRI [2].

1. Femur

The femur is the longest and most robust skeletal segment of the body. It consists of a head, a neck and a diafis, almost cylindrical for almost its entire length, whose lower distal end, the most massive, presents two condyles and articulates with the tibia.

2. Fibrous Capsule

The fibrous capsule is robust and thick put on top of the contour of the acetabulum, to 5-6 mm of the base of the lip, creating in this way the perilabial withdrawal, forward on the outer edge of the lip and, in correspondence of the notch of acetabulum, on the transverse ligament of the acetabulum and on the margin of the obturator foramen. It is inserted distally along the anterior margin of the femoral neck at the level of the intertrochanteric line.

It is very vascularized and for this reason it appears pinkish arthroscopically, while it appears hypointense after being administered through intra-articular contrast. The fibrous capsule has a greater thickness at the level of the upper part and the anterior, while it appears thinner in the back inferior. The outer surface of the fibrous capsule is irregular and is covered by various muscles, connected to the passage of large psoas and iliac muscles.

3. Acetabular Labrum

The acetabular labrum functions as a shock absorber, joint lubricator, and pressure distributor. By increasing the surface area of the acetabulum of 28%, the acetabular labrum helps to distribute load. Furthermore, it works as a seal to keep the synovial fluid within the articular cartilage and maintain fluid pressure.

Numerous studies have been conducted to investigate MRI of the asymptomatic hip, the acetabular labrum in particular. Investigators have identifed many anatomic variants, including labral variants, several sublabral sulci, perilabral sulcus, transverse ligament labral junction sulcus, and anterosuperior cleft. These variants can be confused with labral abnormalities.

The labrum varies 2–3 mm in thickness. It is thickest in the superior and posterior aspects and widest in the anterior and superior aspects of the hip.

Labral shape becomes more variable with advancing age. MRI of the hip may show normal anatomic variants of the labrum. The variants can be of the labrum itself or associated with the labrum. Anatomic variants can easily be mistaken for pathologic findings on MR images [3]. These types of labrum are:

- triangular, in most cases with sharp edge;
- roundish, with more or less sharp edge;
- irregular;
- in rare cases, it may be completely absent.

4. Ligaments

Ligaments that contribute to the joint stability are:

- the ligament of the femoral head (round ligament): is a flattened triangular formation which secures with its apex in the front and top of the dimple of the femoral head, and with its base on the notch of acetabulum through two beams, one for each side of

the notch; in the range between these two bony insertions it merges with the transverse ligament;

- ilofemoral ligament: triangular, rugged, begins at the front of the joint and is closely fused with the capsule. It sticks with the apex at the bottom surface the anterior inferior iliac spine and the base line to the intertrochanteric femoral line.
- ischiofemoral ligament: placed behind the articulation and arranged in a spiral, because from his ischium insertion is brought below and to the acetabulum, at the top and side of the rear face of the femoral neck;
- pubo-femoral ligament: is also triangular with the base of the hip bone at the level of eminence ileus-pectineal, upper branch of the pubic crest and obturator membrane; bottom merges with the capsule and the deep part of the medial ligament beam iliofemoral.

5. Synovial Membrane

The synovial membrane, very extensive, originates on the contour of the articular cartilage of the femoral head, by coating that part of the neck which looks inside the capsule; from the neck it is then reflected on the inner surface of the capsule, which covers both surfaces of the acetabular lip, sheathing the ligament of the femoral head and covering, at the end of the adipose tissue bearing content in acetabular pit.

6. Muscles That Act in Movements

Different movements are generated from different muscular groups. They are respectively:

- for flexion: psoas major and iliacus, helped by pectineus, rectus femoris and sartorius;
- for extension: great gluteus and extensor muscles of the thigh;
- for abduction: small and medius gluteus, helped by tensor fascia lata and by sartorius;
- for adduction: longus adductor, short and large, supported by frail and pectineus;
- for internal rotation: tensor fascia lata and front beam of the small and medium gluteus;
- for external rotation: shutter, twins and femur square, supported by piriformis, maximus gluteus and sartorius.

HIP MRI TECHNIQUE

The hip joint is difficult to image because it is not oriented in the standard planes of the body (axial, coronal, and sagittal), and there is significant variation in hip joint orientation from person to person too.

Patients are typically positioned supine on the examination table. Feet are internally rotated and gently immobilized with tape if necessary, with slight flexion at the knees.

Both hips are examined for suspected bilateral abnormalities, using the body coil with a large field of view to determine the extent of the lesions and to allow comparison between normal and abnormal side.

MR imaging is performed on 1.5 and 3 T scanners using a phased-array surface coil. Coronal T1 and STIR, axial T1 and fat-suppressed T2 sequences are obtained with a large field that includes the proximal femurs, the pelvis, and the sacrum. The remaining sequences use a small field of view and fat-suppression T2 sequences focused on the symptomatic hip [4].

The slice thickness is adjusted to be 4-5mm; thinner slices are used when more details are required.

Images are taken in the following sequences:

- scan views of the hip;
- coronal T1 WI and T2 WI images, performed in all case for localization of subsequent slices and planes, useful to delineate anatomy of the hip;
- axial T1 and T2 WI;
- coronal STIR WI;
- sagittal DP WI;
- if necessary T1 WI axial, coronal and sagittal sequences post intravenous bolus injection of Gadolinium DTPA (dose of 0,1 mmoll/kg in neoplastic and inflammatory cases).

Recent studies have been focused on the role of diffusion weighted MRI because it does not need contrast medium administration.

HIP MRI ANATOMY

Coronal images provide optimal evaluation of the superior labrum, articular cartilage of suprafoveal femoral head and the cartilage over the lateral acetabulum. Hip abductors (and its origin), short external rotators, iliofemoral ligament and iliopsoas attachments are optimally evaluated in this plane too.

Sagittal images provide evaluation of the anterior labrum, articular cartilage of the femoral head and acetabular dome.

Axial images allow visualization of the anterior and posterior acetabular articular cartilage and of the labrum. Iliopsoas tendon (low-signal-intensity structure, anteromedial to the anterior labrum), bursa, sciatic, femoral and obturator nerves, continuity of ligament teres are also well visualized [5].

Some clinicians use a “sagittal oblique” imaging plane, oriented parallel to the long axis of the femoral neck, to evaluate for labral tears and femoroacetabular impingement [6].

The bone structures have homogeneous signal intensity: hypointense on T2-weighted images and hyperintense on T1-weighted sequences.

An intermediate-weighted non-fat-suppressed FSE sequence is favored for cartilages, providing accurate assessment of chondral defects, progressive degeneration and appearance of joint space before diagnostic radiographic imaging.

The intra-articular fat pad lies in the central portion of the acetabulum and has the highest T1 signal intensity of all the structures in the hip (rich of proteogycans) [7].

The T2 map provides water content and collagen fiber orientation; in the deep zone of cartilage, near the subchondral plate, the relaxation times are shorter than closer to the articular face (higher order of collagen in the fibrous joint capsule).

MRI can correctly evaluate osteochondral lesions and subchondral bone (for potential stability of surgery), regularity of fibrocartilaginous labrum.

In 44–56% of asymptomatic hips, the labrum has low signal intensity in all MR sequences. Other MR signal variations include intermediate signal intensity on T1-weighted and proton density–weighted images (58%), intermediate signal intensity on T2-weighted images (37%), and high signal intensity on T2-weighted images (15%) The internal signal variation is more common in the superior and anterior aspects of the labrum [8]. The internal signal intensity may appear globular, linear, or curvilinear and may extend to the labral margins. The incidence of internal signal in general and of internal signal that extends to the labral margins increases with age. Therefore, the task of differentiating a normal labrum that contains internal signal that may extend to the labral margins from an abnormal labrum can be difficult and may require intraarticular administration of gadolinium contrast medium. In most cases (about 56% in asymptomatic patients) labrum presents homogeneous low intensity of the MR signal in its rear portion, while it becomes higher dense moving towards its most anterior portion [8, 9].

T1q or Gd-DTPA sequences discern mainly cartilage and its degeneration [10].

PATHOLOGIES EXPLORED BY HIP MRI

1. Transient and Migratory Osteoporosis

There is a group of conditions that have in common the development of self-limited, spontaneous and progressive pain accompanied by radiographic osteopaenia. This affects one or several joints, most commonly the hip, in different temporal succession.

MR imaging shows:

- bone marrow edema pattern involving femoral head, neck and sometimes the intertrochanteric region;
- inconsistent, mild involvement of the acetabulum;
- small joint effusion, invariably present;
- no focal changes typical of osteonecrosis are found.

Several authors consider transient osteoporosis as a mild variant of reflex sympathetic dystrophy or as a result of a transient ischemic insult to the bone [11].

2. Stress Fracture

The term refers to a failure of the skeleton to withstand submaximal force over time. Two forms of stress fracture have been defined:

- fatigue fracture is classically described in military recruits, athletes and runners in whom normal bone is exposed to repeated abnormal stresses;
- insufficiency fracture results when normal stress is applied to abnormal bone such as bone affected by osteoporosis or Paget disease.

MR imaging facilitates early diagnosis of stress fracture. It appears as:

- bone marrow edema, best depicted on STIR or T2 WI Fat SAT scans. The increased water content of associated medullary edema or hemorrhage results in high-signal intensity against the dark background of suppressed fat;
- fracture line: discrete low signal intensity line (when identifiable).

3. Loose Bodies

Free fragments or joint mice include free floating or adherent intrarticular fragments.

They are most frequently located in the acetabular fossa or in the anterior joint capsule recesses.

A cartilaginous loose body demonstrates low-to-intermediate signal intensity on T1 WI or PD WI images; the osteochondral ones presents a sclerotic rim.

Evaluation on donor site reveals a defect in the chondral surface of the femoral head or acetabulum.

4. Morel Lavallee Lesions

Post-traumatic fluid collections deep to subcutaneous tissue but superficial to fascia lata and iliotibial band, located proximally in the trochanteric region.

These lesions need a diagnosis on MR, in particular Type II and III (because on PD WI FSE images a non-acute hematoma can be disclosed) [12].

5. Hip Dysplasia

MRI is increasingly used for treatment planning and monitoring of more difficult cases of dysplasia. It is now used in the postoperative period after reduction and spica cast placement.

The following findings can be identified in MRI of DH [13]:

- shallow, dysmorphic, chondral, or subchondral acetabulum;
- retroversion and inadequate femoral head coverage (measurement of degree of covering);
- asymmetry of femoral heads;
- delayed ossification (discovered comparing femoral heads), unossified acetabular epiphysis [14];
- degree of femoral head position relative to acetabulum femoral head (and related subluxation or dislocation);
- labral hypertrophy (or mucoid degeneration or tear), morphology and position: its assessment is important for eversion or inversion after surgery [15];
- pulvinar, ligamentum teres or transverse ligament hypertrophy: fibrofatty proliferation prevents adequate femoral head reduction;
- remodeling of femoral head and development of a pseudocapsule when the femoral head is located upper and lateral to the shallow acetabulum;
- information about femoral head perfusion and probability of vascular necrosis after treatment.

Also bony and the cartilagineous acetabular index can be measured correctly by MRI, using an antero-posterior coronal view; these indexes are comparable to that measured in radiographs [16].

Additional findings on T1 and PD images includes hypointense join effusion, hyperintense fat signal of the pulvinar and superolateral dislocation on coronal images [17].

6. Osteoarthritis (OA)

Hip osteoarthritis can be a difficult diagnosis because hip pain can radiate to back and leg, thus miming other conditions, such as sacroiliac joint dysfunction.

MR findings in this affection are:

- sclerosis: of femoral neck, acetabular rim or subtle periosteal bone;
- subcondral acetabular cysts (more in females that in males);
- sclerogeodes changes in femoral head and acetabular side (more in males than in females).

In females osteoarthritis is also reported with anatomic anomalies such as coxa valga or DDH [15].

MRI has been shown to be potentially useful to score progression of disease, using some semi-quantitative scoring systems that are nowadays available. Presence of collateral synovitis and inflammation can be performed with MRI. Quantitative evaluation of joint tissues, cartilage thickness or cartilage composition is possible too [18]. MRI detects early features of osteoarthritis when radiographs are still negative.

Four grades of OA have been described, based on the MR extent of disease:

GRADE 1: chondral inhomogeneity as attenuated chondral signal in T1 WI and PD WI FSE;

GRADE 2: inhomogeneity and discontinuity of the chondral surface, with hypointensity of the femoral head and neck on T1 WI images;

GRADE 3: grade 2 plus irregular morphology of femoral head and acetabulum, cystic changes and indistinct zone between femoral head and acetabulum;

GRADE 4: grade 3 plus femoral head deformity.

ADC ratio of the femoral metaphysis correlates with prognosis for the majority of inflammatory abnormalities.

7. Avascular Necrosis of the Hip (AVN)

AVN is a general term referring to the ischemic death of bone, not specific for a part of it. MRI is the most sensitive mean of diagnosing for AVN, representing the gold standard of non invasive diagnostic evaluation. It has several advantages and allows accurate staging by clearly depicting the size of lesions. It also detects asymptomatic lesions that are undetectable on plane radiographs, facilitating early treatment and better response, with 95% sensitivity [19].

Appearance of AVN with MR imaging is typically:

- reactive interface line: focal serpentine T1-hyper-intense line, which represents blood products, that surrounds edema. It is the most common and first sign of AVN on MRI;
- diffuse edema: low intensity in T1 occurs in advanced stages and is directly correlated with pain [20];
- double-line sign: a second serpiginous hyperintense inner line between normal and ischaemic marrow, which divides peripheral dark (sclerosis) and inner bright (granulation tissue) on T2 WI. This sign is also diagnostic [21];
- osteochondral fragmentation (rim sign);
- secondary degenerative changes.

The FICAT and ARLET classification of AVN uses a combination of plain RX, MRI and clinical features to stage vascular necrosis of the femoral head. Stages are:

- Stage 0: RX normal; MRI normal; no clinical symptoms.
- Stage I: RX normal or minor osteopaenia; MRI edema; pain typically in the groin region.
- Stage II: RX mixed osteopaenia and/or sclerosis with or without subcondral cysts, without any subcondral lucency (crescent sign); MRI characterized by geographic defect; pain and stiffness.
- Stage III: RX with crescent sign and eventual cortical collapse; MRI same findings of RX; pain and stiffness with radiation to knee and limb.
- Stage IV: RX final stage with evidence of secondary degenerative change; MRI same findings of RX; pain and limp [22].

8. Synovitis

Considered one of the most common causes of hip pain and limping in young children, synovitis is a self-limiting acute inflammatory condition affecting the synovial lining of the hip.

MRI features include:

- symptomatic hip joint effusion, synovial soft enhancement especially in T2 WI sequences;
- contralateral joint effusion (same signal, same features);
- synovial thickening, signal alterations and enhancement signal in T2 WI in soft tissue that surrounds synovitis.

There is usually no signal alteration in the adjacent marrow.

9. Synovial Chondromatosis

It is a monoarticular synovial-based cartilage metaplasia with development of intraarticular loose bodies, that may result in destruction of the hyaline cartilage and in progressive OA.

On MR images multiple ossified loose bodies are seen as foci of intermediate signal intensity. Nodules may demonstrate features of fatty marrow on T1 and T2 WI (and appear as parts of high signal intensity).

10. Muscle and Tendon Disorders

Muscle strain, muscle contusion, interstitial hemorrhage and hematoma (with related grade of evolution), but also sequelae of muscle injury are all well-defined features using MRI. Using this technique is possible to study grade and extension of intramuscular edema, assessing fibers' distruction or preservation. MR is useful for studying musculo-tendineous junction and fiber's retraction too [23].

11. Trochanteric Bursitis

The trochanteric (or subgluteal maxima) bursa becomes inflamed by repetitive irritation of the tensor fasciae latae, that slides over the greater trochanter. This a pathology is common in runners and athletes.

MRI shows a thickened, heterogeneous and/or capsulated fluid collection, which appears hyperintense on PD WI FSE images with regular isointense margin [24].

ARTRO-MRI

With the rise of hip-preserving surgery and hip arthroscopy over the past decade, MRI of the hip joint has been established as an important tool for making treatment decisions. MRI is performed in an increasing number of patients with suspected FAI to assess the morphology of femur and acetabulum and to detect lesions of labrum and articular cartilage. Many studies have shown that MRI arthrography is superior to conventional MRI for detecting labral tears and acetabular cartilage defects and demonstrates a higher interobserver agreement. For femoral cartilage lesions, both modalities show comparable results [25].

The MRI arthrography is superior to conventional MRI for detecting labral tears and acetabular cartilage defects; it also shows higher interobserver agreement. Both modalities (with and without artrography) have comparable results for femoral cartilage lesions.

Surgeons are interested to know whether they will encounter extensive cartilage damage or non extensive cartilage at the acetabular rim during surgery, because, in the latter case, a complete removal of the acetabular cartilage lesions will be possible during surgery [25].

ULTRASOUND GUIDED AND THE APPROACH TO THE HIP JOINT

Interventional musculoskeletal ultrasound guided manoeuvres refer to a variety of invasive procedures performed percutaneously, covering diagnostic as well as therapeutic injection of joints, tendon sheats or other peri-articular structures up to more complex manoeuvres like biopsies, removal of foreign bodies and intratumoral therapeutic injections. Ultrasonography has a very important advantage over other imaging methods because it allows the concomitant visualization of the target structure, the needle penetration and tip positioning as well as the contrast deposition [26].

To perform an ultrasound guided procedure, the patient should be supine. The examination is performed with a low frequency (3.5-7.5 MHz) linear array probe or using a convex one (2.5-5 MHz) for obese or muscular patients, in grey scale and Doppler mode (to better evaluate the relationship with the vessels and the nerve. The anterior (superior collicular recess) and the supero-anterior recesses are the most important in musculoskeletal ultrasound assessment because of the sensitivity in depicting synovitis [26].

Before starting the interventional procedure, an ultrasound evaluation of the hip joint must be repeated in order to reconfirm the diagnostic selection criteria for the invasive manoeuvre and to choose the most appropriate approach. The longitudinal antero-superior approach, having the femoral head as the target, is the better possible for drug deposition [26].

Under sterile conditions, a 20-22 G spinal needle is placed on the anterior-superior side of hip joint. After doctor wears sterile gloves, prepares patient's skin above the hip with antiseptic solution, and uses a sterile condom to isolate the transducer followed by application of sterile gel on the scanning area. The needle is introduced inside the anterior capsular recess at the level of femoral head and after femoral head contact, retraction of the needle tip of 1 mm is requested; then contrast is injected under direct visualisation with the ultrasound guide.

Once accurately identified the input point, is possible to administer paramagnetic contrast: it is gadoteric acid, used in doses between 10 and 20 ml, depending on the patient's

constitutional habitus. Immediately after the introduction of the contrast agent the patient is taken to the MRI room to perform MRI scans essential for a correct diagnosis.

MRI- arthrography is performed on a 1.5 T system, using a flexible four- channel body matrix phased-array surface coil and a six-channel spine matrix coil, generally integrated into the examination table [25].

The routine protocol for artro-MRI include the following sequences: a coronal T1-weighted spin-echo sequence (TR/TE); a coronal intermediate-weighted fast spin-echo sequence with fat saturation(T2-STIR); a sagittal water-excitation 3D double-echo steady-state sequence, sagittal T1-weighted spin- echo sequence; moreover a 3D transverse oblique (parallel to the long axis of the femoral neck) water-excitation true fast imaging with steady-state precession (FISP) sequence, used to reconstruct radial reformations for assessing the femoral head-neck junction using the long axis of the femoral neck as a rotation axis. Many experienced surgeons prefer radial proton images with the slices being perpendicular to the femoral neck axis [25].

PATHOLOGIES EXPLORED BY ARTRO-MRI

1. Femoroacetabular Impingement (FAI)

Femoroacetabular impingement of the hip joint (FAI) is increasingly being recognized as one of the causes of hip pain and restriction of hip motion in young adults. FAI refers to abnormal contact between the femur, typically at the junction between the antero-superior femoral head and neck, and the acetabular rim. These repetitive contacts may instigate chondral lesions and labral tears, leading to early degenerative disease [27].

Two main forms of FAI have been described:

- on the femoral head side, or Cam impingement;
- on the acetabular side, or Pincer impingement.

Often there is a combination of both (mixed type), with one type being predominant [28, 29]. FAI is being increasingly acknowledged as a major cause of early ‘primary’ osteoarthritis of the hip [27, 30]. Clinical evidence of femoroacetabular impingement is characterized by anterior inguinal pain and decreased range of motion with flexion, adduction and internal rotation [31].

The arthro MRI constitutes a valid completion diagnostic examination, since it allows to accurately assess the morphology of the labrum, and, moreover, to highlight any injuries. Both types of impingement, being characterized by a “conflict” repeated between the femur and the acetabulum, can determine an altered distribution of the loading forces on acetabular labrum and on adjacent articular hyaline cartilage with consequent possible development of premature hip osteoarthritis.

Radiologist’s task is to help the orthopedic surgeon giving him informations about anatomy, presence and severity of bony contour deformities and of labral and chondral lesions [28].

A. Cam Impingement

In pure cam impingement of the hip, the predominant abnormality is in contour of the anterior/superior femoral head–neck junction, with a normal morphology of the acetabulum.

The symptomatology is characterized by continuous or intermittent hip pain exacerbated the activity physics: it appears, in fact, during exercise or as soon as it is finished, probably because of repeated microtrauma.

Normally, the anterior/superior femoral head–neck junction has a concave configuration; it appears either flattened or convex in cam type impingement. The femoral head may become quite aspherical due to this altered morphology. This abnormal contact results in damage predominately to the acetabular cartilage, in a rather constant location along the anterosuperior acetabular rim.

Some authors have also used the term "pistol grip deformity" when describing this lesion because of the resulting appearance of the proximal femur on an AP radiograph.

Epiphyseal extension is best seen on coronal MRI sequences as they most closely approximate the AP view of the hip. To measure the sphericity of the femoral head, the alpha angle may be the simplest method to perform clinical setting: necessary tools for measurement are available on most clinical workstations. The alpha angle is measured on an oblique image through the center of the femoral neck. A line is drawn along the long axis of the femoral neck, bisecting a circle which outlines the femoral head. A second line is then drawn from the center of the circle to the point at which the femoral head or neck protrudes ahead beyond the confines of the circle. All patients with impingement have an alpha angle of 55° or greater while those without cam impingement have an alpha angle less than 48°.

Asymmetry of the femoral head–neck junction and neck waist can be appreciated by comparing the anterior to posterior bony contours on radial or sagittal sequences. Although MR arthrography is not necessary to assess the morphologic abnormality of the proximal femur, intraarticular gadolinium helps visualize the cartilage and labral lesions which are often associated with femoroacetabular impingement. The normal acetabular labrum should be low signal on all pulse sequences [32, 33, 34]. The Cam form is commoner in young males in the 3rd decade and the femoral head–neck junction is aspheric [27, 35-37]. Cam associated cartilage lesions are much larger in width (circa 10mm) and focal compared to Pincer chondral lesions, and are also evident in the anterosuperior acetabular quadrant. Increased delamination, associated with acetabular cartilage [35], is present in Cam FAI, where the mean flap size is 7.6 mm, with a range of 2–30 mm [36]. Delamination can be evident as hypointense line in the acetabular cartilage on sagittal FS intermediate-weighted or T1-weighted sequences. Normal ranges of hip cartilage with T2 mapping [27, 38] of asymptomatic adult hip have been defined, confirming cartilage symmetric thickness of the hip joint in all regions. dGEMRIC technique allows to save time using some variations such as only use of delayed gadolinium post-contrast imaging of cartilage [27, 39].

Since most of the lesions are localized on the anterior-upper region, the oblique sagittal and axial scans are those that, with greater precision, allow a correct diagnosis. Radial acquisitions also facilitate complete assessment of the femoral head-neck junction, including the anterosuperior quadrant, where the cam deformity is often most pronounced [40]. During the evaluation of a cam impingement MRI arthrography examination is able to detect early stages of pathology: cystic areas can be identified ("herniation pit") as focal areas of hyperintensity in the SF sequence. Reactive edema is also evaluated in anterior impingement.

B. Pincer Impingement

The pincer impingement form, either diffuse or focal, is common when a deep acetabular fossa is identified [27, 31]. This anatomic conformation creates an abnormality in the shape of the acetabulum, also known as pincer lesion. When there is overcoverage of the femoral head by the acetabulum, commoner in females in the 4th decade [11], a cross-sectional image through the acetabulum makes it appear like a pincer gripping the femoral head, rather than a cup in which the femoral head rests. Consequently, when a morphologically normal proximal femur is taken to the extremes of physiologically normal flexion in the presence of a pincer lesion, the rim of the acetabulum impinges on the neck of the femur.

MR measurements derived from conventional radiographs, such as the center edge angle, can be used to assess acetabular morphology and to measure acetabular protrusion [41]. In the Pincer form the labrum can be partially or more fully ossified, with variable avulsion. Labral/acetabular junction ossification may be evident at the demarcation zone of bony apposition of the labrum and acetabular rim [27]. Pincer-associated cartilage lesions of anterior and superior acetabular quadrant involve a large, thin (some 4 mm) circumference. There may be an associated posterior or inferior acetabular margin contrecoup lesion [27, 35].

2. Lip Acetabular Injury

The acetabular labrum is a fibrocartilaginous structure that functions as shock absorber, joint lubricator and pressure distributor. Increasing the surface of acetabulum of 28%, it helps to distribute load. This structure is poorly vascularized.

The acetabular rim syndrome (ARS) is characterised by recurrent episodes of sharp groin pain and painful acetabular impingement. It is most often seen in patients with dysplasia of the hip and is increasingly being recognised as cause of their pain [42]. The acetabular labrum shows hypertrophy, degeneration, and/or tears as a result of an abnormal overload. These changes have been identified as early precursors of osteoarthritis of the hip [43]. Improvements in MRI arthrography have given enhanced visualisation of labral integrity allowing better management. According to the most recent techniques of arthroscopic surgery is often required as diagnostic survey because it allows to confirm clinical suspicion and, secondly, to demonstrate site, extent and type of lesion of the lip itself.

Depending on characteristics of the MR signal, the degeneration of acetabular labrum could be classified in varying degrees following Czerney method [44]:

- IA: area of increased signal intensity in the center of acetabular labrum does not extend to the free edge;
- IB: same of degree IA, but with thickened and deformed labrum; absence of recess;
- IIA: the mean of intra-articular contrast is partially in the acetabular labrum fissured, with a regular triangular appearance, without detachment; evidence of recess;
- IIB: as the degree IIA, but with thickened and deformed labrum; absence of recess;
- IIIA: labrum is detached, there is a triangular shape and the recess;
- IIIB: as the degree IIIA, but with thickened and deformed labrum, without recess.

The diagnosis of acetabular labral tear on MR arthrography is established when gadolinium could be seen traversing a portion of the labrum. Radial-sequence imaging improve detection of labral tears: it displays the labrum in cross section around the entire acetabular rim, however not revealing labral tears not visible on standard imaging planes. Standard imaging planes, particularly the oblique axial plane, sufficiently demonstrate all acetabular labral tears.

The vast majority of labral tears occur in the anterosuperior quadrant [45, 46]. Their shape becomes more variable with advancing age. The incidence of triangular labrum decreases markedly with age, but the incidence of rounded and irregular margins increases [3, 9].

The acetabular labrum exhibits variability in shape, symmetry, and MR signal intensity. The most common labral shape is triangular and occurs in 66–69% of asymptomatic hips. Round (11–16%) and flat (9–13%) configurations are less common. A small percentage of patients (3%) do not have a labrum [3, 8]. The labrum varies 2–3 mm in thickness. It is thickest in the superior and posterior aspects and widest in the anterior and superior aspects of the hip [47].

The role of the diagnostic radiologist is to review for features that confirm the diagnosis, to define the extent and severity of labral avulsion and cartilage lesion, to exclude other diagnoses and the presence of advanced osteoarthritis (which is associated with poorer post-surgical outcomes) [3]. Investigators have identified many MRI anatomic variants which can be misunderstood whit labral degeneration, such as several sublabral sulci, perilabral sulcus, transverse ligament–labral junction sulcus, anterosuperior cleft.

3. Labral Tears

This type of lesion can be seen in patients with developmental dysplasia of the hip, Legg-Calvé-Perthes disease, slipped capital femoral epiphysis, iliopsoas impingement, repetitive or acute trauma, or osteoarthritis [48, 49].

(a) (b)

Figure 1a,b. Fluid collection in peritrochanter bursa at the gluteus tendon insertion. Coronal FSE STIR WI.

Hip MR arthrography has a high accuracy in the detection of labral tears and is the imaging modality of choice in patients with a strong suspicion of labral lesions. These abnormalities include partial tears, complete tears and labral detachment (more common than tears) [50]. A radial imaging provides cross-sectional sections which allow to study labrum and articular joint negating the effects of volume averaging.

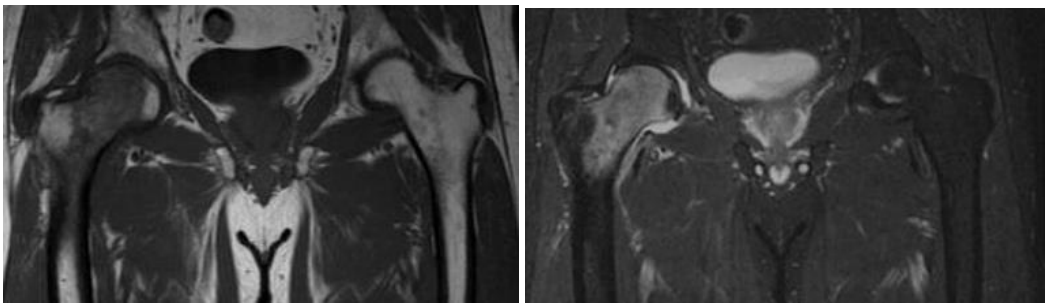

(a) (b)

Figure 2a,b. Stage I AVN in Coronal FSE T1 and STIR WI. Decrease of signal intensity in T1 images in the subchondral spongiosous bone and increased signal in STIR W images . It refers edema intraspongiosous without necrotic bone area.

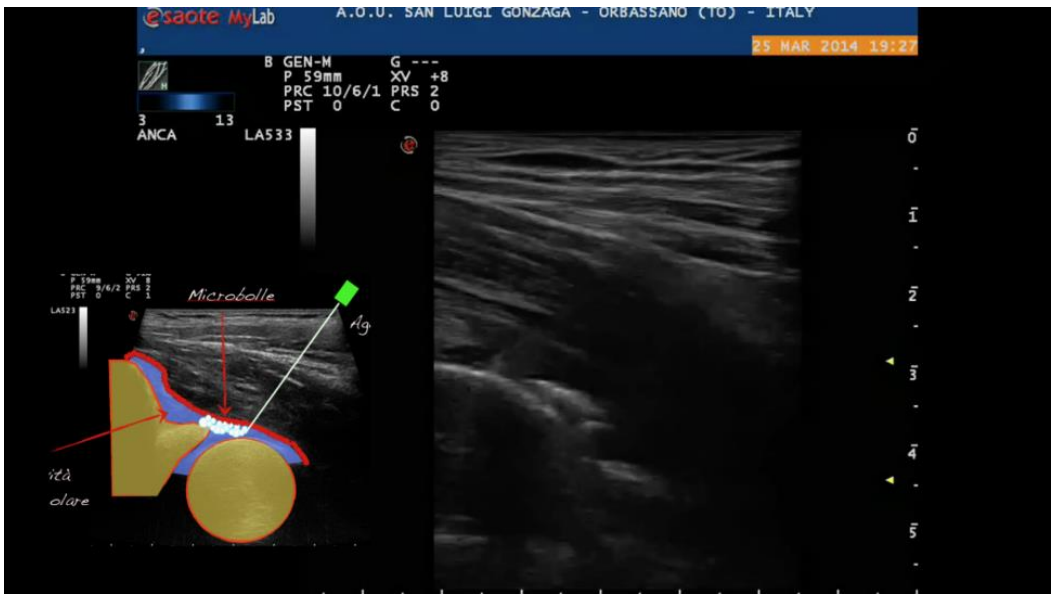

Figure 3. Ultrasound guidance for intraarticular puncture and infusion of gadolinium.

Labral tears are usually localized as anterior, posterior or superior. Tears occur most commonly anteriorly. Tears of the posterior or superior labrum are usually seen in younger patients, after a posterior hip dislocation or in patients with hip dysplasia [51, 52].

The Czerny MR arthrographic classification of labral tears has been reported to have an excellent correlation with arthroscopic findings [44].

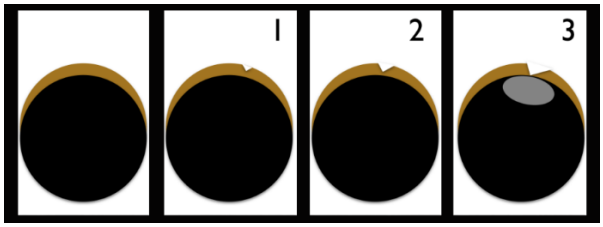

Figure 4. Drawing shows evolution of chondral defect in FAI pathology. From a minimal incision of the chondral layer to transchondral defect and formation of subchondral geodic changes.

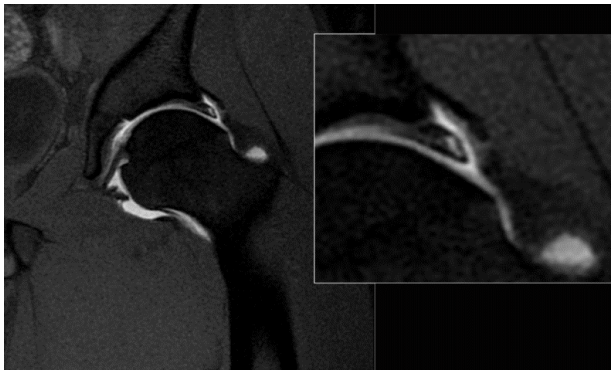

Figure 5. Coronal FSE STIR WI . The labrum and the cartilage are well depicted showing myxoid degeneration in hypertrophic labrum and oblique chondro-labral tear.

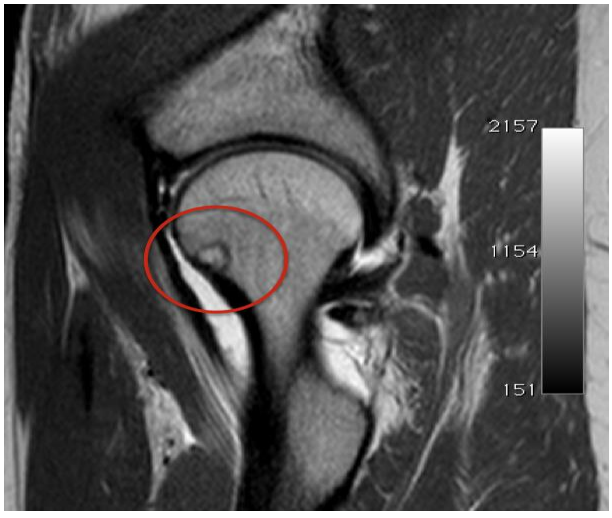

Figure 6. Sagittal FSE T1 WI shows subchondral bone area , sclerotic rims and disomogenous signal intrasubstance to refer as subchondral fracture post labral bone impaction in FAI pincer type.

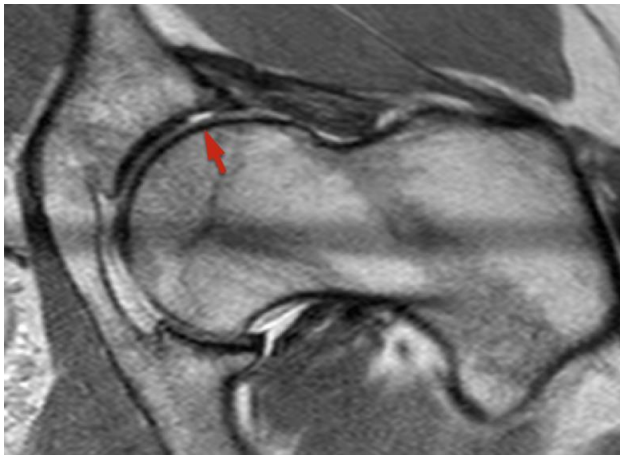

Figure 7. Radial MR image clearly depicts cartilage defect.

REFERENCES

[1] Boutry, N; Fedoux, D; Migaud, H. Rapidly destructive osteoarthritis of the hip: MR imaging findings. *AJR*, 2005, 179, 657-3.

[2] Berquist, TH. *RM dell'apparato muscolo-scheletrico*, 6°edition. Verduci Editore, 2014.

[3] Nguyen, M; Kheyfits, V; Giordano, BD; et al. Hip Anatomic Variants That May Mimic Abnormalities at MRI: Labral Variants. *American Journal of Roentgenology*, 2013, 201, 394-400.

[4] Ladd, LM; Blankenbaker, DG; Davis, KW; et al. MRI of the Hip: Important Injuries of the Adult Athlete, *Current Radiology Reports*, 2014, 51, 1-19.

[5] Stephanie, L; Gold, BA; Burge, AJ; et al. MRI of Hip Cartilage-Joint Morphology, Structure, and Composition. *Clinical Orthopaedics and Related Research*, 2012, 470, 3321–3331.

[6] Chang, CY; Huang, AJ. MR Imaging of Normal Hip. Anatomy. *Magnetic Resonance Imaging Clinics of North America*, 2013, 21, 1-19.

[7] Potter, HG; Schachar, J. High resolution noncontrast MRI of the hip. *Journal of Magnetic Resonance Imaging*, 2010, 31, 268–278.

[8] Aydingöz, U; Oztürk, MH. MR imaging of the acetabular labrum: a comparative study of both hips in 180 asymptomatic volunteers. *Eur Radiol*, 2001, 11, 567–574.

[9] Abe, I; Harada, Y; Oinuma, K; et al. Acetabular labrum: abnormal findings at MR imaging in asymptomatic hips. *Radiology*, 2000, 216, 576–581.

[10] Jazrawi, LM; Alaia, JM; Chang, G; et al. Advances in magnetic resonance imaging of articular cartilage. *J Am Acad Orthop Surg*., 2011, 19, 420–429.

[11] Vane, BC; Malghem, JJ; Lecouvet, FE. Idiopathic bone marrow edema lesions of the femoral head: predictive value of MR imaging findings. *Radiology*, 2003, 212, 527-525.

[12] Gilbert, BC; Bui Mansfield, LT; Dejong, S. MRI of a Morel Lavallee Lesion. *AJR*, 2004, 182 Issue 5, 1347-1348.

[13] Starr, V; Ha, BY. Imaging Update on Developmental Dysplasia of the Hip With the Role of MRI, *Pediatric Imaging*, 2014, 203, 1324-1335.
[14] Kim, HT; Kim, JI; Yoo, CL. Diagnosing childhood acetabular dysplasia using the lateral margin of the sourcil. *Journal of Pediatric Orthopedy*, 2000, 20, 709–717.
[15] Atweh, LA; Kan, JH. Multimodality imaging of developmental dysplasia of the hip. *Pediatric Radiology*, 2012, 43 Issue 1, 166–171.
[16] Pirpiris, M; Payman, KR; Otsuka, NY. The assessment of acetabular index: is there still a place for plain radiography? *Journal of Pediatric Orthopedy*, 2006, 26, 310–315.
[17] Beltran, LS; Rosemberg, ZS; Mayo, JD. DDH in the adolescent and adult on MR. Imaging evaluation of developmental hip dysplasia in the youg adult. *AJR*, 2013, 200, 1077-1088.
[18] Li, W; Abram, F; Beaudoin, G; et al. Human hip joint cartilage: MRI quantitative thickness and volume measurements discriminating acetabulum and femoral head. *IEEE Trans Bio-medical Eng*, 2008, 55, 2731-1740.
[19] Glickstein, MF; Burk, DL; Schiebler, ML; et al. Avascular necrosis versus other diseases of the hip: sensitivity of MR imaging. *Radiology*, 1988, 169, 213-215.
[20] Kim, YM; Kim, HJ. The pattern of bone marrow edema on MRI in osteonecrosis of femoral head. *Journal of Bone Joint Surg Br*, 2007, 82, 837-841.
[21] Sugimoto, H; Okubo, RS; Ohsawa, T. Chemical shift and the double-line sign in MRI of early femoral avascular necrosis. *Journal of Computer Assisted Tomography*, 1992, 16, 727-730.
[22] Jawad, MU; Haleem, AA; Scully, SP. Ficat classification: avascular necrosis of the femoral head. *Clinical Orthopaedics and Related Research*, 2012, 470, 2636-2639.
[23] May, DA; et al. Abnormal signal intensity in skeletal muscle at MR imaging: patterns, pearls and pitfalls. *Radio Graphics*, 2009, 20, 295-315.
[24] Woodley, SJ; Nicholson, HD; Livingstone, V. Lateral hip pain: findings from magnetic resonance imaging and clinical examination. *J orthop and sport*, 2008, 28 Issue 6, 313-328.
[25] Sutter, R. Hip MRI: How useful is intraarticular contrast material for evaluating surgically proven lesions of the labrum and articular cartilage? *AJR*, 2014, 202, 160-169.
[26] Cosmina, MM. Ultrasound Guided Hip Injection Techniques. *Osteoarthritis-Diagnosis, Treatment and Surgery*, 19, 349-366.
[27] Kassarjian, A; Belzile, E. Femoroacetabular impingement. *Semil Muskoskelet Radiology*, 2008, 12, 136-145.
[28] Anderson, SE; Siebenrock, KA; Tannast, M. Femoroacetabular impingement. *Eur Journal of Radiology*, 2012, 81, 3740-3744.
[29] Klaue, K; Durnin, CW; Ganz, R. The acetabular rim syndrome. A clinical presentation of dysplasia of the hip. *J Bone Joint Surg Br*, 1991, 73, 423–429.
[30] Ganz, R; Parvizi, J; Beck, M; et al. Femoroacetabular impingement: a cause for osteoarthritis of the hip. *Clin Orthop Relat Res*, 2003, 417, 1–94.
[31] Tannast, M; Siebenrock, KA; Anderson, SE. Imaging of femoracetabular impingement: radiographic diagnosis - what the radiologist should know. *Invited Review. Am J Roentgen*, 2007, 188, 1540–1552.

[32] Notzli, HP; Wyss, TF; Stoecklin, CH; et al. The contour of the femoral head–neck junction as a predictor for the risk of anterior impingement. *J Bone Joint Surg Br*, 2002, 84, 556–560.

[33] Ito, K; Minka, MA; Leunig, M; et al. Femoroacetabular impingement and the cam-effect: an MRI-based quantitative anatomical study of the femoral head–neck offset. *J Bone Joint Surg Br*, 2001, 83, 171–176.

[34] Siebenrock, KA; Wahab, KH; Werlen, S; et al. Abnormal extension of the femoral head epiphysis as a cause of cam impingement. *Clin Orthop Relat Res*, 2004, 418, 54–60.

[35] Pfirrmann, CW; Mengiardi, B; Dora, C; et al. Cam and pincer femoracetabular impingement: characteristic MR arthrographic findings in 50 patients. *Radiology*, 2006, 240, 778–85.

[36] Pfirrmann, CW; Duc, SR; Zanetti, M; et al. MR arthrography of acetabular cartilage delamination in femoracetabular cam impingement. *Radiology*, 2008, 249, 236–41.

[37] Aprato, A; Massè, A; Faletti, C; Valente, A; Atzori, F; Stratta, M; Jayasekera, N. Magnetic resonance arthrography for femoroacetabular impingement surgery: is it reliable? *J Orthop Traumatol.*, 2013, 14, 201-6.

[38] Watanabe, A; Boesch, C; Siebenrock, KA; et al. T2 mapping of hip articular cartilage in healthy volunteers at 3T, a study of topographic variation. *J Magn Reson Imaging*, 2007, 26, 165–71.

[39] Bittersohl, B; Steppacher, S; Haamberg, T; et al. Cartilage damage in femoroacetabular impingement (FAI): preliminary results on comparison of standard diagnostic vs delayed gadolinium-enhanced magnetic resonance imaging of cartilage (dGEMRIC). *Osteoarthritisand Cartilage*, 2009, 17, 1297-1306.

[40] Rakhra, KS; Sheikh, AM; Allen, D; et al. Comparison of MRI alpha angle measurement planes in femoroacetabular impingement. *Clin Orthop Relat Res*, 2009, 467, 660–665.

[41] Chen, L; Boonthathip, M; Cardoso, F; et al. Acetabulum protrusion and center edge angle: new MR-imaging measurement criteria - a correlative study with measurement derived from conventional radiography. *Skeletal Radiol*, 2009, 38, 123–129.

[42] Klaue, K; Durnin, CW; Ganz, R. The acetabular rim syndrome: a clinical presentation of dysplasia of the hip. *J Bone Joint Surg*, 1991, 73-B, 423-9.

[43] Leunig, M; Werlen, S; Ungersbock, A; et al. Evaluation of the acetabular labrum by MR artrography. *J Bone Joint Surge Br*, 1997, 79, 230-234.

[44] Czerny, C; Hofmann, S; Neuhold, A; et al. Lesions of the acetabular labrum: accuracy of MR imaging and MR arthrography in detection and staging. *Radiology*, 1996, 200, 225–30.

[45] Yoon, LS; Palmer, WE; Kassarijan, A. Evaluation of radial-sequence imaging in detecting acetabular labral tears at hip MR arthrography. *Skeletal Radiology*, 2007, 36, 1029-1033.

[46] Aprato, A; Jayasekera, N; Villar, RN. The accuracy of magnetic resonance arthrography in hip arthroscopic labral revision surgery. *Hip Int.*, 2013 Jan-Feb, 23(1), 99-103. sequence magnetic resonance imaging in evaluation of acetabular labrum. *J Orthop Sci*, 1999, 4, 328–332.

[47] Bharam, S. Labral tears, extra-articular injuries, and hip arthroscopy in the athlete. *Clin Sports Med*, 2006, 25, 279–292.

[48] Ferguson, SJ; Bryant, JT; Ganz, R; et al. An *in vitro* investigation of the acetabular labral seal in hip joint mechanics. *J Biomech*, 2003 2003, 36, 171–17.

[49] Seldes, RM; Tan, V; Hunt, J; et al. Anatomy, histologic features, and vascularity of the adult acetabular labrum. *Clin Orthop Relat Res*, 2001, 382, 232–240.
[50] Blankenbaker, DG; De Smet, AA; Keene, JS. Classification and localization of acetabular labral tears. *Skeletal Radiol*, 2007, 36, 391397.
[51] Lage, LA; Patel, JV; Viller, RN. The acetabular labral tear: an arthroscopic classification. *Arthroscopy*, 1996, 12, 269–272.
[52] Dorrell, JH; Catterall, A; Hase, T; et al. Acetabular labral tear: arthroscopic diagnosis and treatment. *Arthroscopy*, 1999, 15, 138–141.

In: Encyclopedia of Surgery (22 Volume Set)
Editors: Andreas Lehrer and Kristin Mueller
ISBN: 978-1-53618-329-0
© 2020 Nova Science Publishers, Inc.

Chapter 149

A VIRTUAL MODEL IN HIP PRESERVING SURGERY

Paolo Di Benedetto*, MD, PhD, Michele Mario Buttironi, MD and Araldo Causero, MD
Clinica Ortopedica Azienda Sanitaria Universitaria Integrata di Udine,
Udine, Italy

ABSTRACT

In scientific literature, there are many discussions about the conservative surgery of the joints. In particular, speaking about the hip, all papers suggest that the principal goal is to be able to prevent the degeneration of the joint and the subsequent prosthetic replacement. Pathologies such as femoral-acetabular impingement (FAI), sequels of Perthes's disease or developmental dysplasia of the hip (DDH), are considered precursor of osteoarthritis (OA).

To apply correct concepts of preserving hip surgery is paramount a better understanding of the mechanisms leading to the disease. In addition to the pathophysiology, that leads to particular deformity to be treated, the precise spatial awareness allows to design and to implement the best procedures.

Available surgical options for the hip preservation are arthroscopy, which is assuming increasing importance in recent years, the surgical hip dislocation, which allows optimal viewing of the pathology in question and pelvic osteotomy, able to treat the more serious diseases both in adulthood and in childhood.

A better and comprehensive view and understanding of the pathology is essential to choose the most appropriate surgical option. In last years, several methods that allow to create three-dimensional virtual models were developed: from rudimentary models we come to specific patient models that can replicate the motion, simulating the presence of soft tissue and simulate surgical correction. To create these virtual models a data source is required: literature describes various methods capable to start from patient imaging to returning a 3D model. It is possible obtain 3D images from both MRI and TC or other diagnostic investigation. They are becoming more important those methods can evaluate the range of motion and showing what are the portions of bones (and soft tissue) that come into contact. Collision detection can become an important tool, not only for plan a procedure, but also, for some authors considered that as a diagnostic instrument capable

* Corresponding Author's Email: paolo.dibenedetto@asuiud.sanita.fvg.it.

to distinguish different type of disease. In this chapter, some practical applications are described and are shown the future prospects of improvement of these three-dimensional simulations.

Keywords: hip preserving surgery, virtual model of the hip, 3D, arthroscopy, surgical hip dislocation, osteotomy

INTRODUCTION

Internationals registers of arthroplasty show how the number of hip implants maintain an increasing trend: all years the number of hip replacement raise and that denote the magnitude of problem about hip disease. Orthopaedics surgeons have set themselves a question: the only solution is the hip replacement or it is possible undertake surgical procedures that can prevent the degeneration towards osteoarthritis or at least delay it?

In recent years the modification and development of technique that allow surgical treatment of squeals of different childhood conditions, including developmental dysplasia of the hip, slipped upper femoral epiphysis and Perthes' disease, otherwise treatment in adulthood of chondral lesions, labral tears or femoro-acetabular impingement (FAI) become available [1].

We talk about pelvic osteotomies or intracapsular procedures such surgical hip dislocation and hip arthroscopy. Hip preservation surgery has grown in popularity, and in literature was reported a good to excellent short-term outcome. Despite, for example, the successes of hip arthroscopy in last decade, now we saw that correspond an increase in the number of revision hip arthroscopy and hip preservation surgeries. That kind of surgical procedures require a learning curve and are technically demanding. Traditionally, surgeons have relied on 2D imaging for the asses of joint congruency and morphology. Now, with the evolution of the technology, all major authors describe that a three-dimensional (3D) visualization is necessary to ensure best results favouring an easier and safer approach to this surgery. Instead, total hip replacement (THA) has become an option to consider at a later time and always in patients with a diagnosis of osteoarthritis.

HIP ARTHROSCOPY

Since the description of FAI by Ganz and Leunig [2, 3], an improved interest of hip disease in the young adult has emerged. Afterward, thanks to several studies in non-arthritic hip disease, it is better understood the pathophysiology of hip disease and new pathologies, such sub-spine impingement and ischio-femoral impingement, are recognised and well described. Subsequently hip arthroscopy has become more important for the treatment of these diseases [4].

Now we can consider hip arthroscopy indicated in pathologies at their first stages when this type of treatment can be decisive or when it can be able to delay as much as possible a more invasive treatment.

The hip arthroscopic approach may be considered a challenge: the deepness of the joint and the thickness of the soft tissue around the joint leads to a development of specific

arthroscopic instruments. The awareness of spatial orientation is demanding in hip joint due to its depth in the body, surrounding anatomic and neurovascular structures.

Diseases may affect hip are classified in intra and extra-articular: femoro-acetabular impingement (FAI) is actually the first indication for hip arthroscopy. Femoro-acetabular impingement was described first time in 1936 by Smith-Petersen [5] and it is considered a common cause of non-arthritic hip pain. Femoro-acetabular impingement is the result of the continues collision of the head-neck junction and the upper edge of the acetabulum, particularly with hip into flexion, adduction, and internal rotation. It can be classified in *cam-type* impingement that derive from a bump morphology of femoral neck, *pincer-type*, if impingement derive from acetabular rim over coverage or *mixed-type* when both patterns are present; Other diseases that can be treated by arthroscopy are cartilage injuries whit pathognomonic signs such "wave sign" visible usually in CAM and mixed FAI, osteochondral lesion, infrequent and originates often from traumatic dislocation, labral lesion, frequently source of pain, indeed the labrum is rich in vascularization and innervation.

Unfortunately hip arthroscopy is not free of complications: the most important is the fracture of femoral neck after excessive osteochondroplasty for treat FAI [6] due to a wrong pre-operative planning and a non completed knowledge of the patho-morphology of the hip. With the objective of avoiding the complications and achieve better results are being developed many methods for preoperative planning, virtual simulation and intraoperative navigation.

SURGICAL DISLOCATION OF THE HIP

Surgical dislocation of the hip allows to approach to intra-articular and extra-articular diseases of the hip in adult and paediatric patients. Potential danger to the vascularity of femoral head could be considered as a deterrent but complete visualization of femoral head and acetabulum permits a complete observation of mechanism who lead to pathology and treatment of several diseases of hip. Before Ganz et al. description of a safe procedure to access at hip joint [7] avoiding avascular necrosis of femoral head, rarely is mentioned in treatment other than arthroplasty: only in treatment of rheumatoid synovitis [8], synovial chondromatosis [9], pigmented villonodular synovitis [10] and labral tears [11]. Ganz et al. describe a posterior approach to hip but is not the only one: with anterior approach (Smith-Petersen) dislocation results safely but visualization is limited without detachment of *tensor fascia lata* and *gluteus medius*. Anterolateral and direct lateral approach show have the same visualization problem. Posterior approach allow good visualization with tenomytomy of external rotator muscles; it is possible avoid tenomyotomy preforming a trochanteric osteotomy, as describe in Ganz procedure.

In traumatic dislocation of hip, accident of nutrient vessels of femoral head happen more frequently than in surgical dislocation. In particular posterior traumatic dislocation registered higher rate of avascular necrosis of the femoral head (AVN) [12]. The time of dislocation in surgical procedure is always shorter than six hours, considered the critical limit after that may occur complications [13]. Avascular necrosis of femoral head can occur after surgery and the most useful radiological exam to evaluate femoral head is MRI. However is possible assess the perfusion of femoral head in real time during surgery: laser Doppler flowmetry allow the

intra-operatory monitoring [14]. Surgical dislocation of hip require sacrifice of *ligamentum teres*: there are concerns in literature about loss of proprioception since that ligament contain nerve receptors similarly to the anterior cruciate ligament of the knee [15]. Ganz considers possible, in future, preserve *ligamentum teres* and his innervation in many cases, that today require surgical dislocation, with an increase in experience in subluxation of the head procedures [7].

In the end, surgical dislocation of the hip, in expert hands, could be considered a safe procedure useful for many diseases which afflict hip, specially for important deformity and sequels of childhood pathologies.

OSTEOTOMIES

Osteotomies of the pelvis and upper femur serving a useful purpose and long lasting in the general management of post-traumatic and developmental conditions of the hip: are procedures that require a lot of experience by the surgeon.

Femoral Osteotomies

The femoral osteotomies are intended to restore normal anatomy and minimize the risk of evolution in osteoarthritis, but often are associated with pelvic osteotomies. Commonly the target of such surgical procedures is to correct the increased valgus and the increase anteversion in femoral neck: are classified in undertrochanteric, intertrochanteric and trochanteric osteotomies. The first usually are shortening osteotomy with the aim to reduction of femur in case of developmental dysplasia of hip (DHH). The intertrochanteric one is a derotational and varus osteotomy with a cervical-diaphyseal angle of 115°-120° as goal. Trochanteric osteotomies are useful for those cases where an elongation of the femoral neck is necessary but are very difficult procedures and provide great experience of the surgeon to avoid osteonecrosis of femoral head [16].

Pelvis Osteotomies

The aims of pelvic osteotomies are the same as femoral ones: restore a correct anatomy for prevent early joint degeneration. The concept of increasing the coverage of the femoral head allows to increase the acetabular surface subjected to the load. What it makes it challenging pelvic osteotomies is the planning process itself: orientation and shape are factors to be keep in mind. We can classify osteotomies in two big families: reconstruction osteotomies (in turn divided in reorientation and reshaping) and saving osteotomies. Reconstruction procedures are indicated in the absence of chondral damage and in the presence of good joint congruence; reshaping osteotomies are possible only before *cartilago ypsiloformis* is not yet ossified. In contrast, the saving osteotomies are indicated to reduce pain and to delay prosthetic joint replacement [17-20]. A careful preparation, done through knowledge and planning of the procedure to be performed is essential for an optimal result.

VIRTUAL JOINTS MODEL

The biomechanical study of joints during various human activities, through virtual anatomical joints models, can be considered an advantage in many field of medical and orthopaedic research. The main goal leading the orthopaedic surgeon researching in this field is the get "tools" that will improve the results of surgical procedures required for each patient and decreasing complications.

To obtain a virtual joint model we have to start from biomechanics. David Winter, in his book [21], defines biomechanics as an interdisciplinary field that describes, analyses, and assesses human movement: so we can say that biomechanics study human function through a mechanical point of view.

Consequently, biomechanics needs some concepts of physics to be understood: *Statics* studies bodies (bones for example) in state of equilibrium, when transitional and rotational movement are zero. *Dynamics* investigates how forces and torques determinate a movement of bodies or alternatively, in case of impediment to move, bodies undergoes *Deformation*. Therefore, intrinsic proprieties of material under studying are important [22].

Others two important concepts are *Elasticity* and *Plasticity*: the first one is defined such the capability of a material to restore his original shape after the application of load (force) that has deformed it. The second one described the behaviour of a material that have overcome the *elastic limit* and cannot restore his shape and deformation will be considered permanent.

The above concepts are the basis for the studies necessary for the creation of virtual models and subsequent simulations: in particular, *Statics* and *Dynamics* can explain what are the joint loads and what the possible movements depending on the forces involved and as the movements, to be analysed, are not pure movements, but compounds from simpler movements associated. Since the range of joint motion is limited physiologically, when you at the stroke end the surfaces of the bone segments collide: in this case play an important role the deformation, the elasticity and plasticity. An ideal virtual model should take into account the different characteristics of the tissues involved and the different deformation capacity and, in a sense, consider the real joint behaviour. These characteristics lead to an increase of the amount of data that must be analysed by specific software [23] and then, often, the simulations must be simplified in order to work in real time, as be seen, for example, in the work of Wilhelms [24] which introduced a method where the skeleton is simplified to a tree of three concatenated ellipses that represent the bones.

Data Origin

If the virtual models are used to plan surgical procedures, we have to keep in mind the subjective anatomical variation between different patients we are going to study: customization of patient's joint model are to be useful for surgeons. A generic simulation may be useful in understanding the pathogenesis but could be used in clinical practice. Individualized musculoskeletal model is the right way [25].

(a)

(b)

Figure 1a,b. A CT-scan of a 24 years old man with multiple exostoses disease.

But what are the sources of data to be searched to get personalized virtual models? Medical imaging techniques are the answer such Radiographic examination, Computed Tomography (CT), Magnetic Resonance Imaging (MRI), Positron Emission Tomography. All of these techniques can be source of data to generate 3D model to study relationship through bones and other structures; but a critical step is necessary: the segmentation. The imaging

segmentation is the procedure to extract information from medical 2D images to create an anatomical 3D structure: all tissues represented in the image should be recognized and should be separated. The difficulty lies in the fact that the bone is not uniform due to the presence of vessels, fat, connective. Exist software able to do that automatically but often it is necessary do that manually [26] for better results. After have obtained segmented data from patient's scans need further processing to produce virtual model through specific algorithms and software [27, 28]. Another step is gain and the hypothetical 3D joint model it is available, but the model cannot simulate the real human joint without the acquisition of data related to kinematics.

Collision Detection

Starting from a human hip joint 3D model, built by reconstructing three dimensional meshes of joint's tissues (cartilage, bone) and estimating hip rotational centre, another target is the detection of colliding areas between during motion and the precise evaluation of specific range of motion (ROM). Many methods are available for detect collision but most of these are not specific and in particular result very expensive in computation time, then less useful in high speed evaluation such in hip joint range of motion analysis. Important element, in addition to collision detection, are the penetration depths (radial or cylindrical) [29].

Faster and easier methods are paramount for medical hip simulation and can lead to real time evaluation. Furthermore depth penetration assessment can give diagnostic information and would be considered helpful to define treatment [30].

Colliding areas define specific range of motion about that particular hip underwent to analysis: extrapolated information from range of motion, such for example limited internal rotation, could be important findings for a better diagnosis of hip disease [31].

Movements of hip joint can be simplified in two elementary motions: sliding and rotation. Both imply two possible collisions such sliding one and striking one. Different methods of segmentation can better analysed particular collision.

For improve collision detection from pure rotational motion a cylindrical segmentation is needed: the space around the rotatory element is divided in concentric cylinders and then in concentric ring-shaped segment, comprising also fixed element. Hence, when the element during his motion penetrate a segment that correspond to a portion of fixed element is registered. Computational analysis of all registration lead to detection and localization of collision between two elements. Indeed, for detection of collision from sliding motion is more useful another type of segmentation: radial segmentation of space. Starting from a rotational centre, the space is divided by tracing rays from the centre of rotation. The angles between two half-lines are under analysis: if the vertices of the element in motion penetrate the static element, the depth of the intersection between the elements is registered. The analysis of all position of colliding vertex allows to calculate the ROM [29].

From these concepts Arbabi er al. [30] develop a method of real time collision detection for medical evaluation of hip that discern for pincer-type and cam-type Femoral-acetabular impingement. Curvilinear penetration in pincer-type is study by cylindrical segmentation and cam-type by radial segmentation.

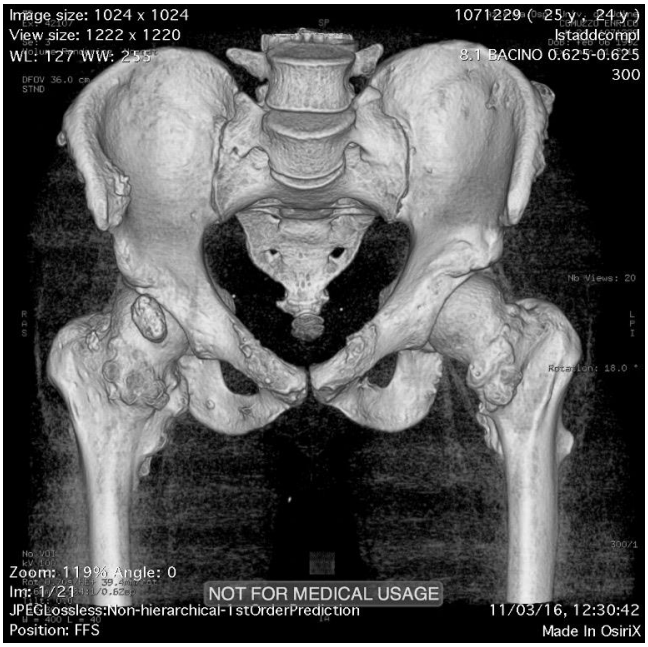

(a)

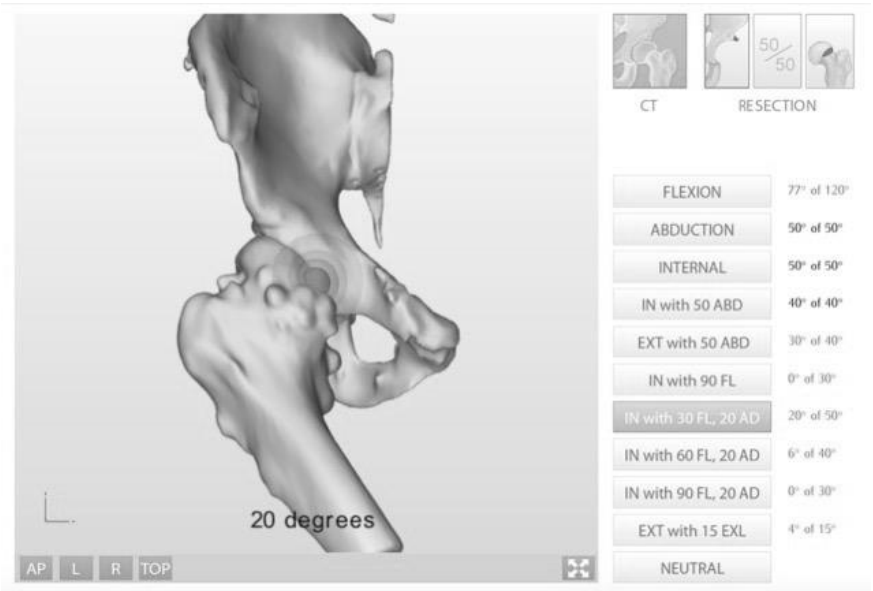

(b)

Figure 2a,b. 3D CT-scan and collision model reconstruction showing the exostoses on the femur colliding with the acetabulum.

Concepts mentioned above demonstrate how collision detection and ROM assessment could have implication in medical assessment and treatment of several diseases that afflicts hip joint.

VIRTUAL MODEL APPLIED IN FEMORAL-ACETABULAR IMPINGEMENT (FAI)

FAI treatment is the principal indication for hip arthroscopy procedures but not the only: specific deformity, who characterized cam or pincer-type FAI, is assessed through precise clinical manoeuvres and radiographic findings. The most relevant are, respectively, the alpha angle of Nötzli at al., defined as the angle between the femoral neck axis and the line connecting the centre of the femoral head to the point of femoral head asphericity [32] and the centre-edge (CE) angle of Wiberg, another one important finding, formed by a line drawn perpendicular to a baseline that passes through the centre of the femoral heads and a line connecting the centre of the femoral head and the superior border of the acetabulum [33].

Many authors have concluded that the alpha angle single measurement must be considered in critical manner. It is demonstrated that often the alpha angle measured on radiographs does not coincide with the size of the deformity found intraoperatively. A measurement on 3D images allows to determine the size and the position of the CAM deformity respect to the head-neck junction of the femur and allow better planning and surgery treatment [34]. The same applies to the pincer-type FAI deformity: 3D images allow better bony acetabulum coverage assessment [34].

Treatment of femoral-acetabular impingement can be performed trough arthroscopic approach or open approach with surgical dislocation of hip; the two procedure seem have comparable outcome [35]. Complication of these kind of joint preserving surgery of the hip (JPSH) have a low rate of complication in many studies (1,9% for arthroscopy; 4,1% for surgical dislocation of hip) [36]. The choice of what surgical procedure undertake should be guided by the complexity of the disease at issue: surgical hip dislocation may be the best treatment in severe deformity or in every cases is needed a comprehensive deformity correction. In particular severe deformities on acetabular side are demanding by arthroscopy [37]. All others cases can be treated, in security, with hip arthroscopy.

Complications about hip Arthroscopy can be several and all due to particular factor such the deepness location of the hip joint, nearness of neurovascular structures at risk for injury, the poor visualization caused by the constrained osseous geometry of the joint, the limited working space caused by strong capsule. All these reasons may lead the surgeon to under-resection or over-resection the bony deformity, most frequent arthroscopy complications.

The above discussion lead to the necessity of tools to make the best approach to the hip for the arthroscopist in order to facilitate the treatment and decrease the complications: to do that a virtual and simulated approach may be the way.

Several software are available for virtual models obtained by imaging investigations; only few of these need “coordinate” to orientate positions of any bone. Trough segmentation, bony landmark are identified and specific algorithms can simulate ROM and identify location of impingement better then 2D images [38].

More accurate software are able to locate and measure the deformity better thanks to a rotation centre of the hip that simulates not only the rotation but also the translatory motion (as occurs in the hip human) [39].

A virtual model of the hip able to consider the deformability of the involved tissues and able to evaluate the type of deformity in real time can become a useful tool, not only for the pre-operative assessment but perhaps also a diagnostic tool capable of even directing the next

treatment. Arbabi et al. in his work [30] developed a computer-assisted method for real time evaluation of hip disease based on assessment of penetration depth of colliding tissues; in particular, he demonstrates the ability of that system to determine difference in penetration depth between cam, pincer, mixed-type of FAI and hip dysplasia. Starting from a normal hip (defined in his study a hip with alpha angle about 40° and CE angle about 20°) his group analysed 25 hip model with all possible combination of above parameters during full range of standing-to-sitting movement [40]. Therefore all possible kind of disease were assessed during standing-to-sitting motion and results that each of 25 hip model correspond to a specific pattern of penetration depth. Dysplastic and normal hips could have a normal range of motion, on the contrary mixed-type of FAI could show lesser range of motion.

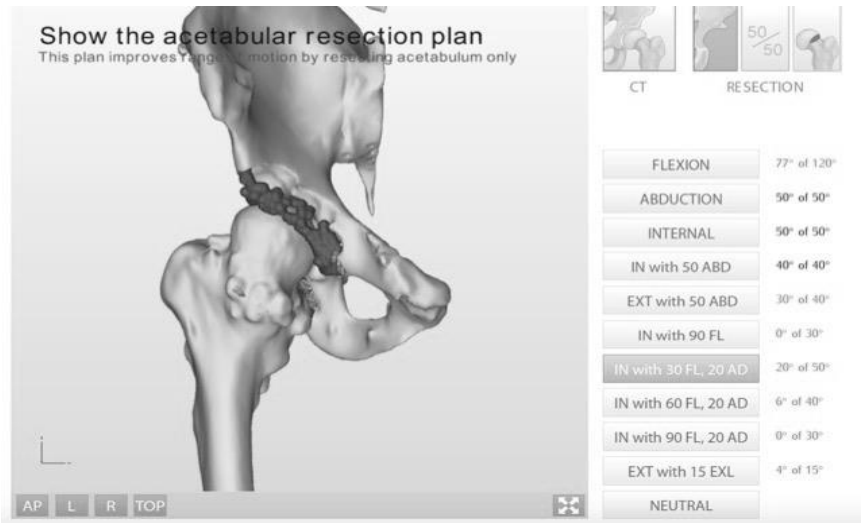

(a)

(b)

Figure 3a,b. The suggested resections by the collision model on the acetabulum (a) and of the femur (b).

(a)

(b)

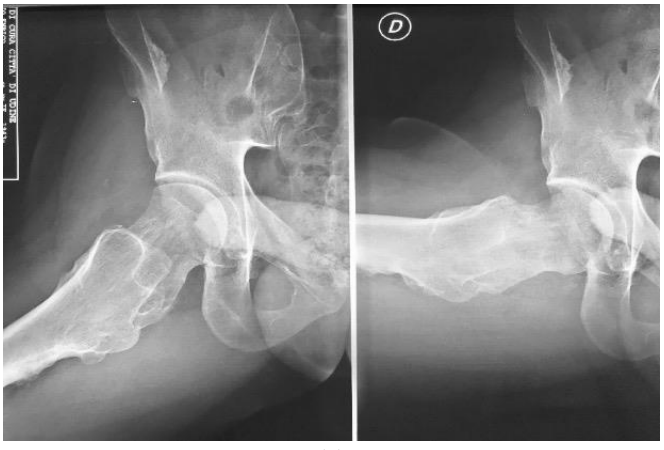

(c)

Figure 4a,b,c. The case of a 24 years old man with the multiple exostoses disease treated with hip arthroscopy by the author according to collision model indications. The preoperative x-ray (a), the post-operative x-ray (b,c).

From preoperative evaluation of 3D images, to simulation of the range of motion and the collision detection to assess hip before and after surgery. The next step is assistance during the surgical procedure: computer-assisted surgery (CAS) applied to joint preserving surgery of the hip (JPSH) allow gaining additional advantages: know the tool position during surgery help to perform better the procedure. A particular system could synchronize intraoperative and perioperative imaging. Surgeon can verify real time, during surgery, to make better and more accurate corrections of the deformation in issue [41]. Furthermore, to the position of instruments, generation of simulated fluoroscopic images from 3D models can be useful to compare with intraoperative fluoroscopy imaging to verify that have properly executed the planned correction in all positions you want to assess [42].

VIRTUAL MODEL APPLIED IN DEVELOPMENTAL DYSPLASIA OF THE HIP (DDH)

Today is passible to ensure a better execution of surgical procedure, thank to the advance in technology that allow 3D preoperative plan and 3D simulation. As we saw earlier, source of data can be multiple: CT, MRI and more. In this section will be exposed a CT-based preoperative and intraoperative navigation system [43]. For hip osteotomy, it start from CT data processed by a specific software to obtain three-dimensional template; another specific modelling software prepare the preoperative surgical plan and then it is transferred to a 3D navigation system.

If a rotational osteotomy [44] is to be performed, we have to find specific points on medical images to plan the osteotomy: first the centre of hip joint that will be the centre of a sphere, with a diameter often between 80-90 mm, that will indicate limits where perform osteotomies.

When osteotomy is plan, simulation of rotational correction of osteotomy can be performed: the fragment is laterally rotated to achieve correct acetabular roof obliquity angle [45] and anteriorly rotated to obtain correct coverage. A similar preoperative plan is also prepared for femoral osteotomies such varus, derotation and rotational of the head. It is also possible simulate the placement of fixation device after correction. If, after simulation, some impingement site was find by colliding software analysis, it is possible plan specific osteochondrolplasty procedure.

Intraoperative assistance of 3D navigation system is paramount: tip of trackable curved chisel is always identifiable on computer and it is important when visualization is poor such in pubic osteotomy. Visual and audible alert advise the surgeon when procedure is not following the plan.

When the osteotomies were performed, it is possible examine the results through specific trackable probe before fixation of fragments. In the same manner, we can achieve femoral osteotomy.

Advantage of this example of virtual model simulation use seem are capability to perform safe osteotomy always under computer control, even in poor visualization condition and a reduction of x-ray intraoperative exposure. However, disadvantage seem are longer operative time and preoperative radiation exposure (CT). It can nevertheless be concluded that the use of these techniques is an advantage for patients, as also reported in the literature [46].

DISCUSSION

Costs

In above paragraphs is described how virtual model can lead to a better knowledge of disease that afflict hip. Usual radiographic assessment such MRI or CT study may be consider useful for diagnosis but, especially when subjective symptoms are not specific, can demonstrate low cost-effectiveness. In Kenney et al. work use of MRI as diagnostic tool is analysed [47] and results show a substantial difference between cost-effectiveness in relation to kind of symptoms pattern are being investigated. That retrospective study proves how little a hip MRI, done to investigate hip pain, influence the treatment.

Is also examine the cost-effectiveness of MRI and the results suggest "that MRI is a poor tool when used in the assessment of patients presenting with pain without a strong clinical suspicion for a specific diagnosis" and "is not cost-effective as a screening tool for hip pain" [47]. Another study conducts by Kahlemberg et al. concluded that the cost per patient for obtain diagnosis of femoral-acetabular impingement is 1500 $ higher than calculated minimum cost [48].

Maybe the cost-effectiveness of virtual model, built starting to MRI (or other radiographic study such CT), could be better: if it has been demonstrated the superiority of virtual models in providing information to identify the correct diagnosis and determine the best treatment possible, the cost-benefit analysis should be encouraging. On the other hand, there is a lack of studies in literature that verify the above data, even if the hypothesis seems plausible.

From Virtual to Real

There are particular cases in which the three-dimensional virtual model is not enough. Objective difficulty of some surgical procedure such peri-acetabular osteotomy (PAO) demonstrates the necessity of an accurate pre-operative planning. A 3D virtual simulation is a great help, but especially for the pelvis, may prove difficult to perfect spatial orientation and awareness of three-dimensionality. How to work around this problem?

The rapid prototyping (RP) can be the answer: it is defined as a set of techniques to achieve physical models useful for features verification of a model. The target is to create a prototype of the bone component to be corrected which faithfully reproduces the size and shape and which is possible to handle. Rapid prototyping is a procedure composed by three fundamentals steps. The first is the creation of a "*Standard Triangulation Language to Layer*" file (STL): in the medical field, the STL file is get from the usual radiological investigations such as MRI or CT scan. The second step involves the STL file verification and preparation before the actual construction of the prototype. The third step consists in the construction of the prototype layer by layer. The deposition of material can occur by different ways; one of these is the "*Fused Deposition Modelling*" (FDM). Ratnadurai D. et al. [49], in his work, speak about the FDM as a method useful, rapid to realize prototype which can be sterilized by gamma radiation and therefore potentially handle able during surgery; also the material with which it is made has characteristics similar to bone. Always from Ratnadurai's work "*in DH*

surgeries, the benefit of using FDM models include helping the orthopaedic surgeons to make decisions in reduction of the hip in acetabular reconstruction, accurate placing of bone grafting, femoral shortening and to determine the suitable implant sizes for the patients." Also Tong K. et al. [50] use template in treatment of DHH for pre-operative and even for post-operative assessment of correction. Tong declares that it is an advantage in peri-acetabular osteotomies have a physical model. In addition, in the field there is a lot of development; It is desirable in the future to have the resources to be able to accomplish on your own and in time of need this type of models.

CONCLUSION

Preserving surgery of the hip joint is experiencing a period of growth under the pressure of new procedures that address in a less invasive with better consciousness of many diseases that would inevitably lead to osteoarthritis (OA), sometimes precociously. Treatment options may be different but target of the intervention remain the same: restoration and conservation of the hip joint function and pain alleviation. Various diseases that lead to osteoarthritis can be treated with different expectations of outcome, dependent on the severity and complexity of the case. Virtual models of the hip, above described, allow a wider knowledge of the deformity and therefore a more accurate diagnosis, better preoperative planning, even a more secure execution of the surgical procedure and a careful post-operative evaluation. Future steps, for orthopaedic surgeons, will be to make easier accessibility to this type of investigations and assessments. This will be possible if the efforts for the development of these technologies will be to simplify the various surgeries. In addition, in the future it would be useful to allow the surgeon to be able to manipulate the data obtained from the patient images individually and to be able to reconstruct the virtual models directly in the operating room to assess the effective correction of the defect and restoring the proper joint biomechanics.

REFERENCES

[1] Leunig M., Ganz R. The evolution and concepts of joint-preserving surgery of the hip. *The bone & joint journal* 2014; 96(1):5-18.

[2] Ganz R., Leunig M., Leunig-Ganz K., Harris W. H. The etiology of osteoarthritis of the hip: an integrated mechanical concept. *Clin Orthop Relat Res* 2008; 466(2):264-272.

[3] Leunig M., Beaule P. E., Ganz R. The concept of femoroacetabular impingement: current status and future perspectives. *Clin Orthop Relat Res* 2009; 467(3):616-622.

[4] Ayeni O. R., Levy B. A., Musahl V., Safran M. R. Current state-of-the-art of hip arthroscopy. *Knee Surg Sports Traumatol Arthrosc* 2014; 22(4):711-713.

[5] Smith-Petersen M. N. The classic: Treatment of malum coxae senilis, old slipped upper femoral epiphysis, intrapelvic protrusion of the acetabulum, and coxa plana by means of acetabuloplasty. 1936. *Clin Orthop Relat Res* 2009; 467(3):608-615.

[6] Zingg P. O., Buehler T. C., Poutawera V. R., Alireza A., Dora C. Femoral neck fractures after arthroscopic femoral neck osteochondroplasty for femoroacetabular impingement. *Knee Surg Sports Traumatol Arthrosc* 2014; 22(4):926-931.

[7] Ganz R., Gill T. J., Gautier E., Ganz K., Krugel N., Berlemann U. Surgical dislocation of the adult hip a technique with full access to the femoral head and acetabulum without the risk of avascular necrosis. *J Bone Joint Surg Br* 2001; 83(8):1119-1124.

[8] Mogensen B., Brattstrom H., Ekelund L., Svantesson H., Lidgren L. Synovectomy of the hip in juvenile chronic arthritis. *J Bone Joint Surg Br* 1982; 64(3):295-299.

[9] Postel M., Courpied J.P., Augouard L.W. [Synovial chondromatosis of the hip. Value of dislocation of the hip for complete removal of pathological synovial membranes]. *Rev Chir Orthop Reparatrice Appar Mot* 1987; 73(7):539-543.

[10] Gitelis S., Heligman D., Morton T. The treatment of pigmented villonodular synovitis of the hip. A case report and literature review. *Clin Orthop Relat Res* 1989; (239):154-160.

[11] Fitzgerald R. H., Jr. Acetabular labrum tears. Diagnosis and treatment. *Clin Orthop Relat Res* 1995; (311):60-68.

[12] Epstein H. C. Traumatic dislocations of the hip. *Clin Orthop Relat Res* 1973; (92):116-142.

[13] Jaskulka R. A., Fischer G., Fenzl G. Dislocation and fracture-dislocation of the hip. *J Bone Joint Surg Br* 1991; 73(3):465-469.

[14] Notzli H. P., Siebenrock K. A., Hempfing A, Ramseier L. E., Ganz R. Perfusion of the femoral head during surgical dislocation of the hip. Monitoring by laser Doppler flowmetry. *J Bone Joint Surg Br* 2002; 84(2):300-304.

[15] Leunig M., Beck M., Stauffer E., Hertel R., Ganz R. Free nerve endings in the ligamentum capitis femoris. *Acta Orthop Scand* 2000; 71(5):452-454.

[16] Leunig M., Ganz R. Relative neck lengthening and intracapital osteotomy for severe Perthes and Perthes-like deformities. *Bull NYU Hosp Jt Dis* 2011; 69 Suppl 1:S62-67.

[17] Ganz R., Klaue K., Vinh T. S., Mast J. W. A new periacetabular osteotomy for the treatment of hip dysplasias. Technique and preliminary results. *Clin Orthop Relat Res* 1988; (232):26-36.

[18] Steel H. H. Triple osteotomy of the innominate bone. A procedure to accomplish coverage of the dislocated or subluxated femoral head in the older patient. *Clin Orthop Relat Res* 1977; (122):116-127.

[19] Salter R. B. Role of innominate osteotomy in the treatment of congenital dislocation and subluxation of the hip in the older child. *J Bone Joint Surg Am* 1966; 48(7):1413-1439.

[20] Chiari K. [Results of pelvic osteotomy as of the shelf method acetabular roof plastic]. *Z Orthop Ihre Grenzgeb* 1955; 87(1):14-26.

[21] A. W. D. *Biomechanics and motor control of human movement*. 2005.

[22] Gibson L. J., Ashby, M. F. Cellular solids: *Structure and properties.* 1999.

[23] Seth A., Sherman M., Eastman P., Delp S. Minimal formulation of joint motion for biomechanisms. *Nonlinear Dyn.* 2010; 62(1):291-303.

[24] Wilhelms J. Animals with anatomy. *IEEE Computer Graphicsand Applications* 1997.

[25] Scheys L., Desloovere K., Spaepen A., Suetens P., Jonkers I. Calculating gait kinematics using MR-based kinematic models. *Gait Posture* 2011; 33(2):158-164.

[26] Blemker S. S., Delp S. L. Three-dimensional representation of complex muscle architectures and geometries. *Ann Biomed Eng* 2005; 33(5):661-673.

[27] Zoroofi R. A., Sato Y., Sasama T., Nishii T., Sugano N., Yonenobu K. et al. Automated segmentation of acetabulum and femoral head from 3-D CT images. *IEEE Trans Inf Technol Biomed* 2003; 7(4):329-343.

[28] William E. Lorensen H. E. C. Marching cubes: A high resolution 3D surface construction algorithm. *Computer graphics and interactive techniques* 1987; Volume 21(Issue 4):Pages 163-169.

[29] Arbabi E., Boulic R., Thalmann D. Fast collision detection methods for joint surfaces. *J Biomech* 2009; 42(2):91-99.

[30] Arbabi E., Chegini S., Boulic R., Tannast M., Ferguson S. J., Thalmann D. Penetration depth method--novel real-time strategy for evaluating femoroacetabular impingement. *J Orthop Res* 2010; 28(7):880-886.

[31] Martin H. D., Kelly B. T., Leunig M., Philippon M. J., Clohisy J. C., Martin R. L. et al. The pattern and technique in the clinical evaluation of the adult hip: the common physical examination tests of hip specialists. *Arthroscopy* 2010; 26(2):161-172.

[32] Notzli H. P., Wyss T. F., Stoecklin C. H., Schmid M. R., Treiber K., Hodler J. The contour of the femoral head-neck junction as a predictor for the risk of anterior impingement. *J Bone Joint Surg Br* 2002; 84(4):556-560.

[33] Wiberg G. Studies on dysplastic acetabulum and congenital subluxation of the hip joint with special reference to the complications of osteoarthritis. *Acta Chir Scand* 1939; 83(Suppl 58).

[34] Kuhn A. W., Ross J. R., Bedi A. Three-dimensional Imaging and Computer Navigation in Planning for Hip Preservation Surgery. *Sports Med Arthrosc* 2015; 23(4):e31-38.

[35] Botser I. B., Smith T. W., Jr., Nasser R., Domb B. G. Open surgical dislocation versus arthroscopy for femoroacetabular impingement: a comparison of clinical outcomes. *Arthroscopy* 2011; 27(2):270-278.

[36] Beaule P. E., Bleeker H., Singh A., Dobransky J. Defining modes of failure after joint-preserving surgery of the hip. *The Bone & Joint Journal* 2017; 99-B(3):303-309.

[37] Nepple J. J., Clohisy J. C., Members A. S. G. Evolution of Femoroacetabular Impingement Treatment: The ANCHOR Experience. *Am J Orthop* (Belle Mead NJ) 2017; 46(1):28-34.

[38] Kubiak-Langer M., Tannast M., Murphy S. B., Siebenrock K. A., Langlotz F. Range of motion in anterior femoroacetabular impingement. *Clin Orthop Relat Res* 2007; 458:117-124.

[39] Puls M., Ecker T. M., Tannast M., Steppacher S. D., Siebenrock K. A., Kowal J. H. The Equidistant Method - a novel hip joint simulation algorithm for detection of femoroacetabular impingement. *Comput Aided Surg* 2010; 15(4-6):75-82.

[40] Bergmann G., Deuretzbacher G., Heller M., Graichen F., Rohlmann A., Strauss J., et al. Hip contact forces and gait patterns from routine activities. *J Biomech* 2001; 34(7):859-871.

[41] Brunner A., Horisberger M., Herzog R. F. Evaluation of a computed tomography-based navigation system prototype for hip arthroscopy in the treatment of femoroacetabular cam impingement. *Arthroscopy* 2009; 25(4):382-391.

[42] Ross J. R., Bedi A., Stone R. M., Sibilsky Enselman E., Leunig M., Kelly B. T. et al. Intraoperative Fluoroscopic Imaging to Treat Cam Deformities: Correlation With 3-Dimensional Computed Tomography. *Am J Sports Med* 2014; 42(6):1370-1376.

[43] Inaba Y., Kobayashi N., Ike H., Kubota S., Saito T. The current status and future prospects of computer-assisted hip surgery. *J Orthop Sci* 2016; 21(2):107-115.

[44] Ninomiya S., Tagawa H. Rotational acetabular osteotomy for the dysplastic hip. *J Bone Joint Surg Am* 1984; 66(3):430-436.

[45] Massie W. K., Howorth M. B. Congenital dislocation of the hip. Part I. Method of grading results. *J Bone Joint Surg Am* 1950; 32-A(3):519-531.

[46] Goradia V. K. Computer-assisted and robotic surgery in orthopedics: where we are in 2014. *Sports Med Arthrosc* 2014; 22(4):202-205.

[47] Keeney J. A., Nunley R. M., Adelani M., Mall N. Magnetic resonance imaging of the hip: poor cost utility for treatment of adult patients with hip pain. *Clin Orthop Relat Res* 2014; 472(3):787-792.

[48] Kahlenberg C. A., Han B., Patel R. M., Deshmane P. P., Terry M. A. Time and Cost of Diagnosis for Symptomatic Femoroacetabular Impingement. *Orthop J Sports Med* 2014; 2(3):2325967114523916.

[49] Ratnadurai D. Y. N. FDM models and FEA in dysplastic hip. *Rapid Prototyping Journal* 2012; 18(3):215 - 221.

[50] Tong K., Zhang Y., Zhang S., Yu B. [Application of computer-aided osteotomy template design in treatment of developmental dysplasia of the hip with steel osteotomy]. *Nan Fang Yi Ke Da Xue Xue Bao* 2013; 33(6):906-909.

In: Encyclopedia of Surgery (22 Volume Set)
Editors: Andreas Lehrer and Kristin Mueller
ISBN: 978-1-53618-329-0
© 2020 Nova Science Publishers, Inc.

Chapter 150

THE LIMITS AND FUTURE OF COLLISION MODELS

Alessandro Aprato[1,*], Filippo Palmesino[1], Luca Ulrich[2], Enrico Vezzetti[2], Matteo Giachino[1] and Alessandro Massè[1]
[1]University of Turin, Turin, Italy
[2]Polytechnic University of Turin, Turin, Italy

ABSTRACT

Introduction of collision models aided surgeons to plan their resection of the femoral and acetabular impinging deformities. Their application on the hip joint is particularly interesting in association with hip arthroscopy because with technique the vision is limited and identifying friction's zones is not easy. Although their large diffusion in the market, they still presents several limits. First, the 3D reconstruction has been used only in the preoperatory phase. Its use inside the operatory room is still not available. Furthermore the actual software lack of a pure automatized program to create the 3D model of the hip. Second, nowadays collision model's software separate and study only the bony part of the hip, erasing from the 3D reconstruction soft tissues. Third, the programs currently developed use statistical data as reference to 3d virtual models and the motion between the hip's bones. They base the motion analysis on the comparison between data extrapolated from the healthy population and data from the patient exam, consequently image processing may be inaccurate. Although according to our opinion collision model are useful even with their actual limits, in this chapter we describe the limits of the actual software and their potential development.

BACKGROUND

Femoroacetabular impingement (FAI) is a recognized leading pathomechanism contributing to a hip arthritis. Actually, FAI individuation is usually based on clinical exam, xrays, MRI or CT scans. All these exams suggest the diagnosis of FAI but they are not able to show the impinging areas. With this preoperatory imaging studies, the success rate of hip

* Corresponding Author's Email: ale_aprato@hotmail.com; Fax: +39 338 6880640.

arthroscopy is reported between 67%-80% [1] and most of the surgical revisions are performed for inaccurate bone resection [2-4]. In order to improve these results, 3D reconstruction services using collision models [5] have been presented in the market (i.e., "Clinical Graphics" and the "Dyonics Plan"); those programs can localize regions of anticipated mechanical impingement in patients with hip pain aiding the surgeons to plan the bone resection.

Even if collision models were created to improve the precision of bone resection, poor scientific evidence is available at the moment. Bedi [6] used collision models either before either after arthroscopy surgery and showed an improvement of hip range of motion (ROM) after resection of the area defined as impinging by the models, unfortunately the post-operative pain was not considered as an endpoint. Unluckily, up to date it's still not available a study comparing the success of the hip arthroscopy using or not preoperative 3d models, so their use is recommended only in revision planning, where they proved a good efficacy [7]. Furthermore actual collision models are thought to reduce the actual complex learning curve for this kind of surgery [8], although no study support this statement.

Even with this poor evidence, according to our opinion, collision model are useful in FAI surgery planning. Unfortunately, some unresolved issues and problems due to current limitations of the programs restrict their diffusion on a large scale. The simplification of the processed images compared to the in vivo situation and the lack of intraoperative applications are the major limits. In this chapter we describe these limits and the potential developments of the actual software.

Analysis Issues

Nowadays collision model's software separate and study only the bony part of the hip, erasing from the 3D reconstruction soft tissues; but those tissues have a relevant role in the development of femoroacetabular impingement (FAI) and even in its physiopathology after development.

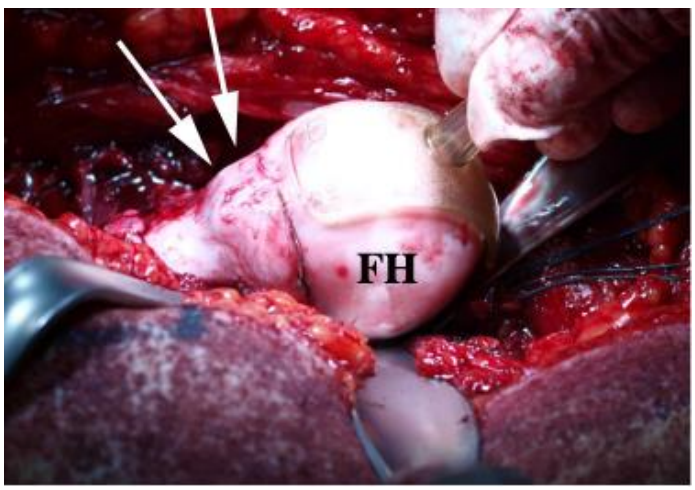

Figure 1. An intraoperative image of a cam deformity showing the cartilaginous layer (arrows) that cover the bump at femoral-neck junction. FH = femoral head.

Three kind of tissues erased from the reconstruction are important in FAI treatment: cartilaginous tissue, the fat pad [9] and the inflammatory reactive tissue.

The cam deformity is often covered by cartilaginous tissue (Figure 1): its thickness varies individually [10] and may anticipate the contact between femur and acetabulum. As a consequence, erasing this tissue from the reconstruction may underestimate the FAI.

Although rare, a fat pad found at the anterior head/neck junction of the hip joint may be the cause of the femoacetabular impingement (Figure 2-3). The fat pad may be due to repeated traumas by the labrum and acetabular margin during the impingement process [9].

Inflammatory reactive tissues (Figure 4) plays a central role in most of hip disease increasing the inflammatory response and boosting the cartilaginous and bone tissue destruction; during the operations it must be extensively removed.

Figure 2. MRI coronal image showing a soft tissue cam-like lesion (arrows) at femoral-neck junction.

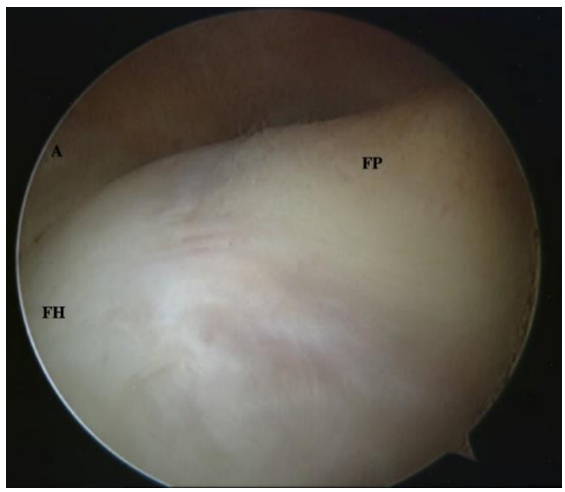

Figure 3. An intraoperative image of a soft tissue cam (fat pad) at femoral-neck junction. FH = femoral head, A = acetabulum, FP = fat pad.

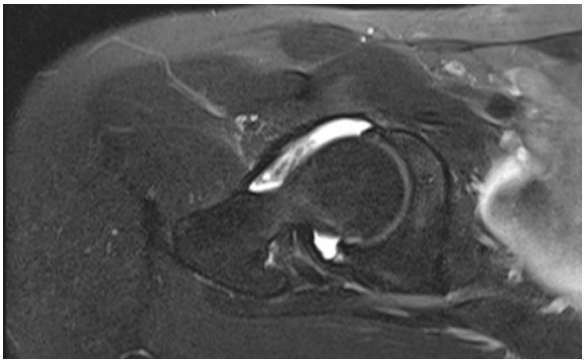

Figure 4. MRI coronal image showing an impinging inflammatory tissue (arrows) at femoral-neck junction.

Algorithm Based Issues

The actual programs use statistical data as reference to develop 3D images and the motion between the hip's bones. They base the motion analysis on the comparison between data extrapolated from the healthy population and data from the patient exam. Therefore image processing may be inaccurate: bones' surfaces are processed not considering only the individual DICOM files themselves but comparing the results of data processing with a library of 3D images from other people. Errors or artifact are manually corrected after the elaboration of the data, this process makes the 3D reconstruction more coherent and requires less specific software but loses accuracy.

Eventually motion simulation may be inaccurate: healthy population presents wide physiologic differences on how the articular faces moves between each other: applying to all these different patients the same algorithm may over or underestimate the FAI; in order to partially resolve this problem new 3D models can use a dynamic center of rotation for the femur instead of a static one [11] [12].

Other Issues

Another important limit of the actual collision models is their preoperative nature: interesting preoperative data are given to the surgeons but without intraoperative data the surgeon should base their correction on their experience and intraoperative tests without a feedback from the software. The use of the collision model inside the operatory field will help the surgeons to avoid over or under-correction. Until now 3D reconstruction of the hip is limited to the preoperatory analysis because of the necessity of high definition image in order to render the DICOM file. Therefore it's limited to files taken from TC or MRI scans, which are not present in the operating room.

Furthermore the actual software lack of a pure automatized program to create the 3D model of the hip and this is another reason why they may not be used in real time during surgery. The need of a skilled technician to elaborate the data is another major limit of the actual solutions.

Future of Collision Model

Although according to our opinion collision model are useful even with their actual limits, we think some improvements may transform them in a perfect tool for the surgeons.

Soft tissue related issues can be partially resolved introducing in the future models different kind of tissue, i.e., density has already been used in finite elements analysis to discriminate cancellous from cortical bone [13]. This improvement may complicate the model and its reconstruction phases but it may be very helpful.

Algorithm related issues may be improved by introducing more variables in the algorithm but, according to our opinion, new software need to focus on the DICOM files in order to visualize images less approximated and as close as possible to the real situations. In order to obtain those results, the programs need to analyze more efficiently the DICOM files and not rely on previously acquired images.

By now, the 3D reconstructions are based on DICOM files of TC or MRI which are not available in the operatory room. According to our point of view, there are two possible ways to solve this problem:

1- *Intraoperatory TC OR MRI*: the continuous development of MRI and CT scans is creating machines that are always smaller and require less time in order to capture the images. In the last five years, few companies created CT scans that are suitable for the operating room (i.e., AIRO from Brainlab [14]). These CT scans are especially suited for spine surgery and they have already proved to improve outcomes [15]. Up to date these machines are not available in most hospitals, are expensive and are not primarily designed for hip surgery; they also require a specially designed operating room and skilled technicians.
2- *3D Fluoroscopy*: the 3D fluoroscopy already proved to obtain reliable intraoperatory images for cam-type femoroacetabular impingement (FAI) [16] and compared to the intraoperatory CT provides an alternative which is less expensive, requires less skilled technicians and can run inside normal operating room without implementing security measures. Even though the main problem with the fluoroscopy stands in the image quality. The latter is lower than TC\MRI's image quality and it represents a bigger challenge for the 3D reconstruction. This issue may be solved either by maximizing the image quality through accurate filter either by creating specific 3D reconstruction's program for fluoroscopy.

To make possible the use of the collision model inside the operatory field the 3d reconstruction programs need to provide the 3D images in real time or in the shortest amount of time possible in order to not prolong too much the duration of the operation. To achieve this goal, the programs should be fully automatized or semi-automatized and the intraoperatory data acquisition and analysis should be as easy as possible.

In conclusion we think the actual collision model represent a good solution for preoperative FAI analysis but a new generation of collision model, based on the suggestions we presented in this chapter, will radically reduce the intraoperative difficulties in FAI treatment.

REFERENCES

[1] Sardana V., Philippon M. J., de Sa D., Bedi A., Ye L., Simunovic N., Ayeni O. R. Revision Hip Arthroscopy Indications and Outcomes: A Systematic Review. *Arthroscopy*. 2015; 31(10):2047-2055.

[2] Aprato A., Jayasekera N., Villar R N. Revision hip arthroscopic surgery: outcome at three years. *Knee Surg. Sports Traumatol. Arthrosc.* 2014; 22(4):932-7.

[3] Ross J. R., Larson C. M., Olusanjo A., Bryan T. K., Asheesh B. Residual Deformity Is the Most Common Reason for Revision Hip Arthroscopy: A Three-dimensional CT Study. *Clin. Orthop. Relat. Res*. 2015; 473(4): 1388–1395.

[4] Mella C., Villalón I. E., Núñez Á., Paccot D., Díaz-Ledezma C., Hip arthroscopy and osteoarthritis: Where are the limits and indications? *SICOT J.* 2015; 1:27.

[5] Röling M. A., Visser M. I, Oei E. H., Pilot P., Kleinrensink G. J., Bloem R. M. A quantitative non-invasive assessment of femoroacetabular impingement with CT-based dynamic simulation--cadaveric validation study. *BMC Musculoskelet. Disord*. 2015; 16: 50.

[6] Bedi A., Dolan M., Hetsroni I., Magennis E., Lipman J., Buly R., Kelly B. T. Surgical treatment of femoroacetabular impingement improves hip kinematics: a computer-assisted model. *Am. J. Sports Med*. 2011; 39 (Suppl):43S-49S.

[7] Krekel P. R., Vochteloo A. J., Bloem R. M., Nelissen R. G., Femoroacetabular impingement and its implications on range of motion: a case report. *J. Med. Case Rep*. 2011; 5:143.

[8] Hoppe D. J., de Sa D., Simunovic N., Bhandari M., Safran M. R., Larson C. M., Ayeni O. R. The learning curve for hip arthroscopy: a systematic review. *Arthroscopy.* 2014; 30(3):389-397.

[9] Jayasekera N., Aprato A., Villar R N. Fat pad entrapment: at the hip: a new diagnosis. *PLoS One*. 2014; 9(2):e83503.

[10] Adam C., Eckstein F., Milz S., Putz R. The distribution of cartilage thickness within the joints of the lower limb of elderly individuals. *J. Anat.* 1998; 193(2):203-214.

[11] Ross J. R., Bedi A., Stone R. M., Sibilsky Enselman E., Leunig M., Kelly B. T., Larson C. M. Intraoperative Fluoroscopic Imaging to Treat Cam Deformities: Correlation With 3-Dimensional Computed Tomography. *Am. J. Sports Med.* 2014; 42(6):1370-1376.

[12] Richards A. M., Coleman N. W., Knight T. A., Belkoff S. M., Mears S. C. Bone density and cortical thickness in normal, osteopenic, and osteoporotic sacra. *J. Osteoporos.* 2010; 2010(504078):1-5.

[13] S. Ali, M. Giachino, A. Bonani, A. Aprato, S. Riyahi-Alam, A. Khattab, C. Bignardi and A. Masse. Pelvic ring fractures: External fixation comparative numerical structural analysis. *IEEE Computer Graphicsand Applications* 2015.

[14] Lian X., Navarro-Ramirez R., Berlin C., Jada A., Moriguchi Y., Zhang Q., Härtl R. Total 3D Airo® Navigation for Minimally Invasive Transforaminal Lumbar Interbody Fusion. *Biomed. Res. Int.* 2016; 2016(5027340):1-8.

[15] Steudel W. I., Nabhan A., Shariat K. Intraoperative CT in spine surgery. *Acta Neurochir. Suppl*. 2011; 109:169-174.

[16] Puls M., Ecker T. M., Tannast M., Steppacher S. D., Siebenrock K. A., Kowal J. H. The Equidistant Method - a novel hip joint simulation algorithm for detection of femoroacetabular impingement. *Comput. Aided Surg*. 2010; 15(4-6):75-82.

In: Encyclopedia of Surgery (22 Volume Set)
Editors: Andreas Lehrer and Kristin Mueller
ISBN: 978-1-53618-329-0
© 2020 Nova Science Publishers, Inc.

Chapter 151

3D CUSTOMIZING IN COMPLEX PRIMARY HIP REPLACEMENT

Alessandro Aprato[1,*], Simone De Vivo[1], Francesco Marra[1], Alberto Nicodemo[2], Alessandro Bistolfi[1] and Alessandro Massè[1]
[1]University of Turin, Turin, Italy
[2]Humanitas Cellini Hospital, Turin, Italy

ABSTRACT

The progress of technology, particularly of Additive Manufacturing, has made possible the creation and the subsequent use of custom made 3D devices in hip surgery. These customized devices may be implantable (cup or stem) or non-implantable (diagnostic models, simulation models, cutting templates). The commonly used additive manufacturing technologies are: FDM (Fusion Deposition Modeling), SLS (Selective Laser Sintering), EBM (Electron Beam Melting). Each of these is used for specific purposes and has advantages and disadvantages.

Several surgical techniques have been described to face most of the hip arthroplasties without the need for custom made devices. However, in complex cases, their use may be useful. 3D models allow surgeons to reach a more accurate diagnosis or to simulate surgery. Thanks to the cutting guides tailored on individual anatomy, surgery may be assisted and simplified, reducing operating times, simplifying the critical steps, decreasing the intra and perioperative risks. In selected complex cases, the use of custom made stems or cups may also lengthen system's life and improve the clinical outcome. High costs and long time required for the production of customized products are the major limit of this technique in primary arthroplasty, although in selected complex cases, their use is advocated by the surgeons.

Keywords: hip arthroplasty, custom implants, 3D models, arthroplasty planning, 3D printing

* Corresponding Author's Email: ale_aprato@hotmail.com; Fax: +39 338 6880640.

INTRODUCTION

Total hip arthroplasty (THA) is widely considered among the most successful surgical procedures in modern surgery. Modifications of techniques and implant materials over the past four decades have improved the longevity of THA and led to excellent results in most patients. Currently, an estimated 2.55 million individuals in the United States are living with a THA, and the number of THA procedures worldwide is taught to increase in the coming decades [1-4].

Over the years, surgical techniques have been improved and materials have been optimized in order to become more compatible and durable.

In this rapid mutable scenario, realisation and use of custom implants gain popularity in the last five years. An attempt to achieve this target was already carried out in the 90s with the use of custom made prostheses, even in first standard implants. They were based on studies of the morphology of the femoral canal and the acetabular cavity and they were produced according to each patient's features. The practice of custom made in first implants has been put aside because of the current wide possibility of choosing the most suitable implant among multiple alternatives [5-7].

However, to date, custom made prostheses are frequently used in complex primary hip arthroplasty with serious diseases of hip joint, where there are major anatomical deformities or bone losses. Congenital hip dysplasia, trauma, tumors, arthritis in Legg Calvé Perthes disease or Paget's disease are the most common causes of major deformities [8-10].

In recent years, the 3D technology is progressing very quickly and custom made solutions have greatly expanded. In fact, 3D reconstructions may be used not only to produce customized prosthetic implants, but also for diagnostic purposes, for a more precise and accurate planning of surgery, to create specific devices that guide and assist the surgical procedure itself.

Technological advancements of Additive Manufacturing (AM) and its application in surgery has been the key to develop customized models. The term 'Additive Manufacturing (AM),' also called 'Layer Manufacturing,' refers to all those technologies that allow building three-dimensional physical models of an object by adding material layer by layer.

Additive construction technologies allow realizing any prototype in a shorter time than traditional processing techniques. 3D printing was born in 1986 thanks to Chuck Hull who invents stereolithography (SteroLithografic Apparatus). Since the invention of stereolithography, additive manufacturing evolved. The development of several new materials and new technologies has extended the fields of application. The rapid prototyping processes can be classified according to layers printing. Today, in orthopaedic surgery, three methods are commonly used: FDM (fusion Deposition Modeling), SLS (Selective Laser Sintering) and EBM (Electron Beam Melting). Each one has advantages and disadvantages and their suitability depends on the aim of the model. Custom made devices may be classified into two broad categories: implantable and non-implantable.

Implantable stem and/or cup may be created and tailored according to the specific individual anatomy of the patient. The implantable components are created with SLS or EBM technologies with titanium/trabecular titanium biocompatible materials.

Not implantable model are pre- or intra-operatively used to plan or to perform specific surgical steps. They may be grouped into:

- diagnostic models, realized with FDM or SLS technology
- models for surgery simulation, made with FDM technology
- patient-specific cutting masks created with SLS or FDM technology

MATERIALS AND METHODS OF 3D PRINTING FOR HIP SURGERY

3D printing is based on a three-dimensional reconstruction of diagnostic images. CT and MRI are commonly used for this purpose because volumetric three-dimensional images can be easily reconstructed from their data. Quality and resolution of the starting diagnostic imaging are essential characteristics to achieve a precise 3D model. Therefore, acquisition protocols should be standardized to avoid low quality reconstruction. Starting from the Dicom format images, segmentation of the anatomic parts is performed. Several software (i.e., Materialise MIMICS Innovation Suite, ITK Snap, 3Dslicer, 3Ddoctor, VMTKLab) have been commercialized for this aim. Regardless of the software, the basic concept of segmentation is always the same. Segmentation is based upon subdivision of voxels into groups. A voxel (volumetric pixel or, more precisely, volumetric picture element) is a volume element representing a signal or colour intensity value in a three-dimensional space, as well as a pixel represents a data in a two-dimensional image. Voxels can be often used to display and analyse scientific data. The value of a voxel can represent various properties. In a computed axial tomography scan, values are Hounsfield units, indicating the material opacity to X rays. In a magnetic resonance imaging or in an ultrasonography different values are acquired. In a first step, these groups of voxels are subdivided by means of an operation called Thresholding, in which the operator defines two threshold values, a minimum and a maximum values, in Hounsfield units, isolating and gathering all the voxels containing Hounsfield values included in this range. Once gathered, voxels shall be edited in order to isolate the various anatomical structures and/or to correct details in the first thresholding step. This step is delicate, in particular for reconstructions concerning the revision cases, for the artefacts, due to prosthetic material and present on CT/MRI images, are going to be deleted, in order to reconstruct images deprived of significant distortions. Artefacts are a serious problem, which affects every segmentation software and can be only lessened. Therefore, it is important to find the most suitable image acquisition protocol, so that images show already a lessening of artefacts and are filtered directly by the machine during the reconstruction step. Once the anatomic structures have been identified, the software permits to calculate a three-dimensional mesh geometry, starting from the previously isolated voxel groups. This mesh can be then exported in various digital formats in order to be interfaced with another software for 3D printing, engineering design or rendering and virtual animation, according to the purpose. Then, the implant or device design starts. According to the doctor's requests, the technician starts a design procedure. This procedure can be aimed at obtaining a prosthetic implant, a surgical guide or a diagnostic device. Once the design step has been completed, if the surgeon's requests have been met, the device production step is started.

According to the specific applications, the most suitable additive manufacturing technology should be chosen. The constant development of new materials permits a wide

choice for each technology, from soft to stiff material, from coloured to biocompatible material.

FDM (FUSED DEPOSITION MODELLING)

This technology is surely the simplest one among all the fast prototyping methods. The process consists in the extrusion and deposition of molten plastic material. The process is repeated until the model is complete. It permits to realize objects with very complex geometries and high mechanical resistance, to the detriment of longer printing times if compared to other technologies. As concerns the 3D FDM printing materials, they are usually thermosetting plastics. The material usually used to carry out three-dimensional models of anatomic parts for diagnostic purposes is polylactic acid (PLA), which can be used more easily than other materials, for its operating temperature is low (200°C approx.). It is available in various colours and it can be opaque or transparent. It is resistant and has excellent mechanical properties, while the final model can be worked easily and reproduces the bone consistency. Many times, PLA is used in combination with polyvinyl alcohol (PVA) for, thanks to the property of being diluted in water, it is used as base material. For the realization of cutting guides, on the contrary, a material with excellent mechanical properties is required, able to resist to possible strong stresses, biocompatible and sterilizable. Nylon 680 and Nylon PA 2200 meet these requirements, even if they can be printed less easily.

Advantages:

- Cheap
- Sterilizable (Nylon)
- Multicolour, if different anatomic structures has to be highlighted (PLA)

Disadvantages:

- Accuracy and definition (0.25-0.5mm) are not high.
- Printing realization time, according to complexity, of tens of hours, therefore not applicable in emergency surgery. If speed is increased, the possibility of error grows.
- Undercuts: they are suspended (or almost hanging in space) zones of the object and the machine can't print them because, without an underlying support, the melted extruded thread would fall. Normally, an undercut up to 45° can be managed, even if some surface imperfection could be got. If the undercut is higher than 45°, some support element must be added (PVA).

Indications: creation of anatomic models useful for planning or surgical simulation. The particular advantage of PLA models is their possibility of simulating the bone consistency: they can be realized with a harder surface part, similar to the cortical substance, and a deep trabecular part, similar to the cancellous bone. If soluble supports are required for the correct realization of models with particularly complex geometry, PVA may be used. Biocompatible

and sterilizable custom-made cut masks or surgical supports may be also created with this technique.

SLS (SELECTIVE LASER SINTERING)

A layer of thin powder, which can be thermoplastic polymer, metal, ceramic element, is applied and rolled with care, so as to create an even surface. The laser hits the geometry section point to point, layer after layer, providing the heat required to carry out the fusion or the sintering of the material. The powder grains, when hit, create the profile of the section defined by slicing, while the exceeding powder is recovered and used for the next layer. Then, the model is extracted from the powder bed and cleaned. Particular post-production working, such as sand blasting, wax infiltration or painting with epoxy resin, is required to eliminate surface porosity.

Advantages: high accuracy and resolution (0.05-0.15mm), sterilizable, no supports
Disadvantages: higher cost than FDM
Indications: cutting masks, anatomic models, custom-made prosthesis.

EBM (ELECTRON BEAM MELTING)

By fusion, a laser electron beam permits to produce objects starting from an empty space at high temperature. Very thick parts with high mechanical properties may be created with this technique. Titanium and chrome cobalt materials can be used. This technology permits to obtain trabecular titanium components, an innovating multi-planar structure that imitates the porous structure of the cancellous bone and is able to facilitate and stimulate the periprosthetic bone growth.

Advantages: extreme accuracy, trabecular titanium
Disadvantages: high cost
Indications: production of custom-made prosthetic components

NOT IMPLANTABLE CUSTOMIZING 3D

1. 3D Diagnostic Model

In literature, preoperative planning of THA is strongly suggested to minimize surgical issues [11, 12]. Planning involves a complete x ray exam of the hip (anteroposterior pelvic view and lateral view of the hip). Full leg x rays may be indicated to evaluate leg length discrepancy. Eventually a computerised tomography (CT) of the pelvis, femur and femoral condyles is often performed. 3D application may increase the accuracy of the plan: reconstruction of hip geometry provides further data about acetabular and femural anatomy, including femoral neck version, centre of rotation, offset, femoral helitorsion and transition

zone between cortical and cancellous bone. From CT scan data, production of the custom-made device (acetabular cup, femoral stem, 3D diagnostic models, osteotomy guides) may be started. Actual technology permits to reproduce accurate anatomic models. Those models may be really helpful in preoperative planning because the physical, and not only digital 3D model is at surgeon's disposal. The surgeon himself may study all the variables (i.e., assess the closeness of anatomic structures to the surgical site, decide the femoral osteotomy level with precision). Models can be created by subtraction, eliminating excess elements and isolating the ones essential for the surgical procedure. Moreover, as already said above, 3D PLA models simulate both the cortical and cancellous bone consistency in a satisfactory way allowing real surgical simulations.

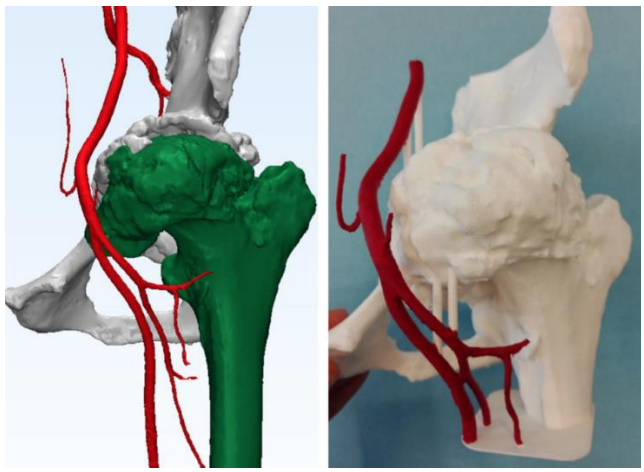

Figure 1. Imaging 3d reconstruction and diagnostic model.

Complexity of the anatomic deformity is not the only indication for 3D models, the simultaneous presence of surgical critical aspects, such as proximity of anatomic structures may require a preoperative evaluation with 3D models. In Figure 1, an illustrative example regards a serious dysplasia with huge front heterotopic ossifications, with subankylosis of the same hip is presented. The heterotopic ossification is very close to the femoral artery. In this specific case, the 3D model, in 1:1 scale, beyond being useful for the creation of cutting masks, was essential in order to assess the distance between femoral head and femoral artery.

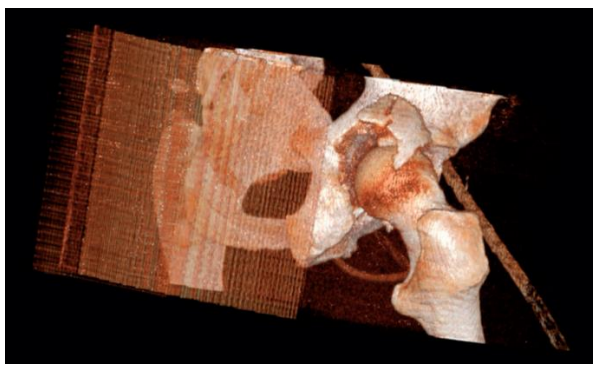

Figure 2. 3D virtual model of an acetabular fracture based on CT scan images.

3D models may also be used to evaluate the correct cup positioning in complex acetabular fractures treated with acute THA. In those cases, the reduction and synthesis of the fracture is followed by the implantation of a one-stage hip prosthesis. The 3D model permits to get a more complete view of the fracture (Figure 2-3), to optimize the surgical reduction and plate positioning and to choose the perfect position of the cup.

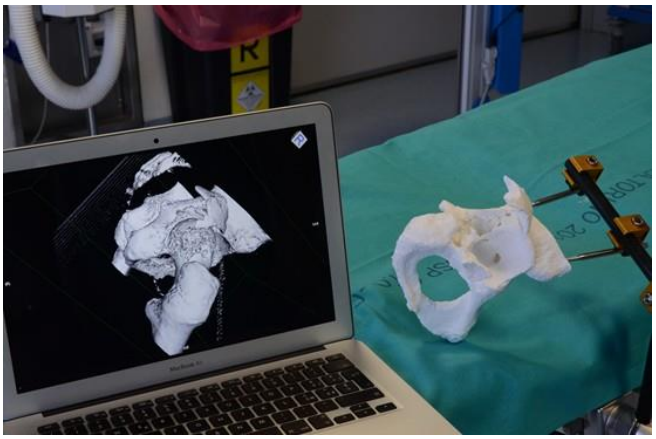

Figure 3. 3D solid model compared with 3D virtual model.

2. Sterile 3D Models

Once the diagnostic models have been created and sterilized, in selected cases, they may be useful to simulate surgery.

Figure 4. Sterile preoperative simulation of posterior wall synthesis.

An example of this application is the reduction and fixation of an acetabular fracture. Reduction may be performed on the 3D model and plates may be bend on it. This may be performed on a sterile tray before incision in order to avoid intraoperative plate bending and to decrease surgical time (Figure 4).

Furthermore sterile 3D models may be used to help the surgeon intraoperatively to choose correct screw direction in complex cases. Direction of the cup's screws may be tried. Eventually, sterile 3D models are useful in acetabular fracture, to practically check the interference between plate screws and cup screws.

3. Custom Osteotomy Guides

Further developments of 3D customizing of non-implantable devices are the patient specific cutting guides. They are custom-made masks created with the aim of guiding the femoral neck cut. The design and realization of a custom-made guide requires a very accurate preoperative study. The best plan for the osteotomy should be chosen. Landmarks on the 3D model of the femur should be carefully chosen in order to be easily identified on the real bone during surgery. Volume of the cutting guide should be chosen according to the type and dimension of surgical approach. The cutting guide is tailored to be perfectly suitable for the patient's anatomy. Therefore, guides are moulded by CAD software, looking for the best precision of the cutting planes, a good stability and the lowest possible encumbrance. Unfortunately, often obtaining a good version of the guide in terms of precision, stability and easiness of use is not easy and requires several attempts and tests. Nylon 680 or PA 2200 are the most frequently used materials because they are radiolucent, biocompatible and sterilizable and present excellent mechanical properties. Since the blade of the saw is not radiolucent, intraoperative fluoroscopic control is possible to check the proper position of the guide (Figure 5).

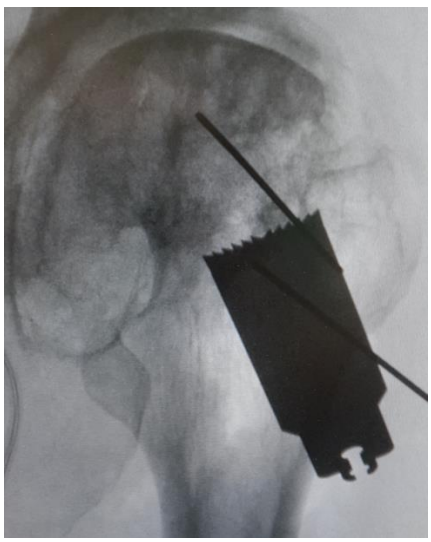

Figure 5. Intraoperative fluoroscopy showing a correct position of the guided neck osteotomy.

IMPLANTABLE 3D CUSTOMIZED COMPONENTS

Complex Primary Hip Replacement

Total hip arthroplasty is well defined in most cases and described principles should be followed to obtain the expected functional results and for long term implant survival [13]. Biomechanics of the hip must be respected: restoration of the centre of rotation, of the lever arm and correct positioning of implants are essential to limit impingement and components wear.

As said above, primary THA may also be complex: anatomical deformities may be an issue for the surgeon. Coxa vara, leg length discrepancy, acetabular dysplasia, Legg-Calve-Perthes disease, epiphysiolysis, heterotopic ossifications, avascular necrosis of femoral head, trauma in acetabular traumatic fractures are the most common ones. Bone dystrophies (Paget's disease, osteoporosis, osteopetrosis, radiated bone) may also complicate the surgical steps. 3D customized implants may be useful in those severe deformities.

In the last decade, introduction of modularity has been as an alternative to monoblock femoral stems. Large use of modular implants has been made in primary complex arthroplasty. As widely proved in literature and by experience, it shows remarkable advantages. The claimed advantage of this type of prosthesis is the possibility of choosing intraoperatively neck version and neck length independently of the stem size. With modular neck, restoration of hip biomechanics including femoral offset and soft tissue tensioning and abductor muscle imbalances, is easier, mostly in complex hip replacement [5-7]. However, an increasing number of recently published reports and studies describe failures of modular femoral neck prostheses. The addition of an interface is associated with complications such as corrosion or stem-neck disassociation [14-15].

Another option for complex hip arthroplasty is the implant of short stem. Short stems may be used in selected morphological anomalies of proximal femur in younger patient with a good bone quality. Unfortunately only a little rate of complex arthroplasty may be safely performed using short femoral stems, for example coxa vara and high dysplastic femoral neck antetorsion are known contraindications [16, 17].

Several surgical techniques have been also proposed to improve implant positioning and stability in complex arthroplasty. Classic shelf augmentation, cotyloplasty, medial protrusion technique and a controlled fracture of the medial wall are the most known. Osteotomy of the iliac ala with distal sliding of the detached fragment, proximal positioning of the acetabular component, proximal femoral shortening osteotomy, sub-trochanteric shortening and/or derotation osteotomy have also been widely used [13, 19]. All of them are still considered as reliable in specific group of patient but 3D technology may decrease their popularity.

Femoral Customizing

Literature reports several studies about custom-made femoral implants for femoral deformities. Each patient with major deformity of proximal femur is a unique case. The complex femoral anatomy in combination with soft tissue and leg length discrepancy precludes the implantation of classical stem in several situations. Use of modular stem or cone type stems can solve most of the cases. When excessive rotational deformity, coxa vara and cortical thinning are present and no anatomical fitting could be achieved with standard stems, a custom femoral implant should be considered. A custom design may improve strain distribution and help to reconstruct hip biomechanics. Abnormal helitorsion of proximal femur is treated creating an asymmetrical proximal part of the stem and neck geometry may be corrected in a triplanar way. The main purpose is to follow canal morphology by varying the implant surface in contact with the bone. This approach is named "fill and fit." It consists in the physiological distribution of stress to the femoral shaft. Stems are normally designed with circular cross section and stem tip has hemispheric shape in order to facilitate the

implantation to the femoral canal and avoiding localized stress shields. All reported custom-made femoral stems are made of titanium alloy. Bone integration is helped by surface settings: specific roughness and hydroxyapatite coatings. In the majority of custom-made femoral stem, the hydroxyapatite coating is applied to the proximal part of the implant although, some authors used a fully hydroxiapatite coated stem [20, 21, 24, 25].

Furthermore custom stems present all the advantages of monoblock design: no stress concentrations at the neck and stem junction and a low rate of aseptic loosening.

The main disadvantages of custom-made femoral stems are the long production time and the high cost. Production times can take up to three months. The work flow includes the selection of images from CT scans and the production of a prototype that has to be sent to the surgeon, who can approve or modify it. This process can be repeated several times before achieving a perfect stem. Costs increase two or three times if compared to the production of a standard stem.

In cases of severe dysplasia, custom-made stems may simplify surgical procedure, avoiding in several cases trochanteric osteotomy, which may increase complication rates. The femoral cut height and direction is either preoperatively decided by CAD measurements, or obtained by creating custom-made cutting guides. Preparation of femoral canal is done with one or two custom-made broches, usually 1 mm smaller than definitive stem. Broaches have the same shape as the custom stem. Femoral anteversion, varus/valgus correction, lateral offset are defined in preoperative planning. In those complex cases, custom-made implants may increase life expectancy of stem and reduce revision rate. Literature showed high rates of stem survival prosthesis (from 93% to 100% in a range from 6 to 14 years follow up). All studies demonstrated a significant improvement in postoperative clinical score compared to preoperative situation. No studies reported major complications after custom-made femoral stem implantation.

Considering the available huge variability of solution (i.e., modularity, short-neck stems) an expert surgeon does not need custom-made prostheses for the standard first total hip arthroplasty. On the other hand, in severe deformities, custom-made femoral stems are a valid choice. According to our point of view, custom-made stems should be used when an accurate preoperative planning shows the impossibility to get a correct anatomic reconstruction and a good fitting. In those cases, the custom implant form is chosen in order to get an excellent stability, to achieve a better distribution of loads and a better reconstruction of hip biomechanics.

Cup Customizing

In severe acetabular deformities, cup placement may be technically difficult. Standard anatomic landmarks may not be identified therefore choosing cup size, inclination, anteversion and coverage may be complex. Several technique have been proposed to solve this issue [26-29]. These techniques use standard acetabular cup or, in more complex cases, of revision cups. Indication for custom-made cup inprimary THA is rare but it should be considered in extreme cases: major alterations of acetabular anatomy, very small or very large dimensions of the acetabular cavity.

Illustrative Cases

Case 1: Diagnostic and Simulation Model for Preoperative THA Planning Plus Custom Cutting Guide for Intraoperative Neck Osteotomy (Figures 6-8)

Diagnosis: bilateral congenital hip dislocation. Severe anatomic alteration of the acetabulum with osseous ankylosis of the hip (locked in extension and outward rotation of 40 degrees). No leg length discrepancy.

Surgical plan: THA

Critical aspects: femoral head deformity with significant apposition of osteophytes, mainly anterior. Proximity of the femoral artery to the anterior osteophytes. Hip ankylosis, impossibility of flexion and internal rotation to help the osteotomy of the femoral neck through posterior-lateral access. Subsequent need of anterior access according to Smith Petersen with on-site osteotomy of the femoral neck.

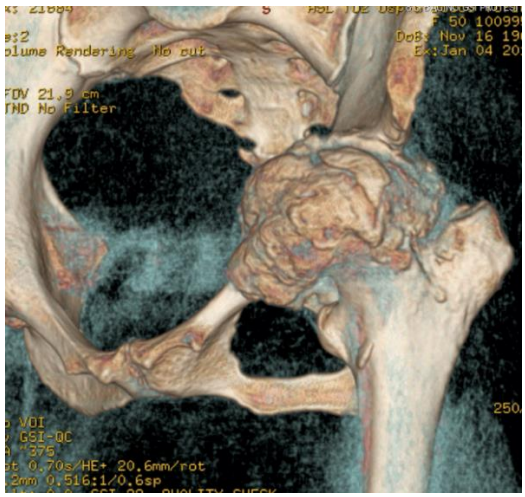

Figure 6. TC 3D reconstruction of affected hip (case 1).

Figure 7. Multicolor 3D model showing real distance between femoral artery and femoral head (case 1).

Figure 8. Post-operative AP x-ray (case 1).

Customizing process: segmentation with separation of acetabulum from femur. Isolation of vascular structures, images acquired with CT scan with vascular phase. Production of two diagnostic and simulation models, one of them with coxofemoral articulation, the other one with the left half pelvis (subtraction of femur and vessels). Design of the femoral cut mask, created for two osteotomies: proximal cut to remove the femoral head and achieve a better visibility on the operating field, distal cut along the correct osteotomy line required for the definitive implant. Diagnostic and simulation model made of polylactic acid for exclusive preoperative use. Cutting guide made of sterilizable Nylon Taulman 680, suitable for intraoperative use. Both components were printed with FDM technology.

Preoperative acquired information: the real distance from artery and femoral head, individuation of a cleavage plane between the two structures, individuation of the femoral artery path (an arched path with anterior convexity).

Custom guide preparation: the guide for osteotomy was created on the complete model to carry out two osteotomies: a cranial osteotomy for the removal of the femoral head and a caudal one for the final osteotomy. Cup positioning was simulated on the model after subtracting the femoral artery and the femur, after preparing the acetabulum with increasing diameter reamer. Cup size has been estimated 46-48 mm, the best cup position at 45 degrees of coverage and 15 degree of anteversion was found.

Surgical procedure: Direct anterior access according to Smith Petersen. Cleavage plan was identified between the articular capsule and the femoral artery, which has been isolated and protected. Osteotomy was performed on site with the custom guide. The guide was made with holes for three pins in order to ensure its anchoring to the femoral neck and its stability while carrying out the osteotomy. The first cranial cut was performed to remove the femoral head, then the final osteotomy was carried out. Finally, the cup positioning met the preoperative design simulated on the 3D model. The final cup had a diameter of 48 mm with version, covering and direction of screws corresponding to what planned on the simulation model.

Case 2: Diagnostic and Simulation Model for Preoperative THA Planning Plus Cutting Guide For Biplane Femoral Osteotomy (Figures 9-11)

Diagnosis: Left hip arthritis on the Paget's disease of ipsilateral femur.

Surgical plan: left THA with long stem implant after biplane femoral correction osteotomy.

Critical aspects: severe deformity of left femur. Varus of 15 degrees and procurvation 4 degrees. Poor bone quality.

Customizing process: 3D femoral model printed by FDM technology, made of polylactic acid. Cutting guide was made of sterilizable and biocompatible Nylon PA 2200. Guide was made with lots for 4 locking pins and design to achieve a correction of the femoral deformity.

Preoperative step: The correction osteotomy was planned at proximal medium third of the femoral diaphysis. The partial (4.5 degrees) and not ideal (15° degrees) correction of the varus was planned; while a complete correction of procurvation was studied (3.7 degrees). In order to get these two corrections on the two planes, the exact distance of the cutting mask positioning was calculated: the distal cut should be made at 14 cm from the greater trochanter tip and the top edge of the guide should be at 11.6 cm. The simulation of the operation was carried out according to the following sequential steps: identification of the correct cut height, guide positioning with 3-mm pins, execution of both osteotomies, guide removal, bone wedge removal, stem implantation.

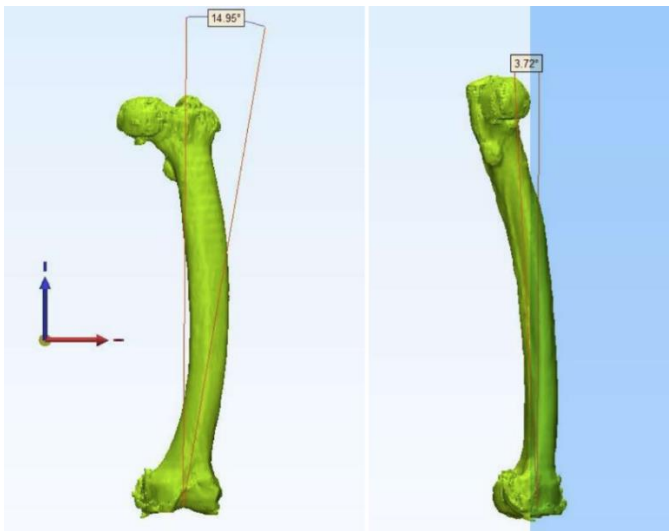

Figure 9. 3D TC reconstruction showing the severe femoral deformity (case 2).



Figure 10. Preoperative planning of biplanar osteotomy using custom made cutting guide (case 2).

Figure 11. Post- operative AP x-ray (case 2).

Surgical technique: Extended posterior lateral access according to Kocher Langebeck in order to expose the femoral diaphysis. Usual acetabular cup implantation technique. Split of the medial vastus and partial disinsertion of the gluteus maximus muscle with exposure of the femur shaft. Custom-made cutting mask was placed as per preoperative plan. Execution of the wedge-shaped biplanar osteotomy. Reduction of the femoral diaphysis and implant of long revision stem.

Case 3: Diagnostic and Simulation Model for Preoperative THA Planning Plus Custom Cup (Figures 12-14)

Diagnosis: bilateral hip arthritis in dysplastic acetabuli.

Surgical plan: bilateral THA with custom made cup and standard stem

Critical aspects: acetabular dimension and shape, anterior and posterior acetabular wall dimensions

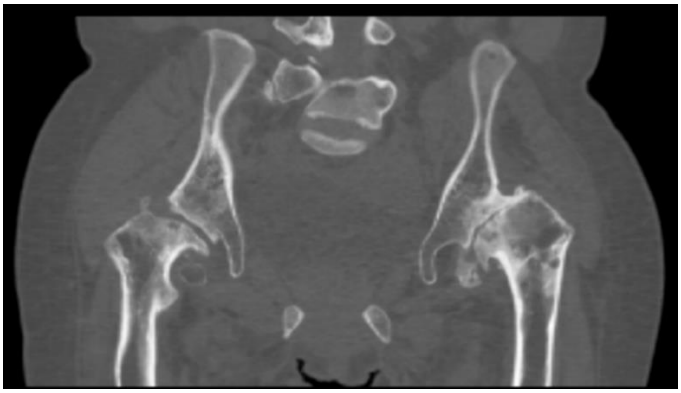

Figure 12. Preoperative slice of CT scan showing the acetabular deformity (case 3).

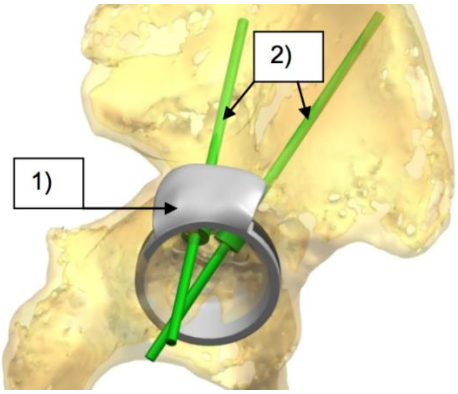

Figure 13. 3D virtual image of custom cup with 1) iliac wing and 2) representation of screws direction (case 3).

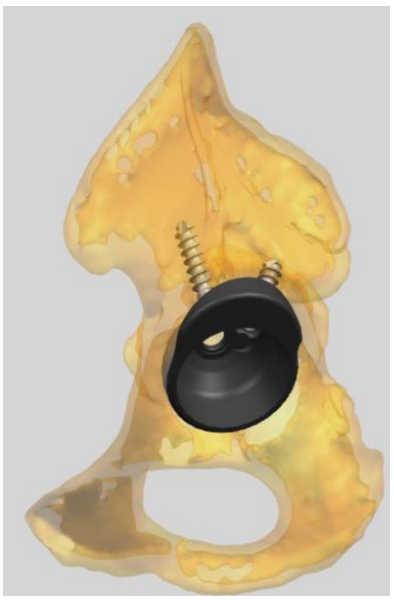

Figure 14. Rendering of proposed cup with screws (case 3).

Surgeon's requests for custom cup: cup compatible with a ceramic 28mm diameter liner (minimum cup diameter 38mm), holes for at least two screws, customized iliac support to improve implant stability ensuring the correct coverage (45°) and anteversion (15°) of the cup as shown in the preoperative 3D planning.

REFERENCES

[1] Callaghan, JJ, Albright, JC, Goetz, DD, Ole-jniczak, JP, Johnston RC. Charnley total hip arthroplasty with cement: minimum twenty year follow-up. *J Bone Joint Surg Am*. 2000; 82(4):487-497.

[2] Knight, SR, Aujla, R, Biswas, SP. Total hip arthroplasty: over 100 years of operative history. *Orthop Rev* (Pavia). 2011; 3(2):e16.

[3] Learmonth, ID, Young, C, Rorabeck, C. The operation of the century: total hip replacement. *Lancet*. 2007; 370(9597):1508-1519.

[4] Kahlenberg, CA, Nwachukwu, BU, Schairer, WW, Steinhaus, ME, Cross MB. Patient Satisfaction Reporting After Total Hip Arthroplasty: A Systematic Review. *Orthopedics*. 2017 Jan 30:1-5.

[5] Bobyn, JD, Tanzer, M, Krygier, JJ, Dujovne, AR, Brooks, CE. Concerns with modularity in total hip arthroplasty. *Clin Orthop Relat Res* 1994;298:27-36.

[6] Blaha, JD. The modular neck: keystone to functional restora- tion. *Orthopedics* 2006;29:804-805.

[7] Chmell, MJ, Rispler, R, Poss, R. The impact of modularity in total hip arthroplasty. *Clin Orthop Relat Res* 1995;319:77- 84.

[8] Tsiampas, DT, Pakos, EE, Georgiadis, GC, Xenakis, TA. Custom-made femoral implants in total hip arthroplasty due to congenital disease of the hip. *Hip Int*. 2016 May 16;26(3):209-14.

[9] Masar, J. Ten-year experience with the Aldinger custom-made total hip arthroplasty: evaluation of the results. *Acta Chir Orthop Traumatol Cech.* 2007 Jun;74(3):175-81.

[10] Hesham, Al-Khateeb, Iris, H. Y. Kwok, Sammy, A. Hanna, Mathew D. Sewell, Aresh Hashemi-Nejad. Custom Cementless THA in Patients with Legg-Calve-Perthes Disease. *J Arthroplasty*. 2014 Apr;29 (4):792-6.

[11] Xu, J, Li, D, Ma, RF, Barden, B, Ding, Y. Application of Rapid Prototyping Pelvic Model for Patients with DDH to Facilitate Arthroplasty Planning: A Pilot Study. *The Journal of Arthroplasty* 30 (2015) 1963–1970.

[12] Sariali, E, MD, Boukhelifa, N, Catonne, Y, Moussellard, HP. Comparison of Three-Dimensional Planning-Assisted and Conventional Acetabular Cup Positioning in Total Hip Arthroplasty. *J Bone Joint Surg Am*. 2016 Jan 20;98(2):108-16.

[13] Boisgard, S, Descamps, S, Bouillet, B. Complex primary total hip arthroplasty. *Orthop Traumatol Surg Res.* 2013 Feb;99(1 Suppl):S34-42.

[14] Fokter, SK , Moličnik, A, Kavalar, R, Pelicon, P, Rudolf, R, Gubeljak, N. Why do some titanium-alloy total hip arthroplasty modular necks fail? *Journal of the mechanical behavior of biomedical materials* 69 (2017) 107–114.

[15] Wodecki, P, Sabbah, D, Kermarrec, G, Semaan, I. New type of hip arthroplasty failure related to modular femoral components: Breakage at the neck-stem junction. *Orthopaedics & Traumatology: Surgery & Research* (2013) 99, 741-744.

[16] Wittenberg, RH, Steffen, R, Windhagen, H, Bucking, P, Winkle, A. Five-year results of a cementless short-hip-stem prosthesis. *Orthop Rev* (Pavia). 2013 Mar 19;5(1):e4.

[17] Gruner, A, Heller, KD. Patient Selection for Shorter Femoral Stems. *Orthopedics.* 2015 Mar;38(3 Suppl):S27-32.

[18] Hartofilakidis, G, Stamos, K, Karachalios, T, Ioannidis, TT, Zacharakis, N. Congenital hip disease in adults. Classification of acetabular deficiencies and operative treatment with ace- tabuloplasty combined with total hip arthroplasty. *J Bone Joint. Surg Am* 1996;78(5):683-92.

[19] Park, MS, Kim, KH, Jeong, WC. Transverse subtrochanteric shortening osteotomy in primary total hip arthroplasty for patients with severe hip developmental dysplasia. *J Arthro- plasty* 2007;22(7):1031-106.

[20] Tsiampas, DT, Pakos, EE, Georgiadis, GC, Xenakis, TA. Custom-made femoral implants in total hip arthroplasty due to congenital disease of the hip: a review. *Hip Int.* 2016 May 16;26(3):209-14.

[21] Koulouvaris, P, Stafylas, K, Sculco, T, Xenakis, T. Custom designed implants for severe distorted proximal anatomy of the femur in young adults followed for 4-8 years. *Acta Orthop.* 2008;79 (2):203-210.

[22] Ortega Briones, A, Smith, S, Rickman, M. Acetabular Fractures in the Elderly: Midterm Outcomes of Column Stabilisation and Primary Arthroplasty. *Biomed Res Int.* 2017;2017:4651518.

[23] Rickman, M1, Young, J, Trompeter, A, Pearce, R, Hamilton, M. Managing acetabular fractures in the elderly with xation and primary arthroplasty: aiming for early weightbearing *Clin Orthop Relat Res.* 2014 Nov;472(11):3375-82.

[24] Hartofilakidis, G, Karachalios, T. Total hip arthroplasty for congenital hip disease. *J Bone Joint Surg Am*. 2004 Feb;86-A(2):242-50.

[25] Yang, S, Cui, Q. Total hip arthroplasty in developmental dysplasia of the hip: review of anatomy, techniques and outcomes. *World J Orthop*. 2012 May 18;3(5):42-8.

[26] Bicanic, G, Barbaric, K, Bohacek, I, Aljinovic, A, Delimar D. Current concept in dysplastic hip arthroplasty: Techniques for acetabular and femoral reconstruction. *World J Orthop*. 2014 Sep 18;5(4):412-24.i.

[27] Russotti, GM, Harris, WH. Proximal placement of the acetabular component in total hip arthroplasty. A long-term follow-up study. *J Bone Joint Surg Am*. 1991 Apr;73(4):587-92.

[28] Hartofilakidis, G, Stamos, K, Karachalios, T. Treatment of high dislocation of the hip in adults with total hip arthroplasty. Operative technique and long-term clinical results. *J Bone Joint Surg Am* 1998; 80: 510-517.

[29] Haddad, FS, Masri, BA, Garbuz, DS, Duncan, CP. Primary total replacement of the dysplastic hip. *Instr Course Lect* 2000; 49: 23-39.

In: Encyclopedia of Surgery (22 Volume Set)
Editors: Andreas Lehrer and Kristin Mueller
ISBN: 978-1-53618-329-0
© 2020 Nova Science Publishers, Inc.

Chapter 152

3D CUSTOMIZING IN REVISION HIP REPLACEMENT

A. Aprato*, A. D'Amelio, F. Marra, M. M. Favuto, D. Mellano and A. Massè
University of Turin, Turin, Italy

ABSTRACT

Revision surgery represents a challenging procedure, especially when it is not a first time revision. 3D technology helps in the comprehension of complex bone defects and drives the surgeon through the treatment planning and the procedure itself. Modern 3D printing may be used to create anatomical models and component trials for surgical preparation; the surgeon may try cup size, positions, screw directions and measurements and thickness of available bone for implants placement, drastically reducing surgery times.

Regarding the femoral side, in the last few years, custom-made implants have been proposed for patients undergoing revision hip surgery. However, nowadays, long-stemmed standard implants or modular distal stems are more cost-effective than custom devices in revision surgery. For this reason, their use is not frequent.

In cases of large acetabular bone loss, the goal is to provide a stable fixation of the cup, trying to fill the periacetabular bone defect and restoring correct centre of rotation of the hip. The custom 3D-printed acetabular implant has been introduced in the last 20 years as an exciting new option to address severe acetabular bone loss. These solutions are built custom-fitted to patient's anatomy, obtained from CT reconstruction, to allow a broad stress distribution and best possible fit between bone and implant surface, and to restore a good joint biomechanics.

Custom-made implant can be a reliable option either in Paprosky III A/B cases or in pelvic discontinuity. According to reported data in various arthroplasty registers, the demand for these implants will increase in the next years. Unfortunately up to date, there is still a lack of consistent published data, but preliminary results encourage this course.

Keywords: hip revision arthroplasty, custom implants, 3D models, revision arthroplasty planning, 3D printing

* Corresponding Author's Email: ale_aprato@hotmail.com; Fax: +39 338 6880640.

INTRODUCTION

Revision hip surgery procedures are becoming increasingly frequent due to the larger number of primary hip replacement performed over the last 20-30 years, according to the data reported by various National registers [1, 2]. The incidence of Total Hip Arthroplasty (THA) is increasing, a doubling of revision procedures is expected by 2026 [3]; consequently the need for hip revision surgeries will increase. Revision surgery often represents a challenging procedure, mostly when it is not a first time revision. The most common causes are aseptic loosening (55.2%), dislocation (11.8%), septic loosening (7.5%) and periprosthetic fractures (6%) [3]. Each of these conditions may be associated with mild or advanced bone loss. The etiology of bone loss after THA is multifactorial. Stress shielding, massive osteolysis, extensive loosening and history of multiple surgeries consist the most common etiologies. The correct identification and classification of the bone loss is mandatory in order to provide a correct solution. 3D technology helps in the comprehension of complex bone defects and drives the surgeon through the treatment planning of the revision surgery. Complex problems affect the acetabular side more often than the femoral one. Several implant solutions were proposed over the years to revise an acetabular cup in a bone loss condition. Custom-made acetabular components, obtained with a 3D technology, may be useful in cases where previous implants have failed resulting in a huge impairment of the periacetabular bone stock. There is still a lack of consistent published data, but preliminary results encourage this course.

The amount of bone loss can be both femoral and acetabular. To describe the amount of femoral bone deficiency, the classifications proposed by AAOS Committee on the Hip [4] and Della Valle Paprosky [5] are commonly used. Usually accurate measuring the osteolysis has been notoriously difficult, particularly in the acetabular area. The patient's diagnostic workup starts with standard X-rays. Plain radiographs are the most common way to assess the osteolysis, due to low cost and easier use. AP pelvis, full-length femur radiographs, and oblique acetabular end views of the involved hip are the most common radiographic projections used during the follow-up of patients underwent Total Hip Arthroplasty. The comparison with previous radiographs is usually the first element for osteolysis measure. A single radiograph has an overall sensitivity for the detection of osteolysis of 40% (which increases to 70% when all four radiographic views of one lesion are analyzed together), and a specificity of 70-90% [6]. In contrast to femoral osteolysis, periacetabular pelvic osteolysis is not well defined on a single AP radiograph of the pelvis. Lateral view of the hip frequently does not give specific information about the pelvis. Multiple radiographic views can be used to evaluate acetabular bone loss preoperatively in planning for revision THA [7]: iliac oblique view and obturator oblique view can be helpful specially to identify posterior column lesions, but must be inspected carefully to recognize stress shielding from an osteolytic lesion; they can be used when dubious osteolytic lesion is evidenced on standard views. Although radiographs can be useful to screen for clinically relevant pelvic osteolysis, CT images are necessary to accurately measure the volumes of the lesions. It is generally accepted that plain radiographs are not sufficiently sensitive for periprosthetic osteolysis evaluation because the measurement of lesion size and their location is often incorrect, and thus, the amount of bone loss can be underestimated. CT-scan is more accurate to define the size, precise location, extent of bone resorption and has more sensitivity (90% of lesions are detected). Size and location of a periprosthetic defect are not the only dimensions of interest in the preoperative

analysis of a failed acetabular implant: up to date surgeons would like to know the quantity and quality of the bone, the further bone loss expected from the implant removal, the quantity of auto or allograft needed, the dimension of the implant to fill the defect. In order to study periacetabular osteolysis, specialized softwares for CT scan image analysis have been developed.

3D PRINTING

Imaging 3D and CT scan are not the only way to perform an accurate preoperative planning. 3D printing is a manufacturing process: materials (such plastic, metal, ceramics, powders, liquids or even living cells) are deposited in layers to create a 3D object from digital data.

The process begins with the acquisition of images (usually images in Digital Imaging and Communications in Medicine [DICOM] format); then the acquired images are uploaded for 3D reconstruction and converted into a 3D printer compatible format. The 3D printer first follows the instructions in the Custom Assisted Design (CAD) file to build the foundation for the object, moving the printhead along the x–y plane. The printer then continues to follow the instructions, moving the printhead along the z-axis to build the object vertically layer by layer [8]. Creating patients-specific models has many practical applications. Modern 3D printing may be used to create anatomical models for surgical preparation, for example the surgeon may try cup size, positions, screw directions and measurements and thickness of available bone for implants placement, drastically reducing surgery times. In the assessment of pelvic discontinuity, a 3D model can give to the surgeon a real prospective of how much bone and which quality it has in ensuring a pelvic ring continuity. Models printed with thermoplastics then can also be sterilized and used as intraoperative templates.

COMPLEX REVISION HIP ARTHROPLASTY

Revision hip arthroplasty, especially when multiple revision, is one of the most complex topic in orthopaedic surgery. Each case represents for the surgeon a specific challenge because of the patient's unique anatomy both on the acetabular and femoral side. Usually revision, presenting bone defects equal or worse than Paprosky III/AAOS III on the femur and Paprosky III on the acetabulum, are considered as complex.

Aims of femoral revision are stable and durable fixation of the implant and restoration of the bone stock. Obtaining the stable fixation of the stem could be challenging because of the severe bone loss. In case of proximal bone defects usually taper conical modular stems designed to get a diaphyseal fixation are used. They allow also to restore lower limb length and femoral neck version. In metaphyseal or diaphyseal bone defects instead, strategies include biological or non-biological solutions. Impaction grafting, structural grafts and so-called composite implants are biological solutions to fill the bone loss. Non-biological solutions include metal meshes, megaprostheses or even total femur replacements [9, 10].

In cases with large acetabular bone loss the aim is to provide a stable fixation of the prosthetic component, trying to fill the periacetabular bone defect and restoring correct centre

of rotation of the hip. Those bone losses may be managed using cemented or uncemented cup implants, in combination with impaction grafting, metal meshes or reconstruction cages, or structural bone grafts [11, 12, 13, 14].

Classification of the bone defects may not be accurate compared to the intraoperative findings for the presence of metal artefacts; those can also impair the right understanding of the relationships between acetabular region and intrapelvic structures. Removal of an excessively medialized prosthetic cup may be dangerous because of proximity of pelvic vessels, ureter and bladder, usually with lot of scar tissues between those structures and the prosthetic component in more complex cases [11]. This represents a challenge either in the phase of preoperative, either intraoperatively. For the functional outcomes, it is very important to restore the correct centre of rotation of the hip and this often should to be obtained with a lateralization and distalization of the acetabular cup [15]. Such needing can be very difficult to satisfy in cases of large bone defect where acetabular solutions at the same time have to play the socket role in the right joint position, fill the gap around it in a mechanical valid manner and reach up in the ilium a good zone with an enough contact area to obtain a stable fixation between the prosthetic component and the cancellous bone.

Surgical approach can be also very demanding. The posterolateral approach is the most widely used and very familiar to hip surgeons. It can be used for complex revisions, with the acetabulum exposed by pulling the femur anteriorly [11, 16]. Release of gluteus maximum, anterior capsule and reflected head of the rectus femoris is often mandatory to get an adequate mobilization of the proximal femur to address the acetabulum. Also the direct anterior approach, since its increased popularity among surgeons, has been described as a valid approach to manage cases of extensive periacetabular bone loss. With this approach, however affected by a long learning curve, the exposure of the entire ilium cranial of the acetabulum can be achieved, and also the pubic bone as well as intrapelvic structures adjacent to the acetabulum can be exposed [17]. Authors then described an extension of the direct anterior approach for accessing the femoral diaphysis that allows for easy access to the lateral aspect of the vastus lateralis and the femoral diaphysis. Using this technique, depending from authors' opinion it should also be possible to access the femur and perform all necessary reconstructive procedures [18]. Some authors use the anterolateral and direct lateral approaches reporting postoperative stability avoiding damages to posterior neurovascular structures. However, the potential postoperative morbidity associated with violation of the abductor complex cannot be ignored [16]. Another approach described for complex acetabular revision cases is the extended iliofemoral approach that provides a better exposure of the anterior column, at the price of a more invasive procedure in terms of surgical time, blood loss and tissue damage [19]. In case of severe intra-pelvic migration of acetabular component then, with the help of general or vascular surgeons, retroperitoneal approach or trans-abdominal approach should be considered to prevent several serious intra-pelvic complications, including vascular injuries, which have been reported when acetabular component removal was attempted through the defect in the inner wall of pelvis [20]. Although single-component revision may be planned, the surgical approach should not limit the ability to perform revision of both the femur and the acetabulum if necessary.

CONVENTIONAL IMPLANTS AND SOLUTIONS

Regarding the femur, as mentioned before, some different solutions including biological or non-biological options have been described to revise a prosthetic component in case of a significant bone loss condition. Among non-biological solutions uncemented femoral fixation has become the preferred method to achieve long-term stability [10]. The most commonly used components in complex revision procedures include extensively porous-coated stems, modular stems with cone-conical constructs, and in selected cases, megaprostheses. Extensively porous-coated stems are the best option for most femoral revisions with a good survivorship reported, even if stress shielding phenomena with thigh pain can be associated. Hamilton examined 905 femoral revisions performed with this type of stems from 1980 to 2006. The cohort showed a re-revision rate of 2.2%, with a 1.3% incidence of aseptic loosening [21]. Weeden and Paprosky evaluated 170 revisions with fully porous-coated stems, and the overall rate of failure in the entire cohort was 4.1%. Follow-up imaging showed evidence of ingrowth in 82% of patients, but 4% of patients presented with a radiographically unstable stem [22]. The highest rates of failure in these series were seen in patients who had worse bone stock with a Paprosky type IIIB condition. Sporer and Paprosky reported a poor survivorship in femurs with canal width greater than 19 mm or large defects in the femoral isthmus. In these cases, the authors recommended impaction grafting or use of a modular tapered stem [23]. Tapered, fluted, porous-coated stems, as the Wagner stem, were developed to address stress shielding associated with extensively porous-coated implants, with a good rate of success. However monoblock tapered implants are commonly affected by risk of instability, for abductor weakness, and leg length discrepancy because of the inherent difficulty in determining the level of implant seating that would provide axial stability. The more recent introduction of modularity allowed surgeons to overcome some difficulties of monoblock stems in ensuring good functional outcome. However, the addition of modularity brings the risks of implant breakage at the modular junction and taper corrosion [24]. Richards examined a series of 115 revision procedures, of which 65% were Paprosky type IIIB or type IV, and reported 87% survivorship at 3-year follow-up [25]. A salvage option could be proximal femoral replacement, despite disadvantages such as early loosening, instability, limb length discrepancy and associated sciatic nerve palsy, and impairment of remaining proximal femoral bone stock. Such implants provide immediate stability and predictable results. In a study reporting results of proximal femoral arthroplasty for nonneoplastic conditions at about 12 years of follow-up, the overall survivorship was 64%, with however almost half of the patients had substantial ambulatory dysfunction (severe limp or inability to walk) [26]. In case of massive bone loss proximal femur replacement can be used and when the distal anchorage cannot be achieved at all, the use of a total femur prosthesis represents a viable alternative [27]. Cemented stem alone have shown very poor results in management of femoral revision in severe bone defect conditions. Coming to the role of biological option, some authors reported encouraging experience in young and active patients affected by Paprosky IIIB or IV bone loss, using cemented stem managed with the modern third-generation cementing techniques in combination with impaction grafting [10]. Risks associated with this technique are intraoperative and early postoperative periprosthetic fracture, stem subsidence, and construct failure. In a Swedish cohort of 1305 patients has been reported a 94% survival at 15 years, with only 0.9% of signs of aseptic loosening [28].

More recent studies showed a 96% stem survival rate at 17-year follow-up, with average reported subsidence of 3 mm [29]. Particulate and cortical structural allograft may be necessary in the setting of Paprosky type IV when proximal femoral replacement prosthesis is undesirable. Proximal femur is removed and the long-stem revision prosthesis is then press-fit or cemented into the proximal femoral allograft, and this allograft prosthetic composite is mated with the distal host femur, with the distal prosthetic portion press-fit or cemented into the canal. Main advantage is the chance to restore bone stock and facilitate reattachment of host soft tissue, even if functional recovery can be unpredictable, and dislocation may necessitate acetabular revision. Recent studies with allograft prosthetic composite in revision surgery have shown a success rates ranged from 66% to 95% [30]. However, the surgical technique is technically demanding, and could be not so easy to obtain an ideal amount of allograft.

Regarding acetabulum combined cavitary and segmental defects, particularly those without superior acetabular coverage, preclude the use of a conventional cementless cup [11]. Such defects have been addressed with the use of allograft in combination with rings and cages, highly porous metal cups and augments with or without a cage [31, 32]. Some authors described also how to convert uncontained defects into contained defects using flexible reconstruction meshes, providing a stable cavity for impaction bone grafting reconstruction and cemented cup fixation [11]. A cementless component alone may not be sufficient in Paprosky type III defects. In type III A defects, if the contact of the component with the remaining host bone is more than 40-60% it is reasonable to expect a durable bone in-growth. Impaction bone grafting allows bone restoration, with different preparations of allograft. Fresh-frozen bone or freeze-dried bone can be used, with the first option characterized by better results but a theoretical risk of transmission of contagious diseases. Irradiation in freeze-dried bone reduces graft immunogenicity and enhances graft incorporation. However freeze-drying can reduce the mechanical properties of the graft and diminish its capacity for structural support [33]. Interesting results came out from the use of demineralised bone matrix and bone morphogenic proteins in impaction bone grafting [34]. In cases with a defect of the superior dome and proximal migration of the acetabular component (Paprosky type III A) use of a hemispherical porous coated component alone cannot ensure a stable fixation. Better results are reached using a structural allograft in association. Paprosky published satisfactory results of severe acetabular defect treated with cemented component and bulk allografts [35]. It was described a technique with the use of distal femoral or proximal tibial allograft and cementless cups to reconstruct the acetabulum, because orientation of the trabecular bone in these allografts provides better mechanical support for the implant compared to a femoral head allograft. Given radiographic signs of loosening as the endpoint, construct survival at 10 years of follow up was 74% [36]. However failure rate is high when structural grafts support areas larger than 50% of the acetabular component. Reinforcement rings are designed to manage minor segmental defects with more than 50% of native bone intact, while in type III defects with moderate superior hip centre displacement, disruption of the teardrop, and Kohler's line was traditionally used the Burch-Schneider cage [12]. In general, structural grafts replacing more than 50% of the acetabulum require protection by a cage. These components allow for restoration of hip centre, and providing uniform load to the allograft, either the morselized or structural grafts, stimulate bone remodelling and incorporation into host bone [31]. However there is a higher risk of neurovascular injury since large exposure of the ileum and ischium is needed to anchor the cage [12]. Recently published data showed

survivorship rates of 87.5% (56 hips) after 11.7 years and 72.2% (18 hips) after 13.5 years [37]. In cases of large acetabular bone defects, the antiprotrusio cage should have a larger contact area with the remaining host bone and rigid primary fixation with screws. Mechanically, reinforcement rings or antiprotrusio cages should be considered as an internal fixation plate for the acetabulum. The placement of the screws is important to prevent micro-motion of the cage and subsequent defragmentation or resorption of the graft [11]. This is important because in case of lack of biologic fixation the Burch-Schneider cage is at risk of breakage or loosening. However, if the graft had enough time to remodel itself before the cage fracture, a subsequent standard cementless acetabular revision could be possible [38], but with another not easy surgical procedure due. Indications for bulk allograft and for morselized allograft with a reconstruction cage in major acetabular defects are still unclear [11]. More recently trabecular metals such tantalum, have been introduced as a powerful tool for reconstruction of the failed acetabular component [39]. The increased porosity, high coefficient of friction, and favourable elastic modulus of porous tantalum compared with traditional titanium mesh or cobalt chromium acetabular components allow for greater bone in-growth potential, implant stability, and host bone preservation. To supplement acetabular fixation when there is segmental bone loss, acetabular augments can be used to fill specific defects. These augments can theoretically replace the need for structural allograft and can be used alone or in combination with other augments. Specific reamers allow to prepare the acetabular defect where augments will be placed. The augments are then impacted into the defect and fixed with screws. However these augments are made with standard shapes and dimensions and so they do not fit every time so good to the host bone. Once the augments are in place, hemispherical cup can be press fitted into the acetabulum with cement placed at the augment-cup interface. So far mid-term follow up results are satisfying with reported success rate around 98% [40, 41]. An alternative option to correct large acetabular defects is the cup-cage construct; a second generation porous cup fixed in the pelvis in combination with an acetabular cage can be placed on top of the cup and secured with screws into the ilium and ischium. In this way the cage removes loading forces on the cup and allows time to optimize ingrowth of new bone into the cup [42]. Cup-cage construct can be used to manage not only Paprosky type III A and III B bone loss but also pelvic discontinuity, with some good results reported [43, 44]. Radiographically stable fixation at 2-year follow-up has been reported with the use of tantalum augment alone, combined with impaction grafting, and with a cage-cup construct [45, 46, 47]. All these solutions showed good results in cases of complex acetabular bone loss, but they could require several surgical steps and in some cases they still have a high failure rate. For this reason industry is ever working on innovation and custom-made components obtained with a 3D technology are an interesting alternative for the surgeon.

IMPLANTS AND SOLUTIONS WITH 3D TECHNOLOGY

The custom 3D-printed acetabular implant has introduced in the last 20 years as an exciting new option to address severe acetabular bone loss. This kind of solution is indicated in complex cases with a multiple revision history associated with poor bone stock. It can be a viable option either in Paprosky III A/B cases or in pelvic discontinuity [48, 49, 50], and according to reported data in various arthroplasty registers, with ageing populations and

trends for total hip replacements in younger patients it is likely that the demand for these implants will increase [51]. The goal of this kind of implants is to allow a restoration of the acetabular anatomy, filling the periacetabular bone defects and restoring hip biomechanics, with a stable fixation of the implant to the host bone. Implant stability is ensured by screws introduced through prepared holes in three flanges spreading from the component and laying on ilium, ischium and pubis. Presence of these flanges, in the beginnings, gave the name to this kind of solutions, known as triflange cup. The implant can be tailored with different zones depending on specific mechanical and biological problem to address. Porous surfaces are used to promote bone on-growth while smooth surfaces can diminish potential irritation of soft-tissues. Depending on the CT scan data, locking screw trajectory and length can be planned to maximize fixation, to obtain the most efficient purchase in host bone and to minimize vascular risk. Previous implants removal has to be performed being careful not to further compromise the residual bone. Then periacetabular bone has to be prepared to receive the customized implant as planned. The aim is to achieve a good amount of contact surface between component and vital bone, without removing too much tissue. The precision-fit of the implant to the remaining patient's bone stock minimizes the need for more bone resection to fit a standard acetabular revision component. At this point 3D printed trial models of the involved hemipelvis and of the customized implant, suitably sterilized so that can be handled by members of the surgical team, provide visual and tactile reproduction of the deficient pelvic bony anatomy and of the mutual relationship with the component. This, besides the mentioned help in the preoperative planning, enables and improves understanding of the anatomy during surgery, facilitating intraoperative decisions. Depending on the patient's specific anatomy and the resulting chosen solution, the main cavity is reamed until the diameter planned, and also the nearby defects can be minimally reamed with smaller dedicated instrumentation to even out any roughness and to allow better fitting of any eventual bumps of the custom implant. Component is fixed to the hemipelvis by the porous metal back surface through a press fit concept, and usually by some locking screws going into ilium, ischium and pubis. Screws can be inserted from holes eventually present inside the cup, or from holes on flanges of the component. Then a liner is introduced inside the metal back either with or without cementation, depending on the implant concept design. Ceramic or new generation polyethylene liners are used.

Also regarding the femoral side, in the last few years, custom-made implants have been proposed for patients undergoing revision hip surgery, with the goals of promoting axial stability and preserving proximal bone stock. Different types of uncemented femoral stems have been designed. These stems were made individually using computer design and manufacturing technology. Custom-made femoral stems have been developed usually for younger patients with the objective to attain contact all around medial and lateral stem in the metaphysis and diaphysis of the femur. These solutions are built custom-fitted to patient's anatomy, obtained from CT reconstruction of the femur, to allow a broad stress distribution and best possible fit between bone and stem surface. However nowadays, long-stemmed standard implants or modular distal stems are more cost-effective than custom devices in revision surgery. For this reason, their use is not frequently seen.

ILLUSTRATIVE CASES

In this paragraph two illustrative cases of acetabular custom implant performed in our department are presented. One case was a pelvic discontinuity and one case was a Paprosky IIIB acetabular defect. The first case was an 81 years old lady affected by osteoarthritis of the left hip and who underwent a primary total hip arthroplasty when she was 70 y.o. Then a first revision of the stem was performed two years later to address the thigh pain. After three years, an aseptic loosening of the acetabular cup was noted; therefore the patient underwent acetabular revision. A new mobilization of the cup occurred then five years later and a new acetabular revision was performed with a standard revision component (Delta TT Revision, Lima Corporate). After few months three subsequent episodes of dislocation occurred, so the patient underwent a changing of the acetabular liner and a dual mobility solution was implanted. All these procedures were performed through a posterolateral approach. The patient had no more dislocation episodes, but started to feel a groin pain, worsening over the following months and affecting before daily activities and then even walking and standing. The patient was referred to our department where, after a new X-ray check (Figure 1) and a CT scan (Figure 2) of the pelvis, a new mobilization of the cup associated to a pelvic discontinuity was diagnosed. No clinical and laboratory signs of infection were registered over the clinical steps. Patient was in good general health conditions. In consideration of patient's age and of previous surgeries the aim was to find the best option to definitively address both the pelvic discontinuity and the cup mobilization. A custom-made acetabular component was proposed. Contrast CT scan images and relevant clinical data were sent to the engineering unit of the medical device company (Lima Corporate). Engineers focused on some topics of the preoperative situation as the periacetabular bone loss in a scenario of a poor bone quality, the need to restore the correct centre of rotation and the need to fill the large cavity in correspondence of the Anterior Inferior Iliac Spine. A 61 mm of diameter Titanium alloy (Ti6Al4V) cup was designed with an augmentation as a support for the iliac wing. Trabecular Titanium was scheduled on surfaces where a contact with the host bone was planned and on the iliac support. Cup was designed to accept one of the Delta liner components (Lima Corporate), with dual mobility and elevated rim option. Iliac posterior (Figure 3), ischial and pubic flanges were designed to obtain primary stabilization through four 6,5 mm locking screws. Other two 6,5 locking screws were planned from inside the cup to reach a good quality bone in the iliac wing avoiding zones impaired by any previous screws. These two screws were custom-made to obtain the desired length. Implantation of the components was planned through standard instruments, except for a customized 37 mm of diameter reamer designed to prepare the cavity in correspondence of the Anterior Inferior Iliac Spine. A 3D trial of the hemipelvis without previous implants and one of the designed custom-made component were printed and provided to be sterilized. They have been used in theatre helping the surgeon in the surgical steps (Figure 4). Planned solution was analysed and approved by our hip team leader. Surgery was performed on June 2016. During component removal, as expected from imaging evaluation, a bleeding from a collateral ramus of the superior gluteal artery was managed by haemostatic matrix with thrombin. Intraoperative samples for bacteriological examination were collected, with negative postoperative result. In contrast with preoperative plan, the surgeon did not insert the pubic screw: this because in that zone the perfect fitting of the component was not obtained,

probably due a suboptimal preparation of the cicatrized soft tissues around. Therefore the hole designed would keep the screws in a different direction, useless to gain more stability than the adequate already obtained. An elevated rim new generation polyethylene liner was implanted (Figure 5). Rehabilitation started on the 2nd post-operative day with allowed partial weight bearing for the first 6 weeks.

Figure 1. Pre-op x-ray of an aseptic acetabular loosening (case 1).

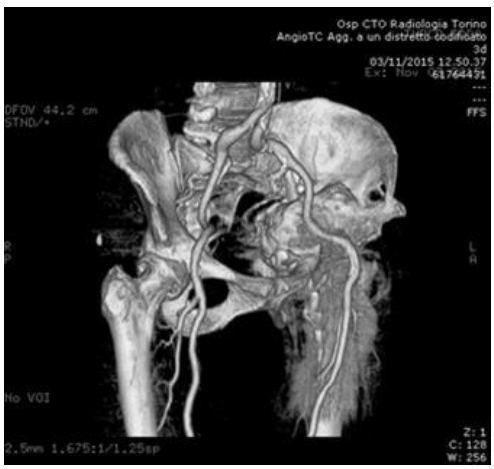

Figure 2. CT scan of the pelvis (case 1).

Figure 3. Custom-made acetabular component project (case 1).

Figure 4. 3D printed hemipelvis intra-op use (case 1).

Figure 5. X-ray of the custom-made cup implanted (case 1).

Figure 6. Pre-op x-ray of an aseptic acetabular loosening on a solved pelvic discontinuity scenario (case 2).

Figure 7. CT scan of the pelvis (case 2).

The second case is a 61 years old lady with an aseptic mobilization of the cup with a Paprosky IIIB acetabular defect in a solved scenario of pelvic discontinuity. The patient underwent a first bilateral total hip replacement for developmental dysplasia of the hip in 1996 at the age of 42 years old. Subsequently a first revision for aseptic loosening of the acetabular cup on the right side was performed in 2002, using a Burch-Schneider ring. After the ring failure occurred nine years later, the patient underwent a third revision of the acetabular side in association with a reconstruction of the posterior column through a femoral head allograft fixed with a reconstruction plate. After one year the patient suffered of a new mobilization of the cup in a pelvic discontinuity scenario, so a forth revision was performed. A rib graft from the patient's chest was splitted and used as autograft to reconstruct the anterior and posterior acetabular columns [52]. Then a stemmed cup was implanted as the fifth acetabular revision. However a new mobilization with a breakage of the stemmed cup occurred after one year. As seen in the pre-operative radiological studies also during surgery was detected the healing of the pelvic discontinuity. So the Paprosky III B defect was then for the sixth time addressed with porous metal revision cup and augment. The surgeon was not able to remove all the metal work resulting from the previous solutions failure. At the beginning of 2016 the patient suffered a new mobilization of the acetabular components (Figure 6). Infection was ever excluded over every clinical step. Despite the patient's age, in consideration of the several previous fails we decided to submit the case for a custom-made acetabular solution. Again the patient underwent a CT scan, and the images and relevant historical data were sent to the engineering unit of the medical device company (Lima Corporate). Engineers focused on problems in hardware removal (i.e., the broken stem had to be removed, while was planned to leave in place the reconstruction plate on the anterior column), bone defects filling and component fixation. The company reported that was technically demanding in this case to minimize the metallic artefacts in the CT scan images due to the presence of the residual hardware (Figure 7). During the component design, attention was paid on the screw holes to possibly obtain a polyaxial screws placement in order to prevent, for example, difficulties encountered with the pubic screw. Here the 3D trials gave an important help in the comprehension of this topic (Figure 8). A 63 mm of diameter

Titanium alloy (Ti6Al4V) bilobate cup was designed with a conical peg of 28 mm of length and 19 mm large at the basis to fill the iliac defect after the broken stem removal (Figure 9). A little ischial flange was designed with holes for two 6,5 locking screws. Iliac stabilization was planned through the peg and a 6,5 locking screw crossing two holes in both the lobes of the cup with 10 degrees of polyaxial freedom. Pubic stabilization was again planned with the possibility to insert a 6,5 locking screw from inside the inferior cup. Trabecular Titanium was scheduled on surfaces where a contact with the host bone was planned and on the iliac support: small meshed trabecular titanium was planned on iliac peg and on inferior acetabular cup, while large meshed was planned on superior integrated augment in order to lighten the component (Figure 10). Cup was designed again to accept one of the Delta liner components (Lima Corporate). No customized instruments were planned from the company to implant the components. Again 3D trials of the acetabular component and of the hemipelvis were provided from the company and sterilized to be used during surgery (Figure 11). Planned solution was analysed and approved by our hip team leader. Surgery was performed on October 2016. Intraoperative samples for bacteriological examination were collected, again with negative results. Previous broken stem removal was successfully performed with a special extractors set (Shukla Medical). Screws were removed too, while other minor hardware components instead were left in place in order to avoid any unnecessary bone removal. Compared to what was planned, the surgeon did not insert the optional pubic screw that could interfere with these residual minor hardware components. Acetabular cavity and superior bone defects were both reamed with a standard 62 mm diameter reamer, while the defect generated from the broken stem removal was reamed with a conical ream. A standard new generation polyethylene liner was implanted (Figure 12). Rehabilitation started on the 2nd post-operative day with allowed touch weight bearing for the first 8 weeks.

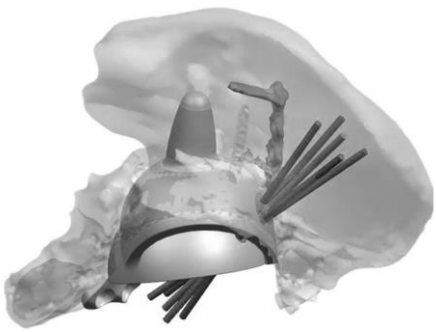

Figure 8. Project of the custom component with related screw polyaxial options (case 2).

Figure 9. Custom-made acetabular component (case 2).

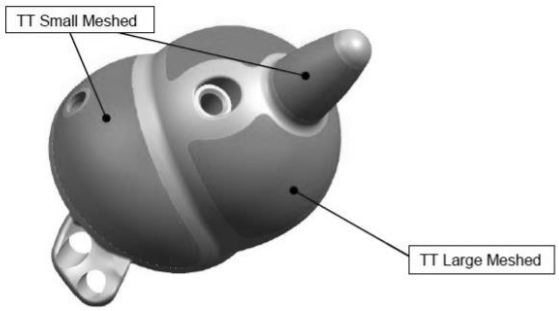

Figure 10. Different surfaces on the component (case 2).

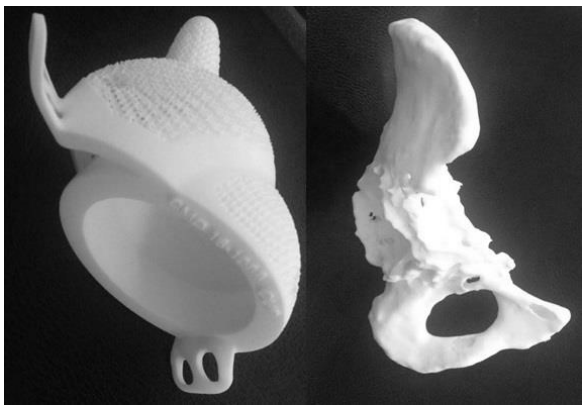

Figure 11. 3D printed component trial and hemipelvis (case 2).

Figure 12. X-ray of the component implanted (case 2).

CONCLUSION

Continuous technological innovation is a great help for hip revision surgery. In complex cases, 3D technology allows to better understand problems of the original situation and to plan the most appropriate solutions in terms of surgical technique and components. The acetabular custom-made component seems to allow a good restoration of the articular

biomechanics, with a single component well fixed to the host bone. This may exclude some possible issues registered with modular constructs. Some improvements are needed to increase the correspondence between the planning and the surgical action. Up to now obtaining the best fit of the custom component with the patient's anatomy is not easy. These solutions are recent and the number of cases of each centre is still small, but first outcomes are encouraging, and further data are required to support their use.

REFERENCES

[1] *The Swedish Hip Arthroplasty Register. Annual Report* 2014.

[2] Australian Orthopaedic Association. *National Joint Replacement Registry. Annual Report* 2016.

[3] Kurtz S, Ong K, Lau E, et al. Projections of primary and revision hip and knee arthroplasty in the United States from 2005 to 2030. *J Bone Joint Surg Am*. 2007;89(4):780-5.

[4] D'Antonio J, McCarthy JC, Bargar WL, et al. Classification of femoral abnormalities in total hip arthroplasty. *Clin Orthop Relat Res.* 1993;(296):133-9.

[5] Della Valle CJ, Paprosky WG. The femur in revision total hip arthroplasty evaluation and classification. *Clin Orthop Relat Res.* 2004;(420):55-62.

[6] Kitamura N, Pappedemos PC, Duffy PR 3rd, et al. The value of anteroposterior pelvic radiographs for evaluating pelvic osteolysis. *Clin Orthop Relat Res.* 2006;453:239-45.

[7] Zimlich RH, Fehring TK. Underestimation of pelvic osteolysis: The value of the iliac oblique radiograph. *J Arthroplasty.* 2000;15(6):796-801.

[8] Ursan I, Chiu L, Pierce A. Three-dimensional drug printing: a structured review. *J Am Pharm Assoc.* 2013;53(2):136-44.

[9] Bianchi L, Galante C, Zagra L. The management of femoral bone stock in THA revision: indications and techniques. *Hip Int.* 2014;24(10): S37-S43

[10] Brown JM, Mistry JB, Cherian JJ, et al. Femoral Component Revision of Total Hip Arthroplasty. *Orthopedics.* 2016;39(6):e1129-39.

[11] Shon WY, Santhanam SS, Choi JW. Acetabular Reconstruction in Total Hip Arthroplasty. *Hip Pelvis.* 2016;28(1):1-14.

[12] Ahmad AQ, Schwarzkopf R. Clinical evaluation and surgical options in acetabular reconstruction: A literature review. *J Orthop.* 2015;12(2):S238-43.

[13] Friedrich MJ, Schmolders J, Michel RD, et al. Management of severe periacetabular bone loss combined with pelvic discontinuity in revision hip arthroplasty. *Int Orthop.* 2014;38(12):2455-61.

[14] Mäkinen TJ, Fichman SG, Watts E, et al. The role of cages in the management of severe acetabular bone defects at revision arthroplasty. *Bone Joint J.* 2016;98-B(1A):73-7.

[15] Kim DH, Cho SH, Jeong ST, et al. Restoration of the center of rotation in revision total hip arthroplasty. *J Arthroplasty.* 2010;25(7):1041-6.

[16] Padgett DE, Lewallen DG, Penenberg BL, et al. Surgical technique for revision total hip replacement. *J Bone Joint Surg Am.* 2009;91(5):23-8.

[17] Krismer M, Nogler M. Revision arthroplasty of the hip : Direct anterior approach. *Orthopade.* 2017;46(2):121-5.
[18] Nogler MM, Thaler MR. The Direct Anterior Approach for Hip Revision: Accessing the Entire Femoral Diaphysis Without Endangering the Nerve Supply. *J Arthroplasty.* 2017;32(2):510-4.
[19] Kaspar S, Winemaker MJ, de V de Beer J. Modified iliofemoral approach for major isolated acetabular revision arthroplasty. *J Arthroplasty.* 2003;18(2):193-8.
[20] Reiley MA, Bond D, Branick RI, Wilson EH. Vascular complications following total hip arthroplasty. A review of the literature and a report of two cases. *Clin Orthop Relat Res.* 1984;(186):23-8.
[21] Hamilton WG, Cashen DV, Ho H, et al. Extensively porous-coated stems for femoral revision: a choice for all seasons. *J Arthroplasty.* 2007;22(4 suppl 1):106-10.
[22] Weeden SH, Paprosky WG. Minimal 11-year follow-up of extensively porous-coated stems in femoral revision total hip arthroplasty. *J Arthroplasty.* 2002;17(4 suppl 1):134-7.
[23] Sporer SM, Paprosky WG. Revision total hip arthroplasty: the limits of fully coated stems. *Clin Orthop Relat Res.* 2003;417:203-9.
[24] Böhm P, Bischel O. Femoral revision with the Wagner SL revision stem: evaluation of one hundred and twenty-nine revisions followed for a mean of 4.8 years. *J Bone Joint Surg Am.* 2001;83(7):1023-31.
[25] Richards CJ, Duncan CP, Masri BA, Garbuz DS. Femoral revision hip arthroplasty: a comparison of two stem designs. *Clin Orthop Relat Res.* 2010;468(2):491-6.
[26] Malkani AL, Settecerri JJ, Sim FH, et al. Long-term results of proximal femoral replacement for non-neoplastic disorders. *J Bone Joint Surg Br.* 1995;77(3):351-6.
[27] Friesecke C, Plutat J, Block A. Revision arthroplasty with use of a total femur prosthesis. *J Bone Joint Surg Am.* 2005;87(12):2693-701.
[28] Ornstein E, Linder L, Ranstam J, et al. Femoral impaction bone grafting with the Exeter stem: the Swedish experience. Survivorship analysis of 1305 revisions performed between 1989 and 2002. *J Bone Joint Surg Br.* 2009;91(4):441-6.
[29] te Stroet MA, Gardeniers JW, Verdonschot N, et al. Femoral component revision with use of impaction bone-grafting and a cemented polished stem: a concise follow-up, at fifteen to twenty years, of a previous report. *J Bone Joint Surg Am.* 2012; 94(23):e1731-4.
[30] Rogers BA, Sternheim A, De Iorio M, et al. Proximal femoral allograft in revision hip surgery with severe femoral bone loss: a systematic review and meta-analysis. *J Arthroplasty.* 2012;27(6):829-36.e1.
[31] Bostrom MP, Lehman AP, Buly RL, et al. Acetabular revision with the Contour antiprotrusio cage: 2- to 5-year followup. *Clin Orthop Relat Res.* 2006;453:188-94.
[32] Issack PS, Nousiainen M, Beksac B, et al. Acetabular component revision in total hip arthroplasty. Part II: management of major bone loss and pelvic discontinuity. *Am J Orthop (Belle Mead NJ).* 2009;38:550-6.
[33] Goldberg VM. Selection of bone grafts for revision total hip arthroplasty. *Clin Orthop Relat Res.* 2000;(381):68-76.
[34] Etienne G, Ragland PS, Mont MA. Use of cancellous bone chips and demineralized bone matrix in the treatment of acetabular osteolysis: preliminary 2-year follow-up. *Orthopedics.* 2004;27(1):s123-6.

[35] Paprosky WG, Magnus RE. Principles of bone grafting in revision total hip arthroplasty. Acetabular technique. *Clin Orthop Relat Res.* 1994;(298):147-55.

[36] Sporer SM, O'Rourke M, Chong P, Paprosky WG. The use of structural distal femoral allografts for acetabular reconstruction. Average ten-year follow-up. *J Bone Joint Surg Am*. 2005;87:760-5.

[37] Regis D, Sandri A, Bonetti I, et al. A minimum of 10-year follow-up of the Burch-Schneider cage and bulk allografts for the revision of pelvic discontinuity. *J Arthroplasty.* 2012;27:1057-63.e1.

[38] Gross AE. Restoration of acetabular bone loss 2005. *J Arthroplasty.* 2006;21(4-1):117-20.

[39] Van Kleunen JP, Lee G, Lementowsky PW, et al. Acetabular revisions using trabecular metal cups and augments. *J Arthroplasty.* 2009;24:64-8.

[40] Weeden SH, Schmidt RH. The use of tantalum porous metal implants for Paprosky 3A and B defects. *J Arthroplasty.* 2007;22:151.

[41] Del Gaizo DJ, Kancherla V, Sporer SM, Paprosky WG. Tantalum augments for Paprosky type IIIa defects remain stable at midterm follow-up. *Clin Orthop Relat Res.* 2012;470:395–401.

[42] Abolghasemian M, Tangsataporn T, Kuzyk PRT, et al. Cup-cage solution for pelvic discontinuity. *Semin Arthroplasty.* 2012;23:171-5.

[43] Ballester Alfaro JJ, Sueiro Fernández J. Trabecular Metal buttress augment and the Trabecular Metal cup-cage construct in revision hip arthroplasty for severe acetabular bone loss and pelvic discontinuity. *Hip Int.* 2010;20 Suppl 7:S119-27.

[44] Kosashvili Y, Backstein D, Safir O. Acetabular revision using an anti-protrusion (ilio-ischial) cage and trabecular metal acetabular component for severe acetabular bone loss associated with pelvic discontinuity. *J Bone Joint Surg Br.* 2009;91:870-6.

[45] Borland WS, Bhattacharya R, Holland JP, Brewster NT. Use of porous trabecular metal augments with impaction bone grafting in management of acetabular bone loss. *Acta Orthop.* 2012;83:347-52.

[46] Ballester Alfaro JJ, Sueiro Fernández J. Trabecular Metal buttress augment and the Trabecular Metal cup-cage construct in revision hip arthroplasty for severe acetabular bone loss and pelvic discontinuity. *Hip Int.* 2010;20(7):S119-27.

[47] Malhotra R, Kancherla R, Kumar V, Soral A. Trabecular metal acetabular revision system (cup-cage construct) to address the massive acetabular defects in revision arthroplasty. *Indian J Orthop.* 2012;46:483-6.

[48] Christie MJ, Barrington SA, Brinson MF, et al. Bridging massive acetabular defects with the triflange cup: 2- to 9-year results. *Clin Orthop Relat Res.* 2001;393:216-27.

[49] Holt GE, Dennis DA. Use of custom triflanged acetabular components in revision total hip arthroplasty. *Clin Orthop Relat Res.* 2004;429:209-14.

[50] Taunton MJ, Fehring TK, Edwards P, et al. Pelvic discontinuity treated with custom triflange component: a reliable option. *Clin Orthop Relat Res.* 2012;470(2):428-34.

[51] Wyatt MC. Custom 3D-printed acetabular implants in hip surgery – innovative breakthrough or expensive bespoke upgrade? *Hip Int.* 2015;25(4):375-9.

[52] Massè A, Aprato A, Turchetto L, et al. Reconstruction With Rib Graft for Acetabular Revision in Pelvic Discontinuity: An Extreme Solution? *Tech Orthop.* 2015;30(4):269-74.

In: Encyclopedia of Surgery (22 Volume Set)
Editors: Andreas Lehrer and Kristin Mueller
ISBN: 978-1-53618-329-0
© 2020 Nova Science Publishers, Inc.

Chapter 153

3D CUSTOMIZING IN ONCOLOGIC HIP AND PELVIC SURGERY

Michele Boffano*, Pietro Pellegrino, Nicola Ratto and Raimondo Piana
Oncologic Orthopaedic Division, Department of Orthopaedics and Traumatology, Orthopaedic and Trauma Center, Turin, Italy

ABSTRACT

Musculoskeletal tumors are a very rare entity and malignant bone tumors such as osteosarcoma are even more rare in the pelvic region. The resection and reconstruction of these tumors lead to some difficulties due to the high risk of incomplete resection and high residual functional impairment. Recently developed 3D technologies give some relevant advantages in the complex tridimensional geometry of the pelvis: a more accurate preoperative evaluation of the margins of resection and of the relationship between noble structures and the tumor, and a new instrument to explain the surgical procedure to the patient.

Computer-assisted orthopaedic surgery (CAOS) is a discipline where computer technology is employed to improve the outcome of orthopaedic surgery. 3D technologies have been also adopted in musculoskeletal oncology and a new discipline, called Computer Assisted Tumor Surgery (CATS), has been introduced. 3D technologies and CATS permit to design and realize patient specific cutting guides, to simulate surgical navigation over a previous planning and intraoperatively navigate the resection.

3D printing of custom made implants for the reconstruction is the more advanced feature of these technologies. Theoretically any kind of anatomical site could be reconstructed after tumor resection with 3D custom implants, but the pelvis is the elective one because of its anatomic peculiarity, the duration of surgery, and the difficulty to obtain stable and long-lasting reconstructions.

3D customizing is an innovative and expanding field in orthopaedic oncology and especially in pelvic lesions. Preoperative study, resection, intraoperative navigation and custom made implants are nowadays viable options for treating pelvic tumors.

* Corresponding Author's Email: mboffano@cittadellasalute.to.it.

Keywords: 3D custom implants, bone sarcomas, hip oncology, pelvic oncology, pelvic reconstruction

1. INTRODUCTION

Musculoskeletal tumors are a very rare entity, and benign or locally aggressive tumors are greatly more frequent than malignant tumors, for about two orders of greatness (and they almost double them). It has been calculated that the annual burden of soft tissue and skeletal malignant neoplasms (so-called sarcomas) is around 30 cases per million worldwide, resulting in nearly 3000 per million cases of benign lesions [1, 2]. Primary malignant bone tumors such as osteosarcoma are very rare in the pelvic region because they are much more frequent in the limbs, especially around the knee. On the other side chondrosarcomas and Ewing's sarcomas quite commonly affect the pelvis. The surgical resection is usually one of the key-point of the treatment in primary bone tumors, especially if we consider that chondrosarcoma does not respond to chemotherapy and radiotherapy. Pelvic lesions are complex also for their huge dimensions: in the pelvic cavity a tumor can grow for a long time and achieve a large diameter usually without pain or relevant symptoms. Alternatively around the hip joint (acetabulum and/or proximal femur) a lytic bone lesion usually become symptomatic very soon with pain during walking or weight-bearing, if not with a pathologic fracture.

Soft tissue sarcomas are more common than bone sarcomas and, when in the pelvic area, they usually invade the bone and require a bone resection to obtain clear margins. Therefore, in a simplified way from a surgical point of view, they could be considered as a bone sarcoma with soft tissues invasion.

On the other side, the pelvic ring is greatly affected by metastases. Following US and Canadian surveys metastatic bone disease involves along their life 50% of all patients with a primitive cancer and 30% of patients with a new diagnosis of carcinoma. Metastases involve in order spine, pelvis, and long bones [3–5].

This point radically modifies the surgical indications, with the predominance of non-surgical or minimally invasive surgical treatments, as described by recently published Italian Guidelines for metastatic disease of the pelvis [6]. Nevertheless, an early cancer diagnosis and new chemotherapy protocols determine an improvement in overall long-term survival sometimes obtaining the chronicization of the disease with a continue request of long-lasting and complex surgical interventions, mostly in the pelvic area.

The main problems for the surgeon facing a pelvic tumor are: the complex three-dimensional (3D) geometry and the proximity (or sometimes the invasion) of important organs (bladder, rectum, prostate, etc.) and neurovascular structures (iliac or femoral vessels, femoral or sciatic nerves). This complex and restricted working space can explain the high complication rate usually observed in pelvic bone tumor surgery. Potential complications in pelvic oncologic surgery are: massive bleeding, infection, local recurrence, vascular or neural damage, visceral organs damage, deep vein thrombosis, failure of the reconstruction, wound dehiscence often requiring flaps or advanced medications. These complications can deal to an amputation (usually hip disarticulation or hindquarter amputation) or even to the exitus. A particular focus is on the local recurrence rate ranging from 28 to 35%. An accurate resection with wide margins is required since it is highly associated with a low local recurrence rate [7].

Clear and adequate margins affect positively the outcome of the treatment of sarcomas. The concept of margins in orthopaedic oncology was introduced by Enneking [8].

Enneking classified the margins into 4 categories: intralesional, marginal, wide and radical. To obtain an adequate surgical margin is the principal goal of oncologic surgery. Pelvic surgery magnifies the problem: it is impossible to obtain radical margins due to the anatomic conformation (with the exception, of course, of a hindquarter amputation in selected cases). Enneking also divided the pelvis in four main surgical areas zones to classify the tumors in the pelvis: zone 1, the iliac wing; zone 2, the periacetabular area; zone 3, the pubic branches; zone 4, the sacrum. The tumor can involve one or more areas.

The reconstruction becomes more complex when the zone 2 is involved by the neoplasm and it should be partially or completely resected.

In this complex field, 3D techniques seem to be very attractive in studying, planning, explaining, and finally reconstructing complex cases.

The possibility of digitally recreating the 3D geometry of the tumor gives some relevant advantages:

- An easier case study for the surgeon with an accurate preoperative evaluation of the margins of resection and the relationship between potentially involved noble structures and the tumor
- An instrument to explain the surgical procedure to the patient
- An instrument to design and realize patient specific cutting guides
- The simulation of a surgical navigation over a previous planning
- The project of custom made implants for the reconstruction.

2. DIAGNOSIS

The diagnosis of a primitive or metastatic tumor of the pelvic ring or around the hip joint could be very demanding. Symptoms are seldom clear, with masses that could easily reach big dimensions. Sometimes the clinical onset is dramatic, due to periacetabular fractures or viscera compression.

Traditional X-Ray Imaging represents the first diagnostic approach but a further study with second level diagnostic exams such as Computed Tomography (CT) scans and Magnetic Resonance Imaging (MRI) is mandatory. Both CT and MRI are commonly used with contrast medium, to enhance vascularization and relationship with the major vessels of the pelvis. A biopsy is nearly always required, especially in case of suspected primitive malignant or benign aggressive lesion. In the pelvis the usual approach is a core needle CT guided biopsy following the general rules for biopsy according to the future definitive surgical access. The biopsy could be avoided only in case of a clear history of metastatic disease [6] or if the Imaging is absolutely indicative for a benign calm lesion.

When the histologic diagnosis is obtained, the orthopaedic oncology surgeon can face mainly 4 different clinical situations potentially dealing with 3D technologies:

1) *Benign lesions requiring an intralesional or marginal treatment.* These lesions are benign or aggressive-benign tumors (e.g., simple bone cysts, aneurismal bone cysts

or ABC, giant cell tumors of the bone or GCT, osteochondromas). The treatment could range from the marginal excision of the lesion to the intralesional removal of the pathologic intraosseous lesion (usually curetting) and the following filling of the residual cavity with bone grafts or bone cement. Some recent studies modified the surgical strategies with an increasing indication to mininvasive or not surgical treatments. Curopsy [9] has been described for the diagnosis and the simultaneous treatment of benign cystic lesions. ABCs were traditionally curetted out and then filled in with bone grafts; recently multiple exclusive embolizations [10] or the injection of demineralized bone matrix [11] or mesenchimal cells have been used with promising results. Systemic administration of Denosumab was recently introduced for the treatment of GCTs [12] but the protocols are still unclear whether it is should be considered a neoadjuvant or an exclusive pharmacological treatment and in the first case whether the surgical treatment should be an extended curettage or a resection. In these lesions 3D technologies are useful in the pre-operative study and surgical planning combining CT and MRI, but rarely 3D printed implants have to be considered.

2) *Malignant primary bone tumors responsive to neoadjuvant treatments* (e.g., osteosarcoma, Ewing's sarcoma). Once obtained a diagnosis, a general staging with chest and abdomen CT scans is mandatory, because unfortunately lung and liver metastases are quite frequent even at the diagnosis. If the lesion needs preoperative chemotherapy and/or radiotherapy, a pre-treatment CT and MRI scan ideally have to be performed. A CT or MRI scan is usually performed during therapy cycles and a full general and local restaging is repeated at the end of the therapy protocol, in order to monitor tumor evolution. In some cases (e.g., responsive Ewing's sarcoma) the tumor could disappear and the oncologic treatments could be the only definitive therapeutic approach. When a surgical treatment is indicated a 3D planning and evaluation of the bone resection is advisable. An inadequate bone resection leads to positive margins or a high recurrence rate. On the other side an excessive resection can be impossible to reconstruct with a poor functional outcome. The reconstruction could be obtained with soft tissue or combined procedures (hip transposition or flailing hip), with allografts, or with available off-the-shelves prostheses (stemmed cups, ice-cream cones, saddle prostheses). In the case of a reconstruction with custom made implants, the decision should be made in advance (before the last or the second last chemotherapy cycle) allowing the time to produce the implant but foreseeing a potential wider margin of resection.
3) *Malignant primary bone tumors not responsive to neoadjuvant treatments (e.g., chondrosarcoma).* These tumors usually require, after a local and general staging, a surgical treatment. 3D reconstruction helps to identify noble structures and the level of resection. If customized cutting guides or implants are requested, they should be designed on the latest CT and MRI available. An immediate preoperative Imaging should be repeated in order to confirm the planned resection and reconstruction excluding a local tumor progression. Often tumors belonging to this group are slow growing malignant tumors, for example low grade chondrosarcomas are quite common in the pelvis. This tumor behaviour allows to plan surgery without a predefined schedule depending on chemotherapy or radiotherapy protocols and

therefore, when needed, the design and production of a 3D custom-made prosthetic reconstruction could be performed.

4) *Metastatic bone lesions.* Metastastic bone lesions according to the most recent guidelines could be treated as primary bone tumors if they are solitary lesions of a good prognosis primary neoplasm. The multidisciplinary approach and the coordination with the oncologist and the radiotherapist are fundamental in these patients. A 3D planning of metastatic surgery is useful both in case of intralesional treatment or resection. The use of cutting guides or other specific instruments are advisable. The reconstruction could range from traditional techniques (e.g., Harrington procedure) to modular or stemmed revision acetabular implants adapted to the post-oncologic bone defect.

3. Computer Assisted Tumor Surgery, Patient Specific Instrumentation and Other Applications

Introduced about two decades ago, Computer-assisted orthopaedic surgery (CAOS) is an active research discipline where computer technology is employed to improve the outcome of orthopaedic surgical procedures.

CAOS combines the practice of the orthopaedic surgery with disciplines, such as engineering, computer science, and robotics. CAOS is mostly used in knee implant surgery because of the precision the surgeon gets with femoral and tibial bone cuts. It is also used to navigate acetabular components placement where a correct cup inclination is crucial. CAOS has been recently introduced in musculoskeletal oncologic surgery to enhance surgical precision in the resection of malignant and benign lesions, and in particular in the treatment of malignant pelvic and sacral tumors. This subdiscipline has been called Computer Assisted Tumor Surgery (CATS).

The use of computer technology is applied in each phase: pre, intra and postoperatively in complex musculoskeletal tumor surgery [13], as summarized in Figure 1.

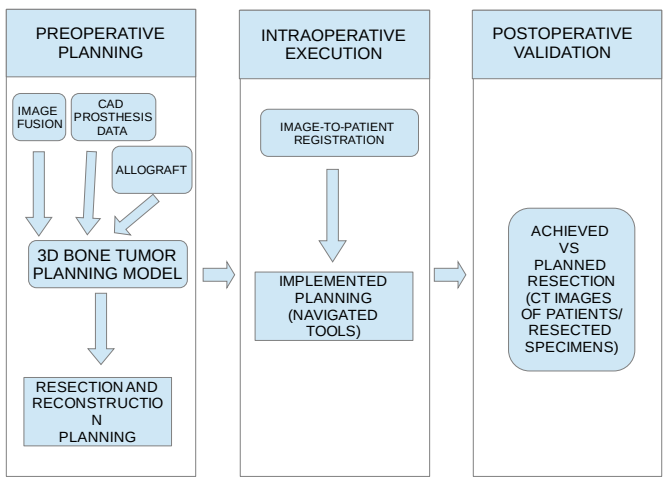

Figure 1. Workflow for CAOS (Computer Assisted Orthopedic Surgery) [14].

Preoperative computer-assisted planning is as important as the intraoperative computer navigation. The better and more detailed the planning, the greater the chance the surgical goals will be achieved when the surgeons implement the planning intraoperatively.

The intraoperative navigation control is followed by a post-operative validation between achieved and planned resection, even performed on CT control of the resected specimen.

The first step is the creation of a digital patient image, most commonly using MRI and CT scan of the anatomical region of interest, showing both precise good bone details and the exact extension of the tumor into the surrounding soft tissues.

The opportunity of merging MRI and CT images with the same spatial coordinates generates fusion images that combine the characteristics of each imaging modality.

At the same time, the possibility to develop 3D images allows to highlight and distinguish the tumor from the normal tissues and its spatial relationship to noble structures (e.g., main nerves or blood vessels).

CAOS also enables the elaboration of functional imaging [positron emission tomography (PET)], which may have the additional benefit of distinguishing the tumor from scar tissue in patients with tumor recurrence who had had previous resection or radiotherapy.

Thanks to the use of different colors in the 3D model, oncology surgeons can obtain a better mental picture of the tumor location and accurately define the surgical resection planes with specific orientation on the virtual patient image.

Preoperative planning also consists in selecting the best surgical approach and defining the location of the noble structures to detect and protect during surgery.

The next step is designing the reconstructive planning after tumor resection. Based on precise 3D resection planning and preoperative CT images, a prosthetic or an allograft reconstruction are possible.

In fact, computer-aided design (CAD) medical engineering software allows surgical simulations of complex tumor resections and the design of custom-made prostheses for bone reconstruction.

In selected patients, CAOS approach facilitates a precise planning and the execution of technically demanding joint-preserving tumor resections and reconstructions with custom CAD prostheses in one-step surgical procedure.

The planned resections should have not only clear tumor margins but also the correct orientation to fit a custom CAD prostheses.

Data about the custom prosthesis can be imported into the navigation system. Surgeons can check and modify the design of the custom CAD prosthesis before approving the project to the manufacturer.

Many Authors illustrated the evolution and clinical results of the CAOS technique at their institution [14, 15].

Wong and Kumta described the largest series of patients [15] with the longest follow-up of at least 3 years. They suggest that CAOS may be helpful in safe tumor resection and may lead to better functional and oncologic outcomes.

Nevertheless, the time period of CAOS development is still relatively short, thus long-term follow-up studies have not been possible yet.

The potential benefits of using CAOS include potential improved reliability of sizing and positioning joint implants, improved accuracy of reconstructed limb length, improved accuracy of prosthetic component alignment, impact on functional outcomes and implant durability.

On the other hand, an increased time required to perform the operation, an increased hospital costs from the additional equipment, software and surgical times, the need for additional images before surgery (such as CT scan) to provide landmarks for surgical planning are the main points against the use of CAOS.

For these reasons, the CAOS technique should not be used for simple resections, but limited to resections at complex anatomic sites or to more technically demanding procedures after an adequate learning curve.

3.1. 3D Allografts

In addition to intraoperative guidance of bone tumor resections, Docquier et al. [16] and Gerbers et al. [17] reported that the same resection planes could be reproduced under navigational guidance to shape the allograft. A better matching of the allograft to the resection defect will improve host-allograft contact, with less chance of nonunion.

Bone allograft reconstruction is an accepted procedure for the recovery of the original anatomy following a pathological or traumatic defect. The use of bone allograft after bone tumor resection has been described with acceptable results in osteoarticular, transepiphyseal, and intercalary reconstructions.

Despite their high complication rate and their slow incorporation into the host bed, biological massive allografts are recommended for great defects such as traumatic or pathological defects of the pelvis. Clinical reports suggest that this approach preserves the long-term bone stock and limb functionality. Furthermore, long-term follow-up studies support and promote the use of allografts instead of prosthetic implants, especially in younger patients.

The selection of the closest anatomical match between the host and the donor is crucial in order to avoid alteration of the joint kinematics and load distribution, leading to articular fractures or joint degeneration.

The bone banks provide bone allografts that are usually collected based on manually measuring anatomical dimensions. In this case, the selection of the bone allograft occurs according to size and shape evaluated on X-ray images between donors and patients.

The use of a CT based registration at the bone bank allows a more accurate comparison between donor and host and therefore a more appropriate selection of the best fitting allograft than the radiograph-based method.

Ritacco et al. [18] described the three steps to obtain a three dimensional virtual bone models from host to donor*: image acquisition, image segmentation, and 3D bone reconstruction.*

A CT scan is generally used for *image acquisition* with identical protocols in host and donor.

Image segmentation is a process, using a specific software that makes the images obtained easier to analyze. The bone after the segmentation process is isolated from the other tissues and structures such as muscles, fat, and skin.

The result of image segmentation is a set of segments or a set of contours extracted from the image that collectively covers the entire 3D bone model, which can be modified to create 3D reconstructions. This tool allows to determine a match by overlapping the host with available donors.

The selection criteria of the graft for a pelvic reconstruction are usually based on the correspondence of the pubis and sacroiliac joint and the acetabular size.

Moreover, this optimal handling of the bone bank limits a potential waste of bone allografts.

After this process, the resection planes might be defined preoperatively. The use of specific softwares allows to transfer the target plane coordinates from the patient to the allograft in order to exactly recreate the same bone gap of the resected tumor.

Furthermore, the support of a navigation system ensures an intraoperative resection of the whole tumor volume with a tumor-free margin and avoids the creation of important gaps at the graft-host junction that could potentially interfere with union and stability. This system also allows to prepare the allograft simultaneously by another surgeon or before tumor resection, since the planes were defined preoperatively. Therefore, the operating time results significantly reduced.

The procedure is even more accurate having the opportunity to simulate and navigate surgery with prototypes. Using a 3D plaster printing based on the CT data, it is possible to define the best reference points and their relationship with resection planes.

3.2. Intraoperatory Procedures: 3D Computer Navigation - Patient-Specific Instruments

Custom pelvic prostheses are used to reconstruct the bone defect following complex pelvic bone tumor resection. CAOS allows the engineers to design and tailor-made an implant that matches exactly to the anticipated bone loss after tumor resection. However, the degree of fitting of the custom implant greatly depends on the ability of the surgeons to reproduce intraoperatively the resection as planned.

Pelvic tumor surgery is challenging because of the complex bony anatomy and the close proximity to pelvic organs and neurovascular structures. Accurate resections with wide margins are the most important prognostic factor in managing pelvic bone tumors.

A local recurrence rate of up to 70% is observed after a marginal resection, and 92% after an intralesional resection [19].

To date, three modalities are possible to perform free margin resections and the closest to pre-operative planning: free-hand resections, 3D computer navigation and patient specific Instrument (PSI).

Free-hand resections are certainly the least accurate, despite the surgeon can train on plastic three-dimensional models printed on patient image data.

In recent years, intraoperative 3D navigation and PSI guides have been described with good results.

3D Printing and PSI Development

Rapid prototyping (RP), whether CT or MRI based, allows to create quickly and precisely 3D devices that help oncologic surgeons to study the shape of neoplasms and tailor surgical solutions.

There are six main processes to obtain physical objects via RP: stereolithography (SLA), selective laser sintering (SLS), fused deposition modeling (FDM), laminated object manufacturing (LOM), electron beam melting (EBM), and inkjet printing.

An intraoperative alternative to computer navigation is Patient-Specific Instrument (PSI). Following the previous use for total knee and hip arthroplasty, for pedicle screw insertion and for corrective osteotomy, PSI has recently also been adapted to bone tumor surgery.

The PSI is a customized tool, designed to have bone-specific contact surfaces aiming to guide a saw or a drill into the desired resection planes or positions. These cutting guides are designed on the basis of patient 3D reconstructed imaging and computer-aided design (CAD) software, allowing surgeons to plan surgeries based on the patient's unique anatomy. The blocks of the PSI consist of three components: (1) a surface of contact, that conforms to the footprints contour predetermined by the surgeons, so that the blocks could be positioned consistently near the site of the planned resections without translation; (2) three-planar cutting slot in the blocks, based on the unique orientation of the resection planes defined during virtual simulation in the software; (3) cylindrical guides for the insertion of Kirschner wires to fix the PSI to pelvic bone after correctly positioning the PSI. In addition, PSI provides calibration marks to control over the cutting depth to prevent a soft tissue tear by the saw. These marks represent the distance along the associated direction line measured between the outer edge of the PSI and the deepest bone structure to be cut.

Following surgeons' indications about the surgical approach or exposure, the nearby soft tissues, the defined position and the direction for the placement of PSI, the engineers combine the different components of PSI and create an unique contact interface between the PSI and the host bone.

Orthopaedic surgeons could also practice and familiarize with the proper placement of the PSI on pelvic bone models, fabricated on a 3D printing machine, before approving the final design. The final product is made of a thermoplastic material, with high chemical resistance and high tensile strength, stable to temperatures up to 130°C and thus sterilizable for the use in the operating theatre.

Intraoperatively, surgeons can generally use a standard surgical approach and soft tissue dissection. A possible limit to the technique might be the need for an adequate exposure of the bone surface to optimally fit to it without interfering with soft tissues (ligaments, muscles insertions, etc.). However, Gouin [20] showed that PSI requires only a limited extra bone exposure (less than 10 mm).

Comparing free-hand cutting of pelvic bone tumors with PSI cutting, a significant difference was demonstrated [7]. In fact, free-hand cutting is not accurate enough to ensure wide margins: the errors on the desired safe margin averaged 5.3 mm, with a standard deviation ranging from 2.7 to 5.3 mm among the experienced surgeons, and two resections out of twelve were intralesional. Instead, PSI enables the surgeon to intraoperatively replicate the planned resections with a very good cutting accuracy. Wong et al. [21] reported a millimetric accuracy during a PSI-assisted bone tumor resection of the femur. Khan et al. [22] also investigated bone-cutting accuracy and reported a 2-mm location accuracy during a PSI-assisted multiplanar resection on a cadaveric femur.

The observed level of accuracy suggests that a 5-mm safe margin should be sufficient to obtain clear surgical margins when using PSI. This decrease in the level of desired safe margins allows to perform resections closer to the tumor boundary, offering the possibility to

preserve for example the sacroiliac or the hip joint, a specific portion of a supporting bone, muscle insertions, or nerve roots.

Similarly, a recent cadaveric study compares navigation-assisted and PSI techniques in simulated pelvic bone resections [23]. The mean average deviation error from the planned resection was not different for the navigation and the PSI groups: in both techniques it was less than 2 mm. The mean time required for the bone resection in the navigation group, instead, was significantly greater than that in the PSI group. In fact, Cartiaux [24] showed a similar trend. In this study, the time required for a pelvic resection was 49 minutes for navigation assistance versus 6.9 minutes with PSI assistance.

The increased operative time in the navigation group can be due to the time required for the placement of patient's tracker, system calibration and image-to-patient registration prior to the navigated bone resections. In addition, surgeons have to manually control the direction of the sawblade for the resection under visual guidance on the navigation display, as the existing navigation system does not support a navigated saw.

The greatest risk of PSI is the wrong positioning of its components on the bone surface that leads to a complete lack of precision during the bone-cuts. Further studies are needed to investigate how much bone contact surface is necessary for an accurate placement of the PSI.

According to the actual results, the PSI can be performed safely and provides a good cutting accuracy.

The intraoperative use of the PSI appeared to be quick and easy-to-handle and to require minimal operative setup.

3D Computer Navigation

Computer Navigation is a passive system of image-guided techniques that provides a real-time, interactive, 3D digital map of a patient's anatomy.

A process called "registration" allows to associate the patient's imaging information and anatomical landmarks using an intraoperative navigated device.

This procedure increases spatial accuracy during dissection, surgical resection and instrumentation through a continuous control of images by the surgeon on a video monitor.

Image-based intraoperative computer navigation is currently utilized in craniomaxillofacial tumor surgery, and several studies have demonstrated that the computer navigation technology can improve the precision of various orthopaedic surgical procedures, such as vertebral pedicle screw insertion, joint arthroplasty, and trauma surgery.

Krettek et al. [25] and Hufner et al. [26] have been the first reporters of the use of CT-based navigation in pelvic and sacral tumor resection. They used navigation tools to guide the orientation of osteotomies during surgery and concluded that computer-assisted surgery is a potential method to increase the accuracy in tumor resections involving anatomic and surgical complexity.

In the following years, several centers started reporting the clinical applications and the results of computer navigation and CAOS in orthopaedic oncology.

The first interesting results were obtained by Cartiaux and al., with simulation on plastic pelvic models. They affirmed that the probability for an experienced surgeon to obtain a 10-mm surgical margin with a 5-mm tolerance above or below was only 52% (95% CI 37–67). Also, the degree of host-graft contact for reconstruction was found to be poor.

This group went on to demonstrate in another experimental study that cutting accuracy was significantly improved with computer navigation guidance [27]. In a simulated sawbone model, the error of navigated cutting was only 2.8 mm, whereas that of the non-navigated group was 5.2 mm.

Cho et al. [28] confirmed the accuracy of bone resection in patients operated under computer navigation guidance with CT-MR fusion images, allowing easier joint-preserving resection.

The same group [29] also described as navigation-guided resection is possible without CT images, avoiding the exposure to radiation. Direct patient-to-MRI registration could be obtained during surgery by registering the preoperatively placed fiducial markers (absorbable pins).

Li et al. [30] and Aponte-Tinao et al. [31] described their early results of multiplanar osteotomies around bone tumors using the CAOS technique. Better limb function is achieved after reconstruction if unaffected bone and soft tissue structures are retained.

The source of errors in using CAOS systems is primarily represented by mismatches between the pre-operatively acquired images and the real-time intraoperative patient anatomy. Consequently, the most recent process optimization strategies have focused on acquiring patient imaging intraoperatively through CT or MRI. Even without the intraoperative imaging, navigated accuracy errors of less than 0.5 mm are routinely reported [32].

The increase of the operative time and costs are relevant related issues.

Further studies are required to investigate the cost-effectiveness of navigational procedures, even if comparing it to conventional surgical techniques is difficult due to the low number of patients in the actual case series. While it is expected that the additional time will decrease as surgeons become more familiar with navigation procedures.

Another important limitation is the ability to store accurate image-to-patient registration only concerning the bone. Soft tissues do not appear the same compared to the preoperative virtual images. Consequently, computer navigation allows surgeons to perform accurate bone resection, although soft tissue resection still requires a conventional surgical technique.

4. THE RECONSTRUCTION

Tailored solution are not a novelty in orthopaedic surgery, although not involving 3D. During pioneer years, THA have been built following silicone moulds [33] with disastrous results [34]. Nevertheless, custom made implants have been extensively used in hip [35], knee [36] or humerus [37] showing good outcomes.

Oncologic surgery soon made the most with 3D printing, starting with maxillofacial surgery and neurosurgery, but involving just later most of the other surgical specialties [38].

Orthopaedic oncology has an historical background of custom made implants; in fact, the first custom made implant for limb salvage procedure had been implanted in Wien in 1975 [39]. From the early 90s the use of custom made prostheses began to be commonly accepted [40].

Orthopaedic oncology received many benefits from 3D technologies, especially in pelvic surgery where the increasing use of 3D printing gave the possibility to build custom made implants in an easier and (theoretically) less expensive way.

In literature several case reports and small series are reported [41]**.** Clavicular, scapular, vertebral, knee and pelvic implants have been described [42]. Virtually any kind of anatomical site could be reconstructed with 3D custom implants for bone or soft tissue tumors, but pelvic is the elective one. Custom made implants in orthopaedic oncology are nowadays a reality in surgical reconstruction of massive periacetabular defects. As previously described, pelvis has a complex 3D anatomy and very important close neurovascular structures. Moreover, being the fulcrum of high forces, implants with the highest probability of ingrowth are the most suitable for long term survival. 3D printing permits easily to add pins, to fit short stems in case of poor bone quality, to guide screw holes, till to foresee screws length. All these features allow, in selected cases, to merge ideal qualities of bespoke shape with high-tech surfaces, in order to minimize the limb loss of function.

Nevertheless, custom made implants are a small part of global reconstructions. Still highly expensive, they need to be implanted in super-specialized centers, with a solid environment of clinicians, surgeons, engineers, and manufacturers. Postoperative care as well needs to be tailored on the patient. When a custom made component is planned and implanted in an oncologic patient, it is the result of a strong cooperation and a solid workflow.

Choosing a custom made implant presents several benefits that may lead to relevant advantages for the surgeon and subsequently for the patient.

1) *Surgical margins.* The choice of a custom made implant permits to clarify preoperatively surgical resections, magnifying the chance to obtain adequate surgical margins.
2) *Surgical time.* Preoperative planning, with predetermined screw length, permits an easy-to-fix implant. Custom made cutting guides or navigation add further advantages. The combination of these two techniques potentially shortens surgical timings, preventing infections and improving general clinical conditions in high complexity patients. A shorter surgical time means frequently lower blood loss and a better recovery for the patient. In addition, a shorter surgical time reduces the cost of surgery.
3) *Reconstruction quality.* 3D printing technique permits highly congruent implants that improve significantly bone-metal interface, creating a wider surface to promote integration. Recent studies described the functional improvement and the lower revision rate in comparison to older techniques for 3D custom implants [43]. Moreover, finite element analysis have been used [41] to evaluate the different behaviour of implants, in order to identify more stressed zones and to use the more technically efficient design.

A biomechanically efficient design of 3D printed components can obviate to those situations where muscular forces are modified due to extensive resections.

A shorter surgical time, wider margins with lower recurrence rate, lower revision rate, and a faster recovery can improve the Quality of Life (QoL) of the patient and determine less expensive global costs counterpointed to an expensive implant.

On the other side, there are many problems that may affect significantly the use of 3D implants

1) *Learning curve.* Resection of pelvic tumors is highly demanding from a surgical point of view. Few centers treat a sufficient number of cases to train skilled young surgeons. The importance to be precise and safe is even more requested in pelvic surgery. Moreover, computer assisted resections need further skills that are partially independent from specific oncologic surgical abilities [44]. Nevertheless, this problem affects globally pelvic oncologic surgery and not specifically 3D assisted surgery.
2) *Intraoperative resection changes.* This is the main topic to explore when using a custom implant. In fact custom implants works properly to fill a predefined bone loss. Some problems may emerge if a wider resection is needed. If preoperative imaging is done as closer as possible to the interventions, very few intraoperative changes are expected. In most of the cases intraoperative changes are probably due to a lack of accuracy in the preoperative planning more than an effective problem with 3D printed implants. In some cases the implant could be adapted without compromising the final result. In extreme cases, it would be better to convert the reconstructive procedure to "traditional" solutions (hip transposition, allograft, reconstruction cages).
3) *Routine use.* It is important to keep in mind that the use of custom 3D printed implants it is not an every-day solution. One problem is the effective time needed to properly plan resection, design, print, and sterilize the implant. In rapidly growing, poor responding masses, like in some cases of malignant soft tissue tumors involving the bone, a custom made implant could not be the best option. In fact, during the whole design and manufacturing time, tumor may grow putting at risk not only the effectiveness of the implant but the feasibility of limb salvage as well. In some other cases (i.e., fractured metastatic patients) the patient may not have a real QoL improvement from a custom implant. Life expectancy, pain control and residual function have to be carefully evaluated to choose the best treatment option. Case centralization in highly specialized center is the best way to control and use in the proper way all the existing techniques.
4) *Costs.* A 3D implant requires a huge organization. 3D printing, although its enormous expansion during these years, is still expensive. The entire organization, from Computer Assisted Drafting (CAD) till physical manufacturing of the definitive implant, involves many people. Sometimes cutting guides are printed with SLS or FDM, while EBM printers are used for the implant. Additional intraoperative navigation increases the costs. Nevertheless, no cost-effectiveness [45] studies are available to support one option against the others.

Like many other innovations, 3D printing implants seems to be very promising and they could make a radical difference in complex reconstructive cases.

3D printed implants and global planning could substantially help the surgeon**.** Like many others, these technologies have some limitations too.

1) *Presence of previous metal implants:* metal implants lead to artifacts. Either if diamagnetic steel, titanium or CrCoMo, all metal implants are quite incompatible with 3D printing implants. Advanced MRI and CT scanners, even if with metal signaling suppression, do not have the sufficient detecting power to avoid completely

the scattering phenomenon [20]. Nevertheless, 3D printed specimens could be used to preoperatively evaluate and to explain to the patient some difficult situations, such as complications after a previous surgery (heterotopic ossifications, failed synthesis, etc.). New radiotransparent implant (PEEK, composite carbon fibers-PEEK) are recently available. Their potential interference with navigation systems or 3D planning softwares has yet to be studied [46, 47]

2) *Technical feasibility:* to allow good quality of all procedures, good quality images are mandatory. If neither narrow slice CT scan nor MRI could be performed due to technical problems, no 3D reconstruction/planning could be hypothesized.
3) *Potential metal allergies:* to our knowledge, there are no reported cases of allergic reactions to custom metal implants in literature. These implants, being usually printed in titanium alloys, have very low allergenic potential; titanium is commonly used in metal allergic patients. Nevertheless, in highly reactive patients with documented allergy (i.e., patch tests), the use of a metal printed implant has to be carefully assessed.

5. Technical Tips for Custom-Made Pelvic Reconstructions and Clinical Cases

- If the posterior acetabular column is free from neoplastic disease, it is still possible to perform an extraarticular resection of the hip joint supported by PSI cutting guides or intraoperative navigation. A geometrical triplanar periacetabular osteotomy ("Ganz osteotomy") preserving the posterior column could be planned to allocate the acetabular custom-made prosthesis (clinical case in Figures 2-5). An intact posterior column allows to reach a sitting position sooner. Avoiding the posterior interruption of the pelvic ring the primary stability is increased, even if associated to a pubic resection. Postoperative rehabilitation could be faster, achieving 90° of flexion of the hip in the first weeks. The implant as well is subjected to limited stresses when the patient seats, still existing a "bone buttress" than counteracts shear forces.
- *The choice of materials.* A wide range of materials is available at present. Usually the bulk structure of a pelvic custom-made prosthesis is based on Titanium or Titanium alloys. The bone-prostheses interface is usually primarily fixed with screws but an integration is fundamental for the secondary or long term stability of the implant. Different porous or bioactive materials are available (e.g., Trabecular Titanium, Trabecular Metal, hydroxyapatite …) [48–50] to obtain bone ingrowth at the contact surface. The introduction of these materials is quite recent but they are widely used in general orthopaedics and in orthopaedic oncology and there is no evidence that these materials could increase the recurrence rate. Porous materials could be also used to reattach tendons and muscles in their anatomic position to improve final function but the contact with nerves, vessels, and visceral pelvic organs should be avoided. An accurate planning of the position of porous material reattachment areas is mandatory in the design phase. Silver coating [51–53] has been demonstrated useful to decrease local infection rate in tumor megaprostheses but there are only preliminary results about pelvic reconstructions.

- The fixation with the residual bone is fundamental but strictly conditioned by the tumor extension. As a general rule a stable primary fixation with the sacrum or the iliac wing using screws or short stems and porous surfaces could be obtained (clinical case in Figures 6-9). The pubic fixation is still debated. As described by several Authors [54, 55] only a minor amount of load is conducted through pubic symphysis during walking and standing activities. As a further confirmation, trauma surgery showed how pubic fixation is seldom strictly required. Nevertheless, pubic fixation may improve primary stability in the early postoperative phases but it cannot be considered a reliable site for an exclusive fixation. An ingrowth fusion with a porous or bioactive contact surface is possible at distance, to improve overall stability and eventually decrease forces acting on ischial and iliac contact areas. Generally no worries should be made in case of a secondary failure and the patient should be informed about this potential event.
- The hip joint articularity is an extremely debated topic. The use of a retentive snap cup or a double mobility cup generates a different range of motion and consequently a different stability of the components. Whether to have a restricted or a free articularity can generate an advantage from a biomechanical point of view has a complex answer. Different aspects should be considered: soft tissues and muscles excision, nerve resection, primary bone stability, and the type of femoral implant. Recent studies showed that a double mobility cup can prevent joint dislocation without restricting the range of motion and without increasing stress forces on the acetabular area.

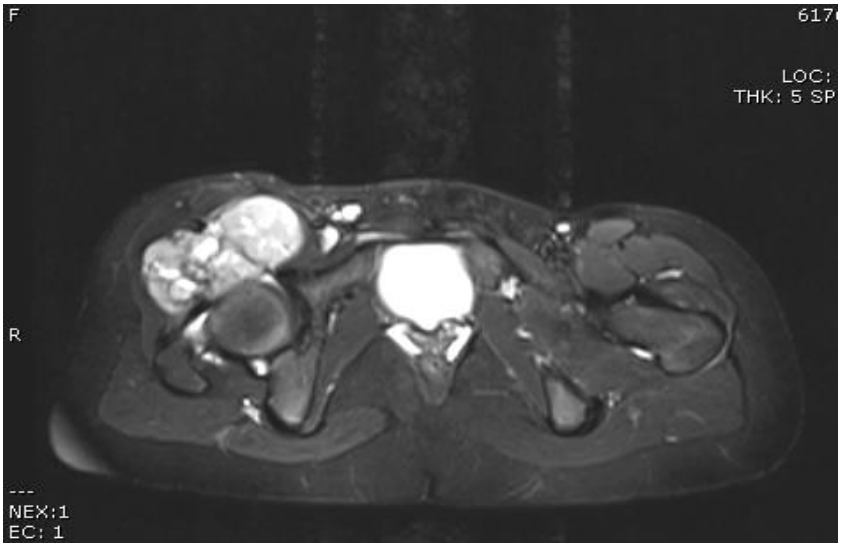

Figure 2. Girl 13 years old, biphasic synovialsarcoma of the hip joint. Chemotherapy was administered according to current protocols.

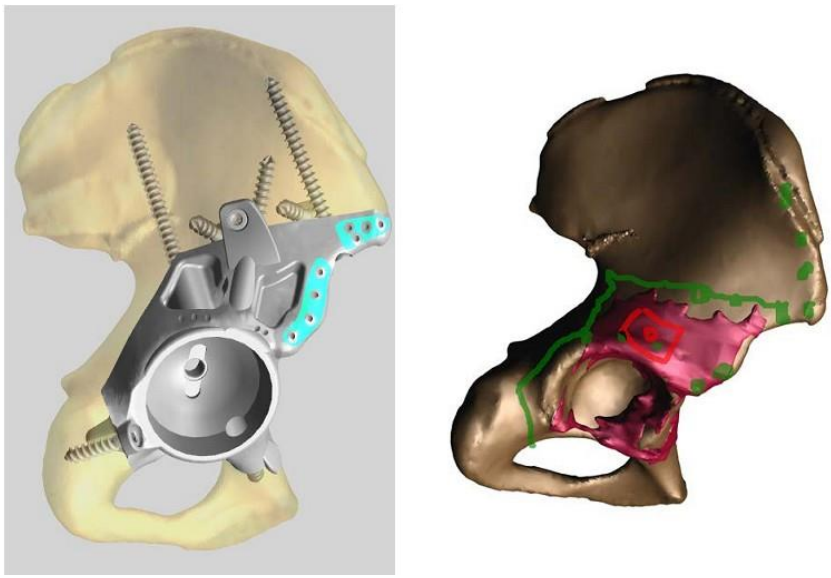

Figure 3. A custom made TiAlVa alloy prosthesis was realized with Trabecular Titanium bone- implant interfaces and fixation with screws to the ilium, ischium and posterior column. Porous surfaces and holes were added in correspondence of main muscle groups attachments (glutei muscles and rectus femoris).

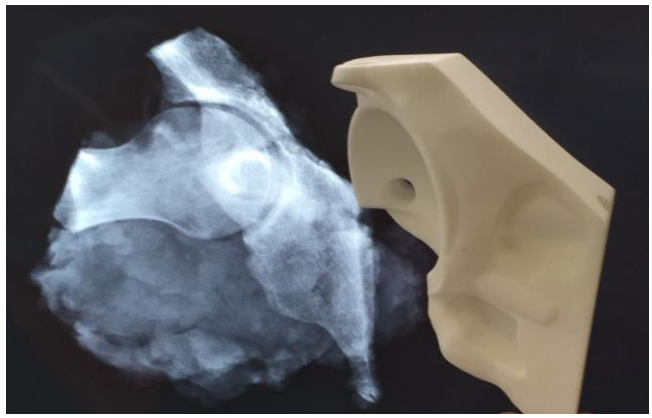

Figure 4. An extraarticular resection of the hip joint involving femoral head till the greater trochanter was necessary: a geometrical triplanar periacetabular osteotomy ("Ganz osteotomy") preserving the uninvolved posterior column was planned and performed using PSI cutting guides.

- The removal of the resected neoplastic lesion and the insertion of the custom-made prosthetic components should take into consideration noble structures (nerves, vessels, visceral organs,…) and soft tissues. Cutting guides and other PSI devices are realized taking into consideration how to avoid or not to stretch too much major nerves and vessels. The removal of a resected pelvic tumor is as critical as the prosthesis insertion. The integrity of the tumoral mass should be preserved for oncologic purpose. The insertion of the prosthesis and all the instruments to provide its fixation should be respectful of the anatomic structures.

Figure 5. Postoperative Xray control of the reconstruction. The patient started to walk one week later, and with partial load bearing two months later. At 3 months, full weight bearing was possible, unaided at 5 months. At one year of follow up, the patient was free from disease and was walking without limping or pain. Monopodalic load bearing on the operated side was possible without Trendelemburg sign.

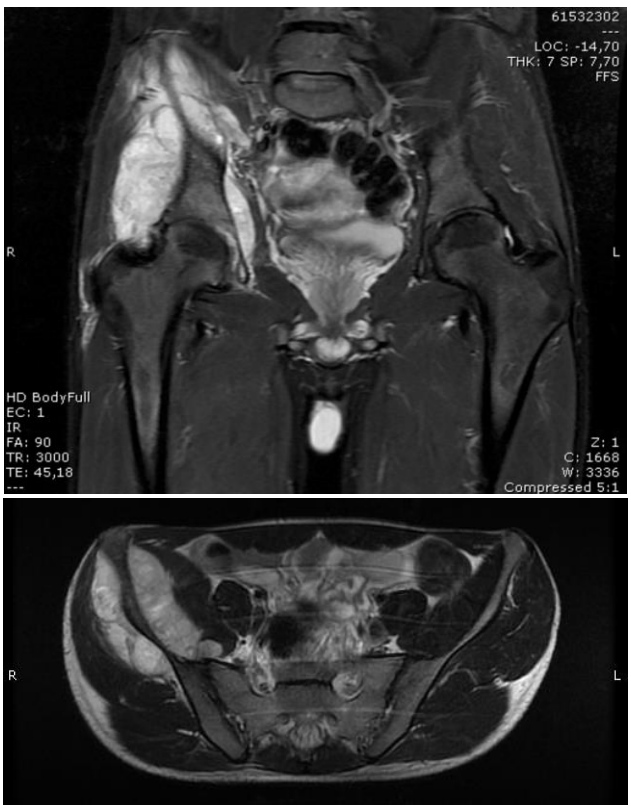

Figure 6. A-B Boy, 17 years old. Osteoblastic osteosarcoma right hemipelvis. Pre-chemotherapy MRI showing the extension of the tumor and the involvement of sacroiliac and hip joint. Post-chemotherapy staging showed a reduction of the tumoral mass in the soft tissues but confirmed the presence of neoplastic disease in the bone structures previously involved.

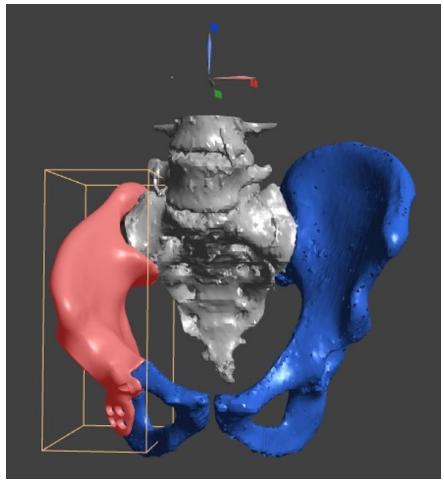

Figure 7. The resection of the tumor and the reconstruction were studied with 3D planning CA based softwares using CT and MRI. A Titanium hemipelvic endoprosthesis was realized with Trabecular Metal (TM™) plates at the sacral and pubic bone-prosthesis interfaces.

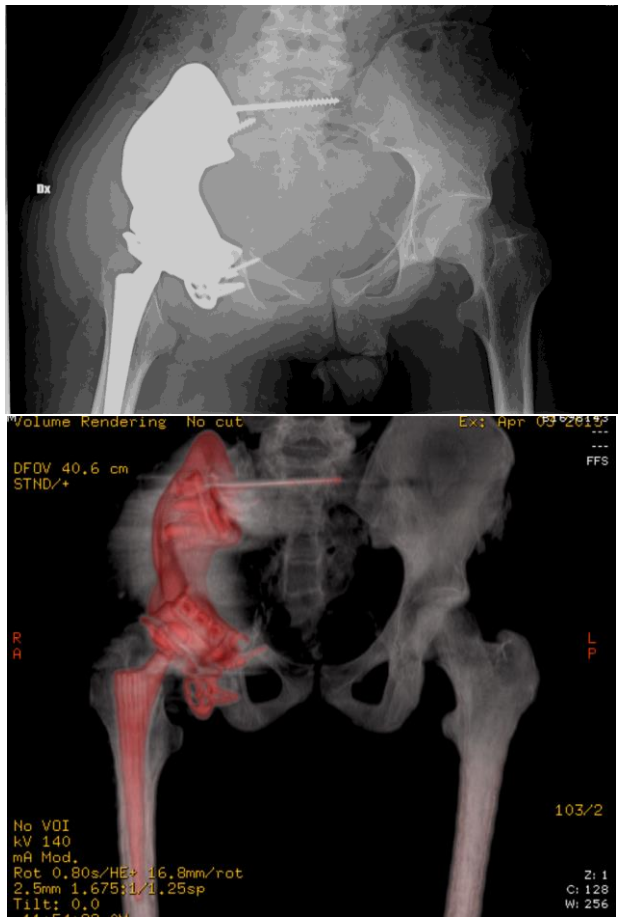

Figures 8-9. The prosthesis was fixed in the sacrum and pubic rami with screws. The glutei and rectus femoris muscles were sutured to the implant using special TM holes. Full-weightbearing was obtained after 6 months. Signs of radiologic bone ingrowth were evident 2 months post-operatively.

CONCLUSION

3D customizing is an innovative and expanding field in orthopaedic oncology and especially in pelvic lesions. Preoperative study, resection, intraoperative navigation and custom made implants are nowadays viable options for treating pelvic tumors.

All these procedures should be performed in high specialtized and selected centers due to technical and learning curve reasons.

A continuous constructive confrontation is advisable among the orthopaedic surgeons of the main reference centres and the engineers of the producing companies in order to improve the implant design and overall the patients' function and QoL.

REFERENCES

[1] AJCC *Cancer Staging Manual Amin*, M. B., Edge, S., Greene, F., Byrd, D. R., Brookland, R. K., Washington, M. K., Gershenwald, J. E., Compton, C. C., Hess, K. R., Sullivan, D. C., Jessup, J. M., Brierley, J. D., Gaspar, L. E., Schilsky, R. L., Balch, C. M., Winchester, D. P., Asare, E. A., Madera, M., Gress, D. M., Meyer, L. R. (Eds.), Springer International Publishing, 2017.

[2] Fletcher, CDM, Unni, KK, Mertens, F, World Health Organization, International Agency for Research on Cancer, editors. Pathology and genetics of tumours of soft tissue and bone. Lyon: *IARC* Press; 2002. 427 p. (World Health Organization classification of tumours).

[3] Harrington, KD. Metastatic disease of the spine. *J Bone Joint Surg Am.* 1986 Sep;68(7):1110–5.

[4] Jemal, A, Siegel, R, Ward, E, Murray, T, Xu, J, Thun, MJ. Cancer Statistics, 2007. *CA Cancer J Clin.* 2007 Jan 1;57(1):43–66.

[5] Aaron, AD. Treatment of metastatic adenocarcinoma of the pelvis and the extremities. *J Bone Joint Surg Am*. 1997 Jun;79(6):917–32.

[6] Capanna, R, Ruggieri, P, Piana R, Campanacci, DA, Di Martino, A, Daolio, P, et al. Linee Guida SIOT ed algoritmo di trattamento nelle localizzazioni metastatiche del bacino. *G Ital Ortop E Traumatol.* 2016 Dec 28;42:366–75.

[7] Cartiaux, O, Docquier, P-L, Paul, L, Francq, BG, Cornu, OH, Delloye, C, et al. Surgical inaccuracy of tumor resection and reconstruction within the pelvis: An experimental study. *Acta Orthop*. 2008 Jan;79(5):695–702.

[8] Enneking, WF, Spanier, SS, Goodman, MA. A system for the surgical staging of musculoskeletal sarcoma. *Clin Orthop*. 1980 Dec;(153):106–20.

[9] Reddy, KIA, Sinnaeve, F, Gaston, CL, Grimer, RJ, Carter, SR. Aneurysmal bone cysts: do simple treatments work? *Clin Orthop*. 2014 Jun;472(6):1901–10.

[10] Rossi, G, Mavrogenis AF, Papagelopoulos PJ, Rimondi E, Ruggieri P. Successful treatment of aggressive aneurysmal bone cyst of the pelvis with serial embolization. *Orthopedics*. 2012 Jun;35(6):e963-968.

[11] Donati, D, Frisoni, T, Dozza, B, DeGroot, H, Albisinni, U, Giannini, S. Advance in the treatment of aneurysmal bone cyst of the sacrum. *Skeletal Radiol.* 2011 Nov;40(11):1461–6.

[12] Chawla, S, Henshaw, R, Seeger, L, Choy, E, Blay, J-Y, Ferrari, S, et al. Safety and efficacy of denosumab for adults and skeletally mature adolescents with giant cell tumour of bone: interim analysis of an open-label, parallel-group, phase 2 study. *Lancet Oncol*. 2013 Aug;14(9):901–8.

[13] Wong, K-C, Kumta, S-M. Use of Computer Navigation in Orthopedic Oncology. *Curr Surg Rep*. 2014;2:47.

[14] Cho, HS, Oh, JH, Han, I, Kim, H-S. The outcomes of navigation-assisted bone tumour surgery: minimum three-year follow-up. J Bone *Joint Surg Br*. 2012 Oct;94(10):1414–20.

[15] Wong, KC, Kumta, SM. Computer-assisted tumor surgery in malignant bone tumors. *Clin Orthop*. 2013 Mar;471(3):750–61.

[16] Docquier, P-L, Paul, L, Cartiaux, O, Delloye, C, Banse, X. Computer-Assisted Resection and Reconstruction of Pelvic Tumor Sarcoma. *Sarcoma.* 2010;2010:1–8.

[17] Gerbers, JG, Ooijen, PMV, Jutte, PC. Computer-assisted surgery for allograft shaping in hemicortical resection: a technical note involving 4 cases. *Acta Orthop.* 2013 Apr;84(2):224–6.

[18] Ritacco, LE, Farfalli, GL, Milano, FE, Ayerza, MA, Muscolo, DL, Aponte-Tinao, L. Three-Dimensional Virtual Bone Bank System Workflow for Structural Bone Allograft Selection: A Technical Report. *Sarcoma*. 2013;2013:1–5.

[19] Jeys, L, Matharu, GS, Nandra, RS, Grimer, RJ. Can computer navigation-assisted surgery reduce the risk of an intralesional margin and reduce the rate of local recurrence in patients with a tumour of the pelvis or sacrum? *Bone Jt J*. 2013 Oct;95–B(10):1417–24.

[20] Gouin, F, Paul, L, Odri, GA, Cartiaux, O. Computer-Assisted Planning and Patient-Specific Instruments for Bone Tumor Resection within the Pelvis: A Series of 11 Patients. *Sarcoma*. 2014;2014:842709.

[21] Wong, KC, Kumta, SM, Sze, KY, Wong, CM. Use of a patient-specific CAD/CAM surgical jig in extremity bone tumor resection and custom prosthetic reconstruction. *Comput Aided Surg Off J Int Soc Comput Aided Surg*. 2012;17(6):284–93.

[22] Khan, FA, Lipman, JD, Pearle, AD, Boland, PJ, Healey, JH. Surgical technique: Computer-generated custom jigs improve accuracy of wide resection of bone tumors. *Clin Orthop.* 2013 Jun;471(6):2007–16.

[23] Wong, K-C, Sze, K-Y, Wong, IO-L, Wong, C-M, Kumta, S-M. Patient-specific instrument can achieve same accuracy with less resection time than navigation assistance in periacetabular pelvic tumor surgery: a cadaveric study. *Int J Comput Assist Radiol Surg*. 2016 Feb;11(2):307–16.

[24] Cartiaux, O, Paul, L, Francq, BG, Banse, X, Docquier, P-L. Improved accuracy with 3D planning and patient-specific instruments during simulated pelvic bone tumor surgery. *Ann Biomed Eng*. 2014 Jan;42(1):205–13.

[25] Krettek, C, Geerling, J, Bastian, L, Citak, M, Rücker, F, Kendoff, D, et al. Computer aided tumor resection in the pelvis. *Injury.* 2004 Jun;35(1):79–83.

[26] Hüfner, T, Kfuri, M, Galanski, M, Bastian, L, Loss, M, Pohlemann, T, et al. New indications for computer-assisted surgery: tumor resection in the pelvis. *Clin Orthop.* 2004 Sep;(426):219–25.

[27] Cartiaux, O, Banse, X, Paul, L, Francq, BG, Aubin, C-É, Docquier, P-L. Computer-assisted planning and navigation improves cutting accuracy during simulated bone

tumor surgery of the pelvis. *Comput Aided Surg Off J Int Soc Comput Aided Surg*. 2013;18(1–2):19–26.

[28] Cho, HS, Oh, JH, Han, I, Kim, H-S. Joint-preserving limb salvage surgery under navigation guidance. *J Surg Oncol.* 2009 Sep 1;100(3):227–32.

[29] Cho, HS, Park I-H, Jeon I-H, Kim Y-G, Han I, Kim H-S. Direct application of MR images to computer-assisted bone tumor surgery. *J Orthop Sci Off J Jpn Orthop Assoc*. 2011 Mar;16(2):190–5.

[30] Li J, Wang Z, Guo Z, Chen G-J, Yang M, Pei G-X. Irregular osteotomy in limb salvage for juxta-articular osteosarcoma under computer-assisted navigation. *J Surg Oncol.* 2012 Sep 15;106(4):411–6.

[31] Aponte-Tinao, LA, Ritacco, LE, Ayerza, MA, Muscolo, DL, Farfalli, GL. Multiplanar osteotomies guided by navigation in chondrosarcoma of the knee. *Orthopedics*. 2013 Mar;36(3):e325-330.

[32] Satcher RL. How intraoperative navigation is changing musculoskeletal tumor surgery. *Orthop Clin North Am*. 2013 Oct;44(4):645–56.

[33] Salvi, V. Identifit: a silicone mould used to intraoperatively construct a cementless femoral stem. *Chir Organi Mov*. 1992 Dec;77(4):443–5.

[34] Robinson, RP, Clark, JE. Uncemented press-fit total hip arthroplasty using the Identifit custom-molding technique. A prospective minimum 2-year follow-up study. *J Arthroplasty*. 1996 Apr;11(3):247–54.

[35] Al-Khateeb, H, Kwok, IHY, Hanna, SA, Sewell, MD, Hashemi-Nejad A. Custom cementless THA in patients with Legg-Calve-Perthes Disease. *J Arthroplasty*. 2014 Apr;29(4):792–6.

[36] Batta, V, Coathup, MJ, Parratt, MT, Pollock, RC, Aston, WJ, Cannon, SR, et al. Uncemented, custom-made, hydroxyapatite-coated collared distal femoral endoprostheses: up to 18 years' follow-up. *Bone Jt J.* 2014 Feb;96–B(2):263–9.

[37] McGrath, A, Sewell, MD, Hanna, SA, Pollock, RC, Skinner, JA, Cannon, SR, et al. Custom endoprosthetic reconstruction for malignant bone disease in the humeral diaphysis. *Acta Orthop Belg.* 2011 Apr;77(2):171–9.

[38] Malik, HH, Darwood, ARJ, Shaunak, S, Kulatilake, P, El-Hilly, AA, Mulki, O, et al. Three-dimensional printing in surgery: a review of current surgical applications. *J Surg Res*. 2015 Dec;199(2):512–22.

[39] Kotz, RI. Progress in musculoskeletal oncology from 1922 – 2012. *Int Orthop.* 2014 May;38(5):1113–22.

[40] Schindler, OS, Cannon, SR, Briggs, TW, Blunn, GW. Stanmore custom-made extendible distal femoral replacements. Clinical experience in children with primary malignant bone tumours. *J Bone Joint Surg Br.* 1997 Nov;79(6):927–37.

[41] Wong, KC, Kumta, SM, Geel, NV, Demol, J. One-step reconstruction with a 3D-printed, biomechanically evaluated custom implant after complex pelvic tumor resection. *Comput Aided Surg*. 2015 Jan 2;20(1):14–23.

[42] Fan, H, Fu, J, Li, X, Pei, Y, Li, X, Pei, G, et al. Implantation of customized 3-D printed titanium prosthesis in limb salvage surgery: a case series and review of the literature. *World J Surg Oncol* [Internet]. 2015 Dec [cited 2017 Jan 20];13(1). Available from: http://www.wjso.com/content/13/1/308.

[43] Danışman, M, Mermerkaya, MU, Bekmez, Ş, Ayvaz, M, Atilla, B, Tokgözoğlu AM. Reconstruction of periacetabular tumours with saddle prosthesis or custom-made

prosthesis, functional results and complications. *Hip Int J Clin Exp Res Hip Pathol Ther*. 2016 Mar 23;26(2):e14-18.

[44] Farfalli, GL, Albergo, JI, Ritacco, LE, Ayerza, MA, Milano FE, Aponte-Tinao LA. What Is the Expected Learning Curve in Computer-assisted Navigation for Bone Tumor Resection? *Clin Orthop Relat Res.* 2017 Mar;475(3):668–75.

[45] Tack, P, Victor, J, Gemmel, P, Annemans, L. 3D-printing techniques in a medical setting: a systematic literature review. *Biomed Eng Online.* 2016 Oct 21;15(1):115.

[46] Koff, MF, Shah, P, Koch, KM, Potter, HG. Quantifying image distortion of orthopedic materials in magnetic resonance imaging. *J Magn Reson Imaging JMRI.* 2013 Sep;38(3):610–8.

[47] Zimel, MN, Hwang, S, Riedel, ER, Healey, JH. Carbon fiber intramedullary nails reduce artifact in postoperative advanced imaging. *Skeletal Radiol.* 2015 Sep;44(9):1317–25.

[48] Kamiński, P, Szmyd, J, Ambroży, J, Jurek, W, Jaworski, JM. Use of Trabecular Titanium Implants for Primary Hip Arthroplasty. *Ortop Traumatol Rehabil.* 2016 Oct 28;18(5):461–70.

[49] Konan, S, Duncan, CP, Masri, BA, Garbuz, DS. Porous tantalum uncemented acetabular components in revision total hip arthroplasty: a minimum ten-year clinical, radiological and quality of life outcome study. *Bone Jt J.* 2016 Jun;98–B(6):767–71.

[50] John, TK, Ghosh, G, Ranawat, CS, Ranawat, AS, Meftah, M. Performance of Non-Cemented, Hemispherical, Rim-Fit, Hydroxyapatite Coated Acetabular Component. *J Arthroplasty*. 2015 Dec;30(12):2233–6.

[51] Donati, F, Di Giacomo, G, D'Adamio, S, Ziranu, A, Careri, S, Rosa, M, et al. Silver-Coated Hip Megaprosthesis in Oncological Limb Savage Surgery. *BioMed Res Int.* 2016;2016:1–6.

[52] Schmidt-Braekling, T, Streitbuerger, A, Gosheger, G, Boettner, F, Nottrott, M, Ahrens H, et al. Silver-coated megaprostheses: review of the literature. *Eur J Orthop Surg Traumatol Orthop Traumatol*. 2017 Mar 6;

[53] Schmolders, J, Koob, S, Schepers, P, Pennekamp, PH, Gravius, S, Wirtz, DC, et al. Lower limb reconstruction in tumor patients using modular silver-coated megaprostheses with regard to perimegaprosthetic joint infection: a case series, including 100 patients and review of the literature. *Arch Orthop Trauma Surg*. 2017 Feb;137(2):149–53.

[54] Dalstra, M, Huiskes, R. Load transfer across the pelvic bone. *J Biomech.* 1995 Jun;28(6):715–24.

[55] Icke, C, Koebke, J. Normal stress pattern of the pubic symphysis. *Anat Cell Biol.* 2014;47(1):40.

In: Encyclopedia of Surgery (22 Volume Set)
Editors: Andreas Lehrer and Kristin Mueller
ISBN: 978-1-53618-329-0
© 2020 Nova Science Publishers, Inc.

Chapter 154

THE ROLE OF SURGICAL RESECTION IN HEPATOCELLULAR CARCINOMA: ANATOMIC VERSUS PARENCHYMA-SPARING RESECTION AND THEIR ONCOLOGICAL OUTCOMES

Simone Famularo*, MD, Alessandro Giani, MD, Fabio Uggeri, MD, Cristina Ciulli, MD, Luca Nespoli, MD, Giulia Lo Bianco, MD, Luca Arzuffi, MD, Luca Gianotti, MD, ScD and Fabrizio Romano, MD

School of Medicine and Surgery, University of Milan-Bicocca, Italy
Department of Surgery, HPB Unit, San Gerardo Hospital, Monza, Italy

ABSTRACT

Surgical resection is an optimal curative approach to hepatocarcinoma. When transplantation is not feasible, hepatectomy is the first choice to effectively treat HCC. The 5-year overall survival for the disease stages that benefit from this approach, ranges from 50 to 70%. Unfortunately, only 20-30% of patients are eligible for curative intervention. Moreover, the 5-year-recurrence rate after surgery is close to 70%.

Over the last decades, the attempt to reduce recurrence rate, together with a more thorough understanding of the mechanism underlying this phenomenon has lead experts to ask themselves what the best surgical procedure could be. Defining the right extent of the resection is often difficult and unequivocal guidelines have yet to be established. Currently, most international guidelines suggest that the anatomic resection (AR) of a liver segment may allow the removal of the segmental portal bed, preventing microvascular invasion and satellitosis which may be the cause of intrahepatic metastasization (currently ranging between 20 and 70%). Nevertheless, many reports have shown a similar rate of local recurrence (almost 15%) in cases of parenchyma-sparing resection (PSR), where the cancer nodule is removed regardless of the portal segment extension. A recent meta-analysis showed no significant differences in

* Corresponding Author's Email: simone.famularo@gmail.com.

recurrence rate in the two procedures (RR 1.28, 95%CI: 0.59-2.76; p:0.53). No clear advantages can be proven in terms of overall survival, either: the 5-year overall survival rate is 64.9% for AR and 61.1% for PSR. Moreover, PSR was proved to be a safe and oncologically correct technique for cirrhotic patients, for whom preserving as much parenchyma as possible is mandatory to reduce the impact of postoperative liver failure or ascites.

In this chapter, we will focus on the indications to surgery in HCC, on how to perform a liver resection, and on the different indications to the two main surgical approaches to hepatocellular carcinoma. We will discuss long-term outcomes; different theories on the causes of recurrence after resection, and how this evidence could possibly lead to an extension of the indications to a surgical curative approach in primary liver carcinoma.

1. INTRODUCTION

Hepatocellular Carcinoma (HCC) is one of the 5 most common malignancies worldwide and the third most common cause of cancer related mortality, accounting for 500,000 deaths globally every year. Although more common in East Asia, the incidence of HCC is constantly increasing in the Western world [1]. Hepatic resection is the first-line therapeutic option and is accepted as a safe treatment, with a proven impact on prognosis and with a low operative mortality, result of the recent innovations in surgical techniques and perioperative management [2]. These advances have improved the outcomes of hepatic resection for HCC, reducing operative morbidity and mortality [3]. However, only 20 to 30% of HCC patients can be candidates to surgical resection because of a poor hepatic reserve function, either caused by underlying chronic liver disease or by HCC multifocal distribution. Although hepatic resection is considered to be a curative treatment for hepatocellular carcinoma, HCC recurrence rate after surgery is quite high, approaching 50% in the first 3 years and reaching 70% in the first 5 years after curative resection [4, 5]. Thus, long term results after surgery remain unsatisfactory. This poor prognosis is commonly alleged to the high incidence of intrahepatic metastasis and of multicentric de novo HCC [6] which develop in accordance with the precancerous status of the remnant diseased liver [7]. With respect to intrahepatic recurrence, macro-portal invasion and intrahepatic metastasis were considered to be the strongest risk factors to affect postoperative prognosis.

However, the role of the different recurrence mechanisms still needs to be clarified. Previously, portal vein dissemination caused by the spreading of HCC cells through the portal vein and its branches was considered the main route for intrahepatic metastasization. This led to the notion that anatomical resection, whose limits are defined by the area of the venous, may prevent intrahepatic metastasization of HCC [8, 9, 10]. Based on this premise, Makuuchi et al. [11] described a correct anatomic resection as the systematic removal of the tumor-bearing hepatic segment confined by its portal tributaries. From a theoretical standpoint, this procedure may be effective in preventing intrahepatic metastasis of HCC. Based on the portal blood flow dissemination theory [12], some authors [13, 14] have used AR for HCC, showing oncological and survival benefits for AR over non-anatomical resections (NAR). However, their results have been debated and no definite conclusion can be drawn from them.

Other authors have reported that AR may prevent hepatic recurrence and prolong survival [15]. In their systematic review of 18 observational studies involving a total of 9036 patients,

Cucchetti et al. [12] showed that AR provided a better 5-year overall survival (OS) and disease-free survival (DFS) rate than NAR. Other meta-analyses such as the one by Zhou et al. [16] reported similar results. This data reinforces the theory that AR may reduce the risk of intrahepatic metastasization through portal flow. In a large research project based on Japanese national data analysis, Eguchi et al. [8] also proved a higher RFS rate in AR than in NAR, but a significant statistical difference has not been observed for patients with an HCC larger than 5cm. Despite the advantages shown by these studies, AR can be more difficult to perform and carries more risks than NAR for patients with a low preoperative liver function (e.g., those with cirrhosis). Generally speaking, a larger part of liver parenchyma is resected in AR than in NAR, leading to an increased risk of intraoperative bleeding and to a longer operation time. In clinical practice, surgeons tend to prefer AR when HCC patients display a good liver function, a small-sized tumor, and no cirrhosis.

The evidence of HCC recurrence occurring even in cases treated by hepatic resection and liver transplantation lead to the development of new theories on the pathogenesis of intrahepatic metastasization. According to this new insight, HCC metastatic cells may spread by first migrating through the tumor blood flow (TBF) and then rehoming to the remnant liver [17, 18]. Sakon et al. [19] defined three different patterns of intrahepatic recurrence of HCC as detailed below. Local Intrahepatic Metastasis (IM) (1): HCC recurrence around the tumor by direct spread of the tumor through portal blood flow or venous drainage; Systemic IM (2): HCC recurrence caused by circulating tumor cells (CTCs); MC (3): multicentric HCC recurrence caused by de novo development of HCC. HCC circulating tumor cells have been detected in 81-88% of patients at the time of surgery [20]. Early circulating tumor cells are thought to be spread by portal vein branches [21]. AR aims to resect the liver and the supplying portal vessels respectively in accordance with Couinaud's segments. Thus, theoretically, AR should resect micrometastases (MMTs) within the anatomical segment and reduce the risk of recurrence. It is therefore reasonable to postulate that AR would be more effective than NAR in clearing MMTs and circulating tumor cells, thus decreasing local recurrence (LR) caused by "nearby" MMTs, but not distant recurrence (DR).

Nonanatomic resection (NAR) focuses on achieving a margin-negative liver resection without considering Glisson's pedicle distribution. Because of the high prevalence of underlying liver conditions such as chronic hepatitis and cirrhosis, NAR is often preferred for patients with hepatocellular carcinoma, since it allows sparing of as much liver parenchyma as possible [22]. A cirrhotic liver has a very limited capacity for regeneration and this affects long-term prognosis, which is benefited by parenchyma sparing resections.

Due to the unbalanced distribution of AR and NAR, it was difficult to reach a consensus concerning the advantage of AR in previous studies. Recent studies have failed to confirm the benefits of AR [23, 24] on survival. Okamura et al. and Marubishi et al. [6, 25] have questioned the advantages of AR and showed the incidence of HCC recurrence to be similar on comparing AR and NAR groups. Thus, the effective superiority of AR compared to non-anatomic resection (NAR) remains controversial. Therefore, surgeons must maintain a balance between radical surgery and the need to preserve the function of the remnant liver, which is the focus of the dispute between AR and NAR. No clear advantages could be shown for either of the two techniques in terms of overall survival: the 5-year overall survival rate was 64.9% for AR and 61.1% for PSR. To date, no randomized controlled study has compared outcomes of these two resection methods. The main problem that surgeons face while operating on patients with cirrhosis is balancing the need to achieve a radical

intervention while simultaneously preventing the development of postoperative liver failure that could ensue from the removal of too much liver parenchyma. This problem is the basis of the dispute between AR, a theoretically more radical procedure from an oncologic point of view, and NAR, which reduces the risk of postoperative hepatic failure. The oncological advantage of AR has been actively studied and discussed for decades. The available data is insufficient to prove the prognostic advantage of AR due to the reasons listed below.

First, the definition and surgical technique for AR are not standardized among institutions. Second, the baseline characteristics vary considerably in previous studies making it difficult to determine the pure prognostic advantage of AR, even by meta-analyses, due to the heterogeneity of the target population. Third, because of the significant differences in the preoperative liver function in AR and non-AR populations, a simple prognostic comparison cannot be free from selection bias.

In this chapter we will briefly focus our attention on the surgical indication in HCC, on how to perform a liver resection, and on the different indications to the two main surgical approaches to hepatocellular carcinoma. We will discuss long-term outcomes; the different theories on the mechanisms of recurrence after resection, and show how this evidence could possibly lead to a future extension of the surgical curative approach to primary liver carcinoma.

2. INDICATION TO SURGERY

Hepatocellular carcinoma (HCC) is often associated with liver cirrhosis [26]. As a result, the choice of treatment of this pathology is complex and subject to much debate. There is the need to obtain a radical oncological cure, and, at the same time, to ensure the preservation of as much functioning liver parenchyma as possible, considering that it is frequently already compromised by the underlying liver disease. Liver transplantation is theoretically the only possibility for handling both HCC and liver cirrhosis, but this option is not always viable due to the limited availability of organ donors [27]. Moreover, for patients exceeding Milano Criteria, and therefore excluded from transplant, hepatic resection seems the best chance for obtaining a prognostic improvement, reducing morbidity and mortality rates [28].

Nowadays, the most largely accepted algorithm able to direct HCC therapy is based on the Barcelona Clinic Liver Cancer (BCLC) classification (Table 1) developed and validated by the European Association for the Study of Liver Disease (EASL) and by the American Association for the Study of Liver Disease (AASLD) at the end of the last century [29–31] and constantly updated at consensus conferences [32]. In order to determine the patient's prognosis, this classification takes into account preoperative liver status, based on Child-Pugh class, bilirubin levels, presence of portal hypertension, general physical status and local tumor characteristics [33, 34]. It also provides recommendations on therapeutic options, as shown in Table 2. Liver resection, PEI (Percutaneous Ethanol Injection) and thermal ablation with radiofrequency (RFA) are indicated as radical treatments for early-stage tumors. Patients with multiple, large or macrovascular invasive HCC are addressed to palliative treatments, such as TACE (Trans-Arterial Chemo-Embolization), chemotherapy with new agents or others supportive treatments [30].

Table 1. BCLC classification

Stage	*PST*	*Tumour characteristics*	*Liver functional status*
Stage 0: very early stage HCC	0	Single < 2 cm	No portal hypertension and normal bilirubin
Stage A: early HCC			
A1	0	Single < 5 cm	No portal hypertension and normal bilirubin
A2	0	Single < 5 cm	Portal hypertension and normal bilirubin
A3	0	Single < 5 cm	Portal hypertension and abnormal bilirubin
A4	0	3 tumours < 3 cm	Child-Pugh A-B
Stage B: intermediate HCC	0	Large multinodular (single tumour > 5 cm or 2-3 tumours of which at least one is > 3 cm)	Child-Pugh A-B
Stage C: advanced HCC	1-2	Any tumour with radiological evidence of vascular invasion or extrahepatic spread	Child-Pugh A-B
Stage D: end-stage HCC	3-4	Any	Child-Pugh C

PST: Performance Status Test

Table 2. Treatment schedule according to BCLC classification

Stage	*Treatment intention*	*First/Second Line treatment*
Stage 0	Radical	Surgical resection
Stage A: early HCC		
A1	Radical	Surgical resection
A2	Radical	Surgical resection → OLT/Percutaneous treatment
A3	Radical	OLT/Percutaneous treatment
A4	Radical	OLT/Percutaneous treatment
Stage B: intermediate HCC	Palliative	Trans-Arterial Chemo-Embolization
Stage C: advanced HCC	Palliative	New agents
Stage D: end-stage HCC	Symptomatic	Supportive treatment

OLT: Orthotopic Liver Transplantation

In early stage HCC, both surgery and radiofrequency are indicated as first-line treatments, with certain specifications: patients that present multiple comorbidities, elderly patients and, in wider terms, all patients that cannot tolerate a general anesthesia are addressed to radiofrequency. An increased level of bilirubin, portal hypertension or the presence of multiple nodules are also indications to radiofrequency [32]. In selected patients with multinodular HCC, surgical treatment can be associated with intraoperative radiofrequency; this is done, for instance, to achieve radicality on hepatocarcinoma nodules located in anatomically unfavorable positions. Starting from EASL and AASLD recommendations, many local guidelines have been developed by the main liver study groups.

It is universally accepted that, apart from liver transplantation, and consistently with a BCLC treatment schedule, hepatic resection is the best course of treatment for “very early” or “early” stage HCC. Nevertheless, several single-center reports describe benefits from surgical treatment even for patients with microvascular invasive, multinodular or large HCC. Especially for stage B HCC, the lack of indications to a curative treatment strongly contrasts

with clinical practice where, in many centers, patients are addressed to hepatic resection, with a largely demonstrated increase in overall survival (OS) and disease-free survival (DFS) [35-39]. This led to the diffusion of alternative local algorithms, to guide the selection of patients who are eligible to a surgical treatment.

In 2005, Ng et al. demonstrated that even large or multinodular HCC can safely undergo surgical treatment. On a large multi-institutional database of patients treated with hepatic resection in 5 major hepatobiliary centers in Asia, Europe and The United States, they showed a 5-year overall survival of 39% [35]. Ishizawa et al. showed that an adequate patient selection, according to the Child-Pugh class, allows for a dramatic increase in overall survival rates (up to 56%) among Child-Pugh A patients, even in the presence of multiple tumors or portal hypertension [36]. In 2013, Torzilli et al. definitely demonstrated how an update of EASL/AASLD therapeutic guidelines was needed. They conducted a retrospective multicentric survey, showing how, in current clinical practice and in opposition to the existing guidelines, more and more centers recur to surgery for patients with multinodular, large and macrovascular invasive HCC with acceptable short- and long-term results [37]. Almost simultaneously, Bolondi and a panel of experts, proposed a sub-classification of BCLC stage B HCC in order to tailor therapeutic interventions, taking into account the widely emerging data and expert opinions [40, 41]. The staging system was extended as depicted in Table 3.

Taking the lead from this sub-classification, Ciria et al. reported an increase in 5-year overall survival to 62.9%, 28.1% and 15.4%, respectively for B1, B2 and B3-4 stages. They therefore suggested to include this new criteria in the official guidelines [38].

Table 3. BCLC sub-staging

Sub-stage	*Child-Pugh score*	*Up-to-7 criterion**	*PST*	*PVTT*
B1	5-7	IN	0	NO
B2	5-6	OUT	0	NO
B3	7	OUT	0	NO
B4	8-9	ANY	0-1	NO

* Up-to-7 criterion combines the number of nodules and the major tumour diameter, with the sum being no more than 7.

To our knowledge, the most recent paper on the subject was published in 2018 by Liang et al. It consisted in a systematic review and meta-analysis of Asian data comparing the surgical approach and TACE in intermediate stage HCC. This publication confirmed once again the superiority of hepatic resection in terms of overall survival, without any significant increase in 30-day mortality rates [39]. Given the complexity of the criteria for the surgical approach and their non-universal acceptance, an update in official recommendations is needed. In the meanwhile, a multidisciplinary evaluation of each single case is desirable and useful, in our opinion, since different specialists are potentially involved in the treatment and follow-up of an HCC patient [42].

3. ANATOMIC RESECTION (AR) AND PARENCHYMA-SPARING-RESECTION (PSR)

3.1. Generalities

Recent technical improvements have made hepatectomy for hepatocarcinoma (HCC) an increasingly safe form of curative treatment. However, the long-term survival of patients remains unsatisfactory due to the high rates of recurrence, estimated between 70 and 80% after 5 years [43, 44]. Recurrence can be intrahepatic or multicentric. While different kinds of treatment may suppress liver fibrosis and thus prevent multicentric recurrence, intrahepatic recurrence seems to be closely related to local vascular invasion, thus making anatomical resection (AR) the best technique to prevent it, from a theoretical standpoint [45].

Microportal invasion and intrahepatic metastasis were once considered to be the most important factors leading to recurrence and were associated with poor prognosis [46, 47]. On this basis, Makuuchi et al. first described AR in 1985 [48]. The procedure is based on the systematic removal of a liver segment with its tributary portal branches and should theoretically allow the elimination of intrahepatic micro metastasis improving patient survival. The long-term outcome after resection of hepatocellular carcinoma, however, is also influenced by factors related to the characteristics of the tumor and by the underlying liver disease.

Today the choice between anatomical resection (AR) and non anatomical (NAR) resection for HCC is controversial. From an oncological point of view, AR appears to be superior to NAR, enabling to obtain negative margins and leading to a better 2-year recurrence rate for high grade aggressive tumors, as it permits the removal of satellite lesions and microvascular invasion [23]. Moreover, the better control of the vascular pedicle in AR allows for a reduced intraoperative blood loss, leading to a lower rate of postoperative morbidity and mortality [49]. In fact, NAR results in a higher incidence of biliary fistula and infection because of the higher percentage of remnant devitalized liver tissue [7]. To understand the vascular and biliary anatomy of the liver is mandatory for a successful AR. Since HCC usually develops over a background of liver cirrhosis, it is important that anatomical resection be able to clear the tumor and still leave a sufficient amount of liver to avoid postoperative liver failure.

The concept of anatomical resection is based on the division of the liver into segments first described by Healy in 1953 [50] and updated by Couinaud in 1957 [51]. Nowadays, from a surgical-functional point of view, we no longer divide the liver into lobes, according to classic topographic anatomy, but, more correctly, into segments based on portal, arterial and biliary branching. The liver, as proposed by Couinaud [51], is therefore divided into four sectors, each delimited by a branch of the portal vein; sectors are further divided into segments for a total of eight, conventionally indicated with the corresponding Roman number. The projection, on the upper surface of the liver, of the course of the mean hepatic vein (the main portal fissure, corresponds to the ideal line connecting the left margin of the cava vein to the bottom of the gallbladder) divides the organ into two hemi-livers: right and left, provided with an autonomous vascular and biliary supply. The two hemi-livers are in turn divided into two sectors from the left and right portal fissures (Figure 1). The right portal fissure corresponds to the course of the right hepatic vein and is projected on an ideal line that from

the right margin of the vena cava points anteriorly to the middle point between the right margin of the liver and the right margin of the gallbladder (Figure 1). The left portal fissure corresponds to the course of the left hepatic vein and is projected on an ideal line that from the left margin of the vena cava reaches the left margin of the liver (Figure 1). Starting from the right lobe of the liver and moving towards the left, you can distinguish:

- The *right lateral sector*: formed by the VII° (above) and VI° segment (below)
- The m*edial right sector*: formed by the VIII ° (above) and V° segment (below)
- The l*eft medial sector:* formed by the I° and IV° segments (lateral) and by the IV° and III ° segments (medial)
- The l*eft lateral sector*: formed by the II° segment (Figure 2)

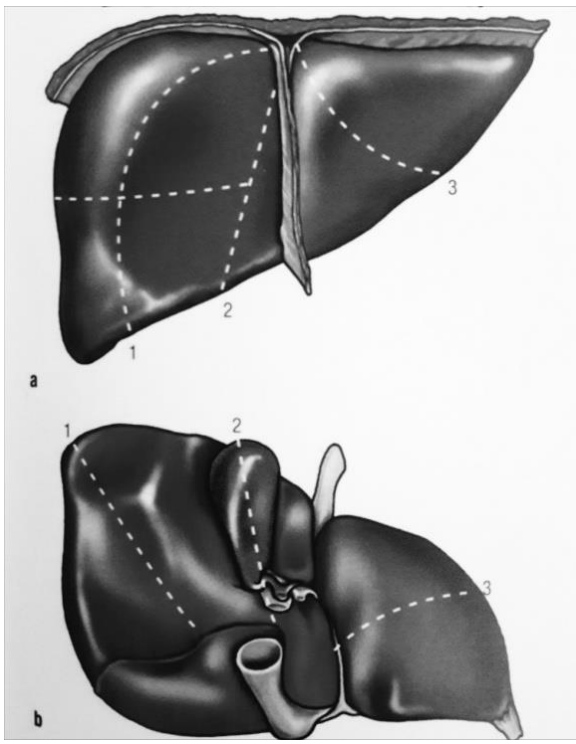

Figure 1. Representation on the anterior (a) and inferior (b) surface of the liver, of the portal fissures and of the division in segments: 1) right portal fissure; 2) main or median portal fissure; 3) right portal fissure.

The scientific committee of the International Hepato-Pancreato-Biliary Association proposed the Brisbane 2000 Terminology of Liver Anatomy and resection [52] to define a universal terminology with which to refer to liver anatomy. According to this terminology, first the liver is divided into two parts, the main liver and the caudate lobe (called I° segment by Couinaud). Then the main liver is divided into the right and left liver. The practical applications of this subdivision is proven by the fact that this terminology has gained wide acceptance removing most of the confusion that existed in the past.

Figure 2. Subdivision of the liver into segments according to Couinaud.

To perform a precise anatomical liver dissection it is necessary to accurately identify the segments and the portal fissures during resection. Different methods of segment identification are employed both in conventional hepatic surgery and in laparoscopy. The most widely tested methods are the tattooing method [48, 53] and the Glissonian approach [54, 55], which is especially simple to perform. Other techniques have been experimented; some Authors inject intravenous indocyanine green after clamping the Glissonian pedicle to better define the resection margins [56]. The aim of this section is to describe the various techniques currently used to perform an anatomical resection of the liver in the presence of HCC.

3.2. Anatomical Resection

As already described, anatomical resection refers to the resection of the tumor-involved segment or section, together with its portal vein branch, resected *en bloc*. This approach includes: left or right hepatectomy, hemihepatectomy, segmentectomy and sub-segmentectomy, sectionectomy and trisectionectomy, based on Couinaud's classification. In sectionectomy, the resection line is defined by a demarcation on the liver surface after ligation of the sectional pedicle and of the trunk of the hepatic vein exposed on the resected surface [42].

3.2.1. Glissonian Approach

The approach to the Glissonean pedicle has enabled us to obtain new knowledge of liver anatomy which lead to an improvement of surgical techniques. This approach starts with an extra fascial access to the hepatic hilum. The secondary Glissonean pedicles are taped and ligated at the hepatic hilum without parenchyma dissection. Dissection starts above the hilar plate so that the surgeon does not have to take into account possible artery and bile duct anatomic variations. Tertiary branches can be approached through the hepatic hilum or

through the liver parenchyma at the margin between segments [57]. The Glisson capsule is made up of connective tissue covering the peduncle, which in turn contains the hepatic artery, portal vein and bile duct. The Glisson capsule is connected to the liver capsule and to the hepatoduodenal ligament forming a thick plate on the inferior face of the liver, which is referred to as the "hilar plate."

The first dissection of the hepatoduodenal ligament elements during hepatectomy was performed around 1950 and the procedure was defined as the first hepatectomy with controlled method [58]. By contrast, a few years later, other Authors started dissecting the liver parenchyma, approaching and ligating the portal pedicles intra-hepatically [59, 60]. These two approaches are recognized as being the basic techniques for anatomic liver resection [61]. Couinaud et al. [62] and Takasaki et al. [54] first reported the Glissonian approach to the hepatic hilus respectively in 1985 and 1986. Couinaud [63] later described three different ways to approach Glissonean pedicles: *the intrafascial, the extrafascial,* and *the extrafascial and transfissural approaches.*

The *intrafascial approach* involves a conventional dissection of the hepatoduodenal ligament. Dissection is performed below the hilar plate, making the procedure unsafe, and surgeons have to take into account possible anatomic variations of the hepatic artery and bile ducts. In the *extra-fascial approach,* instead, the pedicle is dissected first through the hepatic parenchyma and then extra-hepatically at the hilum. In the *extra-fascial and transfissural approach* the main portal fissure or left supra-hepatic fissure are opened after dissecting the liver parenchyma, and surgeons can therefore appreciate the direction and distribution of the pedicles that arise from the hilar plate. This procedure involves major hepatic transections along the main portal branches or the umbilical fissure [59, 60]. The extrafascial approach is further separated into the *intrahepatic* and *extrahepatic* approaches depending on the presence or absence of parenchymal destruction. Intrahepatic isolation can possibly lead to unexpected injury of the portal pedicle or hepatic vein, therefore extrahepatic Glissonean pedicle isolation should be considered the ideal procedure [64].

To approach the right Glissonean pedicle the procedure provides that, after cholecystectomy, the cystic plate be dissected. Behind the cystic plate, the right anterior Glissonian pedicle can then be recognized and approached carefully after having detached the hilar plate from the liver parenchyma. Subsequently, the pedicle is completely dissected and clamped to confirm the extension of the area supplemented by its flow. The right, posterior pedicle can then be taped after the main pedicle is. Afterwards, the tape is pulled at the ramification between the anterior and right posterior pedicle. This procedure allows us to evidence the area of altered parenchymal staining after clamping and the site of the neoplasm as confirmed by ultrasound. At this point the pedicle must be ligated and dissected before going further with the liver section [55].

The approach to the left pedicle was first described by Couinaud in 1985 [62]. Dissection starts to the left of the hilus and is then conducted along the ventral surface of the Arantius duct. Finally the pedicle is encircled and clamped. Some liver surgeons have attempted to reproduce these methods in laparoscopy, but, due to the anatomic complexity of the liver and to the inherent limitations of the laparoscopic technique, this has proven difficult. The recent introduction of robotic techniques has enhanced the possibilities of performing minimally invasive liver surgical procedures. Recently, Lee et al. [65] reported a series of 10 patients subjected to an extrahepatic right approach of the Glissonean pedicle by robotic route. Four robotic ports and one assistant port were used. The falciform and ipsilateral coronary ligament

were sectioned, the inferior and posterior sides of the liver freed from the diaphragm and the plane of the inferior vena cava exposed. The liberation of the right liver is achieved through the section of accessory hepatic veins. The selected Glissonean pedicle is then dissected by the extrafascial approach, at the hepatic hilus for the right resections and at the level of the round ligament for medial and lateral sectionectomy.

When resection is first conducted along the right or left side of the round ligament, parenchymal transection is performed to expose Glissonian pedicles. In right posterior sectionectomy, the gallbladder is retracted upwards to expose the hepatic hilus and the portal branches that supply the I° segment, which are sectioned to expose the main portal branches. Once the pedicle has been identified, it is encircled and closed with a laparoscopic clamp. Clamping produces an ischemic demarcation on the line of hepatic transection that is then marked with an electrocautery hook. Finally, an intraoperative ultrasound examination is performed to confirm the location of the neoplasm and the extension of surgical margins.

3.2.2. Indocyanine Green

In hepatobiliary surgery, the fluorescence and bile excretion of indocyanine green (ICG) can be used for real-time visualization of biological structures. Intra-operatory fluorescence imaging can be used to identify subcapsular hepatic tumors and to define the limits of hepatic segments. The limits of hepatic segments can be visualized through the injection of ICG in the portal vein or after intravenous injection following the closure of the portal pedicle proximal to the region that has to be removed. This technique enables the identification of liver segments before surgical resection and during parenchymal transection for anatomic resections. Intraoperative fluorescence imaging is able to localize the neoplastic lesion thanks to the biliary secretion disorders that are characteristic of the neoplastic tissue of hepatocellular carcinoma and of the hepatic parenchyma surrounding adenocarcinoma [66].

Fluorescence imaging following portal injection of IGC was used for the first time in 2008 for the identification of hepatic segments [67]. Since then, the technique has been improved by combining a more diluted ICG solution (2.5 mg) to an imaging system able to merge fluorescence images with color images [68]. The concomitant injection of indigo-carmine solution (an organic salt derived from indigo by sulfonation) and IGC can increase the rate of identification of the liver segments, especially in patients affected with cirrhosis or that have undergone previous surgery, where the presence of connective tissue can mask the hepatic surface [69].

In addition to identifying hepatic segments after portal injection of ICG (*positive staining technique*), hepatic segments can also be identified as ischemic areas through intravenous injection of ICG after closure of the corresponding portal pedicle (*negative staining technique*) [68, 70]. Intraoperative fluorescence imaging may also allow us to estimate portal uptake in veno-occlusive regions of the liver during hepatectomy [71].

The use of indocyanine green in localizing the neoplastic lesion in need for removal is also useful in minimally invasive surgery, where the possibilities of inspection and manipulation are limited compared to open surgery. Furthermore, the negative staining technique is particularly useful in laparoscopy where injection of ICG into the portal vein is technically difficult [70, 72]. When the V° VI° VII° VIII° liver segments have to be approached, different difficulties may arise that make it harder to perform the operation in laparoscopy, while intraoperative ultrasound may be difficult due to the impossibility of freely handing the ultrasound probe.

In this regard, Ueno et al. [56] reported a new technique for liver segment identification in laparoscopic surgery. They previously performed a laparoscopic splenectomy concomitant with interventional radiology for hypersplenism to reduce intraoperative blood loss. With this technique the authors tried to overcome the difficulty of dye injection during laparoscopic intraoperative ultrasound. At first they mobilized the liver, then, from the right femoral artery, they inserted a 3 French (Fr) sheath catheter, under the guide of preoperative simulation images. Two other catheters of 3 and 1.9 Fr respectively were inserted into the celiac artery and into the targeted arterial branches. After confirming the perfusion area through arteriography, a mixed dye solution including ICG was injected into the target and the branches were embolized using gelatin particles.

The mixed dye solution was composed of: 2 mL of a diluted IGC solution, 2 mL of indigo carmine water, 1 mL of Sonazoid solution and 1 mL of a contrast medium. As an embolic agent 1 mm of porous gelatin particles were mixed with 3 mL of a mixed dye solution and 10 mL of a contrast medium. At this point about 3 ml of mixed dye solution were slowly injected into the target and the targeted branches were then embolized. When performed under fluoroscopy monitoring, this technique requires a hybrid operating room. Immediately after the injection of the dye solution mixture, visual alterations can be observed on the surface of the liver, along with ICG fluorescent margins, that define the intraparenchymal cutting line.

3.3. Parenchyma Sparing Liver Resection

Liver resection often represents the treatment of choice for both primary and secondary liver malignancies [73]. Depending on tumor location, dimension and diffusion major resections may be required to achieve an adequate oncologic result. Volume of remnant liver is crucial to avoid postoperative liver failure, especially in cirrhotic patients or in patients submitted to neoadjuvant chemotherapy. In order to reduce the substantial morbidity and mortality associated with major liver resections, attention has focused on the technical possibility of sparing as much liver as possible while aiming at achieving, at the same time, an effective oncological result.

A better knowledge of tumor biology and of its influence on local recurrence and survival, and the development of intraoperative ultrasound skills, constitute the basis of the so-called “parenchymal sparing liver surgery.” The term parenchymal sparing resection (PSR) encompasses a wide range of resections, ranging from non anatomical, small, wedge resection to more complex non-anatomical atypical resections.

3.3.1. Preoperative and Intraoperative Planning

The prerequisite for PSR is a careful and meticulous evaluation of the relationship between hepatic lesions of hepatic veins and the glissonian pedicles. This evaluation allows the planning of the ideal anatomical roadmap for a proper resection, preserving an adequate blood inflow and outflow from the spared parenchyma. CT scanning and MRI are usually employed preoperatively for this purpose and give the possibility for different image reconstruction techniques, including 3D imaging [74, 75]. Although displaying a suboptimal sensitivity for smaller (<1 cm) lesions, triphasic CT scanning allows us to obtain an optimal

vascular and lesion assessment. Moreover, it allows for concomitant volumetric assessment of the remnant liver [76].

MRI, with the use of liver-specific contrast agents, offers a good sensitivity for smaller hepatic nodules also. Moreover, it provides a good visualization of the biliary tree anatomy, useful for planning an ideal resection plane. Intraoperative imaging through ultrasound (IOUS) is essential in PSR, since it allows the localization of even small or deep-located nodules and "navigation" into the liver following the planned resection plane precisely, visualizing and preserving vascular and biliary structures [77]. IOUS allows for a complete investigation of the vascular anatomy of the liver: hepatic veins and accessory hepatic veins can be visualized, as well as the presence of communicating vessels within adjacent hepatic veins. These communicating vessels allow us to perform a PSR even in the presence of a neoplastic involvement of a hepatic vein at a hepatic-caval confluence. They preserve an adequate venous outflow from the spared parenchyma. A successful PSR, especially in complex cases, requires excellent expertise in using this technique, as well as high quality equipment.

3.3.2. Surgical Techniques

The definition of PSR encompasses different kinds of liver resection able to maximize the liver remnant volume if compared with other, more extended, techniques.

4. LONG TERM OUTCOMES AND RISK FACTORS

One of the best curative approaches for hepatocellular cancer is liver resection [78]. This procedure is the first choice of treatment when transplantation is not feasible. Hepatic resection for HCC is safe and now displays a low operative mortality due to an improvement in pre-operative management, surgical technique and postoperative care [2]. The most important concern is the high rate of postoperative recurrence of HCC. This situation affects about 50%-60% of patients during the first 3 years and 70-90% during the first 5 years after curative hepatectomy [79, 80]. During the last decades, authors have tried to understand the pathological mechanism of HCC metastasization and the best surgical approach to reduce the recurrence rate of this tumor. Some authors underline that microscopic vascular invasion and peripheral spread of the primary tumor could cause subclinical metastases and that these could be the most important factors affecting the long term prognosis of these patients [46, 81]. Based on this premise, an extensive resection should be the best treatment for HCC. On the other hand, a massive resection can be difficult to operate on a damaged liver. HCCs frequently arise in cirrhosis. The cirrhotic liver has a limited capacity for regeneration [82]. In these cases a limited resection is mandatory, since another important cause of mortality after hepatic resection is liver failure. A limited resection could improve long term survival allowing us to preserve hepatic function and leave room for other therapeutic options [83]. The most widespread methods for patients undergoing liver resection for HCC are anatomic resection (AR) and non anatomic resection (NAR) [12, 16]. There is limited evidence supporting one of these techniques over the other [7, 84]. Several studies have compared these two techniques but they do not clearly show the advantages of AR over NAR. There are studies showing that AR improves overall survival and disease free survival since it allows

for a complete removal of tumor bearing portal tributaries [83, 85–88]. Other evidence shows no advantages of AR when compared to NAR [25, 45, 89]. AR is often indicated in patients with low-degree liver damage, while NAR is usually considered the best approach when preserving liver parenchyma and function is mandatory. The best treatment must balance resectability and preservation of liver function. The conclusion of this debate is very difficult due to the heterogeneity of studies and to the absence of randomized controlled trials. Long term outcomes can be evaluated in terms of overall survival (OS), disease free survival (DFS) and local recurrence (LR). In their study, Yamamoto et al. described a 1- and 2-year OS rate of 92.1% and 85.8% for AR and NAR, respectively, and DFS rates of 78.2% and 63%. These data suggest that there is no significant difference in terms of OS and DFS between the two groups. Furthermore, a longer hospital stay and a greater blood loss was found during surgery in the AR group. A better DFS was found in some AR subgroups. For example AR was better than NAR for patients with a tumor size of 2-5 cm suggesting that there is no difference in surgical technique when tumor size is less than 2 cm [90]. This finding could be referred to a higher tendency of larger HCCs to form intrahepatic or other organ metastasis. In the HCV positive subgroup, authors found a better DFS in the AR group. This group of patients could benefit from AR since HCV patients have a higher rate of intrahepatic metastasis compared to HBV positive patients [91]. Cucchetti et al. compared AR and NAR in Child A patients. In this study, the authors stratified the population according to time to recurrence (early vs late), tumor diameter and tumor differentiation, finding no difference between NAR and AR. AR is better than NAR when tumor diameter is larger, when there is microvascular invasion, in G3-G4 degrees and in early recurrence. On the contrary, for small, G1-G2 degree tumors, AR loses its superiority. Another important finding is that there is no difference in the rate of late recurrence in the two groups.

The rationale is to approach the patients through AR when the tumor is larger, in the presence of microvascular invasion or when the tumor is poorly differentiated. NAR is recommended when liver functionally is low or when there are no unfavorable tumor features [86]. These features can be identified during preoperative workup. Some authors related tumor size to tumor differentiation and to the presence or absence of microvascular invasion. Others identified tumor size, number, and Edmondson grade as microvascular invasion predictors. These data could be useful for surgical decision making [92, 93]. Tanaka et al. compared AR to NAR in 125 patients undergoing hepatic resection for HCC. In this study, the 1-, 3- and 5-year hepatic recurrence rates were found to be 20%, 53% and 64% in AR as opposed to 21%, 52% and 76% in NAR. The 1-, 3- and 5- year OS were respectively 96%, 70% and 54% in AR and 97%, 91% and 61% in NAR. This study showed no significant difference between anatomic and non anatomic liver resection.

At a univariate and multivariate analysis, type of resection was found not to affect survival. Furthermore, AR and NAR showed no difference in number and site of recurrent locations. In this study, authors also studied patients undergoing a second liver resection for recurrence. In patients with liver cirrhosis, the tax of second resections was higher in the non-anatomic resection group. Anyway, the proportion of patients surviving after recurrence was 16% in AR as opposed to 36% in NAR. This data probably depends on a better preservation of liver parenchyma in non anatomic resection compared to anatomic resection.

In the end, looking at patients in which a recurrence with three or more nodules has occurred, no differences were found in AR groups compared to NAR groups. Moreover, no patient had a recurrence at the margins of the resection [23].

Marubashi et al. studied recurrence patterns after NAR and AR. In this study they observed substantial differences between the two groups. Liver function of patients in the NAR group was worse than in the AR group. ICG15R, Child-Pugh score, and degree of live damage were also better in AR patients. On the contrary, AR groups included patients with a larger tumor size, higher serum tumor markers and a higher tax of microvascular invasion.

Univariate and multivariate analysis have shown that the type of liver resection was not a risk factor for tumor recurrence. This study underlined that serum AST, tumor size, multiplicity, serum albumin level and estimated blood loss were independent risk factors for HCC recurrence. Authors evaluated three different aspects of HCC recurrence: area of HCC recurrence, number of recurrent tumors and location of the recurrence. Comparing HCC recurrence patterns no difference could be detected between the two different groups. Only 1.4% of patients had a local recurrence, in the other cases recurrence was the result of systemic dissemination or de novo development. This study confirmed that the type of surgical resection to HCC is not a risk factor of recurrence. It also confirmed how the selection of the surgical method should be based on the clinical status of the patient [94]. These studies underline that the type of surgical resection is not a risk factor for HCC recurrence and consequently, does not affect long term outcomes. These results suggest there are others factor that influence prognosis more than the type of surgery.

Some studies report that HCV infection, Child-Pugh class B, AST $\geq$ 35 UI/L, PLT <14 X 10^4 microliter, ICG-R15 $\geq$25%, AFP $\geq$20 ng/mL, cancer spread and cirrhosis affect DFS. Child-Pugh class B, PLT <14 X 10^4 microliter, ICG-R15 $\geq$25%, AFP $\geq$20 ng/mL, cancer spread, cirrhosis and infiltration into the capsule seem to affect OS, instead [45]. Another study found that preoperative serum AST, prothrombin time, tumor size, albumin, multiplicity and estimated blood loss were independent risk factors for HCC recurrence. This study further demonstrated that the resection method does not affect HCC recurrence [94]. These data suggest that the clinical status influences long-term prognosis more than the kind of liver resection.

Tomimaru et al. studied retrospectively a selected population affected by HCC. Authors selected a population with a small solitary HCC ($\leq$ 3cm) without macroscopic vascular invasion and with an adequate underling liver function. This study showed no differences in short-term and long-term outcomes. Furthermore, univariate analysis proved that the presence of HBV, HCV, microscopic invasion and number of microscopic tumors affect DFS. HCV and microscopic vascular invasion were linked to DFS in multivariate analysis as well. On the other hand, the number of microscopic tumors, HCV and liver cirrhosis were related to OS at univariate analysis, while only the number of microscopic tumors was connected to OS at multivariate analysis [95]. These results underline the importance of the patients' clinical background and of tumor features. The presence of a chronic inflammation of the liver, cirrhosis, the presence of microvascular inflammation or multiple nodules are risk factors for recurrence and affect short-term and long-term outcomes.

Eguchi et al. compared AR and NAR in a cohort of 5781 patients with a single HCC. Stratifying patients for tumor size, they found that HCCs ranging from 2 cm to 5 cm benefit from AR rather than NAR. Furthermore, in HCCs smaller than 2 cm, no difference was found in long-term survival. Authors also stratified patients for liver function. In this respect, differences between AR and NAR disappeared, also, for tumors larger than 2 cm [84]. Our group tried to compare long term outcomes of NAR and AR. In this study we used a propensity score analysis to reduce biases. We analyzed retrospectively 455 patients. We

found an OS of 47.6 months for AR and 56.5 months for NAR (p= 0.169). The median DFS was 29.2 months for AR and 24.9 months for NAR (p=0.337). At univariate analysis, we found that the presence of cirrhosis, BCLC stage, microvascular invasion, satellitosis, surgical resection margins, postoperative liver failure, postoperative ascites, number of nodules, size of nodules and ALBI grade were associated with a reduction in OS. Using a multivariate regression model, we found that cirrhosis, microvascular invasion, BCLC grade B, presence of satellitosis, postoperative ascites, grade 3-4 Clavien-Dindo classification and ALBI grade 2 were independently associated with OS. Furthermore, cirrhosis, BCLC grade, microvascular invasion, presence of satellitosis, postoperative ascites and number of nodules were all associated with early recurrence (DFS < 2 years). At the multivariate Cox regression model: presence of cirrhosis, grade B BCLC, microvascular invasion and satellitosis were independently associated with the risk of recurrence.

Our study demonstrated no differences between AR and NAR as well. Furthermore, we also appreciated the importance of liver function and tumor characteristics as the most important factors affecting OS and DFS. In the end, studies suggested that the type of surgery is not an independent risk factor for HCC recurrence. Tumor-related factors appear to be more relevant than type of surgery in affecting the risk of HCC recurrence.

5. Recurrence Pattern after Resection: Intra-Hepatic Metastasis or De-Novo Recurrence

Pattern of recurrence is a main topic in HCC therapeutic strategies. The peculiarity of this tumor is the background parenchyma in which it develops. In the majority of cases it is characterized by a chronic inflammatory state rather than by outright cirrhosis. In fact, when a new nodule is diagnosed, or when the tumor arises as a multinodular disease, no clinical or biochemical features are able to distinguish between the occurrence of a de-novo nodule (multicentric occurrence, MO), favoured by the chronic underlying inflammatory state of the liver, and the real intrahepatic metastasization (IM) of a primitive lesion. The ability to distinguish between these two occurrences would affect our interpretation of the phenomenon and change the current figures on hepatocarcinoma recurrence.

These considerations become fundamental when we consider that multinodular disease currently has no indication to curative treatment although it could possibly be the expression of de-novo multicentric carcinogenesis rather than of intrahepatic metastasization. The effect of cirrhosis on recurrence has been recently investigated by Sasaki et al. [96], who compared cirrhotic and healthy patients. Their results showed how cirrhosis can affect the pattern of recurrence, increasing the chances of MO [19] over IM.

However, they reported a comparable rate of early recurrence, which they interpreted as the expression of the metastatic potential intrinsic in hepatocellular carcinoma. Thus, a cirrhotic liver, when compared to a healthy one, seems to be characterized by the possibility of metastasization, as well as by the occurrence of de-novo neoplasm through the chronic inflammatory boost of the underlying cirrhosis. In the last decade, experimental genetic analysis has allowed us to improve our knowledge of recurrence patterns in HCC. Studies on Asian databases described an IM rate of between 50-70% after liver surgery [97–99]. The same authors reported how the IM pattern seems to have a worse prognosis compared to

tumors that recur with a MO pattern [98–100]. A recent meta-analysis has confirmed this trend on seven reports [100], all of them on Asiatic data. To the best of our knowledge, no western data is available in literature regarding the incidence of the two patterns. Many efforts have been made to understand the different conditions that lead to IM rather than MO. Most studies point out the main role of the MVI as "primum-movers" in the metastasization pathway [101–103].

The role of microvascular invasion in recurrence was first explored by Makuuchi et al. in 1985 [48]. The authors reported a rate of 73% of 62 HCC patients showing a microscopic tumor thrombus in the portal venous branch. From this manuscript came the proposal of a resection technique able to cut off the tumour portal supply according to Coinaud segmentation. This approach should allow the reduction of the rate of recurrence. Up to now, there is still no accord among the multiple experiences all over the world concerning the real impact of this approach on recurrence. According to a recent systematic review, the rate of microscopic portal vein thrombosis in the tumor area is definitely smaller than expected, varying according to different tumor sizes: 0.5% for early cancer, 16.2% for tumors of less than 2 cm, 17.4% when size is <5cm, as high as 64% for tumors larger than 5 cm [104]. Furthermore, the theory of cancer spread through portal circulation is not able to explain the rate of recurrence after transplantation, a very rare but possible occurrence.

Over the last few years, especially through the Osaka Hospital (Japan) experience, new data has emerged that could clarify the mechanism of intrahepatic metastasization. CT studies during arterial portography and hepatic arteriography allowed Sakon et al. to define three different patterns of intrahepatic recurrence. 1) Local IM: HCC recurrence around the tumor, caused by direct spread through the portal blood flow or venous drainage; 2) Systemic IM: HCC recurrence caused by circulating tumor cells; 3) MC: multicentric HCC recurrence caused by de-novo development of hepatocarcinoma [17–19, 104]. These authors also evidenced the role of tumor blood flow (TBF) drainage, which appears at CT scan as the vascular supply area of the tumor, which is not always directly related to the segmental portal branch distribution around the nodule. They stated how the different patterns of recurrence are significantly associated with different TBF drainage patterns.

Local diffusion is the manifestation of anatomical dissemination (depicted by the portal vein type at TBF drainage) rather than non-anatomical (represented by the marginal or hypovascular TBF type). More recently, Marubashi et al. underlined the importance of overcoming the old theory of portal vein dissemination as the main route for intrahepatic metastasization, favoring the tumor blood flow drainage theory over the systemic rehoming theory [6].

Given the different types of recurrence that can occur in the context of hepatocarcinoma, there are still few reports about the real impact of surgery on reducing recurrence rate. As already discussed, most physicians assume that, when metastasization is due to MVI, a radical excision of the anatomical liver segment with its portal vascularization, should achieve the best outcome in terms of recurrence [10, 105, 106]. However, many authors have reported no differences between AR and PSR in long term-oncological outcomes [107, 108]. A recent, combined Asian and Western-based study [109] showed no differences in long-term outcomes between the two surgical techniques. AR seems to reduce the rate of early recurrence in cancers with MVI or with a G3-4 differentiation pattern according to Edmonson's histological classification. Early recurrence has been defined as a possible clinical indicator of the metastasization pattern in HCC [100, 101, 109]. Marubashi et al. [6]

compared the two surgical techniques and their respective patterns of recurrence. No significant differences were evident in the local dissemination rate after surgery, neither when comparing intrahepatic and extrahepatic recurrences, nor on the localization of the recurrent nodules. These results reflect the difficulty in estimating the real impact of different recurrence patterns on long terms outcomes.

Lesions characterized by a different tumor burden can express different carcinogenic potentials. This power is independent of the surgical technique. In fact, according to the "re-homing theory" [17, 18], used to explain recurrence after transplantation, once the hepatocellular nodule acquires the features of invasiveness, metastasization can equally occurin the liver and in the blood flow, so that neither of the currently available therapies can possibly reduce or cancel the risk of recurrence.

Others studies, analyzing recurrence patterns after surgical resection, presented similar results. Local dissemination after PSR apparently concerns just a minority of cases, most HCC recurrences being apparently caused by systemic dissemination of circulating tumor cells or multicentric occurrence of de-novo HCC [6, 22]. According to these considerations, it may be easy to understand the importance of finding a procedure able to distinguish between IM and MO.

Different efforts have been made to distinguish the two patterns by genetic analyses. CGH-arrays, microsatellite instability, loss of heterozygosity and other genetic features have been diffusely employed to characterize the differences between a primitive nodule and its recurrence. More recently, variations of the mitochondrial DNA of hepatocellular carcinoma were explored, with interesting results and good sensitivity and specificity [110]. These procedures, however, are affected by the impossibility of predicting a recurrence pattern during the preoperative work-up.

Genetic analysis can only be performed on histological specimens, so that the real nature of the treated lesion can only be recognized a-posteriori. Shimada et al. [111] reported C hepatitis infection, a platelet count of<10x10^4/microl; tumor size and histological gradeas independent factors in differentiating MO from IM. Nakano et al. [111, 112] reported that a tumor capsule was rarely observed in IM patients. Different authors stated that large and multinodular HCC have always presented a high incidence of recurrence, and that these types of multinodular HCCs were more usually identified as IM [113, 114]. More recently, a recurrence-free interval of over 18 months after initial hepatic resection has been suggested as a cut-off point to differentiate MO from IM in clinical practice [115]. Other authors have pointed out a cut-off of 2 years for RFS [116].

However, some retrospective series do not support this clinical approach, recording no difference in outcomes when time to recurrence is employed to distinguish between different recurrent patterns and to predict different outcomes of AR and PSR. Until now, no reliable and universally accepted clinical models are available to predict the pattern of recurrence of HCC. To conclude, PSR seems comparable to AR as a treatment for hepatic cancer. Where recurrence is concerned, distant intrahepatic recurrence is more common than surgical hedge relapse or distant metastases. This evidence further points towards the need for a reinterpretation of the mechanism underlying recurrence in hepatocarcinoma, revisiting the portal-flow-theory and our general approach to the disease.

6. EXTENDING THE ROLE OF SURGERY: FROM BENCHMARK TO BEDSIDE

To better address these clinical questions, molecular characterization has been performed on multiple liver tumor specimens through various analyses, using new biological mechanisms and molecular markers. In recent years, a better knowledge of mutational and epigenetic events deregulating the signaling pathways involved in tumor progression, and the definition of different genetic variants of HCC, have allowed a better of recurrence patterns, the prediction of disease outcomes and the identification of potential prognostic markers and targets for molecular-based personalized therapies [117, 118]. Some studies used the HBV-DNA integration pattern, the X chromosome inactivation assay, and comparative genomic hybridization (CGH) as possible markers of tumor clone origin [119, 120]. However, all of these methods have inherent limitations. They can be applied only to HCC patients with integrated HBV-DNA, only to female patients or require expensive equipment and reagents, respectively.

Moreover, HBV integration testing through southern blotting requires a consistent amount of DNA genome [121]. Micro-satellite polymorphism, including loss of heterozygosity (LOH) and microsatellite instability (MSI) are important genetic features in carcinogenesis. LOH analysis of specific DNA microsatellite loci were performed in the attempt to distinguish IM of monoclonal origin, from multiclonal MO [98, 122]. Compared to other molecular methods, the test of microsatellite polymorphism with Polymerase Chain Reaction (PCR) and Polyacrylamide Gel Electrophoresis (PAGE) shows many advantages. Moreover, it can be used on small quantities of DNA genome that can be acquired from tiny specimens such as fine-needle biopsy specimens. DNA microarray technology is currently employed in identifying specific gene expression signatures of HCC. Recently, this technique has been used to predict early HCC recurrence due to intrahepatic metastasis; however, no well-defined predictors for late recurrence have been discovered. Some studies have focused on the characteristics of non-tumorous liver to predict late recurrence due to de novo hepatocarcinogenesis. These studies were based on the idea of "field cancerization" but did not lead to conclusive results [123]. In another study [124], the gene expression signature of primary metastatic HCCs was found to be similar to that of the corresponding IMs, implying that the genetic deregulation responsible for metastasization initiates within the primary tumor. The Adrenomedullin (AM) gene was identified as a leader gene overexpressed in HCCs with IM, while a different gene expression profile was observed in multicentric HCCs [124].

Several studies based on large-scale genome sequencing have been performed to identify the driver genes in carcinogenesis [125–128]. The objective was to detect the most frequently mutated genes among many different singular cases. However, identifying the driver genes in the long list of less frequent mutation proved difficult. One important new trend for delineating HCC biomarkers is the proteomic approach. It allows us to identify variations in levels of protein expression in liver tissue or plasma during the progression from liver fibrosis, cirrhosis or steatohepatitis to HCC [129]. The same approach was used with reference to molecular diagnosis and metastatic recurrence of HCC [130]. However, research focusing on the study of the pathogenesis of IM and MO by proteomic approach is at its beginning; studies are few and performed on a limited number of patients. Therefore, it is not

currently possible to estimate whether the newly identified proteins are effectively potential biomarkers for identifying the multinodular HCCs of clonal origin and for discriminating between IM and MO cases.

Many efforts have also been dedicated to the exploration of new biologic mechanisms and molecular markers of multifocal HCC through omic analysis. The omic strategy includes the research of diagnostic and progression markers through genomic, proteomic and metabolomic analyses in order to evaluate gene, protein and metabolic deregulations. In this field, an undoubtedly innovative research has been recently published by Miao et al. [131], who performed a multi-omic analysis to differentiate MO from IM by decoding molecular differences between the two multifocal HCC models. This would allow us to identify molecular markers for diagnosis and prognosis, as well as therapeutic targets. They analyzed intrahepatic HCC lesions and matched non-cancerous liver tissue and blood obtained from representative patients with HBV-related multifocal HCC undergoing tumor resection and marked by distinct post-surgical courses. The samples were subjected to multi-omic analyses, integrating genomics and transcriptomics; the results, further validated by a cohort of 174 HCC patients, were correlated with clinicopathological data.

The determination of HBV integration in the different lesions clearly suggested the existence of different tumor clonality. The evaluation of genomic alterations showed how the enrichment of pathways including cell cycle, p53 signaling, histidine metabolism, G2/M checkpoint, and Ran (Ras-related nuclear protein)-mediated mitotic spindle regulation was associated with clonal metastasization rather than with the synchronous development of distinct clones. Protein analysis showed a significant difference in the synchronous development of multicentric primary HCC and metastatic disease. Validation analysis confirmed the upregulation of six out of seven genes: Histidine ammonia-lyase (HAL), stratifin 14-3-3γ (SFN), kinesin superfamily protein 15 (KIF15), dual-specificity protein kinase (TTK), Budding uninhibited by benzimidazoles 1 homolog (BUB1) and minichromosome maintenance complex component 4 (MCM4).

Different clinicopathologic features of HCCs were significantly associated with at least one of these genes. In addition, the evaluation of the relationships between the expression of the above genes and metastatic potential and postsurgical recurrence strongly suggested that TTK expression could be an independent prognostic indicator for HCC patients. In addition it could differentiate MO from IM. Multi-omic profiling could provide essential information for evaluating the aggressiveness of the existing lesion and for applying personalized therapies, including post-surgical treatments. It must be considered that cases of IM, with several nodules exhibiting different molecular alterations, require multi-omic analysis of each new nodule in order to identify critical molecular lesions which could be the targets of specific treatments.

Although the multi-omic strategy potentially opens new groundbreaking perspectives for diagnosis, prognosis and treatment of multifocal HCC, it still presents important limitations. The analysis should be extended to wider and more heterogeneous cohorts. Moreover, its clinical application could be seriously limited by the complexity of the analysis and by the elevated costs. Nonetheless, the innovative results of the multi-omic approach promotes new efforts to overcome these drawbacks.

REFERENCES

[1] El-Serag HB, Mason AC. Rising Incidence of Hepatocellular Carcinoma in the United States. *N Engl J Med.* 1999;340(10):745–50.

[2] Fan ST, Lo CM, Liu CL, Lam CM, Yuen WK, Yeung C, et al. Hepatectomy for hepatocellular carcinoma: toward zero hospital deaths. *Ann Surg.* 1999 Mar;229(3):322–30.

[3] Torzilli G. No-Mortality Liver Resection for Hepatocellular Carcinoma in Cirrhotic and Noncirrhotic Patients. *Arch Surg.* 1999;134(9):984.

[4] Belghiti J, Panis Y, Farges O, Benhamou JP, Fekete F. Intrahepatic recurrence after resection of hepatocellular carcinoma complicating cirrhosis. *Ann Surg.* 1991 Aug;214(2):114–7.

[5] Poon RT-P, Fan ST, Lo CM, Liu CL, Wong J. Long-term survival and pattern of recurrence after resection of small hepatocellular carcinoma in patients with preserved liver function: implications for a strategy of salvage transplantation. *Ann Surg.* 2002 Mar;235(3):373–82.

[6] Marubashi S, Gotoh K, Akita H, Takahashi H, Sugimura K, Miyoshi N, et al. Analysis of Recurrence Patterns After Anatomical or Non-anatomical Resection for Hepatocellular Carcinoma. *Ann Surg Oncol.* 2015 Jul;22(7):2243–52.

[7] Ueno S, Kubo F, Sakoda M, Hiwatashi K, Tateno T, Mataki Y, et al. Efficacy of anatomic resection vs nonanatomic resection for small nodular hepatocellular carcinoma based on gross classification. *J Hepatobiliary Pancreat Surg.* 2008;15(5):493–500.

[8] Eguchi S, Kanematsu T, Arii S, Okazaki M, Okita K, Omata M, et al. Comparison of the outcomes between an anatomical subsegmentectomy and a non-anatomical minor hepatectomy for single hepatocellular carcinomas based on a Japanese nationwide survey. *Surgery.* 2008;143(4):469–75.

[9] Kobayashi A, Miyagawa S, Miwa S, Nakata T. Prognostic impact of anatomical resection on early and late intrahepatic recurrence in patients with hepatocellular carcinoma. *J Hepatobiliary Pancreat Surg.* 2008 Oct 4;15(5):515–21.

[10] Wakai T, Shirai Y, Sakata J, Kaneko K, Cruz PV, Akazawa K, et al. Anatomic Resection Independently Improves Long-Term Survival in Patients with T1–T2 Hepatocellular Carcinoma. *Ann Surg Oncol.* 2007;14(4):1356–65.

[11] Makuuchi M, Imamura H, Sugawara Y, Takayama T. Progress in surgical treatment of hepatocellular carcinoma. *Oncology.* 2002;62 Suppl 1:74–81.

[12] Cucchetti A, Cescon M, Ercolani G, Bigonzi E, Torzilli G, Pinna AD. A comprehensive meta-regression analysis on outcome of anatomic resection versus nonanatomic resection for hepatocellular carcinoma. *Ann Surg Oncol.* 2012 Nov;19(12):3697–705.

[13] Kamiyama T, Nakanishi K, Yokoo H, Kamachi H, Matsushita M, Todo S. The impact of anatomical resection for hepatocellular carcinoma that meets the Milan criteria. *J Surg Oncol.* 2010 Jan 1;101(1):54–60.

[14] Yamazaki O, Matsuyama M, Horii K, Kanazawa A, Shimizu S, Uenishi T, et al. Comparison of the outcomes between anatomical resection and limited resection for

single hepatocellular carcinomas no larger than 5 cm in diameter: a single-center study. *J Hepatobiliary Pancreat Sci.* 2010 May;17(3):349–58.

[15] Kaibori M, Kon M, Kitawaki T, Kawaura T, Hasegawa K, Kokudo N, et al. Comparison of anatomic and non-anatomic hepatic resection for hepatocellular carcinoma. *J Hepatobiliary Pancreat Sci.* 2017 Nov;24(11):616–26.

[16] Zhou Y, Xu D, Wu L, Li B. Meta-analysis of anatomic resection versus nonanatomic resection for hepatocellular carcinoma. *Langenbecks Arch Surg.* 2011 Oct;396(7):1109–17.

[17] Sakon M, Nagano H, Shimizu J, Kondo M, Nakamori S, Dono K, et al. Hepatic resection of hepatocellular carcinomas based on tumor hemodynamics. *J Surg Oncol.* 2000 Mar;73(3):179–81.

[18] Sakon M, Ogawa H, Fujita M, Nagano H. Hepatic resection for hepatocellular carcinoma based on tumor hemodynamics. *Hepatol Res.* 2012;43(2):155–64.

[19] Sakon M, Nagano H, Nakamori S, Dono K, Umeshita K, Murakami T, et al. Intrahepatic recurrences of hepatocellular carcinoma after hepatectomy: analysis based on tumor hemodynamics. *Arch Surg.* 2002 Jan;137(1):94–9.

[20] Xu W, Cao L, Chen L, Li J, Zhang XF, Qian HH, et al. Isolation of circulating tumor cells in patients with hepatocellular carcinoma using a novel cell separation strategy. *Clin Cancer Res.* 2011 Jun 1;17(11):3783–93.

[21] Funaki NO, Tanaka J, Seto SI, Kasamatsu T, Kaido T, Imamura M. Hematogenous spreading of hepatocellular carcinoma cells: possible participation in recurrence in the liver. *Hepatology.* 1997 Mar;25(3):564–8.

[22] Cho SH, Chun JM, Kwon HJ, Han YS, Kim SG, Hwang YJ. Outcomes and recurrence pattern after non-anatomic liver resection for solitary hepatocellular carcinomas. *Korean J Hepatobiliary Pancreat Surg.* 2016 Feb;20(1):1–7.

[23] Tanaka K, Shimada H, Matsumoto C, Matsuo K, Nagano Y, Endo I, et al. Anatomic versus limited nonanatomic resection for solitary hepatocellular carcinoma. *Surgery.* 2008;143(5):607–15.

[24] Kaibori M, Matsui Y, Hijikawa T, Uchida Y, Kwon AH, Kamiyama Y. Comparison of limited and anatomic hepatic resection for hepatocellular carcinoma with hepatitis C. *Surgery.* 2006 Mar;139(3):385–94.

[25] Okamura Y, Ito T, Sugiura T, Mori K, Uesaka K. Anatomic versus nonanatomichepatectomy for a solitary hepatocellular carcinoma: a case-controlled study with propensity score matching. *J Gastrointest Surg.* 2014 Nov;18(11):1994–2002.

[26] Nakashima T, Kojiro M. Pathologic Characteristics of Hepatocellular Carcinoma. *Semin Liver Dis.* 1986;6(03):259–66.

[27] Dutkowski P, Linecker M, DeOliveira ML, Müllhaupt B, Clavien PA. Challenges to liver transplantation and strategies to improve outcomes. *Gastroenterology.* 2015 Feb;148(2):307–23.

[28] Bruix J, Llovet JM. Prognostic prediction and treatment strategy in hepatocellular carcinoma. *Hepatology.* 2002 Mar;35(3):519–24.

[29] Llovet JM, Fuster J, Bruix J, of the Barcelona-Clínic Liver Cancer Group. The Barcelona approach: Diagnosis, staging, and treatment of hepatocellular carcinoma. *Liver Transpl.* 2004;10(S2):S115–20.

[30] Llovet J, Brú C, Bruix J. Prognosis of Hepatocellular Carcinoma: The BCLC Staging Classification. *Semin Liver Dis.* 1999;19(03):329–38.

[31] Bruix J, Sherman M, Llovet JM, Beaugrand M, Lencioni R, Burroughs AK, et al. Clinical Management of Hepatocellular Carcinoma. Conclusions of the Barcelona-2000 EASL Conference. *J Hepatol.* 2001;35(3):421–30.

[32] Bruix J, Sherman M, American Association for the Study of Liver Diseases. Management of hepatocellular carcinoma: an update. *Hepatology*. 2011 Mar;53(3):1020–2.

[33] Cillo U, Vitale A, Grigoletto F, Farinati F, Brolese A, Zanus G, et al. Prospective validation of the Barcelona Clinic Liver Cancer staging system. *J Hepatol*. 2006 Apr;44(4):723–31.

[34] Marrero JA, Fontana RJ, Barrat A, Askari F, Conjeevaram HS, Su GL, et al. Prognosis of hepatocellular carcinoma: Comparison of 7 staging systems in an American cohort. *Hepatology*. 2005;41(4):707–15.

[35] Ng KK, Vauthey JN, Pawlik TM, Lauwers GY, Regimbeau JM, Belghiti J, et al. Is Hepatic Resection for Large or Multinodular Hepatocellular Carcinoma Justified? Results from a Multi-Institutional Database. *Ann Surg Oncol.* 2005;12(5):364–73.

[36] Ishizawa T, Hasegawa K, Aoki T, Takahashi M, Inoue Y, Sano K, et al. Neither multiple tumors nor portal hypertension are surgical contraindications for hepatocellular carcinoma. *Gastroenterology*. 2008 Jun;134(7):1908–16.

[37] Torzilli G, Belghiti J, Kokudo N, Takayama T, Capussotti L, Nuzzo G, et al. A snapshot of the effective indications and results of surgery for hepatocellular carcinoma in tertiary referral centers: is it adherent to the EASL/AASLD recommendations?: an observational study of the HCC East-West study group. *Ann Surg.* 2013 May;257(5):929–37.

[38] Ciria R, López-Cillero P, Gallardo AB, Cabrera J, Pleguezuelo M, Ayllón MD, et al. Optimizing the management of patients with BCLC stage-B hepatocellular carcinoma: Modern surgical resection as a feasible alternative to transarterialchemoemolization. *Eur J Surg Oncol.* 2015 Sep;41(9):1153–61.

[39] Liang L, Xing H, Zhang H, Zhong J, Li C, Lau WY, et al. Surgical resection versus transarterial chemoembolization for BCLC intermediate stage hepatocellular carcinoma: a systematic review and meta-analysis. *HPB.* 2018 Feb;20(2):110–9.

[40] Bolondi L, Burroughs A, Dufour JF, Galle PR, Mazzaferro V, Piscaglia F, et al. Heterogeneity of patients with intermediate (BCLC B) Hepatocellular Carcinoma: proposal for a subclassification to facilitate treatment decisions. *Semin Liver Dis.* 2012 Nov;32(4):348–59.

[41] Mazzaferro V, Llovet JM, Miceli R, Bhoori S, Schiavo M, Mariani L, et al. Predicting survival after liver transplantation in patients with hepatocellular carcinoma beyond the Milan criteria: a retrospective, exploratory analysis. *Lancet Oncol.* 2009 Jan;10(1):35–43.

[42] Li SQ, Huang T, Shen SL, Hua YP, Hu WJ, Kuang M, et al. Anatomical versus non-anatomicalliverresection for hepatocellular carcinoma exceeding Milan criteria. *Br J Surg.* 2017 Jan;104(1):118–27.

[43] Zoli M, Marchesini G, Melli A, Viti G, Marra A, Marrano D, et al. Evaluation of liver volume and liver function following hepatic resection in man. *Liver*. 1986 Oct;6(5):286–91.

[44] Asahara T, Dohi K, Katayama K, Itamoto T, Okamoto Y, Nakahara H, et al. Factors affecting postoperative prognosis in the solitary-nodule type of hepatocellular carcinoma: experience of 132 cases in our institute. *Hiroshima J Med Sci.* 1998 Sep;47(3):99–104.

[45] Hirokawa F, Kubo S, Nagano H, Nakai T, Kaibori M, Hayashi M, et al. Do patients with small solitary hepatocellular carcinomas without macroscopically vascular invasion require anatomic resection? Propensity score analysis. *Surgery.* 2015 Jan;157(1):27–36.

[46] Park JH, Koh KC, Choi MS, Lee JH, Yoo BC, Paik SW, et al. Analysis of risk factors associated with early multinodular recurrences after hepatic resection for hepatocellular carcinoma. *Am J Surg*. 2006;192(1):29–33.

[47] Vauthey JN. Simplified Staging for Hepatocellular Carcinoma. *J Clin Oncol.* 2002;20(6):1527–36.

[48] Makuuchi M, Hasegawa H, Yamazaki S. Ultrasonically guided subsegmentectomy. *Surg Gynecol Obstet.* 1985;161:346–50.

[49] Helling TS, Blondeau B. Anatomic segmental resection compared to major hepatectomy in the treatment of liver neoplasms. *HPB.* 2005;7(3):222–5.

[50] Healey JE. Anatomy of the Biliary Ducts within the Human Liver. *AMA Arch Surg.* 1953;66(5):599.

[51] Couinaud C. *Le foie: études anatomiques et chirurgicales*. 1957. 530 p.

[52] Strasberg SM, Belghiti J, Clavien PA, Gadzijev E, Garden JO, Lau WY, et al. The Brisbane 2000 Terminology of Liver Anatomy and Resections. *HPB.* 2000;2(3):333–9.

[53] Ahn KS, Kang KJ, Park TJ, Kim YH, Lim TJ, Kwon JH. Benefit of Systematic Segmentectomy of the Hepatocellular Carcinoma. *Ann Surg.* 2013;258(6):1014–21.

[54] Takasaki K. Glissonean pedicle transection method for hepatic resection: a new concept of liver segmentation. *J Hepatobiliary Pancreat Surg.* 1998;5(3):286–91.

[55] Yamamoto M, Katagiri S, Ariizumi SI, Kotera Y, Takahashi Y. Glissonean pedicle transection method for liver surgery (with video). *J Hepatobiliary Pancreat Sci.* 2012 Jan;19(1):3–8.

[56] Ueno M, Hayami S, Sonomura T, Tanaka R, Kawai M, Hirono S, et al. Indocyanine green fluorescence imaging techniques and interventional radiology during laparoscopic anatomical liver resection (with video). *Surg Endosc*. 2017;32(2):1051–5.

[57] Takasaki K, Yamamoto M. Surgical Anatomy of the Liver in the Glissonean Pedicle Approach: What We Need to Know. In: *Venous Embolization of the Liver*. 2011. p. 23–7.

[58] Foster JH. Survival after liver resection for secondary tumors. *Am J Surg*. 1978;135(3):389–94.

[59] Lin TY, Chen KM, Liu TK. Total right hepatic lobectomy for primary hepatoma. *Surgery*. 1960 Dec;48:1048–60.

[60] Ton That Tung, Tung TT, Quang ND. A New Technique for Operating on the Liver. *Lancet.* 1963;281(7274):192–3.

[61] Bismuth H. Surgical anatomy and anatomical surgery of the liver. *World J Surg.* 1982 Jan;6(1):3–9.

[62] Couinaud CM. A simplified method for controlled left hepatectomy. *Surgery.* 1985 Mar;97(3):358–61.

[63] Couinaud C. Liver Anatomy: Portal (and Suprahepatic) or Biliary Segmentation. *Dig Surg.* 1999;16(6):459–67.

[64] Sugioka A, Kato Y, Tanahashi Y. Systematic extrahepatic Glissonean pedicle isolation for anatomical liver resection based on Laennec's capsule: proposal of a novel comprehensive surgical anatomy of the liver. *J Hepatobiliary Pancreat Sci.* 2017;24(1):17–23.

[65] Lee JH, Han DH, Jang DS, Choi GH, Choi JS. Robotic extrahepatic Glissonean pedicle approach for anatomic liver resection in the right liver: techniques and perioperative outcomes. *Surg Endosc.* 2016 Sep;30(9):3882–8.

[66] Ishizawa T, Saiura A, Kokudo N. Clinical application of indocyanine green-fluorescence imaging during hepatectomy. *Hepatobiliary Surg Nutr.* 2016 Aug;5(4):322–8.

[67] Aoki T, Yasuda D, Shimizu Y, Odaira M, Niiya T, Kusano T, et al. Image-guided liver mapping using fluorescence navigation system with indocyanine green for anatomical hepatic resection. *World J Surg.* 2008 Aug;32(8):1763–7.

[68] Inoue Y, Arita J, Sakamoto T, Ono Y, Takahashi M, Takahashi Y, et al. Anatomical Liver Resections Guided by 3-Dimensional Parenchymal Staining Using Fusion Indocyanine Green Fluorescence Imaging. *Ann Surg.* 2015 Jul;262(1):105–11.

[69] Miyata A, Ishizawa T, Tani K, Shimizu A, Kaneko J, Aoki T, et al. Reappraisal of a Dye-Staining Technique for Anatomic Hepatectomy by the Concomitant Use of Indocyanine Green Fluorescence Imaging. *J Am Coll Surg.* 2015 Aug;221(2):e27–36.

[70] Ishizawa T, Zuker NB, Kokudo N, Gayet B. Positive and Negative Staining of Hepatic Segments by Use of Fluorescent Imaging Techniques During Laparoscopic Hepatectomy. *Arch Surg* [Internet]. 2012;147(4). Available from: http://dx.doi.org/10.1001/archsurg.2012.59.

[71] Inoue Y, Saiura A, Arita J, Takahashi Y. Hepatic Vein-Oriented Liver Resection Using Fusion Indocyanine Green Fluorescence Imaging. *Ann Surg.* 2015 Dec;262(6):e98–9.

[72] Ishizawa T, Gumbs AA, Kokudo N, Gayet B. Laparoscopic segmentectomy of the liver: from segment I to VIII. *Ann Surg.* 2012 Dec;256(6):959–64.

[73] Viganò L, Russolillo N, Ferrero A, Langella S, Sperti E, Capussotti L. Evolution of long-term outcome of liver resection for colorectal metastases: analysis of actual 5-year survival rates over two decades. *Ann Surg Oncol.* 2012 Jun;19(6):2035–44.

[74] Sahani DV, Bajwa MA, Andrabi Y, Bajpai S, Cusack JC. Current status of imaging and emerging techniques to evaluate liver metastases from colorectal carcinoma. *Ann Surg.* 2014 May;259(5):861–72.

[75] Lang H, Radtke A, Liu C, Frühauf N, Peitgen H, Broelsch C. Extended left hepatectomy?modified operation planning based on three-dimensional visualization of liver anatomy. *Langenbecks Arch Surg* [Internet]. 2003;389(4). Available from: http://dx.doi.org/10.1007/s00423-003-0441-z.

[76] Kishi Y, Abdalla EK, Chun YS, Zorzi D, Madoff DC, Wallace MJ, et al. Three hundred and one consecutive extended right hepatectomies: evaluation of outcome based on systematic liver volumetry. *Ann Surg.* 2009 Oct;250(4):540–8.

[77] Donadon M, Costa G, Torzilli G. State of the art of intraoperative ultrasound in liver surgery: current use for staging and resection guidance. *Ultraschall Med.* 2014 Dec;35(6):500–11; quiz 512–3.

[78] Lai EC, Fan ST, Lo CM, Chu KM, Liu CL, Wong J. Hepatic resection for hepatocellular carcinoma. An audit of 343 patients. *Ann Surg.* 1995 Mar;221(3):291–8.
[79] Colecchia A, Schiumerini R, Cucchetti A, Cescon M, Taddia M, Marasco G, et al. Prognostic factors for hepatocellular carcinoma recurrence. *World J Gastroenterol.* 2014 May 28;20(20):5935–50.
[80] Shim JH, Jun MJ, Han S, Lee YJ, Lee SG, Kim KM, et al. Prognostic nomograms for prediction of recurrence and survival after curative liver resection for hepatocellular carcinoma. *Ann Surg.* 2015 May;261(5):939–46.
[81] Kamiyama T, Nakanishi K, Yokoo H, Kamachi H, Tahara M, Kakisaka T, et al. Analysis of the risk factors for early death due to disease recurrence or progression within 1 year after hepatectomy in patients with hepatocellular carcinoma. *World J Surg Oncol.* 2012 Jun 14;10:107.
[82] Yamanaka N, Okamoto E, Kawamura E, Kato T, Oriyama T, Fujimoto J, et al. Dynamics of normal and injured human liver regeneration after hepatectomy as assessed on the basis of computed tomography and liver function. *Hepatology.* 1993 Jul;18(1):79–85.
[83] Yasui M, Harada A, Torii A, Nakao A, Nonami T, Takagi H. Impaired liver function and long-term prognosis after hepatectomy for hepatocellular carcinoma. *World J Surg.* 1995;19(3):439–43.
[84] Eguchi S, Kanematsu T, Arii S, Okazaki M, Okita K, Omata M, et al. Comparison of the outcomes between an anatomical subsegmentectomy and a non-anatomical minor hepatectomy for single hepatocellular carcinomas based on a Japanese nationwide survey. *Surgery.* 2008;143(4):469–75.
[85] Hasegawa K, Kokudo N, Imamura H, Matsuyama Y, Aoki T, Minagawa M, et al. Prognostic impact of anatomic resection for hepatocellular carcinoma. *Ann Surg.* 2005 Aug;242(2):252–9.
[86] Cucchetti A, Qiao GL, Cescon M, Li J, Xia Y, Ercolani G, et al. Anatomic versus nonanatomic resection in cirrhotic patients with early hepatocellular carcinoma. *Surgery.* 2014 Mar;155(3):512–21.
[87] Yan L. *Operative Techniques in Liver Resection.* Springer; 2015. 354 p.
[88] Shindoh J, Makuuchi M, Matsuyama Y, Mise Y, Arita J, Sakamoto Y, et al. Complete removal of the tumor-bearing portal territory decreases local tumor recurrence and improves disease-specific survival of patients with hepatocellular carcinoma. *J Hepatol.* 2016 Mar;64(3):594–600.
[89] Marubashi S, Gotoh K, Akita H, Takahashi H, Ito Y, Yano M, et al. Anatomical versus non-anatomical resection for hepatocellular carcinoma. *Br J Surg.* 2015 Jun;102(7):776–84.
[90] Yamamoto T, Yagi S, Uryuhara K, Kaihara S, Hosotani R. Clinical factors that affect the outcomes after anatomical versus non-anatomical resection for hepatocellular carcinoma. *Surg Today.* 2017 Feb;47(2):193–201.
[91] Miyagawa S, Kawasaki S, Makuuchi M. Comparison of the characteristics of hepatocellular carcinoma between hepatitis B and C viral infection: tumor multicentricity in cirrhotic liver with hepatitis C. *Hepatology.* 1996 Aug;24(2):307–10.
[92] Kim BK, Han KH, Park YN, Park MS, Kim KS, Choi JS, et al. Prediction of microvascular invasion before curative resection of hepatocellular carcinoma. *J Surg Oncol.* 2008 Mar 1;97(3):246–52.

[93] Pawlik TM, Delman KA, Vauthey JN, Nagorney DM, Ng IOL, Ikai I, et al. Tumor size predicts vascular invasion and histologic grade: Implications for selection of surgical treatment for hepatocellular carcinoma. *Liver Transpl.* 2005 Sep;11(9):1086–92.

[94] Marubashi S, Gotoh K, Akita H, Takahashi H, Sugimura K, Miyoshi N, et al. Analysis of Recurrence Patterns After Anatomical or Non-anatomical Resection for Hepatocellular Carcinoma. *Ann Surg Oncol.* 2014;22(7):2243–52.

[95] Tomimaru Y, Eguchi H, Marubashi S, Wada H, Kobayashi S, Tanemura M, et al. Equivalent outcomes after anatomical and non-anatomical resection of small hepatocellular carcinoma in patients with preserved liver function. *Dig Dis Sci.* 2012 Jul;57(7):1942–8.

[96] Sasaki K, Shindoh J, Margonis GA, Nishioka Y, Andreatos N, Sekine A, et al. Effect of Background Liver Cirrhosis on Outcomes of Hepatectomy for Hepatocellular Carcinoma. *JAMA Surg.* 2017 Mar 15;152(3):e165059.

[97] Sakamoto M, Hirohashi S, Tsuda H, Shimosato Y, Makuuchi M, Hosoda Y. Multicentric independent development of hepatocellular carcinoma revealed by analysis of hepatitis B virus integration pattern. *Am J Surg Pathol.* 1989 Dec;13(12):1064–7.

[98] Morimoto O, Nagano H, Sakon M, Fujiwara Y, Yamada T, Nakagawa H, et al. Diagnosis of intrahepatic metastasis and multicentric carcinogenesis by microsatellite loss of heterozygosity in patients with multiple and recurrent hepatocellular carcinomas. *J Hepatol*. 2003 Aug;39(2):215–21.

[99] Li Q, Wang J, Juzi JT, Sun Y, Zheng H, Cui Y, et al. Clonality analysis for multicentric origin and intrahepatic metastasis in recurrent and primary hepatocellular carcinoma. *J Gastrointest Surg.* 2008 Sep;12(9):1540–7.

[100] Yang SL, Luo YY, Chen M, Zhou YP, Lu FR, Deng DF, et al. A systematic review and meta-analysis comparing the prognosis of multicentric occurrence and vs. intrahepatic metastasis in patients with recurrent hepatocellular carcinoma after hepatectomy. *HPB.* 2017 Oct;19(10):835–42.

[101] Zhou L, Rui JA, Wang SB, Chen SG, Qu Q. Early recurrence in large hepatocellular carcinoma after curative hepatic resection: prognostic significance and risk factors. *Hepatogastroenterology.* 2014 Oct;61(135):2035–41.

[102] Hung HH, Lei HJ, Chau GY, Su CW, Hsia CY, Kao WY, et al. Milan criteria, multi-nodularity, and microvascular invasion predict the recurrence patterns of hepatocellular carcinoma after resection. *J Gastrointest Surg.* 2013 Apr;17(4):702–11.

[103] Hirokawa F, Hayashi M, Asakuma M, Shimizu T, Inoue Y, Uchiyama K. Risk factors and patterns of early recurrence after curative hepatectomy for hepatocellular carcinoma. *Surg Oncol.* 2016 Mar;25(1):24–9.

[104] Zhong Y, Deng M, Xu R. Reappraisal of evidence of microscopic portal vein involvement by hepatocellular carcinoma cells with stratification of tumor size. *World J Surg.* 2015 May;39(5):1142–9.

[105] Regimbeau JM, Kianmanesh R, Farges O, Dondero F, Sauvanet A, Belghiti J. Extent of liver resection influences the outcome in patients with cirrhosis and small hepatocellular carcinoma. *Surgery.* 2002;131(3):311–7.

[106] Hasegawa K, Kokudo N, Imamura H, Matsuyama Y, Aoki T, Minagawa M, et al. Prognostic Impact of Anatomic Resection for Hepatocellular Carcinoma. *Ann Surg.* 2005;242(2):252–9.

[107] Takano S, Oishi H, Kono S, Kawakami S, Nakamura M, Kubota N, et al. Retrospective analysis of type of hepatic resection for hepatocellular carcinoma. *Br J Surg*. 2000 Jan;87(1):65–70.

[108] Ercolani G, Grazi GL, Ravaioli M, Del Gaudio M, Gardini A, Cescon M, et al. Liver resection for hepatocellular carcinoma on cirrhosis: univariate and multivariate analysis of risk factors for intrahepatic recurrence. *Ann Surg.* 2003 Apr;237(4):536–43.

[109] Cucchetti A, Qiao GL, Cescon M, Li J, Xia Y, Ercolani G, et al. Anatomic versus nonanatomic resection in cirrhotic patients with early hepatocellular carcinoma. *Surgery.* 2014 Mar;155(3):512–21.

[110] Li SL, Su M, Peng T, Xiao KY, Shang LM, Xu BH, et al. Clinicopathologic Characteristics and Prognoses for Multicentric Occurrence and Intrahepatic Metastasis in Synchronous Multinodular Hepatocellular Carcinoma Patients. *Asian Pac J Cancer Prev.* 2013;14(1):217–23.

[111] Shimada M, Hamatsu T, Yamashita Y, Rikimaru T, Taguchi K, Utsunomiya T, et al. Characteristics of multicentric hepatocellular carcinomas: comparison with intrahepatic metastasis. *World J Surg.* 2001 Aug;25(8):991–5.

[112] Nakano S, Haratake J, Okamoto K, Takeda S. Investigation of resected multinodular hepatocellular carcinoma: assessment of unicentric or multicentric genesis from histological and prognostic viewpoint. *Am J Gastroenterol.* 1994 Feb;89(2):189–93.

[113] Ikeda K, Arase Y, Kobayashi M, Saitoh S, Someya T, Hosaka T, et al. Significance of multicentric cancer recurrence after potentially curative ablation of hepatocellular carcinoma: a longterm cohort study of 892 patients with viral cirrhosis. *J Gastroenterol.* 2003;38(9):865–76.

[114] Arii S, Yamaoka Y, Futagawa S, Inoue K, Kobayashi K, Kojiro M, et al. Results of surgical and nonsurgical treatment for small-sized hepatocellular carcinomas: A retrospective and nationwide survey in Japan. *Hepatology.* 2000;32(6):1224–9.

[115] Huang ZY, Liang BY, Xiong M, Zhan DQ, Wei S, Wang GP, et al. Long-term outcomes of repeat hepatic resection in patients with recurrent hepatocellular carcinoma and analysis of recurrent types and their prognosis: a single-center experience in China. *Ann Surg Oncol*. 2012 Aug;19(8):2515–25.

[116] Portolani N, Coniglio A, Ghidoni S, Giovanelli M, Benetti A, Tiberio GAM, et al. Early and late recurrence after liver resection for hepatocellular carcinoma: prognostic and therapeutic implications. *Ann Surg.* 2006 Feb;243(2):229–35.

[117] Frau M, Feo F, Pascale RM. Pleiotropic effects of methionine adenosyltransferases deregulation as determinants of liver cancer progression and prognosis. *J Hepatol.* 2013 Oct;59(4):830–41.

[118] Calvisi DF, Frau M, Tomasi ML, Feo F, Pascale RM. Deregulation of signalling pathways in prognostic subtypes of hepatocellular carcinoma: novel insights from interspecies comparison. *Biochim Biophys Acta.* 2012 Aug;1826(1):215–37.

[119] Lam CT, Tang CMC, Lau KW, Lung ML. Loss of heterozygosity on chromosome 11 in esophageal squamous cell carcinomas. *Cancer Lett.* 2002;178(1):75–81.

[120] Piao Z, Kim H, Malkhosyan S, Park C. Frequent chromosomal instability but no microsatellite instability in hepatocellular carcinomas. *Int J Oncol* [Internet]. 2000; Available from: http://dx.doi.org/10.3892/ijo.17.3.507.

[121] Chen YJ, Yeh SH, Chen JT, Wu CC, Hsu MT, Tsai SF, et al. Chromosomal changes and clonality relationship between primary and recurrent hepatocellular carcinoma. *Gastroenterology.* 2000 Aug;119(2):431–40.

[122] Ng IOL, Guan XY, Poon RTP, Fan ST, Lee JMF. Determination of the molecular relationship between multiple tumour nodules in hepatocellular carcinoma differentiates multicentric origin from intrahepatic metastasis. *J Pathol.* 2003 Mar;199(3):345–53.

[123] Utsunomiya T, Shimada M, Imura S, Morine Y, Ikemoto T, Mori M. Molecular signatures of noncancerous liver tissue can predict the risk for late recurrence of hepatocellular carcinoma. *J Gastroenterol.* 2010 Feb;45(2):146–52.

[124] Nakata T, Seki N, Miwa S, Kobayashi A, Soeda J, Nimura Y, et al. Identification f genes associated with multiple nodules in hepatocellular carcinoma using cDNA microarray: multicentric occurrence or intrahepatic metastasis? *Hepatogastroenterology.* 2008 May;55(84):865–72.

[125] Fujimoto A, Totoki Y, Abe T, Boroevich KA, Hosoda F, Nguyen HH, et al. Whole-genome sequencing of liver cancers identifies etiological influences on mutation patterns and recurrent mutations in chromatin regulators. *Nat Genet.* 2012;44(7):760–4.

[126] Totoki Y, Tatsuno K, Yamamoto S, Arai Y, Hosoda F, Ishikawa S, et al. High-resolution characterization of a hepatocellular carcinoma genome. *Nat Genet.* 2011 May;43(5):464–9.

[127] Guichard C, Amaddeo G, Imbeaud S, Ladeiro Y, Pelletier L, Ben Maad I, et al. Integrated analysis of somatic mutations and focal copy-number changes identifies key genes and pathways in hepatocellular carcinoma. *Nat Genet.* 2012;44(6):694–8.

[128] Furuta M, Ueno M, Fujimoto A, Hayami S, Yasukawa S, Kojima F, et al. Whole genome sequencing discriminates hepatocellular carcinoma with intrahepatic metastasis from multi-centric tumors. *J Hepatol.* 2017;66(2):363–73.

[129] Beretta L. Comparative analysis of the liver and plasma proteomes as a novel and powerful strategy for hepatocellular carcinoma biomarker discovery. *Cancer Lett.* 2009 Dec 1;286(1):134–9.

[130] Qin LX, Tang ZY. Recent progress in predictive biomarkers for metastatic recurrence of human hepatocellular carcinoma: a review of the literature. *J Cancer Res Clin Oncol.* 2004 Sep;130(9):497–513.

[131] Miao R, Luo H, Zhou H, Li G, Bu D, Yang X, et al. Identification of prognostic biomarkers in hepatitis B virus-related hepatocellular carcinoma and stratification by integrative multi-omics analysis. *J Hepatol.* 2014 Oct;61(4):840–9.

In: Encyclopedia of Surgery (22 Volume Set)
Editors: Andreas Lehrer and Kristin Mueller
ISBN: 978-1-53618-329-0
© 2020 Nova Science Publishers, Inc.

Chapter 155

LAPAROSCOPIC LIVER RESECTION FOR HEPATOCELLULAR CARCINOMA PATIENTS: INDICATIONS AND BENEFITS

Zenichi Morise*, MD, PhD
Department of Surgery, Fujita Health University School of Medicine
Toyoake, Japan

ABSTRACT

The treatment options for hepatocellular carcinoma (HCC) include liver resection (LR), liver transplantation (LT), transarterial chemoembolization, and local ablation therapy. LR and LT, and local ablation therapy (for small tumors only) provide the best hope for cure. However, most patients with HCC have underlying chronic liver disease (CLD) and are thus at high risk for development of postoperative complications - sometimes fatal- and metachronous multicentric recurrent lesions occurring from the preneoplastic CLD background. Although appropriate treatment is selected for HCC patients with CLD depending on the tumor condition and liver function, a large number of patients are not able to undergo any treatment because of poor liver function and/or complicated tumor condition. This is especially true after repeated treatments for the disease.

In our experience of laparoscopic LR (LLR), LLR could expand the indication of LR to severe CLD patients due to its lower damages to the liver and surrounding tissue, especially to collateral circulation around the cirrhotic liver. Child-Pugh score, not class, is one of the promising candidates as a selection indicator which correlates well to our indication criteria of surface small LLR to severe CLD patients, patient's performance status, and prognosis. Portal hypertension should also be counted in the selection criteria.

For repeat LLR, there are only small number of reports with small number of patients to date. These studies generally reported that repeat LLR has better short-term outcomes than open (reduced bleedings, less or similar morbidity and shorter hospital stay) without compromising the long-term outcomes. The fact that complete adhesiolysis can be avoided in repeat LLR is also reported. In the comparison of previous procedures,

* Corresponding Author's Email: zmorise@fujita-hu.ac.jp.

it is reported that the operation time for repeat LLR was shorter for the patients previously treated with LLR than open. Furthermore, it is speculated that LLR for minor repeat LR of cirrhotic liver can be minimized the deterioration of liver function by LR. However, further experience and evaluation of anatomical resection or resections exposing major vessels as repeat LLR, especially after previous anatomical resection, are needed.

It is thought that the features of LLR could lead to expanding the indications for LR to those patients in the settings of severe CLD, repeat LR, and bridging to LT. There should be a chance to prolong the overall survival of the patients by using LLR as a powerful local therapy which can be applied repeatedly with minimal deterioration of liver function.

INTRODUCTION

General Situation of the Treatments for Hepatocellular Carcinoma (HCC) Patients with Chronic Liver Disease (CLD)

The treatment options for HCC include liver resection (LR) [1], liver transplantation (LT) [2], transarterial chemoembolization, and local ablation therapy [3]. LR, LT and local ablation therapy (only for small tumors) provide the best hope for cure [3-6]. However, most patients with HCC have underlying chronic liver disease (CLD) and are thus at high risk for development of postoperative complications and metachronous multicentric recurrent lesions occurring from the preneoplastic CLD background.

Currently, the choice of LR, LT, local ablation therapy or transarterial chemoembolization is made for each patient depending on the tumor condition and liver function [7]. However, a large number of HCC patients are not able to undergo any such treatment because of poor liver function and/or complicated tumor condition. This is especially true after repeated treatments for the recurrent disease.

Among the treatment options mentioned above, LT should be ideal for HCC patients with CLD in the aspect of removing both existing tumors and injured/preneoplastic underlying liver. However, it cannot be applied on a large scale due to the high prevalence of HCC and the limited access to LT consequent to donor shortage [8]. LT is also restricted to patients with minimal risk of tumor recurrence under immunosuppression [9]. Expansion of the criteria for LT in HCC patients is still under trial and discussion [10, 11]. Therefore, LR has traditionally been accepted as the preferred treatment for resectable HCC in patients with adequate liver reserve [6, 12, 13].

When considering LR to HCC patients with CLD, not only the oncological therapeutic effects, but also the residual liver function and the degree of invasive surgical stress, especially to the diseased liver should be considered. Patients with CLD have various symptoms [14] and a high risk of morbidity and mortality following anesthesia and surgery depending on their Child-Pugh (CP) class [15, 16]. For severe CLD patients, even limited LR often leads to refractory ascites, which can be a fatal complication [17, 18].

Considerable progress made over the past 10 years in screening, early radiologic diagnosis, treatment of the underlying CLD, and surgical techniques has resulted in revision of the indications for LR [19]. Furthermore, improved liver function assessment and understanding of segmental liver anatomy from using more accurate imaging studies, as well

as surgical technical progress, are the most important factors that have reduced the mortality rate of HCC; today, the expected 5-year survival after LR is 38%-61%, depending on the stage of the disease [20]. Despite these advances, however, less than 30% of HCC patients are eligible for LR [21, 22].

Emerging evidence from laparoscopic (L)LR [23, 24] may lead to expansion of the indication for LR in the therapeutic system for HCC patients with CLD. In this article, the current reports on LLR for HCC patients with CLD are reviewed and our experiences are described.

LLR for HCC Patients with CLD

The beginnings of LLR were at the start of the 1990s, with its initial reports [25-27] being published in 1991 and 1992. Thereafter, the indication of LLR has been expanded as a less invasive procedure than conventional open (O)LR for hepatic lesions. LLR has the benefit of earlier intake, recovery and discharge, and reduced postoperative pain, like other laparoscopic procedures [28]. A meta-analysis of 26 studies found that, although LLR was associated with longer operating times, the oncologic outcomes were not different from OLR [29]. Furthermore, studies showed the specific advantages associated with LLR, such as reduced blood loss, decreased portal clamp time, and decreases in overall and liver-specific complications at least for selected patients and within the technical capabilities of each experienced center.

The safety and feasibility of LLR and its short-term benefits for HCC patients with CLD have also been demonstrated [30-32]. LLR may be particularly advantageous for HCC patients with CLD, who often develop refractory ascites with OLR, a potentially fatal complication [17, 18]. LLR has the advantage of minimal ascites, due to the preservation of venous and lymphatic collateral circulation [35], which lowers the risk of water/electrolyte imbalance and hypoproteinemia that could trigger fatal liver failure. This feature could be the most remarkable advantage of LLR.

Patients who undergo LR are exposed to three different types of stresses: 1) general, whole-body surgical stress; 2) reduced liver function due to reduced liver volume after resection; and, (3) surgery-induced injury to the environment surrounding the liver and liver parenchyma (caused by disruption of the collateral blood and lymphatic circulation with laparotomy and mobilization of the liver, and parenchymal injury by compression of the liver) [33]. LR is the procedure that the liver protected inside the subphrenic rib cage is resected. In OLR, the cage is opened with a big subcostal incision and a lift of the costal arch, and then the liver is picked up for resection with the dissection of retroperitoneal attachments. On the other, in LLR, laparoscope and forceps intrude into the cage directly from the caudal direction ("Caudal approach" [34-36], Figure 1) and perform LR in the small targeted area without damages to the surrounding area. Furthermore, the same surgical view under position changes, acquired by the adjustments of laparoscope's positioning and rotation in LLR, allows for handling large-volume liver/tumor by postural changes. This leads to the reduction of compression damage on the liver. Our previous report of the caudal approach posterior sectionectomy in the left lateral position [34] posed the novel concept of "caudal approach" in LLR. Although the supine to semi-lateral positioning had been employed for the other resections, the transection plane of posterior sectionectomy was horizontal in the supine

position and gravity obstructs the exposure of the plane. A clear view from the caudal direction and an easy access to postural changes are among the advantages of LLR (Figure 1). Our procedure is a laparoscopic posterior sectionectomy with parenchymal transection prior to mobilization in the left lateral position. It facilitates exposure of the cutting plane during the transection in caudal-to-cranial one direction. The transection plane is well-opened between the retroperitoneal-fixed posterior section and the remnant liver falling down to left by gravity. Moreover, the segmentectomy or partial resection of segment (S)7 should be performed in the deeper and smaller cranial subphrenic space and S6 is an obstacle under the laparoscopic caudal view even in the left lateral position. We employed the semi-prone position with only partial dissection of the retroperitoneum for those resections [37]. LLR can facilitate minimal dissection around the liver and minimal compression on the liver with the intrusion and manipulation of laparoscope and forceps to the small target area ("Caudal approach" Figure 1) under postural changes. Therefore, LLR's reduction of surgery-induced injuries in HCC patients with CLD lowers the risk of refractory ascites, resulting in a reduced risk of successive complications and facilitating a smoother recovery without liver failure.

The impact of LLR on this issue should depend on the severity of the background CLD, the operative technique (extent of dissection of the peritoneal attachments and adhesions), and extent of resection. Our previous study compared the short-term results of liver surface small LLR for patients with severe CLD (CP-B/C and indocyanine green retention rate at 15 min (ICGR15) ≥ 40%) to those for patients with mild-moderate CLD [38]. Although the study was a small number, retrospective unmatched study, it revealed comparable perioperative outcomes, including postoperative ascites production, between patients with severe and mild-to-moderate CLD in LLR.

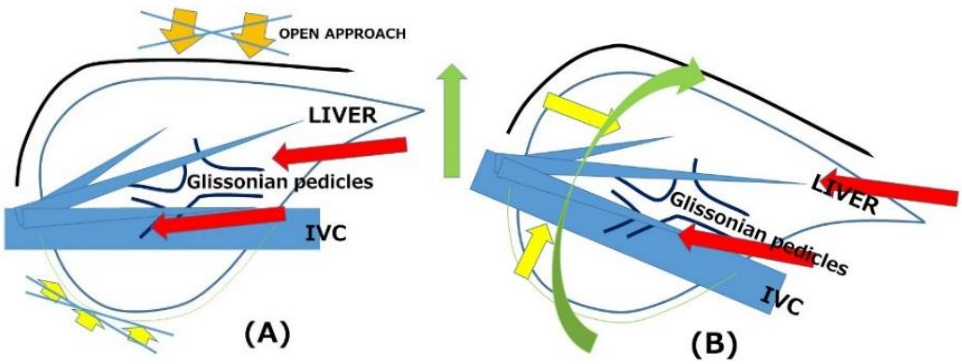

Figure 1. Schema of laparoscopic liver resection (LLR, A), and position changes in LLR (B).
Red arrows indicate the directions of the view and manipulation. In the open approach, the subcostal cage containing the liver is opened with a large subcostal incision, and instruments are used to lift the costal arch up (A, cross mark). The liver is dissected and mobilized (picked up) from the retroperitoneum (A, cross mark). A: In the laparoscopic caudal approach, the laparoscope and forceps intrude into the subcostal cage from caudal direction, and surgery is performed with minimal alteration and destruction of the surrounding structures. B: In the laparoscopic approach, the same surgical view under position changes (tilting the bed and rotation of the patient's body), acquired by the adjustments of laparoscope's positioning and rotation, allows for handling large-volume liver/tumor by postural changes.

Repeat LLR

As mentioned above, HCC arises in metachronous multicentric fashion inside the liver with its preneoplastic CLD backgrounds. Intrahepatic recurrences after previous resection of HCC with the need for repeat treatments often occur.

LR is now actively applied to those lesions, when the lesions are resectable and there is no other uncontrollable/distant disease, and the opportunity for repeat LR has increased [39-42]. Currently, indications of LLR have been expanded with the accumulation of experiences and technical/conceptual and instrumental developments [24, 43-45]. Postoperative adhesions with the need for adhesiolysis are known to increase the operation time of subsequent surgeries and the incidence of bowel injury [46, 47]. Therefore, increased rates of complications and conversion from laparoscopic to open surgery had been reported in repeat laparoscopic surgery [48]. Although a previous surgical history had been among the contraindications for laparoscopic surgery, many laparoscopic procedures, such as cholecystectomy [47, 48], appendectomy [49], colectomy [50], and gastrectomy [51], can be applied to those patients nowadays with technical and instrumental improvements. However, since LLR still remains a technically demanding procedure, the indications and efficacy of repeat LLR are under discussion. Adequate dissection of adhesion and mobilization of the involved liver should be performed before repeat LR. Visualization and dissection of the hepatoduodenal ligament and hilar area, often crucial in LR, can be disrupted by adhesion. The deformity of the liver surrounded by the scars and adhesion makes the localization of tumors and the important structures (vessels) difficult. The fact that liver capsule bleeds easily during adhesiolysis and mobilization leads to increase the intraoperative bleeding and create a suboptimal operative field [52]. These changes after previous surgery can increase the risks of intraoperative injury to vascular and biliary structures.

Although the reports of repeat LLR are gradually increasing, only 16 reports of small series were found out under Medline-search with the words “repeat” and “laparoscopic liver resection” and their re-quotations [53-68]. Belli et al. [55] reported that LLR facilitates more meticulous dissection of adhesions strained by the pneumoperitoneum using magnified laparoscopic view. The fact that complete adhesiolysis can be avoided when the adhesion does not affect the current operative procedure (which is on the same line of LLR characteristics mentioned in the previous section “LLR for HCC patients with CLD”) is also reported as a possible advantage of repeat LLR [59, 64]. In comparison with repeat OLR, these studies generally reported that repeat LLR has better short-term outcomes (similar or longer operation time, reduced bleedings, reduced blood transfusion rate, less or similar morbidity and shorter hospital stay) without compromising the long-term outcomes. Each report concluded that repeat LLR is feasible and safe for selected patients. However, those studies are the mixtures of the patients with HCC and metastases. Five studies of repeat LLR, which only include HCC patients [55, 59, 61, 62, 66], reported the outcomes for the series of 12, 6, 3, 20 and 8 patients. The conclusions of all studies are that repeat LLR is a safe and feasible procedure even for recurrent HCC in CLD patients. Belli et al. [55] again mentioned that the adhesiolysis was easier and the operation time was shorter in repeat LLR for the patients with previous LLR compared to previous OLR. They also referred the advantages of LLR for the management during the long history with repeat oncogenesis in CLD patients. Kanazawa et al. [62] mentioned that the complication rate and the hospital stay had been decreased in their institute by the introduction of LLR for recurrent HCC patients. Repeat

LLR requires smaller (than open) working space between adhesions where laparoscope and forceps can intrude and do manipulation. This fact allows for minimal adhesiolysis and a direct approach to the tumor especially in repeat small LLR [58, 59, 64]. Therefore, some studies showed that operation time and bleeding amount were similar in primary and repeat LLR [53, 64], although the short-term results from primary and repeat OLR are usually very different especially in operative time (longer in repeat) and intraoperative blood loss (larger in repeat). Operation time and bleeding amount could be reduced with the usage of laparoscopic approach for repeat partial resection. Furthermore, one of the possible advantages speculated for minor repeat LLR of CLD liver is that the deterioration of liver function can be minimized with the minimal dissection (Table 1).

Table 1. The summary of present status of repeat LLR

- Operation time was shorter and the adhesiolysis was easier for the patients previously treated with LLR than open LR.
- LLR facilitates more meticulous dissection of adhesions strained by the pneumoperitoneum using magnified laparoscopic view.
- Complete adhesiolysis can be avoided in repeat LLR when the adhesion does not affect the current operative procedure, since it requires smaller (than open) working space between adhesions. (This allows that operation time and bleeding amount are similar to primary LLR, although those from open LR are longer and larger.)

LLR could prolong the overall survival of the HCC patients with CLD as a powerful local therapy which can be applied repeatedly with minimal deterioration of liver function.

Challenges:

Further evaluations of anatomical resection or resections exposing major vessels after previous anatomical resection are needed.

LLR Indications to Severe CLD Patients

For the treatment selection of HCC, the Barcelona clinic liver cancer (BCLC) staging system/treatment algorithm [69] and the Japan Society of Hepatology clinical guidelines for HCC (JSH guideline) [70] are used in Western countries and Japan, respectively. Both systems include not only tumor condition but also background liver condition for the treatment selection. The two differ in that the BCLC algorithm uses CP classification (CP) [71] for assessments of liver function, while the JSH guideline uses the liver damage (LD) classification of the Liver Cancer Study Group of Japan [72], which has ICGR15 as one of the essential elements.

ICGR15 is a useful modality for assessing hepatic functional reserve and predicting postoperative mortality [73-75]. The extent of the liver resected in each patient is basically planned according to the tumor condition and location. However, HCC patients sometimes develop postoperative liver failure due to poor liver functional reserve after the planned resection. ICGR15 has been an excellent tool for predicting how much liver volume could be resected in each patient's liver condition [74], On the other hand, nontumorous functioning

liver parenchyma is resected minimally in liver surface tumorectomy or small partial resection. In those cases, the most important point for preoperative evaluation is, not how much liver volume could be resected, but whether the patient and the liver could tolerate the surgical stress. As mentioned before, LLR minimizes the surgery-induced injury caused by disruption of the collateral blood and lymphatic circulation and compression on the liver parenchyma, and leads to decreased postoperative ascites and liver failure [33]. The decision-making process during liver surface small partial LLR should be different from the other liver resections.

Our Experiences of LLR for HCC Patients with CLD

Among 152 patients, 19 had more than 30% ICGR15 and HCC. The details of these patients are presented in Table 2. The 19 patients were composed of 6, 11 and 2 patients with CP-A, B and C, respectively. By LD classification, they included 2, 12 and 5 patients of LD-A, B and C, respectively. There was discrepancy between the liver functional assessments of CP and LD. The patients with high ICGR15 values tended to be classified into higher grade of liver dysfunction in the LD classification. Based on liver functional criteria only of BCLC and JHS, there were already 2 and 5 patients out of LR indication in this group, respectively. We applied liver surface small LLR to the CP-B/C (up to CP score of 10) patients only when the patients could have been doing light or household labor for more than 6 months before their surgery, in a stable condition (good performance status).

Excluding the 1 patient whose follow-up period is less than 24 mo and the 1 patient who underwent LT at 15 months after LLR, 7 patients died of HCC or liver disease within 24 months after LLR (D group). When the D patients were compared to the group of 10 patients who survived more than 24 months (A group), there are significant difference in CP scores between the groups (Table 3). The values of ICGR15 are similar in the A and D groups. All of the D patients, but only 3 of the 11 A patients, had esophageal varices before surgery. All of the A patients, excluding the patients with LT at 15 months, had 50,000 or more blood platelet counts, and 5 out of 7 D patients had below 60,000.

It is thought that ICGR15 above 30%-40% is out of their reliable range and not well-correlated with actual liver function. Thus, it may not be suitable for the liver functional selection criteria of surface small LLR, even though it is very useful and simple criteria for judging how much liver volume can be resected in the range below 30%-40%. Although the difficult judgements for the objective presences of ascites and encephalopathy should be needed, CP score is a promising candidate for selection indicator of surface small LLR, correlating well to our indication criteria, patient's performance status, and prognosis after the surgery. Portal hypertension [76], indicated by the presence of esophageal varices and low platelet counts, should be also counted in the selection of surface small LLR.

Table 2. Our cases of laparoscopic liver resection (LLR) for severe chronic liver diseases (CLD)

Age	Sex	Tumor location	Tumor size (mm)	Conversion	Previous surgery	LT after LLR	ICGR15 (%)	CP		Platelet ($X10^4/\mu l$)	Prognosis (month)	
73	F	S3	18				37.7	A	6	14.7	5	A
66	M	S3	47		Splenectomy		31.1	B	7	26	5.1	D
53	M	S5-6	28				41.2	B	7	8.3	11.2	D
63	M	S5-6	40				52	B	9	4.5	12	D
68	F	S8	13				58.2	C	10	4	14.1	D
75	F	S3	20				42.5	B	9	5.8	17.4	D
67	M	S8	20	HALS			55	B	8	5	19.3	D
69	F	S8	24		LLR		33.5	B	7	5.8	22.7	D
72	M	S5	16		LLR		42.3	A	5	8.6	27.8	A
64	M	S4,S2-3	41				42.8	B	7	8.9	28.5	D
81	F	S7	100				78.3	A	5	36.6	28.6	A
62	M	S3	24		LLRX3		43.5	B	8	7.2	30.5	A
68	F	S4	23				40	B	9	6.7	35.4	D
80	F	S3	18		LLR		40.4	B	7	8.8	35.7	D
50	M	S5	22			15M	48.9	C	10	4.8	35.9	AD
67	M	S8	11		LLR		39	A	6	5	47.9	A
67	F	S8-4,S5,S6	32	Open			34.6	A	6	7.2	58.7	D
40	M	S6	20			60M	52.5	B	7	6	75.6	D
61	M	S5	15				70.8	A	5	11.9	127.8	A

S: segment, HALS: hand-assisted laparoscopic surgery, LT: liver transplantation, CP: Child-Pugh classification and score, EVL: patients who underwent endoscopic varices ligation before LLR, A: alive, D: dead of hepatocellular carcinoma or liver disease, AD: dead of the other cause.

Table 3. Parameters of liver function in the patient groups of those who survived more than 24 months (A*) and who died of HCC or liver disease within 24 months (D)

Platelet counts, $\times 10^4/\mu L$		
Group	A (n = 10)	D** (n = 6)
Mean+/-SD	10.740+/-9.426	5.567+/-1.516
Unpaired t two-tailed P-value = 0.2093		
CP score		
Group	A (n = 10)	D (n = 7)
Mean+/-SD	6.50+/-1.35	8.14+/-1.21
Unpaired t two-tailed P-value = 0.0216#		
ICGR15, %		
Group	A (n = 10)	D (n = 7)
Mean+/-SD	48.420+/-14.600	44.786+/-10.560
Unpaired t two-tailed P-value = 0.5828		

*1 patient who underwent liver transplantation at 15 months after LR was excluded from group A; **1 patient after splenectomy was excluded from group D; # statistically different. CP: Child-Pugh classification score; HCC: Hepatocellular carcinoma; ICGR15: Indocyanine green retention rate at 15 min.

Most reported cases of repeat LLR underwent minor resection for HCC patients with CLD, as mentioned above. The impact of alterations to hepatic parenchyma and intrahepatic structural anatomy from the previous LR could be relatively small in such cases. However, in our experience of 33 repeat and 12 three or more-time repeat LLRs, three patients who underwent anatomical resection or resections exposing major vessels (including S8 segmentectomy after 4-times LLR [77]) after previous anatomical resection developed postoperative bile leakage and more than 30 days postoperative hospital stay. Since anatomical alterations and surrounding scars and/or adhesion of hilar and intrahepatic vessel structures should have big impacts on anatomical resection or resections exposing major vessels as repeat LLR after previous anatomical resection, further experiences and evaluations of such repeat LLR are needed.

CONCLUSION

The characteristics mentioned above indicate that LLR may be superior to OLR under certain conditions. The LLR could also be an optional bridging therapy to LT for certain HCC patients with severe CLD [31]. The recent development of LLR and accumulation of experience could lead to an expansion of the indication for LLR [45]. Although the number of studies reported has been small and comprising various settings, we believe that the features of LLR that have come to light will lead to expanding the indications for LR to HCC patients with background CLD, particularly in the settings of severe CLD, repeat LR and bridging to LT.

REFERENCES

[1] Capussotti L, Ferrero A, Viganò L, Polastri R, Tabone M. Liver resection for HCC with cirrhosis: surgical perspectives out of EASL/AASLD guidelines. *Eur J Surg Oncol*. 2009;35:11-15. [PMID: 17689043 DOI: 10.1016/j.ejso.2007.06.005].

[2] Hwang S, Lee SG, Belghiti J. Liver transplantation for HCC: its role: Eastern and Western perspectives. *J Hepatobiliary Pancreat Sci.* 2010;17:443-448. [PMID: 19885638 DOI: 10.1007/s00534-009-0241-0].

[3] Lau WY, Leung TW, Yu SC, Ho SK. Percutaneous local ablative therapy for hepatocellular carcinoma: a review and look into the future. *Ann Surg.* 2003;237:171-179. [PMID: 12560774 DOI: 10.1097/01.SLA.0000048443.71734.BF].

[4] Mazzaferro V1, Regalia E, Doci R, Andreola S, Pulvirenti A, Bozzetti F, Montalto F, Ammatuna M, Morabito A, Gennari L. Liver transplantation for the treatment of small hepatocellular carcinomas in patients with cirrhosis. *N Engl J Med*. 1996;334:693-699. [PMID: 8594428 DOI: 10.1056/NEJM199603143341104].

[5] Ryder SD. Guidelines for the diagnosis and treatment of hepatocellular carcinoma (HCC) in adults. *Gut.* 2003;52(Suppl 3):iii1-8. [PMID: 12692148 PMCID: PMC1867754].

[6] Morise Z, Kawabe N, Tomishige H, Nagata H, Kawase J, Arakawa S, Yoshida R, Isetani M. Recent advances in the surgical treatment of hepatocellular carcinoma. *World J Gastroenterol*. 2014;20 (39):14381-92. [PMID: 25339825 DOI: 10.3748/wjg.v20.i39.14381.].

[7] Llovet JM, Fuster J, Bruix J. The Barcelona approach: diagnosis, staging, and treatment of hepatocellular carcinoma. *Liver Transpl.* 2004;10:S115–S120. [PMID: 14762851 DOI: 10.1002/lt.20034].

[8] Llovet JM, Fuster J, Bruix J. Intention-to-treat analysis of surgical treatment for early hepatocellular carcinoma: resection versus transplantation. *Hepatology* 1999;30:1434–1440. [PMID: 10573522 DOI: 10.1002/hep.510300629].

[9] Cucchetti A, Vitale A, Gaudio MD, Pinna AD. Harm and benefits of primary liver resection and salvage transplantation for hepatocellular carcinoma. *Am J Transplant* 2010; 10: 619-627. [PMID: 20121741 DOI: 10.1111/j.1600-6143.2009.02984.x].

[10] Yao FY, Ferrell L, Bass NM, Watson JJ, Bacchetti P, Venook A, Ascher NL, Roberts JP. Liver transplantation for hepatocellular carcinoma: Expansion of the tumor size limits does not adversely impact survival. *Hepatology* 2001; 33: 1394-1403. [PMID: 11391528 DOI: 10.1053/jhep.2001.24563].

[11] Fujiki M, Takada Y, Ogura Y, Oike F, Kaido T, Teramukai S, Uemoto S. Significance of des-gamma-carboxy prothrombin in selection criteria for living donor liver transplantation for hepatocellular carcinoma. *Am J Transplant* 2009; 9(10): 2362-71. [PMID: 19656125 DOI: 10.1111/j.1600-6143.2009.02783.x].

[12] Bruix J, Reig M, Sherman M. Evidence-based diagnosis, staging, and treatment of patients with hepatocellular carcinoma. *Gastroenterology* 2016;150:836–853. [PMID: 26795574 DOI: 10.1053/j.gastro.2015.12.041].

[13] Bruix J, Castells A, Bosch J, Feu F, Fuster J, Garcia-Pagan J, Visa J, Bru C, Rodes J. Surgical resection of hepatocellular carcinoma in cirrhotic patients: prognostic value of

preoperative portal pressure. *Gastroenterology*. 1996;111:1018-22. [PMID: 8831597 DOI:10.1016/ S0016-5085(96)70070-7].

[14] Hoeper MM, Krowka MJ, Strassburg CP. Portopulmonary hypertension and hepatopulmonary syndrome. *Lancet.* 2004;363(9419):1461-1468. [PMID: 15121411 DOI: 10.1016/S0140-6736(04)16107-2].

[15] Ziser A, Plevak DJ, Wiesner RH, Rakela J, Offord KP, Brown DL. Morbidity and mortality in cirrhotic patients undergoing anesthesia and surgery. *Anesthesiology.* 1999;90:42-53. [PMID: 9915311].

[16] Mansour A, Watson W, Shayani V, Pickleman J. Abdominal operations in patients with cirrhosis: still a major surgical challenge. *Surgery.* 1997;122:730-735. [PMID: 9347849].

[17] Belghiti J, Hiramatsu K, Benoist S, Massault P, Sauvanet A, Farges O. Seven hundred forty-seven hepatectomies in the 1990s: an update to evaluate the actual risk of liver resection. *J Am Coll Surg*. 2000;191:38-46. [PMID: 10898182].

[18] Lai EC, Fan ST, Lo CM, Chu KM, Liu CL, Wong J. Hepatic resection for hepatocellular carcinoma. An audit of 343 patients. *Ann Surg.* 1995;221:291-298. [PMID: 7717783 PMCID: PMC1234572].

[19] Rahbari NN, Mehrabi A, Mollberg NM, Muller SA, Koch M, Buchler MW, Weitz J. Hepatocellular carcinoma: current management and perspectives for the future. *Ann Surg* 2011; 253: 453-469. [PMID: 21263310 DOI: 10.1097/SLA.0b013e31820d944f].

[20] Torzilli G, Belghiti J, Kokudo N, Takayama T, Capussotti L, Nuzzo G, Vauthey JN, Choti MA, De Santibanes E, Donadon M, Morenghi E, Makuuchi M. A snapshot of the effective indications and results of surgery for hepatocellular carcinoma in tertiary referral centers: is it adherent to the EASL/AASLD recommendations?: an observational study of the HCC East-West study group. *Ann Surg.* 2013;257:929-37. [PMID: 23426336 DOI: 10.1097/SLA.0b013e31828329b8].

[21] El-Serag HB, Marrero JA, Rudolph L, Reddy KR. Diagnosis and treatment of hepatocellular carcinoma. *Gastroenterology* 2008; 134: 1752-1763. [PMID: 18471552 DOI: 10.1053/j.gastro.2008.02.090].

[22] Forner A, Reig ME, de Lope CR, Bruix J. Current strategy for staging and treatment: the BCLC update and future prospects. *Semin Liver Dis* 2010; 30: 61-74. [PMID: 20175034 DOI: 10.1055/s-0030-1247133].

[23] World Consensus Conference on Laparoscopic Surgery. The international position on laparoscopic liver surgery: The Louisville Statement, 2008. *Ann Surg* 2009; 250(5): 825-30. [PMID: 19916210 DOI: 10.1097/SLA.0b013e3181b3b2d8].

[24] Wakabayashi G, Cherqui D, Geller DA, Buell JF, Kaneko H, Han HS, Asbun H, O'Rourke N, Tanabe M, Koffron AJ, Tsung A, Soubrane O, Machado MA, Gayet B, Troisi RI, Pessaux P, Van Dam RM, Scatton O, Abu Hilal M, Belli G, Kwon CH, Edwin B, Choi GH, Aldrighetti LA, Cai X, Cleary S, Chen KH, Schön MR, Sugioka A, Tang CN, Herman P, Pekolj J, Chen XP, Dagher I, Jarnagin W, Yamamoto M, Strong R, Jagannath P, Lo CM, Clavien PA, Kokudo N, Barkun J, Strasberg SM. Recommendations for laparoscopic liver resection: a report from the second international consensus conference held in Morioka. *Ann Surg*. 2015;261:619-29. [PMID: 25742461 DOI: 10.1097/SLA.0000000000001184].

[25] Reich H, McGlynn F, DeCaprio J, Budin R. Laparoscopic excision of benign liver lesions. *Obstet Gynecol* 1991; 78 (5 Pt 2): 956-958. [PMID: 1833688].

[26] Katkhouda N, Fabiani P, Benizri E, Mouiel J. Laser resection of a liver hydatid cyst under videolaparoscopy. *Br J Surg*. 1992;79(6):560-1. [PMID: 1535261].

[27] Gagner M, Rheault M, Dubuc J. Laparoscopic partial hepatectomy for liver tumor. *Surg Endosc* 1992; 6: 97-98. (abstract).

[28] Viganò L, Tayar C, Laurent A, Cherqui D. Laparoscopic liver resection: a systematic review. *J Hepatobiliary Pancreat Surg* 2009; 16(4): 410-21. [PMID: 19495556 DOI: 10.1007/s00534-009-0120-8].

[29] Mirnezami R, Mirnezami AH, Chandrakumaran K, Abu Hilal M, Pearce NW, Primrose JN, Sutcliffe RP. Short- and long-term outcomes after laparoscopic and open hepatic resection: systematic review and meta-analysis. *HPB* 2011; 13(5): 295–308. [PMID: 21492329 DOI: 10.1111/j.1477-2574.2011.00295.x].

[30] Belli G, Fantini C, Belli A, Limongelli P. Laparoscopic liver resection for hepatocellular carcinoma in cirrhosis: longterm outcomes. *Dig Surg* 2011; 28: 134-140. [PMID: 21540599 DOI: 10.1159/000323824].

[31] Morise Z, Kawabe N, Kawase J, Tomishige H, Nagata H, Ohshima H, Arakawa S, Yoshida R, Isetani M. Pure laparoscopic hepatectomy for hepatocellular carcinoma with chronic liver disease. *World J Hepatol* 2013 Sep 27; 5(9): 487-495. [PMID: 24073300].

[32] Tranchart H, Di Giuro G, Lainas P, Roudie J, Agostini H, Franco D, Dagher I. Laparoscopic resection for hepatocellular carcinoma: a matched-pair comparative study. *Surg Endosc* 2010; 24(5): 1170-6. [PMID: 19915908 DOI: 10.1007/s00464-009-0745-3].

[33] Morise Z, Ciria R, Cherqui D, Chen KH, Belli G, Wakabayashi G. Can we expand the indications for laparoscopic liver resection? A systematic review and meta-analysis of laparoscopic liver resection for patients with hepatocellular carcinoma and chronic liver disease. J Hepatobiliary *Pancreat Sci*. 2015;22:342–352. [PMID:25663288 DOI: 10.1002/jhbp.215].

[34] Tomishige H, Morise Z, Kawabe N, Nagata H, Ohshima H, Kawase J, Arakawa S, Yoshida R, Isetani M. Caudal approach to pure laparoscopic posterior sectionectomy under the laparoscopy-specific view. *World J Gastrointest Surg* 2013;5:173-7. PMID: 23977419 DOI: 10.4240/wjgs.v5.i6.173.

[35] Soubrane O, Schwarz L, Cauchy F, Cauchy F, Perotto LO, Brustia R, et al. A conceptual technique for laparoscopic right hepatectomybased on facts and oncologic principles: the caudal approach. *Ann Surg*. 2015;261:1226-31. PMID: 24854453 DOI: 10.1097/SLA.0000000000000737.

[36] Wakabayashi G, Cherqui D, Geller DA, Han HS, Kaneko H, Buell JF. Laparoscopic hepatectomy is theoretically better than open hepatectomy: preparing for the 2nd International Consensus Conference on Laparoscopic Liver Resection. *J Hepatobiliary Pancreat Sci*. 2014;21:723-731. PMID: 25130985 DOI: 10.1002/jhbp.139.

[37] Morise Z. Laparoscopic liver resection for posterosuperior tumors using caudal approach and postural changes: A new technical approach. *World J Gastroenterol*. 2016;22:10267-10274. PMID: 28058008 DOI: 10.3748/wjg.v22.i47.10267.

[38] Morise Z, Sugioka A, Kawabe N, Umemoto S, Nagata H, Ohshima H, Kawase J, Arakawa S, Yoshida R. Pure laparoscopic hepatectomy for hepatocellular carcinoma patients with severe liver cirrhosis. *Asian J Endosc Surg* 2011; 4(3): 143-6. [PMID: 22776279 DOI: 10.1111/j.1758-5910.2011.00081.x].

[39] Petrowsky H, Gonen M, Jarnagin W, Lorenz M, DeMatteo R, Heinrich S, Encke A, Blumgart L, Fong Y. Second liver resections are safe and effective treatment for recurrent hepatic metastases from colorectal cancer: a bi-institutional analysis. *Ann Surg* 2002; 235: 863-871 PMID: 12035044 DOI: 10.1097/00000658-200206000-00015.

[40] Wanebo HJ, Chu QD, Avradopoulos KA, Vezeridis MP. Current perspectives on repeat hepatic resection for colorectal carcinoma: a review. *Surgery* 1996; 119: 361-371 PMID: 8643998 DOI: 10.1016/S0039-6060(96)80133-4.

[41] Morise Z, Sugioka A, Fujita J, Hoshimoto S, Kato T, Hasumi A, Suda T, Negi H, Hattori Y, Sato H, Maeda K. Does repeated surgery improve the prognosis of colorectal liver metastases? *J Gastrointest Surg*. 2006 Jan;10(1):6-11. PMID: 16368485 DOI: 10.1016/j.gassur.2005.09.006.

[42] Itamoto T, Nakahara H, Amano H, Kohashi T, Ohdan H, Tashiro H, Asahara T. Repeat hepatectomy for recurrent hepatocellular carcinoma. *Surgery* 2007; 141: 589-597 PMID: 17462458 DOI: 10.1016/j.surg.2006.12.014.

[43] Nguyen KT, Gamblin TC, Geller DA. World review of laparoscopic liver resection-2,804 patients. *Ann Surg* 2009; 250: 831-841 PMID: 19801936 DOI: 10.1097/ SLA.0b013e3181b0c4df.

[44] Buell JF, Thomas MT, Rudich S, Marvin M, Nagubandi R, Ravindra KV, Brock G, McMasters KM. Experience with more than 500 minimally invasive hepatic procedures. *Ann Surg* 2008; 248: 475-486 PMID: 18791368.

[45] Morise Z, Wakabayashi G. First quarter century of laparoscopic liver resection. *World J Gastroenterol*. 2017;23(20):3581-3588. PMID: 28611511 DOI: 10.3748/wjg.v23. i20.3581.

[46] Beck DE, Ferguson MA, Opelka FG, Fleshman JW, Gervaz P, Wexner SD. Effect of previous surgery on abdominal opening time. *Dis Colon Rectum* 2000; 43: 1749-1753 PMID: 11156462 DOI: 10.1007/BF02236862.

[47] Karayiannakis AJ, Polychronidis A, Perente S, Botaitis S, Simopoulos C. Laparoscopic cholecystectomy in patients with previous upper or lower abdominal surgery. *Surg Endosc* 2004; 18: 97-101 PMID: 14569455 DOI: 10.1007/ s00464-003-9001-4.

[48] Wiebke EA, Pruitt AL, Howard TJ, Jacobson LE, Broadie TA, Goulet RJ, Canal DF. Conversion of laparoscopic to open cholecystectomy. An analysis of risk factors. *Surg Endosc* 1996; 10: 742-745 PMID: 8662431 DOI: 10.1007/BF00193048.

[49] Wu JM, Lin HF, Chen KH, Tseng LM, Tsai MS, Huang SH. Impact of previous abdominal surgery on laparoscopic appendectomy for acute appendicitis. *Surg Endosc* 2007; 21: 570-573 PMID: 17103279 DOI: 10.1007/s00464-006-9027-5.

[50] Law WL, Lee YM, Chu KW. Previous abdominal operations do not affect the outcomes of laparoscopic colorectal surgery. *Surg Endosc* 2005; 19: 326-330 PMID: 15624064 DOI: 10.1007/ s00464-004-8114-8.

[51] Nunobe S, Hiki N, Fukunaga T, Tokunaga M, Ohyama S, Seto Y, Yamaguchi T. Previous laparotomy is not a contraindication to laparoscopy-assisted gastrectomy for early gastric cancer. *World J Surg* 2008; 32: 1466-1472 PMID: 18340481 DOI: 10.1007/s00268-008-9542-8.

[52] Szomstein S, Lo Menzo E, Simpfendorfer C, Zundel N, Rosenthal RJ. Laparoscopic lysis of adhesions. *World J Surg* 2006; 30: 535-540 PMID: 16555020 DOI: 10.1007/ s00268-005-7778-0.

[53] Ome Y, Hashida K, Yokota M, Nagahisa Y, Yamaguchi K, Okabe M, Kawamoto K. The feasibility and efficacy of pure laparoscopic repeat hepatectomy. *Surg Endosc*. 2018;[Epub ahead of print]. PMID: 29344784 DOI: 10.1007/s00464-018-6066-7.

[54] Noda T, Eguchi H, Wada H, Iwagami Y, Yamada D, Asaoka T, Gotoh K, Kawamoto K, Takeda Y, Tanemura M, Umeshita K, Doki Y, Mori M. Short-term surgical outcomes of minimally invasive repeat hepatectomy for recurrent liver cancer. *Surg Endosc.* 2018;32(1):46-52. PMID: 28639044 DOI: 10.1007/s00464-017-5632-8.

[55] Belli G, Cioffi L, Fantini C, D'Agostino A, Russo G, Limongelli P, Belli A. Laparoscopic redo surgery for recurrent hepatocellular carcinoma in cirrhotic patients: feasibility, safety, and results. *Surg Endosc.* 2009;23:1807-11. PMID: 19277781 DOI: 10.1007/s00464-009-0344-3.

[56] Nguyen KT, Laurent A, Dagher I, Geller DA, Steel J, Thomas MT, Marvin M, Ravindra KV, Mejia A, Lainas P, Franco D, Cherqui D, Buell JF, Gamblin TC. Minimally invasive liver resection for metastatic colorectal cancer: a multi-institutional, international report of safety, feasibility, and early outcomes. *Ann Surg*. 2009;250:842-8. PMID: 19806058 DOI: 10.1097/SLA.0b013e3181bc789c.

[57] Ahn KS, Han HS, Yoon YS, Cho JY, Kim JH. Laparoscopic liver resection in patients with a history of upper abdominal surgery. *World J Surg*. 2011;35:1333-9. PMID: 21452069 DOI: 10.1007/s00268-011-1073-z.

[58] Shafaee Z, Kazaryan AM, Marvin MR, Cannon R, Buell JF, Edwin B, Gayet B. Is laparoscopic repeat hepatectomy feasible? A tri-institutional analysis. *J Am Coll Surg*. 2011;212:171-9. PMID: 21276531 DOI: 10.1016/j.jamcollsurg.2010.10.012.

[59] Hu M, Zhao G, Xu D, Liu R. Laparoscopic repeat resection of recurrent hepatocellular carcinoma. *World J Surg*. 2011;35:648-55. PMID: 21184074 DOI: 10.1007/s00268-010-0919-0.

[60] Cannon RM, Brock GN, Marvin MR, Buell JF. Laparoscopic liver resection: an examination of our first 300 patients. *J Am Coll Surg*. 2011;213:501-7. PMID: 21624840 DOI: 10.1016/j.jamcollsurg.2011.04.032.

[61] Tsuchiya M, Otsuka Y, Maeda T, Ishii J, Tamura A, Kaneko H. Efficacy of laparoscopic surgery for recurrent hepatocellular carcinoma. *Hepatogastroenterology*. 2012;59:1333-7. PMID: 22591625 DOI: 10.5754/hge12302.

[62] Kanazawa A, Tsukamoto T, Shimizu S, Kodai S, Yamamoto S, Yamazoe S, Ohira G, Nakajima T. Laparoscopic liver resection for treating recurrent hepatocellular carcinoma. *J Hepatobiliary Pancreat* Sci. 2013;20:512-7. PMID: 23404252 DOI: 10.1007/s00534-012-0592-9.

[63] Montalti R, Berardi G, Laurent S, Sebastiani S, Ferdinande L, Libbrecht LJ, Smeets P, Brescia A, Rogiers X, de Hemptinne B, Geboes K, Troisi RI. Laparoscopic liver resection compared to open approach in patients with colorectal liver metastases improves further resectability: Oncological outcomes of a case-control matched-pairs analysis. *Eur J Surg Oncol*. 2014;40:536-44. PMID: 24555996 DOI: 10.1016/j.ejso.2014.01.005.

[64] Isetani M, Morise Z, Kawabe N, Tomishige H, Nagata H, Kawase J, Arakawa S. Pure laparoscopic hepatectomy as repeat surgery and repeat hepatectomy. *World J Gastroenterol*. 2015;21:961-8. PMID: 25624731 DOI: 10.3748/wjg.v21.i3.961.

[65] Shelat VG1, Serin K, Samim M, Besselink MG, Al Saati H, Gioia PD, Pearce NW, Abu Hilal M. Outcomes of repeat laparoscopic liver resection compared to the primary

resection. *World J Surg.* 2014;38:3175-80. PMID: 25138071 DOI: 10.1007/s00268-014-2728-3.

[66] Goh BKP, Teo JY, Chan CY, Lee SY, Cheow PC, Chung AYF. Laparoscopic repeat liver resection for recurrent hepatocellular carcinoma. *ANZ J Surg*. 2017;87(10):E143-E146. PMID: 27117542 DOI: 10.1111/ans.13628.

[67] Hallet J, Sa Cunha A, Cherqui D, Gayet B, Goéré D, Bachellier P, Laurent A, Fuks D, Navarro F, Pessaux P; French Colorectal Liver Metastases Working Group, Association Française de Chirurgie. Laparoscopic Compared to Open Repeat Hepatectomy for Colorectal Liver Metastases: a Multi-institutional Propensity-Matched Analysis of Short- and Long-Term Outcomes. *World J Surg*. 2017;41(12):3189-3198. PMID: 28717911 DOI: 10.1007/s00268-017-4119-z.

[68] Chan AC, Poon RT, Chok KS, Cheung TT, Chan SC, Lo CM. Feasibility of laparoscopic re-resection for patients with recurrent hepatocellular carcinoma. *World J Surg*. 2014;38(5):1141-6. PMID: 24305932 DOI:10.1007/s00268-013-2380-3.

[69] Bruix J, Sherman M Management of hepatocellular carcinoma: An update. *Hepatology*. 2011; 53: 1020–1022. [PMID: 21374666 DOI: 10.1002/hep.24199].

[70] Kudo M, Izumi N, Kokudo N, Matsui O, Sakamoto M, Nakashima O, Kojiro M, Makuuchi M; HCC Expert Panel of Japan Society of Hepatology. Management of hepatocellular carcinoma in Japan: Consensus-Based Clinical Practice Guidelines proposed by the Japan Society of Hepatology (JSH) 2010 updated version. *Dig Dis.* 2011;29(3):339-64. [PMID: 21829027 DOI: 10.1159/000327577].

[71] Pugh RN, Murray-Lyon IM, Dawson JL, Pietroni MC, Williams R. Transection of the oesophagus for bleeding oesophageal varices. *Br J Surg.* 1973 Aug;60(8):646-9. No abstract available. [PMID: 4541913].

[72] Omagari K, Ohba K, Kadokawa Y, Hazama H, Masuda J, Kinoshita H, Matsuo I, Ohnita K, Mizuta Y, Hayashida K, Kohno S. Comparison of the grade evaluated by "Liver damage" of Liver Cancer Study Group of Japan and Child-Pugh classification in patients with hepatocellular carcinoma. *Hepatol Res*. 2006;34:266-72. [PMID: 16460997 DOI: 10.1016/j.hepres.2005.05.010].

[73] Lau H, Man K, Fan ST, Yu WC, Lo CM, Wong J. Evaluation of preoperative hepatic function in patients with hepatocellular carcinoma undergoing hepatectomy. *Br J Surg*. 1997;84:1255-9. [PMID: 9313707].

[74] Makuuchi M, Kosuge T, Takayama T, Yamazaki S, Kakazu T, Miyagawa S, Kawasaki S. Surgery for small liver cancers. *Semin Surg Oncol.* 1993;9:298-304. [PMID: 8210909].

[75] Nonami T, Nakao A, Kurokawa T, Inagaki H, Matsushita Y, Sakamoto J, Takagi H. Blood loss and ICG clearance as best prognostic markers of post-hepatectomy liver failure. *Hepatogastroenterology*. 1999;46:1669-72. [PMID: 10430318].

[76] Molina V, Sampson-Dávila J, Ferrer J, Fondevila C, Díaz Del Gobbo R, Calatayud D, Bruix J, García-Valdecasas JC, Fuster J. Benefits of laparoscopic liver resection in patients with hepatocellular carcinoma and portal hypertension: a case-matched study. *Surg Endosc*. 2017 Dec 7. [Epub ahead of print] [PMID: 29218665 DOI: 10.1007/s00464-017-5930-1].

[77] Morise Z, Isetani M, Kawabe N, Tomishige H, Nagata H, Arakawa S, Ikeda M, Kamio K. Case report of the fourth laparoscopic liver resection and review of repeat laparoscopic resection for recurrent hepatocellular carcinoma in cirrhotic liver. *Hepatoma Res* 2016;2:253-8. DOI:10.20517/2394-5079.2016.09.

In: Encyclopedia of Surgery (22 Volume Set)
Editors: Andreas Lehrer and Kristin Mueller
ISBN: 978-1-53618-329-0
© 2020 Nova Science Publishers, Inc.

Chapter 156

POST-CRANIOTOMY TEMPOROMANDIBULAR DYSFUNCTION: PATHOPHYSIOLOGY, DIAGNOSIS AND TREATMENT

Thiago Martinelli, Fernando Akio Maeda, Claudio Fróes de Freitas and Andre Luiz Ferreira Costa*
Department of Orthodontics and Radiology, University of City of São Paulo (UNICID), São Paulo, SP, Brazil

ABSTRACT

Several surgical procedures can be used to perform craniotomy, such as the classical pterional, pre-temporal and other fronto-temporal approaches. However, they are all based on the dissection of the temporal muscle, which can lead to temporal muscle atrophy, pain in the temporomandibular joint or masticatory muscles, weakness of the jaw closure, and development of signs and symptoms of temporomandibular joint dysfunction, all significantly compromising the patient's quality of life. This type of temporomandibular dysfunction has been frequently neglected as only good results of the primary disease are considered. The following review presents a synopsis of the pathophysiology of post-craniotomy temporomandibular dysfunction and a practical approach to its evaluation and treatment.

Keywords: temporal muscle atrophy, risk factors, facial pain, temporomandibular joint, myofascial pain

INTRODUCTION

Orofacial pain can arise from a variety of disorders, including atypical idiopathic facial pain, temporomandibular dysfunction (TMD), dental pain, soft tissue diseases, neuralgia and

* Corresponding Author's Email: alfcosta@gmail.com.

headaches (Romero-Reyes & Uyanik, 2014). TMD is considered the main cause of pain in the orofacial region from odontogenic origin (Ahmad & Schiffman, 2016).

The aetiology of TMD is considered multifactorial, being comprehended in a biopsychosocial context (Manfredini, 2010; Marklund & Wanman, 2010). Although the prevalence of TMD changes depends on their pathology, it is reported that 75% of the general population have asymptomatic TMD (Costa, D'Abreu & Cendes, 2008).

The three cardinal features of TMD are orofacial pain, joint noise and restricted jaw function. Pain is the most common complaint and the primary cause for patients asking for help and treatment, thus being the principal goal of diagnosis and treatment (Manfredini, 2010).

As TMD is a musculoskeletal disorder affecting the temporo-mandibular joint (TMJ) and masticatory muscles, the pain exacerbated by the mandibular function is a pathognomonic sign of TMD (Kapur, Kamel & Herlich, 2003). It has been reported that nearly 50% of all TMDs are masticatory myalgias or masticatory muscle pain (Herb, Cho & Stiles, 2006). Myofascial pain and dysfunction of the masticatory muscles are more often stimulated by stress-related para-functional habits (i.e., clenching and grinding) (Herb et al., 2006).

TMJ pain from an articular disorder may conversely lead to myofascial pain (Herb et al., 2006). This is thought to happen due to reflex muscle contractions during mastication (Costa, Campos, Franca & D'Abreu, 2011; Okeson, 1985). Patients present with tenderness and hyperalgesia at sites distant from the joint, which may also include various trigger points (Herb et al., 2006; Murray & Peck, 2007).

It is known that any surgical incision in the masticatory muscles can affect their integrity, which, in turn, directly affects their function (Costa et al., 2014). Masticatory and cervical muscle disorders may result in changes in the mastication pattern, increasing the efforts of masticatory muscles, which may be followed by painful complications that could severely compromise the patient's quality of life (Costa et al., 2014; Figueiredo et al., 2006; Rocha-Filho, Fujarra, Gherpelli, Rabello & de Siqueira, 2007; Yasuda et al., 2010). Therefore, the dissection of masticatory muscles may cause cosmetic and functional problems in the patients (de Andrade Junior, de Andrade, de Araujo Filho & Carcagnolo Filho, 1998; Rocha-Filho et al., 2007; Yasuda et al., 2010).

A wide variety of brain pathology may require surgical intervention, with craniotomy being the most commonly used surgical access approach. Patients who undergo craniotomy to treat intracranial pathologies may suffer a severe limitation regarding maximum mouth opening and develop different degrees of pain in the masticatory muscles and TMJ function (de Andrade Junior et al., 1998; Figueiredo et al., 2006; Rocha-Filho et al., 2007; Yasuda et al., 2010).

A closer look at these patients, especially with clinical analysis methods, reveals negative consequences because of injuries to temporal muscle resulting from the surgical approach, including muscle atrophy due to direct harm, ischemia, inadequate muscle tension, or muscle denervation (Abdulazim et al., 2012; Rocha-Filho et al., 2007; Yasuda et al., 2010). These post-operative side effects may arise after pterional and fronto-temporal craniotomy required in treatment procedures for refractory epilepsy, brain tumours or cerebral aneurysms (Yasuda et al., 2010).

Despite the increased awareness of the consequence of effective pain management following surgical procedures, an inadequate pain relief for post-craniotomy TMD still poses a significant clinical problem (Costa et al., 2014).

In this review, we focus on the primary research literature on the pathophysiology, diagnosis and treatment of post-craniotomy TMD for priority directions in reducing the associated complications.

PATHOPHYSIOLOGY

The pathological processes underlying the symptoms of post-craniotomy TMD involve the temporal muscle (Figueiredo et al., 2007) as its adequate function depends on proper innervation, vascularization, muscle tension and integrity of the muscle fibers. The functional integrity of the muscle requires a perfect innervation, an excellent vascular supply, muscle tension and inappropriate repair of the muscle at the site of original attachment (Kadri & Al-Mefty, 2004; Miyazawa, 1998; Oikawa, Mizuno, Muraoka & Kobayashi, 1996).

It is necessary an overview of the temporal muscle anatomy to better understand the pathophysiological data.

a) Muscle Components

The fan-shaped temporal muscle is composed of a central portion and three muscle bundles, namely, antero-medial, antero-lateral, and middle lateral (Kadri & Al-Mefty, 2004). The antero-medial muscle bundle is originated from the infra-temporal crest of the higher wing of the sphenoid bone, passing inferiorly and being inserted into the anterior region of the medial surface of the coronoid process and temporal crest. The antero-lateral muscle bundle is positioned on the lateral surface of the aponeurosis of the central part of the temporal muscle, and the cranio-medial region of this bundle is adjoined with the fleshy part of the temporal muscle. The middle lateral muscle bundle is observed as a thin sheet on the lateral surface of the temporal muscle aponeurosis in the middle region of its main part (Shimokawa, Akita, Soma & Sato, 1998).

b) Innervation

The anterior division of the mandibular nerve innervates the temporal muscle. This nerve frequently presents three branches: masseteric, middle deep temporal and buccal nerves. The anterior deep temporal nerve is a branch of the buccal nerve that can give rise to one or more branches. The buccal and anterior temporal nerves pass through the lateral pterygoid muscle, between the upper and lower heads of the muscle at its anterior aspect. Next, the anterior deep temporal nerve separates from the buccal nerve and divides into many tiny branches that supply the antero-lateral and antero-medial bundles, including the anterior part of the main portion of the temporal muscle (Kadri & Al-Mefty, 2004).

The middle and posterior deep temporal nerves run through the superior surface of the upper head of the lateral pterygoid muscle. The middle deep temporal nerve can originate separately or share a trunk with the masseteric nerve, which separates after leaving the foramen ovale, and innervates the middle part of the main portion of the temporal muscle and

the middle lateral bundle. The posterior deep temporal nerve originates from the masseteric nerve as one or many tiny branches before it reaches the superior border of the upper head of the lateral pterygoid muscle, turning downwards to innervate the masseter muscle. The posterior deep temporal nerve supplies the posterior part of the main portion of the temporal muscle, with the masseteric and deep temporal nerves being related to the dorsal root of the zygoma (Kadri & Al-Mefty, 2004).

c) Vascular Components

In men, the blood supply to the temporal muscle is mainly derived from the anterior and posterior deep temporal arteries. There is an extra blood supply originating from the middle temporal artery, a branch of the superficial temporal artery (Cheung, 1996).

Effects of the Surgery on the Temporal Muscle

Alteration of the temporal muscle during neurosurgical procedures often results in tissue trauma, including fibre atrophy, presence of fibrotic tissue within the muscle, and reduction in muscle strength (Costa et al., 2014; de Andrade Junior et al., 1998; Rocha-Filho et al., 2007). Other abnormalities include cosmetic deformities (anterior temporal hollow) and functional handicaps (Kadri & Al-Mefty, 2004; Park et al., 2015). The post-operative sequelae of the temporal muscle may be originated from the following factors:

Consequences of Denervation

The return of motor function of a denervated muscle depends not only on the restoration of nerve supply, but also on the capacity of the muscle to respond (Wang, Gu, Xu, Shen & Li, 2001). After denervation, the skeletal muscle undergoes a sequence of morphological, physiological, biochemical, functional, and metabolic changes (Kadri & Al-Mefty, 2004; Wang et al., 2001). With prolonged denervation, the blood supply deteriorates and fibrosis progresses with ultimate replacement of muscle by fat tissue. All three deep temporal nerves are positioned superficially to the sub-periosteum and may be injured by dissection of the soft tissue. Therefore, sub-periosteal dissection is of vital importance in preserving the nerves (Kadri & Al-Mefty, 2004).

Consequences of Devascularisation

Muscular ischemia due to prolonged retraction or interruption of blood supply can produce irreversible damage after micro-vascular occlusion caused by propagation of thrombus, causing fibrosis and atrophy (Kadri & Al-Mefty, 2004; Miyazawa, 1998).

Integrity of the Fibres and Muscle Tension

Muscle tension is critical in conserving functionality and preventing atrophy from disuse (Kadri & Al-Mefty, 2004; Zager, DelVecchio & Bartlett, 1993) as muscular attachments should be preserved to maintain the contraction of the muscle. Nevertheless, the injured fibres become fibrotic and present scars, thus harming the vascular and nerve supply to the distal part of the flap, which increases atrophy and asymmetry after surgery (Kadri & Al-Mefty, 2004). Preservation of the muscle fibres and restoration of the muscle alignment as similar as

possible to that prior to surgery is crucial to minimise post-operative deformities of the muscle (Park et al., 2015).

Post-Craniotomy TMD

It has been shown that patients undergoing the same procedure for craniotomy may or may not develop muscle atrophy and/or TMD (Costa et al., 2014; de Andrade Junior et al., 1998). Dissection of the temporal muscle has an immediate effect, generating hypomobility caused by weakness and retraction of the TMJ muscles (Park et al., 2015). These factors can induce degenerative or adaptive changes in the joint tissue (Costa et al., 2014).

TMJ is often and intensively affected in patients who underwent craniotomy (Costa et al., 2014; de Andrade Junior et al., 1998; Rocha-Filho et al., 2007; Yasuda et al., 2010). It is interesting to note that the degree of joint impairment differs among these patients.

In post-craniotomy patients, many factors such as masticatory muscle weakness, dental malocclusions and bruxism can affect the dynamic balance or equilibrium between the components of the masticatory system (Costa et al., 2014). Bruxism is a non-painful disorder characterised as a repetitive jaw-muscle activity, such as clenching or grinding of the teeth and/or bracing or thrusting of the mandible (Lobbezoo et al., 2013).

Bruxism with undesirable occlusal patterns may lead to damage to joint tissues at molecular level, thus predisposing to joint intra-capsular dysfunction, joint effusion and pain (Costa et al., 2014).

In general, TMD can be influenced by concurrent myofascial pain and/or bruxism. Moreover, degenerative lesions in muscle fibers and inflammation after craniotomy can compromise the normal joint biomechanics, producing deleterious effects or degenerative changes in the TMJ (Costa et al., 2014).

DIAGNOSIS

The presence of concomitant bruxism is considered a risk factor for post-craniotomy TMD that can affect the surgical outcomes, being recognised as a causal agent involved in its initiation and/or perpetuation (Costa et al., 2014). Therefore, it is important that the physician determines the diagnosis of TMJ before surgery.

The diagnosis is clinical and uncomplicated, with evaluation being based on the patient's information, history and clinical analysis of TMJ. A TMD specialist can provide a global vision of the joint and mastication muscles by searching for pain/tenderness on palpation, joint noises, jaw function limitation, masticatory muscle pain, para-function habits (e.g., clenching, bruxism, nail biting) and anomalies of occlusal functions (Ahmad & Schiffman, 2016).

TREATMENT

Patients always present pain and mouth opening limitation during the first post-operative months (Yasuda et al., 2010), with the individuals showing gradual improvement over time.

However, in some patients, symptoms may persist by reaching the joint and affecting structures (disc or cartilage) in the TMJ (Costa et al., 2014; Kadri & Al-Mefty, 2004).

Because the clinical presentation of post-craniotomy TMD is heterogeneous, the treatment should be individualised for each patient depending on pain severity, comorbidities, and level of functional impairment.

The management includes physical therapy to re-establish the mandibular function as soon as possible, with manual therapies (e.g., jaw exercises and re-education) being shown to be effective to reduce pain and recover mobility/function in the patients (Melis, 2013).

Manual therapy using soft tissue techniques, mobilisation, exercises and manipulation is proposed to reduce local ischemia, stimulate proprioception, break fibrous adhesions, generate synovial fluid production and reduce pain (Kalamir, Bonello, Graham, Vitiello & Pollard, 2012).

Active and passive range of motion exercises target to re-establish physiological movements by means of opening, laterotrusion, protrusion and retrusion movements have been shown to significantly reduce pain and injury, in addition to increasing the range of motion (Kalamir et al., 2012; Michelotti, Parisini, Farella, Cimino & Martina, 2000).

REFERENCES

Abdulazim, A., Filis, A., Sadr-Eshkevari, P., Schulte, F., Sandu, N., & Schaller, B. (2012). Postcraniotomy function of the temporal muscle in skull base surgery: Technical note based on a preliminary study. *Scientific World Journal,* 2012, 427081.

Ahmad, M., & Schiffman, E. L. (2016). Temporomandibular Joint Disorders and Orofacial Pain. *Dent Clin North Am,* 60(1), 105-124.

Cheung, L. K. (1996). The vascular anatomy of the human temporalis muscle: implications for surgical splitting techniques. *Int J Oral Maxillofac Surg,* 25(6), 414-421.

Costa, A. L., Campos, L. S., Franca, M. C., Jr., & D'Abreu, A. (2011). Temporomandibular disorders in patients with craniocervical dystonia. *Arq Neuropsiquiatr,* 69(6), 896-899.

Costa, A. L., D'Abreu, A., & Cendes, F. (2008). Temporomandibular joint internal derangement: Association with headache, joint effusion, bruxism, and joint pain. *J Contemp Dent Pract,* 9(6), 9-16.

Costa, A. L., Yasuda, C. L., Franca, M., Jr., de Freitas, C. F., Tedeschi, H., de Oliveira, E., & Cendes, F. (2014). Temporomandibular dysfunction post-craniotomy: evaluation between pre- and post-operative status. *J Craniomaxillofac Surg,* 42(7), 1475-1479.

de Andrade Junior, F. C., de Andrade, F. C., de Araujo Filho, C. M., & Carcagnolo Filho, J. (1998). Dysfunction of the temporalis muscle after pterional craniotomy for intracranial aneurysms. Comparative, prospective and randomized study of one flap versus two flaps dieresis. *Arq Neuropsiquiatr,* 56(2), 200-205.

Figueiredo, E. G., Deshmukh, P., Nakaji, P., Crusius, M. U., Crawford, N., Spetzler, R. F., & Preul, M. C. (2007). The minipterional craniotomy: technical description and anatomic assessment. *Neurosurgery,* 61(5 Suppl 2), 256-264; discussion 264-255.

Figueiredo, E. G., Deshmukh, V., Nakaji, P., Deshmukh, P., Crusius, M. U., Crawford, N., ... Preul, M. C. (2006). An anatomical evaluation of the mini-supraorbital approach and

comparison with standard craniotomies. *Neurosurgery,* 59(4 Suppl 2), ONS212-220; discussion ONS220.

Herb, K., Cho, S., & Stiles, M. A. (2006). Temporomandibular joint pain and dysfunction. *Curr Pain Headache Rep,* 10(6), 408-414.

Kadri, P. A., & Al-Mefty, O. (2004). The anatomical basis for surgical preservation of temporal muscle. *J Neurosurg,* 100(3), 517-522.

Kalamir, A., Bonello, R., Graham, P., Vitiello, A. L., & Pollard, H. (2012). Intraoral myofascial therapy for chronic myogenous temporo-mandibular disorder: a randomized controlled trial. *J Manipulative Physiol Ther,* 35(1), 26-37.

Kapur, N., Kamel, I. R., & Herlich, A. (2003). Oral and craniofacial pain: diagnosis, pathophysiology, and treatment. *Int Anesthesiol Clin,* 41(3), 115-150.

Lobbezoo, F., Ahlberg, J., Glaros, A. G., Kato, T., Koyano, K., Lavigne, G. J., ... Winocur, E. (2013). Bruxism defined and graded: an international consensus. *J Oral Rehabil,* 40(1), 2-4.

Manfredini, D. (2010). *Current concepts on temporomandibular disorders*. London: Quintessence.

Marklund, S., & Wanman, A. (2010). Risk factors associated with incidence and persistence of signs and symptoms of temporomandibular disorders. *Acta Odontol Scand,* 68(5), 289-299.

Melis, M. (2013). The role of physical therapy for the treatment of temporomandibular disorders. *J Orthod Sci,* 2(4), 113-114.

Michelotti, A., Parisini, F., Farella, M., Cimino, R., & Martina, R. (2000). [Muscular physiotherapy in patients with temporomandibular disorders. Controlled clinical trial]. *Minerva Stomatol,* 49(11-12), 541-548.

Miyazawa, T. (1998). Less invasive reconstruction of the temporalis muscle for pterional craniotomy: modified procedures. *Surg Neurol,* 50(4), 347-351; discussion 351.

Murray, G. M., & Peck, C. C. (2007). Orofacial pain and jaw muscle activity: a new model. *J Orofac Pain,* 21(4), 263-278; discussion 279-288.

Oikawa, S., Mizuno, M., Muraoka, S., & Kobayashi, S. (1996). Retrograde dissection of the temporalis muscle preventing muscle atrophy for pterional craniotomy. Technical note. *J Neurosurg,* 84(2), 297-299.

Okeson, J. P. (1985). *Fundamentals of occlusion and temporomandibular disorders*. St. Louis: Mosby.

Park, J. H., Lee, Y. S., Suh, S. J., Lee, J. H., Ryu, K. Y., & Kang, D. G. (2015). A Simple Method for Reconstruction of the Temporalis Muscle Using Contourable Strut Plate after Pterional Craniotomy: Introduction of the Surgical Techniques and Analysis of Its Efficacy. *J Cerebrovasc Endovasc Neurosurg,* 17(2), 93-100.

Rocha-Filho, P. A., Fujarra, F. J., Gherpelli, J. L., Rabello, G. D., & de Siqueira, J. T. (2007). The long-term effect of craniotomy on temporalis muscle function. *Oral Surg Oral Med Oral Pathol Oral Radiol Endod,* 104(5), e17-21.

Romero-Reyes, M., & Uyanik, J. M. (2014). Orofacial pain management: current perspectives. *J Pain Res,* 7, 99-115.

Shimokawa, T., Akita, K., Soma, K., & Sato, T. (1998). Innervation analysis of the small muscle bundles attached to the temporalis: truly new muscles or merely derivatives of the temporalis? *Surg Radiol Anat,* 20(5), 329-334.

Wang, H., Gu, Y., Xu, J., Shen, L., & Li, J. (2001). Comparative study of different surgical procedures using sensory nerves or neurons for delaying atrophy of denervated skeletal muscle. *J Hand Surg Am,* 26(2), 326-331.

Yasuda, C. L., Costa, A. L., Franca, M., Jr., Pereira, F. R., Tedeschi, H., de Oliveira, E., & Cendes, F. (2010). Postcraniotomy temporalis muscle atrophy: a clinical, magnetic resonance imaging volumetry and electromyographic investigation. *J Orofac Pain,* 24(4), 391-397.

Zager, E. L., DelVecchio, D. A., & Bartlett, S. P. (1993). Temporal muscle microfixation in pterional craniotomies. Technical note. *J Neurosurg,* 79(6), 946-947.

BIOGRAPHICAL SKETCHES

Thiago Martinelli, DDS

Currently Master student in Dentistry program of UNICID – University of Sao Paulo City.

Fernando Akio Maeda, DDS, MSc, PhD

Associate professor of Master's degree program and Undergraduation Dentistry; UNICID – University of Sao Paulo City.

- DDS – 2005 - São Paulo State University - UNESP (FOA, Araçatuba, Brazil).
- MSc in Restorative Dentistry - 2009 - University of São Paulo – USP (FORP, Ribeirão Preto, Brazil).
- PhD in Dental Materials – 2010 - University of São Paulo – USP (FOUSP – São Paulo, Brazil).

Claudio Fróes de Freitas, DDS, MSc, PhD

Head of Master's degree program and Undergraduation Dentistry; UNICID – University of Sao Paulo City.

- DDS – 1986 - São Paulo State University - UNESP (FOSJC, São José dos Campos, Brazil).
- MSc - 1989 - University of São Paulo – USP (FOUSP, São Paulo, Brazil).
- PhD – 1991 - University of São Paulo – USP (FOUSP – São Paulo, Brazil).

Andre Luiz Ferreira Costa, DDS, MSc, PhD

Associate professor of Master's degree program and Undergraduation – Dentistry/UNICID – University of Sao Paulo City.

- Postdoctrol Fellowship:
  - Laboratory of Neuroimaging/Department of Neurology; Faculty of Medical Sciences; UNICAMP
  - Department of Diagnostic Imaging/The Ottawa Hospital; University of Ottawa; Canada
- PhD program; Laboratory of Neuroimaging/Dept of Neurology; Faculty of Medical Sciences; UNICAMP
- Master of Dental Science degree (Oral and Maxillofacial Radiology); School of Dentistry, UNICAMP-(Piracicaba-SP, Brazil)
- Internship: Oral and Maxillofacial Radiology; School of Dentistry, USP-(Ribeirão Preto-SP, Brazil)
- DDS: School of Dentistry/USP-(Ribeirão Preto-SP, Brazil)

In: Encyclopedia of Surgery (22 Volume Set)
Editors: Andreas Lehrer and Kristin Mueller
ISBN: 978-1-53618-329-0
© 2020 Nova Science Publishers, Inc.

Chapter 157

MEDICAL AND SURGICAL ADVANCES IN BRONCHOSCOPY

Jack A. Kastelik[1,*], MD, Mahmoud Loubani[2], MD, Kate Dixon[3] and Keyvan Moghissi[3], MD

[1]Department of Academic Respiratory Medicine, University of Hull, Hull York Medical School, Castle Hill Hospital, Cottingham East Yorkshire, UK
[2]Department of Cardiothoracic Surgery University of Hull, Hull York Medical School Castle Hill Hospital, Cottingham, East Yorkshire, UK
[3]Yorkshire Laser Centre, Goole and District Hospital, Goole, East Yorkshire, UK

ABSTRACT

Bronchoscopy has become an important procedure, which is performed for diagnostic and therapeutic purposes. There has been very important expansion in the application of bronchoscopy due to technological developments. Bronchoscopic techniques have acquired use as diagnostic procedures in the context of infection or malignancy. Over recent years, procedures such as endobronchial ultrasound have become widely used. Similarly, new technologies such as navigational bronchoscopy are becoming more commonly used. In addition, bronchoscopy has extended its application into interventional procedures. For example, in the context of Chronic Obstructive Pulmonary Disease, bronchoscopic insertion of endobrochial valves has become widely used. Bronchoscopy also can be used for photodynamic therapy in the context of lung cancer. In this chapter the medical and surgical advances in bronchoscopy will be described.

Keywords: bronchoscopy, endobronchial valves, endobronchial ultrasound, photodynamic therapy

[*] Corresponding Author's Email: jack.kastelik@hey.nhs.uk.

INTRODUCTION

Bronchoscopy has become an important procedure, which is performed for diagnostic and therapeutic purposes. It is a common procedure with over 500,000 bronchoscopies being performed in the USA each year (Ernst, Silvestri, and Johnstone 2003, Silvestri et al. 2012). Due to technological developments, as well as improvements in imaging bronchoscopy, techniques have become more complex. The first bronchoscopy was performed by Gustav Killian in 1897 to remove a foreign body from the patient's main bronchus (Batra and Yarmus 2018). Subsequently, the rigid bronchoscope became an important tool for examination of the proximal bronchi. The main limitations of rigid bronchoscopy include the requirements for general anaesthesia and the fact that it only allows visualization of the carina and main bronchi (Annigeri and Patil 2017). In 1967 Shigeto Ikeda introduced flexible bronchoscopy, which allowed for visualization beyond the main bronchi. Flexible bronchoscopy has other advantages compared with rigid bronchoscopy. The procedure is performed under an awake sedation, seldom requiring general anaesthesia. The technique is easier to master, compared to rigid bronchoscopy, which may be technically more difficult. Over recent years, due to technological developments, there have been new techniques introduced such as auto-fluorescence bronchoscopy, endobronchial ultrasound, electromagnetic navigational bronchoscopy, photodynamic therapy bronchoscopy and endobronchial valves (Mehta et al. 2018)

FLEXIBLE FIBREOPTIC BRONCHOSCOPY

Flexible fibreoptic bronchoscopes have glass fibres, which allow for light to be transported from the light source to the distal part of the scope, delivering images from the end of the scope to a high definition screen (Du Rand et al. 2013). The flexible fibreoptic bronchoscope has instrumentation and suctioning channels, therefore it allows for both the examination of the bronchial tree and introduction of instruments such bronchial brushes or bronchial biopsy forceps. Therapeutic scopes have a larger instrument channel allowing for the introduction of instruments which can be used for diagnostic and therapeutic purposes (Du Rand et al. 2011).

Fiberoptic bronchoscopy is usually undertaken in the endoscopy suite or operating theatre, supported by staff capable of preparing the equipment, managing the collected samples and caring for sedated patients. The operator needs to be skilled in the administration of awake sedation, potential indications or contraindications and complications of the procedure, as well as having extensive knowledge of bronchial anatomy and pathology (Wahidi et al. 2011). The learning of bronchoscopy skills is a complex process (Rayl, Pittman, and Shuster 1988, Silvestri et al. 2012). However, the historical apprenticeship type of learning of bronchoscopy skills is gradually changing with the wider application of simulation technology (Kvale and Mehta 2001, Silvestri 2008). This approach, based on simulation training of the procedural skills in the laboratory, reduces the stress of the learning of complex procedures, when compared to learning in clinical settings; it can used in conjunction with lectures or web based teaching (Blum, Powers, and Sundaresan 2004, Davoudi and Colt 2009, Haponik et al. 2000, Torrington 2000).

Fiberoptic bronchoscopy can incorporate auto-fluorescence, which has higher sensitivity to detect early or precancerous changes, though it is mainly used for diagnostic purposes. Therefore, procedures such as bronchial washing, bronchial brushing and bronchial or trans-bronchial biopsies are the most common procedures undertaken during bronchoscopy (Du Rand et al. 2013). One of the other important aspects of fiberoptic bronchoscopy includes bronchial secretion clearance, which may be of particular use in patients on mechanical ventilation. From the diagnostic aspect, perhaps the most common application of fiberoptic bronchoscopy is in the diagnosis of lung cancer. This is of particular importance in patients with visible endobronchial tumours which can be biopsied during the procedure; additionally, it can be used pre operatively to plan surgery. Moreover, fiberoptic bronchoscopy performed by a skilled operator can be used for retrieval of a foreign body, although a rigid bronchoscopy may be more appropriate (Du Rand et al. 2011). The rigid bronchoscope may allow better access for the removal of the foreign body, controlling of bleeding, ability to introduce larger instruments and, as it is performed under general anaesthesia, better oxygenation control as well as more appropriate access to interventional procedures if required.

PHOTODYNAMIC THERAPY

Photodynamic therapy (PDT) is a treatment which comprises of a chemical photosensitizer, a matching wavelength of light, usually generated by laser, and oxygen, which is present in all living tissues. The interaction between light and photosensitizer, in the presence of oxygen, generates singlet oxygen and other cytotoxic species leading to cell death (Allison and Moghissi 2013). For central lung cancer PDT is carried out bronchoscopically, as a two-step procedure (Moghissi and Dixon 2008, 2003, Okunaka and Kato 2002, Ikeda et al. 2011). The first step, pre-sensitization, involves intravenous administration of photosensitizer, which is distributed throughout the body; a higher concentration will be retained within the cancer compared with normal, surrounding tissues. The second step is illumination, during which the pre-sensitized cancer tissue in the airway is exposed to an appropriate laser light transmitted via an optical fiber, which is passed through the bronchoscope. The cancer tissue containing photosensitizer, in the presence of oxygen, is activated by the laser light, prompting destruction of cancerous tissue. The pre-requisite for bronchoscopic PDT is the presence of an endo-luminal, biopsy proven, malignant tumour in the airway, following standard investigations and staging procedures. Standard treatment for malignant broncho-pulmonary tumours consists of surgery, radiotherapy and chemotherapy. However, a number of other "non-standard" options have recently become available, all of which are basically local therapies. PDT is one such option with a number of important attributes. PDT is the only method amongst non-standard therapies, which specifically targets cancer with the exclusion of healthy surrounding tissue.

Bronchoscopic PDT in lung cancer can be used in the context of an early stage central endobronchial cancer with the aim of 'curative intent' (Ikeda et al. 2011, Moghissi et al. 2007). Also, PDT can be considered in locally advanced inoperable endobronchial cancer (Moghissi et al. 2007, Okunaka and Kato 2002). Here, the aim is to open up a lobar or main stem bronchus, which is blocked by cancer, thus allowing pulmonary ventilation. There is an

increasing tendency to use PDT in such cases within a multi modal protocol (Ikeda et al. 2011). Another application of PDT is in metachronous, endobronchial tumours of the residual lung after previous resection for local bronchial stump recurrence as an induction therapy prior to surgery and for rare bronchial tumours, such as carcinoid and adenoid cystic carcinoma (Moghissi et al. 2007, Moghissi and Dixon 2003, Ross et al. 2006, Akopov et al. 2017, Moghissi and Dixon 2017). However, in practice all cases fall within endobronchial malignancies confined to bronchial mucosa with no parenchymal lesion and without nodal or distant metastases. PDT can be offered with curative intent for locally advanced cancers, which are bulky endobronchial tumours with no distant metastases but with atelectasis. In these, PDT offers palliation with survival benefit in some.

Prior to bronchoscopic PDT, an informed consent should include information on photosensitivity skin reaction to direct or indirect sunlight exposure. Bronchoscopic assessment should aim to delineate the extent and topography of tumour using white light and auto fluorescence bronchoscopy. Currently, Photofrin (Porfimer Sodium) is the photosensitizer of choice. The interval between drug administration and treatment allows wide distribution in the body and retention predominantly in cancer tissues. There are two methods available for illumination. During the first method, which is performed under general anesthesia, the rigid bronchoscope is initially inserted, through which the flexible fiberoptic bronchoscope is subsequently introduced. Exposure to light of the pre-sensitized tissue is undertaken via an optical fiber; this is passed through the biopsy channel of the flexible fiberoptic bronchoscope. The second method uses a flexible fiberoptic bronchoscope under awake sedation and local anesthesia. The optical fiber is passed through the biopsy channel of the flexible fiberoptic bronchoscope, directing the laser light to the target. Bronchoscopic PDT under general anaesthesia is the preferred method, except when this is not possible or rejected by the patient, as it allows for better airway protection, reduces coughing and improves patient comfort. Current literature suggests that PDT in the context of an early lung cancer may achieve long survival in between 60 -70% of cases (Ikeda et al. 2011, Okunaka and Kato 2002). In locally advanced cases PDT offers good palliation with improved pulmonary function and survival benefit in some cases (Moghissi et al. 2007, Moghissi et al. 1999). It is relevant to point out that PDT can be used with standard treatments, notably chemo-radiation; it is a treatment, which can be repeated. The only problem can be photosensitivity skin reaction over a variable duration, according to the photosensitizer employed, hence the need for effective patient counseling.

ENDOBRONCHIAL VALVES

Patients with Chronic Obstructive Pulmonary Disease (COPD) have increased lung compliance and airway resistance, due to small airway obstruction leading to air trapping, resulting in the increase in total lung capacity (TLC) and residual volume (RV) leading to hyperinflation (Herth et al. 2016). During exercise the respiratory rate is increased which, in turn, leads to a shorter time for lung emptying; this, in turn, increases end expiratory lung volume and produces dynamic hyperinflation, thus leading to increased work in breathing and symptoms of breathlessness. Lung volume reduction surgery seems to affect those changes, probably through a combination of improvement of lung recoil, changes in lung size and its

effects on respiratory muscles. Lung volume reduction surgery involves resection of emphysematous lung with the aim of reducing lung volume. In recent years non-surgical procedures, in the form of endobronchial valve insertion, have become more widely used. The Valve for Emphysema Palliation Trial (VENT) compared endobronchial valve placement with best medical therapy (Sciurba et al. 2010). The endobronchial valves were placed unilaterally in the lobes that had the worst emphysema. Results showed that at 6 months there was significant increase of FEV_1 by 60 ml and the 6 minutes walk by 19.1 meters (5.8%) in the endobrocnhial valve group compared with the medical treatment group. The other important finding of the VENT study was that patients with intra-lobar heterogeneous emphysema of more than 15% and the presence of complete fissures had the best improvements in FEV_1 and the 6 minute walk. The IMPACT study showed that patients with homogenous emphysema and who had no collateral ventilation in the targeted lobes can also benefit from endobronchial valve treatment (Valipour et al. 2016). The benefits observed were related to improvements in the FEV_1, 6 minutes walk and quality of life. Similarly, the STELVIO study showed significant improvement in patients with emphysema who had endobronchial valve insertion compared with the control group at 6 months in mean FEV_1 measurements by 178% and mean 6 minutes walk distance by 23.3% (Hartman et al. 2018, Klooster, Hartman, et al. 2017). In the LIBERATE study, endobronchial valves were evaluated in patients with heterogenous emphysema and little or no collateral ventilation in the target lobe, showing improvement in lung function, exercise tolerance and St George's Respiratory Questionnaire scores (Criner et al. 2018). In the endobronchial valve group the improvements in FEV_1 were 0.106 L ($p < 0.001$), 6 minutes walk of 39.31 meters ($p = 0.002$) and for St George's Respiratory Questionnaire Score reduction by 7.05 points ($p = 0.004$). Pneumothorax was observed in 26% of cases.

Endoscopic lung volume reduction can be performed using a flexible bronchoscope. This form of treatment can be used for patients with severe COPD who have been carefully assessed. The currently accepted criteria for endoscopic lung volume reduction include FEV_1 ranging from 15% to 50% of predicted and residual volume of more than 175% of predicted (Herth et al. 2017). Patients should be advised to stop smoking, their medication should be maximized and they should have been through a pulmonary rehabilitation process. In addition, the patients should be stable prior to procedure and should be able to undergo general anesthesia or awake sedation. Radiological imaging should exclude other pathologies and provide evidence of the presence of complete fissures. In some cases, imaging may not be able to definitively confirm the absence of collateral ventilation in the lobes targeted for endobronchial valve insertion, even using more advanced imaging technology. For this reason the most accepted method for precisely assessing collateral ventilation status is the Chartis Diagnostic System (Pulmonx) (Slebos et al. 2017). The procedure of endoscopic valve insertion and the Chartis measurements are recommended to be performed under general anesthesia as this allows for better airway management. There are recommended settings of ventilation, such as low ventilation frequency and long expiratory settings as, these are less likely to affect the Chartis measurements (Slebos et al. 2017). During the Chartis procedure, patients require adequate levels of sedation whilst still being able to produce tidal breathing for negative collateral ventilation to be detected. However, because the patients have advanced COPD, during the procedure they need to be monitored for respiratory failure and carbon dioxide retention. Therefore, sedation used needs to be easily reversible; most commonly, agents used are short acting benzodiazepines and opiates. Similarly, good

secretion management is of importance. The use of positive pressure ventilation is recommended for both the Chartis measurements and the placement of the valves. Although the procedure can be performed under awake sedation there are clear advantages of general anesthesia and positive pressure ventilation (Slebos et al. 2017, Shah et al. 2017). The patient is more comfortable; coughing and the management of secretions may be easier. In fact, if Chartis assessment is inconclusive under awake sedation, measurements may be improved when performed under general anaesthesia, especially in patients who have fissure completeness above 80%. In addition, it is recommended that Chartis measurements and the placement of valves is undertaken at the same time, thus reducing the risks of COPD exacerbation due to repeat bronchoscopies if procedures were performed separately.

The decision where to place the endobronchial valve is determined by imaging that locates the distribution of disease and characterizes fissures, as well as findings of the Chartis measurements. Imaging characteristics of the targeted lobes should include assessment for the presence of fissures, absence of collateral ventilation, presence of emphysema and low perfusion on perfusion scintigraphy (Slebos and Shah 2016, Koegelenberg et al. 2015, Herth et al. 2016). Valve placement also needs to take into consideration careful assessment of the bronchial anatomy. This should consider the size of the bronchi as well as their proximity, since this determines the order of the valve placement. It is normal practice to first place valves in the more distal bronchi to avoid valve overlap, which may prevent placement of subsequent valves into the more distal segments. The depth marker on the endobronchial delivery catheter allows assessment of the distance of valve protrusion post placement.

The most common complications of insertion of endobronchial valve include pneumothorax, infection and misplacement of the valve (Herth et al. 2017, Slebos et al. 2017). These complications require rapid intervention, such as treatment of infection; this would usually involve nebulised bronchodilators, systemic corticosteroids and antibiotics. Pneumothorax has been reported to occur in around 20 to 30% of cases (Klooster et al. 2015, Klooster, Slebos, et al. 2017). The majority, around 80% of cases of pneumothorax, occur in the first 2 days post procedure, with one in ten occurring after 6 days and around 10% between day 3 and 5 post procedure (Skowasch et al. 2016). The management of pneumothorax should follow international guidelines and involve rapid chest drain insertion to avoid tension pneumothorax (MacDuff, Arnold, and Harvey 2010). There are currently two endobronchial valve systems: Zephyr that has been more widely used and Spiration endobronchial valve. There are other options such as self-acting coils, use of biodegradeable sclerosant or thermal vapour.

ENDOBRONCHIAL ULTRASOUND

Mediastinoscopy is the gold standard for mediastinal lymph node staging in the context of lung cancer. Imaging, such as computed tomography (CT), Positron Emission Tomography (PET) or Magnetic Resonance Imaging (MRI) in some cases, provide non-invasive methods for mediastinal lymph node staging (Whitson et al. 2013, Rintoul et al. 2009). Other options for staging mediastinal lymph nodes include Endobronchial Ultrasound (EBUS), Endoscopic Ultrasound (EUS) or blind Trans-Bronchial Fine Needle Aspiration (TBFNA) sampling. CT and PET can identify mediastinal lymph node involvement in NSCLC with sensitivity of 60%

to 85%, specificity of 84% to 94% and accuracy of 78% to 96% (Groth and Andrade 2008). Cervical mediastinoscopy has sensitivity of 86% to 93% and diagnostic accuracy of 93% to 96% (Annema et al. 2010, Yasufuku et al. 2011). It has been reported to have morbidity of 0.6% to 1.1% (Hammoud et al. 1999). EBUS is a less invasive procedure compared with cervical mediastinoscopy and can be performed under awake sedation as well as under general anaesthesia.

Accurate staging of lung cancer is important for prognostic and therapeutic reasons. EBUS was introduced in the early 1990's. The early technology introduced a radial probe, which allowed for visualization of the airway wall with close proximity to the exterior of the airways (Herth, Becker, and Ernst 2003). With improvement, it allowed for the use of a radial probe with a flexible catheter and a balloon to perform biopsies, including transbronchial needle aspiration but not real time procedures. Convex probe development resulted in the ability to perform real time visualization of the lymph nodes with real time ability to biopsy lymph nodes. EBUS, using a convex probe allows for lymph node staging and biopsy, diagnosis of mediastinal tumours and diagnosis of lymph nodes of unknown aetiology, for example in the context of undiagnosed TB or sarcoid, or biopsy of a pulmonary neoplasm (Gompelmann, Eberhardt, and Herth 2012, Herth and Eberhardt 2007). The EBUS convex probe is a 7.5 MHz transducer, placed at the tip of the scope; it is a linear, curved array scanning parallel to the scope insertion. The images are produced by directly contacting the probe with the bronchial wall, or they can be enhanced by attaching a balloon to the end of the scope. The scope also allows for visualization of the bronchial tree with conventional flexible bronchoscopy imaging. EBUS can also use Doppler mode to identify blood vessels. Radial probe EBUS can be used to assess the airway wall and its layers and to localize lymph nodes close to the trachea and bronchi, thus allowing subsequent lymph node biopsies, though not under real time ultrasound guidance, to localize lung lesions and subsequently guide placement of a guide sheath for biopsy. EBUS allows for a 22-gauge needle to be inserted through the working channel allowing for real time ultrasound guided transbronchial needle aspiration.

EBUS can be performed under general anaesthesia with an 8.5 mm or larger endotracheal tube as EBUS is slightly larger than a conventional fiberoptic bronchoscope. The endotracheal tube should be placed just below the glottis to allow for good apposition against the tracheal wall to provide good quality of images. This is of particular importance when sampling station 2 lymph nodes. The advantages of general anaesthesia include better control of oxygenation, improved sampling of smaller lymph nodes - less than 10 mm in diameter - by using intermittent apnoea, thus reducing patients' movement. The main disadvantages include the possible side effects of the anaesthetic agents, including hypotension and nausea, trauma from intubation and a longer recovery time. There was no difference in outcomes of EBUS performed under general anaesthesia compared with EBUS performed under conscious sedation, with reported sensitivity of 94.8% and 94% and 94% accuracy of EBUS performed under GA and conscious sedation respectively (Gompelmann, Eberhardt, and Herth 2012, Herth and Eberhardt 2007). Numerous studies have reported EBUS and EUS as relatively safe procedures with reported serious complications ranging between 0.05% to 1.43% (von Bartheld, van Breda, and Annema 2014). The most commonly reported complications, which are relatively minor, include cough, low oxygen levels that improve post procedure and, occasionally, high temperature which is self-limiting or may require antibiotic therapy.

EBUS can access American Thoracic Society (ATS) stations 2, 3, 4, 7, 10, 11; mediastinoscopy can sample stations 1, 2, 3, 4, 7 and EUS stations 2L, 4L, 7, 8, 9 (Groth and Andrade 2008). Using a fiberoptic bronchoscope mediastinal lymph nodes can be sampled but this is performed without direct visualization and was, not surprisingly, reported to have a wide diagnostic yield ranging between 40 to 75% (Groth and Andrade 2008). This inconsistency in diagnostic yield is the main disadvantage of the TBFNA. In a randomized controlled study EBUS diagnostic yield was 80%, which was statistically significant higher compared with that of TBFNA of 71% ($p < 0.005$) (Herth, Becker, and Ernst 2004). The use of the linear probe allows for real time procedure, with EBUS reported sensitivity of 89% to 99% and a diagnostic yield of 85% to 99% (Herth, Eberhardt, et al. 2006, Herth, Ernst, et al. 2006). Dong et al performed a meta-analysis, which pooled results from 1066 patients who had both EBUS and surgical analysis of the lymph nodes, revealing sensitivity of 0.90 (CI 0.84 to 0.96) (Dong et al. 2013). The findings were not greatly dissimilar to the earlier meta-analysis (Gu et al. 2009). Yasufuku et al, in a randomized controlled study which analyzed EBUS and mediastinoscopy for assessment of nodal staging, showed that both procedures had similar diagnostic accuracy of 93%, with no difference in sensitivity and negative predictive values (Yasufuku et al. 2011). In contrast, Um et al reported, in a prospective study of 127 patients who had both EBUS and mediastinoscopy, a significantly higher 93% accuracy for EBUS compared with that of 89% for mediastinoscopy (Um et al. 2015). However, Annema et al in a randomized controlled study, compared surgical staging with that performed with EBUS and EUS, showing that surgical sensitivity for detection of cancer was 79% and was similar to that of 85% for combined EBUS and EUS (Annema et al. 2010). The important finding of this study was that mediastinoscopy increased sensitivity by 9% if performed in cases where EBUS/EUS node sampling showed no evidence of cancer. In another study, Liberman et al prospectively assessed 166 patients already diagnosed or investigated for suspected lung cancer who underwent EBU/EUS and surgical mediastinal staging in the same setting and reported that EBUS had diagnostic accuracy of 91%, EUS of 88% and combined EBUS/EUS of 97% (Liberman et al. 2014). Therefore, based on currently available research EBUS has similar or slightly higher diagnostic yield when compared with mediastinoscopy. Moreover, combining EBUS with EUS may increase the diagnostic yield.

When performing EBUS, the planning of the procedure should be undertaken based on the most recent imaging, including CT and PET. It is good practice not only to review the images with respect to the lymph node characteristics and FDG uptake but also to compare radiological measurements of the lymph nodes with those of EBUS. Once the appropriate lymph nodes are visualized, a biopsy can be performed under real time. 10 to 15 needle passes are recommended and each lymph node should be sampled 1 to 3 times depending on the size of sample obtained (Gompelmann, Eberhardt, and Herth 2012). Many centers perform on site cytology analysis, which allows for decision whether the samples obtained are adequate to provide diagnosis; the decision can then be made whether additional sampling is required. Current practice is that samples should be sufficient for mutation testing, as systemic therapy requires analysis for EGFR, ALK and PD-L1. There are important issues related to the cytological analysis of the collected samples. The presence of lymphocytes can assist confirmation that the lymph node was sampled and is predictive of adequate sampling; the absence of lymphocytes has a negative predictive value for adequacy of sampling. There are potential issues of bronchial contamination that may result in false positive results. Sampling of the lymph nodes should be performed from more proximal to more distal e.g. N3

nodes followed by N2 nodes followed by N1 nodes as, otherwise, there is potential for contamination and upstaging of disease. EBUS can also be used for the diagnosis of sarcoidosis, TB or metastatic cancer from other sites. In cases of suspected TB, samples are required to be sent for histology and cytology, as well as microbiology and mycobacterial cultures. In some cases of chronic sarcoidosis where the nodes are fibrotic, a mediastinoscopy may be required for diagnosis. The role of EBUS in diagnosing lymphoma is not clear as diagnostic yield is variable; therefore, surgical biopsy may be more appropriate.

The learning curve for EBUS is variable even for the experienced bronchoscopists (Kemp et al. 2010). There is evidence that diagnostic yield of 90% can be achieved with around 50 procedures (Bellinger et al. 2014). Overall the learning curve depends on which node stations are sampled. For example, identification and sampling of stations significant in size, 7 subcarinal or para-tracheal 4R or 4L, would be much easier to master than small hilar nodes. In experienced hands even less than 5 mm nodes can be sampled. The American College of Chest Physicians (ACCP) recommends at least 50 procedures to establish proficiency in EBUS (Ernst, Silvestri, and Johnstone 2003). The ATS and European Respiratory Society (ERS) recommend at least 40 procedures under supervision (Bolliger et al. 2002). Others have observed that the learning curve was 10 procedures (Groth et al. 2008). The learning curve can be improved by the use of simulation training (Stather et al. 2012).

VIRTUAL BRONCHOSCOPIC NAVIGATION

Virtual bronchoscopic navigation, also called navigational bronchoscopy, involves the use of flexible bronchoscopy guided by virtual bronchoscopy to reach peripheral lung lesions (Asano, Eberhardt, and Herth 2014, Silvestri et al. 2012). Navigational bronchoscopy, when used with an ultra thin computed tomography, has been reported to have a diagnostic yield of between 65.4% to 81.6% (Asano, Eberhardt, and Herth 2014). When using an EBUS guided sheath, the diagnostic yield from the sampling of peripheral lesions has been reported at between 63.3% and 84.4%. The use of virtual bronchoscopy compared to the EBUS guided sheath improved the diagnostic yield. The navigational bronchoscopy has its advantages as, for an experienced bronchoscopist, there is very short learning curve which may not require additional training. The procedure is shorter compared to the EBUS guided sheath therefore associated with improved patient comfort with low complication rate, around 1% (Asano, Eberhardt, and Herth 2014). The main disadvantages are related to relatively high costs of the equipment which is the main limiting factor (Asano, Eberhardt, and Herth 2014, Silvestri et al. 2012).

CONCLUSION

In conclusion, due to technological improvements there have been interesting developments in the field of bronchoscopy. The use of new technologies has been applied in investigational procedures such as mediastinal nodes sampling using EBUS, thus reducing the need for mediastinoscopy. Moreover, navigational bronchoscopy may become more widely used for sampling of peripheral lung lesions. This new technique can be undertaken and easily learned by experienced bronchoscopists. Similarly, insertion of endobronchial valves

for patients with emphysema, or those with persistent air leak, are performed using flexible bronchoscopy. There is no doubt that, together with technological advances, new bronchoscopic techniques will be developed, widening the application of diagnostic and therapeutic bronchoscopic options.

REFERENCES

Akopov, A. L., Rusanov, A. A. Papayan, G. V. Kazakov, N. V. Gerasin, A. V. and Urtenova, M. A. 2017. "Endobronchial photodynamic therapy under fluorescence control: Photodynamic theranostics." *Photodiag-nosis Photodyn Ther* no. 19:73-77. doi: 10.1016/j. pdpdt.2017.05.001.

Allison, R. R., and Moghissi, K. 2013. "Oncologic photodynamic therapy: clinical strategies that modulate mechanisms of action." *Photodiagnosis Photodyn Ther* no. 10 (4):331-41. doi: 10.1016/j.pdpdt.2013.03.011.

Annema, J. T., van Meerbeeck, J. P., Rintoul, R. C., Dooms, C., Deschepper, E., Dekkers, O. M., De Leyn, P., Braun, J., Carroll, N. R. Praet, M., de Ryck, F., Vansteenkiste, J., Vermassen, F,. Versteegh, M. I., Veselic, M., Nicholson, A. G., Rabe, K. F., and Tournoy, K. G. 2010. "Mediastinoscopy vs endosonography for mediastinal nodal staging of lung cancer: a randomized trial." *JAMA* no. 304 (20):2245-52. doi: 10.1001/jama.2010.1705.

Annigeri, R. V., and Patil, R. S. 2017. "A Retrospective Analysis on Anesthetic Management during Rigid Bronchoscopy in Children with Foreign Body Aspiration: Propofol and Sevoflurane with Controlled Ventilation." *Anesth Essays Res* no. 11 (4):871-874. doi: 10.4103/ aer.AER_154_17.

Asano, F., Eberhardt, R., and Herth, F. J. 2014. "Virtual bronchoscopic navigation for peripheral pulmonary lesions." *Respiration* no. 88 (5):430-40. doi: 10.1159/000367900.

Batra, H., and Yarmus, L. 2018. "Indications and complications of rigid bronchoscopy." *Expert Rev Respir Med* no. 12 (6):509-520. doi: 10.1080/17476348.2018.1473037.

Bellinger, C. R., Chatterjee, A. B., Adair, N., Houle, T., Khan, I. and Haponik, E. 2014. "Training in and experience with endobronchial ultrasound." *Respiration* no. 88 (6):478-83. doi: 10.1159/000368366.

Blum, M. G., Powers, T. W. and Sundaresan, S. 2004. "Bronchoscopy simulator effectively prepares junior residents to competently perform basic clinical bronchoscopy." *Ann Thorac Surg* no. 78 (1):287-91; discussion 287-91. doi: 10.1016/j.athoracsur. 2003.11.058.

Bolliger, C. T., Mathur, P. N., Beamis, J. F., Becker, H. D., Cavaliere, S., Colt, H., Diaz-Jimenez, J. P., Dumon, J. F., Edell, E., Kovitz, K. L., Macha, H. N., Mehta, A. C., Marel, M., Noppen, M., Strausz, J., and Sutedja, T. G. 2002. "ERS/ATS statement on interventional pulmonology. European Respiratory Society/American Thoracic Society." *Eur Respir J* no. 19 (2):356-73.

Criner, G. J., Sue, R. Wright, S. Dransfield, M. Rivas-Perez, H. Wiese, T. Sciurba, F. C. Shah, P. L. Wahidi, M. M. de Oliveira, H. G. Morrissey, B. Cardoso, P. F. G. Hays, S. Majid, A. Pastis, Jr., N. Kopas, L. Vollenweider, M. McFadden, P. M. Machuzak, M. Hsia, D. W. Sung, A., Jarad, N., Kornaszewska, M., Hazelrigg, S., Krishna, G,.

Armstrong, B., Shargill, N. S., and Slebos, D. J. 2018. "A Multicenter RCT of Zephyr(R) Endobronchial Valve Treatment in Heterogeneous Emphysema (LIBERATE)." *Am J Respir Crit Care Med*. doi: 10.1164/rccm.201803-0590OC.

Davoudi, M., and H. G. Colt. 2009. "Bronchoscopy simulation: a brief review." *Adv Health Sci Educ Theory Pract* no. 14 (2):287-96. doi: 10.1007/s10459-007-9095-x.

Dong, X., X. Qiu, Q. Liu, and J. Jia. 2013. "Endobronchial ultrasound-guided transbronchial needle aspiration in the mediastinal staging of non-small cell lung cancer: a meta-analysis." *Ann Thorac Surg* no. 96 (4):1502-7. doi: 10.1016/j.athoracsur.2013.05.016.

Du Rand, I. A., Barber, P. V., Goldring, J., Lewis, R. A., Mandal, S., Munavvar, M., Rintoul, R. C., Shah, P. L., Singh, S., Slade, M. G., and Woolley, A. 2011. "British Thoracic Society guideline for advanced diagnostic and therapeutic flexible bronchoscopy in adults." *Thorax* no. 66 Suppl 3:iii1-21. doi: 10.1136/thoraxjnl-2011-200713.

Du Rand, I. A., Blaikley, J. Booton, R. Chaudhuri, N. Gupta, V. Khalid, S. Mandal, S. Martin, J. Mills, J. Navani, N. Rahman, N. M. Wrightson, J. M. and Munavvar, M. 2013. "British Thoracic Society guideline for diagnostic flexible bronchoscopy in adults: accredited by NICE." *Thorax* no. 68 Suppl 1:i1-i44. doi: 10.1136/thoraxjnl-2013-203618.

Ernst, A., Silvestri, G. A., and Johnstone, D. 2003. "Interventional pulmonary procedures: Guidelines from the American College of Chest Physicians." *Chest* no. 123 (5):1693-717.

Gompelmann, D., Eberhardt, R., and Herth, F. J. 2012. "Endobronchial ultrasound." *Endosc Ultrasound* no. 1 (2):69-74. doi: 10.7178/eus.02.003.

Groth, S. S., and Andrade, R. S. 2008. "Endobronchial ultrasound-guided transbronchial needle aspiration for mediastinal lymph node staging in non-small cell lung cancer." *Semin Thorac Cardiovasc Surg* no. 20 (4):274-8. doi: 10.1053/j.semtcvs.2008.11.004.

Groth, S. S., Whitson, B. A., D'Cunha, J., Maddaus, M. A., Alsharif, M., and Andrade, R. S. 2008. "Endobronchial ultrasound-guided fine-needle aspiration of mediastinal lymph nodes: a single institution's early learning curve." *Ann Thorac Surg* no. 86 (4):1104-9; discussion 1109-10. doi: 10.1016/j.athoracsur.2008.06.042.

Gu, P., Y. Z. Zhao, L. Y. Jiang, W. Zhang, Y. Xin, and B. H. Han. 2009. "Endobronchial ultrasound-guided transbronchial needle aspiration for staging of lung cancer: a systematic review and meta-analysis." *Eur J Cancer* no. 45 (8):1389-96. doi: 10.1016/j.ejca.2008.11.043.

Hammoud, Z. T., Anderson, R. C., Meyers, B. F., Guthrie, T. J., Roper, C. L., Cooper, J. D., and Patterson, G. A. 1999. "The current role of mediastinoscopy in the evaluation of thoracic disease." *J Thorac Cardiovasc Surg* no. 118 (5):894-9.

Haponik, E. F., Russell, G. B., Beamis, Jr., J. F., Britt, E. J., Kvale, P., Mathur, P., and Mehta, A. 2000. "Bronchoscopy training: current fellows' experiences and some concerns for the future." *Chest* no. 118 (3):625-30.

Hartman, J. E., Klooster, K., Groen, H., Ten Hacken, N. H. T., and Slebos, D. J. 2018. "Cost-effectiveness of endobronchial valve treatment in patients with severe emphysema compared to standard medical care." *Respirology*. doi: 10.1111/resp.13295.

Herth, F., Becker, H. D., and Ernst, A. 2004. "Conventional vs endobronchial ultrasound-guided transbronchial needle aspiration: a randomized trial." *Chest* no. 125 (1):322-5.

Herth, F. J., Becker, H. D., and Ernst, A., 2003. "Ultrasound-guided transbronchial needle aspiration: an experience in 242 patients." *Chest* no. 123 (2):604-7.

Herth, F. J., and Eberhardt, R., 2007. "Actual role of endobronchial ultrasound (EBUS)." *Eur Radiol* no. 17 (7):1806-12. doi: 10.1007/s00330-006-0497-6.

Herth, F. J., Eberhardt, R., Vilmann, P., Krasnik, M., and Ernst, A., 2006. "Real-time endobronchial ultrasound guided transbronchial needle aspiration for sampling mediastinal lymph nodes." *Thorax* no. 61 (9):795-8. doi: 10.1136/thx.2005.047829.

Herth, F. J., Ernst, A., Eberhardt, R., Vilmann, P., Dienemann, H., and Krasnik, M., 2006. "Endobronchial ultrasound-guided transbronchial needle aspiration of lymph nodes in the radiologically normal mediastinum." *Eur Respir J* no. 28 (5):910-4. doi: 10.1183/09031936.06.00124905.

Herth, F. J. F., D. J. Slebos, G. J. Criner, and P. L. Shah. 2017. "Endoscopic Lung Volume Reduction: An Expert Panel Recommendation - Update 2017." *Respiration* no. 94 (4):380-388. doi: 10.1159/000479379.

Herth, F. J., Slebos, D. J., Rabe, K. F., and Shah, P. L. 2016. "Endoscopic Lung Volume Reduction: An Expert Panel Recommendation." *Respiration* no. 91 (3):241-50. doi: 10.1159/000444090.

Ikeda, N., Usuda, J., Kato, H., Ishizumi, T., Ichinose, S., Otani, K., Honda, H., Furukawa, K., Okunaka, T., and Tsutsui, H. 2011. "New aspects of photodynamic therapy for central type early stage lung cancer." *Lasers Surg Med* no. 43 (7):749-54. doi: 10.1002/lsm.21091.

Kemp, S. V., El Batrawy, S. H., Harrison, R. N., Skwarski, K., Munavvar, M., Rosell, A., Cusworth, K., and Shah, P. L. 2010. "Learning curves for endobronchial ultrasound using cusum analysis." *Thorax* no. 65 (6):534-8. doi: 10.1136/thx.2009.127274.

Klooster, K., Hartman, J. E., Ten Hacken, N. H., and Slebos, D. J. 2017. "One-Year Follow-Up after Endobronchial Valve Treatment in Patients with Emphysema without Collateral Ventilation Treated in the STELVIO Trial." *Respiration* no. 93 (2):112-121. doi: 10.1159/000453529.

Klooster, K., Slebos, D. J., Zoumot, Z., Davey, C., Shah, P. L., and Hopkinson, N. S. 2017. "Endobronchial valves for emphysema: an individual patient-level reanalysis of randomised controlled trials." *BMJ Open Respir Res* no. 4 (1):e000214. doi: 10.1136/bmjresp-2017-000214.

Klooster, K., ten Hacken, N. H., Hartman, J. E., Kerstjens, H. A., van Rikxoort, E. M., and Slebos, D. J. 2015. "Endobronchial Valves for Emphysema without Interlobar Collateral Ventilation." *N Engl J Med* no. 373 (24):2325-35. doi: 10.1056/NEJMoa1507807.

Koegelenberg, C. F., Theron, J., Dheda, K., Bruwer, J. W., Allwood, B. W., Vorster, M. J., von Groote-Bidlingmaier, F., Slebos, D. J., Shah, P. L., and Herth, F. J. 2015. "Recommendations for the use of endoscopic lung volume reduction in South Africa: Role in the treatment of emphysema." *S Afr Med J* no. 105 (10):810-5. doi: 10.7196/SAMJnew.8147.

Kvale, P. A., and Mehta, A. C. 2001. "Training bronchoscopists for the new era." *Clin Chest Med* no. 22 (2):365-72, ix.

Liberman, M., J. Sampalis, A. Duranceau, V. Thiffault, R. Hadjeres, and P. Ferraro. 2014. "Endosonographic mediastinal lymph node staging of lung cancer." *Chest* no. 146 (2):389-397. doi: 10.1378/chest.13-2349.

MacDuff, A., Arnold, A., and Harvey, J., 2010. "Management of spontaneous pneumothorax: British Thoracic Society Pleural Disease Guideline 2010." *Thorax* no. 65 Suppl 2:ii18-31. doi: 10.1136/ thx.2010.136986.

Mehta, A. C., Hood, K. L., Schwarz, Y., and Solomon, S. B. 2018. "The Evolutional History of Electromagnetic Navigation Bronchoscopy: State of the Art." *Chest*. doi: 10.1016/j.chest.2018.04.029.

Moghissi, K., and Dixon, K. 2003. "Is bronchoscopic photodynamic therapy a therapeutic option in lung cancer?" *Eur Respir J* no. 22 (3):535-41.

Moghissi, K., and Dixon, K. 2008. "Update on the current indications, practice and results of photodynamic therapy (PDT) in early central lung cancer (ECLC)." *Photodiagnosis Photodyn Ther* no. 5 (1):10-8. doi: 10.1016/j.pdpdt.2007.11.001.

Moghissi, K., and Dixon, K. 2017. "Photodynamic therapy (PDT) for adenoid cystic carcinoma of the tracheo-bronchial tree: Report of 4 cases." *Photodiagnosis Photodyn Ther* no. 18:95-97. doi: 10.1016/j.pdpdt.2017.02.002.

Moghissi, K., Dixon, K., Stringer, M., Freeman, T., Thorpe, A., and Brown, S. 1999. "The place of bronchoscopic photodynamic therapy in advanced unresectable lung cancer: experience of 100 cases." *Eur J Cardiothorac Surg* no. 15 (1):1-6.

Moghissi, K., Dixon, K., Thorpe, J. A., Stringer, M., and Oxtoby, C. 2007. "Photodynamic therapy (PDT) in early central lung cancer: a treatment option for patients ineligible for surgical resection." *Thorax* no. 62 (5):391-5. doi: 10.1136/thx.2006.061143.

Okunaka, T., and Kato, H. 2002. "[Photodynamic therapy for lung cancer: state of the art and expanded indications]." *Nihon Geka Gakkai Zasshi* no. 103 (2):258-62.

Rayl, J. E., Pittman, J. M., and Shuster, J. J. 1988. "Preclinical training in bronchoscopic diagnosis of cancer." *Chest* no. 93 (4):824-7.

Rintoul, R. C., Tournoy, K. G., El Daly, H., Carroll, N. R., Buttery, R. C., van Kralingen, K., van Meerbeeck, J. P., Rabe, K. F., and Annema J. T. 2009. "EBUS-TBNA for the clarification of PET positive intra-thoracic lymph nodes-an international multi-centre experience." *J Thorac Oncol* no. 4 (1):44-8. doi: 10.1097/JTO.0b013e3181914357.

Ross, P., Jr., Grecula, J., Bekaii-Saab, T., Villalona-Calero, M., Otterson, G., and Magro C. 2006. "Incorporation of photodynamic therapy as an induction modality in non-small cell lung cancer." *Lasers Surg Med* no. 38 (10):881-9. doi: 10.1002/lsm.20444.

Sciurba, F. C., Ernst, A., Herth, F. J., Strange, C., Criner, G. J., Marquette, C. H., Kovitz, K. L., Chiacchierini, R. P., Goldin, J., and McLennan, G. 2010. "A randomized study of endobronchial valves for advanced emphysema." *N Engl J Med* no. 363 (13):1233-44. doi: 10.1056/NEJMoa0900928.

Shah, P. L., Herth, F. J., van Geffen, W. H., Deslee, G., and Slebos, D. J. 2017. "Lung volume reduction for emphysema." *Lancet Respir Med* no. 5 (2):147-156. doi: 10.1016/s2213-2600(16)30221-1.

Silvestri, G. A. 2008. "The evolution of bronchoscopy training." *Respiration* no. 76 (1):19-20. doi: 10.1159/000127579.

Silvestri, G. A., Feller-Kopman, D., Chen, A., Wahidi, M., Yasufuku, K., and Ernst, A. 2012. "Latest advances in advanced diagnostic and therapeutic pulmonary procedures." *Chest* no. 142 (6):1636-44. doi: 10.1378/chest.12-2326.

Skowasch, D., Fertl, A., Schwick, B., Schafer, H., Hellmann, A., and Herth, F. J. 2016. "A Long-Term Follow-Up Investigation of Endobronchial Valves in Emphysema (the LIVE Study): Study Protocol and Six-Month Interim Analysis Results of a Prospective Five-Year Observational Study." *Respiration* no. 92 (2):118-26. doi: 10.1159/000448119.

Slebos, D. J., and Shah, P. L. 2016. “Go with the Flow: The Importance of the Assessment of Collateral Ventilation in Endobronchial Valve Treatment.” *Respiration* no. 91 (4):269-70. doi: 10.1159/000444330.

Slebos, D. J., Shah, P. L., Herth, F. J., and Valipour, A.2017. “Endobronchial Valves for Endoscopic Lung Volume Reduction: Best Practice Recommendations from Expert Panel on Endoscopic Lung Volume Reduction.” *Respiration* no. 93 (2):138-150. doi: 10.1159/000453588.

Stather, D. R., MacEachern, P., Chee, A., Dumoulin, E., and Tremblay, A. 2012. “Evaluation of clinical endobronchial ultrasound skills following clinical versus simulation training.” *Respirology* no. 17 (2):291-9. doi: 10.1111/j.1440-1843.2011.02068.x.

Torrington, K. G. 2000. “Bronchoscopy training and competency: how many are enough?” *Chest* no. 118 (3):572-3.

Um, S. W., Kim, H. K., Jung, S. H., Han, J., Lee, K. J., Park, H. Y., Choi, Y. S., Shim, Y. M., Ahn, M. J., Park, K., Ahn, Y. C., Choi, J. Y., Lee, K. S., Suh, G. Y., Chung, M. P., Kwon, O. J., Kim, J., and Kim, H. 2015. “Endobronchial ultrasound versus mediastinoscopy for mediastinal nodal staging of non-small-cell lung cancer.” *J Thorac Oncol* no. 10 (2):331-7. doi: 10.1097/jto.0000000000000388.

Valipour, A., Slebos, D. J., Herth, F., Darwiche, K. Wagner, M., Ficker, J. H., Petermann, C., Hubner, R. H., Stanzel, F., and Eberhardt, R. 2016. “Endobronchial Valve Therapy in Patients with Homogeneous Emphysema. Results from the IMPACT Study.” *Am J Respir Crit Care Med* no. 194 (9):1073-1082. doi: 10.1164/rccm.201607-1383OC.

von Bartheld, M. B., van Breda, A., and Annema, J. T. 2014. “Complication rate of endosonography (endobronchial and endoscopic ultrasound): a systematic review.” *Respiration* no. 87 (4):343-51. doi: 10.1159/000357066.

Wahidi, M. M., Jain, P., Jantz, M., Lee, P., Mackensen, G. B., Barbour, S. Y., Lamb, C., and Silvestri, G. A. 2011. “American College of Chest Physicians consensus statement on the use of topical anesthesia, analgesia, and sedation during flexible bronchoscopy in adult patients.” *Chest* no. 140 (5):1342-50. doi: 10.1378/chest.10-3361.

Whitson, B. A., Groth, S. S., Odell, D. D., Briones, E. P., Maddaus, M. A., D'Cunha, J., and Andrade, R. S. 2013. “True negative predictive value of endobronchial ultrasound in lung cancer: are we being conservative enough?” *Ann Thorac Surg* no. 95 (5):1689-94. doi: 10.1016/ j.athoracsur.2012.09.057.

Yasufuku, K., Pierre, A., Darling, G., de Perrot, M., Waddell, T., Johnston, M., da Cunha Santos, G., Geddie, W., Boerner, S., Le, L. W., and Keshavjee, S. 2011. “A prospective controlled trial of endobronchial ultrasound-guided transbronchial needle aspiration compared with mediastinoscopy for mediatinal lymph node staging of lung cancer.” *J Thorac Cardiovasc Surg* no. 142 (6):1393-400 e1. doi: 10.1016/ j.jtcvs.2011.08.037.

In: Encyclopedia of Surgery (22 Volume Set)
Editors: Andreas Lehrer and Kristin Mueller
ISBN: 978-1-53618-329-0
© 2020 Nova Science Publishers, Inc.

Chapter 158

CANINE FOSSA PUNCTURE FOR THE MANAGEMENT OF MAXILLARY SINUSITIS

Federico Sireci[1], MD, Francesco Martines[2], Francesca De Bernardi,[3],MD, Salvatore Poma[4], MD, Francesco Dispenza[2], MD, Bruno Galletti[5], Francesco Galletti[5] and Frank Rikki Canevari[6]

[1]ENT Section, ARNAS Fatebenefratelli Hospital, Palermo Italy
[2]ENT Section, Bio.Ne.C. Department, University of Palermo, Italy
[3]Department of Otorhinolaryngology, University of Insubria, Varese, Italy
[4]ENT Section, Villa Sofia-Cervello Hospital, Palermo Italy
[5]Department of Otorhinolaryngology, University of Messina, Italy
[6]Department of Otorhinolaryngology – Head and Neck Surgery, University of Genoa, Genoa, Italy

ABSTRACT

Chronic rhinosinusitis (CRS) with nasal polyposis (NP) is a common chronic disease that often affects maxillary sinus. Endoscopic sinus surgery (ESS) is the most common procedure to treat the maxillary sinus lesions by a middle meatal antrostomy (MMA) and the introducing of new microdebrider blades of 15, 40, 70, and 120° improved this approach.

Nevertheless in some cases, angled microdebrider are not sufficient and canine fossa puncture (CFP) is performed as an alternative method to obtain a complete access to the maxillary antrum.

INTRODUCTION

Chronic rhinosinusitis (CRS) with nasal polyposis (NP) is a common chronic disease that seriously affects the quality of life [1]. The blockage of the ostiomeatal complex is the most common factor influencing the pathogenesis of this inflammatory process [2]. Endoscopic

sinus surgery (ESS) is the most common procedure for treating CRS that is refractory to medical treatment.

Although the majority of maxillary sinus lesions can be removed through the widened natural ostium performing partial uncinectomy and middle meatal antrostomy (MMA), some patients have extensive disease that is difficult to handle purely endoscopically.

In fact, endoscopic surgery of natural ostium allow to clear the posterior lateral wall, the posterior region of the roof, and the posterior wall of the maxillary sinus but no anterior and inferior regions. Failure to remove massive polyposis and fungal debris from the maxillary sinus may result in an early postoperative recurrence of symptoms and disease for the patient [3].

One solution is the traditional Caldwell Luc approach performed through the anterior wall of the maxillary sinus. However, this is associated with significant morbidity such as facial numbness or paresthesia (9%) for damage of the infraorbital and anterior superior alveolar nerves, oroantral fistulas (1%), gingivolabial wound dehiscences (1.5%), and dacryocystitis (2.5%). This technique has been outdated by endoscopic medial maxillectomy useful to treat benign tumors, not inflammatory disease [4]. Canine fossa puncture (CFP) has been proposed as an alternative method of obtaining access to the maxillary antrum.

Although few studies have demonstrated the benefits of CFP in management of the severely diseased maxillary sinus, the efficacy and superiority of this method compared with conventional MMA, require further investigation above all considering new microdebrider blades of 15, 40, 70, and 120° that can be inserted through the antrostomy [5].

The aim of this study is to review the literature about the indications of CFP in patients with severe maxillary sinus disease and compare this surgical procedure with maxillary sinus clearance through MMA.

CANINE FOSSA PUNCTURE TECHNIQUE

CFP consist in a trocar placed in the canine fossa [6]. The landmarks in canine approach are: the mid pupillary line and horizontal line running along the lower border of nasal ala and lateral aspect of canine fossa high above the 3rd and 4th teeth (canine and premolar), infero lateral to infra orbital foramen. The trocar should be aimed towards the maxillo ethmoid angle to avoid pterygopalatine fossa and orbital lesions. In most patients the trocar was inserted using a gentle twisting motion. In some patients with thicker bone, gentle tapping with a hammer was required for the trocar to be inserted [7, 8]. After removal of the trocar a 4-mm microdebrider blade was placed through the passage created by the trocar. The microdebrider blade was visualized in the maxillary sinus with a 40 or 70° endoscope via the middle meatal antrostomy. Polyps and diseased tissue can be removed from the maxillary sinus using the microdebrider.

DISCUSSION

Nowadays, middle meatal antrostomy (MMA) is considered the gold standard in the treatment of maxillary sinusitis. Anyway critical areas such as inferior, lateral, anterior wall, recessus zygomaticus and recessus alveolaris and recessus prelacrimalis of maxillary sinus

are difficult to approach. For this reason, medial maxillectomy or external approaches such as Caldwell Luc approach or CFP are required [6].

The efficacy of this manoeuvre on the outcome after FESS has been investigated in few studies. Lee et al have compared the results of performing a canine fossa puncture with clearance of polyps via a middle meatal antrostomy. No benefit of the canine fossa procedure over conventional middle meatal antrostomy was seen after 12 months follow up, however series are small in both groups (11 CFP V.S. 13 MMA). The authors concluded that although canine fossa puncture is a useful method for removing severe mucosal disease that cannot be reached through the MMA, it does not guarantee a better subjective or objective surgical outcome in patients with nasal polyposis [3]. However, Seiberling et al in a case control studies have found that patients with the same disease who had a canine fossa puncture had a better outcome than those who did not. In fact, all patients were administered the chronic sinusitis survey (CSS) that evidenced a subscore better in the CFP group (Mann-Whitney test, P 0.02) [9].

In the last years, the advent of angled microdebrider blade (15, 40, 70, 120°) modified sinus endoscopic surgery allowing to reach critical areas of maxillary sinus but we have few references in literature that compare these instruments with CFP approach. Beswick et al quantified the maxillary sinus volume and mucosal surface area (SA) that is accessible endoscopically via a middle meatal antrostomy in eight cadaver maxillary sinuses configured with image guidance software. In particular the authors demonstrated that mean maxillary sinus volume was 16.5 + 2.5 cm^3 and mean SA was 31.0 + 2.3 cm^2. The 15, 40, 70 and 120° microdebriders accessed an average of 10, 25, 41, and 66%, respectively, of the SA, and of 2, 9, 17, and 36%, respectively, of the volume. There was a trend toward improved accessibility of the superior half versus the inferior half of the maxillary sinus. When instruments of different degrees were combined to maximize accessibility, 81% of the SA of the sinus could be accessed. However authors did not quantify volume and area of maxillary sinus exposed [10].

Feldt et al in a sample of cadavers showed that a significant greater amount of debris was left after the transnasal endoscopic technique (TN) approach compared with canine fossa trephination (CFT) (3.88 cm^3 vs 2.88 cm^3, $p = 0.015$). Median blade utilization was significantly higher with the TN approach vs CFT (4 vs 1, $p < 0.002$).

Therefore, although using new curved blades, critical areas such as antero-medial portion of MS cannot be reached and tretaed by antrostomy and therefore CFP has to be performed. According to literature, CFP can be performed only in unilateral lesions. In fact Byun et al assigned randomly twelve patients to the CFP and thirteen to MMA groups who completed the follow-up, questionnaires (SNOT-20 and VAS), and postoperative CT evaluation.SNOT-20 and VAS scores improved significantly at 3, 6, and 12 months postprocedure in both groups. However, significant improvement of SNOT-20 at 12 months and VAS scores for purulent discharge, foul odor, and postnasal drip at 6 and 12 months were observed in the CFP group compared with the MMA group. Postoperative CT scan evidenced that the volume of mucosal thickening was significantly greater in the MMA group than in the CFP group. In addition, CFP was not effective in patients with bilateral CRS and diffuse NP but provided better management and subjective and objective surgical outcomes in patients with unilateral CRS accompanying NP 2. Among unilateral NP, there are anthrocoanal polyps (ACP). ACP is relatively unusual in the sinonasal tract. It occurs predominantly in children and young adults and originates from the maxillary antrum with extension into the nasopharynx or

oropharynx. Simple excision of the polyp via limited surgical procedures such as simple polypectomy results in high recurrence rates. Complete removal of the polyp in the antrum, including its site of origin, is essential to minimize recurrence. However, a broad base such as a lateral, inferior, or anterior location of the polyp makes eradication difficult via a MMA. In this situation, some authors choose the traditional Caldwell-Luc operation, even in children [11]. However, the increased morbidity of this procedure, including facial numbness, facial swelling, risk for injury of the tooth buds and roots, and possible asymmetric facial growth, makes it less favorable than endoscopic sinus surgery. In fact, CFP is considered an alternative method of accessing almost the entire maxillary antrum in young/adult population. Few studies have reported the efficacy of the CFP approach in treating ACP in the pediatric population (≤ 15 years old) and the long-term effect on changes in the maxillary sinus volume and surgical outcome has not been determined. Jae Yong Lee et al studied a little sample of seven patients with ACP removed via the CFP approach. After a mean follow-up period of 43.9 months, the authors compared the changes in the maxillary sinus volume between the operated and normal sides, using the pre- and postoperative CT data. No contractures or decrease in the maxillary sinus volume on the diseased side were observed in any of the patients on postoperative CT. None of the patients showed evidence of recurrence on the endoscopic and CT examinations and only two patients complained of mild facial swelling and tingling sensation, which resolved spontaneously within 2 weeks [13]. Therefore, CFP can be performed to treat ACP in young but also in children when MMA is not sufficient.

Important indications to CFP are chronic odontogenic sinusitis (COS). Approximately 5–15 % of the population suffers from chronic rhinosinusitis, and in 10–12 % of them, it is of dental origin [13]. It is produced by periapical granulomas or small inflammatory cysts of the molars or bicuspids, chronic oroantral fistula (OAF), large odontogenic cysts occupying a great part of the maxillary sinus, and foreign bodies (dental fillings, teeth roots, and implants) pressed throughout the root canal or fistula into the antrum.

Venetis et al presented 20 cases with odontogenic sinusitis, 5 (25%) in which a foreign body was removed from maxillary sinus by combined transnasal and canine fossa endoscopic approach. The surgical procedure was performed with conventional instrumentation through the widened antrorhinostomy or through a bony window at the anterior sinus wall. At the end of the procedure, the window was repositioned and stabilized with two to three absorbable sutures. In two cases, with sizeable foreign bodies, the preservation of the bony window was impossible, and a modified Caldwell–Luc operation was performed with preservation of the healthy sinus mucosa [14]. According to Barziliai et al we avoid Caldwell–Luc operation because it is associated with significant morbidity such as facial numbness or paresthesia (9%) for damage of the infraorbital and anterior superior alveolar nerves, oroantral fistulas (1%), gingivolabial wound dehiscences (1.5%), and dacryocystitis (2.5%) [15]. Actually, Caldwell-Luc procedure is rational in cases of fungal disease and in endoscopic medial maxillectomy for treating inverted papilloma.

In the literature, different opinions about approach to fungal maxillar sinusitis are reported. In most of the patients it can be removed through the MMA using various curved instruments and saline irrigation without great difficulty. Also, if fungal invasion into sinus tissue is confirmed by histological examination, a systemic antifungal treatment postoperatively is paramount to reduce disease and potential recurrences [16].

Instead, there are no indications to perform CFP and/or Caldwell- Luc approach in maxillar sinus malignant tumor. According to the literature, endoscopic medial maxillectomy

can be considered as first choice in difficult maxillary sinus tumor removal because an unnatural opening like CFA or Caldwell Luc in locally invasive disease with malignant potential as the tumor can extend through this opening in recurrent cases [17, 18, 19, 20, 21].

CONCLUSION

Although angled microdebrider improved endoscopic approaches to maxillary sinus, literature showed that canine fossa puncture is a minimally invasive technique useful in selected cases and without postoperative complications.

REFERENCES

[1] Fokkens W, Lund fV, Bachert C, et al., (2005). EAACI position paper on rhinosinusitis and nasal polyp's executive summary. *Allergy*. 60:583–601. 2761.

[2] Sireci F, Dehgani Mobaraki P, Nicolotti M, et al., (2017) *Indications to Canine Fossa Puncture in Management of Maxillary Sinusitis*: Review of Literature. Cepal review.

[3] Lee JY, Lee SH, Hong HS, Lee JD, Cho SH (2008). Is the canine fossa puncture approach really necessary for the severely diseased maxillary sinus during endoscopic sinus surgery? *The Laryngoscope.* 118(6):1082-7.

[4] DeFreitas J, Lucente FE (1988). The Caldwell-Luc procedure: institutional review of 670 cases. 1975–1985. *Laryngoscope.* 98:1297–1300.

[5] Sathananthar S, Nagaonkar S, Paleri V, Le T, Robinson S, Wormald PJ (2005). Canine fossa puncture and clearance of the maxillary sinus for the severely diseased maxillary sinus. *The Laryngoscope*. 115 (6):1026-9.

[6] Anand V, Santosh S, Aishwarya A (2008). Canine fossa approaches in endoscopic sinus surgery - our experience. *Indian J. Otolaryngol. Head Neck Surg*. 60 (3):214-7.

[7] Petersen RJ (1973). Canine fossa puncture. *Laryngoscope.* 83 (3):369-71.

[8] Sireci F, Speciale R, Sorrentino R, Turri-Zanoni M, Nicolotti M, Canevari FR (2016). Nasal packing in sphenopalatine artery bleeding: therapeutic or harmful? *Eur. Arch. Otorhinolaryngol.*

[9] Seiberling K, Ooi E, MiinYip J, Wormald PJ (2009). Canine fossa trephine for the severely diseased maxillary sinus. *American journal of rhinology & allergy*. 23 (6):615-8.

[10] Beswick DM, Rodriguez KD, Olds CE, Kass JI, Schaitkin BM (2015). Quantification of maxillary sinus accessibility via a middle meatal antrostomy. *Am. J. Rhinol. Allergy*. 29 (5):394-6.

[11] Myers EN, and Cunningham MJ (1986). Modified Caldwell-Luc approach for the treatment of antral choanal polyps. *Laryngoscope*. 96:911–913.

[12] Lee JY, Baek BJ, Kim DW, Byun JY, Lee SW, Hong HS (2009). Changes in the maxillary sinus volume and the surgical outcome after the canine fossa puncture approach in pediatric patients with an antrochoanal polyp: results of a minimum 3-year follow-up. *Am. J. Rhinol. Allergy*. 23 (5):531-4.

[13] Martines F, Salvago P, Ferrara S, Mucia M, Gambino A, Sireci F (2014). Parietal subdural empyema as complication of acute odontogenic sinusitis: a case report. *J. Med. Case Rep.* 21; 8:282.

[14] Venetis G, Bourlidou E, Liokatis PG, Zouloumis L (2014). Endoscopic assistance in the diagnosis and treatment of odontogenic maxillary sinus disease. *Oral Maxillofac Surg.* 18 (2):207-12.

[15] Barzilai G, Greenberg E, Uri N (2005). Indications for the Caldwell-Luc approach in the endoscopic era. *Otolaryngol. Head Neck Surg.* 132 (2):219-20.

[16] Pagella F, Matti E, Giourgos G, Colombo A, De Bernardi F, Castelnuovo P (2009). Is canine fossa access necessary for successful maxillary fungus ball treatment? *Rhinology*. 47 (4):385-8.

[17] Pagella F, Giourgos G, Matti E, Canevari FR, Carena P (2011). Endoscopic treatment of maxillary inverted papilloma. *Rhinology*. 49 (3):369-74.

[18] Sireci F, Nicolotti M, Battaglia P, Sorrentino R, Castelnuov P, Canevari FR. (2017) Canine fossa puncture in endoscopic sinus surgery: report of two cases. *Brad. J. Otorhinolaryngol.* pii: S1808-8694(17)30040-X. dei: 10.1016/j.bjorl.2017.03.001.

[19] Sireci F, Canevari FR. (2017) Mininvasive surgical approach in endoscopic sinus surgery: when, why and how? *The Rhinologist*, 3:42-4.

[20] Galletti B, Bucolo S, Abbate G, Canton Bascuas M, Romano G, Fera, G, Freni F. [Upper maxillary cysts: embryogenic and surgical considerations in our cases]. *Acta Otorhinolaryngol. Ital.* 2000;20 (3):177-86.

[21] Galletti C, Cammaroto G, Galletti F, Camps-Font O, Gay-Escoda C, Bara-Casaus JJ. Dental implants after the use of bichat's buccal fat pad for the sealing of oro-antral communications. A case report and literature review. *J. Clin. Exp. Dent.* 2016;8(5):e645-e649.

In: Encyclopedia of Surgery (22 Volume Set)
Editors: Andreas Lehrer and Kristin Mueller
ISBN: 978-1-53618-329-0
© 2020 Nova Science Publishers, Inc.

Chapter 159

COMPLICATIONS AND THEIR MANAGEMENT IN ENDOSCOPIC SINUS SURGERY (ESS)

Federico Sireci[1,*], MD, Francesco Martines[2], Pietro Salvago[2], MD, Claudio Sbacchi[1], MD, Vincenzo Immordino[1], MD, Francesco Galletti[3], Bruno Galletti[3], Giovanni Cimino[1], MD, Francesco Dispenza[2], MD and Frank Rikki Canevari[4]

[1]ENT Section, ARNAS Fatebenefratelli Hospital, Palermo Italy
[2]ENT Section, Bio.Ne.C. Department, University of Palermo, Italy
[3]Department of Otorhinolaryngology, University of Messina, Italy
[4]Department of Otorhinolaryngology – Head and Neck Surgery, University of Genoa, Genoa, Italy

ABSTRACT

Endoscopic sinus surgery (ESS) is one of the most commonly performed procedures in otolaryngology. ESS complications should be distinguished in minor and major based on the treatment they need and the permanent sequelae they can cause. Over the years it has gone from an incidence of complications in endoscopic surgery of 8% for the major and 21% for the minor to a percentage of 0 -1.5% and 1.1-20.8%, respectively. This is due to the considerable diffusion of the technique with a progressive increase over the years of the surgical experience but their presence help to educate otolaryngologists and patients about complication rates in ESS in a modern context. A complication occurs when injuries to anatomical structures defined in the literature "risk areas" are created. The surgeon must know and identify these areas because these are important land mark that guide our interventions respecting the anatomical boundaries.

The aim of this chapter is to describe principle complications and their management.

* Corresponding Author's Email: federicosireci@hotmail.it.

INTRODUCTION

"An undesirable, unintended and direct result of an operation affecting the patient which would not have occurred had the operation gone as well as could reasonably be hoped" [1]. This is the current definition of surgical complication. These are distinct and classified according to gravity in 5 degrees [2].

FESS complications should be distinguished in minor and major based on the treatment they need and the permanent sequelae they can cause (Table 1) [3, 4].

Over the years there has been an incidence of complications in endoscopic surgery of 8% for the major and 21% for the minor at a percentage of 0 -1.5% and 1.1-20.8%, respectively. This is due to the considerable diffusion of the technique with a progressive increase over the years of the surgical experience. Ramakrishnan et al. in a 2012 retrospective study of 63823 patients report the following percentages for major complications: 0.17% rhinoliquorrea, 0.07% orbital lesions, 0.76% massive hemorrhage with need for transfusion [4, 5]. Regarding the complications in pediatric age, they are negligible with percentages below 1%, especially if the synechia are excluded. [6]. A complication occurs when injuries to anatomical structures defined in the literature "risk areas" are created. The surgeon must know and identify these areas because these are not actually such, but they are important points of reference that guide our interventions respecting the anatomical boundaries. At present the major risk areas are summarized by the acronym "CLOSE" (C = Cribriform plate; L = Lamina papiracea; O = Cell onodi; S = Sphenoid; E = anterior ethmoidal artery) [7].

To better understand the possible complications, we will avoid addressing them by referring to this acronym but we will describe the main FESS steps highlighting for each of these the possible risks.

Table 1. Classification of surgical complications according to Dindo et al.

Grade	Definition
Grade I	Any deviation from the normal postoperative course without the need for pharmacological treatment or surgical, endoscopic, and radiological interventions
	Allowed therapeutic regimens are: drugs as antiemetics, antipyretics, analgetics, diuretics, electrolytes, and physiotherapy. This grade also includes wound infections opened at the bedside
Grade II	Requiring pharmacological treatment with drugs other than such allowed for grade I complications
	Blood transfusions and total parenteral nutrition are also included
Grade III	Requiring surgical, endoscopic or radiological intervention
Grade IIIa	Intervention not under general anesthesia
Grade IIIb	Intervention under general anesthesia
Grade IV	Life-threatening complication (including CNS complications)* requiring IC/ICU management
Grade IVa	Single organ dysfunction (including dialysis)
Grade IVb	Multiorgan dysfunction
Grade V	Death of a patient
Suffix "d"	If the patient suffers from a complication at the time of discharge (see examples in Table 2), the suffix "d" (for "disability") is added to the respective grade of complication. This label indicates the need for a follow-up to fully evaluate the complication.

*Brain hemorrhage, ischemic stroke, subarrachnoidal bleeding, but excluding transient ischemic attacks.
CNS, central nervous system; IC, intermediate care; ICU, intensive care unit.

Table 2. Classification of complications of nasal sinus surgery

<table>
<tr><td>Minor complications</td><td>Major complications</td></tr>
<tr><td>Temporary (not to be treated)</td><td>Treatable</td></tr>
<tr><td>- Subcutaneous periorbital emphysema
- Periorbital bruising
- Dental and/or labial pain/paresthesia</td><td rowspan="4">- Orbital hematoma
- Reduction of the visus
- Diplopia
- Epiphora (which requires dacryocystorhinostomy)
- Bleeding that requires transfusion
- Liquorrea
- Meningitis
- Brain abscess
- Focal cerebral hemorrhage</td></tr>
<tr><td>Temporary (to be treated)</td></tr>
<tr><td>- Symptomatic synechia
- Epistaxis
- Pranasal sinus infections</td></tr>
<tr><td>Permanent</td></tr>
<tr><td rowspan="2">- Pain/paresesia dental and lip
- Loss of smell</td><td>Not treatable</td></tr>
<tr><td>- Death
- Blindness
- Diplopia
- Central nervous system deficiency</td></tr>
</table>

UNCINECTOMY

During this maneuver the risk areas are two: the lamina papiracea and the lacrimal duct (Figure 1).

CT scan is important to study the lamina papiracea in subjects who have never undergone surgery or who have had facial trauma because they may present spontaneous dehiscences or protrusions of the orbital fat within the ethmoid or maxillary sinus.

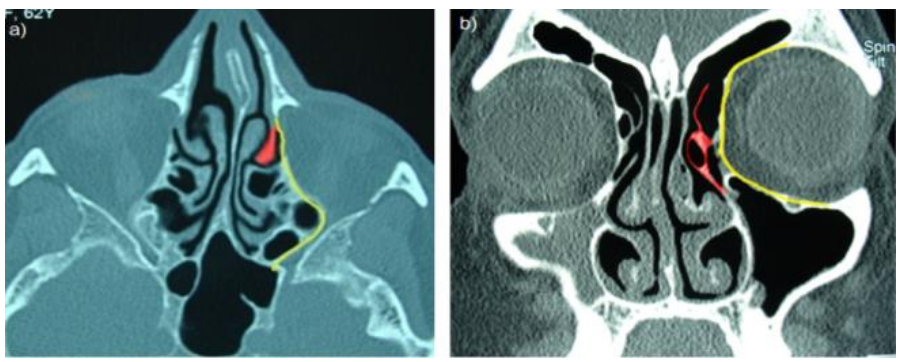

Figure 1. Risk areas during uncinectomy. The uncinate process is highlighted in red; in yellow the lamina papiracea.

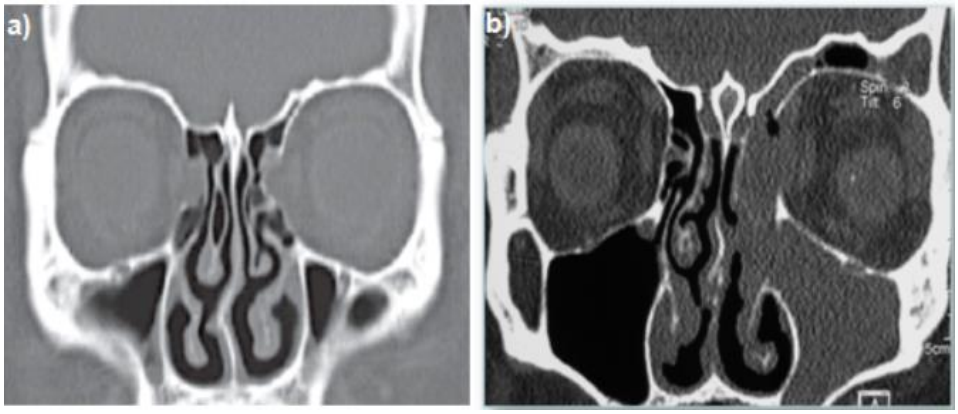

Figure 2. a) Spontaneous dehiscence of lamina papiracea; b) Lamina papiracea dehiscence in a patient with chronic rhinosinusitis.

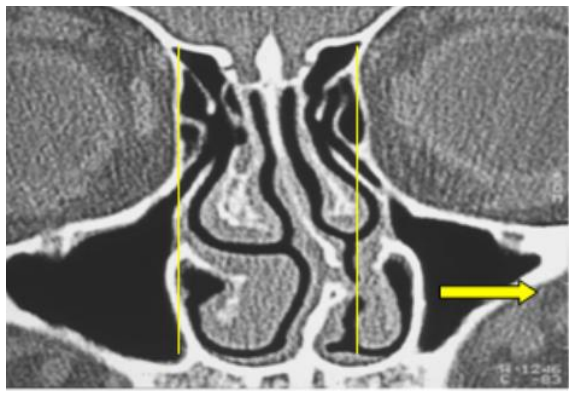

Figure 3. Medial wall of the maxillary sinus very lateralized with respect to the lamina papiracea.

Important is the evaluation of the projection of the medial wall of the orbit on the medial wall of the maxillary sinus. If the medial wall of the maxillary sinus is lateralized respect to the orbit (as in the "Silent Sinus Syndrome"), the uncinate process will be horizontalized, lateralized and leaning against the lamina papiracea. In these cases, during the uncinectomy, a downward correction of the backbiting forceps is necessary to avoid damaging the papyracea lamina and entering the orbital environment through the inferior-medial angle of the orbit.

Intraoperative safety measures are the execution of the Stankiewicz maneuver that allows us to evaluate infractions of the lamina papiracea and the use of the debrider with a tangential direction respect to orbit in order to prevent the aggression of endoorbitary structures. The use of the scalpel to dissect the uncinate process is by now a disused technique because it increases the risk of violating the orbital environment. Nasolacrimal duct lesion is a rare complication not reported in the latest cases because the hardest consistency of nasolacrimal bone is easily perceived by the operator. However, if it should be damaged, it is important to perform a dacryocystorhinostomy (DCR) intraoperatively to ensure proper drainage of lacrimal secretions. An untreated nasolacrimal duct lesion manifests clinically in the immediate postoperative period but in these cases a follow-up of some months (3-6 months) is recommended because often the epiphora resolves spontaneously. Only in 15% of cases can it occur even after the postoperative period [8, 9].

MIDDLE ANTROSTOMY

In addition to the risk areas described for the uncinectomy, it is possible to damage the sphenopalatine artery. This artery emerges from the sfenopalatin foramen delimited by the orbital process and the sphenoid process of the palatal bone placed in the posteromedial corner of the maxillary sinus. Therefore it is important to have an appropriate equipment (dessy bipolar forceps). The sphenopalatine artery and its septal branch vascularizes the posterior portion of the nasal septum that can be used as a closing flap in the skull base surgery, therefore it is desirable to preserve them. In surgical procedures within the maxillary sinus, other risk areas are the maxillary artery behind posterior wall of the maxillary sinus, the infrorbital nerve (V2) that runs in the median portion of the orbital floor and the superior alveolar nerve on the floor of maxillary sinus [10, 11, 12].

FRONTAL SINUS

The risk areas are represented by the anterior ethmoid artery and the lateral lamella of the lamina cribra.

The anterior ethmoid artery is a branch of the ophthalmic artery that runs from the orbit to the endocranium passing through the ethmoid roof. Anatomical studies on cadaver evidenced that in 91% of cases it is located inside the cranial base, therefore protected by the bone structure, while in 9% of cases it runs inside a mesentery suspended below the cranial base and therefore it is partial or total dehiscence [13].

The artery runs behind the first ethmoid foveola and often is protected by the cranial portion of the ethmoid bulla therefore frontal recess can be opened without decomposing the bulla can represent a measure of safety. The lesion of this artery can lead to an early intra or post-operative bleeding or to a massive intraorbitary bleeding with suffering of the optic nerve. For this reason, in the surgery of the frontal recess, the use of sharp instruments is recommended. In case of direct lesion of the anterior ethmoidal artery, it is sufficient to cauterize it with a bipolar forceps, possibly with a three or four-handed operation to maintain cleaned operating field, allowing an optimal visualization of the bleeding point. If the artery is retracted into an orbit by causing an intra-orbital hematoma, a lateral cantotomy of urgency can prevent the loss of visual function.

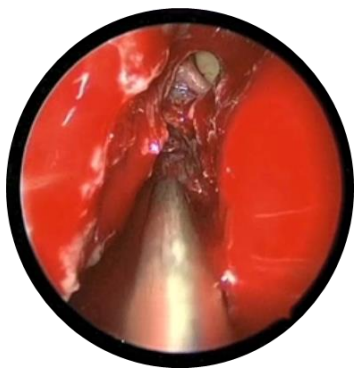

Figure 4. Dehiscent anterior ethmoidal artery in the left nasal fossa.

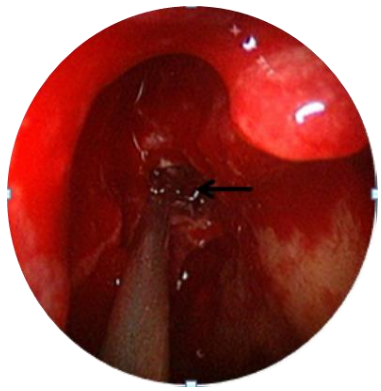

Figure 5. Rhinoliquoral fistula on the roof of the right nasal fossa ethmoid.

The lateral lamina of the cribra is very thin and in this area the dura mater is adherent to the periosteum so that a minimal bone infraction causes a tear of the dura with consequent rhinoliquorrea. In the preoperative planning it is important to evaluate the orientation and the length of the lateral lamina. Keros proposed an anatomical classification that measures the height of the lamina itself respect to the ethmoidal fovea determining so the depth of the olfactory fossa. There are 3 type: Keros I (1-3 mm) present in 12%; Keros II (3-7 mm) present in 70% and Keros III (7-16 mm) present in 18% [13]. A very long lateral lamina with a deep olfactory fossa increase surgical risk. Another parameter to be evaluated is the anatomical orientation of the lamina itself: if the lateral lamina is in a horizontal position, greater is the risk of CSF. It should also be noted that in 12% of patients there is an asymmetry between the two sides of 2 mm and that in about 6% of cases there are spontaneous dehiscences of the ethmoid roof [13]. In the frontal recess surgery safety measures are keeping intact, if possible, the ethmoid bulla, the use of sharp instruments and the execution of maneuvers from posterior to anterior and from medial to lateral.

If a CSF occurs, it must be recognized and repaired immediately in order to avoid further complications such as meningitis and/or pneumoencephaly. The administration of intrathecal fluorescein, useful in the exact topodiagnosis of a fistula, is not necessary if the diagnosis of the complication is intraoperative while it is advisable if the diagnosis is post-operative. The repair of an iatrogenic fistula of the lateral lamina involves the isolation of the area of the liquorrea, the preparation of the area bordering the defect, demucosization of the surrounding areas, removing all the bony asperities in order to obtain a more homogeneous operative field and that allows the placement of the graft. The use of autologous grafts that allow a correct integration of the graft into the receiving site is preferable. For small fistulas (3mm) it may be sufficient to use an overlay technique using mucoperiosteal taken from the septum or middle turbinate. In the larger size fistulas a multilayer technique is used, regularizing the bone edges and using the muscular fascia (fascia or temporalis muscle fascia) to better activate the function of the fibroblasts. The use of biological glues is not to be considered a closing technique but can be useful in stabilizing the grafts using it as a glue of the edges of the same. Nasal packing with the purpose of supporting the grafts must also be avoided, because their positioning and/or removal can lead to dislocation of the grafts themselves. In the literature are also described cases of occult liquorrea with spontaneous resolution with a reported percentage of 3% [15].

ETHMOIDECTOMY

The anterior ethoidectomy provides for the opening and removal of the ethmoid bulla after the breakdown of the uncinate process. The risk areas are laterally the lamina papiracea and above the anterior ethmoid artery and the lateral lamina of the lamina cribra. Papyracea lamina lesions may result in orbital complications. The appearance of post-operative orbitary ecchymosis is frequent. This complication does not compromise the orbital function and should be treated with the early nasal molding, the administration of broad-spectrum antibiotic and reminding the patient not to blow their nose for at least 20 days in order to avoid orbit emphysema. The presence of pneumorobita must be monitored because if it is stable it does not require further treatment whereas if it is evolving it may require the insertion of needles aspiration through the transpalpebral way to decrease the orbital tension caused by emphysema.

In case of exposure of orbital fat, it is recommended to refrain to reposition it to the endorbitary level and to limit the cauterization of herniated fat. Parameters that must be evaluated in case of orbital complication are the perception of the red color that indicate a lesion of optic nerve, the diplopia and the orbital pain of ocular movements, possible index of damage to the extrinsic orbital musculature. Safety measures in the decomposition of the bulla are its opening in the inferior medial angle, its subdivision in the medium lateral direction with sharp instruments and the use of the debrider with a tangential direction to the orbit itself.

Posterior ethmoidectomy involves the decomposition of the second portion of the basal lamina of the middle turbinate. The risk points in this case are the lower wall, the lamina papiracea, the ethmoid roof and the sphenoidal etmoid interface. Excessive removal of the inferior wall, formed by the third portion of the basal lamina of the middle turbinate, causes a destabilization of the middle turbinate itself which can lateralize and close the posterior ethmoid with the consequent formation of iatrogenic mucoceles. Regarding the lamina papiracea are worth the considerations made for the anterior etmoidectomy, remembering that the closer you get to the orbital apex, the more the medial rectus muscle approaches the papyraceae, thus increasing the risk of damage to the ocular muscles. The ethmoidal roof at the junction between posterior ethmoid and the sphenoid planum is frequently found in a lower plane with respect to the anterior etmoid simulating a sort of “hammock” stretched between these structures. The evaluation of the ethmoid roof trend must be made with the CT scans in sagittal projection in order to avoid a lesion of the ethmoid roof with consequent liquor fistula. Another possible site for complications at the ethmoid roof is the posterior ethmoidal artery. This usually occurs in a bone channel near the ethoidosphenoidal junction. One of his lesions is a rare occurrence. At the level of the ethmoid sphenoid interface the presence of Onodi cells should be evaluated. This is a cell of the posterior ethmoid, present between 4-42% of patients, which pneumatizes the supero-lateral face of the sphenoid sinus and may contain the optic nerve inside (4-8% of cases) and in rare cases the dehiscent internal carotid artery which are therefore at risk of injury during posterior ethoectomy [16]. The Onodi cell should be evaluated by comparing the three projections of the CT. Its incorrect evaluation may lead to optic nerve lesions and/or cataclysmic hemorrhages caused by internal carotid lesions.

Safety measures in the posterior ethoidectomy are its opening in the inferomedial angle of the second portion of the middle turbinate and therefore its decomposition in the first later lateral direction then using sharp instruments and making a lower correction in the decomposition of the most cranial portion. If surgical measures are required in the posterior portion of the posterior ethmoid it is advisable to first perform a sphenoidotomy to identify lateral and upper anatomical limits.

The surgical operations performed on the middle turbinate provide for a partial removal, for correction of a paradoxical curvature, a removal of its lateral component, in case of decomposition of a bullosa or subtotal removal, if the pathology to be treated requires the creation of large cavities. The risks in the treatment of turbinates are represented by its cranial insertion and its relationship with the olfactory shower. Torsion maneuvers can lead to a destabilization of the middle turbinate, which lateralizes in the postoperatrix, predisposing to the formation of mucocels or even causing a fracture of its cranial insertion with lesion of the dura mater and rhinoliquorrea. The section of the middle turbinate must always be conducted inferiorly to a line passing through the armpit of the turbinates (middle, upper and upper) so as to respect the lamina of the croissants seat of the olfactory mucosa. In the decomposition of the medium turbinate it is advisable to use sharp tools, the progressive decomposition of the same avoiding rough maneuvers and the respect of the lamina of the croissants keeping a lower level to the lamina itself.

SPHENOIDOTOMY

The sphenoidal sinus can be approached with two main approach: the direct paraseptal and the transetmoidal [17]. The common point of the two approaches is the identification and enlargement of the natural sphenoid sinus ostium. A non-natural sphenoid opening may expose the optic nerve to damage because the anterior wall of the sphenoid is inserted laterally and perpendicular to the orbital apex. This perpendicular insertion may determine, in case of fracture at its insertion point, an injury to the orbital apex by the insertion of bone spicules. The finding of the natural ostium provides further security of the surgical maneuvers in the presence of Onodi cells.

In the direct paraseptal transnasal approach, the landmarks are represented from the choanal border, then continuing vertically and medially to the tail of the middle turbinate, the tail of the superior and superior turbinate. The natural ostium of the breast is located at the top of the upper turbinate. This, depending on the pneumatization of the sphenoidal rostrum, can be felt in a medial position, and therefore directly visible, or in a more lateral position, hidden from the tail of the upper turbinate itself. The risk points in this approach are the posterior portion of the olfactory area and the sepal branch of the sphenopalatine artery on the anterior wall of the sphenoid itself. A lesion of the olfactory area may result in alterations in the olfactory function and if the anatomical disorientation continues, a lesion of the skullbase with consequent rhinoliquorrea. A lesion of the sepal branch of the sphenopalatine artery leads to a hemorrhage of simple control but compromises the vascularization of septal flaps useful in the reconstruction of the cranial base. Safety measures are the finding of the natural sphenoid sinus ostium maintaining a direction of the instruments parallel to the plane of the nasal floor and the visualization of the axilla of the superior turbinate that identifies the

olfactory area. The septal branches start in an area that moves from the lower portion of the upper turbinate to the upper portion of the middle turbinate tail. Their preservation can be achieved by limiting the sphenoidotomy to an upper plane with respect to the vascular area or, if necessary a wider sphenoidotomy, looking for the subperiosteal plane of the anterior wall of the sphenoid and by detaching the mucoperiosteal in caudal direction exposing the bone wall which at this point it can be removed up to the coanal edge, preserving the vascularization.

In transetmoidal way, the landmarks are, after the opening of the posterior ethmoid, represented in sequence by the body of the superior turbinate, by its tail and then by the natural ostium of the sphenoid sinus. The superior turbinate is to be found in the medial and inferior potion of the most anterior portion of the posterior ethmoid. Once the upper turbinate body has been identified, it continues in its progressive section up to the finding of the natural sphenoid ostium. The risk areas are the same as those of the transnasal route (olfactory area and the septal branch of the sphenoplatin artery). Safety measures are the finding of the middle turbinate axilla that indicates the olfactory region, the correction of the section plane in caudal direction parallel to the nasal floor. The insertion of a curved instrument at the level of the sphenoethmoid recess and its finding by transethmoidal way provides us with a further security of the correct finding of the superior turbinate and of the ethmoidal sphenous recess.

The sphenoid sinus has a wide variability of its pneumatization. The risk areas are represented by the anatomical structures of the neighboring regions that imprint, more or less clearly, the profiles of the walls of the sphenoid. The most critical area is represented by the lateral wall where the internal carotid artery and the optic nerve run. These can be dehiscent and therefore more exposed to iatrogenic lesions [18, 19, 20, 21]. For a correct anatomical orientation it is necessary to identify the intrasphenoidal points of recognition which indicate the position of the confined anatomical structures.

REFERENCES

[1] Sokol DK, Wilson J. (2008) What is a surgical complication? *World J Surg*. 32(6):942-4.

[2] Dindo D, Clavien PA. (2008) What is a surgical complication? *World J Surg*. 32(6):939-41.

[3] Re M, Gioacchini FM, Pasquini E. (2013) Il rischio professionale nella chirurgia endoscopica nasosinusale. In: *Torgraf eds. Il rischio professionale clinico-assistenziale in otorinolaringoiatria*. 435-459.

[4] Sireci F, Speciale R, Sorrentino R, Turri-Zanoni M, Nicolotti M, Canevari FR. (2016) Nasal packing in sphenopalatine artery bleeding: therapeutic or harmful? *Eur Arch Otorhinolaryngol*.

[5] Ramakrishnan VR, Kingdom TT, Nayak JV, Hwang PH, Orlandi RR.(2012) Nationwide incidence of major complications in endoscopic sinus surgery. *Int Forum Allergy Rhinol*. 2(1):34-9.

[6] Chan KH, Kraai TL, Richter GT, Wetherall S, Todd JK. (2009) Toxic shock syndrome and rhinosinusitis in children. *Arch Otolaryngol Head Neck Surg*. 135(6):538-42.

[7] Weitzel EK, Floreani S, Wormald PJ. (2008) Otolaryngologic heuristics: a rhinologic perspective. *ANZ J Surg.* 78(12):1096-9.

[8] Bolger WE, Parsons DS, Mair EA, Kuhn FA (1992). Lacrimal drainage system injury in functional endoscopic sinus surgery. Incidence, analysis, and prevention. *Arch Otolaryngol Head Neck Surg.* 118(11):1179-84.

[9] Sireci F, Canevari FR. (2017) Mininvasive surgical approach in endoscopic sinus surgery: when, why and how? *The Rhinologist.* 3:42-48.

[10] Sireci F, Dehgani Mobaraki P, Nicolotti M, Vitali M, Tomazic PV, Faralli M, Longari F Canevari FR. (2017) *Indications to Canine Fossa Puncture in Management of Maxillary Sinusitis: Review of Literature*. Cepal review.

[11] Sireci F, Nicolotti M, Battaglia P, Sorrentino R, Castelnuovo P, Canevari FR. (2017) Canine fossa puncture in endoscopic sinus surgery: report of two cases. *Brad J Otorhinolaryngol*. pii: S1808-8694(17)30040-X. dei: 10.1016/j.bjorl.2017.03.001.

[12] Martines F, Salvago P, Ferrara S, Mucia M, Gambino A, Sireci F. (2014) Parietal subdural empyema as complication of acute odontogenic sinusitis: a case report. *J Med Case Rep*. 21;8:282.

[13] Moon HJ, Kim HU, Lee JG, Chung IH, Yoon JH. (2001) Surgical anatomy of the anterior ethmoidal canal in ethmoid roof. *Laryngoscope*. 111(5):900-4.

[14] Keros P. (1962) [On the practical value of differences in the level of the lamina cribrosa of the ethmoid]. *Z Laryngol Rhinol Otol*. 41:809-13.

[15] Bachmann G, Petereit H, Djenabi U, Michel O. (2002) [Measuring beta-trace protein for detection of perilymph fistulas]. *HNO.* 50(2):129-33.

[16] Dessi P, Moulin G, Castro F, Chagnaud C, Cannoni M. (1994) Protrusion of the optic nerve into the ethmoid and sphenoid sinus: prospective study of 150 CT studies. *Neuroradiology.* 36(7):515-6.

[17] Montana F, Salvago P, Dispenza F. (2018) Pleomorphic Adenoma of the Nasal Septum: A Rare Case Report of A 14 Year-Old Patient. *Euromediterranean Biomedical Journal.* 13 (06) 028–030.

[18] Sethi DS, Stanley RE, Pillay PK. (1995) Endoscopic anatomy of the sphenoid sinus and sella turcica. *J Laryngol Otol.* 109(10):951-5.

[19] Labadie RF, Davis BM, Fitzpatrick JM. (2005) Image-guided surgery: what is theaccuracy? *Curr Opin Otolaryngol Head Neck* Surg. 13(1):27-31.

[20] Martines F, Salvago P, Ferrara S, Messina G, Mucia M, Plescia F, Sireci F. (2015) Factors influencing the development of otitis media among Sicilian children affected by upper respiratory tract infections. *Braz J Otorhinolaryngol*. pii: S1808-8694(15)00091-9.

[21] Galletti C, Cammaroto G, Galletti F, Camps-Font O, Gay-Escoda C, Bara-Casaus JJ. Dental implants after the use of bichat's buccal fat pad for the sealing of oro-antral communications. A case report and literature review. *J Clin Exp Dent*. 2016;8(5):e645-e649.

In: Encyclopedia of Surgery (22 Volume Set)
Editors: Andreas Lehrer and Kristin Mueller
ISBN: 978-1-53618-329-0
© 2020 Nova Science Publishers, Inc.

Chapter 160

SURGICAL CORRIDORS IN THE TRANSPHENOIDAL SKULL BASE SURGERY

Federico Sireci[1,*], MD, Giulia Danè[2], MD, Francesco Martines[3], Francesco Dispenza[3], MD, Francesco Galletti[4], Giorgio Peretti[5], Matteo Vitali[6], MD and Frank Rikki Canevari[5]

[1]ENT Section, ARNAS Fatebenefratelli Hospital, Palermo, Italy
[2]Department of Otorhinolaryngology-Head and Neck Surgery, IRCCS San Raffaele Hospital, Vita-Salute University, Milan, Italy
[3]ENT Section, Bio.Ne.C. Department, University of Palermo, Palermo, Italy
[4]Department of Otorhinolaryngology, University of Messina, Italy
[5]Department of Otorhinolaryngology – Head and Neck Surgery, University of Genoa, Genoa, Italy
[6]Neurosurgery Section, SS Antonio Biagio e Cesare Arrigo Hospital, Alessandria, Italy

ABSTRACT

Sphenoid sinus is very close to important and vulnerable structures of the skull base and therefore a delayed diagnosis and treatment can be potentially lethal. Endoscopic sinus surgery is a safe and effective technique that allows a direct route to the sphenoid sinus and therefore is considered the gold standard for the surgical approach to this region. Over the years, the indications for transnasal approaches in skull base surgery have extended in order to obtain an adequate resection of the pathology as with other conventional approaches, with a minor morbidity and an equal efficiency.

Many classifications, divided in base of intracranial pathology or intracranial anatomical landmarks, have been proposed to define the transnasal corridors in base of the localization through the middle cranial base. In this chapter, we propose a review of classification of transsphenoidal skull base approaches and show the main transnasal

* Corresponding Author's Email: federicosireci@hotmail.it.

corridors to the sphenoid sinus based on the anatomical sphenoidal target and extension of pathology.

INTRODUCTION

Endoscopic surgery of the sphenoid sinus has been a great challenge in the past years for both otorhinolaryngologysts and neurosurgeons, because of the difficulty in performing surgical maneuvers in a deep space (sphenoid sinus) through narrow structures (nasal cavities).[1-3].

Otorhinolaryngologists have used the endoscopic techniques to replace the conventional "open" approaches since early '80s [4, 5]. Metson et al. reported in 1996 a direct approach to the sphenoid sinus thanks to the development of rigid nasal scopes and the evolution of the technologies [6, 28].

Jho et al. in the '90s proposed a pure endoscopic transnasal paraseptal approach for the treatment of pituitary adenomas [7]. In the early years of this experience, the corridor used was a direct transnasal approach from one or two nostrils [8-11].

The cooperation of multidisciplinary groups, the experiences in anatomical cadaveric endoscopic study and the improvement of technologies and endoscopic instrumentations have led to an extension of the surgical indications [12-17, 28-30].

In the last ten years, many classifications of transnasal corridors in skull base surgery have been proposed [18-23].

Extended sellar and parasellar endoscopic surgery needs a preoperative planning of the surgical corridor, and this planning should be based on the anatomical sphenoidal target.

In this chapter we propose a classification of the surgical corridors in the transsphenoidal skull base surgery, based on the anatomical subdivision of the sphenoid sinus into four regions

1. NASAL CORRIDORS

In transsphenoidal skull base surgery, a wide exposure of the sphenoidal landmarks is required to avoid surgical complications.

There are three main surgical corridors to this region:

- Direct transnasal (paraseptal);
- Transethmoidal;
- Transethmoido-pterygoidal.

To simplify the approaches, we divide the sphenoid sinus into four anatomical regions: sellar region, lateral parasellar region, suprasellar region and clival region.

1.1. Direct Transnasal (Paraseptal) Corridor

This approach to the sella allows a rapid access to the sphenoid sinus by using the natural way of access to the sphenoidal ostium. When advancing tangentially through the nasal cavity, the first anatomical landmark is the choanal border. Then, proceeding vertically medial to the middle turbinate, the second anatomical landmark to seek is the tail of the superior turbinate. Sphenoidal ostium is located superomedially and dorsally to the tail of the superior turbinate. After its identification, the natural sphenoidal ostium is opened inferomedially using circular forceps, microdebrider or nasal drill.

When the natural ostium has a lateral position and it is not clearly visible, the access to the sphenoidal cavity is obtained with a transrostral approach: in this case, the anterior sphenoidal wall is drilled directly medially an superiorly the tail of superior turbinate in order to avoid lesions of the choanal branch of the sphenopalatine artery, then the removal of anterior wall of sphenoid sinus proceed superolaterally to reach natural ostium.

1.2. Transethmoidal Corridor

In this approach, the sphenoidal ostium is reached through the dissection of the ethmoidal cells. The surgical procedure begins with uncinectomy, antrostomy and ethmoidal bulla removal. The second step is the opening of the posterior ethmoid, after the identification of the second portion of the middle turbinate (an essential anatomical landmark). The access to the posterior ethmoid sinus is obtained penetrating the second portion of the middle turbinate in a medial and inferior position with a j-courette and then enlarging with circular forceps. The third step is the identification of the superior turbinate, this structure represents the medial wall of the posterior ethmoid. The natural ostium of the sphenoid sinus is at this point identified and widened through the dissection of the inferior portion of the superior turbinate in a tangential direction.

1.3. Transethmoido-Pterygoidal Corridor

The key point of this approach is the identification and the cauterization of two vascular structures: the sphenopalatine artery and the vidian artery. After a wide transethmoidal procedure, the approach continues with a partial resection of the middle turbinate and a wide posterior antrostomy. The subperiosteal dissection between the tail of inferior and middle turbinates allows to reach the origin of the sphenopalatine artery which is coagulated and then resected. The ablation of the posterior wall of the maxillary sinus permits the exposure of the contents of the pterygopalatine fossa and the consequent detection of the vidian canal with his coagulation.

At this point, a drilling of the base of the pterygoid and of the lateral part of basisphenoid is performed, in order to obtain a direct exposition of the lateral wall of the sphenoid sinus.

2. SPHENOID REGIONS

2.1. Sellar Region

The sellar region is delimitated inferiorly by the sellar floor, superiorly by the superior intercavernous sinus and laterally by the cavernous sinus.

The paranasal direct corridor is the preferred approach to reach this region. A bilateral procedure is recommendable in order to obtain an adequate anatomical space to permit a 3- or 4-hands surgical technique and therefore an easier control of surgical complications, as intercavernous sinus bleeding.

The approach is usually extended anteriorly with the removal of 1 cm of the posterior part of the nasal septum and inferiorly, by a subperiostal dissection, to the sphenoidal floor with the exposure of the T made by the union of the sphenoidal floor with the septal rostrum.

The transethmoidal corridor is preferred when the anatomical variations of the ethmoid sinus decrease the anatomical spaces, or in case of a necessary extension of the approach to the medial part of the cavernous sinus.

A partial removal of the middle turbinate could be required to obtain a correct exposition of the sphenoidal floor.

2.2. Lateral Parasellar Region

The lateral parasellar region is delimitated medially by the medial part of the cavernous sinus, superiorly by the optic nerve, inferiorly by the vidian artery and laterally by the ethmoido-sphenoidal junction.

The surgical corridors to reach this region are the transethmoidal approach and the transethmoido-pterygoidal approach; this choice depends on the pneumatization of the sphenoidal sinus and of his pterygoidal recess.

In case of a non-pneumatized pterygoidal recess, a transethmoidal corridor permits an adequate view of the lateral parasellar region. Instead, in the presence of a pneumatization of the pterygoidal recess, a transethmoido-pterygoidal corridor is preferred, in order to have a direct view of the infero-lateral part of the sphenoidal wall.

In both corridors, a posterior antrostomy, a wide ethmoidectomy with the exposition of the lamina papyracea and a direct exposure of the optical apex is required. The corridors are completed with a controlateral direct paraseptal approach and a removal of 2cm of the posterior part of the nasal septum.

2.3. Suprasellar Region

The suprasellar region is delimitated inferiorly by the intercavernous sinus, laterally by the optic nerves and anteriorly by the ethmoido-planum junction.

In this region, a wide exposure is required in order to avoid complications in narrow anatomical spaces, in which many neuro-vascular structures are present.

The approach to this region requires a wide bilateral transethmoidal corridor with the removal of the middle turbinate and a direct exposition of the ethmoido-planum junction and of the orbital apex bilaterally.

Before the widening of the sphenoidal ostium, a septal flap is created (in accord with the Hadad procedure) in order to reconstruct the skull base defect.

2.4. Clival Region

The clival region is delimitated superiorly by the sellar floor, laterally by the carotid arteries, and inferiorly by the sphenoidal floor. The clival bone extends inferiorly in the rhinopharyngeal region.

The preferred corridor for the clival region is a bilateral direct paraseptal corridor, in this case a drilling of the sphenoidal floor between the two vidian artery (from the "T" to the clival region) is performed. A removal of 2 cm of the posterior part of the nasal septum (from the sphenoidal floor to the inferior choanal region) is required to adequately expose this region.

This corridor can be extended inferiorly with a rhinopharyngeal procedure, in order to expose the inferior clival region.

DISCUSSION

During last years, transnasal surgical approaches to the sphenoid sinus have been a great challenge for surgeons, because of the difficulty to adequately visualize a deep anatomical region and of the presence of important anatomical structures in contact with the sphenoidal walls [24, 25].

For many years, the most popular technique has been the sublabial transeptal approach, while other authors reported transethmoidal and transpalatal routes [26, 27].

The experience in endoscopic sinus surgery (ESS) and anatomical endoscopic studies have permitted to extend such approaches from a simple opening of the sphenoid sinus (i.e. during transnasal procedure for inflammatory disease) to the endoscopic surgery of sphenoid sinus for the removal of benign tumors [3-6, 28-32]. Then, the transsphenoidal approaches were proposed for skull base surgery.

Since Jho in early 1990 described his experience in endoscopic approach to the sellar region, transsphenoidal surgery had a fast development [7, 9, 10, 11, 13, 33, 34]. Growing experiences in endoscopic sinus surgery and the cooperation between Otorhinolarynglogysts and Neurosurgeons have led to an increasing interest in the transnasal endoscopic approaches to the middle skull base [9, 12, 15, 22, 23, 35].

Endoscopic skull base surgery started with mini-invasive targets, but nowadays is evolving, in order to obtain a good result with minimal access to permit an adequate resection, as with other conventional approaches [11, 14, 17, 19, 20, 36-38]. Evolving in skull base surgery required new closure strategies as multilayer closure and Hadad septal flap [16, 39-41].

In the last ten years, many classifications have been proposed, dividing the transnasal corridors according with the localization and of the extension of the pathology along the middle cranial base [11, 12, 18-22, 36-38]. However, there is a little consensus nowadays about the codification of the available approaches.

The best classification about surgical endoscopic transnasal corridors to the sphenoid sinus should consist of three types: trasnasal, transethmoidal and transethmoido-pterygoidal.

The difference in the extension and in the widening of the corridor depends on the anatomical sphenoidal target. For this reason, the sphenoid sinus can be divided in four anatomical regions.

REFERENCES

[1] Cheung, D. K., Martin, G. F., Rees, J. (1992) Surgical approaches to sphenoid sinus. *J. Otolaryngol*., 21: 1 - 8.

[2] Cakmak, O., Shohet, M. R., Kern, E. B. (2000) Isolated sphenoid sinus lesions. *Am. J. Rhinol*., 14:13 - 19.

[3] Castelnuovo, P., Pagella, F., Semino, L., De Bernardi, F., Delù, G. (2005) Endoscopic treatment of the isolated sphenoid lesions. *Eur. Arch. Otorhinolaryngol.,* 262: 142 - 147.

[4] Stammberger, H. (1986) Endoscopic endonasal surgery-concepts in treatment of recurring rhinosinusitis. Part II. Surgical technique. *Otolaryngol. Head Neck Surg.,* 94: 147 - 156.

[5] Wigand, M. E. (1981) Transnasal ethmoidectomy under endoscopic control. *Rhinology,* 19: 7 - 15.

[6] Metson, R., Gliklich, R. E. (1996) Endoscopic treatment of sphenoid sinusitis. *Otolaryngol. Head Neck Surg.,* 114: 736 - 744.

[7] Jho, H. D., Carrau, R. L., Ko, Y., Daly, M. A. (1997) Endoscopic pituitary surgery: an early experience. *Surg Neurol.,* 47(3):213 - 22; discussion 222 - 3.

[8] Bolger, W. E., Keyes, A. S., Lanza, D. C. (1999) Use of superior meatus and superior turbinate in the endoscopic approach to the sphenoid sinus. *Otolaryngol. Head Neck Surg*., 120: 308 - 31.

[9] Locatelli, D., Castelnuovo, P., Santi, L., Cerniglia, M., Maghnie, M., Infuso, L. (2000) Endoscopic approaches to the cranial base: perspectives and realities. *Childs Nerv. Syst.,* 16(10-11):686 - 91.

[10] Har-El, G., Swanson, R. M. (2001) The superiorturbinectomy approach to isolated sphenoid sinus disease and to sella turcica. *Am. Jour. Rhinol.,* 15: 149 - 156.

[11] Castelnuovo, P., Pistochini, A., Locatelli, D. (2006) Different surgical approaches to the sellar region: focusing on the "two nostrils four hands technique". *Rhinology,* 44(1):2 - 7.

[12] Cavallo, L. M., Messina, A., Cappabianca, P., Esposito, F., De Divitis, E., Gardner, P., Tschabitscher, M. (2005) Endoscopic endonasal surgery of the midline skull base:anatomical study and clinical considerations. *Neurosurg. Focus*, 15: 19(1):E2.

[13] Cappabianca, P., de Divitiis, E. (2004) Endoscopy and transsphenoidal surgery. *Neurosurgery,* 54(5):1043 - 48; discussions 1048 - 50. Review.

[14] Frank, G., Pasquini, E., Mazzatenta, D. (2001) Extended trasnsphenoidal apporach. *J. Neurosurg*., 95: 917 – 918.

[15] Frank, G., Pasquini, E. (2002) Endoscopic endonasal approaches to the cavernous sinus: surgical approaches. *Neurosurgery*, 50: 675 – 679.

[16] Locatelli, D., Vitali, M., Custodi, V. M., Scagnelli, P., Castelnuovo, P., Canevari, F. R. (2009) Endonasal approaches to sellar and para sellar regions: clousure techniques using biomaterials. *Acta Neurochir.*, 151: 1431 - 7.

[17] Locatelli, D., Canevari, F. R., Acchiardi, I., Castelnuovo, P. (2010) The endoscopic diving technique in pituitary and cranial base surgery: technical note. *Neurosurgery*, 66: E400-1.

[18] Schwartz, T. H., Fraser, J. F., Brown, S., Tabaee, A., Kacker, A., Anand, V. K. (2008) Endoscopic cranial base surgery: classification of operative approaches. *Neurosurgery*, 62(5):991 - 1002; discussion 1002 - 5.

[19] Kassam, A., Snyderman, C. H., Mintz, A., Gardner, P., Carrau, R. L. (2005) Expanded endonasal approach: the rostrocaudal axis. Part I. Crista galli to the sella turcica. *Neurosurg. Focus*, 19(1):E3. Review.

[20] Kassam, A., Snyderman, C. H., Mintz, A., Gardner, P., Carrau, R. L. (2005) Expanded endonasal approach: the rostrocaudal axis. Part II. Posterior clinoids to the foramen magnum. *Neurosurg. Focus*, 19(1):E4.

[21] Couldwell, W. T., Weiss, M. H., Rabb, C., Liu, J. K., Apfelbaum, R. I., Fukushima, T. (2004) Variations on the standard transsphenoidal approach to the sellar region, with emphasis on the extended approaches and parasellar approaches: surgical experience in 105 cases. *Neurosurgery*, 55(3):539-47; discussion 547 - 50.

[22] Stamm, A. M. (2006) Transnasal endoscopy-assisted skull base surgery. *Ann. Otol. Rhinol. Laryngol.*, Suppl. 196:45 - 53.

[23] Castelnuovo, P., Dallan, I., Battaglia, P., Bignami, M. (2010) Endoscopic endonasal skull base surgery: past, present and future. *Eur. Arch. Otorhinolaryngol*., 267(5):649 - 63. Epub 2010 Jan. 9.

[24] Rhoton, A. L. The sellar region. *Neurosurgery*, (2002) 51 suppl1: 335 - 374.

[25] Sethi, S. D., Stanley, R. E., Pillay, P. K. (1995) Endoscopic anatomy of the sphenoid sinus and sella turcica. *J. Laryngol. Otol*., 109: 951 - 955.

[26] Spencer, W. R., Levine, J. M., Couldwell, W. T., Brown-Wagner, M., Moscatello, A. (2000) Approaches to the sellar and parasellar region: a retrospective comparsion of the endonasal-transsphenoidal and sublabial-trassphenoidal approaches. *Otolaryngol. Head Neck Surg.*, 122: 367 - 369.

[27] Hardy, J. (1971) Transsphenoidal hypophysectomy. *J. Neurosurg.*, 34: 582 - 594.

[28] Setlif, R. (1993) The hummer. *Paper presented at the International Endoscopic Sinus Symposium*, Philadelphia, PA.

[29] Canevari, F. R., Giourgos, G., Pistochini, A. (2014) The endoscopic transnasal paraseptal approach to a sphenoid sinus osteoma: case report and literature review. *Ear Nose Throat J.*, 93(4-5):148.

[30] Vitali, M., Canevari, F. R., Cattalani, A., Grasso, V., Somma, T., Cavallo, L. M., Barbanera, A. (2017) High altitude exposure as possible predisposing factor for pituitary adenoma apoplexy: histologically confirmed case report. *J. Neurosurg. Sci.*, doi:10.23736/S0390-5616.17.03987-X.

[31] Castelnuovo, P., Gera, R., Di Giulio, G., Canevari, F. R., Benazzo, M., Emanuelli, E., Galli, J., Di Girolamo, S., Staffieri, A. (2000) Paranasal sinus mucose. *Acta Otorhinolaryngol. Ital*., 20: 6 - 15.

[32] Pagella, F., Giourgos, G., Matti, E., Canevari, F. R., Carena, P. (2011) Endoscopic treatment of maxillary inverted papilloma. *Rhinology*, 49: 369 - 374.

[33] Cappabianca, P., Cavallo, L. M., de Divitiis, O., Solari, D., Esposito, F., Colao, A. (2008) Endoscopic pituitary surgery. *Pituitary,* 11(4): 385 - 90. Review.

[34] De Divitiis, E. (2006) Endoscopic transsphenoidal surgery: stone-in-the-pond effect. *Neurosurgery,* 59(3):512 - 20; discussion 512 - 20.

[35] Maroon, J. C. (2005) Skull base surgery: past, present, and future trends. *Neurosurg. Focus*, 15; 19(1):E1.

[36] Cavallo, L. M., de Divitiis, O., Aydin, S., Messina, A., Esposito, F., Iaconetta, G., Talat, K., Cappabianca, P., Tschabitscher, M. (2007) Extended endoscopic endonasal transsphenoidal approach to the suprasellar area: anatomic considerations--part 1. *Neurosurgery,* 61(3 Suppl):24 - 33; discussion 33 - 4.

[37] Wang, Q., Lan, Q., Lu, X. J. (2010) Extended endoscopic endonasal transsphenoidal approach to the suprasellar region: anatomic study and clinical considerations. *J. Clin. Neurosci*., 17(3):342 - 6. Epub 2010 Jan. 13.

[38] Cappabianca, P., Cavallo, L. M., Esposito, F., De Divitiis, O., Messina, A., De Divitiis, E. (2008) Extended endoscopic endonasal approach to the midline skull base: the evolving role of transsphenoidal surgery. *Adv. Tech. Stand. Neurosurg*., 33:151 - 99.

[39] Seda, L., Camara, R. B., Cukiert, A., Burattini, J. A., Mariani, P. P. (2006) Sellar floor reconstruction after transsphenoidal surgery using fibrin glue without grafting or implants> technical note. *Surg. Neurol.,* 66: 46 - 49.

[40] Hadad, G. Bassagasteguy, L., Carrau, R. L., Mataza, J. C., Kassam, A., Snyderman, C. H., Mintz, A. (2006) A novel reconstructive technique after endoscopic expanded andonasal approaches: vascular pedicle nasoseptal flap. *Laryngoscope,* 116: 1882 - 1886.

[41] Castelnuovo, P., Delù, G., Locatelli, D., Padoan, G., De Bernardi, F., Pistocchini, A., Bignami, M. (2006) Endonasal endoscopic duraplasty: our experience. *Skull Base*, 16: 19 - 24.

[42] Sireci, F., Speciale, R., Sorrentino, R., Turri-Zanoni, M., Nicolotti, M., Canevari, F. R. (2017) Nasal packing in sphenopalatine artery bleeding: therapeutic or harmful? *Eur. Arch. Otorhinolaryngol.,* 274(3):1501-1505. doi: 10.1007/s00405-016-4381-y.

In: Encyclopedia of Surgery (22 Volume Set)
Editors: Andreas Lehrer and Kristin Mueller
ISBN: 978-1-53618-329-0
© 2020 Nova Science Publishers, Inc.

Chapter 161

THE ROLE OF ENDOSCOPIC SINUS SURGERY IN PEDIATRIC PATIENTS WITH CYSTIC FIBROSIS

Marco Berlucchi[1,*], Vittorio Rampinelli[2], Marco Ferrari[2], Piercarlo Poli[3], Luigi Fomasi[3], Silviana Timpano[3] and Rita Padoan[3]

[1]Department of Pediatric Otorhinolaryngology, Spedali Civili di Brescia, Brescia, Italy
[2]Department of Otorhinolaryngology, University of Brescia, Brescia, Italy
[3]Unit of Cystic Fibrosis, Department of Pediatric, University of Brescia, Brescia, Italy

ABSTRACT

Cystic fibrosis (CF) is the most common life threatening autosomal recessive disorder affecting Caucasians. Molecular genetic mutations in the CF transmembrane conductance regulator (CFTR) gene alter function of CFTR protein, which leads to dysfunction in chloride channel on epithelial surface of exocrine glands. In the head and neck area, the pathology involves mostly paranasal sinuses starting from childhood. Chronic and recurrent rhinosinusitis with or without nasal polyposis and mucocele of sinuses are the main disorders observed in CF patients. About 20-25% of these patients will require sinus surgery. Regarding surgical treatment, endoscopic sinus surgery (ESS) for management of paranasal sinus diseases in CF patients is undoubtedly a challenge for the surgeon. Moreover, evidence-based guidelines regarding the precise indications for surgery are currently lacking. Even if ESS is undeniably needed for management of sinonasal complications and can improve CF-related nasal symptoms, its role with regards to timing of surgery and consequent improvement of pulmonary function is not well described. Moreover, underlying medical issues such as acquired coagulopathies and advanced pulmonary disease, raise perioperative morbidity in these patients, with consequent and prolonged hospitalization. Indeed, the surgeon is often faced with distorted anatomy, due to anomalous development of nasal and paranasal structures or multiple revision operations. Therefore, multidisciplinary management of paranasal sinus disease in patients affected by CF is pivotal to achieve the correct surgical indication, prepare the patient for surgery, and address possible perioperative complications. The

* Corresponding Author's Email: marco.berlucchi@tin.it.

authors describe the indications of ESS in CF patients, analyzing personal experience in the diagnosis and treatment of CF-related sinus disorders. Finally, data on follow-up after ESS, pulmonary function, and nutritional status will be presented.

INTRODUCTION

Cystic fibrosis (CF) is the most common life-threatening autosomal recessive genetic disease in the Caucasian population, and it is estimated that over 100,000 worldwide are affected. Thanks to advances in CF therapies, overall survival has increased. At present, more than 50% of those affected reach adulthood in USA, Europe, and Australia [1, 2].

CF is a multiorgan disease, with morbidity and mortality determined in the great majority of cases by progressive respiratory failure. As for the lower airways, at the basis of sinonasal manifestations there is a functional defect in the cystic fibrosis transmembrane conductance regulator (CFTR) gene, located on the long arm of chromosome 7. This gene encodes for a protein expressed on the epithelium of the airways where it works as a channel for chloride and bicarbonate and a regulator of other ion transport channels. The imbalance between ion transport channels (low Cl^- secretion, Na^+ hyper-reabsorption, reduced pH of airway surface liquid due to defective HCO_3^- secretion) lead to airway surface dehydration, causing thick and viscous secretions, chronic infections, and inflammation.

Generally, the clinician and the multidisciplinary team that deals with the treatment of the patient focus on lung disease, which, due to its characteristics, is the most fearsome manifestation. For this reason, the sinonasal manifestations of the disease are often underdiagnosed and not adequately treated. The patient himself, when the symptoms of the manifestation appear, may not give them an adequate relevance or do not have a wellness status as a comparison in case of an event that has always been present, and does not report symptoms to the clinician.

To date, the relationship between sinonasal manifestations and pulmonary disease has not been fully elucidated and there are several interesting theories that correlate aggravation of sinonasal status with a worsening of lung function, even after lung transplantation. However, it is certain that sinonasal symptomatology worsens the patient's quality of life, and therefore manifestations of the upper airways must be sought by the clinician through correct medical history, also considering the underestimations referred by the patient.

To date, considerable progress has been made in medical and surgical treatment of ENT pathologies in CF, and it is now possible to successfully treat such manifestations and improve the patient’s quality of life.

In CF patients, a clinical picture of chronic/recurrent rhinosinusitis is generally observed and may be associated or not with nasal polyps. Moreover, a mucocele of sinus can develop in some patients. Another characteristic of sinonasal involvement is hypoplasia/aplasia of some paranasal sinuses that is usually found at imaging.

PHYSIOPATHOLOGY

In the sinonasal epithelium there are two layers of liquid with different densities. A first fluid delineates and wets the eyelashes and is low in density, while the second is represented

by a layer of high-density, superficial mucus that has the function of trapping inhaled particles and transporting them through coordinated ciliary beat in the digestive tract [3]. This mechanism is called mucociliary clearance and is obviously an innate defense mechanism, guarding the upper (and inferior) airways.

The mechanisms of mucociliary clearance in the patient with CF are dysfunctional; due to altered anionic transport of mutated CFTR, there is a noticeable change in the viscoelastic properties of mucus, with increase in viscosity from 30 to 60 times above normal: the dense secretions obstruct the sinus ostia and create a state of hypoxia with edema and secondary ciliary dyskinesia; obviously this scenario facilitates bacterial colonization.

Bacteria release many substances that reduce the frequency of ciliary beats and help to create a chronic inflammatory state, promoting hyperplasia of mucus producing cells, along with squamous metaplasia and loss of cilia. Macroscopically, all these effects lead to stasis of infected mucus, inflammation, and alteration of gas exchange. The increase in $PaCO_2$ that is established also promotes edema and decreases mucus ciliary clearance [4].

In this complex pathogenic picture, anatomical anomalies, nasal polyposis, and mucoceles can be found.

ALTERATION OF THE ANATOMY OF THE PARANASAL SINUSES

In recent years, the use of CT has been widely used pre-operatively to evaluate the anatomy of the sinonasal tract of patients with CF.

An often-observed feature is the lack of development or hypoplasia of the frontal and sphenoid sinuses. These sinuses develop mainly in the post-natal period and the pathogenic mechanisms underlying CF somehow hinder their normal development [5]. The same mechanisms are also be responsible for reduced postnatal growth of the sinuses present at birth (maxillary and ethmoid).

It is hypothesized that chronic inflammatory status and reduced ventilation that reduce pneumatization are at the basis of this alteration. This hypothesis is supported by the fact that in the course of chronic otitis media there is no pneumatization of the mastoid.

Another possible finding is demineralization of bone walls, and in particular the medial wall of the maxillary sinus (which can also be medialized). It is also important to underline that a bone demineralization framework with medialization of the medial wall of the maxillary sinus is strongly suggestive for mucocele.

NASAL POLYPOSIS

CF patients have a high incidence of nasal polyposis associated with chronic rhinosinusitis, which is present in up to 48% of patients [6]. On the contrary, in the child without CF nasal polyposis is an extremely rare phenomenon, and in fact the finding of nasal polyposis in the pediatric age must make the clinician evoke possible previously undiagnosed CF.

Nasal polyps in non-CF patients are benign proliferations of mucosal cells, characterized histologically by edema, hyperplasia of mucus producing cells of the epithelium, thickening

of the basal membrane, and the presence of numerous leucocytes, especially eosinophils (eosinophil-mediated inflammation).

CF related polyps have characteristics in common with those in the general population: focal edema, hyperplasia, atrophy or metaplasia of the epithelium, lamina propria which presents small vessels, and focal accumulations of inflammatory cells. Specific features of CF-related polyps are: thin basal membrane, lack of eosinophils, presence of neutrophil-mediated inflammation, acid mucin in the glands, continuous and fenestrated capillaries, and the presence of morphologically atypical plasma cells [7].

The physio-pathogenetic mechanisms underlying the formation of nasal polyps in CF remain unclear to date, as well as those of the healthy population. It is also not clear why some patients with polyposis have symptoms, while others remain asymptomatic.

MUCOCELE

Mucocele is a secreting mucus cyst, delineated by epithelium, which can localize and grow within a paranasal sinus with a concentric expansion [8]. It is a benign disorder, but with the accumulation of secretions it increases in size until the surrounding bone structures are moved and eroded. Thus, ocular and intracranial complications can arise. They can become infected, and in this case are referred to as mucopioceles.

Mucocele is believed to be formed due to obstruction of the sinus ostium. In the non-CF population it is typically a sinonasal adult disease, with onset generally in the third and fourth decades. The most frequently affected sinuses are the frontal and the ethmoid, and less frequently the sphenoid and maxillary [9]. It is a rare sinonasal disease in childhood, and in most cases is associated with CF. The mucocele is indeed part of the sinonasal complications typical of the disease [10], with a prevalence of up to 16% of patients with upper-airway disorders [11]. Some authors also suggest also that when the mucocele(s) is diagnosed in the first months of life, its formation had likely begun during intrauterine life [8].

The detection of mucocele in a child without a diagnosis of CF requires diagnostic investigation and a sweat test.

MICROBIOLOGY

The bacteria typically isolated from nasal material cultures of the patient with CF are *Pseudomonas aeruginosa, Staphylococcus aureus, Escherichia coli, Burkholderia cepacia, Acinetobacter spp, Stenotrophomonas maltophilia, Haemophilus influenzae, Streptococci,* and anaerobia.

The frequency of colonization of the lower airways by *Pseudomonas* in patients with chronic rhinosinusitis and polyposis is high; such colonization starts from the upper airways and then descends into the lower airways [12].

The association between cultures of the upper and the lower airways is verified, and has also demonstrated from a genotypical point of view: it is therefore correct to think that the paranasal sinuses can act as a reservoir for recurrent pulmonary infections in the disease [13]. It is therefore particularly important to improve the health of the sinuses as much as possible.

Hence the importance of considering and actively searching for the presence of sinonasal symptoms during patient interview. Moreover, for these reasons sinonasal surgery is indicated in preparation for lung transplantation.

CLINICAL MANIFESTATIONS

Symptomatology is due to chronic/recurrent rhinosinusitis associated with or not nasal polyposis. Patients can complain of nasal obstruction, anterior and posterior rhinorrhea, hyposmia/anosmia, headache, facial pain, and fever. Moreover, day and night oral respiration, snoring, decreased sleep quality, halitosis, changes in voice, and otalgia are other signs and symptoms that can be found.

When a mucocele is present, ocular signs and symptoms such as proptosis, epiphora, visual disturbances, and alterations of ocular motility may be observed. Mucocele can have a presentation without classical symptomatology and only with atypical manifestations. It is therefore essential not only to keep in mind the possibility of mucocele, but to seek it actively, especially in unclear and atypical situations.

DIAGNOSIS

If sinonasal manifestations are evident on history, the patient must be undergone careful ENT assessment, and, in particular, rhinoscopy under local anesthesia must be performed. At nasal endoscopy, it is possible to identify sinonasal anatomic anomalies (i.e., nasal septum deviation, concha bullosa, hypertrophy of the inferior turbinate), pathological nasal secretions, nasal polyps (Figure 1), and bulging of the medial wall of the maxillary sinus (Figure 2) and/or anterior wall of sphenoid suspicious for mucocele.

Figure 1. Nasal polyps (asterisks) associated with dense secretions completely obstructing the right nasal fossa.

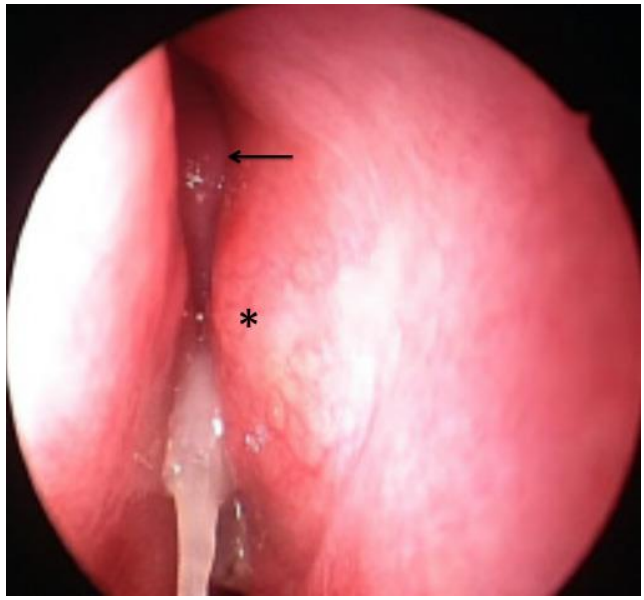

Figure 2. Bulging of the medial wall of the left maxillary sinus (asterisk). The left middle turbinate is still visible (arrow).

The next diagnostic step is represented by imaging such as CT or MR of the paranasal sinuses. These radiologic studies allow overall assessment of the patient's sinonasal anatomy, identifying the sinonasal pathology and its extension.

Usually, mucocele appears as a complete opacification of a single sinus. As the mucocele expands, it remodels the local anatomy by slowly compressing surrounding structures, with consequent resorption of the neighboring bony walls (Figure 3).

Imaging (CT and/or MR) is needed to confirm diagnosis and identify bony changes and intraorbital (Figure 4) or intracranial extension of the expansive fluid-collection(s).

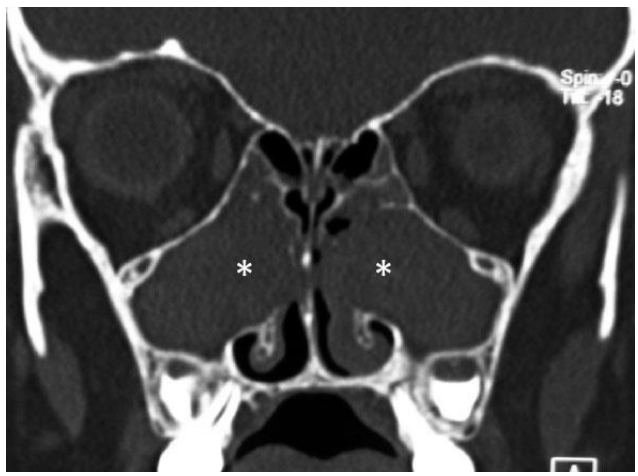

Figure 3. At coronal CT scan, a bilateral mucocele (white asterisks) of the maxillary sinus associated with erosion of its medial wall is found.

Figure 4. At axial CT scan, a left ethmoidal mucocele (white asterisk) is observed. Moreover, erosion of the lamina papyracea (white arrows) associated with displacement of the left medial rectus muscle is evident.

Cases of bilateral maxillary mucoceles have been described, with CT showing a typical figure called "hourglass image," which is formed by bilateral mucoceles occluding nasal cavities [8].

In the literature, however, it is believed that the findings that can be visualized by imaging cannot be considered to be a reliable measure for outcomes after medical or surgical intervention. Some authors analyzed CT scans performed in patients with CF before and after surgery, graduating them with the Lund-Mackay (LM) score, and found that despite medical or surgical treatment there was no significant difference in the LM score of scans before and after intervention. Although CT is an important diagnostic step, performing multiple scans to monitor the disease is not useful and does not correlate with exacerbations of the disease or medical or surgical treatment. The study states that LM is a useful method of CT analysis, but does not provide adequate stratification for analysis of changes in opacification of the sinuses over time, especially in the case of partial opacification [14].

Although this study has not highlighted changes in CT, it underlines however that following intervention, improvements of symptomatology have been noted in the literature and hypothesizes that the benefit of surgery can be demonstrated by other parameters that analyze the quality of life [5, 15-16].

TREATMENT

In the last few decades, life expectancy of individuals suffering from cystic fibrosis (CF) has significantly improved, resulting in new medical perspectives for these patients. Life-saving treatments, indeed, have been progressively associated with interventions aimed to improve quality of life [17].

Since the sinonasal tract is involved in the majority of CF patients, otolaryngologists have a significant role in the multi-disciplinary management of these patients [17].

Management of chronic rhinosinusitis (CRS) in CF is challenging and is based on the combination of both medical and surgical therapy [18]. Appropriate medical therapy typically includes oral and/or intravenous antibiotics, topical and/or systemic steroids, and saline

irrigations [19-20]. In the literature, surgery is indicated when CRS does not respond to conservative maximal medical therapy and is performed in 20–60% of patients with CF [21-23]. This variable frequency of surgically treated patients mirrors the absence of consensus on indications and timing for surgery. In fact, no universally accepted guidelines for the surgical management of CRS in CF-patients are available.

Despite the large number of studies on this topic published during the last decade, the majority of these combined data from both adults and children, thus precluding firm conclusions on these exceedingly different groups of patients. Furthermore, only a few studies reached a good level of evidence [19-20].

The decision to indicate surgery is typically based on a combination of factors: clinical and/or radiological evidence of sinonasal disease (i.e., massive obstructive polyposis, diplopia, mucocele), patient-reported symptoms, sinusitis-related detriment of quality of life, overall health and nutrition status, occurrence of faltering growth, pulmonary conditions including recent pneumonia exacerbations and lung function parameters, patient personality, and patient-physician relationship [24, 25]. In the literature, there is conflicting evidence whether genotype correlates with severity of sinonasal disease and need for surgery. Some studies have demonstrated a relationship between homozygous F508 mutations and the degree of sinusitis, presence of polyps, and need for surgery [26-27]. Other studies, however, failed in showing an association between the homozygous F508 genotype and need for sinus surgery [17, 28].

CT and MRI definitely help in selecting patients who need surgery, depicting two clinical-radiological scenarios: 1) the most typical finding requiring surgery is the complete opacification of the nasal cavities due to massive polyposis and dense nasal secretions, with possible decalcification of the bony boundaries (i.e., ethmoidal roof, lamina papyracea); 2) other patients present with mucocele(s).

To date, 153 patients affected by CF are regularly followed at Unit of Cystic Fibrosis, Department of Pediatric, University of Brescia – Italy. Between December 2003 and May 2017, based on the aforementioned concepts, 43 (28%) of these patients underwent surgical treatment at Department of Pediatric Otorhinolaryngology, Spedali Civili di Brescia, Brescia - Italy. Thirty-seven and six children were operated for mucocele of paranasal sinus and CRS associated with massive nasal polyposis, respectively.

Surgical Notes

Historically, surgery consisted of open approaches to the sinuses (i.e., Caldwell-Luc procedure). Currently, endoscopic sinus surgery (ESS) is considered the mainstay of treatment of refractory inflammatory disease of the paranasal sinuses in CF patients. All our patients underwent such surgical conservative procedure. The key concept of ESS is widening the sinus ostia and removing obstructive nasal polyps to improve mucous drainage, provide proper ventilation of air spaces, and guarantee adequate penetration of topical medications (Figure 5).

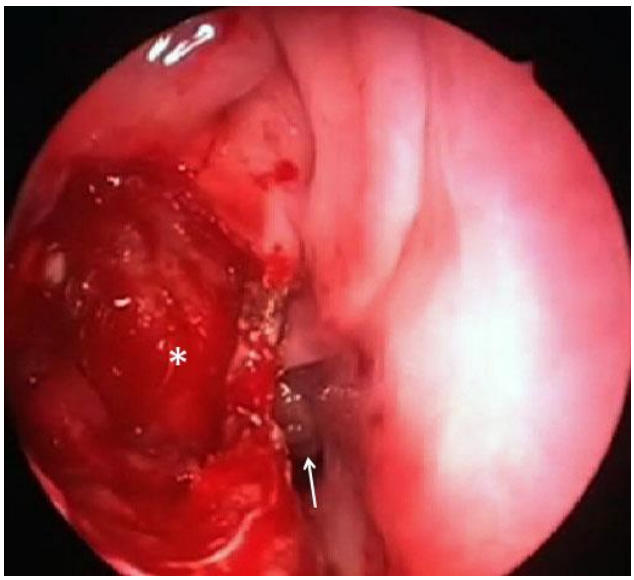

Figure 5. A right wide middle antrostomy (white asterisk) is observed at endoscopic view. Mild adenoidal hypertophy (white arrow) is present.

A number of general perils of ESS are emphasized when operating CF patients. The development of the paranasal sinuses can be incomplete, thus resulting in distorted and misleading anatomical configurations that can favor disorientation of the surgeon and subsequent complications. Continuous infections and multiple operations can subvert the sinonasal anatomy, further hindering the anatomical orientation during surgery. Thinning of the bony boundaries, typically involving the lamina papyracea and skull base, can facilitate the inadvertent injury of orbital and intracranial structures. Moreover, the bony lamellae of the nasoethmoidal complex are frequently resorbed, leading to the lack of anatomical landmarks that usually guide the surgeon during dissection. Furthermore, the active inflammatory process results in massive, dense secretions and increased bleeding. All the above-mentioned factors make ESS challenging and augment the risk of surgical complications, such as orbital injury and iatrogenic cerebrospinal fluid leak.

As an additional remark, underlying systemic alterations, such as acquired coagulopathies and advanced pulmonary disease, further raise the perioperative morbidity and lengthen hospitalization. Therefore, multidisciplinary management is of utmost importance not only to ensure the correct indications for surgery, but also to provide adequate preoperative preparation and minimize the possibility of perioperative complications. In particular, preoperative medical treatment with antibiotics and steroids associated with chest physiotherapy is mandatory to improve pulmonary function and nasal status. The surgical technique should also be customized in accordance with the physiopathology of CF: narrow and “minimalist” sinusotomies should be avoided in favor of wide and regular communications between sinuses and the nasal cavity; on the other hand, unnecessary mucosal stripping is strongly discouraged to minimize bone exposure and subsequent granulation. In line with this concept, a systematic review by Crockett et al. concluded that large maxillary antrostomies or modified medial maxillectomies provide significant improvement of the quality of life and sinus symptom scores, shorten hospitalization, and

reduce the need for antibiotics [29]. By virtue of the chronic nature of CF and the necessity to recurrently manage symptoms, less invasive procedures, such as simple polypectomy, have also been proposed. However, early recurrence of nasal polyps is more likely in patients undergoing polypectomy alone than in those undergoing polypectomy associated with functional sinus surgery (ethmoidectomy and antrostomy) [30]. Balloon catheter sinuplasty has recently been introduced for the treatment of CRS in pediatric patients. It is safe and effective and has the advantage of not requiring tissue removal, thus sparing most of the sinonasal mucosal lining [31]. Consequently, although no studies on the efficacy of balloon catheter sinuplasty in patients with CF are currently available, the procedure should be considered as a promising alternative to standard ESS.

As an additional refinement, when dealing with complex, recurrent cases, a neuronavigation system may be helpful to maintain anatomical orientation and avoid dreadful complications.

Outcomes

In view of the abovementioned criticisms, ESS can be considered as a safe procedure in patients with CF when performed by expert surgeons [32].

Patients who mainly benefit from surgery are those developing CRF due to both CF and anatomic variants compromising the spontaneous ventilation of sinuses, resulting in nasal edema/polyposis and drainage obstruction.

A recent review by Liang et al. reported that sinonasal symptoms (nasal obstruction, rhinorrhea, headaches, facial pain, and olfaction impairment), which were evaluated with validated questionnaires and/or subjective reports, invariably improve following sinus surgery [19]. Accordingly, improvement of CF-related CRS signs (polyposis, edema, mucopurulence, crusting, and/or scarring) was demonstrated in more than 50% of the included studies [19]. For instance, Virgin et al. reported significant improvement of both SNOT-22 and Lund-Kennedy score at one year after surgery [18]. Shatz et al. found a significant reduction of prescriptions for intravenous antibiotics for pneumonia after ESS [33]. However, this finding was not confirmed by other authors [34]. In fact, there is conflicting evidence whether ESS significantly modifies pulmonary outcomes in CF patients [19]. Kempainen and colleagues found no difference in number of days spent in hospital pre- and post-operatively [34]. Interestingly, patients who show the greatest sinonasal-related benefit from surgery are those with higher baseline pulmonary function: CF patients with a baseline %FEV1 above >70% predicted exhibited greater improvements in sinus symptoms after surgery than those undergoing medically alone [17].

Although several studies have recommended ESS in patients undergoing lung transplantation [33], this practice has largely lost popularity. Leung et al. demonstrated that lung allograft re-colonization occurs regardless of prior sinus surgery, concluding that prophylactic ESS is not beneficial [35].

Stringent and multidisciplinary follow-up is of paramount relevance to ensure adequate postoperative medical therapy and, ultimately, optimize surgical outcomes: ESS followed by intensive post-operative medical therapy (2 weeks of antibiotics, 6 months of nasal irrigations, and 12 months of topical nasal steroids) resulted in eradication of pathogenic sinonasal bacteria for up to 1 year [22].

It is important to highlight and counsel the patient's family that ESS does not provide a definitive cure for CF-related CRS: being a genetic, systemic disease, CF prevents normalization of sinonasal mucosa, though adequately managed.

Therefore, patients and their family should be made aware about the need to undergo multiple ESS procedures throughout their life; in fact, the revision rate for CF-related CRS ranges between 20% and 100% after a period of 2–4 years from primary surgery; this rate increases parallel to the severity of polyposis at primary presentation [36]. Intuitively, recurrence is particularly common when surgical intervention is incomplete and/or when adjunct treatment with antibiotics is inadequate.

Regarding our cohort of study, a recurrence of disease was observed in 6/6 (100%) patients who were operated for CRS associated with nasal polyposis, whereas no recurrence was found in 37 children operated for paranasal mucocele with a mean follow-up of 52 months after surgery. Finally, data about pulmonary function and nutritional status did not change after surgery (Table 1).

Table 1. Pulmonary function and nutritional status evaluated before and after ESS

	Before surgery (1 month)	After surgery (1 month)	p-value
FEV_1 % predicted value	97,2	97,9	0,7
BMI (z-score)	-0,22	-0,27	0,19

ESS: endoscopic sinus surgery.

CONCLUSION

CF is a multisystem disease, frequently involving the sinonasal tract and manifesting with recurrent CRS with or not nasal polyposis and the tendency to develop paranasal mucoceles.

Evidence-based guidelines on the surgical management of CF-related CRS are lacking. Some evidence suggests that ESS could improve nasal symptoms and is strongly recommended to manage sinonasal complications. On the other hand, the timing of surgery and its role in improvement of pulmonary function remain a controversial issue.

When it occurs, mucocele of paranasal sinus is an absolute surgical indication and ESS is considered the surgical approach of choice.

However, ESS for CF-patients is challenging because of technical complexity and unfavorable underlying medical conditions that complicate perioperative medical management.

Consequently, a multidisciplinary approach to CF patients is the pivotal strategy to ensure the adequacy of surgical indication, optimize the general status of the patient, and manage possible perioperative complications.

REFERENCES

[1] Cystic Fibrosis Foundation. Cystic Fibrosis Foundation Patient Registry Annual Data Report. Cyst. Fibros. Found. Patient Regist (2017). *Annu. Data Report.* Bethesda 1–15.

[2] Ahern, S., Sims, G., Esler, M., Oldroyd, J., Dean, J., Bell, S. (2016). *The Australian Cystic Fibrosis Data Registry Annual Report*. Monash Univ. 1–52.

[3] Chaaban, M.R., Kejner, A., Rowe, S.M., Woodworth, B.A. (2013). Cystic fibrosis chronic rhinosinusitis: a comprehensive review. *Am J Rhinol Allergy,* 27(5):387-95.

[4] Kang, S.H., Dalcin Pde, T., Piltcher, O.B., Migliavacca Rde, O. (2015). Chronic rhinosinusitis and nasal polyposis in cystic fibrosis: update on diagnosis and treatment. *J Bras Pneumol,* 41(1):65-76.

[5] Gysin, C., Alothman, G.A., Papsin, B.C. (2000). Sinonasal disease in cystic fibrosis: clinical characteristics, diagnosis, and management. *Pediatr Pulmonol,* 30(6):481-9.

[6] Robertson, J.M., Friedman, E.M., Rubin, B.K. (2008). Nasal and sinus disease in cystic fibrosis. *Paediatr Respir Rev,* 9(3):213-9.

[7] Beju, D., Meek, W.D., Kramer, J.C. (2004). The ultrastructure of the nasal polyps in patients with and without cystic fibrosis. *J Submicrosc Cytol Pathol,* 36(2):155-65.

[8] Di Cicco, M., Costantini, D., Padoan, R., Colombo, C. (2005). Paranasal mucoceles in children with cystic fibrosis. *Int J Pediatr Otorhinolaryngol,* 69(10):1407-13.

[9] Capra, G.G., Carbone, P.N., Mullin, D.P. (2012). Paranasal sinus mucocele. *Head Neck Pathol,* 6(3):369-72.

[10] Nicollas, R., Facon, F., Sudre-levillain, I., Forman, C., Roman, S., Triglia, J.M. (2006) Pediatric paranasal sinus mucoceles: etiologic factors, management and outcome. *Int J Pediatr Otorhinolaryngol,* 70(5):905-8.

[11] Horesh, E., Colin, A.A., Casiano, R., Wester, S.T. (2015). An atypical presentation of sinus mucopyocele in a pediatric cystic fibrosis patient. *Clin Ophthalmol,* 9:821-4.

[12] Roby, B.B., Mcnamara, J., Finkelstein, M., Sidman, J. (2008). Sinus surgery in cystic fibrosis patients: comparison of sinus and lower airway cultures. *Int J Pediatr Otorhinolaryngol,* 72(9):1365-9.

[13] Mainz, J.G., Koitschev, A. (2009). Management of chronic rhinosinusitis in CF. *J Cyst Fibros*, 8 Suppl 1:S10-4.

[14] Mcmurphy, A.B., Morriss, C., Roberts, D.B., Friedman, E,M. (2007). The usefulness of computed tomography scans in cystic fibrosis patients with chronic sinusitis. *Am J Rhinol,* 21(6):706-10.

[15] Nishioka, G.J., Cook, P.R. (1996). Paranasal sinus disease in patients with cystic fibrosis. *Otolaryngol Clin North Am,* 29(1):193-205.

[16] Yung, M.W., Gould, J., Upton, G.J. (2002). Nasal polyposis in children with cystic fibrosis: a long-term follow-up study. *Ann Otol Rhinol Laryngol,* 111(12 Pt 1):1081-6.

[17] Ayoub, N., Thamboo, A., Habib, A.R., Nayak, J.V., Hwang, P.H. (2017). Determinants and outcomes of upfront surgery versus medical therapy for chronic rhinosinusitis in cystic fibrosis. *Int Forum Allergy Rhinol,* 7(5):450-458.

[18] Virgin, F.W., Rowe, S.M., Wade, M.B., et al. (2012). Extensive surgical and comprehensive postoperative medical management for cystic fibrosis chronic rhinosinusitis. *Am J Rhinol Allergy,* 26(1):70–75.

[19] Liang, J., Higgins, T.S., Ishman, S.L., et al. (2013). Surgical management of chronic rhinosinusitis in cystic fibrosis: a systematic review. *Int Forum Allergy Rhinol*, 3:814–822.

[20] Liang, J., Higgins, T., Ishman, S.L., et al. (2014) Medical management of chronic rhinosinusitis in cystic fibrosis: a systematic review. *Laryngoscope,* 124:1308– 1313.

[21] Mainz, JG., Schien, M., Naehrlich, L., Kading, M., Thoss, K., Frey, G., et al. (2010). Prevalence of CF- related chronic rhinosinusitis--results from a multicentre interdisciplinary study. *J Cyst Fibros, 33rd European Cystic Fibrosis Conference* p. 118 120.

[22] Aanaes, K., Rasmussen, N., Pressler, T., et al. (2012). Extensive endoscopic image-guided sinus surgery decreases BPI-ANCA in patients with cystic fibrosis. *Scand J Immunol,* 76(6):573–579.

[23] Ramsey, B., Richardson M.A. (1992). Impact of sinusitis in cystic fibrosis. *The Journal of allergy and clinical immunology,* 90(3 Pt 2):547–552.

[24] Soler, Z.M., Rudmik, L., Hwang, P.H, et al. (2013). Patient- centered decision making in the treatment of chronic rhinosinusitis. *Laryngoscope*, 123:2341–2346.

[25] Rudmik, L., Soler, Z.M., Mace, J.C., et al. (2015). Using pre- operative SNOT-22 score to inform patient decision for endoscopic sinus surgery. *Laryngoscope*, 125–1522:1517.

[26] Jorissen, M.B., De Boeck, K., Cuppens, H. (1999). Genotype-phenotype correlations for the paranasal sinuses in cystic fibrosis. *Am J Respir Crit Care Med*, 159:1412–1416.

[27] Berkhout, M.C., van Rooden, C.J., Rijintjes, E., et al. (2014). Sinonasal manifestations of cystic fibrosis: a correla- tion between genotype and phenotype? *J Cyst Fibros*, 13:442–448. 23.

[28] Do, B.A., Lands, L.C., Saint-Martin, C., et al. (2014). Effect of the F508del genotype on outcomes of endoscopic sinus surgery in children with cystic fibrosis. *Int J Pediatr Otorhinolaryngol*, 78:1133–1137.

[29] Crockett, D.J., Wilson, K.F., Meier, J.D. (2013). Perioperative strategies to improve sinus surgery outcomes in patients with cystic fibrosis: a systematic review. *Otolaryngol Head Neck Surg,* 149(1):30-9.

[30] Crockett, D.M., McGill, T.J., Healy, G.B., Friedman, E.M., Salkeld, L.J. (1987). Nasal and paranasal sinus surgery in children with cystic fibrosis. *Ann Otol Rhinol Laryngol*, 96(4):367- 72.

[31] Sedaghat, A.R., Cunningham, M.J. (2011). Does balloon catheter sinuplasty have a role in the surgical management of pediatric sinus disease? *Laryngoscope*, 121(10):2053-4.

[32] Macdonald, K.I., Gipsman, A., Magit, A., Fandino, M., Massoud, E., Witterick, I.J., et al. (2012). Endoscopic sinus surgery in patients with cystic fibrosis: a systematic review and meta-analysis of pulmonary function. *Rhinology*, 50(4):360-9.

[33] Shatz, A. (2006). Management of recurrent sinus disease in children with cystic fibrosis: a com- bined approach. *Otolaryngol Head Neck Surg*, 135: 248-252.

[34] Kempainen, R.R., Sajan, J.A., Pylkas, A.M., et al. (2012). Effect of endoscopic sinus surgery on pulmonary status of adults with cystic fibrosis. *Otolaryngol Head Neck Surg*, 147(3):557-62.

[35] Leung, M.K., Rachakonda, L., Weill, D., Hwang, P.H. (2008). Ef- fects of sinus surgery on lung transplantation out- comes in cystic fibrosis. *Am J Rhinol*, 22:192– 196.

[36] Rickert, S., Banuchi, V.E., Germana, J.D., Stewart, M.G., April, M.M. (2010). Cystic fibrosis and endoscopic sinus surgery: Relationship between nasal polyposis and likelihood of revision endoscopic sinus surgery in patients with cystic fibrosis. *Arch Otolaryngol Head Neck Surgery*, 136 (10):988–992.

In: Encyclopedia of Surgery (22 Volume Set)
Editors: Andreas Lehrer and Kristin Mueller
ISBN: 978-1-53618-329-0
© 2020 Nova Science Publishers, Inc.

Chapter 162

POSTOPERATIVE PANCREATIC FISTULA FOLLOWING DISTAL PANCREATECTOMY

Jennifer L. Olson, MD and Richard J. Bold*, MD
Division of Surgical Oncology, UC Davis Comprehensive Cancer Center,
Sacramento, CA, US

1. INTRODUCTION

Post-operative pancreatic fistula (POPF) is one of the most dreaded complications in any pancreatic operation given its associated morbidity and mortality. The amylase-rich fluid can cause inflammation, become infected, or cause serious bleeding from neighboring vasculature. POPF are at least as common after distal pancreatectomy than traditional pancreaticoduodenectomy, occurring in approximately 14-30% of all operations [1-3]. Unlike pancreaticoduodenectomy, there is no pancreatic ductal anastomosis at risk for leakage and disruption; it has been hypothesized that the intact sphincter of Oddi as well as the normal parenchymal texture accounts for the relatively high incidence of POPF following distal pancreatectomy. In a recent meta-analysis, the average rate of clinically relevant POPF was 15.5% with severe POPF requiring reoperation or resulting in organ failure and/or death was 1.3% [4].

2. DEFINITION

In 2005, a consensus definition was published by the International Study Group for Pancreatic Fistula (ISGPF) which has now been widely accepted [5]. Previously, definitions would be established for an individual study declaring a volume of amylase-rich output at a set time point. The 2005 consensus definition declares that "any measurable volume of drain fluid on or after postoperative day 3, with an amylase content greater than 3 times the upper normal serum value" is a POPF. The severity of the leak does not linearly correlate with the

* Corresponding Author's Email: rjbold@ucdavis.edu; Fax: (916) 703-5267.

increase in amylase. ISGPF then divided the POPF into 3 groups correlating with clinical consequences. The clinical parameters used to grade were overall clinical condition (well or ill appearing/bad), persistent drainage after 3 weeks, signs of infection, sepsis, readmission, and treatments including reoperation, parenteral nutrition, antibiotics, somatostatin analogues, and drain placement. Increased length of stay is included as a diversion from usual management [5].

In 2016, the guidelines were updated which downgraded a type A fistula to a "biochemical leak" instead of a POPF. The clinically relevant B and C fistulae criteria were further clarified. Interventions included an alteration of management to include percutaneous or endoscopic interventions for fluid collections or angiographic procedures for POPF-related bleeding. Grade C includes any POPF which require reoperation or that lead to organ failure defined by the need for re-intubation, hemodialysis, or inotropic agents [6].

Table 1. 2005 ISGPF POPF grading scale

Grade A	"Transient fistula" with no clinical impact lasting less than 3 weeks.
Grade B	Change in management required. Signs of infection without sepsis possible.
Grade C	Significant alteration in management required. Possible sepsis or critical illness. Possible reoperation required. Risk of death.

Table 2. 2016 ISGPF POPF grading scale

Biochemical Leak (No POPF)	Amylase-rich drainage lasting less than 3 weeks
Grade B	Change in management required. Signs of infection without sepsis possible.
Grade C	Significant alteration in management required. Possible sepsis and/or organ failure. Possible reoperation required. Risk of death.

While the standardized definition has aided comparative research, there is no diagnosis or ICD code for pancreatic fistula limiting database research to those maintained by individual centers. Distal pancreatectomy is performed less often than pancreaticoduodenectomy thus requiring more time for patient accrual. Also, the routine clinical pathways can vary greatly between hospitals and between surgeons, thus the simple requirement of a deviation from expected course can have a myriad of interpretations.

3. CLINICAL COURSE

POPF influences the clinical course in many ways. Length of stay (LOS) is increased as patients require ongoing drain management, additional imaging and procedures, and care for any other resultant complications. LOS for an uncomplicated distal pancreatectomy is impacted by the surgical approach and by institutional postoperative care pathways ranging from 5 to 12 days. When a patient experiences a grade B/C POPF, the median LOS increases to 19 days with a range of 7-69 days. Delayed gastric emptying is another common complication of pancreatic resection which can be exacerbated by a POPF [7, 8].

Undrained or inadequately drained pancreatic leaks can lead to critical consequences. The amylase-rich fluid can degrade the surrounding tissue including the splanchnic vessels

leading to major hemorrhage. When bacteria are introduced into the fluid collection, an intraabdominal abscess can lead to sepsis. In a retrospective analysis of 908 patients who underwent pancreatic resection, culture of the pancreatic fistula effluent revealed bacteria in 2/3 of the patients [9]. Organisms are almost always gram-negative rods or anaerobes which likely represent enteric bacterial translocation or seeding at the time of the operation [10]. Mortality attributed to complicated POPF are as high as 5% [9].

Oncologic outcomes are also influenced. Prolonged hospitalization and convalescence delay initiation of chemotherapy. Whether due to the delay or absence of adjuvant systemic therapy, or the impact of the complication on overall health status, recurrence-free survival for pancreatic adenocarcinoma is decreased after POPF [11].

4. PATIENT FACTORS

Many patient factors have been shown to predispose patients to POPF. Some are disputed such as increased BMI and malignancy [12-14]. Malignancy is reported to both increase and decrease the rate of POPF. It can alter the gland by enlarging the duct after an obstructive process facilitating identification for directed ligation. The pancreatic gland following neoadjuvant radiation is more fibrotic/firm and may be associated with a lower POPF. Pancreatic texture is widely accepted as a risk factor with a firm pancreas conferring a lower risk compared to a soft gland texture [3, 4]. Texture is a subjective assessment of soft and firm that cannot be determined prior to the operation and attempts to define texture radiographically have not been successful [15]. Poor nutritional status by different measures may increase POPF risk although it doesn't stand up to multivariable analysis and the difference of albumin between groups is subclinical [12, 16]. Knowledge of patient factors influencing POPF does not change patient selection but may influence preoperative counseling and post-operative decision making.

5. SURGICAL TECHNIQUES

5.1. Approach

Distal pancreatectomy can be performed open, laparoscopically, or robotically. The laparoscopic approach is popular given the advantages in hospitalization and recovery time for minimally invasive surgery. Given the absence of required anastomoses to create, the technical feasibility is within the scope for most pancreatic surgeons. Several studies have compared outcomes including POPF and have shown that the laparoscopic and robotic approach are safe. [15, 17-20].

5.2. Division

Division of the pancreas can be performed by scalpel, stapler, or energy device in an open surgery and stapler or energy device in a minimally invasive approach. There are many

studies comparing scalpel versus stapler without a clear advantage or disadvantage for any particular method. The comparisons within and across studies are often confounded by other technical aspects discussed later are not always controlled.

Stapler types include GIA and TA, single and multi-fire, and varying staple height from 1.0 to 2.5 mm with 2 to 6 rows of staples. A soft pancreas is considered more amenable to stapler division. Kawai et al., [21] studied the effect of pancreatic thickness on stapler efficacy finding 12 mm as a cutoff. Other groups adjust the staple height to accommodate the size and others exclude patients with a firm pancreas from the staple group. Compressing the gland before firing the stapler, closing the stapler slowly, and holding the device shut for a longer time have been suggested to lower the incidence of POPF [21-26].

Energy devices include unipolar and bipolar cautery, ultrasonic/harmonic scalpel, and a high-energy radiowave device which all coagulate, seal, and cut. The small trials for these instruments have shown them to be safe alternatives but without a clear influence on POPF rate or other advantage [21, 27-29].

5.3. Reinforcement

The pancreatic stump exposes the transected main pancreatic duct (PD) as well as smaller pancreatic ducts, all of which can contribute to a pancreatic leak or fistula. Many methods have been explored to reinforce the cut edge to decrease the number of POPF. Direct ligation with silk or slowly absorbing monofilament suture of the main pancreatic duct is often performed when the duct can be identified regardless of the method of pancreatic division [26]. PD ligation is one of the more consistent maneuvers which decreases POPF [7].

5.3.1. Oversewing

After scalpel division, the stump is often oversewn to compress and target the smaller ducts. Slowly absorbing monofilament is generally used with either individual or running stitches; mattress sutures are common [24, 26]. Although direct ligation of the transected duct would seem to reduce POPF and has been widely recommended, there is little comparative evidence to demonstrate its utility. However, limited data would suggest that the use of a non-absorbable suture should be avoided in closure of the pancreatic stump.

5.3.2. Fibrin

The coagulation factor fibrin can be employed in a number of ways to reinforce the transected pancreas although compelling evidence of its efficacy is lacking. It is available in multiple formulations allowing for spraying, injecting, and overlaying a patch including Tisseel (Baxter International Inc.), FloSeal (Baxter International Inc.), Evicel (Ethicon), TachoSil (Nycomed Pharma), Barillas P (CSL Behring), Thrombin-JMI (King Pharmaceuticals), Quixil (Omrix Biopharmaceuticals S. A. – Ethicon) [30].

Randomized controlled trials have been performed with favorable but not consistent results. In a small study, after scalpel division, duct ligation, and suture reinforcement, half of the patients received fibrin spray treatment which decreased the POPF rate from 40% to 15% [31]. Comparing application of fibrin spray after scalpel division and duct ligation either as a simple spray application versus when followed by suture compression forming a “fibrin

sandwich," the sandwich group had a significant reduction in POPF (27% to 9%) [32]. Suc et al., [33] injected fibrin into the pancreatic duct which did not influence the POPF rate. TachoSil, an absorbable collagen fleece coated with fibrinogen and thrombin available in Europe was used in two RCTs buttressing either scalpel or stapler divided stumps and did not affect POPF rate [34, 35].

5.3.3. Mesh

Meshes of various biochemical compositions can be secured over the cut end and some studies have shown promising results in decreasing POPF. Vicryl mesh, a polyglactin polymer available from Ethicon, was shown to be safe and effective with no grade B/C fistulae in a group of 26 patients after scalpel division [36]. Polyglycolic acid (PGA) mesh is a bioabsorbable synthetic polymer with cellulose-like structure which significantly decreased the rate of clinical fistulae after stapler division/reinforcement [37].

5.3.4. Intraductal Injection

Intraductal fibrin injection described above was designed to transiently obstruct the duct. Alternatively, a prolamine injection was administered in 51 patients who did not develop any POPF. The authors note that the substance was sometimes seen to extravasate from the cut edge or smaller ducts and hypothesized that the application was successful for addressing both the main and any branch ducts.

5.3.5. Biologic Patches

Biologic patches can be employed to reinforce the pancreatic stump and to provide a barrier between the pancreas and underlying vessels. Neighboring available structures that have been reported on are the omentum, round ligament of the liver, and a seromuscular jejunal layer. In a randomized controlled trial, there was minimal improvement in POPF after the round ligament was mobilized, introduced to the pancreatic stump through a defect created in the lesser omentum and then secured in place [38]. The jejunum was used as a patch by securing the stapler-divided, PD ligated stump to a loop of jejunum with interrupted seromuscular sutures after mobilization of the duodenojejunal flexure without opening the enteric lumen. There was no improvement in the POPF rate [39].

5.3.6. Pancreaticoenteric Anastomoses

Pancreaticoenteric anastomosis is sometimes employed during reoperation for pancreatic fistula so it was hypothesized that a preemptive anastomosis during the initial operation would be effective. Two randomized controlled trials have been performed that fail to show a significant decrease in POPF from a more standard approach. A pancreaticojejunostomy in which the first jejunal loop was used for an anastomosis and for a seromuscular parenchymal patch was trialed in 136 patients dividing the patients between anastomosis and stapler division/reinforcement [40]. Pancreaticogastrostomy in comparison to ultrasonic division with ductal ligation and suture reinforcement also did not show improvement [41].

5.4. Spleen-Preserving Distal Pancreatectomy

Distal pancreatectomy can be performed removing the spleen en bloc or leaving the spleen in situ to receive its blood supply via the short gastric arteries. In a retrospective study, Goh et al., found that 0/21 patients versus 14/117 experienced grade B/C POPF after a spleen-preserving procedure [42]. Other retrospective studies have shown no difference in the rate of fistula formation [14, 15].

5.5. Preoperative Endoscopic Adjuncts

Suspecting the intact Sphincter of Oddi to be a major contributor to increased pancreatic ductal pressure and resultant fistulization, preoperative endoscopic intervention has been trialed. These maneuvers have been directed at endoscopic measures to reduce the pressure gradient across the sphincter of Oddi and therefore reduce the pressure within the main pancreatic duct.

5.5.1. Botox Injection

Temporary paralysis of the Sphincter of Oddi could allow for ductal decompression during the postoperative period. A small German trial of preoperative Sphincter of Oddi Botox administration injected 100 units of Botox into the sphincter of Oddi 0-10 days before the operation. None of the 24 patients who were able to undergo their scheduled resection experienced a grade B/C fistula or any endoscopic intervention [43].

5.5.2. Stent Placement

In a randomized controlled trial for patients with planned distal pancreatectomy, 58 patients were divided into a control group compared to endoscopic stent placement into the pancreatic duct proximal to the pancreatic parenchymal transection site. The patients who underwent endoscopic stent placement had the stent placed at the time of the laparotomy with the endoscopist and surgeon working together to place the 5 or 7 Fr stent near but not within the planned stapled transection line. There were no endoscopic complications but also no reduction in POPF rate. The POPF that occurred in the intervention arm was attributed to stent migration [44].

6. PERIOPERATIVE DRAIN PLACEMENT

Drain placement and management varies widely between surgical practices. A drain is necessary to diagnose a biochemical leak or POPF in order to sample the amylase content. A biochemical leak, in fact, requires a surgical drain as any intervention to place a drain postoperatively would upgrade it to a grade B fistula.

6.1. Prophylactic Surgical Drainage

Surgical drains are often placed near the pancreatic stump. Closed suction is most often encountered, either a Jackson-Pratt or a Blake drain of 12 to 15 French. Some surgeons argue against routine drainage because a closed suction drain promotes fistulization, may introduce infection to a sterile fluid collection, increases one's leak rate without clinical consequence, and many patients still require additional drain placement. While the other side points out that a controlled, self-limiting pancreatic leak is better than an undrained collection with a delayed diagnosis and intervention.

A major randomized controlled trial in 2001 included both pancreaticoduodenectomy and distal pancreatectomy and showed that prophylactic surgical drainage did not improve the rate or grade of POPF. 40 of the total patients underwent distal pancreatectomy with 15 receiving a right and a left upper quadrant drain, although the positions were described in relation to the anastomoses of the pancreaticoduodenectomy patients. Subsequent analysis did not delineate the type of surgery but did show equivalence between the groups. There was no difference in in-hospital mortality, intraabdominal abscess, total number of complications, or even length of stay. 13% of patients with surgical drains still needed an interventional radiology procedure. The most common IR procedure was a drain placement for abscess, fluid collection, or hemorrhage, but also included retained drain and 2 inferior vena caval filter. They concluded that routine drain placement is not beneficial after pancreatic surgery [45].

More recently, a randomized controlled trial was conducted for just patients undergoing distal pancreatectomy acknowledging the different profile of complications. 344 patients were included divided into groups with and without routine drainage that were randomized for pancreatic texture and surgical approach. Primary outcome was any grade 2 or higher complication. There was no statistical difference between the groups for complications overall or clinically relevant pancreatic fistula. There were 2 deaths in the no drain group, both of which did develop a pancreatic fistula which was suggested to have contribute to their deaths by delay in drainage. Thus, their conclusion is that routine drainage is not absolutely necessary but due to the seriousness of the complications of no drainage, it is understandable if some surgeons continue to routinely place drains [46].

A more nontraditional suggestion was posited by Sugiyama et al., after a retrospective cohort study showed improved outcomes for drain fixation. Fixation of the drainage tip to nearby retroperitoneal tissue with a loose loop of absorbable suture decreased the number of additional postoperative procedures required and did not interfere with drain removal [47].

The available trials suggest that routine surgical drainage is not required for distal pancreatectomy. However, while trials may randomize for pancreatic texture, it has not been independently explored or discussed in a subgroup analysis.

7. POSTOPERATIVE MANAGEMENT

7.1. Postoperative Minimally Invasive Drain Placement

The first step in stable patients with undrained or inadequately drained peripancreatic fluid collections suspicious for POPF is drainage. Postoperatively, drains can be placed

minimally invasively by interventional radiology using CT or ultrasound guidance. In a retrospective analysis of 365 patients requiring IR drain placement after distal pancreatectomy, it was shown to be effective in the majority of cases and identified risk factors for the need for reoperation. The fluid collections were 2.3 to 16 cm, averaging 7.3 cm; presumably smaller collections did not require drainage and any critically ill patients requiring drainage were operatively drained. Drains were placed between post-operative days 2 and 120 (median of 23.5 days) and were in place for 3 to 220 days (median 40 days). 95% of the drains effectively drained the collection so that no reoperation was required. 40% needed readjustment or upsizing and the need for secondary manipulation was a risk factor in needing a reoperation. The authors emphasized the need for placement of the largest caliber of drain possible [10].

Any intervention or deviation from the expected clinical course, by definition, redefines a pancreatic leak to be a grade B or C fistula which can include the following treatment strategies in addition to drain placement.

7.2. Somatostatin Analogue

Somatostatin is a potent inhibitor of pancreatic secretions thus making it a promising target for drug therapy in the treatment of pancreatic leak. Several trials have been conducted assessing its use in routine postoperative management to prevent fistula formation. Its use as a treatment for diagnosed leaks is widely accepted although direct evidence of the effect on decreased drainage and any associated morbidity and length of stay is lacking. Administration is contraindicated in hyperglycemic patients as somatostatin also inhibits insulin. Side effects are most commonly gastrointestinal: nausea, vomiting, diarrhea, and abdominal pain [48].

The randomized controlled trials which address prophylactic use of octreotide center on pancreaticoduodenectomy with distal pancreatectomy as an exclusion criteria or a minor component of the whole. While some European studies showed some improvement in the POPF rate, two influential RCTs which argue against routine usage are from 1997 and 2000. In 1997, 120 patients undergoing pancreaticoduodenectomy for cancer were randomized between no octreotide and 150ug of subcutaneous octreotide every eight hours for the first five postoperative days. The octreotide group had a 12% rate of POPF vs 6% for the control group and the difference was not significant [49]. A similar negative result was seen in 2000 for pancreaticoduodenectomy patients receiving 250ug of octreotide versus placebo every eight hours for five days. Bilimoria et al., retrospectively examined patients who had distal pancreatectomy only for multiple factors including administration of prophylactic octreotide. 62 patients received 100ug to 300ug of octreotide given at the same interval. 18% of octreotide patients had a leak versus 30% of the control group but the difference was not statistically significant [7].

Octreotide was the first available somatostatin analogue. Vapreotide and Pasirotide are newer, longer-acting, more potent substitutes. In a randomized controlled trial of vapreotide given routinely after pancreatic resection every 12 hours for seven days, there was no decrease in POPF or related conditions. 52 of the 275 patients had undergone distal pancreatectomy [50]. Pasireotide is also dosed twice daily and was given for 7 days in the 2014 randomized placebo-controlled trial. Of the 539 pancreatic resection patients, 80 underwent distal pancreatectomy performed with a variety of division and reinforcement

techniques. 17% of the total patients receiving Pasireotide withdrew for nausea. Notably, there was a statistically significant decrease in POPF from 17% to 8%. Length of stay was also impacted; median LOS was one day shorter with administration of the drug [48]. Subsequent cost analysis questioned the impact of the improvement in rate and length of stay but ultimately found that despite the high cost of the drug, the cost savings for interventions and daily hospitalization supported the routine use of prophylactic Pasireotide [51].

7.3. Dietary Management

Classically, patients with suspected or confirmed pancreatic leaks would be made NPO in order to disrupt the gastropancreatic neurohormonal signaling. A more modern approach encourages oral nutrition whenever tolerated.

7.3.1. Oral Nutrition

In a small subgroup analysis within a retrospective study, patients with low output pancreatic fistulae were observed to spontaneously close with no improvement when receiving parenteral nutrition [1]. A randomized controlled trial comparing the treatment of POPF after any pancreatic resection with parenteral nutrition until resolution of the fistula versus enteral nutrition through an endoscopically nasojejunal tube showed an advantage for the enteral nutrition [52]. In a group of post-distal pancreatectomy patients with POPF, patients were randomized between parenteral nutrition and oral nutrition. Oral nutrition was well tolerated and was not associated with increased length of stay or other complications [53].

7.3.2. Fluid Restriction

When 330 patients undergoing pancreatic resection (96 distal pancreatectomy) were randomized between a liberal and restricted fluid management plan, there was no advantage or disadvantage between the two groups. The liberal arm delivered a standard maintenance fluid rate of 12ml/kg/hr with 250ml boluses for urine output below 0.5ml/kg/hr. The restricted arm delivered half of that rate with boluses for low urine below 0.25ml/kg/hr. There was no effect on POPF rate although there was a slight decrease in the rate of delayed gastric emptying. Two patients did develop chronic renal failure but the rate was equal between the study arms and was attributed to related POPF [54].

7.4. Endoscopic Intervention

Preoperative endoscopic Botox injection and stent placement were previously discussed. There is also a role for post-operative POPF management again suspecting the Sphincter of Oddi to be a major contributor to the increased intraductal pressure and fistulization. Goasguen et al reported overall success in treatment of prolonged POPF with endoscopic pancreatic sphincterotomy. Of the total 10 patients, 6 had undergone distal pancreatectomy and had a POPF diagnosed between postoperative day 3 and 21. 23 to 106 days after

diagnosis, endoscopic sphincterotomy with or without stent placement was performed with successful POPF resolution 1-12 days post procedure [55].

CONCLUSION

The risk of pancreatic fistula formation after distal pancreatectomy is considerable by any definition of POPF. Review of the literature for the lowest risk surgical technique is confounded by the inter-trial variability in all of the many factors. The inability to compare outcomes across hospitals limits the application of some research conclusions. While there is not a single tool or pharmacological agent that can substantially decrease the rate of POPF, early postoperative recognition in those patients at higher risk may limit the clinical consequence.

REFERENCES

[1] Sheehan, M. K., et al., Distal pancreatectomy: does the method of closure influence fistula formation? *Am Surg*, 2002. 68(3): p. 264-7; discussion 267-8.

[2] Yeo, C. J., et al., Six hundred fifty consecutive pancreaticoduodenectomies in the 1990s: pathology, complications, and outcomes. *Ann Surg*, 1997. 226(3): p. 248-57; discussion 257-60.

[3] Jimenez, R. E. and Hawkins, W. G. Emerging strategies to prevent the development of pancreatic fistula after distal pancreatectomy. *Surgery*, 2012. 152(3 Suppl 1): p. S64-70.

[4] Eshmuminov, D., et al., Systematic review and meta-analysis of postoperative pancreatic fistula rates using the updated 2016 *International Study Group Pancreatic Fistula definition in patients undergoing pancreatic resection with soft and hard pancreatic texture.* HPB (Oxford), 2018.

[5] Bassi, C., et al., Postoperative pancreatic fistula: an international study group (ISGPF) definition. *Surgery*, 2005. 138(1): p. 8-13.

[6] Bassi, C., et al., The 2016 update of the International Study Group (ISGPS) definition and grading of postoperative pancreatic fistula: 11 Years After. *Surgery*, 2017. 161(3): p. 584-591.

[7] Bilimoria, M. M., et al., Pancreatic leak after left pancreatectomy is reduced following main pancreatic duct ligation. *Br J Surg*, 2003. 90(2): p. 190-6.

[8] Liang, S., Hameed, U. and Jayaraman, S. Laparoscopic pancreatectomy: indications and outcomes. *World J Gastroenterol*, 2014. 20(39): p. 14246-54.

[9] Vin, Y., et al., Management and outcomes of postpancreatectomy fistula, leak, and abscess: results of 908 patients resected at a single institution between 2000 and 2005. *J Am Coll Surg*, 2008. 207(4): p. 490-8.

[10] Cronin, C. G., et al., Interventional radiology in the management of abdominal collections after distal pancreatectomy: a retrospective review. *AJR Am J Roentgenol*, 2011. 197(1): p. 241-6.

[11] Sahakyan, M. A., et al., Laparoscopic distal pancreatectomy for pancreatic ductal adenocarcinoma: Long-term oncologic outcomes after standard resection. *Surgery*, 2017. 162(4): p. 802-811.
[12] Goh, B. K., et al., Critical appraisal of 232 consecutive distal pancreatectomies with emphasis on risk factors, outcome, and management of the postoperative pancreatic fistula: a 21-year experience at a single institution. *Arch Surg*, 2008. 143(10): p. 956-65.
[13] Seeliger, H., et al., Risk factors for surgical complications in distal pancreatectomy. *Am J Surg*, 2010. 200(3): p. 311-7.
[14] Fahy, B. N., et al., Morbidity, mortality, and technical factors of distal pancreatectomy. *Am J Surg*, 2002. 183(3): p. 237-41.
[15] Jutric, Z., et al., Preoperative computed tomography scan to predict pancreatic fistula after distal pancreatectomy using gland and tumor characteristics. *Am J Surg*, 2016. 211(5): p. 871-6.
[16] Sierzega, M., et al., Nutritional status affects the rate of pancreatic fistula after distal pancreatectomy: a multivariate analysis of 132 patients. *J Am Coll Surg*, 2007. 205(1): p. 52-9.
[17] Daouadi, M., et al., Robot-assisted minimally invasive distal pancreatectomy is superior to the laparoscopic technique. *Ann Surg*, 2013. 257(1): p. 128-32.
[18] de Rooij, T., et al., Single-Surgeon Learning Curve in 111 Laparoscopic Distal Pancreatectomies: Does Operative Time Tell the Whole Story? *J Am Coll Surg*, 2017. 224(5): p. 826-832.e1.
[19] Klompmaker, S., et al., Nationwide Evaluation of Patient Selection for Minimally Invasive Distal Pancreatectomy Using American College of Surgeons' National Quality Improvement Program. *Ann Surg*, 2017. 266(6): p. 1055-1061.
[20] Magge, D., et al., Comparative effectiveness of minimally invasive and open distal pancreatectomy for ductal adenocarcinoma. *JAMA Surg*, 2013. 148(6): p. 525-31.
[21] Kawai, M., et al., Stump closure of a thick pancreas using stapler closure increases pancreatic fistula after distal pancreatectomy. *Am J Surg*, 2013. 206(3): p. 352-9.
[22] Kajiyama, Y., et al., Quick and simple distal pancreatectomy using the GIA stapler: report of 35 cases. *Br J Surg*, 1996. 83(12): p. 1711.
[23] Misawa, T., et al., Safe and quick distal pancreatectomy using a staggered six-row stapler. *Am J Surg*, 2008. 195(1): p. 115-8.
[24] Diener, M. K., et al., DISPACT trial: a randomized controlled trial to compare two different surgical techniques of DIStal PAnCreaTectomy - study rationale and design. *Clin Trials*, 2008. 5(5): p. 534-45.
[25] Diener, M. K., et al., Efficacy of stapler versus hand-sewn closure after distal pancreatectomy (DISPACT): a randomised, controlled multicentre trial. *Lancet*, 2011. 377(9776): p. 1514-22.
[26] Knaebel, H. P., et al., Systematic review and meta-analysis of technique for closure of the pancreatic remnant after distal pancreatectomy. *Br J Surg*, 2005. 92(5): p. 539-46.
[27] Sugo, H., et al., Distal pancreatectomy using the harmonic scalpel. *Surgery*, 2000. 128(3): p. 490-1.
[28] Suzuki, Y., et al., Randomized clinical trial of ultrasonic dissector or conventional division in distal pancreatectomy for non-fibrotic pancreas. *Br J Surg*, 1999. 86(5): p. 608-11.

[29] Fronza, J. S., et al., Laparoscopic distal pancreatectomy using radiofrequency energy. *Am J Surg*, 2010. 199(3): p. 401-4; discussion 404.
[30] Fingerhut, A., et al., Use of sealants in pancreatic surgery: critical appraisal of the literature. *Dig Surg*, 2009. 26(1): p. 7-14.
[31] Suzuki, Y., et al., Fibrin glue sealing for the prevention of pancreatic fistulas following distal pancreatectomy. *Arch Surg*, 1995. 130(9): p. 952-5.
[32] Ohwada, S., et al., Fibrin glue sandwich prevents pancreatic fistula following distal pancreatectomy. *World J Surg*, 1998. 22(5): p. 494-8.
[33] Suc, B., et al., Temporary fibrin glue occlusion of the main pancreatic duct in the prevention of intra-abdominal complications after pancreatic resection: prospective randomized trial. *Ann Surg*, 2003. 237(1): p. 57-65.
[34] Montorsi, M., et al., Efficacy of an absorbable fibrin sealant patch (TachoSil) after distal pancreatectomy: a multicenter, randomized, controlled trial. *Ann Surg*, 2012. 256(5): p. 853-9; discussion 859-60.
[35] Sa Cunha, A., et al., Stump closure reinforcement with absorbable fibrin collagen sealant sponge (TachoSil) does not prevent pancreatic fistula after distal pancreatectomy: the FIABLE multicenter controlled randomized study. *Am J Surg*, 2015. 210(4): p. 739-48.
[36] Matsumoto, I., et al., Transpancreatic Mattress Suture with Vicryl Mesh Around the Stump During Distal Pancreatectomy: A Novel Technique for Preventing Postoperative Pancreatic Fistula. *J Am Coll Surg*, 2016. 223(2): p. e1-5.
[37] Jang, J. Y., et al., Effect of Polyglycolic Acid Mesh for Prevention of Pancreatic Fistula Following Distal Pancreatectomy: A Randomized Clinical Trial. *JAMA Surg*, 2017. 152(2): p. 150-155.
[38] Hassenpflug, M., et al., Teres Ligament Patch Reduces Relevant Morbidity After Distal Pancreatectomy (the DISCOVER Randomized Controlled Trial). *Ann Surg*, 2016. 264(5): p. 723-730.
[39] Olah, A., et al., Randomized clinical trial of techniques for closure of the pancreatic remnant following distal pancreatectomy. *Br J Surg*, 2009. 96(6): p. 602-7.
[40] Kawai, M., et al., Randomized Controlled Trial of Pancreaticojejunostomy versus Stapler Closure of the Pancreatic Stump During Distal Pancreatectomy to Reduce Pancreatic Fistula. *Ann Surg*, 2016. 264(1): p. 180-7.
[41] Sudo, T., et al., Distal pancreatectomy with duct-to-mucosa pancreaticogastrostomy: a novel technique for preventing postoperative pancreatic fistula. *Am J Surg*, 2011. 202(1): p. 77-81.
[42] Goh, B. K., Re: Distal pancreatectomy: risk factors for surgical failure in 302 consecutive cases. *Ann Surg*, 2008. 247(2): p. 392-3; author reply 393.
[43] Hackert, T., et al., Sphincter of Oddi botulinum toxin injection to prevent pancreatic fistula after distal pancreatectomy. *Surgery*, 2017. 161(5): p. 1444-1450.
[44] Frozanpor, F., et al., The effect of prophylactic transpapillary pancreatic stent insertion on clinically significant leak rate following distal pancreatectomy: results of a prospective controlled clinical trial. *Ann Surg*, 2012. 255(6): p. 1032-6.
[45] Conlon, K. C., et al., Prospective randomized clinical trial of the value of intraperitoneal drainage after pancreatic resection. *Ann Surg*, 2001. 234(4): p. 487-93; discussion 493-4.

[46] Van Buren, G., 2nd, et al., A Prospective Randomized Multicenter Trial of Distal Pancreatectomy With and Without Routine Intraperitoneal Drainage. *Ann Surg*, 2017. 266(3): p. 421-431.

[47] Sugiyama, M., et al., Secure placement of a peripancreatic drain after a distal pancreatectomy. *Am J Surg*, 2010. 199(2): p. 178-82.

[48] Allen, P. J., et al., Pasireotide for postoperative pancreatic fistula. *N Engl J Med*, 2014. 370(21): p. 2014-22.

[49] Lowy, A. M., et al., Prospective, randomized trial of octreotide to prevent pancreatic fistula after pancreaticoduodenectomy for malignant disease. *Ann Surg*, 1997. 226(5): p. 632-41.

[50] Sarr, M. G., The potent somatostatin analogue vapreotide does not decrease pancreas-specific complications after elective pancreatectomy: a prospective, multicenter, double-blinded, randomized, placebo-controlled trial. *J Am Coll Surg*, 2003. 196(4): p. 556-64; discussion 564-5; author reply 565.

[51] Ma, L. W., et al., The Cost of Postoperative Pancreatic Fistula Versus the Cost of Pasireotide: Results from a Prospective Randomized Trial. *Ann Surg*, 2017. 265(1): p. 11-16.

[52] Klek, S., et al., Enteral and parenteral nutrition in the conservative treatment of pancreatic fistula: a randomized clinical trial. *Gastroenterology*, 2011. 141(1): p. 157-63, 163.e1.

[53] Fujii, T., et al., Oral Food Intake Versus Fasting on Postoperative Pancreatic Fistula After Distal Pancreatectomy: A Multi-Institutional Randomized Controlled Trial. *Medicine (Baltimore)*, 2015. 94(52): p. e2398.

[54] Grant, F., et al., Prospective Randomized Controlled Trial of Liberal Vs Restricted Perioperative Fluid Management in Patients Undergoing Pancreatectomy. *Ann Surg*, 2016. 264(4): p. 591-8.

[55] Goasguen, N., et al., Endoscopic management of pancreatic fistula after distal pancreatectomy and enucleation. *Am J Surg*, 2009. 197(6): p. 715-20.

In: Encyclopedia of Surgery (22 Volume Set)
Editors: Andreas Lehrer and Kristin Mueller
ISBN: 978-1-53618-329-0
© 2020 Nova Science Publishers, Inc.

Chapter 163

MININVASIVE SURGICAL APPROACH IN ENDOSCOPIC SINUS SURGERY (ESS)

Federico Sireci[1], MD, Francesco Galletti[2] and Frank Rikki Canevari[3]

[1]ENT Section, ARNAS Fatebenefratelli Hospital, Palermo, Italy
[2]Department of Otorhinolaryngology, University of Messina, Italy
[3]Department of Otorhinolaryngology – Head and Neck Surgery, University of Genoa, Genoa, Italy

ABSTRACT

The minimally invasive sinus technique, (MIST) is different from minimally invasive sinus surgery. MIST implies a treatment philosophy and surgical model that is quite different from functional endoscopic sinus surgery (FESS).

The goals of this article are to discuss the origins of functional sinus surgery as it relates to the evolution of FESS and MIST, define MIST as a philosophy and surgical model, discuss treatment of surgical sinus disease, and challenge the rationale for our departure from Messerklinger's "functional" concepts into what will be referred to as "contemporary FESS." Many authors address the reduced revision rate (compared with FESS) following initial intervention with MIST, the potential to markedly reduce the rate of intranasal synechiae, and the reduction in immediate postoperative morbidity.

Keywords: minimally invasive, sinusitis, endoscopic sinus surgery

INTRODUCTION

Since its introduction in the mid-1980s, functional endoscopic sinus surgery (FESS) has become the standard surgical intervention for patients with chronic sinusitis refractory to medical therapy. In fact, FESS represented a targeted intervention, aimed at restoring normal sinus mucosal physiology as first described by Messerklinger in 1978 [1].

Through his endoscopic examination of the nose, Messerklinger describes a pattern of shifting light reflexes seen on the mucosal surface of the sinuses representing mucociliary movement that we now recognize as mucociliary transport or clearance. Using endoscopy in conjunction with time-lapse photography, he examined the direction of mucus movement and found that clearance was directed from the larger sinuses to their respective ostia. He also noted that contact between mucosal surfaces leads to disruption of mucociliary movement, thereby causing retention of secretions with subsequent obstruction of the subordinate maxillary, frontal, and anterior ethmoid sinuses. Furthermore, he recognized that contact is most likely to occur in the narrow transition spaces (i.e., ethmoidal infundibulum, hiatus semilunaris superior, and nasofrontal recess). Although contact may be a result of a number of causes, such as inflammation from environmental irritants, allergic rhinitis, viral infection, or anatomic distortions, these factors are most influential to the disruption of sinus physiology and development of sinusitis when they directly affect the aforementioned transition spaces. The theory that transition spaces represent the primary physiologic/anatomic bottleneck for the development of sinusitis is further supported by the high frequency with which the computerized tomography (CT) and clinical examination findings show inflammation limited to the maxillary, frontal, and anterior ethmoid sinuses; the posterior ethmoid and sphenoid sinuses do not drain into transition spaces.

Another critical realization in the development of FESS was that mucosal damage and mucociliary dysfunction is a reversible process. Before Messerklinger, most believed that mucosal damage found in chronic sinusitis was irreversible, and, therefore, procedures such as the Caldwell- Luc involved stripping of the sinus mucosa. In his clinical experience with more than 2,500 patients, Stammberger [2] showed that once the transition spaces are cleared of disease, the larger sinuses usually heal without being touched, even if mucosal damage seemed “almost irreversible”. Recent studies examining mucociliary clearance have shown that patients with chronic sinusitis have impaired mucociliary movement and that FESS is capable of correcting mucociliary dysfunction in these patients, thus showing the reversibility of disease [3-6]. To create optimal conditions for reversal of disease to occur, surgical intervention should avoid destruction of cilia and emphasize mucosal preservation.

Senior et al. [7] showed the favorable long-term results of FESS, with 98.4% of 72 patients having improvement compared with before surgery over an average 7.8-year follow-up period. Although there was a steep initial learning curve, many studies have since highlighted the relative paucity of complications associated with the procedure. In a study of 250 patients undergoing FESS, Levine [8] reported that minor complications developed in 8.3% of patients, while major complications developed in only 0.7%. In comparison, a study of 670 patients undergoing the Caldwell- Luc procedure, the previous gold standard intervention for chronic maxillary sinusitis, showed a 19% major complication rate [9]. Finally, because FESS is based on a minimally invasive approach compared with conventional surgeries, there were less overall postoperative discomfort and shorter hospital stays.

Although FESS initially established itself as a less invasive, more targeted, and more effective technique than its predecessors, conventional FESS has evolved beyond this description. Originally, proponents emphasized that FESS provides a conservative and effective surgical intervention, rarely requiring a middle meatal antrostomy or stripping of diseased nasal mucosa. However, over time, there has been a departure from these

conservative principles, with a tendency toward more aggressive intervention. As a result, surgeons have excessive freedoms in the nose, and sinus procedures are not standardized.

Although endoscopy offered a window for more precise visualization of nasal pathology, advances in other sinus instrumentation lagged. The original instruments used in FESS offered minimal precision, were associated with shear damage to normal mucosal tissue, and caused inadvertent stripping of mucus membranes. Technologic breakthroughs, coupled with a surgical model based on Messerklinger's principles [1], led to the next major advance in rhinology: powered instrumentation and the minimally invasive sinus technique (MIST).

DISCUSSION

Since its introduction in the literature in 1994 [9-10], MIST has grown in popularity worldwide. In the 2002, the first formal outcome study that compare MIST to FESS was published [11]. This study used the Chronic Sinusitis Survey (CSS) as the quality of life outcome instrument to assess improvement after MIST.

The outcome from MIST as measured by the CSS medication, CSS symptom, and CSS total subscales either equaled or surpassed those after FESS; the follow-up period for the MIST study was 23 months compared with 12 months of FESS and the surgical revision rate after MIST was 5.9% compared with an average of 10% after FESS. Furthermore, the results seen after MIST were consistent across the spectrum of disease severity (using CT grades I-IV), disproving the opinion that the procedure was only effective for minimal disease. These findings strongly support the recommendation that MIST be considered the initial surgical intervention for the treatment of chronic sinusitis. It strongly suggests that an excellent quality of life for chronic sinus sufferers could be achieved with minimal surgical manipulation of the nose and sinuses, it validates Messerklinger's transition space theory [1] and the reversibility of diseased nasal membranes, and it contradicts the rationale for the routine creation of a middle meatal antrostomy.

In fact, creation of a middle meatal antrostomy is occasionally required. Absolute indications include the biopsy of an antral mass, presence of $\geq$ 1 accessory ostia leading to maxillary recirculation, resection of a maxillary sinus fungal ball or inverted papilloma, and to allow for the application of topical medications or outpatient antral lavage in select cases. The concern with creation of a middle meatal antrostomy is not whether it works but whether it is necessary. Silva et al. [12] recently reported their study in which, for every surgical candidate with chronic rhinosinusitis, they performed a middle meatal antrostomy on one maxillary sinus but not the other. The results show no difference in the postoperative control of maxillary sinus symptoms or disease between the 2 sides. Thus, the potential risks of increased middle meatal scarring, interruption of mucociliary clearance and improper ostial function, development of maxillary recirculation by not including the natural ostia in the middle meatal antrostomy, and the likely need for revision maxillary surgery preclude the routine creation of a middle meatal antrostomy. Furthermore, authors conclude that the proper size of a middle meatal antrostomy can't be establish. Turbinate tissue is critical to proper nasal and sinus physiology. Routine resection of the middle turbinate often leads to edema and/or stenosis of the nasofrontal duct, and can produce compensatory glandular hypertrophy of the remaining nasal tissue. Powered shaving (i.e., thinning) of the lateral aspect of the

middle turbinate and powered resection of the lateral wall of concha bullosa, including the natural bullosa ostium, can each improve middle meatal airflow without incurring the risks associated with turbinate resection.

Another, less formal outcome study on MIST titled "Minimally Invasive Sinus Surgery in the Geriatric Patient" was published in 2001 [13]. The study used a geriatric population (ages 65 - 93 years) of 100 patients undergoing MIST for chronic sinusitis, to assess whether, because of their age, they had a higher potential for intraoperative or postoperative complications. The study patients also assessed subjectively the quality of life outcome after surgery, 6 months postoperatively. Of patients, 84% reported feeling significantly better, 10% somewhat better, and 6% unchanged. In comparison, another study of 119 patients with chronic sinusitis showed that 80.2% of patients had relief after FESS. Interestingly, 8 of 10 patients who reported feeling "somewhat better" after MIST, and 2 of 6 who had no improvement, had previously undergone aggressive FESS elsewhere.

The study also assessed whether there was any exacerbation of preexisting medical conditions or an increase in surgical morbidity after MIST. The 100 patients presented a spectrum of preexisting medical conditions, including hypertension, coronary disease, gastrointestinal disorders, diabetes, bronchitis and asthma, thyroid disorders, gout, stroke, renal disease, prostate disease, dysrhythmias, and others. Verifying the efficacy of MIST for the treatment of chronic sinusitis, the results highlight the fact that minimal medical/surgical morbidity is experienced by geriatric patients after MIST, making the procedure equally safe for the oldest and potentially most frail portion of the population.

A more recent article evaluated the efficacy of various middle meatal stents used during MIST [14]. Retention time for the Gelfilm stent was 5 days, whereas it was closer to 8 days for MeroGel, which is a statistically significant difference. Visible middle meatal synechiae on the right side (Gelfilm) developed in 4 patients, and none were seen on the left. The perioperative morbidity associated with the use of stents was negligible and not side specific. Mero- Gel appeared to be an excellent middle meatal spacer during sinus surgery. Compared with the literature, in which the rates of middle meatal synechiae vary from 27% to 4%, the overall synechia rate in this study was only 2% (0% for the MeroGel side).

A rationale has been provided for the aggressive ethmoidectomy now seen in contemporary FESS, however, to our knowledge, the basis for it remains unproven. It has been shown in both animal and human studies that osteitis of ethmoid [15, 16] serves as a nidus for recurrent infection or mucosal inflammation and, therefore, may be responsible for persistent/ recurrent disease after medical/surgical intervention. Thus, it is proposed that aggressive removal of all ethmoid sinus partitions will theoretically minimize the risk of recurrence.

Recent studies have shown that single-photon emission computed tomography bone scanning of the paranasal sinuses in patients with chronic sinusitis may be helpful in identifying foci of osteitis preoperatively [17]. These foci were correlated with histopathology of osteitis in 94% of cases examined. Therefore, CT absence of osteitis can address to MIST technique.

Regarding frontal sinus surgery, new mini-invasive approaches such as sinus balloon have been proposed. Currently the literature shows discordant results on this device so for our experience we recommend surgical approaches to this sinus with traditional surgery based on the principles proposed by Messerklinger to respect the sinus drainage paths [18]. About to

the sphenoid sinus, we consider mini-invasive to carve the rescue flap to be repositioned on the spenotomy to prevent stenosis, iatrogenic mucocele and favor natural drainage [19].

REFERENCES

[1] Messerklinger, W.: *Endoscopy of the Nose*. Baltimore, MD, Urban and Schwarzenberg, 1978.

[2] Stammberger, H.: Endoscopic endonasal surgery–Concepts in treatment of recurring rhinosinusitis. Part II. Surgical technique. *Otolaryngol. Head Neck Surg.,* 94:147 - 156, 1986.

[3] Katsuhisa, I., Takeshi, O., Masayuki, F., et al.: Restoration of the muco- ciliary clearance of the maxillary sinus after endoscopic sinus surgery. *J. Allergy Clin. Immunol.,* 99:48 - 52, 1997.

[4] Asai, K., Haruna, S., Otori, N., et al.: Saccharin test of maxillary sinus mucociliary function after endoscopic sinus surgery. *Laryngoscope,* 110:117 - 122, 2000.

[5] Elwany, S., Hisham, M., Gamaee, R.: The effect of endoscopic sinus surgery on mucociliary clearance in patients with chronic sinusitis. *Eur. Arch. Otorhinolaryngol.,* 255:511 - 514, 1998.

[6] Min, Y. G., Yun, Y. S., Song, B. H., et al.: Recovery of nasal physiology after functional endoscopic sinus surgery: Olfaction and mucocili- ary transport. *ORL J. Otorhinolaryngol. Relat. Spec.,* 57:264 - 268, 1995.

[7] Senior, B. A., Kennedy, D. W., Tanabodee, J., et al.: Long-term results of functional endoscopic sinus surgery. *Laryngoscope,* 108:151 - 157, 1998.

[8] Levine, H. L.: Functional endoscopic sinus surgery: Evaluation, surgery, and follow-up of 250 patients. *Laryngoscope*, 100:79 - 84, 1990.

[9] Setliff, R. C. III, Parsons, D. S.: The "Hummer": New instrumentation for functional endoscopic sinus surgery. *Am. J. Rhinol.,* 8:275 - 278, 1996.

[10] Setliff, R. C.: Minimally invasive sinus surgery: Rationale and technique. *Otolaryngol. Clin. North Am.,* 29:115 - 129, 1996.

[11] Catalano, P. J., Roffman, E.: Outcome of patients with chronic sinusitis after the minimally invasive sinus technique. *Am. J. Rhinol.,* 17:17 - 22, 2003.

[12] Sireci, F., Nicolotti, M., Battaglia, P., Sorrentino, R., Castelnuovo, P., Canevari, F. R. (2017) Canine fossa puncture in endoscopic sinus surgery: report of two cases. *Braz. J. Otorhinolaryngol.*, pii: S1808-8694(17)30040-X. dei: 10.1016/j.bjorl.2017.03.001.

[13] Catalano, P. J., Setliff, R. C. III, Catalano, L. A.: Minimally invasive sinus surgery in the geriatric patient. *Oper. Tech. Otolaryngol. Head Neck Surg.,* 12:85 - 90, 2001.

[14] Sireci, F., Canevari, F. R. (2017) Mininvasive surgical approach in endoscopic sinus surgery: when, why and how?. *The Rhinologist,* 3:42 - 4.

[15] Kennedy, D. W., Senior, B. A., Gannon, F. H., et al.: Histology and histomorphometry of ethmoid bone in chronic sinusitis. *Am. J. Rhinol.*, 108:502 - 507, 1998.

[16] Sireci, F., Speciale, R., Gallina, S., Sorrentino, R., Canevari, F. R. Clarithromycin in the Management of Chronic Rhinosinusitis: Preliminary Results of a Possible Its New Use. *Indian J. Otolaryngol. Head Neck Surg.,* 2018 Mar.; 70(1):87 - 91.

[17] Catalano, P. J., Dolan, R. W., Shah, R., et al.: Correlations between bone SPECT scintigraphy and histopathology of the ethmoid bone in chronic sinusitis. *American Rhinologic Society*, May 2004.

[18] Koskinen, A., Mattila, P., Myller, J., Penttilä, M., Silvola, J., Alastalo, I., Huhtala, H., Hytönen, M., Toppila-Salmi, S. Comparison of intra-operative characteristics and early post-operative outcomes between endoscopic sinus surgery and balloon sinuplasty. *Acta Otolaryngol.*, 2017 Feb; 137(2):202 - 206. doi: 10.1080/ 00016489.2016.1227476.

[19] Rivera-Serrano, C. M., Snyderman, C. H., Gardner, P., Prevedello, D., Wheless, S., Kassam, A. B., Carrau, R. L., Germanwala, A., Zanation, A. Nasoseptal "rescue" flap: a novel modification of the nasoseptal flap technique for pituitary surgery. *Laryngoscope*, 2011 May; 121(5):990 - 3.

In: Encyclopedia of Surgery (22 Volume Set)
Editors: Andreas Lehrer and Kristin Mueller
ISBN: 978-1-53618-329-0
© 2020 Nova Science Publishers, Inc.

Chapter 164

POWERED ADENOIDECTOMY

Max M. April*, MD
Department of Otolaryngology, New York University/Langone Medical Center
New York, NY, US

ABSTRACT

Powered adenoidectomy was first described by Dr. Peter Koltai in 1997 [1]. This technique allows for constant suction and more precision in the removal of adenoid tissue.

Keywords: adenoidectomy, powered adenoidectomy, microdebrider adenoidectomy

INTRODUCTION

First performed in the mid 1990s, the initial powered adenoidectomy was performed with a bendable microdebrider blade. There were several issues, including frequent blade clogging due to the angle of the bend. The inner cannula would also get separated from the outer cannula making the blade unusable. The issues with those blades were improved with prebent standard blades. In addition, I designed a blade appropriately sized for most children (RADenoid blade 4mm opening and 11 cm length with a 40 degree curve which is manufactured by Medtronic, Figure 1A) and a larger one (4.5 mm opening, 13 cm in length with a 45 degree curve also manufactured by Medtronic, Figure 1B), intended for adolescents and young adults (my royalty agreement with Medtronic expired in 2010). More recently, Olympus has produced a similar blade for their Diego handpiece. (Figure 2)

Once mastered, powered adenoidectomy is a technique that improves visualization and accuracy. It has advantages over the previously used curretage and suction cautery methods.

* Corresponding Author's Email: max.april@nyumc.org.

(a)

(b)

Figure 1a,b. A photograph showing the (a) pediatric RADenoid blade 11 cm. (Medtronic) and (b) adolescent RADenoid blade 13 cm. (Medtronic).

(a)

(b)

(c)

Figure 2. A. This figure shows the Olympus version of the adenoid blade. B. This image depicts the straight hand piece while C depicts the angled hand piece, both of which can be used with their adenoid blade.

METHODS

When powered adenoidectomy is performed, with or without tympanostomy tubes or other procedures such as frenulectomy (but usually not tonsillectomy), a laryngeal mask airway (LMA) may be used. In smaller children, a flexible LMA can be used depending on the anesthesiologist's experience. When using a flexible LMA, it is quite important to lubricate the tongue blade for easier manipulation when putting the child in the proper position (Figure 3). Often the LMA has to be repositioned slightly for an adequate airway. Care must be taken not to place the tongue blade handle at too sharp an angle onto the Mayo Stand (use the mouthgag with the right side open for a right handed surgeon) or it may cause a kink in the flexible LMA and reduce ventilation. Once the proper position is obtained with good ventilation (Figure 4), the hard and soft palate are both closely examined. The identification of a submucosal cleft palate is extremely important. The hard palate is palpated to confirm there is not a notch of the posterior portion. The soft palate is visualized with the surgeon's headlight to confirm the lack of a zona pellucida (mucosa without underlying muscle) in the midline. If there is a submucosal cleft, many otolaryngologists recommend that an adenoidectomy not be performed to prevent velopharyngeal incompetence (VPI). In this situation, a superior adenoidectomy can be considered [2]. The use of a microdebrider enhances the surgeon's ability to remove the superior portion of adenoid tissue to improve nasal obstruction and, for patients with ear symptomatology, remove adenoid tissue in the fossa of Rosenmuller. A less recognized potential cause of VPI after adenoidectomy is the short soft palate. Upon careful palpation (Figure 5), there are many more instances of a short soft palate than a submucosal cleft. Again, a powered adenoidectomy is an excellent method to remove most of the adenoid tissue, but be sure to leave an inferior ledge, which will improve postoperative palatal closure and lessen nasal escape.

After inspection, palpation, and chosing the plan of the specific adenoidectomy, drip 0.5 ml of oxymetazoline 0.05% (Figure 6) into each nasal passage. A minimum of instruments should be set up on the Mayo stand (Figure 7), including 2 red rubber catheters (8 French), 2 tonsil clamps, a mirror, antifog, and 2 tonsil sponges soaked with afrin. Using afrin prior to any other step may reduce blood loss and is known to improve nasal patency, especially in the Post-Anesthesia Care Unit (PACU). Tape the eyes, then place the head drape. Securing the head drape with tape avoids possible trauma from a towel clamp. A red rubber catheter (unless the patient is latex sensitive) is placed through each nostril to elevate the soft palate. The catheters are brought out through the oral cavity and clamped with a hemostat with the curve pointing up. The catheters are clamped to elevate the palate, but with little tension. If they are clamped tighter, there would be better exposure, but would produce more palatal swelling. With the clamp tip pointed up, the surgeon can intermittently retract the catheter with the ring finger when more exposure is needed (Figure 8). This technique is often helpful in smaller children and those with a relatively small oral cavity. The microdebrider blade allows the surgeon precise removal of exact tissue, but there is a learning curve. Because there is constant suction, there is a potential for damage to surrounding structures, especially the uvula, buccal mucosa, and lips. It is important to use the mirror, having first been dipped in antifog solution, to cover the opening (Figure 9) of the microdebrider blade both on entry and removal of the blade. The console was set at 1500 rpm, but now 2000 rpm is used (Figure 10) in oscillating mode. The oral stabilizer should have the opening on the side of the

surgeon's dominant hand. For right handed surgeons the opening of the mouthgag is on the right side. That enables a better angle for the microdebrider blade to get into the nasopharyngeal choana (Figure 11). The tongue blade selected should be the one that points the endotracheal tube or the LMA tube toward the anesthesiologist.

When ready to begin powered adenoidectomy, recognize the position the nasopharynx is in; this may vary depending on many factors. The angle of the nasopharynx often appears with the inferior most portion of the adenoid tissue higher than the superior aspect (Figure 12). That may promote deeper dissection with the blade in the infero-lateral portions of the nasopharynx. As that is where the blood supply eminates, dissection too deep in those areas produces much more bleeding, which in turn leads to more cauterization and then more pain. Be aware of that angle in every case and bring the debrider blade more superficial, removing only lymphoid tissue and not entering the underlying muscle. In smaller children, starting in the left choana, using care not to damage the torus tubarius, the adenoid tissue is removed in two passes from superior to inferior. In older children, a third pass (in the midline) is necessary.

> Early in their powered adenoidectomy experience, surgeons will need to pack the nasopharynx with a tonsil sponge soaked in oxymetazoline, then wring it dry for a few minutes prior to obtaining hemostasis with the suction cautery. As surgeons improve their technique, there is less bleeding and many times packing is not necessary. Suction cautery is set on a low wattage–less than 20 watts. The low setting may reduce thermal damage to the eustachian tube. The foot pedal control for the suction cautery has several advantages, including reduction of surgeon fatigue and more effective cauterization with less powerful suction, when less of the suction port on the hand piece is covered. That cannot be accomplished with the hand controlled cautery.

When adenoidectomy is performed without tonsil surgery, the postoperative course is very predictable. Antibiotics are not prescribed unless there is an active infection. Halitosis is present for a week. Most children tolerate a normal diet the day of surgery. Most children can return to school and all activities the next day. Rarely, older children may complain of neck discomfort or younger children may not want to look up or to the side for a few days after surgery. Subluxation is always a consideration, especially in children with Down Syndrome. There is very little in our literature about this neck discomfort, which prompted a recent survey of *American Society of Pediatric Otolaryngology* (ASPO) members [3]. Our experience is that a few doses of NSAIDs remedy the discomfort. If there is a low grade fever, then an antibiotic is also prescribed.

More advanced considerations: Recurrence of adenoid tissue and the need for more than one adenoidectomy is often brought up by parents. Since we began performing adenoidectomy with a microdebrider, revision adenoidectomy has been very unusual. That being said, approximately once a month, a patient presents with nasal symptomatology after a previous adenoidectomy. It is often after a cautery adenoidectomy. It may be that cautery adenoidectomy is less effective in removing all the lymphoid tissue, especially with a large adenoid.

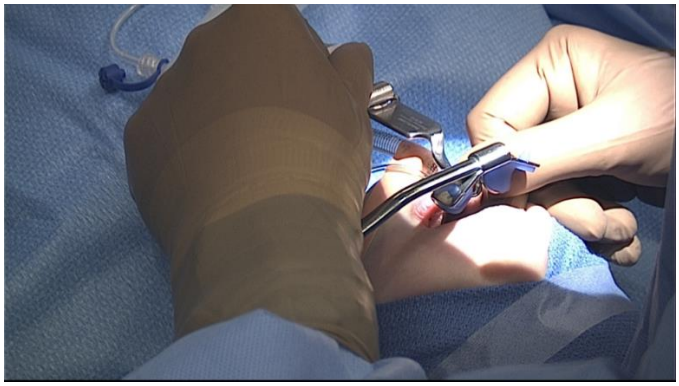

Figure 3. Oral Stabilizer (mouthgag) being placed with lubrication on the tongue blade to decrease the possibility of displacement of the Laryngeal Mask Airway (LMA).

Figure 4. This surgical image depicts the position of the flexible LMA having been pulled back after the tongue blade has been inserted and the oral stabilizer opened. This manuever is the key to the procedure's success and requires excellent communication with the anesthesiologist. It is imperative to confirm that the distal end of the tongue blade does not create an acute angle of the flexible LMA, reducing the ventilation. Most cases require that the LMA be pulled back and that the Mayo stand not be raised too high as not to limit the airway.

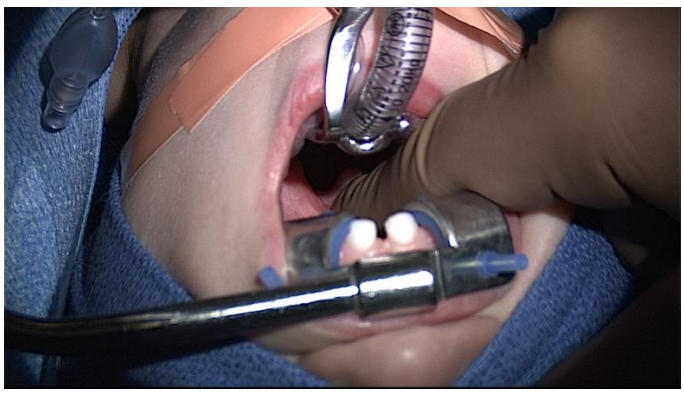

Figure 5. This surgical image indicates how the surgeon should palpate the soft palate to confirm whether or not it reaches the posterior pharyngeal wall. If it does not reach that far, more of the inferior tissue is conserved to reduce postoperative nasal emission.

Figure 6. This surgical image demonstrates the application of topical oxymetazoline placed with an angiocatheter prior to the placement of the oral stabilizer to allow for nasal decongestion and improve nasopharyngeal hemostasis.

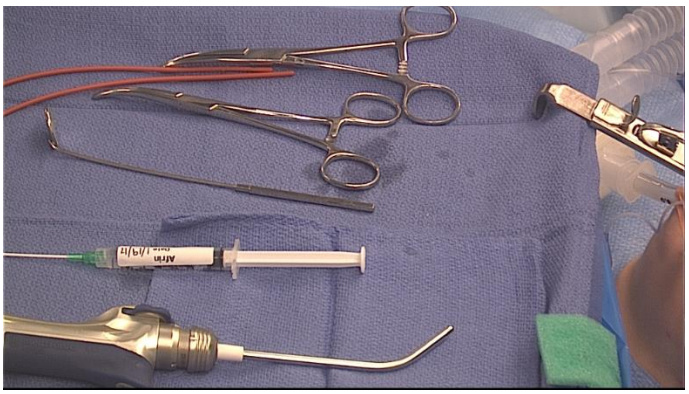

Figure 7. This photograph shows the surgical set up for adenoidectomy with only essential equipment. With less equipment used the overall cost for each case is reduced and the operating room can order more case carts, reducing the need for flash sterization and improving instrument longevity. Note the position and angle of the antifog applicator (green-lower left) for ease of use; also note that the cloth towel is covering the metal Mayo stand. The endotracheal tube and extension tubing is routed above the drapes so accidental disruption is avoided.

Figure 8. Introperative photo showing how the temporary extra retraction of the red rubber catheter with the fourth finger produces improved visualization, especially superiorly in the choanal area without uvular swelling, which is worsened by continuous tight retraction of the soft palate.

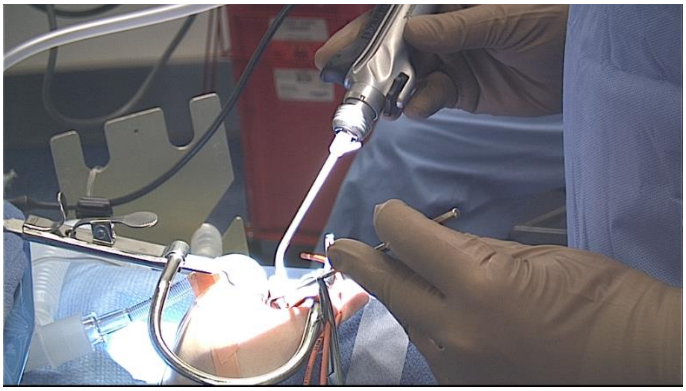

Figure 9. An intraoperative example of how to use the mirror to cover the suction hole when entering and exiting the mouth to avoid trauma to surrounding anatomy such as the uvula, buccal mucosa, or tongue.



Figure 10. The console of microdebrider (Medtronic) set at 2000 RPM in oscillating mode with endoscrub function off.

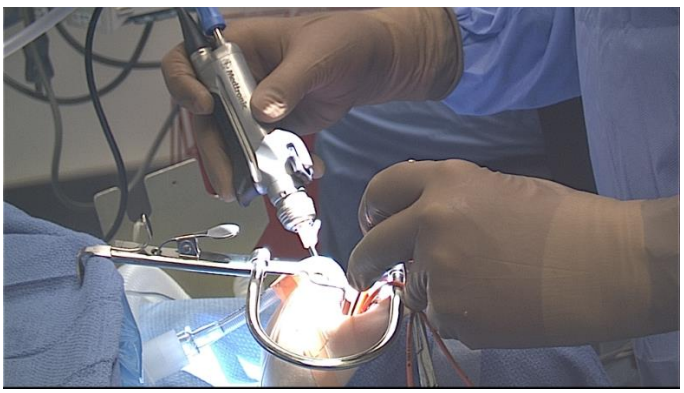

Figure 11. This intraoperative photograph shows the commencement of powered adenoidectomy. Temporary retraction of the left red rubber catheter and the angle of the microdebrider (with open right side for right handed surgeon) starts in the left choana.

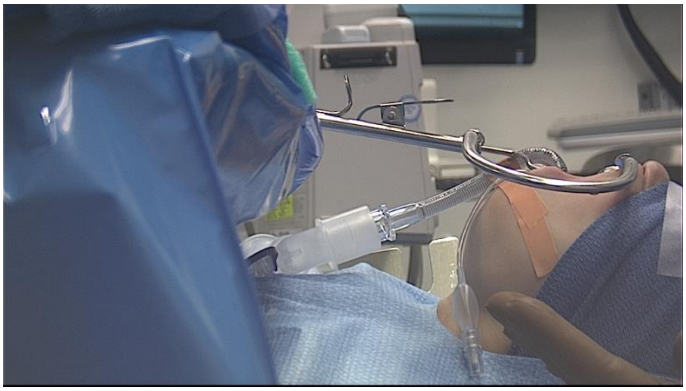

Figure 12. This intraoperative photograph indicates why it is imperative to appreciate the angle of the nasopharynx for each case. This angle is dependent on multiple variables, including the patient's age, tongue size, angle of the tongue blade, as well as the use of an endotracheal tube or LMA. Often the position of the inferior portion of the nasopharynx is higher than the choanal portion, as depicted by my external hand position. Care must be taken to debride lymphoid tissue more superficially when operating on the inferior portion of the adenoid, especially in the lateral aspect.

Figure 13. This photograph was taken 2 years after the powered adenoidectomy. Notice the healed smooth nasopharynx and structure emanating from the torus tubarius. There is no adenoid regrowth. The superior portion of the torus has a small notch and all the adenoid tissue had been removed from there.

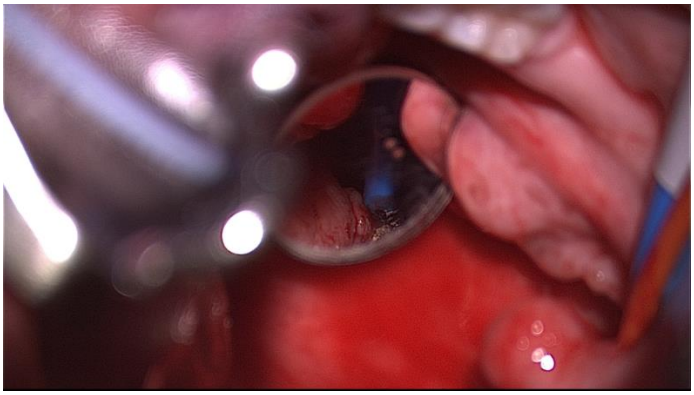

Figure 14. This intraoperative photo shows the structure emanating from the left torus tubarius, which should not be mistaken for adenoid tissue.

The torus tubarius is not a perfectly straight structure. There is always a small notch behind the superior portion of the torus tubarius on both sides that has adenoid tissue. If that tissue is not removed, it may hypertrophy long after the surgery. This can be seen in the healed nasopharynx approximately 2 years after adenoidectomy (Figure 13). Also note in this postoperative photograph the complete removal of all adenoid tissue and the smooth, healed nasopharynx, which reduces the adherence of bacteria and biofilm and which may improve surgical results for rhinosinusitis and middle ear issues.

Another observation is there is often a structure seen emanating from the midportion of the torus (Figures 13 and 14). It is seen much more prominently in children having adenoidectomy for non otologic reasons. It may be a dilator of the eustachian tube and should not be mistaken for adenoid tissue.

REFERENCES

[1] Koltai, Peter J., Axay S. Kalathia, Paul Stanislaw, Heidi A. Heras. 1997. "Power-assisted Adenoidectomy." *Archives Otolaryngology Head & Neck Surgery.* 123 (7):685-8.

[2] Kakani, Rajesh S., Noreen D. Callan, and Max M. April. 2000. "Superior Adenoidectomy in Children with Palatal Abnormalities" *ENT Journal* 79 (4):300-5.

[3] Timen, Micah, Marisa Earley, and Max M. April. "Current Practice in Adenoidectomy: A Survery of Pediatric Otolaryngologists and Review of the Literature." *Podium presentationat SENTAC,* Orlando Florida, Dec 3, 2016.

In: Encyclopedia of Surgery (22 Volume Set)
Editors: Andreas Lehrer and Kristin Mueller
ISBN: 978-1-53618-329-0
© 2020 Nova Science Publishers, Inc.

Chapter 165

INTRACAPSULAR TONSILLECTOMY: MY SURGICAL APPROACH (MAX M. APRIL, MD, FAAP, FACS)

Max M. April*, MD
Department of Otolaryngology, New York University/Langone Medical Center
New York, NY, US

ABSTRACT

This chapter reviews the thought process that I have developed in my practice over the last 16 years. It will not include references and comparisons to the experience of others. It will describe how I evaluate patients, discuss options with parents, and perform intracapsular tonsillectomy, as well as my postoperative instructions.

Keywords: intracapsular tonsillectomy, partial tonsillectomy, tonsillotomy, tonsillectomy, pediatric sleep apnea

INTRODUCTION

When evaluating children with obstructive symptoms, perform the history first. Apnea or gasping for air, restless sleep, frequent awakenings, snoring, tiredness during the day, and enuresis should all be discussed. In addition, dysphasia for solids and speech articulation with emphasis on hyponasality should also be reviewed. There are many times when parents answer clearly and convincingly regarding the above symptomatology. There are other times when the answers are not so apparent. In those cases, I recommend that parents observe their child's sleep two hours after the child goes to sleep for at least one hour. Ask the parents to make video and audio of the worst episodes, then edit these to show only the times where

* Corresponding Author's Email: max.april@nyumc.org.

they are concerned before sharing them with the otolaryngologist; the editing will save a lot of time during your office hours.

Prior to 2000, during the risk/benefit discussion, there were many times when I would recommend a formal sleep study, a polysomnographic evaluation (PSG), to determine whether ET/A should be undertaken. When discussing a 2% chance of postoperative bleeding, possible dehydration, and missing school for up to 2 weeks, it was prudent to have objective evidence from a PSG as a comparison point. I rarely would operate without an abnormal PSG. Now that intracapsular tonsillectomy gives us very little chance of bleeding, as well as a quick return to normal activity/school, balanced with only a small chance of tonsil regrowth, the pro/con risk/benefit question takes on a different process. Is restless sleep and snoring an indication for surgical intervention? There have been many parents that have described Powered Intracapsular Tonsillectomy and Adenoidectomy (PITA) as life changing for their child. I suspect that many of these children may have "passed" a PSG, but in reality their upper airway obstruction and sleep disordered breathing was treated with PITA, and in fact, had a large impact on their development. I would like to be able to conduct a study where like groups are compared and both study and define neurocognitive changes after resolution of what was previously diagnosed as primary snoring (normal PSG). However, neurocognitive changes are extremely difficult to study and to compare, especially after surgical intervention.

Other potential indications for surgery such as infectious episodes including sinusitis, pharyngitis, non-streptococcal tonsillitis, and streptococcal tonsillitis are reviewed through the electronic medical record. Three diagnoses that virtually eliminate the possiblity of PITA are periodic fever with apthous stomatitis, pharyngitis and cervical adenitis (PFAPA), previous peritonsillar abscesses, and possibly pediatric autoimmune neuropsychiatric disorders associated with streptococcal infections (PANDAS), although the role of tonsil surgery in PANDAS is very controversial.

In my experience, the physical exam is paramount in discussing which surgical procedure should be considered. I evaluate tonsil size in more than just two dimensions, which is represented by the standard 1+ to 4+ scale. There are exophytic tonsils and endophytic tonsils. In addition, the endoscopic evaluation of the tonsil length and anterior to posterior size is important. There are times when a transoral evaluation of tonsil size is very different than a nasopharyngeal endoscopic examination. Inferior tonsil hypertrophy may involve laryngeal obstruction that cannot be truly appreciated transorally. I like to think that a better scale to measure tonsil size would be one based on volume rather than one based on a two dimensional measurement. When there is a larger anterior/posterior dimension, swallowing difficulties and hyponasality are more affected. Parental observation of the upper airway endoscopy in the office is also extremely helpful in the surgical discussion (video X). If only one parent is present at the visit, I suggest that they video the endoscopy with their phone to show the other parent; one video is often worth a tremendous amount of dialogue.

Early in my career, I remember that almost all children undergoing ET had 4+ tonsils. If the tonsils were smaller than 4+ and the adenoid was large, then adenoidectomy alone was often the chosen option. More recently, there have been many patients that have 2-3+ tonsils and have abnormal sleep (video X). There are times I have evaluated a child for another reason, seen 4+ tonsils, and asked the parents if the child snores. The answer has at times been an emphatic "no." My explanation is that there is a unique equation for each patient that adds up the anatomic airway (tonsils, adenoid, tongue, jaw position) and the physiologic

contributions (underlying muscle tone, medical issues, and medications) explaining whether there is obstruction manifested by snoring. With the low complication profile of PITA, perhaps the diagnosis of primary snoring should be addressed surgically thereby improving sleep for these children.

There are certain diagnoses that should only have an extracapsular tonsillectomy performed. These include periodic fever syndrome (PFAPA), previous peritonsillar abscesses, pediatric autoimmune neuro psychiatric disorders associated with streptococcal infections (PANDAS), and those where asymmetry and malignancy is a concern. I also may recommend extracapsular tonsillectomy for endophytic tonsils, cryptic debris, and tonsilliths, especially in adolescent patients, unless there are extenuating circumstances where bleeding is more than the usual concern (coagulopathies, platelet disorders, or patients who are Jehovah's witnesses) or they are patients who use their voices professionally and scarring is more than the usual concern.

INTRACAPSULAR TONSILLECTOMY TECHNIQUE

Beginning Technique

After completion of the adenoidectomy (see Chapter 164), approach the right tonsil with the curved microdebrider blade (irrigation of the blade is not necessary). The photographs presented will be either from a 3 year old boy (Figure 1) with obstructive sleep apnea (witnessed apnea and awakening nightly) or a 5 year old girl (Figure 2) with recurrent streptococcal tonsillitis and snoring (her parents chose PITA because of her underlying neurologic issues).

For the first 10 years of intracapsular tonsillectomy, the microdebrider was set to 1500 RPM, and for the last 6 years, it has been set at 2000 RPM. It is extremely important that the unitiated surgeon be aware how much potential damage the microdebider can cause if absolute precautions are not adhered to. When one observes instructors or video procedures, the use of the microdebider appears to be simple, but that is the result of the surgeon's experience. Mastering the hand, foot, and eye coordination takes time. It is imperative that surgeons focus their most heightend awareness while performing the surgery because these blades are extremely sharp and any break in concentration can produce unintended damage.

After setting the microdebrider speed, the oral stabilizer is used, and the tongue blade size chosen. Usually, I recommend using the smaller tongue blade (how often would a size 2.5 work better?) to decrease the trauma between the tongue blade and the mandible (Figure 3). Upon entry into the oral cavity, the opening of the blade should be covered with the Hurd elevator. The coated Hurd elevator is used to retract the uvula superiorly (Figure 4), which exposes the most superior aspect of the tonsil. The coated Hurd protects the patient from thermal burns from transmission through a non-coated intrument. The microdebrider is used to engage the most superior aspect (Figure 5), and the dissection is carried from superior to inferior. The best approach is to identify the proper level of dissection at the most superior level (video X). The difference in retraction can be seen in the example of the 5 year old in Figure 6, where the retraction is not sufficient and in Figure 7, where there is more superior retraction, which allows the dissection to begin in the proper plane. Using the ipsilateral hand

for the same size tonsil is safer because the anterior tonsillar pillar prevents the blade from removing too much tissue. It is a more conservative resection, but does take more time to perform.

The initial surgery I performed in my beginning experience involved taking the tonsil tissue to the level of the anterior and posterior tonsillar pillar. This process removed between 75 and 80 percent of most tonsils and improved the airway and the obstruction. Once surgeons acquire more experience, they can perform deeper dissections and remove more of the tonsil tissue.

Once the superior aspect of the tonsil has been addressed, the Hurd elevator is used in several different ways. It can be used to retract the most posterior tonsil tissue off the posterior pharyngeal wall to allow easier removal and prevent injury to the posterior pharyngeal wall. It can also be used to retract the inferior most tonsil tissue away from the base of tongue to facilitate resection (Figure 8). The anterior tonsillar pillar can also be retracted with the elevator to further the anterior tonsil dissection. The tonsil tissue is cauterized with a suction cautery (foot pedal controlled) on the most inferior 3/4 of the fossa. The superior ¼ is not cauterized until after the red rubber catheters are removed (after obtaining hemostasis in the nasopharynx) because there is more space with the catheters out (Figure 9) and less opportunity to produce thermal damage to the mucosa. Using a foot pedal controlled suction cautery (15-20 watts) is quite helpful because one can suction with the hole open when cauterizing superiorly. If using the finger controlled suction cautery (holding the cautery button down and covering the suction port), one must use extreme care not to accidentally cauterize the uvula, which would cause increased pain, and when the uvula swells, more trouble breathing and swallowing in the postoperative period.

After the lower portion of the right tonsil is cauterized, use the debrider for the left tonsil. When inexperienced, the ipsilateral hand should hold the debrider of the tonsil that is being resected. Using the ipsilateral hand prevents going too deep and potentially through the capsule, which would increase pain and potential bleeding. When removing the debrider blade, confirm that your foot is not on the pedal and that the Hurd is used to cover the opening so the uvula is not injured. Always watch with extreme vigilance until the debrider has been completely removed from the oral cavity so the buccal mucosa or lip do not become collateral damage. Following this step, cauterize the lower portion of the tonsil. Remove the tonsil sponges from the nasopharynx and cauterize the adenoid bed. Remove the red rubber catheters (video X) because the exposure is much better without them retracting the soft palate and pullling the tonsil pillars closer, then cauterize the superior portion of the tonsil fossa (Figure 10). It is important to concentrate on the superior portion, especially with the cautery because that is the most common area of “recurrent” tonsil tissue after PITA. The handheld cautery is very useful, especially in a surgeon’s early experience to “get” tissue that may have not been debrided. Spending more time with the cautery on that tissue will electrodissect it. It is important to make the tonsillar fossa as smooth as possible when finished. Use the cautery for even more removal of uneven areas, which are potential areas of biofilm adherence, and in turn could promote tonsil regrowth. The best analogy is the goal of mastoidectomy, to make the cavity as smooth as possible. The tongue blade is let down one notch and iced saline is used to irrigate the oral cavity and the nasopharynx.

Early on, we noticed that children recovering from PITA complained about tongue discomfort or that their tongue was cut. It was a new complaint, one rarely seen after ET. Most likely the reason is that there is less tonsil pain so now the patients notice the tongue

pain. One maneuver that has helped reduce the tongue pain is using iced saline irrigation, and then after the mouthgag is removed, the tongue is massaged with an iced saline soaked gauze. I used the above techique for the first few years of my intracapsular tonsillectomy experience, only for patients with obstructive symptomatology. For early adapters of IT, I suggest using this technique until surgeons are completely comfortable with this procedure.

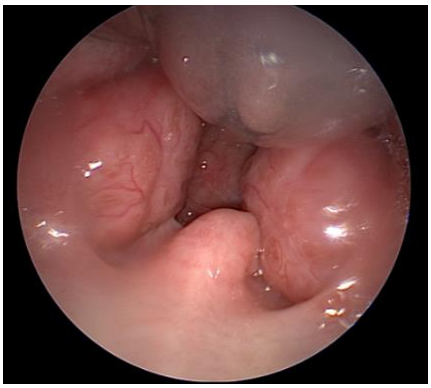

Figure 1. A 3 year old boy with 4+ thick exophytic tonsils is shown. The surgeon is placing the oral stabilizer.

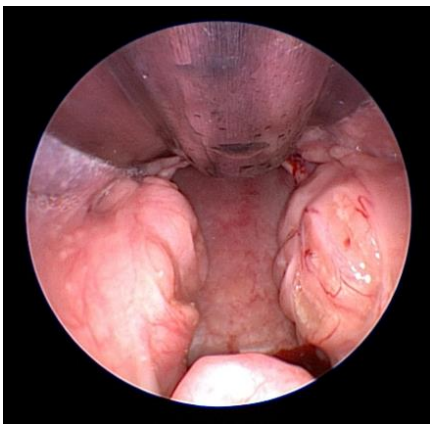

Figure 2. A 5 year old girl with recurrent tonsillitis and right exophytic and left endophytic tonsils.

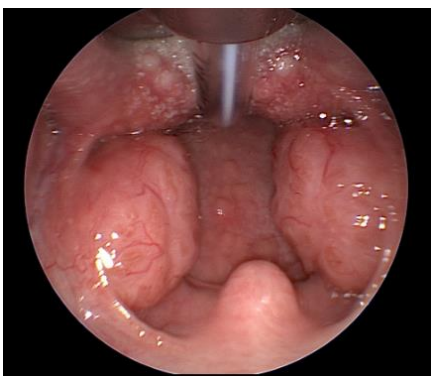

Figure 3. A 3 year old with size 2 tongue blade in place is shown in this endoscopic image.

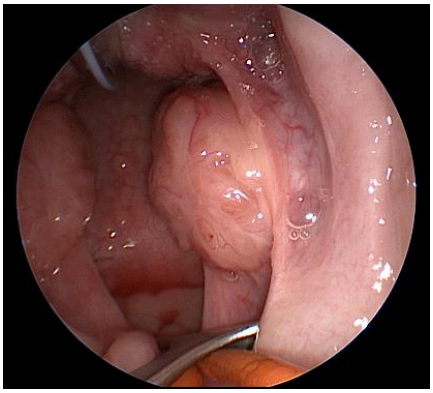

Figure 4. This endoscopic image shows the beginning of the procedure, with retraction of the soft palate with a coated Hurd elevator.

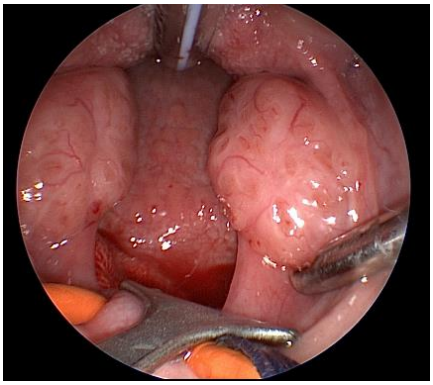

Figure 5. This endoscopic image shows more retraction of the soft palate to allow engagement of the most superior portion of the tonsil.

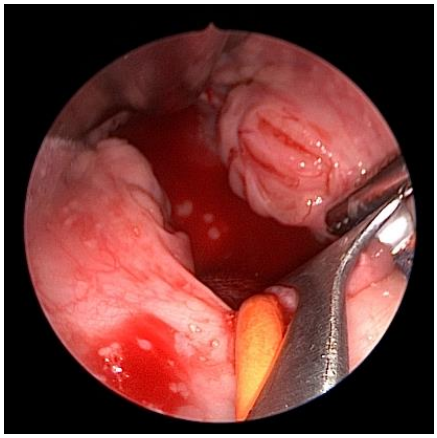

Figure 6. This photo shows not enough retraction superiorly. If the dissection started at this point, less tonsil tissue is removed.

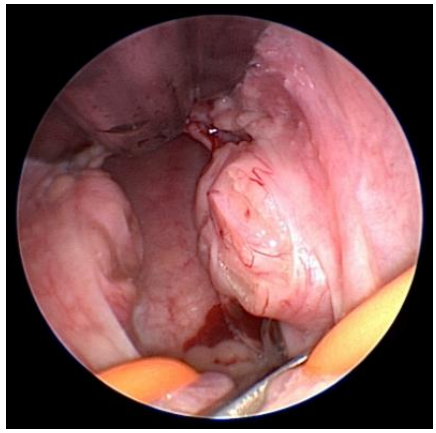

Figure 7. With more superior retraction, the deeper portion of the tonsil can be engaged with the debrider blade.

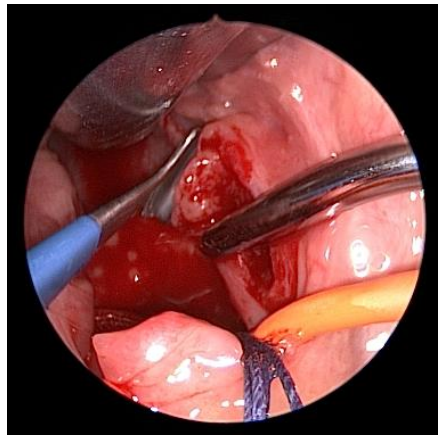

Figure 8. The coated Hurd elevator can be used to bring the inferior tonsil tissue away from the base of the tongue to reduce injury.

Figure 9. Cautery of the superior portion of the tonsil fossa is more effective without the red rubber catheters in place, thereby giving more exposure to the area.

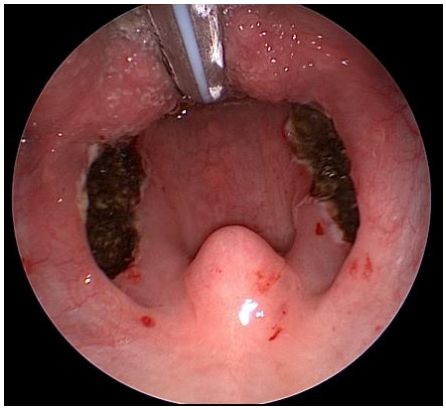

Figure 10. Completion of the procedure in the 3 year old.

More Advanced Technique

With more experience and the inclusion of children with infectious indications, several modifications were made for PITA. For a right handed surgeon, the right tonsil is addressed, but the dissection is continued deeper with different retraction maneuvers (video X), including pushing the posterior pillar more anteriorly, which in turn pushes more tonsil tissue to be debrided. Retracting the anterior pillar more also allows more access for increased removal of tissue. Another change was that the left tonsil was then debrided with the Hurd elevator placed behind the posterior pillar (video X) , creating a tourniquet effect (Figure 11). Not only does this technique cause less bleeding, but using the contralateral hand is a more aggressive removal of tissue (Figure 12). It is much easier to go too deep with this technique, and there is a higher learning curve. Because the dissection of the left tonsil is quicker, one does not need to cauterize in between debriding the two tonsils. Without changing from debrider to cautery twice, the procedure is less time consuming. There are patients with cryptic debris or tonsilliths that can make the shaving much more challenging, often in the superior pole area. These crypts must be closely followed (Figure 13) and all of the debris removed or there is a much higher likelihood of tonsil regrowth. In patients with infectious indications for surgery, a more deep dissection can be considered: this is known as extended IT. Extended IT is my procedure of choice, especially in voice professionals (Figure 14) or in children that have underlying muscular issues where ET may have too much negative impact on speech, voice, and swallowing. These patients often have more discomfort and certainly more otalgia, both of which should be included in the preoperative discussion. When healed, they still have their anterior and posterior tonsillar pillars, as well as the preoperative pharyngeal height. Please review the multiple surgical videos of IT (videos X-X).

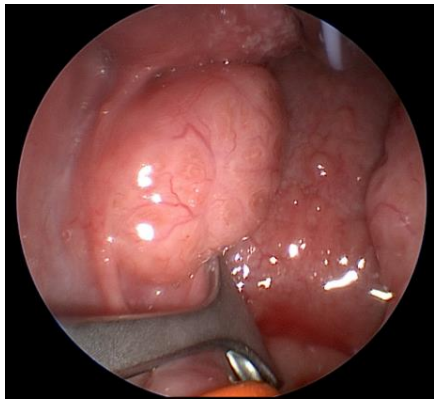

Figure 11. The beginning retraction of the left tonsil with the Hurd elevator.

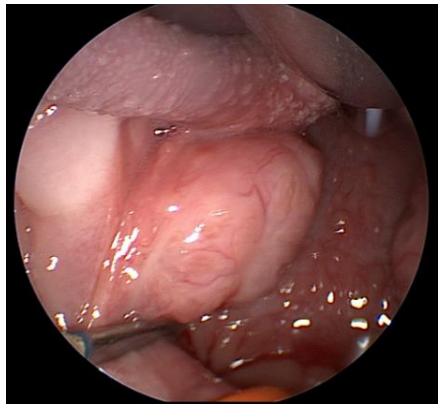

Figure 12. More retraction is at risk. With the use of the right hand debriding the left tonsil, the dissection is quicker and more aggressive.

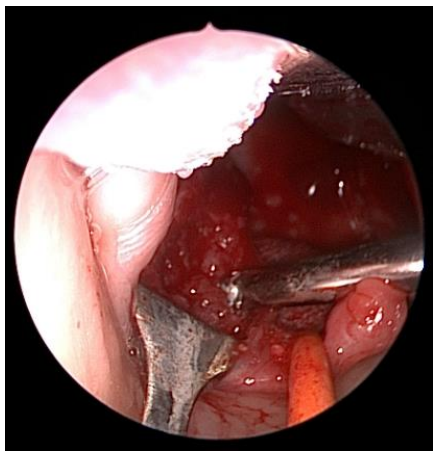

Figure 13. In patients with endophytic or cryptic tonsils, the soft palate retraction is needed for deeper dissection and to follow the cryptic debris.

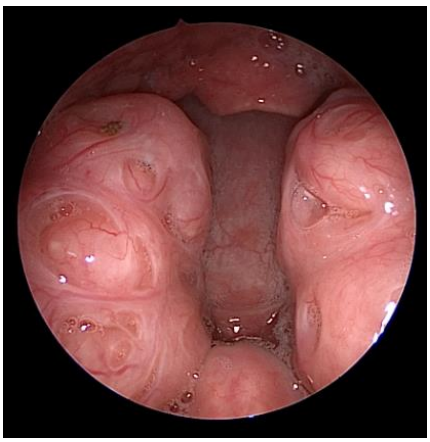

Figure 14. An example of large cryptic tonsils in a Broadway performer. PITA was chosen despite the cryptic tonsils, to reduce impact on her voice.

POSTOPERATIVE CARE

Initially, narcotics were prescribed after IT. After several years of parents saying that their child never used the prescription, that practice was changed. Since 2010, a narcotic prescription is not given after the surgery, with very few exceptions. Acetaminophen and NSAIDs are used as needed in the postoperative period, including the PACU, if necessary. It is still recommended not to use NSAIDs for 1 week prior to surgery, especially not for the 48 hours prior to surgery. Whereas ET would be cancelled if there were NSAIDs given in the 2 days prior to surgery, there have been instances when IT was performed with some hesitation, but without bleeding (as of yet). There are some children that take no medication for pain postoperatively. Some patients are given acetaminophen (10 mg/kg) once or twice a day and some children need medication more often. Older patients are given medication if requested for pain, while it is recommended to give younger children either acetaminophen or NSAIDs, if they are not eating or drinking well, even if they are not complaining of pain. The worst case scenario, which rarely occurs, is using acetaminophen alternating with NSAIDs (10 mg/kg).

Antibiotics are not routinely used intraoperatively or postoperatively. The exceptions include a purulent rhinosinusitis or tonsillitis at the time of surgery. Halitosis is almost universal (much more common since not using antibiotics as the American Academy of Otolaryngology Head and Neck Surgery (AAO-HNS) recommended in 2011). This halitosis usually resolves in a week. Increased fluid intake helps somewhat. If neck pain develops a few days after surgery, NSAIDs are recommended (see Chapter 164).

Postoperative dietary restrictions are few. For the first few days, the child should not eat anything hard or scratchy, such as pizza or pretzels. Eating almost anything else is not a concern. Many parents describe stopping at the child's favorite food establishment for chicken nuggets, burgers, or pasta on the way home from the hospital.

Activity and return to school are variable and up to parental decision. Some children return to school the next day, but the usual time period is 2-4 days after surgery. There are no

physical activity restrictions for younger children, but older patients should not participate in organized sports for one week.

One last topic that must be addressed is what happens if completion tonsillectomy is necessary in the future. The reasons for this may include a peritonsillar abscess (certainly a recurrent one) after PITA or continued streptococcal infections or tonsilliths. I have performed 3 completion tonsillectomies after PITA. All three procedures were very straight forward and there was no excessive bleeding or pain.

In: Encyclopedia of Surgery (22 Volume Set)
Editors: Andreas Lehrer and Kristin Mueller
ISBN: 978-1-53618-329-0
© 2020 Nova Science Publishers, Inc.

Chapter 166

INTRACAPSULAR TONSILLECTOMY: MY SURGICAL APPROACH (ROBERT F. WARD, MD, FACS)

Robert F. Ward, MD
Department of Otolaryngology, New York University/Langone Medical Center,
New York, NY, US

ABSTRACT

This chapter, like the next one by Dr. John Bent, will highlight the differences and similarities between my approach to intracapsular tonsillectomy and adenoidectomy relative to what has been described by Dr. Max April in chapter 165.

Keywords: intracapsular tonsillectomy, partial tonsillectomy

INTRODUCTION

I am in agreement with Dr. Bent (see Chapter 167) that intracapsular tonsillectomy has been one of the biggest advances in pediatric otolaryngology during my career. It has certainly advanced patient safety and demonstrated equal efficacy to extracapsular tonsillectomy. The main risk in tonsillectomy has always been postoperative hemorrhage. With the use of the intracapsular tonsillectomy technique, postoperative hemorrhage has become an insignificant concern. Only one of my patients has required follow-up for a post tonsillectomy bleeding episode and this turned out to be the result of an undiagnosed von Willebrand's disorder. Even in this case, the bleeding was not truly life-threatening, but rather recurrent and of low impact.

As has been mentioned by Dr. April, I do discuss the two types of tonsillectomy with all families before their child's surgery. Very frequently the parents indicate that they have been misinformed about intracapsular tonsillectomy and believe the procedure is associated with more bleeding than with extracapsular tonsillectomy. Many parents are also concerned that

after intracapsular tonsillectomy there is the risk for the tonsils to regrow very frequently. This certainly has not been our experience [1]. In my experience, the development of tonsil regrowth to the point where the child experiences obstructive symptoms again is less than 1%. Likewise, this tends to occur in the very young children. In our paper [1], we did not see any significant regrowth in children over the age of five when the ITA was performed.

I agree with Dr. April that there are certain diagnostic situations that indicate only an extracapsular tonsillectomy should be performed. These include: periodic fever syndrome, pediatric autoimmune neuropsychiatric disorders associated with strep infections, and cases of pediatric tonsillar malignancies.

However, I do think that over time we will see more and more intracapsular tonsillectomies performed for recurrent streptococcal infections. While the literature includes only a few papers suggesting that the efficacy of intracapsular tonsillectomy is equal to that of extracapsular tonsillectomy for the control of recurrent tonsillitis, anecdotally, I have performed over 40 intracapsular tonsillectomies for the treatment of recurrent strep infections. Of these, I have taken one patient who initially underwent a coblation tonsillotomy for recurrent strep infections back to the operating room for a completion tonsillectomy.

I agree with Dr. Bent that Powered Intracapsular Tonsillectomy and Adenoidectomy (PITA) seems to be more effective than extracapsular tonsillectomy in treating hypertrophic tonsils. However, I still favor Extracapsular Tonsillectomy and Adenoidectomy (ETA) for small, endophytic, and contracted tonsils. For larger endophytic tonsils, I tend to perform an Intracapsular Tonsillectomy and Adenoidectomy (ITA). These cases are a bit more challenging than the exophytic tonsillar tissue, but still can be done effectively.

PREOPERATIVE CONSIDERATIONS

I echo the preoperative considerations suggested by Dr. Bent. I would like to emphasize the specific issue regarding children who demonstrate abnormal speech patterns and the ensuing consideration of tonsillectomy and adenoidectomy. These particular children do require preoperative speech evaluation. If there is any anatomical suggestion of palatal dysfunction, I would strongly recommend PITA. It has been demonstrated that a tonsillectomy and adenoidectomy are not contraindicated for children with hypernasal speech or with a bifid uvula.

Dr. April's observation regarding the potential for lateral pharyngeal wall scarring seen after ETA may worsen not only sleep issues, but also the hypernasal speech issues. This type of scarring is never seen after ITA. Likewise, if there are hypertrophic tonsils noted in a patient who is to undergo a posterior pharyngeal flap for velopharyngeal insufficiency, we perform an IT concurrently with the posterior pharyngeal flap. We presented our results for IT and concomitant posterior pharyngeal flap for velopharyngeal dysfunction at The Society for Ear, Nose and Throat Advances in Children (SENTAC). In 12 patients we had no problems in performing the two procedures together. The risk of scarring of the palatopharyngeus and palatoglossus muscles is much less with IT than with ET.

INTRACAPSULAR TONSILLECTOMY TECHNIQUE

Before beginning intracapsular tonsillectomy, I perform the adenoidectomy with a curved microdebrider. There are times that the tonsils are so enlarged that the nasopharynx cannot be adequately accessed with a mirror; therefore, I will perform the IT before the adenoidectomy. For the first several years, starting in 2000, I performed IT, patients were orally intubated for the combination of adenoidectomy and tonsillectomy. In the last few years, several of our anesthesiologists have favored a laryngeal mask airway (LMA) for adenoidectomy. I think that this is also possible to use LMA in many cases for intracapsular tonsillectomy. As has been mentioned by Dr. April, I favor using a smaller tongue blade for IT. When using a LMA, I believe that for the stabilization and correct fitting of the laryngeal mask airway, it is necessary to use a larger tongue blade.

In keeping with the AAO-HNS guidelines we typically give intraoperative steroids during the course of IT. Intravenous antibiotics are not routinely given. As Dr. Bent has discussed, we occasionally will use postoperative antibiotics in a child that shows evidence of mucopurulent secretions emanating from the nasopharynx or when mucopurulent secretions are found in the oral endotracheal tube at the end of the procedure.

I start the procedure by elevating the soft palate with a red rubber catheter. I typically place the catheter in the right nostril and try to elevate and "hide" the uvula with the single catheter. It is been my experience that if two catheters are used, the uvula is left protruding in the midline and is at a higher risk for injury with the debrider blade.

I favor using the microdebrider over the coblator or other methods. This tool allows for cleaner removal of the lymphoid tissue without generating any significant thermal injury to the surrounding tissues. I began performing PITA with the debrider set at 1500 RPMs. Throughout my experience, I have continued to use this setting, even though I've experimented with slightly higher rpms. It is important to have the debrider blade set on the oscillating setting. As will be discussed by Dr. Bent, the slower speed does allow more tissue to be suctioned into the blade and transected than at higher RPMs. In my experience, the need for powerful suction on the debrider is extremely important. Again, this allows for more of the tissue to be suctioned into the blade and seems to cause less bleeding. Being right-handed, I start with the left tonsil for the same reason that most right-handed surgeons perform septoplasty from the left nostril. It is generally easier to operate with a surgical instrument directed towards the surgeon rather than away. This also places the hand in a more natural pronated position. For the right-handed surgeon, removing the right tonsil first places the hand in a less desirable supinated position.

Before any cauterization, I attempt to shave both tonsils. I follow Dr. April’s pointers in using the hurd elevator to help deliver the tonsillar tissue. I also strongly agree that recurrent tonsil growth most commonly happens at the superior pole region. In particular, I spend as much time as necessary trying to clear as much of the superior tonsillar tissue as possible. I agree with Dr. April on the concept of the extended PITA, particularly when indications for surgery involve recurrent infections, cryptic tonsils, or tonsil stones.

After intracapsular removal of the tonsils, I usually place cold wet gauze in the area of both tonsils. This seems to help to decrease any oozing from the tonsillar beds. I then use the suction cautery on a setting of 25 Watts. I do not distinguish any difference in cauterization from the inferior or superior poles. I do not think that the extent of cauterization on the

remaining lymphoid tissue impacts on the degree of postoperative pain. I irrigate the nasopharyngeal and tonsil beds copiously prior to removing the mouth gag. I have found that reopening the mouth gag is not necessary.

POSTOPERATIVE CARE

I follow the postoperative care instructions that have been described by Drs. April and Bent. I recommend a combination of acetaminophen and NSAIDs. I do not suggest any dietary restrictions. I allow the children to eat anything they are comfortable with. The level of activity and the return to school is variable, as has been suggested. In the younger children, I do not suggest any restrictions of activity. In the older children, I ask that they refrain from organized physical activity for one week.

I typically see patients 1 to 2 weeks after surgery. I agree with Dr. Bent that routine follow-up is perhaps unnecessary. In those children with unusual findings in the operating room or who have preoperative documented obstructive sleep apnea, I do believe that they should be seen postoperatively and may need a follow-up sleep study performed.

REFERENCE

[1] Doshi, Hardik H., David E. Rosow, Robert F. Ward, and Max M. April. 2011. “Age-related tonsillar regrowth in children undergoing powered intracapsular tonsillectomy.” *International Journal of Pediatric Otorhinolaryngology*, 75(11):1395-8.

In: Encyclopedia of Surgery (22 Volume Set)
Editors: Andreas Lehrer and Kristin Mueller
ISBN: 978-1-53618-329-0
© 2020 Nova Science Publishers, Inc.

Chapter 167

INTRACAPSULAR TONSILLECTOMY: MY SURGICAL APPROACH (JOHN P. BENT, MD)

John P. Bent*, MD
Department of Otolaryngology-Head & Neck Surgery,
Pediatrics Albert Einstein Medical College/Children's Hospital at Montefiore
Bronx, NY, US

ABSTRACT

This chapter highlights the differences between my approach to intracapsular tonsillectomy and adenoidectomy (ITA) relative to what Dr. April described in Chapter 165.

Keywords: intracapsular tonsillectomy, partial tonsillectomy, tonsillotomy

INTRODUCTION

Among surgeons who are willing to consider performing ITA or ETA, most tend to prefer one technique over the other. Given the right circumstances, I strongly prefer ITA. ITA represents one of the biggest advances in pediatric otolaryngology, during my career, in terms of advancing patient outcomes and safety. I have completed over 2,000 ITAs and have never taken a patient back to surgery for hemorrhage. The marked reduction in pain essentially obviates the need for narcotics. By taking postoperative exsanguination and death from narcotic-induced respiratory depression "off the table," ITA eliminates the two main causes of dreaded post-tonsil mortality.

Undoubtedly, my bias influences my evaluation, and the consent process, but I try to keep all patient encounters transparent and objective. After the discussion of potential risks, benefits, and alternatives, nearly all families to whom I recommend ITA accept my

* Corresponding Author's Email: jbent@montefiore.org.

recommendation. If they choose ETA despite my recommendation, I ask them why. Often their answer reflects a lack of understanding, for instance they may say "I don't want my child to go back under anesthesia if the tonsil regrows," not appreciating that the risk of going back under anesthesia is roughly equivalent between the two procedures. It is important for families to appreciate that the return to the operating room (OR) with regrowth after ITA is elective and controlled, whereas with post-ETA tonsil hemorrhage it is both emergent and potentially life-threatening. Once parents comprehend this, it is rare that they choose ETA when ITA is indicated.

Those surgeons whose training and experience lead them to favor ETA often report that when they offer their patients ITA, families usually choose ETA. Most likely this reflects their own bias. In general these surgeons either trained before ITA was commonplace, or their residency program offered limited or no ITA training. For the last 18 years, having taught ITA to 3-4 residents/year – residents who were also exposed to attending physicians who favored ETA--they have all, as far as I am aware, embraced ITA.

I agree with Dr. April's approach, with the following additions.

PREOPERATIVE CONSIDERATIONS

The decision to order sleep studies should be guided by AAO-HNS guidelines, and does not have any bearing on whether to perform ITA or ETA. Sleep studies are most useful when one suspects severe obstruction, in that they can guide postoperative care plans (such as the need for hospitalization or intensive care) and serve as a measure for improvement if repeat studies are indicated postoperatively. Sleep studies are also useful for when the history and/or physical exam is underwhelming, yet family or another provider strongly advocates for surgery.

Isolated tonsil asymmetry is not a risk factor for malignancy. Rather, it is a manifestation of asymmetrically positioned tonsils of equivalent volume. In asymmetric tonsils, ITA works well when indicated.

Tonsil hypertrophy after organ transplantation may suggest posttransplantation lymphoproliferative disorder. In our tertiary practice this is the most common tonsil neoplasm, and when this or any other malignancy is suspected, ETA should be performed. ITA works well for hypertrophic tonsils with tonsilliths, as long as the surgeon is careful to obliterate all crypts.

Sickle cell anemia tends to lead to auto-infarction of the spleen, which often leads to compensatory hypertrophy of the tissue in Waldeyer's ring. Rates of recurrent tonsil hypertrophy are very high in these patients, so in this setting, I prefer ETA.

Children may present with both allergic rhinitis and tonsillectomy and adenoidectomy (T&A) hypertrophy. If their symptoms cannot be controlled with allergy treatment, parents should be alerted that T&A surgery will not alleviate allergies. Most children I see with suspected recurrent tonsil and/or adenoid tissue growth have allergic rhinitis without recurrent T&A growth.

Teenage females with obstructive sleep apnea (OSA) plus any symptoms suggesting hypothyroidism (such as sluggishness, cold intolerance, or hair loss) should have a screening thyroid-stimulating hormone (TSH) level obtained before considering surgery for tonsil

obstruction. This pertains to either ITA or ETA. Very rarely clinically significant hypothyroidism will be diagnosed. Also regardless of whether planning to perform ETA or ITA, children with suspected or confirmed severe OSA should have preoperative cardiac echocardiography to rule out right heart dilation.

Retrospective study has confirmed our suspicion that ETA is not more beneficial than ITA for reducing OSA [1]. Dr. April has astutely observed that the lateral pharyngeal scarring often seen after ETA (and never seen after ITA) may worsen sleep by pulling the palate inferiorly and thereby narrowing the pharyngeal aperture. Because of the multiple variables influencing sleep apnea, it would be very difficult to confirm this hypothesis through randomized controlled trials (RCTs). Nevertheless, there is no basis for the argument that ITA is "partial" and therefore less effective than "total" ETA. If anything, the inverse may be true because ITA results in less palatal tethering.

Children who demonstrate abnormal speech patterns suggesting hypernasality (as opposed to the typical hyponasality caused by T&A hypertrophy) may need a preoperative speech evaluation. If they are found to have hypernasal speech or if they have a bifid uvula (with or without hypernasality), a T&A is not contraindicated. However, there is greater reason to perform ITA relative to ETA; not only does the powered instrument allow precise superior adenoidectomy, but the lack of postoperative scarring in the tonsil fossae will allow the child the best chance for normal speech and for the lack of palatal tethering mentioned above.

Some patients have difficult-to-treat conditions leaving them more at risk for persistent sleep apnea after tonsil surgery. These include patients with morbid obesity, macroglossia, micrognathia, other craniofacial malformations, laryngotracheal obstruction, and/or unfavorable Mallampati classifications. Given the uncertain impact of residual (1+ or smaller) tonsil tissue on OSA, and the possibility that ETA might be eventually recommended for a patient with residual OSA after ITA, I will often perform an ETA on these children simply to spare them the burden of having to consider an ETA, perhaps for the wrong reasons, at a later date.

Other children are particularly vulnerable to postoperative pain and dehydration; therefore, there is greater reason to consider ITA. These include children with asthma, failure-to-thrive, developmental delays, autistic spectrum disorders, other communication disorders, and syndromic conditions, including Down's syndrome. Note that Down's syndrome patients are vulnerable to both postoperative OSA, as well as postoperative pain and dehydration. This necessitates a more detailed conversation with the family. In most cases, ITA is the better operation for these children.

Teenagers tend to have more chronic tonsil inflammation than younger children, which usually results in more intraoperative bleeding, for both ETA and ITA. Because teenagers can usually be reasoned with to drink even when they have pain, and because their larger blood volume makes them less likely to exsanguinate from hemorrhage, ETA is less dangerous for them. ITA is often still the better choice.

Retrospective study suggests that ITA works as well as ETA for recurrent tonsillitis [2]. This has not been studied prospectively. Intuitively, IT should reduce infection by making the tonsil more resistant to biofilm adhesion and readily penetrated by the host's circulating immune factors. Anecdotally, I have found IT to be extremely effective for reducing recurrent tonsillitis and pharyngitis in hypertrophic tonsils, certainly as effective as ETA. However, patients should not have ITA if they have a recurring tonsillitis indication but small,

contracted and/or endophytic tonsils. In my experience these patients often continue to have recurring infection even after ETA. Bluestone's classic study did not measure tonsil size. This is an area that warrants further study in a prospective manner.

INTRACAPSULAR TONSILLECTOMY TECHNIQUE

Unlike Dr. April, I do not find it necessary to cover the blade on entering the oral cavity, although I agree with him regarding the great care required by the surgeon. The instruments settings allow for the blade to rotate into a closed setting if desired. I prefer to leave the blade open to use as suction if needed. When using the blade to suction, it is important to only touch tissue with the blunt tip rather than the open suction port. Do NOT engage the uvula or non lymphoid into the blade's open suction or the tissue will become traumatized, leading to unnecessary postoperative pain. The surgeon should keep his/her foot OFF of the foot pedal until ready to shave tissue, so as to avoid inadvertently shaving lips, tongue, or uvula.

Like Dr. April, I started performing ITA with 1500 RPMs. I now use 3000 RPMs. Supposedly a slower speed allows more tissue to be suctioned into the blade and is therefore more aggressive. The difference is subtle, and I do not think it matters much. Occasionally, a neophyte circulator will set the machine to 5000 RPMs, at which a less effective resection is more evident.

I wholeheartedly agree with Dr. April's pointers on using the Hurd elevator to deliver tonsil tissue while protecting the posterior pillar and tongue base. However, not all patients have a recess between the tonsil and these structures. These anatomic variations are made important by this operation, but have not been described. When tonsil tissue extends to the medial edge of the posterior pillar or onto the tongue base, it is far preferable to leave residual tissue that can then be cauterized than to shave into the tongue or pillar.

Shaving both tonsils before cauterizing saves time. Only rarely is there enough bleeding for this to seem unwise. When I first did this procedure I cauterized prudently so as to minimize pain, using the well-established principle of ETA surgery. However, with time it became evident that the extent of cauterizing intact lymphoid tissue did not correlate with pain. The exception to this principle is that any cautery of adjacent tissue or through a defect in the tonsil capsule markedly increases pain. As a routine, I aggressively cauterize all residual tonsil tissue, as it results in some thermo-desiccation of tissue that cannot be safely shaved.

I try to maximize tonsil removal without penetrating the tonsil capsule. When it is unclear if more tissue should be shaved, I will err on the side of leaving excess tissue to minimize the risk of capsule penetration. I do not distinguish between routine and extended IT. I find that otalgia and significant pain are uncommon and do not correlate with the amount of lymphoid resection or cautery used.

I do not distinguish between inferior or superior tonsil tissue when applying cautery and I generally do not find it necessary to take time to let down the red rubber catheters. Dr. April's observation that this move improves visibility is worth remembering when better exposure is needed.

The left side is easier for a right-handed surgeon, and vice versa, so starting there facilitates a smooth pace of surgery. I always use my contralateral hand for the blade and my

ipsilateral hand for the Hurd. Dr. April's point that this is a more aggressive posture is well-taken. I do not have a script for where I start, rather I remove whatever seems easiest. The more tissue that is removed, the more difficult the procedure becomes. The most difficult aspect of the procedure is knowing when to stop. As one approaches the capsule, the tonsil changes color from a greyish pink hue to a redder appearance. The tissue begins to bleed more easily. The existence of crypts indicate that more tissue can be resected. One can gently probe the crypts with the Hurd or blade tip to assess the crypt depth, and then resect more tissue until the crypt is obliterated.

It is best to hold the handpiece near where it connects to the blade, rather than on the side further from the patient where the suction attaches. By holding the instrument closer to the patient, it is possible for the surgeon to gently rest 1-2 fingers on the patient's face or the Crowe-Davis retractor, which gives better balance.

Most tonsils have a shape somewhat akin to an upside-down teardrop: they are thin inferiorly like the pointed top of a teardrop, and thick superiorly, like the broad base of a teardrop. Consequently, one should be prepared to very cautiously resect tissue inferiorly, as there is usually not much there. As Dr. April mentioned, recurrent tonsil growth most commonly happens superiorly; by lateralizing the superior aspect of the anterior pillar with the Hurd, the surgeon can seek and resect most of the superior tonsil. Some tonsil tissue will often "hide" on the posterior-medial surface of the superior anterior pillar. To effectively expose this tissue, only 1-2 mm of the Hurd should be engaged to lateralize the anterior pillar; if too much of the Hurd engages the anterior pillar, it will cover rather than expose the remaining tonsil.

There is no need to routinely suction the stomach post-operatively. It adds an unnecessary minute to the procedure and does not reduce nausea. Exceptions would be if the patient has severe GERD, was known to have swallowed blood intraoperatively, or was thought to have possibly violated the nil per os (NPO) instructions.

Similarly, there is no need to completely close the Crowe-Davis and then re-open it a moment later to check for bleeding. That makes sense in ETA if the surgeon is worried about an artery on stretch, but it does not apply to ITA. I have not considered Dr. April's technique of closing the retractor 1 notch for irrigation, but that makes good sense, in that tongue discomfort is probably the biggest source of postoperative irritation.

In keeping with AAO-HNS guidelines, we always give intraoperative steroids; antibiotics are not given as routine but occasionally a child will have severe sinusitis for which we opt to begin antibiotics with an IV dose.

POSTOPERATIVE CARE

Caregivers are educated that a fever beginning 24-48 hours after surgery, and halitosis shortly thereafter, are normal. No dietary restrictions are given. Instead, the importance of hydration is emphasized, especially via water intake. Parents are told to practice common sense and offer "what you would want if you had a sore throat." Many children return to a nearly normal diet within 24 hours.

Children are given permission to return to all normal activities, including school and sports as soon as they have no pain or fever. This can take anywhere from 1-7 days. In

general, younger children tend to struggle more the first 24 hours, but recover faster than teens. Children under 3 years old, without additional comorbidities, can be safely managed as outpatients after ITA [3]; if problems arise during induction, extubation or in recovery, overnight admission merits greater consideration

Only three of my more than 2,000 patients have had postoperative bleeding. Two responded to cold-water gargles. The third, a college student, required silver nitrate. Both the pain and the risk of bleeding after IT parallel that experienced after adenoidectomy, because in both cases a thin layer of residual lymphoid tissue protects underlying soft tissue, nerves, and blood vessels. The difference in postoperative bleeding between ITA and ETA patients (who continue to suffer postoperative bleeding in 1-5% of case) is staggering. Although our literature recognizes the difference, in my opinion, the magnitude of the difference has been under-represented in published material. Children die after ETA every year, usually from exsanguination or narcotic overdose. I am not aware of any child ever dying after ITA. The significance of this point cannot be overemphasized.

All patients have 24/7 access for concerns and receive a call from a physician extender 5-10 days postoperatively. Routine follow-up is unnecessary, unless a child experiences unexpected problems. Children with documented severe OSA preoperatively or ongoing sleep disordered breathing should be considered for postoperative sleep study.

ACKNOWLEDGMENT

I would like to thank Dr. April for taking the initiative to serve as editor of this important publication and for inviting me to contribute my perspective.

REFERENCES

[1] Mukhatiyar P, K. Nandalike, H.W. Cohen, S. Sin, M. Gangar, J.P. Bent, and R. Arens. (2016) Intracapsular and extracapsular tonsillectomy and adenoidectomy in pediatric obstructive sleep apnea. *JAMA–Otolaryngology Head & Neck Sur*gery 142 (1):25-31.

[2] Schmidt R, A. Herzog, S. Cook, R. O'Reilly, E. Deutsch, and J. Reilly. (2007) Powered intracapsular tonsillectomy in the management of recurrent tonsillitis. *Otolaryngology Head & Neck Surgery* 137 (2):338-40.

[3] Bent J,P., M.M. April, R.F. Ward, A. Sorin, B. Reilly, and G. Weiss. (2004) Ambulatory powered intracapsular tonsillectomy and adenoidectomy in children younger than 3 years. Archives *Otolaryngology Head & Neck Surgery* 130 (10) : 1197-1200.

In: Encyclopedia of Surgery (22 Volume Set)
Editors: Andreas Lehrer and Kristin Mueller
ISBN: 978-1-53618-329-0
© 2020 Nova Science Publishers, Inc.

Chapter 168

EXTRACAPSULAR TONSILLECTOMY IN 2017

Lyuba Gitman and Nira A. Goldstein
Division of Pediatric Otolaryngology, State University of New York Downstate Medical Center, Brooklyn, NY, US

ABSTRACT

There are multiple techniques that have been described for extracapsular tonsillectomy. This chapter will review the current literature and provide multiple videos of the techniques.

Keywords: tonsillectomy, extracapsular tonsillectomy, PEAK plasmablade, complete tonsillectomy, monopolar cautery tonsillectomy

INTRODUCTION

Although tonsillectomy historically ranks as one of the most common surgical procedures performed, numbers declined with the advent of antibiotics in the middle of the 20th century, with a steady decline since the 1970s. Currently, the operation is performed at what appears to be about half the rate of 40 to 50 years ago [1]. Nevertheless, tonsillectomy or adenotonsillectomy (T&A) remains one of the leading pediatric surgical procedures in the United States [2]. Thirty years ago, approximately 90% of tonsillectomies in children were performed for infections (otitis media, chronic, or recurrent tonsillitis). Currently, upper airway obstruction (obstructive sleep apnea) is the main current indication with close to 80% of tonsillectomies done for this reason versus 20% for infection [3]. However, the complications associated with the procedure have not changed much over time. Tonsillectomy versus T&A are often grouped together, but tonsillectomy and adenoidectomy are separate operations with distinct indications.

This chapter describes extracapsular tonsillectomy in the current times (2017), including newer techniques using new technology, such as bipolar electrocautery, radiofrequency ablation, PEAK plasma blade, and laser tonsillectomy, as well as a brief comparison of

extracapsular versus intracapsular tonsillectomy (discussed in further detail in Chapter 170), and the complications associated with these procedures.

HISTORY OF TONSILLECTOMY

Removal of the tonsils has been practiced since antiquity, with Cornelius Celsus describing blunt removal of inflamed tonsils by using a finger in the first century A.D. in Rome. Later, in the 1600s, other practitioners used a modified guillotine-type instrument that had initially been used for uvulotomy to perform tonsillotomy. Snares were also used for tonsillotomy during this period [1].

Early tonsillectomies were hindered by the lack of anesthesia; therefore, surgeons tried to operate as quickly as possible. To speed up the procedure, Shulder's guillotine was introduced, and to simplify this, a reverse guillotine was used for enucleation [1].

In 1917, Samuel J. Crowe reviewed a series of 1000 tonsillectomies performed at Johns Hopkins Hospital between 1911 and 1917. Crowe also described his operative technique. The patient was placed in the recumbent position, with the foot of the table elevated slightly. Ether vapor was used for anesthesia. A special mouth gag, subsequently called the Crowe-Davis mouth gag, was used to open the mouth, retract the tongue, and direct the anesthetic agent to the hypopharynx. The tonsils were removed by sharp dissection. All bleeding points were clamped and ligated with black silk. Crowe's work laid the foundation for cold-knife dissection tonsillectomy. Prior to sutures becoming popular for hemostasis, other early agents for controlling bleeding included pressure and caustic agents; later on catgut, and silk noose ties were used [1]. The delivery of an inhalational anesthetic via a tube placed endotracheally became a more routine practice in the 1950s as a result of the recognized advantages of providing protection against aspiration and pulmonary abscesses, which were frequent and serious complications of tonsil surgery [4]. However, initially, these inhalation agents were extremely flammable, which limited the use of electrosurgical devices. Thus, electrical instruments in tonsil surgery, although previously attempted, did not gain popularity at this time because of both the anesthetic hazards and the lack of knowledge of electric currents and inexperience of surgeons with electrical instrumentation. The use of a monopolar electrosurgical unit in tonsil surgery started to become more common in the 1960s; however, at that point it served only to achieve hemostasis at the end of the procedure. It was not until the early 1980s that a suction coagulator and the "electrocautery" blade were introduced as primary instruments to actually remove tonsil tissue, a so-called "hot tonsillectomy" [4]. The more recent advents of newer technology all aim to decrease intra-operative blood loss and operative time, as well as minimize post-operative pain and morbidity as much as possible.

INDICATIONS

Prior to discussion of the tonsillectomy technique, or any surgery technique, it is vital to know the indications for the procedure. Tonsillectomy is a major surgery with potential morbidity and even mortality. Careful preoperative management and evaluation are necessary. The two major categories of indications are infectious and obstructive.

Table 1. [6] Paradise criteria for tonsillectomy

Criterion	Definition
Minimum frequency of sore throat episodes	7 or more episodes in the preceding year, OR 5 or more episodes in each of the preceding 2 y, OR 3 or more episodes in each of the preceding 3 y
Clinical features (sore throat plus the presence of one or more qualifies as an episode)	Temperature > 38.3°C OR Cervical lymphadenopathy (tender lymph nodes or >2 cm), OR Tonsillary exudates, OR Positive culture for group A beta-hemolytic streptococcus
Treatment	Antibiotics had been administered in conventional dosage for proved or suspected streptococcus episodes
Documentation	Each episode and its qualifying features had been substantiated by contemporaneous notation in a clinical record, OR *If not fully documented*, subsequent observance by the clinician of 2 episodes of throat infection with patterns of frequency and clinical features consistent with the initial history

With infections, recurrent and/or chronic tonsillitis, as well as greater than one previous peritonsillar abscess are the usual accepted indications for tonsillectomy. A Cochrane review of the effectiveness of adenotonsillectomy by Burton and Glasziou in 2009 concluded that the benefits of surgery were the greatest for those patients fulfilling the "Paradise criteria," [5] with documented cultures and antibiotic use for the infections (Table 1) [6].

Upper airway obstruction, including sleep disordered breathing (SDB) and obstructive sleep apnea syndrome (OSAS), has replaced recurrent pharyngitis as the most common indication for the removal of tonsils and/or adenoids in children [7]. The estimated prevalence of OSAS among children is approximately 1% to 5%, and untreated OSAS in children leads to cardiovascular and metabolic comorbidities, cognitive and learning deficits, and behavioral problems [8]. Although there are functional, neuromuscular, and other anatomical factors that contribute to pediatric OSAS, adenotonsillar hypertrophy is considered the most common cause of childhood OSAS, and adenotonsillectomy is the first line of treatment [8]. Although polysomnography is the gold standard for diagnosing OSAS/SDB in children, it is unnecessary to perform in every case and does not establish the effects of the sleep disorder on the child's well-being. The initial approach to a child with suspected SDB should include a detailed history, including possible described (or recorded) pauses in breathing, as well as an assessment of comorbid conditions such as behavioral problems, poor school performance, decreased quality of life, failure to thrive, and enuresis, followed by physical examination [6].

Other reasons for extracapsular tonsillectomy include asymmetric enlargement with suspicion of neoplasm, recurrent hemorrhagic tonsillitis, and recurrent tonsillitis not fulfilling the "Paradise criteria." Modifying factors for extracapsular tonsillectomy include: a child with multiple antibiotic allergies; specific clinical syndromes such as periodic fever, aphthous stomatitis, pharyngitis and adenitis (PFAPA); and rarely, dysphagia not responsive to more conservative treatment modalities. At times, urgent tonsillectomy is indicated, such as severe obstructive sleep apnea with associated hypoxemia unresponsive to oxygen or sepsis secondary to tonsillitis (when all other sources have been ruled out) that is not responding to broad-spectrum systemic antibiotics.

Intracapsular tonsillectomy has been accepted by many otolaryngologists as a technique that achieves the dual goal of surgical efficacy and reduced morbidity in the treatment of pediatric sleep apnea secondary to adenotonsillar hypertrophy. The technique, which involves leaving a thin rim of lymphoid tissue in the tonsillar fossae, and supporting data are reviewed in other chapters. In brief, interest in this technique has grown as a number of studies report advantages such as less pain and earlier return to diet and activity while still maintaining similar complications rates and low rate of tonsillar regrowth [9]. Proponents of intracapsular tonsillectomy cite equivalent outcomes for obstructive symptoms, with the possible benefit of reduced pain and morbidity because there is no breach of the tonsillar capsule or underlying pharyngeal musculature [10]. The potential downsides, however, to intracapsular tonsillectomy are infection in the tonsillar remnant, thus making infectious indications a potential contraindication to intracapsular tonsillectomy, as well as regrowth of tonsillar tissue. Although there is a paucity of studies in the literature with long term follow-up of tonsillar regrowth after intracapsular tonsillectomy, in a recent systematic review (2012) of randomized controlled trials comparing intracapsular with total tonsillectomy in the pediatric population done by Walton et al., there was no significant difference in regrowth of tonsillar tissue between the groups [10]. Some studies also demonstrate a higher likelihood of OSAS refractory to treatment with intracapsular tonsillectomy compared to extracapsular (total) tonsillectomy when comorbid diagnoses such as asthma and/or obesity exist [8]. In their systematic review, Walton et al. demonstrated that recovery-related outcomes, including secondary hemorrhage rate and number of days until pain free, for intracapsular tonsillectomy were superior to total tonsillectomy specifically in the pediatric population with obstructive symptoms [10].

PRE-OPERATIVE EVALUATION

Once the proper indications are met for tonsillectomy (+/- adenoidectomy), several steps should be taken prior to surgery. For any child with potentially loose teeth, dental consultation may be obtained. As stated above, sleep studies are not usually necessary for children with upper airway obstruction unless the diagnosis or the need for surgery is in question [6]. Children with a personal or family history of easy bruising or extensive bleeding should have coagulation tests performed pre-operatively. Those with von Willibrand or sickle cell disease require preoperative hematological optimization. Children with sickle cell disease require intravenous hydration while children with certain types of von Willibrand disease require preoperative desmopressin acetate (DDAVP). Those with coexisting medical conditions, such as asthma, cardiac disease, and seizures, should be assessed and optimized prior to surgery. There is no consensus regarding obtaining lateral neck films for children with Down syndrome to evaluate the cervical spine, however, caution should always be used in positioning this patient population given the high incidence of atlantoaxial instability [2]. A post-operative intensive care unit or observation bed is reserved for children less than 3 years old, as well as those with severe OSAS, significant medical problems, obesity, recent respiratory infection, neurologic delay, or craniofacial abnormalities [2, 6].

ANESTHESIA CONSIDERATIONS

General anesthesia is administered via a curved RAE endotracheal tube, which is placed in the midline of the lower lip and taped securely. Perioperative narcotics are avoided in patients with OSAS. Intra-operative corticosteroids may decrease postoperative pain and emesis and improve recovery following tonsillectomy. Most published studies recommend a dose of 0.5 mg/kg IV at the start of surgery (with maximum dose of 16 mg) [2, 6]. Multiple studies also demonstrate that ketorolac tromethamine (a parenteral nonsteroidal anti-inflammatory drug) should be avoided in the perioperative period (intra-operatively and within 24 hours after surgery) because it may increase bleeding.

PROCEDURE

Tonsillectomy can be performed via "cold" dissection technique or "hot" electrocautery technique. Many studies have debated the merits of each technique. With hot tonsillectomy techniques, thermal energy is used to cut and coagulate tissue in an effort to reduce operative time and intraoperative bleeding [2]. Evidence suggests, however, that none of the hot tonsillectomy techniques offer concurrent reductions in intra- and post-operative bleeding and pain compared with traditional cold-steel dissection with packs or ties [11]. Nevertheless, diathermy remains the most commonly used hot tonsillectomy technique. Although electrocautery for extracapsular tonsillectomy has been shown to increase post-operative pain in many studies, if dissection is performed carefully, this can be minimized. Later in this chapter, various new developments/instruments for "hot" tonsillectomy technique are reviewed.

The following is a Step-by-Step Outline of a "Hot" Extracapsular Tonsillectomy [2]

- A headlight is mandatory for adequate visualization.
- The table is positioned so that the surgeon has nonobstructed access to the patient's head, while the anesthesiologist has access to the intravenous line and endotracheal tube.
- A shoulder roll is placed between the scapulae, the head is placed on a head "doughnut," and a head drape is placed to cover the eyes. Caution needs to be exercised when using towel clamps as the face and/or eyes are at risk of being clamped under the head drape. Alternatively, a piece of tape can be used to hold the head drape.
- The patient is placed in Rose's position by lowering the head, unless there is concern for atlanto-axial or other conditions affecting the cervical spine.
- An appropriately sized Crowe-Davis, McGiver, or Dingman mouth gag is carefully inserted, avoiding dental injury, and then suspended on a Mayo stand brought into the field. A wet tonsil sponge may be placed in the hypopharynx at this point to prevent leakage of anesthetic gases that can cause an intraoperative fire.

- Red rubber catheters are lubricated with soapy water, then inserted into the nasal cavity following the floor of the nose bilaterally in order to retract the soft palate. The catheters are brought out of the oral cavity and clamped to elevate the palate.
- The superior pole of one tonsil is pulled medially with an Allis clamp, which grasps the tonsil with the tines in a superior to inferior orientation. The mucosa overlying the superior pole is then incised with a protected straight electrosurgery tip (10 to 20 watts) at the junction between the tonsil and mucosal fold.
- Once the incision is made, the cautery tip can be used to identify the avascular plan between the tonsillar capsule and tonsillar fossa. Correct identification of this plane is essential.
- If the plane is not easily identified, a Metzenbaum scissors or tonsil clamp can be placed through the incision to help identify the plane.
- After the plane is identified, the Allis clamp can then regrasp the tonsil capsule and mucosal fold at the superior pole of the tonsil and be used to provide tension for the rest of the procedure.
- Dissection between the tonsillar capsule and fossa proceeds from superior to inferior, while an assistant suctions the plume.
    1. Medial traction is applied to the tonsil with the Allis clamp so that the cautery can gently lyse the intervening fibers without deeply penetrating the muscular fossa.
    2. Traction on the tonsil is continually re-assessed to provide maximum tension and visualization of the fibers, as well as the blood vessels between the tonsil capsule and fossa.
    3. Dissection is performed with only the tip of the cautery, staying right on the tonsillar capsule to limit the delivery of current to surrounding tissues. This is because muscular penetration by the cautery tip can result in increased postoperative pain and possibly a greater risk of postoperative bleeding.
- The cautery continues around the inferior pole of the tonsil until the tonsil can be completely removed. The plane between the inferior palatine and lingual tonsil must be established to prevent over-aggressive removal of lingual tonsil, which is accomplished by sweeping the cautery from lateral to medial when cauterizing at the inferior pole.
- After the tonsil is removed, hemostasis is established with a suction cautery (15 to 30 watts), and a Hurd dissector to retract the anterior and posterior tonsillar pillars for visualization. The cautery should not burn deeply; rather the bleeding tissue should be pulled into the suction lumen and then cauterized. Also note: the superior pole of the tonsil can be visualized with a laryngeal mirror for better hemostasis in this region.
- Visible vessels or persistent bleeding may require a figure of eight stitch using a plain or chromic gut suture on a semicircular needle. Hemostatic sutures must be placed superficially to prevent deeper vascular injury.
- Other hemostatic techniques include prolonged packing, ties, bismuth, bipolar cautery, Avitene™ microfibrillar collagen, and topical thrombin.
- Before removing the contralateral tonsil, the mouth gag should be taken down for one minute between sides to minimize the chances of tongue edema.

- Once both tonsils are safely removed, the nasopharynx and oropharynx are irrigated to assure hemostasis and to identify residual adenoid or tonsil tissue that could be aspirated. The red rubber catheters are removed. An appropriately sized nasogastric tube is used to empty the stomach.
- The mouth gag can be taken down for one minute to allow the tissue to relax, and then re-opened to ensure hemostasis. Once complete, the mouth gag should be removed with the thumb pressing down on the lower lip area to prevent premature extubation.
- The child is then extubated by the anesthesiologist, though the surgical team should supervise the process and ensure that there is no excessive bleeding or other difficulties, such as laryngospasm [2].

POST-OPERATIVE CARE

As discussed above, observation overnight in the inpatient ward or intensive care unit is recommend post-tonsillectomy for children less than 3 years old, children with severe OSAS, children with significant associated medical problems, neurological delay, or craniofacial abnormalities, or those with recent respiratory infections. The remaining patients may be safely discharged after 3 to 4 hours of observation after surgery in the post-operative anesthesia care unit, provided that there are no significant desaturations, no bleeding, and the child is tolerating an oral diet [2].

Clinicians should not routinely administer or prescribe perioperative antibiotics to children undergoing tonsillectomy [6].

There is no consensus on activity resumption after tonsillectomy with or without adenoidectomy, with every child responding differently to surgery. Some general principles include avoiding strenuous activity for 1 to 2 weeks after surgery and returning to school or daycare 5 to 7 days after surgery. There are many approaches to postoperative diet, ranging from soft diet for 1 to 2 weeks to resumption of normal diet on the same day as surgery. Hard foods, or foods that may cause discomfort, should be avoided initially (up to 1 week) [2].

The surgeon should advocate for pain management after tonsillectomy and educate caregivers about the importance of managing and reassessing pain [6]. Narcotics are avoided in children with OSAS to prevent respiratory depression.

POST-OPERATIVE MORBIDITY/COMPLICATIONS

The complication rate for tonsillectomy has declined over the years, although the types of complications remain the same: bleeding, alterations in voice, aspiration, oropharyngeal stenosis, pneumonia, and rarely, death [1]. The potential for significant morbidity, even death, is inherent in the procedure. Traditional, “cold-knife” surgical techniques utilizing the scalpel, guillotine, or snare have largely been replaced with techniques utilizing cautery, or “hot” technique, to limit intraoperative bleeding [9]. However, use of electrocautery is fraught with its own complications of prolonged pain, poor oral intake, risk of dehydration, and increased risk of post-operative, secondary bleeding.

Post-tonsillectomy bleeding is the main and most dangerous complication connected with this procedure. It creates anxiety, prolongs morbidity, and increases healthcare costs [12]. Primary bleeding is defined as postoperative bleeding within 24 hours of the initial surgery. Secondary or delayed bleeding, which is more common in this day and age, is defined as bleeding that occurs >24 hours after the procedure. Although variable rates have been described in the literature, from 0.2% to 3% for primary hemorrhages and 1 to 7% for secondary hemorrhages [13], the general consensus is that on average there is about a 1 to 2% risk of post-tonsillectomy hemorrhage [2]. Multiple studies also demonstrate a lower hemorrhage rate in patients undergoing tonsillectomy for pharyngeal obstruction only, as compared to those with infectious indications [14].

Another major complication/morbidity is post-operative pain, which is associated with poor oral intake, and possibly dehydration requiring monitoring in the emergency room or at times, re-admission. Because of swelling from surgery, there is a chance of airway obstruction in which the child is continuously desaturating post-operatively, which at times may require observation in an intensive care unit, parenteral steroids, racemic epinephrine, and consideration of re-intubation, if necessary. Post-obstructive pulmonary edema may be another reason for desaturations post-operatively, which results from increased intrathoracic venous and hydrostatic pressure relieved by intubation or surgery. Pink frothy secretions usually accompany desaturations, and diuretics and/or re-intubation with positive pressure ventilation may be necessary [2].

Atlantoaxial subluxation (Grisel's syndrome) is rare with tonsillectomy alone. Children present with persistent torticollis 1 to 2 weeks after surgery. Neurological or orthopedic consultation may be required. Mandible dislocation, although rare, is also a possibility secondary to patient movement while in suspension with the mouth gag in place [7].

Iatrogenic complications after tonsillectomy include dental injury from intubation or mouth gag insertion, requiring urgent laryngoscopy and bronchoscopy for any newly discovered missing teeth. Oropharyngeal stenosis may occur, caused by excessive removal of the deep lower tonsil pole and adjacent lingual tonsil tissue. Internal carotid artery injury after deep cautery, suturing, or dissection may occur, as the artery lies within 5 to 30 mm of the lateral tonsil fossa [2]. Lingual nerve palsy, caused by pressure from the tongue blade of the mouth gag may also occur, however, this complication is generally temporary. Cautery burns, either perioral or intra-oral, caused by operator error or equipment malfunction may also pose serious problems, on rare occasions requiring further surgery for reconstruction. Since the advent of general endotracheal intubation with protection of the airway, aspiration and pneumonia occur more rarely than they once did; however, there is always a possibility of aspiration of refluxed gastric contents during induction if the child was not nil per os (NPO), as well as a risk of aspiration of blood/tissue during the procedure.

Lastly, persistent OSAS, especially in obese children or children with other craniofacial deformities, is a well-described risk that all parents/caretakers must be counseled on thoroughly, as is the possibility of tonsillar regrowth. There is a theoretical increased chance of regrowth when intracapsular tonsillectomy is performed; however, there is a paucity of evidence-based articles in the current literature with long-term follow-up for tonsillar regrowth after partial tonsillectomies [9].

HOT VS. COLD TONSILLECTOMY

Although tonsillectomies remain one of the most commonly performed pediatric surgeries in the United States, there is an absence of universal agreement on the surgical method and extent of removal [9]. Ideally, tonsillectomy should be fast, bloodless, and associated with rapid and uncomplicated recovery [12]. Diathermy involves the use of high-frequency electrical current to cut tissue, remove the tonsil, and control blood loss. Electrosurgical instruments all achieve cutting and simultaneous hemostasis by sealing the blood vessel lumen by virtue of tissue heating [13]. Cold knife dissection traditionally refers to the method where the tonsil is cut away and blood loss is then controlled with ties, stitches, or diathermy [15]. Although "hot" techniques using electrodissection have become more popular as they provide advantages of diathermy for hemostasis intraoperatively as compared to cold-knife dissection, there is a question of whether this statistically significant difference is clinically significant, especially in children over a certain weight [16]. To further complicate the question, there are multiple studies that demonstrate not only increased pain, but also the same or even increased rate of secondary post-tonsillectomy hemorrhage when compared to "cold-knife" techniques. In a prospective, randomized, single-blind, controlled clinical trial published in 2000, Nunez et al. demonstrated that the hot dissection tonsillectomy group took 7.5 more doses of analgesics than the cold dissection group. The hot dissection group also took 2.5 more days than the cold dissection group to regain a normal diet. Nunez concluded that hot dissection tonsillectomy increases morbidity in pediatric patients in the recovery period following hospital discharge [16]. In another prospective study of 440 patients who underwent electrodissection tonsillectomy published in 2001, Blomgren et al. concluded that monopolar electrodissection tonsillectomy was fast and resulted in little intraoperative bleeding. However, postoperative hemorrhages were shown to be common in this group, and the mean use of analgesics was greater than 10 days [12], thus concluding that even though monopolar electrodissection technique for tonsillectomy has its advantages, it is far from optimal and better methods still needed to be developed [12].

In their systematic review of hot versus cold tonsillectomy published in 2003, Robert et al. compared monopolar electrocautery versus cold knife dissection tonsillectomy. Pooled data from 6 articles meeting their selection criteria confirmed much of the above, demonstrating that electrodissection increases pain in comparison to sharp dissection, and that postoperative hemorrhage rates are not significantly different when comparing the two methods [17]. However, as previous studies demonstrated, they also verify that intraoperative blood loss and operative time are less with monopolar electrocautery techniques [17].

A recent Cochrane review published in 2011 by Pinder et al., comparing the two methods, found two relevant studies that fulfilled their inclusion criteria. Their findings were similar to those discussed above and concluded that there was not enough evidence to demonstrate that diathermy was more effective than cold dissection. No differences were found in either the primary or secondary hemorrhage rates when comparing cold versus hot techniques. This finding may be due to the fact that the studies included in this Cochrane review were insufficiently powered to pick up small differences in such rates. They also comment that there was some evidence that patients who had diathermy tonsillectomy had less bleeding during the operation but more pain afterwards, however, more research was needed [15].

EXTRACAPSULAR VS. INTRACAPSULAR TECHNIQUES

As discussed earlier, the techniques of tonsillectomy can be broadly divided into 2 major categories: extracapsular (total tonsillectomy, subcapsular) and intracapsular (partial tonsillectomy, "subtotal" tonsillectomy, tonsillotomy). Extracapsular tonsillectomy involves dissecting as described above, lateral to the tonsil in the plane between the tonsillar capsule and the pharyngeal musculature, and the tonsil is generally removed as a single unit. Partial tonsillectomy, or intracapsular, involves removal of most of the tonsil while preserving a rim of lymphoid tissue and tonsillar capsule. As discussed above, the indications for which technique is used differ slightly: either extracapsular or intracapsular tonsillectomy can be performed for the pediatric patient with OSAS, however for patients undergoing the procedure for infectious causes (tonsillitis/peritonsillar abscess), the extracapsular technique is recommended. The most common extracapsular techniques use a "cold" knife (sharp dissection), monopolar electrocautery, bipolar electrocautery (or bipolar scissors), or harmonic scalpel. Intracapsular techniques may use the microdebrider, bipolar radiofrequency ablation (which can be used to remove the entire tonsil as well), and carbon dioxide laser [18].

The following is a review of the various techniques/technology that have been introduced to tonsillectomy since the 1980s.

BIPOLAR ELECTROCAUTERY/BIPOLAR SCISSORS

In bipolar diathermy, a current passes through the tissue between the tips of a pair of forceps. The electrical energy is concentrated in a small area, therefore, the tissue heats extremely rapidly, resulting in coagulation of blood vessels [15]. Bipolar administration of radiofrequency currents results in less electrical energy being leaked to distant tissues, and thus more precise coagulation [13]. In a randomized controlled study (1997), comparing bipolar diathermy using binocular microscope to cold knife dissection, Kujawski et al. demonstrated less intraoperative hemorrhage in the bipolar group, no episodes of primary hemorrhage in either group, and no difference in secondary hemorrhage between the groups, although there were few secondary hemorrhages in either group. There was also no difference in the mean operating time between the two groups, however, both times were significantly longer than the average for monopolar dissection (36.9 minutes for diathermy and 35.9 minutes for dissection) [15].

In 2000, Pizzuto et al. published a prospective randomized study comparing microbipolar dissection (bipolar dissection with microscope, MBPD) to hot knife and cold knife/cautery techniques using 400 consecutive patients presenting for tonsillectomy. They found that postoperative bleeding of any kind was significantly less in the microbipolar dissection group (compared to both hot and cold knife), the need for postoperative intervention for bleeding was also significantly less in the MBPD group, and the return to normal activity occurred 2 days earlier for the MBPD group. Intraoperative blood loss was similar in all treatment groups, however, operative time was 3 to 5 minutes longer for MBPD (24.2 min) than for cold knife with cautery (21.1 min) or hot knife (16.5 min) respectively [19].

In contrast, Schrotzlmair et al., in their prospective study published in 2015, assessed postoperative pain in 48 patients who underwent bipolar tonsillectomy on one side using a microscope or magnifying glasses and on the other side using unsupported vision. In terms of their primary outcome, post-operative pain, they found that patients did not suffer less pain when magnification devices had been used. Secondarily, the authors comment that there was no statistically significant difference in operative time when comparing the use of microscope versus magnifying glasses versus unaided vision. Due to the relatively low number of patients, and consequently low number of bleeding complications, a statistical comparison between the treatment groups with regard to postoperative hemorrhage could not be drawn [20].

One of the main issues with bipolar tonsillectomy is the greater surgical time, as compared to monopolar tonsillectomy, in part because of the frequent need to clean char from the bayonet forceps [13]. Bipolar electrosurgical scissors combine the blunt dissecting capacity and precise cutting of cold scissors with a technology that allows for coagulation of vessels before their division. In addition, because the layer of plastic fused to one blade of the scissors is harder than steel, it continuously cleans and sharpens the opposite blade, thus preventing the accumulation of char that slows the use of most bipolar instruments [13]. These instruments were introduced in the US market in the spring of 1997 [13]. Isaacson et al. first published a pilot study in 1998 on 30 consecutive pediatric tonsillectomies demonstrating their favorable experience using bipolar electrosurgical scissors. They describe their technique, which deviates slightly from the classic hot or cold knife method. The back surface of the 7-inch Metzenbaum scissors is insulated with a strip of polyvinyl chloride electrical tape. The tonsil is grasped near is superior pole with a curved tenaculum and drawn medially, while the uvula is distracted superiorly by an assistant using a Yankauer suction. With the tonsil on tension, the superior edge of the anterior pillar is incised with the scissors in electrified mode (bipolar power setting 20). The anterior pillar mucosa is then incised from superior to inferior with the scissor in nonelectrified mode. A pocket is created by blunt dissection between the lateral tonsillar surface and the superior constrictor muscle. Identified vessels are coagulated and then divided with the scissors in electrified mode. Dissection is carried to the inferior pole, dividing the posterior tonsillar pillar mucosa sharply. The scissors are again set in electrified mode to slowly divide the inferior pole vessels and lymphoid tissue to complete the dissection. Minor bleeding during dissection can be controlled by using the tips of the scissors as a bipolar forceps on either side of the bleeding point. A monopolar suction cautery supplements bipolar coagulation as needed [13]. In the pilot study, the average operative time for tonsillar removal was 6 minutes. There were no immediate or delayed post-tonsillectomy hemorrhages in a 2 week follow up of the thirty patients who underwent tonsillectomy with bipolar scissors. In an update, the authors comment that out of 209 consecutive tonsillectomies using this instrument, there were no immediate postoperative hemorrhages and only 4 delayed episodes [13].

Raut et al. studied bipolar scissors, comparing this instrument to cold dissection tonsillectomy in a prospective, randomized trial in 200 patients undergoing surgery for chronic tonsillitis. The morbidity rate, including pain scores and primary and secondary hemorrhage rates, was similar to that of cold dissection. The median amounts of intraoperative blood loss were significantly less than with cold dissection, however, the mean operating time was increased in the bipolar scissors group (20 minutes) when compared to cold dissection (13 minutes) [1]. There was no statistically significant difference in the pain

scores between the two methods. The primary and secondary hemorrhage rates were unaffected by the surgical method [21].

In a 2007 publication, the National Prospective Tonsillectomy Audit (NPTA), however, demonstrated an increase in postoperative hemorrhage using bipolar electrodissection or bipolar scissors as compared to the cold knife technique. The NPTA was established to investigate the occurrence of complications after tonsillectomy, especially postoperative hemorrhage, as well as risk factors for such complications. Data were collected electronically on more than 40,000 patients who underwent tonsillectomy in England and Northern Ireland between July 2003 and September 2004. For hemorrhage, compared with the cold steel group, bipolar diathermy tonsillectomy had an odds ratio of 2.47 (1.81-3.36) and bipolar diathermy scissors tonsillectomy an odds ratio of 3.20 (2.09-4.90). Use of bipolar diathermy for hemostasis only after cold steel dissection carried an intermediate risk, with an odds ratio of 1.67 (1.16-2.13) [14].

RADIOFREQUENCY ABLATION/COBLATION

Coblation tonsillectomy (see Chapter 169) is a variation of bipolar electrosurgery that generates lower temperatures (40 to 70 degrees Celsius) with the aim of minimizing thermal damage to surrounding tissues [11]. It can be used to perform an extracapsular or intracapsular tonsillectomy [18]. A series of electrodes on the tip of the coblation probe are bathed in a conducting saline solution that flows continuously through an irrigation sheath. Radiofrequency energy ionizes the saline to form a localized plasma layer of sodium ions. The heat generated by these ions cuts tissue and seals small blood vessels [11]. Coblation was initially introduced into the surgical world in the 1990s [22], and the coblation technique specifically for tonsillectomy began to be used in 2001 [23]. A systematic review of electrosurgery tonsillectomy in adults and children found that operative time was longest for coblation (24.5 minutes) and shortest for monopolar diathermy (15.5 minutes) [11]. The mean number of days to return to normal activity was similar for coblation, diathermy, and cold-steel dissection [22]. The data from the NPTA demonstrated an increased risk of postoperative hemorrhage using coblation compared to cold knife technique, with an adjusted odds ratio of 3.07 (2.03-4.65) [14]. This data demonstrated that for coblation both primary and secondary hemorrhage rates were high when compared to cold steel tonsillectomy [23].

In 2006, Mowatt et al. performed a meta-analysis of fifty primary studies (including randomized controlled trials, non-randomized comparative studies, prospective case series, and population based registry reports) in order to compare cold steel dissection with monopolar and bipolar diathermy, as well as with coblation technique. They found that coblation was associated with higher rates of secondary hemorrhage compared to cold steel dissection [22].

It appears that although it has been claimed that by operating at lower temperatures than diathermy, coblation may result in less tissue damage and improved healing, the literature demonstrates that it does not actually decrease the risk of post-operative bleeding, especially that of secondary hemorrhage.

ARGON PLASMA COAGULATION

Argon plasma coagulation (APC) is a monopolar form of coblation and may be used for extracapsular tonsillectomy. This non-contact technique uses a stream of ionized argon gas instead of saline as the medium for the electrical current. The current flows between the hand piece and the tissue and is dispersed to a neutral electrode attached to the patient [11]. The procedure is performed in a similar fashion to the general "hot" technique described above: the superior pole is grasped with forceps; the anterior pillar is then dissected with the APC dissector under activation of the plasma beam; the appropriate peritonsillar plane is identified and the tonsil is dissected from the tonsillar fossa under continuous APC activation until the lower pole of the tonsil is reached, with the tonsil removed in its entirety. With this method, similar to other "hot" techniques, dissection and coagulation are done in one step. In cases with increased vascularization, the speed of dissection may be decreased to allow sufficient coagulation [24].

Two randomized controlled trials (RCTs) assessed APC tonsillectomy. One RCT published in 2001 of 201 patients found no difference between argon plasma coagulation and cold steel dissection (with packs or ties) with respect to pain during the 10-day follow-up, but the operative time was significantly shorter with argon coagulation. This study also demonstrated that the rates of postoperative hemorrhage (total) were similar to those of cold steel dissection. The authors conclude that the APC technique does not face the general problem of electrosurgery or thermal coagulation techniques in which the postoperative pain is often increased compared with conventional cold techniques [24]. The other RCT (n = 40), published in 2003, found that operative time and pain less than 2 weeks after the procedure were similar for patients undergoing argon plasma coagulation, and for patients who had undergone cold-steel dissection or diathermy [25]. Both studies demonstrated that the mean intraoperative blood loss and mean duration of operative time were significantly lower compared with conventional tonsillectomy [11].

ULTRASONIC/HARMONIC SCALPEL

The ultrasonic scalpel (brand name: Harmonic scalpel, produced by Ethicon Endo-Surgery Inc, Cincinnati, Ohio) can be used to perform an extracapsular tonsillectomy. This instrument has a blade that vibrates at 55.5 kHz (55,500 cycles/second) over a distance of 80 micrometers to cut tissue. The heat generated in the tissue (between 50 and 100 degrees Celsius) by the blade's movement coagulates the blood vessels [11] at a temperature lower than other hot methods such as diathermy or lasers, while simultaneously allowing for precise cutting. The blade oscillations dissect tissues by creating intra-cellular cavities as pressure waves are conducted through the tissues. The expansion and contraction of these cavities results in lysis of cellular connections, resulting in tissue dissection [18]. Although in theory no additional instrument is needed given its dual function, many studies describe the use of diathermy for full coagulation after the use of the ultrasonic scalpel [11].

One systemic review found five RCTs and four non-randomized comparative studies regarding the use of the ultrasonic scalpel in children and adults [26]. The pain scores less than 7 days after surgery were similar for the ultrasonic scalpel tonsillectomy, diathermy, and

cold-steel dissection. Two weeks after surgery, the pain was significantly worse after the ultrasonic-scalpel technique when compared to cold knife, however, the pain was better when compared to diathermy. There was a greater risk of secondary hemorrhage after ultrasonic scalpel tonsillectomy compared with cold-steel dissection. The follow-up period in more than half of the studies in this systemic review was too short or not stated, so the rates of secondary hemorrhage may also be underestimated [11].

In contrast to the above findings, in their meta-analysis comparing outcomes of tonsillectomies performed using the ultrasonic scalpel with tonsillectomies performed using cold knife combined with electrocautery for hemostasis, Alexiou et al. found no significant difference between compared groups regarding operative time, postoperative bleeding, and averaged postoperative pain. However perioperative bleeding was significantly less in the ultrasonic scalpel group [27]. In many of the existing studies, additional techniques were used to control bleeding (using diathermy after dissection with the ultrasonic scalpel, for example).

It is crucial to point out that the evidence base for this procedure is small, and generally of a low quality with significant heterogeneity in the results, as demonstrated above. The outcomes in the studies this systemic review describes were poorly assessed and reported, and most of the RCTs were small [26], thus putting into question both the internal and external validity of the available data on this technique.

LASER (CO2, KTP)

The carbon dioxide laser, potassium titanyl phosphate (KTP) laser, and contact diode laser are the most commonly used lasers, and although traditionally they have been described for extracapsular tonsillectomies, they are increasingly being used for partial/intracapsular tonsillectomy as well. In this method, energy is delivered through a flexible optical fiber that is used as a scalpel to dissect tissue and separate the tonsil from the tonsillar bed while simultaneously coagulating vessels [28]. In the literature, however, other techniques are often used to control bleeding after laser dissection of the tonsil [11].

A systemic review published in 2006 found four RCTs, two non-randomized comparative studies, and one case series of laser tonsillectomy in adults and children. Most used the KTP laser. The pain within 24 hours was lower after laser tonsillectomy than after cold-steel dissection, but was subsequently greater less than 2 weeks postoperatively. Three studies found that wound healing was slower after laser tonsillectomy compared with cold-steel dissection. Whereas the mean intraoperative blood loss was lower with KTP-laser tonsillectomy compared to cold-steel dissection, there were slightly increased rates of postoperative hemorrhage. Despite using laser safety precautions, one patient in a case series sustained a burn to the tongue [11]. One prospective randomized study of 60 patients using the CO2 laser with the power set to 10 to 15 watts demonstrated a significant decrease in operative time and amount of intraoperative blood loss as compared to conventional “cold” knife techniques, with no statistical difference in the two groups when looking at postoperative pain. Of note there were no postoperative hemorrhages reported in either group, with follow up between 2 weeks and 1 month post-operatively [28]. The authors here thus conclude that in a hospital where a laser machine and expertise are available, it is justifiable to use this technique as an effective method of performing tonsillectomy.

PEAK PLASMABLADE

Recently the PEAK plasma blade has been used for extracapsular tonsillectomy (Video). The PEAK PlasmaBlade is a new electrosurgical device that uses pulsed radiofrequencies to generate a plasma-mediated discharge along the exposed rim of an insulated blade, creating an effective cutting edge while the blade stays near the patient's body temperature. One advantage of the hand piece for tonsillectomy is that it has a suction port, which obviates the need for an assistant to hold a Yankauer suction during the procedure. A recent study compared monopolar cautery extracapsular tonsillectomy, coblation extracapsular tonsillectomy, and PEAK PlasmaBlade extracapsular tonsillectomy. There was less bleeding and less frequent return to the emergency department for treatment [29] after the use of the PEAK PlasmaBlade.

POWERED INSTRUMENTS: MICRODEBRIDER

The microdebrider as an instrument was initially introduced by Koltai et al. in 1997 for adenoidectomy, and in 2002 for intracapsular tonsillectomy [7]. The microdebrider is a powered rotary shaving device with continuous suction, made up of a tube and connected to a hand piece, which in turn, is connected to a motor with foot control and a suction device [18]. Tissue reduction with the microdebrider is achieved by mechanically shaving the tonsillar tissue from the inferior medial pole proceeding superior laterally, preserving the tonsillar capsule along with a thin rim of tonsillar tissue. No significant heat is generated, thus avoiding any thermal damage to surrounding tissue [9].

Since the time of the microdebrider's introduction, multiple studies have demonstrated the safety and efficacy of microdebrider intracapsular tonsillectomy, making it a valuable treatment option for the appropriate candidates–importantly, children with tonsillar hypertrophy and obstructive sleep apnea [7]. The existing literature supports the evidence that intracapsular tonsillectomy (using any technique) has fewer incidences of delayed hemorrhage, less postoperative pain, and an earlier return to daily activities [9]. In their prospective, double-blinded study of 156 patients comparing intracapsular microdebridement, intracapsular coblation, and extracapsular electrocautery dissection published in 2009, Wilson et al. found that postoperative recovery following intracapsular adenotonsillectomy in children with OSAS is significantly earlier with the use of either the coblator or microdebrider versus traditional extracapsular tonsillectomy with electrocautery. The authors also demonstrated that the microdebrider and coblator for intracapsular tonsillectomy were equivalent in all parameters studied (intraoperative time, surgeon's perception of difficulty, postoperative pain, return to diet and activity, postoperative complications, cost) with the exception of shorter operative time and less cost for the microdebrider [9].

Major downsides of this technique include the possibility of recurrent tonsillitis, thus making an infection-related indication a relative contraindication to intracapsular tonsillectomy using any method, as well as tonsillar regrowth and the possible need for reoperation. In a retrospective cohort study published in 2016 looking at the charts of 89 children who underwent either intracapsular or extracapsular tonsillectomy for OSAS, Mukhatiyar et al. found that both are effective modalities to treat OSAS with comparable

surgical outcomes on short-term follow up, however, in the subset of patients with asthma and obesity, the OSAS was likely to be refractory to treatment with a partial technique, as compared to extracapsular tonsillectomy and adenoidectomy [8]. For this reason the decision of which technique to use, as in all surgery, involves looking at the patient as a whole. Lastly, microdebrider-assisted intracapsular tonsillectomy is criticized for increased intraoperative blood loss [7]. Although statistically significant in many studies, the difference in intraoperative blood loss with the microdebrider compared to electrocautery is (for the most part) not clinically significant [7]. It does, nevertheless, become significant in those children (or adults) with a low weight or for those with bleeding disorders or other risk factors for hemorrhage [23], which again emphasizes the importance of looking at all factors and weighing the risks and benefits of each technique based on the individual patient.

VESSEL SEALING SYSTEM

Energy-based vessel sealing systems use different technologies to provide a similar dissection-ligation effect. Thermal welding uses the simultaneous application of heat and pressure (instead of using electric current) to cut and coagulate tissue and blood vessels. Unlike diathermy, no electric current passes through the tissue. At the tip of the cautery forceps, a low voltage current activates a heating element. Tissue that is grasped using the forceps is vaporized (temperatures 300 to 400 degrees C), while the vessels are sealed by a combination of heat and the clamping pressure of the forceps [16]. The manufacturer claims that it produces less heat and minimizes collateral tissue damage [27].

No identified RCTs assessed thermal welding in children, but the technique was used in adults in several studies. In their randomized controlled study, Karatzias et al. found no difference in operative time between thermal welding and bipolar diathermy. Patients in the thermal welding group had less postoperative pain during the two week follow-up and returned to normal diet more quickly compared to bipolar diathermy [30]. There was no difference found between thermal welding and bipolar diathermy in both the mean intraoperative blood loss and in the rates of postoperative hemorrhage [30]. However, it is important to note that given this is a relatively newer technique, the existing evidence in today's literature consists of small patient numbers, therefore, further studies are necessary in order to support many of the above conclusions.

The LigaSure Vessel Sealing System (LS) is a hemostatic electrosurgical device that consists of a handpiece with a ratcheted scissors mechanism that grasps and compresses the tissue and an electrosurgical generator that senses the density of the tissue bundle, automatically adjusting the amount of energy to deliver the optimal amount to denature collagen and elastin within the vessel wall and connective tissue [27].

In a randomized clinical trial comparing LigaSure to cold-steel dissection, Lachanas et al. found that the mean operative time was significantly shorter and the pain was lower in the 2 weeks following the use of the vessel sealing system when compared to cold-steel dissection with packs or ties [31]. The mean intraoperative blood loss was lower using the LigaSure compared with cold-steel dissection, however, the rates of postoperative hemorrhage were similar in both groups [31].

In their meta-analysis of 7 studies comparing outcomes of tonsillectomies performed using *all* vessel sealing systems (including thermal welding, LigaSure, and the BiClamp device) with tonsillectomies performed using conventional technique, Alexiou et al. found that operative time was shorter and perioperative bleeding significantly less in the Vessel Sealing System group. They also found that vessel sealing yielded significantly less postoperative bleeding and pain as compared to conventional techniques [27]. This meta-analysis, however, was limited because of significant methodological heterogeneity among the studies, as well as the fact that the analysis pooled studies of 3 different devices [27].

COST

As demonstrated above, there are a variety of options in today's world for how to perform tonsillectomy or T&A, each with its own advantages and disadvantages. Though a full discussion regarding cost analysis is beyond the scope of this chapter, it is important to note that there is significant variation in adenotonsillectomy hospital costs per case among individual surgeons [32]. As Meier et al. (2015) discuss in their study of 26,626 patients who underwent same-day adenotonsillectomy (alone), there are dramatic differences among surgeons' mean cost per case, suggesting that individual providers bear personal responsibility for much of the cost variations of the procedure. The authors found that intrahospital variation among surgeons was impacted by the time in the operating room and the instruments each surgeon chose. The data suggest that increased costs do not necessarily equate to improved outcomes as measured by postsurgical complications. In fact, in this particular study, the authors found that the surgeons with higher mean costs tended also to have higher complication rates, although the difference was not statistically significant [32].

SUMMARY

There are many factors to consider when choosing the technique for tonsillectomy or T&A. This chapter provides a general summary of these, as well as the advantages and disadvantages of not only each instrument, but also those of extracapsular versus intracapsular tonsillectomy. As we move forward, overall cost considerations will undoubtedly influence the choice of technique.

REFERENCES

[1] Younis, R. T. and R. H. Lazar. 2002. "History and Current Practice of Tonsillectomy." *Laryngoscope,* 112: 3-5.

[2] Goldsmith, Ari J. and Richard M. Rosenfeld. 2002. "Tonsillectomy, Adenoidectomy, and UPPP." In *Surgical Atlas of Pediatric Otolaryngology*, edited by Charles D. Bluestone and Richard M. Rosenfeld, 379-406. Hamilton, Ontario: BC Decker Inc.

[3] "Tonsillectomy Facts in the U.S.: From *ENT Doctors*. http://www.entnet.org/content/tonsillectomy-facts-us-ent-doctors Accessed May 30, 2017.

[4] Nabili, V. and J. A. Koempel. 2005. "Electrocautery Tonsillectomy: Common Practice Since the 1930s?" *Otolaryngology Head Neck Surgery* 133:818-819.

[5] Burton, M. J. and P. P. Glasziou. 2009. "Tonsilletomy or Adeno-tonsillectomy Versus Non-surgical Treatment for Chronic/Recurrent Acute Tonsillitis." *Cochrane Database of Systemic Reviews* 1:CD001802.

[6] Baugh, R. F., S. M. Archer, R. B. Mitchell, R. M. Rosenfeld, R. Amin, J. J. Burns, D. H. Darrow, T. Giordano, R. S. Litman, K. K. Li, M. E. Mannix, R. H. Schwartz, G. Setzen, E. R. Wald, E. Wall, G. Sandberg, M. M. Pateland The American Academy of Otolaryngology-Head and Neck Surgery Foundation. 2011. "Clinical Practice Guideline: Tonsillectomy in Children." *Otolaryngology Head Neck Surgery* 144(1 Suppl):S1-30.

[7] Gallagher, T. Q., L. Wilcox, E. McGuire, and C. S. Derkay. 2010. "Analyzing Factors Associated with Major Complications After Adenotonsillectomy in 4776 Patients: Comparing Three Tonsillectomy Techniques." *Otolaryngology Head Neck Surgery* 142:886-892.

[8] Mukhatiyar, P., K. Nandalike, H. W. Cohen, S. Sin, M. Gangar, J. P. Bent, and R. Arens. 2016. "Intracapsular and Extracapsular Tonsillectomy and Adenoidectomy in Pediatric Obstructive Sleep Apnea." *JAMA Otolaryngology Head Neck Surgery* 142(1):25-31.

[9] Wilson, Y. L., D. M. Merer,and A. L. Moscatello. 2009. "Comparison of Three Common Tonsillectomy Techniques: A Prospective Randomized, Double-blinded Clinical Study." *Laryngoscope* 119:162-170.

[10] Walton, J., Y. Ebner, M. G. Stewart, and M. M. April. 2012. "Systematic Review of Randomized Controlled Trials Comparing Intracapsular Tonsillectomy with Total Tonsillectomy in a Pediatric Population." *Archives Otolaryngology Head Neck Surgery* 138(3):243-249.

[11] Scott, A. 2006. "Hot Techniques for Tonsillectomy*." Issues in Emerging Health Technologies*: 93. Ottawa, Ontario: Canadian Agency for Drugs and Technologies in Health.

[12] Blomgren, K., Y. H. Qvarnberg, and H. J. Valtonen. 2001. "A Prospective Study on Pros and Cons of Electrodissection Tonsillectomy." *Laryngoscope* 111:478-482.

[13] Isaacson, G. and W. Szeremeta. 1998. "Pediatric Tonsillectomy with Bipolar Electrosurgical Scissors." *American Journal of Otolaryngology* 19(5):291-295.

[14] Lowe, D., J. van der Meulen, D. Cromwell, J. Lewsey, L. Copley, J. Browne, M. Yungand P. Brown. 2007. "Key Messages from the National Prospective Tonsillectomy Audit." *Laryngoscope* 117:717-724.

[15] Pinder, D. K., H. Wilson,and M. P. Hilton. 2011. "Dissection Versus Diathermy for Tonsillectomy." *Cochrane Database System Review 3*:CD002211.

[16] Nunez, D. A., J. Provanand M. Crawford 2000. "Postoperative Tonsillectomy Pain in Pediatric Patients: Electrocautery (Hot) vs Cold Dissection and Snare Tonsillectomy--A Randomized Trial." *Archives Otolaryngology Head Neck Surgery* 126:837-841.

[17] Leinbach, R. F., S. J. Markwell, J. A. Colliver, and S. Y. Lin. 2003. "Hot Versus Cold Tonsillectomy: A Systematic Review of the Literature." *Otolaryngology Head Neck Surgery* 129:360-364.

[18] Aremu, S. K. 2012. "A Review of Tonsillectomy Techniques and Technologies." In *Otolaryngology*, edited by Prof. Balwant Singh Gendeh. InTech: World's Largest

Science, Technology & Medicine Open Access book publisher. Accessed January 26, 2017.

[19] Pizzuto M.P., L. Brodsky, L. Duffy, J. Gendler, and E. Nauenberg. 2000. "A Comparison of Microbipolar Cautery Dissection to Hot Knife and Cold Knife Cautery Tonsillectomy." *International Journal of Pediatric Otorhinolaryngology* 52:239-246.

[20] Schrötzlmair, F., L. Geerke, U. Kisser, C. Reichel, S.Vögele, and K. Stelter K. 2015. "Optical Magnification Devices in Tonsillectomy: A Prospective Randomized Clinical Study." *European Archives of Otorhinolaryngology* 272:3031-3037.

[21] Raut V., N. Bhat, J. Kinsella, J.G. Toner, A.R. Sinnathuray, and M. Stevenson. 2001. "Bipolar Scissors Versus Cold Dissection Tonsillectomy: A Prospective, Randomized, Multi-unit Study." *Laryngoscope* 111:2178-2182.

[22] Mowatt G., J. A. Cook, C. Fraser, W. S. McKerrow, and J. M. Burr. 2006. "Systematic Review of the safety of Electrosurgery for Tonsillectomy." *Clinical Otolaryngology* 31:95-102.

[23] Blanchford H., and D. Lowe. 2013. "Cold Versus Hot Tonsillectomy: State of the Art and Recommendations." *ORL Journal of Otorhinolaryngology Related Specialities* 75:136-141.

[24] Bergler W., K. Huber, N. Hammerschmitt, and K. Hormann. 2001. "Tonsillectomy with Argon Plasma Coagulation (APC): Evaluation of Pain and Hemorrhage." *Laryngoscope* 111(8): 1423-1429.

[25] Skinner L. J., M. P. Colreavy, E. Lang, B. O'Hare, D. A. Charles, and C. I. Timon. 2003. "Randomized Controlled Trial Comparing Argon Plasma Coagulation Tonsillectomy with Conventional Techniques." *Journal of Laryngology & Otolaryngology* 117(4): 298-301.

[26] Lond. 2006. "*Interventional Procedures Overview of Tonsillectomy Using Ultrasonic Scalpel."* National Institute for Health and Clinical Excellence. [Interventional procedures programme 242].

[27] Alexiou V.G., M. S. Salazar-Salvia, P. N. Jervis, and M. E. Falagas. 2001. "Modern Technology-assisted vs Conventional Tonsillectomy." *Archives Otolaryngology Head Neck Surgery* 137(6):558-570.

[28] Ishlah W., A.M. Fahmi, and N. Srinovianti. 2005. "Laser Versus Dissection Technique of Tonsillectomy." *Medical Journal of Malaysia* 60(1):76-80.

[29] Lane J.C., J. Dworkin-Valenti, L. Chiodo, and M. Haupert. 2016. "Postoperative Tonsillectomy Bleeding Complications in Children: A Comparison of Three Surgical Techniques." *International Journal of Pediatric Otorhinolaryngology*. 88:184-8. doi: 10.1016/j.ijporl.2016.07.007. Epub 2016 Jul 11.

[30] Karatzias G. T., V. A. Lachanas, and V. G. Sandris. 2006. "Thermal Welding Versus Bipolar Tonsillectomy: A Comparative Study." *Otolaryngology Head Neck Surgery* 134(6):975-8.

[31] Lachanas V. A., E. P. Prokopakis, C. A. Bourolias, A. D. Karatzanis, S. G. Malandrakis, E. S. Helidonis, and G. A. Velegrakis. 2005. "Ligasure Versus Cold Knife Tonsillectomy." *Laryngoscope* 115(9):1591-4.

[32] Meier J. D., Y. Zhang, T. H. Greene, J. L. Curtis, and R. Srivastava. 2015. "Variation in Pediatric Adenotonsillectomy Costs in a Multihospital Network." *Laryngoscope* 125:1215-1220.

In: Encyclopedia of Surgery (22 Volume Set)
Editors: Andreas Lehrer and Kristin Mueller
ISBN: 978-1-53618-329-0
© 2020 Nova Science Publishers, Inc.

Chapter 169

COBLATION INTRACAPSULAR TONSILLECTOMY

Sophie Shay, MD and Nina L. Shapiro, MD
Department of Head and Neck Surgery, David Geffen School of Medicine,
University of California Los Angeles, Los Angeles, CA, US

INTRODUCTION

Coblation® technology is a relatively new instrumentation for tonsillectomy. Since the early 2000's, it has gained increased acceptance and use amongst otolaryngologists. Given its potential for decreased postoperative morbidity, decreased postoperative pain, faster return to a normal diet, and faster return to normal activity, more surgeons have considered utilization of this technique. The primary method for tonsillectomy with the coblation wand has been that of extracapsular tonsillectomy, with perioperative bleeding rates similar to those of other techniques published in the literature [1]. More recent development of wands with larger contact surfaces, enabling tissue ablation, has led to use of this technique for intracapsular tonsillectomy.

Coblation® uses a radiofrequency bipolar electrical current to ablate and coagulate soft tissue at a frequency lower than standard bipolar diathermy, thus avoiding thermal injury. The device conducts the current through normal saline located between the device tip and soft tissue, whereby the saline is converted into an ionized sodium plasma layer. The sodium ions are capable of breaking down molecular and intracellular bonds in the tissue, thereby vaporizing the tissue at temperatures between 40-70° C. Irrigation of saline also reduces the amount of thermal energy transmitted to surrounding soft tissues, thus decreasing the amount of postoperative pain [6–8].

In recent years, intracapsular tonsillectomy has become more popular, with increasing evidence that near-complete removal of pharyngeal tonsils, leaving the lateral-most portion of the capsule intact is associated with reduced rates of bleeding and postoperative pain, while having similar outcomes in eliminating obstructive tissue [2]. The trend towards performing intracapsular tonsillectomy for obstructive sleep apnea and sleep disordered breathing has been seen in European countries such as Austria, Sweden, and the United Kingdom [12]. Hultcranz et al reported a 0.8% postoperative bleeding rate for intracapsular tonsillectomy,

compared to 3.4% for extracapsular tonsillectomy [15]. Without showing any differences in obstructive sleep apnea symptoms, this study also reported decreased rates of readmission, number of days using analgesics, and nosocomial infections at 6-months follow-up. Zhang et al reported a 6.1% rate of tonsillar regrowth with 5 year follow-up, suggesting a low rate of tonsillar tissue regrowth following intracapsular tonsillectomy [11].

Many advocate for the use of coblation in performing intracapsular tonsillectomy as a method to further decrease perioperative morbidity, though the literature demonstrating this technique as superior to more traditional methods remains controversial [2, 7, 13, 14, 16, 17]. A randomized, blinded controlled study by Chang reported that by postoperative days 5-6, patients who had coblation intracapsular tonsillectomy had significantly better pain control, diet resumption, and normal activity level compared to coblation total tonsillectomy [17]. Using the Swedish National Registry for Tonsil Surgery, Sunnergren et al found a 1.2% postoperative bleeding rate requiring readmission, with a mean for 4.2 days using analgesics amongst 1,676 patients [13]. In a study of 415 patients, Duarte et al reported that patients who had coblation intracapsular tonsillectomy resumed normal diets 5.4 days after surgery, compared to 8.0 days for those who underwent coblation extracapsular tonsillectomy ($p = 0.022$), and had better postoperative pain control [16]. When adenoidectomy was performed in conjunction with coblation intracapsular tonsillectomy compared to extracapsular tonsillectomy, Babademez et al (2016) reported decreased rates of symptomatic and subclinical adenoid regrowth [18].

Coblation® has been shown to be an effective and safe surgical tool for intracapsular tonsillectomy. In particular, coblation intracapsular tonsillectomy may be associated with lower rates of postoperative pain, decreased postoperative bleeding, faster return to normal activity, and quicker return to a normal diet. Coblation intracapsular tonsillectomy represents an important technique in the surgical management of adenotonsillar hypertrophy.

COBLATION INTRACAPSULAR TONSILLECTOMY ADENOIDECTOMY TECHNIQUE

For performance of intracapsular tonsillectomy/adenoidectomy using a Coblation® instrument, the PROCISE MAX® wand is recommended. This provides a broader tip, in order to adequately ablate the bulky lymphoid tissue. The larger tip also minimizes intraoperative plugging of the wand's contact screen, and allows for better intraoperative coagulation.

The patient is placed in the standard Rose position and intubated with an oral RAE tube. A Crow-Davis mouth gag is placed and suspended. The Coblation® device is set on a setting of '7' for coblation ('cut' equivalent) and '3' for coagulation. A 1-liter intravenous fluid bag of saline is hung for irrigation, and the suction is attached to a standard suction device on continuous suction when the device pedal is activated. (VIDEO X) The wand is placed first on the right tonsil, and in a 'painting' motion, the tonsil tissue is ablated (on 'coblate 7') until the lymphoid tissue abutting the fossa is visualized. The defect should look concave. In using the coblate function, one needs to very lightly touch the tissue to create an ablation effect. The wand is intermittently used to coagulate the small intra-tonsillar vessels throughout the procedure. The entire base of the thin layer of capsule at the fossa is then coagulated with the

coblation wand on ‘coagulate 3’. Irrigation flow needs to be clear, as does suctioning, in order for the wand to function. When using the coagulation function, the wand screen is placed flatly on the tissue. Gentle pressure can be given to coagulate, as the coagulation function is relatively weak compared to a similarly designed suction electrocautery device. As the maximum temperature of the wand is 70 degrees Celsius (as opposed to 450 degrees Fahrenheit for an electrocautery wand), there is a significantly lower risk of deep tissue and/or vessel injury when coagulating. The left tonsil is ablated in the same fashion as the right. No other instruments are needed during the tonsillectomy.

For the coblation adenoidectomy, a single red-Robinson catheter is placed into the right nasal cavity, grasped intraorally with a curved hemostat, and used as a palatal elevator. Under indirect visualization with a laryngeal mirror, the adenoidectomy is performed. The PROCISE MAX ® wand is bent slightly, in order to access the adenoids. The wand should take on a C-shape. Bending the distal end of the wand into an L-shape will lead to plugging of the tip. The wand is then utilized to ablate the adenoids, beginning at the left choana, and continuously moving first laterally, and then inferiorly, also in a ‘painting’ motion, until Passavant’s ridge is reached. As with the tonsillectomy, coagulation is used intermittently as needed, as well as at the conclusion of the adenoidectomy for any continued bleeding.

Especially in children with large tonsils and adenoids, the wand may become plugged with lymphoid tissue. It will not function when plugged, as both the suction and the irrigation need to be continuous when the coblation instrument is used. To avoid plugging, the wand is placed in a basin of saline, and the coblation pedal is activated while moving the wand in and out of the saline. If this does not clear the tip, temporary disconnection of the suction tubing, followed by flushing the wand with a 10cc syringe of saline will clear the tip.

Coblation® intracapsular tonsillectomy/adenoidectomy is an extremely safe, effective technique, especially in patients undergoing the procedure for chronic obstructive symptoms. The procedure requires only one instrument, whereby adjuvant need for electrocautery devices, bipolar instruments, or sutures are rarely, if ever, necessary. As with most new technologies and techniques, there is a steep ‘learning curve’ when first performing this technique. The primary challenge is the surgeon’s sense of how much, or how little, direct tissue contact is needed to maximize ablation, minimize wand plugging, and maximize coagulation, all while maintaining appropriate visualization and tissue planes. Once this comfort level is achieved, the technique is easily reproducible, with extremely consistent results in patient outcomes.

REFERENCES

[1] Walner D. L., S. P. Miller, D. Villines, and G.S. Bussell. 2012. “Coblation tonsillectomy in children: incidence of bleeding.” *The Laryngoscope*. 122(10):2330-2336. doi:10.1002/lary.23526.

[2] Arya A., A. J. Donne, and A. Nigam. 2003. “Double-blind randomized controlled study of coblation tonsillotomy versus coblation tonsillectomy on postoperative pain.” *Clinical Otolaryngology and Allied Sciences*. 28(6):503-506.

[3] Magdy E. A., S. Elwany, A. S. el-Daly, M. Abdel-Hadi, and M. A. Morshedy. 2008. “Coblation tonsillectomy: a prospective, double-blind, randomised, clinical and

histopathological comparison with dissection-ligation, monopolar electrocautery and laser tonsillectomies." *Journal of Laryngology Otology*. 122(3):282-290. doi:10.1017/S002221510700093X.

[4] Timms M. S. and R. H. Temple. 2002. "Coblation tonsillectomy: a double blind randomized controlled study." *Journal of Laryngology Otology*. 116(6):450-452. doi:10.1258/002221502 1911031.

[5] Hultcrantz E. and E. Ericsson. 2004. "Pediatric tonsillotomy with the radiofrequency technique: less morbidity and pain." *The Laryngoscope*. 114(5):871-877. doi:10.1097/00005537-20040 5000-00016.

[6] Temple R. H. and M. S. Timms. 2001. "Paediatric coblation tonsillectomy." *International Journal of Pediatric Otorhinolaryngology*. 61(3):195-198.

[7] Chang K. W. 2005. "Randomized controlled trial of coblation versus electrocautery tonsillectomy." *Otolaryngology--Head & Neck Surgery* 132(2):273-280. doi:10.1016/j.otohns.2004.11.002.

[8] Chinpairoj S., M.D. Feldman, J. C. Saunders, and E.R. Thaler. 2001. "A comparison of monopolar electrosurgery to a new multipolar electrosurgical system in a rat model." *The Laryngoscope*. 111(2):213-217. doi:10.1097/00005537-200102 000-00005.

[9] Ericsson E. and E. Hultcrantz. 2007. "Tonsil surgery in youths: good results with a less invasive method." *The Laryngoscope*. 117(4):654-661. doi:10.1097/mlg.0b013e318030ca69.

[10] E. Hultcrantz, A. Linder, and A. Markstrnt. 1993. "Tonsillectomy or tonsillotomy?--A randomized study comparing postoperative pain and long-term effects." *International Journal of Pediatric Otorhinolaryngology*. 51(3):171-176.

[11] Zhang Q., D. Li, and H. Wang. 2014. "Long term outcome of tonsillar regrowth after partial tonsillectomy in children with obstructive sleep apnea." *Auris Nasus Larynx*. 41(3):299-302. doi:10.1016/j.anl.2013.12.005.

[12] Sarny S., W. Habermann, G. Ossimitz, and H. Stammberger. 2013. "What lessons can be learned from the Austrian events?" *ORL Journal for Oto-Rhino-Laryngology and Its Related Specialities*. 75(3):175-181. doi:10.1159/000342319.

[13] Sunnergren O., C. Hemlin, E. Ericsson et al., 2014. "Radiofrequency tonsillotomy in Sweden 2009-2012." *European Archives Oto-Rhino-Laryngology* 271(6):1823-1827. doi:10.1007 /s00405-013-2867-4.

[14] Hadjisymeou S., P. C. Modayil, H. Dean, N. E. Jonas, and D. J. Tweedie. 2014. "Our experience. Coblation intracapsular tonsillectomy (tonsillotomy) in children. *Clinical Otolaryngology* 39(5):301-307. doi:10.1111/coa.12278.

[15] Hultcrantz E., E. Ericsson, C. Hemlin, et al., 2013. "Paradigm shift in Sweden from tonsillectomy to tonsillotomy for children with upper airway obstructive symptoms due to tonsillar hypertrophy." *European Archives of Oto-Rhino-Laryngology* 270(9):2531-2536. doi:10.1007/s00405-013-2374-7.

[16] Duarte V. M., Y .F. Liu, and N. L. Shapiro. 2014. "Coblation total tonsillectomy and adenoidectomy versus coblation partial intracapsular tonsillectomy and adenoidectomy in children." *The Laryngoscope*. 124(8):1959-1964. doi:10.1002/ lary.24632.

[17] Chang K. W. 2008. "Intracapsular versus subcapsular coblation tonsillectomy." *Otolaryngology--Head & Neck Surgery* 138(2): 153-157. doi:10.1016/j.otohns.2007.11.006.

[18] Bababemez M. A., F. Gul, E. Muz, T. Muderris, and H. Kale. 2017. "Impact of partial and total tonsillectomy on adenoid regrowth." *The Laryngoscope*. 127(3):753-756 doi:10.1002/ lary.25982.

In: Encyclopedia of Surgery (22 Volume Set)
Editors: Andreas Lehrer and Kristin Mueller
ISBN: 978-1-53618-329-0
© 2020 Nova Science Publishers, Inc.

Chapter 170

THE RESULTS OF INTRACAPSULAR VS. EXTRACAPSULAR TONSILLECTOMY

Benjamin J. Rubinstein, MD and Craig S. Derkay, MD
Department of Otolaryngology, Eastern Virginia Medical School
Norfolk, VA, US

ABSTRACT

Intracapsular tonsillectomy and traditional extracapsular tonsillectomy are both efficacious for treatment of pediatric obstructive sleep apnea (OSA) associated with adenotonsillar hypertrophy. Preliminary research suggests a role for intracapsular techniques in recurrent tonsillitis, but data is limited and extracapsular tonsillectomy remains predominant. With intracapsular tonsillectomy, pediatric patients recover faster, use less pain medication, and have a lower risk of dehydration and hemorrhage postoperatively. Extracapsular tonsillectomy is superior in terms of regrowth rates, though reoperation after intracapsular tonsillectomy is rare. Intracapsular tonsillectomy has the potential to reduce the financial footprint of tonsil surgery. The benefits of intracapsular tonsillectomy have been described in well-designed clinical trials and meta analyses.

INTRODUCTION

Intracapsular tonsillectomy and traditional electrocautery tonsillectomy have both proven efficacious for treatment of pediatric obstructive sleep apnea (OSA) associated with adenotonsillar hypertrophy [1-6]. While electrocautery tonsillectomy is superior in terms of regrowth rates, it is associated with not-insignificant rates of postoperative hemorrhage and pain with associated dehydration [1, 7-10]. The 21st century has seen the adoption of various technologies to replace cold steel and electrocautery extracapsular tonsillectomy without significant improvement in postoperative outcomes [10]. Intracapsular tonsillectomy has increasingly been investigated as an alternative to extracapsular tonsillectomy to reduce pain, hemorrhage, and hospital readmission. With intracapsular tonsillectomy, pediatric patients

recover faster, use less pain medication, and have a lower risk of dehydration and hemorrhage postoperatively. The benefits of intracapsular tonsillectomy have been described in well-designed clinical trials and meta analyses [7, 11-13].

POSTOPERATIVE PAIN

Otolaryngologists have become accustomed to counseling their patients' families that "the next two weeks are going to be tough." Despite scheduled or PRN dosing of narcotic and/or non-narcotic pain medications, children continue to experience moderate pain following total tonsillectomy. Postoperative regimens are also hampered by caregiver non-compliance. Given the unreliable metabolism of acetaminophen/codeine and its lack of superiority over acetaminophen alone, codeine has fallen out of favor.

Systematic reviews have suggested the safety of non-steroidal anti-inflammatory drugs (NSAIDs), but uncertainty remains with updated analyses unable to exclude an increased risk of bleeding [8, 14, 15]. The most recent Cochrane review on the matter noted a "non-significant increase in the risk of bleeding requiring surgical intervention," with an odds ratio of 1.69 and a confidence interval of 0.71 to 4.01. Bleeding events not requiring surgical intervention were not significantly increased in their analysis [15]. Another meta-analysis in the same year that included 36 randomized controlled trials found no increased risk of bleeding after or during tonsillectomy when NSAIDs were utilized [16]. As individual institutions have examined their own experience with NSAIDs, the debate has continued regarding the safety of NSAIDs relative to narcotics [17, 18].

Intracapsular tonsillectomy results in significantly less postoperative pain than total tonsillectomy. Children stop using pain medication 2.5 days earlier when randomized to microdebrider intracapsular tonsillectomy. These children are 2.5 times more likely to be off pain medication at one week, and 39% take their last dose of pain medication at postoperative day 3 versus 18% in the electrocautery tonsillectomy group [19]. In a randomized, double-blind, paired control study, Lister removed one tonsil by electrocautery and the contralateral by microdebrider intracapsular tonsillectomy in each patient. Children reported significantly less pain on the tonsillotomy side for the first 9 postoperative days. While 80% of the children reported otalgia, it was always unilateral and on the side of the electrocautery tonsillectomy [20]. The benefit of reduced postoperative pain with intracapsular tonsillectomy holds true when using the coblator [21, 22] or bipolar scissors [23]. The reduced perioperative morbidity is related to surgical technique, rather than the instrument, likely secondary to preservation of a biologic dressing over the pharyngeal musculature and decreased thermal injury to the tissues [9, 10, 19, 20, 23].

POSTOPERATIVE RECOVERY

Reduced postoperative discomfort in children manifests as a quicker return to normal activity and normal diet. Chang randomized children to intracapsular versus subcapsular coblation and reported improved diet and activity levels in intracapsular patients throughout the postoperative course [22]. Patients return to a normal diet and activity level 1.5-2.5 days

earlier when the intracapsular techniques are compared to extracapsular tonsillectomy [21]. The addition of QuikClot for hemostasis allows decreased cauterization, and time to full recovery is inversely related to total intraoperative cauterization. Patients treated with this intracapsular technique using QuickClot experience cessation of narcotic use in 3 days and complete recovery (normal diet, normal activity, and no narcotics) in 4.5 days [24]. Meta-analysis has shown that even when reviewing only randomized clinical trials, children use less pain medication (2.5 days) and recover to normal diet faster (2.15 days) with intracapsular techinques [7].

When children recover faster with less discomfort, families can return to their normal lifestyle and productivity without distress. When considering the success of a tonsillectomy, it is essential to consider the entire experience of the postoperative course, including any unplanned stressors. Imagine the frustrating process of struggling with a child who arrives at a point of dehydration requiring phone calls to the office, emergency department visits, and possible readmission. Schmidt reviewed data from 2944 patients and identified a rate of ER evaluation for postoperative pain or dehydration of 3% for intracapsular tonsillectomy compared with 5.4% for total tonsillectomy [25]. Other retrospective studies have similarly favored the intracapsular technique due to lower rates of re-admission for dehydration at only 0.4%-1.3% [26, 27]. At Columbia/Cornell, the intracapsular group had a 0.3% rate of readmission or ED visit versus 8.3% in the total tonsillectomy group [28]. While some studies find readmission rates to be similar between the two techniques, data has not been published to support lower readmission rates in total tonsillectomy patients [7]. The psychological and financial impact of these postoperative events on families can be surmised but has yet to be studied.

POSTOPERATIVE HEMORRHAGE

Intracapsular tonsillectomy carries a lower rate of postoperative hemorrhage than total tonsillectomy. Francis found that pooled bleeding rates were 1.5% for partial tonsillectomy versus 4.2% for total tonsillectomy, though their meta-analysis could not "prove" superiority of partial tonsillectomy. Children having surgery for obstruction were less likely to bleed than those with recurrent infection, and this effect was predominantly driven by late bleeds (1.9 vs. 3.9%). Analysis of partial tonsillectomy in the setting of surgery for recurrent tonsillitis was limited by small sample size [29]. Schmidt's retrospective review showed a 1.5% vs. 5.3% bleeding rate for pediatric intracapsular vs. electrocautery tonsillectomy in patients with recurrent tonsillitis. This same review showed a smaller, but significant, difference in post-tonsillectomy bleed rates between patients undergoing surgery for obstruction using intracapsular vs. extracapsular techniques (1.1% vs. 2.4% respectively) [25].

Currently unpublished data covering 4395 tonsillectomies for any indication at a tertiary children's hospital found combined bleeding rates (managed in the ED or in the OR) of 2.6%, 4.3%, and 0.5% for electrocautery tonsillectomy, coblation tonsillectomy, and microdebrider intracapsular tonsillectomy respectively. Rates of hemorrhage requiring return to the OR were dramatically different at 1.2% (electrocautery), 1.6% (coblation), and 0.2% (microdebrider). Of children experiencing bleeding, the surgical indication was obstruction in 61% and recurrent tonsillitis (or both) in 39% [30].

Extensive reviews have echoed the improved safety profile of intracapsular technique and note its increasing utilization. A large review of randomized controlled trials found that intracapsular tonsillectomy for obstruction is associated with a 0.7% rate of late hemorrhage compared with 2% in total tonsillectomy for obstruction [11-13]. A recent retrospective review also showed lower bleeding rates for intrascapular (0.2%) vs. total tonsillectomy (2.9% total, 1.6% return to OR), though it should be noted that intracapsular patients tended to be younger and have a lower BMI [1]. Given the low incidence of post tonsillectomy hemorrhages overall and variations in both reporting and surgical technique, smaller prospective trials often do not reveal these benefits. In the age of decreasing postoperative antibiotics and more liberal use of NSAIDs, these small differences may become more pronounced [31].

Caring for a child with a post-tonsillectomy bleed is an unforgettable experience for the families and the provider. The experience of a life-threatening complication for the parents and child usually includes a trip to the ER along with uncomfortable interventions. Research to date has not specifically investigated the impact on quality of life of a post tonsillectomy bleed. In the debate between various tonsillectomy techniques, researchers should use caution when solely comparing rates of post-tonsillectomy bleeding with those of tonsillar regrowth or recurrent sleep apnea in assessing outcomes.

TREATMENT EFFICACY AND REGROWTH RATES

Intracapsular tonsillectomy is as efficacious as total tonsillectomy for treating obstruction and is durable in the vast majority of patients. In his large retrospective review, Chang found that intracapsular patients had a statistically similar average change in AHI compared to total tonsillectomy patients (5.6% ± 8.6% and 8.6% ± 12.9%, respectively). A similar percentage of patients showed improvement in AHI in both groups. In this study, 2.0% of patients underwent surgery for tonsillar regrowth [1].

Mukhatiyar showed no difference in treatment failure between intracapsular and extracapsular techniques as measured by pre and post-operative polysomnogram. In both studies, children were older and more obese in the extracapsular groups. It is interesting to note that the Mukhatiyar study suggests that intracapsular tonsillectomy tends to be recommended by practitioners to younger patients because of their intrinsically higher risk of pain and bleeding. This recommendation seems contrary to the understanding that older children tend to be at a higher risk for post tonsillectomy hemorrhage [27, 32] and the risks of regrowth tend to be higher in the younger patients [33]. Mukhatiyar suggests the superiority of extracapsular technique in the obese asthmatic population, however this assertion was based on analysis of a very small sample size and did not hold true for asthma or obesity independently. Effectiveness of intracapsular technique has been demonstrated in children with severe obstructive sleep apnea as measured by polysomnogram with the average obstructive apnea hypopnea index decreasing from 25.5 to 3.9 [34]. The reduction of symptoms and resolution of sleep apnea has been consistently demonstrated by retrospective and prospective trials alike [3-6].

Regrowth rates in intracapsular tonsillectomy are low, estimated at 0.5%-6.1%, with a low proportion of these patients needing reoperation for infection or obstruction [26, 35, 36].

Chang identified 2% of patients with tonsillar regrowth that resulted in a return to the OR for secondary tonsillectomy. Sorin studied 278 patients and identified a 3.2% rate of regrowth with snoring, though only 0.7% required secondary tonsillectomy due to the return of OSA [35].

Little research has focused on the relative efficacy of intracapsular tonsillectomy for recurrent tonsillitis. Schmidt retrospectively reviewed 116 patients who underwent either extracapsular or intracapsular tonsillectomy for recurrent tonsillitis and did not show any difference in the number of patients with at least one postoperative sore throat infection in the first year of post-operative observation (14% vs. 16% respectively) [37]. For all patients undergoing intracapsular or total tonsillectomy, randomized trials have suggested no difference in the rate of tonsillitis, though follow-up duration is limited [11]. It should be noted that patients with total tonsillectomy are not free from visible regrowth, tonsillitis, or peritonsillar abscess, though certainly the rates of regrowth are substantially lower [13].

There has been concern that younger patients might be more likely to need reoperation due to regrowth or tonsillitis in the future [13, 33]. This argument must be balanced against considerations that younger populations are also at a higher risk for dehydration and are particularly likely to benefit from a less morbid procedure. For this reason, some institutions are favoring intracapsular tonsillectomy for their younger population [2]. In fact, some centers are successfully treating patients younger than 3 years old in an ambulatory fashion without complications using intracapsular surgery (provided they have adequate supervision, <30 minute access to a hospital, and an uneventful post-anesthesia care unit course) [38]. Increasingly, tonsil surgery is being performed in an ambulatory fashion, even when guidelines would suggest that patients be admitted due to age or comorbidities [39]. Surgeons shoulder the responsibility to offer the technique that offers the best outcome for the majority of patients and to reach a plan along with parents through a shared decision making process.

COST CONSIDERATIONS

In the current medical environment, cost containment is paramount, and intracapsular tonsillectomy offers an opportunity to reduce the financial footprint. In a prospective, randomized, double blinded study, microdebrider intracapsular tonsillectomy was more cost effective ($2,205) than both intracapsular coblation ($2,837) and electrocautery tonsillectomy ($2,825). Decreased cost was driven by the shorter operative time for bilateral tonsillectomy with the microdebrider (16 minutes) (cautery = 21 min, coblation = 20 min). The microdebrider ($100) was also less expensive than the coblation wand ($200) [21]. Some institutions have seen slightly increased surgical time for the microdebrider, but it is anticipated that this difference may decrease with experience [40]. At my institution, surgical time (mouth gag in till mouth gag out) for tonsillectomy and adenoidectomy averages 19.8 minutes with the microdebrider [24].

Reduction in PACU time, ER visits, unplanned re-admissions, narcotic use, and postoperative complications further contribute to potential cost savings. For example, Stucken demonstrated a decrease in PACU time of 82 minutes for intracapsular tonsillectomy patients [19, 28]. Intracapsular tonsillectomy is proving safe to perform in patients younger than 3 years old in an ambulatory fashion without any increased risk of dehydration or readmission

compared to older children [38]. It would seem logical that future research may uncover previously unmeasured financial benefits for intracapsular tonsillectomy in which caregivers are able to return to work sooner and are resting better at night, allowing for a more productive workday.

CONCLUDING THOUGHTS

Intracapsular tonsillectomy has been revived as an effective treatment that reduces cost and morbidity without sacrificing efficacy. Quality of life and return to productivity in the families should be factored strongly into our decision-making regarding surgery. Particularly in an age where observation is emerging as a reasonable alternative to tonsillectomy, we need to be certain about our goals for surgery [41, 42]. The more frequent significant complications associated with total tonsillectomy include readmission due to dehydration and hemorrhage. These complications occur in an emergent and stressful fashion, which is both financially and psychologically costly for patients, families, and physicians.

The principal drawback of intracapsular tonsillectomy, regrowth and the potential for reoperation, occurs in the setting of routine outpatient follow-up and occasionally results in ambulatory surgery. Certainly, this scenario could cause a degree of suffering for the child and psychologic distress for the family, but not in a fashion consistent with the potential for post-traumatic stress. Further research will hopefully elucidate the role of intracapsular tonsillectomy for recurrent tonsillitis, and prospective studies will help solidify our understanding of long-term complication rates between the two techniques.

REFERENCES

[1] Chang D. T., A. Zemek, and P. J. Koltai. 2016. “Comparison of Treatment Outcomes between Intracapsular and Total Tonsillectomy for Pediatric Obstructive Sleep Apnea.” *International Journal of Pediatric Otorhinolaryngology* 91:15-18.

[2] Mukhatiyar P., K. Nandalike, H. W. Cohen, et al. 2016. “Intracapsular and Extracapsular Tonsillectomy and Adenoidectomy in Pediatric Obstructive Sleep Apnea.” *JAMA Otolaryngology Head & Neck Surgery.* 142(1)() :25-31.

[3] Tunkel D. E., K. S. Hotchkiss, K. A. Carson, and L. M. Sterni. 2008. “Efficacy of Powered Intracapsular Tonsillectomy and Adenoidectomy.” *Laryngoscope.* 118(7):1295-1302.

[4] Chan K. H., N. R. Friedman, G. C. Allen, et al. 2004. “Randomized, Controlled, Multisite Study of Intracapsular Tonsillectomy Using Low-temperature Plasma Excision.” *Archives of Otolaryngology Head & Neck Surgery.* 130(11):1303-1307.

[5] Mangiardi J., K. D. Graw-Panzer, J. Weedon, T. Regis, H. Lee, and N. A. Goldstein. 2010. “Polysomnography Outcomes for Partial Intracapsular Versus Total Tonsillectomy.” *International Journal of Pediatric Otorhinolaryngology.* 74(12):1361-1366.

[6] Reilly B. K., J. Levin, S. Sheldon, K. Harsanyi, and M. E. Gerber. 2009. "Efficacy of Microdebrider Intracapsular Adenotonsillectomy as Validated by Polysomnography." *Laryngoscope.* 119(7):1391-1393.

[7] Acevedo J. L., R. K. Shah, and S. E. Brietzke. 2012. "Systematic Review of Complications of Tonsillotomy Versus Tonsillectomy." *Otolaryngology--Head and Neck Surgery: Official Journal of American Academy of Otolaryngology--Head and Neck Surgery.* 146(6):871-879.

[8] Baugh R. F., S. M. Archer, R. B. Mitchell, et al. 2011. "Clinical Practice Guideline: Tonsillectomy in Children." *Otolaryngology--Head and Neck Surgery: Official Journal of American Academy of Otolaryngology-Head and Neck Surgery.* 144(1 Suppl):S1-30.

[9] Koempel J. A., C. A. Solares, and P. J. Koltai. 2006. "The Evolution of Tonsil Surgery and Rethinking the Surgical Approach to Obstructive Sleep-disordered Breathing in Children." *The Journal of Laryngology and Otology.* 120(12):993-1000.

[10] Oomen K. P., V. K. Modi, and M. G. Stewart. 2012. "Evidence-based Practice: Pediatric Tonsillectomy." *Otolaryngologic Clinics of North America.* 45(5):1071-1081.

[11] Walton J., Y. Ebner, M. G. Stewart, and M. M. April. 2012. "Systematic Review of Randomized Controlled Trials Comparing Intracapsular Tonsillectomy with Total Tonsillectomy in a Pediatric Population." *Archives of Otolaryngology--Head & Neck Surgery.* 138(3):243-249.

[12] Wang H., Y. Fu, Y. Feng, J. Guan, and S. Yin. 2015. "Tonsillectomy Versus Tonsillotomy for Sleep-disordered Breathing in Children: A Meta Analysis." *PloS One.* 10(3):e0121500.

[13] Windfuhr J. P., K. Savva, J. D. Dahm, and J. A. Werner. 2015. "Tonsillotomy: Facts and Fiction. "*European Archives of Oto-rhino-laryngology: Official Journal of the European Federation of Oto-Rhino-Laryngological Societies.* 272(4):949-969.

[14] Cardwell M., G. Siviter, and A. Smith. 2005. "Non-steroidal Anti-inflammatory Drugs and Perioperative Bleeding in Paediatric Tonsillectomy." *The Cochrane Database of Systematic Reviews.* (2):CD003591.

[15] Lewis S. R., A. Nicholson, M. E. Cardwell, G. Siviter, and A. F. Smith. 2013. "Nonsteroidal Anti-inflammatory Drugs and Perioperative Bleeding in Paediatric Tonsillectomy." *The Cochrane Database of Systematic Reviews.* (7):CD003591.

[16] Riggin L., J. Ramakrishna, D. D. Sommer, and G. Koren. 2013. "A 2013 Updated Systematic Review & Meta-analysis of 36 Randomized Controlled Trials; No Apparent Effects of Non steroidal Anti-inflammatory Agents on the Risk of Bleeding after Tonsillectomy. *Clinical Otolaryngology.* 38(2):115-129.

[17] D'Souza J. N., R. J. Schmidt, L. Xie, J. P. Adelman, and H. C. Nardone. 2015. "Postoperative Nonsteroidal Anti-inflammatory Drugs and Risk of Bleeding in Pediatric Intracapsular Tonsillectomy." *International Journal of Pediatric Otorhinolaryngology.* 79(9):1472-1476.

[18] Bakshi S. S. "Letter to the Editor." 2015. *International Journal of Pediatric Otorhinolaryngology.* 79(12):2492.

[19] Derkay C. S., D. H. Darrow, C. Welch, and J. T. Sinacori. 2006. "Post-tonsillectomy Morbidity and Quality of Life in Pediatric Patients with Obstructive Tonsils and Adenoid: Microdebrider Vs Electrocautery." *Otolaryngology--Head and Neck Surgery: Official Journal of American Academy of Otolaryngology-Head and Neck Surgery.* 134(1):114-120.

[20] Lister M. T., M. J. Cunningham, B. Benjamin, et al. 2006. "Microdebrider Tonsillotomy Vs Electrosurgical Tonsillectomy: A Randomized, Double-blind, Paired Control Study of Postoperative Pain." *Archives of Otolaryngology--Head & Neck Surgery.* 132(6):599-604.

[21] Wilson Y. L., D. M. Merer, and A. L. Moscatello. 2009. "Comparison of Three Common Tonsillectomy Techniques: A Prospective Randomized, Double-blinded Clinical Study." *The Laryngoscope.* 119(1):162-170.

[22] Chang K. W. "Intracapsular Versus Subcapsular Coblation Tonsillectomy." 2008. *Otolaryngology--Head and Neck Surgery: Official Journal of American Academy of Otolaryngology-Head and Neck Surgery.* 138(2):153-157.

[23] Cohen M. S., A. E. Getz, G. Isaacson, J. Gaughan, and W. Szeremeta. 2007. "Intracapsular vs. Extracapsular Tonsillectomy: A Comparison of Pain." *The Laryngoscope.* 117(10):1855-1858.

[24] Derkay C. S., H. A. Baydoun, and L. Stone. 2015. "Intraoperative Use of QuikClot during Adenotonsillectomy: A Prospective Pediatric Trial." *The Annals of Otology, Rhinology, and Laryngology.* 124(5):384-391.

[25] Schmidt R., A. Herzog, S. Cook, R. O'Reilly, E. Deutsch, and J. Reilly. 2007. "Complications of Tonsillectomy: A Comparison of Techniques." *Archives of Otolaryngology--Head & Neck Surgery.* 133(9):925-928.

[26] Solares C. A., J. A. Koempel, K. Hirose, et al. 2005. "Safety and Efficacy of Powered Intracapsular Tonsillectomy in Children: A Multi-center Retrospective Case Series." *International Journal of Pediatric Otorhinolaryngology.* 69(1):21-26.

[27] Gallagher T. Q., L. Wilcox, E. McGuire, and C. S. Derkay. 2010. "Analyzing Factors Associated with Major Complications after Adenotonsillectomy in 4776 Patients: Comparing Three Tonsillectomy Techniques." *Otolaryngology--Head and Neck Surgery: Official Journal of American Academy of Otolaryngology-Head and Neck Surgery.* 142(6):886-892.

[28] Stucken E. Z., E. Grunstein, J. Haddad Jr., et al. 2013. "Factors Contributing to Cost in Partial versus Total Tonsillectomy." *The Laryngoscope.* 123(11):2868-2872.

[29] Francis D. O., C. Fonnesbeck, N. Sathe, M. McPheeters, S. Krishnaswami, and S. Chinnadurai. 2017. "Postoperative Bleeding and Associated Utilization following Tonsillectomy in Children: A Systematic Review and Meta-analysis." *Otolaryngology–Head and Neck Surgery.* 156(3):442-455.

[30] Day W. G., T. Mingo, and C. S. Derkay. 2017. "Descriptive Study of Post-tonsillectomy Hemorrhage Requiring Return to the Operating Room at a Tertiary Children's Hospital." *Paper presented at the annual meeting for the Virginia Society of Otolaryngology*, Richmond, Virginia, May 19 and 20, 2017.

[31] Mueller J., D. Boeger, J. Buentzel, et al. 2015. "Population-based Analysis of Tonsil Surgery and Postoperative Hemorrhage." *European Archives of Oto-rhino-laryngology: Official Journal of the European Federation of Oto-Rhino-Laryngological Societies.* 272(12):3769-3777.

[32] Harounian J. A., E. Schaefer, J. Schubart, and M. M. Carr. 2016. "Pediatric Adenotonsillectomy and Postoperative Hemorrhage: Demographic and Geographic Variation in the US." *International Journal of Pediatric Otorhinolaryngology.* 87:50-54.

[33] Doshi H. K., D. E. Rosow, R. F. Ward, and M. M. April. 2011. "Age-related Tonsillar Regrowth in Children Undergoing Powered Intracapsular Tonsillectomy." *International Journal of Pediatric Otorhinolaryngology.* 75(11):1395-1398.

[34] Mostovych N., L. Holmes, N. Ruszkay, A. LaHurd, R. Heinle, and H. Nardone. 2016. "Effectiveness of Powered Intracapsular Tonsillectomy in Children with Severe Obstructive Sleep Apnea." *JAMA Otolaryngology--Head & Neck Surgery.* 142(2):150-156.

[35] Sorin A., J. P. Bent, M. M. April, and R. F. Ward. 2004. "Complications of Microdebrider-assisted Powered Intracapsular Tonsillectomy and Adenoidectomy." *The Laryngoscope.* 114(2):297-300.

[36] Zhang Q., D. Li, and H. Wang. 2014. "Long Term Outcome of Tonsillar Regrowth after Partial Tonsillectomy in Children with Obstructive Sleep Apnea." *Auris, nasus, larynx.* 41(3):299-302.

[37] Schmidt R., A. Herzog, S. Cook, R. O'Reilly, E. Deutsch, and J. Reilly. 2007. "Powered Intracapsular Tonsillectomy in the Management of Recurrent Tonsillitis." *Otolaryngology Head & Neck Surgery.* 137(2):338-340.

[38] Bent J. P., M. M. April, R. F. Ward, A. Sorin, B. Reilly, and G. Weiss. 2004. "Ambulatory Powered Intracapsular Tonsillectomy and Adenoidectomy in Children Younger than 3 Years." *Archives of Otolaryngology--Head & Neck Surgery.* 130(10):1197-1200.

[39] Amoils M., K. W. Chang, O. Saynina, P. H. Wise, and A. Honkanen. 2016. "Postoperative Complications in Pediatric Tonsillectomy and Adenoidectomy in Ambulatory vs Inpatient Settings." *JAMA Otolaryngology--Head & Neck Surgery.* 142(4):344-350.

[40] Sobol S. E., R. F. Wetmore, R. R. Marsh, J. Stow, and I. N. Jacobs. 2006. "Postoperative Recovery after Microdebrider Intracapsular or Monopolar Electrocautery Tonsillectomy: A Prospective, Randomized, Single-blinded Study." *Archives of Otolaryngology--Head & Neck Surgery.* 132(3):270-274.

[41] Volsky P. G., M. A. Woughter, H. A. Beydoun, C. S. Derkay, and C. M. Baldassari. 2014. "Adenotonsillectomy Vs Observation for Management of Mild Obstructive Sleep Apnea in Children." *Otolaryngology--Head and Neck Surgery: Official Journal of American Academy of Otolaryngology-Head and Neck Surgery.* 150(1):126-132.

[42] Marcus C. L., R. H. Moore, C. L. Rosen, et al. 2013. "A Randomized Trial of Adenotonsillectomy for Childhood Sleep Apnea." *The New England Journal of Medicine.* 368(25):2366-2376.

In: Encyclopedia of Surgery (22 Volume Set)
Editors: Andreas Lehrer and Kristin Mueller
ISBN: 978-1-53618-329-0
© 2020 Nova Science Publishers, Inc.

Chapter 171

THE MANAGEMENT OF POST-TONSILLECTOMY PAIN IN CHILDREN

David E. Tunkel, MD and Grace X. Tan, MD
Department of Otolaryngology, Head and Neck Surgery
Johns Hopkins University School of Medicine, Baltimore, MD, US

ABSTRACT

Pain management for children following tonsillectomy is challenging and controversial, particularly concerning the use of opioids and non-steroidal anti-inflammatory drugs (NSAIDs). We discuss a variety of pharmacologic and non-pharmacologic interventions that can be used pre-, intra-, and post-operatively for analgesia and review the evidence for their efficacy and side effects. We focus on the technique of partial intracapsullar tonsillectomy and its benefits in reducing post-tonsillectomy pain.

Keywords: tonsillectomy, pain, analgesia, opioids, obstructive sleep apnea (OSA)

INTRODUCTION

Tonsillectomy, with or without adenoidectomy, is the second most common procedure performed in children in the United States (US) [1]. Most patients undergo tonsillectomy as an ambulatory procedure, though some may require a one-night hospitalization. Pain after tonsillectomy is well-characterized, lasting 7-14 days and worsening over the first post-operative week. Hence, the majority of postoperative pain management occurs in the home setting. The challenges of effective post-tonsillectomy analgesia is reflected by the numerous pharmacologic and non-pharmacologic approaches that have been studied, in efforts to safely improve comfort after this procedure.

Poor pain control leads to parental anxiety, clinic calls, emergency room visits, and readmissions. Recent studies have shown that the common reasons for unplanned post-tonsillectomy encounters in emergency departments include uncontrolled pain, dehydration,

nausea, respiratory issues, and bleeding—all of which may be related to pain and the methods used for analgesia [2, 3]. Additionally, tonsillectomy surgery is performed most commonly for treatment of children with sleep disordered breathing and obstructive sleep apnea syndrome (OSAS). Children with such sleep-related breathing disturbances have unique risks using the most common postoperative analgesics.

Many factors are at play in adequate post-tonsillectomy pain control. They include: parental/caregiver factors, such as their socioeconomic status, race, cultural background, ability to assess pain, and medical literacy; child/patient factors, such as anxiety levels, and refusal or inability to take medications due to pain; medication factors, such as their palatability, strength, type, and adverse effects; as well as system factors, such as access to analgesics and the adequacy of discharge instructions [4, 5, 6]. Surgical techniques used for tonsillectomy, such as "hot" dissection versus "cold" dissection techniques, or total (extracapsular) versus partial (intracapsular) methods of removal, can also affect the severity and duration of postoperative pain [7, 8].

The main focus for post-tonsillectomy analgesia has been the use of medications, namely acetaminophen, opioids, and non-steroidal anti-inflammatory agents (NSAIDs). We will discuss commonly used medications such as ibuprofen and other NSAIDs, where their effect on postoperative bleeding are still debated, and opioids, where focus has been on postoperative respiratory depression that may be related to phamarcogenomics. This chapter will discuss contemporary issues with commonly used pharmacologic agents and will also discuss non-pharmacologic interventions that may aid in pain management. Often, multimodal approaches may be needed to minimize opioid requirements [9]. We will also discuss some of the technical details of tonsillectomy that may reduce pain, with a focus on the powered intracapsular tonsillectomy/adenoidectomy approach. While the term *tonsillectomy* is used throughout the chapter, we recognize that tonsillectomy is performed along with adenoidectomy in most children—the discussion in this chapter applies to *adenotonsillectomy* as well.

PAIN MANAGEMENT WITH MEDICATIONS: CONTEMPORARY ISSUES

Acetaminophen

Acetaminophen, alone or in combination, is perhaps the most commonly used analgesic administered after tonsillectomy in children. Acetaminophen alone may be inadequate for pain control; in fact, many studies of pain management show breakthrough pain in a substantial subset of children even with combinations of medications [10]. Interestingly, one randomized study comparing acetaminophen with acetaminophen/codeine found no difference in pain control after tonsillectomy in children [11]. The potential for hepatic injury exists with the use of acetaminophen, particularly in high sustained doses [12].

Narcotics/Opioids

Codeine (in combination with acetaminophen) was likely the most frequently prescribed post-tonsillectomy analgesic for children until a 2009 report of a codeine-related post-tonsillectomy death associated with an ultra-rapid metabolizer genotype made physicians question its usage. After reports of similar cases, an FDA investigation identified 13 pediatric deaths and 3 overdoses associated with codeine between 1969 and 2012—8 of which were in tonsillectomy patients [13]. Many of the affected children were ultra-rapid metabolizers of codeine—they carried a genotypic variation of the enzyme cytochrome P450 2D6 pathway, causing rapid conversion of codeine to high levels of the active morphine metabolite, with resultant respiratory depression. Because children with OSAS are more sensitive to the respiratory depressant effects of narcotics than children without such sleep-related airway disease [14], these adverse events are most likely to occur in young children with OSAS.

In 2013, a Boxed Warning and Contraindication was placed on the use of codeine after tonsillectomy and/or adenoidectomy in children. This Boxed Warning and Contraindication applies to all children undergoing tonsillectomy, as it is impractical and costly to identify children at-risk from either the ultra-rapid metabolizer genotype or from severe sleep apnea prior to surgery [15]. It is notable that codeine use is also limited by a sizeable subset of patients who cannot metabolize this drug to the active form, resulting in poor analgesic effect.

Additionally, many opioids, including hydrocodone and tramadol, share the same cytochrome P450 CYP2D6 metabolic pathway as codeine. Despite this, hydrocodone is becoming more widely used as an alternative to codeine. Tramadol has been suggested as an alternative to codeine, as it may cause less sedation compared to codeine, with similar analgesic effects [16, 17]. However, a recent report of respiratory depression in a CYP450 2D6 ultra-rapid metabolizer led the FDA to announce a review of tramadol use in children [18, 19].

Oxycodone and morphine, on the other hand, are not metabolized by the cytochrome P450 2D6 pathway [8] and have been proposed as alternatives to codeine. However, when oral morphine was compared to ibuprofen in a recent study, it caused far greater numbers of respiratory events in the immediate postoperative period [20]. Another study of oral morphine given as a "rescue analgesic" in addition to acetaminophen and ibuprofen showed no measurable benefit [21].

Use of opioids other than codeine for post-tonsillectomy pain may still have risk, particularly for children with OSAS. Opioids have been shown to depress ventilation and precipitate apnea to a greater extent in children with OSAS compared to controls [22]. Furthermore, children with OSAS are reported to have a reduced opioid requirement to achieve the same level of post-operative analgesia. Brown et al. hypothesized that recurrent hypoxemia found in severe OSAS may lead to up-regulation of central opioid receptors, thereby leading to an increased response to smaller doses of opioids [14].

Hence, the issues with opioid-based analgesia after tonsillectomy in children is not simply one of genotypes and metabolic differences. Although pharmacogenomic profiling of patients undergoing surgery could help stratify risk, the severity of obstructive sleep apnea, the age of the child, the presence of obesity or other co-morbid conditions, and the ability to accurately dose and administer medications all play a role in the decision to safely use opioids. Clinicians should assess the risk of respiratory compromise in children undergoing tonsillectomy to guide opioid use, narcotic dosage, and duration/location of postoperative

monitoring. Additionally, the comparative efficacy of analgesia with other non-opioid classes of medications—as discussed later in this chapter—should be understood as we provide alternatives to the long-used codeine-based regimens.

NSAIDs

Non-steroidal anti-inflammatory drugs (NSAIDs), most frequently ibuprofen, have been extensively studied, and are now commonly used, as an effective method to relieve post-tonsillectomy pain without opioids. Ibuprofen has been shown to be effective for post-tonsillectomy analgesia in a number of studies over the past 20 years. Despite this, many providers have been, and some still are, hesitant to prescribe NSAIDs because of concerns that such medications may increase the frequency and severity of post-tonsillectomy bleeding [23]. However, two large systematic reviews of studies investigating the use of NSAIDs post-tonsillectomy failed to show significant difference in rates of bleeding between NSAIDs, placebos, and opioids, including rates of bleeding requiring admission or surgery [24, 25]. Additionally, when compared to opioids, ibuprofen-based analgesia has the benefit of decreased post-operative nausea and vomiting [25, 26]. Furthermore, in the aforementioned trial of oral morphine versus ibuprofen after tonsillectomy, ibuprofen proved equally effective compared to morphine in treating post-tonsillectomy pain, with fewer respiratory issues [20].

The increased use of ibuprofen for pain management after the Boxed Warning for codeine has led to single-institution comparison studies of bleeding after tonsillectomy with ibuprofen or codeine-based regimens. Mattos et al. in Pittsburgh found no increased bleeding with ibuprofen use, although the rate of "any bleeding" was over 8% with or without ibuprofen [27]. Bedwell et al. reported a series of 666 children after tonsillectomy, and found no difference in emergency room utilization between ibuprofen and codeine regimens [28]. While the ibuprofen group in this study had a statistically non-significant trend toward more bleeds (3.5% vs. 1.7%), there was no observed difference in bleeds that required return to the operating room. Most recently, Pfaff et al. studied over 6000 children after tonsillectomy, during a period when codeine use stopped and ibuprofen use started [29]. The number of admissions and/or operations for bleeding after surgery remained unchanged.

Ketorolac deserves mention, as the American Academy of Otolaryngology-Head and Neck Surgery *Clinical Practice Guideline:Tonsillectomy in Children* specifically discusses avoidance of ketorolac because of postoperative bleed rates of 4.4% to 18% associated with this drug [30]. However, this increased risk of bleeding with ketorolac appears to be principally in adults after tonsillectomy, rather than in children [31].

The debate about NSAID use will continue, as experienced clinicians disagree and studies have conflicting results. Liu et al. reviewed a regimen of alternating doses of acetaminophen and ibuprofen as an effective means for post-tonsillectomy analgesia, with 90.4% of patients reporting adequate pain control in their retrospective study [32]. However, Merry et al. found that this regimen of combined acetaminophen and ibuprofen was not superior in analgesia to either medication given alone [33]. Perhaps relevant to this text about powered intracapsular tonsillectomy, DeSouza et al. found increased primary (1.6% vs. 0.5%) and secondary (3.8% vs 1.1%) bleeding in children after powered intracapsular tonsillectomy, when ibuprofen-based regimens were compared with opioids [34].

Other Medications

A variety of medications have been suggested or studied as adjuncts or alternatives to acetaminophen, opioids, and NSAIDs. These include: preoperative administration of oral montalukast [35]; intra-operative intravenous dexamethasone [36]; postoperative oral steroids; perioperative ketamine in subcutaneous, intravenous, and spray formulations [37, 38, 39]; clonidine [40]; and oral pregabalin [41]. COX-2 inhibitors such as celecoxib may reduce inflammation and pain without potential bleeding risk, but a recent study of this medication did not show a sustained reduction of pain after tonsillectomy [42]. While benefits have been demonstrated for some of these drugs, only additional study and experience will lead to broader acceptance and use for children after tonsillectomy.

Operative Adjuncts

In some studies, intra-operatively, pre-incisional peritonsillar infiltration of local anesthetic and/or steroids [43, 44] have been shown to be effective in producing post-tonsillectomy analgesia. Treating the wound bed with hyaluronic acid [45] and cold water [46] intra-operatively may reduce pain. On the other hand, one recent study using polyglycolic aicd sheeting to coat the tonsillar fossa found increased pain in treated adults [47]. Other non-pharmacologic methods include honey [48], acupuncture [49], and even imagery [50], which are low-risk and relatively well-tolerated. However, the studies of many of these methods are heterogeneous, with some demonstrating conflicting results with regard to pain reduction [51].

Parental Education

As post-tonsillectomy pain control is largely managed by the child's caregiver in the outpatient setting, it is crucial that the caregiver is educated on how to assess pain levels in their child at regular intervals. This can be done using behavioral pain scales [52], which are easy to use. However, while parents often do recognize pain, they do not give prescribed analgesics at the recommended doses for a variety of reasons [53]. One study showed that parents reported significant pain in their child during the first day at home after tonsillectomy, but 24% of these children received one dose or less of prescribed analgesics [54]. On the third postoperative day, 2/3 of parents observed significant pain in their child, but 41% of the children received one dose or less of analgesics.

Teaching done by nurses prior to discharge may reinforce the use of pharmacologic and non-pharmacologic options for pain control [55]. Nonetheless, the advantages of parental counseling are not straightforward. One recent study of home phone calls to caregivers made by nurses, four times over ten days after tonsillectomy, showed improved oral intake and adherence to analgesic use, but did not show any difference in pain intensity scores or use of health care resources [56]. Perhaps most importantly, in the event that opioids are administered in the post-operative setting, it is imperative that the caregiver is instructed on the risks of oversedation, as well as what to do if such an event occurs [57].

SURGICAL TECHNIQUES AND PAIN

A number of surgical techniques and instrumentation are available to perform tonsillectomy. Techniques can be divided into "cold" and "hot" dissection, to accomplish total or partial removal of the tonsils. Instrumentation includes cold dissection tools, monopolar and bipolar electrocautery, coblation devices, microdebriders, lasers, harmonic scalpel, argon plasma coagulation, and other devices [58].

A 2007 survey of pediatric otolaryngologists in the US showed that more than 50% use monopolar electrocautery for a total tonsillectomy. Use of cold dissection has declined from 7.0% to less than 1%, while coblation has risen in popularity from 0% to 15.9% over the 15 years leading up to 2007 [59].

Cold dissection appears to result in less postoperative pain compared to the use of monopolar electrocautery, but has fallen out of favor with many surgeons due to longer operative times and increased operative blood loss [60]. Coblation is a technique growing in popularity among surgeons [61]. It delivers bipolar radiofrequency through a saline field, with less heat generated compared to most other cautery techniques. While some reports of coblation tonsillectomy noted reduced postoperative pain, a Cochrane review concluded that there was insufficient evidence to show that coblation tonsillectomy is associated with reduced pain [62].

Partial Intracapsular Tonsillectomy

Partial tonsillectomy has been studied for the past 17 years, mainly since its introduction to the US by Peter Koltai and others [63]. Also called *tonsillotomy* or *intracapsular tonsillectomy*, this technique can be performed with microdebrider, laser, radiofrequency devices, bipolar scissors, or coblator, among other methods. Reduction of pain with this technique is expected, as the pharyngeal constrictor muscles and the tonsillar pillars are not violated. In fact, when compared with conventional tonsillectomy, powered intracapsular tonsillectomy with the microdebrider was shown to have reduced pain and reduced analgesic use at all measured points during the first 9+ days of recovery, with fewer days to return to a normal diet and activity [64]. A randomized blinded study, where microdebrider partial tonsillectomy was performed on one side and monopolar electrocautery tonsillectomy on the other, showed reduced throat pain and no otalgia on the microdebrider side during the first 9 days after surgery [65]. Similar benefits of reduced pain after intracapsular tonsillectomy were reported for partial tonsillectomy procedures performed with scissors [66], radiofrequency devices [67], carbon dioxide laser [68], and coblation [69].

After over two decades of partial tonsillectomy experience, several systematic reviews have been published that address intracapsular tonsillectomy. Acavedo et al. reviewed 33 studies that compared tonsillotomy with tonsillectomy, and found fewer cases of dehydration requiring medical care, reduced days of analgesic use, and a quicker return to normal diet with tonsillotomy [70]. Walton et al. reviewed 16 randomized controlled trials of intracapsular tonsillectomy versus conventional tonsillectomy, and found significantly reduced pain in 9 studies, no difference in pain in 4 studies, and several studies reporting improved pain without sufficient analysis of significance [71]. These authors found reduced

analgesic use and sooner return to a normal diet in the majority of the level-1 evidence they reviewed. A recent meta-analysis of tonsillotomy versus tonsillectomy by Wang et al. excluded all but ten studies, all ten from outside the US [72]. Only three studies addressed pain and these showed improved pain-free days with tonsillotomy.

OUR PROTOCOL

At the Johns Hopkins Bloomberg Children's Center, we prescribe acetaminophen 12.5mg/kg/dose to be given orally every 4 hours for 24 hours after surgery for all children, followed by the same dose of acetaminophen on an as needed basis, up to a maximum dose of 75mg/kg/day or 4g daily. For children without a specific contraindication to NSAID use, we also prescribe ibuprofen 10mg/kg/dose every 6 hours as needed for pain, to start in the first few hours after surgery. Opioids are not used for children less than 6 years of age or for any child scheduled for overnight observation after surgery. Postoperative overnight observation is scheduled almost exclusively for respiratory monitoring of children with clinical risk factors or documented severe obstructive sleep apnea. It is prudent that young children and/or children with such risk factors avoid opioids. For children over the age of 6 years undergoing surgery on an ambulatory basis, we prescribe acetaminophen with hydrocodone. We also prescribe acetaminophen combined with oxycodone or hydrocodone for most teenagers after tonsillectomy. For children with insufficient analgesia while hospitalized, opioids may be administered on a case by case basis, at reduced dose in a monitored setting, after discussion with senior surgical staff.

CONCLUSION

Pain management following tonsillectomy in children remains difficult. Approaches for effective analgesia as well as improved patient and caregiver satisfaction should combine pre-operative counseling about pain management options with the use of both pharmacologic and non-pharmacologic methods to reduce pain. While considerable debate continues about the use of opioids, otolaryngologists should understand the risks of opioids in young children with obstructive sleep disorders after tonsillectomy. Similar debate about bleeding risks with NSAID use persists, but a growing body of evidence supports efficacy and safety. We will learn more with continued use and study of these medications. Surgical technique can be modified to control pain as well, and the partial, or intracapsular, tonsillectomy techniques have been shown to reduce the severity and duration of pain after surgery.

REFERENCES

[1] Sun, Gordon H., Katherine A. Auger, Oluseyi Aliu, Stephen W. Patrick, Sonya DeMonner, and Matthew M. Davis. 2013. "Variation in inpatient tonsillectomy costs within and between US hospitals attributable to postoperative complications." *Medical Care* 51(12):1048-1054.

[2] Duval, Melanie, Jacob Wilkes, Kent Korgenski, Rajendu Srivastava, and Jeremy Meier. 2015. "Causes, costs, and risk factors for unplanned return visits after adenotonsillectomy in children." *International Journal of Pediatric Otorhinolaryngology* 79(10):1640-1646.

[3] Curtis, Jonathan L, D. Brandon Harvey, Scott Willie, et al. 2015. "Causes and costs for ED visits after pediatric adenotonsillectomy." *Otolaryngology Head and Neck Surgery* 152(4):691–96.

[4] Dorkham, Mariana C., George A. Chalkiadis, Britta S. Ungern Sternberg, and Andrew J. Davidson. 2014. "Effective postoperative pain management in children after ambulatory surgery, with a focus on tonsillectomy: barriers and possible solutions." *Pediatric Anesthesia* 24(3):239-248.

[5] Longard, Julie, Alison Twycross, Anna M. Williams, Paul Hong, and Jill Chorney. 2016. "Parents' experiences of managing their child's postoperative pain at home: an exploratory qualitative study." *Journal of Clinical Nursing* 25(17-18): 2619–2628.

[6] Bhattacharyya, Neil, and Nina L. Shapiro. 2014. "Associations Between Socioeconomic Status and Race with Complications After Tonsillectomy in Children." *Otolaryngology Head and Neck Surgery* 151(6): 1055–60.

[7] Oomen, Karin P.Q., Vikash K. Modi, and Michael G. Stewart. 2012. "Evidence-based practice: pediatric tonsillectomy." *Otolaryngologic Clinics of North America* 45(5):1071-1081.

[8] Lauder, Gillian, and Anthony Emmott. 2014. "Confronting the challenges of effective pain management in children following tonsillectomy." *International Journal of Pediatric Otorhinolaryngology* 78(11):1813-1827.

[9] White, Paul F. 2008. "Multimodal analgesia: its role in preventing postoperative pain." *Current Opinion in Investigational Drugs* 9,(1):76-82.

[10] Rømsing, Janne, Steen Hertel, Anne Harder, and Mette Rasmussen. 1998. "Examination of acetaminophen for outpatient management of postoperative pain in children." *Pediatric Anesthesia* 8(3):235-239.

[11] Moir, Melinda S., Ellen Bair, Pam Shinnick, and Anna Messner. 2000. "Acetaminophen versus acetaminophen with codeine after pediatric tonsillectomy." *Laryngoscope* 110(11):1824-1827.

[12] Star, Kristina, and Imti Choonara. 2015. "How safe is paracetamol?" *Archives of Disease in Childhood* 100(1):73-74.

[13] US Food and Drug Administration. 2013. FDA Drug Safety Communication: safety review update of codeine use in children; new Boxed Warning and Contraindication on use after tonsillectomy and/or adenoidectomy. https://www.fda.gov/downloads/drugs/drugsafety/ucm339116.pdf

[14] Brown, Karen A, André Laferrière, Indrani Lakheeram, and Immanuela Ravé Moss. 2006. "Recurrent hypoxemia in children is associated with increased analgesic sensitivity to opiates." *The Journal of the American Society of Anesthesiologists* 105(4):665-669.

[15] Kuehn, Bridget M. 2013. "FDA: no codeine after tonsillectomy for children." *JAMA* 309 (11):1100-1100.

[16] Benini, Franca, and Egidio Barbi. 2014. "Doing without codeine: why and what are the alternatives?" *Italian Journal of Pediatrics* 40(1):1.

[17] Friedrichsdorf, Stefan J., Andrea C. Postier, Timothy A. Lander, et al. 2015. "Tramadol versus codeine/acetaminophen after pediatric tonsillectomy: A prospective, double-blinded, randomized controlled trial." *Journal of Opioid Management* 11(4):283-294.

[18] Orliaguet, Gilles, Jamil Hamza, Vincent Couloigner, et al. 2015. "A case of respiratory depression in a child with ultrarapid CYP2D6 metabolism after tramadol." *Pediatrics* 135(3):e753-e755.

[19] US Food and Drug Administration. 2015. *FDA Drug Safety Communication: FDA evaluating the risks of using the pain medicine tramadol in children aged 17 and younger*.

[20] Kelly, Lauren E., Doron D. Sommer, Jayant Ramakrishna, et al. 2015. "Morphine or Ibuprofen for post-tonsillectomy analgesia: a randomized trial." *Pediatrics* 135(2):307-313.

[21] Oremule, B., M. Johnson, L. Sanderson, et al. 2015. "Oral morphine for pain management in paediatric patients after tonsillectomy and adenotonsillectomy." *International Journal of Pediatric Otorhinolaryngology* 79(12):2166-2169.

[22] Waters, Karen A., Fergus McBrien, Penny Stewart, Murray Hinder, and Sally Wharton. 2002. "Effects of OSA, inhalational anesthesia, and fentanyl on the airway and ventilation of children." *Journal of Applied Physiology* 92(5):1987-1994.

[23] Charles, Christopher S. St., Bruce H. Matt, Mark M. Hamilton, and Barry P. Katz. 1997. "A comparison of ibuprofen versus acetaminophen with codeine in the young tonsillectomy patient." *Otolaryngology Head and Neck Surgery* 117(1):76-82.

[24] Riggin, L., J. Ramakrishna, D.D. Sommer, and G. Koren. 2013. "A 2013 updated systematic review & meta-analysis of 36 randomized controlled trials; no apparent effects of non steroidal anti-inflammatory agents on the risk of bleeding after tonsillectomy." *Clinical Otolaryngology* 38(2):115-129.

[25] Lewis, Sharon R., Amanda Nicholson, Mary E. Cardwell, Gretchen Siviter, and Andrew F. Smith. 2013. "Nonsteroidal anti-inflammatory drugs and perioperative bleeding in paediatric tonsillectomy." *Cochrane Database of Systematic Reviews.* DOI: 10.1002/14651858.CD003591.pub3

[26] Møiniche, Steen, Janne Rømsing, Jørgen B. Dahl, and Martin R. Tramer. 2003. "Nonsteroidal antiinflammatory drugs and the risk of operative site bleeding after tonsillectomy: a quantitative systematic review." *Anesthesia & Analgesia* 96(1):68-77.

[27] Mattos, Jose L., Jacob G. Robison, Jesse Greenberg, and Robert F. Yellon. 2014. "Acetaminophen plus ibuprofen versus opioids for treatment of post-tonsillectomy pain in children." *International Journal of Pediatric Otorhinolaryngology* 78(10):1671-1676.

[28] Bedwell, Joshua R., Matthew Pierce, Michelle Levy, and Rahul K. Shah. 2014. "Ibuprofen with acetaminophen for postoperative pain control following tonsillectomy does not increase emergency department utilization." *Otolaryngology Head and Neck Surgery* 151(6): 963-966.

[29] Pfaff, Julia A., Kevin Hsu, and Sri Kiran Chennupati. 2016. "The use of ibuprofen in posttonsillectomy analgesia and its effect on posttonsillectomy hemorrhage rate." *Otolaryngology Head and Neck Surgery* 155(3):508-13.

[30] Baugh, Reginald F., Sanford M. Archer, Ron B. Mitchell, et al. 2011. "Clinical practice guideline tonsillectomy in children." *Otolaryngology Head and Neck Surgery* 144(1)suppl:S1-S30.

[31] Chan, Dylan K., and Sanjay R. Parikh. 2014. "Perioperative ketorolac increases post-tonsillectomy hemorrhage in adults but not children." *Laryngoscope* 124(8):1789-1793.

[32] Liu, Christopher, and Seckin O. Ulualp. 2015. "Outcomes of an alternating ibuprofen and acetaminophen regimen for pain relief after tonsillectomy in children." *Annals of Otology, Rhinology & Laryngology* 124(10):777-781.

[33] Merry, Alan F., Kylie-Ellen Edwards, Zahoor Ahmad, et al. 2013. "Randomized comparison between the combination of acetaminophen and ibuprofen and each constituent alone for analgesia following tonsillectomy in children." *Canadian Journal of Anesthesia/Journal canadien d'anesthésie* 60(12):1180-1189.

[34] D'Souza, Jill N., Richard J. Schmidt, Li Xie, Julie P. Adelman, and Heather C. Nardone. 2015. "Postoperative nonsteroidal anti-inflammatory drugs and risk of bleeding in pediatric intracapsular tonsillectomy." *International Journal of Pediatric Otorhinolaryngology* 79(9):1472-1476.

[35] Ince, Ilker, Ozgur Yoruk, Ali Ahiskalioglu, et al. 2015. "Does montelukast have an effect on post-tonsillectomy pain control in children? a randomized trial study. *Otolaryngology Head and Neck Surgery* 153(2):269-74.

[36] Thimmasettaiah, Nagaraj Bangalore, and Ravi Gowda Chandrappa. 2012. "A prospective study to compare the effects of pre, intra and post operative steroid (dexamethasone sodium phosphate) on post tonsillectomy morbidity." *Journal of Pharmacology and Pharmacotherapeutics* 3(3): 254.

[37] Javid, Mihan, Mohammad Hajijafari, Asghar Hajipour, Jalil Makarem, and Zahra Khazaeipour. 2012. "Evaluation of a low dose ketamine in post tonsillectomy pain relief: a randomized trial comparing intravenous and subcutaneous ketamine in pediatrics." *Anesthesiology and Pain Medicine* 2(2): 85-89.

[38] Jahromi, Seyed Abbas Hosseini, Seyedeh Masoumeh Hosseini Valami, and Sevak Hatamian. 2012. "Comparison between effect of lidocaine, morphine and ketamine spray on post-tonsillectomy pain in children." *Anesthesiology and Pain Medicine* 2(1): 17-21.

[39] Asadi, Hosein Kimiaei, Mahshid Nikooseresht, Lida Noori, and Fatholah Behnoud. 2016. "The effect of administration of ketamine and paracetamol versus paracetamol singly on postoperative pain, nausea and vomiting after pediatric adenotonsillectomy." *Anesthesiology and Pain Medicine* 6(1)e31210.

[40] Ericsson, Elisabeth, Metha Brattwall, and Stefan Lundeberg. 2015. "Swedish guidelines for the treatment of pain in tonsil surgery in pediatric patients up to 18 years." *International Journal of Pediatric Otorhinolaryngology* 79(4): 443-450.

[41] Park, Soo Seog, Dong-Hyun Kim, In-Chul Nam, Il-Hwan Lee, and Jae-Woong Hwang. 2015. "The effectiveness of pregabalin for post-tonsillectomy pain control: a randomized controlled trial." *PloS One* 10(2):e0117161.

[42] Murto, Kimmo, Christine Lamontagne, Colleen McFaul, et al. 2015. "Celecoxib pharmacogenetics and pediatric adenotonsillectomy: a double-blinded randomized controlled study." *Canadian Journal of Anesthesia/Journal canadien d'anesthésie* 62(7):785-797.

[43] Turhan, K.S. Cakar, E.A. Salviz, S. Beton, et al. 2015. "Peritonsillar infiltration with levobupivacaine for posttonsillectomy pain relief: does concentration have any effect? A double-blind randomized controlled clinical study. *European Review for Medical and Pharmacological Sciences* 19(7):1276-1284.

[44] Dostbil, Aysenur, Mine Celik, Ozgur Yoruk, et al. 2014. "Pre-emptive peritonsillar dexamethasone vs. levobupivacaine infiltration for relief of post-adenotonsillectomy pain in children: a controlled clinical study." *International Journal of Pediatric Otorhinolaryngology* 78(9):1467-1471.

[45] Hancı, Deniz, and Huseyin Altun. 2015. "Effectiveness of hyaluronic acid in post-tonsillectomy pain relief and wound healing: a prospective, double-blind, controlled clinical study." *International Journal of Pediatric Otorhinolaryngology* 79(9):1388-1392.

[46] Shin, Jae Min, Jang Yul Byun, Byoung Joon Baek, and Jae Yong Lee. 2014. "Effect of cold-water cooling of tonsillar fossa and pharyngeal mucosa on post-tonsillectomy pain." *American Journal of Otolaryngology* 35(3):353-356.

[47] Miyaguchi, Shin-ichi, Arata Horii, Rumi Kambara, et al. 2016. "Effects of covering surgical wounds with polyglycolic acid sheets for posttonsillectomy pain." *Otolaryngology Head and Neck Surgery* 155(5):876-878.

[48] Hwang, Se Hwan, Jee Nam Song, Yeon Min Jeong, Yeon Ji Lee, and Jun Myung Kang. 2016. "The efficacy of honey for ameliorating pain after tonsillectomy: a meta-analysis." *European Archives of Oto-Rhino-Laryngology* 273, (4):811-818.

[49] Tsao, Gabriel J., Anna H. Messner, Jeannie Seybold, et al. 2015. "Intraoperative acupuncture for posttonsillectomy pain: A randomized, double-blind, placebo-controlled trial." *Laryngoscope* 125(8):1972-1978.

[50] Huth, Myra Martz, Marion E. Broome, and Marion Good. 2004. "Imagery reduces children's post-operative pain." *Pain* 110 (1):439-448.

[51] Hollis, Lance, Martin J. Burton, and Jean Millar. 1999. "Perioperative local anaesthesia for reducing pain following tonsillectomy." *Cochrane Database of Systematic Reviews*. DOI: 10.1002/14651858.CD001874

[52] Sutters, Kimberly A., Danielle Holdridge-Zeuner, Steven Waite, et al. 2012. "A descriptive feasibility study to evaluate scheduled oral analgesic dosing at home for the management of postoperative pain in preschool children following tonsillectomy." *Pain Medicine*. 13 (3):472-483.

[53] Lennon, Paul, Mohamed Amin, and Michael P. Colreavy. 2013. "A prospective study of parents' compliance with their child's prescribed analgesia following tonsillectomy." *Ear Nose and Throat Journal* 92(3):134-40.

[54] Fortier, Michelle A., Jill E. MacLaren, Sarah R. Martin, Danielle Perret-Karimi, and Zeev N. Kain. 2009. "Pediatric pain after ambulatory surgery: Where's the medication?" *Pediatrics* 124 (4):e588-e595.

[55] Norinkavich, K.M., Gail Howie, and Patricia Cariofiles. 1994. "Quality improvement study of day surgery for tonsillectomy and adenoidectomy patients." *Pediatric Nursing* 21 (4):341-344.

[56] Paquette, Julie, Sylvie Le May, Jacinthe Lachance Fiola, et al. 2013. "A randomized clinical trial of a nurse telephone follow-up on paediatric tonsillectomy pain management and complications." *Journal of Advanced Nursing* 69 (9):2054-2065.

[57] Schymik, Frank A., Ellen M. Lavoie Smith, and Terri Voepel-Lewis. 2015. "Parental analgesic knowledge and decision making for children with and without obstructive sleep apnea after tonsillectomy and adenoidectomy." *Pain Management Nursing* 16 (6):881-889.

[58] Younis, Ramzi T., and Rande H. Lazar. 2002. "History and current practice of tonsillectomy." *Laryngoscope* 112 (S100):3-5.

[59] Walner, David L., Noah P. Parker, and Robert P. Miller. 2007. "Past and present instrument use in pediatric adenotonsillectomy." *Otolaryngology Head and Neck Surgery* 137 (1):49-53.

[60] Leinbach, Robert F., Stephen J. Markwell, Jerry A. Colliver, and Sandra Y. Lin. 2003. "Hot versus cold tonsillectomy: a systematic review of the literature." *Otolaryngology Head and Neck Surgery* 129 (4):360-364.

[61] Setabutr, Dhave, Eelam A. Adil, Tabrez K. Adil, and Michele M. Carr. 2011. "Emerging trends in tonsillectomy." *Otolaryngology Head and Neck Surgery* 145 (2): 223-229.

[62] Burton, Martin J., and Carolyn Doree. 2007. "Coblation versus other surgical techniques for tonsillectomy." *Cochrane Database of Systematic Reviews.* DOI: 10.1002/14651858.CD004619.pub2.

[63] Koltai, Peter J., C. Arturo Solares, Edward J. Mascha, and Meng Xu. 2002. "Intracapsular partial tonsillectomy for tonsillar hypertrophy in children." *Laryngoscope* 112 (S100):17-19.

[64] Koltai, Peter J., C. Arturo Solares, Jeffery A. Koempel, et al. 2003. "Intracapsular tonsillar reduction (partial tonsillectomy): reviving a historical procedure for obstructive sleep disordered breathing in children." *Otolaryngology Head and Neck Surgery* 129 (5): 532-538.

[65] Lister, Matthew T., Michael J. Cunningham, Barry Benjamin, et al. 2006. "Microdebrider tonsillotomy vs electrosurgical tonsillectomy: a randomized, double-blind, paired control study of postoperative pain." *Archives of Otolaryngology–Head & Neck Surgery* 132 (6):599-604.

[66] Vlastos, Ioannis M., Kostas Parpounas, John Economides, et al. 2008. "Tonsillectomy versus tonsillotomy performed with scissors in children with tonsillar hypertrophy." *International Journal of Pediatric Otorhinolaryngology* 72 (6): 857-863.

[67] Hultcrantz, Elisabeth, and Elisabeth Ericsson. 2004. "Pediatric tonsillotomy with the radiofrequency technique: less morbidity and pain." *Laryngoscope*114 (5):871-877.

[68] Hultcrantz, Elisabeth, Arne Linder, and Agneta Markström. 1999. "Tonsillectomy or tonsillotomy?—A randomized study comparing postoperative pain and long-term effects." *International Journal of Pediatric Otorhinolaryngology* 51 (3):171-176.

[69] Babademez, Mehmet Ali, Müge Fethiye Yurekli, Baran Acar, and Emre Günbey. 2011. "Comparison of radiofrequency ablation, laser and coblator techniques in reduction of tonsil size." *Acta Oto-laryngologica* 131 (7):750-756.

[70] Acevedo, Jason L., Rahul K. Shah, and Scott E. Brietzke. 2012. "Systematic review of complications of tonsillotomy versus tonsillectomy." *Otolaryngology Head and Neck Surgery* 146 (6):871-879.

[71] Walton, Joanna, Yaniv Ebner, Michael G. Stewart, and Max M. April. 2012. "Systematic review of randomized controlled trials comparing intracapsular

tonsillectomy with total tonsillectomy in a pediatric population." *Archives of Otolaryngology–Head & Neck Surgery* 138 (3):243-249.

[72] Wang, Hui, Yangyang Fu, Yanmei Feng, Jian Guan, and Shankai Yin. 2015. "Tonsillectomy versus tonsillotomy for sleep-disordered breathing in children: a meta analysis." *PloS One* 10 (3):e0121500.

In: Encyclopedia of Surgery (22 Volume Set)
Editors: Andreas Lehrer and Kristin Mueller
ISBN: 978-1-53618-329-0
© 2020 Nova Science Publishers, Inc.

Chapter 172

CONCLUSION AND FUTURE QUESTIONS

Max M. April*, MD
Department of Otolaryngology, New York University/Langone Medical Center,
New York, NY, US

ABSTRACT

This textbook has reviewed the last 16 years of the surgical procedure of tonsillectomy (IT vs ET) and relayed the results and complications of both procedures. Surgical technique has been described and captured on video for surgeons new to these options, as well as surgeons looking to advance their skills. This last chapter will address some of the still unanswered questions regarding intracapsular tonsillectomy.

Keywords: intracapsular tonsillectomy, partial tonsillectomy, tonsillotomy, subcapsular tonsillectomy, pediatric sleep apnea, sleep disordered breathing, tonsillectomy, and adenoidectomy

INTRODUCTION

The current literature has documented the efficacy and safety of IT, as well as the results in pediatric obstructive sleep apnea. We can now further evaluate the role of IT in children with recurrent tonsil infections, the need for admission of children under 3, the difference in anesthetic regimens, and the need for postoperative narcotic/ nonsteroidal usage. We will also evaluate the timing of PACU observation, the cost of the overall procedure, return to presurgical activity level, effect on swallowing, effect on voice, future lingual tonsil hypertrophy, and the potential effect on the incidence of obstructive sleep apnea in adults.

* Corresponding Author's Email: max.april@nyumc.org.

METHODS

Recurrent Tonsil Infections

The results of IT in children with recurrent tonsillitis was studied in 2009 [1]. Schmidt et al, found that 17 out of 117 children that underwent ET and 8 out of 49 children that had IT had at least one postoperative infection, numbers which were not statistically significant. As the surgical technique of IT has progressed, deeper dissection and more tonsil tissue removal has become common. In addition, it is important to electrocauterize the remaining tonsil tissue to eradicate any crypts and make the fossa as smooth as possible to dcrease potential biofilm adherence.

We all realize that ET is not a perfect operation for recurrent streptococcal tonsillitis, but it has become our treatment recommendation when all else fails. Future studies are needed to determine whether IT results are similar to ET results for children with recurrent tonsillitis.

Another question is whether leaving some tonsil tissue after PITA can actually be protective in the future. Other centers have begun to study whether there are immunologic benefits after PITA.

Admission for Children under 3

Guidelines recommend that all children 3 and under be admitted to the hospital for tonsillectomies. These guidelines are based on studies of children under 3 years who underwent ET with the need for pain control and hydration. The age of 3 does seem arbitrary, but many medical centers require admission for children under the age of three who are having tonsil surgery. How many 4 or 5 year olds have been operated on as an outpatient, with these recommendations in mind, when they may be smaller or more medically frail than many 3 year olds?

In 2004, ambulatory PITA was first described [2]. We started using this ambulatory procedure because many parents would describe how little care and attention they needed to give to their children after PITA. Since 2002, there have been very few children admitted to the hospital as a planned admission after PITA. The reasons include underlying medical problems that need monitoring (cardiac, neurologic, pulmonary, and severe OSA) or a known bleeding disorder. To my knowledge, there have been no children scheduled for an outpatient PITA that had to be admitted because of either poor oral intake or pain control.

We have performed outpatient PITA on several children under 2. How then did we get to the guideline of children under 3, or those with an AHI over 10, needing to be admitted to the hospital for monitoring? These recommendations are based on a study that is unlikely to be repeated. At Johns Hopkins Hospital, in 1989, a child who was admitted to the pediatric floor postoperatively following a complete tonsillectomy died.

As part of the root cause analysis of this death, a study was undertaken at Johns Hopkins to perform a polysomogram on each patient with the diagnosis of OSA the night following surgery in the Pediatric Intensive Care Unit (PICU) [3]. The need for intervention, which was mostly to awaken or reposition the child, was higher in children under 3 and those with an AHI over 10.

In retrospect, the use of narcotics was almost universal and most likely influenced the data. Further study should be undertaken that would monitor children under 3 or those with an AHI over 10 postoperatively after PITA or ET without narcotics. These findings would document whether or not interventions are truly needed for children under three with OSA who undergo PITA.

Anesthetic Considerations

There are many questions to answer with regard to the depth of anesthesia needed because of less pain experienced after extubation. Future studies should compare different regimens to determine the optimal recommendation for anesthesia depth. Could less intraoperative narcotic and sedative medication be used, potentially shortening the Post-Anesthesia Care Unit (PACU) stay further? Not going through the capsule vastly reduces the need for narcotic medication postoperatively, and the use of NSAIDs are not a problem. In addition, with concerns about multiple anesthetics in young children, IT may allow the otolaryngologist to address a moderate symptom, such as mild dysphagia or hyponasal speech. During the days of complete tonsillectomy, the potential complications would have prevented otolaryngologists from considering surgery for these more moderate symptoms.

Postoperative Pain Control without Narcotics

Since the FDA issued the black box warning against the use of codeine in the postoperative care of children after tonsillectomy, many otolaryngologists have had to make abrupt changes to their care of children and their postoperative instructions. These details are clearly reviewed in chapter 171 by Drs. Tan and Tunkel. We have not had a postoperative bleed after IT that has required a second anesthetic to control the bleeding. We suggest acetaminophen only for the day of surgery, but if that is not sufficient, it can be supplemented with ibuprofen. Without the fear of narcotic overdosage, the safety of this procedure as an outpatient is enhanced. In addition, without narcotics, there are less gastroenterologic complaints. There is also less nausea and less constipation, both contributing to more oral intake of liquids and food and a smoother and quicker recovery.

Timing of PACU Observation

When ET was first documented to be a safe ambulatory procedure, the recommendations were that children be observed for 6 hours after surgery in the PACU. If there was inadequate oral intake or inadequate pain control, children would then be admitted. Over the years, this recommendation has been reduced to 3 to 4 hours in the PACU. Many centers have strict rules for this observation period. In a busy ambulatory surgery center, that requirement can limit the number of surgeries performed in a day as to allow enough PACU beds available. With PITA, our PACU observation time is no longer a set minimum. Each child must meet minimal requirements to be discharged and that time is most often between one and two

hours. Therefore PITA significantly shortens the recovery time needed in the PACU and the schedule for each day is not limited because by PACU space.

Overall Cost of Tonsil Surgery

We attempted to look at the cost differences between ET and IT, including the instrumentation cost [4]. In IT, each microdebrider blade adds approximately 90 dollars US, whereas in ET, a handheld cautery costs approximately 10 dollars US. Other costs start with the need for polysomnography (PSG) preoperatively. A study should be undertaken that examines the following: safety of surgery for patients that did or did not have a preoperative PSG; PACU time and medication usage; the cost of inpatient monitoring; when children can resume school and activity levels and the parents can resume work; visits to the ED for dehydration; pain control and bleeding; and future revision completion tonsillectomy. The emotional cost of an emergency procedure to control postoperative hemorrhage, let alone the need for a second anesthetic a week later, is difficult to quantify, but also must be considered.

Return to Presurgical Activity Level

Following ET, most children miss 7 to 10 days of school. Older patients may miss up to 2 weeks. That clearly affects the time when parents can return to work. Following PITA, we have found that most children miss 2 to 4 days of school. If surgery is scheduled for Thursday or Friday, most children return to school on Monday, with parents free to return to work.

The overall cost to society of children mising school and parents missing work is difficult to measure, but cutting this time by using IT, rather than ET, is sizeable.

In addition, most surgeons recommend no physical activity for 14 days after ET, even if the return to school is earlier. Our recommendation after PITA is that children may return to full activity including sports in 1 week.

Effect on Swallowing

Anecdotally, many children have improved swallowing following tonsillectomy and in fact have had dramatic dietary changes. This benefit should be compared between the two tonsillectomy procedures, both of which should be performed with adenoidectomy to control for the improved nasal airway and possible improved sense of smell and taste with improved nasal function. Many parents have described that their children with large tonsils have "marathon meals," meaning they spend a long time chewing their food. These children chew their food for a long time so they can swallow it past the large tonsils. Reducing the size of the tonsils can create a dramatic improvement in their eating.

In children who have neurologic issues such as cerebral palsy, ET could cause more harm than good with regard to swallowing.

Figure 1. This image depicts the scar tissue in the soft palate and lateral pharyngeal wall after ET.

Figure 2. In IT, the scar tissue shown in Figure 1 is avoided. This photograph is of a 5 year old one month after PITA. Note the improved palatal function and preservation of both the anterior and posterior pillar.

Not only is the recovery much more difficult with regard to pain control, but after ET, the swallowing and velopharyngeal closure can take months to improve. The scar tissue in the soft palate and lateral pharyngeal wall after ET (Figure 1) is avoided with IT (Figure 2). We have found much less swallowing difficulty after IT and quicker return to baseline. This issue could be studied in a prospective manner.

Effect on Voice

A discussion of postoperative voice includes two distinct different subjects. The first is hypernasality, and the second concerns professional (or almost professional) voice patients. A

study looking at nasal escape or other measurable qualities of hypernasality after both the ET and the IT procedures should be measured. It appears that the length of hypernasality after IT is much shorter than it is after ET. Prior to IT, it was common to see hypernasality for many months after ET. If hypernasality persisted for more than 6 months, a referral to speech therapy was warranted. Every year or two such a referral occurred. Since otolaryngologists began using IT, the majority of children no longer have hypernasality after 2 to 3 weeks, and I have not referred any patients for speech therapy for continued nasal escape of air. I suspect it is due to the improved velopharyngeal closure without scarring and improved pharyngeal muscle function. One study we considered was to measure nasal escape by nasometry at different postoperative intervals comparing ET to IT. The difficulty was the cooperation needed for nasometry. There may be an easier and more tolerated test to measure this nasal air escape after surgery.

When considering ET for those patients that use their voice professionally, there was always great concern whether pharyngeal scarring would affect vocal quality. There are many performers that may benefit medically from tonsil surgery that were not offered surgery, because of potential harm to their voice or vocal quality. When discussing IT with these patients, consideration of using a LMA for anesthesia is discussed, possibly reducing fear of intubation trauma. A study should be performed evaluating vocal function after IT versus vocal function after ET.

Overall Experience

How many times have you spoken to parents about tonsil surgery for their children, and the parents start the conversation with "my tonsillectomy was the worst experience of my childhood?" We have all heard these stories, which can certainly impact the decision making process when these parents are considering tonsillectomy for their child. An advantage of IT is that these discussions start out in a different way with the otolaryngologist saying, "Please forget your tonsillectomy experience. It is different now." That can be very reassuring for many parents.

Future Lingual Tonsil Hypertrophy

To this day, I have only performed lingual tonsillectomy in patients that had ET previously, and almost always these patients had ET at a young age. Could it be that ET at an early age promotes lingual tonsil hypertrophy or that leaving some tonsil tissue with IT reduces future lingual tonsil growth? I have discussed this with leaders in the field of surgery for sleep apnea in adults. In that population it would be very interesting to study how many of their patients that had lingual tonsillectomy as an adult had ET and at what age. In my experience, adolescents or young adults who had ET at a young age–often age 2 or 3 are those that present with lingual tonsil hypertrophy. Those patients should have PSG to document whether the lingual tonsils are causing obstruction, especially in the supine position.

Future Obstructive Sleep Apnea

Another topic that our colleagues that treat obstructive sleep apnea in adults could help us address is the contribution of ET or IT to Mallampati classification. It is apparent that those patients with class III or class IV are much more difficult to treat surgically. A retrospective study could look at what percentage of adult sleep apnea patients are in each category of the Mallampati classification.

It could be that scarring after ET reduces the height of the palate and its relative position to the tongue. The comparative study looking at patients after IT will have to wait several years to accumulate enough comparison data.

CONCLUSION

Since 2000, when I began performing IT, my practice has changed tremendously. There are several reasons, including increased patient and parental satisfaction. My own input of time, as well as the need to support patients and parents, has decreased. We do not have ancillary staff that responds to patient calls at night or on weekends. The amount of attention patients and parents need after IT is drastically reduced.

In my practice, I do not perform ET 2 weeks prior to a vacation or a meeting, so if there is a postoperative complication, I can be available. I have no such limitation after PITA, and therefore can schedule surgeries up to a few days prior to my vacation. I have yet to regret that change in policy. We have not had a postoperative bleed after IT, and the questions parents have had were easily handled by our staff. Finally, my overall satisfaction with practicing pediatric otolaryngology has improved so much, especially when many parents comment postoperatively, "This was really easy, just like you said it would be".

I hope this book will help you attain similar results, as well as improve the quality of life for many tonsillectomy patients.

REFERENCES

[1] Schmidt, Richard J., A. Herzog, Stephen Cook, Robert O'Reilly, Ellen Deutcsh, and James Reilly. 2007. “Powered Intracapsular Tonsillectomy in the Management of Recurrent Tonsillitis.” *Otolaryngology Head and Neck Surgery* 137(2):338-40.

[2] Bent, John P., Max M. April, Robert F. Ward, Alex Sorin, Brian Reilly, and G. Weiss. 2004. “Ambulatory Powered Intracapsular Tonsillectomy and Adenoidectomy in Children Younger than 3 Years.” *Archives Otolaryngology—Head and Neck Surgery* 130 (10):1197-1200.

[3] McColley, Susanna A., Max M. April, John L. Carroll, Robert M. Naclerio, and Gerald M. Loughlin. 1992. “Respiratory Compromise after Adenotonsillectomy in Children with Obstructive Sleep Apnea.” *Archives Otolaryngology—Head and Neck Surgery* 118(3):940-3.

[4] Stucken, Emily Z., Eli Grunstein, Joseph Haddad, et al. 2013. “Factors Contributing to Cost in Partial Versus Total Tonsillectomy.” *Laryngoscope* 123(11):2868-72.

In: Encyclopedia of Surgery (22 Volume Set)
Editors: Andreas Lehrer and Kristin Mueller
ISBN: 978-1-53618-329-0
© 2020 Nova Science Publishers, Inc.

Chapter 173

DIEP FLAP BREAST RECONSTRUCTION: TECHNICAL TIPS TO OPTIMIZE OUTCOMES AND AVOID COMPLICATIONS

Koichi Tomita [*] ***and Kenji Yano***
Department of Plastic and Reconstructive Surgery,
Graduate School of Medicine,
Osaka University, Osaka, japan

ABSTRACT

Progress in microsurgery techniques has popularized the use of the perforator flap, which enables minimal invasion into the donor site without sacrificing muscle. In breast reconstruction as well, one procedure that has become increasingly common is the transplantation of subcutaneous fat from the lower abdomen as a deep inferior epigastric perforator (DIEP) flap to the affected area. Recent developments in 3D imaging are also quite significant, allowing for 3D photography and 3D printing to be done even at the individual patient level. We have also come to rely more heavily on 3D imaging technology for breast reconstruction employing DIEP flaps, and have reported on its utility. In the present chapter, we focus on our experiences thus far, and present tips for safe maneuvering of DIEP flaps, as well as the implementation status of 3D imaging technology and its utility with regard to breast reconstruction using DIEP flaps.

Keywords: DIEP flap, breast reconstruction, 3-dimensional imaging, 3-dimensional printing

INTRODUCTION

In recent years, a dramatic increase in the number of breast cancer patients has led to a concomitant and daily increase in the needs and awareness surrounding breast reconstruction. Currently, breast reconstruction methods can be divided into the following three categories:

[*] Corresponding Author's Email: ktomita9@hotmail.co.jp.

1) transplantation of self tissue to the affected breast (following full or partial mastectomy); 2) use of a breast prosthesis (following full mastectomy); and 3) use of remaining breast tissue to 'clean up' the breast form (following partial mastectomy). Each method has its own set of pros and cons, and decisions concerning the application of any of these are made through conversations between the patient and physician as they consider patient preference, illness, and social background factors. The biggest advantage of breast reconstruction using self tissue such as subcutaneous abdominal fat is that it allows physicians to recreate soft breasts with a natural texture. However, for many years, this technique necessitated sacrificing muscle from the donor site. With the recent emergence of the concept of the perforator flap, this problem may have been resolved, at least from the standpoint of functional sacrifice [1].

Developments in 3D imaging technology have been substantial in recent years, and 3D photography and 3D printing have progressed to the point of being used at the individual level. Along with those developments, this technology is being applied in a variety of medical fields. Plastic surgery, where most surgeries are performed on the surface of the body, is one field that likely benefits from these developments substantially, and many attempts have been made to incorporate 3D imaging technology into treatments of various plastic surgery-related conditions [2, 3]. In recent years, we have become more heavily reliant on the use of 3D imaging technology for breast reconstruction using deep inferior epigastric perforator (DIEP) flaps [4, 5], and have reported on its utility [6]. In the present chapter, we focus on our experiences thus far, and provide tips on the safe maneuver of DIEP flaps. We also describe how we incorporate 3D imaging technology for DIEP flap breast reconstruction and report on the utility of this technology.

ANATOMY

Abdominal fat tissue is nourished by the superior epigastric vessels, the superficial and deep inferior epigastric vessels, and intercostal vessels. After branching off from the external iliac vessels, the deep inferior epigastric vessel (the feeding vessel of the DIEP flap) typically runs inward and upward, and from roughly 3-5 cm caudal of the arcuate line, courses cranially along the underside of the rectus abdominis muscle. Following this, many bifurcations occur in the vessels running through the muscle, yielding medial and lateral branches; notably, not all vessel types bifurcate. In addition, prior to bifurcating into medial/lateral branches, some will branch medially; this medial branch does not pass through the muscle, but directly enters the skin flap near the umbilicus (Figure 1). From blood vessels that pass through the muscles, several thick perforator branches thread through the anterior sheath of the rectus abdominis muscle to reach the adipose tissue, where they radiate out to nourish subcutaneous fat tissue. Most perforator branches are localized to the periphery of the umbilicus, and reportedly, an average of 6 perforator branches on each side with a diameter of 0.5 mm or larger, as well as 1-3 branches with diameters of 1 mm or larger, are found [7].

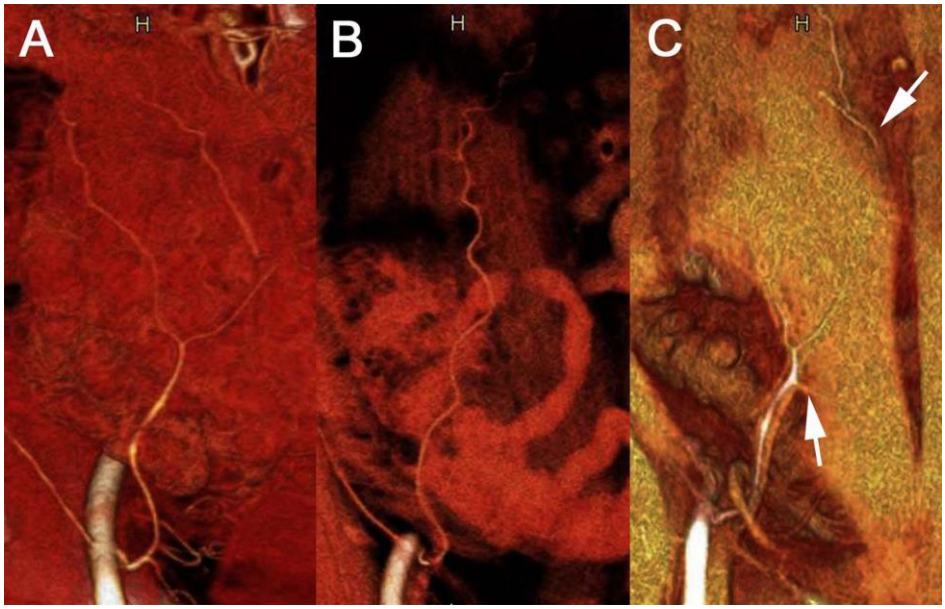

Figure 1. Variations in blood flow of the deep inferior epigastric vessels (all on the right side).
(A) Vessel types that can be divided into medial and lateral branches.
(B) Vessel type that does not make large bifurcations, but rather remains one vessel.
(C) Prior to bifurcating into medial/lateral branches, this type will branch medially. That branch does not pass through the muscle, but directly enters the skin flap (arrow).

PREOPERATIVE PREPARATION

1. Selection of Applicable Cases

The color Doppler method is used to confirm the presence of perforator branches of a certain diameter in the lower abdomen around the umbilicus [8]. If none are found, then either a free or pedicled rectus abdominis musculocutaneous flap is selected. In addition, the patient must have enough subcutaneous abdominal fat to repair the defective tissue. While we do not exclude outright any young women who wish to become pregnant in the future, we do feel they should avoid this procedure, if at all possible.

2. Preoperative Blood Vessel Evaluation and Selection of Perforator Branches

Of utmost importance is confirmation of the paths of the deep inferior epigastric vessels as well as the perforator branches. Previously, these were both evaluated only through color Doppler, but with the emergence of multidetector computed tomography (MDCT), all patients who can tolerate contrast agent now undergo a preoperative abdominal MDCT. This first evaluates the intramuscular route of the deep inferior epigastric vessels through 3D CT imaging, and then branch types mentioned above are categorized.

Perforator branches are then mapped, and those that could be included in the flap are selected in advance (Figure 2). Selection criteria involve, first and foremost, perforator branch thickness; as a rule, we select the thickest vessel (regardless of whether it is on the right or left side). If several vessels fulfill the selection criteria, we turn to other criteria such as the least intramuscular penetration (and thus greater ease of detachment), a strong network with the superficial inferior epigastric vessels, or a vessel on the side with no scars. If we are unsatisfied with the thickness of the perforator branch, we may consider including a total of 2 or 3 branches. However, in addition to the criteria mentioned above, those are selected in a combination that would minimize muscle sacrifice. In general, if perforator branches that originate from the medial and lateral branches are both included in the same flap, the muscular body between them must be cut, leading to more muscle damage. On the other hand, if perforator branches on the same side are selected, muscle damage is minimized, but the intercostal nerves that cut across between the branches must be cut and then rejoined. In addition, if too many perforator branches from the caudal end are included, the length of the vascular pedicle is shortened.

3. Preoperative Evaluation of Required Tissue Amount and Decisions Concerning the Use of Bipedicled DIEP Flaps

One disadvantage of using DIEP flaps is that the blood flow volume is lower than that of the rectus abdominis musculocutaneous flaps (RAMFs), which limits where it can be grafted [9]. Therefore, if a large amount of tissue is required for the transplant, a bipedicled DIEP flap should be considered [10]. At our institution, we simplify the surgical plan by pre-determining the necessary tissue volume as well as that of the flap that can be harvested using 3D imaging data and abdominal fat thickness, respectively [6].

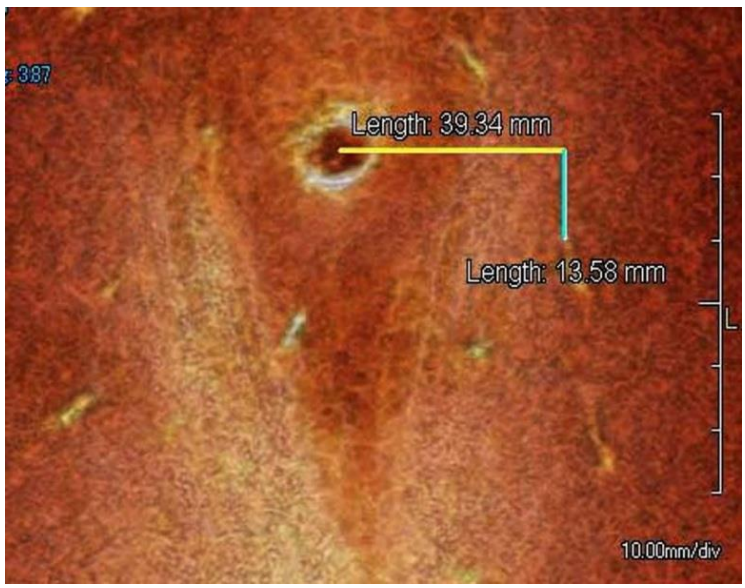

Figure 2. 3D CT mapping of perforator branches. Measurements were taken to determine the distance from the umbilicus (landmark).

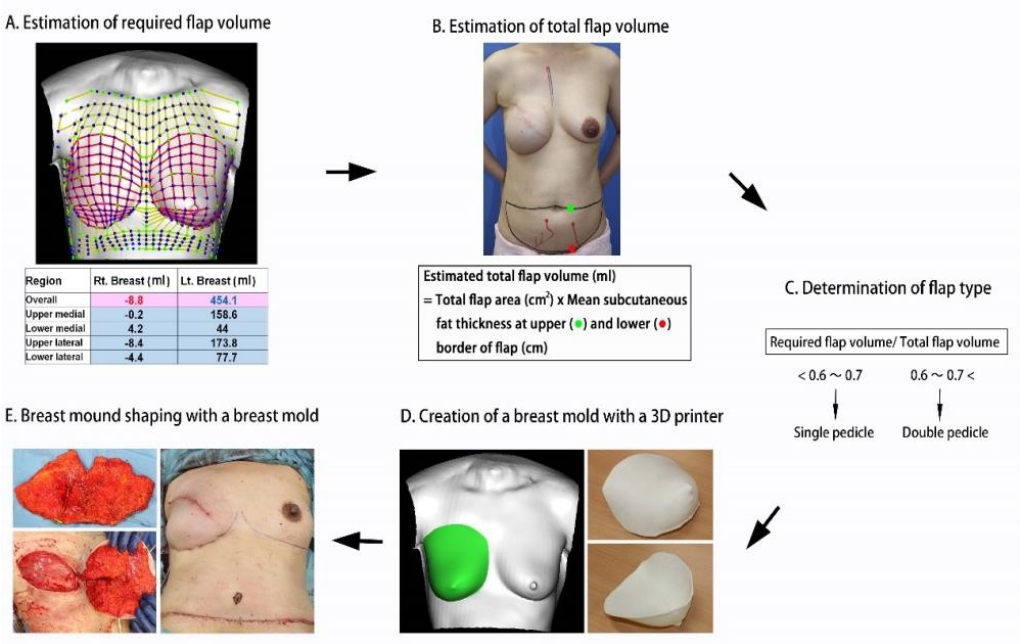

Figure 3. Use of 3D imaging for breast reconstruction using a DIEP flap (Reprinted from ref. 6).

To predetermine the necessary tissue volume, preoperative measurements of both breasts are first made using image analysis software (Breast Rugle®, Medic Engineering, Kyoto) (Figure 3A). For one-stage immediate reconstruction, the volume of the opposite (healthy) side is considered the necessary amount of tissue volume. For two-stage immediate reconstruction and delayed reconstruction, the difference in breast volume between the healthy and affected sides is considered the necessary tissue volume. Because we calculate both the volume of mammary gland tissue to be extracted and that of remaining breast skin tissue for one-stage immediate reconstruction, the necessary tissue volume may be slightly exaggerated in the evaluation. However, in our experience, the amount of error is not to the level that would affect the decision concerning whether a bipedicled DIEP flap would be required or not, and perioperative correction is possible by measuring the excised tissue.

The measurement of extractable flap volume is somewhat affected by the flap extraction method, but we have found that this can be estimated by the following equation: (Total flap volume, ml) = (mean subcutaneous fat thickness (cm) after excluding the skin thickness at the center of the rectus abdominis) x (total flap area (cm^2) as calculated by the imaging software) (Figure 3B). It also depends on the thickness, number, and location of the perforator branches, but if the estimate of necessary tissue volume exceeds 60-70% of the estimated total flap volume, then we plan for a bipedicled DIEP flap (Figure 3C). However, if the numbers are borderline and difficult to determine, then perforator branches on both sides are preserved. After the flap is maneuvered epifascially, a perforator branch on one side is clipped, and perioperative determination is done with indocyanine green fluorescent imaging [11]. Even in these cases, a preoperative estimate of the percentage of the total required flap tissue is extremely useful for perioperative determination of whether or not an additional blood vessel is required.

TIPS ON MANEUVERING THE FLAP

In addition to the perforator branch that was selected through the MDCT perforator branch mapping, all viable perforator branches should be marked preoperatively on the abdominal skin using a color Doppler device and Doppler blood flow meter, as this makes perioperative identification of the targeted perforator branch relatively easy. With regard to flap design, the upper end of the umbilicus should represent the cranial margin for a transverse flap, and the caudal end should have a convex boat-shaped design. Below we describe how to maneuver a transverse flap.

First, the skin around the perimeter of the umbilicus is cut down to the fascia in the shape of a ring. After isolating the umbilicus, the skin for the entire flap is dissected. For the caudal end of the flap, the deep fascia is reached by going down perpendicularly. However, in that process, it is important to not damage the superficial inferior epigastric vessels. From these vessels, a thick vein is selected, followed to some extent to the proximal part, and then included in the flap. This can be used after flap transplantation if veins become problematic. For the cranial end of the flap, the superficial fascia is peeled back about 2-3 cm in the cranial direction, and this will lead to the deep fascia. By doing this, any mismatch in thickness between the cranial and caudal ends of the flap can be resolved when the harvested flaps are sewn together. It also enables the transplantation of more tissue than required.

Following this, the flap is peeled back and elevated laterally along the fascia. In this process, a more controlled peeling is possible with the use of a needle-shaped scalpel electrode. Once the lateral border of the anterior sheath of the rectus abdominis muscle is reached, careful peeling is done using dissecting scissors, and the perforator branches that were marked preoperatively are identified and preserved. An incision is made in the anterior sheath roughly 1 cm caudal and 3-5 mm lateral of the targeted perforator branch. From that point, the presence of the perforator branch underneath the anterior sheath is confirmed. In this way, initial confirmation of the presence of perforator branches farther under the anterior sheath makes it possible to avoid damaging perforator branches in cases where the perforator branch is attached as it runs along the anterior sheath.

Figure 4. Preoperative condition of patient who underwent mastectomy on the right side.

After dissecting the anterior sheath along muscle fibers and opening it up roughly 5 cm, the muscle is divided longitudinally along the muscle fibers in a retrograde fashion from the arterial flow, exposing the blood vessel that will form the pedicle. In thin muscle branches, it is best to stay as far from the vascular pedicle as possible while using bipolar cautery to carefully clot and dissect. Thicker branches should be handled with a microclip, as the peeling is performed until the blood vessel reaches the underside of the muscle body. Motor branches of the intercostal nerve that run transversely should be preserved as much as possible. If the intercostal nerve must be dissected because it is between perforator branches, postoperative muscular atrophy can be prevented by re-stitching the nerve following the flap harvest. When peeling back the blood vessels, it is important to envision this process as a "peeling the surrounding tissue away from the blood vessel, i.e., leaving only the blood vessel in place", rather than tugging on the blood vessel to peel it away from the surrounding tissue. This will minimize any mechanical damage to the perforator branch. In cases for which the perforator branch is threaded through tendinous intersections, it is impossible to just isolate the perforator branch safely, so rather than trying to achieve the impossible, they are maneuvered along with the tendinous intersections.

After confirming separation of the blood vessel from the muscle body, a new 5-cm incision is made on the anterior sheath, from the lateral margin of the rectus abdominis in the caudal direction, and then the presence of the deep inferior epigastric vessels that insert into the underside of the muscle body from the lateral side of the muscle body is confirmed. This is then peeled back in the cranial direction and connected with the blood vessel that was peeled back earlier. During this process, it is very important to avoid damaging the thick intercostal nerve running transversely from the lateral side. The peeling is also conducted in the caudal direction until the bifurcation of the external iliac vessels is reached.

After the entire flap is peeled back to the fascia, the region of transplantable flap with stable blood flow is determined through subjective evaluation such as flap color or blood color, as well as objective evaluations such as perioperative ICG fluorescent angiography [11]. Any regions with insufficient blood flow are excised.

BREAST MOUND FORMATION BY CREATING A BREAST MOLD THROUGH 3D PRINTING

Using the aforementioned imaging software, it is possible to create a mold image of the breast on the opposite side, using 3D data obtained preoperatively. After this, the data that are transformed to a mirror image can be printed on a 3D printer. This enables the creation of a breast mold on the affected side, which can be gas sterilized and used perioperatively (Figure 3D). Following anastomosis/de-epithelialization of the flap, it is inserted into the mold, with careful attention being paid to the vascular pedicle (for one-stage immediate reconstruction accompanying nipple/areola resection, a part of the de-epithelialization is done later). First, after determining the most appropriate flap placement that will avoid placing tension on the vascular pedicle, any part of the flap that does not fit in the mold is resected (Figure 3E). In the event that the cranial side of the flap is thicker, adipose tissue from under the superficial fascia is removed and adjustments are made. When adjusting the amount of flap, one must remember that the chest wall protrudes out slightly in the front, rather than being flat. Using a

measuring spoon as an analogy, the whole spoon leveled off would be excessive; it is important to have not quite a full measuring spoon. In addition, as the breast molds are created according to the form of the body surface, the volume of breast skin is not taken into consideration. As a result, immediately after surgery, the reconstructed breast is slightly bigger than that on the healthy side, but as the flap tends to shrink postoperatively by about 5-10% [12], we feel that this works out quite nicely. In patients with high breast projection, breast mound construction is performed using several absorbable sutures to stabilize the flap on the caudal side. This work can be done prior to the anastomosis, but we opt to perform these procedures afterwards, primarily because it allows for some time to observe the condition of the anastomosis, and because it enables easier de-epithelialization of the flap.

POSTOPERATIVE MAINTENANCE

For 24 hours after surgery, a Doppler blood flow meter and the Doppler method should be used to monitor the flap blood flow every 4 hours. For 1 week after that, blood flow should be checked roughly three times a day. The patient should become ambulatory the day after surgery, and activity levels should be increased gradually thereafter. The abdominal suction drain should be removed between postoperative day 7 and 10, after which the patient can be discharged.

REPRESENTATIVE CASE

A 42-year-old female underwent mastectomy and sentinel node biopsy at another institution for cancer in her right breast, and was referred to our institution for delayed reconstruction (Figure 4). First, we inserted a subcutaneous tissue expander and performed mastopexy of the opposite breast, followed by reconstruction using a DIEP flap 4 months later. While the preoperative 3D analysis estimated that roughly 525 ml of tissue would be required, the total estimated flap volume was roughly 810 ml (roughly 65%). As such, we planned for a bipedicled DIEP flap that included one perforator branch from the right side medial row as well as 2 perforator branches from the left side medial and lateral rows (Figure 5A). Following mastopexy of the healthy side, a breast mold was created based on 3D data obtained after the breast form had stabilized. The lateral branch of the deep inferior epigastric vessels on the right side was anastomosed to the main trunk of the deep inferior epigastric vessels on the left (Figure 5B), and the right deep inferior epigastric vessels were anastomosed to the internal mammary vessels. After de-epithelialization, the flap was inserted into the breast mold, and excess flap tissue was excised (of the total 805 g of flap tissue, 560 g transplanted) and the breast mound constructed (Figure 5C). After inserting the flap into the subcutaneous pocket in the anterior chest, an inframammary fold was created using Nava's technique [13] (Figure 5D). Postoperatively, the flap showed complete engraftment, and the patient had a soft and symmetrical breast (Figure 6).

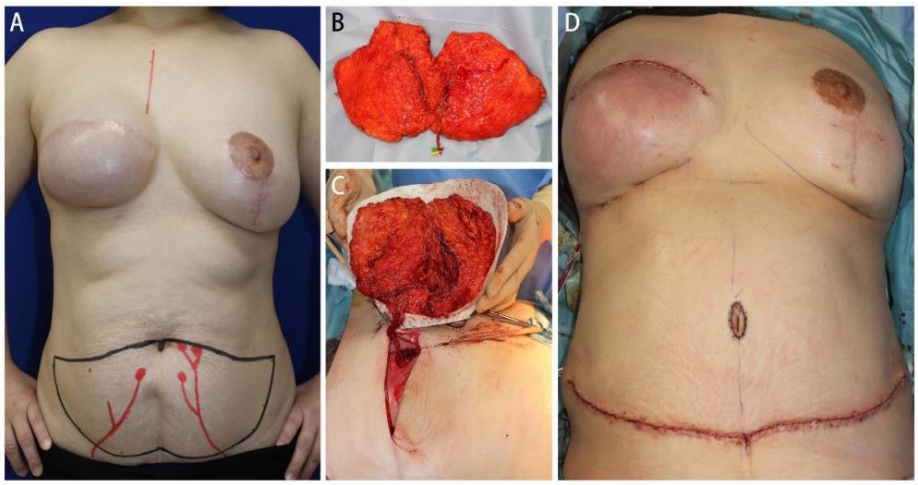

Figure 5. Perioperative findings. (A) Following subcutaneous insertion and expansion of the tissue expander, and then mastopexy of the other breast, we planned a bipedicled DIEP flap that included one perforator branch on the right side medial row and two perforator branches from the left side medial and lateral rows. (B) Anastomosis of the lateral branch of the right deep inferior epigastric vessel and the main trunk of the left deep inferior epigastric vessel. (C) The flap was inserted into the breast mold. Excess flap tissue was excised and the breast mound was formed. (D) After inserting the flap into the anterior chest subcutaneous pocket, we used Nava's technique to create an inframammary fold.

Figure 6. Postoperative status at 10 months. A sufficient amount of tissue was transplanted, allowing for reconstruction of a soft and symmetrical breast.

CONCLUSION

We have documented some of our recent experiences and innovations with breast reconstruction using DIEP flaps. From the perspective that DIEP flaps minimize muscle sacrifice, allowing for transplant of tissue with a relatively large volume and area, we feel that

this technique is an extremely useful option for breast reconstruction. In addition, with recent progress in vascular anatomy studies, as well as the prevalence of MDCT and 3D imaging technologies, increasingly safe and accurate preoperative plans and simulations are now possible. We anticipate even more developments in this standard procedure that uses self tissue for breast reconstruction following mastectomy.

REFERENCES

[1] Blondeel N., Vanderstraeten G.G., Monstrey S.J., Van Landuyt K., Tonnard P., Lysens R., Boeckx W.D., Matton G., (1997). The donor site morbidity of free DIEP flaps and free TRAM flaps for breast reconstruction. *Br J Plast Surg* 50, 322-330.

[2] Nishimoto S., Sotsuka Y., Kawai K., Fujita K., Kakibuchi M., (2014). Three-dimensional mock-up model for chondral framework in auricular reconstruction, built with a personal three-dimensional printer. *Plast Reconstr Surg* 134, 180e-181e.

[3] Sotsuka Y., Nishimoto S., (2014). Making three-dimensional mandible models using a personal three-dimensional printer. *J Plast Reconstr Aesthet Surg* 67, 576-578.

[4] Koshima I., Soeda S., (1989). Inferior epigastric artery skin flaps without rectus abdominis muscle. *Br J Plast Surg* 42, 645-648.

[5] Blondeel P.N., (1999). One hundred free DIEP flap breast reconstructions: a personal experience. *Br J Plast Surg* 52, 104-111.

[6] Tomita K., Yano K., Hata Y., Nishibayashi A., Hosokawa K., (2015). DIEP Flap Breast Reconstruction Using 3-dimensional Surface Imaging and a Printed Mold. *Plast Reconstr Surg Glob Open* 3, e316.

[7] Itoh Y., Arai K., (1993). The deep inferior epigastric artery free skin flap: anatomic study and clinical application. *Plast Reconstr Surg* 91, 853-863; discussion 864.

[8] Yano K., Hosokawa K., Nakai K., Kubo T., Hattori R., (2003). Monitoring by means of color Doppler sonography after buried free DIEP flap transfer. *Plast Reconstr Surg* 112, 1177.

[9] Kroll S.S., (2000). Fat necrosis in free transverse rectus abdominis myocutaneous and deep inferior epigastric perforator flaps. *Plast Reconstr Surg* 106, 576-583.

[10] Blondeel P.N., Boeckx W.D., (1994). Refinements in free flap breast reconstruction: the free bilateral deep inferior epigastric perforator flap anastomosed to the internal mammary artery. *Br J Plast Surg* 47, 495-501.

[11] Losken A., Zenn M.R., Hammel J.A., Walsh M.W., Carlson G.W., (2012). Assessment of zonal perfusion using intraoperative angiography during abdominal flap breast reconstruction. *Plast Reconstr Surg* 129, 618e-624e.

[12] Blondeel P.N., Hijjawi J., Depypere H., Roche N., Van Landuyt K., (2009). Shaping the breast in aesthetic and reconstructive breast surgery: an easy three-step principle. Part II--Breast reconstruction after total mastectomy. *Plast Reconstr Surg* 123, 794-805.

[13] Nava M., Quattrone P., Riggio E., (1998). Focus on the breast fascial system: a new approach for inframammary fold reconstruction. *Plast Reconstr Surg* 102, 1034-1045.

BIOGRAPHICAL SKETCH

Koichi Tomita

Affiliation:
Department of Plastic and Reconstructive Surgery
Graduate School of Medicine, Osaka University

Education:
Osaka University, Medical School M.D., 2000
Osaka University, Graduate School of Medicine Ph.D., 2007

Business Address:
2-2 C11 Yamadaoka Suita, 5650871 Osaka, Japan

Research and Professional Experience:

Dr. Tomita's research has concentrated in the area of reconstructive microsurgery, including breast reconstruction, facial nerve reconstruction, and head and neck reconstruction. Clinical research areas of interest include breast reconstruction using 3-dimensional imaging and facial nerve reconstruction using multiple motor sources. Basic research areas of interests includes improvement of peripheral nerve regeneration using adipose-derived stem cells and in vivo molding of soft tissue using an absorbable mold.

Professional Appointments:

Since 2007 Assistant Professor, Osaka University

2009-2011 Research fellow, Blond McIndoe Research Laboratories, University of Manchester

Honors:

2009-2011 Uehara memorial foundation research fellowship

2013, 2014 President's incentive award, Osaka University

Publications Last 3 Years:

1. Nishibayashi A, Tomita K, Kiya K, Yano K, Hosokawa K. Differentiated adipose-derived stem cells promote the recovery of nociceptor function in rats. *Neuroreport*, in press
2. Tomita K, Nishibayashi A, Yano K, Hosokawa K. Differential reanimation of the upper and lower face using two interpositional nerve grafts in total facial nerve reconstruction. *Plastic and Reconstructive Surgery Global Open*, 3(10) e544, 2015
3. Tomita K, Nishibayashi A, Yano K, Hosokawa K. Adipose-derived stem cells protect against endoneurial cell death: Cell therapy for nerve autografts. *Microsurgery*, 35(6) 474-80, 2015
4. Tomita K, Yano K, Nishibayashi A, Hosokawa K. Effects of subcutaneous versus submuscular tissue expander placement on breast capsule formation. *Plastic and Reconstructive Surgery Global Open*, 3(6) e432, 2015

5. Tomita K, Yokoi-Fukai M, Ishihara T, Morita K, Hosokawa K. Use of translocated deep inferior epigastric vessels for free flap reconstruction of gluteal defect. *Plastic and Reconstructive Surgery Global Open*, 3 (6) e433, 2015
6. Nishibayashi A, Hata Y, Hori Y, Tomita K, Matsuda K, Yano K, Hosokawa K. Angiosarcoma on untreated facial capillary malformations. *ePlasty*, 15:e34, 2015
7. Matsuda K, Tomita K, Fukai M, Kubo T, Hayashi A, Shibata M, Hosokawa K. Vein/arterial grafts harvested within the incision for a free groin flap. *Plastic and Reconstructive Surgery Global Open*, 3(6) e407, 2015
8. Matsuda K, Kubo T, Fukai M, Kikuchi M, Hikasa H, Nakajima Y, Tomita K, Hosokawa K, Shibata M. Free perivascular tissue flap transfer. *Journal of Plastic, Reconstructive and Aesthetic Surgery*, 68(7) 973-8, 2015
9. Tomita K, Yano K, Hata Y, Nishibayashi A, and Hosokawa K. DIEP Flap Breast Reconstruction Using 3-Dimensional Surface Imaging and a Printed Mold. *Plastic and Reconstructive Surgery Global Open*, 3(3) e316, 2015
10. Tomita K, Yano K, Sugio Y, Ishihara T, Nishibayashi A, Matsuda K, Hosokawa K. Breast reconstruction following breast-conserving surgery with a subcutaneous tissue expander and latissimus dorsi flap. *Plastic and Reconstructive Surgery Global Open*, 2(10) e231, 2014
11. Hata Y, Osuga K, Uehara S, Yano K, Kikuchi M, Tomita K, Matsuda K, Kubo T, Fujiwara T, Hosokawa K. Topological analysis for arteriovenous malformations via computed tomography angiography: Part 2: Practical application. *Plastic and Reconstructive Surgery Global Open*, 2(9) e207, 2014
12. Hata Y, Osuga K, Kubo T, Matsuda K, Tomita K, Kikuchi M, Fujiwara T, Yano K, Hosokawa K. Topological analysis for arteriovenous malformations via computed tomography angiography: Part 1: Mathematical concepts, Yuki Hata, et al., Plastic and Reconstructive Surgery Global Open, 2(8) e205, 2014
13. Tanigawa T, Kanazawa S, Ichibori R, Fujiwara T, Magome T, Shingaki K, Miyata S, Hata Y, Tomita K, Matsuda K, Kubo T, Tohyama M, Yano K, Hosokawa K. (+)-Catechin protects dermal fibloblasts against oxidative stress-induced apoptosis. *BMC Complementary and Alternative Medicine*, 14:133, 2014
14. Ichibori R, Fujiwara T, Tanigawa T, Kanazawa S, Shingaki K, Torii K, Tomita K, Yano K, Osaka Twin Research Group, Sakai Y, Hosokawa K. Objective assessment of facial skin aging and the associated environmental factors in Japanese monozygotic twins. *Journal of Cosmetic Dermatology*, 13(2):158-63, 2014
15. Imagawa Y, Tomita K, Kitahara K, Yano K, Hosokawa K. Repair of symptomatic perineal hernia with a titanium mesh. *Hernia*, 18(4):587-90, 2014
16. Tashima H, Fujikawa M, Izumi K, Matsuda K, Tomita K, Hosokawa K. Anatomic evaluation of the internal mammary vessels using multidetector CT angiography images in 100 Asian patients. *ePlasty* 14:e9, 2014
17. Izumi K, Fujikawa M, Tashima H, Saito T, Sotsuka Y, Tomita K, Hosokawa K. Immediate reconstruction using free medial circumflex demoral artery perforator flaps after breast-conserving surgery. *Journal of Plastic, Reconstructive and Aesthetic Surgery* 66(11):1528-33, 2013
18. Tomita K, Nishibayashi A, Yano K, Hosokawa K. Differentiated adipose-derived stem cells promote reinnervation of rat skin flaps. *Plastic and Reconstructive Surgery Global Open* 1(3):e22, 2013

19. Tomita K, Yano K, Nishibayashi A, Fukai M, Miyasaka M, Hosokawa K. The role of latissimus dorsi myocutaneous flap in secondary breast reconstruction after breast-conserving surgery. *ePlasty* 13:e28, 2013
20. Tomita K, Madura T, Sakai Y, Yano K, Terenghi G, Hosokawa K. Glial differentiation of human adipose-derived stem cells: Implications for cell-based transplantation therapy. *Neuroscience* 236(16):55-65, 2013
21. Nishibayashi A, Tomita K, Yano K, Hosokawa K. Correction of complex chest wall deformity in Poland's syndrome using a modified Nuss procedure. *Journal of Plastic, Reconstructive and Aesthetic Surgery* 66(2):e53-e55, 2013

In: Encyclopedia of Surgery (22 Volume Set)
Editors: Andreas Lehrer and Kristin Mueller
ISBN: 978-1-53618-329-0
© 2020 Nova Science Publishers, Inc.

Chapter 174

EFFECT OF RADIOTHERAPY ON IMPLANT-BASED IMMEDIATE BREAST RECONSTRUCTION WITH OR WITHOUT ACELLULAR COLLAGEN MATRIX: POTENTIAL STRATEGIES TO IMPROVE OUTCOME

Baek Kim [*] ***and Rajgopal Achuthan***
Department of Breast Surgery, St. James's University Hospital, Leeds, UK

ABSTRACT

Implant-based immediate breast reconstruction has evolved rapidly over the past decade. The emergence of human, porcine, and bovine acellular collagen matrices (ACM) has had significant impact resulting in a marked rise in implant-based immediate reconstructions. The matrices are used to provide improved lower pole coverage of the reconstructed breast enabling a one-stage reconstruction with a fixed volume implant or an expander in cases where a larger volume reconstruction is required. This is in contrast to the technique of complete submuscular tissue expander reconstruction, which was associated with limited implant or expander volume as well as restricted lower pole projection. Understandably, implant-based immediate breast reconstruction with ACM is therefore increasingly utilised in oncological and risk reducing settings.

Post-mastectomy radiotherapy remains a key adjuvant treatment modality as it improves locoregional control as well as overall survival in breast cancer patients. However, its use in patients who have undergone implant-based reconstruction can be detrimental with potential for complications such as infection, mastectomy flap necrosis, capsular contracture, and explantation necessitating revisional surgery. Therefore, managing this group of patients requires careful multidisciplinary approach and planning. The main purpose of this review article is to examine the effect of post-mastectomy radiotherapy on the outcome of implant-based immediate breast reconstruction with or without acellular collagen matrix. We will additionally examine the literature to determine if there is any potential protective benefit of ACM usage in patients who receive post-mastectomy radiotherapy. The review will also attempt to identify potential strategies that can be utilised to improve outcome in these patients. The strategies will

[*] Corresponding Author's Email: kimbaek@doctors.net.uk.

focus on patient and surgical risk factors, alternative reconstructive options including autologous reconstruction, as well as adjunctive surgical techniques to improve patient outcome.

Keywords: breast reconstruction, radiotherapy, mastectomy, implant, acellular dermal matrix, acellular collagen matrix

INTRODUCTION

Immediate breast reconstruction [IBR) has been shown to be oncologically safe [1, 2], cost-effective [3], and importantly reduce psychological morbidity [4]. Expander/implant-based breast reconstruction accounts for 65% of all breast reconstruction in the United States [5]. Acellular collagen matrix (ACM), otherwise commonly known as acellular dermal matrix, is being used increasingly [6] in expander/implant-based IBR. ACM provides improved lower pole coverage of the reconstructed breast enabling a one-stage reconstruction with a fixed volume implant or an expander in cases where a larger volume reconstruction is required. ACM improves the aesthetic outcome of expander/implant-based IBR. This is in contrast to the traditional complete submuscular tissue expander reconstruction with disadvantages of limited implant/expander volume, the need for multiple visits for expansion, as well as limited lower pole projection.

Post-mastectomy radiotherapy (PMRT) remains a key adjuvant treatment modality where indicated, and has been shown to improve locoregional control as well as overall survival [7]. The oncological benefit of PMRT is recognized but it is associated with potential side effects including tissue fibrosis, reduction in dermal blood flow, and tissue hypoxia. As a result patients, particularly with implant-based reconstructions, can suffer from complications such as infection, mastectomy flap necrosis, capsular contracture, and explantation. Our aim is to examine the effect of PMRT on the outcome of expander/implant-based IBR with or without the use of ACM. We will attempt to identify strategies that can be utilised to improve outcomes in these patients. The strategies will focus on patient and surgical risk factors, alternative reconstructive options, as well as adjunctive surgical modalities to improve patient outcome.

THE EMERGENCE OF ACELLULAR COLLAGEN MATRIX

Traditional two-stage reconstruction involves submuscular expander insertion at the time of skin-sparing mastectomy. Raising the pectoralis major muscle fibers and the fibers of serratus anterior muscle laterally provides lower pole coverage of the expander. Expansion with saline is performed gradually to achieve the desired reconstructed breast volume. A subsequent operation is performed where the expander is exchanged for a permanent implant. However, it is difficult to create a natural ptotic breast, and the initial implant or expander volumes are limited by the anatomical boundaries.

ACM allows better lower pole coverage of the reconstructed breast, and hence a more natural aesthetic reconstruction. It is sutured on to the lower edge of the pectoralis major muscle and to the inframammmary fold. It acts as a mechanical support, and allows more precise positioning of the expander or implant. Greater intraoperative filling volume is

possible using ACM [5]. This in turn enables one-stage IBR, which has the potential to be cost-effective [8]. Human ACM, more commonly utilised in the United States, include AlloDerm, Neoform, DermaMatrix, and FlexHD [9]. They are created by treating human cadaveric skin to remove all cellular and immunogenic components. This leaves a basement membrane and cellular matrix that provides a scaffold. In Europe, human tissue products are not used widely due to regulatory restrictions and hence Porcine (e.g., Strattice) and bovine ACM (e.g., Surgimend and Veritas) are utilised instead [10-12] (Figure 1).

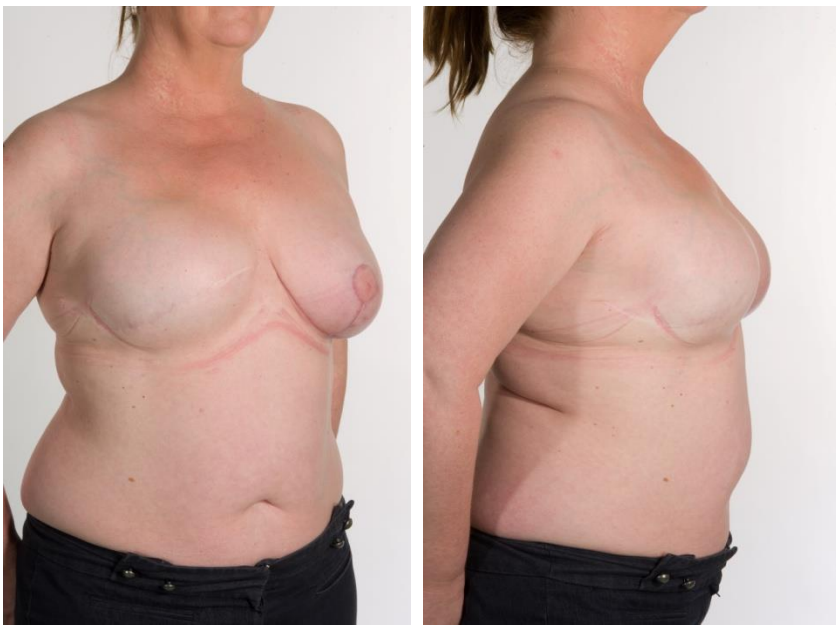

(a) (b)

Figure 1. Post-operative images of a patient who underwent implant-based immediate breast reconstruction with ACM on the right with contralateral left breast reduction for symmetry.

CRITERIA FOR ADMINISTRATION OF POST-MASTECTOMY RADIOTHERAPY

Post-mastectomy radiotherapy (PMRT) is beneficial in patients particularly those where the risk of loco-regional recurrence is greater than 20% [13]. Tumour size and nodal status are key factors in determining which patients are offered PMRT. Typically in patients with T3 or T4 disease and those with four or more positive axillary lymph nodes PMRT is indicated [13]. Other important factors in decision to offer PMRT include tumour grade, presence of lymphovascular invasion, age less than 40 years, close margins of less than 1mm, and the presence of significant extracapsular nodal spread [13].

The degree of nodal involvement is important in the decision making to offer PMRT. A meta-analysis of Early Breast Cancer Trialists Collaborative Group (EBCTCG) showed that for patients with four or more positive axillary nodes, PMRT reduced overall recurrence (RR 0.79) and breast cancer mortality (RR 0.87). For patients with negative axillary nodes, PMRT did not confer benefit with regards to recurrence and survival rates. In the patients with one to

three positive axillary nodes, PMRT resulted in recurrence and survival benefits even in the presence of other systemic therapies [14]. However, the question remains as to whether all patients with one to three positive axillary lymph nodes would benefit from PMRT given their relatively lower risk of recurrence. Yao et al. examined the United States National Cancer Data Base, and stated that PMRT is being increasingly utilised in patients with one to three positive axillary lymph nodes; the proportion of patients receiving PMRT in this subgroup increased from 23.9% in 2003 to 36.4% in 2011 [15]. The SUPREMO [Selective Use of Postoperative Radiotherapy After Mastectomy) trial investigates outcome in such patients who have less than four positive axillary lymph nodes and the results of the trial is awaited [16]. A population-based study by the Swedish Western and Southeastern group found that omission of PMRT in patients with one to three positive axillary nodes did not influence survival [17].

Tumour size is another predictor of risk with PMRT improving outcomes in patients with large tumours. Historically, patients with T3 and T4 tumours have been offered PMRT [18]. However, Taghian et al. report that patients with T3N0 tumours treated by mastectomy should not routinely receive PMRT due to the low rate of loco-regional failure [19].

A subset of patients with T1 and T2 tumours with one to three positive nodes may be offered radiotherapy. A recent meta-analysis by Li et al. supports the use of PMRT in this group of patients due to achievement of significant reduction in loco-regional recurrence [20]. A retrospective study from the British Columbia Cancer Agency showed that the risk of loco-regional recurrence at 10 years was 12.7% for T1 or T2 tumours with one to three positive axillary lymph nodes. This study showed that age <45 years, >25% positive lymph nodes, medial tumours, and negative oestrogen receptor status independently increased the risk of loco-regional recurrence [21]. This is corroborated by a study by Jwa et al. who concluded that PMRT may be beneficial for patients with non-luminal breast cancer with one to three positive axillary lymph nodes [22]. A further study by Truong et al. concluded that nodal ratio (positive/excised nodes) of greater than 0.2 was associated with locoregional recurrence rate of >20%, and hence these patients may benefit from PMRT [23]. Study by Trovo et al. also identified pre-menopausal status, oestrogen receptor negative cancer, grade 3 tumours, and the presence of lymphovascular invasions as potential risk factors for loco-regional failure after mastectomy and should therefore prompt consideration for PMRT [24].

Therefore, selection of patients for PMRT requires a careful multidisciplinary approach to optimise oncological outcome in patients, and the above potential predictive factors should be taken into account when deciding which patients should be offered PMRT.

THE EFFECT OF POST-MASTECTOMY RADIOTHERAPY ON IMPLANT-BASED IMMEDIATE BREAST RECONSTRUCTION WITHOUT ACM

A Dutch study [25] reported in 2000 showed that complication rates following IBR with submuscular expanders was 27% in the PMRT group compared to 13% in those without PMRT (median follow-up 30 months). Christante et al. [26] report an explantation rate of 31% in patients who underwent PMRT after immediate expander reconstructions, in contrast to 6% in those who did not receive PMRT.

Another study by Reefy et al. [27] showed that capsular contracture rate was 85% in patients who required PMRT or had previous radiotherapy as opposed to 13% who did not receive radiotherapy. A study [28] from Memorial Sloan-Kettering Cancer center showed that at median follow-up of 86 months, the rate of permanent implant removal or replacement was 29% at 7 years post-radiotherapy. Cordeiro et al. performed a comparison analysis of non-irradiated implanted based reconstruction versus implant-based reconstruction followed by PMRT. With mean follow up time of 56.8 months, implant loss rate was 0.5% in the former as opposed to 9.1% in the latter. Grade III to IV capsular contracture rate was 11.1% and 27.6% respectively. Aesthetic results, as assessed by surgeons, were inferior in patients who received PMRT [29]. A meta-analysis by Barry et al. [30] showed that radiotherapy exposure after implant-based IBR was associated with a 4.2 fold increase (95% CI, 2.4-7.2) in post-operative complications compared to no radiotherapy.

THE EFFECT OF POST-MASTECTOMY RADIOTHERAPY ON IMPLANT-BASED IMMEDIATE BREAST RECONSTRUCTION WITH ACM

In a study by Colwell et al. [31] where ACM was used, complication rates increased to 25.2% in patients who underwent radiotherapy compared to 13.9% without radiotherapy ($p = 0.005$). Similarly, Clemens et al. [32] from M.D. Anderson reported a complication rate of 43.3% in patients who received radiotherapy compared to 15.6% in those without radiotherapy, where both groups underwent reconstruction using ACM. In particular, mastectomy flap necrosis was seen in 26.7% in the radiotherapy group versus 7.5% in the non-radiotherapy group. Rawlani et al. [9] reported outcomes in ACM-based reconstruction patients receiving radiotherapy ($n = 26$) versus the no radiotherapy ($n = 95$). Complication rate was 30.8% in the former group versus 13.7% in the latter group; mastectomy flap necrosis and implant exposure were both high at 15.4% in the radiotherapy group versus 4.2% in the non-radiotherapy group. In a study by Salzberg et al. [33] evaluating the use of one-stage implant-based IBR with ACM, radiotherapy was received by 4.5% of patients where the complication rate was 14.3% versus 3.9% in the non-radiotherapy group. These studies show that radiotherapy seems to be detrimental in patients who undergo implant-based reconstruction using ACM (Figure 2).

Figure 2. Complication following implant-based immediate breast reconstruction with acellular collagen matrix.

COMPARISON OF OUTCOME IN IMPLANT-BASED IMMEDIATE BREAST RECONSTRUCTION WITH OR WITHOUT ACM (IN GROUPS NOT REQUIRING ADJUVANT PMRT)

A Meta-Analysis from Kim et al. [5] reviewed 48 relevant studies comparing complication rates in patients with with human ACM versus submuscular implant/expander reconstruction. AlloDerm was used in the majority of studies. Total complication rate of 15.4% was noted in the ACM group (n = 2037) as opposed to 14% in the submuscular group (n = 12,847). There was a small increase in infection (5.3% vs. 4.7%), flap necrosis (6.9% vs. 4.9%), and seroma rates (4.8% vs. 3.5%) in the ACM group compared to the submuscular group. However, the rates of reconstructive failure were similar at 3.8% in both the ADM and in the submuscular group. ACM is tested to confirm the absence of microbial contamination, but is not sterile [34]. This may account for the higher infection rate in the ACM group. The higher flap necrosis rate may be explained by greater intraoperative filling volume in the ACM group (mean = 264.9ml) versus the submuscular group (mean = 187.1ml). The minor increase in the overall complication rates may be explained by the learning curve of a new surgical technique. This suggestion is corroborated by study from Colwell et al. [31]; complication rate was 21.4% in the surgeons' first year of performing the procedure, but 10.9% in the subsequent years. Studies with longer follow-ups are required, as the mean follow-up time was 13.8 months in the ACM group, compared to 28.3 months in the submuscular group.

IMPACT OF RADIOTHERAPY ON IMPLANT-BASED IMMEDIATE BREAST RECONSTRUCTION WITH OR WITHOUT ACM

There are comparatively few studies which directly compare the effect of radiotherapy on implant-based IBR with or without ACM. A study by Seth et al. [35] compares the effect of PMRT in the ACM group versus the non-ACM group. They found no significant increase in complication rate with PMRT in the ACM group (n = 74), but significant increase in complication rate was observed in the non-ACM group (n = 49). However, in a study by Parks et al. [36], which compared ACM (n = 27) versus non-ACM (n = 37) reconstruction, radiation significantly increased the rate of expander loss only in the ACM group. It is worth noting that the evidence for the effect of radiotherapy on ACM versus non-ACM implant reconstructions is based on Level III studies. Additionally, the number of patients included for analysis is small. No definitive conclusion can be drawn at present regarding whether ACM has any protective effects against the detrimental effect against radiation. Further level I direct comparison studies with longer-term follow-up are required.

STRATEGIES TO REDUCE COMPLICATION RATES IN PATIENTS WHO REQUIRE POST-MASTECTOMY RADIOTHERAPY

Predicting which patients require PMRT may enable better pre-operative planning and reduce complication rates. Christante et al. [26] reported that T2 tumours, positive axillary

lymph node status, and the number of positive sentinel lymph nodes were independent predictors of PMRT. Therefore, performing upfront sentinel node biopsy prior to reconstruction may provide useful information to assess the likelihood of PMRT. Mannu et al. compared complication rates prior to and after introduction of upfront sentinel node biopsy for patients undergoing mastectomy and IBR. They reported significant reduction in complication rates after introduction of upfront sentinel node biopsy. This was attributed to the fact that prior to the usage of upfront sentinel node biopsy, the proportion of patients receiving unexpected radiotherapy after implant-based reconstructions was higher [37]. Upfront sentinel node biopsy helped identify these patients allowing better planning and avoiding implant-based approaches.

Delayed reconstruction can be an alternate approach in patients who are at high likelihood of receiving PMRT, and indeed Michigan Breast Reconstruction Outcome study showed that immediate reconstruction confers two-fold increased odds for complications compared to delayed reconstruction [38]. This finding is supported by Sullivan et al. who reported higher complication rate and capsular contractures in immediate tissue expander reconstruction compared to delayed expander reconstruction [39]. A survey of breast surgeons in the United Kingdom and United states showed that when PMRT was planned, the surgeon's preference was for delayed or delayed-immediate breast reconstruction [40, 41]. However, this is counter-balanced against the desire of the patient who may wish to pursue an immediate type of reconstruction. Delayed reconstruction more frequently results in the need for recruitment of autologous tissue with associated donor site morbidities. Furthermore, delayed reconstruction using expander/implant solely is likely to result in inferior aesthetic outcome due to loss of the skin envelope following a mastectomy. Importantly this latter technique is not advised in patients who have received PMRT.

Another approach when PMRT is expected is to consider the delayed-immediate breast reconstruction [42]. In this approach skin-sparing mastectomy is performed with a submuscular expander/implant with an ACM, enabling skin-preservation. The use of an ACM in this setting allows for achievement of the desired volume circumventing the need for multiple expansions, which can potentially delay PMRT. Rozen et al. recommends full expansion of the expander prior to radiotherapy with an aim of maximising the amount of regional tissue available for future reconstructive procedure [43]. Once radiotherapy is complete, the definitive delayed reconstruction can be performed.

Nava et al. compared outcome in three groups [44]; patients receiving PMRT on permanent implant versus tissue expander, and patients who did not require radiotherapy. Reconstructive failure rate was 40% in the tissue expander group, compared to 6.4% in the permanent implant group, and 2.3% in the control group. However, the underlying pathophysiology as to why permanent implants tolerate radiotherapy better than expanders in this study remains unclear.

There is evidence to support the use of polyurethane implants in patients who are likely to need or have already received PMRT [45]. Ideally following radiotherapy, in the setting of an implant/expander reconstruction, one considers revisional surgery for complications such as capsular contracture by transfer of autologous tissue from another site. In patients where this is not feasible or who have strong desire to avoid donor site morbidity, the use of polyurethane implants can be considered. The timing of exchange or revision of expander to permanent implant after PMRT can impact outcome. A study by Peled et al. [46] showed that delaying the expander-implant exchange to greater than 6 months after radiotherapy resulted

in a significant reduction in post-operative complication rates compared to less than 6 months (7.7% versus 22.4%; p = 0.036).

An alternative approach may be to pursue autologous IBR, but some patients may not have sufficient tissue for fully autologous reconstruction, and evidences suggest that radiotherapy has detrimental effects [30] on autologous reconstructions such as fat necrosis, which may be a complication of less significance as compared to loss of an implant reconstruction. An online risk calculator tool such as the Breast Reconstruction Risk Assessment Score (http://www.BRAscore.org) may aid in perception of risks for different types of breast reconstruction for the patients and clinicians involved. This assessment tool takes account of radiotherapy status [47]. Other surgical approaches have been reported as alternatives to ACM. One such technique is the autologous dermal sling-based IBR [48]. The inferior dermal sling consists of a de-epithelised skin flap created from the lower pole of the breast when using a Wise pattern approach. This provides lower pole support in a similar fashion to ACM. This approach is suitable only in patients with an appropriate degree of ptosis where skin-reducing mastectomies are considered. Another technique is the use of dermal autografts. Lynch et al [49] performed wide excision of the pre-existing abdominal scars to provide the lower pole coverage instead of ACM. The techniques of inferior dermal sling and dermal autografts are cost effective, but further research is required to determine outcomes in the setting of radiotherapy.

Further considerations include the site of skin sparing mastectomy incision with the inframammary incision reported to have a higher rate of wound breakdown and implant loss following radiotherapy. The authors attribute this to the inframammary position having a higher rate of moist desquamation due to its dependent position. Furthermore, tissue coverage at the inframammary position is less compared to peri-areolar based incision [50].

Ribuffo et al. describe protective effects of lipofilling after expander based IBR and PMRT. This is followed by exchange of the expander to an implant after at least 3 months from the completion of fat grafting. They have reported encouraging early results with reduced explantation rates in patients who were treated in this manner [51]. Serra-Renom et al. similarly utilise fat grafting after PMRT in patients who received expander implant breast reconstruction. They reported low capsular contracture rates at follow up time of 12 months [52]. Furthermore, Panettiere et al. reported lipofilling in 61 consecutive patients who underwent implant-based breast reconstruction followed by PMRT. Improvements in aesthetic outcome, explantation rates, and capsular contracture rates were reported in those treated with lipofilling [53].

It is important to examine general surgical and patient risk factors specific to implant-based IBR. A meticulous surgical approach and addressing modifiable potential risk factors is likely to minimise risk of complications in this potentially high risk patient group who may additionally require PMRT. A published guideline from the Association of Breast Surgery and the British Association of Plastic, Reconstructive, and Aesthetic Surgeons advise a cautious approach in patients undergoing an implant-based ADM IBR with body mass index >30, simultaneous axillary lymph node dissection, PMRT, smoking, and mastectomy weight >600 gram [54]. Surgical site infection in patients with implant-based IBR may lead to subsequent implant loss. Barr et al. have produced a peri-operative ‘theatre implant checklist’ for surgical site infection prevention in implant-based breast surgery. This checklist is based on current review of literature and considers important aspects such as peri-operative

antibiotics usage, alcohol-based skin preparation, laminar air flow, minimal theatre traffic, irrigation of implant pocket, double gloving, and conductive warming [55].

Another strategy may be to consider neoadjuvant chemotherapy (NACT). In general, patients who are likely require PMRT have larger tumours with axillary nodal metastases. These patients would also be obligate candidates for chemotherapy. Historically, these patients would have undergone mastectomy, adjuvant chemotherapy, followed by PMRT. Instead, these patients could potentially undergo NACT, followed by mastectomy depending upon tumour response to NACT. Analysis of the NSABP B-18 and B-27 NACT trials showed low rate of loco-regional failure in patients who achieve complete pathological response (cPR). Potentially those patients achieving cPR post-NACT who then requiring a mastectomy could potentially be spared PMRT. The NSABP B-51 trial is currently recruiting patients with an aim of answering this question [56].

DISCUSSION

This review highlights the detrimental effect of radiotherapy on implant-based IBR with or without ACM. Currently there is lack of evidence to show that ACM has any protective effect against radiotherapy. However, the use of ACM is advocated in general, especially when the likelihood of PMRT is low. It is worth noting that most studies were centre or surgeon-specific. Few multicentre studies have been published; a Danish study examined outcome from 9 different centres [57], and the Michigan Breast Reconstruction Outcome Study project involved 23 surgeons from 12 institutions [38]. In the future, more multicentre studies with longer-term follow-ups are required. Currently in the United Kingdom, the National Implant Breast Reconstruction Audit (iBRA) is collecting data on all type of implant reconstruction performed with over 1700 patients recruited (http://www.ibrastudy.com).

Potential strategies to improve patient outcome in implant based breast reconstruction
Consider risk factors to help select appropriate patients • As outlined in the ABS and BAPRAS guideline for ADM assisted breast reconstruction • The Breast Reconstruction Risk Assessment score (http://www.BRAscore.org)
Anticipate need for PMRT based on pre-operative tumour characteristics (utilise upfront sentinel lymph node biopsy)
If PMRT anticipated, consider -ACM implant/expander reconstruction; also consider polyurethane implant -Autologous immediate reconstruction -Delayed-immediate reconstruction with skin envelope preservation -Delayed reconstruction -Neoadjuvant chemotherapy
Minimise potential risks during surgery -'Theatre implant checklist' -Scar placement for skin sparing mastectomy
Consider adjunctive procedure post-radiotherapy -Lipofilling procedure -If revisional surgery is required, ideally tissue transfer is indicated -In patients who decline tissue transfer, consider revisional surgery with polyurethane implant

Figure 3. Potential strategies to improve patient outcome in immediate implant-based reconstruction in setting of post-mastectomy radiotherapy.

The aesthetic outcome in implant-based IBR deteriorates with time, particularly without ACM use [58]. Studies show that IBR with ACM results in superior aesthetic outcome and reduced rates of capsular contracture, compared to IBR without ACM [59].

With development of surgical technology, ACM has resulted in improvement of implant-based IBR aesthetically and in terms of enabling direct to implant one-stage IBR with its associated advantages. However, similar problems are faced with regards to PMRT and its associated detrimental effects. This chapter has highlighted potential strategies currently described in the literature in order to improve patient outcome (Figure 3).

REFERENCES

[1] Eriksen C, Frisell J, Wickman M, Lidbrink E, Krawiec K, Sandelin K. Immediate reconstruction with implants in women with invasive breast cancer does not affect oncological safety in a matched cohort study. *Breast Cancer Res Treat.* 2011 Jun;127(2):439-46. PubMed PMID: 21409394. Epub 2011/03/17. eng.

[2] Romics L, Jr., Stallard S, Weiler-Mithoff E. Borkimelo (skin-sparing) mastectomia es azonnali emlorekonstrukcio onkologiai biztonsagossaga a recidivaarany, recidivalokalizacio es a rekonstrukcios technika fuggvenyeben. hun. *Orv Hetil*. 2013 Feb 3;154(5):163-71. PubMed PMID: 23395741. Epub 2013/02/12. [Oncologic safety of skin-sparing mastectomy followed by immediate breast reconstruction: rate and localization of recurrences, and impact of reconstruction techniques].

[3] Palit TK, Miltenburg DM, Brunicardi FC. Cost analysis of breast conservation surgery compared with modified radical mastectomy with and without reconstruction. *Am J Surg.* 2000 Jun;179(6):441-5. PubMed PMID: 11004327. Epub 2000/09/27. eng.

[4] Al-Ghazal SK, Fallowfield L, Blamey RW. Comparison of psychological aspects and patient satisfaction following breast conserving surgery, simple mastectomy and breast reconstruction. *European journal of cancer.* 2000 Oct;36(15):1938-43. PubMed PMID: 11000574. Epub 2000/09/23. eng.

[5] Kim JY, Davila AA, Persing S, Connor CM, Jovanovic B, Khan SA, et al. A meta-analysis of human acellular dermis and submuscular tissue expander breast reconstruction. *Plastic and reconstructive surgery.* 2012 Jan;129(1):28-41. PubMed PMID: 22186498. Epub 2011/12/22. eng.

[6] Pannucci CJ, Antony AK, Wilkins EG. The impact of acellular dermal matrix on tissue expander/implant loss in breast reconstruction: an analysis of the TOPS database. *Plast Reconstr Surg.* 2013 Mar 15. PubMed PMID: 23508050. Epub 2013/03/20. Eng.

[7] Dragun AE, Huang B, Gupta S, Crew JB, Tucker TC. One decade later: trends and disparities in the application of post-mastectomy radiotherapy since the release of the American Society of Clinical Oncology clinical practice guidelines. *Int J Radiat Oncol Biol Phys.* 2012 Aug 1;83(5):e591-6. PubMed PMID: 22768990. Epub 2012/07/10. eng.

[8] Johnson RK, Wright CK, Gandhi A, Charny MC, Barr L. Cost minimisation analysis of using acellular dermal matrix (Strattice) for breast reconstruction compared with standard techniques. European journal of surgical oncology: *the journal of the European Society of Surgical Oncology and the British Association of Surgical Oncology*. 2013 Mar;39(3):242-7. PubMed PMID: 23266307. Epub 2012/12/26. eng.

[9] Rawlani V, Buck DW, 2nd, Johnson SA, Heyer KS, Kim JY. Tissue expander breast reconstruction using prehydrated human acellular dermis. *Ann Plast Surg.* 2011 Jun;66(6):593-7. PubMed PMID: 21233698. Epub 2011/01/15. eng.

[10] Apte A, Walsh M, Chandrasekharan S, Chakravorty A. Single-stage immediate breast reconstruction with acellular dermal matrix: Experience gained and lessons learnt from patient reported outcome measures. European journal of surgical oncology: *The journal of the European Society of Surgical Oncology and the British Association of Surgical Oncology.* 2016 Jan;42(1):39-44. PubMed PMID: 26651226.

[11] Ohkuma R, Buretta KJ, Mohan R, Rosson GD, Rad AN. Initial experience with the use of foetal/neonatal bovine acellular dermal collagen matrix (SurgiMend) for tissue-expander breast reconstruction. *Journal of plastic, reconstructive & aesthetic surgery: JPRAS.* 2013 Sep;66(9):1195-201. PubMed PMID: 23768943.

[12] Mofid MM, Meininger MS, Lacey MS. Veritas(R) bovine pericardium for immediate breast reconstruction: a xenograft alternative to acellular dermal matrix products. *European journal of plastic surgery.* 2012 Oct;35(10):717-22. PubMed PMID: 23002328. Pubmed Central PMCID: 3443340.

[13] Vilarino-Varela M, Chin YS, Makris A. Current indications for post-mastectomy radiation. *International seminars in surgical oncology: ISSO.* 2009;6:5. PubMed PMID: 19203387. Pubmed Central PMCID: 2647547.

[14] Ebctcg, McGale P, Taylor C, Correa C, Cutter D, Duane F, et al. Effect of radiotherapy after mastectomy and axillary surgery on 10-year recurrence and 20-year breast cancer mortality: meta-analysis of individual patient data for 8135 women in 22 randomised trials. *Lancet.* 2014 Jun 21;383(9935):2127-35. PubMed PMID: 24656685.

[15] Yao K, Liederbach E, Lutfi W, Wang CH, Hou N, Karrison T, et al. Increased utilization of postmastectomy radiotherapy in the United States from 2003 to 2011 in patients with one to three tumor positive nodes. *Journal of surgical oncology.* 2015 Dec;112(8):809-14. PubMed PMID: 26486998.

[16] Kunkler IH, Canney P, van Tienhoven G, Russell NS, Group MESTM. Elucidating the role of chest wall irradiation in 'intermediate-risk' breast cancer: the MRC/EORTC SUPREMO trial. *Clinical oncology.* 2008 Feb;20(1):31-4. PubMed PMID: 18345543.

[17] Nordenskjold AE, Fohlin H, Albertsson P, Arnesson LG, Chamalidou C, Einbeigi Z, et al. No clear effect of postoperative radiotherapy on survival of breast cancer patients with one to three positive nodes: a population-based study. Annals of oncology: official journal of the European Society for Medical Oncology/*ESMO.* 2015 Jun;26(6):1149-54. PubMed PMID: 25839671.

[18] Recht A, Edge SB, Solin LJ, Robinson DS, Estabrook A, Fine RE, et al. Postmastectomy radiotherapy: clinical practice guidelines of the American Society of Clinical Oncology. *Journal of clinical oncology: Official journal of the American Society of Clinical Oncology.* 2001 Mar 1;19(5):1539-69. PubMed PMID: 11230499.

[19] Taghian AG, Jeong JH, Mamounas EP, Parda DS, Deutsch M, Costantino JP, et al. Low locoregional recurrence rate among node-negative breast cancer patients with tumors 5 cm or larger treated by mastectomy, with or without adjuvant systemic therapy and without radiotherapy: results from five national surgical adjuvant breast and bowel project randomized clinical trials. Journal of clinical oncology: *Official journal of the American Society of Clinical Oncology.* 2006 Aug 20;24(24):3927-32. PubMed PMID: 16921044.

[20] Li Y, Moran MS, Huo Q, Yang Q, Haffty BG. Post-mastectomy radiotherapy for breast cancer patients with t1-t2 and 1-3 positive lymph nodes: a meta-analysis. *PLoS One.* 2013;8(12):e81765. PubMed PMID: 24312582. Pubmed Central PMCID: 3849378.

[21] Truong PT, Olivotto IA, Kader HA, Panades M, Speers CH, Berthelet E. Selecting breast cancer patients with T1-T2 tumors and one to three positive axillary nodes at high postmastectomy locoregional recurrence risk for adjuvant radiotherapy. *Int J Radiat Oncol Biol Phys*. 2005 Apr 1;61(5):1337-47. PubMed PMID: 15817335.

[22] Jwa E, Shin KH, Lim HW, Jung SY, Lee S, Kang HS, et al. Identification of Risk Factors for Locoregional Recurrence in Breast Cancer Patients with Nodal Stage N0 and N1: Who Could Benefit from Post-Mastectomy Radiotherapy? *PLoS One.* 2015;10(12):e0145463. PubMed PMID: 26691445. Pubmed Central PMCID: 4686923.

[23] Truong PT, Woodward WA, Thames HD, Ragaz J, Olivotto IA, Buchholz TA. The ratio of positive to excised nodes identifies high-risk subsets and reduces inter-institutional differences in locoregional recurrence risk estimates in breast cancer patients with 1-3 positive nodes: an analysis of prospective data from British Columbia and the M. D. Anderson Cancer Center. *Int J Radiat Oncol Biol Phys.* 2007 May 1;68(1):59-65. PubMed PMID: 17321065.

[24] Trovo M, Durofil E, Polesel J, Roncadin M, Perin T, Mileto M, et al. Locoregional failure in early-stage breast cancer patients treated with radical mastectomy and adjuvant systemic therapy: which patients benefit from postmastectomy irradiation*? Int J Radiat Oncol Biol Phys.* 2012 Jun 1;83(2):e153-7. PubMed PMID: 22386375.

[25] Contant CM, van Geel AN, van der Holt B, Griep C, Tjong Joe Wai R, Wiggers T. Morbidity of immediate breast reconstruction (IBR) after mastectomy by a subpectorally placed silicone prosthesis: the adverse effect of radiotherapy. European journal of surgical oncology: *The journal of the European Society of Surgical Oncology and the British Association of Surgical Oncology.* 2000 Jun;26(4):344-50. PubMed PMID: 10873353. Epub 2000/06/30. eng.

[26] Christante D, Pommier SJ, Diggs BS, Samuelson BT, Truong A, Marquez C, et al. Using complications associated with postmastectomy radiation and immediate breast reconstruction to improve surgical decision making. *Arch Surg.* 2010 Sep;145(9):873-8. PubMed PMID: 20855758. Epub 2010/09/22. eng.

[27] Reefy S, Patani N, Anderson A, Burgoyne G, Osman H, Mokbel K. Oncological outcome and patient satisfaction with skin-sparing mastectomy and immediate breast reconstruction: a prospective observational study. *BMC cancer.* 2010;10:171. PubMed PMID: 20429922. Pubmed Central PMCID: 2873394. Epub 2010/05/01. eng.

[28] Ho A, Cordeiro P, Disa J, Mehrara B, Wright J, Van Zee KJ, et al. Long-term outcomes in breast cancer patients undergoing immediate 2-stage expander/implant reconstruction and postmastectomy radiation. *Cancer.* 2012 May 1;118(9):2552-9. PubMed PMID: 21918963. Epub 2011/09/16. eng.

[29] Cordeiro PG, Albornoz CR, McCormick B, Hu Q, Van Zee K. The impact of postmastectomy radiotherapy on two-stage implant breast reconstruction: an analysis of long-term surgical outcomes, aesthetic results, and satisfaction over 13 years. *Plastic and reconstructive surgery.* 2014 Oct;134(4):588-95. PubMed PMID: 25357021.

[30] Barry M, Kell MR. Radiotherapy and breast reconstruction: a meta-analysis. *Breast Cancer Res Treat.* 2011 May;127(1):15-22. PubMed PMID: 21336948. Epub 2011/02/22. eng.

[31] Colwell AS, Damjanovic B, Zahedi B, Medford-Davis L, Hertl C, Austen WG, Jr. Retrospective review of 331 consecutive immediate single-stage implant reconstructions with acellular dermal matrix: indications, complications, trends, and costs. *Plastic and reconstructive surgery.* 2011 Dec;128(6):1170-8. PubMed PMID: 22094736. Epub 2011/11/19. eng.

[32] Clemens MW, Kronowitz SJ. Acellular dermal matrix in irradiated tissue expander/implant-based breast reconstruction: evidence-based review. *Plastic and reconstructive surgery.* 2012 Nov;130(5 Suppl 2):27S-34S. PubMed PMID: 23096982. Epub 2012/11/01. eng.

[33] Salzberg CA, Ashikari AY, Koch RM, Chabner-Thompson E. An 8-year experience of direct-to-implant immediate breast reconstruction using human acellular dermal matrix (AlloDerm). *Plastic and reconstructive surgery.* 2011 Feb;127(2):514-24. PubMed PMID: 21285756. Epub 2011/02/03. eng.

[34] Liu AS, Kao HK, Reish RG, Hergrueter CA, May JW, Jr., Guo L. Postoperative complications in prosthesis-based breast reconstruction using acellular dermal matrix. *Plastic and reconstructive surgery.* 2011 May;127(5):1755-62. PubMed PMID: 21228744. Epub 2011/01/14. eng.

[35] Seth AK, Hirsch EM, Fine NA, Kim JY. Utility of acellular dermis-assisted breast reconstruction in the setting of radiation: a comparative analysis. *Plastic and reconstructive surgery.* 2012 Oct;130(4):750-8. PubMed PMID: 23018687. Epub 2012/09/29. eng.

[36] Parks JW, Hammond SE, Walsh WA, Adams RL, Chandler RG, Luce EA. Human acellular dermis versus no acellular dermis in tissue expansion breast reconstruction. *Plastic and reconstructive surgery.* 2012 Oct;130(4):739-46. PubMed PMID: 23018685. Epub 2012/09/29. eng.

[37] Mannu GS, Navi A, Morgan A, Mirza SM, Down SK, Farooq N, et al. Sentinel lymph node biopsy before mastectomy and immediate breast reconstruction may predict post-mastectomy radiotherapy, reduce delayed complications and improve the choice of reconstruction. *International journal of surgery.* 2012;10(5):259-64. PubMed PMID: 22525383.

[38] Alderman AK, Wilkins EG, Kim HM, Lowery JC. Complications in postmastectomy breast reconstruction: two-year results of the Michigan Breast Reconstruction Outcome Study. *Plastic and reconstructive surgery.* 2002 Jun;109(7):2265-74. PubMed PMID: 12045548. Epub 2002/06/05. eng.

[39] Sullivan SR, Fletcher DR, Isom CD, Isik FF. True incidence of all complications following immediate and delayed breast reconstruction. *Plastic and reconstructive surgery.* 2008 Jul;122(1):19-28. PubMed PMID: 18594356. Epub 2008/07/03. eng.

[40] Lee M, Reinertsen E, McClure E, Liu S, Kruper L, Tanna N, et al. Surgeon motivations behind the timing of breast reconstruction in patients requiring postmastectomy radiation therapy. Journal of plastic, reconstructive & aesthetic surgery: *JPRAS*. 2015 Nov;68(11):1536-42. PubMed PMID: 26277336. Pubmed Central PMCID: 4659387.

[41] Duxbury PJ, Gandhi A, Kirwan CC, Jain Y, Harvey JR. Current attitudes to breast reconstruction surgery for women at risk of post-mastectomy radiotherapy: A survey of UK breast surgeons. *Breast.* 2015 Aug;24(4):502-12. PubMed PMID: 26021276.

[42] Kronowitz SJ, Robb GL. Radiation therapy and breast reconstruction: a critical review of the literature. *Plastic and reconstructive surgery.* 2009 Aug;124(2):395-408. PubMed PMID: 19644254. Epub 2009/08/01. eng.

[43] Rozen WM, Ashton MW. Radiotherapy and breast reconstruction: oncology, cosmesis and complications. *Gland surgery*. 2012 Aug;1(2):119-27. PubMed PMID: 25083434. Pubmed Central PMCID: 4115692.

[44] Nava MB, Pennati AE, Lozza L, Spano A, Zambetti M, Catanuto G. Outcome of different timings of radiotherapy in implant-based breast reconstructions. *Plastic and reconstructive surgery*. 2011 Aug;128(2):353-9. PubMed PMID: 21788827. Epub 2011/07/27. eng.

[45] Pompei S, Arelli F, Labardi L, Marcasciano F, Caravelli G, Cesarini C, et al. Breast reconstruction with polyurethane implants: preliminary report. *European journal of plastic surgery.* 2012;35(6):441-7.

[46] Peled AW, Foster RD, Esserman LJ, Park CC, Hwang ES, Fowble B. Increasing the time to expander-implant exchange after postmastectomy radiation therapy reduces expander-implant failure. *Plastic and reconstructive surgery*. 2012 Sep;130(3):503-9. PubMed PMID: 22929235. Epub 2012/08/30. eng.

[47] Kim JY, Mlodinow AS, Khavanin N, Hume KM, Simmons CJ, Weiss MJ, et al. Individualized Risk of Surgical Complications: An Application of the Breast Reconstruction Risk Assessment Score. *Plastic and reconstructive surgery Global open.* 2015 May;3(5):e405. PubMed PMID: 26090295. Pubmed Central PMCID: 4457268.

[48] Goyal A, Wu JM, Chandran VP, Reed MW. Outcome after autologous dermal sling-assisted immediate breast reconstruction. *Br J Surg.* 2011 Sep;98(9):1267-72. PubMed PMID: 21560123. Epub 2011/05/12. eng.

[49] Lynch MP, Chung MT, Rinker BD. A Comparison of Dermal Autograft and Acellular Dermal Matrix in Tissue Expander Breast Reconstruction: Long-term Aesthetic Outcomes and Capsular Contracture. *Ann Plast Surg.* 2015 Jun;74 Suppl 4:S214-7. PubMed PMID: 25389715.

[50] Peled AW, Foster RD, Ligh C, Esserman LJ, Fowble B, Sbitany H. Impact of total skin-sparing mastectomy incision type on reconstructive complications following radiation therapy. *Plastic and reconstructive surgery*. 2014 Aug;134(2):169-75. PubMed PMID: 24732652.

[51] Ribuffo D, Atzeni M, Guerra M, Bucher S, Politi C, Deidda M, et al. Treatment of irradiated expanders: protective lipofilling allows immediate prosthetic breast reconstruction in the setting of postoperative radiotherapy. *Aesthetic plastic surgery*. 2013 Dec; 37(6):1146-52. PubMed PMID: 24114295.

[52] Serra-Renom JM, Munoz-Olmo JL, Serra-Mestre JM. Fat grafting in postmastectomy breast reconstruction with expanders and prostheses in patients who have received radiotherapy: formation of new subcutaneous tissue. *Plastic and reconstructive surgery.* 2010 Jan;125(1):12-8. PubMed PMID: 20048576.

[53] Panettiere P, Marchetti L, Accorsi D. The serial free fat transfer in irradiated prosthetic breast reconstructions. *Aesthetic plastic surgery*. 2009 Sep;33(5):695-700. PubMed PMID: 19484176.

[54] Martin L, O'Donoghue JM, Horgan K, Thrush S, Johnson R, Gandhi A, et al. Acellular dermal matrix (ADM) assisted breast reconstruction procedures: joint guidelines from

the Association of Breast Surgery and the British Association of Plastic, Reconstructive and Aesthetic Surgeons. European journal of surgical oncology: *The journal of the European Society of Surgical Oncology and the British Association of Surgical Oncology*. 2013 May;39(5):425-9. PubMed PMID: 23321393.

[55] Barr SP, Topps AR, Barnes NL, Henderson J, Hignett S, Teasdale RL, et al. Infection prevention in breast implant surgery - A review of the surgical evidence, guidelines and a checklist. European journal of surgical oncology: *the journal of the European Society of Surgical Oncology and the British Association of Surgical Oncology.* 2016 May;42(5):591-603. PubMed PMID: 27005885.

[56] Chapman CH, Jagsi R. Postmastectomy Radiotherapy After Neoadjuvant Chemotherapy: A Review of the Evidence. *Oncology (Williston Park). 2*015 Sep;29(9):657-66. PubMed PMID: 26384802.

[57] Hvilsom GB, Friis S, Frederiksen K, Steding-Jessen M, Henriksen TF, Lipworth L, et al. The clinical course of immediate breast implant reconstruction after breast cancer. *Acta Oncol.* 2011 Oct;50(7):1045-52. PubMed PMID: 21604960. Epub 2011/05/25. eng.

[58] Clough KB, O'Donoghue JM, Fitoussi AD, Nos C, Falcou MC. Prospective evaluation of late cosmetic results following breast reconstruction: I. Implant reconstruction. *Plastic and reconstructive surgery.* 2001 Jun;107(7):1702-9. PubMed PMID: 11391188.

[59] Ibrahim AM, Koolen PG, Ganor O, Markarian MK, Tobias AM, Lee BT, et al. Does acellular dermal matrix really improve aesthetic outcome in tissue expander/implant-based breast reconstruction? *Aesthetic plastic surgery.* 2015 Jun;39(3):359-68. PubMed PMID: 25894022.

BIOGRAPHICAL SKETCHES

Baek Kim

Affiliation: Department of Oncoplastic Breast Surgery, St. James's University Hospital, Leeds

Education: University of Cambridge

Business Address: Department of Oncoplastic Breast Surgery, St. James's University Hospital, Beckett Street, Leeds, LS9 7TF, United Kingdom

Research and Professional Experience:

- MD, Doctor of Medicine, University of Leeds. I was awarded an MD for my research thesis titled 'Xenobiotic transporter expression in breast cancer patients treated with neoadjuvant systemic therapy: implications for therapy'
- FRCS in General Surgery, The Royal College of Surgeons of England.

Professional Appointments: Specialist Registrar in General Surgery, Yorkshire deanery

Honors: FRCS MD MA

Publications Last 3 Years:

'Notch inhibition stops chemotherapy-induced activity of Multi-drug Resistance associated Protein-1 in breast cancer'. B Kim, SL Stephen, SM Bell, AM Hanby, K Horgan, SL Perry, J Richardson, EA Roundhill, EMA Valleley, ET Verghese, BJ Williams, TA Hughes, JL Thorne. BMC cancer. 2015 Sep 11; 15.

Comment on 'Causes of false-negative sentinel node biopsy in patients with breast cancer (British Journal of Surgery 2013; 100(6): 775-783)' B Kim, ET Verghese, K Horgan. British Journal of Surgery 2013 Sep;100(10): 1398-9.

'Cytokeratin-19 based one-step nucleic acid amplification (OSNA) should not replace histopathology for sentinel lymph node assessment in breast cancer: a meta-analysis'. JP Tiernan, ET Verghese, A Nair, S Pathak, *B Kim*, J White, H Thygesen, K Horgan, AM Hanby. British Journal of Surgery 2014 Mar; 101(4):298-306.

'Evaluation of the usage and influence of groin ultrasound in primary and secondary healthcare settings'. B Kim, P Robinson, H Modi, H Gupta, K Horgan, R Achuthan. Hernia 2015 Jun; 19(3); 367-71.

'*Variation in the management of ductal carcinoma in situ: Results of the Mammary Fold National Practice Survey'.* L Ashken, C Ives, *B Kim*, S Potter, T Rattay, D Remoundos, B Zeidan and K Williams. European Journal of Surgical Oncology 2016 Jun 1. pii: S0748-7983(16)30175-5.

'Serial MRI scans help in assessing early response to neoadjuvant chemotherapy and tailoring breast cancer treatment'. H Fatayer, N Sharma, D Manuel, *B Kim*, A Keding, T Perren, G Velikova, M Lansdown, A Shaaban, B Dall. European Journal of Surgical Oncology 2016 Apr 20. pii: S0748-7983(16)30033-6.

'Diagnostic accuracy of faecal calprotectin in patients with suspected colorectal cancer'. J Turvill, A Aghashoseini, N Sivarajasingham, K Abbas, K Lasithiotakis, M Choudhry, K Polyzois, D Volanaki, F Langlands, *B Kim*, J Roos, H Andrew, S Mellen, D Turnock, A Jones. British Journal of General Practice 2016 Jun 6. pii: bjgpjul-2016-66-648-turvill-fl-p.

Rajgopal Achuthan

Affiliation: Department of Oncoplastic Breast Surgery, St. James's University Hospital, Leeds

Education: MBBS, University of Delhi, India

Business Address: Department of Oncoplastic Breast Surgery, St. James's University Hospital, Beckett Street, Leeds, LS9 7TF, United Kingdom

Research and Professional Experience:

- PhD, Doctor of Philosophy, University of Leeds.
- FRCS in General Surgery, The Royal College of Surgeons, Glasgow.

Professional Appointments: Consultant Oncoplastic Breast and General Surgeon, St. James's University Hospital, Leeds

Honors: MS (Surgery), FRCS, PhD

Publications Last 3 Years:

'An observational study on the expression levels of MDM2 and MDMX proteins, and associated effects on P53 in a series of human liposarcomas'. N Touqan, CP Diggle, ET Verghese, S Perry, K Horgan, W Merchant, R Anwar, AF Markham, IM Carr IM, R Achuthan. BMC Clin Pathol. 2013 Dec 13;13(1):32.

'The role of magnetic resonance imaging in preoperative planning for patients undergoing therapeutic mammoplasty'. G Hicks, Turton P, S Rajan, A Nunn, N Sharma, Achuthan R. ISRN Oncol. 2013 Dec 17;2013:260260.

'Evaluation of the usage and influence of groin ultrasound in primary and secondary healthcare settings'. B Kim, P Robinson, H Modi, H Gupta, K Horgan, R Achuthan. Hernia 2015 Jun; 19(3); 367-71. BMC Clin Pathol. 2013 Dec 13;13(1):32.

'Management of breast cancer in an Asian man with post-traumatic stress disorder: a case report'. F Patel, R Achuthan, L Hyklova, AM Hanby, V Speirs. J Med Case Rep. 2016 Mar 29;10(1):77.

In: Encyclopedia of Surgery (22 Volume Set)
Editors: Andreas Lehrer and Kristin Mueller
ISBN: 978-1-53618-329-0
© 2020 Nova Science Publishers, Inc.

Chapter 175

PATIENT SATISFACTION FOLLOWING AUTOLOGOUS OR HETEROLOGOUS BREAST RECONSTRUCTION

Laura Sita-Alb*, Laura Duta and Lucian Fodor
Plastic and Reconstructive Surgery Unit, Emergency County Hospital,
Cluj Napoca, Romania

ABSTRACT

The" Health" cannot be anymore defined just from a physiological point of view, a good self-esteem, sexuality and quality of life are essential for a healthy patient. Today medicine is more and more direct towards the patient, giving them more choices, control and information. To be able to accurately measure health care outcomes, patient satisfaction data cannot be disregarded.

Every year more than 60.000 American patients are subjected to a mastectomy, a surgery that is highly mutilating especially for young women, and from this 20-40% will undergo a breast reconstruction. In front of a large variety of solutions the patient should be aware of her opportunities. Whether or not a candidate for an autologous, prosthetic or autologous and prosthetic breast reconstruction the patients should know what to expect.

What is, indeed, the best technique, an autologous or a heterologous reconstruction? And if is an autologous, which one gives the best results: the abdominal flaps (pedicled or perforator) the latissimus dorsi flap, the gluteal flaps or a combination of flaps with prosthetic reconstruction? In the past years a large number of studies assessing patient satisfaction and quality of life were published, comparing different techniques (autologous versus autologous, autologous versus heterologous, heterologous versus heterologous) in their attempt to improve patient health-care.

Lately there is a unanimous finding that shows that patients are mostly satisfied, and have a higher long-term satisfaction following an abdominal autologous breast reconstruction, when compared to any other reconstruction techniques.

Keywords: patient satisfaction, breast reconstruction, autologous breast reconstruction, prosthesis breast reconstruction, DIEP flap, abdominal flaps

* Corresponding Author's Email: laura.sita.alb@gmail.com.

INTRODUCTION

The concept of health, in modern times, cannot just be defined as freedom from pain or physical disease. It involves the overall condition of being sound in body and mind, completed by psychosocial well-being and sexual well-being. A healthy and satisfied patient, as a member of society, sets the grounds for a healthy and happy society. Ergo, modern medicine tends to focus on the patient as an individual, giving the patient a voice with regard to treatment decisions by providing multiple options, the necessary knowledge, information and medical data, including other patients' reported outcomes. In order to accurately measure health care outcomes, patient satisfaction data cannot be disregarded.

Over 296,000 American women were diagnosed with breast cancer in 2013 [1], ranking breast cancer in 1st place in non-skin cancer neoplasms in the American female population [2]. Although early stage diagnosed patients are presented with the choice of conservative treatment, more than 25% undergo mastectomy [3, 4]. This is a mutilating process, harming female femininity, affecting not only the patient's life but their partners and families as well, and is connected to numerous psychosocial disorders [5-10]. Less than 40% of thus traumatized patients will proceed to a breast reconstruction, viewed by many as a way to restore one's self-image, and the final step in breast cancer treatment. Faced with a world of solutions, the patient should be aware of the multiple options available. This is where the doctor's experience and knowledge, along with other patient's experience and reported outcomes, should guide the patient in finding the best solution for herself.

WHAT DO PATIENTS EXPECT ONCE DECIDING PRO RECONSTRUCTION?

The most frequent motive pro reconstruction is a return to normalcy and a feeling of wholeness that a restored breast can generate for its recipients, along with the psychosocial benefits resulting from increased self-esteem and better performance in social circles [11]. For most women, breast reconstruction represents the final step in cancer treatment and healing [11]. That being said, most women do not know what to expect in the aftermath of reconstruction and proceed towards surgery with different expectations than the final outcome. For example, most patients are anxious for nipple reconstruction, unaware of the lack of sensation afterwards, or expect perfect symmetry post-unilateral prosthesis reconstruction [11]. Unfulfilled or unrealistic expectations represent a major source of post-reconstruction dissatisfaction, underlining once more the importance of patient education beforehand. In order to avoid such discomfort, both surgeon and patient should move forward from starting on common ground.

HOW CAN WE QUANTIFY THE IMPACT OF BREAST RECONSTRUCTION ON A PATIENT'S QUALITY OF LIFE?

Moving forward, the quality of a surgeon's work should be validated by the positive impact it has on a patient's life. Due to the great pallet of options, how does the surgeon

decide the best fit for each case? Most times, the emotional cancer patient can be overwhelmed with information and technical aspects of reconstruction possibilities. Relying on the premise that the surgeon knows best, the patient may end up with unsatisfactory results due to making the wrong decision. As a solution, patients' reported outcomes came to the scene, thereby providing data to create a bridge between surgical knowledge and patient expectations.

Table 1. Breast-Q reconstruction module [13]

Quality of Life	Satisfaction with	Expectations for
PSYCHOSOCIAL WELL-BEING • body image • self-esteem • confidence • emotional integrity	BREASTS • breast appearance • clothing • bra fit • rippling (implant related)	STAFF PROVIDED SUPPORT • care • emotional support
SEXUAL WELFARE/BODY IMAGE • sexual confidence • sexual attractiveness (with/without clothes) • lack of self-consciousness during intercourse	NIPPLES (NAC) • shape • color • natural aspect • projection	PAIN • during 1st week post-reconstruction
PHYSICAL WELL-BEING CHEST/UPPER BODY • pain • breast area related distress • activity limitation • discomfort-induced sleep problems ABDOMEN/TRUNK (TRAM/DIEP flaps) • abdominal weakness leading to activity impairment • negative physical consequences BACK/SHOULDER (LD flap) • negative physical consequences • arm and shoulder activity impairment	ABDOMEN • appearance • scars • navel position BACK • scar appearance • scar location OUTCOME • overall assessment • met expectations (esthetic appearance) • impact upon life • decision toward surgery CARE • information • medical staff • surgeon • office staff	RECOVERY • during 1st week post-reconstruction COPING • during 1st year post-reconstruction BREAST APPEARANCE • 1 year post-reconstruction PSYCHOSOCIAL WELL-BEING • 1 year post-reconstruction

Starting in 2012, BREAST-Q (Table 1) has been largely embraced by the medical community as a means to quantify and convey patient reported data regarding breast surgery. It is a computer software program developed by Pusic et al. [12], designed to analyse a women's perspective concerning breast surgery by evaluating and quantifying different parameters associated with satisfaction post-breast surgery. The parameters included in the reconstruction module can be reviewed in Table 1 [13].

Other means for analyzing outcomes have been developed, from a panel of specialists evaluating photographs and measuring a set of established parameters [14], to computer

program aesthetic assessment of reconstructive results (BCCT.core)[15], all in the attempt to make the best decision for each patient.

TIMING OF RECONSTRUCTION: NO RECONSTRUCTION, IMMEDIATE OR DELAYED RECONSTRUCTION

Reasons for Breast Reconstruction Refusal

The vast majority of patients (60-80%) [16] choose not to undergo breast restoration surgery after mastectomy. The most cited reason for reconstruction refusal is to avoid additional surgery, while other common reasons include low level of education, older patients or patients presenting comorbidities, fear of a reconstructed breast shielding cancer recurrence [17, 18], financial aspects, or the need for chemotherapy [19]. Studies trying to establish the reasons why women refuse to undergo a reconstruction procedure found that 62% of the patients cited a lack of information regarding the reconstruction procedure as an important factor in influencing their decision [20].

Immediate vs. Delayed Breast Reconstruction

Whether we perform breast restoration surgery by using alloplastic or autologous material, we can opt for immediate reconstruction (at the same time as the mastectomy) or delayed reconstruction (weeks, years). A consensus is starting to take shape concerning the indications and contraindications for immediate and delayed reconstruction, with minor differences between different centers' protocols.

There is no absolute contraindication for breast reconstruction, but relative contraindications include morbid obesity (BMI≥40 kg/m^2), and current smoking status. Senior citizens can benefit from breast reconstruction without any particular age-related contraindication [21].

Immediate reconstruction is the preferred choice for most patients, as it generates better aesthetic results, hence higher satisfaction rates [22]. The requirement for postoperative radiation therapy can be regarded as a relative contraindication concerning immediate breast reconstruction; in cases of T3 and T4 tumours, positive axillar lymph nodes and inflammatory breast cancer, it is recommended to delay the reconstruction procedures [21].

Delayed reconstruction is generally associated with lower satisfaction rates compared to immediate reconstruction, but long-term results reveal no differences related to the satisfaction levels reported by the two groups [23].

The majority of breast reconstructions worldwide uses *alloplastic material*. Although immediate reconstructions are preferred and studies reported higher satisfaction with immediate reconstruction than delayed ones [24], there are studies that highlight the incidence of higher complication rates associated with immediate implant-based procedures [25], but no difference in reconstruction failure rates related to the timing of the reconstruction [26].

When radiation therapy is required, opting for a prosthesis-based reconstruction is not advised, because of the multiple complications risks.

For autologous flap reconstructions, immediate reconstruction is associated with the advantage of fewer surgeries and better aesthetic results [27]. In delayed reconstructions, the skin is contracted, with thin and scarred skin flaps. Some studies found higher rates of complications in the delayed group, such as the risk of thrombosis [28], while others did not find statistical discrepancies concerning minor versus major complications related to the timing of autologous (free TRAM) breast restoration [29].

The immediate flap-based breast reconstruction might affect radiation delivery and alter the aesthetic results as well [30]; therefore, the patient should be aware of the possible risks. Recent studies reveal no statistically significant discrepancies when speaking of local recurrences, metastases or patient survival, whether a TRAM flap reconstruction or no reconstruction is done [31].

In an attempt to establish the best moment to proceed to a delayed reconstruction following post-mastectomy radiotherapy, when comparing results and complications, it was found that a 12-month delay after radiotherapy gave less complications, less vascular thrombosis and better results when using a free abdominal flap [32].

Studies reveal that women choosing to undergo a breast reconstruction procedure have a different socioeconomic status than those who refuse breast reconstruction, are wealthier [33], more educated, with greater access to medical services.

A study of more than 54,000 breast reconstructions found that immediate reconstruction enhances breast cancer specific survival [34]. A possible explanation lies in the fact that this type of reconstruction was chosen by younger women, diagnosed at an early stage, without lymph node involvement, and lower chances of receiving radiation therapy.

ALLOPLASTIC BREAST RECONSTRUCTIONS

The great majority of breast reconstruction (BR) worldwide is done with prostheses; over 76,000 implant-based BR (representing 79% of all BR procedures) were reported in 2011 in the United States [35]. Even though recent studies reveal a higher satisfaction rate with autologous reconstructions, up to 70-80% of BR are implant-based [36], although a decreasing pattern is observed mostly in specialized centers.

The explanation for this percentage is mostly due to the fact that free flap autologous reconstructions are done only in specialized centers that cannot support the great amount of reconstructions, and different BR options must be generally approachable. Other possible explanations might be shortened surgery time and hospital admission duration, cultural acceptance regarding implants, better reimbursement from insurance companies [37], and fewer contraindications from an oncological point of view [38].

Indications: Implant-based reconstructions are favorable in small breasted women with no or minimum breast ptosis [39] and good skin quality. They are also indicated for bilateral reconstructions [40] and patients diagnosed in early stages, preferably sentinel node-free [41].

Breast reconstruction using a prosthesis can be chosen while doing the mastectomy surgery (immediate), either by placing a tissue expander concomitant with the mastectomy to maintain the skin envelope coverage, followed by a permanent prosthesis (delayed) [42].

FACTORS THAT INFLUENCE OUTCOME AND SATISFACTION IN ALLOPLASTIC BREAST RECONSTRUCTIONS (TABLES 2, 3)

Timing of Reconstruction

Regaining consciousness in the early post-surgery aftermath and acknowledging an amputated breast is associated with great physiological distress, this being the reason why immediate restoration of the breast has the benefit of preventing the process [43], by recreating the volume of the breast and also the shape, to the patient's greater satisfaction [44, 45]. There are some limitations, however, such as the need for surgical revision in the years to come [46, 47]. As previously discussed, the timing of the surgery influences the satisfaction. Immediate BR is preferred when possible, as the inframammary fold is preserved, no skin contraction occurs and minimal scars are generated.

On the other hand, patients requiring radiation therapy [48] or possessing large breasts with advanced ptosis might benefit more from a two-stage reconstruction [49] or delayed reconstruction, as the expander will be placed right after or some time after mastectomy, in order to maintain the natural breast envelope proceeded by definitive implant.

Radiotherapy

It is documented that radiotherapy, regardless of the timing of administration, favors complications and implant failure risk [50], as well as lower satisfaction levels regarding surgical results, and a significant impact on the patient's physical, psychosocial and sexual wellbeing [51]. The highest dissatisfaction rates were associated with radiation therapy on immediately implant reconstructed breasts compared to delayed, as the radiation leads to capsular contraction [52]. Long-term felt pain post-radiation and capsular contraction [53] accompanied by the imperative secondary surgical procedures [54, 55] concluded in breast restoration failure [56, 57].

Breast implants nowadays can be chosen based on their content (saline or silicone**)**, form (round or anatomic) and outer shell (textured or non-textured) [38]. With regard to form (round or anatomic), no unanimous opinion has been reached, while pros and cons and complication data have been found to be similar [58].

Although implant-based breast restoration is paired with great satisfaction [59], when considering content, studies indicate that silicone implants are preferred to saline ones by a vast majority of patients [60, 61], due to the more natural feel they generate as they are softer than saline implants.

In response to implant coating, textured shells were adopted as a solution for capsular contraction [62, 63]. Despite some controversy over the years [64, 65], textured implants have also proven their efficiency in keeping the implant in place [66], as well as not having a ripple aspect as seen often after long-term deflation of saline-filled implants [59].

Smoking is a well-known factor to increase surgical complications, more precisely in prosthetic BR. Smoking increases the risks of complications by 2-3 times compared to non-smoking patients, reaching a complication rate of 37.9%. Ex-smokers (up to 1 year after) also have higher complication rates [67].

Other factors, such as *obesity*, have been proven to increase the risk of complications at approximate twice for a BMI>30, compared to normal weighted women. Women with a BMI>25 prefer to undergo an autologous abdominal flap BR. Also *elderly patients*, those over 65 years of age, are prone to develop perioperative complications [26].

Breast restoration using a prosthesis is preferred by women under 40 years of age, compared to women between 40 and 60 years of age who prefer abdominally-based flap reconstructions [2, 68].

Concerning patient-related factors that might influence outcome and satisfaction, it was found that *diabetes* is not an independent complication predictive factor or implant reconstruction failure [50].

Immediately reconstructed breasts using prosthesis only and those combining implants and ADMs (Acellular Dermal Matrix) were equally appreciated by their recipients, with insignificant discrepancies regarding the final result between the two [69]. The combined method of reconstructed breasts lacked the natural sensation when compared to implant-based restoration, but the recipient's overall satisfaction was equal [69].

Limitations

It is known that breast implants should not be retained for a lifetime, that revision surgery and implant change might be needed. The decreased satisfaction with implant BR when compared to autologous abdominal reconstruction could be related to the complications and the possibility of secondary surgery that accompanies this procedure. Mild to severe capsular contracture is reported in numerous studies, with percentage varying between 2% to 83% [70], with increased chances in the irradiated groups [71]; reoperations for implant removal or replacement was found in 30% of cases, with a total reoperation rate of about 45-50% [72].

To conclude, patients with irradiated breasts, with multiple scars, with skin deficit, with poor soft tissue or with severe breast deformities should not undergo an implant-based BR alone. The procedures more suitable in these situations are either an autologous BR or a combination of an autologous flap, such as latissimus dorsi flap, that brings enough soft tissue to cover an implant.

AUTOLOGOUS BREAST RECONSTRUCTION

Restoring the breast from the patient's own tissues using flaps rather than alloplastic material has proven to be the generator of most satisfying results [73, 74], to such an extent that studies trying to objectively quantify the self-recognition (using functional MRI to assess brain activity) of one's DIEP flap reconstructed breast concluded few discrepancies in evaluating the natural and the restored breast [75].

In choosing a flap, the possibilities are numerous. Flaps for breast restoration can be pedicled or free, myocutaneous or cutaneous. Donor sites are also numerous, with the abdomen as the most frequently used.

FACTORS THAT INFLUENCE OUTCOME AND SATISFACTION IN AUTOLOGOUS BREAST RECONSTRUCTIONS (TABLE 2)

Table 2. Patient-related factors influencing breast reconstruction outcome, satisfaction and complications

	Alloplastic	Autologous
Radiation	• Capsular contracture • Infection • Wound-related complications • Lower satisfaction overall	• Poor cosmesis • Fat necrosis
Chemotherapy	• No influence (if waiting 6-8 weeks before reconstruction)	• No influence (no waiting needed)
Smoking	• Skin necrosis • Infection • Reconstructive failure	• Negative influence • Flap necrosis • Fat necrosis • Abdominal hernia
Obesity	• Reconstructive failure	• Flap complications • Donor site complications
Age	• No influence	• No influence
Medical Commorbidities	• Hypertension: pre-op complications; premature prosthesis removal • Diabetes Mellitus: no independent influence	• Hypertension: surgical complications; donor, receptor site complications • Diabetes Mellitus: infection; vascular disease; surgical and post-op complications
Prior Surgery	• Breast conserving treatment: capsular contracture; inferior esthetic outcome • Multiple scars on irradiated tissue: inferior outcome	• Abdominal scars: minor complications

Table 3. Surgical factors influencing alloplastic breast reconstruction outcomes and complications

	Alloplastic
Implant Properties	• SHAPE: No influence • CONTENT: silicone greater satisfaction over saline
Reconstruction Timing	• Greater satisfaction with immediate reconstruction
Single Stage Breast Reconstruction	• Direct-to-implant: lower aesthetic results
Use of ADMs, Autologous, Fat Grafts	• + ADMs: risk of seroma, reconstructive failure, infection • + AUTOLOGOUS: lower risk of implant related complications • + FAT GRAFTS: improve overall aspect of reconstructed breast; greater satisfaction with outcome; risk of fat necrosis, oil cysts, infection

Timing of Reconstruction

Autologous reconstructions, as the implant-based ones, can be immediate or delayed. Immediate BR, when possible, is preferred in autologous reconstructions also; it results in fewer interventions, good aesthetic results [27], better skin quality, and lower rates of free flap thrombosis [28]. Recent studies show that immediate reconstruction with TRAM flap does not change the rates of local recurrences, metastasis or patient survival when compared to no reconstruction. Furthermore, immediate TRAM flap BR does not interfere with long-term results, even when radiation therapy is necessary after mastectomy [31]. Still, patients are persuaded to first finish their radiotherapy and then proceed to BR, as this associates with better long-term results [76]. For optimum results, the appropriate delay should be at least 12 months.

Radiation Therapy

Even though numerous studies show that the immediate use of flaps does not interfere with cancer spread, recurrence or overall survival, the aesthetic results are altered when radiotherapy is involved.

When trying to compare different autologous flaps that received radiotherapy, no great differences were observed. A study that compared breast restoration using free DIEP flap to pedicled TRAM flap found similar fat necrosis rates in the two groups.

Smoking also interferes with autologous reconstructions results. Using a latissimus dorsi or TRAM pedicled flap in a smoking patient seems to have fewer complications [22]. Smoking was found to increase the incidence of necrosis rates in fat tissue and flaps. The predisposition to wound infection when using free TRAM flaps was also increased [77]. In pedicled TRAM flaps, smoking was found to increase the wound healing period, infections and flap complications. At least 1 month of smoking abstinence is necessary to increase the chances of free flap survival [78].

Other factors, such as *diabetes*, stir continuous debate. Diabetes is cited among the majority of contraindications for free flaps and even pedicle abdominal flaps. Studies that specifically compared results of free flap outcomes in BR did not find any differences in complications and outcomes for type I diabetes, type II diabetes or diabetes-free patients in 896 free TRAM flaps [79]. Another study of 1533 free flaps did not find diabetes to be an independent complication generator in breast reconstruction, but they found that diabetes is a risk factor in extremities free flaps reconstructions [80].

Obesity has also proven to generate up to 2 times more flap complications [81]. However, despite this complication rate, autologous BR is more suited to obese patients, as women with a BMI>25 are more likely to receive abdominally-based flaps [2], and satisfaction rates after this type of BR are similar to normal BMI patients [82]. In prosthesis-based BR in obese patients, decreased esthetic satisfaction was found, but there were no differences in satisfaction when autologous TRAM flaps were used for BR [83].

Choosing the Right Autologous Flap (Table 4)

Latissimus Dorsi (LD) Flap

The first flap described in the literature, more than 100 years ago, for breast reconstruction is the LD flap [84]. Its utility has been recognized, not only as autologous reconstruction, but also in covering implants in autologous and alloplastic reconstruction combined. If harvested with a skin paddle, it has the ability to compensate for skin loss [84-86] but, when used on its own, it offers a small restorative volume as it suffers atrophy, thus the recipient is preferred to be thin or small breasted [87, 88]. LD flap can be used to provide coverage for a prosthesis instead of pectoralis or serratus muscle with superior esthetic outcomes [89]. The introduction of ADMs on a large scale and perfected microvascular techniques facilitating free tissue transfer, accompanied by complications such as pain and seroma at the harvest site [90-94], shoulder girdle impaired mobility [95-97], together with torso contour alteration [88], lead LD flaps in breast surgery to fall from grace.

Long-term surveillance data state the requirement for secondary surgery in 10 years after breast reconstruction using combined LD flap and implant, in more than 50% of patients [98], restricting the use of LD flaps to limited cases. Statistically, over the past years, the use of LD flaps has been decreasing in favor of free flaps or allografts [89, 99]. When compared to acellular dermal matrix for implant cover, complication profiles have been similar, even though LD enjoyed better cosmetic results [100]. When compared to an abdominal flap, patients undergoing LD reconstructions were less satisfied than women receiving TRAM or DIEP flaps [101].

In terms of patient appreciation, long-term surveillance of LD flap use in breast reconstruction suggests great satisfaction from its recipients, data quantified using not only patient reports (BREAST-Q) but medical staff evaluation and computer analysis programs (BCCT.core) as well [87, 102].

All in all, even if cast to the background in favor of other techniques [89], the LD flap is cited among the "workhorse" flaps for breast restoration, with innovative use and perfecting harvest techniques [103] in addition to the ones we know.

Table 4. Surgical factors influencing autologous breast reconstruction outcomes and complications

	Autologous
Flaps	• Flap options: pTRAM, fTRAM, DIEP, SIEA, TUG, SGAP, IGAP, FCI, PAP, LD • No significant difference in complication incidence in free flaps vs pedicled • pTRAM vs free flaps: fat tissue necrosis; flap loss (total to partial) in obese patients • DIEP vs fTRAM: donor site morbidity, abdominal hernia, partial flap loss • SIEA vs fTRAM and DIEP: small pedicle diameter and length, small flap, risk of fat necrosis and thrombosis • Gluteal and thigh flaps: good option for slender, small breasted patients • High satisfaction with overall outcome and long term results
Reconstruction Timing	• Greater satisfaction and better aesthetic outcome in immediate reconstruction
Fat Grafts	• Better symmetry and cosmetic outcome

Abdominal Flaps

When choosing to undergo an autologous restoration of the breast, the most common site used in harvesting a flap is the lower abdomen [104]. Rather than implant reconstructed breasts, the autologous tissue offers the possibility of acquiring a more natural appearance and consistency for the restored breast [105]. At the same time, the patient's satisfaction increases when excess abdominal tissue is transferred in the process of autologous reconstruction [106]. Even though postoperative recovery is more demanding, secondary surgery is rarely necessary [2], so the appeal of this kind of reconstruction is explainable to active women of society.

The abdomen offers three major flap possibilities: the TRAM (transverse rectus abdominis musculocutaneous), the DIEP (deep inferior epigastric artery perforator) and the SIEA (superficial inferior epigastric artery).

The TRAM flap was the first to be introduced for breast reconstruction [107] 37 years ago. In time, the TRAM flap has suffered numerous alterations regarding its composition and tailoring as to limit donor-site suffering.

In 1992, *the DIEP flap* era began in breast reconstruction [108]. Over the years, operative technique refinement and perfecting has led to establishing the DIEP flap as the most elected breast restoration method using autologous tissue [104, 109]. Adding to its appeal is the possibility of solving chronic lymphedema in some cases by incorporating lymph nodes from the inguinal region in the tissue transfer process [110].

However, both TRAM and DIEP flap dissection damage the abdominal wall (TRAM by including muscle and DIEP by injuring the rectus abdominis muscle fascia), thus allowing the possibility of herniation, although post-DIEP herniation occurred in considerably fewer cases than post-TRAM herniation [111-113]. As a solution to the problem, the SIEA flap comes to mind, since it does not involve tampering with the abdominal wall muscular structure, by its adipocutaneous nature [88, 104]. Its limitation, however, lies in inconstant superficial epigastric artery presence and the reduced dimension, often insufficient for reconstructing a breast [109, 112, 114].

When considering patient satisfaction and quality of life, recent studies trying to quantify these parameters using BREAST-Q modules found greater appreciation of autologous abdominal flap breast reconstruction as opposed to prosthesis [115], also when compared to LD autologous reconstruction [101].

At the same time, when comparing pedicle TRAM flaps to free abdominal flaps, patients reported greater appreciation for the pedicle flap in the immediately postoperative period, with equivalent scores of satisfaction as time went by [116]. The offered explanation consists of operation timing, as pedicled flaps were chosen to restore breasts after skin preserving mastectomy followed by immediate reconstruction, whereas patients requiring adjuvant tumor-related treatment benefited from delayed reconstruction resulting in physiological distress that ended after breast reconstruction [116]. Another study comparing the outcomes of pedicle TRAM flaps to free abdominal flaps found that pedicle TRAM was associated with more flap necrosis than free abdominal flaps [117]. Comparison of donor site morbidity between pedicle TRAM and DIEP showed that TRAM patients needed abdominal closure with mesh in 44.2% of cases. Also, the hernia or bulge after pedicle TRAM flap was 21.2% as opposed to 3.1% for the DIEP patients [118].

Quality-of-life 5 years post-autologous breast restoration using the DIEP flap was found to be high among its recipients, even similar to that of the general population [119].

Gluteal and Thigh Flaps

Not all patients are candidates for abdominal flap breast reconstruction, as slender patients with no excess tissue on their lower abdomen are unsuitable for DIEP or TRAM flap breast reconstruction. To fulfill their wish for autologous reconstruction, the gluteal area and the inner thigh have proven to be more than suitable. Depending on the needed breast volume, a superior or inferior gluteal artery perforator (sGAP/iGAP) flap is suitable for slightly larger breasts whereas a transverse upper gracilis myocutaneous (TUG) flap is suitable for medium to small sized breasts [109, 120].

Introduced to the breast reconstruction field approximately 10 years apart, sGAP (1993 [121]) and iGAP (2004 [122]) offer the advantage of better projection to the reconstructed breast when compared to their abdominal alternatives [123]. The vascular pedicle provided by the iGAP is longer than the sGAP one, but can lead to asymmetric gluteal projection and infragluteal crease. Also, skin tone may differ, making them better suited for skin-sparing mastectomy reconstructions [123]. In order to preserve gluteal area symmetry, a double iGAP unilateral breast reconstruction has been described [123]. Concerning disadvantages, slight discomfort in the sitting position has been brought to attention in iGAP reconstruction cases [109].

Another reliable option regarding breast reconstruction when considering younger patients, presenting firmer breasts and less ptosis, is the fasciocutaneous infragluteal (FCI) free flap, which has been shown to offer adequate volume even in slender patients [124].

The TUG flap, used in breast reconstruction since 2004 [125-127], offers a good option for small to medium breasted patients, but requires a minute and laborious dissection to isolate the vascular pedicle, as attention must be paid to the saphenous vein and inguinal lymph nodes in an attempt to avoid lymphorrhea [128] and to the the posterior cutaneous nerve of the thigh to preserve thigh skin physiological sensation. In response to this predicament, the profunda femoris artery perforator flap was described recently [129], its pedicle trajectory allowing the avoidance of lymphatic structures; it also offers a longer pedicle than the TUG flap, with similar characteristics [129].

As microsurgical skills are more and more refined among surgeons, various combinations of free flaps can be used for remarkable cosmetic outcomes, even in bilateral breast reconstruction, offering the surgeon the possibility of molding the flaps to create the desired and suitable shape for every patient opting for autologous breast restoration, regardless of the BMI.

CONCLUSION

- Breast reconstruction represents an immensely important step towards physical and mental healing in the aftermath of breast cancer.

- Providing patient tailored information, presenting the patient with a wide pallet of options and leading her towards the best personal fit, assisted by patient reported reception of reconstruction, can lead to increased level of satisfaction with the results [130].
- Educating the patient in knowing what to expect in the immediate post-reconstruction period and leading the patient to realistic expectations sets the ground for a satisfying outcome.
- Immediate reconstruction when opposed to delayed reconstruction generates greater levels of satisfaction, but long-term results suggests no difference between the two groups.
- Skin and nipple preserving mastectomies followed by immediate reconstruction are favored.
- In case of alloplastic materials, direct-to-implant reconstruction, covering the implant with ADMs/synthetic meshes, and respecting the integrity of pectoralis and serratus muscles enjoys better reception.
- When comparing the combination of ADMs with implants versus latissimus dorsi flaps with implant, patients reported better aesthetics with the second option.
- Autologous reconstruction is reported to enjoy better long-term satisfaction as no secondary surgery is required in the majority of cases.
- The lower abdomen is the go-to donor site and the DIEP flap the go-to flap for long-term satisfaction.
- In obese patients, implant-based reconstruction was met with lower levels of satisfaction regarding cosmetic outcome in comparison to autologous reconstruction.
- Delayed autologous reconstruction is associated with better outcomes in patients requesting radiotherapy.
- Complications throughout the breast reconstruction process leads to lower overall satisfaction outcomes, especially if associated with requiring secondary intervention.
- Long-term surveillance (more than 5 years) revealed that QOL in patients with DIEP flap reconstructed breasts is similar to general population QOL.

All this being said, there are cases when the esthetic outcome pleases the patient more than the surgeon [131], suggesting the utmost importance of breast restoration treatment for cancer patients, as the esthetic aspect of the matter is not the most appraised one [69].

REFERENCES

[1] American Cancer Society, *Breast Cancer Facts and Figures* 2013-2014, 2014, http://www.cancer.org/acs/groups/content/@research/documents/ document/acspc-042725.pdf.

[2] Ballard, TN; Kim, Y; Cohen, WA; Hamill, JB; Momoh, AO; Pusic, AL; Kim, HM; Wilkins, EG. Sociodemographic predictors of breast reconstruction procedure choice: Analysis of the Mastectomy Reconstruction Outcomes Consortium Study Cohort. *Plastic Surgery International* 2015;2015:150856. doi: 10.1155/2015/150856.

[3] Hartmann, LC; Schaid, DJ; Woods, JE; Crotty, TP; Myers, JL; Arnold, PG; Petty, PM; Sellers, TA; Johnson, JL; McDonnell, SK; Frost, MH; Jenkins, RB. Efficacy of bilateral prophylactic mastectomy in women with a family history of breast cancer. *New England Journal of Medicine* 1999;340(2):77-84.

[4] Deppen, SA; Aldrich, MC; Hartgeetal, DP. Cancer screening: the journey from epidemiology to policy. *Annals of Epidemiology* 2012;22(6):439–445.

[5] Foibar, P; Steward, SL; Chang, S; D'Onofrio, C; Banks, PJ; Bloom, JR. Body image and sexual problems in young women with breast cancer. *Psycho-Oncology* 2006;15(7):579–594.

[6] Rennekerand, R; Cutler, M. Psychological problems of adjustment to cancer of the breast. *Journal of the American Medical Association* 1952;148(10):833–838.

[7] Frost, MH; Schaid, DJ; Sellers, TA; Slezak, JM; Arnold, PG; Woods, JE; Petty, PM; Johnson, JL; Sitta, DL; McDonnell, SK; Rummans, TA; Jenkins, RB; Sloan, JA; Hartmann, LC. Long-term satisfaction and psychological and social function following bilateral prophylactic mastectomy. *Journal of the American Medical Association* 2000;284(3):319–324.

[8] Asken, MJ. PsychoemotionaL aspects of mastectomy: a review of recent literature. *American Journal of Psychiatry* 1975;132(1):56–59.

[9] Roberts, MM; Furnival, IG; Forrest, AP. The morbidity of mastectomy. *British Journal of Surgery* 1972;59(4):301–302.

[10] Maguire, P. The psychological and social sequelae of mastectomy. In: *Modern Perspectives in the Psychiatric Aspects of Surgery*, J. G. Howells, Ed., pp. 390–421, Brunner/Mazel, New York,NY,USA,1976.

[11] Pusic, AL; Klassen, AF; Snell, L; Cano, SJ; McCarthy, C; Scott, A; Cemal, Y; Rubin, LR; Cordeiro, PG. Measuring and managing patient expectations for breast reconstruction: impact on quality of life and patient satisfaction. *Expert Review of Pharmacoeconomics & Outcomes Research* 2012;12(2):149-58. doi: 10.1586/erp.11.105.

[12] Pusic, AL; Klassen, AF; Scott, AM; Klok, JA; Cordeiro, PG; Cano, SJ. Development of a new patient-reported outcome measure for breast surgery: the BREAST-Q. *Plastic and Reconstructive Surgery* 2009;124(2):345-353.

[13] Breast Q, *Users Manual*. Version 1.0, 2012.

[14] Mori, H; Umeda, T; Osanai, T; Hata, Y. Esthetic evaluation of immediate breast reconstruction after nipple sparing or skin-sparing mastectomy. *Breast Cancer* 2005;12:299-303.

[15] Preuss, J; Lester, L; Saunders, C. BCCT.core - can a computer program be used for the assessment of aesthetic outcome after breast reconstructive surgery? *The Breast* 2012;21(4):597-600. doi: 10.1016/j.breast.2012.05.012.

[16] American Cancer Society. *Breast Cancer Facts & Figures 2013-2014*. Atlanta: American Cancer Society, Inc. 2013.

[17] Alderman, AK; Jagsi, R. Discussion: Immediate post-mastectomy breast reconstruction followed by radiotherapy: risk factors for complications. *Breast Cancer Research and Treatment* 2010;121:635–637.

[18] Shameem, H; Yip, CH; Fong, E. Immediate breast reconstruction after mastectomy--why do women choose this option? *Asian Pacific Journal of Cancer Prevention* 2008;9:409–412.

[19] Morrow, M; Li, Y; Alderman, AK; Jagsi, R; Hamilton, AS; Graff, JJ; Hawley, ST; Katz, SJ Access to breast reconstruction and patient perspectives on decision making. *JAMA Surgery* 2014;149(10):1015-1021. doi: 10.1001/jamasurg.2014.548.

[20] Héquet, D; Zarca, K; Dolbeault, D; Couturaud, B; Ngô, C; Fourchotte, V; De La Rochefordière, A; Féron, JG; Fitoussi, A; Bélichard, C; Reyal, F; Laki, F; Hajage, D; Sigal, B; Asselain, B; Alran, S; Institut Curie Breast Cancer Group, Roman Rouzier. *Reasons of not having breast reconstruction: a historical cohort of 1937 breast cancer patients undergoing mastectomy*. Springerplus 2013;2:325. doi: 10.1186/2193-1801-2-325.

[21] Zhong, T; Spithoff, K; Kellett, S; Boyd, K; Brackstone, M; Hanrahan, R; et al. Breast cancer reconstruction surgery (immediate and delayed) across Ontario: Patient indications and appropriate surgical options. *Breast Reconstruction Expert Panel*, January 5, 2016.

[22] Eric, E; Mihic, N; Krivokuca, D. Breast reconstruction following mastectomy; patient's satisfaction. *Acta Chirugica Belgica* 2009;109:159-166.

[23] Zhong, T; McCarthy, C; Min, S; Zhang, J; Beber, B; Pusic, AL; Hofer SO. Patient satisfaction and health-related quality of life after autologous tissue breast reconstruction: a prospective analysis of early postoperative outcomes. *Cancer* 2012;118(6):1701-1709. doi: 10.1002/cncr.26417.

[24] Fernández-Delgado, J; López-Pedraza, MJ; Blasco, JA; Andradas-Aragones, E; Sánchez-Méndez, JI; Sordo-Miralles, G. Satisfaction with and psychological impact of immediate and deferred breast reconstruction. *Annals of Oncology* 2008;19(8):1430-1434. doi: 10.1093/annonc/mdn153.

[25] Alderman, AK; Wilkins, EG; Kim, HM; Lowery, JC. Complications in postmastectomy breast reconstruction: two-year results of the Michigan Breast Reconstruction Outcome Study. *Plastic and Reconstructive Surgery* 2002;109:2265-2274.

[26] McCarthy, CM; Mehrara, BJ; Riedel, E; Davidge, K; Hinson, A; Disa, JJ; Cordeiro, PG; Pusic, AL. Predicting complications following expander/implant breast reconstruction: an outcomes analysis based on preoperative clinical risk. *Plastic and Reconstructive Surgery* 2008;121:1886-1892. doi: 10.1097/PRS.0b013e31817151c4.

[27] Chevray, PM. Timing of breast reconstruction: immediate versus delayed. *Cancer Journal* 2008;14:223-229.

[28] Masoomi, H; Clark, EG; Paydar, KZ; Evans, GR; Nguyen, A; Kobayashi, MR; Wirth, GA. Predictive risk factors of free flap thrombosis in breast reconstruction surgery. *Microsurgery* 2014;34:589-594. doi: 10.1002/micr.22250.

[29] DeBono, R; Thompson, A; Stevenson, JH. Immediate versus delayed free TRAM breast reconstruction: an analysis of perioperative factors and complications. *British Journal of Plastic Surgery* 2002;55:111-116.

[30] Kronowitz, JS; Robb, LG. Breast reconstruction with post-mstectomy radiation therapy: current issues. *Plastic and Reconstructive Surgery* 2004;114:950-960.

[31] Lee, HH; Hou, MF; Wei, SY; Lin, SD; Luo, KH; Huang, MY; Ou-Yang, F; Huang, CJ. Comparison of long-term outcomes of postmastectomy radiotherapy between breast cancer patients with and without immediate flap reconstruction. *PLoS One* 2016;11(2):e0148318. doi: 10.1371/journal.pone.0148318.

[32] Baumann, DP; Crosby, MA; Selber, JC; Garvey, PB; Sacks, JM; Adelman, DM. Optimal timing of delayed free lower abdominal flap breast reconstruction after postmastectomy radiation therapy. *Plastic and Reconstructive Surgery* 2011;127(3): 1100-1106. doi: 10.1097/ PRS.0b013e3182043652.

[33] Morrow, M; Scott, SK; Menck, HR; Mustoe, TA; Winchester, DP. Factors influencing the use of breast reconstruction postmastectomy: A National Cancer Database Study. *Journal of the American College of Surgeons* 2001;192(1):1-8.

[34] Bezuhly, M; Temple, C. Sigurdson, LI; Davis, RB; Flowerdew, G; Cook, EF. Immediate postmastectomy reconstruction is associated with improved breast cancer-specific survival: evidence and new challenges from the Surveillance, Epidemiology, and End Results database. *Cancer* 2009;115(20):4648–4654. doi: 10.1002/cncr.24511,

[35] http://www.plasticsurgery.org/Documents/newsresources/statistics/2011statistics/20011_Stats_Full_Reportpdf.

[36] Gurunluoglu, R; Gurunluoglu, A; Williams, SA; Tebockhorst, S. Current trends in breast reconstruction: survey of American Society of Plastic Surgeons 2010. *Annals of Plastic Surgery* 2013;70:103–110. doi: 10.1097/SAP.0b013e31822ed5ce.

[37] Albornoz, CR; Bach, PB; Mehrara, BJ; Disa, JJ; Pusic, AL; McCarthy, CM; Cordeiro, PG; Matros, E. A paradigm shift in U.S. Breast reconstruction: increasing implant rates. *Plastic and Reconstructive Surgery* 2013;131:15-23. doi: 10.1097/PRS.0b013e3182729cde.

[38] O'Shaughnessy, K. Evolution and update on current devices for prosthetic breast reconstruction. *Gland Surgery* 2015;4(2):97-110. doi: 10.3978/j.issn.2227-684X.2015.03.09.

[39] Roostaeian, J; Pavone, L; Da Lio, A; Lipa, J; Festekjian, J; Crisera, C. Immediate placement of implants in breast reconstruction: patients selection and outcomes. *Plastic and Reconstructive Surgery*, 2011;127:1407-1416. doi: 10.1097/PRS.0b013e318208d0ea.

[40] Baildam, AD. Breast reconstruction state of the art. *Breast* 2006;15 Suppl 2:S27-30.

[41] Spear, SL; Spittler, CJ. Breast reconstruction with implants and expanders. *Plastic and Reconstructive Surgery* 2001;107:177-188.

[42] Salhab, M; Al Sarakbi, W; Joseph, A; Sheards, S; Travers, J; Mokbel, K. Skin-sparing mastectomy and immediate breast reconstruction: patient satisfaction and clinical outcome. *International Journal of Clinical Oncology* 2006;11:51-54.

[43] Ganz, PA. Psychological and social aspects of breast cancer. *Oncology* (Williston Park) 2008;22(6):642-646.

[44] Racano, C; Fania, PL; Motta, GB; Belloni, C; Lazzarini, E; Isoardi, R; Boccù, C; Duodeci, S; D'Agosto, M; Ragni, L. Immediate and delayed two-stage post-mastectomy breast recon-struction with implants. Our experience of general surgeons. *Minerva Chirugica* 2002;57:135-149.

[45] Kim, SW; Lee, HK; Kang, SM; Kang, TH; Yoon, CS; Ko, SS; Hur, MH; Kang, SS; Seul, CH; Gu, JS. Short-term outcomes of immediate breast reconstruction using an implant or tissue expander after mastectomy in breast cancer patients. *Breast Cancer* 2016;23(2):279-285. doi: 10.1007/s12282-014-0570-y.

[46] Robertson, S; Wengström, Y; Eriksen, C; Sandelin, K.. Breast surgeons performing immediate breast reconstruction with implants - assessment of resource-use and patient

reported outcome measures. *Breast* 2012;21(4):590-596. doi: 10.1016/j.breast. 2012.01.003.

[47] Gibney, J. Use of a permanent tissue expander for breast reconstruction. *Plastic and Reconstructive Surgery* 1989;84:607-620.

[48] Kronowitz, SJ. State of the art and science in postmastectomy breast reconstruction. *Plastic and Reconstructive Surgery* 2015;135:755e-771e. doi: 10.1097/PRS. 0000000000001118.

[49] Hodgson, EL; Malata, CM. Implant-based breast reconstruction following mastectomy. *Breast Disease* 2002;16:47-63.

[50] Alderman, A; Gutowski, K; Ahuja, A; Gray, D; Postmastectomy Expander Implant Breast Reconstruction Guideline Work Group. ASPS clinical practice guideline summary on breast reconstruction with expanders and implants. *Plastic and Reconstructive Surgery* 2014;134:648e-655e. doi: 10.1097/PRS.0000000000000541.

[51] Albornoz, CR; Matros, E; McCarthy, CM; Klassen, A; Cano, SJ; Alderman, AK; VanLaeken, N; Lennox, P; Macadam, SA; Disa, JJ; Mehrara, BJ; Cordeiro, PG; Pusic, AL. Implant breast reconstruction and radiation: a multicenter analysis of long-term health-related quality of life and satisfaction. *Annals of Surgical Oncology* 2014;21:2159-2164. doi: 10.1245/s10434-014-3483-2.

[52] Giacalone, PL; Rathat, G; Daures, JP; Benos, P; Azria, D; Rouleau, C. New concept for immediate breast reconstruction for invasive cancers: feasibility, oncological safety and esthetic outcome of postneoadjuvant therapy immediate breast reconstruction versus delayed breast reconstruction: a prospective pilot study. *Breast Cancer Research and Treatment* 2010;122:439-451. doi: 10.1007/s10549-010-0951-7.

[53] Behranwala, KA; Dua, RS; Ross, GM; Ward, A; A'hern, R; Gui, GP. The influence of radiotherapy on capsule formation and aesthetic outcome after immediate breast reconstruction using biodimensional anatomical expander implants. *Journal of Plastic, Reconstructive & Aesthetic Surgery* 2006;59:1043-1051.

[54] Losken, A; Carlson, GW; Schoemann, MB; Jones, GE; Culbertson, JH; Hester, TR. Factors that influence the completion of breast reconstruction. *Annals of Plastic Surgery* 2004;52:258-262.

[55] Wong, JS; Ho, AY; Kaelin, CM; Bishop, KL; Silver, B; Gelman, R; Harris, JR; Hergrueter, CA. Incidence of major corrective surgery after post-mastectomy breast reconstruction and radiation therapy. *Breast Journal* 2008;14:49-54. doi: 10.1111/ j.1524-4741.2007.00522.x.

[56] Cowen, D; Gross, E; Rouannet, P; Teissier, E; Ellis, S; Resbeut, M; Tallet, A; Cowen, VV; Azria, D; Hannoun-Levi, JM. Immediate post-mastectomy breast reconstruction followed by radiotherapy: risk factors for complications. *Breast Cancer Research and Treatment* 2010;121:627-634. doi: 10.1007/s10549-010-0791-5.

[57] Krueger, EA; Wilkins, EG; Strawderman, M; Cederna, P; Goldfarb, S; Vicini, FA; Pierce, LJ. Complications and patient satisfaction following expander/implant breast reconstruction with and without radiotherapy. *International Journal of Radiation Oncololgy, Biology, Physics* 2001;49:713-21.

[58] Nahabedian, MY. Shaped versus round implants for breast reconstruction: indications and outcomes. *Plastic and Reconstructive Surgery. Global Open* 2014;2:e116. doi: 10.1097/GOX. 000000 0000000068.

[59] Handel, N; Cordray, T; Gutierrez, J; Jensen, JA. A long-term study of outcomes, complications, and patient satisfaction with breast implants. *Plastic and Reconstructive Surgery* 2006;117:757-772.

[60] Macadam, SA; Ho, AL; Cook, EF Jr; Lennox, PA; Pusic, AL. Patient satisfaction and health-related quality of life following breast reconstruction: patient-reported outcomes among saline and silicone implant recipients. *Plastic and Reconstructive Surgery* 2010;125:761-771. doi: 10.1097/PRS.0b013e3181cb5cf8.

[61] McCarthy, CM; Klassen, AF; Cano, SJ; Scott, A; Vanlaeken, N; Lennox, PA; Alderman, AK; Mehrara, BJ; Disa, JJ; Cordeiro, PG; Pusic, AL. Patient satisfaction with postmastectomy breast reconstruction: a comparison of saline and silicone implants. *Cancer* 2010;116:5584-5591. doi: 10.1002/cncr.25552.

[62] Capozzi, A; Pennisi, VR. Clinical experience with polyurethane-covered gel-filled mammary prostheses. *Plastic and Reconstructive Surgery* 1981;68:512-520.

[63] Herman, S. The Meme implant. *Plastic and Reconstructive Surgery* 1984;73:411-414.

[64] Cohney, BC; Cohney, TB; Hearne, VA. Nineteen years' experience with polyurethane foam-covered mammary prosthesis: a preliminary report. *Annals of Plastic Surgery* 1991;27:27-30.

[65] Dunn, KW; Hall, PN; Khoo, CT. Breast implant materials: sense and safety. *British Journal of Plastic Surgery* 1992;45:315-321.

[66] Calobrace, MB; Hammond, D. Anatomic gel implants: from concept to device. *Plastic and Reconstructive Surgery* 2014;134:4S-9S. doi: 10.1097/PRS.0000000000000608.

[67] Goodwin, SJ; McCarthy, CM; Pusic, AL; Bui, D; Howard, M; Disa, JJ; Cordeiro, PG; Mehrara, BJ. Complications in smokers after postmastectomy tissue expander/implant breast reconstruction. *Annals of Plastic Surgery* 2005;55:16-20.

[68] Albornoz, CR; Bach, PB; Pusic, AL; McCarthy, CM; Mehrara, BJ; Disa, JJ; Cordeiro, PG; Matros, E. The influence of sociodemographic factors and hospital characteristics on the method of breast reconstruction, including microsurgery: a U.S. population-based study. *Plastic and Reconstructive Surgery* 2012;129(5):1071-1079. doi: 10.1097/PRS.0b013e31824a29c5.

[69] Dieterich, M; Angres, J; Stubert, J; Stachs, A; Reimer, T; Gerber, B. Patient-reported outcomes in implant-based breast reconstruction alone or in combination with a titanium-coated polypropylene mesh – a detailed analysis of the BREAST-Q and overview of the literature. *Geburtshilfe und Frauenheilkinde* 2015;75(7):692-701.

[70] Momoh, AO; Ahmed, R; Kelley, BP; Aliu, O; Kidwell, KM; Kozlow, JH; Chung, KC. A systematic review of complications of implant-based breast reconstruction with pre-reconstruction and post-reconstruction radiation therapy. *Annals of Surgical Oncology* 2014;21(1):118-124. doi:10.1245/s10434-013-3284-z.

[71] Cordiero, PG; Pusic, AL; Disa, JJ; McCormick, B; VanZee, K. Irradiation after immediate tissue expander/implant breast reconstruction: outcomes, complications, aesthetic results, and satisfaction among 156 patients. *Plastic and Reconstructive Surgery* 2004;113:877–881.

[72] Inamed Corporation. *Summary of safety and effectiveness data: McGhan silicone filled breast implants*. Tech. Rep. PMA P020056, Inamed Corporation, Santa Barbara CA, USA, 2004.

[73] Andrade, WN; Baxter, N; Semple, JL. Clinical determinants of patient satisfaction with breast reconstruction. *Plastic and Reconstructive Surgery* 2001;107:46–54.

[74] Alderman, AK; Wilkins, EG; Lowery, JC; Kim, M; Davis, JA. Determinants of patient satisfaction in postmastectomy breast reconstruction. *Plastic and Reconstructive Surgery* 2000:106:769–776.

[75] Caterson, SA; Fox, SE; Tobias, AM; Lee, BT. Functional MRI to evaluate "Sense of Self" following perforator flap breast reconstruction. *PLoS One* 2012;7(11):e49883. doi: 10.1371/journal.pone.0049883.

[76] Allen, R; Heitland, A. Autogenous augmentation mammaplasty with microsurgical tissue transfer. *Plastic and Reconstructive Surgery* 2003;112:91-100.

[77] Selber, JC; Kurichi, JE; Vega, SJ; Sonnad, SS; Serletti, JM. Risk factors and complications in free TRAM flap breast reconstruction. *Annals of Plastic Surgery* 2006;56:492-497.

[78] Spear, SL; Ducic, I; Cuoco, F; Hannan, C. The effect of smoking on flap and donor-site complications in pedicled TRAM breast reconstruction. *Plastic and Reconstructive Surgery* 2005;116(7):1873-1880.

[79] Miller, RB; Reece, G; Kroll, SS; Chang, D; Langstein, H; Ziogas, A; Robb, G; Evans, GR. Microvascular breast reconstruction in the diabetic patient. *Plastic and Reconstructive Surgery* 2007;119(1):38-48.

[80] Las, DE; de Jong, T; Zuidam, JM; Verweij, NM; Hovius, SE; Mureau, MA. Identification of independent risk factors for flap failure: A retrospective analysis of 1530 free flaps for breast, head and neck and extremity reconstruction. *Journal of Plastic, Reconstructive & Aesthetic Surgery* 2016;69(7):894-906. doi: 10.1016/j.bjps. 2016.02.001.

[81] Chang, DW; Wang, B; Robb, GL; Reece, GP; Miller, MJ; Evans, GR; Langstein, HN; Kroll, SS. Effect of obesity on flap and donor-site complications in free transverse rectus abdominis myocutaneous flap breast reconstruction. *Plastic and Reconstructive Surgery* 2000;105:1640-1648.

[82] Sinha, S; Ruskin, O; D'Angelo, A; McCombe, D; Morrison, WA; Webb, A. Are overweight and obese patients who receive autologous free-flap breast reconstruction satisfied with their postoperative outcome? A single-centre study. *Journal of Plastic, Reconstructive & Aesthetic Surgery* 2016;69(1):30-36. doi: 10.1016/j.bjps. 2015.08.036.

[83] Atisha, DM; Alderman, AK; Kuhn, LE; Wilkins, EG. The impact of obesity on patient satisfaction with breast reconstruction. *Plastic and Reconstructive Surgery* 2008;121:1893-1899. doi: 10.1097/ PRS.0b013e3181715198.

[84] Olivari, N. The latissimus flap. *British Journal of Plastic Surgery* 1976;29:126-128.

[85] McCraw, JB; Dibbell, DG; Carraway, JH. Clinical definition of independent myocutaneous vascular territories. *Plastic and Reconstructive Surgery* 1977;60(3):341–352.

[86] Schneider, WJ; Hill, HL Jr; Brown, RG. Latissimus dorsi myocutaneous flap for breast reconstruction. *British Journal of Plastic Surgery* 1977;30(4):277–281.

[87] Kim, Z; Kang, SG; Roh, JH; Park, JH; Lee, J; Kim, S; Lim, CW; Lee, MH. Skin-sparing mastectomy and immediate latissimus dorsi flap reconstruction: a retrospective analysis of the surgical and patient-reported outcomes. *World Journal of Surgical Oncology* 2012;10:259. doi: 10.1186/1477-7819-10-259.

[88] Schmauss, D; Machens, HG; Harder, Y. Breast reconstruction after mastectomy. *Frontiers in Surgery* 2016;2:71. doi: 10.3389/ fsurg.2015.00071.

[89] Leff, DR; Bottle, A; Mayer, E; Patten, DK; Rao, C; Aylin, P; Hadjiminas, DJ; Athanasiou, T; Darzi, A; Gui, G. Trends in immediate postmastectomy breast reconstruction in the United Kingdom. *Plastic and Reconstructive Surgery. Global Open* 2015;3(9):e507. doi: 10.1097/GOX.0000000000000484.

[90] Clough, KB; Louis-Sylvestre, C; Fitoussi, A; Couturaud, B; Nos, C. Donor site sequelae after autologous breast reconstruction with an extended latissimus dorsi flap. *Plastic and Reconstructive Surgery* 2002;109:1904–1911.

[91] Menke, H; Erkens, M; Olbrisch, RR. Evolving concepts in breast reconstruction with latissimus dorsi flaps: results and follow-up of 121 consecutive patients. *Annals of Plastic Surgery* 2001;47:107–114.

[92] Schwabegger, A; Ninković, M; Brenner, E; Anderl, H. Seroma as a common donor site morbidity after harvesting the latissimus dorsi flap: observations on cause and prevention. *Annals of Plastic Surgery* 1997;38:594–597.

[93] Munhoz, AM; Montag, E; Fels, KW; Arruda, EG; Sturtz, GP; Aldrighi, C; Gemperli, R; Ferreira, MC. Outcome analysis of breast-conservation surgery and immediate latissimus dorsi flap reconstruction in patients with T1 to T2 breast cancer. *Plastic and Reconstructive Surgery* 2005;116:741–752.

[94] Pinsolle, V; Grinfeder, C; Mathoulin-Pelissier, S; Faucher, A. Complications analysis of 266 immediate breast reconstructions. *Journal of Plastic, Reconstructive & Aesthetic Surgery* 2006;59:1017–1024.

[95] Thomson, HJ; Potter, S; Greenwood, RJ; Bahl, A; Barker, J; Cawthorn, SJ; Winters, ZE. A prospective longitudinal study of cosmetic outcome in immediate latissimus dorsi breast reconstruction and the influence of radiotherapy. *Annals of Surgical Oncology* 2008;15:1081–1091. doi: 10.1245/s10434-007-9772-2.

[96] Forthomme, B; Heymans, O; Jacquemin, D; Klinkenberg, S; Hoffmann, S; Grandjean, FX; Crielaard, JM; Croisier, JL. Shoulder function after latissimus dorsi transfer in breast reconstruction. *Clinical Physiology and Functional Imaging* 2010;30:406–412. doi: 10.1111/j.1475-097X.2010.00956.x.

[97] Fraulin, FO; Louie, G; Zorrilla, L; Tilley, W. Functional evaluation of the shoulder following latissimus dorsi muscle transfer. *Annals of Plastic Surgery* 1995;35:349–355.

[98] Tarantino, I; Banic, A; Fischer, T. Evaluation of late results in breast reconstruction by latissimus dorsi flap and prosthesis implantation. *Plastic and Reconstructive Surgery* 2006;117(5):1387–1394.

[99] Reefy, S; Patani, N; Anderson, A; Burgoyne, G; Osman, H; Mokbel, K. Oncological outcome and patient satisfaction with skin-sparing mastectomy and immediate breast reconstruction: a prospective observational study. *BMC Cancer* 2010;10:171. doi: 10.1186/1471-2407-10-171.

[100] Lee, J; Bae, Y. Use of latissimus dorsi muscle onlay patch alternative to acellular dermal matrix in implant-based breast reconstruction," *Gland Surgery* 2015;4(3):270-276. doi: 10.3978/j.issn.2227-684X.2015.01.07.

[101] Yueh, JH; Slavin, SA; Adesiyun, T; Nyame, TT; Gautam, S; Morris, DJ; Tobias, AM; Lee, BT. Patient satisfaction in postmastectomy breast reconstruction: a comparative evaluation of DIEP, TRAM, latissimus flap, and implant techniques. *Plastic and Reconstructive Surgery* 2010;125(6):1585–1595. doi: 10.1097/PRS.0b013e3181cb6351.

[102] Kim, KD; Kim, Z; Kuk, JC; Jeong, J; Choi, KS; Hur, SM. Long-term results of oncoplastic breast surgery with latissimus dorsi flap reconstruction: a pilot study of the objective cosmetic results and patient reported outcome. *Annals of Surgical Treatment and Research* 2016;90(3):117-123. doi: 10.4174/astr.2016.90.3.117.

[103] Lee, MA; Miteff, KG. The scarless latissimus dorsi flap provides effective lower pole prosthetic coverage in breast reconstruction. *Plastic and Reconstructive Surgery. Global Open* 2014;2(5):e147. doi: 10.1097/GOX.0000000000000089.

[104] Pollhammer, MS; Duscher, D; Schmidt, M; Huemer, GM. Recent advances in microvascular autologous breast reconstruction after ablative tumor surgery. *World Journal of Clinical Oncology* 2016;7(1):114-121. doi: 10.5306/wjco.v7.i1.114.

[105] Nahabedian, MY. Achieving ideal breast aesthetics with autologous reconstruction. *Gland Surgery* 2015;4(2):134-144. doi: 10.3978/j.issn.2227-684X.2015.03.03.

[106] Ziswiler-Gietz, J; Makrodimou, M; Harder, Y; Banic, A; Erni, D. Outcome analysis of breast reconstruction with free transverse rectus abdominis musculocutaneous (TRAM) flaps. *Swiss Medical Weekly* 2008;138(7-8):114-120. doi: 2008/07/smw-12069.

[107] Holstrom, H. The free abdominoplasty flap and its use in breast reconstruction: An experimental study and clinical case report. *Scandinavian Journal of Plastic and Reconstructive Surgery* 1979;13:423-7.

[108] Allen, RJ; Treece, P. Deep inferior epigastric perforator flap for breast reconstruction. *Annals of Plastic Surgery* 1994;32:32-8.

[109] Healy, C; Ramakrishnan, V. Autologous microvascular breast reconstruction. *Archives of Plastic Surgery* 2013;40(1):3-10. doi: 10.5999/aps.2013.40.1.3.

[110] Saaristo, AM; Niemi, TS; Viitanen, TP; Tervala, TV; Hartiala, P; Suominen, EA. Microvascular breast reconstruction and lymph node transfer for postmastectomy lymphedema patients. *Annals of Surgery* 2012;255(3):468–473. doi: 10.1097/ SLA.0b013e3182426757.

[111] Egeberg, A; Rasmussen, MK; Sørensen, JA. Comparing the donor site morbidity using DIEP, SIEA or MS-TRAM flaps for breast reconstructive surgery: a meta-analysis. *Journal of Plastic, Reconstructive & Aesthetic Surgery* 2012;65:1474-1480. doi: 10.1016/j.bjps.2012.07.001.

[112] Granzow, JW; Levine, JL; Chiu, ES; Allen, RJ. Breast reconstruction with the deep inferior epigastric perforator flap: history and an update on current technique. *Journal of Plastic, Reconstructive & Aesthetic Surgery* 2006;59:571-579. doi: 10.1016/ j.bjps.2006.01.004.

[113] Gill, PS; Hunt, JP; Guerra, AB; Dellacroce, FJ; Sullivan, SK; Boraski, J; Metzinger, SE; Dupin, CL; Allen, RJ. A 10-year retrospective review of 758 DIEP flaps for breast reconstruction. *Plastic and Reconstructive Surgery* 2004;113:1153-1160. doi: 10.1097/01. PRS.00001 10328.47206.50.

[114] Hadad, I; Ibrahim, AM; Lin, SJ; Lee, BT. Augmented SIEA flap for microvascular breast reconstruction after prior ligation of bilateral deep inferior epigastric arteries. *Journal of Plastic, Reconstructive & Aesthetic Surgery* 2013;66:845-847. doi: 10.1016/j.bjps.2012.09.010.

[115] Sgarzani, R; Negosanti, L; Morselli, PG; Vietti Michelina, V; Lapalorcia, LM;, Cipriani, R. Patient satisfaction and quality of life in DIEAP flap versus implant breast

reconstruction. *Surgery Research and Practice* 2015;2015:405163. doi: 10.1155/2015/405163.

[116] Schwitzer, JA; Miller, HC; Pusic, AL; Matros, E; Mehrara, BJ; McCarthy, CM; Lennox, PA; Van Laeken, N; Disa, JJ. Satisfaction following unilateral breast reconstruction: a comparison of pedicled TRAM and free abdominal flaps. *Plastic and Reconstructive Surgery. Global Open* 2015;3(8):e482. doi: 10.1097/GOX.0000000000000458.

[117] Andrades, P; Fix, RJ; Danilla, S; Howell, RE 3rd; Campbell, WJ; De la Torre, J; Vasconez, LO. Ischemic complications in pedicle, free, and muscle sparing transverse rectus abdominis myocutaneous flaps for breast reconstruction. *Annals of Plastic Surgery* 2008;60:562-567. doi: 10.1097/SAP.0b013e31816fc372.

[118] Knox, AD; Ho, AL; Leung, L; Tashakkor, AY; Lennox, PA; Van Laeken, N; Macadam, SA. Comparison of outcomes following autologous breast reconstruction using the DIEP and pedicled TRAM flaps: a 12-year clinical retrospective study and literature review. *Plastic and Reconstructive Surgery* 2016;138(1):16-28. doi: 10.1097/PRS. 0000000000001747.

[119] Hunsinger, V; Hivelin, M; Derder, M; Klein, D; Velten, M; Lantieri, L. Long-term follow-up of quality of life following DIEP flap breast reconstruction. *Plastic and Reconstructive Surgery* 2016;137(5):1361-1371. doi: 10.1097/PRS.0000000000002047.

[120] Yu, SC; Kleiber, GM; Song, DH. An algorithmic approach to total breast reconstruction with free tissue transfer. *Archives of Plastic Surgery* 2013;40:173-180. doi: 10.5999/aps.2013.40.3.173.

[121] Allen, RJ; Tucker, C Jr. Superior gluteal artery perforator free flap for breast reconstruction. *Plastic and Reconstructive Surgery* 1995;95:1207–1212.

[122] Guerra, AB; Metzinger, SE; Bidros, RS; Gill, PS; Dupin, CL; Allen, RJ. Breast reconstruction with gluteal artery perforator (GAP) flaps: a critical analysis of 142 cases. *Annals of Plastic Surgery* 2004;52:118–125.

[123] Satake, T; Muto, M; Ogawa, M; Shibuya, M; Yasumura, K; Kobayashi, S. Unilateral breast reconstruction using bilateral inferior gluteal artery perforator flaps. *Plastic and Reconstructive Surgery. Global Open* 2015;3(3):e314. doi: 10.1097/GOX.0000000000000287.

[124] Papp, C; Windhofer, C; Michlits, W. Autologous breast augmentation with the deepithelialized fasciocutaneous infragluteal free flap: a 10-year experience. *Annals of Plastic Surgery* 2011;66:587-592. doi: 10.1097/SAP.0b013e3181d376bf.

[125] LoTempio, MM; Allen, RJ. Breast reconstruction with SGAP and IGAP flaps. *Plastic and Reconstructive Surgery* 2010;126:393-401. doi: 10.1097/PRS.0b013e3181de236a.

[126] Schoeller, T; Wechselberger, G. Breast reconstruction by the free transverse gracilis (TUG) flap. *British Journal of Plastic Surgery* 2004;57:481-482.

[127] Wechselberger, G; Schoeller, T. The transverse myocutaneous gracilis free flap: a valuable tissue source in autologous breast reconstruction. *Plastic and Reconstructive Surgery* 2004;114:69-73.

[128] Fattah A, Figus A, Mathur B, et al. The transverse myocutaneous gracilis flap: technical refinements. *J Plast Reconstr Aesthet Surg* 2010;63:305-13.

[129] Allen, RJ; Haddock, NT; Ahn, CY; Sadeghi, A. Breast reconstruction with the profunda artery perforator flap. *Plastic and Reconstructive Surgery* 2012;129:16e-23e. doi: 10.1097/PRS.0b013e3182363d9f.

[130] Kane, RL. *Understanding Health Care Outcomes Research*, Jones and Barlett Publisher, Sudbury MA, USA, 2005.

[131] Gerber, B; Krause, A; Kuchenmeister, I; Reimer, T; Makovitzky, J; Kundt, G; Friese, K. Skin sparing mastectomy with autologous immediate reconstruction: oncological risks and aesthetic results. *Zentralblatt fur Gynakologie* 2000;122:476–482.

[132] Hunsinger, V; Hivelin, M; Derder, M; Klein, D; Velten, M; Lantieri, L. Long-term follow-up of quality of life following DIEP flap breast reconstruction. *Plastic and Reconstructive Surgery* 2016;137(5):1361-1371. doi: 10.1097/PRS.0000000000002047.

In: Encyclopedia of Surgery (22 Volume Set)
Editors: Andreas Lehrer and Kristin Mueller
ISBN: 978-1-53618-329-0
© 2020 Nova Science Publishers, Inc.

Chapter 176

WHAT COMES AFTER A FREE FLAP FAILURE FOR BREAST RECONSTRUCTION?

Lucian Fodor[1,*], Raluca Sobec[1], Laura Sita[1] and Dragos Zamfirescu[2]

[1]Plastic and Reconstructive Surgery Unit, Emergency Hospital, Cluj Napoca, Romania
[2]Zetta Clinic, Bucharest, Romania

ABSTRACT

Free flaps for breast reconstruction are among the most used procedures nowadays. Most common free flap procedures are DIEP, SGAP, IGAP, FCI and gracilis. The success rates in experienced centers range between 93-97%. Failure of a free flap can have many causes and the result can be a disaster for the patient, with loss of the new breast and donor area scars or other complications. When a salvage procedure fails, the question raised is what to do next.

Choosing an implant or expander-based procedure can be a good choice for these patients. Choosing a second free flap can be a risky procedure, taking into consideration the psychological effect of another failure. When the gluteal area or thigh is used as a donor site, the other one can be used for harvesting. If DIEP was used, this donor area cannot be used again, and other locations should be selected.

The cause of the failure should be carefully evaluated. When prothrombotic systemic disease is ruled out and the quality of recipient vessels are suitable for anastomosis, a second free flap can be used.

Keywords: breast reconstruction, free flap, implants, failure, obesity

* Corresponding Author's Email: lucifodor@outlook.com.

INTRODUCTION

There are many possibilities for breast reconstruction (BR), including breast silicone implants or expanders, or flaps, or a combination of these. Pedicled flaps, such as the transverse rectus abdominis muscle (TRAM) was widely used a few decades ago. With developing microsurgical techniques, free flaps are more often used nowadays, and perforator free flaps are used more frequently. Among the most used are the deep inferior epigastric perforator (DIEP), the gluteal artery perforator (GAP) flap, and the fasciocutaneous infragluteal (FCI) flap.

Replacing tissue with tissue-like is of great importance in BR. The chances of long-term complications are reduced for vascular free flaps compared with implants [1-3]. Success rates in breast reconstruction exceed 93-97% in experienced centers. There is no doubt that requests for BR are increasing yearly.

Patients with a family history of breast cancer or have BRCA mutations are interested in prophylactic mastectomy on the contralateral side [4-6]. Autologous tissue BR has the advantage of offering better symmetry, especially in cases with breast ptosis. The DIEP flap is the workhorse for free flap BR and its use also improves the abdominal aspect. While most free flap BR are successful in most centers, a total failure is disappointing both for the surgeon and for the patient. When failure occurs, some authors [7] prefer reconstruction with a prosthetic device which has a higher chance of success. In bilateral cases, using a free flap for the contralateral side offers an easier opportunity for tailoring the flap and a better match with the prosthetic side.

In a retrospective study conducted on 2306 free flaps for BR, obesity, hypertension or prolonged operation were associated with flap failure [8]. A hidden patient hypercoagulability predisposition can lead to multiple free flap failures [9]. A hematological workup can reveal anomalies of protein S activity, Factor VIII, plasminogen activator inhibitor or antiphosphatidyl antibodies. These tests are not done routinely before any free flap procedure. However, when a complication is encountered, all these parameters needs to be evaluated.

A review of the morbidity of BR in obese patients was performed by Fisher et al. [10]. In a study on 15937 BR performed between 2005 and 2010, obesity was present in 27.1%. Grade III obesity was encountered in 4%. It is interesting that the author did not find a difference in first month complications between autologous and implant-based procedures [10]. However, obese patients have a greater perioperative risk and more medical complications. In a study by Garvey et al on 990 BR in obese patients, 548 had free flaps and 442 had implant-based BR [11]. In this study, the authors found a higher failure rate in the implant-based group (15.8%) than in the free flaps group (1.5%).

Efforts to analyze several parameters for free flaps have been made by experienced surgeons in order to prevent complications and elaborate a strategy for reconstruction. Damen et al. [12] evaluated 406 consecutive free flaps (164 used for unilateral and 121 for bilateral BR). The most common recipient vessels for free flap BR are the internal mammary ones [13, 14]. For the DIEP flap, many authors use a single perforator and consider it sufficient for perfusion. Damen et al. [12] is in favor of using a single perforator when the vein diameter is greater than 1.5mm. Nahabedian et al. [15] considers a single perforator flap safe if the diameter is greater than 1.5mm and the flap weight is less than 750gr. Several recommendations have been described by experienced surgeons to reduce complication rates.

Blondeel [16] prefers a single or two perforators located at the musculocutaneous junction. The larger the perforator, the greater the chance for flap survival. When a large perforator is present, it is preferred to two small perforators [17].

The best solution to overcome a failed BR has not been established and authors' opinions vary. Rao et al. [7] reported a 3.5% failure rate on 342 free flaps where reconstruction with tissue expanders and implants was performed. An average of 2.25 additional procedures were necessary in these cases to achieve the final result. In a study on 688 patients, Hamdi et al. [18] reported 14 patients who required tertiary BR. Eight patients had a second free flap, and two required another reconstruction due to failure. A failed solution cannot be solved with the same way of thinking. Identifying the cause of failure as precisely as possible can lead the surgeon to choose the best next solution. According to Hamdi et al. [18], a second free flap can be offered as a solution for a failed one. When an abdominal area was used, other donor areas, such as the buttock or thigh, are good options.

Figure 1A. The mastectomy area in a young female with no abdominal fat deposits.

Figure 1B. The donor area for FCI flap - the left side was used.

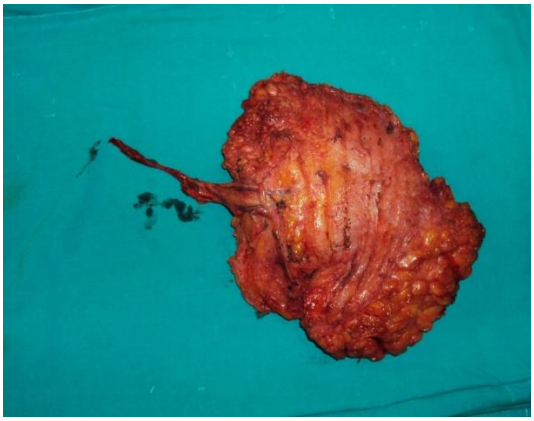

Figure 1C. The flap.

Figure 1D. The flap became congestive on the second day after surgery. A salvage procedure was tried but was only partial successful.

Figure 1E. A few weeks after surgery with a partial flap loss.

Figure 1F. Six months after - the remaining flap became fibrotic and was removed.

Figure 1G. A second free flap was used from the contralateral buttock - 18 months after reconstruction.

Figure 1H. The donor area 18 months after surgery.

According to Mohan et al. [19], DIEP is the first choice for BR in a failed or unsatisfactory implant reconstruction. Implant-based BR is a useful and very common method. Unfortunately, there are cases with unsatisfactory results or long-term complications after implant- or expander-based procedures [20, 21]. The most common late complication is by far capsular contracture [22]. The free flap BR has the advantage of having good long-standing results and fewer revisions compared with other methods.

In a retrospective analyses of 902 free flaps for BR, Baumeister et al. [23] identified 13 patients who had a second free flap after a primary failure. After analyzing possible causes of the failure, the re-operative strategy was changed. For most, more proximal recipient vessels or different recipient vessels were used. A different flap type was used in these cases and success was achieved in 11 of 13 patients. Reconsideration of a second free flap procedure should be done after carefully analyzing the cause of the failure, using a sensitive approach to the patient, and changing the surgical strategy [23]. Massenburg et al. [8] used a contralateral latissimus dorsi (LD) flap for secondary or tertiary reconstructions.

Some authors are in favor of a second tissue transfer after a primary failure [24], while other authors are in favor of this strategy even though it concerns other regions of the body. In a large number of free flap cases (3361) performed in the head and neck, after careful analysis of the outcome of the failed free flap, Wei et al. [25] performed a second free flap and found it reliable for most patients.

Choosing the best solution after a free flap failure is not a simple task, based solely on the surgeon's preference (Figures 1A-H). If the patient is very anxious, we suggest an implant-based solution. In cases with hypercoagulability, such as anticardiolipin antibodies and free flap failure, we suggest an implant only or an implant combined with a LD pedicle flap.

REFERENCES

[1] Claro F, Jr., Figueiredo JC, Zampar AG, Pinto-Neto AM. Applicability and safety of autologous fat for reconstruction of the breast. *The British journal of surgery*. 2012;99(6):768-80. Epub 2012/04/11.

[2] Hvilsom GB, Holmich LR, Steding-Jessen M, Frederiksen K, Henriksen TF, Lipworth L, et al. Delayed breast implant reconstruction: a 10-year prospective study. *Journal of plastic, reconstructive & aesthetic surgery:* JPRAS. 2011;64(11):1466-74. Epub 2011/08/26.

[3] McCarthy CM, Mehrara BJ, Riedel E, Davidge K, Hinson A, Disa JJ, et al. Predicting complications following expander/implant breast reconstruction: an outcomes analysis based on preoperative clinical risk. *Plastic and reconstructive surgery*. 2008;121(6): 1886-92. Epub 2008/06/04.

[4] Hartmann LC, Schaid DJ, Woods JE, Crotty TP, Myers JL, Arnold PG, et al. Efficacy of bilateral prophylactic mastectomy in women with a family history of breast cancer. *The New England journal of medicine.* 1999;340(2):77-84. Epub 1999/01/14.

[5] Herrinton LJ, Barlow WE, Yu O, Geiger AM, Elmore JG, Barton MB, et al. Efficacy of prophylactic mastectomy in women with unilateral breast cancer: a cancer research network project. *Journal of clinical oncology : official journal of the American Society of Clinical Oncology.* 2005;23(19):4275-86. Epub 2005/03/30.

[6] Rebbeck TR, Friebel T, Lynch HT, Neuhausen SL, van 't Veer L, Garber JE, et al. Bilateral prophylactic mastectomy reduces breast cancer risk in BRCA1 and BRCA2 mutation carriers: the PROSE Study Group. *Journal of clinical oncology : official journal of the American Society of Clinical Oncology*. 2004;22(6):1055-62. Epub 2004/02/26.

[7] Rao SS, Parikh PM, Goldstein JA, Nahabedian MY. Unilateral failures in bilateral microvascular breast reconstruction. *Plastic and reconstructive surgery*. 2010;126(1): 17-25. Epub 2010/07/03.

[8] Massenburg BB, Sanati-Mehrizy P, Ingargiola MJ, Rosa JH, Taub PJ. Flap Failure and Wound Complications in Autologous Breast Reconstruction: A National Perspective. *Aesthetic plastic surgery*. 2015;39(6):902-9. Epub 2015/10/22.

[9] Davison SP, Kessler CM, Al-Attar A. Microvascular free flap failure caused by unrecognized hypercoagulability. *Plastic and reconstructive surgery*. 2009;124(2):490-5. Epub 2009/08/01.

[10] Fischer JP, Cleveland EC, Nelson JA, Kovach SJ, Serletti JM, Wu LC, et al. Breast reconstruction in the morbidly obese patient: assessment of 30-day complications using the 2005 to 2010 National Surgical Quality Improvement Program data sets. *Plastic and reconstructive surgery*. 2013;132(4):750-61. Epub 2013/10/01.

[11] Garvey PB, Villa MT, Rozanski AT, Liu J, Robb GL, Beahm EK. The advantages of free abdominal-based flaps over implants for breast reconstruction in obese patients. *Plastic and reconstructive surgery*. 2012;130(5):991-1000. Epub 2012/10/26.

[12] Damen TH, Morritt AN, Zhong T, Ahmad J, Hofer SO. Improving outcomes in microsurgical breast reconstruction: lessons learnt from 406 consecutive DIEP/TRAM flaps performed by a single surgeon. *Journal of plastic, reconstructive & aesthetic surgery : JPRAS*. 2013;66(8):1032-8. Epub 2013/05/07.

[13] Lorenzetti F, Kuokkanen H, von Smitten K, Asko-Seljavaara S. Intraoperative evaluation of blood flow in the internal mammary or thoracodorsal artery as a recipient vessel for a free TRAM flap. *Annals of plastic surgery*. 2001;46(6):590-3. Epub 2001/06/19.

[14] Saint-Cyr M, Youssef A, Bae HW, Robb GL, Chang DW. Changing trends in recipient vessel selection for microvascular autologous breast reconstruction: an analysis of 1483 consecutive cases. *Plastic and reconstructive surgery*. 2007;119(7):1993-2000. Epub 2007/05/24.

[15] Nahabedian MY, Momen B, Galdino G, Manson PN. Breast Reconstruction with the free TRAM or DIEP flap: patient selection, choice of flap, and outcome. *Plastic and reconstructive surgery*. 2002;110(2):466-75; discussion 76-7. Epub 2002/07/27.

[16] Blondeel PN. One hundred free DIEP flap breast reconstructions: a personal experience. *British journal of plastic surgery*. 1999;52(2):104-11. Epub 1999/08/06.

[17] Chevray PM. Breast reconstruction with superficial inferior epigastric artery flaps: a prospective comparison with TRAM and DIEP flaps. *Plastic and reconstructive surgery*. 2004;114(5):1077-83; discussion 84-5. Epub 2004/10/01.

[18] Hamdi M, Andrades P, Thiessen F, Stillaert F, Roche N, Van Landuyt K, et al. Is a second free flap still an option in a failed free flap breast reconstruction? *Plastic and reconstructive surgery*. 2010;126(2):375-84. Epub 2010/08/04.

[19] Mohan AT, Al-Ajam Y, Mosahebi A. Trends in tertiary breast reconstruction: literature review and single centre experience. *Breast.* 2013;22(2):173-8. Epub 2012/07/17.

[20] Visser NJ, Damen TH, Timman R, Hofer SO, Mureau MA. Surgical results, aesthetic outcome, and patient satisfaction after microsurgical autologous breast reconstruction following failed implant reconstruction. *Plastic and reconstructive surgery*. 2010;126(1):26-36. Epub 2010/07/03.

[21] Hamdi M, Blondeel P, Van Landuyt K, Tondu T, Monstrey S. Bilateral autogenous breast reconstruction using perforator free flaps: a single center's experience. *Plastic and reconstructive surgery*. 2004;114(1):83-9; discussion 90-2. Epub 2004/06/29.

[22] Levine SM, Lester ME, Fontenot B, Allen RJ, Sr. Perforator flap breast reconstruction after unsatisfactory implant reconstruction. *Annals of plastic surgery*. 2011;66(5):513-7. Epub 2011/02/09.

[23] Baumeister S, Follmar KE, Zenn MR, Erdmann D, Levin LS. Strategy for reoperative free flaps after failure of a first flap. *Plastic and reconstructive surgery*. 2008;122(3):962-71. Epub 2008/09/04.

[24] Bui DT, Cordeiro PG, Hu QY, Disa JJ, Pusic A, Mehrara BJ. Free flap reexploration: indications, treatment, and outcomes in 1193 free flaps. *Plastic and reconstructive surgery*. 2007;119(7):2092-100. Epub 2007/05/24.

[25] Wei FC, Demirkan F, Chen HC, Chuang DC, Chen SH, Lin CH, et al. The outcome of failed free flaps in head and neck and extremity reconstruction: what is next in the reconstructive ladder? *Plastic and reconstructive surgery*. 2001;108(5):1154-60; discussion 61-2. Epub 2001/10/18.

In: Encyclopedia of Surgery (22 Volume Set)
Editors: Andreas Lehrer and Kristin Mueller
ISBN: 978-1-53618-329-0
© 2020 Nova Science Publishers, Inc.

Chapter 177

RECONSTRUCTION OF THE NIPPLE-AREOLAR COMPLEX

Dragos Zamfirescu[1,*], Lucian Fodor[2], Matei Iordache[3] and Andreea Bularda[3]

[1]Zetta Clinic, Bucharest, Romania
[2]Plastic and Reconstructive Surgery Unit, Cluj Napoca, Romania
[3]Bucharest Emergency Hospital, Bucharest, Romania

ABSTRACT

Nipple areolar reconstruction (NAC) progressed in parallel with breast reconstruction. Being a part of the complex process of the reconstruction of the breast, it also represents an important asset in the evaluation of the overall quality of this process. Patients associate this stage with the end of the treatment and with a sense of completeness.

It can be done during the primary or secondary breast reconstruction or later. Ideal reconstruction of the NAC requires symmetry in position, size, shape, projection, texture, and pigmentation.

Numerous techniques for nipple-areola complex (NAC) reconstruction are described. NAC reconstruction techniques comprise of composite nipple grafts, local flaps, flaps with autologous graft augmentation, flaps with alloplastic augmentation and flaps with allograft augmentation.

The local flaps are the most frequently described techniques for the nipple reconstruction with no significant difference in complications' rate among the various types of techniques. In literature, complications in nipple reconstruction are almost 50% after graft, 8% after local flap, and 5% in case of flaps with autologous graft/ alloplastic/allograft augmentation, while complications in areola reconstruction are 10% after graft, and less than 2% after areola tattoo. Flaps appear to be more reliable than grafts in nipple reconstruction, while tattoo is thought to be safer than graft in areola reconstruction.

The loss of projection is considerable (45%-75%). Overcorrection of 25-50% of the desired result is advisory when adopting local flaps, in order to prevent loss of projection.

* Corresponding Author's Email: Dragos Zamfirescu; dragoszamfirescu@gmail.com.

The use of flaps with autologous graft/alloplastic/allograft augmentation (cartilage, fat, calcium hydroxylapatite, acellular dermal matrix, collagen) showed a minor loss of nipple projection but may expose to a relative increased number of postoperative flap necrosis.

Keywords: nipple reconstruction, flap, cartilage, skin graft

INTRODUCTION

Reconstruction of the nipple and the areola was first introduced as a concept in the 1940s and has evolved ever since in parallel with reconstruction of the breast following cancer treatment, leading to the development of countless techniques, but lacking a complete list until now. The nipple-areola complex is the last phase of breast reconstruction, albeit a very important part in this elaborate process. It is associated with a sense of completeness and of reaching the last stage of the treatment. It is usually performed in the second or third stage of the process, frequently after radio- and chemotherapy have been performed. Reconstruction has to take into consideration symmetry in all aspects: position, size, texture, shape, permanent projection and pigmentation. Nipple reconstruction is usually the first phase and can be undertaken using local flaps, grafts or flaps consisting of autologous graft, allograft or alloplastic augmentation, while the use of tattooing and of skin grafting have been described for areolar reconstruction as frequent and easy possibilities. Although considered a simple surgery, reconstruction of the nipple and areola has important psychological aspects when evaluating the quality of the entire reconstructive process [1-4].

HISTORY

The history of the nipple-areola complex (NAC) reconstruction began in the 1940s with Adams using the labial minus grafts for reassembling [5, 6]. Evolution followed some 30 years later with the nipple-sharing concept introduced by Millard which harvested tissue from the contralateral nipple [7]. This journey of progression over time included diverse grafts (toe pulp, cartilages) [8], then flaps composed of local flaps (such as the T flap in the 1980s) [9], culminating with the 1980-1990 period when the traditional flaps were defined, such as the F flap, Z flap, star flap or skate flap. Finally, synthetic materials have been used alongside allografts in the newest techniques.

INDICATIONS

Normal Areola Characteristics

One of the first aspects to be taken into consideration when planning a nipple-areolar complex reconstruction is the aspect of the normal areola. The normal areola is generally placed where the most projection can be achieved on the reconstructed breast. Several

measurements and aspects should be taken into consideration, such as size, shape, diameter and color, adapting them to the contralateral breast [10].

Measurements should be made so as to symmetrize the two NACs, adapting the distance between the areola to the inframammary fold and the distance between the nipple and the notch, matching those of the normal nipple [11].

The real challenge arises when a bilateral reconstruction is required. In this case, several standard numbers are taken into consideration: an areola medium diameter of 4 cm, with a nipple of 1.3 cm in diameter and 0.9 in projection [12].

Timing

One of the most important aspects of the problem is time. The timing of the operation results from a multidisciplinary decision. Frequently it is performed 3-5 months after the last operation, as adjuvant therapy may hinder correct healing [13].

Patient Selection – A Multidisciplinary Decision

The whole treatment process results from the decisions made by a multidisciplinary team that consists of an oncologist who conducts the work and the surgical team formed by a general surgeon and/or a plastic surgeon [10].

Many patients are candidates for a reconstructive procedure. Most surgical operations performed for breast cancer use a skin-sparing mastectomy which frequently leads to the loss of the nipple, with an important psychological impact by affecting the aesthetic aspect and the sense of completeness [3].

Although nipple-sparing mastectomies provide a big upgrade in the psychological matter, they are rarely performed mostly due to the characteristics of the tumor, such as its adjacency to the nipple or its size.

Surgical Techniques

Surgical techniques vary, based on the possibilities offered by the type of the previously practiced mastectomy (nipple-sparing versus skin-sparing), the quality of the local skin, the presence or absence of scars, the excess and the aspect of the contralateral NAC complex, the surgeon's preference and last, but not least, the patient's choice [10, 14].

Achieving Long-Lasting Projection

Representing perhaps the ultimate objective of the NAC reconstruction, achieving long-lasting projection is the result of the action of two factors: the flap's contraction and the retraction forces of the local tissues that act upon the flap. The first is an inevitable effect, taking place to different extents from patient to patient but leading to loss in projection and/or

volume. The second can be influenced by wisely choosing a variant with a subdermal pedicle which releases the flap from the adjacent tissues and provides vascularization through the subdermal plexus, which is a far better option than the vascularization provided by the subcutaneous tissue or by scarred or previously irradiated tissues [1].

Nipple Projection Loss

The main issue in the reconstruction of the nipple is the postoperative loss that may occur, either in terms of projection or of volume, regardless of the technique used [15]. Consequently, it is recommended that the reconstructed nipple be double the size of the intended future form [16, 17].

RECONSTRUCTION OF THE NAC

Reconstruction of the nipple-areolar complex can be divided into its two main components: reconstruction of the areola and reconstruction of the nipple [1].

I. Nipple Reconstruction

If the volume of the contralateral nipple is big enough, it can be used as a graft for the future nipple. Otherwise, the preferred option is that of a local flap, such as the F flap, the Z flap, the skate flap or the star flap.

1) Composite Nipple Graft

Amongst the different procedures used for nipple reconstruction, the nipple-sharing technique remains a frequently used option when the contralateral nipple is prominent [5, 7]. Taking advantage of the fact that it uses the same kind of tissue, it represents a good option when a 5-6 mm projection excess is present, making these patients the ideal candidates [10].

The first phase of the operation consists in performing de-epithelialization of the new site for the nipple. Then the distal half (40-50%) of the existing nipple is removed and sutured at the site of the new nipple, while the donor nipple can be closed by using interrupted sutures covered by a tie over or purse-string suture. The last step is reconstruction of the areola which can be harvested from the contralateral one if there is an excess of tissue or from other sites (i.e., the inner thigh) [18, 19] Figure 1.

This is a suitable technique in cases of large nipples. Above all other surgical options, it best matches the attributes of the contralateral nipple when it comes to shape, structure, color or long-term projection [20].

Unfortunately, the use of this procedure is sometimes limited, mostly because of patients' reservations considering potential complications, such as morbidity of the donor site or discomfort for the patient, fear or unacceptance of contralateral surgery or decrease in that nipple's sensation. Also, surgeons seem loathe to use the healthy nipple because of the risk of morbidity, including pain, numbness or scarring [20].

Comparing the reconstructed nipple to the other one, it needs to be mentioned that overall satisfaction was good. In a study performed on 57 patients, Zenn et al. found that the overall appearance satisfaction was high (in 96% of patients). The same study proved a small decrease in sensation, 47% in the donor site lot weighed it to be normal, compared to 35% of the patients who had their nipples reconstructed. The largest discrepancy lay in that of the comparison between the erectile functions of the nipples, with 87% of the patients declaring that the donor nipple had normal erectile function, compared to only 42% of the patients who declared that they had erectile function 3 months after the operation [21].

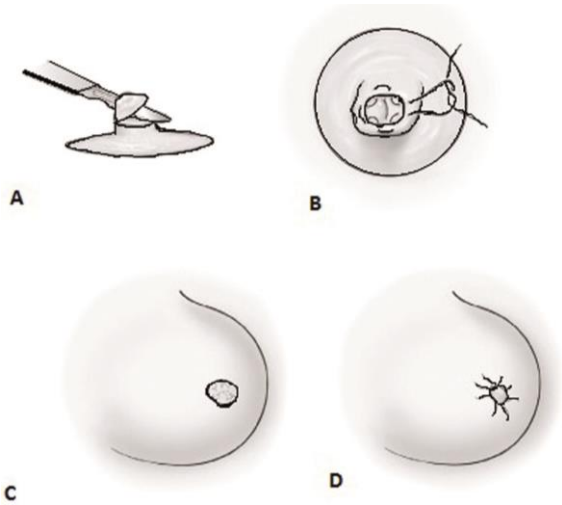

Figure 1. Nipple reconstruction with composite graft. A. Harvesting the composite graft from the contralateral nipple. B. Closing the donor site. C. Deepithelialization at the position of the new nipple. D. Suturing of the composite nipple graft.

2) Traditional Flaps

The local flaps are the most frequently described techniques for the nipple reconstruction with no significant difference in complications' rate among the various types of techniques. In literature, complications in nipple reconstruction are almost 50% after graft, 8% after local flap, and 5% in case of flaps with autologous graft/alloplastic/allograft augmentation, while complications in areola reconstruction are 10% after graft, and less than 2% after areola tattoo [4]. Flaps appear to be more reliable than grafts in nipple reconstruction.

a) Skate Flap

Initially described in 1984 by Little, the skate flap is a widely used traditional flap, thus leading to multiple attempts over time to modify it. Taking into consideration the fact that one of the important aspects in reconstruction is symmetry, the skate flap is a good option when a projected appearance is desired, offering a long-lasting effect [22, 23].

The design of the flap consists in a central axis, a line that is tangential to the base of the nipple. It is recommended to rotate it so as the line does not include the flap's limbs or its central part [23]. The line, which also represents the diameter of the new areola, will be the base for the flap. Its length should be three times that of the nipple circle. Afterwards the line is split into three and a semicircular line that unites the two edges of the line is drawn. The

dissection begins from the lateral third progressing towards the center of the flap, from thin to thick, including a layer of approximatively 7-8 mm of fat in the middle part of the nipple, thereby offering bulk and vascularization to the nipple [10, 23] Figure 2.

Special care must be taken not to dissect beyond the base of the flap. Subsequently, the two lateral thirds, or the wings of the flap, are rotated, encircling the base and then sutured one to the other. The last phase of the nipple reconstruction is the suturing of the central third to the other two-thirds [22, 23].

The conventional design consists of the de-epithelization of the rest of the areola and covering it with a full-thickness graft [24, 25].

Having a good long-term projection rate over time attested to by multiple studies, the skate flap represents a widely used flap variant for reconstruction of the nipple [10]. When it comes to disadvantages of using the skate flap, nipple projection loss should be mentioned, varying from 40% to 75% [26, 27].

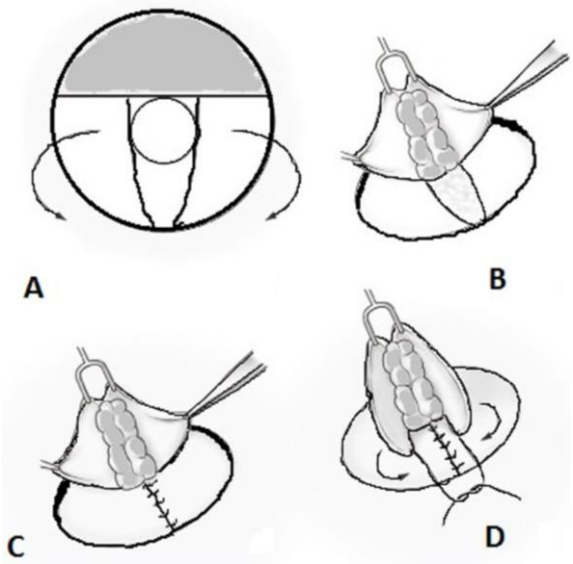

Figure 2. Skate flap. A. The superior part is deepithelializated. B. The wings of the skate are split thickness dissected and the central part is elevated with dermis and fat. C. Closing of the donor defect of the body. D. The wings covered the body to form a cone.

b) Star Flap

The star flap consists of three wings with the same base, beginning from a central point. As in the case of the skate flap, the width of the central wing establishes the nipple's width. The dissection begins from the lateral flaps, raising them carefully as to include subcutaneous fat, continuing to the central wing [22]. One of the lateral wings is rotated around the base of the nipple and sutured into position. Then the other wing is also rotated, suturing it to the base of the previous one. In the final phase, the central wing covers the previous two, forming the tip of the reconstructed nipple. The final aspect results in a T scar [28] Figure 3.

Although it is a good option with excellent results, it has the downside that, due to its final form, it may lead to skin ischemia, postponing the curative process. Another noteworthy disadvantage of the star flap is the lack of projection [10, 29].

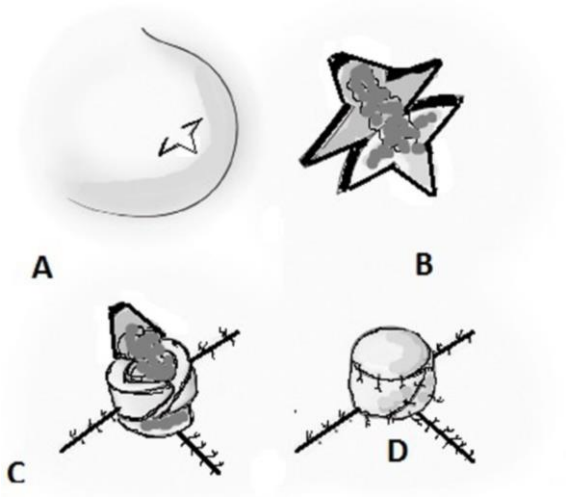

Figure 3. The rays of the star are elevated including subcutaneous fat tissue. One of the lateral wings is rotated around the base of the nipple and sutured into position. Then the other wing is also rotated, suturing it to the base of the previous one. The central wing covers the previous two, forming the tip of the reconstructed nipple.

c) F Flap

An alternative for nipple reconstruction, the F flap is a good option when the contralateral nipple cannot be used, either because it is too small or because the patient refuses, or if the cancer was bilateral. It consists of an adipocutaneous flap which has two limbs and permits primary closure. The two limbs, which are vascularized from the same central base, are then folded into each other. The two limbs can be created asymmetrically based on the new nipple's size [30, 31] Figure 4.

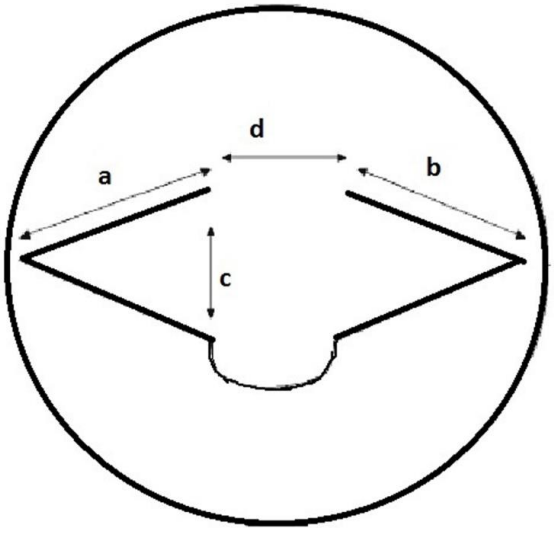

Figure 4. A, B are side flaps. C is the central flap, covering the nipple. The tip of the A flap is sutured to point E. The tip of the B flap is sutured to point D.

In the first phase the selected area is tattooed, after which the two flaps are raised with all the layers of the skin, including the underlying adipose tissue used for the best results in nipple volume. The volume increases proportionally to the thickness of the skin. The two limbs are crossed, usually placing the longest one more inferior than the other [30, 31].

d) Z Flap

The Z flap has been described in several pathologies, although it is a rather new technique. A good option for treatment of the inverted nipple [32, 33], it is also employed when the quality of the skin is not optimal or when the local circumstances are not favorable for an F flap [30]. In addition, it has been described as an alternative in the reconstruction of the nipple.

Although it has two limbs, as the previous flap, each of them has its own pedicle. Two separate pedicles translate into a more reliable vascularization, thereby lowering the possibility of necrosis. The areola's position is set and, following the same manner as in the case of the F flap, it is tattooed in the new spot [30, 31].

The design of the flap consists of two pedicles equal in width and in distance one from the other and with the future nipple [32]. The flaps are raised similarly to the F flap, in full-thickness, after which they are sutured directly one to the other, being careful not to roll nor plicate them [33]. An important aspect to take into consideration is the thickness of the two limbs which should be equal to half of the future nipple [30] Figure 5.

There are several complications which may occur at some time after the operation, such as: initial inadequate nipple projection or loss of nipple projection over time, necrosis (a rare complication that may occur if one of the two pedicles is insufficient), or fading of the areola [30, 33].

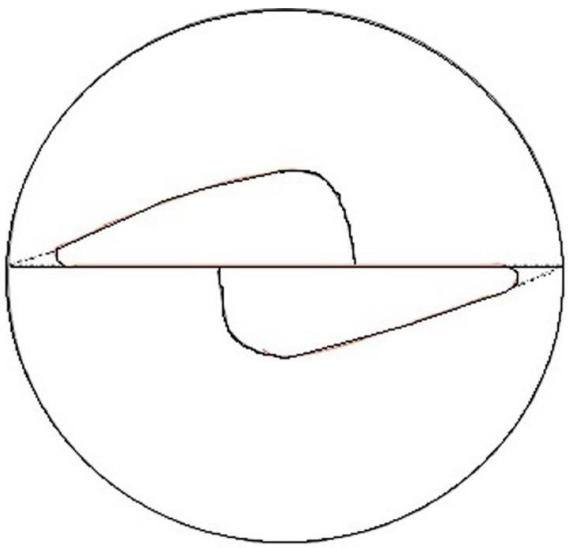

Figure 5. Z. The two pedicles are equal in width and in distance one from the other and with the future nipple. The flaps are raised similarly to the F flap, in full-thickness, after which they are sutured directly one to the other. The thickness of the two limbs which should be equal to half of the future nipple.

e) C-V Flap

The name of the flap describes it accurately. This flap is formed of three limbs, the V representing the shape of two identical limbs placed one opposite to the other, both starting from the center of the flap. The third limb is C-shaped or has a circular display with its diameter created so as to have the same width as the V parts [22] Figure 6.

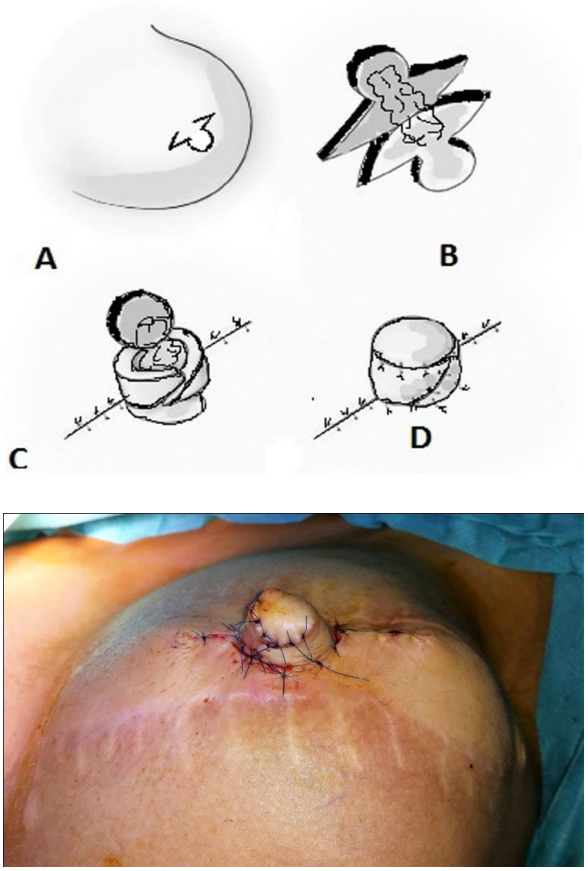

Figure 6. A, B. The two lateral wings are elevated including subcutaneous fat tissue. One of the lateral wings is rotated around the base of the nipple and sutured into position. Then the other wing is also rotated, suturing it to the base of the previous one. The central wing covers the previous two, forming the tip of the reconstructed nipple.

The two V flaps will be the foundation of the nipple, offering projection. They are sutured together in a similar manner to the skate flap by rotating them along the future base. The C part is placed over these two, forming a rounded tip [22] Figure 7A-D.

Several studies have proven the good overall results of the C-V flap [34, 35]. Losken et al. proved maintaining of the projection at 5 years after reconstruction with an 81% overall satisfaction rate, while Valdatta et al. showed that, although a 32% projection loss was noticed after a year with a 17% increase in diameter, the volume of the neonipple was maintained.

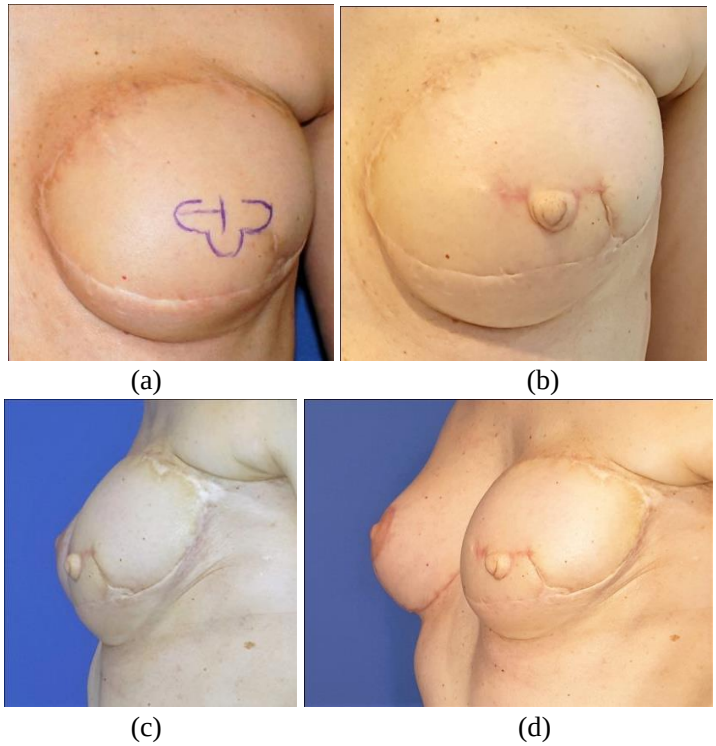

Figure 7. A-D. Nipple reconstruction by the CV (CU) flap. Preop drawing of the flap and 8 months postop result.

3) Purse-String Flap Techniques

These types of flaps have the advantage of creating projection of the NAC complex by mobilizing the adjacent breast tissue. There are several of these procedures, such as the bell flap, the top hat flap or the double opposing periareolar/purse-string flap [36].

The *bell flap* was first described in 1996 by Eng. Named after its design, it facilitates slight areolar projection by suturing it in a purse-string manner [37]. Since its effects are transitory, with a possible projection loss of up to 73% after 1 year, the use of the bell flap has been actively limited to cases of small contralateral nipple projection [26].

The *top-hat flap* is not a true flap on its own. This technique implies the placing of four incisions, 2-4 mm one from the other. The projection of the nipple is established by the tension formed from a nonabsorbable string suture that passes from one incision to the adjacent one. Gamboa-Bobadilla et al. found this technique to be successful with a 6 mm nipple projection 18 months after the operation and a 90% overall reconstruction satisfaction [38].

The *double opposing periareolar flap* is derived from the skate flap. It was designed to offer both projection of the nipple and good scarring of the donor site. This technique elevates the lateral wings with slim layers of fat, while the central part is elevated with subcutaneous fat so as to grant projection [22]. Particular to this flap is the fact that the areolar contour is incised, allowing the areolar flaps to glide along the subcutaneous layer. Subsequently, the nipple is formed in a similar manner to those described before. Shestak's result in a study conducted in 2007 described no flap losses and no dehiscence. Nipple projection was constant with comparable results to those of the skate flap [39, 40].

4) Flaps Adjacent to Scars

Unlike the previously mentioned flap techniques, these flaps are designed to avoid compromised blood supply scarred tissue. Several of these flaps are the S Flap, the Double Opposing Tab Flap or the H Flap [10].

They consist of the creation of a circle with a diameter three times the size of the new nipple, which centers it. Afterwards, having the mastectomy scar as the central line, the different letters or shapes are drawn, leading to the formation of two identical flaps. They are then lifted and sutured, beginning from the base and ending at the tips. The next step implies the de-epithelization for the future areola which will be harvested and processed to meet the required shape [10, 30].

These flaps are a good choice for reconstruction, being a durable option over time, especially in terms of nipple projection [41].

5) Flaps with Autologous Graft Augmentation

This concept was introduced in an attempt to overcome the main problem of projection loss after local flap reconstruction. The alternatives include the use of fat or cartilage grafts [1, 42].

Fat grafting is an easy and increasingly popular technique. It harvests fat from the abdomen or from other regions, processing it and injecting it into the location of the future nipple which was previously drawn. After some time, the fat is resorbed and then the flap can be formed and sutured. This type of grafting is particularly useful for patients with thin subdermal fat [43].

Cartilage grafts offer good nipple projection and represent a rather simple alternative. They can be harvested either from the costal cartilage (Figure 8 A-D) or from the ear and then covered by a skin graft or a flap. Although it is believed that they offer long term projection [34, 35], cartilage grafts are not widely used and accepted due to donor site morbidity.

Guerra and colleagues proved excellent results in their study of 454 patients which used a costal cartilage graft and an arrow flap. Their patients lost only 4% of the cartilage graft due to ischemia or infection [44].

6) Flaps with Alloplastic Augmentation

Being one of the newest techniques employed for nipple reconstruction, this method uses materials such as calcium hydroxyapatite or hyaluronic acid, which provide a durable projection but, being non-self, may lead to infection and exclusion [3, 45, 46].

7) Flaps with Allograft Augmentation

Representing a top-of-the-generation product, the acellular dermal allograft is an increasingly popular method for nipple reconstruction as it has the best properties of an implantable material, with little to no rejection or resorption, rarely leading to infections and having a small projection loss [1]. The material is cut according to the required size, rolled upon itself, and then sewn to the adjacent tissue [47, 48].

An alternative to the previous allograft augmentation techniques is the Cook nipple, a cylinder forged to erase size errors which could lead to inequality [1].

(a)

(b)

(c)

(d)

Figure 8. A-D. Nipple projection with costal cartilage graft harvested on the time of breast reconstruction and banked in the inframammary fold pocket.

8) Loss of Projection

The loss of projection is considerable (45%-75%). Overcorrection of 25-50% of the desired result is advisory when adopting local flaps, in order to prevent loss of projection. The use of flaps with autologous graft/alloplastic/allograft augmentation (cartilage, fat, calcium hydroxylapatite, acellular dermal matrix, collagen) showed a minor loss of nipple projection but may expose to a relative increased number of postoperative flap necrosis [4].

II. Areolar Reconstruction

The two most commonly performed techniques for areolar reconstruction are tattooing or skin grafting, or a combination of the two [1]. Skin grafting, when employed, is usually performed at the same time as the nipple reconstruction and has the advantage of a similar texture to the contralateral nipple, while tattooing is usually performed 6-8 weeks later than the nipple reconstruction [1, 49].

1) Skin Grafting

The full-thickness graft is the choice when it comes to skin grafting. It has to meet the required size of the reconstructed areola. The donor site from which it can be harvested is usually the inguinal crease, although it can also be gathered from the contralateral areola, the retroauricular region, the upper region of the internal thigh/groin region, the inferior abdomen, or whenever there is excessive breast skin [50].

Following the harvest of the graft, the next required step involves the processing of the recipient site by de-epithelization that serves as a reliable base for the graft. The graft is then binded to the bed, using interrupted, nonabsorbable sutures [51].

Skin grafting has the advantages of providing an aspect that resembles that of a normal areola; it has the required texture, it is normally pigmented and it has a wrinkled surface [1].

2) Tattooing

Tattooing may be the first choice in the reconstruction of the areola [52]. Although it may seem less natural, it can be preferred as it has the advantage of not requiring a donor site (Figures 9-11). In most cases, unilateral tattooing is used when the color is easy to reproduce, and bilateral in cases of pale areolae. Usually it consists of a mix of colors (based on titanium oxide and iron) [53, 54] tattooed successively which best reproduce the aspect of the areola, avoiding a less natural effect of the reconstruction. Tattooing is performed first if the nipple is reconstructed using a graft but, in the case of using a flap, the harvest site will be tattooed first, the rest after skin closure [1]. There are times when tattooing is recommended to be done several weeks after the nipple reconstruction, with the mention that it may be required to be a tone darker because the color fades a bit in time [55].

(a)

(b)

(c)

(d)

Figure 9. Complete breast reconstruction, including areola tattooing.

(a)

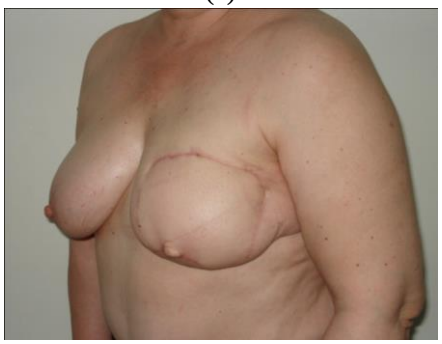

(b)

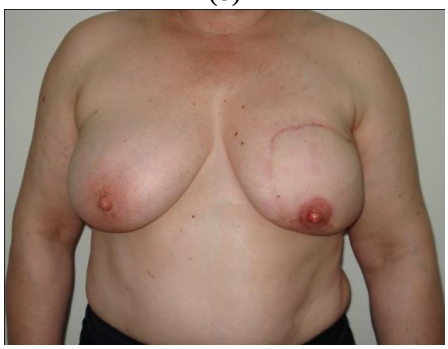

(c)

(d)

Figure 10. Complete breast reconstruction, including areola tattooing.

(a)

(b)

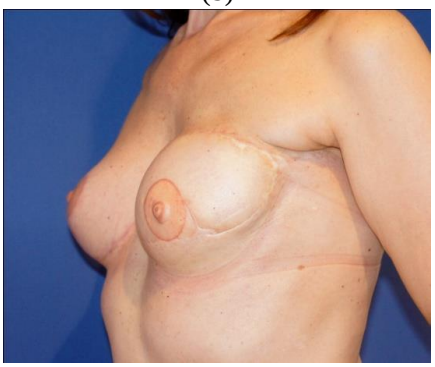

(c)

(d)

Figure 11. Areola tattooing 8 months after breast reconstruction, symmetrization mastopexy and nipple reconstruction.

Special care must be taken with the technique used. Placing the ink superficially leads to its loss, while placing it deeper results in the macrophages disposing of the ink. Either way, the result is premature pigment fading [55]. Furthermore, the sterility of the operation is also an aspect, as it may lead to viral transmission or disease.

The normal evolution after this intervention is performed is that of sloughing and crusting which may go on for as long as 3-5 days. It is recommended that the area be kept moistened with dressings changed daily [1].

CONCLUSION

Reconstruction of the nipple-areolar complex is the last step in breast reconstruction. It is associated with a sense of completeness and of success of the whole process. In order to achieve the best results, it must have regard to achieving symmetry with the contralateral NAC complex, placing them in the correct spot, respecting the correct size and color, in a "like to like" manner, preserving the results in time with the least nipple projection or volume loss.

Classically it is formed in two steps, the first being the nipple reconstruction, and the second being the areola reconstruction, performed either by tattooing or by using a skin graft, keeping in mind that the most common complication to counteract is the loss of projection and/or of volume.

Although, in chronological order, reconstruction of the nipple-areolar complex is the last after several other steps, it may be the most important one, being correlated with overall patient satisfaction.

REFERENCES

[1] Nimboriboonporn, A; Chuthapisith, S. Nipple-areola complex reconstruction. *Gland Surgery* 2014;3(1):35-42.

[2] Few, JW; Marcus, JR; Casas, LA; Aitken, ME; Redding, J. Long-term predictable nipple projection following reconstruction. *Plastic and Reconstructive Surgery* 1999;104(5):1321-1324.

[3] Evans, KK; Rasko, Y; Lenert, J; Olding, M. The use of calcium hydroxylapatite for nipple projection after failed nipple-areolar reconstruction: early results. *Annals of Plastic Surgery* 2005;55(1):25-29.

[4] Sisti, A; Grimaldi, L; Tassinari, J; Cuomo, R; Fortezza, L; Bocchiotti, MA; Roviello, F; D'Aniello, C; Nisi, G. Nipple-areola complex reconstruction techniques: A literature review. *European Journal of Surgical Oncology* 2016;42(4):441-465.

[5] Adams, WM. Free transplantation of the nipples and areola. *Surgery* 1944;15:186.

[6] Adams, WM. Labial transplant for correction of loss of the nipple. *Plastic and Reconstructive Surgery* 1946;1949;4:295-298.

[7] Millard, DR Jr. Nipple and areola reconstruction by split-skin graft from the normal side. *Plastic and Reconstructive Surgery* 1972;50(4):350-353.

[8] Brent, B; Bostwick, J. Nipple-areola reconstruction with auricular tissues. *Plastic and Reconstructive Surgery* 1977;60(3):353-361.
[9] Chang, WH. Nipple reconstruction with a T flap. *Plastic and Reconstructive Surgery* 1984;73(1):140-143.
[10] Patel, MK; Nahabedian, YM. Reconstruction of the nipple-areola complex. In: Neligan CP, editor. *Plastic Surgery,* Third edition, Volume 5 - Breast, Elsevier Saunder, 2013.
[11] Mohamed, SA; Parodi, PC. A modified technique for nipple-areola complex reconstruction. *Indian Journal of Plastic Surgery* 2011;44(1):76-80. doi: 10.4103/0970-0358.81450.
[12] Sanuki, J; Fukuma, E; Uchida, Y. Morphologic study of nipple-areola complex in 600 breasts. *Aesthetic Plastic Surgery* 2009;33(3):295-297.
[13] Nahabedian, MY. Nipple reconstruction. *Clinics in Plastic Surgery* 2007;34(1):131-137.
[14] Munhoz, AM; Montag, E; Filassi, JR; Gemperli, R. Immediate nipple-areola-sparing mastectomy reconstruction: An update on oncological and reconstruction techniques, *World Journal of Clinical Oncology* 2014;5(3):478–494. doi: 10.5306/wjco.v5.i3.478.
[15] Bhatty, MA; Berry, RB. Nipple-areola reconstruction by tattooing and nipple sharing. *British Journal of Plastic Surgery* 1997;50(5):331-334.
[16] Kroll, SS. Nipple reconstruction with the double opposing flap. *Plastic and Reconstructive Surgery* 1999;104:511–514.
[17] Little, JW. Nipple-areolar reconstruction. In: Spear SL, editor. *Surgery of the Breast: Principles and Art*. Philadelphia; Lippincott-Raven Publisher; 1998.
[18] Mendelson, BC. Results of nipple areola reconstruction. *Australia and New Zealand Journal of Surgery* 1983;53(1):63–66.
[19] Asplund, O. Nipple and areola reconstruction. A study in 79 mastectomized women. *Scandinavian Journal of Plastic and Reconstructive Surgery* 1983;17(3):233–240.
[20] Lee, TJ; Noh, HJ; Kim, EK; Eom, JS. Reducing donor site morbidity when reconstructing the nipple using a composite nipple graft. *Archives of Plastic Surgery* 2012;39(4):384-389.
[21] Zenn, MR; Garofalo, JA. Unilateral nipple reconstructionwith nipple sharing: time for a second look. *Plastic and Reconstructive Surgery* 2009;123(6):1648–1653.
[22] Riccio, AC; Zeiderman, RM; Chowdhry, S; Wilhelmi, JB. Review of nipple reconstruction techniques and introduction of v to y Technique in a bilateral wise pattern mastectomy or reduction mammaplasty. *Eplasty* 2015;15:e11.
[23] Tyrone, JW; et al. Nipple areola reconstruction. In: Hultman CS editor. *Breast Reconstruction (Breast Disease)* (Vol. 16). IOS Press, 2003.
[24] Little, JW 3rd. Nipple-areolar reconstruction. *Advances in Plastic Surgery* 1987;3(43).
[25] Nipple Areola Reconstruction available on http://www.breastre construction.org/ SecondaryProcedures/NippleAreolaReconstruction.html. Accessed 31.05.2016.
[26] Shestak, KC; Gabriel, A; Landecker, A; Peters, S; Shestak, A; Kim, J. Assessment of long-term nipple projection: A comparison of three techniques. *Plastic and Reconstructive Surgery* 2002;110(3):780-786.
[27] Zhong, T; Antony, A; Cordeiro, P. Surgical outcomes and nipple projection using the modified skate flap for nipple-areolar reconstruction in a series of 422 implant reconstructions. *Annals of Plastic Surgery* 2009;623:591–595.

[28] Gurunluoglu, R; Shafighi, M; Williams, SA; Kimm, GE. Incorporation of a preexisting scar in the star-flap technique for nipple reconstruction. *Annals of Plastic Surgery* 2012;68(1):17-21.

[29] Alfano, C; Tenna, S; Caggiati, A; Campanella, A. Nipple reconstruction by local flaps: a long-term comparative study between star and skate techniques. *Acta Chirurgiae Plasticae* 2004;46(4):127-131.

[30] Fitoussi, A; Berry, MG; Couturaud, B; Salmon, RJ. *Oncoplastic and Reconstructive Surgery for Breast Cancer: The Institut Curie Experience*. 2009.

[31] Fitoussi, A-D; Pollet, A-G; Couturaud, B; Laki, F; Salmon, R-J. Nipple and areola reconstruction by tattooing, "F" and "Z" flaps. *Annales de chirurgie plastique et esthétique* 2008;53(4):348-357.

[32] Lee, J; Lee, S; Bae, Y. Trans-nipple double Z-plasty for benign periareolar disease with inverted nipple. *Aesthetic Plastic Surgery* 2013;37:327-331.

[33] Lee, J; Bae, Y. Correction of inverted nipple using trans-nipple Z-plasty. *Journal of Breast Disease* 2015;3(1):21-25.

[34] Valdatta, L; Montemurro, P; Tamborini, F; Fidanza, C; Gottardi, A; Scamoni, S. Our experience of nipple reconstruction using the C-V flap technique: 1 year evaluation. *Journal of Plastic, Reconstructive & Aesthetic Surgery* 2009;62(10):1293–1298.

[35] Losken, A; Mackay, GJ; Bostwick, J 3rd. Nipple reconstruction using the C-V flap technique: a long-term evaluation. *Plastic and Reconstructive Surgery* 2001;108(2): 361–369.

[36] Van Laeken, N; Genoway, K. Nipple reconstruction using a two-step purse-string suture technique. *Canadian Journal of Plastic Surgery* 2011;19(2):56-59.

[37] Eng, JS. Bell flap nipple reconstruction – a new wrinkle. *Annals of Plastic Surgery* 1996;36(5):485–488.

[38] Gamboa-Bobadilla, GM. Nipple reconstruction: the top hat technique. *Annals of Plastic Surgery* 2005;54(3):243–246.

[39] Shestak, KC; Nguyen, TD. The double opposing periareola flap: a novel concept for nipple-areola reconstruction. *Plastic and Reconstructive Surgery* 2007;119(2):473–480.

[40] Hammond, DC; Khuthaila, D; Kim, J. The skate flap purse-string technique for nipple-areola complex reconstruction. *Plastic and Reconstructive Surgery* 2007;120(2):399–406.

[41] Kroll, SS; Reece, GP; Miller, MJ; Evans, GR; Robb, GL; Baldwin, BJ; Wang, BG; Schusterman, MA. Comparison of nipple projection with the modified double-opposing tab and star flaps. *Plastic and Reconstructive Surgery* 1997;99(6):1602-1605.

[42] Winocour, S; Saksena, A; Oh, C; Wu, PS; Laungani, A; Baltzer, H; Saint-Cyr, M. A systematic review of comparison of autologous, allogeneic, and synthetic augmentation grafts in nipple reconstruction. *Plastic and Reconstructive Surgery* 2016;137(1):14e-23e.

[43] Bernard, RW; Beran, SJ. Autologous fat graft in nipple reconstruction. *Plastic and Reconstructive Surgery* 2003;112(4):964-968.

[44] Guerra, AB; Khoobehi, K; Metzinger, SE; Allen, RJ. New technique for nipple areola reconstruction: arrow flap and rib cartilage graft for long-lasting nipple projection. *Annals of Plastic Surgery* 2003;50(1):31–37.

[45] Panettiere, P; Marchetti, L; Accorsi, D. Filler injection enhances the projection of the reconstructed nipple: an original easy technique. *Aesthetic Plastic Surgery* 2005;29: 287-294.

[46] Lennox, K; Beer, KR. Nipple contouring with hyaluronics postmastectomy. *Journal of Drugs in Dermatology* 2007;6:1030-1033.

[47] Nahabedian, MY. Secondary nipple reconstruction using local flaps and AlloDerm. *Plastic and Reconstructive Surgery* 2005;115(7):2056-2061.

[48] Garramone, CE; Lam, B. Use of AlloDerm in primary nipple reconstruction to improve long-term nipple projection. *Plastic and Reconstructive Surgery* 2007;119:1663-1668.

[49] Vandeweyerm E. Simultaneous nipple and areola reconstruction: a review of 50 cases. *Acta Chirurgica Belgica* 2003;103(6):593–595.

[50] Kargül, G; Deutinger, M. Reconstruction of the breast areola complex. Comparison of different techniques. *Handchirurgie, Mikrochirurgie, Plastische Chirurgie* 2001;33(2): 133-137.

[51] Chang, BW; Slezak, S; Goldberg, NH. Technical modifications for on-site nipple-areola reconstruction. *Annals of Plastic Surgery* 1992;28(3):277–280.

[52] Pauchot, J; Fleury, M; Pluvy, I; Oulharj, S; Tropet, Y; Obert, L. Stencil technique for areola tattooing. A simple solution for quickly performed, homogeneous tattoos with regular edges. *JPRAS Open* 2015;3:10-12. doi:10.1016/j.jpra.2014.12.003.

[53] Rees, TD. Reconstruction of the breast areola by intradermal tattooing and transfer. Case report. *Plastic and Reconstructive Surgery* 1975;55(5):620–621.

[54] Spear, SL; Convit, R; Little, JW 3rd. Intradermal tattoo as an adjunct to nipple-areola reconstruction. *Plastic and Reconstructive Surgery* 1989;83(5):907–911.

[55] Garg, G; Thamim GP. Micropigmentation: tattooing for medical purposes. *Dermatologic Surgery* 2005;31(8 Pt 1):928–931.

In: Encyclopedia of Surgery (22 Volume Set)
Editors: Andreas Lehrer and Kristin Mueller
ISBN: 978-1-53618-329-0
© 2020 Nova Science Publishers, Inc.

Chapter 178

DEALING WITH COMPLICATIONS AFTER FREE FLAP BREAST RECONSTRUCTION

Raluca Sobec*[*]*, Ioana Tichil and Lucian Fodor
Plastic and Reconstructive Surgery Unit, Emergency County Hospital,
Cluj Napoca, Romania

ABSTRACT

Breast reconstruction using free flaps is a procedure often performed by plastic surgeons. Like any other procedure, it is not without complications, which may occur whether it is an immediate or delayed, unilateral or bilateral reconstruction, with or without pre- or post-operative radiotherapy, in obese or smoking patients. Both the clinical setting and the surgeon's experience are closely related to the rate of these complications. Complications may imply hematomas, infections, vascular impairment, partial or total flap loss, wound dehiscence, hypertrophic scars or donor site complications. More specific to the use of microsurgical techniques are vascular complications: arterial or venous thrombosis and venous congestion.

How do we avoid complications and, if despite all methods of prevention, complications arise, how do we deal with them? The most severe and feared are vascular complications. If they occur, a challenging decision must be made: do we "watch and wait", use conservative methods to prevent impairment, or return the patient to the operating room. Timing of this decision by balancing clinical and objective findings will be the focus of this chapter. For instance, hematomas can lead to external vascular obstruction, and unrecognized or delayed recognition of vascular thrombosis will lead to partial or even total flap loss. Sometimes, partial flap loss is more challenging to deal with in the long-term than total flap loss.

What we intend to highlight in this chapter are: risk factors leading to higher rates of complications, early signs of complications, ways to monitor postoperative patients, and a systematic approach to treatment.

Keywords: free flap, breast reconstruction, complication, flap failure

[*] Corresponding Author's Email: ralucasobec@yahoo.com.

INTRODUCTION

Although breast reconstruction is an ever-expanding field and the overall number of procedures has increased, still less than half of mastectomy patients undergo reconstruction [1]. Breast reconstruction can be performed either as an immediate or a delayed procedure. Currently, the most common is implant-based because of the short operating time, quick recovery and no donor site complications [2]. On the other hand, autologous breast reconstruction, despite the greater risks involved, provides higher levels of patient satisfaction due to the natural shape and consistency of the reconstructed breast, along with long-lasting esthetic results [1]. A wide range of complications associated with this procedure has been reported, with rates varying across different studies. Early complications occur within 30 days [1] of the procedure, such as edema, hematoma, vascular complications, infection and wound dehiscence, whereas delayed complications occur after 30 days, such as hypertrophic scarring and donor site complications. Avoiding complications is primarily a process of thorough patient selection based on an extensive knowledge of the risk factors involved and choosing the optimal reconstructive procedure, well-timed within the clinical setting.

DEALING WITH RISK FACTORS: ANALYSES AND PROPHYLAXIS

A wide range of free flaps can be used for autologous breast reconstruction, yet the most frequently employed are the abdominal-based ones, such as the deep inferior epigastric perforators (DIEP) flap, the muscle-sparing transverse rectus abdominis muscle (TRAM) flap, and the TRAM flap. Risk factors implicated in performing these procedures have been extensively researched and varying data have been reported. Risk factors can be either patient- or procedure-related.

Patient-Related Risk Factors

Radiation

Pre- and post-operative radiation therapy has been implicated in vessel damage and impaired wound healing. To date, several reports have quantified the impact of radiation therapy on free flap breast reconstruction. In a cohort study involving 199 patients, Fracol et al. reported an increase in intraoperative vascular complications (14% vs 7%) as well as wound infections (4% vs 0.5%), but no significant difference in postoperative thrombosis, flap loss, mastectomy flap necrosis, hematoma, seroma, fat necrosis or wound healing in irradiated vs non-irradiated sites [3]. Kelly et al. suggested that immediate free flap breast reconstruction can be considered even when post-mastectomy radiation therapy is involved [4]. Mirzakeigi et al. raised concerns of volume loss and fat necrosis, but did not advise against immediate reconstruction [5].

Chemotherapy

While it has not been implicated in flap loss and microvascular impairment, chemotherapy has been known to increase overall complications, such as wound healing and fat necrosis. Timing of chemotherapy does not significantly affect outcome [6].

Smoking

Smoking causes nicotine-induced vasospasm, tissue hypoxia due to elevated carbon monoxide, and increased platelet aggregation leading to hypercoagulability status which can cause flap vascularity impairment and donor site morbidity. Cessation of smoking must occur at least four weeks prior to surgery [7]. Smokers have twice the chance of developing donor site complications after DIEP flap harvesting for breast reconstruction compared to non-smokers [8].

Obesity/BMI

A BMI of over 30 independently increases the overall risk of complications due to prolonged intraoperative time, technical difficulties, and associated comorbidities [6]. Some surgeons advise their patients with a BMI of over 30 to lose weight before breast reconstruction surgery with free flaps [9].

Age

Increasing age is usually associated with other medical comorbidities, implicated in overall poorer surgical outcomes. However, complication rates, including vascular thrombosis following autologous breast reconstruction, do not appear to be significantly higher, leading to the conclusion that age is not an independent risk factor and elderly patients, if fit, can benefit from free flap breast reconstruction [10].

Medical Comorbidities

Diabetes and hypertension impact blood vessels structurally and functionally, leading to a higher possibility of both minor and major complications. Good control of glycemic and blood pressure values is mandatory.

Mastectomy Type

Skin-sparing mastectomies (SSM) and nipple-sparing mastectomies (NSM) present the obvious advantage of retaining the original skin envelope and use the free flap to recreate the volume and shape of the breast with good final overall esthetic results. However, they provide difficult access to the internal mammary vessels, which may lead to unforeseen vascular complications. On the other hand, in the case of both SSM and NSM, an implant-based type of reconstruction is usually preferred. This may sometimes lead to unsatisfactory results and salvage procedures, including reconstruction with autologous tissue, may be required to correct them. In a recently published study, Roostaeian et al. found that capsular contracture was incriminated in 62% of cases of implant removal. Accompanying high rates of radiation therapy also lead to recipient vessel scarring 5.23 times more often. This led them to conclude that major complications are more likely to occur when performing salvage reconstruction. However, the procedure can be safely performed with additional preoperative planning with success rates similar to primary flap-based reconstructions [2].

Prior Abdominal Surgery

Abdominal scars raise the question of viable perforators. Adequate preoperative assessment using computed tomography angiography is most useful. Intraoperative bipedicled perforator flaps or supercharging across scars can allow the usage of large volumes of tissue crossing the midline. However, when in doubt, muscle-sparing TRAM flaps are recommended [11].

Nulliparity

Santanelli et al. recently related nulliparity to several perfusion-related complications (PRC), including fat necrosis and partial flap loss, due to a weaker pattern of perforators, as well as smaller angiosomes. Their recommendation for PRC risk reduction is the use of medial row perforators combined with crystalloid/colloid fluid infusion [12].

PROCEDURE-RELATED RISK FACTORS

VTE Prophylaxis

Venous thromboembolism prophylaxis can be achieved based on accurate risk assessment by physical measures, using compression stockings, intermittent calf compression, and low molecular weight heparin on the day prior to surgery. The use of anticoagulants is a much-debated topic. The recent reduced operative times and complication rates, as well as the employment of perforator flaps, has led to faster mobilization, which has made for fewer combined antithrombotic regimens. Recent studies highlight the risk that multiple antithrombotics increase the hematoma reoperation rate [13].

Anesthetic Management

Anesthetic management should aim to provide a high cardiac output with a systolic blood pressure over 100mmHg, low peripheral vascular resistance, normothermia, excellent analgesia and good urine output, as well as mild hemodilution Hematocrit: 30-35% [14], and ensure good flap perfusion. Optimal intraoperative fluid management should adequately provide all of the above. However, overzealous fluid administration targeting supranormal blood pressure values is not recommended, for it will result in interstitial edema which could compromise blood flow and gas exchange at flap microcirculation levels [13]. On the other hand, fluid under-resuscitation may place the patient at risk for postoperative flap thrombosis [15]. It is also recommended that vasoconstrictive drugs should be avoided.

Timing of Reconstruction

There is a consensus in the literature that immediate reconstruction lowers the overall number of procedures, hospital stays, and medical system costs, thereby providing the patient with the best possible outcome and limiting complication rates. It has been agreed that

reconstruction can be safely performed even when radiotherapy is involved [3-5]. When performing delayed reconstruction, however, we must rely on mastectomy skin flaps which are mostly scarred, contracted and far less compliant, as well as face higher rates of vascular complications [16].

Free Flap Choice

Generally, for free flap breast reconstruction, abdominal-based flaps, such as DIEP and TRAM flaps, are preferred. They have proved to be safe and reliable with well-documented donor site morbidity. Lately, with the progression of microsurgical techniques and postoperative monitoring, DIEP flaps have become the reconstructive method of choice, due to the lower risk of abdominal bulge and hernia when compared with free TRAM flaps [9]. Another abdominal flap which was described for breast reconstruction is the superficial inferior epigastric artery (SIEA) flap. Although less common and mostly reserved for patients who either require a small-sized breast reconstruction or have insufficient abdominal tissue or extensive abdominal scarring, free flaps from the thigh or buttock can also be used. Such flaps are the superior gluteal artery perforator (SGAP), the inferior gluteal artery perforator (IGAP), the fasciocutaneous infragluteal (FCI), the transverse upper gracilis (TUG), and the profunda artery perforator (PAP) flaps. However, fairly recent employment of these flaps has not led to extensive literature documenting complications and outcomes, compared to abdominal-based free flap breast reconstruction.

Intraoperative Management

Technical issues resulting in arterial thrombosis or venous insufficiency have been known to be dominant factors in overall flap failure rates. Most notably, operative time has been proved to be an independent risk factor for flap loss [17]. Operative time can be prolonged for various reasons: combined mastectomy and reconstructive procedures, especially if bilateral, high complexity and technical difficulty in secondary procedures due to extensive scarring impacting both flap harvest and anastomoses, and/or surgeon inexperience with microsurgery. Ways to minimize operative time include having experienced surgeons perform the procedure, two teams working simultaneously, good preoperative mapping of perforators used for safe and expedited flap harvest, use of microvascular anastomotic coupler for venous anastomoses, and the employment of mechanical sutures for subcutaneous wound closure. Ultimately, ischemia time is an important consideration when discussing microvascular complications, as well as a good predictor of flap outcome [17]. Morris et al. studied changes in flaps submitted to 4, 6, and 8h of ischemia and noticed a significant extent of necrosis when compared with controls, leading them to conclude that an ischemia time no longer than 2h is desirable [18]. Prolonged ischemia time has also been associated with microvascular thrombosis and venous congestion in flaps with adequate perforators. It has been hypothesized that metabolic and structural changes occur within blood vessels during ischemia, and reperfusion further traumatizes the anastomosis site [19].

The internal mammary vessels are frequently used as recipient vessels for free flap breast reconstruction. There are studies showing the presence of tachycardia related to internal

mammary vessels anastomoses [20]. Some studies did not find higher complication rates in patients who developed the internal mammary artery tachycardia syndrome [20], but others noticed an increased incidence of complications, such as vascular impairment, venous thrombosis or wound healing related problems [21].

Blood Loss and Transfusions

Anemia and hypovolemia have been known to complicate procedure outcome, patient morbidity and overall recovery. Currently, it is largely accepted that blood transfusions after free flap breast surgery should be administered based on clinical signs of hypovolemia and hemoglobin levels less than 7g/dl. This is most likely to occur in cases of bilateral reconstruction and preoperative anemia. However, blood transfusions are regarded with much skepticism, due to possible involvement of increased microvascular complication rates. The bottom line is that intraoperative efforts must be made to limit blood loss, and adequate perioperative fluid resuscitation must be conducted in order to efficiently avoid hypovolemia.

DEALING WITH COMPLICATIONS

Postoperative Monitoring

The first 72 hours after free flap breast reconstructions are when microvascular complications arise; therefore, close monitoring is mandatory, hourly during the first 24 hours and three-hourly for the next two days. It is well established that early detection and prompt reoperation of perfusion problems can increase flap salvage. Surgeons and their Residents, as well as trained specialized nursing staff, must conduct clinical observation. The color, consistency, temperature and capillary refill of the flap need to be recorded, along with continuous drain monitoring. Recently, objective tools have been used to increase diagnostic accuracy, such as implantable and surface Doppler monitoring, quantitative fluorescence, near-infrared spectrophotometry, visible light spectroscopy, thermography, transcutaneous oxygen measurements, and microanalysis [22]. However, to date no one method has been found to be ideal and various factors may interfere in clinical findings, so that objective measurements must be balanced along with the surgeon's experience when making the decision to take the patient back to the operating room. Such early complications requiring early detection and timely intervention are:

Edema

Postoperative edema that was not present intraoperatively could have many causes, such as an inflammatory byproduct of flap manipulation or a sign of fluid overload, or an early sign of perfusion problems [14, 19]. It must be carefully monitored and interpreted along with other clinical findings, such as flap color, temperature and capillary refill. If prolonged flap edema produces harmful pressure on the anastomosis site leading to microvascular complications, this can by eased by selective removal of sutures and prompt revision of the fluid chart.

Hematoma

Whether it appears from a flap bleeding source or from an anterior thoracic wall bleeding source, being in the microsurgical anastomosis neighborhood, before or after drains removal, makes a hematoma a serious threat for the proper arterial inflow and venous outflow of the flap. Any compression of the flap's pedicle may lead to partial or total loss of the flap. There are studies highlighting surgical management of a hematoma as high as 13%, not only to remove the hematoma, but also to correct the secondary complications: venous congestion or flap thrombosis [13].

Hematoma in the reconstructed breast is not an often seen complication, usually ranging from 2.89-4.4% [9, 23, 24]. A higher incidence of breast hematoma was encountered after double free flap breast reconstruction [24].

Microvascular Complications

Microvascular complications are probably the worst and the most frightening complications for the Plastic Surgeon. These kinds of complications are the easiest way to lose a flap, and a high percentage are due to the surgeon's microsurgical skills. When referring to microvascular complications, we include arterial and venous thrombosis and also venous congestion.

Tamoxifen, a selective estrogen-receptor modulator frequently used in breast cancer patients, was debated for a long time regarding its possible pro-thrombotic effect on free flap breast reconstruction. Some authors considered tamoxifen to be a thrombotic risk factor, others considered that the prothrombotic effect would be minimized by stopping the tamoxifen two weeks prior to free flap breast reconstruction surgery [25], and others did not consider it as affecting in any way the thrombotic complications of the flap [26]. We prefer to reduce as much as possible any thrombotic risks, so we tell our patients to withhold the tamoxifen for two weeks before free flap breast reconstruction surgery.

Arterial Thrombosis

Clinical aspects of arterial thrombosis include a pale and cold flap, absent capillary refill, or absent Doppler signal at the perforator site. Arterial thrombosis may appear intraoperatively, immediate or late postoperatively. No matter when it happens, it is an emergency and needs re-exploration of the anastomosis in an attempt to save the flap. If the flap cannot be saved after re-exploration of the anastomosis, it needs to be removed.

It is also known that intraoperative microanastomotic technical problems are associated with higher delayed arterial thrombosis [27]. Arterial thrombosis can lead to partial or even total flap loss. In a study on 169 free flap breast reconstruction with DIEP flaps (125 cases) and SIEA (44 cases), Coroneos et al. concluded that higher rates of arterial thrombosis were met in SIEA flap breast reconstruction compared with DIEP flap [28]. Lower SIEA free flap success rates were found in other studies, too, compared with DIEP free flaps, with total necrosis of the flaps as high as 12% [29].

Venous Congestion

Venous congestion occurs intraoperatively in 3.3% of DIEP flaps and 1% of TRAM flaps [30]. Lower incidences are related to secondary venous anastomosis (frequently superficial inferior epigastric vein to cephalic vein) [29]. During abdominal-based flap dissection, the

superficial venous system is interrupted, and it is up to the deep venous system to provide adequate drainage. Venous insufficiency is not a routine issue on the ipsilateral side, but problems may arise concerning the contralateral side because of restricted drainage across the midline [23]. If noticed intraoperatively, venous congestion must be addressed. Solutions vary from simple to complex. In the case of DIEP flaps, most used is the second DIE vena comitante which can be anastomosed to the second internal mammary vein. It is not advisable to use the distal stump of the IM vein because it may have valves. If this does not provide sufficient relief, the superficial inferior epigastric vein (SIEV) usually preserved during flap dissection can either be anastomosed to the main pedicle or to the cephalic, circumflex scapular or toracodorsal vein, according to the surgeon's preference. If neither vein can be used, the contralateral DIE venous system or the cephalic end of the ipsilateral DIE vein can be considered as options. If no additional procedures offer sufficient relief, flap reduction must be considered [22].

Authors have reported a reduction of venous congestion incidence by primarily performing two venous anastomoses; however, this has not become routine practice [31]. If no venous congestion is noted intraoperatively but it occurs postoperatively, it requires urgent exploration of the venous anastomosis and, if viable, performing a secondary anastomosis to relieve outflow is advised. In selected cases of mild venous congestion, conservative measures may apply, such as leach therapy or the topical use of nitroglycerine [32].

Venous Thrombosis

Venous thrombosis occurs more often than arterial thrombosis with reported rates as high as 10% [33] and has higher salvage rates [34]. Clinical findings are similar to venous congestion: edema, bluish discoloration, accelerated capillary refill. Urgent exploration of the venous anastomoses must be conducted. Early detection has been reported with the use of an implantable Doppler probe and venous flow coupler [35].

Infection

As in any other infection, the clinical signs are edema, erythema and local warmth, induration, possibly the presence of pus. Treatment ranges from oral antibiotics to intravenous antibiotics, depending on the severity of the infection. Sometimes surgical debridement might be necessary. Fortunately, low incidences of flap infection are encountered [23]. Compared with bilateral free flap breast reconstruction, the incidence of infections seems to be higher in unilateral free flap breast reconstruction [24].

Wound Dehiscence

Wound dehiscence is secondary to local infection or marginal necrosis, with or without partial flap loss. Surgical debridement is usually necessary, followed by secondary wound closure. In small wound dehiscence, conservative management might be sufficient for a good result. In case of wound dehiscence secondary to local infection, antibiotic treatment must be added.

PERFUSION-RELATED COMPLICATIONS

Fat Necrosis

Fat necrosis is a well-established perfusion-related complication that has been known to occur in up to 19.1% of cases [36]. There is general consensus that, if it occurs, fat necrosis should be managed conservatively, and any contour defects can be addressed at a later date by using fat grafting. Preventing such complications, however, has been the focus of much research. Recently, Lee et al. suggested that preoperative volumetric planning using computerized tomographic angiography can aid in decreasing perfusion-related complications [36].

Flap Failure

Current flap failure rates reported by specialized centers range from 0.5% to 2.5% [9, 23], with partial flap failure rates higher than total flap failure. Leading causes are venous congestion and thrombosis [9, 23, 37]. Flap failure is a major setback in patient care with a negative impact on the patient's psychological status. Therefore, adequate counseling and support must be provided. Also, it adds to overall costs, increases hospital stay, and raises the need for a further procedure. For all these reasons, strenuous efforts must be made to identify the cause of flap failure, as such cases can provide valuable lessons. The questions are: was it failure to plan, failure to execute, failure to monitor, or the association of multiple risk factors.

Accurately identifying the cause can improve future conduct and influence further reconstructive decisions. For instance, cases of essential thrombocytosis or thrombophilia [23, 38] have been diagnosed post flap failure and this has guided the decision of further performing an implant-based breast reconstruction instead of another free flap. Both partial and total flap loss must be managed with early debridement in order to prevent infection and salvage as much viable tissue as possible. In the case of primary reconstruction post skin-sparing mastectomy, skin flaps can provide sufficient wound coverage for primary closure and allow for delayed reconstruction. Other options would be to consider another free flap from the thigh or buttock and attempt a primary reconstruction, or to perform an implant-based reconstruction with a *latissimus dorsi* (LD) flap. On the other hand, for delayed reconstructions in case of flap failure, there is not enough skin to primarily close the wound after debridement and, in order to avoid using a skin graft, another free flap reconstruction should be considered, as well as an LD flap.

Donor Site Complications

These generally include seroma, hematoma formation, infection, delayed wound healing and scarring. More specific to the use of abdominal-based free flaps for breast reconstruction are mesh complications, hernia and abdominal bulge. Morbidity associated with thigh and buttock based flaps is related to long-term contour defects that may represent a challenge in

correcting. In this regard, least impairing, in our opinion, is the FCI flap when small to medium volumes are employed for breast reconstruction in patients with insufficient abdominal tissue, leading to high levels of patient satisfaction.

Recently, Mirzabeigi et al. reviewed an under-reported complication of abdominal-based free flaps: chronic wound healing. In a study reviewing 1218 patients, they found 13.7% cases of delayed wound healing, which was related to abdominal wall sequelae, such as hernia. Risk factors for delayed wound healing at 30 days leading to chronic abdominal wounds were found to be obesity, smoking, bilateral reconstruction, preoperative chemotherapy, and the use of abdominal mesh. Their recommendation in dealing with this complication was to perform early postoperative debridement and primary wound closure in order to improve patient outcomes [39].

Scarring

Body image is very important when talking about self-esteem. Scars are part of a patient's life after any surgery. When talking about scars after breast reconstruction, we need to deal with scars at the place of reconstruction and at the donor site. Studies show that patients usually prefer donor site scars for breast reconstruction in a body area that they do not see [40, 41]. For example, the LD flap scar was preferred over the DIEP flap scar [41]; even better, the SGAP scar was preferred over the DIEP flap scar [40].

On the other hand, when talking about post breast reconstruction scars, more than half the patients prefer the scar after immediate DIEP flap reconstruction, compared with LD, expander/implant or delayed DIEP flap reconstruction [40].

Like any other scars, these scars might transform into hypertrophic or, even worse, keloid scars. The methods of treatment for these pathologic scars vary from surgical treatment to intralesional corticosteroid injections, laser therapy, silicone sheet, radiotherapy or a combination of these methods.

Other Complications

Other rare complications have been encountered when dealing with free flap breast reconstruction methods. Internal mammary artery tachycardia syndrome was described in those patients in whom the anastomosis of the flap's pedicle was performed at the internal mammary vessels. This tachycardia syndrome was more frequent in cases of anastomosis to the internal mammary vessels compared to the thoracodorsal vessels (58% vs 23%) [20]. A case of cardiac tamponade followed by cardiac arrest was reported, secondary to left internal mammary vessels isolation for microsurgical anastomosis for breast reconstruction [42].

CONCLUSION

When an acute thrombotic event is identified early in the first few hours after surgery, we are in favor of trying a salvage procedure. However, when late onset of thrombosis is

identified or unrecognized, in our experience all efforts at salvage are in vain and only put the patient under stress.

REFERENCES

[1] Duraes, E. F., Schwarz, G., Durand, P., Moreira-Gonzalez, A., Duraes, L. C., de Sousa, J. B., Djohan, R. S., Zins, J. & Bernard, S. L. (2015). Complications Following Abdominal-Based Free Flap Breast Reconstruction: Is a 30 days Complication Rate Representative? *Aesthetic Plast Surg.*, *39*(5), 694-9.

[2] Roostaeian, J., Yoon, A. P., Ordon, S., Gold, C., Crisera, C., Festekjian, J., Da Lio, A. & Lipa, J. E. (2016). Impact of Prior Tissue Expander/Implant on Postmastectomy Free Flap Breast Reconstruction. *Plastic and reconstructive surgery.*, *137*(4), 1083-91.

[3] Fracol, M. E., Basta, M. N., Nelson, J. A., Fischer, J. P., Wu, L. C., Serletti, J. M. & Fosnot, J. (2016). Bilateral Free Flap Breast Reconstruction After Unilateral Radiation: Comparing Intraoperative Vascular Complications and Postoperative Outcomes in Radiated Versus Nonradiated Breasts. *Annals of plastic surgery.*, *76*(3), 311-4.

[4] Kelley, B. P., Ahmed, R., Kidwell, K. M., Kozlow, J. H., Chung, K. C. & Momoh, A. O. (2014). A systematic review of morbidity associated with autologous breast reconstruction before and after exposure to radiotherapy: are current practices ideal? *Ann Surg Oncol.*, *21*(5), 1732-8.

[5] Mirzabeigi, M. N., Smartt, J. M., Nelson, J. A., Fosnot, J., Serletti, J. M. & Wu, L. C. (2013). An assessment of the risks and benefits of immediate autologous breast reconstruction in patients undergoing postmastectomy radiation therapy. *Annals of plastic surgery.*, *71*(2), 149-55.

[6] Voineskos, S. H., Frank, S. G. & Cordeiro, P. G. (2015). Breast reconstruction following conservative mastectomies: predictors of complications and outcomes. *Gland Surg.*, *4*(6), 484-96.

[7] Chang, D. W., Reece, G. P., Wang, B., Robb, G. L., Miller, M. J., Evans, G. R., Langstein, H. N. & Kroll, S. S. (2000). Effect of smoking on complications in patients undergoing free TRAM flap breast reconstruction. *Plastic and reconstructive surgery.*, *105*(7), 2374-80.

[8] Klasson, S., Nyman, J., Svensson, H. & Velander, P. (2016). Smoking increases donor site complications in breast reconstruction with DIEP flap. *Journal of plastic surgery and hand surgery*, 1-5.

[9] Seidenstuecker, K., van Waes, C., Munder, B. I., Claes, K. E., Witzel, C., Roche, N., Stillaert, F., Mahajan, A. L., Andree, C. & Blondeel, P. N. (2016). DIEAP flap for safe definitive autologous breast reconstruction. *Breast.*, *26*, 59-66.

[10] Song, D., Slater, K., Papsdorf, M., Van Laeken, N., Zhong, T., Hazen, A., Vidal, D. & Macadam, S. A. (2016). Autologous Breast Reconstruction in Women Older Than 65 Years Versus Women Younger Than 65 Years: A Multi-Center Analysis. *Annals of plastic surgery.*, *76*(2), 155-63.

[11] Nykiel, M., Hunter, C. & Lee, G. K. (2015). Algorithmic approach to the design and harvest of abdominal flaps for microvascular breast reconstruction in patients with abdominal scars. *Annals of plastic surgery.*, *74* Suppl 1, S33-40.

[12] Santanelli, F., Longo, B., Cagli, B., Pugliese, P., Sorotos, M. & Paolini, G. (2015). Predictive and protective factors for partial necrosis in DIEP flap breast reconstruction: does nulliparity bias flap viability? *Annals of plastic surgery.*, *74*(1), 47-51.

[13] Halle, M., Docherty Skogh, A. C., Friberg, A. & Edsander-Nord, A. (2016). Breast free flap complications related to haematoma formation - do the risks of multiple antithrombotics outweigh the benefits today? *Journal of plastic surgery and hand surgery*, 1-5.

[14] Booi, D. I. (2011). Perioperative fluid overload increases anastomosis thrombosis in the free TRAM flap used for breast reconstruction. *European journal of plastic surgery.*, *34*(2), 81-6.

[15] Nelson, J. A., Fischer, J. P., Grover, R., Mirzabeigi, M. N., Nelson, P., Wes, A. M., Au, A., Serletti, J. M. & Wu, L. C. (2015). Intraoperative perfusion management impacts postoperative outcomes: an analysis of 682 autologous breast reconstruction patients. *Journal of plastic, reconstructive & aesthetic surgery: JPRAS.*, *68*(2), 175-83.

[16] Masoomi, H., Clark, E. G., Paydar, K. Z., Evans, G. R., Nguyen, A., Kobayashi, M. R. & Wirth, G. A. (2014). Predictive risk factors of free flap thrombosis in breast reconstruction surgery. *Microsurgery.*, *34*(8), 589-94.

[17] Wong, A. K., Joanna Nguyen, T., Peric, M., Shahabi, A., Vidar, E. N., Hwang, B. H., Niknam Leilabadi, S., Chan, L. S. & Urata, M. M. (2015). Analysis of risk factors associated with microvascular free flap failure using a multi-institutional database. *Microsurgery.*, *35*(1), 6-12.

[18] Morris, S. F., Pang, C. Y., Zhong, A., Boyd, B. & Forrest, C. R. (1993). Assessment of ischemia-induced reperfusion injury in the pig latissimus dorsi myocutaneous flap model. *Plastic and reconstructive surgery.*, *92*(6), 1162-72.

[19] Marre, D. & Hontanilla, B. (2013). Increments in ischaemia time induces microvascular complications in the DIEP flap for breast reconstruction. *Journal of plastic, reconstructive & aesthetic surgery: JPRAS.*, *66*(1), 80-6.

[20] Sachanandani, N. S., Kale, S. S., Skolnick, G. B., Barbour, J. R. & Myckatyn, T. M. (2015). Tachycardia in breast reconstructive microsurgery: Affirmation of the IMA tachycardia syndrome. *Journal of plastic, reconstructive & aesthetic surgery: JPRAS.*, *68*(6), 787-91.

[21] Fischer, J. P., Nelson, J. A., Mirzabeigi, M. N., Serletti, J. M. & Kanchwala, S. (2012). Perioperative hemodynamics in free flap breast reconstruction: incidence, predictors, and management of tachycardia. *Annals of plastic surgery.*, *69*(4), 356-60.

[22] Ozturk, C. N., Ozturk, C., Ledinh, W., Bozkurt, M., Schwarz, G., O'Rourke, C. & Djohan, R. (2015). Variables affecting postoperative tissue perfusion monitoring in free flap breast reconstruction. *Microsurgery.*, *35*(2), 123-8.

[23] Damen, T. H., Morritt, A. N., Zhong, T., Ahmad, J. & Hofer, S. O. (2013). Improving outcomes in microsurgical breast reconstruction: lessons learnt from 406 consecutive DIEP/TRAM flaps performed by a single surgeon. *Journal of plastic, reconstructive & aesthetic surgery: JPRAS.*, *66*(8), 1032-8.

[24] Wormald, J. C., Wade, R. G. & Figus, A. (2014). The increased risk of adverse outcomes in bilateral deep inferior epigastric artery perforator flap breast reconstruction compared to unilateral reconstruction: a systematic review and meta-analysis. *Journal of plastic, reconstructive & aesthetic surgery: JPRAS.*, *67*(2), 143-56.

[25] Mirzabeigi, M. N., Nelson, J. A., Fischer, J. P., Kovach, S. J., Serletti, J. M., Wu, L. C. & Kanchwala, S. (2015). Tamoxifen (selective estrogen-receptor modulators) and aromatase inhibitors as potential perioperative thrombotic risk factors in free flap breast reconstruction. *Plastic and reconstructive surgery.*, *135*(4), 670e-9e.

[26] Salibian, A. A., Bokarius, A. V., Gu, J., Lee, Y., Wirth, G. A., Paydar, K. Z., Kobayashi, M. R. & Evans, G. R. (2016). The Effects of Perioperative Tamoxifen Therapy on Microvascular Flap Complications in Transverse Rectus Abdominis Myocutaneous/Deep Inferior Epigastric Perforator Flap Breast Reconstruction. *Annals of plastic surgery*.

[27] Fosnot, J., Jandali, S., Low, D. W., Kovach, S. J., 3rd, Wu, L. C. & Serletti, J. M. (2011). Closer to an understanding of fate: the role of vascular complications in free flap breast reconstruction. *Plastic and reconstructive surgery.*, *128*(4), 835-43.

[28] Coroneos, C. J., Heller, A. M., Voineskos, S. H. & Avram, R. (2015). SIEA versus DIEP Arterial Complications: A Cohort Study. *Plastic and reconstructive surgery.*, *135*(5), 802e-7e.

[29] Acosta, R., Smit, J. M., Audolfsson, T., Darcy, C. M., Enajat, M., Kildal, M. & Liss, A. G. (2011). A clinical review of 9 years of free perforator flap breast reconstructions: an analysis of 675 flaps and the influence of new techniques on clinical practice. *Journal of reconstructive microsurgery.*, *27*(2), 91-8.

[30] Kim, D. Y., Lee, T. J., Kim, E. K., Yun, J. & Eom, J. S. (2015). Intraoperative venous congestion in free transverse rectus abdominis musculocutaneous and deep inferior epigastric artery perforator flaps during breast reconstruction: A systematic review. *Plast Surg (Oakv).*, *23*(4), 255-9.

[31] Enajat, M., Rozen, W. M., Whitaker, I. S., Smit, J. M. & Acosta, R. (2010). A single center comparison of one versus two venous anastomoses in 564 consecutive DIEP flaps: investigating the effect on venous congestion and flap survival. *Microsurgery.*, *30*(3), 185-91.

[32] Gdalevitch, P., Van Laeken, N., Bahng, S., Ho, A., Bovill, E., Lennox, P., Brasher, P. & Macadam, S. (2015). Effects of nitroglycerin ointment on mastectomy flap necrosis in immediate breast reconstruction: a randomized controlled trial. *Plastic and reconstructive surgery.*, *135*(6), 1530-9.

[33] Nahabedian, M. Y., Momen, B., Galdino, G. & Manson, P. N. (2002). Breast Reconstruction with the free TRAM or DIEP flap: patient selection, choice of flap, and outcome. *Plastic and reconstructive surgery.*, *110*(2), 466-75, discussion 76-7.

[34] Bui, D. T., Cordeiro, P. G., Hu, Q. Y., Disa, J. J., Pusic, A. & Mehrara, B. J. (2007). Free flap reexploration: indications, treatment, and outcomes in 1193 free flaps. *Plastic and reconstructive surgery.*, *119*(7), 2092-100.

[35] Um, G. T., Chang, J., Louie, O., Colohan, S. M., Said, H. K., Neligan, P. C. & Mathes, D. W. (2014). Implantable Cook-Swartz Doppler probe versus Synovis Flow Coupler for the post-operative monitoring of free flap breast reconstruction. *Journal of plastic, reconstructive & aesthetic surgery: JPRAS.*, *67*(7), 960-6.

[36] Lee, K. T. & Mun, G. H. (2016). Volumetric Planning Using Computed Tomographic Angiography Improves Clinical Outcomes in DIEP Flap Breast Reconstruction. *Plastic and reconstructive surgery.*, *137*(5), 771e-80e.

[37] Massenburg, B. B., Sanati-Mehrizy, P., Ingargiola, M. J., Rosa, J. H. & Taub, P. J. (2015). Flap Failure and Wound Complications in Autologous Breast Reconstruction: A National Perspective. *Aesthetic Plast Surg.*, *39*(6), 902-9.

[38] Senchenkov, A., Lemaine, V. & Tran, N. V. (2015). Management of perioperative microvascular thrombotic complications - The use of multiagent anticoagulation algorithm in 395 consecutive free flaps. *Journal of plastic, reconstructive & aesthetic surgery: JPRAS.*, *68*(9), 1293-303.

[39] Mirzabeigi, M. N., Wilson, A. J., Fischer, J. P., Basta, M., Kanchwala, S., Kovach, S. J., Serletti, J. M. & Wu, L. C. (2015). Predicting and managing donor-site wound complications in abdominally based free flap breast reconstruction: improved outcomes with early reoperative closure. *Plastic and reconstructive surgery.*, *135*(1), 14-23.

[40] Joyce, C. W., Murphy, S., Kelly, J. L. & Morrison, C. M. (2015). Scar Wars: Preferences in Breast Surgery. *Archives of plastic surgery.*, *42*(5), 596-600.

[41] Lindegren, A., Halle, M., Docherty Skogh, A. C. & Edsander-Nord, A. (2012). Postmastectomy breast reconstruction in the irradiated breast: a comparative study of DIEP and latissimus dorsi flap outcome. *Plastic and reconstructive surgery.*, *130*(1), 10-8.

[42] Pratt, G. F., Faris, J. G., Lethbridge, M. & Teh, L. G. (2009). Breast reconstruction with a free DIEP (TRAM) flap complicated by cardiac tamponade and arrest: a case report. *Journal of plastic, reconstructive & aesthetic surgery: JPRAS.*, *62*(3), e73-5.

In: Encyclopedia of Surgery (22 Volume Set)
Editors: Andreas Lehrer and Kristin Mueller
ISBN: 978-1-53618-329-0
© 2020 Nova Science Publishers, Inc.

Chapter 179

MANAGING COMPLICATIONS IN FREE-FLAP BREAST RECONSTRUCTION

Gordon K. Lee[1], Jarom N. Gilstrap[1] and Jennifer E. Cheesborough[2]
[1]Plastic Surgery at Stanford University, Stanford, CA, US
[2]Northwestern University, Evanston, IL, US

ABSTRACT

Breast cancer treatment remains on the forefront of healthcare in the United States, affecting nearly one in eight women in their lifetime [1]. With increasing awareness and policy changes, such as the Women's Health and Cancer Rights Act of 1998 [2], breast reconstruction rates have continuously climbed over the last two decades, a nearly 35% increase since 2000 [3]. Breast reconstruction with free autologous tissue, gaining widespread popularity in the 1990's, can provide a natural, aesthetic breast shape while avoiding many of the pitfalls associated with implant-based reconstruction [4-6]. The number of available donor sites and flap types has also increased dramatically in recent years. Today, autologous tissue constitutes close to 20% of breast reconstruction [7].

CONSIDERATIONS FOR FREE-FLAP RECONSTRUCTION

There is no one "best" method for breast reconstruction, as evidenced by the variety of methods seen in practice today. However, there may be a "perfect" method for an individual patient. Appreciating several factors when deciding on the method of reconstruction is critical. Among these are:

- *Patient factors*- obesity and other comorbid conditions, bleeding disorders, tobacco use, available donor tissue, lifestyle, previous surgery, recreational and occupational activities, preference, and need for adjuvant therapy.
- *Surgeon/Facility factors*- Surgeon training/background and comfort with microsurgical practices, availability of operating room equipment, personnel and adequate post-operative monitoring.

- *Mastectomy and incision type*- Traditional modified radical mastectomy, skin-sparing mastectomy, nipple-sparing mastectomy (including incision for approach) and surgical technique of extirpative surgeon.

TIMING

The timing of reconstruction plays a role in outcomes. Immediate autologous reconstruction is usually reserved for patients with early stage cancer who do not require post-operative radiation. Several studies have demonstrated the benefits of reconstruction for the breast cancer patient's body image and quality of life [8, 9]. Delayed reconstruction is usually recommended for patients who will require radiation, although this remains controversial. Delayed reconstruction is also indicated for those patients who underwent mastectomy at a center that does not have a plastic surgeon available for immediate reconstruction, those who have lost their implant-based reconstruction due to infection, and for patients who elected to postpone their reconstruction in order to begin adjuvant therapy. Compared with the aesthetic results obtained from immediate reconstructions in which the majority of the breast skin is maintained, delayed reconstructions yield modest results [10-12]. More recently, a delayed-immediate approach has been developed for individuals with intermediate disease whose radiotherapy needs are undetermined prior to mastectomy and lymph node assessment [13].

RISK FACTORS

Several factors have been linked to increased risk of complication in free tissue-based reconstruction. Factors include: Smoking [14], obesity [15-18], diabetes [19], breast size, bleeding disorders, and previous abdominal surgery [20, 21].

COMPLICATIONS AND MANAGEMENT

Understanding the diagnosis and management options of free flap complications is vital to patient care. Complications will be divided into three categories and discussed in depth:

Complications Related to Reconstructed Breast:

Anastomotic failure, total free flap loss, partial flap loss [22-24], fat necrosis [25], mastectomy flap necrosis, hematoma, seroma, infection, pneumothorax

Complications Related to Donor Site:

Hematoma, seroma, delayed wound healing, dehiscence, abdominal skin flap necrosis, numbness/altered sensation, abdominal wall weakness, hernia [26, 27]

Complications Related to Prolonged Surgical Time:

Myocardial infarction, cerebrovascular accident, venous thromboembolism, pressure ulcers, compressive neuropathies

COMPLICATIONS RELATED TO THE RECONSTRUCTED BREAST

Anastomotic Failure

Creation of a patent microsurgical anastomosis is a skill requiring practice and refinement, however, even the most experienced microsurgeon will occasionally experience problems with a vessel requiring revision. A published failure rate of 3-5% means that if one does enough free flaps, one will eventually fail (Figure 1).

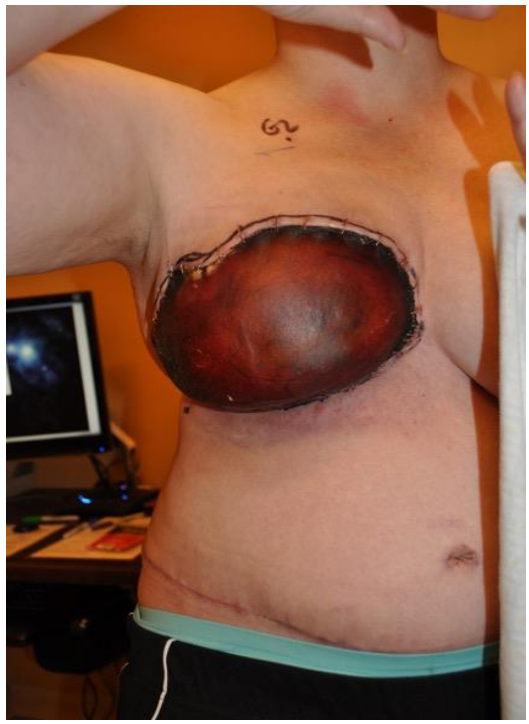

Figure 1. Total flap loss.

Diagnosis

Anastomotic failure can be either arterial or venous in origin and can be subdivided into complete occlusion or insufficient flow. Arterial occlusion is diagnosed clinically as a pale, cool flap with poor turgor (Figure 2), whereas a venous problem will manifest as a swollen, purple flap with rapid capillary refill and brisk, dark bleeding (Figure 3). Timing is key and early recognition of vascular compromise is vital to flap salvage (Figures 4 and 5). These issues can be identified in the operating room or may not be apparent until the post-operative period. Thrombosis typically occurs within the first 48 hours in 80% of patients. Monitoring the free flap during the postoperative phase is critical to ensuring flap survival in the event of anastomotic failure. When recognized early and managed promptly, compromised flaps have a 75% salvage rate when taken back to the operating room. Thus, all personnel responsible for flap monitoring must be knowledgeable about the appearance and evaluation of the healthy and compromised flap.

Figure 2. Arterial insufficiency presents as a pale flap with poor turgor and slow capillary refill. Be cognizant of the donor site skin tone as well when examining the flap.

Figure 3. Venous congestion presents as a purple, swollen flap with brisk capillary refill and dark red bleeding.

Figure 4. Venous congestion requires emergent return to the operating room for exploration. If intervened upon early in the course, the flap is potentially salvageable.

Figure 5. Later in the course the flap will demarcate as partial or complete flap loss.

The most important variable to flap salvage is early identification and early action. Studies have demonstrated that venous thrombosis alone is more common than either arterial or combined arterial and venous thrombosis [24]. While physical examination is the gold standard, many methods and technologies are available to aid in the diagnosis of anastomotic failure. Intraoperatively, one can look for visible pulse, Doppler signal, Flicker test (Figure 6), milking the vessel, laser flowmetry, indocyanine green angiography (Figure 7), etc. Similar modalities for flap monitoring are available in the post-operative period. In fact, a healthy debate continues regarding modalities of post-operative monitoring with such devices as the implantable doppler, Vioptix, etc. (Figure 8). However, clinical examination remains the gold standard.

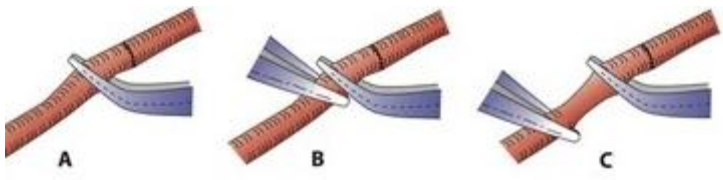

Figure 6A. This test is somewhat traumatic. Occlude the vessel with forceps distal to the anastomosis (A). Place another forceps just distal to the first (B). Milk the vessel for several millimeters away from the anastomosis (C). Occlude the emptied vessel, and release the proximal forceps.

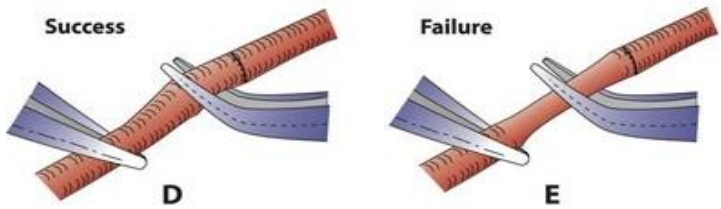

Figure 6B. You should see rapid filling from proximal to distal (D). If you don't see rapid filling, then there is anastomotic failure (E).

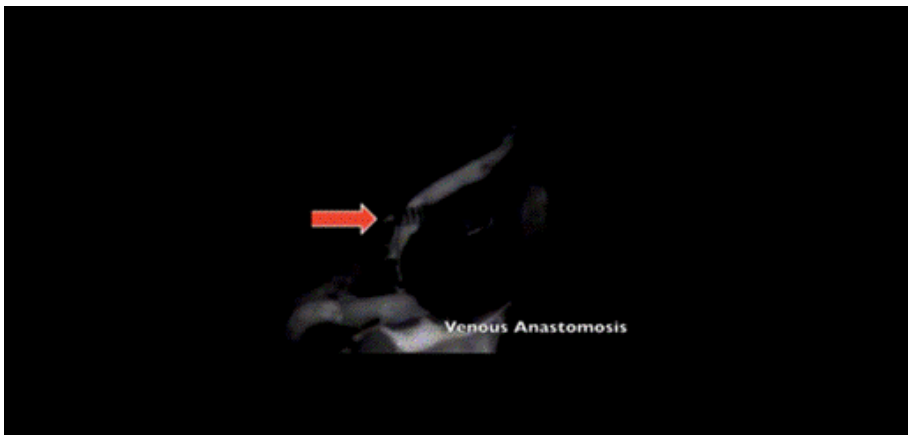

Figure 7. ICG angiography- patent couple venous anastomosis (red arrow). The patent arterial anastomosis can also be seen at the bottom of the photograph.

Figure 8. Vioptix System relies on tissue oxygen perfusion and is available for monitoring through smart devices.

Management

Re-operative exploration of the compromised or potentially compromised flap is required. Removing sutures to relieve pressure on the flap caused by skin closure can be performed, but even in the case of clinical improvement after this maneuver, exploration is still essential. One should visualize the anastomosis and perform exercises to determine where the problem may lie. Technical errors (back wall stitch, narrowing, intimal damage, twisting, kinking of the vessels) are the most common reasons for anastomotic failure (Diagram 1). These are solved by takedown and revision of the problematic anastomosis or

anastomoses. Thrombectomy, heparin flush and tissue plasminogen activator (tPA) flush may also be useful, depending on the situation encountered. One should always perform an examination of the lumen and remove any damaged portions of the vessel. A step-wise approach to evaluation of the vessels is outlined below.

1. Look for kinking of the vessels: Kinking can often be identified on re-exploration, however the vessel may kink only when the flap is inset. Vessel 'lie' should be meticulously observed. Sometimes a small stay stitch will help prevent kinking or twisting. Occasionally, the vessels need to be shortened due to excess length of one or both of the vessels (usually the artery is longer). A vessel that is too long may have folded in the excess portions, requiring an adjustment in placement of the vessel or flap inset. A vessel that is too short may kink at an anchor point. Oftentimes, further dissection of the recipient vessel or anchor point is all that is required. Occasionally an interposition vein graft is required. Kinking may also be prevented by using gel-foam or local tissue to pad a gentle curve of the vessels.
2. Look for twisting of the vessels: A vessel may be twisted unknowingly prior to anastomosis and go unnoticed while the vessel is flaccid. When the vessel clamps are removed and flow is re-established, this problem may become more apparent. A twisted vessel typical requires revision of the anastomosis. Marking the orientation of the donor and recipient vessels prior to anastomosis may aid in identifying and preventing any twisting.
3. Look for excess vessel traction. Stretch should not be an issue, as an anastomosis should never be performed under tension. However, shifting of the flap on inset can cause tension on the vessels. Undue tension can cause fracture of the endothelial lining and ultimately vessel thrombosis. If tension is the culprit for flap compromise, the anastomosis may need to be taken-down, examined for intimal damage and revised. An interposition vein graft can be used to achieve additional pedicle length necessary for proper flap inset. Adjusting the flap orientation, further vessel dissection to achieve additional pedicle length or placement of an interposition vein graft will help to reduce tension on the vascular pedicle.
4. Look for any areas of vasospasm: Vasospasm is the subject of much debate. It can be caused by intrinsic factors triggered by rigorous dissection and vessel handling. Extrinsic factors may also be present, such as administration of sympathomimetics. The best approach is warming, gentle vessel dilation, sympathectomy by adventitial stripping and use of vasodilatory agents. Multiple classes of agents have been studied and used for this effect, including phosphodiesterase inhibitors (papavarine, phentophylline, amrinone), local anesthetics (lidocaine), calcium channel blockers (nicardipine, verapamil, nifedipine, magnesium sulfate), direct vasodilators (sodium nitroprusside, prostaglandin E1, nitroglycerine, hydralazine) and alpha antagonists (phentolamine, chlorpromazine) [28]. Recent animal studies suggest that topical magnesium sulfate may be most effective in its spasmolytic effects [29].
5. Look for signs of external compression. Hematoma is the most common reason for external compression compromising flap blood flow and requires immediate evacuation (Figure 9). Surrounding pressure must be prevented (hemostasis) and often times, the anastomosis will require revision. Additionally, 'leaking' anastomoses may trigger intraluminal activation of the clotting cascade, exacerbating

the problem. One must be aware of the vessel lie in regards to adjacent structures such as the ribs and pectoralis major when utilizing the internal mammary vessels as recipients. A tight overlying skin closure may also provide external compression and flap compromise. At the time of initial closure/flap inset, some amount of flap swelling should be expected and planned for. Finally, the surgeon must be aware of other types of sabotage in the way of external compression (abdominal binders, surgical bras, heating pads, patient lying on the flap, etc.). The weight of the flap itself is not typically a site of external compression.

Figure 9. Large, expanding hematoma. Note as well the congested appearance of the flap. Often times, a hematoma may cause compression of the venous drainage and lead to congestion of the flap.

If an early thrombus is present, one must address the underlying issues as illustrated above. Unexplained thrombosis is an ominous sign. If no other factors can be identified, one can only redo the anastomosis and hope. The "No Reflow Phenomenon" [30-32] is related to tissue reperfusion injury at the level of the capillaries and often times is not a salvageable event.

Hypercoagulable states are the subject of much debate. Patients with cancer are often hypercoagulable at baseline. Additionally patients may be on medications that increase risk of venous thromboembolism (tamoxifen, oral contraceptives, etc.). Still other patients may have a native hypercoagulable state due to Factor V Leiden or lupus anticoagulant, for example. Others clues to hypercoagulability (unexplained miscarriages, family or personal history of VTE) should be elicited pre-operatively.

Patent anastomosis, but clinical flow insufficiency, may become apparent. More often this is venous in origin leading to a turgid, hyperemic flap. A patent anastomosis but venous insufficiency should be super-charged whenever possible. In the case of a TRAM flap, use of the SIEV coupled to the retrograde IMV, thoracodorsal or thoracoacromial system can provide a useful bailout (Figure 10). Arterial insufficiency is harder to diagnose and often times only manifests weeks later in the form of fat necrosis. Debate remains regarding actual flow rates to flap size/volume.

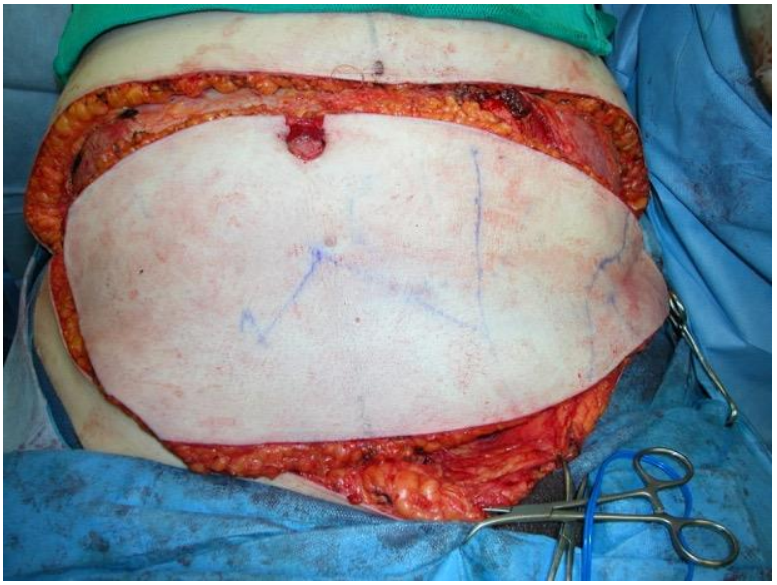

Figure 10. This flap has been raised on the deep inferior epigastric system, however, note the congested appearance. This flap required supercharging with the superficial inferior epigastric vein.

A clot indicates activation of the coagulation cascade. For this purpose, the surgeon may need to perform a thrombectomy (typically using a size 2 or 3 Fogarty catheter) and heparinize the flap, in addition to revising the anastomosis. In late thromboses, thrombolytic therapy (tPA, streptokinase, urokinase, etc.) may also be considered. If used, thrombolytics should be restricted to flow through the flap by allowing drainage through an unused venous outflow tract, rather than systemic administration.

When a free flap 'goes down,' and salvage is unsuccessful, there are four options:

1. Perform a second free flap, if the patient is medically stable.
2. Perform a pedicled flap: May be possible to perform a pedicled latissimus flap or TRAM flap, under the right circumstances.
3. Implant-based reconstruction: Placement of tissue expanders, if possible
4. Delayed reconstruction: Close incisions.

It is imperative that informed consent includes the possibility flap failure and secondary options and that this be discussed with the patient pre-operatively.

Total Free Flap Loss

Diagnosis

Total flap loss represents vascular compromise (Figure 11). This may be an unrecognized flow problem at the level pedicle or it may be at the capillary level, as in the case of the no-reflow phenomenon. The problem will often be readily apparent in the first several postoperative days, but may present later.

Figure 11. Total flap loss.

Management

Integral to the treatment of flap loss is identification of etiology for failure. The only thing worse than a total flap loss is a second total flap loss. Care should include timely debridement and immediate or delayed reconstruction. The decision for reconstruction should again be approached with the patient and appropriate options discussed. Discussion may include consideration of a second free flap or placement of a tissue expander with or without a pedicled latissimus dorsi flap for additional soft tissue coverage.

Partial Flap Loss

Diagnosis

Partial flap loss may be very apparent with areas of demarcated skin or may be more insidious in nature, in the form of fat necrosis (Figure 12 and 13). Both of these entities represent insufficient flow. This is different than mastectomy flap necrosis, which is principally dependent on patient factors and technique of the extirpative surgeon. Partial flap loss may be due to non-occlusive clots at the level of the anastomosis, emboli originating at the anastomosis, insufficient flow volume to flap size (zone 4 necrosis, for example) or any other insult to the intrinsic blood flow of the flap (such as prolonged ischemia time leading to reperfusion injury). In many cases, as with any anastomosis failure, the primary cause is technical error. In regard to flow size to flap volume, the advent of free abdominal tissue transfer based on the deep inferior epigastric artery has improved outcomes. While technically a Mathes and Nahai type III muscle [33], the rectus abdominis muscle does show a dominance of the inferior epigastric artery, leading to much less distal flap loss and fat necrosis than the superior epigastric-based pedicled TRAM. However, some degree of flow discrepancy may occur and the answer to specific flap mass to flow rate has yet to be

elucidated. At this point, flap size to pedicle size and flow relies on clinical judgment and acumen of the operating surgeon and a sound understanding of Taylor's angiosome theory [34]. The evolution of intraoperative indocyanine green angiography has, minimized flap loss when utilized. Evidence shows that on-table ICG angiography allows the surgeon to preemptively debride portions of the flap that show insufficient flow, thus precluding any need for later debridement [35-39].

Figure 12. Partial flap necrosis.

Figure 13. Fat necrosis.

Management

The management of partial flap loss is an evolving field. Management of partial flap loss is primarily to allow the flap to demarcate, debride necrotic portions and revise as necessary (Figure 14). Adjunct techniques to supplement for the loss of tissue would include fat grafting, local tissue rearrangement, and/or prosthetic implants. It is not absolutely necessary to remove every bit of fat necrosis, rather only that which is palpable and clinically relevant.

Figure 14A. Spotty areas of superficial skin necrosis.

Figure 14B. These areas are debrided and allowed to heal by secondary intention.

Figure 14C. Although additional scarring is present, this patient went on to have a good result with excellent symmetry and breast shape.

Fat Necrosis

Diagnosis

Fat necrosis is caused by saponification of dead or damaged fat tissue after trauma or ischemia to the breast (Figure 13). At a microscopic level, the initial change is disruption of fat cells where vacuoles with the remnants of necrotic fat cells are formed. Lipid-laden macrophages, multinucleated giant cells, and acute inflammatory cells then engulf them. Fibrosis develops during the reparative phase peripherally enclosing an area of necrotic fat and cellular debris. Eventually, fibrosis may replace the area of degenerated fat with a scar, or loculated and degenerated fat may persist for years within the scar tissue. Clinically, fat necrosis presents as a firm lump or lumps and can be associated with pain or discomfort and erythema. It can be seen in the breast after needle biopsy, lumpectomy, radiotherapy or other trauma. In the setting of breast reconstruction, fat necrosis may represent insufficient flow to portions of the transferred flap or tissue trauma.

Management

While a new mass in the reconstructed breast may be distressing to the patient, in a post-mastectomy reconstruction, this typically does not represent cancer recurrence. Certainly, in a patient who had partial breast removal (lumpectomy), a new mass warrants a complete cancer work up. Mammography of fat necrosis will often reveal stippled, curvilinear calcifications within the periphery creating the appearance of lucent "bubbles," with low-density centers. Ultrasound typically reveals a hypoechoic mass with well-defined nodular margins. Management requires patient reassurance and excision/revision versus non-surgical management depending on symptomology and patient wishes. Adjunct techniques to supplement for the loss of volume would include fat grafting, local tissue rearrangement, and/or prosthetic implants. As noted above, only clinically significant fat necrosis need be removed.

Figure 15. Mastectomy flap necrosis.

Mastectomy Flap Necrosis

Diagnosis

Mastectomy flap necrosis is damaged, poorly perfused breast skin, which presents as an area of demarcating necrosis within the first days to weeks after mastectomy (Figure 15). This

is due to patient factors, including smoking/nicotine use, obesity, diabetes, previous breast size and radiation. Mastectomy flap necrosis is also related to surgical technique of the extirpative surgeon, such intraoperative tissue handling and plane of dissection.

Management

The management of mastectomy flap necrosis is evolving with the use of ICG angiography, allowing reconstructive surgeons to preemptively excise devascularized skin at the time of initial reconstruction if tumescent is not utilized during mastectomy. Another strategy to address this vexing issue to bury the immediate free flap without performing de-epithelialization and plan to bring the patient back several days later, excise demarcated breast skin, perform de-epithelialization and inset the flap [40]. This technique, however, does require a return trip to the operating room. At this time, the most commonly employed strategy is to try to identify any questionable areas of breast skin intraoperatively and preemptively debride. For postoperative necrosis, recommendations include debridement and revision (Figure 16).

(a)

(b)

Figure 16A-E. (Continued).

(c) (d)

(e)

Figure 16A-E. Mastectomy flap necrosis, requiring serial debridement, wound care and ventual skin grafting.

Hematoma

Diagnosis

As with all operations, hematoma formation is a risk of free flap breast reconstruction. A hematoma will typically present as an expanding mass and overlying ecchymosis (Figure 17). However, in the case of a hematoma in free flap breast reconstruction, there is added concern for flap compromise due to pressure on the pedicle. Evidence shows that hematomas are not prevented by drain placement.

Management

Hematoma after breast reconstruction mandates prompt diagnosis and evacuation if there is clinical compromise to the flap. Re-exploration should be performed in the operating room in order to thoroughly examine the anastomosis (especially the venous anastomosis) and ensure hemostasis. Hemoglobin should be checked regularly and be kept above 10g/dL and hypovolemia treated with fluid and blood products, rather than sympathomimetics. There is mounting evidence in the head and neck literature demonstrating that the perivascular

sympathectomy performed with vessel dissection blunts the effect of sympathomimetic medications, however this has not been studied in the breast reconstruction literature and should be avoided, if possible.

Figure 17. Hematoma.

Seroma

Diagnosis

Seromas may present both in the donor site as well as the reconstructed breast site. They typically present later in the clinical course (Figure 18). They typically do not cause external compression and vascular compromise.

Figure 18. Right sided breast seroma.

Management

Seromas may be treated symptomatically with aspiration under sterile conditions and/or closed suction drainage. Occasionally, a seroma may be refractory to serial aspiration and require placement of a drain or use of sclerosing therapy. Sclerosing agents should be avoided in the area of the vascular anastomosis.

Infection

Diagnosis

Infection, as with all surgical procedures, represents a real risk especially if there is prolonged surgical time or the patient experiences intraoperative hypothermia (Figure 19). Complicating the diagnosis, typical signs of infection (such as erythema) can occasionally be mistaken or masked as vascular compromise. For this reason, the operating surgeon should be liberal in obtaining cultures, particularly at the time of re-exploration or revision. As an added risk in the free flap patient, infection can be a trigger for vessel thrombosis. Infection presents as erythema, pain, warmth, purulent drainage, and can cause breast skin or flap necrosis.

Figure 19. Superficial cellulitis.

Management

Evidence regarding prevention of surgical site infection follows the 2006 Surgical Care Improvement Project (SCIP) protocol. Patients should receive preoperative antibiotics. Antibiotics should be re-dosed appropriately intraoperatively and attention should be given to maintain normal body temperature. Abscesses or deep-seated infections should be treated with drainage, debridement and appropriate antibiotic coverage. There is no evidence for prophylactic antibiotics beyond the immediate perioperative period.

Pneumothorax

Diagnosis

Pneumothorax is a possible complication of rib resection and exposure of the internal memory vessels. Classically, this presents at the time of occurrence as a visible rent in the

parietal pleura and audible sucking sound. Intraoperatively, irrigation fluid can be introduced into the trough created by rib resection and if bubbles are observed rising through the fluid, it is likely the pleura has been violated. Rarely, pneumothorax can present in the postoperative period with hypoxia, tachycardia and shortness of breath. Workup should include chest and abdominal x-rays.

Management

Optimally, pneumothorax is identified at the time of occurrence. This typically does not require treatment unless a lung injury occurs. The patient is receiving positive pressure ventilation, and use of a closed suction subcutaneous drain in the breast reconstruction pocket is sufficient to remove any residual air and prevent subcutaneous emphysema. Typically, there is no need for placement of a chest tube. A post-operative chest radiograph can be obtained if there is concern for pleural violation. There is no evidence supporting routine postoperative chest radiograph. Should the patient present with a post-operative symptomatic pneumothorax, a chest tube should be placed.

Poor Cosmetic Outcome

Diagnosis

Modern breast reconstruction has in many ways 'raised the bar' in terms of patient expectations of cosmetic outcome. More and more patients expect a rapid return to 'normal' life with a reconstructed breast indistinguishable from or better than their pre-operative status. Critical to management of cosmetic concerns is establishing patient expectations early with regards to their final outcome. A suboptimal cosmetic outcome may be due to several factors including effacement of the inframammary fold, asymmetry, contour irregularities, skin tone differences (between donor skin and breast skin), fat necrosis, etc.

Management

Cosmetic revision should be addressed primarily with expectant management as much as possible, as the patient will experience a certain amount of settling in the year after surgery. However, revisional surgery including liposuction, fat grafting, etc., may safely be performed six weeks after the initial reconstruction. Further discussion regarding cosmetic revision is beyond the scope of this chapter.

COMPLICATIONS RELATED TO THE DONOR SITE

Abdominally-Based (Free TRAM, ms-TRAM, DIEP, SIEA)

Hernia/Abdominal Wall Weakness

Diagnosis

In an effort to minimize dysfunction of the abdominal wall, advancements have been made in techniques to decrease rectus muscle and fascia injury, leading to advocacy for the

DIEP flap [41-43]. In 2006, Garvey, et al., demonstrated a 16% hernia rate in pedicled TRAM versus 1% in the DIEP cohort [44] Several subsequent studies demonstrated conflicting or equivocal results [45, 46]. More recently, in a large multi-center database search including 8246 patient, Fischer et al., demonstrated surgically-repaired abdominal wall hernias in 7% of pedicled TRAM patients, 5.7% in free TRAM patients and 1.8% in DIEP patients (Figure 20 and 21) [27]. Abdominal wall weakness or hernia may be subclinical or asymptomatic and go unnoticed unless found incidentally by CT scan for other reasons. However, symptomatic or clinically apparent abdominal bulges or hernias should be addressed surgically. The primary advantage of the SIEA flap over those based upon the deep inferior epigastric or superior epigastric system is the lack of penetration of the abdominal fascia and muscle thus eliminating the risk of subsequent abdominal wall weakness/bulge or hernia.

Figure 20. Abdominal bulge.

Figure 21. Abdominal bulge.

Management

The average time to hernia repair after abdominally-based breast reconstruction is approximately 1 year [27]. Treatment involves exposure of the rectus fascia with primary closure and mesh reinforcement. The authors recommend that at the time of initial reconstruction, the fascia and abdominal musculature be carefully evaluated as it may be advised to place mesh prophylactically to prevent post-operative hernias and bulges.

Hematoma

Diagnosis

Abdominal hematomas are experienced in a small percentage of the patients undergoing abdominal-based breast reconstruction. They present as expanding masses and ecchymosis as well as increased sanguinous drain output.

Management

Hematomas should be treated with re-exploration to remove the hematoma, irrigate and obtain hemostasis,

Seroma

Diagnosis

Seromas more commonly present in the abdominal donor site, rather than at the site of breast reconstruction. They will typically present several weeks to months after the time of initial surgery. Abdominal seromas are similar to those occurring in cosmetic abdominoplasty and present as fullness which may or may not be ballotable and occasionally uncomfortable. Erythema is a sign of underlying infection.

Management

Decreased seroma formation has been linked with placement of intermittent quilting sutures [47, 48]. Seromas may safely be treated when symptomatic with aspiration under sterile conditions and/or closed suction drainage. Occasionally, a seroma may be refractory to serial aspiration and require use of drains, sclerosing agents or even surgical removal of the seroma cavity.

Wound Dehiscence

Diagnosis

Wound dehiscence or abdominal flap necrosis may occur at the site of abdominal closure and typically occurs centrally, at the site of highest tension (Figure 22 and 23). This is most often due to ischemia from tight closure and will appear pale intraoperatively, followed by a progression to local purpura and finally frank necrosis of the skin and underlying fat with associated wound failure. The risk of this complication is increased when there is a T-junction as may occur at the site of the transposed umbilicus. This may be very discouraging to the patient, who has had an otherwise successful operation.

Management

Optimal management is avoidance of high-tension closure. Occasionally, paucity of abdominal tissue on an otherwise small-framed patient may dictate a tighter closure than desired. Progressive tension sutures can be used and the wound may be temporarily supported with an incisional negative pressure device (wound vac). The patient should be advised to remain in a flexed position at the waist for several days to weeks to minimize tension on the abdominal closure. Should the patient develop an open wound despite all precautions, the wound should be managed conservatively with moist dressings, debridement as indicated, and healing by secondary intention. A wound vac may also speed wound closure.

Figure 22. Abdominal wound failure. Notice the central location, representing the area of most distal perfusion as well as the area of highest tension.

Figure 23. Abdominal wound failure.

Bowel Perforation/Enterocutaneous Fistula

Diagnosis

While no portion of the harvest of an abdominal flap for breast reconstruction should proceed to the intra-abdominal cavity, there is a small risk of bowel perforation with harvest of abdominally-based flaps based upon the deep inferior epigastric system. The patient will present postoperatively with inability to tolerate oral intake and nausea/vomiting. Abdominal radiographs should be obtained and will show subphrenic air and air-fluid levels.

Management

The patient will require exploratory laparotomy with general surgery to identify and repair the enterotomy.

Numbness/Altered Sensation

Diagnosis

Peri-incisional and peri- and infra-umbilical numbness is a common occurrence following abdominal-based breast reconstruction. This altered sensation is due to transection of the local cutaneous nerves or a cutaneous neuropraxia from retraction. Patients may also experience a burning or tingling sensation in a similar distribution associated with nerve regeneration. Occasionally patients may complain of pain or burning in the thigh or groin due to injury of the lateral femoral cutaneous nerve or the ilioinguinal nerve, similar to that seen in abdominoplasty.

Management

Local changes in sensation; numbness, burning, and tingling may be treated expectantly, with return of normal sensation in six months to one year. Patients may be instructed in desensitization techniques to help in the meantime. If the lateral femoral cutaneous nerve or ilioinguinal nerve is injured or tethered by suture, it may require operative intervention depending upon the severity and persistence of symptoms.

Thigh-Based Flaps, Such as Gracilis Flaps

Lymphedema

Diagnosis/Management

While uncommon, lymphedema is a potential and devastating complication in patients undergoing a transversely-oriented upper gracilis (TUG) flap. Care should be taken to avoid carrying the dissection too deeply/anteriorly over the femoral triangle. The best treatment is avoidance. A thorough discussion of treatment modalities for lower extremity lymphedema is beyond the scope of this book.

Seroma

Diagnosis/Management

While perhaps not as prevalent as in abdominal or gluteal-based breast reconstruction, seroma formation represents a potential risk and drains should be placed at the time of surgery. Seromas are treated when symptomatic with aspiration under sterile conditions and/or closed suction drainage. Occasionally, a seroma may be refractory to serial aspiration and sclerosing therapy or seroma cavity excision may be necessary. Additionally, formation of a lymphocele in this area may be considered in the differential for persistent, refractory fluid collections.

Contour Deformity

Diagnosis/Management

Contour deformity of the upper thigh may be of particular concern to the patient (Figure 24). Contour deformities may be addressed with liposuction or lipofilling as indicated. Deformity of the vulva due to excessive tension at the closure is difficult to treat. Placement of the scar below the groin crease minimizes this deformity but leads to a more visible scar. Careful pre-operative discussion regarding these risks is vital.

Figure 24. Medial thigh contour irregularity and scarring following a tranverse upper gracilis (TUG) flap.

Gluteal-Based Flaps

Bleeding

Diagnosis/Management

Special mention of bleeding risks, particularly intraoperative bleeding is central to discussion of gluteal-based flaps. Great care must be taken when approaching the proximal portion of the gluteal artery at its origin from the internal iliac artery, as there is an extensive surrounding venous plexus (ominously referred to as Medusa's Head). Bleeding occurring in this vicinity can be significant and it is often deep and difficult to reach and control.

Nerve Injury

Diagnosis/Management

The sciatic and posterior femoral cutaneous nerves take a course exiting from between the pyriformis and superior gemellus and may be especially prone to irritation or injury while harvesting an inferior gluteal artery perforator flap, as the sciatic nerve travels with the vascular pedicle. Rough handling of this nerve can be a cause of great discomfort with the patient for months after surgery.

Figure 25. Superior gluteal artery perforator (SGAP) donor site. Patients should be counseled regarding scarring and resulting contour irregularity in the donor site.

Buttock Distortion

Diagnosis/Management

While superior gluteal artery flaps are thought to provide a form of buttock-lift, often the change in contour is not in line with a patients' expectations (Figure 25). Particular care must be taken regarding contour irregularity associated with the inferior gluteal artery flap, as it may efface the inferior gluteal crease and pull the buttock down. This deformity is much harder to hide under clothing.

Seroma

Diagnosis/Management

The gluteal donor sites are notorious for seroma formation. Often in order to prevent this, drains are left in place for two to three weeks.

Complications Related to Prolonged Surgical Time

Myocardial infarction: Appropriate preoperative evaluation and optimization are essential to prevention of complications related to prolong surgical time.

Cerebrovascular accident: Appropriate preoperative evaluation and optimization are essential to prevention of complications related to prolong surgical time.

Venous thromboembolism: Preoperative, as well as postoperative chemical and mechanical DVT prophylaxis are critical to the care of the free flap patient.

Pressure ulcers: Pressure ulcer formation can occur within hours [49]. Appropriate padding of all bony prominences is important to preventing this untoward complication.

Compressive neuropathies: Finally, the surgeon must be aware of proper padding and positioning of both arms and legs in order to prevent or minimize this uncomfortable complications.

CONCLUSION

Free flap reconstruction is a common and well-established method for breast reconstruction. Although the flap selection, microsurgical technique and countless other variables may change, the general approach to diagnosing and managing free-flap complications remains the same. Key to this is a logical and algorithmic approach to the early and late problems seen in free-flap reconstruction.

REFERENCES

[1] *What are the key statistics about breast cancer?* 2016. (Accessed 2/26/16, 2016, at http://www.cancer.org/cancer/breastcancer/detailedguide/breast-cancer-key-statistics).

[2] Congress U. *Women's Health and Cancer Rights Act*. 1998.

[3] 2015 *Reconstructive Plastic Surgery Statistics*. 2015. (Accessed 2/25/16, 2016, at http://www.plasticsurgery.org/Documents/news-resources/statistics/2015-statistics/reconstructive-procedure-trends-2015.pdf).

[4] Holmstrom H. The free abdominoplasty flap and its use in breast reconstruction. An experimental study and clinical case report. *Scandinavian journal of plastic and reconstructive surgery* 1979;13:423-27.

[5] Hartrampf CR, Scheflan M, Black PW. Breast reconstruction with a transverse abdominal island flap. *Plastic and reconstructive surgery* 1982;69:216-25.

[6] Grotting JC. The free abdominoplasty flap for immediate breast reconstruction. *Annals of plastic surgery* 1991;27:351-4.
[7] 2014 *Reconstructive Breast Procedures*. 2014. (Accessed 2/25/16, 2016, at http://www.plasticsurgery.org/Documents/news-resources/statistics/2014-statistics/plastic-surgery-statsitics-full-report.pdf).
[8] Elder EE, Brandberg Y, Bjorklund T, et al. Quality of life and patient satisfaction in breast cancer patients after immediate breast reconstruction: a prospective study. *Breast* (Edinburgh, Scotland) 2005;14:201-8.
[9] Dean C, Chetty U, Forrest AP. Effects of immediate breast reconstruction on psychosocial morbidity after mastectomy. *Lancet* (London, England) 1983;1:459-62.
[10] Kroll SS, Coffey JA, Jr., Winn RJ, Schusterman MA. A comparison of factors affecting aesthetic outcomes of TRAM flap breast reconstructions. *Plastic and reconstructive surgery* 1995;96:860-4.
[11] Kronowitz SJ. Immediate versus delayed reconstruction. *Clinics in plastic surgery* 2007;34:39-50; abstract vi.
[12] Miller MJ, Rock CS, Robb GL. Aesthetic breast reconstruction using a combination of free transverse rectus abdominis musculocutaneous flaps and breast implants. *Annals of plastic surgery* 1996;37:258-64.
[13] Kronowitz SJ. Delayed-immediate breast reconstruction: technical and timing considerations. *Plastic and reconstructive surgery* 2010;125:463-74.
[14] Klasson S, Nyman J, Svensson H, Velander P. Smoking increases donor site complications in breast reconstruction with DIEP flap. *Journal of plastic surgery and hand surgery* 2016:1-5.
[15] Dayicioglu D, Tugertimur B, Munzenmaier K, et al. Outcomes of Breast Reconstruction After Mastectomy Using Deep Inferior Epigastric Perforator Flap After Massive Weight Loss. *Annals of plastic surgery* 2016;76 Suppl 4:S286-9.
[16] Hanwright PJ, Davila AA, Hirsch EM, et al. The differential effect of BMI on prosthetic versus autogenous breast reconstruction: a multivariate analysis of 12,986 patients. *Breast* (Edinburgh, Scotland) 2013;22:938-45.
[17] Lee TJ, Oh TS, Kim EK, et al. Risk factors of mastectomy skin flap necrosis in immediate breast reconstruction using low abdominal flaps. *Journal of plastic surgery and hand surgery* 2016:1-5.
[18] Ochoa O, Chrysopoulo M, Nastala C, Ledoux P, Pisano S. Abdominal wall stability and flap complications after deep inferior epigastric perforator flap breast reconstruction: does body mass index make a difference? Analysis of 418 patients and 639 flaps. *Plastic and reconstructive surgery* 2012;130:21e-33e.
[19] Wang XL, Liu LB, Song FM, Wang QY. Meta-analysis of the safety and factors contributing to complications of MS-TRAM, DIEP, and SIEA flaps for breast reconstruction. *Aesthetic plastic surgery* 2014;38:681-91.
[20] Seidenstuecker K, Munder B, Mahajan AL, Richrath P, Behrendt P, Andree C. Morbidity of microsurgical breast reconstruction in patients with comorbid conditions. *Plastic and reconstructive surgery* 2011;127:1086-92.
[21] Voineskos SH, Frank SG, Cordeiro PG. Breast reconstruction following conservative mastectomies: predictors of complications and outcomes. *Gland surgery* 2015;4:484-96.

[22] Galanis C, Nguyen P, Koh J, Roostaeian J, Festekjian J, Crisera C. Microvascular lifeboats: a stepwise approach to intraoperative venous congestion in DIEP flap breast reconstruction. *Plastic and reconstructive surgery* 2014;134:20-7.

[23] Khansa I, Chao AH, Taghizadeh M, Nagel T, Wang D, Tiwari P. A systematic approach to emergent breast free flap takeback: Clinical outcomes, algorithm, and review of the literature. *Microsurgery* 2013;33:505-13.

[24] Bui DT, Cordeiro PG, Hu QY, Disa JJ, Pusic A, Mehrara BJ. Free flap reexploration: indications, treatment, and outcomes in 1193 free flaps. *Plastic and reconstructive surgery* 2007;119:2092-100.

[25] Lee KT, Lee JE, Nam SJ, Mun GH. Ischaemic time and fat necrosis in breast reconstruction with a free deep inferior epigastric perforator flap. *Journal of plastic, reconstructive & aesthetic surgery: JPRAS* 2013;66:174-81.

[26] Macadam SA, Zhong T, Weichman K, et al. Quality of Life and Patient-Reported Outcomes in Breast Cancer Survivors: A Multicenter Comparison of Four Abdominally Based Autologous Reconstruction Methods. *Plastic and reconstructive surgery* 2016;137:758-71.

[27] Shubinets V, Fox JP, Sarik JR, Kovach SJ, Fischer JP. Surgically Treated Hernia following Abdominally Based Autologous Breast Reconstruction: Prevalence, Outcomes, and Expenditures. *Plastic and reconstructive surgery* 2016;137:749-57.

[28] Vargas CR, Iorio ML, Lee BT. A Systematic Review of Topical Vasodilators for the Treatment of Intraoperative Vasospasm in Reconstructive Microsurgery. *Plastic and reconstructive surgery* 2015;136:411-22.

[29] Hyza P, Streit L, Schwarz D, Kubek T, Vesely J. Vasospasm of the Flap Pedicle: The Effect of 11 of the Most Often Used Vasodilating Drugs. Comparative Study in a Rat Model. *Plastic and reconstructive surgery* 2014;134:574e-84e.

[30] Widgerow AD. Ischemia-reperfusion injury: influencing the microcirculatory and cellular environment. *Annals of plastic surgery* 2014;72:253-60.

[31] Kucukcelebi A, Ozcan M. The beneficial effect of cyclosporin-A on the no-reflow phenomenon in rat skin island flaps. *British journal of plastic surgery* 1992;45:512-4.

[32] Punch J, Rees R, Cashmer B, Wilkins E, Smith DJ, Till GO. Xanthine oxidase: its role in the no-reflow phenomenon. *Surgery* 1992;111:169-76.

[33] Mathes SJ, Nahai F. Classification of the vascular anatomy of muscles: experimental and clinical correlation. *Plastic and reconstructive surgery* 1981;67:177-87.

[34] Taylor GI, Palmer JH. 'Angiosome theory.' *British journal of plastic surgery* 1992;45: 327-8.

[35] Duggal CS, Madni T, Losken A. An outcome analysis of intraoperative angiography for postmastectomy breast reconstruction. *Aesthetic surgery journal / the American Society for Aesthetic Plastic surgery* 2014;34:61-5.

[36] Munabi NC, Olorunnipa OB, Goltsman D, Rohde CH, Ascherman JA. The ability of intra-operative perfusion mapping with laser-assisted indocyanine green angiography to predict mastectomy flap necrosis in breast reconstruction: a prospective trial. *Journal of plastic, reconstructive & aesthetic surgery: JPRAS* 2014;67:449-55.

[37] Quilichini J, Le Masurier P, Guihard T. [Increasing the reliability of SIEA flap using peroperative fluorescent angiography with indocyanine green in breast reconstruction]. *Annales de chirurgie plastique et esthetique* 2010;55:531-8.

[38] Wu C, Kim S, Halvorson EG. Laser-assisted indocyanine green angiography: a critical appraisal. *Annals of plastic surgery* 2013;70:613-9.
[39] Yamaguchi S, De Lorenzi F, Petit JY, et al. The "perfusion map" of the unipedicled TRAM flap to reduce postoperative partial necrosis. *Annals of plastic surgery* 2004;53:205-9.
[40] Liao EC, Labow BI, May JW, Jr. Skin banking closure technique in immediate autologous breast reconstruction. *Plastic and reconstructive surgery* 2007;120:1133-6.
[41] Koshima I, Soeda S. Inferior epigastric artery skin flaps without rectus abdominis muscle. *British journal of plastic surgery* 1989;42:645-8.
[42] Allen RJ, Treece P. Deep inferior epigastric perforator flap for breast reconstruction. *Annals of plastic surgery* 1994;32:32-8.
[43] Rozen WM, Ashton MW. Improving outcomes in autologous breast reconstruction. *Aesthetic plastic surgery* 2009;33:327-35.
[44] Garvey PB, Buchel EW, Pockaj BA, et al. DIEP and pedicled TRAM flaps: a comparison of outcomes. *Plastic and reconstructive surgery* 2006;117:1711-9; discussion 20-1.
[45] Ireton JE, Kluft JA, Ascherman JA. Unilateral and Bilateral Breast Reconstruction with Pedicled TRAM Flaps: An Outcomes Analysis of 188 Consecutive Patients. *Plastic and reconstructive surgery Global open* 2013;1:1-7.
[46] Chun YS, Sinha I, Turko A, Lipsitz S, Pribaz JJ. Outcomes and patient satisfaction following breast reconstruction with bilateral pedicled TRAM flaps in 105 consecutive patients. *Plastic and reconstructive surgery* 2010;125:1-9.
[47] Lee J, Bae Y, Jung JH, et al. Effects of Quilting Suture Interval on Donor Site Seromas After Breast Reconstruction With Latissimus Dorsi Muscle Flap: A Randomized Trial. *Clinical breast cancer* 2016.
[48] Nagarkar P, Lakhiani C, Cheng A, Lee M, Teotia S, Saint-Cyr M. No-drain DIEP Flap Donor-site Closure Using Barbed Progressive Tension Sutures. Plastic and reconstructive surgery *Global open* 2016;4:e672.
[49] Gefen A. How much time does it take to get a pressure ulcer? Integrated evidence from human, animal, and in vitro studies. *Ostomy/wound management* 2008;54:26-8, 30-5.

In: Encyclopedia of Surgery (22 Volume Set)
Editors: Andreas Lehrer and Kristin Mueller
ISBN: 978-1-53618-329-0
© 2020 Nova Science Publishers, Inc.

Chapter 180

THE EFFECT OF SLEEVE GASTRECTOMY ON METABOLIC COMORBIDITIES

Jaime Ruiz-Tovar*, MD, PhD and Carolina Llavero†
Obesity Unit, Clinica Garcilaso, Madrid, Spain

ABSTRACT

Impaired glucose tolerance, hypertension, and dyslipidemia have been described as metabolic syndrome (MS). MS is associated with an increased cardiovascular risk, and a close association between morbid obesity and MS has been highlighted in several clinical studies. Disease risk increases with increasing body mass index (BMI). Bariatric surgery has been shown to be effective in achieving and maintaining weight change and reducing obesity related comorbidities.

Sleeve gastrectomy (SG) is a restrictive bariatric procedure that involves subtotal gastric resection of the fundus and body to create a long, tubular gastric conduit constructed along the lesser curvature of the stomach. There is little long-term information available because this procedure has only recently been used as a primary weight loss surgery procedure.

Recent reports have shown that SG may have similar resolution rates of the MS and a weight loss curve similar to that of the Roux-en-Y bypass. In this chapter we will review the available evidence about the remission of diabetes mellitus, dyslipidemia and hypertension after SG.

INTRODUCTION

Impaired glucose tolerance, hypertension, and dyslipidemia have been described as metabolic syndrome (MS). MS is associated with an increased cardiovascular risk [1], and a close association between morbid obesity and MS has been highlighted in several clinical studies. Disease risk increases with increasing body mass index (BMI) [2, 3]. Bariatric

* Corresponding Author's Email: jruiztovar@gmail.com.
† Carolina Llavero, RN.

surgery has been shown to be effective in achieving and maintaining weight change and reducing obesity related comorbidities [4].

Sleeve gastrectomy (SG) is a restrictive bariatric procedure that involves subtotal gastric resection of the fundus and body to create a long, tubular gastric conduit constructed along the lesser curvature of the stomach. There is little long-term information available because this procedure has only recently been used as a primary weight loss surgery procedure. It was originally described as a first-stage bariatric procedure followed by Roux-en-Y gastric bypass or duodenal switch in high-risk patients.

However, with the benefit of low risk due to less invasiveness, ease of surgery, and success in terms of sustained weight loss, surgeons have accepted SG as a primary bariatric procedure. Most bariatric surgeons calibrate the sleeve with 32-40F bougies, and the use of smaller diameter bougies is associated with higher weight loss rates [5-7].

SG not only reduces the volume of the stomach, which makes it a restrictive procedure, but also changes gastrointestinal hormone levels such as serum ghrelin, peptide YY (PYY) and glucagon-like peptide 1 (GLP-1). Recent reports have shown that LSG may have similar resolution rates of the MS and a weight loss curve similar to that of the Roux-en-Y bypass [8-10]. However, there is still little mid- and long-term information available about the metabolic effects of SG.

EFFECT OF SLEEVE GASTRECTOMY ON TYPE 2 DIABETES MELLITUS

The mechanisms underlying type 2 diabetes mellitus (T2DM) remission following SG have yet to be fully determined, but some studies have reported favorable changes in insulin sensitivity [11]. Abbatini et al. [12] have demonstrated a near-normalization of insulin resistance in patients treated with SG. The improvement in insulin sensitivity is thought to be primarily due to weight loss, reduction in inflammatory mediators, and decreased caloric intake, although the contribution of weight-independent mechanisms seems very likely. In our recently published study, we could not demonstrate a correlation between weight loss and reduction in glucose levels [13]. It has been established that diabetes improvement appears before a significant weight loss occurs [14]. Despite a progressive reduction of glucose levels in our case series, this did not achieve statistically significance up to 3 months after surgery; however, it was associated with a loss of excessive BMI by 45.6%.

Some authors have reported glycemic control in >80% of patients after 1 month. In our series, including diabetic and euglycemic patients, significant differences from preoperative glucose values could only be observed after 3 months. However, 83.3% of our diabetic patients discontinued their hypoglycemic medication after 1 month, similar to other reported findings [13, 14]. The exclusion of the proximal small intestine was initially thought to play a major role in the rapid improvement in the metabolic control of diabetes. Therefore, malabsorptive or mixed bariatric procedures were considered to be much more effective than purely restrictive ones. In this way, additional mechanisms, such as ileal interposition, have been added to sleeve gastrectomy with the aim of achieving better metabolic results [15].

However, diverse studies have demonstrated that SG as a unique bariatric procedure, compared with Roux-en-Y gastric bypass, achieves similar improvements in the glucose homeostasis [9, 16, 17]. Some studies have shown that SG is associated with a marked

reduction in the secretion of ghrelin, an orexigenic peptide produced by the gastric fundus and involved in mealtime hunger regulation. Ghrelin also exerts several diabetogenic effects (increases in somatotropin/growth hormone, cortisol, and epinephrine); therefore, its suppression could contribute to improve glucose homeostasis [18, 19]. Previous studies have shown diabetes resolution occurring in 66-80% of patients undergoing SG, and the maintenance of reduced plasma levels after 15 months follow-up. In our series, the short-term results are in line with those described in the literature, and good glycemic control persisted after a minimum follow-up of 24 months [13], thus confirming the midterm effectiveness of glycemic control described by other groups [10,19].

EFFECT OF SLEEVE GASTRECTOMY ON LIPID PROFILE

Diverse studies have shown a significant reduction in cardiovascular risk, with increased high-density lipoprotein (HDL) cholesterol and decreased triglycerides after 1 year [7, 20]. As with glucose homeostasis, there is also a lack of long-term results describing changes in the lipid profile. One year after surgery, increases in HDL of 12% and reductions in triglycerides of up to 23% have been described. We have observed an increase of 30% in HDL levels and a reduction of >60% in triglyceride levels, and these levels were maintained after a minimum follow-up of 24 months; however, total cholesterol and low-density lipoprotein cholesterol levels were not significantly changed. A relationship between lipid profile changes and weight loss or BMI changes during followup could not be demonstrated [13].

Low serum lipid profiles in morbidly obese patients may be affected by alterations in the expression of a recently described receptor that mediates the absorption of dietary cholesterol in the intestine; abnormal intestinal flora; or serum leptin levels [7, 21, 22]. Our data highlight this paradox, with SG achieving an excess BMI loss of 76.9% in 1 year and no change in total cholesterol values [13]. Increases in serum cholesterol have even been noted during the weight loss period, with cholesterol being mobilized from adipose tissue as it is metabolized [7].

It has been known for more than 40 years that some extremely obese subjects have normal serum cholesterol, although they still have a high cardiovascular risk [23]. On the other hand, weight loss is associated with a lower cardiovascular risk. This means that other cardiovascular risk factors must improve after weight loss. The triglyceride:HDL ratio has been described as one of the strongest predictor of a heart attack and of other cardiovascular complications [24]. Ratio levels >4 are associated with a high cardiovascular risk. In our patients, we observed a significant reduction in this ratio from 4.2 to 3.5 after 1 year, which was maintained at 3.4 2 years after surgery [13]. The triglyceride:HDL ratio has been proposed as an early marker of insulin resistance, which improves with SG. The improvement in diabetes could be one of the factors contributing to decreased cardiovascular risk. Vila et al. [25] recently reviewed published studies about lipid changes after different types of weight loss surgery, but there were no data on sleeve gastrectomies. In general, malabsorptive procedures improved all variables of the lipid profile, while the restrictive procedures tended to primarily increase HDL and reduce triglycerides, as we observed for SG. However, decreased global cardiovascular risk was similarly observed following both restrictive and malabsorptive procedures.

EFFECT OF SLEEVE GASTRECTOMY ON HYPERTENSION

Obesity surgery also improves hypertension. Slight weight loss is associated with a significant reduction in blood pressure values. Following Buchwald classification, an excess weight loss of 1% correlates with a reduction of 2 mmHg in diastolic blood pressure [26]. Different studies have demonstrated that bariatric surgery globally reduces hypertension rate to 50%, represented as treatment discontinuation and a 25% reduction in the amount of antihypertensive drugs needed [27]. In contrast to effects on T2DM, improvements in blood pressure values are achieved several months postoperatively.

Moreover, the improvement in hypertension seems to be independent of the bariatric technique performed, although a greater reduction is obtained in those patients with greater weight loss [28]. Resolution of hypertension has been described in 43% of cases following adjustable gastric banding, in 69% after gastric bypass, and in 83% after biliopancreatic diversion. Surprisingly, in our series of morbidly obese patients undergoing SG with a hypertension rate of 30%, this comorbidity showed complete resolution in all patients (100%), allowing discontinuation of all antihypertensive treatment 6 months after surgery. We observed a mean reduction of 37 mmHg in systolic blood pressure and of 19 mmHg in diastolic blood pressure; however, this reduction did not show any correlation with weight loss. We cannot currently explain these extraordinary results in our patients.

REFERENCES

[1] Bray GA. Medical consequences of obesity. *J. Clin. Endocrinol. Metab.* 2004;89:2583–9.

[2] Sullivan PW, Ghushchyan VH, Ben-Joseph R. The impact of obesity on diabetes, hyperlipidemia and hypertension in the United States. *Qual. Life Res*. 2008;17:1063–71.

[3] Nguyen NT, Magno CP, Lane KT, Hinojosa MW, Lane JS, Association of hypertension, diabetes, dyslipidemia and metabolic syndrome with obesity:findings from the National Health and Nutrition Examination Survey 1999 to 2004. *J. Am. Coll. Surg*. 2008;207:928–34.

[4] Buchwald H, Avidor Y, Braunwald E et al. Bariatric surgery: a systematic review and meta-analysis. *JAMA* 2004;292:1724–37.

[5] Cottam D, Qureshi FG, Mattar SG et al. Laparoscopic sleeve gastrectomy as an initial weight-loss procedure for high-risk patients with morbid obesity. *Surg. Endosc*. 2006;20:859–63.

[6] Melissas J, Daskalakis M, Koukouraki S et al. Sleeve gastrectomy— a "food limiting" operation. *Obes. Surg*. 2008;18:1251–6.

[7] Zhang F, Strain GW, Lei W et al. Changes in lipid profiles in morbidly obese patients after laparoscopic sleeve gastrectomy. *Obes. Surg*. 2011;21:305–9.

[8] Langer FB, Reza Hoda MA et al. Sleeve gastrectomy and gastric banding: effects on plasma ghrelin levels. *Obes. Surg*. 2005;15:1024–9.

[9] Peterli R, Wolnerhanssen B, Peters T et al. Improvement in glucose metabolism after bariatric surgery: comparison of laparoscopic Roux-en-Y gastric bypass and

laparoscopic sleeve gastrectomy: a prospective randomized trial. *Ann. Surg*. 2009;250:234–41.

[10] Vidal J, Ibarzabal A, Romero F et al. Type 2 diabetes mellitus and the metabolic syndrome following sleeve gastrectomy in severely obese patients. *Obes. Surg*. 2008;18:1077–82.

[11] Rizzello M, Abbatini F, Casella G et al. Early postoperative insulinresistance changes alter sleeve gastrectomy. *Obes. Surg*. 2010;20:50–5.

[12] Abbatini F, Rizzello M, Casella G et al. Long-term effects of sleeve gastrectomy, gastric bypass and adjustable gastric banding on type 2 diabetes. *Surg. Endosc*. 2010;24:1005–10.

[13] Ruiz-Tovar J, Oller I, Tomas A et al. Midterm impact of sleeve gastrectomy, calibrated with a 50-Fr bougie, on weight loss, glucose hemostasis, lipid profiles and comorbidities in morbidly obese patients. *Am. Surg*. 2012;78:969–74.

[14] Shah PS, Todkar JS, Shah SS. Effectiveness of laparoscopic sleeve gastrectomy on glycemic control in obese Indians with type 2 diabetes mellitus. *Surg. Obes. Relat. Dis*. 2010;6:138–41.

[15] DePaula AL, Macedo AL, Mota BR, Schraibman V. Laparoscopic ileal interposition associated to a diverted sleeve gastrectomy is an effective operation for the treatment of type 2 diabetes mellitus patients with BMI 21–29. *Surg. Endosc*. 2009;23:1313–20.

[16] Woelnerhanssen B, Peterli R, Steinert RE et al. Effects of postbariatric surgery weight loss on adipokines and metabolic parameters: comparison of laparoscopic Roux-en-Y gastric bypass and laparoscopic sleeve gastrectomy-a prospective randomized trial. *Surg. Obes. Relat. Dis.* 2011;7:561–8.

[17] Chambers AP, Stefater MA, Wilson-Perez HE et al. Similar effects of Roux-en-Y gastric bypass and vertical sleeve gastrectomy on glucose regulation in rats. *Physiol. Behav*. 2011;105:120–3.

[18] Li F, Zhang G, Liang J et al. Sleeve gastrectomy provides a better control of diabetes by decreasing ghrelin in the diabetic Goto- Kakizaki rats. *J. Gastrointest. Surg*. 2009;13:2302–8.

[19] Nosso G, Angrisani L, Saldalamacchia G et al. Impact of sleeve gastrectomy on weight loss, glucose homeostasis, and comorbidities in severly obese type 2 diabetic subjects. *J. Obes*. 2011;2011:340867.

[20] Marantos G, Daskalakis M, Karkavitsas N et al. Changes in metabolic profile and adipoinsular axis in morbidly obese premenopauseal females treated with restrictive bariatric surgery. *World J. Surg*. 2011;35:2022–30.

[21] Hauser H, Dyer JH, Nandy A et al. Identification of a receptor mediating absorption of dietary cholesterol in the intestine. *Biochemistry* 1998;37:17843–50.

[22] Vierhapper H, Heinze G, Nowotny P, Bieglmayer C. Serum concentrations of dehydroepiandrosterone sulphate and leptin in obese patients with normal serum cholesterol. *Metabolism* 2003;52:379–81.

[23] Vierhapper H, Nardi A, Grosser P. Prevalence of paradoxically normal serum cholesterol in morbidly obese women. *Metabolism* 2000;49:607–10.

[24] Gaziano JM, Hennekens CH, O'Donnell CJ et al. Fasting triglycerides, high-density lipoprotein, and risk of myocardial infarction. *Circulation* 1997;96:2520–5.

[25] Vila M, Ruiz O, Belmonte M et al. Changes in lipid profile and insulin resistance in obese patients after Scopinaro biliopancreatic diversion. *Obes. Surg*. 2009;19:299–306.

[26] Buchwald H, Estok R, Fahrbach K et al. Weight and type 2 diabetes after bariatric surgery: systematic review and meta-analysis. *Am. J. Med*. 2009;122:248–56.
[27] Sjöström L, Lindroos AK, Peltonen M et al. Swedish Obese Subjects Study Scientific Group. Lifestyle, diabetes, and cardiovascular risk factors 10 years after bariatric surgery. *N. Engl. J. Med*. 2004;351:2683–93.
[28] Sjöström CD, Peltonen M, Wedel H et al. Differentiated long-term effects of intentional weight loss on diabetes and hypertension. *Hypertension* 2000;36:20–5.

In: Encyclopedia of Surgery (22 Volume Set)
Editors: Andreas Lehrer and Kristin Mueller
ISBN: 978-1-53618-329-0
© 2020 Nova Science Publishers, Inc.

Chapter 181

THE LEFT-HANDED SLEEVE GASTRECTOMY: THE TECHNIQUE TO AVOID POSTOPERATIVE GASTRIC STENOSIS OR GASTRIC TWIST

Pierre Blanc [*] ***and Christophe Breton*** [†]
Clinique chirurgicale mutualiste, Saint-Etienne, France

ABSTRACT

Background Laparoscopic sleeve gastrectomy (LSG) is an effective bariatric procedure. The objective of this study is to describe a series of patients who were subjected to LSG without post operative gastric stenosis (GS) or gastric twist (GT). *Methods* From January 2011 to October 2015, 200 patients with morbid obesity underwent LSG in our institution. Out of 200 patients, 160 (80%) were women. The mean age was 44 years with a BMI of 40,4 kg/m2 (35 to 70). *Results* The mean age was 44 years (range 20-67), with a mean initial BMI of 40,4 kg/m2 (range 35-70). From the 200 patients who underwent LSG, 160 (80%) were women. The average operative time was 60 minutes, and the mean hospital stay was 3 days (range 2-5). There were two fistulas at the upper part of the sleeve that required endoscopic treatment, and there were two haemorrhages with one that required a surgical treatment. No GS or GT was found. No mortality was reported during the follow-up (range 1month-2 years). Average weight loss at 2 year was 35 Kg (30 to 80). *Conclusions* To avoid gastric stenosis or gastric twist during sleeve gastrectomy, the technique must be meticulously standardised. To avoid these rare complications, the fundus should be well mobilised and the stomach should be divided with the stapler inserted through a trocar placed on the midline (the left-handed technique), directed toward the angle of His, so no angulation of the stapler would be required.

Keywords: sleeve gastrectomy, complication, technique, gastric twist, gastric stenosis

[*] Corresponding Author's Email: Pblanc@mutualite-loire.com.
[†] Corresponding Author's Email: Cbreton@mutualite-loire.com.

INTRODUCTION

Laparoscopic sleeve gastrectomy (LSG) in morbid obesity has proved to be a safe and reproducible technique [1, 2]. LSG has become an integral part of the surgical treatment for morbid obesity, and it is being recognized as a valid stand-alone procedure for the surgical management of morbid obesity. LSG, however, is not free of complications [3]. The occurrence of gastric stenosis (GS) or gastric twist (GT) has been rarely published [4]. The purpose of the present study is to describe our technique and the tips and tricks to decrease the risk of these complications.

MATERIALS AND METHODS

From January 2011 to October 2015, 200 patients with morbid obesity were included in a prospective protocol and underwent LSG at the department of bariatric surgery, Clinique Chirurgicale Mutualiste, Saint-Etienne, France.

The patients were eligible for bariatric surgery according to the French National Institute of Health's criteria for bariatric surgery (H. A. S.), which include patients with a body mass index (BMI) of 35 kg/m2 and associated comorbidities or a BMI of 40 kg/m2 and who have failed conservative management.

All patients were evaluated preoperatively by a multidisciplinary team including an endocrinologist, a psychologist, a dietician, a bariatric nurse and a surgeon. All patients underwent preoperative screening, including physical examination (comorbidities, use of medication, BMI), nutritional status (laboratory tests), psychological examination, screening for obstructive sleep apnea, preoperative upper endoscopic evaluation, preoperative abdominal tomography and a preoperative upper gastrointestinal study. The exclusion criteria were the presence of severe esophagitis, Barrett's esophagus, hiatal hernia, as well as the presence of alcoholism, drug addiction, or psychological disorders.

Surgical Procedure

The surgeon stands between the legs (French position). The abdomen is entered under direct vision, without previous insufflation, using Kii-Fios© first entry trocar (Applied, Rancho Santa margarita, CA) on the left midclavicular line. LSG is performed using three to five ports (Figure 1). The greater curvature is mobilized using Harmonic Scalpel (ACE 45©, Ethicon endosurgery, Cincinatti, OH). The left crus is exposed and the lipoma of the angle of His is not removed in order to avoid stapling the esophagus. The gastro-pancreatic adhesions are dissected to have good mobilization of the stomach. The linear stapler (Echelon© or PowerEchelon©, Ethicon endosurgery, Cincinatti, OH) is used only with the left hand, through the port located 18 cm under the xiphoïd process on the midline (Figure 2). Before dividing the stomach, the anesthesiologist introduces a 37-F bougie MID-Sleeve© (Medical Innovation Developpement, Dardilly, France) inside the gastric lumen up to the antrum. The balloon of the MID-Sleeve© is placed in the antrum and insufflated with 40 ml of water. The stomach is divided along the gastric tube, in order to do a reproducible technique and to avoid

any narrowing of the tubular stomach. The stapler is placed at the end of the vessels along the lesser curvature (Figure 3). The gastric tube calibration is mobilized before each gastric section. We begin the division of the stomach 6 cm from the pylorus up to 1 cm from the angle of His using one 4,8 mm green staple and four to five 3,8 mm gold staples, leaving a gastric tubular pouch with a capacity of 120 ml (Ethicon endosurgery, Cincinnati, OH). In all patients, a methylene blue test under pressure (120 ml) was performed to test the permeability of the stapler line and to check for any GS or twist. The specimen is removed through the patient's medial trocar which is dilated digitally. The patient can drink water 6 hours after the surgery and can eat homogenized food on the first postoperative day. Furthermore, elastic compression stockings and subcutaneous low molecular weight heparin injection is administrated until 2 weeks postoperatively. A proton pump inhibitor (esomeprazole 40 mg) is prescribed for 6 weeks to prevent marginal ulcer formation. Outpatient clinic visits are scheduled at, 1, 4 and 12 months and then every year.

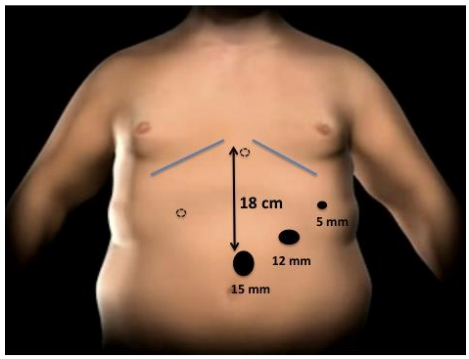

Figure 1. Port placement.

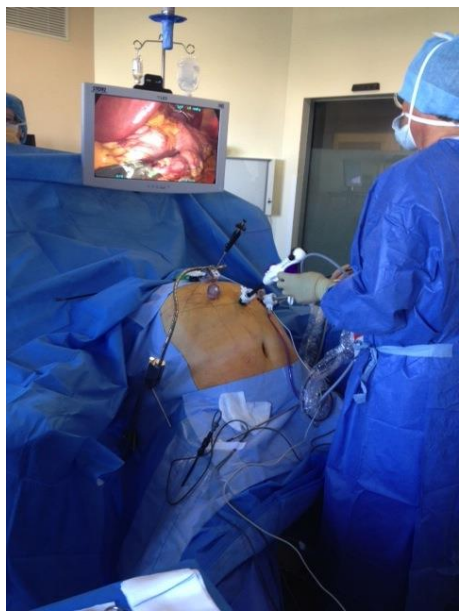

Figure 2. The operating room table is placed in the reverse-trendelenburg position at a 20°-30° angle. The stapler is used with left hand.

RESULTS

The mean age was 44 years (range 20-67), with a mean initial BMI of 40,4 kg/m2 (range 35-70). From the 200 patients who underwent LSG, 160 (80%) were women. The average operative time was 60 minutes, and the mean hospital stay was 3 days (range 2-5). There were two fistulas at the upper part of the sleeve that required endoscopic treatment, two haemorrhages with one that required a surgical treatment. No GS or GT was found. No mortality was reported during the follow-up (range 1month-2 years). Average weight loss at 2 year was 35 Kg (30 to 80).

DISCUSSION

LSG has recently emerged as a reproducible surgical technique with good results regarding weight loss and resolution of comorbidities [1, 2]. The technique is well described in the literature [5-7]. Realization of a small gastric sleeve seems to be important for a better result regarding weight loss and to decrease the likelihood of dilatation of the tube, have according to the Laplace law, less chance to dilate.

LSG have to leave the stomach with no fixations along the entire greater curvature and the posterior wall of the stomach. The LSG is a technically easier intervention than the gastric bypass or duodenal switch but, but it still requires an experienced bariatric surgeon. In order to realize a tight sleeve, three technical features are critical: first a complete mobilisation of the gastric fundus with a full exposition of the left crus, second the posterior proper traction on the dorsal layer of the stomach when placing the linear stapler (to avoid realization of a wide gastric sleeve), third firing of the linear stapler at the end of the vessels located on the lesser curvature, and slightly lateral to the angle of His (to avoid lesion of the esophagus). The complication rate for LSG has been 2,9%-15,3% with an overall reported mortality rate of 0,1-0,39% according to recent studies [3]. Among the complications which occur following a LSG, GS or GT are uncommon complications (ranges from 0,1 to 3,9%); however, when they occur, they can cause either obstruction through the gastric lumen or delayed gastric emptying [4]. In our study, no GS or GT was found. The major tip to avoid a GT is to think that the LSG is a « left-handed technique." Indeed, the surgeon has to use the stapler only with the left hand through the port located in the midline (Figure 2). We advise to completely divide the posterior pancreatico-gastric adhesions and to expose the left crus during the greater curvature dissection. It is important to free the upper part of the retroperitoneal fundus from the left crus. The stretch of the stomach should not to be too much and must be the same between the anterior wall and the posterior wall of the stomach. The anatomical landmarks are the end of the short vessels on the lesser curvature (Figure 3). The twisting may also occur by misalignment of the staples in the same plane. With the left handed technique, at the end of the stapling, the gastric section is in a horizontal plan (Figure 4-5). According to the literature GS can be produced by sharp angulations of the stapler. With the left handed technique, there is no need to use the angulation and this risk is minimised. The use of a small calibration tube or the stapling without a tube could also result in GS. Therefore, to avoid a GS, we recommend the stapling to be performed along a specific 37 Fr MID-sleeve© calibration tube mobilized before each stapling.

Figure 3. The stapler is placed against the endoluminal bougie. The posterior wall of the stomach is gently grasped and pull anteriorly.

CONCLUSION

To avoid gastric stenosis or gastric twist during sleeve gastrectomy, the technique must be meticulously standardised. To avoid these rare complications, the fundus should be well mobilised and the stomach should be divided with the stapler inserted through a trocar placed on the midline (the left-handed technique), directed toward the angle of His, so no angulation of the stapler would be required.

CONFLICT OF INTEREST

The authors declare that they have no conflict of interest.

Ethical Approval

All procedures performed in studies involving human participants were in accordance with the ethical standards of the institutional and/or national research committee and with the 1964 Helsinki declaration and its later amendments or comparable ethical standards.

Informed Consent

For this type of study, formal consent is not required.

REFERENCES

[1] Laville M, Romon M, Chavrier G, Guy-Grand B, Krempf M, Chevallier JM, Marmuse JP, Basdevant A. Recommendations regarding obesity surgery. *Obes Surg*. 2005 Nov-Dec;15(10):1476-80.

[2] Chazelet C, Verhaeghe P, Perterli R, Fennich S, Houdart R, Topart R, Tussiot J, Skawinski P, Serraille G, Catheline JM, Merabet M, Dehaye B, Pautot V, Juglard G, Sala JJ. Longitudinal sleeve gastrectomy as a stand-alone bariatric procedure: results of a multicenter retrospective study. *Journal de Chirurgie*. 2009; 146(4):368-372. DOI: 10.1016/j. jchir.2009.08.021.

[3] Frezza E, Womiak S, Gee L. Complications after laparoscopic sleeve gastrectomy for morbid obesity. *Obes Surg*. 2009;19:684-7.

[4] Burgos AM, Csendes A, Braghetto I. Gastric stenosis after sleeve gastrectomy in morbidly obese patients. *Obes Surg*. 2013;23:1481-6.

[5] Dhahri A, Verhaeghe P, Hajji H, Fuks D, Badaoui R, Deguines JB, Regimbeau JM. Sleeve gastrectomy: *Technique and results.: Journal of Visceral Surgery*. 2010;147S: e39—e46. 10.1016/j.jviscsurg. 2010.08. 016.

[6] Gadiot RPM, Biter LU, Zengerink HJF, de Vos tot Nederveen Cappel RJ, Elte JWF, Cabezas MC, Mannaerts GHH. Laparoscopic sleeve gastrectomy with an extensive posterior mobilization: Technique and preliminary results. *Obes Surg*. 2012;22:320-329. DOI 10.1007/s11695-011-0488-9.

[7] Blanc P, Breton C, Kaczmarek D, Bourbon M, Burgard G, Hugonnier G, Regairaz C. Gastrectomie en manchon: trucs, astuces et controverses techniques. *Journal de coeliochirurgie*, 2013;86:11-17.

In: Encyclopedia of Surgery (22 Volume Set)
Editors: Andreas Lehrer and Kristin Mueller
ISBN: 978-1-53618-329-0
© 2020 Nova Science Publishers, Inc.

Chapter 182

WEIGHT REGAIN FOLLOWING SLEEVE GASTRECTOMY

Melanie Lauti*, Andrew G. Hill and Andrew D. MacCormick
Department of Surgery, South Auckland Clinical Campus,
University of Auckland, Auckland, Middlemore Hospital, New Zealand

ABSTRACT

Weight regain has long been recognised as a complication of bariatric surgery with recent work suggesting that it may be most common following sleeve gastrectomy. Weight regain is an important complication due to its association with recurrence of diabetes, deterioration in quality of life and economic implications. Despite this, weight regain remains inconsistently reported and poorly understood.

The phenomenon of weight regain following bariatric surgery has no consensus definition. In the small number of series where it is reported, the definition may be any weight regain or an increase in an arbitrarily chosen value such as an increase of 10kg, 5kg/m^2 or 25%EWL from the post-operative weight loss nadir. The result is that reported rates of regain vary from 6% at two years to 76% at six years post-operatively.

The causes of weight regain after sleeve gastrectomy have not been definitively established. A systematic review revealed five possible contributors: technical factors, sleeve dilatation, ghrelin levels, maladaptive lifestyle behaviours and lack of adequate follow-up support. Further studies are required to understand the underlying mechanisms definitively.

The management of weight regain following sleeve gastrectomy is not well described. Management guidelines are difficult to formulate given the variability in definition, incomplete understanding of its etiology and lack of robust evidence for revision procedures. Currently, management varies from observation to major revision surgery and is generally tailored to the patient and is dependent on the options available at the treating bariatric service.

Weight regain following sleeve gastrectomy is a common complication with significant implications. To date, its understanding and management have been hampered by the lack of a standardized definition and paucity of robust studies. Once these issues

* Corresponding Author's Email: m.lauti@auckland.ac.nz.

are addressed, the identification and management of weight regain following sleeve gastrectomy will be able to be optimised.

Keywords: sleeve gastrectomy, weight regain

INTRODUCTION

Weight regain following bariatric surgery is a well-recognised phenomenon of long-term outcome reporting. The Swedish Obese Subjects (SOS) study was the first long-term, prospective controlled trial to observe and compare the effects of bariatric surgery to usual care [1]. In their study that included over 2,000 patients undergoing bariatric surgery, weight regain began in the second year then tended to level off after eight to ten years through to twenty years. The applicability of these results to contemporary bariatric practice must be interpreted with the knowledge that this study population used different surgical selection criteria to those currently recommended and the majority of the study population underwent the now obsolete vertical banded gastroplasty (VBG). Furthermore, the attrition after ten years of follow-up was significant. More relevant to current practice is the Utah-based prospective study that compared long-term weight loss in the severely obese undergoing Roux-en-Y gastric bypass (RYGB) with those who had no surgery [2]. In this study, an excellent follow-up rate of 93% of the original 418 surgical patients was obtained. Their results demonstrated a 7% (95% CI 5%-10%) increase in mean unadjusted weight loss from year two to six following surgery. It appears that weight regain following bariatric surgery is a phenomenon common to all procedure types. Recent work, however, suggests that the proportion of patients who regain weight following sleeve gastrectomy (SG) may be higher than after RYGB [3].

The significance of weight regain following bariatric surgery is unclear. Even in the presence of the weight regain outlined above, bariatric surgical recipients still overall reap the benefits of reduced incidence of diabetes, cardiovascular disease and overall mortality as well as significant rates of diabetes remission [1, 2]. When the relationship between weight regain and comorbidities is further explored, however, important trends emerge. Brethauer et al. (2013) reported on a Cleveland Clinic cohort of 162 diabetic patients who had undergone a RYGB on average five years previously with remission rates of 71% and 61% in the short- and long-term respectively [4]. They further demonstrated that diabetes recurrence following partial or complete remission was associated with an increase in body mass index (BMI) of $5 kg/m^2$ or more following the weight loss nadir (OR 13, 95% CI 1 – 99).

The SOS study employed a battery of generic and condition-specific quality of life (QOL) measures to assess health-related quality of life (HRQL) at regular intervals over ten years following bariatric surgery [5]. The pattern of change in HRQL largely followed that of weight change over the same period, particularly in mental well-being domains. That is, a gradual reduction in HRQL was associated with the slow weight regain occurring between one and six years post-operatively. Importantly, and similarly to the metabolic effects however, overall HRQL net gains were noted in all domains at ten years when compared to baseline.

Bariatric surgery is a cost effective approach to the treatment of obesity, particularly in diabetic patients [6, 7]. How weight regain affects these estimated cost benefits is less clear

and has previously not been incorporated into economic analyses. Sheppard et al. (2013) attempted to elucidate the direct costs of weight regain by systematic review [8]. Their efforts were hampered by a lack of adequate reporting with respect to regain rates, cost of revision procedures and relevant Canadian literature. They conclude that economic analyses to date have not incorporated the financial impact of assessing and managing weight regain which is likely to have a significant effect on the cost effectiveness of bariatric surgery as a treatment for obesity. Certainly, simulation modelling has confirmed that weight regain could significantly affect cost effectiveness [9].

Weight regain following bariatric surgery is likely to have important consequences with respect to diabetes, HRQL and health economics. The magnitude of these effects, however, remains uncertain given the paucity of the literature that specifically investigates the weight regain phenomenon.

DEFINITIONS AND RATES

Despite the recognised phenomenon of weight regain following sleeve gastrectomy, there are no reporting guidelines nor standardised definitions endorsed by relevant societies. Thus the existing literature is heterogeneous such that it is difficult to know exactly what clinicians mean by weight regain, what a clinically significant amount of weight regain is and how common the problem is. Table 1 presents the currently employed weight regain definitions and Table 2 the weight regain rates for sleeve gastrectomy series with at least two years of follow-up.

Interestingly, the most commonly employed definition in the literature, an increase of greater than 10kg from nadir (Table 1), differs from that most commonly employed by bariatric experts [24]. The International Bariatric Club (IBC), a group of recognised experts in bariatric surgery, responded to a social media poll using the definition for weight regain following sleeve gastrectomy as achieving a BMI > 35kg/m^2 [24, 25]. Neither of these definitions are ideal. The first does not define the significance in the individual, nor does it allow for comparisons and has even been described as random by those who employ it [26]. The second definition is a flawed static measure [27], assumes a nadir weight of below 35 and is unsuitable for low BMI bariatric cohorts. These points further emphasise the need for an expert group consensus regarding the definition for weight regain.

A further difficulty concerning definitions is that the term ‘failure’ in the literature has been used to refer to progressive weight regain, insufficient weight loss and even symptomatic reflux. Oftentimes, these terms are lumped together, grouping patients together for revision surgery when in fact they are likely to have very different underlying mechanisms causing ‘failure’. Until care is taken to standardise these reporting terms in the bariatric literature, there will be ongoing difficulties in interpreting the evidence that is available.

Despite the plethora of published sleeve gastrectomy series, only a minority report weight regain rates (Table 2). The weight regain rate refers to the proportion of patients who increase their body weight from the nadir achieved following bariatric surgery. Table 2 clearly demonstrates the heterogeneity of the available literature. The series tend to be small, have different patient cohorts, differ in surgical technical and post-operative care and variably define how they categorise patients as having regained weight. The only trend demonstrated

by these series is that the proportion of patients with weight regain tends to increase with the time from surgery. Again, the lack of standardised reporting makes any further generalisations impossible.

Table 1. Weight regain definitions employed in the literature for sleeve gastrectomy series with at least two years of follow-up (updated from Lauti et al. [10])

Origin of definition *(author, country, year [ref])*	Definition reported
Abdallah et al., Egypt, 2014 [11]	An increase of body weight of more than 10kg
Bohdjalian et al., Austria, 2010 [12]	An increase of body weight of more than 10kg
Braghetto et al., Chile, 2012 [13]	Greater than 10kg
Brethauer et al., United States, 2013 [4]	An increase in BMI of 5kg/m or more above the weight loss nadir
Carmeli et al., Israel, 2015 [14]	Regaining of weight after successful loss defined as a BMI > 35kg/m^2
Casella et al., Italy, 2016 [15]	Weight increase > 10kg from weight loss nadir
de Hollanda et al., Spain, 2015 [16]	The difference between body weight at last follow-up and nadir weight and expressed in kilograms or as a percent of maximal WL
Homan et al., Netherlands, 2015 [17]	25% EWL regain with respect to the minimal weight after LSG or when a patient met the criteria for bariatric surgery again, established by the International Federation for the Surgery of Obesity
Jimenez et al., Spain, 2012 [18]	Any weight regain after T2DM remission to last follow-up
Langer et al., Austria, 2010 [19]	An increase in body weight of more than 10kg from the nadir
Liu et al., Hong Kong, 2015 [20]	%REWL was greater than 25% where %REWL is the percentage of rebound in excess weight loss calculated as the percentage difference between the %EWL measured and the best %EWL achieved during post-operative follow-up
Nedelcu et al., France, 2015 [21]	After an initial successful weight loss (defined as EWL > 50%)
Obeidat et al., Jordan, 2015 [22]	An increase in body weight of more than 10kg from the nadir
Quezada et al., Chile, 2016 [23]	EWL ≤ 50% after having EWL > 50%

Ref, reference; kg, kilograms; BMI, body mass index; m, metres; WL, weight loss; EWL, excess weight loss; LSG, laparoscopic sleeve gastrectomy; T2DM, type II diabetes mellitus; REWL, rebound in excess weight loss.

ETIOLOGY

The aetiology of weight regain following sleeve gastrectomy is not definitively understood. A recent systematic review summarised the proposed contributors to this problem currently discussed in the literature [10]. These were technical factors, sleeve dilatation, hormonal factors, lack of follow-up support and maladaptive lifestyle behaviours pertaining to diet and exercise. Unfortunately, no studies have robustly investigated any of these proposed mechanisms and it appears the aetiology of weight regain is likely multifactorial.

Technical Factors

Technical factors refer to operative technique that influences the initial sleeve size. Specifically, the size of the calibration bougie, the distance from the pylorus where the antrum is divided and ensuring complete excision of the gastric fundus.

From its inception as a component of the biliopancreatic diversion with duodenal switch (BPD-DS) to its evolution as a stand-alone procedure, the remnant sleeve has become progressively smaller [33-35]. Weiner et al. (2007) described their early series initially using no calibration, then a 44F bougie and eventually a 32F bougie as they had noticed an association between larger remnant gastric volume and treatment failure or early weight regain (not defined) [35]. Four years later, this same group decided upon a 42F bougie as their cohort had experienced more staple-line leaks with the smaller bougie [36]. The recent inaugural report from the Metabolic and Bariatric Surgery Accreditation and Quality Improvement Program (MBSAQIP) confirmed an increase in leaks with a calibration bougie size less than 38F and reported better weight loss results (2.45 percentage points of BMI reduction for bougie size ≥ 40, $p < 0.001$) with larger bougies but weight regain was not assessed [37]. Interestingly, expert consensus has increased the average size of the bougie to 36F due to the increasing belief that leaks are increased with the narrower sleeves [38, 39]. Due to the design and reporting of studies investigating the effect of bougie size, the true relationship between weight regain and bougie size remains unknown [40-43].

The second technical factor contributing to weight regain proposed in the literature relates to where the antrum is divided in relation to the pylorus. In 2011, Weiner et al. (2011) proposed that a dilated antrum acted as a new reservoir within two to four years in patients with weight regain when the distal resection margin of the stomach was 4-6cm from the pylorus [36]. This has been further investigated by two short-term studies. A retrospective study reported 22% of 110 patients regained at least 10kg from their nadir weight when the stomach was divided 6cm from the pylorus compared to only 4% when the division occurred 2cm proximal to the pylorus ($p = 0.003$) at two years [22]. A similar, though not statistically significant, finding also at two years was reported in a randomized trial of 105 patients where 9% and 2% of patients regained at least 10kg from their nadir weight with a 6cm and 2cm antrum remnant respectively [11]. An adequately powered randomized trial with long-term follow-up would provide definite evidence to confirm that a larger remnant antrum contributes to weight regain.

Himpens et al. (2010) conceptualized the ‘neofundus’ as a cause for weight regain when too much gastric fundus is left adjacent to the gastro-oesophageal junction when dividing the stomach [32]. They hypothesized that the resulting conical- rather than cylindrical-shaped sleeve is then prone to dilatation due to the relative distal stenosis predisposing to subsequent weight regain. Weiner et al. (2011), however, felt this was a better explanation for early poor weight loss outcomes rather than later regain based on their own series [36]. Unfortunately, it continues to be difficult to elucidate further a s published series continue to group insufficient weight loss, progressive weight regain and even general procedure failure together, highlighting yet again the great need for standardised language and reporting in this area [44, 45].

Table 2. Weight regain rates reported in the literature for sleeve gastrectomy series with at least two years of follow-up (updated from Lauti et al. [10])

Author Country Year [ref]	Number of patients	Patient cohort	Mean pre-operative BMI *kg/m^2 (n)*	Bougie size *French*	Antral division from pylorus *cm*	Follow-up period *years*	Follow-up schedule	Mean post-operative BMI *kg/m^2 (n)*	Mean %EWL *% (n)*	Regain rate *% (n)*	Definition used
Abdallah et al. Egypt 2014 [11]	105	Morbidly obese patients aged between 18-60 years	51.7 (105)	38	2 or 6	2	2 weeks then 3, 6, 12 and 24 months	NR	66.5 (105)	**5.7% (6)**	More than 10kg from nadir
Nocca et al. France 2008 [28]	163	BMI > 40 with high-volume eating disorder BMI >35 high-volume eating disorder and severe comorbidities BMI >50 Sweet-eating disorders were a contra-indication	45.9 (163)	36	Where the calibration tube makes contact with the greater curve	2	1,6,12, 18 and 24 months	31.6 (98)	61.5 (98)	**10.2% (10)**	NR
Obeidat et al. Jordan 2015 [22]	125	Patients selected according to the 1991 NIH guidelines with all patients having a BMI of >40 or >35 with a major co-morbidity	46.1 (110)	38	2 or 6	2	1 week then 1, 3, 6, 12 and 24 months	NR	73.2 (110)	**12.7 (14)**	An increase in body weight of more than 10 kg from the nadir
Braghetto et al. Chile 2009 [29]	15	NR	39.7 (15)	32	2-3	2-3	NR	NR	NR	**20.0% (3)**	NR
Bohdjalian et al. Austria 2010 [12]	26	NR	48.2 (26)	48	Division described as starting opposite the nerve of Latarjet [30]	5	3, 6, 9, 12, 18, 24 months then annually	NR	55.0 (22)[a]	**19.2% (5)**	More than 10kg from nadir
Liu et al. Hong Kong 2015 [20]	140	Asia-Pacific Bariatric Surgery Group consensus guidelines 2005 initially then the International Federation for the Surgery of Obesity and Metabolic	41.0 (140)	58.6% with a bougie less than 40 and 41.4% with a bougie above 40	6	5	1, 6, 12, 18, 24 months then annually	33.7 (52)	57.2 (52)	**29.5% (NR)**	Rebound in excess weight loss greater than 25%

Author Country Year [ref]	Number of patients	Patient cohort	Mean pre-operative BMI *kg/m^2 (n)*	Bougie size *French*	Antral division from pylorus *cm*	Follow-up period *years*	Follow-up schedule	Mean post-operative BMI *kg/m^2 (n)*	Mean %EWL *% (n)*	Regain rate *% (n)*	Definition used
		Disorders – Asia Pacific Chapter consensus statement. BMI >35 or >30 with inadequately controlled T2DM or metabolic syndrome									
Braghetto et al. Chile 2012 [13]	560	NR	38.4 (560)	32 or 40 [31]	2-3 [31]	5+	NR	29.9 (60)	57.3 (60)	**39.5% (NR)**	Greater than 10kg
Himpens et al. Belgium 2010 [32]	53	Patients selected according to 1991 NIH guidelines and were volume eaters but not diabetics nor subject to significant reflux disease	39.5 (41)	34	6	6	On a regular basis until 3 years	31.1 (30)[b] 30.1 (41)	53.3 (30)[b] 57.3 (41)	**75.6% (31)**[c]	NR
Casella et al. Italy 2016 [15]	182[d]	NR	45.9 (182)	48	4-6	6	3, 6, 9, 12, 18 and 24 months then annually	30.2 (148)[e]	67.3 (148)	**26.3% (39)**[f]	Weight increase greater than 10kg from weight loss nadir
Felsenreich Austria 2016 [26]	53[g]	NR	48.9 (49)[h]	42-48	6	10	NR	35.5 (49)[h] 36.4 (32)[i] 34.7 (11)[j] 28.7 (6)[k]	54 (49)[h] 52.5 (32)[i] 52.8 (11)[j] 73.5 (6)[k]	**58.5% (31)**	Weight regain of 10kg or more from their nadir weight

BMI, body mass index; %EWL, percent of excess weight lost; NR, not reported.

[a] Excludes the four patients converted to gastric bypass – three for weight regain, one for reflux.

[b] Excludes the 11 patients who had a duodenal switch between three and six years but includes two resleeve procedures.

[c] Of the 53 consecutive patients, 12 patients were unable to be followed-up.

[d] In eight of these cases the sleeve was a revision procedure (six following gastric banding and two following vertical banded gastroplasty).

[e] 32 patients excluded for not attending follow-up and a further four excluded as they underwent biliopancreatic diversion with duodenal switch for insufficient weight loss within 18 months.

[f] Amount of weight regained was between 11-20kg for 27 patients, 21-30kg for nine patients and >30kg for three patients.

[g] In 11 of these case the sleeve was a revision procedure (ten following LAGB and one following gastric stimulation).

[h] Four patients excluded, two cases who had acute conversions to RYGB for leak and two subsequent deaths for reasons not relating to bariatric surgery.

[I] Excludes 17 converted cases and two deaths from reasons unrelated to bariatric surgery.

[j] Includes only the 11 converted cases to (ten to RYGB and one DS) for weight regain

[I] Includes only the six converted cases to RYGB for GORD.

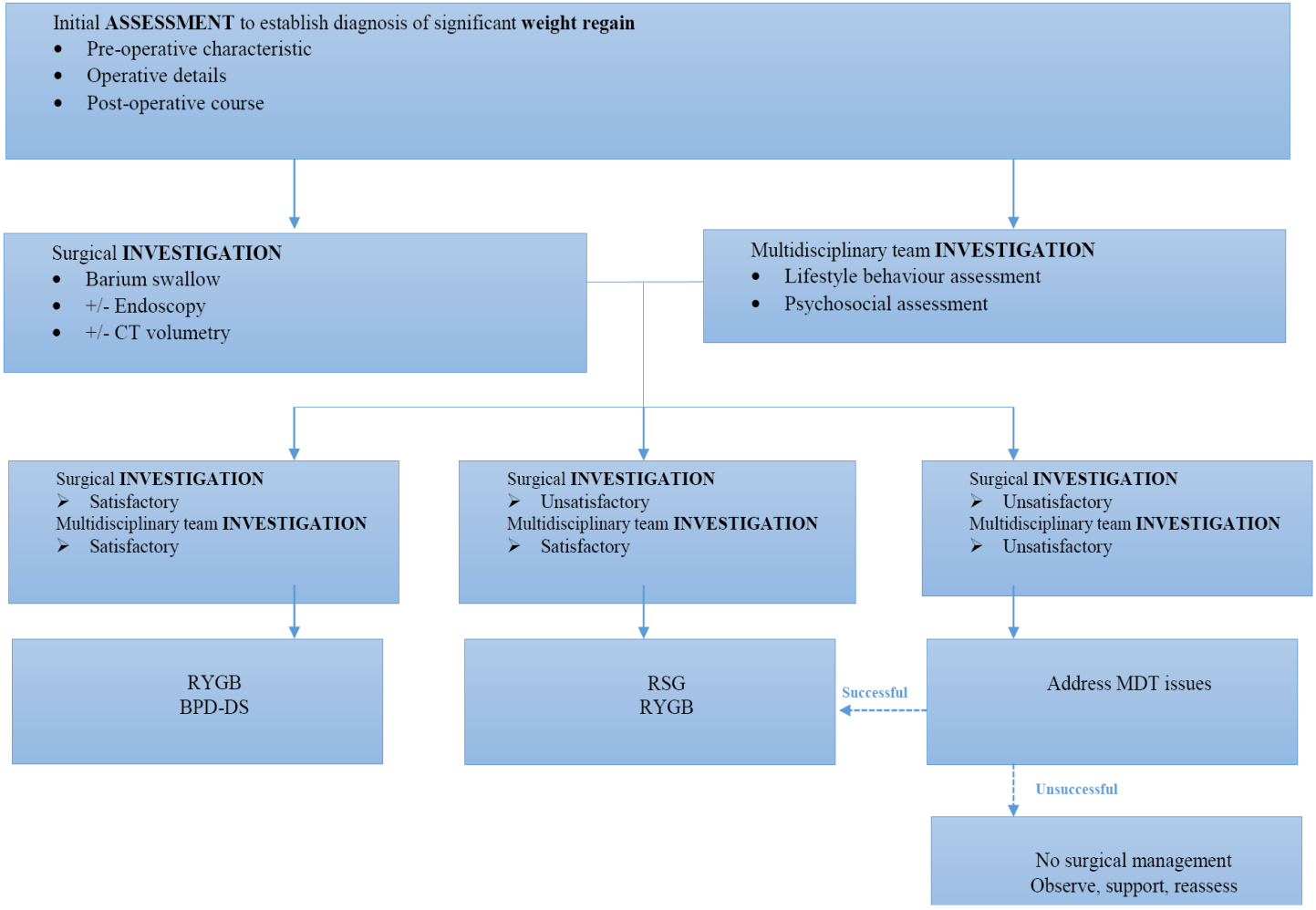

Figure 1. Proposed algorithm for the assessment and management of weight regain following sleeve gastrectomy.

While technical factors may certainly play a role in weight regain, the true manner in which they do so is far from elucidated. Currently, the lack of standardised language continues to be a significant barrier which, if improved, could further our understanding in this area. However, achieving high level evidence in this area will always be arduous given the need for prospective randomized trials with long-term follow-up and the difficulties these incur.

Sleeve Dilatation

It seems inevitable that any sleeve will increase in size with increasing time since surgery. Braghetto et al. (2009) demonstrated that a sleeve doubles in size two to three years post-operatively and postulated that this may be a cause for weight regain [29]. Reporting on their cohort at five years, they describe that 15.7% of their patients had regained weight by five years associated with a further increase in gastric volume [13]. However, as they also report a regain rate of 39.5% in their five-year cohort, it remains unclear how much sleeve dilatation truly contributes to weight regain. A recently published series of sleeve gastrectomy cases with ten year follow-up reports weight regain in 58% of patients (31/53) and stated that endoscopy revealed sleeve dilatation as the leading but not mandatory cause for weight regain [26].

Hormonal Factors

The restrictive effect of a sleeve gastrectomy on caloric intake is further enhanced by the loss of hunger mediated by oxygenic ghrelin levels that become reduced with excision of the gastric fundus [46-51]. One small series of twelve patients noted that the three patients who had regained at least 10kg of weight from nadir at five years had slightly higher ghrelin levels than those who did not, though this was not statistically significant [12]. Further studies are needed to explore this mechanism further.

Follow-up Support

The importance of follow-up support or a lack of follow-up support in contributing to weight regain following sleeve gastrectomy has been proposed by several authors [32, 52, 53]. Himpens et al. (2010) noted that weight regain coincided with discharge from follow-up at three years post-operatively [32]. Sarela et al. (2012) proposed that the lifelong follow-up provided by their National Health Service was responsible for less weight regain [52]. Lombardo et al. (2015) concluded that more follow-up visits may reduce weight regain based on a retrospective study comparing a group of patients that had more follow-up visits than the other. Patients themselves have identified follow-up care as an important influence on their ability to maintain healthy nutritional and exercise behaviors to minimize weight regain [54]. To date, however, there have been no randomized trials to clarify the relationship between follow-up care and weight regain.

Lifestyle Behaviors

Lifestyle behaviors contributing to high-energy diets and physical inactivity are implicated in the etiology of obesity itself and thus unsurprisingly have also been identified as potential contributors to significant weight regain following sleeve gastrectomy [55]. Furthermore, patients who have experienced weight regain following sleeve gastrectomy themselves acknowledge that appropriate nutrition and exercise behaviors are the cornerstone to minimizing weight regain [54].

The effect of lifestyle behaviors on weight regain following sleeve gastrectomy has not been comprehensively investigated. In a small series of patients followed-up at five years, Kehagias et al. (2013) attributed a gradual decline in %EWL to maladaptive eating and lack of exercise as assessed by data obtained from annual dietary questionnaires [56]. Keren et al. (2014) developed a lifestyle modification score based on two questions from the Bariatric Analysis and Reporting Outcome System (BAROS) and found this correlated well with lifestyle change and weight loss results [57-59]. Qualitative data from almost 40 patients who had experienced weight regain following sleeve gastrectomy suggests that the ability of patients to maintain healthy lifestyle behaviors beyond the short-term is influenced by health, psychological health, financial status and follow-up support [54]. Prospective studies evaluating behavioral interventions are required to assess the effect of lifestyle modification on weight regain following sleeve gastrectomy.

MANAGEMENT

There is no universally recognized definitive management for weight regain following sleeve gastrectomy. The literature in this area is limited by non-uniform reporting, an incomplete understanding of its underlying mechanism(s) and a lack of robust prospective studies. Furthermore, even though longer term outcome data following sleeve gastrectomy is now being reported, the outcome data for subsequent revision procedures remains largely short-term. What is recognized is that treatment needs to be individualized [39] and that the management options may limited by a lack of institutional expertise or experience.

Proposed Algorithm (Figure 1)

Initial assessment of a patient with weight regain begins with a review of the case. The preoperative characteristics of the patient including initial weight measures, co-morbidities and psychosocial factors. The operative details need to be considered. These include surgeon experience, bougie size, division of the antrum in relation to the pylorus together with the operative assessment and management of the hiatus. Finally, the post-operative course of the patient must be reviewed. Their weight loss curve needs to be assessed for a rapid weight loss phase, achieving a satisfactory weight loss nadir before the onset of weight regain. Given that the weight loss nadir usually occurs between 12 and 24 months following surgery, it is the authors' view that the need for revision surgery prior to two years is likely to be attributable

to the phenomenon of insufficient weight loss rather than weight regain. Once a clinical picture of significant weight regain has been established, the patient requires investigation.

Investigations for weight regain following sleeve gastrectomy require a multi-disciplinary approach. Surgical assessment requires a barium swallow and/or endoscopy to exclude remnant fundus and grossly dilated sleeve. Sleeve capacity can accurately be assessed by the addition of volumetric studies, however how these are performed and interpreted varies between centres. The remainder of the multi-disciplinary team must investigate the patient for maladaptive lifestyle behaviours pertaining to nutrition and physical activity and contributing psycho-social factors. Ideally such a team should consist of a nurse specialist, dietician, psychologist, exercise physiologist and social worker. Pragmatically, however, this is not always possible and institutions must optimize their resources to the best of their ability.

If both assessment and investigations from surgical and allied health teams reveal no underlying cause(s) for the weight regain, then a more aggressive bariatric procedure should be considered. Most experts would perform a RYGB as the procedure of choice with BPD-DS as second choice [39]. In the instance when an anatomical abnormality is the only potential cause detected, it may be appropriate to consider fundectomy or resleeve gastrectomy (RSG) for retained fundus or large gastric volume. These cases should also include consideration of direct conversion to RYGB as this has the most evidence base. Finally, if a patient has both surgical and non-surgical abnormalities in their assessment, it is the authors' opinion that the non-surgical issues should be addressed in the first instance. Only once behavioural and psychosocial factors have been addressed, should patients proceed to revision surgery to maximise their chance of success.

Revision Surgery

In many instances, patients presenting with weight regain following sleeve gastrectomy may proceed to revision surgery. Although a recent consensus from experts reported RYGB and BPD-DS as the first and second choice of procedure respectively, the reality is that there a variety of revision procedures being undertaken and these are institution dependent. Unfortunately, as weight regain remains variably defined, is often grouped together with insufficient weight loss or sleeve failure and is not definitively understood, the evidence in this area is limited. What can be stated, however, is that re-operative surgery for weight regain appears to be safe and generally demonstrates improved weight loss and co-morbidity reduction [60]. Complication rates do appear to be higher than after primary bariatric surgery, though the benefits tend to outweigh the risks with appropriate case selection and management [60, 61]. These complication rates vary by expertise/institution and are likely to continue to improve as surgical experience in bariatric revision surgery unavoidably grows.

The terms resleeve and fundectomy are not clearly defined but appear to refer to the same procedure. It was originally safely described in a case report in the context of revising a BPD-DS for weight regain and subsequently as part of the second stage procedure [62, 63]. Himpens et al. (2010) where among the first to publish undertaking this revision surgery in their six year series for isolated SG [32]. Other than stating that two patients successfully underwent a resleeve operation for weight regain with findings of neofundus formation on barium swallow, no further information was given. Nedelcu et al. (2015) has published the largest series of resleeve gastrectomy (RSG) in 61 patients for progressive weight regain (29),

insufficient weight loss (28) or symptomatic gastroesophageal reflux disease (4) following clearance from a multidisciplinary team after a median period of 37 months from SG [21]. To proceed with RSG, radiological findings of an upper gastric pouch dilatation, huge unresected fundus on barium swallow or a gastric tube volume of more than 250ml on CT volumetry was required. Early post-operative complications included a perigastric haematoma and two stenoses all treated with endoscopic stenting. Weight loss results were available for only 33 patients (54%) but did demonstrate reasonable weight loss at a mean follow-up interval of 20 months (range 12-72). Only one series to date has produced a series of RSG specifically for weight regain [64]. Cesana et al. (2014) described 11 patients with progressive weight regain and persistence of comorbidities with associated persistence of gastric fundus and/or antrum on upper gastrointestinal series. However, they identified these patients early within the first two post-operative years, weight regain was not defined and it could be that these patients had insufficient weight loss rather than significant weight regain. Regardless, there results confirmed the feasibility, safety and satisfactory weight loss results for RSG at one year. Longer-term studies with well-defined selection criteria are required to increase the level of evidence in this area.

Generally, expert bariatric surgeons opt for RYGB as the revision procedure for weight regain following sleeve gastrectomy [39]. Certainly, the effectiveness is of this operation as a primary procedure is well established [1, 2]. Its role as a revision procedure for weight regain after SG is less clear but has the most amount of evidence of all revision procedures after SG. Langer et al. (2010) were the first to publish a series of SG to RYGB conversions specifically for weight regain [19]. They described revising SG to RYGB in five patients who had regained at least 10kg of weight from the nadir weight and were high-volume non-sweet eaters. The interval from SG to conversion was between 24-63 months and early follow-up suggested this could be undertaken safely with further weight loss. This same group report on their 10 year cohort in which 11 patients underwent conversion to RYGB for weight regain [26]. Again, the conversions appeared to be safe and weight loss results were similar to those who had not required a revision procedure for weight regain suggesting durability. Quezada et al. (2016) corroborated these findings in their SG to RYGB revision series of 50 patients [23]. Twenty-eight of these patients were analysed separately from the indication of weight regain defined as EWL $\leq$ 50% after having EWL > 50% and found the revision procedure to be feasible, well-tolerated and render similar weight loss results to non-converted patients at three years in the 72% of patients who were able to be followed up. A prospective trial comparing RSG with conversions to RYGB would significantly increase the level of evidence currently in the literature. Such a study, however, would need to be meticulously designed with well-defined selection criteria and would pragmatically be difficult to undertake with adequate power.

BPD-DS is a radical procedure with a significant malabsorptive component. SG was originally developed as a modification to BPD-DS for the super obese and thus 'revision' of a SG to BPD-DS is not a new concept [33]. Thus its effectiveness for weight loss in higher BMI patients is established [65]. Whilst obesity-related outcomes are better when compared with RYGB, this is at the expense of higher complication and malnutrition rates [66]. The use of BPD-DS as a revision procedure for weight regain following sleeve gastrectomy has a comparatively smaller literature base. Homan et al. (2015) retrospectively reviewed a cohort of such patients where regain was defined as a gain of 25% EWL with respect to the minimal weight after SG, or when a patient met the criteria for bariatric surgery again (as established

by the International Federation for the Surgery of Obesity) [17]. They reported on 25 patients who had undergone secondary surgery because of insufficient weight loss or weight regain with superior weight loss outcomes following BPD-DS, percent of total body weight loss (%TBWL) of 27% (range 7%-50%), compared with 9% (range -16%-35%) following RYGB ($p = 0.004$) after a median follow-up of 34 (range 14–79) months. Furthermore, three patients (27%) patients who underwent RYGB as the revision procedure regained weight. The significance of these results needs to be balanced against the study's retrospective design, small numbers, increased nutritional deficiencies in the BPD-DS group and baseline differences as the patients converted to RYGB had lower pre-revision weight measures than those converted to BPD-DS. Furthermore, the indications of insufficient weight loss and weight regain were analysed together despite their likely different underlying aetiologies. Dapri et al. (2011) reported a small (n = 26) retrospective series comparing BPD-DS with RSG also for insufficient weight loss or weight regain (not defined) [67]. BPD-DS was selected for patients with polyphagia and RSG for patients with hyperphagia once psychological disorders had been excluded. They also found superior weight loss outcomes following BPD-DS but again with associated higher rates of complications with mean follow-up of 23 months (range 13–38) in the context of similar limitations to the series of Homan et al. (2015). While expert bariatric surgeons consider the BPD-DS the second choice for revision of SG, there is no robust evidence available supporting this in patients with weight regain following sleeve gastrectomy. Thus when proceeding to BPD-DS, it should only occur in centres experienced in both the procedure and follow-up care to minimise the recognised high rates of complications and malnutrition.

CONCLUSION

Weight regain following sleeve gastrectomy is a common complication with significant implications. To date, its understanding and management have been hampered by a lack of a standardised definition and paucity of robust studies. Once these issues are addressed, the identification and management of weight regain following sleeve gastrectomy will be able to be optimised.

REFERENCES

[1] Sjostrom L. Review of the key results from the Swedish Obese Subjects (SOS) trial - a prospective controlled intervention study of bariatric surgery. *Journal of Internal Medicine.* 2013;273(3):219-34.

[2] Adams TD, Davidson LE, Litwin SE, Kolotkin RL, LaMonte MJ, Pendleton RC, et al. Health benefits of gastric bypass surgery after 6 years. *JAMA: the Journal of the American Medical Association.* 2012;308(11):1122-31.

[3] Jammu GS, Sharma R. A 7-year clinical audit of 1107 cases comparing sleeve gastrectomy, Roux-en-Y gastric bypass, and mini-gastric bypass, to determine an effective and safe bariatric and metabolic procedure. *Obesity Surgery.* 2016;26(5):926-32.

[4] Brethauer SA, Aminian A, Romero-Talamas H, Batayyah E, Mackey J, Kennedy L, et al. Can diabetes be surgically cured? Long-term metabolic effects of bariatric surgery in obese patients with type 2 diabetes mellitus. *Annals of Surgery.* 2013;258(4):628-37.

[5] Karlsson J, Taft C, Ryden A, Sjostrom L, Sullivan M. Ten-year trends in health-related quality of life after surgical and conventional treatment for severe obesity: the SOS intervention study. *International Journal of Obesity.* 2007;31(8):1248-61.

[6] Hoerger TJ, Zhang P, Segel JE, Kahn HS, Barker LE, Couper S. Cost-effectiveness of bariatric surgery for severely obese adults with diabetes. *Diabetes Care.* 2010;33(9):1933-9.

[7] Clegg A, Colquitt J, Sidhu M, Royle P, Walker A. Clinical and cost effectiveness of surgery for morbid obesity: a systematic review and economic evaluation. *International Journal of Obesity & Related Metabolic Disorders: Journal of the International Association for the Study of Obesity.* 2003;27(10):1167-77.

[8] Sheppard CE, Lester EL, Chuck AW, Birch DW, Karmali S, de Gara CJ. The economic impact of weight regain. *Gastroenterology Research and Practice.* 2013:379564.

[9] Wang BC, Wong ES, Alfonso-Cristancho R, He H, Flum DR, Arterburn DE, et al. Cost-effectiveness of bariatric surgical procedures for the treatment of severe obesity. *The European Journal of Health Economics.* 2014;15(3):253-63.

[10] Lauti M, Kularatna M, Hill AG, MacCormick AD. Weight regain following sleeve gastrectomy - a systematic review. *Obesity Surgery.* 2016;26(6):1326-34.

[11] Abdallah E, El Nakeeb A, Yousef T, Abdallah H, Ellatif MA, Lotfy A, et al. Impact of extent of antral resection on surgical outcomes of sleeve gastrectomy for morbid obesity (a prospective randomized study). *Obesity Surgery.* 2014;24(10):1587-94.

[12] Bohdjalian A, Langer FB, Shakeri-Leiden Muhler S, Gfrerer L, Ludvik B, Zacherl J, et al. Sleeve gastrectomy as sole and definitive bariatric procedure: 5-Year results for weight loss and ghrelin. *Obesity Surgery.* 2010;20(5):535-40.

[13] Braghetto I, Csendes A, Lanzarini E, Papapietro K, Carcamo C, Molina JC. Is laparoscopic sleeve gastrectomy an acceptable primary bariatric procedure in obese patients? Early and 5-year postoperative results. *Surgical Laparoscopy, Endoscopy & Percutaneous Techniques.* 2012;22(6):479-86.

[14] Carmeli I, Golomb I, Sadot E, Kashtan H, Keidar A. Laparoscopic conversion of sleeve gastrectomy to a biliopancreatic diversion with duodenal switch or a Roux-en-Y gastric bypass due to weight loss failure: Our algorithm. *Surgery for Obesity and Related Diseases.* 2015;11(1):79-85.

[15] Casella G, Soricelli E, Giannotti D, Collalti M, Maselli R, Genco A, et al. Long-term results after laparoscopic sleeve gastrectomy in a large monocentric series. *Surgery for Obesity and Related Diseases.* 2015.

[16] de Hollanda A, Ruiz T, Jimenez A, Flores L, Lacy A, Vidal J. Patterns of Weight Loss Response Following Gastric Bypass and Sleeve Gastrectomy. *Obesity Surgery.* 2015;25(7):1177-83.

[17] Homan J, Betzel B, Aarts EO, Van Laarhoven KJHM, Janssen IMC, Berends FJ. Secondary surgery after sleeve gastrectomy: Roux-en-Y gastric bypass or biliopancreatic diversion with duodenal switch. *Surgery for Obesity and Related Diseases.* 2015;11(4):771-7.

[18] Jimenez A, Casamitjana R, Flores L, Viaplana J, Corcelles R, Lacy A, et al. Long-term effects of sleeve gastrectomy and Roux-en-Y gastric bypass surgery on type 2 diabetes mellitus in morbidly obese subjects. *Annals of Surgery.* 2012;256(6):1023-9.

[19] Langer FB, Bohdjalian A, Shakeri-Leidenmuhler S, Schoppmann SF, Zacherl J, Prager G. Conversion from sleeve gastrectomy to Roux-en-Y gastric bypass--indications and outcome. *Obesity Surgery.* 2010;20(7):835-40.

[20] Liu SYW, Wong SKH, Lam CCH, Yung MY, Kong APS, Ng EKW. Long-term Results on Weight Loss and Diabetes Remission after Laparoscopic Sleeve Gastrectomy for A Morbidly Obese Chinese Population. *Obesity Surgery.* 2015;25(10):1901-8.

[21] Nedelcu M, Noel P, Iannelli A, Gagner M. Revised sleeve gastrectomy (re-sleeve). *Surgery for Obesity and Related Diseases.* 2015;11(6):1282-8.

[22] Obeidat F, Shanti H, Mismar A, Albsoul N, Al-Qudah M. The Magnitude of Antral Resection in Laparoscopic Sleeve Gastrectomy and its Relationship to Excess Weight Loss. *Obesity Surgery.* 2015;25(10):1928-32.

[23] Quezada N, Hernandez J, Perez G, Gabrielli M, Raddatz A, Crovari F. Laparoscopic sleeve gastrectomy conversion to Roux-en-Y gastric bypass: experience in 50 patients after 1 to 3 years of follow-up. *Surgery for Obesity and Related Diseases.* 2016;12(8):1611-5.

[24] Nedelcu M, Khwaja HA, Rogula TG. Weight regain after bariatric surgery—how should it be defined? *Surgery for Obesity and Related Diseases.* 2016;12(5):1129-30.

[25] Khwaja HA, Nedelcu M, Galvao Neto M, Lagardere AO, Schauer PR, Deitel M, et al. The International Bariatric Club--a worldwide web educational network for bariatric professionals. *Obesity Surgery.* 2013;23(12):2121-3.

[26] Felsenreich DM, Langer FB, Kefurt R, Panhofer P, Schermann M, Beckerhinn P, et al. Weight loss, weight regain, and conversions to Roux-en-Y gastric bypass: 10-year results of laparoscopic sleeve gastrectomy. *Surgery for Obesity and Related Diseases.* 2016.

[27] van de Laar AW, Acherman YI. Weight loss percentile charts of large representative series: a benchmark defining sufficient weight loss challenging current criteria for success of bariatric surgery. *Obesity Surgery.* 2014;24(5):727-34.

[28] Nocca D, Krawczykowsky D, Bomans B, Noel P, Picot MC, Blanc PM, et al. A prospective multicenter study of 163 sleeve gastrectomies: results at 1 and 2 years. *Obesity Surgery.* 2008;18(5):560-5.

[29] Braghetto I, Cortes C, Herquinigo D, Csendes P, Rojas A, Mushle M, et al. Evaluation of the radiological gastric capacity and evolution of the BMI 2-3 years after sleeve gastrectomy. *Obesity Surgery.* 2009;19(9):1262-9.

[30] Langer FB, Bohdjalian A, Felberbauer FX, Fleischmann E, Reza Hoda MA, Ludvik B, et al. Does gastric dilatation limit the success of sleeve gastrectomy as a sole operation for morbid obesity? *Obesity Surgery.* 2006;16(2):166-71.

[31] Braghetto I, Korn O, Valladares H, Gutierrez L, Csendes A, Debandi A, et al. Laparoscopic sleeve gastrectomy: surgical technique, indications and clinical results. *Obesity Surgery.* 2007;17(11):1442-50.

[32] Himpens J, Dobbeleir J, Peeters G. Long-term results of laparoscopic sleeve gastrectomy for obesity. *Annals of Surgery*. 2010;252(2):319-24.

[33] Lagace M, Marceau P, Marceau S, Hould FS, Potvin M, Bourque RA, et al. Biliopancreatic Diversion with a New Type of Gastrectomy: Some Previous Conclusions Revisited. *Obesity Surgery*. 1995;5(4):411-8.

[34] Gumbs AA, Gagner M, Dakin G, Pomp A. Sleeve gastrectomy for morbid obesity. *Obesity Surgery*. 2007;17(7):962-9.

[35] Weiner RA, Weiner S, Pomhoff I, Jacobi C, Makarewicz W, Weigand G. Laparoscopic sleeve gastrectomy--influence of sleeve size and resected gastric volume. *Obesity Surgery*. 2007;17(10):1297-305.

[36] Weiner RA, Theodoridou S, Weiner S. Failure of laparoscopic sleeve gastrectomy--further procedure? *Obesity Facts*. 2011;4 Suppl 1:42-6.

[37] Berger ER, Clements RH, Morton JM, Huffman KM, Wolfe BM, Nguyen NT, et al. The Impact of Different Surgical Techniques on Outcomes in Laparoscopic Sleeve Gastrectomies: The First Report from the Metabolic and Bariatric Surgery Accreditation and Quality Improvement Program (MBSAQIP). *Annals of Surgery*. 2016;264(3):464-73.

[38] Rosenthal RJ, International Sleeve Gastrectomy Expert P, Diaz AA, Arvidsson D, Baker RS, Basso N, et al. International Sleeve Gastrectomy Expert Panel Consensus Statement: best practice guidelines based on experience of >12,000 cases. *Surgery for Obesity and Related Diseases*. 2012;8(1):8-19.

[39] Gagner M, Hutchinson C, Rosenthal R. Fifth International Consensus Conference: current status of sleeve gastrectomy. *Surgery for Obesity and Related Diseases*. 2016;12(4):750-6.

[40] Spivak H, Rubin M, Sadot E, Pollak E, Feygin A, Goitein D. Laparoscopic sleeve gastrectomy using 42-French versus 32-French bougie: the first-year outcome. *Obesity Surgery*. 2014;24(7):1090-3.

[41] Beumer JD, Shenfine J. Laparoscopic sleeve gastrectomy using 42-French versus 32-French bougie. *Obesity Surgery*. 2014;24(7):1094.

[42] Cal P, Deluca L, Jakob T, Fernandez E. Laparoscopic sleeve gastrectomy with 27 versus 39 Fr bougie calibration: a randomized controlled trial. *Surgical Endoscopy*. 2016;30(5):1812-5.

[43] Hawasli A, Jacquish B, Almahmeed T, Vavra J, Roberts N, Meguid A, et al. Early effects of bougie size on sleeve gastrectomy outcome. *American Journal of Surgery*. 2015;209(3):473-7.

[44] Noel P, Nedelcu M, Nocca D, Schneck AS, Gugenheim J, Iannelli A, et al. Revised sleeve gastrectomy: Another option for weight loss failure after sleeve gastrectomy. *Surgical Endoscopy and Other Interventional Techniques*. 2014;28(4):1096-102.

[45] Iannelli A, Schneck AS, Noel P, Ben Amor I, Krawczykowski D, Gugenheim J. Re-sleeve gastrectomy for failed laparoscopic sleeve gastrectomy: a feasibility study. *Obesity Surgery*. 2011;21(7):832-5.

[46] Kojima M, Hosoda H, Date Y, Nakazato M, Matsuo H, Kangawa K. Ghrelin is a growth-hormone-releasing acylated peptide from stomach. *Nature*. 1999; 402(6762):656-60.

[47] Cohen R, Uzzan B, Bihan H, Khochtali I, Reach G, Catheline JM. Ghrelin levels and sleeve gastrectomy in super-super-obesity. *Obesity Surgery*. 2005;15(10):1501-2.

[48] Langer FB, Reza Hoda MA, Bohdjalian A, Felberbauer FX, Zacherl J, Wenzl E, et al. Sleeve gastrectomy and gastric banding: effects on plasma ghrelin levels. *Obesity Surgery.* 2005;15(7):1024-9.

[49] Himpens J, Dapri G, Cadiere GB. A prospective randomized study between laparoscopic gastric banding and laparoscopic isolated sleeve gastrectomy: results after 1 and 3 years. *Obesity Surgery.* 2006;16(11):1450-6.

[50] Karamanakos SN, Vagenas K, Kalfarentzos F, Alexandrides TK. Weight loss, appetite suppression, and changes in fasting and postprandial ghrelin and peptide-YY levels after Roux-en-Y gastric bypass and sleeve gastrectomy: a prospective, double blind study. *Annals of Surgery.* 2008;247(3):401-7.

[51] Lee HM, Wang G, Englander EW, Kojima M, Greeley GH, Jr. Ghrelin, a new gastrointestinal endocrine peptide that stimulates insulin secretion: enteric distribution, ontogeny, influence of endocrine, and dietary manipulations. *Endocrinology.* 2002;143(1):185-90.

[52] Sarela AI, Dexter SP, O'Kane M, Menon A, McMahon MJ. Long-term follow-up after laparoscopic sleeve gastrectomy: 8-9-year results. *Surgery for Obesity and Related Diseases.* 2012;8(6):679-84.

[53] Lombardo M, Bellia A, Mattiuzzo F, Franchi A, Ferri C, Elvira P, et al. Frequent Follow-Up Visits Reduce Weight Regain in Long-Term Management after Bariatric Surgery. *Bariatric Surgical Practice and Patient Care.* 2015;10(3):119-25.

[54] Lauti M, Stevenson S, Hill AG, MacCormick AD. Patient perspectives about follow-up care and weight regain following sleeve gastrectomy. *Obesity Surgery.* 2016;26(11):2724-31.

[55] Wilding JPH. Pathophysiology and aetiology of obesity. *Medicine.* 2011;39(1):6-10.

[56] Kehagias I, Spyropoulos C, Karamanakos S, Kalfarentzos F. Efficacy of sleeve gastrectomy as sole procedure in patients with clinically severe obesity (BMI </=50 kg/m(2)). *Surgery for Obesity and Related Diseases.* 2013;9(3):363-9.

[57] Keren D, Matter I, Lavy A. Lifestyle modification parallels to sleeve success. *Obesity Surgery.* 2014;24(5):735-40.

[58] Oria HE, Moorehead MK. Bariatric analysis and reporting outcome system (BAROS). *Obesity Surgery.* 1998;8(5):487-99.

[59] Oria HE, Moorehead MK. Updated Bariatric Analysis and Reporting Outcome System (BAROS). *Surgery for Obesity and Related Diseases.* 2009;5(1):60-6.

[60] Brethauer SA, Kothari S, Sudan R, Williams B, English WJ, Brengman M, et al. Systematic review on reoperative bariatric surgery American Society for Metabolic and Bariatric Surgery Revision Task Force. *Surgery for Obesity and Related Diseases.* 2014;10(5):952-72.

[61] Shimizu H, Annaberdyev S, Motamarry I, Kroh M, Schauer PR, Brethauer SA. Revisional bariatric surgery for unsuccessful weight loss and complications. *Obesity Surgery.* 2013;23(11):1766-73.

[62] Gagner M, Rogula T. Laparoscopic reoperative sleeve gastrectomy for poor weight loss after biliopancreatic diversion with duodenal switch. *Obesity Surgery.* 2003;13(4):649-54.

[63] Baltasar A, Serra C, Perez N, Bou R, Bengochea M. Re-sleeve gastrectomy. *Obesity Surgery.* 2006;16(11):1535-8.

[64] Cesana G, Uccelli M, Ciccarese F, Carrieri D, Castello G, Olmi S. Laparoscopic re-sleeve gastrectomy as a treatment of weight regain after sleeve gastrectomy. *World Journal of Gastrointestinal Surgery.* 2014;6(6):101-6.
[65] Colquitt JL, Pickett K, Loveman E, Frampton GK. Surgery for weight loss in adults. *The Cochrane Database of Systematic Reviews.* 2014(8).
[66] Sovik TT, Aasheim ET, Taha O, Engstrom M, Fagerland MW, Bjorkman S, et al. Weight loss, cardiovascular risk factors, and quality of life after gastric bypass and duodenal switch: a randomized trial. *Annals of Internal Medicine.* 2011;155(5):281-91.
[67] Dapri G, Cadiere GB, Himpens J. Laparoscopic repeat sleeve gastrectomy versus duodenal switch after isolated sleeve gastrectomy for obesity. *Surgery for Obesity and Related Diseases.* 2011;7(1):38-43.

BIOGRAPHICAL SKETCHES

Melanie Lauti

Affiliation: University of Auckland

Education: BSc, BMedSci(Hons), MBChB, PGDipSurgAnat

Business Address: Department of Surgery, University of Auckland, South Auckland Clinical Campus, Middlemore Hospital, Private Bag 93311 Otahuhu, Auckland 1650, New Zealand

Professional Appointments: Research Fellow and Advanced General Surgery Trainee

Publications from the Last 3 Years:

1. Lauti M, Stevenson S, Hill AG, MacCormick AD. Patient perspectives about follow-up care and weight regain following sleeve gastrectomy. *Obesity Surgery*, 2016. 26(11): p. 2724-2731.
2. Lauti M, Kularatna M, Hill AG, MacCormick AD. Weight regain following sleeve gastrectomy – a systematic review. *Obesity Surgery*, 2016. 26(6): p. 1326-34.
3. Lauti M, Gormack SE, Thomas JM, Morrow JJ, Rahman H, MacCormick AD. What Does the Excised Stomach from Sleeve Gastrectomy Tell us? *Obesity Surgery*, 2016. 26(4): p. 839-42.
4. Mavor S, Lauti M, MacCormick AD. A case of bariatric surgery during pregnancy. New Zealand Medical Journal, 2016. *New Zealand Medical Journal*, 2016. 129(1447): p. 91-93.
5. Sheikh L, Lauti M, Poole G. Gallbladder torsion: A rare indication for acute laparoscopic cholecystectomy. New Zealand Medical Journal, 2016. 129(1438): p. 60-63.
6. Alyami, H, M. Lauti, and A.G. Hill, Preparing a presentation. *ANZ Journal of Surgery*, 2016. 86(6): p. 509-11.

Andrew Graham Hill

Affiliation: University of Auckland

Education: BHB, MBChB, MD, EdD, FACS, FRACS

Business Address: Department of Surgery, University of Auckland, Private Bag 93311 Otahuhu, Auckland 1650, NEW ZEALAND

Research and Professional Experience:

Professional Appointments: Professor of Surgery

Publications from the Last 3 Years:

Refereed Papers:

1. 2016, Bhusal P, Harrison J, Sharma M, Jones DS, Hill AG, Svirskis D. Controlled release drug delivery systems to improve post-operative pharmacotherapy. *Drug Delivery and Translational Research*, October:2190-3948
2. 2016, Lauti M, Stevenson S, Hill AG, MacCormick AD. Patient perspectives about follow-up care and weight gain following sleeve gastrectomy. *Obesity Surgery*, 26:2724-2731
3. 2016, Hamill JK, Rahiri JL, Liley A, Hill AG. Intra-peritoneal local anesthetic in pediatric surgery: a systematic review. European *Journal of Pediatric Surgery*, 26:469-475
4. 2016, Hamill JK, Hill AG. A history of the treatment of appendicitis in children: lessons learned. *ANZ J Surgery*, 86:762-767
5. 2016, Svirskis D, Chandramouli K, Bhusal P, Alphonso J, Chow J, Patel D. Ramakrishna R, Yeo SJ, Stowers R, Hill A, Munro J, Young SW, Sharma M. Injectable thermosensitive gelling delivery system for the sustained release of lidocaine. *Therapeutic Delivery*, 7:359-368
6. 2016, Doolan-Noble F, Lyndon M, Hill A, Gray J, Gauld R. Developing and implementing a framework for system level measures: lessons from New Zealand. *Asia Pacific Journal of Health Management*, 11:18-26
7. 2016, Firth MJ, Sharples KJ, Hinder VA, Macapagal J, Sarfati D, Derrett SL, Hill AG, Brown C, Reid PMJ, Lawrenson RA, Atmore C, Keating JP, Jeffery M, Secker AH, De Groot C, Jackson CGCA, Findlay MPN. Methods of a national colorectal cancer cohort study: the PIPER project. *NZMJ*, 129:25-36
8. 2016, Lin JX, Krishna S, Su'a B, Hill AG. Optimal dosing of botulinum toxin for treatment of chronic anal fissure: a systematic review and meta-analysis. *Diseases of the Colon and Rectum*, 59:886-894
9. 2016, Singh PP, Lemanu D, Soop M, Bissett IP, Harrison J, Hill AG. Perioperative simvastatin therapy in major colorectal surgery: a prospective, double blind randomized controlled trial. *Journal of the American College of Surgeons*, 223:308-320

10. 2016, Ekeroma A, Kenealy T, Latu R, Hill A. Who are the successful reproductive health clinician-researchers? Pacific Journal of Reproductive Health, 1:128-131
11. 2016, Alexander Z, Su'a B, Lyndon M, Hill CTG, Singh P, Hill AG. The effect of oral simvastatin on fibrinolytic activity following colorectal surgery-a pilot study. *Journal of Surgical Research*, 205:28-32
12. 2016, Lauti M, Kularatna M, Hill AG, MacCormick AD. Weight regain following sleeve gastrectomy-a systematic review, *Obesity Surgery*, 26:1326-1334
13. 2016, Barazanchi AWH, Fagan PV, Smith BB, Hill AG. Routine neurectomy of inguinal nerves during open onlay mesh hernia repair: a meta-analysis of randomized trials. *Annals of Surgery*, 264:64-72
14. 2016, Tan JP, Barazanchi AW, Singh PP, Hill AG, MacCormick AD. Predictors of acute diverticultis severity: a systematic review. *International Journal of Surgery*, 26:43-52
15. 2016, Alyami H, Lauti M, Hill AG. Preparing a presentation. *ANZ Journal of Surgery*, 86:509-511
16. 2016, Sammour T, Singh PP, Su'a B, Zargar K, Hill AG. Peritoneal cytokine levels can predict anastomotic leak on the first post-operative day. *Diseases of the Colon and Rectum*, 59:551-556
17. 2016, Ekeroma AJ, Biribo S, Herman J, Hill A, Kenealy T. Health research systems in six Pacific Island countries and terrritories. *Journal of Research and Development*, 4:1
18. 2016, Yule MS, Krishna S, Rahiri JL, Hill AG. Trampoline associated injuries are more common in children in spring-time. *NZMJ*, 129:37-43
19. 2016, Stowers MDJ, Manuopangai L, Hill AG, Gray JR, Coleman B, Munro JT. Enhanced recovery after surgery (ERAS) in elective hip and knee arthroplasty reduces length of hospital stay. *ANZ J Surgery*, 86:475-479
20. 2016, Hamill J, Rahiri JL, Liley A, Hill AG. Rectus sheath and transversus abdominis plane blocks in children: a systematic review and meta-analysis of randomised trials. *Paediatric Anaesthesia*, 26:363-371
21. 2016, Stowers MDJ, Munro JT, Hill AG. Transexamic acid in total joint arthroplasty. *ANZ Journal of Surgery*, 86:219-220
22. 2016, Stowers M, Munro JT, Hill AG. Enhanced recovery after surgery in elective total arthroplasty-the new standard of perioperative care. *ANZ Journal of Surgery*, 86:327-328
23. 2016, Sammour T, Hill AG. Access to surgical care in developing countries. *JAMA Surgery*, 151:263-264
24. 2016, Alyami H, Su'a B, Sundram F, Alyami M, Lyndon M, Yu TC, Henning M, Hill AG. Teaching medical students history taking content: a systematic review. *American Journal of Educational Research*, 4:227-233
25. 2016, Ekeroma AJ, Shulruf B, McCowan L, Hill AG, Kenealy T. Development and use of a research productivity assessment tool for clinicians in low resource settings in the Pacific Islands: a Delphi study. *Health Research Policy and Systems*, 14:9
26. 2015, Joshi GP, Jaschinski T, Bonnet F, Kehlet H, and the PROSPECT collaboration. Optimal pain management for radical prostatectomy surgery: what is the evidence? *BMC Anesthesiology*, 15:159
27. 2015, Ekeroma A, Kenealy T, Shulruf B, Hill A. Educational and wider interventions that increase research activity and capacity of clinicians in low to middle income countries: a systematic review and narrative synthesis. *Journal of Research and Development*, 3:120

28. 2015, Chong V, Hill AG, MacCormick AD. Accurate triage of lower gastrointestinal bleed (LGIB)-cohort study. *International Journal of Surgery*, 25:19-23
29. 2015, Hamill JK, Liley A, Hill AG. Rectus sheath block for laparoscopic appendicectomy: a randomized clinical trial. *ANZ Journal of Surgery*, 85:951-956
30. 2015, Alyami H, Alyami M, Sundram F, Cheung G, Hill AG. Visualising psychiatric formulation. *Australasian Psychiatry*, 23:575-580
31. 2015, Su'a BU, Hill AG. Opiates in ERAS-still not convinced. *ANZ Journal of Surgery*, 85:795
32. 2015, Su'a BU, Hill AG. Perioperative use of chewing gum affects the inflammatory response and reduces postoperative ileus following major colorectal surgery. *Evidence Based Medicine*, 20:185-186
33. 2015, Currie A, Jenkins JT, Faiz O, Kennedy RH, Ljungqvist O, Demartines N, Hjern F, Norderval S, Lassen K, Koczas T, Nugren J, Gustafsson U, Kornfield D, Slim K, Hill A, Soop M, Carlander J, Lundberg O, Fearon K. The impact of enhanced recovery protocol compliance on elective colorectal cancer resection: results from an international registry. *Annals of Surgery*, 261:1153-1159
34. 2015, Lemanu DP, Singh PP, Rahman H, Hill AG, Babor R, MacCormick AD. Five-year results after laparoscopic sleeve gastrectomy. *SOARD*, 11:518-524
35. 2015, Ekeroma AJ, Kenealy T, Shulruf B, Nosa V, Hill A. Building capacity for research and audit: outcomes of a training workshop for Pacific physicians and nurses. *Journal of Education and Training Studies*, 3:179-192
36. 2015, Hill AG. Preoperative prediction of risk in colorectal surgery. *ANZ Journal of Surgery*, 85:397
37. 2015, Sammour T, Hayes IP, Hill AG, Macrae FA, Winter DC. Familial colorectal cancer syndromes: an overview of management. *Expert Review of Gastroenterology and Hepatology*, 9:757-764
38. 2015, Hamill JK, Cope AM, Liley A, Hill AG. Validity and reliability of a pain location tool for pediatric abdominal surgery. *Pain Management Nursing*, 16:380-387
39. 2015, Doolan-Noble F, Lyndon M, Gray J, Hau S, Hill AG, Gauld R. How well does your healthcare system perform? Tracking progress toward the triple aim using system level measures. *New Zealand Medical Journal*, 128:44-50
40. 2015, Stowers M, Lemanu DP, Hill AG, Fulcher ML. Cervical orthoses in preventing brachial plexus and spinal cord injury: a systematic review. *New Zealand Journal of Sports Medicine*, 42:18-23
41. 2015, Taneja A, Singh PP, Tan JP, Hill DJ, Connolly AB, Hill AG. Efficacy of general practitioners with specialty interests for surgical procedures. *ANZ Journal of Surgery*, 85:344-348
42. 2015, Su'a BU, Pollock TT, Lemanu DP, Maccormick AD, Connolly AB, Hill AG. Chewing gum and postoperative ileus in adults: a systematic review and meta-analysis. *International Journal of Surgery*, 14:49-55
43. 2015, Sammour T, Hill AG. Five-year follow-up of a randomized controlled trial on warming and humidification in laparoscopic colonic surgery-impact on small bowel obstruction and oncologic outcomes. *International Surgery*, 100:608-616
44. 2015, Stowers MDJ, Lemanu DP, Hill AG. Health economics in ERAS in abdominal surgery. *Canadian Journal of Anaesthesia*, 62:219-230

45. 2014, Lyndon MP, Strom JM, Alyami HM, Yu TC, Wilson NC, Singh PP, Lemanu DP, Yielder J, Hill AG. The relationship between academic assessment and psychological distress among medical students: a systematic review. *Perspectives on Medical Education*, 3:405-416
46. 2014, Stowers MDJ, Lemanu DP, Coleman B, Hill AG, Munro J. Perioperative care in enhanced recovery for hip and knee arthroplasty. *Journal of Orthopaedic Surgery*, 22:383-392
47. 2014, Taneja A, Su'a B, Hill AG. Efficacy of patient-initiated follow up clinics in secondary care: a systematic review. *Internal Medicine Journal*, 44:1156-1160
48. 2014, Srinivasa S, Singh P, Lemanu D, MacCormick A, Taylor M, Hill AG. Goal-directed fluid therapy in major elective rectal surgery. *International Journal of Surgery*, 12:1467-1472
49. 2014, Fernando A, Consedine N, Hill AG. Mindfulness for surgeons. *ANZ Journal of Surgery*, 84:722-724
50. 2014, Singh PP, Lemanu DP, Taylor MH, Hill AG. The association between preoperative glucocorticoids and long-term survival and cancer recurrence after colectomy: follow-up analysis of a previous randomized controlled trial. *British Journal of Anaesthesia*, 113 Suppl 1:i68-i73
51. 2014, Yu TC, Hamill JKM, Evans SM, Price NR, Morreau PN, Upadhyay VA, Ferguson RS, Best EJ, Hill AG. Duration of postoperative intravenous antibiotics in children with complicated appendicitis: a propensity score-matched comparison study. *European Journal of Pediatric Surgery*, 24:341-349
52. 2014, Ekeroma AJ, Kenealy T, Shulruf B, McCowan LME, Hill AG. Building reproductive health research and audit capacity and activity in the Pacific islands (BRRACAP) study: methods, rationale and baseline results. *BMC Medical Education*, 14:121
53. 2014, Hamill JK, Lyndon M, Liley A. Hill AG. Where it hurts: a systematic review of pain-location tools for children. *Pain*, 155:851-858
54. 2014, Lemanu DP, Singh PP, Stowers MDJ, Hill AG. A systematic review to assess the cost-effectiveness of enhanced recovery after surgery in colorectal surgery. *Colorectal Disease*, 16:338-346
55. 2014, Hamill JK, Liley A, Hill AG. Historical aspects of appendicitis in children. *ANZ Journal of Surgery*, 84:307-310
56. 2014, Hill AG. Is perioperative care still an issue now that we have the Robot? *ANZ Journal of Surgery*, 84:201-202
57. 2014, Henning MA, Sollers J, Strom JM, Hill AG, Lyndon MP, Cumin D, Hawken SJ. Junior doctors in their first year: mental health, quality of life, burnout and heart rate variability. *Perspectives on Medical Education*, 3:136-143
58. 2014, Sammour T, Hill AG. Full time research during surgical training: career killer or stepping-stone? *ANZ Journal of Surgery*, 84:104-105
59. 2014, Singh PP, Zeng ISL, Srinivasa S, Lemanu DP, Connolly AB, Hill AG. Systematic review and meta-analysis of serum C-reactive protein levels to predict anastomotic leak after colorectal surgery. *British Journal of Surgery*, 101:339-346

Andrew D. MacCormick

Affiliation: University of Auckland/Counties Manukau Health

Education: BHB, MBChB, PhD, FRACS

Business Address: Middlemore Hospital, Private Bag 93311, Otahuhu, Auckland 1640, New Zealand

Professional Appointments: Senior Lecturer/Consultant Surgeon

In: Encyclopedia of Surgery (22 Volume Set)
Editors: Andreas Lehrer and Kristin Mueller
ISBN: 978-1-53618-329-0
© 2020 Nova Science Publishers, Inc.

Chapter 183

THE UTILISATION OF ENHANCED RECOVERY AFTER SURGERY PROGRAMMES IN SLEEVE GASTRECTOMY

Daniel P. Lemanu, PhD,
Andrew G. Hill, MD, EdD,
and Andrew D. MacCormick, PhD
Department of Surgery, South Auckland Clinical Campus,
University of Auckland, Auckland, Middlemore Hospital, New Zealand

ABSTRACT

Enhanced Recovery After Surgery (ERAS), or fast track programmes, integrate multiple evidence based perioperative care interventions to standardise and optimise perioperative care. Their use has been shown to reduce perioperative morbidity and, as a result, reduce the length of hospital stay. They have also been shown to be cost effective.

The use of ERAS was initially popularised in colorectal surgery but there is now an increasing volume of evidence demonstrating the effectiveness of ERAS in the setting of bariatric surgery. The early literature reporting on ERAS in bariatric surgery was in the setting of laparoscopic roux-en-Y gastric bypass (LRYGB) where case series demonstrated a reduction in the length hospital stay. However, the use of ERAS has now been evaluated in patients undergoing sleeve gastrectomy (SG) with a recent randomised controlled trial showing a similar reduction in length of hospital stay as well as improved cost effectiveness without increasing perioperative morbidity.

Whilst consensus regarding ERAS constituents was reached in a recent report detailing guidelines for its implementation in bariatric surgery, it is important to know that some recommendations are based on data extrapolated from non-bariatric surgery. Also, length of stay remains only a proxy of surgical recovery and that the aim of ERAS is to reduce perioperative morbidity which should be a primary focus of future studies.

1. INTRODUCTION

Surgical treatment, in the form of Bariatric surgery, is now recognized as an effective treatment for severe obesity [1]. It is the only evidence-based method to significantly improve and sustain weight loss as well as cause resolution of obesity related comorbidities such as type 2 diabetes mellitus (T2DM) [2]. Bariatric surgery includes a variety of procedures, which are mostly performed laparoscopically. The most common procedures performed today are laparoscopic adjustable gastric band and laparoscopic roux-en-Y gastric bypass.

Laparoscopic sleeve gastrectomy (SG) has become an established bariatric procedure effecting weight loss by way of restricting caloric intake as well as reducing plasma levels of ghrelin. There is an established body of evidence showing that SG produces excellent short-term weight loss and is effective at resolving obesity related comorbidities [3-6]. There is also growing evidence showing that these short-term results are sustained at long-term follow-up [7-10].

Despite its effectiveness, the established benefits of SG can come at the expense of significant short-term morbidity. This can significantly impair surgical recovery leading to prolonged postoperative convalescence, increased costs and sub-optimal surgical outcomes such as weight regain and return of obesity related comorbidity [11-15].

Enhanced recovery after surgery (ERAS), or fast track programmes, incorporate multiple evidence-based perioperative care interventions in order to standardize and optimize perioperative care. Initially pioneered in colorectal surgery, ERAS has been shown to reduce perioperative morbidity, reduce postoperative length of hospital stay and reduce costs [16-18]. It has now been adapted in bariatric surgery with the aim to reduce the morbidity and cost associated with various bariatric procedures and there is now an established body of evidence evaluating its efficacy in SG [19].

The aim of this chapter is to discuss the use of ERAS in patients undergoing SG. It will discuss how the concept of ERAS was developed, the perioperative care interventions used and the how it has been implemented in SG.

2. THE DEVELOPMENT OF ERAS

ERAS programmes were initially pioneered by Kehlet et al. in the setting of colorectal surgery [20-22]. They were aimed at addressing the profound inflammatory response associated with surgery. This inflammatory response, characterized by the release of pro-inflammatory cytokines, has been shown to be associated with increased rates of perioperative morbidity and mortality and prolonged convalescence [23].

Optimising perioperative care was postulated as a means of manipulating the inflammatory response to surgery. This was in light of the realization that many of the established and historical perioperative care interventions in practice were outdated and potentially harmful. The inherent biological redundancy of the inflammatory response [24] has meant that single interventions have not been particularly effective. With this understanding, the idea of perioperative care optimization was shifted from looking at the individual effects of perioperative care interventions to the effect that each intervention had collectively on surgical recovery. This idea of collective effect is the basis of ERAS.

ERAS programmes incorporate multiple evidence based perioperative care interventions in order to optimize and standardize perioperative care. They have become an established means of reducing perioperative morbidity, length of hospital stay and costs associated with colorectal surgery. In their randomized trial of ERAS compared to standard perioperative care following hemicolectomy, Anderson et al. demonstrated earlier mobilization and return to diet as well as reduced length of hospital stay [25]. This was similar to the findings of two earlier studies by Delaney et al. and Gatt et al. which found in patients undergoing colectomy, reduced length of hospital stay in ERAS patients compared with non-ERAS patients, including those with significant preoperative comorbidity, without increased readmission rates or complications rates [26, 27]. Varadhan et al. published the results of a systematic review and meta-analysis of six randomized controlled trials, that again showed reduced length of hospital stay following elective colorectal surgery [17]. However, they also reported significantly reduced risk of postoperative complications in patients having surgery within an ERAS programme.

Due to the success of ERAS programmes in the setting of colorectal surgery, their use began to permeate to other surgical specialties. Stowers et al. reviewed the literature reporting the use of ERAS in hip and knee arthroplasty and found reduced length of hospital stay and morbidity [28]. Scott et al. published the review of ERAS in patients undergoing elective hip and knee arthroplasty in Scottish orthopaedic units and found nationwide uptake of ERAS associated with lower blood transfusion rates, earlier postoperative mobilization and shorter length of hospital stay [29]. Cerantola et al. published recommended guidelines for ERAS implementation in patients undergoing radical cystectomy [30]. Wijk et al. reported on their results when implementing an ERAS programme in the setting of elective abdominal hysterectomy and found reduced length of hospital stay without an increase in postoperative morbidity [31].

Mechanick et al. recommended uptake of ERAS in bariatric surgery in their guidelines for perioperative care in the support of the bariatric patient [32]. This subsequently was followed by published reports of bariatric units' experience with ERAS across a variety of bariatric procedures. Though the volume of literature was small, it appeared to provide similar results to those reported in other surgical specialties. McCarty et al. found improved postoperative recovery in patients having gastric bypass after optimizing perioperative care [33]. Bamabagade et al. halved length of hospital stay following laparoscopic gastric bypass [34]. Grantcharov et al. similarly found reduced length of hospital stay following gastric resection within the setting of an ERAS programme but also reported reduced postoperative morbidity [35]. ERAS has subsequently been implemented and evaluated in the setting of patients undergoing SG. Lemanu et al. reported, in their randomized controlled trial, a significant reduction in length of hospital stay without increasing postoperative morbidity or readmission rates. There was also a reduction in hospital costs [19].

3. PERIOPERATIVE CARE INTERVENTIONS

Previous systematic reviews and clinical guidelines have been published with recommendations based on the best available evidence on how to compose an ERAS programme. These guidelines will be summarized in this section. However, it is important to

bear in mind that these recommendations have limitations. Firstly, whilst there is standardization of perioperative care within individual studies, there is significant heterogeneity in the reported literature with respect to the perioperative care interventions which are used when comparing studies resulting in no standardization of ERAS composition between surgical units. Secondly, the evidence for perioperative care interventions used in bariatric surgery is largely extrapolated from data within the colorectal literature.

A summary of the evidence for ERAS in Bariatric surgery has recently been published by the ERAS guidelines group [36, 37].

3.1. Preoperative

3.1.1. Preoperative Counseling and Education

There is a paucity of data that details the effect of preoperative counseling and education on postoperative recovery in the bariatric literature. It has been shown to be effective in the setting of colorectal surgery to reduce anxiety and improve patient compliance to postoperative ERAS protocols. Similar findings have been demonstrated with preoperative ward visits and psychological interventions [38].

3.1.2. Prehabilitation (Exercise, Smoking and Alcohol Cessation, Nutritional Optimization)

Prehabilitation is the concept of initiating the recovery process preoperatively in order to enhance preoperative functional and physiological capacity. It is comprised of three components; preoperative exercise, smoking and alcohol cessation and nutrition optimization [39]. The concept of preoperative exercise is based on the analogy of comparing surgery to a marathon – the fitter you are before the race, the better you will perform and recover. This appeared to translate well in the setting of orthopaedic and abdominal surgery [40-43]. However, the results do not appear to apply as well to patients undergoing bariatric surgery. This may relate to fact that this subgroup of patients are chronically inactive and do not reach a threshold of preoperative physical fitness that is able to be translated into improved clinical outcomes.

Excessive consumption of energy-rich but nutrient-deplete foods causes nutritional deficiency in morbidly obese patients and this can be exacerbated postoperatively due to reduced absorption of nutrients, particularly fat dependent vitamins and trace minerals [44-46]. For this reason, and in order to optimize postoperative dietary behaviour, formal assessment by a dietician preoperatively is recommended.

It is well reported that smoking has significant deleterious effects on postoperative recovery. In particular, it increases the risk of postoperative infection and thromboembolic complications [47, 48]. Guidelines recommend smoking cessation for a minimum of four weeks prior to surgery. Similarly, hazardous drinking poses undue risk of poor outcomes following surgery and it is recommended that patients abstain from alcohol for at least four weeks prior to surgery.

3.1.3. Preoperative Weight Loss

Preoperative weight loss has been shown to be positively associated with postoperative weight loss by Livhits et al. [49]. It is also thought to reduce liver volume improving intraoperative visualization. Most bariatric centres achieve this by enforcing low or very low calorie diet regimes though care must be taken in diabetic patients so as not to induce hypoglycaemia.

3.1.4. Optimisation of Hospital Environment

Whilst there are no published reports in literature detailing the effect of optimizing the hospital environment on postoperative recovery in patients undergoing bariatric surgery, mention has been made by Zargar-Shoshtari et al. suggesting that there was a positive influence of well-lit postoperative wards, which enable and encourage social interaction on patient mood and anxiety levels. This could potentially be reinforced by preoperative hospital visits and familiarization with ward staff prior to admission [38].

3.1.5. Preoperative fasting

Historically, patients are kept nil per month for six hours and two hours for solid food and clear fluids respectively. Recent studies demonstrate residual gastric volumes and gastric emptying rates are the same for obese and non-obese patients. Therefore, the recommendation is to maintain preoperative fasting for six hours and two hours for clear fluids in the bariatric setting as in non-obese patients [50, 51].

3.1.6. Carbohydrate Loading

Preoperative carbohydrate loading with iso-osmolar drinks two to three hours prior to surgery is an established practice in colorectal ERAS programmes [52]. It is shown to counteract the deleterious effects of preoperative fasting by attenuating postoperative insulin resistance, reducing protein losses and subsequently maintaining lean body mass. It is safe in diabetic patients and is recommended in patients undergoing bariatric surgery [53].

3.1.7. Glucocorticoid Administration

Preoperative glucocorticoid (GC) administration has been reviewed in other surgical specialties. It attenuates the stress response of surgery leading to reduced length of hospital stay and complication rates [24]. There is less data in bariatric surgery with only a previous case series by McCarty et al. finding preoperative GC to be associated with reduced length of hospital stay [33]. More traditionally, preoperative GC has been used to prophylactically address postoperative nausea and vomiting (PONV). It is also shown to be safe in patients with T2DM.

3.2. Intraoperative

3.2.1. Perioperative Fluid Management

The literature on intravenous fluid (IVF) administration in obese patients largely reports on liberal versus restrictive fluid regimens with earlier non-randomised studies demonstrating reduced rates of postoperative rhabdomyolysis, for which there is a recognized increased

incidence in obese patients [54-57]. However, more recent data would suggest that there is little if in fact in difference in rates of rhabdomyolysis between liberal and restrictive IVF regimes. Instead, proponents of ERAS recommend instigation of early postoperative oral intake as a means to maintain haemodynamic parameters [58]. The literature on the use of goal-directed fluid therapy is sparse but Jain et al. found haemodynamic parameters could be sufficiently maintained when using stroke volume as a guide, which resulted in smaller total fluid volumes being administered without complication [59].

3.2.2. Postoperative Nausea and Vomiting (PONV)

Multimodal antiemetic regimens are strongly advocated and supported by studies reported in the current bariatric literature. The multimodal approach includes the use of a combination of antiemetic agents as opposed to using only one or even two agents, avoiding volatile agents in favour of propofol for induction and maintenance of anaesthesia, reducing excessive IVF administration and avoiding opiates [60-62].

3.2.3. Standardised Anaesthesia

Due to the presence of obesity related comorbidity and differences in physiological parameters, obese patients often provide anaesthetists with significant challenges during the perioperative period. Particular attention must be paid to pressure areas with respect to on table positioning and great care taken to avoid hypothermia [57]. Positive end expiratory pressure can be utilized to improve intraoperative oxygenation and reduce the risk of pulmonary atelectasis [63-65]. Whilst the evidence for neuromuscular block as a means to aid in surgical performance is minimal, there is good evidence to suggest anaesthetic depth monitoring using the bispectral index and ensuring full reversal of neuromuscular blockade does improve surgical recovery [36].

3.2.4. Prophylactic Nasogastric Tube

The literature on the role of prophylactic nasogastric tubes (NGT) showed that they did not confer an additional benefit to the patient postoperatively [66, 67]. There is no difference in the rates of anastomotic leakage when comparing patients with NGT and those without. It significantly impairs time to instigation of oral intake postoperatively, which has been shown to be positively associated with surgical recovery and length of hospital stay, and it is widely recommended that NGT be removed prior to reversal of anaesthesia.

3.2.5. Prophylactic Abdominal Drain

The literature on prophylactic abdominal drainage in the setting of bariatric surgery is sparse with no randomized controlled trials evaluating their efficacy. They are traditionally used to help with both early identification of and facilitate non-operative management of anastomotic leak. However, recent recommendations have suggested that the use of prophylactic abdominal drains is unnecessary based largely on data extrapolated from other abdominal surgical subspecialties [68].

3.2.6. Other Novel Interventions

Various other interventions have been investigated which may be applicable to bariatric surgery. Previous studies have investigated whether warming and humidifying insufflation

carbon dioxide reduces peritoneal inflammation [69]. Whilst there have been shown to be small benefits to surgical recovery in other specialties, there are no data evaluating its efficacy in bariatric surgery. Intraperitoneal local anaesthetic works by blocking nociceptive peritoneal pathways. Its use is supported by a previous systematic review as a means of improving pain and recovery and recovery after abdominal surgery [70]. It was utilized in the ERAS protocol formulated by Lemanu et al. but ongoing research is required to evaluate its efficacy [19].

3.3. Postoperative

3.3.1. Multimodal Analgesia

Similar to the approach to anti-emesis, multimodal analgesia is advocated as the preferred approach to postoperative analgesia by proponents of ERAS. It encourages the use of regional anaesthesia and avoidance of opiates in favour of non-steroidal anti inflammatories, intravenous acetaminophen and local anaesthetic [61]. If opioids are required, it suggested that favour be shown toward utilizing patient controlled regimes with an increased refractory period between doses [71]. Research into the use of medications such as gabapentin or pregablin is ongoing [72].

3.3.2. Supplemental Oxyngenation

Whilst the evidence for the use of supplemental oxygen is sparse in the setting of bariatric surgery, it is an important issue to consider due to the high rates of both diagnosed and undiagnosed obstructive sleep apnoea (OSA) as well the relationship between obesity and tissue hypoperfusion and low oxygen tension in subcutaneous tissues [73, 74]. Research into the use of postoperative supplemental oxygenation in the setting of colorectal surgery found a significant reduction in the incidence of wound infection [75]. Further investigation is required to evaluate its efficacy in bariatric surgery though is still strongly recommended.

3.3.3. Early Postoperative Nutrition

Early postoperative nutrition is safe and strongly recommended in the setting of bariatric surgery. It generally involves starting clear fluids only a few hours after surgery and then consultation with a dietician to ensure adequate dietary composition. Generally it is recommended that patients have small but frequent meals with special care taken to maintain adequate fibre and protein uptake and avoiding concentrated sugars which can lead to dumping syndrome. Fluids should be consumed slowly over the course of the day at regular intervals in order to maintain adequate hydration. It is recommended to aim for an intake of approximately 1-1.5L per day [76].

3.3.4. Thromboprophylaxis

Venous thromboembolism (VTE) is a major cause of significant morbidity and mortality following bariatric surgery. It is important to instigate a standardized approach to VTE prophylaxis and ensure that it is well adhered to. It needs to combine early mobilization with both mechanical and pharmacological methods that some authors advocate be used for three to four weeks postoperatively [77, 78].

3.3.5. Non-Invasive Positive Pressure Ventilation

The routine use of continuous positive airway pressure (CPAP) is recommended in patients with diagnosed OSA. However, unless patients are super obese, have oxygen saturations less than 90% with oxygen supplementation or have obesity related hypoventilation syndrome, routine use is not recommended [36].

4. IMPLEMENTING ERAS IN SG

4.1. Current Evidence

There is now an increasing body of evidence evaluating the use of ERAS in the setting of SG. Lemanu et al. published the first and only randomized controlled trial evaluating ERAS versus standard care in patients undergoing SG [19]. They found that patients undergoing surgery within an ERAS programme had a significantly shorter median length of hospital stay of one day compared to two days in the standard care group without an increase in 30 day postoperative complication rates. There was no difference in readmission rate. A comparative analysis was also performed comparing the ERAS and standard care groups to a propensity score matched historical cohort who had surgery prior to the beginning of the randomized controlled trial to account for any cross-over between the two intervention groups and found significant shorter length of stay in the intervention groups compared to the historical cohort (three days) and similar readmission rates. Cost effectiveness analysis also showed significant cost reduction in the ERAS group versus the historical cohort.

Awad et al. published their experience [79] of ERAS in SG. They reported a mean length of hospital stay of 2.3 days with 28% of patients being discharged day one postoperatively. Importantly, they reported low rates of morbidity and a 30 day readmission rate of 2.7%. They concluded that ERAS was safe and effective at reducing convalescence. Lyass et al. also reported their series and had similar experiences with an acceptably low complication rate of 5.7% with no anastomotic leaks or complications requiring re-operation. Readmission rate was also acceptably low at 3.5% [80].

Two studies reported on the experience with ERAS in patients undergoing SG and LRYGB without differentiating the individual results between the two surgical interventions. Mannaerts et al. performed SG in patients with BMI >60kg/m^2 and reported reduced procedural time, reduced length of hospital stay and increased cost effectiveness [81]. However, they did report an increased complication rate post ERAS implementation that they attributed to increased vigilance in reporting (81). Matlok et al. reported on their consecutive series of LRYGB and SG and found a reduced length of hospital stay (mean of 2.9 days) with no adverse effect seen in complication rates (10.5%) or readmission rates (1.7%) [82].

Barreca et al. also reported on the experience with ERAS in patients undergoing LRYGB and SG. Of the 288 patients they reported on, 65 underwent SG [83]. They reported a complication rate of 6.1% with a readmission rate of 4.6%. Of the 65 patients, 60% were discharged day one postoperatively without an increase in readmission or complication rates when compared to those discharged after two or more days. They concluded by saying ERAS was safe and effective in reducing hospital stay without increasing postoperative complication rates.

4.2. Limitations

It is important to recognize the limitations of ERAS within SG. There is significant heterogeneity in ERAS programme composition between units. This makes it difficult to accurately compare results between bariatric units and this limits accurate evaluation of ERAS efficacy and safety. This limitation has been recognized with ERAS across other surgical specialties.

As has been highlighted previously, ERAS studies, particularly in the early phases of its inception, come predominantly from the colorectal literature. Whilst it is possible to transfer concepts across into the setting of bariatric surgery, it is important to recognize that bariatric surgery procedures may incur different physiological responses than those seen in other surgical specialties. Therefore, what may be effective in colorectal or orthopaedic surgery may not necessarily transfer into bariatric surgery. Similarly and importantly, interventions that may not necessarily be favourable in other surgical settings may in fact provide benefit in a bariatric population, but these interventions may easily be discarded given the only published data on them shows them to be non-efficacious in the non-bariatric setting.

Ongoing evaluation and continued publication of results is an important aspect of quality assessment and control. One of the limitations of the published literature on ERAS, particularly with randomized studies, is an inability to adequately blind participants and medical staff. The effect that this has it there is often cross over between participant groups usually from the non-ERAS group to the ERAS group which can potentially underestimate the effect of ERAS programmes.

A long-term concern is the ability to maintain an effective ERAS programme over time. ERAS involves significant clinical commitment and resource which is often easy to provide in the early stages of development, implementation and follow up. This enthusiasm can wane with attrition, which can lead to sub-optimal results. For this reason, it is important that part of ongoing approach to ERAS performance includes an assessment of compliance to protocol interventions.

It is important to recognize that ERAS does not substitute for clinical judgment. Care providers must be acutely aware that ERAS is a guide to treatment and that a certain level of flexibility must be accounted for when patients are not progressing as expected within an ERAS programme. Treating patients on the basis of their illness must remain a higher priority than compliance to protocol. There is in fact a suggestion that a patient not progressing as expected within the ERAS programme may be an indicator of postoperative morbidity.

Lastly, the ERAS literature reports widely on length of hospital stay and cost-effectiveness. However, it is important to recognize that length of stay and cost are only proxy indicators of surgical recovery. The underlying ethos of ERAS implementation needs to be patient focused with explicit emphasis on putting forward ERAS as a means of reducing perioperative morbidity with length of hospital stay being a secondary outcome.

4.3. Unanswered Questions and Future Directions for Ongoing Research

Whilst the volume of literature evaluating ERAS in SG continues to grow it is important to recognize that unanswered questions remain that can direct further research.

Patient compliance to protocol can influence whether or not they have a successful outcome within an ERAS programme. Novel approaches to improve compliance to protocol at various stages of the ERAS programme may help to improve surgical recovery. One such example is evaluating the use of mobile health technologies such as text-messaging to provide continued encouragement to patients preoperatively to adhere to weight loss instruction or postoperatively to allow an easy means of communication of patients become unwell following discharge with problems which are minor and may not necessarily require readmission to hospital.

The optimal ERAS programme has yet to be composed for patients undergoing SG. Novel interventions to modulate pain may allow increased mobility and greater ability to tolerate oral diet postoperatively. Preoperative exercise has not shown to be effective at improving recovery but this may be due incorrect exercise prescriptions for obese patients who are chronically inactive and further research may evolve prehabilitation into an effective intervention for SG patients.

Only the short-term outcomes of surgery have been evaluated in any depth following SG within an ERAS programme. It is yet unknown whether or not the short-term benefits of ERAS translate into favourable long-term outcomes with no long term follow up weight loss or comorbidity resolution data available. Further research is required to determine what the long-term outcomes of these patients are relevant to the end goal of the surgical procedure.

Finally, by implementing ERAS and standardizing perioperative care, a clinical petrie dish is created that can act as platform for further clinical trials. This benefit of ERAS needs to be better recognized and the potential harnessed to further our understanding of clinical outcomes following SG.

CONCLUSION

In conclusion, ERAS is a concept that appears to have been successfully applied to SG from its initial development in colorectal surgery. The literature evaluating its composition and efficacy continues to grow and despite its limitations remains as an effective method to reduce perioperative morbidity and postoperative convalescence. Ongoing research is required to ensure that ERAS continues to evolve in the setting of SG in order to optimize its efficacy for this group of high-risk patients.

REFERENCES

[1] Fisher BL, Schauer P. Medical and surgical options in the treatment of severe obesity. *Am J Surg.* 2002;184(6B):9S-16S.

[2] Franco JV, Ruiz PA, Palermo M, Gagner M. A review of studies comparing three laparoscopic procedures in bariatric surgery: sleeve gastrectomy, Roux-en-Y gastric bypass and adjustable gastric banding. *Obes Surg.* 2011;21(9):1458-68.

[3] Leyba JL, Aulestia SN, Llopis SN. Laparoscopic Roux-en-Y gastric bypass versus laparoscopic sleeve gastrectomy for the treatment of morbid obesity. A prospective study of 117 patients. *Obes Surg.* 2011;21(2):212-6.

[4] Lakdawala MA, Bhasker A, Mulchandani D, Goel S, Jain S. Comparison between the results of laparoscopic sleeve gastrectomy and laparoscopic Roux-en-Y gastric bypass in the Indian population: a retrospective 1 year study. *Obes Surg*. 2010;20(1):1-6.

[5] Topart P, Becouarn G, Ritz P. Comparative early outcomes of three laparoscopic bariatric procedures: sleeve gastrectomy, Roux-en-Y gastric bypass, and biliopancreatic diversion with duodenal switch. *Surg Obes Relat Dis.* 2012;8(3):250-4.

[6] Himpens J, Dobbeleir J, Peeters G. Long-term results of laparoscopic sleeve gastrectomy for obesity. *Ann Surg*. 2010;252(2):319-24.

[7] Bohdjalian A, Langer FB, Shakeri-Leidenmuhler S, Gfrerer L, Ludvik B, Zacherl J, et al. Sleeve gastrectomy as sole and definitive bariatric procedure: 5-year results for weight loss and ghrelin. *Obes Surg.* 2010;20(5):535-40.

[8] Sarela AI, Dexter SP, O'Kane M, Menon A, McMahon MJ. Long-term follow-up after laparoscopic sleeve gastrectomy: 8-9-year results. *Surg Obes Relat Dis.* 2012;8(6):679-84.

[9] D'Hondt M, Vanneste S, Pottel H, Devriendt D, Van Rooy F, Vansteenkiste F. Laparoscopic sleeve gastrectomy as a single-stage procedure for the treatment of morbid obesity and the resulting quality of life, resolution of comorbidities, food tolerance, and 6-year weight loss. *Surg Endosc*. 2011;25(8):2498-504.

[10] Lemanu DP, Singh PP, Rahman H, Hill AG, Babor R, MacCormick AD. Five-year results after laparoscopic sleeve gastrectomy: a prospective study. *Surg Obes Relat Dis*. 2015;11(3):518-24.

[11] Akkary E, Duffy A, Bell R. Deciphering the sleeve: technique, indications, efficacy, and safety of sleeve gastrectomy. *Obes Surg.* 2008;18(10):1323-9.

[12] Shi X, Karmali S, Sharma AM, Birch DW. A review of laparoscopic sleeve gastrectomy for morbid obesity. *Obes Surg*. 2010;20(8):1171-7.

[13] Birkmeyer NJ, Dimick JB, Share D, Hawasli A, English WJ, Genaw J, et al. Hospital complication rates with bariatric surgery in Michigan. *JAMA.* 2010;304(4):435-42.

[14] Birkmeyer JD, Finks JF, O'Reilly A, Oerline M, Carlin AM, Nunn AR, et al. Surgical skill and complication rates after bariatric surgery. *N Engl J Med.* 2013;369(15):1434-42.

[15] Aurora AR, Khaitan L, Saber AA. Sleeve gastrectomy and the risk of leak: a systematic analysis of 4,888 patients. *Surg Endosc*. 2012;26(6):1509-15.

[16] Spanjersberg WR, Reurings J, Keus F, van Laarhoven CJ. Fast track surgery versus conventional recovery strategies for colorectal surgery. *Cochrane Database Syst Rev*. 2011(2):Cd007635.

[17] Varadhan KK, Neal KR, Dejong CH, Fearon KC, Ljungqvist O, Lobo DN. The enhanced recovery after surgery (ERAS) pathway for patients undergoing major elective open colorectal surgery: a meta-analysis of randomized controlled trials. *Clin Nutr* (Edinburgh, Scotland). 2010;29(4):434-40.

[18] Lemanu DP, Singh PP, Stowers MD, Hill AG. A systematic review to assess cost effectiveness of enhanced recovery after surgery programmes in colorectal surgery. *Colorectal Dis.* 2014;16(5):338-46.

[19] Lemanu DP, Singh PP, Berridge K, Burr M, Birch C, Babor R, et al. Randomized clinical trial of enhanced recovery versus standard care after laparoscopic sleeve gastrectomy. *Br J Surg*. 2013;100(4):482-9.

[20] Kehlet H, Wilmore DW. Fast-track surgery. *Br J Surg*. 2005;92(1):3-4.

[21] Kehlet H, Wilmore DW. Evidence-based surgical care and the evolution of fast-track surgery. *Ann Surg*. 2008;248(2):189-98.
[22] Kehlet H. Multimodal approach to postoperative recovery. *Curr Opin Crit Care*. 2009;15(4):355-8.
[23] Kehlet H, Dahl JB. Anaesthesia, surgery, and challenges in postoperative recovery. *Lancet* (London, England). 2003;362 (9399):1921-8.
[24] Srinivasa S, Kahokehr AA, Yu TC, Hill AG. Preoperative glucocorticoid use in major abdominal surgery: systematic review and meta-analysis of randomized trials. *Ann Surg*. 2011;254(2):183-91.
[25] Anderson AD, McNaught CE, MacFie J, Tring I, Barker P, Mitchell CJ. Randomized clinical trial of multimodal optimization and standard perioperative surgical care. *Br J Surg.* 2003;90(12):1497-504.
[26] Gatt M, Anderson AD, Reddy BS, Hayward-Sampson P, Tring IC, MacFie J. Randomized clinical trial of multimodal optimization of surgical care in patients undergoing major colonic resection. *Br J Surg.* 2005;92(11):1354-62.
[27] Delaney CP, Zutshi M, Senagore AJ, Remzi FH, Hammel J, Fazio VW. Prospective, randomized, controlled trial between a pathway of controlled rehabilitation with early ambulation and diet and traditional postoperative care after laparotomy and intestinal resection. *Dis Colon Rectum.* 2003;46(7):851-9.
[28] Stowers MD, Lemanu DP, Coleman B, Hill AG, Munro JT. Review article: Perioperative care in enhanced recovery for total hip and knee arthroplasty. *J Orthop Surg* (Hong Kong). 2014;22(3):383-92.
[29] Scott NB, McDonald D, Campbell J, Smith RD, Carey AK, Johnston IG, et al. The use of enhanced recovery after surgery (ERAS) principles in Scottish orthopaedic units--an implementation and follow-up at 1 year, 2010-2011: a report from the Musculoskeletal Audit, Scotland. *Arch Orthop Trauma Surg*. 2013;133(1):117-24.
[30] Cerantola Y, Valerio M, Persson B, Jichlinski P, Ljungqvist O, Hubner M, et al. Guidelines for perioperative care after radical cystectomy for bladder cancer: Enhanced Recovery After Surgery (ERAS((R))) society recommendations. *Clin Nutr* (Edinburgh, Scotland). 2013;32 (6):879-87.
[31] Wijk L, Franzen K, Ljungqvist O, Nilsson K. Enhanced Recovery after Surgery Protocol in Abdominal Hysterectomies for Malignant versus Benign Disease. *Gynecol Obstet Invest.* 2016;81 (5):461-7.
[32] Mechanick JI, Kushner RF, Sugerman HJ, Gonzalez-Campoy JM, Collazo-Clavell ML, Guven S, et al. American Association of Clinical Endocrinologists, The Obesity Society, and American Society for Metabolic & Bariatric Surgery Medical Guidelines for Clinical Practice for the perioperative nutritional, metabolic, and nonsurgical support of the bariatric surgery patient. *Surg Obes Relat Dis*. 2008;4(5 Suppl):S109-84.
[33] McCarty TM, Arnold DT, Lamont JP, Fisher TL, Kuhn JA. Optimizing outcomes in bariatric surgery: outpatient laparoscopic gastric bypass. *Ann Surg.* 2005;242(4):494-8; discussion 8-501.
[34] Bamgbade OA, Adeogun BO, Abbas K. Fast-track laparoscopic gastric bypass surgery: outcomes and lessons from a bariatric surgery service in the United Kingdom. *Obes Surg.* 2012;22(3):398-402.
[35] Grantcharov TP, Kehlet H. Laparoscopic gastric surgery in an enhanced recovery programme. *Br J Surg*. 2010;97(10):1547-51.

[36] Thorell A, MacCormick AD, Awad S, Reynolds N, Roulin D, Demartines N, et al. Guidelines for Perioperative Care in Bariatric Surgery: Enhanced Recovery After Surgery (ERAS) Society Recommendations. *World J Surg*. 2016;40(9):2065-83.

[37] Lemanu DP, Srinivasa S, Singh PP, Johannsen S, MacCormick AD, Hill AG. Optimizing perioperative care in bariatric surgery patients. *Obes Surg*. 2012;22(6):979-90.

[38] Zargar-Shoshtari K, Hill AG. Optimization of perioperative care for colonic surgery: a review of the evidence. *ANZ J Surg.* 2008;78(1-2):13-23.

[39] Carli F, Zavorsky GS. Optimizing functional exercise capacity in the elderly surgical population. *Curr Opin Clinl Nutr Metab Car*e. 2005;8(1):23-32.

[40] Nielsen PR, Jorgensen LD, Dahl B, Pedersen T, Tonnesen H. Prehabilitation and early rehabilitation after spinal surgery: randomized clinical trial. *Clin Rehabil*. 2010;24(2):137-48.

[41] Carli F, Charlebois P, Stein B, Feldman L, Zavorsky G, Kim DJ, et al. Randomized clinical trial of prehabilitation in colorectal surgery. *Br J Surg.* 2010;97(8):1187-97.

[42] Gillis C, Li C, Lee L, Awasthi R, Augustin B, Gamsa A, et al. Prehabilitation versus rehabilitation: a randomized control trial in patients undergoing colorectal resection for cancer. *Anesthesiology*. 2014;121(5):937-47.

[43] Dunne DF, Jack S, Jones RP, Jones L, Lythgoe DT, Malik HZ, et al. Randomized clinical trial of prehabilitation before planned liver resection. *Br J Surg.* 2016;103(5):504-12.

[44] Harbottle L. Audit of nutritional and dietary outcomes of bariatric surgery patients. *Obes Rev*. 2011;12(3):198-204.

[45] Shankar P, Boylan M, Sriram K. Micronutrient deficiencies after bariatric surgery. *Nutrition* (Burbank, Los Angeles County, Calif). 2010;26(11-12):1031-7.

[46] Aarts EO, Janssen IM, Berends FJ. The gastric sleeve: losing weight as fast as micronutrients? *Obes Surg*. 2011;21(2):207-11.

[47] Tonnesen H, Nielsen PR, Lauritzen JB, Moller AM. Smoking and alcohol intervention before surgery: evidence for best practice. *Br J Anaesth*. 2009;102(3):297-306.

[48] Tonnesen H, Faurschou P, Ralov H, Molgaard-Nielsen D, Thomas G, Backer V. Risk reduction before surgery. The role of the primary care provider in preoperative smoking and alcohol cessation. *BMC Health Serv Res*. 2010;10:121.

[49] Livhits M, Mercado C, Yermilov I, Parikh JA, Dutson E, Mehran A, et al. Preoperative predictors of weight loss following bariatric surgery: systematic review. *Obes Surg*. 2012;22(1):70-89.

[50] Practice guidelines for preoperative fasting and the use of pharmacologic agents to reduce the risk of pulmonary aspiration: application to healthy patients undergoing elective procedures: a report by the American Society of Anesthesiologist Task Force on Preoperative Fasting. *Anesthesiology*. 1999;90(3):896-905.

[51] Smith I, Kranke P, Murat I, Smith A, O'Sullivan G, Soreide E, et al. Perioperative fasting in adults and children: guidelines from the European Society of Anaesthesiology. *Eur J Anaesthesiol*. 2011;28(8):556-69.

[52] Awad S, Varadhan KK, Ljungqvist O, Lobo DN. A meta-analysis of randomised controlled trials on preoperative oral carbohydrate treatment in elective surgery. *Clin Nutr* (Edinburgh, Scotland). 2013;32(1):34-44.

[53] Li L, Wang Z, Ying X, Tian J, Sun T, Yi K, et al. Preoperative carbohydrate loading for elective surgery: a systematic review and meta-analysis. *Surg Today*. 2012;42(7):613-24.

[54] de Menezes Ettinger JE, dos Santos Filho PV, Azaro E, Melo CA, Fahel E, Batista PB. Prevention of rhabdomyolysis in bariatric surgery. *Obes Surg.* 2005;15(6):874-9.

[55] Domi R, Laho H. Anesthetic challenges in the obese patient. *J Anesth.* 2012;26(5):758-65.

[56] Schuster R, Alami RS, Curet MJ, Paulraj N, Morton JM, Brodsky JB, et al. Intra-operative fluid volume influences postoperative nausea and vomiting after laparoscopic gastric bypass surgery. *Obes Surg.* 2006;16(7):848-51.

[57] Ogunnaike BO, Jones SB, Jones DB, Provost D, Whitten CW. Anesthetic considerations for bariatric surgery. *Anesth Analg.* 2002;95(6):1793-805.

[58] Matot I, Paskaleva R, Eid L, Cohen K, Khalaileh A, Elazary R, et al. Effect of the volume of fluids administered on intraoperative oliguria in laparoscopic bariatric surgery: a randomized controlled trial. *Arch Surg* (Chicago, Ill: 1960). 2012;147(3): 228-34.

[59] Jain AK, Dutta A. Stroke volume variation as a guide to fluid administration in morbidly obese patients undergoing laparoscopic bariatric surgery. *Obes Surg.* 2010;20(6):709-15.

[60] Gan TJ, Diemunsch P, Habib AS, Kovac A, Kranke P, Meyer TA, et al. Consensus guidelines for the management of postoperative nausea and vomiting. *Anesth Analg*. 2014;118(1):85-113.

[61] Ziemann-Gimmel P, Goldfarb AA, Koppman J, Marema RT. Opioid-free total intravenous anaesthesia reduces postoperative nausea and vomiting in bariatric surgery beyond triple prophylaxis. *Br J Anaesth.* 2014;112(5):906-11.

[62] Benevides ML, Oliveira SS, de Aguilar-Nascimento JE. The combination of haloperidol, dexamethasone, and ondansetron for prevention of postoperative nausea and vomiting in laparoscopic sleeve gastrectomy: a randomized double-blind trial. *Obes Surg.* 2013;23(9):1389-96.

[63] Talab HF, Zabani IA, Abdelrahman HS, Bukhari WL, Mamoun I, Ashour MA, et al. Intraoperative ventilatory strategies for prevention of pulmonary atelectasis in obese patients undergoing laparoscopic bariatric surgery. *Anesth Analg*. 2009;109(5):1511-6.

[64] Bergland A, Gislason H, Raeder J. Fast-track surgery for bariatric laparoscopic gastric bypass with focus on anaesthesia and peri-operative care. Experience with 500 cases. *Acta Anaesthesiol Scand.* 2008;52(10):1394-9.

[65] Imberger G, McIlroy D, Pace NL, Wetterslev J, Brok J, Moller AM. Positive end-expiratory pressure (PEEP) during anaesthesia for the prevention of mortality and postoperative pulmonary complications. *Cochrane Database Syst Rev*. 2010(9): Cd007922.

[66] Nelson R, Edwards S, Tse B. Prophylactic nasogastric decompression after abdominal surgery. *Cochrane Database Syst Rev*. 2007(3):Cd004929.

[67] Huerta S, Arteaga JR, Sawicki MP, Liu CD, Livingston EH. Assessment of routine elimination of postoperative nasogastric decompression after Roux-en-Y gastric bypass. *Surgery*. 2002;132(5):844-8.

[68] Petrowsky H, Demartines N, Rousson V, Clavien PA. Evidence-based value of prophylactic drainage in gastrointestinal surgery: a systematic review and meta-analyses. *Ann Surg*. 2004;240(6):1074-84; discussion 84-5.

[69] Sammour T, Kahokehr A, Hill AG. Meta-analysis of the effect of warm humidified insufflation on pain after laparoscopy. *Br J Surg.* 2008;95(8):950-6.

[70] Kahokehr A, Sammour T, Srinivasa S, Hill AG. Systematic review and meta-analysis of intraperitoneal local anaesthetic for pain reduction after laparoscopic gastric procedures. *Br J Surg*. 2011;98(1):29-36.

[71] Maund E, McDaid C, Rice S, Wright K, Jenkins B, Woolacott N. Paracetamol and selective and non-selective non-steroidal anti-inflammatory drugs for the reduction in morphine-related side-effects after major surgery: a systematic review. *Br J Anaesth.* 2011;106(3):292-7.

[72] Chaparro LE, Clarke H, Valdes PA, Mira M, Duque L, Mitsakakis N. Adding pregabalin to a multimodal analgesic regimen does not reduce pain scores following cosmetic surgery: a randomized trial. *J Anesth.* 2012;26(6):829-35.

[73] Fleischmann E, Kurz A, Niedermayr M, Schebesta K, Kimberger O, Sessler DI, et al. Tissue oxygenation in obese and non-obese patients during laparoscopy. *Obes Surg.* 2005;15(6):813-9.

[74] Eichenberger A, Proietti S, Wicky S, Frascarolo P, Suter M, Spahn DR, et al. Morbid obesity and postoperative pulmonary atelectasis: an underestimated problem. *Anesth Analg.* 2002;95(6):1788-92, table of contents.

[75] Greif R, Akca O, Horn EP, Kurz A, Sessler DI. Supplemental perioperative oxygen to reduce the incidence of surgical-wound infection. *N Engl J Med*. 2000;342(3):161-7.

[76] Stocker DJ. Management of the bariatric surgery patient. *Endocrinol Metab Clin North Am*. 2003;32(2):437-57.

[77] Dobesh PP, Wittkowsky AK, Stacy Z, Dager WE, Haines ST, Lopez LM, et al. Key articles and guidelines for the prevention of venous thromboembolism. *Pharmacotherapy*. 2009;29(4):410-58.

[78] Magee CJ, Barry J, Javed S, Macadam R, Kerrigan D. Extended thromboprophylaxis reduces incidence of postoperative venous thromboembolism in laparoscopic bariatric surgery. *Surg Obes Relat Dis.* 2010;6(3):322-5.

[79] Awad S, Carter S, Purkayastha S, Hakky S, Moorthy K, Cousins J, et al. Enhanced recovery after bariatric surgery (ERABS): clinical outcomes from a tertiary referral bariatric centre. *Obes Surg*. 2014;24(5):753-8.

[80] Lyass S, Link D, Grace B, Verbukh I. Enhanced recovery after surgery (ERAS) protocol for out-patient Laparoscopic Sleeve Gastrectomy in Ambulatory Surgery Cente - safe and effective. *Surg Obes Relat Dis.*11(6):S198.

[81] Mannaerts GH, van Mil SR, Stepaniak PS, Dunkelgrun M, de Quelerij M, Verbrugge SJ, et al. Results of Implementing an Enhanced Recovery After Bariatric Surgery (ERABS) Protocol. *Obes Surg.* 2016;26(2):303-12.

[82] Matlok M, Pedziwiatr M, Major P, Klek S, Budzynski P, Malczak P. One hundred seventy-nine consecutive bariatric operations after introduction of protocol inspired by the principles of enhanced recovery after surgery (ERAS$^{(R)}$) in bariatric surgery. *Med Sci Mon.* 2015;21:791-7.

[83] Barreca M, Renzi C, Tankel J, Shalhoub J, Sengupta N. Is there a role for enhanced recovery after laparoscopic bariatric surgery? Preliminary results from a specialist obesity treatment center. *Surg Obes Relat Dis*. 2016;12(1):119-26.

In: Encyclopedia of Surgery (22 Volume Set)
Editors: Andreas Lehrer and Kristin Mueller
ISBN: 978-1-53618-329-0
© 2020 Nova Science Publishers, Inc.

Chapter 184

LAPAROSCOPIC DUODENOJEJUNAL BYPASS WITH SLEEVE GASTRECTOMY

Chih-Kun Huang, MD, Michelle Bernadette C. Lim-Loo, MD, Thakoon Poonthananiwatkul, MD, Vivek Kulkarni, MD, and Abhishek Katakwar
Body Science and Metabolic Disorders International (B.M.I) Medical Center,
China Medical University Hospital, Taichung, Taiwan

ABSTRACT

There has been a rapid rise in the number of laparoscopic sleeve gastrectomy (SG) for treating morbidly obese patients in the recent few years. This has eventually the most popular bariatric procedure to date. Being only anatomically restrictive, SG has limited effects on glucose homeostasis in type II diabetes mellitus (T2DM) for lack of foregut hormone modulation mechanism. Gastric bypass has been proposed and proven to remit T2DM better than SG due to the foregut exclusion. According to these findings, duodenojejunal bypass (DJB) has been developed to accompany SG to possibly give a better result of diabetes remission than SG alone. The technique DJB-SG involves SG, exclusion of duodenum except the first portion, and bypassing the proximal jejunum. Both the Roux-en-Y and loop fashion for anastomosis of duodenum and jejunum have been adopted. In this chapter, we present both methods of combined SG with DJB as a treatment for morbid obesity and obesity with T2DM.

Keywords: sleeve gastrectomy, duodenojejunostomy bypass, morbid obesity, type 2 diabetes mellitus

INTRODUCTION

The prevalence of obesity is increasing day by day and is the epidemic of the 21st century [1]. In a recent analysis by WHO, it was found that 1.9 billion people aged 18 years or more

were overweight, out of which 600 million were obese. The world obesity population has doubled over the last two decades [2]. Obesity is associated with many diseases. Some of them are diabetes, hypertension, hyperlipidemia, asthma, degenerative bone disease, obstructive sleep apnea, which cause debilitating problems in the obese and add to the cost of health care [3]. Increased body mass index (BMI), abdominal fat and weight gain are important risk factors associated with the development of T2DM. About 90% of people with T2DM are obese [4]. Bariatric surgery is now a well-established procedure for treating morbid obesity and its associated comorbidities.

The evolution of bariatric procedures has progressed over time in an attempt to constantly improve outcomes while minimizing adverse effects. A rapid increase in SG for treating the morbidly obese patients is seen in the recent years. This is becoming the most popular procedure to date owing to its technical simplicity and less malnutrition. It was first performed by Hess in 1988 as a part of the biliopancreatic division [5]. In 1999, Gagner, Jossart and de Csepel developed a laparoscopic approach to duodenal switch (DS), which Gagner later performed in humans [6]. The first international consensus summit for SG concluded that its indications were increasing as a standalone procedure aside from being a part of a staged procedure for the super obese [7].

Recent studies of the biochemical mechanism of bariatric procedures have lead us to understand how anatomical changes in the digestive tract would result in hormonal modifications of decreasing ghrelin and an exaggerated incretin effect. This drives weight loss and improved glucose metabolism [8-12]. Duodenal switch and Roux-en-Y gastric bypass (RYGB) are undeniably more effective for weight loss and diabetes control than SG alone, but not without consequences. Certain anatomical structures are crucial to maintain some physiologic environments to decrease unwanted morbidities. Hess developed the DS with preservation of the pylorus to address the issue of duodenogastric bile reflux as seen in biliopancreatic division patients. This also eliminated marginal ulcers and dumping syndrome [13]. Marceau then used this principle and modified it by cross-stapling the duodenum with an end-to-side duodenoileostomy. The limb lengths were variable and adjusted to have a common limb length of 100cm [14]. Cross-stapling was later discontinued as some patients had recanalization. Thus, an end-to-end duodenoileostomy remained as the standard approach for this procedure. Although DS has one of the best results in weight loss and diabetes control, it is not well tolerated by the Asian population. It is reserved for a very small number of patients due to fear of nutritional complications. On the other hand, RYGB may present with anemia, malnutrition, marginal ulcers and dumping syndrome, which adds to the patient morbidity and may be debilitating.

Duodenojejunal bypass (DJB) was first reported by Rubino and Marescaux in 2004 in an animal model, where bypassing the duodenum and proximal jejunum without gastric restriction achieved glycemic control in nonobese T2DM rats [15]. As an individual procedure, DJB has been also tried as a treatment of T2DM in humans. In 2007, Cohen et al. published DJB to achieve diabetic remission in low BMI T2DM patients, two of which were followed for nine months [16]. A Korean study demonstrated DJB in non-obese patients to exert positive influence on insulin resistance and β-cell function of pancreas. However, the overall effectiveness was not satisfactory as remission was achieved in only 13% of the cases and diabetic improvement was seen in only 27% of cases [17].

Kasama et al. published his case series of DJB-SG in 2009 and was the first to describe DJB-SG in a Roux-en-Y fashion (RYDJB-SG) [18]. The procedure of which is almost similar to a DS with a modification in the size of the gastric tube and the limb lengths [13]. Twenty-one patients with a high risk of gastric cancer were included in the study, as endoscopic surveillance for gastric cancer was feasible. Surgical safety and efficacy for treatment of morbid obesity was established [18]. In 2010, Pernaute et al. published the technique of single anastomosis duodeno-ileal bypass with SG or SADI-S. This is another adaptation of the DS, where the duodeoilestomy anastomosis was done in a loop fashion [19]. In 2011, the SADI-S was further modified as a loop fashion of the DJB-SG (LDJB-SG) and was reported by Huang et al. [20].

MECHANISM OF ACTION

The DJB-SG has two components: the vertical SG and bypassed foregut. It works on the principle of hindgut theory where the proximal 200-300cm jejunum is diverted. Chyme is transported quickly to the distal small bowel to increase the incretin secretion and decrease anti-incretin substances, which would otherwise be secreted from the diverted proximal small bowel. Incretins are the hormones secreted from the hindgut, and anti-incretins are substances secreted from foregut. This concept of hormone secretion from the small bowel playing a role in pancreatic insulin secretion is termed entero-insular axis [8].

The glucagon-like-polypeptide (GLP-1) and peptide YY (PYY) are believed to be the most important incretins and are secreted from the L-cells in the distal ileum and colon in response to meal ingestion. These hormones exercise important glucoregulatory effects, including the glucose–dependent potentiation of insulin secretion by pancreatic β-cells [9]. These are also suppressors of food intake and are known to act on the hypothalamic appetite regulation [10]. Secretion of GLP -1 is increased several fold after gastric bypass surgery, which is postulated to achieve glycemic control by improving β-cell function [11].

Sleeve gastrectomy acts as the restrictive component helping to decrease overall food intake owing to the reduced stomach size. Ghrelin is an enteric peptide known to increase appetite and cause diabetogenic effects by suppressing insulin secretion and glucose metabolism pathways [12]. As ghrelin levels decrease after SG, the diabetogenic effects are likewise decreased and help to achieve better sugar control.

Hormonal Study

Chih-Kun Huang conducted a study on the incretin effect of LDJB-SG in T2DM patients with BMI <35 Kg/m^2. It was a prospective observational study conducted from May 2013 to March 2014, which included 27 patients, 23 females and four males. The mean age was 51.5 ± 8.6 years, mean weight at 74.5 ± 13.7 kg, and mean BMI at 28.38 ± 4.3 kg/m^2. All patients have T2DM with mean duration of 10.2 ± 5.6 years, and underwent LDJB-SG with a 200cm afferent limb. The C-peptide, ghrelin, GLP-1 and PYY were measured over time alongside an oral glucose tolerance test (OGTT).

Hormones were analyzed by calculating time courses, the area under the plasma concentration time profile (AUC), and maximum plasma concentration (Cmax). Follow-up comparisons were analyzed using the paired t-test. When 20% of the cells had expected values of <5, a Fisher exact test was used instead. All statistical tests were two-tailed and were calculated with SPSS statistical software (version 15.0; SPSS Inc., Chicago, IL). A p-value <0.05 was considered statistically significant.

The LDJB-SG resulted in significant weight loss and good glycemic control. The mean BMI reduced to 22.16 ± 2.75 Kg/m^2 at six months postoperatively ($p < 0.01$). Fasting sugar and glycated hemoglobin (HbA_1c) reduced from 160.66 ± 46.70 gm/dL and 9.31 ± 1.8% to 111.22 ± 26.64 mg/dL and 6.28 ± 1.1% at six months ($p < 0.01$).

Ghrelin

At six months, fasting ghrelin levels of 21.99 ± 11.27 pg/mL ($p < 0.05$) were significantly lower than that of the preoperative level 98.58 ± 71.09 pg/mL. Preoperative ghrelin AUC-120 of 82.13 ± 49.36 pg/mL/min dropped to 43.12 ± 26.42 pg/mL/min ($p < 0.05$) and 17.90 ± 9.01 pg/mL/min ($p < 0.05$) at one and six months, respectively. However, the fall was more prominent at six months as signified by a lower AUC and Cmax (see Figure 1).

Glucagon-Like Polypeptide -1

Preoperative fasting levels of 37.04 ± 54.62 pg/mL reduced to 20.05 ± 15.70 pg/Ml ($p < 0.05$) at six months. An exaggerated response was observed at one month as suggested by a higher fasting level of 71.11 ± 66.36 pg/mL ($p = 0.06$) and a C-max of 510.34 ± 292.56 pg/mL ($p < 0.05$). Peak GLP-1 was noted at 30 minutes in all the visits, and AUC-120 increased from 139.37 ± 109.93 pg/mL/min preoperatively to 349.10 ± 187.35 pg/mL/min at one month ($p < 0.05$) and 185.75 ± 118.81 pg/mL/min at six months ($p = 0.06$) (see Figure 1).

Peptide YY

At one month, AUC-120 changed from 137.10 ± 93.20 pg/mL/min preoperatively to 454.50 ± 134.85 pg/mL/min ($p < 0.05$) and 136.57 ± 134.53 pg/mL/min at six months ($p = 0.987$) postoperatively. Preoperative fasting PYY levels of 78.91 ± 103.23 ng/mL increased to 124.09 ± 78.01 ng/mL ($p < 0.05$) at one month and expressed an exaggerated postprandial response, followed by a fall in fasting level to 49.73 ± 56.11 ng/mL ($p = 0.169$) at six months (see Figure 1).

From these results, we infer that DJB-SG causes a decrease in ghrelin and an exaggerated incretin response. This leads to a decrease in hunger, increase in satiety and a better glucose control.

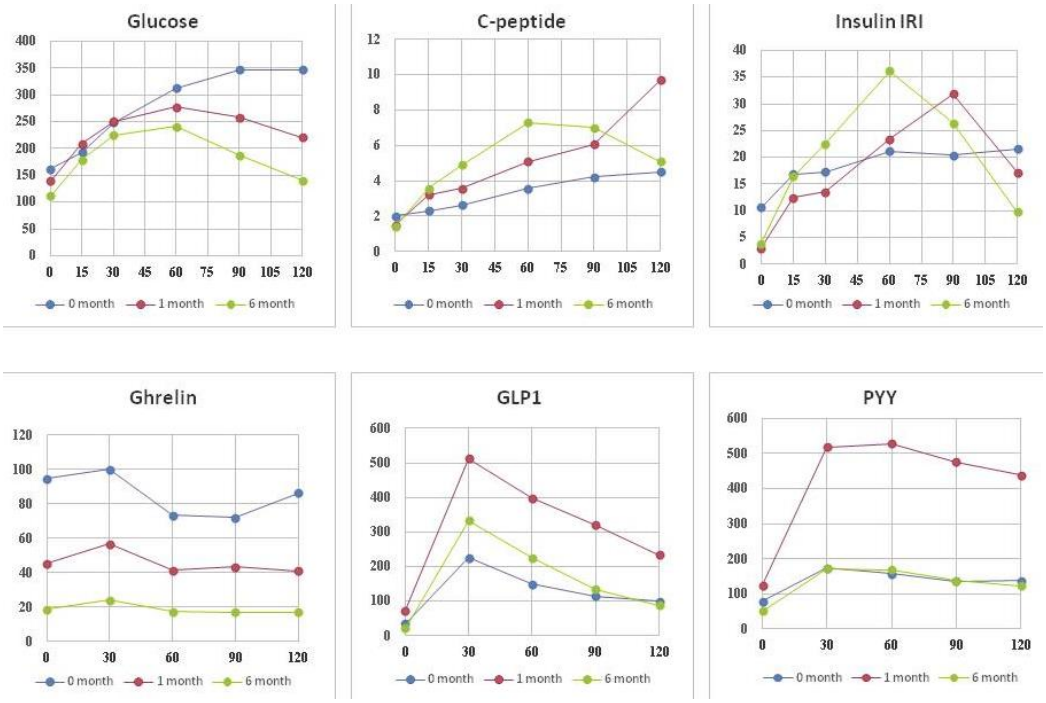

Figure 1. Measurement of C-peptide and hormone levels at zero, one and six months against time in minutes alongside an oral glucose tolerance test.

Advantages

A number of other advantages are noteworthy from DJB-SG. It allows screening of the stomach for gastric cancer, which is quite difficult to perform after RYGB [21-23]. This is especially beneficial for the high-risk populations. The anatomical preservation of the pylorus, being a physiologic valve, has several functions. It serves as a natural barrier for the gastric mucosa against pancreatic and biliary juices thereby preventing bile reflux gastritis [24]. It also regulates gastric emptying, leading to less occurrence of dumping syndrome. Likewise, more gastric size is preserved, improving the absorption of iron, calcium, vitamin B_{12}, and protein [23, 24].

Another advantage of DJB-SG is its versatility of conversion to another procedure as indicated, such as in cases of leaks or strictures. The LDJB-SG may be easily converted into DS by transecting of the afferent limb and anastomosing it to the efferent limb distally. In the RYDJB-SG, adjustment of the Y-limb to lengthen the Roux limb could convert it to DS. Transformation of the DJB-SG to RYGB is also feasible, by transecting the duodenojejunal anastomosis, resection of distal gastric tube and bringing up the alimentary limb for a gastrojejunal anastomosis.

When comparing with RYDJB-SG, a loop technique could display some advantages. The single anastomosis by loop fashion offers a reduced operative time and decreases potential complications from another anastomosis of the Roux-en-Y jejuno-jejunostomy. Also, only a single mesenteric (Petersen) defect needs to be closed in a loop technique [24].

Marginal ulcer is also unreported in the loop technique, probably due to the immediate neutralization of the gastric acid by the bile upon entry into the duodenum.

THERAPEUTIC OUTCOMES

Earlier studies of DJB involving non-obese patients with diabetes showed some clinical improvement, including HbA_1c and fasting blood glucose over three months which remained controlled at one year. Decreased medication requirements were noted; although, the patients did not have a remission of diabetes [25, 26]. The procedures in these studies did not include an SG, which defines the postoperative weight loss being a strong predictive factor in diabetes remission. The effect on glucose metabolism however, is still multifactorial. Literature review reported up to 97% of morbidly obese SG patients had an improvement or resolution of T2DM at a mean of 13 months. Though, this drops to 60.8% at five years, with a 13% recurrence rate [27]. Combining LSG and DJB together should result in a synergistic weight loss and glycemic control.

The series by Kasama's group observed the weight loss and glucose metabolism effect of DJB-SG on the morbidly obese with associated diabetes. At one year, percent excess weight loss (EWL) was 99.4%, with 91% of subjects achieving glycemic control of HbA_1c below 7% at one month. A meal tolerance test conducted showed a significant reduction of glucose area under the curve (AUC) and an increase in insulin AUC at six months. Continuous glucose monitoring done on selected patients showed a dramatic response of glycemic control. The patients had decreasing insulin requirement on the first postoperative day, to no diabetic medication on the second postoperative day [22]. A preliminary study by Kasama et al. in 2009 involving 21 patients who underwent DJB-SG showed that short term percent excess BMI loss at one year was similar to their previous series of RYGB, and superior to LSG and gastric banding. Resolution of diabetes at 93% was also better than their series of LSG (67%). They likewise showed 100% and 85.7% resolution of hyperlipidemia and hypertension, respectively [14]. In 2012, Raj et al. randomized 57 morbidly obese patients to DJB-SG and RYGB. At one year, the BMI and percent EWL between the two procedures were not statistically significant. The remission rate for diabetes was similar at 80% and 81%, respectively. Resolution of hypertension and dyslipidemia was also similar between groups, with all subjects having 100% resolution of dyslipidemia [28]. A medium-term study of 120 obese patients with diabetes showed preoperative body weight and BMI to have decreased from 105.7 Kg and 38.5 Kg/m^2 to 74.9 Kg and 27.2 Kg/m^2 at one year respectively, and reached a plateau up to five years. Changes in HbA_1c and fasting blood glucose showed a drop from 8.9 to 6.0 and 194 to 105, respectively, at one year follow-up and maintained thereafter for five years. There was an improvement in OHA and insulin use by the first postoperative year and it continued for five years. The number of patients that were off medications increased from 5% to 86%; 48% using OHA decreased to 10%; 15% using insulin decreased to 1.8%; and 30% using both OHA and insulin decreased to 2.7%. The reported remission rate was at 63.6% [21].

In 2013 Huang et al. published a report on performing DJB-SG using a loop fashion in a lower BMI population with diabetes. At six months, the mean BMI of 28.4 dropped to 22.4, with 91% of the subjects achieving HbA_1c below 7.0 without medications [15]. Another study

by Lee et al. compared the LDJB-SG with SG alone. They reported LDJB-SG to have a better weight loss in lower BMI (23.9 versus 26.1) and more EWL (87.2% versus 67.5%) at one year. Diabetes remission rate was also higher with LDJB-SG at 93% versus SG at 87% [23]. A comparison with gastric bypass in the morbidly obese showed better weight loss in LDJB-SG with a drop of BMI from 38 to 25.9, and EWL at 80.3% versus BMI 27 and EWL 63.4%. However, LDJB-SG showed higher total cholesterol and low-density cholesterol levels compared to a gastric bypass [24]. In contrast, Huang et al. found no statistical difference in the outcomes between LDJB-SG and RYGB in diabetic patients with BMI less than 35 Kg/m^2. Weight loss reported a BMI drop in LDJB-SG from 28.2 to 22.4 versus RYGB at 27.8 to 21.9. The glycemic control of HbA_1c below 7 for LDJB-SG was at 73.3% versus RYGB at 63.3% [29].

INDICATIONS AND CONTRAINDICATIONS

DJB-SG can be used in the treatment of morbid obesity or obesity with T2DM [30].

Indications	
Body mass index (BMI) ≧35 Kg/m^2 with co-morbidities or BMI ≧40 Kg/m^2	
Class III Obese	BMI > 40 Kg/m^2 with DM
	BMI > 37.5 Kg/m^2 with DM for Asians
Class II Obese	BMI 35kg - 39.9 Kg/m^2 with DM
	BMI 32.5 - 37.4 Kg/m^2 with DM for Asians
	Surgery is recommended if poor glycemic control
	Surgery may be considered if adequate glycemic control
Class I Obese	BMI 30-34.9 Kg/m^2 with poor glycemic control
	BMI 27.5-32.4 Kg/m^2 with poor glycemic control for Asians
Overweight	BMI < 27.5 Kg/m^2 in experimental cases with informed consent
Absolute Contraindications	
Psychiatric illness: active psychosis, purgative behaviors, untreated or undertreated psychopathology and medical nonadherence	
Drug abuse/alcohol abuse	
Relative contraindications	
Type 1 DM	
C-peptide <1	
Duodenal ulcer	
Severe GERD (Grade C and D)	
Barretts' esophagus	
Bile reflux gastritis	
Chronic pancreatitis	

PROCEDURE

Preoperative Considerations

A comprehensive, multidisciplinary bariatric management program is utilized for the preoperative preparation and postoperative management of patients. The program should

include a support group and ancillary personnel to help provide nutritional information, psychological care and an exercise program. Prior to the operation, patients are assessed by a multidisciplinary team which includes a surgeon, endocrinologist, anesthesiologist, psychiatrist, and dietician. Every patient undergoes a routine preoperative work-up and counseling. Esophagogastroduodenoscopy is consistently performed to screen for neoplasm, peptic ulcer, reflux esophagitis, hiatal hernia, and H. pylori infection. Smokers are additionally sent for smoking cessation counseling [29].

Patients are admitted one day prior to their scheduled surgery to stabilize the blood glucose level to less than 200 mg/dL, with a continuous insulin infusion as necessary. All patients are instructed to be on a clear liquid diet at admission [31]. A single dose of cephalosporin and pantoprazole are given half an hour prior to the start of the surgery. Antithrombotic devices and low molecular weight heparin are both prescribed to prevent deep venous thrombosis and thromboembolic events.

Duodenojejunal Bypass and Sleeve Gastrectomy Operative Technique

The addition of DJB to SG makes the procedure more technically challenging, translating to longer operative times and a longer hospital stay duration compared to RYGB or LSG alone. The identification of important landmarks, performing certain maneuvers, and careful manipulation of structures makes the procedure more time consuming. Some advancement in laparoscopic skills are required to perform adequate duodenal dissection and transection, as well as a watertight anastomosis to complete a safe and successful surgery. The addition of another entero-entero anastomosis in the Roux-en-Y technique, and the necessary closure of mesenteric defects to avoid future internal herniation also contributes to the added operative time. Although there is more intraabdominal manipulation involved, blood loss should be almost similar to LSG at minimal amounts in an uneventful procedure. However, the surgeon must be mindful in troubleshooting during inadvertent circumstances.

Roux-en-Y Technique

After general anesthesia, the patient is placed on supine position with legs separated. Five ports are used in this procedure. The laparoscope port is placed at the supra-umbilicus and a 5 mm port is placed at the sub-xiphoid space for liver retraction. Two 12 mm ports are then placed at the left subcostal margin and a 10 mm port caudal from the left subcostal margin. A 15 mm blade port is placed at the right upper abdomen for specimen retrieval.

Sleeve gastrectomy is performed with a 36 Fr bougie using linear staplers starting at 4 cm from the pylorus. Sutures over-sewing the staple line are added at the remnant stomach to prevent leakage and bleeding. The posterior wall of the duodenum is carefully dissected and devascularized. The duodenum is then divided with a 60 mm endoscopic linear stapler Endo GIA curved tip with tri-staple ^{TM} (Covidien, USA) at 1-2 cm distal to the pylorus. The biliopancreatic limb is measured 50-100 cm from the ligament of Treitz and divided with a white cartridge linear stapler. The total alimentary tract is measured to 150-200 cm and a linear stapler is used to create the jejunojejunostomy. The entry hole of the jejunosjejunostomy and mesenteric defect are closed by hand-sewn technique. Division of the

omentum is done to help avoid tension on the anastomosis in an antecolic reconstruction. Two layers of running sutures with absorbable material are then used to create the duodenojejunal end-to-side anastomosis [14, 21, 22].

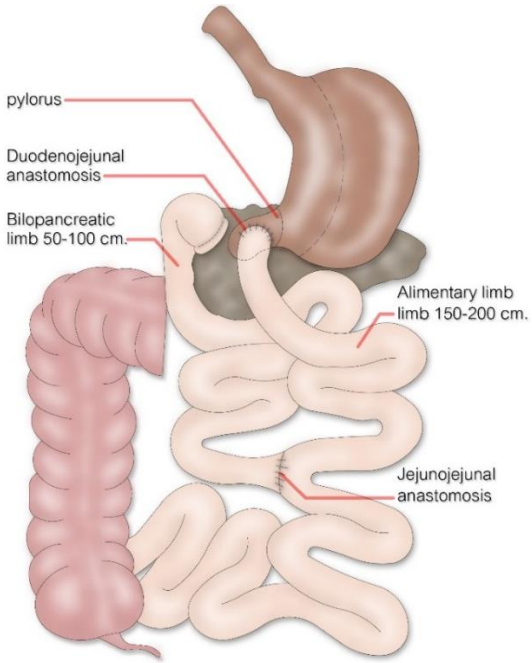

Figure 2. Schematic diagram of the Roux-en-Y technique.

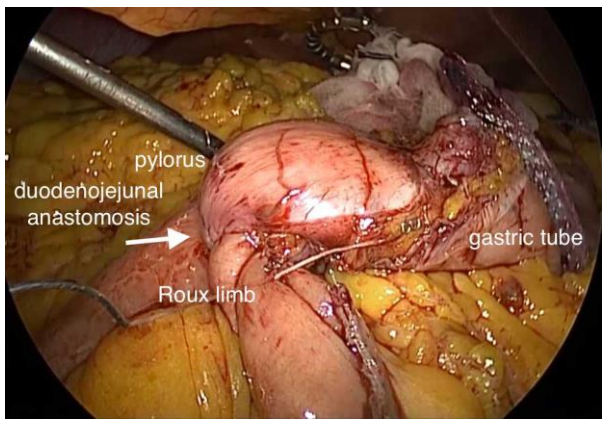

Figure 3. Completed anastomosis of the duodenum to the Roux limb of jejunum.

Loop Technique

The patient is placed on a supine position with abducted arms after initiation of general anesthesia. Five ports are used. Two 12 mm ports are placed at either side of the umbilicus at the midclavicular line. The left port is used for the laparoscope. A 15 mm port is placed at the umbilicus, and two 5 mm ports are placed at both subcostal margins.

Either a Nathanson liver retractor or T-shaped liver suspension tapes can be used to retract the liver to give a good exposure of both the stomach and the duodenum. Sleeve gastrectomy is done over a 38 Fr bougie using a linear stapler beginning at 4 cm proximal to the pyloric ring. A tunnel is then created posterior to the first part of duodenum at 2 cm distal to the pylorus using a Goldfinger dissector (Ethicon Endo Surgery, USA) without devascularization of the duodenum. Transection of the duodenum is performed using the Endo GIA TM 45 mm Curved Tip Articulating Vascular/Medium Reload with Tri-Staple ™ (Covidien, USA). The jejunum is measured at 200-300 cm from the ligament of Treitz. A 1.5 cm enterotomy is then created on the jejunum and the first part of the duodenum. A totally hand-sewn side-to-side anastomosis is created using a 3/0 absorbable suture. An anti-torsion suture is placed between the stomach antrum and the jejunum 4 cm proximal from the duodenojejunostomy. The Petersen's defect is repaired with a continuous non-absorbable suture and a Jackson-Pratt drain is placed behind the duodenojejunostomy up to the SG at the end of the operation [15].

Pearls

Identification of anatomical relationships is important to guide dissection and avoid inadvertent injury to nearby structures. Before doing transection, the common bile duct must be identified. This runs vertically down behind the first part of the duodenum and lies to the right of the gastroduodenal artery serving to label the junction between the first and second portion of the duodenum. Careful and clear dissection of the duodenum off the pancreas should be done with extreme caution to avoid its injury and bleeding due to the multiple small vasculatures and proximity of the gastroduodenal artery. An addition of a traction suture at the antrum of the gastric tube to pull the stomach laterally allows countertraction of the duodenum, facilitating its dissection, as well as, avoiding excessive manipulation of the duodenum and risking injury to its wall and vasculature. In super obese patients where there is abundant periduodenal fat thus rendering difficulty in dissecting a tunnel below the duodenum, it may be necessary to sacrifice the right gastroepiploic vessels. Once a tunnel is fully dissected between the duodenum and pancreas using a Goldfinger dissector (see Figure 6), a vascular tape may be inserted and used to lift the duodenum during insertion of the stapler (see Figures 7 and 8). Using a curved tipped stapler allows easier passage through the created tunnel for the transection of the duodenum (see Figure 9). Special care must be taken not to injure the common bile duct, pancreas and major vessels surrounding the first part of duodenum.

Duodenojejunal anastomosis may be done in an end-to-side or side-to-side fashion. An end-to-side anastomosis may require some devascularization of the posterior aspect of the transected duodenum. A side-to-side anastomosis at 1cm distal to the pylorus is important to avoid its injury. This is also prevented by using a temporary stay suture over the pylorus and proximal jejunum, which also facilitates the hand-sewn anastomosis. Using a linear or circular stapler for anastomosis may risk injury to the pylorus. The Roux-en-Y techniques also includes another entero-entero anastomosis adding to the operative time. In the loop technique, where only a single anastomosis is done, an anti-torsion suture anchors the proximal jejunum to the stomach to prevent torsion or kinking of the jejunal limbs. Closure of Petersen and mesentery defects is necessary to avoid future potential internal herniation.

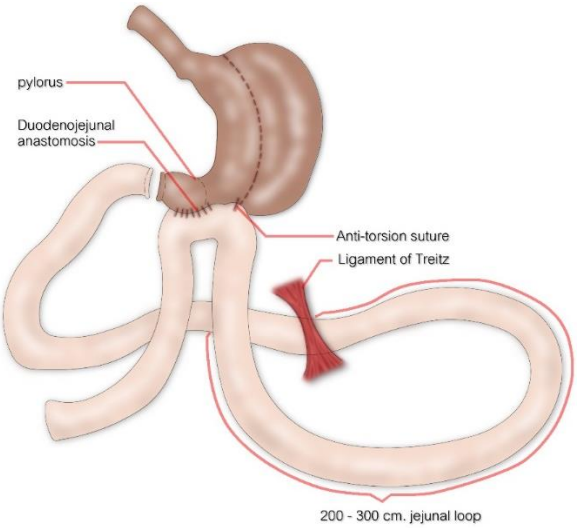

Figure 4. Schematic diagram of the loop technique.

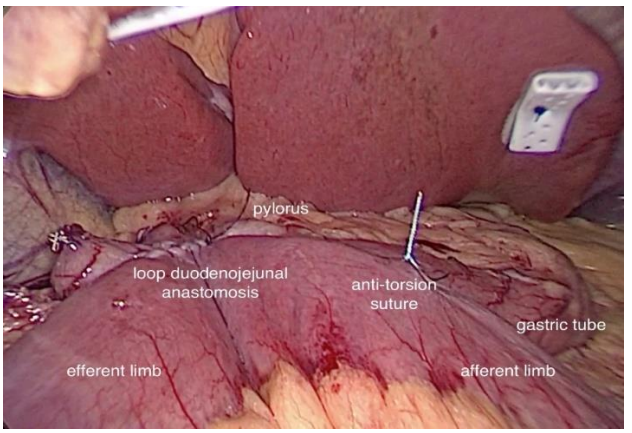

Figure 5. Completed duodenojejunal anastomosis in loop fashion.

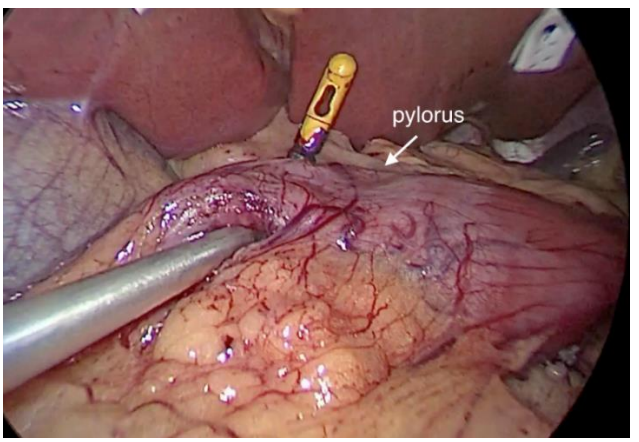

Figure 6. Creation of a tunnel between the duodenum and pancreas using a Goldfinger dissector.

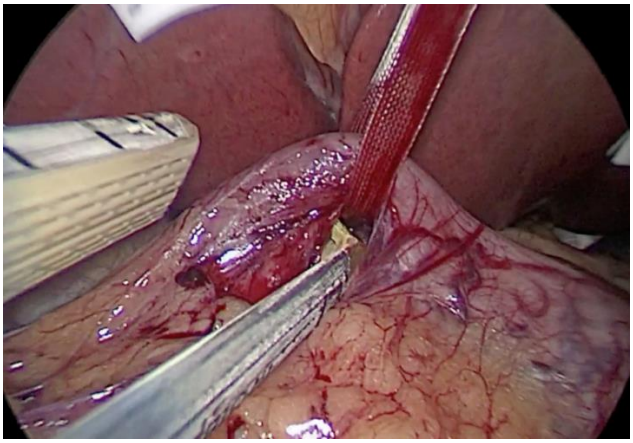

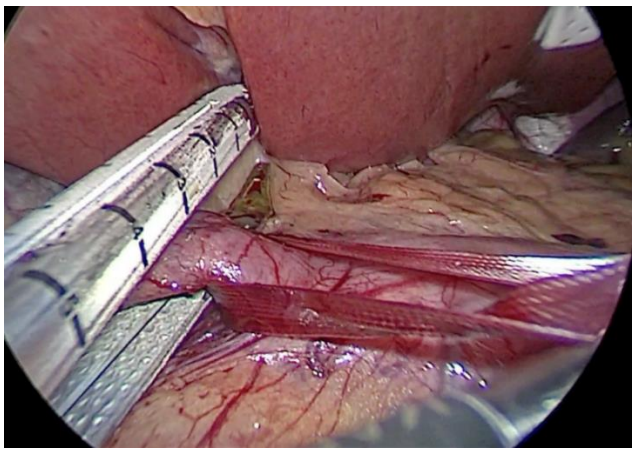

Figures 7 and 8. Insertion of a vascular tape using the Goldfinger dissector to maneuver the duodenum, facilitating stapler application through the created tunnel.

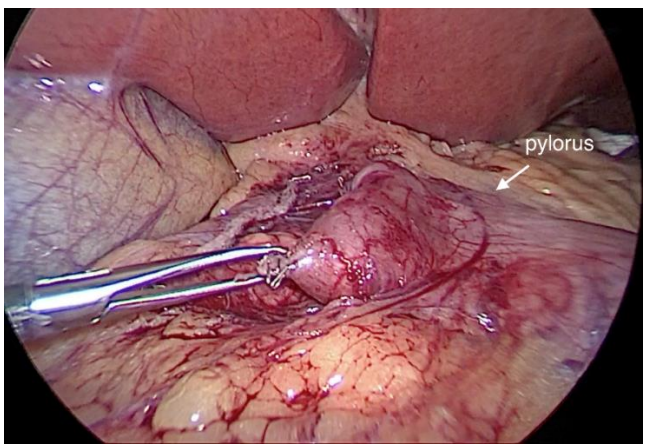

Figure 9. Transection of the duodenum.

Postoperative Care and Follow-Up

Upon completion of the operation, extubation, and recovery from anesthesia effects, patients are then transferred to the surgical ward. Deep breathing exercises and early mobilization are encouraged for postoperative pulmonary care. Opioid analgesics are used for pain control. Clear liquid diet is initiated once the patient regains full consciousness. Patients can usually be discharged three days after surgery once they are able to tolerate oral fluids and pass flatus with no evidence of tachycardia.

A follow-up visit is scheduled at the outpatient clinic one week after discharge. Diet progression is continued as any routine bariatric diet. Medications for diabetes are adjusted accordingly based on close monitoring of the fasting plasma glucose (FPG) level. All patients may be given prophylactic proton pump inhibitors [29].

Subsequent follow-ups are carried out at one, three, six, nine and 12 months after the operation. The nutritional status of the patient must be reviewed by a dietician at every follow-up. Weight, blood pressure, FPG, HbA_1c, and C-peptide levels should also be documented.

Pitfalls

This procedure presents some disadvantages. It is important to note that the DJB-SG is irreversible. Long-term data are necessary to evaluate if it can replace RYGB as the gold standard bariatric procedure. In addition, this procedure might not be appropriate for less skilled surgeons or super obese patients because of the technical challenge involved, as reflected by the long operative time.

As performing a DJB may require some manipulation on the duodenum during dissection, inexperienced surgeons may cause inadvertent harm to the duodenal wall. Damage proximal to the transection may be remedied with the duodenojejunal anastomosis. However, a duodenal injury distal to the transection may cause a possible leak if it is not adequately repaired.

A common scenario encountered during a DJB procedure includes some bleeding after the transection of the duodenum. This may range from bothersome oozing from small multiple branching vessels, to a potentially disastrous bleeding gastroduodenal artery. Oozing may be controlled with hemostatic agents or by packing with gauze until adequate hemostasis has been achieved. Further manipulation may result in more tissue injury and worsen the hemorrhage. A damaged gastroduodenal artery resulting to torrential bleeding would require either a suture repair or ligation, or even conversion to an open laparotomy as necessary.

Injury to the common bile duct during dissection may occur if duodenal transection was done too distally and close to the second duodenum. Avulsions and small duct lacerations should be repaired primarily with a T-tube limb passed through the repair. However, a complete transection may call for a complete biliary reconstruction.

Another disadvantage in transecting the first part of the duodenum is the preclusion of endoscopic modalities to approach the Ampulla of Vater for management of patients who develop complicated choledocholithiasis and biliary obstruction. Hence, patients found to have cholelithiasis preoperatively are offered to undergo concomitant cholecystectomy during

the index surgery, or it may be offered as an elective procedure if cholelithiasis develops postoperatively, even without symptoms.

COMPLICATIONS

Hemorrhage

Incidence of bleeding from SG is reported to be at 1-6% [32], and 0.94% in RYGB [33] which may be intraluminal or intraperitoneal. Intraluminal bleeding may present as hematemesis or melena. This can be managed similarly for any other upper gastrointestinal bleed. Intraperitoneal bleeding may present as a serial drop in hemoglobin with signs of hypovolemic shock. This can be managed conservatively or by re-laparoscopy as necessary according to the patient's condition [22]. Patients' presentation may range from asymptomatic to tachycardia with impending hypovolemic shock. Potential sources of hemorrhage could be from the trocar site, staple lines, duodenal bed, anastomotic sites, or iatrogenic injuries to the surrounding structures [21-23, 33]. Resuscitation and re-laparoscopy is imperative if the patient begins to show signs of hypovolemic shock. This allows immediate diagnosis, evacuation of hemoperitoneum, identification and control of the bleeding source.

Leak

Leak is a dreaded complication where peritonitis and sepsis can potentially lead to morbidity and mortality. The leak may occur either at the staple line or at the anastomosis. The incidence of leaks from a gastric staple line and enteric anastomosis occurs up to 5% [32]. The patient may present with signs of a systemic inflammatory response syndrome, abdominal pain, nausea, vomiting, and an altered mental status. A combination of fever, tachycardia and tachypnea is 58% sensitive and 99% specific for detecting a leak [34]. Diagnosis in the early postoperative period necessitates immediate re-exploration, peritoneal toilette, and primary repair if tissue viability would permit. Management of late leaks may allow the liberty of a conservative approach depending on the patient's clinical condition. This includes adequate resuscitation, drainage of abscess and use of an endoscopic stent in a gastric leak [32]. A duodenojejunal anastomotic leak would warrant a reoperation with conversion to a Roux-en-Y configuration or into RYGB with removal of the distal stomach and the first part of the duodenum [15].

Sleeve Gastrectomy Related Complications

Gastroesophageal Reflux Disease

Most surgeons have agreed that SG should be contraindicated to patients with severe gastroesophageal reflux disease and Barrett's esophagus [35]. The prevalence of erosive esophagitis and reflux symptoms increase after undergoing SG with a de novo incidence of 23% at one year [36, 37]. Reported in DJB-SG series are from 30% to 65% esophagitis and

20% new occurrence of reflux symptoms [29]. Although these symptoms may be treated with proton-pump inhibitors, close clinical follow-up is necessary to monitor for progression of the disease. Braghetto et al. followed 231 patients after SG and reported Barrett's esophagus at 1.2% occurring at three to five years after surgery [36]. Conversion to RYGB may be another option for progressive or intractable reflux symptoms.

Gastric Tube Stricture

The reported incidence of gastric sleeve stricture in DJB-SG series is around 2.5%, [21-23, 28]. Symptoms may present early due to tissue edema or kinking of the gastric tube, and may be managed conservatively with intravenous hydration and bowel rest. It can also have a delayed presentation with the most common site of stricture at the incisura angularis. Short segment strictures may be managed with endoscopic dilatation. Longer segment strictures would require laparoscopic seromyotomy [32]. Conversion to RYGB may be another option after failure of seromyotomy [22, 23].

Duodenojejunal Bypass Related Complications

Internal Hernia

Internal hernias would present with signs and symptoms of abdominal pain, bowel obstruction or gangrene. Physical examination and an imaging modality may facilitate diagnosis. Internal hernias may occur either at the Petersen or mesenteric defect. Incidence is reported to be at less than 1% in RYDJB-SG series [21, 28]. Although the incidence is low, closure of the defects prevents potential internal hernia. This may be complicated by ischemia and necrosis in 7-42%, and increasing associated mortality [39]. A trocar site hernia may occur in open fascial defects of greater than 10mm or if dilatation was done to facilitate extraction of the gastric specimen [40].

Marginal Ulcers

Marginal ulcer is a potentially serious complication of the gastrojejunal anastomosis, and may progress into complications of bleeding, perforation, or stenosis. It has been reported to occur up to 12% after RYGB [41], contrary to being nearly unreported in duodenal switch and SADI-S [13, 42, 43]. The series by Huang et al. reported no incidence of marginal ulcer after LDJB-SG [29], whereas Seki et al. has reported minimal incidence at 0.49% of RYDJB-SG [21]. The presence of the pylorus may play a role as a protective barrier. The loop technique likewise allows alkaline juice to immediately neutralize the gastric acid in the anastomosis site. In contrast, the Roux-en-Y fashion technique still renders direct contact of the gastric acid to the intestinal mucosa.

Dumping Syndrome

Changes in the digestive anatomy and glucose metabolism resulting to dumping syndrome may become debilitating for the patients occurring at 15-76% after RYGB. However, this is not reported after duodenal switch [42, 43]. The preservation of the pylorus

allows a more delayed and regulated gastric emptying. The series by Kasama et al. reported only 4% of subjects having symptoms that were suggestive of dumping syndrome including abdominal pain, fatigue, facial flushing, perspiration tachycardia, and hypoglycemia [3].

Malnutrition

To date, there has not been any literature focusing on the nutritional aspect of DJB-SG. The series by Lee et al. in 2014 and 2015 compared the nutritional status of DJB-SG to SG alone, showing no difference of nutritional status at one year after surgery. This is possibly also due to the pyloric preservation which prevents dumping syndrome. Preservation of acid and intrinsic factors also facilitates more absorption of iron, calcium, vitamin B12 and protein [23, 24]. At the present time, DJB-SG follows the same vitamin supplementation guidelines as for RYGB. A more prospective study is needed to determine how DJB-SG will affect nutritional deficiency.

CONCLUSION

Loop and Roux-en-Y DJB-SG both show promising results in the treatment of morbid obesity and obesity with T2DM in the Asian population. DJB-SG is at least comparable to other bariatric procedures but with less adverse effects. Hence it could be considered as an alternative option. However, more studies are needed to evaluate the long-term outcomes of diabetes remission and nutritional consequences. Furthermore, these studies are expected to test the applicability and outcome for the Western population.

REFERENCES

[1] Ramachandran, A; Snehalatha, C. Rising Burden of Obesity in Asia. *Journal of Obesity*, 2010 June; vol 2010, Article ID 868573, 8 pages

[2] World Health Organisation. Obesity and overweight. *Fact Sheet* June 2016. www.who.int/mediacentre/factsheets/fs311/en.

[3] Ogden, CL; Yanovski, SZ; Carroll, MD; Flegal, KM. The epidemiology of obesity. *Gastroenterology*. 2007 May;132(6), 2087-2102.

[4] Mitchell, NS; Catenacci, VA; Wyatt, HR; Hill, JO. Obesity: overview of an epidemic. *Psychiatric Clinics of North America*. 2011 December; 34(4), 717–732.

[5] Guirat A. The Sleeve Gastrectomy: Evidences and Controversies. *Journal of Obesity and Weight Loss Therapy*. 2014;4: 213. doi:10.4172/2165-7904.1000213.

[6] Regan, JP; Inabnet, WB; Gagner, M. Early experience with two-stage laparoscopic roux-en-Y gastric bypass as an alternative in the super-super obese patient. *Obesity Surgery*. 2003;13, 861–864.

[7] Deitel, M; Crosby, RD; Gagner, M. The First International Consensus Summit for Sleeve Gastrectomy (SG), New York City, October 25–27, 2007. *Obesity Surgery* (2008) 18: 487-496.

[8] Nuack, MA. Incretin based therapies for type 2 diabetes mellitus; properties functions and clinical implications. *The American Journal of Medicine*. 2011; 124(1 Suppl), S3-18.

[9] Doyle, ME; Egan, JM. Mechanisms of Action of GLP-1 in the Pancreas. *Pharmacology & therapeutics*. 2007;113(3), 546-593.

[10] Van, DG; Thiele, TE. Glucagon-like peptide-1 (7-36) amide: a central regulator of satiety and interoceptive stress. *Neuropeptides*. 1999;33, 406–414.

[11] Salehi, M; Prigeon, RL; D'Alessio, DA. Gastric bypass surgery enhances glucagon-like peptide-1-stimulated postprandial insulin secretion in humans. *Diabetes*. 2011;60, 2308–2314.

[12] Nakazato, M; Murakami, N; Date, Y; Kojima, M; Matsuo, H; Kangawa, K; Matsukura, S. A role for ghrelin in the central regulation of feeding. *Nature*. 2001; 409, 194-198.

[13] Hess, DS; Hess, DW. Biliopancreatic diversion with a duodenal switch. *Obesity Surgery*, 1998; 8(3), 267-82.

[14] Marceau, P; Hould, FS; Simard, S; Lebel, S; Bourque, RA; Potvin, M; Biron, S. Biliopancreatic diversion with duodenal switch. *World Journal of Surgery*, 1998; 22(9), 947-54.

[15] Rubino, F; Marescaux, J. Effect of Duodenal–Jejunal Exclusion in a Non-obese Animal Model of Type 2 Diabetes: A New Perspective for an Old Disease. *Annals of Surgery*, 2004;239 (1), 1–11.

[16] Cohen, RV; Schiavon, CA; Pinheiro, JS; Jose Luiz Correa; Francesco Rubino. Duodenal-jejunal bypass for the treatment of type 2 diabetes in patients with body mass index of 22–34 kg/m^2: a report of 2 cases. *Surgery for Obesity and Related Diseases*, March - April 2007;3 (2),195–197.

[17] Heo, Y; Ahn, JH; Shin, SH; Lee, YJ. The effect of duodenojejunal bypass for type 2 diabetes mellitus patients below body mass index 25 kg/m^2: one year follow-up. *Journal of the Korean Surgical Society*, 2013 Sep; 85(3),109-115.

[18] Kasama, K; Tagaya, N; Kanehira,N; Oshiro,T; Seki, Y; Kinouchi, M; Umezawa, A; Negishi,Y; Kurokawa, Y. Laparoscopic Sleeve Gastrectomy with Duodenojejunal Bypass: Technique and Preliminary Results. *Obesity Surgery*, 2009;19(10), 1341-1345.

[19] Sánchez-Pernaute, A; Herrera, MA; Pérez-Aguirre, ME; Talavera, P; Cabrerizo, L; Matía, P; Díez-Valladares, L; Barabash, A; Martín-Antona, E; García-Botella, A; García-Almenta, EM; Torres. Single anastomosis duodeno-ileal bypass with sleeve gastrectomy (SADI-S). One to three-year follow-up. *Obesity Surgery*. December 2012; 20 (12), 1720–1726.

[20] Huang, CK; Goel, R; Tai, CM; Yen, YC; Gohil, VD; Chen, XY. Novel metabolic surgery for Type2 Diabetes Mellitus: Loop Duodenojejunal Bypass with Sleeve Gastrectomy. *Surgical Laparoscopy Endoscopy & Percutaneous Techiques*, 2013 Dec; 23(6), 481-5.

[21] Seki, Y; Kasama, K; Haruta, H; Watanabe, H; Yokoyama, R; Porciuncula, JPC; Umezawa, A; Kurokawa, Y. Five-Year-Results of Laparoscopic Sleeve Gastrectomy with Duodenojejunal Bypass for Weight Loss and Type 2 Diabetes Mellitus. *Obesity Surgery*, 2016 September 19.

[22] Seki, Y; Kasama, K; Umezawa, A; Kurokawa Y. Laparoscopic Sleeve Gastrectomy with Duodenojejunal Bypass for Type 2 Diabetes Mellitus. *Obesity Surgery*, 2016 September; 26(9), 2035-2044.

[23] Lee, WJ; Almulaifi, AM; Tsou, JJ; Ser, KH; Lee, YC; Chen, SC. Duodenal–jejunal bypass with sleeve gastrectomy versus the sleeve gastrectomy procedure alone: the role of duodenal exclusion. *Surgery for Obesity and Related Diseases*, 2015 July-August; 11 (4), 765-770.

[24] Lee, W. J., Lee, K. T., Kasama, K., Seiki, Y., Ser, K. H., Chun, S. C., Chen, J. C., Lee, Y. C.. Laparoscopic single-anastomosis duodenal-jejunal bypass with sleeve gastrectomy (SASGDJB): short-term result and comparison with gastric bypass. *Obesity Surgery*, 2014 January; 24(1),109-113.

[25] Ferzli, GS; Dominique, E; Ciaglia, M; Bluth MH; Gonzalez A; Fingerhut A. Clinical Improvement After Duodenojejunal Bypass for Nonobese Type 2 Diabetes Despite Minimal Improvement in Glycemic Homeostasis. *World Journal of Surgery*, 2009; 33:972–979.

[26] Paik KY; Kim, W; Song, KH; Kwon, HS; Kim, MK; Kim, E. The preliminary clinical experience with laparoscopic duodenojejunal bypass for treatment of type 2 diabetes mellitus in non-morbidly obese patients: the 1-year result in a single institute. *Surgical Endoscopy*, 2012; 26 (11), 3287–3292.

[27] Switzer, NJ; Prasad, S; Debru, E; Church, N; Mitchell, P; Gill, R. Sleeve Gastrectomy and Type 2 Diabetes Mellitus: a Systematic Review of Long-Term Outcomes. *Obesity Surgery*, 2016 July; 26(7), 1616-1621.

[28] Raj, P, Kumaravel, R, Chandramaliteeswaran C, Rajpandian, S, Palanivelu, C. Is Laparoscopic Duodenojejunal Bypass with Sleeve an Effective Alternative to Roux En Y Gastric Bypass in Morbidly Obese Patients: Preliminary Results of a Randomized Trial. *Obesity Surgery*, 2012; 22:422-426.

[29] Huang, CK; Tai, C. M; Chang, PC; Malapan, K; Tsai, CC; Yolsuriyanwong, K. Loop Duodenojejunal Bypass with Sleeve Gastrectomy: Comparative Study with Roux-en-Y Gastric Bypass in Type 2 Diabetic Patients with a BMI <35 kg/m^2, First Year Results. *Obesity Surgery*, 2016 October; 26(10), 2291-3201.

[30] Rubino, F; Nathan, DM; Eckel, RH; Schauer, PR; Alberti, KGMM; Zimmet, PZ et al. Metabolic Surgery in the Treatment Algorithm for Type 2 Diabetes: A Joint Statement by International Diabetes Organizations. *Diabetes Care*. 2016 Jun; 39(6), 861-877.

[31] Huang, CK, Ahluwalia, JS, Garg, A, Taweerutchana, V, Ooi, A, Chang, PC, Hsin MC. Novel metabolic/bariatric Surgery -loop duodenojejunal bypass with sleeve gastrectomy (LSGDJB). In: Huang CK, Editor. *Essentials and Controversies in Bariatric Surgery*. Rijeka, Croatia: InTech; 2014; 133-144.

[32] Sarkhosh, K; Birch, DW; Sharma, A; Karmali, S. Complications associated with laparoscopic sleeve gastrectomy for morbid obesity: a surgeon's guide. Canadian *Journal of Surgery*, 2013 October; 56(5): 347-352.

[33] Heneghan, HM; Meron-Eldar, S; Yenumula, P; Rogula, T; Brethauer, S A; Schauer, PR. Incidence and management of bleeding complications after gastric bypass surgery in the morbidly obese. *Surgery for Obesity and Related Diseases*, 2012; 8, 729-735.

[34] Kolakowski, S; Kirkland, ML; Scuricht, AL. Routine postoperative upper gastrointestinal series after Roux-en-Y gastric bypass. *Archives of Surgery*, 2007; 142:930-4.

[35] Gagner, M. 5th International Consensus Summit for Sleeve Gastrectomy: Is There a Consensus. *Bariatric Times* 12, 2015 (4 Suppl A): A22-A23.

[36] Tai, C. M., Huang, C. K., Lee, Y. C., Chang, C. Y., Lee, C. T., Lin, J. T. Increase in gastroesophageal reflux disease symptoms and erosive esophagitis 1 year after laparoscopic sleeve gastrectomy among obese adults. *Surgical Endoscopy*, 2013; 27:1260–1266.

[37] Braghetto, I; Csendes A. Prevalence of Barrett's Esophagus in Bariatric Patients Undergoing Sleeve Gastrectomy. *Obesity Surgery*, 2016 April; 26(4):710-714.

[38] Geubbels, N; Lijftogt, N; Fiocco, M; van Leersum, N J; Wouters, MW; de Brauw, LM. Meta-analysis of internal herniation after gastric bypass surgery. *The British Journal of Surgery*, 2015 April; 102, 451–460.

[39] Markogiannakis, H; Messaris, E; Dardamanis, D; Pararas, N; Tzertzemelis, D; Giannopoulos, P; Larentzakis, A; Lagoudianakis, E; Manouras, A; Bramis I. Acute mechanical bowel obstruction: clinical presentation, etiology, management and outcome. *World Journal of Gastroenterology*, 2007; 13:432.

[40] Chiu, CC; Lee, WJ; Wang, W; Wei, PL; Huang, MT. Prevention of trocar wound hernia in laparoscopic bariatric operations. *Obesity Surgery*, 2006; 16(7), 913–918.

[41] Csendes, A; Burgos, AM; Altuve, J; Bonacic, S. Incidence of marginal ulcer 1 month and 1 to 2 years after gastric bypass: a prospective consecutive endoscopic evaluation of 442 patients with morbid obesity. *Obesity Surgery*, 2009 February; 19(2),135-138.

[42] Anthone, GJ; Lord, RVN; DeMeester, T; Crookes, PF. The duodenal switch operation for the treatment of morbid obesity. *Annals of Surgery*, 2003; 238(4),618–628.

[43] Biertho, L; Simon-Hould, S; Marceau, S; Lebel, S; Lescelleur, O; Biron, S. Current outcomes of laparoscopic duodenal switch. *Annals of Surgical Innovation and Research*, 2016; 10: 1.

In: Encyclopedia of Surgery (22 Volume Set)
Editors: Andreas Lehrer and Kristin Mueller
ISBN: 978-1-53618-329-0
© 2020 Nova Science Publishers, Inc.

Chapter 185

LAPAROSCOPIC SLEEVE GASTRECTOMY: PAYING ATTENTION TO THE DETAIL

F. Frattini[1,*], M. Lavazza[1], V. Quintodei[1], R. Delpini[1], F. Martignoni[1], A. Bacuzzi[2], E. Piantanida[3], S. Rausei[1], L. Boni[1] and G. Dionigi[1]

[1]Department of Surgery, Research Center for Endocrine Surgery, University of Insubria, Varese, Italy
[2]Department of Anesthesiology, Ospedale di Circolo- Fondazione Macchi Varese, Varese, Italy
[3]Endocrine Unit, University of Insubria, Varese, Italy

ABSTRACT

As reported by the last IFSO worldwide survey on bariatric surgery, sleeve gastrectomy became the second most performed bariatric/metabolic procedure in the world just after gastric bypass.

Sleeve gastrectomy had a wide diffusion probably due to the easy surgical technique, although it must not be considered safe from complications, which can be severe and even life-threatening. Technical tips, and standardization of the procedure are required in order to minimize complications such as gastric leaks, stenosis and bleeding. To ensure high quality standard of this surgical treatment, dissection and resection should be done using appropriate technology.

The aim of this review is to present various technical aspects and tips reported in literature in order to optimize the surgical procedure in safety and effectiveness. In particular we focused our attention to trocars positioning, dissection of the greater curvature, dissection of the angle of His, bougie caliber, application of the stapler and haemostasis.

* Corresponding Author's Email: francescofrattini79 @gmail.com.

INTRODUCTION

The last global survey of bariatric/metabolic surgery of the International Federation for the Surgery of Obesity and Metabolic Diseases (IFSO), published in 2015, showed an increase from 0% to 37% of sleeve gastrectomy procedures performed between 2003 and 2013 in all the considered geographical areas [1].

The diffusion of this obesity surgical treatment is encouraged by the easy surgical technique required and its standardization, supported by the effective short-term weight loss.

According to the literature, the worldwide diffusion of sleeve gastrectomy determined an increase of complication rate from 1% to 7% [2, 3].

The most relevant complications after sleeve gastrectomy are gastric leaks, bleeding and stenosis. Gastric leak is a challenging complication due to the possible consequences in terms of morbidity and mortality. In fact, gastric fistula may prolong hospital stay and may cause abdominal sepsis and multiple organ failure. Moreover this complication may require further surgical or endoscopic procedures.

Because of this serious complication it is rightful to ask if sleeve gastrectomy is as an easy procedure as it is described. It is mandatory to point out the steps of the procedure in order to understand the critical technical and anatomical aspects.

Pneumoperitoneum

Pneumoperitoneum is not always an easy and uneventful procedure because of the thickness of the subcutaneous adipose component of the abdominal wall in obese patients, particularly in women.

There is no consensus about the pneumoperitoneum technique in sleeve gastrectomy. Three principally different techniques exist: initial pneumoperitoneum by Verres needle, open Hasson technique, and direct placement of an optical trocar with a 0° or 30° laparoscope. In a large nationwide survey dealing with Roux-en-Y gastric bypass (LRYGB), the most common way to perform pneumoperitoneum was the Veress needle technique before placing the first trocar (59%), followed by the optical trocar (30%), and the open Hasson technique (11%). The injuries were evenly distributed between the Veress technique and direct placement of an optical trocar, while no injuries occurred with the Hasson technique [4]. As suggested by Kassir et al. [5] the entry site of Veress needle is the Palmer's point, in the left subcostal margin on the midclavicular line.

Trocars Position

Trocars number and position are quite variable and not so standardizable as it changes with surgeon's experience and preference. Positioning trocars is still a controversial subject. Right placement of the trocars is essential for the ergonomic setting of the surgeon and for an effective approach to the angle of His. The best position of the first trocar is still controversial, as there is no evidence to support any particular technique. The correct fixed anatomical landmark in obese patients is not the umbilicus but the xiphoid process. The 12-

mm trocar on the patient's right side is important because the stapler for gastric resection is positioned from this trocar. As described by Ruiz de Angulo [6] the two first cartridges guide the rest of the gastric section. This trocar should not be placed too high in order to start resection on the antrum without excessive articulation of the stapler, oriented directly to the angle of His. On the other hand, this trocar must not be placed too low because it could be difficult to complete gastric resection upward to the angle of His without excessive tension.

Because of the thickness of the abdominal wall in the obese patients and the greater risk of trocar incisional hernia after weight loss, trocars must be positioned with an angle of 45° with the abdominal wall.

Bougie Size

Sizing the sleeve with calibrated oro-gastric bougie is mandatory. The bougie guides the stapling resection and helps to stay away from the incisura angularis and the gastro-esophageal junction (GEJ). The choice of the most suitable bougie is important in order to avoid stenosis and leak for too tight sleeve and failure in weight loss for too dilated sleeve. As stated by the international consensus summit and the international sleeve gastrectomy expert panel consensus, the optimal bougie size ranges from 32 to 36 F [7, 8]. The 36 F bougie is the most used.

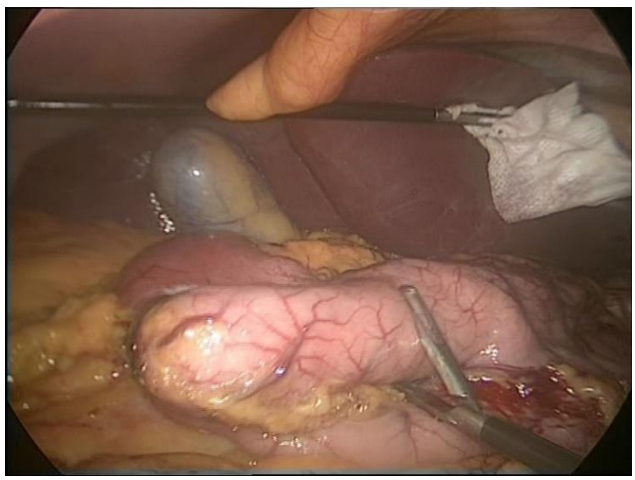

Figure 1. Oro-gastric bougie positionment.

Greater Curvature Dissection

Greater curvature is mobilized and dissected from 5-10 cm proximal to the pylorus up to the angle of His. Dissection must preserve the antrum in order to maintain the antral pumping function, and, in the same time, it must be careful to avoid bleeding from the omental flap.

A complete mobilization of the fundus with the exposure of the left diaphragmatic pillar is of utmost importance. Posterior gastric wall should be fully mobilized through the section of the short gastric vessels and division of the adhesions to the pancreas. In this way anterior and posterior gastric walls are prepared symmetrically to allow optimal positioning of the

stapler, avoiding the twisting of the sleeve. The dissection of the GEJ should not be too extended in order to preserve its microvascular pattern and to avoid impairment of the hiatus and the phreno-esophageal membrane. An aggressive dissection of GEJ could predispose to the leak of the proximal third of the sleeve and to transhiatal herniation of the sleeve.

Several energy tools are used for the greater curvature dissection, such as ultrasound and radiofrequency devices. The best device should guarantee an optimal sealing effect both on the gastro-omental ligament and on the short gastric vessels, minimizing the bleeding of the omental flap. Devices must be suitable for an effective and fast dissection of thick tissues as the omentum in the obese patients. Moreover said instruments must to be suitable for gastro-splenic ligament dissection and safe control of the short gastric vessels.

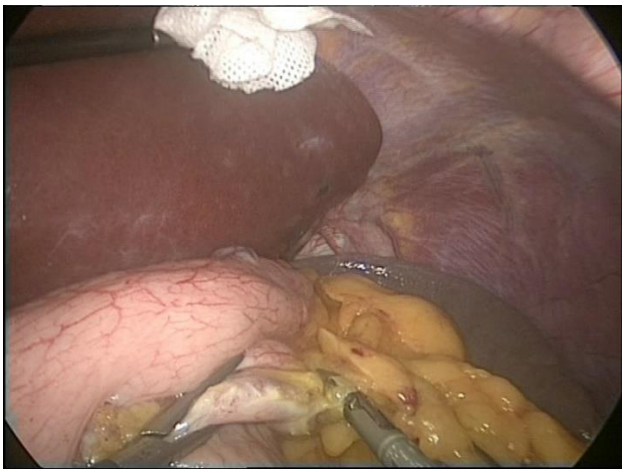

Figure 2. Greater curvature dissection.

The risk of spleen lesions is particularly high in the greater curvature dissection, due to the gastric fundus at the His angle possibility to be redundant, and its proximity to the upper pole of the spleen.

The intraoperative investigation of hiatal hernia should be systematically performed, particularly if it is diagnosed by the preoperative endoscopy and/or the upper gastrointestinal swallow study; once hiatal hernia is found, it should be repaired.

Resection

The gastric transection using a flexible linear 60-mm stapler is performed after the positioning of the oro-gastric bougie along the lesser curvature. The surgeon inserts the stapler form the trocar in the right flank and starts the transection 5-6 cm from the pylorus, at the lower end of the crow's foot along the bougie.

The first firing of the stapler must be far from the incisura in order to avoid stenosis, twisting, and a possible concomitant gastric leak. The transection proceeds in a linear regular way towards the angle of His. During the stapling it is important to maintain a moderate symmetric lateral traction. Direction of the staple-line should be maintained along the lesser curvature with a correct use of the stapler. The last firing should stay 1-1.5 cm away from the GEJ in order to protect the distal part of the esophagus, avoiding stenosis and gastric leak.

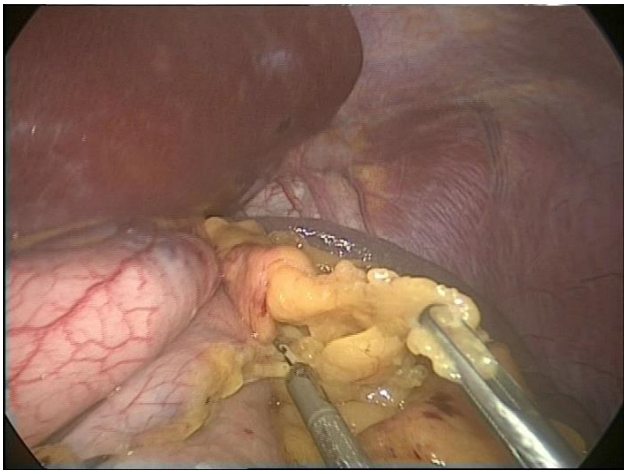

Figure 3. Greater curvature dissection.

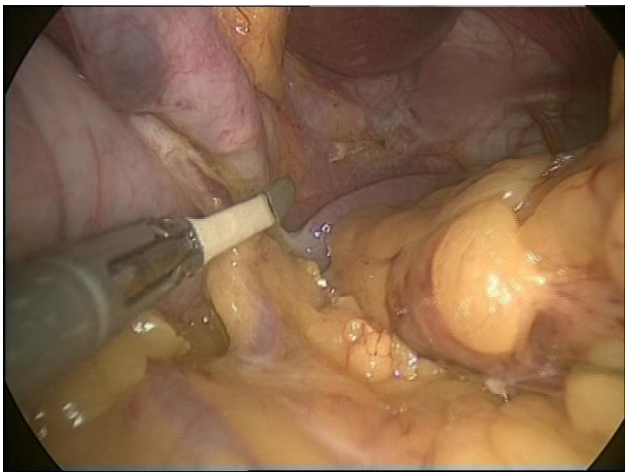

Figure 4. Short gastric vessels dissection.

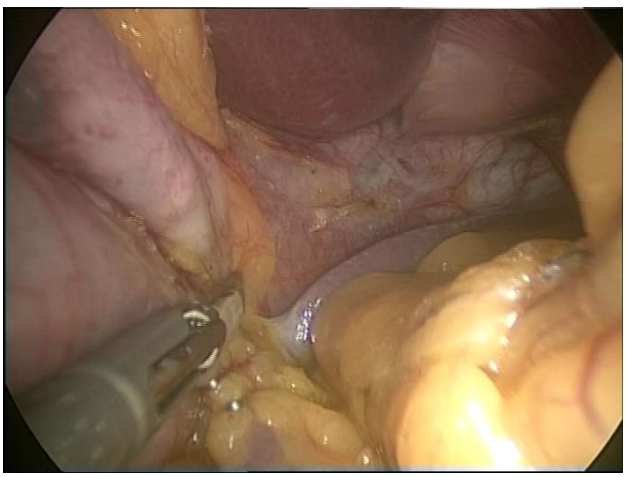

Figure 5. Left diaphragmatic pillar exposure.

It is appropriate to modulate height firing according to the thickness of the gastric wall. In fact, staple mismatch is one of the causative factors of gastric leak after sleeve gastrectomy. The choice of the optimal height cartridge is a controversial topic: too high cartridges predispose to the bleeding of the staple-line but allow a rightful closing; too small cartridges may prevent an adequate sealing and predispose to leaks, particularly in case of stenotic or twisted sleeve or in case of redo surgery. Surgeons are implementing various measures to reduce these complications such as buttressing material, fibrin sealing, oversewing, and metal clips. Higher staple height should be used combined with buttress material in case of thicker and scarred stomach as occurred in redo surgery. The new powered technology of the flex staplers could be a further and appropriate tool to ensure a closer, safer and bloodless staple-line, thanks to its greater stability.

Leak Test

Staple-line leak is the most serious and challenging complication of sleeve gastrectomy. The reported incidence varies from 0% to 8%. The 80% of gastric leaks affect the upper third of the sleeve, below the GEJ. The main causes include high pressure of the gastric sleeve, stenosis of the incisura, sleeve twisting, direct damage or microvascular injury of the GEJ, excessive tension or misfiring of the stapler. Leaks after sleeve gastrectomy are classified as acute, early, late, and chronic. They can result in significant morbidity and mortality. Early diagnosis and treatment is important in the management of a leak. However, it can be treated safely via various management options, depending on the time of diagnosis and size of the leak. Intraoperative methylene blue and air leak tests are routinely used to evaluate for leak; however, there is minimal literature and consensus on the utility of these tests [9]. Some studies demonstrated that leak tests sensitivity is very low. Although intraoperative leak tests are very common, they are unable to detect a leak and do not impact on postoperative leak rate [10, 11, 12]. These intraoperative leak tests continue to be performed in the daily practice, even if they would serve the purpose only in selected cases, with evidence or high suspicion of stapler misfire.

Figure 6. Stapler firing during sleeve gastrectomy.

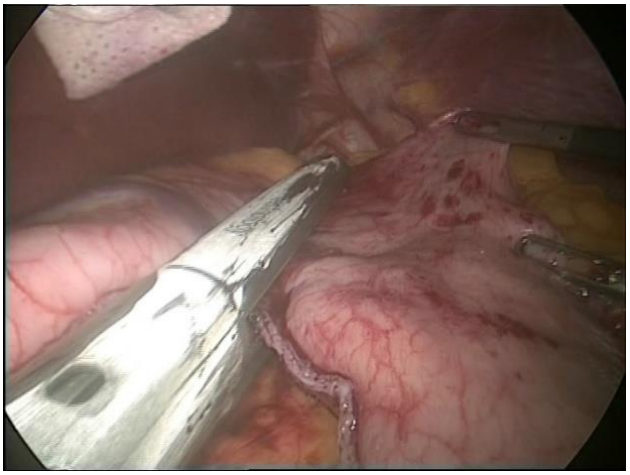

Figure 7. Stapler firing during sleeve gastrectomy.

Figure 8. Stapler firing during sleeve gastrectomy.

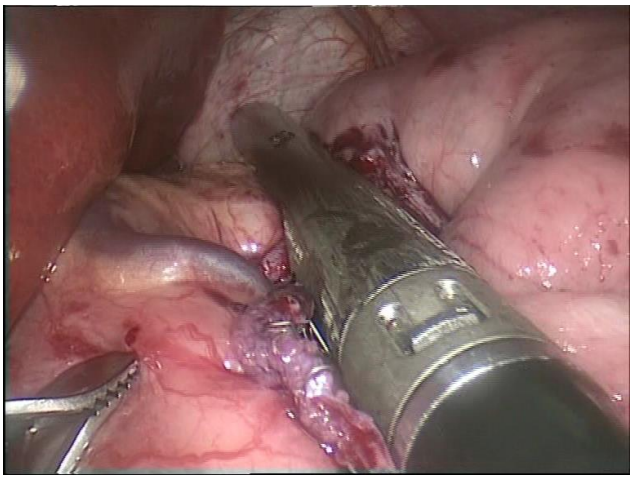

Figure 9. Stapler firing during sleeve gastrectomy.

Haemostasis

Haemorrhage is a recognised complication of bariatric surgery; it can compromise healing of staple-lines and anastomoses or result in abscesses with attendant risk of late staple-line leaks. The long stapler line is mostly responsible for postoperative bleeding (0%-20% of the cases) [8]. Other possible bleeding sites are the omentum, trocar sites, and iatrogenic injury of the liver or the spleen. Intraluminal bleeding is uncommon.

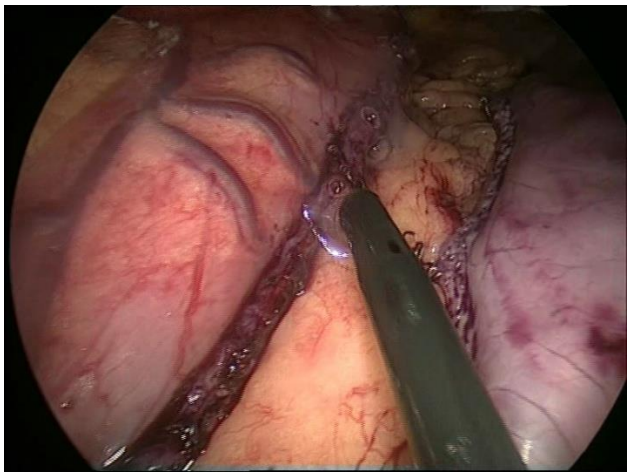

Figure 10. Application of sealant material on the staple-line.

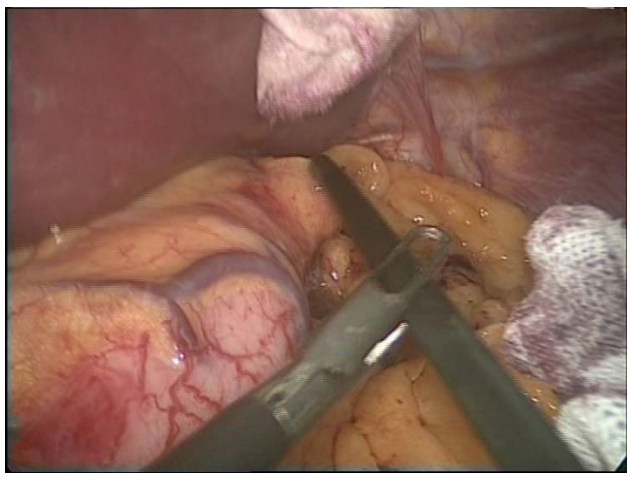

Figure 11. Application of sealant material on the staple-line.

A meticulous haemostasis of the staple-line, the greater omentum and the trocar sites is essential. Dissection of the greater curvature must be accurately performed with the appropriate use of the energy device, in order to allow an effective clotting and sealing effect. The choice of the most suitable height firing of the staple-line contributes to minimize the bleeding. During the last years, several tools have been proposed to reinforce the staple-line and prevent staple-line bleeding such as oversewing, absorbable synthetic buttress material (synthetic glycolidetrimethylene carbonate copolymer Gore®Seamguard® Bioabsorbable

Staple Line Reinforcement), biologic cross-linked buttressing (Bovine pericardium strips, Peri-strips Dry® and PSD Veritas®Baxter), biologic absorbable non-cross-linked buttressing (porcine small intestinal submucosa, Surgisis Biodesign®), thrombin matrix (Floseal®, Baxter) [13]. Several trials and reviews reported a reduced rate of bleeding with buttress materials, oversewing or use of sealing materials but without strong statistical differences [3, 14, 15]. The international consensus expert panels of sleeve gastrectomy reported that buttressing of staple-line is practiced by the majority of surgeons. Techniques of staple-line reinforcement could be also cost-effective particularly in patients with high risk of bleeding (antiaggregant or anticoagulant therapy).

DISCUSSION

Sleeve gastrectomy began to be used as first step procedure of a variation of biliopancreatic diversion with duodenal switch in super-obese, high-risk patients. Subsequently, thanks to the good results in safety and weight loss, sleeve gastrectomy was proposed as a single procedure. Recently it has become a common performed procedure with a consistent increase in the last years. In fact, it is the second most performed bariatric procedure after Roux-en-Y gastric bypass, as reported in the last IFSO survey. This gain of popularity, as described by Zellmer et al. [16], is due to the relative ease of the procedure, short operative time, and good outcome in terms of weight loss, comparable to gastric bypass. Whether the sleeve gastrectomy is really such an easy and an uneventful procedure is still a controversial topic. The procedure could be challenging especially in obese patients with BMI > 45-50 kg/m^2. The anatomical aspects which can influence complexity of the procedure and length of operating time include large gastric fundus, cascade gastric fundus, strict adhesions to the upper pole of the spleen.

Despite of a recent systematic review and meta-analysis reported a substantial decrease in sleeve gastrectomy complication rate [17, 18], leaks after sleeve gastrectomy still varies between 0% and 18% [19]. The wide diffusion of sleeve gastrectomy, even in low-volume centres, could lead to an underestimation of leak rate as the incidence reported in literature is usually related to high-volume centres and experienced surgeons. For this reason it is mandatory to keep national registers of sleeve gastrectomy procedures in order to collect realistic leak rate and overall complication rate.

To minimize surgeon-related risk factors, each step of the sleeve gastrectomy must be standardized. The International Consensus Summit represents a viable and effective resource, sharing an updated overview about preoperative and intraoperative aspects of sleeve gastrectomy.

Moreover each step of the procedure must be performed with a great attention to the detail, bleeding during dissection manoeuvre, excessive tension in the stapling procedures, choice of the more appropriate height cartridge to avoid bleeding and leak of the staple-line, choice of the most suitable haemostatic device and agents considering also the patient's risk factors for bleeding.

CONCLUSION

Sleeve gastrectomy is often defined as an easy bariatric procedure but still presents harmful complications, even life-threatening, and could be technically challenging in some cases. Only standardizing the procedures and carrying out meticulously each step of the operation, can be a viable and effective way to prevent and control the surgical complications. Attention to detail makes the difference.

REFERENCES

[1] Angrisani L, Santonicola A, Iovino P, Formisano G, Buchwald H, Scopinaro N. Bariatric Surgery Worldwide 2013. *Obes. Surg*. 2015; 25 (10): 1822-32.

[2] Gagner M, Buchwald JN. Comparison of laparoscopic sleeve gastrectomy leak rates in four staple-line reinforcement options: a systematic review: *Surg. Obes. Relat. Dis*. 2014; 10 (4): 713-723.

[3] Rached AA, Basile M, El Masri H. Gastric leaks post sleeve gastrectomy: review of its prevention and management. *World J. Gastroenterol.* 2014; 20 (38): 13904-13910.

[4] Sundbom M, Ottosson J. Trocar injuries in 17446 laparoscopic gastric bypass- a nationwide survey from the Scandinavian Obesity Surgery Registry. *Obes. Surg*. 2016; 26 (9): 2127-30.

[5] Kassir R, Blanc P, Lointier P, Tiffet O, Berger J, Ben Amor I, Gugenheim J. Laparoscopic entry techniques in obese patient: Veress needle, direct trocar insertion or open entry technique? *Obes. Surg*. 2014; 24: 2193-2194.

[6] De Angulo DR, Munitiz V, MAngeles Ortiz M, Martinez de Haro LF, Parrilla P. Positioning trocars for performing sleeve gastrectomy. Points of controversy. *Obes. Surg*. 2015; 25: 854.

[7] Gagner M, Hutchinson C, Rosenthal R. Fifth International Consensus Conference: current status of sleeve gastrectomy. *Surg. Obes. Relat. Dis.* 2016; 12: 750-756.

[8] Rosenthal RJ for the International Sleeve Gastrectomy Expert Panel. International Sleeve gastrectomy Expert panel Consensus Statement: best practice guidelines based on experience of >12000 cases. *Surg. Obes. Relat. Dis.* 2012; 8: 8-19.

[9] Sethi M, Zagzag J, Patel K, Magrath M, Somoza E, Parikh M, Saunders JK, Ude-Welcome A, Schwack B, Kurian MS, Fielding GA, Ren-Fielding CJ. Intraoperative leak testing has no correlation with leak after laparoscopic sleeve gastrectomy. *Surg. Endosc*. 2016; 30: 883-891.

[10] Sakran N, Goiten D, Raziel A, Keidar A, Beglaibter N, Grinbaum R, Matter I, Alfici R, Mahajna A, Waksman I, Shimonov M, Assalia A. Gastric leaks after sleeve gastrectomy: a multicenter experience with 2834 patients. *Surg. Endosc.* 2013; 27: 240-245.

[11] Aurora Ar, Khaitan L, Saber AA. Sleeve gastrectomy and the risk of leak: a systematic analysis of 4888 patients. *Surg. Endosc*. 2012; 26: 1509-1515

[12] Parikh M, Issa R, McCrillis A, Saunders JK, Ude-Welcome A, Gagner M. Surgical strategies that may decrease leak after laparoscopic sleeve gastrectomy: a systematic review and meta-analysis of 9991 cases. *Ann. Surg*. 2013; 257: 231-237.

[13] Iossa A, Abdelgawad M, Watkins BM, Silecchia G. Leaks after laparoscopic sleeve gastrectomy: overview of pathogenesis and risk factors. *Langenbecks. Arch. Surg*. 2016; 401: 757-766.

[14] Gentileschi P, Camperchioli I, D'Ugo S, Benavoli D, Gaspari AL. Staple line reinforcement during sleeve gastrectomy using three different techniques: a randomized trials. *Surg. Endosc*. 2012; 26(9): 2623-2629.

[15] D'Ugo S, Gentileschi P, Benavoli D, Cerci M, Gaspari A, Berta RD, Moretto C, Bellini R, Basso N, Casella G, Soricelli E. Comparative use of different techniques for leak and bleeding prevention during laparoscopic sleeve gastrectomy: a multicenter study. *Surg. Obes. Relat. Dis.* 2014; 10(3): 450-454.

[16] Zellmer JD, Mathiason MA, Kallies KJ, Kothari SN. Is laparoscopic sleeve gastrectomy a lower risk bariatric procedure compared with laparoscopic Roux-en-Y gastric bypass? A meta-analysis. *Am. J. Surg*. 2014; 208: 903-910.

[17] Brethauer SA, Hammel JP, Schauer PR (2009) Systematic review of sleeve gastrectomy as staging and primary bariatric procedure. *Surg. Obes. Relat. Dis.* 5(4):469-475.

[18] Shikora SA, Mahoney CB. Clinical benefit of gastric staple line reinforcement in gastrointestinal surgery: a meta-analysis. *Obes. Surg.* 2015; 25(7): 1133-1141.

[19] Gagner M, Deitel M, Erickson AL et al. Survey on laparoscopic sleeve gastrectomy at the Fourth International Consensus Summit on Sleeve Gastrectomy. *Obes. Surg*. 2013;23: 2013-7.

In: Encyclopedia of Surgery (22 Volume Set)
Editors: Andreas Lehrer and Kristin Mueller
ISBN: 978-1-53618-329-0
© 2020 Nova Science Publishers, Inc.

Chapter 186

LAPAROSCOPIC EXPERIMENTAL SURGERY MODELS

Natalie Bath[1], MD, Demetrius Litwin[1], MD
and Paulo N. Martins[2,*], MD, PhD
[1]Department of Surgery, UMass Memorial Medical Center, University Campus, Worcester, MA, US
[2]Department of Surgery, Division of Organ Transplantation, UMass Memorial Medical Center, University Campus, Worcester, MA, US

ABSTRACT

Laparoscopy and minimally invasive surgery has continued to play an increasingly large role across all surgical fields including general surgery, gynecology, colorectal surgery, hepatobiliary surgery, and urology. By minimizing trauma to the abdominal wall, allowing faster recovery postoperatively, decreasing length of hospital stay, and improving cosmesis, laparoscopy has become the gold standard approach for many operations due to these improved outcomes. However, laparoscopic surgery demands its own unique set of surgical skills due to loss of tactile feedback, operating within a three-dimensional space as seen on a two-dimensional monitor, and the importance of recognizing spatial relationships. A learning curve is found to exist as one is further developing these skills. In order to further develop these skills prior to utilizing them in the operating room, live animal models and laparoscopic simulators have been developed. Live animal models including pigs, rabbits, and rats have been used for training, and it has been found that *in vivo* models appear to most closely resemble operating on patients; therefore, animal models are the ideal training model to be used in laparoscopic surgery training. As laparoscopy continues to become more popular throughout surgery, it also continues to evolve in order to further reduce the invasiveness of surgery as seen in robotic surgery, single incision laparoscopic surgery (SILS), and natural orifice translumenal endoscopic surgery (NOTES). These surgical techniques are the future of laparoscopic surgery and as their use becomes more widespread, training on experimental models specific to these methods will become even more important in order to optimize surgical outcomes for patients.

* Corresponding Author's Email: paulo.martins@umassmemorial.org.

Keywords: laparoscopic surgery, experimental laparoscopy, learning curve, animal models, laparoscopic simulator, future laparoscopy

ABBREVIATIONS

dVSS	de Vinci Skills Simulator
FLS	Fundamentals of Laparoscopic Surgery
MISTVR	Minimally Invasive Surgery Trainer
NOTES	natural orifice translumenal endoscopic surgery
OSATS	Objective Structured Assessment
SEP	Sim-Surgery Educational Plateform
SILS	Single Incision Laparoscopic Surgery
TAPP	Transabdominal Preperitonal Practice
TEP	Totally Extraperitonal
VR	Virtual Reality

IMPORTANCE OF LAPAROSCOPIC TRAINING

Laparoscopic surgery requires a unique and at times more complex skill set than open surgery. In order to further develop these skills prior to utilizing them in the operating room, live animal models and laparoscopic simulators have been developed. Live animal models including pigs, rabbits, and rats have been used for training, and it has been found that *in vivo* models appear to most closely resemble operating on a live patient.

Laparoscopic surgery traces its roots to the early twentieth century when pioneers such as Dimitri Ott, Georg Kelling, and Hans Christian Jacobeus first began using laparoscopy as a diagnostic technique (Vecchio 2000). However, it was not until the early 1980s that a paradigm shift was made in the field of laparoscopy when laparoscopic procedures evolved from an invasive diagnostic tool to an efficient instrument for surgical treatment (Buia 2015). Over the last thirty years, laparoscopy has played an increasingly more predominant role across all surgical sub-specialties. As procedures become more complex and technically challenging, a need for additional robust laparoscopic skills training has been created. With ongoing improvements in surgical training, imaging, tools and instruments, laparoscopic surgery has been able to be safely used in innumerable fields. Additionally, experimental laparoscopic surgery helps to create a path for continuing evolution and new roles for laparoscopy to play in the future.

Laparoscopy has multiple advantages over open surgery such as minimizing trauma to the abdominal wall, which ultimately results in faster recovery, reduced hospital stay, and faster return to normal activity. As a result, laparoscopy has become the gold standard for many procedures despite lack of randomized controlled trials. Moreover, laparoscopy has been able to be used for oncological surgeries without providing inferior oncological results when compared to open surgery (Buia 2015).

Open appendectomy has been performed since the late 1800s with laparoscopic appendectomy gaining popularity during the 1980s. Meta-analyses comparing the two

procedures have indicated that while operating times were increased with open appendectomies, there was found to be shorter hospital stay, less postoperative pain, faster recovery, and lower complication rates found in the laparoscopic appendectomy group. Meta-analysis of randomized controlled trials comparing laparoscopic to open appendectomy have found that although operative time was shorter for the open procedure, laparoscopic surgery was associated with earlier consumption of liquid and solid diet, shorter hospital stay, decreased use of oral and parenteral analgesics, and decreased wound infection amongst several other advantages (Li 2010; Ohtani 2012).

Similar to appendectomy, open cholecystectomy initially was the gold standard for treatment of symptomatic cholelithiasis for over one hundred years. However, with the gaining prevalence of minimally invasive techniques, laparoscopic cholecystectomy gained prominence in the 1980s and allowed a greater liberalization of indications for surgery (Antoniou 2014). Meta-analyses comparing these two approaches have showed that while no significant differences were found between these approaches with regards to mortality, complication rates, and operative time, laparoscopic cholecystectomy is associated with significantly shorter hospital stay and quicker overall recovery (Keus 2006).

The benefits of laparoscopy can also be extended to anti-reflux and adrenal surgery. Open Nissen fundoplication during which the gastric fundus is wrapped around the distal esophagus has been used in treatment for moderate to severe gastroesophageal reflux disease since the 1950s, but the laparoscopic technique was not introduced until 1991 by Dallemagne (Memon 2015). It was hypothesized that the benefits of laparoscopic surgery including less post-operative pain, faster recovery time, improved cosmesis, and reduced rate of wound infection could also be conferred to laparoscopic anti-reflux surgery. However, initial studies demonstrated complications including esophageal and gastric perforation, paraesophageal herniation and wrap migration into the chest (Peters 2009). As experience with laparoscopic anti-reflux surgery has increased in addition to improved surgical techniques and training, the laparoscopic approach has proved to be a safe and effective alternative to an open technique in that laparoscopy allows a faster recovery, reduced risk of complications, and similar treatment outcomes between groups.

Despite the fact that minimally invasive surgery has facilitated improved surgical outcomes amongst various specialties, there are drawbacks to laparoscopy over open surgery. Work hour restrictions for residents, cost of operating room time, and increased learning curve for laparoscopic training creates the need for surgical trainees to acquire a large part of these skills outside of the operating room and in a more efficient manner (Roberts 2006; Trehan 2015; Alaker 2016). Furthermore, laparoscopic surgery requires a unique and at times more complex skill set than open surgery, which furthers the need for training facilities outside of the operating room in order for these skills to be further developed without putting the patient's safety at risk (Alaker 2016). In order to fill the need for additional training outside the operating room, surgical simulation has emerged as an opportunity to instruct surgical trainees on how to safely develop laparoscopic skills away from the time and financial constraints of the operating room. These simulators allow the issues of patient safety and risk management concerns to be addressed more efficiently and effectively while also helping trainees acquire skills needed to perform complex procedures before utilizing these skills on live patients (Roberts 2006).

LAPAROSCOPIC SURGERY LEARNING CURVE

Laparoscopy has continued to evolve over the last two decades, and this evolution has allowed it to gain a larger presence amongst many fields ranging from bariatric surgery to colorectal surgery to urology. As laparoscopic surgery has become increasingly more widespread as the method of choice for many procedures, this increased exposure has allowed surgeons across specialties to apply basic laparoscopic skills to more technically demanding surgeries. For both the novice and expert laparoscopic surgeon, a learning curve exists when learning how to perform basic and advanced tasks, respectively. Specific to laparoscopic surgery, laparoscopy requires a new, different skill set than what is required by open surgery. Laparoscopy can prove to be difficult to learn and is very different from open surgery due to loss of tactile perception, using a two-dimensional video screen to work within a three-dimensional space, spatial relationships, developing ambidextrous skills, and the fulcrum effect (Grantcharov 2009; Greco 2010; Buckley 2014). Due to these added challenges, a steeper learning curve exists within laparoscopic surgery when compared to open surgery, and it is during this phase that an increased incidence of serious complications may occur (Grantcharov 2009). As a result, it is imperative that trainees complete adequate training prior to operating on patients. In order to facilitate the teaching and assessment of trainees' fundamental knowledge and technical skills in laparoscopy, The Fundamentals of Laparoscopic Surgery (FLS) program was developed. The FLS curriculum consists of five simulation stations, which aim to teach and assess basic laparoscopic surgery skills: peg transfer, precision cutting, loop ligation, and suturing with extracorporeal and intracorporeal knot tying (Zendejas 2016). The FLS curriculum, which originally evolved from the McGill Inanimate System for Training and Evaluation of Laparoscopic Skills (MISTELS), also consists of web-based didactics, hands-on skills training and a written exam. Both the Society of American Gastrointestinal and Endoscopic Surgeons (SAGES) and the American College of Surgeons (ACS) have endorsed the FLS training program, which is now a prerequisite for board eligibility in general surgery. The FLS program has been found to be effective in regards to training; however, fewer studies exist which further explore the validity of the assessment component of FLS (Fried 2004).

Acquisition of skill in both laparoscopic and open surgery by trainees has been described in the literature as a "learning curve". The learning curve can be defined as the observation that repetitive performance of motor skills results in improvement over time. This improvement is most notable early on with sequentially smaller improvements as the number of repetitions increase (Feldman 2009). The learning curve can be divided into three main parameters: the starting point, the learning rate, and learning plateau. The starting point is the skill level at which performance begins. It is at the starting point and early portion of the curve that higher incidence of complications, increased rates of conversion to laparoscopic to open, and longer operating times are seen to be experienced. The learning rate is the slope along the curve which is measured by how quickly a level of performance is reached, and the learning plateau is the plateau or asymptote level at which performance flattens and no longer improves (Cook 2007). When applied to surgical skills, learning curves vary between surgeons and are influenced by multiple factors including a surgeon's innate ability, previous experience, motivation, available technology, task complexity, case-mix and operative findings, and other members of the surgical team (Cook 2004; Sachdeva 2007). In

applications to surgery, identifying where a trainee's skill level is located on their own learning curve can help to predict whether or not the trainee's skills will continue to improve. Traditionally, learning curves have been statistically analyzed by dividing the curve into halves or thirds with subsequent comparison of outcomes between earlier and later time periods. Although this approach may be useful for quantifying improvements over a period of time, it does not describe the underlying curve itself and does not allow for precise estimation of where the curve flattens and at what level this occurs. Furthermore, it does not allow for the estimation of individual skill differences between surgeons (Feldman 2009). By fitting an inverse curve to the performance curve of trainees, the learning curve effect can be estimated including the starting point, speed of learning, and plateau. Although not calculated on a regular basis amongst trainees, this technique may have a role in laparoscopic simulation when comparing groups of trainees who have been exposed to different educational interventions (Feldman 2009).

Although it has been shown that laparoscopic simulation helps trainees progress along the learning curve, some trainees possess an aptitude for laparoscopic skills which others may lack. This innate ability may allow for others to progress more quickly along the learning curve, and conversely, a lack of ability may prevent others from achieving adequate laparoscopic skills. In a study which examined this hypothesis, two groups of medical students with disparate innate ability were selected. Innate ability was defined as exceptional visuospatial ability, depth perception and psychomotor ability as measured by validated tests. Each group was tested on a laparoscopic skill trainer until they achieved proficiency in performing a laparoscopic appendectomy. The mean number of attempts to complete the procedure for the more skilled group was six attempts versus fourteen in the less skilled group. Furthermore, three participants in the less skilled group did not reach proficiency after eighteen attempts. This study demonstrated that high innate ability is directly related to a faster learning curve in achieving proficiency for a laparoscopic task (Buckley).

Aptitude testing can further be applied to more difficult laparoscopic skills such as laparoscopic suturing and intracorporeal knot tying. As indicated in previously mentioned studies, aptitude can be used to predict the rate at which a trainee is able to become proficient at basic skills. In turn, one's aptitude can also be used to predict how quickly one is able to achieve proficiency at more complex laparoscopic procedures. Students in the high aptitude group were found to have higher visual spatial, perceptual and psychomotor ability than those in the low aptitude group. After didactic teaching on how to perform laparoscopic suturing, students in each group were asked to perform this task. Figure 1 compares path length, economy of movement, and time scores between surgical novices with low or high aptitude. Group A achieved proficiency faster than group B. In the low-aptitude group, 30% achieved proficiency after a mean attempt of fourteen while 40% demonstrated improvement but did not achieve proficiency over the course of sixteen attempts; 30% failed to progress altogether and were unable to progress along the learning curve as seen in Figure 1.1B. Group A achieved proficiency in a shorter amount of time in both economy of movement and time scores as shown in Figure 3C and 1E, respectively. Figures 1D and 1F demonstrate the results seen in group B: 30% reached proficiency, 40% showed improvement but did not reach proficiency, and 30% failed to progress. Figure 1 demonstrates the mean number of attempts to achieve proficiency. For group A the average was seven (range, 4−10) in comparison to group B who required on average fourteen attempts (range, 10−16). In group B, 30% failed to progress and dropped out of the study. From this study, it can be concluded that distinct

learning curves based on innate ability also exist for technically more challenging tasks such as laparoscopic suturing. A significant proportion of those with lower aptitude were unable to achieve proficiency, which brings up the question of whether or not aptitude should be used to select surgical trainees. However, these tasks were performed in a simulated environment; therefore, it is unclear whether or not these skills would be transferrable to the operating room (Buckley 2014).

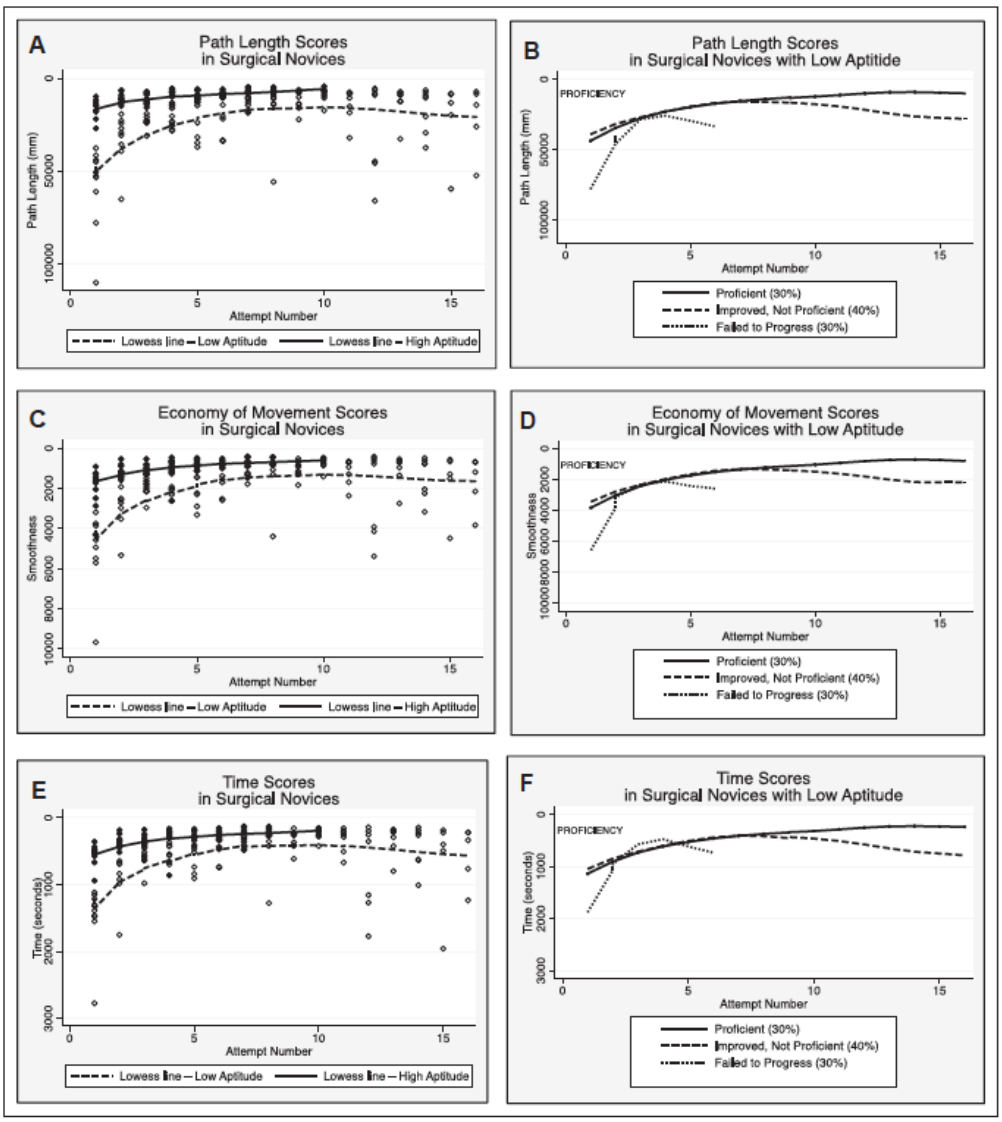

Source: Buckley, C.E., et al., The impact of aptitude on the learning curve for laparoscopic suturing. *The American Journal of Surgery*, 2014. **207**(2): p. 263-270.

Figure 1. (A) Comparison of path length scores in surgical novices and (B) path length scores for all attempts in those with low aptitude. (C) Comparison of economy of movement scores in surgical novices and (D) economy of movement scores for all attempts in those with low aptitude. (E) Comparison of time scores in surgical novices and (F) time scores for all attempts in those with low aptitude.

Although it has been established that separate learning curves exist for those with and without an innate aptitude for laparoscopy, it is important to further delineate what makes this distinction between groups and whether or not this discrepancy is surmountable. Visual-spatial ability is thought to play a large role in achieving proficiency in both open and laparoscopic procedures. A group of thirty-seven surgical residents were asked to complete six tests in order to assess visual-spatial ability. After these tests were completed, residents were then asked to complete a Z-plasty procedure. This procedure consists of one or more Z-shaped incisions being made with the diagonals forming one straight line and two triangular sections, which is used for cosmetic reasons or can be functional in order to elongate and relax scars. Residents with higher visual-spatial scores performed better in the Z-plasty procedure in comparison to those with lower scores. However, after additional practice, residents with lower scores were also able to achieve competency (Wanzel 2002). This finding suggests that despite the fact that learning curves differed between the groups, additional practice and feedback may be able to make up for the innate differences between groups. In a separate study that examined visual-spatial ability and manual dexterity among dental students, surgical residents, and staff surgeons, it was found that higher visual-spatial ability scores were associated with a more skilled performance among surgical novices. However, superior visual-spatial ability among the more advanced trainees and experts was not found to correlate with superior performance on procedures. Therefore, these findings suggest that although aptitude testing may not be able to be used to predict who will perform well in a surgical career; however, it may be able to predict who would likely benefit from additional surgical training prior to entering the operating room (Wanzel 2003).

As previously stated, it has been established that laparoscopic procedures are associated with a learning phase during which there is an increased prevalence of serious complications. The learning curve for laparoscopic procedures is typically based on the time to procedure completion and the number of complications; however, multiple factors play a role in complications in the operating room in addition to surgeon experience such as the entire team involved in patient care at that time. In addition to describing time to proficiency, learning curve patterns may potentially also be used to identify surgical trainees who will be unable to achieve proficiency despite additional training (Grantcharov 2004). A virtual-reality trainer was used to measure the following parameters which has previously been validated in studies: time to complete task, number of errors, and economy of motion score (Taffinder 1998). Figure 2 shows the four learning curves that were identified: surgeons who (1) demonstrated proficiency from the beginning of the learning session (5.4%); (2) advanced with practice and achieved predefined expert criteria between two and nine repetitions (70.3%); (3) slow and steady acquisition of skills but unable to achieve proficiency level within ten repetitions (16.2%); and (4) underperformed from the beginning and showed no tendency to skills improvement (8.1%) (Grantcharov 2009; Kramp 2016). Trainees in the first group demonstrated impressive innate ability, potentially indicating a strong future in minimally invasive surgery; whereas those in the fourth group not only did not demonstrate any aptitude for laparoscopic surgery at the beginning, but they also failed to show any progression towards achieving proficiency. Although the role of surgeon involves skills such as communication and strong clinical judgment, technical skills play a large role. Therefore, one's performance on laparoscopic trainers should not be viewed in isolation; however, technical performance should be taken into consideration in order to help determine one's success in pursuing a surgical career (Grantcharov 2009).

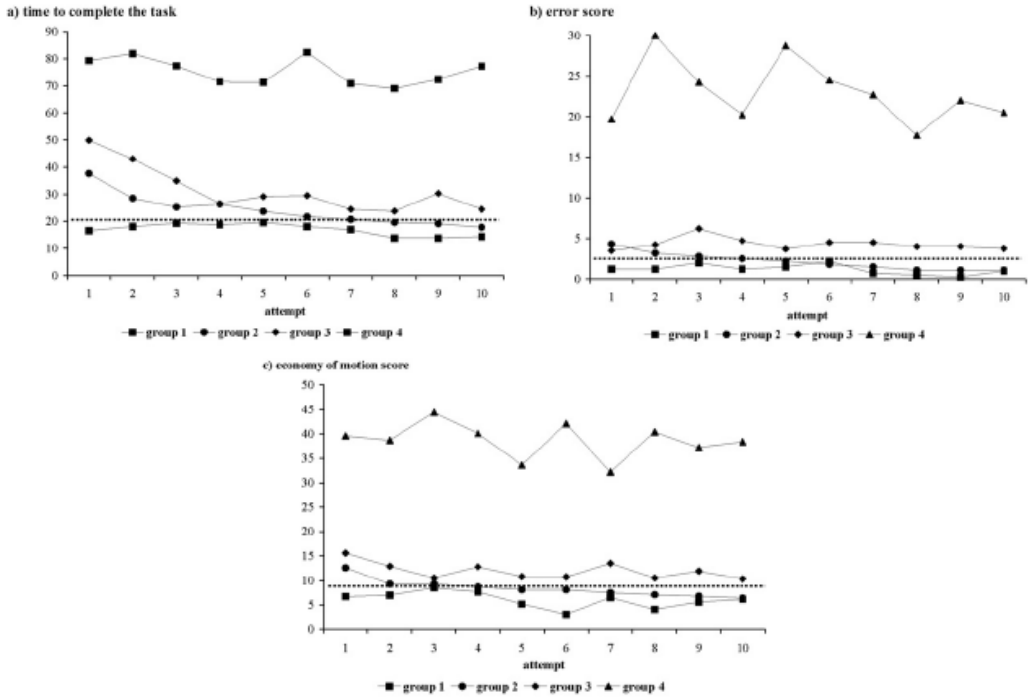

Source: Grantcharov, T.P. and P. Funch-Jensen, Can everyone achieve proficiency with the laparoscopic technique? Learning curve patterns in technical skills acquisition. *The American Journal of Surgery*, 2009. **197**(4): p. 447-449.

Figure 2. Learning curves. Time to perform the task. (a) Error scores. (b) Economy-of-motion scores. (c) Dotted line indicates the proficiency level for each parameter.

In addition to visual-spatial ability, several other cognitive abilities can be assessed in order to more completely understand one's aptitude in laparoscopy. A cognitive aptitude test may be used to assess trainees prior to laparoscopic simulator training. Ultimately, a surgeon's cognitive aptitude is related to the learning curve for minimally invasive surgery and the possibility of success in achieving proficiency (Luursema 2010; Luursema 2012). Spatial memory describes the ability to record information about one's environment and its spatial orientation. It can be viewed as an indicator of one's ability to learn the procedural aspects of tasks. Spatial memory is also related to the early learning phase of basic laparoscopic tasks (Luursema 2010). Perceptual speed is the ability to quickly identify a given shape or dissimilar shape from a number of alternatives. It is related to efficiency of movement in early learning, and it is also related to the associative phase of learning, which indicates that part of laparoscopic tasks might become automated during training. The fourth element of cognitive ability is reasoning ability. Increases in perceptual speed, a skill crucial due to the time critical nature of laparoscopic surgery, are found to be related to improved laparoscopic performance. The fourth element, reasoning ability, was found to be related to early learning of laparoscopic procedures. Reasoning ability was found to be less of an influence as skill level increased (Keehner 2006).

Since laparoscopic surgery requires a different mental skill set, it should be expected that the cognitive abilities of visual-spatial ability, spatial memory, perceptual speed, and reasoning ability should predict the learning curve for basic tasks on a laparoscopic simulator.

Laparoscopic surgery requires each of these skills; therefore trainees who perform exceedingly well on cognitive aptitude tests are expected to show high levels of performance in the following areas: (1) number of practice sessions in order to achieve proficiency; (2) time to task completion; (3) damage to surrounding tissue; (4) efficiency of movement on basic laparoscopic simulator tasks. Despite these expectations, cognitive aptitude was found to neither be related to total number of sessions required to achieve proficiency in a task, nor did it predict learning rate during training. Participants with lower cognitive aptitude scores were not found to require more practice sessions to reach proficiency in comparison to those with higher scores. Although trainees became quicker and more efficient in performing basic laparoscopic tasks on a simulator, damage to surrounding tissue remained constant. Cognitive aptitude did not affect the amount of tissue damage that was found. Although learning rates for trainees with discrepancies between their cognitive aptitude scores were similar, trainees with higher levels of cognitive aptitude were found to consistently outperform those with lower levels. Overall, there was no effect of cognitive aptitude on the learning curve across multiple sessions (Groenier 2014).

All four aspects of cognitive aptitude were associated with higher efficiency of movement. Visual-spatial and reasoning ability were associated with less time to complete a given task. The role of cognitive aptitude did change, however, when the influence of a cognitive ability was corrected for the effect of the other cognitive abilities. Perceptual speed remained positively associated with efficiency of movement; spatial memory and perceptual speed were associated with the amount of tissue damage.

ANIMAL MODELS OF LAPAROSCOPIC SURGERY TRAINING

Operating skills can be acquired via three methods, all of which have benefits and drawbacks. The first method involves the use of bench models, for which benefits include lower cost, ready availability, and reuse of materials (Martin 1997). Basic laparoscopy skills may be learned and further honed on trainer boxes or with virtual reality models, but as the trainee becomes more skilled, the need for more challenging and life-like models is required for skills to be further developed. As a result, animal models have become a popular way to simulate procedures in the operating room. The porcine model is the most commonly used model due to the pig's anatomical and physiological similarities to humans (Kobayashi 2012). The second method involves practicing of skills in the animal laboratory. The animal model represents an important step in the training process due to the fact that the direct step from the pelvic trainer model to the operating room may be too difficult for a trainee. The animal model also allows trainees to gain confidence in trocar use and positioning (Piechaud 2006). Although this method is expensive and also presents the issue of limited resources and funding, the use of animals very closely simulates operating on actual patients. The cadaver as a model also offers a very effective way to gain an understanding of anatomy through a laparoscopic view. Cadavers also provide macroscopic anatomy and improved spatial perception of anatomy. However, cadavers present certain disadvantages due to the fact that they do not bleed, the visual field is also clear, and no hemostasis can be done (Piechaud 2006). The third method takes place in the operating room under the supervision of a preceptor where trainees can gain real life experience. The drawback to this method is that

this can potentially be a dangerous situation in which trainees are further developing their skills on real patients. Training in the operating room is also limited by the fact that time and financial constraints limit the ability for trainees to perfect their skills here.

As more complex procedures are now being performed with laparoscopy in addition to shortened residency work hours, the need for intensive, efficient laparoscopy training is necessary for novices. This training can be conducted in a safe, controlled, and standardized environment within a simulation center; however, limited access to training centers does not always make this training possible. In order to provide additional training to general surgeons and graduating surgical residents, intensive training programs have been developed throughout the country as an alternative to simulation centers. Most intensive training programs are set up at locations throughout the country where general surgeons, residents, and fellows can travel to in order to complete an intensive training program over the course of several days. Intensive training programs may consist of lectures, laparoscopic videos, and practical training either on animal training models or laparoscopic trainers. Skill improvement is assessed using objective structured assessment of technical skill (OSATS). Most participants are found to have an improvement in their overall performance after finishing these courses (Castillo 2015).

For those that have access to simulation centers at their local institutions, there are numerous methods that can be used for preclinical training including virtual reality, box trainer simulators, operations on cadavers, or animal models. Although virtual reality or box trainer simulators have been used successfully by beginning trainees to acquire skills, they may be too simple and do not correlate closely enough to the actual procedure in the operating room. Therefore, human cadaveric and animal models have been introduced for more real-to-life training. Animal models have been found to be the ideal model due their realistic anatomy and surgical workflow similar to humans. Animal models are also ideal because they allow pathological findings such as cholelithiasis and inflammatory findings to be present, which is not possible in virtual reality or cadaveric models. Animal models are needed for two purposes. First, they allow new, minimally invasive procedures to be evaluated for their feasibility and effectiveness in comparison to standard techniques. Secondly, animal models provide training that most accurately resembles operating on real patients; therefore, it may also be used for training of both conventional and new methods of laparoscopic surgery (Ryska 2016). Due to both of these considerations, animal models are used throughout multiple surgical sub-specialties for preclinical training.

HEPATOBILIARY SURGERY

Training in laparoscopic hepatobiliary surgery with animal models has not gained large traction internationally due in part to its level of difficulty; however, success has been found when using the porcine model for training. Several differences exist between human and porcine liver anatomy, which can present a challenge to new trainees, but with the appropriate amount of preoperative preparation, the porcine model can offer a very realistic training model for laparoscopic liver surgery (Figures 3−6) (Martins 2013). Bovine and porcine livers are most frequently used due to their similarity to human livers in terms of size and density. These animals are also farm animals that are readily available and relatively inexpensive

(Ong 2013). The porcine liver has three hepatic ducts (left, right and middle) and join to form the common hepatic duct at the hepatic porta. The cystic duct is relatively long prior to joining the common hepatic duct, which also makes the porcine model a good model for laparoscopic cholecystectomy. The hepatic vein and inferior vena cava (IVC) confluence is intraparenchymal in pigs, which makes this dissection more challenging than in humans.

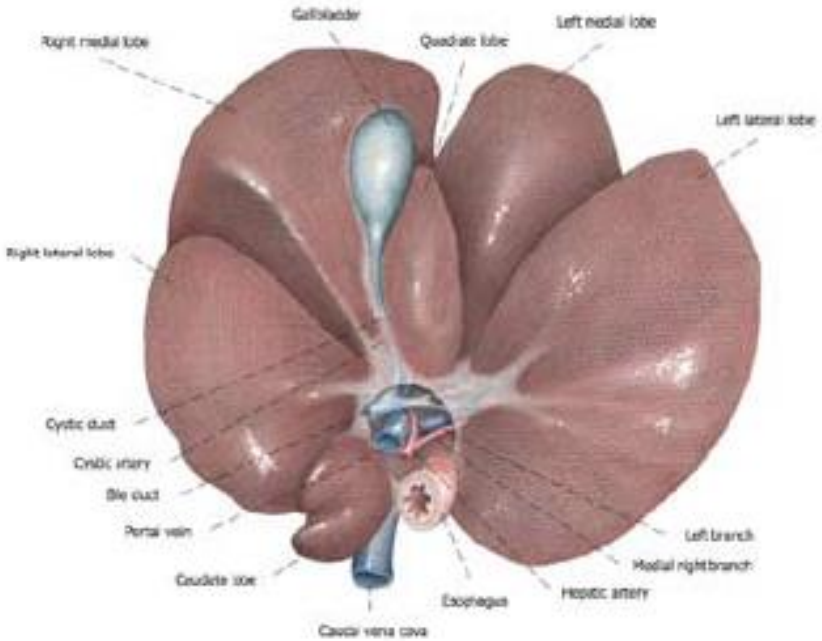

Source: Komorowski Andrzej, L., et al., Porcine Model In The Laparoscopic Liver Surgery Training, in Polish *Journal of Surgery*. 2015. p. 425.

Figure 3. Caudoventral view of the visceral aspect of an isolated swine liver. © 2015 Andrzej L. Komorowski et al., published by De Gruyter Open. This chapter is distributed under the terms of the Creative Commons Attribution 4.0 Public License. (CC BY 4.0). Figure was not altered.

The IVC and intraparenchymal hepatic veins have extremely thin walls and the nearby diaphragm is easily damaged. Although external morphology of the porcine liver differs from the human liver, the segmental anatomy in regards to its vascularity and biliary tree is very similar to the human liver. Novice trainees were able to successfully perform Pringle maneuvers, left lateral segmentectomy and division of the liver ligaments. With appropriate preparation, the porcine model appears to be an adequate model for laparoscopic hepatobiliary surgery (Komorowski 2015). In other studies, laparoscopic left hepatectomy was successfully completed using a four-portal technique without the use of specialized instruments such as a LigaSure device, which further helps to decrease operative cost as seen in Figures 5, 6, 7, 8, and 9. This procedure offers a safe, feasible technique for laparoscopic left hepatectomy in pigs, which could additionally serve as a useful model for investigating liver disease, regeneration and offer preclinical information in order to improve hepatobiliary surgical procedures (Zhang 2014). Dogs have also been used in animal models to help surgeons further develop technical skills necessary to perform laparoscopic common bile duct

exploration. Previously it has been difficult to find a suitable animal model that possesses a bile duct diameter large enough to accommodate a fiber optic choledochoscope required for stone extraction. The dog model has been found to be an effective and reliable model, which will allow surgeons to not only further hone skills but to also develop new techniques in laparoscopic bile duct exploration (Crist 1994).

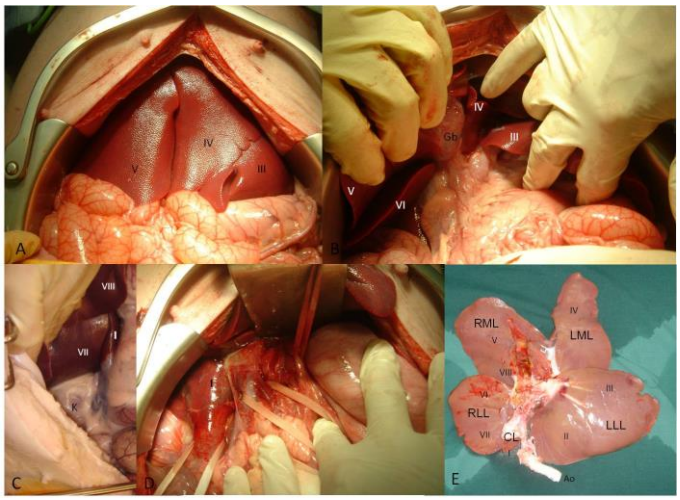

Figure 4. View of pig liver. Figure courtesy of Dr. Paulo Martins, MD PhD.

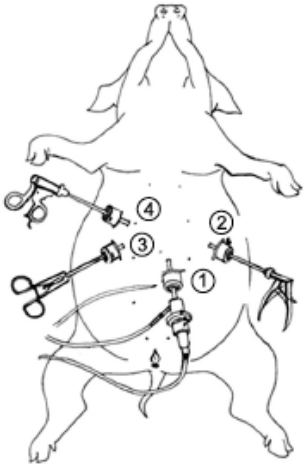

Source: Zhang, H., et al., Laparoscopic left hepatectomy in swine: a safe and feasible technique. *Journal of Veterinary Science*, 2014. **15**(3): p. 417−422.

Figure 5. Portal locations. Portal 1 (laparoscope) was located 2−3 cm below the umbilicus along the ventral midline (portal 1 was shifted 2−3 cm to the left male pigs). Portals 2 and 3 were 3−5 cm cranial to portal 1 and 8-10 cm to the left and right of the ventral midline, respectively. Portal 4 was 3−5 cm cranial to portal 3 and 8−10 cm to the left of the ventral midline. These portals were used to introduce various laparoscopic instruments.

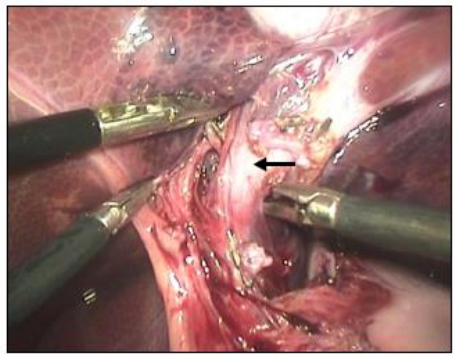

Source: Zhang, H., et al., Laparoscopic left hepatectomy in swine: a safe and feasible technique. *Journal of Veterinary Science*, 2014. **15**(3): p. 417−422.

Figure 6. Intraoperative view. The left branches of the portal vein (arrow) were dissected and then clamped with medium titanium clips before cutting.

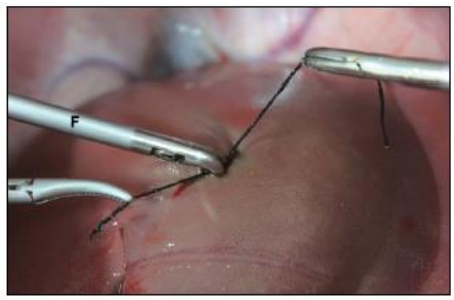

Source: Zhang, H., et al., Laparoscopic left hepatectomy in swine: a safe and feasible technique. *Journal of Veterinary Science*, 2014. **15**(3): p. 417−422.

Figure 7. Simulated intraoperative view. A knot was tied between the ends of the snipped sutures with the aid of needle-holding forceps (F).

Source: Zhang, H., et al., Laparoscopic left hepatectomy in swine: a safe and feasible technique. *Journal of Veterinary Science*, 2014. **15**(3): p. 417−422.

Figure 8. Simulated intraoperative view. A knot was tied with the aid of needle-holding forceps (F) inserted from the third trocar.

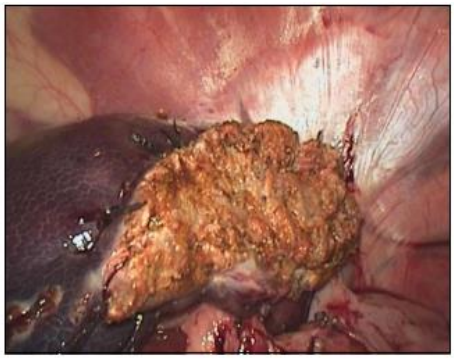

Source: Zhang, H., et al., Laparoscopic left hepatectomy in swine: a safe and feasible technique. *Journal of Veterinary Science*, 2014. 15(3): p. 417−422.

Figure 9. Intraoperative view. The raw area observed immediately after liver resection.

COLORECTAL SURGERY

Laparoscopy has been prevalent in colorectal surgery for many years at this point in time. New advances are being made within this sub-specialty with techniques such as natural orifice translumenal endoscopic surgery (NOTES). NOTES is an emerging technique that combines both endoscopic and laparoscopic approaches and uses natural body orifices as an entry site to the peritoneal cavity. This technique has already been applied to cholecystectomy and appendectomy but a purely NOTES technique has yet to be implemented in colorectal surgery. Hybrid techniques combining NOTES and laparoscopic techniques have yielded promising results in colorectal procedures such as colon resections. In order to further investigate this method, an experimental model using sheep was employed. Sheep were used to perform excision of the left colon using a transvaginal approach, which was chosen due to the similarity of external genital organs to female human genitals. Additionally, sheep share with humans a similar position of the left colon within the abdominal cavity. The totally transvaginal approach appears to be feasible in an animal model; however, application to the human population should be used with caution due to the technically challenging nature of the procedure and lack of long-term outcomes in the human patient population (Alba 2012). In addition to sheep models, porcine and rat models have also been used in colorectal surgery in order to further investigate sealing techniques of colorectal anastomoses in both *ex vivo* and *in vivo* models (Holmer 2011). Porcine models were used to evaluate the feasibility, safety, and efficacy of using a LigaSure device for dividing and sealing rectal stump during colorectal anastomosis creation versus a conventional stapler. The LigaSure device was found to be feasible in this experimental model but is less reliable than a stapler leading to a significantly greater fail rate (Sánchez-De Pedro 2014).

UROLOGY

Laparoscopy has gained increased importance in urology over the last twenty years, which has led to the development of laparoscopic reconstructive procedures such as

pyeloplasty, pelvic floor reconstruction, and radical prostatectomy. Training models include dry-lab, *ex vivo* animal models, and live animal models to be used for laparoscopic, robotic and endourologic training (Soria 2010; Aydin 2016). On porcine models, trainees are able to perform laparoscopic nephrectomy, ureteropelvic anastomosis, and suturing an incision on the bladder. Video trainers remain important in urologic laparoscopy training, but porcine laparoscopy has gained increased importance. Laparoscopic training on porcine models confers the benefits of training on animal models in general including haptic feedback, handling vitalized tissues that respond and bleed, and an overall similarity to real operative procedures; however, pig genitourinary anatomy is not identical to that of the human, which presents some limitations to this model. The pig has no retroperitoneal fat. The kidneys are adherent to the posterior abdominal wall and covered by a thin layer of peritoneum, which makes retroperitoneal dissection training difficult. Additionally, the ureter is thick and fatty with a narrow lumen. These anatomical limitations of the porcine model make human cadavers a popular alternative in urologic laparoscopic training (Katz 2003).

BARIATRIC SURGERY

Obesity continues to be a growing problem in the United States with an estimated 15.8 million adults qualifying for bariatric surgery (Ponce). Bariatric surgery techniques target weight loss through restriction, malabsorption, or a mix of both. The two most popular weight loss surgeries currently being performed are vertical sleeve gastrectomy (restrictive) and Roux-en-Y gastric bypass (mixed). Within laparoscopic and bariatric surgery, there has been a tendency for large laboratory animals such as pigs to be used. Bariatric experimental surgery on animals is useful for developing and perfecting techniques. Animal experimentation in bariatric surgery can also be used to study the relationship between metabolism and surgery in order to find improvements in treatment in the co-morbidities associated with morbid obesity. Lastly, research in this area can also focus on manipulating intake via central and vagal control (Del Castillo Dejardin 2004). Although it is now an abandoned malabsorptive technique, the jejunoileal bypass was previously the most studied bariatric surgical technique. Genetically-determined Zucker-type obese rats were used for the first time in bariatric research. From this research, subsequent studies of hormonal mechanisms responsible for weight loss and resolution of co-morbidities such as type 2 diabetes took place (Polyzogopoulou 2003). Current studies are aimed at further investigating the relationship between metabolism and surgery, specifically with gastric bypass in Zucker-type obese rats. This animal research looks at peptide hormones such as ghrelin, which regulates food intake and therefore plays a role in weight loss. In addition to Zucker-type obese rats, dogs and pigs have been used with the restrictive and mixed techniques with the goal of improving techniques for laparoscopy. Gastric persistalsis in reduction of intake is also being studied in rats, dogs, pigs, and rabbits in order to discover new options for patients in bariatric surgery. In order to draw meaningful conclusions, it is important to use obese animals in this area of research (Del Castillo Dejardin 2004).

GENERAL SURGERY

Inguinal hernia repair is one of the most frequently performed surgical procedures with over 800,000 hernia repairs performed annually in the USA. Despite the common nature of this procedure, key problems still exist following repair including complications secondary to invasive fixation of mesh, poor quality of tissue ingrowth induced by the mesh, and early mesh migration to and penetration into neighboring organs after implantation (Scheidbach 2004; Panaro 2015). Porcine animal models have been used for laparoscopic training purposes for hernia repairs for quite some time, but this animal model is further being utilized in order to compare surgical approaches and type of mesh used in hernia repairs. Polypropylene mesh is a common mesh used in millions of hernia repair operations, but variations in the type of polypropylene mesh used in repair result in a difference in their biocompatibility and handling characteristics during surgery. Porcine models may be used to further characterize these differences between mesh including shrinkage, chronic inflammatory reaction, and mesh incorporation into the surrounding tissue (Scheidbach 2004). Studies have also been done using the porcine model in order to further investigate various approaches to hernia repair including NOTES technique, totally extraperitoneal (TEP) and transabdominal preperitoneal (TAPP) (Dhumane 2013). Although this area of research may not purely focus on laparoscopic training, the results of such studies have a direct impact on the future standard of care in inguinal hernia repairs in patients.

PEDIATRIC SURGERY

Laparoscopic training outside of the operating room is of particular importance in pediatric surgery due to the increasingly complicated surgeries that are now being performed laparoscopically; however, the number of pediatric patients requiring these complicated procedures is usually small, which makes training outside of the operating room of the utmost importance in order to reduce complications and operating error. The porcine model is the most widely used animal model in laparoscopic training in fields such as adult minimally invasive surgery, colorectal, urologic and gynecological surgery. Despite this fact, very few studies have described the role of animal models for laparoscopic training in the pediatric population. Although the pig can be used in pediatric surgery training, the rabbit model could be helpful for pediatric surgery training due to its smaller size, which is comparable to the operative field encountered when operating on neonates and small children (Kirlum 2005). The piglet also poorly simulates the pediatric population due to its larger size weighing between 20 and 40 kg. In comparison, a rabbit that weighs 3−4 kg will have an abdominal cavity that measures approximately 15 cm long, 10 cm wide, and 8 cm high, which mimics the dimensions of the abdominal cavity in a newborn baby. Rabbits have been found to be good surgical models for repair of inguinal hernia and hiatal hernia due to their patent inguinal ring with retractile or intraabdominal testes and naturally gaping diaphragmatic hiatus, respectively. In contrast, it is difficult to mobilize the esophagus or perform cholecystectomy in the pig model due to its huge, multi-lobulated liver (Esposito 2016). Laparoscopic nephrectomy can also be challenging to perform in the porcine model due to the difficult access to the kidneys caused by large, distended bowel loops. Nephrectomy is more

straight-forward in the rabbit model due to the anterior location of the kidneys and scant intraabdominal and perineal fat (Molinas 2004). Other laparoscopic procedures can be performed additionally including intestinal anastomosis, splenectomy, and congenital diaphragmatic hernia repair. In an analysis of trainees' performances on rabbit versus porcine models, it was found that surgeons had higher performance scores and statistically shorter operative times for advanced procedures in the rabbit model. Overall, the rabbit model appears to provide a viable approach to technical training in basic and advanced laparoscopic procedures (Esposito 2016).

ALTERNATIVES TO ANIMAL SURGERY IN LAPAROSCOPIC SURGERY

Due to high costs, regulatory constraints, opposed public opinion, and complex logistics (maintenance, anesthesia) associated with animal experiments, other alternatives for training have been proposed. Simulation-based training allows trainees to further hone their laparoscopic skills in a safe, non-threatening environment prior to entering the operating room. The repetition of tasks and simulated procedures has been shown to reduce the risk of adverse surgical events and further decrease operating time (Hyltander 2002). Although training that occurs in the OR, on cadaver, and animal models may be a better method than simulation training, it appears that skills acquired in a simulation setting are transferable to the OR such as laparoscopic suturing and knot tying skills (Sutherland 2006; Al-Kadi 2013; Zendejas 2013). Simulation-based training can lead to demonstrable benefits of surgical skills in the operating room, and it is an effective way to teach laparoscopic surgery skills, increase translation of laparoscopic skills to the OR, and increase patient safety (Vanderbilt 2015). Numerous laparoscopic training tools exist, each of which have their own benefits and drawbacks.

A box trainer is a simple box that uses a camera, screen, light source and instruments. It incorporates conventional laparoscopic equipment in order to perform basic skills. It can be used for training on animal parts in addition to synthetic inanimate models. Complex task trainers are hybrid models that provide visual, audio and touch cues and use integrated hardware in order to replicate a clinical setting. They may also be composed of a partial component of a simulator or body part such as an arm or a leg. Video trainers are more sophisticated box trainers that have embedded motion sensors and recorders which measure distance and direction moved in order to calculate economy of movement. Table 1 lists the different types of training tools and their individual capabilities (Vanderbilt 2015; Alaker 2016).

In addition to physical box trainers and video trainers, virtual reality plays an increasingly large role in laparoscopic training; multiple modalities that utilize virtual reality for laparoscopic simulation training exist. Virtual reality uses screen-based computer software and hardware similar to that used in laparo-endoscopic surgery. Virtual reality (VR) can further be broken down into low-fidelity and high-fidelity groups. Low fidelity VR simulators use computer-training programs that provide an abstract environment to teach basic laparo-endoscopic skills whereas high-fidelity uses motorized instruments in order to provide haptic feedback and more closely resembles live tissue. Minimally Invasive Surgical Trainer – Virtual Reality (MIST VR), a part-task virtual reality laparoscopic simulator, not only

simulates surgical tasks and operations but is also able to provide an objective assessment of psychomotor skills by the operator. It will then generate an overall score, taking into consideration errors committed and time taken to complete six different tasks. When assessing surgical novices and practicing surgeons, experienced surgeons scored consistently and significantly better than their counterparts in all tasks, suggesting that the simulator is measuring surgically relevant parameters. Therefore, MIST-VR appears to be a validated tool in objectively assessing laparoscopic skills (Chaudhry 1999). In a systematic review and meta-analysis comparing virtual reality to other simulation models, it was found that virtual reality simulation was significantly more effective than video trainers and at least as good as box trainers in laparoscopic simulation training (Nagendran 2013; Alaker 2016). Moreover, virtual reality training appears to be a superior training method in comparison to standard laparoscopic training in the operating room (Gurusamy 2009; Al-Kadi 2012; Larsen 2012; Willaert 2013).

Table 1. Laparoscopic training tools, definitions, and procedures commonly used in surgery

Type of simulation	Definition	Camera Navigation	Clipping and cutting	Suturing and knot tying	Lifting and grasping	Dissection
Box Trainer	A box that incorporates conventional laparoscopic equipment to perform basic skills, is versatile, and enables training on animal parts and synthetic models	+	+	+	+	+
Task Trainer	A partial component of a simulator or simulation modality such as an arm, leg or torso		+	+		+
MIST-VR	Virtual reality simulator with six different tasks to simulate maneuvers performed during laparoscopic cholecystectomy in a computerized environment	+	+		+	+
LapMentor/ LapMentor II	Virtual reality simulator consisting of camera and two calibrated working instruments. Motion of the instruments is translated to a two-dimensional computer screen for student practices	+	+	+	+	+
LapSim	A computer-based simulator creating a virtual laparoscopic setting through a computer operating system, a video monitor, a laparoscopic interface containing two pistol-grip instruments, and a diathermy pedal without haptic feedback	+	+	+	+	+

Type of simulation	Definition	Camera Navigation	Clipping and cutting	Suturing and knot tying	Lifting and grasping	Dissection
EndoTower	EndoTower software consists of an angled telescope simulator composed of rotating camera and telescopic components.	+	+			
MISTELS/FLS trainer	McGill Inanimate System for Training and Evaluation of Laparoscopic Skills (MISTELS)- this inexpensive, portable, and flexible system allows students to practice in a virtual Endotrainer box		+	+	+	
SIMENDO VR	Computer software used to train eye-hand coordination skills by camera navigation and basic drills.	+		+	+	
URO Mentor	A hybrid simulator, consisting of a personal computer based system linked to a mannequin with real endoscopes. Cystoscopic and ureteroscopic procedures are performed using either flexible or semi rigid endoscopes	+	+		+	+
Da Vinci Skills Simulator	A portable simulator containing a variety of exercises and scenarios specifically designed to give users the opportunity to improve their proficiency with surgical controls.	+	+	+	+	+

Vanderbilt, A.A., et al., *Randomized Controlled Trials: A Systematic Review of Laparoscopic Surgery and Simulation-Based Training.* Global Journal of Health Science, 2015. **7**(2): p. 310−327. This is an open-access article distributed under the terms and conditions of the Creative Commons Attribution license (http://creativecommons.org/licenses/by/3.0/). Table was not altered

Virtual or box trainer simulators have been shown to be effective at the beginning of training; however, fresh-frozen cadavers are another method of providing laparoscopic training that more closely resembles operating on patients. Cadavers provide full haptic and tactile feedback, which is vital in laparoscopic simulation and is unfortunately difficult to incorporate into virtual systems (Buckley 2014). They can also be stored at a low temperature for an indefinite amount of time (Sharma 2012). In comparison of cost, an initial fee is incurred to purchase with a small added cost for maintenance for simulators whereas cadaver bodies are typically donated free of charge; however, high cost is associated with maintenance of a cadaver laboratory and cremation of used bodies. Other drawbacks to use of cadavers for training include limited availability, avital tissues, and inability to injure vasculature or other structures (Sharma 2012; Ryska 2016).

Robotic surgery continues to grow in popularity worldwide. Although it is a derivative of minimally invasive surgery, the skills required to perform robotic surgery are unique from those required in either open or laparoscopic surgery. There are currently four commercially available simulators: the da Vinci Skills simulator (dVSS), the Mimic dV-Trainer (dV-Trainer), the Robotic Surgical Simulator, and Sim-Surgery Educational Platform (SEP). All four trainers are able to assess robotic skill. Three of the four simulators (dVSS, dV-Trainer, RoSS) demonstrate the ability to improve basic robotic skills, with proficiency-based training being the most effective training style. The skills obtained on a VR training curriculum appear to be similar to those obtained through dry laboratory simulation (Bric 2016).

An alternative to virtual reality simulators and fresh frozen cadavers is the Open-source Heidelberg laparoscopy phantom (OpenHELP), which combines realistic anatomy and tissue properties with reusable simulation specimens. OpenHELP is based on a digital three-dimensional model obtained from a CT scan of a male body and uses a flexible torso, via an elastic abdominal wall, or rigid, with a plastic shell, filled with artificial organs made from silicon casts. Pneumoperitoneum could successfully be attained by both methods (Kenngott 2015). As NOTES become more prevalent, training models specific for this technique are needed. A new training model for the NOTES procedures was developed known as the endoscopic-laparoscopic interdisciplinary training entity (ELITE). This model is composed of a synthetic package with all the intrabdominal organs, including the greater omentum. The synthetic appendix is made from gelatin material, which allows for dissection with high-frequency tools. The ELITE training model appears to be well suited for the training of NOTES procedures (Gillen 2012).

In addition to *in vivo* training, pieces of animal tissues may also be removed from the animal specimen and be used to recreate the anatomic conditions of a specific procedure. When used for this purpose, the animal tissue is traditionally placed in a pelvic trainer or dry box in order to more closely simulate a specific laparoscopic surgery for the trainee. Animal tissue may also be placed in human body simulators in order to more closely imitate both human anatomy and realistic operating conditions by including real tissue that will allow tactile feedback and will respond when being manipulated. The advantages of using pieces of animal tissue include high availability, low cost, lack of need for anesthesia, and no animal maintenance (van Velthoven 2006).

LAPAROSCOPIC SURGERY IN SMALL ANIMAL MODELS

A wide variety of small animal models exist in order to provide a sophisticated training model for the advanced laparoscopic trainee. Each of these models not only have advantages and disadvantages, but they also possess characteristics which may make them better suited for certain surgical sub-specialties over other small animal models. Overall, the ideal training model should provide the skills required, be inexpensive, universally available, and anatomically and physiologically identical to the anesthetized patient. Mice, rats, rabbits, and guinea pigs are universally accepted and are bred for both surgical and medical research due to cheaper costs, easy handling and care, and a more favorable public opinion. Although primates such as monkeys and apes most closely represent humans physiologically and anatomically, the use of primates is limited only to special circumstances in which any other

animal model would be deemed unreliable. Animal models are typically utilized for reproduction of the following systems for training purposes due to the relative ease of reproducing surgical conditions: musculoskeletal, genitourinary, integumentary, vascular, cardiothoracic, and digestive system (Hassan 2005).

Mice, despite being studied extensively and being ideal for immunologic or oncologic studies, are too small to be used in laparoscopic procedures. On the other hand, the larger animal model, the rat, has been previously used for laparoscopic training such as in transperitoneal laparoscopic research (Gutt 1998). The rat model is inexpensive and easily handled due to size. This model has previously been described as a model for retroperitoneal mini laparoscopic nephrectomy, but the rat can also be used universally throughout laparoscopic sub-specialties as a way for the trainee to acquire advanced laparoscopic skills and microsurgical suturing skills (Kaouk 2000). However, due to the limited workspace, the rat model requires the trainee to have already acquired the skills necessary to work with 3-mm instruments in a very small space.

In comparison to the rat model, the rabbit model is not only inexpensive but also provides a larger workspace, which makes it a more realistic model. This model has been used as an *in vivo* training model for laparoscopic skills such as knot-tying, suturing, and using cutting and coagulation modes for dissection (Molinas 2004). The rabbit model has been shown to be well-suited for the use as a new training tool that emphasizes the repetition of simple procedures due to its ability to easily monitor progress when comparing learning curves between experienced and inexperienced surgeons such as gynecologists and medical students, respectively. With additional practice, shorter operating times and fewer complications were noted. This small animal model is also being used in experimental settings to evaluate the oxidative stress production on a transplanted kidney during laparoscopy (Demirbas 2004). As previously discussed, the rabbit model provides a very realistic model for pediatric surgery training due to the small operative field similar to that seen in the pediatric population. Due to the potential risks of carbon dioxide pneumoperitoneum in the neonate and infant population, the concept of gasless laparoscopy was first developed in the rabbit model. In the gasless model, the animals were neither intubated nor mechanically ventilated. After incision was made and the peritoneum was entered, an abdominal wall elevator was inserted which provided excellent visualization of the abdominal cavity (Luks 1995).

At the Center for the Development of Advanced Medical Technology (CDAMTec) in Japan, both wild-type and genetically modified pigs are used as multi-purpose models for medical skill education, the development of therapeutic strategies, and innovations for new tools for endo- and laparoscopic procedures. Unlike dogs, few spontaneous disease models exist in pigs. Pigs also share similar immune systems with humans as seen in inbred pigs such as the Clawn minipig, which further allows genetically modified pigs to be used in experimental models for liver, intestine, kidney, pancreas, and lung transplantation (Kobayashi 2012). At the CDAMTec research center, three different types of pigs are used: domestic pigs, miniature pigs, and genetically modified miniature pigs as seen in Figures 10 and 1.11. Pigs may vary in size from 30 to 40 kg as young pigs to approximately 100 kg once at mature body weight. Domestic pigs are easily obtained and are inexpensive since they are well established as a food source. Miniature pigs are generally easier to handle; however, they are more expensive than domestic pigs due to their limited annual production for experimental use in Japan. A mature miniature pig weighs 40 to 50 kg, similar to the weight seen in immature domestic pigs. In order to use the pigs available more effectively, after they

have been euthanized, their tissues can undergo "second use" after being donated to other researchers for additional experiments, which ultimately results in fewer total number of experimental animals needed for research and decreases the other resources that are set aside for the proper care and disposal of animals after being euthanized (Tanaka 2006).

Source: Kobayashi, E., et al., The pig as a model for translational research: overview of porcine animal models at Jichi Medical University. *Transplantation Research*, 2012. **1**: p. 8−8.

Figure 10. Domestic pig used in experimental research. This is an Open Access article distributed under the terms of the Creative Commons Attribution License (http://creativecommons.org/licenses/by/ 2.0), which permits unrestricted use, distribution, and reproduction in any medium, provided the original work is properly cited.

Source: Kobayashi, E., et al., The pig as a model for translational research: overview of porcine animal models at Jichi Medical University. *Transplantation Research*, 2012. **1**: p. 8−8.

Figure 11. Miniature pigs used for experimental research. KCG pig (top), Mexican hairless pig (middle), Clawn pig (bottom). This is an Open Access article distributed under the terms of the Creative Commons Attribution License (http://creativecommons.org/licenses/by/2.0), which permits unrestricted use, distribution, and reproduction in any medium, provided the original work is properly cited.
This figure was not altered.

Table 2. Advantages and disadvantages of *ex-vivo* and *in-vivo* models

Models	Applications	Advantages	Disadvantages
Ex-vivo (non-perfused) models	• Compare the efficacy of different antenna configurations. • Trial of different energy settings	• Allow histological examination of whole lesion to study zones of tissue after thermal energy (i.e., ablation) applied • Inexpensive • Larger study sample size • Easy to manipulate during experiment • Does not require ethical approval/animal license	• Non-physiological • Homogenous parenchyma • Absence of respiratory excursion and motion of subject being studied • Lack of cooling effect secondary to tissue perfusion • Inability to study heat sink effect
In-vivo models	• Study of lesion evolution over time • Histological examination of lesion • Study of heat sink effect • Study of systemic responses to thermal energy applied • Study of effect of large volume thermal energy applied to tissues (in larger animals)	Small animals • Easier to handle • Cheaper • Ability to have larger sample size Large animals • Closer resemblance to human anatomy and physiology (for example, the liver)	Small animals • Small organ volume (i.e., liver) • Not suitable for the study of large volume thermal energy application (i.e., ablation) Large animals • Size and temperament poses challenges during anesthesia • Difficult vascular access in porcine models • Limited by strict ethic regulation • Small study sample size
Isolated perfused *ex-vivo* models	• Study of lesion evolution over time • Study of heat sink effect • Study of early inflammatory response	• Cheaper than *in-vivo* experiments • Does not require ethical approval • Greater control of perfusion characteristics (i.e., in liver, portal vein and hepatic arterial flows and pressures)	• Expensive • Expertise in animal handling and anesthesia is required • Duration of study is limited to the lifespan of the model • Absence of interacting organ systems • Inability to assess the impact of thermal energy on end organs • Perfusion circuit itself may activate some degree of systemic response

Source: Ong, S. L., G. Gravante, M. S. Metcalfe and A. R. Dennison (2013). "History, ethics, advantages and limitations of experimental models for hepatic ablation." *World Journal of Gastroenterology : WJG* **19**(2): 147-154.

LIMITATIONS OF ANIMAL MODELS

Animal models in laparoscopic training act as a great tool to help trainees improve their laparoscopic skills in a setting that closely resembles operating on patients. However, animal experimentation has several drawbacks including cost, availability, time required to provide adequate care to the animals both before and after operative intervention, and the ethical implications of using animals for medical experimentation. From a legal perspective, these experiments are likely to continue on animals until viable alternatives exist for testing prior to introduction of certain surgical procedures to the general public or until legislation allows the introduction of surgical treatment to the general public without first being tested on animals.

The Greeks described animal experimentation almost 2500 years ago when both Aristotle and Erasistratus performed studies on live animals (Singer 1922; Wilson 1959). Once general anesthesia emerged in the 1840s, this allowed unconscious animals to be studied, which led to a turning point in the medical and scientific communities' ability to use animal models in

surgical experimentation. Animals can be used either as *ex vivo* or *in vivo* models. The major limitations of *ex vivo* models include absence of blood flow and vitalized tissues, which will respond to movement and maneuvers performed by the surgeon, and they also have limited lifespans during which valid data can be obtained. The absence of other interacting organs in ex-vivo models may also affect the extent of systemic responses during experimentation. The use of living animals with in-vivo studies requires specific laboratory facilities and research teams with expertise in anesthetizing and handling different species. The size of the animal also poses a barrier, for example when a larger animal such as a pig or cow needs to be anesthetized, moved, or examined post-operative (Hildebrand 2007; Ong 2013). The advantages and disadvantages of *ex vivo* and *in vivo* models for experimentation are compared in Table 2.

FUTURE OF LAPAROSCOPIC SURGERY

Laparoscopic surgery has evolved immensely from its initial use as a diagnostic procedure to the first laparoscopic cholecystectomy being performed in 1985 to its widespread use across all surgical subspecialties. Laparoscopy has further developed over the last thirty years in part due to the development of new instruments, which allows more complex operations to be performed. Laparoscopic camera equipment is now available in high-definition, with automatic focus and zoom, and three-dimensional images. Several different types of energy devices are now available including monopolar electrocautery scissors, ultrasonic coagulating shears, and electrothermal bipolar vessel sealers, which can be used for dissection and division of tissue, bowel, and vascular structures (Blackmore 2014). The development of new surgical instruments and imaging devices expands not only the type of surgery but also the surgical fields that are now able to use laparoscopy. In addition to these new contributions to the field, laparoscopy continues to evolve through different methods in which laparoscopic surgery can be performed including robotic surgery, single incision laparoscopic surgery (SILS), natural orifice translumenal endoscopic surgery (NOTES), and three-dimensional laparoscopy.

Robotic surgery was first seen in the field of urology and cardiac surgery with over 50,000 robotic prostatectomies being performed in 2007 in the USA alone. It was not used in colorectal surgery until 2002 (Blackmore 2014). Robotic surgery confers several advantages including high-definition three-dimensional visualization, increased freedom of movement, and minimization of tremor. These advantages provide for a more controlled, delicate dissection compared to laparoscopy. Several urologic procedures are now routinely being performed robotically including radical prostatectomy, transperitoneal and retroperitoneal partial nephrectomy, radical nephrectomy with caval thrombectomy, and pyeloplasty (Rogers 2008; Abaza 2011; Patel 2013; Stepanian 2016). Studies have indicated that robotic-assisted partial nephrectomy is associated with excellent outcomes in terms of perioperative complications and functional results when performed by experienced surgeons. Robotic surgery could potentially also be applied to removal of complex tumors (Novara). Robotic technology has also been extended to liver surgery and represents an accepted alternative to open and laparoscopic techniques in certain cases. Robotic liver surgery allows precise dissection and microsuturing in narrow operative fields, and with this technology, there is

greater potential for more major resections and difficult segmentectomies to be performed through minimally invasive methods. Current data suggests that robotic liver resections have at the very least similar perioperative and postoperative outcomes while conferring the general benefits of minimally invasive surgery. Advantages of minimally invasive robotic surgery appear to be able to be applied additionally to right hepatectomy for living liver donors including faster post-operative recovery. Similar early allograft dysfunction, complications, and one-year recipient liver function were found between the open and robotic groups (Chen 2016). The technology used in robotic surgery also helps integrate and facilitate newer technologies such as near-infrared fluorescence (Giulianotti 2016). However, there are limitations to robotic surgery, which include higher associated costs and the need for specialized training for the primary surgeon, secondary surgeon, and OR nurses.

The next step to decrease the invasiveness and improve cosmesis of laparoscopic surgery is to decrease the size and number of incisions made as seen in single incision laparoscopic surgery (SILS). Through this technique, all instruments are introduced into the body cavity through a single access port. As laparoscopy has resulted in decreased trauma to the abdominal wall, improved pain control, and quicker recovery post-operatively, single-site incision surgery has further capitalized on these advantages of minimally invasive surgery by decreasing the number of incisions made. However, SILS requires a skill set and has ergonomic demands, which cannot directly be adapted from laparoscopic surgery. Therefore, in order to avoid higher complication rates as seen in both early laparoscopic cases and now initial SILS cases, evidence- and competency-based SILS curriculum should be instituted.

The first reported SILS cholecystectomy was performed in 1995 with new applications to other fields such as appendectomies and complex bariatric procedures. As was seen in the early days of laparoscopic surgery, increased complication rates at the advent of SILS makes it clear that appropriate training should occur before utilizing this technique on patients. The Laparoendoscopic Single-site Surgery Consortium for Assessment and Research (LESSCAR) set out a 2009 whitepaper, which addresses some of the issues regarding appropriate training for new techniques. LESSCAR recommends a stepwise format for training with a progression from inanimate models to animal procedures to supervised human SILS cases. These are the same principles that can be applied to laparoscopic or robotic training. As seen in case studies that examine SILS outcomes, there exists a significant learning curve even for laparoscopic surgeons who adopt SILS as seen through greater operative time and increased conversion from single to multi-port laparoscopy. Skills required for SILS do not appear to be automatically conferred from laparoscopic surgery, which further makes it important that adequate, safe training is available in order to make surgeons proficient (Pucher 2013). Needlescopic cholecystectomy is an additional method, which further reduces traumatic stress during and after surgery and hastens full recovery. A meta-analysis comparing needlescopic versus laparoscopic cholecystectomy indicated that needlescopic is not only safe and effective procedure for management of gallstone disease, but it is superior to laparoscopy for less post-operative pain and better cosmetic results despite being associated with longer operative time and higher conversion rate.

Natural orifice translumenal endoscopic surgery (NOTES) has gained traction in the surgical community as a technique to further advance minimally invasive techniques towards being truly non-invasive (Figure 12). This method requires a flexible endoscope to be inserted via a natural orifice such as the mouth, anus, vagina or umbilicus in order to gain access to the abdominal cavity thereby without leaving a scar. NOTES has gained popularity as a method

to perform cholecystectomy or appendectomy. NOTES is truly a non-invasive surgery since it eliminates external postoperative wounds and other advantages including reduction in trauma to the abdominal wall, decreased recovery time, decreased clinical costs, and improved overall cosmetic results (Spivak 1997; MacFadyen 2005; Richards 2005; Ponsky 2006). Initial clinical outcomes following transvaginal hybrid NOTES cholecystectomy indicate that this method appears to be safe when performed by appropriately trained surgeons and may result in a faster return to normal activities and decreased postoperative pain (Sodergren 2015).

As with any new operative technique, appropriate training and investigation into post-operative outcomes should be performed prior to routine use of the NOTES technique. Differences between laparoscopic and NOTES procedures are that the NOTES technique requires the surgeon to operate an endoscope and other instruments through a single access point, rather than three or four other ports as frequently used in laparoscopy. Many NOTES procedures are currently being performed via hybrid fashion in which both an endoscope and trans-abdominal instruments are used; however, there is still significant loss of traction and the in-line instrument approach using the instrument ports in the endoscope hand-piece remain unfamiliar to most surgeons. Additionally, there is no gastrointestinal lumen to support the endoscope; thus, the distal end of the endoscope is manipulated in the open abdominal cavity using the incision site, internal organs and gravitational force to navigate and position the endoscope and instruments. As a result, the middle section of the endoscope is prone to rolling and twisting in the abdomen. Similar to SILS, the skill set required to operate an endoscope and associated surgical instruments is unique and cannot be directly transferred from laparoscopic and endoscopic skills (Korzeniowski 2016). Virtual reality simulators have found to be effective training tools for other minimally invasive techniques; however, a virtual reality trainer specific to NOTES procedures is required in order to proceed with further training. As a result, the natural orifice virtual surgery (NOViSE) simulator was developed due to the lack of established curriculum for NOTES training. NOViSE is a first prototype whose main focus is teaching the endoscopic manipulation skills required for NOTES and includes integration of a force-feedback-enabled virtual reality simulator for NOTES training with a virtual flexible endoscope. NOViSE is currently only able to simulate trans-gastric hybrid cholecystectomy procedure using a flexible endoscope as seen in Figure 12. Promising initial results following its implementation as a training device indicate that may be able to contribute to surgical training and to improving technical skills for NOTES procedures without putting patients at risk (Korzeniowski 2016).

One of the challenges of laparoscopic surgery is that surgeons face the loss of depth perception and spatial orientation due to the fact that they are working in a three-dimensional (3D) space but being guided by two-dimensional (2D) images. This disadvantage leads to a high visual and cognitive load. Therefore, 3D imaging was developed as an alternative to conventional 2D imaging. 3D imaging was introduced as early as the 1990s; however, its use is still not standard at hospitals, which may be secondary to the degraded view of the operative field resulting from poor image resolution, the necessity to wear uncomfortable eyewear (which alone can lead to eye strain, headaches, dizziness, and physical discomfort), and high cost. However, as technology has further evolved and high-definition monitors are now available, these disadvantages may be minimized when using the newest technology (Sorensen 2016). Overall, 3D laparoscopy appears to confer a reduction in performance time, is more affordable than robotic systems, and a reduction in errors is observed when compared

to 2D technology. Most importantly, however, 3D laparoscopy allows improved depth perception, which is significant due to the fact that most common laparoscopic injuries occur due to visual misperceptions (Way 2003).

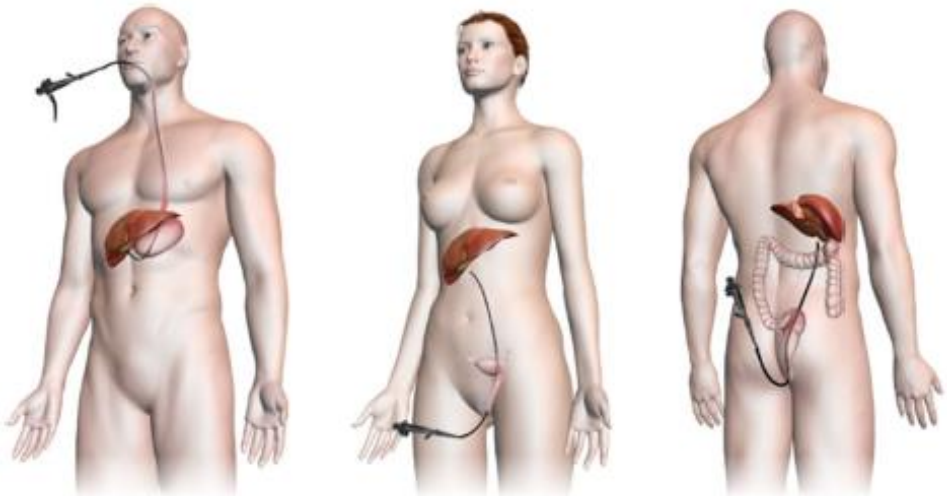

Source: Korzeniowski, P., et al., NOViSE: a virtual natural orifice transluminal endoscopic surgery simulator. *International Journal of Computer Assisted Radiology and Surgery*, 2016: p. 1−13

Figure 12. NOTES approaches via trans-gastric (left), trans-vaginal (middle), and trans-rectal (right).
This article is distributed under the terms of the Creative Commons Attribution 4.0 International License (http://creativecommons.org/licenses/by/4.0/), which permits unrestricted use, distribution, and reproduction in any medium, provided you give appropriate credit to the original author(s) and the source, provide a link to the Creative Commons license, and indicate if changes were made.

CONCLUSION

The prevalence of laparoscopy throughout surgery has increased exponentially over the past thirty years. As laparoscopy as a field has continued to grow, its applications are being applied to both new surgical procedures that previously were only being performed open, and an increasing number of surgical subspecialties are using laparoscopy. As a result, laparoscopic experimental surgery models have played a crucial role in surgical training, which ultimately impacts the diversity of surgical procedures that may be safely performed in patients. Animal models are the ideal training model to be used in laparoscopic surgery training because they confer the benefits of ideal haptic feedback, handling vitalized tissues that respond and bleed, and an overall similarity to real operative procedures. Animal experimental models have been crucial to the development of new techniques and procedures and for the training of surgeons in laparoscopic surgery. Due to its success, laparoscopy and other minimally invasive procedures have been applied to more complex surgeries in fields such as hepatobiliary, transplant, colorectal, and pediatric surgery. Laparoscopy and other minimally invasive techniques such as robotic surgery and NOTES require their own set of surgical skills, which makes it imperative that proper training is available prior to both novice surgeons using basic techniques and experienced surgeons using advanced or new techniques

on patients. Laparoscopic trainers, virtual reality, cadavers, and *in vivo* animal models are all options for laparoscopic training with in-vivo animal models providing the most real-to-life models for practice due to their anatomical and physiologic similarities to humans. As minimally invasive surgery continues to evolve from laparoscopy to robotic, single-incision laparoscopic surgery, and NOTES procedures, the need for additional animal training will be a necessity in order to ensure optimal outcomes for patients.

REFERENCES

Abaza, RR. Robotic surgery and minimally invasive management of renal tumors with vena caval extension. *Current opinion in urology*, 2011, 21(2), 104−109.

Al-Kadi, AS; Donnon, T. Using simulation to improve the cognitive and psychomotor skills of novice students in advanced laparoscopic surgery: a meta-analysis. *Med. Teach.*, 2013, 35 Suppl 1, S47−55.

Al-Kadi, AS; Donnon, T; Oddone Paolucci, E; Mitchell, P; Debru, E; Church, N. The effect of simulation in improving students' performance in laparoscopic surgery: a meta-analysis. *Surg. Endosc.*, 2012, 26(11), 3215−3224.

Alaker, M; Wynn, GR; Arulampalam, T. Virtual reality training in laparoscopic surgery: A systematic review & meta-analysis. *Int. J. Surg.*, 2016, 29, 85−94.

Alba Mesa, F; Amaya Cortijo, A; Romero Fernandez, TM; Komorowski, AL; Sanchez Hurtado, MA; Sanchez Margallo, FM. Totally transvaginal resection of the descending colon in an experimental model. *Surgical Endoscopy*, 2012, 26(3), 877−881.

Antoniou, SA; Antoniou, GA; Koch, OO; Pointner, R; Granderath, FA. Meta-analysis of laparoscopic vs open cholecystectomy in elderly patients. *World Journal of Gastroenterology: WJG*, 2014, 20(46), 17626−17634.

Aydin, A; Raison, N; Khan, MS; Dasgupta, P; Ahmed, K. Simulation-based training and assessment in urological surgery. *Nat. Rev. Urol.*, 2016, 13(9), 503−519.

Blackmore, AE; Wong, MT; Tang, CL. Evolution of laparoscopy in colorectal surgery: an evidence-based review. *World J. Gastroenterol.*, 2014, 20(17), 4926−4933.

Bric, JD; Lumbard, DC; Frelich, MJ; Gould, JC. Current state of virtual reality simulation in robotic surgery training: a review. *Surgical Endoscopy*, 2016, 30(6), 2169−2178.

Buckley, CE; Kavanagh, DO; Nugent, E; Ryan, D; Traynor, OJ; Neary, PC. The impact of aptitude on the learning curve for laparoscopic suturing. *The American Journal of Surgery*, 2014, 207(2), 263−270.

Buckley, CE; Kavanagh, DO; Traynor, O; Neary, PC. Does aptitude matter? *Journal of the American College of Surgeons*, 215(3), S116.

Bui, A; Stockhausen, F; Hanisch, E. Laparoscopic surgery: A qualified systematic review. *World J. Methodol*, 2015, 5(4), 238−254.

Castillo, R; Buckel, E; León, F; Varas, J; Alvarado, J; Achurra, P; Aggarwal, R; Jarufe, N; Boza, C. Effectiveness of Learning Advanced Laparoscopic Skills in a Brief Intensive Laparoscopy Training Program. *Journal of Surgical Education*, 2015, 72(4), 648−653.

Chaudhr, A; Sutton, C; Wood, J; Stone, R; McCloy, R. Learning rate for laparoscopic surgical skills on MIST VR, a virtual reality simulator: quality of human-computer interface. *Annals of The Royal College of Surgeons of England*, 1999, 81(4), 281−286.

Chen, PD; Wu, CY; Hu, RH; Ho, CM; Lee, PH; Lai, HS; Lin, MT; Wu, YM. Robotic liver donor right hepatectomy – a pure, minimally invasive approach. *Liver Transplantation*, 2016, 22 (11), 1509−1518.

Cook, JA; Ramsay, CR; Fayers, P. Using the literature to quantify the learning curve: A case study. *International Journal of Technology Assessment in Health Care*, 2007, 23(2), 255−260.

Cook, JA; Ramsaya, CR; Fayers, P. Statistical evaluation of learning curve effects in surgical trials. *Clinical Trials*, 2004, 1(5), 421−427.

Crist, DW; Davoudi, MM; Parrino, PE; Gadacz, TR. An experimental model for laparoscopic common bile duct exploration. *Surg. Laparosc. Endosc.*, 1994, 4(5), 336−339.

Del Castillo Dejardin, D; Sabench Pereferrer, F; Hernandez Gonzale, M; Blanco Blasco, S; Abello Sala, M. The evolution of experimental surgery in the field of morbid obesity. *Obes. Surg.*, 2004, 14(9), 1263−1272.

Demirbas, M; Samli, M; Aksoy, Y; Guler, C; Kilinc, A; Dincel, C. Comparison of changes in tissue oxidative-stress markers in experimental model of open, laparoscopic, and retroperitoneoscopic donor nephrectomy. *Journal of endourology*, 2004, 18(1), 105−108.

Dhumane, P; Donatelli, G; Chung, H; Dallemagne, B; Marescaux, J. Feasibility of transumbilical flexible endoscopic preperitoneoscopy (FLEPP) and its utility for inguinal hernia repair: experimental animal study. *Surg. Innov.*, 2013, 20(1), 5−12.

Esposito, CC. Training Models in Pediatric Minimally Invasive Surgery: Rabbit Model Versus Porcine Model: A Comparative Study. *Journal of laparoendoscopic & advanced surgical techniques. Part A*, 2016, 26(1), 79−84.

Feldman, LS; Cao, J; Andalib, A; Fraser, S; Fried, GM. A method to characterize the learning curve for performance of a fundamental laparoscopic simulator task: Defining "learning plateau" and "learning rate". *Surgery*, 2009, 146(2), 381−386.

Fried, GM; Feldman, LS; Vassiliou, MC; Fraser, SA; Stanbridge, D; Ghitulescu, G; Andrew, CG. Proving the Value of Simulation in Laparoscopic Surgery. *Annals of Surgery*, 2004, 240(3), 518−528.

Gillen, S; Gröne, J; Knödgen, F; Wolf, P; Meyer, M; Friess, H; Buhr, HJ; Ritz, JP; Feussner, H; Lehmann, KS. Educational and training aspects of new surgical techniques, experience with the endoscopic–laparoscopic interdisciplinary training entity (ELITE) model in training for a natural orifice translumenal endoscopic surgery (NOTES) approach to appendectomy. *Surgical Endoscopy*, 2012, 26(8), 2376−2382.

Giulianotti, PC; Bianco, FM; Daskalaki, D; Gonzalez-Ciccarelli, LF; Kim, J; Benedetti, E. Robotic liver surgery: technical aspects and review of the literature. *Hepatobiliary Surgery and Nutrition*, 2016, 5(4), 311−321.

Grantcharov, TP; Funch-Jensen, P. Can everyone achieve proficiency with the laparoscopic technique? Learning curve patterns in technical skills acquisition. *The American Journal of Surgery*, 2009, 197(4), 447−449.

Grantcharov, TPTP. [Evaluation of surgical competence]. *Ugeskrift for læger*, 2004, 166(21), 2023−2025.

Greco, EFEF. Identifying and classifying problem areas in laparoscopic skills acquisition: can simulators help? *Academic medicine*, 2010, 85(10 suppl), S5−S8.

Groenier, M; Schraagen, JMC; Miedema, HAT; Broeders, IAJM. The role of cognitive abilities in laparoscopic simulator training. *Advances in Health Sciences Education*, 2014, 19(2), 203−217.

Gurusamy, KS; Aggarwal, R; Palanivelu, L; Davidson, BR. Virtual reality training for surgical trainees in laparoscopic surgery. *Cochrane Database Syst Rev*, 2009, (1), Cd006575.

Gutt, CNC. Standardized technique of laparoscopic surgery in the rat. *Digestive surgery*, 1998, 15(2), 135−139.

Hassan, A; Kadima, KB; Remi-adewumi, BD; Awasum, CA; Abubakar, MT. Animal models in surgical training, choice and ethics. *Nigerian journal of surgical research*, 2005, 7(3−4), 260−267.

Hildebrand, P; Kleemann, M; Roblick, U; Mirow, L; Bruch, HP; Bürk, C. Development of a perfused ex vivo tumor-mimic model for the training of laparoscopic radiofrequency ablation. *Surgical Endoscopy*, 2007, 21(10), 1745−1749.

Holmer, C; Winter, H; Kröger, M; Nagel, A; Jaenicke, A; Lauster, R; Kraft, M; Buhr, HJ; Ritz, JP. Bipolar radiofrequency-induced thermofusion of intestinal anastomoses—feasibility of a new anastomosis technique in porcine and rat colon. *Langenbeck's Archives of Surgery*, 2011, 396(4), 529−533.

Hyltander, A; Liljegren, E; Rhodin, PH; Lönroth, H. The transfer of basic skills learned in a laparoscopic simulator to the operating room. *Surgical Endoscopy And Other Interventional Techniques*, 2002, 16(9), 1324−1328.

Kaouk, JH; Gill, IS; Meraney, AM; Desai, MM; Carvalhal, EF; Fergany, AF; Sung, GT. Retroperitoneal minilaparoscopic nephrectomy in the rat model. *Urology*, 2000, 56(6), 1058−1062.

Katz, RR. Cadaveric versus porcine models in urological laparoscopic training. *Urologia internationalis*, 2003, 71(3), 310−315.

Keehner, M; Lippa, Y; Montello, DR; Tendick, F; Hegarty, M. Learning a spatial skill for surgery: How the contributions of abilities change with practice. *Applied cognitive psychology*, 2006, 20(4), 487−504.

Kenngott, HG; Wünscher, JJ; Wagner, M; Preukschas, A; Wekerle, AL; Neher, P; Suwelack, S; Speidel, S; Nickel, F; Oladokun, D; Maier-Hein, L; Dillmann, R; Meinzer, HP; Müller-Stich, BP. Open HELP (Heidelberg laparoscopy phantom): development of an open-source surgical evaluation and training tool. *Surgical Endoscopy*, 2015, 29(11), 3338−3347.

Keus, F; de Jong, J; Gooszen, HG; Laarhoven, CJ. Laparoscopic versus open cholecystectomy for patients with symptomatic cholecystolithiasis. *Cochrane Database of Systematic Reviews*, 2006, (4), CD006231

Kirlum, HJ; Heinrich, M; Tillo, N; Till, H. Advanced Paediatric Laparoscopic Surgery: Repetitive Training in a Rabbit Model Provides Superior Skills for Live Operations. *Eur. J. Pediatr. Surg.*, 2005, 15(03), 149−152.

Kobayashi, E; Hishikawa, S;Teratani, T; Lefor, AT. The pig as a model for translational research: overview of porcine animal models at Jichi Medical University. *Transplantation Research*, 2012, 1, 1−8.

Komorowski Andrzej, L; Mituś Jerzy, W; Hurtado Miguel Angel, S; Margallo Francisco Miguel, S. Porcine Model In The Laparoscopic Liver Surgery Training. *Polish Journal of Surgery*, 2015, 87, 425.

Korzeniowski, P; Barrow, A; Sodergren, MH; Hald, N; Bello, F. NOViSE: a virtual natural orifice transluminal endoscopic surgery simulator. *International Journal of Computer Assisted Radiology and Surgery*, 2016, 1−13.

Kramp, KH; van Det, MJ; Hoff, C; Veeger, NJ; ten Cate Hoedemaker, HO; Pierie, JP. The predictive value of aptitude assessment in laparoscopic surgery: a meta-analysis. *Med. Educ.*, 2016, 50(4), 409−427.

Larsen, CR; Oestergaard, J; Ottesen, BS; Soerensen, JL. The efficacy of virtual reality simulation training in laparoscopy: a systematic review of randomized trials. *Acta. Obstet. Gynecol. Scand.*, 2012, 91(9), 1015−1028.

Li, X; Zhang, J; Sang, L; Zhang, W; Chu, Z; Li, X; Liu, Y. Laparoscopic versus conventional appendectomy - a meta-analysis of randomized controlled trials. *BMC Gastroenterology*, 2010, 10(1), 1−8.

Luks, FI; Peers, KHE; Deprest, JA; Lerut, TE. Gasless laparoscopy in infants: The rabbit model. *Journal of Pediatric Surgery*, 1995, 30(8), 1206−1208.

Luursema, JM; Buzink, SN; Verwey, WB; Jakimowicz, JJ. Visuo-spatial ability in colonoscopy simulator training. *Advances in Health Sciences Education*, 2010, 15(5), 685−694.

Luursema, JM; Verwey, WB; Burie, R. Visuospatial ability factors and performance variables in laparoscopic simulator training. *Learning and Individual Differences*, 2012, 22(5), 632−638.

MacFadyen, BV; Cuschieri, A. Endoluminal surgery. *Surgical Endoscopy and Other Interventional Techniques*, 2005, 19(1), 1−3.

Martin, JA; Regehr, G; Reznick, R; Macrae, H; Murnaghan, J; Hutchison, C; Brown, M. Objective structured assessment of technical skill (OSATS) for surgical residents. *British Journal of Surgery*, 1997, 84(2), 273−278.

Martins, P; Markmann, JF; Hertl, M; (2013). *Liver transplantation in the pig. Experimental Organ Transplantation*. H. Chen and S. Quin, Nova Science Publishers, 271−296.

Memon, MA; Subramanya, MS; Hossain, MB; Yunus, RM; Khan, S; Memon, B. Laparoscopic Anterior Versus Posterior Fundoplication for Gastro-esophageal Reflux Disease: A Meta-analysis and Systematic Review. *World Journal of Surgery*, 2015, 39(4), 981−996.

Molinas, CR; Binda, MM; Mailova, K; Koninckx, PR. The rabbit nephrectomy model for training in laparoscopic surgery. *Human Reproduction*, 2004, 19(1), 185−190.

Nagendran, M; Gurusamy, KS; Aggarwal, R; Loizidou, M; Davidson, BR. Virtual reality training for surgical trainees in laparoscopic surgery. *Cochrane Database Syst. Rev.*, 2013, (8), Cd006575.

Novara, G; La Falce, S; Kungulli, A; Gandaglia, G; Ficarra, V; Mottrie, A. Robot-assisted partial nephrectomy. *International Journal of Surgery*, 2016, 36, 554−559.

Ohtani, H; Tamamori, Y; Arimoto, Y; Nishiguchi, Y; Maeda, K; Hirakawa, K. Meta-analysis of the Results of Randomized Controlled Trials that Compared Laparoscopic and Open Surgery for Acute Appendicitis. *Journal of Gastrointestinal Surgery*, 2012, 16(10), 1929−1939.

Ong, SL; Gravante, G; Metcalfe, MS; Dennison, AR. History, ethics, advantages and limitations of experimental models for hepatic ablation. *World Journal of Gastroenterology: WJG*, 2013, 19(2), 147−154.

Panaro, F; Matos-Azevedo, AM; Fatas, JA; Marin, J; Navarro, F; Zaragoza-Fernandez, C. Endoscopic and histological evaluations of a newly designed inguinal hernia mesh implant, Experimental studies on porcine animal model and human cadaver. *Ann. Med. Surg. (Lond)*, 2015, 4(2), 172−178.

Patel, M; Porter, J. Robotic retroperitoneal partial nephrectomy. *World Journal of Urology*, 2013, 31(6), 1377−1382.

Peters, MJ; Mukhtar, A; Yunus, RM; Khan, S; Pappalardo, J; Memon, B; Memon, MA. Meta-Analysis of Randomized Clinical Trials Comparing Open and Laparoscopic Anti-Reflux Surgery. *Am. J. Gastroenterol.*, 2009, 104(6), 1548−1561.

Piechaud, PT; Pansadoro, A. Transfer of skills from the experimental model to the patients. *Curr. Urol. Rep.*, 2006, 7(2), 96−99.

Polyzogopoulou, EV; Kalfarentzos, F; Vagenakis, AG; Alexandrides, TK. Restoration of Euglycemia and Normal Acute Insulin Response to Glucose in Obese Subjects With Type 2 Diabetes Following Bariatric Surgery. *Diabetes*, 2003, 52(5), 1098−1103.

Ponce, J; DeMaria, EJ; Nguyen, NT; Hutter, M; Sudan, R; Morton, JM. American Society for Metabolic and Bariatric Surgery estimation of bariatric surgery procedures in 2015 and surgeon workforce in the United States. *Surgery for Obesity and Related Diseases*, 2016, 12(9), 1637−1639.

Ponsky, JL. Endoluminal surgery: past, present and future. *Surgical Endoscopy And Other Interventional Techniques*, 2006, 20(2), S500−S502.

Pucher, PH; Sodergren, MH; Singh, P; Darzi, A; Parakseva, P. Have we learned from lessons of the past? A systematic review of training for single incision laparoscopic surgery. *Surg. Endosc.*, 2013, 27(5), 1478−1484.

Richards, WO; Rattner, DW. Endoluminal and transluminal surgery: no longer if, but when. *Surgical Endoscopy And Other Interventional Techniques*, 2005, 19(4), 461−463.

Roberts, KE; Bell, RL; Duffy, AJ. Evolution of surgical skills training. *World J. Gastroenterol.*, 2006, 12(20), 3219−3224.

Rogers, CG; Singh, A; Blatt, AM; Linehan, WM; Pinto, PA. Robotic Partial Nephrectomy for Complex Renal Tumors, Surgical Technique. *European Urology*, 2008, 53(3), 514−523.

Ryska, O; Serclova, Z; Martinek, J; Dolezel, R; Kalvach, J; Juhas, S; Juhasova, J; Bunganic, B; Laszikova, E; Ryska, M. A new experimental model of calculous cholecystitis suitable for the evaluation and training of minimally invasive approaches to cholecystectomy. *Surgical Endoscopy*, 2016, 1−8.

Sachdeva, AK; Russell, TR. Safe Introduction of New Procedures and Emerging Technologies in Surgery: Education, Credentialing, and Privileging. *Surgical Oncology Clinics of North America*, 2007, 16(1), 101−114.

Sánchez-De Pedro, F; Moreno-Sanz, C; Morandeira-Rivas, A; Tenías-Burillo, JM; Alhambra-Rodríguez De Guzmán, C. Colorectal anastomosis facilitated by the use of the LigaSure® sealing device: comparative study in an animal model. *Surgical Endoscopy*, 2014, 28(2), 508−514.

Scheidbach, H; Tamme, C; Tannapfel, A; Lippert, H; Köckerling, F. *In vivo* studies comparing the biocompatibility of various polypropylene meshes and their handling properties during endoscopic total extraperitoneal (TEP) patchplasty: an experimental study in pigs. *Surgical Endoscopy And Other Interventional Techniques*, 2004, 18(2), 211−220.

Sharma, M; Horgan, A. Comparison of Fresh-Frozen Cadaver and High-Fidelity Virtual Reality Simulator as Methods of Laparoscopic Training. *World Journal of Surgery*, 2012, 36(8), 1732−1737.

Singer, CJ. *Greek biology and Greek medicine*. Oxford: Clarendon Press, 1922.

Sodergren, MH; Markar, S; Pucher, PH; Badran, IA; Jiao, LR; Darzi, A. Safety of transvaginal hybrid NOTES cholecystectomy: a systematic review and meta-analysis. *Surgical Endoscopy*, 2015, 29(8), 2077−2090.

Sorensen, SM; Savran, MM; Konge, L; Bjerrum, F. Three-dimensional versus two-dimensional vision in laparoscopy: a systematic review. *Surg. Endosc.*, 2016, 30(1), 11−23.

Soria, F; Delgado, MI; Rioja, LA; Blas, M; Pamplona, M; Duran, E; Uson, J; Sanchez, FM. Ureteral double-J wire stent effectiveness after endopyelotomy: an animal model study. *Urol. Int.*, 2010, 85(3), 314−319.

Spivak, H; Hunter, JG. Endoluminal surgery. *Surgical Endoscop.*, 1997, 11(4), 321−325.

Stepanian, S; Patel, M; Porter, J. Robot-assisted Laparoscopic Retroperitoneal Lymph Node Dissection for Testicular Cancer: Evolution of the Technique. *European Urology*, 2016, 70(4), 661−667.

Sutherland, LM; Middleton, PF; Anthony, A; Hamdorf, J; Cregan, P; Scott, D; Maddern, GJ. Surgical simulation: a systematic review. *Ann. Surg.*, 2006, 243(3), 291−300.

Taffinder, NN. Validation of virtual reality to teach and assess psychomotor skills in laparoscopic surgery: results from randomised controlled studies using the MIST VR laparoscopic simulator. *Studies in health technology and informatics*, 1998, 50, 124−130.

Tanaka, H; Kobayashi, E. Education and research using experimental pigs in a medical school. *Journal of Artificial Organs*, 2006, 9(3), 136−143.

Trehan, A; Barnett-Vanes, A; Carty, MJ; McCulloch, P; Maruthappu, M. The impact of feedback of intraoperative technical performance in surgery: a systematic review. *BMJ Open*, 2015, 5(6), e006759.

van Velthoven, RF; Hoffmann, P. Methods for laparoscopic training using animal models. *Current Urology Reports*, 2006, 7(2), 114−119.

Vanderbilt, AA; Grover, AC; Pastis, NJ; Feldman, M; Granados, DD; Murithi, LK; Mainous, AG. Randomized Controlled Trials: A Systematic Review of Laparoscopic Surgery and Simulation-Based Training. *Global Journal of Health Science*, 2015, 7(2), 310−327.

Vecchio, R; MacFayden, BV; Palazzo, F. History of laparoscopic surgery. *Panminerva. Med.*, 2000, 42(1), 87−90.

Wanzel, KR; Hamstra, SJ; Anastakis, DJ; Matsumoto, ED; Cusimano, MD. Effect of visual-spatial ability on learning of spatially-complex surgical skills. *The Lancet*, 2002, 359(9302), 230−231.

Wanzel, KR; Hamstra, SJ; Caminiti, MF; Anastakis, DJ; Grober, ED; Reznick, RK. Visual-spatial ability correlates with efficiency of hand motion and successful surgical performance. *Surgery*, 2003, 134(5), 750−757.

Way, LW; Stewart, L; Gantert, W; Liu, K; Lee, CM; Whang, K; Hunter, JG. Causes and Prevention of Laparoscopic Bile Duct Injuries: Analysis of 252 Cases From a Human Factors and Cognitive Psychology Perspective. *Annals of Surgery*, 2003, 237(4), 460−469.

Willaert, W; Van De Putte, D; Van Renterghem, K; Van Nieuwenhove, Y; Ceelen, W; Pattyn, P. Training models in laparoscopy: a systematic review comparing their effectiveness in learning surgical skills. *Acta. Chir. Belg.*, 2013, 113(2), 77−95.

Wilson, LGL. Erasistratus, Galen, and the pneuma. *Bulletin of the history of medicine*, 1959, 33, 293−314.

Zendejas, B; Brydges, R; Hamstra, SJ; Cook, DA. State of the evidence on simulation-based training for laparoscopic surgery: a systematic review. *Ann. Surg.*, 2013, 257(4), 586−593.

Zendejas, B; Ruparel, RK; Cook, DA. Validity evidence for the Fundamentals of Laparoscopic Surgery (FLS) program as an assessment tool: a systematic review. *Surg. Endosc.*, 2016, 30(2), 512−520.

Zhang, H; Liu, T; Wang, Y; Liu, HF; Zhang, JT; Wu, YS; Lei, L; Wang, HB. Laparoscopic left hepatectomy in swine: a safe and feasible technique. *Journal of Veterinary Science*, 2014, 15(3), 417−422.

In: Encyclopedia of Surgery (22 Volume Set)
Editors: Andreas Lehrer and Kristin Mueller
ISBN: 978-1-53618-329-0
© 2020 Nova Science Publishers, Inc.

Chapter 187

EXPERIMENTAL MODELS OF SEPSIS

Norbert Nemeth[1,*], Mihai Oltean[2] and Bela Fulesdi[3]
[1]Department of Operative Techniques and Surgical Research,
Faculty of Medicine, University of Debrecen,
Debrecen, Hungary
[2]The Transplantation Institute, Sahlgrenska University Hospital,
Gothenburg, Sweden
[3]Department of Anesthesiology and Intensive Care,
Faculty of Medicine, University of Debrecen,
Debrecen, Hungary

ABSTRACT

Sepsis is a clinical syndrome manifesting as a complex systemic response to infection. In spite of significant developments in diagnostic, monitoring and intensive care, sepsis remains a major cause of morbidity and mortality as well as a significant economic burden. Despite inherent limitations, experimental models remain an essential tool for understanding the intricate mechanisms and pathways activated during sepsis and for developing new therapeutic approaches. However, most strategies proved as effective experimentally, have been disappointing in the clinical trials conducted so far. These unsatisfactory attempts in translating the treatment options to bedside may be attributed to the involvement of multiple mediators and pathways in sepsis with only few components being recognized and targeted but also to general or specific shortcomings of each animal model. Herein, we provide a brief overview of the pathophysiology of sepsis and concise descriptions of relevant experimental models including considerations for further refinements (i.e., animal age, gender and co-morbidities) that are further required to ensure an effective translation of the findings into the clinical setting.

Keywords: sepsis, animal models, clinical versus experimental sepsis

[*] Corresponding Author's Email: nemeth@med.unideb.hu.

ABBREVIATIONS

ARDS	acute respiratory distress syndrome
AST	*aspartate aminotransferase*
ATP	adenosine triphosphate
CASP	colon ascendens stent peritonitis model
CLP	cecal ligation and puncture model
DIC	disseminated intravascular coagulation
EVLW	extra-vascular lung water
GCS	Glasgow Coma Scale
HR	heart rate
ICU	intensive care unit
IL	interleukin
LPS	lipopolysaccharide
MAP	mean arterial pressure
MODS	multiorgan dysfunction syndrome
MOF	multiple organ failure
NFκB	nuclear factor kappa B
NO	nitric oxide
NOD	nucleotide-binding oligomerization domain-like (*receptor)*
PEEP	*positive* end-expiratory pressure
PiCCO	Pulse index Continuous Cardiac Output monitoring device
SIRS	systemic inflammatory response syndrome
SOFA	sequential organ failure assessment (score)
TLR	toll-like receptor
TNF-α	tumor necrosis factor alpha

INTRODUCTION

The last decades witnessed a tremendous increase in the volume of research and number of publications on sepsis, both in clinical and experimental setting (Figure 1). Despite the advancement of the diagnostic and therapeutic possibilities and the accumulating evidence-based treatment options, sepsis remains a main cause of death in the intensive care units (ICU) of developed countries. According to a recent report, there have been 31.5 million cases of sepsis annually, among them 19.4 million severe cases, with potentially 5.3 million deaths occurring annually (Daniels 2011; Fleischmann 2016).

A better understanding of the pathophysiology of the sepsis and the development of novel therapeutical methods require a great deal of animal experimentation. Publications on animal sepsis have increased in logarithmic fashion in the past decades (Figure 1). Although rodents remain the most common species used, other species are also subjected to sepsis studies (Figure 2). Depending on the goals of each particular study and the peculiarities of various models and species, each existing model has different advantages but also result in several limitations and difficulties when extrapolating results into the clinical scenarios or trials (Fink 2001; Esmon 2004; Bara 2014; Kingsley 2016).

Planning and conducting a sepsis study on animals requires careful consideration of numerous essential aspects that may influence the results, conclusions and the as well as the reproducibility of the study. In this chapter we aimed to briefly overview the clinical problem, pathophysiology, the animal models, their advantages and limitations.

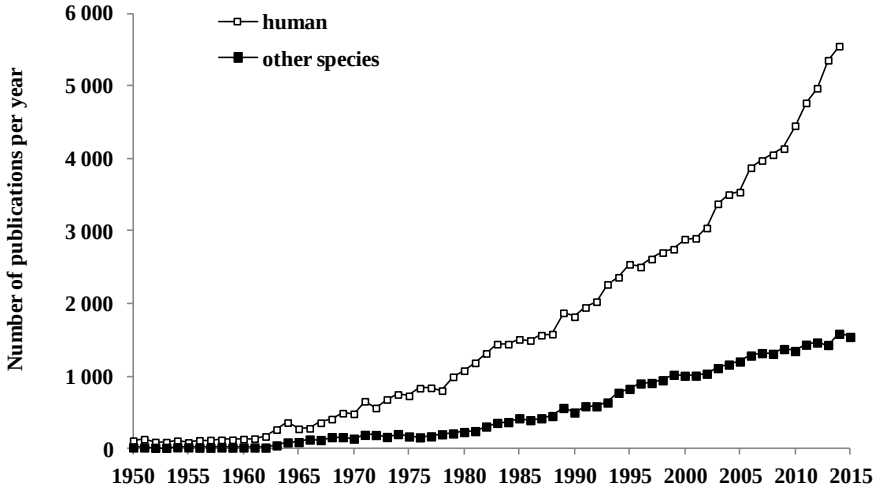

Figure 1. Number of publications per year on the human and animal sepsis (PubMed search, 12 November 2016).

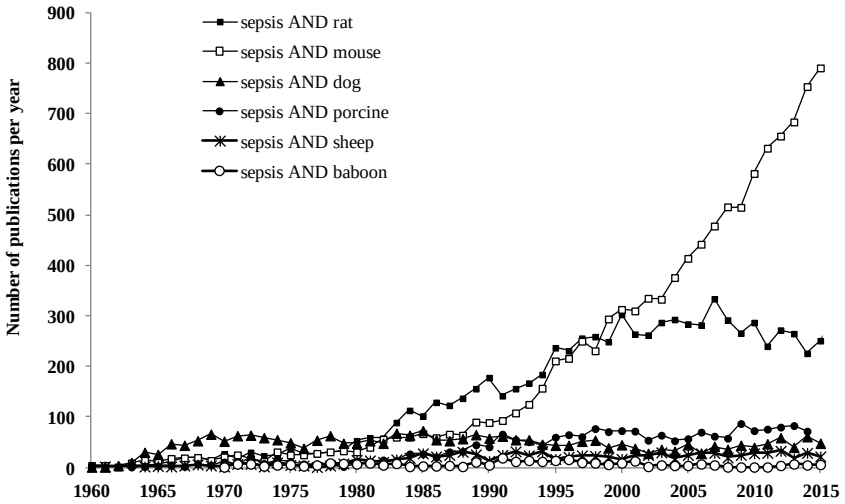

Figure 2. Number of publications per year on animal sepsis by species (PubMed search, 12 November 2016).

In the last decades, increasing number of papers have been published on sepsis, both in clinical and experimental settings (Figure 1).

To better understand the pathophysiology of sepsis and to develop therapeutic methods, experiments conducted on animals are still necessary. Publications on animal sepsis have increased significantly in the past decades (Figure 1). Although the most common species are

rodents, other animals such as dog, pig, sheep and non-human primates are also used in sepsis studies in a significant number (Figure 2). However, the models are different; besides their advantages, animal models have several limitations and difficulties when extrapolating results. These issues have been discussed in the literature intensively in the last decades (Wichterman 1980; Fink 2001; Schulz 2002; Esmon 2004; Remick 2005; Rittirsch 2007; Chiavolini 2008; Poli-de-Figueiredo 2008; Dyson 2009; van der Poll 2012; Ward 2012; Ziaja 2012; Bara 2014; Chen 2014; Efron 2014; Fink 2014; Shrum 2014; Lilley 2015; Kingsley 2016; Lewis 2016). To plan and conduct a sepsis model using animals, there are numerous essential aspects to consider.

CLINICAL DEFINITIONS OF SEPSIS

It is noteworthy that the past three decades have seen various definitions for sepsis and severe sepsis. Initially, sepsis was defined as a clinical response arising from infection, independently from the cause of infection (bacterial, viral or fungal) (American College of Chest Physicians/Society of Critical Care Medicine Consensus Conference 1992). This initial definition also introduced the concept of systemic inflammatory response syndrome (SIRS).

It has been postulated that sepsis and SIRS have similar clinical appearance, although, major differences exist among the underlying causes (i.e., infections and non-infections causes such as, burns, trauma). At this stage, sepsis was defined based on simple clinical criteria such as: body temperature >38°C or <36°C; pulse rate >90/minutes; breathing frequency >20/minutes and/or pCO_2 <30 mmHg; leukocyte count >12 G/l or lower than 4 G/l along with more than 10% immature forms. For making the diagnosis of sepsis, two of the above listed parameters were necessary to be present. At that time, severe sepsis was defined as basic symptoms of sepsis plus organ dysfunctions, hypotension and hypoperfusion related to infection. Consequently, a very large number of patients were diagnosed as having sepsis based on these criteria.

The next attempt to revise this definition retained these clinically determined criteria, further stating that an expanded list of signs and symptoms of sepsis may better reflect the clinical response to infection, but also included several biochemical markers for use in septic patients (Table 1) (Levy 2003). In its very recent definition, sepsis is described as a "*life threatening organ dysfunction caused by a dysregulated host response to infection"* (Singer 2016).

The key points to be taken into account according to this newly developed definition are heterogeneity of the patients that is influenced by underlying co-morbidities, concurrent injuries (such as surgery), medications and source of infections. This statement differentiates sepsis from infection. Sepsis is an aberrant or dysregulated host response and the presence of organ dysfunction. Accordingly, the main definitions of the septic process are as follows:

- *Sepsis* is defined as life-threatening organ dysfunction caused by a dys-regulated host response to infection.
- *Organ dysfunction* can be identified as an acute change in total SOFA score >2 points consequent to the infection.

- *Septic shock* is a subset of sepsis in which underlying circulatory and cellular/metabolic abnormalities are profound enough to substantially increase mortality. Patients with septic shock can be identified with persisting hypotension requiring vasopressors to maintain MAP >65 mmHg and having a serum lactate level, >2 mmol/L (18 mg/dL) despite adequate volume resuscitation.

The main categories of Sequential Organ Failure Assessment Score (SOFA Score) are summarized in Table 2 (Vincent 1996).

Table 1. Diagnostic criteria for sepsis according to the 2001 definition (Levy 2003)

Infection
Documented or suspected *and* some of the following:
General parameters
Fever (core temperature >38.3°C)
Hypothermia (core temperature <36°C)
Heart rate >90 bpm or >2 SD above the normal value for age
Tachypnea: >30 bpm
Altered mental status
Significant edema or positive fluid balance (>20 ml/kg over 24 h)
Hyperglycemia (plasma glucose >110 mg/dl or 7.7 mM/l) in the absence of diabetes
Inflammatory parameters
Leukocytosis (white blood cell count >12,000/μl)
Leukopenia (white blood cell count <4,000/μl)
Normal white blood cell count with >10% immature forms
Plasma C reactive protein>2 SD above the normal value
Plasma procalcitonin >2 SD above the normal value
Hemodynamic parameters
Arterial hypotension (systolic blood pressure <90 mmHg, mean arterial pressure <70, or a systolic blood pressure decrease >40 mmHg in adults or <2 SD below normal for age)
Mixed venous oxygen saturation >70%
Cardiac index >3.5 l min^{-1} m
Organ dysfunction parameters
Arterial hypoxemia ($PaO_2/FIO2$ <300)
Acute oliguria (urine output <0.5 ml kg^{-1} h^{-1} or 45 mM/l for at least 2 h)
Creatinine increase ≥0.5 mg/dl
Coagulation abnormalities (international normalized ratio >1.5 or activated partial thromboplastin time >60 s)
Ileus (absent bowel sounds)
Thrombocytopenia (platelet count <100,000/μl)
Hyperbilirubinemia (plasma total bilirubin >4 mg/dl or 70 mmol/l)
Tissue perfusion parameters
Hyperlactatemia (>3 mmol/l)
Decreased capillary refill or mottling

Table 2. The Sequential Organ Failure Assessment or Sepsis-related Organ Failure Assessment score (SOFA) score (Vincent 1996)

	0	1	2	3	4
Respiration					
PaO2/FiO2 (mmHg)	>400	<400	<300	<200 with respiratory support	<100 with respiratory support
Coagulation					
Platelets ($x10^3/\mu L$)	>150	<150	<100	<50	<20
Liver					
Bilirubin (µmol/L)	<1.2	1.2−1.9	2.0−5.9	6.0−11.9	>12
Cardiovascular					
	MAP >70 mmHg	MAP <70 mmHg	Dopamine < 5 or dobutamine any dose	Dopamine 5.1-15 or epinephrine <0.1 or norepinephrine < 0.1	Dopamine >15 or epinephrine >0.1 or norepinephrine >0.1
Central nervous system					
GCS	15	13−14	10−12	6−9	< 6
Renal					
Creatinine (µmol/L)	<110	110−170	171−299	300−440	> 440
Urine output (mL/D)				< 500	< 200

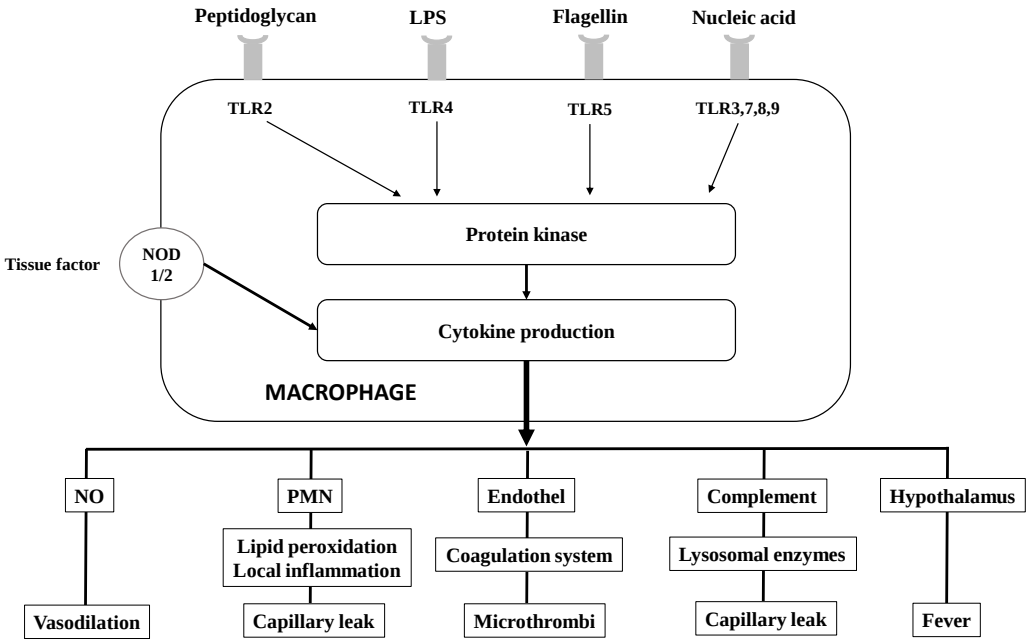

Figure 3. The involvement of macrophages in the septic process.

A BRIEF OVERVIEW ON THE PATHOPHYSIOLOGY OF SEPSIS

In recent decades it has become clear that different pathogens exert their action by interacting with specific targets (represented by toll-like receptors) at the surface of various cell types. In case of non-infectious origin, SIRS is evoked through the activation of the nucleotide-binding oligomerization domain-like (NOD) receptors. Macrophages are key actors in the process as activation of their NF-κB by protein kinases results in the production of pro- and anti-inflammatory cytokines triggering the general inflammatory process (Figure 3). As it is demonstrated in the figure, the "cytokine storm" causes gradual changes at the level of capillary function and coagulation system. These complex changes determine the severity of SIRS and sepsis in their later course (Brides 2005; Remick 2007; Wynn 2010; Nduka 2011; Dellinger 2013; Semeraro 2015; Bhan 2016). In the view of this, in the following sections, we summarize the main pathophysiological alterations and their consequences in different organ systems.

Causes of Capillary Dysfunction in Sepsis

The capillary network is responsible for the transport of oxygen and the main nutritional products to the tissues. Its function is influenced by the distribution of the capillary network in certain tissue, by the actual condition of the capillaries (dilated or constricted), by the inter-capillary distance and by hemorheological factors (Further details in Chapter 34).

Sepsis is currently considered as a microcirculatory disorder (Astiz 1995; Ince 2005, 2016; Trzeciak 2007, 2008; Tyagi 2009; Ostergaard 2015). The microcirculatory failure usually is generalized; however, it is often tested on the sublingual surface and/or on skin (Young 1995; Trzeciak 2007, 2008; Wester 2011; Kiss 2015). Factors leading to microcirculatory problems in sepsis are complex. Several mechanisms act on the pre-capillary, capillary and post-capillary regions of the microcirculation, as summarized in Table 3.

The mechanisms leading to deterioration of micro-rheological factors are dominantly non-specific. Red blood cell deformability can be impaired by (1) local metabolic and acid-base changes (pH, lactate concentration, oxygenation level, micro-environmental osmolarity); (2) decrease in ATP and consequent failure of active pump mechanisms, a condition that leads to alteration in surface to volume ratio; as well as by (3) reactive oxygen species (Baskurt 2007; Piagnerelli 2003; Nemeth 2012). Red blood cells can be damaged mechanically as well due to the presence of thrombi and micro-thrombi (DIC), or even by the associated mechanical trauma to blood during therapeutic efforts such as the direct removal of toxins from the bloodstream by high-volume hemofiltration (Kameneva 2007; Borthwick 2013).

Enhanced red blood cell aggregation is a common observation in manifest sepsis. In most of the clinical and experimental studies, the developed sepsis and severe sepsis has been found with increased fibrinogen and plasma viscosity, impaired red blood cell deformability and markedly enhanced erythrocyte aggregation (Chien 1972; Baskurt 1997; Kirschenbaum 2000; Piagnerelli 2003; Pöschl 2003; Alt 2004; Sordia 2006; Moutzouri 2007; Reggiori 2009). The rise in fibrinogen concentration is one of the factors that lead to enhanced

erythrocyte aggregation. Furthermore, free radical effects, ultrastructural alterations of the cell surface glycocalyx as well as cellular morphology changes might also influence red blood cell aggregation in its magnitude and kinetics (Baskurt 2007, 2012; Nemeth 2012). However, it has been also shown in a porcine model of fulminant sepsis that during the early phase of the process, the red blood cell aggregation might be decreased (Nemeth 2015, 2016), probably due to the early fibrinogen consumption (Asakura 2014; Semeraro 2015), the direct effect of NO and the bacteria themselves *(Escherichia coli)* on erythrocytes.

Table 3. Events and factors leading to microcirculatory disturbances in sepsis (based on papers by Piagnerelli 2003; Spronk 2004; Lundy 2009)

Event, factor	Dominant site of the effect
vasodilatation and vasopressor hyporeactivity (vasoplegia)	arterioles
redistribution of organ blood flow, hemodynamic changes	
congestion, intravascular pooling	arterioles, venules
opening AV shunts	
endothelial cell activation, endothelial dysfunction	arterioles, capillaries, venules
hemorrhage	
decreased neutrophil deformability	
enhanced neutrophil aggregation	
impaired red blood cell deformability	
microthrombi, DIC	
increased plasma viscosity	
increased microvascular permeability	capillaries
edema formation	
neutrophil adhesion and aggregation	capillaries, venules

Deformability of neutrophils also decreases and their aggregation increases in severe sepsis and septic shock (Yodice 1997; Nishino 2005; Brown 2006). Adhered leukocytes affect local flow pattern and rigid cells may plug microcapillaries. Furthermore, altered blood rheology drives margination of the leukocytes: increased erythrocyte aggregation enhances axial flow, resulting in a widening cell deprived layer (Poiseuille-zone) in the vicinity of the endothelial surface, and so the flow pattern facilitates leukocyte tethering and margination (Nash 2008).

Capillary perfusion is usually described by the term ‘capillary driving pressure’ and by the actual condition of the pre- and post-capillary sphincters. Low volume state during sepsis may be attributed to 2 main factors: (1) Due to the peripheral vasodilation, a large amount of fluid is stored in the dilated vessels; and (2) due to capillary leak, a large amount of fluid may leave the intravascular compartment thus resulting in an interstitial fluid accumulation. Capillary leakage is also believed to be the consequence (at least in part) of the excessive NO production of the endothelium. From experimental observations, it is known that high levels of NO decreases the cyclic opening-closing function of the endothelial tight junctions and it is believed that this is a key factor in capillary leakage (Gomez-Jimenez 1995; Morel 2013). Additionally, activated leucocytes and complement enzymes may also damage capillary wall integrity.

Based on experimental observations, dominantly precapillary sphincters in gram-positive sepsis are dilated, while in case of gram-negative pathogens, this phenomenon occurs at the level of postcapillary sphincters. Thus, capillary perfusion itself is also influenced by the actual pathogen causing the septic process. Taking into account that capillary driving pressure is also influenced by systemic blood pressure, low systemic blood pressure that develops in severe sepsis, may result in a decreased capillary driving pressure. Due to local regulatory mechanisms, when driving pressure decreases, capillary sphincters get further dilated in order to enhance local blood flow. Unfortunately, as shown in Figure 3, coagulation system is also activated during the septic process leading to micro-thrombi formation and thus resulting in worsening of the local oxygen and nutritional transport.

Alterations in lymphatic flow also show a blend picture in sepsis. Endotoxaemia can be associated with an increase in thoracic duct lymph flow (Kutner 1967; Williemas 1973; Smith 1988). When the thoracic duct was ligated in a canine model of peritonitis sepsis, it had a negative effect on liver function and survival; bacterial count in peritoneal fluid, endotoxin level in portal vein, nitrite and AST level were significantly elevated (Guler 1999). In a porcine model, Lattuada and Hedenstierna (Lattuada 2006) found that during endotoxin sepsis (LPS infusion), the lymph flow from the abdomen increased. The flow was measured by ultrasonic probe placed around the thoracic duct. They have also observed that mechanical ventilation with high PEEP impedes lymphatic drainage and also cold increases the lymph production, while flow increased and lymphatic drainage of abdominal edema improved by spontaneous breathing (Lattuada 2006). Elias and co-workers in their ovine model found that endotoxin (i.v., 3.3 – 33 μg/kg) reduces lymphatic pump activity, contributing to the edema formation in sepsis (Elias 1987). Intrahepatic lymph stasis in endotoxaemia in rats can be caused by decreased pumping activity of extra- and intrahepatic large lymph vessels (Shibayama 1992). It has been showed in LPS-induced sepsis model in guinea pigs that there is an early increase in mesenteric lymph flow rate being mediated by vascular hyperpermeability and plasma albumin leakage (Nemoto 2011).

Microcirculatory and Mitochondrial Distress Syndrome

As described above, the excessive systemic reaction to the inflammatory insult finally leads to a critical imbalance of oxygen and nutritional products supply and demand. In the recent decade, it has been speculated that compensatory mechanisms in sepsis may be described as a 2-phase process. In the beginning, microvascular compensation dominates. During this phase, the decreased tissue perfusion and tissue hypoxia result in enhanced production of potent vasodilatory substances (mainly NO) (Gomez-Jimenez 1995). This reaction aims to increase the tissue perfusion. Whenever this compensation fails, in the second mitochondrial phase, cells are trying to turn into an “energy-saving mode” by decreasing their energy needs. The main actor in this process is again the overproduced NO. It passes easily through the cellular and mitochondrial membranes as oxygen and blocks cytochrome oxidase at complex IV. This compensatory mechanism however is a double-edged sword; although it decreases cellular energy need (and thus contributes to survival) but only until a certain limit: as a secondary consequence of complex IV block, reactive nitrogen species (most importantly peroxinitrites) are produced. Large amounts of reactive nitrogen species contribute to cell necrosis in severe, end-stage states of sepsis.

Multiple Organ Failure (MOF) in Sepsis

The continuum of sepsis is depicted in Figure 4. Based on the underlying pathophysiological mechanisms, different organs may be affected during the septic process (Albert 2004; Langenberg 2005; Remick 2007; Wynn 2010; Nduka 2011; Bhan 2016; Doi 2016).

- In the *cardiovascular system*, newly developing atrial fibrillation can be considered as early warning sign of developing sepsis. Beside this, decreased central venous and mean arterial blood pressures as well as a decreased peripheral vascular resistance are typical signs of septic cardiovascular affection. Cardiac contractility may eventually be higher in the early phase of sepsis, however, in the late phase of septic shock, cardiac contractility also decreases due to inappropriate oxygenation of the myocardium. Recent clinical observations suggest that PiCCO monitoring enables checking the cardiovascular consequences.
- *Pulmonary consequences:* Based on experimental and pathological observations, there is an inflammatory exudate accumulation within the alveoli. This exudate worsens the effectiveness of the alveolo-capillary gas exchange. It contributes to the washout of the surfactant, thus leading to alveolar collapse and atelectasis formation. Additionally capillary leak also affects the pulmonary capillaries and contributes to extravascular fluid accumulation within the lung. This extravascular lung water may lead to further compression of the alveoli (due to extraalveolar forces) and also leads to an increase of the alveolo-capillary distance that worsens gas exchange. The most sensitive parameter that describes the function of the alveolo-capillary gas exchanges is PaO_2/FiO_2 ratio. Extravascular lung water can be measured by PiCCO monitoring (EVLW).
- *Consciousness disturbances* of different severity are early signs of sepsis development. At early stages, sepsis causes confusions or delirious states. The correct terminology for the cerebral affection in sepsis is sepsis-associated encephalopathy. This is a multifactorially-determined functional disturbance that develops along with the progression of the septic process, leading to somnolence, or coma in late phases. Cerebral functions can be monitored by the GCS score and EEG.
- In early stages of systemic hypoperfusion, the urine output decreases and septic patients are prone to development of acute kidney injury. Along with the advancement of severe sepsis, oliguria may turn to anuria and serum creatinine progressively increases.
- Hypoperfusion of the liver has different consequences: albumin and vitamin K-dependent coagulation factor production decreases. In severe cases where parenchymal damage is advanced, bilirubin increases (by canalicular damage and hepatocytolysis) (>70 mmol/l) and icterus may develop.
- Severe hypoperfusion also affects gastrointestinal organs. As a consequence, bowel ischemia, ileus, pancreas apoplexy and acalculous cholecystitis may develop.

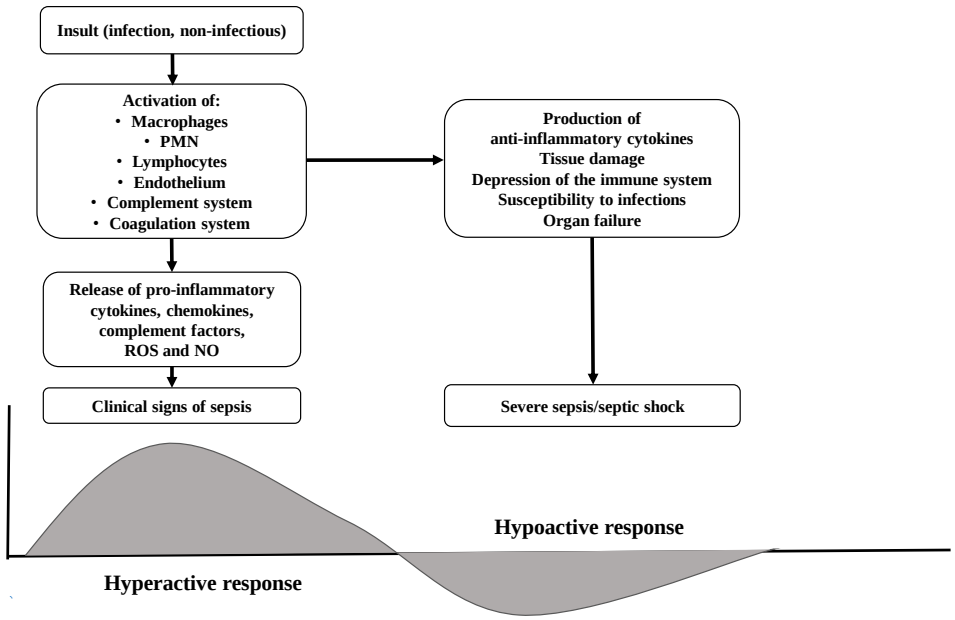

Figure 4. The continuum of sepsis.

EXPERIMENTAL MODELS FOR STUDYING SEPSIS

According to Fink (2001), the 'ideal' animal sepsis model should be (1) capable of predicting both positive and negative results of a trial; (2) inexpensive; (3) reproducible (within and among laboratories); (4) humane and fully respecting the 3Rs; (5) able to provide a mortality endpoint; (6) characterized by hemodynamic, hematologic, and biochemical features similar to those observed in human sepsis (Fink 2001). Unfortunately there is no 'ideal' model known to date.

Experimental sepsis can be induced via generating toxemia by intravenous or intraperitoneal administration of live bacteria (pure or mixed cultures), inhalation, intrabronchial instillation, implantation or seeding into tissues or by disruption of the host-barriers (mechanically or by ischemia), or in combination. Behind these major approaches to develop sepsis models, there are numerous variations and sub-models that can be classified in the following main categories:

- endotoxin models
- bacteremia models
- peritonitis models
- pneumonia models
- meningitis models
- soft tissue infection models (abscess models)

Table 4 summarizes some major characteristics of these models. Each of these strategies reproduces one or several pathophysiological mechanisms activated during sepsis, yet the

multitude of existing approaches indicate limitations of each model to mimic the clinical scenario. Many of the limitations depend on the species of animals or bacteria used while others depend on technical and conceptual details behind each model.

Not only the way of sepsis induction, but the choice of the animal species itself is also crucial. Table 5 gives a summary of various species in consideration of sepsis models (based on Fink 2001).

Following sections provide the technical description of the methods for inducing experimental sepsis as well as brief considerations on their advantages and limitations.

Endotoxin Models

Endotoxin is a lipoprotein-carbohydrate complex that can be found in the cell wall of all gram-negative bacteria. Endotoxins were originally isolated by André Boivin (Bactéries et Virus, Paris, Presses Universitaires de France, 1941).

The simplest way is to inject single bolus of LPS intravenously (as the most common way) or intraperitoneally. The pro-inflammatory processes occur suddenly and last briefly when endotoxicosis is induced by LPS injection (single bolus). Endotoxin can be administered via intraperitoneal injection as well (Laschke 2007). In case of infection, the inflammatory stimulus is much more obvious with gradual development and persisting longer. It has been shown that TNF-α concentration is much higher and showing a peak around 60-90 minutes after LPS injection (i.v. or i.p.) compared to a focal infection model (e.g., fecal peritonitis) (Eskandari 1992; Fink 2001). After endotoxin administration, plasma concentration of host response mediators such as TNF-α, IL-1, IL-6 and IL-10 rapidly increase as an acute and transient elevation. LPS binds to TLR-4 and so activates inflammatory pathways, including NF-κβ.

The sensitivity of various animal species to LPS and the physiologic and immunologic response to this stimulus is different. Humans are very sensitive to LPS; in volunteers 2−4 ng/kg LPS may produce obvious symptoms. In mice 1−25 ng/kg LPS is needed to generate septic symptoms. A very interesting study aimed at reaching a similar IL-6 response in mice and humans revealed that 2 ng of endotoxin administered intravenously in humans were enough to elicit the same IL-6 plasma levels as 500 ng given intraperitoneally to mice (Copeland 2005). Other species such as rabbit, pig and sheep are also sensitive to endotoxin, similarly to human. Interestingly, the rodents or even monkeys such as baboons are resistant to endotoxin. About 5 μg/kg LPS is lethal in sheep, 100 μg/kg is the LD_{80} in rabbits, while mice and baboons needs incomparably higher dose for lethality (LD_{70} dose is about 6 mg/kg in baboon; LD_{100} dose is about 20−80 mg/kg in the mouse) (Fink 2001). Overall, endotoxemia models are relatively far from the clinical sepsis scenario. Furthermore, the resistance of rodents to LPS also puts a serious limitation of extrapolating the results to the human (Kingsley 2016).

There are several techniques and materials for increasing the sensitivity of rodents to LPS such as D-galactosamine, a non-ionic polyoxyethylene-polypropylene copolymer (Pluronic F127), carageenan, berrylium phosphate, lead acetate or carbon tetrachloride. Administration of platelet-activating factor or heat-killed bacteria a week prior to LPS injection can also cause enhanced sensitivity (Katschinski 1992; Rabinovici 1993; Fink 2001; Gumenscheimer 2002).

Rittirsch and co-workers reported in their paper that the LPS endotoxemia differs from cecal ligation and puncture (CLP) model in rodents. After LPS infusion, the symptoms such as rapid hypothermia developed within a few hours, together with leukopenia followed by leukocytosis. The scenario is also characterized by an early increase and high transient levels of pro-inflammatory cytokines (IL-1β, TNF-α, IL-6) and the protective effect of anti-TNF-α is shown. In CLP model, the symptoms developed within 12−24 hours, leukocytosis or leukopenia was also present, whereas, the pro-inflammatory cytokines (IL-1β, TNF-α, IL-6, C5a) were expressed later at moderately high levels. Anti-LPS or anti-TNF-α were not protective (Rittirsch 2007).

Intravenous, intraperionoteal or intraarticular administration of zymosan (a polysaccharide cell wall component derived from *Saccharomyces cerevisiae*), producing a prolonged activation of the alternative complement pathway and generalized inflammation, is another example for endotoxaemia models, mostly in rodents (mouse, rat) and rabbit (Sharkey 1984; Volman 2005; Cash 2009; Guerra 2016; Hong 2016;).

Bacteremia Models

Intravenous administration of live *Escherichia coli* is used for studying sepsis since decades. The early studies used typically large animals (dogs, pigs, monkeys) (Guenter 1969; Cryer 1971; Hinshaw 1976; Wichterman 1980). Later, rodent usage has been also spread out widely. Contrary to the rapid bolus infusion, which results in rapid hypoglycemia and death, further models have been established to provide more time for the response reactions approaching closer to the clinical scenarios. Postel et al. developed a canine model in which the animals were continuously infused with *Pseudomonas aeruginosa* for 5 hours (10^6/ml/min for 2−5 hours or $4x10^7$/ml/min for 5 hours), and observed the animals for 24 hours. This model provided more time for developing wider response reactions and for observation of kinetics (Postel 1975).

In sepsis models with bacterial infusion, the exact number of bacteria can be estimated only that might influence the reproducibility compared to the better standardized endotoxin infusion models (Fink 2001). The most commonly used bacteria are the gram-negative *Escherichia coli*. Other gram-positive bacteria, such as *Staphylococcus aureus*, *Staphylococcus epidermidis*, *Streptococcus pyogenes* or *Pseudomonas aeruginosa*, or fungi such as *Candida albicans* can be also used in various animal species (mouse, rat, rabbit, dog, pig, sheep, baboon).

PERITONITIS MODELS

The surgical models are particularly relevant models of sepsis since a significant number of sepsis cases are the result of intraabdominal leakage of intestinal content after abdominal surgery or perforated diverticulitis or appendicitis (Browne 1976; Wichterman 1980; Krisher 2001; Wryzykowski 2005; Catry 2016). These models generate a polymicrobial sepsis which closely resembles the clinical situation in terms of mechanism and clinical course. The

peritonitis may be induced by perforating the bowel or by instillation of bacteria or fecal material in the peritoneal cavity.

Cecal Ligation and Puncture (CLP)

This simple and reproducible model has become a gold standard in sepsis research because of its relative technical simplicity and versatility (Wichterman 1980; Hubbard 2005; Dejager 2011; Toscano 2011; Schabbauer 2012; Siempos 2014). Nonetheless, ensuring reproducibility requires that a few important details should be carefully considered throughout the procedure including preoperative fasting of the animals to generate similar intestinal contents as well as consistency in several other technical details. In addition, short-acting methods of anesthesia (i.e., isoflurane inhalation) should be chosen in order to minimize prolonged anesthesia-induced cardiovascular alterations postoperatively (Hubbard 2005). Following midline incision, the cecum is identified and carefully exteriorized. Then, the cecum is ligated distal to the ileocecal valve and perforated using one or two needle punctures (Figure 5). Both the length of the ligated cecum (Singleton 2003) and the needle size (Ebong 1999; Otero-Anton 2001) can be used to influence the CLP outcome and give a lethal or nonlethal sepsis. For instance, two punctures created with an 18G needle result in 100% mortality in BALB/c mice, while the same procedure yields mortality rates of 50% or 0% when performed with 21G or 25G needles, respectively (Ebong 1999).

The cecum is gently compressed to expel a small amount of intestinal content through the perforation, thereafter is returned to the abdomen and the wound is closed in two layers. The cecum will become necrotic within 24 hours but it may ultimately be resected to remove the source of infection as part of the treatment strategy.

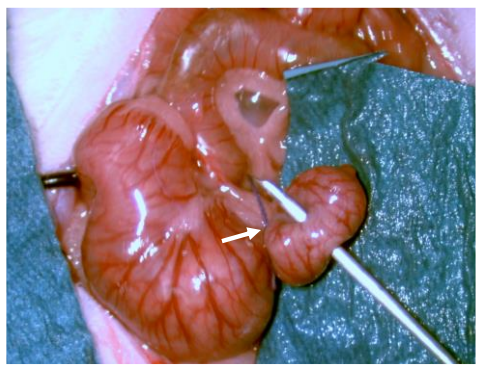

Figure 5. Cecal ligation and puncture (CLP) in anesthetized rat. White arrow shows the site of the ligature. The excluded cecum punctured through by a 19 G needle.

The postoperative care is a significant element of this particular experimental model as fluid resuscitation and antibiotic treatment may influence significantly both the pathophysiology and animal survival (Zanotti-Cavazzoni 2009). In the rat, this model induces a complex cardiovascular response with an early, hyperdynamic phase characterized by increased cardiac output, increased tissue perfusion and decreased peripheral resistance. This is followed by a late, hypodynamic phase characterized by reduced microvascular blood flow

in various tissues and increased peripheral resistance (Yang 2002; Yang 1999). Results in mice and rats indicate that fluid resuscitation (typically isotonic saline as subcutaneous injection) and antibiotics may increase the 48 hour survival rate from 0 to around 20−40% (Hollenberg 2001) depending on type of fluid, volume and concentration (Zanotti-Cavazzoni 2009).

Colon Ascendens Stent Peritonitis (CASP)

The model of colon ascendens stent peritonitis (Zantl 1998) is more recent than the previously described CLP and has been introduced following numerous observations that animals undergoing cecal ligation and puncture often develop only localized peritonitis (Schabbauer 2012). The cecal perforations are spontaneously covered by the surrounding intestinal loops leading to abscess formation (Maier 2004). This in its turn may result in two different pathologic conditions not entirely comparable (diffuse peritonitis vs. large abscess) and with different response to various treatment alternatives.

The surgery is preceded by the preparation of plastic venous catheters of variable sizes. In the rat model, the survival rate is strictly dependent on the diameter of the implanted stent and a stent diameter of 14G leads to 100% mortality whereas smaller stent diameters generates sublethal models (16G stent leads to a 71% mortality whereas mortality is 53% when a 18G stent is used) (Lustig 2007). Similarly, approximately 70% of the mice expired within 48 hours when a 16G stent was used whereas the death rate dropped to 50% with an 18G stent (Maier 2004). After creating a marking at a distance of 3 mm from the tip, the catheter is circumferentially incised with a 1 mm scalpel beyond the marking sparing only a narrow bridge of plastic.

Inhalational anesthesia is advocated by the majority of the authors (ether, isoflurane, sevoflurane) (Lohner 2013; Islam 2016; Schöneborn 2016) due to the lower impact on the hemodynamics as well as the short postoperative recovery. The abdominal wall is opened through midline incision and the ascending colon is exposed using soft cotton earbuds. After adequate exposure of the ascending colon, the prepared catheter is inserted into the lumen of the ascending colon through the antimesenteric wall approximately 10 mm from the ileocecal valve and fixed with two stitches of non-absorbable suture (7/0) (Figure 6). Thereafter, the inner needle of the stent is removed and the stent is cut at the marked site. To verify the adequate intraluminal placement of the stent and the immediate initiation of the fecal leakage, stool is milked from the cecum into the ascending colon and the stent is filled until a small drop of stool appears at its end. The procedure is completed through abdominal wall closure in two layers and fluid resuscitation (Zantl 1998).

Bacterial Suspension Inoculation (Intraabdominal Abscess Models)

Classic models include the inoculation of defined bacterial isolates (e.g., *E. coli*, *B. fragilis*) mixed with barium sulfate and autoclaved rat fecal material, suspended and loaded into gelatin capsule and implanted intraperitoneally, or agar pellets containing bacteria, or suspension containing hemoglobin, mucin and bacteria *(E. coli)*, or impregnated fibrin clot (Onderdonk 1976; Wichterman 1980; Fink 2001; Kingsley 2016). Inoculation of autologous

feces and other clinically-relevant model dominantly in pigs (for instance simulating the case of bowel anastomosis insufficiency), in which a definitive amount (e.g., 0.5 g/kg) of autologous feces is suspended in saline solution (e.g., 200 ml), incubated (e.g., for 6 hours at 38°C) and inoculated into the peritoneal cavity through drains, or via incision and/or Veres needle (Chvojka 2008; Zsikai 2012) (Table 6).

Interventions that Partly Destroy Barriers of Gastrointestinal Tract

Intestinal ischemia models. An example is the creation of an ischemic bowel loop results in severe diffuse peritonitis (Wichterman 1980). Hau and Simmons (1977) and which reported 90% mortality rate within 10 days after making a loop of terminal ileum ischemia in dogs. Simpler intestinal ischemia-reperfusion models with longer follow-up period, allowing time for development of symptoms, are also capable for mimicking abdominal sepsis.

Cholecystitis models. In the canine study of Perbellini and co-workers, *E. coli* was injected directly into the gall bladder after ligating the cystic artery. The ischemic and infected gall bladder showed similarities to clinically seen cholecystitis (Perbellini 1978; Wichterman 1980).

Pneumonia Models

In this simple and clinically relevant model type, *Streptococcus pneumoniae*, *Klebsiella pneumoniae*, *Pseudomonas aeruginosa* are the most common bacteria which are introduced via a tracheal route (tube in rodents, or even with bronchoscope in large animals), or via nasal route (Fink 2011; Kinglsey 2016).

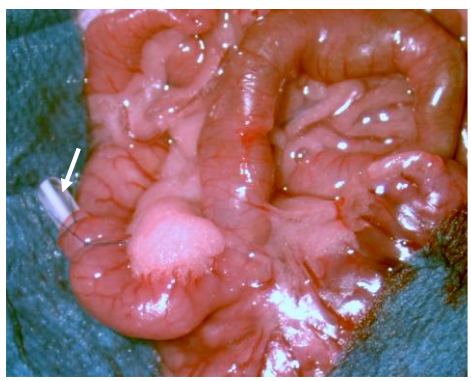

Figure 6. Colon ascendens stent peritonitis (CASP) in anesthetized rat. White arrow shows the fixed stent (size: 16 G).

Meningitis Models

Several murine models have been developed using intracerebral, intraperitoneal, intravenous, intranasal or intracisternal inoculation methods (Chiavolini 2008). In the latter category, a well-established model is inoculation by injecting 10 μL of bacterial suspension into the cisterna magna using a 32 G needle (Mook-Kanamori 2012; 2015).

Meningitis in rats can be produced by intranasal inoculation of *Haemophilus influenzae* in newborn rats, or in young adult animals by intraperitoneal inoculation (Smith 1984).

Streptococcus pneumoniae is also used for meningitis models. Intraperitoneal route provokes hematogenous meningitis. The intranasal inoculation can act non-hematogenously as well along the olfactory nerves (Chiavolini 2008).

Soft Tissue Infection Models (Abscess Models)

Intramuscular abscess models. Hermreck and Thal (1969) described a model in which 5-cm wicks of umbilical tape were seeded with the dog's own feces and immersed into porcine mucin solution. These wicks then were embedded into the thigh (unilaterally) of the dog subcutaneously and intramuscularly. The animals were followed-up for a week.

Dermal abscess models. In 1964, Walker et al. published a rat model mimicking dermal abscess. *Pseudomonas aeruginosa*, isolated from a patient with septicemia after second and third degree burn injury, was used to seed subcutaneous tissues. On the dorsum, a 5×7 cm area was excised (~20% of the body surface), and the fascia in the base of the wound was seeded by the bacterial culture. The area then was covered with split-thickness (0.012 inch) skin autograft. In their study, a comparison was made with intraperitoneal and subcutaneous injection of the bacterial culture as well (Walker 1964).

Intramuscular, subdermal bacterial injections, subcutaneous pockets filled with gauze and injected bacteria, infected cotton suture are further examples for soft tissue infections models (Fink 2001).

Extrapolation of the Results: Experimental versus Clinical Sepsis

The final goal of all medical research is and must be the benefit to the patient, by exploring and understanding the nature of various disorders and its pathophysiology mechanisms as well as developing preventive or therapeutic agents. In this process, animal studies are still necessary, since in the translational process, there must be a stage of *in vivo* study before any human application.

Unfortunately, numerous pharmacological agents which have been promising and effective in animal models, failed in large well-designed human clinical trials (e.g., methylprednisolone sodium succinate, IL1-RA, CDP571, BN 5021, BB-822, TCV-309, TAK-242, lenercept, tifacogin) (Fink 2014; Lakshmikanth 2016).

Practically speaking, all the experimental sepsis models fail to reproduce entirely the clinical scenario. This explains the relatively large number of models used to induce severe systemic infections and continuous search for a better mirror to the clinical situation. Accordingly, numerous authors have discussed the comparability of animal sepsis models and human sepsis (Wichterman 1980; Fink 2001; Esmon 2004; Rittirsch 2007; Nemzek 2008; Poli-de-Figueiredo 2008; Dyson 2009; Fink 2014; Lilley 2015).

In the clinical practice, the most frequent infection sites are the lung, the abdomen and urinary tract. Gram-positive and gram-negative infections show almost the same frequency, followed by fungi and parasites. The initial insult or infection activates the innate immune system bursting the pro-inflammatory cascades and mediators with SIRS as result. Anti-

inflammatory factors appear as compensatory mechanism but any imbalance can cause further deterioration: exaggerated pro-inflammatory effect results in uncontrolled, excessive inflammatory response and consecutive effects; stronger anti-inflammatory steps may lead to immunosuppression (Rittirsch 2007).

Virtually all the experimental sepsis models in rodents fail to reproduce entirely the clinical scenario due to limitations related to design or the species used. Moreover, seemingly minor technical details (Ebong 1999; Singleton 2003) or the choice of the animals used in terms of age and gender impacts on the pathophysiology and the outcome (Turnbull 2003). Compared with humans, rodents are quite resistant to endotoxin, have a distinct hemodynamic profile, and limited blood volume (Copeland 2005). All these factors explain the relatively large number of models used to induce severe systemic infections and the ongoing search for refined designs to better mirror the clinical situation.

Microbiological Actors Causing Sepsis

In human sepsis, gram-positive bacteria and fungi act for causing sepsis in higher incidence than gram-negative organisms, however, in animal studies mostly gram-negative bacteria have been used (Poli de Figueiredo 2008).

Experimental Considerations Related to the Pathomechanism of Sepsis

In clinical scenario, usually there is a septic focus which intermittently or persistently scatters bacteria. Different ways of sepsis induction act differently, as it has been discussed previously and overviewed in Table 4.

The Time Factor (Follow-Up)

For development of sepsis, time is needed that differs according to the way of induction (Table 4). Endotoxemia and infusion of bacteria provide prompt effects, while infection site models obviously need more time to develop the response reactions and the septic symptoms. The choice of the model depends on the primary aim of the study itself.

Inter-Species Differences in Sensitivity and Immune Response

Several inter-species differences have been discussed in previous sub-sections. To list some other ones, it is interesting to mention that *Salmonella typhi* does not cause systemic infection in rodents, but causes typhoid fever in humans. *Salmonella typhimurium* causes systemic infection in rodents, but has low virulence in humans (Piper 1996; Poli de Figueiredo 2008).

Table 4. Summary of various septic models by its nature, origin, most commonly used species, advantages and disadvantages (based on papers by Fink 2001; Esmon 2004; Volman 2005; Rittirsch 2007; Poli de Figueiredo 2008; Engel 2011; Mai 2012; Fink 2014; Kingsley, 2016)

Sepsis origin	Model	Species	Characteristic hemodynamic response	Persistent inflammatory response	Cytokine response characteristics	Advantages	Disadvantages	Special notes
Toxemia	Endotoxin (LPS) administration	*Most commonly used:* mouse, rat *More rarely used:* rabbit, dog, pig, sheep, non-human primates	immediate early hypodynamic phase	no	Early rise of TNF-α, rapid transient increase	Easy model. LPS dosage is well-controllable. Innate immune system activation can be well studied. Well-suited to test the mechanism of inflammatory cascade activation and the efficacy of anti-inflammatory compounds.	Far from clinical scenario. Different sensitivity amongst the species (relatively endotoxin resistant species: rodents, cat, dog; sensitivity with enhanced response: rabbit, sheep, non-human primates). Dose dependency (concentration and way of administration)	Toxin can be given: i.v., i.a., i.p. LPS effect can be enhanced by administration of D-galactosamine, pluronic F 127, carageenan, lead acetate, beryllium phosphate, carbon tetrachloride, platelet-activating factor, co-administration of heat-killed bacteria (e.g., *P. acnes*, *C. parvum*, *M. bovis*), mostly in rodents.
	TLR agonist administration (i.v.)	rodents	Not specified.	no	Rapid immune activation and inflammation, elevation of IL-6 and IFN-β within 2 h	Technically easy model.	Nonspecific indicator of inflammation, short half-time of agents, immunological effects often controversial	Mostly TLR-9, TLR-7, TLR-3 agonists
	Administration of zymosan	rodents (most frequently rabbits), rarely in sheep	early drop in cardiac index and stroke volume index	no	Prolonged activation of the alternative complement pathway, generalized inflammation	Easy to perform. Can be used for studying sterile peritonitis, MODS and acute lung injury as well.	Early mortality rate is high.	Toxin can be given: i.v., i.a., i.p., intraarticularly. Acute inflammation peaking within few hours. Marked hypoxaemia, interstitial edema, pulmonary neutrophil sequestration.

Table 4. (Continued)

Sepsis origin	Model	Species	Characteristic hemodynamic response	Persistent inflammatory response	Cytokine response characteristics	Advantages	Disadvantages	Special notes
Bacteremia	Intravascular infusion of live bacteria	rodents, dog, pig, sheep, non-human primates	hypotensive shock	no	Rise of TNF-α and IL-1β, rapid transient increase	DIC presents.	Relatively far from clinical scenario.	Most commonly used bacteria: *E. coli* Others: *S. aureus*, *P. aeruginosa*, *S. pyogenes*, *S. epidermidis*, *C. albicans* Variations: Bolus (single or multiple), increasing concentration via infusion pump.
Peritonitis	cecal ligation and puncture (CLP)	most commonly rodents	hemodynamic and metabolic phases	yes	moderate increase	Clinically highly relevant.	Not specified.	-
	colon ascendens stent peritonitis (CASP)		prolonged hemodynamic instability	yes	steady, continuous systemic increase	Clinically highly relevant. Lethality is accompanied by MOF.	Not specified.	-
	polymicrobial peritoneal contamination and infection (PCI)		early hyperdynamic response	yes		Clinically highly relevant.	Not specified.	e.g., intraperitoneal injection of a human feces suspension
	implantation model (implanting fibrin clot impregnated with live bacteria)	rat dog, pig		yes	Similar to human sepsis.	Clinically highly relevant.	Not specified.	Most commonly used bacteria: *E. coli* Others: *B. fragilis* in combination with *E. coli*

Sepsis origin	Model	Species	Characteristic hemodynamic response	Persistent inflammatory response	Cytokine response characteristics	Advantages	Disadvantages	Special notes
	faecal peritonitis (inoculation of autologous faeces or faecal suspension)	pig	early hyperdynamic response	yes	Similar to human sepsis.	Clinically highly relevant.	Not specified.	-
Pneumonia	Direct administration of bacteria (*S. pneumoniae*, *P. aeruginosa*, *K.pneumoniae*) via trachea or nasal route	mouse, rat	absent	yes	Strain-specific (e.g., TNF-α decrease after *S. pneumoniae* infection)	Clinically relevant.	Not specified.	-
	Instillation of living bacteria into bronchi via bronchoscope	pig	Not specified.	yes	Not specified.	Clinically highly relevant.	Not specified.	-
Soft tissue infection	Injecting bacteria or implanting contaminated materials into soft tissue	rodents, dog	Not specified.	yes	Not specified.	Clinically relevant.	Not specified.	Intramuscular, subdermal bacterial injections, subcutaneous pockets filled with contaminated gauze or cotton suture
Meningitis	Inoculation of bacteria (intracerebral, intraperitoneal, intravenous, intranasal, intracisternal)	mostly rodents	Not specified.	yes	Strain-specific.	Clinically relevant.	Not specified.	Most commonly used bacteria: *H. influenza*, *S. pneumoniae*

Table 5. Summary of advantages and disadvantages of various animal species in sepsis studies (based on Fink 2001, with additions and modifications)

Species	Advantages	Disadvantages
mouse *(Mus musculus)*	inexpensive, inbred or transgenic strains available, immunological reagents widely available	repetitive blood sampling is difficult, problematic hemodynamic measurements – special instruments needed, moderately resistant to LPS
rat *(Rattus norvegicus)*	inexpensive, inbred, outbred or transgenic strains available, immunological reagents widely available, most hemodynamic measurements feasible, chronic instrumentation feasible, faecal flora shows certain similarities to that of human	very resistant to LPS
guinea pig *(Rattus norvegicus)*	inexpensive, various outbred strains available, immunological reagents available, most hemodynamic measurements feasible, chronic instrumentation feasible, very sensitive to LPS	gram-positive faecal flora, coprophagy (caecotrophia)
rabbit *(Oryctolagus cuniculus)*	inexpensive, most hemodynamic measurements feasible, chronic instrumentation feasible, very sensitive to LPS, septic acute lung injury reminiscent of human ARDS	gram-positive faecal flora, caecotrophia
sheep *(Ovies aries)*	relatively inexpensive for a large animal, faecal flora similar to that of human, well-suited for hemodynamic measurements, repetitive blood sampling and chronic instrumentation, septic acute lung injury reminiscent of human ARDS – so good for studying pulmonary pathophysiology, very sensitive to LPS, often are used in chronic, examples for unanesthetized models	chronic study is difficult
pig *(Sus scrofa domestica)*	relatively inexpensive, renal, cardiovascular and digestive anatomy and physiology as well as faecal flora close to human, well-suited for hemodynamic measurements and repetitive blood sampling, septic acute lung injury reminiscent of human ARDS, relatively sensitive to LPS	chronic study is difficult (acute or subacute models only)
cat *(Felis catus)*	well-suited for hemodynamic measurements and repetitive blood sampling, but not a typical species for sepsis study rather for research on central nervous system	heightened public concerns as companion animal
dog *(Canis familiaris)*	faecal flora similar to that of human, well-suited for hemodynamic measurements and repetitive blood sampling, chronic instrumentation feasible	heightened public concerns as companion animal, moderately resistant to LPS, relatively expensive, postal venous hypertension after endotoxic challenge
nonhuman primates, e.g., baboons *(Papio doguera*, *Papio anubis*, *Papio cynocephalus*, *etc.)*, cynomolgus macaque *(Macaca fascicularis)*, rhesus macaque *(Macaca mulatta)*	well-suited for hemodynamic measurements and repetitive blood sampling, antibodies against human proteins commonly cross-react, studies to closely replicate the human inflammatory response	heightened public concerns, very expensive, chronic instrumentation difficult, very resistant to LPS, potential zoonotic disease transmission

The evolutionary adaptation and environmental factors have rendered rodents much less sensitive to bacterial products including endotoxin, as discussed previously. In addition to that, rodents usually react to endotoxemia differently than humans. Cecal ligation and puncture in the rat elicits a biphasic cardiovascular response. An early hyperdynamic phase is usually found during the first 6 hours, and it is characterized by increased cardiac output and tissue perfusion, increased oxygen delivery and oxygen consumption as well as decreased peripheral resistance (Wang 1996; Yang 1999). If inadequately resuscitated, these are replaced by a late, hypodynamic phase towards the end of the first 24 hours after the initiation of sepsis. This late phase is characterized by reduced microvascular blood flow in various tissues, decreased oxygen delivery and increased peripheral resistance. These changes are the key events leading to the development of MOF and ultimately to death. Besides a different cardiovascular response, the immunologic response in rodents differs from humans. A murine study reported similar outcome (mortality and morbidity) but significant differences in the kinetics of cytokine production Thus, TNF-α usually peaks at 1–2 hrs after endotoxin challenge in both rodents and humans but normalizes by 4 hrs and 2.5–10 hrs, respectively (Remick 2000).

Normovolemic septic patients typically present increased cardiac output, hypotension, decreased peripheral resistance and oliguria. In dogs, for instance, the endotoxemia is associated with hypotension but with increased peripheral resistance (Wichterman 1980; Kaszaki 1997). The differences between animal species in response to living bacteria infusion can be different. For instance, *E. coli* may cause either hypodynamic or hyperdynamic circulatory response (Fink, 2001).

Concerning species-specific differences, it is important to mention that pigs and sheep may express marked pulmonary hypertension and increased pulmonary endothelial permeability and other characteristics of acute lung injury after injection of endotoxin or gram-negative bacteria. The reason is that the pulmonary intravascular macrophages (PIM) are embedded within the endothelial liming of pulmonary arterioles (Traber 1978; Judges 1986; Fink 2001).

In a chronically instrumented pig model, Haberstroh and co-workers used a relatively low dose of viable *P. aeruginosa* for 84 hours. They found triphasic hemodynamic response: (1) pulmonary hypertension and decrease in cardiac output (0−12 hours), (2) normalization (12-60 hours), and (3) secondary rise in pulmonary arterial pressure, systemic artery hypotension and increased cardiac output (60−84 hours) (Haberstroh 1995; Fink 2001).

Effect of Age, Gender, and Co-Morbidities

Age is an important issue both in clinical and experimental scenarios (Watters 2001; Starr 2014). In most of the experimental models, the animals are usually young adults and healthy animals, without co-morbidities. Agent is a toxin or a defined type of micro-organism. The treatment protocol (if any) is standardized and initiated soon after the onset of sepsis. The animals are usually anesthetized. Coprophagy is common.

Table 6. Methodological summary of some selected recent sepsis studies in pigs with different sepsis induction methods and various anesthesia protocols and observation periods

Strain, Sex, Weight	Method of inducing sepsis	Protocol	Anesthesia, drugs, fluid administration	Other related interventions	Duration of observation	Reference
domestic outbred stock, either sex, 15 kg	LPS i.v.	Ultrapure *E. coli* LPS (strain 0111:B4) dissolved in sterile water. A total amount of 0.03 mg LPS/kg was infused intravenously over 30 min.	ketamine (20 mg/kg), atropine (0.4 mg) and azaperone 40 mg/ml (1.5 ml), i.m., isoflurane (end tidal cc: 1%), morphine, 50-100 mg pentobarbital i.v., 1 mkg/kg/h, i.v., mechanical ventillation (PEEP=5 cmH_2O, FiO_2=0.3), Ringer acetate, 8 ml/kg/h	preparation and cannulation of external jugular vein l.d., carotid artery l.d., pulmonary artery catheter, tracheostomy, urinary bladder catheter via skin incision	6 hours	Thorgersen 2010
domestic outbred stock, either sex, 15 kg	living bacteria i.v.	Live *E. coli* (strain LE392; ATCC 33572) infused intravenously at an increasing rate: 3.75×10^7 bacteria/h from 0 to 60 min, 1.5×10^8 bacteria/h from 60 to 90 min, and 6.0×10^8 bacteria/h from 90 to 240 min			6 hours	Thorgersen 2010
domestic outbred stock, either sex, 25-35 kg	living bacteria i.v.	Live *E. coli* (strain LE392; ATCC 33572) $1.5x10^8$/ml infused intravenously at an increasing rate. In low dose: total of $4x10^9$ bacteria, increase from 4 ml/h after 60 min to 16 ml/h after 90 min, thereafter constant. In high dose: total of $16x10^9$ bacteria, increase from 4 ml/h after 30 min to 16 ml/h after 60 min, to 64 ml/h after 90 min, thereafter constant.			3 hours	Castellheim 2008
domestic outbred stock, either sex, 25-35 kg	living bacteria into the bronchus	Live *E. coli* (strain LE392; ATCC 33572) 20 ml of $1.5x10^9$/ml suspension instilled into each main bronchus via a flexible bronchoscope			5 hours	Castellheim 2008
domestic outbred stock, females, 16-18 kg	living bacteria i.v.	*Escherichia coli* suspension ($2.5x10^5$/ml; strain: ATCC 25922,) infused intravenously at an increasing rate: 2 ml in the first 30 min, then 4 ml in 30 min and afterwards 16 ml/h for 2 hours. A total of 9.5×10^6 *E. coli* within 3 hours	Induction: i.m. 15 mg/kg ketamin and 1 mg/kg xylazin, maintenance i.m., pressure support mechanical ventilation (PaO_2: 100−130 mmHg, $PaCO_2$: 35−45 mmHg).	preparation and cannulation of external jugular vein l.s. (thermodilution sensors, pressure monitoring, blood sampling, fluid and anesthetic drug intake), femoral artery l.s. (thermodilution sensors, pressure monitoring, blood sampling) (tracheostomy inferior (assisted ventilation)	8 hours	Nemeth 2015

Strain, Sex, Weight	Method of inducing sepsis	Protocol	Anesthesia, drugs, fluid administration	Other related interventions	Duration of observation	Reference
domestic outbred stock, either sex, 27−35 kg	faecal peritonitis (autologous faeces inoculation)	0.5 g/kg of autologous faeces suspended in 200 ml saline was inoculated into the peritoneal cavity through drains.	Induction: i.v. 0.5 mg atropine, 1 to 2 mg/kg propofol 2% and 2 mg/kg ketamine. Mechanically ventillation (PEEP=10 cmH_2O, FiO_2=0.4, tidal volume: 10 ml/kg) Surgical anaesthesia: intravenous 5-10 mg/kg/hour thiopental and 5-15 µg/kg/hour fentanyl. Pancuronium (4 to 6 mg/hour), infusion of Plasma Lyte solution (7−15 ml/kg/hour), 20% glucose to maintain blood glucose levels between 4.5 and 7 mmol/l.	central venous and pulmonary artery catheters, external jugular vein and femoral artery cannulation. Midline laparotomy, drainage, urinary bladder catheterization via epicystostomy.	22 hours (after 8 hours of stabilization)	Chvojka 2008
Vietnamese minipig, either sex, 24 ± 3 kg	faecal peritonitis (autologous faeces inoculation)	0.5 g/kg of autologous faeces suspended in 200 ml saline was incubated for 6 hours at 38 °C, then the suspension was intraperitoneally inoculated via a small incision above the umbilical scar and through a Veres-needle.	Anesthesia for sepsis induction: i.m. 20 mg/kg ketamin and 2 mg/kg xylazin, then 6 mg/kg/h i.v. propofol. After the induction process, animals were sedated and analgesic was used (4 mg/kg ketamin, 0.6 mg/kg nalbuphin). 15 hours later the animals were re-anaesthetized for invasive monitoring. Ringer-lactate 15 ml/kg/h, Voluvel 6% 130 kDa/0.4 5 ml/kg/h, and in case of need: 0.015 µg/kg/h i.v.	Unilateral preparation and cannulation of external jugular vein (pressure monitoring, sampling, infusion). Endotracheal intubation. Unilateral preparation and cannulation of femoral artery and vein (thermodilution sensors, pressure monitoring). Urinary bladder catheterization via inguinal incision.	24 hours (measurements started 15 hours after sepsis induction)	Zsikai 2012

In humans, sepsis often is seen at extreme ages (neonates or elderly), the origin is more often an infection site usually not recognized or frequently, the infection is polymicrobial. The treatment is initiated usually late (hours or days) after the start of infection and frequently the antibiotics are ineffective and are very different between cases. The presence of the co-morbidities is increasingly common (atherosclerosis, hypertension, diabetes mellitus, cancer, etc.) (Esmon 2004).

Gender differences have been also observed. Receptors for sex hormones have been identified on various immune cells, suggesting direct effects of these hormones on immune function (Albertsmeier 2014).

There are models with immunosuppressed host and so-called sequential challenge models. Co-morbidities can be induced by acute ethanol ingestion, CCl_4-induced cirrhosis, hemorrhagic shock, trauma, splenectomy, thermal injury, etc., mostly in rodents (Fink 2001).

Anesthesia, Drugs, Resuscitation

The clinical management of septic animals versus septic patients is a very important point of view, such as volume therapy, electrolytes, antibiotics, ventilation, etc. These protocols in experiments have unquestionable importance (Naumann 2015). Table 6 summarizes methodological details of some selected porcine sepsis models, which include the sepsis induction, the instrumentation, the anesthesia, drugs, resuscitation protocols as well as the follow-up periods are different.

CONCLUSION

Unfortunately, sepsis remains a severe clinical challenge with numerous unsolved problems. Animal models are both useful and necessary to explore the pathophysiology and develop effective therapeutic strategies. Nonetheless, besides their advantages, the experimental models of sepsis have numerous limitations that need to be considered when translating the experimental findings into clinical trials.

Some of the main factors have to be taken into consideration when planning, conducting and evaluating experimental sepsis models:

- the method of sepsis induction
- the agent (type of toxin or microorganism)
- choice of animal species
- species-specific characteristics in immune response sensitivity, in physiological and even anatomical features
- age and gender of the animals
- effect of anesthesia, drugs, fluid intake, resuscitation
- co-morbidities (absence or presence)
- duration of the follow-up (observation period)

In general it can be also concluded that small animal models (e.g., mouse, rat) are useful to test certain pathophysiological pathways and for developing/testing drugs, while large animal models (e.g., pig, non-human primates) may provide a better scenario for testing novel treatment strategies being closer to the clinical practice by size, physiology and opportunities for intervention.

REFERENCES

Albert, M; Losser, MR; Hayon, D; Faivre, V; Payen, D. Systemic and renal macro- and microcirculatory responses to arginine vasopressin in endotoxic rabbits. *Crit. Care Med.*, 2004, 32(9), 1891–1898.

Albertsmeier, M; Pratschke, S; Chaudry, I; Angele, MK. Gender-specific effects on immune response and cardiac function after trauma hemorrhage and sepsis. *Viszeralmedizin.*, 2014, 30(2), 91–96.

Alt, E; Amann-Vesti, BR; Madl, C; Funk, G; Koppensteiner, R. Platelet aggregation and blood rheology in severe sepsis/septic shock: relation to the Sepsis-related Organ Failure Assessment (SOFA) score. *Clin. Hemorheol. Microcirc.*, 2004, 30(2), 107–115.

American College of Chest Physicians/Society of Critical Care Medicine Consensus Conference: definitions for sepsis and organ failure and guidelines for the use of innovative therapies in sepsis. *Crit. Care Med.*, 1992, 20(6), 864–874.

Asakura, H. Classifying types of disseminated intravascular coagulation: clinical and animal models. *J. Int. Care*, 2014, 2(1), 20–26.

Astiz, ME; DeGent, GE; Lin, RY; Rackow, EC. Microvascular function and rheologic changes in hyperdynamic sepsis. *Crit. Care Med.*, 1995, 23(2), 265–271.

Bara, M; Joffe, AR. The ethical dimension in published animal research in critical care: the public face of science. *Crit. Care.*, 2014, 18(1), R15–R21.

Baskurt, OK; Neu, B; Meiselman, HJ. *Red Blood Cell Aggregation*. Boca Raton: CRC Press, 2012.

Baskurt, OK; Temiz, A; Meiselman, HJ. Red blood cell aggregation in experimental sepsis. *J. Lab. Clin. Med.*, 1997, 130(2), 183–190.

Baskurt, OK. Mechanisms of blood rheology alterations. In: Baskurt OK, Hardeman MR, Rampling MW, Meiselman HJ, editors. *Handbook of Hemorheology and Hemodynamics*. Amsterdam: IOS Press, 2007. pp. 170–190.

Bhan, C; Dipankar, P; Chakraborty, P; Sarangi, PP. Role of cellular events in the pathophysiology of sepsis. *Inflamm. Res,*. 2016, 65(11), 853–868.

Borthwick, EM; Hill, C; Rabindranath, KS; Maxwell, AP; McAuley, DF; Blackwood, B. High-volume haemofiltration for sepsis. *Cochrane Database Syst. Rev., 1*, 2013, CD008075.

Bridges, EJ; Dukes, S. Cardiovascular aspects of septic shock: pathophysiology, monitoring, and treatment. *Crit. Care Nurse.*, 2005, 25(2), 14–40.

Brown, KA; Brain, SD; Pearson, JD; Edgeworth, JD; Lewis, SM; Treacher, DF. Neutrophils in development of multiple organ failure in sepsis. *The Lancet*, 2006, 368(9530), 157–169.

Browne, MK; Leslie, GB. Animal models of peritonitis. *Surg. Gynecol. Obstet.*, 1976, 143(5), 738–740.

Cash, JL; White, GE; Greaves, DR. Chapter 17. Zymosan-induced peritonitis as a simple experimental system for the study of inflammation. *Methods in Enzymology (Chemokines, Part B)*, 2009, 461, 379–396.

Castellheim, A; Thorgersen, EB; Hellerud, BC; Pharo, A; Johansen, HT; Brosstad, F; Gaustad, P; Brun, H; Fosse, E; Tonnessen, TI; Nielsen, EW; Mollnes, TE. New biomarkers in an acute model of live Escherichia coli-induced sepsis in pigs. *Scand. J. Immunol.*, 2008, 68(1), 75–84.

Catry, J; Brouquet, A; Peschaud, F; Vychnevskaia, K; Abdalla, S; Malafosse, R; Lambert, B; Costaglioli, B; Benoist, S; Penna, C. Sigmoid resection with primary anastomosis and ileostomy versus laparoscopic lavage in purulent peritonitis from perforated diverticulitis: outcome analysis in a prospective cohort of 40 consecutive patients. *Int. J. Colorectal. Dis.*, 2016, 31(10), 1693–1699.

Chen, P; Stanojcic, M; Jeschke, MG. Differences between murine and human sepsis. *Surg. Clin. North. Am.*, 2014, 94(6), 1135–1149.

Chiavolini, D; Pozzi, G; Ricci, S. Animal models of Streptococcus pneumoniae disease. *Clin. Microbiol. Rev.*, 2008, 21(4), 666–685.

Chien, S; Usami, S; Dellenback, J; Magazinovic, V. Blood rheology after hemorrhage and endotoxin. *Adv. Exp. Med. Biol.*, 1972, 33, 75–93.

Chvojka, J; Sykora, R; Krouzecky, A; Radej, J; Varnerova, V; Karvunidis, T; Hes, O; Novak, I; Radermacher, P; Matejovic, M. Renal haemodynamic, microcirculatory, metabolic and histopathological responses to peritonitis-induced septic shock in pigs. *Crit. Care.*, 2008, 12(6), R164. http://ccforum.biomedcentral.com/articles/10.1186/cc7164.

Copeland, S; Warren, HS; Lowry, SF; Calvano, SE; Remick, D. Acute inflammatory response to endotoxin in mice and humans. *Clin. Diagn. Lab. Immunol.*, 2005, 12(1), 60–67.

Cryer, PE; Herman, CM; Sode, J. Carbohydrate metabolism in the baboon subjected to gram-negative (*E. coli*) septicemia. I. Hyperglycemia with depressed plasma insulin concentrations. *Ann. Surg.*, 1971, 174(1), 91–100.

Daniels, R. Surviving the first hours in sepsis: getting the basics right (an intensivist's perspective). *J. Antimicrob. Chemother.*, 2011, 66(Suppl 2), 11–13.

Dejager, L; Pinheiro, I; Dejonckheere, E; Libert, C. Cecal ligation and puncture: the gold standard model for polymicrobial sepsis? *Trends Microbiol.*, 2011, 19(4), 198–208.

Dellinger, RP; Levy, MM; Rhodes, A; Annane, D; Gerlach, H; Opal, SM; Sevransky, JE; Sprung, CL; Douglas, IS; Jaeschke, R; Osborn, TM; Nunnally, ME; Townsend, SR; Reinhart, K; Kleinpell, RM; Angus, DC; Deutschman, CS; Machado, FR; Rubenfeld, GD; Webb, SA; Beale, RJ; Vincent, JL; Moreno, R. Surviving Sepsis Campaign Guidelines Committee including the Pediatric Subgroup. Surviving sepsis campaign: international guidelines for management of severe sepsis and septic shock: 2012. *Crit. Care Med.*, 2013, 41(2), 580–637.

Doi, K. Role of kidney injury in sepsis. *J. Int. Care*, 2016, 4, 17–22.

Dyson, A; Singer, M. Animal models of sepsis: why does preclinical efficacy fail to translate to the clinical setting? *Crit. Care Med.*, 2009, 37(1 Suppl), S30–S37.

Ebong, S; Call, D; Nemzek, J; Bolgos, G; Newcomb, D; Remick, D. Immunopathologic alterations in murine models of sepsis of increasing severity. *Infect. Immun.*, 1999, 67(12), 6603–6610.

Efron, PA; Mohr, AM; Moore, FA; Moldawer, LL. The future of murine sepsis and trauma research models. *J. Leukoc. Biol.*, 2015, 98(6), 945–952.

Elias, RM; Johnston, MG; Hayashi, A; Nelson, W. Decreased lymphatic pumping after intravenous endotoxin administration in sheep. *Am. J. Physiol.*, 1987, 253(6 Pt 2), H1349–H1357.

Engel, AL; Holt, GE; Lu, H. The pharmacokinetics of Toll-like receptor agonists and the impact on the immune system. *Expert Rev. Clin. Pharmacol.*, 2011, 4(2), 275–289.

Eskandari, MK; Bolgos, G; Miller, C; Nguyen, DT; DeForge, LE; Remick, DG. Anti-tumor necrosis factor antibody therapy fails to prevent lethality after cecal ligation and puncture or endotoxemia. *J. Immunol.*, 1992, 148(), 2724–2730.

Esmon, CT. Why do animal models (sometimes) fail to mimic human sepsis? *Crit. Care Med.*, 2004, 32(5 Suppl), S219−S222.

Fink, MP. Animal models of sepsis and the multiple organ dysfunction syndrome. In: Souba WW, Wilmore DW, editors. *Surgical Research*. Amsterdam: Elsevier Academic Press, 2001, pp. 875−891.

Fink, MP. Animal models of sepsis. *Virulence*, 2014, 5(1), 143–153.

Fleischmann, C; Scherag, A; Adhikari, NK; Hartog, CS; Tsaganos, T; Schlattmann, P; Angus, DC; Reinhart, K. International Forum of Acute Care Trialists. Assessment of Global Incidence and Mortality of Hospital-treated Sepsis. Current Estimates and Limitations. *Am. J. Respir. Crit. Care Med.*, 2016, 193(3), 259–272.

Franks, Z; Carlisle, M; Rondina, MT. Current challenges in understanding immune cell functions during septic syndromes. *BMC Immunology*, 2015, 16, 11–16.

Gomez-Jimenez, J; Salgado, A; Mourelle, M; Martin, MC; Segura, RM; Peracaula, R; Moncada, S. L-arginine: nitric oxide pathway in endotoxemia and human septic shock. *Crit. Care Med.*, 1995, 23(2), 253-258.

Guenter, CA; Fiorica, V; Hinshaw, LB. Cardiorespiratory and metabolic responses to liver *E. coli* and endotoxin in the monkey. *J. Appl. Physiol.*, 1969, 26(6), 780–786.

Guerra, GC; de Menezes, MS; de Araújo, AA; de Araújo Júnior, RF; de Medeiros, CA. Olmesartan prevented intra-articular inflammation induced by zymosan in rats. *Biol. Pharm. Bull.*, 2016, 39(11), 1793–1801.

Guler, O; Ugras, S; Aydin, M; Dilek, FH; Dilek, ON; Karaayvaz, M. The effect of lymphatic blockage on the amount of endotoxin in portal circulation, nitric oxide synthesis, and the liver in dogs with peritonitis. *Surg. Today*, 1999, 29(8), 735–740.

Gumenscheimer, M; Mitov, I; Galanos, C; Freudenberg, MA. Beneficial or deleterious effects of a preexisting hypersensitivity to bacterial components on the course and outcome of infection. *Infect. Immun.*, 2002, 70(10), 5596–5603.

Haberstroh, J; Breuer, H; Lücke, I; Massarrat, K; Früh, R; Mand, U; Hagerdorn, L; von Specht, BU. Effect of recombinant human granulocyte colony-stimulating factor on hemodynamic and cytokine response in a porcine model of *Pseudomonas* sepsis. *Shock*, 1995, 4(3), 216–224.

Hau, T; Simmons, RL. Animal models of peritonitis. *Surg. Gynecol. Obstet.*, 1977, 144(5), 755–756.

Hermreck, AS; Thal, AP. Mechanisms for the high circulatory requirements in sepsis and septic shock. *Ann. Surg.*, 1969, 170(4), 677–695.

Hinshaw, LB; Beller, BK; Archer, LT; Benjamin, B. Hypoglycemic response of blood to live *Escherichia coli* organisms and endotoxin. *J. Surg. Res.*, 1976, 21(3), 141–150.

Hollenberg, SM; Dumasius, A; Easington, C; Colilla, SA; Neumann, A; Parrillo, JE. Characterization of a hyperdynamic murine model of resuscitated sepsis using echocardiography. *Am. J. Respir. Crit. Care Med.*, 2001, 164(5), 891–895.

Hong, Y; Sun, LI; Sun, R; Chen, H; Yu, Y; Xie, K. Combination therapy of molecular hydrogen and hyperoxia improves survival rate and organ damage in a zymosan-induced generalized inflammation model. *Exp. Ther. Med.*, 2016, 11(6), 2590–2596.

Hubbard, WJ; Choudhry, M; Schwacha, MG; Kerby, JD; Rue, LW; 3rd. Bland, KI; Chaudry, IH. Cecal ligation and puncture. *Shock.*, 2005, 24(Suppl 1), 52–57.

Ince, C; Mik, EG. Microcirculatory and mitochondrial hypoxia in sepsis, shock, and resuscitation. *J. Appl. Physiol.*, 2016, 120(2), 226–235.

Ince, C. The microcirculation is the motor of sepsis. *Crit. Care.*, 2005, 9(Suppl 4), S13–S19.

Islam, S; Jarosch, S; Zhou, J; Parquet Mdel, C; Toguri, JT; Colp, P; Holbein, BE; Lehmann, C. Anti-inflammatory and anti-bacterial effects of iron chelation in experimental sepsis. *J. Surg. Res.*, 2016, 200(1), 266–273.

Judges, D; Sharkey, P; Cheung, H; Craig, I; Driedger, AA; Sibbald, WJ; Finley, R. Pulmonary microvascular fluid flux in a large animal model of sepsis: evidence for increased pulmonary endothelial permeability accompanying surgically induced peritonitis in sheep. *Surgery*, 1986, 99(2), 222–234.

Kameneva, MV; Antaki, JF. Mechanical trauma to blood. In: Baskurt OK, Hardeman MR, Rampling MW, Meiselman HJ, editors. *Handbook of Hemorheology and Hemodynamics*. Amsterdam: IOS Press, 2007, pp. 206–227.

Kaszaki, J; Wolfrad, A; Boros, M; Baranyi, L; Okada, H; Nagy, S. Effects of antiendothelin treatment on the early hemodynamic changes in hyperdynamic endotoxemia. *Acta Chir. Hung.*, 1997, 36(1-4), 152–153.

Katschinski, T; Galanos, C; Coumbos, A; Freudenberg, MA. Gamma interferon mediates Proprionibacterium acnes-induced hypersensitivity to lipopolysaccharide. *Infect. Immun.*, 1992, 60(5), 1994–2001.

Kingsley, SM; Bhat, BV. Differential paradigms in animal models of sepsis. *Curr. Infect. Dis. Rep.*, 2016, 18(9), 26–36.

Kirschenbaum, LA; Aziz, M; Astiz, ME; Saha, DC; Rackow, EC. Influence of rheologic changes and platelet-neutrophil interactions on cell filtration in sepsis. *Am. J. Respir. Crit. Care Med.*, 2000, 161(5), 1602–1607.

Kiss, F; Molnar, L; Hajdu, E; Deak, A; Molnar, A; Berhes, M; Szabo, J; Nemeth, N; Fulesdi, B. Skin microcirculatory changes reflect early the circulatory deterioration in a fulminant sepsis model in the pig. *Acta Cir. Bras.*, 2015, 30(7), 470–477.

Klag, T; Cantara, G; Sechtem, U; Athanasiadis, A. Interleukin-6 kinetics can be useful for early treatment monitoring of severe bacterial sepsis and septic shock. *Infect Dis Rep.*, 2016, 8(1), 6213. http:// www.pagepress.org/journals/index.php/idr/ article/view/6213/ 5524

Krisher, SL; Browne, A; Dibbins, A; Tkacz, N; Curci, M. Intra-abdominal abscess after laparoscopic appendectomy for perforated appendicitis. *Arch. Surg.*, 2001, 136(4), 438–441.

Kutner, FR; Schwartz, SI; Adams, JT. The effect of adrenergic blockade on lymph flow in endotoxin shock. *Ann. Surg.*, 1967, 165(4), 518–527.

Lakshmikanth, CL; Jacob, SP; Chaithra, VH; de Castro-Faria-Neto, HC; Marathe, GK. Sepsis: in search of cure. *Inflamm. Res.*, 2016, 65(8), 587–602.

Langenberg, C; Bellomo, R; May, C; Wan, L; Egi, M; Morgera, S. 2005. Renal blood flow in sepsis. *Crit. Care.*, 9(4), R363–R374.

Laschke, MW; Menger, MD; Wang, Y; Lindell, G; Jeppsson, B; Thorlacius, H. Sepsis-associated cholestasis is critically dependent on P-selectin-dependent leukocyte recruitment in mice. *Am. J. Physiol. Gastrointest. Liver Physiol.*, 2007, 292(5), G1396–G1402.

Lattuada, M; Hedenstierna, G. Abdominal lymph flow in an endotoxin sepsis model: influence of spontaneous breathing and mechanical ventilation. *Crit. Care Med.*, 2006, 34(11), 2792–2798.

Levy, MM; Fink, MP; Marshall, JC; Abraham, E; Angus, D; Cook, D; Cohen, J; Opal, SM; Vincent, JL; Ramsay, G. International Sepsis Definitions Conference. 2001 SCCM/ ESICM/ACCP/ATS/SIS International Sepsis Definitions Conference. *Intensive Care Med.*, 2003, 29(4), 530–538.

Lewis, AJ; Seymour, CW; Rosengart, MR. Current murine models of sepsis. *Surg. Infect. (Larchmt).*, 2016, 17(4), 385–393.

Lilley, E; Armstrong, R; Clark, N; Gray, P; Hawkins, P; Mason, K; López-Salesansky, N; Stark, AK; Jackson, SK; Thiemermann, C; Nandi, M. Refinement of animal models of sepsis and septic shock. *Shock*, 2015, 43(4), 304–316.

Lohner, R; Schwederski, M; Narath, C; Klein, J; Duerr, GD; Torno, A; Knuefermann, P; Hoeft, A; Baumgarten, G; Meyer, R; Boehm, O. Toll-like receptor 9 promotes cardiac inflammation and heart failure during polymicrobial sepsis. *Mediators Inflamm.*, 2013, 2013, 261049. https://www.hindawi.com/journals/mi/2013/261049/.

Lundy, DJ; Trzeciak, S. Microcirculatory dysfunction in sepsis. *Crit. Care Clin.*, 2009, 25(4), 721–731.

Lustig, MK; Bac, VH; Pavlovic, D; Maier, S; Gründling, M; Grisk, O; Wendt, M; Heidecke, CD; Lehmann, C. Colon ascendens stent peritonitis – a model of sepsis adopted to the rat: physiological, microcirculatory and laboratory changes. *Shock*, 2007, 28(1), 59–64.

Mai, S; Khan, M; Liaw, P; Fox-Robichaud, A. Experimental sepsis models. In: Azevedo L, editor. *Sepsis - An ongoing and significant challenge*. InTech, 2012. http://www.intechopen.com/ books/sepsis-an-ongoing-and-significant-challenge/experimental-sepsis-models.

Maier, S; Traeger, T; Entleutner, M; Westerholt, A; Kleist, B; Hüser, N; Holzmann, B; Stier, A; Pfeffer, K; Heidecke, CD. Cecal ligation and puncture versus colon ascendens stent peritonitis: two distinct animal models for polymicrobial sepsis. *Shock*, 2004, 21(6), 505–511.

Martins, GS. Sepsis, severe sepsis and septic shock: changes in incidence, pathogens and outcomes. *Expert Rev. Anti Infect. Ther.*, 2012, 10, 701−706.

Mook-Kanamori, B; Geldhoff, M; Troost, D; van der Poll, T; van de Beek, D. Characterization of a pneumococcal meningitis mouse model. *BMC Infect. Dis.*, 2012, 12, 71.

Mook-Kanamori, BB; Valls Serón, M; Geldhoff, M; Havik, SR; van der Ende, A; Baas, F; van der Poll, T; Meijers, JC; P Morgan, B; Brouwer, MC; van de Beek, D. Thrombin-

activatable fibrinolysis inhibitor influences disease severity in humans and mice with pneumococcal meningitis. *J. Thromb. Haemost.*, 2015, 13(11), 2076–2086.

Morel, J; Li, JY; Eyenga, P; Meiller, A; Gustin, MP; Bricca, G; Molliex, S; Viale, JP. Early adverse changes in liver microvascular circulation during experimental septic shock are not linked to an absolute nitric oxide deficit. *Microvasc. Res.*, 2013, 90, 187–191.

Moutzouri, AG; Skoutelis, AT; Gogos, CA; Missirlis, YF; Athanassiou, GM. Red blood cell deformability in patients with sepsis: a marker for prognosis and monitoring of severity. *Clin. Hemorheol. Microcirc.*, 2007, 36(4), 291–299.

Nash, GB; Watts, T; Thornton, C; Barigou, M. Red cell aggregation as a factor influencing margination and adhesion of leukocytes and platelets. *Clin. Hemorheol. Microcirc.*, 2008, 39(1-4), 303–310.

Naumann, DN; Dretzke, J; Hutchings, S; Midwinter, MJ. Protocol for a systematic review of the impact of resuscitation fluids on the microcirculation after haemorrhagic shock in animal models. *Systematic Reviews*, 2015, 4, 135–141.

Nduka, OO; Parrillo, JE. The pathophysiology of septic shock. *Crit. Care Nurs. Clin. North Am.*, 2011, 23(1), 41–66.

Nemeth, N; Berhes, M; Kiss, F; Hajdu, E; Deak, A; Molnar, A; Szabo, J; Fulesdi, B. Early hemorheological changes in a porcine model of intravenously given E. coli induced fulminant sepsis. *Clin. Hemorheol. Microcirc.*, 2015, 61(3), 479–496.

Nemeth, N; Fulesdi, B. Concerning hemorheological disturbances in sepsis. De omnibus dubitandum est… *Series on Biomechanics*, 2016, 30(1), 20–26.

Nemeth, N; Miko, I; Furka, A; Kiss, F; Furka, I; Koller, A; Szilasi, M. Concerning the importance of changes in hemorheological parameters caused by acid-base and blood gas alterations in experimental surgical models. *Clin. Hemorheol. Microcirc.*, 2012, 51(1), 43–50.

Nemoto, K; Sato, H; Tanuma, K; Okamura, T. Mesenteric lymph flow in endotoxemic guinea pigs. *Lymphat. Res. Biol.*, 2011, 9(3), 129–134.

Nemzek, JA; Hugunin, KM; Opp, MR. Modeling sepsis in the laboratory: merging sound science with animal well-being. *Comp. Med.*, 2008, 58(2), 120–128.

Nishino, M; Tanaka, H; Ogura, H; Inoue, Y; Koh, T; Fujita, K; Sugimoto, H. Serial changes in leukocyte deformability and whole blood rheology in patients with sepsis or trauma. *J. Trauma*, 2005, 59(6), 1425–1431.

Onderdonk, AB; Bartlett, JG; Louie, T; Sullivan-Seigler, N; Gorbach, SL. Microbial synergy in experimental intra-abdominal abscess. *Infect. Immun.*, 1976, 13(1), 22–26.

Ostergaard, L; Granfeldt, A; Secher, N; Tietze, A; Iversen, NK; Jensen, MS; Andersen, KK; Nagenthiraja, K; Gutiérrez-Lizardi, P; Mouridsen, K; Jespersen, SN; Tonnesen, EK. Microcirculatory dysfunction and tissue oxygenation in critical illness. *Acta Anaesthesiol. Scand.*, 2015, 59, 1246–1259.

Otero-Anton, E; Gonzalez-Quintela, A; Lopez-Soto, A; Lopez-Ben, S; Llovo, J; Perez, LF. Cecal ligation and puncture as a model of sepsis in the rat: influence of the puncture size on mortality, bacteremia, endotoxemia and tumor necrosis factor alpha levels. *Eur. Surg. Res.*, 2001, 33(2), 77–79.

Perbellini, A; Shatney, CH; MacCarter, DJ; Lillehei, RC. A new model for the study of septic shock. *Surg. Gynecol. Obstet.*, 1978, 147(1), 68–74.

Piagnerelli, M; Boudjeltia, KZ; Vanhaeverbeek, M; Vincent, JL. Red blood cell rheology in sepsis. *Intensive Care Med.*, 2003, 29(7), 1052–1061.

Piper, RD; Cook, DJ; Bone, RC; Sibbald, WJ. Introducing critical appraisal to studies of animal models investigating novel therapies in sepsis. *Crit. Care Med.*, 1996, 24(12), 2059–2070.

Poli-de-Figueiredo, LF; Garrido, AG; Nakagawa, N; Sannomiya, P. Experimental models of sepsis and their clinical relevance. *Shock*, 2008, 30(Suppl 1), 53–59.

Pöschl, JMB; Leray, C; Ruef, P; Cazenave, JP; Lindekamp, O. Endotoxin binging to erythrocyte membrane and erythrocyte deformability in human sepsis and *in vitro*. *Crit. Care Med.*, 2003, 31(3), 924–928.

Postel, J; Schloerb, PR; Furtado, D. Pathophysiologic alterations during bacterial infusions for the study of bacteremic shock. *Surg. Gynecol. Obstet.*, 1975, 141(5), 683–692.

Rabinovici, R; Bugelski, PJ; Esser, KM; Hillegass, LM; Griswold, DE; Vernick, J; Feuerstein, G. Tumor necrosis factor-primed rats. *J. Pharmacol. Exp. Ther.*, 1993, 267(3), 1550–1557.

Reggiori, G; Occhipinti, G; De Gasperi, A; Vincent, JL; Piagnerelli, M. Early alterations of red blood cell rheology in critically ill patients. *Crit. Care Med.*, 2009, 37(12), 3041–3046.

Remick, DG; Newcomb, DE; Bolgos, GL; Call, DR. Comparison of the mortality and inflammatory response of two models of sepsis: lipopolysaccharide vs. cecal ligation and puncture. *Shock*, 2000, 13(2), 110–116.

Remick, DG; Ward, PA. Evaluation of endotoxin models for the study of sepsis. *Shock*, 2005, 24(Suppl 1), 7–11.

Remick, DG. Pathophysiology of sepsis. *Am. J. Pathol.*, 2007, 170(5), 1435–1444.

Rittirsch, D; Hoesel, LM; Ward, PA. The disconnect between animal models of sepsis and human sepsis. *J. Leukoc. Biol.*, 2007, 81(1), 137–143.

Schabbauer, G. Polymicrobial sepsis models: CLP versus CASP. *Drug Discovery Today: Disease Models*, 2012, 9(1), e17–e21.

Scheer, C; Fuchs, C; Rehberg, S. Biomarkers in severe sepsis and septic shock: just listen to the heart? *Crit. Care Med.*, 2016, 44(4), 849–850.

Schöneborn, S; Vollmer, C; Barthel, F; Herminghaus, A; Schulz, J; Bauer, I; Beck, C; Picker, O. Vasopressin V1A receptors mediate the stabilization of intestinal mucosal oxygenation during hypercapnia in septic rats. *Microvasc. Res.*, 2016, 106, 24–30.

Schultz, MJ; van der Poll, T. Animal and human models for sepsis. *Ann. Med.*, 2002, 34(7-8), 573–581.

Semeraro, N; Ammollo, CT; Semeraro, F; Colucci, M. Coagulopathy of acute sepsis. *Semin. Thromb. Hemost.*, 2015, 41(6), 650–658.

Sharkey, P; Judges, D; Driedger, AA; Cheung, H; Finley, RJ; Sibbald, WJ. The effect of an infusion of zymosan-activated plasma on hemodynamic and pulmonary function in sheep. *Circ. Shock*, 1984, 12(2), 79–93.

Shibayama, Y; Urano, T; Nakata, K. Changes in hepatic lymph vessels in endotoxaemia. *J. Pathol.*, 1992, 168(3), 325–330.

Shrum, B; Anantha, RV; Xu, SX; Donnelly, M; Haeryfar, SMM; McCormick, JK; Mele, T. A robust scoring system to evaluate sepsis severity in an animal model. *BMC Research Notes*, 2014, 7, 233. http://www.biomedcentral.com/1756-0500/7/233.

Siempos, II; Lam, HC; Ding, Y; Choi, ME; Choi, AM; Ryter, SW. Cecal ligation and puncture-induced sepsis as a model to study autophagy in mice. *J. Vis. Exp.*, 2014, 84, e51066–e51072. [article with video link: http://www.jove.com/video/51066/].

Singer, M; Deutschman, CS; Seymour, CW; Shankar-Hari, M; Annane, D; Bauer, M; Bellomo, R; Bernard, GR; Chiche, JD; Coopersmith, CM; Hotchkiss, RS; Levy, MM; Marshall, JC; Martin, GS; Opal SM; Rubenfeld, GD; van der Poll, T; Vincent, JL; Angus, DC. The Third International Consensus Definitions for Sepsis and Septic Shock (Sepsis-3). *JAMA.*, 2016, 315(8), 801–810.

Singleton, KD; Wischmeyer, PE. Distance of cecum ligated influences mortality, tumor necrosis factor-alpha and interleukin-6 expression following cecal ligation and puncture in the rat. *Eur. Surg. Res.*, 2003, 35(6), 486–491.

Smith, AL; Greenfield, MD; Toothaker, RD. Experimental meningitis in the rat: Haemophilus influenzae. *Infection*, 1984, 12(Suppl 1), S11–S22.

Smith, L; Andreasson, S; Saldéen, T; Risberg, B. Combined monitoring of thoracic duct and lung lymph during E. coli sepsis in awake sheep. *Lymphology*, 1988, 21(3), 169–177.

Sordia, T; Tatarishvili, J; Mchedlishvili, G. Hemorheological disorders in the microcirculation during septic shock in rats. *Clin. Hemorheol. Microcirc.*, 2006, 35(1-2), 223–226.

Spronk, PE; Zandstra, DF; Ince, C. Bench-to-bedside review: Sepsis is a disease of the microcirculation. *Crit. Care*, 2004, 8(6), 462–468.

Starr, ME; Saito, H. Sepsis in old age: review of human and animal studies. *Aging Dis.*, 2014, 5(2), 126–136.

Thorgersen, EB; Hellerud, BC; Nielsen, EW; Barratt-Due, A; Fure, H; Lindstad, JK; Pharo, A; Fosse, E; Tonnessen, TI; Johansen, HT; Castellheim, A; Mollnes, TE. CD14 inhibition efficiently attenuates early inflammatory and hemostatic responses in Escherichia coli sepsis in pigs. *FASEB J.*, 2010, 24(3), 712–722.

Toscano, MG; Ganea, D; Gamero, AM. Cecal ligation puncture procedure. *J. Vis. Exp.*, 2011, 51, 2860–2864. [article with video link: http://www.jove.com/video/2860/].

Traber, DL; Schlag, G; Redl, H; Strohmair, W; Traber, LD. Pulmonary microvascular changes during hyperdynamic sepsis in an ovine model. *Circ. Shock*, 1987, 22(2), 185–193.

Trzeciak, S; Cinel, I; Dellinger, PR; Shapiro, NI; Arnold, RC; Parrillo, JE; Hollenberg, SM. Microcirculatory Alterations in Resuscitation and Shock (MARS) Investigators. Resuscitating the microcirculation in sepsis: the central role of nitric oxide, emerging concepts for novel therapies, and challenges for clinical trials. *Acad. Emerg. Med.*, 2008, 15(5), 399–413.

Trzeciak, S; Dellinger, RP; Parrillo, JE; Guglielmi, M; Bajaj, J; Abate, NL; Arnold, RC; Colilla, S; Zanotti, S; Hollenberg, SM. Early microcirculatory perfusion derangements in patients with severe sepsis and septic shock: relationship to hemodynamics, oxygen transport, and survival. *Ann. Emerg. Med.*, 2007, 49(1), 88–98.

Turnbull, IR; Wlzorek, JJ; Osborne, D; Hotchkiss, RS; Coopersmith, CM; Buchman, TG. Effects of age on mortality and antibiotic efficacy in cecal ligation and puncture. *Shock*, 2003, 19(4), 310–313.

Tyagi, A; Sethi, AK; Girotra, G; Mohta, M. The Microcirculation in Sepsis. *Indian J. Anaesth.*, 2009, 53(3), 281–293.

van der Poll, T. Preclinical sepsis models. *Surg. Infect. (Larchmt).*, 2012, 13(5), 287-292.

Vincent, JL; Moreno, R; Takala, J; Willatts, S; De Mendonça, A; Bruining, H; Reinhart, CK; Suter, PM; Thijs, LG. The SOFA (Sepsis-related Organ Failure Assessment) score to describe organ dysfunction/failure. *Intensive Care Med.*, 1996, 22(7), 707–710.

Volman, TJ; Hendriks, T; Goris, RJ. Zymosan-induced generalized inflammation: Experimental studies into mechanisms leading to multiple organ dysfunction syndrome. *Shock*, 2005, 23(4), 291–297.

Walker, H; Mason, Ad; Jr. Raulston, G. Surface infection with *Pseudomonas aeruginosa*. *Ann. Surg.*, 1964, 160, 297–305.

Wang, P; Chaudry, IH. Mechanism of hepatocellular dysfunction during hyperdynamic sepsis. *Am. J. Physiol.*, 1996, 270(5 Pt 2), R927–R938.

Ward, PA. New approaches to the study of sepsis. *EMBO Mol. Med.*, 2012, 4(12), 1234–1243.

Watters, JM; O'Rourke, K. Effects of age and gender. In: Souba WW, Wilmore DW, editors. *Surgical Research*. Amsterdam: Elsevier Academic Press, 2001, pp. 167−174.

Wester, T; Häggblad, E; Awan, ZA; Barratt-Due, A; Kvernebo, M; Halvorsen, PS; Mollnes, TE; Kvernebo, K. Assessments of skin and tongue microcirculation reveals major changes in porcine sepsis. *Clin. Physiol. Funct. Imaging*, 2011, 31(2), 151–158.

Wichterman, KA; Baue, AE; Chaudry, IH. Sepsis and septic shock: a review of laboratory models and a proposal. *J. Surg. Res.* 1980, 29(2), 189–201.

Williams, JS; Clermont, HG. Thoracic duct lymph flow and acid phosphatase response to steroid in experimental shock. *Ann. Surg.*, 1973, 178(6), 777–780.

Wolfard, A; Kaszaki, J; Szabo, C; Balogh, Z; Nagy, S; Boros, M. Effects of selective nitric oxide synthase inhibition in hyperdynamic endotoxemia in dogs. *Eur. Surg. Res.*, 1999, 31(4), 314–323.

Wynn, JL; Wong, HR. Pathophysiology and treatment of septic shock in neonates. *Clin. Perinatol.*, 2010, 37(2), 439–479.

Wyrzykowski, AD; Feliciano, DV; George, TA; Tremblay, LN; Rozycki, GS; Murphy, TW; Dente, CJ. Emergent right hemicolectomies. *Am. Surg.*, 2005, 71(8), 653–656.

Yang, S; Chung, CS; Ayala, A; Chaudry, IH; Wang, P. Differential alterations in cardiovascular responses during the progression of polymicrobial sepsis in the mouse. *Shock*, 2002, 17(1), 55-60.

Yang, S; Cioffi, WG; Bland, KI; Chaudry, IH; Wang, P. Differential alterations in systemic and regional oxygen delivery and consumption during the early and late stages of sepsis. *J. Trauma*, 1999, 47(4), 706–712.

Yodice, PC; Astiz, ME; Kurian, BM; Lin, RY; Rackow, EC. Neutrophil rheologic changes in septic shock. *Am. J. Respir. Crit. Care Med.*, 1997, 155(1), 38–42.

Young, JD; Cameron, EM. Dynamics of skin blood flow in human sepsis. *Intensive Care Med.*, 1995, 21(8), 669–674.

Zanotti-Cavazzoni, SL; Guglielmi, M; Parrillo, JE; Walker, T; Dellinger, RP; Hollenberg, SM. Fluid resuscitation influences cardiovascular performance and mortality in a murine model of sepsis. *Intensive Care Med.*, 2009, 35(4), 748–754.

Zantl, N; Uebe, A; Neumann, B; Wagner, H; Siewert, JR; Holzmann, B; Heidecke, CD; Pfeffer, K. Essential role of gamma-interferon in survival of colon ascendens stent peritonitis, a novel murine model of abdominal sepsis. *Infect. Immun.*, 1998, 66(5), 2300–2309.

Ziaja, M. Sepsis and septic encephalopathy: characteristics and experimental models. *Folia Neuropathol.*, 2012, 50(3), 231–239.

Zimmermann, T; Laszik, Z; Nagy, S; Kaszaki, J; Joo, F. The role of the complement system in the pathogenesis of multiple organ failure in shock. *Prog. Clin. Biol. Res.*, 1989, 308, 291–297.

Zsikai, B; Bizanc, L; Sztanyi, P; Vida, G; Nagy, E; Jiga, L; Ionac, M; Erces, D; Boros, M; Kaszaki, J. [Clinically relevant sepsis model in minipigs]. *Magy Seb.*, 2012, 65(4), 198–204. [Article in Hungarian].

In: Encyclopedia of Surgery (22 Volume Set)
Editors: Andreas Lehrer and Kristin Mueller
ISBN: 978-1-53618-329-0
© 2020 Nova Science Publishers, Inc.

Chapter 188

BARIATRIC EXPERIMENTAL SURGERY MODELS

Osman Bilgin Gulcicek*, MD
University of Health Sciences
Istanbul Bagcilar Training and Research Hospital,
Department of General Surgery,
Istanbul, Turkey

ABSTRACT

Obesity has recently become a major health problem. To treat obesity, there are non-surgical and surgical methods. However, surgical methods are more effective in managing obesity. Bariatric surgical methods are classified as restrictive, malabsorptive and combined methods. But sleeve gastrectomy and gastric plication are the most popular methods.

These techniques are easily applicable in clinic and have fewer complications. Both methods provide sufficient weight loss and decrease ghrelin and leptin levels. To plan an experimental surgery study for treating obesity, especially in small animals, these two techniques should be preferred for success of the experiments.

Keywords: obesity, sleeve gastrectomy, gastric plication, experimental

INTRODUCTION

Obesity is defined as accumulation of abnormal or excessive fat tissue leading to cardiovascular system diseases, diabetes mellitus, metabolic syndrome, musculoskeletal disorders and psychiatric problems. Obesity is recognized as a major health problem today (Ewing 2011; Blackburn 1987).

* Corresponding Author's Email: drosmanbilgin@hotmail.com; Fax: +90212 440 42 42.

The diagnosis of obesity is done by calculating body mass index (BMI; weight in kilograms divided by length in squared meters, kg/m^2). Patients with a BMI of over 40 kg/m^2 are considered morbidly obese (National Institutes of Health 2010).

To treat obesity, there are non-surgical modalities like diet, changes in habits and medical treatment. But these approaches have limited effects on weight loss (Lo´pez-NavaBrevie`re 2015). Additionally, these strategies are not affecting obesity continuously. However, surgery is considered to be effective in managing obesity (Benaiges 2015).

Bariatric surgery can be classified as restrictive (gastric plication, sleeve gastrectomy, adjustable gastric banding, intragastric balloon), malabsorptive (biliopancreatic diversion, biliopancreatic diversion with duodenal switch) and combined methods (Roux-en-Y gastric bypass, mini gastric bypass).

All these surgical procedures are conducted according to the recommendations of the American Society of Bariatric Surgery (Gastrointestinal surgery for severe obesity 1992).

Adjustable gastric banding was first applied in 1980s by Kuzmak. Gastric band is wrapped around the proximal stomach and there is a small gastric pouch on the upper side. This gastric band is connected to the port, placed under the skin through the catheter (Kuzmak 1991).

Intragastric balloon is a method which is based on inflating the balloon inserted into the stomach endoscopically and thus reducing the stomach volume (Benjamin 1988).

Biliopancreatic diversion was popularized first by Italian surgeon Scopinaro in 1979. This procedure reduces the duration of food interaction with digestive enzymes and absorption surface and abbreviates the transit time of food through the stomach.

It includes partial distal gastrectomy, transection of the small bowel approximately halfway between the ligament of Treitz and ileocecal valve, roux-en-Y gastroenterostomy and an anastomosis of biliopancreatic limb with the alimentary limb 50 cm before the ileocecal valve forming a common channel (Kamal 2012).

Biliopancreatic diversion with duodenal switch was described by Tom R. De Meester. İt is actually an anti-reflux surgery. In this procedure, anastomosis is made between roux leg and first part of duodenum. So biliopancreatic diversion is modified by preserving pyloric sphincter (Alan 2008).

Roux-en-Y gastric bypass was developed from the weight loss that was observed in patients undergoing surgery (partial stomach resection and Billroth-2 anastomosis) for ulcers. Today, it is the most commonly used bariatric method in United States. It was performed as a loop bypass with a larger stomach. In this procedure, stomach is divided horizontally and jejunum is transected from 40−50 cm distal part of Treitz ligament. There is an anastomosis between distal jejunum and new gastric pouch. The other anastomosis is performed between the proximal jejunum and distal jejunum, 75−150 cm away from the first anastomosis. This prevents the bile reflux to the esophagus and new stomach pouch after the surgery (Mason 1967).

Mini gastric bypass was first developed by Robert Rutledge in 1997. It is a simplified form of roux-en-Y gastric bypass. İn this procedure, a long narrow tube of the stomach along the lesser curvature is created. A loop of the small intestine is brought up and hooked to this tube at about 180−200 cm from the Treitz ligament (Rutledge 2001).

There are two important hormones in obesity surgery: Ghrelin and leptin. Ghrelin was discovered by Davis and described by Kojima in 1991.

It is expressed by specialized enterochromaffin cells located in the fundal region of the stomach. There is a proportional correlation between BMI and ghrelin decrease (Davis 1954; Kojima 2001).

Leptin is produced by adipocytes and secreted into blood. It is directly proportional with BMI and amount of body fat. Plasma leptin level is reduced in people who lose weight (Tadokoro 2015; Dagogo 1996). Decreasing plasma leptin and ghrelin levels by the operations of sleeve gastrectomy and gastric plication are shown in an experimental study (Gulcicek 2016). Sleeve gastrectomy and gastric plication have been performed with gradually increasing frequency in recent years. Both procedures can also be applied laparoscopically (Shen 2013).

Sleeve gastrectomy was first described in 1993 by Marceau et al. It was initially applied as a first stage of biliopancreatic diversion, duodenal switch and gastric bypass operations. Until 2003, it has been applied alone. It is a two-stage operation; dissection of the stomach and resection of the stomach. Greater curvature of the stomach is mobilized by the division of gastrocolic and gastrosplenic ligaments.

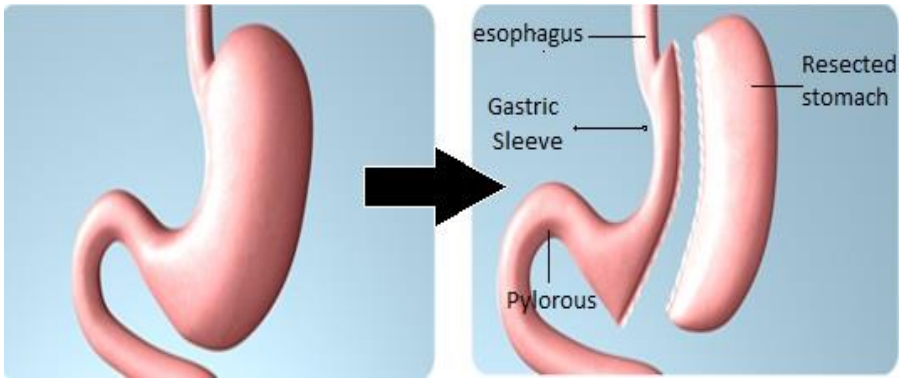

Figure 1. Sleeve gastrectomy.

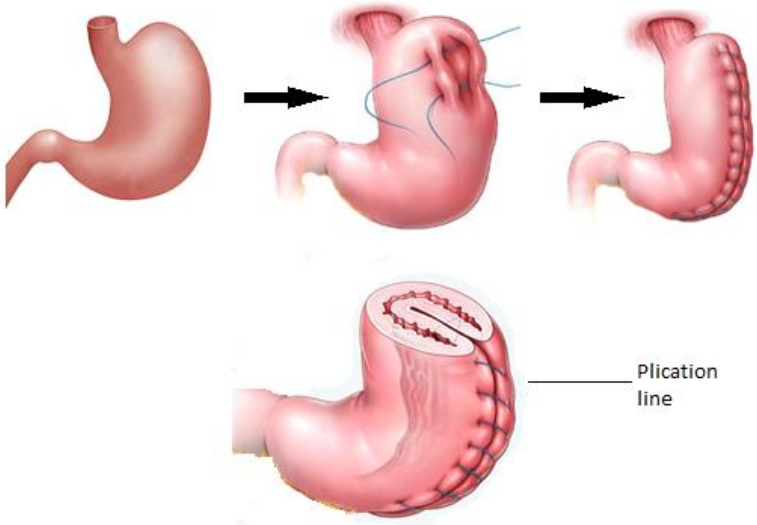

Figure 2. Gastric plication.

This dissection should be extended to the left crus of the diaphragm for the complete resection of the fundus. The second stage involves resection of the greater curvature of the stomach from antrum to angle of His throughout latarjet nerve. About 2/3 of the stomach is removed with this surgery (Figure 1) (Marceau 1998). Two mechanisms are judged with the weight loss after sleeve gastrectomy: Mechanical restriction by reducing the volume of the stomach and a decline in appetite by subtracting the fundus where ghrelin is produced (Weiner 2007).

Gastric plication was first described by Taleppour and Amoli in 2007. In this technique, as in sleeve gastrectomy, gastrocolic omentum is divided and the short gastric arteries are dissected.

Then, greater curvature of stomach is plicated over itself by two layered continuous non-absorbable sutures with the help of 32−36 F plug catheters. By this way, the lumen of the stomach is reduced (Figure 2) (Talebpourand 2007).

The amount of ghrelin production is reduced in the fundus because of the dissection of short gastric arteries in gastric plication.

ANATOMY OF THE STOMACH IN RATS

General anatomical features of the rat stomach are similar to those of human stomach. It is located in the left side of the abdominal cavity as in humans and adjacent to the left lobe of the liver, esophagus, colon and spleen.

When observed with the naked eye, it consists of two main sections of different colors: Cutan section and glandular section (Figure 3).

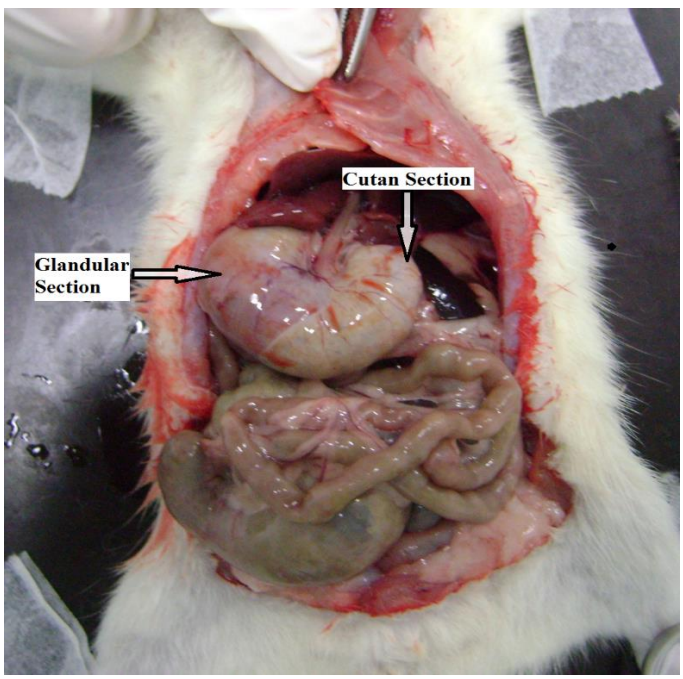

Figure 3. Front view of the stomach of rat.

Cutan section forms the proximal part of the stomach; it is adjacent to the esophagus and its color is lighter. Cutan part is thin-walled and lined with keratinized squamous epithelium. It is responsible for storage and digestion of food. The section which constitutes the large part of the stomach is glandular section.

Glandular section is thick-walled and consists of columnar epithelium. In lamina propria of this section, there are pepsin and HCl secreting cells. This section continues to the duodenum and small intestine as in human (Barlow 2009).

HOW TO CREATE OBESE RATS?

For bariatric experimental surgery, obese rats should be used. Therefore we need to select the rats which are already obese or we need to create obese rats.

Standard diet of experimental animals includes 50% carbohydrates, 25% protein and 5% fat. If we use high-fat diet (35% carbohydrates, 20% protein and 45% fat; d12451, Research Diets, New Brunswick, NJ, USA) for about 28 days, we can get obese rats (Tuncer 2007).

Another method is that when we add 25 grams of butter into 100 grams of standard diet, we'll get diet containing 65% fat. Daily weights of animals are recorded. When the desired weight is reached, we could use these animals for experimental obesity models (XZhou 1998).

BARIATRIC SURGICAL MODELS OF THE RATS

All surgical procedures for obesity mentioned above can be applied to rats.

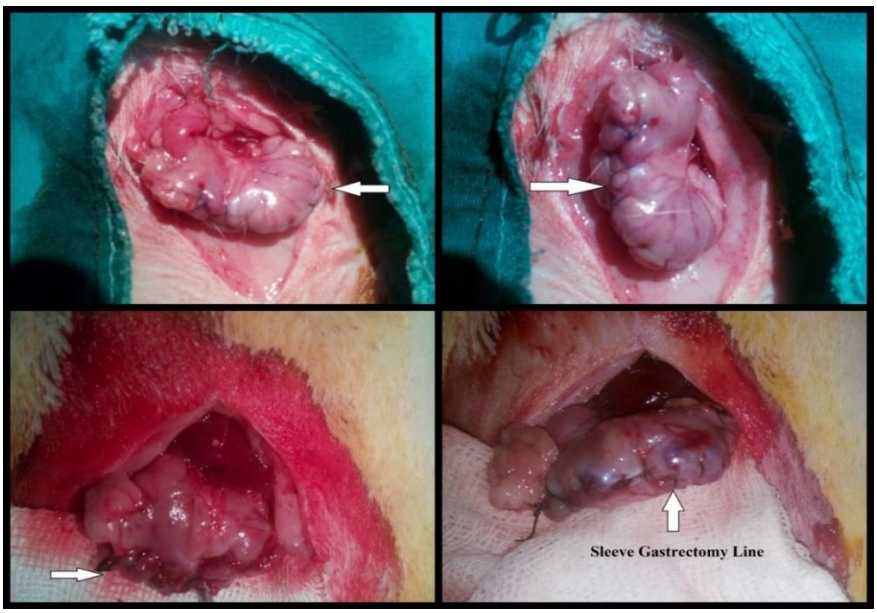

Figure 4. Sleeve gastrectomy on rat stomach.

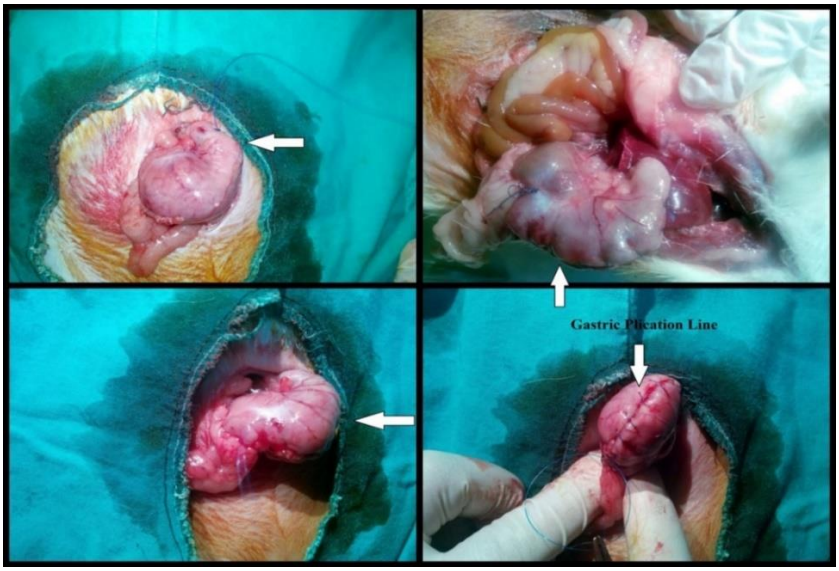

Figure 5. Gastric plication on rat stomach.

For sleeve gastrectomy, 3 cm midline incision is done under sterile conditions. Gastrocolic and gastrosplenic ligaments and short gastric arteries are dissected from 0.5cm proximal to the pylorus to diaphragmatic crus. 50−70% of the stomach is excised. Then, the inner layer is closed by continuous 5/0 polypropylene sutures and the outer layer is closed with continuous extramucosal sutures by 5/0 polypropylene (Figure 4) (Gulcicek 2016).

For gastric plication, the same steps are done. Stomach is not excised. After the dissection of ligaments, plication of the greater curvature is done with two layered extramucosal continuous sutures by 5/0 polypropylene (Figure 5) (Gulcicek 2016).

After the operation, abdomen layers are closed duly and after 5 hours, all rats are fed ad libitum.

CONCLUSION

All surgical procedures for obesity mentioned above for humans can be applied on rats. However, gastric plication and sleeve gastrectomy are the most popular bariatric surgical methods used in recent years.

Technically, it is easier to apply these methods on small experimental animals and complication rates are much less than the other methods. The short operation time and optimal use of anesthetic agents increase the success rate of the experiments.

REFERENCES

Barlow, Z., Cairl, B. (2009) *Rat Anatomy*.

Benaiges, D., Goday, A., Pedro-Botet, J., Ma´s, A., Chillaro´n, J. J., Flores-Le Roux, J. A. Bariatric surgery: to whom and when? *Minerva Endocrinol*, 2015; 40(2): 119−28.

Benjamin, S. B., Maher, K. A., Cattau, E. L. Jr., Collen, M. J., Fleischer, D. E., Lewis, J. H. (1988) Double-blind controlled trial of the Garren- Edwards gastric bubble: an adjunctive treatment for exogenous obesity. *Gastroenterology*, 95: 581−588.

Blackburn, G. L., Kanders, B. S. Medical evaluation and treatment of the obese patients with cardiovascular disease. *Am. J. Cardiol.*, 1987; 60: 55−8.

Dagogo, J. S., Fanelli, C., Paramore, D., Brothers, J., Landt, M. Plasma leptin and insulin relationships in obese and nonobese humans (abstract). *Diabetes*, 1996; 45: 695−8.

Davis, J. C. The relation between the pancreatic alpha cells and certain cells in the gastric mucosa. *J. Pathol. Bacteriol*., 1954; 67: 237−40.

Ewing, B. T., Thompson, M. A., Wachtel, M. S., Frezza, E. E. A cost- benefit analysis of bariatric surgery on the South Plains region of Texas. *Obes. Surg*., 2011; 21: 644−9.

Gastrointestinal surgery for severe obesity: National Institutes of Health Consensus Development Conference Statement. *Am. J. Clin. Nutr.*, 1992; 55 (2 Suppl.):615S–619S.

Gulcicek, O. B., Ozdogan, K., Solmaz, A., Yigitbas, H., Altınay, S., Gunes, A., Celik, D. S., Yavuz, E., Celik, A., Celebi, F. Metabolic and histopathological effects of sleeve gastrectomy and gastric plication: an experimental rodent model. *Food and Nutrition Research*, 2016, 60: 30888.

Kojima, M., Hosoda, H., Date, Y. Ghreline: discovery of natural endogenous ligand for the growth hormone secretgogue receptor. *Trends Endocrinol. Metab*., 2001; 12: 118−22.

Kuzmak, L. I., Rickert, R. R. Pathologic Changes in the Stomach at the Site of Silicone Gastric Banding. *Obes. Surg*., 1991 ;1: 63−68.

Lo´pez-NavaBrevie`re, G., Bautista-Castan˜o, I., Jimenez, A., de Grado, T., Fernandez-Corbelle, J. P. The Primary Obesity Surgery Endolumenal (POSE) procedure: one-year patient weight loss and safety outcomes. *Surg. Obes. Relat. Dis*., 2015; 11(4): 861−5.

Marceau, P., Hould, F. S., Simard, S., Lebel, S., Bourque, R. A., Potvin, M., Biron, S. Biliopancreatic diversion with duodenal switch. *World J. Surg*., 1998; 22: 947−54.

Mahawar, K. Bariatric Surgery: The Past, the Present, and the Future. Webmed Central, *Bariatric and Metabolic Surgery*, 2012; 3(7): WMC003610.

Mason, E. E., Ito, C. Gastric bypass in obesity. *Surg. Clin. North. Am.*, 1967; 47: 1345−1351.

National Institutes of Health (2010) NIH consensus statement *Gastrointestinal surgery for severe obesity*.

Rutledge, R. The mini-gastric bypass: experience with the first 1,274 cases. *Obes. Surg.*, 2001;11: 276−280.

Shen, D., Ye, H., Wang, Y., Ji, Y., Zhan, X., Zhu, J., Li, W. Comparison of short-term outcomes between laparoscopic greater curvature plication and laparoscopic sleeve gastrectomy. *Surg. Endosc.*, 2013; 27(8): 2768−74.

Saber, A. A., Elgamal, M. H., McLeod, M. K. Bariatric Surgery: The Past, Present, and Future. *Obes. Surg*., 2008; 18(1):121−128.

Tadokoro, S., Ide, S., Tokuyama, R., Umeki, H., Tatehara, S., Kataoka, S., Satomura, K. Leptin promotes wound healing in the skin. *PLoS One*, 2015; 10(3): 1−16.

Talebpourand, M., Amoli, B. S. Laparoscopic total gastric vertical plication in morbid obesity. *J. Laparoendosc. Adv. Surg. Tech. A*, 2007; 17(6): 793−8.

Tuncer, B. B., Barıs, E. et al. Evaluation Of Tooth And Surrounding Tissues In Experimental Induced Obese Rats With High Fat İntake A Pilot Study. *GU Diş Hek Fak Derg*., 24(3):167−171, 2007.

Weiner, R. A., Weiner, S., Pomhoff, I., Jacobi, C., Makarewicz, W., Weigand, G. Laparoscopic sleeve gastrectomy influence of sleevesize and resected gastric volume. *Obes. Surg*., 2007; 17: 1297-1305.

Zhou, X., De Schepper, J., De Craemer, D., Delhase, M., Gys, G., Smitz, J., and Hooghe-Peters, E. L. (1998) Pituitary growth hormone release and gene expression in cafeteria-diet-induced obese rats. *Journal of Endocrinology*, 1998; 159: 165–72.

In: Encyclopedia of Surgery (22 Volume Set)
Editors: Andreas Lehrer and Kristin Mueller
ISBN: 978-1-53618-329-0
© 2020 Nova Science Publishers, Inc.

Chapter 189

ANIMAL MODELS OF HEART FAILURE

Mouer Wang*, MD
Cardiovascular Institute, Stanford University, Stanford, CA, US

ABSTRACT

Cardiovascular diseases (CVD) often lead to heart failure (HF). HF prevalence is continuously rising and represents one of the leading causes of death and an economic burden in the western societies. The study of potential novel therapeutic options and interventions requires reliable animal models to evaluate myocardial progressive structural and functional changes. Indeed, during the past 40 years, basic and translational scientists have used small animal models to understand the pathophysiology of HF and improve prevention and treatment of patients suffering from congestive HF (CHF). Each species and animal model has advantages and disadvantages and the choice of one model over another should take them into account for a good experimental design.

The aim of this chapter is to describe and highlight the features of some commonly used small animal (rats and mouse) surgical models of cardiovascular diseases leading to HF.

Keywords: heart failure, rat, mouse, left anterior descending (LAD) artery ligation, aortic banding, aorto-caval fistula (ACF)

ABBREVIATIONS

ACF	aorto-caval fistula
CHF	chronic heart failure
CVD	cardiovascular diseases
HF	heart failure
LAD	left anterior descending
LV	left ventricle

* Corresponding Author's Email: mouerw@yahoo.com.

INTRODUCTION

Heart failure is a clinical syndrome characterized by cardiac dysfunction and myocardial structural abnormality (e.g., hypertrophy and dilated cardiomyopathy) resulting in inability of the heart to eject sufficient blood to the metabolizing tissues. Heart failure is a leading cause of morbidity and mortality, posing a major health and economic burden in the western world. Nearly 5 million Americans and 6.5 million Europeans suffer from heart failure, which accounts for 20% of all hospitalizations among patients over the age of 65, and its related complications result in one million admissions with an annual mortality rate of 8–10%. Moreover, heart failure has enormous economic impact because of the high costs of the treatment, frequent hospitalizations, and poor quality of life. Therefore, understanding the basic mechanisms leading to the development of heart failure and its complications, as well as the discovery of innovative adequate treatment for heart failure are crucial in order to improve the outcome of this devastating disease.

Humans present with heart failure of varying severity and of uncertain duration, produced by a wide variety of causes. This variability, and confounding effects of treatment, complicates the study of the pathophysiology and progression of the heart failure.

The ideal model should be able to reproduce each of the aspects of the progression of clinical heart failure. However, none of the models available is able to entirely reproduce heart failure. While some models reproduce neuroendocrine changes, others better reproduce the remodeling that occurs during chronic heart failure. Nevertheless, the progress that has been made so far and the expected future achievements in this field would not have been possible without the continuous development of experimental models of heart failure and hypertrophy in small and large animals, where each one has its unique advantages and limitations. There are three main surgical models of heart failure in rodents: coronary artery ligation to induce myocardial infarction; transverse aortic constriction to create a model of pressure overload; and aortocaval fistula to increate a model of volume overload.

RAT LEFT ANTERIOR DESCENDING (LAD) ARTERY LIGATION

The surgical method, first developed by Pfeffer and coworkers, consists of ligating the left coronary artery (Pfeffer 1979). In this procedure, left thoracotomy is performed on the anesthetized rat, and the heart is rapidly exteriorized by gentle pressure on the right side of the thorax. The left coronary artery is either ligated or heat cauterized between the pulmonary artery outflow tract and the left atrium. The heart is then returned to its normal position and the thorax immediately closed. Several modifications have been introduced to improve performance and to reduce animal mortality, and left coronary artery ligation is the most common method used to induce acute myocardial damage in rat and other animal models. If the left coronary artery is not completely ligated, heart failure may occur as a consequence of chronic myocardial ischemia. Complete occlusion of the left coronary artery results in myocardial infarction of variable sizes with occurrence of overt heart failure after 3–6 weeks in a subset of animals with large infarcts. The impairment of left ventricular function is related to the loss of myocardium. Failure is associated with left ventricular dilatation, reduced systolic function and increased filling pressures. The progression of left ventricular

dysfunction and myocardial failure is associated with neurohumoral activation similar to that seen in patients with chronic heart failure (CHF). In particular, it was shown that ACE (angiotensin-converting-enzyme) activity in the left ventricle correlated inversely with left ventricular function and that ACE activity in the kidney was only increased late after the induction of heart failure. Depressed myocardial function is associated with altered calcium transients. The density of L-type calcium channels, as evaluated by antagonist binding was shown to be decreased in moderate to severe stages of congestive heart failure. Furthermore, it was shown that after 4, 8 and 16 weeks following coronary artery ligation, SR (sarcoplasmic reticulum)-Ca^{2+} -ATPase mRNA and protein levels decrease continuously with increasing severity of congestive heart failure. Interestingly, SR-Ca^{2+} -ATPase activity was found to be more depressed than expected from the reduction in protein levels. Although a high initial mortality and induction of mild failure in most cases may be a disadvantage of this model, it seems to be very useful for long-term studies of pharmacological interventions on the neurohumoral activation.

One important modification is temporary occlusion followed by reperfusion, allowing flow recovery through the previously occluded coronary artery bed. Left coronary artery ligation can thus be used to evaluate diverse parameters resulting from either permanent ischemia or ischemia/reperfusion.

Preparation of the Operation

The operating surface is first prepared by disinfecting the area with 70% ethanol.

All surgical instruments are to be sterilized with a hot bead sterilizer before surgery (and in between individual rat surgeries). These instruments include: surgical scissors (2), forceps (1), curved forceps (1), needle holder (2), and a chest retractor.

Adjust the temperature of a homeothermic blanket system (heating pad), to be used to maintain the body temperature of the animal at 37±1℃, in order to prevent a dramatic fall in body temperature; the size of an infarct is dependent on the duration of occlusion as well as body temperature. Prior to the induction of anesthesia, animals will be examined to identify any pre-existing conditions that may complicate surgical outcome; physical examination will include visual inspection and measurement of heart rate, respiratory rate, and body temperature and body weight. Prior to anesthesia, each animal will receive a dosage of buprenorphine (0.1−2.5 mg/kg SQ).

Operative Steps

4. Rats are then anesthetized with 80 mg/kg of pentobarbital; the correct level of anesthesia is verified through the limb withdrawal response by applying pressure of the rat nail bed (toe-pinch reflex) and periodically throughout the procedure.
5. An electric shaver is then used to shave the fur form the neck and chest areas.
6. The shaved areas are to be scrubbed and disinfected with betadine solution followed by wiping the area with 70% alcohol; this betadine and alcohol scrub and disinfection procedure is to be repeated three times(Figure 1).

Figure 1. Disinfection of surgical field.

7. The anesthetized animal is then placed in a supine position on a homeothermic blanket system (heating pad) in order to maintain body temperature.
8. Intubation is then performed by insertion of the endotracheal tube (polyethylene size 90; PE 90) where the tubing is beveled on the edge for ease of entrance through the larynx.

Figure 2. Open the thorax.

Figure 3. Pericardium is opened.

9. Mechanical ventilation is then achieved by connecting the endotracheal tube to Kent Scientific ventilator (TOPO Dual Mode) cycling at 80 breaths per minute and a tidal volume of 1.2 ml per 100 gram body weight.
10. Once steady breathing is established, the chest is opened at the left fourth intercostal space, by using hemostats or round end scissors to open the space, but without cutting the tissue so that the risk of bleeding can be reduced (Figure 2).

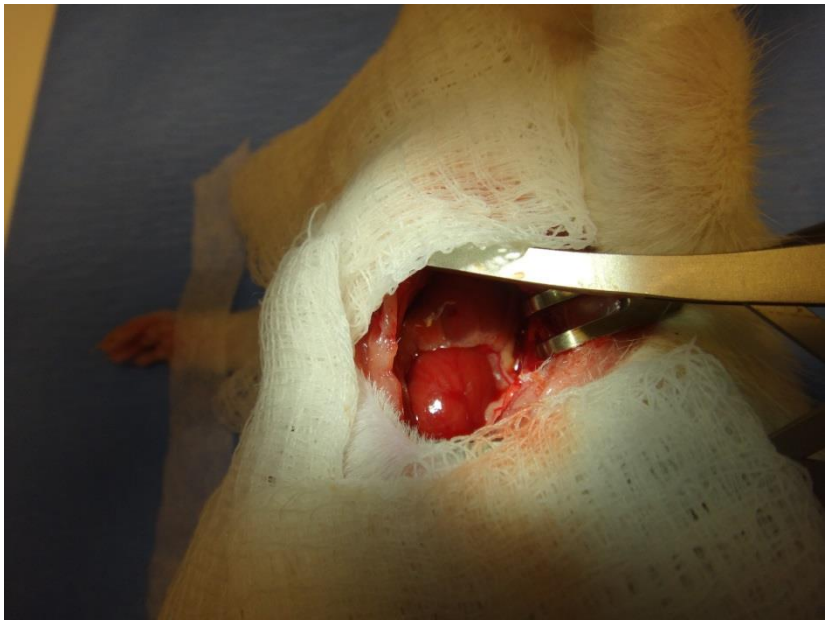

Figure 4. LAD is identified.

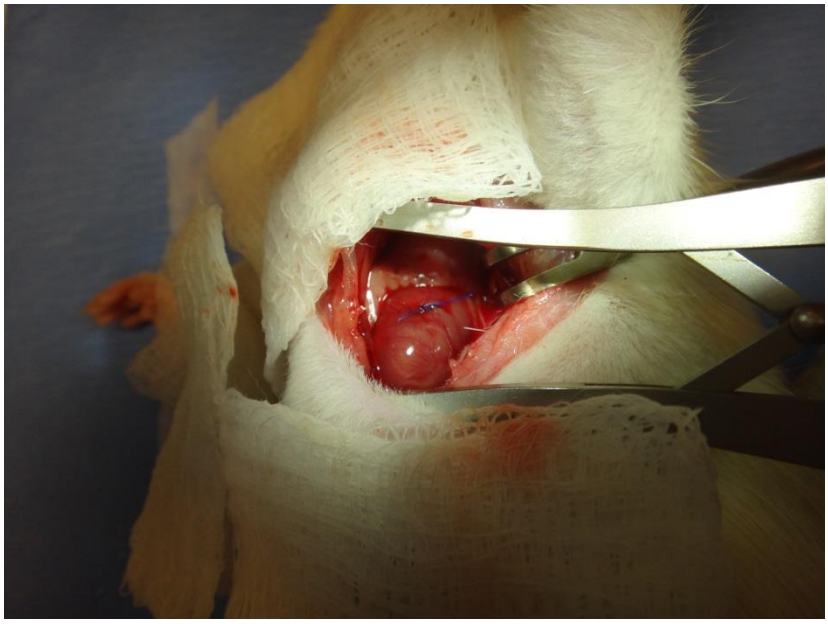

Figure 5. LAD is ligated using a 6-0 proline suture.

11. A chest retractor is then positioned within the fourth intercostal space in order to spread the ribs so that the left ventricle (LV) is exposed, taking maximal care not to damage the lung.
12. The pericardium is then opened, but left in place if possible (Figure 3).

Figure 6. Thorax cavity is closed.

Figure 7. Skin is closed using 6-0 proline suture.

13. The proximal left anterior descending (LAD) artery will be identified with the use of a surgical stereo microscope, and the LAD is then ligated using a 6-0 proline suture. Proper ligation of the LAD will be confirmed by observing blanching of myocardial tissue distal to the suture as well as dysfunction of the anterior wall; as observed during the transient LAD ligation (Figure 4 and Figure 5).
14. The chest retractor is then removed and the ribs are drawn together using a 2-0 proline suture with an interrupted suture pattern.
15. Once the ribs are closed, the outflow of the ventilator is again briefly (1−2 seconds) pinched off to ensure proper breathing (Figure 6).

The skin is closed using 6-0 proline suture with a continuous suture pattern (Figure 7).

Post-Operative Recovery

Once the surgery is complete, the body temperature (by a rectal thermometer), respiratory rate (by visual inspection), heart rate (by palpitation), and abnormal signs of pain are to be monitored until the animal becomes ambulatory. The rat will be removed from the ventilator and then be placed in an animal cage and allowed to recover from anesthesia.

RAT AORTIC BANDING

Placing a ligature around the ascending aorta induces pressure overload of the left ventricle, eventually resulting in left ventricular hypertrophy and failure. Aortic coarctation results in a very short reactive hyperreninemia of less than 4 days. Thereafter, the circulating

renin–angiotensin system is no longer activated, but the ventricular ACE activity begins to rise. After a period of several weeks, ventricular ACE activity may decrease again to normal values which may be related to normalization of wall stress with increasing hypertrophy. Numerous studies have been performed using aortic banding in rats to evaluate different aspects of left ventricular hypertrophy. Furthermore, after several months, a subset of animals goes into failure. In a recent study, chronic experimental aortic constriction imposed by banding of the ascending aorta in weanlings resulted in compensated left ventricular hypertrophy of the adult rats for several weeks. After 20 weeks of aortic banding, two distinct groups could be identified: rats without change in LV systolic pressure development and those with a significant reduction in left ventricular systolic pressure. The latter group exhibited increased left ventricular volumes, reduced ejection fraction and clinical signs of overt heart failure. Left ventricular hypertrophy and failure was associated with increased beta-myosin heavy chain mRNA and atrial natriuretic factor mRNA. Interestingly, a decrease in SR-Ca -ATPase mRNA levels by the polymerase chain reaction occurred in left ventricular myocardium from failing animals after 20 weeks of banding but not in nonfailing hypertrophied hearts. From this data, it was suggested that the decrease in SR-Ca –ATPase mRNA levels may be a marker of the transition from compensatory hypertrophy to failure in these animals. During compensated hypertrophy, while catecholamine levels are normal, there is activation of the local myocardial renin–angiotensin system, which may be important for the development of myocardial failure. With the development of heart failure, plasma catecholamine levels can increase.

This model seems to be well suited for studying the transition from hypertrophy to failure at the level of the myocardium. Nevertheless, one should keep in mind that considerable differences in the function of subcellular systems exist between rat and human myocardium.

Preparation of the Operation

Keep rat (approximately 200g body weight) under antibiotic umbrella 24 hr before surgery by administering amoxicillin orally (dose: 500 mg/L of water).Sterilize all surgical tools (such as scissors, forceps, clip applicator, suture needles, and needle holder) by autoclaving at 121℃ for 15 min. Use a heating pad to maintain the animal body temperature around 37℃ to avoid a rapid decrease in heart rate. Keep the rat on top of a temperature controlled heating pad in the supine position.

Remove fur from the neckline and left chest region of the rat (preferably using an electric shaver).Disinfect surgical site with povidone-iodine solution and then with 70% ethyl alcohol. Use a sterile drape to expose only the surgical site during the operative procedure. Note: As an additional option for the animal care, 0.25% Bupivicaine ID (2.5 mg/kg) can be incorporated prior to incising at each incision site for local anesthesia/analgesia.

Insert a 16 G I.V. Catheter into the rat's trachea through mouth. Connect the tracheal cannula to a rodent ventilator for maintaining a respiratory rate of 50 breaths/min, tidal volume of 1.70 ml and inspiration time of 0.60 sec(for rat with 200g body weight).

Operative Steps

1. After skin incision, the upper half of the sternum was divided in the midline using scissors.
2. The thymus was removed and aortic arch was carefully dissected free of the surrounding tissues (Figure 8 and Figure 9).

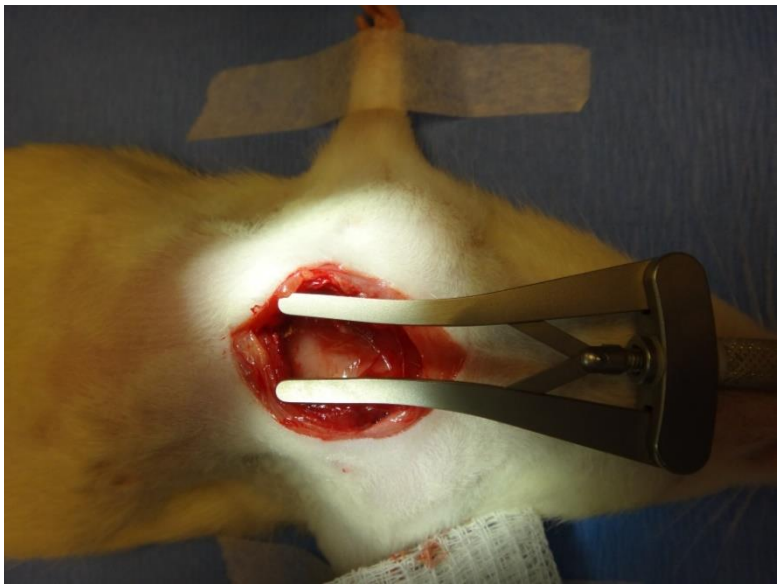

Figure 8. Upper half of the sternum was divided.

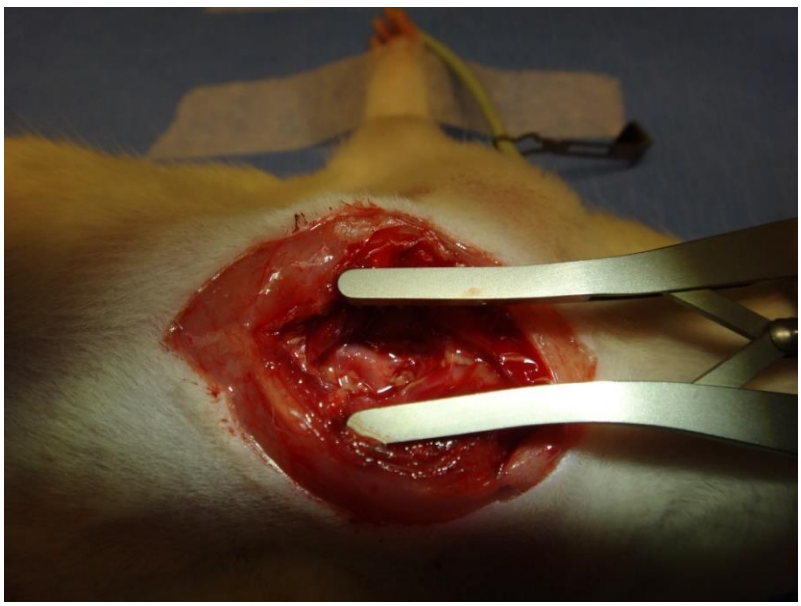

Figure 9. Thymus was removed and aortic arch exposed.

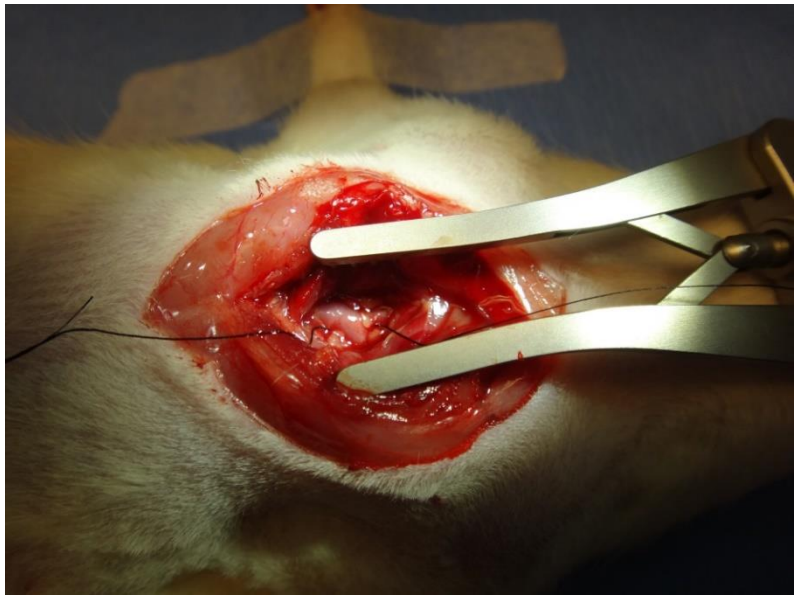

Figure 10. Suture is placed between the innominate and left carotid arteries.

3. Following identification of the transverse aorta, a small piece of a 5.0 silk suture is placed between the innominate and left carotid arteries (Figure 10).
4. Two loose knots are tied around the transverse aorta and a small piece of a 26½ gauge blunt needle is placed parallel to the transverse aorta. The first knot is quickly tied against the needle, followed by the second and the needle promptly removed in order to yield a constriction(Figure 11 and Figure 12).

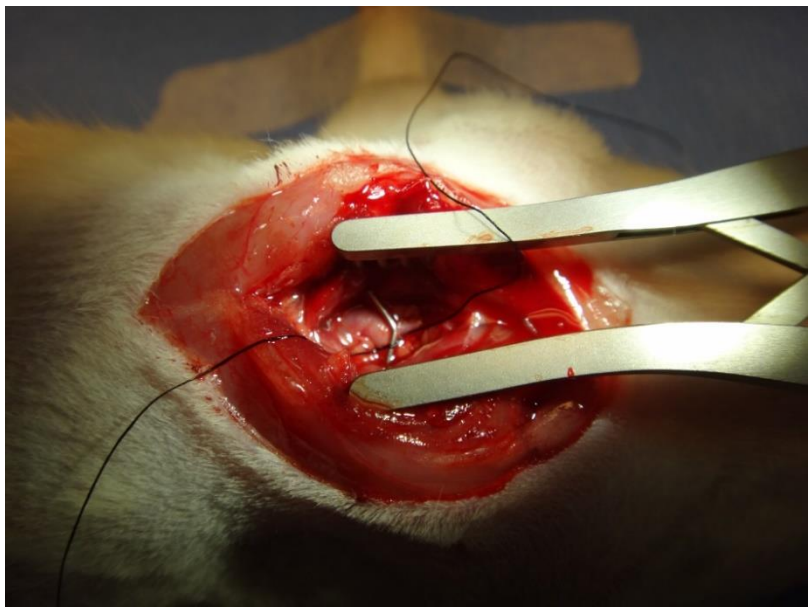

Figure 11. Small piece of a 26½ gauge blunt needle is placed.

Figure 12. Needle removed.

Figure 13. Sternotomy closed.

5. The sternotomy and the skin incision were closed with 5-0 sutures (Figure 13).

Post-Operative Recovery

Remove tracheal cannula from the rat once spontaneous breathing is re-established.

Allow the animal to recover on the heating pad by gradually lowering the anesthesia and ventilator assisted respiration.

Postoperatively, the animals were kept in separate cages and allowed free access to water and standard laboratory diet. Analgesia with buprenorphine 0.05 mg/kg subcutaneously was provided every 12 hour for 48 hours.

MOUSE CORONARY LIGATION MODEL

One of the most widely used models of heart failure in mice is the left coronary artery ligation procedure, adapted from rat. In some protocols, the artery is occluded permanently, but recently procedures for temporary occlusion have been introduced to reproduce human ischemia/reperfusion injury (Michael 1995). In this method the left anterior descending coronary artery is occluded and then reperfused, allowing flow recovery through the previously occluded coronary artery bed. Reperfusion is monitored visually, and the infarct can be analyzed by histopathological techniques, and can be documented in real time by noninvasive high frequency. The areas at risk and the infarct size are revealed by staining with Evans blue dye and triphenyltetrazolium chloride and are assessed by computerized planimetry. This model has confirmed the benefits of reperfusion, since infarct size was found to be significantly lower than after permanent occlusion of the coronary artery. The method has been further modified to analyze ischemic preconditioning of the heart. In this method, the left coronary artery is repeatedly occluded to subject the heart to several rounds of brief ischemia and reperfusion followed by permanent occlusion. This approach has identified several ischemia-induced genes that confer tolerance to a subsequent ischemic event (West 2008).

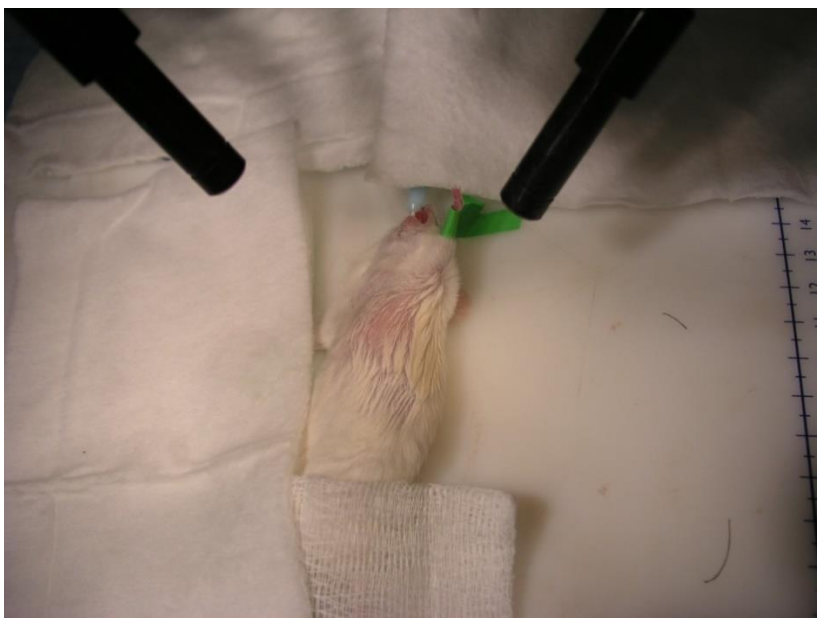

Figure 14. Intubated mouse on surgical area.

Preparation of the Operation

Before proceeding to surgery, anesthetize mouse that is 6 weeks of age or older by inhalation of 2−5% isoflurane. Perform a toe pinch to confirm that the animal is sufficiently anesthetized.

The unconscious mouse is placed on its back on a warm pad to maintain a constant temperature of 37°C. The precordial chest on the left side is shaved.

Secure the mouse to an intubation device with an isoflurane-filled chamber. Insert a tube of 0.2 inner diameter into the mouse's trachea through mouth, then place the intubated mouse on an aseptic surgical area (37°C by a temperature controller) and connect the endotracheal tube to a ventilator (rate of 120 per min, pressure of 4−6 mmH_2O) (Figure 14); disinfect the area with betadine and 75% ethanol.

Apply ophthalmic ointment to the mouse's eyes.

Operative Steps

6. Use sterile scissors to make a 1.5 cm incision along the mid-axillary line. Scissors are used rather than a scalpel to avoid injury to the underlying tissue in mice (Figure 15). Then, use blunt-tip vessel scissors to dissect and retract the precordial muscle from the chest wall.
7. Perform a left thoracotomy between the third and fourth ribs to visualize the anterior surface of the heart and left lung.
8. Further retract the thoracic wall using a suitable retractor in order to improve visualization and accessibility. Remove the pericardium by using toothed forceps and blunt-tipped scissors (Figure 16).

Figure 15. Section of skin.

Figure 16. Left thoracotomy.

9. Ligate the left coronary artery by placing the needle (attached with 7-0 suture) beneath the artery with a band of myocardium between the ligature and the artery (Figure 17). A successful occlusion of coronary artery is verified by hypokinesis/akinesis of the anterior left ventricular wall and by the alterations of ECG recording (*e.g.*ST segment elevation, QRS broadening)
10. Close the chest by placing two stitches (6-0 suture) on the third and fourth ribs.

Figure 17. Ligate the left coronary artery.

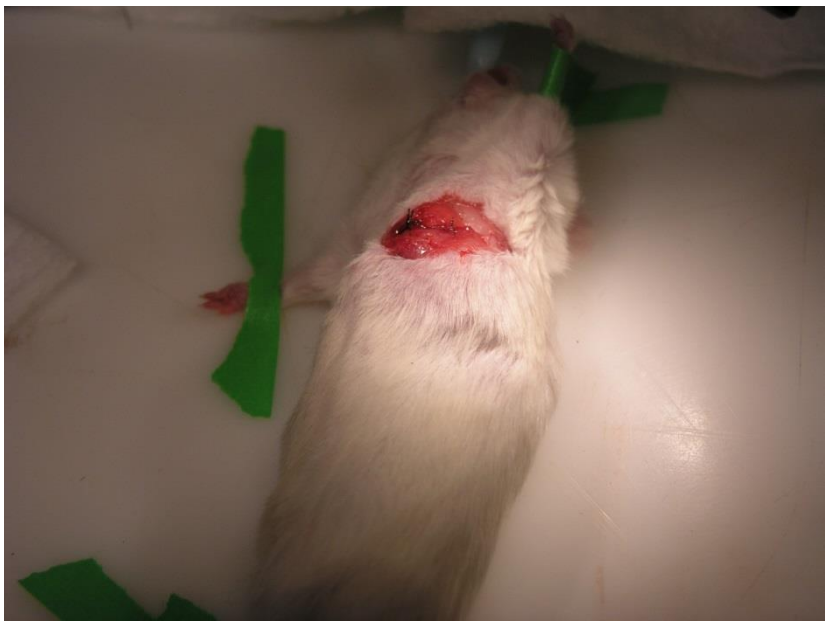

Figure 18. Close chest.

Use 5-0 suture to close the skin (Figure 18).

Post-Operative Recovery

For post-operative analgesia, administer a single intraperitoneal injection of buprenorphine (0.05 mg/kg). The animals will spontaneously recover within 2−5 min after stopping isoflurane anesthesia. Finally, place the mouse in a warm cage and provide 0.6 mg/ml of buprenorphine in the drinking water to prevent post-operative distress. Closely monitor the mouse for the first 24 hours after surgery.

Echocardiography is performed to evaluate cardiac function 3 days after myocardial infarction.

MOUSE AORTIC BANDING

The technique for transverse aortic constriction has also been adapted for use in mice (Rockman 1991).After anesthetic and thoracotomy of an adult mouse (an 8-week-old mouse is most commonly used), a 27-gauge needle is placed alongside the transverse aorta between the innominate and left carotid arteries. A nylon suture is tied around the vessel and needle, which is then withdrawn, leaving a 0.4-mm-diameter aperture. By this method, a stable, relatively reproducible 35–45 mm Hg gradient can be introduced across the experimental constriction. The intraoperative mortality reported in the original paper was around 10%, which remains the approximate value in current studies. Crucially, Rockman et al. have been able to show that the molecular pathways activated in their postoperative mouse hearts were identical to other animal and cellular models of cardiac hypertrophy (Rockman 1994). The

disadvantages of this approach are that, in absolute terms, intraoperative mortality is high, and as aortic banding is more technically demanding in the mouse than the rat, results are operator-dependent, with heart failure developing within weeks of the procedure in the surviving mice. However, the cost savings by using mice, and the huge range of genetic reagents available, may mitigate these disadvantages. It is not clear how applicable this system is to cardiac hypertrophy/failure due to aortic stenosis in humans, but it has allowed several advances in understanding the molecular control mechanisms underlying left ventricular hypertrophy.

Preparation of the Operation

The operating field is disinfected with 75% isopropyl alcohol. Make sure the heating pad is on and at the right temperature. A recommended system is a circulating water pump connected to a therapy pad that is maintained at 37°C ± 1°C. It is important to maintain normal body temperature during surgery as to avoid a rapid decrease in heart rate. Surgical tools are sterilized in a hot bead sterilizer before surgery. For this procedure, you will need the following surgical instruments: blunt scissors, course curved forceps × 2, fine 45° angled forceps × 2, angled spring scissors, chest retractor, and needle holder.

Cotton applicators should be on hand in case of bleeding.

Mice are anesthetized in an induction chamber with 2% isoflurane mixed with 0.5−1.0 L/min 100% O_2.Hair clippers are used to shave the fur from the neckline to mid chest level. The mouse is placed in a supine position atop a heating pad in order to maintain body temperature. A rubber band is placed over the animal's front teeth to extend the neck. Using curved forceps in one hand, the tongue is gently manipulated to the side. With the other hand, endotracheal intubation is performed using PE 90 tubing. The endotracheal tube is then connected to a Harvard volume-cycled rodent ventilator cycling at 125−150 breaths/minute and a tidal volume of 0.1−0.3ml. During the surgical procedure, anesthesia is maintained at 1.5−2% isoflurane with 0.5−1.0 L/min 100% O_2. Correct level of anesthesia is verified by applying pressure on the mouse nail bed (toe-pinch reflex).

The surgical field is disinfected with betadine solution followed by 70% alcohol. This procedure is repeated three times.

To prevent contamination of the surgical field during the operation, a sterile drape is placed over the mouse leaving only the operation field exposed.

A set of sterile gloves is used for each individual mouse.

Operative Steps

11. Partial thoracotomy to the second rib is performed under a surgical microscope and the sternum retracted using a chest retractor (Figure 19).
12. Fine tip 45° angled forceps are used to gently separate the thymus and fat tissue from the aortic arch.

Figure 19. Partial thoracotomy.

13. Following identification of the transverse aorta, a small piece of a 6.0 silk suture is placed between the innominate and left carotid arteries (Figure 20; 21).

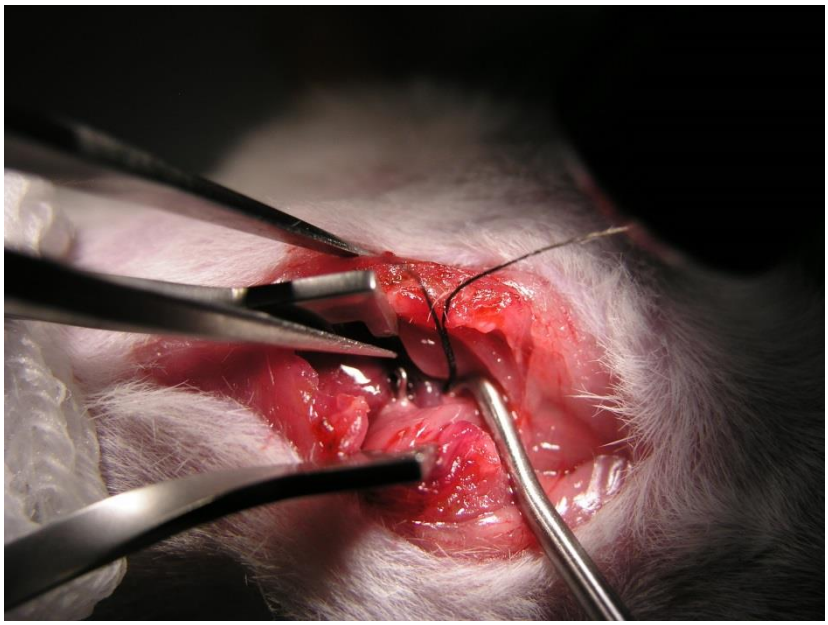

Figure 20. Identification of the transverse aorta.

Figure 21. Suture is placed between the innominate and left carotid arteries.

14. Two loose knots are tied around the transverse aorta and a small piece of a 27½ gauge blunt needle is placed parallel to the transverse aorta (Figure 22). The first knot is quickly tied against the needle, followed by the second (Figure 23) and the needle promptly removed in order to yield a constriction of 0.4 mm in diameter (Figure 24).

Figure 22. Small piece blunt needle is placed parallel to the transverse aorta.

Figure 23. The second knot.

15. The chest retractor is removed and the outflow of the ventilator pinched off for 2 seconds to re-inflate the lungs (Figure 25).

Figure 24. Needle removed and yield a constriction of 0.4 mm in diameter.

Figure 25. Chest retractor is removed.

16. The chest cage is closed using a 6.0 proline suture with an interrupted suture pattern (Figure 26).
17. The skin is closed using a 6.0 proline suture with a continuous suture pattern (Figure 27).

Figure 26. Chest cage is closed.

Figure 27. Skin is closed using a 6.0 proline suture.

Post-Operative Recovery

For post-operative analgesia, the mouse is injected with buprenorphine (0.1 mg/kg) intraperitoneally. If there are signs of dehydration after surgery, sterile saline is given intraperitoneally.

Anesthesia is gradually lowered to the off position and the endotracheal tube removed when signs of spontaneous breathing occur.

The mouse is moved to the prone position and allowed to recover on a heating pad.

AORTO-CAVAL FISTULA (ACF)

The rat aortocaval fistula (ACF) model is considered to be a model of high-output heart failure, its long-term renal and cardiac manifestations are similar to those seen in patients with low-output heart failure. These include Na^+-retention, cardiac hypertrophy and increased activity of both vasoconstrictor/antinatriuretic neuro hormonal systems and compensatory vasodilating/natriuretic systems. Progression of cardiorenal pathophysiology in this model is largely determined by balance between opposing hormonal forces, as reflected in states of heart failure decompensation that are characterized by overactivation of vasoconstrictive/Na^+-retaining systems.

Since this model mimics high cardiac output clinical heart failure, it may be suitable to study myocardial alterations, mainly cardiac hypertrophy characterizing these patients.

Thus, ACF serves as a simple, cheap, and reproducible platform to investigate the pathogenesis of heart failure and to examine efficacy of new therapeutic approaches (Liu 1991).

Preparation of the Operation

Male Sprague-Dawley rats weighing 250 to 300 g were anesthetized with pentobarbital sodium (40 mg/kg of body weight).Use a heating pad to maintain the animal body temperature around 37°C to avoid a rapid decrease in heart rate. Take care to avoid dehydration of the animal before and during surgery. Check the pedal reflex to confirm successful anesthesia.

Operative Steps

18. Dissecting the vena cava and the aorta from the surrounding tissues, but not from each other (Figure 28).
19. Miniature vessels clamp was placed approximately 10 mm distal to the origin of the renal arteries (Figure 29).
20. 1.5 mm opening was cut into the lateral wall of the vena cava and the aorta.
21. Vena cava to aorta side-to-side anastomosis was made by continuous 0.6 size proline suture (Figure 30).
22. After the vessel clamps were released, arterial blood could be seen vigorously entering the vena cava through the fistula and mixing with the darker venous blood (Figure 31).
23. Time of occlusion of both vessels did not exceed 10 minutes.

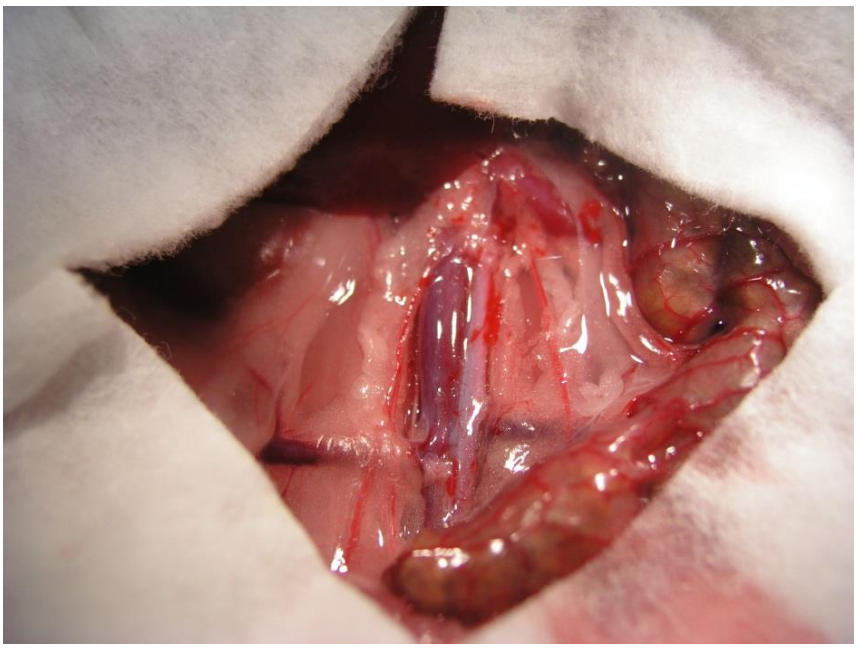

Figure 28. Dissecting the vena cava and the aorta.

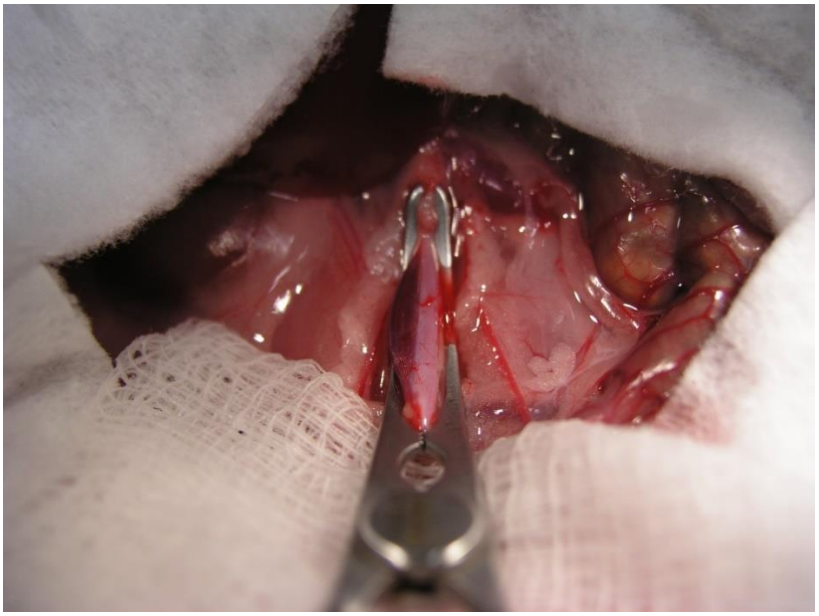

Figure 29. Clamp was placed on vena cava and aorta.

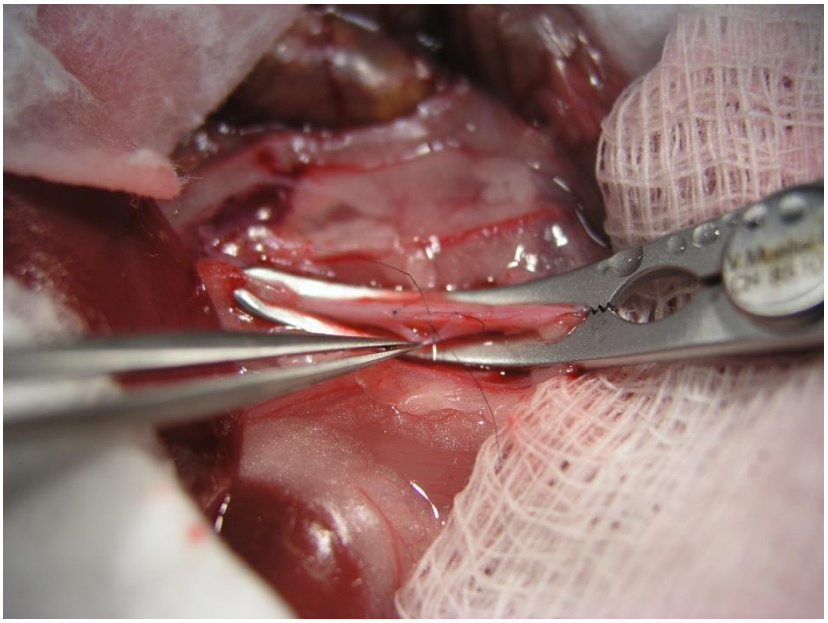

Figure 30. Vena cava to aorta side-to-side anastomosis.

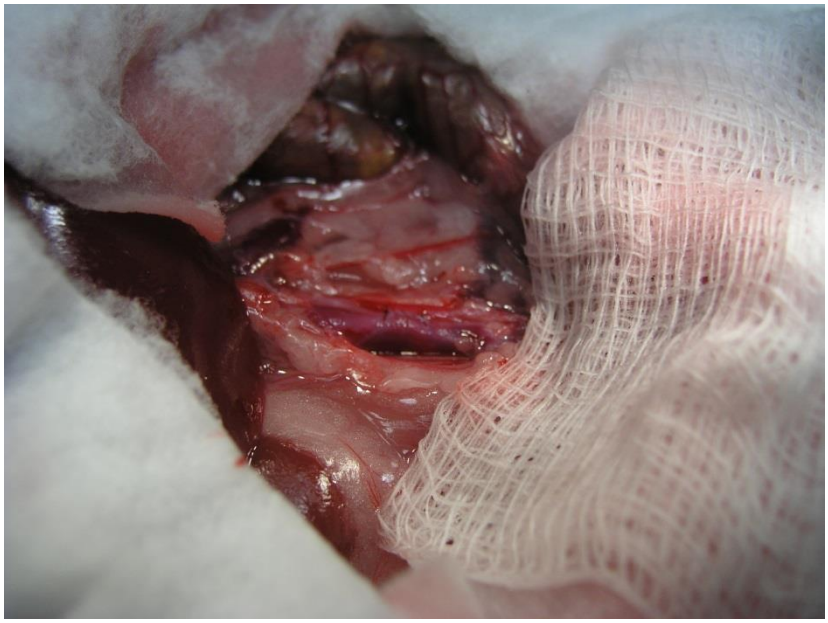

Figure 31.Vessel clamps are released.

POST-OPERATIVE RECOVERY

For post-operative analgesia, administer a single intraperitoneal injection of buprenorphine (0.05 mg/kg). Place the rat in a warm cage and closely monitor the rat for the first 24 hours after surgery.

CONCLUSION

The use of animal models has proven to be an extremely valuable tool in understanding the pathophysiology of complex cardiovascular disease mimicking congestive HF. The ideal animal model of cardiovascular disease will mimic the human subject metabolically and pathophysiologically, will be large enough to permit physiological and metabolic studies, and will develop end-stage disease comparable to those in humans. Given the complex multifactorial nature of CVD, no species or animal model will be similar to the human disease and thus the models should be chosen according to the study aim. Animal models may also be relevant to study the effects of new pharmacological interventions on hemodynamics, neurohumoral activation and survival under preclinical conditions. At present, transgenic models of congestive HF are essential for understanding the molecular alterations underlying the development of the disease, as they allow the identification of genes that are causative for HF and to characterize molecular mechanisms responsible for the development and progression of the disease. Animal models which mimic distinct features of human HF will play an important role in unravelling the consequences of gene transfer and molecular techniques to correct disturbed subcellular processes in the failing heart. These experiments

are indispensable and these rodent models will continue to held an important role, not only in expanding our knowledge about the mechanisms underlying HF, but also in developing novel therapeutic strategies for this syndrome.

REFERENCES

Liu Z, Hilbelink DR, Crockett WB, Gerdes AM. Regional changes in hemodynamics and cardiac myocyte size in rats with aortocaval fistulas. Developing and established hypertrophy. *Circ. Res.* 1991;69:52–58.

Michael LH, Entman MI, Hartley CJ, Youker KA, Zhu J, Hall SR, Hawkins HK, Berens K, Ballantyne CM. Myocardial ischemia and reperfusion: a murine model. *American Journal of Physiology* 1995; 269(6):H2147–H2154.

Pfeffer MA, Pfeffer JM and Fishbein MC. Myocardial infarct size and ventricular function in rats. *Circulation Research* 1979; 44 (4):503–512.

Rockman HA, Ross RS, Harris AN, Knowlton KU, Steinhelper ME, Field LJ, et al. Segregation of atrial-specific and inducible expression of an atrial natriuretic factor transgene inan *in vivo* murine model of cardiac hypertrophy. *Proc. Natl. Acad. Sci. USA* 1991;88(18):8277–81.

Rockman HA, Wachhorst SP, Mao L, Ross Jr J. ANG II receptor blockade prevents ventricular hypertrophy and ANF gene expression with pressure overload in mice. *Am. J. Physiol.* 1994;266(6 Pt 2):H2468–75.

West MB, Rokosh G, Obal D et al. Cardiac myocytespecific expression of inducible nitric oxide synthase protects against ischemia/reperfusion injury by preventing mitochondrial permeability transition, *Circulation* 2008; 118(19):1970–1978.

In: Encyclopedia of Surgery (22 Volume Set)
Editors: Andreas Lehrer and Kristin Mueller
ISBN: 978-1-53618-329-0
© 2020 Nova Science Publishers, Inc.

Chapter 190

HEPATOPANCREATOBILIARY SURGERY EXPERIMENTAL MODELS

Paulo N. Martins*, MD, PhD, Natalie Bath, MD and Adel Bozorgzadeh, MD
Department of Surgery, Division of Organ Transplantation,
UMass Memorial Medical Center, University Campus, Worcester, MA, US

ABSTRACT

Well-characterized animal models of human diseases are fundamental for the analysis of pathophysiologic mechanisms and the development of new treatment strategies. A better understanding of the underlying pathophysiology of hepatopancreatobiliary (HPB) disease may lead to more targeted therapeutic options, potentially leading to improved survival. We will focus this chapter on rodent HPB models. Owing to the low cost of experiments, easily handling, and availability of a variety of genetically modified strains, rodents have become a popular model organism for such experiments.

Despite some limitations, the use of rodent models in HPB surgery provides essential investigative tools to study many important phenomena in HPB research. Due to the availability of large varieties of genetically modified species and monoclonal antibodies, more relevant and more specific questions can be answered utilizing rodent models. Most of these procedures only require basic surgical skills, and they have been performed with high reproducibility, which has been tolerated very well with minimal operative mortality. However, some procedures require microsurgical skills to be performed accurately and reproducibly. Increased knowledge of the rat and mouse liver surgical anatomy and more advanced microsurgical skills permit individualized dissection, and individual ligature of vascular and biliary branches.

Here we will review the HPB anatomy; techniques for hepatectomy, bile duct ligation, and portal systemic shunts; models of cirrhosis; models of acute liver failure; models of hepatocellular carcinoma (HCC) and cholangiocarcinoma (CCC); model of hepatic metastases of colon carcinoma; pancreatitis; and common bile duct (CBD) stricture.

* Corresponding Author's Email: paulo.martins@umassmemorial.org; Fax: 508-856-1102.

Keywords: hepatopancreatobiliary surgery, hepatectomy technique, cirrhosis, acute liver failure

ABBREVIATIONS

CBD	common bile duct
CBDL	common bile duct ligation
CCC	cholangiocarcinoma
CCL4	carbon tetrachloride
CDL	closed duodenal loop
CL	caudate lobe
CP	caudate process
DEN	diethylnitrosamine
DMNA	dimethylnitrosamine
FL	falciform ligament
GB	Gallbladder
HCC	hepatocelular carcinoma
HCV	hepatitis C virus
HPB	hepatopacreaticobiliary
IRL	inferior right lobe
LLL	left lateral lobe
LML	left middle lobe
ML	Middle lobe
PB	phenobarbital
PH	partial hepatectomy
PVL	portal vein ligation
RL	right lobe
RLL	right lower lobe
RML	right middle lobe
SRL	superior right lobe
TAA	Thioacetamide

LIVER ANATOMY

Introduction

The rat is the most used experimental model in hepatopancreatobiliary (HPB) surgical research because of many factors, in particular because it is easy to handle and inexpensive (Rodriguez 1999; Martins 2003). In hepatic regeneration, liver metastasis, transplantation immunology and hepatic disease studies, the rat is by far the most frequently used model. On the other hand, the majority of studies that led to advances in techniques of liver resection and transplantation have used the porcine and canine model. Virtually all procedures in liver surgery can be performed in the rat including segmental liver resections, porto-systemic

shunts, transplantation of full and partial organs, and vascular embolizations. As a result of the great anatomical variability of liver anatomy such as its extrahepatic biliary tract and vascularization, the knowledge of anatomy is advantageous because it permits individualized dissection, parenchymal section, ligature of specific vascular and biliary branches, and avoids damage of other structures.

The objective of this study was to systematically describe and illustrate the surgical anatomy of the rat liver to facilitate the planning and performance of HPB surgery studies in this animal.

Liver Anatomy

The rat and mouse livers are multi-lobulated as in other mammals (Lorente 1995; Flower 1872; Martins 2007). In rats, the liver mass represents approximately 5% of the total body weight compared to 2.5% in adult humans.

Surfaces

With the rat placed in decubitus position, the rat liver has three surfaces: superior, inferior and posterior. A sharp, well-defined margin divides the inferior from the superior surface. Unique from the human liver, the other margins of the liver are also sharp. Although the rat liver is lobulated, it has rather uniform surfaces since the lobes lie flat against each other as seen in Figure 1A. The only exception to this is the posterior caudate lobe, which is separated from the remainder liver by the stomach.

The *superior (parietal) surface*, convex as a whole, comprises a part of the left lateral and medial lobes and fits under the vault of the diaphragm. It is completely covered by peritoneum except along the line of attachment of the falciform ligament. The line of attachment of the falciform ligament divides the liver into two parts, termed the right and left lobes. In comparison to the human liver in which the right lobe is much larger than the left, the rat left and right liver have approximately the same volume.

The *inferior (visceral) surface* is uneven, concave, and it is in close proximity to the stomach, duodenum, right colic flexure, the superior part of the pancreas, the right kidney and suprarenal gland. The rat liver inferior surface does not have the fossae in the shape of the letter “H” as in humans. This surface is almost completely invested by peritoneum. Through the porta (transverse fissure) travels the portal vein, the hepatic artery and nerves, the hepatic duct and lymphatics. Liver impressions (colic, renal, duodenal, and suprarenal) are not as evident as in human livers.

The *posterior surface* it is not covered by peritoneum over some part of its extent, and it is in direct contact with the diaphragm. It extends obliquely between the caudate lobe and the bare area of the liver. The inferior vena cava is completely intrahepatic.

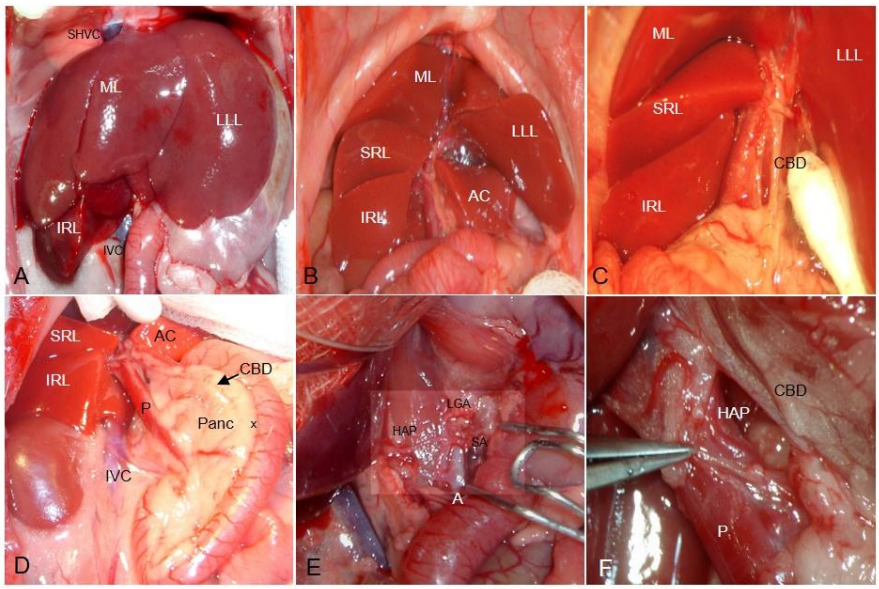

Abbreviations: AC: anterior caudate lobe, CBD common bile duct, Panc pancreas**,** CT celiac trunk, PHA proper hepatic artery, SA splenic artery, A aorta, LGA left gastric artery, Ly lymph node, S stomach, D duodenum, RK right kidney, SHVC supra-hepatic vena cava, GB gallbladder, FL falciform ligament , P portal vein, IVC inferior vena cava, RLL right lower lobe, ML middle lobe, RML right middle lobe, LML left middle lobe, CL caudate lobe, LLL left lateral lobe, RL right lobe.

Figure 1. Rat liver "in-situ". (A) Anterior view, (B) Anterior view after separating the lobes, (C) Porta hepatis, (D) Portal vein and common bile duct descending in the pancreatic tissue along the duodenum (the point of insertion of the CBD in the duodenum is marked with a X), (E) Celiac trunk and its branches: proper hepatic, left gastric and splenic arteries. (F) Magnification of the portal triade: portal vein, CBD, proper hepatic artery and a hilar lymph node.

Ligaments

Similar to the human liver, the rat liver is connected to the under surface of the diaphragm and to the anterior wall of the abdomen by five ligaments: the *falciform*, the *coronary*, two *lateral* which are peritoneal folds, and the *round ligament* − a fibrous cord which represents the obliterated umbilical vein. The liver is also attached to the lesser curvature of the stomach by the hepatogastric ligament and to the duodenum by the hepatoduodenal ligament.

Liver Lobes

The rat's liver lobes, like the human liver, are named after the portal branches that supply them due to the fact that the portal system is the most constant anatomical reference among mammals (Flower 1872; Lorente 1995; Martins 2007) (See Figures 1−6).

The *middle* or *median lobe* is the largest lobe, accounting for approximately 38% of the liver weight. It is fixed between the diaphragm and abdominal wall by the falciform ligament.

It is in continuity with the left lateral lobe and is subdivided by a vertical fissure (main fissure or umbilical fissure) into a large right medial lobe (2/3 of the volume of the medial lobe) and a smaller left medial lobe (1/3 of the volume). The right medial lobe has both left and right hepatic vascular components. (Lorente 1995; Kogure 1999; Martins 2007).

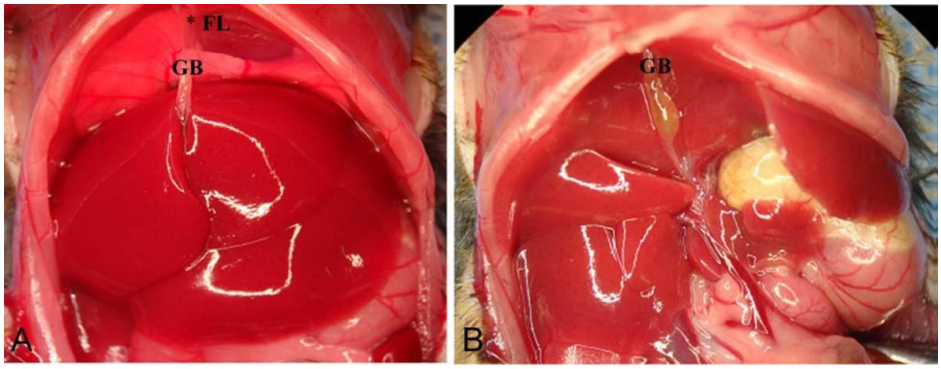

Abbreviations: GB: gallbladder, FL: falciform ligament.

Figure 2. A, B. Anterior view of the mouse liver showing the location of the gallbladder and falciform ligament. B) Visceral view of the mouse liver.

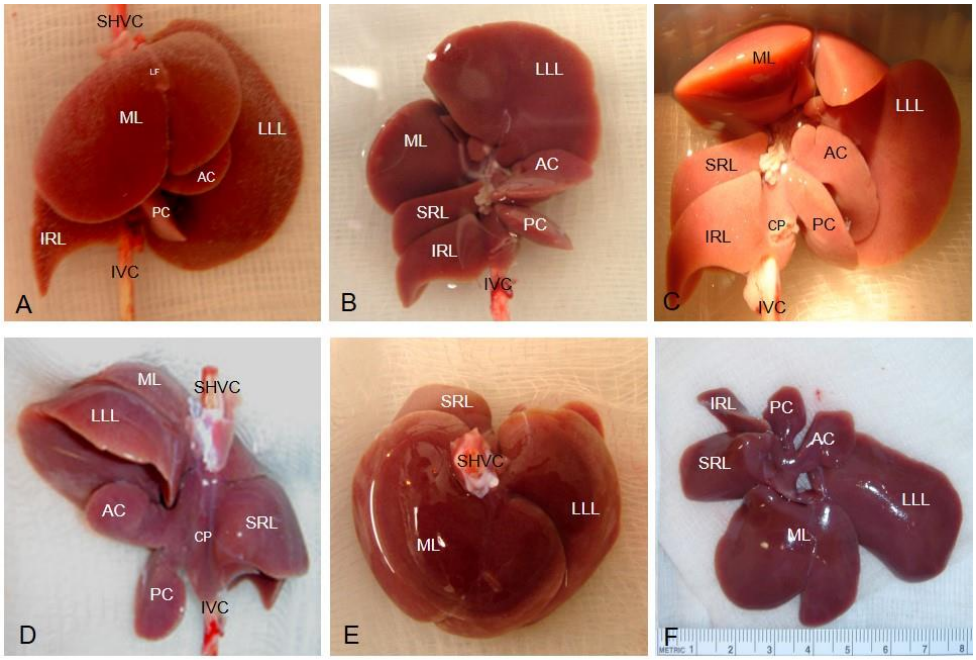

Abbreviations: the same as in Figure 1 and 2.

Figure 3. Rat liver "ex-situ". (A) Anterior view, (B) Inferior (visceral) view (C) Anterior after separating the lobes, (D) posterior view, (E) Superior view with the lobes in normal position, (F) Superior view with lobes flattened and separated from each other (note here a millimetric scale on the bottom). When the liver is ex-situ, the anterior and posterior caudate lobes are on the same plane (see in E), and the anterior lobe lies superiorly. Note in D that the inferior vena cava is completely intrahepatic (a plastic catheter is inside the inferior vena cava.

The *right lobe*, located to the right of the vena cava and posteriorly in the right hypochondrium, is almost completely covered by the medial lobe. It comprises approximately 22% of the liver weight and is divided by a horizontal fissure into two pyramidal-shaped lobules, the superior (SRL, superior right lobe, also called right posterior lobe) and inferior (IRL, inferior right lobe, also called right anterior lobe) lobules.

The *left lateral lobe* is flattened and situated in the epigastric and left hypochondriac regions over the anterior aspect of the stomach. Its medial portion is covered by the left part of the medial lobe. Its upper surface is slightly convex and is molded on the diaphragm. It has no fissures.

The *caudate lobe* is situated behind the left lateral lobe and to the left of the vena porta and inferior cava vein. It comprises 8 to 10% of the liver weight and is divided into two portions: the *paracaval portion* (*caudate process*) - which accounts for 2 to 3% of the liver mass, encircles the inferior vena cava and bridges the caudate lobes and the right lateral lobe; and the *Spiegel lobe*, which has an *anterior* (superior) and a *posterior* (inferior) portion in form of discs, each representing 4% of the liver mass. The anterior part of the caudate lobe is located anterior to the esophagus and stomach and its pedicle lies superior, while the posterior is located behind these structures and its pedicle lies inferior (Figure 3). Both are covered by a very thin layer of peritoneum, the hepatoduodenal and hepatogastric ligaments.

Liver Vasculature

The origin and course of the major vessels are similar to those of humans; no variability in vessel origin was identified in this small number of animals. However, there have been many variations of the liver vasculature described (Flower 1872; Greene 1963; Castaing 1980; Brand 1995; Lorente 1995; Wu 2005; Martins 2007). The most common anatomy of liver vasculature and biliary system is shown on Figure 4.

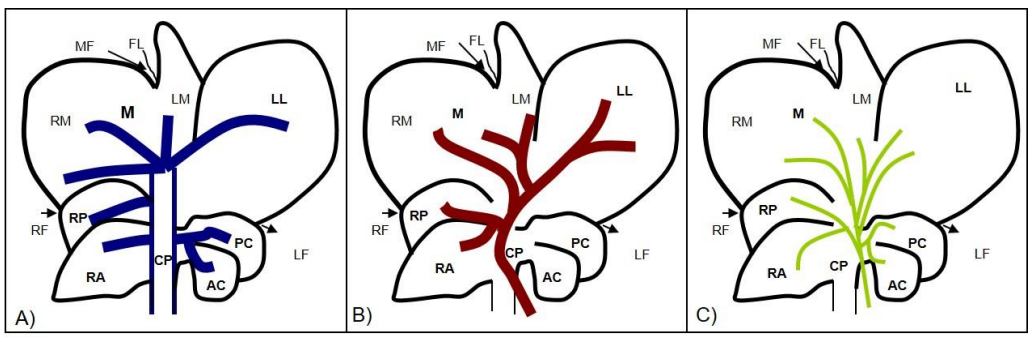

Abbreviations: the same as in Figure 2.

Figure 4. Most common anatomy of the hepatic veins (A), portal vein (B) and biliary system (C) of the rat.

Hepatic Artery

The liver is supplied by the hepatic artery proper, which originates from the common hepatic artery. The celiac trunk, which is relatively longer in rats than in humans, originates at the anterior or right aspect of the abdominal aorta just below the diaphragm pillars, ascends closely to the aorta for 5 to 7 mm and branches into the common hepatic, left gastric and splenic arteries (Brand 1995) (Figure 1E). The common hepatic artery runs within the pancreas and bifurcates at the level of the portal vein into hepatic artery proper and gastroduodenal artery. The hepatic proper artery has a diameter between 0.2 to 0.5 mm and length between 4 to 5 mm. The hepatic artery proper runs at the posterior surface of the portal vein, and at the liver hilum it divides into the right and left branches (Figure 1F). The arterial branches run on the anterior surface of the portal vein, pass behind the major hepatic ducts and follow a parallel course with the portal vein branches as they divide into their main lobar ramifications. Sometimes two lobar arteries accompany one single lobar portal vein. The most visible branches are for the superior right lateral, inferior right lateral and medial lobes. In addition to the four branches to the main hepatic lobes, the hepatic artery proper gives off a branch, which can be difficult to visualize, called hepato-esophageal artery. This branch arises on the hepatic pedicle between the caudate and left lobes measuring 10 to 12 mm in length and 0.1 mm in diameter and supplies the lower two-thirds of the esophagus (Leneman 1967). It was not found in the literature description of the intrahepatic arterial branches.

Portal Vein

The extrahepatic portal vein is located posterior and lateral to the hepatic artery and common bile duct (Figure 1C−D). It is formed from the superior mesenteric vein, the gastrosplenic vein, and the gastroduodenal vein Innocenti P (1978). The pancreaticoduodenal vein and inferior mesenteric vein drain into the superior mesenteric vein. In this series, the range of diameter and length of the portal vein was 2 to 4 mm and 4 to 7 mm, respectively.

The rat liver has three main portal branches, which determine the following fissures: left portal fissure, right portal fissure and main portal fissure. The left portal fissure separates the right lower lobe (RLL) from the middle lobe (ML), the main fissure separates the right middle lobe (RML) from the left middle lobe (LML), and the left fissure (corresponding to the fossa for the ductus venosus in the human liver), which separates the caudate lobe (CL) from the left lateral lobe (LLL). At the porta hepatis the common portal vein gives branches first to the right lobe (RL), then to the CL, then to ML and last to the LLL (Lorente 1995; Martins 2007). The left, right, and caudate lobes have one primary portal branch, whereas the middle lobe has two portal branches. The right portal vein immediately divides into two branches, one for the superior right lobule and inferior right lobule. The portal branch to the caudate lobe is very short, branching into two main veins, one for anterior and one for the posterior Spiegel lobe. Other very small veins, originating directly from the main portal vein and its left and right branches, supply the paracaval portion (caudate process).

Hepatic Veins

The inferior right lobe and the superior right lobe drain into the inferior vena cava in most cases by one branch each, but each of them can be drained by two veins. In humans, they correspond to the right hepatic and inferior right hepatic vein, the latter representing a variation of the normal anatomy. The middle lobe has two or three large hepatic veins (right, middle and left median veins) (Lorente 1995; Kogure 1999; Martins 2007). The right and left portions of the middle lobe are drained each by one vein. As in humans, the vein draining the left portion of the middle lobe (left medial vein) may enter the vena cava separately or may join the vein draining left lateral lobe (left hepatic vein) to form a common trunk before joining the suprahepatic cava vein (Gershbein 1954; Lorente 1995). The left and caudate lobes are drained in most cases by two large hepatic veins (left and right) that open separately into the vena cava, but in some cases they can be united by a common trunk. The caudate process drains into the intrahepatic vena cava through multiple branches (Figure 4).

Biliary Tract

While the mouse has a gallbladder, the rat does not. The extrahepatic biliary ducts of the rat are formed by first order branches of each liver lobe. Second order branches exist for the superior and inferior caudate lobes, right middle lobe and caudate process. The rat biliary tract has many anatomical variations.

Most commonly each lobe is drained by its own bile ducts. The left lateral lobe is most frequently (in 62.5% of cases) drained by two biliary branches. The middle lobe is drained by branches from the right middle lobe (1 to 4 branches) and left medial lobe. In 57.5% of cases each caudate lobe has one branch that join together to form a common branch before draining into the common bile duct (CBD) (Lorente 1995). The superior part of the caudate process drains into branches of the right lateral lobe or the main biliary trunk, while the inferior part of it drains into the branches of the caudate process or to the branch of the right lateral lobe. (Figure 4) (Lorente 1995; Martins 2007).

The common bile duct is formed by the junction of the main hepatic ducts. The main hepatic ducts join together on the caudate process (Figure 1C). In this series, the CBD ranged from 12 to 16 mm of length and from 0.6 to 1 mm of diameter, but it can be up to 45 mm long (Mann 1920; Hebel 1976; Lorente 1995). The CBD descends to the left of the hepatic artery and the portal vein on the surface of the caudate process and portal vein, then along the right border of the lesser omentum, keeping some distance from them (Figure 1D). A long extent of the CBD is completely imbedded in the pancreas, which has a diffuse and lobulated appearance. The CBD opens at the medial side of the descending portion of the duodenum, a little below its middle and about 10 to 22 mm from the pylorus (Figure 1C, D and F). The extrahepatic biliary system of the rat has also small intercommunicating branches.

Correlation between Rodent and Human Liver Anatomy and Limitations

The anatomical relationship between the human and rat liver is still undefined (Kogure 1999; Kano 2000). The phylogenetic distance between primates and rodents is more than 80 million years. The functional anatomy of the liver in the rat has been considered different

from humans but similar to the pig (Lorente 1995). The classical description of the human liver segmentation by Couinaud divided the human liver into eight segments, and this constitutes the basis of hepatic resections (Figure 6B). Three hepatic veins divide the liver into four sectors (right lateral sector, right paramedian sector, left paramedian sector, and left lateral sector) and each sector receives a portal pedicle, which bifurcates and supplies each lobe (I-VIII). Later, Couinaud classified the paracaval portion of the caudate lobe as an independent segment (IX) (Bismuth 1982; Couinaud 1994; Kogure 1999).

The nomenclature of the rat liver lobes is not uniform (Gershbein 1954; Nettelblad 1954; Lorente 1995; Kogure 1999). Most authors consider the rat liver to be divided into four lobes: *left lateral lobe*, *medial lobe* (left medial and right medial), *caudate lobe* (anterior or inferior, and posterior or superior), and *right lobe*. Lorente et al. divided the rat liver into two parts, superior liver and inferior liver, and six sectors: sector 1 or caudate process (CP), sector 2 or caudate lobe (CL), sector 3 or right liver lobe (RLL), sector 4 or right portion of right medial lobe (RML), sector 5 central and left part of the right medial lobe (RML) plus the left medial lobe (LML), and sector 6 made up by the left lateral lobe (LLL) (Figure 1−6) (Lorente L 1995). In a recent study from Kongure et al., comparing the rat and human liver, it was shown that the hepatic lobes of the rat are equivalent to the human liver. The rat caudate lobe (Spiegel lobe and paracaval portion) corresponds to segments I and IX, the rat left lobe corresponds to segment II, the rat middle lobe corresponds to segments III, IV, V, and VIII, and the right lobe to segments VI and VII (Kogure 1999). The human caudate lobe, although seems to be only one structure, is functionally divided into three parts (Couinaud 1994). In the rat, the three functional subdivisions of the caudate lobe are individualized structures.

In the rat, the mass of each lobe is relatively constant. Thus, the two anterior lobes, the two right liver lobes, and the two omental lobes (forming the caudate lobe) comprise approximately 70%, 22%, 8% of the liver, respectively (Figure 6A). Additionally, each lobe has its own pedicle containing a portal triad. These unique aspects of rat liver anatomy make resections of various extents simple and highly reproducible when performing experiments (Rodriguez 1999). In the rat, the left hemi-liver consists of the LLL, CL and LML while the right hemi-liver represents RL (SRL+IRL) and the RML. In comparison to the human liver in which the right hemi-liver has a greater volume than the left, the left and right hemi-livers in rats have similar volumes (Figure 6).

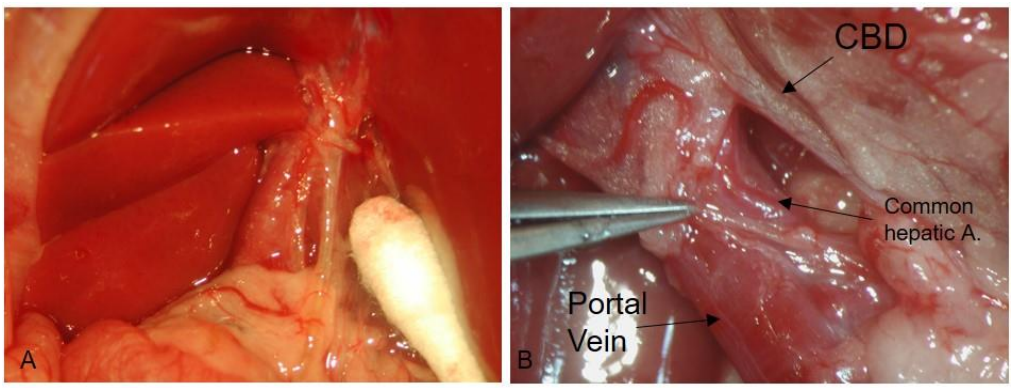

Figure 5. (A, B) Liver hilum.

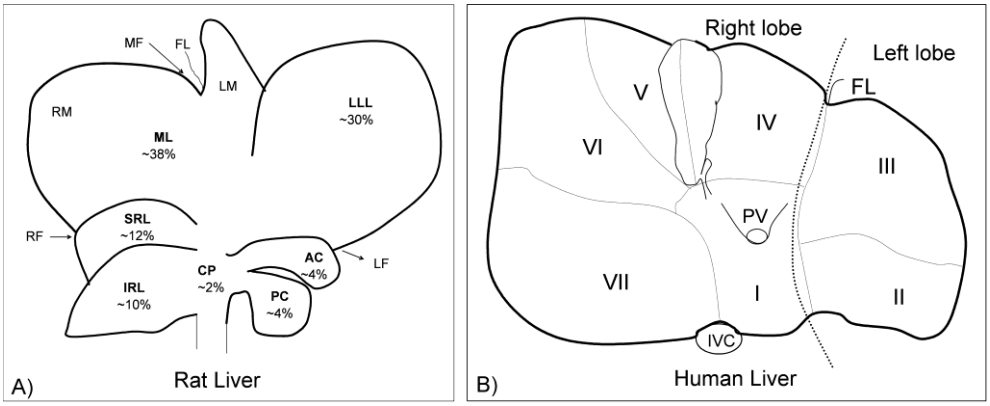

Abbreviations: CP caudate process, AC anterior caudate lobe, PC posterior caudate lobe, SRL superior right lateral lobe, IRL inferior right lateral lobe, ML median lobe, RML right portion of the medial lobe, LML left portion of the medial lobe, LLL left lateral lobe, MF median fissure, LF left fissure, RF right fissure and FL falciform ligament, PV portal vein, IVC inferior vena cava.

Figure 6. A) Visceral surface of the rat liver showing lobes and their mean relative weight. The liver mass of which lobe in the rat is quite constant. The caudate lobe is formed by the CP, AC and PC, the right liver lobe is formed by SRL and IRL, and the medial lobe formed by LM and RM. B) Visceral surface of a human liver showing division into segments according to Couinaud's nomenclature. The segment VIII is superior to the segment V and cannot bee see in this figure. According to Kongure K, in the rat, CL, LLL, LML, RML, (IRL+SRL) represent in humans segments I and IX, the segment II, segments III, IV, V, and VIII; and the segments VI and VII, respectively. In the rat, the left hemi-liver consists of the LLL, CL and LML while the right hemi-liver represents RL (SRL+IRL) and the RML.

Differently from humans, dogs, pigs and mice, rats do not have gallbladders. However, other mammals, like the horse and deer, do not have it either. The functional implications of that are not known (Mann 1920). Small intrahepatic bile ducts in rats are thought to correspond to bile ductules in humans and large bile ducts in rats may correspond to human interlobular bile ducts (Alpini 1996). The extrahepatic biliary ducts of the rat are more superficial and the CBD is proportionally longer compared to the human liver. Second order branches exist for the superior and inferior caudate lobes, right middle lobe and caudate process. There are many anatomical variations. For a thorough description of the rat biliary system, see Lorente (Lorente 1995). The extrahepatic biliary system of the rat has also intercommunicating branches that implies existence of a biliary network (Lorente 1995). This also implies that it may be difficult to produce cholestasis selectively in one of the hepatic lobes. The branches of the left middle lobe generally drain into branches of the left lateral lobe, implying the existence of a biliary functional inter-relationship between the left middle lobe and the left lateral lobe. The resection of the left lateral lobe can result in extrahepatic cholestasis of the left middle lobe in some animals. Thus, caution is necessary when trying to translate conclusions from hepatic resection models to humans (Lorente 1995; Lorente 1995; Martins 2007).

Unique from the human CBD, which has a short intra-pancreatic course and lies to the right of the portal vein and in close proximity to it and the hepatic artery, the rat CBD has a long trajectory inside the pancreas and to the left of the hepatic artery and the portal vein, which results in some distance between it and the hepatic artery and portal vein (Figure 1D). The CBD can be easily cannulated for experiments to measure bile flow, liver function or for

anastomosis using a splint in liver transplantation. Most studies that cannulated the common bile duct used a polyethylene tubing (PE-10, inner diameter of 0.28 mm, outer diameter of 0.61 mm). However, a 24 gauge catheter can also be inserted into the CBD.

The origin and course of the major extrahepatic vessels are similar to humans. However, the branching pattern of the rat portal vein is different from humans. In the rat, the portal vein trifurcates, while in humans it bifurcates (Kogure 1999). Due to the fact that the rat liver is lobulated, there is no interdigitation between portal and venous pedicles; however, each one of the six sectors receives a portal pedicle and has its own venous pedicle (Lorente 1995). However, at microscopic level interdigitations may occur (Gershbein 1954). The inferior vena cava, differently from humans, is completely intrahepatic. The hepato-esophageal artery provides the liver with supra and infra-diaphragmatic systems of collateral circulation, once its ascending branches anastomose with branches of the mediastinal arteries and its descending branches communicate with the cardiac branches of the gastric artery. Thus, in experiments designed to provide arterial supply deprivation to the liver, the hepato-esophageal artery as a collateral route should be considered and previously ligated (Delong 1953).

Pancreas Anatomy

Rats are commonly used as experimental models for partial and total pancreatectomy. It is important to note that the biliary system in rats has numerous anatomical variations. After introducing latex dye into the biliopancreatic duct, portal vein and arteries, pancreas anatomy present in rats was further delineated as seen in a study by ME Kara, et al. (Kara 2005). The pancreas was subsequently divided into three parts following latex injection: biliary, duodenal, and gastrosplenic. The biliopancreatic and pancreatic ducts, biliary, and duodenal portions of the pancreas can be visualized with relative ease by retracting the duodenum caudally. The gastrosplenic portion of the pancreas was seen between the descending duodenum and transverse colon on the right side just caudal to the liver. In order to visualize the pancreas in its entirety, it was necessary to remove the stomach and duodenum. This maneuver also permitted visualization of the pancreaticoduodenal, right gastroepiploic and splenic vessels, and portal vein.

In the study by Kara, et al., the biliopancreatic duct diameter and length of ducts was found to be 1.01 ± 0.03 and 28.86 ± 0.59 mm, respectively. The anterior pancreatic duct originated from the biliopancreatic duct on different sides and was found to drain the entire gastrosplenic portion and part of the duodenal portion of the pancreas. The posterior pancreatic duct opened into the biliopancreatic duct and was found to do this at the level of the papilla in more than 1/3 of specimens, which is an important consideration when ligating the biliopancreatic duct at the level of the duodenal opening. The posterior pancreatic duct also carries the exocrine secretion from the duodenal portion of the pancreas to the biliopancreatic duct. Numerous minor ducts were also noted that drained all three portions of the pancreas directly into the biliopancreatic duct (Kara 2005). A thorough understanding of the anatomy found in the rat pancreas is imperative when using this model to study pancreatic transplantation and regeneration, treatment of pancreatitis, and metabolic or endocrine studies (Figures 5−11).

See Figures 7−11.

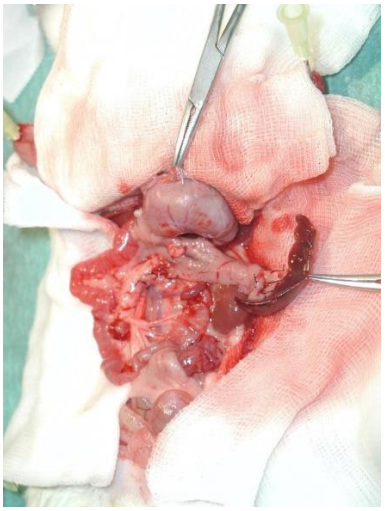

Figure 7. Rat pancreas.

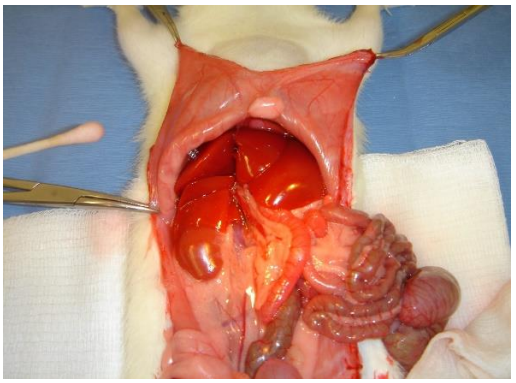

Figure 8. Rat pancreas.

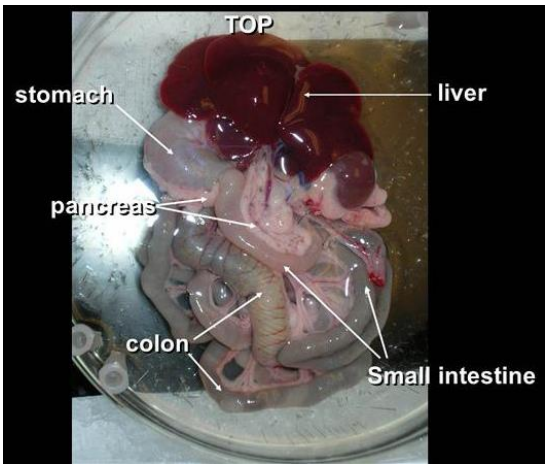

Figure 9. Image of rat pancreas illustrating the viscera, immediately post-harvest, in the dissection dish. Note the pins located around the edge of the dish and the black acrylic sheet under the dish. Schloithe AC, Woods CM, Saccone GTP. An isolated rat pancreas preparation for studying pancreatic spinal mechanosensitive and chemosensitive afferent activity. Version 1.0, April 26, 2011 [DOI: 10.3998/panc.2011.13]. The Pancreapedia. www.pancreapedia.org. Free use under Creative Commons Sharealike license.

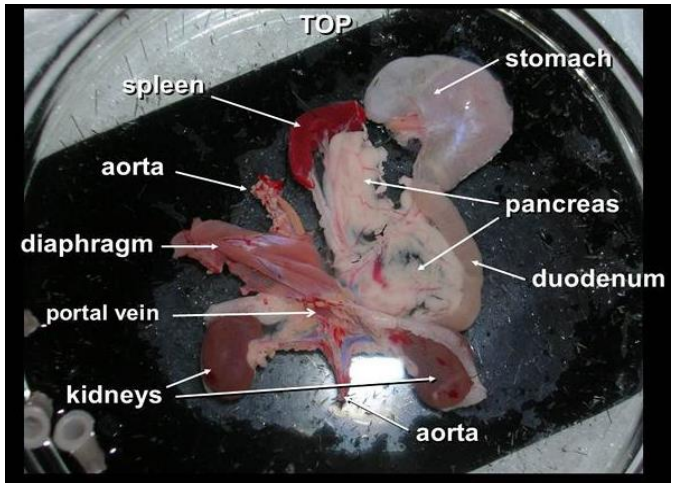

Figure 10. Image of a preliminary dissection of rat pancreas. Note that the aorta is oriented roughly north-south with the kidneys on either side. The stomach is positioned upper most, the duodenal segment on the right, the pancreas central and the spleen on the upper left. Schloithe AC, Woods CM, Saccone GTP. An isolated rat pancreas preparation for studying pancreatic spinal mechanosensitive and chemosensitive afferent activity. Version 1.0, April 26, 2011 [DOI: 10.3998/panc.2011.13]. The Pancreapedia. www.pancreapedia.org. Free use under Creative Commons Sharealike license.

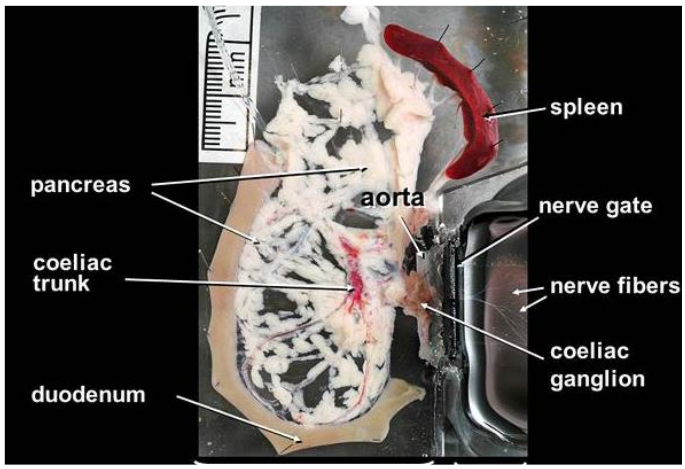

Figure 11. Image of the final preparation of rat pancreas (with duodenal segment retained for orientation) pinned in the Krebs-bath. Note that the duodenal segment is normally removed. The spleen is usually retained as it provides a means of maintaining the pancreas in a stretched state without the direct insertion of pins in the pancreas. The nerve trunks with teased bundles and fibers are visible in the nerve-bath. A scale bar is included in the image (1 division = 1 mm). Schloithe AC, Woods CM, Saccone GTP. An isolated rat pancreas preparation for studying pancreatic spinal mechanosensitive and chemosensitive afferent activity. Version 1.0, April 26, 2011 [DOI: 10.3998/panc.2011.13]. The Pancreapedia. www.pancreapedia.org. Free use under Creative Commons Sharealike license.

HEPATECTOMY MODELS

Introduction

Hepatic resections in rodents are performed to study liver regeneration, acute liver failure, tumor dormancy of hepatic metastasis, hepatic function, and response to stress and trauma (Higgins 1931; Bucher 1964; Weinbren 1965; Aleksandrowicz 1981; Rozga 1986; Lin 1990; Panis 1990; de Jong 1995; de Jong 1998; Lu 1999; Fausto 2005). Each lobe has its own pedicle containing a portal triad, and as a result hepatic resections of various extents in rodents are simple and highly reproducible. Hepatectomies both in the rat and mouse require basic surgical skills and have been performed with high success rates (Higgins 1931; Weinbren 1965; Pinto 1987; Lorente 1995; Rodriguez 1999; Fausto 2005; Madrahimov 2006; Martins 2007). In this review, we outline various models, different techniques and limitations of hepatic resections.

Models of Liver Resection

The classic rat model of partial hepatectomy in rats is based on the seminal experiments by Higgins and Anderson from 1931 (Higgins 1931). These investigations demonstrated that resection of the two anterior lobes (median and left lateral lobes) is easy to perform and creates a highly standardized liver reduction of approximately 70%. The classical 70% hepatectomy model in rats is the most popular because it has been extensively studied and can be accomplished in an expedited fashion with a single ligature of the common pedicle (Higgins 1931; Rodriguez 1999). It is also commonly employed in auxiliary liver transplantation models (Wang 2002).

In other models, 90%, 95% and 97% liver tissue resections are employed to study liver regeneration and acute liver failure (Gaub 1984; Emond 1989; Madrahimov 2006). In the 90% hepatectomy the right lobes, median lobe, and the left lateral lobe are resected. In the 95% hepatectomy model, the anterior caudate lobe is also removed, while in the 97% hepatectomy the anterior and posterior caudate lobes are removed, and only the paracaval portion remains. Other extents of resection can also be performed, however with more technical difficulty and higher complication rates (Figure 12).

In the mouse the relative volume of the lobes slightly differs from the rat. The right superior lobe represents 16.6 ± 1.4%, the right inferior 14.7 ± 1.4%, the median lobe 26.2 ± 1.9%, and the left lateral lobe represents 34.4 ± 1.9% (Inderbitzin 2004), while in the rat it represents approximately 22%, 10%, 38%, 30%, respectively (Lorente 1995; Madrahimov 2006; Martins 2007). On the other hand, in humans, the average volume ratios of the left lateral segments (II and III), left medial segment (IV), caudate lobe (I and IX), right anterior segments (V and VIII), and right posterior segments (VI and VII) are 17%, 14%, 2%, 37%, and 30%, respectively (Leelaudomlipi 2002).

Commonly performed partial hepatectomies in mice remove 60% (ML+LL), 75% (ML+LL+IRL) and 83% (ML+LL+IRL+CL) of the liver parenchyma (Inderbitzin 2004, Inderbitzin 2006). Twenty-one days after resection of the ML and LL in the mouse, the

remaining lobes IRL, SRL, AC, and PC represent 55%, 26%, 9%, and 10%, respectively (Nikfarjam 2004).

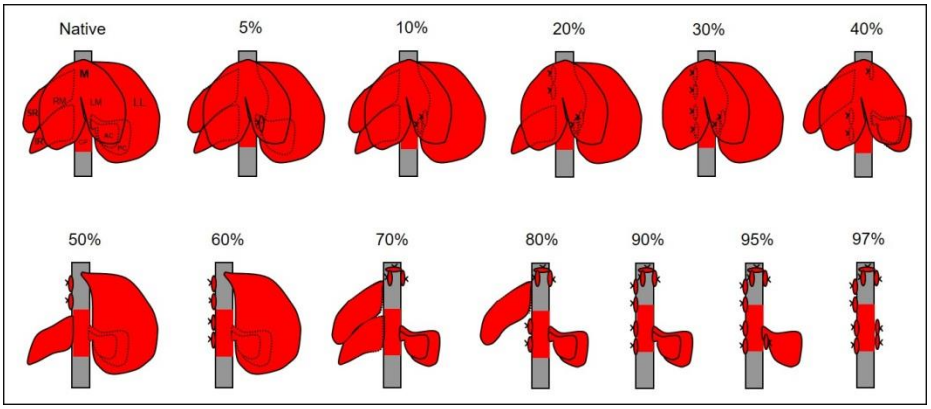

Figure 12. Schematic description of partial hepatectomies in the rat (anterior view of the liver) and approximate parenchymal volumes. These values slightly change in the mouse (refer to the text). Hepatectomies ranging from 5 to 95% of total liver weight can be easily performed with high reproducibility using microsurgical techniques, since the parenchymal mass of which lobe is relatively constant. Approximately, the percentages of liver weight per lobe are: SRL 12%, IRL 10%, ML 38% (RML 25% and LML 13%), LLL 30%, AC 4%, PC 4%, CP 2-3%. In the classic 70%-hepatectomy, the left lateral (LL) and the medial (ML) lobes are removed. Isolated resections of the MLL or LLL should preferentially not be performed since cholestatic and vascular complications are more common.

The Liver Regeneration Model

The process of hepatic regeneration in rodents and humans are similar, and the results obtained from rodents are applicable to the human liver (Fausto 2001). The rat 70% hepatectomy is the most valuable and most extensively studied animal model for liver regeneration (Higgins 1931; Rodriguez 1999; Fausto 2005).

The hepatic regeneration process is triggered promptly after injury, and in the rat, the DNA replication begins as early as 16 hours after resection. After a 70%-hepatectomy in the rat, the weight of the liver remnant at 24 and 72 hours is 45% and 70% of the original liver weight, respectively. Between 7 and 14 days, the liver volume is 93%, and by day 20 it completely recovers its original volume by hyperplasia of the remaining lobes (Higgins 1931). Also in humans, the regeneration process occurs quickly. The liver mass doubled at 7 days in the donor liver and 14 days in the recipient after right-lobe transplantation. Donor and recipient livers reached their original weight by 60 days after surgery. However, despite recovery of parenchymal weight the regeneration and remodeling processes continue.

The speed of liver regeneration is proportional to the amount of hepatic tissue resected. (Marcos 2000). Interestingly, it has also been shown that the regenerative capacity of individual remnant lobes is significantly different (Inderbitzin 2006). In addition, too large (>85%) or too small (<30%) resections may result in slow cell proliferation (Fausto 2001).

Models for Assessment of Hepatic Metastasis

Models of hepatectomy have been used in studies of liver metastasis after direct hepatic inoculation, or after intraportal or intra-splenic injection of tumor cells. The induction of tumor by carcinogens in the rat with spontaneous liver metastases closely mimics the natural history of colon cancer. However, only a low yield of primary cancer, e.g., colonic cancer (in less than 50% of cases) and liver metastases (approx. 25%) is obtained after 6 months of latency. Direct intraportal injection of colon carcinoma cells is the most frequently used model. Although it bypasses the natural evolution of colon cancer, this simple model produces liver metastases 6 weeks after injection of tumor cells in up to 100% of cases. This model has been used to study tumor biology, tumor induced angiogenesis, surgical and adjuvant therapy for liver metastasis, as well as the influence of hepatic regeneration on reactivation of dormant metastases and tumor growth (Panis 1990).

In this model, 8 weeks after injection of colon carcinoma cells (DHD K12 cells) into the portal vein of BD IX rats, 60% of animals did not show apparent liver metastases. However, after a 70% hepatectomy, 12 weeks after the injection of colon carcinoma cells, 62% of these animals developed macroscopic metastases compared to 20% in sham operated controls. This means that liver micrometastases may have been present at 8 weeks and had not developed until stimulation by liver regeneration after hepatectomy (Panis 1990; Panis 1992). In cases of random spread of hepatic metastases, tumorectomy alone, non-anatomical resections (wedge resection), and segmentectomies may be employed.

Models of Acute Liver Failure

Models of acute liver failure are important to investigate the underlying molecular mechanisms and to test liver-support strategies. These models are divided into: toxic-induced, surgically induced (partial hepatectomy, clamping) or mixed. Surgical models of acute liver failure are divided into: total hepatectomy, partial hepatectomy, and partial or total liver devascularization (Rahman 2000).

Small-for-Size Syndrome

Models of hepatic resection and partial liver transplantation have also been used to study small for size syndrome. One study showed that immediately after classical 70% hepatectomy the hepatic arterial blood flow decreased (from 0.4 ± 0.12 to 0.33 ± 0.03 ml/min/g liver), the portal venous inflow increased (from 0.90 ± 0.30 to 2.20 ± 0.26 ml/min/g liver), the total hepatic blood flow increased (from 1.30 ± 0.39 to 2.53 ± 0.26 ml/min/g liver), and the portal pressure elevated (from 8.80 ± 0.7 to 11.9 ± 1.7 cm H_2O) (Lin 1990).

Portal hyperperfusion in small-for-size livers, in cases of major hepatic resections or transplantation, may seriously impair postoperative liver regeneration. The altered physiologic state results in increased portal blood flow, which induces shear stress and damage to sinusoidal endothelial cells and Kupffer cell activation which contributes to acute liver failure (Glanemann 2005). In these models, a major hepatic resection (e.g., 90%) or a total hepatectomy followed by small-for-size graft (25 to 30% of original volume) liver

transplantation are performed (Panis 1997; Glanemann 2005; Yao 2007; Zhong 2007). When transplantation is used as a model, a classical 70% hepatectomy is performed in the donor animal before harvesting the organ.

Following a 70% resection, nearly 100% of rats survive (Emond 1989). Larger resections result in hyperperfusion of the remnant liver and ischemia/reperfusion injury (small-for-size syndrome) with subsequent massive fatty change, congestion, and centrilobular necrosis (Panis 1997). Panis and colleagues showed increased necrosis following progressive increase in the hepatectomy extent (Panis 1997). Following a 75%, >85%, and >90% hepatectomy, survival rates were 100%, 18% and 0%, respectively. The increased mortality associated with large resections can be reduced by administration of glucose solution (Gaub 1984; Roger 1996). The survival rate of 90%-hepatectomy could be increased from 5% to 60% by addition of glucose 20% in drinking water (Gaub 1984, Emond 1989). Roger introduced the 95% hepatectomy with survival rate of only 20%, even with addition of glucose (Roger 1996). Madrahinov reported a 1-week survival rate of 100% and 66% following a 90% and 95%, respectively. However, in this study, all animals died of liver failure within 4 days after a 97% hepatectomy (Madrahimov 2006).

Eguchi et al. described a model of resection-ligation (Eguchi 1997). In this model, the left lateral and median lobes (68%) were resected, and the ligated right liver lobes (24%) were left in place; the caudal lobes (8%) were left intact. They reported a 90% mortality rate at 48hr after surgery, proceeded by grade III encephalopathy beginning at 22−24hr, and associated with deterioration of liver function tests, and increased ammonia and lactate levels.

In the mouse, Inderbitzin et al. showed that liver regeneration was excellent in up to 75% partial hepatectomy. On the other hand, 83% resection resulted in animal death after 2−4 days (Inderbitzin 2006). However, in this experiment only one subcutaneous dose (1ml) of glucose 1% was given postoperatively. One other study showed that all of the 70%-hepatectomized mice were alive at 1 week, but the 90%-hepatectomized mice all died within 24 hours after hepatectomy despite free access to glucose 10% (Makino 2005).

Techniques of Liver Resection

Liver resections in rodents are very well tolerated with minimal operative mortality. So far, four techniques for hepatic resection in rodents have been described:

1. *The classical technique* (Ligature *en-bloc* at the base of the lobe). Although this is the most commonly used technique, it carries the highest risk for injuries because the mass ligature may compromise elements of other pedicles. The risk of vena cava stenosis and liver congestion is particularly high when only one ligature for both the median and left lateral lobes' pedicles is performed, due to compression of the vein after mass ligation. This procedure can be performed through conventional (open), or laparoscopic technique (Higgins 1931; Ralli 1951; Krahenbuhl 1998). However, the laparoscopic approach does not seem to provide any advantage over other techniques. It is time-consuming and requires specialized and costly equipment.
2. *The hemostatic clip technique*. This is a slight modification of the classical technique, where titanium clips are applied to the pedicle instead of using sutures. This procedure is fast, but is associated with similar complications of the mass ligature

technique. In addition, concerns with interference on the regeneration process have been raised, although this has not been confirmed in subsequent investigations (Schaeffer 1994; Nikfarjam 2004).

3. *The vessel-oriented parenchyma-preserving technique*. This technique reported by Madrahimov requires no prior ligation at the liver hilum (Madrahimov 2006). Sequential piercing sutures, proximal to clamp, are positioned according to topographic vascular anatomy. Although this technique is faster than the microsurgical technique (described below), it may cause injury of other vascular branches since vessels are not individually visualized. Therefore, it is not recommended for resection of the right or left segments of the median lobe.
4. *The vessel-oriented microsurgical technique*. This technique, first reported by Kubota et al., is similar to the technique for clinical hepatectomies (Kubota 1997). The portal vein and hepatic artery branches are ligated prior to the resection of the lobe, and the hepatic veins are ligated within the lobe during parenchyma resection (in a similar fashion of the parenchyma preserving technique). The advantages of this technique are reduced risk of bleeding from the stump and reduced risk of vena cava constriction. It is also more appropriate for segmental hepatectomies, e.g., resection of the right or left portion of the median lobe, after delineation of the ischemic line following the ligature. The disadvantages include requirement of microsurgical skills and equipment, risk of portal vein injury during dissection, and its more time-consuming nature (Kubota 1997).

Liver Resections Using Microsurgical Techniques

Hepatic resection may be improved by microsurgical techniques because they permit individualized dissection and ligature of small vascular and biliary branches of the median and left lateral liver lobes, while avoiding damage to the remaining lobes and other complications (tear of extra-hepatic biliary tree and biliary fistula, vena cava stenosis). This contributes to reduce complications and make results more homogenous.

To our knowledge, the first description of the use of microsurgery to perform hepatectomy in rodents was from Holmin in 1982. However, he used a microscope (10x magnification) not to perform the parenchymal dissection and resection but to perform a portocaval shunt before a total hepatectomy in a rat model of acute liver failure (Holmin 1982). In fact, Rodriguez in 1999 was the first to report the use of a microscope to perform vascular isolation of individual pedicles for partial hepatectomies in the rat (Rodriguez 1999). In a study from Higgins, utilizing the classical technique without optical magnification, the postoperative mortality rate following a 70% hepatectomy was 25% (n = 220), Rodriguez reported no morbidity and 0% mortality (n = 20) utilizing the microscopic approach (Higgins 1931, Rodriguez 1999). Another study published by Greene et al. obtained 96% survival rate after 70% hepatectomy in the mouse model using magnifying operative loupes (Greene 2003).

Non-Conventional Anatomical Resections

Microsurgical techniques permit anatomical segmentectomies. Isolated resection of the left lateral lobe or median lobe as well as segmental resections of the left or right portion of the median lobe represents a technical challenge. Although the left lateral lobe is easily resectable, care should be taken to avoid ligature of the branches to the median lobe, which will lead to ischemia of the lateral aspect of this lobe. In addition, some biliary ducts of the left median lobe may drain into branches of the left lateral lobe, implying the existence of a biliary functional interrelationship between the left medial lobe and the left lateral lobe. Thus, the isolated resection of either the left lateral lobe or median lobe may sometimes result in cholestasis of the adjacent lobe (Lorente 1995; Lorente 1995).

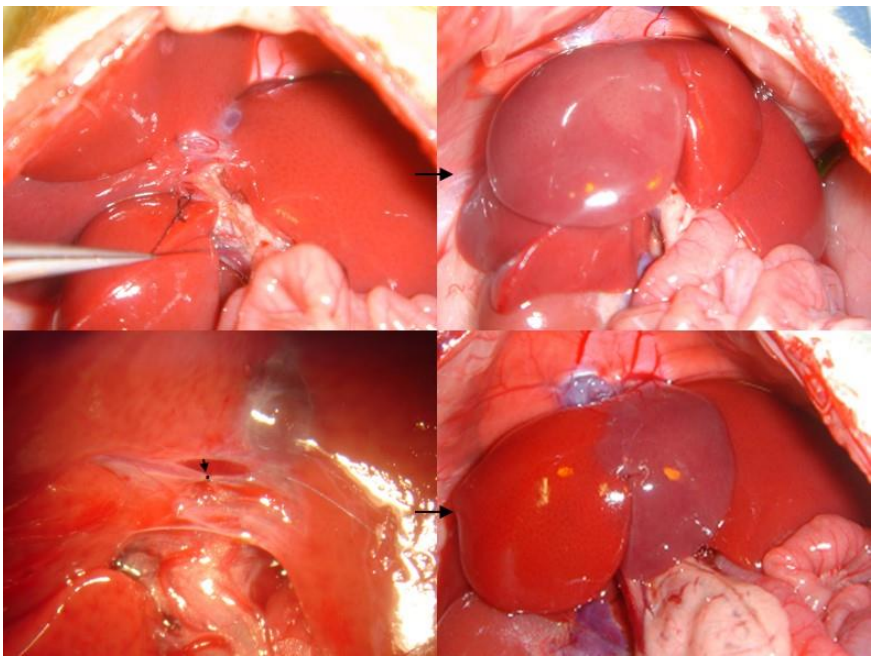

Figure 13. Ligature of the inferior pedicle of the median lobe of the rat liver. This pedicle (shown here suture ligated) supplies the right portion of the right median lobe (RML). The superior pedicle of the median lobe is depicted here by the asterisk (*). C and D) Ligation of the superior pedicle of the median lobe (in Figure C, magnification 20X). The superior pedicle of the median lobe supplies the left portion (LML) and is shown here suture ligated (arrow). The location of inferior pedicle of the median lobe is marked here by the asterisk (*). Shortly after these ligations, an ischemic line (dotted line) on the medial lobe ML (B and D) equivalent to the Cantlie's line can be seen on the falciform ligament insertion line, from the suprahepatic vena cava to the main liver fissure (umbilical fissure). The resection of the RML (equivalent in humans to segments IV, V and VIII) and the LML (equivalent to segment III in humans) can only be performed using microsurgical techniques. Dissection and ligation should be very careful to avoid injuries of the vascular and biliary system of the adjacent segment. Scale bar 0.6cm.

Isolated resection of the right or left sectors of the median lobe and resection of the superior or inferior aspect of the left lateral lobe requires delicate dissection of the hilar region and intrahepatic ligation of individual vascular and biliary branches. For resection of the right portion of the median lobe (which represents segments IV, V and VIII in humans

according to Kongure), the inferior pedicle of the median lobe (which is the first portal branch to the median lobe together with the arterial branch) should be ligated *en-bloc* and divided (Kogure 1999). The superior pedicle of the median lobe lies close to the superior aspect of the superior right lobe. For resection of the left portion of the median lobe (which represents segments III in humans), the second portal branch (superior pedicle) to this lobe should be ligated and divided (Kogure 1999). It lies in close proximity to the hepatic vein draining the left portion of this lobe and can be easily visualized after removal of the overlying peritoneum (Figure 13).

The left lateral lobe also has two vascular pedicles (inferior and superior) and two independent venous drainages, which permits anatomical segmentectomies in this lobe (Lorente 1995; Madrahimov 2006; Martins 2007). The first vascular pedicle, inferior to part of the LLL, lies on the bottom of this lobe while the second is located superior-posterior and close to the left hepatic vein (Figure 14). In either one of these segmentectomies (left medial or right medial), after ligating the vascular pedicle, the ischemic line can be visualized on both surfaces of the liver. Then, the parenchyma can be resected 2 mm away from the perfused area. These segmentectomies are more difficult to perform in the mouse because the structures are much smaller and more delicate (the mouse is in average 20 times smaller than a rat).

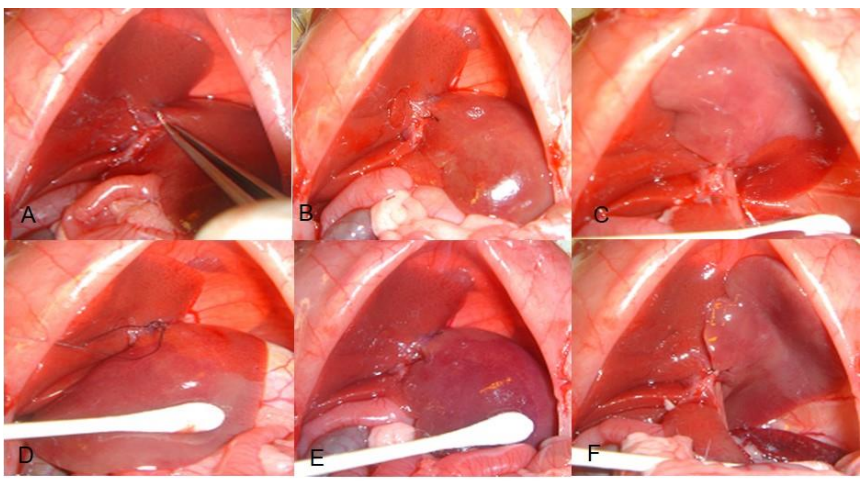

Figure 14. A-C) Ligature of the inferior vascular pedicle of the left lateral lobe (arrow) of the rat liver demarcates an ischemic line (dotted line) on the anterior (B) and posterior (C) surface of this lobe. This ischemic area represents ¾ of the LLL and either represents an individual segment, equivalent to the human segment III, or is a subsegment of the LLL. D-F) After ligature of the inferior pedicle (arrow), the superior vascular pedicle was ligated (*) and the whole left lateral lobe turned to be ischemic. The area supplied by the superior pedicle may be the equivalent of the segment II in humans. Magnification 2X.

The individual isolation of the portal vein branch from the arterial branch and bile duct may be necessary in some experiments that investigate individual effects of arterial or portal isolation. This dissection is difficult to perform, since they are fragile and closely adherent and surrounded by connective tissue. One maneuver that helps this dissection is flushing pressured saline solution with a syringe close to the pedicle elements. The author successfully

used this technique to perform vascular dissection in a kidney transplantation model (Martins 2006). Hydrodissection can display the correct plane of dissection while reducing risks of injuries.

The main advantage of hepatectomies employing microsurgical techniques is that it is possible to perform several extents of hepatectomy, including segmental resections, while reducing the risks of vascular and cholestatic complications.

Limitations of Rodent Models of Hepatic Resections

The use of rat and mouse models in liver surgery research is limited by their small size and limited knowledge on the liver anatomy (Lorente 1995; Lorente 1995; Martins 2007). As in humans, the rat and mouse liver vasculature and biliary system show a great anatomical variability. In addition, the liver anatomy of rodents and its correlation to the human liver is not completely understood.

Table 1. Comparison of rat and human liver

Rat Liver	Human Liver
Multi-lobulated liver	Liver lobes have no clear anatomical divisions (liver appears to be single anatomic unit)
Long celiac trunk	Short celiac trunk
Inferior vena cava is intra-hepatic	Inferior vena cava is retroperitoneal
Gallbladder absent	Gallbladder present
CBD lies to the left of portal vein and has a long intra-pancreatic trajectory	CBD lies to the right of the portal vein and has a short pancreatic trajectory
Collateral arterial circulation is common (Hepato-esophageal artery)	Collateral arterial circulation is uncommon
Intercommunications between portal and venous pedicle is common	Vein intercommunications is not common
Divisions of the caudate lobe is distinct	Caudate lobe has no clear-cut anatomical subdivisions
Trifurcation of the portal vein	Bifurcation of the portal vein
"Left-" and "right liver" have similar volume	"Right liver" volume is superior to the "left liver"

The best anatomical model proposed so far is from Kongure and colleagues. In this model, the whole left lateral lobe corresponds to the human segment II and the left median lobe corresponds to segment III. However, his study did not consider that the left lateral lobe has two individual vascular supplies and drainages, which are prerequisites for segmental denomination. Based on topography and proportions, the small superior segment of the left lateral lobe could be considered equivalent to the human segment II and the larger inferior segment to the human segment III. If this is the case, the left median lobe would be equivalent to the segment IV, while the right median lobe would be equivalent only to segments V and VIII. The falciform ligament in humans runs from a point to the left of the vena cava to a point to the left of the gallbladder, and the area between the falciform ligament and the Cantlie's line (imaginary line from the vena cava to the gallbladder) represents the segment IV. Kongure proposed the equivalence of the rat segments assuming that the location of the rat falciform ligament is the same as in humans. If we consider the falciform ligament to define the nomenclature of the rat liver lobes, the left median lobe could be the equivalent to segment III because it lies directly to the left of the falciform ligament. However, in the

mouse, which is phylogenetically much closer to the rat, the falciform ligament lies between the vena cava and gallbladder, located in the main liver fissure (Figure 2. The main fissure marks the division of the medial lobe into left and right portions. Similarly, to the mouse, the rat falciform ligament runs between the vena cava and the main liver fissure (the rat has no gallbladder) and may have the equivalent position to the Cantlie's line in humans. Taking these facts into consideration, the rat left median lobe could be the equivalent to segment IV, and not to segment III.

One pitfall of segmentectomies of the right or left portion of the median lobe is that they may be associated with liver congestion in the animals in which the vein draining the left portion of the median lobe joins the left hepatic vein (draining the left lateral lobe) to form a common trunk before draining to the vena cava. In addition, some biliary ducts of the left median lobe may drain into branches of the left lateral lobe, implying the existence of a biliary functional interrelationship between the left medial lobe and the left lateral lobe. Thus, the isolated resection of either the left lateral lobe or median lobe may sometimes result in cholestasis of the adjacent lobe (Lorente 1995; Lorente 1995; Martins 2007).

Results obtained in rodent models cannot be fully translated to humans because the kinetics of liver regeneration in different species is not the same. The amount of remnant hepatic tissue compatible with life in rodents seems to be less than in humans. While in humans the maximum amount of liver that can be tolerated is 70−80% of the original volume, rodents can survive even after a 90−95% hepatectomy (Shirabe 1999; Fan 2000; Renz 2000; Leelaudomlipi 2002; Schindl 2005; Madrahimov 2006). Table 1 compares rat to human livers.

Models of acute liver failure based only on reduction of liver mass (hepatectomy) are in general not reversible and not associated with the same level of tissue damage and necrosis commonly seen in clinical setting (caused by toxic and viral agents). In order to overcome this problem one can subsequently add liver stress after liver resection with tissue ischemia (clamping) or toxic agents. Another model proposed a combination of major liver resection with hepatocyte transplantation as a possible approach to recover liver function (Roger 1996).

CIRRHOSIS, PORTAL HYPERTENSION MODELS, AND PORTOCAVAL SHUNTS

Portal hypertension models are important to the study of the pathophysiology of liver disturbances, liver regeneration, complications and treatment approaches. The models can be categorized as toxic (e.g., carbon tetrachloride (CCl_4), alcohol), nutritional (feeding choline deficient or methionine deficient diet), surgical (partial portal vein ligation, bile duct ligation), immunological (heterologous serum, schistosomiasis), and genetic (Rhino mice) (Tsukamoto 1990; Orloff 2001; Abraldes 2006; Abraldes 2006) (Table 2). Other toxic agents that have been used in diverse animal models to produce cirrhosis, include carbon tetrachloride, dimethylnitrosamine, thioacetamine, monocrotaline, and alcohol (Groszmann 1982; Proctor 1984; Tsukamoto 1985; Dashti 1989; Perazzo 1999). Rodents are the most utilized models because of low cost and easy handling. The most common model of cirrhosis is the CCL_4 model. It can be given via injection, inhalation, or orally. Liver cirrhosis is expedited by giving phenobarbital added to the drinking water (cirrhosis obtained in 4 to 6 weeks).

Acute administration of carbon tetrachloride induces acute hepatitis. Continuous administration induces chronic liver injury that leads to cirrhosis. Route of administration varies among laboratories, but the most effective are oral, intraperitoneal or inhalatory routes. Twelve to 15 weeks after CCl_4 administration, the rats develop micronodular cirrhosis (Proctora 1982; Kobayashi 2000; Hernandez-Munoz 2001; Constandinou 2005; Abraldes 2006).

Cirrhosis induced by thioacetamide (TAA) is another widely used model of toxic cirrhosis. The toxin affects both perivenular and periportal areas. It has been used in rats and mice (Li 2002, Okuyama 2005). TAA can be administered in drinking water or by intraperitoneal injection (Li 2002; Luo 2004; Popov 2006). Intraperitoneal injection offers much more consistent results (Popov 2006). This model develops macronodular cirrhosis with portal hypertension in 12 weeks (Abraldes 2006).

Table 2. Experimental Models of Hepatic Fibrosis/Cirrhosis. Adapted from Tsukamoto H, et al.

Species		Method	Fibrosis	Cirrhosis
Toxic				
• Carbon tetrachloride (CCl_4)	Rats	Subcutaneous injection, 0.1-0.2ml/100g of body weight twice weekly	>6 weeks	>12 weeks
	Rats	Inhalation twice weekly plus sodium phenobarbital in drinking water	>1-2weeks	>4 weeks
		Intraperitoneal injection 3 days weekly		
• Dimethylnitrosamine (DMNA)	Rats	Oral administration 2 days weekly	>4 weeks	>13 weeks
	Dogs	TAA in drinking water (300mg/L)		
• Thioacetamide (TAA)	Rats		>3-4weeks >2-3 months	>13 weeks >3months
Nutritional	Rats/mice	High-fat/low-choline, low-protein diet	>6weeks	>12-24 weeks
Immunologic				
• Heterologous serum	Rats	Low-protein/low-methionine diet plus ethionine (0.5%)	>4weeks	>12weeks
• Bacterial cell wall	Rats	Swine serum, intraperitoneal injection twice weekly	>5 weeks	>10 weeks
• Marine schistosomiasis	Rats	Streptococcal cell wall, single intraperitoneal injection (20mg/g of body weight)	>6weeks	--
• Endotoxin	Mice	Subcutaneous injection, 50 *cercariae* of *Schistosoma mansoni*	>6weeks	--
	Rabbits	*E. coli* endotoxin injection into the common bile duct (0.2/mg) followed 24 h later by 0.1/mg via marginal ear vein	--	>9 days
Biliary				
	Rats	Common bile duct ligation	>4 weeks	--
	Dogs	Common bile duct ligation	>4 weeks	--
	Monkeys	Common bile duct ligation	>2months	>6 months
Alcoholic				
	Baboons	Ethanol-containing liquid diet, *ad lib*	>6 months	>24 months
	Rats	Continuous intragastric infusion of ethanol and a high-fat diet	>3 months	--
Genetic				
	Rhino mice	Mutant with the anatomical recessive gene	>6 months	--

Dimethilnitrosamine induced cirrhosis (DMNA) DMNA is another hepatotoxin that induces hepatocellular necrosis. After continuous administration (generally intraperitoneal) the rats develop fibrosis with portal hypertension, which may be present as early as 5 weeks despite the fact that animals do not have cirrhosis nor features of hyperdynamic circulation (Veal 2000). Overt cirrhosis with ascites develops in 13 weeks (Jenkins 1985; Tsukamoto 1990).

Diet induced cirrhosis is seen in diets deficient in choline and methionin, or a diet with low protein and choline and enriched with fat, induces liver steatosis associated with marked oxidative stress that induces inflammation and fibrosis (Tsukamoto 1990; Nanji 2004). Cirrhosis develops after 12 to 24 weeks.

Partial Portal Vein Ligation

Partial portal vein ligation model (PVL) has been widely used in the study of the pathophysiology of portal hypertension. This model has been developed in rats, mice, and rabbits (Vorobioff 1983; Colombato 1992; Castaneda 2000; Iwakiri 2002; Fernandez 2004). The portal vein is freed from surrounding tissue after a midline abdominal incision. A ligature (silk 3-0) is placed around a blunt-tipped needle lying along the portal vein. Subsequent removal of the needle yields a calibrated stenosis of the portal vein that has the diameter of the needle. In the conventional rat PVL model a 20G needle is used (0.889 mm diameter) (Vorobioff 1983, Colombato 1992, Castaneda 2000). By using needles of greater caliber, less severe stenosis and thus less severe degrees of portal hypertension are induced (Lozeva 2004, Abraldes 2006). The diameters of the needles and resulting levels of stenosis are as follows: 16G: 1.651mm, 18G: 1.270 mm, 20G: 0.889 mm. The conventional needles for mice and rabbits are 27G (Iwakiri 2002; Fernandez 2004).

Bile Duct Ligation

Cholestasis is a common pathological condition that can be reproduced in rodents by surgical ligation of the common bile duct. Common bile duct ligation (CBDL) is a model of secondary biliary cirrhosis. Evaluation of the various time-related changes after BDL is paramount for the interpretation of available data as well as for the design of future studies.

A Systematic Chronological Evaluation of Hepatocellular Injury and Proliferation, Hepatic Inflammation or the Development of Liver Fibrosis Following BDL

The intervention consists of the isolation of the common bile duct followed by a double ligature. The first ligature is made below the junction of the hepatic ducts and the other above the pancreatic duct. The portion of the bile duct between the two ligatures can be resected to avoid recannulation. Mortality is high after the fifth week (20%). The use of prophylactic antibiotics (Ampicilin 100 mg/Kg s.c. or similar) before surgery and weekly administration of

vitamin K (50 mcg subcutaneous) notably improve the survival of CBDL rats. At 2 weeks rats develop mild portal hypertension and at 4 weeks severe portal hypertension, hyperdynamic circulation and portal-systemic shunting of 30−60% (Franco 1979; Beck 1995).

Serum levels of ALT and biliary infarcts increased after BDL, peaking at days 2 and 3 respectively. Following acute or chronic tissue loss, hepatocytes mount a proliferative response. BDL induced a distinct peak of hepatocellular proliferation at day 5, approximately 48 hours after the peak of histologically detectable hepatocellular injury. After the initial peak on day 5, continuous proliferation was observed at a low level. The proportion of continuously proliferating hepatocytes is in the range of 1 to 3% (Ezure 2000; Georgiev 2008).

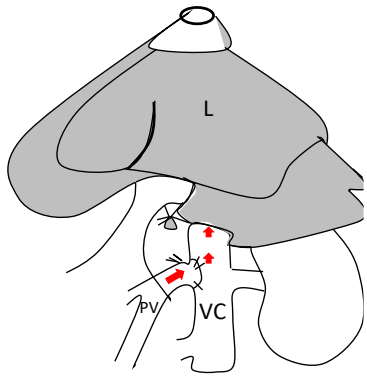

Figure 15. End-to-side portacaval shunt. *Abbreviations:* L liver. VC vena cava, PV portal vein. Adapted from Castaing D, et al.

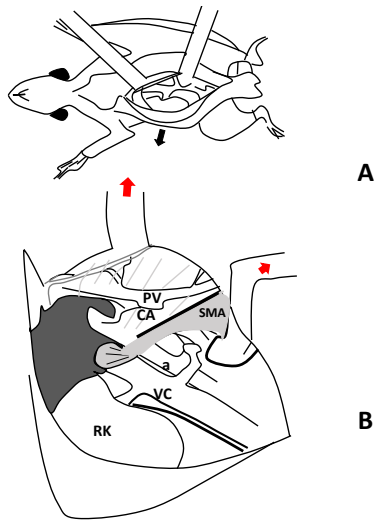

Figure 16. A) Ventral view of rat abdomen with retractors in place. The median lobe of the liver, the abdominal viscera and the mesoduodenum are covered with a wet gauze and retracted to the left. Vena cava, portal vein, right kidney and celiac area are exposed. B) Right lateral view of the infra-hepatic area. CA celiac axis**,** RK right kidney**,** VC vena cava**,** PV portal vein**,** A aorta, SMA superior mesenteric artery**.** Adapted from Castaing D, et al.

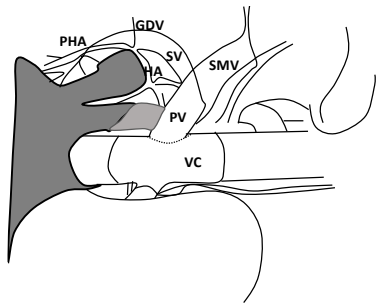

Figure 17. Anatomical configuration after the shunt. GDV gastroduodenal vein, HA hepatic artery, LGA left gastric artery, PV portal vein, SV splenic vein, VC vena cava**.** Adapted from Castaing D, et al.

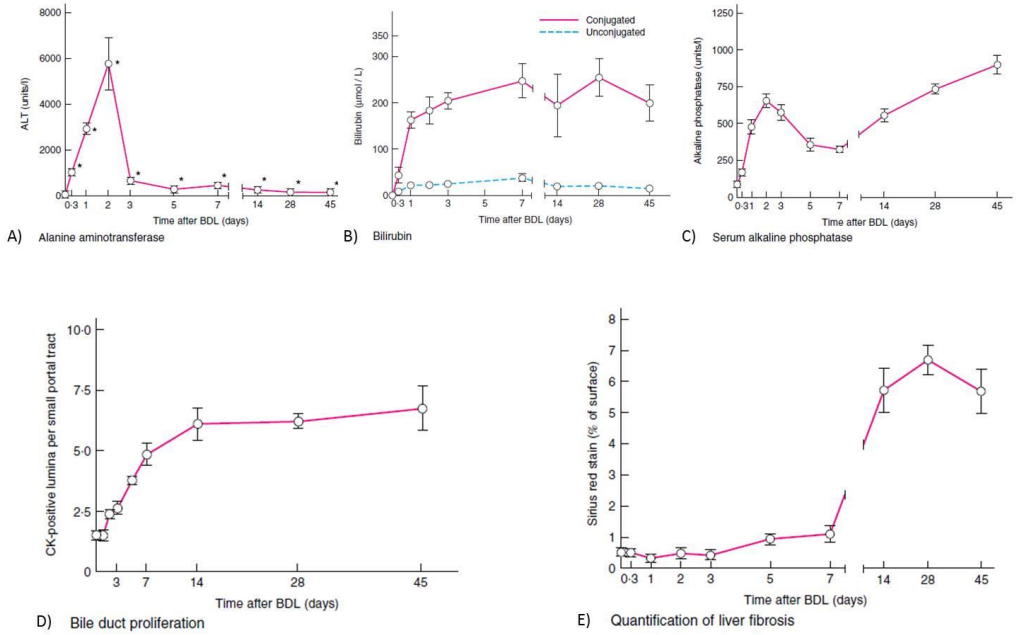

Figure 18. Liver injury was determined by A) serum alanine aminotransferase (ALT) levels. Serum levels of A) conjugated and unconjugated bilirubin and B) alkaline phosphatase. Percentage of liver surface stained with Sirius red. Values are mean (s.e.m.) for five to six individual animals per time point. *$P < 0{\cdot}050$ *versus* sham-operated control (two-tailed Mann–Whitney test). Adapted from Georgiev, et al.

Serum levels of alkaline phosphatase and bilirubin are classical markers of obstructive cholestasis in the clinical setting (Pratt 2005). Raised serum levels of alkaline phosphatase are due to *de novo* synthesis in the liver (Kaplan 1970). Interestingly, serum levels of alkaline phosphatase were not found to increase progressively after BDL. A first peak during the acute phase was followed by decreasing levels from day 3 to day 7, indicating that the acute injury triggers a massive production and release of this enzyme.

BDL results in an increase in serum markers of cholestasis such as bilirubin and alkaline phosphatase. Conjugated and unconjugated bilirubin levels increased steadily and in parallel until day 7 and remained high thereafter (Figure 18). Alkaline phosphatase production is

induced after BDL in rats and its release from the canalicular membrane of hepatocytes is modulated by bile acids. Serum levels of alkaline phosphatase showed a biphasic course, peaking on day 2 and then increasing steadily from day 7 onwards; cell proliferation reached a steady state in the biliary epithelial cells (BEL) compartment by day 1.

Neutrophils contribute to cholestatic liver injury after BDL for 3 days, whereas Kupffer cells are believed to abrogate acute cholestatic liver injury through the release of interleukin 6 (Gujral 2003; Gujral 2004; Gehring 2006). Little attention has been paid to the role of lymphocytes, which are known to modulate liver fibrosis in other models of liver disease (Wynn 2004; Novobrantseva 2005). The histological analysis indicated that both B and T cells were present in the portal tracts of mice after day 5 of BDL. Interestingly, both cell types accumulated mainly during the phase of collagen deposition and thus may also be involved in the process of fibrogenesis following BDL (Gujral 2003; Georgiev 2008).

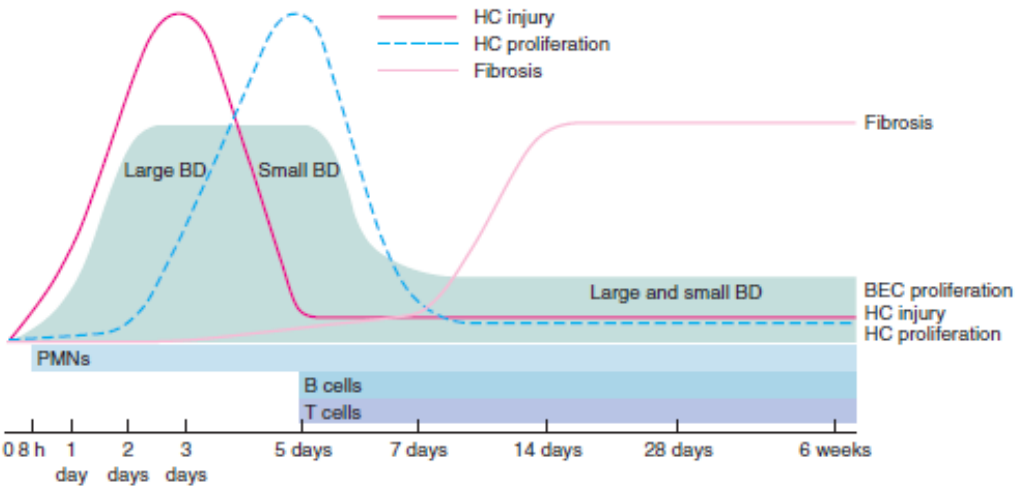

Figure 19. Overview of dynamic changes following bile duct ligation in mice. BD, bile duct; BEC, biliary epithelial cell; HC, hepatocyte; PMN, polymorphonuclear leucocyte.

This model develops biliary fibrosis-cirrhosis in 4 to 6 weeks. Histology shows marked cholangiolar proliferation and expansive portal fibrosis (Figure 19), but the architectural disturbances typical of cirrhosis are seldom found (Kountouras 1984). See Figures 18−19.

PORTOCAVAL SHUNTS

In 1877, Dr. Eck described experiments using portalcaval shunt in dogs (Eck fistula) (Rocko 1985). Lee and Fisher in 1961 perfected the technique of portocaval shunt in the rat so that it became a reproducible model (Lee 1961). Before this technique was established, others have tried to interpose prosthetic tubes between the portal vein and IVC with high mortality rates (Whitaker 1946; Bernstein 1954).

Technique

The peritoneum over the inferior IVC is cut. Then, with a curved forceps the vena cava is mobilized from the inferior aspect of the liver to the right renal vein. Next, the peritoneum covering the portal vein is open, the portal vein is mobilized, and the gastroduodenal vein is doubly ligated and cut. A small vascular spoon clamp is placed on the IVC between the liver and the renal veins, partially obstructing its flow. A 4−5 mm incision is made on the IVC and flushed with heparinized saline. Next, the distal portal vein is ligated with 6-0 silk tie flush to the liver. The proximal portal vein is clamped with a small vascular clip, and the portal vein is cut above the stump of the gastroduodenal vein. The portal vein lumen is flushed with saline and two 7-0 prolene sutures are placed on the corners. The anastomosis is completed on a running fashion. First the posterior wall, followed by the anterior wall. After completion of the anastomosis the caval clamp is released and hemostasis accomplished with gentle compression with cotton swabs. The portal clamping time is of critical importance for the success of the procedure and it should be less than 30 minutes (see Figures 15−17) (Castaing 1980).

PANCREATITIS MODEL

A better understanding of the underlying pathophysiology of severe acute pancreatitis may lead to more targeted therapeutic options, potentially leading to improved survival. Animal models of acute pancreatitis are therefore an essential investigative tool for these aims to be achieved.

There are several models of acute pancreatitis, and they can be divided as invasive and non-invasive (Su 2006). Non-invasive models of acute pancreatitis are: hormone-induced, alcohol induced, immune-mediated, diet-induced, gene knockout and L-arginine; while invasive models are: and invasive models including closed duodenal loop, antegrade pancreatic duct perfusion, biliopancreatic duct injection, combination of secretory hyperstimulation with minimal intraductal bile acid exposure, vascular-induced, ischemia/reperfusion and duct ligation (Su 2006).

Independent of the model used, the pathophysiology event of experimental acute pancreatitis consists of the activation of pancreatic enzymes within acinar cells, the release of these activated enzymes in the interstitium, the autodigestion of the pancreas, and the release of activated pancreatic enzymes and other factors into the circulation that result in the development of systemic effects. An ideal model of acute pancreatitis should be easily reproducible, be able to adjust the severity of the inflammation and, and the morphology and pathophysiology should resemble that of the human situation.

Animal models of acute pancreatitis, induced by acute ethanol application alone, have been difficult to produce and require prior sensitization with other agents to allow significant pancreatic damage to occur (Letko 1991; Siech 1991; Quon 1992; Foitzik 1994; Luthen 1994; Andrzejewska 1998). Existing alcohol-induced models are relatively simple and cheap to perform. Acute ethanol administration selectively lessened pancreatic blood flow and microcirculation, suggesting that the effect of alcohol might increase ischemia damage during the evolvement of acute pancreatitis with or without underlying chronic disease. Another

advantage of this model is that it allows alcohol to directly damage the pancreas by the influence of toxic ethanol metabolites, and perhaps by limitations of pancreatic regeneration. Reproducibility, however, has not been successfully achieved. Furthermore, there is a lack of correlation with the clinical setting.

Closed Duodenal Loop Model

Experimental acute pancreatitis in animals may be produced by creating a closed duodenal loop (CDL). This technique involves surgically closing above and below the duodenal papilla while bile is diverted into the jejunum via an implanted cannula. Evidence of edema, hemorrhage and necrosis of the pancreas developed within 9 to 11 hours. The model was first developed by Pfeffer et al. (Pfeffer 1957). It is relatively simple and is reproducible.

Since the permanent ligation of the duodenum often caused death of the animal within a short period, some investigators have attempted temporary ligation of the duodenum in rats (Ferrie 1978, Orda 1980). This allowed them to examine the progression of acute pancreatitis at an extended time and to investigate potential therapies. In a study by Orda et al., the authors injected a mixture of sodium taurocholate and trypsin into a temporary CDL to induce acute pancreatitis in rats (Orda 1980). They found that the acute pancreatitis induced was mild, associated with a mortality rate of 45%.

Antegrade Pancreatic Duct Perfusion Model

The main pancreatic duct can be made permeable by the perfusion of glycodeoxycholic acid (GDOC) along the main pancreatic duct. Other methods include the administration of intragastric ethanol, the stimulation of pancreatic secretion into an obstructed duct, or causing acute hypercalcemia (Farmer 1983; Wedgwood 1986; Widdison 1992).

The advantages of the pancreatic duct perfusion model are its reliability and reproducibility. The severity of the acute pancreatitis may be varied within well-defined time intervals according to the volumes and perfusion pressures. The etiology and the morphological changes closely resemble the human situation. This model is suitable for studying the early pathophysiology and subsequent progression of the disease. It is the ideal model to assess potential therapeutic agents. The major disadvantage of this model is its complexity (ductal cannulation and perfusion). Other disadvantages include the need to use large animals.

Biliopancreatic Duct Injection Model

Various compounds have been infused into the pancreatic duct to induce acute pancreatitis (EL 1901; Beck 1964; Papp 1966; Sum 1970; Aho 1980). Following a duodenotomy, a retrograde injection of bile salts (with or without activated pancreatic enzymes) into the pancreatic duct at the ampulla leads to severe acute pancreatitis. The severity of the disease can be manipulated by changing either the pressure or the concentration of bile salt used. Acute severe pancreatitis develops within 2 to 24 hours and is

characterized by edema, necrosis and hemorrhage. Almost any form of detergent injected into the pancreatic duct under pressure will cause acute pancreatitis in laboratory animals such as dogs and rats (Musa 1976; Aho 1980; Aho 1980; Aho 1983). One of the best standardized compounds to use to develop acute pancreatitis is sodium taurocholate. Infusion of 0.2 ml/kg of 3%, 4.5% or 5% solution induced acute hemorrhagic pancreatitis with 72 hour mortality rates of 24%, 71% and 100%, respectively (Aho 1980; Aho 1980; Aho 1983). This model is appropriate for studies of systemic issues.

The retrograde injection of bile salts into the pancreatic duct of animals is an easy, effective and reproducible model for creating a severe, rapidly evolving and lethal variety of acute hemorrhagic pancreatitis.

It is also technically challenging to control constant pressure recordings and hence produce a standard degree of injury. Another disadvantage of this technique is the injection pressure with which the solution is applied to cause severe acute pancreatitis (Arendt 1993).

Ischemia/Reperfusion Model

In 1995, Hoffman et al. developed a model to study the microcirculation of the pancreas in the rat after complete (interruption of arterial blood supply to the pancreas) and reversible ischemia of the pancreas using intravital fluorescence microscopy (Hoffmann 1995). Complete ischemia of the pancreas was achieved by isolating arteries from surrounding tissue of gastroduodenal artery, left gastric artery, splenic artery and caudal pancreaticoduodenal artery. Complete but reversible ischemia of the pancreas was induced by occluding the four vessels using microvascular clips. The clips were taken out at 30 minutes, 1 hour or 2 hours after ischemia to produce reperfusion.

The duration of ischemia and of reperfusion is responsible for the severity of post-ischemic inflammatory reaction. In addition, there was a rise in the concentration of serum amylase after 1 and 2 hours of ischemia (Hoffmann 1995). Similar results were observed by another group after 2 hours of ischemia and 4 hours of reperfusion (Broe 1982).

Duct Ligation Model

Acute pancreatitis may be induced by ligating the distal bile duct at the level of the duodenum (Baxter 1985). This creates an early development of acute pancreatitis, obstructive jaundice and cholangitis in the rat. The duct ligation model was developed in an attempt to resemble the clinical situation of gallstones, motility disorders of the sphincter, edema and strictures at the papilla, tumors of the papilla, and parasites impacting the terminal biliopancreatic duct. Surgical ligation of the pancreatic duct alone has not been successful in inducing acute pancreatitis.

Most laboratory animals developed chronic lesions in the pancreas characterized by atrophy and apoptosis of acinar and ductal tissue but not significant necrosis or inflammation (Walker 1987). The ligation of the pancreatic duct in rodents has become an established model for chronic pancreatic atrophy and is often used for studying pancreatic regeneration (Lerch 1993; Lerch 1994). Ligation of this common biliopancreatic duct in the rat, however, causes a clinical syndrome resembling the multi-system organ failure observed in man.

Ligation of the pancreatic duct alone, bile and pancreatic duct separately, or the common biliopancreatic duct leads to severe acute pancreatitis with mortality rates approaching 100% within 2 weeks of induction (Senninger 1986; Cavuoti 1988) (See Table 3).

Models of chronic pancreatitis in rodents do not closely resemble the same process in humans. Prolonged feeding with ethanol to rodents does not induce chronic pancreatitis and alternative approaches have been suggested (Goto 1995; Van Laethem 1996; Puig-Divi 1999; Vaquero 1999; Gonzalez 2011).

Table 3. Summary of non-invasive experimental models of acute pancreatitis

Model	Advantages	Disadvantages	Clinical relevance
Hormone-induced	• Causes acute pancreatitis in animals (e.g., rats, mice, dogs, Syrian hamsters) • Can induce acute pancreatitis by various routes such as IV (preferred), subcutaneous or intraperitoneal • Allows accurate control of infusion rate, thereby enabling control of timing and severity of acute pancreatitis • Useful for studying cell biology, gut endocrine interactions (secretin, CCK levels), pathogenesis of acute pancreatitis-related pulmonary pathology, systemic disease manifestation, and healing and regeneration of damaged tissue after toxic substance has been discontinued • Simple; inexpensive	• Only mild acute pancreatitis develops • Negligible mortality • High variability in course and severity of underlying acute pancreatitis; unsuitable for controlled studies	• Pulmonary injury in rats resembles early stages of ARDS in humans • Structural changes of acinar cells are similar to human acute pancreatitis • Specific changes to intracellular membrane systems of acinar cells resemble acute pancreatitis in humans • Simulates acute pancreatitis induced by anti-cholinesterase insecticide poisoning in humans
Alcohol-induced	• Useful for studying changes to pancreatic blood flow and microcirculation, effect on pancreatic acinar damage by alcohol-related free oxygen radical generation, metabolites and effect on pancreatic regeneration • Used in several animal models (rats, cats, dogs) • Various routes of ethanol administration (IV, oral, direct intragastric instillation) • Simple, inexpensive • Selectively decreases pancreatic blood flow and microcirculation • Gene knockout animals may be used to determine effect of genetic factors on development of acute alcohol-related pancreatic injury	• Animal models of pancreatitis, induced by acute ethanol application alone, have been difficult to produce significant pancreatic damage, thus require prior sensitization with other agents • Lack of reproducibility	• Lack of correlation with clinical situation
Immune-mediated	• Possible application in field of drug or toxin-induced acute pancreatitis	• Difficult to set up in laboratory • Time-consuming • Limited reproducibility • Expensive • High early mortality rate, difficult for studying pathogenesis or treatment options	• Uncertain

Table 3. (Continued)

Model	Advantages	Disadvantages	Clinical relevance
		• Development of secondary diabetes due to the involvement of islets of Langerhans	
Diet-induced	• Simplest method to study acute hemorrhagic pancreatitis • Well-established • Inexpensive	• Species-specific; may only be used in mice, whose small size causes technical difficulties	• Produces severe necrotizing pancreatitis similar to that seen in humans
	• High reproducibility • No surgical procedure involved • Mortality rate can be controlled at any desired level between 0% and 100% by modifying feeding protocol • Useful for studying pathophysiology for acute pancreatitis and potential experimental treatment by measuring survival, biochemistry, histology, changes in hematocrit, pH and blood gases • Produces hemorrhage and necrosis with lethal course • Inflammatory lesions are homogeneously distributed	• Sex-specific; female mice • Variable onset of acute pancreatitis • Requires careful monitoring to ensure that intake of CDE diet is same in different experimental groups	• Gross and histological appearance of pancreatic and peripancreatic inflammation, and clinical and biochemical course of diet-induced pancreatitis, resemble human disease • Ascites, acidosis, hypoxia, hypovolemia similar to human acute pancreatitis`
Gene knockout	• Useful for studying function or effect of specific gene of interest • Avoids use of pharmacological manipulations that often cause side effects	• Time-consuming • Expensive • Complex • Altering specific gene from time of its conception could mean that other protein expressions may result to compensate for mutation • Mutation may stimulate unforeseen phenotypic changes if gene is expressed in different tissues • Expression of two genes may overlap and the alteration in single gene may mask abnormal phenotype	• Extrapolation of experimental data to humans is difficult
L-arginine (Arg)	• High reproducibility • Ability to achieve selective dose-dependent pancreatic acinar cell necrosis • Suitable for investigating early and late phases of acute pancreatitis • Useful for investigating insulo-acinar axis, extrapancreatic organ damage and its mechanisms	• Long-term administration of Arg produces chronic pancreatitis induction	• In clinical situation, circulatory, pulmonary, renal and hepatic failure (multi-organ failure) significantly affects morbidity and mortality of acute pancreatitis

Adapted from Su KH, et al.

CHOLELITHIASIS

There are several models in animals that are used to study the pathophysiology and treatment of gallstones (Brenneman 1972; MacPherson 1987; Rege 1993; Cona 2016). However, there is no animal model that forms spontaneous gallstones like in humans. Most of them involve dietary manipulation. The most popular is the hamster (*Mesocricetus auralus*) model. The diet in this model consists in fat-free, high sugar, and adequate protein. Ninety percent of these animal develop gallstones in 3 months (Dam 1952). Rats are not commonly used for gallstone research because they do not have a gallbladder. Mouse models are become more popular because the extensive genetic characterization, the availability of knockout, transgenic and inbred strains. The incidence of gallstones in mice treated with lithogenic diet is very variable. While only 14% of C57BL/6J mice fed with diet consisting of 15% dairy fat, 50% sucrose, 20% casein, 1% cholesterol, 0.5% cholic acid, cellulose, vitamins and mineral for 18 weeks developed gallstones, 100% of C57L/J and A/J mice developed gallstones after the same time (Paigen 1995).

HEPATOCELLULAR CARCINOMA (HCC) MODELS

Hepatocellular carcinoma (HCC) is the most common primary malignancy of the liver. Establishing animal models of HCC is essential to study the pathophysiology of carcinogenesis, perform drug screening, and conduct various therapeutic experiments. A wide range of HCC animal models are currently available: chemically induced models, xenograft models, and genetically modified models in mice (Schotman 1998; Heindryckx 2009; Li 2011). No model, however, is ideal for all purposes. This review analyses several mouse models useful for HCC research and points out their advantages and weaknesses. Chemically induced HCC mice models mimic the injury-fibrosis-malignancy cycle by administration of a genotoxic compound alone or, if necessary, followed by a promoting agent.

Chemically Induced

Several chemical agents can promote tumor formation when administered in high doses and long duration. The advantage of chemically induced models is the similarity with the injury-fibrosis-malignancy cycle seen in humans. This makes them the favorite models for HCC research.

Diethylnitrosamine

N-nitrosodiethylamine (DEN) is often used as a carcinogenic reagent. Mouse tumors induced by DEN harbour activating mutations in the *H-ras* proto-oncogene. Administration of a high dose induces HCC after a period of latency. The time needed after a single DEN-injection to develop HCC does not only depend on the administered dose, but also on sex, age and strain of mice. A dose-dependent formation of carcinomas after a single injection (5–90

mg/kg) of DEN in 15-day-old mice is observed after 45–104 weeks. When B6C3F1 mice are exposed to a single dose of 5.0 mg/kg DEN, it takes approximately 64 weeks to develop HCC (Heindryckx 2009).

A two-stage model in which the initiation by a genotoxic compound is followed by a promotion phase is often used for inducing HCC. DEN can be used as an initiator and phenobarbital (PB) as a promoting agent. Several mechanisms might be responsible for the tumour promoting effect of PB. First, PB can increase the expression of cytochrome P-450 a 100-fold, leading to an enhanced effect of DEN. Another two-step carcinogenesis model is known as the Solt-Farber protocol (Farber 1977). In this model, initiation by a hepatocarcinogenic compound is followed by a partial hepatectomy (PH). Partial hepatectomy induces hepatic cell proliferation of the liver, leading to a fast expansion of the initiated cells (See Table 4).

Table 4. Summary of chemically induced HCC-models

	Time to develop tumors	Percent of mice with HCC	Remarks	References
Single administration	45-104 weeks (dose dependent)	80-100% in male	Poorly reproducible	Chen et al. (1993); Frey et al. (2000); Hacker et al. (1991); Park et al. (2008); Teoh et al. (2008); Zimmers et al. (2008)
Short-term administration	40-60 weeks	100% in male		Shiota et al. (1999)
Long-term administration	20-35 weeks	100% in male. 30% in female	Very aggressive tumors (H-ras mutations)	Finnberg et al. (2004)
+ Pentobarbital	20-40 weeks		B-catenin activation	Goldsworthy and Fransson-Steen (2002); Klaunig et al. (1988); Weghorst and Klaunig (1989)
+ Partial hepatectomy	4-8 weeks (in rats)			Farber et al. (1977); Klinman and Erslev (1963)
Peroxisome proliferators	50-100 weeks (dose dependent)	Depends on strain, dose and PP-agent	PP tumorigenicity in humans not known	Hays et al. (2005); Reddy et al. (1976); Takashima et al. (2008)
Aflatoxine	Early HCC in 52 weeks. High grade HCC 92-110 weeks	Considerable interstrain differences: DBA/2J: 90% C57BL/N: 25-66%	Suitable model for AFB-induced HCC in humans	McGlynn et al. (2003); Ghebranious and Sell (1998)
CCl4	104 weeks	50-94% (dose dependent) in male and female		Confer and Stenger (1966); Farazi et al. (2006); Weisburger (1977)
Choline deficient diet	50-52 weeks	100%	Steatohepatitis	De Lima et al. (2008); Knight et al. (2000); Liquori et al. (2009)
Thioacetamide	50-80 weeks	70-100%		

Adapted from Heindryckx F et al.

Peroxisome Proliferators

Peroxisome proliferators (ethyl clofenapate ciprofibrate, fenofibrate, clofibrate) induce hepatomegaly, peroxisome proliferation in hepatocytes and induction of several hepatic enzymes.

Aflatoxin B_1

The hepatotoxin aflatoxin B_1 (AFB), produced by certain fungi of the *Aspergillus* genus such as *Asparagillus flavum*, is known to be a hepatic carcinogen. When 7-day-old mice are exposed to 6 mg/kg body weight of AFB, in a bolus injection, HCC is developed after 52 weeks (McGlynn 2003). In 90% of the DBA/2J mice (susceptible strain for HCC) HCC occurs after AFB exposure, while only 25% of the C57BL/N mice (relatively resistant strain for HCC) develop HCC after AFB exposure.

Xenograft Models

In xenograft models, the tumors are formed by injecting human cancer cells from a lab culture in immune deficient mice. Athymic (nude) or severe combined immune deficient (SCID) mice are often used as hosts. Tumor xenografts can be established either by direct implantation of biopsy material or by inoculation of human tumor cell lines. First, the ectopic model, in which human tumor cells are injected subcutaneously in the flank of mice. Second, the orthotopic model, where tumor cells are injected intrahepatically into the mice. The advantage of xenograft mouse models is the short time span needed for the development of tumors. However, the resemblance between xenograft tumors and human tumors is rather poor. Thus, most researchers prefer to use models in which tumors arise in a background that resembles the natural history of HCC (Heindryckx 2009).

Transgenic Mouse Models

Genetically modified mouse models are engineered to reproduce pathophysiological and molecular features of human HCC (by simulating hepatitis B or C, over-expressing growth factors, or induction of oncogenes) (Heindryckx 2009). It is a unique model for assessing the effects of oncogenes either alone or in combination with other oncogenes or carcinogenic agents. The transgenic mouse models are the ones that most resemble the human HCC. Transgenic mouse models of HBV or HCV infection have provided reliable experimental proof that viral genes could initiate or promote liver carcinogenesis. Most HBV transgenic mouse models focus on the HBx gene, which encodes HBV X protein (HBx)−a transcriptional transactivator that stimulates expression of a broad range of proto-oncogenes, including c-fos, c-myc and c-jun (Li 2011).

In contrast to wild-type CD1 mice, which do not normally develop spontaneous liver tumors and have a lifespan of approximately 24 months, the majority of HBx transgenic mice died from clear cell HCC at 11 to 15 months of age.

In a similar fashion, Sell et al. constructed HBsAg transgenic C57BL/6 mice (Table 4). The 50-4 strain of these mice had a high HBsAg content in hepatocytes, premalignant changes, nodules, adenomas and HCC; exposure to diethylnitrosamine or aflatoxin accelerated the development of HCC, and produced considerably more tumor nodules in the liver.

HBV and HCV Transgenic Mice Do Not Develop Liver Cirrhosis

To avoid such problems, Yang et al. developed a modified surgical technique, in which a piece of Gelfoam is inserted into the liver incision after delivery of HCC cells. The Gelfoam both facilitates hemostasis and forms a pocket that secures the injected tumor cells (Yang 1992). These techniques have the major disadvantage of possible inadvertent tumor seeding along the needle track or into the bloodstream.

To reproduce the extensive liver disease that is associated with advanced HCC, Tang et al developed another orthotopic mouse model. HCC cells transfected with vectors carrying the gene for the [beta]-subunit of human choriogonadotropin ([beta]-hCG) were injected into the left liver lobe of SCID mice. In this model, urine levels of [beta]-hCG can be used as a surrogate marker of tumor burden (Tang 2010).

Several HCV transgenic mouse model systems have been established expressing HCV structural proteins (core, E1, E2 and p7) or nonstructural proteins (NS2, NS3, NS4A, NS4B, NS5A and NS5B) individually or in various combinations are available (Li 2011). As early as 3 months of age, HCV core gene transgenic mice developed hepatic steatosis. In mice aged up to 12 months, steatosis slowly progressed without neoplastic changes. At month 16, 25% of the male transgenic mice of the C21 line had developed HCC, but no female mice of the C21 line had developed tumors (Moriya 1998).

Animal models of spontaneous HCC development and metastasis can be used to study the mechanism of HCC progression as well as the best mode of intervention. Futakuchi et al. have established a rat model of *in vivo* HCC lung metastasis based on sequential intraperitoneal injection of diethylnitrosamine and administration of drinking water containing the carcinogen N-nitrosomorpholine for 16 weeks, by which time all animals had developed HCC. By week 23, lung metastasis had occurred in 100% of these animals (Futakuchi 1999).

Most experiments to test the effects of potential drug treatments in animal models of HCC involve the subcutaneous implantation of human hepatoma cells in immunocompromised mice (e.g., SCID mice). Although researchers have expressed doubts and criticisms about the validity of using effects on tumor xenografts to predict clinical activity

Establishing high-quality orthotopic models is, however, technically more challenging than the construction of subcutaneous xenograft models. Conventional techniques of intrahepatic tumor implantation involve direct placement of tumor fragments or injection of free tumor cells.

CHOLANGIOCARCINOMA MODELS

Several carcinogenesis models of cholangiocarcinoma (CCC) have been established in animals (Thamavit 1978; Elmore 1993; Cheifetz 1996; Sirica 1996; Lee 1997; Lai 1999; Al-Bader 2000; Yeh 2004; Sirica 2008; Yang 2011; Ko 2013; Ikenoue 2016). There are several CCC animal models: xenograft and orthotopic models, carcinogen-induced CCC model, and genetically engineered mouse model for CCA. Recent advancements in cell and molecular biology make it possible to mimic the pathogenicity of human cholangiocarcinoma using various animal models.

One model obtained CCC using Syrian hamsters being treated with *Clonorchis sinensis* or *Opisthorchis viverrini* followed by dimethylnitrosamine (DMN) (Thamavit 1978; Flavell 1983; Lee 1997). In another model Syrian hamsters were treated with DMN followed by bile duct ligation also develop CCC (Cheifetz 1996). In these models, CCC develops about 24 weeks after the initial insult, with a yield rate of only 10%. One of the better characterized rat models of CCC has been the furan model described by Sirica et al., which leads to the development of intestinal-type CCC in the caudate lobe of the liver (Elmore 1993; Sirica 1996).

Oral administration of thioacetamide (TAA) in drinking water to male Sprangue-Dawley rats provides a reproducible animal model for development of CCC with a high yield rate. Drinking water with TAA 300 mg/l was administered orally. Multifocal bile ductular proliferation with intestinal metaplasia (presence of goblet cells) and increasing histologic atypia (biliary dysplasia) was observed by the 9th week of TAA administration. Biliary cytokeratin (CK19)-expressing invasive intestinal-type CCC with stromal desmoplasia was evident at the 16th week, and by the 22nd week the yield rate for CCCs had increased to 100%. The progression from normal cholangioles to biliary dysplasia to invasive CCC was accompanied by up-regulation of the proto-oncogenes c-met and c-erbB-2, tyrosine kinase receptors over-expressed in human CCCs. In the first 6 months of follow-up, no systemic metastases or tumor-related deaths were observed in this model. (Yeh 2004).

Yamada and coworkers created a mouse CCC model that transfected the biliary epithelium directly with plasmids containing oncogenes. The common bile duct located below the liver was clamped with a small animal surgical clip to prevent the injected material from rapidly flowing into the duodenum. The bile duct draining the left lateral liver lobe was identified, and a ligature (6-0 silk) was placed loosely around the duct. Another ligature was placed around the base of the gallbladder where it meets the cystic duct. Ectopic oncogene expression in the biliary tract was achieved by the SB transposon transfection system with transduction of murine constitutively active AKT and human YAP. The solution was injected into the gallbladder with enough pressure to allow the solution to distend the biliary system and reach the whole the intrahepatic biliary tree. The ligature around the left lateral liver lobe duct was then tied off so as not to allow the plasmid solution to flow from this bile duct to the common bile duct. Following plasmid injection and the left lateral bile duct ligation, the common bile duct was unclamped. The ligature around the base of the gallbladder was then tied and a cholecystectomy performed. Then, each animal was injected with 1 μg of IL-33 for 3 days (Leake 2015; Yamada 2015).

COLON CARCINOMA METASTASES

Tumor models have a key role in oncology. They are powerful tools guiding clinical research and practice (Demicheli 2001). Most transplantable tumor therapy experiments utilize ectopic (usually subcutaneous) injection of tumor cells. Ectopically transplanted tumors do not necessarily reproduce the biology of orthotopically grown tumors. The response of the primary tumor to therapy is usually what is evaluated in most tumor models. There is a need to place more emphasis on tumor models in which metastases are the primary target to therapy.

The limitations of animal models are that they usually respond better to anti-cancer therapy than in the clinical settings.

Most transplantable tumors are very fast growing (doubling times measured in days) while human tumors (with doubling times measured in months). Experimental tumors tend to be highly responsive to cytotoxic anti-cancer drugs, since this drugs target rapidly dividing cells. Most transplantable tumors are highly immunogenic because it is difficult to obtain truly syngeneic tumors. These tumors therefore become especially vulnerable to various host immune effector mechanisms.

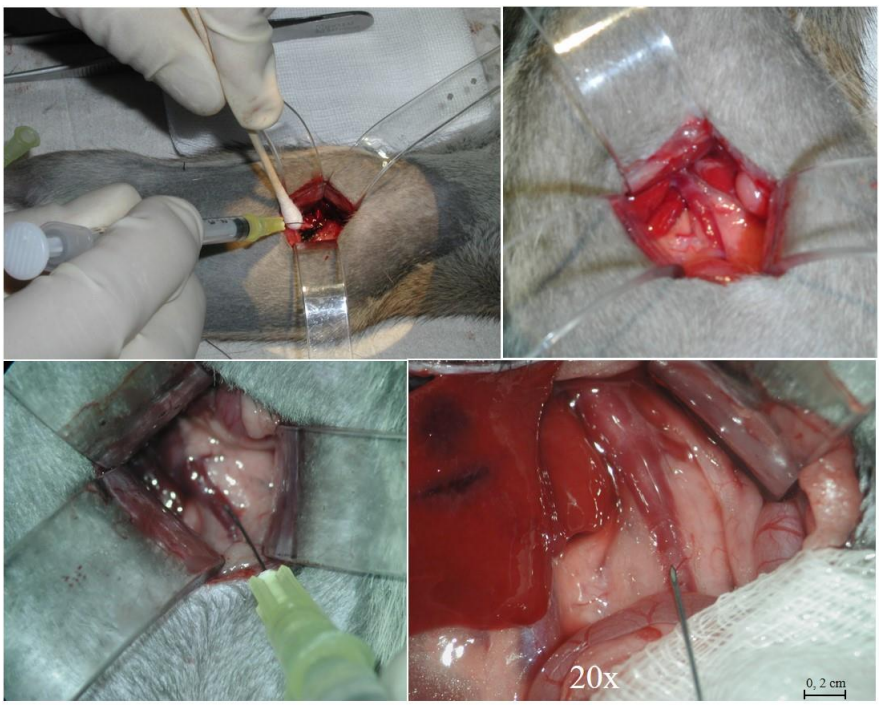

Figure 20. Technique of portal injection to inoculate colon cancer cells DKDK12 (CAMR, Salisburg-Withshire, UK) in the rat liver. This reproduces the metastatic process of colon cancer. A 30G needle is used to minimize bleeding.

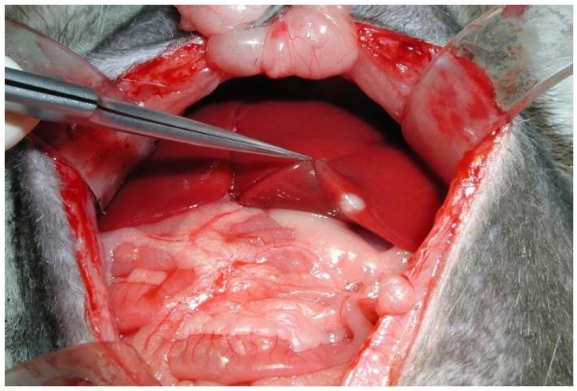

Figure 21. Isolated liver tumor of colon cancer cells DKDK12 (CAMR, Salisburg-Withshire, UK) injected in the rat portal vein 2 weeks prior.

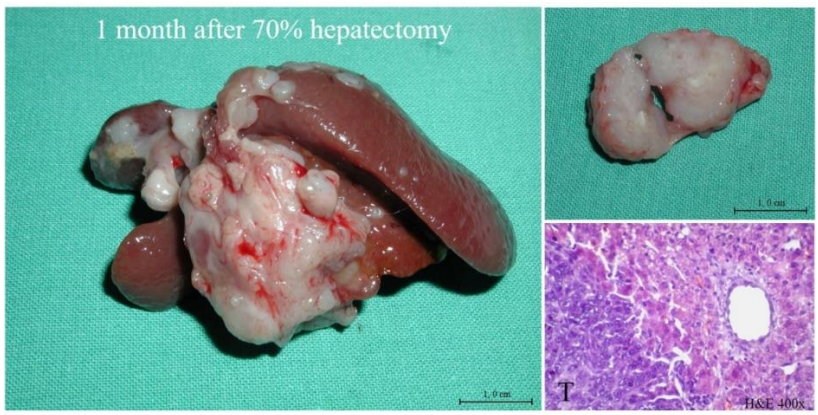

Figure 22. Metastatic tumor of colon cancer cells DKDK12 (CAMR, Salisburg-Withshire, UK) injected in the rat portal vein 4 weeks prior.

Over recent years, the interest in the development of experimental models for colorectal liver metastases has increased due to the need for new adjuvant therapies to improve the treatment of both colorectal cancer and liver metastases. The induction of colon cancer by carcinogens in the rat with spontaneous liver metastases closely mimics the natural history of colon cancer but only a low yield of both colonic cancer (less than 50%) and liver metastases (approx. 25%) is obtained after 6 months of latency. Direct intraportal injection of colon carcinoma cells is the most used model. Although it bypasses the natural history of colon cancer, this simple model produces up to 100% of liver metastases 6 weeks after injection of cells. This model has been used to study morphology, neovascularization, surgical and adjuvant therapy (Panis 1991). See Figures 20−22.

In using animal models for preclinical assessment of anti-metastatic agents, it is necessary that appropriate cell lines, routes of administration and target organs used, be appropriately matched for the information sought (Chambers 1999).

REFERENCES

Abraldes, JG; Iwakiri, Y; Loureiro-Silva, M; Haq, WC; Sessa, Groszmann RJ. Mild increases in portal pressure upregulate vascular endothelial growth factor and endothelial nitric oxide synthase in the intestinal microcirculatory bed: leading to a hyperdynamic state. *Am. J. Physiol. Gastrointest. Liver Physiol.*, 2006, 290(5), G980−987.

Abraldes, JG; Pasarin, M; Garcia-Pagan, JC. Animal models of portal hypertension. *World J. Gastroenterol*., 2006, 12(41), 6577−6584.

Aho, HJ; Koskensalo, SM; Nevalainen, TJ. Experimental pancreatitis in the rat. Sodium taurocholate-induced acute haemorrhagic pancreatitis. *Scand. J. Gastroenterol*., 1980, 15(4), 411−416.

Aho, HJ; Nevalainen, YJ. Experimental pancreatitis in the rat. Ultrastructure of sodium taurocholate-induced pancreatic lesions. *Scand. J. Gastroenterol.*, 1980, 15(4), 417−424.

Aho, HJ; Nevalainen, YJ; Aho, AJ. Experimental pancreatitis in the rat. Development of pancreatic necrosis; ischemia and edema after intraductal sodium taurocholate injection. *Eur. Surg. Res.*, 1983, 15(1), 28−36.

Al-Bader, A; Mathew, TC; Abul, H; Al-Sayer, H; Singal, PK; Dashti, HM. Cholangiocarcinoma and liver cirrhosis in relation to changes due to thioacetamide. *Mol. Cell. Biochem.*, 2000, 208(1−2), 1−10.

Aleksandrowicz, R; Gawlik, Z; Wisniewska, IE; Tarlowska, H. Physiological aspects of the partial hepatectomy in rats. *Acta. Physiol. Pol.*, 1981, 32(6), 681−692.

Alpini, G; Roberts, S; Kuntz, SM; Ueno, Y; Gubba, S; Podila, PV; LeSage, G; LaRusso, NF. Morphological, molecular, and functional heterogeneity of cholangiocytes from normal rat liver. *Gastroenterology*, 1996, 110(5), 1636−1643.

Andrzejewska, A; Dlugosz, JW; Jurkowska, G. The effect of antecedent acute ethanol ingestion on the pancreas ultrastructure in taurocholate pancreatitis in rats. *Exp. Mol. Pathol.*, 1998, 65(2), 64−77.

Arendt, T. Bile-induced acute pancreatitis in cats. Roles of bile, bacteria, and pancreatic duct pressure. *Dig. Dis. Sci.*, 1993, 38(1), 39−44.

Baxter, JN; Jenkins, SA; Day, DW; Roberts, NB; Cowell, DC; Mackie, CR; Shields, R. Effects of somatostatin and a long-acting somatostatin analogue on the prevention and treatment of experimentally induced acute pancreatitis in the rat. *Br. J. Surg.*, 1985, 72(5), 382−385.

Beck, IT; Kahn, DS; Solymar, J; McKenna, RD; Zylberszac, B. The role of pancreatic enzymes in the pathogenesis of acute pancreatitis. III. Comparison of the the pathological and biochemical changes in the canine pancreas to intraductal injection with bile and trypsin. *Gastroenterology*, 1964, 46, 531−542.

Beck, PL; Lee, SS. Vitamin K1 improves survival in bile-duct-ligated rats with cirrhosis. *J. Hepatol.*, 1995, 23(2), 235.

Bernstein, DECS. Simple technique for portocaval shunt in the rat. *J. Appl. Physiol.*, 1954, 14, 469.

Bismuth, H. Surgical anatomy and anatomical surgery of the liver. 1982; *World J. Surg*., 6(1), 3−9.

Brand, MI; Kononov, A; Vladisavljevic, A; Milsom, JW. Surgical anatomy of the celiac artery and portal vein of the rat. *Lab. Anim. Sci.*, 1995, 45(1), 76−80.

Brenneman, DE; Connor, WE; Forker, EL; DenBesten, L. The formation of abnormal bile and cholesterol gallstones from dietary cholesterol in the prairie dog. *J. Clin. Invest.*, 1972, 51(6), 1495−1503.

Broe, PJ; Zuidema, GD; Cameron, JL. The role of ischemia in acute pancreatitis: studies with an isolated perfused canine pancreas. *Surgery*, 1982, 91(4), 377−382.

Bucher, NL; Swaffield, MN. The rate of incorporation of labelled thymidine into the deoxyribonucleic acid of regenerating rat liver in relation to the amount of liver excised. *Cancer. Res*., 1964, 24, 1611−1625.

Castaing, DHD; Bismuth, D (1980). *Anatomy of the liver and portal system of the rat*. Paris, Masson Co.

Castaneda, B; Debernardi-Venon, W; Bandi, JC; Andreu, V; Perez-del-Pulgar, S; Moitinho, E; Pizcueta, P; Bosch, J. The role of portal pressure in the severity of bleeding in portal hypertensive rats. *Hepatology*, 2000, 31(3), 581−586.

Cavuoti, OP; Moody, FG; Martinez, G. Role of pancreatic duct occlusion with prolamine (Ethibloc) in necrotizing pancreatitis. *Surgery*, 1988, 103(3), 361−366.

Chambers, AF. The metastatic process: basic research and clinical implications. *Oncol. Res.*, 1999, 11(4), 161−168.

Cheifetz, RE; Davis, NL; Owen, DA. An animal model of benign bile-duct stricture, sclerosing cholangitis and cholangiocarcinoma and the role of epidermal growth factor receptor in ductal proliferation. *Can. J. Surg.*, 1996, 39(3), 193−197.

Colombato, LA; Albillos, A; Groszmann, RJ. Temporal relationship of peripheral vasodilatation, plasma volume expansion and the hyperdynamic circulatory state in portal-hypertensive rats. *Hepatology*, 15(2), 323−328.

Cona, MM; Liu, Y; Yin, T; Feng, Y; Chen, F; Mulier, S; Li, Y; Zhang, J; Oyen, R; Ni, Y. Rat model of cholelithiasis with human gallstones implanted in cholestasis-induced virtual gallbladder. *World J. Methodol.*, 2016, 6(2), 154−162.

Constandinou, C; Henderson, N; Iredale, JP. Modeling liver fibrosis in rodents. *Methods Mol. Med.*, 2005, 117, 237−250.

Couinaud, C. The paracaval segments of the liver. *Journal of Hepato-Biliary-Pancreatic Surgery*, 1994, 1(2), 145−151.

Dam, H; Christensen, F. Alimentary production of gallstones in hamsters. *Acta. Pathol. Microbiol. Scand.*, 1952, 30(2), 236−242.

Dashti, H; Jeppsson, B; Hagerstrand, I; Hultberg, B; Srinivas, U; Abdulla, M; Bengmark, S. Thioacetamide- and carbon tetrachloride-induced liver cirrhosis. *Eur. Surg. Res.*, 1989, 21(2), 83−91.

de Jong, KP; Brouwers, MA; Huls, GA; Dam, A; Bun, JC; Wubbena, AS; Nieuwenhuis, P; Slooff, MJ. Liver cell proliferation after partial hepatectomy in rats with liver metastases. *Anal. Quant. Cytol. Histol.*, 1998, 20(1), 59−68.

de Jong, KP; Lont, HE; Bijma, AM; Brouwers, MA; de Vries, EG; van Veen, ML; Marquet, RL; Slooff, MJ; Terpstra, OT. The effect of partial hepatectomy on tumor growth in rats: *in vivo* and *in vitro* studies. *Hepatology*, 1995, 22(4 Pt 1), 1263−1272.

Delong, RP. Revascularization of the rat liver following interruption of its arterial supply. *Surg. Forum*, 1953, 4, 388−392.

Demicheli, R. Tumour dormancy: findings and hypotheses from clinical research on breast cancer. *Semin. Cancer Biol.*, 2001, 11(4), 297−306.

Eguchi, S; Lilja, H; Hewitt, WR; Middleton, Y; Demetriou, AA; Rozga, J. Loss and recovery of liver regeneration in rats with fulminant hepatic failure. *J. Surg. Res.*, 1997, 72(2), 112−122.

EL, O. The etiology of acute hemorrhagic pancreatitis. *Johns Hopkins Hosp. Bull.*, 1901, 12, 182−190.

Elmore, LW; Sirica, AE. Intestinal-type" of adenocarcinoma preferentially induced in right/caudate liver lobes of rats treated with furan. *Cancer Res.*, 1993, 53(2), 254−259.

Emond, J; Capron-Laudereau, M; Meriggi, F; Bernuau, J; Reynes, M; Houssin, D. Extent of hepatectomy in the rat. Evaluation of basal conditions and effect of therapy. *Eur. Surg. Res.*, 1989, 21(5), 251−259.

Ezure, T; Sakamoto, T; Tsuji, H; Lunz, 3rd JG; Murase, N; Fung, JJ; Demetris, AJ. The development and compensation of biliary cirrhosis in interleukin-6-deficient mice. *Am. J. Pathol*., 2000, 156(5), 1627−1639.

Fan, ST; Lo, CM; Liu, CL; Yong, BH; Chan, JK; Ng, IO. Safety of donors in live donor liver transplantation using right lobe grafts. *Arch. Surg*., 2000, 135(3), 336−340.

Farber, E; Solt, D; Cameron, R; Laishes, B; Ogawa, K; Medline, A. Newer insights into the pathogenesis of liver cancer. *Am. J. Pathol.*, 1977, 89(2), 477−482.

Farmer, RCMS; Reber, HA. Acute pancreatitis: the role of duct permeability. *Surg. Forum*, 1983, 34, 224−227.

Fausto, N. Liver regeneration: from laboratory to clinic. *Liver Transpl.*, 2001, **7**(10), 835−844.

Fausto, N; Riehle, KJ. Mechanisms of liver regeneration and their clinical implications. *J. Hepatobiliary Pancreat. Surg.*, 2005, 12(3), 181−189.

Fernandez, M; Vizzutti, F; Garcia-Pagan, JC; Rodes, J; Bosch, J. Anti-VEGF receptor-2 monoclonal antibody prevents portal-systemic collateral vessel formation in portal hypertensive mice. *Gastroenterology*, 2004, 126(3), 886−894.

Ferrie, MM; O'Hare, R; Joffe, SN. Acute and chronic pancreatitis in the rat caused by a closed duodenal loop. *Digestion*, 1978, 18(3−4), 280−285.

Flavell, DJ; Lucas, SB. Promotion of N-nitrosodimethylamine-initiated bile duct carcinogenesis in the hamster by the human liver fluke, Opisthorchis viverrini. *Carcinogenesis*, 1983, 4(7), 927−930.

Flower, MW. Sur la disposition et la nomenclature des lobes du foi chez les mammifères. *J. de Zool.*, 1872, 1, 420−425.

Foitzik, T; Lewandrowski, KB; Fernandez-del Castillo, C; Rattner, DW; Klar, E; Warshaw, AL. Exocrine hyperstimulation but not pancreatic duct obstruction increases the susceptibility to alcohol-related pancreatic injury. *Arch. Surg.*, 1994, 129(10), 1081−1085.

Franco, D; Gigou, M; Szekely, AM; Bismuth, H. Portal hypertension after bile duct obstruction: effect of bile diversion on portal pressure in the rat. *Arch. Surg.*, 1979, 114(9), 1064−1067.

Futakuchi, M; Hirose, M; Ogiso, T; Kato, K; Sano, M; Ogawa, K; Shirai, T. Establishment of an *in vivo* highly metastatic rat hepatocellular carcinoma model. *Jpn. J. Cancer Res.*, 1999, 90(11), 1196−1202.

Gaub, J; Iversen, J. Rat liver regeneration after 90% partial hepatectomy. *Hepatology*, 1984, 4(5), 902−904.

Gehring, S; Dickson, EM; San Martin, ME; van Rooijen, N; Papa, EF; Harty, MW; Tracy, Jr. TF; Gregory, SH. Kupffer cells abrogate cholestatic liver injury in mice. *Gastroenterology*, 2006, 130(3), 810−822.

Georgiev, P; Jochum, W; Heinrich, S; Jang, JH; Nocito, A; Dahm, F; Clavien, PA. Characterization of time-related changes after experimental bile duct ligation. *Br. J. Surg.*, 2008, 95(5), 646−656.

Gershbein, LL; Elias, H. Observations on the anatomy of the rat liver. *Anat. Rec.*, 1954, 120(1), 85−98.

Glanemann, M; Eipel, C; Nussler, AK; Vollmar, B; Neuhaus, P. Hyperperfusion syndrome in small-for-size livers. *Eur. Surg. Res.*, 2005, 37(6), 335−341.

Gonzalez, AM; Garcia, T; Samper, E; Rickmann, M; Vaquero, EC; Molero, X. Assessment of the protective effects of oral tocotrienols in arginine chronic-like pancreatitis. *Am. J. Physiol. Gastrointest. Liver Physiol.*, 2011, 301(5), G846−855.

Goto, M; Nakano, I; Kimura, T; Miyahara, T; Kinjo, M; Nawata, H. New chronic pancreatitis model with diabetes induced by cerulein plus stress in rats. *Dig. Dis. Sci.*, 1995, 40(11), 2356−2363.

Greene, AK; Puder, M. Partial hepatectomy in the mouse: technique and perioperative management. *J. Invest. Surg.*, 2003, 16(2), 99−102.

Greene, E. C. (1963). *Anatomy of the rat*. New York, Hafner Publishing Company.

Grisham, JW. A morphologic study of deoxyribonucleic acid synthesis and cell proliferation in regenerating rat liver: autoradiography with thymidine-H3. *Cancer Res.*, 1996, 22, 842−849.

Groszmann, RJ; Kravetz, D; Bosch, J; Glickman, M; Bruix, J; Bredfeldt, J; Conn, HO; Rodes, J; Storer, EH. Nitroglycerin improves the hemodynamic response to vasopressin in portal hypertension. *Hepatology*, 1982, 2(6), 757−762.

Gujral, JS; Farhood, A; Bajt, ML; Jaeschke, H. Neutrophils aggravate acute liver injury during obstructive cholestasis in bile duct-ligated mice. *Hepatology*, 2003, 38(2), 355−363.

Gujral, JS; Liu Farhood, A; Hinson, JA; Jaeschke, H. Functional importance of ICAM-1 in the mechanism of neutrophil-induced liver injury in bile duct-ligated mice. *Am. J. Physiol. Gastrointest. Liver Physiol.*, 2004, 286(3), G499−507.

Hebel, RSM. (1976). *Anatomy of the Laboratory Rat.* Baltimore, Williams and Wilkins Co.

Heindryckx, F; Colle, I; Van Vlierberghe, H. Experimental mouse models for hepatocellular carcinoma research. *Int. J. Exp. Pathol.*, 2009, 90(4), 367−386.

Hernandez-Munoz, R; Diaz-Munoz, M; Suarez-Cuenca, JA; Trejo-Solis, C; Lopez, V; Sanchez-Sevilla, L; Yanez, L; De Sanchez, VC. Adenosine reverses a preestablished CCl4-induced micronodular cirrhosis through enhancing collagenolytic activity and stimulating hepatocyte cell proliferation in rats. *Hepatology*, 2001, 34 (4 Pt 1), 677−687.

Higgins, GMAR. Restoration of the liver of the white rat following partial surgical removal. *Arch. Path. Lab. Med.*, 1931, 12, 186−202.

Hoffmann, TF; Leiderer, R; Waldner, H; Arbogast, S; Messmer, K. Ischemia reperfusion of the pancreas: a new *in vivo* model for acute pancreatitis in rats. *Res. Exp. Med. (Berl)* 1995, 195(3), 125−144.

Holmin, T; Alinder, G; Herlin, P. A microsurgical method for total hepatectomy in the rat. *Eur. Surg. Res.*, 1982, 14(6), 420−427.

Ikenoue, T; Terakado, Y; Nakagawa, H; Hikiba, Y; Fujii, T; Matsubara, D; Noguchi, R; Zhu, C; Yamamoto, K; Kudo, Y; Asaoka, Y; Yamaguchi, K; Ijichi, H; Tateishi, K; Fukushima, N; Maeda, S; Koike, K; Furukawa, Y. A novel mouse model of intrahepatic cholangiocarcinoma induced by liver-specific Kras activation and Pten deletion. *Sci. Rep.*, 2016, 6, 23899.

Inderbitzin, D; Gass, M; Beldi, G; Ayouni, E; Nordin, A; Sidler, D; Gloor, B; Candinas, D; Stoupis, C. Magnetic resonance imaging provides accurate and precise volume determination of the regenerating mouse liver. *J. Gastrointest. Surg.*, 2004, 8(7), 806−811.

Inderbitzin, D; Studer, P; Sidler, D; Beldi, G; Djonov, V; Keogh, A; Candinas, D. Regenerative capacity of individual liver lobes in the microsurgical mouse model. *Microsurgery*, 2006, 26(6), 465−469.

Innocenti, PCR; Falcone, A; Gargano, E; Piattelli, E. Anatomia chirurgica del sistema portale nel rato. *Boll. Soc. It. Biol. Sper.*, 1978, 54, 2421−2425.

Iwakiri, Y; Cadelina, G; Sessa, WC; Groszmann, RJ. Mice with targeted deletion of eNOS develop hyperdynamic circulation associated with portal hypertension. *Am. J. Physiol. Gastrointest. Liver Physiol.*, 2002, 283(5), G1074−1081.

Jenkins, SA; Grandison, A; Baxter, JN; Day, DW; Taylor, I; Shields, R. A dimethylnitrosamine-induced model of cirrhosis and portal hypertension in the rat. *J. Hepatol.*, 1985, 1(5), 489−499.

Kanno, N; LeSage, G; Glaser, S; Alvaro, D; Alpini, G. Functional heterogeneity of the intrahepatic biliary epithelium. *Hepatology*, 2000, 31(3), 555−561.

Kaplan, MM; Righetti, A. Induction of rat liver alkaline phosphatase: the mechanism of the serum elevation in bile duct obstruction. *J. Clin. Invest.*, 1970, 49(3), 508−516.

Kara, ME. The anatomical study on the rat pancreas and its ducts with emphasis on the surgical approach. *Ann. Anat.*, 2005, 187(2), 105−112.

Ko, KS; Peng, J; Yang, H. Animal models of cholangiocarcinoma. *Curr. Opin. Gastroenterol.*, 2013, 29(3), 312−318.

Kobayashi, N; Ito, M; Nakamura, J; Cai, J; Gao, C; Hammel, JM; Fox, IJ. Hepatocyte transplantation in rats with decompensated cirrhosis. *Hepatology*, 2000, 31(4), 851−857.

Kogure, K; Ishizaki, M; Nemoto, M; Kuwano, H; Makuuchi, M. A comparative study of the anatomy of rat and human livers. *J. Hepatobiliary Pancreat. Surg.*, 1999, 6(2), 171−175.

Kountouras, J; Billing, BH; Scheuer, PJ. Prolonged bile duct obstruction: a new experimental model for cirrhosis in the rat. *Br. J. Exp. Pathol.*, 1984, 65(3), 305−311.

Krahenbuhl, L; Feodorovici, M; Renzulli, P; Schafer, M; Abou-Shady, M; Baer, HU. Laparoscopic partial hepatectomy in the rat: a new resectional technique. *Dig. Surg.*, 1998, 15(2), 140−144.

Kubota, T; Takabe, K; Yang, M; Sekido, H; Endo, I; Ichikawa, Y; Togo, S; Shimada, H. Minimum sizes for remnant and transplanted livers in rats. *Journal of Hepato-Biliary-Pancreatic Surgery*, 1997, 4(4), 398−404.

Lai, GH; Sirica, AE. Establishment of a novel rat cholangiocarcinoma cell culture model. *Carcinogenesis*, 1999, 20(12), 2335−2340.

Leake, I. Biliary tract. A new mouse model that closely resembles human cholangiocarcinoma. *Nat. Rev. Gastroenterol. Hepatol*., 2015, 12(3), 122.

Lee, JH; Rim, HJ; Sell, S. Heterogeneity of the "oval-cell" response in the hamster liver during cholangiocarcinogenesis following Clonorchis sinensis infection and dimethylnitrosamine treatment. *J. Hepatol.*, 1997, 26(6), 1313−1323.

Lee, SH; Fisher, B. Portacaval shunt in the rat. *Surgery*, 1961, 50, 668−672.

Leelaudomlipi, S; Sugawara, Y; Kaneko, J; Matsui, Y; Ohkubo, T; Makuuchi, M. Volumetric analysis of liver segments in 155 living donors. *Liver Transpl.*, 2002, 8(7), 612−614.

Leneman, F; Burton, S. The hepato-esophageal artery of the rat. Brief report. *Acta. Anat. (Basel)*, 1967, 68(3), 334−343.

Lerch, MM; Adler, G. Experimental pancreatitis. *Current Opinion in Gastroenterology*, 1993, 9(5), 752−759.

Lerch, MM; Adler, G. Experimental animal models of acute pancreatitis. *Int. J. Pancreatol.*, 1994, 15(3), 159−170.

Letko, G; Nosofsky, T; Lessel, W; Siech, M. Transition of rat *pancreatic* juice edema into acute pancreatitis by single ethanol administration. *Pathol. Res. Pract.*, 1991, 187(2−3), 247−250.

Li, X; Benjamin, IS; Alexander, B. Reproducible production of thioacetamide-induced macronodular cirrhosis in the rat with no mortality. *J. Hepatol.*, 2002, 36(4), 488−493.

Li, Y; Tang, ZY; Hou, JX. Hepatocellular carcinoma: insight from animal models. *Nat. Rev. Gastroenterol. Hepatol.*, 2011, 9(1), 32−43.

Lin, PW. Hemodynamic changes after hepatectomy in rats studied with radioactive microspheres. *J. Formos. Med. Assoc.*, 1990, 89(3), 177−181.

Lorente, LAM; Duran, HJ; Cejalvo, D; Lloris, JM; Arias, J. Extrahepatic biliary anatomy in wistar rats. *Surg. Res. Comm., 1995*, 17, 31−38.

Lorente, LAM; Rodriguez, J; Duran, MC; Duran, HJ; Alonso, S; Arias, J. Surgical Anatomy of the liver in Wistar rats. *Surg. Res. Comm.*, 1995, 17, 113−121.

Lozeva, V; Montgomery, JA; Tuomisto, L; Rocheleau, B; Pannunzio, M; Huet, PM; Butterworth, RF. Increased brain serotonin turnover correlates with the degree of shunting and hyperammonemia in rats following variable portal vein stenosis. *J. Hepatol.*, 2004, 40(5), 742−748.

Lu, MD; Chen, JW; Xie, XY; Liang, LJ; Huang, JF. Portal vein embolization by fine needle ethanol injection, experimental and clinical studies. *World J. Gastroenterol.*, 1999, 5(6), 506−510.

Luo, B; Liu, L; Tang, L; Zhang, J; Ling, Y; Fallon, MB. ET-1 and TNF-alpha in HPS, analysis in prehepatic portal hypertension and biliary and nonbiliary cirrhosis in rats. *Am. J. Physiol. Gastrointest. Liver Physiol.*, 2004, 286(2), G294−303.

Luthen, RE; Niederau, C; Grendell, JH. Glutathione and ATP levels, subcellular distribution of enzymes; and permeability of duct system in rabbit pancreas following intravenous administration of alcohol and cerulein. *Dig. Dis. Sci.*, 1994, 39(4), 871−879.

MacPherson, BR; Pemsingh, RS; Scott, GW. Experimental cholelithiasis in the ground squirrel. *Lab. Invest.*, 1987, 56(2), 138−145.

Madrahimov, N; Dirsch, O; Broelsch, C; Dahmen, U. Marginal hepatectomy in the rat: from anatomy to surgery. *Ann. Surg.*, 2006, 244(1), 89−98.

Makino, H; Togo, S; Kubota, T; Morioka, D; Morita, T; Kobayashi, T; Tanaka, K; Shimizu, T; Matsuo, K; Nagashima, Y; Shimada, H. A good model of hepatic failure after excessive hepatectomy in mice. *J. Surg. Res.*, 2005, 127(2), 171−176.

Mann, FCBS; Forster, JP. The extrahepatic biliary tract in common domestic and laboratory animals. *Anat. Rec.*, 1920, 18, 47−66.

Marcos, A; Fisher, RA; Ham, JM; Shiffman, ML; Sanyal, AJ; Luketic, VA; Sterling, RK; Fulcher, AS; Posner, MP. Liver regeneration and function in donor and recipient after right lobe adult to adult living donor liver transplantation. *Transplantation*, 2000, 69(7), 1375−1379.

Martins, PN. Kidney transplantation in the rat: a modified technique using hydrodissection. *Microsurgery*, 2006, 26(7), 543−546.

Martins, PN; Neuhaus, P. Surgical anatomy of the liver, hepatic vasculature and bile ducts in the rat. *Liver Int.*, 2007, 27(3), 384−392.

Martins, PNA; Filatenkov, A. Microsurgical techniques for experimental kidney transplantation and general guidelines to establish studies about transplantation immunology. *Acta Cirurgica Brasileira*, 2003, 18, 355−380.

McGlynn, KA; Hunter, K; LeVoyer, T; Roush, J; Wise, P; Michielli, RA; Shen, FM; Evans, AA; London, WT; Buetow, KH. Susceptibility to Aflatoxin B, sub>1,/sub>-related Primary Hepatocellular Carcinoma in Mice and Humans. *Cancer Research*, 2003, 63(15), 4594−4601.

Moriya, K; Fujie, H; Shintani, Y; Yotsuyanagi, H; Tsutsumi, T; Ishibashi, K; Matsuura, Y; Kimura, S; Miyamura, T; Koike, K. The core protein of hepatitis C virus induces hepatocellular carcinoma in transgenic mice. *Nat. Med.*, 1998, 4(9), 1065−1067.

Musa, BE; Nelson, AW; Gillette, EL; Ferguson, HL; Lumb, WV. A model to study acute pancreatitis in the dog. *J. Surg. Res.*, 1976, 21(1), 51−56.

Nanji, AA. Animal models of nonalcoholic fatty liver disease and steatohepatitis. *Clin. Liver Dis.*, 2004, 8(3), 559−574, ix.

Nettelblad, SC. (1954). *Die Lobierung und innere Topographie der Säugerleber; nebst Beiträgen zur Kenntnis der Leberentwicklung beim Goldhamster (Cricetus auratus)*, Karger.

Nikfarjam, M; Malcontenti-Wilson, C; Fanartzis, M; Daruwalla, J; Christophi, C. A model of partial hepatectomy in mice. *J. Invest. Surg.*, 2004, 17(5), 291−294.

Novobrantseva, TI; Majeau, GR; Amatucci, A; Kogan, S; Brenner, I; Casola, S; Shlomchik, MJ; Koteliansky, V; Hochman, PS; Ibraghimov, A. Attenuated liver fibrosis in the absence of B cells. *J. Clin. Invest.*, 2005, 115(11), 3072−3082.

Okuyama, H; Nakamura, H; Shimahara, Y; Uyama, N; Kwon, YW; Kawada, N; Yamaoka, Y Yodoi, J. Overexpression of thioredoxin prevents thioacetamide-induced hepatic fibrosis in mice. *J. Hepatol.*, 2005, 42(1), 117−123.

Orda, R; Hadas, N; Orda, S; Wiznitzer, T. Experimental acute pancreatitis. Inducement by taurocholate sodium-trypsin injection into a temporarily closed duodenal loop in the rat. *Arch. Surg.*, 1980, 115(3), 327−329.

Orloff, WD; in Souba, WW. Portal hypertension and portocaval shunt. *Surgical Research*. Academic Press. San Diego, 2001.

Paigen, B. Genetics of responsiveness to high-fat and high-cholesterol diets in the mouse. *Am. J. Clin. Nutr.*, 1995, 62(2), 458s−462s.

Panis, Y; McMullan, DM; Emond, JC. Progressive necrosis after hepatectomy and the pathophysiology of liver failure after massive resection. *Surgery*, 1997, 121(2), 142−149.

Panis, Y; Nordlinger, B. Experimental models for hepatic metastases from colorectal tumors. *Ann. Chir.*, 1991, 45(3), 222−228.

Panis, Y; Nordlinger, B; Delelo, R; Herve, JP; Infante, J; Kuhnle, M; Ballet, F. Experimental colorectal liver metastases. Influence of sex, immunological status and liver regeneration. *J. Hepatol.*, 1990, 11(1), 53−57.

Panis, Y; Ribeiro, J; Chretien, Y; Nordlinger, B. Dormant liver metastases: an experimental study. *Br. J. Surg.*, 1992, 79(3), 221−223.

Papp, M; Makara, GB; Hajtman, B; Csaki, L. A quantitative study of pancreatic blood flow in experimental pancreatitis. *Gastroenterology* 1966, 51(4), 524−528.

Perazzo, J; Eizayaga, F; Romay, S; Bengochea, L; Pavese, A; Lemberg, A. An experimental model of liver damage and portal hypertension induced by a single dose of monocrotaline. *Hepatogastroenterology*, 1999, 46(25), 432−435.

Pfeffer, RB; Stasior, O; Hinton, JW. The clinical picture of the sequential development of acute hemorrhagic pancreatitis in the dog. *Surg. Forum*, 1957, 8, 248−251.

Pinto, M; Herzberg, H; Barnea, A; Shenberg, E. Effects of partial hepatectomy on the immune responses in mice. *Clin. Immunol. Immunopathol.*, 1987, 42(1), 123−132.

Popov, Y; Patsenker, E; Bauer, M; Niedobitek, E; Schulze-Krebs, A; Schuppan, D. Halofuginone induces matrix metalloproteinases in rat hepatic stellate cells via activation of p38 and NFkappaB. *J. Biol. Chem.*, 2006, 281(22), 15090−15098.

Pratt, DS. *Harrison's Principles of Internal Medicine*. F. A. Kasper DL, Longo DL, Braunwald E, Hauser SL, Jameson JL. New York, McGraw-Hill**,** 1813−1816. 2005

Proctor, E; Chatamra, K. High yield micronodular cirrhosis in the rat. *Gastroenterology*, 1982, 83(6), 1183−1190.

Proctor, E; Chatamra, K. Standardized micronodular cirrhosis in the rat. *Eur. Surg. Res.*, 1984, 16(3), 182−186.

Puig-Divi, V; Molero, X; Vaquero, E; Salas, A; Guarner, F; Malagelada, J. Ethanol feeding aggravates morphological and biochemical parameters in experimental chronic pancreatitis. *Digestion*, 1999, 60(2), 166−174.

Quon, MG; Kugelmas, M; Wisner, JR; Chandrasoma, P; Valenzuela, JE. Chronic alcohol consumption intensifies caerulein-induced acute pancreatitis in the rat. *Int. J. Pancreatol.*, 1992, 12(1), 31−39.

Rahman, TM; and Hodgson, HJ. Animal models of acute hepatic failure. *Int. J. Exp. Pathol.*, 2000, 81(2), 145−157.

Ralli, EPDM. Simplified technique of partial hepatectomy in the rat with fat liver. *Proc. Soc. Exp. Biol.*, 1951, 77, 188−190.

Rege, RV; Dawes, LG; Ostrow, JD. Animal models of pigment gallstones. *Adv. Vet. Sci. Comp. Med.*, 1993, 37, 257−287.

Renz, JF; Busuttil, RW. Adult-to-adult living-donor liver transplantation: a critical analysis. *Semin. Liver Dis.*, 2000, 20(4), 411-424.

Rocko, JM; Swan, KG. The Eck-Pavlov connection. *Am. Surg.*, 1985, 51(11), 641−644.

Rodriguez, G; Lorente, L; Duran, HJ; Aller, MA; Arias, J. A 70% hepatectomy in the rat using a microsurgical technique. *Int. Surg.*, 1999, 84(2), 135−138.

Roger, V; Balladur, P; Honiger, J; Delelo, R; Baudrimont, M; Robert, A; Calmus, Y; Capeau, J; Nordlinger, B. A good model of acute hepatic failure: 95% hepatectomy. Treatment by transplantation of hepatocytes. *Chirurgie*, 1996, 121(6), 470−473.

Rozga, J; Jeppsson, JB; Bengmark, S. Portal branch ligation in the rat. Reevaluation of a model. *Am. J. Pathol.*, 1986, 125(2), 300−308.

Schaeffer, DO; Hosgood, G; Oakes, MG; St Amant, LG; Koon, CE. An alternative technique for partial hepatectomy in mice. *Lab. Anim. Sci.*, 1994, 44(2), 189−190.

Schindl, MJ; Redhead, DN; Fearon, KC; Garden, OJ; Wigmore, SJ. The value of residual liver volume as a predictor of hepatic dysfunction and infection after major liver resection. *Gut*, 2005, 54(2), 289−296.

Schotman, SN; Schraa, EO; Marquet, RL; Zondervan, PE; Ijzermans, JN. Hepatocellular carcinoma and liver transplantation: an animal model. *Transpl. Int.*, 1998, 11 Suppl 1, S201−205.

Senninger, N; Moody, FG; Coelho, JC; Van Buren, DH. The role of biliary obstruction in the pathogenesis of acute pancreatitis in the opossum. *Surgery*, 1986, 99(6), 688-693.

Shirabe, K; Shimada, M; Gion, T; Hasegawa, H; Takenaka, K; Utsunomiya, T; Sugimachi, K. Postoperative liver failure after major hepatic resection for hepatocellular carcinoma in the modern era with special reference to remnant liver volume. 1999; *J. Am. Coll. Surg.*, 188(3), 304−309.

Siech, M; Heinrich, P; Letko, G. Development of acute pancreatitis in rats after single ethanol administration and induction of a pancreatic juice edema. *Int. J. Pancreatol.*, 1991, 8(2), 169−175.

Sirica, AE. Biliary proliferation and adaptation in furan-induced rat liver injury and carcinogenesis. *Toxicol. Pathol.*, 1996, 24(1), 90−99.

Sirica, AE; Zhang, Z; Lai, GH; Asano, T; Shen, XN; Ward, DJ; Mahatme, A; Dewitt, JL. A novel "patient-like" model of cholangiocarcinoma progression based on bile duct inoculation of tumorigenic rat cholangiocyte cell lines. *Hepatology*, 2008, 47(4), 1178−1190.

Su, KH; Cuthbertson, C; Christophi, C. Review of experimental animal models of acute pancreatitis. *HPB (Oxford)*, 2006, 8(4), 264−286.

Sum, PT; Bencosme, SA; Beck, IT. Pathogenesis of bile-induced acute pancreatitis in the dog. Experiments with detergents. *Am. J. Dig. Dis.*, 1970, 15(7), 637−646.

Tang, TC; Man, S; Lee, CR; Xu, P; Kerbel, RS. Impact of metronomic UFT/ cyclophosphamide chemotherapy and antiangiogenic drug assessed in a new preclinical model of locally advanced orthotopic hepatocellular carcinoma. *Neoplasia*, 2010, 12(3), 264−274.

Thamavit, W; Bhamarapravati, N; Sahaphong, S; Vajrasthira, S; Angsubhakorn, S. Effects of dimethylnitrosamine on induction of cholangiocarcinoma in Opisthorchis viverrini-infected Syrian golden hamsters. *Cancer Res.*, 1978, 38(12), 4634−4639.

Tsukamoto, H; French, SW; Benson, N; Delgado, G; Rao, GA; Larkin, EC; Largman, C. Severe and progressive steatosis and focal necrosis in rat liver induced by continuous intragastric infusion of ethanol and low fat diet. *Hepatology*, 1985, 5(2), 224−232.

Tsukamoto, H; Matsuoka, M; French, SW. Experimental models of hepatic fibrosis: a review. *Semin. Liver Dis.*, 1990, 10(1), 56−65.

Van Laethem, JL; Robberecht, P; Resibois, A; Deviere, J. Transforming growth factor beta promotes development of fibrosis after repeated courses of acute pancreatitis in mice. *Gastroenterology*, 1996, 110(2), 576−582.

Vaquero, E; Molero, X; Tian, X; Salas, A; Malagelada, JR. Myofibroblast proliferation, fibrosis, and defective pancreatic repair induced by cyclosporin in rats. *Gut*, 1999, 45(2), 269−277.

Veal, N; Oberti, F; Moal, F; Vuillemin, E; Fort, J; Kaassis, M; Pilette, C; Cales, P. Splenorenal shunt blood flow is an accurate index of collateral circulation in different models of portal hypertension and after pharmacological changes in rats. *J. Hepatol.*, 2000, 32(3), 434−440.

Vorobioff, J; Bredfeldt, JE; Groszmann, RJ. Hyperdynamic circulation in portal-hypertensive rat model: a primary factor for maintenance of chronic portal hypertension. *Am. J. Physiol.*, 1983, 244(1), G52−57.

Walker, NI. Ultrastructure of the rat pancreas after experimental duct ligation. I. The role of apoptosis and intraepithelial macrophages in acinar cell deletion. *Am. J. Pathol.*, 1987, 126(3), 439−451.

Wang, J; Tahara, K; Hakamata, Y; Mutoh, H; Murakami, T; Takahashi, M; Kusama, M; Kobayashi, E. Auxiliary partial liver grafting in rats: effect of host hepatectomy on graft regeneration, and review of literature on surgical technique. *Microsurgery*, 2002, 22(8), 371−377.

Wedgwood, KR; Farmer, RC; Reber, HA. A model of hemorrhagic pancreatitis in cats−role of 16,16-dimethyl prostaglandin E2. *Gastroenterology*, 1986, 90(1), 32−39.

Weinbren, K; Taghizadeh, A. The mitotic response after subtotal hepatectomy in the rat. *Br. J. Exp. Pathol.*, 1965, 46(4), 413−417.

Whitaker, WL. Portal vein ligation and the Eck fistula in the rat. *Proc. Soc. Exp. Biol. Med.*, 1946, 61, 420−423.

Widdison, AL; Alvarez, C; Reber, HA. The low-pressure duct perfusion model of acute pancreatitis. *Eur. Surg. Res.*, 1992, 24 Suppl 1, 55−61.

Wu, SH; Xu, YX; Yin, T; Song, XH; Wang, JJ; Li, R. Fabrication and data harvesting of casting sample of rat liver blood vessels. *Hepatobiliary Pancreat. Dis. Int.*, 2005, 4(4), 582−584.

Wynn, TA. Fibrotic disease and the T(H)1/T(H)2 paradigm. *Nat. Rev. Immunol.*, 2005, 4(8), 583−594.

Yamada, D; Rizvi, S; Razumilava, N; Bronk, SF; Davila, JI; Champion, MD; Borad, MJ; Bezerra, JA; Chen, X; Gores, GJ. IL-33 facilitates oncogene-induced cholangiocarcinoma in mice by an interleukin-6-sensitive mechanism. *Hepatology*, 2005, 61(5), 1627−1642.

Yang, H; Li, TW; Peng, J; Tang, X; Ko, KS; Xia, M; Aller, MA. A mouse model of cholestasis-associated cholangiocarcinoma and transcription factors involved in progression. *Gastroenterology*, 2011, 141(1), 378−388, 388.e371−374.

Yang, R; Rescorla, FJ; Reilly, CR; Faught, PR; Sanghvi, NT; Lumeng, L; Franklin, TD; Jr. Grosfeld, JL. A reproducible rat liver cancer model for experimental therapy: introducing a technique of intrahepatic tumor implantation. *J. Surg. Res.*, 1992, 52(3), 193−198.

Yao, A; Li, X; Pu, L; Zhong, J; Liu, X; Yu, Y; Zhang, F; Kong, L; Sun, B; Wang, X. Impaired hepatic regeneration by ischemic preconditioning in a rat model of small-for-size liver transplantation. *Transpl. Immunol.*, 2007, 18(1), 37−43.

Yeh, CN; Maitra, A; Lee, KF; Jan, YY; Chen, MF. Thioacetamide-induced intestinal-type cholangiocarcinoma in rat: an animal model recapitulating the multi-stage progression of human cholangiocarcinoma. *Carcinogenesis*, 2004, 25(4), 631−636.

Zhong, Z; Theruvath, TP; Currin, RT; Waldmeier, PC; Lemasters, JJ. NIM811, a mitochondrial permeability transition inhibitor, prevents mitochondrial depolarization in small-for-size rat liver grafts. *Am. J. Transplant.*, 2007, **7**(5), 1103−1111.

In: Encyclopedia of Surgery (22 Volume Set)
Editors: Andreas Lehrer and Kristin Mueller
ISBN: 978-1-53618-329-0
© 2020 Nova Science Publishers, Inc.

Chapter 191

ANIMAL MODELS OF ACUTE GRAFT-VERSUS-HOST AND HOST-VERSUS-GRAFT RESPONSES AND DISEASE

Abraham Matar[1] and Raimon Duran-Struuck[2,*]
[1]Department of Surgery, Emory University School of Medicine, Atlanta, GA, US
[2]Department of Pathobiology, University of Pennsylvania
School of Veterinary Medicine, Philadelphia, PA, US

ABSTRACT

This chapter aims to provide insight into the strengths and weaknesses of animal models for the study of host-versus-graft (HVG) and graft-versus-host (GVH) responses and disease. As with any complex biological process in which animal models are used, careful assessment of their strengths and weaknesses is paramount. There is no one Universal or "best" animal model. Large animal models such as the dog, pig, or non-human primate, approximate the clinical scenario with much higher fidelity than rodents. However, rodents can be genetically manipulated with ease for the understanding of mechanistic processes that are difficult to investigate in large animals. This chapter will address both large and small animal models used to examine GVH and HVG responses/disease. We will also discuss how these approaches have reached impacted the bedside after being tested at the bench side and cage side.

Keywords: host-versus-graft (HVG), graft-versus-host (GVH) responses, mouse, dog, pig, nonhuman primate, bone marrow transplantation, liver, spleen, small bowel transplantation

* Corresponding Author's Email: rdura@upenn.edu.

ABBREVIATIONS

ALS	anti-lymphocyte serum
BMT	bone marrow transplantation
CyA	cyclosporine A
DLA	Dog leukocyte antigen
GVHD	Graft-versus-host disease
GVHR	Graft-versus-host responses
H2	histocompatibility system
HSCT/HCT	hematopoietic stem cell transplantation/ hematopoietic cell transplantation
HVG	Host-versus-graft
KI	knockin
KO	knockout
MHC	Major histocompatibility complex
miHA	minor histocompatibility antigens
MMF	mycophenolate mofetil
MTX	methotrexate
PBCs	Peripheral blood cells
SBT	Small bowel transplantation
SOT	Solid organ transplantation
TBI	total body irradiation

INTRODUCTION

> "It should be noted that marrow grafting could not have reached clinical application without animal research, first in inbred rodents and then in outbred species."
>
> E. Donnall Thomas, the Nobel Prizes, 1990

Animal research, as mentioned by Dr. E. Donnall Thomas in 1990 during his Nobel Prize award, has been crucial for the understanding of bone marrow transplantation (BMT) as a clinical therapy (Ladiges 1990). His studies extensively used both mice and dogs as animal models. Other important models used in BMT research are rats, cats, pigs and non-human primates. The mouse is an excellent animal model because of the similarities in physiological and pathological traits that it shares with other animals and humans. The field of BMT research has taken full advantage of these qualities, and mice have become one of the most commonly used BMT animal models.

Transplantation (organ and hematopoietic) began in the early 20th century. Several studies published between 1949−1953 (Owen 1945; Billingham 1953) documented that organs removed and immediately transplanted back into the same individual (autotransplants) were not rejected. However, organs from genetically different animals but from the same species (allografts) would eventually fail several days after transplantation. After the identification of the antigens that comprise the major histocompatibility complexes (MHC) in the 1960's, transplantation between genetically different individuals became feasible (Copelan 2006). In the veterinary medical field, it was observed that freemartin cattle (a cow

with masculinized behavior and non-functioning ovaries that is genetically a female, but is sterilized in utero by the hormones from a male twin) did not exhibit similar rejection patterns as observed in allogeneic transplantation (1945). This led to studies that hypothesized the presence of "tolerance" *in utero* which was lost soon after birth. Years later (1956−1959), the immune system was identified as the responsible mechanism for differentiating between "self" and "non-self."

GVHD AFTER BONE MARROW TRANSPLANTATION

Mice and other rodents were first used as animal models for BMT research when scientists and physicians began investigating irradiation-induced bone marrow injury after the World War II. It was observed that after lethal total body irradiation (TBI), restoring bone marrow would rescue the animal's immune system (Thomas 1975a; Thomas 1975b; Jacobson 1951). With the development of inbred strains of mice, many discoveries in the field of immunology, immunogenetics, and radiation oncology have taken place. Important early transplant studies by Van Bekkum and de Vries were summarized by E. Donnall Thomas and Rainer Storb (Thomas 1975a; Thomas 1975b). They discovered that: (1) the delivery of bone marrow intravenously was efficient in rescuing the immunoablated recipient animal; (2) donor bone marrow would cause a "secondary disease" or "runt disease" in mice from which the recipient animals would die unless they were genetically identical [This disease was later identified as GVHD]; (3) genetic factors dictated the severity of GVHD; and (4) the use of immunosuppressive agents (such as methotrexate) was able to ameliorate the GVHD reaction in allogeneic transplants, implicating the immune system as the culprit in GVHD (Thomas 1975a; Thomas 1975b).

Hematopoietic stem cell transplantation (HSCT) is most commonly used for the treatment of hematologic and lymphoid neoplasias and less commonly for non-neoplastic diseases. Mice are the premier animal model for researching novel therapies for the cure of many of these neoplastic and non-neoplastic diseases. Furthermore, mice are used extensively for the study of BMT-related complications such as GVHD. Acute GVHD and leukemic relapse remain the two major obstacles to successful outcomes after allogeneic bone marrow transplantation. We will concentrate on common mouse models that are used to understand the major factors governing graft versus host responses (GVHR) and its side effect, GVHD. These effects are closely intertwined with GVL effects.

Although HSCT is a lifesaving treatment for many patients, the side effects limit its success and wider application. Graft versus host disease (GVHD) is the most common complication and can affect up to 75% of patients. First described in 1962, GVHD was later classically characterized by Billingham as a syndrome in which a graft from an immunocompetent donor recognizes non-self antigens and attacks the immunocompromised cells of the allogeneic recipient (Shlomchik 2007). GVHD can present both acutely and chronically. Acute GVHD (aGVHD) is most often categorized as disease onset within 100 days of transplant, and is a rapidly progressive illness with a strong inflammatory component. In addition to the significant morbidity and mortality of aGVHD, it has also been found to be a powerful predictor of chronic GVHD risk (Copelan 2006), which displays more autoimmune and fibrotic features (Martin 2004). Chronic GVHD was categorized when the

disease developed 100 days post-BMT. Clearly this method of categorization of GVHD has had to be modified with the much-improved post-transplant pharmacological approaches where acute GVHD has been observed beyond 100 days. Acute and chronic GVHD is being divided nowadays based on their immunological profiles. While acute GVHD is a CD8 T cell driven, chronic GVHD has been dominated by the generation of allo-antibody and resembles more an antibody-mediated auto-immune condition.

ACUTE GVHD

The induction of acute GVHD is a stepwise process divided into an afferent and an efferent phase (Ferrara 2009). Multiple well-written reviews have been published (Copelan 2006; Shlomchik 2007; Duran-Struuck 2008a). The afferent phase is characterized by donor T cell activation which can be broken down into three steps. First, an inflammatory environment is propagated as a direct result of the pre-transplant conditioning protocol (Ferrara 2009). Next, MHC-peptide complexes are presented on the surface of host antigen presenting cells (APCs) and recognized by mature T cells through the T cell receptor (TCR). Once engaged with the TCR, host APCs produce co-stimulatory signals which activate the T cells. Activated T cells then produce further cytokines, such as IL-2, which act in an autocrine manner to induce clonal expansion. In the efferent phase, these activated T cells produce inflammatory cytokines, recruit additional effector cells, induce the expression of HLA proteins and focus the attack on target organs. This is a self-perpetuating disease state that is difficult to control. 15% of annual HSCT patients die from aGVHD, and this mortality rate can reach 50% for chronic GVHD (Copelan 2006; Ferrara 2009). For these reasons, it is imperative that we develop a better understanding of the mechanism of induction and the factors underlying the severity of disease.

Crucial insights into the pathophysiology of GVHD have been provided by both small and large animal models of GVHD. These insights have in turn, led to improved clinical outcomes of patients suffering from GVHD.

There are multiple approaches to mitigate GVHD. These combine the use of pharmacological and biologicals (Table 1). In general, all of these are aimed at targeting T cells but often impact more than one immunological cell subset rendering the animal (or patient) significantly immunossupressed.

MURINE MODELS OF BONE MARROW TRANSPLANTATION AND ACUTE GVHD

Murine animal models have been crucial for the elucidation of immunobiology questions related to bone marrow transplantation. When compared to other species, mice have several advantages that have facilitated these advances. Mouse models are attractive because of their small mass, large litter size, short pregnancy period, the availability of diverse stocks and strains as well as the use of transgenic, knockout (KO) and knock-in (KI) mice have made them the most valuable and versatile experimental animal model for biomedical research. Additionally, mice are relatively inexpensive. Large populations of mice can be maintained in

facilities designed specifically for rodents. Several inbred strains are available and have been well characterized; inbred strains have allowed for large experiments where all individuals are genetically identical (as compared to outbred stocks). Knockout and transgenic technology has enabled the study of specific immunological mechanisms by providing a tool that keeps most genetic factors constant. Of all animals, the murine immune system is the best defined. In fact, the major histocompatibility factor (H2) system, was discovered in mice in the 1940's (Snell 1980). Besides man, mice have the highest number of available biological reagents. Some of these reagents include, but are not limited to, monoclonal antibodies, cytokines and growth factors.

Table 1. GVHD treatment/sparing strategies

Biologicals		CELLULAR TARGETS	EFFECT
a)Cells	Regulatory T cells (Tregs)	T cells, B cells and innate cells	Direct cell:cell contact immunosuppression/kill and cytokine mediated
	Mesechymal stromal cells	T cells and innate cells	Cytokine mediated and through indirect increases of Tregs
	Chimeric antigen Receptors on T cells (CARs)	Tumor targets	Direct cytotoxicity and kill of tumors
b)Antibodies	Anti-thymocyte globulin (ATG)	T-cell	Apoptosis
	Anti-CD52	T cell & B cell	Apoptosis
	Anti-CD20 (Rituximab)	B-cell	Apoptosis
	Anti-CD2, CD3, CD5 monoclonal antibodies	T-cell	Apoptosis
	Infliximab (monoclonal antibody)	TNF-a	Anti-TNF
Non-pharmacological	Reduced intensity conditioning	Decreased pre-transplant organ damage	Decreased TNF-α, IL-1 and LPS translocation
	Extra-corporeal photopheresis	T-cell apoptosis	8-MOP T cell sensitization
Pharmacological	Glucocorticoids (1st line)	Lymphocytes, monocytes	Anti-inflammatory and apoptosis
	Mycophenolate mofetil (MMF)	T-cell	Inhibition of monophosphate dehydrogenase
	Rapamycin (Sirolimus)	T-cell	Inhibits (G1→S) phase transition
	Cyclosporine	T-cell	Calcineurin inhibitor through cyclophilin
	Tacrolimus	T-cell	Calcineurin inhibitor through FK506 binding protein
	Etanercept (Enbrel)	TNF-α	Soluble TNF-α receptor

Mouse models of GVHD can be separated into animals in which GVHD is directed to either MHC class I or class II, both, or isolated to multiple minor antigens (miHAs). Although multiple miHA mismatches are present across major MHC mismatches, their impact is usually limited relative to that induced by full MHC disparities (Reddy 2008). The GVHD that develops in response to a full (class I and II) MHC disparity is dependent on CD4 T cells and CD8 T cells. These systems result in an inflammatory "cytokine storm," capable of inducing GVHD in target tissues without the requirement for cognate T cell interaction

with MHC on tissue (Teshima 2002). In contrast to CD4-dependent GVHD, CD8 T cells induce GVHD primarily by using their cytolytic machinery, which requires the TCR to engage MHC on target tissue (Duran-Struuck 2008a). The induction of GVHD to multiple miHAs results in a process that involves either CD8 T cells, CD4 T cells, or both, depending on the strain combination (Table 2).

Table 2. H2 haplotypes of common used mouse strains

Strain	H-2 complex			
	MHC-I		MHC-II	
	K	D	A	E
Common strains				
AKR/J	k	k	k	k
C3H/HeJ	k	k	k	k
BALB/c	d	d	d	d
C57BL/6	b	b	b	b
CBA/J	k	k	k	k
DBA/2	d	d	d	d
Congenic strains				
BALB.B	b	b	b	b
BALB.K	k	k	k	k
C3H.SW	b	b	b	b
B6.C-H2^{BM1}	bm1	b	b	b
B6.C-H2^{BM12}	b	b	bm12	b
Recombinant strains				
A	d	k	k	k
B10a	k	d	k	k

These mouse models have helped dissect and shape the complex immunopathology of GVHD. It is critical to understand that no single mouse model can be considered the most appropriate for clinical BMT, because clinical BMT recipients that are MHC matched with the donor also have multiple miHA disparaties. In the laboratory, both MHC and miHA disparate systems can induce aspects of GVHD which are clinically relevant. These permit the isolation of immunological pathways for understanding the mechanisms of GVHD.

Radiation, as a form of myeloablation, is most commonly utilized in mice. Inbred mouse strains (including congenics) demonstrate variable sensitivity to radiation (Duran-Struuck 2008b). The higher the TBI dose, the more intense the inflammatory arm (cytokine storm) of GVHD will be. BMT models utilizing low TBI doses and high donor T cell doses result in GVHD dominated by later onset T cell-dependent pathology (Reddy 2008). Other forms of chemotherapy conditioning with cyclophosphamide, fludarabine, and busulfan can also be delivered in mouse systems, however, these are more commonly used in large animal studies.

Like many animal models, mice have limitations and major differences. First, mouse BMTs are usually supplemented with T cells from the spleen in order to induce GVHD. This is because BM itself, even across MHC barriers, does not cause GVHD. In larger species, such as humans and pigs, BM-derived T cells are sufficient for inducing GVHD (Duran-Struuck 2015; Duran-Struuck 2016; Duran-Struuck 2017). Currently, most of the BMTs in humans are performed with peripheral blood cells (PBCs) only. PBC transplants in mice are rarely used because of size limitations and blood volume limitations. Second, mouse pre and peri-transplant preparatory regimens do not follow the protocols used in humans, who are

gradually rendered immunosuppressed over a number of days. Mice are generally given a myeloablative irradiation dose 2−24 hours prior to the intravenous delivery of the bone marrow graft.

BMT and its applications in mice have been used in a plethora of research fields. Here we will concentrate on the use of these animal models for BMT biomedical research and immunobiology. More specifically, we discuss the use of BMT for the study of GVHD and for its anti-leukemia (GVL) effects, since leukemia relapse and GVHD, as mentioned before, remain the two major obstacles for successful BMT.

Many of the pivotal concepts in BMT have been elucidated by studying the donor:recipient combinations in mice. As described by Shlomchik (Shlomchik 2007), these can be divided into: (a) MHC identical, minor histocompatibility antigen (b) MHC disparate in different background strains (c) MHC disparate in identical background strains (d) the use of strains where single MHC-I or MHC-II alleles differ by a small number of peptides (e) Parent → F1 models.

These combinations have been very important in addressing the involvement of specific cell subsets causing GVHD. T cells have been identified to be important factors for the development of GVHD (Ferrara 1999). As an example, different transplant combinations have induced immune responses mediated by $CD4^+$ T cells, $CD8^+$ T cells, or a combination of both. It should be noted that besides effector T cells, other cell lines such as B cells (Rowe 2006), natural Killer cells (NKCs) (Sentman 1989), and T regulatory cells (Tregs) (Nguyen 2006) have been identified to have an impact in the development or protection of the GVH response. Therefore, the use of mouse models has aided in polarizing the immune system in an effort to dissect the involvement of each one of the multiple factors involved in GVHD. Such "clean" studies, most likely, would have not been able in larger, outbred species because of the genetic variability between animals.

In summary, mouse models, including KI and KO systems, and the use of phenotyping markers (monoclonal antibodies), availability of agonist/antagonists of chemokines, cytokines, co-stimulatory molecules, have proven to be crucial for the elucidation of BMT engraftment and GVHD pathophysiological processes. Clinical applications of many of the concepts discovered in mice have proven to be necessary in pre-clinical large animal models. In our case, we used the pig.

LARGE ANIMAL MODELS OF GVHD

1. Canine Models

Progress in experimental bone marrow transplantation in canines has provided for the translation of dog experimental findings to the clinic. The therapeutic application of marrow grafting in dog has been applied to a variety of human diseases. Dog models of total body irradiation, engraftment and graft-versus-host disease have been (and continue to be) used to address existing clinical problems of hematopoietic cell transplantation and GVHD. Domestic dogs with spontaneously occurring lymphomas and other cancers are used for cellular therapies (as an example, at the University of Pennsylvania (Panjwani 2016) novel chimeric antigen receptor (CARs) T cell approaches are being studied in domestic dogs). Clinical

parameters necessary for implementing safe autotransplant approaches in conjunction with high dose radiation and/or chemotherapy have been studied in dogs. Chemicals, radiation, antisera and monoclonal antibodies have been (and continue to be) developed in laboratory bred dogs as a model for human transplantation. Interestingly, the demand for enhanced clinical medical care in domestic dogs has pushed this model beyond experimental use. As a GVHD model, the refinement of approaches that suppress the immune system either nonspecifically using radio/chemo ablation, or directed to specific immune cells continues to be an area of research in which the dog continues to play a big part.

Much of the early work in large animals studying GVHD was at first performed in canines. The Seattle group led the way with early experiments demonstrating the importance of HLA matching in preventing GVHD after BMT. Crucial to these efforts was the development of a reproducible model of lethal acute GVHD in which dogs receiving between 8.5 − 9.2 Gy TBI and dog leukocyte antigens (DLA)-nonidentical unrelated marrow grafts without any immunosuppression died shortly after transplant due to effects of GVHD (Atkinson 1982). Using this model as a foundation, a major contribution to the understanding of GVHD by the Seattle group was studying the effects of different immune suppression regimens on GVHD. Many of these early immunosuppressants tested in the canine model are the same ones used today in clinical BMT, including cyclosporine A (CyA), mycophenolate mofetil (MMF), and methotrexate (MTX) (Table 1).

In the early 1980s, E. Donald Thomas and colleagues reported GVHD-free survival in 12/13 animals receiving treatment with methotrexate following supralethal levels of TBI and hematopoietic grafts from DLA matched littermates. This was compared to animals who did not receive methotrexate, in which 16/28 animals developed and died of GVHD. Thomas went on to examine the effect of combination Cyclosporin A and methotrexate (MTX) as a prophylaxis against GVHD (Deeg 1984). They showed that combination MTX and CyA was superior to MTX alone in prophylaxing against GVHD in recipients conditioned with 9 Gy of TBI and receiving DLA-haploidentical transplants (Deeg 1984). This initial work sparked controlled clinical trials assessing the efficacy of combination MTX and CyA for GVHD prophylaxis. Yu et al. demonstrated the synergistic effect of mycophenolate mofetil (MMF) and cyclosporine for the prevention of GVHD in this model (Yu 1998). Dogs receiving either MMF or CyA alone after transplant had increased survival compared to control dogs not receiving any immunosuppression, but all dogs eventually died secondary to GVHD. Groups of animals receiving combination MMF and CyA had greater than 50% survival. Kuhr et al. tested RDP58, a novel anti-inflammatory peptide derived from the HLA class I heavy chain, in prophylaxing against GVHD in this model (Kuhr 2006). Unfortunately, in five dogs that engrafted after transplant, all five developed acute GVHD and were euthanized at 20 days after HCT, not significantly prolonging survival compared to control animals. Similarly, FTY720, also known as Fingolimod, which is the first oral disease modifying drug for the treatment of multiple sclerosis, did not significantly increase survival after the development of GVHD in this model (Lee 2003). Denileukin diftitox, also known as Ontak, an anti-IL2 receptor immunotoxin was unable to mitigate GVHD or increase survival (Mielcarek 2006). The addition of glucocorticoids to tacrolimus or tacrolimus/MTX combination did not show a synergistic effect with respect to the prevention of GVHD or increasing survival compared to tacrolimus or tacrolimus/MTX combination alone (Yu 1997).

More recently, Zorn et al. showed the reduced incidence of GVHD in a canine model of DLA-homozygous donor and DLA-heterozygous recipient transplant using CD6-depleted

bone marrow (Zorn 2009). In a control group of 7 canines treated with 10 Gy TBI and receiving unmanipulated bone marrow, all animals died of GVHD within 1 month of transplantation. Animals treated with the same preparatory regimen but receiving CD6-depleted bone marrow using a mouse-anti-human antibody which cross reacts with the canine CD6 antigen, had a significantly reduced incidence of GVHD without jeopardizing the engraftment.

2. Primate Models

Non-human primates (NHP) have been used in transplantation for several decades. Leukaphoresis can be performed in NHPs (Pathiraja 2013) as an alternative to BMT. Not until relatively recently have been MHC-characterized colonies made available for experimental purposes (to mimic allogeneic BMT has been performed like in mice or humans). Two NHP models, one in *cynomolgus macaques (cynos)* and one in *rhesus macaques (rhesus)* have genotyped and characterized their MHC to better design transplant studies. A population of cynos has been naturally isolated on the small island of Mauritius. The Mauritian Islands have been naturally separated from the main land Asia for hundreds of thousands of years. Over five hundred years ago Asian cynos were brought by settlers to the islands from Asia as few founder animals. This geographic isolation has allowed for some natural inbreeding to occur, narrowing their genetic MHC diversity to 6 different haplotypes (PHS 1996; O'Connor 2007). This makes the Mauritius cyno a particularly attractive model for immunological studies. No studies focusing in GVHD have yet been reported using these animals, but have been recently made available commercially and will be an invaluable tool for studies of GVHD biology. There is a recent study which extensively describes the leukocyte populations within the lymphohematopoietic organs (bone marrow, peripheral blood, thymus, lymph nodes and spleen) from these animals providing a platform upon which to build from (Duran-Struuck 2017; Zitsman 2016). No other study exists to date that describes in such careful detail all these cell subsets in GVHD target organs. It is a matter of time that these are further utilized for studies of GVHD.

Under a closely managed breeding program at Yerkes National Primate Research Center and the direction of Kean and colleagues, the NHP GVHD model has been established. This new model is currently being used as a valuable tool to pre-clinically screen novel checkpoint blockade immunotherapies (Kaliyaperumal 2014; Miller 2010). As an example, studies from Miller et al. reported that 100% of animals conditioned with 8 – Gy TBI on day 0 developed rapid-onset of severe GVHD involving the skin, GI system, and liver (Miller 2010). Two of three animals receiving leukapheresis-derived grafts succumbed within 7 days, and 1 animal who received a BM-derived graft succumbed at day 22. Clinical disease correlated closely with $CD8^-$predominant lymphocyte expansion and activation. In these animals, expanding $CD4^+$ and $CD8^+$ lymphocytes expressed a memory phenotype as indicated by $CD95^+$ cells. Interestingly, the majority of expanding $CD4^+$ cells expressed a central memory phenotype ($CD28^+/CD95^+$) compared to expanding $CD8^+$ cells which predominantly expressed an effector memory phenotype ($CD28^-/CD95^+$). Regardless, both expanding $CD4^+$ and $CD8^+$ lymphocytes significantly upregulated expression of Ki67, an intra-nuclear marker of proliferation, and downregulated expression of BCl-2, an antiapoptotic protein. Furthermore, untreated animals developing GVHD accumulated high levels of IL-1RA, IL-18, IFNy, and

CCL4. Alternatively, five animals treated with 8 Gy TBI in addition to costimulation blockade (CTLA4Ig and anti-CD40L monoclonal antibody) and sirolimus were initially protected from the severe GVHD observed in the untreated recipients and showed 100% survival at day 30, compared with 0% 30 day survival among the untreated animals. T cell activation in treated animals was significantly reduced, and treated animals retained a cohort of naïve CD4 and CD8 T cells ($CD95^-$) despite alloantigen exposure that was essentially absent in untreated animals. Despite early protection from GVHD, all treated animals did eventually succumb to GVHD. This was hypothesized to be due to a subset of $CD8^+$ T cells ($CD28^-/CD95^+$) exhibiting breakthrough immune activation despite treatment with costimulation blockade and sirolimus. This subset of $CD8^+$ T cells exhibited an activated phenotype as evidenced by Ki67 upregulation and BCl-2 downregulation.

3. Swine Models

Studies and descriptions of GVHD in swine have mostly been performed by Sachs and colleagues. The pig is arguably one of the best models for the study GVHD, in particular skin GVHD (Duran-Struuck 2016). To date, the most extensive swine studies of HSCT and GVHD come from the Massachusetts General Hospital (MGH). Over a period of 40 years, David Sachs has developed a herd of partially inbred, MHC-defined miniature swine that have allowed for the study of different clinical HSCT scenarios including minor antigen mismatch, haploidentical match, and full MHC mismatch (Cina 2006). The development of acute GVHD in swine involves the same organ systems as in humans, including skin, liver, gastrointestinal system, and bone marrow (Duran-Struuck 2015). Skin GVHD is the earliest and most common manifestation in swine. Lesions usually involve the neck, back and abdomen of animals, often becoming confluent and ulcerative in nature. Histologically, a differentiating feature of swine GVHD is a denser infiltrate of neutrophils into the skin. This is seen in addition to the classic lymphocytic infiltrate seen in human. An extensive review of swine as a model for GVHD has recently been published (Duran-Struuck 2015).

Early studies from MGH showed that in a haploidentical model (parent to F1), 100% of recipients (n = 18) irradiated with 900 cGY of TBI successfully engrafted after allogeneic BMT. All but one recipient developed varying intensities of skin GVHD, which directly correlated with the degree of T cell depletion in the infused marrow. Similarly to humans, attempts at preventing GVHD by depleting the graft of T cells led to graft failure (Pennington 1988; Popitz-Bergez 1988; Sakamoto 1988).

Table 3. Major histocompatibility complexes in mice, pigs and men

Species	MHC-I	MHC-II
Mouse	H2-K, D, L	H2- A, E, O
Human	HLA- A, B, C	HLA- DR, DQ, DP

In mice, the administration of IL-2 post BMT between HLA-mismatched recipient/donor pairs reduces the incidence of GHVD. The effect of high dose IL-2 therapy on GHVD in swine was studied in a series of single haplotype mismatch and full haplotype mismatch transplants (Kozlowski 2000). In fully mismatched bone marrow transplants, high dose IL-2

therapy had no effect on the development of GVHD, and all swine eventually succumb to severe GVHD. However, in the context of single haplotype (class II) mismatched BMT, high dose IL-2 significantly reduced the incidence and severity of GVHD, which translated into increased survival.

Over time, the MGH group has developed a model of haploidentical hematopoietic cell transplantation using a novel reduced intensity conditioning regimen consisting of low dose total body irradiation, T cell depletion using a CD3 immunotoxin, and a short course of cyclosporine. This regimen results in stable multilineage chimerism without significant GVHD, and can induce immunological tolerance to solid organ grafts including kidney, lung, and vascularized composite allografts (Cina 2006; Hettiaratchy 2004).

GVHD AFTER SOLD ORGAN TRANSPLANTATION

The first description of GVHD after solid organ transplantation (SOT) in the literature was by Starzl et al. in 1984, who described GVHD in a patient after undergoing a combined pancreas and splenic transplant (Starzl 1984). Since then, there have been a number of case series retrospectively analyzing GVHD after SOT, specifically liver and small bowel allografts. However, due to the relatively rare incidence of GVHD after SOT, prospective studies of GVHD in humans are impractical. To date, no dedicated large animal model of acute GVHD after SOT exists, most likely related to its rare clinical incidence. Several rat models of GVHD after liver transplantation exist, and we will review those here.

1. Liver

1.1. Experimental

Xue et al. established a reproducible model of acute GVHD after liver transplantation and donor splenocyte infusion in Lewis rats. In this model, the level of chimerism after liver transplantation was shown to correlate with the development of acute GVHD (Xue 2009). Another subsequent study by the same group assessed the effect of tacrolimus vs. rapamycin on GVHD in this model (Xu 2010). They found that rapamycin significantly increased survival compared to tacrolimus, and this survival was associated with higher percentages of CD4+CD25+FoxP3+ T regulatory cells in the circulation and tissues. Finally, the infusion of either donor or recipient derived mesenchymal stem cells (MSCs) prior to the development of aGVHD symptoms (days 0–6) led to the abrogation of typical aGVHD symptoms seen in this model and led to significantly increased survival (Xia 2012). Interestingly, MSCs infused between days 8–14, after the typical symptoms of aGVHD started, had no effect on GVHD or survival. The group hypothesized that the mechanism of MSC protection against aGVHD was via the induction of Tregs, as MSC-infused rats had higher amounts of Tregs in the blood and intestines.

Another recent model of aGVHD after liver transplantation in rats involved preconditioning recipients with sublethal irradiation plus treatment with anti-CD8a mAB to deplete radioresistant NK cells (Yu 2016). Subsequent transplantation of liver allografts alone without a cellular graft consistently resulted in lethal aGVHD. Interestingly, in an attempt to

abrogate aGVHD in this model, donor livers were perfused *ex vivo* with a media containing a TCRab mAB, and then transplanted using the same preparatory regimen. *Ex vivo* T cell depletion of liver grafts prevented aGVHD without any accompanying effect on graft function. This strategy may be a viable clinical option in high risk donor and recipient pairs undergoing liver transplantation.

1.2. Clinical

It has been almost 30 years since a case of acute GVHD after orthotopic liver transplant (OLT) was first described in the literature by Burdick et al. (Burdick 1988). Since that sentinel report in 1988, there have been numerous case reports describing GVHD after OLT, as well as several large series reporting on incidence and outcomes (Taylor 2004a; Taylor 2004b; Smith 2003). The three prerequisites that Billingham set forth in his initial description of GVHD after *bone marrow transplant* hold true for the development of GVHD after solid organ transplant. It is estimated that a donor liver graft retains between 1×10^9 and 1×10^{10} passenger leukocytes within its parenchyma and portal tracts even after aggressive flushing with cold preservative solution[53]. This is equivalent or greater to the number of donor lymphocytes transplanted during an HSCT. In the first few weeks following OLT, these donor leukocytes can often be detected in the recipient blood.

As expected, compared to cell transplantation, GVHD after OLT has a much lower incidence, estimated at 1−1.5% (Akbulut 2012). Despite its low incidence, GVHD after OLT carries a dismal prognosis, with a mortality of 85−90% (Smith 2003). GVHD after OLT manifests anywhere between 1−8 weeks following transplantation and produces a similar clinical picture of GVHD after HSCT with symptoms including rash, fevers, diarrhea, and pancytopenia. Marked neutropenia and thrombocytopenia can often precipitate life-threatening infection or hemorrhage. One notable difference is the absence of hepatic and biliary dysfunction as GVHD is restricted to host derived tissues.

Several retrospective analyses have identified risk factors for the development of GVHD after OLT. The most important risk factor appears to be the sharing of HLA antigens between recipient and donor, specifically the use of an HLA homozygous donor. This results in complete one way HLA antigen match in the GVH direction, predisposing to GVHD. Kamei et al. analyzed 8 cases of fatal GVHD after OLT in Japan, and found that all eight cases had one-way HLA matching in the GVH direction in the three loci, HLA-A, HLA-B, and HLA-DR (Kamei 2006). The authors concluded that the risk of fatal GVHD after OLT was likely associated with the number of loci (with the one-way HLA matching) and those with mismatching at all 3 loci (HLA-A, -B, -DR) were at highest risk. In another retrospective series of 12 patients who developed GVHD after OLT by Smith et al. identified several risk factors including close matching at HLA antigens, recipient age >65, and age difference >40 years between donor and recipient (Smith 2003).

Due to the rare incidence of GVHD after OLT and its generally vague presenting symptoms of fever, rash, and diarrhea, the diagnosis of GVHD is not always made immediately. Often times, drug reactions and infectious processes, such as cytomegalovirus (CMV) are investigated first as these are much more common. The strongest supportive evidence for a diagnosis of GVHD, short of a biopsy, is a large number of circulating donor derived T cells in the peripheral blood, referred to as chimerism. These donor cells may be identified by flow cytometry, serologic typing, or PCR-based analysis. In the case of sex

differences between donor and recipient, fluorescence in situ hybridization (FISH) analysis can distinguish donor and recipient lymphocytes (Kanehira 2009). It is important to remember that the majority of liver transplant recipients will have detectable donor-derived lymphocytes in the peripheral blood for the first two weeks, but usually taper off by that time (Schlitt 1993). Therefore, the presence of large numbers of donor-derived lymphocytes several weeks after transplant in the setting of fever, rash, diarrhea, etc. should prompt immediate investigation.

Due to the rare incidence of GVHD after OLT and variable patient scenarios, a standardized and proven treatment modality is lacking. Instead, the literature contains various case reports reporting on different treatment strategies, often in a small cohort of patients. Nevertheless, the majority of these reports revolve around several different therapeutic approaches including the use of corticosteroids, increasing/reducing the dose of immunosuppression, and the use of antibody preparations such as antithymocyte globulin (ATG) or OKT3 to eliminate donor lymphocytes. Each has had variable success, and as such, not one agreed regimen yet exists.

The use of corticosteroids for the treatment of GVHD is based on the HSCT experience, in which steroids are the mainstay of treatment and have largely been successful. Although the exact mechanism by which corticosteroids dampen the GVH reaction is not completely understood, it is thought to be a combination of their lymphocytic and anti-inflammatory properties. The use of corticosteroids appears to be the first line approach by many clinicians based on a review of the literature. In the most comprehensive literature review to date, Akbulut et al. reviewed 87 cases of GVHD after OLT (Akbulut 2012). They reported the use of corticosteroids in 61 of 87. Of those 61 patients, 43 died. In the majority of patients who had a suboptimal response to corticosteroids, a variety of other agents were added to attempt to control GVHD. Of these agents, ATG and basiliximab were the most commonly used adjuncts. Regardless, mortality rates did not significantly differ based on the treatment regimen used and remained high.

Another approach is to reduce the level of immunosuppression, thereby allowing the host immune system to reconstitute and mount an immune response to eliminate the donor lymphocytes mediating the GVHD response. The theoretical downside to this approach is the risk of liver rejection in the absence of host immunosuppression. A prospective series of three patients by Chinnakolta et al. suggested that later onset of GVHD (>8 weeks) and lower levels of donor chimerism (<20%) may be predictive factors of favorable GVHD response to withdrawal of immunosuppression (Chinnakotla 2007). In that report, two patients with late onset GVHD (10 weeks, 18 weeks) and low levels of peripheral blood donor chimerism (7%, 11%) underwent withdrawal of immunosuppression and experienced reduction of donor chimerism levels and rapid resolution of symptoms. Both patients did experience mild cases of acute cellular rejection in response to immunosuppression withdrawal, but these were successfully treated with a short course of steroids. A third patient who developed symptoms of GVHD at 2 weeks and had 26.5% donor chimerism in the peripheral blood did not immediately respond to withdrawal of immunosuppression and had worsening of clinical symptoms, eventually dying of uncontrolled sepsis on day 63.

2. Intestine

2.1. Experimental

The first published report of intestinal transplantation came in 1959 by Richard Lillehei, who reported an experimental model for isolated intestinal transplantation in canines (Lillehei 1959). With the introduction of cyclosporine and later tacrolimus, intestinal transplantation has now become a viable clinical option for patients with short bowel syndrome (SBS) who are total parenteral nutrition dependent. Early studies by Lillehei demonstrated that some dogs who died early after intestinal transplantation had relatively normal graft histology, but did have enlarged mesenteric lymph nodes, suggesting that GVHD could develop after intestinal transplantation (Lillehei 1963). Later, a heterotopic small bowel transplant model was developed in rats by Monchik at el, in which GVHD reproducibly led to recipient death within 12–20 days (Monchik 1971). That model was used as a foundation for further studies which showed that immunocompetent T cells in the intestinal grafts were necessary for the induction of GVHD (Kirkman 1984). Donor T cells adoptively transferred from recipient spleens of intestinal transplants were able to induce a graft vs. host reaction in animals syngeneic to the recipient (Pomposelli 1985). Deltz et al. also showed that the extent of GVHD correlated closely with the amount of lymphoid tissue contained within the donor intestinal graft (Deltz 1981). Interestingly Shaffer et al. attempted to abrogate the development of GVHD in this model and were able to demonstrate the effectiveness of pretreatment of donor rats with antilymphocyte serum (ALS) prior to small bowl transplantation (SBT) (Shaffer 1988). ALS prior to SBT prevented GVHD in recipient rats without adversely affecting graft function in both heterotopic and orthotopic allograft models.

There are few large animal models of SBT, likely due to the cost and technical difficulty of the operation. Hale et al. developed a model of heterotopic small bowel allotransplantation in non-human primates (rhesus macaque and baboons) that led to long-term graft survival using an immunosuppressive regimen of Cyclosporine 40 mg/kg/day, Solu-Medrol 2 mg/kg/day, and Azathioprine 5 mg/kg/day (Hale 1991). Graft survival using this immunosuppressive regimen was 75.3 days, and three long-term survivors were euthanized for presumed sepsis with viable grafts. Importantly, there was no incidence of GVHD.

Miura et al. compared the efficacy of heterotopic vs. orthotopic small bowel transplantation in MHC inbred miniature swine and found that orthotopic SBT was superior (Miura 2016). All heterotopic grafts underwent ischemic changes soon after transplantation, presumably due to a compartment-syndrome type process in the limited abdominal space. However, when the native small bowel was removed and orthotopic small bowel allografts were transplanted into swine, all grafts were viable on autopsy and showed no signs of ischemia. Furthermore, compared to recipients of orthotopic small bowel allografts, those swine receiving heterotopic allografts had higher elevation of serum inflammatory cytokines and had a significantly faster progression to lethal metabolic acidosis. In both heterotopic and orthotopic SBT, there was no incidence of GVHD.

2.2. Clinical

Clinically, GVHD following small bowel transplant (SBT) is more common than after other solid organ transplants due to the significant amount of lymphoid tissue contained within the small bowel, particularly the ileum. Several case series reporting on GVHD after

SBT have described the incidence between 5−10% (Andres 2010; Mazariegos 2004; Wu 2011). However, because SBT is a much more recent endeavor compared to liver transplantation, there is less published literature regarding GVHD after SBT. Therefore, we will focus on three large retrospective analyses describing the incidence of GVHD after intestinal transplantation (ITx).

In 2004, Mazariegos et al. reviewed 250 adult and pediatric patients receiving ITx between 1990 and 2003 at a single transplant center (Mazariegos 2004). There was a mix of isolated small bowel transplants (44.8%), combined liver and small bowel transplants (36.8%), multivisceral transplants (12.8%), and modified multivisceral transplants without liver (5.6%). Immunosuppression regimens were also quite variable and evolved overtime from a baseline tacrolimus and steroid therapy to include cyclophosphamide, daclizumab, or antibody preconditioning with either thymoglobulin or Campath.

Of the 250 patients included in the study, GVHD was clinically suspected in 23 (9.2%) (6 adults, 17 children) patients based on clinical presentation including skin rash, diarrhea, lymphadenopathy, liver dysfunction, or oral mucosal ulceration. The median onset of GVHD was 1.2 months, which is consistent with acute GVHD. Risk factors for the development of GVHD included multivisceral transplantation and crossmatch negative patients. Multivisceral transplant recipients were twice as likely to develop GVHD as those receiving isolated small bowel transplants, most likely related to the increased lymphoid tissues in multivisceral grafts. Crossmatch negative patients were also more likely to develop GVHD as would be hypothesized, as recipient neutralizing antibodies would have a deleterious effect on donor graft T cells.

Of the 14 histopathological confirmed cases of GVHD, seven patients had increased donor-cell chimerism supportive of the GVHD diagnosis. Donor cell chimerism in those 7 patients was a median of 7.9%, and ranged from 0−35.9%. The majority of confirmed cases of GVHD were mild (Grade I-II) and confined to the skin, although several included the GI tract. There was only 1 case of chronic GVHD. Fortunately, of the 23 cases of suspected GVHD, there were only 2 deaths and neither directly attributed to GVHD. GVHD was resolved in the other 21 patients. 4 patients resolved spontaneously without intervention while the others resolved after either steroid boluses or a methylprednisolone taper.

In 2010, Andres et al. reviewed 46 pediatric patients who underwent SBT between 1999 and 2009 (Andres 2010). Of the 46 patients, 5 (10.8%) developed GVHD as determined by clinical diagnosis. Similarly to the previous study, those patients receiving multivisceral transplants were more likely to develop GVHD as two of the five patients received combined liver-intestinal transplants and three patients underwent multivisceral transplants. There was no GVHD observed after isolated SBT. The median time to GVHD was 47 days (16−333 days). All five GVHD patients had skin manifestation, two had concomitant GI symptoms and three interestingly had respiratory symptoms. Histopathological diagnosis of GVHD was made in four of the five patients, and donor chimerism levels were supportive of the diagnosis in two patients. In contrast to the study by Mazariegos et al, the majority of GVHD observed in this study was severe (Grade III-IV). All five patients were initially treated with high dose steroids (HDS), and four of the five patients had a partial response to therapy defined as a decrease in stage of GVHD. Of the five patients who developed GVHD in this study, three died due to complications of GVHD within four months of diagnosis, a stark contrast to previous studies.

In 2011, Wu et al. reviewed 241 adult and pediatric patients who underwent intestinal transplantation during a 13 year time span between 1994 and 2007 (Wu 2011). The incidence of GVHD was 9.1% (22/241) as determined by clinical diagnosis and confirmed by histopathological evidence. Of the 10 patients with available flow cytometric analysis, four had confirmed macrochimerism (>1%) and the remaining six had detectable microchimerism (<1%). The median onset was twice that of the previous study by Mazariegos et al. (2.5 months vs. 1.2 months). Risk factors associated with the development of GVHD included age, diagnosis, type of graft, and the presence of splenectomy. Children less than 5 years of age were more likely to develop GVHD than were adults (13.2% vs. 4.7%). Interestingly, patients requiring transplant for intestinal atresia were more likely to develop GVHD than those with other diagnoses including gastroschisis, necrotizing enterocolitis, or Hirschsprung's disease (22.2% vs. 2.6%). Consistent with previous studies, recipients of multivisceral transplants were at higher risk of GVHD than those recipients of isolated SBT (12.4% vs. 4.6%). Finally, the addition of recipient splenectomy was also associated with a higher rate of GVHD (13.6 vs. 6.8%). Crossmatch status was not associated with GVHD in this study. Of the 22 cases of GVHD, all involved the skin and all but three were considered mild (grade I-II). Despite the majority of GVHD cases being grade I-II, 17/22 patients died in follow-up, with infection being the most common cause of mortality. The authors concluded that treatment with corticosteroids and increased immunosuppression was inadequate to control GVHD in this series.

Although younger age appears to be associated with a higher chance of developing GVHD and a higher GVHD-associated mortality, it is unclear in these studies whether age is an independent risk factor or whether this association is affected by other variables. In Wu et al. children < 5 were more likely to receive a multivisceral transplant which may have been a factor. Alternatively, one hypothesis to the association between younger age and GVHD could be the underdeveloped immune system of children and their inability to mount an immune response. Similarly, the inability to mount an immune response could be the mechanism by which recipients of recipient splenectomy seem to be more prone to GVHD as in the study by Wu et al.

The most glaring difference between the results of Mazariegos et al. and Wu et al. were the responses to treatment after development of GVHD as well as the GVHD-associated mortality. The vast majority of patients reviewed by Mazariegos et al. that were suspected of having GVHD (n=23), either resolved spontaneously or responded promptly to corticosteroids and adjustment of tacrolimus doses. On the other hand, patients treated with corticosteroids and increased immunosuppression in the series by Wu et al. did not respond to conventional therapy and 77% of patients died of GVHD-related complications according to the authors.

SPLEEN

Small and large animal models of spleen transplantation are uncommon due to the fact that clinical splenic transplantation is rare. The spleen is not a vital organ for survival, and thus justifying long term immunosuppression for splenic transplantation is difficult. However, there have been several studies in large animals assessing the use of splenic transplantation to

induce mixed hematopoietic chimerism and immunological tolerance. The rationale is that the spleen is a relatively rich source of hematopoietic progenitor cells. Dor et al. showed that spleen allografts can be accepted across full MHC mismatch barriers in miniature swine (Dor 2005). The acceptance of splenic allografts and continued viability was associated with multilineage chimerism in thymus, bone marrow and blood. Importantly, this multilineage chimerism was associated with donor-specific hyporesponsiveness and did not cause GVHD. Interestingly, two swine that were tolerant of splenic grafts were then transplanted with donor-MHC matched kidney allografts without immunosuppression which were both accepted. The authors concluded that splenic transplantation in miniature swine could result in hematopoietic cell engraftment in the absence of GVHD.

HOST-VERSUS-GRAFT (HVG) RESPONSES

Very few studies have investigated the causality of host-versus-graft responses after BMT. In general, graft loss has always been considered an unwelcomed outcome of BMT, especially when the anti-leukemia graft-versus-host responses sought were not harnessed. Host-versus-graft responses are known as rejection (in solid organ transplantation) or marrow failure/loss (in BMT patients). Little is known about the immunological processes involved in loss of donor bone marrow. The use of reduced intensity conditioning (RIC) regimens in BMT has facilitated the transplantation of patients who previously would have not been considered suitable candidates due to the toxicity of the myeloablative preparatory regimens (Li 2012). Although the risk of complications due to conditioning is decreased with non-myeloablative conditioning, the risk of graft loss is increased. Graft loss can be caused by several factors; i) rejection, ii) the inability of the stem cells (SCs) to engraft due to the lack of "space" (Salomon 1990) or iii) poor donor graft quality (Zeng 1997). These causes may lead to different immunological responses. Rejection of the donor graft implies an active immunological process whereby donor cells sensitize the host (through cellular and/or humoral mechanisms). Conversely, if the loss of donor cells is not immunological, but due to a deficiency in stem cell "fitness" or stem cell quality, there may not be immunological consequences (e.g., sensitization). Some factors related to graft loss include donor/recipient MHC mis/match, the degree of host myeloablation, the level of immunosuppression post-HCT, the degree of host immune competence related to immediate preparatory regimens, the level of T cell depletion of the donor graft and pre-sensitization to donor antigens as is seen in aplastic anemia patients. Clinical studies assessing immune responses of patients following graft loss and after re-exposure of donor antigen have not been extensively investigated. A recent study investigated the immunological responses after graft loss in the MGH MHC defined miniature swine (Duran-Struuck 2012). In this study, recipients underwent reduced intensity conditioning and received cytokine mobilized peripheral blood mononuclear cells (PBMCs) which were haplo-mismatched at both MHC I and II. The RIC regimen consisted of CD3-immunotoxin, 100cGy of TBI and 45 days of cyclosporine A. Cellular and humoral anti-donor responses were studied before and after re-exposure to donor antigen and anti-donor (HVG) immune responses among transplanted and naïve animals exposed to donor antigen were compared. The data this study presented highlighted two important findings. First, peri-transplant conditioning could modify how the immune system responded to a graft

and that not all graft rejection was the same. Second, absence of *in vitro* evidence of sensitization by the means utilized (MLRs and antibody binding) did not correlate with absence of a sensitized response leading to the loss of the donor graft. Animals that lost their HCT graft following conditioning regained normal cellular proliferative and cytotoxic allo-responses to donors. These responses were similar in quality to a naïve animal and without any detectable anti-donor antibody responses. Interestingly and to the authors' surprise, whereas animals that lost chimerism might have been expected to have immune responses to donor antigen comparable to naïve animals, this was incorrect. Only after a second donor antigen exposure (without immunosuppression and in the form of a donor leukocyte infusion) in animals which lost chimerism, eventually induced a sensitized cellular immune response that differed from naïve animals. The studies suggested that the initial exposure to donor cells induced an immune response that may have contributed to graft loss but were not detectable with the immunological tools commonly used.

Immunologically, HCT recipients which presumably rejected their grafts, had a much higher host $CD8^+/CD4^+$ Tc ratio when measured by CFSE assays. Sensitized animals at a cellular level had very low CD4+ T cell proliferation. It was postulated that lack of antibody production in animals that rejected their graft was that $CD8^+$ T cell responses may have overwhelmed the ability of $CD4^+$T cells to provide sufficient B cell help (also known as immune deviation). Similar to the findings reported in the swine studies, immunological responses with a dominant $CD8^+$ T cell population have been observed in patients that rejected their grafts (Kraus 2003).

In conclusion, and of clinical importance, a remarkable finding was the observation that allo-antibodies were never induced after graft loss or after leukocyte infusions. This does have important clinical implications since allo-antibodies are generally tested in the clinic to assess for sensitization (Gandini 2000). Hence, the data supporting allo-antibodies following graft loss may not be a reliable indicator for lack of sensitization and re-transplantation decisions based on their presence may be misleading. More studies are needed to provide further insight into the immunological responses after graft loss which may serve as a guide for modifications of preparatory regimens when subsequent re-transplantation of immune-sensitized hosts is considered.

CONCLUSION

We hope that this chapter provides insight of the strengths and weaknesses of animal models to study HVG and GVH responses and disease. There is no one best animal model. They all have their advantages and disadvantages. Clearly, large animal models (dog, pig, NHPs) approximate the clinical scenario with more fidelity than rodents do for the reasons discussed. The most important factor for the researcher will remain to identify the pre-clinical model that can best answer the experimental question. Often, more than one model may be necessary prior to translation to the bedside and begin clinical trials.

REFERENCES

Akbulut S, Yilmaz M, Yilmaz S. Graft-versus-host disease after liver transplantation: a comprehensive literature review. *World Journal of Gastroenterology* 2012; 18(37):5240–5248.

Andres AM, Santamaria ML, Ramos E, Sarriá J, Molina M, Hernandez F, Encinas JL, Larrauri J, Prieto G, Tovar JA. Graft-vs-host disease after small bowel transplantation in children. *J. Pediatr. Surg*. 2010; 45(2):330–336; discussion 336.

Atkinson K, Shulman HM, Deeg HJ, Weiden PL, Graham TC, Thomas ED, Storb R. Acute and chronic graft-versus-host disease in dogs given hemopoietic grafts from DLA-nonidentical littermates. Two distinct syndromes. *The American Journal of Pathology* 1982; 108(2):196–205.

Billingham RE, Brent L, Medawar PB. Actively acquired tolerance to foreign cells. *Nature* 1953; 172:603–606.

Burdick JF, Vogelsang GB, Smith WJ, Farmer ER, Bias WB, Kaufmann SH, Horn J, Colombani PM, Pitt HA, Perler BA, Merritt WT, Williams GM, Boitnott JK, Herlong HF. Severe graft-versus-host disease in a liver-transplant recipient. *The New England Journal of Medicine* 1988; 318(11):689–691.

Chinnakotla S, Smith DM, Domiati-Saad R, Agura ED, Watkins DL, Netto G, Uemura T, Sanchez EQ, Levy MF, Klintmalm GB. Acute graft-versus-host disease after liver transplantation: role of withdrawal of immunosuppression in therapeutic management. Liver transplantation: *official publication of the American Association for the Study of Liver Diseases and the International Liver Transplantation Society*. 2007; 13(1):157–161.

Cina RA, Wikiel KJ, Lee PW, Cameron AM, Hettiarachy S, Rowland H, Goodrich J, Colby C, Spitzer TR, Neville DM Jr, Huang CA. Stable multilineage chimerism without graft versus host disease following nonmyeloablative haploidentical hematopoietic cell transplantation. *Transplantation* 2006; 81(12):1677–1685.

Copelan EA. Hematopoietic stem-cell transplantation. *N Engl J Med*. 2006; 354(17):1813–1826.

Deeg HJ, Storb R, Appelbaum FR, Kennedy MS, Graham TC, Thomas ED. Combined immunosuppression with cyclosporine and methotrexate in dogs given bone marrow grafts from DLA-haploidentical littermates. *Transplantation* 1984; 37(1):62–65.

Deltz E, Muller-Hermelink HK, Ulrichs K, Thiede A, Muller-Ruchholtz W. Development of graft-versus-host reaction in various target organs after small intestine transplantation. *Transplantation Proceedings* 1981; 13(1 Pt 2):1215–1216.

Dor FJ, Tseng YL, Kuwaki K, Gollackner B, Ramirez ML, Prabharasuth DD, Cina RA, Knosalla C, Nuhn MG, Houser SL, Huang CA, Ko DS, Cooper DK. Immunological unresponsiveness in chimeric miniature swine following MHC-mismatched spleen transplantation. *Transplantation* 2005; 80(12):1791–1804.

Duran-Struuck R, Hartigan A, Clouthier SG, Dyson MC, Lowler K, Gatza E, Tawara I, Toubai T, Weisiger E, Hugunin K, Reddy P, Wilkinson JE. Differential susceptibility of C57BL/6NCr and B6.Cg-Ptprca mice to commensal bacteria after whole body irradiation in translational bone marrow transplant studies. *J. Transl. Med*. 2008b; 6:10.

Duran-Struuck R, Huang CA, Orf K, Bronson RT, Sachs DH, Spitzer TR. Miniature Swine as a Clinically Relevant Model of Graft-Versus-Host Disease. *Comp. Med*. 2015; 65(5):429–443.

Duran-Struuck R, Matar A, Crepeau R, Gusha A, Schenk M, Hanekamp I, Pathiraja V, Spitzer TR, Sachs DH, Huang CA. Lack of antidonor alloantibody does not indicate lack of immune sensitization: studies of graft loss in a haploidentical hematopoietic cell transplantation Swine model. *Biol. Blood Marrow Transplant* 2012; 18(11):1629–1637.

Duran-Struuck R, Matar AJ, Crepeau RL, Teague AG, Horner BM, Pathiraja V, Spitzer TR, Fishman JA, Bronson RT, Sachs DH, Huang CA. Donor Lymphocyte Infusion-Mediated Graft-versus-Host Responses in a Preclinical Swine Model of Haploidentical Hematopoietic Cell Transplantation. *Biol. Blood Marrow Transplant*. 2016; 22(11): 1953–1960.

Duran-Struuck R, Reddy P. Biological advances in acute graft-versus-host disease after allogeneic hematopoietic stem cell transplantation. *Transplantation* 2008a; 85(3):303–308.

Duran-Struuck R, Sondermeijer HP, Buhler L, Alonso-Guallart P, Zitsman J, Kato Y, Wu A, McMurchy AN, Woodland D, Griesemer A, Martinez M, Boskovic S, Kawai T, Cosimi AB, Wuu CS, Slate A, Mapara MY, Baker S, Tokarz R, D'Agati V, Hammer S, Pereira M, Lipkin WI, Wekerle T, Levings MK, Sykes M. Effect of Ex Vivo-Expanded Recipient Regulatory T Cells on Hematopoietic Chimerism and Kidney Allograft Tolerance Across MHC Barriers in Cynomolgus Macaques. *Transplantation* 2017; 101(2):274–283.

Ferrara JL, Levine JE, Reddy P, Holler E. Graft-versus-host disease. *Lancet* 2009; 373(9674):1550–1561.

Ferrara JL, Levy R, Chao NJ. Pathophysiologic mechanisms of acute graft-vs.-host disease. Biol *Blood Marrow Transplant*. 1999; 5(6):347–356.

Gandini G, Franchini M, de Gironcoli M, Vassanelli A, Benedetti F, Turrini A, Benini F, Aprili G. Detection of an anti-RhD antibody 2 years after sensitization in a patient who had undergone an allogeneic BMT. *Bone Marrow Transplant.* 2000; 25(4):457–459.

Hale DA, Waldorf KA, Kleinschmidt J, Pearl RH, Seyfer AE. Small intestinal transplantation in nonhuman primates. *Journal of Pediatric Surgery*. 1991; 26(8):914–920.

Hettiaratchy S, Melendy E, Randolph MA, Coburn RC, Neville DM Jr, Sachs DH, Huang CA, Lee WP. Tolerance to composite tissue allografts across a major histocompatibility barrier in miniature swine. *Transplantation* 2004; 77(4):514–521.

Jacobson LO, Simmons EL, Marks EK, Eldredge JH. Recovery from radiation injury. *Science*. 1951; 113 (2940):510–511.

Kaliyaperumal S, Watkins B, Sharma P, Furlan S, Ramakrishnan S, Giver C, Garcia A, Courtney C, Knight H, Strobert E, Elder E, Crenshaw T, Blazar BR, Waller EK, Westmoreland S, Kean LS. CD8-predominant T-cell CNS infiltration accompanies GVHD in primates and is improved with immunoprophylaxis. *Blood* 2014; 123(12):1967–1969.

Kamei H, Oike F, Fujimoto Y, Yamamoto H, Tanaka K, Kiuchi T. Fatal graft-versus-host disease after living donor liver transplantation: differential impact of donor-dominant one-way HLA matching. Liver transplantation: *official publication of the American Association for the Study of Liver Diseases and the International Liver Transplantation Society*. 2006; 12(1):140–145.

Kanehira K, Riegert-Johnson DL, Chen D, Gibson LE, Grinnell SD, Velgaleti GV. FISH diagnosis of acute graft-versus-host disease following living-related liver transplant. *The Journal of Molecular Diagnostics*: *JMD* 2009; 11(4):355–358.

Kirkman RL, Lear PA, Madara JL, Tilney NL. Small intestine transplantation in the rat--immunology and function. *Surgery* 1984; 96(2):280–287.

Kozlowski T, Sablinski T, Basker M, Kitamura H, Spitzer TR, Fishman J, Sykes M, Cooper DK, Sachs DH. Decreased graft-versus-host disease after haplotype mismatched bone marrow allografts in miniature swine following interleukin-2 treatment. *Bone Marrow Transplantation* 2000; 25(1):47–52.

Kraus AB, Shaffer J, Toh HC, Preffer F, Dombkowski D, Saidman S, Colby C, George R, McAfee S, Sackstein R, Dey B, Spitzer TR, Sykes M. Early host CD8 T-cell recovery and sensitized anti-donor interleukin-2-producing and cytotoxic T-cell responses associated with marrow graft rejection following nonmyeloablative allogeneic bone marrow transplantation. *Exp*. *Hematol.* 2003; 31(7):609–621.

Kuhr CS, Lupu M, Little MT, Zellmer E, Sale GE, Storb R. RDP58 does not prevent graft-versus-host disease after dog leukocyte antigen-nonidentical canine hematopoietic cell transplantation. *Transplantation* 2006; 81(10):1460–1462.

Ladiges WC, Storb R, Thomas ED. Canine models of bone marrow transplantation. *Lab. Anim*. *Sci*. 1990; 40:11–15.

Lee RS, Kuhr CS, Sale GE, Zellmer E, Hogan WJ, Storb R, Little MT. FTY720 does not abrogate acute graft-versus-host disease in the dog leukocyte antigen-nonidentical unrelated canine model. *Transplantation* 2003; 76(8):1155–1158.

Li HW, Sykes M. Emerging concepts in haematopoietic cell transplantation. *Nat. Rev. Immunol*. 2012; 12(6):403–416.

Lillehei RC, Goldberg S, Goott B, Longerbeam JK. The present status of intestinal transplantation. *American Journal of Surgery* 1963; 105:58–72.

Lillehei RC, Goott B, Miller FA. The physiological response of the small bowel of the dog to ischemia including prolonged *in vitro* preservation of the bowel with successful replacement and survival. *Annals of Surgery* 1959; 150:543–560.

Martin PJ, Carpenter PA, Sanders JE, Flowers ME. Diagnosis and clinical management of chronic graft-versus-host disease. *Int. J. Hematol*. 2004; 79(3):221–228.

Mazariegos GV, Abu-Elmagd K, Jaffe R, Bond G, Sindhi R, Martin L, Macedo C, Peters J, Girnita A, Reyes J. Graft versus host disease in intestinal transplantation. *Am. J. Transplant*. 2004; 4(9):1459–1465.

Mielcarek M, Georges GE, Storb R. Denileukin diftitox as prophylaxis against graft-versus-host disease in the canine hematopoietic cell transplantation model. *Biol. Blood Marrow Transplant*. 2006; 12(9):899–904.

Miller WP, Srinivasan S, Panoskaltsis-Mortari A, Singh K, Sen S, Hamby K, Deane T, Stempora L, Beus J, Turner A, Wheeler C, Anderson DC, Sharma P, Garcia A, Strobert E, Elder E, Crocker I, Crenshaw T, Penedo MC, Ward T, Song M, Horan J, Larsen CP, Blazar BR, Kean LS. GVHD after haploidentical transplantation: a novel, MHC-defined rhesus macaque model identifies CD28- CD8+ T cells as a reservoir of breakthrough T-cell proliferation during costimulation blockade and sirolimus-based immunosuppression. *Blood* 2010; 116(24):5403–5418.

Miura K, Sahara H, Waki S, Kawai A, Sekijima M, Kobayashi T, Zhang Z, Wakai T, Shimizu A, Yamada K. Development of the Intestinal Transplantation Model With Major

Histocompatibility Complex Inbred CLAWN Miniature Swine. *Transplant. Proc*. 2016; 48(4):1315–1319.

Monchik GJ, Russell PS. Transplantation of small bowel in the rat: technical and immunological considerations. *Surgery* 1971; 70(5):693–702.

Nguyen VH, Zeiser R, Negrin RS. Role of naturally arising regulatory T cells in hematopoietic cell transplantation. *Biol. Blood Marrow Transplant*. 2006; 12(10):995–1009.

O'Connor SL, Blasky AJ, Pendley CJ, Becker EA, Wiseman RW, Karl JA, Hughes AL, O'Connor DH. Comprehensive characterization of MHC class II haplotypes in Mauritian cynomolgus macaques. *Immunogenetics* 2007; 59(6):449–462.

Owen RD. Immunogenetic consequences of vascular anastomoses between bovine twins. *Science* 1945; 102:400–401.

Panjwani MK, Smith JB, Schutsky K, Gnanandarajah J, O'Connor CM, Powell DJ Jr, Mason NJ. Feasibility and Safety of RNA-transfected CD20-specific Chimeric Antigen Receptor T Cells in Dogs with Spontaneous B Cell Lymphoma. *Mol. Ther*. 2016; 24(9):1602–1614.

Pathiraja V, Matar AJ, Gusha A, Huang CA, Duran-Struuck R. Leukapheresis protocol for nonhuman primates weighing less than 10 kg. *J Am Assoc Lab Anim Sci*. 2013 Jan; 52(1):70-7.

Pennington LR, Sakamoto K, Popitz-Bergez F, Pescovitz MD, McDonough MA, MacVittie TJ, Gress RE, Sachs DH. Bone marrow transplantation in miniature swine. I. Development of the model. *Transplantation* 1988; 45:21–26.

PHS. Public Health Service. Draft Public Health Service Guideline on Infectious Disease Issues in Xenotransplantation, *Fed. Regist*. 1996; 61(185): 49920–49932.

Pomposelli F, Maki T, Kiyoizumi T, Gaber L, Balogh K, Monaco AP. Induction of graft-versus-host disease by small intestinal allotransplantation in rats. *Transplantation* 1985; 40(4):343–347.

Popitz-Bergez FA, Sakamoto K, Pennington LR, Pescovitz MD, McDonough MA, MacVittie TJ, Gress RE, Sachs DH. Bone marrow transplantation in miniature swine. II. Effect of selective genetic differences on marrow engraftment and recipient survival. *Transplantation* 1988; 45:27–31.

Reddy P, Negrin R, Hill GR. Mouse models of bone marrow transplantation. *Biol. Blood Marrow Transplant* 2008; 14(1 Suppl 1):129–135.

Rowe V, Banovic T, Macdonald KP, Kuns R, Don AL, Morris ES, Burman AC, Bofinger HM, Clouston AD, Hill GR. Host B cells produce IL-10 following TBI and attenuate acute GVHD after allogeneic bone marrow transplantation. *Blood* 2006; 108(7):2485–2492.

Sakamoto K, Sachs DH, Shimada S, Popitz-Bergez FA, Pennington LR, Pescovitz MD, McDonough MA, MacVittie TJ, Katz SI, Gress RE. Bone marrow transplantation in miniature swine. III Graft-versus-host disease and the effect of T cell depletion of marrow. *Transplantation* 1988; 45:869–875.

Salomon O, Lapidot T, Terenzi A, Lubin I, Rabi I, Reisner Y. Induction of donor-type chimerism in murine recipients of bone marrow allografts by different radiation regimens currently used in treatment of leukemia patients. *Blood* 1990; 76(9):1872–1878.

Schlitt HJ, Kanehiro H, Raddatz G, Steinhoff G, Richter N, Nashan B, Ringe B, Wonigeit K, Pichlmayr R. Persistence of donor lymphocytes in liver allograft recipients. *Transplantation* 1993; 56(4):1001–1007.

Sentman CL, Kumar V, Koo G, Bennett M. Effector cell expression of NK1.1, a murine natural killer cell-specific molecule, and ability of mice to reject bone marrow allografts. *J. Immunol*. 1989; 142:1847–1853.

Shaffer D, Maki T, DeMichele SJ, Karlstad MD, Bistrian BR, Balogh K, Monaco AP. Studies in small bowel transplantation. Prevention of graft-versus-host disease with preservation of allograft function by donor pretreatment with antilymphocyte serum. *Transplantation* 1988; 45(2):262–269.

Shlomchik WD. Graft-versus-host disease. *Nat. Rev. Immunol*. 2007; 7(5):340–352.

Smith DM, Agura E, Netto G, Collins R, Levy M, Goldstein R, Christensen L, Baker J, Altrabulsi B, Osowski L, McCormack J, Fichtel L, Dawson DB, Domiati-Saad R, Stone M, Klintmalm G. Liver transplant-associated graft-versus-host disease. *Transplantation* 2003; 75(1):118–126.

Snell GD. The major histocompatibility complex: its evolution and involvement in cellular immunity. *Harvey Lect*. 1980; 74:49–80.

Starzl TE, Iwatsuki S, Shaw BW, Jr., Greene DA, Van Thiel DH, Nalesnik MA, Nusbacher J, Diliz-Perez H, Hakala TR. Pancreaticoduodenal transplantation in humans. *Surg Gynecol Obstet*. 1984; 159(3):265–272.

Taylor AL, Gibbs P, Bradley JA. Acute graft versus host disease following liver transplantation: the enemy within. American journal of transplantation: *official journal of the American Society of Transplantation and the American Society of Transplant Surgeons*. 2004a; 4(4):466–474.

Taylor AL, Gibbs P, Sudhindran S, Key T, Goodman RS, Morgan CH, Watson CJ, Delriviere L, Alexander GJ, Jamieson NV, Bradley JA, Taylor CJ. Monitoring systemic donor lymphocyte macrochimerism to aid the diagnosis of graft-versus-host disease after liver transplantation. *Transplantation* 2004b; 77(3):441–446.

Teshima T, Ordemann R, Reddy P, Gagin S, Liu C, Cooke KR, Ferrara JL. Acute graft-versus-host disease does not require alloantigen expression on host epithelium. *Nat. Med*. 2002; 8(6):575–581.

Thomas ED, Storb R, Clift RA, Fefer A, Johnson FL, Neiman PE, Lerner KG, Glucksberg H, Buckner CD. Bone marrow transplantation. *N. Engl. J. Med*. 1975a; 292:832–843.

Thomas ED, Storb R, Clift RA, Fefer A, Johnson L, Neiman PE, Lerner KG, Glucksberg H, Buckner CD. Bone-marrow transplantation (second of two parts). *N. Engl. J. Med*. 1975b; 292(17):895–902.

Wu G, Selvaggi G, Nishida S, Moon J, Island E, Ruiz P, Tzakis AG. Graft-versus-host disease after intestinal and multivisceral transplantation. *Transplantation* 2011; 91(2):219–224.

Xia X, Chen W, Ma T, Xu G, Liu H, Liang C, Bai X, Zhang Y, He Y, Liang T. Mesenchymal stem cells administered after liver transplantation prevent acute graft-versus-host disease in rats. *Liver Transpl*. 2012; 18(6):696–706.

Xu G, Wang L, Chen W, Xue F, Bai X, Liang L, Shen X, Zhang M, Xia D, Liang T. Rapamycin and tacrolimus differentially modulate acute graft-versus-host disease in rats after liver transplantation. *Liver Transpl.* 2010; 16(3):357–363.

Xue F, Chen W, Wang XG, Liang L, Bai XL, Wang LY, Wang HP, Liang TB. Establishment of an acute graft-versus-host disease model following liver transplantation in donor-dominant one-way major histocompatibility complex matching rats. *Transplant. Proc*. 2009; 41(5):1914–1920.

Yu C, Seidel K, Fitzsimmons WE, Sale G, Storb R. Glucocorticoids fail to enhance the effect of FK506 and methotrexate in prevention of graft-versus-host disease after DLA-nonidentical, unrelated marrow transplantation. *Bone Marrow Transplantation* 1997; 20(2):137–141.

Yu C, Seidel K, Nash RA, Deeg HJ, Sandmaier BM, Barsoukov A, Santos E, Storb R. Synergism between mycophenolate mofetil and cyclosporine in preventing graft-versus-host disease among lethally irradiated dogs given DLA-nonidentical unrelated marrow grafts. *Blood* 1998; 91(7):2581–2587.

Yu E, Ueta H, Kimura H, Kitazawa Y, Sawanobori Y, Matsuno K. Graft-Versus-Host Disease Following Liver Transplantation: Development of a High-Incidence Rat Model and a Selective Prevention Method. *Am. J. Transplant*. 2017; 17(4):979–991.

Zeng D, Dejbakhsh-Jones S, Strober S. Granulocyte colony-stimulating factor reduces the capacity of blood mononuclear cells to induce graft-versus-host disease: impact on blood progenitor cell transplantation. *Blood* 1997; 90(1):453–463.

Zitsman JS, Alonso-Guallart P, Ovanez C, Kato Y, Rosen JF, Weiner JI, Duran-Struuck R. Distinctive Leukocyte Subpopulations According to Organ Type in Cynomolgus Macaques. *Comp. Med*. 2016; 66(4):308–323.

Zorn J, Herber M, Schwamberger S, Panzer W, Adler H, Kolb HJ. Tolerance in DLA-haploidentical canine littermates following CD6-depleted marrow transplantation and donor lymphocyte transfusion. *Exp. Hematol*. 2009; 37(8):998–1006.

In: Encyclopedia of Surgery (22 Volume Set)
Editors: Andreas Lehrer and Kristin Mueller
ISBN: 978-1-53618-329-0
© 2020 Nova Science Publishers, Inc.

Chapter 192

MICROFLUIDIC DEVICES AND MICRO-DISSECTED TISSUE TO PREDICT THERAPEUTIC RESPONSE IN PATIENTS WITH PROSTATE CANCER

***Robin Guay-Lord*[*], *Muhammad Abdul Lateef*[*], PhD, *Kayla Simeone*[*], *Benjamin Péant, PhD, *Jennifer Kendall-Dupont, Anne-Marie Mes-Masson, PhD, *Thomas Gervais, PhD and Fred Saad*[†], MD**

CRCHUM, Departments of Molecular Biology, Surgery and Medicine, Faculty of Medicine, University of Montreal, Montreal, Quebec, Canada

ABSTRACT

Given the genetic and epigenetic diversity of prostate tumors and their variable response to chemotherapy, therapeutic strategies against prostate cancer have experienced a framework shift from broad cytotoxic drugs to a more personalized level of medicine. This personalized approach not only results in superior medical care by improving effectiveness while diminishing toxicities, but it also directly impacts health economics and patient quality of life. In this scope, we present a novel model that allows empirical testing of therapeutic agents on *ex vivo* patient-derived tissues, cultured in a non-perfused microfluidic device. The proposed model relies on the micro-dissection of tumor biopsies and samples obtained through surgical resection of the prostate (radical prostatectomy or transurethral resection of the prostate) to produce micro-dissected tissue (MDT) samples, which are trapped in a microfluidic device and exposed to various combinations of drugs. Confocal microscopy and flow cytometry analysis are used to determine the viability of the drug-treated MDTs. These analytical methods are a promising way to determine therapeutic response or resistance and to help identify the optimal treatment plan for an individual patient in less than two weeks after tissue procurement. The presented model is simple to operate, cost effective, offers high-throughput potential through multiplexing,

[*] Each author contributed equally to this project.
[†] Corresponding Author's Email: fred.saad@umontreal.ca.

and is clinically relevant to predict *in vivo* therapeutic response, thus making it a new tool with the potential to significantly improve the current treatment of prostate cancer.

Keywords: microfluidics, micro-dissected tissue, prostate cancer, therapeutic response, lab-on-a-chip, organotypic tissue

ABBREVIATIONS

2D	two-dimensional
3D	three-dimensional
BPH	Benign Prostate Hyperplasia
CNC	Computer Numerical Control
CSRA	Chemosensitivity and Resistance Assay
CTO	Cell Tracker Orange CMTMR
ECM	Extracellular Matrix
FBS	Fetal Bovine Serum
$HBSS_{antibio}$	HBSS, 55 mg/L gentamicin and 0.6 mg/L amphotericin
$HBSS_{complete}$	HBSS, 10% FBS, 55 mg/L gentamicin and 0.6 mg/L amphotericin
HBSS	Hanks' Balanced Salt Solution
LOC	Lab-on-a-Chip
MDT	Micro-Dissected Tissue
MEMS	Microelectromechanical System
PBS	Phosphate-Buffered Saline
PDMS	Poly (dimethylsiloxane)
PDX	Patient-Derived Xenograft
PMMA	Poly (methylmethacrylate)
RPMI	Roswell Park Memorial Institute
SG	Sytox Green
SOP	Standard Operating Procedure
TURP	Transurethral Resection of the Prostate

INTRODUCTION

Despite the impressive stride forward in early diagnostics, prostate cancer remains the second leading cause of death by cancer in western countries. Given the genetic and epigenetic diversity of prostate tumors and their variable response to different agents, therapeutic treatment plan efficacy has become a challenge. Recently, therapeutic strategies against prostate cancer have experienced a framework shift from broad cytotoxic drugs to a more personalized level of medicine. This personalized approach not only results in superior medical care by enhancing effectiveness while minimizing drug-induced toxicities, but it also directly impacts health economics and potentially improve patient quality of life. To attain this goal, much effort has focused on predictive biomarkers that provide a statistical probability of response, however this approach has proven to be unpredictable and not always straightforward (Ginsburg 2001).

In this context, direct testing of therapeutic agents on the biopsied tumor mass, or on cell cultures derived from tumor tissues, has been proposed as a viable complementary method to predict patient response. So far, preclinical models used to address therapeutic efficacy and specificity have largely relied on monolayer (2D) cultures, either of cell lines or tumor explants. These often provide an imperfect measure of what is observed in xenografts or patients, largely because they do not take into account the tumor heterogeneity and the complexity of the tumor microenvironment (Justice 2009). Considering the limited amount of tissue available from biopsies and the long assay time to execute multiplexed drug resistance tests, the direct testing of treatment on biopsied tumor mass has not been feasible until recently.

In this chapter, we present a new model that relies on the application of microfluidic technologies coupled to micro-dissected tissue (MDT)-based sampling to assess the chemosensitivity profile of tumor tissues in a patient-specific manner. We first review the history and the advantages of microfluidics for drug screening applications in oncology. We then describe the design and fabrication of the microfluidic platform along with the methodology to produce the MDT samples and trap them into the microfluidic device for further culturing and maintenance. Finally, the MDTs can be treated with various therapeutic agents on-chip to allow confocal microscopy and flow cytometry analysis of MDT response to treatment.

EVOLUTIONARY HISTORY OF MICROFLUIDIC TECHNOLOGY

First introduced in 1990 in the seminal work of Manz et al., the concept of lab-on-a-chip (LOC) today has deeply influenced modern analytical chemistry and biology (Manz 1990). The idea behind LOC technologies is to miniaturize and integrate all the necessary steps for a particular assay in a low-cost and portable format, with fast analysis time and digital-like capabilities for efficient processing of biological samples. These LOC systems offer multiple benefits over their macroscale counterparts, including improved throughput and automation, which will be further detailed in this chapter. The history of LOCs is closely related to microfluidics where the science and technologies involve controlling small volumes of fluid at the sub-millimeter scale (Whitesides 2006). Some of the earliest applications integrating the concept of microfluidics and LOCs were used for analytical chemistry techniques: gas-phase chromatography (de Mello 2002; Terry 1979), high-pressure liquid chromatography (de Mello 2002; Manz 1990) and capillary electrophoresis (Kim 1996; Mathies 1992; Woolley 1994). Since then, a great number of biological applications ranging from genomics to cellular assays have been miniaturized and integrated into LOC devices. For instance, in fundamental research, LOC devices, which reproduce organ functionality, have been developed to study human physiology in an organ-specific context (Huh 2011). Often named "organs-on-chips," various new *in vitro* models have been reported to study organ-specific functions of brain (Park 2009), liver (Kane 2006; Lee 2007), kidney (Jang 2010), gut (Kimura 2008), breast (Song 2009), and bone (You 2008). In a clinical context, LOCs have been used to provide a high-throughput platform to manipulate and probe tissue samples for drug screening (Astolfi 2016; Pak 2015).

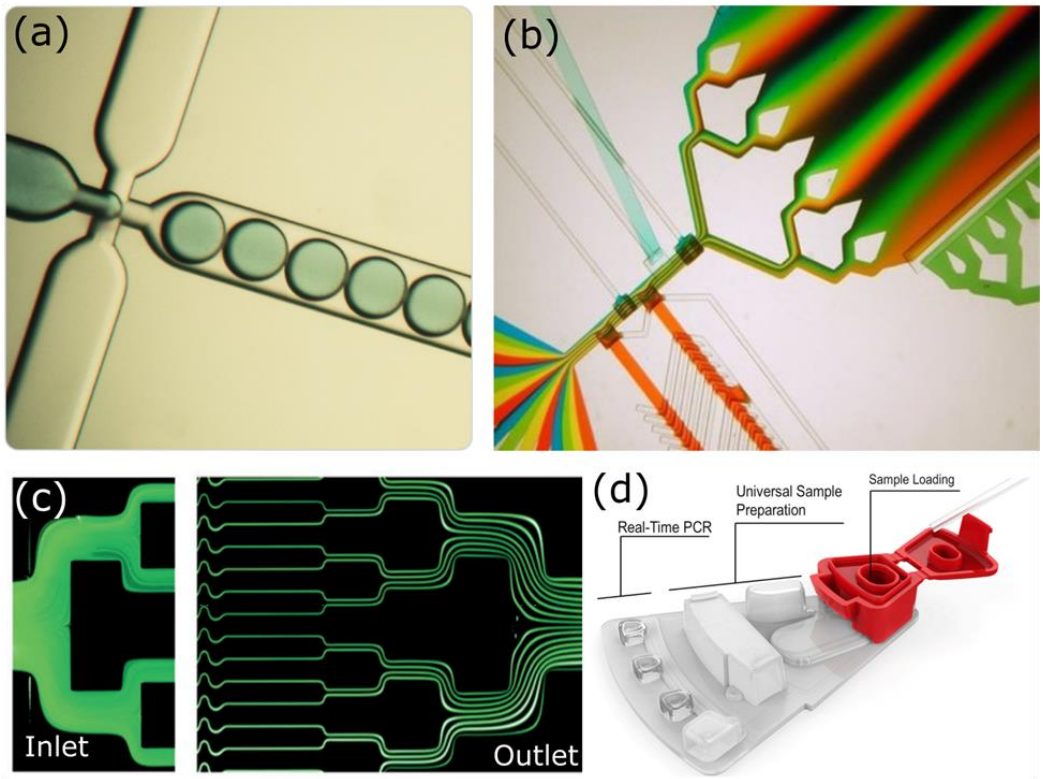

Figure 1. Common applications of microfluidics: (a) Droplets-based microfluidics are a promising tool for many chemical and biological assays that require controlled and rapid mixing and accurate temperature control. Image courtesy of Dolomite Microfluidics. (b) Microfluidic devices can be used to generate gradients of reagents with precise spatial and temporal control. Image courtesy of Albert Folch, University of Washington. (c) Inertial microfluidics is frequently used to separate particles or cells in a continuous flow for high-throughput sorting applications. Image reproduced with permission from (Di Carlo, 2009) (d) Lab-on-a-CD devices use the centrifugal force of a rotating compact-disk as pumping force to move the fluid in the device and execute an assay. Image courtesy of GenePoc.

What are the benefits of downsizing these procedures to a micrometer-scale and combining them in a microfluidic device? The most obvious advantage is a reduction in sample size and reagent consumption, which is not trivial when reagents are expensive (e.g., antibodies, chemotherapeutics and small molecules) or when samples are scarce (e.g., tissue biopsies). Furthermore, the high surface-to-volume ratio of the microfluidic channels facilitates heat transfer, enabling quick temperature changes and accurate temperature control. At the small scale of microfluidic devices, diffusive mixing occurs much faster than in a macroscale environment, which yields faster chemical reactions and reduced overall time per analysis. Alternatively, the long and narrow microfluidic channels boast a low Reynolds number (Re <1), resulting in laminar flow that enables precise spatiotemporal control of the fluids in the channels. One could take advantage of the precious characteristic to manipulate, trap and probe cells aggregates or whole-sections of tissues without direct physical contact on the sample reducing potential environmental contamination. Particularly for biological applications, another advantage of microfluidics is the ability to tailor and customize the cellular microenvironment in the device by using micro-fabrication techniques to pattern

molecules in the device or by exploiting the laminar nature of the flow to create physiologically relevant gradients (Young 2010). Furthermore, the dimensions of the microfluidic channel can be adjusted to enable precise manipulation of biological samples of varying size ranging from individual cells to sub-milliliter tissues. Few of the most common applications of microfluidics are illustrated in Figure 1. Moreover, the small scale of these LOC platforms enables the design of portable, low-cost devices that could be used in a variety of point-of-care applications ranging from bedside care to global healthcare.

The development of soft lithography (Whitesides 2001) techniques using polymers enables the fabrication of microfluidic devices suitable for cell culture by forming the device in an optically transparent, oxygen permeable, cheap and flexible elastomer: poly (dimethylsiloxane) (PDMS). These PDMS devices have already been used as biological platforms to study cells and can be used to provide an *in vitro* framework more representative of the *in vivo* behaviour of cells. The versatile and high-throughput nature of soft lithography microfluidics has been vastly exploited to develop new biological techniques towards expanding our comprehension of human physiology. Particularly in personalized cancer models, microfluidics is emerging as a promising tool to develop new clinically relevant therapeutic models that could improve chemotherapy outcome by minimizing drug-induced toxicities. In the next section, we will review the most commonly used models for drug sensitivity screening in oncology and describe how microfluidics can provide new preclinical models for improved patient-specific prediction of therapeutic outcome of a drug.

General Description of Common Cancer Models

Biological assays that help evaluate the effect of a drug on a patient-derived tissue are generally referred to as chemosensitivity and resistance assays (CSRAs). CSRAs have been developed and used in clinical trials for a few decades as a way to characterize the chemosensitivity of a particular patient in order to prescribe the optimal treatment for that patient (Bellamy 1992). Generally, these assays require patient-derived tumor samples to be preserved, *ex vivo,* and exposed to different therapeutic agents. These assays investigate different clinical end-points (cell-death, tumor growth, ATP production) to determine the patient's chemosensitivity profile.

In vitro 2D Monolayer Cell Culture Model

Common *in vitro* CSRAs utilize tumor cell monocultures derived from cancer cell lines or patient-specific tumor cells (Figure 2A) for anti-cancer drug screening and development (Abaan 2013; Boyd 1997). However, increasing evidence suggest that two dimensional (2D) monoculture models can develop irreversible genetic changes and loss of heterogeneity of the cell populations over time (Bounaix Morand du Puch 2016; Huh 2011; Sung 2013). Furthermore, these 2D models lack key features of *in vivo* tissues such as 3D complex architecture, presence of extracellular matrix as well as immune and stromal components, which have been shown to play a crucial role in cancer progression and drug resistance (Junttila 2013; Morgan 2016).

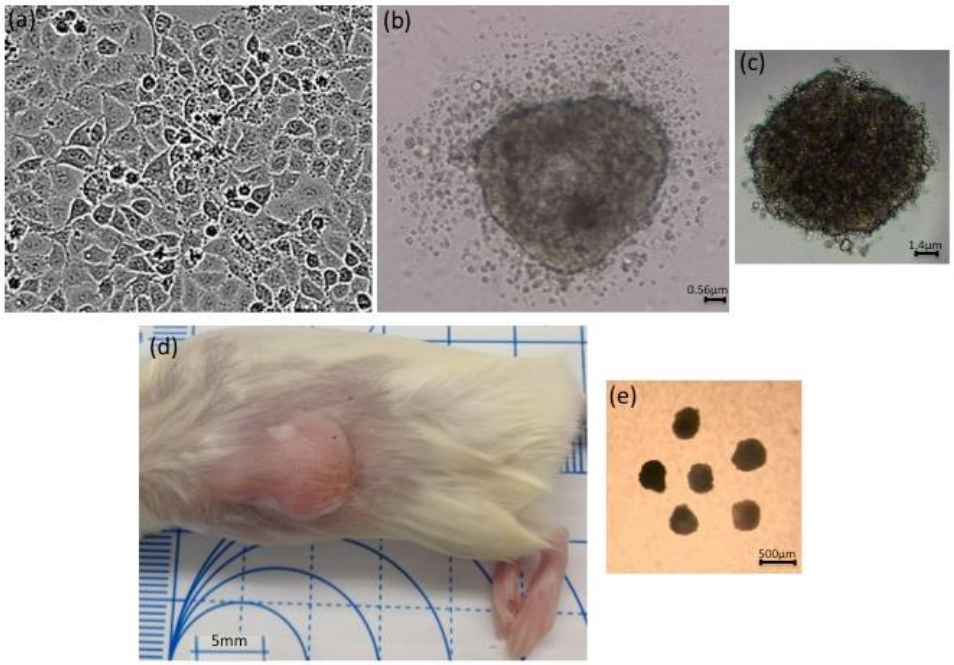

Figure 2. Common cancer models used to evaluate chemosensitivity and resistance to therapeutic agents. A) *In vitro* 2D monolayer cell culture B) *In vitro* matrix-assisted 3D culture C) *In vitro* 3D hanging droplet spheroid culture D) *In vivo* patient-derived xenograft model E) *Ex vivo* 3D Micro-dissected Tissues model. Acknowledgment to Dr. Mes-Massons' post-doctorate students, Zied Boudhra and Patra Bishnubrata for the 2D and 3D *in vitro* models.

In vitro 3D Cell Culture Models

Matrix-Assisted 3D Culture

Natural hydrogels, such as collagen and Matrigel, can be used to produce extracellular matrices (ECMs) acting as scaffolds that provide the cells with 3D growth architecture (Figure 2B) close to *in vivo* conditions. The presence of ECM during cellular growth has been reported to have great influence on key cell characteristics such as morphology, differentiation, polarity and gene expression, in comparison to conventional 2D cultures (Kenny 2007; Sung 2013; Yamada 2007). Likewise, co-culturing of cancer cells in ECM conditions with other non-cancerous cellular components present in the cell's microenvironment has been shown to affect the proliferation rate, drug sensitivity and protein secretion of cancer cells (Pak 2015; Sadlonova 2005; Xu 2013). These studies highlight the strong influence of cell-cell and cell-matrix interactions on the cell's response to drugs.

Spheroids

Generally, a spheroid originates from a self-aggregating cell that forms a sphere-like shape (Figure 2C). With size varying from a few micrometers up to a few millimeters, spheroids mimic the spatial heterogeneity of tumors, consisting of three primordial layers; proliferating cells on the peripheral layer, quiescent cells in the central layer and necrotic cells in the aggregate center. Furthermore, the 3D nature of the spheroids allows the study of drug

response and the effect of hypoxia through its ability to transport natural gradients of oxygen nutrients and metabolic waste.

For those reasons, spheroids have been generally adopted as a new therapeutic model and a number of microfluidic devices have been designed to allow the formation of spheroids as well as to study the chemosensitivity of these spheroids on-chip (Hirschhaeuser 2010; Shield 2009; Weiswald 2015). For instance, Torisawa et al. have reported a microfluidic device that allows on-chip generation of multicellular spheroids and long-term analysis of cellular viability following treatment of the spheroids in the chip (Torisawa 2007). While spheroids provide a 3D structure that better reflects *in vivo* tumor architecture than 2D monocultures, these models still fail to include components of tumor microenvironment that highly influence tumor cell behaviour.

Organoid Culture

Organoid culture models have emerged in effort to include both the *in vivo* microenvironment and the complex architecture of tumors. Organoids are derived from the stem cells that are grown in ECM, which allow the cells to differentiate and migrate to recreate the specific architecture and function of an organ (Morgan 2016). Fully-grown organoids are composed of multiple cell types and exhibit intra- and inter-cellular communication networks as well as cell signalling pathways that reflect the physiological *in vivo* behaviour of organs. Furthermore, the organoids can be cultured for a long period of time while maintaining histological, immunohistological and genetic properties of the tissue, making them ideal for drug sensitivity assays, clearly observed by Santo et al. through the generation gut-specific crypt-villus structures originating from a single intestinal stem cell (Sato 2009).

***In vivo* Patient-Derived Xenograft Model**

Patient-Derived Xenograft

At the other end of the experimental continuum, *in vivo* CSRAs are most commonly carried out on patient-derived xenografts (PDXs). To generate a PDX, a small portion of a patient's tumor tissue is engrafted subcutaneously in an immune-compromised mouse, where it grows *in vivo* (Figure 2D) in conditions that maintain the local human tumor microenvironment. Such models have the advantage of retaining key characteristics of the original tumor tissue such as tumor heterogeneity, complex 3D architecture, and genetic makeup. Furthermore, genetic analysis revealed that the PDX tumors share the same genetic mutations in the stromal cells and immune cells, with some minor exception. These exceptions may be attributed to the fact that PDX tumors are generated in immune-compromised mice and that tumor stromal cells can be infiltrated by host stromal cells (De Wever 2003; Marangoni 2007; Reyal 2012). Recently published reports suggest that the genetic expression profile of the donor and the PDX tumor were similar but those of the cell lines generated from the same donor tumor showed a very different profile (Bertotti 2011; Fichtner 2008; Julien 2012; Zhang 2013). While PDXs are an interesting model for drug screening and studying treatment effects on cancer progression, these models still present limitations that need to be addressed. For instance, it normally takes 3−4 months to generate a

PDX tumor model that corresponds to a donor tumor, making it inappropriate to determine the chemosensitivity of a patient before the first treatment is initiated. Additionally, as these mice lack a functional immune system, their use in immune drug screening is impractical. Moreover, these models require a lot of resources and are extremely costly to maintain (Ellis 2010). In effort to bridge the gap between 2D/3D monocultures and PDXs, a wide selection of *in vitro* microfluidics-based assays of varying complexity has been developed to improve our understanding of therapeutic response.

Ex vivo 3D Models

Organotypic Tissue Slices

Although the biological models presented thus far help to understand how the 3D architecture and cell-matrix contacts influence the therapeutic outcome of a drug, matching the *in vitro* complexity of *in vivo* tumors is still an unmet challenge. Instead of artificially recreating the complex microenvironment of a tissue, one step towards this goal is to produce organotypic cultures that preserves both *in vitro* tissue viability and the original structure of the tissue in an *ex vivo* environment. These models generally require the tumor tissue to be extracted by surgery and sectioned in smaller pieces to allow diffusion of oxygen and nutrients to the center of the tissue. As it preserves some of the tissue's original *in vivo* architecture and maintains cell-matrix interactions from the primary tissue, organotypic cultures offer the potential of predicting *in vivo* behaviour of the tissue. It is an outstanding tool used to characterize the therapeutic outcome of a drug for a specific patient tissue. Black first described this tool in 1951 where epithelial carcinomas (breast, colon, kidney, ovary, etc.) are extracted by surgery and sliced free hand to a size of approximately 0.5 cm by 0.5 cm and a thickness of 1 mm (Black 1951). The therapeutic response is evaluated by monitoring dehydrogenase activity of the tissues fragments exposed to various chemotherapy treatments or enzyme inhibitors.

A few years later, Thomlinson and Gray used histological analyses to study the mass transport limitation in human lung tumors and showed that large tumors exhibit an hypoxic core in their center (Thomlinson 1955). Based on the diffusive properties of metabolites and the general intake of nutrients by the tissue, they determined a critical diameter that a tumor core should not exceed: if one dimension of the cultured tissue is inferior to this critical diameter, the diffusion of metabolites through the tissue is enough to prevent depletion of nutrients. In this scope, different research groups began to slice tissue biopsies in thin slices (300–400 μm) before cultivating them to prevent diffusion-limited hypoxia (Figure 3). For instance, van Midwoud et al. reported that it is possible to study the metabolism of a precision-cut rat liver slice culture on-chip for a minimum period of 24 hours under continuous perfusion (van Midwoud 2010). Later, Chang et al. introduced a microfluidic device compatible with a 96-well plate allowing long-term culture of mouse brain slices and parallel chemosensitivity testing on the individual slices (Chang 2014).

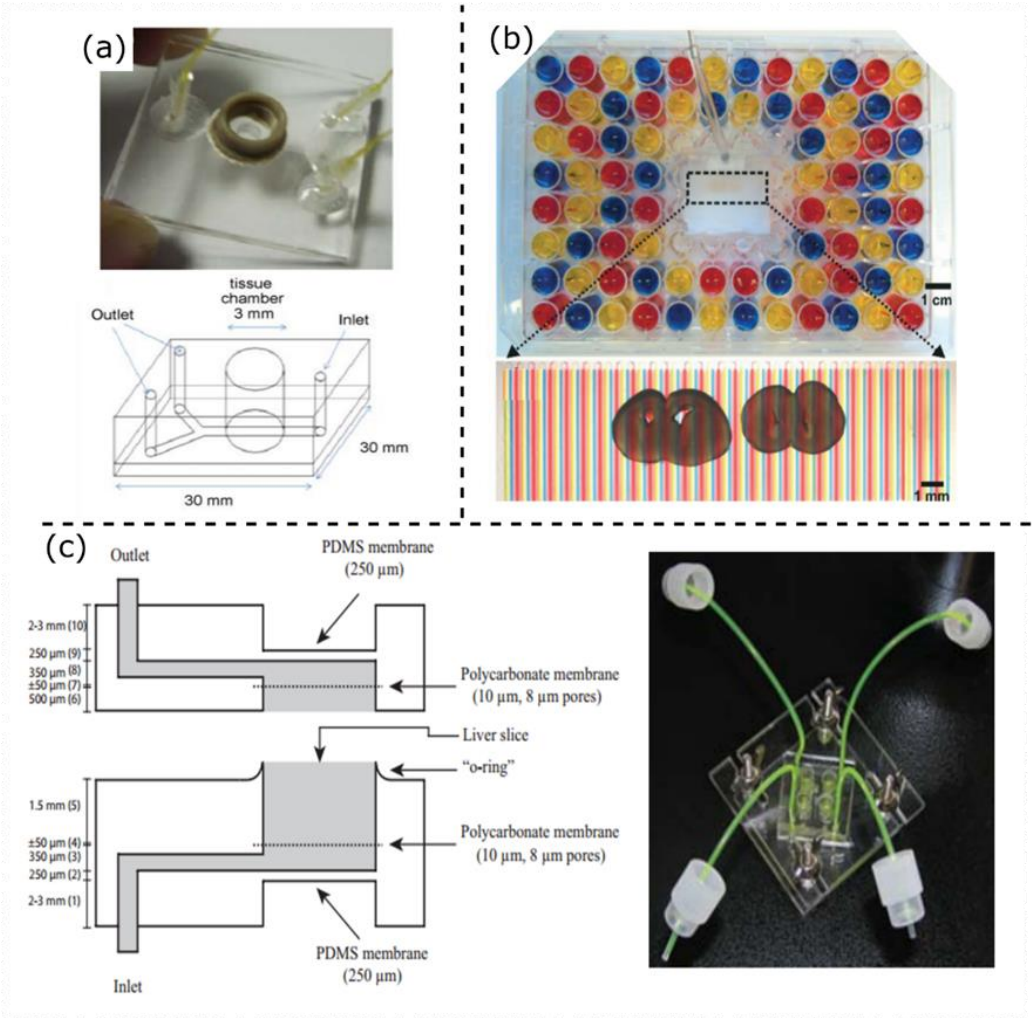

Figure 3. Organotypic models published previously in the literature. (a) Microfluidic chip that was used by Hattersley et al. to culture liver tissue biopsies. The device comprises a large tissue chamber where the tissue is perfused and can remain viable for over 70h. Image reproduced with permission from (Hattersley, 2008). (b) Microfluidic device reported by Chang et al. that allows organotypic culture of liver slices and parallel chemosensitivity screening on single liver slices. The multi-layered device is compatible with a 96-wells plate and enables the treatment of the sliced tissue with multiple compounds for high-throughput screening assays. Image reproduced with permission from (Chang, 2014). (c) Microfluidic platform developed by van Midwoud et al. to culture rat liver slices under continuous perfusion to study the metabolism and toxicology of the liver slices. Image reproduced with permission from (van Midwoud, 2010).

The main shortcoming of organotypic slice culture relies on the manipulation of large tissue slices without damaging the structure of the tissue, making such a model inappropriate for high-throughput drug screening on a large number of tissue slices. Moreover, long-term culture of large tissue slices usually requires continuous perfusion of the system to prevent hypoxia and nutrient starvation. Such perfusion and associated fluidic connections are cumbersome thus reducing the number of tissue slices that can be multiplexed in a single device, once again affecting the high-throughput screening capabilities of the model.

Micro-Dissected Tissue Culture

In effort to address these shortcomings, our group developed a new model for high-throughput *in vitro* study of therapeutic drug response on *ex vivo* patient-derived tissues (Figure 4). Briefly, tumor samples are micro-dissected and loaded in a microfluidic device where they are trapped and cultured. The micro-dissected tissue (MDT) samples are exposed to various therapeutic agents in the device and therapeutic response is quantified to determine the optimal treatment for that particular patient. The novelty of the presented model relies on the micro-dissection of the patient's tumor biopsy to enable precise spatiotemporal control of MDTs in a microfluidic device. The device consists of parallel fluidic channels to help trap and cultivate multiple MDTs thus assessing chemosensitivity of the tissue in a simple, high-throughput and multiplexed manner. Moreover, the micro-dissection of the tumor sample in sub-milliliter samples eliminates the need for continuous perfusion. The small diameter of the MDTs allows simple diffusion of oxygen through the PDMS matrix, enough to prevent hypoxia in the center. This novel biological model for drug screening combines the physiological relevance of the sliced tissue culture with the simple manipulations of small spheroid-sized tissue sample. The following sections of this chapter will allow in-depth understanding of this new MDT-based organotypic model, highlighting its clinically relevant chemosensitivity screening potential.

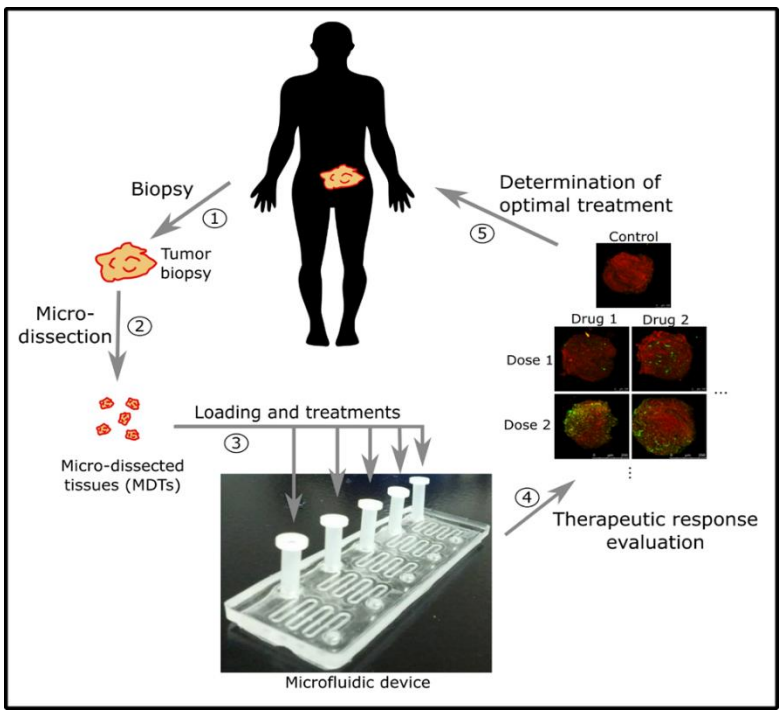

Figure 4. Presentation of the proposed personalized treatment model. 1) A tumor biopsy is extracted through biopsy or surgery. 2) Micro-dissection of the tumor biopsy to produce micro-dissected tissues (MDTs). 3) Loading and trapping of the MDTs in the microfluidic device, followed by treatment with different therapeutic agents directly in the device. 4) Evaluation of the therapeutic response with confocal microscopy and fluorescence activated cell sorting. 5) Results are interpreted and used to select the most effective treatment for that patient.

MICROFLUIDIC PLATFORM

Design and Fabrication of the Microfluidic Platform

Microfluidic devices dedicated to cell culture have certain requirements that distinguish them from micro-scale devices used commonly for analytical chemistry or physics. In the case of a microfluidic device that traps and preserves *ex vivo* tissues, design considerations of particular importance are: (1) the choice of material for the device, (2) choice of trapping mechanism, and (3) geometry and dimensions of the channels. We will review each of these considerations and present the important design characteristics of the microfluidic device. We will then describe the fabrication process to produce the microfluidic chip.

Description of Polymer Used for Microfluidic Design

The development of soft lithography by Whitesides and his group in the late 1990s opened new avenues for microfluidic-based cellular applications (Whitesides 2001). Soft lithography comprises a set fabrication technique similar to photolithography, but uses silicon rubber instead due to low-cost and easy fabrication than conventional silicon-based materials. PDMS has several unique properties that make it an ideal choice of material for cell culture applications. First and foremost, unlike silicon or glass, PDMS has a high gas permeability that ensures sufficient oxygen supply to the cells in the device, eliminating the need for separate oxygen chambers. This property is particularly important when cultivating cells that have high metabolic demands like cancer cells. Another advantage of PDMS is its optical transparency and low autofluorescence, both in the visible and infrared regions. This property has been vastly exploited to couple microfluidic devices with imaging modalities that allow assessing the viability of the tissue directly on-chip. Moreover, PDMS is fairly cheap and easy to mold, making it ideal for rapid prototyping and mass production of microfluidic devices. Finally, to form enclosed micro-channels, PDMS can be bonded to different materials (e.g., PDMS, glass, polystyrene) using simple methods such as oxygen plasma treatment.

Sample Trapping Mechanism

As mentioned previously, there are numerous advantages provided by microfluidic devices, particularly when working with biological samples. These devices have the ability to enclose a biological sample in a chamber allowing for easy perfusion and use of smaller volumes of reagents than conventional macro-scale techniques (i.e., 96-wells plate). Microfluidic devices are transparent such that samples can be imaged directly on-chip, eliminating the need to manipulate the sample once it is loaded in the device. For all those reasons, research groups have used microfluidic chips to trap and enclose various types of tissue samples of different sizes ranging from single-cells to tissue slices. For specific sub-microliter particle trapping, such as spheroids, cell aggregates and MDTs, numerous trapping mechanisms have been reported. These mechanisms include acoustic (Liu 2007), mechanical (Khoury 2010), resistive (Ruppen 2014) and sedimentation trapping (Ruppen 2015). The

latter mechanism seems to be more adapted for clinical applications, as it doesn't require complex instruments and continuous perfusion to operate the trap. Furthermore, when tissues sediment in well-like traps, they are protected from the high sheer stress induced in the main fluidic channel.

Two conditions must be met for sedimentation trapping to occur. First, the tissue sample being trapped needs to be denser than the surrounding medium for it to sediment to the bottom of the trap. Second, the sedimentation time has to be shorter than the travelling time over the trap. Cells are slightly denser than the medium in which they are cultured because the organelles and proteins they contain are denser than water. This is exploited in petri-dish cultures where cells need to sediment to the bottom of the dish and adhere to its surface to form a 2D cell layer. In steady-state regime, bigger spheres of equal density sediment faster, which explains why a tissue sample of 500 microns in diameter sediments roughly 10 000 times faster than single cells of about 5 µm in diameter, allowing the former to be trapped in less than a second in such small wells.

Configuration of the Microfluidic Platform

An example of channel configuration is shown in Figure 5A, where a whole microfluidic platform is seen from the top. The platform is made up of two fluidic levels: the top level shown in black contours where the samples circulate and the bottom level shown in red where the samples sediment. Five independent channels fit on a 2.5 cm by 7.5 cm surface (equivalent to the surface of a standard glass slide), making it possible to trap up to 25 individual tissue samples and to submit them to five different treatment conditions. The channel length was optimized so that the samples could be controlled using a 20 µL micropipette. Some distance was left between the traps so that each sample would have access to a maximum amount of nutrients from the medium in non-perfused conditions. Each channel is laid out in a serpentine fashion and can be viewed entirely in the field of view of a low magnification stereoscope.

As shown in Figure 5B, the inlet of each channel has a micro-reservoir which facilitates the loading of the samples into the system. The bottom of this micro-reservoir is lower than the rest of the inlet, at the same level as the channels to which it directly connects.

In the current design presented within this manuscript, the channel cross-section is 600 µm by 600 µm. The gravitational square-bottom traps are 600 µm in width by 500 µm in height. The total length of the channel is about 78 mm. Each independent system contains a volume of 29 µL. These dimensions have been tested to accommodate cylindrical tissue samples with dimensions of approximately 350 to 400 µm in diameter by 300 µm in height, and could easily be scaled to better accommodate samples of slightly different sizes.

Diffusion is the main transport mechanism *in vivo* between capillaries and the surrounding tissue. Similarly, within the microfluidic platform, the tissue samples access the nutrients from the medium and discard their cellular waste by diffusion between the channel and the traps. When fresh medium is added to the channels, our simulations show that only the channel (top fluidic layer) fills with fresh medium whereas the medium within the traps mostly recirculates (Astolfi 2016). Gradually, nutrients from the channel diffuse into the traps and metabolic waste diffuse into the main channel. Since diffusion times depend on the size of the molecules, small molecules such as oxygen diffuse rapidly into the traps whereas larger

molecules such as glucose take more time to reach the tissue. Following Einstein's approximation, $t \approx x^2/ 2D$, a molecule such as glucose with a diffusion constant (D) in water of 600 $\mu m^2/s$ would take approximately 3.5 minutes to diffuse a 500 µm distance (x) to the bottom of the traps. When the nutrients reach the tissue, it is expected that diffusion also occur within the tissue, as would be the case *in vivo*.

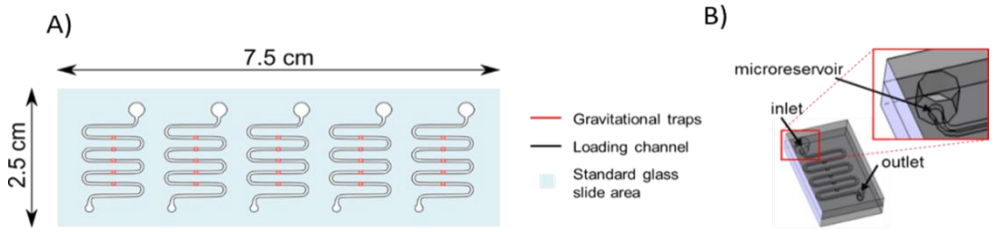

Figure 5. Channel Configuration of the microfluidic device. A) Microfluidic platform viewed from the top. The top channels are shown in black contours and the traps are shown in red. B) 3D view of a single assembled system.

Microfluidic Platform Fabrication

The platform fabrication process includes the following steps: mold fabrication, PDMS casting and cooking, assembly of the platform, bubble dislodging, sterilization, surface treatment, and pre-loading of channels with saline solution. Two molds are needed to fabricate the platforms. The first Poly (methyl methacrylate) (PMMA) mold, with features that form both fluidic levels (channels and traps) in the bottom layer of the platform, was fabricated by computer numerical control (CNC) milling using a flat endmill of 1 mm in diameter (Figure 5A). The second PMMA mold, with features that form the inlet and outlet holes in the top layer, was also fabricated by CNC milling using a flat endmill of 3.57 mm in diameter (Figure 5A). Liquid PDMS is prepared by combining a base polymer to a curing agent at a ratio of 10:1. This carefully mixed liquid PDMS can then be poured in the mold, degassed and cured in the oven for 1 hour. Once the top and bottom layers of the device are unmolded and cleaned, they can be assembled by oxygen plasma treatment. A nylon hollow cylinder is inserted into each inlet hole, acting as a fluid reservoir. A schematic and an actual real life image of the assembled platform are shown in Figure 6.



Figure 6. Schematic and real life image of the assembled platform.

EXPERIMENTAL PROCEDURE FOR PREPARATION, LOADING AND TREATMENT OF MICRO-DISSECTED TISSUE

Micro-dissected tissue (MDT), being the main focus of this chapter, is a new concept that has recently entered the scientific era. The micro-dissection of scarce tumor tissue samples, cut into sub-millimeter size, allows easy handling and tissue maintenance once trapped in microfluidic devices. Given the architecture of the devices, it is possible to simultaneously test multiple therapeutic agents, giving information on specific patient sensitivity or resistance to particular treatments. Furthermore, this high-throughput biological model exhibits a personalized medicine approach technique that will further help clinicians make therapeutic decisions.

The tissue processing of patient samples is organized in multiple steps, which include tissue harvest and acquisition, the production and culturing of the MDTs allowing tissue viability to be maintained. Once the viability of MDTs is attained in cultured conditions, it is possible to proceed to chemotherapy treatment of the samples permitting the ability to determine the chemosensitivity of an individual patient in a time frame suitable for clinical decision-making.

Criteria for Tumor Tissue Resection

There is one major criterion that is common for all MDT processing projects: the targeted tissue must be palpable or must have visible tumor areas present during the surgical procedure. The cancerous regions must be clearly identified by either a pathologist or a clinician performing the surgery.

Other criteria have been established depending on the solid tumor being processed and on the type of study performed. For example, prostate cancer patients may be enrolled in the study when the cancer targeted can be obtained by a biopsy specimen (of the primary tumor or a metastatic lesion) or by a transurethral resection of the prostate (TURP).

Tissue Micro-Sectioning of Prostate Cancer Biopsy Samples

Tissue Acquisition of Patient Samples

From past experiences and after the optimization of multiple conditions to attain maximum cell viability, a standard operating procedure (SOP) has been written to ensure proper procurement of tissue samples from clinicians. This procedure takes into account the collection, detection of malignancy and transportation of cancerous specimens. The sampling procedure has been fabricated to facilitate safe and efficient handling of the tumor sample with high integrity and quality, which is crucial for the preparation of the MDTs.

The SOP for tissue acquisition of prostate cancer specimen:

Tissue procurement of the prostate is usually done by ultrasound guided trans-rectal biopsies or can be done at the time of radical prostatectomy in patients undergoing surgery.

1) By using true-cut biopsy needles one can obtain specimens of 2 mm in diameter × 20 mm in length.
2) 5–6 biopsies of the suspected prostate region with palpable or visible tumor should be obtained.
3) Biopsy specimens should be kept in Hanks' Balanced Salt Solution (HBSS, #311-516-CL, Wisent Inc., Saint-Bruno-de-Montarville, Canada) supplemented with 10% fetal bovine serum (FBS, BD Biosicences) and 55 mg/L gentamicin (Wisent) and 0.6 mg/L amphotericin (Wisent) ($HBSS_{complete}$) and further transported on ice in aseptic conditions.

HBSS is a balanced salt solution that helps maintain tissue pH and osmotic balance. This solution thus provides water and essential inorganic ions such as calcium and magnesium to support vital cellular activity. Additionally, HBSS contains glucose, a main nutrient allowing viability of tissue biopsy to be sustained for a longer period of time. Recent studies have compared HBSS to regular phosphate-buffered saline (PBS) in terms of tissue viability and have shown that HBSS better supports whole tissue maintenance compared to PBS thus making it tissue specific (Astolfi 2016).

For solid tumors that require the identification of cancerous regions by a pathologist, here is the SOP for tissue processing and sectioning by the pathologist:

1) A sterile scalpel is used to cut the tumor where there is suspicion of tumor cells.
2) Freeze a fresh, unfixed tissue sample, up to 2.0 cm in diameter, at optimal cutting temperature (OCT) in a suitable tissue mold onto the specialized metal grids that fit onto the cryostat.
   NOTE: Approximate freezing times at -24 ºC using a cold chuck ranges between 20–60 seconds depending on tissue depth.
3) Cut sections 5−15 μm-thick in the cryostat at −20°C. If necessary, adjust the temperature of the cutting chamber ± 5°C, according to the tissue under study. A hairbrush is useful to help guide the emerging section over the knife blade.
4) Within the first minute of cutting the tissue section, transfer it directly onto a microscope slide at room temperature. By letting the slide touch the tissue, the tissue section will melt onto the slide. This must be accomplished within the first minute of cutting the section to avoid freeze-drying of the tissue. The slide is then coated with Poly-L-lysine to improve adherence of the section to the slide.
5) To evaluate tissue preservation and orientation, stain the first couple of slides with toluidine blue (1−2% w/v in H_2O), hematoxylin, and eosin, or any aqueous stain.
6) The pathologist examines the slides and determines the approximate probability of tumor cell in the sample.
7) Using a clean and sterile blade, the mirror section of the tumor sample is cut and placed in $HBSS_{complete}$.
8) The sample is picked up by a technician and transported on ice to the processing laboratory
9) The tumor tissue is either processed right away or stored at 4 ºC for no more than 24 hours in $HBSS_{complete}$.

Microfluidic Chip Preparation

The microfluidic devices must be prepared one day prior to micro-dissection of the patient sample. It is important that the microfluidic chips go through several decontamination and sterilization procedures. Firstly, the devices are treated with 100% ethanol to decontaminate the chips followed by 70% ethanol incubation at room temperature for 15 minutes in to allow sterilization. Next, they are treated overnight in a humidified cell culture incubator (37°C, 5% CO_2, 95% ambient air) with a 10 mg/mL triblock copolymer, Pluronic F-108 (Sigma-Aldrich, St-Louis, USA) to reduce cell adhesion on the PDMS surfaces. The following day, the devices are re-sterilized through 70% ethanol incubation for 15 minutes at room temperature. Lastly, they are thoroughly rinsed using sterile HBSS supplemented with 55 mg/L gentamicin and 0.6 mg/L amphotericin ($HBSS_{antibio}$) and placed at 4˚C until the MDTs are produced and ready to be loaded in the devices.

Generation of Micro-Dissected Tumor Tissue

Detail of Micro-Dissection Protocol

Prostate cancer biopsy samples are approximately 2 cm in length and 1 mm in diameter. These fragments are cut into 1 to 2 mm long fragments and immediately embedded in low melting-point agarose supplemented with 10% FBS, which is kept in a liquid form at 40^0C. The agarose solidifies on ice to obtain a supporting structure around the tissue. The excess agarose is then removed and the fragments are repositioned vertically and glued to the stage for slicing into 300 µm thick slices using a traditional vibratome. These slices were further punched, using a 400 µm biopsy punch, into disk-like tumor micro-sections, MDTs. On average, a single prostate cancer biopsy can produce 80 MDTs, thus with 5–6 biopsies, we can easily obtain between 400 to 480 MDTs from one single patient sample. The MDTs obtained from each biopsy are pooled together in a petri plate, submerged in $HBSS_{antibio}$, to ensure randomized selection of the MDTs allowing drug testing of heterogeneous tissues. The MDTs obtained are then carefully loaded in the customized microfluidic chips under a stereomicroscope and cultured in specific culture medium, Roswell Park Memorial Institute (RPMI 1640) (#350-045-CL, Wisent Inc.) medium used for prostate cancer sample culturing. For the loading procedure, the hollow nylon cylinders that form the inlet reservoirs are removed and the microfluidic device is placed under a stereomicroscope. For each individual channel, 5 MDTs are collected using a P20 micropipette and introduced in the inlet, where they sediment to the bottom of the channel. By aspirating fluid from the outlet of the device, flow is induced in the microfluidic channels allowing the MDTs to travel in the channel to attain the wells. Once the MDTs are above the wells the flow is stopped for approximately 1 to 2 seconds allowing them to sediment to the bottom of the traps. The same procedure is repeated to fully load the 5 channels of the device, resulting in a total number of 25 MDTs per device (for visual comprehension, the whole process is illustrated in Figure 7). Furthermore, This $RPMI_{complete}$ medium used does not contain phenol but is supplemented with L-glutamine, 10% FBS, 55 mg/L gentamicin and 0.6 mg/L amphotericin and allows whole cell overall survival of MDTs in our microfluidic devices to be between 60 to 95% (Astoli, 2016).

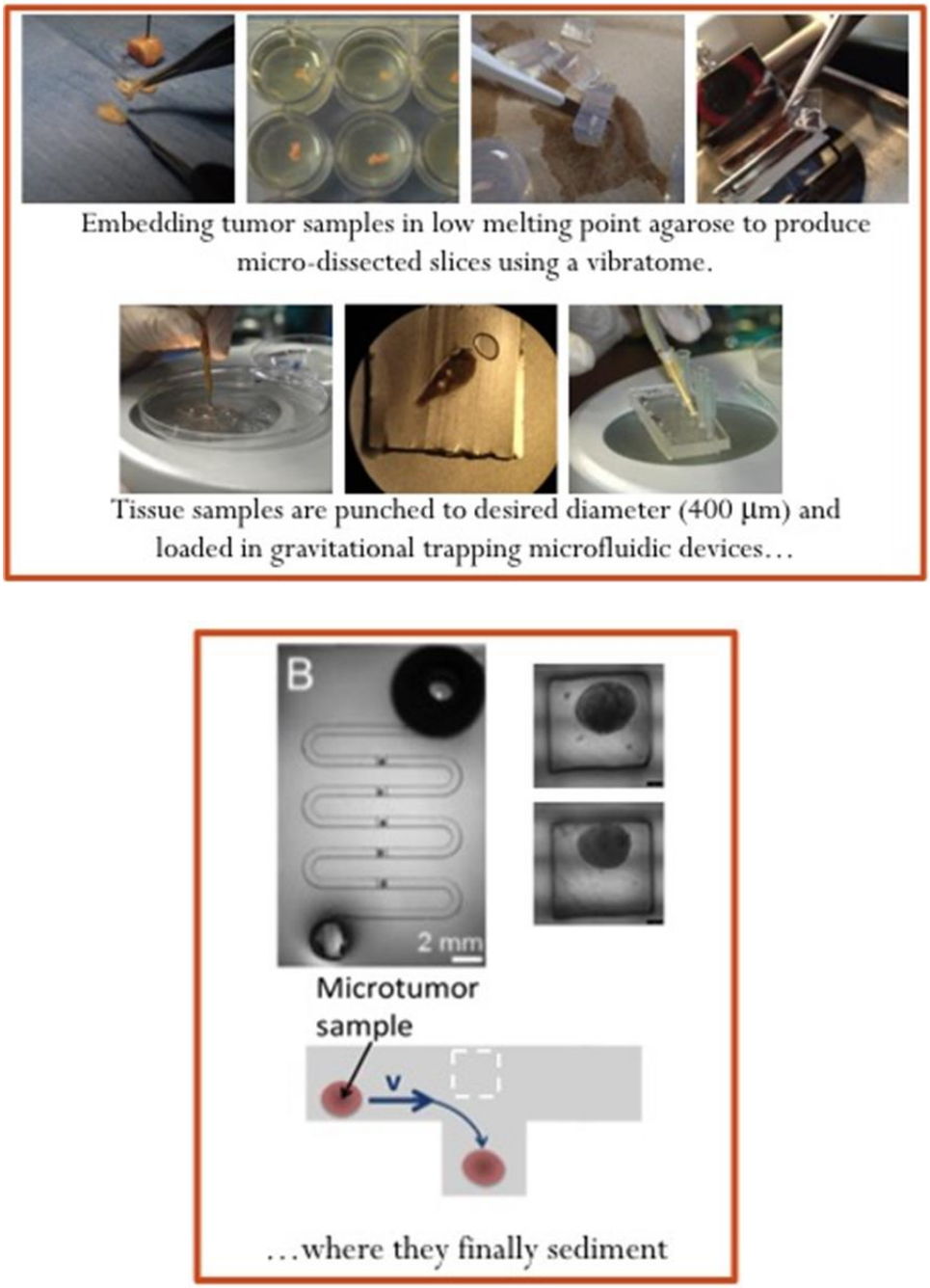

Figure 7. Overview of the procedure to produce micro-dissected tissue (MDT), to load them into a microfluidic system and to analyze their viability using two complementary methods.

Tissue Sectioning Reproducibility

The distribution of size of the MDTs produced was determined by confocal microscopy analysis. Using maximum projection imaging, the diameter of each MDT was calculated as the average of two perpendicular diameter measurements. Upon analysis, the diameter of the

MDTs remained relatively stable with time and slight variability was detected. This variability was further explained by differences in mechanical properties of the tumor tissues, especially their elasticity, by wear and tear of the biopsy punch and slight differences in sectioning procedure between users. It was clearly noted that tissue with higher elasticity could easily be stretched out during sectioning due to compression force applied by the biopsy punch and can later be brought back into its original configuration.

Irrespective of the tumor type, the diameters of 247 produced MDTs seem to follow a normal distribution with an average (μ) of 380 μm and a standard deviation (σ) of 43 μm (Figure 8) (Astolfi 2016). The ratio σ/μ being less than 12% indicates that the sectioning procedure is highly reproducible.

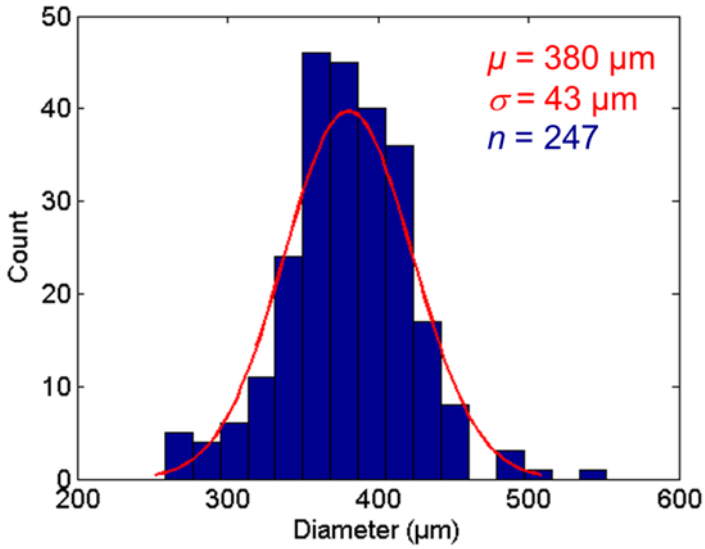

Figure 8. Histogram (blue bars) with normal fit (red curve) representing the diameter of microsections of xenograft models of various cell lines.

Culturing of Micro-Dissected Tissues and Chemotherapy Treatments

To ensure cell viability and tumor survival of the MDTs at harvest day, $HBSS_{antibio}$ was replaced by fresh $RPMI_{complete}$ medium. The MDTs are continuously incubated at 37^0C, 5% CO_2 for the remaining period. The medium is changed 24 hours subsequent to harvest day to ensure proper circulation of nutrients and avoid glucose deprivation, followed by 24 to 48 hours of recovery period to acclimatize the MDTs within the systems before further treatment with different therapeutic agents.

The concentration of the chemotherapy agents used to treat the MDTs was determined by the IC_{50} obtained by monolayer cell line cultures that are generally used to generate xenografts. Recent studies have demonstrated that at a concentration of 10 times the IC_{50} of chemotherapy agent results in a significant increase in mortality fraction in spheroids compared to lower concentrations and control (Das 2013). The treatment plan for the MDTs may differ depending on the objective of the project and on the solid tumor being processed. Specifically, for prostate cancer samples processed at the CRCHUM, the MDTs were treated

with Docetaxel, and/or Bicalutamide, common prostate cancer treatment drugs. The IC_{50} of Docetaxel being 1 nM, was calculated in our lab through a metabolic assay, WST-1-based, using various prostate cell lines, all-resulting in similar values. Additionally, through clonogenic assays our lab has determined the IC_{50} of Bicalutamide for 22RV1 cell line to be 10 μM.

Particularly in our lab, these treatments were given alone, sequentially or in combination at a concentration of 10 nM for Docetaxel and 100 μM for Bicalutamide. Generally, a cycle of chemotherapy includes a 24-hour incubation period with the chemotherapy agent followed by removal of treatment and a 48-hour recovery period. In order to allow comparison with clinical treatment plan and patient survival, two cycles of chemotherapy are completed on the MDTs. Explicitly, after the recovery period from MDT processing, the chemotherapy agents were diluted in $RPMI_{complete}$ medium in order to attain the desired concentrations. The $RPMI_{complete}$ medium previously in the microfluidic devices was replaced with the medium containing the chemotherapy agent. The chemotherapy treatment was removed and replaced with fresh medium after 24 hours of treatment and thus repeated after 24 to 48 hours of recovery period. Many chemotherapy agents take several days before effects are apparent hence why final day analysis are done 48 hours after the second treatment has been completed.

The MDTs are analyzed at different time points in order to determine initial and final viability of the MDTs. In addition, controls are consistently used throughout the procedure to act as a comparable group of untreated samples ensuring reliability of the results. Initial MDT viability measures are determined by confocal imaging and flow cytometry on harvest day (day 0) and then on first cycle treatment day (day 2). Finally, samples are analyzed, by the same two methods, 48 hours after the second cycle (day 8), comparing untreated samples to treated samples being able to estimate the patients' response to treatment.

The complete process takes approximately 8−10 days and the samples are collected and analyzed in less than two weeks. This method utilized as a 3D cancer model can help determine the chemosensitivity of an individual patient in a time frame suitable for clinical decision-making. Furthermore, this method can help decide which treatment plan will be most effective for an individual thus excluding the use of ineffective therapies for that patient.

METHODS FOR ANALYSIS OF TREATMENT RESPONSE

Two methods were developed to follow cancer cell survival and MDT response to treatment over several days: confocal microscopy of live and dead cells (time point assay) and flow cytometry (endpoint assay) to discriminate the MDT cells according to their viability stage (alive, early apoptotic or dead).

An Automated Analysis of Confocal Microscopy Images to Determine Cancer Cell Response to Treatment

Since PDMS is completely transparent, it allows for direct imaging of the MDTs under the microscope. By confocal microscopy, MDTs trapped in the microfluidic platforms were

imaged at different time points to follow the evolution of cell viability during the 8-day culture period. The combination of CellTracker™ Orange CMTMR (CTO, Thermo Fisher Scientific), which stains viable cells, and Sytox Green (SG, Thermo Fisher Scientific) which stains nucleic acids of dead cells, gives a measure of the viability of cells (Figure 9A). To minimize detection of auto-fluorescence, non-labelled MDTs incubated under the same conditions as the stained MDTs were imaged first to calibrate the upper threshold settings of the microscope (laser power and photomultiplier gains). Labeled MDTs were then imaged directly through the microfluidic platforms using an inverted confocal microscope equipped with a 10X or 20X dry objective (Figure 9A).

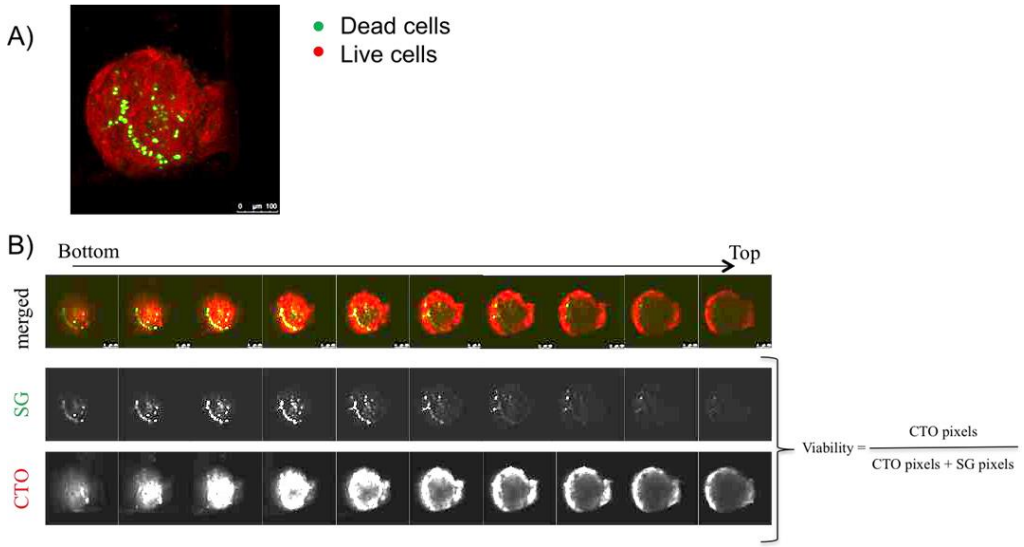

Figure 9. Overview of the confocal microscopy imaging of live and dead cells. A) 3D projection of a confocal image of an MDT stained with CTO and SG. B) Individual z-stack images used for viability analysis of the same MDT. Top row is the merged color stacks. Middle and lower rows are the Sytox Green (SG = dead cells) and Cell Tracker Orange (CTO = live cells) channels respectively.

From confocal microscopy images, overall cell viability was evaluated by calculating the ratio of the area of the CTO-positive signal over the summed areas of the CTO- and SG-positive signals. An algorithm applied a median filter to all images to reduce noise and then determined the red and green signal contours in order to apply a threshold algorithm only to those pixels near the contours (Figure 9B), for each fluorescent marker. This threshold method separates the pixels in two groups, background and foreground, so that their intra-class variance is minimal. Once both thresholds were applied, the numbers of CTO-positive and SG-positive pixels were calculated. The sample viability was evaluated by the ratio of CTO pixels divided by the sum of CTO and SG pixels [$V_{iability}$=CTO/(CTO+SG)].

Characterization of Treatment Response of Each Cell Type Using Flow Cytometry Assays

Flow cytometry was employed as an endpoint assay to analyze the cell population (epithelial, immune or stromal cells) and their viability before and after the MDTs had been

exposed to different chemotherapy agents. MDTs were analyzed at different time points to reflect the evolution of cell death over the 8-day incubation period. All fifteen MDTs from the three channels were pooled in the same tube for analysis. A single cell suspension of MDTs was obtained through enzymatic digestion using a combination of crude and type 1A collagenase and mechanical action of gentle repeated pipetting. The resulting suspension is analyzed by flow cytometry. All medium fractions collected from the three channels during the medium changes and stored at 4°C were also pooled together with the digested MDT suspension. This step was added to take into account all the live and dead cells that had been washed out of the systems during medium changes in the microfluidic platform. Single cells from the homogenous cell suspension were then stained with the apoptotic fluorescent dyes Annexin V for apoptosis and DRAQ7™ for dead cells, unstained cells were considered as viable cells for flow cytometry analyses. The cell survival was gated in forward and side scatter graphs, as shown in Figure 10. A survival state was associated for each cell according to its dye staining (live, early apoptotic or dead).

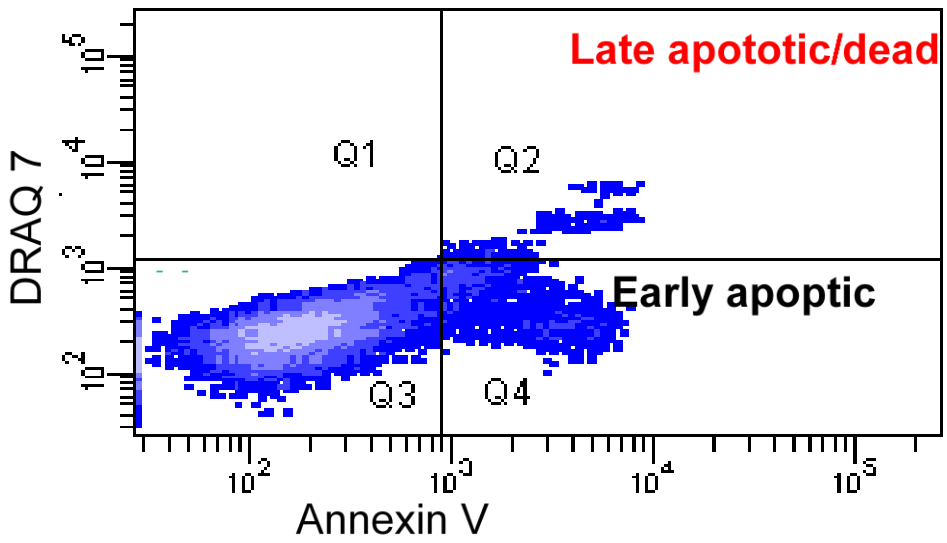

Figure 10. Typical representation of flow cytometry analysis. Each cell (represented by a blue dot) obtained from the MDT was associated to one of three viability categories according to its fluorescence intensity in both DRAQ7 and Annexin V detection channels: early apoptotic cells (Annexin V-stained only), late apoptotic / dead cells (DRAQ7-stained), and live cells (non stained).

Preliminary Analysis of Treatment Response

Patient A was a TURP sample that had developed a castration-resistant prostate cancer (CRPC). The MDTs prepared from this patient sample were cultured for 8 days in the microfluidic platforms and received two complete treatment cycles (for details, see section Culturing of Micro-Dissected Tissues and Chemotherapy Treatments). Confocal 3D projection imaging of treated MDTs allowed for quantitative evaluation and effect of two common prostate cancer treatment drugs. The viability of prostate cancer MDTs is shown below with the live cells in red (CTO) and dead cells in green (SG). The percent viability of

the control samples at 95.8% ± 3.1% was compared with the 2 treatment conditions, Drug A at 90.5% ± 2.4% and Drug B at 83.1% ± 2.8% (Figure 11), indicating a decrease in viability in the Drug B treated samples with respect to the control. In parallel, flow cytometry technique was used to confirm MDT viability and drug sensitivity. The percent viability of the control MDT samples at 62.4% ± 10.1% was compared with the 2 treatment conditions, Drug A at 63.1% ± 4.8% and Drug B at 35.2% ± 2.3% (Figure 12). The preliminary results from both techniques show an increase in Drug B sensibility compared to Drug A. However, the viability results of flow cytometry were quite inferior to those obtained by confocal microscopy. Differences between these two techniques were explained by the identification of early apoptotic cells in the flow cytometry analysis (Figure 12), which might still appear CTO-positive in the dual-stain confocal microscopy analysis.

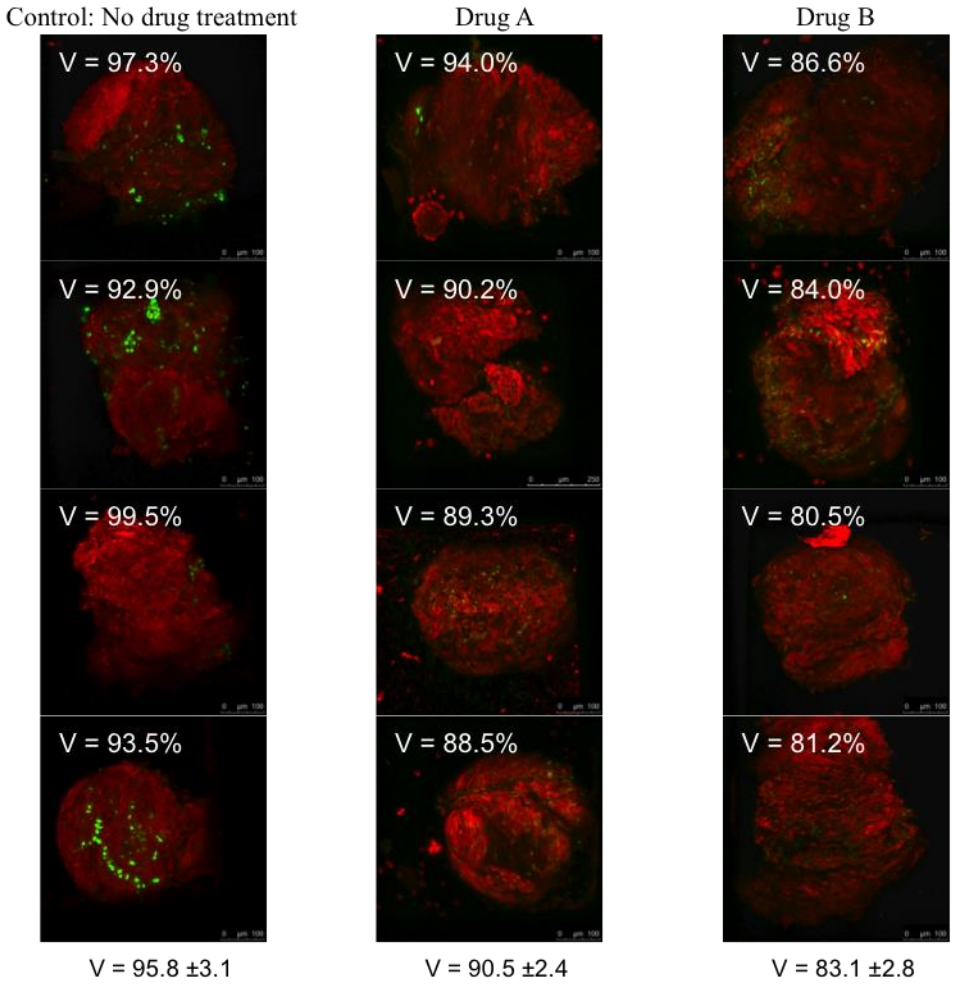

Figure 11. 3D projections of confocal z-stack images for prostate. Patient A taken 8 days after surgery. Treatment applied for a 24 hr period 2 days and 6 days after surgery. 1) control, 2) Drug A and 3) Drug B.

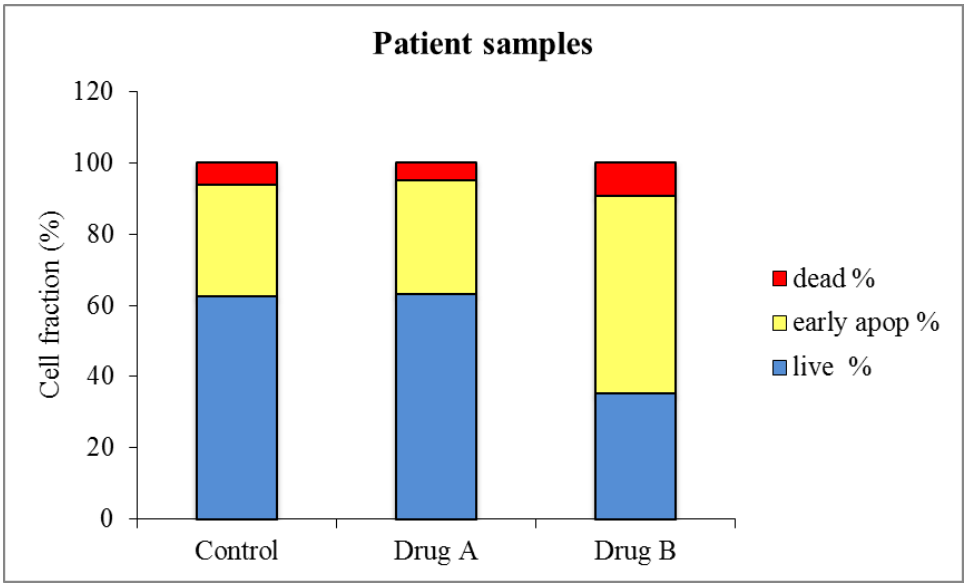

Figure 12. Flow cytometry survival analysis of MDTs from patient A. MDTs were treated with Drug A or Drug B. Each treatment was applied for a 24 hr period 2 days and 6 days after surgery.

Advantages and Disadvantages of Each Viability Analysis Technique

To compare the potential of confocal microscopy and flow cytometry to evaluate the cancer cell sensitivity to different treatments, it is necessary to analyze advantages and disadvantages of each technique.

Confocal Microscopy

Confocal microscopy gives information about the spatial distribution and the morphology of MDTs. Since samples are imaged on-chip, this technique is fast and makes it possible to easily follow the treatment effect at different time points and the survival evolution of a single MDT in response to one treatment or to a sequence of treatments. On the other hand, mortality is generally underestimated due to the washing out of dead cells during medium changes and staining protocols as well as the staining of early apoptotic cells by “live” dyes. The limited imaging depth of the confocal microscopy (around 100 μm) creates a “black” unanalyzed region in the center of the MDT. This being a strong limitation to estimate the effect of drugs on the survival of cancer cells in the middle of the MDTs.

Flow Cytometry

Flow cytometry is a better quantitative technique to evaluate the overall survival of cells and to allow the discrimination of early apoptotic cells. These early apoptotic cells are the starting point of cell death processes that are accounted as dead cells for the purpose of

evaluating cell survivability fraction. However, this technique is uniquely an endpoint analysis as it necessitates the digestion of MDTs, thus preventing the ability to monitor sample viability over time. This technique also needs a high quantity of cells (at least 15 MDTs) and gives an average reading of the whole microfluidic platforms which reduces the ability to perform statistical analyses.

Overall, these two techniques are complementary to each other and were adapted to measure the overall survival of MDTs within the microfluidic platforms.

CONCLUSION

Strategies toward the management of cancer have changed significantly over the last decade and focused on a personalized medical approach. The major challenge of this approach is to identify treatments that will significantly increase patient survival. One solution proposed is the direct testing of patient tumor material that should allow empirical evaluation of therapeutic responses to a wide concentration and variety of agents. This idea led to the development of a novel high-throughput and low-cost tool for monitoring drug sensitivity of patient tissue. This tool associates a novel technique of micro-dissection, to produce sub-microliter cancer tissue samples, and microfluidic technologies, to generate a biocompatible, gas-permeable and optically transparent platform suitable for cell biology and imaging application. The new *ex vivo* micro-dissected cancer tissue model, which retains the original 3D tumor architecture, should closely mimic the type of responses expected in patients. This rapid and direct approach would influence clinical decision-making and allow the tailoring of therapeutic strategies for individual patients within an acceptable time frame. This would reduce not only the economic burden on the health care system but also the inconvenience and risk of exposing patients to drugs with little chance of response as well as the optimization of therapies in patients more likely to respond.

REFERENCES

Abaan OD, Polley EC, Davis SR, Zhu YJ, Bilke S, Walker RL, Pineda M, Gindin Y, Jiang Y, Reinhold WC, Holbeck SL, Simon RM, Doroshow JH, Pommier Y, Meltzer PS. The exomes of the NCI-60 panel: a genomic resource for cancer biology and systems pharmacology. *Cancer Res.* 2013; 73(14):4372–82.

Astolfi M, Péant B, Lateef MA, Rousset N, Kendall-Dupont J, Carmona E, Monet F, Saad F, Provencher D, Mes-Masson A-M, Gervais T. Micro-dissected tumor tissues on chip: an ex vivo method for drug testing and personalized therapy. *Lab. Chip.* 2016; 16:312–325.

Bellamy WT. Prediction of response to drug therapy of cancer. A review of in vitro assays. *Drugs* 1992; 44(5):690–708.

Bertotti A, Migliardi G, Galimi F, Sassi F, Torti D, Isella C, Corà D, Di Nicolantonio F, Buscarino M, Petti C, Ribero D, Russolillo N, Muratore A, Massucco P, Pisacane A, Molinaro L, Valtorta E, Sartore-Bianchi A, Risio M, Capussotti L, Gambacorta M, Siena S, Medico E, Sapino A, Marsoni S, Comoglio PM, Bardelli A, Trusolino L. A molecularly annotated platform of patient-derived xenografts identifies HER2 as an

effective therapeutic target in cetuximab-resistant colorectal cancer. *Cancer Discov.* 2011; 1(6):508–23.

Black MM, Kleiner IS, Speer FD. Effects of enzyme inhibitors on in vitro dehydrogenase activity of cancer tissue slices. *Proc. Soc. Exp. Biol. Med.* 1951; 77(4):611–5.

Black MM, Speer FD. Effects of cancer chemotherapeutic agents on dehydrogenase activity of human cancer tissue in vitro. *Am. J. Clin. Pathol.* 1953; 23(3):218–27.

Bounaix Morand du Puch C, Nouaille M, Giraud S, Labrunie A, Luce S, Preux P-M, Labrousse F, Gainant A, Tubiana-Mathieu N, Le Brun-Ly V, Valleix D, Guillaudeau A, Mesturoux L, Coulibaly B, Lautrette C, Mathonnet M. Chemotherapy outcome predictive effectiveness by the Oncogramme: pilot trial on stage-IV colorectal cancer. *J. Transl. Med.* 2016; 14(1):10.

Boyd MR. The NCI In Vitro Anticancer Drug Discovery Screen. In *Anticancer Drug Development Guide* (pp. 23–42). Totowa, NJ: Humana Press; 1997.

Chang TC, Mikheev AM, Huynh W, Monnat RJ, Rostomily RC, Folch A, Folch A. Parallel microfluidic chemosensitivity testing on individual slice cultures. *Lab. Chip.* 2014; 14(23):4540–51.

de Mello A. On-chip chromatography: the last twenty years. *Lab. Chip.* 2002; 2(3):48N–54N.

De Wever O, Mareel M. Role of tissue stroma in cancer cell invasion. *J. Pathol.* 2003; 200(4):429–47.

Ellis LM, Fidler IJ. Finding the tumor copycat: Therapy fails, patients don't. *Nat. Med.* 2010; 16(9):974–975.

Fichtner I, Rolff J, Soong R, Hoffmann J, Hammer S, Sommer A, Becker M, Merk J. Establishment of patient-derived non-small cell lung cancer xenografts as models for the identification of predictive biomarkers. *Clin. Cancer Res.* 2008; 14(20):6456–68.

Ginsburg GS, McCarthy JJ. Personalized medicine: revolutionizing drug discovery and patient care. *Trends Biotechnol.* 2001; 19(12):491–496.

Hirschhaeuser F, Menne H, Dittfeld C, West J, Mueller-Klieser W, Kunz-Schughart LA. Multicellular tumor spheroids: An underestimated tool is catching up again. *J. Biotechnol.* 2010; 148(1):3–15.

Huh D, Hamilton GA, Ingber DE. From 3D cell culture to organs-on-chips. *Trends Cell Biol.* 2011; 21(12):745–754.

Jang K-J, Suh K-Y. A multi-layer microfluidic device for efficient culture and analysis of renal tubular cells. *Lab. Chip.* 2010; 10(1):36–42.

Johnson JI, Decker S, Zaharevitz D, Rubinstein L V, Venditti JM, Schepartz S, Kalyandrug S, Christian M, Arbuck S, Hollingshead M, Sausville EA. Relationships between drug activity in NCI preclinical in vitro and in vivo models and early clinical trials. *Br. J. Cancer* 2001; 84(10):1424–31.

Julien S, Merino-Trigo A, Lacroix L, Pocard M, Goéré D, Mariani P, Landron S, Bigot L, Nemati F, Dartigues P, Weiswald L-B, Lantuas D, Morgand L, Pham E, Gonin P, Dangles-Marie V, Job B, Dessen P, Bruno A, Pierré A, De Thé H, Soliman H, Nunes M, Lardier G, Calvet L, Demers B, Prévost G, Vrignaud P, Roman-Roman S, Duchamp O, Berthet C. Characterization of a Large Panel of Patient-Derived Tumor Xenografts Representing the Clinical Heterogeneity of Human Colorectal Cancer. *Clin. Cancer Res.* 2012; 18(19):5314−28.

Junttila MR, de Sauvage FJ. Influence of tumour micro-environment heterogeneity on therapeutic response. *Nature* 2013; 501(7467):346–354.

Justice BA, Badr NA, Felder RA. 3D cell culture opens new dimensions in cell-based assays. *Drug Discov. Today* 2009; 14(1–2):102–7.

Kane BJ, Zinner MJ, Yarmush ML, Toner M. Liver-specific functional studies in a microfluidic array of primary mammalian hepatocytes. *Anal. Chem.* 2006; 78(13):4291–8.

Kenny PA, Lee GY, Myers CA, Neve RM, Semeiks JR, Spellman PT, Lorenz K, Lee EH, Barcellos-Hoff MH, Petersen OW, Gray JW, Bissell MJ. The morphologies of breast cancer cell lines in three-dimensional assays correlate with their profiles of gene expression. *Mol. Oncol.* 2007; 1(1):84–96.

Keysar SB, Astling DP, Anderson RT, Vogler BW, Bowles DW, Morton JJ, Paylor JJ, Glogowska MJ, Le PN, Eagles-Soukup JR, Kako SL, Takimoto SM, Sehrt DB, Umpierrez A, Pittman MA, Macfadden SM, Helber RM, Peterson S, Hausman DF, Said S, Leem TH, Goddard JA, Arcaroli JJ, Messersmith WA, Robinson WA, Hirsch FR, Varella-Garcia M, Raben D, Wang XJ, Song JI, Tan AC, Jimeno A. A patient tumor transplant model of squamous cell cancer identifies PI3K inhibitors as candidate therapeutics in defined molecular bins. *Mol. Oncol.* 2013; 7(4):776–90.

Khoury M, Bransky A, Korin N, Konak LC, Enikolopov G, Tzchori I, Levenberg S. A microfluidic traps system supporting prolonged culture of human embryonic stem cells aggregates. *Biomed. Microdevices* 2010; 12(6):1001–1008.

Kim E, Xia Y, Whitesides GM. Micromolding in Capillaries: Applications in Materials Science. *J. Am. Chem. Soc.* 1996; 118(24):5722–5731.

Kimura H, Yamamoto T, Sakai H, Sakai Y, Fujii T. An integrated microfluidic system for long-term perfusion culture and on-line monitoring of intestinal tissue models. *Lab. Chip.* 2008; 8(5):741–6.

Lee PJ, Hung PJ, Lee LP. An artificial liver sinusoid with a microfluidic endothelial-like barrier for primary hepatocyte culture. *Biotechnol. Bioeng.* 2007; 97(5):1340–6.

Liu J, Kuznetsova LA, Edwards GO, Xu J, Ma M, Purcell WM, Jackson SK, Coakley WT. Functional three-dimensional HepG2 aggregate cultures generated from an ultrasound trap: Comparison with HepG2 spheroids. *J. Cell. Biochem.* 2007; 102(5):1180–1189.

Manz A, Graber N, Widmer HM. Miniaturized total chemical analysis systems: A novel concept for chemical sensing. *Sensors Actuators B Chem.* 1990; 1(1–6):244–248.

Manz A, Miyahara Y, Miura J, Watanabe Y, Miyagi H, Sato K. Design of an open-tubular column liquid chromatograph using silicon chip technology. *Sensors Actuators B Chem.* 1990; 1(1–6):249–255.

Marangoni E, Vincent-Salomon A, Auger N, Degeorges A, Assayag F, de Cremoux P, de Plater L, Guyader C, De Pinieux G, Judde J-G, Rebucci M, Tran-Perennou C, Sastre-Garau X, Sigal-Zafrani B, Delattre O, Diéras V, Poupon M-F. A new model of patient tumor-derived breast cancer xenografts for preclinical assays. *Clin. Cancer Res.* 2007; 13(13):3989–98.

Mathies RA, Huang XC. Capillary array electrophoresis: an approach to high-speed, high-throughput DNA sequencing. *Nature* 1992; 359(6391):167–169.

Morgan MM, Johnson BP, Livingston MK, Schuler LA, Alarid ET, Sung KE, Beebe DJ. Personalized in vitro cancer models to predict therapeutic response: Challenges and a framework for improvement. *Pharmacol. Ther.* 2016;165:79-92.

Pak C, Callander NS, Young EWK, Titz B, Kim K, Saha S, Chng K, Asimakopoulos F, Beebe DJ, Miyamoto S. MicroC ^{3}: an ex vivo microfluidic cis-coculture assay to test

chemosensitivity and resistance of patient multiple myeloma cells. *Integr. Biol.* 2015; 7(6):643–654.

Pampaloni F, Reynaud EG, Stelzer EHK. The third dimension bridges the gap between cell culture and live tissue. *Nat. Rev. Mol. Cell Biol.* 2007; 8(10):839–845.

Park J, Koito H, Li J, Han A. Microfluidic compartmentalized co-culture platform for CNS axon myelination research. *Biomed. Microdevices* 2009; 11(6):1145–53.

Reyal F, Guyader C, Decraene C, Lucchesi C, Auger N, Assayag F, De Plater L, Gentien D, Poupon M-F, Cottu P, De Cremoux P, Gestraud P, Vincent-Salomon A, Fontaine J-J, Roman-Roman S, Delattre O, Decaudin D, Marangoni E. Molecular profiling of patient-derived breast cancer xenografts. *Breast Cancer Res.* 2012; 14(1):R11.

Ruppen J, Cortes-Dericks L, Marconi E, Karoubi G, Schmid RA, Peng R, Marti TM, Guenat OT. A microfluidic platform for chemoresistive testing of multicellular pleural cancer spheroids. *Lab Chip* 2014; 14(6):1198–1205.

Ruppen J, Wildhaber FD, Strub C, Hall SRR, Schmid RA, Geiser T, Guenat OT. Towards personalized medicine: chemosensitivity assays of patient lung cancer cell spheroids in a perfused microfluidic platform. *Lab. Chip.* 2015; 15(14):3076–3085.

Sadlonova A, Novak Z, Johnson MR, Bowe DB, Gault SR, Page GP, Thottassery J V, Welch DR, Frost AR. Breast fibroblasts modulate epithelial cell proliferation in three-dimensional in vitro co-culture. *Breast Cancer Res.* 2005; 7(7):R46.

Sato T, Vries RG, Snippert HJ, van de Wetering M, Barker N, Stange DE, van Es JH, Abo A, Kujala P, Peters PJ, Clevers H. Single Lgr5 stem cells build crypt–villus structures in vitro without a mesenchymal niche. *Nature* 2009; 459(7244):262–265.

Shield K, Ackland ML, Ahmed N, Rice GE. Multicellular spheroids in ovarian cancer metastases: Biology and pathology. *Gynecol. Oncol.* 2009; 113(1):143–148.

Song JW, Cavnar SP, Walker AC, Luker KE, Gupta M, Tung Y-C, Luker GD, Takayama S. Microfluidic Endothelium for Studying the Intravascular Adhesion of Metastatic Breast Cancer Cells. *PLoS One* 2009; 4(6):e5756.

Sung KE, Su X, Berthier E, Pehlke C, Friedl A, Beebe DJ. Understanding the Impact of 2D and 3D Fibroblast Cultures on In Vitro Breast Cancer Models. *PLoS One* 2013; 8(10):e76373.

Terry SC, Jerman JH, Angell JB. A gas chromatographic air analyzer fabricated on a silicon wafer. *IEEE Trans. Electron Devices* 1979; 26(12):1880–1886.

Thomlinson RH, Gray LH. The histological structure of some human lung cancers and the possible implications for radiotherapy. *Br. J. Cancer* 1955; 9(4):539–49.

Torisawa Y, Takagi A, Nashimoto Y, Yasukawa T, Shiku H, Matsue T. A multicellular spheroid array to realize spheroid formation, culture, and viability assay on a chip. *Biomaterials* 2007; 28(3):559–66.

van Midwoud PM, Groothuis GMM, Merema MT, Verpoorte E. Microfluidic biochip for the perifusion of precision-cut rat liver slices for metabolism and toxicology studies. *Biotechnol. Bioeng.* 2010; 105(1):184–194.

Venditti JM, Wesley RA, Plowman J. Current NCI Preclinical Antitumor Screening in Vivo: Results of Tumor Panel Screening, 1976–1982, and Future Directions. *Adv. Pharmacol.* 1984; 20:1–20.

Weiswald L-B, Bellet D, Dangles-Marie V. Spherical Cancer Models in Tumor Biology. *Neoplasia* 2015; 17(1):1–15.

Whitesides GM. The origins and the future of microfluidics. *Nature* 2006; 442(7101):368–373.

Whitesides GM, Ostuni E, Takayama S, Jiang X, Ingber DE. Soft Lithography in Biology and Biochemistry. *Annu. Rev. Biomed. Eng.* 2001; 3(1):335–373.

Woolley AT, Mathies RA. Ultra-high-speed DNA fragment separations using microfabricated capillary array electrophoresis chips. *Proc. Natl. Acad. Sci. U. S. A.* 1994; 91(24):11348–52.

Xu Z, Gao Y, Hao Y, Li E, Wang Y, Zhang J, Wang W, Gao Z, Wang Q. Application of a microfluidic chip-based 3D co-culture to test drug sensitivity for individualized treatment of lung cancer. *Biomaterials* 2013; 34(16):4109–4117.

Yamada KM, Cukierman E. Modeling Tissue Morphogenesis and Cancer in 3D. *Cell* 2007; 130(4):601–610.

You L, Temiyasathit S, Lee P, Kim CH, Tummala P, Yao W, Kingery W, Malone AM, Kwon RY, Jacobs CR. Osteocytes as mechanosensors in the inhibition of bone resorption due to mechanical loading. *Bone* 2008; 42(1):172–9.

Young EWK, Beebe DJ. Fundamentals of microfluidic cell culture in controlled microenvironments. *Chem. Soc. Rev.* 2010; 39(3):1036–48.

Zhang X, Claerhout S, Prat A, Dobrolecki LE, Petrovic I, Lai Q, Landis MD, Wiechmann L, Schiff R, Giuliano M, Wong H, Fuqua SW, Contreras A, Gutierrez C, Huang J, Mao S, Pavlick AC, Froehlich AM, Wu MF, Tsimelzon A, Hilsenbeck SG, Chen ES, Zuloaga P, Shaw CA, Rimawi MF, Perou CM, Mills GB, Chang JC, Lewis MT. A renewable tissue resource of phenotypically stable, biologically and ethnically diverse, patient-derived human breast cancer xenograft models. *Cancer Res.* 2013; 73(15):4885–97.

In: Encyclopedia of Surgery (22 Volume Set)
Editors: Andreas Lehrer and Kristin Mueller
ISBN: 978-1-53618-329-0
© 2020 Nova Science Publishers, Inc.

Chapter 193

OF MICE AND RATS: ANIMAL MODELS FOR USE IN LAPAROSCOPY AND LAPAROTOMY WITH HUMAN OVARIAN CANCER CELL LINE INTRAPERITONEAL XENOGRAFTS

Philippe Sauthier[1,2,3,*], MD, Anne-Marie Mes-Masson[1,2,4], PhD, Louise Champoux[1,2], Michèle Bally[1], PhD and Diane M. Provencher[1,2,3], MD

[1]Centre de recherche du Centre hospitalier de l'Université de Montréal (CRCHUM), Montreal, Canada
[2]Institut du Cancer de Montréal, Montreal, Canada
[3]Department of Obstetrics and Gynecology, Division of Gynecologic Oncology, Université de Montréal, Montreal, Canada
[4]Department of Medicine, Université de Montréal, Montreal, Canada

ABSTRACT

Experimental models of human diseases are crucial not only for understanding the biological and genetic factors that influence the phenotypic characteristics of the disease but also for developing rational intervention strategies. These models often require trial and error adaptation for which limited guidance exists; for example in epithelial ovarian cancer (EOC), a human disease characterized by intraperitoneal dissemination. In this chapter, we provide a detailed stepwise methodology that facilitates laparoscopic or laparotomy approaches in rodent models with EOC xenograft and report outcomes of our experiments.

We compared two immunocompromised rodent intraperitoneal xenograft models for their suitability for laparoscopic or laparotomy techniques. Intraperitoneal xenografts were obtained by injecting nude rats (HSD: RH−*rnu*) with one of the three human EOC cell lines (TOV−112D, TOV−21G, SKOV−3) and nude mice (SWISS−CD−1) with TOV−112D. Laparoscopy or laparotomy was performed using a customized operating

* Corresponding Author's Email: philippe.sauthier@umontreal.ca; Fax: (514) 412−7604.

table. Rats and mice developed intraperitoneal macroscopic tumors within 2 to 3 months after injection. In some animals, these were associated with hemorrhagic ascites. Anesthesia, when measured by the number of injections, was more difficult in mouse than in rat laparoscopies and, in both animals, an incisional hernia was sometimes observed. The rat tolerated and survived surgical laparoscopy or laparotomy. In contrast, the mouse was more fragile perioperatively, the number of surgical acts was more limited and survival rate was lower. While the nude mouse was most cost−effective, requiring less operative time and smaller volumes of anesthetic. Our results suggest that the nude rat is better suited to oncological experimentation that involves laparotomy or laparoscopy. Further studies are needed to confirm whether the biological characteristics of the disease are similar in rat and mouse models.

Keywords: ovarian cancer, xenograft, rodent models, laparoscopy, laparotomy

INTRODUCTION

Laparoscopic surgery has been applied in oncology for several years. It has remained controversial in animal models as in clinical practice (Dargent 2000; Hopkins 2000; Canis 2001), although in the last two decades it has gained acceptance in defined clinical settings (Barakat 2013). A number of studies have demonstrated the feasibility of this technique, particularly in human epithelial ovarian cancer (EOC) (Deffieux 2006; Nezhat 2013). Laparoscopy can offer highly satisfactory surgical staging of cancer, including human EOC (Pomel 1995; Pratt 2000). The main concerns with laparoscopy have been the implantation of tumors in trocar puncture sites (Childers 1994), peritoneal carcinomatosis (Fondrinier 2002; Ramirez 2003), modification of tumor growth parameters, and the influence of the laparoscopic environment (CO2) (LeMoine 1998; Shen 2008). A low rate (1%) of parietal implantation was found in early work (Childers 1994) but further studies found variable rates ranging from 1% up to 18% (Ramirez 2003; Curet 2004; Vergote 2005). Of note, over 100 cases of parietal metastases have been reported in the literature after laparoscopic cholecystectomy (Martinez 1995). In gynecological oncology, such metastases have been documented with invasive ovarian cancer (Hopkins 2000), borderline ovarian tumors (Morice 2004), cancer of the cervix (Agostini 2003), cancer of the endometrium (Sanjuan 2005) and even after laparoscopic surgery for benign disease (benign implants) (Carlson 2002). Nevertheless, some would argue that the presence of parietal metastases after laparoscopy or after paracentesis for ovarian cancer in human seems to have no significant impact on survival (Kruitwagen 1996; Vergote 2005).

In an ovarian cancer animal model, the surgical wound resulting from laparoscopy was suggested to induce little surgical stress on enhancing tumor growth compared with laparotomy, possibly because it minimally influences the secretion of VEGF (Vascular Endothelial Growth Factor) and MMP2 (Matrix Metalloproteinases) (Lee 2013). Moreover, in a rat ovarian cancer model, peritoneal closure is reported to reduce port site metastases (Agostini 2002).

Numerous hypotheses have been put forward for explaining wound or port site implants which implicate immune responses, pneumoperitoneum (Lecuru 2002), carbon dioxide (CO2), tumoral laceration, smoke, water vapor and contaminated instruments (Brundell 2002; Ramirez 2003; Curet 2004). However tumor implantation was not affected by CO2, helium,

or nitrous oxide gas in an animal model. Thus, CO2 insufflation does not appear to increase tumor spread compared with other gasses (Agostini 2002; Hopkins 2002). Further characterization of this phenomenon can only be carried out with an animal model (Canis 1998; Agostini 2001; Lecuru 2001; Bourdel 2008). Use of experimental models for laparoscopy has been reviewed (Canis 2000). The models that are traditionally used are large, (Volz 1996) thereby reproducing conditions of human surgery, including instruments. However these models are expensive and immune-competent and therefore they may reject human tumoral transplants (Reymond 2000). Several immune-incompetent animal models have been developed, such as the nude mouse, the nude rat and the nude rabbit (Hajduch 1992). From an oncological viewpoint, the nude mouse is well characterized, whereas the rat is far less so and the rabbit not at all. Laparoscopy in the rat has been studied for colic resection (Allendorf 1997), rectal tumor resection (Braumann 2008), retroperitoneal dissection (Sandoval 1996) and cecum ligature (Berguer 1997). The metabolic effect of this type of surgery has been described in detail in the rat (Bouvy 1996). In summary, the rat has become an interesting surgical model, primarily owing to its lower cost than that of large animals.

A few animal models develop ovarian tumors spontaneously (Vanderhyden 2003). Intraperitoneal or sub-cutaneous xenograft models have been described for a mouse adenocarcinoma in the previously immune-incompetent rat (Rose 1996), an ovarian adenocarcinoma in a rat of the same species (Sugiyama 1990) and for ovarian tumors of human origin (Sawada 1982; Lecuru 2001; Rubin 2003). The influence of laparoscopy on the tumoral intra-abdominal behavior in the rat was studied after the implantation of mammary cancer (Mathew 1996) and adenocarcinoma of the colon (Jacobi 1997). Likewise, an intraperitoneal xenograft model in the mouse that mimics the dynamic progression of human ovarian cancer might provide a valuable surrogate for studying the biological properties of ovarian cancer as well as for testing new therapeutic strategies in preclinical trials (Lin 2007). In human EOC, a large number of cell lines have been sourced from patient samples, although only a small number is derived solely from chemotherapy- and radiation therapy-naïve women. Our laboratory has previously described such cell lines, which were obtained from solid tumors and readily formed tumors in mice (Provencher 2000). We report details of our procedure for conducing laparoscopy or laparotomy in xenograft rodent models with EOC as well as our findings.

METHODS

Animals

Following approval by the local Institutional Review Board and the Comité Institutionel de la Protection des Animaux (CIPA) animal care guidelines, rodents such as female (Swiss−CD−1) nude mice (Charles Rivers Laboratories) and female (Hsd:RH−*rnu)* nude rats (Harlan Sprague Dawley Laboratories) were maintained on site at the Hôpital Notre-Dame animal facilities. These rats have a non-functional cystic thymus and accept allografts and xenografts.

Mice were housed in groups of five and rats in groups of four. All animals were acclimatized to a sterile environment controlled for temperature and light cycle. They had access to adequate food and water ad libitum. Tumor cell injections were performed when attained weight was 30 grams in mice and 60 grams in rats. At the time of their surgery, mice weighed approximately 50 grams whereas rats weighed about 200 grams. An ear punch allowed identification and surveillance of each animal.

All animals were clinically evaluated twice weekly and observed for 12 weeks or until there were obvious clinical signs of a tumor. Euthanasia was practiced on animals at 12 weeks or when tumors were larger than 1 cm on clinical examination. During autopsy, the tumors, as well as the trocar and laparotomy scar tissues were excised for pathological analysis (Figure 1a,b).

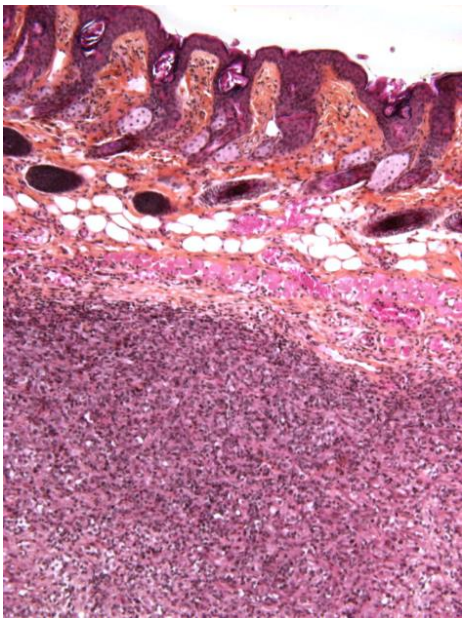

(a)

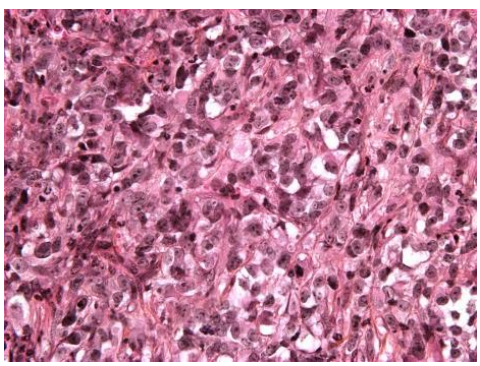

(b)

Figure 1a,b. (a) Undifferentiated carcinoma in the scar tissue (low-magnification) and (b) undifferentiated carcinoma in the scar tissue (high-magnification).

Human EOC Cell Lines Preparation and Injection

We grew and prepared TOV-21G and TOV-112D EOC cell lines obtained from chemotherapy- and radiotherapy-naïve patients, as previously reported (Provencher 2000). Briefly, TOV-112D was derived from an aggressive FIGO Stage IIIc grade 3 endometrioid adenocarcinoma. TOV-21G was established from a less aggressive FIGO IIIc clear cell carcinoma. The SKOV-3 EOC cell line was derived from ascitic cells of a patient with an ovarian adenocarcinoma previously treated with Thiotepa and obtained from American Type Culture Collection. Before their injection in rodents, tumor cells were diluted in phosphate-buffered saline with a pH of 7.4 containing Mg+ but without Ca++ in a volume of 1 ml for the rats and 0.5 ml for the mice. A total of 14 mice were injected at passage (p66) with 10^6 cells from the TOV-21G cell line as described earlier (Provencher 2000). Rats were injected with one of the three tumoral cell lines. Either 10^6 or 10^7 cells were injected in order to determine optimum seeding of tumors in the rat model. Six (6) rats were injected with TOV-112D cells at passage (p74), 6 were injected with TOV-21G at passage (p56), and 2 were injected with SKOV-3. Intraperitoneal tumor growth was assessed by clinical observation of rodent abdominal distension, which guided the appropriate time for surgery.

EQUIPMENT

Operating Table

We custom built a laparoscopic table for small animals. It is adapted to the size of the animal, its height can be modified, and unlike commercially available laparoscopic tables, it allows for a variable Trendelenburg position (Figure 2a,b and c). Furthermore, this laparoscopic table is equipped with an optical system that can be fixed to reduce the interference caused by hand shaking movements and it enables one sole operator to work in a sterile environment.

(a)

Figure 2a,b,c. (Continued).

(b)

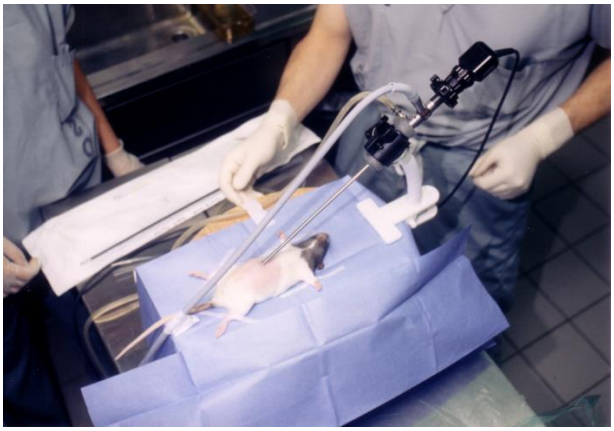

(c)

Figure 2a,b,c. (a) Operating table in horizontal position; (b) operating table in Trendelenburg position and (c) operating table in action.

Laparoscopy

Surgical laparoscopy was carried out with a conventional system. This consisted of a monitor (Trinitron™, Sony™), a cold light source (Xenon 611™, Karl Storz™), a CO2 insufflator (Cabot Medical™), a camera (Autoexposure™, Karl Storz™), and an optical system with a diameter of 5 mm angled at 30 (Karl Storz™). Alternatively we also tested optical systems of 2 mm and 5 mm in diameter (Origin System). In addition, the instruments for laparoscopic surgery comprised a pair of scissors, prehensile and biopsy forceps, 1.7 mm in diameter (Origin System). We also used #15 scalpel blades, 3-0 absorbable sutures (Vicryl, Ethicon) and non-absorbable sutures (Surgilon™, Davis+Geck™), cutaneous sutures (Steristrips Skin Closures™, 3M™), 22G catheters (Jelco™, Critikon™), compresses, and 1 ml syringes with 26G needles.

PROCEDURE

Anaesthesia

All surgeries were done in a sterile environment. Slow anesthesia was performed on the animals over 15 to 30 minutes. For rats, Pentobarbital 50 mg/kg was given intraperitoneally for induction, and additional doses of 25 mg/kg were injected as necessary. For mice, a combination of Ketamine 100 mg/kg, Xylazine 10 mg/kg and Acepromazine 0.1 mg/kg was administered by intraperitoneal injection, repeating the injection with half the dose as maintenance. Control of the anesthesia was carried out by pinching a hind paw, then observing the animal reactions and monitoring respiratory movements. As soon as the anesthesia was deemed sufficient, the animal was laid out on its back with its forelegs splayed out at right angles and attached with cutaneous sutures (Steristrips™). This procedure was intended to verify for perioperatory respiratory failure.

Laparoscopy

The initial pneumoperitoneum was induced by means of a 22G catheter in the abdominal right lower quadrant of the animal with a CO2 air flow controlled at 3 to 5 mm Hg. A bursa, 4 mm in diameter and 1 cm below the xiphoid appendix, was created, supported with a 3-0 absorbable suture. The abdominal wall was then incised with a #15 scalpel blade at the centre of the bursa and the optical system was rapidly introduced. The bursa was tightened with a simple knot to ensure that there was no leak. The insufflation system was then fixed to the optical system allowing the surgical instruments to be introduced under direct vision, without trocar, laterally in the left and right iliac fossae. They were made impermeable by an identical bursa to that of the optical system. After the surgery, the instruments were withdrawn while still under direct vision and the bursae were closed. An analgesic (Buprenorphine 0.1 mg/kg) was injected subcutaneously immediately postoperatively and 24 hours later for pain control.

Laparotomy

Laparotomies were carried out with the same operative table under the same anesthesia protocol. In each case, a xyphopubic median incision was made with a cold knife #15 blade. The wound was closed with a continuous plane sunk suture with a 3-0 non-absorbable suture.

Surgery

Surgery, whether by laparotomy or laparoscopy, entailed the observation of the intra-abdominal tumor spread status and the tumor was manipulated and resected when possible. The extent of the tumoral invasion was evaluated according to the peritoneal cancer indexes described by Chauffert (PCIC) (Chauffert 1992) and Eggermont (PICE) (Eggermont 1988) (Table 29.2).

RESULTS

Intraperitoneal xenografts were successfully initiated by injecting one of the three human EOC cell lines (TOV-112D, TOV-21G, SKOV-3) to 14 nude rats (Hsd:RH-*rnu*) and the TOV-21G cell line to 14 nude mice (SWISS-CD-1).

All animals survived the initial tumoral injection but one rat, injected with 10^7 TOV-21G cells, had to be sacrificed early due to rapid and excessive tumor spread. Over the observation period, a total of 6 rats and 2 mice developed an intraperitoneal macroscopic tumor with 6 rats and 5 mice also having a hemorrhagic ascite. At the time of surgery, only 4 rats and 1 mouse had developed a tumor. All tumors were macroscopic with an index of 2 to 3 on the PCIC and PCIE. These tumors appeared in the rat on average 63.5 days after the injection of TOV-112D, 97.3 days after the injection of TOV-21G, and 75 days after the injection of SKOV-3 – for an overall mean induction time of 82.3 days (range of 52 to 150 days). In the mouse, the time to development of tumors was on average 83.5 days (range of 58 to 109 days) after the injection of TOV- 21G.

Laparotomies were carried out on 6 rats and 7 mice and laparoscopies on 7 rats and 7 mice. In rats, laparotomy had a mean duration of 15.8 minutes and required a mean anesthetic volume of 0.38 ml/animal and a mean of 2.0 injections/animal whereas laparoscopy had a mean duration of 16.9 minutes and required a mean anesthetic volume of 0.44 ml/animal and a mean of 2.1 injections/ animal. In mice, the comparative mean anesthetic volumes and mean injections required were 0.13 ml and 1.7 injection/animal and 0.21 ml and 2.3 injection/animal, respectively for laparotomy and laparoscopy. Laparotomy took 9.1 minutes on average and laparoscopy 13.4 minutes in mice. The per-operative characteristics are summarized in Table 1.

The post-operative observation of animals with tumors at the time of surgery showed progression in 5 out of 7 cases and one case of total spontaneous remission. The existence of tumors in the scar tissue was only confirmed histologically in two cases, in mice operated by laparoscopy. None of these two mice showed signs of visible macroscopic tumors but all had ascites. The analysis of the extracted tumors confirmed the existence of extremely undifferentiated carcinomas. The characteristics and the analysis of the tumors in the scar tissue are shown in (Figure 1a and b) and tumor evaluation after laparoscopy or laparotomy are summarized in Table 2.

Complications occurred resulting in the death of one mouse, after laparoscopy, immediately post−operatively with no obvious cause at autopsy. One rat was found dead 72 hours after laparotomy and 2 mice died on the 4th and 6th day after the operation, one for no identifiable reason and the other from complete evisceration**.** Several post-cicatrical hernias were observed over time. One rat developed a hernia in the 12 hours following the operation. It was treated surgically the following day, but reoccurred several days later. Neither infections nor bleeding were observed. One mouse developed articular swelling of an unknown origin that regressed spontaneously. Another mouse showed signs of cutaneous discoloring with bluish stripes developing over its back. Post-operative evolution is summarized in Table 2.

Table 1. Types of tumoral lines, number (#) of animals with presence of tumor or ascites and surgical parameters

	Rat model										Mouse model	
Lines	TOV−112D				TOV−21G				SKOV−3		TOV−21G	
Operation	LAP		LSC		LAP		LSC		LAP	LSC	LAP	LSC
Number of animals	2	1	2	1	2*	1	2	1	1	1	7	7
Number of cells/injection	10^7	10^6	10^7	10^6	10^7	10^6	10^7	10^6	10^7	10^7	10^6	10^6
Number of animals with tumor at time of surgery	2	0	0	0	0	1	0	0	0	1	1	0
Number of animals with ascites at time of surgery	0	0	0	0	0	0	2	1	0	0	0	4
Number of animals with cicatrical tumor	0	0	0	0	0	0	0	0	0	0	0	2
Total number of animals with tumors (at time of surgery or at autopsy)	2	0	0	0	1*	1	1	0	0	1	2	0
Total number of animals with ascites (at time of surgery or at autopsy)	0	1	1	1	0	0	2	0	1	0	0	5
Mean number of injections of anesthetic during surgery	2.0		2.1		2.0		2.1		2.0	2.1	1.7	2.3
Mean duration of surgery by type and by cell line (min)	15.8		16.9		15.8		16.9		15.8	16.9	9.1	13.4
Mean volume of anesthetic injected by surgery type and cell line (ml/animal)	0.38		0.44		0.38		0.44		0.38	0.44	0.13	0.21
Number of deaths <48 h of surgery by surgery type and cell line	0		0		0		0		0	0	0	1
Number of deaths > 48 h after surgery by surgery type and cell line	1		0		0		0		0	0	2	0
Number of animals with hernia by surgery type and cell line	1		1		1		0		1	0	0	2

LAP = laparotomy; LSC = laparoscopy.

* One rate was sacrificed.

Table 2. Evolution of the models and characteristics of the tumors

Animal #	Lines	No	PCIC[1]	PCIE[2]	Time [days]	Evolution	Death	Time of post− operative death
Rat #3	TOV−112D	10^7	2	2	75	Unknown	Spontaneous	48 h
Rat #5	TOV−112D	10^7	2	2	52	Remission	Autopsy	12th week
Rat #9	TOV−21G	10^7	3	3	67	Progression	Autopsy	No operation
Rat #12	TOV−21G	10^7	2	2	150	Progression	Autopsy	12th week
Rat #7	TOV−21G	10^6	1	1	75	Progression	Autopsy	12th week
Rat #14	SKOV−3	10^7	3	3	75	Progression	Autopsy	2nd week
Mouse #2	TOV−21G	10^6	1	1	58	Progression	Autopsy	4th week
Mouse #3	TOV−21G	10^6	2	2	109	Progression	Autopsy	8th week

[1] Peritoneal Cancer Index of Chauffert (PCIC):

[2] Peritoneal Cancer Index of Eggermont (PCIE):

[0] = No tumour 1 = Tumoral nodule < 1 mm.

[2] = Tumoral nodule > 1 mm 3 = Diffuse carcinomatosis with ascite.

[0] = No tumour.

[1] = Nodule of between 1 and 3 mm 2 = Moderate tumour 3 = Abundant tumour replacing the cavity.

DISCUSSION

We described our methods for successful EOC xenograft models amenable to either laparotomy or laparoscopy in rodents. We encountered no problems for injecting animals with tumoral lines extracted from untreated solid ovarian human tumors and animals withstood cell line injection well. The observation of cutaneous discoloring with bluish stripes in one of the mice remains unexplained, however this phenomenon was also observed in an earlier study (Provencher 2000). General anesthesia by subcutaneous injection is preferred by others to avoid any kind of interference with tumor development (Lecuru 2001). Anesthesia posed no particular problem in the rat, neither in laparoscopy nor in laparotomy. The total quantity of anesthetic and number of injections per rat were comparable. In the mouse, the anesthesia was particularly difficult when performing laparoscopy, as evidenced by a high number of re−injections and mean anesthetic volume that was almost twice as high compared with that needed for laparotomy. Nonetheless, mice required smaller anesthetic volumes than rats overall.

As the dimensions of the abdominal cavity in the mouse are small, the number of acts and manipulations remains very limited despite using instruments of 1.7 mm in diameter. We tested an optical system 2 mm in diameter, which frequently had to be repositioned due to its restricted visual field. Nonetheless, this optical system can be useful in diagnostic laparoscopy. The use of a 5 mm optical system and thus vision that extends over the entire pelvic cavity is possible in the rat.

Coagulation attempts with monopolar instruments were carried out and were feasible as long as an isolated 2 mm trocar was used (Veress needle).

Postoperative complications are more serious in mice than in rats. Our results in the rat were similar to those reported by Canis (Canis 1998). The frequently observed incisional hernias are probably explained by the fact that the animals are able to access their abdominal sutures. They can chew and tear off their sutures or their clips. For this reason, it would be preferable to close the wounds without suture material (sutures or clips), possibly using biological glue.

The tumors developed after the injection of 10^7 cells and it appears that this concentration is a minimal concentration required to induce tumors in this animal model. In his study, Rubin (1993) injected 4×10^7 to 2.5×10^9 cells per animal of the SKOV-3 and SKOV-7 lines and Lecuru (2001) injected 27×10^6 IGR-OV1 and 36×10^6 NIH: OVCAR-3 cells per animal. As the volume injected is already 1 ml (maximum injectable intraperitoneal volume tolerated by the rat), we felt that the viscousness would be too high if the number of cells were to exceed 10^7. It would seem preferable to inject 10^7cells and to repeat the injection 48 hours later. This warrants further consideration.

All the tumors in the rats were sizeable as confirmed by the intraperitoneal cancer indexes, PCIC and PCIE (Table 29.2). They appeared after a relatively long time after injection (mean of 82.3 days in the rats and 83.5 days in the mice). This is significantly longer than in the IGR-OV1 model (7−21 days) and even in the NIH: OVCAR-3 model (14−21 days) (Lecuru 2001). This parameter is important to consider when planning studies of this kind. The rat, contrary to the mouse, tolerates the growth of intraperitoneal tumors well. This enabled us to stagger the surgery, sometimes by a few days, which may be of practical use. In contrast, for mice, abdominal distension quickly progressed to serious deterioration of the

animal condition translating into a need for emergency surgery. In rodents the distribution of intraperitoneal tumors was similar to that observed in women with EOC. It should be noted that surgery consisted of a close examination of the cavity and that maximal cytoreduction could only be carried out in a few cases. The examination of the abdominal cavity was more precise with laparoscopy.

Tumoral implants were sometimes found in the laparoscopy incision scars in the mice (Figure 1a and b). These mice showed no signs of visible tumors but had ascites. No rats developed tumors in any incision sites in our pilot study. The number of animals studied is too small to draw conclusions but the presence of tumoral ascite has already been evoked as a factor that favors parietal tumoral implants (Kruitwagen 1996).

The nude rat therefore seems more robust as a model of human ovarian cancer and could enable an in−depth study of the influence of laparoscopy on the *in vivo* and *ex vivo* behavior of tumoral lines. Using rats involves a greater infrastructure in terms of animal husbandry and a higher daily cost. These factors need to be taken into consideration as the animals are generally housed in small sterile units. Furthermore, the acquisition cost of nude rats is higher than that of nude mice.

The operating table we custom built enabled us to carry out all required laparoscopic acts we wanted in a sterile environment. Its size is well adapted to the height of the animals and the adjustable Trendelenburg position was extremely useful allowing leverage for manipulation of the instruments (Figure 1a, b and c). The camera being fixed, enables stability while providing gentle rotation to visualize the specific operating field. In this respect, our custom table may offer an advantage over the existing commercial operating table (Kaps Co., Frankfurt, Germany™) (Berguer 1997).

CONCLUSION

The use of laparoscopy in oncology today raises certain concerns and requires more detailed investigations. Our experience suggests that the nude rat is a good animal model of human epithelial ovarian cancer. Animals tolerate laparoscopy and laparotomy well and have a high survival rate. Although it is better characterized from an oncological point of view, the nude mouse has proved to be less reliable in terms of tumor growth in our study. Most importantly, it is more fragile perioperatively and its overall survival is not as good as that of the rat. Furthermore, the restricted size of this animal greatly limits the surgical acts as surgical instruments are not very well adapted for this type of animal despite recent development of operating tables for laparoscopy on small animals. The nude rat, therefore, currently appears to be the ideal model for studying the concept of laparoscopy in oncology. Nevertheless, more in-depth studies are needed to fully characterize the biology of xenograft EOC tumorigenesis in the rat.

FUNDING

This project was possible thanks to the support of the Jocelyne Gauvin research fund.

REFERENCES

Agostini A, Robin F, Aggerbeck M, Jais JP, Blanc B, Lecuru F. Influence of peritoneal factors on port− site metastases in a xenograft ovarian cancer model. *BJOG* 2001; 108(8):809−812.

Agostini A, Robin F, Jais JP, Aggerbeck M, Vildé F, Blanc B, Lécuru F. Impact of different gases and pneumoperitoneum pressures on tumor growth during laparoscopy in a rat model. *Surg. Endosc*. 2002; 16(3):529−532.

Agostini A, Robin F, Jais JP, Aggerbeck M, Vildé F, Blanc B, Lécuru F. Peritoneal closure reduces port site metastases: results of an experiment in a rat ovarian cancer model. *Surg. Endosc.* 2002; 16(2): 289−291.

Agostini A, Carcopino X, Franchi F, Cravello L, Lecuru F, Blanc B. Port site metastasis after laparoscopy for uterine cervical carcinoma. *Surg. Endosc.* 2003; 17(10):1663−1665.

Allendorf JD, Bessler M, Whelan RL. A murine model of laparoscopic−assisted intervention. *Surg. Endosc.* 1997; 11(6):622−624.

Barakat RR, Berchuck A, Markman M, Randall ME. *Principles and Practice of Gynecologic Oncology*. 6th edition. Philadelphia: Williams and Wilkins. 2013.

Berguer R, Alarcon A, Feng S, Gutt C. Laparoscopic cecal ligation and puncture in the rat. Surgical technique and preliminary results. *Surg. Endosc.* 1997; 11(12):1206−1208.

Bourdel N, Matsuzaki S, Bazin JE, Darcha C, Pouly JL, Mage G, Canis M. Postoperative peritoneal dissemination of ovarian cancer cells is not promoted by carbon−dioxide pneumoperitoneum at low intraperitoneal pressure in a syngenic mouse laparoscopic model with controlled respiratory support: a pilot study. *J. Minim. Invasive. Gynecol*. 2008; 15(3):321−326.

Bouvy ND, Marquet RL, Hamming JF, Jeekel J, Bonjer HJ. Laparoscopic surgery in the rat. Beneficial effect on body weight and tumor take. *Surg. Endosc.* 1996; 10(5):490−494.

Braumann C, Balague C, Guenther N, Menenakos C, Jacobi CA. Application of a solid tumor model to evaluate tumor recurrence after an open or laparoscopic rectal resection in rats. *Surg. Laparosc. Endosc. Percutan. Tech.* 2008; 18(4):348−352.

Brundell SM, Tucker K, Texler M, Brown B, Chatterton B, Hewett PJ. Variables in the spread of tumor cells to trocars and port sites during operative laparoscopy. *Surg. Endosc*. 2002; 16(10):1413−1419.

Canis M, Botchorishvili R, Wattiez A, Mage G, Pouly JL, Bruhat MA. Tumor growth and dissemination after laparotomy and CO2 pneumoperitoneum: a rat ovarian cancer model. *Obstet. Gynecol.* 1998; 92(1):104−108.

Canis M, Botchorishvili R, Wattiez A, Pouly JL, Mage G, Manhes H, et al. Cancer and laparoscopy, experimental studies: a review. *Eur. J. Obstet. Gynecol. Reprod. Biol.* 2000; 91(1):1−9.

Canis M, Rabischong B, Botchorishvili R, Tamburro S, Wattiez A, Mage G, Pouly JL, Bruhat MA. Risk of spread of ovarian cancer after laparoscopic surgery. *Curr. Opin. Obstet. Gynecol.* 2001; 13(1): 9−14.

Carlson NL, Krivak TC, Winter WE, 3rd, Macri CI. Port site metastasis of ovarian carcinoma remote from laparoscopic surgery for benign disease. *Gynecol Oncol* 2002;85(3): 529−531.

Chauffert B, Dimanche−Boitrel MT, Genne P, Petit JM, Onier N, Jeannin JF. [Experimental chemotherapy of peritoneal carcinomatosis of colonic origin in rats]. *Gastroenterol. Clin. Biol.* 1992; 16(3):215−219.

Childers JM, Aqua KA, Surwit EA, Hallum AV, Hatch KD. Abdominal−wall tumor implantation after laparoscopy for malignant conditions. *Obstet. Gynecol.* 1994; 84(5):765−769.

Curet MJ. Port site metastases. *Am. J. Surg.* 2004; 187(6):705−712.

Dargent D. [Laparoscopic surgery in gynecologic oncology]. *J. Gynecol. Obstet. Biol. Reprod.* (Paris) 2000; 29(3):282−284.

Deffieux X, Castaigne D, Pomel C. Role of laparoscopy to evaluate candidates for complete cytoreduction in advanced stages of epithelial ovarian cancer. *Int. J. Gynecol. Cancer.* 2006; 16 Suppl 1:35−40.

Eggermont AM, Steller EP, Marquet RL, Jeekel J, Sugarbaker PH. Local regional promotion of tumor growth after abdominal surgery is dominant over immunotherapy with interleukin−2 and lymphokine activated killer cells. *Cancer Detect. Prev.* 1988; 12(1−6):421−429.

Fagotti A, Ferrandina G, Fanfani F, Garganese G, Vizzielli G, Carone V, Salerno MG, Scambia G. Prospective validation of a laparoscopic predictive model for optimal cytoreduction in advanced ovarian carcinoma. *Am. J. Obstet. Gynecol*. 2008; 199(6): 642.e1−6.

Fondrinier E, Descamps P, Arnaud JP, Pezet D. [Carbon dioxide pneumoperitoneum and peritoneal carcinosis: review]. *J. Gynecol. Obstet. Biol. Reprod.* (Paris) 2002; 31(1): 11−27.

Hajduch M, Kod'ousek R. "Nude rabbit" with aplasia of B−lymphoid structures. *Acta. Univ. Palacki. Olomuc. Fac. Med.* 1992; 134:51−54.

Hopkins MP, von Gruenigen V, Gaich S. Laparoscopic port site implantation with ovarian cancer. *Am. J. Obstet. Gynecol.* 2000; 182(3):735−736.

Hopkins MP. The myths of laparoscopic surgery. *Am. J. Obstet. Gynecol.* 2000; 183(1):1−5.

Hopkins MP, von Gruenigen V, Haller NA, Holda S. The effect of various insufflation gases on tumor implantation in an animal model. *Am. J. Obstet. Gynecol*. 2002; 187(4): 994−996.

Jacobi CA, Ordemann J, Bohm B, Zieren HU, Liebenthal C, Volk HD. The influence of laparotomy and laparoscopy on tumor growth in a rat model. *Surg. Endosc.* 1997; 11(6):618−621

Kadar N. Laparoscopic management of gynecological malignancies. *Curr. Opin. Obstet. Gynecol.* 1997; 9(4):247−255.

Kruitwagen RF, Swinkels BM, Keyser KG, Doesburg WH, Schijf CP. Incidence and effect on survival of abdominal wall metastases at trocar or puncture sites following laparoscopy or paracentesis in women with ovarian cancer. *Gynecol. Oncol.* 1996; 60(2):233−237.

Le Moine MC, Navarro F, Burgel JS, Pellegrin A, Khiari AR, Pourquier D, et al. Experimental assessment of the risk of tumor recurrence after laparoscopic surgery. *Surgery* 1998; 123(4):427−431.

Lecuru F, Agostini A, Camatte S, Robin F, Aggerbeck M, Jaiss JP, et al. Impact of pneumoperitoneum on visceral metastasis rate and survival. Results in two ovarian cancer models in rats. *BJOG* 2001; 108(7):733−737.

Lecuru F, Guilbaud N, Agostini A, Augereau C, Vilde F, Taurelle R. Description of two new human ovarian carcinoma models in nude rats suitable for laparoscopic experimentation. *Surg. Endosc.* 2001; 15(11):1346−1352.

Lécuru F, Agostini A, Camatte S, Robin F, Aggerbeck M, Jaïs JP, Vilde F, Taurelle R. Impact of pneumoperitoneum on tumor growth. *Surg. Endosc*. 2002; 16(8):1170−1174.

Lee JW, Park YA, Cho YJ, Kang KH, Choi JJ, Lee YY, Kim TJ, Choi CH, Kim BG, Bae DS. The effect of surgical wound on ovarian carcinoma growth in an animal model. *Anticancer Res.* 2013; (8):3177−3184.

Lin XJ, Chen XC, Wang L, Wei YQ, Kan B, Wen YJ, He X, Zhao X. Dynamic progression of an intraperitoneal xenograft model of human ovarian cancer and its potential for preclinical trials. *J. Exp. Clin. Cancer Res*. 2007; 26(4):467−474.

Martinez J, Targarona EM, Balague C, Pera M, Trias M. Port site metastasis. An unresolved problem in laparoscopic surgery. *A review. Int. Surg.* 1995; 80(4):315−321.

Mathew G, Watson DI, Rofe AM, Baigrie CF, Ellis T, Jamieson GG. Wound metastases following laparoscopic and open surgery for abdominal cancer in a rat model. *Br. J. Surg.* 1996; 83(8):1087−1090.

Morice P, Camatte S, Larregain−Fournier D, Thoury A, Duvillard P, Castaigne D. Port−site implantation after laparoscopic treatment of borderline ovarian tumors. *Obstet. Gynecol.* 2004; 104(5 Pt 2):1167−1170.

Nezhat FR, Pejovic T, Finger TN, Khalil SS.Role of minimally invasive surgery in ovarian cancer. *J. Minim. Invasive Gynecol.* 2013 Nov−Dec; 20(6):754−765.

Pomel C, Provencher D, Dauplat J, Gauthier P, Le Bouedec G, Drouin P, Audet−Lapointe P, Dubuc− Lissoir *J.Gynecol Oncol*. 1995 Sep; 58(3):301−306.

Pratt BL, Greene FL. Role of laparoscopy in the staging of malignant disease. *Surg. Clin. North Am.* 2000; 80(4):1111−1126.

Provencher DM, Lounis H, Champoux L, Tetrault M, Manderson EN, Wang JC, et al. Characterization of four novel epithelial ovarian cancer cell lines. *In Vitro Cell Dev. Biol. Anim.* 2000; 36(6):357−361.

Ramirez PT, Wolf JK, Levenback C. Laparoscopic port−site metastases: etiology and prevention. *Gynecol. Oncol.* 2003; 91(1):179−189.

Reymond MA, Tannapfel A, Schneider C, Scheidbach H, Kover S, Jung A. Description of an intraperitoneal tumour xenograft survival model in the pig. *Eur. J. Surg. Oncol.* 2000; 26(4):393−397.

Rose GS, Tocco LM, Granger GA, DiSaia PJ, Hamilton TC, Santin AD, et al. Development and characterization of a clinically useful animal model of epithelial ovarian cancer in the Fischer 344 rat. *Am. J. Obstet. Gynecol.* 1996; 175(3 Pt 1):593−599.

Rubin SC, Kairemo KJ, Brownell AL, Daghighian F, Federici MG, Pentlow KS, et al. High−resolution positron emission tomography of human ovarian cancer in nude rats using 124I−labeled monoclonal antibodies. *Gynecol. Oncol.* 1993; 48(1):61−67.

Sandoval BA, Sulaiman TT, Robinson AV, Stellato TA. Laparoscopic surgery in a small animal model. A simplified technique of retroperitoneal dissection in the rat. *Surg. Endosc.* 1996; 10(9):925−927.

Sanjuan A, Hernandez S, Pahisa J, Ayuso JR, Torne A, Martinez Roman S. Port-site metastasis after laparoscopic surgery for endometrial carcinoma: two case reports. *Gynecol. Oncol.* 2005; 96(2): 539−542.

Sawada M, Matsui Y, Hayakawa K, Nishiura H, Okudaira Y, Taki I. Human gynecologic cancers heterotransplanted into athymic nude rats. *Gynecol. Oncol.* 1982; 13(2):220−228.

Shen MY, Huang IP, Chen WS, Chang JT, Lin JK. Influence of pneumoperitoneum on tumor growth and pattern of intra−abdominal tumor spreading: in vivo study of a murine model. *Hepatogastroenterology* 2008; 55(84):947−951.

Sugiyama T, Nishida T, Yokota D, Ushijima K, Imaishi K, Hirakawa N, et al. An experimental model for advanced ovarian cancer. *Kurume Med. J.* 1990; 37(1):15−21.

Vanderhyden BC, Shaw TJ, Ethier JF. Animal models of ovarian cancer. *Reprod. Biol. Endocrinol.* 2003; 1:67−82.

Vergote I, Marquette S, Amant F, Berteloot P, Neven P. Port−site metastases after open laparoscopy: a study in 173 patients with advanced ovarian carcinoma. *Int. J. Gynecol. Cancer.* 2005; 15(5):776−779.

Volz J, Koster S, Weiss M, Schmidt R, Urbaschek R, Melchert F. Pathophysiologic features of a pneumoperitoneum at laparoscopy: a swine model. *Am. J. Obstet. Gynecol.* 1996; 174(1 Pt 1):132−140.

In: Encyclopedia of Surgery (22 Volume Set)
Editors: Andreas Lehrer and Kristin Mueller
ISBN: 978-1-53618-329-0
© 2020 Nova Science Publishers, Inc.

Chapter 194

ORGAN BIOENGINEERING THROUGH DECELLULARIZATION AND RECELLULARIZATION APPROACHES

Maria Jaramillo, PhD and Basak E. Uygun*, PhD
Center for Engineering in Medicine, Massachusetts General Hospital,
Department of Surgery, Harvard Medical School,
Massachusetts General Hospital, Boston, MA, US

ABSTRACT

Organ transplantation has been used for over a century for the treatment of end organ failure. Despite vast advances in the field, the main challenge remains the availability of good quality donor organs. Scientists around the world are working on the development of alternative options for donor organs available for transplantation, including development of decellularization-based artificial organs, which is the focus of this chapter.

Organ and tissue decellularization has a number of advantages, including preservation of the extracellular matrix architecture and composition, which provide signals necessary for cell function and survival. The preserved vascular architecture in the scaffolds allows for connecting the bioengineered organ to the blood torrent upon transplantation. In addition, ECM scaffolds have been found to elicit low to negligible immune response which is a major advantage, eliminating the need for long-lasting use of potentially harmful immunosuppression therapy in transplant patients.

While very promising to increase the pool of donor organs, the decellularization/recellularization approach for bioengineered organs has a number of challenges. These include methods for decellularization with minimal damage to the extracellular matrix composition and architecture, choice of cells type and source for replacing the functions of organ in question and achieving long-term viability of the engineered organ *in vivo*. Here, we discuss each of these challenges and present current progress in the field for different organs including liver, heart, kidney and lungs.

* Corresponding Author's Email: BUYGUN@mgh.harvard.edu.

Keywords: decellularization, recellularization, organ engineering

ABBREVIATIONS

ECM	Extracellular Matrix
EPC	endothelial progenitor cells
hiPSC	human induced pluripotent stem cells
HUVEC	Human umbilical vein endothelial cells
MSC	Mesenchymal Stem cells
SDS	Sodium dodecyl sulfate

INTRODUCTION

According to the United Network for Organ Sharing (UNOS), there are currently over 120,000 people in need of organ transplants in the United States, from which over 75,000 are on an active waiting list. However, it is estimated that only 30,000 to 35,000 transplants will be performed by the end of this year. This highlights the need for strategies to increase the pool of available organs. Several approaches have been developed to this end, including the formation of organizations devoted to education regarding organ donation to increase donor participation and research in areas including organ preservation, organ rehabilitation and organ engineering.

Organ engineering refers to the development of biological substitutes to replace or aid damaged and diseased tissues, thus maintaining physiological homeostasis in the patient. This involves the use of biomaterials, cells and other microenvironmental signals to mimic the niche of native organs such that their functions are recapitulated and maintained. Several strategies have been adopted for these purposes, including encapsulation of donor cells in biomaterials that provide immunogenic barriers while promoting cell survival and allowing proper cell function. Another approach that is quickly gaining interest is the concept of 3D printing, however, one of the most promising approaches and our main focus for this chapter is the development of artificial organs by decellularization and recellularization of native tissues and whole organs.

Organ decellularization consists of the complete removal of cells and cellular components from native tissues. This offers a number of advantages, including perhaps the closest recapitulation of physical and chemicals microenvironmental signals of tissues as well as low biomaterial immunogenicity. In addition, this offers a potentially abundant source of scaffolds, as, in contrast to organ transplantation, organs used for decellularization do not require such strict parameters such as minimal ischemia time, and preservation of the ECM can be achieved more easily than preservation of cell functions. Organs are then decellularized and repopulated with healthy cells, which can be derived from different sources such as allogeneic primary cells, expanded autologous cells, cells differentiated from different sources of stem cells (embryonic, induced pluripotent, adult) amongst others.

In the next sections, we will talk about different strategies used for tissue decellularization, including methods used to evaluate successful removal of cellular

components. We will discuss several approaches for recellularization and will review some of the most notable advances in the field. Because each organ has a different function, organ engineering approaches have to be tailored to satisfy the physical and chemical requirements, therefore we will discuss research work in different organs. Finally, we will review other aspects of decellularization and recellularization organ engineering like introduction of non-parenchymal cells such as endothelial cells for proper vascularization and function of these replacement organs and their immunogenicity.

DECELLULARIZATION

Organ decellularization is typically achieved by subjecting tissues/organs to treatments that disrupt cell integrity, while preserving structure and composition of the extracellular matrix. Most commonly, these treatments are chemical agents, although several physical treatments have been successfully used alone or in combination with chemical treatment to ensure appropriate removal of cellular components from tissues and organs. Ultimately, all methods have a number of advantages and disadvantages, which have to be taken into consideration along with the tissue-specific requirements to come up with the best possible specific strategies for decellularization.

CHEMICAL METHODS

Detergents

Perhaps the most commonly used method for organ and tissue decellularization is the use of detergents that emulsify oils, disrupting the lipid bilayer of the cellular membrane, hence promoting cell lysis. Addition of fluid flow through whole organ perfusion or tissue agitation ensures efficient removal of remaining cellular components. Detergents can be classified into ionic, non-ionic or Zwitterionic detergents.

Ionic detergents have a charged hydrophilic group. They disrupt lipids and proteins, hence strongly disturbing the cellular structures, making them more effective at removing cellular components. Because of the fact that they can interact and denature proteins, they are considered the most destructive and they have a greater effect on the chemical composition of ECM. Additionally, they are harder to "rinse" than other types of detergents, which presents an obstacle to subsequent recellularization of the tissues due to its cytotoxic effects. The most commonly used ionic detergent is sodium dodecyl sulfate (SDS). It is routinely used for decellularization of tissues such as heart valves (Korossis 2002), tubular structures such as trachea (Hung 2016) and blood vessels (Schaner 2004), and whole organs including heart (Oberwallner 2014), liver (Uygun 2010) and kidneys (Wang 2015).

Non-ionic detergents are neutral and hydrophilic. They are highly capable of breaking lipid-lipid interactions, but due to their limited ability to interact with proteins, are unable to break protein-protein interactions and have reduced ability to break lipid-protein interactions. Because of this, they have weaker decellularization potential, but are better at maintaining the chemical composition of the ECM. The most commonly used non-ionic detergent is Triton

X-100, which is typically used in addition to SDS. In a few cases, it has been reported to promote appropriate decellularization alone in tissues such as ligaments (ACL) (Vavken 2009; Xu 2014) and annulus fibrosus (Xu 2014), suggesting to be more appropriate for decellularization of tissues with relatively low cellularity.

Finally, Zwitterionic detergents are considered to be "in between" ionic and non-ionic detergents. They have a net neutral charge, but are able to disturb protein interactions, without altering their native charge, hence are less damaging to the ECM composition than non-ionic detergents. 3-[(3-cholamidopropyl)dimethylammonio]-1-propanesulfonate (CHAPS) is the most widely used Zwitterionic detergent in decellularization approaches, and has been reported to efficiently decellularize tissues such as lung (Tsuchiya 2016). When compared to decellularization with SDS, it has been proven to preserve composition of components such as collagen and elastin, which have a strong effect in mechanical integrity, suggesting that CHAPS may be a better choice for highly cellular tissues whose function is highly dependent on its mechanical properties.

Osmotic Decellularization

Osmotic decellularization, consisting of alternation of hypertonic and hypotonic solution for cell disruption and removal, has been used alone and in combination with other methods such as detergent-based decellularization. Typically, TRIS-based buffers and Phosphate Buffered Saline (PBS) solutions are used. Hypotonic solutions force movement of water into the cell, causing cells to burst, which is followed by use of hypertonic solutions that promote non-histone protein dissociation from DNA. This method is gentler than the use of detergents, and it is considered to lead to better preservation of ECM, so it is typically used for tissue with low cellularity such as heart valves (Meyer 2006), cartilage (Schneider 2016) and cornea (Yam 2016).

Enzymes

Enzymatic decellularization consists of removing cellular components with the aid of enzymes that break down cellular components; some of such enzymes are trypsin, nucleases and dispase. Nucleases are enzymes that break down nucleic acids (DNA and RNA), but usually do not act on other cellular components, therefore are typically used in conjunction with other treatments that aid penetration of nucleases into the cells. There are other enzymes such as trypsin that promote breakdown of serine-containing proteins, which are very efficient at breaking down cells; however, because they are non-specific, they also interact with ECM proteins. Lipases are a good candidate for decellularization as they specifically disrupt the lipid bilayer of the cell membranes without disrupting ECM proteins, however, rather limited success at complete cellular removal has been achieved by the use of lipases alone (Crapo 2011).

PHYSICAL METHODS

Sonication

Sonication has been used mostly in combination with other methods for decellularization of tissues such as larynx (Hung 2013), trachea (Hung 2016), cardiovascular tissues (Azhim 2011), cartilage (Azhim 2013) and small intestine (Oliveira 2013). It has been shown to be advantageous in cases when perfusion decellularization is not possible due to the limited diffusion of chemical agents. In such cases, sonication has shown to enhance the degree of removal of cellular components through passive diffusion of decellularizing agents. It has been observed that sonication greatly speeds up the decellularization process, decreasing exposure time to chemical agents which typically show higher disruption of chemical composition.

Freeze/Thaw

This method is rarely used alone, but typically used as a critical step of decellularization in combination with other methods discussed here. Freezing promotes ice crystal formation of water, which, unlike most other materials, increases volume in its frozen form. This increase in water volume damages cell membrane, leading to break down of the cells. Typically, ice crystal formation can be reduced by cooling at low rates; hence, decellularization by thawing is better achieved by rapid freezing of tissue.

Irreversible Electroporation

Irreversible electroporation (IRE) is a novel technique that is currently being explored. It consists of applying non-thermal pulsed electric fields to disrupt the cellular membrane while maintaining the integrity of the ECM. This method has been explored as an *in-vivo* decellularized method (Golberg 2016), where the scaffolds are decellularized in live animals, however, it has also been used in *ex-vivo* perfusion models (Sano 2010).

Evaluation and Success Parameters

Biochemical evaluation of decellularization is typically performed by quantifying cellular components such as DNA and actin to estimate the amount of cellular material removed. In addition, preservation of ECM composition is evaluated by estimating concentration of ECM proteins such as laminin, elastin, collagen and fibronectin, or other components such as glycosaminoglycans (GAG). Quantification of these is typically done by standard assays such as ELISA, PicoGreen and immunostaining, however, due to the destructive nature of these methods, recent studies have highlighted the need to develop new methods that do not require damage to the decellularized tissue, thus promoting maintenance of its integrity for subsequent use. Some of the suggested technique include analysis of perfusate (Jörn 2015),

but also more sophisticated methods such as computer tomography, which has been used for monitoring DNA content in real time (Geerts 2016).

Another parameter that is typically evaluated in most applications is the maintenance of the microstructural integrity of the scaffolds. For most tissues, the maintenance of a capillary network is essential, and this can be investigated by corrosion casting and a number of microscopy techniques including angiography and scanning electron microscopy. Furthermore, perfusion of dyes that can be removed by additional perfusion can be used to visualize capillary integrity after decellularization. In addition to capillary network integrity, other parameters such as topography have been evaluated through technique such as atomic force microscopy; the significance of it being that material characteristics such as roughness can alter cell behavior.

Additionally, for tissues that serve a mechanical function or tissues that need to be able to withstand mechanical loads, bulk physical parameters need to be evaluated. This is the case for tissues such as bone, tendon, cartilage, cardiac valves, lungs, muscle, blood vessels and many others. Depending on the tissue requirements, stress, strain, tensile strength, elasticity and compliance need to be evaluated.

Overall, there is no standardized set of parameters to define success in decellularization except for DNA content which is defined as 1) less than 50 ng of dsDNA per mg of dry weight; 2) DNA fragments less than 200 bp in length; and 3) no visible nuclear material in histologic analysis with DAPI or H&E, according to Faulk et al. (Faulk 2015). When performing such evaluation, it is important to keep in mind that every tissue serves a different function and hence, preservation of certain characteristics may be more important. For instance, in the case of liver engineering, the conservation of biochemical composition may be of higher importance, as hepatocyte function and viability is highly dependent on the chemical microenvironment. Alternatively, tissues such as cartilage are relatively acellular and the biggest functional requirement is the ability to withstand mechanical loads, hence, higher importance is given to the maintenance of physical characteristics. This highlights the need for a comprehensive compilation of data to define tissue-specific parameters and tolerance levels that will allow optimizing decellularization procedures based on specific requirements.

RECELLULARIZATION

After successful decellularization of organs and tissues, the next step is to repopulate the decellularized scaffolds with cells that will carry out vital functions of the organ. The main challenge in this step is the identification of a reliable and abundant cell source that will replace the functions of the native organ. There are a number of constraints in this step which include development of strategies for cell delivery, retention and maintenance. However, perhaps the biggest challenge is the establishment of an abundant cell source, which we will discuss in the following sections.

In-vitro Expansion and Maintenance of Primary Cells

Most cells in the body have a limited ability to expand and maintain a functional phenotype in an in-vitro setting. This phenomenon is not well understood but its investigation could lead to the development of strategies to generate an abundance of functional cells to be used in cell/tissue engineering applications. Unfortunately, despite the great promise of this field for regenerative medicine applications, very limited advances have been made in this area.

A recent study describes genetic modification of primary human hepatocytes to express Human Papilloma Virus (HPV) genes, which mediate expression of receptors-associated hepatocyte proliferation *in vivo*. Exposure of the genetically modified hepatocytes to proliferation-inducing cytokines promotes their expansion amounting to up to a trillion cells per single hepatocyte. Removal of proliferation signals leads to polarization and induction of function in the hepatocytes (Levy 2015). Genetic engineering strategies has also been exploited for the expansion and maintenance of beta-cells using Cre/loxP-based reversible immortalization (Kobayashi 2006), however, these approaches rely on use of viral vectors, which could cause activation of oncogenes, hence, tumorigenicity. Other studies have concentrated on manipulation of the *in vivo* microenvironment rather than the cells, including the development of scaffolds with appropriate physical and chemical cues that have been found to promote limited expansion and functionality of cells such as alveolar cells and hepatocytes (Shamis 2011).

A number of tissues rely on progenitor cells with proliferation potential for repair of damaged tissue and cell turnover. Isolation of these cells, with subsequent expansion and induction of terminally differentiated phenotype, constitutes another strategy for organ engineering relying on primary human cells. The difficulty of this approach is isolation and identification of these cells from live patients; however, some advances have been made with the use of progenitor cells derived from stem cells, which will be further discussion in a later section.

To conclude this section, it is important to note that use of primary cells would require immunological matching of cells to patient, and potentially immunosuppression to avoid rejection of the transplanted graft. Recent studies have also explored the possibility of silencing genes involved in immune rejection (Figueiredo 2013), which in conjunction with successful strategies for expansion and maintenance of primary cells, would make the possibility of the creation of universal cell banking for off-shelve regenerative medicine applications a reality.

Cell Recovery from Discarded Organs

A new strategy that has emerged as an alternative approach is to recover cells from marginal organs deemed unacceptable for transplantation. While very little work has been done in this field, a few recent studies have shown that a number of cells including beta cells (Matsumoto 2007) and hepatocytes (Izamis 2013; Izamis 2015; Uygun 2016) can be recovered from organs exposed to warm ischemia for up to one hour by perfusion with preservation solutions that restore ionic concentrations of the cells and ATP generation. The

resulting cells have been isolated at yields and levels of functionality comparable to those of primary cells.

Stem Cell Differentiation

Perhaps one of the most explored options is differentiation of functional cells from a number of different stem cell sources. Depending on their origin, cells can be pluripotent, multipotent, or have the ability to become a very limited number of cells. Stem cells are most commonly categorized into pluripotent, mesenchymal or tissue-specific stem cells.

Pluripotent stem cells include embryonic stem cells derived from the inner mass of the embryonic blastocyst and induced pluripotent stem cells, which are somatic cells that have been genetically engineered to express a number of genes characteristic of embryonic stem cells, giving these cells their pluripotency characteristics. Both cell types have two main features: their ability to self-renew indefinitely (making them a potentially unlimited cell source) and to differentiate into cells derived from the three germ layers of embryonic development (mesoderm, ectoderm and endoderm). Differentiation programs are based on developmental studies that identify specific signals that determine their fate, which are then recapitulated in an *in-vitro* setting. Most commonly, these signals are chemical cues such as cytokines and small molecules, but can also be in the form of physical cues, such as substrates with varying mechanical properties. Despite their enormous potential, success of pluripotent stem cell differentiation has been limited partly due to the fact that they rely on developmental studies using non-human models; hence translation of these observations into development of human systems is imprecise. Challenges in this field remain, including low functionality and maturity of the resulting cells. In terms of complex cell types, such as hepatocytes, that carry a large number of diverse functions, a challenge has been the recapitulation of all the functions. This last requirement can be bypassed by the alternative strategy of creating auxiliary grafts that instead of replacing the entire organ will aid it by providing the function that is aberrated in the patient. This strategy could be used in deficiency diseases, such as Alpha-1 antitrypsin (AAT) deficiency. Hepatocytes in AAT-deficient patients often carry out other vital functions such as albumin production, lipid metabolism, carbohydrate metabolism and drug metabolism. In such cases, creation of a graft with differentiated cells that produce AAT and be transplanted in the patients, auxiliary to their native liver to aid rather than replace the marginal organ.

Mesenchymal stem cells are naturally occurring adult cells that are not terminally differentiated hence maintain the ability to differentiate into a limited number of tissues within the mesodermal lineage (bone, cartilage, muscle, adipose tissue and blood; although some studies report limited differentiation into ectoderm and endoderm lineages). Their sources include cells derived from adipose tissue, bone marrow, tooth bud and umbilical cord which are readily accessible and can be patient-specific.

Finally, some tissues have fast cell turnover and rely on resident stem cells to continually replace aged or damaged cells. Some of these include oval cells in the liver, epithelial lining of the stomach and intestine and skin. These cells typically can differentiate into just one or two cell types, and can be isolated using cell-specific markers.

ADVANCES

In the following sections, we will discuss and summarize some of the most prominent advances in the field of decellularized tissue-based organ engineering of a number of specific systems.

Liver

First reports of whole liver decellularization date back to 2009 (Baptista 2009). Being a highly cellular organ, and because the lipid content can be higher than in most other tissues, liver decellularization is most often achieved by the use of detergent, which preserves a significant amount of the chemical composition and the architectural integrity of the liver including its vascular network. Because of the highly vascular content, decellularization is typically done by perfusion through one of the main vessels (typically portal vein).

Report of recellularization first appeared in 2010 (Uygun 2010) when rat livers were recellularized using freshly isolated primary rat hepatocytes, which performed hepatic functions (albumin and urea secretion, and drug metabolism protein expression) comparable to those found when hepatocytes were maintained under static collagen sandwich culture conditions, which to date, remains the gold-standard for culture of human hepatocytes. In addition, the recellularized grafts were transplanted into rats that underwent unilateral nephrectomy to prepare a viable site for auxiliary liver graft transplantation. The renal vein and artery were used as ports to create blood source. Efflux was established within 5 min of unclamping and the recellularized graft was kept for 8 h before evaluating damage to the hepatocytes due to the arterial blood flow and the resulting shear stress, which was found to be minimal. A later study showed that the recipient survival could be extended to 24 h by the addition of a heparin layer on recellularized liver grafts (Bruinsma 2015). However, thrombogenicity of the grafts still remains a problem.

Subsequent studies have been conducted in larger animal models including rabbits, sheep, and porcine livers (Kajbafzadeh 2012; Nari 2013; Wang 2015). One study using porcine livers (Barakat 2012) evaluated recellularization using human fetal hepatocytes and stellate cells, and the recellularized grafts were kept under perfusion culture for up to two weeks, during which they showed metabolic activity including oxygen and glucose consumption, lactate and urea production, and albumin secretion.

Several cells have been investigated as potential sources for recellularization. A number of studies have investigated the use of MSC (He 2013; Jiang 2014) and have reported differentiation of these cells within the scaffolds (with addition of soluble chemical cues) to be superior to differentiation of the same cells under 2D culture conditions. However, neither report compared hepatic functions of differentiated cells to those found in primary hepatocytes, making it hard to determine whether maturation is achieved to physiologically-relevant levels. Other studies have used MSC for recellularization in conjunction with primary hepatocytes, and have shown that this co-culture configuration improves engraftment and function of the primary hepatocytes (Kadota 2014).

Finally, there are two alternative approaches to both decellularization and recellularization that are worth discussing. First, there have been a few reports of efficient

liver decellularization using IRE (Golberg 2016; Sano 2010). This method has been used for decellularization of livers under ex-vivo perfusion, which can be subsequently recellularized, however, due to the regenerative potential of liver, has also been explored as a method for *in vivo* decellularization and recellularization, as it has been demonstrated that after IRE treatment, liver regeneration occurs in the absence of scar formation. Other methods for *in vivo* decellularization and recellularization have been developed, including detergent-based decellularization of a single lobe in-vivo through surgical by-pass circulation with a perfusion chamber system (Pan 2016). In this study, decellularized lobe was subsequently recellularized *in vivo* with primary hepatocytes from donor rats. Alternatively, the idea of transplanting decellularized livers to allow for "spontaneous" in-vivo recellularization has also been explored, but the resulting grafts were inferior when compared to *in vitro* recellularized grafts (Sabetkish 2015).

Lung

Lung decellularization was first reported in 2010 in studies in mice and rat lungs (Ott 2010; Price 2010) and using a combination of methods, including hypertonic/hypotonic solutions, detergents and enzymes. Because of the function of the lung, preservation of its mechanical integrity is of utmost importance, hence, decellularization protocols have been developed avoiding or minimizing use of ionic detergents, which have been shown to lead to greater loss of elastin and collagen that confer lungs their mechanical properties, including tensile strength and elastic behavior (Petersen 2012). A number of strategies have been developed to maximize cell removal while promoting maximal retention of ECM components, and in turn mechanical properties. These include: use of zwitterionic detergents such as sulfobetaine-10 (Nagao 2013), or non-ionic detergent such as Triton X-100 or CHAPS. Alternative ionic detergents such as ethoxylated sodium lauryl ether sulfate (SLES), have been developed solely for decellularization purposes. SLES is weaker than traditionally used SDS, and because of its ethoxylation, the lauryl alcohol content is reduced, hence exhibiting lower protein denaturation (Kawasaki 2015). Alternative approaches have focused on modification of delivery of decellularization reagents. For instance, it has been suggested that perfusion route has an effect on efficiency of decellularization, with intratracheal route being suggested as the preferred method (Maghsoudlou 2013; Tsuchiya 2016; Wang 2016). In addition, some studies focus on optimization of physical parameters such as flow rate and pressure, which can be increased to speed up the decellularization process, hence, minimize exposure (da Palma 2015; Khalpey 2015). Despite, or partly due to the large number of studies evaluating decellularization methods in lungs, there is little consensus about which method leads to best decellularization. Because these studies are often performed in different animal systems, there is very little real time monitoring of the progression of decellularization, and so much variability in terms of concentrations, physical parameters, and timing used, reports often come to contradicting conclusions, highlighting the need for a comprehensive evaluation of these methods in a systematic way that would allow for standardization of lung decellularization protocols.

Recellularization of lungs has been attempted using adult and fetal alveolar cells (Price 2010; Song 2011), airway epithelial cells (Gilpin 2014), lung cancer cells (Mishra 2012) , MSC (Bonvillain 2013), human iPSC-derived alveolar epithelial cells (Ghaedi 2013), hESC

(Nakayama 2013), basal epithelial stem cells isolated and expanded from human lungs (Gilpin 2016) and fibroblasts (Sun 2014). In general, these studies have demonstrated that decellularized scaffolds are capable of supporting cell engraftment and in some cases, differentiation. It has also been suggested that when recellularizing lungs with progenitor cells (either fetal or stem cell-derived), the addition of mechanical forces such as stress and strain are important as these provide differentiation signals to the cells (Bonvillain 2013). Interestingly, decellularized rhesus monkey lungs have been used as a model to demonstrate decellularized matrix specificity to cell type by performing differentiation studies of hESC showing that differentiation of these cells in lung scaffolds showed better epithelial airway differentiation than if the cells were seeded on scaffolds derived from other tissues (Nakayama 2013).

Finally, there have been a few reported studies of evaluation of function of the decellularization-based engineered lungs in an *in vivo* setting. This was first attempted in 2010 (Ott 2010) when rat lungs were recellularized with lung endothelial and epithelial cells and transplanted into recipient rats after 5 days of *ex vivo* culture. The rats first underwent pneumonectomy (left lung) and the grafts were transplanted by anastomosis of the graft to pulmonary artery, pulmonary vein and left main bronchus of the recipient. No bleeding, edema or leakage was observed within one hour of transplant, and blood gas levels showed improvement when compared to the levels after pneumonectomy. The grafts were maintained for up to 6 hours, however, complications were observed at this time-point, including edema, which was probably because of pulmonary secretions.

Heart

Heart valves were amongst the first tissues explored for decellularization/recellularization tissue engineering approaches. Despite this, whole heart decellularization was not explored until 2008 (Ott 2008) in a seminal study that produced decellularized hearts from rats via coronary perfusion of SDS. Since then, a number of protocols have been developed exploring different chemical agents (Triton X-100, EDTA, deoxycholic acid , Sodium Azide, Soponin, Glycerol), perfusion routes (pulmonary, aortic or coronary) and physical parameters, however, there is little consensus regarding the best method for whole-heart decellularization.

Decellularization success parameters are typically retention of chemical components, especially, elastin and GAG. Biomechanical characterization often involves stress-relaxation which analyzes elastic moduli and viscosity, and tensile-failure tests which also can be used to estimate elastic modality and viscosity in addition to load limit (Bronshtein 2013).

Recellularization of heart tissue has been explored using a number of cell types, including myoblast cell lines (Akhyari 2011), adult and fetal cardiomyocytes from different sources (Wainwright 2010), as well as supporting cell types present in the heart. Cardiomyocytes recellularization has been attempted using primary rat cardiomyocytes. They have been shown to gain myocardial organization and express cardiac markers, and exhibit synchronized beating (Eitan 2009). A different study using neonatal cardiomyocytes from mouse to recellularize porcine hearts showed maintenance of cell viability and measurable electrical activity within five days of recellularization (Weymann 2014). Similarly, recellularization of human hearts with human cardiomyocytes has shown that the cells align in a muscle-like fiber manner, exhibit calcium dynamics and action potential propagation (Sanchez 2015).

Pluripotent stem cells and MSC (Sarig 2012) have been seeded onto decellularized hearts both to test the cytocompatibility of the scaffolds with these cells, but also for their ability to differentiate within the scaffolds. In the absence of differentiation signals, it was shown that hiPSC were able to engrafts and survive for up to seven days, however, it was also observed that by the end of the culture, there was a significant loss of pluripotency markers (Carvalho 2012). In addition, hiPSC-derived cardiomyocytes have been used to recellularize human heart ventricular scaffolds resulting in increased expression of ion channels and increase in electrophysiological responses (Garreta 2016).

Recellularization with fibroblasts was shown to regain some of the lost components during decellularization process such as GAGs, which enabled to gain strength (Eitan 2009). Finally, it has been suggested that recellularization success is dependent on the source of the scaffolding tissue. A recent study compared recellularization success in hearts prepared from adult and fetal rats and found that fetal scaffolds provide better engraftment and proliferation of neonatal cardiomyocytes and adult cardiac progenitor cell (Silva 2016).

Very few translational studies involving transplantation of decellularized matrix-based engineered hearts have been performed. The first reported of such studies involved transplantation of porcine scaffolds using ascending aorta and the superior vena cava as an inlet and outlet of the blood stream, respectively, with closure of vena cava, pulmonary veins and pulmonary artery circulation. The results of this study showed that the scaffold integrity was adequate to endure surgical procedure, and artery perfusion was achieved. Additional procedures were performed with scaffold pre-recellularized with MSC, however, blood flow in this model was not achieved. Alternatively, MSC were injected into the scaffold immediately prior to transplantation, which allowed for establishment of blood flow and some degree of engraftment of the cells was confirmed after 3 days (Kitahara 2016).

Finally, several groups have attempted to engineer bioreactors for cardiac heart engineering in order to ensure small variability in decellularization/recellularization process, but also to efficiently deliver a variety of signals that will promote cell engraftment, viability, proper function and/or differentiation, and in some cases, even provide real time monitoring of the grafts. One example is a modular bioreactor developed to maintain recellularized hearts under controlled perfusion and medium conditioning (oxygenation, temperature and pH control), which also provides myocardial stretching, electrophysiological stimulation and/or monitoring (Hülsmann 2013).

Kidney

Kidney decellularization was first achieved in rat models (Ross 2009) and shortly after tested in large animal models (Nakayama 2010; Vishwakarma 2014). Decellularization of kidneys is typically achieved by detergent-based methods, with SDS being deemed the most successful (Wang 2015), hence the most commonly used. Transplantation studies with SDS-decellularized porcine kidneys have been performed which showed maintenance of vascular structure as suggested by lack of blood extravasation (Orlando 2012), intact microarchitecture of the glomerulal structures, and when seeded with primary human cells, promoted their survival and viability (Sullivan 2012). Furthermore, SDS decellularization has been successfully attempted in human kidneys (Orlando 2013), which exhibit preserved

vasculature, microstructure and maintenance of growth factors within the matrix (Peloso 2015).

Decellularized kidney recellularization has been performed using murine stem cells (Bonandrini 2014; Guan 2015), iPSC-derived tubular epithelial cells (Caralt 2015), renal epithelial cells (Uzarski 2015) and adipose-derived MSC (Rafighdoust 2015). Addition of chemical signals, such as chondroitin sulfate has been used to improve seeding and differentiation of stem cells into renal epithelial cells (Rafighdoust 2015). In terms of stem cells, it has been found that seeding and culture in decellularized scaffolds promotes a decrease in pluripotency and increase in mesoendodermal markers (Bonandrini 2014). Finally, it has been suggested that recellularization with different cell types can be achieved by perfusion seeding of epithelial cells through the ureter, and non-parenchymal cells through arterial route (Willenberg 2015).

Pancreas

Pancreas is perhaps one of the most complex organs in terms of decellularization, which is probably reflected by the very small number of published studies in the field. It has been suggested that success has been hampered by the complex architecture of pancreas and very delicate vascular structure, which is easily disrupted by common decellularization methods (Willenberg 2015).

Decellularization of rat pancreas was first reported in 2013 (Goh 2013). In this study, decellularization was achieved by perfusion with SDS at low concentration, and the decellularized scaffolds were subsequently seeded with acinar and beta cell lines, which showed an increase in functionality. A very recent study successfully achieved human pancreas recellularization with triton X-100 and recellularized with primary human beta cells and endothelial cells, showing viability and insulin secretion after 4 days in perfusion culture (Peloso 2016).

VASCULARIZATION/ENDOTHELIALIZATION

Every tissue in the body relies in some degree of vascularization for its survival and proper functioning. Vascular structures are in charge of ensuring delivery of nutrients and oxygen to each cell to guarantee its survival, but in many cases, cell signals are also delivered from the cells into the blood-stream through the same capillary structures, for systemic delivery and homeostasis. Liver and pancreas are two organs that are highly vascularized, both due to the high metabolic requirements of the cells and the delivery of cell-products, which include albumin and insulin respectively. This highlights the need for decellularization protocols that maintain the integrity of capillary network.

Blood vessels, regardless of size, are lined by a specialized epithelium that performs a number of functions, from providing a selective barrier between blood and tissues to production of signals that aid functioning of parenchymal cells. Importantly, endothelial cells prevent blood coagulation and fibrinolysis by a number of mechanisms, including the production of prostacyclin and nitric oxide that prevent platelet aggregation, activation of

anticoagulation pathways and thrombin inhibition through heparin-rich domains in their cell surface. Transplantation studies have shown that in the absence of endothelium, decellularized scaffolds fail due to blood clot formation. For this and more reasons, in addition to maintenance of capillary structure, it is important to develop approaches for appropriate endothelial coverage of the vasculature of decellularized tissues.

Challenges

Success of decellularization-based artificial organs is highly dependent on the achievement of adequate re-endothelialization of the vascular networks, which remains one of the greatest obstacles in this field. A number of factors contribute to the difficulty of achieving adequate endothelial coverage, including challenges in delivering endothelial cells exclusively to capillary networks, poor engraftment, insufficient spreading of endothelial cells, poor formation of tight junctions and other functional morphological characteristics of endothelial cells and identification of highly available cell sources.

At the initial stages of development of this field, it was hypothesized that decellularized matrix possessed a sort of "postal code" that would allow specific cells to attach to the appropriate locations within the scaffolds (Bonvillain 2012). However, a number of studies found that when a mixed population of cells was seeded onto decellularized organ scaffolds, cell engraftment was heterogeneous. Some studies have nevertheless found that maintenance of phenotype and differentiation into specific cell types is improved when cells are seeded onto their appropriate site (Petersen 2010). Approaches for cell delivery into specific sites vary greatly depending on the organs, with some organs having several routes for cell delivery that can be used to orchestrate the spatial organization of cells. Improved engraftment of endothelial cells can be promoted by a number of approaches including use of capture antibodies that will recruit endothelial cells through surface markers, preparation of coatings that improve endothelial cell attachment, functionalization of matrix with angiogenic factors and signals that promote endothelial cell proliferation and spreading. In addition, it is also important to provide signals that will induce organization of cells into functional structures that will provide barrier functions, including tight junctions, adherent junctions and adhesive structures that regulate specific permeability of cells. Finally, like with other aspects of organ engineering, a significant challenge is the identification of an abundant cell source. In terms of reendothelialization, some of the candidate cell sources include: primary cells from cadaveric tissues, stem cell-derived endothelial cells and progenitor endothelial cells from patient circulation.

Advances

As previously mentioned, one strategy for spatial control of cell organization consists of using specific routes for cell delivery. This can more easily be used in organs with separate luminal networks such as lung that contains circulatory and airway networks. Specifically, re-endothelialization is achieved by perfusion seeding on endothelial cells through pulmonary vein and/or artery (Ren 2015) while alveolar epithelial cells are to be seeded via the trachea (Ott 2010). In cases where multiple routes are not an option, spatial organization was

attempted through injection of parenchymal cells into the parenchymal space, in combination with perfusion seeding of endothelial cells through the vasculature (Zhou 2016). Sequential seeding can also be exploited so that parenchymal cells are first introduced through vascular perfusion filling the parenchymal space, followed by perfusion of endothelial cells (Kadota 2014). Finally, it has been suggested that simply adjusting the posture of the decellularized organ during cell-seeding increased cell homogeneity and cell retention (Stabler 2016).

In terms of improved endothelial cell capture, spreading and survival, some strategies have been developed based on previous studies for endothelialization of engineered vascular grafts, valves and devices such as cardiovascular stents. These include CD133 or CD31 antibody conjugation to the decellularized scaffolds to increase capture of endothelial cells through surface marker capture (Jackson 2014; Ko 2015; Vossler 2015). This is achieved by activation of carboxylic groups in the ECM to induce amide bond formation with primary amines in antibodies, which was found to increase endothelial cell adhesion under sheer conditions. Similarly, conjugation of other factors used for improvement of endothelial cell attachment include fibronectin (Ren 2015) and heparin-gelatin mixtures that both increased attachment and migration of endothelial cells, while also providing an antithrombotic coating to reduce blot clot formation (Bao 2015; Hussein 2016). The aforementioned study highlights an alternative approach to overcome the challenge of blood clot formation that relies on reduction of thrombogenicity independent of endothelial cells. One example is a recent study that explored layer-by-layer heparinization of decellularized organ matrices, resulting in decreased blood clot formation (Bruinsma 2015).

In terms of selection of cell source, the same alternatives previously mentioned for parenchymal cell source have been explored. In this section, we will focus on endothelial progenitors cells due to their numerous unique advantages. Endothelial progenitor cells are naturally occurring cells that participate in vessel formation, remodeling and repair. They can be isolated from a number of sources including peripheral blood, bone marrow and umbilical source, and selected by surface marker labeling methods. Finally, certain subsets of EPC have been found to be highly proliferative making them a potentially abundant source. Several groups have explored their use for endothelialization approaches, including a recent study where EPC were isolated and expanded from bone marrow and seeded into liver scaffolds through portal vein perfusion. The resulting scaffolds exhibited coverage of the lining of tubular structures by endothelial cell marker expressing cells, suggesting at the very least, maintenance of endothelial cells markers, however, further analysis is required to assess their maturation (Zhou 2016). EPC from cord blood have also been utilized for recellularization of decellularized rat lungs, although their viability after perfusion culture was lower compared to recellularization using other endothelial cell sources such as HUVEC (Ren 2015).

OTHER CONSIDERATIONS

Monitoring Decellularization

As previously mentioned, current methods for evaluating completion of decellurization consist of destructive methods that render the scaffolds unusable for further applications. This is acceptable in animal studies where homogeneity of the organs is higher, hence, the results obtained in one experiments are typically representative of subsequent experiments. However,

due to variability of lifestyles in human subjects, variability of the organs is greater, and the possibility of developing a "one-size fits all" protocol is unfeasible. A great way to exemplify this is by mentioning dietary effects on variation of lipid contents in liver, which may increase difficulty of liver decellularization in humans, requiring the use of additional components that, while helping with removal of excess fat from fatty livers, may induce greater loss of important components in non-fatty organs. This highlights the need for creation of non-destructive and real-time monitoring methods that allow for the monitoring of decellularization progress, so that protocols can be modified to optimize decellularization in real time.

A limited number of studies have shown promise in using non-destructive techniques for monitoring various attributes of decellularized matrix scaffolds. This includes evaluation of perfusates, which have been used to determine appropriate removal of detergent from matrix through biochemical assays (Zvarova 2016). This has also been used to determine degree of removal of cellular components through rheological measurements (Jörn 2015). More sophisticated techniques such as phase-based x-ray tomography (Hagen 2015) which have been used to acquire high resolution images of the scaffolds, hence allowing for evaluation of their architectural integrity. Similarly, it has been shown that methods such as computer tomography can be used to estimate certain parameters such as Hounsfield unit of tissue, which was found to be correlated with DNA content in tissue, hence, in combination with other methods, such as perfusate analysis, could be an adequate method for non-destructive monitoring of decellularization (Geerts 2016).

Monitoring Recellularization

Equally important to the development of non-destructive methods for monitoring decellularization, it is essential to develop approaches to evaluate status of the engineered organs after recellularization. A number of these methods are in existence, as they rely on the same principles used to evaluate function or organs in-vivo, such as measurement of electrical properties of heart, biochemical secretions from liver and pancreas that can be measured from perfusates (albumin, insulin, glucose levels). However, these are end points that are typically measured days after cell seeding to determine the function of the organs before implantation. Evaluation of additional parameter earlier in the process may prove beneficial, as they would provide information that can be used to change culture parameters that could aid optimize conditions for survival of the cells within the scaffolds.

Some novel techniques for monitoring recellularization include the evaluation of dynamic changes in physical parameters, such as hydrodynamic pressure, which increases with appropriate endothelialization (Uzarski 2015). Furthermore, methods such as perfusion with Resazurin has been found to be a non-cytotoxic method to assess metabolic activity of the grafts, hence can be used to determine cell engraftment, proliferation and survival (Ren 2015).

Immunogenicity

The ultimate goal of organ engineering is to develop fully functional tissue substitutes that will not elicit a host immune reaction, hence, bypassing the need for immunosuppression, which leaves patients vulnerable to infections and long-term complications such as cardiovascular diseases and increased risk for cancer. In addition to incomplete removal of cellular component, which has been extensively discussed in previous sections, immune response can be elicited both by the scaffold itself or cells used for recellularization. These issues have been addressed by a number of groups, and will be discussed in the following paragraphs.

The main activators of immune response from xenogeneic sources are DNA and Galα1-3Galβ1-4GlcNAc-R (alpha-Gal), a membrane epitope present in most mammals except primates (including humans). Theoretically, complete removal of cell and cellular components should render decellularized scaffold from other species usable for organ engineering applications for human use, however, other aspects should be considered such as differences in size and architecture of organ/tissues, and removal of pathogens. The possibility of using decellularized tissues from xenogeneic sources has most extensively been evaluated in heart valves, and it has been established that collagen and elastin from bovine and porcine sources does not elicit a response from human dendritic cells, B cells, or T cells, suggesting immunocompatibility (Bayrak 2013). Despite this, availability of human organs from cadaveric donors is abundant, hence, still remains the most desirable source for decellularized scaffolds.

As discussed earlier, cells from xenogeneic sources express a number of epitopes that elicit responses from the immune system of humans, making human sources the most viable alternative. Cells recovered from cadaveric donors would require HLA typing and possibly blood matching and cross matching and despite this, transplantation of these cells may still require immune therapy. From the sources mentioned earlier, iPS-derived cells, and some MSC-derived cells are perhaps the most non-immunogenic, as they can be patient-specific. A number of other stem cells, including ESC and some of the resident stem cells present in a number of tissues have been found to have little to no expression of HLA and elicit no immune responses, suggesting immune privileged status of these cells.

CONCLUSION

Engineering of functional organs through decellularization/recellularization of cadaveric organs is a field with great promise for the alleviation of current limitations to organ transplantation, including limited availability of donor organs. Decellularization can be achieved by a number of physical and chemical methods, all with several advantages and disadvantages, as well as success rates that depend on the specific characteristics of the organs themselves. Adequate recellularization is dictated by a number of parameters, including availability of a reliable and abundant cell source that needs to be successfully delivered into the scaffold, where it should remain both viable and functional. Recellularization also requires addition of non-parenchymal cells that support proper functioning of the organs. Particularly important is inclusion of endothelial cells that in

addition to their supportive function, provide a functional vasculature, which is fundamental to the survival of the grafts. Other interactions yet to be investigated, include the incorporation of innervation into the engineered organs, however, most visceral organs function well without a nerve supply, and even in traditional transplantation approaches, innervations of the donor organ is not performed (Sanatani 2004). Finally, studies with several tissues including a recent work using decellularized liver scaffolds have shown some degree of inflammatory response in rats implanted with porcine liver matrices (Wang 2016). Crosslinking has been suggested as a possible method to overcome immunogenicity associated with use of xenogeneic scaffolds (Boer 2015, Wang 2016) and has led to promising results.

REFERENCES

Akhyari P, Aubin H, Gwanmesia P, Barth M, Hoffmann S, Huelsmann J, Preuss K, Lichtenberg A. The Quest for an Optimized Protocol for Whole-Heart Decellularization: A Comparison of Three Popular and a Novel Decellularization Technique and Their Diverse Effects on Crucial Extracellular Matrix Qualities. *Tissue Eng. Part C: Methods* 2011; 17 (9): 915−926.

Azhim A, Ono T, Fukui Y, Morimoto Y, Furukawa K, Ushida T. Preparation of decellularized meniscal scaffolds using sonication treatment for tissue engineering. *Conf. Proc. IEEE Eng. Med. Biol. Soc.* 2013; 2013 6953−6.

Azhim A, Yamagami K, Muramatsu K, Morimoto Y, Tanaka M. The use of sonication treatment to completely decellularize blood arteries: a pilot study. *Conf. Proc. IEEE Eng. Med. Biol. Soc.* 2011; 2011: 2468−71.

Bao J, Wu Q, Sun J, Zhou Y, Wang Y, Jiang X, Li L, Shi Y, Bu H. Hemocompatibility improvement of perfusion-decellularized clinical-scale liver scaffold through heparin immobilization. *Sci. Rep.* 2015; 5: 10756.

Baptista PM, Orlando G, Mirmalek-Sani SH, Siddiqui M, Atala A, Soker S. Whole organ decellularization - a tool for bioscaffold fabrication and organ bioengineering. *Conf. Proc. IEEE Eng. Med. Biol. Soc.* 3−6 Sept. 2009; 2009: 6526−6529.

Barakat O, Abbasi S, Rodriguez G, Rios J, Wood RP, Ozaki C, Holley LS, Gauthier PK. Use of Decellularized Porcine Liver for Engineering Humanized Liver Organ. *J. Surg. Res.* 2012; 173 (1): e11−e25.

Bayrak A, Pruger P, Stock UA, Seifert M. Absence of immune responses with xenogeneic collagen and elastin. *Tissue Eng. Part A.* 2013; 19 (13−14): 1592−600.

Boer U, Schridde A, Anssar M, Klingenberg M, Sarikouch S, Dellmann A, Harringer W, Haverich A, Wilhelmi M. The immune response to crosslinked tissue is reduced in decellularized xenogeneic and absent in decellularized allogeneic heart valves. *Int. J. Artif. Organs.* 2015; 38 (4): 199−209.

Bonandrini B, Figliuzzi M, Papadimou E, Morigi M, Perico N, Casiraghi F, Dipl C, Sangalli F, Conti S, Benigni A, Remuzzi A, Remuzzi G. Recellularization of well-preserved acellular kidney scaffold using embryonic stem cells. *Tissue Eng. Part A.* 2014; 20 (9−10): 1486−98.

Bonandrini B, Figliuzzi M, Papadimou E, Morigi M, Perico N, Casiraghi F, Sangalli F, Conti S, Benigni A, Remuzzi A,Remuzzi G. Recellularization of Well-Preserved Acellular Kidney Scaffold Using Embryonic Stem Cells. *Tissue Eng. Part A.* 2014; 20 (9−10): 1486−1498.

Bonvillain RW, Danchuk S, Sullivan DE, Betancourt AM, Semon JA, Eagle ME, Mayeux JP, Gregory AN, Wang G, Townley IK, Borg ZD, Weiss DJ, Bunnell BA. A Nonhuman Primate Model of Lung Regeneration: Detergent-Mediated Decellularization and Initial *In Vitro* Recellularization with Mesenchymal Stem Cells. *Tissue Engineering. Part A.* 2012; 18 (23−24): 2437−2452.

Bonvillain RW, Scarritt ME, Pashos NC, Mayeux JP, Meshberger CL, Betancourt AM, Sullivan DE, Bunnell BA. Nonhuman Primate Lung Decellularization and Recellularization Using a Specialized Large-organ Bioreactor. *J. Vis. Exp.* 2013; (82): 50825.

Bronshtein T, Au-Yeung GCT, Sarig U, Nguyen EB-V, Mhaisalkar PS, Boey FYC, Venkatraman SS, Machluf M. A Mathematical Model for Analyzing the Elasticity, Viscosity, and Failure of Soft Tissue: Comparison of Native and Decellularized Porcine Cardiac Extracellular Matrix for Tissue Engineering. *Tissue Eng. Part A.* 2013; 19 (8): 620−630.

Bruinsma BG, Kim Y, Berendsen TA, Ozer S, Yarmush ML, Uygun BE. Layer-by-layer heparinization of decellularized liver matrices to reduce thrombogenicity of tissue engineered grafts. *J. Clin. Transl. Res.* 2015; 1 (1): 04.

Caralt M, Uzarski JS, Iacob S, Obergfell KP, Berg N, Bijonowski BM, Kiefer KM, Ward HH, Wandinger-Ness A, Miller WM, Zhang ZJ, Abecassis MM, Wertheim JA. Optimization and critical evaluation of decellularization strategies to develop renal extracellular matrix scaffolds as biological templates for organ engineering and transplantation. *Am. J. Transplant* 2015; 15 (1): 64−75.

Carvalho JL, de Carvalho PH, Gomes DA, Goes AM. Characterization of Decellularized Heart Matrices as Biomaterials for Regular and Whole Organ Tissue Engineering and Initial In-vitro Recellularization with Ips Cells. *J. Tissue Sci. Eng.* 2012; Suppl 11 002.

Crapo PM, Gilbert TW, Badylak SF. An overview of tissue and whole organ decellularization processes. *Biomaterials* 2011; 32 (12): 3233−3243.

Da Palma RK, Campillo N, Uriarte JJ, Oliveira LVF, Navajas D, Farré R. Pressure- and flow-controlled media perfusion differently modify vascular mechanics in lung decellularization. *J. Mech. Behav. Biomed. Mater.* 2015; 49 69−79.

Eitan Y, Sarig U, Dahan N, Machluf M. Acellular Cardiac Extracellular Matrix as a Scaffold for Tissue Engineering: *In Vitro* Cell Support, Remodeling, and Biocompatibility. *Tissue Eng. Part C: Methods.* 2009; 16 (4): 671−683.

Faulk DM, Wildemann JD, Badylak SF. Decellularization and Cell Seeding of Whole Liver Biologic Scaffolds Composed of Extracellular Matrix. *J. Clin. Exp. Hepatol.* 2015; 5 (1): 69−80.

Figueiredo C, Wedekind D, Müller T, Vahlsing S, Horn PA, Seltsam A, Blasczyk R. MHC Universal Cells Survive in an Allogeneic Environment after Incompatible Transplantation. *Biomed. Res. Int.* 2013; 2013 796046.

Garreta E, de Oñate L, Fernández-Santos ME, Oria R, Tarantino C, Climent AM, Marco A, Samitier M, Martínez E, Valls-Margarit M, Matesanz R, Taylor DA, Fernández-Avilés F,

Izpisua Belmonte JC, Montserrat N. Myocardial commitment from human pluripotent stem cells: Rapid production of human heart grafts. *Biomaterials* 2016; 98 64−78.

Geerts S, Ozer S, Jaramillo M, Yarmush ML, Uygun BE. Nondestructive Methods for Monitoring Cell Removal During Rat Liver Decellularization. *Tissue Eng Part C: Methods.* 2016; 22 (7): 671−678.

Ghaedi M, Calle EA, Mendez JJ, Gard AL, Balestrini J, Booth A, Bove PF, Gui L, White ES, Niklason LE. Human iPS cell–derived alveolar epithelium repopulates lung extracellular matrix. *J. Clin. Invest.* 2013; 123 (11): 4950−4962.

Gilpin SE, Charest JM, Ren X, Tapias LF, Wu T, Evangelista-Leite D, Mathisen DJ, Ott HC. Regenerative potential of human airway stem cells in lung epithelial engineering. *Biomaterials* 2016; 108 111−119.

Gilpin SE, Guyette JP, Gonzalez G, Ren X, Asara JM, Mathisen DJ, Vacanti JP, Ott HC. Perfusion decellularization of human and porcine lungs: Bringing the matrix to clinical scale. *J. Heart Lung Transplant.* 2014; 33 (3): 298−308.

Goh SK, Bertera S, Olsen P, Candiello JE, Halfter W, Uechi G, Balasubramani M, Johnson SA, Sicari BM, Kollar E, Badylak SF, Banerjee I. Perfusion-decellularized pancreas as a natural 3D scaffold for pancreatic tissue and whole organ engineering. *Biomaterials* 2013; 34 (28): 6760−72.

Golberg A, Bruinsma BG, Jaramillo M, Yarmush ML, Uygun BE. Rat liver regeneration following ablation with irreversible electroporation. *Peer J.* 2016; 4 e1571.

Guan Y, Liu S, Sun C, Cheng G, Kong F, Luan Y, Xie X, Zhao S, Zhang D, Wang J, Li K, Liu Y. The effective bioengineering method of implantation decellularized renal extracellular matrix scaffolds. *Oncotarget* 2015; 6 (34): 36126−38.

Hagen CK, Maghsoudlou P, Totonelli G, Diemoz PC, Endrizzi M, Rigon L, Menk RH, Arfelli F, Dreossi D, Brun E, Coan P, Bravin A, De Coppi P, Olivo A. High contrast microstructural visualization of natural acellular matrices by means of phase-based x-ray tomography. *Sci. Rep.* 2015; 5: 18156.

He H, Liu X, Peng L, Gao Z, Ye Y, Su Y, Zhao Q, Wang K, Gong Y, He F. Promotion of Hepatic Differentiation of Bone Marrow Mesenchymal Stem Cells on Decellularized Cell-Deposited Extracellular Matrix. *Biomed. Res. Int.* 2013; 2013: 406871.

Hülsmann J, Aubin H, Kranz A, Godehardt E, Munakata H, Kamiya H, Barth M, Lichtenberg A, Akhyari P. A novel customizable modular bioreactor system for whole-heart cultivation under controlled 3D biomechanical stimulation. *J. Artif. Organs.* 2013; 16 (3): 294−304.

Hung SH, Su CH, Lee FP, Tseng H. Larynx decellularization: combining freeze-drying and sonication as an effective method. *J. Voice.* 2013; 27 (3): 289−94.

Hung SH, Su CH, Lin SE, Tseng H. Preliminary experiences in trachea scaffold tissue engineering with segmental organ decellularization. *Laryngoscope* 2016; 126 (11): 2520−2527.

Hussein KH, Park KM, Kang KS, Woo HM. Heparin-gelatin mixture improves vascular reconstruction efficiency and hepatic function in bioengineered livers. *Acta Biomater.* 2016; 38 82−93.

Izamis ML, Calhoun C, Uygun BE, Guzzardi MA, Price G, Luitje M, Saeidi N, Yarmush ML, Uygun K. Simple Machine Perfusion Significantly Enhances Hepatocyte Yields of Ischemic and Fresh Rat Livers. *Cell Med.* 2013; 4 (3): 109−123.

Izamis M-L, Perk S, Calhoun C, Uygun K, Yarmush ML, Berthiaume F. Machine Perfusion Enhances Hepatocyte Isolation Yields From Ischemic Livers. *Cryobiology* 2015; 71 (2): 244−255.

Jackson JR, Ko IK, Abolbashari M, Huling J, Zambon J, Kim C, Orlando G, Yoo J, Aboushwareb T, Atala A. CD31 Antibody Conjugation Improves Re-Endothelialization of Acellular Kidney Scaffolds for Whole Organ Engineering. *J. Am. Coll. Surg.* 2014; 219 (3): S141.

Jiang WC, Cheng YH, Yen MH, Chang Y, Yang VW, Lee OK. Cryo-chemical decellularization of the whole liver for mesenchymal stem cells-based functional hepatic tissue engineering. *Biomaterials* 2014; 35 (11): 3607−3617.

Jörn H, Hug A, Shahbaz TB, Alexander K, Volker RS, Artur L, Payam A. Rheology of perfusates and fluid dynamical effects during whole organ decellularization: A perspective to individualize decellularization protocols for single organs. *Biofabrication* 2015; 7 (3): 035008.

Kadota Y, Yagi H, Inomata K, Matsubara K, Hibi T, Abe Y, Kitago M, Shinoda M, Obara H, Itano O, Kitagawa Y. Mesenchymal stem cells support hepatocyte function in engineered liver grafts. *Organogenesis* 2014; 10 (2): 268−277.

Kajbafzadeh AM, Javan-Farazmand N, Monajemzadeh M, Baghayee A. Determining the Optimal Decellularization and Sterilization Protocol for Preparing a Tissue Scaffold of a Human-Sized Liver Tissue. *Tissue Eng Part C: Methods* 2012; 19 (8): 642−651.

Kawasaki T, Kirita Y, Kami D, Kitani T, Ozaki C, Itakura Y, Toyoda M, Gojo S. Novel detergent for whole organ tissue engineering. *J. Biomed. Mater. Res. A.* 2015; 103 (10): 3364−3373.

Khalpey Z, Qu N, Hemphill C, Louis AV, Ferng AS, Son TG, Stavoe K, Penick K, Tran PL, Konhilas J, Lagrand DS, Garcia JGN. Rapid Porcine Lung Decellularization Using a Novel Organ Regenerative Control Acquisition Bioreactor. *ASAIO J.* 2015; 61 (1): 71−77.

Kitahara H, Yagi H, Tajima K, Okamoto K, Yoshitake A, Aeba R, Kudo M, Kashima I, Kawaguchi S, Hirano A, Kasai M, Akamatsu Y, Oka H, Kitagawa Y, Shimizu H. Heterotopic transplantation of a decellularized and recellularized whole porcine heart. *Interact. Cardiovasc. Thorac. Surg.* 2016; 22 (5): 571−579.

Ko IK, Peng L, Peloso A, Smith CJ, Dhal A, Deegan DB, Zimmerman C, Clouse C, Zhao W, Shupe TD, Soker S, Yoo JJ, Atala A. Bioengineered transplantable porcine livers with re-endothelialized vasculature. *Biomaterials* 2015; 40 72−79.

Kobayashi N. Cell Therapy for Diabetes Mellitus. *Cell Transplant.* 2006; 15 (10): 849-854.

Korossis SA, Booth C, Wilcox HE, Watterson KG, Kearney JN, Fisher J, Ingham E. Tissue engineering of cardiac valve prostheses II: biomechanical characterization of decellularized porcine aortic heart valves. *J. Heart Valve Dis.* 2002; 11 (4): 463−71.

Levy G, Bomze D, Heinz S, Ramachandran SD, Noerenberg A, Cohen M, Shibolet O, Sklan E, Braspenning J, Nahmias Y. Long-term culture and expansion of primary human hepatocytes. *Nat. Biotech.* 2015; 33 (12): 1264−1271.

Maghsoudlou P, Georgiades F, Tyraskis A, Totonelli G, Loukogeorgakis SP, Orlando G, Shangaris P, Lange P, Delalande JM, Burns AJ, Cenedese A, Sebire NJ, Turmaine M, Guest BN, Alcorn JF, Atala A, Birchall MA, Elliott MJ, Eaton S, Pierro A, Gilbert TW, De Coppi P. Preservation of micro-architecture and angiogenic potential in a pulmonary

acellular matrix obtained using intermittent intra-tracheal flow of detergent enzymatic treatment. *Biomaterials* 2013; 34 (28): 6638−6648.

Matsumoto S, Noguchi H, Naziruddin B, Onaca N, Jackson A, Nobuyo H, Teru O, Naoya K, Klintmalm G,Levy M. Improvement of pancreatic islet cell isolation for transplantation. *Proc. (Bayl. Univ. Med. Cent.).* 2007; 20 (4): 357−362.

Meyer SR, Chiu B, Churchill TA, Zhu L, Lakey JR, Ross DB. Comparison of aortic valve allograft decellularization techniques in the rat. *J. Biomed. Mater. Res A.* 2006; 79 (2): 254−62.

Mishra DK, Thrall MJ, Baird BN, Ott HC, Blackmon SH, Kurie JM, Kim MP. Human Lung Cancer Cells Grown on Acellular Rat Lung Matrix Create Perfusable Tumor Nodules. *Ann. Thorac. Surg.* 2012; 93 (4): 1075−1081.

Nagao RJ, Ouyang Y, Keller R, Lee C, Suggs LJ, Schmidt CE. Preservation of Capillary-beds in Rat Lung Tissue Using Optimized Chemical Decellularization. *J. Mater. Chem. B Mater. Biol. Med.* 2013; 1 (37): 4801−4808.

Nakayama KH, Batchelder CA, Lee CI, Tarantal AF. Decellularized Rhesus Monkey Kidney as a Three-Dimensional Scaffold for Renal Tissue Engineering. *Tissue Eng. Part A.* 2010; 16 (7): 2207−2216.

Nakayama KH, Lee CCI, Batchelder CA, Tarantal AF. Tissue Specificity of Decellularized Rhesus Monkey Kidney and Lung Scaffolds. *PLoS One* 2013; 8 (5): e64134.

Nari G, Cid M, Comín R, Reyna L, Juri G, Taborda R,Salvatierra N. Preparation of a three-dimensional extracellular matrix by decellularization of rabbit livers. *Rev. Esp. Enferm. Dig.* 2013; 105. (3): 6.

Oberwallner B, Brodarac A, Choi YH, Saric T, Anic P, Morawietz L, Stamm C. Preparation of cardiac extracellular matrix scaffolds by decellularization of human myocardium. *J. Biomed. Mater. Res. A.* 2014; 102 (9): 3263−72.

Oliveira AC, Garzon I, Ionescu AM, Carriel V, Cardona Jde L, Gonzalez-Andrades M, Perez Mdel M, Alaminos M, Campos A. Evaluation of small intestine grafts decellularization methods for corneal tissue engineering. *PLoS One* 2013; 8 (6): e66538.

Orlando G, Booth C, Wang Z, Totonelli G, Ross CL, Moran E, Salvatori M, Maghsoudlou P, Turmaine M, Delario G, Al-Shraideh Y, Farooq U, Farney AC, Rogers J, Iskandar SS, Burns A, Marini FC, De Coppi P, Stratta RJ, Soker S. Discarded human kidneys as a source of ECM scaffold for kidney regeneration technologies. *Biomaterials* 2013; 34 (24): 5915−25.

Orlando G, Farney AC, Iskandar SS, Mirmalek-Sani SH, Sullivan DC, Moran E, AbouShwareb T, De Coppi P, Wood KJ, Stratta RJ, Atala A, Yoo JJ, Soker S. Production and implantation of renal extracellular matrix scaffolds from porcine kidneys as a platform for renal bioengineering investigations. *Ann. Surg.* 2012; 256 (2): 363−70.

Ott HC, Clippinger B, Conrad C, Schuetz C, Pomerantseva I, Ikonomou L, Kotton D, Vacanti JP. Regeneration and orthotopic transplantation of a bioartificial lung. *Nat. Med.* 2010; 16 (8): 927−933.

Ott HC, Matthiesen TS, Goh S-K, Black LD, Kren SM, Netoff TI, Taylor DA. Perfusion-decellularized matrix: using nature's platform to engineer a bioartificial heart. *Nat. Med.* 2008; 14 (2): 213−221.

Pan J, Yan S, Gao JJ, Wang YY, Lu ZJ, Cui CW, Zhang YH, Wang Y, Meng XQ, Zhou L, Xie HY, Zheng J, Zheng MH, Zheng SS. In-vivo organ engineering: Perfusion of

hepatocytes in a single liver lobe scaffold of living rats. *Int. J. Biochem. Cell Biol.* 2016; 80 124−131.

Peloso A, Petrosyan A, Da Sacco S, Booth C, Zambon JP, O'Brien T, Aardema C, Robertson J, De Filippo RE, Soker S, Stratta RJ, Perin L, Orlando G. Renal Extracellular Matrix Scaffolds From Discarded Kidneys Maintain Glomerular Morphometry and Vascular Resilience and Retains Critical Growth Factors. *Transplantation* 2015; 99 (9): 1807−16.

Peloso A, Urbani L, Cravedi P, Katari R, Maghsoudlou P, Fallas ME, Sordi V, Citro A, Purroy C, Niu G, McQuilling JP, Sittadjody S, Farney AC, Iskandar SS, Zambon JP, Rogers J, Stratta RJ, Opara EC, Piemonti L, Furdui CM, Soker S, De Coppi P, Orlando G. The Human Pancreas as a Source of Protolerogenic Extracellular Matrix Scaffold for a New-generation Bioartificial Endocrine Pancreas. *Ann. Surg.* 2016; 264 (1): 169−79.

Petersen TH, Calle EA, Colehour MB, Niklason LE. Matrix Composition and Mechanics of Decellularized Lung Scaffolds. *Cells Tissues Organs* 2012; 195 (3): 222−231.

Petersen TH, Calle EA, Zhao L, Lee EJ, Gui L, Raredon MB, Gavrilov K, Yi T, Zhuang ZW, Breuer C, Herzog E, Niklason LE. Tissue-engineered lungs for *in vivo* implantation. *Science* 2010; 329 (5991): 538−41.

Price AP, England KA, Matson AM, Blazar BR, Panoskaltsis-Mortari A. Development of a Decellularized Lung Bioreactor System for Bioengineering the Lung: The Matrix Reloaded. *Tissue Eng. Part A.* 2010; 16 (8): 2581−2591.

Rafighdoust A, Shahri NM, Baharara J. Decellularized kidney in the presence of chondroitin sulfate as a natural 3D scaffold for stem cells. *Iran. J. Basic Med. Sci.* 2015; 18 (8): 788−98.

Ren X, Moser PT, Gilpin SE, Okamoto T, Wu T, Tapias LF, Mercier FE, Xiong L, Ghawi R, Scadden DT, Mathisen DJ, Ott HC. Engineering pulmonary vasculature in decellularized rat and human lungs. *Nat. Biotech.* 2015; 33 (10): 1097−1102.

Ren X, Tapias LF, Jank BJ, Mathisen DJ, Lanuti M, Ott HC. Ex vivo Non-invasive Assessment of Cell Viability and Proliferation in Bio-engineered Whole Organ Constructs. *Biomaterials* 2015; 52 103−112.

Ross EA, Williams MJ, Hamazaki T, Terada N, Clapp WL, Adin C, Ellison GW, Jorgensen M, Batich CD. Embryonic Stem Cells Proliferate and Differentiate when Seeded into Kidney Scaffolds. *J. Am. Soc. Nephrol.* 2009; 20 (11): 2338−2347.

Sabetkish S, Kajbafzadeh A-M, Sabetkish N, Khorramirouz R, Akbarzadeh A, Seyedian SL, Pasalar P, Orangian S, Beigi RSH, Aryan Z, Akbari H, Tavangar SM. Whole-organ tissue engineering: Decellularization and recellularization of three-dimensional matrix liver scaffolds. *J. Biomed. Mater. Res. A.* 2015; 103 (4): 1498−1508.

Sanatani S, Chiu C, Nykanen D, Coles J, West L, Hamilton R. Evolution of heart rate control after transplantation: conduction versus autonomic innervation. *Pediatr. Cardiol.* 2004; 25 (2): 113−8.

Sanchez PL, Fernandez-Santos ME, Costanza S, Climent AM, Moscoso I, Gonzalez-Nicolas MA, Sanz-Ruiz R, Rodriguez H, Kren SM, Garrido G, Escalante JL, Bermejo J, Elizaga J, Menarguez J, Yotti R, Perez del Villar C, Espinosa MA, Guillem MS, Willerson JT, Bernad A, Matesanz R, Taylor DA, Fernandez-Aviles F. Acellular human heart matrix: A critical step toward whole heart grafts. *Biomaterials* 2015; 61 279−89.

Sano MB, Neal RE, Garcia PA, Gerber D, Robertson J, Davalos RV. Towards the creation of decellularized organ constructs using irreversible electroporation and active mechanical perfusion. *Biomed. Eng. Online* 2010; 9 (1): 83.

Sarig U, Au-Yeung GCT, Wang Y, Bronshtein T, Dahan N, Boey FYC, Venkatraman SS, Machluf M. Thick Acellular Heart Extracellular Matrix with Inherent Vasculature: A Potential Platform for Myocardial Tissue Regeneration. *Tissue Eng. Part A.* 2012; 18 (19−20): 2125−2137.

Schaner PJ, Martin ND, Tulenko TN, Shapiro IM, Tarola NA, Leichter RF, Carabasi RA, Dimuzio PJ. Decellularized vein as a potential scaffold for vascular tissue engineering. *J. Vasc. Surg.* 2004; 40 (1): 146−53.

Schneider C, Lehmann J, van Osch GP, Hildner F, Teuschl AH, Monforte X, Miosga D, Heimel P, Priglinger E, Redl H, Wolbank S, Nurnberger S. Systematic comparison of protocols for the preparation of human articular cartilage for use as scaffold material in cartilage tissue engineering. *Tissue engineering. Part C, Methods.* 2016.

Shamis Y, Hasson E, Soroker A, Bassat E, Shimoni Y, Ziv T, Sionov RV, Mitrani E. Organ-Specific Scaffolds for *In Vitro* Expansion, Differentiation, and Organization of Primary Lung Cells. *Tissue Eng Part C: Methods.* 2011; 17 (8): 861−870.

Silva AC, Rodrigues SC, Caldeira J, Nunes AM, Sampaio-Pinto V, Resende TP, Oliveira MJ, Barbosa MA, Thorsteinsdóttir S, Nascimento DS, Pinto-do-Ó P. Three-dimensional scaffolds of fetal decellularized hearts exhibit enhanced potential to support cardiac cells in comparison to the adult. *Biomaterials* 2016; 104 52−64.

Song JJ, Kim SS, Liu Z, Madsen JC, Mathisen DJ, Vacanti JP, Ott HC. Enhanced *In Vivo* Function of Bioartificial Lungs in Rats. *Ann. Thorac. Surg.* 2011; 92 (3): 998−1006.

Stabler CT, Caires LC, Mondrinos MJ, Marcinkiewicz C, Lazarovici P, Wolfson MR, Lelkes PI. Enhanced Re-Endothelialization of Decellularized Rat Lungs. *Tissue Eng. Part C: Methods.* 2016; 22 (5): 439−450.

Sullivan DC, Mirmalek-Sani S-H, Deegan DB, Baptista PM, Aboushwareb T, Atala A, Yoo JJ. Decellularization methods of porcine kidneys for whole organ engineering using a high-throughput system. *Biomaterials* 2012; 33 (31): 7756−7764.

Sun H, Calle E, Chen X, Mathur A, Zhu Y, Mendez J, Zhao L, Niklason L, Peng X, Peng H, Herzog EL. Fibroblast engraftment in the decellularized mouse lung occurs via a β1-integrin-dependent, FAK-dependent pathway that is mediated by ERK and opposed by AKT. *Am. J. Physiol. Lung Cell Mol. Physiol.* 2014; 306 (6): L463−L475.

Tsuchiya T, Mendez J, Calle EA, Hatachi G, Doi R, Zhao L, Suematsu T, Nagayasu T, Niklason LE. Ventilation-Based Decellularization System of the Lung. *Biores. Open Access.* 2016; 5 (1): 118−26.

Tsuchiya T, Mendez J, Calle EA, Hatachi G, Doi R, Zhao L, Suematsu T, Nagayasu T, Niklason LE. Ventilation-Based Decellularization System of the Lung. *Biores. Open Access.* 2016; 5 (1): 118−126.

Uygun BE, Izamis M-L, Jaramillo M, Chen Y, Price G, Ozer S, Yarmush ML. Discarded Livers Find a New Life: Engineered Liver Grafts Using Hepatocytes Recovered From Marginal Livers. *Artif. Organs.* 2016; n/a-n/a.

Uygun BE, Soto-Gutierrez A, Yagi H, Izamis M-L, Guzzardi MA, Shulman C, Milwid J, Kobayashi N, Tilles A, Berthiaume F, Hertl M, Nahmias Y, Yarmush ML, Uygun K. Organ reengineering through development of a transplantable recellularized liver graft using decellularized liver matrix. *Nature Med.* 2010; 16 (7): 814−820.

Uzarski JS, Bijonowski BM, Wang B, Ward HH, Wandinger-Ness A, Miller WM, Wertheim JA. Dual-Purpose Bioreactors to Monitor Noninvasive Physical and Biochemical

Markers of Kidney and Liver Scaffold Recellularization. *Tissue Eng Part C: Methods.* 2015; 21 (10): 1032−1043.

Uzarski JS, Su J, Xie Y, Zhang ZJ, Ward HH, Wandinger-Ness A, Miller WM, Wertheim JA. Epithelial Cell Repopulation and Preparation of Rodent Extracellular Matrix Scaffolds for Renal Tissue Development. *J. Vis. Exp.* 2015; (102): e53271.

Vavken P, Joshi S, Murray MM. TRITON-X is most effective among three decellularization agents for ACL tissue engineering. *J. Orthop. Res.* 2009; 27 (12): 1612−8.

Vishwakarma SK, Bhavani PG, Bardia A, Abkari A, Murthy GS, Venkateshwarulu J, Khan AA. Preparation of natural three-dimensional goat kidney scaffold for the development of bioartificial organ. *Indian J. Nephrol.* 2014; 24 (6): 372−5.

Vossler JD, Ju YM, Williams JK, Goldstein S, Hamlin J, Lee SJ, Yoo JJ, Atala A. CD133 antibody conjugation to decellularized human heart valves intended for circulating cell capture. *Biomedical materials* 2015; 10 (5): 055001−055001.

Wainwright JM, Czajka CA, Patel UB, Freytes DO, Tobita K, Gilbert TW, Badylak SF. Preparation of Cardiac Extracellular Matrix from an Intact Porcine Heart. *Tissue Eng. Part C: Methods.* 2010; 16 (3): 525−532.

Wang Y, Bao J, Wu Q, Zhou Y, Li Y, Wu X, Shi Y, Li L, Bu H. Method for perfusion decellularization of porcine whole liver and kidney for use as a scaffold for clinical-scale bioengineering engrafts. *Xenotransplantation.* 2015; 22 (1): 48−61.

Wang Z, Wang Z, Yu Q, Xi H, Weng J, Du X, Chen D, Ma J, Mei J, Chen C. Comparative study of two perfusion routes with different flow in decellularization to harvest an optimal pulmonary scaffold for recellularization. *J. Biomed. Mater. Res. A.* 2016; 104 (10): 2567−2575.

Weymann A, Patil NP, Sabashnikov A, Jungebluth P, Korkmaz S, Li S, Veres G, Soos P, Ishtok R, Chaimow N, Pätzold I, Czerny N, Schies C, Schmack B, Popov AF, Simon AR, Karck M,Szabo G. Bioartificial Heart: A Human-Sized Porcine Model – The Way Ahead. *PLoS One* 2014; 9 (11): e111591.

Willenberg BJ, Oca-Cossio J, Cai Y, Brown AR, Clapp WL, Abrahamson DR, Terada N, Ellison GW, Mathews CE, Batich CD, Ross EA. Repurposed biological scaffolds: kidney to pancreas. *Organogenesis* 2015; 11 (2): 47−57.

Xu H, Xu B, Yang Q, Li X, Ma X, Xia Q, Zhang Y, Zhang C, Wu Y, Zhang Y. Comparison of decellularization protocols for preparing a decellularized porcine annulus fibrosus scaffold. *PLoS One* 2014; 9 (1): e86723.

Yam GH-F, Yusoff NZBM, Goh T-W, Setiawan M, Lee XW, Liu YC, Mehta JS. Decellularization of human stromal refractive lenticules for corneal tissue engineering. *Sci. Rep.* 2016; 6 26339.

Zhou P, Huang Y, Guo Y, Wang L, Ling C, Guo Q, Wang Y, Zhu S, Fan X, Zhu M, Huang H, Lu Y, Wang Z. Decellularization and Recellularization of Rat Livers With Hepatocytes and Endothelial Progenitor Cells. *Artif. Organs* 2016; 40 (3): E25−E38.

Zvarova B, Uhl FE, Uriarte JJ, Borg ZD, Coffey AL, Bonenfant NR, Weiss DJ, Wagner DE. Residual Detergent Detection Method for Nondestructive Cytocompatibility Evaluation of Decellularized Whole Lung Scaffolds. *Tissue Eng. Part C: Methods* 2016; 22 (5): 418−428.

In: Encyclopedia of Surgery (22 Volume Set)
Editors: Andreas Lehrer and Kristin Mueller
ISBN: 978-1-53618-329-0
© 2020 Nova Science Publishers, Inc.

Chapter 195

WOUND HEALING AND SCARRING

A. Samandar Dowlatshahi*, MD
Plastic and Reconstructive Surgery,
Harvard Medical School, Boston, MA, US

ABSTRACT

Wounding is ubiquitous in clinical as well as experimental surgery. It is defined as any violation of tissue integrity in a live subject. The success of an experimental model in surgical research depends on control and predictability of the wounding as well as wound healing processes. Wounds typically are thought of in the context of skin wounds. In reality, even procedures deep within the torso, such as a model to study solid organ transplantation, rely on wound healing at every level: from the microvascular anastomosis, to the fascial layers that were obligatorily violated and to the skin at the site of the incision. In some circumstances, wound healing itself is the subject of study, such as in hernia or wound healing research. In experimental models, where it is not the subject matter in itself, any impaired tissue healing can contribute to morbidity and experiment failure. It is therefore critical for the surgical scientist to have a basic understanding of wound physiology and mechanisms of tissue regeneration and scarring, as well as animal-specific differences.

Keywords: wound healing, wound physiology, wounding, experimental wound models, surgical tissue handling, atraumatic technique, scarring, skin, tissue regeneration

ABBREVIATIONS

CCL	C-C Motif Chemokine Ligand
CD	Cluster of Differentiation
DNA	Deoxyribonucleic Acid
ECM	Extracellular Matrix

* Corresponding Author's Email: drdowlat@gmail.com.

FGF	Fibroblast Growth Factor
IL	Interleukin
MIP	Macrophage Infectivity Potentiator
miRNA	Micro RNA
MMP	Matrix Metalloproteinase
PDGF	Platelet Derived Growth Factor
RNA	Ribonucleic Acid
siRNA	Small Interfering RNA
TF	Tissue Factor
TGF	Transforming Growth Factor
VEGF	Vascular Endothelial Growth Factor

INTRODUCTION

From the beginning of recorded history, wound healing has been the subject of awe and fascination to healers, scientists, physicians, and even the layman in the form of "home remedies," throughout all cultures. The principles of primary and secondary intention healing were laid out by Galen in the first century A.D. Major advances occurred throughout the 19th and 20th centuries in particular with the advent of large-scale geopolitical conflicts, improving our understanding of the physiologic processes involved. The impetus underlying these advances was first and foremost the desire to save the lives of wounded warriors and civilian casualties, and decrease human suffering and physical morbidity.

Our advanced understanding of the physiologic processes involved has not only impacted clinical care but it also allowed for the development of more elaborate and sophisticated experimental models.

Every type of live tissue has, embedded within its genetic coding, mechanisms for tissue repair secondary to injury and wounding. Wounding does not only imply mechanical injury, but also includes tissue injury in a broader sense, such as chemical injury, radiation and reperfusion injury. It is critical to understand the difference between repair and regeneration. Regeneration refers to the reconstitution, or re-creation of the injured cells to result in an organ or tissue with its original integrity and architecture. It is a remarkable biochemical and physiologic pathway unique to select organs and animals and is the subject of regenerative medicine. Wound healing, on the other hand, leads to creation of repair tissue, which differs in varying degrees from the original tissue. In terms of skin, the resulting tissue is referred to as scar, which has a different cellular and extracellular composition as compared to native skin. In cartilage healing, the substrate is known as fibrocartilage. Virtually all types of human and animal tissue have a genetically programmed response to wounding.

PHYSIOLOGY OF WOUND HEALING

Three Integrated Phases

Tissue wounding results in a series of physiologic processes that occur both consecutively and also simultaneously, traditionally defined as the phases of hemostasis and

inflammation, proliferation, and remodeling (Childs 2017). They can also be referred to as the wound healing cascade, resulting in the formation of repair tissue, restoring the wounded organ's integrity and function.

Hemostasis and Inflammation

Immediately at wounding, the process of hemostasis begins. The key step which sets this process in motion is the exposure of blood components to the sub-endothelial layers of the vessel wall. This leads to vasoconstriction, as well as formation of a blood clot which in turn serves as a barrier against microbial invasion, at the same time minimizing blood loss. Our current understanding is that the blood clot is the epicenter that orchestrates wound chemotaxis, triggering the subsequent wound healing phases of inflammation and proliferation by attracting progenitor cells. It contains several growth factors and cytokines (Midwood 2004; Huntington 2005).

Hemostasis is initiated by the extrinsic pathway whereby Tissue Factor (TF) which is expressed by sub-endothelial tissues (vascular smooth muscle cells, pericytes and adventitial fibroblasts), comes in contact with circulating factor VII and creates the FVIIa-TF complex (Schecter 2000; Mackman 2007). This, activates FIX and FX. FXa and its cofactor FVa form the prothrombinase complex which leads to the activation of prothrombin to thrombin. The latter then converts the soluble plasma fibrinogen to fibrin which, in turn, is insoluble and leads to thrombocyte entrapment in the nascent clot. Thrombin also activates factors V and VIII, which both feed back into the cycle of factor X activation. Thrombin itself is also pro-inflammatory, leading to vasodilatation, edema, and a release of cytokines such as C-C Motif chemokine Ligand 2 (CCL2), Interleukin 8 (IL-8) and IL-6 (Levy 2016).

The role of fibrin in wound healing is substantial. It promotes stromal cell proliferation, binds to integrin CD11b/CD18 on monocytes and neutrophils, Fibroblast Growth Factor 2 (FGF-2) as well as Vascular Endothelial Growth Factor (VEGF) (Sahni 1998).

Degranulating platelets also release chemoattractants and growth factors such as Transforming Growth Factor β (TGF-β), Platelet Derived Growth Factor (PDGF), VEGF, CCL5, monocyte chemoattractant protein-1, CCL2, CCL3, Macrophage Inflammatory Protein 1α (MIP1α), TGF-α, C5a, C3a and nerve growth factor. (Maraganore 1993; Frank 2000).

Interferon-γ, IL-1β and TNF-α promote the transmigration of neutrophils across the capillary wall by means of adhesion and diapedesis. Current research indicates that macrophages within the wound require the guidance of neutrophils in the process of wound repair (Peters 2005). In the presence of infectious agents, as well as devitalized tissue, the neutrophil response appears to be enhanced. This is another reason why atraumatic technique is critical in controlling the amount of inflammation in the postoperative period; traumatic tissue handling can lead to tissue injury, necrosis, and inflammation.

Mast cells and macrophages also contribute to the inflammatory phase of wound healing. Once the monocyte leaves the blood vessel, it differentiates into a macrophage, now functioning as antigen presenting cell and phagocyte. It also secretes numerous growth factors such as TGF-β, TGF-α, PDGF, basic FGF (bFGF) and VEGF. Mast cells hereby modulate the inflammatory response and their influence extends throughout the entirety of the wound healing cascade. They have even been implicated in the pathogenesis of hypertrophic scarring as well as delayed healing (Noli 2001).

Proliferation

This phase has classically been described as taking place between two and 21 days post-injury. It overlaps with the inflammatory phase and begins with the gradual degradation of the blood clot which functions as a provisional matrix. During this phase, fibroblasts deposit extracellular matrix and proliferate. Within three to five days, they become the predominant cell type in the wound. They deposit collagen onto a fibronectin and glycosaminoglycan matrix resulting in scar tissue. In the skin, this collagen is initially histologically disorganized and is primarily of type III; it will eventually undergo remodeling and the ratio of type I to type III collagen reaches a ratio of 4:1, similar to native skin.

Granulation tissue refers to the beefy, dark red colored tissue which appears within days in open wounds. It consists of fibroblasts, macrophages, as well as sprouting blood vessels which explains its tendency to bleed, similar to a pyogenic granuloma. It is not only seen in cutaneous wounds. Even areas affected by chronic inflammation such as tendinitis, can often have an appearance and histopathologic similarity to granulation tissue.

In the case of skin healing, the proliferative phase is accompanied by epithelial resurfacing. This is clinically one of the most visible elements of wound healing and can be followed by visual inspection of the wound on a day-to-day basis. Within hours of injury, the keratinocytes at the margin of the wound undergo morphologic changes and migrate across the wound. Once the wound is resurfaced, a keratinocyte layering process takes place, increasing the thickness of the restored epidermal layer. This process is also visible when a thin skin graft thickens over time.

In conjunction with fibroblast and keratinocyte proliferation and migration of the latter, wound contraction can also contribute to wound closure. It is mediated by the presence of myofibroblasts, which are fibroblasts at the wound margin that differentiate into protomyofibroblasts and subsequently to myofibroblasts, when subjected to mechanical tension and PDGF. (Hermanns-Le 2015) The extent of wound contraction for non-cutaneous wounds remains to be determined. Interestingly, keratinocytes also appear to have a cytoskeleton allowing for contractility and may also contribute to skin wound contraction (Gniadecki 2001).

Remodeling

During this phase, the structural elements of the skin, and in particular the ECM, undergo changes. This is a balanced act of extracellular matrix (ECM) degradation and synthesis, partly modulated by matrix metalloproteinases (MMP). Collagen cross-linking also takes place, increasing wound tensile strength. Lysyl oxidase is the primary cross-linking enzyme. (Kobayashi 1994) This phase of healing lasts at least one year and results in a mature scar. The initial erythema associated with ongoing inflammation and scar maturation eventually resolves and corresponds to regression of the dense capillary network.

Despite this length of time, the end-result of wound healing consists of repair tissue, and is different from unwounded skin. Its tensile strength can only reach a maximum of 80% of unwounded skin and the orientation and organization of sub-epithelial collagen is dissimilar to the reticular pattern in native dermis. In fetal wound healing on the other hand, the end-result is scarless tissue regeneration, with a restoration of normal epidermal and dermal

architecture. (Beanes 2002, Buchanan 2009) It was once thought that scarless skin healing was associated with factors present in the amniotic fluid, but this hypothesis has been refuted (Buchanan 2009).

MODIFYING FACTORS IN WOUND HEALING

Colonization and Infection

Colonized wounds show no immune response, in contrast with infected tissue. Infection, in contrast to colonization, indicates that a threshold number of bacteria are present in the wound and have overcome host resistance, leading to slowing down fibroblast proliferation and ECM synthesis. Bacterial loads greater than 10^5 organisms per gram of tissue is the historically accepted threshold. (Robson 1990) In our clinical experience, however, this number is no longer of absolute relevance. Depending on the vascularity of the wound bed, the presence of ionizing radiation, level of oxygenation as well as tissue edema, the state of the immune system and the anatomical location, varying degrees of bacterial burden are tolerated and may or may not lead to an overwhelming immune response as seen in infected wounds. In consequence, the clinical presentation of an infected wound can vary, traditionally described as the presence of pus with associated tissue inflammation (tumor, calor, rubor, functio laesa), and be as subtle as increased drainage, or discolored appearing granulation tissue with increased friability. The virulence of the offending organism is another variable which is difficult to quantify.

The mechanisms by which bacteria affect the wound microenvironment are multiple. The organism's attempt at neutralizing the offending agent leads to release of proinflammatory cytokines, leading to inflammation and pain. Pain in itself has been shown to delay the immune response. (White 2009) Biofilm represents an accumulation of microorganisms within a matrix of extracellular material and has prompted interest in recent years because of its ability to shield itself from this host inflammatory response (Nouvong 2016).

Vascularization: Angiogenesis and Vasculogenesis

Wound healing requires blood supply, enabling tissue oxygenation, delivery of nutrients, and removal of waste products. Small wounds can heal by means of diffusion, as seen in the initial stages of free skin graft healing. Larger wounds require neovascularization. This process is divided into vasculogenesis and angiogenesis. The former refers to the formation of new blood vessels from marrow-derived stem cells, the latter is described as the sprouting of capillaries from already present blood vessels at the wound margins. In reality, these processes overlap. Their regulation is sophisticated and is primarily driven by proangiogenetic factors and cytokines originating from platelets, macrophages, leucocytes as well as local circumstances such as hypoxia. It is important to note that most of these key players are located within the hemostatic plug that eventually undergoes ECM and cellular changes during the proliferative and remodeling phases of healing.

Platelets induce migration of endothelial cells to the wound site. Macrophages secrete TGF-β, TGF-α, PDGF, bFGF and VEGF which drive angiogenesis. (Okizaki 2016) VEGF-A and IL-8 are proangiogenetic factors which originate from leucocytes. (Labler 2009) The VEGF mechanism of action consists of ligation with endothelial tyrosine kinase receptors, in particular VEGFR-2 and VEGFR-3. Many of the endothelial signal transmission pathways in vascularization involve tyrosine kinase receptors. The endothelial cell receptors Tie-1 and Tie-2, and VEGFR are the only known endothelial tyrosine kinases (Singh 2009; Savant 2015).

Once activated, endothelial cells proliferate and migrate. The ECM also contributes to this process of vascularization. (Sottile 2004) A significant element of the ECM, the basement membrane, is required in order to stabilize the tubular configuration of endothelial cell clusters. In addition to a structural and stabilizing role, the vessel basement membrane induces polarization of the endothelial cells.

The Role of Ischemia and Tissue Oxygenation

Ischemia and hypoxia designate different processes. Ischemia relates to hypoperfusion. Hypoxia will often be present in hypoperfused, ischemic tissues, but itself is defined by a lack of oxygen supply relative to oxygen demand. In consequence, tissue hypoxia can be induced by either increasing tissue oxygen demand (e.g., wound healing, wound infection with oxygen consumption to create reactive oxygen species such as oxygen free radicals), decreasing arterial oxygen supply (e.g., pulmonary fibrosis, anemia inefficient cardiac circulation, altitude), or increasing the resistance to oxygen diffusion (e.g., tissue fibrosis, radiation, edema). Tissue hypoxia will amplify angiogenetic pathways which, in turn, are linked into all three phases of wound healing. This has several implications for experimental surgery. One must keep in mind that within a wound, there may be local pockets of extreme hypoxia leading to focal apoptotic cell nests with a significantly different micro-environment and resulting cell behavior.

The Role of Micro RNA

In order to go from protein-coding gene to protein, the deoxyribonucleic acid (DNA) is transcribed to messenger ribonucleic acid (RNA), which is translated to protein. Micro RNAs (miRNAs) are 19−22 nucleotides long and are noncoding RNA which, in conjunction with small interfering RNAs (siRNAs) modulate both transcription and translation. 1048 miRNAs are encoded in the human genome. The role of miRNAs in wound healing is established, but poorly understood (Shilo 2007).

Endothelial cell capillary sprouting for instance can be inhibited by knockdown of the miRNAs Dicer and Drosha. (Kuehbacher 2007; Kuehbacher 2008) On the other hand, there exist antiangiogenic miRNAs such as miR-92a, miR-17, and miR-320, just to name a few.

Other proangiogenic miRNAs are miR-17-92, miR-126, miR-130a, miR-210, miR-296 and miR378 (Banerjee 2011).

miRNAs also play a role in the proliferative phase of wound healing (miR-184, miR-205, miR-210) as well as the inflammatory phase (miR-105 targets TLR2, miR-140 targets the PDGF receptor, miR-146a and miR-125b target TNF-α) (Banerjee 2011).

The purpose here is not to provide an exhaustive list, but to demonstrate that known chemokines have now been shown to have another layer of regulatory factors as seen in the miRNAs which adds another level of fine-control and complexity. It also offers a potential therapeutic strategy; modulating a group of functionally related genes in a pathway by targeting a single miRNA, as opposed to targeting a single gene at a time, as in conventional gene therapy.

In wound healing research, the most fascinating phenomenon is scarless wound healing as observed in mammalian fetal skin. (Beanes 2002) miRNA may explain some of these findings, as a number of these (miRNA-29b, miRNA-29c, miRNA-192) have been found to be differentially induced during different phases of gestation and may play a role in scarless cutaneous healing (Cheng 2010).

PRACTICAL IMPLICATIONS FOR EXPERIMENTAL SURGERY

Animal Models for Wound Healing

Role and Limitations of In vitro Models

In-vitro studies allow to study the effect of agents on specific cell types in a controlled environment. In particular, the presence or absence of confounding cell lines and chemokines can be controlled for, which is of particular interest in wound healing research because of the numerous cell-to-cell and cell-to-ECM interactions involved. They are however unable to completely reproduce biological conditions relevant to clinical wound healing. Furthermore, unlike many other physiologic processes, wound healing always involves biomechanical factors such as wound contraction as well as periodic changes in repair-tissue tensile strength that cannot be studied in an *ex-vivo* construct, or even by computerized simulation. The animal study is therefore the logical next step. It should be noted that that the number of articles in Pubmed pertaining to animal wound healing models has exponentially increased since 1980.

Small Mammal Wound Healing Models

Rodents and small mammals find widespread use in wound healing models. They are inexpensive and require minimal space, food and water. They also exhibit accelerated wound healing as compared to humans, which shortens the duration of experiments. Small mammal anesthesia is relatively facile, and inexpensive. Due to their size, facilities with limited space are not an issue and animal transportation is easily accomplished, especially in studies with larger numbers. Wound healing experiments are typically carried out on the back of the animal, where partial and full thickness wounding can be reproducibly accomplished. Lastly, the availability of numerous knock out rodents allows the animal model to be more refined and specific to the needs of the study in question.

Limitations include the difficulty in securing dressings, wound care, a different hair growth cycle as compared with humans, the extremely thin skin (50μm) and the presence of the subcutaneous panniculus carnosus muscle which aids in wound contraction. (Davidson 1998; Wong 2011). Furthermore, certain studies requiring larger numbers can be successfully accomplished with fewer animals of larger size. Murine models have been preferentially used for burn research but it has been shown that they have a physiologic response to injury that is dissimilar to what is seen in humans. (Seok 2013) Lastly, mice can only tolerate 30% Total Body Surface Area Burns, which in humans will only begin to induce a systemic inflammatory response (Pereira 2005).

Porcine Wound Healing Models

Of all animals, porcine skin is structurally as well as histologically the most similar to humans. (Lindblad 2008) Porcine collagen, cutaneous blood supply and follicular hair structure is similar to humans, as well as a similar physiologic response to wounding. The skin turnover time is 30 days, similar to human epidermis. The greatest downside is the cost compared to smaller animals, in terms of animal acquisition, as well as feeding, space requirement, dedicated vivarium and more complex anesthesia monitoring modalities. Miniature breeds are now available, weighing 12−45 kg as compared to the >100 kg domestic pig.

On the other hand, the swine model is much more convenient to use: partial thickness defects can be easily created using dermatomes or hydrodissection (salt split technique), ischemic wound models are easier to achieve by elevation of a skin flap and interposition of a barrier. Serial wound biopsies are easier to obtain because of the larger size and surface area. The thickness and architecture of the subcutaneous fat is also more similar to humans, whereas in a rodent model, a full thickness skin wound can often extend straight to muscle fascia. Lastly, wound healing is greatly dependent on wound hygiene as well as dressings utilized in wound care. Poorly applied dressings lead to contamination, shear, desiccation or maceration, and can affect the study outcome. Wound care is greatly facilitated in larger animal models.

With the increasing incidence of diabetes and diabetic wounds, studying the altered wound healing in the setting of diabetes is of particular interest. Streptozotocin can be utilized to induce a diabetic state in swine. (Sheets 2016) Hypertrophic scar models can be studied using Red Duroc pigs (Zhu 2003; Gallant 2004; Zhu 2004). Chronic, non-ischemic wounds can be created by irradiation and wounding. (Bernatchez 1998) Infected wound models are created by using different pathogens, most commonly Staph Aureus (Breuing 2003; Hirsch 2008).

Tissue Handling and Atraumatic Technique

As experimental models increase in complexity, it becomes more important to pay attention to adequate tissue handling, as this correlates directly with the ability of the tissues to heal. This is relevant for skin wound healing research, but also when the abdominal cavity or chest wall is entered and procedures on internal organs carried out. For microsurgeons this

is obvious, as they have seen a vessel readily thrombose following a poorly placed stitch or aggressive grasping of the vessel wall during microvascular anastomosis. Meticulous technique is required when handling other tissues as well, and will determine outcome.

Instruments and Tissue Handling

All too often, instruments of poor quality, or even damaged instruments are made available to the experimental surgeon. Not only does this violate the core ethical values pertaining to animal research, in which animals are to be treated as living beings and respected as one would respect a human being (poor instruments are never acceptable in clinical surgery), but also, due to the more difficult circumstances in a laboratory, as well as smaller size of the anatomical structures, it becomes even more important to use clean and precisely engineered instruments that are in good shape.

Grasping instruments such as forceps and retractors should be utilized only when necessary, and for the shortest time possible. The most atraumatic instrument used for retraction is a sharp hook or double hook. Crushing of tissues must be prevented at all cost, as it will lead to obligatory tissue ischemia and injury. Therefore, when using forceps, preference is usually given to toothed forceps, except when handling nerves and blood vessels. Here, every effort is made to not grab the structure itself, but to use the vessel adventitia or the epineurium as a handle. Aggressive tissue handling will lead to perineurial scar formation, vessel thrombosis, skin injury and resulting wound dehiscence or delayed healing. In tendon surgery, careful handling will prevent adhesion formation and possibly failure of the experiment. Brutalization of bowel loops leads to bowel adhesions and possible serosal injury.

Bleeding and Hemostasis

The use of cautery and other hemostatic agents is fortunately less common today in the animal operating theatre than in the clinical setting where the monopolar electrocautery appears to be the only instrument able to cut tissue. The degree of thermal trauma caused by cautery has been well documented, and linked to poor wound healing, as well as adjacent organ injury. Most tissues will stop bleeding spontaneously or with gentle pressure. Visible vessels should be precisely cauterized or ligated. Thermal methods of cautery include the monopolar, bipolar and the handheld battery-powered cautery. The latter is the least traumatic and can be used as precisely as a knife. The only downside is the limited battery life. Surgifoam has been found to be very useful immediately post-anastomosis in microsurgical cases where it can be applied in a thinly cut sheet to cease bleeding from the anastomotic suture line.

Dissection and Desiccation

The most atraumatic dissection is carried out sharply with scissors or knife. The scalpel blade is the cheapest instrument in the operating room and fresh blades should therefore be

used liberally. Atraumatic dissection is a largely acquired skill but obeys a few guiding principles. Tissue planes are always present and should be followed when possible. This allows for a rapid and precise dissection, following the naturally present tissue planes. When this plane is entered, it opens up and can be easily followed with good traction and counter-traction. Blood staining makes the identification of tissues more difficult and must be prevented. Blunt dissection can be considered an atraumatic technique when following the tissue planes. However, uncoordinated and aggressive spreading with scissors or a vascular clamp is usually indicative of lack of anatomical knowledge on the part of the surgeon, and leads to more bleeding and crush-avulsive tissue trauma.

Tissue desiccation must be prevented at all cost. Dry tissue is dead tissue. The operating room lights expedite this process because they act as a heat source. Lengthy procedures are at higher risk for tissue desiccation. Certain tissues such as tendon, nerves, blood vessels and bone are also at higher risk. The paratenon dries within seconds of air exposure. It is critical to moisten the tissues intermittently. The more practical solution for lengthy cases is the placement of saline-moistened sponges onto the tissues. This cannot be overemphasized.

Skin Closure

In animal surgery, skin closure is as important as it is in clinical surgery. If the skin edges are not precisely aligned at the end of the procedure, delayed wound healing can occur, with the high likelihood of wound separation, colonization and infection. Wound margin eversion will ensure uninterrupted healing and can be simply achieved with careful technique.

Planning

A well-conceived operation will ensure ease of execution. This pertains to all aspects of the procedure, including good lighting (which is often lacking), and operating theatre ergonomics (surgeon fatigue is directly correlated with the quality of the work delivered). Probably the most important point is not to compromise with any of the steps of the operation. When one compromises with the lighting for instance, then one compromises with a dull blade, poor instruments, uncomfortable posture, one thing after the next leading to fatigue, frustration and failure. Furthermore, in animal studies, often the same procedure is performed a number of times in repetition. Meticulous and standardized technique will provide reproducible and more consistent data.

CONCLUSION

Wound healing is a necessary prerequisite in all experimental surgery, whether or not it is wound healing itself that is being studied. Wound healing is broken down into various phases but in reality they overlap: hemostasis, inflammation, proliferation and remodeling. Each phase is characterized by up and down regulation of specific processes, in turn driven by chemokines that originate both from the repair tissue itself as well as the adjacent wound bed.

Vascularization and oxygenation are rate-limiting factors which are at the core of all wound healing. Despite certain advantages of small mammalian animal models, the swine model is best suited for wound healing *in-vivo* studies, albeit at higher cost and logistical effort. Atraumatic tissue handling will ensure minimal tissue injury and uninterrupted healing in all experimental surgery procedures.

REFERENCES

Banerjee J, Chan YC, and Sen CK. MicroRNAs in skin and wound healing. *Physiol. Genomics* 43(10): 543−556.

Beanes SR, Hu FY, Soo C, Dang CM, Urata M, Ting K, Atkinson JB, Benhaim P, Hedrick MH, and Lorenz HP. Confocal microscopic analysis of scarless repair in the fetal rat: defining the transition. *Plast. Reconstr. Surg.* 109(1): 160−170.

Bernatchez SF, Parks PJ, Grussing DM, S. L. Matalas SL, and Nelson GS. Histological characterization of a delayed wound healing model in pig. *Wound Repair Regen.* 6(3): 223−233.

Breuing K, Kaplan S, Liu P, Onderdonk AB, and Eriksson E. Wound fluid bacterial levels exceed tissue bacterial counts in controlled porcine partial−thickness burn infections. *Plast. Reconstr. Surg.* 111(2): 781−788.

Buchanan EP, Longaker MT and Lorenz HP. Fetal skin wound healing. *Adv. Clin. Chem.* 48: 137−161.

Cheng J, Yu H, Deng S, and Shen G. MicroRNA profiling in mid- and late-gestational fetal skin: implication for scarless wound healing. *Tohoku. J. Exp. Med.* 221(3): 203−209.

Childs DR, and Murthy AS. Overview of Wound Healing and Management. *Surg. Clin. North Am.* 97(1): 189−207.

Davidson JM. Animal models for wound repair. *Arch. Dermatol. Res.* 290 Suppl: S1−11.

Frank S, Kampfer H, Wetzler C, Stallmeyer B, and Pfeilschifter J. Large induction of the chemotactic cytokine RANTES during cutaneous wound repair: a regulatory role for nitric oxide in keratinocyte-derived RANTES expression. *Biochem. J.* 347 Pt 1: 265−273.

Gallant CL, Olson ME, and Hart DA. Molecular, histologic, and gross phenotype of skin wound healing in red Duroc pigs reveals an abnormal healing phenotype of hypercontracted, hyperpigmented scarring. *Wound Repair Regen.* 12(3): 305−319.

Gniadecki R, Olszewska H, and Gajkowska B. Changes in the ultrastructure of cytoskeleton and nuclear matrix during HaCaT keratinocyte differentiation. *Exp. Dermatol.* 10(2): 71−79.

Hermanns−Le, T, Pierard GE, Jennes S, and Pierard−Franchimont C. Protomyofibroblast Pathway in Early Thermal Burn Healing. *Skin Pharmacol. Physiol.* 28(5): 250−254.

Hirsch T, Spielmann M, Zuhaili B, Koehler T, Fossum M, Steinau HU, Yao F, Steinstraesser L, Onderdonk AB, and Eriksson E. Enhanced susceptibility to infections in a diabetic wound healing model. *BMC Surg.* 8: 5.

Huntington J, Molecular A. recognition mechanisms of thrombin. *J. Thromb. Haemost.* 3(8): 1861−1872.

Kobayashi H, Ishii M, Chanoki M, Yashiro N, Fushida H, Fukai K, Kono T, Hamada T, Wakasaki H, and Ooshima A. Immunohistochemical localization of lysyl oxidase in normal human skin. *Br. J. Dermatol.* 131(3): 325−330.

Kuehbacher A, Urbich C, and Dimmeler S. Targeting microRNA expression to regulate angiogenesis. *Trends. Pharmacol. Sci.* 29(1): 12−15.

Kuehbacher A, Urbich C, Zeiher AM, and Dimmeler S. Role of Dicer and Drosha for endothelial microRNA expression and angiogenesis. *Circ. Res.* 101(1): 59−68.

Labler L, Rancan M, Mic L, Harter L, Mihic-Probst D, and Keel M. Vacuum−assisted closure therapy increases local interleukin-8 and vascular endothelial growth factor levels in traumatic wounds. *J. Trauma.* 66(3): 749−757.

Levy JH, Sniecinski RM, Welsby IJ, and Levi M. Antithrombin: anti-inflammatory properties and clinical applications. *Thromb.* 115(4): 712−728.

Lindblad WJ. Considerations for selecting the correct animal model for dermal wound-healing studies. *J. Biomater. Sci. Polym. Ed.* 19(8): 1087−1096.

Mackman N, Tilley RE, and Key NS. Role of the extrinsic pathway of blood coagulation in hemostasis and thrombosis. *Arterioscler. Thromb. Vasc. Biol.* 27(8): 1687−1693.

Maraganore JM. Thrombin, thrombin inhibitors, and the arterial thrombotic process. *Thromb. Haemost.* 70(1): 208−211.

Midwood KS, Williams LV, and Schwarzbauer JE. Tissue repair and the dynamics of the extracellular matrix. *Int. J. Biochem. Cell Biol.* 36(6): 1031−1037.

Noli C, and Miolo A. The mast cell in wound healing. *Vet. Dermatol.* 12(6): 303−313.

Nouvong A, Ambrus AM, Zhang FR, L. Hultman L, and Coller HA. Reactive oxygen species and bacterial biofilms in diabetic wound healing. Physiol Genomics: *physiol. Genomics* 00066 02016.

Okizaki S, Ito Y, Hosono K, Oba K, Ohkubo H, Kojo K, Nishizawa N, Shibuya M, Shichiri M, and Majima M. Vascular Endothelial Growth Factor Receptor Type 1 Signaling Prevents Delayed Wound Healing in Diabetes by Attenuating the Production of IL-1beta by Recruited Macrophages. *Am. J. Pathol.* 186(6): 1481−1498.

Pereira CT, and Herndon DN. The pharmacologic modulation of the hypermetabolic response to burns. *Adv. Surg.* 39: 245−261.

Peters T, Sindrilaru A, Hinz B, Hinrichs R, Menke A, Al-Azzeh EA, Holzwarth K, Oreshkova T, Wang H, Kess D, Walzog B, Sulyok S, Sunderkotter C, Friedrich W, Wlaschek M, Krieg T, and Scharffetter-Kochanek K. Wound-healing defect of CD18(-/-) mice due to a decrease in TGF-beta1 and myofibroblast differentiation. *EMBO J.* 24(19): 3400−3410.

Robson MC, Stenberg BD, and Heggers JP. Wound healing alterations caused by infection. *Clin. Plast. Surg.* 17(3): 485−492.

Sahni A, Odrljin T, and Francis CW. Binding of basic fibroblast growth factor to fibrinogen and fibrin. *J. Biol. Chem.* 273(13): 7554−7559.

Savant S, La Porta S, Budnik A, Busch K, Hu J, Tisch N, Korn C, Valls AF, Benest AV, Terhardt D, Qu X, Adams RH, Baldwin HS, Ruiz de Almodovar C, Rodewald HR, and Augustin HG. The Orphan Receptor Tie1 Controls Angiogenesis and Vascular Remodeling by Differentially Regulating Tie2 in Tip and Stalk Cells. *Cell. Rep.* 12(11): 1761−1773.

Schecter AD, Spirn B, Rossikhina M, Giesen PL, Bogdanov V, Fallon JT, Fisher EA, Schnapp LM, Y. Nemerson Y, and Taubman MB. Release of active tissue factor by human arterial smooth muscle cells. *Circ. Res.* 87(2): 126−132.

Seok J, Warren HS, Cuenca AG, Mindrinos MN, Baker HV, Xu W, Richards DR, McDonald-Smith GP, Gao H, Hennessy L, Finnerty CC, Lopez CM, Honari S, Moore EE, Minei JP, Cuschieri J, Bankey PE, Johnson JL, Sperry J, Nathens AB, Billiar TR, West MA, Jeschke MG, Klein MB, Gamelli RL, Gibran NS, Brownstein BH, Miller-Graziano C, Calvano SE, Mason PH, Cobb JP, Rahme LG, Lowry SF, Maier RV, Moldawer LL, Herndon DN, Davis RW, Xiao W, Tompkins RG. Inflammation and L. S. C. R. P. Host Response to Injury. Genomic responses in mouse models poorly mimic human inflammatory diseases. *Proc. Natl. Acad. Sci. USA* 110(9): 3507−3512.

Sheets AR, Massey CJ, Cronk SM, Iafrati MD, and Herman IM. Matrix- and plasma-derived peptides promote tissue-specific injury responses and wound healing in diabetic swine. *J. Transl. Med.* 14(1): 197.

Shilo S, Roy S, Khanna S, and Sen CK. MicroRNA in cutaneous wound healing: a new paradigm. *DNA Cell Biol.* 26(4): 227−237.

Singh HCS, Milner CS, Aguilar MM, Hernandez NP, and Brindle NP. Vascular endothelial growth factor activates the Tie family of receptor tyrosine kinases. *Cell Signal.* 21(8): 1346−1350.

Sottile J. Regulation of angiogenesis by extracellular matrix. *Biochim. Biophys. Acta.* 1654(1): 13−22.

White RJ. Wound infection-associated pain. *J. Wound Care* 18(6): 245−249.

Wong VW, Sorkin M, Glotzbach JP, Longaker MT, and Gurtner GC. Surgical approaches to create murine models of human wound healing. *J. Biomed. Biotechnol.* 2011: 969618.

Zhu KQ, Engrav LH, Gibran NS, Cole JK, Matsumura H, Piepkorn M, Isik FF, Carrougher GJ, Muangman PM, Yunusov MY, and Yang TM. The female, red Duroc pig as an animal model of hypertrophic scarring and the potential role of the cones of skin. *Burns* 29(7): 649−664.

Zhu KQ, Engrav LH, Tamura RN, Cole JA, Muangman P, Carrougher GJ, and Gibran NS. Further similarities between cutaneous scarring in the female, red Duroc pig and human hypertrophic scarring. *Burns* 30(6): 518−530.

In: Encyclopedia of Surgery (22 Volume Set)
Editors: Andreas Lehrer and Kristin Mueller
ISBN: 978-1-53618-329-0
© 2020 Nova Science Publishers, Inc.

Chapter 196

ORGAN PRESERVATION

Cheng Yang[1], MD, PhD, Jiawei Li[1], MD and Ruiming Rong[1,2,*], MD, PhD

[1]Department of Urology, Zhongshan Hospital, Fudan University, Shanghai Key Laboratory of Organ Transplantation; Shanghai, China
[2]Department of Transfusion, Zhongshan Hospital, Fudan University, Shanghai, China

ABSTRACT

Organ transplantation has become a preferred clinical therapy for end-stage organ disease. Since the first kidney transplant was successfully performed in 1954, organ transplantation developed rapidly and more methods for transplantation have quickly emerged. Therefore, based on this background, the method with which to preserve organs for a long time and the ideal method for organ preservation could become meaningful problems that require discussion by specialists and doctors. In this chapter, we discuss the addition of materials in preservation solutions, list the main preservation solutions, and describe gene therapy in organ preservation and clinical trials. Some classic preservation solutions are still used in clinical works, such as University of Wisconsin solution and Histidine-tryptophan-ketoglutarate solution; however, others are mainly based on these classic solutions with the addition of some materials. Recent studies have found that new materials such as gas molecules added into a solution can provide better protection for organ preservation, and we are glad to see more studies about how to better preserve donor organs even while machine preservation appears to be most prominent.

Keywords: organ preservation, kidney transplantation, liver transplantation, heart transplantation, lung transplantation, pancreatic transplantation, RNA Interference

[*] Corresponding Author's Email: rong.ruiming@zs-hospital.sh.cn; Fax: +86-21-64037269.

ABBREVIATIONS

BNP-1	bovine neutrophil peptide-1
CO-RMs	carbon monoxide release molecules
DGF	delayed graft function
EC	Euro-Collins
EGF	epidermal growth factor
HC-A	hyperosmolar citrate adenine
HES	hydroxy-ethyl starch
HOC	Hypertonic citrate
HTK	Histidine-tryptophan-ketoglutarate
IGF-1	insulin-like growth factor-1
IGL-1	Institute George-Lopez
LPD	low-potassium dextran
MDA	malondialdehyde
NGF	nerve growth factor
PBS	Phosphate-buffered sucrose
PEG	polyethylene glycol
PGD	primary graft dysfunction
PKR	protein kinase.
PRRs	pattern recognition receptors
RIG1	retinoic acid inducible gene 1
ROS	reactive oxygen species
SCOT	Solution de conservation des organes et des tissus
siRNA	small interfering RNA
SMO	shanghai multi-organ preservation
SP	substance P
UW solution	University of Wisconsin solution

1. INTRODUCTION

With the development of organ transplantation, solid organ preservation has become a significant focus in the transplantation field. Considerable attention is given to the *ex vivo* period as this segment represents a vulnerable timeframe whereby organs are susceptible to ongoing cellular damage that is further compounded by reperfusion injury upon re-anastomosis (Korte 2016). In the late 1960s, two important studies demonstrated that kidneys could be safely preserved for 30 hours by cold storage and for as long as 72 hours by continuous perfusion. With this evidence, some experts considered hypothermia, which can be utilized to decrease the metabolic activity of donor organs during the *ex vivo* period. However, hypothermia is unable to abolish all cellular damage, as metabolism persists at approximately 5−10% of normal levels. In addition, hypothermia can lead to Na^+/K^+-ATPase alterations, ATP depletion, the dysregulation of Ca^{2+} homeostasis, mitochondrial perturbations, xanthine oxidase accumulation, and increased levels of reactive oxygen species (ROS), which may have deleterious effects on cellular viability. Therefore, preservation

solutions have been implemented in conjunction with hypothermia for additional cellular protection. In 1988, Belzer et al. presented the opinions that proper solid organ storage solution should obey the following principles: (1) minimize hypothermic-induced cell swelling; (2) prevent intracellular acidosis; (3) prevent the expansion of the interstitial space during the flush-out period; (4) prevent injury from oxygen-free radicals (especially during reperfusion); and (5) provide substrates for regenerating high-energy phosphate compounds during reperfusion (Belzer and Southard 1988). According to these principles, numerous solutions are commercially available while others remain institutionally derived.

2. HISTORY OF PRESERVATION SOLUTIONS

Kidney transplantation remains limited by four problems: (1) a high rate of delayed graft function; (2) early loss of kidneys from chronic rejection; (3) donor kidney shortages; and (4) the need for immunomodulation treatments. However, improved cold storage methods can significantly impact the first 3 of these 4 major problems, so the development of new types of organ preservation solutions can be a new strategy for organ transplantation. After the introduction of static Collins solution by Collins in 1969, prolonged kidney preservation became feasible. Currently, the principle solutions for kidney preservation are University of Wisconsin (UW) solution, Histidine-tryptophan-ketoglutarate (HTK) solution, Celsior solution, Institute George-Lopez (IGL-1) solution, Polysol solution, Euro-Collins solution, hypertonic citrate (HOC) or Marshall solution, and Phosphate-buffered sucrose (PBS). Considering their electrolyte composition, these solutions are divided into intracellular-type and extracellular-type. Intracellular solutions are characterized by high potassium and low sodium concentrations, which is necessary to prevent cell swelling. Because the Na^+/K^+-ATPase is inactive during cold storage, a solution in the extracellular space with an Na^+/K^+ balance equal to the intracellular compartment reaches Donnan equilibrium, preventing sodium and chloride from entering the cell. Intracellular-type solutions such as UW are considered important to preserve cell viability. The extracellular-type of solution, such HTK, has low potassium and high sodium concentrations. Recent studies have suggested that this composition is equal to, or even better than, the intracellular type, as potassium can induce vasospasm.

3. THE IMPROVEMENT OF PRESERVATION SOLUTIONS BY ADDING MATERIALS

Growth Factors

Growth factors are cytokines that can stimulate cell growth. MeAnuhy et al. found that when a variety of growth factors were mixed into the UW solution, such as an antimicrobial peptide (bovine neutrophil peptide-1, BNP-1, also referred to as bactenecin), a neuropeptide (substance P, SP), a neurotrophin (nerve growth factor, NGF), and two polypeptide growth factors (epidermal growth factor (EGF) and insulin-like growth factor-1, IGF-1), dog kidneys were successfully preserved for 6 days. The serum creatinine level was lower in the normal

UW solution group than in the normal group 3 days after storage for 4 days, and the canine kidney function for 6 days was the same as that of the normal group (McAnulty 2002). Another animal experiment showed that the addition of growth factor and FRl67653 (a P38 mitogen-activated protein kinase inhibitor) to the UW solution significantly improved the preservation of a pig kidney, reduced ischemia-reperfusion injury, and reduced the incidence of long-term renal fibrosis and infection (Desurmont 2011). These studies suggest that the addition of growth factors to the organ preservation solution can improve the effect of simple cryopreservation of organs; further research is needed to explore potential applications.

Trimetazidine

Trimetazidine can enhance myocardial oxygen supplementation, maintain mitochondrial function and reduce vascular resistance and is mainly used in the clinical treatment of angina. In a study of acute coronary ischemia, trimetazidine was shown to protect mitochondrial structures and improve mitochondrial function via enhanced oxidative phosphorylation and a reduction in the production of reactive oxygen species. Faure et al. evaluated the mitochondrial protective effects of trimetazidine added to UW liquid and Celsior solution and showed that pig kidneys were saved at low temperature for more than 72 hours (Faure 2003). Belous et al. also found that hypothermia, especially combined with an elevated extracellular calcium concentration, would significantly increase mitochondrial calcium intake, and the increased calcium concentration would eventually lead to the irreversible damage of mitochondrial structure and function (Belous 2003). Mitochondrial damage is closely related to acute rejection, which is induced by ischemia reperfusion and could cause delayed graft function (DGF) and chronic graft rejection. Thus, the protective effect of trimetazidine in reducing mitochondrial damage might be the main mechanism by which ischemia reperfusion injuries are decreased. However, some studies found opposite results, suggesting that the role of trimetazidine in reducing ischemia reperfusion injury is not obvious (Abreu Lde 2011). Therefore, the use of trimetazidine in organ preservation solution still needs further study.

Thrombin Inhibitors

Recently, studies have shown that adding Melagatran, a type of thrombin inhibitor, to the UW solution can improve the recovery of renal function after ischemia reperfusion in porcine kidneys. Compared with the control group, the survival rate of the experimental group was significantly improved at 7 days after the operation, and kidney damage and the inflammatory response were significantly reduced (Giraud 2009). Moreover, the addition of a thrombin inhibitor to the preservation solution can prevent the occurrence of chronic diseases such as renal interstitial fibrosis, tubular atrophy and infection.

Small Interfering RNA (siRNA)

RNA interference is a way to down-regulate specific proteins by limiting gene expression and siRNA is one of the common tools. It has been demonstrated that cysteine-aspartate 3

(caspase-3) siRNA can be directly added to HOC solution for the preservation of porcine kidney, which can reduce the level of caspase-3 and cell death, improve kidney oxygenation and acid-base balance, thereby reducing ischemia-reperfusion injury (Yang 2011; Hosgood 2011; Nicholson 2011). The main challenge of applying siRNA to preservation solution is its safety, which includes the choice of vector, ectopic expression of the transgene, and the adverse effects of gene expression.

Polyethylene Glycol

Polyethylene glycol (PEG) was able to reduce the hypoxic ischemic injury of renal tubular cells. Hauet et al. added 30 g/L polyethylene glycol (20000 U) to UW solution and high sodium UW solution and found that the renal tubules in the PEG group were significantly smaller than renal tubules that had been maintained in the UW solution alone in porcine autologous kidney transplantation model 7 days after the operation (Hauet 2002).

Calcium Channel Blockers

Organ preservation can be regarded as a mitochondrial function protectant. Mitochondria produce ATP and maintain the intracellular calcium balance, and mitochondrial calcium overload is a characteristic change during ischemia reperfusion injury. Calcium channel blockers such as nitrendipine can inhibit ischemia reperfusion injury and improve the effect of cryopreservation (Sasaki 1999).

Fluorocarbon (Peflanca)

The capacity of Fluorocarbon dissolved oxygen is 20 to 25 times higher in the plasma, and the oxygen saturation curve also shows that low temperature is conducive to the release of oxygen. Studies found that the addition of fluorocarbon to UW solution can increase organ oxygen supplementation and improve the level of oxidative phosphorylation during cryopreservation. During pancreas preservation, the fully oxidized fluorocarbon can maintain the preservation solution at approximately 85% oxygen saturation for more than 18 hours. Compared with the UW solution, this method can increase the recovery of islet function and improve the effect of pancreas transplantation.

Gas Molecules

Recently, gas molecules have become a focus in organ preservation. In addition to traditional oxygen, the effects of gasses such as hydrogen, nitric oxide, hydrogen sulfide and carbon monoxide, on reducing ischemia reperfusion injury and the potential mechanisms involved have been explored. Among these findings, carbon monoxide release molecules (CO-RMs) have received more attention. The molecule is a transition metal carbonyl

compound that can control the release of carbon monoxide into tissues. A recent study confirmed that the addition of CO-RMs to the preservation solutions can significantly reduce renal, liver and heart ischemia reperfusion injury. Gas molecules will have broad clinical prospects for the protection of transplanted organs (Wei 2010; Soni 2012; Jain 2012; Mehta 2012).

Chinese Medicine Ingredients

Recently, Chinese researchers added some traditional Chinese medicine ingredients to organ preservation solution and achieved encouraging results. Wang et al. used *Salvia miltiorrhiza* irrigation in a rat pancreas-duodenal kidney transplantation model and found that the levels of serum amylase, serum creatinine and serum malondialdehyde (MDA) in the treatment group were significantly lower than in the control group, and the pathological damage of the pancreas and kidney was also reduced after transplantation. That is because *Salvia miltiorrhiza* scavenges oxygen free radicals and protects against ischemia-reperfusion injury. Zhou et al. used ginseng extract in the HC-A kidney preservation solution for cryopreserved isolated canine kidneys, and the results showed that, compared with the control group, ultrastructural tissue damage was significantly reduced in the treatment group, and serum creatinine was significantly decreased, suggesting that ginseng extract can help reduce renal ischemia reperfusion injury. Another study also confirmed that Astragalus, dodder, oxymatrine and other traditional Chinese medicines can reduce of ischemia- reperfusion injury, suggesting that the addition of some traditional Chinese medicine ingredients to the organ preservation solution can improve the effect of existing preservation solutions. Chinese medicine has already shown advantages and is expected to become a field of study for organ preservation materials.

4. MAIN PRESERVATION SOLUTIONS

General without Organ Specificity

University of Wisconsin Solution

In 1988, Belzer et al. developed an excellent organ preservation solution at Wisconsin University named UW solution (University of Wisconsin), which has become the gold standard among organ preservation solutions (Belzer and Southard 1988). UW solution combines metabolically inert substrates, such as lactobionate and raffinose, with hydroxy-ethyl starch (HES) as a colloid, an ATP precursor (adenosine) and oxygen radical scavengers (glutathione and allopurinol). The principal benefit of this solution is that it is associated with good outcomes of short and long term kidney preservation. Its disadvantages are due to the high viscosity, which compromises the microcirculation, and the high potassium concentration that can produce vasoconstriction with hyperaggregation of HES. Two kinds of UW solution have been utilized for HMP and CS. In CS, UW-CSS is the main solution, while UW-G is used for HMP. Lactobionate is replaced by gluconate and the potassium level is

reduced in UW-G, resulting in a consistency that more closely resembles an extracellular solution (Catena 2013).

Histidine-Tryptophan-Ketoglutarate Solution

HTK was introduced in 1980 by Bretschneider and was originally used as a cardioplegic solution (Yuan 2010). HTK contains histidine and tryptophan as membrane stabilizers as well as antioxidants and ketoglutarate for anaerobic metabolism. HTK studies have shown conflicting results. However, its low viscosity may improve microperfusion. Because of this characteristic, HTK is recommended in HMP at low pressures and high perfusion volumes (Yuan 2010; Catena 2013).

Celsior Solution

Celsior solution is a colloid that was developed in 1994 and was originally used in heart transplantation before being extended to other abdominal organs. It combines the osmotic efficacy of UW (lactobionate and mannitol) with the potent buffering ability of HTK (histidine) (Yuan 2010). Colloid solutions contain added macromolecules that do not pass the cellular membrane and thus prevent tissue edema caused by the hydrostatic pressure of HMP (Catena 2013).

Institute-George-Lopez

IGL-1, a fairly new preservation solution developed in France (Faure 2003), combines the advantages of UW and Celsior (Yuan 2010). Polyethylene glycol is bound to cell and tissue surfaces, thus stabilizing them from adverse interactions. Studies suggest that this feature modifies the inherent immunogenicity of donor tissue as a consequence of ischemia-reperfusion injury (Eugene 2004). Badet et al. demonstrated a reduced incidence of delayed graft function (DGF) compared with kidneys preserved with UW. However, a recently published multi-center study showed no significant difference in DGF when IGL-1 was compared with UW (Badet 2005; Catena 2013; Codas 2009).

Polysol

Polysol was recently introduced with the goal of facilitating the transplantation of ischemically damaged organs (Yuan 2010). Therefore, amino acids, vitamins, potent buffers, and antioxidants have been added to support metabolism under hypothermic conditions. The solution has also been tested during HMP (Bessems 2005). A case study by Schreinemachers et al. demonstrated superior graft survival with Polysol compared with UW in a porcine renal autotransplant model (Schreinemachers 2009; Doorschodt 2009; Florquin 2009; van den Bergh 2009; Weerman 2009). Further reports by the same group have shown beneficial effects of Polysol for kidneys damaged by warm ischemia (Schreinemachers, Doorschodt, Florquin, Idu, et al. 2009). Polysol is currently used in experimental trials only. While recent reports on Polysol appear to be promising, more clinical data are necessary to evaluate its efficacy and benefits (Bessems 2005; Catena 2013).

Hypertonic Citrate

HOC, or Marshall's solution, an intracellular-mimicking medium, is extensively used for clinical transplantation in the United Kingdom and Australia (Wilson 2007). HOC uses

mannitol as the impermeable solute and citrate as its buffer to aid calcium extension from the cell while maintaining a physiologic pH. As a hypertonic solution, HOC prevents the entry of fluid into cells. Experimental trials using canine kidneys have demonstrated it to be effective for preservation periods of up to 72 hours (Kay 2009; Catena 2013).

Lifor Solution

Lifor solution is a type of anti-extracellular organ preservation solution developed on the basis of the comprehensive analysis of UW solution. It has low viscosity, low osmotic pressure, is rich in ATP and other nutrients, and the formula is simple and inexpensive. In 2007, Stowe et al. reported for the first time that Lifor preservation solution was used to preserve an isolated pig heart (Stowe 2007). Recently, a series of studies have shown that Lifor solution is superior to UW solution in reducing renal ischemia-reperfusion injury, alleviating cell apoptosis and improving renal blood flow and renal vascular resistance (Gage 2009; Regner 2010). In preserving small intestine, the effect is similar to UW solution, but the cost is low. However, Lifor solution is still in the experimental stage, and its effects need to be further evaluated.

Kyoto Solution

Kyoto solution is a type of extracorporeal multi-organ preservation solution that was developed by Kyoto University in Japan; it was initially used as a lung preservation solution (Chen 2004; Nakamura 2004; Wada 2004). The preservation solution uses trehalose and gluconic acid as non-permeable molecules, effectively reducing cell edema, which can replace the kapok and lactose acid in UW solution, but at a lower cost. Until now, the preservation solution has been used for clinical lung and kidney preservation and has shown benefits over UW solution (Chen 2004; Yoshida 2002). However, the use of Kyoto solution in liver, pancreas and small intestine preservation is still under research (Zhao 2008).

Solution De Conservation Des Organes Et Des Tissus

Solution de conservation des organes et des tissus (SCOT) is a multi-organ preservation solution developed by the University of Poitiers, France, with high sodium ion and low potassium ion concentration, which uses PEG 20 kDa (19 842 U, 30 g/L) as a colloidal component of the preservation solution. Animal experiments showed that the preservation effect in the kidney, liver and islet transplantation are better than with UW solution; therefore, it has been used in clinical kidney preservation (Billault 2006).

Shanghai Multi-Organ Preservation Solution

With the rapid development of organ transplantation in China, multiple organ transplantation has become increasingly common. Although simple solutions are still advantageous for domestic transplantations, high prices have become a huge problem. Some researchers invented a new kind of solution named shanghai multi-organ preservation (SMO) solution, which is based on UW solution. SMO solution uses Xylitol as energy and ligustrazine as an oxygen scavenger. In animal models, SMO showed significant protective function in the liver and kidney compared to HTK, and the effect was the same as UW.

Kidney Preservation Solutions

Collins Solution

Collins solution was designed in the 1960s and was considered the preservation solution of choice for more than 15 years until organ preservation was revolutionized by the introduction of UW solution in 1988 (Latchana 2014). Collins solution is a high potassium, high magnesium, low sodium intracellular liquid type solution. By maintaining glucose concentration at 420 mol/L, Collins used this liquid to successfully save the kidneys for 30 hours at 4°C, and after transplantation, the kidneys showed good function. In 1976, the European Transplantation Organization improved Collins solution and removed the negative effects of magnesium ions, forming the Euro-Collins (EC) solution. They recommended the solution as a standard preservation solution for clinical kidney transplantation. Thus, EC solution was widely used in Europe (de Boer 1999).

Hyperosmolar Citrate Adenine Solution

Hyperosmolar citrate adenine (HC-A) solution, also known as hypertonic citrate adenine solution, was jointly developed by the Second Military Medical University Changzheng Hospital and Shanghai Blood Center in 1979. Its main components are potassium, sodium, magnesium sulfate, citrate, mannitol and adenine. HC-A solution is the main irrigation and cryopreservation solution for organ transplantation in China. It has a simple preparation, good stability, and low price. Currently, the utility of HC-A solution has been widely affirmed after 20 years of use.

HCA-II Solution

HC-A solution has been used for more than 20 years. With the further study of preservation, the inadequacies in this solution have gradually appeared. In recent years, combined with the latest organ preservation theory, the HC-A preservation formula has undergone comprehensive improvement. In accordance with the preservation of the composition of the elements, a phosphate buffer system has been added, and a cell membrane protective agent and the antioxidant ligustrazine have been incorporated, which increased energy substrate content and osmotic pressure. HCA-II organ preservation solution was developed after animal experiments and a number of clinical applications in the transplant center confirmed that HCA-II preservation solution was significantly better than HC-A liquid for kidney preservation. Compared with the HTK solution, kidneys could be saved for 36 h, 48 h and 72 h. After 72 h, the apoptotic index was significantly lower in kidney tissue that had been stored in HCA-II solution compared to kidney tissue that had been stored in HTK solution. The results of an animal model of canine kidney transplantation showed that the preservation effect was better than that of HTK and was equivalent to that of UW preservation solution. HC is the upgraded liquid product. And the product has a national patent and is expected to officially enter production in 2007.

Heart Preservation Solutions

According to the systematic review of Demmy et al. as many as 167 HPSs were used for heart preservation in the USA in the middle of the 1990s. At present, the histidine-tryptophan-ketoglutarate (HTK) solution, the University of Wisconsin (UW) solution and the Celsior solution are most commonly used for heart preservation.

HTK (or Custodiol) was introduced by Bretschneider in the 1970s as a cardioplegic solution and has subsequently been used in organ preservation for the heart, liver and pancreas. Its usage has been increasingly popular in cardiac surgery because a single administration of cold HTK in the coronary vascular bed provides reliable protection from IRI for at least 2 h.

The Euro-Collins solution is an intracellular HPS with high concentrations of glucose (194 mmol/l) and K^+ (115 mmol/l) that includes bicarbonate and phosphate buffer systems. The Stanford solution is similar to Euro-Collins with the exception of an even higher glucose level (250 mmol/l) and a lower K^+ concentration (27 mmol/l).

The UW solution, developed by Belzer et al. typically has a low Na^+ concentration, although an extracellular modification of this HPS that includes 125 mmol/l Na^+ also exists. Along with intracellular-type HPSs, there are several widely accepted extracellular solutions with high Na^+ and low K^+ concentrations.

The most common extracellular HPS is Celsior. Celsior is enriched with the reactive oxygen species scavengers lactobionate and glutathione, which ensures the prevention of oxidative stress during reperfusion. In contrast to other HPSs, Celsior contains 20 mmol/l glutamate, which has anti-ischemic activity and exerts cardio-protective effects. In addition, Celsior, HTK and the Stanford solution contain the polyatomic alcohol mannitol, which can prevent edema and quench reactive oxygen species (Minasian 2015).

However, the high molecular weight compounds within UW, such as hydroxyethyl starch (HES), result in a highly viscous solution that has been implicated, in part, in organ dysfunction, thereby supporting the development of less viscous alternatives, including Celsior (CEL) and histidine- tryptophan-ketoglutarate (HTK).

Many targeted approaches to cardiac organ preservation have been attempted, including the development of Plegisol, which arose from the initial St. Thomas solution used for cardioplegia, albeit with slight modifications, including the addition of a buffering system. In contrast to the aforementioned acellular approaches, Papworth solution was centered on the inclusion of donor blood in its composition. The different metabolic demand and physiology of the lung supported the construction of pulmonary specific solutions, including Perfadex (PER), which has been authorized to be used in pulmonary transplantations by the Food and Drug Administration (FDA) in the United States (Latchana 2014).

Liver Preservation Solutions

Preservation solutions for donor liver are required to preserve homeostasis, support liver metabolism and delay cell damage. Several solutions are currently available: University of Wisconsin (UW), Histidine-Tryptophan-Ketoglutarate (HTK), Celsior (CS) and the most recent Institute Georges Lopez-1 (IGL-1). They all differ in terms of composition, ion balance, viscosity, osmolality and cost.

UW is a high viscosity colloid solution due to the presence of hydroxyethyl starch (HES), high potassium and low sodium concentrations (125 mmol/l and 27 mmol/l, respectively). Despite its widespread use, UW carries some side effects: high viscosity might result in impaired flushing with microcirculatory disturbances; high potassium concentration might provoke cardiac arrest in the recipient upon liver reperfusion; and finally, ischemic-type biliary lesions are not rare.

HTK represents an alternative to UW and possesses advantages that can be summarized as lower viscosity, lower potassium content (10 mmol/l, thus avoiding the risk of hyperkalemia) and better buffering properties. HTK was believed equivalent to UW for SCS but less expensive; however, recent findings highlighted HTK-associated disadvantages. In a large single-center series and a retrospective analysis of the UNOS database, the survival of grafts from standard or ECD donors did not differ when grafts were preserved with HTK or UW; however, in subgroup analyses, HTK-preserved grafts achieved significantly inferior survival after exposure to long-lasting cold ischemia or procurement from DCD donors. Furthermore, two different clinical trials from Meine et al. and Gulsen et al. reported relevant increases in the incidence of NAS in patients receiving grafts from DCD donors preserved with HTK. The reason that HTK is associated with worse outcomes after LT is not fully understood; the lack of antioxidants and oncotic agents might be an explanation. To summarize, the available evidence points towards the avoidance of HTK as a preservation solution for livers.

Celsior solution has low viscosity, high sodium and low potassium concentration (100 mmol/l and 15 mmol/l, respectively) and combines the best aspects of both UW and HTK. It retains the buffering properties of HTK (histidine) and the presence of impermeants as in UW (lactobionic acid).

Sodium and potassium concentrations in IGL-1 are switched compared to UW ($[Na^+]$ = 120 mmol/l, $[K^+]$ = 25 mmol/l) and HES is replaced by polyethylene glycol, resulting in lower viscosity. These properties could improve liver wash-out during procurement and reduce IRI. IGL-1 has been previously tested in a rat model of isolated liver perfusion and in a pig model of auto-transplantation, showing better preservation of cell integrity. Dondero et al., in a recent randomized trial that included fatty livers, failed to demonstrate the superiority of IGL-1 and found that it is at least as effective as UW and is less expensive. However, the outcome of steatotic donor grafts was not the primary endpoint of this study, which was probably underpowered to draw solid conclusions. Randomized clinical trials comparing IGL-1 to other preservation solutions are still missing, but the recent large series analysis from Adam et al. confirmed good outcomes and postulated possible advantages for IGL-1. Further investigation is therefore needed to confirm this hypothesis.

Identifying the best preservation solution is a difficult task since randomized trials have shown conflicting results; however, some conclusions can be drawn from large studies or clustering data from different trials. In a recent meta-analysis, Zuluaga et al. reported no differences in LT outcomes when UW was compared to CS or HTK. In particular, no differences were observed in terms of EAD, 1-year patient survival and the occurrence of NAS. Adam et al. partly confirmed this observation in their recent retrospective analysis of the European Liver Transplant Registry that included more than 48,000 LTs. Grafts preserved with UW, IGL-1 or CS showed similar 3-year graft survival; however, IGL-1 was associated with a better preservation of partial liver grafts as shown by higher graft survival in this group. Notably, grafts preserved with HTK exhibited significantly inferior survival three

years post-LT when compared to grafts preserved with other preservation solutions, and based on multivariate analysis, HTK was an independent risk factor for graft loss.

All available preservation solutions were developed with the purpose of preventing hepatocyte death during the ischemic storage phase. Other cell populations, including cholangiocytes, are probably not so well protected from IRI. Two recent studies that focused on the pathological aspects of the common bile duct have revealed that the bile duct epithelium is seriously injured at the end of SCS in up to 88% of cases. These findings indicate that the bile duct of almost all grafts suffers relevant injury, which might be responsible for NAS development. These complications add relevant morbidity and significantly reduce long-term graft survival, representing a rising concern due to the increased transplantation of DCD grafts, which is associated with markedly higher rates of biliary complications. Improved bile duct preservation might be offered by MP, which has been associated with better preservation of the bile duct in experimental settings (Gilbo 2016).

Pancreas Preservation Solutions

Islets are most often infused into the patient with an open laparotomy incision immediately after processing while the patient is still in the operating room. Alternatively, islets may be cultured and infused postoperatively via a percutaneous approach. Islets are infused into the portal system using a stump of the splenic vein, via direct puncture of the portal, or by cannulation of the umbilical vein. With a significant tissue volume infused into the portal vein, the elevation of portal pressure may lead to a reduction in blood flow and portal vein thrombosis. Because of this risk, heparin anticoagulation is recommended. Portal pressure is monitored closely during islet infusion and should not exceed 25–27 cm H_2O (18.4–20 mm Hg). When pellet volume is <20 mL and the liver is healthy, portal pressure usually does not increase substantially. If portal pressure does increase during the infusion of a large volume of unpurified islets, portal infusion should be discontinued and the remaining islets should be dispersed into the peritoneal cavity or injected into the leaves of the mesentery or omentum, bowel subserosa, gastric submucosa, or intra-muscular space. Although islets transplanted into these alternative sites have been shown to survive in animal models, whether this approach is effective in the clinical setting is unknown (Witkowski 2014; Savari 2014; Matthews 2014).

Only a few studies have adequately evaluated lower temperature conditions in islet culture/preservation before our report. Frankel et al. reported the comparison of 8°C storage with 22°C storage or 37°C culture for 1 week using islets from obese (ob/ob) mice. They showed that the glucose-stimulated insulin release was better maintained by storage at 8°C in tissue culture medium with a high concentration (18 mM) of glucose and an additional pre-incubation period of 4 h at 37°C than by storage at 22°C or 37°C. In addition, 8°C storage in a high-potassium "intracellular medium" resulted in a better subsequent glucose-stimulated insulin release and islet morphology in comparison to a 37°C culture in traditional culture medium. Korbutt et al. reported the survival of rat pancreatic b-cells after 96 h of storage at 4°C. After 4°C storage in Collins solution with albumin and benzamidine, b-cells exhibited a higher insulin content than after culture in HAM's F10 at 20°C or 37°C, although their capacity for subsequent insulin synthesis and release was comparable. It was demonstrated

that storage with UW solution plus pefabloc at 4°C was superior to culture at 20°C or 37°C; however, the experiments used unpurified islets (Noguchi 2015).

The first step after surgical dissection is to flush the extracted pancreas with a chilled preservation solution. This is usually done with University of Wisconsin (UW) solution. UW solution gives equivalent or superior results to other perfusations in many but not all studies by preventing the loss of amylase and inducing a slight shrinkage of the acinar cells, which in turn improves the density separation of islets and the viability of the cells. Other preservation solutions include Celsior, HTK, IGL-1 and others. The flushing step cools the pancreas and removes debris and thrombi.

Cold storage and transport of the pancreas is vital to islet yield and viability; warm ischemia has been found to damage tissue; however, cold ischemia time beyond 8 h also results in reduced yields and a lower quality of human islets. In most studies, shorter cold ischemic time is associated with better islet yields. Transport using a two-layer method where the pancreas rests on a substrate in the top layer of a perfluorocarbon "bath" appears to give slightly improved outcomes and showed promising results in pancreas tissues from humans (Deters 2011; Stokes 2011; Gunton 2011).

Lung Preservation Solutions

The procurement of lungs for transplantation is a challenging task since lung tissue is at a high risk of ischemic and hypoxic injuries, which can result in life-threatening primary graft dysfunction (PGD). During the first successful LTx surgeries, cooling was the only technique of preservation. The application of various organ preservation solutions emerged over the following decades. To extend the cold ischemic time, intracellular-type solutions such as Euro-Collins or University of Wisconsin solution were used when available. As understanding of the pathological and pharmaceutical pathways of lung preservation developed, practice shifted towards extracellular-type preservation solutions, primarily the low-potassium dextran (LPD) solution. The LPD solution is understood to work via the following two mechanisms: the low-potassium concentration maintains a low pulmonary artery (PA) pressure during perfusion and the dextran acts as an oncotic agent, increasing the intravascular pressure to prevent interstitial lung edema.

There are distinct advantages to using an extracellular-type LPD solution in lung procurement. LPD is the accepted standard pulmoplegic solution and shows superior preservation effects. In addition to potassium and dextran, other pharmaceutical agents are currently used in cold ischemic lung procurement, such as prostaglandins and/or methylprednisolone to prevent vasoconstriction (due to the cold flush) and inflammatory responses (Andreasson 2014; Dark 2014; Fisher 2014).

5. Gene Therapy in Organ Preservation

RNA interference (RNAi) is a highly conserved biological phenomenon in all eukaryotes, including renal cells. In the late 1990s, due to the development of molecular biology and genetics, the biological understanding of RNA evolved from simply an intermediate between

DNA and protein to a dynamic and versatile regulator that functions in genes and cells in all living organisms. In 1998, as a milestone, Fire et al. injected a few molecules of double-stranded RNA (dsRNA) into Caenorhabditis elegans and found that dsRNAs could specifically interfere with the protein expression of an endogenous gene. This molecule was named small interfering RNA (siRNA) and mediates RNAi. siRNA is able to recognize and degrade homologous host mRNA. Therefore, the gene from which the mRNA is transcribed is silenced, which is referred to post-transcriptional gene silencing.

Although RNAi exists naturally, synthetic artificial siRNA exerts similar effects as natural endogenous micro-RNA (miRNA). Both sense and antisense strands of siRNA can be synthesized separately and annealed to form double-stranded siRNA duplexes in vitro. After the siRNA is delivered into the cytoplasm, the artificial siRNA silences the target gene using similar biological processes as endogenous miRNA. Since the introduction of 21-nucleotide artificial siRNAs that can trigger gene silencing in mammalian cells, synthetic siRNA has generated much interest in biomedical research, including in the kidney. siRNA as a strategic molecule has been expected to impact the field of innovative therapy. Because siRNA is highly efficient at gene silencing, it is possible to develop specific siRNA-based drugs that could target any genes, including those that have no known pharmacological antagonists or inhibitors. Different types of synthetic siRNA have been tested for their efficacy in various disease models, including cancer, autoimmune disorders, cardiovascular injuries, and organ transplantation, including native and transplanted organ injuries.

In addition to the *in vitro* delivery of siRNA, ex vivo/in vivo siRNA delivery to target organs is an indispensable step before its clinical application. If it was directly delivered into the kidneys, siRNA could obtain higher local concentrations, which would result in improved gene silencing efficacy. During kidney transplantation, ex vivo local delivery of siRNA into the donor kidney is feasible because it could be facilitated by the unique structure of the kidney and the characteristics of kidney transplantation. Recently, we utilized an *ex vivo* isolated porcine kidney reperfusion system to assess the efficacy of naked caspase-3 siRNA. The caspase-3 siRNA was directly infused into the renal artery (locally) and autologous blood perfusate (mimic systemic delivery) before 24-hour cold storage (CS), followed by an additional reperfusion for 3 hours. The results demonstrated that the caspase-3 siRNA improved ischemic re-perfusion (IR) injury with reduced caspase-3 expression and apoptosis, better renal oxygenation and acid–base homeostasis (Yang 2013; Jia 2013). These promising proof-of-principle observations provide valuable guidance for the further development of siRNA in clinical practice.

Cold ischemia injury activates multiple signaling pathways and upregulates several genes, subsequently causing cell apoptosis and death and resulting in organ damage. In addition to single siRNA delivery, siRNA cocktails have been used for better efficacy to silence multiple genes. Recently, Min's group demonstrated that the perfusion and preservation of donor hearts with siRNA solution can attenuate cold I/R injury during heart transplantation, and an siRNA cocktail that contains 3 siRNAs that target C3, RelB, and TNFα showed a synergistic protective effect compared with single siRNAs (Zheng et al. 2009). Based on their previous study, the authors further reported that treatment with siRNA targeting the C3, Fas, and RelB genes successfully attenuated I/R injury and improved renal graft function in a murine kidney transplantation model (Zheng 2016). MMPs also play an important role in injury to the transplanted kidney. MMP expression is increased in patients with chronic antibody-mediated rejection, and because of the role of MMPs in fibrotic renal

diseases, MMPs have been suggested as a possible common pathway for chronic allograft nephropathy in the transplanted kidney (Yan 2012). In a rat kidney cold perfusion model, the inhibition of MMP-2 during perfusion via MMP-2 siRNA led to a decrease in MMP-2 levels in the perfusate, as well as a decrease in LDH, NGAL, and CcO release after 22 hours of perfusion (Moser 2016).

Long-term pancreatic cold ischemia contributes to decreased islet number and viability after isolation and culture, leading to poor islet transplantation outcomes in patients with type 1 diabetes. Silencing Bbc3 by transfecting Bbc3 siRNA into islets *in vitro* prior to cold preservation improved post-preservation mitochondrial viability (Omori 2016). In a lung isolated preservation model, isolated lungs were exposed to 6 hours of cold ischemia (4°C), followed by 2 hours of warm (37°C) reperfusion with a solution that contained 10% of fresh whole blood and mechanical ventilation with constant low driving pressure. siRNA that targeted Fas was administered intratracheally, as was control small interfering RNA. The results revealed that silencing Fas gene expression reduced edema formation (bronchoalveolar lavage protein concentration and lung histology) and improved lung compliance (Del Sorbo 2016).

Although siRNA therapy for organ preservation is effective and promising, off-target effects are one of the major obstacles for further clinical translation. The induction of various side effects may be caused by unexpected perturbations between RNAi molecules and cellular components. The off-target effects of siRNA were first reported by Jackson and colleagues in 2003 (Baan 2016). Broadly speaking, off-target effects can be siRNA specific or non-specific. The former is caused by limited siRNA complementarity to non-targeted mRNAs. The latter, resulting in immune- and toxicity-related responses, is due to the construction of the siRNA sequence, its modification or the modification of the delivery vehicle. RNA-sensing pattern recognition receptors (PRRs), localized in endosomes, are the most important components of the innate immune system. The responses of PRRs to siRNAs are either TLR-mediated or non-TLR-mediated. The PRR responses are also associated with siRNA sequence specific side effects and have recently attracted lots of attention from researchers (Kabilova 2012). RNA-sensing TLRs (TLR3 and TLR7) are predominantly located intracellularly and recognize nucleic acids released from invading pathogens. The non-TLR-mediated innate immune responses triggered by siRNA binding are linked to the RNA-regulated expression of protein kinase (PKR) and retinoic acid inducible gene 1 (RIG1), which further induce caspase-3 and NF-κB expression, respectively. The activation of PRRs generates excessive cytokine release and subsequent inflammation (Robbins 2009; Judge 2009; MacLachlan 2009). Based on this second type of off-target RNAi effects, our group further investigated the mechanism of how short-acting caspase-3 siRNA impaired post-transplanted kidneys. The results suggested that the amplified inflammatory responses in caspase-3 siRNA preserved auto-transplant kidneys were associated with TLR3, TLR7 and PKR activation, which may be due to systemic compensative responses, although persistent actions initiated by short-acting caspase-3 siRNA cannot be completely excluded (Yang 2013; Li 2013). In the future, better siRNA designs will decrease these off-target effects to a minimum and acceptable level.

6. CURRENT CLINICAL TRIALS OF ORGAN PRESERVATION

Twenty-five current clinical trials of organ preservation solutions have already been registered on *clinicaltrials.gov*; 19 of them focus on solid organ transplantation. At the time of writing, 6 trials have been completed and relevant articles were published online. These trials have not focused on changing the recipes or inventing a kind of new solution but have addressed the use of new machines for the preservation of organs, especially marginal organs, which can be more complex. Thus, *clinicaltrials.gov* has published many trials mainly based on machine organ preservation, and several of them are still recruiting participants.

The Clinical Trial of Hydrogen-Rich Celsior Solution Applied in Aging DBD Liver/Kidney Transplantation (HRCSDBD) was sponsored by Renji Hospital, Shanghai, China, in 2015. This prospective, randomized clinical trial proposes to investigate whether hydrogen-rich Celsior solution improves the quality of aging grafts in liver/kidney transplantation. The study is based on the findings of the protective effects of hydrogen gas, which has been reported to display antioxidant properties and protective effects against organ dysfunction induced by various ischemia reperfusion injuries (Abe 2012; Buchholz 2011).

The Evaluation of a Marine OXYgen Carrier: HEMO2Life® for hypOthermic Kidney Graft preservation, Before Transplantation (OXYOP) study was received on December 22, 2015, provided by University Hospital, Brest. It was an interventional study that aimed to evaluate the use of an oxygen carrier HEMO2Life® as an additive in organ preservation solution in kidney transplantation for patients with end-stage renal disease.

The University of Bologna sponsored a trial about hypothermic oxygenated perfusion versus static cold storage for marginal graft (PIO) in 2017, and it is still recruiting participants. This trial aims to assess the impact of hypothermic oxygenated perfusion (PIO) of marginal human kidney and liver compared with static cold storage (SCS).

7. PERSPECTIVE

Although organ preservation solutions have become quite common, the method with which to protect donor organs can still be a valuable research topic in basic and clinical studies. To date, donor organs are different from those retrieved two decades ago, and new solutions and techniques have developed rapidly. However, due to the shortage of donor organs, just the consideration of new techniques is inadequate, and effective strategies to extend the donor pool are advocated.

CONFLICT OF INTEREST

The authors declare that no conflicts of interest exist.

ACKNOWLEDGMENT

This study was supported by the National Natural Science Foundation of China (81270832, 81400752).

REFERENCES

Abe T, Li XK, Yazawa K, Hatayama N, Xie L, Sato B, Kakuta Y, Tsutahara K, Okumi M, Tsuda H, Kaimori JY, Isaka Y, Natori M, Takahara S, Nonomura N. Hydrogen-rich University of Wisconsin solution attenuates renal cold ischemia-reperfusion injury. *Transplantation* 2012; 94(1): 14−21.

Abreu Lde A, Kawano PR, Yamamoto H, Damiao R, Fugita OE. Comparative study between trimetazidine and ice slush hypothermia in protection against renal ischemia/reperfusion injury in a porcine model. *Int. Braz. J. Urol*. 2011; 37(5): 649−656.

Andreasson AS, Dark JH, Fisher AJ. Ex vivo lung perfusion in clinical lung transplantation--state of the art. *Eur. J. Cardiothorac Surg*. 2014; 46(5): 779−788.

Baan CC. Basic sciences in development: What changes will we see in transplantation in the next five years? *Transplantation* 2016.

Badet L, Petruzzo P, Lefrancois N, McGregor B, Espa M, Berthillot C, Danjou F, Contu P, Aissa AH, Virieux SR, Colpart JJ, Martin X. Kidney preservation with IGL-1 solution: a preliminary report. *Transplant Proc*. 2005; 37(1): 308−311.

Belous A, Knox C, Nicoud IB, Pierce J, Anderson C, Pinson CW, Chari RS. Altered ATP-dependent mitochondrial Ca2+ uptake in cold ischemia is attenuated by ruthenium red. *J. Surg. Res*. 2003; 111(2): 284−289.

Belzer FO, Southard JH. Principles of solid-organ preservation by cold storage. *Transplantation* 1988; 45(4): 673−676.

Bessems M, Doorschodt BM, van Vliet AK, van Gulik TM. Machine perfusion preservation of the non-heart-beating donor rat livers using polysol, a new preservation solution. *Transplant Proc*. 2005; 37(1): 326−328.

Billault C, Vaessen C, Van Glabeke E, Rolland E, Ourahma S, Dimitru L, Richard F, Eugene M, Barrou B. Use of the SCOT solution in kidney transplantation: preliminary report. *Transplant Proc*. 2006; 38(7): 2281−2282.

Buchholz BM, Masutani K, Kawamura T, Peng X, Toyoda Y, Billiar TR, Bauer AJ, Nakao A. Hydrogen-enriched preservation protects the isogeneic intestinal graft and amends recipient gastric function during transplantation. *Transplantation* 2011; 92(9): 985−992.

Catena F, Coccolini F, Montori G, Vallicelli C, Amaduzzi A, Ercolani G, Ravaioli M, Del Gaudio M, Schiavina R, Brunocilla E, Liviano G, Feliciangeli G, Pinna AD. Kidney preservation: review of present and future perspective. *Transplant Proc*. 2013; 45(9): 3170−3177.

Chen F, Fukuse T, Hasegawa S, Bando T, Hanaoka N, Kawashima M, Sakai H, Hamakawa H, Fujinaga T, Nakamura T, Wada H. Effective application of ET-Kyoto solution for clinical lung transplantation. *Transplant Proc*. 2004; 36(9): 2812−2815.

Chen F, Nakamura T, Wada H. Development of new organ preservation solutions in Kyoto University. *Yonsei Med. J*. 2004; 45(6): 1107−1114.

Codas R, Petruzzo P, Morelon E, Lefrancois N, Danjou F, Berthillot C, Contu P, Espa M, Martin X, Badet L. IGL-1 solution in kidney transplantation: first multi-center study. *Clin. Transplant*. 2009; 23(3): 337−342.

de Boer J, De Meester J, Smits JM, Groenewoud AF, Bok A, van der Velde O, Doxiadis, II, Persijn GG. Eurotransplant randomized multicenter kidney graft preservation study comparing HTK with UW and Euro-Collins. *Transpl. Int*. 1999; 12(6): 447−453.

Del Sorbo L, Costamagna A, Muraca G, Rotondo G, Civiletti F, Vizio B, Bosco O, Martin Conte EL, Frati G, Delsedime L, Lupia E, Fanelli V, Ranieri VM. Intratracheal Administration of Small Interfering RNA Targeting Fas Reduces Lung Ischemia-Reperfusion Injury. *Crit. Care Med*. 2016; 44(8): e604−613.

Desurmont T, Giraud S, Cau J, Goujon JM, Scepi M, Roumy J, Chatauret N, Thuillier R, Hauet T. Trophic factor and FR167653 supplementation during cold storage rescue chronic renal injury. *J. Urol*. 2011; 185(3): 1139−1146.

Deters NA, Stokes RA, Gunton JE. Islet transplantation: factors in short-term islet survival. *Arch. Immunol. Ther. Exp. (Warsz)*. 2011; 59(6): 421−429.

Eugene M. Polyethyleneglycols and immunocamouflage of the cells tissues and organs for transplantation. *Cell Mol. Biol. (Noisy-le-grand)*. 2004; 50(3): 209−215.

Faure JP, Baumert H, Han Z, Goujon JM, Favreau F, Dutheil D, Petit I, Barriere M, Tallineau C, Tillement JP, Carretier M, Mauco G, Papadopoulos V, Hauet T. Evidence for a protective role of trimetazidine during cold ischemia: targeting inflammation and nephron mass. *Biochem. Pharmacol*. 2003; 66(11): 2241−2250.

Gage F, Leeser DB, Porterfield NK, Graybill JC, Gillern S, Hawksworth JS, Jindal RM, Thai N, Falta EM, Tadaki DK, Brown TS, Elster EA. Room temperature pulsatile perfusion of renal allografts with Lifor compared with hypothermic machine pump solution. *Transplant Proc*. 2009; 41(9): 3571−3574.

Gilbo N, Catalano G, Salizzoni M, Romagnoli R. Liver graft preconditioning, preservation and reconditioning. *Dig. Liver Dis*. 2016; 48(11): 1265−1274.

Giraud S, Thuillier R, Belliard A, Hebrard W, Nadeau C, Milin S, Goujon JM, Manguy E, Mauco G, Hauet T, Macchi L. Direct thrombin inhibitor prevents delayed graft function in a porcine model of renal transplantation. *Transplantation* 2009; 87(11): 1636−1644.

Hauet T, Goujon JM, Baumert H, Petit I, Carretier M, Eugene M, Vandewalle A. Polyethylene glycol reduces the inflammatory injury due to cold ischemia/reperfusion in autotransplanted pig kidneys. *Kidney Int*. 2002; 62(2): 654−667.

Kabilova TO, Meschaninova MI, Venyaminova AG, Nikolin VP, Zenkova MA, Vlassov VV, Chernolovskaya EL. Short double-stranded RNA with immunostimulatory activity: sequence dependence. *Nucleic. Acid Ther*. 2012; 22(3): 196−204.

Kay MD, Hosgood SA, Bagul A, Nicholson ML. Comparison of preservation solutions in an experimental model of organ cooling in kidney transplantation. *Br. J. Surg*. 2009; 96(10): 1215−1221.

Korte C, Garber JL, Descourouez JL, Richards KR, Hardinger K. Pharmacists' guide to the management of organ donors after brain death. *Am. J. Health Syst. Pharm*. 2016; 73(22): 1829−1839.

Latchana N, Peck JR, Whitson B, Black SM. Preservation solutions for cardiac and pulmonary donor grafts: a review of the current literature. *J. Thorac. Dis*. 2014; 6(8): 1143−1149.

McAnulty JF, Reid TW, Waller KR, Murphy CJ. Successful six-day kidney preservation using trophic factor supplemented media and simple cold storage. *Am. J. Transplant*. 2002; 2(8): 712−718.

Minasian SM, Galagudza MM, Dmitriev YV, Karpov AA, Vlasov TD. Preservation of the donor heart: from basic science to clinical studies. *Interact. Cardiovasc. Thorac. Surg*. 2015; 20(4): 510−519.

Moser MA, Arcand S, Lin HB, Wojnarowicz C, Sawicka J, Banerjee T, Luo Y, Beck GR, Luke PP, Sawicki G. Protection of the Transplant Kidney from Preservation Injury by Inhibition of Matrix Metalloproteinases. *PLoS One*. 2016; 11(6): e0157508.

Noguchi H, Miyagi-Shiohira C, Kurima K, Kobayashi N, Saitoh I, Watanabe M, Noguchi Y, Matsushita M. Islet Culture/Preservation Before Islet Transplantation. *Cell Medicine* 2015; 8(1): 25−29.

Omori K, Kobayashi E, Komatsu H, Rawson J, Agrawal G, Parimi M, Oancea AR, Valiente L, Ferreri K, Al-Abdullah IH, Kandeel F, Takahashi M, Mullen Y. Involvement of a proapoptotic gene (BBC3) in islet injury mediated by cold preservation and rewarming. *Am. J. Physiol. Endocrinol. Metab*. 2016; 310(11): E1016−1026.

Regner KR, Nilakantan V, Ryan RP, Mortensen J, White SM, Shames BD, Roman RJ. Protective effect of Lifor solution in experimental renal ischemia-reperfusion injury. *J. Surg. Res*. 2010; 164(2): e291−297.

Robbins M, Judge A, MacLachlan I. siRNA and innate immunity. *Oligonucleotides*. 2009; 19(2): 89−102.

Sasaki S, Yasuda K, McCully JD, LoCicero J, 3rd. Calcium channel blocker enhances lung preservation. *J. Heart Lung Transplant*. 1999; 18(2): 127−132.

Schreinemachers MC, Doorschodt BM, Florquin S, Idu MM, Tolba RH, van Gulik TM. Improved renal function of warm ischemically damaged kidneys using Polysol. *Transplant Proc*. 2009; 41(1): 32−35.

Schreinemachers MC, Doorschodt BM, Florquin S, van den Bergh Weerman MA, Reitsma JB, Lai W, Sitzia M, Minor TM, Tolba RH, van Gulik TM. Improved preservation and microcirculation with POLYSOL after transplantation in a porcine kidney autotransplantation model. *Nephrol. Dial. Transplant*. 2009; 24(3): 816−824.

Soni HM, Jain MR, Mehta AA. Mechanism(s) Involved in Carbon Monoxide-releasing Molecule-2-mediated Cardioprotection During Ischaemia-reperfusion Injury in Isolated Rat Heart. *Indian J. Pharm. Sci*. 2012; 74(4): 281−291.

Stowe DF, Camara AK, Heisner JS, Aldakkak M, Harder DR. Ten-hour preservation of guinea pig isolated hearts perfused at low flow with air-saturated Lifor solution at 26{degrees}C: comparison to ViaSpan solution. *Am. J. Physiol. Heart Circ. Physiol*. 2007; 293(1): H895-901.

Wei Y, Chen P, de Bruyn M, Zhang W, Bremer E, Helfrich W. Carbon monoxide-releasing molecule-2 (CORM-2) attenuates acute hepatic ischemia reperfusion injury in rats. *BMC Gastroenterol*. 2010; 10: 42−50.

Wilson CH, Asher JF, Gupta A, Vijayanand D, Wyrley-Birch H, Stamp S, Rix DA, Soomro N, Manas DM, Jaques BC, Peaston R, Talbot D. Comparison of HTK and hypertonic citrate to intraarterial cooling in human non-heart-beating kidney donors. *Transplant Proc*. 2007; 39(2): 351−352.

Witkowski P, Savari O, Matthews JB. Islet autotransplantation and total pancreatectomy. *Adv. Surg*. 2014; 48: 223−233.

Yan Q, Sui W, Wang B, Zou H, Zou G, Luo H. Expression of MMP-2 and TIMP-1 in renal tissue of patients with chronic active antibody-mediated renal graft rejection. *Diagn. Pathol*. 2012; 7: 141−146.

Yang B, Hosgood SA, Nicholson ML. Naked small interfering RNA of caspase-3 in preservation solution and autologous blood perfusate protects isolated ischemic porcine kidneys. *Transplantation* 2011; 91(5): 501−507.

Yang C, Jia Y, Zhao T, Xue Y, Zhao Z, Zhang J, Wang J, Wang X, Qiu Y, Lin M, Zhu D, Qi G, Qiu Y, Tang Q, Rong R, Xu M, Ni S, Lai B, Nicholson ML, Zhu T, Yang B. Naked caspase 3 small interfering RNA is effective in cold preservation but not in autotransplantation of porcine kidneys. *J. Surg. Res*. 2013; 181(2): 342−354.

Yang C, Li L, Xue Y, Zhao Z, Zhao T, Jia Y, Rong R, Xu M, Nicholson ML, Zhu T, Yang B. Innate immunity activation involved in unprotected porcine auto-transplant kidneys preserved by naked caspase-3 siRNA. *J. Transl. Med*. 2013; 11: 210−220.

Yoshida H, Okuno H, Kamoto T, Habuchi T, Toda Y, Hasegawa S, Nakamura T, Wada H, Ogawa O, Yamamoto S. Comparison of the effectiveness of ET-Kyoto with Euro-Collins and University of Wisconsin solutions in cold renal storage. *Transplantation* 2002; 74(9): 1231−1236.

Yuan X, Theruvath AJ, Ge X, Floerchinger B, Jurisch A, Garcia-Cardena G, Tullius SG. Machine perfusion or cold storage in organ transplantation: indication, mechanisms, and future perspectives. *Transpl. Int*. 2010; 23(6): 561−570.

Zhao X, Koshiba T, Nakamura T, Tsuruyama T, Li Y, Bando T, Wada H, Tanaka K. ET-Kyoto solution plus dibutyryl cyclic adenosine monophosphate is superior to University of Wisconsin solution in rat liver preservation. *Cell Transplant*. 2008; 17(1−2): 99−109.

Zheng X, Lian D, Wong A, Bygrave M, Ichim TE, Khoshniat M, Zhang X, Sun H, De Zordo T, Lacefield JC, Garcia B, Jevnikar AM, Min WP. Novel small interfering RNA-containing solution protecting donor organs in heart transplantation. *Circulation* 2009; 120(12): 1099−1107, 1091 p following 1107.

Zheng X, Zang G, Jiang J, He W, Johnston NJ, Ling H, Chen R, Zhang X, Liu Y, Haig A, Luke P, Jevnikar AM, Min WP. Attenuating Ischemia-Reperfusion Injury in Kidney Transplantation by Perfusing Donor Organs With siRNA Cocktail Solution. *Transplantation* 2016; 100(4): 743−752.

In: Encyclopedia of Surgery (22 Volume Set)
Editors: Andreas Lehrer and Kristin Mueller
ISBN: 978-1-53618-329-0
© 2020 Nova Science Publishers, Inc.

Chapter 197

MACHINE ORGAN PRESERVATION

Hazel L. Marecki, MD, Isabel Brüggenwirth and Paulo N. Martins*, MD, PhD
Department of Surgery, Division of Organ Transplantation
University of Massachusetts Medical School,
Worcester, MA, US

ABSTRACT

Ex-vivo machine perfusion is a promising way to better preserve organs prior to transplantation. Since the 1930s, researchers have explored machine perfusion as preservation method, but only recently has interest been renewed in this technology as a means to resuscitate extended criteria donor organs. Hypothermic machine perfusion has become the standard in kidney preservation and has been shown to be superior to simple cold storage in resuscitation of inferior quality organs. Now, new results show that normothermic machine perfusion of the kidney may be a yet more powerful tool in donor organ resuscitation. In livers as well, making machine perfusion technology clinically available holds the promise of expanding the donor pool through more effective preservation of extended criteria donor livers, showing potential in decreasing delayed graft function, primary non-function and biliary strictures, all common failure modes of transplanted extended criteria donor livers. However, the precise settings and clinical role for liver machine perfusion has not yet been established. In research, there are two schools of thought regarding both liver and heart perfusion: normothermic machine perfusion, closely mimicking physiologic conditions, and hypothermic machine perfusion, as a means of resuscitative cold storage. A new compromise has been introduced for liver preservation (and applied to kidney preservation as well) called subnormothermic or rewarming machine perfusion as a method to minimize the ischemia reperfusion injury following cold storage but also replenish energy stores prior to transplantation. In hearts, recent preclinical trials show hypothermic perfusion superior to simple cold storage, but normothermic perfusion has been used to extend the storage time and shows promise in resuscitating hearts donated after cardiac death (DCD). In lung allograft transplantation as well, normothermic machine perfusion offers to increase

* Corresponding Author's Email: paulo.martins@umassmemorial.org.

function of extended criteria donor grafts and provides a modality for pretransplantation assessment of function. The pancreas shows the highest rate of discard due to unsuitability of any transplanted organ and therefore perhaps stands the most to gain from experimentation in normothermic perfusion as means of extended criteria organ resuscitation.

Keywords: machine perfusion, liver transplantation, heart transplantation, kidney transplantation, lung transplantation, pancreatic transplantation, preservation

ABBREVIATIONS

ATP	adenosine triphosphate
CS	cold storage
DCD	donation after cardiac death
DGF	Delayed graft function
ECD	extended criteria donor
HMP	Hypothermic Machine Perfusion
HOPE	hypothermic oxygenated perfusion
IRI	Ischemia Reperfusion Injury
ITBL	ischemic type biliary lesions
LDH	lactate dehydrogenase
NMP	Normothermic Machine Perfusion
PNF	Primary non-function
RMP	Rearming Machine Perfusion
RV	right ventricle
SCS	simple cold storage
SNMP	Sub-Normothermic Machine perfusion
WI	warm ischemia

INTRODUCTION

The shortage of organ transplantation donors is a worldwide problem. For example, 1,410 patients on the liver transplant waiting list died in 2015. Because of the exponential discrepancy between organ demand and supply, more organs of inferior quality are used every year. However, many of these organs are still discarded. The use of extended criteria donors (ECD) is a promising way to expand the available donor pool. In particular, donation after cardiac death (DCD) liver grafts has become increasingly important as they have become a larger proportion of the donor pool; over 18% of the total donor pool in 2015 (UNOS 2016). DCD kidney grafts are used successfully for clinical transplantation, with outcomes very similar to brain-dead donor grafts, however poorer outcomes have delayed the use of other DCD organs. Due to warm ischemic damage, DCD liver grafts, carry higher risks for delayed graft function (DGF), primary non-function, and biliary complications following transplantation (Saidi 2013). Biliary complications in DCD organs are a major source of morbidity, graft loss, and even mortality long-term after liver transplantation. These

complications are much more common in DCD grafts (20−40% compared to 5% in grafts from brain-dead donors) (Jay 2011). The most troublesome biliary complication is the ischemic-type biliary lesions (ITBL), also called ischemic cholangiopathy.

The risk of ischemic cholangiopathy in grafts from DCD donors is 10 times higher than for brain dead donors (Jay 2011). Eventually, up to 50−65% of the patients with ITBL will require a retransplantation or may die (Merion 2006; Verdonk 2006). Most of DCD organs are discarded because of prolonged warm ischemia time, with most centers declining when longer than 30min. Because of poor results with DCD liver grafts after conventional cold storage preservation, interest in liver machine preservation was renewed (Guarrera 2010). For similar reasoning, interest in lung, heart, and pancreatic machine perfusion has been renewed as well, with aim to expand the donor pool through the resuscitation of extended criteria donor grafts.

Machine perfusion allows the opportunity to repair the damage of warm ischemia and cold storage, reawakens metabolic functions and measures the viability of a graft *ex-vivo* prior to transplantation. However, the simplicity and low cost of cold storage (CS) have kept it the standard of care for transplantation centers. Growing data supports the use of liver machine perfusion preservation, but the variability of systems, techniques, settings, and costs have interfered with standardization and global use. Likewise, heart, lung and pancreatic machine perfusion preservation have a growing body of data demonstrating potential superiority, but the technology has not yet been widely commercialized (Tolboom 2016; Karcz 2010).

The main categorization of machine perfusion preservation has traditionally been by perfusion temperature. Hypothermic machine perfusion (HMP) has been an attractive option to avoid further warm ischemic time and minimize graft metabolic requirements for ease of transport, while still providing oxygenation and metabolic support. Contrarily, much research supports the use of normothermic machine preservation (NMP) to most closely mimic the physiologic environment with oxygenation, nutrition, and full metabolic support. In addition, NMP has the advantage of more thoroughly testing organ functionality (for example bile production and lactate clearance in liver) prior to transplantation, which cannot be tested during hypothermic perfusion preservation. Other researchers have advocated for temperature profiles somewhere in between. Subnormothermic (SNMP) or rewarming machine preservation (RMP) represent some of the newest approaches to both liver and now kidney perfusion in their attempts to maximally increase graft metabolism while minimizing reperfusion injury resulting after cold storage. Optimal temperature, mode of oxygenation, ideal perfusate, perfusion cannulation, and pressure and flow settings are debated, but with little consensus as to ideal perfusion settings, even in kidney where the technology is clinically available. This chapter compiles a summary of the history of machine organ preservation, its most promising research, successful clinical applications, and what the future may hold for kidney, liver, heart, lung and pancreatic machine perfusion preservation.

KIDNEY MACHINE PERFUSION PRESERVATION

History and Introduction

The stilted progression of machine preservation is perhaps best explained by the history of kidney machine preservation. In the 1960s, Belzer et al. started experiments studying

hypothermic machine perfusion (HMP) in canine kidneys and the first successful human transplantation of a hypothermically machine perfused kidney took place in 1968 (Belzer 1967). The perfusion preservation of kidneys first became part of clinical practice in the late 1960s using a perfusate of blood and cryoprecipitated plasma. By the 1970s, HMP was used to preserve and transport kidneys, extending the time grafts could be stored prior to subsequent successful transplantation.

However, after the definition of irreversible coma in 1968, the term brain death became accepted in the early 1970s. Consequently, centers shifted to procure organs from heart beating instead of non-heart-beating (NHB) donors, with increased success rates. The majority of transplant centers abandoned the practice of donation after circulatory death (DCD) due to associated higher complication and failure rates. Additionally, in 1980, the development of UW Solution allowed for 72 hour kidney preservation by simple CS, and use of MP was largely discontinued. Only young trauma patients were considered suitable candidates for DCD donation and these pristine organs were preserved equally well by either static cold storage (SCS) or HMP (Belzer 1980).

Over the last few decades, more marginal donors, as well as DCD donors are accepted to overcome organ shortage which has re-sparked interest in machine perfusion worldwide. Substantial experimental work on machine organ preservation contributed to improved clinical results in extended criteria donor kidney preservation. An international multicenter trial of 672 paired kidneys found that HMP reduced the risk of DGF, and decreased serum creatinine (Moers 2009). Therefore, machine perfusion became the method of choice to obtain good long-term preservation and for the preservation of marginal kidneys.

By 2008, nearly half of U.S. kidney transplants from extended criteria donors (ECD) and 70% of those from DCD donors were machine perfused (Catena 2013). During perfusion, a recirculating perfusate is continuously pumped through the organ vasculature, which can be non-oxygenated or oxygenated. A heat exchanger regulates perfusate temperature at hypothermic (0−4ºC), sub-normothermic (20−30ºC) or normothermic (37ºC) temperatures.

The machine itself generally consists of a circulatory pump (which perfuses the organ *ex vivo*, after procurement) and renal artery cannulation (Jochmans 2016). Continuous perfusion (from procurement to implantation) and pre-implantation perfusion (after a period of SCS and just before transplantation) are the two most commonly used modalities. During perfusion, the kidney is supplied with nutrients and oxygen, has waste products removed, and can be treated with therapeutic agents. Historical challenges which persist today include understanding the metabolic requirement of the *ex vivo* perfused organ, understanding the effect of simple cold storage and the capacity to alleviate reperfusion injury, the development of *ex vivo* viability biomarkers, maintenance of endothelial cell integrity, and the engineering the ideal perfusate delivery system and settings (Belzer 1980).

Hypothermic Kidney Perfusion

Our discussion begins with HMP modalities as these are currently the only widely clinically available machine perfusion technique. HMP places kidney grafts under continuous circulation of a cold perfusate (0−4ºC) through the cannulated renal artery immediately after procurement. Circulation of the perfusate is achieved through a device that generates either a continuous or pulsatile flow by a roller pump. HMP maintains hemodynamic stimulation of

the vasculature, known to play a critical role in renal function under normal physiologic conditions. HMP may reduce ischemia-reperfusion (I/R) injury as was suggested by decreased levels of genes that are correlated with I/R injury in HMP kidneys compared to SCS-treated kidneys (Wszola 2014). Zhang et al. observed increased apoptosis in cold stored kidneys versus HMP kidneys in a canine DCD model, with phospho-AKT and ezrin expression induced in the HMP group, implying that cell proliferation, turnover, and renewal are positively influenced by HMP (Zhang 2016). A meta-analysis conducted between 1971 and 2001 showed HMP to be associated with a decreased relative risk of DGF of 0.80 (95% CI = 0.67−0.96) compared to SCS (Jochmans 2015). In 2009, a large randomized controlled trial was conducted comparing continuous HMP with SCS of 336 kidney pairs using the LifePort™, which showed an overall reduced risk of DGF in HMP kidneys compared to SCS kidneys (20.8% vs. 26.5%, $p = 0.05$) with increased one-year graft survival from 90% in SCS kidneys to 94% in HMP kidneys ($p = 0.04$) (Moers 2009).

HMP is thought to be of particular benefit in more marginal ECD grafts, which are particularly prone to IRI, DGF and PNF. A study compared ECD kidneys that were subjected to CS followed by HMP to kidneys that were treated with SCS throughout and HMP-treated organs showed markedly reduced expression of cytokines and soluble intracellular adhesion molecular type 1 (Tozzi 2013). In a study on 91 randomized ECD kidney pairs, HMP compared to SCS significantly reduced the risk of DGF (adjusted odds ratio (OR) = 0.46; 95% CI = 0.21−0.99), reduced PNF (3% vs. 12%, $p = 0.04$) and increased 1-year graft survival (92.3% vs. 80.2%, $p = 0.02$) (Treckmann 2011).

One category of ECD donors is the DCD donor (previously referred to as non-heart-beating) whose cardiac arrest occurs before organ procurement, exposing kidneys to an unavoidable extra period of warm ischemia (WI). Warm ischemia makes DCD organs particularly prone to the development of DGF. The literature reveals conflicting data on HMP in DCD kidneys. Many studies suggest that HMP of DCD kidneys leads to better outcomes, but other studies are not able to show a significant difference in DGF or graft survival. In the multi-center Eurotransplant trial on 82 DCD kidney pairs, HMP showed a reduced risk of DGF compared to SCS kidneys (53.7% vs. 69.5% respectively, $p = 0.025$) (Jochmans 2010). In 2010, Watson et al. published results on a RCT comparing HMP with SCS for 45 DCD kidney pairs which showed no beneficial effect on 1- or 3-year graft survival or DGF for hypothermic machine perfused kidneys (Watson 2010). These contradicting outcomes of the world's currently largest RCTs may be related to timing of HMP throughout procurement and transplantation. Hosgood et al. showed in a porcine kidney transplant model that the beneficial effect of MP disappears when kidneys are not pumped immediately after procurement (Hosgood 2011). In the Eurotransplant trial, kidneys were pumped immediately after retrieval at the donor center, whereas in the U.K. trial, kidneys were cold stored during transfer and HMP was started subsequently. New data suggests that alternative temperature profiles besides hypothermic may be more clearly beneficial in DCD kidneys, particularly those treated with an unavoidable period of SCS (Bagul 2008; Hosgood 2013; Hosgood 2011).

HMP Preservation Solutions

Countless preservation solutions have been created and trialed, all with different compositions aimed to prevent IRI and maximize graft survival and function. Early preservation solutions consisted of diluted blood and ringers lactate solution. Currently, the most commonly used preservation solutions are University of Wisconsin (UW), histidine-tryptophan-ketoglurate (HTK), Celsior, Institute George-Lopez (IGL-1), Polysol, EuroCollins, hypertonic citrate or Marshall solution (HOC), and phosphate-buffered sucrose (PBS).

In 1987, Belzer and colleagues developed the University of Wisconsin (UW) solution (also known as KPS-1 or Belzer's solution) and this became the gold standard among organ preservation solutions. In the European Multicenter Trial, the use of UW versus EuroCollins solution significantly reduced the rate of DGF (10% vs. 23%) (Ploeg 1992). UW shows good outcome of short- and long-term kidney preservation, but the main disadvantage is its high viscosity mainly due to hydroxyl ethyl starch (HES) (Catena 2013). For HMP, UW-G is used, in which a more extracellular solution is achieved through replacing lactobionate by gluconate and reducing the potassium level (Catena 2013).

Some institutions favor low-viscosity HTK solution to preserve DCD kidneys. HTK was introduced in 1980 by Bretschneider and is recommended in HMP at low pressures and in high perfusion volumes. More recently, Rauen and De Groot developed Custodiol-N solution as improved modification of the former HTK solution with iron chelators to inhibit cold-induced free radical-mediated injury, shown to be efficacious in protecting rat livers during HMP (Stegemann 2010). Developed in 1994, Celsior solution is a colloid and combines the osmotic efficacy of UW (lactobionate and mannitol) with the potent buffering ability of HTK (histidine), with the benefit of reduced tissue edema from hydrostatic pressure since Celsior contains macromolecules that do not pass the cellular membrane (Catena 2013).

The fairly new preservation solution IGL-1 combines the advantages of UW and Celsior with high sodium concentration and polyethylene glycol (PEG, 35 kDa), substituting HES. A non-randomized prospective multi-center study showed the same effectiveness for IGL-1 versus UW solution, but lower costs favor the former (Codas 2009). Polysol, a new low-viscosity preservation solution, is introduced to facilitate transplantation of ischemically damaged organs. Amino acids, vitamins, potent buffers, and anti-oxidants have been added to support metabolism during HMP (Bessems 2005). One of the main components is PEG 35, a low-molecular-weight colloid that does not increase viscosity as seen with HES-containing solutions. Polysol is currently used in experimental settings only, but recent reports seem promising. A study in a porcine auto-transplant model reports better preservation of microcirculation and renal function after 20-h SCS preservation compared to UW (Schreinemachers 2009).

HOC, or Marshall's solution is extensively used for clinical transplantation in the U.K. and Australia. HOC is an intracellular solution with high potassium content, mannitol as the impermanent ion, and citrate as its buffer. The hypertonic character of HOC prevents entry of fluid into the cells and has shown to be effective for 72-h canine kidney preservation (Kay 2009).

Oxygenation during HMP

In HMP, oxygenation plays a central role of importance for reconditioning organs after ischemic time. Lack of oxygen leads to ATP decrease, which can be as large as 80% for kidneys (Jassem 2004). Continuous oxygenation during perfusion is thought to be useful to support the metabolic demand of the organ. However, high concentrations of oxygen are believed to favor the production of oxygen free radicals and promote adverse effects on tissue during long-term oxygenated preservation (Stegemann 2010; Rauen 2004). Many studies strongly suggest oxygen to be a constitutive adjunct in HMP, improving functional outcome of the graft. Hoyer and colleagues showed that HMP with 100% oxygen results in higher flow and lower renal resistance (RR) during perfusion and improved graft function as compared to oxygen-free HMP (Hoyer 2014). Positive results for oxygenated HMP were confirmed with a 3 month post-transplant follow-up by showing lower serum and peak creatinine levels and injury markers, which correlated with improved longer term outcomes of lower serum creatinine, less proteinuria and less chronic kidney fibrosis (Thuillier 2013). Kron et al. investigated the effects of 1 hour hypothermic oxygenated perfusion (HOPE) following a period of CS and immediately prior to transplantation, with dramatic improvements in graft function after transplantation as shown by decreased nuclear injury, macrophage activation, endothelium activation, tubular damage, and improved graft function (Kron 2016). Grafts exposed to warm ischemia, simulating DCD, seem to particularly benefit from oxygenated perfusion with restored ATP stores in DCD porcine kidneys, but no added benefit of oxygenation was found in kidneys without injury (Buchs 2011).

Commercial Hypothermic Machine Perfusion Devices

As HMP is gaining recognition, more perfusion machines are becoming available. (For more details see the chapter Isolated Kidney Perfusion Models). The most commonly used device in Europe and the USA is the pressure-driven LifePort Kidney Transporter (Organ Recovery Systems, Itasca, IL, USA). Another commercially available system is the flow-driven Waters Medical RM3 (Birmingham, AL, USA). In both systems, the operator can modify the systolic perfusion pressure, with flow and resistance recorded over time. Relevant differences between the systems are related to the way both devices generate and control flow and pressure. The RM3 uses a flow-driven system, which requires 50% higher systolic pressures (45 vs. 30 mm Hg) to obtain similar flow rates. A comparative study on both systems demonstrated minimal differences in early kidney recovery, but significantly higher levels of post-transplant fibrosis in kidneys preserved by RM3 compared to LifePort (Wszola 2013). Another study showed favorable results for the LifePort device compared to RM3 with shorter duration of DGF after transplant, lower incidences of interstitial fibrosis and tubular atrophy in biopsies taken within 1-year post transplant, and lower renal resistance during perfusion (Wszola 2013).

Sub-Normothermic Kidney Perfusion

The interest in sub-normothermic machine perfusion (SNMP) increased as an attempt to alleviate or prevent organ injury caused by a sometimes unavoidable period of SCS preservation, which seems to be especially damaging to DCD organs. In a porcine model of renal I/R injury, oxygenated SNMP demonstrated better protection of the organ compared to cold storage. Moreover, SNMP grafts showed nearly twofold better values of creatinine clearances compared to oxygenated HMP. SNMP also permits higher pressure perfusion with reduced risk of endothelial and vascular impairment, as higher temperatures increase vascular compliance (Hoyer 2014). Higher temperatures also lead to higher metabolic demands requiring active oxygenation and sufficient perfusion flow. The use of SNMP in clinical kidney transplantation has not yet been reported.

Gradual Rewarming

Another experimental machine perfusion temperature profile is gradual rewarming based on the hypothesis that ischemic damage results from the abrupt temperature shift from hypo- to normothermia, leading to mitochondrial dysfunction and proapoptotic signal transduction (Hoyer 2016). Recent studies have investigated the effect of the controlled oxygenated rewarming (COR), a concept that originated in liver perfusion due to logistical necessities of a period of SCS prior to machine perfusion. Schopp et al. reported a nearly twofold increase in renal clearances of creatinine and urea after COR of pig kidneys compared to controls. This was accompanied by significantly improved renal oxygen consumption and less cellular apoptosis (Schopp 2015). Similarly, Mahboub et al. demonstrated lower levels of transaminases, and heat shock protein 70, ICAM-1, VCAM-1 mRNA expressions were decreased in gradually rewarmed kidneys. Kidneys that underwent gradual rewarming suffered less renal parenchymal tubular injury and showed better endothelial preservation (Mahboub 2015). These data suggest that a gradual increase in temperature results in better energetic recovery, less cellular injury, and ultimately superior function of kidneys subjected to COR, however, there have been no clinical applications in kidney perfusion to date.

Normothermic Kidney Perfusion

In contrast to cold preservation, the concept of normothermic machine perfusion (NMP) is to closely replicate the physiological environment and maintain cellular metabolism during preservation. With aerobic metabolism restored, the kidney grafts regain function and minimize cold ischemic insult, thought to be preferred in the resuscitation of DCD and ECD kidneys. NMP has been shown to replenish ATP stores and up-regulate repair mechanisms such as heat shock protein 70, which aids repair due to oxidative damage (Hosgood 2013). However, the act of rewarming may aggravate inflammatory processes and increase graft injury, particularly without optimal perfusion settings, nutrients and oxygenation profiles. Proinflammatory cytokines, such as IL-6, are upregulated in response to ischemic injury and were released in the kidney during reperfusion after NMP (Hosgood 2013). Alternatively, IL-

6 can also have anti-inflammatory properties in resolving tissue damage after an initial inflammatory response (Nechemia-Arbely 2008).

Ex-vivo NMP should most ideally be used throughout the preservation interval, which is logistically difficult due to tenuous perfusion requirements. Alternatively, NMP can be implemented for a shorter period prior to transplantation as a form of graft resuscitation. One practical proposed approach is to use 1−2 hours of NMP as a restorative period prior to transplantation to allow graft function and replenish ATP stores (Bagul 2008; Hosgood 2013; Hosgood 2011). NMP-resuscitated kidneys had less tubular injury, improved blood flow and oxygenation and were metabolically more stable as compared to the cold stored kidneys. In 2011, Hosgood et al. reported the first case of successful kidney transplantation in man after the organ was cold stored for 11h, followed by 35 min of *ex vivo* NMP. The 55-year old recipient had slow graft function, but ultimately remained dialysis independent (Hosgood 2011). A pilot clinical study compared 18 ECD kidneys that received 1h of pre-implantation blood-based NMP with 47 matched SCS controls. Significantly lower DGF rates were observed with pre-implantation NMP (5.6% vs. 36.2%, $p = 0.014$) (Hosgood 2013).

Since DCD and ECD organs poorly tolerate the effects of hypothermia in SCS, a more novel approach of NMP totally avoids storage in hypothermic conditions. A study by Kaths et al. demonstrated that NMP with an erythrocyte-based solution could replace hypothermic storage techniques. NMP kidneys showed similar serum creatinine levels and creatinine clearance post-transplant compared to SCS grafts. After 10 days follow-up, NMP animals had serum creatinine and blood urea nitrogen values comparable to basal levels, whereas SCS grafts showed elevated values (Kaths 2016). Recently, Hosgood et al. reported the successful transplantation of a pair of human kidneys that were deemed unsuitable for transplantation due to inadequate perfusion, but subsequently were transplanted after perfusion and assessment using *ex vivo* NMP (Hosgood 2016).

Normothermic Preservation Solutions

Continuous perfusion with an oxygenated solution to support aerobic metabolism is key under normothermic conditions. During NMP, the perfusate can be based on either a natural oxygen carrier such as blood or an artificial-based medium. Early preservation solutions consisted of diluted blood and Ringers lactate solution. From 1985 until 1993 Collins or Euro-Collins solution was the commonly used solution, and from 1993 onwards, this shifted to UW, which is still the gold standard for abdominal organ preservation today (Wight 2003).

Brasile et al. were the first to develop an acellular normothermic solution based on perfluorocarbon (PFC) emulsion and enriched tissue culture-like medium containing essential and non-essential amino acids, lipids and carbohydrates (Brasile 1994). PFCs are inert solutions that have a high capacity for dissolving oxygen. New, more stable, PFCs are now being developed mainly as blood substitutes. Humphreys et al. recently used a commercially made PFC to provide oxygenation and reduce ischemic injury to the kidney during warm ischemia by retrograde infusion through the urinary system (Humphreys 2006). These new generation PFCs could potentially be developed as normothermic preservation solutions. However, due to complexity of manufacturing, they are very expensive. A more stable pyridoxalated haemoglobin polyoxyethylene (PHP) solution has proven to be more successful and Brasile et al. have since replaced the PFC with this solution (Stubenitsky 2000). Other

solutions such as Lifor (an artificial preservation medium containing a non-protein oxygen carrier, nutrients and growth factors) have also been used during NMP. Some studies have shown higher flow rates in Lifor perfused kidneys compared to UW (Gage 2009; Olschewski 2010). The most newly reported acellular solution is Hemarina-M101, extracellular hemoglobin derived from a marine invertebrate. It has been formulated into an oxygen carrier mainly as a blood substitute. M101 has been used in SCS to deliver oxygen with favorable results and functions over a wide range of temperatures (4−37ºC) (Thuillier 2011).

A blood-based solution during NMP was previously considered limited due to hemolysis, platelet activation, deterioration of red blood cell oxygen-carrying capacity, high intra-renal resistance and tissue edema (Thiara 2007). However, results of an isolated perfusion system with 1 unit of compatible packed red blood cells mixed with a priming solution and added protective agents are promising. In a series of 18 ECD kidneys, DGF was 5.6% compared to 36% in similarly matched recipients of a kidney undergoing SCS (Nicholson 2013).

Normothermic Machine Perfusion Viability Assessment

In contrast to HMP, kidney function can be evaluated during NMP by directly assessing functional measures such as blood perfusion, renal blood flow and urine output. Recently, Hosgood et al. used *ex vivo* NMP to develop a novel scoring system for pre-transplant assessment of marginal kidneys (Hosgood 2015). Based on assessment scores from their clinical series, it became clear that kidneys with a score of 1 to 4 could be transplanted successfully. Kidneys with a score of 5 would be considered very high-risk and unlikely to be suitable for transplantation. In their study on 36 kidneys, grafts with an assessment score of 3 had a significantly higher incidence of DGF (38%) compared to kidneys with a score of 1 (6%) or 2 (0%) ($p = 0.024$). The ability to assess organs adequately prior to transplantation is an especially important benefit of *ex-vivo* machine perfusion and is an especially powerful use for NMP.

LIVER MACHINE PRESERVATION

History and Introduction

In 1935, Alexis Carrel and Charles Lindbergh designed the first liver perfusion machine using pressure-controlled, oxygenated normothermic perfusate in a glass device (Dutkowski 2008). In spite of significant technical advances, no system has been proven to clinically significantly extend the length of *ex vivo* organ viability as compared to CS in preservation solutions such as University of Wisconsin (UW), Histidine-Tryptophane-Ketoglutarate (HTK) and Celsior. After the first unsuccessful attempts of hypothermic perfusion of human livers by Starzl et al. in 1967, the clinical use and development of human liver perfusion devices did not move forward (Starzl 1967). Because of the success of cold storage preservation in UW solution, there was no need to use machine preservation until the use of marginal livers became necessary due to increased discrepancy between demand and supply. Several clinical trials now support the preferred use of machine perfusion in grafts which

have been subjected to warm ischemic time, but the ideal machine perfusion set-up and settings are still very much debated. In 2010, Guarrera et al. reported the first successful human liver transplantations following hypothermic machine perfusion preservation (Guarrera 2010). More recently, Dutkowski has examined matched case analyses of HMP vs. cold storage with marked decrease of intrahepatic cholangiopathy, biliary complications and improved 1 year graft survival (Dutkowski 2015). In 2016, Bral et al. published the first clinical normothermic machine perfusion transplantation series, demonstrating feasibility and safety, but bringing to light the questions of ideal methodology (Bral 2016).

Liver Perfusion Route

Given the unique physiology of liver perfusion *in vivo*, several perfusion routes have been advocated for machine liver perfusion. Portal vein only perfusion is commonly used in rat liver perfusion for simplicity reasons, but is generally believed inferior for larger animal models and humans. Arguments for hepatic artery perfusion include perhaps superior oxygen supply to the peribiliary vascular plexus (Bruggenwirth 2016). Although it has been reported that the biliary ducts also have blood supply from the portal vein (Slieker 2012), the biliary tract is mainly supplied with arterial blood through the Peribiliary vascular plexus (PVP) and therefore, any injury to the PVP may contribute to the ischemic death of the biliary epithelial cells after transplantation (Nishida 2006). The importance of hepatic artery perfusion is illustrated by the high incidence of biliary necrosis and strictures after hepatic artery thrombosis (HAT) in patients after liver transplantation (Mourad 2014). Additionally, during early reperfusion, the O2 delivery is heavily dependent on arterial flow and as a result, dual perfusion is superior to portal perfusion in bile production as well as output of phospholipid, cholesterol and bilirubin (Foley 1999, 2003). Combined arterial and portal machine perfusion of DCD porcine livers also results in a better preservation of the PVP and less arteriolonecrosis (Op den Dries 2014).

Hepatic artery perfusion alone seems to be less beneficial than portal vein or dual perfusion (Compagnon 2001). All trials of NMP, SNMP or rewarming machine perfusion (RMP) utilized dual perfusion circuits, as these methods attempt to approximate physiologic conditions and maximize oxygenation. Most HMP studies also utilized dual perfusion circuits with few studies demonstrating portal vein perfusion only. Portal vein only studies state goals such as simplifying machine perfusion or improving machine portability. No study argues portal vein only perfusion to be superior or even comparable to the benefits of a dual perfusion system (with the exception of Schlegel et al. in the setting of HMP (Shlegel 2015). Dual porcine machine perfusion through hepatic artery (HA) and portal vein (PV) appears to be more effective at alleviating reperfusion injury than either portal vein or hepatic artery alone (Foley 1999).

The physiology of liver perfusion is notably complex, and is an additional reason for dual perfusion that it most closely mimics *in vivo* mechanics. For example, one study showed the principle of *ex vivo* flow competition: arterial pressure alters portal flow (Monbaliu 2012). For reasons of functional rejuvenation of liver tissue as well as providing consistent physiology-mimicking perfusion, most researchers choose dual perfusion in porcine machine liver perfusion models, and this practice has transferred over to the first trials in human livers.

Normothermic Liver Perfusion

The tenant of NMP has long been the replication of physiologic parameters to minimize ischemia and maximize *ex vivo* metabolism. Hence, most NMP trials utilize modified heparinized blood solutions or Steen solution plus erythrocytes as the perfusate (Monbaliu 2012; St Peter 2002; Reddy 2005; Xu 2012; Knaak 2014; Liu 2014; Schon 2001). Other studies have utilized Celsior (Gringeri 2012), Steen (Boehnert 2013), Custodiol (Minor 2013), or UW gluconate (Obara 2013) or Modified nutritive Williams' medium E (Izamis 2014) as perfusate. Liu et al directly compared Steen Solution vs. Steen with erythrocytes vs. whole blood with the result that aspartate aminotransferase (AST), alanine aminotransferase (ALT) and LDH production was decreased and bile production was increased with improved histology in the groups with erythrocytes or whole blood, emphasizing the importance of an oxygen carrier in NMP. All NMP studies utilized dual perfusion routes, mimicking physiology and perfused for a minimum of 3 hours up to as long as 24 hours (Liu 2014). Early studies were aimed to lengthen liver storage up to 72 hours (Butler 2002). Other proponents of NMP claimed that it decreased ischemia reperfusion injury and resulted in superior bile production (Imber 2002; St Peter 2002). All NMP studies utilize oxygenators. Perfusion was controlled by either pressure of flow with flow being less popular at 5 out of 16 studies and a few studies using flow for hepatic artery (HA) and pressure for portal vein (PV) or vice versa. Goal pressures ranged from 50−100 mm Hg for the hepatic artery and 3−10 mm Hg for the PV. Flows ranged from 150−700 mL/min for HA and 950−1750 mL/min for the PV, with a few studies reporting flow as a function of liver weight at HA 0.16−0.25mL/min/g and PV as 0.22−0.8 mL/min/g.

The benefits of NMP are nearly undisputed in the literature, but the addition of NMP into clinical practice is logistically complicated. Now that CS is the established standard preservation, and most centers lack perfusion machines, some period of CS in clinical practice is unavoidable. Four hours of CS prior to NMP results in statistically significant reduction in bile and Factor V production, reduction of glucose stores, increased release of AST and ALT, and base excess and endothelial injury, as shown through increased hyaluronic acid as well as necrosis in histology, and none of these parameters were normalized if NMP was performed following CS (St Peter 2002).

Subnormothermic and Rewarming Liver Perfusion

The unavoidable period of CS has brought upon newer variations of NMP where the liver is perfused either at subnormothermic temperatures or the perfusate is gradually rewarmed from cold storage to normothermic temperatures. Initial perfusion at a cold temperature enables replenishment of cellular energy stores in order to reduce ischemia reperfusion injury upon rewarming. Subnormothermic Machine perfusion (SNMP) was shown to improve tissue energetics, peroxidation and increased bile production (Minor 2013) as well as better recover homeostasis, oxygen consumption, bile production and histology (Knaak 2014) However, others have found decreased bile production, increased AST/ALT and worse histology using SNMP (21C) versus NMP (38.5) (Nassar 2016). Temperature controlled rewarming has been found to result in decreased release of LDH and superior mechanistic properties of the livers such as pressure curves (Obara 2013). Gradually warming warm-ischemic treated livers to

normothermic perfusion or subnormothermic perfusion was also shown to lower liver enzyme release, increase ATP stores, improve bile production and improve histology as compared to hypothermic or subnormothernic perfusions (Minor 2013; Furukori 2016). Most recently, rewarming perfusion was shown to improve international normalized ratio (INR) (marker of coagulation factor production), bile production as well as minimize sinusoidal endothelial cell injury and activation of Kupffer cells. However, extending the rewarming phase to 60 or 120 min rather than 20-30min decreased synthetic liver functions perhaps by increasing anaerobic respiration time (Banan 2016). Preliminary studies also suggest a period of in situ subnormothermic extracorporeal membrane oxygenation (ECMO) prior to rewarming compounds the benefits of subnormothermic machine perfusion (SNMP) on resuscitation of livers after (warm ischemic time) WIT (Hagiwara 2016). Others found that gradual increase of perfusate flow and oxygen throughout the rewarming period minimized AST/ALT release (Morito 2016). Controlled oxygenated rewarming perfusion (COR) was also shown to be superior in recovering energy stores and minimizing hepatocellular and mitochondrial damage after 18 hours of CS as compared to NMP (Hoyer 2016). COR also resulted in lower mitochondrial caspase-9-activity. Significantly lower enzyme leakage and higher bile production were also observed during reperfusion. The first clinical application of COR has recently been successfully applied in liver transplantation (Hoyer 2016).

Hypothermic Liver Perfusion

In contrast to NMP settings, HMP settings are by definition, not particularly physiologic, with perfusate temperature most commonly defined as 4 C. Many porcine HMP studies used KPS-1 Solution (Jain 2004, Monbaliu 2007, Vekemans 2007), while many others used UW Solution or Belzer MP (Obara 2012; Schlegel 2013). Bessems at al. was unique in comparing Celsior perfusate versus Polysol with the result that Celsior solution was more damaging than Polysol, increasing AST/ALT and intravascular resistance to a greater extent (Bessems 2006). (For more detailed discussion of perfusion solutions see above where we discussed kidney perfusion). Most studies, besides the exceptions noted in section “perfusion routes,” used a dual circuit (portal vein and hepatic artery perfusion) and most recent studies seem to agree that dual circuit HMP seems more beneficial. In many studies, the lengths of perfusion for HMP were much longer than NMP, up to 24 hours, as HMP is looked at as a potential means to extend the storage time of donated livers. Most studies since 2013 have focused on recovery of donor livers from warm ischemia time and have shorter perfusion times ranging from 1 to 4 hours. Most studies used pressure-controlled circuits with hepatic pressures 20−30 mm Hg (exception Monbaliu with increasing pressures to 55 then 70) and portal pressures 3−13mm Hg with the majority limited to less than 7 mm Hg.

Studies in 2005 through 2007 focused on defining the capabilities of HMP. HMP was shown to maintain superior oxygen consumption and decrease ALT when compared to cold storage (Jain 2004). A portable perfusion machine was shown to maintain a liver for 24 hours with no significant histological damage (van der Plaats 2006). The pattern of decreasing HA vascular resistance over the first 6 hours of perfusion was first noted by Monbaliu et al. Also noted in this study was the introduction of anoxic vacuoles by HMP, likely due to lack of oxygenation in this study, and inability of their HMP livers to produce bile *ex vivo*. Another study showed increased ATP stores after HMP, indicating better preservation of energy stores

as well as use of an oxygenator directly protecting against anoxic vacuolization (Vekemans 2007).

Predicting Pretransplantation Viability

A strong argument for the use of machine preservation is the added ability to assess viability of donor liver grafts prior to transplantation. Proposed outcome measures include flow and pressure characteristics and perfusate enzymes such as AST and LDH. The assessment of liver grafts is complicated by its unique dual blood supply, and the wide ranged and low flow portal system. Obara et al. found that hepatic arterial pressure, AST and LDH correlated well with warm ischemia time (WIT) during HMP (Obara 2012). Logically, oxygen consumption, complement/factor V production, bile production, and hyaluronic acid (marker of endothelial injury) have been used as outcomes and their levels correlated to damage found in histology. Other recent studies suggest the use of microRNA profiles of perfusate samples as indicators of WI injury and prediction of PNF. One miRNA, miR-22, was correlated to transplantation survival outcome, but is believed to have low diagnostic potential (Khorsandi 2015). Further work must be done to establish the best *ex-vivo* markers of WI injury and reperfusion injury to determine the best predictors of good transplantation outcomes.

When focusing on histologic changes caused by warm ischemia, it is important to perform reperfusion with whole blood because it magnifies ischemia reperfusion injury (IRI). Whole blood has all the key players of ischemia reperfusion injury, namely the complement system, white blood cells, and platelets. One cannot expect to see all the changes associated with IRI if the liver is not perfused with blood experimentally. Likewise, clinically it is difficult to assess the degree of IRI during HMP as the liver becomes metabolically less active and NMP allows for improved functional assessment *ex vivo* prior to transplantation. Despite many failed attempts to quantify in an experimental setting the impact of HMP using whole blood reperfusion, Op Den Dries et al. showed after 30 minutes WI and no CS, that HA flow and ATP content increased after HMP, while AST and LDH decreased significantly. HMP-treated livers also showed improved histology and lower caspase-3 levels. This study was also significant for the use of miRNA and the establishment of miRNA profiles in the porcine model which may be helpful in profiling livers damaged by WI (Op den Dries 2013). After 60 minutes WI and 5 hours CS, Schlegel et al. found that the effects of 1 hour of hypothermic oxygenated portal perfusion on NAD^+, CO_2, Cytochrome C, AST, HMGB1, histology, TNFα resulted in decreased cytochrome C, HMGB1, AST and better histology with reduced Kupffer cell activiation (decreased TNFα). This study also compared low perfusion pressures to high perfusion pressures, showing that low pressure perfusion (3 mm Hg) was superior to high (8 mm Hg) (Schlegel 2013). Liu et al. studied pH, AST, L-fatty acid binding protein (L-FABP), ATP and redox-activated iron after 0−120 minutes WI and no CS, attempting to create a damage index predictive of ischemia reperfusion injury. AST level and pH in the perfusate proved the most valuable predictors studied (Liu 2014).

Shifting attention to potential *ex-vivo* assessment, a recent review by Verhoeven et al. showed that bile production during NMP correlated well with early graft survival, as did bilirubin and phospholipid concentration, which are increased by NMP (Verhoeven 2014). Impaired secretion of phospholipids after CS may result in a high bile salt/phospholipid ratio

known to be toxic to cholangiocytes and associated with the development of ITBL. Hepatocyte injury is generally measured by release of AST, ALT, and LDH into the perfusate, and is correlated with both warm ischemia time and poorer survival post transplantation. Traditionally, energy status is recorded by ATP levels, hyaluronic acid and thrombomodulin have become established markers for endothelial injury. Inflammatory markers such as TNF-α levels are shown to correlate positively on histology with Kupffer cell activation. Peribiliary epithelial and vascular injury is represented by arteriolosclerosis and changes in the luminal size of the portal vein branch, but these changes were only present after reperfusion. Lastly, a particular profile of miRNA in the bile is associated with later development of ischemic type biliary injury (Khorsandi 2015).

Future of Clinical Liver Machine Perfusion

Nearly a century of experimental *ex-vivo* machine perfusion of livers has left modern medical science in much the same place it started: What is the clinical role for *ex vivo* liver perfusion and how can it best be implemented? Recent breakthroughs finally may show what clinical liver machine perfusion may look like. Simple cold storage in UW Solution has become the gold standard worldwide such that any proposed perfusion must accept some period of interim cold storage prior to perfusion and that the perfusion must add some benefit beyond simple cold storage. At one point, the goal was to increase the length of the organ's viability as compared to cold storage, but with modern transportation and the organ donation system, machine perfusion has not been rigorously shown to be effective in this regard. Modern goals of machine perfusion look towards restoring organ damage, for example extending donor criteria by alleviating damaging effects of warm ischemia in DCD livers. Additionally, modern perfusion systems look to test viability and predict dysfunction of donated livers prior to transplantation. Reviewing the successes and pitfalls of various machine perfusion techniques can show us where the greatest successes have been and where future studies should focus their energies.

As early as 1970, Belzer et al. showed the promise of NMP in maintaining livers *ex-vivo* by showing equivalent outcomes after 8−10 hours NMP as compared to immediate transplantation. Schon et al. showed that 4 hours of NMP could reverse histology, bile production, alpha GST and AST levels after WI injury, and prevent the PNF seen within 24 hours of non-perfused livers (Schon 2001). However, many of these studies included no CS time. Brockmann et al. also showed improved survival with 5 or 20 hours of NMP, particularly in organs that had been severely ischemic (after 40 minutes of WI injury) (Brockmann 2009).

Of the porcine liver hypothermic machine preservation (HMP) studies, results have shown promising resuscitation of WI damaged livers, but the aspect of reperfusion injury remains largely untested. Obara et al. showed promise with the HA normalized pressure recovery to baseline with 2−3 hours of HMP. Li et al. were only able to show slightly delayed morphologic change, apoptosis and release of AST/ALT with cold storage as compared to CS (Li 2015). De Rougemont et al. showed HMP increased glutathione stores and arterial pressure and HMP liver recipients survived whereas CS recipients did not (de Rougemont 2009).

In trials of transplantation after HMP, no benefit is seen as compared to cold storage (Guarrera 2004) except in the resuscitation of unsalvageable livers after 60 min warm ischemia (de Rougemont 2009) where transplants were viable only after HMP, and had improved GSH stores and arterial pressure. Many pig liver transplant studies showed survival rates after WI and HMP as low as 33% (Vekemans 2009) and 20% (Fondevila 2011), speaking both to the technical difficulty of the porcine transplantation model and the livers sensitivity to warm ischemia. Most promising were livers with only 30 min warm ischemia for which HMP improved survival from 0% in CS to 75% in HMP with lower AST and LDH (Shigeta 2012). While histologically and biochemically HMP-treated porcine livers were better preserved as compared to CS, the liver viability is still less than excellent in these preclinical trials.

The clearest side by side demonstration of the effects of NMP, HMP, and rewarming machine perfusion (RMP) comes from a study by Shigeta et al. who studied porcine livers after 60 min WI and 2 hours CS and compared n = 3 orthotopic liver transplantations after 2 hours of either NMP, HMP, or RMP. In 24 hours, the study found that all NMP and HMP livers suffered PNF with 0% survival, with 75% survival and improved histology in the RMP group (Shigeta 2013). Others have been able to show 100% survival after no warm ischemia and preservation at 21°C RMP with total alleviation of post reperfusion syndrome, lower AST/ALT and less centrilobular necrosis. RMP transplants were perfused in UW gluconate solution with added branched chain amino acids, with the SNP livers perfused using cell-free bovine-derived hemoglobin with hetastarch colloid (Fontes 2015).

The porcine model has provided a stepping stone and a wealth of iterative learning about *ex-vivo* liver machine perfusion preservation. With physiological, anatomical and immunological properties similar to humans, porcine livers have allowed the modeling of warm ischemia and ischemia reperfusion injury as well as establishing markers predictive of post-transplantation outcomes. With SNP and RMP, studies are showing clinically applicable methodology which is improving post-transplantation outcomes with modeled extended criteria donors. The potentials of SNP and RMP perfusions are clear to see, as more and more researchers are publishing results preferring these temperature settings. It has not been fully defined how slowly livers should be rewarmed, the critical temperature the liver must reach, and the length of warm perfusion needed to maximize metabolic parameters. Finally, researchers are producing clinically viable solutions to extending liver donation criteria to include DCD livers. Future studies should focus on essential requirements for limits of recoverable warm ischemic time, limits for length of CS prior to perfusion, in addition to perfusion settings, and upon ideal perfusion time to maximize liver viability. Additionally, studies which follow porcine perfusion transplantation models for three to six month would expand our understanding of the development of ischemic cholangiopathy and consequent biliary stenosis, and potentially protective role of machine perfusions. Before clinical implementation of machine perfusion preservation, *ex-vivo* markers which reliably predict major transplantation outcomes, such as primary non-function and early allograft dysfunction, must be established.

Lastly, we turn our attention towards machine preservation which has been implemented in human trials. Implementation of HMP after a period of CS for ECD human livers was shown to improve ATP stores and result in increased bile, bilirubin and bicarbonate production, but was not able to reduce hepatobiliary injury as measured by AST, ALT, LDH and gamma-glutamyl transferase as tested with NMP simulated transplantation (Westerkamp

2016). However, in a matched graft study of two European hospitals, DCD livers treated with oxygenated HMP prior to transplantation had reduced ALT, cholangiopathy, biliary complications and improved 1-year graft survival compared to SCS-treated DCD grafts, and decreased necessity of retransplantation (18% SCS to 0% HMP) (Dutowski 2015). The first ECD human liver was transplanted after resuscitation with NMP in 2015 (Perera 2016) with subsequent studies summarizing their results (Mergental 2016). Recently, a single-center study in Canada showed the feasibility of ten human DCD livers treated with NMP for a mean of 11.5 hours prior to transplantation, with a small decrease in six-month graft survival in NMP-treated livers (80%) versus SCS livers (100%), demonstrating the technical difficulty of implementing liver NMP clinically (Bral 2016). Additionally, the superiority of COR and SNMP in porcine livers sparked the first successful application of COR in liver transplantation (Hoyer 2016). Rewarming therapies, the newest methodology in machine preservation, may become the ultimate compromise with their ability to capture advantages of relative convenience as compared to NMP, longevity of storage comparable to HMP or SCS, optimal resuscitation in predictive animal models, and *ex-vivo* assessment prior to transplantation. After nearly 60 years of experimental liver machine perfusion, we may soon see its role develop in clinical medicine. Now that trials are honing in on the particulars of a protocol for superior liver machine preservation, trials need to be thorough about reporting their perfusion results to allow for comparison and pooled analysis among clinical trials (Karangwa 2016).

Heart Machine Preservation

As with the liver, technical difficulty in cannulation and determination of perfusion settings has limited clinical applicability of machine perfusion. However, the heart is unique in that current preservation techniques and transplantation guidelines severely limit the number of usable grafts which can be matched with a recipient. Nearly 50% of discarded heart donations could have been used if a suitable recipient was available within the time constraints of modern heart transplantation (DiMaio 2013). Additionally, DCD heart donations are critically limited due to the unavoidable period of warm ischemia. HMP has produced encouraging results in porcine hearts subjected to warm ischemia, increasing energy stores, decreasing lactate levels and increasing contractility as compared to CS in simulated transplantation (Van Caenegem 2016). HMP has the capability to better preserve ultrastructure compared to CS as seen by electron microscopy with decreased muscle fiber and endothelial cell damage and less apoptosis (assessed by TUNEL) as compared to cold storage (Michel 2015). Most perfusion attempts have focused on perfusion via the aorta, which is limited by aortic valve incompetence. One recent study showed promising results of canine hearts treated with hypothermic retrograde perfusion via the coronary sinus, allowing for 14 hour preservation, increased pre-load recruitable stroke work and decreased creatinine kinase release as compared to SCS hearts, but unfortunately showing no differences in histological assessment of cell death (TUNEL) (Brant 2016.) Retrograde perfusion raises concerns over inferior right ventricle (RV) perfusion, and canine hearts did show decreased RV perfusion, with no RV dysfunction noted upon transplantation. The same retrograde system as applied to human hearts showed preservation of oxidative metabolism and low lactate-to-alanine ratios, suggesting superior RV tissue protection (Cobert 2014). Another

concern with regards to machine perfusion of the heart in general is the resultant interstitial edema which results in graft weight increase prior to transplantation, but this edema has not been clearly proven to diminish graft function (Brant 2016).

Normothermic perfusion has also been trialed in heart resuscitation prior to transplantation, as a reconditioning method following cold storage and prior to transplantation. As found in the liver, NMP more closely mimics human physiology resulting in superior *ex-vivo* assessment of organ functionality. Phase I Trials of the prospective multicenter European Trial to evaluate the safety and performance of the Organ Care System for heart transplants (PROTECT) and effectiveness evaluation (PROCEED) both showed promising results for heart NMP with whole blood perfusate, with 100% and 93% survival at 30 days, comparable to CS (McCurry 2008). It has since been found that functional parameters such as stroke work, ejection fraction and ventricular relaxation measured during NMP better predict myocardial performance as compared to metabolic parameters (White 2015). One study found rat hearts subjected to WI and CS time had improved contractility after normothermic reconditioning (Tolboom 2015). The same group recently compared normothermic resuscitation to subnormothermic (SNMP) at 20ºC with superior preservation in the SNMP group with decreased troponin-t levels and higher ATP stores (Tolboom 2016). As has been found in liver perfusion, there may be a role for SNMP or rewarming perfusion as a compromise between the longevity benefits of hypothermic perfusion and the resuscitation and assessment capabilities of normothermic perfusion. As researchers learn more about heart machine preservation, many hope that clinical implementation of machine perfusion will increase the quality of DCD and ECD grafts and enable distant procurement for dramatic increase of the heart donor pool.

Lung Machine Preservation

As with DCD hearts, DCD lungs are fragile and often critically damaged by warm ischemia. Indeed, 80% of potential brain death donor lungs are injured in the intensive care unit and deemed unusable for transplantation (Cypel 2009.) Therefore, machine perfusion capable of reconditioning and repairing damaged grafts possesses the potential to drastically increase the donor pool. Lung machine preservation is unique among organ machine perfusion in that evaluation of high-risk graft function is a necessity rather than an improvement, and machine perfusion could additionally be used to treat and repair lung grafts. Preclinical trials have thus far focused on hyperoncotic perfusates to intentionally draw fluid from the intravascular space to decrease lung edema. A few early trials showed promising results with HMP. HMP was used as a delivery system for oxygen free radical scavengers in canine heart-lungs with improved histology and lower resulting creatinine phosphokinase in the treated heart-lungs (Hajjar 1986). HMP was also shown to ameliorate IRI in rat lungs subjected to WI, with replenished energy stores, decreased vascular resistance, increase pulmonary compliance and improved pulmonary oxygenation (Nakajima 2011). The same group showed similar promising results in canine hearts with 2 hour HMP (Steen perfusate) following WI and 12 hour SCS time with elimination of microthrombi histologically, improved energy stores and improved physiologic lung functions (Nakajima 2012).

Although only a small number of medical centers have begun to use lung machine preservation, early results show benefit in conditioning and resuscitation of lung grafts thought to be unsuitable for transplantation. In a study aimed to assess clinical feasibility, high risk lungs were treated with 4 hours of normothermic perfusion and then 20 of 23 high-risk lungs were transplanted, with no difference between these high risk grafts and regular lung grafts transplanted in the same time period (Cypel 2011). NMP was therefore useful in restoration of high risk graft function and a useful tool in the elimination of truly unsuitable grafts. Additionally, lung NMP has been found an effective delivery system for antibiotics and gene therapies to better optimize the fragile grafts for transplantation (Nakajima 2016). One anti-inflammatory cytokine, IL-10 was upregulated by an adenoviral vector delivered through 12 hours of NMP in discarded lung grafts, which resulted in superior arterial oxygen pressure and decreased pulmonary vascular resistance, suggestive of successful lung injury repair (Cypel 2009). Still in its early days, there is a long and promising road ahead for lung machine preservation, reconditioning, and therapeutics.

Pancreatic Machine Preservation

As in the organs mentioned previously, machine perfusion of the pancreas holds promise for decreasing IRI and expanding the donor pool through superior resuscitation of DCD and ECD organs. Historically, HMP of the pancreas has been shown to extend storage times to 24 to 48 hours as compared to SCS (Tersigni 1975). However, machine perfusion of the pancreas, particularly at normal to high pressures, has been associated with edema, congestion and ultimately early venous thrombosis and graft failure, due to the delicacy of the pancreatic vessels (Wright 1990; Karcz 2010). Further research delineated that tight control over arterial pressure in the range of 15−30 mm Hg with UW eliminated endothelial damage and improved graft function (Florack 1983). Difficulty with determining proper settings for pancreatic machine perfusion has been due to research optimizing the wrong endpoints: islet cell yield instead of whole-organ preservation (Barlow 2013). For example, high pressure perfusion resulting in endothelial damage and tissue edema actually improves islet cell yield (Taylor 2010), without improving transplantation outcomes. In addition to sensitivity to perfusion settings, pancreatic perfusion also faces a question of arterial cannulation: splenic or superior mesenteric separately or together.

Recently, pancreatic perfusions preservation has shifted interest from HMP to NMP due to promise in more thorough resuscitation of energy stores, warm ischemic damage, and pancreatic function prior to transplantation. Pancreatic NMP models began as early as 1926 by Babkin and Starling to assess exocrine and endocrine responses (Babkin 1926), and then later as a research model for transplantation following HMP preservation (Pegg 1982). Recent efforts have focused on NMP as a concept for preservation of DCD and ECD livers. However, despite potential benefits of pancreatic MP, the pancreas has proved to be a difficult organ to machine perfuse. Some researchers have attempted *ex vivo* co-perfusion of kidney and pancreas with the kidney functioning as a dialysis organ, hoping for tighter pH control and decreased pancreatic damage, but with limited success (Kuan 2016). The pancreas is particularly susceptible to ischemic damage, both increasing the necessity and relevance of an optimal preservation of DCD livers, but increasing the complexity and physiologic requirements of an *ex-vivo* perfusion system. Insulin production and vascular resistance

during NMP have both been shown to correlate well to pancreatic injury. While there are no current clinical applications, and relatively few animal studies in pancreatic machine perfusion, the technical limitations will likely be overcome in the future in order to expand the number of usable pancreatic allografts.

CONFLICT OF INTEREST

The authors of this chapter have no conflicts of interest to disclose.

REFERENCES

Babkin BP, Starling EH. A method for the study of the perfused pancreas. *J. Physiol.* 1926; 61: 245.

Bagul A, Hosgood SA, Kaushik M, Kay MD, Waller HL, Nicholson ML. Experimental renal preservation by normothermic resuscitation perfusion with autologous blood. *Br. J. Surg.* 2008; 95(1): 111–118.

Banan B, Xiao Z, Watson R, Xu M, Jia J, Upadhya GA, Mohanakumar T, Lin Y, Chapman W. Novel strategy to decrease reperfusion injuries and improve function of cold-preserved livers using normothermic *ex vivo* liver perfusion machine. *Liver Transpl.* 2016;22(3):333–343.

Barlow AD, Hosgood SA, Nicholson ML. Current state of pancreas preservation and implications for DCD pancreas transplantation. *Transplantation* 2013; 95(12):1419–1424.

Belzer FO & Southard JH. The future of kidney preservation. *Transplantation* 1980; 30(3):161–165.

Belzer FO, Ashby BS & Dunphy JE. 24-hour and 72-hour preservation of canine kidneys. *Lancet* 1967; 2(7515):536–538.

Bessems M, Doorschodt BM, Dinant S, de Graaf W, van Gulik TM. Machine perfusion preservation of the pig liver using a new preservation solution, polysol. *Transplant Proc.* 2006;38(5):1238–1242.

Boehnert MU, Yeung JC, Bazerbachi F, Knaak JM, Selzner N, McGilvray ID, Rotstein OD, Adeyi OA, Kandel SM, Rogalla P, Yip PM, Levy GA, Keshavjee S, Grant DR, Selzner M. Normothermic acellular *ex vivo* liver perfusion reduces liver and bile duct injury of pig livers retrieved after cardiac death. *Am. J. Transplant.* 2013;13(6):1441–1449.

Bral M, Gala-Lopez B, Bigam D, Kneteman N, Malcom A, Livingstone S, Andres A, Emamaullee J, Russell L, Coussios C, West LJ, Friend PJ, Shapiro AMJ. Preliminary Single Centre Canadian Experience of Human Normothermic *Ex Vivo* Liver Perfusion: Results of a Clinical Trial. *Am. J. Transplant.* 2016; 17(4):1071–1080.

Brant S, Holmes C, Cobert M, Powell L, Shelton J, Jessen M, Peltz M. Successful transplantation in canines after long-term coronary sinus machine perfusion preservation of donor hearts. *J. Heart Lung Transplant.* 2016;35(8):1031–1036.

Brasile L, Delvecchio P, Amyot K, Haisch, Clarke J. Organ preservation without extreme hypothermia using an Oxygen supplemented perfusate. *ABB.* 1994;22(4):1463–1468.

Brockmann J, Reddy S, Coussios C, Pigott D, Guirriero D, Hughes D, Morovat A, Debabrata R, Winter L, Friend PJ. Normothermic perfusion: a new paradigm for organ preservation. *Ann. Surg.* 2009;250(1):1–6.

Brüggenwirth IMA, Burlage LC, Porte RJ, Martins PN. Is single portal vein perfusion the best approach for machine preservation of liver grafts? *J. Hepatol.* 2016;64(5):1194–1195.

Buchs J, Lazeyras F, Ruttimann R, Nastasi A, Morel P. Oxygenated hypothermic pulsatile perfusion versus cold static storage for kidneys from non heart-beating donors tested by in-line ATP resynthesis to establish a strategy of preservation. *Perfusion* 2011;26(2):159–165.

Butler AJ, Rees MA, Wight DG, Casey ND, Alexander G, White DJ,Friend PJ. Successful extracorporeal porcine liver perfusion for 72 hr. *Transplantation* 2002; 73(8):1212–1218.

Catena F, Coccolini F, Montori G, Vallicelli C, Amaduzzi A, Ercolani G, Ravaioli M, Gaudio MD, Schiavina R, Brunocilla E, Liviano G, Feliciangeli G, Pinna AD. Kidney preservation: review of present and future perspective. *Transplant Proc*. 2013;45(9): 3170–3177.

Cobert ML, Merritt ME, West LSM, Ayers C, Jessen ME, Peltz M. Metabolic characteristics of human hearts preserved for 12 hours by static storage, antegrade perfusion, or retrograde coronary sinus perfusion. *J. Thorac. Cardiovasc.* 2014;148(15): 2310–2315.

Codas, R. Petruzzo P, Morelon A, Lefrancois N, Danjou F, Berthillot C, Contu P, Espa M, Martin X, Badet L. IGL-1 solution in kidney transplantation: first multi-center study. *Clin. Transplant*. 2009;23(3):337–342.

Compagnon P, Clément B, Campion JP, Boudjema K. Effects of hypothermic machine perfusion on rat liver function depending on the route of perfusion. *Transplantation* 2001;72(4):606-614.

Cypel M, Liu M, Rubacha M, Yeung J, Hirayama S, Ankaru M, Sato M, Medin J, Davidson B, Perrot M, Waddell T, Slutsky A, Keshavjee S. Functional repair of human donor lungs by IL-10 gene therapy. *Sci. Transl. Med.* 2009;1(4):4ra9.

Cypel M, Yeung JC, Liu M, Anraku M, Chen A, Karolak W, Sato M, Laratta J, Azad S, Madonik M, Chow CW, Chaparro C, Hutcheon M, Singer LG, Slutsky AS, Yasufuku K, Perrot M, Pierre AF, Waddell TK, Keshavjee S. Normothermic *ex vivo* lung perfusion in clinical lung transplantation. *N. Engl. J. Med.* 2011;364(15):1431–1440.

de Rougemont O, Breitenstein S, Leskosek B, Weber A, Graf R, Clavien PA, Dutowski P. One hour hypothermic oxygenated perfusion (HOPE) protects nonviable liver allografts donated after cardiac death. *Ann. Surg.* 2009;250(5):674–683.

DiMaio JM, Morse M, Teeter WA, Cobert ML, West LM, Jessen ME, Peltz M. Donor hearts not offered or rejected for transplantation—a lost opportunity? *J. Heart Lung Transplant*. 2013;3: S156.

Dutkowski P, Polak WG, Muiesan P, Schlegel A, Verhoeven C, Scalera I, DeOliveira M, Kron P, Clavien PA. First Comparison of Hypothermic Oxygenated Perfusion Versus Static Cold Storage of Human Donation After Cardiac Death Liver Transplants: An International-matched Case Analysis. *Ann. Surg.* 2015;262(5):764–771.

Dutkowski P, de Rougemont O, Clavien PA. Alexis Carrel: genius, innovator and ideologist. *Am. J. Transplant*. 2008; 8(10):1998–2003.

Florack G, Sutherland DE, Heil J, Squifflet JP, Najarian JS. Preservation of canine segmental pancreatic autografts: cold storage versus pulsatile machine perfusion. *J. Surg. Res*. 1983;34(5):493–504.

Foley DP, Ricciardi R, Traylor AN, McLaughlin TJ, Donohue SE, Wheeler SM, Meyers WC, Quarfordt SH. Effect of hepatic artery flow on bile secretory function after cold ischemia. *Am. J. Transplant.* 2003;3(2):148–155.

Foley DP, Vittimberga FJ, Quarfordt SH, Donohue SE, Traylor AN, MacPhee J, McLaughlin T, Ricciardi R, Callery MP, Meyers WC. Biliary secretion of extracorporeal porcine livers with single and dual vessel perfusion. *Transplantation* 1999;68(3):362–368.

Fondevila C, Hessheimer AJ, Maathuis M-HJ, Munoz J, Taura P, Calatayud D, Leuvenik H, Rimola A, Ploeg RJ, Garcia-Valdecasas JC. Superior preservation of DCD livers with continuous normothermic perfusion. *Ann. Surg.* 2011;254(6):1000–1007.

Fontes P, Lopez R, van der Plaats A, Vodovotz Y, Minervini M, Scott V, Soltys K, Shiva S, Paranjpe S, Sadowsky D, Barclay D, Zamora R, Stolz D, Demetris A, Michalopoulos G, Marsh JW. Liver preservation with machine perfusion and a newly developed cell-free oxygen carrier solution under subnormothermic conditions. *Am. J. Transplant.* 2015;15(2):381–394.

Furukori M, Matsuno N, Meng LT, Shonaka T, Nishikawa Y, Imai K, Obara H, Furukawa H. Subnormothermic Machine Perfusion Preservation With Rewarming for Donation After Cardiac Death Liver Grafts in Pigs. *Transplant Proc.* 2016;48(4):1239–1243.

Gage F, Leeser DB, Porterfield NK, Graybill JC, Gillern JS, Hawksworth JS, Kindal RM, Thai N, Falta EM, Tadaki DK, Brown TS, Elster EA. Room temperature pulsatile perfusion of renal allografts with Lifor compared with hypothermic machine pump solution. *Transplant proc.* 2009;41(9):3571–3574.

Gringeri E, Bonsignore P, Bassi D, D'Amico FE, Mescoli C, Polacco M, Buggio M, Luisetto R, Boetto R, Noaro G, Ferrigno A, Boncompagni E, Freitas I, Vairetti MP, Carraro A, Neri D, Cillo U. Subnormothermic machine perfusion for non-heart-beating donor liver grafts preservation in a Swine model: a new strategy to increase the donor pool? *Transplant Proc.* 2012;44(7):2026–2028.

Guarrera JV, Estevez J, Boykin J, Boyce R, Rashid J, Sun S, Arrington B. Hypothermic machine perfusion of liver grafts for transplantation: technical development in human discard and miniature swine models. *Transplant Proc.* 2004:37(1):323–325.

Guarrera JV, Henry SD, Samstein B, Odeh-Ramadan R, Kinkhabwala M, Goldstein MJ, Ratner LE, Renz JF, Lee HT, Brown RS Jr., Emond JC. Hypothermic machine preservation in human liver transplantation: the first clinical series. *Am. J. Transplant.* 2010;10(2):372–381.

Hagiwara M, Matsuno N, Meng LT, Furukori M, Watanabe K, Shonaka T, Imai K, Obara H, Nishikawa Y, Furukawa H. Applicability of Combined Use of Extracorporeal Support and Temperature-Controlled Machine Perfusion Preservation for Liver Procurement of Donors After Cardiac Death in Pigs. *Transplant Proc.* 2016;48(4):1234–1238.

Hajjar G, Toledo-Pereyra LH, Mackenzie GH. Effect of 24-hour preservation with oxygen free radical scavengers on isolated-perfused canine heart-lungs. *P. R. Health Sci. J.* 1986;5(1):19–25.

Hosgood SA & Nicholson ML. First in man renal transplantation after *ex vivo* normothermic perfusion. *Transplantation* 2011;92(7):735–738.

Hosgood SA, Mohamed IH, Bagul A, Nicholson ML. Hypothermic machine perfusion after static cold storage does not improve the preservation condition in an experimental porcine kidney model. *Br. J. Surg.* 2011;98(7): 943–950.

Hosgood SA, Barlow AD, Hunter JP, Nicholson ML. *Ex vivo* normothermic perfusion for quality assessment of marginal donor kidney transplants. *Br. J. Surg.* 2015;102(11): 1433–1440.

Hosgood SA, Saeb-Parsy K, Hamed MO, Nicholson ML. Successful Transplantation of Human Kidneys Deemed Untransplantable but Resuscitated by *Ex Vivo* Normothermic Machine Perfusion. *Am. J. Transplant.* 2016;16(11):3282–3285

Hosgood SA, Patel M. & Nicholson ML. The conditioning effect of *ex vivo* normothermic perfusion in an experimental kidney model. *J. Surg. Res*. 2013;182(1):153–160.

Hoyer DP, Paul A, Luer S, Reis H, Efferz P, Minor T. End-ischemic reconditioning of liver allografts: Controlling the rewarming. *Liver Transpl.* 2016;22(9):1223–1230.

Hoyer DP, Mathe Z, Gallinat A, Canbay A, Treckmann J, Rauen U, Paul A, Minor T. Controlled Oxygenated Rewarming of Cold Stored Livers Prior to Transplantation: First Clinical Application of a New Concept. *Transplantation* 2016;100(1):147–152.

Hoyer DP, Gallinat A, Swoboda S, Wohlschläger J, Rauen U, Paul A, Minor T. Subnormothermic machine perfusion for preservation of porcine kidneys in a donation after circulatory death model. *Transpl. Int.* 2014;27(10):1097–106.

Humphreys MR, Ereth MH, Sebo TJ, Slezak JM, Dong Y, Blute ML, Gettman MT. Can the kidney function as a lung? Systemic oxygenation and renal preservation during retrograde perfusion of the ischaemic kidney in rabbits. *BJU Int*. 2006;98(3):674–679.

Imber CJ, St Peter SD, Lopez de Cenarruzabeitia I, Pigott D, James T, Taylor R McGuire J, Hughes D, Butler A, Rees M, Friend PJ. Advantages of normothermic perfusion over cold storage in liver preservation. *Transplantation* 2002; 73:701– 709.

Izamis ML, Efstathiades A, Keravnou C, Georgiadou S, Martins PN, Averkiou MA. Effects of Air Embolism Size and Location on Porcine Hepatic Microcirculation in Machine Perfusion. *Liver Transplant.* 2014;20:601– 611.

Jain S, Lee CY, Baicu S, Duncan H, Jones JW Jr., Clemens MG, Brassil J, Taylor MJ, Brockbank KGM. Hepatic function in hypothermically stored porcine livers: comparison of hypothermic machine perfusion vs cold storage. *Transplant Proc.* 2004;37(1):340–341.

Jassem W & Heaton ND. The role of mitochondria in ischemia/reperfusion injury in organ transplantation. *Kidney Int*. 2004;66(2):514–7.

Jay CL, Lyuksemburg V, Ladner DP, Wang E, Caicedo J, Holl JL, Abecassis MM, Skaro AI. Ischemic cholangiopathy after controlled donation after cardiac death liver transplantation: a meta-analysis. *Ann. Surg*. 2011; 253(2):259– 264.

Jochmans I, Moers C, Smits J, Leuvenik HGD, Treckmann J, Paul A, Rahmel A, Squifflet J-P, van Heurn E, Monbaliu D, Ploeg RJ, Pirenne J. Machine perfusion versus cold storage for the preservation of kidneys donated after cardiac death: a multicenter, randomized, controlled trial. *Ann. Surg*. 2010;252(5):756–64.

Jochmans I, O'Callaghan JM, Pirenne J, Ploeg RJ. Hypothermic machine perfusion of kidneys retrieved from standard and high-risk donors. *Transplant Int*. 2015;28(6):665–676.

Jochmans I, Akhtar MZ, Nasralla D, Kocabayoglu P, Boffa C, Kaisar M, Brat A, O'Callaghan J, Pengel LHM, Knight S, Ploeg RJ. Past, present and future of dynamic

kidney and liver preservation and resuscitation. *Am. J. Transplant.* 2016;16(9)2545–2555.

Karangwa SA, Dutkowski P, Fontes P, Friend PJ, Guarrera JV, Markmann JF, Mergental H, Minot T, Quintini C, Selzner M, Uygun K, Watson CJ, Porte RJ. Machine Perfusion of Donor Livers for Transplantation: A Proposal for Standardized Nomenclature and Reporting Guidelines. *Am. J. Transplant*. 2016; 16(10)2932–2942.

Karcz M, Cook HT, Sibbons P, Gray C, Dorling A, Papalois V. An ex-vivo model for hypothermic pulsatile perfusion of porcine pancreata: hemodynamic and morphologic characteristics. *Exp. Clin. Transplant*. 2010;8(1):55– 60.

Kaths JM, Echeverri J, Goldaracena N, Louis KS, Chun Y-M, Linares I, Weibe A, Foltys DB, Yip PM, John R, Mucsi I, Ghaneker A, Bagli D, Grant DR, Robinson LA, Selzner M. Eight-Hour Continuous Normothermic *Ex Vivo* Kidney Perfusion Is a Safe Preservation Technique for Kidney Transplantation: A New Opportunity for the Storage, Assessment, and Repair of Kidney Grafts. *Transplantation* 2016;100(9):1862–1870.

Kay MD, Hosgood SA, Bagul A, Nicholson ML. Comparison of preservation solutions in an experimental model of organ cooling in kidney transplantation. *Br. J. Surg.* 2009;96(10):1215–21.

Khorsandi SE, Quaglia A, Salehi S, Jassem W, Vilca-Melendez H, Prachalias A, Srinivasan P, Heaton N. The microRNA Expression Profile in Donation after Cardiac Death (DCD) Livers and Its Ability to Identify Primary Non Function. *PLoS One.* 2015;10(5): e0127073.

Knaak JM, Spetzler VN, Goldaracena N, Louis KS, Selzner N, Selzner M. Technique of subnormothermic *ex vivo* liver perfusion for the storage, assessment, and repair of marginal liver grafts. *J. Vis. Exp.* 2014;(90):e51419.

Kron P, Schlegel A, de Rougemont O, Oberkofler CE, Clavien P-A, Dutowski P. Short, Cool, and Well Oxygenated - HOPE for Kidney Transplantation in a Rodent Model. *Ann. Surg*. 2016;264(5):815– 822.

Kuan KG, Wee MN, Chung WY Kumar R, Torge Mees S, Dennison A, Maddern G, Markus T. A Study of Normothermic Hemoperfusion of the Porcine Pancreas and Kidney. *Artif Organs.* 2017;41(5):490–495.

Li P, Liu Y-F, Yang L. Advantages of dual hypothermic oxygenated machine perfusion over simple cold storage in the preservation of liver from porcine donors after cardiac death. *Clin. Transplant.* 2015;29(9):820–828.

Liu Q, Nassar A, Farias K, Buccini L, Baldwin W, Mangino M, Bennett A, O'Rourke C, Okamoto T, Diago Uso T, Fung J, Abu-Elmagd K, Miller C, Quintini C. Sanguineous normothermic machine perfusion improves hemodynamics and biliary epithelial regeneration in donation after cardiac death porcine livers. *Liver Transpl.* 2014;20(8):987–999.

Liu Q, Vekemans K, Iania L, Komuta M, Parkkinen J, Heedfeld V, Wylin T. Assessing warm ischemic injury of pig livers at hypothermic machine perfusion. *J. Surg. Res.* 2014;186(1):379−389.

Mahboub P, Ottens P, Seelen M, Hart NT, Goor HV, Ploeg R, Martins PN, Leuvenink H. Gradual Rewarming with Gradual Increase in Pressure during Machine Perfusion after Cold Static Preservation Reduces Kidney Ischemia Reperfusion Injury. *PloS One.* 2015;10(12):e0143859.

McCurry K, Jeevanandam V, Mihaljevic T, Couper G, Elanwar M, Saleh H, Ardehali A. The 1-year follow-up results of the PROTECT patient population using the organ care system. *J. Heart Lung Transplant.* 2008;27 (2 Supp):S166.

Mergental H, Perera MTPR, Laing RW, Muisan P, Issac JR, Smith A, Stephenson BTF, Cilliers H, Neil DAH, Hubscher. Transplantation SG, Afford SC, Mirza DF. Transplantation of Declined Liver Allografts Following Normothermic Ex-Situ Evaluation. *Am. J. Transplant.* 2016;16(11):3235– 3245

Merion RM, Pelletier SJ, Goodrich N, Englesbe MJ, Delmonico FL. Donation after cardiac death as a strategy to increase deceased donor liver availability. *Ann. Surg*. 2006; 244(4):555– 562.

Michel S, La Muraglia GM II, Madariaga MLL, Titus JS, Selig MK, Farkash EA, Allan JS, Anderson LM, Madsen JC. Twelve-Hour Hypothermic Machine Perfusion for Donor Heart Preservation Leads to Improved Ultrastructural Characteristics Compared to Conventional Cold Storage. *Ann. Transplant.* 2015;20:461– 468.

Minor T, Efferz P, Fox M, Wohlschlaeger J, Lüer B. Controlled oxygenated rewarming of cold stored liver grafts by thermally graduated machine perfusion prior to reperfusion. *Am. J. Transplant.* 2013;13(6):1450–1460.

Moers C, Smits JM, Maathuis M-HJ, Treckmann J, van Gelder F, Napieralski BP, van Kasterop-Kutz M, Homan van der Heide JJ, Squifflet J-P, van Heurn E, Kirste GR, Rahmel A, Leuvenink HGD, Paul A, Pirenne J, Ploeg RJ. Machine perfusion or cold storage in deceased-donor kidney transplantation. *N. Engl. J. Med*. 2009; 360(1):7– 19.

Monbaliu D, Vekemans K, De Vos R, Brassil J, Heedfeld V, Qiang L, D'hollander M, Roskams T, Pirenne J. Hemodynamic, biochemical, and morphological characteristics during preservation of normal porcine livers by hypothermic machine perfusion. *Transplant Proc.* 2007;39(8):2652– 2658.

Monbaliu DR, Debbaut C, Hillewaert WJA, Brassil JM, Laleman WJC, Sainz-Barriga M, Kravitz D, Pirenne J, Segers P. Flow competition between hepatic arterial and portal venous flow during hypothermic machine perfusion preservation of porcine livers. *Int. J. Artif. Organs.* 2012;35(2):119– 131.

Morito N, Obara H, Matsuno N, Enosawa S, Watanabe K, Furukori M, Furukawa H. Regulated Oxygenation of Rewarming Machine Perfusion for Porcine Donation After Cardiac Death Liver Transplantation. *Transplant Proc.* 2016;48(4):1244– 1246.

Mourad MM, Liossis C, Gunson BK, Mergental H, Isaac J, Muisan P, Mirza D, Perera TPR, Bramhall SR. Etiology and management of hepatic artery thrombosis after adult liver transplantation. *Liver Transpl.* 2014;20(6):713– 723.

Nakajima D, Chen F, Okita K, Motoyama H, Hijiya K, Ohsumi A, Sakamoto J, Yamada T, Sato M, Aoyama A, Bando T, Date H. Reconditioning lungs donated after cardiac death using short-term hypothermic machine perfusion. *Transplantation* 2012;94(10):999–1004.

Nakajima D, Chen F, Yamada T, Sakamoto J, Osumi A, Fujinaga T, Shoji T, Hiroaki S, Toru B, Date H. Hypothermic machine perfusion ameliorates ischemia-reperfusion injury in rat lungs from non-heart-beating donors. *Transplantation* 2011;92(8):858–863.

Nakajima D, Cypel M, Bonato R, Muachuca TN, Iskender I, Hashimoto K, Linacre V, Chen M, Coutinho R, Azad S, Martinu T, Waddell TK, Hwang DM, Husain S, Liu M, Keshavjee S. Ex Vivo Perfusion Treatment of Infection in Human Donor Lungs. *Am. J. Transplant.* 2016;16(4):1229–1237.

Nassar A, Liu Q, Farias K, D'Amico G, Tom C, Grady P, Bennett A, Diago Uso T, Eghtesad B, Kelly D, Fung J, Abu-Elmagd K, Miller C, Quintini C. *Ex vivo* normothermic machine perfusion is safe, simple, and reliable: results from a large animal model. *Surg. Innov.* 2015;22(1):61– 69.

Nassar A, Liu Q, Farias K, Buccini L, Baldwin W, Bennet A, Mangino M, Irefin S, Cywinski J, Okamoto T, Diago Uso T, Iuppa G, Soliman B, Miller C, Quintini C. Impact of Temperature on Porcine Liver Machine Perfusion From Donors After Cardiac Death. *Artif. Organs.* 2016; 40(10):999–1008.

Nechemia-Arbely Y, Barkan D, Pizov G, Shriki A, Rose-John S, Galun E, Axelrod JH. IL-6/IL-6R axis plays a critical role in acute kidney injury. *J. Am. Soc. Nephrol.* 2008;19(6):1106–1115.

Nishida S, Nakamura N, Kadono J, Komokata T, Sakata R, Madariaga JR, Tzakis AG. Intrahepatic biliary strictures after liver transplantation. *J. Hepatobiliary Pancreat. Surg.* 2006;13(6):511– 516.

Obara H, Matsuno N, Enosawa S, Shigeta T, Huai-Che H, Hirano T, Muto M, Kasahara M, Uemoto S, Mizunuma H. Pretransplant screening and evaluation of liver graft viability using machine perfusion preservation in porcine transplantation. *Transplant Proc.* 2012;44(4):959– 961.

Obara H, Matsuno N, Shigeta T, Hirano T, Enosawa S, Mizunuma H. Temperature controlled machine perfusion system for liver. *Transplant Proc.* 2013;45(5):1690–1692.

Olschewski P, GaB P, Ariyakhagorn V, Jasse K, Hunold G, Mensel M, Schoning W, Schmitz V, Neuhaus P, Puhl G. The influence of storage temperature during machine perfusion on preservation quality of marginal donor livers. *Cryobiology*. 2010;60(3):337–343.

Op den Dries S, Sutton ME, Karimian N, de Boer MT, Wiersema-Buist J, Gouw ASH, Leuvenink HGD, Lisman T, Porte RJ. Hypothermic oxygenated machine perfusion prevents arteriolonecrosis of the peribiliary plexus in pig livers donated after circulatory death. *PLoS One.* 2014;9(2):e88521.

Pegg DE, Klempnauer J, Diaper MP, Taylor MJ. Assessment of hypothermic preservation of the pancreas in the rat by a normothermic perfusion assay. *J. Surg. Res.* 1982;33(3): 194–200.

Perera T, Mergental H, Stephenson B, Roll GR, Cilliers H, Liang R, Angelico R, Hubscher S, Neil DA, Reynolds G, Isaac J, Adams DA, Afford S, Mirza DF, Muisan P. First human liver transplantation using a marginal allograft resuscitated by normothermic machine perfusion. *Liver Transpl.* 2016;22(1):120–124.

Ploeg RJ, van Bockel JH, Langendijk PTH, Groenewegen M, van der Woude FJ, Persijn GG, Thorogood J, Hermans J. Effect of preservation solution on results of cadaveric kidney transplantation. *Lancet* 1992;340(8812):129–137.

Rauen U & de Groot H. New insights into the cellular and molecular mechanisms of cold storage injury. *J. Investig. Med.* 2004;52(5):299–309.

Reddy S, Greenwood J, Maniakin N, Bhattacharjya S, Zilvetti M, Brockmann J, James T, Pigott D, Friend PJ. Non heart-beating donor porcine livers: the adverse effect of cooling. *Liver Transpl.* 2005;11:35–38.

Saidi RF. Utilization of expanded criteria donors in liver transplantation. *Int. J. organ Transplant Med.* 2013; 4(2):46–59.

Schlegel A, Rougemont O de, Graf R, Clavien P-A, Dutkowski P. Protective mechanisms of end-ischemic cold machine perfusion in DCD liver grafts. *J Hepatol.* 2013;58(2):278–286.

Schon MR, Kollmar O, Wolf S, Schrem H, Matthes M, Akkoc N, Schnoy NC, Neuhaus P. Liver transplantation after organ preservation with normothermic extracorporeal perfusion. *Ann. Surg.* 2001; 233:114–123.

Schopp I, Reissberg E, Luer B, Efferz P, Minor T. Controlled Rewarming after Hypothermia: Adding a New Principle to Renal Preservation. *Clini. Transl. Sci.* 2015;8(5):475–478.

Schreinemachers MCJM, Doorschodt BM, Florquin S, Idu MM, Tolba RH, van Gulik TM. Improved renal function of warm ischemically damaged kidneys using Polysol. *Transplant proc*. 2009; 41(1):32–35.

Shigeta T, Matsuno N, Obara H, Mizunuma H, Kanazawa H, Tanaka H, Fukuda A, Sakamoto S, Kasahara M, Uemoto S, Enosawa S. Functional recovery of donation after cardiac death liver graft by continuous machine perfusion preservation in pigs. *Transplant Proc.* 2012;44(4):946– 947.

Shigeta T, Matsuno N, Obara H, Kanazawa H, Tanaka H, Fukuda A, Sakamoto S, Kasahara M, Mizunuma H, Enosawa S. Impact of rewarming preservation by continuous machine perfusion: improved post-transplant recovery in pigs. *Transplant Proc*. 2013;45(5):1684–1689.

Slieker JC, Farid WRR, van Eijck CHJ Lange JF, van Bommel J, Metselaar HJ, de Jonge J, Kazemier G. Significant contribution of the portal vein to blood flow through the common bile duct. *Ann. Surg.* 2012;255(3):523–527.

St Peter SD, Imber CJ, Lopez I, Hughes D, Friend PJ. Extended preservation of non-heart-beating donor livers with normothermic machine perfusion. *Br. J. Surg.* 2002;89(5):609–616.

Stegemann J, Hirner A, Rauen U, Minor T. Use of a new modified HTK solution for machine preservation of marginal liver grafts. *J. Surg. Res.* 2010;160(1):155–162.

Stubenitsky BM, Booster M, Brasile L, Araneda D, Haisch C, Kootstra G. Exsanguinous metabolic support perfusion--a new strategy to improve graft function after kidney transplantation. *Transplantation* 2000;70(8):1254–1258.

Taylor MJ, Baicu SC. Current state of hypothermic machine perfusion preservation of organs: The clinical perspective. *Cryobiology* 2010;60(3 Suppl):S20–35.

Tersigni R, Toledo-Pereyra LH, Pinkham J, Najarian JS. Pancreaticoduodenal preservation by hypothermic pulsatile perfusion for twenty-four hours. *Ann. Surg.* 1975;182(6):743–748.

Thiara APS, Hoel TN, Kristiansen F, Karlsen HM, Fiane AE, Svennevig JL. Evaluation of oxygenators and centrifugal pumps for long-term pediatric extracorporeal membrane oxygenation. *Perfusion* 2007;22(5):323–326.

Thuillier R, Dutheil D, Trieu MTN, Mallet V, Allain G, Rousselor M, Denizot M, Goujon J-M, Zal F, Hauet T. Supplementation with a new therapeutic oxygen carrier reduces chronic fibrosis and organ dysfunction in kidney static preservation. *Am. J. Transplant.* 2011;11(9):1845–1860.

Thuillier R, Allain G, Celhay O, Hebrard W, Barrou B, Badet L, Leuvenink HGD, Hauet T. Benefits of active oxygenation during hypothermic machine perfusion of kidneys in a preclinical model of deceased after cardiac death donors. *Journal Surg. Res.* 2013;184(2):1174–1181.

Tolboom H, Makhro A, Rosser BA, Wilhelm MJ, Bogdanova A, Falk V. Recovery of donor hearts after circulatory death with normothermic extracorporeal machine perfusion. *Eur. J. Cardiothorac. Surg*. 2015;47(1):173– 9.

Tolboom H, Olejníčková V, Reser D, Rosser B, Wilhelm MJ, Gassmann M, Bogdanova A, Falk V. Moderate hypothermia during *ex vivo* machine perfusion promotes recovery of hearts donated after cardiocirculatory death. *Eur. J. Cardiothorac Surg.* 2016;49(1):25–31.

Tozzi M, Franchin M, Soldini G, Ietto G, Chiappa C, Maritan E, Villa F, Carcano G, Dionigi R. Impact of static cold storage VS hypothermic machine preservation on ischemic kidney graft: inflammatory cytokines and adhesion molecules as markers of ischemia/reperfusion tissue damage. Our preliminary results. *Int. J. Surg.* 2013;11(Suppl 1):S110–114.

Treckmann J, Moers C, Smits JM, Gallinat A, Maathuis M-HJ, van Kasterop-Kutz M, Jochmans I, Homan van der Heide JJH, Squifflet J-P, van Heurn E, Kirste GR, Rahmel A, Leuvenink HGD, Pirenne J, Ploeg RJ, Paul A. Machine perfusion versus cold storage for preservation of kidneys from expanded criteria donors after brain death. *Transplant Int.* 2011;24(6):548–554.

United Network for Organ Sharing. Available at: http://www. unos.org/. Accessed March 17, 2016.

van Caenegem O, Beauloye C, Bertrand L, Horman S, Lepropre S, Sparavier G, Vercruysse J, Bethuyne N, Poncelet AJ, Gianello P, Demuylder P, Legrand E, Beaurin G, Bontemps F, Jacquet LM, Vanoverschelde J-L. Hypothermic continuous machine perfusion enables preservation of energy charge and functional recovery of heart grafts in an *ex vivo* model of donation following circulatory death. *Eur. J. Cardiothorac Surg.* 2016;49(5):1348–1353.

van der Plaats A, Maathuis MHJ, 't Hart NA, Bellekom AA, Hofker HS, van der Houwen EB, Verkerke GJ, Leuvenink HGD, Verdonck P, Ploeg RJ, Rakhorst G. The Groningen hypothermic liver perfusion pump: functional evaluation of a new machine perfusion system. *Ann. Biomed Eng.* 2006;34(12):1924–1934.

Vekemans K, Liu Q, Brassil J, Komuta M, Pirenne J, Monbaliu D. Influence of flow and addition of oxygen during porcine liver hypothermic machine perfusion. *Transplant Proc.* 2007;39(8):2647– 2651.

Vekemans K, Liu Q, Heedfeld V, Van de Val K, Wylin T, Pirenne J, Monbaliu D. Hypothermic Liver Machine Perfusion With EKPS-1 Solution vs Aqix RS-I Solution: In Vivo Feasibility Study in a Pig Transplantation Model. *Transplant Proc.* 2009;41(2): 617– 621.

Verdonk RC, Buis CI, Porte RJ, Haagsma EB. Biliary complications after liver transplantation: a review. *Scand. J. Gastroenterol Suppl*. 2006; (243):89–101.

Verhoeven CJ, Farid WRR, de Jonge J, Metselaar HJ, Kazemier G, van der Laan LJW. Biomarkers to assess graft quality during conventional and machine preservation in liver transplantation. *J. Hepatol.* 2014;61(3):672– 684.

Watson CJE, Wells AC, Roberts RJ, Akoh JA, Friend PJ, Akyol M, Calder FR, Allen JE, Jones MN, Collet D, Bradley JA. Cold machine perfusion versus static cold storage of kidneys donated after cardiac death: a UK multicenter randomized controlled trial. *Am. J. Tranplant.* 2010;10(9):1991–1999.

Westerkamp AC, Karimian N, Matton APM, Mahboub P, van Rijn R, Wiersema-Buist J, de Boer MT, Leuvenink HGD, Gouw A, Lisman T, Porte RJ. Oxygenated Hypothermic Machine Perfusion After Static Cold Storage Improves Hepatobiliary Function of Extended Criteria Donor Livers. *Transplantation* 2016;100(4):825–835.

White CW, Ambrose E, Müller A, Li Y, Le H, Hiebert B, Arora R, Lee TW, Dixon I, Tian G, Nagendran J, Hryshko L, Freed D. Assessment of donor heart viability during *ex vivo* heart perfusion. *Can J Physiol Pharmacol.* 2015;93(10):893–901.

Wright FH, Wright C, Ames SA, Smith JL, Corry RJ. Pancreatic allograft thrombosis: donor and retrieval factors and early postperfusion graft function. *Transplant Proc*. 1990;22(2):439–441.

Wszola M, Kwiatkowski A, Diuwe P, Domagala P, Gorski L, Kiesek R, Berman A, Perkowska-Ptasinska A, Durlik M, Paczek L, Chmura A. One-year results of a prospective, randomized trial comparing two machine perfusion devices used for kidney preservation. *Transplant Int.* 2013;26(11):1088–1096.

Wszola M, Kwiatkowski A, Domagala P, Wirowska A, Bieniasz M, Diuwe P, Kiesek R, Durlik M, Chmura A. Preservation of kidneys by machine perfusion influences gene expression and may limit ischemia/reperfusion injury. *Prog. Transplant.* 2014;24(1): 19–26.

Xu H, Berendsen T, Kim K, Soto-Gutierrez A, Bertheium F, Yarmush ML, Hertl M. Excorporeal normothermic machine perfusion resuscitates pig DCD livers with extended warm ischemia. *J. Surg. Res.* 2012;173(2):e83–88.

Zhang Y, Fu Z, Zhong Z, Wang R, Hu L, Xiong Y, Wang Y, Ye Q. Hypothermic Machine Perfusion Decreases Renal Cell Apoptosis During Ischemia/Reperfusion Injury via the Ezrin/AKT Pathway. *Artificial organs*. 2016;40(2):129–135.

In: Encyclopedia of Surgery (22 Volume Set)
Editors: Andreas Lehrer and Kristin Mueller
ISBN: 978-1-53618-329-0
© 2020 Nova Science Publishers, Inc.

Chapter 198

MICROCIRCULATION

Norbert Nemeth[1, *] and Andrea Szabo[2]
[1]Department of Operative Techniques and Surgical Research, Faculty of Medicine, University of Debrecen, Debrecen, Hungary
[2]Institute of Surgical Research, Faculty of Medicine, University of Szeged, Szeged, Hungary

SUMMARY

In this chapter, we give a brief overview of the structural and functional aspects of the microcirculation with particular interest in the rheology of microcirculation. A summary of the up-to-date methodology for dynamic observation and quantification of microcirculatory characteristics and hemorheological changes is also given. A special emphasis is put on the applicability of the diverse methodological approaches in different experimental models and human diseases. Finally, we provide highlights of the key findings of vasoregulatory and inflammatory microcirculatory changes as well as rheological alterations seen in local and systemic circulatory disorders in clinically-relevant animal models of human diseases.

Keywords: microcirculatory perfusion, microcirculatory inflammation, hemorheology, methods, key findings

ABBREVIATIONS

CT	computed tomography
DIC	disseminated intravascular coagulation
EC	endothelial cells
EI	elongation index
ESR	erythrocyte sedimentation rate
FCD	functional capillary density

[*] Corresponding Author's Email: nemeth@med.unideb.hu.

Htc	hematocrit
IDF	incident dark field
IVM	intravital microscopy
LORCA	laser-assisted optical rotational cell analyzer
MCHC	mean cell hemoglobin concentration
MCV	mean corpuscular volume
MFI	microvascular flow index
Micro-CT	Micro-computed tomography
MRI	magnetic resonance imaging
NIRS	near-infrared spectroscopy
NO	nitric oxide
OPS	orthogonal polarization spectral imaging
PMNs	polymorphonuclear neutrophil leukocytes
PPV	proportion of perfused vessels
SDF	sidestream dark-field imaging

INTRODUCTION

It is noteworthy that most of the cardinal clinical symptoms and signs of inflammation (redness/*rubor*, swelling/*tumor*, increased heat/*calor*, pain/*dolor*, and loss of function/*functio laesa*) can be linked to changes in microcirculation. Due to recent methodological improvements, assessment of the underlying contributory microcirculatory mechanisms has greatly improved in the last decades. Microcirculatory examinations provide not only excellent diagnostic opportunities, but have also been shown to predict clinical outcome and quantitatively express the therapeutic benefits of experimental and clinical interventions.

Microcirculation research is an extremely broad field in the aspects of physiology, pathophysiology, clinical medicine and methodology. Therefore it is challenging attempt to give a detailed outline of these topics. In this chapter, we aimed to overview briefly the morphological and functional aspects of microcirculation, including micro-rheology and a summary of the up-to-date methodology. We also depict some of the major findings and technical aspects of experimental surgical research.

A BRIEF OVERVIEW OF THE STRUCTURE AND FUNCTION OF MICROCIRCULATION

Structure and Function

The microcirculation represents the highest vascular surface of the cardiovascular system consisting of blood vessels with a diameter of <150 μm. The main function of the microcirculation is to deliver oxygen to the cells and maintain tissue oxygenation. Small arteries can give rise to several arterioles as its diameter decreases toward the periphery. Arterioles have an external muscular coat with circumferentially arranged smooth muscle cells while the terminal (precapillary) arterioles (having an internal diameter of 15 to 20 μm)

are surrounded by only one layer of smooth muscle cells. Arterioles show active changes in diameter, and account for a majority of total vascular resistance, therefore the smallest arterioles play a dominant role in the regulation of blood flow. At the level of vessels with the lowest diameter, parenchymal cell lay in close proximity to the capillaries, so that passive diffusion ensures an efficient supply of oxygen to the tissues. Because of the high permeability of the arteriolar and capillary wall to oxygen, the release of oxygen starts from oxyhemoglobin in the red blood cells, a further passaging across the capillary wall and the interstitium reaching the mitochondria where it is consumed by its reaction with cytochrome c oxidase. As the endothelial barrier is highly permeable to lipid-soluble and small water-soluble molecules, it ensures the exchange of not only gases, but also nutrients and waste products. In certain tissues such as the mesentery, precapillary sphincters (smooth muscle surrounding the entrance of a capillary) regulate the opening state of the capillary network according to the needs of the tissue segment. Capillaries drain into larger vessels, the postcapillary venules which are the most reactive sites of inflammation within the microvasculature and these veins contain intercellular endothelial junctions that allow transvascular protein exchange and trafficking of circulating cells including leukocytes into the interstitium. Indeed, venules represent the major site of leukocyte trafficking (leukocyte–endothelial cell adhesion). Larger venules that are draining the postcapillary venules, also possess smooth muscle in their media layer (Pries 2003; Pries 2008).

Regulatory Mechanisms in the Microvasculature

Arterioles show dramatic active changes in their diameter, and therefore arterioles account for a majority of total vascular resistance (capillaries and venules accounting for less than 25% of vascular resistance), therefore, the smallest arterioles are mostly liable for the regulation of blood flow under resting conditions. During intense vasodilation, however, this role is shifted toward the larger arterioles (Granger 1988).

Intact microcirculation is characterized by a high proportion of perfused capillaries with low level of flow heterogeneity. Open and closed states of the capillaries generally meet the metabolic needs of the surrounding tissues. Modulation of precapillary sphincters is partly under the influence of systemic factors (i.e., sympathetic stimulation, circulating factors and metabolites), being also dynamically regulated by local factors. In general, regional blood flow is regulated by myogenic, metabolic, and neurohumoral mechanisms. Myogenic autoregulation is the intrinsic ability of a blood vessel to constrict or dilate in response to a change in intraluminal pressure which is further modulated by shear stress-induced release of nitric oxide (NO) (Davis 2008; Davis 2012). According to the metabolic theory of autoregulation, local capillary blood flow meets the metabolic needs of the underlying tissue (Granger 1975).

It appears that there is an important interplay between vascular endothelial cells (EC) and smooth muscle cells. For instance during the phenomenon of endothelium-dependent vasodilation, ECs control the tone of adjacent vascular smooth muscle cells through the production and liberation of vasoactive substances (e.g., NO, prostaglandins, endothelin, … etc.) and the tone of the blood vessel wall has certain retroactive effect on the activity of ECs (Granger 2010).

Apart from being a selective barrier to fluids and solutes, EC regulate vasomotor tone and exhibit various anti-inflammatory and anti-thrombogenic properties. Intact EC functions are also secured by the endothelial glycocalyx layer which not only separates blood cells from the EC membrane, but also influences local hematocrit, flow, oxygen transport, and interactions between blood cells and the vessel wall (Reitsma 2007). EC activation can be evoked by a variety of chemical stimuli (e.g., cytokines) and physical/shear stress. ECs also play an active role in mediating an inflammatory response. Likewise, an endothelium-mediated vasodilation occurs in response to hypoxia which is mediated by the release of vasodilating prostaglandins and NO (Jackson 1983; Vallet 1994; Vallet 1998; Vallet 2002; Michiels 1993). Similar vasodilatory response is evoked by the release of metabolites (adenosine, lactate, H^+, and K^+) from the affected tissues (Nakhostine 1993). Neurohumoral modulation depends on vessel size and the distribution of adrenergic receptors within the particular tissue type (Watts 2008). During inflammation, EC activation leads to characteristic alterations in microvascular function (e.g., impaired vasomotor function, thrombus formation, leukocyte adhesion and increased microvascular permeability). During this process, reduction in endothelial glycocalyx thickness and mobilization of endothelium-derived P-selectin from Weibel-Palade bodies occur, causing a rapid initiation of leukocyte rolling, which is followed by a later release of E-selectin (Ley 2007; Langer 2009). These changes contribute to the propagation of the inflammatory response (Aird 2003). A balance between the production of reactive oxygen (superoxide) and nitrogen (NO) species has been implicated in the EC response to inflammation by influencing activating nuclear transcription factors for both pro-inflammatory and anti-inflammatory proteins.

Rheology in Microcirculation

Briefly, the main parameters determining blood viscosity are the plasma viscosity (as the characteristic of suspension fluid), the hematocrit (as the quantity of suspended corpuscle), the red blood cell deformability and aggregation. Main determinants of plasma viscosity are the state of hydration, concentration of large plasma proteins with elongated configuration (especially fibrinogen) and triglyceride level. Hematocrit derives from red blood cell count and mean corpuscular volume (MCV). Factors forming blood cell deformability are absolute cell volume, the surface-volume ratio, cell morphology, intracellular viscosity, cell membrane viscosity and elastic characteristics. Determinants of red blood cell aggregation include composition of plasma as suspension medium macromolecule (mainly fibrinogen concentration), surface features of red blood cells (glycocalyx composition), morphological and mechanical characteristics of the cell and shear rate (Chien 1975; Meiselman 1981; Cokelet 2007a, b; Mohandas 2008; Baskurt 2009; Saldanha 2013).

It is well known that the wall shear rate and the shear stress is the highest in the territory of the microcirculation (Table 1) (McDonald 1974; Lipowsky 1995; Lipowsky 2005; Chandran 2012).

Table 1. Quantitative and morphological data of various vessels types with flow velocity and wall shear rate distribution along the systemic circulatory system (McDonald 1974; Lipowsky 1995; Chandran 2012, Baskurt 2012)

Vessel	Mean diameter [mm]*	Number of vessels*	Mean length [mm]*	Total cross section [cm^2]*	Total volume [mL]*	Percentage of total blood volume [%]*	Mean diameter [mm] #	Mean flow velocity [cm/s] #	Wall shear rate [s^{-1}] #
Aorta	19 – 45	1		2 – 16	60	11	16 – 32	6	150 – 300
Arteries	4	40	150	5	75		0.1 – 6	15 – 50	200 – 2 000
	1.3	500	45	6.6	30				
	0.45	6 000	13.5	9.5	13				
	0.15	110 000	4	19.4	8				
Arterioles	0.05	2.8 x 10^6	1.2	55	7	5	0.04	0.5	1 000
Capillaries	0.008	2.7 x 10^9	0.65	1 357	88		0.005 – 0.01	0.05 – 0.1	400 – 1 600
Venules	0.1	1 x 10^7	1.6	785.4	126		0.02 – 0.1	0.2 – 0.5	800 – 400
Veins	0.28	660 000	4.8	406.4	196	67	0.2 – 10	15 – 20	120 – 320
	0.7	40 000	13.5	154	208				
	1.8	2 100	45	53.4	240				
	4.5	110	150	17.5	263				
Venae cavae	5 – 14	2		0.2 – 1.5	92		20	10.15	40 – 60

* in dogs (Chandran 2012), # estimated values in human (McDonald 1974; Lipowsky 1995; Baskurt 2012)

Blood and Plasma Viscosity

The blood is non-newtonian, thixotrop and viscoelastic fluid. Blood behaves as a non-newtonian fluid, i.e., its viscosity depends on the shear rate, and can be described by typical Casson-type curves. Non-newtonian characteristics of blood are hematocrit and shear rate dependent. At lower shear rate, the blood viscosity increases (thixotropic effect) due to the viscosity elevating effect of red blood cell aggregation. At higher flow velocity (i.e., higher shear rate), the cells disaggregate and elongate in the direction of the flow due to their deformability and elastic features. This makes the blood viscoelastic. The Maxwell-model serving for its characterization includes reversible elastic deformation and movement connected with the viscous energy (Cokelet 2007b; Chandran 2012).

The connection between *blood viscosity and hematocrit* (Htc) shows exponential rather than linear function ($\log\eta = k + k'Htc$, where k and k' are constants characteristic of the blood sample (Cokelet 2007a, b). The hematocrit/viscosity rate presented in the function of the hematocrit shows a connection reminding of a bell-shaped curve, with typical maximum value, which reflects the maximum of oxygen transporting capacity of blood ("optimal" hematocrit), i.e., the most red blood cells possible (the highest hematocrit possible) measured at speed gradient resulting from the lowest viscosity possible (Ernst 1983; Bogar 2005).

Main determining factors of *plasma viscosity* are its water content and the macromolecules with elongated configuration, as the fibrinogen concentration, globulin fractions and triglyceride level are important factors (Harkness 1971; Cokelet 2007b; Kesmarky 2008; Kwaan 2010). It is important to note, that while in several stages of circulation, the apparent viscosity of blood is not constant due to the intravascular interactions and distribution of different shear rate profile and the formed elements, mainly the red blood cells, the intravascular plasma viscosity can be considered constant. So the plasma viscosity maintains shear stress on the endothelium at the cell-poor or sometimes even cell-free zone in the direct vicinity of the ECs (Poiseuille-zone) due to the axial flow profile in vessels with diameter approximately under 300 μm. Moreover, the plasma viscosity provides the shear force in case of the so-called plasma-skimming, when at a certain point and at a certain site, there is no formed element and only plasma in the capillary (Cokelet 2007b; Kesmarky 2008).

Red Blood Cell Deformability

Red blood cell deformability is an ability of passive transformation appearing under the influence of shear stress, and it depends on the absolute volume, surface/volume ratio of the cells, morphological characteristics, viscoelastic properties of the cell membrane and intracellular viscosity (hemoglobin content) (Chien 1975; Meiselman 1981; Cokelet 2007a,b; de Oliveira 2010).

Mature red blood cells of mammals and humans are without nucleus, so the intracellular (cytoplasm) viscosity is mainly determined by the properties of hemoglobin solution. When the mean cell hemoglobin concentration (MCHC) increases above 37 g/dl, the intracellular viscosity increases precipitously, affecting the deformability of the whole cell, and thus also the tissue perfusion and the oxygenation due to impeded passage in the microcirculation. MCHC is regulated within a relatively narrow range (30−35 g/dl), where ATP-dependent Na^+, K^+ transporters participating in the cell volume regulation play the key roles (Chien 1975; Cokelet 2007b; Mohandas 2008; Baskurt 2012a).

Viscoelastic characteristics of red blood cells are complex (Thurston 2007). Viscosity property derives from membrane viscosity and cytoplasm viscosity. The elasticity feature consists of surface expansion, shearing and bending elements (Thurston 2007; Kim 2012). Surface area expansion (or compression) modulus (K) reflects the stored elastic energy, which develops through isotropic surface expansion or shrinkage of the membrane: $T_t = K\ (\Delta A/A_0)$, where T_t is the stress force, ΔA is the surface change, A_0 is the original surface. The shear module (μ) expresses the elastic energy which derives from membrane extension at same surface: $Ts = (\mu(\lambda^2 - \lambda^{-2}))/2$, where Ts is the shear stress, λ is the extension rate. Bending (fluxural) modulus (B) expresses the energy which is required for bending the membrane from one curve into another curve: $M = B\ (C_1 + C_2 - C_0)$, where M is the momentum of bending, C_1 and C_2 are the curves, C_0 is the curve of stress free state (Kim 2012).

Motion of red blood cells can be described in a complex way, depending on the flow conditions; rolling, rotation, swinging, elongation, elastic deformation due to collisions, the combination of all the above, in their hardly modellable complexity. When suspending the cells (such as in plasma) in a low viscosity medium, their motion is similar to that of solids. As the flow rate increases, most of the cells flow along the same path ($C = 0$), where they rotate around their symmetrical axis (perpendicular to the shear level) (Bitbol 1986). If the cells are suspended in a higher viscosity medium over a critical speed-gradient, their behavior

is similar to that of fluid drops. The membrane transmits the momentum towards the cytoplasm, while maintaining the orientation of flow. At low and moderate speed gradient, the biconcave shape of cells remains stable, but at higher values they elongate and gain an ellipsoid shape. Under the effect of pulsatility and in the course of oscillation flow, the inclination angle of the cells is not equal and therefore it becomes chaotic. In smaller veins, especially in the capillaries, the friction has an increased role not only between the cells, but also in the relationship of endothelium and blood cells. The erythrocytes flow in a formation reminding of doughnuts flattened in their middle, where they are the thinnest (Goldsmith 1972; Pries 2003, 2008; Popel 2005; Dupire 2012).

Therefore, the deformability participates to a different extent in the different stages of circulation. Worsening deformability, i.e., the enhanced rigidity of red blood cells, in the mass flow zone of circulation (vessel diameter >300 μm) may lead to elevated blood viscosity. Red blood cells with reduced deformability can cause the most significant problem in the microcirculation (vessel diameter <100 μm), more precisely in the zone of so-called individual flow. Here, capillaries with diameter of 3–5 μm may also occur, not to mention the fenestration through the red pulp of the spleen to gaps of even smaller diameter. For passing through these capillaries, the appropriate deformability is essential.

Red Blood Cell Aggregation

Erythrocyte aggregation means the reversible connection of cells which happens at low shear rate or during stasis. Red blood cells initially arrange next to each other in a rouleaux formation, resembling a stack of coins. It takes place within few seconds: the simpler rouleaux form in 1–5 seconds. Over a period of further 10 to 60 seconds arranging in a two- then three-dimensional shape until the effects maintaining the aggregation are present (Baskurt 2012a). In anticoagulated blood samples, the aggregates coagulate into larger balls, then due to the gravity, start to sink. This provides the background of the erythrocyte sedimentation rate (ESR), since if the aggregation is fast and/or extensive, the erythrocyte sedimentation will also be more intensive (Hardeman 2007).

The process of red blood cell aggregation is not yet completely clear. At present there are two model theories to explain the aggregation development. (1) The aggregation of red blood cells approaching each other happens via non-covalent cross-connections of macromolecules (large proteins with elongated structure, such as fibrinogen, or *in vitro* with different polymers) (*bridging model*). This weak linkage dissolves as the disaggregation forces such as the electrostatic repulsion (due to negative charge, zeta potential: -15.7 mV), membrane tension, deformation and mechanical shear stress prevail (the aggregates can be completely dispersed at above 20–40 s^{-1} shear rate). This model supposes that the protein or polymer concentration is high on the cell surface. Absorbing macromolecules non-specifically binding to cell surface structures through their size and quantity may compensate the electrostatic repulsion, facilitating the aggregation. (2) According to the other explanation, the macromolecules are not able to penetrate as far as the membrane just because of the glycocalyx structure of cell surface (5–50 nm), therefore close to the cell surface, a layer deficient in macromolecules or depletion zone develops (*depletion model*). As two red blood cells approach each other, due to the osmotic gradient between the macromolecule concentration being in plasma phase and the depletion zone, a “pulling” force may develop, which makes the aggregation. The higher is the macromolecule concentration, the more

intensive may this gradient be, causing enhanced aggregation (Baskurt 2012a; Saldanha 2013).

There is no unambiguous opinion pro or contra the absolute justification of the two theories, though most of the evidences promote the depletion model. However, the existence of direct intercellular or even cross-binding connections cannot be excluded. Carvalho et al. analyzed structures similar to $\alpha_{IIb}\beta_3$ glycoprotein complexes existing on platelets' surface, facilitating the direct binding of fibrinogen also in red blood cells by their spectroscopy techniques based on atomic-force microscopy. These receptors existing also in the erythrocytes, have lower affinity than that of platelets, the receptor-fibrinogen binding can be broken-up with less energy (Carvalho 2010). Is it possible that both models are true together? Depletion energies are essential for the "allurement" of the cells, and when in this situation, they are close to each other and real cross-binding may develop? No univocal explanation of this hypothesis exists so far.

It is a fact that various plasma proteins, and *in vitro* the polymers with different molecular size influence the development of aggregation process, and to a different degree. Red blood cell aggregability studies indicate that aggregation ability is influenced by cellular factors and is independent from the properties of the plasma (Baskurt 2012a). Aggregability can be measured comparatively *in vitro* in various macromolecule solutions. It has been proved that from the plasma proteins, fibrinogen, C-reactive protein and immunoglobulin M have the effects of facilitating and enhancing red blood cell aggregation. Further, immunoglobulin G and haptoglobin show rather increasing effect, while transferrin, coeruloplasmin and albumin do not influence erythrocyte aggregation (Baskurt 2012a; Saldanha 2013). *In vitro* the high molecular weight macromolecules and polymers such as 60 or 73 kDa dextran, or the 360 kDa polyvinylpyrrolidon (PVP), and the 36kDa polyethylen-glycol (PEG) promote/enable red blood cell aggregation, but their versions with lower kDa have no effect on the aggregation (e.g., PEG 10, 10.5 or 18.1 kDa dextran). Armstrong et al. stated that if hydrodynamic radius of macromolecules or polymers is more than 4 cm, they have an effect of enhancing the aggregation; if it is less than 4 cm, they do not influence the aggregation (Armstrong 2004).

When there are few red blood cells in a certain area, where other conditions of aggregation are normally available, they have less chance to get close to each other. Therefore, the aggregation depends on the hematocrit as well: the aggregation index (AI, which increases by the extent of aggregation) shows nearly linear connection, positive correlation between 20–40% Htc, between 40–50% Htc the curve is less precipitous, while between 50–60%, the AI does not change significantly by (adding) a unit of Htc (Baskurt 2012a).

For the aggregation to occur, the existence of biconcave cell form is crucial. Ovalocyte, spherocyte, echinocyte, sphero-echinocyte cell forms are not or less capable to aggregate. During the aggregation, according to the principle of the least energy loss, the process is going towards the binding on the maximal surface. That is why biconcave form is advantageous, and that is why rouleaux formation develops relatively quickly and then from these with the terminal and side connections geometrical shapes having smaller surface (Reinhart 1980; Meiselman 1981).

All in all, the process and extent of the aggregation depends on the shear rate, concentration of plasma fibrinogen, hematocrit and on cellular properties, like cell surface glycocalyx composition of red blood cells (type of depletion zone, glycoproteins enabling possible direct connections), and the formal characteristics of the cell (biconcave form). All

these can vary in a very complex way in different diseases, pathological states, and it also provides a background to a great diversity in the comparison of mammalian species and the human.

Micro-Rheology and Microcirculation

Fåhræus observed in 1958, that by enhanced aggregation, the axial flow in the glass capillary (d = 95 μm, flow rate = 3.3 mm/s) i.e., the aggregation of red blood cells along the flow axis is more expressed and the cell-free side zone is wider. The parabolic flow rate profile developing due to the laminal flow and the presence of circulating particles (blood cells) dimming it to some extent, creates the phenomenon typically appearing in the range under 200–300 μm vein diameter, the axial migration of red blood cells (Figure 1). It means that within the vein's cross section, the distribution and velocity of red blood cells are not even, which leads to the dynamic reduction of hematocrit, to the Fåhræus-effect. Below approximately 30 μm diameter, down to about 10 μm, the apparent blood viscosity decreases with the diameter (Fåhræus-Lindqvist effect) (Fahraeus 1931). Along the vessel wall, a side plasma zone deficient of red blood cells develops or being even cell-free (Poiseuille-zone), which reduces the friction, hereby the hydrodynamic resistance between the vascular wall and the flowing fluid. If the flow rate is high enough, every formed element aggregates towards the flow axis. When the speed gradient and pressure conditions enable the development of red blood cell aggregation (typically in the area of postcapillary venules and venules), the size of particles (aggregates) flowing along the axis increases, the Poiseuille-zone widens, also facilitating the margination of white blood cells (Bishop 2001; Baskurt 2008; Nash 2008) (Figure 1).

In the microcirculation approaching the individual flow stage (capillaries) due to the extremely variable ramifications, connections, bends, endothelial surface features, red blood cell distribution, the tissue hematocrit is highly variable (Wells 1964; Lipowsky 2005; Popel 2005; Pries 2008).

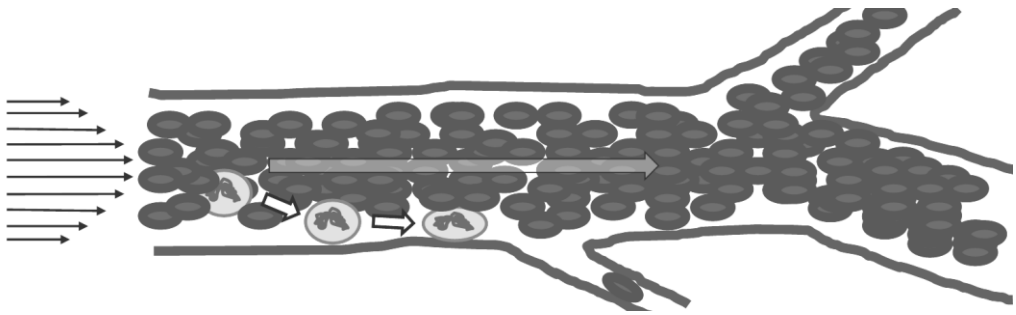

Figure 1. Schematic drawing of the circulatory pattern in vessels with diameter <100 μm. Due to the parabolic flow velocity profile (the flow speeds up along the axis of the vessel), the axial migration of red blood cells occur. In the vicinity of the endothelium, the cell-poor/cell-free plasma zone, the Poiseuille-zone is formed, allowing room for leukocytes. Increased red blood cell aggregation makes the axial flow more expressed with widening Poiseuille zone, driving the leukocyte tethering, margination, and also slowing down their rolling (based on Baskurt 2008; Nash 2008; Yalcin 2011).

Table 2. Brief overview of the available methodology for the detection of functional characteristics of the microvasculature

Method	Species/tissue	Parameters	Indications	Limitations	Reference
Nailfold videocapillaroscopy	human/nailfold	Capillary distribution (density), morphological abnormalities, blood velocity,	chronic diseases (diabetes, vasculitis, arteritis)	Only human application	Awan 2010
Conventional fluorescence intravital microscopy	animal models/superficial tissue layers	FCD, red blood cell velocity, blood flow, microvascular permeability, PMN-endothelial interactions	ischemia-reperfusion, shock (hypovolemic, septic) wound healing, tumors	1) restricted imaging depths (~100–200 µm) dramatic depth- and tissue-dependent deterioration of spatial resolution 2) need of fluorescence labeling 3) light toxicity 4) motion artifacts (peristalsys, breathing) 5) difficult and time-consuming (off-line) analysis	Menger 1992
Confocal microscopy, two- and multiphoton microscopy	animal models/superficial tissue layers	(morphology), microvascular permeability, subcellular events	ischemia-reperfusion, shock (hypovolemic, septic) wound healing, tumors	See #1-5 at fluorescence IVM 6) photobleaching of chromophores 7) photodamage of the tissue at the focal plane 8) signal overlapping with tissue endogenous fluorescence 9) restricted range of applicable fluorescent proteins restricted range of applicable fluorescent proteins due to limited excitation wavelengths	Paramsothy 2010; Denk 1990; Zipfel 2003

Method	Species/tissue	Parameters	Indications	Limitations	Reference
OPS, SDF, IDF	human and animal models/superficial tissue layers	vascular density, vessel diameter, red blood cell velocity, heterogeneity of perfusion (microvascular blood flow)	ischemia-reperfusion, shock (hypovolemic, septic) wound healing, tumors	1) restricted imaging depths 2) motion artifacts (peristalsys, breathing) 3) difficult and time-consuming (off-line) analysis	Groner 1999; Goedhart 2007; Hernandez 2013; Gilbert-Kawai 2016
Laser Doppler perfusion monitoring	human and animal models/superficial tissue layers	flux, velocity and concentration of the moving blood cells	human: skin animals: perfusion deficit situations (ischemia-reperfusion, shock (hypovolemic, septic) wound healing, tumors)	1) influence of tissue optical properties (on the perfusion signal) 2) motion artifact 3) lack of quantitative units for perfusion 4) lack of knowledge of the depth of measurement and the biological zero signal	Leahy 1999; Rajan 2009; Steenbergen 2012
Laser Doppler perfusion imaging, Laser speckle imaging	human and animal models/superficial tissue layers	perfusion (in arbitrary units), heterogeneity	human: skin animals: perfusion deficit situations (ischemia-reperfusion, shock (hypovolemic, septic) wound healing, tumors)		Essex 1991; Boas 2010
Reflectance spectroscopy (in combination with Laser Doppler perfusion imaging)	human and animal models/superficial tissue layers	the oxygen saturation of hemoglobin, regional amount of hemoglobin, velocity and flow of the blood in microcirculation	Measurement of perfusion, oxygenation (in response to ischemia-reperfusion, septic shock, anemia, burn injury)		Sakr 2010; Menzebach 2008; Hölzle 2010; Merz 2010; Scheeren 2011,2016
NIRS	human and animal models/skeletal muscle, brain	microvascular reactivity, blood flow directly, vascular compliance	macro– microcirculatory uncoupling	low spatial resolution	De Blasi 1994, 2008
Protoporphyrin IX—Triplet State Lifetime Technique	human and animal models (skin)	mitochondrial oxygen tension (local treatment with 5-aminolevulinic acid; ALA)	sepsis	topical use, laser safety concerns	Harms 2015

OPS: orthogonal polarization spectral imaging, SDF: sidestream dark-field imaging, IDF: incident dark-field technology, NIRS: near-infrared spectroscopy

Several other factors should be considered to better understand circulation conditions in the field of microcirculation such as the extremely variable microvascular network geometry. The vesselcross section can almost never be described as a regular circle. Elasticity of vessel wall, hemodynamic features, flow profile and parameters (e.g., Reynolds number, Womersley number) have to be taken into consideration as well (Pries 2008; Chandran 2012). Thus, *in vivo* models have a great significance in further studying the connection of hemorheological factors and microcirculatory characteristics, which can provide simultaneous data on most of the above parameters.

So, the microcirculation possesses characteristic micro-hemodynamic features. Due to the decreasing size of the microvessels, the major pressure drop occurs in the first-order arterioles (based on the Hagen-Poiseuille equation), therefore constriction status of these vessels has the highest influence on the regional flow. Local capillary flow, however, is controlled by third-order, small-sized terminal arterioles. Efficacy of perfusion can be termed by a parameter called the "functional capillary density" (FCD) which reflects the length of perfused capillaries within a given area (Honig 1982). Reduced FCD results in a reduced surface area for capillary exchange and an increase in diffusion distance (Hepple 2000). Recruitment of capillaries depends on morphological features of vessels/endothelium of the given region and also on blood rheology factors (i.e., hematocrit, viscosity, blood cell deformability and aggregation), cellular factors, immune function, and coagulation function). Deterioration of microcirculatory perfusion is marker of severity for many forms of circulatory disorders such as hemorrhagic, cardiogenic, and septic shock, also reflecting the outcome of the disease (Sakr 2004; Fang 2006; den Uil 2010). Hence, microcirculation might be considered an important prognostic indicator in different clinical scenarios.

METHODS FOR DYNAMIC EXAMINATION OF MICROCIRCULATORY FUNCTIONS

There are numerous invasive and non-invasive methods for investigating the microcirculation. The limitation of this chapter does not allow to overview all the methods and their developments in details. Table 2 gives a brief overview of the currently available methodology for the detection of functional characteristics of the microvasculature.

Videomicroscopic Techniques

Direct visualization of the microcirculation with different types of *in vivo* microscopic methods (IVM) enables not only examination of the architecture of arterioles, capillaries and venules, but also provides an opportunity for continuous detection and quantification of dynamic functional changes. Apart from nailfold capillaroscopy, most organs can be reached via surgical exposure of the tissues for IVM examinations. Using meticulous microsurgical techniques, an access of the microscope objectives and the required tissue depth can be achieved by maintaining the proper physiological conditions without causing any disturbance of the patency of the microcirculation. Because of optical consideration (limited penetration of light into the tissue, scattering), limited depth for examination of the tissue is a

characteristic feature of IVM methodology. For this reason, an appropriate imaging modality enabling examination of the required tissue depth should be chosen for all experimental studies. By these methods, the dynamics of microcirculatory environment can be assessed over time and space with the required resolution closely approximating the natural microcirculatory environment.

Nailfold Videocapillaroscopy

This non-invasive technique involves a conventional light microscope combined with a video camera and a recording system. It is suitable for the evaluation of capillary density, morphological abnormalities and blood flow in the nailfold area (Awan 2010). Main indications: chronic diseases such as diabetes, vasculitis and arteritis

Fluorescence Intravital Microscopy

In the earliest studies, bright-field transillumination of relatively translucent tissues was employed (Hoole 1800; Wagner 1839), but trans- and epi-illumination techniques (with microsurgical exposure of the tissue of interest) and the use of incident ultraviolet illumination and its combination with specific fluorescence tracers enabled observation of individual cells and cell-vessel wall interactions in later IVM studies (Ellinger 1929; Irwin 1953; Zweifach 1954; Reese 1960; Menger 1991). Epifluorescence microscopy has enabled detection of the dynamics of individual cells within the microcirculation (Endrich 1980). The spatial resolution has been further improved by the use of confocal microscopy (Villringer 1989), but these techniques still resolve structures 100–200 micrometers below the organ surface. By using the combination of IVM with high-resolution video recordings and an off-line analysis, dynamic microcirculatory processes could be analyzed in sufficient details (Menger 1991).

Due to atraumatic microsurgical techniques in experimental settings, almost all organs and tissues could be reached for IVM examinations (brain: Rovainen 1993; spine: Ishikawa 1999, heart: Tillmanns 1974, lung: Kuhnle 1993, liver: Menger 1991, pancreas: Klar 1990, intestine: Bohlen 1978, kidney: Steinhausen 1981, lymph nodes: von Andrian 1996, and bone marrow: Mazo 1998). A large range of vascular, cellular and molecular functions can be assessed by using specific fluorescent markers. Specifically, individual microvessels (from 3–5 μm in diameter), plasma, red blood cells, platelets and circulating immune cells can be visualized (Table 3, Figure 2).

The widefield fluorescence IVM methodology was advanced to the laser scanning confocal technology, two- and multiphoton and spinning disk microscopy, which made deep tissue imaging (at a single cell as well as subcellular level) also possible (Denk 1990; Zipfel 2003; for review see Pittet 2011 and Masedunskas 2012). Clinical applications of the new imaging technologies such as laser endomicroscopy have made *in vivo* real-time microscopic imaging and diagnostics also possible (Paramsothy 2010).

Table 3. Most common fluorescence labeling techniques used in fluorescence IVM studies

Targets	Fluorescence markers	Derived microcirculatory parameters	References
Red blood cells	FITC	red blood cell velocity, blood flow, functional capillary density	Ruh 1998
PMNs	Rhodamine 6G, Acridin orange	PMN-endothelial interactions	Saetzler 1997; Massberg 1998
Platelets	Rhodamine 6G (ex vivo)	platelet-PMN-endothelial interactions	Massberg 1998
Plasma (or plasma proteins)	FITC-dextrans (40-2000 kDa) tetramethylrhodamine-labelled BSA FITC-albumin	microvascular permeability microvascular permeability microvascular permeability (two-photon IVM)	Persson 1985 von Dobschuetz 2004 Egawa 2013
Hepatocytes	Rhodamine 123	mitochondrial membrane potential	Sun 2001
Hepatocytes	NADH autofluorescence	mitochondrial respiration	Roesner 2006
Kupffer cells	non-occluding fluorescent beads	Kupffer cell activation	Watanabe 2007

PMN: polymorphonuclear leukocytes, FITC (fluorescein-isothiocyanate), BSA (bovine serum albumin),

OPS-SDF-IDF Techniques

Using these methods, microvessels can be observed via visualization of their hemoglobin-containing red blood cell content. By means of epi-illumination of superficial tissue layers (up to 2–3 mm in depth) with polarized light (Groner 1999) or incident light (Goedhart 2007), photons are reflected from the deeper tissue parts, providing illumination of the superficial layers. As the reflected-scattered light is absorbed by hemoglobin (at the isobestic point oxygenated and deoxygenated hemoglobin of 530 nm wavelength) within the red blood cells, they appear as black or grey points flowing along the vessels (Groner 1999; Goedhart 2007; Leahy 2012; Lehmann 2012).

The orthogonal polarization spectral (OPS) imaging device (Cytometrics, Philadelphia, PA, USA) uses linearly polarized green light source to illuminate the tissue. The reflected polarized light is blocked by an orthogonally polarized analyzer, while depolarized scattered light can pass through to the camera (providing a dark-field image). The OPS imaging was introduced by Groner et al. in 1999, which was followed by the more advanced Sidestream Dark-Field (SDF) imaging in 2007, introduced by Goedhart (produced by the Microvision Medical B.V., Amsterdam, the Netherlands; the device being called Microscan) (Goedhart 2007; Milstein 2012). Another SDF system (CapiScope HVCS) is produced by KK Technology (Honiton, UK) (reviewed by Massey 2016). Microscan and CapiScope HVCS have similar image size (720 × 480 and 752 × 480 pixels, respectively) and resolution (1.45 × 1.58 and 0.92 × 0.92 μm/pixel, respectively). An improved version of the latter one is the Capiscope HVCS-HR which has higher resolution (0.81 × 0.81 μm/pixel). The newest generation of videocapillaroscopy is based on the incident dark field (IDF) principle (Braedius Scientific™) (Hernandez 2013). Recently, a new device based similarly on IDF imaging (Cytocam) was developed with improved optical lenses, a high-resolution (0.66 × 0.66 μm/pixel) computer-controlled image sensor, higher image size (2208 × 1648 pixels),

and with an application for automatic data analysis (Aykut 2015; van Elteren 2015; Gilbert-Kawai 2016).

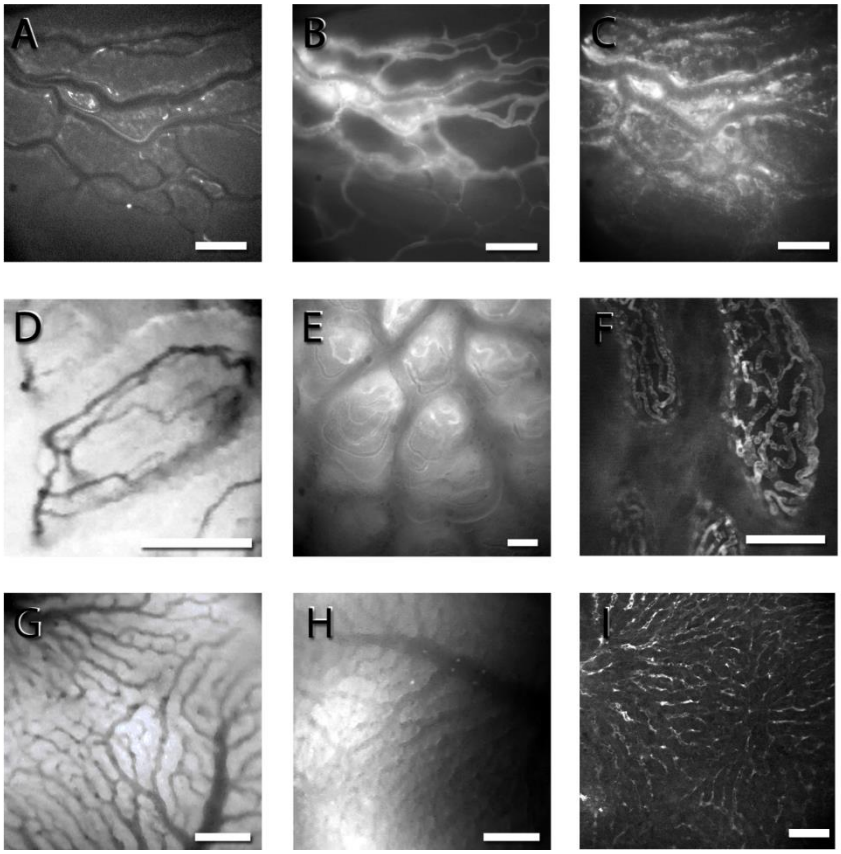

Figure 2. Representative micrographs showing the intestine and the liver with conventional fluorescence IVM (A-C, E, H), OPS (D, G) and laser scanning confocal microscopy (F, I). FITC-labeled red blood cells (A), plasma labeling (B) and rhodamine 6G-labeled leukocytes in the longitudinal muscle layer of the rat ileum (C); OPS images of the intestinal villi (D) and liver hepatic sinusoids (G) in Sprague-Dawley rats. FITC labeling of the microvessels in the intestinal villi in BALB/c mice as detected with fluorescence IVM (E) and in the intestinal villi (F) and the liver (I) in rats using laser scanning confocal microscopy. Bar denotes 100 µm.
The IVM images were taken by using a Zeiss Axiotech Vario 100HD IVM microscope, 100W HBO mercury lamp, Acroplan 20× water immersion objective, Carl Zeiss GmbH, Jena, Germany) and a CCD camera (Teli CS8320Bi, Toshiba Teli Corporation, Osaka, Japan). The OPS images were taken by the Cytoscan A/R device (Cytometrics, Philadelphia, PA, USA). (Original recordings of AS).

As these hand-held microscopes do not require any dye and allow for non-invasive visualization of the microcirculation in patients particularly in the oral cavity. For analysis of microcirculation with SDF/IDF devices, De Backer et al. have proposed the use of the following parameters: proportion of perfused vessels (PPV), perfused vessel density, microvascular flow index (MFI), and heterogeneity index (De Backer 2007). Further approaches together with those used in conventional fluorescence IVM are summarized in Table 4.

Table 4. Commonly used parameters for different IVM methods (partially based on ref. by Massey 2016)

Parameter	Definition	Method where the parameter is used	Reference
Red blood cell (or plasma) velocity (RBCV) (μm/s)	Velocity of red blood cells or plasma	conventional fluorescence IVM, OPS, SDF, IDF	Lehr 1993; Groner 1999
Total vessel density (mm/mm^2)	Total length of vessels is divided by the total surface of the analyzed area	conventional fluorescence IVM, OPS, SDF, IDF	Donati 2013; Bezemer 2008
Functional capillary density (FCD) (mm/mm^2)	Total length of capillaries with red blood cell flow referred to the observation area	conventional fluorescence IVM, OPS, SDF, IDF	Lehr 1993; Groner 1999
Functional vessel density #1 (mm/mm^2)	Total length of perfused vessels (sluggish or continuous) referred to the observation area	OPS, SDF, IDF	Donati 2013
De Backer score (vessel density) (1/mm)	Calculated based on the line crossing method when the image is divided by three vertical and three horizontal lines. This score is calculated as the number of vessels crossing the lines divided by the total length of the lines.	SDF, IDF	De Backer 2007; Donati 2013, Bezemer 2008, Sakr 2010
Microvascular flow index (MFI) (arbitrary units)	Based on flow characterization (absent, intermittent, sluggish or normal) of vessels using the line crossing method (in four quadrants of the recorded images) An average of the scores is used.	SDF, IDF	De Backer 2007, Donati 2013, Bezemer 2008
Proportion of perfused vessels for large vessels (PPVl) (%)	100 × number of perfused vessels divided by the total number of vessels	IVM, OPS, SDF, IDF	Donati 2013, Bezemer 2008, Sakr 2010
Proportion of perfused vessels (length) (PPV) (%)	100 × length of perfused vessels divided by the total length of vessels	conventional fluorescence IVM, OPS, SDF, IDF	De Backer 2007
Perfused vessel density #2 (1/mm)	Vessel density x PPV	SDF, IDF	Bezemer 2008
Flow heterogeneity index	The difference between highest and the lowest MFI is divided by the mean flow velocity	SDF, IDF	De Backer 2007, Donati 2013
PMN rolling (defined as rodamine 6G-labaled cells moving at a velocity less than 40% of that of the erythrocytes in the centerline of the microvessel) (1/mm/s or % of total PMNs)	The number of rolling cells devided by the vessel circumference	conventional fluorescence IVM	Lehr 1993, Bajory 2002
PMN adhesion (cells that did not move or detach from the endothelial lining within an observation period of 30 s) ($1/mm^2$)	The number of cells devided by mm^2 of endothelial surface	conventional fluorescence IVM	Lehr 1993

Laser Doppler Flowmetry

The background of laser Doppler monitoring is the "Doppler shift" phenomenon (Doppler 1942). When a monochromatic laser light enters the tissues and meets moving blood cells, it undergoes changes in wavelength (Doppler shift), but remains unchanged if the beam of light hits static tissue structures. Magnitude and frequency changes of wavelength correlate with the number of moving blood cells (Stern 1975). The Doppler technique provides "perfusion units" which cannot be transformed in terms of flow (e.g., ml/min), but rather a flux unit without dimension, since it is an integral over the velocity and the number of moving red blood cells in the tissue territory laying under the probe (Obeid 1990; Leahy 1999, 2012; Friedriksson 2012;).

There are two major approaches of perfusion measurements, the laser Doppler perfusion monitoring and laser Doppler perfusion imaging (Rajan 2009; Friedriksson 2012; Leahy 2012).

Laser Doppler Perfusion Monitoring

In this one-point measurement method, a fiber-optic probe is used to deliver the laser light to the tissue, and another fiber to detect the back-scattered photons recording the integrated perfusion in a sampling volume in real time. The measurement depth and sampling volume depend on the wavelength (usually 630, 780 and 830 nm are used) and the fiber separation used. In the skin, (using 780 nm wavelength), the measuring depth is 0.5–1 mm and the measurement volume is approximately 1 mm^3. The main manufacturers of laser Doppler instruments are Perimed AB (Stockholm, Sweden), Moor Instruments Ltd. (Axminster, UK), Transonic Systems Inc. (Ithaca, New York, USA), Oxford Optronix Ltd (Oxford, UK) and LEA Medizintechnik (Giessen, Germany).

Laser Doppler tissue flowmetry method can be widely applied both in the clinical and research work to study local or systemic effect of heat, reflex vasodilation, microcirculatory changes following occlusion, or the effects of vasoactive drugs, as well as endothelial reactivity using provocation tests (ischemia, heat) (Obeid 1990; Neviere 1996; Rajan 2009; Friedriksson 2012; Leahy 2012).

However, numerous factors may influence the results. This method considerably and sensitively indicates the changes occurring in microcirculation, but at the same time, several factors may influence the measurements. These factors on one hand include the thickness of the examined tissue, its anatomical structure, optical properties (pigmentation), possible morphological alteration and vascularity. On the other hand, from the patient's side, the gender, age, hormonal and neurological effects and drugs may affect the results of the measurement. From the side of the device, the displacement and contamination of the probe, kinking of fiber optics, distance of emission and receiving optical fibers, wavelength of laser light and biological zero signal may also be considered as influencing factors. Disturbing artifacts or "noises" may develop through the movement of optic fiber or from the affected tissue (e.g., breathing, intestinal peristalsis). External factors such as temperature, humidity, air movement also influence the measurement; therefore, it is very important to ensure standard circumstances. However, performing comparative studies (e.g., before and after intervention) is difficult, because to ensure the same conditions in all parameters is almost

impossible (Obeid 1990; Neviere 1996; Nemeth 2003; Rajan 2009; Friedriksson 2012; Leahy 2012).

In pathophysiological processes–such as sepsis or ischemia-reperfusion– associated with acute changes of tissue microcirculation, laser Doppler technique is highly justified. In experimental models, probes available in various versions can be applied in several ways (Nemeth 2003; Rajan 2009; Friedriksson 2012; Leahy 2012):

- probe touched directly to the surface of skin or in open surgery of the organ (manual or preferred trestle fixing)
- probe fixed on the surface of the organ (stitches)
- in laparoscopy introduced via trocar and touched to the surface of examined intraperitoneal organ or the peritoneum
- introduced in endoscopy and touched to the surface of mucosa (multichannel endoscopy, fiber optic probe)
- implanted between tissue layers or bone mortise for monitoring

Depending on the wavelength of the applied laser, the depth of the tissue area that can be examined may range from 0.1 to 0.8 mm, e.g., by applying laser with 780 mm wavelength and probe with 0.5 mm diameter, this tissue depth is 0.73 mm in muscles, 0.52 mm in the liver and 0.5 mm in the skin. The duration of the examination and positioning of probe should be taken into consideration. The 0.5 mW energy derives from laser light, and in the examined tissue, it may also influence the state of capillaries after some time (Friedriksson 2012).

The probe stabilization is essential. Overpressure of the tissues may cause local microcirculatory disturbance; if too loose, displacing or fixing may lead to inaccurate measurements and several artifacts.

Several solutions are known for the right interpretation of the recorded signal in the literature. For instance, the native values measured and assessed at a certain interval by the device can be used. Within this interval (e.g., data of stable signal over 10 or 20 seconds), the values can be averaged. Relative changes compared to initial values, moving average, Fourier transformation and various timeline analysis methods can also be used for analyzing laser Doppler recordings (Obeid 1990; Nemeth 2003, 2014b; Rajan 2009; Friedriksson 2012; Leahy 2012).

An organ may show different laser Doppler signals with different recorded patterns depending on the functional and morphological state of microvasculature. Therefore, it is important to observe the characteristics of the recorded signal and decide how to analyze and interpret the data. Signals recorded in skin, liver, kidney and muscles vary within a relatively small range, but they are never consistent. In other organs such as bowel, omentum or pancreas, the signals oscillate between wider ranges, so the averaging is difficult in these cases; it may even be misleading if we analyze a data set of t an inadequate period with their extremes (Nemeth 2003, 2014b).

During a prolonged monitoring, when the probe of the device is fixed in a steady, permanent position and the microcirculation is being monitored for half an hour or even longer, the extent and dynamics of changes can be analyzed separately. This point of view is of particular importance in examinations which aim to follow organic microcirculatory effects of different materials and surgical maneuvers.

Regarding the several factors which influence the measured values, examining the changes in correlation with the baseline values is an extremely useful data analyzing method. Thus it can be expressed as a percentage to what extent a certain tissue area changes during a surgery. It is a very important point to indicate baseline value, as it was mentioned, intensity of laser Doppler signal is not constant in any of the tissue areas, more or less irregularities, periodicity and artifacts appear. Should we use any data analysis and interpretation method, it has to beconsistent and standardized.

Laser Doppler Perfusion Imaging (Laser Doppler Scanner Technology)

A laser Doppler perfusion imaging technology maps the perfusion from a larger area by scanning the laser beam over the area of interest without having any direct contact with the tissues (Essex 1991; Fredriksson 2012; Steenbergen 2012 a, b). These instruments provide perfusion map of an area with a (normally) heterogeneous perfusion and also gives the average of perfusion of the examined area in a single measurement. The main manufacturers of laser Doppler perfusion imagers are Perimed AB and Moor Instruments Ltd. Using stepwise changes in the illuminating laser beam wavelength or different wavelength simultaneously, the spatial resolution can be increased up to 0.1 mm.

Laser Doppler Flowmetry Combined with Reflectance Spectrometry

The more recent technology (the O2C device, Lea, Giessen, Germany) combines the laser Doppler technique and reflection spectroscopy. Using specific probes, white light (wavelengths 500–800 nm) and laser light (wavelength 830 nm) are introduced simultaneously. The absorbed portion of the light spectrum is absorbed on erythrocytes assuming the color of the hemoglobin as measured by oxygen saturation, while laser light reflects perfusion (based on the Doppler shift). The sum of all erythrocytes and their velocity provides a measure of blood flow (volume flow). The following parameters can be measured simultaneously with this technology: oxygen saturation of hemoglobin at the venous end of the capillaries, regional amount of hemoglobin as a measure of blood volume and capillary density, velocity and flow of the blood within the microcirculation. This method has been employed to assess the microvascular response in patients with septic shock (Sakr 2004; Sakr 2010) and in anemia (Menzebach 2008), to estimate flap viability (Hölzle 2010) and wound healing in burn injury (Merz 2010).

Laser Speckle Imaging

A speckle image is created when an object is illuminated by laser light. The backscattered light will forms a random interference pattern consisting of dark and bright areas (speckle pattern). In case of a moving object (e.g., red blood cells) in the underlying tissue, the speckle pattern changes over time depending on the extent of movements within the examined area. As a result, the level of blurring differs resulting in various extent of speckle contrast (Briers 1999; Briers 2012; Boas 2010; Steenbergen 2012b). Consequently, changes in microcirculatory perfusion characteristics under a surface (within a typical depth range of 1–5

mm, max. 15 mm) can be analyzed. The resolution depends on the characteristics of detector as well as the size of examined surface and the distance of the detector. Using this method, preclinical and clinical detection of the skin (Choi 2004; Rege 2011; Sandker 2014) and even cerebral blood flow (Parthasarathy 2010; Qin 2012) could be performed.

It was recently demonstrated that the distribution of blood flow within tissue beds can noninvasively be visualized also by the motion-contrast laser speckle imaging which leads to enhanced visibility of distinct vascular beds, including capillaries (Liu 2013).

Near-Infrared Spectroscopy

Near-infrared spectroscopy (NIRS) is a non-invasive technique that assesses the redox state of microcirculatory hemoglobin by measuring oxyhemoglobin, deoxyhemoglobin, total hemoglobin and other chromophores (myoglobin, cytochrome aa3) in mostly the venous system (De Blasi 1994; Pareznik 2006). Vascular occlusion tests allow quantification of the rate of decay of microcirculatory oxygen saturation thus representing the metabolic status of the underlying tissue (muscle) (De Blasi 2008).

Measurements of O_2 Tension and Saturation

Conventional oximetry (hemoglobin oxygen saturation measurement) is widely used in the clinical practice and is based on the assessment of differences in the absorption spectra of oxy- and deoxy-hemoglobin. Interestingly, it was first applied *in vivo* within the microcirculation to obtain oxygen saturation in single vessels using IVM (Pittman 1975; Pittman 2013). Transcutaneous arterial oxygen pressures can simultaneously be measured using standard pulsoximetry, whereas transcutaneous venous carbon monoxide tensions with CO_2-sensitive electrodes (Fromy 1997).

Phosphorescence quenching microscopy is based on the collisional quenching phenomenon which occurs when excited phosphor decays back to the ground state by emitting a photon (phosphorescence) or by transferring energy to nearby oxygen molecules. This enables measurements of the O_2 tensions (Vinogradov 2002). The energy transfer to oxygen results in the formation of the reactive species singlet oxygen, which can then react with nearby organic molecules, thereby resulting in the consumption of the original oxygen molecule.

Oxygen tensions in the microcirculation can be measured using oxygen-sensitive polarographic microcathodes (Buerk 2004). Oxygen saturation can also be non-invasively measured using the Resonance Raman microspectroscopy (Ward 2006). The phosphorescence quenching approach (Vinogradov 2002) and oxygen electrodes (Buerk 2004) can also measure oxygen tensions in the interstitium.

In vivo Measurements of Mitochondrial Functions and Oxygen Tensions

The “Protoporphyrin IX–Triplet State Lifetime Technique” is a new approach developed for the measurement of mitochondrial function and oxygen tension (mitoPO2) *in vivo* (Mik

2006, Harms 2015). A recently developed non-invasive technique is able to measure a decline in mitoPO2 after pressure-induced cessation of blood supply (called oxygen disappearance rate), also providing estimates of mitochondrial oxygen consumption. The oxygenation data was validated in a sepsis study in rats with the use of reflectance spectroscopy (combined laser Doppler) in the skin. They also demonstrated the feasibility of the non-invasive technology to assess mitochondrial function in the human skin.

Further Methods

Due to the limitations of the chapter, further special methods are just briefly summarized, referring to detailed handbooks (e.g., Leahy 2012).

Subsurface Spectroscopy (Tissue Viability Imaging)

For tissue viability imaging (TiVi), further possibilities are based on wideband spectroscopy of backscattered light (subsurface spectroscopy) for mapping local red blood cell concentration. The sequential photo recordings are being analyzed by a software package, allowing studies of dynamic skin reactions (using agent or effects that cause vasodilatation or vasoconstriction) (O'Doherty 2012).

Optical Microangiography

Because of the high spatiotemporal resolution and the small dimension, microvasculature imaging is technologically challenging. Optical microangiography (OMAG) is capable of resolving three-dimensional distribution of dynamic blood perfusion by imaging the endogenous light scattering from moving red blood cells. The technique is based on Fourier domain optical coherence tomography (FDOCT) (Wang 2012).

Photoacoustic Tomography

Photoacoustic tomography (PAT) detects endogenous or exogenous optical absorption contrast acoustically. When red blood cells are irradiated by a short-pulsed laser beam, a transient thermoelastic expansion occurs that induces high-frequency ultrasonic (photoacoustic) waves. The device encodes the red blood cell distribution and makes a reconstruction of a three-dimensional microvascular image. Using multi-wavelength measurements, differentiation of oxyhemoglobin and deoxyhemoglobin is also possible. Based on PAT, photoacoustic microscopy (PAM) and photoacoustic computed tomography (PACT) methods are known (Hu 2012).

High Frequency Ultrasound Imaging

Maximal imaging frequency of clinical ultrasound systems are typically 12−15 MHz, providing resolution on structures of >300 μm. The micro-ultrasound devices (preclinical imaging) have been developed for the range of 15–80 MHz (Foster 2012).

Micro-CT, Nano-SPECT-CT, NMR

Micro-computed tomography (Micro-CT) is a powerful tool to study small animals, corrosion specimens or biopsies. The resolution of Micro-CT is about 1–100 μm in rotating state, ~50–100 μm in rotating scanner in plane. Micro-SPECT and micro-PET resolution is about 1–2 mm, while micro-magnetic resonance imaging (MRI) provides a resolution about 100–200 μm in plane and ~0.5–10 mm slice thickness (Kline 2012). Boundaries of the nuclear magnetic response imaging (NMRI) techniques and applications (MR angiography, MR perfusion imaging, functional MRI) widen, providing more possibilities to investigate structural and functional state of the vasculature as well (Kerskens 2012).

Brief Overview on Methods for Assessment of Rheological Parameters

Methods for Measuring Blood and Plasma Viscosity

For the determination of blood viscosity, only those measuring devices are suitable, which can determine viscosity at different shear rates (Cokelet 2007a, b). The shearing tension or speed gradient profile may be generated under the effect of gravitational force (e.g., in capillary viscometers), or through rotational motion with a certain angular velocity, produced by a built-in mechanism (rotational viscometers) (Baskurt 2009).

Most of the viscometers were the capillary type until the 1960s, rotational viscometers appeared later. In the capillary-type ones, the flow rate profile can be determined from the position-time data of fluid column, and the shearing tension can be calculated from the geometry of tube. The geometry of rotational viscometers can be various: cone-plate, cone-in-cone or coaxial cylinder (or Couette-system) in speed-gradient controlled or shearing tension controlled form. The fluid to be measured can be filled in between the two elements (e.g., ‘bob’ and ‘cup’). One element can be rotated by adjusted angular velocity. The torque relocated to the non-rotated element to an extent is depending on the viscosity of the fluid. The torque is tested by laser reflection, and the viscosity can be calculated at a certain shear rate-gradient. Oscillation flow viscometers are also known, which are suitable for the investigation of viscous and elastic components. The viscous component can be calculated from the amplitude of speed gradient, and the elastic component is calculated from phase delay of shearing tension in relation to the speed gradient (Rosencranz 2006; Hardeman 2007).

For the measurement of plasma viscosity–based on the newtonian characteristics–viscometers, whose method does not depend on shear rate gradient, are suitable. The dynamic

viscosity of the fluid can be calculated from fluid flow rate in a system with a certain geometry, from position-time data (U-tube or capillary viscometers: e.g., Ostwald, Coulter-Harkness, Rheomed, Luckham viscometers), or in the falling ball viscometers (e.g., Haake-type) from the effect of drag force applying the Navier-Stokes equation: $F = 6\pi r\eta v$, where F is the frictional force, r is the radius of the spherical object, η is the fluid viscosity, v is the particle's velocity. With a simpler method: $\eta = k(\rho_1-\rho_2)t$, where k is constant, ρ_1 is the density of the particles, ρ_2 is the density of the fluid, t is the duration of ball falling (Rosencranz 2006; Hardeman 2007; Baskurt 2009).

Methods for Testing red Blood Cell Deformability

For the determination of red blood cell deformability, several methods and various approaches are known. The best-known and still in use techniques are based on the filtration method, the micropipette aspiration technique, microchannel methods and the ektacytometry (Hardeman 2007; Baskurt 2009).

Filtration technique has been used since the 1960s: measuring the passage of blood cell suspension through a filter with a certain pore diameter/size (~200 000 pores), the cells' deformability can be concluded; due to the clogging of pores, the permeability of the filtering membrane gradually decreases. The initially used classical paper filters were replaced by polycarbonate filter membranes containing cylindrical channels (diameter: 3, 5 or 8 μm, length: 10 μm). The Reid-Dormandy type filtration method utilized the filtration of red blood cell aggregation through the filter with 5 μm in diameter. Improving the principle, Dormandy and his colleagues prepared the St. George's filtrometer. The oligopore (23–30 pores) and the single pore technique (Single Erythrocyte Rigidometer, SER) are more sophisticated methods; here mainly the time of change in conductivity between the two sides of the filter correlate with presence of red blood cells just passing through the pore, where the process is analyzed by the attached computer according to the pores transit time histogram (Cell Transit Analyzer, CTA) (Hardeman 2007; Baskurt 2009; Musielak 2009).

With the *micropipette aspiration method*, a single cell can be examined, which is wholly or partly aspirated into a glass capillary with 1–5 μm diameter. From the measurement of the negative pressure and the length of the aspirated membrane phase provides shearing elastic module, while the aspiration of the whole cell gives the deformability. It requires serious technical skills (Hardeman 2007; Baskurt 2009; Musielak 2009).

The basic principle of the *microchannel method* is that the cell suspension is flowing through one or two parallel channels, or through an artificial microchannel network, while the movement of red blood cells, the transit time, and position of the cells can be visually analyzed (Baskurt 2009; Musielak 2009; Reinhart 2015).

The *ektacytometry* is based on the diffraction analysis of laser beam (wavelength: 670 nm) reflected from red blood cells suspended in high-viscosity (preferably ~30 mPas) macromolecule solution (e.g., 70 kDa dextran or 350 kPa polyvinylpyrrolidone isotonic solution) and elongated due to the shear stress, providing the elongation index (EI) in the function of shear stress (Chien 1975; Chasis 1986; Hardeman 2007). The shear stress on the sample is generated by the motor or vacuum device, while the laser diffraction pattern is captured by a CCD camera and projected on a screen. The EI can be calculated from the analyzed picture by the software diffractrogram: EI = (L-W) / (L + W), where L is the length

and W is the width of the diffractogram. Different shearing geometries are used in ektacytometer devices: plane-plane rotational system in the Rheodyn device, Couette-system in laser-assisted optical rotational cell analyzer (LORCA), or vacuum-driven slit-flow technique in the Rheoscan device (Hardeman 2007; Baskurt 2009; Musielak 2009). Besides the classical deformability measurements, some modern ektacytometers are capable of testing osmotic gradient deformability (i.e., deformability test at constant shear stress over an osmotic gradient range) and membrane mechanical stability (deformability test before and after a period pf mechanical shearing at definitive magnitude and duration) (Hardeman 2007; Baskurt 2009).

Further deformability measurement methods are the rheoscope technique (a combination of ektacytometry and microscopy), atomic-force microscopy, the laser optical tweezers and magnetic twisting cytometry (Hardeman 2007; Musielak 2009).

Methods for Testing Red Blood Cell Aggregation

Several indirect and direct methods are known for the determination of red blood cell aggregation. The classical and modern methods (Westergren, Seditainer, Automatic ESR) based on the already mentioned measurement of erythrocyte sedimentation rate (ESR) are widely used and well standardized methods. Also known is the determination of zeta sedimentation rate (by centrifugation) and the determination of indirect aggregation parameters (aggregation index = $(\eta_{low} - \eta_{high}) / \eta_{high}$, where η is the blood viscosity determined at a certain low and a higher speed gradient) from the results of blood viscosity measured at low speed gradient (e.g., 1 s^{-1}). By microscopy techniques or rheoscope the morphology of aggregates can also be examined and their size and red blood cell count per aggregate can be determined. By this method, the heteroaggregates (white blood cell, platelet, red blood cell) can also be separated. Ultrasound techniques enable non-invasive *in vivo* examinations (mainly B-mode echography) of aggregation developing in a certain vascular region (Hardeman 2007; Baskurt 2009, 2012b).

In clinical and experimental hemorheological studies, the most commonly used methods are based on the principles of photometry. The presence of aggregates increases the light transmission of blood sample related to a certain wavelength, as in this case the width of plasma phase (or other suspending medium) between the particles increases. In the course of disaggregation, the cells dispersed on a larger surface decreasing the plasma phase width and so the light-transmittance. When cells start to aggregate during stasis or at low shear rate, the plasma phase width and the light-transmittance increase. Furthermore, red blood cell aggregates reflect light differently compared to the individual cells. Based on these principles, different devices are available to analyze the light transmission (e.g., Myrenne MA-1 erythrocyte aggregometer), or the reflection of light (laser) from the aggregating cells (syllectometry, e.g., LORCA). Using these methods, both the extent and the dynamics of aggregation can be examined (Hardeman 2007; Baskurt 2009, 2012b).

Thoughts on the Link between Microcirculatory and Micro-Rheological Investigations

The examination of rheological conditions of microcirculation and their interaction cannot be simplified to the correlation of Poiseuille's law related to the rigid-walled, straight regular pipes. The large region of microcirculation is not even homogenous from rheological point of view. In addition to the vein diameter and vascular geometry, the viscosity cannot be considered constant due to axial migration of red blood cells (Fåhræus and Fåhræus-Lindqvist effect), phase separation, very diverse and changeable, unsteady distribution of tissue hematocrit (microvascular hematocrit), and the particularities of the zone of individual flow (Fahreus 1931, 1958; Wells 1964; Lipowsky 2005; Pries 2008).

Therefore, in the isolated organs, in perfusion *ex vivo* models, the solutions ensuring the stability of vessel diameter (maximal dilatation or maximal constriction) could only show a thorough picture if we hypothesized and presumed that the viscosity is constant at every stage of the circulation. This is however, obviously not true. That is why a more detailed investigation of the role of micro-rheological parameters in the microcirculation is required (Wells 1964; Lipowsky 2005; Popel 2005).

Parallel investigations of hemodynamic, microcirculatory, hemorheological, acid-base parameters, hematological and hemostaseological factors may provide enough information to evaluate and understand the dynamics of these changes and their interactions (Baskurt 2007; Nemeth 2014b).

MAIN MICROCIRCULATORY AND MICRO-RHEOLOGICAL FINDINGS IN VARIOUS PATHOPHYSIOLOGICAL PROCESSES

Ischemia/Reperfusion

Ischemia/reperfusion injury causes all of the microcirculatory symptoms which can develop during local or systemic circulatory disorders (Ames 1968; Menger 1992; Anaya-Prado 2002; Eltzschig 2011). It appears that the ECs are primary targets during the pathogenesis of ischemia/reperfusion-induced reactions (including inflammation). Being a major source of the xanthine oxidase-derived radicals (Granger 1981; Granger 1986; McCord 1985), a microvascular dysfunction (increased capillary permeability) develops. The xanthine oxidase-derived radicals further attract neutrophils (PMNs), thus augmenting tissue injury (Hernandez 1987). The endothelium-derived oxidants promote neutrophil adhesion to ECs via endothelial production of chemotactic factors (Yoshida 1992) as well as by activation of transcription factors (e.g., NFκB), causing an increased expression of adhesion molecules on ECs (Ichikawa 1997). Bioavailability of NO (an endogenous inhibitor of PMN adhesion) is reduced via its interaction with superoxide (Grisham 1998). This is accompanied by an activation of interstitial immune cells (macrophages and mast cells) with resultant generation of inflammatory mediators causing a chemotactic gradient which facilitates neutrophil emigration into the interstitium (Kanwar 1998). Lymphocytes may also be involved in the modulation of PMN-related reactions by releasing soluble factors, such as TNF–α or INF–γ (Osman 2009).

Micro-rheological parameters can be altered during ischemia and reperfusion by several pathways (Baskurt 2007). Impaired red blood cell deformability may contribute to an increased blood viscosity and cause perfusion problems in the capillaries (Wells 1964; Maeda 1996; Lipowsky 2005; Popel 2005). The enhanced red blood cell aggregation elevates blood viscosity and increases the flow resistance in the microcirculation (Baskurt 2007; Baskurt 2008). When erythrocyte aggregation is enhanced, the axial migration of the red blood cells in the vessel becomes more expressed, resulting in a widening cell-poor zone at the vicinity of the endothelium (Poiseuille-zone) (Fahraeus 1958). Widening Poiseuille-zone facilitates leukocyte tethering and margination; furthermore, the wide cell-poor zone slows down the rolling (Nash 2008; Yalcin 2011) (Figure 1). Additionally, altered blood rheology has an impact on the shear stress profile on the endothelial surface, thus modulating numerous vascular functions (Gori 2007, 2011; Pober 2008; Chandran 2012).

During ischemia, the local metabolic changes such as decrease in pH, increase of H^+ and lactate, affects blood cells (Weed 1969; Johnson 1985; Reinhart 2002). The pH of stagnant blood decreases in the area excluded from the circulation during the ischemia, which turns the red bloods cells' discocyte shape into a stomacyte or sphero-stomacyte form (Reinhart 1980). The echinocyte and sphero-echinocyte forms may appear when the ATP depletion and calcium accumulation are dominant (Reinhart 1980). Both morphological transformations result in worsened micro-rheological characteristics: impairment of red blood cells' deformability and disturbed aggregation (Meiselman 1981; Mohandas 2008).

During stasis, hematocrit increases locally and the altered fluid distribution results in elevated protein concentration, leading to increased plasma viscosity. These factors together with the less deformable erythrocytes and aggregates formation result in an increased local blood viscosity (Koppensteiner 1996; Baskurt 2007; Nemeth 2014a). Furthermore, the mechanical trauma to red blood cells has to be taken into consideration (Kameneva 2007). The hypoxia leads to impaired EC barrier function (Gori 2007, 2011). By revascularization, the metabolites flushing into the systemic circulation together with the damaged erythrocytes may cause further changes in the microcirculation and even in remote organs (Anaya-Prado 2002; Eltzschig 2011; Nemeth 2015b).

During reperfusion, the nascent oxygen-centered free radicals initiate harmful chain reactions in the erythrocytes: damaging the cell membrane (lipid peroxidation), the transmembrane and structural proteins (receptors, ion pumps) by sulfhydryl cross-links and transforming the hemoglobin molecules (methemoglobin, Heinz-body formation) (McCord 1985; Baskurt 1997, 2007). Red blood cells are rich in iron, which catalyzes the free radical reactions through the Fenton-reaction; making these cells highly sensitive to oxidative stress (Baskurt 1997; Kayar 2001). The "second" assault of free-radicals happens by the activated PMNs during the inflammatory process that is triggered by an ischemic injury of the tissues.

NO plays an important role in the local flow regulation over the complex hemodynamic changes during ischemia-reperfusion (Anaya-Prado 2002; Eltzschig 2011). The NO has a beneficial effect on red blood cells, improving their deformability, and erythrocytes also act as an enzymatic source of NO (Bor-Kucukatay 2003; Baskurt 2007). However, in the presence of NO and $\bullet O_2^-$, peroxynitrite anion formation can jeopardize the red blood cells (Baskurt 2007).

The macro-hemorheological changes are also non-specific and are related to the acute phase reactions: increase of plasma viscosity by elevated fibrinogen concentration and α_2-macroglobulin, increase in immunoglobulin levels, decrease in albumin level, rise in

leukocyte count, increase or decrease of platelet count, as well as hemoconcentration and erythrocytes' micro-rheological changes (Koppensteiner1996; Baskurt 2007; Nemeth 2014a).

In the microcirculatory bed, the "no-reflow" phenomenon is characteristic for tissue ischemia-reperfusion. Despite of restarting the circulation in large-caliber vessels, there is a significant slow-down or total arrest in the microcirculatory flow (Ames 1968). In the background of this paradoxical phenomenon, numerous factors can be listed: microvascular spasm, swelling of ECs, bleb formation on the endothelial surface, increased capillary permeability, interstitial edema, micro-thrombi, neutrophil adhesion and plugging, and local acidosis (Menger 1992; Reffelmann 2002; Granger 2010; Vollmar 2011). The presence of red blood cells with impaired deformability and enhanced aggregation contributes further to the microcirculatory disturbance (Pries 2003, 2008; Lipowsky 2005; Popel 2005).

Systemic Circulatory Disorders

Hypovolemia-induced microcirculatory (arteriolar) vasoconstriction develops on the basis of an increased sympathetic activation causing A1 vasoconstriction and inverse A4 vasodilation with resultant reduction of capillary cross-sectional area and endothelial swelling (Mazzoni 1992; Szopinski 2011). Furthermore, an arteriolar hypo-responsiveness develops via up-regulation of inducible NO synthase and endothelin-1 (Liu 2005; van Meurs 2008). Widening gap junctions of the capillary endothelium is typical reaction seen also at sepsis causing tissue infiltration of PMNs (Czabanka 2007), which creates a positive feedback loop of microcirculatory derangement and obstruction of the capillary lumen (Ivanov 2006). Furthermore, red blood cell deformability is diminished (Baskurt 1998; Baskurt 2007). As a result, FCD is reduced and the oxygen delivery and removal of waste products are impaired. Similar reactions are seen in cardiogenic shock (Mazzoni 1992; Moore 2015).

Sepsis

The pathophysiology of sepsis includes several points which link it to the rheology of blood, since it is a disorder of the microcirculation (Levy 2003; Spronk 2004; Ince 2005; Trzeciak 2007, 2008; Lundy 2009; Nduka 2011; Hernandez 2013). The microcirculatory deterioration in sepsis is multifactorial. Septic process affects the entire microcirculation, disturbing micro-vascular blood flow and vascular resistance. The amount of blood entering the capillaries is affected by hemodynamic changes, redistribution of organ flow, vasodilatation and vasoplegia, as well as by opening arterio-venous shunts. Rigid blood cells may easily plug the capillaries. As result of dysfunction of the huge endothelial surface along the microcirculation, the perfusion further decreases due to increased adhesiveness for platelets, leukocytes and even erythrocytes. Microvascular thrombosis (as part of DIC) increased capillary permeability, edema and enhanced red blood cell aggregation also contributes to perfusion problems (Spronk 2004; Ince 2005; Moutzouri 2007; Trzeciak 2007; Lundy 2009; Ostergaard 2015). In a developed manifest sepsis, fibrinogen concentration increases (Baskurt 1997; Baskurt 2007; Reggiori 2009). However, in early stage, due to the fibrinogen consumption and other direct effects on blood cells, a decrease in erythrocyte aggregation might be also observed (Nemeth 2015a). Since several endothelial functions are

controlled by the shear stress via mechanotransducers, any changes in the rheology of circulating blood, and consequently in shear forces and flow profile on the vascular wall, may influence the endothelial functions (Gori 2007; Chiu 2011; Chandran 2012). Altered rheology can cause further progression in the pathophysiological process that may result in rheological changes again, as a part of a vicious circle (Baskurt 2007).

EXPERIMENTAL SURGICAL CONSIDERATIONS INVESTIGATING MICROCIRCULATION AND MICRO-RHEOLOGY

Most of the surgical investigations, by their nature, involve animal models. Using the well-defined, animal protection and laboratory animal science considerations (van Zutphen 2001), correctly designed animal experimentation is still important nowadays. Several questions exist that cannot be examined by *in vitro* methods or in tissue cultures: sufficient information can only be obtained by complex investigation in organ systems or in organs *in vivo*. Extrapolatability of the questions, i.e., their extrapolation to the original clinical issue in human references, is a further determining factor.

In view of factors determining the blood and plasma viscosity, red blood cell deformability and aggregation, and microcirculation, it is clear, that with respect to laboratory animal species, we have to expect significant interspecies and gender differences (Usami 1969; Chien 1971; Chen 1994; Popel 1994; Windberger 2003, 2007; Szabo 2006; Nemeth 2010). We have to carefully consider all these aspects when deciding on the necessity of adaptation and methodological standardization of measuring methods.

For humans the currently known hemorheological measuring methods or a measurement technique guideline is available (Baskurt 2009). This guideline covers the sampling and sample handling instructions and recommendations beside the special measurement technique details. With respect to animal experimentation, no such guideline is available; therefore, in addition to exploring the interspecies and gender hemorheological differences, we have to examine the handling and preparation details of blood samples required during the experiments, where considerable interspecies differences can also be anticipated. They can seriously influence the results, their evaluation, assessment and extrapolatability.

Another question is the way and location of blood sampling. In addition to the animal welfare considerations, such as the quantity of blood sample and the repeatability (van Zutphen 2001), we have to consider the possible arterio-venous micro-rheological differences (Nemeth 2014b).

In the detectability of the alterations, the different sensitivity and specifications of hemorheological measuring instruments and devices, such as cell size/pore size ratio during filtrometry or the orientation of cells and the viscosity of suspending medium in the ektacytometry examinations of EI need to be considered (Hardeman 2007; Baskurt 2009; Nemeth 2014a). A detailed analysis of these issues, the standardization and comparative hemorheological tests may contribute to the safe planning, performing of the experimental surgical models and to the evaluability of the obtained results with objective data.

In microcirculatory and micro-rheological investigations of animal experiments, several issues have to be taken into consideration (Nemeth 2014a):

- *Concerns a priori:* planning of experiments and techniques; counting on inter-species and gender differences (additionally: the estrus cycle of animals); careful planning of blood sampling and handling (site of sampling, required blood sample volume versus available sample volume, anticoagulant, storage); sample preparation protocols (centrifugation, buffers, etc.); standardized measurement conditions depending on the method/device.
- *Concerns a posteriori:* extrapolation, reliability.

All of these issues are important for critical revision and correct evaluation of the results, so they could be comparable and may provide useful information for the clinical medicine.

CONCLUSION

Adequate microcirculation and restored micro-rheology strikingly influence tissue oxygenation and overall tissue survival during experimental and clinical surgical interventions. Dynamic assessment of the microcirculatory functions can be conducted by numerous methods. The required spatial resolution and tissue depth as well as the type of tissue/organ of interest critically necessitate the use of appropriate microcirculatory methodology when visualization is concerned. Vascular and circulatory (cellular and micro-rheological) elements of the microcirculation have dynamic interactions and these usually show parallel changes in different surgical models. By using appropriate and up-to-date methodology, these changes can be dynamically assessed and the effect of alleviating therapies be accurately judged by using proper quantification. These findings provide a rational basis for tailoring future life-saving interventions.

REFERENCES

Aird, WC. The role of the endothelium in severe sepsis and multiple organ dysfunction syndrome. *Blood*, 2003, 101(10), 3765–3777.

Ames, A; 3rd, Wright, RL; Kowada, M; Thurston, JM; Majno, G. Cerebral ischemia. II. The no reflow phenomenon. *Am. J. Pathol.*, 1968, 52(2), 437–453.

Anaya-Prado R, Toledo-Pereyra LH, Lentsch AB, Ward PA. Ischemia/reperfusion injury. *J. Surg. Res.*, 2002, 105(2), 248–258.

Armstrong, JK; Wenby, RB; Meiselman, HJ; Fisher, TC. The hydrodynamic radii of macromolecules and their effect on red blood cell aggregation. *Biophys. J.*, 2004, 87(6), 4259–4270.

Awan, ZA; Wester, T; Kvernebo, K. Human microvascular imaging, a review of skin and tongue videomicroscopy techniques and analysing variables. *Clin. Physiol. Funct. Imaging*, 2010, 30(2), 79−88.

Aykut, G; Veenstra, G; Scorcella, C; Ince, C; Boerma, C. Cytocam-IDF (incident dark field illumination) imaging for bedside monitoring of the microcirculation. *Intensive Care Med. Exp.*, 2015, 3(1), 4. http: //icm-experimental.springeropen.com/articles/ 10.1186/ s40635-015-0040-7.

Bajory, Z; Hutter, J; Krombach, F; Messmer, K. The role of endothelin-1 in ischemia-reperfusion induced acute inflammation of the bladder in rats. *J. Urol.*, 2002, 168(3), 1222−1225.

Baskurt, OK; Boynard, M; Cokelet, GC; Connes, P; Cooke, BM; Forconi, S; Hardeman, MR; Jung, F; Liao, F; Meiselman, HJ; Nash, G; Nemeth, N; Neu, B; Sandhagen, B; Shin, S; Thurston, G; Wautier, JL. International Expert Panel for Standardization of Hemorheological Methods, New guidelines for hemorheological laboratory techniques. *Clin. Hemorheol. Microcirc.*, 2009, 42(2), 75–97.

Baskurt, OK; Gelmont, D; Meiselman, HJ. Red blood cell deformability in sepsis. *Am. J. Respir. Crit. Care Med.*, 1998, 157(2), 421–427.

Baskurt, OK; Neu, B; Meiselman, HJ. Determinants of red blood cell aggregation. In, Baskurt OK, Neu B, Meiselman HJ, editors. *Red Blood Cell Aggregation*. Boca Raton, CRC Press, 2012. pp. 9–29.

Baskurt, OK; Neu, B; Meiselman, HJ. Measurement of red blood cell aggregation. In, Baskurt OK, Neu B, Meiselman HJ, editors. *Red Blood Cell Aggregation*. Boca Raton, CRC Press, 2012. pp. 63–132.

Baskurt, OK; Temiz, A; Meiselman, HJ. Red blood cell aggregation in experimental sepsis. *J. Lab. Clin. Med.*, 1997, 130(2), 183–190.

Baskurt, OK. *In vivo* correlates of altered blood rheology. *Biorheology*, 2008, 45(6), 629–638.

Baskurt, OK. Mechanisms of blood rheology alterations. In: Baskurt OK, Hardeman MR, Rampling MW, Meiselman HJ, editors. *Handbook of Hemorheology and Hemodynamics*. Amsterdam, IOS Press, 2007. pp. 170–190.

Bezemer, R; Khalilzada, M; Ince, C. Recent advancements in microcirculatory image acquisition and analysis. In, *Yearbook of intensive care and emergency medicine*. Berlin, Springer, 2008. p. 677–690.

Bishop, JJ; Popel, AS; Intaglietta, M; Johnson, PC. Rheological effects of red blood cell aggregation in the venous network, a review of recent studies. *Biorheology*, 2001, 38, 263–274.

Bitbol, M. Red blood cell orientation in orbit C = 0. *Biophys. J.*, 1986, 49(5), 1055–1068.

Boas, DA; Dunn, AK. Laser speckle contrast imaging in biomedical optics. *J. Biomed. Opt.*, 2010, 15(1), 011109.

Bogar, L; Juricskay, I; Kesmarky, G; Kenyeres, P; Toth, K. Erythrocyte transport efficacy of human blood, a rheological point of view. *Eur. J. Clin. Invest.*, 2005, 35(11), 687–690.

Bohlen, HG; Henrich, H; Gore, RW; Johnson PC. Intestinal muscle and mucosal blood flow during direct sympathetic stimulation. *Am. J. Physiol.*, 1978, 235, H40–H45.

Bor-Kucukatay, M; Wenby, RB; Meiselman, HJ; Baskurt, OK. Effects of nitric oxide on red blood cell deformability. *Am. J. Physiol. Heart Circ. Physiol.*, 2003, 284(5), H1577–H1584.

Briers, JD; McNamara, PM; O'Connell, ML; Leahy MJ. Laser Speckle Contrast Analysis (LASCA) for measuring blood flow. In: Leahy MJ, editor. *Microcirculation imaging*. Weinheim, Wiley-Blackwell, 2012. pp. 147−164.

Briers, JD; Richards, G; He XW. Capillary Blood Flow Monitoring Using Laser Speckle Contrast Analysis (LASCA). *J. Biomed. Opt.*, 1999, 4(1), 164−175.

Buerk, DG. Measuring tissue PO2 with microelectrodes. *Methods Enzymol.*, 2004, 381, 665−690.

Carvalho, FA; Connell, S; Miltenberger-Miltenyi, G; Pereira, SV; Tavares, A; Ariëns, RA; Santos NC. Atomic force microscopy-based molecular recognition of a fibrinogen receptor on human erythrocytes. *ACS Nano*, 2010, 4(8), 4609–4620.

Chandran, KB; Rittgers, SE; Yoganathan AP. Rheology of blood and vascular mechanics. In, Chandran KB, Rittgers SE, Yoganathan AP, editors. *Biofluid Mechanics*. CRC Boca Raton, Press, 2012. pp. 109–154.

Chasis, JA; Mohandas N. Erythrocyte membrane deformability and stability, two distinct membrane properties that are independently regulated by skeletal protein associations. *J. Cell Biol.*, 1986, 103(2), 343–350.

Chen, D; Kaul DK. Rheologic and hemodynamic characteristics of red cells of mouse, rat and human. *Biorheology*, 1994, 31(1), 103–113.

Chien, S; Usami, S; Dellenback, RJ; Bryant CA. Comparative hemorheology – hematological implications of species differences in blood viscosity. *Biorheology*, 1971, 8(1), 35–57.

Chien, S. Biophysical behavior of red cells in suspension. In: Surgenor DM, editor. *The red blood cell*. New York, Academic Press, 1975. pp. 1031–1133.

Chiu, JJ; Chen S. Effects of disturbed flow on vascular endothelium, pathophysiological basis and clinical perspectives. *Physiol. Rev.*, 2011, 91(1), 327–387.

Choi, B; Kang, NM; Nelson JS. Laser speckle imaging for monitoring blood flow dynamics in the in vivo rodent dorsal skin fold model. *Microvasc. Res.*, 2004, 68(2), 143−146.

Cokelet, GR; Meiselman HJ. Basic aspects of hemorheology. In: Baskurt OK, Hardeman MR, Rampling MW, Meiselman HJ, editors. *Handbook of Hemorheology and Hemodynamics*. Amsterdam, IOS Press, 2007a pp. 21–33.

Cokelet, GR; Meiselman HJ. Macro- and micro-rheological properties of blood. In, Baskurt OK, Hardeman MR, Rampling MW, Meiselman HJ, editors. *Handbook of Hemorheology and Hemodynamics*. Amsterdam, IOS Press, 2007b pp. 45–71.

Czabanka, M; Peter, C; Martin, E; Walther A. Microcirculatory endothelial dysfunction during endotoxemia –insights into pathophysiology, pathologic mechanisms and clinical relevance. *Curr. Vasc. Pharmacol.*, 2007, 5(4), 266–275.

Davis, MJ; Hill, MA; Kuo L. Local regulation of microvascular perfusion. In, Tuma RF, Duran WN, Ley K, editors. *Handbook of Physiology, Microcirculation*. 2nd edition. Amsterdam, Elsevier Academic Press, 2008. pp. 161−284.

Davis, MJ. Perspective, physiological role(s) of the vascular myogenic response. *Microcirculation*, 2012, 19(2), 99−114.

De, Backer, D; Hollenberg, S; Boerma, C; Goedhart, P; Büchele, G; Ospina-Tascon, G; Dobbe, I; Ince C. How to evaluate the microcirculation, report of a round table conference. *Crit. Care.* 2007, 11(5), R101. http, //ccforum.com/content/11/5/R101.

De, Blasi, RA; Ferrari, M; Natali, A; Conti, G; Mega, A; Gasparetto A. Noninvasive measurement of forearm blood flow and oxygen consumption by near-infrared spectroscopy. *J. Appl. Physiol., (1985)* 1994, 76(3), 1388−1393.

De Blasi, RA. Is muscle StO2 an appropriate variable for investigating early compensatory tissue mechanisms under physiological and pathological conditions? *Intensive Care Med.*, 2008, 34(9), 1557−1559.

de Oliveira, S; Saldanha, C. An overview about erythrocyte membrane. *Clin. Hemorheol. Microcirc.*, 2010, 44(1), 63–74.

den Uil, CA; Lagrand, WK; van der Ent, M; Jewbali, LS; Cheng, JM; Spronk, PE; Simoons, ML. Impaired microcirculation predicts poor outcome of patients with acute myocardial infarction complicated by cardiogenic shock. *Eur. Heart J.*, 2010, 31(24), 3032–3039.

Denk, W; Strickler, JH; Webb WW. Two-photon laser scanning fluorescence microscopy. *Science*, 1990, 248(4951), 73−76.

Donati, A; Domizi, R; Damiani, E; Adrario, E; Pelaia, P; Ince C. From macrohemodynamic to the microcirculation. *Crit. Care. Res. Pract.*, 2013, 2013, 892710.

Doppler, JC. *Uber das farbige Licht der Doppelsterne und einiger anderer Gestirne des Himmels. In, Versuch einer das Bradley'sche berrations-theorem als integrirrenden Theil in sich schlissenden allgemeineren Theorie. Prag, In Commission bei Borrosch & Andre, 1842.*

Dupire, J; Socol, M; Viallat A. Full dynamics of a red blood cell in shear flow. *Proc. Natl. Acad. Sci. USA*, 2012, 109(51), 20808–20813.

Egawa, G; Nakamizo, S; Natsuaki, Y; Doi, H; Miyachi, Y; Kabashima K. Intravital analysis of vascular permeability in mice using two-photon microscopy. *Sci. Rep.*, 2013, 3, 1932.

Ellinger, P; Hirt A. Mikroscopische Untersuchungen an lebenden Organen. I. Mitt. Metodik, Intravitalmikroskopie. *Zeitschrift für Anatomie und Entwicklungs-Geschichte*, 1929, 80, 791−802.

Eltzschig, H; Eckle T. Ischemia and reperfusion – from mechanism to translation. *Nature Medicine*, 2011, 17(11), 1391–1401.

Endrich, B; Asaishi, K; Götz, A; Messmer K. Technical report--a new chamber technique for microvascular studies in unanesthetized hamsters. *Res. Exp. Med. (Berl).*, 1980, 177(2), 125−134.

Ernst, E; Matrai A. Zum Thema 'optimaler Hämatocrit' – Rationale der Hämodilutionstherapie. *Herz Kreislauf.*, 1983, 9, 409–415.

Essex, TJ; Byrne PO. A laser Doppler scanner for imaging blood flow in skin. *J. Biomed. Eng.*, 1991, 13(3), 189−194.

Fåhraeus, R; Lindqvist T, The viscosity of the blood in narrow capillary tubes. *Am. J. Physiol.* 1931, 96, 562–568.

Fåhraeus, R. The influence of the rouleau formation of the erythrocytes on the rheology of the blood. *Acta Med. Scand.*, 1958, 161(2), 151–165.

Fang, X; TangW; Sun, S; Huang, L; Chang, YT; Castillo, C; Weil MH. Comparison of buccal microcirculation between septic and hemorrhagic shock. *Crit. Care Med.*, 2006, 34 (12 Suppl), S447–S453.

Foster, FS. High frequency ultrasound for the visualization and quantification of the microcirculation. In, Leahy MJ, editor. *Microcirculation imaging*. Weinheim, Wiley-Blackwell, 2012. pp. 293−312.

Fredriksson, I; Larsson, M; Strömberg T. Laser Doppler flowmetry. In, Leahy MJ, editor. *Microcirculation imaging*. Weinheim, Wiley-Blackwell, 2012. pp. 67−86.

Fromy, B; Legrand, MS; Abraham, P; Leftheriotis, G; Cales, P; Saumet JL. Effects of positive pressure on both femoral venous and arterial blood velocities and the cutaneous microcirculation of the forefoot. *Cardiovasc. Res.*, 1997, 36(3), 372−376.

Gilbert-Kawai, E; Coppel, J; Bountziouka, V; Ince, C; Martin D. A comparison of the quality of image acquisition between the incident dark field and sidestream dark field video-microscopes. *BMC Med. Imaging* 2016, 16, 10.http, //bmcmedimaging. biomedcentral. com/articles/10.1186/ s12880-015-0078-8

Goedhart, PT; Khalilzada, M; Bezemer, R; Merza, J; Ince C. Sidestream Dark Field (SDF) imaging, a novel stroboscopic LED ring-based imaging modality for clinical assessment of the microcirculation. *Opt. Express.*, 2007, 15(23), 15101–15114.

Goldsmith, HL; Marlow J. Flow behavior of erythrocytes, I. Rotation and deformation in dilute suspensions. *Proc. R. Soc. Lond.*, B 1972, 182, 351–384.

Gori, T; Forconi S. Endothelium and hemorheology. In: Baskurt OK, Hardeman MR, Rampling MW, Meiselman HJ, editors. *Handbook of Hemorheology and Hemodynamics*. Amsterdam, IOS Press, 2007. pp. 339–350.

Gori, T; Münzel T. Oxidative stress and endothelial dysfunction, therapeutic implications. *Ann. Med.*, 2011, 43(4), 259–272.

Granger, DN; Höllwarth, ME; Parks DA. Ischemia-reperfusion injury, role of oxygen-derived free radicals. *Acta Physiol. Scand Suppl.*, 1986, 548, 47–63.

Granger, DN; Rutili, G; McCord JM. Superoxide radicals in feline intestinal ischemia. *Gastroenterology*, 1981, 81(1), 22−29.

Granger, DN; Senchenkova E. *Inflammation and the Microcirculation*. San Rafael, Morgan & Claypool Life Sciences, 2010.

Granger, DN. Physiology and pathophysiology of the microcirculation. *Dialogues Cardiovasc Med.*, 1988, 3, 123–140.

Granger, HJ; Goodman, AH; Cook BH. Metabolic models of microcirculatory regulation. *Fed. Proc.*, 1975, 34(11), 2025−2030.

Grisham, MB; Granger, DN; Lefer DJ. Modulation of leukocyte–endothelial interactions by reactive metabolites of oxygen and nitrogen, relevance to ischemic heart disease. *Free Radic. Biol. Med.*, 1998, 25(4-5), 404−433.

Groner, W; Winkelman, JW; Harris, AG; Ince, C; Bouma, GJ; Messmer, K; Nadeau RG. Orthogonal polarization spectral imaging, a new method for study of the microcirculation. *Nat. Med.*, 1999, 5(10), 1209−1212.

Hardeman, MR; Goedhart, PT; Shin S. Methods in hemorheology. In, Baskurt OK, Hardeman MR, Rampling MW, Meiselman HJ, editors. *Handbook of Hemorheology and Hemodynamics*. Amsterdam, IOS Press, 2007. pp. 242–266.

Harkness, J. The viscosity of human blood plasma, its measurement in health and disease. *Biorheology*, 1971, 8(3), 171–193.

Harms, FA; Bodmer, SI; Raat, NJ; Mik EG. Cutaneous mitochondrial respirometry, non-invasive monitoring of mitochondrial function. *J. Clin. Monit. Comput.*, 2015, 29(4), 509−519.

Hepple, RT; Hogan, MC; Stary, C; Bebout, DE; Mathieu-Costello, O; Wagner PD. Structural basis of muscle O2 diffusing capacity, evidence from muscle function in situ. *J. Appl. Physiol.*, 2000, 88(2), 560–566.

Hernandez, G; Bruhn, A; Ince C. Microcirculation in sepsis, new perspectives. *Curr. Vasc. Pharmacol.*, 2013, 11(2), 161−169.

Hernandez, LA; Grisham, MB; Twohig, B; Arfors, KE; Harlan, JM; Granger DN. Role of neutrophils in ischemia–reperfusion-induced microvascular injury. *Am. J. Physiol.*, 1987, 253(3 Pt 2), H699−H703.

Hölzle, F; Rau, A; Loeffelbein, DJ; Mücke, T; Kesting, MR; Wolff KD. Results of monitoring fasciocutaneous, myocutaneous, osteocutaneous and perforator flaps, 4-year experience with 166 cases. *Int. J. Oral Maxillofac. Surg.*, 2010, 39(1), 21−28.

Honig, CR; Odoroff, CL; Frierson JL. Active and passive capillary control in red muscle at rest and in exercise. *Am. J. Physiol.*, 1982, 243(2), H196–H206.

Hoole, S. *The select works of Antony van Leeuwenhoek, containing his microscopical discoveries in many of the works of nature*. Fleet-Street, Black-Horse Court, 1800.

Hu, S; Wang LV. Photoacustic tomography of microcirculation. In, Leahy MJ, editor. *Microcirculation imaging*. Weinheim, Wiley-Blackwell, 2012. pp. 259−278.

Ichikawa, H; Flores, S; Kvietys, PR; Wolf, RE; Yoshikawa, T; Granger, DN; Aw TY. Molecular mechanisms of anoxia/reoxygenation-induced neutrophil adherence to cultured endothelial cells. *Circ. Res.*, 1997, 81(6), 922−931.

Ince, C. The microcirculation is the motor of sepsis. *Crit. Care.*, 2005, 9(Suppl 4), S13–S19.

Irwin, JW; Macdonald, J; 3rd. Microscopic observations of the intrahepatic circulation of living guinea pigs. *Anat. Rec.*, 1953, 117(1), 1−15.

Ishikawa, M; Sekizuka, E; Sato, S; Yamaguchi, N; Shimizu, K; Kobayashi, K; Bertalanffy, H; Kawase T. *In vivo* rat closed spinal window for spinal microcirculation, observation of pial vessels, leukocyte adhesion, and red blood cell velocity. *Neurosurgery.*, 1999, 44, 156–161.

Ivanov, KP; Mel'nikova NN. Leukocytes as a cause of microcirculatory dysfunction. *Bull. Exp. Biol. Med.*, 2006, 141(6), 666–668.

Jackson, WF; Duling BR. The oxygen sensitivity of hamster cheek pouch arterioles. *In vitro* and in situ studies. *Circ. Res.*, 1983, 53(4), 515−525.

Johnson, RM. pH effects on red blood cell deformability. *Blood Cells*, 1985, 11(2), 317–321.

Kameneva, MV; Antaki JF. Mechanical trauma to blood. In, Baskurt OK, Hardeman MR, Rampling MW, Meiselman HJ, editors. *Handbook of Hemorheology and Hemodynamics*. Amsterdam, IOS Press, 2007. pp. 206–227.

Kanwar, S; Hickey, MJ; Kubes P. Postischemic inflammation, a role for mast cells in intestine but not in skeletal muscle. *Am. J. Physiol.*, 1998, 275(2 Pt 1), G212−G218.

Kayar, E; Mat, F; Meiselman, HJ; Baskurt OK. Red blood cell rheological alterations in a rat model of ischemia-reperfusion injury. *Biorheology*, 2001, 38(5-6), 405–414.

Kerskens, CM; Piech, RM; Meaney JFM. Imaging blood circulation using Nuclear Magnetic Resonance. In: Leahy MJ, editor. *Microcirculation imaging*. Weinheim, Wiley-Blackwell, 2012. pp. 349−385.

Kesmarky, G; Kenyeres, P; Rabai, M; Toth K. Plasma viscosity, a forgotten variable. *Clin. Hemorheol. Microcirc.*, 2008, 39(1-4), 243–246.

Kim, Y; Kim, K; Park YK. Measurement techniques for red blood cell deformability, recent advances. In, *Blood Cell – An Overview of Studies in Hematology*. Moschandreou TE, ed. InTech, 2012. pp. 167–194.

Klar, E; Endrich, B; Messmer K. Microcirculation of the pancreas. A quantitative study of physiology and changes in pancreatitis. *Int. J. Microcirc. Clin. Exp.*, 1990, 9, 85–101.

Kline, TL; Ritman EL. Studying microcirculation with Micro-CT. In, Leahy MJ, editor. *Microcirculation imaging*. Weinheim, Wiley-Blackwell, 2012. pp. 313−348.

Koppensteiner, R. Blood rheology in emergency medicine. *Semin. Thromb. Hemost.*, 1996, 22(1), 89–91.

Kuhnle, GE; Leipfinger, FH; Goetz AE. Measurement of microhemodynamics in the ventilated rabbit lung by intravital fluorescence microscopy. *J. Appl. Physiol.*, 1993, 74, 1462–1471.

Kvietys, PR. *The Gastrointestinal Circulation*. San Rafael, Morgan & Claypool Life Sciences, 2010.

Kwaan, HC. Role of plasma proteins in whole blood viscosity, a brief clinical review. *Clin. Hemorheol. Microcirc.*, 2010, 44(3), 167–176.

Langer, HF; Chavakis T. Leukocyte-endothelial interactions in inflammation. *J Cell Mol Med.*, 2009, 13(7), 1211–1220.

Leahy, MJ; de, Mul, FF; Nilsson, GE; Maniewski R. Principles and practice of the laser-Doppler perfusion technique. *Technol. Health Care*, 1999, 7(2-3), 143−162.

Leahy, MJ. editor. *Microcirculation imaging*. Weinheim, Wiley-Blackwell, 2012.

Lehmann, C. editor. *Intravital microcirculation imaging*. Lengerich, Pabst Science Publishers, 2012.

Lehr, HA; Leunig, M; Menger, MD; Nolte, D; Messmer K. Dorsal skinfold chamber technique for intravital microscopy in nude mice. *Am. J. Pathol.*, 1993, 143(4), 1055−1062.

Levy, MM; Fink, MP; Marshall, JC; Abraham, E; Angus, D; Cook, D; Cohen, J; Opal, SM; Vincent, JL; Ramsay G, International Sepsis Definitions Conference. 2001 SCCM/ESICM/ACCP/ATS/SIS International Sepsis Definitions Conference. *Intensive Care Med.*, 2003, 29(4), 530–538.

Ley, K; Laudanna, C; Cybulsky, MI; Nourshargh S. Getting to the site of inflammation, the leukocyte adhesion cascade updated. *Nat Rev Immunol.*, 2007, 7(9), 678–689.

Lipowsky, HH. Microvascular rheology and hemodynamics. *Microcirculation*, 2005,12(1), 5–15.

Lipowsky, HH. Shear stress in the circulation. In, Bevan J, Kaley G, editors. Flow Dependent Regulation of Vascular Function. *Clinical Physiology Series*. New York, Oxford University Press, 1995. pp. 28–45.

Liu, LM; Dubick MA. Hemorrhagic shock-induced vascular hyporeactivity in the rat, relationship to gene expression of nitric oxide synthase, endothelin-1, and select cytokines in corresponding organs. *J. Surg. Res.*, 2005, 125(2), 128–136.

Liu, R; Qin, J; Wang RK. Motion-contrast laser speckle imaging of microcirculation within tissue beds *in vivo*. *J. Biomed. Opt.*, 2013, 18(6), 060508.

Lundy, DJ; Trzeciak S. Microcirculatory dysfunction in sepsis. *Crit. Care Clin.*, 2009, 25(4), 721–731.

Maeda, N. Erythrocyte rheology in microcirculation. *Jpn. J. Physiol.*, 1996,46(1), 1–14.

Masedunskas, A; Milberg, O; Porat-Shliom, N; Sramkova, M; Wigand, T; Amornphimoltham, P; Weigert R. Intravital microscopy, a practical guide on imaging intracellular structures in live animals. *Bioarchitecture*, 2012, 2(5), 143−157.

Massberg, S; Enders, G; Leiderer, R; Eisenmenger, S; Vestweber, D; Krombach, F; Messmer K. Platelet-endothelial cell interactions during ischemia/reperfusion, the role of P-selectin. *Blood*, 1998, 92, 507–515.

Massey, MJ; Shapiro NI. A guide to human *in vivo* microcirculatory flow image analysis. *Crit. Care*, 2016, 20, 35. http: //ccforum.biomedcentral.com/articles/10.1186/s13054-016-1213-9

Mazo, IB; Gutierrez-Ramos, JC; Frenette, PS; Hynes, RO; Wagner, DD; von, Andrian UH. Hematopoietic progenitor cell rolling in bone marrow microvessels, parallel contributions by endothelial selectins and vascular cell adhesion molecule 1. *J. Exp. Med.*, 1998, 188, 465–474.

Mazzoni, MC; Intaglietta, M; Cragoe, EJ; Jr. Arfors, KE. Amiloride-sensitive Na+ pathways in capillary endothelial cell swelling during hemorrhagic shock. *J. Appl. Physiol.*, 1992, 73(4), 1467–1473.

McCord, JM; Roy RS; Schaffer SW. Free radicals and myocardial ischemia. The role of xanthine oxidase. *Adv. Myocardiol.*, 1985, 5, 183–189.

McCord, JM. Oxygen-derived free radicals in post-ischemic tissue injury. *N. Engl. J. Med.*, 1985, 312, 159–163.

McDonald. *Blood Flow in Arteries*. Baltimore, The Williams and Wilksin Co, 1974. pp. 356–378.

Meiselman, HJ. Morphological determinants of red blood cell deformability. *Scand. J. Clin. Lab. Invest.*, 1981, 41(Suppl. 156), 27–34.

Menger, MD; Marzi, I; Messmer K. *In vivo* fluorescence microscopy for quantitative analysis of the hepatic microcirculation in hamsters and rats. *Eur. Surg. Res.*, 1991, 23, 158–169.

Menger, MD; Steiner, D; Messmer K. Microvascular ischemia-reperfusion injury in striated muscle, significance of 'no-reflow'. *Am. J. Physiol.*, 1992, 263(6 Pt 2), H1892–H1900.

Menzebach, A; Mutz, C; Scheeren TW. Microcirculatory monitoring of a Jehovah's Witness suffering from haemorrhagic shock. *Eur. J. Anaesthesiol.*, 2008, 25(1), 81−83.

Merz, KM; Pfau, M; Blumenstock, G; Tenenhaus, M; Schaller HE, Rennekampff HO. Cutaneous microcirculatory assessment of the burn wound is associated with depth of injury and predicts healing time. *Burns.*, 2010, 36(4), 477−482.

Michiels, C; Arnould, T; Knott, I; Dieu, M; Remacle, J. Stimulation of prostaglandin synthesis by human endothelial cells exposed to hypoxia. *Am. J. Physiol. Cell Physiol.*, 1993, 264(4 Pt 1), C866–C874.

Mik, EG; Stap, J; Sinaasappel, M; Beek, JF; Aten, JA; van, Leeuwen, TG; Ince C. Mitochondrial PO2 measured by delayed fluorescence of endogenous protoporphyrin IX. *Nat. Methods*, 2006, 3(11), 939−945.

Milstein, DMJ; Bezemer, R; Ince C. Sidestream Dark-Filed (SDF) video microscopy for clinical imaging of the microcirculation. In, Leahy MJ, editor. *Microcirculation imaging*. Weinheim, Wiley-Blackwell, 2012. pp. 37−52.

Mohandas, N; Gallagher PG. Red cell membrane, past, present, and future. *Blood*, 2008, 112(10), 3939–3948.

Moore, JP; Dyson, A; Singer, M; Fraser J. Microcirculatory dysfunction and resuscitation, why, when, and how. *Br. J. Anaesth.*, 2015, 115(3), 366−375.

Moutzouri, AG; Skoutelis, AT; Gogos, CA; Missirlis, YF; Athanassiou GM. Red blood cell deformability in patients with sepsis, a marker for prognosis and monitoring of severity. *Clin. Hemorheol. Microcirc.*, 2007, 36(4), 291–299.

Musielak, M. Red blood cell-deformability measurement, review of techniques. *Clin. Hemorheol. Microcirc.*, 2009, 42(1), 47–64.

Nakhostine, N; Lamontagne D. Adenosine contributes to hypoxia-induced vasodilation through ATP-sensitive K+ channel activation. *Am. J. Physiol.*, 1993, 265(4 Pt 2), H1289–H1293.

Nash, GB; Watts, T; Thornton, C; Barigou M. Red cell aggregation as a factor influencing margination and adhesion of leukocytes and platelets. *Clin. Hemorheol. Microcirc.*, 2008, 39(1-4), 303–310.

Nduka, OO; Parrillo JE. The pathophysiology of septic shock. *Crit. Care Nurs. Clin. North Am.*, 2011, 23(1), 41–66.

Nemeth, N; Berhes, M; Kiss, F; Hajdu, E; Deak, A; Molnar, A; Szabo, J; Fulesdi B. Early hemorheological changes in a porcine model of intravenously given E. coli induced fulminant sepsis. *Clin. Hemorheol. Microcirc.*, 2015a, 61(3), 479–496.

Nemeth, N; Furka, I; Miko I. Hemorheological changes in ischemia-reperfusion, an overview on our experimental surgical data. *Clin. Hemorheol. Microcirc.*, 2014a, 57(3), 215−225.

Nemeth, N; Kiss, F; Furka, I; Miko I. Gender differences of blood rheological parameters in laboratory animals. *Clin. Hemorheol. Microcirc.*, 2010, 45(2-4), 263−272.

Nemeth, N; Kiss, F; Klárik, Z; Tóth, E; Mester, A; Furka, I; Miko I. Simultaneous investigation of hemodynamic, microcirculatory and arterio-venous micro-rheological parameters in infrarenal or suprarenal aortic cross-campling model in the rat. *Clin. Hemorheol. Microcirc*., 2014b, 57(4), 339−353.

Nemeth, N; Lesznyak, T; Brath, E; Acs, G; Nagy, A; Pap-Szekeres, J; Furka, I; Miko I. Changes in microcirculation after ischemic process in rat skeletal muscle. *Microsurgery*, 2003, 23(5), 419−423.

Nemeth, N; Toth, E; Nemes B. Agents targeting ischemia-reperfusion injury. In, Huifang C, Shiguang Q, editors. *Current Immunosuppressive Therapy in Organ Transplantation*. Hauppauge, New York, Nova Science Publishers, 2015b pp. 487–533.

Neviere, R; Mathieu, D; Chagnon, JL; Lebleu, N; Millien, JP; Wattel, F. Skeletal muscle microvascular blood flow and oxygen transport in patients with severe sepsis. *Am. J. Respir. Crit. Care Med.*, 1996, 153(1), 191–195.

O'Doherty, J; Leahy, MJ; Nilsson GE. Tissue viability imaging. In, Leahy MJ, editor. *Microcirculation imaging*. Weinheim, Wiley-Blackwell, 2012. pp. 165−196.

Obeid, AN; Barnett, NJ; Dougherty, G; Ward G. A critical review of laser Doppler flowmetry. *J. Med. Eng. Technol.*, 1990, 14(5), 178–181. 37, 43–69.

Pries, AR; Secomb TW. Blood flow in microvascular networks. In, Tuma RF, Duran WN, Ley K, editors. *Handbook of Physiology*, *Microcirculation*. 2nd edition. Amsterdam, Elsevier Academic Press, 2008. pp. 3−36.

Pries, AR; Secomb TW. Rheology of the microcirculation. *Clin. Hemorheol. Microcirc.*, 2003, 29(3-4), 143–148.

Qin, J; Shi, L; Dziennis, S; Reif, R; Wang RK. Fast synchronized dual-wavelength laser speckle imaging system for monitoring hemodynamic changes in a stroke mouse model. *Opt. Lett*., 2012, 37(19), 4005−4007.

Rajan, V; Varghese, B; van, Leeuwen, TG; Steenbergen W. Review of methodological developments in laser Doppler flowmetry. *Lasers Med. Sci.*, 2009, 24(2), 269–283.

Reese, AJ. The effect of hypoxia on liver secretion studied by intravital fluorescence microscopy. *Br. J. Exp. Pathol.*, 1960, 41, 527−535.

Reffelmann, T; Kloner RA. The "no-reflow" phenomenon, basic science and clinical correlates. *Heart*, 2002, 87(2), 162–168.

Rege, A; Murari, K; Seifert, A; Pathak, AP; Thakor NV. Multiexposure laser speckle contrast imaging of the angiogenic microenvironment. *J. Biomed. Opt.*, 2011, 16(5), 056006.

Reggiori, G; Occhipinti, G; De, Gasperi, A; Vincent, JL; Piagnerelli M. Early alterations of red blood cell rheology in critically ill patients. *Crit. Care Med.*, 2009, 37(12), 3041–3046.

Reinhart, WH; Chien S. Red cell rheology in stomatocyte-echinocyte transformation, roles of cell geometry and cell shape. *Blood*, 1980, 67(4), 1110–1118.

Reinhart, WH; Gaudenz, R; Walter R. Acidosis induced by lactate, pyruvate, or HCl increases blood viscosity. *J. Crit. Care*, 2002, 17(1), 38–42.

Reinhart, WH; Piety, NZ; Goede, JS; Shevkoplyas SS. Effect of osmolality on erythrocyte rheology and perfusion of an artificial microvascular network. *Microvasc. Res.*, 2015, 98, 102–107.

Reitsma, S; Slaaf, DW; Vink, H; van, Zandvoort, MA; oude, Egbrink MG. The endothelial glycocalyx, composition, functions, and visualization. *Pflugers Arch.*, 2007, 454(3), 345–359.

Roesner, JP; Vagts, DA; Iber, T; Eipel, C; Vollmar, B; Nöldge-Schomburg GF. Protective effects of PARP inhibition on liver microcirculation and function after haemorrhagic shock and resuscitation in male rats. *Intensive Care Med.*, 2006, 32(10), 1649−1657.

Rosencranz, R; Bogen SA. Clinical laboratory measurement of serum, plasma, and blood viscosity. *Am. J. Clin. Pathol*., 2006, 125(Suppl), S78 –S86.

Rovainen, CM; Woolsey, TA; Blocher, NC; Wang, DB; Robinson OF. Blood flow in single surface arterioles and venules on the mouse somatosensory cortex measured with videomicroscopy, fluorescent dextrans, nonoccluding fluorescent beads, and computer-assisted image analysis. *J. Cereb. Blood Flow. Metab.*, 1993, 13(3), 359–371.

Ruh, J; Ryschich, E; Secchi, A; Gebhard, MM; Glaser, F; Klar, E; Herfarth C. Measurement of blood flow in the main arteriole of the villi in rat small intestine with FITC-labeled erythrocytes. *Microvasc. Res.*, 1998, 56(1), 62−69.

Saetzler, RK; Jallo, J; Lehr, HA; Philips, CM; Vasthare, U; Arfors, KE; Tuma RF. Intravital fluorescence microscopy, impact of light-induced phototoxicity on adhesion of fluorescently labeled leukocytes. *J. Histochem. Cytochem.*, 1997, 45, 505–513.

Sakr, Y; Dubois, MJ; De, Backer, D; Creteur, J; Vincent JL. Persistent microcirculatory alterations are associated with organ failure and death in patients with septic shock. *Crit. Care Med.*, 2004, 32(9), 1825–1831.

Sakr, Y; Gath, V; Oishi, J; Klinzing, S; Simon, TP; Reinhart, K; Marx G. Characterization of buccal microvascular response in patients with septic shock. *Eur. J. Anaesthesiol*., 2010, 27(4), 388−394.

Saldanha, C. Fibrinogen interaction with the red blood cell membrane. *Clin. Hemorheol. Microcirc.*, 2013, 53(1-2), 39–44.

Sandker, SC; Hondebrink, E; Grandjean, JG; Steenbergen W. Laser speckle contrast analysis for quantifying the Allen test, a feasibility study. *Lasers Surg. Med.*, 2014, 46(3), 186−192.

Scheeren, TW. Journal of Clinical Monitoring and Computing 2015 end of year summary, tissue oxygenation and microcirculation. *J. Clin. Monit. Comput.*, 2016, 30(2), 141−146.

Scheeren, TW. Monitoring the microcirculation in the critically ill patient, reflectance spectroscopy. *Intensive Care Med.*, 2011, 37(6), 1045−1046.

Spronk, PE; Zandstra, DF; Ince C. Bench-to-bedside review, Sepsis is a disease of the microcirculation. C*rit. Care*, 2004, 8(6), 462–468.

Steenbergen, W. Fast Full-Field Laser Doppler Perfusion Imaging. In, Leahy MJ, editor. *Microcirculation imaging*. Weinheim, Wiley-Blackwell, 2012. pp. 113−134.

Steenbergen, W. Speckle effects in Laser Doppler Perfusion Imaging. In, Leahy MJ, editor. *Microcirculation imaging*. Weinheim, Wiley-Blackwell, 2012. pp. 135−146.

Steinhausen, M; Zimmerhackl, B; Thederan, H; Dussel, R; Parekh, N; Esslinger, HU; von, Hagens, G; Komitowski, D; Dallenbach FD. Intraglomerular microcirculation, measurements of single glomerular loop flow in rats. *Kidney Int.*, 1981, 20, 230–239.

Stern, MD. *In vivo* evaluation of microcirculation by coherent light scattering. *Nature*, 1975, 254(5495), 56–58.

Sun, CK; Zhang, XY; Zimmermann, A; Davis, G; Wheatley AM. Effect of ischemia-reperfusion injury on the microcirculation of the steatotic liver of the Zucker rat. *Transplantation.*, 2001, 72(10), 1625−1631.

Szabo, A; Vollmar, B; Boros, M; Menger MD. Gender differences in ischemia-reperfusion-induced microcirculatory and epithelial dysfunction in the small intestine. *Life Sci.*, 2006, 78(26), 3058–3065.

Szopinski, J; Kusza, K; Semionow M. Microcirculatory responses to hypovolemic shock. *J. Trauma*, 2011, 71(6), 1779–1788.

Thurston, GB; Henderson NM. Viscoelasticity of human blood. In, Baskurt OK, Hardeman MR, Rampling MW, Meiselman HJ, editors. *Handbook of Hemorheology and Hemodynamics*. Amsterdam, IOS Press, 2007. pp. 72–90.

Tillmanns, H; Ikeda, S; Bing RJ. The effects of nicotine on the coronary microcirculation in the cat heart. *J. Clin. Pharmacol.*, 1974, 14, 426–433.

Trzeciak, S; Cinel, I; Dellinger, PR; Shapiro, NI; Arnold, RC; Parrillo, JE; Hollenberg SM. Microcirculatory Alterations in Resuscitation and Shock (MARS) Investigators. Resuscitating the microcirculation in sepsis, the central role of nitric oxide, emerging concepts for novel therapies, and challenges for clinical trials. *Acad. Emerg. Med.*, 2008, 15(5), 399–413.

Trzeciak, S; Dellinger, RP; Parrillo, JE; Guglielmi, M; Bajaj, J; Abate, NL; Arnold, RC; Colilla, S; Zanotti, S; Hollenberg SM. Early microcirculatory perfusion derangements in patients with severe sepsis and septic shock, relationship to hemodynamics, oxygen transport, and survival. *Ann. Emerg. Med.*, 2007, 49(1), 88–98.

Usami, S; Chien, S; Gregersen MI. Viscometric characteristic of blood of the elephant, man, dog, sheep, and goat. *Am. J. Physiol.*, 1969, 217(3), 884–890.

Vallet, B; Winn, MJ; Asante, NK; Cain SM. Influence of oxygen on endothelium-derived relaxing factor/nitric oxide and K(+)-dependent regulation of vascular tone. *J. Cardiovasc. Pharmacol.*, 1994, 24(4), 595–602.

Vallet, B. Endothelial cell dysfunction and abnormal tissue perfusion. *Crit. Care Med.*, 2002, 30(5 Suppl), S229−S234.

Vallet, B. Vascular reactivity and tissue oxygenation. *Intensive Care Med.*, 1998, 24(1), 3−11.

van, Elteren, HA; Ince, C; Tibboel, D; Reiss IK; de Jonge, RC. Cutaneous microcirculation in preterm neonates, comparison between sidestream dark field (SDF) and incident dark field (IDF) imaging. *J. Clin. Monit. Comput.*, 2015, 29(5), 543−548.

van Meurs, M; Wulfert, FM; Knol, AJ; De Haes, A; Houwertjes, M; Aarts, LP; Molema, G. Early organ-specific endothelial activation during hemorrhagic shock and resuscitation. *Shock*, 2008, 29(2), 291–299.

van Zutphen, LFM; Baumans, V; Beynen, AC; editors. *Principles of Laboratory Animal Science*. Amsterdam, Elsevier, 2001.

Villringer, A; Haberl, RL; Dirnagl, U; Anneser, F; Verst, M; Einhäupl KM. Confocal laser microscopy to study microcirculation on the rat brain surface *in vivo*. *Brain Res.*, 1989, 504(1), 159−160.

Vinogradov, SA; Fernandez-Seara, MA; Dupan, BW; Wilson DF. A method for measuring oxygen distributions in tissue using frequency domain phosphorometry. *Comp. Biochem. Physiol. A Mol. Integr. Physiol.*, 2002, 132(1), 147−152.

Vollmar, B; Menger M. Intestinal ischemia/reperfusion, microcirculatory pathology and functional consequences. *Langenbecks Arch. Surg.*, 2011, 396(1), 13–29.

von Andrian, UH. Intravital microscopy of the peripheral lymph node microcirculation in mice. *Microcirculation*, 1996, 3(3), 287–300.

von Dobschuetz, E; Pahernik, S; Hoffmann, T; Kiefmann, R; Heckel, K; Messmer, K; Mueller-Hoecker, J; Dellian M. Dynamic intravital fluorescence microscopy--a novel method for the assessment of microvascular permeability in acute pancreatitis. *Microvasc. Res.*, 2004, 67(1), 55−63.

Wagner, Z. *Erlauterungstaflen zur Physiologie und Entwicklungsgeschichte*. Leipzig, Leopold Voss, 1839.

Wang, RK; Subhash HM. Optical microangiography, theory and application. In, Leahy MJ, editor. *Microcirculation imaging*. Weinheim, Wiley-Blackwell, 2012. pp. 197−258.

Ward, KR; Torres, Filho, I; Barbee, RW; Torres, L; Tiba, MH; Reynolds, PS; Pittman, RN; Ivatury, RR; Terner J. Resonance Raman spectroscopy, a new technology for tissue oxygenation monitoring. *Crit. Care Med.*, 2006, 34(3), 792−799.

Watanabe, R; Munemasa, T; Matsumura, M; Fujimaki M. Fluorescent liposomes for intravital staining of Kupffer cells to aid *in vivo* microscopy in rats. *Methods Find. Exp. Clin. Pharmacol.*, 2007, 29(5), 321−327.

Watts, SW; Kanagy, NL; Lombard JH. Receptor-mediated events in the microcirculation. In, Tuma RF, Duran WN, Ley K, editors. *Handbook of Physiology, Microcirculation*. 2nd edition. Amsterdam, Elsevier Academic Press, 2008. pp. 285−348.

Weed, RI; LaCelle, PL; Merrill EW. Metabolic dependence of red cell deformability. *J. Clin. Invest.*, 1969, 48(5), 795–809.

Wells, RE. Jr. Rheology of blood in the microvasculature. *N. Engl. J. Med.*, 1964, 270, 832–839.

Windberger, U; Bartholovitsch, A; Plasenzotti, R; Korak, KJ; Heinze G. Whole blood viscosity, plasma viscosity and erythrocyte aggregation in nine mammalian species, reference values and comparison of data. *Exp. Physiol.*, 2003, 88(3), 431–440.

Windberger, U; Baskurt OK. Comparative hemorheology. In, Baskurt OK, Hardeman MR, Rampling MW, Meiselman HJ, editors. *Handbook of Hemorheology and Hemodynamics*. Amsterdam, IOS Press, 2007. pp. 267–285.

Yalcin, O; Wang, Q; Johnson, PC; Palmer, AE, Cabrales P. Plasma expander viscosity effects on red cell-free layer thickness after moderate hemodilution. *Biorheology*, 2011, 48(5), 277–291.

Yoshida, N; Granger, DN; Anderson, DC; Rothlein, R; Lane, C; Kvietys PR. Anoxia/reoxygenation-induced neutrophil adherence to cultured endothelial cells. *Am. J. Physiol.*, 1992,262(6 Pt 2), H1891−H1898.

Zipfel, WR; Williams, RM; Webb WW. Nonlinear magic, multiphoton microscopy in the biosciences. *Nat. Biotechnol.*, 2003, 21(11), 1369−1377.

Zweifach, BW. Direct observation of the mesenteric circulation in experimental animals. *Anat. Rec.*, 1954, 120(1), 277−291.

In: Encyclopedia of Surgery (22 Volume Set)
Editors: Andreas Lehrer and Kristin Mueller
ISBN: 978-1-53618-329-0
© 2020 Nova Science Publishers, Inc.

Chapter 199

EXPERIMENTAL GENE THERAPY USING NAKED DNA

Eiji Kobayashi*, MD, PhD
Department of Organ Fabrication, Keio University School of Medicine, Tokyo, Japan

ABSTRACT

Experimental surgery using animal models is indispensable for applying new science developments to human clinical surgery. In recent years, attempts have been made to apply gene transfer technology in the surgical field as well as various naked genes.

In this chapter, we first introduced non-viral *in vivo* gene transfer techniques that we have applied thus far. In addition to describing the historical background of the development of the gene gun, we showed cancer treatment research and organ transplant research models implemented in small animals. We also introduced the hydrodynamic approach, which involves using catheter techniques via the arteries and veins of the target organ. We used a rat model to demonstrate that gene transfer can be effectively performed on the liver and muscles due to the characteristics of this organ and tissue. This approach was then extended to pig models. Finally, we introduced DVA vaccine in pigs via electroporation, which is a technique that is already clinically used in the veterinary field.

These advanced surgical technologies and models are expected to contribute to future research.

Keywords: gene therapy, naked DNA, pig, gene gun, hydrodynamic method, DNA vaccine

ABBREVIATIONS

AAV	Adeno-Associated Vector
ALT	Auxiliary Liver Transplantation
APC	Antigen presenting cell
CAT	Chloramphenicol acetyltransferase
CTLA4Ig	Cytotoxic T-Lymphocyte Antigen 4-Immunoglobulin

* Corresponding Author's Email: organfabri@keio.jp; Fax: +81-3-5315-4089.

GFP	Green fluorescent protein
HBs	Hepatitis B virus surface
IVIS	In Vivo Imaging System
LacZ	beta-galactosidase
OLT	Orthotopic Liver Transplantation
Tg	transgenic

GENE GUN TECHNOLOGY IN LIVING ANIMALS

The gene gun was developed as a device to physically deliver genes to the target cell by accelerating the delivery of small particles coated with DNA using blasts from gunpowder or high-pressure gas (Figure 1). The process should be of value for studying transient and stable gene expression within intact cells and tissues (Klein 1988).

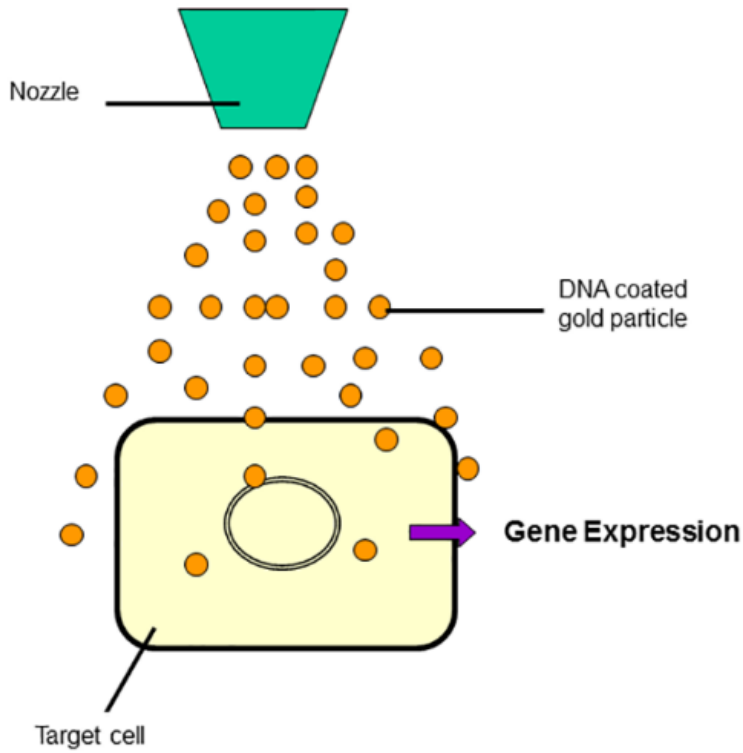

Figure 1. Theoretical schema of high-velocity microprojectiles for delivering nucleic acids into living cells. Small gold particles coated with naked DNA were acetated by blast wind of gunpowder or high-pressure gas. Transient expression of external genes was observed in the living cells of animals and plants.

The historical background of this technological development has been summarized previously (Belyantseva 2016). A process was developed for delivering foreign genes into maize cells that did not require the removal of cell walls and was capable of delivering DNA into embryogenic and nonembryogenic tissues. A plasmid harboring a chloramphenicol

acetyltransferase (CAT) gene was adsorbed into the surface of microscopic tungsten particles (microprojectiles). These microprojectiles were then accelerated to velocities sufficient for penetrating the cell walls and membranes of maize cells in a suspension culture. High levels of CAT activity were consistently observed after the bombardment of cell cultures into the cultivars of black Mexican sweet corn, and these levels were comparable to the CAT levels observed after the electroporation of protoplasts. Measurable increases in CAT levels were also observed in two embryogenic cell lines after bombardment. Because this process circumvents the difficulties associated with regenerating whole plants from protoplasts, the particle bombardment process provides significant advantages over existing DNA delivery methods for the production of transgenic maize plants.

In the 1900s, modifications were made to substitute gunpowder with high-pressure helium gas for injection and to allow its delivery while holding the gene gun in the hand instead of within a chamber. The gene gun is now commercialized and is commonly used in experiments. The following is also a summary of the Helios® Gene Gun, which is a representative gene gun (Belyantseva 2016). The mechanical energy of compressed helium gas is used for the biolistic delivery of exogenous DNA, mRNA, or siRNA to bombard tissue with micron- or submicron-sized DNA- or RNA-coated gold particles, which can penetrate and transfect cells *in vitro* or *in vivo*. Helios Gene Gun-mediated transfection has several advantages: (1) It is simple and can be learned in a short time; (2) it is designed to overcome cell barriers, even those as tough as the plant cell membrane or stratum corneum in the epidermis; (3) it can transfect cells deep inside a tissue such as specific neurons within a brain slice; (4) it can deliver practically of any size of mRNA, siRNA, or DNA; and (5) it works well with various cell types, including non-dividing, terminally differentiated cells that are difficult to transfect such as neurons or mammalian inner ear sensory hair cells, which is particularly important for inner ear research.

We have made attempts at *in vivo* gene transfer (Yoshida 1997). For the first time anywhere in the world, we attempted to introduce marker genes *in vivo* into the liver of a rat that was directly exposed under general anesthesia. DNA-coated Au particles were accelerated by pressurized He gas to supersonic velocities to introduce a gene into the cells. Experimental and theoretical analyses both revealed a heterogeneous distribution of the particles in each shot (1 mg Au = 2.4×10^7 particles with 2 μg [32P] DNA = 2.5×10^{11} moles). To introduce genes into the liver of living rats, the best results were obtained with a newly developed handheld gene delivery system. The beta-galactosidase gene was introduced into the rat liver with Au particles using He at 250 psi and was expressed (1.2 μunits/μg protein) in a limited area of the liver surface (8 × 8 mm, depth 0.5 mm). When the same gene gun was used on a monolayer of cultured COS7 cells (about 5 μm thick), the cells in the central area of heavy bombardment were killed. Cell death caused by the influx of Ca^{2+} was prevented by the use of a cytosol-type culture medium. This method is extremely useful because genes can be easily introduced into living plants and animals without using viral vectors (Figure 2). We introduced experimental gene therapies that we have performed to date using mice, rats (Figure 3), and hamsters. Later, the possible use of this technique for the *in vivo* topical introduction of anticarcinogenic cytokines, among other genes, was examined, and the research area of this technique was expanded (Yang 1995).

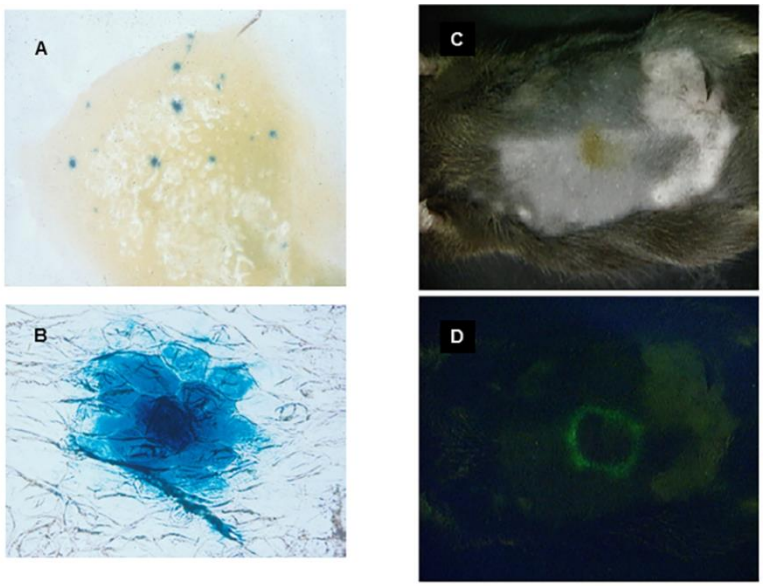

Figure 2. Expression of marker genes in a plant and mouse by Helios Gene Gun. LacZ Expression (A and B) in lemon. GFP gene was applied on the surface of mouse back skin (C) and a circular fluorescent intensity was observed under excitation light (D).

Figure 3. Application of gene gun in mice and rats. Eye protector and ear plugs were prepared. Gene gun was applied on a mouse which received it with sufficient anesthesia (A). Under inhalation anesthesia, the rat liver was exposed (B).

APPLICATION FOR ORGAN TRANSPLANTATION

We have conducted experiments to determine whether this technique could be used to introduce genes into the liver. Genes can be easily introduced into the surface of the rat liver with a gene gun while also introducing the green fluorescent protein (GFP) gene as a marker gene (Figure 4). This direct introduction of DNA into liver allografts before transplantation has been considered an effective strategy for inducing protective immunity against infections and malignancies (Nakamura 2003). We examined the feasibility of the gene gun-mediated vaccination of liver grafts. Using plasmids expressing luciferase and GFP, the expression of introduced genes was tested in a graft liver. The protein expression was observed in the graft liver of hepatectomized rats and was significantly enhanced. A short course of tacrolimus

(FK506) also evoked the expression of these proteins. The effects of primary immunization of the liver on the humoral response were then tested using an expression plasmid encoding the hepatitis B virus surface (HBs) antigen and were compared to those of skin immunization alone. The results showed that local immunization of the liver strongly induced antibody formation. Furthermore, the combination of an immunized partial liver graft with tacrolimus significantly enhanced antibody production against HBs antigen. A DNA vaccine delivered to the liver is a possible strategy for preventing infectious diseases associated with liver transplantation under tacrolimus treatment.

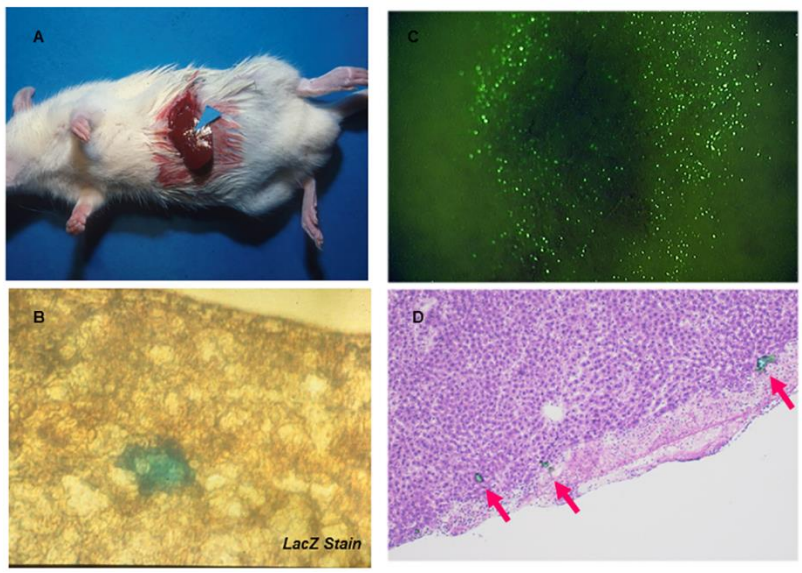

Figure 4. *In vivo* gene transfer with a marker gene in the rat liver. LacZ gene was applied on the rat liver (A &B). Circle GFP expression was observed on the surface of the rat liver (C & D). Reproduced from: Nakamura M, Wang J, Murakami T, Ajiki T, Hakamata Y, Kaneko T, Takahashi M, Okamoto H, Mayumi M, Kobayashi E. DNA immunization of the grafted liver by particle-mediated gene gun. *Transplantation* 2003; 76(9):1369−1375. Copyright ©2003 by Wolters Kluwer Health, Inc. Reproduced with permission. http://journals.lww.com/transplantjournal/pages/default.aspx.

APPLICATION FOR CANCER THERAPY

In addition, we have conducted research in the field of cancer research by expressing anticarcinogenic cytokines in the oral mucosa (Wang 2001) and muscle (Ajiki 2003). We examined the immunological effects of topical introduction into the oral mucosa by targeting the antigen presenting cell (APC) of macrophages.

Malignant melanoma in the oral cavity has a highly metastatic potential. Curative surgery is required to resect an extensive amount of oral tissue and often results in dysfunction as well as a severe cosmetic deformity in patients with the disease. An alternative technology for the local and sustained delivery of cytokines for cancer immunotherapy has been shown to induce tumor regression, suppress metastasis, and lead to the development of systemic antitumor immunity. However, local immunization of the oral cavity has not previously been studied. We examined the efficacy of particle-mediated oral gene transfer on luciferase and GFP

production (Wang 2001). The results showed that these proteins were expressed as significantly higher in the oral mucosa than in the skin, stomach, liver, and muscle. Using an established hamster oral melanoma model, particle-mediated oral gene gun therapy with interleukin (IL)-12 cDNA was then evaluated. The results indicated that the direct bombardment with mouse IL-12 cDNA suppressed tumor formation and improved the survival rate. A skin tumor model created by inoculation with melanoma cells was also significantly inhibited by the oral bombardment of IL-12 cDNA coupled with an irradiated melanoma vaccine administrated to the oral mucosa compared with a treatment of a percutaneous vaccine. IL-12 gene gun therapy, combined with an oral mucosal vaccine, induced interferon-gamma mRNA expression in the host spleen for an extended period. These results suggest that immunization of the oral mucosa may induce systemic antitumor immunity more efficiently than immunization of the skin and that the oral mucosa may be one of the most suitable tissues for cancer gene therapy using particle-mediated gene transfer. To characterize the effects of the oral mucosa-mediated genetic vaccination, we also compared the antigen-specific immune responses of the oral mucosal DNA vaccine with those of flank skin vaccination against the influenza virus and the malaria parasite (Wang 2003). DNA vaccines against the influenza A/WSN/33 (H1N1) hemagglutinin and the malaria *Plasmodium berghei* circumsporozoite protein were each administered three times at 3-week intervals into the oral mucosa, skin, or liver of hamsters. The effects of the vaccines were evaluated by assessing antigen-specific antibody production and cell-mediated killing activity. Furthermore, the *in vivo* malaria challenge test was also performed after the vaccination. No significant specific antibody production was observed in any case, but interferon-gamma production and cell-mediated killing activity were strongly induced in splenic lymphocytes from hamsters given the oral vaccination. In the *in vivo* malaria experiment after the vaccination, the oral mucosal vaccination significantly delayed the blood appearance on the day that the parasites were compared with the other immunization sites ($p<0.05$). These results suggest that gene immunization via the oral mucosa may induce cell-mediated immunity more efficiently than immunization via the skin or liver and that the oral mucosa may be one of the most suitable tissues for gene gun-based DNA vaccination against infectious diseases.

In evaluations of *in vivo* gene transfer using a gene gun, the muscle showed lasting effects (Figure 5). We then performed the following experiment. The immune response was modulated by genetic adjuvants using plasmid vectors expressing cytokines. Skeletal muscle can express a foreign gene intramuscularly administered via a needle injection, and the potential of muscle as a target tissue for somatic gene therapy in treating cancer has been explored. We investigated the efficacy of particle-mediated intramuscular transfection modified with a local anesthetic agent, bupivacaine, for luciferase and GFP expression. The results indicated that these proteins were more efficiently expressed and persisted longer in muscle modified in this way compared with the needle-injection method. Using an established rat sarcoma model, particle-mediated intramuscular gene gun therapy combined with IL-12 and IL-18 cDNA was evaluated. The growth of the distant sarcoma was significantly inhibited by particle-mediated intramuscular combination gene therapy, and the survival rate was also improved (Figure 6). Furthermore, after the combination gene gun therapy, significant levels of interferon-gamma were maintained, and a high activity level of tumor-specific cytotoxic T lymphocytes was induced. These results suggest that the sustained local delivery of IL-12 and IL-18 cDNA using intramuscular gene gun therapy modified with

bupivacaine can induce long-term antitumor immunity and has the great advantage of inhibiting the disseminated tumor (Ajiki 2003). However, it became evident that this method is not quite as effective as a long-term immunosuppressive therapy, as the expression of the genes is temporary and its effects are not expected to last for a long period of time (Ajiki, Transplantation 2003).

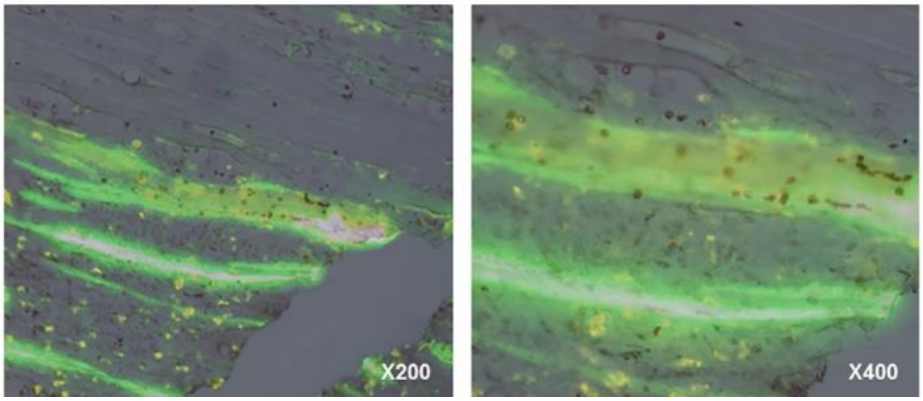

Figure 5. GFP expression in the regenerative muscle fibers in rats. Efficacy of gene transfection by a gene gun is independent of the cell cycle, but acts more effectively in BrdU positive myofibers.

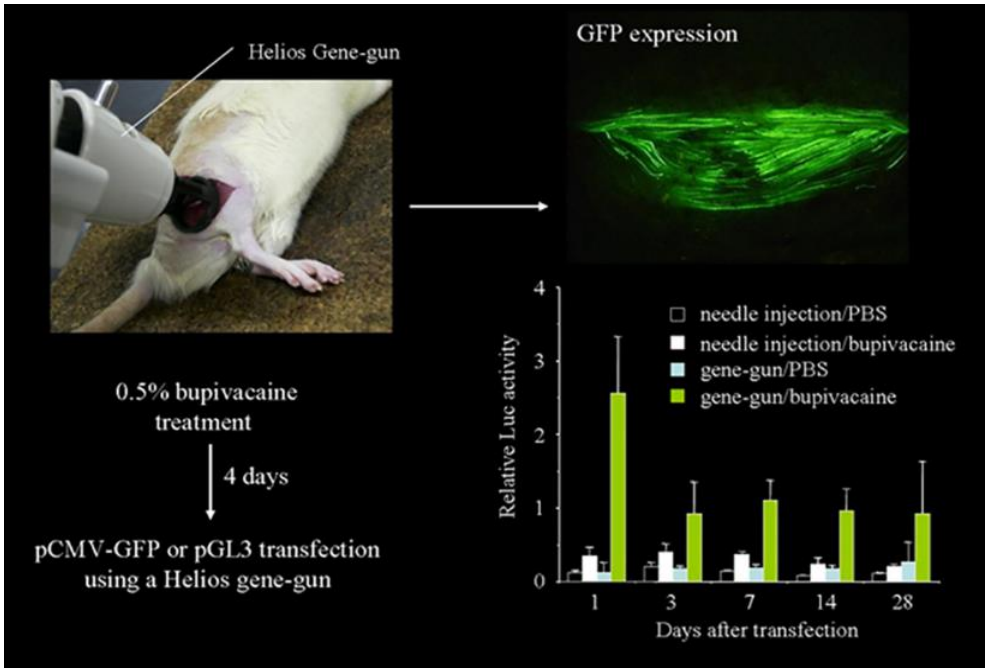

Figure 6. Long-term GFP gene expression in the rat muscle treated by a gene gun. Adapted from: Ajiki T, Murakami T, Kobayashi Y, Hakamata Y, Wang J, Inoue S, Ohtsuki M, Nakagawa H, Kariya Y, Hoshino Y, Kobayashi E. Long-lasting gene expression by particle-mediated intramuscular transfection modified with bupivacaine: combinatorial gene therapy with IL-12 and IL-18 cDNA against rat sarcoma at a distant site. *Cancer Gene Ther.* 2003; 10(4):318-329. Copyright ©2003 by Nature Publishing Group. Adapted with permission. http://www.nature.com/cgt/index.html.

Experiments have recently been conducted to introduce genes into the muscle using this technique (Tsai 2016). Tsai et al. investigated the possible underlying mechanisms associated with myostatin propeptide gene delivery via a gene gun in a rat denervation muscle atrophy model and evaluated the gene expression patterns. In a rat botulinum toxin-induced nerve denervation muscle atrophy model, we evaluated the effects of wild-type (MSPP) and mutant-type (MSPPD75A) myostatin propeptide gene delivery and observed changes in gene activation associated with the neuromuscular junction, muscle, and nerve. Muscle mass and muscle fiber size were moderately increased in myostatin propeptide-treated muscles ($p<0.05$). Moreover, the enhanced gene expression of muscle regulatory factors, neurite outgrowth factors (IGF-1, GAP43), and acetylcholine receptors was observed. Their results demonstrated that myostatin propeptide gene delivery, especially the mutant-type of MSPPD75A, attenuates muscle atrophy through myogenic regulatory factors and acetylcholine receptor regulation. Their data showed that myostatin propeptide gene therapy might be a promising treatment for nerve denervation-induced muscle atrophy.

HYDRODYNAMIC APPROACH FROM RATS TO PIGS

The hydrodynamic approach was developed as a method for injecting DNA with a large amount of solvent via blood vessels (Figure 7). This technique is similar to the aforementioned gene gun method in that it enables *in vivo* gene transfer without using viral vectors. Liu et al. described this technique as follows (Liu 2001). The need for a safe and efficient method for gene delivery has stimulated the recent emergence of vectorless methods (e.g., naked DNA) as promising alternatives to the available viral- and non-viral-based systems. Among these methods, hydrodynamic-based gene delivery through the systemic injection of DNA offers a convenient, efficient, and powerful means for high-level gene expression in mice. This new gene delivery method, as well as the potential mechanism underlying the hydrodynamic-based DNA transfer into cells, has potential applications for gene function analysis, protein expression, and gene therapy in whole animals.

We have conducted studies focusing on the superior characteristics of the liver and muscles as target organs and tissues for gene expression (Sato 2003). We applied a non-viral gene transfer method using the rapid injection of naked DNA into the graft limb in rats. Naked DNA (beta-galactosidase-, luciferase-, or GFP-expressing plasmid) was used to test an intravascular gene transfer approach under various conditions on the Lewis rat limb. Then, in a rat limb transplantation model, these marker genes were administered preoperatively (Day 2) or perioperatively (Day 0) to the graft limb using the authors' "venous protocol." The expression level of luciferase was observed over a long period using a noninvasive living image acquisition IVIS system. The effective intravascular delivery of a gene to the rat limb was achieved using a rapid bolus injection of naked DNA through the femoral caudal epigastric vein. Using this procedure, the limb graft with the marker gene perioperatively in place was safely transplanted. After limb transplantation, sustained marker gene expression was observed for more than 2 months. This was the first report showing that the method of the rapid injection of naked DNA into a limb can be applied to gene modification for organ transplantation.

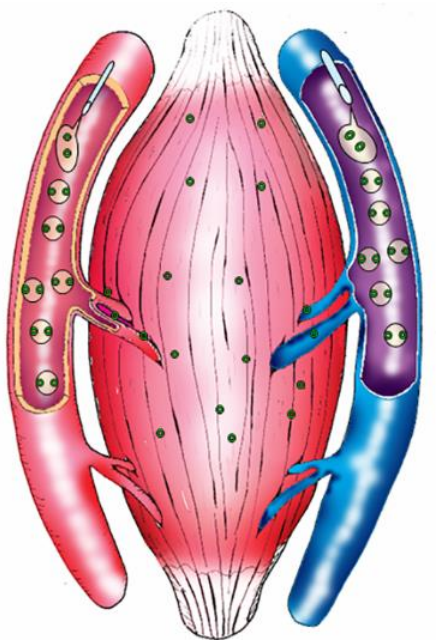

Figure 7. Theoretical schema of a hydrodynamic method by use of naked DNA. A large volume of saline with naked DNA was injected through either an artery or vein in rats.

APPLICATION OF A CATHETER-BASED TECHNIQUE IN RAT MODELS

We examined a non-viral gene transfer method using the rapid injection of naked DNA targeting the liver and applied it in a rat model of liver transplantation (Inoue 2004). Inbred Dark Agouti and Lewis rats were used. To test the efficacy and adverse effects of systemic or local (catheter-based) injection, different volumes of phosphate-buffered saline containing naked DNA encoding beta-galactosidase (LacZ) were injected. Luciferase expression was followed over time with non-invasive imaging, and the cytotoxic T-lymphocyte antigen 4-immunoglobulin (CTLA4Ig) protein was tested functionally via allogenic heart transplantation. Gene transfer was then tested in rat auxiliary liver transplantation (ALT) and orthotopic liver transplantation (OLT). The timing of gene transfer was evaluated in the ALT model, and OLT was performed using a liver graft to which luciferase or the CTLA4Ig gene was transferred two days before. LacZ was expressed extensively in a volume-dependent manner; however, a large volume often induced recipient death. After the local delivery of CTLA4Ig cDNA to the liver, the survival time of Dark Agouti heart grafts increased with increases in CTLA4Ig serum levels. Liver grafts injected with naked DNA at the time of donation did not survive, but livers grafted two days after gene transfer survived. Successful expression of luciferase and production of CTLA4Ig were finally confirmed in the rat that underwent OLT. We successfully applied a non-viral hydrodynamic gene transfer method to the rat liver and showed its potential in liver grafting. The high incidence of graft failure when this procedure is performed on the day of organ donation is a potential limitation that needs to be overcome prior to clinical application.

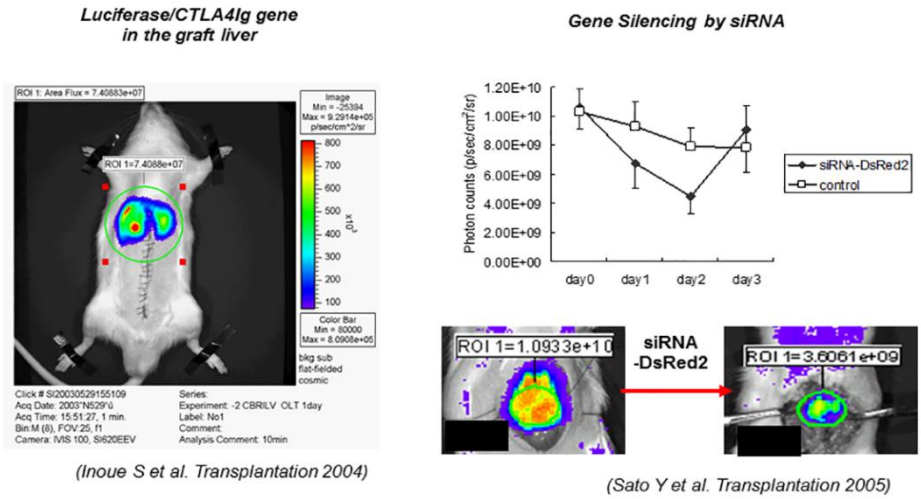

Figure 8. Liver targeting gene therapy in transplantation research. Reproduced from: Sato Y, Ajiki T, Inoue S, Fujishiro J, Yoshino H, Igarashi Y, Hakamata Y, Kaneko T, MurakamidT, Kobayashi E. Gene silencing in rat liver and limb grafts by rapid injection of small interference RNA. *Transplantation*, 2005; 79(2):240−243. Copyright ©2005 by Wolters Kluwer Health, Inc. Reproduced with permission. http://journals.lww.com/transplantjournal/pages/default.aspx. Also reproduced from: Inoue S, Hakamata Y, Kaneko M, Kobayashi E. *Transplantation*, 2004; 77(7):997−1003. Copyright ©2004 by Wolters Kluwer Health, Inc. Reproduced with permission. http://journals.lww.com/transplantjournal/pages/default.aspx.

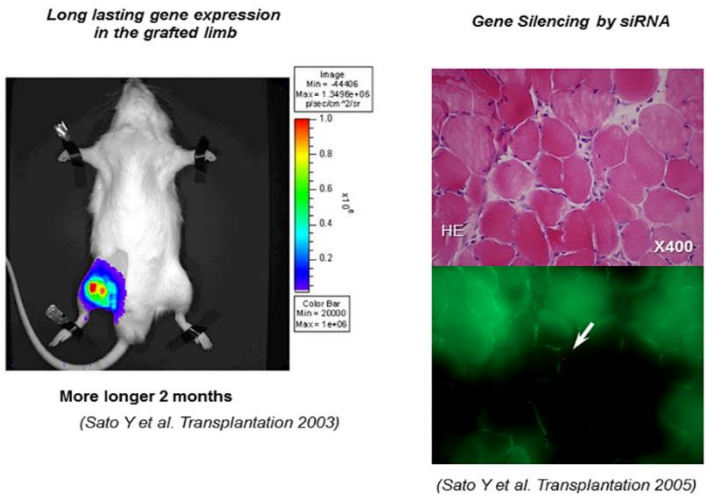

Figure 9. Limb targeting gene therapy in a rat model. Reproduced from: Sato Y, Ajiki T, Inoue S, Fujishiro J, Yoshino H, Igarashi Y, Hakamata Y, Kaneko T, Murakamid T, Kobayashi E. Gene silencing in rat liver and limb grafts by rapid injection of small interference RNA. *Transplantation*. 2005; 79(2):240−243. Copyright ©2005 by Wolters Kluwer Health, Inc. Reproduced with permission. http://journals.lww.com/transplantjournal/pages/default.aspx. Also reproduced from: Sato Y, Ajiki T, Inoue S, Hakamata Y, Murakami T, Kaneko T, Takahashi M, Kobayashi E. A novel gene therapy to the graft organ by a rapid injection of naked DNA I: long-lasting gene expression in a rat model of limb transplantation. *Transplantation* 2003 (Nov 15); 76(9):1294−1298. Copyright ©2003 by Wolters Kluwer Health, Inc. Reproduced with permission. http://journals.lww.com/transplantjournal /pages/default.aspx.

We introduced a non-viral method of gene transfer to donor grafts using an organ-selective injection technique to up-regulate gene expression. Based on the attractive methodology of RNA interference for silencing the expression of a particular gene, we also applied our catheter-based injection method to transfer small interference RNA (siRNA)-GFP into the liver and limb grafts (Figures 8 and 9) (Sato 2005). We quantified the interfering activity after the systemic delivery of siRNA into the liver of Alb-DsRed2 transgenic (Tg) rats using an *in vivo* bioimaging system. Then, using GFP Tg Lewis rats as donors, the preoperative rapid injection of siRNA resulted in the transient down regulation of GFP expression in both the liver and limb transplantation models. Genetic modification by siRNA may provide new therapeutic options for the down regulation of endogenous antigenicity.

APPLICATION IN LARGE ANIMAL MODELS

For the first time worldwide, we successfully performed gene transferance with a pig liver as the target using this technique (Yoshino 2006). We attempted to transfect naked plasmid DNA into the porcine liver using a modified hydrodynamic method. We transferred plasmid DNA to a part of the liver using an angio-catheter to reduce damage to the liver. To discern the injection conditions, naked plasmid DNA encoding GFP was transferred for use as a marker gene. The GFP gene was markedly expressed in the gene-transferred pig livers (Figure 10). In large animals, in addition to the naked gene quantity, the solution volume containing the plasmid DNA, and the injection speed, the additional treatments for the portal vein and the preparation of the hepatic artery are crucial. We found that the following injection conditions were needed: 3 mg of plasmid DNA, a solution volume of 150 ml, and an injection speed of 5 ml/s. The portal vein and the hepatic artery were clamped during gene delivery, and the blood flow of the portal vein was flushed out using normal saline. The CTLA4-Ig gene was used to test for the secretory protein. The CTLA4-Ig gene was injected with a large volume of solution via the hepatic vein specifically into the left outer lobe of the liver. CTLA4-Ig was detected in the blood of the pigs at a maximum serum level of 161.7 ng/ml 1 day after gene transfer, and CTLA4-Ig was detected for several weeks. This new technique of inserting a catheter into only a selected portion of the liver reduces liver toxicity and increased gene transfer efficiency.

With this method, gene transfer efficiency is increased by washing out the blood in the liver using a balloon catheter. This catheter technique was also applied to monkeys using AAV vector therapy (Mimuro 2013). This method results in high transfer efficiency in the liver, and studies using rats (Kobayashi 2016) and pigs (Sendra 2016) are currently underway to develop the technique for use in clinical practice.

DVA VACCINATION BY ELECTROPORATION IN PIGS

The development of a safe DNA vaccination strategy is underway following advances concerning the *in vivo* electroporation technique (Liu 2011). Advances have been made in research using pigs in particular for preclinical application (Ramanathan 2009, Luo 2016). We also evaluated universal influenza vaccines on pigs using the electroporation technique

(Figure 11). A conduction needle was inserted into the medial thigh area of a pig under general anesthesia, and the naked target DNA was injected into the central region. Gene transfer was completed by immediate conduction.

This technique has already been used in clinical practice and has been tested on hepatitis B (Yang 2017) and HIV (Huang 2017), and its effects are being revealed.

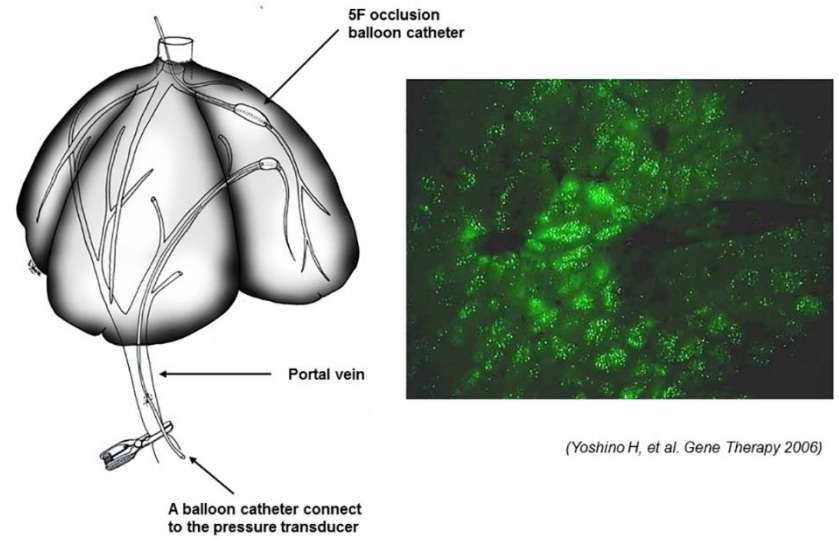

Figure 10. Naked plasmid DNA transfer to the porcine liver. Reproduced from: Yoshino H, Hashizume K, Kobayashi E. Naked plasmid DNA transfer to the porcine liver using rapid injection with large volume. *Gene Ther*. 2006; 13(24):1696−1702. Copyright ©2006 by Nature Publishing Group. http://www.nature.com/gt/index.html.

Figure 11. DNA vaccine by electroporation in pigs.

CONCLUSION

We have described the gene gun, catheter-based hydrodynamic approaches, and the electroporation technique as experimental *in vivo* gene transfer methods that do not use viral vectors while also presenting the data from our experiments via a historical background.

REFERENCES

Ajiki T, Murakami T, Kobayashi Y, Hakamata Y, Wang J, Inoue S, Ohtsuki M, Nakagawa H, Kariya Y, Hoshino Y, Kobayashi E. Long-lasting gene expression by particle-mediated intramuscular transfection modified with bupivacaine: combinatorial gene therapy with IL-12 and IL-18 cDNA against rat sarcoma at a distant site. *Cancer Gene Ther.* 2003; 10(4): 318−329.

Ajiki T, Takahashi M, Hakamata Y, Murakami T, Kariya Y, Hoshino Y, Kobayashi E. Difficulty of achieving long-term graft survival of MHC-disparate composite graft using CTLA4IG. *Transplantation* 2003; 76(2): 438; author reply 438−439. No abstract available.

Belyantseva IA. Helios (®) Gene Gun-Mediated Transfection of the Inner Ear Sensory Epithelium: Recent Updates. *Methods Mol. Biol.* 2016; 1427: 3−26.

Huang Y, Zhang L, Janes H, Frahm N, Isaacs A, Kim JH, Montefiori D, McElrath MJ, Tomaras GD, Gilbert PB Predictors of durable immune responses six months after the last vaccination in preventive HIV vaccine trials. *Vaccine* 2017 Jan 25. pii: S0264-410X(16)30879-9. doi: 10.1016/j.vaccine.2016.09.053. [Epub ahead of print].

Inoue S, Hakamata Y, Kaneko M, Kobayashi E. Gene therapy for organ grafts using rapid injection of naked DNA: application to the rat liver. *Transplantation* 2004; 77(7): 997−1003.

Klein TM, Fromm M, Weissinger A, Tomes D, Schaaf S, Sletten M, Sanford JC. Transfer of foreign genes into intact maize cells with high-velocity microprojectiles. *Proc. Natl. Acad. Sci. U S A.* 1988; 85(12): 4305−4309.

Kobayashi Y, Kamimura K, Abe H, Yokoo T, Ogawa K, Shinagawa-Kobayashi Y, Goto R, Inoue R, Ohtsuka M, Miura H, Kanefuji T, Suda T, Tsuchida M, Aoyagi Y, Zhang G, Liu D, Terai S. Effects of fibrotic tissue on liver-targeted hydrodynamic gene delivery. *Mol. Ther. Nucleic Acids.* 2016; 5:e359. doi: 10.1038/mtna.2016.63.

Liu D, Knapp JE. Hydrodynamics-based gene delivery. *Curr. Opin. Mol. Ther.* 2001; 3(2): 192−197. Review.

Liu MA. DNA vaccines: an historical perspective and view to the future. *Immunol. Rev.* 2011; 239(1): 62−84. doi: 10.1111/j.1600-065X.2010.00980.x. Review.

Luo X, Liang X, Li J, Shi J, Zhang W, Chai W, Wu J, Guo S, Fang G, Zhou X, Zhang J, Xu K, Zeng J, Niu L. The effects of irreversible electroporation on the colon in a porcine model. *PLoS One* 2016; 11(12):e0167275. doi: 10.1371/journal.pone.0167275.

Mimuro J, Mizukami H, Hishikawa S, Ikemoto T, Ishiwata A, Sakata A, Ohmori T, Madoiwa S, Ono F, Ozawa K, Sakata Y. Minimizing the inhibitory effect of neutralizing antibody for efficient gene expression in the liver with adeno-associated virus 8 vectors. *Mol. Ther.* 2013; 21(2): 318−323. doi: 10.1038/mt.2012.258.

Nakamura M, Wang J, Murakami T, Ajiki T, Hakamata Y, Kaneko T, Takahashi M, Okamoto H, Mayumi M, Kobayashi E. DNA immunization of the grafted liver by particle-mediated gene gun. *Transplantation* 2003; 76(9): 1369−1375.

Ramanathan MP, Kuo YC, Selling BH, Li Q, Sardesai NY, Kim JJ, Weiner DB. Development of a novel DNA SynCon tetravalent dengue vaccine that elicits immune responses against four serotypes. *Vaccine* 2009; 27(46): 6444−53. doi: 10.1016/j.vaccine.2009.06.061.

Sato Y, Ajiki T, Inoue S, Fujishiro J, Yoshino H, Igarashi Y, Hakamata Y, Kaneko T, Murakamid T, Kobayashi E. Gene silencing in rat-liver and limb grafts by rapid injection of small interference RNA. *Transplantation* 2005; 79(2): 240−243.

Sato Y, Ajiki T, Inoue S, Hakamata Y, Murakami T, Kaneko T, Takahashi M, Kobayashi E. A novel gene therapy to the graft organ by a rapid injection of naked DNA I: long-lasting gene expression in a rat model of limb transplantation. *Transplantation* 2003; 76(9): 1294−1298.

Sendra L, Miguel A, Pérez-Enguix D, Herrero MJ, Montalvá E, García-Gimeno MA, Noguera I, Díaz A, Pérez J, Sanz P, López-Andújar R, Martí-Bonmatí L, Aliño SF.

Studying closed hydrodynamic models of “in vivo” DNA perfusion in pig liver for gene therapy translation to humans. *PLoS One* 2016 3; 11(10): e0163898. doi: 10.1371/journal.pone.0163898.

Tsai SW, Tung YT, Chen HL, Yang SH, Liu CY, Lu M, Pai HJ, Lin CC, Chen CM. Myostatin propeptide gene delivery by gene gun ameliorates muscle atrophy in a rat model of botulinum toxin-induced nerve denervation. *Life Sci.* 2016; 146: 15−23. doi: 10.1016/j.lfs.2015.12.056.

Wang J, Murakami T, Hakamata Y, Ajiki T, Jinbu Y, Akasaka Y, Ohtsuki M, Nakagawa H, Kobayashi E. Gene gun-mediated oral mucosal transfer of interleukin 12 cDNA coupled with an irradiated melanoma vaccine in a hamster model: successful treatment of oral melanoma and distant skin lesion. *Cancer Gene Ther.* 2001; 8(10): 705−712.

Wang J, Murakami T, Yoshida S, Matsuoka H, Ishii A, Tanaka T, Tobita K, Ohtsuki M, Nakagawa H, Kusama M, Kobayashi E. Predominant cell-mediated immunity in the oral mucosa: gene gun-based vaccination against infectious diseases. *J. Dermatol. Sci.* 2003; 31(3): 203−210.

Yang FQ, Rao GR, Wang GQ, Li YQ, Xie Y, Zhang ZQ, Deng CL, Mao Q, Li J, Zhao W, Wang MR, Han T, Chen SJ, Pan C, Tan DM, Shang J, Zhang MX, Zhang YX, Yang JM, Chen GM. Phase IIb trial of in vivo electroporation mediated dual-plasmid hepatitis B virus DNA vaccine in chronic hepatitis B patients under lamivudine therapy. *World J. Gastroenterol.* 2017; 23(2): 306−317. doi: 10.3748/wjg.v23.i2.306.

Yang NS, Sun WH. Gene gun and other non-viral approaches for cancer gene therapy. *Nat. Med.* 1995; 1(5): 481−483. No abstract available.

Yoshida Y, Kobayashi E, Endo H, Hamamoto T, Yamanaka T, Fujimura A, Kagawa Y. Introduction of DNA into rat liver with a hand-held gene gun: distribution of the expressed enzyme, [32P] DNA, and Ca2+ flux. *Biochem. Biophys Res. Commun.* 1997; 234(3): 695−700.

Yoshino H, Hashizume K, Kobayashi E. Naked plasmid DNA transfer to the porcine liver using rapid injection with large volume. *Gene Ther.* 2006; 13(24):1696−1702.

In: Encyclopedia of Surgery (22 Volume Set)
Editors: Andreas Lehrer and Kristin Mueller
ISBN: 978-1-53618-329-0
© 2020 Nova Science Publishers, Inc.

Chapter 200

ROBOTIC SURGERY IN EXPERIMENTAL MEDICINE

Sandra S. Y. Kim, David Ian Harriman, MD and Christopher Nguan*, MD
Department of Urologic Sciences
University of British Columbia, Vancouver, British Columbia

ABSTRACT

Robotic assisted surgery has become a vitally important surgical modality developed through experimentation, innovation and collaboration between engineers, scientists, and surgeons. Digitalization of the surgeon-patient interaction allows for previously unheard of feats of engineering in procedural medicine including increased degrees of freedom of dexterity beyond human capability, telesurgery across great distances, and augmented reality. Animal models for training and testing these robotic platforms have been developed along the way which have helped the field progress. There remains a lack of randomized control trials comparing robot-assisted surgery versus other surgical modalities, however preliminary studies are promising. Despite initial upfront costs, the appeal of robot-assisted surgery continues to increase and its use will continue to expand as knowledge of how best to implement the technology continues to advance.

Keywords: robotic surgery, telesurgery, daVinci, Zeus

ABBREVIATIONS

BMI	Body Mass Index
CI	Confidence Interval
FDA	Federal Drug and Administration
LOS	Length of Stay
MIS	Minimally invasive surgery
NASA	National Aeronautics and Space Administration

* Corresponding Author's Email: chris.nguan@ubcurology.com.

HISTORY OF ROBOTIC SURGERY

Robotic technology was originally developed so manufacturing industries could perform precise, repetitive and potentially dangerous jobs with intent on improving quality, efficiency and safety. The progression of robotics into the operating theatre seemed pre-ordained as there are many parallels in the ongoing challenges to improve accuracy and precision of surgical techniques to optimize patient outcomes.

Minimally invasive surgery (MIS) has a long history, as Georg Kelling first developed and performed laparoscopic surgery using a Nitze cystoscope in a dog in 1901 Germany (Hatzinger 2006). Hans Christian Jacobaeus from Sweden went on to perform the first clinical laparoscopic operation and since then, MIS adoption has steadily increased with both hand-assisted and pure laparoscopic techniques having been validated and successfully incorporated into many surgical fields around the world (Hatzinger 2006). The advantages of laparoscopic surgery over open surgery are well described and include: smaller incisions, shorter postoperative hospital stays, quicker return to normal function, decreased risk of wound infection and better cosmesis (Lanfranco 2004; Kim 2002; Fuchs 2002). Drawbacks of MIS are also recognized, specifically: loss of 3D vision, reduction of tactile feedback, amplification of tremor through rigid laparoscopic instruments, range of motion limitation, and poor ergonomics that put additional stress on the operating surgeon. In fact, these issues in MIS are thought to contribute to the steep learning curve to master complex MIS procedures (Lanfranco 2004; Prasad 2001). Robotic surgical systems were envisioned to overcome the limitations of standard laparoscopy and to further bolster the penetration of MIS procedures in more complex and restrictive scenarios.

The first surgical robots used computer interfaces and an effector arm to carry out surgical procedures. In 1985, the PUMA 560 (Programmable Universal Manipulation Arm), an industrial robot, became one of the earliest robots to be used in a clinical setting for stereotactic CT-guided brain biopsy (Kwoh 1988). ROBODOC (Integrated Surgical Systems) is comprised of a preoperative planning computer workstation and a five-axis robotic arm with a high speed milling device to more precisely core out the femur for improved placement of orthopedic implants (Bargar 1998).

In the early 1990s, NASA, the US military and researchers at Stanford combined efforts to develop telepresence robotic systems (Satava 2002). The initial impetus of telepresence robotic surgery was to provide surgical care to people over great distances per a battlefield situation, or in remote locations such as in space or deep sea scenarios (Lanfranco 2004). The first robot to incorporate telepresence technology was AESOP (Automated Endoscopic System for Optimal Positioning; Computer Motion Inc.) and approved by the FDA in December 1993. The Zeus robotic system complemented the AESOP robot and further extended its capabilities, representing the first ‘master-slave’ system with a separate surgeon console and robotic system (Lanfranco 2004). In a master-slave configuration, a human operator manipulates control interfaces which translate those movements to instruments manipulating the patient’s anatomy; no autonomous motions are made by the robot itself. Intuitive Surgical Systems developed their own telepresence robot during the late 1990s, the daVinci robotic surgical system. These rival companies eventually elected to merge together to promote the daVinci system, resulting in the discontinuation of the Zeus platform.

The daVinci surgical system has become the de facto standard in medical robotics, and is currently the dominant surgical robotic system in clinical practice. The coincidental miniaturization and evolution of stereoscopic imaging, instrumentation, hardware and software engineering combined to make surgical robotics possible. Operations that were previously thought to be impossible without resorting to traditional open methods of surgery can now often be tackled in a minimally invasive fashion with robotic assistance. Robotic surgery remains at the frontier of surgical innovation and continues to advance the limits of conventional thinking in minimally invasive surgery.

TYPES OF TELEPRESENCE ROBOTS

There has been rapid progress in surgical robotics and their applications, and robotic MIS systems are now widely available with uses ranging from endoluminal, laparoscopic, single port to natural orifice based procedures (Barbash 2010; Lanfranco 2004; Davies 2000). The development and technology of each telesurgical system is reviewed here.

AESOP: Automated Endoscopic System for Optimal Positioning

AESOP was the first telesurgical robotic device. It was originally developed from a research grant from NASA for the development of a robotic arm to be used in the US space program (Ballantye 2002). The current iteration of AESOP is voice controlled and commands a robotic endoscope holder with 7 degrees of freedom. Urologists at John Hopkins demonstrated the success of AESOP as a surgical assistant in 17 different urological procedures (Partin 1995). The success of AESOP led to further developments in surgical robots and an influx of interest from medical technology companies.

ARTEMIS: Advanced Robotics and Telemanipulator System for Minimally Invasive Surgery

ARTEMIS was developed by scientists experienced in the nuclear and industrial applications fields, at the Karlsruhe Research Centre (Rininsland 1993). ARTEMIS is a master-slave robotic system comprised of 2 robotic arms that are controlled by a surgeon through a control console and a 3-D endoscopic system (Schurr 2000). ARTEMIS also gave the surgeon six degrees of freedom with a flexible distal robotic arm, allowing for precise motion in surgery (Rininsland 1999).

Zeus Surgical System

The Zeus robot was developed in 1999 and is a comprehensive surgical robotic system in which the surgeon controls two robotic arms attached to the bed rails of the operating table. The third arm is an AESOP for visualization, which is voice controlled. The surgeon sits

upright in a cockpit-like console facing a 2-dimensional viewing system of the operating field (Maseo 2010).

daVinci Surgical System

The daVinci Surgical System consists of 3 separate parts; 1) a master console consisting of a work station, computer and 3D display system; 2) a control tower which houses the 3D video capture equipment and synchronizers; and 3) a patient side cart comprised of a motorized wheeled platform and a vertical post with four robotic arms suspended from it. The master console translates a full 7 degrees of freedom to the instruments of the patient side cart, while the high definition stereoendoscopic cameras are mixed to provide true 3D stereoscopic views of the operative field back to the surgeon console. By converting the standard "analog" interaction of the surgeon with the patient to a digital process, the system allows for adjunctive benefits to the operator: tremor filtration, motion scaling, swapping of controls and arms, control of additional robotic arms greater than the number of master controllers through hot swapping, and all the while providing a seated, ergonomic approach to surgery which promotes the efficient and effective conduct of a potentially prolonged operation. Finally, research conducted at Intuitive and academic centers worldwide can provide surgical platform "plugins" to add novel functionality to the standard robotic system.

Typically, major operations require the assistance of an additional person at the bedside, but with the latest versions of the daVinci robot, the patient side cart's four arms are able to be controlled by two concurrent master controller units controlled by one primary surgeon and one assistant. Although telesurgery across distances is possible with the daVinci surgical system, in North America, the FDA does not allow the use of this functionality and requires the patient and surgeon always be in the same room (Maseo 2010).

The daVinci system has evolved over time where in 1999, the original daVinci system ("Standard") had a 2-dimensional viewing screen and 3 robotic arms, a 4th arm was added in 2003. In 2006, the daVinci S was released that had 3-dimensional high definition vision. In 2009, the daVinci Si was produced with a dual console option to aid with operative teaching and assistance, the Firefly Fluorescence Imaging System to aid in real-time visualization of tissue perfusion, the option for single site surgery, system integration with complex imaging modalities and advanced instrumentation for finer tasks. The most recent model was produced in 2014 and is termed the daVinci Xi. This model is the first major overhaul since 1999 and has redesigned instrument arm architecture to facilitate anatomical access from any position, increased flexibility of visualization through repositioning of the endoscope through any port, and a smaller footprint.

SPORT Surgical System

Titan Medical Incorporation based in Toronto, Ontario is currently developing the Single Port Orifice Robotic Technology (SPORT) surgical system, unveiled in early 2016, with the aim to expand the field of robotics surgery by lowering the cost barrier to allow for pervasive use in all surgical specialties. The SPORT is a single-incision surgical system with multi-articulated instruments, camera with 3D high definition view of the surgical field, ergonomic

work station, single-arm mobile patient cart, with single-use replaceable tips. This surgical system is not yet available for sale.

CURRENT ROBOTIC APPLICATIONS

Cardiac Surgery (Table 1)

MIS cardiac surgery became reality with advances in perfusion strategies, myocardial protection and access techniques (Bush 2013). Robotic cardiac valve and bypass surgery have become a mainstay of the discipline with use cases including: atrial septal defect closure on a beating heart, atrial fibrillation ablation and cardiac tumor resections (Gao 2010; Schilling 2012). Advantages of robotic assistance include improved cosmesis, shorter recovery and comparable outcomes to traditional techniques with the main disadvantage being prolonged operative times (Bush 2013).

Mitral valve surgery is the most common robotic assisted cardiac procedure performed, the first case performed in 1998 with an early prototype of the daVinci surgical system (Carpentier 1998). Within a week after the first robot-assisted mitral valve repair, Mohr et al. performed 5 more robotic mitral valve repairs as well as a coronary revascularization procedure (Mohr 1999). Between 2006 and 2009, Mihaljevic et al. compared key outcomes grouped by surgical technique for 759 patients undergoing mitral valve repair (Mihaljevic 2011). On average, the robot-assisted procedures took 42 minutes longer than complete sternotomy, 39 minutes longer than partial sternotomy, and 11 minutes longer than right mini-anterolateral thoracotomy ($p<0.05$). The increased robot operative time was offset by decreased blood transfusion rates as well as lower rates of pleural effusion and atrial fibrillation compared to standard open or MIS methods, leading to significantly reduced hospital stay (median 4.2 days vs. 5.2, 5.8 and 5.1 days respectively; $p<0.05$).

As briefly alluded to above, robotic assisted surgery has also been employed for total endoscopic coronary artery bypass grafting (TECAB). A multicenter, prospective study by Argenziano et al. assessed the safety and efficacy of TECAB surgery (Argenziano 2006). Of 85 patients undergoing TECAB surgery, 5 were converted to open procedures, 1 required reintervention for bleeding and 1 experienced myocardial infarction. Mean hospital length of stay was 5.1 +/- 3.4 days. Angiographic success, defined as patient anastomosis, was 91% and the authors concluded non-inferiority to traditional techniques. More recently, robotic surgical techniques in the absence of cardiac bypass have been performed with encouraging results (Bush 2013). From these studies, it has been demonstrated that the use of robot-assisted CABG can be successful in properly chosen operative candidates.

General Surgery

Contemporary results in the field of General Surgery show modest benefit of surgical robotics over traditional laparoscopic methods across a range of operations (Maseo 2010). Additionally, it has been estimated that per-procedure cost increases of up to $1500 are incurred as a result of robot assistance (Barbash 2010). As such, adoption of robotic

laparoscopic techniques in General Surgery have been variable and limited with an eye towards gaining further evidence and ongoing cost containment.

Table 1. Compilation of procedures performed by surgical robots as reported in humans

Cardiac	Atrial fibrillation ablation Coronary artery bypass graft Cardiac septal defect repair: Atrial septal defect Coronary revascularization Intracardiac tumor resections Left lead implantation for pacemaker Lobectomy Mammary artery harvest Valve surgery: Mitral valve repair
General Surgery	Acid reflux surgery Bariatric surgery: gastric bypass, gastrectomy, fundoplication Cholecystectomy Colorectal resections: colectomy, low anterior resection, rectopexy, rectal resections Esophageal surgery Heller myotomy Hernia repair Pancreatectomy Splenectomy
Gynecology	Adnexal surgery Endometrial ablation Hysterectomy Lymphadenectomy Myomectomy Oophorectomy Sacrocolpopexy Tubal re-anastomosis
Neurosurgery	Image guided surgery: tumor resection, biopsy, endoscopic fenestration, ventriculostomy Myelomeningocele repair Pedicle screw placement under image guidance Transoral odontoidectomy
Orthopedic Surgery	Knee arthroplasty Image guided intra-articular injection Spine surgery Total hip arthroplasty: femur preparation/coring, acetabular cup placement
Otolaryngology	Marsupialization of a vallecular cyst Obstructive sleep apnea hypopnea syndrome treatment Parathyroidectomy Resection of head and neck tumors: laryngeal, oropharyngeal, hypopharyngeal, oral cavity Thyroidectomy Transoral robotic surgery
Urology	Cystectomy Nephrectomy: partial, radical, donor Dismembered Pyeloplasty Radical prostatectomy Ureteral Reconstruction Vasovasostomy

A large study out of the University of Illinois at Chicago assessed outcomes for 676 robotic cholecystectomies compared to 289 laparoscopic cholecystectomies (Gangemi 2016). Statistically significant differences were identified favoring robotic cholecystectomy with decreased minor biliary injuries (p = 0.049), decreased open conversion (p<0.001) and reduced blood loss (p<0.001). Mean hospital stay and number of biliary anomalies identified intraoperatively were comparable across groups. Overall, this study indicates benefit of robotic versus laparoscopic cholecystectomy. Robotic multi-port (n = 4) and single site cholecystectomy (n = 5) has been safely performed in a pediatric population (mean age 14) (Ahn 2015). Median console time was 47 minutes (range, 44−58) for multi-port cholecystectomy and 69 minutes (range, 66−86) for single site cholecystectomy. Eight of 9 patients were discharged home on day 0 with no complications. Both techniques were deemed safe in a pediatric population with possibly increased anesthetic time with single-site surgery for the trade-off of potential improved cosmesis and functional recovery.

Robotic colorectal surgery has also garnered increasing interest and a recent meta-analysis composed of data from 2 randomized controlled trials and 22 non-randomized controlled trials (5 prospective and 17 retrospective) representing 3318 patients (robotic n = 1852; laparoscopic n = 1466) compared outcomes for robotic assisted versus laparoscopic colorectal surgery (Zhang 2016). Length of hospital stay, conversion rates and blood loss were significantly reduced in the robotic group (p<0.05) while the operation times (SMD = 0.78, 95% CI 0.54 – 1.02) and total costs (SMD = 1.23, 95% CI 1.01−1.45) trended in favor of laparoscopic surgery while not reaching statistical significance between groups. A separate study by Shiomi et al. assessed the advantages of robotic assisted surgery (n^{tot} = 127; n^{obese} = 52) compared to laparoscopic surgery (n^{tot} = 109; n^{obese} = 30) for lower rectal cancer and visceral obesity cases, defined as visceral fat area ≥ 130 cm^2 (Shiomi 2016). Robotic assisted surgery had lower overall complication rate (9.4% vs. 23.9%; p = 0.007), less blood loss (p = 0.007), shorter length of stay (p<0.01) with comparable operative time and pathological results. Visceral obesity cases displayed decreased blood loss, length of stay and complication rate in favor of the robotic group (all p<0.05). These results suggest that robotic assisted surgery may have advantages for challenging surgical locations and patient factors.

Gynecology

Multiple studies have compared the daVinci surgical system to standard laparoscopic myomectomy. These are technically challenging operations and many surgeons prefer open surgical approaches compared to MIS for this reason. Advincula et al., demonstrated that the use of surgical robots was associated with fewer intraoperative complications and decreased blood loss with a mean of 196 mL 95% CI [50, 700] compared to 365 mL 95% CI [75, 1550] (p<0.05), increased operative time with a mean of 231 minutes 95% CI [199, 263] for the robot-assisted surgery compared to mean of 154 minutes 95% CI [138,170] (p<0.05), decreased mean hospital stay (1.5 days 95% CR [1, 3] compared to 3.6 days 95% CR [3, 8] (p<0.05), and increased cost compared to traditional laparoscopic methods. The largest study comparing the daVinci surgical system to laparoscopic and open myomectomy approaches demonstrated the ability to resect larger masses with the robot (223g 95% CI [85.2, 391.5]) compared to laparoscopy (96.65g 95% CI [49.5, 227.3]) (p<0.001). Additionally, robotic

surgical time was 181 minutes 95% CI [151, 265] compared to laparoscopy (115 minutes 95% CI [98, 200]) compared to open procedure time of 126 minutes 95% CI [95, 177] (p<0.010) (Barakat 2011). Patients undergoing the open procedure had increased LOS? of 3 days, 1 day for laparoscopic, compared to 1 day for robot-assisted surgery (p<0.001) (Barakat 2011). The findings of these studies suggest that the use of surgical robots may benefit patients with complex, multiple myomas who would traditionally not be considered candidates for a minimally invasive approach.

Uterine cancer is one of the most common cancers in women, and surgical treatment consists of combination of a hysterectomy, bilateral salpingo-oophorectomy, and pelvic and para-aortic lymphadenectomy (Weinberg 2011). The largest study to date comparing 377 robot-assisted surgeries to historical data of 131 patients undergoing open surgery for staging of endometrial cancer demonstrated that the conversion rate from robotic surgery to open surgery was 2.9% (Paley 2011). The robotic surgery group had a decreased blood loss of 46.9 mL compared to 197.6 mL (p<0.0001) for open procedures, decreased intraoperative and postoperative complications (6.4% compared to 20.6% p<0.0001), a higher lymph node count of 15.5 compared to 13.1 (p = 0.007) as well as a shorter LOS (1.4 days compared to 5.3 days for open procedure, (p<0.0001) (Paley 2011).

The utility of the daVinci robot treating early stage cervical cancer with radical hysterectomy has been evaluated, given the complexity of performing laparoscopic radical hysterectomy. A study done by Nam et al. compared 32 cases each of robot-assisted as well as open hysterectomy with similar patient and tumor demographics. There was no significant difference between the operative time between the robotic and open procedures (218.8 +/- 78.3 minutes, 209.9 +/- 87.8 minutes respectively, p = 0.654), with similar number of lymph nodes sampled (20.2 +/- 9.4, 24.2 +/- 11.1 respectively, p = 0.121), and decreased blood loss (220.0 +/- 134.7 mL, 531.5 +/- 435.5 mL respectively, p = 0.002) (Nam 2010).

Ovarian cancer requires operative staging including: exploratory laparotomy with hysterectomy, adenectomy, abdominal-pelvic washing, omentectomy, pelvic and paraaortic lymphadenectomy, and peritoneal biopsies, as well as debulking of resectable metastatic tumor (Weinberg 2011). One study done by Magrina et al., compared 25 cases of daVinci-assisted robotic surgery for staging of endothelial ovarian cancer compared to 27 laparoscopic surgery and 119 open surgery cases over 3 years (Magrina 2011). Despite confounding variables in this study, the authors demonstrated that the robotic, laparoscopic and open treatment arms were associated with: mean operative times of 314.8 minutes, 253.8 minutes, and 260.7 minutes respectively (p<0.05), decreased blood loss of 164.0 mL, 266.7 mL, and 1307.0 mL respectively (p = 0.001), and mean length of hospital stay of 4.2, 3.2, and 9.2 days respectively (p = 0.08) (Magrina 2011).

Currently there are no substantial randomized trials with long-term outcomes comparing robotic surgery efficacy and safety in Gynecology compared to traditional surgical approaches to definitively change pattern of practice, but studies remain ongoing and robotics in Gynecology remains an emerging field.

Neurosurgery

The field of neurosurgery has undergone monumental changes as a result of revolutions in stereotactic and minimally invasive surgery (Nathoo 2005) NOT IN LIST. MIS

Neurosurgery has directly led to improved patient outcomes and new surgical options for tumors that were previously thought to be unresectable, all the while improving safety for patients in these critical operations.

The initial types of robots helped surgeons perform basic stereotactic tasks, the first one of which was the PUMA 560 used to predetermine the trajectory of a brain biopsy procedure (Kwoh 1988). NeuroMate (Integrated Surgical Systems, 1987, Sacramento, California) was the first surgical robot to be approved by FDA comprises a system with 6 degrees of freedom that can be used for biopsy procedures, stereoencephalography, endoscopy, as well as deep brain stimulation with its ability to properly and accurately orient, position, hold, and manipulate tools in a 3D space with high precision and accuracy (Nathoo 2005; Haegelen 2010). NeuroArm, developed at the University of Calgary in 2001, is an ambidextrous robot designed to work within an MRI which allows the neurosurgeon to perform operations while leveraging real-time MRI scans throughout the procedure (Sutherland 2013). NeuroArm was used in 2008 to remove a brain tumor from a 21 year old patient, and since then has shown positive clinical results in other cranial neoplasia cases (Sutherland 2013; Pandya 2009).

Spine surgery saw the development of SpineAssist (Mazor Robotics, Caeserea, Israel), the predecessor to the Renaissance surgical system from the same company, which was FDA approved in 2011. Both of these surgical systems consist of a miniature robot securely attached to the operating table coordinated with real-time fluoroscopy to assist in accurate placement of spinal pedicle screws (Devito 2010). A retrospective study comparing the use of SpineAssist showed that 3204 of 3271 (97.9%) pedicle screws were appropriately placed on targeted positions by the robot (Devito 2010).

The daVinci surgical system has also been used in Neurosurgery for spinal schwannoma removal, transoral odontoidectomy, and intrauterine repair of myelomeningocele, with inconclusive outcome reports comparing robot-assisted to conventional open methodologies (Perez-Cruet 2012). However, daVinci is limited in this capacity due to reduced instrumentation availability and need for multiple access ports (Doulgeris 2015).

Current studies of robotics in Neurosurgery draw inconclusive results due to lack of good quality clinical trials and current evidence is comprised primarily of case reports or on *in vivo* models. However the increasing number of case reports from institutions illustrates the desire of surgeons to investigate this emerging technology in the context of Neurosurgery.

Orthopedics

Although the field of Orthopedic surgery pioneered surgical robotics, their use has not gained the widespread popularity and growth as seen in other surgical specialties. The external fixation of limbs in optimal position presents fewer challenges to accessing the operative field and providing adequate exposure compared to other surgical specialties which work with mobile viscera and soft tissues (Yen 2010).

Traditional knee replacement surgery (TKR) involves intraoperative sizing guides to assist the surgeon determine the appropriate implant size to ensure a tight fit between the bone and prosthetic. Intraoperative cutting errors and resulting gaps can lead to delays in bone growth and increased use of bone cement in such cases. Many surgical robots were developed for the purposes of knee arthroplasty, with only few of them having clinical success throughout the world. These robots include the CASPAR system (URS Ortho Rastatt,

Germany), RGA system (formerly known as ACROBOT), ROBODOC system (Curexo Technology Corporation, Fremont, California, USA), and the Robotic Arm Interactive Orthopedic System (RIO; MAKO Surgical Corporation, Fort Lauderdale, Florida, USA), with the most commonly used orthopedic surgical robots being the ACROBOT and ROBODOC systems (Netravali 2013).

The Active Constraint ROBOT (ACROBOT) was first developed in Imperial College in London, United Kingdom (Jakopec 2003) and is now known as the Stanmore Sculptor Robotic Guidance Arm (RGA) system (Stanmore Implants, Elstree, UK) (Netravali 2013). Its main parts include a high-speed cutter mounted on a robotic device that uses 3D reconstruction and visual guidance to precisely target and core out long bones for implants (Cobb 2006). The ACROBOT allows free movement inside a predetermined safe region, however, motion at the boundaries becomes progressively more stiff, preventing inadvertent errors (Jakopec 2003). A prospective double-blind randomized control trial by Cobb et al., compared conventional and robot-assisted unicompartmental knee arthroplasty in 27 patients using the ACROBOT system showed increased operating time but significantly better alignment that achieved near normal coronal plane alignment within 2 degrees of the targeted position with the ACROBOT, while only 40% (6/15) of the conventional method resulted in this degree of accuracy (Cobb 2006). Likewise, the difference between tibiofemoral angles planned and achieved favored ACROBOT assistance (0.65 +/- 0.59 degrees vs -0.84 +/- 2.75 degrees respectively, $p = 0.001$). Three other studies done by Coon, Pearle et al., and Plate et al., also evaluated the use of robot-assisted unicompartmental knee arthroplasty, which all demonstrated more accurate implant placement, improvements in restoration of natural knee kinematics, and positive outcomes for implant survival as a result of accurate placement of implants (Coon 2009; Pearle 2010; Plate 2013).

ROBODOC is one of the first clinically successful robots, and is the first robot to be approved by the FDA to be used in orthopedic surgery (Karthik 2015).

Robot-assisted total hip arthroplasty (THR) was originally performed with ROBODOC in 1992 and has been used in over 24,000 surgeries worldwide with data showing improved patient outcomes, with more precise implant positioning and elimination of intraoperative femoral fractures (Bargar 1998). A study done by Harris et al., compared the surgical outcomes of hip replacements performed in three different centers with 69 ROBODOC-assisted total hip replacement compared to 65 control cases. As with knee replacement surgery, the robot-assisted procedure was associated with longer operative times (258 minutes, which was later reduced to 90 minutes with surgeon experience, compared to 134 minutes for the control group, $p<0.0001$) (Bargar 1998). Blood loss was reported to be higher in the robot-assisted group (1189 mL compared to 644 mL compared to the conventional open surgical method, $p<0.0001$), and average length of stay was not significantly different between the two groups (8.2 days for the ROBODOC and 7.5 days vs. control) (Barger 1998). Postoperative complications including intraoperative fractures, dislocations, partial sciatic nerve palsy, deep vein thrombosis and pulmonary embolism were evaluated with no significant differences in complication rates between the two treatment groups, other than no intraoperative femoral fractures in the ROBODOC group compared to three in the control group ($p<0.01$) (Barger 1998). The modified Harris hip scores postoperatively showed no difference in the first year favoring the robotic group (89.4 for the ROBODOC vs 86.6 for the control group), and two years (88.5 for the ROBODOC vs. 91.1 for the control group) (Bargar 1998).

The innovative motion (INNOMOTION, Innomedic, Herxheim & FZK Karlsruhe Germany & TH Gelsenkir, Germany) allows for robot-guided intraarticular injections into the many joint articulations of the foot under CT or MRI guidance, including: calcaneocuboid, subtalar, tarsometatarsal, talonavicular, and tibiotalar joints. INNOMOTION was successful in infiltrating all 16 joints of patients (N = 16) with no intra or postinterventional complications. Small case studies to date have shown that patients had relief of pain following injections with a preinterventional pain measurement visual analogue scale (VAS) 5.3 +/- 2.33 to a score of 1.1+/- 1.45 postinterventionally (Wiewiorski 2009).

Surgical robotics in Orthopedic surgery has a long and storied history, and remains an active area of research and development. Given the current widespread use of mechanical instruments in the field of Orthopedic surgery, lends the specialty especially well transition into the world of robotics surgery.

Otolaryngology

The field of Otolaryngology has traditionally performed procedures involving large incisions and extensive surgical dissections to adequately perform head, neck and airway surgeries to minimize damage to vital structures (Oliveira 2012). Thus the nature of these surgical procedures can lead to significant tissue damage, extended time to functional recovery, decreased cosmesis, and decreased quality of life (Garg 2010). Robotic assisted surgery is well poised to positively affect these negative patient outcomes (Oliveira 2012).

The daVinci robot is currently used for Transoral Robotic Surgery (TORS) and was FDA approved in 2009 (Moore 2009). TORS surgery involves the use of the oral cavity as an entry site, and was first carried out by McLeod and Melder for marsupialization of a vallecular cyst in 2005 (McLeod 2005). This technique was further adapted and developed by Weinstein and O'Malley in 2006 on three human patients with tongue base cancers (O'Malley 2006).

There are few studies to date looking into the functional surgical outcomes associated with patients undergoing TORS for oncologic resection in the head and neck. Case reports of a variety of different surgical procedures performed in head and neck regions from the oropharynx, laryngopharynx, oral cavity, skull base surgery (infratemporal and parapharyngeal fossae), thyroid glands, and in pediatric airways have been documented (Garg 2010). The most comprehensive study thus far was done by Boudreaux et al. in 2009 with 36 patients with laryngeal, oropharyngeal, hypopharyngeal, and oral cavity tumors. Although 36 patients were recruited for the study, only 29 (81%) underwent successful robotic resections with negative surgical margins reported in all 29 patients (Boudreaux 2009). Of the 7 patients who failed to undergo successful robotic resection of their tumors, the biggest factor was adequate and appropriate exposure of the surgical site, extensive infiltrative tumor requiring free-flap reconstruction, or patients opting for chemotherapy or chemoradiotherapy treatments instead (Boudreaux 2009). The mean robotic operative time was 99 +/- 32.6 minutes, mean estimated blood loss was 51 +/- 42 mL and no transfusion was required for any cases (Boudreaux 2009). The mean hospital stay was 2.9 +/- 2.9 days, and 16 of the 29 patients (55%) were able to return to oral nutrition prior to discharge. Postoperative complications were limited to bleeding in 4 patients, one whom required cautery and another as a result of coumadin therapy several days postoperatively. 21 patients (21/29, 72%) undergoing TORS were safely extubated prior to exiting the operating room, and 7 patients required

postoperative intubation with only one patient requiring a planned short term tracheotomy tube placement. This study demonstrated that TORS is a safe surgical alternative for patients with suitable airway anatomy and limited tumor disease pathology, however, further studies comparing TORS to conventional open procedures will need to be carried out to further elucidate the benefits of using the daVinci robot in these procedures.

The use of TORS has also been extended to non-malignant lesions in the head and neck. Vicini et al., in 2012 assessed the utility of TORS in treating obstructive sleep apnea hypopnea syndrome in 20 patients. The mean operative time was 42.5 +/- 15.2 minutes, with a mean setup time of 31.2 +/- 18.2 minutes and estimated blood loss was at 27.7 +/- 13.6 mL (Vicini 2012). There were no serious intraoperative or postoperative complications in this study other than minor bleeding managed non-surgically in three patients (Vicini 2012). Evaluation of the surgical outcome was done through the apnea hypopnea index (AHI) score and Epworth sleepiness scale (ESS) with improvements of 24.6 +/-22.2 for AHI and 5.9 +/- 4.4 for ESS, and using cutoff values of AHI, ESS, and oxygen saturation levels postoperatively, 12 (60%) of the patients were considered to be cured (Vicini 2012).

The use of the daVinci has been evaluated more extensively in the case of thyroidectomies, comparing it to the conventional open method. The first case was performed by Lobe et al., in 2005 who used a transaxillary robotic technique to resect a thyroid nodule in one patient and placement of a vagal nerve stimulator for intractable seizures in another (Lobe 2005). A recent systematic review and meta-analysis looked at 11 articles comparing robot-assisted thyroidectomy to conventional open procedures. The mean operative time for robot-assisted thyroidectomy was increased compared to conventional open methods by 48.1 minutes 95% CI [33.6, 62.7] in total thyroidectomies and by 37.3 minutes 95% CI [12, 62.5] in subtotal thyroidectomies (Sun 2014). Conversion from robot-assisted to open cases was required in 2 out of 243 cases (0.8% cases). Length of hospital stay was decreased in the robot-assisted thyroidectomy group by -0.006 days 95% CI [-0.25, 0.24]. There was no significant difference between the two patient groups in terms of postoperative complications including hematoma or seroma formation, recurrent laryngeal nerve injury, hypocalcemia, or chyle leak, (Sun 2014). Postoperatively, the conventionally open procedure treated patients had increased severity of voice symptoms at postoperative day 1 (p = 0.008), first month postoperatively (p = 0.049), 3 months postoperatively (p = 0.043), but not at 6 months (Tae 2012).

The feasibility of skull base surgery was first demonstrated by O'Malley and Weinstein in humans in a patient who underwent parapharyngeal cystic neoplasm resection in the infratemporal fossa with no adverse surgical events such as damage to many vital structures (carotid artery, jugular vein, cranial nerves) (Oliveira 2012). Further development of appropriate instruments for Otolaryngology in terms of size, function, and flexibility will be needed prior to execution of more robot-assisted skull base surgery in Otolaryngology patients (Oliveira 2012).

Urology

The field of Urology has been a frontrunner in exploring surgical robots use in a spectrum of operations. The first reports of the use of the daVinci robot in surgery were described by Partin et al. in 1995 who utilized robotic assistance as surgical assistant

substitutes during 17 laparoscopic procedures (Burch bladder suspension (N = 2), nephrectomy (N = 4), nephropexy (N = 1), orchiopexy (N = 1), pelvic lymph node dissection (N = 1), pyeloplasty (N = 3), retroperitoneal lymph node sampling (N = 2), varix ligation (N = 2), and ureterolysis (N = 1) (Partin 1995). The study reported no increase in total operative time when the robotic arms were used, and no difference between the set up and take down times for the robot-assisted surgeries compared to the conventional laparoscopic surgical assists (p>0.05) (Partin 1995). DaVinci robot-assisted prostatectomy (DVP) is the most frequently performed robotic procedure worldwide, and has supplanted both laparoscopic and open approaches at many centers (Barbash 2010). There remains insufficient data to determine if robotic prostatectomy can decrease the long term rates of impotence and incontinence which are potential complications of this operation. However, introduction of robotic Urology has changed the landscape of radical prostatectomy operations as a whole, as it has leveled the steep learning curve of laparoscopic prostatectomy and allowed an entire population of MIS-naive surgeons seemingly the ability to offer an MIS approach to this procedure overnight (Barbash 2010).

The literature supports the fact that DVP leads to significantly less blood loss secondary to improved visualization of the dorsal venous complex coupled with the tamponade effect of the pneumoperitoneum compared to conventional open or laparoscopic methods (Jain 2015; Skolarus 2010; Krambeck 2009).

Comparing robot-assisted radical prostatectomy to traditional open procedures, the current studies show longer operative time for robot-assisted laparoscopic prostatectomy (2.3 hours for open and 4.8 hours for robot-assisted, p<0.001) in the early phases of the learning curve with decreased operative time with increased robot-assisted surgical cases (N = 200) (163 minutes for open and 160 minutes for robot-assisted) (Menon 2002; Tewari 2003). Transfusion rates were lower in the robot-assisted group compared to the open surgical treatment group with a relative ratio of 4.51 95% CI [1.35, 15.03] (p = 0.01) (Ficarra 2009). Only a single study by Tewari et al., looked into mean catheterization time which demonstrated a lower catheterization time in robot-assisted treatment group of 15.8 days for open compared to 7 days (p<0.05) (Tewari 2003). The current studies comparing the various surgical modalities show similar rates of complication in prostatectomies in the different treatment groups, with the exception of the study done by Tewari et al., which demonstrated a 20% intraoperative complication rate for open surgical group (N = 100) compared to 5% in the robot-assisted surgical group (N = 200) (p<0.05) (Tewari 2003).

Comparison of laparoscopic prostatectomy to robot-assisted prostatectomy showed similar mean operative time after 20 robot cases (Ficarra 2007). The cumulative weighted mean difference for the mean operative time were overlapping in laparoscopic compared to robot-assisted treatment groups with a faster operative time in the laparoscopic group of -19.39 minutes 95% CI [-49.34, 88.13] (p = 0.58) and an increased weighted mean difference blood loss in the laparoscopic group of 19.45 mL 95% CI [-112.53, 106.73] compared to robot-assisted prostatectomy (Ficarra 2009). Robot-assisted prostatectomy did not have significant differences with regards to transfusion rate, in-hospital stay, or catheterization time, with conflicting results with regards to overall complication rates (Ficarra 2009). The cumulative analysis of very limited data looking into urinary incontinence after robot-assisted or laparoscopic prostatectomy shows a similar relative risk of 0.87 95% CI [0.54, 1.39] (p = 0.56) for the two groups, and one study looking into recovery of erectile function demonstrated a median time to erectile function recovery of 440 days for open prostatectomy

compared to 180 days for robot-assisted prostatectomy ($p<0.5$) and median time to intercourse of 700 days for open compared to 340 days for robot-assisted procedures ($p<0.05$) (Ficarra 2009; Tewari 2003).

The oncologic outcomes following DVP (biochemical recurrence, positive surgical margins) appear similar between robot-assisted and conventional open radical prostatectomy (Masterson 2013; Barocas 2010). A cumulative analysis of studies found similar reports of positive surgical margins amongst robot-assisted and laparoscopic prostatectomy with a relative risk of 1.08 95% CI [0.97, 1.19] ($p = 0.17$) (Ficarra 2009). Recent systematic review and meta-analysis looking into the current studies of oncological outcomes associated with robot-assisted prostatectomy showed positive surgical margins with a mean of 15% in all cases and 9% in localized cancers (Novara 2012). Only very few studies reported follow up over 5 years with a 7 year biochemical recurrence-free survival being 80% for robot-assisted prostatectomy (Novara 2012). Cumulative analysis comparing robot-assisted prostatectomy to open prostatectomy showed similar positive surgical margins with an odds ratio of 1.25 ($p = 0.19$) and similar biochemical recurrence survival estimate hazard ratio of 0.9 ($p = 0.526$) (Novara 2012). Looking into robot-assisted prostatectomy compared to laparoscopic prostatectomy, the studies also demonstrate similar positive surgical margins with an odds ratio of 1.12 ($p = 0.47$) and similar biochemical recurrence survival estimate hazard ratio of 0.5 ($p = 0.141$) (Novara 2012).

The promising results of DVP and the demonstration of technical success of the platform in a restricted space performing complex reconstruction, paved the way for expansion of daVinci applications to other urological procedures. MIS radical nephrectomy procedures for renal cell carcinoma is a prime example of the benefits of minimally invasive surgery as there are well documented reductions in (LOS), pain, improved cosmesis and earlier return to activity. However, MIS partial nephrectomy, in which only a portion of the kidney is removed which harbors a tumor, followed by reconstruction of the remaining kidney, is a much more technically challenging operation and one for which daVinci has proven effective (Fergany 2000). The operation is often stressful as the renal hilum is clamped, depriving the kidney of blood during the resection, but also instituting a time limit to complete the procedure within 30 minutes. A retrospective review of daVinci partial nephrectomies performed at four large centers in Europe and United States by Benway et al. (N = 183), reported a mean ischemic time of 23.9 minutes (range: 10−51 minutes), a mean total operative time of 210 minutes (range: 86−370 minutes) with the robot, and a mean estimated blood loss of 131.5 mL (range: 10−900 mL), the tumor size was positively correlated with both the operative time ($p = 0.003$) and warm ischemic time ($p = 0.005$), with a mean tumor size of 2.87 cm (range: 1.0−7.9 cm). Two cases (1%) were converted to open partial nephrectomies due to failure to progress (extensive perinephric scarring in one patient and another failure to identify tumor in intraoperative ultrasounds). A total of 18 (9.8%) complications were reported in the study with 15 (8.2%) being major in nature, such as two postoperative bleeds requiring transfusion, two postoperative urine leaks (stent placement and drainage), hepatic laceration in one patient and splenic laceration in another, two chylous leaks, three pseudoaneurysms requiring embolization, one subscapsular renal hematoma, and two patients suffering from postoperative stroke and one myocardial infarction, with no fatalities. There were 3 (1.6%) minor complications such as incisional cellulitis and self-resolving gross hematuria, with no reported disease-specific mortalities. However, continued

investigation of the efficacy of daVinci partial nephrectomy is required to document long term outcomes (Wu 2014).

The current gold standard treatment for muscle invasive bladder cancer is radical cystectomy. Laparoscopic radical cystectomy leads to lower morbidity and comparable oncological outcomes compared to open radical cystectomy (Haber 2007). The familiar benefits and MIS approach including: decreased hospital stay and blood loss, and early recovery from ileus are also reported benefits of daVinci robot-assisted radical cystectomy (Nix 2010). Staging pelvic lymph node dissection during these operations can be challenging via laparoscopy, but robot approaches yield numbers similar to that of the open procedure (Hellenthal 2011). It should also be noted that currently the preference is to complete the urinary diversion step of radical cystectomy via extracorporeal technique, although methods have recently been developed to facilitate a completely intracorporeal reconstruction (Pruthi 2010). A study evaluating the learning curve for robot-assisted radical cystectomy was appraised at 14 different institutions (N = 496) (Hayn 2010). Mean operative time for daVinci cystectomy was 441 minutes, 368 minutes, and 307 minutes for surgeons who had performed<30, 30−50, or >50 cases respectively (p<0.0001) The median lymph node yield increased by 73% amongst surgeons who had done<30 or >50 cases (p<0.0001), with lymph node yields of 13, 18, or 20 for surgeons who had performed<30, 30−50, or >50 cases respectively (p<0.0001) The mean estimated blood loss was 477 mL (N = 476), 283 mL (N = 193), and 451 mL (N = 419) with surgeons who had performed<30, 30−50, or>50 cases respectively (p<0.0001). The mean length of hospital stay was found to be 12 days, 10 days, and 12 days in the groups with surgeons who had performed<30, 30−50, or >50 cases respectively (p = 0.4889) and 21%, 27%, and 26% of cases performed by surgeons who had performed<30, 30−50, or >50 cases respectively required transfusions (p = 0.2923). Positive margins were found in 12%, 10%, and 6% of cases performed by surgeons who had performed<30, 30−50, or >50 cases respectively (p = 0.6054).

Benefits

Surgical robotics originally had foundations in the US military's desire to deliver specialized care in forward hospitals without risking these specialized human assets' lives. Following the advent of telesurgical robotics, refinement in the platform followed parallel developments in the fields of computational power and complexity, hardware miniaturization, and videoendoscopy. While traditional open surgery allows for wide operative field visualization and manipulation and the recruitment of surgical assistants, traditional laparoscopy suddenly handcuffed the surgeon, limiting their range of motion, degrees of freedom and taking away depth perception during conduct of the operation. For these reasons, surgeons wishing to implement laparoscopy into their practice must undertake specific training in MIS techniques as there is a steep learning curve to relearn how to conduct procedures under such restrictive conditions. Surgeons were willing to continue to push MIS procedures over traditional open procedures despite the difficulties inherent in the surgical modality as there quickly became obvious benefits to patient postoperative recovery and return to normal function. At this point, surgical robotics fortuitously matured into a viable entity and quickly gained popularity as it severely flattened the learning curve to deliver MIS style surgical approaches. The robot added back increased dexterity and range of motion,

improved visualization and depth perception, motion scaling and tremor filtration, and did away with the fulcrum effect; all factors which made minimally invasive surgery distinctly foreign, now made entirely intuitive (Prajapati 2012; Lanfranco 2004; Davies 2000).

Incorporation of robotic MIS has promoted the undertaking of surgical procedures previously thought to be too technically challenging or complex using laparoscopic methods. The development of "endowrist" technology which places an additional joint next to the tip of the instrument allows for fine, dextrous movements and a full 6 degrees of freedom, further increased the impression of deploying and controlling miniaturized virtual "hands" in the operative field. To many, it was essentially inconceivable to perform complex MIS procedures on the brain or spine, or pelvis, and the field of robotics has shown that these are not only feasible, but also often with improved patient outcomes.

Limitations

Despite its accelerating popularity and traction in the health care delivery landscape, there remain some disadvantages to surgical robotics, and there are currently no definitive high quality clinical trials comparing robotics to other MIS procedures. Furthermore, compared to other surgical methods such as their laparoscopic counterparts, there are very little long-term follow-up studies on patients of robotics-assisted surgery (Lafranco 2004; Maseo 2010; Weinberg 2011; Karthik 2015).

With any new technology comes additional cost, and robotic surgery is no exception. The capital cost of acquiring the daVinci surgical system is on the order of $3−5 million dollars (Turchetti 2012; Barbash 2010). The robotic instruments are the principal driver in incremental cost as they are disposable consumables which may be used a maximum of 10 cases before being decommissioned through an internal mechanism (Maseo 2010). A study published in the New England Journal of Medicine by Barbash and Sherry showed that on average across 20 different types of surgeries, the incorporation of robots into the procedure adds about $1600, or 6% to the cost (Barbash 2010). Intuitive Surgical is the sole provider of commercially available surgical robots and enjoys a monopoly in the market to date. The prohibitive cost of implementing a robotic surgery program can prevent more widespread adoption outside of large, academic centers (Kim 2002). Contemporary surgical training programs in North America particularly in the USA often teach trainees operations via robotics approaches first, and thus this generation of surgeons and those following are destined to accept these technologies as just a part of the standard armamentarium in the delivery of patient care. Even still, it is important to recognize that like any surgical procedure, it is estimated that one would need to perform 150 to 250 procedures prior to becoming proficient, and anywhere between 8 to 150 cases to reach a plateau on the learning curve (Barbash 2010; Jain 2015).

Another limitation of surgical robots is their physical presence in the operating rooms (Lafranco 2004). These machines are large, and take up valuable operating room real estate, particularly in already crowded operating rooms with other essential equipment and personnel. Questions have been raised as to safe conduct of procedures in these cramped quarters, however, these concerns may be circumvented with future development of smaller robots, or larger operating rooms built with these technologies in mind (Savata 2001). Already, between the daVinci Standard and the most recently released version, the daVinci

Xi, there has been a significant reduction in footprint and resources required for the robotics platform in the OR.

The primary limitation in preventing widespread use of surgical robots is the prohibitive cost of purchasing and maintaining the robot, prolonged operative time which can further prolong surgical wait lists, and the need for specially trained operating staff and surgeons. It is predicted that with time, these limitations will be overcome; some through market competition, and some through "network effects" in that the more robots are in use, the more robotic operations are integrated, the more robots are purchased, and so on.

Training Models

Intuitive surgical has developed the daVinci Skills Simulator™ which consists of various modules designed to gain comfort in basic robotic skills such as endowrist manipulation, camera and clutching, fourth arm integration, system setting, needle and control driving and energy and dissection (Intuitive Surgical 2016). Cho et al. prospectively assessed if this trainer could improve performance (Cho 2013). 12 subjects were randomized into 2 groups, virtual reality plus standard training (n = 6) versus standard training alone (n = 6), to assess needle control and suturing. Participants were evaluated across two time points with the intervention group undergoing virtual reality training in between. Those subjects in the virtual reality group displayed significantly improved performance skills (p = 0.028) and suturing time (7.1 ± 1.54 minutes versus 10.55 ± 1.93 minutes, respectively; P= .018). Improved performance following robotic virtual reality simulation training has also been verified by other investigators (Foell 2013).

Robotic training on inanimate objects has gained popularity. Finan et al. created a dry lab in which the procedure for robotic hysterectomy was broken down into critical steps of the operation (i.e., identification of ureter, suturing vaginal cuff, etc.) (Finan 2010). They used objects such as balloons, rubber bands, nails, a 'beer huggie', foley catheters and plywood to model female anatomy. 16 residents were put through the dry lab training and graduated to live surgery if they showed proficiency at the critical steps as judged subjectively by an expert. 10 of 16 residents were granted permission to move onto live surgery performing key parts or the entire robotic hysterectomy with no complications to date.

Animal models are another mainstay of robotic surgical training. Mehrabi et al. used a small (rat) and large (porcine) animal model to evaluate performance improvement over time for visceral and vascular robotic surgical procedures (Mehrabi 2006). 4 trainees with different experience level underwent a baseline evaluation in a porcine model for cholecystectomy, gastrotomy, anastomosis of small intestine and aorta. Following this, training on a rat model performing 4 procedures each of gastrotomy and anastomosis of colon, aorta and small intestine was performed. Finally, re-evaluation on the porcine procedures occurred to conclude the study. Operative times significantly improved for everything except cholecystectomy (11 min and 8 min for cholecystectomies; p = 0.24, 18 and 10 min for gastrotomies; p = 0.002, 28 and 18 min for anastomosis of small intestine; p = 0.007, and 25 and 12 min for anastomosis of the aorta; p = 0.049). Also, complication rates and performance quality significantly improved for all procedures across time points as gauged by expert evaluators (p<0.05). In the field of Urology, a novel robot-assisted partial nephrectomy model consisting of an ex vivo porcine kidney with an implanted Styrofoam ball mimicking

the tumor was developed and tested by Hung et al. (Hung 2012). This study divided participants into 3 groups based on number of robotic cases completed: expert (>100 cases; n = 13), intermediate (1−100 cases; n = 9), and novice (0 cases; n = 24). Partial nephrectomy using the daVinci Si was performed by each group, with each procedures being judged by 3 blinded expert reviewers using the validated Global Operative Assessment of Laparoscopic Skills tool (Vassiliou 2005). Expert surgeons outperformed the other groups in all performance metrics ($p<0.05$) and felt the model may be beneficial for residents and fellows, but they were unsure how useful it would be for more experienced surgeons.

Hung et al. designed a study to gauge the relative performance of three standardized robotic training methods: virtual reality using the da Vinci Skills Simulator™, structured inanimate tasks and a live porcine model (Hung 2013). Two groups were identified consisting of urology residents (novice) with median (range) of 0 (0−20) robotic cases (n = 38) and faculty surgeons (expert) with median (range) of 300 (30−2000) robotic cases (n = 11). Blinded experts graded performance using the Global Evaluative Assessment of Robotic Skills tool (Goh 2012). As expected, experts received higher scores than novices over all three training methods ($p<0.001$). Performance on all three methods was found to be strongly correlated ($p<0.001$) indicating cross method validity, thus signifying the training value of each of these training methods.

Telesurgery

The master-slave configuration of the daVinci robotic surgical system has the primary surgeon sitting at a console that is connected to robotic effector arms via a series of cables. A logical extension of this set up is to increase the distance between the console and the robot to allow greater access to expert robotic surgical therapy. Telesurgery over great distances has the potential to deliver quality surgical care to people of remote areas without the added costs of travel and logistics. Additional benefits are quite intuitive, as clearly identified by two of the original collaborators of the technology; NASA and the USA army. Both of these groups hope to be able to deliver surgical care to their personnel either in space or on the battlefield (Satava 2002). Additional advantages include surgeon safety, as there are reports of surgeon morbidity when travel is required (Cazac 2014), and telementoring whereby novice surgeons can receive active feedback from expert surgeons across the world (Ballantyne 2002).

Pre-surgical telesurgery trials have been performed with encouraging results. Nguan et al. used an Internet-based virtual private network (VPN) with data transfer speeds of 17 Mb/s to assess robot-assisted laparoscopic pyeloplasty in a porcine model over a distance of 2848 km with the daVinci system (Nguan 2008). Surgical anastomotic times for the 6 porcine pyeloplasties were evaluated. Despite connection latency of 370 ms, the procedure was feasible with average anastomosis of 20.7 +/- 4.7 min. In a separate study, Nguan et al. performed 18 total robotic-assisted pyeloplasties with the Zeus system on a porcine model using real-time (n = 6), Internet-based VPN (n = 6) and satellite network connections (n = 6) (Nguan 2008). Latency and operative time did not reach statistical significance between groups and were as follows: real time (0 ms; 41.3 +/- 15.0 min), VPN (66.3 ms; 47.0 +/- 24.1 min) and satellite (560.7 ms; 51.8 +/- 4.7 min). Both the landline and satellite groups had 2 of 6 anastomoses display mild leak with pressure test of 100 cmH2O whereas the real time procedures had no such leak. Finally, despite no statistically significant results between

groups, surgeons subjectively reported that pyeloplasty was more difficult with delays between actions and response in the landline and satellite groups.

Innovative communication systems are necessary to achieve more widespread accessibility to telesurgery while also minimizing latency of data transfer. Sterbis et al. have shown that telesurgery is feasible over public Internet (Sterbis 2008). Using a combination of telementoring and telesurgical approaches, 4 robotic assisted porcine nephrectomies were carried out with the primary surgeon greater than 1200 miles away. Data transfer delays were between 450 to 900 ms, however blood loss was minimal, there were no inter-operative complications and all surgeries were successfully performed. A group from the University of Washington, in collaboration with the US military is attempting to develop a fully mobile, wireless robotic telesurgery system (Lum 2007). This group implemented a study in which a surgical robot was deployed in the Simi Valley desert of California for experiments on an inanimate model with communication facilitated via an Unmanned Aerial Vehicle in the HAPs/MRT (High Altitude Platform/Mobile Robotic Telesurgery) project. Time delay between console and robot was 200 ms for video stream and 20 ms for robotic control signals with no loss of signal. This communication system, along with the development of deployable surgical robot systems such as "The Trauma Pod" with the purpose of being a rapidly deployable robotic system with no human personnel that can be telesurgically controlled to perform critical life-saving procedures on wounded soldiers on the battlefield, could be used to perform complex care to people in disaster areas, on the battlefield or in other remote areas (Garcia 2009).

In 2001, a surgeon in New York performed the first long distance telesurgical operation by performing a laparoscopic cholecystectomy on a patient in Strasbourg, France over 14000 km away (Marescaux 2001). This was accomplished with the Zeus robotic system and a dedicated fiber optic line, known as Asynchronous Transfer Mode (ATM), with a rate of data transfer of 10 Mb/s. The 68 year old patient who was operated on recovered well from the surgery without complication. In Canada, telesurgery has been practiced between McMaster University in Hamilton, Ontario and North Bay, Ontario located 400 km apart, also with the Zeus robotic system (Anvari 2005). Between 2003 and 2005, Dr. Anvari and colleagues were able to perform 21 robot-assisted laparoscopic telesurgeries using an internet protocol virtual private network with 15 Mb/s of bandwidth which included 13 fundoplications, 3 sigmoid resections, 2 right hemicolectomies, 2 inguinal hernia repairs and 1 anterior resection. Latency experienced by the telerobotic surgeon was 135−140 ms. Surgeries were performed in a comparable time to on-site laparoscopic surgery with no significant surgical complications or increases in post-operative stay.

Despite the excitement, there are several concerns regarding telesurgery that has limited widespread acceptance. First, remote locations that may benefit from telesurgery may not currently have skilled individuals to set up the robot platform required for surgery or take control of the operation should a complication arise. Second, hospital and communication infrastructure in non-urban centers may be insufficient to accommodate the data quality and bandwidth required in a mission critical telesurgery setup where unreliable data transfer could be catastrophic (Korte 2014). Third, the financial cost of robotic surgery is prohibitive in many remote locations. Finally, latency in communication speeds does present technical challenges. Perez et al. used the robotic daVinci Trainer to determine impact of communication latency on telesurgical performance (Perez 2016). As latency of data transfer increases, this appears to have an expanding effect on performance. Deterioration in

performance was initially identified with delays in data transfer of 300 ms with many surgeons being unable to perform complex tasks with delays greater than 700 ms. Ultimately, a dedicated, reliable, rapid connection with appropriate resources and personnel on the other end is required to ensure a safe procedure.

CONCLUSION AND FUTURE DEVELOPMENTS

Robotic surgery has become widely available throughout major cities globally. Initial costs of acquiring, setting up and training personnel in a surgical robotics program remain prohibitive in many areas of the world. Despite this, robotic assisted laparoscopic surgical platforms will continue to evolve and further penetrate surgical specialties, driven by a desire to conduct ever more complex operations at no incremental morbidity to the patient.

Surgical robots are unique in that they have the capacity to integrate and interface between other technologies widely used in the operating rooms. Preoperative imaging results (computed tomography or magnetic resonance imaging) can be integrated with the daVinci surgeon console to help surgeons more accurately target pathologies. Simulated complex procedures could also potentially be practiced prior to live surgery to improve outcomes (Lanfranco 2004). Furthermore, the original goal of long-distance surgeries might eventually become possible to bring care to remote areas with limited access to skilled surgeons.

The continued growth and development of new technological advances in medicine, coupled with the efforts of surgeons and researchers to further improve patient care will continue to fuel the development of new approaches to tackle procedures thought to be inaccessible. The expansion of the surgical robotics market with additional manufacturers will help lower the cost of entry for many institutions. Robotic surgery has demonstrated promising results thus far with respect to patient outcomes despite formal clinical trials and is likely to take its place in the standard armamentarium of patient care.

REFERENCES

Advincula AP, Xu X, Goudeau S 4th, Ransom SB. Robot-assisted laparoscopic myomectomy versus abdominal myomectomy: a comparison of short-term surgical outcomes and immediate costs. *J. Minim. Invasive Gynecol.* 2007; 14(6):698−705.

Ahn N, Signor G, Singh TP, Stain S, Whyte C.Robotic single- and Multisite Cholecystectomy in Children. *J. Laparendosc. Adv. Surg. Tech. A* 2015; 25:1033−1035.

Amr AN, Giese A, Kantelhardt SR. Navigation and robot-aided surgery in the spine: historical review and state of the art. *Dove Press* 2014; 2014(1):19−26.

Anvari M, McKinley C, Stein H. Establishment of the world's first telerobotic remote surgical service for provision of advanced laparoscopic surgery in a rural community. *Ann. Surg.* 2005; 241(3):460−464.

Anvari M, Birch D, Bamehriz F, Gryfe, R, Chapman T. Robotic-assisted laparoscopic colorectal surgery. *Surg. Laparosc. Endosoc. Percutan. Tech.* 2004; 14(6):311−315.

Argenziano M, Katz M, Bonatti J, Srivastava S, Murphy D, Poirier R, Loulmet D, Siwek L, Kreaden U, Ligon D; TECABResults of the prospective multicenter trial of robotically

assisted totally endoscopic coronary artery bypass grafting. *Ann. Thorac. Surg*. 2006; 81(5):1666−74.

Ballantyne, GH. Robotic surgery, telerobotic surgery, telepresence, and telementoring. Review of early clinical results. *Surg. Endosc.* 2012; 16(10):1389−1402.

Barbash GI and Glied SA. New technology and health care costs - the case of robot-assisted surgery. *N. Engl. J. Med.* 2010; 363(8): 701−704.

Bargar WL, Bauer A, Börner M. Primary and revision total hip replacement using the Robodoc system. *Clin. Orthop. Relat. Res.* 1998(354); 354:82−91.

Barakat EE, Bedaiwy MA, Zimberg S, Nutter B, Nosseir M, Falcone T. Robot-assisted, laparoscopic, and abdominal myomectomy a comparison of surgical outcomes. *Obstet. Gynecol.* 2011; 117(2 pt 1):256−265.

Barocas DA, Salem S, Kordan Y, Herrell SD, Chang SS, Clark PE, David R, Baumgartner R, Phillips S, Cookson MS, Smith JA Jr. Robotic assisted laparoscopic prostatectomy versus radical retropubic prostatectomy for clinically localized prostate cancer: Comparison of short-term biochemical recurrence-free survival. *J. Urol.* 2010; 183(3):990−996.

Benway BM, Bhayani SB, Rogers CG, Porter JR, Buffi NM, Figenshau RS, Mottrie A. Robot-assisted partial nephrectomy: an international experience. *Eur. Urol.* 2010; 57(5):815−820.

Bodner J, Kafka-Ritsch R, Lucciarini P, Fish JH, Schmid T. A critical comparison of robotic versus conventional laparoscopic splenectomies. *World J. Surg.* 2005; 29(8):982−985.

Bodner J, Prommegger R, Profanter C, Schmid T. Thoracoscopic resection of mediastinal parathyroids: current status and future perspectives. *Minim. Invasive Ther. Allied. Technol.* 2004; 13(3):199−204.

Bozkurt M, Apaydin N, Isik C, Bilgetekin YG, Acar HI, Elhan A. Robotic arthroscopic surgery: a new challenge in arthroscopic surgery part-I: robotic shoulder arthroscopy: a cadaveric feasibility study. *Int. J. Med. Robot.* 2011; 7(4):496−500.

Bush B, Nifong WL, Chitwood, RW. Robotics in Cardiac Surgery: Past, Present, and Future. *Rambam. Maimonides Med. J.* 2013; 4(3):1−8.

Cadierre GB, Himpens J. Feasibility of robotic laparoscopic surgery: 146 cases. *World J. Surg.* 2001; 25(11):1467−1477.

Carpentier A, Loulmet D, Aupecle B, Kieffer JP, Tournay D, Guibort P, Fiemeyer A, Méléard D, Richomme P, Cardon C. Computer assisted open heart surgery. First case operated on with success. *C. R. Acad. Sci. III.* 1998; 321(5):427−442.

Cazac C and Radu G. Telesurgery - an efficient interdisciplinary approach used to improve the health care system. *J. Med. Life.* 2014; 7(3):137−141.

Chammas MF Jr, Kim FJ, Barbarino A, Hubert N, Feuiliu B, Coissard A, Hubert J. Asymptomatic rectal and bladder endometriosis: a case for robotic-assisted surgery. *Can. J. Urol.* 2008; 15(3):4097−4100.

Chitwood WR Jr, Nifong LW, Elbeery JE, Chapman WH, Albrecht R, Kim V, Young JA. Robotic mitral valve repair: trapezoidal resection and prosthetic annuloplasty with the da vinci surgical system. *J. Thorac. Cardiovasc. Surg.* 2000; 120(6):1171−1172.

Cho JS, Hahn KY, Kwak JM, Kim J, Baek SJ, Shin JW, Kim SH. Virtual reality training improves da Vinci performance: a prospective trial. *J. Laparoendosc. Adv. Surg. Tech. A* 2013; 23(12):992−998.

Cobb J, Henckel J, Gomes P, Harris S, Jakopec M, Rodriguez F, Barrett A, Davies B. Hands-on robotic unicompartmental knee replacement: a prospective, randomised controlled study of the acrobot system. *J. Bone. Joint. Surg. Br*. 2006; 88(2):188−197.

Coon TM. Integrating robotic technology into the operating room. *Am. J. Orthop*. 2009; 38(2):7−9.

Davies B. A review of robotics in surgery. *Proc. Inst. Mech. Eng*. 2000; 214(1):129−140.

Deane LA, Lee JH, Box GN, Melamud O, Yee DS, Abraham JB, Finley DS, Borin JF, McDougall EM, Clayman RV, Ornstein DK. Robotic versus standard laparoscopic partial/wedge nephrectomy: a comparision of intraoperative and perioperative results from a single institution. *J. Endourol.* 2008; 22(5):947−952.

Devito DP, Kaplan L, Dietl R, Pfeiffer M, Horne D, Siberstein B, Hardenbrook M, Kiriyanthan G, Barzilay Y, Bruskin A, Sackerer D, Alexandrovsky V, Stüter C, Burger R, Maeurer J, Donald GD, Schoenmayr R, Friedlander A, Knoller N, Schmieder K, Pechlivanis I, Kim IS, Meyer B, Shoham M. Clinical acceptance and accuracy assessment of spinal implants guided with SpineAssist surgical robot: retrospective study. *Spine.* (Phila Pa 1976). 1010; 35(24):2109−2015.

Dharia P SP, Steinkampf MP, Witten SJ, Malizia BA. Robotic tubal anastomosis: surgical technique and cost effectiveness. *Fertil. Steril.* 2008; 90(4):1175−1179.

Doulgeris JJ, Gonzalez-Blohm SA, Filis AK, Shea ™, Aghayev K, Vironis FD. Robotics in Neurosurgery: Evolution, Current Challenges, and Compromises. *Cancer Control.* 2015; 22(3):352−359.

Fergany AF, Hafez KS, Novick AC. Long-term results of nephron sparing surgery for localized renal cell carcinoma: 10-year followup. *J. Urol.* 2000; 163(2):442−445.

Ficarra V, Cavalleri S, Novara G, Aragona M, Artibani W. Evidence from robot-assisted laparoscopic radical prostatectomy: a systematic review. *Eur. Urol.* 2007; 51(1): 9−11.

Ficarra V, Novara G, Artibani W, Cestari A, Galfano A, Graefen M, Guazzoni G, Guillonneau B, Menon M, Montorsi F, Patel V, Rassweiler J, Van Poppel H. Retropubic, laparoscopic, and robot-assisted radical prostatectomy: a systematic review and cumulative analysis of comparative studies. *Eur. Urol.* 2009; 55(5): 1037−1063.

Finan MA, Clark ME, Rocconi RP. A novel method for training residents in robotic hysterectomy. *J. Robot. Surg*. 2010; 4:33−39.

Foell K, Finelli A, Yasufuki K, Bernardini MQ, Waddell TK, Pace KT, Honey RJ, Lee JY. Robotic surgery basic skills training: Evaluation of a pilot multidisciplinary simulation-based curriculum. *Can. Urol. Assoc. J*. 2013; 7(11−12):430−434.

Fuchs KH. Minimally invasive surgery. *Endoscopy.* 2002; 34:154−159.

Gangemi A, Danilkowicz R, et al. Could ICG-aided robotic cholecystectomy reduce the rate of open conversion reported with laparoscopic approach? A head to head comparison of the largest single institution studies. *J. Robot. Surg*. 2016; Epub; PMID: 27435700.

Ganpule A, Chhabra JS, Desai M. Chicken and porcine models for training in laparoscopy and robotics. *Curr. Opin. Urol.* 2015; 25(2):158−162.

Ganpule A, Chhabra JS, Desai M. Chicken and porcine models for training in laparoscopy and robotics. *Curr. Opin. Urol.* 2015; 25(2):158−162.

Gao C, Yang M, Wang G, Wang J, Xiao C, Wu Y, Li J. Excision of atrial myxoma using robotic technology. *J. Thorac. Cardiovasc. Surg*. 2010; 139(5):1282−1285.

Gao C, Yang M, Wang G, Wang J, Xiao C, Wu Y, Li J. Totally endoscopic robotic atrial septal defect repair on the beating heart. *Heart Surg. Forum* 2010; 13(3):e155−158.

Garcia P, Rosen J, Kapoor C, Noakes M, Elbert G, Treat M, Ganous T, Hanson M, Manak J, Hasser C, Rohler D, Satava R. Trauma Pod: a semi-automated telerobtoic surgical system. *Int. J. Med. Robot.* 2009; 5(2):136−146.

Garg A, Dwivedi RC, Sayed S, Katna R, Komorowski A, Pathak KA, Rhys-Evans P, Kazi R. Robotic surgery in head and neck cancer: a review. *Oral Oncol*. 2010; 46(8):571−576.

Geller EJ, Siddiqui NY, Wu JM, Visco AG. Short-term outcomes of robotic sacrocolpopexy compared with abdominal sacrocolpopexy. *Obstet. Gynecol*. 2008; 112(6):1201−1206.

Giep BN, Giep HN, Hubert HB. Comparison of minimally invasive surgical approaches for hysterectomy at a community hospital: robotic-assisted laparoscopic hysterectomy, laparoscopic-assisted vaginal hysterectomy and laparoscopic supracervical hysterectomy. *J. Robot. Surg.* 2010; 4(3):167−175.

Goh AC, Goldfarb DW, Sander JC, et al. Global evaluative assessment of robotic skills: validation of a clinical assessment tool to measure robotic surgical skills. *J. Urol*. 2012; 187:247−252.

Haber GP, Crouzet S, Kamoi K, Berger A, Aron M, Goel R, Desai M, Gill IS, Kaouk JH. Robotic NOTES (Natural Orifice Translumenal Endoscopic Surgery) in reconstructive urology: initial laboratory experience. *Urology* 2008; 71(6): 996−1000.

Haber GP and Gill IS. Laparoscopic radical cystectomy for cancer: oncological outcomes at up to 5 years. *BJU Int*. 2007; 100(1):137−142.

Haegelen C, Touzet G, Reyns N, Maurage CA, Ayachi M, Blond S. Stereotactic robot-guided biopsies of brain stem lesions: Experience with 15 cases. *Neurochirurgie* 2010; 56(5):363−367.

Hanley EJ, Marohn MR, Bachman SL, Talamini MA, Hacker SO, Howard RS, Schenkman NS. Multiservice laparoscopic surgical training using the daVinci surgical system. *Am. J. Surg*. 2004; 187(2):309−315.

Hanna EY, Holsinger C, DeMonte F, Kupferman M. Robotic endoscopic surgery of the skull base: a novel surgical approach. Arch Otolaryngol. *Head Neck Surg*. 2007; 133(12):1209−1214.

Hatzinger M, Häcker A, Langbein S, Kwon S, Hoang-Böhm J, Alken P. Hans-Christian Jacobaeus (1879-1937): The inventor of human laparoscopy and thoracoscopy. *Urologe A* 2006; 45(9):1184−1186.

Hayn MH, Hussain A, Mansour AM, Andrews PE, Carpentier P, Castle E, Dasgupta P, Rimington P, Thomas R, Khan S, Kibel A, Kim H, Manoharan M, Menon M, Mottrie A, Omstein D, Peabody J, Pruthi R, Palou Redorta J, Richstone L, Schanne F, Stricker H, Wiklund P, Chandrasekhar R, Wilding GE, Guru KA. The learning curve of robot-assisted radical cystectomy: results from the international robotic cystectomy consortium. *Eur. Urol.* 2010; 58(2):197−202.

Heemskerk J, de Hoog DE, van Gemert WG, Baeten CG, Greve JW, Bouvy ND. Robot-assisted vs. conventional laparoscopic rectopexy for rectal prolapse: a comparative study on costs and time. *Dis. Colon Rectum*. 2007; 50(11):1825−1830.

Hellenthal NJ, Hussain A, Andrews PE, Carpentier P, Castle E, Dasgupta P, Kaouk J, Khan S, Kibel A, Kim H, Manoharan M, Menon M, Mottrie A, Omstein D, Palou J, Peabody J, Pruthi R, Richstone L, Schanne F, Stricker H, Thomas R, Wiklund P, Wilding G, Guru KA. Lymphadenectomy at the time of robot-assisted radical cystectomy: results from the international robotic cystectomy consortium. *BJU Int.* 2011; 107(4):642−646.

Honl M, Dierk O, Gauck C, Carrero V, Lampe F, Dries S, Quante M, Schwieger K, Hille E, Morlock MM. Comparison of robotic-assisted and manual implantation of a primary total hip replacement. A prospective study. *J. Bone Joint Surg*. 2003; 85-A (8):1470−1478.

Hung AJ, Jayaratna IS, Teruya K,Desai MM, Gill IS, Goh AC. Comparative assessment of three standardized robotic surgery training methods. *BJU Int.* 2013; 112:864−871.

Hung AJ, Ng CK, Patil MB, Zehnder P, Huang E, Aron M, Gill IS, Desai MM. Validation of novel robotic-assisted partial nephrectomy surgical training model. *BJU Int*. 2012; 110(6):870−874.

Intuitive Surgical [Internet]. California; 2016 [cited 2016 Sept 26]. Available from: http://www.intuitivesurgical.com/products/

Jain S, and Gautam G. Robotics in urologic oncology. *J. Minim. Access. Surg*. 2015; 11(4):40−44.

Jakopec M, Rodriguez y Baena F, Harris SH, Gomes P, Cobb J, Davies BL. The hands-on Orthopaedic robot "Acrobot": Early clinical trials of total knee replacement surgery. *IEEE Trans. Rob. Autom.* 2003; 19(5):902−911.

Kakeji Y, Konishi K, Leiri S, Yasunaga T, Nakamoto M, Tanoue K, Baba H, Maehara Y, Hashizume M. Robotic laparoscopic distal gastrectomy: a comparison of the da Vinci and Zeus systems. *Int. J. Med. Robot.* 2006; 2(4):299−304.

Kamath GS, Balaram S, Choi A, Kuteyeva O, Garikipati NV, Steinberg JS, Mittal S. Long-term outcome of leads and patients following robotic epicardial left ventricular lead placement for cardiac resynchronization therapy. *Pacing. Clin. Electrophysiol.* 2011; 34(2):235−240.

Karthik K, Colegate-Stone T, Dasgupta P, Tavakkolizadeh A, Sinha J. Robotic surgery in trauma and orthopaedics: a systematic review. *Bone Joint J*. 2015; 97-B (3):292−299.

Kerr B, O'Leary JP. The training of the surgeon: Dr. Halsted's greatest legacy. *Am. Surg*. 1999; 65:1101−1102.

Kim VB, Chapman WH, Albrecht RJ, Bailey BM, Young JA, Nifong LW, Chitwood WR Jr. Early experience with telemanipulative robot-assisted laparoscopic cholecystectomy using Da Vinci. *Surg. Laparosc. Endosc. Percutan. Tech.* 2002; 12(1):34−40.

Korte C, Nair SS, Nistor V, Low TP, Doarn Cr, Schaffner G. Determining the threshold of time-delay for teleoperation accuracy and efficiency in relation to telesurgery. *Telemed. J. E. Health.* 2014; 20(12):1078−1086.

Krambeck AE, DiMarco DS, Rangel LJ, Bergstralh EJ, Myers RP, Blute ML, Gettman MT. Radical prostatectomy for prostatic adenocarcinoma: a matched comparison of open retropubic and robot-assisted techniques. *BJU Int.* 2009; 103(4):448−453.

Kwoh YS, Hou J, Jonckheere EA, Hayati S. A robot with improved absolute positioning accuracy for CT guided stereotactic brain surgery. *IEEE Trans. Biomed. Eng*. 1988; 35(2):153−161.

Lafranco AR, Castellanos AE, Desai JP, Meyers, WC. Robotics surgery: a current perspective. *Ann. Surg*. 2004; 239(1):14−21.

Le CQ, Lightner DJ, VanderLei L, Segura JW, Gettman MT. The current role of medical simulation in American urological residency training programs: an assessment by program directors. *J. Urol.* 2007; 177(1):288−291.

Lee J, Nah KY, Kim RM, Ahn YH, Soh EY, Chung WU. Differences in postoperative outcomes, function, and cosmesis: open versus robotic thyroidectomy. *Surg. Endosc.* 2010; 24(12):3186−3194.

Lee JY, O'Malley BW, Newman JG, Weinstein GS, Lega B, Diaz J, Grady MS. Transoral robotic surgery of craniocervical junction and atlantoaxial spine: a cadaveric study. *J. Neurosurg. Spine* 2010; 12(1):13−18.

Liu C, Peresic D, Samadi D, Nezhat F. Robotic assisted laparoscopic partial bladder resection for the treatment of infiltrating endometriosis. *J. Minim. Invasive Gynecol*. 2008; 15(6):145−148.

Lobe TE, Wright SK, Irish MS. Novel uses of surgical robotics in head and neck surgery. *J. Laparoendosc. Adv. Surg. Tech. A* 2005; 15(6):647−652.

Loulmet D, Carpentier A, D'Attellis N, Berrebi A, Cardon C, Ponzio O, Aupecle B, Relland JY. Endoscopic coronary artery bypass grafting with the aid of robotic assisted instruments. *J. Thorac. Cardiovasc. Surg.* 1999; 118(1):4−10.

Lum MJ, Rosen J, King H, Friedman DC, Donlin G, Sankaranarayanan G, Harnett B, Huffman L, Doarn C, Broderick T, Hannaford B. Telesurgery via Unmanned Aerial Vehicle (UAV) with a field deployable surgical robot. *Stud. Health Technol. Inform*. 2007; 125:313−315.

Maeso S, Reza M, Mayol JA, Blasco JA, Guerra M, Andradas E, Plana MN. Efficacy of the Da Vinci surgical system in abdominal surgery compared with that of laparoscopy. *Ann. Surg*. 2010; 252(2):254−262.

Magrina JF, Espada M, Munoz R, Noble BN, Kho RM. Robotic adnexectomy compared with laparoscopy for adnexal mass. *Obstet. Gynecol. Obstet. Gynecol*. 2009; 114(3):581−584.

Magrina JF, Zanagnolo V, Noble BN, Kho RM, Magtibay P. Robotic approach for ovarian cancer: perioperative and survival results and comparison with laparoscopy and laparotomy. *Gynecol. Oncol.* 2011; 121(1):100−105.

Marescaux J, Leroy J, Gagner M, Rubino F, Mutter D, Vix M, Butner SE, Smith ML. Transatlantic robot-assisted telesurgery. *Nature* 2001; 413(6854):379−380.

Masterson TA, Cheng L, Boris RS, Koch KO. Open vs. robotic-assisted radical prostatectomy: a single surgeon and pathologist comparison of pathologic and oncologic outcomes. *Urol. Oncol*. 2013; 31(7):1043−1048.

Matthews CA, Reid N, Ramakrishnan V, Hull K, Cohen S. Evaluation of the introduction of robotic technology on route of hysterectomy and complications in the first year of use. *Am. J. Obstet. Gynecol.* 2010; 203(5):499e1−499e5.

McCool RR, Warren FM, Wiggins RH 3rd, Hunt JP. Robotic surgery of the infratemporal fossa utilizing novel suprahyoid port. *Laryngoscope* 2010; 120(9):1738−1743.

McLeod IK, Melder PC. Da Vinci robot-assisted excision of a vallecular cyst: a case report. *Ear Nose Throat. J.* 2005; 84(3):170−172.

Mehrabi A, Yetimoglu CL, Nickkholgh A, Kashfi A, Kienle P, Kostan-tinides L et al. Development and evaluation of a training module for the clinical introduction of the da Vinci robotic system in visceral and vascular surgery. *Surg. Endosc*. 2006; 20:1376−1382.

Menon M, Tewari A, Baize B, Guillonneau B, Vallancien G. Prospective comparison of radical retropubic prostatectomy and robot-assisted anatomic prostatectomy: The Vattikuti urology institute experience. *J. Urol.* 2002; 60(5):864−868.

Mihaljevic T, Jarrett CM, Gillinov AM, Williams SJ, DeVilliers PA, Stewart WJ, Svensson LG, Sabik JF 3rd, Blackstone EH. Robotic repair of posterior mitral valve prolapse versus conventional approaches: potential realized. *J. Thorac. Cardiovasc. Surg*. 2011; 141(1):72−80.

Mohr FW, Falk V, Diegeler A, Autschback R. Computer-enhanced coronary artery bypass surgery. *J. Thorac. Cardiovasc. Surg.* 1999; 117(6):1212−1214.

Moore EJ, Olsen KD, Kasperbauer JL. Transoral robotic surgery for oropharyngeal squamous cell carcinoma: a prospective study of feasibility and functional outcomes. *Laryngoscope* 2009; 119(11):2156−2164.

Mottrie A, Wilson TG. Systemic review and meta-analysis of perioperative outcomes and complications after robot-assisted radical prostatectomy. *Eur. Urol.* 2012; 62(3):431−452.

Muhlmann G, Klaus A, Kirchmayr W, Wykypiel H, Unger A, Holler E, Nehoda H, Aigner F, Weiss HG. DaVinci robot-assisted laparoscopic bariatric surgery: is it justified in a routine setting? *Obes. Surg.* 2003; 13(6):848−854.

Nakamura N, Sugano N, Nishii T, Kakimoto A, Miki H. A comparison between robotic-assisted and manual implantation of cementless total hip arthroplasty. *Clin. Orthop. Relat. Res.* 2010; 468(4):1072−1081.

Nam EJ, Kim SW, Kim S, Kim JH, Jung YW, Paek JH, Lee SH, Kim JW, Kim YT. A case-control study of robotic radical hysterectomy and pelvic lymphadenectomy using 3 robotic arms compared with abdominal radical hysterectomy in cervical cancer. *Int. J. Gynecol. Cancer* 2010; 20(7):1284−1289.

Nathoo N, Cavusoglu MC, Vogelbaum MA, Barnett GH. In touch with robotics: neurosurgery for the future. *Neurosurgery* 2005; 56(3): 421−33.

Netravali NA, Shen F, Park Y, Bargar WL. A perspective on robot assistance for knee arthroplasty. *Adv. Orthop.* 2013; 970703.

Nguan CY, Kwan K, Al Omar M, Beasley KA, Luke PP. Robotic pyeloplasty: experience with three robotic platforms. *Can. J. Urol.* 2007; 14(3):3571−3576.

Nguan CY, Morady R, Wang C, Harrison D, Browning D, Rayman R, Luke PP. Robotic pyeloplasty using internet protocol and satellite network- based telesurgery. *Int. J. Med. Robot.* 2008; 4(1):10−14.

Nguan CY, Miller B, Patel R, Luke PP, Schlacha CM. Pre-clinical remote telesurgery trial of da Vinci telesurgery prototype. *Int. J. Med. Robot*. 2008; 4(4):304−309.

Nifong LW, Rodriquez E, Chitwood WR Jr. 540 consecutive robotic mitral valve repairs including concomitant atrial fibrillation cryoablation. *Ann. Thorac. Surg.* 2012; 94(1):38−42.

Nix J, Smith A, Kurpad R, Nielsen ME, Wallen EM, Pruthi RS. Prospective randomized controlled trial of robotic versus open radical cystectomy for bladder cancer: perioperative and pathologic results. *Eur. Urol.* 2010; 57(2):196−201.

Novara G, Ficarra V, Mocellin S, Ahlering TE, Carroll PR, Graefen M, Guazzoni G, Menon M, Patel VR, Shariat SF, Tewari AK, Van Poppel H, Zattoni F, Montorsi F, Mottrie A, Rosen RC, Wilson TG. Systemic review and meta-analysis of studies reporting oncologic outcome after robot-assisted radical prostatectomy. *Eur. Urol*. 2012; 62(3):382−404.

Novara G, Ficarra V, Rosen RC, Artibani W, Costello A, Eastham JA, Graefen M, Guazzoni G, Shariat SF, Stolzenburg JU, Van Poppel H, Zattoni F, Montorsi F, Mottrie A, Wilson TG. Systematic review and meta-analysis of perioperative outcomes and complications after robot assisted radical prostatectomy. *Eur. Urol.* 2012; 62(3): 431−52.

Oliveira CM, Nguyen HT, Ferraz AR, Watters K, Rosman B, Rahbar, R. Robotic surgery in Otolaryngology and head and neck surgery: a review. *Minim Invasive Surg.* 2012; 2012:286563.

O'Malley BW Jr, Weinstein GS, Snyder W, Hockstein NG. Transoral robotic surgery (TORS) for base of tongue neoplasms. *Laryngoscope* 2006; 116(8):1465−1472.

Paley PJ, Veljovich DS, Shah CA, Everett EN, Bondurant AE, Drescher CW, Peters WA 3rd. Surgical outcomes in gynecologic oncology in the era of robotics: analysis of first 1000 cases. *Am. J. Obstet. Gynecol.* 2011; 204(6):551e1−9.

Pandya S, Motkoski JW, Serrano-Almeida C, Greer AD, Latour I, Sutherland GR. Advancing neurosurgery with image-guided robotics. *J. Neurosurg.* 2009; 111(6):1141−1149.

Park SE and Lee CT. Comparison of robotic-assisted and conventional manual implantation of a primary total knee arthroplasty. *J. Arthroplasty* 2007; 22:1054−1059.

Partin AW, Adams JB, Moore RG, Kavoussi LR. Complete robot-assisted laparoscopic urologic surgery: a preliminary report. *J. Am. Coll. Surg.* 1995; 181(6):552−557.

Paul HA, Bargar WL, Mittlestadt B, Musits B, Taylor RH, Kazanzides P, Zuhars J, Williamson B, Hanson W. Development of a surgical robot for cementless total hip arthroplasty. *Clin. Orthop. Relat. Res*. 1992; 285:57−66.

Payne TN, Dauterive FR. A comparison of total laparoscopic hysterectomy to robotically assisted hysterectomy: surgical outcomes in a community practice. *J. Minim. Invasive Gynecol.* 2008; 15(3):286−291.

Pearle AD, O'Loughlin PF, Kendoff DO. Robot assisted unicompartmental knee arthroplasty. *J. Arthroplasty* 2010; 25:230−237.

Perez M, Xu S, Chauhan S, Tanaka A, Simpson K, Abdul-Muhsin H, Smith R. Impact of delay on telesurgical performance: study on the robotic simulator dV-Trainer. *Int. J. Comput. Assist. Radiol. Surg.* 2016; 11(4):581−587.

Perez-Cruet MJ, Welsh RJ, Hussain NS, Begun EM, Lin J, Park P. Use of the da Vinci minimally invasive robotic system for resection of a complicated paraspinal schwannoma with thoracic extension: case report. *J. Neurosurg.* 2012; 72(1):e209−214.

Plate JF, Mofidi A, Mannava S, Smith BP, Lang JE, Poehling GG, Conditt MA, Jinnah RH. Achieving accurate ligament balancing using robotic-assisted unicompartmental knee arthroplasty. *Adv. Orthop.* 2013; 2013:837167.

Prajapati PM, Solanki AS, Sen DJ. Robotic surgery: A new hope in medical science. *Int. J. Pharm.* 2012; 3(1):10−12.

Prasad SM, Ducko CT, Stephenson ER, Chambers CE, Damiano RJ Jr. Prospective clinical trial of robotically assisted endoscopic coronary grafting with 1-year follow up. *Ann. Surg*. 2001; 233(6):725−732.

Pruitt JC, Lazzara RR, Dworkin GH, Badhwar V, Kuma C, Ebra G. Totally endoscopic ablation of lone atrial fibrillation: initial clinical experience. *Ann. Thorac. Surg*. 2006; 81(4):1325−1331.

Pruthi RS, Nix J, McRackan D, Hickerson A, Nielsen ME, Raynor M, Wallen EM. Robotic-assisted laparoscopic intracorporeal urinary diversion. *Eur. Urol.* 2010; 57(6): 1013−1021.

Rasmus M. Preliminary clinical results with the MRI-compatible guiding system INNOMITON. *Int. J. Cars. S*. 2007; 2(s1):138−145.

Rassweiler J, Henkel TO, Potempa DM, Coptocat MJ, Miller K, Preminger GM, Alken P. Transperitoneal laparoscopic nephrectomy: training, technique, and results. *J. Endourol.* 1993; 7(6):505−516.

Rassweiler JJ, Scheitlin W, Heidenreich A, Laguna MP, Janetschek G, Laparoscopic retroperitoneal lymph node dissection: Does it still have a role in the management of

clinical stage I nonseminomatous testis cancer? A European perspective. *Eur. Urol.* 2008; 54(5):1004−1015.

Rininsland H. ARTEMIS. A telemanipulator for cardiac surgery. *Eur. J. Cardiothorac. Surg*. 1999; 16:S106−111.

Rininsland H. Basics of robotics and manipulators in endoscopic surgery. *Endosoc. Surg. Allied. Technol.* 1993; 1(3):154−159.

Royal College of Physicians and Surgeons of Canada. *Competence by Design* (CBD): Moving towards competency-based medical education. 2016. http://www.royalcollege.ca/portal/page/portal/rc/resources/cbme.

Satava RM. Surgical robotics: the early chronicles: a personal historical perspective. *Surg. Laparosc. Endosc. Percutan. Tech*. 2002; 12(1):6−16.

Schilling J, Engel AM, Hassan M, Smith JM. Robotic excision of atrial myxoma. *J. Card. Surg*. 2012; 27(4):423−426.

Schizas C, Thein E, Kwiatkowski B, Kulik G. Pedicle screw insertion: robotic assistance versus conventional C-arm fluoroscopy. *Acta. Orthop. Belg*. 2012; 78(2):240−245.

Schulz AP, Seide K, Queitsch C, von Haugwitz A, Meiners J, Kienast B, Tarabolsi M, Kammal M, Jugens C. Results of total hip replacement using the Robodoc surgical assistant system: clinical outcome and evaluation of complications for 97 procedures. *Int. J. Med. Robot.* 2007; 3(4):301−306.

Schurr MO, Buess G, Neisius B, Vogues U. Robotics and telemanipulation technologies for endoscopic surgery. A review of the ARTEMIS project. Advanced Robotic Telemanipulator for Minimally Invasive Surgery. *Surg. Endosc.* 2000; 14(4):375−381.

Scott DJ, Young WN, Tesfay ST, Frawley WH, Rege RV, Jones DB. Laparoscopic skills training. *Am. J. Surg*. 2001; 182(2):137−42.

Shiomi A, Kinugasa Y, et al. Robot-assisted versus laparoscopic surgery for lower rectal cancer: the impact of visceral obesity on surgical outcomes. *Int. J. colorectal Dis.* 2016; 31(10):1701−1710.

Skolarus TA, Zhang Y, Hollenbeck BK. Robotic surgery in urologic oncology: Gathering the evidence. *Expert. Rev. Pharmacoecon. Outcomes. Res.* 2010; 10(4):421−432.

Song EK, Seon JK, Park SJ, Jung WB, Park HW, Lee GW. Simultaneous bilateral total knee arthroplasty with robotic and conventional techniques: a prospective, randomized study. *Knee Surg. Sports Traumatol. Arthrosc.* 2011; 19(7):1069−1076.

Sterbis JR, Hanly EJ, Herman BC, Marohn MR, Broderick TJ, Shih SP, Harnett B, Doarn C, Schenkman NS. Transcontinental telesurgical nephrectomy using the da Vinci robot in a porcine model. *Urology* 2008; 71(5):971−973.

Sukovich W, Brink-Danan S, Hardenbrook M. Miniature robotic guidance for pedicle screw placement in posterior spinal fusion: early clinical experience with the SpineAssist. *Int. J. Med. Robot*. 2006; 2(2):114−122.

Sutherland GR, Lama S, Gan LS, Wolfsberger S, Zareinia K. Merging machines with microsurgery: clinical experience with neuroArm. *J. Neurosurg.* 2013; 118(3):521−529.

Tae K, Ji YB, Cho SH, Lee SH, Kim DS, Kim TW. Early surgical outcomes of robotic thyroidectomy by a gasless unilateral axillo-breast or axillary approach for papillary thyroid carcinoma: 2 years' experience. *Head Neck* 2012; 34(5):617−625.

Tae K, Ji YB, Jeong JH, Lee SH, Jeong MA, Park CW. Robotic thyroidectomy by a gasless unilateral axillo-breast or axillary approach: our early surgical experiences: *Surg. Endosc*. 2011; 25(1):221−228.

Tae K, Kim KY, Yun BR, Ji YB, Park CW, Kim DS, Kim TW. Functional voice and swallowing outcomes after robotic thyroidectomy by a gasless unilateral axillo-breast approach: comparison with open thyroidectomy. *Surg. Endosc.* 2012; 26(7):1871−1877.

Takasuna H, Goto T, Kakizawa Y, Miyahara T, Joyama J, Tanaka Y, Kawaii T, Hongo K. Use of a micromanipulator system (NeuRobot) in endoscopic neurosurgery. *J. Clin. Neurosci.* 2012; 19(11):1553−1557.

Tewari A, Srivasatava A, Menon M, Members of the VIP Team. A prospective comparison of radical retrpubic and robot-assisted prostatectomy: experience in one institution. *BJU Int.* 2003; 92(3): 205−210.

Titan Medical Inc [Internet]. Ontario; 2016 [cited 2016 Sept 26]. Available from: http://www.titanmedicalinc.com/technology/

Tolley N, Arora A, Palazzo F, Garas G, Dhawan R, Cox J, Darzi A. Robotic-assisted parathyroidectomy: a feasibility study. *Otolaryngol. Head Neck Surg*. 2011; 144(6):859−866.

Turchetti G, Palla I, Pierotti F, Cuschieri A. Economic evaluation of da Vinci-assisted robotic surgery: a systematic review. *Surg. Endosc.* 2012; 26(3):598−606.

Wang W, Li J, Wang S, Su H, Jiang X. System design and animal experiment study of a novel minimally invasive surgical robot. *Int. J.Med. Robot*. 2016; 12(1):73−84.

Weinberg L, Rao S, Escobar PF. Robotic surgery in Gynecology: An updated systemic review. *Int. J. Gynecol. Obstet.* 2011; 2011:852061.

Wiewiorski M, Valderrabano V, Kretzschmar M, Rasch H, Markus T, Dziergwa S, Kos S, Bilecen D, Jacob AL. CT-guided robotically-assisted infiltration of foot and ankle joints. *Minim. Invasive Ther. Allied Technol.* 2009; 18(5):291−296.

Woo Y and Nacke EA. Robotic minimally invasive mitral valve reconstruction yields less blood product transfusion and shorter length of stay. *Surgery* 2006; 140:263−267.

Wu Z, Li M, Liu B, Cai C, Ye H, Lv C, Yang Q, Sheng J, Song S, Qu L, Xiao L, Sun Y, Wang L. Robotic versus open partial nephrectomy: A systematic review and meta-analysis. *PLoS One* 2014; 9(4):e94878.

Yen PL and Davies BL. Active constraint control for image-guided robotic surgery. *Proc. Inst. Mech. Eng. H*. 2010; 224(5):623−631.

Yoshiki H, Tadano K, Ban D, Ohuchi K, Tanabe M, Kawashima K. Surgical energy device using steam jet for robotic assisted surgery. *Conf. Proc. IEEE Eng. Med. Biol. Soc*. 2015; 2015:6872−6875.

In: Encyclopedia of Surgery (22 Volume Set)
Editors: Andreas Lehrer and Kristin Mueller
ISBN: 978-1-53618-329-0
© 2020 Nova Science Publishers, Inc.

Chapter 201

HISTORY, DEVELOPMENT AND THE IMPORTANCE OF EXPERIMENTAL SURGERY

Huifang Chen*, MD, PhD
and Pierre Daloze†, MD
Laboratory of Experimental Surgery, Department of Surgery,
CRCHUM, University of Montreal,
Montreal, Quebec, Canada

ABSTRACT

It is an aphorism to say that surgery composes both science and art, only one of which still true. The Science has often competently made medical and surgical progress both in the clinic and in research.

In this chapter, the history of medicine and surgery is reviewed in Babylon, Egypt, India, China, Japan, America, Canada, Russia, and during the eighteenth and nineteenth centuries in Europe. The clinical history of surgery remains the basic element of medicine. All medical history in this chapter will guide students through by covering all routine clinical situations, and will give the students the courage and tenacity they need. It also includes a series of clinical cases where surgical skills can be improved. The introduction to confirm the information is efficiently estimated in the history of treatment of bleeding, pain, and infection. We sincerely hope that from this information, the student and resident doctor will learn faster in their initial steps on the way to becoming a proficient and caring professional.

Keywords: experimental surgery, Babylon, Egypt, India, China, Japan, Europe, America, bleeding, pain, infection

* Corresponding Author's Email: hui.fang.chen@umontreal.ca.
† Pierre Daloze, CM, CQ.

ABBREVIATIONS

B.C.	Before Christ
A.D.	Anno Domini (in the year of our Lord)
C.E.	Christian Era

INTRODUCTION

Modern surgery's success is the result of thousands of years of efforts by the pioneers encouraged by the same ideals as surgeons today. Chirourgia, is from the Greek, "cheir" meaning "hand" plus "ergon" meaning "work." A sixteenth century French surgeon named Ambroise Paré defined performing surgery as "to eliminate that which is overmuch, restore that which has been disjointed, separate that which has been integrated, join that which has been divided and repair the deformity of nature." (Bishop1960).

Bleeding, pain and infection were three major barriers for surgeons before the industrial revolution. Successes in these fields have reformed surgery from a delicate "art" into a scientific principle for the treatment of many kinds of diseases (Woodward 1963).

BABYLONIAN SURGERY

Babylonian medicine (Leonardo 1943) and surgery supposedly started off as the most primordial in nature. According to the records from unearthed cuneiform, diseases were assumed to be caused by evil essences and cures were obtained with the help of astrologers. Gradually, things changed and Babylonia became famous as a spiritual center around 2000 B.C. At that time, there was the constant existence of priests. Medical activity in this period also changed, accomplished by a medical god of the moon named Sin. Medical plants were picked up by moonlight to be used for medical preparation. Magic symbols played an important role even in the late Babylonian age.

One of the most famous documents of Babylonian medicine is named the *Code of Hammurabi* from about 2000 B.C. which detailed regulations about the legal side of the medical profession, but also described the usefulness of surgery in Babylonia. It was the first time dealing with operating fees in the *Code of Hammurabi*: "If a physician shall cause on anyone a severe operation wound with a bronze operating-knife and cure him, or if he shall open tumor (abscess or cavity) with a bronze operating-knife and save the eye of the patient, he shall have ten shekel of silver; if it is a slave, his owner shall pay two shekels of silver to the physician."

In spite of such details about management, nothing is known of Babylonian surgical techniques. At the beginning of seventeenth century B.C., the whole Assyro-Babylonian kingdom was destroyed by the war and almost all specific cultural practices and development were suffocated.

The Medes and Persians were a little more progressive in their medicine and surgery than were the Babylonians. Their book named *Zend-Avesta*, was written by Zoroaster himself. According to these fearful writings, the world is administered by good or bad spirits, and both

their religion and medicine were based on a dual deity. At that time, there were three classes of physicians, the knife, the herb, and the word professional, but because of the lagging behind of the three groups, when patients were sick they had to consult Egyptian doctors. At late age, they resorted to inviting the best Greek physicians. The next step in the evaluation of human surgery was in the Nile Valley, in the kingdom of the Pharaohs, where the builders of Pyramids were developing an essential system of medicine and where dogmatic circumcision was being started.

EGYPTIAN SURGERY

Because of literature records, we know much more about Egyptian medicine and surgery. The *Edwin Smith Papyrus* is one of the crucial and brightening documents in surgery which was written in about 3000 B.C., around as old as the Pyramids themselves. The book was standardized and written as a textbook of surgery and not mixed with magic of later centuries, but was incomplete. It started with injuries of the head and sprains of spinal columns, but was missing abdominal organs and lower extremities. Forty-eight ordinary cases were described and each one was carefully examined before the diagnosis was made. The manuscript was exceptional and impressive, and of high scientific class. In the case of an injured head, the pulse was recorded and a digital determination of the wound was attempted in order to decide whether there was a fracture of the skull in the intact surface. The surgeon should have been familiarized with the symptoms from the brain, and discouraged fractured fragment of the bony skull with an elevator. The treatment of wounds was considered to be quite modern, where the wound edges were placed close together and bandages obtained from an embalmer to hold them together in position. Fractures were nicely detailed and there was even excellent technical management, e. g., in the fracture of the clavicle, where the patient should lie flat on the back for a prolonged time, with a sand-bag between the should-blades, a method which is often employed even today to ensure a good therapeutic result. All the details were specifically explained. Bandages and splints of linen soaked in glue were used. A crushed fracture of a vertebra of the neck, caused by an accident with the death of the patient, was specifically expressed and, in a lesion of the spinal cord, paralysis of intestines and bladder was reported (Smith 1972).

In the ancient surgical thesis, which was like "*Secret Book of Physician*," it was advised how to treat a dislocated mandible. It showed directly how to place the doctor's hands to reduce the dislocation. A manuscript of the Fourth Dynasty (2900−2750 B.C.) showed a drill-hole in the mental gap for the purpose of draining an abscess under a molar tooth for which specialized metal instruments, probably made of bronze was approved. Thus, in this age, surgical instruments already existed which appeared in the surgical treatise (The Oriental Institute of the University of Chicago 1930).

The original edition of *Edwin Smith Surgical Papyrus*, perhaps written around 5000 years ago, was an essential book for the practitioner. Another valuable medical commencement was *Kahun Papyrus*, found in Faijum in 1889 by Sir Flinders Petrie. It mainly concerns gynecological subjects which were written around 2000 to 1800 B.C. The Brugsch Papyrus which was very small, consisted of many recipes, but was not very important for surgery. More important is Papyrus Ebers written about 1550 B.C. and found during exploration by

Ebers at Luxor in 1872 A.D. This collection contains many medical texts of various ancient periods, especially dealing with medical treatment. Ebers himself considered that Papyrus was one of the lost sacred books.

From the dig, Egyptians found a variety of instruments, such as knives, hooks, cupping glasses, needles, forceps, etc. These instruments, found in a tomb near Thebes, are characteristic of the Bronze Age. The *Ebers Papyrus* contains almost one thousand prescriptions and therapies. But they mostly contain elements which either were ridiculous or fill us with dread and esteem. In more ancient times, it seems that the real pharmaceutical preparations were known. Later, however, appeals and prayers, magic hymns and sentences had to prepare the prescriptions. In this age, the following wounds were treated; gangrene, pus, pustules, abscesses and especially tumors of different kinds (fatty tumors, abscesses of the neck, enlarged glands, mammary growth), hemorrhoids, and foreign bodies. How did they treat the wounds? They used perfect methods of dressing; bandages of linen, soaked with honey and myrrh, and all had to be removed four days after surgery.

The history of Egyptian medicine has other important sources of information such as hieroglyphics carved in stones and monuments. Many surgical instruments were unearthed, and the discovery of metallic sacred improvement, usually made of gold or silver, describing parts of the human body which presented evidence of deformity or damage. Furthermore, the dead bodies were embalmed and protected, so that both physicians and embalmers had the opportunity to learn the basic knowledge of human anatomy, especially the interior anatomy of the body. The first anatomy book is said to have been written by King A, the son of King Menes who was of the first dynasty that ruled in 5241 B.C. (Manetho) or in 5702 B.C. (Boekh).

From the Papyrus Ebers and other sources, we know that some, but not all Egyptian physicians were priests. Herodotus and Diodorus Siculus were our main sources for the positions of physicians in Egypt in the fifth century B.C. According to the document, Herodotus described: “The art of medicine is thus divided among them: Each physician applies himself to one disease only, and not more. All places abound in physicians; some physicians are for the eyes, others for the head, others for the teeth, others for the intestines, and others for the internal disorders.” According to Diodorus Siculus: “in expeditions and journeys from the country, all treated free of charge, for the physicians received their salary from the state. They provided their services according to a written law compiled by many famous physicians in ancient Egypt…and if after following the laws from this sacred book they are not able to save the patient, they are safe from any allegation, but if they act contrary to the written law, they may expect capital punishment.”

For dentistry, the Papyrus only showed a few prescriptions, but when they examined mummies, it showed that the dentist possessed a certain degree of background in conservative treatment and replacement.

Ophthalmic surgery was relatively deficient. The Papyrus mentioned only cleanup for trichiasis, known as conjunctivitis, inflammatory corneal opacity, abscess of cornea, epiphora, ptosis, myosis, ecchymosis of lids, and milium.

Circumcision and sterilization were old practices in Egypt as established by many headstones of most ancient origin and excavations from 4000 to 5000 year B.C. They showed circumcision on a series of male corpses. The procedure was generally used on girls consisting of excision of the prepuce of the clitoris. It is believed to have been performed on both sexes during the fourteenth year of age.

For centuries, Egypt was the world's principal contributor of sterilization, and castration was either performed by cutting with a knife of flint or by battering the testes to total extinction with a stone. Lithotomy was known from more recent sources and this surgery had been performed constantly for centuries. For many countries, these were a recognized part of medical and surgical training and practice.

Egyptian medicine from various sources and from many centuries of information formed the picture we have today. Priestly influences, tradition and cabalism, scientific cogitation and research were all incorporated later. Only when Persia became predominant did Egyptian culture, arts and sciences become plentiful for later generations, Egypt perpetuated some of the best medical and surgical conceptions (Tomnsend 2005).

CHINESE SURGERY

Chinese medicine and surgery were closely developed and connected with the history of Chinese advancements. There was an Emperor named Shen Nong who lived about 2700 B.C., who was respected as the chief god and primary architect of Chinese medicine. He was also respected as the father of acupuncture and medical herbs (Leonardo 1943).

There was plenty of medical literature recorded in ancient China. The most famous Chinese book was written by the Emperor entitled Huang-Di Nei Jing (2688−2599 B.C.) which represents the most ancient medical texts. Similar to other nations and countries, demonology and magic aided in the development of Chinese medicine. However, the influence of Chinese culture and philosophy gradually changed the exceptional cosmogony combined with a finding of experimentation that was designed into a kind of medicine which is totally different from any other nations except Japan and other Asian countries which were monopolized by Chinese medicine.

Confucius religion regulated the whole theory of the universe and hence also of medicine. The whole life is galvanized by two fundamentals: the positive *Yang*, which is always male and decisive, and the negative *Yin*, being female. These two fundamentals are always in the condition of balance and do not change with time. Yang means sun, force, light and heavenly quality. Yin means humidity, darkness, cold, etc. The domination of Yang or Yin regulates character, sex, sickness or prosperity. Yang, the male predominant, should always be an influence and in suitable relation to Yin. The Yin-Yang theory is still used in Chinese traditional medical practice at present.

Hua Tuo was a famous Chinese surgeon in Eastern Han and Three Kingdoms. He was the first surgeon to perform surgery with the aid of herbal anesthesia, around 1600 years before the practice was adopted by Europeans (Sherer 2004). Hua Tuo performed many laparotomies and the curettement of scapulas of soliders to cure caries of the bone. Bian Que (Pien Ch'iao) was a "marvel doctor" described by a Chinese historian named Sima Qian in his famous history book entitled Shiji, where he was cited with many skills. Another book entitled: Liezi (Tang Wen Pian) described that Bian Que exchanged two patients' hearts to cure their diseases (Kahan 1988; Graham 1961). This was a legendary story which means the concept of organ transplantation was fantasized around 300 CE ago in China (Schlich 2010).

Acupuncture and moxibustion are typical surgical procedures in the history of Chinese medicine which are currently in clinical practice. Moxibustion is a traditional Chinese

medicine treatment using *moxa* made from dry mugwort (*Artemisia argyi*). Modern scientific evidence does not prove moxibustion can prevent or treat cancer (list of unproven and disproven cancer treatment 2013). But it still be widely used in traditional medicine in China, Korea, Japan, Vietnam, and Mongolia. According to the ancient theory, the decisive Yang and Yin are contained in twelve hypothetical and invisible channels named Chin, which are situated deep in the musculature. This channel system is not directly connected with blood vessels and nerves but nevertheless influences the whole human body, particularly the blood circulation. The distribution of Yang and Yin, the vital elements, is always changing, but they keep balancing each other all the time.

Chinese surgery has not made big progress over the past 1,000 years, but fortunately it did during last century due to the peaceful invasion of foreign missionaries. Modern medical schools and hospitals were established in most of provinces of China, not only by European and American doctors, but also by Chinese co-workers who had learned the philosophy and scientific knowledge. Since 1949, the Chinese government has authorized a policy to combine western medicine with Chinese medicine. In each county, there is at least one Chinese medical hospital. In each province, there is one Chinese Traditional Medical School to train Chinese traditional doctors. In any western medical school, there are courses to train medical students to combine western medicine with Chinese traditional medicine. To date, Chinese medicine has been transferred to 171 countries and districts in the world, according to the statistical data from WHO (Chan 2014). Chinese medicine has been legally accepted in Australia, Canada, Austria, Singapore, Vietnam, Thailand, and South Africa, etc., a total of 29 countries and districts. There are 18 countries or districts that have accepted Chinese medicine as their health insurance system (Chan 2008).

The Nobel Prize winners in physiology or medicine in 2015 were William C. Campbell, Satoshi Omura, and Youyou Tu. A number of serious infectious diseases are caused by parasites spread by insects. Malaria is caused by a single-cell parasite that causes fever. Traditional Chinese medicine uses sweet wormwood to treat fever. In the 1970s, after studies of traditional herbal medicines, Youyou Tu managed to extract a substance, artemisinin, which inhibits the malaria parasite. Drugs based on artemisinin have led to the survival and improved health of millions of people (The Nobel Prize in Physiology or Medicine 2015).

JAPANESE SURGERY

As in other countries, Japanese medicine had a mythical period with demons and evil continuity in the early stages. Magical incantations, prayers and sacrifices were the sole treatment methods in the ancient period. Bloodletting, covering of wounds with sawdust, and other very primeval therapies were the surgical treatments (Traditional Japanese Medicine 2017).

Very early on (around 1500 B.C.), Japanese culture and medicine were influenced and impacted by Chinese culture and medicine. Korea was the link between China and Japan, transmitting not only Chinese medicine, mainly for Buddhist acquaints but also to indoctrinate (about 560 A.D.). Young Japanese doctors were sent to China to learn medicine sponsored by Japanese government. They learned midwifery, the treatment of wounds, bandaging and acupuncture. Hospitals took care of old and sick patients in the temple of Nara

and other associations. The Empress Gemmyo equipped the largest hospital for poor, sick people around 758 A.D.

Surgery in the Heian Period (784−1186 A.D.) mainly consisted of incisions and external abscesses with a knife, and cauterization of ulcers and dog bites. Abdominal surgeons liked using the bark of a mulberry tree to suture with threads the intestinal wounds, and also operated on atresia vagina.

The author named Fukuyoshi Omura in the Showa Era (834−847 A.D.) wrote the first dissertation on surgery, based entirely on Chinese surgery. During the Muromachi Period (1334−1568 A.D.), the wound surgeon emerged. Wounded soldiers and weak patients who were unable to do further military work learned medicine and took care of other wounded soldiers when the opportunity arose (Park 2012).

An important improvement was achieved when the Portuguese clergy came to Japan in 1568 A.D. Two physicians named Yariis and Geri-Gori, who belonged to this group, founded the "Surgery of the Southern Barbarian School." They performed brilliant operations, treated the lepers and built hospitals. In 1585 A.D. the Christian religion was totally abrogated from Japan and all foreign physicians were discharged. Two Japanese students continued the practice of Portuguese medicine, settling in Sakai, and thus spreading foreign medicine by practice and by publication of medical books. Worthy of mention is a method of wound treatment and Gense Yamamoto's *Mangai Sbuyo*, a handbook of surgery. Other books were written by various authors concerning internal medicine, surgery, diseases of eyes, diseases of women and children acupuncture and moxa, mouth and tooth diseases, materiamedica and hygiene. 1765 was an important year for obstetrics because Gen-Etsu Kagawa published his work, and succeeded in taking away midwifery from midwives to the medical art.

In fact, Portuguese physicians had developed good and productive relations with Japan, at least for a certain period of time, which induced other nations to try the same. The Dutch were very successful establishing trade relations by starting a mission to come in contact with Japanese patients. In the seventeenth century, many Dutch medical books were translated into Japanese entitled *Geka Soden* (1706). Afterwards, Paré's surgery was so demanded and definitive in Japan that it became almost equivalent with European surgery. Afterword, Dutch books were prohibited until 1702, then they were allowed again and their scientific knowledge was even promoted (1745).

A book on German anatomy, written by Johann Adam Kalmus was translated from Dutch to Japanese by several Japanese physicians, and other books followed. In the eighteenth century, there were many European medical books translated into Japanese, i.e., "*A New Work on Surgery*" or "*Yoi Shinsho"* by Gempaku Sugita and Gentaku Otsuki which mainly translated Lorenz Heister's work. In 1832 the first institutionalized textbook on European surgery was translated into Japanese by Kincho Sugita. Many Japanese doctors followed and translated many medical textbooks. Medicine and especially surgery made great attainments during that time. In 1857, a medical school was established at Yeddo by Dutch physicians and then many medical facilities were established in the Kyoto Medical School and University of Tokyo. Soon, Muller, Hoffmann, Wernich, Gierke, Schultz, Baelz and others taught medical students in these institutes.

During the Meiji Period (1868 to the present), Japanese Medical Science closely followed Europe, America and international advances, building-up many modern medical centers, medical schools, medical institutes. Medicine and surgery are now distinctly state-of-the-art. Japanese medicine has given up the old methods as well as the transitory stage of learning.

The Japan of today has contributed international humanity by their medical practice and major medical research discoveries (Traditional Japanese Medicine 2017).

HINDU SURGERY

In India, the earliest Hindu medicine and surgery developed in the Vedic era. The Vedic era acquired the name from four *Vedas*, which create the Sanskrit language and literature and were nominated as the Rigveda, Yagveda, Sâmaveda and Atharvaveda (1500 B.C.). Among these four, Rigveda and Atharvaveda possessed medico-surgical interest. In this epoch, the surgery of ancient Hindus reached an outstanding level. Atreya, Agnovesa, Charaka, Dhanvantari and Susruta who were the students of the latter, were all the first Indian physicians. During that epoch, the most important medical text books were *Charaka-Sambita* and *Susruta-Sambita*. At that time, Susruta concluded a more succinct treatment of his practice and full consideration of surgery. Susruta classified operations into eight different kinds: incision, division, scarification, puncture, probing, extraction of foreign bodies, evacuation of fluids and suturing. A surgeon who intended to perform this kind of surgery should equip himself with the following tools: blunt instruments, cutting instruments, caustics, probe, horn, leeches, bitter gourd, a tent or bougie made of black stone, cotton, pieces of cloth, thread, jute leaves, honey, clarified better, suet, milk, oil, emollient and astringent fluids, liniments, pastes, fan, cold water, hot water, iron pans and steady, calm and able-bodied assistants. Surgical operations should be performed on a propitious lunar day, star, and moment. The surgeon should be careful not to injure any vital part, vessel, nerve, joint, and bone.

Susruta enumerated 101 blunt instruments, the most important being the human hand. The instruments are usually made of iron. But sometimes made of other materials when iron is not available, like: “hooks, scalpels, scissors, saws, lancets, needles, probes, sounds, directors, trocars, forceps, syringes, catheters, bougies, vaginal and rectal specula.” All the instruments are accurately described for the shapes and applications. There were many kinds of sutures: “winding like a sling, continued and interrupted sutures.” And there were three kinds of needles: “round needles, three-sided needles, and abdomen and scrotum, a needle curved like a bow.”

Before operations, the patients were prepared a diet. If it was an abdominal surgery, the patient should fast. Charaka and Sambita used wine as anesthesia to produce an anaesthesia effect to prevent pain. For the same purpose, Indian hemp (*Cannabis indica*) was used by inhaling the fumes. In 927 A.D., two surgeon brothers operated on a brain tumor of the King Dhar. A drug named Samohini was used for anesthesia. After trepanation of the skull, the tumor was removed and the wound was closed by stitches. The king was aroused by using another drug (Sanjivani). Sambita applied the forceps in case of a tough surgery. He described the procedure of craniotomy and caesarean section methodically.

In ancient Hindus, amputation of limbs was performed and the bleeding was controlled by pressure, boiling oil or cautery, but there was no mention of ligatures to control bleeding. They also could perform perineal lithotomy and via suprapubic operation. The author described detailed procedures for the surgery, pre- and post-surgery for the patient in the book of *Susruta-Samhita*.

Plastic surgery was very crucial in ancient India. At that time, to cut the nose and ears was the retribution reserved for adultery and also often for retaliation. Rhinoplasty was described in detail. The original Hindu method of extracting cataracts is still applied in India. Their surgical work also involved hernioplasty, fractures and luxations. Susruta said: "Surgery is the first and highest division art, least liable to fallacy, pure in itself, perpetual in its applicability, the worthy product of heaven, the sure source of fame on earth." Wise said: "The Hindus were the first scientific cultivators of the most important and essential of all the departments of medical knowledge, practical anatomy." There were several famous universities in ancient India, each university specializing in one branch of knowledge. The Taxila and Benares were the most famous and earliest universities, and their medical schools had distinguished teachers. There were 100 lecture rooms and around 10,000 students in the Nalanda University. There were six considerable blocks of residential buildings, each with four stories.

The birth of Buddha degraded the decency of the Hindu civilization. The Buddhist Period (600 B.C. to A.D. 600) became destructive for anatomy and consequently for surgery, discouraging anatomy and forbidding the dissection of animals because of ethics reasons. However, hospitals for men and animals were elevated and formed all over the country and the acquirement of research in medicine and chemistry achieved great promotion in the following centuries, as many famous astronomers, mathematicians, philosophers, religious leaders, poets and dramatists emerged. In this era, anesthetic drugs or curare were discovered which induced patients' sleep or deep stupor. At that time, A.D. 1550, a famous Hindu physician, Bhava Misra, an important teacher and writer issued a book related to the circulation of blood.

Hindu medicine gradually degraded and fell down, but did not die. Hindu scholars translated the great works of Charaka Sustruta from Sanskrit to Arabic and Persian. In Latin translations of Avicenna, Rhazes, and Serapion, the name of Charaka was frequently mentioned. We conclude this section of Hindu surgery with the words of Charaka: "Not for self, not the fulfillment of any earthly desire of gain, but solely for the good of suffering humanity, should you treat your patients, and so excel all."

Surgery in India reached creditable heights, and can be compared with the Greeks, exceeding Egyptian knowledge of surgery. In these countries, the connection between religion and medicine made it a struggle to adopt surgery as a profession. Surgery gradually succeeded, realized its apex, and finally declined. The one reason we can see is the slump and destruction of surgical science by religious authorities and dogma, and the growth of mysticism and conjecture which controlled the Middle Ages (Fishman 2005).

SURGERY IN CANADA

The history of medicine in Canada was initiated in September 1535 when Jacques Cartier built his castle on the bank of the St. Charles River facing the Indian village of Stadacona, which became sabotaged with scurvy. One colonist, "evidently possessing a knowledge of surgery," held a postmortem examination to try to learn the cause of death and thereby possible save the remaining members of the crew. This was the first autopsy performed in Canada.

Quebec City was originally established by Champlain in 1608. Around 1660 Jean Martinet accepted his brother-in-law Paul Prudhomme as a pupil to teach him the basics of medicine and surgery. This was the first recorded medical system in Canada.

Duchess d'Aiguillon assigned several nuns from Dieppe, obtained a grant of land, and built the Hôtel-Dieu in Quebec City in 1639. Michael Sarrazin, who came to Canada, was a

Surgeon Major of French troops. He was on the staff of the hospital. Later he wrote a book, *Anatomy of Beaver* and enlisted his research concerning Canadian animals and plants.

The small community at Ville-Marie continuously developed into the modern city of Montreal. Originally, Montreal was constructed around the year 1631 as a religious community. A society was arranged with 6 members in the beginning. One of them, Madame de Bullion, granted 42,000 books devoted to a hospital for the new community.

An expedition consisting of a company of 100 soldiers under the command of Paul de Chomedy, Sieur de Maisonneuve, came to New France in 1641, followed by Mademoiselle Jeanne Mance who had the task to create a hospital in Montreal. Without any interruption from the Indians, the colony grew up and a hospital was established under Mademoiselle Mance in October 1644. Very soon, the first wounded patient arrived for treatment. The founder and manager of the hospital, Mille Mance had to have the patient treated by a surgeon.

Around 1773, an ostensibly new disease came to the attention of the Government of Lower Canada, perhaps brought by Scottish soldiers. Sadly the distressed patients wanted to keep their disease secret, afraid it might be syphilis. Medical treatment was far away, and thereafter the disease was epidemically spread when the Government learned about it. Governor-General Carleton immediately assigned a surgeon's colleague to bring mercurial therapy to treat the patients which was effective in many cases. Drs. John Bowman and Robert Jones in Montreal speculated that the disease had nothing to do with syphilis. At that time there was no university for medical education in Canada. The only way was to send Canadians to study abroad or be trained by former army surgeons, mostly Scotsmen and Englishmen. In 1750, this state of affairs was changed by Intendant Bigot, and every physician had to pass an examination. In 1788, the British Parliament decreed that within Lower Canada, and in the towns of Quebec and Montreal, physicians, surgeons and midwives could not practice without a license. The Act of 1847 united the physicians in Lower Canada under the title of "*The College of Physicians and Surgeons of Lower Canada*." In 1826, the first medical society was founded and the first medical journal was published.

As the French and English migration gradually increased, this enlargement of population lead to the spread of epidemic diseases like scurvy (which was a harmful influence to envelop Canada), and smallpox which caused a great number of deaths. The four epidemics of 1703, 1732, 1733, and 1755 were very harsh. Many attempts were made, but without much achievement, until Dr. Latham, a surgeon of the king, launched preventive vaccinations in 1768. Another disease probably was plague, occurring during three epidemics in 1711, 1718, and 1740. It was introduced by a ship coming from Thailand. There were no details of symptoms. Conditions were unhygienic at that time. Many epidemic diseases were liable to be spread.

For the treatment of typhoid fever, ice was used to reduce the temperature in the early 1780s. Asiatic cholera ran its five disasterous epidemics in the colonies (1832, 1834, 1849, 1852 and 1854), and in three months 2,215 people died in Quebec City alone.

In 1815 in Montreal, after the war of 1812 was over, the population was increased to 20,000. It was the center of colonization and commerce. Meanwhile, there were plentiful sick and poor people needing medical care. At that time, the General Hospital of Montreal was established. In 1822, when lectures were presented by Drs. Holmes, Stephenson, Robertson and Caldwell, a medical school was contemplated. A year later, Montreal Medical Institution was established. Since 1829, this institution has existed as McGill University, named after the Hon. James McGill who facilitated the Royal Institution's upgrading of learning to found the university. In June 1829, the governors of "Burnside University of McGill College" had their first meeting to issue the Charter and the commencement of the university.

Quebec City as early as 1837, had a population of approximately 35,000 and Sir John Doratt, MD., inspector of General hospitals, proposed to establish a medical school in Quebec which was an important port at that time. There were numerous incoming vessels and sailors amenable to the transfer of infectious diseases and who suffered from accidents during their activities of loading and unloading. It was also not necessary to send medical students abroad. The curriculum in the new medical school included three years of course participation in the school, and two years of clinic commitment in the hospital.

When Lower Canada and Upper Canada became united in 1840, the medical science profession of Lower Canada already had a good influence and high standards, based on the experiences of the French and British universities, especially the University of Edinburgh and McGill Medical School. Up until 1855 McGill University was piloted and authorized by clergymen. When Sir Edmund Head became Governor-General of Canada, he assigned a physician, Dr. William Dawson as a new principal. Dr. Dawson was born in the town of Pictou, N. S., Canada in 1820. He had accomplished education in the schools of Nova Scotia and Edinburgh. His appointment marked the beginning of steady progress for the Canadian universities.

Lister's teachings on antisepsis were the example as Canadian disciples of Lister: Stewart of Halifax, Malloch of Hamilton, Grasset of Toronto, and Blanchard of Winnipeg. Dr. Chipman and Dr. Tait from Edinburgh taught students at McGill University. In 1884, William Osler, the most characterized alumnus of McGill, became Professor of Medicine at the University of Pennsylvania, later at Johns Hopkins Medical School, and was finally promoted to Professor of Medicine at Oxford.

There were only 25 students in the Montreal Medical Institute in 1823, but in 1920 there were around five hundred students. By then the contemporary McGill University was well established and famous in the world. In the early stages, it required a five-year course for students, and gradually the qualifications became much more ambitious, therefore McGill has always kept the highest possible standards in medicine and surgery (Tomnsend 2005).

SURGERY IN EIGHTEENTH CENTURY

France

During the eighteenth century, surgery had made more progress in France than in other countries. Paris became the outstanding medical and surgical center in Europe and so many medical students wished to study medicine there that the medical schools could not accept all

of them. The barber surgeons were not recognized in the universities and they did not have the permission of institutions in which they were taught. In reality, they had learned in the battleground. It was disputed that such experience was valuable enough to train surgeons with their knowledge of anatomy and pathology. The main reason for the dominance of French surgery in the seventeenth and eighteenth centuries was the war undertaken by Louis XIV and his successors.

The leading surgeons in the early eighteenth century were Mareschal, Méry, Dionis, De La Peyronic and Petit. Georges Mareschal (1658−1736) was the chief surgeon to Louis XIV from 1703 and did surgery for many years at Charité Hospital. A serendipitous fistula bolstered by Louis XIV, which the surgeon Felix had cured, led the king to take a marked interest in surgery which at the commencement of the century was still at the beginning stage of medicine. Felix became the royal surgeon and was acceded by Mareschal. In 1724 Louis XV generated five professorial chairs of surgery at Saint-Côme.

When the Academy of Surgery was established by the king in 1731, due mainly to the efforts of Mareschal and La Peyronie, followed by the authorization of 1743, which clearly separated the surgeons from the barbers, surgery was granted the respectability and rank to which it had long been denied. After that, no one could be a master of surgery without first becoming skilled in arts.

The profession of surgery obtained its liberation in France mainly due to the work of Mareschal and François De La Peronie, the humanitarian surgeon who worked during the course of the eighteenth century to raise the status of his favorite art.

Jean Méry (1645−1722) was the chief surgeon at the Hôtel-Dieu who designed an operation of suprapubic puncture of the bladder. He also focused on the anatomy of the ear. Pierre Dionis trained in anatomy and later operative surgery on cadavers at the Jardin-du-Roiin Paris in the beginning of 1673. He published *L'anatomie de l'bomme, suivant la circulation du sang et les dernières découverts* (Paris, 1690); *Cours d'opérations de chirurgie demontrées au Jardin-du-Roi* (Paris, 1707); and *Traité général des accouchemens* (Paris, 1748). His books were very popular for 50 years, going into numerous editions and translations, even Chinese. He recommended using bands in amputations. Concerning lithotomy, he said the Marian operation was the safest and was perfect, but the suprapubic surgery could also be safe. To his knowledge, M. Bonnet had achieved the highest outstanding rate of operation at Hôtel-Dieu. His earlier work on anatomy was animated by Harvey's discovery of the circulation.

Francois de la Peyronie (1678−1747) was one of the most dominant French surgeons in this period. He was born in Montpellier in 1678 and studied in Paris. He later returned to his native city, where after certification, he soon became the chief surgeon in the Montpellier Hôtel-Dieu. He was requested in Paris in 1714 to treat the Due de Chaulnes whose case he treated very successfully. La Peyronie was hired as a surgeon in Paris. Some years later he became the chief surgeon of the Charité Hospital where he established an extremely large surgical practice. He was well equipped with funding from the Academy of Surgery in Paris in 1731 and the welfare of the Academy was always in his mind. The struggle between the physicians/surgeons and barbers ended in the complete separation of surgeons from barbers in 1743 when La Peyronie successfully made a convincing argument. Indeed he took every step in the first half of the eighteenth century which resulted in the greater well-being, esteem and greatness for the surgical profession. La Peyronie spent a large part of his affluence and

prosperity on the Academy of Surgery of Paris which contributed to making Paris the surgical capital of the world.

The leading scientific surgeon of the first half of the eighteenth century was Jean Louis Petit (1674−1750). He was trained in Paris and in early 1700 he gave lectures in anatomy and surgery. Later he was promoted to director of the Academy of Surgery and was a surgical consultant in Poland and Spain. Petit enormously improved the surgical procedures of circular amputation by cutting the skin and muscle at different levels instead of the beheading method. He also improved how a herniotomy could be performed without opening the sac. Petit was one of the first to perform a cholecystotomy which was first introduced by Fabricius Hildanus in 1618. However the operation was not performed with regularity until a century later. Petit abhorred: "How many people have died because this disease was not perceived of, because no operator could be found who would undertake to rid them of their disease by means of an operation." Petit was the first surgeon to open the mastoid and also invented the screw tourniquet. He published "*Traité des maladies des os*" in 1723 in Paris, and his notable; "*Traité des maladies chirurgicales et des operations*" in 1774 also in Paris.

Jean Baseilhac was born in 1703 of a surgeon's family, at Poyestruc, Department of Hautes-Pyrénees, France. He studied at Hôtel-Dieu at Lyons under the supervision of his uncle, also a surgeon. Two years later he went to Paris to enter the service of surgery at Paris Hôtel-Dieu as a regular undergraduate. In 1740, he was allowed to practice surgery among the working classes. He then proved extraordinary as a lithotomist and improved the surgical methods and devised surgical instruments. He was successful in establishing a special hospital for lithotomy patients in 1753 and stayed in active service until his death.

The Hôtel-Dieu in Paris was founded in 850 as a religious foundation similar to all hospitals in the Middle Ages. The English hospitals became international reformations, but they continued for a long time and their system is followed even now. The physicians and surgeons, like their regulations were for life time assignment and allowed their private practice. People could pray twice a day, and the hospital was provided with its own church.

Jean Astruc (1685−1766) was very experienced in syphilis and obstetrics. Barthélemy Saviard (1656−1702) was a good wound surgeon, who published "*Nouveau recueild' observations chirurgicales* (Paris, 1702). An English translation version appeared in 1740 in London. The author characterized the successful use of a tourniquet in the case of injury to the femoral artery needing ligation or digital constriction for the treatment of aneurysm.

René Jacques Croissant de Garengeot (1688−1759), born in Vetré in Bretagne, advanced almost all parts of operative surgery and was considered a very proficient anatomist. His works were: "*Traité des opérations de chirurgie*…. (Paris, 1731), and *L'operation de la taille par l'appareil lateral, ou la méthode de frère Jacques, corrigée de tous ses défants* (Paris, 1730). He improved many surgical procedures for strangulated hernia, hydrocele, hare-lip, lacrimal fistula and nasal polyps. He performed tracheotomies with a cannula, invented a special tourniquet and restored a nose which had been cut off and had lain for an appreciable time upon the ground.

Henri François le Dran (1685−1773), a surgeon in Paris, wrote many books on surgery and managed his anatomical school at the Charité Hospital of Paris. He was a distinguished teacher and his German students advanced his surgical methods throughout Germany. He was also a good lithotomist and a military surgeon.

François-Sauveur Morand (1697−1773) was the first secretary of the Royal Academy of Surgery in Paris, and a very skilled surgeon even though he was not well educated. He

performed disconnection of the upper arm and, in selected cases, disarticulation of the thigh. He practiced ovariotomy and removed urinary bladder stones. He was the first one to describe a case of osteomalacia in 1753. He used a hot iron to stop bleeding in very urgent cases of hemorrhage, or when the large number of vessels was difficult to ligate.

Claude Nicolas Le Cat (1700−1768) of Rouen, became the chief surgeon of the Hôtel-Dieu in 1729 and later a professor of anatomy and surgery in Rouen Medical School. He was famous as a lithotomist. He was a productive writer and received the "prize-essay writing."

Dominique Anel (1678−1725) of Toulouse was an experienced military surgeon. In 1710 he ligated the brachial artery of a priest in Rome because of traumatic aneurysm. This was regarded as a proud French surgery, earlier the method of John Hunter. In 1712, Anel was set up in Genoa, Italy where he designed his operation for lacrimal fistula with the Anel probe and syringe. Four years later, he returned to Paris practicing ophthalmology.

George Arnaud de Ronsil, a French surgeon practiced for many years in London before 1748. He wrote a valuable "*Dissertation on Hernia* (London, 1748)," and a two-volume work "*Memoiresde chirurgie* (London, 1762)." In 1732, he cut the caecum together with part of the terminal ileum and ascending colon in a case of strangulated hernia with necrosis of the intestines.

Alexis Littré (1658−1726) was the first to construe the type of hernia and the first to recommend the operation of colostomy (1710). His most beneficial publications were involved with pathological anatomy.

Nicolas Andry (1658−1742) of Lyons was the first to use the word: *orthopaedia*, now globally used. His work was designated: *L'orthopaedie, ou l'art de prévenir de corriger dans les enfans les difformités du corps* (Paris 1741). His second work was: *Suite d'orthopedia* (Paris 1742).

Pierre Brasdor (1721−1797), professor of anatomy and surgery in the Paris College of Surgeons, proposed that certain aneurysms be treated by distal ligation which was the first one performed in history. George de la Fave (1699−1781) removed the crystalline of the eye by simple pressure after making an incision with the cataract knife which he created. Furthermore, he transformed the Dran's operation for disarticulation of shoulder. His work "*Principles de chirurgie* (Paris, 1739) was very popular with medical students.

Antoine Louis (1723−1792) of Metz was the perpetual secretary of the Académie de Chirurgie. He organized the Academy activities which impacted the progress of French surgery. His main works were: *Cours de chirurgie pratique sur les plaies d'armes à feu (Paris, 1746); Recueil d'anatomie et de chirurgie, pour servir de base à la théorie des plaies de têtes par contrecoup* (Paris, 1768).

Raphael Bienvenu Sabatier (1732−1811) was a professor at the Académie des Sciences. He was a lecturer on anatomy at the Royal College of Surgeons, Paris. He devoted himself to ophthalmology and surgery. His chief work was *De la méedecine operatoire* (3 volumes, 1978−1810).

Jean Louis Belloq (1730−1807) was a professor of anatomy in Paris and designer of numerous surgical instruments including a cannula for plugging the posterior nares, still known by his name.

The most important French surgeon of the latter part of the eighteenth century was Pierre Joseph Desault (1744−1795). He had studied under Louis and Morand, and after contributing several years as a surgeon of the Charité (1782), Desault became a surgeon in Hôtal-Dieu in 1788. He had numerous surgical students and established the first surgical anatomy in France

and improved the system of operations by designing new instruments, and creating an important surgical journal, the *Journal de Chirurgie* (1791−1792). His bandage for the fractured clavicle is well known even today. His student Bichat, detailed the materials of Desault's surgery in his *Oeuvres Chirurgicales* (3 volumes, 1798−1803).

J. Fr. Deschamps (1740−1824), a student from Moreau and a surgeon in France, wrote a history of lithotomy in 1796. Antoine Portal (1742−1832) was a professor of anatomy and the author of a seven-volume work on the history of anatomy and surgery.

Germany

German surgery in the eighteen century was represented by George Fischer in his exceptional treatise *Chirurgievor Ioo Jahren* (Leipzig, 1876), by which one learns that surgery was proceeding there by itinerant charlatanry and the local barbers. The people themselves were grossly roving and irrational. They believed in charms and relics, and in the efficacies of the travelling stone-cutters, bone-setters and cataract-excision in spite of the opposition of the physicians and numerous commandments issued by their king.

Even the executioners competed with the surgeons. They were supposed to have special knowledge of the means of curing diseases considered to be due to witchcraft. A part of their business was to disjoint joints by the shelf or to break bones upon the wheel, and thus it was presumed that they had special skills in the repair of fractures or dislocations. Only much later do we find a real influence in that respect in Germany.

Lorenz Heister (1683−1758) was the first surgeon of significance of this era. Coming from Frankfort-on-Main, he started his studies in Giessen, but maintained his proper medical education in Leyden and Amsterdam. Under the guidance of Ruysch and Rau he extended and developed his competence in the army hospitals at Brabant and Flanders. He was appointed as professor of anatomy and surgery at the university. Heister started lectures in Latin, but his students were so naïve that he decided to print his text book of surgery first in the German language (Chirurgie, Nurenberg, 1718). The work was widely advanced and soon translated into Latin as *Institutions Chirurgicae* and then into English as *A General System of Surgery* (London, 1743). This book was adored: "The first complete systematic work on the science of surgery," and was still used as a text-book in Vienna as late as 1838. For one hundred and twenty years it served as an aid in education for medical students. Heister wrote around 200 different works. He was a good dentist, and in the field of eye diseases, he depicted that cataracts depend on the cloudiness of the lens.

Albrecht von Haller (1708−1777), of Bern, Switzerland, was a considerable physician in Germany. From 1736−1753 he was a professor of anatomy and surgery at the University of Gottingen. He exerted an excessive influence in Europe and pupils crowded to him from everywhere. Haller issued *Bibliotheca chirurgica* (two volumes, Bern, 1774−1775). Many famous professors respected him: "He placed on a firm foundation the experimental method of dealing with surgical problems which was so unsuccessfully employed by John Hunter, but which increased our knowledge during the present century."

Johann Zacharias Platner (1694−1747) was a professor of anatomy and surgery at Leipzig from 1724 until his death. His *Institutiones chirurgae rationales tum medicae, etc.* (Leipzig, 1745) has been published in several editions and was translated into German and Dutch.

Burchard David Mauchart (1696−1751), professor of anatomy and surgery at Tubingen (1726) worked chiefly on the anatomy and surgery of eyes.

To refresh the story of German army surgeons, the Friedrich Wilhelms Institute was founded in Berlin in 1724, and three years later, King Friedrich Wilhelm I established the Charité Hospital for the clinical training of medical and surgical students of the college. In 1748, a military, medical and surgical school was settled at Dresden; in 1795 the Friedrich Wilhelm Institute of Berlin was restructured into an entirely military medical school which was called the Pépinière.

The three most important German military surgeons of this era were Johann Ulrich Bilguer (1720−1796), Johann Lebrecht Schmucker (1712−1786), and Johnn Christian Anton Theden (1714−1797). Bilguer was born in Chur, Switzerland, studied in Basel and Paris, Schmucker, like Haller entered the army in 1741 and later became surgeon-general of the army. He wrote *De membrorum amputation raris sime administranda (1761)*, because of the too frequent use of amputation. Schmucker, also a Prussian surgeon-general, disagreed to trepanning. He started the therapy of skull injuries by cold poultices. He published *Chirurgische Wahrnehmungen* (2 volumes, 1774) and *Vermischte Chirurgische Schriften* (3 volumes, Berlin, 1776−1782). Theden was a Prussian surgeon-general in 1786. He invented an elastic catheter and a covering of caoutchouc and wrote *Neue Bemerkungen und Erfahrungen Zur Bereicherung der Wundarzneykunst und Medicin* (1771). Famous professors respected the surgical methods described by Theden as they were so remarkable in surgical practice.

In the latter half of the eighteenth century, the leading German surgeon was Carl Caspar von Siebold (1736−1807), the creator of the surgical school of Wurzburg. He was a pupil of Morand in Paris, and of Pott and Bromfield in London. He was the first surgeon in Germany to perform a symphyseotomy. In Wurzburg he taught as a professor of anatomy, surgery and obstetrics.

August Gottlifeb Richter (1742−1812) was a professor of surgery in Gottingen in 1766 and helped to found the scientific discipline of surgery in Germany. He toured widely and advised with the best French and English surgeons of that time. His work *Abbandlung von der Briichen* (1777−1779) mainly explained how the hernia was investigated and was the best monograph up to that time.

In the eighteenth century, surgery made little progress in Austria. In 1785, the Military Medico-Chirurgical Akademie was founded by Emperor Joseph II in Vienna. The courses were taught for two years and clinical instruction was accessible for one hundred students training with the patients of a twelve hundred bed hospital in Vienna. The graduates received Doctor of Surgery degrees and were assigned to army duty as soon as possible.

Giovanni Alessandro Brambilla (1728−1800), a native of Italy and a student of the University of Pavia, became a surgeon in the Austrian army and was an exceptional benefit to the Emperor. He wrote a book of guidance for the professors at the Military Academy (1784) and composed a large atlas of exploration made by the Italian anatomies and physicians.

Great Britain

At the beginning of the eighteenth century, little adequate surgical instruction was available in England. The surgical student usually sought learning with a practicing surgeon.

The convenience for studying anatomy was almost none. By order of Henry VIII, who broke up the abbey, the hospitals were taken from the Church by the government. St. Bartholomew's Hospital was re-built in 1544 and students and beginners were permitted to observe operations. It was not until 1763 that a series of systematic lectures on surgery were distributed there, first given by Percival Pott. At St. Thomas' Hospital in London, lectures on anatomy and surgery were launched by William Cheselden in 1720, and the Anatomical School was begun two years later. In 1785, the medical school was fully established. The Medical School of Guy's Hospital began in 1769 and soon the schools of this hospital and of St. Thomas were collaborating. The surgical lectures were given at St. Thomas and the medical courses at Guy's Hospital.

With the Act of 1540, the barbers and surgeons were combined into one company, but in 1745 the surgeons were able to separate themselves from barbers, and in 1800, George III issued a charter for the consolidation of the Royal College of Surgeons of London.

In Scotland in 1694, Archibald Pitcairn tried to start a medical school at Edinburgh. Only in 1726, was the medical school finally achieved chiefly through the services of John Monro, a retired army surgeon. William Cheselden (1688−1752) was the leading English surgeon in the first half of the eighteenth century. Gradually, the education system was improved and the requirements for better anatomical teaching through a system of private schools was established. William Cheselden was one of the earliest of those private teachers. At the age of twenty-three, he started a course of lectures on anatomy. He published "*Anatomy of the Human Body*" for thirteen editions. His practical point of was to treat it as applied anatomy. His awesome work "Osteographia" is perhaps the finest illustrated book of its kind. He was the best known surgeon to improve the operation of lithotomy.

Other surgeons of high dignity in London who followed Cheselden were: Samuel Sharp (1700−1778) at Guy's Hospital, Edward Nourse (1701−1761) at St. Bartholomew's Hospital; and William Bromfield (1712−1792) at St. George Hospital: all of whom gave courses in anatomy and surgery at their homes, and later moved to their hospitals. Samuel Sharp, a traditional surgeon with great intelligence, was the author of two books on surgery; "*A Critical Enquiry into the Present State of Surgery*" (London, 1750), and a "*Treatise on the Operations of Surgery*" (London, 1751); both of which were prevalent and went through many editions. Sharp devoted much to our present knowledge of the anatomy of hernia. He further designed the modern trephine used for craniotomies in brain surgery.

William Bromfield, also an authentic surgical author, published his "*Chirurgical Observations and Cases*" (two volumes, 1773) which consisted of important extensions to surgical techniques, especially concerning reciprocal lithotomy. William Beckett (1684−1738) of London wrote "*Practical Surgery Illustrated and Improved* (London, 1740). Benjamin Gooch, a surgeon of Norfolk and Norwich Hospital, published "*Cases and Practical Remarks in Surgery*" (London, 1758). He illustrated that in cases of wounds of arteries, ties must be above and below the wound.

James Douglas (1675−1742) was a Scottish physician and his brother, John Douglas, was a surgeon. James was a famous anatomist and obstetrician and his work was "*Description of the Peritoneum*" (London 1730). John Douglas (1680−1742) discoursed on surgery and anatomy in London around 1720 and worked mainly as a lithotomist. His work entitled: "*Lithotomia Douglassiana*" (1720) described the operation of stone. Douglas was a student of Cheselden who was by far his superior.

During the middle of the eighteenth century, the most prominent English surgeon was Peacival Pott (1714−1788). In 1756, Pott was 42 years old, and fell from a horse and suffered an admixture fracture of his ankle. The term *Pott's fracture* has been applied to this kind of fracture since that time. Pott defined the fracture in 1769 in "*Some Few General Remarks on Fra*ctures." His "*Treatise on Ruptures*" was distributed at the end of the year. He then wrote at more frequent intervals, practical and succinct articles about hernia, hydrocele, fistula of lacrimal duct, head injuries, fractures and dislocations, chimney-sweep's cancer, paralysis due to disease of the vertebra, and others. The most accepted of his publications, "*Remarks on that kind of palsy of the lower limbs found to accompany a curvature of spine*" was published in 1779. These kinds of diseases of the vertebra had since been known as *Pott's disease*.

John Hunter (1728−1793), the greatest surgeon in the eighteenth century was equally famous with Paré and Lister as one of the three most dominant surgeons at that time, and the founder of experimental and surgical pathology. John Hunter came to London in 1748, two years after his brother William Hunter had begun to lecture there on anatomy and surgery. Hunter commenced surgery at St. Bartholomew's Hospital under Pott and Cheselden who with Pott and William Hunter were the principle surgical personalities in London in the eighteenth century. By 1754, John Hunter was a partner with his brother in the research of anatomy and physiology. During the two years from 1761 to 1763, Hunter served as a surgeon in the Spanish military campaign. He collected much valuable material for his later writing on gunshot wounds. By 1768 his surgical capability had allowed him to be elected as a surgeon in St. George's Hospital.

For the next twenty-five years Hunter worked enthusiastically in research of anatomy and pathology, and teaching his students. His work was accumulated as a great collection in the form of Hunter's museum of biological exhibits, which finally categorized 13,000 objects. He found that surgery was a science as well as an art. He studied and represented surgical circumstances such as surgical shock, phlebitis, pyemia, inflammatory processes, the lymphatics, and lacrimal ducts in the man. He was the first one to discriminate between hard and soft chancre, and the first one to study teeth experimentally. Hunter's considerable work was on the surgical pathology of the vascular system. He found that if the surgery was not applied to an aneurysm in its primeval state, amputation of a limb was the result for most patients. England became the surgical capital in the eighteenth century, attracting students and patients from many countries due to its excellent surgeons. Because of the great figures who influenced the surgical scene, all the outstanding surgeons were pupils of John Hunter, e.g., Abernethy, Cline, Astley Cooper, Blizard, Carlisle, Hey Leeds, Parkinson, Physick, Dorsey and the great physician Edward Jenner. John Hunter was always active and intelligent, and his interests were boundless.

One of the most famous Edinburgh surgeons of the eighteenth century was Benjamin Bell (1749−1806), a pupil of Munro and a surgeon at the Royal Infirmary. His *System of Surgery* (Edinburgh 1783−1787, 6 volumes) was issued in many editions, and was translated into French and German. He was one of the first surgeons to prevent and treat pain in surgical operations. He was also devoted to the treatment of infections after surgery. He published: "*On the Chirurgical Treatment of Inflammation.*" He also improved the methods of amputation "Save skin" was one of his surgical slogans, and he applied the principle during amputations and the cutting of tumors.

John Bell (1765−1820) became the pupil of Alexander Wood to whom he dedicated the first volume of "*Anatomy of the Human Body*" (1793). He became a Fellow of the Royal

College of Surgeons (1786), lectured on anatomy and surgery for ten years in the extra-mural school at Surgeon's Square, and expanded into a leading consulting and operating surgeon in Edinburgh. He was a creative contributor to surgical literature. He wrote a three-volume work, *The Principles of Surgery* (London, 1801−1808), where chiseling was very attractive. He worked in defending the "doctrine of anastomosing arteries" in order to considerably reduce amputations due to the extensive injury of main arteries. In wounds and operations, he highlighted two points to be attended to: first, securing of arteries so that the patient may not be in danger from bleeding, and second, procuring a speedy adhesion by which pain, infection, waste of tissue and other adverse repercussion of wounds are prevented as much as possible. His brother was Sir Charles Bell, another famous anatomist and physiologist.

Prior to 1784, the eighteenth century had not made much progress in Ireland. The barbers and surgeons had a stabilized company which was created in 1446 when King Henry VI established a federation of barbers "for the promotion and exercise of the art of chirurgery." In 1572, Queen Elizabeth granted a second permit to the barbers and surgeons, and a third charter was given in 1687 by King James II. In 1784, the union between the barbers and the surgeons was dissolved and the Royal College of Surgeons of Ireland was constituted. Medical teaching began in Dublin in 1744 and perhaps the earliest Irish surgical author was William Dease (1752−1798), one of the founders of the Royal College of Surgeons in Dublin and an active lecturer and teacher. The second essential surgical author of Ireland was Sylvester O'Halloran (1728−1807), an outstanding surgeon from Limerick who had studied in Paris, London and Leyden. His work, *A Complete Treatise on Gangrene and Sphacelus, with a New Method of Amputation* was very famous at that time.

SURGERY IN NINETEENTH CENTURY

Great Britain

In the history of surgery in the nineteenth century, important advancements were the introduction of anesthetics, the establishment of aseptic and antiseptic surgery based upon the scientific foundation of the new science of bacteriology, the development of traditional surgery in the treatment of diseases and injuries of extremities with plastic surgery and orthopedic surgery, the rise and progress of abdominal and intracranial surgery, the entry of two nations, the United States and Russia into the fields of educating surgeons, the formation of surgical societies and associations, the removal of restrictions on the study of anatomy, the great progress made in pathology, the founding of museums like those of Hunter and Dupuytren, and the development of ophthalmology, otology, gynecology, dermatology, and laryngology into their present highly functional forms, all of which contributed a positive influence in the development of surgery.

"The Industrial Revolution" era had made more progress in surgery since 1800 than had taken place in the preceding eighteenth hundred years. Due mainly to the fiery effect of Hunterian teachings, London was one of the surgical capitals of the world in 1800. The great surgeons who operated and lectured there, were practically all advocates and adherents of Hunter.

Sir Astley Paston Cooper (1768−1841), more than any other of the surgeons who made the brightness of London glimmer so brilliantly, acquired the mantle of John Hunter.

Cooper came to London in 1784 from Norfolk. Young Cooper was first student of his uncle William, then a surgeon connected to Guy's Hospital. Cooper soon worked with Henry Cline, one of John Hunter's first pupils, who was then at St. Thomas'. Under Cline's supervision, Cooper began extremely hard work in anatomy. For the next two years he established the foundation for his complete knowledge of anatomy and surgical pathology. He appeared at Cline's lectures at St. Thomas', and also sat before Hunter himself at St. George's. He even went to Edinburgh in 1787 where he spent one year for his leading study in surgery. Back in London, Cooper worked under Cline again. Attending John Hunter's lectures, he also acquired much knowledge from work in Hunter's dissecting room. Cooper made so much progress in 1789 that he was assigned a demonstrator position in anatomy at St. Thomas' and then as assistant lecturer to his mentor, Henry Cline.

From that time forward, his progress was constant and he held the posts of lecturer in surgery and anatomy at St. Thomas, became professor of anatomy and finally in 1800 was appointed as a surgeon at Guy's Hospital. During these seven years he adhered forcefully to the great Hunterian principles of learning from anatomy and physiology what could be done in surgery. In 1800, he presented to the Royal Society his important surgical work, *Observation on the effects which take place from the destruction of the membrane Tympani of the Ear and Further Observation*, in which he showed that a breach of the ear drum did not always produce deafness and could, in cases of stoppage of the Eustachian tube, really improve hearing extremely by equalizing the pressure on both side of drum. The Royal Society awarded him the Copley Medal for this work.

Cooper's work, *Treatise on Hernia* (London, 1804, 1807) was the product of an ample bulk of surgical work on this problem performed both on cadavers and on living patients. Cooper was promoted as professor of comparative anatomy at the College of Surgeons (1813) and was then at the peak of his career. The amount of work he did in the lecture hall, in the operating room, and in the anatomy room was excessive. In 1816, Cooper performed his greatest operation to ligate the abdominal aorta, the greatest of the arterial vessels after performing the same style of a research operation in animals was satisfactory. Cooper received a baronetcy for his work in removing an infected sebaceous cyst from the scalp of King George IV.

Cooper, an irresistible personality, was greater as an operator than as a contributor to the science of surgery. His prominence at the height of his career was huge and the size of his practice truly astonishing. He was the greatest of Hunter's surgical pupils.

Sir William Lawrence (1783−1867) was exposed to anatomy for twelve years. In 1806, he was awarded a prize by the Royal College of Surgeons for a publication on hernia. He was an assistant surgeon in St. Bartholomew's hospital (1813), then he became professor of anatomy and physiology at the Royal College of Surgeons. In 1823 he achieved a position as a lecturer on surgery at St. Bartholomew's Hospital and was affiliated with the Aldersgate Medical School. His principal works were *Treatise on the disease of the eye* (1833), and his *lectures on Surgery* (1863).

James Wardrop (1782−1869), who was born in Scotland and educated in Edinburgh, founded the West London Hospital of Surgery (1826) and instructed at the Aldersgate Street Medical School. In 1828 he became the surgeon of King George IV and seven years later began allocution in surgery at the Hunterian Medical School. Wardrop was the author of

Morbid Anatomy of the Eye (Edinburgh 1808−1818, two volumes). He contributed to *Venesection* (1835) which was published in Philadelphia (1857), and was translated into Italian (Pisa, 1839) and German (Leipzig, 1840). Wardrop was an experienced surgeon, performing aneurysm surgery.

Joseph Constantine Carpue (1764−1846) was another important English surgeon in this era. He introduced the Indian operation for rhinoplasty and re-affirmed the value of suprapubic surgery for stone. Samuel Cooper (1780−1848) issued a highly popular *Surgical Dictionary*, (1809) which was the first detailed work in this field. Alexander Copland Hutchinson, a naval surgeon and author, published *Practical Observations on Surgery* (1816) and *Some Further Observations on the Subject of the Proper Period for Amputations in Gunshot Wounds* (1817).

Charles Aston Key (1793−1849) was a surgeon at Guy's Hospital when Cooper induced the authorities to found an autonomous medical school there and Key became a professor of Surgery in 1825. That year he ligated the subclavian artery and five years later he ligated the carotid artery because of an aneurysm. He also introduced some improvements in operations for hernia and lithotomy.

Sir Benjamin Collins Brodie (1783−1862) became Sir Everard Home's pupil at St. Grorge's Hospital in London. He lectured on anatomy at the Great Windmill Street School from 1805 to 1812. He was an assistant to Home, and was a professor of anatomy and surgery with the Royal College of Surgeons. From 1808 Brodie was on the surgical staff of St. George's and in 1822, he became a surgeon there. In 1832, upon the death of Home, he was assigned as one of the Sergeant-Surgeons to the King and later filled the same office for Queen Victoria. Brodie believed strongly in conservative surgery, chiefly as applied to orthopaedics in which he was a pioneer of the work of Liston and Fergusson. For the last thirty years of his life, he stood at the head of the medical profession in London. He was almost equally distinguished as a physiologist. In 1810, he delivered the Croonian lecture before the Royal Society. He did much experimental research on vegetable poisons. He also made admirable improvements in the science of surgery, e.g., his research was related to the diseases of the joints, un-united fracture of femur, and varicose veins of the legs. Brodie's greatest work was *On the Pathology and Surgery of the Disease of the Joints* (London, 1819), in which he presented his knowledge of diseases of articulation and differentiation between local and neurological disorders of the joints. Brodie was a pioneer in the subcutaneous surgery of the limbs, working on varicose veins as early as 1814.

Sir Charles Bell (1778−1842) of Edinburgh made his greatest honor as an anatomist physiologist. He worked as a surgeon and was the chief at the Middelsex Hospital. The following dissertations were contributed by him: *Anatomy of Expression* (1806); *System of Operative Surgery*; *Animal Mechanics* (1828); *Nervous System* (1830). He discovered distinct function of the nerves.

Benjamin Travers (1783−1858), professor of anatomy at Guy's Hospital, and a pupil of Astley Cooper, served as a surgeon at St. Thomas' hospital from 1815. His *Synopsis of the Diseases of the Eye* (1820) was admittedly the best book in English on this subject at that time. He wrote many treatises on the essential nature of soreness, and on the pathology of the nervous system and inflammation. In Edinburgh, there was no chair of surgery at the University until 1831. The professor of anatomy gave instructions for surgery at that time. The Royal College of Surgeons of Edinburgh authorized a chair of surgery in 1804.

John Thomson (1765−1846), the first chair had been a surgeon at the Royal Infirmary since 1800, and had given lectures in surgery. The chair of clinical surgery was created by King George III (1803), who bestowed it with a stipend of fifty pounds a year. James Russell (1755−1836), a surgeon of the Edinburgh Royal Infirmary was the first to hold this clinical chair. Russell had been one of six surgeons selected by the managers of the Royal Infirmary (1800). At the same time he had given up his position as an acting surgeon to the Royal Infirmary. Russell gave much useful information to well-attended classes. He resigned from the chair thirty years later at the age of eighty-one. Russell's practical essay on certain diseases of bones, termed necrosis (Edinburgh, 1794), created one of the first pursuits to give a thorough and detailed illustration of what must have been a common surgical issue.

When John Thomson resigned as the chair of military surgery in 1822, Sir George Ballingall (1786−1855) replaced him. At that time, the country was massively tired of war and was turning its attention to reconstruction and the economy for which a long and expensive operation was necessary. However, Ballingall had the experience in India, at Prince of Wales Island at Java, and with the army in France. He was assured of the need for a complete course of instruction, not only for the injurious incidents of warfare, but also on the diseases to which European troops were especially vulnerable abroad, and on the general hygiene of camps. The East India Company was very helpful, and in addition, the Royal College of Surgeons of Edinburgh modified their administration in military surgery instead of the one or two courses of surgery prescribed. This action of the college was abruptly followed by a corresponding movement on the part of heads of the medical departments of the navy, and the army. In response to Ballingall's efforts, his activities were strongly supported by *Lancet*. Ballingall contributed a lot in teaching his subjects; *Outlines of Military Surgery* and also his *Practical Observations on the Diseases of the European Troops in India* (Edinburgh 1823) which were highly admired at that time. Following his death, the special chair of military surgery was abrogated in 1856.

In Glasgow, the leading surgeon at the beginning of the nineteenth century was John Burns (1775−1850). He began his career as a lecturer on anatomy, and later became Professor of Surgery at the University of Glasgow. He wrote a book on surgery and on midwifery with ten editions. His brother, Allan Burns, began as a demonstrator in John Burns' anatomical school. He was the first to construe the liaison of the falciform process of fascia lata to femoral hernia. He was also the author of a book on the surgical anatomy of the head and neck. In his interesting work, he was the first who suggested the ligation of innominate artery.

The Edinburgh Medical School had been carried on by teachers who had no formal connections with the university until 1726. The Faculty of Medicine, however, consolidated professors as a number of "private lectures." The extra-mural school had been able to develop new branches of education. Thus, special courses and lectures were given by external lecturers in mental diseases, diseases of the ear, neurology, throat and nose, diseases of children, dermatology, applied anatomy, operative surgery, and tropical diseases for many years before a lectureship in these subjects was founded in the university. In 1895, the Extra-mural School was reconstructed and centralized as "The School of Medicine of the Royal College."

France

The French Revolution played an extraordinary part in the development and reforming of their medicine system. In 1792−1793, all the medical faculties and societies in France were terminated. The great wars which began to involve Europe shortly thereafter made it critical however that a source of new medical and surgical experts be maintained. The army's needs came first. The surgical service program was executed into law in 1794, according to the essential requirement for military schools in Paris, Montpellier and Strassbourg. In 1804, the Paris School of Medicine was organized on a large scale, and was established as an institute of medical science which was helpful for solving national problems involving medicine. Soon in 1806, the Imperial University was established as a medical school branch.

French surgery of the nineteenth century is a flaring record of strong identities, men who were magnificent operators like Dupuytren, great organizers such as Baron Larrey, exceptional surgical historians and critics like Malgaigne, schemers of surgical knowledge like Boyer and developers of new growth like Civiale and Leroy. All the characters that have made France great as a nation and many that have increased her strength, can be found in surgeons.

The Napoleonic era was managed by such surgeons as Lassus, Pelletan, Lallement, Percy, Dubois, Boyer and Larrey. Pierre Lassus (1741−1807) was appointed as a professor of surgery in the Ecole de Santé and surgeon to Napoleon I. He published on the history of anatomy, on surgical pathology (1805−1806), and on operative surgery. Philippe Jean Pelletan (1747−1829), a student of Louis and of Sabatier, was promoted as a professor of clinical surgery when the Medical Faculty of Paris was established in 1804. He was also surgeon to Napoleon and chief surgeon at Hôtel-Dieu, after Desault. In 1815 he became a professor of operative surgery and wrote a three-volume work on clinical surgery (1810−1811).

André Marie Lallement (1750−1830) was a professor of surgery in the medical faculty of Paris and surgeon to the Salpetrière. Pierre François Percy (1754−1825) was a professor at the military medical school. Antoine Dubois (1756−1833) was a professor of anatomy at the Ecole de Santé. Alexis Boyer (1757−1833), a pupil of Desault and surgeon at the Charité, wrote a treatise on surgical diseases with 11 volumes (1814−1826) which was accepted as the most authoritative work on surgery in Paris for more than a generation.

Dominique Jean Larrey (1766−1842) played an important role in the growth of surgery. He was the leading military surgeon under Napoleon and an outstanding organizer. He was one of the earliest to perform the amputation at the hip-joint in 1803. Taking part in nearly all of Napoleon's battles, he created the famous "flying ambulances" (1792) to render immediate help to the wounded soldiers. The mortality rate of the French army was most remarkable. Larrey devoted his lifetime to surgery as expressed in his work entitled: "*Mémoires de medicine militaire* (4 volumes, Paris, 1812−1817). Napoleon considered Larrey the most honorable man he had ever known. He was truly the founder of modern military surgery.

Nineteenth century surgery in France was created and promoted by the major professors. Antoine Lembert (1802−1851), Dupuytren's pupil, found a method; the key to unlock the grave problem of successful intestinal suture. Lembert observed that in the approximation of serous tissue to serous, the mucosal tissue to mucosal lays the solution to the problem of intestinal anastomosis. "What is now known as Lembert's suture, which ensures that serous

surface is applied to serous surface in suturing intestine is the bases of all modern gastric and intestinal surgery." Lembert defined his method in 1826.

Dupuytren's work was of importance also as the initial surgeon in the abscission of the lower jaw (1812) and in his successful ligation of external iliac (1815), and subclavian arteries (1819). He was the first surgeon to succeed in the treatment of arterial aneurysms by constriction. He was also the first operator to practice subcutaneous section of sterno-mastoid muscle in the treatment of wry-neck. Dupuytren was a surgical pathologist and his profound knowledge of surgical anatomy and physiology led to his brilliant work with enterotomy. His solid background in pathology led to such notable accomplishments such as his observations of fractures of the lower end of the fibula (Dupuytren's fracture, 1819), of connatural dislocation of the hip joint (1826), and retraction of the fingers from the embarrassment of palmar aponeurosis (1832).

Dupuytren's clinical lectures were interpreted and published by Brierre de Boismont and Buet (Paris, 4 volumes, 1932−1934), and very widely disseminated. Indeed, Dupuytren has hardly ever been exceeded as a surgical teacher. His clinics were popular during his operating career with surgical students from all parts of the world. His lectures related to injuries and diseases of the bone were translated by Le Gros Clark into English and issued by the Sydenham Society in 1847. Perhaps never in the history of surgery has such greatness as a surgeon been linked with such a deficiency of character as a man. Percy appropriately described him as the greatest of surgeons and the meanest of men.

Philibert-Joseph Roux (1780−1854) was a surgeon at the Charité in 1810 and a follower and disciple of Bichat. He was promoted as a professor of surgery in Paris from 1820 and acquired Dupuytren's position in the Hôtel-Dieu in 1835. He made various improvements to surgery, performing the first staphylorraphy in 1819 and was the first to suture the ruptured female perineum in 1832.

Jacques Lisfranc (1790−1847), surgeon at La Pitié, became famous for his surgical methods of the partial dismembering of the foot at the tarso-metatarsal joint in 1815 as well as his dislocation at the shoulder joint. In 1833, he had performed nine rectal cancer resections via the perineum with three post-operative deaths. He also did many surgeries of lithotomy and gynecology, especially amputation of the cervix uteri. As with Dupuytren, Lisfranc was of a very combative nature and became caustic about his surgical contemporaries.

Louis Joseph Sanson (1790−1883), a pupil of Dupuytren, became a surgeon of Hôtel-Dieu in 1825. After Dupuytren's death, he came to the chair of Clinical Surgery in 1836 as a winner of the position by *concours*. Jules Germain Cloquet (1790−1883) published a book on the Anatomy of Hernia (1817) and a classical work on human anatomy with brilliant plates. He succeeded Dubois as professor of clinical surgery (1833) in the Paris Faculty, having been previously a professor of surgical pathology for two years. He developed several new surgical instruments.

During this era, lithotomy and urology flourished in France, as they have always done. Among the leading characters in these fields were Souberbielle, Civiale, Heurteloup and Leroy d'Etiolles.

Joseph Souberbielle (1754−1846) became an experienced supera-pubic lithotomist, performing his operation on more than 1,200 cases. Jean Civiale (1792−1867), expert in urology and lithotrity, performed his first operation on a living patient in January 1824. He had his special "calculus" word at the Necker Hospital and an extensive urological practice. Charles Louis Stanislaus Heurteloup (1793−1864) devised the instruments to simplify them

and improved lithotripsy. He reported *Principles of Lithotripsy* (1831). Jacques Mathieu Delpech (1777−1832), professor of surgery in 1812 was the primary specialist in orthopaedic surgery in France, performing for the first time a subcutaneous division of the Achillis tendon for club-foot (1816). He issued *Del'orthomorphic* (1828). In 1832, he was murdered by a patient who misunderstood that due to an operation for varicocele he had become impotent. Claude Francois Lallemand (1790−1853), professor of clinical surgery at Montpellier in 1819 was admittedly the leading surgeon in southern France. He designed the method of treating erectile tumors by needles. He also invented a method of autoplastic surgery by bending the flap without twisting, and thus eliminating all twisting of the flap.

The so-called third period (1835−1847) in the nineteenth century is as follows:

Charles Gabriel Pravaz (1791−1853) was extraordinary in orthopedics together with Jules Guerin. He was one of the first to set up this science on a stable foundation. He published on orthopedics and created the hypodermic syringe (1851) for the injection of tumors and varices.

Alfred-Armand-Louis-Marie Velpeau (1795−1867) who was a pupil of Brentonneau's, became a surgeon at various hospitals (1934−1967). His first work entitled: "*Traitéd' anatomie chirurgicale*" (1823) was decisive for surgeons. Velpeau also issued three volumes *Nouveau elements de medicine opératoire* which was the most extensive work on operative surgery in France at that time. It is beneficial historical material as it contains surgical procedures. In 1847 it was translated into English by Valentine Mott. *Velpeau's Diseases of the Breast* (1854), was the important reference for surgical clinics.

Jean-Zulema Amussat (1796−1856) started teaching individually even before he graduated from the Medical Faculty of Paris in 1826. Although not a professor, nor affiliated with a great hospital, Amussat made several notable contributions to surgery, especially his premier operation of a lumbar colostomy for obstruction of the colon in 1839. Amussat also created a lithotrite for urinary stones and a procedure for the torsion of arteries. For these contributions as well as for his studies on urethral stricture, he was awarded various prizes by the Paris Academy of Medicine.

Joseph Gensoul (1797−1858) became a chief-surgeon at the Hôtel-Dieu in Lyons (1826). During that year he was the first to cut the whole maxilla and the following year, he was the first one in France to dissect half of the lower jaw. In the same year, he had totally removed the parotid gland. Philipp Frédéric Blandin (1798−1849) continued after Richerand in 1841 as a professor of operative surgery of the Paris faculty and was also a surgeon in the Hôtel-Dieu. Raoul Henri Joseph Scoutettin (1799−1871), a remarkable military surgeon, was a professor at Metz (1836) and later in the military hospital at Strassburg (1840). During the Crimean War, he was the chief of the military hospital in Constantinople. Antoine Joseph Jobert de Lamballe (1799−1867) received Roux as a professor of surgery in the Medical Faculty in Paris in 1854. Jobert's main work was in gynecological surgery, especially in the treatment of vesico-vaginal fistulas, and particularly in plastic surgery.

Stanislaus Laugier (1799−1872), a pupil of Dupuytren, became professor of clinical surgery in the Paris Faculty of Medicine (1848) and succeeded Roux at the Hôtel-Dieu (1854). He was the first to encourage the suturing of divided nerves and the first to notice the desertion of cerebro-spinal fluid from the ear in some cases of fissured skull. Laugier was an interpreter of surgery. Amédée Bonnet (1802−1858) was a surgeon of the Hôtel-Dieu in Lyons who became famous for his special treatment of diseases of joints by fixation with immobile bandages. He also performed construction of the bulb without removing the

muscles of the eye. His essays on the treatment of joint diseases (1845, 1853) were his best works. Auguste Bérard (1802−1846) was the successor of Sanson as professor of clinical surgery at the Medical Faculty of Paris. His work in surgery included contraption on staphylorrhaphy, wound watering, varices and elevated tumors and fracture reductions. Jean Gasoard Blaise Goyrand (1803−1866), a chief surgeon of the hospital made distinguishable contributions on the termination of the tongue, amputations, urethral fistula, fractures of the lower end of the radius Goyrand, and was one of the dominant French provincial surgeons at that time.

Auguste Théodor Vidal de Cassis (1803−1856) wrote *Traité de pathologie externe et de médecine opératoire* (5 volumes, 1838−1841), a widely used manual of surgery which reached a fifth edition in 1860, and was transcribed into German by Bardeleben. He was the first to inject a solution of silver nitrate into the uterus for the treatment of syphilis. Jean Baptiste Lucien Baudens (1804−1857) was a military surgeon and served in Africa from 1830 to 1837. In 1838, he became a professor in the hospital at Lille, and four years later, professor at Val de Grâce. His methods of abscission of the shoulder and amputation of foot were highly recognized, as well as his ice-treatment of wounds. Jules Roux (1807−1877) was a professor in the Medical School of Toulon in 1842. He created a beneficial modification of the technique for disconnections of the foot and was the first to inject iodine into diseased shoulder-joints.

The most important French surgeons of the period 1847−1870 were Malgaigne, Denonvilliers, Gosselin, Richet, Nélaton, Chassaignac, Follin, Broca, Trelat and Dolbeau.

Joseph-François Malgaigne (1806−1865) graduated from Paris in 1831 and then graduated through the various surgical grades. For many years he was a surgeon at the Hospital Saint Louis and later at La Charité. He continued after Blandin in the chair of operative surgery at Paris. Malgaigne's greatest contribution to surgery was his unique manner of evaluating surgical techniques and contraptions by which the new methods of statistical calculation were associated with actual surgical experiments.

A surgeon of outstanding perception and ability as well as a brilliant stylist, his *Histoire de Chirurgie* (Paris, 1840) and his edition of *Ambrose Paré* with a biography of the latter (Paris, 1840), are rich mines for historians as well as for practicing surgeons. Malgaigne's *Manuel de médecine opératoire* (1834) was widely read, and published over seven editions. It was translated into various European languages and even into Arabic. His tremendous surgical work was his *Traité des fractures et des luxations* (Paris 1847−1855), in which he correlated the fruits of his own work in this field with those of his pioneers and contemporaries.

Edouard-Pierre-Marie Chassaignac (1804−1879) devised the ecraseur for stopping hemorrhaging and recommended modification in the treatment of abscesses and infected wounds by drainage. He also protected wounds by complete occlusion. The carotid tubercle is known as *Chassaignac's tubercle.*

A great French surgeon in this period was August Nélaton (1807−1873), a Parisian who studied under Dupuytren at Hôtel-Dieu, as well as at the Foundling Hospital. Nélaton was promoted as a professor of clinical surgery at Paris in 1851 and was a surgeon for many years at Hospital Saint Louis, together with Malgaigne; the two started their significant careers at the same time. The fact that Nélaton was a humble and exceedingly kind man who was friendly to all surgeons and never made an enemy, perhaps inclined the conditions in his favor over Dupuytren. Nélaton was one of the competent clinicians, lecturers and operators of the

great French in the nineteenth century, when France prevailed in surgery in the world. He wrote *Eléments de pathologie chirurgicle* (Paris 5 volumes, 1844−1860). His clinical lectures were translated by an American surgeon, Walter Franklin Atlee, who studied under Nélaton and published them in English (1855). They show the bright precision of a surgical teacher and the innovative methods which Nélaton was constantly putting into practice. Nélaton proposed a flexible rubber catheter and invented the porcelain-headed round probe for bullet wounds. He also emphasized that severed arteries be ligated at both ends within the wound, and brought this creditable practice into clinical use in France. He was also a pioneer of ovariotomy in his country.

Charles Pierre Denonvilliers (1808−1872) became chief of the school of constructive anatomy of the Hôtel-Dieu (1842) and professor of surgery in the same hospital (1856), and later inspector-general of public teaching for medicine. *Denonvilliers' fascia* was named after him. Athanase Léon Gosselin (1815−1887) became professor of surgery of the Paris Medical Faculty (1858), and surgeon to the Charité nine years later. He devoted his work to surgical journals in two volumes (Paris 1873). Louis Alfred Richet (1816−1891) was promoted as professor of clinical surgery at the Paris Medical Faculty (1864). His chief work was the *Traité pratique d'anatomie médico-chirurgicale* (Paris, 1857). Eugène Follin (1823−1867), a pupil of Velpeau, an adequate diagnostician and anatomist, died before he accomplished his six-volume work *Traité elémentaire de pathologie externe*, which was completed and published by Duplay.

Paul Broca (1824−1880) was the prominent pioneer in modern surgery of the brain. He was a surgeon at St. Antoine, La Pitié and finally at the Hospital Necker. He initiated craniometric methods and localized the third frontal contortion of the left brain as the speech center (*Broca's area*) and laid the groundwork for cranial geography. Broca designed the method of diagnosing the site of cerebral tumors by the limitation of the disrupted function.

Ulysse Trélat (1828−1880) became professor of surgical pathology of the Paris Medical Faculty and surgeon to various hospitals, including La Pitié and La Charité. Trélat was one of the first in France to comprehend the importance of Lister's antibiotic method in surgery. He specialized in surgery of the face and neck and produced two clinical treatises in 1877 and 1891.

Henri Ferdinand Dolbeau (1830−1877) succeeded Jobert de Lamballe at the Hôtel-Dieu (1865), after service at Children's Hospital and the Necker. Three years later, he was nominated as a professor of the Medical Faculty of Paris. His important scholarly improvements are on the lithotrity via the perineal route, epispadias, club-foot, chondromatous masses, and spinal bifida.

Other important French surgeons of this period, though less well-known, were Giraldès, Petrequin, Guersant, Guerin, Sédillot, Pozzi and Richard. Paul Louis Benoît Guersant (1800−1870) was a surgeon at Children's Hospital from 1833 to 1860 and wrote a treatise on pediatric surgery (1864−1867), which was translated into English. Jules Réné Guerin (1801−1886) was a student of Boyer and Roux. He was the designer of the *Gatte Médicale de Paris* which was published for forty years. He specialized in orthopedics, practicing mainly in his private hospital. He wrote broadly on osseous abnormality from 1838.

Charles Emmanuel Sédillot studied at Paris and at the Val de Grace and graduated in 1829. He was a pupil of Boyer and Roux. He was promoted as a professor of operative surgery at Val de Grace in 1836 and later was nominated as a professor of surgery at Strassbourg. He was the first to properly amputate at the hip joint in Paris in 1840. He was the

first to perform gastrostomy which was nominated by his name. He also contributed greatly in the surgery of lingual carcinoma, plastic surgery and orthopedics.

Joachim Albin Cardozo Cazado Giraldès (1807−1855), a Portuguese, became a surgeon at the Children's Hospital and at the Central Bureau in Paris. He issued his *Clinical lessons on the surgical diseases of children* in 1869. Joseph Pierre Eleanor Petrequin (1809−1876) became a professor of surgery at Lyons in 1855. He wrote on medical, surgical and topographical anatomy, and on clinical surgery as practiced at the Hôtel-Dieu in Lyons. He distributed two important volumes on the *Chirurgied' Hippocrate* in 1878 among other publications. Felix Adolphe Richard (1822−1872) was an assistant to Nélaton and a surgeon at the Paris Central Bureau (1852). He published his *Pratique Journaliere de la Chirurgie* in 1868.

Italy

The leading Italian surgeons during the first half of the nineteenth century were Palletta, Scarpa, Monteggia, Vacca-Berling-hieri, Porta and Rizzoli. Giovani Battista Palletta (1747−1832) instructed anatomy and clinical surgery when he was the chief surgeon of l'Ospedale Maggiore. Giovanni Battista Monteggia (1762−1815) became co-author with Professor Antonio Scarpa of the five volumes *Istituzioni di Chirurgia* (1802) which extended to seven volumes during its fourth edition in 1830. In 1795 Monteggia became a professor of anatomy and surgery in Milan. Andrea Vacca Berlinghieri (1772−1826) was recognized to the chair of surgery in Pisa in 1801. He remained as an important surgical center. Luigi Porta (1800−1875) studied for three years in Vienna after the fulfillment of his medical courses in Pavia. In 1832, he was appointed as a professor of surgery in Pavia as the successor of Scarpa and achieved international prominence for his special expertise in operations on the vascular system and on the thyroid gland. Francesco Rizzoli (1909−1980) was a professor of surgery and obstetrics at Bologna from 1840. He was identified as the father of Italian orthopedics and established the Orthopedic Institute there which carries his name.

Antonio Scarpa (1752−1832), a pupil of Morgagni at Padua was promoted as a professor of anatomy at Modena and later at Pavia, where he was also a professor of clinical surgery. As an anatomist, he characterized the round window of the ear, Scarpa's triangle of the thigh, Scarpa's fascia, the naso-palaine nerve, and Scarpa's membrane. He published on the surgical treatment of inguinal hernia, cataract and aneurysm. Scarpa was the most famous Italian anatomist and surgeon at that time.

Spain

In Spain, Antonio Gimbernat (1734−1816) detailed (1768) a new operation for femoral hernia together with the discovery of the ligamentous structure in imperative arch which was nominated by his name. Gimbernat (1768) also discovered the Cloquet ganglion in the femoral ring, which he exposed to John Hunter in 1775, and defined totally in 1793. Hunter liked the new method and promised to detail it in his lectures and to use it when he had the opportunity to operate on patients.

Holland

In the Netherlands, the leading surgeons of the first part of the nineteenth century were Hendriksz, Onsensoort, Tilanus and Ranke. Pieter Hendriksz (1779−1845) was a professor of surgery at Leyden and moved to Amsterdam from 1828 to 1832. Anthony Gerard van Onsensoort (1782−1841) was a professor at Utrecht and a dominator on military surgery, on which he produced a treatise in 1832. Christian Bernard Tilanus (1796−1883) studied under Dupuytren and Listranc in Paris and was the first to instruct clinical courses in surgery at the Children's Hospital in Amsterdam where he was employed as the chair of surgery and obstetrics. Hans Rudolph Ranke (1849−1887) studied under von Volkmann and was appointed as a professor of surgery at Groningen in 1876.

Germany

The dominant surgeons in southern Germany and Austria during the first part of the nineteenth century were Franz X. Rudtozffer (1760−1833), professor of surgery at Vienna from 1810 to 1821; Christoph B. Zang (1772−1835), military surgeon; Joseph von Wattmann (1779−1866); and Vincenz Sebastian von Kern (1766−1829), professor of surgery at Laibach (1797) and at Vienna from 1805 to 1824, who exerted an energetic influence on the advancement of surgery and surgical teaching in Germany and northern Italy.

The best-known surgeons in northern Germany during this age were Mursinna, Hasselbach (1759−1816), Langenbeck, von Walther, von Graefe, Dieffenbach and Chelius. Christian L. Mursinna (1744−1823) was appointed as a professor at the Military Medical School in Berlin and was a practicing surgeon at Charité Hospital. Conrad J. M. Langenbeck (1776−1851) instructed anatomy and surgery at Gottingen, was surgeon general of the Hanoverian army in 1814 and professor of anatomy and surgery at Gottingen. He created the operation of iridodesis for an artificial pupil in 1817. His treatise on lithotomy was issued in 1802 and four years later, developed the first volume of his *Bibliothek fur die Chirurgie* which was definitely completed in eight volumes in 1828. A five-volume treatise on the diagnosis and therapeutics of surgical diseases was published during the years 1822−1850.

Philipp F. von Walther (1782−1849) studied at Heidelberg and Vienna and was appointed as a professor and surgeon at Bamberg Hospital when he was 21 years old. The following year, he was promoted as a professor of surgery and physiology at Landshut. In 1818, he was promoted as a professor of surgery at the newly created University of Bonn and in 1830, he held the chair of surgery at Munich. He was recognized as the founder of modern surgery in Bavaria and one of the first to counterpart physiological principles with those of surgery. He produced numerous treatises, the most important being System der Chirurgie. In 1845, he properly construed corneal darkness.

Carl Ferdinand von Graefe (1787−1840) was one of the few tremendous surgeons in a period when the surgical capitals of Europe were Paris and London. Von Graefe, Dieffenbach and Langenback were the pioneers of modern German surgery.

Von Graefe was the founder of modern plastic surgery, developing new methods for the design of artificial noses (rhinoplasty) and eyelids (blepharoplasty). He also guided the palatine suture for the treatment of congenital cleft palate. He was the first in Germany to cut

off the lower jaw, and the primary German surgeon to ligate the innominate artery. He was a professor of surgery and director of the surgical clinic at Berlin University from 1810 to 1840.

Johann Friedrich Dieffenbach (1792−1847), a graduate of Wurzburg, who had also studied under Dupuytren and Delpech, inherited von Graefe's position as director of the surgical department of the University of Berlin (1840). He did extensive improvements in the field of plastic surgery, and later also in orthopedics and internal operations. In 1836, Dieffenbach performed the first successful end-to-end anastomosis of small intestine using Lembert's suture. His myotomies and tenotomies became famous. He cured 140 cases of club-foot by tenotomy, and also made extraordinary progress in strabismus by resecting the tendons of ocular muscles.

Max Joseph von Chelius (1794−1876), a pupil of von Walther, was promoted as a professor of surgery at Heidelberg (1819) and published a handbook on surgery in 1823 which became a classic text book all over Germany. The manual continued as the most widely used textbook in surgery for over twenty-five years, and was translated into many European languages and were continued with eight German editions (1823−1857).

Other great German surgeons of this era were: Karl August Kuhl (1774−1840), professor of surgery at Leipzig, who properly ligated both carotids, the innominate, and subclavian arteries in patients. Kajetan von Textor (1782−1860) a pupil of von Walther, Boyer and Scarpa, was appointed as a professor at Wurzburg and a specialist in resections. Carl Wilhelm Wutzer (1789−1863) was a professor of surgery at Halle and later at Bonn. He designed a special operation for the radical cure of inguinal hernia. Gustav Benedict (1785−1862) was a famous ophthalmologist at Breslau. John Carl George Fricke (1790−1841), a pupil of von Graefe, was a surgeon of Hamburg General Hospital, invented special forceps and a vaginal speculum. Michael Jaeger (1795−1838), wrote decisively on resections and on the diseases of bones and joints. Friedrich August von Ammon (1799−1861) was an eye surgeon, and the author of important treatises on plastic surgery, orthopedics, and ophthalmology. George Mojsi-sovis (1799−1860), was a surgeon at Vienna General Hospital. Leopold Grossheim (1799−1844) published a three volume textbook on operative surgery (1830−1835). Ernst Blasius (1802−1875) was a well known author, and Adolph Wernher (1809−1883) who wrote a four-volume handbook on general and regional surgery that became a very popular and valuable work.

The next sequence of important German surgeons were Johann F. Heyfelder (1798−1869), who wrote an important dissertation on resections and amputations in 1854 and other works. Wilhelm Baum (1799−1883), Gustav B. Gunther (1801−1866), a professor of surgery at Kiel and Franz Schuh (1804−1865), a professor of surgery at Vienna.

Georg Friedrich Louis Stromeyer (1804−1876) was surgeon-general at Hanover and a professor at the Universities of Erlangen, Munich, Freiburg and Kiel. He was recognized as the father of modern German military surgery. He published his extensive *Maximen der Kriegsbeilkunst* in 1855 and was devoted to orthopedic surgery by his procedure of subcutaneous tenotomy for injuredlimbs. He also wrote about the resection of joints.

Franz von Pitha (1810−1875) together with Thedor Billroth published a handbook of general and regional surgery, and was considered an excellent diagnostician.

Bernhard Rudolph Konrad von Langenbeck (1810−1887) was one of the greatest surgeons of all times and a graduate of Gottingen. He followed Dieffenbach at Berlin in 1847. He practiced every branch of surgery, devising no less than 21 major operations, mainly in the difficult field of joint excision, including the ankle, hip, knee, shoulder and elbow. He

launched the German Surgical Society and the Archiv fur klinische Chirurgie, the outstanding European surgical journal. Many of the major surgeons in Europe were Langenbeck's pupils, most remarkably Brillron and Gurlt. As a teacher he was unsurpassed and unique.

Victor von Bruns (1812−1883) of the University of Tubingen was one of the founders of laryngology, being the first one to remove a laryngeal tumor via natural transition. Wenzel von Linhart (1821−1877) was an anatomist, surgeon and author. Albrecht Theodor Middeldorpf (1824−1868) was a professor at Breslau and recommended galvano-cautery. He made various noticeable improvements on the subject of fractures and dislocations. He was the first one to operate for gastric fistula (1859) and oesophageal tumors. Busch (1826−1881), a pupil of Langenbek, was promoted as a professor of surgery at Bonn and wrote considerably on hernia, plastic surgery, orthopedics and gunshot wounds. He also wrote a two-volume textbook on surgery (1857−1869). Carl Ernst Albrecht Wagner (1827−1870), a pupil of Langenbeck, and professor of surgery at Konigsberg, was an experienced operator and a good teacher.

Other important surgeons in the mid-nineteenth century were: Jacob von Heine (1800−1879), planner of famous orthopedic hospital at Cannstatt and remarkable author on orthopedic surgery, who produced a famous treatise on poliomyelitis in 1840, a disease which he accurately characterized as a spinal lesion for the first time. Hermann Demme (1802−1867) was a professor of surgery at Berne. August Burow (1809−1874), a pupil of Dieffenbach and a famous plastic surgeon, ophthalmologist and author. Edward Zeis (1807−1868), a professor of surgery at Marbury and later chief surgeon at the City Hospital of Dresden, published important works on plastic surgery. Benedikt Stilling (1810−1879) of Cassell, the first ovariotomist in Germany, performing the operation via the extraperitoneal route in 1837, he also wrote considerable articles on the treatment of stricture by internal urethrotomy. In 1840 he was the first to use the term "Vasomotor," using it as a "hypothetic designation of nerve thread supplying the blood-vessels." Joseph Blazina (1812−1885) was appointed as a professor of surgery at Prague. Hermann Julius Paul (1824−1877) of Breslau was the author of works on traditional and regional surgery. Renst Ludwig Schillbach (1825−1898) of Jena was the author of a monograph on the resection of bones. August Gustav Herrmann (1831−1874) of Prague was the author of relevant works on military surgery, and Carl Wilhelm von Heine (1838−1877), a professor of surgery at Innsbruck (1869) contributed academically on gangrene and on military surgery.

The most decisive German surgeons of the latter part of the nineteenth century include: Johann Dumreicher (1815−1880) of Vienna; Gotteried F. F. Loeffler (1815−1874), an important military surgeon and author; C. J. F. L. Gustav Simon (1824−1876), medical director of the Hessian army and professor of surgery at Rostock (1861) and later at Heidelberg (1867) founded a private hospital. In 1853, he repaired of vesicovaginal fistulae, gynecology and urological surgery, and he was the first one in Europe to perform a nephrectomy. He was one of the inventors of modern urologic surgery. Gustav Simon published many monographs including treatises on splenectomy and plastic surgery at the Bethanien Hospital (1862); Georg Albert Lucke (1827−1894) became assistant to Blasius at Halle (1854) and later, assistant to Langenbeck at Berlin. He was promoted as a professor of surgery (1865) at Berne and later he obtained the same position at Strassburg. Theodor Billroth (1829−1894) of the island of Rugen, was Langenbeck's tremendous pupil at Berlin (1854). He was a professor of surgery at Zurich (1860−1867) and Vienna (1867−1894). Billroth was the builder and pioneer of modern abdominal surgery, making possible

procedures within peritoneum as Syme, Dupuytren and Langenbeck performed on the extremities. He completed the first resection of the esophagus (1872); first excision from the larynx of cancer (1873), and executed the first resection of pylorus for cancer (1881). He operated numerous intestinal resections and enterorrhaphies. He was an affectionate friend of the famous German composer, Johannes Brahms.

Richard von Volkmann (1830−1889) of Leipzig, a professor of surgery at Halle (1867−1889) was the first to execute the excision of rectum cancer (1878). He furthermore detailed cancer in paraffin-workers and the ischemic compression or paralyses. Von Volkmann was the foremost German defender of Listerian antisepsis. He was the founder of the *Sammlung Klinischer Vortrage* in 1870.

Other influential German surgeons were: Adolf G. J. von Thaden of Holstein, a pupil of Esmarch and surgeon at the city hospital at Altona; Carl Hueter (1838−1882) attended post-graduate courses in Vienna, London and Paris after graduation in 1859. Later he became a private-docent in Berlin where he assisted Langenbeck. He was nominated as a professor of surgery (1868) at Rostock as a successor of Gustav Simon, and the following year he was employed as the chair of surgery at Greifswald. He was a skilled bacteriologist and pathologist as well as a master surgeon and who created much advancement in the technique of excision of the rectum, tracheotomy, resection, etc. He was a creative writer of surgical books. Hermann Mass (1842−1886) became professor of surgery at Freiberg (1877) and he wrote an imperative work on military surgery.

Robert Gersuny (1844−1924) of Teplitz-Schonau, a pupil of Billroth was an innovator of many operative methods in the surgical and gynecological fields. In plastic surgery his name was distinguished for his Paraffinmethode. His book *Arzt und Patient* was transcribed into English and he wrote *Theodor Billroth* (1922), to honor his teacher. Gersuny's Klebesymptom was named after him.

Friendrich Trendelenburg (1844−1924) of Berlin, a pupil of Langenback, was principally interested in strictures of trachea and esophagus. He recommended his tampon-cannula in 1869, and his gastrostomy operation for the therapy of strictures of the esophagus (1877). In the operations on the viscera, he used the high pelvic posture (position), now internationally known as "Trendelenburg's position." He was the first to suture the patella in Germany (1878). He helped in establishing the German Surgical Society (1872), and wrote its history.

The tremendous German historian of surgery was definitely Ernst Julius Gurlt (1825−1899) of Berlin, who was a professor of surgery at Berlin University in 1862. Gurlt engaged in extensive research in the history of modern surgery, which blossomed in his truly great work, *Geschichte der Chirurgie* (3 volumes, Berlin, 1898). In this history, he described the development of the art and science of surgery from its commencement to the Renaissance with a propensity of detail work and an unsurpassed degree of truthfulness. The work was translated in total into English.

Friedrich von Esmarch (1823−1908) was the leading military surgeon of Germany during the last half of the nineteenth century. Esmarch was a professor of surgery at Kiel from 1857 to 1899. He provided service in all the wars and made important improvements to the art of military surgery. He recommended the first aid bandage on the battlefield in the wars of 1869 to 1870. A most valuable contribution was the so called "Esmarch bandage." The benefit was to control hemorrhaging before ligation, which saved many lives on the battlefield. Valuable work by Esmarch was also done in the field of abscission after gunshot wounds.

Paul Kraske (1851−1930) was an assistant under von Volkmann. From 1883 to 1919, he was director of the Chirurgische Klinik of the University of Freiburg. He became brilliant because he discovered a method to remove high location of rectum cancer which bears his name.

Fedor Krause (1857−1927), another prominent German surgeon of Friedland, Silesia, studied under Julius Hirscherg, Robert Koch, C. Friedlaender, Weigert and Volkmann. He was the principle of Augusta Hospital. His main direction was to treat tuberculosis of bones and joints. He was also involved in the therapeutics of neuralgia of facial nerves and in the surgery of brain and spinal cord. His distributed, excellent thesis "*Lebrbuch der Chirurgischen Operationen*" (Berlin and Wien, 1912−1914, was translated into English, Russian and Spanish. His surgical method of destruction of the gasserian ganglion carried his name.

Karl Thiersch (1822−1895) of Munich was a pupil of Stromeyer. He was appointed as a professor of surgery at Erlangen and Leipzig. He became known for his work in skin-grafting. He also published *Der Epithelialkrebs* (Leipzig, 1865) on epithelial cancer, healing of wounds, and phosphorus necrosis.

Ernst von Bergmann (1836−1907) was the successor to von Langenbeck in the chair of surgery at the University of Berlin. He studied at the University of Dorpat. During the crusades of 1870 to 1877, he had great possibilities to expand his knowledge of surgery. He was assigned to the professorship at Wurzburg in 1878 and in 1882 he developed in Berlin as Langenbeck's successor. He was the outstanding German surgeon in the field of head injury and brain surgery. He reported on fatty embolism, diseases of lymph glands, surgery of the joints, ligation of femoral vein, etc. He was the first to recommend sterilization by steam in surgery (1886). The highly illustrated pattern of operating room asepsis was settled by von Bergmann.

Vincenz Czerny (1842−1916) and Anton Wolfler (1850−1917) were two immense surgeons in Germany. Czerny, as a professor first at Freiburg, and later in Heidelberg (1887), he was the first to remove sub-peritoneal uterine fibroids by way of the vagina (1881). He was a pupil of Billroth's and worked in the fields of extirpation of larynx, the esophagus, the kidney, and general visceral surgery. He was the creator of the Institute for Experimental Cancer Research and the Heidelberg Samariterhaus (1906). At Wolfler of Kopezen near Kladrau, Wolfer operated the first gastroenterostomy in 1881. His improvement to surgery of the tongue and kidneys were very beneficial. Together with Kocher he worked and wrote about the dangers of total removal of the thyroid gland. He wrote about struma, erysipelas, amputations and foreign bodies in the stomach and intestines of the man.

Russia

The original Russian surgery began long ago, and early sources of the history of Russian medicine saw the same primitive folk therapies and superstitions which are found in ancient people. In Richter's work *Geschichte der Medizin in Russland* (3 volumes, Moscow, 1813−1817), it was expressed that the early Russians were so healthy and strong that they did not need much medical treatment. But doubtless, they wanted it even though there was a lack of physicians. In the fourth century B.C., after initiation of the Christian religion, the Byzantine priests and hermits took care of the sick people. Prior to the period of the Tatar

aggression and dominance (1223−1370), the tzars and dignitaries had started importing physicians from Western Europe. But the ruthless treatment of the Tatar rules soon kept foreign physicians away from Russia. For instance, a physician Leo, a Venetian Jew, who failed to treat a Muscovite prince for a foot sickness, and Anton, a German physician, who along with Leo was sentenced to death because of failure to cure the disease.

During the following centuries, epidemic diseases and poverty, leprosy and syphilis, repeatedly imperiled all of Russia, killing large percentages of the population because of the lack of medical treatment. In the sixteenth century, Ivan the Terrible (1533−1584) tried to bring in foreign physicians. This had already been tried by his forbearer, who had authorized a German, Hans Schlitte, living in Moscow, to bring German creative people and mechanics into Russia. Schlitte had already selected more than one hundred German artists, physicians, operative surgeons, barber-surgeons, surgical assistants and druggists. But the Hanseatic League and the Livonian Order, for bureaucratic reasons, put most of the party in prison. Eventually, only a few foreign physicians were brought in. At the end of the 16th century, the first Russian medical book was published and the first juridical autopsy was performed in 1623.

The Romanov Empire tried to enhance and institutionalize living conditions. Tzar Feodor built a hospital, which had a staff consisting of physicians and surgeons who gave courses in medicine and surgery to students, who needed to pass an examination after five years of study to get their medical degree.

It was not late in the seventeenth century before real improvement was made, when Peter the Great, whose regime from 1694 to 1724, tried in any way to build up westernized industry and science in Russia. During his European travels in Germany, Holland, England and Austria, he personally studied the art of ship-building and was even taught some medical and surgical training, whereby he performed quite a few of surgeries after he returned to Russia. Couching cataracts, abscess draining and tapping dropsies were performed by him, although not always successfully. He built the first hospital in 1706 and the first medical school in Russia in 1707. In the following years, he controlled many hospitals which had been founded. He also induced many German and Dutch physicians to serve in his army and navy. Regrettably, his female subordinates did not care about medical advancement and social welfare. During the Seven Years War, a large number of wounded soldiers died for lack of adequate medical care, because all hospitals built by Peter the Great had long since crashed and no new hospitals had been set up.

Catherine II (1762−1796), the Great lover, who reigned 34 years, had some permissive propensity, and Russia opened some new hospitals and other welfare institutions. Catherine was induced by Voltaire to accept a vaccination against smallpox together with her son, Grand Duke Paul Thomas Dimsdale. The physician who performed this service, was compensated with the title of Baron, along with $60,000 and a pension for life of $2,500. During Catherine's reign (1769), Ambodik recommended the use of obstetric forceps.

When Catherine died, her son Paul (1796−1801) proved to be an atrocious and weak-minded ruler, but some developments were made during his reign. The Collegium Medicum (1763) was rebuilt as the Medico-Chirurgical Academy (1800) with Sir James Wylie (1768−1854) as the first president. Wylie, an Aberdeen graduate, was the physician to Tzar Paul (1798−1801). Wylie (1808) became Inspector General of the Army Medical Board of Health (1812), and first director of the Medical Department of the Military of War. Medical

teaching up to the middle of the nineteenth century was rather insufficient. The old textbooks of the eighteenth century were used to teach surgery, pathology and chemistry.

In the first half of the nineteenth century, Matvei Mundrov contributed a lot to Russian medical history. He published the first Russian manual in the field of surgery and lectured on military hygiene. The Military Medical Academy of St. Petersburg (1835) became very influential in the improvement of Russian surgery. Conrad Frederick Uden was appointed as the first professor of special pathology and therapy. Ivan Feodorovich Busch (1771−1843) issued the first Russian manual of surgery (1807) and was a distinguished teacher. Salomon, one of his pupils, operated the first lithotripsy and the first ligation of the internal iliac artery in Russia.

Other important surgeons in Russian history were: Simon Zybelin who was promoted as professor of anatomy and surgery in the University of Moscow in 1868; Joseph Czekierski (1777−1826) of Warsaw, who was appointed as professor of surgery and also wrote a four-volume treatise on surgery (1817−1818); Andreas Sydoratzky (1788−1815), a famous lecturer on surgery at the University of Moscow; Elias Bujalski (1789−1864), who wrote *Tabulae Anatomico-Chirurgical*, distributed in 1828 and reprinted in 1852, was also an anatomist in the Military Medico-chirurgical College at St. Petersburg; Karl Daniel von Haart-Man (1792−1877), the author of Casus Chirurgici (1815), was a professor of obstetrics and surgery at the University of Helsingfors (New Finland) which was newly founded (1833). Leo Nagumowitsch (1792−1815) was a well-known military surgeon and author of an essential manual on the treatment of gunshot wounds (1832, Russian). Christian Salomon was appointed as a professor of surgery at St. Petersburg and wrote a two-volume textbook on operative surgery (1840); Ivan Rklisky (1805−1861) wrote a Russian treatise on operative surgery (1847) and was a clinical professor of surgery at St. Petersburg.

Under Alexander II (1855−1881) a powerful pursuit was made to improve and modernize Russian medicine. Most Russians had never seen a physician at all and only military medicine was available. The conditions in abundant rural districts were so poor that there was no chance at all for a physician to ever practice. The tzar, a liberator, tried to solve the internal problems of his country by creating a great network of district assemblies or Zemstvo governments. The plan was excessive and could be carried through only partly. By 1890, there were 1,422 medical centres in 359 districts with 1,068 hospitals and 414 clinics, with a total personnel of 1,805 physicians, 8,046 assistants and 2,454 midwives.

The greatest Russian surgeon and head of social welfare was Nikolai Ivanovich Pirogoff (1810−1881), who graduated from the University of Moscow at 22 years of age and who produced a monograph on the ligation of the abdominal aorta (1832). He then studied two years in Berlin and Gottingen. Returning to Russia (1835), he lectured for five years at Dorpat and then was promoted to professor of surgery in the Military Academy at St. Petersburg. During the Crimean War (1854−1855), he coordinated female nurses to take care of the wounded. He was well known as the first surgeon in Europe, together with James Syme of Edinburg and Robert Liston to apply ether anesthesia (1847). He made 800 post investigations of cholera victims (1848), and taught many pupils. He had extensive opportunities to study from serial wars with abominable torture for the wounded soldiers and people, such as pyemia, erysipelas, hospital gangrene, and purulent edema. He was strongly demanding of medical support from the incompetent government. He had to completely resign his professorship. Pirogoff operated his method of entire osteoplastic amputation of the foot (1854). He was known for his great atlas of 220 topographic, anatomical, delineated

plates (1851−1854) based on frozen sections in three planes. Also for his treatise on military surgery (1864), and for advocating small, barrack-like pavilions to prevent the spread of epidemic diseases. He did his absolute best to promote medical education in his country, and was respected by the Russians as the greatest surgeon in medical history.

An important Military surgeon after Pirogoff was Nikolai Alexandrovich Velyaminov (1855−1920), the pioneer of the first Russian surgical journal (1885), who regulated the Russian Red Cross during the Russo-Japanese War (1904), and was surgical inspector on the staff of Grand Duke Nicholas (1914). Nikolai Vassilievich Skliffosovsky (1936−1904) earlier boosted and recommended antisepsis. He created the Russian clamp for suturing bones in the operative treatment of false joints. In cases of oesophageal narrowing, he successfully operated gastrostomy, and in goitre patients, he ligated the jugular vein. Vladimir Dmitrievich Vladimirov (1837−1903) was the first to use osteoplastic resection of tarsus (1872), a method later improved by Mikulicz (1881). Sergiei Petrovich Kolomnin (1842−1886) was a promoter of ignipuncture. Vladmir Feodorovich Snegirev (1847−1916), a well-known gynecologist, introduced vaporization of the uterus (1898) and published about uterine bleeding in 1885. Alexander Alexievich Bobbroy (1805−1904) created an osteoplastic method of operation for spinal bifida (1892), and was famous for his surgical treatment of liver hydatids (1896−1898). Paul Petrovich Pelechin (1842−) introduced antisepsis into Russia (1868). Peter Ivanovich Dyakonov (1855−1908) in Orel, a professor of surgery at the university, started the annual congress of Russian surgeons (1888), published a book on death from chloroform (1890), on antiseptic wound therapy (1895), and was the editor of *Kirurgiya* (Moscow 1897−1908).

Alexiei Andrevevich Vvemensky (1856−1900) at Tomsk issued papers on lithotrity in children (1887), on calculus in women (1893), and on the topography of the female pelvis (1893). Anton Yakovlvich Krassovski (1823−1898) recommended ovariotomy in Russia (1862) and published a treatise on operative obstetrics (1885). Ivan Petrovich Pavlov (1849−1936) of Ryazan was devoted to pharmacology and especially to physiology. He became (1890) director of the Oldenburg Institute of Experimental Medicine, and the first laboratory of physiological surgery was built under his guidance (1891). Pavlov, who explored the secretory nerves of the pancreas and so-called psychic secretion, received the Nobel Prize (1904) for his research work on the digestive glands. He was honored by the tzar when he died in 1936.

In modern Soviet surgery, there were several physicians who did very interesting research in blood transfusions in dogs. During the World War, the citrate method was introduced and it was the first time blood could be kept for a few days before transfusion. At that time, blood banks showed quite a few impairments, e.g., loss of potassium by the red cells. In blood preserved for 10 days, the concentration of potassium could become dangerous, and also the prothrombin concentration in the blood dropped rapidly. At that time scientists realized that a whole blood transfusion is preferable, but there were many shortcomings needing to be solved.

American Surgery

America Surgery came at last in this age. The first period or colonial period, was recorded by Hunterian principles. Most American surgeons were trained and graduated from Scottish, and English schools of medicine. This period may be extended to 1820. There were

many heroic operations like aneurysms and amputations. The most crucial surgeons in this period were the two Warrens, father and son in Boston. Physick, often called "The Father of America Surgery." Wright Post in New York, Dorsey, the nephew of Physick in Philadelphia, and Nathan Smith in Yale.

The second period, when American surgeons studied in American medical schools, saw the predominant influence of Hunter Wane who graduated from the enormous schools of Paris, which at that time (1820−1850) was the surgical center of the world, and which fascinated many American surgeons. The pioneer of American surgeons was Valentine Mott in New York who did extraordinary work in the field of vascular and osseous surgery. This period also saw the era-making establishment of ether general anesthesia invented by John Collins Warren, Henry Bigelow and George Hayward. In this period, the ovariotomy became a fundamental part of surgery.

In the third period, dating from 1850 to 1900, American surgery progressed rapidly to perfection. Marion Sims made gynecology a science with the help of his pupils Emmet and Thomas. Their practice increasingly developed the capacity of operative surgery, and surgical peculiarities were established. When Langenbeck and Billroth reigned in Europe and when Virchow established cellular pathology, it was very charming for American surgeons to attend German medical schools. American surgeons now went to Berlin, Vienna and Leipzig for their post-doctoral training. In this period, Samul Gross developed surgical pathology securely in America. In this epoch, Johns Hopkins University, undergraduate and graduate schools were well-established. The Mayo Clinic in Rochester, Minnesota, influenced by the two great operators, the Mayo brothers. The patron of American surgery, John B. Murphy of Chicago, managed the surgery of the Mid-West and put every surgeon in America under his control. At Murphy's side there was the figure of the celebrated Swiss-American surgeon, Albert Ochsner.

From 1900 onwards, American surgery gradually became independent. Surgical centers grew and spread through the American continent. Surgery advanced and generated in every direction.With the help of Rontgen rays, the methods of blood transfusion were clarified, general and local anesthesia were gradually well established which made surgery much more successful. Creative methods to overcome surgical shock were developed and many brilliant surgeons moved from America to international surgical centers. In 1930 a Nobel Prize was awarded to an America physician, which encouraged and enhanced American surgery very much. Colossal adversities were overcome and the tiny seed which was sown hopefully was being producing an enjoyable harvest.

Bleeding, infection and pain were the major barriers of surgery before the industrial revolution. During the entire history of medicine and surgery, there is a constant repeatable sad record. The massive and dreaded phenomenon of lethal infection was the main subject running its detrimental epidemic diseases all over the Europe. Many patients died after surgery because of septicemia, pyemia, pueral fever, gangrene, and in almost all cases, the results were the same, death. Up to the end of the eighteenth century the mortality rate of 80% was truly appalling. Thankfully, the mortality rate dropped to 50% in the nineteenth century.

PREVENTION OF INFECTION

Two men were revolutionary for smashing the monster of infection as it obsessed the surgeon. Louis Pasteur (1822−1895), a native of the Jura district was trained as a chemist. He did the evaporation research to induce lactic acid organisms. Their growth could be paused or constricted and even damaged by controlled heat. From this, *Pasteurization* started in the modern food industry and the seed of antisepsis lies within it. At that time, surgeons knew that pus came from infection, and if infection could be prevented there would no putridness.

Luckily, Pasteur's work on lactic acid fermentation attracted the attention of Joseph Lister (1827−1912) during the early 1860's. Lister snatched the key factor and saw immediately that infection could be terminated at the start. The question was how. The Pasteurian method of heat sterilization could not be applied to living tissues. According to the good results obtained at Carlisle where excrement was treated with carbolic acid, Lister began experiments with solutions of carbolic acid of varying concentrations as disinfectant agents. He advised to spray carbolic acid solution in the operating room because he believed that the pathogenic organisms were active in the air. In 1865, Lister started using antisepsis in surgical patients. Lister submitted two era-making articles in the Lancet (1867). The first one was "*On a new method of treating compound fracture, abscesses, etc., with observations on the condition of suppuration*," and the second one, "*On the antiseptic principle in the practise of surgery.*" Robert Koch in Munich in his *Cause of infection in wounds* (1877) illustrated for the first time that many different types of organisms could cause different type of infection, and that each had clear distinctive properties which caused different symptoms.

It became clear that surgical scientists understood that antisepsis was half of the solution to the problem of infection. Ernst von Bergmann and his assistant Schimmelbusch in 1886 expanded the embellished doctrine of sterilization by steam for surgical instruments, gauzes, tissues and dressings which have been taken up throughout the world. To include the operating surgeon's and his assistants' hands (1890) in the category, Halsted recommended the use of rubber gloves. Ten years later, William Hunter at Charing Cross Hospital first used the gauze mask over the face of the operator. This, like rubber gloves, is now universally applied.

Shortly after the effectiveness of antisepsis was established, Lister showed his mortality rate in amputations fell from 43% to 15%. Lister also created catgut ligatures of blood vessels (1880). This is one of the most influential improvements in the history of hemostasis and was widely used in surgery after 1880.

Joseph Lister and Jame Syme of Edinburgh (1869), eight years later became professors of surgery at King's College where Lister continued until his retirement in 1896. He was a respected surgeon in his university. He was of utmost modesty and kindness, and shared his honors with others. Lister had an ample scientific generosity, hospitality and unselfishness, not so common in science.

In the First World War, especially with the great carnage, asepsis was impossible for the primary treatment of the traumas of war. With the widest possible use of antisepsis, coupled with preventive vaccinations against tetanus, the military surgeon could handle the huge disaster lists. The use of sulfa medicines had remarkably reduced infections, and had greatly aided in the battle against wound infections since the First World War. The use of sulfa drugs kept septicemias, gas gangrenes and other fatal infections to a minimum.

Antibiotics have been used for thousands of years to treat infections, and until the last century many people did not know that infections were caused by bacteria, such as pneumonia and diarrhoea which caused lots of human death in the developed world. It was in the late nineteenth century that scientists commenced researching antibacterial chemicals. Paul Ehrlich, a German physician, determined that a chemical named arsphenamine definitely treated syphilis in 1909. This became the first modern antibiotic which was used for over 30 years by Ukrainian-American innovator and microbiologist Selman Waksman, who in his lifetime invented over 20 antibiotics (The Nobel Foundation 1945; Cruickshank 1955). Alexander Fleming (1881−1955) was a Scottish biologist, pharmacologist and biotechnologist. His best discoveries are the enzyme lysozyme in 1923 and the world's first antibiotic benzylpenicillin (Penicillin G) from the mold *Penicilliumnotatum* in 1928, for which he shared the Nobel Prize in Physiology or Medicine in 1945 with Howard Florey and Ernst Boris Chain (Wikipedia contributors 2017; History of Antibody 2015). During World War II, penicillin was widely used to treat troops throughout Europe, and had saved a lot of lives (History of antibiotics 2017).

Paul Ehrlich and his colleagues developed a systematic screening approach which became the cornerstone of drug research strategies in the pharmaceutical industry that resulted in thousands of drugs identified and translated into clinical practice. During the earliest antibiotics research, this process led to the invention of sulfa drugs which treated numerous diseases with its antibacterial activity (Domagk 1935; Hugh 2002) from World War I to present clinical practice.

The discovery of the first three antimicrobials, Salvarsan, Prontosil, and penicillin was the example for identifying further drugs. The period between the 1950s and 1970s was the golden era of discovery of novel antibiotics. Therefore, with the decline of the discovery rate, scientists tried to struggle with the counteraction of pathogens against antibiotics which were transformed by existing antibiotics (Chopra 2002). Combination therapy of coupling antibiotics may increase the efficacy of bacteriophages, and diminish the side effects of antibiotics (Lu and Collins 2009).

ANESTHESIA

The enormous improvement of surgery is due to the revelations and advancement of all methods of anesthesia. Because of the discovery of nitrous oxide, ether and chloroform, the original surgeons performed surgery using these tools. Subsequently the simple drop method of anesthesia intake was upgraded, and the "gas-ether" method progressed. A simple method was to put the patient under nitrous oxide first, then gradually take over by ether, totally without severe side-effects. Thomas L. Bennett in New York City, learned the anesthesia method in England from Hewitt in 1895, and therefore built up the new devices which spread everywhere (Wallin 1972).

In 1858, Albert Niemann used the analgesic chemicals of cocaine, when placed on the tongue. Carl Koller in 1884 recognized that it had the same efficacy on the eyes. Spinal anesthesia, especially for surgery below the diaphragm, came into clinical utilization mainly due to Halsted's initial work. Einhorn found that novocaine and its clinical use by Braun in 1905, brought local anesthesia briskly into clinical utilization. Novocaine was a great

improvement. It was 7 times less toxic than cocaine and it could be sterilized by boiling and kept for a long time without degeneration. Combined with adrenalin its efficacy could be boosted and protracted. Its analogs were less toxic and better than novocaine. In Germany, Karl Ludwig Schleich in 1892 used subcutaneous injections of diminished solutions of cocaine. August Bier and Stovain in 1906 recommended spinal anesthesia. Halsted and Matas made valuable improvements to this technique.

In 1920, a method of combined local and consumption anesthesia was proposed by Crile and Lower in Cleveland which could extremely diminish operative neuroses shock and nausea. Local spinal and regional anesthesia was extensively used in clinic operations. Paravertebral anesthesia was originally designed by Sellheim in 1905, and it was first practiced in urologic surgery by Kappis in 1912 and was pursued by Heinrich Braun's parasacral anesthesia in 1914. Caudal block anesthesia was reported by Stoeckel in 1909, and trans-sacral anesthesia was developed and improved by Danis in 1914. Ethylene anesthesia in genito-urinary operations was recommended by Kretschmer in 1911. Penthosal sodium was applied in the clinics and this improvement was announced by Lundy in 1935.

Oxygen use was started in a compound with nitrous oxide in first stage anesthesia. Cyclopropane was reported as its first clinical application by Neff, Rovenstine and Waters at the University of Wisconsin in 1930. It is the most flammable and fiery of all gases used in anesthesia. Oil-ether colonic anesthesia was recommended in 1913. Other methods were still in experimental stages by brilliant specialists and scientists.

Sevoflurane is a more recent extension to inhalational anesthetics which had been started in clinical use. Compared with isoflurane or halothane, it is less dissoluble in the blood. It has more rapid absorption and introduction than other inhalational agents, an enhanced depth of anaesthesia and faster destruction and rehabilitation. This is distinctly favorable in paediatric and adult anaesthesia. Sevolurane firstly reported in 1972, was approved for clinical application in Japan in 1990, in Germany in 1995, and then in the USA in 1996. It has low blood solubility. Only desflurane and nitrous oxide are lower and produce a rapid wash-in and wash-out in the blood. This may result in a more rapid recovery from anaesthesia in correlation with conventional inhalational anaesthetics, enflurane, halothane and isoflurane. There have been no case reports internationally of sevolurane-associated renal failure. Sevofluane is a great, safe anesthesia medicine in clinics (Frink 1993; Eger 1994; Young 1995; Conzen 1996; Patel 1996; Wallin 1975).

The third great significant addition to modern surgery was the Rountgen Rays (X-ray) by Wilhem Konrad Rontgen (1845−1923) in 1895. Firstly, in cases with imagined foreign bodies or in fractures, an X-ray was helpful for the diagnosis. At that time they composed a diagnosable procedure in medicine and surgery. The examination of internal organs by X-rays followed, and finally the rays were reversed to a curative application. Rontgen's discovery was preceded by Crookes tube. Hertz and Lenard did a bright experiment on electromagnetic circumstance, Rontgen advanced a series experiments until he discovered the elemental nature of the phenomenon. He then presented his dissertation "*On a New Kind of Rays*" to the physical Medical Society of Wurzburg. In the beginning, scientists did not know that X-rays have an unhealthy effect and can burn the skin. Many workers with X-rays lost their limbs even their lives. After the danger was identified, the beneficial methods were well established to prevent X-rays side-effects. At present, X-rays are very safe for the diagnosis and treatment of patients.

CONCLUSION

A surgeon is a doctor who can do surgery. To be a surgeon is to be a member of one of the world's most attractive professions. Research in surgery has never been determinate. In hospitals and laboratories throughout the world, scientists are challenging the unknown, uninterrupted. Surgery around the world, from primitive times to the present day, a completed history of the world of surgery, its origins, progression and celebration owes tremendous gratitude to the man who devoted their lives to the never ending search for new techniques in the treatment of cancer, brain tumors, heart abnormalities, organ transplantations, thoracoplasty, lung or liver lobectomy, vascular surgery, robotic surgery and other dramatic surgical innovations (Alter 2009).

REFERENCES

"Alexander Fleming Biography." *Les Prix Nobel*. The Nobel Foundation. 1945. Retrieved 27 March, 2011. https://sco.m.wikipedia.org/wiki/Alxander_Fleming.

Alter J. *21st Century Innovation in Surgery*. Cherry Lake Publishing, 2009, USA.

Antibiotics https://www.nhs.uk/conditions/Antibiotics/penicillins/Pages.Introduction.aspx, NHS. 5 June, 2014 Retrieved 17 January 2015.

Bishop WJ. *The Early History of Surgery*. Barnes & Noble, Inc., 1960, USA.

Chopra I, Hesse L, O'Neill A (2002) "Discovery and development of new anti-bactorial drugs" in *Pharmacochemistry Library*, vol 32, Trends in Drug Research III, ed. Van der Goot H., editor. (Amsterdam: Elsevier), 213−225.

Chan M. Director-general of WHO. *WHO traditional medicine strategy 2014−2023* [Internet]. https://www.apps.who.int/b/ebwha/pdf_files/WHA61-REC1/A61_REC1-en.pdf. May 24, 2008.

Conzen P, Nuscheler M. New inhalational anesthetics. *Anesthesist* 1996; 45: 674−693.

Cruickshank R."Sir Alexander Fleming, F.R.S." *Nature* 1955; 175 (4459): 663.

Domagk G. (1935) Ein Beitragzur Chemotherapie der bakteriellen. *Dtsch. Med*. Wochenschr. 61, 250.10.1055/s-0028-119486.

Eger II EI. New inhaled anesthetics. *Anesthesiology* 1994; 80: 906−922.

Frank EJ, Brown BR, Sevoflurane. *Bailleres Clin Anaesthesiol* 1993; 7:899−913.

Fishman J & Fishman L. *History Taking in Medicine and Surgery*. Oxford: PasTest 2005, Grossman A. Editor.

Graham AC. The date and composition of liehtzyy. *Asia Major* 1961; 8: 139−198.

Hugh TB. Howard Florey, Alexander Fleming and fairy tale of penicillin. *The Medical Journal of Australia*. 2002; 177(1): 52−53; author 53 53. PMID 12436980.

Kahan BD. PienCh'iao, the legendary exchange of hearts, traditional Chinese medicine, and the modern era of cyclosporine. *Transplant Proc*. 1988; (2 Suppl 2) 2−12.

Leonardo RA. *History of Surgery*. Froben Press, 1943, New York, USA.

List of unproven and disproven cancer treatment – Wikipedia [Internet]. https://en.wikipedia.org/wiki/List_of_disproven_cancer_treatments. America Cancer Society States March 8, 2011, Retrieved September 22, 2013.

Lu TK, Collins JJ (2009). Engineered bacteriophage targeting gene network as adjuvants for antibiotic therapy. *Proc. Natl. Sci*. U.S.A. 106, 4629−463310.1073/pnas.0800442106 (PubMed).

Park HL. Traditional Medicine in China, Korea, and Japan: A Brief Introduction and Comparison. Evidence-Based Complementary and Alternative Medicine Volume 2012, Article ID429103.

Patel SS, Goa KL, Sevoflurane: a review of its pharmacodynamics and pharmacokinetic properties and its clinic use in general anaesthesia. *Drugs* 1996; 51: 658−700.

Schlich T. The *Origins of Organ Transplantation, Surgery and Laboratory Science 1880−1930*. University of Rochester Press, 2010, USA.

Searches related to Traditional Japanese Medicine [Internet]. https//en.wikipedia.org/wiki/kampo (2017).

Sherer A, Epstein F, Constantini S. Hua Tuo, patron of surgeons, or how the surgeon lost his head. *Surgical Neurology*. 2004; 61: 5497−5498.

Smith D & Newton D. In *History Surgery and Medicine*. Schofield & Sims Ltd., Huddersfield, 1972, England.

The History of Antibiotics [Internet]. London: Microbiology Society; 2017 [cited 2017 May 24]. Available from: https://www.microbiologysociety.org/education-outreach/antibiotics-unearthed/antibodics-and-antibiotic-resistance.the-history-of-antibiotics.html.

The History of Antibiotics [Internet]. Elk Grove Village: American Academy of Pediatrics; 2015 November 15 [cited 2017 May 24]. Available from: https://www.healthychildrean.org/English/health-issues/conditions/treatments/Pages/The-History-of-Antibiotics.aspx.

Tomnsend J. A *Painful History of Medicine, Scalpels, Stitches and Scars, a History of Surgery*. Harcourt Education Ltd., 2005, British.

Traditional Japanese Medicine [Internet]. Chinatownconnection.com/www.chinatownconnectional.com/tranditional-japanese-medicine.htm (2017).

The Nobel Prize in Physiology or Medicine 2015 [Internet]. Nobelprize.org. https://www.nobelprize.org/nobel_prize/medicine/laureates/2015/press.html.Oct 05, 2015.

The Oriental Institute of the University of Chicago [Internet]. www.hpps://oi.uchicago.edu/pdf/oip3.pdf. The University of Chicago Press, Chicago, Illinois 1930.

Wallin RF, Napoli MD, Regan BM. Laboratory investigation of a new series of inhalation agents: the halomethylpolyfluoroisopropylethers. In: Frink BR, editor. *Cellular biology and toxicity of anesthetics*. Baltimore: Williams & Wilkins, 1972: 285−295.

Wallin RF, Regan BM, Napoli MD. Sevoflurane: a new inhalational anesthetics agent. *Anesth.Analg*. 1975; 54: 758−766.

Wikipedia contributors. *Antibiotics* [Internet]. San Francisco: Wikipedia, the Free Encyclopedia; 2017 May 21, 11:03 UTC [cited 2017 May 24]. Available from: https://enwikipedia.org/w/index.php?title=Antibiotics&oldid=781460330.

Woodward LT. *The History of Surgery*. Monarch Books, Inc., 1963, USA.

Young CJ, Apfelbaum JL. Inhalational anesthetics: deflurane and sevoflurane. *J. Clin. Anesth.* 1995; 7: 564−577.

In: Encyclopedia of Surgery (22 Volume Set)
Editors: Andreas Lehrer and Kristin Mueller
ISBN: 978-1-53618-329-0
© 2020 Nova Science Publishers, Inc.

Chapter 202

THE DISCOVERY, DEVELOPMENT AND PATENT PROTECTION OF NEW DRUGS IN EXPERIMENTAL AND CLINICAL RESEARCH

Anlun Ma*

Laboratory of Experimental Surgery, Department of Surgery,
University of Montreal, Montreal, Quebec, Canada

ABSTRACT

Inventing novel medical drugs and improving the quality of medical care are becoming more and more important; there is a demand to focus on patients' needs, especially in the current economic climate. However, current drug research and development (R&D) is more complex and challenging, because development of a new drug is under increasing pressure that is very costly, time-consuming, with a high risk and with low success rate. To develop new and effective drugs, to reduce side effects and hospitalizations, and to extend the life of patients, continuous pharmaceutical innovation is one of the gravest responsibilities of pharmaceutical industries. It takes an average of 12 years for a potential new medicine to develop from basic laboratory research to clinical treatment. It includes the *early-phase* basic and preclinical research, which is the process of discovering and identifying an investigational drug and performing initial experiments in animals; the *middle-phase* clinical trials to evaluate the candidate medicine safety, efficacy and overall relationship between benefits and risks; and the *late-phase* post-market safety monitoring. It also includes very important steps to obtain regulatory approval with a new drug application and patent protection.

This chapter describes the current state of pharmaceutical research and development; provides a basic understanding of working on new drug development in basic, preclinical and clinical research; indicates the relationship between patent protection and trademark application for new drugs; considers how well markets are working to deliver new drugs; and discusses how to increase the commercial life of a new drug by extension of the patent term, so as to accomplish our mission with honesty and science, focusing on patient needs, and developing new drugs and therapies for medical diseases.

* Corresponding Author's Email: anlunma@yahoo.com.

Keywords: clinical trials, FDA, investigational new drug, patent protection, pharmaceuticals, research and development

ABBREVIATIONS

ADMET	Absorption, distribution, metabolism, excretion, and toxicity
BLA	Biologics license application
ED50	Median effective dose
FDA	U.S. Food and Drug Administration
GCP	Good clinical practice
GLP	Good laboratory practice
GMP	Good manufacturing practice
HTS	High-throughput screening techniques
IEC	Independent ethics committee
IND	Investigational new drug
IP	Intellectual property
LD50	Median lethal dose
NDA	New drug application
NSF	National Science Foundation
PD	Pharmacodynamics
PhRMA	Pharmaceutical research and manufacturers of America
PK	Pharmacokinetics
PTO	U.S. Patent and Trademark Office
R&D	Research and development
SOP	Standard operating procedure
UHTS	Ultra-high-throughput screening

INTRODUCTION

In humans, drugs of plant or animal origin have been used to treat diseases for more than 3,000 years. They were already recorded in China around 1100 BCE (Before Common Era), and at least 1,900 different remedies were used for people by the end of the 16th century [1, 2]. Since the 18th century, herbal practitioners had been identified in many indigenous populations around the world, but the use of herbal medicines was based on what practitioners knew and what worked, not why or how [3–5]. In the 1780s, William Withering (1741–1799), an English botanist, chemist, physician, and the discoverer of digitalis, was the first person to study the active ingredient in an herbal remedy, to isolate digitalis from the foxglove, and to describe its extraction from various parts of the plants. He published *An Account of the Foxglove and some of its Medical Uses*, which contained records on clinical trials and notes on digitalis's effects and toxicity [6–8]. During the early 19th century, chemists believed that compounds from living organisms were endowed with a vital force and distinguished them from inorganic compounds [1]. In 1828, Friedrich Wöhler (1800–1882), a German chemist, was best known as the first to isolate several chemical elements and describe the organic chemistry of urea [9, 10]. In the late 19th century, pharmacology began to

emerge. Oswald Schmiedeberg (1838–1921), professor of pharmacology at the University of Strasbourg in France, studied the pharmacology of chloroform and chloral hydrate. He is now recognized as the founder of modern pharmacology and is referred to as the "Father of Modern Pharmacology." He published the classic text *Outline of Pharmacology* in 1878 (Figure 1) [11–13].

In the 1920s and 1930s, a number of major advances were made by the modern pharmaceutical industry as both penicillin and insulin were identified and manufactured, and are still produced for patients now. During the post-war period from the 1950s to the 1990s, new antibiotics and analgesics became major advances in drug development. Since the middle of the 19th century, beta blockers, ACE inhibitors, benzodiazepines and a wide range of novel anti-cancer medicines have made massive contributions. In the late period of the 19th century, new classes of biopharmaceutical medicines were developed and attained significant success in the clinical treatment of patients [14].

PHARMACEUTICALS

Pharmaceutical Medicine

Pharmaceutical medicine is the medical and scientific discipline concerned with the discovery, development, evaluation, production, registration, monitoring and marketing of new medicines for the benefit of patients and the healthcare community [15]. The core discipline of pharmaceutical companies is subject to a variety of laws and regulations that regulate the patents, testing, safety, efficacy and marketing of drugs. The largest pharmaceutical companies in the world, such as Novartis, Pfizer, Merck, Johnson & Johnson, GlaxoSmithKline, Eli Lilly, Bayer, Roche, and AstraZeneca, had previously developed natural medical products, such as morphine, quinine and strychnine, and moved into large-scale production of drugs in the middle of the 19th century [16]. Aspirin, a chemically modified version of salicylic acid, showed a much improved efficacy, and this product is still in widespread use today [1]. The pharmaceutical companies may deal in generic and brand name medications, are expected to generate 1 trillion USD in revenue and make up one of the most prominent sectors of the worldwide economy [17].

However, today's pharmaceutical industry is facing troubles that are partly caused by the patent system. The large pharmaceutical companies have invested huge funds to discover new drugs, but they are meeting huge amounts of competition with generic pharmaceutical companies in the marketing. When their drugs are no longer protected by patents that ensure the innovating companies to retain exclusive rights to sell the drugs, the newer generic pharmaceutical companies produce generic drugs and enter the market [1, 18, 19]. Some of the very well-known big companies represent only 40% of the pharmaceutical market, as they have to correspond to only a small fraction of the industry as a whole, with 90% of generic companies which produce the vast majority of all pharmaceuticals sold. The data of Figure 2 show that some larger pharmaceutical companies lost revenue because of initial patent expiry in 2010–2012 [16, 20, 21].

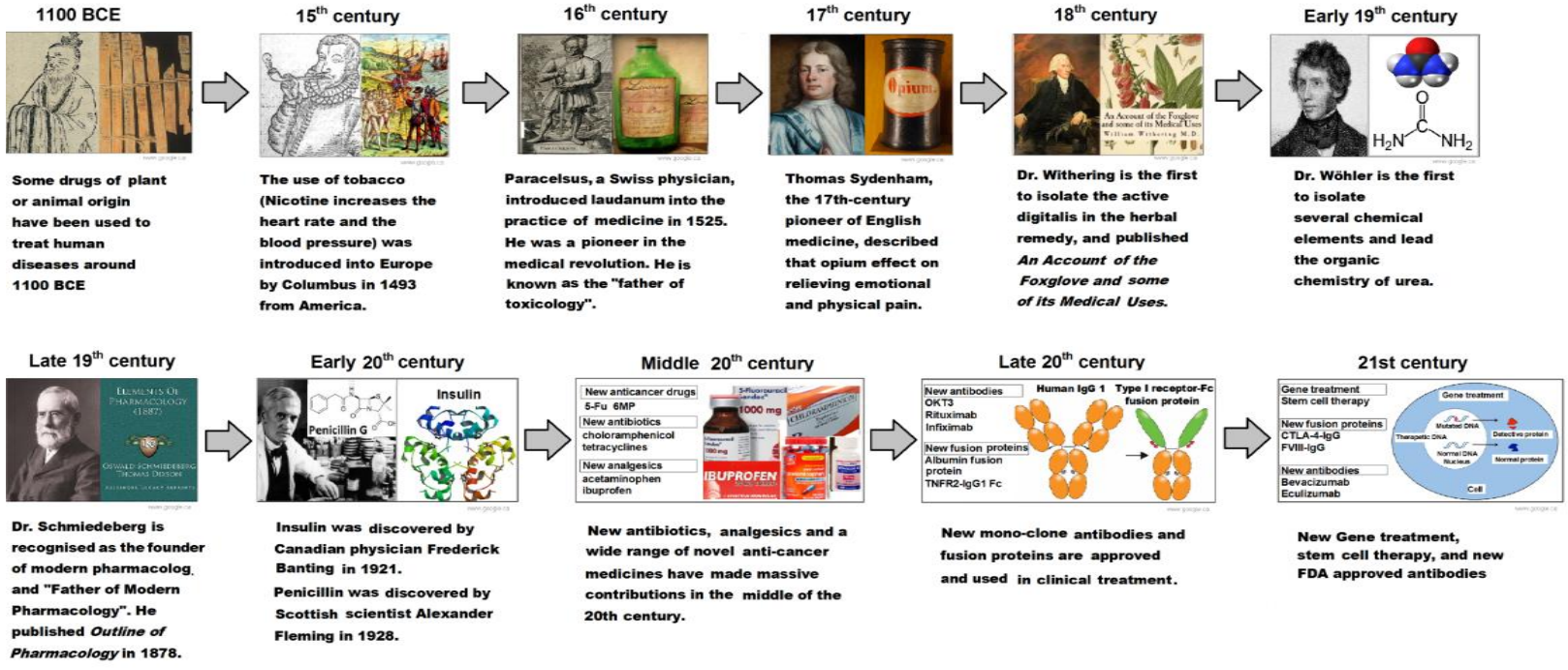

Figure 1. A brief history of chemical and biological medicine development. The timeline shows selected evolutionary landmarks in chemical and biological medicine discovery and development.

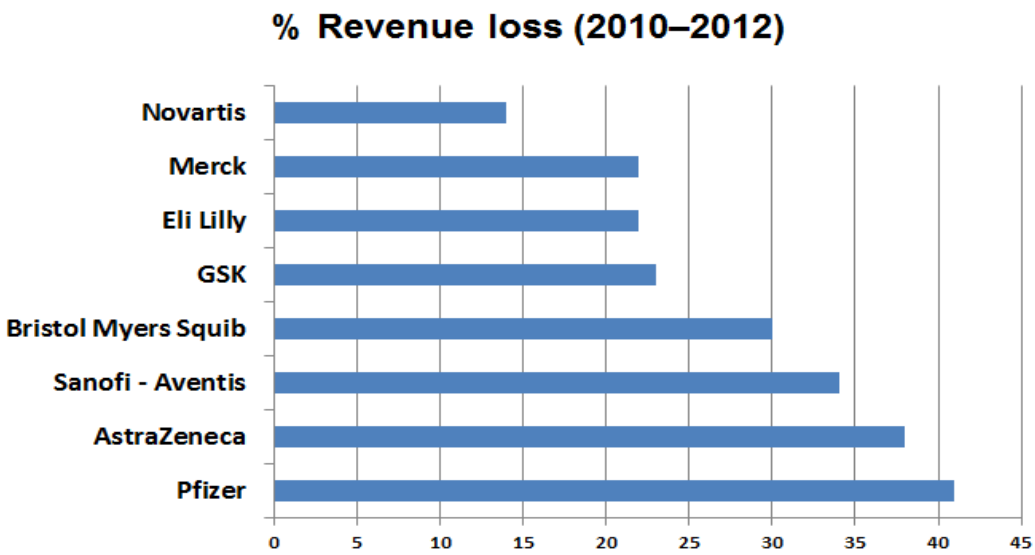

Figure 2. Patent expiry and revenue loss. Some larger pharmaceutical companies lost revenue because of initial patent expiry and low-priced generic drug competition (2010–2012).

Brand Name Drugs and Generic Drugs

Brand name drugs, also called innovator drugs, are drugs that have trade names and have been protected by a patent; they can be produced and sold only by the patent holding company.

A generic drug is a copy of a brand name drug. When the initial patent protection for a brand name drug has expired, generic versions of the drug can be offered for sale after getting the approval from the United States Food and Drug Administration (FDA). Generic drugs are equivalent to a brand name product in dosage, strength, route of administration, performance, and quality [22]. Once the generic drug is manufactured and introduced into the market, the monopoly of the patent holder is removed. This condition will encourage competition in the pharmaceutical market, and this competition and results in a significant drop of drug costs. The initial patent company will have to renew the patent by forming a new version of the drug that is significantly changed compared to its original compound. However, the new version of the compound not only needs new clinical trials, but also has to compete with the original generic molecule in the market, unless drug administration regulators find faults and remove the original from the market. The main difference between the branded drugs and the generic drugs is that the branded drugs are produced by a company which holds the patent for 20 years. However, the generic drugs are made available at the market by the pharmaceutical companies only after the patent protection period expires (after 20 years). Other major differences include cost and risk. Table 1 shows major similarities and differences between brand name drugs and generic drugs. The brand name drugs are far more expensive than the generic drugs.

Table 1. Similarities and differences between brand name and generic drugs

Brand name Drugs	Generic Drugs
Innovator drugs	Copies of brand name drugs
First version sold by the innovator company	Produced after the original patent expires
Similar in safety	Similar in safety
Similar in efficacy	Similar in efficacy
Similar in active compositions	Similar in active compositions
Similar in dosage and administration	Similar in dosage and administration
Difference in the color and shape	Difference in the color and shape
Difference in inactive ingredients	Difference in the inactive ingredients
Difference in the cost (higher price $$$)	Difference in the cost (lower price $)

Biologic Drugs and Biosimilar Drugs

Biologic drugs are drugs that come from living organisms or their cells, and aree often made by using biotechnology. A biologic drug is a large, complex, protein-based molecule with a trade name that is protected by a patent.

A biosimilar drug is almost a copy of an original biologic product that is manufactured by a different generic company [23]. Biosimilars can be manufactured when the original biologic drug patent expires [24].

Generics vs. Biosimilars

There are differences between biosimilars and generic drugs in size, molecular weight, structure, complexity, manufacturing, stability, and approval requirements (Table 2) [25–31].

Table 2. Generic drugs *vs.* biosimilar drugs

Properties	Generics	Biosimilars
Size	Small	Large
Molecular weight	~ 150 Daltons	~ 150,000 Daltons
Structure	Simple and well-defined	Complex with potential Structural variations
Manufacturing	Predictable chemical process to make identical copy	Specialized biological process To make similar copy
Complexity	Easy to fully characterize	Difficult to characterize
Stability	Relatively stable	Sensitive to storage and handing conditions
Adverse immune reaction	Lower potential	Higher potential
Manufacturing quality tests	≤ 50	≥ 250
Approval requirements	Small clinical trials in healthy volunteers	Large clinical trials in patients

Generic Pharmaceutical Companies and Innovative Pharmaceutical Companies

Generic pharmaceutical companies are free to manufacture and sell what are now termed generic drugs, when the original biologic drug patent expires. Generic pharmaceutical companies should submit a drug manufacturer application, an Abbreviated New Drug Application (ANDA), with the FDA before manufacture. Before the FDA approves the application, the generic drug must meet the same standards that the original brand name drug has. They are low in cost and low in risk business, with no need to invest in any research costs; thus, generic pharmaceutical companies never have an unsuccessful product. The products that companies choose to manufacture and sell have shown to be valuable and commercially successful in the market.

By comparison, the innovative pharmaceutical companies (initial patent companies) operate under a completely different business model. They invest huge funds in R&D and bring the new drug to the market. It is a long process which is very expensive, time consuming, and involves extremely high risks, particularly in the clinical trials where the success rate through clinical trials is extremely low (<1% of candidate drugs). Recently, an agreement known as "pay for delay" between the patent holder companies and generic companies has come into play. When a drug patent expires, the patent holder company pays the generic company not to manufacture this product. Then, both the patent holder and the generic company gain higher financial benefits, but the legality of these deals is under question (Table 3) [1, 16].

Table 3. "Pay for delay" agreement between patent holder companies and generic companies

Patent Status	Cost Price	Scrip Price	Annual Profit/1000 scrips	
			Patent Holder	Generic Company
Patent Protection	$1	$10	$9000	$0
Patent Expired		$2	$1000	$1000
Patent holder pays generic company $2000/1000 prescriptions to delay manufacture and sale			$7000	$2000

Cost and Time for New Drug Discovery and Development

Drug discovery and development is the process of bringing a new pharmaceutical drug to the market once a lead compound has been identified through the whole process. It includes pre-clinical research on microorganisms and animals, filing some applications to conduct clinical trials on humans, such as via the United States Food and Drug Administration (FDA) for an investigational new drug (IND) application, and via the U.S. Patent and Trademark Office (PTO) for patent and trademark application, and may include the steps for obtaining regulatory approval with a new drug application (NDA) to the market. As a result, the process for developing new medicines is growing in difficulty and length. On average, it takes more than 10–12 years for a new medicine to complete the journey from basic discovery to the market, including clinical trials of six to seven years on average alone [32–34]. The average cost to each successful drug was estimated to be about $6 billion in 1980, according to the data from National Science Foundation (NSF). By 2004, the cost had grown to more than $17

billion with an average increase of 5 percent per year. The pharmaceutical industry's trade association, Pharmaceutical Research and Manufacturers of America (PhRMA), reported larger expenditures and faster growth on new drug discovery and development. Figure 3 depicts that the average cost of each successful drug was estimated to be $4 billion in 1970, and it had grown to more than $60 billion in 2015. These data are estimated by both PhRMA and NSF. The curve A was reported by PhRMA, and shows annual expenditures for drug research and development profile (1970–2015). Unlike the NSF data, PhRMA's estimates include research and development performed outside the United States as well as further research and development that occur after a drug has gone to the market; the curve B is from the NSF report and shows a data series from 1980 to 2014. It includes only research and development conducted in the United States on drugs that have not yet reached the market [35]. Data from 1980 to 1998 come from the NSF report "Company and Other Funds for Industrial R&D Performance, by Industry and by Size of Company: 1953–98," available at www.nsf.gov/statistics/iris/search_hist.cfm?indx=10; [36]; data from 1999 to 2014 come from the NSF Division of Science Resources Statistics's annual "Research and Development in Industry," available at www.nsf.gov/statistics/industry [37].

These data incorporate the cost of failures. The thousand millions of compounds may be screened in the R&D process, only a few of which will ultimately receive FDA approval. Less than 12 percent of the candidate medicines will be approved by the FDA and enter a phase I clinical study. A study result was reported by the Tufts Center for the Study of Drug Development that showed 21.5 percent of drugs that started phase I trials were eventually approved for marketing during the period of 1980 to 1990, however, in the time period from 2006 to 2015, the success rate was only 9.6% [38, 39]. During drug development, to avoid costly failures, intelligent clinical trial program design is very important and can prevent false negative results. Likewise, success requires a vast amount of teamwork from excellent scientific minds, highly sophisticated technologies, complex project management, gold standard procedures, careful decision-making, and also luck.

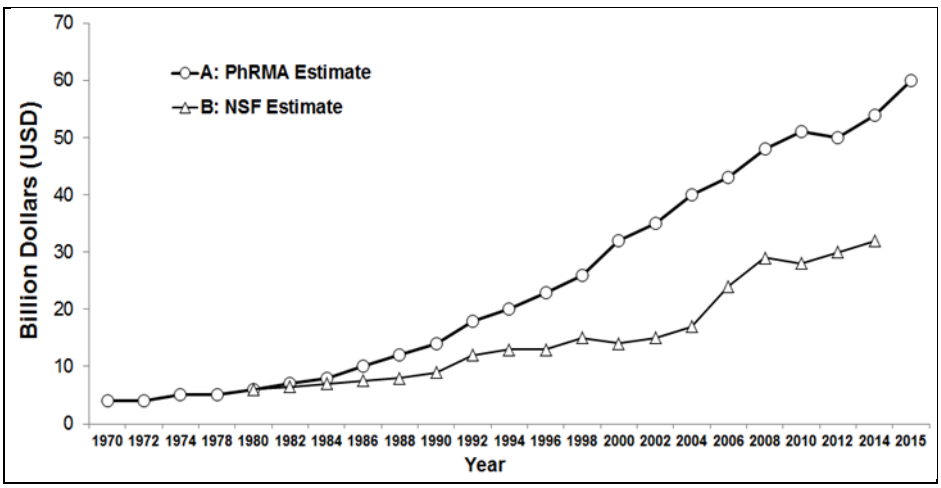

Figure 3. Estimates of annual spending on research and development. The curve A is from PhRMA and shows annual expenditures for drug research and development profiles (1970–2015); the curve B is from NSF and shows data that was only conducted in the United States on drugs that have not yet reached the market (1980–2014).

RESEARCH TEAMS AND GOOD LABORATORY PRACTICES

Research Teams

The excellence of pharmaceutical science and healthcare related research has been recognized internationally. It spans the complete continuum from basic research to translational science and clinical practice. Designing and running experimental or clinical research require the skills of many different types of experts. Each team may be set up at different sites; every research team member and his/her responsibilities should include the following steps.

Principal Investigator (PI)

The principal investigators are responsible for all experimental or pre-clinical and clinical studies, such as to develop the concept of the study, to design the protocol, to submit the application for FDA and PTO approval, and to supervise data collection, analysis, interpretation, and presentation.

Pharmaceutical Chemical and Biological Scientists

Modern drug research and development requires the teamwork of *pharmaceutical* chemical and biological scientists. *Pharmaceutical chemical scientists* can perform research to study a company's current products to find out if they can be improved. They also may discover and develop new chemical compounds and determine their effects with other chemicals. Their duties include maintaining reports, documents and files regarding testing.

Pharmaceutical biological scientists can perform research to gain a better understanding of human diseases; they often work to evaluate new potential active chemical or biological products, determine their effects on biological systems, and improve drug development.

Data Managers

Data managers are responsible for managing the collection of data throughout the course of experimental or clinical research, input the data, work with the PI to identify what data will be tracked, provide data to monitoring agencies, and prepare summaries for interim and final data analysis.

Staff Surgeons, Physicians and Nurses

The surgeons, physicians, nurses, and other staff members are responsible for treating patients according to the clinical trial protocol, assessing and recording how patients respond to the drug in-treatment and the drug side effects they may have, helping to take care of the patients during a clinical trial, working with the PI to report trends of how patients are doing on the treatment, and providing each patient’s medical care.

Patent Agents

The patent lawyers and attorneys have the specialized qualification necessary for representing clients in obtaining patents and acting in all matters and procedures relating to patent law and practice. The patent attorneys and trademark agents also work in some jurisdictions and approach many legal questions during drug development.

Good Laboratory Practices (GLP)

In the preclinical and clinical studies, FDA requires researchers to use good laboratory practices (GLP) that specifically refer to a quality system of management controls for laboratories and organizations to ensure high quality in uniformity, consistency, reliability, reproducibility, safety, animals and their uses. The principles of GLP set the minimum basic requirements for study conduct, personnel, facilities, equipment, written protocols, operating procedures, study reports, and a system of quality assurance (QA) for each study that helps to assure the safety of any FDA-regulated product. GLP regulations set the minimum basic requirements as stated below [40]:

GLP Performance

All study protocols should be performed according to the principles of GLP.

GLP Standard Operating Procedures (SOPs)

Standard Operating Procedures are instructions that are written in detail to achieve uniformity of the performance of a specific function, and help maximum safety and operational efficiency for the fields of pharmaceutical and clinical research. A well-written SOP can be used to satisfy several compliance requirements. The procedures may be useful to operationalize documents such as plans, regulation, compliance, and policies. SOPs should be used by all staff members in their work environment. All high-class processes and procedures should be put on in the standard operating procedures.

GLP Test Systems

All physical, chemical, biochemical and biological studies should precisely follow the SOP procedures.

GLP Responsibilities

The organization of the study should involve management responsibilities, sponsor responsibilities, director responsibilities, PI responsibilities, and study personnel responsibilities.

GLP Facilities and Equipment

All facilities *and equipment* that are now being used for the study should match GLP guidance. Any significant changes to the equipment should be identified. GLP quality equipment systems should have a comprehensive, up-to-date list of all equipment used in the facilities, and should establish a maintenance and calibration program for equipment. Equipment procedures should include the frequency of calibration and maintenance, routine inspection, cleaning, and testing.

GLP Records and Reports

All study reports, specimens, raw data, and other study-related documents should be kept in the archives.

GLP Quality Assurance Program

A system of quality assurance (QA) oversight for each study should assure the safety of an FDA-regulated product.

To evaluate drug safety, the GLP compliant scientists conduct pre-clinical studies, including single dose toxicity, repeated dose toxicity (acute and chronic), reproductive toxicity, mutagenic potential, carcinogenic potential, PK/PD studies, and local tolerance studies [41–43]. These pre-clinical results must be provided in detail before clinical trials. After preclinical testing, researchers with PI review their results and decide whether the drug should be tested in humans.

Pharmaceutical Research and Development Process

Following well-designed plans and established models, the process of new drug development makes sure whether or not a potential new medicine is safe and effective before it reaches the market. The whole process involves six steps: drug discovery, pre-clinical research, patent and an investigational new drug (IND) application, clinical research, FDA review of the new drug application (NDA), and post-market safety monitoring (Figure 4).

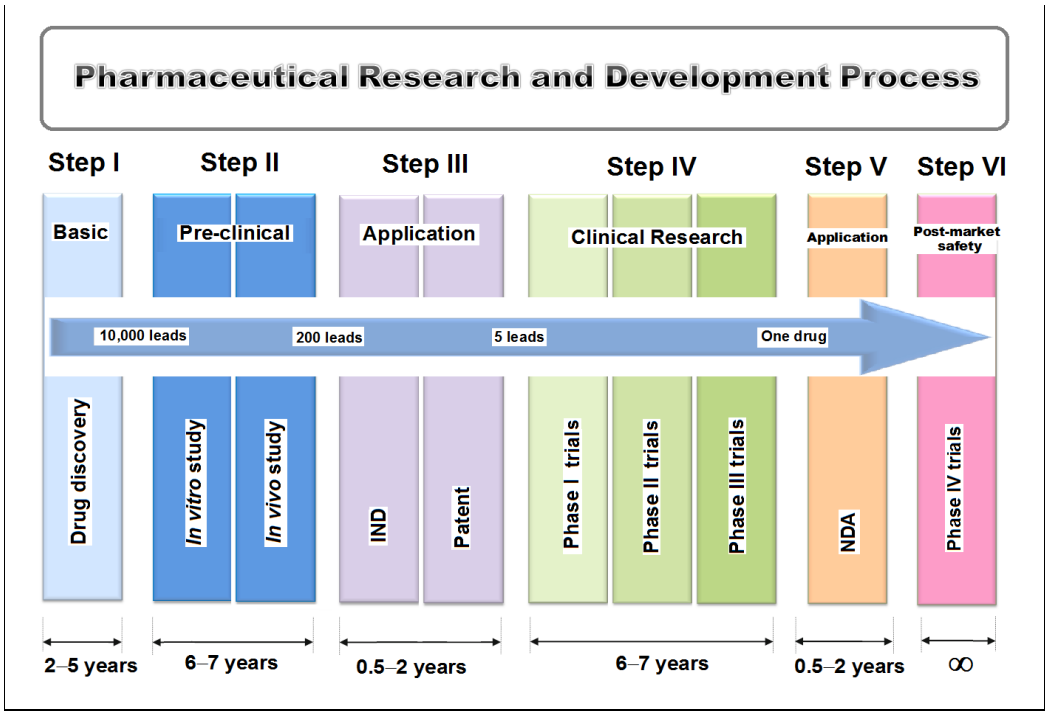

Figure 4. The pharmaceutical research and development process for new drugs. The six steps of the whole process for new drug development: drug discovery in the laboratories, pre-clinical research, patent and investigational new drug (IND) application, clinical research, FDA review of new drug application (NDA), and post-market safety monitoring.

Step I. Drug Discovery

Lead discovery is the first major stage of the R&D process, including the early basic studies, which are designed to identify and evaluate investigational new drugs in the laboratories. Researchers and pharmaceutical companies design, discover, and synthesize chemical or biological molecular compounds to stop or reverse the negative effects of the diseases by blocking signal pathways and disease mechanisms; or by multiple screening testing to find possible beneficial effects against diseases; or by existing drug treatments to find their new unanticipated effects. These drug targets can be a wide variety of things, such as a particular cell type, enzyme, gene, or signal pathway. Recently, the selection for a potential candidate compound within these vast chemical or biological libraries has been simplified by the introduction of High Throughput Screening Techniques (HTS) and Ultra High Throughput Screening (UHTS), which use advances in robotics, automation, miniaturisation and data handling. During this stage, thousands of compounds may be potential candidates for development. Scientists take approximately two to five years to identify and select some promising drug candidates for further development. After this stage of research, there are only a few compounds which look promising and will be studied in the next stage.

Step II. Pre-Clinical Studies

Lead identification is the second major stage of the R&D process, and marks the transition from laboratory basic research into further pre-clinical development. Once promising compounds are discovered, identified and selected, the development process will begin and conduct serial experiments to collect further information. The drug evaluation includes the compound's best dosage and best route to give in animals; the compound's absorption, distribution, metabolism, excretion, and toxicity (ADME-T) testing; the compound's pharmacodynamics (PD, what the drug does to the body) and pharmacokinetics (PK, what the body does to the drug) studies; the compound's potential benefits and mechanisms of action; the compound's effectiveness as compared with similar medicine products; the compound's stability in chemical, light, and moisture conditions; and the compound's side effects in animals, including which organs are targeted by this compound, as well as whether there are any long-term carcinogenic effects or toxic effects on mammalian reproduction (Figure 5).

Lead optimisation is the third stage of the R&D process. In order to increase the efficacy of a drug while decreasing any potential side effects, some attempts will be made to modify the molecular structure in various ways. It may take another six to seven years of research time via *in vitro* and *in vivo* experiments in the pre-clinical study before entering clinical research phase.

During this stage, there are *in vitro* and *in vivo* studies that are carried out to determine whether these candidate compounds are ready to be studied in human research. *In vitro* experiments are conducted in the laboratory on living cells or tissue cultures and *in vivo* studies focus on animal models. Through these studies, it will be understood how the drug works and what the potential side effects on humans might be. Also, it will be determined how to make large enough quantities of the drug to use in the next set of clinical trials. It may not be easy to make large amounts of compounds to use in preclinical stage. The most

important point is that safety evaluation should begin in the early stages in order to provide a preliminary assessment of drug safety before its use in humans.

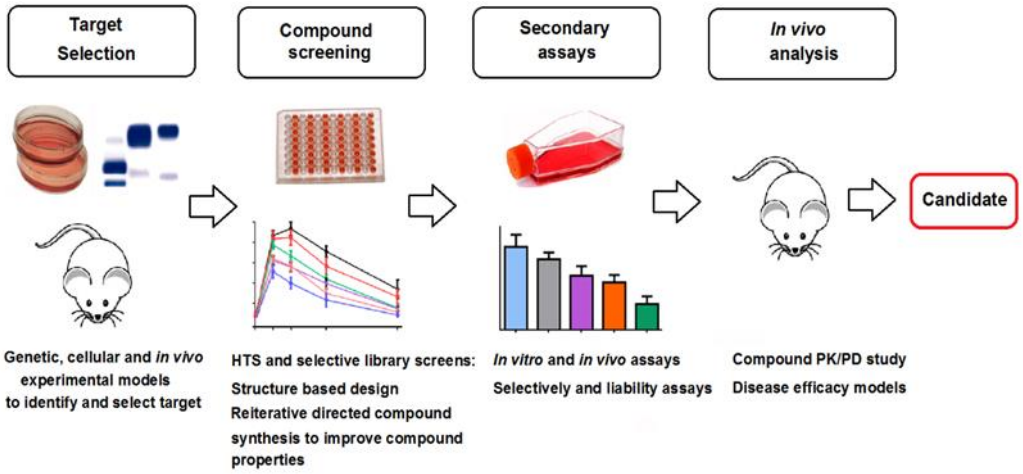

Figure 5. Preclinical research. Preclinical research should evaluate efficacy and toxicity of new drugs *in vitro* and *in vivo*.

In vitro Study

An *in vitro* (Latin: in glass) study is performed using components of an organism that have been isolated from their usual biological surroundings, such as microorganisms and cells which can be studied in an artificial model. They all are called test tube experiments [44, 45]. *In vitro* studies can be miniaturized and automated by yielding high-throughput screening methods for testing molecules in pharmacology and toxicology [46]. Another advantage of *in vitro* methods is that human cells can be studied without extrapolation from an experimental animal's cellular responses [47].

In vivo Study

An *in vivo* (Latin: within the living) study is conducted in living beings, such as microorganisms, animals, humans, or whole plants. An animal study is the main method of *in vivo* studies [44, 45]. *In vivo* studies are often used and preferred over *in vitro* studies because they are better suited for observing the overall effects of an experiment or a compound on a living subject. There are many examples of *in vivo* investigations, such as purified bacterial toxins, therapeutic antibodies, antibiotics, antiviral drugs, and other new protein compounds. In drug discovery, the verification of efficacy *in vivo* is very crucial; sometimes, *in vitro* studies show the potential results of the new drug, but they may be misleading or produce false conclusions [48, 49].

ADME-T Study

In order to know how the body processes the investigational compound, absorption, distribution, metabolism, excretion, and toxicity (ADME-T) testing should be performed in *in vitro* (cell culture) and *in vivo* (animal) models (Figure 6) [50–54].

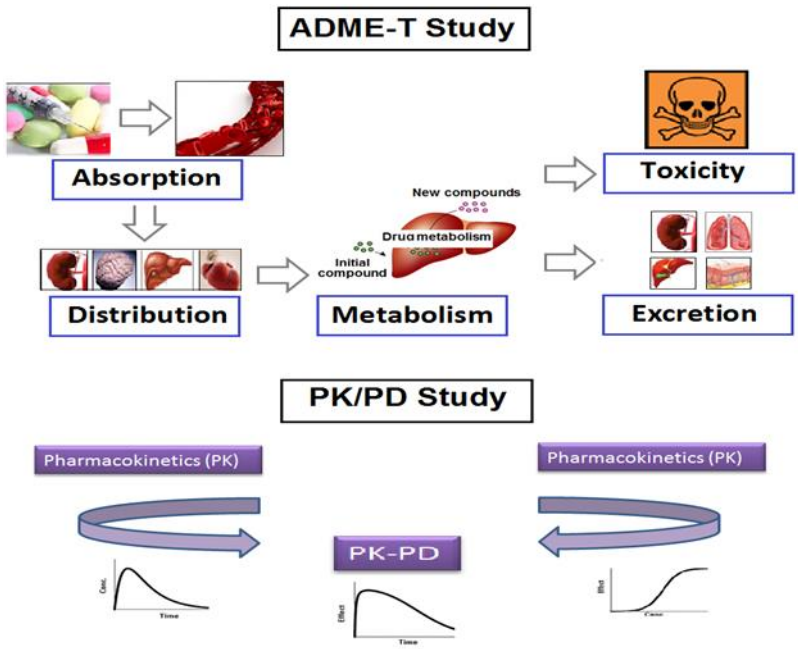

Figure 6. **An ADME-T study and a PK/PD study. ADME-T study and PK/PD studies are performed to evaluate the toxicity and efficacy of new drugs.**

ADME Study

Absorption Study

Absorption studies aim to understand how a drug enters the body and reaches the blood, plasma and sera. Drugs may be introduced into the body by several routes. They may be taken by mouth (orally); given by injection (intravenously, intramuscularly, or subcutaneously); sprayed into the mouth, nose, and lungs (nasally or inhalation); or applied to the skin (cutaneously). Some factors can reduce drug absorption after drug administration, such as poor compound solubility, gastric emptying time, intestinal transit time, chemical instability in the stomach, and the inability to permeate the intestinal wall.

Distribution Study

It is intended to understand where a drug distributes throughout the body after it has been absorbed. The compound needs to be carried to its effector site by the blood. After entry into the systemic circulation, the drug is subjected to numerous distribution processes that tend to lower its plasma concentration. Some factors may affect drug distribution, such as regional blood flow rates, molecular size, binding to serum proteins, and complex forming. Distribution can be a serious problem at some natural barriers like the blood brain barrier.

Metabolism Study

Its purpose is to understand how a drug is changed by the body. A compound begins to break down as soon as it enters the body. The majority of the small molecule drug metabolism is carried out in the liver by redox enzymes. As metabolism occurs, the initial compound is converted into new compounds called metabolites. When metabolites are

pharmacologically inert, the metabolism deactivates the administered dose of the parent drug and this usually reduces the drug effects on the body.

Excretion Study

It is aimed to understand how a compound and its metabolites are removed from the body via excretion. There are three main sites where the drug is excreted.

Urine excretion: The kidneys are the most important excretion pathway for the glomerular filtration of an unbound drug; it passes out through the urine.

Biliary and fecal excretion: Biliary and fecal excretion is another pathway used; the liver passes the drug to the gut until the drug is finally excreted along with waste products or feces.

Breathing and sweat excretion: Excretion via lungs and skin is also another important elimination pathway.

Toxicity Study

The aim of the toxicity study is to identify adverse effects of an investigational compound on humans and animals. Adverse effects depend on two main factors, routes of absorption (oral, inhalation, dermal, and blood) and dose (duration and concentration of exposure). Generally, both acute and chronic toxicity models should be used in a toxicity study. A toxicity study can also be conducted by an *in vivo* study that is performed on non-human animals [55].

Types of Preclinical Toxicity Study

Safety Pharmacology

It is used to determine the effects of the drug on specialized organs (e.g., cardiovascular, respiratory, neurological, etc.).

Chronic Toxicity/Carcinogenicity

It is used to determine the effects of long-term exposure to the drug, including the ability to induce cancer.

Reproductive Toxicity/Teratogenicity

It is used to evaluate effects on reproductive function and the ability to produce birth defects.

Results from preclinical toxicology studies should indicate a minimum and safe starting dose for clinical studies; provide information on a drug treatment regimen that would produce the least amount of toxicity; assess target organ toxicity and reversibility; and provide insight into biomarkers for clinical screening, diagnosis, and monitoring of disease progression.

Factors Influencing of Toxicity Study

There are some factors which may influence results of a toxicity study, such as dosage (acute and chronic exposures), ways of exposure (inhalation, oral, skin and blood absorption), and other factors, such as animal species, age, sex, health, environment, and individual characteristics.

The Dose-Effect Relationship/the Dose-Response Relationship

It is essential to determine dose-effect and dose-response relationships in a toxicity study [56].

The dose-effect relationship is the relationship between dose and effect at the individual level. An increased dose may increase a more severe effect. A dose-effect curve may be obtained at the levels of the whole organism, the cells or the target molecules.

The dose-response relationship is the relationship between the dose and the percentage of individuals showing a specific effect. With increasing dose, a greater number of individuals in the exposed population will usually be affected. The dose-response curve for most toxic effects has a sigmoid shape. There is usually a low dose range where there is no response detected; as the dose increases, the response follows an ascending curve that will usually reach a plateau at a 100% response. The dose-response curve reflects the variations among individuals in a population.

There are some factors to be used to evaluate dose-effect and dose-response relationships.

Dose may be expressed in different ways, such as tissue dose, target dose, and exposure and absorbed dose. The *tissue dose* is the amount of substance in a specific tissue. The *target dose* is the amount of substance bound to the critical molecule and is more exactly associated with the toxic effect. The *exposure dose* is the air concentration of a pollutant inhaled during the period of a certain time. The *absorbed dose* is the amount present in the body at a certain time during or after exposure.

Median Lethal Dose (50% lethal dose, LD50) is the dose which causes the death of 50% (one half) of test animals. LD50 is used mainly to determine acute toxicity. The larger the LD50 value, the lower the toxicity.

Median Lethal Concentration (50% lethal concentration, LC50) is the concentration that kills 50% of the test animals during the observation period.

Median Effective Dose (ED50) is the dose that produces a therapeutic response or desired effect in 50% of the population. It is commonly used as a measure of the reasonable expectancy of a drug effect.

Dose Threshold is a dose level below which no observable effect occurs. Thresholds are thought to exist for certain effects, like acute toxic effects, but not for others, like carcinogenic effects.

Time is often included in the dose concept; it is usually more important for understanding repeated exposures and chronic effects than for single exposures and acute effects.

Effects

Additive effect of drugs occurs in two substances used in combination that produces the same total effect as the sum of the individual effects.

Antagonistic effect of drugs occurs in two substances used in combination that causes a decrease in the effects of both drugs through their interaction.

Synergistic effect of drugs occurs in two substances used in combination that causes an increase in the effects of both drugs via their interaction.

No-Observed-Adverse-Effect-Level (NOAEL) is no adverse effect level, or the highest dose that does not cause a toxic effect, and is an important part of the non-clinical risk assessment.

A successful drug must be absorbed into the bloodstream; distributed to the proper sites of action in the body; metabolized efficiently and effectively; be successfully excreted from

the body; and shown to be non-toxic in the tests. The candidate drug will undergo years of further testing and analysis before potentially being reviewed for approval by the U.S. Food and Drug Administration (FDA). During this period of time, 30% of all drug candidates crash at this step due to toxicity profiles and side effects.

PK/PD Study

Pharmacokinetic (PK)/pharmacodynamics (PD) modeling is a technique that combines the two classical pharmacologic disciplines of PK and PD. PK is the study of how an organism affects a drug, whereas PD is the study of how the drug affects the organism. Both together are evaluated in the PK/PD model. A major goal of PK/PD in clinical pharmacology is the quantitative prediction of drug effects [57, 58]. Before clinical testing, it is important to compare the PK/PD properties of candidate molecules for dose, concentration, efficacy, and toxicity. There are five types of PK/PD modeling: direct PK/PD model, indirect link PK/PD model, indirect response PK/PD model, cell lifespan model, and complex response model. There are the most common factors to be used to evaluate PK/PD study [59].

Dose: The dose is the amount of a drug taken at any one time. This can be expressed as the weight of the drug (e.g., 1 mg), volume of the drug solution (e.g., 1 mL), and the number of dosage forms (e.g., 1 capsule).

Dosing interval time: It is time between drug dose administrations.

Cmax: It is the highest plasma concentration of a drug after administration.

Cmin: It is the lowest (trough) concentration that a drug reaches before the next administration.

Tmax: The amount of time that a drug is present at the maximum concentration in plasma or serum.

Volume of distribution: The apparent volume in which a drug is distributed, such as the parameter related to drug concentration and the drug amount in the body.

Concentration: It is the amount of a drug in a given volume of plasma or serum.

Elimination half-life: It is the time required for the concentration of the drug to reach half of its original value.

Elimination rate constant: The rate at which a drug is removed from the body.

Infusion rate: It is the rate of infusion required to balance the elimination.

Area under the curve: It is the integral part of the concentration-time curve after a single dose or in a steady state.

Clearance: It is the volume of plasma or serum cleared of the drug per unit time.

Bioavailability: It is a term used in pharmacology and refers to the degree and rate at which an administered drug is absorbed by the body's circulatory system. In clinical trials, the bioavailability of a drug is a key factor to be measured in phase I and phase II trials.

Fluctuation: It is the peak trough fluctuation within one dosing interval at a steady state.

Animal Study

Animal testing, known as *in vivo* testing, is the use of non-human animals in experiments, and seeks to control the variables that affect the behavior or biological system under study. Animals are similar to human beings in many ways, e.g., chimpanzees share 99% of their DNA with humans, and mice are 98% genetically similar to humans. Therefore, they are appropriate research subjects, and have contributed to many life-saving cures and medical

treatments [60]. In addition, because of the short life cycles of animals, they become better research subjects than human beings. For example, laboratory rodents live for only two to three years, so they are particularly well-suited to long-term cancer research because of their short lifespans [61].

Choice of Animals

Naive

All animals should be *naïve* in all study groups. They did not encounter an antigen/antibody, pathogen, protein, or drug, and did not have a particular experience or were not subject to a particular experiment [62]. According to Animal Rule (October 2015 edition) from the guidelines of the Food and Drug Administration, Center for Drug Evaluation and Research (CDER), U.S. Department of Health and Human Services, Center for Biologics Evaluation and Research (CBER), The Canadian Council on Animal Care (CCAC) and other similar international and regional authorities, any prior research treatment, even as control group animals, may have the potential infection which can cause stress and alter animal's physiological or biological responses [63]. In addition, according to the guidelines of Institutional Animal Care and Use Committee (IACUC), multiple survival surgical procedures on a single animal are also discouraged [64].

Species

Drug toxicity testing in animals usually requires at least two mammalian species, including one rodent (e.g., rat, mouse) species and one non-rodent (e.g., dog, non-human primate) species prior to human trials [65]. Other species (e.g., rabbit, ferret, hamster, and pig) may be used for special cases, such as vaccine studies.

Number

The number of animals should be determined to ensure scientifically valid results. Well-designed experiments use a sufficient number of animals to achieve the scientific objective, include the necessary control groups and incorporate appropriate statistical analyses.

Sex

The male/female animal composition should be justified in the study groups.

Animal Models

The proper preclinical models which can efficiently predict drug behavior in humans is essential prior to testing a drug in humans. Qualification of an animal model should be under The Animal Model Qualification Program (AMQP) that is supported by CDER and used in drug development under the Animal Rule [66].

Ethical Issues

All proposals to use animals for research must be approved by an Institutional Animal Care and Use Committee (IACUC) set up by each research facility before pursuing animals. Humane treatment is enforced by each facility's IACUC. The most major research institutions' programs are voluntarily reviewed for humane practices by the Association for Assessment and Accreditation of Laboratory Animal Care International (AAALAC) [67, 68].

Three Rs

The moral and ethical questions raised by performing experiments on animals are subject to debate, and viewpoints have shifted significantly over the 20th century [69]. Animal testing in the research has been reduced in recent years for both ethical and cost reasons. The rule of the Three Rs (replacement, reduction, and refinement), first described by W. Russell and R. Burch in 1959, is usually employed to capitalize the first letter of each of the three 'R' principles (Figure 7) [70, 71].

Replacement refers to methods that prefer the use of non-animal methods over animal methods whenever it is possible to achieve the same scientific goals. Replacement methods include the use of:

Animal tissues and cells

Computer models

Established cell lines

Immature forms of vertebrates (worms)

Reduction refers to methods that make researchers obtain comparable levels of information from fewer numbers of animals, or to obtain more information from the same number of animals.

Refinement refers to methods that minimize potential pain, suffering or distress, and enhance animal welfare for the animals used**.**

Today, the 3Rs are guiding principles for a more ethical use of animals in research, and are becoming a framework for conducting high quality science in the academic and industrial sectors with more focus on developing alternative approaches, which avoid the use of animals [72, 73]. There are a number of reasons for this including the need for better models and tools that more closely reflect human biology and predict the efficacy and safety of new medicines.

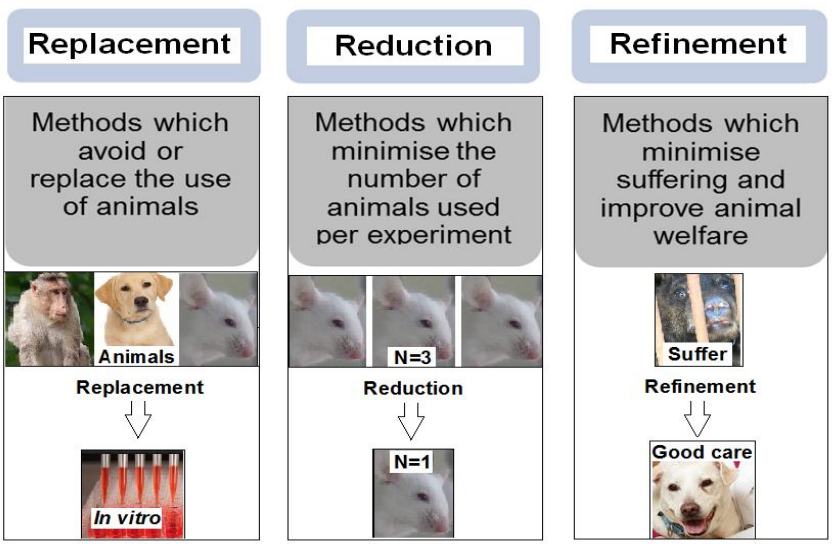

Figure 7. The rule of replacement, reduction and refinement in an animal study. The rule of the 3Rs refers to the use of non-animal methods over animal methods; the use of fewer the numbers of animals to obtain more information from the same number of animals; and to improve animal welfare.

Step III. Two Important Applications for Investigational New Drug and Patent before Clinical Studies

Investigational New Drug and Investigational New Drug Application

After a new candidate drug has been screened for pharmacological activity and toxicity in a pre-clinical study, and has been identified to be a viable candidate for further development, the sponsors should collect all data and information about this product, and ensure that it has no unreasonable risks when it will be used in the next early clinical study in humans. Before clinical trials, all sponsor biotechnology and pharmaceutical companies must submit two important applications, an investigational new drug (IND) application and patent application; both of these applications must be approved respectively by the U.S. Food and Drug Administration (FDA) and U.S. Patent and Trademark Office (PTO). The FDA approval of an IND product is necessary before the drug can be marketed; and the PTO approves that the IND patent can protect the inventions of the pharmaceutical company. These approval processes are lengthy, and sponsor pharmaceutical companies should minimize the time spent on the process as part of a profit maximizing strategy [74].

IND Type

There are three IND types (Figure 9) [75, 76].

An Investigator IND is submitted by a physician who both initiates and conducts an investigation, and under whose immediate direction the investigational drug is administered or dispensed. A physician might submit a research IND to propose studying an unapproved drug, or an approved product for new indication or in a new patient population.

An Emergency Use IND allows the FDA to authorize the use of an experimental drug in an emergency situation that does not allow time for submission of an IND.

A Treatment IND is submitted for experimental drugs showing promise in clinical testing for serious or immediately life-threatening conditions while the final clinical work is conducted and the FDA review takes place.

IND Application with FDA

Generally, IND application should contain data and information in four broad areas [77]:

All Results of Pharmacology and Toxicology Studies

The information should show that all preclinical data ensure that the product is reasonably safe for initial study in human clinical trials. For studies of marketed drugs in new indications, this section should contain data from animal models to support the utility of the drug in the new indication.

Manufacturing Information

The information should ensure that the manufacturing company can adequately produce and supply consistent batches of the drug.

Clinical Trial Plans and Protocols

The information should show that detailed protocols for clinical trials are assessed and whether the initial phase trials will expose subjects to unnecessary risks.

Information About the Investigator

The information should provide the qualifications of clinical investigators – professionals (generally physicians) who oversee the administration of the experimental compound – to assess whether they are qualified to fulfill their clinical trial duties.

IND Review Team

An IND review team is a group of specialists in different scientific fields. Each member has different responsibilities.

Project Managers coordinate all team member activities throughout the review process as the primary contact for the sponsor.

Medical Officers review all clinical study information and data.

Chemists and Biologists evaluate drug stability, quality control, continuity, and the presence of impurities, and review the data to assess responses across different classes of microbes or animals.

*Pharmacokineticists e*valuate the data of drug absorption, distribution, metabolism, excretion and toxicity studies, and interpret blood level data at different time intervals from clinical trials, as a way to assess drug dosages and administration schedules.

Statisticians interpret clinical trial designs and data, and work closely with the medical officers to evaluate protocols, safety, and efficacy data.

IND Approval

Once the IND application is submitted, the FDA review will be a 30 calendar dayprocessing time. The process protects volunteers who participate in clinical trials from unreasonable and significant risk in clinical trials. The FDA responds to IND applicants in one of two ways:

IND approval: The candidate drug will move into phase I clinical trial.

Clinical hold: The candidate drug will be delayed or stopped for the investigation. The FDA can place a clinical hold for specific reasons, including investigators not being qualified; materials for the volunteer participants are misleading; the candidate drug can expose patients to unreasonable or significant risks; and the IND application does not include enough information about the trial risks.

At this step, approximately 85% of all drugs for IND applications are permitted to undergo clinical trials. Figure 8 depicts the application process of an IND.

Patents Protection for Intellectual Property and Patent Application

Intellectual Property

Intellectual property (IP) rights are the protections in law and are granted to the creators of intellectual property. IP rights include patents, trademarks, trade dress, copyright, industrial design rights, and geographical indication which enable people to earn recognition or financially benefit from what they invent or create [78, 79].

In drug development, IP protection provides incentives for investing companies who make the long and costly investments that lead to medical advances. Strong IP protection, in the form of patents and exclusivity, provides the opportunity for companies to potentially recoup investments made to develop new medicines and to fund future research [80].

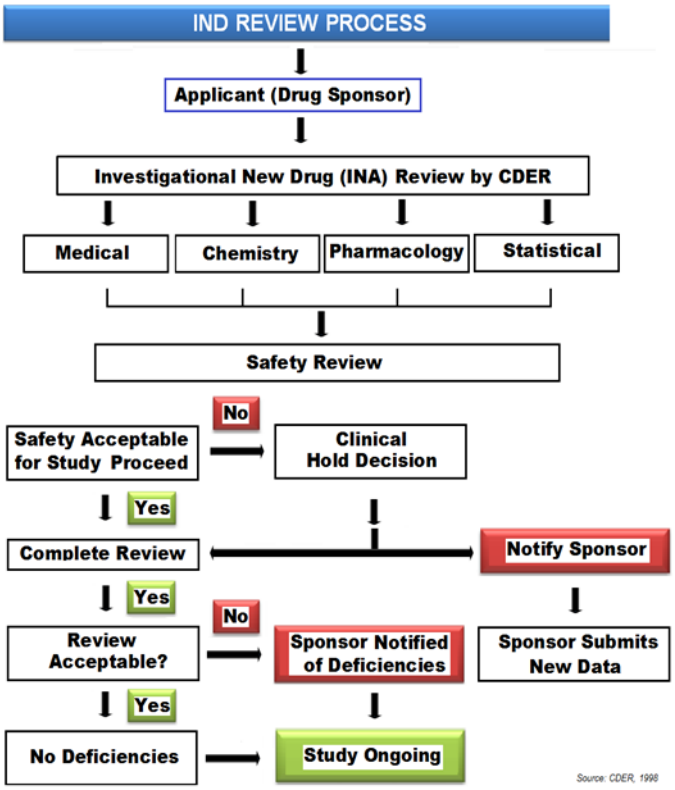

Figure 8. The investigational new drug application review process. The graphic depicts the application process of an IND. It is a 30 calendar day processing time from FDA review a complete IND application to make decision.

Patent and Market Exclusivity

A patent is a limited legal monopoly granted to the owner of an invention that prevents others from making, using, importing or selling the invention without owner permission. It can be a product, a new method, or a technical improvement on how certain objects work [74]. A patent is an exclusive right to grant an inventor market exclusivity over a new invention or medication. Market exclusivity means tremendous economic rewards for the patent holder because it provides the inventor with a monopoly over the invention for the 20 years patent term.

Today, in the field of novel drug development, pharmaceutical companies are facing increased costs for drug development and aggressive competition from generic drug companies, therefore patent protection and the market exclusivity help to ensure a return on investment [81]. It allows the inventor to prevent others from commercially using ideas or inventions without the creator's permission during the life of the patent [18, 79, 82, 83]. Patent protection is granted for a limited period, generally 20 years from the filing date of the application. The patented drugs are temporarily safe from the competition of generic companies. Obtaining a patent and retaining market exclusivity can be a treacherous process, especially in the arena of pharmaceutical patents. In the USA, 74% of all new drug sales tend to occur in the 5 year exclusivity window following drug approval, with an additional 15% of

sales realized in the 3 years following the loss of exclusivity when cheaper generic versions enter the market [84, 85].

Patent Application with PTO

The innovative pharmaceutical organizations should file a patent application to PTO on a new biotechnology and pharmaceutical drug before clinical trials. In this way, the innovating companies can obtain an exclusive right with respect to their inventions without others being able to copy and sell it for a set period of time [86].

The patent application should be filed before FDA approval of IND, because patents are important IP safeguards. There are some reasons for filing a patent application before an IND application with the FDA: i) If pharmaceutical organizations begin the IND application before the patent application, it is possible to lose royalties, market exclusivity, and company value in the process, because other companies may get the patent before them. They will have to license the pharmaceutical from the other companies or abandon the FDA process, and lose millions that have been spent in research and development; ii) the patent application has a lower safety standard than the FDA application, because the patent applicant is not required to provide any clinical evidence of drug safety; iii) the FDA approval may be accelerated for a patented compound; and iv) a patented new drug will attract the interest of potential investors who can provide the capital to support the FDA approval of clinical trials. Application, creating and protecting for a new compound patent requires a very close collaboration between pharmaceutical scientists and lawyers because scientific, legal, and practical considerations must be carefully weighed to best protect an inventor's rights [87, 88].

Patent Problems

When a pharmaceutical company first develops a new patented drug that is used in clinical treatment, it has the exclusive right to be sold under a brand name by which the clinicians can prescribe the drug for patients. The drug is covered under patent protection, which means that only the pharmaceutical company that holds the patent is allowed to manufacture and market the drug, and eventually make a profit from it. Although a drug patent is awarded for around 20 years, in most cases, the lifetime of the patent is no more than 10 years after the drug has finally received FDA approval, because the company application for a new drug patent needs time before the clinical trials. During this short period, pharmaceutical organizations have to recoup all the costs in drug development, together with the manufacturing and marketing costs. After a patent expires, generic drug competition will lead to a dramatic reduction in price and major loss of market share. Thus, it is not surprising that research companies try to extend patent life as much as possible [16, 90].

Step IV. Clinical Trials Studies

While preclinical research answers basic questions about a new drug’s safety, innovating pharmaceutical companies send the data to the FDA for IND approval as soon as possible. Once the FDA has approved, clinical research of new drugs can begin in human trials. Before a clinical trial begins, researchers should review all prior information about the drug to answer clinical research questions and develop clinical research objectives. They should follow good clinical practice (GCP) standards in clinical research.

Good Clinical Practice (GCP) Standards

Clinical trials in humans involve a wide range of practical and ethical problems. Each phase of the trial must be approved by an ethics committee, and all patients must give their prior informed consent to participate. Human clinical trials must be subject to good clinical practice (GCP) standards. GCP is an international ethical and scientific quality standard that is provided by the International Council for Harmonisation of Technical Requirements for Pharmaceuticals for Human Use (ICH) for designing, conducting, recording and reporting clinical trials that involve the participation of human subjects. Regardless of whether a clinical trial is a large, multi-center study in patients, or a small clinical pharmacological study in healthy subjects, the relevant ICH-GCP standard should be followed by the sponsoring companies, the investigators, the ethics committees, and any clinical research organizations [91–94].

The GCP principles provide assurance that the rights, safety and well-being of a clinical trial subjects are protected. They also ensure that the research yields quality scientific data. It is very important to understand the background of the formation of the ICH-GCP guidelines. There are thirteen core principles of ICH-GCP [93, 95–100].

Ethical Principles

Clinical trials should be conducted in accordance with the ethical principles that have their origin in the Declaration of Helsinki (DoH) and that are consistent with GCP and applicable regulatory requirements.

Favourable Benefits vs. Risks

Before a clinical trial is initiated, foreseeable risks and inconveniences should be weighed against the anticipated benefit for the individual trial's subject and society. A clinical trial should be initiated and continued only if the anticipated benefits justify the risks.

Subject Rights

The rights, safety and well-being of the trial subjects override the interests of science and society.

Adequate Supporting Data

The available non-clinical and clinical information on an investigational product should be adequate to support the proposed clinical trial.

Scientifically Sound Protocol

Clinical trials should be scientifically sound and described in a clear, detailed protocol.

Independent Ethics Committee Oversight

A trial should be conducted in compliance with the protocol that has received a prior institutional review board (IRB)/independent ethics committee (IEC) approval or favorable opinion.

Medical Care by Qualified Investigator

The medical care given to subjects, and the medical decisions made on their behalf, should always be the responsibility of a qualified physician or, when appropriate, a qualified dentist.

Qualified Personnel

Each individual involved in conducting a clinical trial should be qualified by education, training and experience to do their respective tasks.

Informed Consent

Freely given informed consent should be obtained from every subject prior to participation in the clinical trial.

Record Keeping

All clinical trial information should be recorded, handled and stored in a way that allows its accurate reporting, interpretation and verification.

Subject Confidentiality

The confidentiality of records that could identify subjects should be protected, respecting the privacy and confidentiality rules in accordance with the applicable regulatory requirements.

GMP Manufacturing of the Investigational Product

Investigational products should be manufactured, handled and stored in accordance with an applicable Good Manufacturing Practice (GMP). They should be used in accordance with the approved protocol.

Quality Assurance and Monitoring

Systems with procedures that assure the quality of every aspect of the clinical trial should be implemented.

Four Distinct Phases of Clinical Studies in Humans

Before a clinical trial begins, researchers should review prior information about the drug questions and objectives. They should focus on two essential questions: does the drug work in patients? Is it safe in humans? Additionally, they should also answer other questions, such as how long the study will last; how many people will be part of the study; who qualifies to participate; whether there will be a control group and other ways to limit research bias; by which way the drug will be given to patients and at what dosage; what assessments will be conducted, when, and what data will be collected, and how the data will be reviewed and analyzed.

A clinical trial is a typical series of research from early-stage, small scale studies to late-stage, large scale studies (Table 4) [101]. Clinical trials take place in four distinct phases; the first three phases (I, II, and III) start before the drug is marketed, and the fourth phase (IV) begins once the drug has been licensed and prescribed. Every phase is considered a separate trial. After completion of a phase, investigators are required to submit all data for FDA

approval before continuing to the next phase. Individual trials may encompass more than one phase. A common example of this is combined phase I/II or phase II/III trials. Therefore, it may be easier to think of early-phase and late-phase studies. The drug development process normally proceeds through all four phases over many years. If the drug successfully passes through phases I, II, and III, it will usually be approved by the national regulatory authority for use in patients. In order to reduce or eliminate bias, all trials will be blinded, and the patients receiving the candidate drug will be unaware of whether they are part of the treatment group or the control group. Also, many trials are double blind; none, neither patients nor physicians, will be aware of group information [102, 103].

Table 4. Four distinct phases of clinical studies in humans

Phase	Goal	Length	Dose	Monitor	Number	Success
Pre-clinical	Efficacy, toxicity, PK/PD in non-human subjects	~ 4 years	Unrestricted dose	Researchers	*In vitro* *in vivo*	
Phase 0	PK/PD in healthy volunteers	Several months to 1 years	Very low dose	Clinical researchers	10 people	
Phase I	Dose-ranging in healthy volunteers	Several months	Sub-therapeutic dose	Clinical researchers	20-100 healthy volunteers	70%
Phase II	Efficacy and side effects in patients	Several months to 2 years	Therapeutic dose	Clinical researchers	100-300 patients	33%
Phase III	Efficacy, effectiveness and safety in patients	1 to 4 years	Therapeutic dose	Clinical researchers	300-3,000 patients	25-30%
Phase IV	Post-marketing surveillance		Therapeutic dose	Physicians	Anyone seeking treatment	N/A

Phase I. Initial Safety Testing in a Small Group of Healthy People

The main goal of a phase I study is to confirm that the results derived from the preclinical study are replicated in human subjects. The studies are usually conducted with a small number of healthy volunteers, generally 20 to 100 healthy volunteers or people with the disease exposed to very low amounts of the candidate drug for short periods (several months) under carefully controlled and monitored conditions. Researchers monitor the pharmacokinetics of a drug which is absorbed, metabolized and eliminated from the body, and also study the drug's pharmacodynamics, which are related to side effects.

Main Goal of Phase I Studies

How the new drug should be given (such as by mouth or injection) and how often?

What are the safest dosages and the highest dose that a person can tolerate (maximum tolerated dose)?

What effects does the drug have on the people taking the drug?

What side effects does the drug have on the people taking the drug?

Phase I Studies Can Be Further Divided

Phase Ia studies (Single ascending dose)

In single dose studies, small groups of patients are given a single dose of the drug while they are observed and tested for a period of time to confirm drug safety. If they do not exhibit any adverse side effects, a new group of a higher dose is then given the drug. If an additional unacceptable toxicity is observed, then the dose escalation is terminated and that dose is declared to be the maximally tolerated dose [104–106].

Phase Ib studies (Multiple ascending dose)

Multiple dose studies investigate the PK and PD of the drug, and evaluate its safety and tolerability. During the studies, patient samples are collected at various time points and analyzed to acquire information on how the drug is processed within the body [105–107].

Data from this phase I studies will be compared with data from the pre-clinical studies to ensure that the drug is working as anticipated. Despite the care and preparation taken, phase I trials are the first time for the drug to appear in human experiments, and the unexpected can happen. In this stage, it will be approximately 70% of tested drugs that will move to the next phase [107].

Phase II. Assess Safety and Efficacy in a Relatively Small Group of Patients

In phase II studies, the primary purpose is to evaluate whether a candidate drug has effectiveness or has side effects in a relative number (up to a few hundred) of patient volunteers with the disease, and with the study length of several months to two years. Many phase II studies evaluate patients receiving the drug compared with patients receiving a different drug treatment, either an inactive substance (placebo), or a different drug that is usually considered the standard of care for the disease. Researchers also analyze optimal dose and schedules for using the drug, and examine the possible short-term side effects and risks associated with the drug. If the drug continues to show promise, researchers should prepare and design a protocol for the next and larger phase III studies. In this stage, it will be approximately 33% of tested drugs which will move on to the next phase [106].

Phase III. Demonstrate Safety and Efficacy in a Large Group of Patients

The main goal of the phase III studies is to generate statistically significant data about the safety, efficacy and the overall benefit-risk relationship of the investigational medicine. Phase III trials may enroll 300 to 3,000 patients with length time of 1 to 4 years, and are the costliest and longest studies, often encompassing hundreds of study sites at hospitals and centers around the world. The companies should ensure high quality production of the medicine for use in this trial, as well as planning for the full-scale production of the medicine after FDA approval. The innovating pharmaceutical company also coordinates closely with research staffs at each trial site to monitor the study; and works with some clinical research organizations (CRO) to aid in recruitment and day-to-day operations of the trials.

A candidate drug may take from six to ten years to complete the first three phases of clinical studies. The time taken is determined by the duration of the disease that is being treated and by the extended time that it can sometimes take to assemble sufficient patients for the trials [1]. People are often surprised that drug development takes such a long time, even though the vast amount of

results that have been generated on the candidate drug before phase III studies fail at this phase with a high failure rate. As of 2010, about 50% of drug candidates either fail during the phase III studies or are rejected by the national regulatory agency [107]. It will be only approximately 25% of the drugs which will move on to the next phase study [106].

Step V. New Drug Application (NDA) to the FDA for the Approval of Marketing

Once a compound has passed its early-phase preclinical trials and late-phase clinical trials, all results and data analysis demonstrates and confirms that the experimental drug is both safe and effective for its intended use; the sponsoring company will submit a New Drug Application (NDA) or Biologics License Application (BLA) to the FDA requesting the approval to market the drug [108].

New Drug Application (NDA)

The purpose of New Drug Application (NDA) is to demonstrate that a drug is safe and effective for its intended use in the human population studies. These applications contain all the results and data analysis from the entire clinical studies, as well as the earlier preclinical results and proposals for the manufacturing and labeling of the new medicine. Pharmaceutical companies must provide information including the development of a safety update report (DSUR), proposed labeling, drug abuse information, patent information, any data from studies that may have been conducted in the world, institutional review board compliance information, and directions for use. It will run up to 100,000 pages or more [106, 109].

FDA Review

Once the FDA receives NDA application, the review team will examine firstly whether the application is complete or not. If it is not complete, the review team can refuse to file the NDA approval. If it is complete, The FDA review members, including scientists, physicians and statisticians, thoroughly examine and evaluate all submitted data and results about the drug to determine whether the benefits outweigh the risks; what information must be included in the drug label; whether the proposed manufacturing process is adequate; and if there is any need for certain prescription criteria or special physician training. The review team has 6 to 10 months to make a decision on whether to approve this drug. The FDA review process includes four steps below:

The FDA review team conducts a full review of the application. The medical officers and the statisticians review clinical data, while pharmacologists review the data from animal studies.

The FDA inspectors travel to clinical multi-center sites around the world to conduct a routine inspection. The Agency looks for evidence of fabrication, manipulation, or withholding of data.

The project managers assemble all individual reviews, other documents, and get together to form an action package. These documents become the record for the FDA review.

The FDA finally makes a decision to approve or not to approve the NAD application. It requires a 6 to 10 month processing time [106, 110].

FDA Approval

When the FDA determines the new drug to be safe and effective for its intended use in humans, it is necessary to work with the applicants to develop and refine prescribing information. Labeling accurately and objectively describes the basis for approval and how best to use the drug [106].

Manufacturing

Once FDA and NAD approval is obtained, the pharmaceutical company should – in accordance with the FDA Good Manufacturing Practices (GMP) regulations – produce the highest standard to ensure drug safety and quality in each step of the manufacturing process, to ensure that the drug is available to patients for many years [106].

Step VI. Post-Market Safety Monitoring (Phase IV Trials)

Despite clinical trials providing important information on the efficacy and safety of a new drug, even when the drug has been launched in the market, it is impossible to have complete information about the safety of a drug after the time of FDA approval. Sometimes, the FDA requires additional studies on the already approved drug; this is known as *phase IV studies*. Phase IV trials can be set up to evaluate the long-term safety of the new medicine. As a much larger number of patients start taking the drug, the company must continue to monitor it carefully for newly found adverse effects of the drug. Periodic reports to the FDA should be submitted on a quarterly basis for the first 3 years, and annually thereafter. The FDA reviews reports of problems with prescription and over-the-counter drugs, and decides to add cautions to the dosage or usage information, as well as other measures for more serious issues [111–114].

CONCLUSION

The research and development of a new medicine is a long, costly, complex and rigorous process, which needs savvy, strategic, organizational, and managerial decisions. Every step should be focused on ensuring the highest level of drug safety in humans. Once a new and effective medicine is identified through the process of drug development, it will be brought to the market as early as possible. In this chapter, we presented a comprehensive overview of the process of drug discovery and development from an early-phase of basic research to final marketing. We discussed basic knowledge about new drug discovery and development; how patent intellectual property protections are established; and how the interplay between the U.S. Patent and Trademark Office and the Food and Drug Administration applications affects the patent approval process.

REFERENCES

[1] Hester RE, Harrison RM. Pharmaceuticals in the environment. *Royal Society of Chemistry;* 2015.

[2] Leung AY. Traditional toxicity documentation of Chinese material medical. *An overview* 2006; 34:319–326.

[3] Buhner SH. *Sacred plant medicine*. Raven Press; 1996.

[4] Sumner J. *The natural history of medicinal plants*. Timber Press; 2000.

[5] Law J. *Big Pharma*, London: Constable & Robinson; 2006.

[6] Haughton C. *Green immigrants*. New York: Harcourt, Brace, Jovanovich; 1980.

[7] Van Bronswijk P, Cohen AF. The first recordings of pharmacological effects. *Br. J. Clin. Pharmacol.* 2008; 66:588–593.

[8] Sheldon P. *The life and times of William Withering: his work, his legacy*. Studley: Brewin Books; 2004.

[9] Kiefer DM. Organic chemicals' mauve beginning. *Chem. Eng. News* 1993; 71:22–23.

[10] Greenwood N, Earnshaw A. *Chemistry of the elements*. Butterworth-Heinemann; 1997.

[11] Schreiber S. Target-oriented and diversity-oriented organic synthesis in drug discovery. *Science* 2000; 287:1964–1969.

[12] Scheindlin S. A brief history of pharmacology. *Modern Drug Discovery* 2001; 4:87–88.

[13] Koch-Weser J, Schechter PJ. Schmiedeberg in Strasbourg 1872–1918: the making of modern pharmacology. *Life Sci*. 1978; 22:1361–1371.

[14] Weatherall M. *In search of a cure: A history of pharmaceutical discovery*. Oxford University Press: New York; 1990.

[15] Dubois DJ, Jurczynska A, Kerpel-Fronius S, Kesselring G, Imamura K, Nell G, Silva H, Stonier P. Fostering competence in medicines development: the IFAPP perspective. *Front Pharmacol.* 2016; 7:377–384.

[16] Taylor D. The Pharmaceutical industry and the future of drug development, Pharmaceuticals in the Environment. *Royal Society of Chemistry;* 2015.

[17] Statista. Global pharmaceutical industry, Statistics & Facts [Internet]. *Statistics and facts about the pharmaceutical industry worldwide* [cited 2017 July 18]. Available from https://www.statista.com/topics/1764/global-pharmaceutical-industry/.

[18] DiMasi JA, Hansen RW, Grabowski HG. The price of innovation: new estimates of drug development costs. *J. Health Econ.* 2003; 22:151–185.

[19] Bunnage ME. Getting pharmaceutical R&D back on target. *Nat. Chem. Biol.* 2011; 7:335–339.

[20] Noor W. 2013 *Pharm Exec Top 50* [Internet]. Pharmaceutical Executive; 2013 [cited 2017 July 18]. Available from http://www.pharmexec.com/2013-pharm-exec-top-50-0.

[21] Boehm G, Yao L, Han L, Zheng Q. Development of the generic drug industry in the US after the Hatch-Waxman Act of 1984. *Acta Pharm. Sin. B*. 2013; 3:297–311.

[22] U.S Food and Drug Administration. Generic drugs [Internet]. *Center for Drug Evaluation and Research*; 2017 [cited 2017 July 19]. Available from https://www.fda.gov/downloads/Drugs/DevelopmentApprovalProcess/SmallBusinessAssistance/ucm127615.pdf.

[23] Blanchard A, D'Iorio H, Ford R. What you need to know to succeed: Key trends in Canada's biotech industry. *Insights;* 2010.

[24] Nick C. The US Biosimilars Act: Challenges facing regulatory approval. *Pharm. Med.* 2012; 26:145–152.

[25] Camacho LH, Frost CP, Abella E, Morrow PK, Whittaker S. Biosimilars 101: considerations for U.S. oncologists in clinical practice. *Cancer Medicine* 2014; 3:889–899.

[26] Niederwieser D, Schmitz S. Biosimilar agents in oncology/haematology: from approval to practice. *Eur. J. Haematol*. 2011; 86:277–288.

[27] Fisher AC, Lee SL, Harris DP, Buhse L, Kozlowski S, Yu L, Kopcha M, Woodcock J. Advancing pharmaceutical quality: An overview of science and research in the U.S. FDA's Office of Pharmaceutical Quality. *Int. J. Pharm*. 2016; 515:390–402.

[28] Eleryan MG, Akhiyat S, Rengifo-Pardo M, Ehrlich A. Biosimilars: potential-implications for clinicians. *Clin Cosmet Investig Dermatol*. 2016; 9:135–142.

[29] Lybecker KM. Essay: when patents aren't enough: why biologics necessitate date exclusivity protection. *William Mitchell Law Rev*. 2014; 40:1427–1442.

[30] EuropaBio. Guide to biological medicines: a focus on biosimilar medicines. *European Medicines Agency*; 2005.

[31] Alten R, Cronstein BN. Clinical trial development for biosimilars. *Semin Arthritis Rheum*. 2015; 44:2–8.

[32] Carlson R. Estimating the biotech sector's contribution to the US economy. *Nature Biotechnology* 2016; 34:247–255.

[33] Scherer FM. The link between gross profitability and pharmaceutical R&D spending. *Health Aff*. 2001; 20:216–220.

[34] Matthew H. The cost of creating a new drug now $5 billion, pushing big pharma to change [Internet]. *Pharma & Healthcare*; 2013 August 11 [cited 2017 July 18]. Available from https://www.forbes.com/sites/matthewherper/2013/08/11/how-the-staggering-cost -of-inventing-new-drugs-is-shaping-the-future-of-medicine/#5de1239 e13c3.

[35] Pharmaceutical Research and Manufacturers of America [Internet]. *Pharmaceutical industry profile*; 2006 [cited 2017 June 30]. Available from http://www.phrma.org/.

[36] Industrial Research and Development Information System (IRIS) [Internet]. *Historical data 1953–2007* [cited 2017 July 18]. Available from www.nsf.gov/statistics/iris/ search_hist.cfm?indx=10.

[37] The National Science Foundation (NSF) [Internet]. *Business and Industrial R&D* [cited 2017 July 18]. Available from www.nsf.gov/statistics/industry.

[38] Medical Marketing and Media (MM&M). R&D costs are on the rise. *MM&M*. 2003; 38:14–15.

[39] Amplion, Biomedtracker, Biotechnology Innovation Organization (BIO). Clinical development success rates 2006–2015 [Internet]. *BIO Industry Analysis*; 2016 [cited 2017 July 19]. Available from https://www.bio.org/sites/default/files/Clinical%20 Development%20Success%20Rates%202006-2015%20-%20BIO,%20Biomed tracker,%20Amplion%202016.pdf.

[40] World Health Organization. *Handbook: Good Laboratory Practice: Quality Practices for Regulated Non-clinical Research and Development* Paperback, 2nd ed, TDR; 2010.

[41] Liem FE, Lehr MJ. Future issues including broadening the scope of the GLP principles. *Ann 1st Super Sanita.* 2008; 44:335–340.

[42] Medicines and Healthcare Products Regulatory Agency [Internet]. *Good laboratory practice (GLP) for safety tests on chemicals*; 2014 [cited 2017 July 18]. Available from https://www.gov.uk/guidance/good-laboratory-practice-glp-for-safety-tests-on-chemicals.

[43] Robinson K. GLPs and the Importance of Standard Operating Procedures [Internet]. *BioPharm International*; 2003 Aug 1 [cited 2017 July 18]. Available from http://www.biopharminternational.com/glps-and-importance-standard-operating-procedures.

[44] American Psychological Association. *The Publication Manual of the American Psychological* Association Washington, 6th ed, Washington, DC, USA: APA; 2010.

[45] Iverson C. *AMA Manual of Style*, 10th ed. Oxford, Oxfordshire: Oxford University Press; 2007.

[46] Quignot N, Hamon J, Bois F. Extrapolating *in vitro* results to predict human toxicity, in *in vitro* toxicology systems. In: Bal-Price A, Jennings P, editor. *Methods in Pharmacology and Toxicology series.* New York, USA: Springer Science; 2014. pp. 531–550.

[47] Akhtar A. The Flaws and human harms of animal experimentation. In: Beauchamp TL, DeGrazia D, editor. *Cambridge Quarterly of Healthcare Ethics*; 2015. pp. 407–419.

[48] Atanasov AG, Waltenberger B, Pferschy-Wenzig EM, Linder T, Wawrosch C, Uhrin P, Temml V, Wang L, Schwaiger S, Heiss EH, Rollinger JM, Schuster D, Breuss JM, Bochkov V, Mihovilovic MD, Kopp B, Bauer R, Dirsch VM, Stuppner H. Discovery and resupply of pharmacologically active plant-derived natural products: A review. *Biotechnol Adv;* 2015.

[49] Lipinski C, Hopkins A. Navigating chemical space for biology and medicine. *Nature* 2004; 432:855–861.

[50] Chung TD, Terry DB, Smith LH. In vitro and in vivo assessment of ADME and PK properties during lead selection and lead optimization, guidelines, benchmarks and rules of thumb. 2015 Sep 9. In: Sittampalam GS, Coussens NP, Brimacombe K, Grossman A, Arkin M, Auld D, Austin C, Baell J, Bejcek B, Chung TDY, Dahlin JL, Devanaryan V, Foley TL, Glicksman M, Hall MD, Hass JV, Inglese J, Iversen PW, Kahl SD, Lal-Nag M, Li Z, McGee J, McManus O, Riss T, Trask OJ Jr., Weidner JR, Xia M, Xu X, editors. *Assay Guidance Manual*. Bethesda (MD): Eli Lilly & Company and the National Center for Advancing Translational Sciences; 2004. pp. 1091–1107.

[51] Wan H. What ADME tests should be conducted for preclinical studies? *ADMET & DMPK* 2013; 1:19–28.

[52] Balani SK, Devishree VS, Miwa GT, Gan LS, Wu JT, Lee FW. Strategy of utilizing *in vitro* and *in vivo* ADME tools for lead optimization and drug candidate selection. *Curr Top Med Chem*. 2005; 5:1033–1038.

[53] Singh SS. Preclinical pharmacokinetics: an approach towards safer and efficacious drugs. *Curr Drug Metab*. 2006; 7:165–182.

[54] Tetko IV, Bruneau P, Mewes HW, Rohrer DC, Poda GI. Can we estimate the accuracy of ADME-Tox predictions? *Drug Discov Today* 2006; 11:700–707.

[55] Ottoboni MA. *The dose makes the poison: a plain-language guide to toxicology*, 2nd edn. New York, N.Y: Van Nostrand Reinhold; 1991.

[56] *Committee on Risk Assessment of Hazardous Air Pollutants, Commission on Life Sciences*, National Research Council. Science and judgement in risk assessment. The National Academic Press; 1994. pp. 56–61.

[57] Pharmacokinetics. In *Mosby's Dictionary of Medicine, Nursing & Health Professions.* Philadelphia, PA: Elsevier Health Sciences; 2006.

[58] Meibohm B, Derendorf H. Basic concepts of pharmacokinetic/pharmacodynamics (PK/PD) modelling. *Int J Clin Pharmacol Ther*. 1997; 35:401–413.

[59] Association for Applied Human Pharmacology working group Pharmacokinetics. *Collection of terms, symbols, equations, and explanations of common pharmacokinetic and pharmacodynamic parameters and some statistical functions.* Association for Applied Human Pharmacology; 2004.

[60] California Biomedical Research Association [Internet]. *CBRA Fact Sheet: Why Are Animals Necessary in Biomedical Research?* [cited 2017 July 18]. Available from: http://www.ca-biomed.org/csbr/pdf/fs-whynecessary.pdf.

[61] Dvorsky G. *Do These Startling Longevity Studies Mean Your Lifespan Could Double?* [Internet]. GIZMODO; 2013 April 30 [cited 2017 July 19]. Available from: http://io9.gizmodo.com/do-these-startling-animal-studies-mean-your-lifespan-co-486041314.

[62] U.S. Department of Health and Human Services, Food and Drug Administration, Center for Drug Evaluation and Research (CDER), Center for Biologics Evaluation and Research (CBER) [Internet]. *Product development under the animal rule guidance for industry*. Animal Rule October 2015 Revision. [cited 2017 July 19]. Available from: https://www.fda.gov/downloads/drugs/guidances/ucm399217.pdf.

[63] Canadian Council on Animal Care (CCAC) [Internet]. *Laboratory animals used in biomedical research Companion Notes*. [cited 2017 July 19]. Available from https://ccac.ca/Documents/Education/Modules/Vivaria/Biomedical_research/Companion-notes.pdf.

[64] Silverman J, Suckow M, Murthy S. *The IACUC Handbook*, 3rd ed. CRC Press; 2014.

[65] U.S. Department of Health and Human Services, Food and Drug Administration, Center for Drug Evaluation and Research (CDER), Center for Biologics Evaluation and Research (CBER) [Internet]. *Guidance for industry M3 (R2) nonclinical safety studies for the conduct of human clinical trials and marketing authorization for pharmaceuticals*. January 2010 Revision 1 ICH. [cited 2017 June 30]. Available from: https://www.fda.gov/downloads/drugs/guidances/ucm073246.pdf.

[66] FDA Drug Development Tools Qualification Programs [Internet]. *The AMQP was established under FDA's Drug Development Tools (DDT) Qualification Programs* [cited 2017 July 19]. Available from http://www.fda.gov/Drugs/DevelopmentApprovalProcess/DrugDevelopmentToolsQualificationProgram/ucm284078.htm.

[67] Christian E. Newcomer, VMD, email to ProCon.org [Internet]. *Federation of American Societies for Experimental Biology*; 2013 October 11 [cited 2017 July 19]. Available from: http://www.faseb.org/portals/2/OPA/FASEB%20Comments%20on%20AAA_LAC%20Strategic%20Plan.pdf.

[68] Americans for Medical Progress (AMP) [Internet]. *Animal research top 10 questions*. 2013 October 15 [cited 2017 July 19]. Available from: https://www.amprogress.org/animal-research/faqs/.

[69] Russell WMS. The 3Rs: past, present, and future. *Anim Welf*. 2005; 14:279–286.

[70] Russell WMS, Burch RL. *The Principles of humane experimental technique*, Methuen, London; 1959.

[71] Badyal D, Desai C. Animal use in pharmacology education and research: The changing scenario. *Indian Journal of Pharmacology* 2014; 46:257–265.
[72] Goodman J, Chandna A, Roe K. Trends in animal use at US research facilities. *Journal of Medical Ethics* 2015; 41:567–569.
[73] Government United Kingdom. Animals Scientific Procedures Act. *Animal research and testing and scientific research and development. Guidance research and testing using animals*; 2013.
[74] Petrova E. *Innovation and Marketing in the Pharmaceutical Industry*, Springer, New York; 2014.
[75] U.S. Food and Drug Administration. *Investigational New Drug (IND) Application* [Internet]. FDA; 2013 [Updated 2016 August 1; cited 2017 June 30]. Available from https://www.fda.gov/drugs/developmentapprovalprocess/howdrugsaredevelopedandapproved/approvalapplications/investigationalnewdrugindapplication/default.htm.
[76] Food and Drug Administration, HHS. Charging for investigational drugs under an investigational new drug application. Final rule. *Fed Regist*. 2009; 74:871–900.
[77] Ferkany, JW, Williams M. The IND Application. *Current Protocols in Pharmacology* 2008; 42:1–23.
[78] World Intellectual Property Organization *(*WIPO*)* [Internet]. *Paris Convention for the Protection of Industrial Property*; 1979 [cited 2017 June 30]. Available from http://www.wipo.int/wipolex/en/treaties/text.jsp?file_id=288514.
[79] The Pharmaceutical Research and Manufacturers of America (PhRMA) [Internet]. *Biopharmaceutical Research & Development*; 2015 [cited 2017 June 30]. Available from http://www.phrma.org/.
[80] Gupta H, Kumar S, Roy SK, Gaud RS. Patent protection strategies. *J Pharm Bioallied Sci*. 2010; 2:2–7.
[81] World Intellectual Property Organization. *WIPO Intellectual Property Handbook: Policy, Law and Use*. Chapter 2: Fields of Intellectual Property Protection WIPO. 2nd ed, 2008. pp. 17–40.
[82] World Trade Organization [Internet]. *What are intellectual property rights?* 2016 [cited 2017 June 30]. Available from https://www.wto.org/english/tratop_e/trips_e/intel1_ e.htm#top.
[83] World Intellectual Property Organization [Internet]. *Patents: Frequently Ask Questions*; 2015 [cited 2017 June 30]. Available from http://www.wipo.int/patents/en/faq_patents.html.
[84] Higgins MJ, Rodriguez D. The outsourcing of R&D through acquisitions in the pharmaceutical industry. *J Financ Econ*. 2006; 80:351–383.
[85] Ding M, Eliashberg J, Stremersch S. *Innovation and Marketing in the Pharmaceutical Industry*. New York, NY Imprint: Springer; 2014. pp. 31–32.
[86] Olson DS. Taking the Utilitarian Basis for Patent Law Seriously: The Case for Restricting Patentable Subject Matter [Internet]. *Temple Law Review*; 2009 [cited 2017 June 30]. Available from http://lawdigitalcommons.bc.edu/cgi/viewcontent.cgi?article = 1277&context=lsfp.
[87] Fernandez DS, Huie J, Hsu J. *Intellectual Property Management in Health and Agricultural Innovation: A Handbook of Best Practices*. Chapter 10.9 The Interface of Patents with the Regulatory Drug Approval Process and How Resulting Interplay Can Affect Market Entry; 2009. pp. 965 –972.

[88] Grubb PW. Patents for Chemicals, Pharmaceuticals and Biotechnology. *In fundamentals of global law, practice and strategy*. Oxford University Press; 1999. pp. 409 –416.

[89] Mackenzie M, Keating P, Cambrosio A. Patents and free scientific information in biotechnology: Making monoclonal antibodies proprietary. *Sci Tech Hum Values* 1990; 15:65–83.

[90] Sauer RM, Corinne Sauer C. Reducing barriers to the development of high quality, low cost medicines: A proposal for reforming the drug approval process [Internet]. *International Policy Press a division of International Policy Network*; 2005 [cited 2017 June 30]. Available from http://www.who.int/intellectualproperty/submissions/Sauerbarriers.pdf.

[91] World Health Organization WHO [Internet]. World Health Organization *WHO Technical Report Series*, No. 850, 1995, Annex 3 Guidelines for good clinical practice (GCP) for trials on pharmaceutical products [cited 2017 June 30]. Available from http://apps.who.int/medicinedocs/pdf/whozip13e/whozip13e.pdf.

[92] MaRS Library [Internet]. *Clinical trials and Good Clinical Practice* (GCP); 2012 [cited 2017 June 30]. Available from https://www.marsdd.com/mars-library/clinical-trials-and-good-clinical-practice-gcp/.

[93] Vijayananthan A, Nawawi O. The importance of Good Clinical Practice guidelines and its role in clinical trials. *Biomed Imaging Interv J*. 2008; 4:5–9.

[94] U.S. Food and Drug Administration. [Internet]. *Good clinical practice* [Updated 2014 October 12; cited 2017 June 30]. Available from https://www.fda.gov/aboutfda/centersoffices/officeofmedicalproductsandtobacco/cder/ucm090259.htm.

[95] Health Canada [Internet]. *Guidance for industry good clinical practice: Consolidated guideline ICH topic E6* [cited 2017 June 30]. Available from http://www.hc-sc.gc.ca/dhp-mps/alt_formats/hpfb-dgpsa/pdf/prodpharma/e6-eng.pdf.

[96] World Health Organization [Internet]. *Handbook for good clinical research practice (GCP): Guidance for implementation* [cited 2017 June 30]. Available from http://www.who.int/medicines/areas/quality_safety/safety_efficacy/gcp1.pdf.

[97] Cingi C, Muluk NB. *The principles of GCP*. Chapter of quick guide to good clinical practice. Springer; 2016. pp 29–32.

[98] Friedman LM, Furberg CD, De Mets DL. Ethical Issues, in *Fundamentals of Clinical Trials*, Springer Science Business Media, New York; 2010.

[99] Verma K. Base of a research: good clinical practice in clinical trials. *J. Clin. Trials* 2013; 3:1–3.

[100] Tobin JJ, Walsh G. Chapter 5. Clinical trial. In *Medical product regulatory affairs. Pharmaceuticals, diagnostics, medical devices*. Weinheim: Wiley-VCH Verlag GmbH & Co. KGaA; 2008.

[101] DeMets D, Friedman L, Furberg C. *Fundamentals of Clinical Trials*. 4th ed. Springer; 2010.

[102] Becker KM. and Whyte JJ. Clinical evaluation of medical devices. *Principles and case studies*. 2nd ed. Totowa: Humana Press; 2006.

[103] Brody T. *Clinical Trials: Study Design, Endpoints and Biomarkers, Drug Safety, and FDA and ICH Guidelines*. London: Academic Press; 2012.

[104] Canadian Cancer Society [Internet]. *Phases of clinical trials*; 2017 [cited 2017 July 19]. Available from http://www.cancer.ca/en/cancer-information/diagnosis-and-treatment/clinical-trials/phases-of-clinical-trials/?region=on.
[105] Norfleet E, Gad SC. Phase I Clinical Trials. in *Shayne Cox Gad, Clinical Trials Handbook*. Wiley; 2009.
[106] U.S. Food and Drug Administration [Internet]. *The Drug Development Process* [cited 2017 July 19]. Available from https://www.fda.gov/forpatients/approvals/drugs/ucm405622.htm.
[107] Arrowsmith J. Trial watch: Phase III and submission failures: 2007–2010. *Nat Rev Drug Discov*. 2001; 10:87–87.
[108] Field MJ, Boat TF. *Rare Diseases and Orphan Products: Accelerating Research and Development*. Washington (DC): National Academies Press; 2010.
[109] U.S. Food and Drug Administration [Internet]. *New Drug Application (NDA)* [cited 2017 July 19]. Available from https://www.fda.gov/Drugs/DevelopmentApprovalProcess/HowDrugsareDevelopedandApproved/ApprovalApplications/NewDrugApplicationNDA/default.htm.
[110] Golan DE. *Principles of pharmacology: the pathophysiologic basis of drug therapy*. Lippincott Williams & Wilkins; 2008.
[111] Richmond Human Resources Management Association [Internet]. *Biopharmaceutical Research & Development: The Process behind New Medicines*; 2015 [cited 2017 June 30]. Available from http://phrma-docs.phrma.org/sites/default/files/pdf/rd_brochure_022307.pdf.
[112] U.S. Food and Drug Administration [Internet]. *The FDA's drug review process: ensuring drugs are safe and effective*; 2014 [cited 2017 July 19]. Available from http://www.fda.gov/drugs/resourcesforyou/consumers/ ucm143534.htm.
[113] U.S. Food and Drug Administration [Internet]. *Fast track, breakthrough therapy, accelerated approval, priority review* [cited 2017 July 19]. Available from http://www.fda.gov/forpatients/approvals/fast/default.htm.
[114] World Health Organization [Internet]. *WHO Drug Information*; 2013 [cited 2017 June 30]. Available from http://apps.who.int/medicinedocs/pdf/s4953e/s4953e.pdf.

In: Encyclopedia of Surgery (22 Volume Set)
Editors: Andreas Lehrer and Kristin Mueller
ISBN: 978-1-53618-329-0
© 2020 Nova Science Publishers, Inc.

Chapter 203

ETHICAL, LEGAL AND EDUCATIONAL ISSUES IN EXPERIMENTAL SURGERY

Kupa Bilolo*, MD
Laboratory of Experimental Surgery, Department of Surgery
Center of Research of Montreal University (CR-CHUM)
University of Montreal, Montreal, Quebec, Canada

ABSTRACT

Experimental surgery is an acceptable procedure using large or small laboratory animals necessary to acquire technical skills crucial to the structured learning of surgery. Use of animal experiments in research and training has given important contributions to surgical progress with a number of important discoveries, which have not only saved millions of human and non-human lives, but also allowed for the increase of human life expectancy, which in some developed countries doubled and continues to rise today. The use of animal models remains indispensable in the foreseeable future and shall comply with minimal ethical standards set out for animal welfare.

The use of non-animals as alternative subjects in experimental surgery also helped to improve good technical skills, although they are being used with limited evidence-based data to support their validity and reliability. Skill acquisition and maintenance of surgical ability should be preserved by active and operative practice, research, and training laboratories. In this chapter, regulations that protect animals and manage their use in experimental surgery are outlined, and some alternative methods used in experimental surgery training and research, such as surgical simulators to help students or trainees to develop skills before practice on real patients are summarized.

Keywords: animal model, experimental surgery, education, ethic, regulations, surgical simulators

* Corresponding Author's Email: kbilolo@hotmail.com.

ABBREVIATIONS

CCAC	Canadian council on animal care
CIOMS	Council for International Organizations of Medical Sciences.
CT	Computer Tomography
dV-SS	da Vinci Skill Stimulator
dV-Trainer	da Vinci-Trainer
IACUC	Institutional Animal Care and Use Committees
IRB	Institutional Review Board
MIST-VR	Minimally Invasive Surgery Trainer Virtual Reality
MRI	Magnetic Resonance Imagery
RAS	Robot-Assisted Surgery
ROSS	Robotic Surgical Simulator
VIPAR	Virtual Interactive Presence and Augmented Reality
VRS	Virtual Reality simulators

INTRODUCTION

In the year 500 B.C., Alcmaeon from Greece and other scientists performed dissections on animals in order to know more about their anatomies (Geller 2007; von Staden 1989). In the 16th century, anatomists and others successful artists like Leonardo de Vinci (1452–1519) were given permission to dissect human corpses and pursued anatomical investigations of muscle and bone structure (Guerrini 2003). An English physician, William Harvey (1578–1657) described completely in detail the circulation of blood via his experiments on live deer (Shackelford 2003; Gregory 2001). Over the centuries, surgical techniques like dissecting living animals were developed and improved (Guerrini 2003; Prioreschi 1998; Maehle 1987). These experiments on living animals have profoundly affected all sectors of medicine, particularly in surgery (Porter 1995; McMullen 1995). Up to the early nineteenth century, there was a significant increase in the use of animals in scientific experiments (Pearce 1912; Davis 1903; Ernst 1902). Innovated surgical procedures and treatments based on research using living animal models were discovered, and continued to develop (Bertoloni 2013; Elliot 1987). Specific examples include a kidney transplantation which was previously performed and perfected in dogs led to the first effective human transplant of a kidney in the mid-1900s (Murray 1955). Heart valve replacement, artificial heart valves as well as the artificial hearts now being used in humans would not have been possible without experimental surgery research using animal models. Techniques of sewing blood vessels together was developed through surgeries on dogs and cats by Alexis Carrel, for which he was even awarded a Nobel Prize in 1912 (Balner 1981; Lee 1961); these research studies on laboratory animals also led to the understanding of organ rejection and how to overcome it (Stuart 1968; Hamburger 1981, Petrini 2013).

In experimental surgery, the principal and obvious purpose is to develop satisfactory surgical techniques; to test the validity and safety of new surgical techniques and also allow for the study of special pathophysiological aspects. This involves the discovery of the causes and conditions which make surgical interference a necessity (Jensen 1996; de la Garza-Rodea

2007). This implicates the interest in understanding physiology, biology, biochemistry, biophysics, etc. in terms of their relationship to general applications in the body and also to comparative aspects (Felts 2000; Dear 2006; Van der Worp 2010). Even though animals differ from people in many ways, they are also very similar to people in many ways. Animals develop many of the same diseases as people, including hemophilia, diabetes, and epilepsy (Swindle 1988). Animals are also susceptible to many of the same bacteria and viruses as people, such as anthrax, smallpox, and malaria (Gay 1986a and 1986b; Gay 1989; Bertoloni 2013). An animal is chosen as an "animal model" for research only if it shares characteristics with people that are relevant to the research. Animal model testing continues to be a natural specific research model, specifically for experimental surgery, where biologic and extremely complex physiologic systems are interrelated, making it a perfect model available for exploring, explaining or predicting the course of diseases or the effects of possible treatments by observing the entire living system (Gay 1986a and 1986b; Gay 1989; Rollin 2007).

Although experiments on living animals led to medical progress with a number of important discoveries, which have not only saved millions of lives human and non-human alike, but also allowed for the increase of human life expectancy (Billingham 1977; Bennett 1990; Pound 2004), they have also contributed to the emergence of many protestation movements between scientific inquiry and public concern. The use of animals for experimentation in research has been debated, defended, and protested by both individuals and organizations and individuals at various levels (Aldhous1999; Dikshit 2012). Attitudes in the continuum relationship between humans and animals spans amongst those who support no regulation of the human use of animals and those who advocate absolute animal liberation from all human use (Festing 2007; Crettaz von Roten 2012). Each year in the world, an estimation of nearly half a million animals are used for teaching exercises or research in surgery (Badyal 2009; Ringach 2010). In conditions of the non-availability of alternative subjects, the researcher or surgeon must be guided at all times by the principles of humane and rigorous experimentation, as well as a sense of moral and legal responsibility for an animal's welfare during their period of care (Festing 1989; Orlans1998; Dolan 2007).

Alternative methods such as computer models and other new teaching approaches such as surgical simulators and training in virtual environments have been used in ways to refine experimental techniques, to reduce the number of animals needed to obtain valid results or to replace animals with other feasible medical research methods (Fanua 2001; Furka 2006). Although these alternative methods are in most cases limited for technology transfer, few difficulties are reproducible (Gruber 2004).

Furthermore, experimental surgery represents an essential stage in the training of surgeons. It's most important aim is the improvement of human health. Balance between observance of the law and respect for the animals should be found and carefully observed in the exercise of this field. At present, it is impossible to advance surgical research without the use of animal models for some aspects of research. This chapter will outline some regulations that protect animals and manage their use in experimental surgery. The developments and advances in surgery are a continuing phenomenon; therefore, there still remains the need to teach practitioners new skills. Experimental surgery research and teaching, using animals is increasingly being questioned concerning the forms of animal use, maintaining animal costs, etc. Thus, a reflection is necessary on the rise in interest of alternatives to the use of live or dead animals, such as the use of surgical simulators, interactive 3D computer models and digital surgery programs.

EDUCATION ISSUES IN EXPERIMENTAL SURGERY

Experimental surgery has been acknowledged as fundamental to as surgeon's education. It simplifies surgical teaching and promotes the surgeon's scientific reasoning (de Montbrun 2012; Palter 2010).

Traditional Teaching Methods in Experimental Surgery

In general, these methods offer the benefits of seeing and learning surgical techniques, an opportunity to refine or improve proficiency in older surgical techniques, and also to help learn and practice the utilization of new surgical equipment. Specifically, animal models, humans or animal cadavers have been employed in these methods because of their analogy in anatomy and physiology compared with males and within species, which is suitable for all surgical and experimental purposes (Dewhurst 2011; Wilson-Sanders 2011; Dewhurst 2012).

Dissection and Vivisection

These practices provide better quality education, offer the best preparation for scientific careers, and help to familiarize trainees with basic operative skills with the hope of developing or improving their manipulative skill and dexterity (Elliot 1987; Connor 1997). However, this practice involves unnecessary pain, suffering, and the unnecessary killing of animals; it undermines conservation efforts and ignores welfare standards during animal capture, preparation, and shipping; it focuses only on descriptive biology to the detriment of creative scientific thinking and research; it causes some students to abandon further science education or careers; and it weakens the respect for life and the humane treatment of animals.

Surgery on Living Animal Model

This form of training is an effective form of a surgical teaching method because its share many of the same features as human surgery, thus replicating human surgery with high-fidelity (Tan 2011, Roberts 2006). As a result, trainees can practice every element of an operation, including not only the technical skills involved in a procedure, but also the avoidance of complications and their management when they arise. With this method, *in vivo* porcine and canine models have been used extensively in endoscopic, laparoscopic and other forms of training, including endoscopic submucosal dissection, cholecystectomy and coronary bypass (Tan 2011). *Ex vivo* animal tissue has also been occasionally used, but offers lower-fidelity simulation than live animals.

Use of this method has caused some concern like structural differences between human and animal anatomy, some ethical concerns, and its expensive and complex requirement in order to monitor hemostatic changes. Although efforts to minimize the need for animal use continues in the estimable future, it appears that animal experimentation is still essential to

enable scientists to have a more precise understanding of human disease, including its diagnosis, prognosis and therapeutic intervention (Kehinde 2013). A featured role in courses on animal ethics, animal welfare, and animal rights at all educational levels and fields should be to seriously consider the ceasing of unethical animal use (Balcombe 2000; Tanaka 2006).

Cadavers Obtained from Ethical Sources

Many body donation programs allow willing individuals to donate deceased, ethically-sourced cadavers for students or researchers to study, offering the chance to gain a deeper understanding of anatomy, physiology, pathology etc., and improve skills (Prioreschi 1998; Chambers 2015). Fresh cadaveric tissue is the gold standard for surgical simulation because of its approximation to living tissue and its anatomic structures, which are encountered in the operating room (Carey 2014). Although this form of method uses dead tissue and thus cannot faithfully emulate all physiological conditions, some cadaveric surgical courses have utilized pressurized systems to perfuse cadaveric tissues with blood, creating high-fidelity models for vascular, microvascular and trauma surgery (Carey 2014; Garret 2001). This method has been used for training flap coverage techniques as well as various endoscopic and laparoscopic operations (Carey 2015; Imakuma 2016).

Unfortunately, the use of human cadavers has caused some concerns (like the poor tissue compliance caused by embalming), thus making some surgeries difficult (Reznick 2006). The limited availability of human cadavers and their costs have restricted their widespread distribution and use (Anastakis 1999). Additionally, they require regular maintenance and special facilities, and are not reusable following certain procedures.

Application of Microsurgery

Microsurgery has expanded the scope of many surgical specialties and is evolving into an integral part of medical training programs. The complexity of microsurgery requires considerable time and resources for adequate training and practice (Chan 2007; Singh 2014). Microsurgery techniques are the only possibility permitted by law to execute experimental surgery research in rodents. These techniques can be performed many times and in a short time, thus improving dexterously surgical techniques and skills (Lahiri 2005; Mucke 2013; Yadav 2016). It is an indispensable tool in virtually all fields of surgery with a promising future. It offers several advantages over the conventional surgery such as cleaner and smaller incisions, lesser hemorrhage, minimal tissue handling and a closer wound approximation. It is a technically demanding procedure and has a steep learning curve. To set up an establishment is costly, and this also includes a restricted area of vision, loss of depth perception and loss of visual reference points.

Experimental microsurgery has the cross-disciplinary features of the sciences and techniques for the growth of medicine, pharmacology, veterinary studies, engineering, etc. Training for vascular anastomosis led to rodent transplantation models. These models were used for immunology and immunosuppressant research. Also, microsurgical techniques led to the master catheter technique for injecting various drugs and gene vectors (Kobayashi 2016).

Alternatives Teaching Methods in Experimental Surgery

In recent years, many scientists were devoted to the progress of animal welfare and development of alternatives to animal use in the life sciences. Starting in 1980, a remarkable decline in the number of animals used in research has been registered, although there has been an increase in the number of biomedical publications (Mukerjee 1997; Stephens 2001 and 2012); and the rise in the use of genetically modified animals has also led to this downward trend to continue (Taylor 2005; Ormandy 2009). However, this data is limited to the Western world, as statistics on animal use in emerging countries are unavailable (Kulpa-Eddy 2007; Rowan 2007).

These non-animal or alternative methods allow researchers or students to repeat the procedure until it can be proficiently and confidently understood. Also, this impacts budgets by dramatically reducing experimental costs (Schöffl 2003; Kurosawa 2008). Studies show that these alternative models reduced the numbers of live animals used by 80–100%. In most developed countries, these replacement alternatives have to meet the essential needs of humans, and have to be considered before animal experiments are proposed while they are also expected to provide satisfactory results (Liebsch 2011).

Changes occurring in healthcare systems around the world and patient safety have further been limited to the training experience of novice surgeons; consequently, these have resulted in extraordinary innovations in surgical simulations (Hutter 2006; Erel 2008; Wignall 2008). Advancements in computing and graphical capabilities offered new innovations in simulator technology. This rapidly incorporated surgical simulation technologies and offered an increasing potential to more closely mimic reality and present entire operations, allowing for the practice of surgeons to develop new skills and maintain those they already possess.

Surgical Simulators Teaching Models

With these teaching methods, trainees repeatedly practice techniques and manage complications in performing the simulated operation until they achieve expertise. This also aids the trainees in the development of critical psychomotor, technical, judgment skills (Gallager 2005); itwill also help in reducing operative times, lower complication rates and improve patient outcomes (Seymour 2008; Zevin 2014).

Surgical simulators originated over 2,500 years ago and have undergone an enormous amount of transformation since the early 1990s, evolving from mannequins of human cadaver models, live animal models (Cooper 2004), and plastic bench-top kits to 3D printing and patient-specific VR systems (Sarker 2007; Owen 2012; Valentine 2016). In recent years, a large number of surgical simulators have emerged that are unique to different surgical specialties, procedures and procedural variations. For example, different bench-top and VR simulators exist for the practice of endoscopic foreign body removal, laparoscopic common bile duct exploration, cleft palate repair and intestinal anastomosis among many others (Satava 2008). Specific simulators also exist for unique complications of a specific surgery, such as a sheep-based simulator for managing vascular emergencies during skull base surgery (Badash 2016). The following is a list of some of the most popular types of surgical simulators in use.

Bench-Top Simulators

These are synthetic stand-alone simulation models that allow for the practice and assessment of surgical skills. They were judged effective and simple, and are commonly used by educators to assess the proficiency of novice surgeons. Some bench-top simulators offer basic surgical techniques with low-fidelity like knot-tying and suturing (Sarker 2007); others combine both synthetic and animal parts with high-fidelity (Valentine 2016), and are able to replicate and train in complete operations, such as fracture fixation, joint replacement and aneurysm repair (Sarker 2007) and other minimally invasive surgeries (de Montbrun 2012).

Virtual Similators Models

These simulators are computer-based systems which allow for the practice of surgical techniques on a computer; the surgical trainee uses tools to manipulate a series of computerized images, thus performing surgery in a virtual environment (Tan 2011). Modern VR simulators create realistic environments that capture minute anatomical details with high accuracy. Therefore, high-fidelity and anatomically correct simulations are offered that are entirely reusable (de Visser 2011). They are designed to teach laparoscopic and endoscopic procedures (de Montbrun 2012), for instance, the MIST-VR system, which is a low-fidelity system designed to teach basic laparoscopic skills, suturing and knot-tying (Wilson 1997). High-fidelity VR systems include LapSim, Lap Mentor, and NeuroTouch. The Lap Mentor is a particularly inclusive system that includes over 65 cases in the fields of general surgery, gynecology, urology, and bariatric surgery. VR simulation has been found to reduce the operative time of surgical trainees and to improve the efficacy of their operative performance (Alaker 2016; Seymour 2008; Kundhal 2009; Hyltander 2002). It has been recommended that these simulators be formally included in surgical curricula (Zevin 2014; Tan 2011). The downside of VR simulations includes high costs, lack of force-feedback, and limited realism of some simulation models (Palter 2010).

Robot-Assisted Simulators Models

Recent developments in surgical simulations have involved the creation of simulation programs for the robot-assisted surgical system, da Vinci. The Robotic Surgical Simulator (RoSS) is a stand-alone device that teaches novice surgeons the skills required for performing robot-assisted surgery (RAS) (Rehman 2013; Liu 2015).

Robot-assisted surgery (RAS) simulators represent a relatively new development in the field of surgical simulation. Currently, there are 4 widely used RAS simulators for the da Vinci System: the SEP-Robot, RoSS, dV-Trainer, and the da Vinci Skills Simulator (Liu 2015). The RoSS and dV-Trainer are stand-alone devices with controls resembling those of the da Vinci system (Liu 2015). The da Vinci Skills Simulator is a hardware pack which loads a VR simulator onto the actual da Vinci device (Lyons 2013).

The da Vinci surgical system was first introduced in the United States in 1999. It involves a surgeon using foot pedals, dual hand controls and a controllable 3D camera to guide a robot through surgical procedures (Liu 2015). The surgeon views a virtual environment rather than

a live endoscopic feed through the user interface. The da Vinci skills simulators are low-fidelity and thus only allow for the practice of individual surgical tasks, like testing hand-eye coordination, tissue manipulation, suturing and knot-tying (Abboudi 2013). They also produce metrics of performance based on completion time, error measures, and motion analysis (Liu 2015).

3D Rapid Prototyping VR Simulators

These technologies involve the use of medical imaging, fused filament deposit, stereo-lithography, scintigraphy, MRI and 3D printers to build synthetic models of patient-specific organs and vasculature, and to create patient-specific 3D models that enable the planning of various operations (Vakharia 2016). Some of the models produced by rapid prototyping are able to replicate actual patients' anatomical structures with remarkable realism (Anderson 2016; Vakharia 2016; Khan 2014).

In the field of neurosurgical simulation, 3D printers are used to create reliable models of patient-specific cerebro-vascular pathology from information provided by CT angiograms (Ryo 2001). When printed with the surrounding bony structures, these models allow the surgeon to plan the trajectory of approach to aneurysms and to test different aneurysm clips for the appropriate size and shape (Vakharia 2016; Kimura 2009). In cardiac surgery, 3D-printed heart models rendered from cross-sectional patient images have been used in simulations to train staff on postoperative critical care (Olivieri 2016).

Patient-Specific VR Simulators

With these simulators, patient CT data is captured and reproduced on a 3D virtual simulator (Endo 2014; Makiyama 2015). This allows the surgeon to practice laparoscopic procedures preoperatively in a virtual environment with accurate renditions of the patient's anatomical variations. The overall accuracy of the simulator is high, capturing structures such as tumors, ureters, and renal arteries and veins with 95–100% accuracy (Makiyama 2015); and time needed for all simulation is relatively short, taking around 2.5 hours for hepatectomy and pancreatectomy simulators. These patient-specific simulators have emerged for use in pancreatectomies, hepatectomies, renal surgery, and hand surgery (Endo 2014; Makiyama 2015), and may be effective tools for the preoperative planning of complicated procedures. Unlike 3D printers, these simulators are also readily reusable and do not consume resources, further supporting their clinical utility.

Virtual Interactive Presence and Augmented Reality (VIPAR)

The VIPAR system utilizes augmented reality technology to enable audiovisual collaboration over the internet with just a 760 ms delay. The visual field of a surgeon in one location is converted into a simulation that is projected to a surgeon elsewhere. As a result, the operating surgeon can be guided in real-time by a more experienced surgeon or collaborate to identify anatomical structures, guide surgical maneuvers, and discuss an overall

surgical approach (Shenai 2011; Shenai 2014; Ponce 2014). VIPAR, known as telementoring, has been used in orthopedic surgery and in neurosurgery for training.

RESEARCH ISSUES IN EXPERIMENTAL SURGERY

Surgical techniques or treatment innovation is usually a result of frequently historical observations or experimentation that brings gradual improvements to existing techniques. Experimental surgery research is very indispensable and fundamental for research methods for making progress in surgery and medicine in general (Souba 2001; Javed 2005; de la Garza-Rodea 2007) (Table 1). In the last three decades, transplant surgery has obtained better results, undoubtedly because of the use of new drugs for immunosuppression perfusion, and organ storage, which were initiated from microsurgical transplantation models in rodents (Di Cataldo 2001) (Table 2).

Experimental surgical research faces two major problems in funding due to inflexible opposition of public opinion.

1. The law forbids the excessive use of large animals, instead of the use of small animals, which require special training of microsurgical techniques.
2. The use of living animals for experimental surgery should be limited to the minimum compatible with the pursuit of legitimate scientific ends (Di Cataldo 2001; Schnaider 2003; Schanaider 2004).

A new process in making decisions regarding resources, strategies to improve extramural funding, and new approaches for selecting research foci are needed to meet the issues and challenges in experimental research (Smythe 2010)

Ethical Issues and Experimental Surgery

Over the centuries, animal experiments were being increasingly prompted by existing clinical problems and carried out with the ultimate goal of developing new therapeutic approaches to tackle these issues. In the second half of twentieth century, the scientific world witnessed considerable progress in the development and acknowledgment of the Three Rs (replacement, reduction, and refinement). This principle has become the overarching principle of several legislative documents regulating animal use in science (Louhimies 2012). Biomedical researchers in both industry and academia have also acknowledged the central importance of the Three Rs and the need for more transparency regarding animal use in biomedical research (Carlsson 2004; Olsson 2011).

Refinement, Reduction and Replacement Principles

Ethical considerations make the relationship with animals very important, especially as communication between both researchers and animals is limited.

Table 1. Advantages and disadvantages of experimental surgery research

Advantages	Disadvantages
This research aids in controlling independent variables for the experiment's aim to remove extraneous and unwanted variables. The control over the irrelevant variables is higher compared to other research types or methods.	Experiments cannot be carried out at times because you cannot manipulate independent variables either due to ethical or practical reasons. Taking for instance a situation wherein you are enthusiastic about the effects of an individual's culture or the tendency to help strangers, you cannot do the experiment. The reason for this is simply because you are not capable of manipulating the individual's culture.
Easy Determination of Cause and Effect Relationship The experimental design of this type of research includes manipulating independent variables to easily determine the cause and effect relationship.	This controls irrelevant variables at times, and this also means creating situations that are somehow artificial.
Due to the control set up by experimenter and the strict conditions, better results can be achieved. Another good thing about experimental research is that experiments can be repeated and results can be checked again. Better results that have been obtained can also give the researcher greater confidence regarding the results.	Affect the efficiency of the results
Experimental research is gaining insights to instruction methods, performing experiments and combining methods for rigidity, determining the best for the population and providing greater transferability.	Results applied to one situation that can only be applied to one situation and may be hard to replicate and lastly difficulty in measuring human response
Surgical training is a multifaceted process that should produce not only a good clinician and technician, but also a good communicator, health advocate and professional.	Results may not be generalized into real-life situations
	Experimental designs are frequently contrived scenarios that do not often mimic the things that happen in the real world.
	Experimental research helps with internal validity; however, this is at the expense of the external validity.
	This research can be time consuming and expensive
	Several areas wherein experiments cannot be utilized due to ethical and practical considerations.
	The degree on which results can be generalized all over situations and real world applications are limited.
	Personal biases
	Unreliable samples

Source: https://occupytheory.org/advantages-and-disadvantages-of-experiments research.

Table 2. Medical advances depended on experimental surgery research

Year	Animal Model	Discovery	Authors
1930s		Modern anesthetics for surgery	
1940s		Heart-lung machine for open-heart surgery	
1950s		Kidney transplants. Cardiac pacemakers and replacement heart valves. Hip replacement surgery	
1960s		Corneal transplants Coronary bypass operations Heart transplants	
1970s		Improved sutures and other surgical techniques	
1980s		Immunosuppressant drugs for organ transplants CAT scanning for improved diagnosis Life-support systems for premature babies	
1990s		Laparoscopic surgical techniques	
2000s		Cell therapy	

Source: Giddens S, Giddens O. Future Techniques in Surgery. 2003; books.google.com.

An important ethical principle of animal use in experimental surgery education or research is that alternatives to live animals should be used whenever possible. One concept of alternatives has been outlined in the book *The Principles of Humane Animal Experimental Techniques*, Charles Thomas, Springfield, IL, by Russell and Burch in 1959, with the principle of 3Rs. This concept constituted a continuing effort to more efficiently use laboratory animals. It has been adopted by a number of scientists and many animal advocacy organizations, and is internationally accepted as criteria for humane animal use in research and testing (Inoue 2007; Russell 2005; Nuremberg Code). This concept established the care that must be taken to conduct research with animals, and according to these principles:

- The number of animals used in an experiment or procedure must be reduced in order to increase the methodological quality and enhance the statistical analysis of data.
- Refinement of the techniques used must have the purpose to decrease the incidence or amount of animal pain and distress, and provide their well-being based on their behavioral needs.
- Replacing experimented animals with *in vitro* and in silico models that could be alternatives in teaching and research. Alternately, live animals may be replaced with non-animal models, such as dummies for an introduction to dissection for teaching the structure of the animal or the human body, mechanical or computer models, audiovisual aids, or *in vitro* modeling. However, there are no alternative scientific methods that allow for the full replacement of animals in experimental surgery education or research studies. Disadvantages for replacement mostly stem from the fact that any models are dependent on pre-existing information. Live organisms are a complex system; some of the variables in physiology and pathology are unknown. Thus, any research study on new biological processes must utilize a living organism at some point. Advantages concerning replacement include the use of pre-existing knowledge for teaching, applying known principles to new systems to look for similarities, and using less expensive animals or models to screen large numbers of agents for toxicity or mutagenicity (Guhad 2005; Mardas 2013).

The concern within the scientific community and in the general public over the use of animals in research and education has put a system for protecting research subjects under increasing pressure. Under the currently dominant regulatory ethics paradigm, experimental surgery protocols for research or teaching issues must be reviewed and approved by an institutional review board (IRB) or equivalent, to protect study subjects and investigators or researchers from the inherent conflicts of interest (Moore 2000; Akelina 2001; Richmond 2002).

In experimental surgery research, reducing the number of animals should not compromise the detection of biological effects nor lead to the repetition of experiments. The refinement is influenced by a study design and sample size calculation, the control of variation, the statistical hypothesis, and the choice of the statistical test used for data analysis and interpretation. Intra-sample variation can be reduced by using animals that are genetically and sanitarily homogenous, in addition to controlling environmental variables (Monamy 2000; Mohammad 2013).

Ethical consideration in experimental surgical studies must consider the suitability of the selected model, management of the animal throughout the study or training, and euthanasia after the study/training; this is all done for an attempt to eliminate or reduce to a minimum the discomfort and pain of the animal model (Snow 2008).

Much still remains to be done to establish total management for animal experiments. Improvement of the effective utilization of these animal experiments is also required from both economical and ethical points of view (Akelina 2001; Ramsey 2007). Before starting surgical training, sufficient education concerning animal ethics and dry laboratory training should be completed; the point of departure in the existing legislation on animal experimentation is the principle of responsible use (Inoue 2007; Hendriksen 2006; Tanaka 2006; Orlans 1996).

REGULATIONS ISSUES AND EXPERIMENTAL SURGERY

Since the beginning of the 21st century, much effort has been dedicated to animal welfare throughout world (Table 3). Animal rights refer to the moral right of animals to be treated with respect and without exploitation. The rights of animals under captivity or domestication have been universally declared as follows: The right to be free from hunger, the right to be free from discomfort, the right to be free from fear and distress, and the freedom to express normal behavior (Table 4).

In scientific studies or training, whereas there are no definite national laws guiding or regulating the use of animals, several laws have been in existence to regulate the action of humans towards animals. These laws have guided how, when and the manner in which to conduct trainings as well as scientific researches on animals. Several institutions and universities have put in place guidelines for the use of animals in scientific studies and trainings (Richmond 2002; Dolan 2007).

For animal use in experimental surgery, legislation required that all live animals operated on for research, teaching or testing purposes must be regulated by laws and regulations clearly described in the Guide for the Care and Use of Laboratory Animals (CCAC 1984); regulations also established the oversight system of the Institutional Animal Care and Use Committees (IACUCs) to evaluate research protocols, review care programs and inspect laboratory facilities, assess and educate laboratory personnel, and investigate complaints about the misuse or mistreatment of animals. (Keune 2014).

Proposals of animal use are reviewed based on the potential for learning new information, or for teaching skills or concepts that cannot be obtained using an alternative (Keune 2014). Also, there must be a provisions ensuring that animal surgeries are performed in as humane a manner as possible, minimizing pain, distress or discomfort. Provisions also include that all personnel with animal contact be trained and be skilled in any experimental procedures that will be performed at each research or educational institution. In addition, analgesics, anesthetics and sedatives must be used when needed (Hampshire 2007). Finally, basic husbandry requirements must be specified, ensuring that pre- and post-operative care are provided in an optimal manner (Flecknell 1987; Wall 2014).

Table 3. Chronology of law and regulations/worldwide

Year	Law/Regulations	Country
1822	"An Act to Prevent the Cruel and Improper Treatment of Cattle" "Martin's Act" or "The Act of 1822"	United Kingdom
1824	Society for the Prevention of Cruelty to Animals (SPCA)	United Kingdom
1828	America's first animal protection act, outlawing cruelty against cattle, sheep and horses	USA
1840	Royal Society for the Prevention of Cruelty to Animals (RSPCA)	United Kingdom
1846	The societe protectrice des animaux (Animal Protection Society)	France
1866	American Society for the Prevention of Cruelty to Animals (ASPCA)	USA
1875	Cruelty to Animals Act of 1876	UK
1876	Victoria Street Society for the Protection of Animals from Vivisection	UK
1877	American Humane Association (AHA)	USA
1883	American Antivivisection Society (AAVS)	USA
1898	British Union for the Abolition of Vivisection (BUAV)	United Kingdom
1954	Humane Society of the United States (HSUS)	USA
1954 - 1957	National Catholic Society for Animal Rights, which is later extended beyond its denominational origins and renamed the International Society for the Animal Rights (ISAR)	USA
1966	Animal Welfare act (Laboratory Animal Welfare Act)	USA
1992	Congress enacts the Animal Enterprise protection Act	USA
2000		

Source: Bickenbach JE. Ethics, law, and policy. 2012; books.google.com.

Table 4. Universal declaration of the right of animals

This declaration hereby proclaims that:
Article 1: All animals are born equal due to life and the same rights to existence.
Article 2: 1. All animals are entitled to respect. 2. Man as an animal shall not arrogate to himself the right to exterminate or inhumanely exploit other animals. 3. All animals have a right to the attention, care and protection of Man.
Article 3: No animal shall be ill-treated or subjected to "animal acts." If an animal must be killed, this should be instantaneous and without distress.
Article 4: Wild animals have a right to liberty in their environment where they should be allowed to procreate. Deprivation of freedom even for educational purposes is an infringement of this right
Article 5: Animals living traditionally in a human environment have a right to live and grow in the rhythm and under the conditions of life and freedom peculiar to their species. Any interference by Man with this rhythm or conditions for purpose of gain is an infringement of this right.
Article 6: All companion animals have the right to complete their natural life span. Abandonment of an animal is a cruel and degrading act.
Article 7: All working animals are entitled to a reasonable limitation of the duration and intensity of work to the necessary nourishment and rest.
Article 8: Animal experimentation, involving physical or psychological suffering is incompatible with the right of animals, whether it be for scientific, medical or commercial or any other form of research. Two replacement methods must be used and developed.
Article 9: Where animals are used in the food industry, they shall be reared, transported, lair aged and killed without the infliction of suffering.
Article 10: 1. No animal shall be exploited to the amusement of Man. 2. Exhibitions and spectacles involving animals are incompatible with their dignity.
Article 11: Any act involving the wanton killing of an animal is biocide, which is a crime against life.
Article 12: 1. Any act involving the mass killing of wild animals is genocide that is a crime against the species. 2. Pollution or destruction of the natural environment leads to genocide.
Article 13: 1. Dead animals shall be treated with respect. 2. Scenes of violence involving animals shall be banned from cinemas and television except if for humane education.
Article 14: Representatives of movements that defend animal rights should have an effective voice at all levels of government. The rights of animals, like human rights, should enjoy the protection of law. To conscientize the scientific community to this rights, the 24th of April has been observed as the day of laboratory animal protection.

Source: Wise S. Rattling the cage: Toward legal rights for animals. 2014; books. google.com.

In several countries, legal precautions guiding the use of animals for research vary in the level of protection given to animals. In response to these worldwide variations, the Council for International Organizations of Medical Sciences published in 1985 a set of International Guiding Principles for Biomedical Research Involving Animals, which were intended to provide a "conceptual and ethical framework" for countries with no legislation. In the United States, the Animal Welfare Act operates as the main federal law relating to laboratory animals (Nuno 2013) (Table 3; Table 4).

CHALLENGES IN EXPERIMENTAL SURGICAL EDUCATION

The Choice of the Animal Model: In experimental surgery research or education training, the choice of an animal model which suits all fields of application is almost impossible. Anatomic considerations such as size of organs, accessibility of the organs and tissues of interest are the primary determinants for model selection.

Outcome Issues: Experimental results should be published, regardless of statistical significance, to avoid conducting redundant studies; medical literature reviews advance that the number of laboratory animals used in past experiments could have been diminished while still obtaining the same statistically valid results.

In some cases, application of one alternative concept may have an adverse effect in another area (i.e., using a "lower" animal, minimizing pain, or distress may require using more animals) (Remie 2001).

The limitations resulting from interspecies differences, the distortion of outcomes arising from experimental environments and protocols, and the poor methodological quality of many animal experiments are likely to be technically and theoretically impossible to overcome.

Ethical Challenge: Industrially farmed animals(like pigs) are less prone to ethical considerations. These animals are more convenient for their fecundity and also are defined by the development of inbred major histocompatibility complex (Bhogal 2006). There is still a lack of communication between researchers and the population, leading to misunderstandings and making researchers unpopular (Plomer 2005).

Surgical Innovation: There are no clear regulations governing innovative surgery. Surgical innovations raise challenging ethical issues since the risks of the novel operation may not be known (Frader 1998; Ergina 2009; Johnson 2012). In addition, even if the risks are known by the innovator, the actual risks to experimental animals when learning the new techniques are unknown (Angelos 2013; Broekman 2016; Geiger 2015; Tan 2011; Reitsma 2002).

CONCLUSION

World health challenges allow surgery as a science to become complex and technically demanding. Experimental surgery as an integral part of surgical training programs to equip generations of surgeons with acquired skills and to meet the challenges of the future.

Training and research in surgical techniques have historically relied on the use of live animal models. These animal experiments have played a vital role in surgery progression and

remain indispensable in the foreseeable future. Focusing on the continuous improvement of these experiments animals' well-being, as well as further development of replacement alternatives for these models are still important.

The recent evolution in technology has brought about extraordinary innovations in surgery training, such as surgical simulation as an alternative to previous methods. Surgical simulation-based training is widely used in surgery education, helping students and trainees to develop good technical skills before practicing on real patients. However, various forms of surgical simulators are often being used with limited evidence-based data to support their validity and reliability. Several factors such as budget constraints, medicolegal concerns, etc. have to be overcome prior to the effective use of the surgical simulators as alternative methods in experimental surgery research and training.

To meet the challenges that occur within healthcare systems around the world remains important; experimental surgery proved to be a cornerstone in advancing surgical processes and improving surgical innovations. Principal goals in experimental surgery education should include using animal models, simulation technology and efforts to standardize technical evaluation techniques. In research, continuous strategies to improve funding and build upon new approaches to differentiate the strengths related to surgical practice should be supported.

REFERENCES

Abboudi H, Khan MS, Aboumarzouk O. Current status of validation for robotic surgery simulators - a systematic review. *BJU. Int.* 2013; 111:194–205.

Akelina Y. Applying the 3 R's: Training course in surgical techniques. *Lab. Anim*. 2001; 30: 48–52.

Alaker M, Wynn GR, Arulampalam T. Virtual reality training in laparoscopic surgery: A systematic review & meta-analysis. *Int. J. Surg*. 2016; 29: 85–94.

Aldhous P, Coghlan A, Copley J. Animal experiments: Let the people speak. *New Sci.* 1999; 162: 26–31.

Anastakis DJ, Regehr G, Reznick RK. Assessment of technical skills transfer from the bench training model to the human model. *Am. J. Surg*. 1999; 177:167–170.

Anderson JR, Thompson WL, Alkattan AK. Three-dimensional printing of anatomically accurate, patient specific intracranial aneurysm models. *J. Neurointerv. Surg*. 2016; 8: 517–520.

Angelos P. Ethics and surgical innovation: challenges to the professionalism of surgeons. *Int.J. Surg.* 2013; 11 Suppl 1: S2–S5.

Badash I, Burtt K, Solorzano CA and Carey JN. Innovations in surgery simulation: a review of past, current and future techniques. *Ann. Transl. Med*. 2016; 4(23): 453.

Badyal DK, Modgill V, Kaur J. Computer simulation models are implementable as replacements for animal experiments. *Altern. Lab. Anim*. 2009; 37:191–195.

Balcombe J. 1st ed. Washington: Humane Society Press; 2000. *The use of animals in higher education: Problems, alternatives and recommendations*. http://www.humanesociety.org /assets/pdfs/ parents educators/the use of animals in higher ed.pdf.

Balner H, Marquet RL. Transplantation biology−past and present: reappraisal of "breakthroughs" since 1955. *Transplant Proc*. 1981; 13(1 Pt 1):13–18.

Bennett BT, Brown MJ, Schoffield JC. *Essentials for animal research: a primer for research personnel*. Beltsville, MD: National Agricultural Library 1990.

Bertoloni MD. Early modern experimentation on live animals. *J. Hist. Biol*. 2013; 46:199–226.

Bhogal N and Combes R. The relevance of genetically altered mouse models of human disease, Alternatives to Laboratory Animals: *ATLA*. 2006; 34(4):429–454.

Billingham RE. Contributions of transplantation to modern biology andmedicine. *Transplant Proc*. 1977; 9(1): xxxix-xlvii. Review.

Broekman ML, Carrière ME, Bredenoord AL. Surgical innovation: the ethical agenda: A systematic review. *Medicine* (Baltimore). 2016; 95(25): e3790. Review.

Canadian council on animal care. *Guide to the care and use of experimental animals*. Vol. 2. Ottawa, Ontario: CCAC, 1984.

Carey JN, Rommer E, Sheckter C. Simulation of plastic surgery and microvascular procedures using perfused fresh human cadavers. *J. Plast. Reconstr. Aesthet. Surg*. 2014; 67: e42–e48.

Carey JN, Caldwell AM, Coughlin RR. Building Orthopaedic Trauma Capacity: IGOT International SMART Course. *J. Orthop. Trauma.* 2015; 29 Suppl 10: S17–S19.

Carlsson HE, Hagelin J, Hau J. Implementation of the 'three Rs' in biomedical research. *Vet.Record*. 2004; 154:467–470.

Chambers S, Deehan D, Gillinder S. Cadaveric surgical training improves surgeon confidence. *Bulletin*. 2015; 97: E1–E4.

Chan WY, Matteucci P, Southern SJ. Validation of microsurgical models in microsurgery training and competence: a review. *Microsurgery* 2007; 27(5):494–499.

Crettaz von Roten F. Public perceptions of animal experimentation across Europe. *Public. Underst. Sci*. 2012.

Connor JT. Cruel knives? Vivisection and biomedical research in Victorian English Canada. *Can. Bull. Med. Hist.* 1997; 14:37–64.

Cooper JB, Taqueti VR. A brief history of the development of mannequin simulators for clinical education and training. *Qual. Saf. Health Care.* 2004; 13 Suppl 1: i11–8.

Davis N. *History of Medicine*. Cleveland Press; Chicago, IL, USA: 1903.

Dear P. The meanings of experience. In: Park K., Daston L., editors. *The Cambridge History of Science*, Volume 3: Early Modern Science. Cambridge University Press; Cambridge, UK: 2006.

de la Garza-Rodea AS, Padilla-Sánchez L, de la Garza-Aguilar J, Neri-Vela R. Some notes on the history of the experimental surgery laboratory. Reflections on its relevance in education and surgical research. *Cir. Cir*. 2007; 75(6):499–505.

de Montbrun SL, Macrae H. Simulation in surgical education. *Clin. Colon Rectal Surg*. 2012; 25: 156–165.

de Visser H, Watson MO, Salvado O. Progress in virtual reality simulators for surgical training and certification. *Med. J. Aust*. 2011; 194: S38–S40.

Dewhurst DG, Kojic ZZ. Replacing animal use in physiology and pharmacology teaching in selected universities in eastern Europe-charting a way forward. *Altern. Lab. Anim*. 2011; 39:15–22.

Dewhurst DG, Hemmi A. A survey of animal use and alternatives in higher education in Europe. University of Edinburgh, UK. ALTEX. 2012; 1:1–14.

Di Cataldo A, Trombatore G, Giraldo R, Rodolico M, Sorbello M, Li Destri. Experimental research and surgery: why, how, and when? *Microsurgery* 2001: 118–120.

Dikshit RK. Animal experiments: Confusion, contradiction, and controversy. *Indian. J.Pharmacol.* 2012; 44: 661–662.

Dolan K. *Laboratory Animal Law: Legal Control of the Use of Animals in Research*. 2nd ed. Blackwell Publisher; Oxford, UK: 2007.

Elliot P. Vivisection and the emergence of experimental physiology in nineteenth-century France. In: Rupke N.A., editor. *Vivisection in Historical Perspective*. Croom Helm; London, UK: 1987. p. 125.

Endo K, Sata N, Ishiguro Y. A patient-specific surgical simulator using preoperative imaging data: an interactive simulator using a three-dimensional tactile mouse. *J. Comput. Surg.* 2014; 1:1–8.

Erel E, Aiyenibe B, Butler PE. Microsurgery simulators in virtual reality: review. *Altern. Lab.Anim.* 2008; 36(2):153–160.

Ernst HC. *Animal Experimentation; A Series of Statements Indicating its Value to Biological and Medical Science*. Little, Brown, and Company; Boston, MA, USA: 1902.

Ergina PL, Cook JA, Blazeby JM, Boutron I, Clavien PA, Reeves BC, Seiler CM, for the Balliol Collaboration. Challenges in evaluating surgical innovation. *Lancet 2009*; 374(9695):1097–1104.

Fanua S, Kim J, Shaw-Wilgis EF. Alternative model for teaching microsurgery. *Microsurgery* 2001; 21:379–382.

Felts JH. Richard Lower: Anatomist and physiologist. *Ann. Int. Med*. 2000; 132:420–423.

Festing S, Wilkinson R. The ethics of animal research. Talking point on the use of animals in scientific research. *EMBO. Rep.* 2007; 8: 526–530.

Festing S. Animal experiments: The long debate. *New Sci*. 1989; 121:51–54.

Flecknell PA. *Laboratory animal anesthesia*. London: Academic Press, 1987.

Frader JE, Caniano DA. Research and innovation in surgery. In: McCullough LB, Jones JW, Brody BA (Eds). *Surgical ethics*. NY: Oxford University Press; 1998. p. 217–241.

Furka I, Brath E, Nemeth N, Miko I. Learning microsurgical suturing and knotting techniques: comparative data. *Microsurgery* 2006; 26: 4–7.

Gallagher AG, Ritter EM, Champion H. Virtual reality simulation for the operating room: proficiency-based training as a paradigm shift in surgical skills training. *Ann. Surg*. 2005; 241: 364–372.

Garrett HE. A human cadaveric circulation model. *J. Vasc. Surg*. 2001; 33:1128–1130.

Gay WI., ed. Methods of animal experimentation. *Research surgery and care of the research animal-Part A: patient care, vascular access, and telemetry*. NY: Academic Press, 1986a; VII.

Gay WI., ed. Methods of animal experimentation. *Research surgery and care of the research animal-Part B: surgical approaches to the organ systems*. NY: Academic Press, 1986b; VII.

Gay WI., ed. Methods of animal experimentation. *Research surgery and care of the research animal-Part C: surgical approaches to the organ systems*. NY: Academic Press, 1989; VII.

Geiger JD, Hirschl RB. Innovation in surgical technology and techniques: Challenges and ethical issues. *Semin. Pediatr. Surg*. 2015; 24(3):115–121. Review.

Geller MJ. Phlegm and breath—Babylonian contributions to hippocratic medicine. In: Finkel I.L., Geller M.J., editors. *Disease in Babylonia*. Brill; Leiden, the Netherlands: 2007

Guerrini A. *Experimenting with Humans and Animals: From Galen to Animal Rights*. Johns Hopkins University Press; Baltimore, MD, USA: 2003.

Guhad F. Introduction to the 3 Rs (refinement, reduction and replacement) Contemp. *Top Lab. Anim. Sci*. 2005; 4: 58–59.

Gregory A. *Harvey's Heart: The Discovery of Blood Circulation*. Icon Books Ltd.; Cambridge, UK: 2001

Gruber FP, Hartung T. Alternatives to animal experimentation in basic research. *ALTEX*. 2004; 21 Suppl 1:3–31.

Hamburger J. Past, present, and future of transplantation. *Transplant Proc*.1981;13(1 Suppl 1):41–43.

Hampshire V, Gonder JC, eds. *Research Anesthesia, Analgesia, and Surgery*. Maryland: Scientists Center for Animal Welfare (SCAW); 2007:225.

Hassan AZ, B Kadima, D Remi-adewumi, A Awasum and T Abubakar. Animal models in surgical training: Choice and ethics. *Nigerian Journal of Surgical Research* 2006; 7(3).

Hendriksen CF. Developments in the area of animal experiments in biomedical research. *Ned.Tijdschr. Geneeskd*. 2006; 150(52):2857–2862.

Hutter MM, Kellogg KC, Ferguson CM. The impact of the 80-hour resident workweek on surgical residents and attending surgeons. *Ann. Surg.* 2006; 243: 864–871; discussion 871–875.

Hyltander A, Liljegren E, Rhodin PH. The transfer of basic skills learned in a laparoscopic simulator to the operating room. *Surg. Endosc.* 2002; 16:1324–1328.

Imakuma ES, Ussami EY, Meyer A. Laparoscopic training model using fresh human cadavers without the establishment of penumoperitoneum. *J. Minim. Access. Surg*. 2016; 12: 190–193.

Inoue T, Kodama Y. Future Alternatives in "3Rs": Learning from History; *Proceedings of the 6th World Congress on Alternatives & Animal Use in the Life Sciences*; Tokyo, Japan. 21–25 August 2007; pp. 257–260.

Javed MS, Harrison E, Taylor I. The role of research in surgical training. *Bulletin of the Royal College of Surgeons of England*. 2005; 85(4):120–123.

Jensen SL, Gregersen H, Shokouh-Amiri MH, Moody FG, eds. *Essentials of Experimental Surgery: Gastroenterology*. Amsterdam, the Netherlands: Harwood Academic Publishers; 1996.

Johnson J, Rogers W. Innovative surgery: the ethical challenges. *J. Med. Ethics*. 2012; 38(1):9–12.

Kehinde EO. They see a rat; we seek a cure for diseases: the current status of animal experimentation in medical practice. *Med. Princ. Pract*. 2013; 22 Suppl 1:52–61.

Keune JD, Kodner IJ. The importance of an ethics curriculum in surgical education. *World J. Surg.* 2014; 38(7):1581–586.

Khan IS, Kelly PD, Singer RJ. Prototyping of cerebral vasculature physical models. *Surg. Neurol. Int.* 2014; 5:11.

Kimura T, Morita A, Nishimura K. Simulation of and training for cerebral aneurysm clipping with 3-dimensional models. *Neurosurgery* 2009; 65:719–25; discussion 725–726.

Knight A. Systematic reviews of animal experiments demonstrate poor human clinical and toxicological utility. *Altern. Lab. Anim.* 2007; 35(6): 641–59.

Kulpa-Eddy J, Snyder M, Stokes W. A review of trends in animal use in the united states (1972–2006); *Proceedings of the 6th World Congress on Alternatives & Animal Use in the Life Sciences;* Tokyo, Japan. 21–25 August 2007; pp. 163–165.

Kundhal PS, Grantcharov TP. Psychomotor performance measured in a virtual environment correlates with technical skills in the operating room. *Surg. Endosc*. 2009; 23:645–649.

Kurosawa TM. *Alternatives to animal experimentation v.s. animal school*. Yakugaku Zasshi. 2008; 128:741–746.

Kobayashi E, Haga J.Translational microsurgery. A new platform for transplantation research. *Acta. Cir. Bras*. 2016; 31(3):212–217. Review

Lahiri A, Lim AYT, Oifen Z, Lim BH. Microsurgical skills training: A new concept for simulation of vessel wall suturing. *Microsurgery* 2005; 25:21–24.

Lee SH, Fisher B. Portacaval shunt in the rat. *Surgery* 1961; 50: 668–672.

Liebsch M, Grune B, Seiler A, Butzke D, Oelgeschla¨ger M and Pirow R. Alternatives to animal testing: current status and future perspectives. *Arch. Toxicol.* 2011; 85: 841–858.

Liu M, Curet M. A review of training research and virtual reality simulators for the da Vinci surgical system. *Teach Learn Med*. 2015; 27:12–26.

Louhimies S. Eu Directive 2010/63/EU: "Implementing the three Rs through policy" *ALTEX. Proc*. 2012; 1:27–33.

Lyons C, Goldfarb D, Jones SL. Which skills really matter? Proving face, content, and construct validity for a commercial robotic simulator. *Surg. Endosc*. 2013; 27:2020–2030.

Maehle A.-H., Tröhler U. Animal experimentation from antiquity to the end of the eighteenth century: Attitudes and arguments. In: Rupke N.A., editor. *Vivisection in Historical Perspective*. Croom Helm; London, UK: 1987.

McMullen E. Anatomy of a physiological discovery: William Harvey and the circulation of the blood. *J. Roy. Soc. Med*. 1995; 88:49–498.

Makiyama K, Yamanaka H, Ueno D. Validation of a patient-specific simulator for laparoscopic renal surgery. *Int. J. Urol*. 2015; 22: 572–576.

Mardas D, Mohammad AA, Bas B, Francesca C, Pierre C, Rodger C. A framework program for the teaching of alternative methods (replacement, reduction, refinement) to animal experimentation. *Altex.* 2013; 28: 341–352.

Mohammad AA, Mohammed Z, Karukayil JM. Alternatives to animals in education, research and risk assessment: An overview with special reference to Indian context. *ALTEX*. 2013; 2: 5–19.

Monamy V. *Animal Experimentation: A Guide to the Issues*. Cambridge University Press; Cambridge, UK: 2000.

Moore FD. Ethical problems special to surgery: Surgical teaching, surgical innovation, and the surgeon in managed care. *Arch. Surg*. 2000; 135(1):14–16.

Murray JE, Lang S, Miller BF. Observations on the natural history of renal homotransplants in dogs. *Surg. Forum* 1955; 5: 241–244.

Mucke T, Borgmann A, Ritschl LM, Loeffelbein DJ, Wolff KD. Microvascular training of medical srudents and surgeons-a comparative prospective study. *J. craniomaxillofac surg*. 2013; 41(8): e187–e190.

Mukerjee M. Trends in animal research. *Sci. Am*. 1997; 276:86–93.

Nuffield Council on Bioethics. The Ethics of Research Involving Animals. Nuffield Council on Bioethics; London, UK: 2005. *The context of animal research: Past and present.*

Nuno HF. *Animal Experiments in Biomedical Research: A Historical Perspective*. 2013; 19.

Nuremberg Code. *Regulations and Ethical Guidelines, Office of Human Subjects Research*, National Institutes of Health. http://ohsr.od.nih.gov/guidelines/nuremberg.html.

Olivieri LJ, Su L, Hynes CF. "Just-In-Time" Simulation Training Using 3-D Printed Cardiac Models After Congenital Cardiac Surgery. *World J. Pediatr. Congenit. Heart Surg*. 2016; 7:164–8. 10.1177/2150135115623961

Olsson IAS, Robinson P, Sandøe P. Ethics of animal research. In: Hau J, Schapiro SJ, editors. *Handbook of Laboratory Animal Science-Volume I: Essential Principles and Practices*. 3rd ed. CRC Press; Boca Raton, FL, USA: 2011.

Orlans FB. History and ethical regulation of animal experimentation: An international perspective. In: Kuhse H., Singer P., editors. *A Companion to Bioethics*. Blackwell Publishing; Oxford, UK: 1998.

Orlans FB. *In the Name of Science: Issues in Responsible Animal Experimentation*. Oxford University Press; Cary, NC, USA: 1996.

Ormandy EH, Schuppli CA, Weary DM. Worldwide trends in the use of animals in research: The contribution of genetically-modified animal models. *Altern. Lab. Anim*. 2009; 37: 63–68.

Owen H. Early use of simulation in medical education. *Simul. Healthc*. 2012; 7:102–116.

Palter VN, Grantcharov TP. Simulation in surgical education. *CMAJ*. 2010; 182:1191–1196.

Pearce RM. Research in medicine. II. The development of laboratories for the medical sciences. *Popul. Sci. Month*. 1912; 80: 548–562.

Petrini C. Experimentation in organ transplants compared with clinical trials: ethical problems. *Clin. Ter*. 2013; 164(4): e287–e291.

Plomer A. *The law and ethics of medical research: International bioethics and human rights*. London: Cavendish Publishing; 2005.

Ponce BA, Jennings JK, Clay TB. Telementoring: use of augmented reality in orthopaedic education: AAOS exhibit selection. *J. Bone Joint Surg. Am*. 2014; 96: e84.

Porter R. The eighteenth century. In: Conrad L.I., Neve M., Nutton V., Porter R., Wear A., editors. *The Western Medical Tradition: 800 BC-1800 AD*. Cambridge University Press; Cambridge, UK: 1995.

Pound P, Ebrahim S, Sandercock P, Bracken MB, Roberts I. Where is the evidence that animal research benefits humans? *BMJ*. 2004; 328:514–517.

Prioreschi P. *A History of Medicine*, Volume 3: Roman Medicine. Horatius Press; Omaha, NE, USA: 1998.

Ramsey KM, Weijer C. Ethics of surgical training in developing countries. *World J. Surg.* 2007; 31(11):2067–2069; discussion 2070–2071.

Rehman S, Raza SJ, Stegemann AP. Simulation-based robot-assisted surgical training: a health economic evaluation. *Int. J. Surg*. 2013; 11:841–846.

Reitsma AM, MorenoJD. Ethical regulations for innovative surgery: the last frontier? *J. Am*. Coll. Surg.2002; 194792801.

Remie R. The PVC rat and other alternatives in microsurgical training. *Lab. Anim*. 2001; 30:48–52.

Reznick RK, MacRae H. Teaching surgical skills-changes in the wind. *N. Engl. J. Med*. 2006; 355:2664–2669.

Richmond J. Refinement, reduction, and replacement of animal use for regulatory testing: future improvements and implementation within the regulatory framework. *ILAR. J.* 2002; 43: S63–S68.

Ringach D. A civil conversation about animals in research. *Science* 2010; 327:1351.

Roberts KE, Bell RL, Duffy AJ. Evolution of surgical skills training. *World J. Gastroenterol*. 2006; 12:3219–3224.

Rogers DA. Ethical and educational considerations in minimally invasive surgery training for practicing surgeons. *Semin. Laparosc. Surg.* 2002; 9(4): 206–211.

Rollin BE. The ethics of animal research. Talking point on the use of animals in scientific research. *EMBO. Rep*. 2007; 8:521–525.

Rowan AN. A brief history of the animal research debate and the place of alternatives. *AATEX*. 2007; 12: 203–211.

Russell WM. The three Rs: Past, present and future. *Anim. Welf.* 2005; 14:279–286.

Ryo M, Schigeaki K. HDTV single camera 3D system and its application in microsurgery. Sterioscopic display and virtual reality systems. *Proc.* 2001; SPIE2177: 31–34.

Satava RM. Historical review of surgical simulation--a personal perspective. *World J. Surg.* 2008; 32:141–148.

Sarker SK, Patel B. Simulation and surgical training. *Int. J. Clin. Pract.* 2007; 61: 2120–2125.

Shackelford J. *William Harvey and the Mechanics of the Heart*. Oxford University Press; New York, NY, USA: 2003.

Schanaider A, Sylva PC. The use of animal in experimental surgery. *Acta. Cir. Bras.* 2004; 19(4): 441–447.

Schnaider TB, Souza C. Ethics and animal experiments. *Rev. Bras. Anestesiol*. 2003; 53(2):278–285.

Schöffl H, Froschauer SM, Dunst KM, Hager D, Kwasny O, Huemer GM. Strategies for the reduction of live animal use in microsurgical training and education. *Microsurgery* 2003; 23(2):147–152.

Seymour NE. VR to OR: a review of the evidence that virtual reality simulation improves operating room performance. *World J. Surg*. 2008; 32:182–188.

Shenai MB, Dillavou M, Shum C. Virtual interactive presence and augmented reality (VIPAR) for remote surgical assistance. *Neurosurgery* 2011; 68:200–207; discussion 207.

Shenai MB, Tubbs RS, Guthrie BL. Virtual interactive presence for real-time, long-distance surgical collaboration during complex microsurgical procedures. *J. Neurosurg.* 2014; 121:277–284.

Smythe WR. The future of academic surgery. *Acad. Med.* 2010; 85(5):768–774.

Singh M, Saxena A. Microsurgery: A Useful and Versatile Tool in Surgical Field. *Surgery Curr. Res.* 2014; 4: 194.

Snow SJ. *Blessed Days of Anaesthesia: How Anaesthetics Changed the World*. Oxford University Press; New York, NY, USA: 2008.

Souba WW, Wilmore DW, eds. *Surgical Research.* San Diego, CA: Academic Press. 2001: 1414.

Stephens ML, Goldberg AM, Rowan AN. The first forty years of the alternatives approach: Refining, reducing, and replacing the use of laboratory animals. In: Salem DJ, Rowan

AN, editors. *The State of the Animals*: 2001. Humane Society Press; Washington, DC, USA: 2001. pp. 121–135.

Stephens ML. Pursuing Medawar's challenge for full replacement. *ALTEX. Proc*. 2012;1: 23–26.

Stuart FP. Transplantation. *Curr. Probl. Surg*. 1968: 3–51. Review.

Swindle MM and ADAMS RJ, editors. *Experimental surgery and physiology: induced animal models of human disease*. Baltimore, MD: Williams and Wilkins, 1988.

Swindle MM. *Swine in the Laboratory: Surgery, Anesthesia, Imaging, and Experimental Techniques*, 2nd ed. Boca Raton, FL: CRC Press; 2007:402.

Tan VK, Chow PK. An approach to the ethical evaluation of innovative surgical procedures. *Ann. Acad. Med. Singapore* 2011; 40(1):26–29. Review.

Tan SS, Sarker SK. Simulation in surgery: a review. *Scott. Med. J.* 2011; 56:104–109.

Tanaka H, Kobayashi E. Education and research using experimental pigs in a medical school. *J. Artif. Organs*. 2006; 9(3):136–143.

Taylor K, Gordon N, Langley G, Higgins W. Estimates for worldwide laboratory animal use in 2005. *ATLA.* 2008; 36: 327–342.

Vakharia VN, Vakharia NN, Hill CS. Review of 3-Dimensional Printing on Cranial Neurosurgery Simulation Training. *World Neurosurg.* 2016; 88:188–198.

Valentine R, Padhye V, Wormald PJ. Simulation Training for Vascular Emergencies in Endoscopic Sinus and Skull Base Surgery. Otolaryngol. *Clin. North Am*. 2016; 49:877–877.

Van der Worp HB, Howells DW, Sena ES, Porritt MJ, Rewell S, O'Collins V, Macleod MR. Can animal models of disease reliably inform human studies*? PLoS Med.* 2010; 7.

von Staden H. *Herophilus: The Art of Medicine in Early Alexandria*. Cambridge University Press; Cambridge, UK: 1989.

Wall AE. Ethics in global surgery. *World J. Surg.* 2014; 38(7):1574–1580. Review.

Wignall GR, Denstedt JD, Preminger GM, Cadeddu JA, Pearle MS, Sweet RM, McDougall EM. Surgical simulation: a urological perspective. *J. Urol*. 2008; 179(5):1690–1699.

Wilson MS, Middlebrook A, Sutton C. MIST VR: a virtual reality trainer for laparoscopic surgery assesses performance. *Ann. R. Coll. Surg. Engl*. 1997; 79: 403–404.

Wilson-Sanders SE. Models for biomedical research, testing and education. *ILAR. J*. 2011; 52:126–152.

Yadav YR, Parihar V, Ratre S, Kher Y, Iqbal M. Microneurosurgical skills training. *J.Neurol. Surg. A Cent. Eur. Neurosurg*. 2016; 77(2):146–154.

Zevin B, Aggarwal R, Grantcharov TP. Surgical simulation in 2013: why is it still not the standard in surgical training? *J. Am. Coll. Surg*. 2014; 218:294–301.

In: Encyclopedia of Surgery (22 Volume Set)
Editors: Andreas Lehrer and Kristin Mueller
ISBN: 978-1-53618-329-0
© 2020 Nova Science Publishers, Inc.

Chapter 204

VETERINARY CARE AND MANAGEMENT OF RODENT AND LARGE ANIMAL MODELS IN TRANSPLANTATION RESEARCH

Patrick Lester[1], James Marx[2], Portia S. Allen[1], Bram V. Lutton[3] and Raimon Duran-Struuck[2,*]

[1]Unit for Laboratory Animal Medicine,
University of Michigan,
Ann Arbor, MI, US
[2]Department of Pathobiology, School of Veterinary Medicine,
Pennsylvania, Philadelphia, PA, US
[3]Department of Biology, Endicott College,
Beverly, MA, US

ABSTRACT

Transplantation research cannot be accomplished without the use of animal models. This chapter aims to provide the reader with husbandry, medical, regulatory and ethical considerations when working with animals undergoing transplantation from a veterinary perspective. Successful implementation of novel pre-clinical transplant treatments/approaches, require close collaboration between research and veterinary teams. Here we provide a review of the regulatory guidelines and medical and husbandry care of small rodents (rats and mice) and large animals (swine and non-human primates).

Keyword: rodents, swine, dogs, nonhuman primates, husbandry, medical, regulatory and ethical considerations

[*] Corresponding Author's Email: rdura@upenn.edu.

ABBREVIATIONS

AAALAC	Association for Assessment and Accreditation of Laboratory Animal Care
AWA	Animal Welfare Act
CMV	cytomegalovirus
EBV	Epstein Bar Virus
GVHD	graft-versus-host disease
HCT	hematopoietic cell transplant
IACUC	Institutional Animal Care and Use Committee
NHP	non-human primates
NSG	NOD/SCID common gamma chain receptor knockout
PTLD	post-transplant proliferative disease
USDA	United States Dept. of Agriculture

INTRODUCTION

The importance animals have had in advancements in biomedical research cannot be overemphasized. Their use, whether mammalian or non-mammalian, has been required for meaningful cures as no *in vitro* approach can recapitulate biological responses with the same fidelity as *in vivo* systems. In the field of transplantation research and immunology, *in vivo* experimentation has been pivotal for progress in achieving treatments that have saved innumerable patient's lives. Currently, no novel transplant approach may advance to clinical trials unless proof of principle has been demonstrated first in small (mainly mouse) and then large (dog/pig or non-human primate or NHPs) animal models. This chapter is intended to help the transplant biologist, scientist or clinician (regardless of their level of training) understand the important role of the regulatory, ethical, husbandry and medical care required when working with animals in transplantation from the veterinary point of view.

REGULATIONS GUIDING ANIMAL USE IN BIOMEDICAL RESEARCH

Research centers are tasked with adhering to important rules/regulations placed to protect animals used in research. To some degree these regulations may seem an overburden, and sometimes may delay research, however they were originally placed for the prevention of the unethical use of animals and the maintenance of high quality research. Transplant investigators are directly, indirectly (or both) impacted by these regulations mandated by the United States, Department of Agriculture (USDA) and the Public Health Service (PHS). Here we provide a synopsis of such regulations. The goal is to aid the personnel using animals in transplantation better understand what veterinarians, animal welfare offices (IACUCs), and principal investigators have to comply with.

The Guide for the Care and Use of Laboratory Animals

(The Guide) provides multiple in-depth performance measures for evaluating an institution's animal care program, including the veterinary care and surgical program. The *Guide*, denotes an entire section dedicated to adequate veterinary care, addressing procurement, transportation, disease control, medical management, emergency care, and record keeping. In addition, performance measures for surgery are described such as training, pre-surgical planning, surgical facilities, asepsis, intra-operative monitoring, post-operative care, pain and distress, and euthanasia (National Research, 2011). Some important key points are needed for providing adequate veterinary care; (i) oversight of animal care and use to ensure that the program meets applicable standards for animal health and welfare; (ii) knowledge of the current and proposed use of animals in the institution's research, testing, teaching, and production programs; (iii) application of appropriate treatment or control measures, including euthanasia if indicated, following the diagnosis of an animal disease or injury; (iv) consultation with researchers on animal methodologies, surgery, and peri-surgical care; and (v) delivery of competent professional judgment to select the most appropriate agents to alleviate pain or distress in order to assure humane treatment of animals while avoiding undue interference with experimental goals.

Although the *Guide* provides detailed indices for minimal standards regarding animal welfare, practices, and animal care, additional references and veterinary professional association position statements and guidance documents should be reviewed and incorporated. The overall responsibility for veterinary care relies upon the attending veterinarian to provide direction to investigative staff and personnel involved in the care and welfare of animals and for guidance on best practices for the institution's surgical programs. Guidance from the attending veterinarian is a necessary component to ensure an institution's primary goal, which should be to establish a program with systematic internal review and self-oversight in order to maximize humane care, animal welfare, and scientific integrity.

The Animal Welfare Act and Public Health Service Policy

The two main regulatory documents governing animal use in biomedical research are the Animal Welfare Act (AWA), enforced by the USDA, and the Public Health Service Policy, administered by the Office of Laboratory Animal Welfare at the National Institutes of Health. The main difference between these is the species which are covered. The AWA, originally the Laboratory Animal Welfare Act of 1966, regulates all mammals used in research, including NHP and swine, but excludes rats of the genus *Rattus*, and mice of the genus *Mus*, that are bred for use in research. The Public Health Service Policy covers all live vertebrate animals used or intended for use in research, research training, experimentation, or biological testing at institutions supported by Public Health Service funds. Both documents mandate that: 1) institutions have an Institutional Animal Care and Use Committee (IACUC); 2) provide adequate veterinary care; 3) provide adequate training for all personnel involved in research; 4) primary investigators have considered alternatives to painful procedures; 5) a veterinarian is consulted about appropriate use of anesthetics and analgesics for surgical or potentially painful procedures. For researchers involved in transplantation medicine, regulations specifically addressing surgical procedures include appropriate provision for pre-operative

and post-operative care of the animals in accordance with established veterinary medical and nursing practices; all survival surgery is performed using aseptic procedures, including surgical gloves, masks, sterile instruments, and aseptic techniques in well maintained surgical suites. Use of neuromuscular blockers in animal research is strictly regulated and only permitted with specific scientific justification. Any protocol requiring multiple major surgical procedures on an animal (surgical intervention that penetrates and exposes a body cavity or produces substantial impairment of physical or physiologic functions) requires special consideration and approval by the IACUC.

AAALAC international (previously known as the Association for Assessment and Accreditation of Laboratory Animal Care) is a private, nonprofit agency that provides voluntary accreditation and assessment of animal care programs with the goal to promote animal welfare. In the United States, AAALAC utilizes the *Guide for the Care and Use of Laboratory Animals and the Guide for the Care and Use of Agricultural Animals in Research and Teaching* (*Ag Guide)(Guide for the Care and Use of Agricultural Animals in Research and Teaching, 2010)* as primary references for programmatic assessments. The process to achieve accreditation is multi-factorial. Institutions must first draft a program description and submit for review. Afterwards, a site visit assessment will occur consisting of AAALAC Council on Accreditation members and ad hoc consultants. The number of site evaluators and days spent for the site visit will vary depending upon the size and complexity of the institution's program. Large academic or industry settings with multiple satellite facilities may require an entire business week for the site visit. The site visit report will be reviewed by the entire AAALAC Council on Accreditation to determine if the institution meets requirements for accreditation. According to the AAALAC International website there are greater than 950 organizations in 41 countries that have received AAALAC International accreditation ("AAALAC International," 2017). For centers in which transplantation studies are being performed and which require NIH funding, AAALAC accreditation is highly desired and often expected.

COMMON ANIMAL MODELS USED IN TRANSPLANTATION RESEARCH

Rodents in Transplantation Research

Both the rat and mouse have made significant contributions in the field of transplant medicine. Recently, however, the mouse has replaced the rat as the workhorse of biomedical research, for many reasons. Its small size and ability to breed rapidly enables researchers to house large populations easily. Specifically, production of genetically modified animals can be done in months, while large animal species requires years (Betthauser 2000; Cozzi 1995). Further, other than humans, there are more biological reagents available to test mouse and rat proteins and chemicals than any other species. Lastly, and not trivially, current USDA Animal Welfare regulations (as previously mentioned) do not cover mice and rats of the genus *Mus* or *Rattus* breed for research, greatly easing the regulatory burden placed on the researcher.

These advantages for the use of the mouse also extend to the field of transplantation medicine, where the work with the mouse forms the launching pad for many future investigations, both in animals and humans. Overcoming immune rejection of allografts is

one of the major limitations in the field of transplantation. In addition to using rodents to test potential pharmacological methods for immunosuppression and graft acceptance, there are two other factors that have enabled rodents to play a valuable role in transplantation medicine by bypassing the risk of tissue/organ rejection. First, many strains of mice (and some rat strains) are genetically inbred to the point of being genetically identical (Fox 2007). This requires over 20 generations of inbreeding, having large populations of animals which are essentially genetically identical twins, eliminates much of the risk of rejection in these animals. One limitation a researcher must be aware of when using inbred strains of mice is genetic drift, which is the gradual accumulation of mutations within an inbred strain of mice. It is important to mention that mice of the same strain from different vendors are likely no longer genetically identical due to genetic drift (Fox 2007). Genetic drift may lead to gain or loss of function of genes which may impact transplant outcomes (by adding or removing major/minor immunostimulatory antigens). Despite this, the ability to freely perform syngeneic and allogeneic transplants (please refer to Chapter 27, GVHD) within mice has been a valuable research tool for transplantation scientists.

Over the last 50 years, there have been dramatic improvements in the ability to generate genetically modified immunosuppressed mice. The first immunosuppressed mouse was the nude mouse, which resulted from a spontaneous mutation of the FOXN1 gene resulting in the elimination of the thymus and subsequently T-lymphocyte-mediated cellular immunity. Shortly after this, the SCID (mutation of the protein kinase, DNA-activated, catalytic polypeptide gene) and RAG (mutation of the recombination activating gene 1 or 2) mice were developed, which were able to eliminate both the B- and T- lymphocytes (Croy 2001). A myriad of other proteins in the immune system have been eliminated and combined in mice, further impairing or eliminating key cell populations responsible for rejection. Currently, the most advanced form of this is the NOD/Scid common gamma chain knockout mouse (NSG) (Racki 2010), which also lacks NK cells, has laid the cornerstone for the generation of the humanized mouse (Kalscheuer 2012; Li 2014). Further refinement of this model has included the addition of human transgenes such as major histocompatibility factors and human cytokines which have further "humanized" these animals.

Using these severely immunocompromised models has allowed for further "humanizing" the mouse by allowing the engraftment human hematopoietic stem cells (mainly bone marrow stem cells). Other organs have been co-transplanted to aid in the maturation of such human stem cells (human thymus and fetal liver) (Shultz 2003; Shultz 2012; Shultz 2007). Forced expression of human cytokines within the mouse has enhanced the level of engraftment of the transferred human stem cells into these mice. Tolerance to tissues (such as skin) can be assessed after a human immune system has been developed in the mouse. These mice, though extremely useful for transplant studies, continue to be met with significant limitations. Mainly, the co-existence of human and mouse cells within the mouse is an artificial biological system which has often not translated well into the clinic (Shultz 2010; Yeoman 1993).

Non-Human Primates in Transplantation Research

Old world monkeys, mainly *rhesus macaques (Macaca mulatta), cynomolgus macaques (Macaca fascicularis)* and Hymadryas baboons (*Papio hymadryas)* are some of the most utilized non-human primate animal models in transplantation research. Monkeys have a

unique role because of their close phylogenetic relationship to humans. Their susceptibility to human infectious agents and response to experimentally induced diseases are critically important to the advancement of medicine. Baboons are preferred for studies of xeno-transplantation because they are larger and considered to be hardier compared to macaques (Mohiuddin 2015). In transplantation many of the human-specific monoclonal antibodies and immunosuppressive agents cross-react (Kawai 2000; Kawai 1999) with NHPs. Despite these similarities to humans, due to ethical concerns, NHPs are among the least utilized animal models used in research.

Some notable clinically relevant differences between rodents and NHP models are briefly described. Mouse pre-transplant preparatory regimens do not follow the protocols used in humans, where gradual immunosuppressive therapies are given over days/ weeks in the clinic. In addition, it is difficult to evaluate clinically relevant treatment-related complications in rodent models. As an example, cytomegalovirus (CMV) observed in monkeys during transplant closely mimics CMV reactivation in humans (Han 2010). Furthermore, the fact that mice are kept in an extremely clean environment does not immunologically mimic what occurs post-transplant in outbred (non-SPF) species and humans. Toll-like receptors and T cell memory has been shown to interfere with rejection/tolerance studies (Yamada 2012). Thus, for some studies, the ideal pre-clinical model is one which can address the applicability of murine findings with responses to conditioning regimens that approximate humans. Hence, non-human primate models have the obvious advantage of similarity to humans.

Development of monkey models with specific ancestry and with known genetics is important for transplantation. Monkeys have one offspring (when compared to other species such as swine which can have 8−10) and their gestation is long (five and a half months) compared to other commonly used species such as swine (a little under 4 months), hence developing a colony is time consuming and costly. In this aspect, pigs have a clear advantage as they are easier to breed as previously mentioned. There is currently available a colony of *cynomolgus macaques* in the Mauritius Islands that have been naturally inbred. These animals were transported five hundred years ago to the Islands in ships by settlers. These few founder monkeys have over the past five centuries expanded their colony and currently are the best (natural) genetically characterized colony of macaques (Greene 2008; O'Connor 2007), making them attractive for studies of allogeneic transplantation(Duran-Struuck 2016; Zitsman 2016). There are other colonies commercially available, but their genetics is not as well described.

Swine in Transplantation Research

Swine have been increasingly used in biomedical research both as general large-animal biological models in teaching and research, and for the study of specific disease conditions due to their anatomic and physiologic characteristics.

As previously alluded, murine studies have been critical for determining immunological and molecular mechanisms of disease and therapy. However, results obtained in murine models with respect to studies of hematopoietic cell transplant (HCT) or solid organ often cannot be extrapolated to large animals or man (Storb, 2003; van Bekkum 1984). In addition, and as mentioned, it is difficult to evaluate clinically relevant HCT treatment-related complications in rodent models. The swine model has the most extensive panel of reagents

available for any mammalian species (other than human and mouse) (Haverson 2001; Lunney1986; Pescovitz 1994; Pescovitz 1998; Pescovitz 1990; Pescovitz 1985; Saalmuller, 1996; Saalmuller 1994; Saalmuller1994a, 1994b; Saalmuller 1994; Saalmuller 1994; Saalmuller 1989; Saalmüller 1989; Zuckermann 1998). The ideal pre-clinical model in which to address applicability of murine findings would involve a large animal with responses to conditioning regimens and to HCT that resemble those of humans. Primate HCT models have the obvious advantage of similarity to humans (as discussed), but they are extremely expensive and the animals are difficult to breed. Dog models are more practical and have been widely used (Cain 1989; Ladiges 1990). Studies of hematopoietic and solid organ transplantation have been extended to miniature swine as a unique preclinical model of HCT (Sakamoto 1988; Duran-Struuck 2015). A selective breeding program to develop and maintain miniature swine with defined MHC genes as a large animal model for studies of transplantation biology was initiated over thirty years ago by Sachs (Sachs 1976). At present, there are three different well-described MHC haplotypes commercially available, swine leukocyte antigen (SLA)^{a}, SLA^{c}, and SLA^{d}. They provide most of the transplantation combinations relevant to humans and have been the swine most utilized in transplantation research.

BIOLOGY AND HUSBANDRY

Biology and Husbandry of Rodents

The research mouse (*Mus musculus*) and rat (*Rattus norvigicus*) have been bred and developed for more than 80 years and subsequently have been well-characterized. They belong to the order rodentia, family Muridae, subfamily murinae. The rat is in the genus *Rattus*, while the mouse in the genus *Mus*. The rodents are characterized by continuously growing incisors and otherwise are widely adapted between the species. Both mice and rats are considered to be nocturnal, omnivorous, social and intelligent species capable of being trained for experimental purposes. In addition, both can be domesticated well and can develop positive social relations with people (Fox 2007; Fox 2015).

The care and housing of mice and rats has become quite refined over the last 60 years. There are several commercially available feeds which are nutritionally complete for most strains of mice which have not been genetically modified. Care must be exercised with some strains of mice which have been adapted to have special dietary requirements. Mice and rats used in transplantation will be immunosuppressed either genetically (SCID, Nude, NSG etc.), chemically (i.e., cyclophosphamide, etc.), or by gamma irradiation (Duran-Struuck 2009; Duran-Struuck 2008). These mice are highly susceptible to Pseudomonas infections, transmitted through the water (Duran-Struuck 2009). These normally benign infections can be highly lethal in immunocompromised mice. Therefore, mice housed in biomedical research facilities typically receive, either hyperchlorinated, acidified or reverse osmosis treated water, which has been shown to be effective at preventing these organisms from colonizing the mice. In some instances, antibiotics are added to the water. Studies have shown that each of these water treatments is able to support normal growth and activity in mice (Hall 1980; Les 1968).

Because of the extensive use of immunosuppressed rodents in transplant studies, a significant effort is invested to control normally benign, but often lethal diseases in such animals. Strict husbandry, handling and quarantine procedures are necessary to prevent infections. Even with the strictest of controls, occasional outbreaks occur in facilities. These outbreaks can be devastating to a research program, particularly depending on the time of the outbreak and mice involved (Fox 2007; Jacoby 1998). The importance of strict adherence to an institutions biosecurity procedures cannot be overstated.

Biology and Husbandry of Non-Human Primates

There are specific regulatory requirements pertaining to space and enrichment required for each non-human primate species (*Guide for the care and use of laboratory animals*, 1985). Here, we will focus on a few important aspects pertaining to Old World monkeys.

Monkeys live in troops and are social animals. Research centers must have a plan to address the social needs of these NHP species. Hence, individual animals that are overaggressive or debilitated should be individually housed and must be appropriately monitored. Since they are a social species, single housing must be documented and justified as per the AWA. When arriving at a new institution, the macaques should be quarantined for a period of time to allow them to acclimate to the new environment and allow for testing of potentially infectious agents, including TB, to prevent the introduction of an agent to the established colony.

In general, macaques and baboons adapt well to the research environment. The temperatures required for housing are relatively broad (60−85°F). Their light cycle can be set at 12 hour light-12 hour dark to permit for a normal biorhythm. Macaques are relatively small (max of 8−10kg) and baboons are larger (20−30 kg) with males being larger than females. Their anatomic similarities with humans are evident, however their size may sometimes be a limiting factor for use in human-specific procedures (i.e., leukapheresis) (Pathiraja 2013).

Old World monkeys are frugivorous. In the wild they mostly eat fruit and their diet is supplemented with roots, bark, grass and some small mammals. Baboons, being larger than the macaques, may eat larger prey. In the laboratory they adapt to biscuit diet with relative ease. Commercial vendors guarantee a balanced diet (i.e., Lab Diet). Old World Monkeys require to be provided with vitamin C, and special attention should be focused at the expiration date to ensure vitamin C's full viability. Monkeys also require daily fruits, vegetables, legumes and foraging substrates (seeds, hay, etc.) to encourage species-specific behaviors.

NHPs can harbor dangerous zoonotic diseases (such as cercopithecine herpes virus 1, aka Herpes B) (Elmore 2008) that can be lethal to humans. These diseases, mostly viral, can become reactivated and shed during periods of stress (captivity/shipping) and immunosuppression (peri-transplant periods). Specific pathogen-free (SPF) production colonies are rapidly being developed and will become the standard. These SPF animals will be useful in minimizing zoonotic exposure of unwanted pathogens to laboratory and veterinary personnel (Yee 2016). In addition, minimizing herpetic diseases (not-necessarily zoonotic) which kill animals during their period of immunosuppression (i.e., gamma-herpes virus inducing lymphomas) or non-herpetic infections such as cytomegalovirus (CMV) (Burwitz 2016; Duran-Struuck 2016; Russell 2016), may decrease the number of animals lost

post-transplant due to infection/viral reactivation. Currently animals suspected of having a contagious disease must be isolated from other healthy animals in the colony. Transplanted and immunosuppressed animals are already isolated (in HEPA-filtered cages when possible) to prevent them from acquiring (any) infections from the environment or conspecifics. Of note, such animals should always have visual and hearing company to minimize stress (which is detrimental for the animal's well-being). It is important that selection of companionship should be consulted with the veterinary team who will take the proper heath and psychological considerations.

Biology and Husbandry of Swine

There are many breeds of swine; however, miniature swine are very popular as laboratory animals. Swine bred for the food industry are often too big to be used in biomedical research. The connotation of "miniature" does not denote them being small when compared to humans. They are small compared to commercially used pigs (which weigh >500 kg). Miniature swine are of human size (50−110 kg). Some of the most commonly used breeds include Yucatan, Hanford, Sinclair, Hormel, and Gottingen.

Swine, like mice and NHPs have some important husbandry requirements. Newly received pigs to the facility should be given a minimum of 72 hours to adjust to the new environment. Physical exams and screening tests for parasites can be performed during the quarantine. Diet changes should be gradual over several days, with fiber increased if stress-induced diarrhea develops.

Shipping fever (stress-induced viral infections/reactivations and secondary bacterial infections) is not uncommon, and fecal assessment for parasites must be performed to minimize introducing (or reintroducing) pathogenic agents into the herd to be used for transplant.

Housing of animals is important. In general, swine are best housed in pens. These may be constructed of chain-link fencing or stainless steel or aluminum. Wood should be avoided because of pigs' ability to chew it and its costly sanitation. From a welfare perspective, wood shavings is beneficial as it allows for rooting, a normal swine behavior. However, when animals are to undergo anesthesia and require to be fasted (at least overnight), access to wood shavings is often not favored due to the risk of intussusceptions secondary to the ingestion of flooring material.

Flooring for swine is of great importance. Smooth flooring (epoxy or similar) should be avoided in order to minimize injury. Swine are hooved animals and have significant difficulties ambulating in smooth floors, particularly when floors are wet. In general, floors should provide some traction. This can be done by mixing sand with the epoxy or cement to maintain it rough/granular. More importantly, the use of abrasive surfaces is very beneficial for animals that are kept for long-term (as often occurs in tolerant animals used in pre-clinical transplantation). This allows for normal wear of the hooves and minimizes sedation for hoof trimming. Pigs with overgrown hooves can develop musculoskeletal conditions and be more prone to injuries. Raised flooring has been found to be useful as a means to keep excreta away from pigs, which aids in sanitation and can be valuable when working with immune-suppressed pigs. The use of slatted fiberglass floors with grit to provide hoof wear is generally ideal in these situations. These flooring options are expensive; however, they allow

for good sanitation and since they are lightweight and easy to remove from pens, also minimize the risk of injury to animal care workers.

Continuous access to water is necessary and very important as swine are susceptible to salt poisoning following dehydration. Acute sodium (and water imbalances) can lead to significant brain swelling and herniation resulting in a neurologic syndrome that frequently leads to death. The use of water buckets is discouraged as they are prone to being turned and difficulties in drinking due to neck anatomy/conformation. Auto-watering systems are preferred, however these can be dangerous when animals run against them (potential of penetrating trauma), especially during periods of recovery post-anesthesia. From a practical standpoint and for transplantation studies, the availability of metabolic cages for large animals permits easy quantification of feces/urine. The level of dehydration can be difficult to assess by physical exam, but indication of dehydration can be detected using eyelid, axillary or inguinal skin tenting and confirmed through blood analysis.

Swine have unique biological attributes which make them well-positioned for biomedical research. Their cardiovascular system is similar to that of humans (Swindle 2012). They have a predominant right-sided dominance of the coronary arterial supply to the myocardium (like in humans). They are the premier species targeted to be used for xenotransplantation (swine into the man). This is due, in part, to the similarities they share with humans and the ethical acceptance of their use in contrast to NHPs.

There have been numerous studies describing the similarities and differences in skin histology between swine and humans. Both have well-defined dermal papillae and rete ridges (Laber 2009). The size, distribution and orientation of blood vessels in the dermis of the pig are similar to those found in human skin. The epidermal turnover time, type of keratinous proteins found within the skin and lipid composition of the stratum corneum is very similar between humans and swine (Lavker 1991; Miller 1998; Nicolaides 1968). This makes them unique for skin and composite tissue transplant studies and graft-versus-host disease (GVHD) (Duran-Struuck 2015; Horner 2009; Leonard 2014). As an allogeneic model of transplantation, swine have been an excellent model for the study of GVHD, a side effect of allogeneic bone marrow transplantation. A clinical GVHD scoring system has been developed in swine (Duran-Struuck 2015) that mimics exactly what is performed in hospitals.

Histologically, the stomach of both humans and pigs has a glandular epithelium, although pigs have a muscular and mucoid glandular structure called the torus pyloricus, which is located near the pyloric sphincter. The pig GI tract is very long, extending as much as fifteen times the length of the body (Laber 2009). The anatomy of the colon is significantly different. It has a centrifugal and centripetal loop, thus coiling within itself and occupying a significant part of the abdominal cavity. Physiologically, pigs and humans are both omnivores, and they share similar characteristics with regards to digestion and intestinal transport. Indeed, this likeness may also help to explain their similarity in liver metabolism as will be discussed next.

The pig has been readily utilized as an animal model for hepatic studies (Wolf 1997). Interestingly, some studies claim that the metabolic function of porcine liver may be more similar to humans than other non-human primate species (Drougas 1996). Physiologically, one important function of the liver in both humans and swine is the synthesis of albumin, the most abundant protein in plasma. There is 65% similarity between human and porcine albumin, although serum albumin concentration is lower in pigs than in primates (Hammer 1998; Platt 2000). Bilirubin can be used as a measure of functional capacity of the liver.

Serum bilirubin concentrations are closely monitored and used for GVHD scoring in the clinic (Ferrara 2009).

The lymphoid organs, mainly the lymph nodes, spleen, thymus and bone marrow are targets of GVHD and are also the locations where allogeneic immune responses are primed (Ferrara 2009). The most important gross and histopathological differences between swine and humans are in the characteristics of the lymph nodes and thymus. The lymph nodes of swine display a unique histological characteristic: the typical cortex and medulla are reversed with germinal centers located in the interior of the gland (Laber 2009).

Lastly, and of interest in transplant immunology studies, the pig has a very large thymus, part of which extends out of the thoracic cavity. As a result, thymus biopsies are very easy to perform and are minimally invasive as there is no need to enter the thoracic cavity.

Anesthesia

There are no absolute regulations in the United States that require a veterinarian or licensed veterinary technician to provide or oversee anesthesia for complex surgical procedures within biomedical research. The primary source of guidance, as mandated by Public Health Service Policy on Humane Care and Use of Laboratory Animals (and utilized by AAALAC International for institutional program assessment) is the *Guide for the Care and Use of Laboratory Animals (Guide)*. The *Guide* indicates that research teams should be provided appropriate education and training to ensure that they have the necessary knowledge and expertise for the specific animal procedures proposed, including aseptic surgical technique, anesthesia, and analgesia. Additional guidance regarding surgical and anesthesia training is published by the Academy of Surgical Research ("Guidelines for training in surgical research with animals. Academy of Surgical Research," 2009).

Although most veterinarians and veterinary technicians receive anesthesia training as part of their curriculum, the type of training may not have been specific or advanced enough to adequately perform anesthesia for complex transplantation surgeries. As a result, veterinary personnel may not be fully proficient to perform anesthesia for complex surgical procedures until additional training or experience is acquired. Each institution should develop a surgical and anesthesia training program, to ensure that surgical procedures including anesthesia are performed in such a manner to maximize animal health and welfare, to minimize distress or adverse effects and to meet scientific goals. To assist with training requirements there are currently multiple organizations that offer training material such as the American Association for Laboratory Animal Science (AALAS), (https://www.aalas.org), Laboratory Animal Welfare Training Exchange (LAWTE), (http://www.lawte.org), and the Academy of Surgical Research (ASR), (http://surgicalresearch.org) which also offers anesthesia-related certification (Surgical Research Anesthetist-SRA). In addition, advanced training may also be acquired through collaborations with research institutions currently performing complex transplantation surgery. Board certified veterinarians from the American College of Veterinary Anesthesia and Analgesia (ACVAA) and American College of Laboratory Animal Medicine (ACLAM) or anesthesia medical personnel within human

hospitals associated with biomedical research institutions can be consulted regarding best anesthesia practices for complex transplant surgeries.

A thorough review on veterinary anesthesia including pharmacology, equipment, and monitoring is published within the veterinary literature (Beckman 2013; Fish 2008; P.A. 2016; Grimm 2015; Murphy 2012). However, the basics of anesthesia and pain management will be reviewed in this chapter by species. Significant overlap between NHPs and swine naturally occurs based on their size and close physiology. Rodents, on the other hand, and based on their small size and metabolism, require alternative approaches. We subsequently discuss anesthesia approaches in these commonly used species in transplantation.

Anesthesia of Mice and Rats

The small size and high metabolic rate of mice and rats makes anesthesia a unique challenge in this species. Routes of anesthesia and anesthetic monitoring used in other species are all available in the mouse, but many are technically very difficult or challenging, making them unacceptable/unusable/impractical to routine mouse transplantation surgery. Despite this, there is a strong growing body of literature which is advancing the field of murine anesthesia, improving the efficacy and assessment of a surgical plane of anesthesia, prediction of impending anesthetic complications and potential clinical interventions (Erickson 2016; Jaber 2014). This section will also address the most commonly used anesthetic protocols in mice, including practical anesthetic support and monitoring procedures.

In order to safely perform surgery on any animal, transplant or otherwise, the animal must be safely anesthetized to a plane where it is unconscious (and therefore unable to experience pain) and does not move in response to a noxious stimulus. Animals will reach a plane of unconsciousness before losing the withdrawal response to a noxious stimulus, however, confirming this plane of anesthesia in animals is difficult to do reliably. The need to maintain immobility during surgery mandates that animals be anesthetized until they do not move in response to the noxious stimulus. When an animal is anesthetized to the loss of consciousness and has lost the withdrawal response to a noxious stimulus (i.e., toe pinch), it is referred to as being at a surgical plane of anesthesia (Campagna 2003; Fish 2008; Tranquilli 2007). Ideally, the animal will not be anesthetized (also referred as "deep") enough as to have lost its autonomic reflexes, but that is difficult to assess in rodents, particularly in mice, as we discuss below.

Inhalant vs. Injectable Anesthesia

The current recommendation for all rodent surgeries is the use of inhalant isoflurane (Fish 2008). This anesthetic has been shown to reliably induce (and maintain) a surgical plane of anesthesia in both mice and rats. The inhalant anesthetics, across species, have been demonstrated to have a very steep dose response curve, meaning that almost 100% of animals can be maintained at a specific plane of anesthesia, in the case of transplant studies, a surgical plane of anesthesia. This is beneficial as it prevents animals to migrate towards a deeper, potentially more dangerous plane of anesthesia (Campagna 2003).

The use of bolus injectable anesthetics has a much more variable response. This variable response to the anesthetic bolus results in unreliable outcomes. Often this approach may result

in animals not reaching an adequate plane of anesthesia for surgery or becoming too deep and dying during the procedure. These deaths are attributed to responses to the anesthetic regimen, independent of the surgical intervention(s). This scenario is rarely observed with inhalant anesthetics. An important reason pertains to the mechanisms of clearance of the inhalant anesthetics. Inhalants are rapidly cleared through the lungs. Hence, the anesthetic dose can rapidly be titrated in all animals which are adequately ventilating (Tranquilli 2007).

Injectable anesthesia is an important part of anesthesia for most veterinary species, however this is done with intravenous access, where the dose administered can be carefully titrated to the animal's response. While intravenous access is possible in the mouse, it is technically difficult to establish and maintain, requiring bolus, intraperitoneal dosing. The disadvantage of this is that with the variable response to injectable anesthetics, discussed above, it may result in some animals receiving an anesthetic overdose, and others receiving an inadequate dose to achieve a surgical plane of anesthesia. To date, there is very little information on the appropriate re-dosing of animals which fail to reach the desired surgical plane of anesthesia. Most information is based on anecdotal, untested procedures.

The delivery of isoflurane does require specialized anesthetic equipment, including an anesthetic gas vaporizer, induction chamber and waste anesthetic gas scavenger system (Herrmann 2013) It is beyond the scope of this chapter to go into a detailed discussion of these components, except to say that there are a variety of portable rodent anesthesia setups which can be used to effectively and safely anesthetize mice with inhalant anesthetics.

The most significant side effect associated with isoflurane anesthesia is a profound, dose-dependent hypotension. For routine transplant surgeries, where little data collection occurs, it can be a potential variable which will confound results. Especially for heart, gastrointestinal and other solid organ models that require good perfusion for the survival of such organ. Generally, the largest complication that may occur is a consequence of inadequate monitoring of the plane of anesthesia. Hypotension may result in a normal compensatory increase in heart rate, which may be interpreted as an inadequate plane of anesthesia. Fluid support may be able to help address this complication (addressed below). The newer inhalant anesthetics, sevoflurane and desflurane, have been successfully used in mice, however, there is much less data on the use of these inhalants when compared with isoflurane (Herrmann 2013).

Common Injectable Anesthetic Protocols for Mice

The most commonly used injectable anesthetic protocols in rodents are ketamine in combination with either xylazine or xylazine and acepromazine. Generally, studies testing the effects of the different anesthetic protocols in mice report that the addition of acepromazine to the ketamine/xylazine combination dramatically increases the efficacy of the anesthetic protocol. This combination has been shown to provide effective anesthesia for both mouse and rat liver transplantation surgeries (He 2010). Researchers must keep in mind the following factors as they initiate a surgical protocol is: (i) the profound variability in dosing requirements; (ii) the species and strain of animal being used; (iii) the condition of the animal at the time of surgery and; (iv) the skill of the surgeon. Therefore, initial dosing recommendations must be used only as starting guidelines and the final anesthetic protocol will need to be adjusted to the specific surgical conditions. The ketamine/xylazine/acepromazine protocol is a good example of multimodal anesthesia, with the combination of the three different classes of drugs limiting the dose required to achieve the anesthetic goals

of the surgery, thereby minimizing the side-effects associated with each individual drug (Table 1). The role of monitoring in the side-effect prevention is addressed later in this chapter. Injectable drugs undergo hepatic and/or renal excretion, (He 2010) meaning that transplantation involving these organs may require significant adjustments of their dosing. Other older injectable anesthetic protocols have been used in the past, including barbiturates, but these are less utilized in transplantation compared to the ketamine-based protocols.

Table 1. Anesthetics for rodents

Drug	Classification	Post op Analgesia	Main Side Effect
Ketamine	Dissociative Anesthetic	Yes	Respiratory Suppression at high doses
Xylazine	Alpha adrenergic Agonist	No	Bradycardia and hypotension
Acepromazine	Phenothiazine	No	Hypotension
Isolfurane	Inhalant	No	Hypotension
Common Anesthetic protocols for mice to achieve a surgical plane anesthesia			
Isoflurane (Recommended): 3-4% for induction 1.5-2.5% for maintenance of anesthesia			
Ketamine 80-120 mg/kg, Xylazine 8-10 mg/kg, acepromazine 1-2 mg/kg Intraperitoneal. Provides approximately 30-40 minutes of surgical plane anesthesia.			

Doses from:

1. Erickson, R. L. *et al.* Intraperitoneal Continuous-Rate Infusion for the Maintenance of Anesthesia in Laboratory Mice (Mus musculus). *Journal of the American Association for Laboratory Animal Science: JAALAS* **55**, 548-557 (2016).
2. Arras, M., Rettich, A., Cinelli, P., Kasermann, H. P. & Burki, K. Assessment of post-laparotomy pain in laboratory mice by telemetric recording of heart rate and heart rate variability. *BMC Vet Res* **3**, 16, doi:10.1186/1746-6148-3-16 (2007).
3. Buitrago, S., Martin, T. E., Tetens-Woodring, J., Belicha-Villanueva, A. & Wilding, G. E. Safety and efficacy of various combinations of injectable anesthetics in BALB/c mice. *Journal of the American Association for Laboratory Animal Science: JAALAS* **47**, 11-17 (2008).

Anesthetic Support and Monitoring

The small size and high metabolic rate of mice makes routine monitoring of mice particularly challenging. The resting mouse heart rate ranges between 500−700 beats per minute and even under anesthesia will range from 250−450 beats per minute, depending on the anesthetic protocol (Erickson 2016). Further, many common ECG machines and pulse oximeters are unable to accurately monitor such high heart rates. Specialized, potentially expensive monitoring equipment is therefore required. Monitoring of blood pressure in mice can be achieved in conscious mice using tail plethysmography, however this technique requires the mice be kept at relatively high temperatures to ensure adequate blood flow to the tail, which is impractical in mice. The blood pressure can be accurately measured in anesthetized mice following carotid catheterization. This would entail an additional surgical procedure during the murine transplant surgery. Placement of central arterial pressure measurements would be appropriate if the information provided would lead to medical treatments. Hence, these approaches though medically appropriate may be impractical in these species as they would prolong the anesthetic time and would further risk anesthetic complications.

The four most practical methods to monitor mouse anesthesia are: 1) body temperature; 2) respiratory rate and pattern; 3) skin/mucus membrane color; and 4) response to a noxious stimulus. The body temperature also needs to be closely monitored under anesthesia because the mouse rapidly loses heat due to the high ratio of surface area to body volume. Studies

have shown that mice can rapidly have the body temperature drop to below 30° C in less than 20 minutes. Rats are more resistant to this drop in body temperature, but they too will experience hypothermia if they do not receive supplemental heat (Malkinson 1993). The most obvious complication associated with hypothermia is a delayed recovery from anesthesia, but in other species, anesthetic-induced hypothermia is associated with cardiac arrhythmias, increased risk of infection and coagulopathies (Tranquilli 2007), all of which could complicate the results of any transplant surgery. When providing supplemental heat to the animal, it is important to use a circulating water blanket, as opposed to an electric heating pad, as these pads may have hot spots which can do thermal injury to the animal.

Respiratory rate of rodents is easily monitored under general anesthesia and will depend on the anesthetic being administered. Mice being maintained with a ketamine/ xylazine/acepromazine protocol will normally have respiratory rates of +/-150 breaths per minute and will be at significant risk of anesthetic arrest when the rate goes below 80 to 120 breaths per minute. Adverse outcomes are strain-dependent (Marx JO unpublished- personal experience), (Jaber 2014). Mice maintained under isoflurane will have respiratory rates in the area of 60 breaths per minute (Erickson 2016). Further, the depth of anesthesia can be closely monitored by respiratory rate, with changes in respiratory rate correlating to changes in depth of anesthesia.

The color of the skin on the feet and nose and mucus membranes can be used as an indicator of peripheral perfusion of rodents and potentially hypoxia. This finding may be difficult to detect in some rodents (if high skin pigmentation) and marked changes in the color of the skin and mucus membranes should be interpreted as profound changes in the animal's condition.

Lastly, the test most commonly used to assess if the animal has lost its movement in response to a noxious stimulus is the toe pinch, in which a firm pinch is applied to the foot of the mouse. This should be performed before beginning any surgical procedure. Care must be taken to apply a strong stimulus, while realizing that it is easy to injure the foot with a pinch if too aggressive. The 300 gram Touch Test Device (North Coast Medical, Gilroy, CA) can be used to deliver a uniform, non-injurious noxious stimulus to the foot (Erickson 2016). It must be remembered that this noxious stimulus is a fairly mild stimulus and more anesthetic may be required for more painful procedures.

The larger size of rats makes monitoring anesthesia much easier than in mice. The heart rate of 330−450 beats per minute and respiratory rate of 85 breathes per minute can be easily monitored with many pulse oximeters and by visual monitoring. Monitoring the temperature of rats is also important, although they will lose heat much more slowly than mice, due to the larger relative body volume: surface area ratio.

ANESTHESIA OF SWINE AND NON-HUMAN PRIMATES IN TRANSPLANTATION

NHP Anesthesia Basics

Inhalant anesthetics are favored over injectable ones for their safety as mentioned earlier. Rebreathing anesthesia machines may be preferred over non-rebreathing circuits in order to

minimize waste gas exposure from higher flow rates required with non-rebreathing circuits. This is also beneficial for warming of gases to prevent hypothermia. Ideally the rebreathing bag should be five times the animal's estimated tidal volume and the anesthesia system should be pressure checked for leaks (e.g., soda lime canister connection, breathing tubing, one way valves, or rebreathing bag) prior to use. The anesthetic plan including pre-operative and post-operative care should be reviewed with veterinary personnel prior to transplantation surgery. For personnel and animal safety concerns, most macaques and baboons are immobilized first with a dissociative such as ketamine or the dissociative-benzodiazepine combination, tiletamine-zolazepam (Telazol®) (Murphy 2012). Ketamine can also be combined with a benzodiazepine such as midazolam or diazepam or an alpha-2 agonist such as dexmedetomidine or xylazine for additional sedation and muscle relaxation (Lee 2010; Flynt 2010; Haag 2010; Taylor 2010; Theriault 2008; Reed 2008; Niekrasz 2008). Non-ketamine neuroleptanalgesic combinations have also been described for brief immobilization of macaques (Kimura 2007; Ochi 2014; Votava 2011). After immobilization, the NHP can be fitted with a facemask to provide supplemental oxygen while an intravenous catheter is placed for fluid and drug administration. At this point, the NHP may be induced for endotracheal intubation using an inhalant such as isoflurane or sevoflurane by face-mask. Alternatively, the NHP may be induced with an intravenous bolus of a sedative-hypnotic such as propofol (Authier 2006; Fowler 2001) or alphaxalone and subsequently intubated. Both propofol and alphaxalone can cause apnea so careful titration to promote intubation is warranted. Once intubated, the NHP can be maintained on an inhalant anesthetic with oxygen or in combination with an intravenous continuous infusion of a full mu agonist opioid (e.g., fentanyl, alfentanil, sufentanil, or remifentanil), benzodiazepine (e.g., midazolam), sedative-hypnotic (e.g., propofol or alphaxalone) or a combination for a balanced anesthesia approach (Bauer 2007; Casoni 2015; Valverde 2000). This approach minimizes adverse alterations in cardiac output, blood pressure, and respiratory functions typically associated with higher anesthetic doses, and provides additional muscle relaxation and analgesia. Furthermore, studies have demonstrated that the addition of NMDA antagonists such as ketamine during surgery and prior to intense surgical stimuli may reduce the development of central sensitization and potential post-operative hyperalgesia (Pozzi 2006; Wagner 2002). Total intravenous anesthesia such as a continuous infusion of propofol and a short acting mu agonist opioid is commonly used for neurosurgical anesthesia and may be an alternative to inhalant anesthesia especially for shorter transplantation surgical procedures. Advantages include not having to utilize an anesthetic machine and reductions in waste anesthetic gases. However, unlike inhalant anesthetics that can be rapidly titrated to defined MAC level targets and monitored via expired concentrations, intravenous anesthetics must be titrated to predetermined pharmacodynamic parameters which may vary between species and may not be defined for NHPs. In addition, NHPs receiving continuous infusions of intravenous anesthetics should be intubated and supplemented with oxygen to ensure proper hemoglobin saturation and to protect the airway against possible regurgitation during surgery. For these reasons, a balanced anesthetic regimen consisting of a combination of an inhalant with additional analgesics and/or sedatives is preferred for NHP transplantation surgical anesthesia until additional studies are performed outlining the use of total intravenous anesthesia in research animals involving transplantation. If a full mu agonist opioid is utilized as a premedicant or during the intra-operative period, a partial mu opioid such as buprenorphine should be withheld until the post-operative recovery period, as it may reverse the analgesic

efficacy of the full mu agonist. Sedative, anesthetic, and analgesic doses for non-human primates are outlined in Tables 2 and 3.

Table 2. Post-operative analgesics for rodents [98, 129]

Drug	Classification	Dose in mice
Buprenorphine	Partial mu opiate agonist	0.05-0.1 mg/kg
Buprenorphine Sustained Release	Partial mu opiate agonist	Mice 0.5-1.0 mg/kg SC Rats 1.0-1.2 mg/kg SC
Meloxicam	NSAID	Mouse: 5 mg/kg PO or SC Rat: 1-2 mg/kg PO or SC
Lidocaine	Local anesthetic short acting	10 mg/kg locally
Bupivacaine	Local anesthetic long acting	6 mg/kg locally

Doses from:

1. Flecknell, P. A. Analgesia of small mammals. *The veterinary clinics of North America. Exotic animal practice* **4**, 47-56, vi (2001).
2. Hawk, C., Leary, S. & Morris, T. (Blackwell Pub., Ames, IA, 2005

Table 3. Non-human primate (macaque & baboon) sedative - immobilization combinations and intravenous anesthesia

Drug or Drug Combination	Dose
Ketamine	5 - 15 mg/kg IM
Ketamine: Xylazine	10 mg/kg: 0.15 - 0.25mg/kg IM
Ketamine: Diazepam	15 mg/kg: 0.3 - 1 mg/kg IM
Ketamine: Midazolam	5 - 15 mg/kg: 0.05 - 0.15 mg/kg IM
Ketamine: Dexmedetomidine	5 -10 mg/kg: 10 - 30 mcg/kg IM
Midazolam: Dexmedetomidine	3 mg/kg: 0.015 mg/kg IM
Tiletamine - Zolazepam (Telazol®)	2 - 6 mg/kg IM
Alphaxalone: Dexmedetomidine[a]	5 mg/kg: 10mcg/kg IM
Alphaxalone: Diazepam[b]	5 mg/kg: 0.5 mg/kg IM
Intravenous Anesthesia (generally preceded by ketamine +/- sedative)	
Propofol	2 - 8 mg/kg IV to effect 18 - 24 mg/kg/h continuous intravenous infusion
Alphaxalone	1-3 mg/kg IV bolus 0.01 - 0.13 mg/kg/min continuous intravenous infusion
Propofol: Fentanyl	Propofol: 2.4 - 7.2 mg/kg/h Fentanyl: 10-25 mcg/kg/h continuous intravenous infusion
Inhalant Anesthetics	
Isoflurane	3-5% induction 0.5 - 3% Maintenance
Sevoflurane	4-8% Induction 1.25 - 4% Maintenance

Drug dosages adapted from the following: Murphy KL, Baxter MG, Flecknell PA. Anesthesia and Analgesia in Nonhuman Primates. In: Abee CR, Mansfield K, Tardif S, Morris T, eds. *Nonhuman Primates in Biomedical Research*: Academic Press, an imprint of Elsevier; 2012:403-435.

Anesthetic monitoring should be based upon direct assessment of the animal including jaw tone, eye position, palpebral-corneal reflexes, heart rate, pulse quality, respiratory rate and depth, temperature, mucous membrane color and capillary refill time. Additional

monitoring equipment that is useful for complex transplantation surgery includes pulse oximetry for hemoglobin saturation, capnography to assess ventilation and alterations in cardiac output, blood pressure (direct arterial, oscillometric, or doppler), arterial blood gas analyzer to assess acid-base status and electrolytes, electrocardiography, and hematology analysis such as hematocrit and total protein to assess dilution of plasma proteins secondary to fluid administration ("American College of Laboratory Animal Medicine Recommendations for Monitoring Anesthetized Veterinary Patients," 2009; Duke-Novakovski 2015; Flegal 2009; Fox 2008; Fox 2009; Yeung 2014). A more detailed description of nonhuman anesthesia is provided by Murphy et al. (Murphy 2012).

Since post-operative care may involve multiple drugs, blood sampling, monitoring, or fluid administration requiring intravenous or arterial access, pre-surgical planning and additional equipment such as jacketed tethering systems and infusion pumps may be warranted. Since transplant surgeries can be very challenging, a dedicated research area with well-trained staff and coordination with veterinary care is required to minimize complications associated with surgery and immunosuppressive therapy, enhance monitoring, and maximize animal welfare. Cooper and Wagner, provide a review of NHP xenotransplantation (Cooper 2012).

Anesthesia in Swine

Anesthesia for transplant surgery in swine is very similar to techniques used for non-human primate anesthesia. Swindle at al. provides a thorough review of swine anesthesia, analgesia, and post-operative monitoring (Swindle 2016). Solid food is generally removed 6−8 hours prior to surgery and longer for lower gastrointestinal surgery. Water is provided until the time of surgery and may be supplemented with nutritional fluids or glucose for prolonged fasting to prevent hypoglycemia (Swindle 2016a; Swindle 2016b). Swine are generally immobilized and sedated with a combination of ketamine and xylazine, ketamine and dexmedetomidine, or the combination of tiletamine-zolazepam (Telazol®). Tiletamine-zolazepam is preferred in larger pigs due to smaller injection volumes and diminished stress with injection. However, if cardiac transplantation surgery will be performed, alpha-2 agonists (e.g., xylazine or dexmedetomidine) and tiletamine-zolazepam should be used with caution or avoided due to cardiac arrhythmias and cardiac depressant effects. In these cases ketamine and midazolam can be used for pre-induction sedation. Swine should be pre-oxygenated prior to intubation, which can be performed in dorsal or sternal decumbency. Endotracheal intubation can be challenging in swine as the larynx is angled relative to the trachea. Standard veterinary laryngoscope blades may need extensions (3−5 cm) for swine > 50kg (Swindle 2016b). After sedation and venous access is achieved, swine can be induced with propofol or a combination of propofol and fentanyl with titration to avoid apnea. Anticholinergic agents such as atropine or glycopyrrolate are generally not needed for routine use, but can be used to decrease secretions or treat bradycardia associated with alpha-2 agonists and mu opioids. Anesthesia should be maintained with an inhalant such as isoflurane or sevoflurane with oxygen as a carrier gas. Similar to non-human primate anesthesia, inhalants can be used in conjunction with a continuous intravenous infusion of a mu opioid such as fentanyl, sufentanil, or remifentanil to provide additional analgesia, or in combination with propotol or midazolam for a balanced anesthesia approach. In order to achieve adequate

steady-state plasma levels, opioids such as fentanyl, sufentanil, or remifentanil should be administered with a loading dose bolus (during induction or immediately afterwards) prior to initiating a continuous intravenous infusion. The use of a balanced anesthesia approach allows for lower doses of each individual anesthetic agent if used alone thus decreasing overall cardiodepressant effects and hypotension. Hypotension is primarily treated by correcting fluid losses, titrating anesthetic depth, and the use of intravenous inotropes such as dobutamine (2−10 mcg/kg/min), dopamine (2−10 mcg/kg/min), or epinephrine (1−10 mcg/min) titrated to response. Thermal support (e.g., warm intravenous fluids, circulating warm-water blanket, and/or forced-air warming) should be provided during anesthesia to prevent hypothermia. Sedative, anesthetic, and analgesic doses for swine are outlined in Tables 4 and 5.

Anesthetic monitoring should include electrocardiogram, capnography, pulse oximetry, blood pressure monitoring, be it peripheral or invasive, body temperature, and assessment of muscular tone and/or withdraw reflexes. For many transplant procedures, attention should also be given to periodic blood gas monitoring. Bispectral index (BIS) monitoring via electroencephalogram has been evaluated in swine in conjunction with various anesthetic regimens (Jaber 2015; Martin-Cancho 2006; Martin-Cancho 2004) and surgical models (Baars 2013; Kurita 2012). Overall, its utility is limited to the delineation of light versus deep anesthetic planes and cannot be used as the sole mechanism for anesthetic plane determination.

FLUID SUPPORT

Rodents

In addition to warming anesthetized rodents, providing fluid support is very beneficial to helping maintain the animal's vitals in a healthy range. In both humans and most routine veterinary species, the administration of intravenous fluids is considered essential to maintain blood pressure and normal renal and cardiac function (Tranquilli 2007). Unfortunately, and as discussed above, intravenous access is difficult/limited in most rodents, meaning that routine fluid administration is done either into the subcutaneous space or intraperitoneally. While these routes of administration are far inferior to intravenous administration, anecdotal evidence suggests that they will help maintain the animal during a transplant surgical procedure, particularly in prolonged surgeries (Tranquilli 2007). One mL of warmed, isotonic crystalloid fluids (LRS) is frequently administered intraperitoneally after induction of anesthesia. These fluids will need to be given subcutaneously for intra-abdominal surgeries.

Non-Human Primates

Published reviews of fluid therapy for small animals can be utilized as guidelines for fluid therapy in NHPs and swine in a surgical transplantation research setting (Boller 2015; Byers 2016; Mazzaferro 2013). The goals or choice of fluid therapy should be made based upon the types of fluids lost, comorbid disease processes, hydration and electrolyte status.

Isotonic crystalloids (e.g., 0.9% sodium chloride, lactated ringers, Normosol-R) are the mainstay of therapy for replacing fluid losses during surgery or dehydration in the perioperative setting. Maintenance fluids comprised of lower sodium concentrations (e.g., 0.45% sodium chloride) are generally used to replace sensible and insensible fluid losses once dehydration has been corrected. Maintenance fluid rates can be calculated based upon resting energy expenditures. The formula for resting energy expenditure (REE), (ml H_20 per 24 hours) = [(30 × body weight kg) +70] can be used as a starting point, yet body weight, serum osmolality, biochemical chemistries, electrolytes and urine-specific gravity should also be monitored and evaluated. Intraoperative fluid rates are generally 5−10ml/kg/h to replace sensible and insensible losses. Fluid losses during surgery can be corrected with isotonic crystalloids using 2−3 times the volume loss to replace intravascular fluid deficits. Treatment of shock relies upon the blood volume of the animal. When treating hypovolemic shock, isotonic crystalloids should be administered at ¼ total shock dose increments. Afterwards, blood pressure, central venous pressure, mucous membrane color, capillary refill time, heart rate, pulse pressure, and serum lactate can be monitored to assess perfusion (Boller 2015). Additional ¼ total blood volume crystalloid boluses may be repeated one to two times or until perfusion parameters have stabilized (Mazzaferro 2013). Hypertonic saline, synthetic colloids (hydroxyethyl starches or dextrans), or blood products can be used in combination with crystalloids to enhance and prolong intravascular volume expansion. Crystalloids to replace the fluids drawn into the intravascular space from the interstitial compartment should follow the use of hypertonic saline or colloids (Mazzaferro 2013). Since the volume expansion due to crystalloid therapy is relatively short (20−30 minutes), colloids may be considered for longer surgical procedures in order to provide sustained expansion of the intravascular space and decrease the potential to dilute coagulation factors and plasma proteins(Boller 2015). Adverse effects of synthetic colloid therapy include volume overload and coagulopathies with higher doses. The use of synthetic colloids such as hydroxyethyl starch for intravenous fluid resuscitation has been questioned due to recent reports of kidney failure and coagulopathies in critically ill human patients, yet additional research is needed to fully assess their impact in veterinary medicine (Cazzolli 2015).

Swine

Perioperative care of swine undergoing transplantation requires the standard of care typical of any surgical event (Swindle 2013): vascular access for fluid therapy and pharmaceutical administration, preemptive and sustained analgesic therapy, normothermic maintenance, and proper anesthetic monitoring. Vascular access can be easily achieved via percutaneous catheter placement in a superficial peripheral vessel, such as the auricular or cephalic veins. The Seldinger technique, with or without ultrasound guidance, has gained popularity for use in swine for the percutaneous catheterization of the external jugular or femoral veins to avoid surgical subcutaneous cutdown procedures which have been classically favored for catheterization of these vessels (Flournoy 2009; Larsson 2015; Izer 2016). Standard fluid therapy rates are utilized intraoperatively to maintain blood pressure at 60−70 mmHg for adequate perfusion. Placing the fluid lines through a fluid warmer immediately prior to administration will also assist in maintaining adequate body temperature

during the procedure. Serum and hematological parameters can be taken from the catheters and continued physical exams can be performed without sedating the pig when awake.

Pain Management

Pain can be described as an unpleasant sensory and emotional experience associated with actual or potential tissue damage, or described in terms of such damage (Merskey 1994). In addition, it is generally assumed that events or procedures noted to be painful in humans will also be painful in animals. Although mandated or highly recommended by regulations and the *Guide*, pain associated with transplantation surgeries, procedures, or immunosuppressive therapy should be treated and addressed from an ethical and a scientific perspective to reduce confounding research variability secondary to stress or adverse physiologic effects of untreated or poorly treated pain. In addition, the American College of Laboratory Animal Medicine, American Animal Hospital Association, and the American College of Veterinary Anesthesiologists have published position statements indicating the need to address pain in companion and research animals ("American College of Laboratory Animal Medicine Position Statement on Pain and Distress in Research Animals," 2016; "American College of Veterinary Anesthesiologists' Position Paper on the Treatment of Pain in Animals," 2006; Epstein 2015). Hence, managing pain in animals undergoing surgery is of key importance for both animal welfare and experimental outcomes. Below we discuss some approaches to the management of pain in rodents, NHPs and swine.

Analgesia in Rodents

Assessment of Pain

Proper administration of analgesics is complicated by two factors in rodents, 1) the difficulty in assessing pain and 2) the rapid metabolism of drugs, including analgesics, requiring an increase in dosing frequencies compared to other species (Brown 2004; Flecknell 2001). Rodents, like many other prey species, have evolutionary adapted to mask overt signs of pain until the pain is extreme that becomes debilitating, at which point becomes visually clear. Studies have shown that training and practice in identifying the subtle signs of pain can significantly improve the ability of trained professionals to recognize pain. Cases of pain may be identified by non-specific signs of disease, such as decreased movement, poor hair coat, and loss of body condition (Flecknell 2011). However, it must be remembered that these are non-specific signs of pain and may be indicative of other health issues with the animals. Rodents can exhibit signs typical of other species, such as lameness, abnormal gait and increased aggression which are easily recognized as being due to pain. Recent publications have reported ***facial grimace scoring*** for both the mouse and the rat. They utilize a series of changes in the facial appearance of the animals to pain and appear to be a valuable tool in pain assessment of rodents (Leach 2012; Matsumiya 2012). In addition, subtle signs such as abdominal stenting and stretching are indicative of abdominal pain (Flecknell 2001).

When pain is either identified or suspected, analgesic therapy is indicated, however this must be done within the context of the experimental goals of the project. Non-steroidal anti-

inflammatory drugs (NSAIDs) may be unacceptable for studies focusing on the immune systems response to a challenge. Critical evaluation of this conflict in transplant studies is critical as many analgesics, in addition to the NSAIDs, may impact the immune system. Therefore, discussions with the veterinary team should be started early during the design of the study in order to avoid administration of drugs that can affect the results of the transplant studies. As a team, veterinarians and researchers should work together to find the proper analgesic regimen. Typically, there are three main pharmaceutical approaches to post-surgical pain in rodents. These are local anesthetics, NSAIDs and opiates (Table 2).

Local anesthetic/analgesia therapy consists primarily of either lidocaine or bupivacaine, both working by blocking sodium influx into the nerve cells, preventing nerve activation (Lemke 2000). Lidocaine has a more rapid mechanism of action and shorter duration, while bupivacaine has a longer onset to action, but significantly longer duration of action. Studies combining the two drugs, to optimize the beneficial effects of each, yield inconsistent results (de Jong 1981; Ribotsky1996).

The systemic analgesics Meloxicam and Carprofen are currently the most commonly used NSAID in rodents (Fish 2008). Its reported duration of action is 12 to 24 hours, however many times this appears to be an over estimate of its duration of action. Meloxicam has the advantage of being an oral and injectable drug. While these drugs are associated with minimal side effects (Ratsep 2013), they are unlikely to be adequate alone for the control of pain in more invasive surgical procedures (Roughan 2016). Opiate analgesia is an important part of any post-operative analgesic plan (Lemke 2000). While not without side effects and regulatory control, their efficacy warrants their inclusion in most rodent surgical models. Currently, the partial mu agonist buprenorphine is the most commonly used post-operative analgesic in mice. There are two commonly used formulations, a regular product, which is reported to provide relief for 4−8 hours, and a sustained release product, which although labeled for 72 hour dosing intervals, studies indicate that its duration of action may be variable depending on the nature of the painful stimulus (Guarnieri 2012; Healy 2014; Kendall 2014; Kendall 2016; Seymour 2016).

In summary, it cannot be overemphasized that pain management needs to be tailored to each specific experiment and the investigator needs to communicate with the veterinary staff in order for the team to understand how these agents may impact the experimental outcomes.

Analgesia in NHPs

There is limited information regarding validated pain scoring systems for NHPs and pain is most commonly based upon physiologic or behavioral indices. In the wild, NHPs and swine generally mask signs of pain or distress as a means of adaptation and survival. This makes the recognition of pain or distress especially mild to moderate pain in the laboratory setting more challenging to assess. Although there are multiple publications and reviews describing pain assessment and analgesic therapy in laboratory research animals,(Fish 2008; Flecknell 2016; Morton 1985) additional information is still warranted especially correlating analgesic plasma concentrations to clinical analgesia and specific pain indices. Multimodal therapy consisting of analgesics with different mechanisms of action that target different aspects of the pain pathway is generally recommended for post-surgical pain (Lamont 2008). Commonly used agents consist of local anesthetics prior to surgical closure with the addition

of a systemic NSAID, opioid or both. Ideally, analgesics should be administered preemptively prior to surgery to reduce potential central sensitization and development of chronic pain (Wagner 2002). A thorough review of analgesic therapy is beyond the scope of this chapter and reviews of analgesic therapy for NHPs have been published (Murphy 2012). The primary NSAIDs used in NHPs are meloxicam and carprofen. Allison, et al. demonstrated that carprofen 2.2 mg/kg administered intramuscularly (IM) as a solo agent or in combination with buprenorphine 0.01 mg/kg IM to baboons before laparotomy surgery provided sufficient post-operative analgesia (Allison 2007). Bauer et al., explored the utility of three meloxicam formulations, oral, IM, and a sustained release based upon a biodegradable polymer matrix (Meloxicam SR®, 10mg/ml ZooPharm, Fort Collins, CO) in maintaining therapeutic analgesic plasma concentrations. Mild to severe skin lesions were reported with the original formulation of meloxicam SR, yet were not noted in a modified formulation. Results from the study indicated that a single dose of the sustained release formulation provided therapeutic plasma levels for 72 hours compared to 12−24 hours with a single IM dose and very low concentrations associated with oral dosing (Bauer 2014).

Table 4. Non-human primate (macaque & baboon), sedative - premedication and analgesic agents immobilization combinations and intravenous anesthesia

Drug	Dose
Opioids	
Buprenorphine	0.005 - 0.03 mg/kg SQ/IM/IV Q6-12h
Morphine	0.1 - 2 mg/kg SQ/IM q3-6h
Fentanyl	5 - 10 mcg/kg IV bolus followed by 10-25 mcg/kg/h continuous intravenous infusion
Nonsteroidal Anti-Inflammatories	
Carprofen	2 -4 mg/kg SQ/IM Daily
Meloxicam	0.2 mg/kg SQ Daily
Local Anesthetics	
Lidocaine	1-4 mg/kg SQ infiltration
Bupivacaine	1-2 mg/kg SQ infiltration

Drug dosages adapted from the following: Murphy KL, Baxter MG, Flecknell PA. Anesthesia and Analgesia in Nonhuman Primates. In: Abee CR, Mansfield K, Tardif S, Morris T, eds. *Nonhuman Primates in Biomedical Research*: Academic Press, an imprint of Elsevier; 2012:403-435.

The pharmacokinetics of a buprenorphine sustained release product based upon the same biodegradable polymer formulation as Meloxicam SR® have also been researched in macaques. Nunamaker et al. reported that the sustained release buprenorphine formulation-Buprenorphine SR® (ZooPharm, Fort Collins, CO) 0.2 mg/kg subcutaneously provided plasma serum concentrations greater than the human therapeutic threshold (0.1 ng/ml) for up to five days (Nunamaker 2013). Immediate release buprenorphine 0.03 mg/kg IM was best administered every 12 hours to ensure plasma levels exceeding the human theoretical threshold. Injection reactions were reported in 40% of macaques with Buprenorphine SR® and reactions ranged from mild erythema to a raised plaque (Nunamaker 2013). Kelly et al. demonstrated consistent buprenorphine plasma concentrations exceeding the human theoretical threshold (0.1 ng/ml) for over 12 hours when administered at a dose of 0.03 mg/kg IM to rhesus macaques (Kelly 2014). The results of these studies with sustained release

analgesics are promising as there is a clinical need to develop sustained acting analgesic therapy in NHPs in order to minimize the stress of restraint and pain associated with multiple injections. However, in the absence of a sustained release formulation, if immediate release buprenorphine will be used for post-surgical analgesia, the authors recommend dosing at 0.03 mg/kg at a minimum frequency of every 12 hours preferably in combination with a NSAID for multimodal anesthesia. Sedative, anesthetic, and analgesic doses for non-human primates are outlined in Tables 3 and 4.

The *Guide* indicates that preemptive analgesia should be utilized to enhance surgical stability and to optimize postoperative care and pain management (National Research Council 2011). In these efforts, Carlson, et al., evaluated the pharmacokinetics and plasma concentrations of two fentanyl transdermal formulations, a transdermal patch (25 mcg/h) commonly used in human patients and companion animals, and a new transdermal fentanyl solution (Recuvyra®, Elanco, Greenfield IN) for use in cynomolgus macaques. Unlike with the fentanyl patch, macaques dosed with the fentanyl solution at 2.6 mg/kg demonstrated adverse effects such as bradycardia, severe respiratory depression, and hypothermia. However, a dose of 1.95 mg/kg was tolerated without adverse effects. Although the transdermal fentanyl solution provided higher plasma levels, significant variations in plasma concentrations and pharmacokinetic parameters were noted with the fentanyl solution groups (Carlson 2016). Advantages of both fentanyl formulations include chronic steady-state plasma levels for continuous analgesia. Major disadvantages for using transdermal patches in primates include variability and time for absorption (patches should be placed 12 hours in advance), requirement for jacket to protect patch from removal, and accidental overdose if ingested. Major disadvantages with the fentanyl solution include rapid absorption and potential overdose once applied, requiring the need for continuous reversal with an opioid antagonist until plasma concentrations are reduced below adverse effect levels. Additional studies are warranted before transdermal fentanyl solutions can be routinely used in NHPs.

Analgesia in Swine

Postoperative pain assessments must be conducted and the analgesic regimen adjusted based on the outcome. Evaluation of pain in swine is challenging but has been reviewed (Ison 2016). The evaluator must be familiar with normal swine behavior in the housing environment and the animals should be acclimated to personnel and handling prior to the postoperative period. Evaluations should include assessment of spontaneous behaviors (e.g., ambulation, rooting behavior, posture), interactive behaviors (e.g., approaches personnel, seeks solitude when personnel enter enclosure), and a clinical assessment encompassing vital parameters, incisional palpation, and nutritional status. Example postoperative evaluations are available in published literature (Castel 2014; Ison 2016; Swindle 2015) but development of model-specific assessment systems is ideal. Scoring systems are commonly used as they provide an objective outcome for these subjective assessments and may be as simple as a visual analog scale or as complex as a variable rating scale (Ison 2016). Consultation with a veterinarian during development and implementation of postoperative pain assessments is strongly encouraged.

Administration of analgesics prior to a surgical procedure, or preemptively, is considered appropriate veterinary care and must be part of the perioperative preparations. Analgesic

administration prior to the painful stimulus prevents the initial neuron signaling cascade (i.e., pain reflex) that establishes central sensitization and hyperalgesia post-surgery. Multimodal analgesic therapy, as with non-human primates, is comprised of pharmacologic agents with different mechanisms of action and is preferred for the reasons previously mentioned. This most typically involves an opioid derivative (e.g., fentanyl, oxymorphone, buprenorphine) combined with a NSAID (e.g., carprofen, meloxicam, ketoprofen) and/or a regional/local nerve block (e.g., lidocaine, bupivacaine), for which multi-holed wound soaker catheters, with or without an elastomeric pump, have become popular.

Table 5. Swine: Premedication and analgesic agents

Drug	Dose
Phenothiazines	
Acepromazine	0.2-1 mg/kg SQ/IM
Anticholinergics	
Atropine	0.05 mg/kg IM
Glycopyrrolate	0.004 - 0.01 mg/kg SQ/IM
Benzodiazipines	
Midazolam	0.1 - 0.5 mg/kg SQ/IM/IV
Diazepam	0.5 - 10 mg/kg SQ/IM
Opioids *Most opioids are relatively short acting in swine, require frequent dosing or continuous rate infusions*	
Buprenorphine	0.01- 0.1 mg/kg SQ/IM Q6-12h
Oxymorphone	0.15 mg/kg SQ/IM QID
Meperidine	2-10 mg/kg SQ/IM QID
Fentanyl*	0.02 - 0.05 mg/kg SQ/IM q2h or IV bolus followed by 30-100mcg/kg/h continuous intravenous infusion
Fentanyl patch*	5 mcg/kg/h Topically q72h
Sufentanil	5-10 mcg/kg IM q2h or IV bolus followed by 10-30 mcg/kg/h continuous intravenous infusion
Remifentanil	30-60 mcg/kg/h
Nonsteroidal Anti-Inflammatories	
Carprofen	2 mg/kg SQ/IM/PO BID
Meloxicam	0.4 mg/kg SQ/IM Daily
Ketoprofen	1-3 mg/kg SQ/IM/PO BID
Local Anesthetics	
Lidocaine	1-4 mg/kg SQ infiltration
Bupivacaine	1-2 mg/kg SQ infiltration

Drug dosages adapted from the following: Swindle MM, Sistino J. Anesthesia, Analgesia, and Perioperative Care. In: Swindle MM, Smith AC, eds. *Swine in the Laboratory, Surgery, Anesthesia, Imaging, and Experimental Techniques*. 3rd ed. Boca Raton: CRC Press; 2016:39-87; Swindle, Michael M. "Anesthesia & Analgesia in Swine." *Sinclair Bio-resources*. Website. Accessed 17 Jan. 2017. <http://www.sinclairresearch.com/assets/sites/2/Anesthesia-Analgesia-Small.pdf>.

*Not recommended as single agents for post–operative analgesia since absorption and efficacy is highly variable.

Continuous rate infusion systems should be considered peri- and post-operatively to maintain steady and efficacious analgesic plasma concentrations, tailored to the individual

animal. As maintenance of exteriorized vascular catheters can be challenging in swine, sustained-release formulations of various analgesics available as FDA-approved human pharmaceuticals have been proposed for use in this species. Several transdermal patch delivery systems, including fentanyl and buprenorphine, have been evaluated in swine (Thiede 2014; Wilkinson 2001). Swine skin is similar to human skin (Swindle 2012) but swine have distinct differences in skin pH, body temperature, and subcutaneous adipose depots which may affect the pharmacokinetics in swine compared to humans. Overall, literature and experience indicate breed and inter-individual variability in drug absorption with transdermal delivery systems, resulting in the potential of under- or over-dosing the patient. Combined with a lack of information regarding the therapeutic analgesic threshold in swine for many analgesics, the utility of sustained release formulations in swine pain management may be limited. Sedative, anesthetic, and analgesic doses for swine are outlined in Tables 5 and 6.

Table 6. Swine: Sedative - immobilization combinations and intravenous anesthesia

Drug Combination	Dose
Ketamine: Xylazine	15 - 20 mg/kg: 2 mg/kg SQ/IM
Ketamine: Midazolam	33 mg/kg: 0.5 mg/kg SQ/IM
Ketamine: Dexmedetomidine	10 mg/kg: 10 mcg/kg SQ/IM
Tiletamine - Zolazepam (Telazol®)	2 - 8.8 mg/kg SQ/IM
Tiletamine - Zolazepam (Telazol®): Xylazine	4 - 6 mg/kg: 2.2 mg/kg SQ/IM
Alphaxalone: Dexmedetomidine[a]	5 mg/kg: 10 mcg/kg IM
Alphaxalone: Diazepam[b]	5 mg/kg: 0.5 mg/kg IM
Intravenous Anesthesia	
Propofol	4 - 20 mg/kg IV to effect 12 - 20 mg/kg/h continuous intravenous infusion
Propofol: Midazolam: Fentanyl	Propofol: 2 - 4.4 mg/kg/h Midazolam: 0.4 - 0.7 mg/kg/h Fentanyl: 0.003 - 0.005 mg/kg/h continuous intravenous infusion

Drug dosages adapted from the following: Swindle MM, Sistino J. Anesthesia, Analgesia, and Perioperative Care. In: Swindle MM, Smith AC, eds. *Swine in the Laboratory, Surgery, Anesthesia, Imaging, and Experimental Techniques*. 3rd ed. Boca Raton: CRC Press; 2016:39-87; Swindle, Michael M. "Anesthesia & Analgesia in Swine." *Sinclair Bio-resources*. Website. Accessed 17 Jan. 2017. <http://www.sinclairresearch.com/assets/sites/2/Anesthesia-Analgesia-Small.pdf>.

[a] Santos M, Bertran de Lis BT, Tendillo FJ. Effects of intramuscular dexmedetomidine in combination with ketamine or alfaxalone in swine. *Veterinary anaesthesia and analgesia.* Jan 2016;43(1):81-85.

[b] Santos Gonzalez M, Bertran de Lis BT, Tendillo Cortijo FJ. Effects of intramuscular alfaxalone alone or in combination with diazepam in swine. *Veterinary anaesthesia and analgesia.* Jul 2013;40(4):399-402.

EUTHANASIA

Rodents

The American Veterinary Medical Association periodically publishes a well-researched guide on acceptable methods of euthanasia for all animals (Cima 2013). Achieving the most humane method of euthanasia has been extensively researched. The most common method of

rodent euthanasia is performed by carbon dioxide administration. Current research studying this method has focused on minimizing the time the animals experience pain and distress during the period of hypoxia, hypercarbia and the production of carbonic acid in the lungs and mucosa. Hypercarbia in the brain leads to unconsciousness (Conlee, Stephens, Rowan, & King, 2005). The rate of chamber displacement with carbon dioxide is an important area of study in the field of laboratory animal medicine. The effects of carbon dioxide and isoflurane in neonatal mice and rats are limited. Hence, they often require extremely long periods of time in the carbon dioxide chamber to attain death (Pritchett-Corning 2009). Mice and rats may also be euthanized by injections of pentobarbital or by cervical dislocation or decapitation, but general anesthesia is required for these techniques to be employed, unless a scientific justification is given for their usage.

NHPs and Swine

Methods of euthanasia for non-human primates and swine are outlined in the American Veterinary Medical Association Guidelines for the Euthanasia of Animals: 2013 edition (Leary 2013). Intravenous administration of a barbiturate euthanasia solution (e.g., concentrated sodium pentobarbital) is an acceptable method for euthanasia for both non-human primates and swine. Non-human primates and swine should be sedated and immobilized prior to euthanasia to minimize stress and facilitate placement of an intravenous catheter. Euthanasia may also be performed at the end of a non-recovery transplantation surgery while the animal is anesthetized for surgery.

POST-TRANSPLANT MEDICAL COMPLICATIONS IN ANIMALS

There are many side effects related to transplantation. Here we briefly mention some of them which are life-threatening, and encountered in mice, swine and non-human primates.

Graft-versus-Host Disease Post-Hematopoietic Cell Transplantation

Graft-versus-host disease (GVHD) occurs mainly due to activation of alloreactive T-cells in the donor hematopoietic cell (HC) inoculum. This is an aggressive immune driven reaction where all epithelial and lymphohematopoietic tissues of the host are attacked by the donor T cells that are present in the stem cell graft. Briefly, the pathophysiology of GVHD can be summarized as a three step process. In phase one, the conditioning regimen (irradiation, chemotherapy) causes the damage and activation of host tissues. In this phase, the gut is especially affected. Translocation of bacteria and bacterial toxins (lipopolysaccharide or LPS) through the gut mucosa stimulates the secretion of inflammatory cytokines. Donor T cell activation occurs in phase two. In phase three, the effector functions from mononuclear phagocytes induced by LPS and other stimulatory molecules that leak through the intestinal mucosa during phase one and two, induces the damage to target host tissues. Activated macrophages along with cytotoxic T lymphocytes secrete inflammatory cytokines which

cause further target damage through cell apoptosis. Most therapeutic approaches to reduce GVHD rely on immunosuppression and/or *ex vivo* removal of donor T-cells from the donor bone marrow graft. Immunosuppression is required to avoid this condition. Unfortunately, sometimes animals (and humans) are refractory to high doses of steroids. This is an area of intense research. Please refer to Chapter 27 for more details.

Infections

Bacterial/Protozoal

Animals are most at risk of infection during their neutropenic period (especially when neutrophils are under 500 cells/uL). Continued monitoring of their white blood cell counts is often required, particularly in protocols that are severely myeloablative. Often, antibiotic therapy needs to be used aggressively. Close collaboration with the veterinarian in order to choose the right antibiotic, dose and route for compliance (in each species) helps minimize side effects and antibiotic resistance. Often, animals may develop veterinary-specific diseases with clinical symptoms that overlap expected transplantation side effects (Crepeau 2012). Swine and monkeys may develop respiratory fungal infections. Placement of animals in HEPA-filtered cages or Bio-Bubbles is encouraged to minimize unwanted air-borne illnesses. In severely immunosuppressed animals, fungal pneumonias can translocate to the blood leading to life-threatening fungemias. Mice are usually in barrier rooms and housed in micro-isolator cages where their environment is controlled. This setup minimizes fungal/protozoal infections. Similar arrangements for larger animals are not as standard and can be costly for researchers. Despite being able to control the environment, mice (and large animals) can still become sick after the peri-transplant regimen by pathogens that enter the bloodstream via other routes (skin, gut). Close monitoring of experimental and control animals may lead the investigator to rule in/out potential causes (Duran-Struuck 2009).

Viral Diseases

Viral diseases often appear when patients have deficiencies in their T cell responses. Hence, these can occur in patients that have normal neutrophil counts, but which are receiving (or have received) immunosuppressive regimens that impede the function or deplete T cells. We discuss briefly two of the most common viral diseases which are observed in immunosuppressed animals.

i. *Epstein Bar Virus (NHPs)/Porcine lymphotropic herpesvirus (in swine)*. EBV and PLHV are common herpetic diseases that can reactivate post-transplant. These lead to a condition known as post-transplant lymphoproliferative disease (PTLD). In PTLD the B cell population aggressively expands as a result of a primary herpesviral infection (or reactivation) of B cells that are no longer kept “in check” by CD8 cytotoxic T cells. Therefore, immunocompromised transplant patients with depressed T cells (which include CD8 T cells) are at the highest risk. The variability of the patient population, both clinically and pathologically, complicates the ability to study this disease (Duran-Struuck 2015).

Swine and monkeys undergoing HCT or solid organ transplantation develop PTLD with a presentation resembling human PTLD. Supportive markers suggestive of PTLD (in addition to an acute increase of lymphocytes) include elevations of LDH, a serum marker shown to be increased in humans and pigs (Duran-Struuck 2015; Matar 2015) with PTLD (it has yet not been documented in NHPs). Increases in LDH in general precede (24−48 hours) the increase of the B cell population (Matar 2015). Like in humans, leukocytosis and generalized lymphadenopathy is commonly observed in NHPs and swine.

Treatment is centered on the ability to regain T cell immunity. There are three general approaches. First, decreasing the level of immunosuppression is a first line of defense by harnessing the cytotoxic cells of the host. This approach however risks the rejection of the graft rejection or GVHD. Second, infusion of rituximab (an anti-CD20 monoclonal antibody which targets CD20 on the surface of B cells) is commonly utilized in humans and has shown to be very successful (Tobinai 1998). Rituximab works in NHPs but it does not work in pigs as the anti-CD20 antibody does not cross-react with swine B cells. A third, and more novel approach consists in exploiting cellular immunotherapies. The least refined, but previously widely used approach included doing donor leukocyte infusions (DLIs) from EBV+ donors (usually from the same graft donor). The approach comes with significant risk, mainly GVHD. A cleaner cellular approach is the expansion of anti-EBV (or anti-PLHV in swine) cytotoxic T cells *in vitro* prior to infusion. Interestingly, limited GVHD has been observed with this approach (Bollard 2004) and are currently favored over bulk DLIs. More recently, the development of genetically engineered T cells by modifying their T cell receptors or creating a chimeric antigen receptor (CAR) have shown to be promising (Till 2012).

ii. *Cytomegalovirus:* Cytomegaloviruses (CMV) are betaherpesviruses that are commonly found in all species including human, NHPs and swine. The incidence is high but CMV rarely causes overt disease in immunocompetent individuals (Nakamae 2009). CMV is transmitted horizontally and is clinically associated with immunosuppression. Immunodeficient monkeys or swine that are infected with CMV develop necrotizing encephalitis, enteritis, lymphadenitis and/or interstitial pneumonia. CMV, therefore, poses great threat to animal models (and patients) undergoing immunosuppressive therapies**.** Animals at risk of developing CMV need to have their serum assessed for viremias and treated with antivirals. It is the authors experience that gancyclovir at 12.5 mg/kg IV BID works best in cynomolgus macaques. These doses are higher than what is given to humans (5 mg/kg) but human doses do not clear cynomolgus CMV. Antivirals (in general) have significant side-effects. Notably, bone marrow (BM) suppression is one of the most serious ones. Foscarnet or Cidofivir can also be used as adjunctive therapy, but are BM and nephrotoxic respectively. Failure to treat CMV in T cell-deficient animals can lead to death(Komanduri 1998). In essence, balancing the benefits and drawbacks of antivirals makes treatment of CMV difficult. Similar to EBV, discontinuation of immunosuppression and infusion of anti-CMV T cells is becoming more common (Zhou 2009). However, as previously mentioned, careful assessment of the side-effects encountered with T cell therapies must be thoughfully considered.

ETHICS OF TRANSPLANTATION RESEARCH FROM THE VETERINARY PERSPECTIVE

Animal research has had a critical role in scientific and medical advances during the past century. However, the use of animals has been a subject of heated debate. As with most ethical issues, there is a wide spectrum of views on the use of animals in science and medicine, and stewardship toward animals in general, ranging from absolutists concerned with the natural rights of animals to those who view animals only as an exploitable resource. These viewpoints have contributed to the development of ethical principles for animal use, which in turn have shaped regulations by the United States Department of Agriculture and the Public Health Service, and supported by organizations such as the American Association of Laboratory Animal Science (AALAS) AAALAC, and the AVMA.

Evolutionary theory purports that a hierarchy of moral standing exists among animals. In other words, the most complex animals, mammals, are at the top, progressing backward through the tree of life past the less complex vertebrates - birds, then reptiles, amphibians and fish - followed by the invertebrates, which lack any sort of regulatory care due to their relatively primitive nervous systems. A wealth of scientific research clearly illustrates that animals with advanced nervous systems, such as NHPs and marine mammals, have demonstrated abilities that humans can relate to and value, such as advanced social behavior, the ability to react to both positive and negative stimuli, intelligence and even self-awareness. What once seemed to be a clear cognitive distinction between humans and other animals has become less apparent; with that, the fading historical assumption of a clear moral distinction between humans and animals suggests that gradations in moral value is wise to apply to animals. Thus, scientists and medical professionals who work with animals have adopted several practical ethical principles to justify their work, and the most predominant among these is utility.

Modern principled thought has shifted from whether animals have moral status to how much moral status they have and what rights come with that status. It is important to note that there have been hundreds of years of philosophical argument surrounding the consequentialist theory that correlates with the principle of utility, namely utilitarianism. This theory was initially developed by the philosophers, Jeremy Benthem and John Stuart Mills, during the 19th and 20th centuries. The arguments, and frequently misunderstandings, that surround the theory of utilitarianism focus on the idea that the benefits of the research to people outweigh the costs to the animals; said in another far less popular way, “the ends justify the means.” However, despite the fact that this phrase suggests a clear lack of compassion is contradictory; in reality the sentiment is quite the opposite. When working alongside the scientists and medical professionals doing transplant work, for what they believe to be a “greater good,” it is clear that they feel sincere compassion for the animals in their care.

The utilitarian argument claims that moral status is derived from an animal’s capacity to suffer, along with the experience of enjoying its life. In respect to these facets of life experience, many animals are no different than humans. They can certainly feel pain, as well as experience pleasure. Therefore, per one utilitarian position, they should have the same moral status as humans and deserve equal treatment. However, as previously mentioned, a different utilitarian position held by many advocates of animal research claims that animals

cannot be considered morally equal to humans. This claim states that the benefits to humans from animal experimentation outweigh the harm done to animals.

Since most animals do not have the cognitive capabilities of humans and do not possess complete autonomy, such as the rational choice to pursue specific life goals, their moral life experience does not compare with that of human beings. This exclusion of animals from the same level of human moral experience supports the claim that the potential human benefits of the research outweigh the harm done to animals. But for many people this begs the question, what about the fact that infants and mentally handicapped individuals frequently lack complex cognitive capacities, full autonomy, or even both traits? The reply by animal research advocates is that the infants will, in time, meet the complete criteria of an adult human; moreover, the utility of animals in research may lead to treatments for individuals with these various cognitive deficits. An important caveat to this premise, of course, is that these innovative methods to correct aberrant genetic mutations in humans, such as genetic engineering with zinc-finger nucleases and CRISPr-Cas9 remain a separate and rather challenging relatively current ethical issue.

Thus, proponents of a more centrist position usually advocate a few basic principles that must always be followed when utilizing animals in scientific research and medicine. These are commonly known as the three *Rs: replacement, reduction, and refinement*. The first principle, *replacement*, calls for the preferential use of less complex organisms whenever possible. For example, bacteria and yeast, invertebrates such as nematode worms and fruit flies, and representatives of each of the other four groups of vertebrates, are all commonly used model organisms, and all are preferred over mammals for discovery science as well as medicine, *to a point*. Scientists and medical professionals pursue alternatives to using live animals, such as replacement with non-animal models like physical or digital models during a practical introduction to Anatomy and Physiology. A related example discussed in science education involves the question of reducing the use of surplus animals in high school and undergraduate school biology labs. In educational settings such as these, living animals (or at one time free-living animals) may not have worth relative to alternatives in a costs/benefits argument. Additionally, mechanical or computer models, audiovisual student aids, and *in vitro* modeling have proven useful for certain learning outcomes allowing for reduced use of living organisms. In fact, each Institutional Animal Care and Use Committee (IACUC) protocol requires referenced information about the alternatives that have been considered, why they were rejected, and how the Principal Investigator searched for them.

That said, disadvantages to replacement can be significant. In a system as complex as a live organism, many variables in physiology and pathophysiology remain unknown. This is critical in the argument for the use of animals in research. It must be recognized that treatments, be they surgical, drug-based, or another and aimed to being used in humans, will be significantly safer and most likely superior when first tested in animal models; indeed, there are no closer models to human beings than mammals, and large-animal mammalian models in particular.

The second principle, *reduction*, requires minimizing the number of animals needed to perform an experiment or teach a concept. This alternative is also required in IACUC protocols, where justification of the species to be used and the numbers needed for each experimental group are required. By examining these parameters, the IACUC can determine if thoughtful experimental design was employed to minimize overall animal use.

The third principle, *refinement*, requires constantly improving upon experimental protocols to minimize pain or distress of animals being used for scientific and medical purposes whenever possible. This expectation is addressed in numerous questions throughout the IACUC protocol as well. Examples of refinement include setting the earliest possible endpoint for experiments using animals, ensuring that all those who work with animals, both directly and indirectly, receive excellent training before performing any procedure (as previously discussed), and penalizing any person or institution failing to follow federally mandated guidelines, such as improper drug dosing and numerous other potential problems.

The reality is that the fields of science and medicine have felt entitled to perform invasive procedures on animals, including all forms of vertebrates, for the sake of improving the lives of other people; and animals certainly have suffered in various ways inside the facilities required to care for them as humanely as possible. For example, animals feel fear and anxiety, they react to disturbances in their natural routines, are separated from family members and prevented from play opportunities, sometimes are placed in abnormal housing with individuals of the same species, they can be affected by unnatural diets and food acquisition, reduced movement, and so forth. Therefore, it is crucial for both discovery science and applied science investigators, as well as animal care staff, to do everything possible to minimize the discomfort and maximize the enrichment of each individual animal that lives its life for the benefit of humanity.

CONCLUSION

In essence, animals will continue to be key players in transplantation research. We hope that the reader has now a better understanding of the husbandry, medical, regulatory and ethical considerations that need to be taken into consideration when working with research animals. We have established the basis for successful veterinary, anesthetic, analgesic and ethical arguments that support pre-clinical studies in pursuit of advances in transplantation biology and medicine.

REFERENCES

AAALAC International. (2017). Retrieved from http://www.aaalac.org/.

Allison SO, Halliday LC, French JA, Novikov DD, & Fortman JD. Assessment of buprenorphine, carprofen, and their combination for postoperative analgesia in olive baboons (Papio anubis). *J. Am. Assoc. Lab. Anim. Sci.* 2007; *46*(3): 24−31.

American College of Laboratory Animal Medicine *Position Statement on Pain and Distress in Research Animals*. (2016). Retrieved from https://www.aclam.org/Content/files/files/Public/Active/ACLAMPositionStatementPainand Distress- BOD PC final.pdf.

American College of Laboratory Animal Medicine *Recommendations for Monitoring Anesthetized Veterinary Patients*. (2009). Retrieved from http://www.acvaa.org/.

American College of Veterinary *Anesthesiologists' Position Paper on the Treatment of Pain in Animals*. (2006). Retrieved from http://www.acvaa.org/docs/Pain_Treatment.

Authier S, Chaurand F, Legaspi M, Breault C, & Troncy E. Comparison of three anesthetic protocols for intraduodenal drug administration using endoscopy in rhesus monkeys (Macaca mulatta). *J. Am. Assoc. Lab. Anim. Sci.* 2006;*45*(6): 73−79.

Baars JH, Rintisch U, Rehberg B, Lahrmann KH, & von Dincklage F. Prediction of motor responses to surgical stimuli during bilateral orchiectomy of pigs using nociceptive flexion reflexes and the bispectral index derived from the electroencephalogram. *Vet. J.* 2013;195(3): 377−381. doi:10.1016/j.tvjl.2012.07.011.

Bauer A, Baschnegger H, Renz V, Brandl U, Brenner P, Thein E, Christ, F. Comparison of propofol and isoflurane anesthesia in orthotopic pig-to-baboon cardiac xeno-transplantation. *Xenotransplantation* 2007; 14(3): 249−254. doi:10.1111/ j.1399−3089.2007.00383.x.

Bauer C, Frost P, & Kirschner S. Pharmacokinetics of 3 formulations of meloxicam in cynomolgus macaques (Macaca fascicularis). *J. Am. Assoc. Lab. Anim. Sci.* 2014; 53(5): 502−511.

Beckman B. Anesthesia and pain management for small animals. *Vet. Clin. North. Am. Small Anim. Prac.* 2013; 43(3): 669−688. doi:10.1016/j.cvsm.2013.02.006.

Betthauser J, Forsberg E, Augenstein M, Childs L, Eilertsen K, Enos J, . . . Bishop M. Production of cloned pigs from in vitro systems. *Nat. Biotechnol.* 2000; 18(10): 1055−1059.

Bollard CM, Aguilar L, Straathof KC, Gahn B, Huls MH, Rousseau A, . . . Heslop H. E. (2004). Cytotoxic T lymphocyte therapy for Epstein-Barr virus+ Hodgkin's disease. *J Exp Med, 200*(12), 1623−1633.

Bollard CM, Kuehnle I, Leen A, Rooney CM, & Heslop HE. Adoptive immunotherapy for posttransplantation viral infections. *Biol. Blood Marrow Transplant.* 2004; 10(3): 143−155.

Boller E, & Boller M. Assessment of Fluid Balance and the Approach to Fluid Therapy in the Perioperative Patient. *Vet. Clin. North Am. Small Anim. Pract.* 2015; 45(5): 895−915. doi:10.1016/j.cvsm.2015.04.011.

Brown CJ, & Donnelly TM. Rodent husbandry and care. *Vet Clin North Am Exot Anim Pract,* 2004; 7(2): 201−225, v. doi:10.1016/j.cvex.2004.02.005.

Burwitz BJ, Malouli D, Bimber BN, Reed JS, Ventura AB, Hancock MH, . . . Sacha JB. Cross-Species Rhesus Cytomegalovirus Infection of Cynomolgus Macaques. *PLoS. Pathog.* 2016;12(11): e1006014. doi:10.1371/journal.ppat.1006014.

Byers CG. Fluid Therapy: Options and Rational Selection. *Vet. Clin. North Am. Small Anim. Pract*. doi:10.1016/j.cvsm.2016; 09: 007.

Cain GR, & Champlin RE. Long-term complete chimerism and stable hematopoiesis in Beagles after fetal liver hematopoietic stem cell transplantation. *Am. J. Vet. Res.* 1989; 50:1282−1284.

Campagna JA, Miller KW, & Forman SA. Mechanisms of actions of inhaled anesthetics. *N. Engl. J. Med.* 2003; 348(21), 2110-2124. doi:10.1056/NEJMra021261.

Carlson AM, Kelly Iii R, Fetterer DP, Rico PJ, & Bailey EJ. Pharmacokinetics of 2 Formulations of Transdermal Fentanyl in Cynomolgus Macaques (Macaca fascicularis). *J. Am. Assoc. Lab. Anim. Sci.* 2016; *55*(4): 436−442.

Caro A, Hankenson FC, & Marx JO. A Comparison of Novel Thermoregulatory Devices Used During Anesthesia of C57BL/6 Mice and the Corelation of Body Temperature and Physiological Parameters. *J. Am. Assoc. Lab. Anim. Sci*. 2013 Sep; 52(5):577−83.

Casoni D, Amen EM, Brecheisen M, Kuennecke B, Muggler T, & Bergadano A. A combination of alfaxalone and medetomidine followed by an alfaxalone continuous rate infusion in cynomolgus monkeys (Macaca fascicularis) undergoing pharmacoMRS. *Vet. Anaesth. Analg.* 2015; 42(5): 552−554. doi:10.1111/vaa.12267

Castel D, Willentz E, Doron O, Brenner O, & Meilin S. Characterization of a porcine model of post-operative pain. *Eur. J. Pain,* 2014; *18*(4): 496−505. doi:10.1002/j.1532−2149. 2013.00399.x.

Cazzolli D, & Prittie J. The crystalloid-colloid debate: Consequences of resuscitation fluid selection in veterinary critical care. *J. Vet. Emerg. Crit. Care (San Antonio),* 2015; 25(1), 6−19. doi:10.1111/vec.12281.

Cima G. AVMA Guidelines for the Euthanasia of Animal: 2013 Edition. *Javma-Journal of the American Veterinary Medical Association* 2013; 242(6), 715−716.

Conlee KM, Stephens ML, Rowan AN, & King LA. Carbon dioxide for euthanasia: concerns regarding pain and distress, with special reference to mice and rats. *Lab. Anim.* 2005; 39(2): 137−161. doi:10.1258/0023677053739747.

Cooper DKC, & Wagner R. (2012). Xenotransplantation. In CR. Abee, K. Mansfield, S. Tardif, & T. Morris (Eds.), *Nonhuman Primates in Biomedical Research*. Amsterdam: Academic Press, an imprint of Elsevier.

Cozzi E, & White DJ. The generation of transgenic pigs as potential organ donors for humans. *Nat. Med.* 1995; 1(9): 964−966.

Crepeau R, Matar A, Spitzer TR, Robson S, Pathiraja V, Sachs DH, . . . Duran-Struuck R. Edema and tetraparesis in a miniature pig after allogeneic hematopoietic cell transplantation. *Comp. Med*. 2012; 62(4), 298−302.

Croy BA, Linder KE, & Yager JA. Primer for non-immunologists on immune-deficient mice and their applications in research. *Comp. Med*. 2001; 51(4): 300−313.

de Jong RH, & Bonin JD. Mixtures of local anesthetics are no more toxic than the parent drugs. *Anesthesiology* 1981; 54(3): 177−181.

Drougas JG, Barnard SE, Wright JK, Sika M, Lopez RR, Stokes KA, . . . Pinson, CW. A model for the extended studies of hepatic hemodynamics and metabolism in swine. *Lab. Anim. Sci.* 1996; 46(6): 648−655.

Duke-Novakovski T, & Carr A. Perioperative Blood Pressure Control and Management. *Vet. Clin. North Am. Small Anim. Pract.* 2015; 45(5): 965−981. doi:10.1016/j.cvsm. 2015.04.004.

Duran-Struuck R, & Dysko RC. Principles of bone marrow transplantation (BMT): providing optimal veterinary and husbandry care to irradiated mice in BMT studies. *J. Am. Assoc. Lab. Anim. Sci.* 2009; 48(1): 11−22.

Duran-Struuck R, Hartigan A, Clouthier SG, Dyson MC, Lowler K, Gatza E, . . . Wilkinson JE. (2008). Differential susceptibility of C57BL/6NCr and B6.Cg-Ptprca mice to commensal bacteria after whole body irradiation in translational bone marrow transplant studies. *J. Transl. Med. 6*, 10. doi:10.1186/1479-5876-6-10.

Duran-Struuck R, Huang CA, Orf K, Bronson RT, Sachs DH, & Spitzer, TR. Miniature Swine as a Clinically Relevant Model of Graft-Versus-Host Disease. *Comp. Med.* 2015; 65(5), 429−443.

Duran-Struuck R, Matar AJ, & Huang CA. (2015). Myeloid Leukemias and Virally Induced Lymphomas in Miniature Inbred Swine: Development of a Large Animal Tumor Model. *Front Genet. 6*, 332. doi:10.3389/fgene.2015.00332.

Duran-Struuck R, Sondermeijer HP, Buhler L, Alonso-Guallart P, Zitsman J, Kato Y, Sykes M. (2016). Effect of ex vivo Expanded Recipient Regulatory T Cells on Hematopoietic Chimerism and Kidney Allograft Tolerance across MHC Barriers in Cynomolgus Macaques. *Transplantation* doi:10.1097/TP.0000000000001559.

Elmore D, & Eberle R. Monkey B virus (Cercopithecine herpesvirus 1). *Comp. Med.* 2008; 58(1): 11−21.

Epstein M, Rodan I, Griffenhagen G, Kadrlik J, Petty M, Robertson S, & Simpson W. 2015 AAHA/AAFP Pain Management Guidelines for Dogs and Cats. *J. Am. Anim. Hosp. Assoc.* 2015; 51(2): 67−84. doi:10.5326/jaaha-ms-7331.

Erickson RL, Terzi MC, Jaber SM, Hankenson FC, McKinstry-Wu A, Kelz MB, & Marx JO. Intraperitoneal Continuous-Rate Infusion for the Maintenance of Anesthesia in Laboratory Mice (Mus musculus). *J. Am. Assoc. Lab. Anim. Sci.* 2016; 55(5), 548−557.

Ferrara JL, Levine JE, Reddy P, & Holler E. Graft-versus-host disease. *Lancet* 2009; 373(9674): 1550−1561.

Fish R, & Fund CJMML. (Eds.). (2008). *Anesthesia and analgesia in laboratory animals* (2nd ed.). London, Burlington, MA: Elsevier Academic Press.

Fish RE, & ScienceDirect. (2008). *Anesthesia and analgesia in laboratory animals*. Amsterdam; Boston: Elsevier/Academic Press.

Flecknell P, Leach M, & Bateson M. Affective state and quality of life in mice. *Pain* 2011; 152(5): 963−964. doi:10.1016/j.pain.2011.01.030.

Flecknell PA. (2001). Analgesia of small mammals. *Vet Clin North Am Exot Anim Pract, 4*(1), 47−56, vi.

Flecknell PA, & ScienceDirect. (2016). *Laboratory animal anaesthesia*. Amsterdam: Academic Press.

Flegal MC, Fox LK, & Kuhlman SM. Principles of anesthesia monitoring−respiration. *J. Invest. Surg.* 2009; 22(1), 76. doi:10.1080/08941930802708167.

Flournoy WS, & Mani S. Percutaneous external jugular vein catheterization in piglets using a triangulation technique. *Lab. Anim.* 2009; 43(4): 344−349. doi:10.1258/la.2009.0080092.

Fowler KA, Huerkamp MJ, Pullium JK, & Subramanian T. Anesthetic protocol: propofol use in Rhesus macaques (Macaca mulatta) during magnetic resonance imaging with stereotactic head frame application. *Brain Res. Protoc.* 2001; 7(2): 87−93.

Fox JG. (2007). *The mouse in biomedical research* (2nd ed.). Amsterdam; Boston: Elsevier, AP.

Fox JG. (2015). *Laboratory Animal Medicine* (3rd ed.). Amsterdam; New York: Academic Press.

Fox LK, Flegal MC, & Kuhlman SM. Principles of anesthesia monitoring−body temperature. *J Invest Surg*, 2008; 21(6): 373−374. doi:10.1080/08941930802411937.

Fox LK, Flegal MC, & Kuhlman SM. (2009). Principles of anesthesia monitoring-capnography. *J. Invest. Surg.* 2009; 22(6): 452−454. doi:10.3109/08941930903316506.

Fudge M, Coleman RE, & Parker SB. A minimally invasive percutaneous technique for jugular vein catheterization in pigs. *Contemp. Top. Lab. Anim. Sci.* 2002; 41(1), 38−42.

Greene JM, Burwitz BJ, Blasky AJ, Mattila TL, Hong JJ, Rakasz EG, O'Connor DH. Allogeneic lymphocytes persist and traffic in feral MHC-matched mauritian cynomolgus macaques. *PLoS. One.*, 2008; 3(6): e2384. doi:10.1371/journal.pone.0002384 [doi].

Grimm KA, Lamont LA, Tranquilli WJ, Greene SA, & Robertson SA. (2015). *Veterinary anesthesia and Analgesia: The Fifth Edition of Lumb and Jones* (5th ed.). Philadelphia: Wiley-Blackwell.

Guarnieri M, Brayton C, DeTolla L, Forbes-McBean N, Sarabia-Estrada R, & Zadnik P. Safety and efficacy of buprenorphine for analgesia in laboratory mice and rats. *Lab. Anim (NY).* 2012; 41(11): 337−343. doi:10.1038/laban.152.

Guide for the Care and Use of Agricultural Animals in Research and Teaching. (2010). Federation of Animal Science Societies. Champaign (IL).

Guide for the care and use of laboratory animals. (1985). Washington: U.S. Government Printing Office.

Guidelines for training in surgical research with animals. Academy of Surgical Research. *J. Invest. Surg.* 2009; 22(3), 218−225. doi:10.1080/08941930902904542.

Hall JE, White WJ, & Lang CM. Acidification of drinking water: its effects on selected biologic phenomena in male mice. *Lab. Anim. Sci.* 1980; 30(4 Pt 1), 643−651.

Hammer C. Potential barriers to xenogeneic organ transplantation. *Schweizerische Medizinische Wochenschrift* 1998; 128(24): 931−934.

Han D, Berman DM, Willman M, Buchwald P, Rothen D, Kenyon NM, & Kenyon NS. Choice of immunosuppression influences cytomegalovirus DNAemia in cynomolgus monkey (Macaca fascicularis) islet allograft recipients. *Cell Transplant.* 2010; 19(12): 1547−1561. doi:ct2140han [pii];10.3727/096368910X513973 [doi].

Haverson K, Saalmuller A, Alvarez B, Alonso F, Bailey M, Bianchi AT, . . . Zwart R. (2001). Overview of the Third International Workshop on Swine Leukocyte Differentiation Antigens. *Vet. Immunol. Immunopathol. %20;80*(1−2), 5−23.

He S, Atkinson C, Qiao F, Chen X, & Tomlinson S. Ketamine-xylazine-acepromazine compared with isoflurane for anesthesia during liver transplantation in rodents. *J. Am. Assoc. Lab. Anim. Sci.* 2010; 49(1): 45−51.

Healy JR, Tonkin JL, Kamarec SR, Saludes MA, Ibrahim SY, Matsumoto RR, & Wimsatt JH. Evaluation of an improved sustained-release buprenorphine formulation for use in mice. *Am. J. Vet. Res.* 2014; 75(7): 619−625. doi:10.2460/ajvr.75.7.619.

Herrmann IK, Castellon M, Schwartz DE, Hasler M, Urner M, Hu G, . . . Beck-Schimmer B. Volatile anesthetics improve survival after cecal ligation and puncture. *Anesthesiology* 2013; 119(4): 901−906. doi:10.1097/ALN.0b013e3182a2a38c.

Horner BM, Randolph MA, Duran-Struuck R, Hirsh EL, Ferguson KK, Teague AG, . . . Huang CA. Induction of tolerance to an allogeneic skin flap transplant in a preclinical large animal model. *Transplant. Proc.* 2009; 41(2): 539−541.

Institute for Laboratory Animal R, & ebrary I. (2009). *Recognition and alleviation of pain in laboratory animals*. Washington, D.C.: National Academies Press.

Ison SH, Clutton RE, Di Giminiani, P, & Rutherford KMD. A Review of Pain Assessment in Pigs. *Frontiers in Veterinary Science* 2016; 3(108): doi:10.3389/fvets.2016.00108.

Izer J, Wilson R, Hernon K, & Undar A. (2016). Ultrasound-guided vessel catheterization in adult Yorkshire cross-bred pigs. *Vet. Anaesth. Analg.* doi:10.1111/vaa.12407.

Jaber S, Hankenson FC, Kelz MB, McKinstry-Wu A, & Marx JO. (2014). Dosing, variability, and complications using repeat boluses for extension of a surgical plane of anesthesia in laboratory mice. *J. Am. Assoc. Lab. Anim. Sci.* 2014; 53(6): 684−91.

Jaber SM, Sullivan S, Hankenson FC, Kilbaugh TJ, & Margulies SS. Comparison of Heart Rate and Blood Pressure with Toe Pinch and Bispectral Index for Monitoring the Depth of Anesthesia in Piglets. *J. Am. Assoc. Lab. Anim. Sci.* 2015; 54(5): 536−544.

Jaber SM, Sullivan S, & Margulies SS. Noninvasive metrics for identification of brain injury deficits in piglets. *Dev. Neuropsychol.* 2015; 40(1): 34−39. doi:10.1080/87565641. 2014.969733.

Jacoby RO, & Lindsey JR. Risks of Infection among Laboratory Rats and Mice at Major Biomedical Research Institutions. *ILAR J.* 1998; 39(4), 266−271.

Kalscheuer H, Danzl N, Onoe T, Faust T, Winchester R, Goland R, . . . Sykes MA model for personalized in vivo analysis of human immune responsiveness. *Science Translational Medicine* 2012; 4(125): 125ra130.

Kawai T, Andrews D, COLVIN RB, Sachs DH, & Cosimi AB. Thromboembolic complications after treatment with monoclonal antibody against CD40 ligand [letter]. *Nat. Med.* 2000; 6(2): 114.

Kawai T, Sachs DH, & Cosimi AB. Tolerance to vascularized organ allografts in large animal models. *Curr.Opin.Immunol.* 1999; 11: 516−526.

Kelly KR, Pypendop BH, & Christe KL. Pharmacokinetics of buprenorphine following intravenous and intramuscular administration in male rhesus macaques (Macaca mulatta). *J. Vet. Pharmacol. Ther.* 2014; 37(5): 480-485. doi:10.1111/jvp.12113.

Kendall LV, Hansen RJ, Dorsey K, Kang S, Lunghofer PJ, & Gustafson DL. Pharmacokinetics of sustained-release analgesics in mice. *J. Am. Assoc. Lab. Anim. Sci.* 2014; 53(5): 478−484.

Kendall LV, Wegenast DJ, Smith BJ, Dorsey KM, Kang S, Lee NY, & Hess AM. Efficacy of Sustained-Release Buprenorphine in an Experimental Laparotomy Model in Female Mice. *J. Am. Assoc. Lab. Anim. Sci.* 2016;55(1): 66−73.

Kimura T, Koike T, Matsunaga T, Sazi T, Hiroe T, & Kubota M. Evaluation of a medetomidine-midazolam combination for immobilizing and sedating Japanese monkeys (Macaca fuscata). *J. Am. Assoc. Lab. Anim. Sci.* 2007; 46(4), 33−38.

Komanduri KV, Viswanathan MN, Wieder ED, Schmidt DK, Bredt BM, Jacobsen MA, & McCune JM. Restoration of cytomegalovirus-specific CD4+ T-lymphocyte responses after gancyclovir and highly active antiretroviral therapy in individuals infected with HIV-1. *Nature Med.* 1998; 4(8): 953−956.

Kurita T, Uraoka M, Morita K, & Sato S. Influence of progressive hemorrhage and subsequent cardiopulmonary resuscitation on the bispectral index during isoflurane anesthesia in a swine model. *J. Trauma. Acute Care Surg.* 2012; 72(6): 1614−1619. doi:10.1097/TA.0b013e3182569e9c.

Laber KE, Whary MT, Bingel SA, Goodrich JA, AC, S., & MM, S. (2009). Biology and Diseases of Swine. In *Laboratory Animal Medicine* (2nd Edition ed.). London, UK: Academic Press.

Ladiges WC, Storb R, & Thomas ED. Canine models of bone marrow transplantation. *Lab. Anim. Sci.* 1990; 40: 11−15.

Lamont LA. Multimodal pain management in veterinary medicine: the physiologic basis of pharmacologic therapies. *Vet. Clin. North Am. Small Anim. Pract.* 2008; 38(6), 1173−1186, v. doi:10.1016/j.cvsm.2008.06.005.

Larsson N, Claesson Lingehall H, Al Zaidi N, Claesson J, Jensen-Waern M, & Lehtipalo Percutaneously inserted long-term central venous catheters in pigs of different sizes. *Lab. Anim.* 2015;49(3): 215−219. doi:10.1177/0023677215575222.

Lavker RM, Dong G, Zheng PS, & Murphy GF. Hairless micropig skin. A novel model for studies of cutaneous biology. *Am. J. Pathol.* 1991; 138(3): 687−697.

Leach MC, Klaus K, Miller AL, Scotto di Perrotolo M, Sotocinal SG, & Flecknell PA. The assessment of post-vasectomy pain in mice using behaviour and the Mouse Grimace Scale. *PLoS One.* 2012; 7(4): e35656. doi:10.1371/journal.pone.0035656.

Leary S, Underwood W, Anthony R, Cartner S, Corey D, Grandin T, . . . Meyer, R. (2013). *AVMA Guidelines for the Euthanasia of Animals*. Retrieved from Schaumburg, IL.

Lee VK, Flynt KS, Haag LM, & Taylor DK. Comparison of the effects of ketamine, ketamine-medetomidine, and ketamine-midazolam on physiologic parameters and anesthesia-induced stress in rhesus (Macaca mulatta) and cynomolgus (Macaca fascicularis) macaques. *J. Am. Assoc. Lab. Anim. Sci.* 2010; 49(1): 57−63.

Lemke KA, & Dawson SD. Local and regional anesthesia. *Vet. Clin. North Am. Small. Anim. Pract.* 2000; 30(4), 839−857.

Leonard DA, Kurtz JM, Mallard C, Albritton A, Duran-Struuck R, Farkash EA, . . . Cetrulo CL, Jr. Vascularized composite allograft tolerance across MHC barriers in a large animal model. *Am. J. Transplant.* 2014; 14(2): 343−355. doi:10.1111/ajt.12560.

Les EP. Effect of acidified-chlorinated water on reproduction in C3H-HeV and C57BL-5J mice. *Lab. Anim. Care.* 1968;18(2): 210−213.

Li HY, YG, Sykes M. (2014). Thymic education of human T cells and regulatory T cell development in humanized mice. In L. Y. G.-M. Poluektova, J.V.; Manz,M.G.; Tager, A.M. (Ed.), *Humanized mice for HIV research* (Vol. 10). New York: Springer.

Lunney JK, Pescovitz MD, & Sachs DH. (1986). The swine major histocompatibility complex: Its structure and function. In M. E. Tumbleson (Ed.), *Swine in biomedical research* (1 ed., pp. 1821−1836). New York: Plenum Press. (Reprinted from: In File).

Malkinson TJ, Veale WL, & Cooper KE. Experimental characterization and applications of an anesthetized animal model for thermoregulatory investigations. *Biomed. Sci. Instrum*. 1993; 29: 369−376.

Martin-Cancho MF, Carrasco-Jimenez MS, Lima JR, Ezquerra LJ, Crisostomo V, & Uson-Gargallo J. Assessment of the relationship of bispectral index values, hemodynamic changes, and recovery times associated with sevoflurane or propofol anesthesia in pigs. *Am. J. Ve.t Res.* 2004; 65(4): 409−416.

Martin-Cancho MF, Lima JR, Luis L, Crisostomo V, Lopez MA, Ezquerra LJ, . . . Uson-Gargallo J. Bispectral index, spectral edge frequency 95% and median frequency recorded at varying desflurane concentrations in pigs. *Res. Vet. Sci.* 2006; 81(3): 373−381. doi:10.1016/j.rvsc.2006.01.003.

Matar AJ, Patil AR, Al-Musa A, Hanekamp I, Sachs DH, Huang CA, & Duran-Struuck R. Effect of Irradiation on Incidence of Post-Transplant Lymphoproliferative Disorder after Hematopoietic Cell Transplantation in Miniature Swine. *Biol. Blood Marrow Transplant*. 2015 Oct;21(10):1732−8.

Matsumiya LC, Sorge RE, Sotocinal SG, Tabaka JM, Wieskopf JS, Zaloum A, . . . Mogil JS. Using the Mouse Grimace Scale to reevaluate the efficacy of postoperative analgesics in laboratory mice. *J. Am. Assoc. Lab. Anim. Sci.* 2012; 51(1): 42−49.

Mazzaferro E, & Powell LL. Fluid therapy for the emergent small animal patient: crystalloids, colloids, and albumin products. *Vet. Clin. North Am. Small Anim. Pract.* 2013; 43(4): 721−734. doi:10.1016/j.cvsm.2013.03.003.

Merskey H, Bogduk N, & International Association for the Study of, P. (1994). *Classification of chronic pain: descriptions of chronic pain syndromes and definitions of pain terms*. Seattle: IASP Press.

Miller SJ, Burke EM, Rader MD, Coulombe PA, & Lavker RM. Re-epithelialization of porcine skin by the sweat apparatus. *J. Invest. Dermatol.* 1998; 110(1): 13−19. doi:S0022202X97880402 [pii];10.1046/j.1523−1747.1998.00087.x [doi].

Mohiuddin MM., Reichart B, Byrne GW, & McGregor CG. Current status of pig heart xenotransplantation. *Int. J. Surg*, 2015; 23(Pt B), 234−239. doi:10.1016/j.ijsu. 2015.08.038.

Morton DB, & Griffiths PH. Guidelines on the recognition of pain, distress and discomfort in experimental animals and an hypothesis for assessment. *Vet. Rec.* 1985; 116(16): 431−436.

Murphy KL, Baxter MG, & Flecknell PA. (2012). Anesthesia and Analgesia in Nonhuman Primates. In C. R. Abee, K. Mansfield, S. Tardif, & T. Morris (Eds.), *Nonhuman Primates in Biomedical Research* (pp. 403−435). Amsterdam: Academic Press, an imprint of Elsevier.

Nakamae H, Kirby KA, Sandmaier BM, Norasetthada L, Maloney DG, Maris MB, . . . Boeckh M. Effect of conditioning regimen intensity on CMV infection in allogeneic hematopoietic cell transplantation. *Biol. Blood Marrow Transplant.* 2009;15(6): 694−703.

National Research C. (2011). *Guide for the care and use of laboratory animals*. Washington, D.C.: National Academies Press.

National. Research. Council. (1992). Recognition and Alleviation of Pain and Distress in Laboratory Animals *Recognition and Alleviation of Pain and Distress in Laboratory Animals*. Washington (DC).

Nicolaides N, Fu HC, & Rice GR. The skin surface lipids of man compared with those of eighteen species of animals. *J. Invest. Dermatol.* 1968; 51(2): 83−89.

NRC. (2011). *Guide for the care and use of laboratory animals*. Washington, D.C.: National Academies Press.

Nunamaker EA, Halliday LC, Moody DE, Fang WB, Lindeblad M, & Fortman JD. Pharmacokinetics of 2 formulations of buprenorphine in macaques (Macaca mulatta and Macaca fascicularis). *J. Am. Assoc. Lab. Anim. Sci.* 2013; 52(1): 48−56.

O'Connor SL, Blasky AJ, Pendley CJ, Becker EA, Wiseman RW, Karl JA, . . . O'Connor DH. Comprehensive characterization of MHC class II haplotypes in Mauritian cynomolgus macaques. *Immunogenetics* 2007; 59(6): 449−462. doi:10.1007/s00251-007-0209-7 [doi].

Ochi T, Nishiura I, Tatsumi M, Hirano Y, Yahagi K, Sakurai Y, . . . Koyama H. Anesthetic effect of a combination of medetomidine-midazolam-butorphanol in cynomolgus monkeys (Macaca fascicularis). *J. Vet. Med. Sci.* 2014; 76(6): 917−921.

Pathiraja V, Matar AJ, Gusha A, Huang CA, & Duran-Struuck R. Leukapheresis protocol for nonhuman primates weighing less than 10 kg. *J. Am. Assoc. Lab. Anim. Sci.* 2013; 52(1): 70−77.

Pennington L, Sakamoto K, Popitz-Bergez FA, Pescovitz MD, McDonough MA, MacVittie TJ, Sachs DH. bone marrow transplantation in miniature swine I. development of the model. *Transplantation* 1988; 45(1): 21−26.

Pescovitz MD, Aasted B, Canals A, Dominguez J, Vizcaino JS, Pospisil R, . . . Davis WC. Analysis of monoclonal antibodies reactive with the porcine CD2 antigen. *Vet.Immunol Immunopathol.* 1994; 43(1−3): 229−232.

Pescovitz MD, Book BK, Aasted B, Dominguez J, Bullido R, Trebichavsky I, . . . Saalmuller A. Analyses of monoclonal antibodies reacting with porcine wCD6: results from the Second International Swine CD Workshop. *Vet. Immunol. Immunopathol.* 1998; 60(3−4): 285−289.

Pescovitz MD, Book BK, Aasted B, Dominguez J, Bullido R, Trebichavsky I, . . . Saalmuller A. Analyses of monoclonal antibodies reacting with porcine CD5: results from the Second International Swine CD Workshop. *Vet. Immunol. Immunopathol.* 1998; 60(3−4): 269−273.

Pescovitz MD, Book BK, Aasted B, Dominguez J, Ezquerra A, Trebichavsky I, . . . Saalmuller A. Analyses of monoclonal antibodies reacting with porcine CD3: results from the Second International Swine CD Workshop. *Vet. Immunol. Immunopathol.* 1998; 60(3−4): 261−268.

Pescovitz MD, Hsu SM, Katz SI, Lunney JK, Shimada S, & Sachs DH. Characterization of a porcine CD1-specific mAb that distinguishes CD4/CD8 double-positive thymic from peripheral T lymphocytes. *Tissue Antigens.* 1990; 35: 151−156.

Platt JL. Physiologic barriers to xenotransplantation. *Transplant. Proc.* 2000; 32(7): 1547−1548. doi:S0041-1345(00)01342-7 [pii].

Popitz-Bergez FA, Sakamoto K, Pennington LR, Pescovitz MD, McDonough MA, MacVittie TJ, . . . Sachs DH. Bone marrow transplantation in miniature swine. II. Effect of selective genetic differences on marrow engraftment and recipient survival. *Transplantation* 1988; 45: 27−31.

Pozzi A, Muir WW, & Traverso F. Prevention of central sensitization and pain by N-methyl-D-aspartate receptor antagonists. *J. Am. Vet. Med. Assoc.* 2006; 228(1): 53−60. doi:10.2460/javma.228.1.53.

Pritchett-Corning KR. Euthanasia of Neonatal Rats with Carbon Dioxide. *Journal of the American Association for Laboratory Animal Science* 2009; 48(1), 23−27.

Racki WJ, Covassin L, Brehm M, Pino S, Ignotz R, Dunn R, . . . Greiner DL. NOD-scid IL2rgamma(null) mouse model of human skin transplantation and allograft rejection. *Transplantation* 2010; 89(5): 527−536.

Ratsep MT, Barrette VF, Winterborn A, Adams MA, & Croy BA. Hemodynamic and behavioral differences after administration of meloxicam, buprenorphine, or tramadol as analgesics for telemeter implantation in mice. *J. Am. Assoc. Lab. Anim. Sci.* 2013; 52(5): 560−566.

Ribotsky BM, Berkowitz KD, & Montague JR. Local anesthetics. Is there an advantage to mixing solutions? *J. Am. Podiatr. Med. Assoc.* 1996; 86(10): 487−491. doi:10.7547/8750 7315-86-10-487.

Roughan JV, Bertrand HG, & Isles HM. Meloxicam prevents COX-2-mediated post-surgical inflammation but not pain following laparotomy in mice. *Eur. J. Pain.* 2006; 20(2): 231−240. doi:10.1002/ejp.712.

Russell JN, Marsh AK, Willer DO, Ambagala AP, Dzamba M, Chan JK, . . . MacDonald KS. A novel strain of cynomolgus macaque cytomegalovirus: implications for host-virus co-evolution. *BMC Genomics* 2016; 17: 277. doi:10.1186/s12864-016-2588-3.

Saalmuller A. Characterization of swine leukocyte differentiation antigens. *Immunol. Today* 1996; 17:352−354.

Saalmuller A, Aasted B, Canals A, Dominguez J, Goldman T, Lunney JK, . . . Pospisil R. Analyses of monoclonal antibodies reactive with porcine CD6. *Vet. Immunol. Immunopathol.* 1994; 43: 243−247.

Saalmuller, A., Aasted, B., Canals, A., Dominguez, J., Goldman, T., Lunney, J. K., . . . Salmon, H. Analyses of mAb reactive with porcine CD8. *Vet. Immunol. Immunopathol.* 1994a; 43:249−254.

Saalmuller A, Aasted B, Canals A, Dominguez J, Goldman T, Lunney JK, . . . Salmon H. Analyses of monoclonal antibodies reactive with porcine CD5. *Vet. Immunol. Immunopathol.* 1994b; 43, 237−242.

Saalmuller A, Aasted B, Canals A, Dominguez J, Goldman T, Lunney JK, . . . Salmon H. Analysis of mAb reactive with the porcine SWC1. *Vet. Immunol. Immunopathol.* 1994; 43, 255−258.

Saalmuller A, & Bryant J. Characteristics of porcine T lymphocytes and T-cell lines. *Vet. Immunol. Immunopathol.* 1994; 43: 45−52.

Saalmuller A, Hirt W, & Reddehase MJ. Phenotypic discrimination between thymic and extrathymic CD4-CD8- and CD4+CD8+ porcine T lymphocytes. *Eur. J. Immunol.* 1989; 19: 2011−2016.

Saalmüller A, Hirt W, & Reddehase MJ. Phenotypic discrimination between thymic and extrathymic $CD4^{-}CD8^{-}$ and $CD4^{+}CD8^{+}$ porcine T lymphocytes. *Eur. J. Immunol.* 1989; 19: 2011−2016.

Sachs DH, Leight G, Cone J, Schwartz S, Stuart L, & Rosenberg S. Transplantation in miniature swine. I. Fixation of the major histocompatibility complex. *Transplantation* 1976; 22: 559−567.

Sakamoto K, Sachs DH, Shimada S, Popitz-Bergez FA, Pennington LR, Pescovitz MD, . . . Gress RE. Bone marrow transplantation in miniature swine. III Graft-versus-host disease and the effect of T cell depletion of marrow. *Transplantation* 1988; 45: 869−875.

Seymour TL, Adams SC, Felt SA, Jampachaisri K, Yeomans DC, & Pacharinsak C. Postoperative Analgesia Due to Sustained-Release Buprenorphine, Sustained-Release Meloxicam, and Carprofen Gel in a Model of Incisional Pain in Rats (Rattus norvegicus). *J. Am. Assoc. Lab. Anim. Sci.* 2016; 55(3): 300−305.

Shultz LD, Banuelos S, Lyons B, Samuels R, Burzenski L, Gott B, . . . Greiner DL. NOD/LtSz-Rag1nullPfpnull mice: a new model system with increased levels of human peripheral leukocyte and hematopoietic stem-cell engraftment. *Transplantation* 2003; 76(7): 1036−1042.

Shultz LD, Brehm MA, Garcia-Martinez JV, & Greiner DL. Humanized mice for immune system investigation: progress, promise and challenges. *Nat. Rev. Immunol.* 2012; 12(11): 786−798. doi:10.1038/nri3311.

Shultz LD, Ishikawa F, & Greiner DL. Humanized mice in translational biomedical research. *Nat. Rev. Immunol.* 2007; 7(2): 118−130.

Shultz LD, Saito Y, Najima Y, Tanaka S, Ochi T, Tomizawa M, . . . Ishikawa F. Generation of functional human T-cell subsets with HLA-restricted immune responses in HLA class I expressing NOD/SCID/IL2r gamma(null) humanized mice. *Proc. Natl .Acad. Sci. U.S.A*, 2010;107(29), 13022−13027.

Storb R. Allogeneic hematopoietic stem cell transplantation−yesterday, today, and tomorrow. *Exp. Hematol.* 2003; 31(1): 1−10.

Swindle M, & Sistino J. (2015). Anesthesia, Analgesia, and Perioperative Care. *Swine in the Laboratory* (pp. 39−88): CRC Press.

Swindle, M., & Sistino, J. (2016). Anesthesia, Analgesia, and Perioperative Care *Swine in the Laboratory* (pp. 39−88): CRC Press.

Swindle MM, Makin A, Herron AJ, Clubb FJ, Jr, & Frazier KS. Swine as models in biomedical research and toxicology testing. *Vet. Pathol.* 2012; 49(2): 344−356. doi:10.1177/0300985811402846.

Swindle MM, & Sistino J. (2016). Anesthesia, Analgesia, and Perioperative Care. In M. M. Swindle & A. C. Smith (Eds.). *Swine in the Laboratory, Surgery, Anesthesia, Imaging, and Experimental Techniques* (3rd ed., pp. 39−87). Boca Raton: CRC Press.

Swindle MM, & Smith AC. Best practices for performing experimental surgery in swine. *J. Invest. Surg.* 2013; 26(2): 63−71. doi:10.3109/08941939.2012.693149.

The piglet as a model for perinatal fatty acid metabolism in man. *Nutr. Rev.* 1984; 42(7): 257−258.

Theriault BR, ReedDA, & Niekrasz MA. Reversible medetomidine/ketamine anesthesia in captive capuchin monkeys (Cebus apella). *J. Med. Primatol.* 2008*; 37 Suppl 1*, 74−81. doi:10.1111/j.1600-0684.2007.00267.x.

Thiede AJ, Garcia KD, Stolarik DF, Ma J, Jenkins GJ, & Nunamaker EA. Pharmacokinetics of sustained-release and transdermal buprenorphine in Gottingen minipigs (Sus scrofa domestica). *J. Am. Assoc. Lab. Anim. Sci.* 2014; 53(6): 692−699.

Till BG, Jensen MC, Wang J, Qian X, Gopal AK, Maloney DG, . . . Press OW. CD20-specific adoptive immunotherapy for lymphoma using a chimeric antigen receptor with both CD28 and 4-1BB domains: pilot clinical trial results. *Blood* 2012; 119(17), 3940−3950. doi:blood-2011-10-387969 [pii];10.1182/blood-2011-10-387969 [doi].

Tobinai K, Kobayashi Y, Narabayashi M, Ogura M, Kagami Y, Morishima Y, . . . Murate T. Feasibility and pharmacokinetic study of a chimeric anti-CD20 monoclonal antibody (IDEC-C2B8, rituximab) in relapsed B-cell lymphoma. The IDEC-C2B8 Study Group. *Ann. Oncol.* 1998; 9(5): 527−534.

Tranquilli WJ, Thurmon JC, Grimm KA, & Lumb WV. (2007). *Lumb & Jones' veterinary anesthesia and analgesia* (4th ed.). Ames, Iowa: Blackwell Pub.

Valverde CR, Mama KR, Kollias-Baker C, Steffey EP, & Baggot JD. Pharmacokinetics and cardiopulmonary effects of fentanyl in isoflurane-anesthetized rhesus monkeys (Macaca mulatta). *Am. J. Vet. Re.* 2000; 61(8): 931−934.

van Bekkum DW. Conditioning regimens for marrow grafting. *Semin. Hematol.* 1984; 21: 81−90.

Votava M, Hess L, Schreiberova J, Malek J, & Stein K. Short term pharmacological immobilization in macaque monkeys. *Vet. Anaesth. Analg*, 2011; 38(5): 490−493. doi:10.1111/j.1467-2995.2011.00637.x.

Wagner AE, Walton JA, Hellyer PW, Gaynor JS, & Mama KR. Use of low doses of ketamine administered by constant rate infusion as an adjunct for postoperative analgesia in dogs. *J. Am. Vet. Med. Assoc.* 2002; 221(1): 72−75.

Wilkinson AC, Thomas ML, 3rd, & Morse BC. (2001). Evaluation of a transdermal fentanyl system in yucatan miniature pigs. *Contemp Top Lab Anim Sci*, 2001; 40(3): 12−16.

Wolf P, Meyer C, Boudjema K, Kieny R, Cinqualbre J, Jaeck D, Azimzadeh A. The pig as a model in liver xenotransplantation. *Vet. Res.* 1997; 28(3): 217−222. doi:S092842499 7820044 [pii].

Yamada Y, Boskovic S, Aoyama A, Murakami T, Putheti P, Smith RN, Kawai T. Overcoming memory T-cell responses for induction of delayed tolerance in nonhuman primates. *Am. J. Transplant.* 2012; 12(2): 330−340. doi:10.1111/j.1600−6143.2011. 03795.x.

Yee JL, Vanderford TH, Didier ES, Gray S, Lewis A, Roberts J, Bohm RP. Specific pathogen free macaque colonies: a review of principles and recent advances for viral testing and colony management. *J. Med. Primatol.* 2016; 45(2): 55−78. doi:10.1111/jmp.12209.

Yeoman H, Gress RE, Bare CV, Leary AG, Boyse EA, Bard J, . . . DeLuca D. Human bone marrow and umbilical cord blood cells generate CD4+ and CD8+ single-positive T cells in murine fetal thymus organ culture. *Proc. Natl. Acad. Sci. USA*, 1993; 90:10778−10782.

Yeung KR, Lind JM, Heffernan SJ, Sunderland N, Hennessy A, & Makris A. Comparison of indirect and direct blood pressure measurements in baboons during ketamine anaesthesia. *J. Med. Primatol*. 2014; 43(4), 217−224. doi:10.1111/jmp.12113.

Zhou W, Longmate J, Lacey SF, Palmer JM, Gallez-Hawkins G, Thao L, . . . Diamond DJ. Impact of donor CMV status on viral infection and reconstitution of multifunction CMV-specific T cells in CMV-positive transplant recipients. *Blood* 2009; 113(25): 6465−6476.

Zitsman JS, Alonso-Guallart P, Ovanez C, Kato Y, Rosen JF, Weiner JI, & Duran-Struuck R. Distinctive Leukocyte Subpopulations According to Organ Type in Cynomolgus Macaques. *Comp. Med.* 2016; 66(4): 308−323.

Zuckermann FA, Pescovitz MD, Aasted B, Dominguez J, Trebichavsky I, Novikov B, . . . Saalmuller A. Report on the analyses of mAb reactive with porcine CD8 for the second international swine CD workshop. *Vet. Immunol. Immunopathol*. 1998; 60(3−4): 291−303.

In: Encyclopedia of Surgery (22 Volume Set)
Editors: Andreas Lehrer and Kristin Mueller
ISBN: 978-1-53618-329-0
© 2020 Nova Science Publishers, Inc.

Chapter 205

PRE-OPERATIVE AND POSTOPERATIVE CARE IN EXPERIMENTAL SURGERY

Yanxin Hu*, MD
Laboratory of Experimental Surgery, Department of Surgery, CRCHUM,
University of Montreal, Montreal, Quebec, Canada

ABSTRACT

Experimental animal surgery is currently practised in research, drug/device/ procedure testing, teaching, and production in the fields of medical science, biology and veterinary medicine. The main purpose for experimenting on animals is to replace human body by animal models in the studies of pharmaceutical and biological research and industry. An experimental animal is a biological system, and most of the experimental surgeries on animals are complicated processes, especially survival surgeries. In addition to improve surgical techniques, preoperative/postoperative care is essential to guarantee surgery success and recovery after surgery so as to avoid unfavorable responses and anomalous experimental results. With the objective of contributing to research in experimental surgery, this chapter presents the principal regulations of pre- and postoperative care in experimental surgery which are adhered for animal welfare. In order to achieve reliable, reproducible and precise results, in compliance with animal welfare regulations, pre- and postoperative cares including quarantine, restraint, acclimatization, health inspection, necessary fasting, recovery from anesthesia, fluid/electrolyte balance, anti-infection, and pain relief, have to be adopted in practicing successful and humane experimental surgery.

Keywords: pre-postoperative care, quarantine, analgesia, infection

* Corresponding Author's Email: yanxinhu2655@gmail.com.

INTRODUCTION

Experimental animal surgery should focus on all procedure of the perioperative care of the animal, including pre- and postoperative management, which cannot be arbitrarily divided. Proper management of animal greatly increases the success rate of surgery. It improves animal well-being during the recovery period, alleviates the sufferings of the animal and enhances validity of the study. The term pre-/postoperative care refers to the activities before and after a surgical procedure, which ensure to provide the best possible care for an animal selected for experimental surgery. It is the responsibility of the research or teaching institution to ensure that all personnel are qualified and trained to conduct surgical procedures. In this chapter a brief description of the fundamental concepts and management of pre- and postoperative care of experimental animal surgery is given.

PRE-OPERATIVE MANAGEMENT

Animal Identification

Properly identify the animals prior to surgery. Obtain all information needed to specifically identify individual animal from animal suppliers, including sex, age, weight, colony history, and health records. In some instances, medical and vaccination histories can also be helpful in evaluating their health status.

Acclimatization

Always acclimatize the animals to the facility for a period of adaptation prior to surgery (Obernier 2006). The effects of stress on the animal have the potential for influencing experimental outcomes and jeopardizing the animal welfare. An animal stress-reduction plan should be available. Proper restraint and handling will help to prevent injury and minimize stress to the animal and ensure the validity of experimental results. It is important to provide a period of adaptation prior to undergoing surgical procedures in which the animals can adjust their physiologic and metabolic systems to stabilize to a new environment and adapt to an alternate form of restraint or frequent handling. This acclimatization period will increase the reliability of the results obtained from the experimental protocol which are not to be compromised by uncontrolled environmental influences. The length of time for acclimation will depend on the type and duration of animal transportation, the species, and the intended use of the animals. It has been reported in the literature the proper time for acclimation for mice, rats, guinea pigs, nonhuman primates, and goats, and for other species as well (Conour 2006; Landi 1982; Prasad 1978; Tuli 1995; Sanhouri 1989; Kagira 2007).

Animal Health Status Evaluation

The experimental animals are living animals with characteristics and health issues that may influence or be of concern while conducting a study. An appropriate protocol for the experiments using animals is primarily based on exhaustive evaluation of clinical conditions, including influences on the research and the welfare of the animals (Burkholder 2012).

It is essential to obtain sufficient, detailed and reliable health information from animal suppliers to establish the length of quarantine, define the potential risks to personnel and animals, and determine whether therapy is required before animals are released from quarantine (Butler 1995). The animal health status should be evaluated before undergoing a surgical procedure, usually during a quarantine period when the animals are kept separate from conditioned animals of known health status. Information from suppliers about animal quality should be sufficient. Only animals exhibiting good health and normal behavior should be included in a study. Pre-existing health conditions may negatively affect the success of the surgical procedures. Experimental animal surgery usually can be scheduled after performing the physical examinations appropriate to the species and necessary laboratory examinations to determine the presence of abnormalities or conditions which could affect the outcome of the surgical procedure and impact the study results (Lerche 2008; Roberts 2008).

Physical examination: It is important to develop a standardized physical exam process according to animal species. In general, it should include the following.

A. General information
B. Visual inspection and behavioral status assessment: The animals should be alert and behaving normally and should have clear eyes and a smooth coat without trauma.
C. Physical exam from head to tail. If necessary, include vital signs monitoring, depending on the feasibility and experimental design.

Laboratory examination: The necessity of laboratory examination is determined by the research protocol, animal species, animal health history and the duration of the studies. Laboratory evaluation of blood, urine, and feces are frequently-used laboratory examinations in assessing animal health status. The medical image-aided diagnosis, such as radiography, ultrasonic imaging, computed tomographic imaging, nuclear magnetic resonance, and endoscopy technique may be needed especially by the research protocols. In many animal species, viral infections are common without clinical signs of disease, but may cause clinical diseases when the animals are subjected to surgery. The infections also interfere in getting true results when conducting immune-response experiments, as the pre-existing viral infections modify the animal immune-system. Serologic testing is convenient and useful for detecting viral infections without clinical signs of disease (Ward 2006).

Proper Handling and Restraint

Use proper handling and restraint methods to avoid animal and personnel injuries. Acclimating animals to restrain and frequent handling prior to surgical procedures reduces stress in animals and also minimizes stress and fear for personnel during handling (Flecknell 1991). Before handling and restraint, information about the various animal behaviours is of

considerable importance. All the procedures should be careful, accurate, rapid but without being rough. To initially restrain a rat, for example, the handler should gently grasp it around the shoulders. The handler's thumb can then be placed under the rat's mandible, to prevent bites, and the rat's hind limbs can be supported with the other hand. Restraint should be firm but not too tight as this will impede the animal's respiration.

Antimicrobial Control

Indiscriminate use of antibiotics should be avoided. Antibiotics may interfere with an experimental protocol, either by a direct interaction or by influencing pharmacokinetics/ metabolism of the compounds under investigation. The indications for antibiotics in a particular animal surgery should be critically reviewed. Antibiotics might be indicated prophylactically for certain surgical protocols or when known breaks in sterility occur, but should not be used as a substitute for proper aseptic techniques.

POSTOPERATIVE CARE

Postoperative care begins as the animal is recovering from anesthesia. Common general postoperative complications include postoperative fever, pain, atelectasis, wound infection, deep vein thrombosis and subsequent embolism, due to anaesthesia and surgical wound. They may either be general or specific to the type of surgery, and can be dangerous to animal life such as deep vein thrombosis. For survival animal surgery, an effective postoperative plan and its implementation can minimise surgical complications by improving its physiologic status and enhance the animal's recovery. It should be tailored to the procedure and individualized for the well-being of each animal. The research staff and the animal care staff both contribute to the well-being of the animal. Specific surgical procedures requiring intensive postoperative care should be scheduled by considering the availability of experienced personnel to be on duty. Careful observation is necessary for postoperative animals with detailed daily record, for keeping all personnel involved in understanding the animal recovery process (Field 2007). For most animals, comfort care is beneficial but in some small rodents, excessive care will disturb and stress the animals.

Recovery from Anesthesia

The animal should be kept under observation during recovery from anesthesia until that animal is able to hold itself in a sternal position (able to hold its head up) without risk of injury. Since *anesthetized* rodents and rabbits can rest on their chest steadily, they must be surveilled until regaining consciousness upon seeing their ambulation. The duration of the recovery depends on the anesthetic protocol and on administration time of the last dose. In general, when using injectable agents, the animals need longer recovery period than the animals using inhalational anaesthesia. The animal must be able to maintain normal

physiology. Heart rate, respiration, and hydration should be stable and within normal limits for the species.

To avoid being hurt from cage mates, animals should recover from anesthesia in individual cage. Provide a clean, warm, quiet, and comfortable space/cage without sharp corners or projections. Water bowl should be removed from the cage to prevent accidental drowning. To prevent vomiting, gastric contents reflux and aspiration pneumonia, we should preserve the airway by keeping the animal intubated until appearance of swallowing reflex or cough. Preoperative fasting can reduce postoperative vomiting. Rodents intended for surgery may be fasted or fed as indicated by the protocol; as postoperative vomiting does not occur in rodents, fasting is not required. But short fasting can enhance the effect of certain anesthetic agents (Toth 2000). The body position adopted postoperatively is designed with gravity assistance to prevent suffocation through obstruction of the airway, both mechanical obstruction caused mostly by the tongue to fall to the back of the pharynx, and fluid obstruction, usually by vomit. Most animal species are placed in sternal recumbency. In ruminants it prevents the aspiration of rumen contents but also promotes release of rumen gases. Lying on either side postoperative is adopted for rabbits, dogs and cats. For animals taking longer to recover, turn the animal from side to side periodically to prevent development of hypostatic pneumonia.

When vomiting occurs, lower animal's head will be than the body to prevent aspiration of gastric fluid. Severe retching or coughing during recovery may indicate aspiration of blood, fluids or vomitus. If an aspiration event occurs, the animal's upper airway should be cleared by vacuum extractor or syringe. Other management of an aspiration includes observation, oxygen, antibiotics and corticosteroids therapy.

Postoperative respiratory depression is often associated with anesthesia, and it can be limited by choice of appropriate anesthesia protocol. For timely detection of respiratory depression, one should carefully observe the animal's respiratory rate and breathing pattern. If respiration is shallow or infrequent, a respiratory stimulant such as doxapram (which is a central respiratory stimulant with a brief duration of action) can be administered (Martindale 1996). Continuous postoperative oxygenation is beneficial for most animals. The small animals waking up in the incubator can get continued oxygen supply directly through chamber. For large animals, place the tail end of an oxygen catheter near the nares.

Hypothermia

Perioperative hypothermia is one of the major unpredictable *causes* of *perioperative* death. It is common in the early postoperative period which is associated with physiological derangements, due to direct thermoregulation inhibition by anesthetics. Exposed body cavities during surgical procedures might cause further heat loss. Small animals are particularly *more susceptible* because of the higher surface area-to-volume ratio, which facilitates heat loss through the skin (Brown 1969).

It is advocated that postoperative animals should be placed in a quiet recovery room with soft lighting where the room temperature should be about 24 °C, and certain facilities like resuscitation equipment must be ready to be used by competent personnel. In most cases, small animals can be placed in the ordinary cage free of airflow (Archibald 1968). Surgery table with metal surface can be insulated with mats. Mechanical sources of heat, such as hair

dryers, heating pads and infra-red lamps, are dangerous. Supplementary heating sources should be used carefully to avoid serious burns. Circulating warm-water blankets are ideal for unconscious animals. Using a towel or blanket as the cage padding is preferable rather than using the bedding such as wood chips or shavings, which may stick to the animal's mouth, eyes, nose or wound (Heine 1998; Ruys 1991).

Infection

Postoperative infection is a common phenomenon in experimental surgery. It is inevitable to use antibiotics, but use of antibiotics sometimes will seriously interfere with the experiment.

Strict aseptic operation and good tissue handling techniques during surgery are essential to prevent postoperative wound infection. Antibiotics should not be used in place of surgical asepsis. If antibiotics are being used, for example when the operation involves a contaminated viscus, they should be administered before surgery to ensure that they reach to effective concentration locally. However, antibiotics should also be used postoperatively when possible contaminations have occurred during surgical operation procedure, to prevent further spreading of infection. Careful attention to body temperature increasing within 72 hours after surgery might indicate bacterial infection or antibiotic resistance.

An appropriate antibiotic should be selected carefully, based on potential organism and probable sensitivity, and also should be administered at an adequate dose at the recommended frequency to minimize the development of resistance. Except for undesirable interference by antibiotics with an experiment, some other areas are also considered: dosage (also extrapolation of dose information from other species), antibiotic toxicity, routes of administration, and use of combinations of antibiotics, etc.

Fluid/Electrolyte Balance

Dehydration is a feature commonly observed after operation. Body fluids must be maintained within physiologic limits postoperatively. In most cases, weight loss represents a lack of fluid; by monitoring preoperative and postoperative weight changes, one can better guide the amount of fluid. Other signs like color of mucous membranes, heart rate, and blood pressure may also be the indications of dehydration. Liquid supplementation after surgery is important to prevent postoperative dehydration. If the animal is completely awake, give the liquid by oral administration. In the situation of fasted animals required by experiment protocol, or when the animals may not be able to eat or drink, fluids must be administrated by subcutaneous, intraperitoneal or intravenous injection of glucose saline. A regular evaluation of body fluid volume, electrolytes, and pH is needed before parenteral administration.

Pain Relief

It should be assumed that a surgical procedure can cause pain not only in people but also in the animal. As a subjective emotion, pain can be experienced even in the absence of

physical tissue damage, and the level of feeling can be modified by other emotions including fear, memory and stress (Nolan 2015). Different levels of postoperative pain and distress should be expected after surgery but it can be difficult to detect because of individual and species variation. As many animals may tolerate pain without demonstrating obvious signs, the animal must be closely observed to recognize the signs of pain and evaluate the severity of pain. Each species shows pain in different ways and criteria for assessing pain in various species also differ (Morton 1985). Reducing mobility or restlessness, abnormal posture, screaming, lack of eating food and drink, and signs of depression are the common signals of the animals feeling pain (Roughan 2009; Bateson 1991; Carstens 2000; Hawkins 2002; Holton 1998; Hughes 1983; Hughes 2008; Martini 2000; Roughan 2000; 2003; 2004; Sneddon 2006). If there is doubt about the presence of pain, an analgesic should be administered. Pain can be assumed to have been present if administration of analgesics causes amelioration of these signs and thus analgesia should be continued.

Analgesic drugs can be classified into two categories: non-steroidal anti-inflammatory drugs which alleviate pain by reducing local inflammatory responses, such as aspirin and acetaminophen (paracetamol); the opioid analgesics (narcotic agonists) such as morphine, pethidine, and buprenorphine, which act on the brain for controlling neurologic pain with high potency and long duration of action. The dosage and the period of the analgesic administration depend on how invasive the surgery is and how severe is the pain (Mathews 2008). For those surgeries such as laparotomy, thoracotomy, craniotomy, the opioid analgesics should be used for 24–72h postoperative. For the use of analgesics, one should consider the possible side effects, mainly respiratory and/ or cardiovascular depression and other interactions. Analgesics use should be balanced by potential beneficial effects and possible detrimental effects.

In addition to clinical side effects, the use of analgesics has the risk of interference with experimental results and might confound data obtained from the study.

CONCLUSION

Perioperative care is the care that is given before, during and after surgery. It is a systemic procedure which requires integrated planning. This period is used to prepare the animal both physically and psychologically for the surgical procedure and after surgery. In experimental animal science, cares of animals before and after operation are very important, which will directly affect the results of the experiment. It has been stated that caring for an experimental animal is like caring of a sick child (Mathews 1968). The process begins with animal health status evaluation. Using animals with pre-existing health conditions may not affect the operation itself, but pre-existing diseases might affect the whole experimental results. Surgeons should not only consider that they are conducting operations but they also have to ensure that the animals are well housed, well fed, and free of unnecessary pain. Recent advances in anesthesia, monitoring, pain assessment and analgesia provide many opportunities for improving perioperative quality, and promoting high standards of animal welfare.

REFERENCES

Archibald, J. The postoperative care of animals. *Canad. Med. Ass. J.* 1968; 98:897–899.

Bateson, P. Assessment of pain in animals. *Anim. Behav.* 1991; 42:827–839.

Brown, J. H., Lee, A. K. Bergmann's Rule and Climatic Adaptation in Woodrats (Neotoma). *Evolution* 1969; 23:329–338.

Burkholder, T., Foltz, C., Karlsson, E., Linton, C. G., Smith, J. M. Health Evaluation of Experimental Laboratory Mice. *Curr. Protoc. Mouse Biol.* 2012; 2:145–165.

Butler, T. M., Brown, B. G., Dysko, R. C., Ford, E. W., Hoskins, D. E., Klein, H. J., Levin, J. L., Murray, K. A., Rosenberg, D. P., Southers, J. L., Swenson, R. B. Medical management. In: Bennett, B. T., Abee, C. R., Hendrickson, R., editors. *Nonhuman Primates in Biomedical Research: Biology and Management*. San Diego: Academic Press; 1995. p. 255–334.

Carstens, E., Moberg G. P. Recognizing pain and distress in laboratory animals. *ILAR J.* 2000; 41:62–71.

Conour, L. A., Murray, K. A., Brown, M. J. Preparation of animals for research: Issues to consider for rodents and rabbits. *ILAR J.* 2006; 47:283–293.

Field, K., Bailey, M., Foresman, L. L., Harris, R. L., Motzel, S. L., Rockar, R. A., Ruble, G., Suckow, M. A. Medical records for animals used in research, teaching and testing: Public statement from the American College of Laboratory Animal Medicine. *ILAR J.* 2007; 48:37–41.

Flecknell, P. A. Small Mammals. In: Anderson, R. S., Edney, A. T. B., editors, *Practical Animal Handling*. Pergamon: Oxford; 1991. p. 177–187.

Hawkins, P. Recognizing and assessing pain, suffering and distress in laboratory animals: A survey of current practice in the UK with recommendations. *Lab. Anim.* 2002; 36:378–395.

Heine, W. O. *Environmental management in laboratory animal units: Basic Technology and hygiene: methods and practise* (eBook). Berlin: PABST Science Publichers; 1998.

Holton, L. L., Scott, E. M., Nolan, A. M., Reid, J., Welsh, E., Flaherty, D. Comparison of three methods used for assessment of pain in dogs. *J. Am. Vet. Med. Assoc.* 1998; 212:61–66.

Hughes, H. C, Lang, C. M. Control of pain in dogs and cats. In: Kitchell, R. L., Erickson, H. H., editors. *Animal Pain: Perception and Alleviation*. Bethesda, M. D.: American Physiological Society; 1983. p. 207–216.

Kagira, J. M., Ngotho, M., Thuita, J. K., Maina, N. W., Hau, J. Hematological changes in vervet monkeys (Chlorocebus aethiops) during eight months' adaptation to captivity. *Am. J. Primatol.* 2007; 69:1053–1063.

Karas, A., Danneman P., Cadillac J. Strategies for assessing and minimizing pain. In: Fish, R., Brown, M., Danneman, P., Karas, A., editors. *Anesthesia and Analgesia in Laboratory Animals*. San Diego: Academic Press; 2008. p. 195–218.

Landi, M. S., Kreider, J. W., Lang, C. M., Bullock, L. P. Effects of shipping on the immune function in mice. *Am. J. Vet. Res.*1982; 43:1654–1657.

Lerche, N. W., Yee, J. L., Capuano, S. V., Flynn, J. L. New approaches to tuberculosis surveillance in nonhuman primates. *ILAR J.* 2008; 49:170–178.

Martindale: *The Extra Pharmocopoeia*, 30th ed, p.1225.

Martini, L., Lorenzini, R. N., Cinotti, S., Fini, M., Giavaresi, G., Giardino, R. Evaluation of pain and stress levels of animals used in experimental research. *J. Surg. Res.* 2000; 88:114–119.

Mathews, K. A. Update on Management of Pain: Preface. *Vet. Clin. Small.* 2008; 38:xi–xiii.

Morton, D. B., Griffiths, P. H. Guidelines on the recognition of pain, distress and discomfort in experimental animals and a hypothesis for assessment. *Vet. Rec.* 1985; 116:431–436.

Nolan, A: *Do animals feel pain like we do?* The conversation [Internet]. Melbourne Victoria: The Conversation Trust; 2015 [cited 2017 Jun 8]. Available from https://theconversation.com/do-animals-feel-pain-like-we-do-42508.

Obernier, J. A., Baldwin, R. L. Establishing an appropriate period of acclimatization following transportation of laboratory animals. *ILAR J.* 2006; 47:364–369.

Prasad, S., Gatmaitan, B. R., Oconnell, R. C. Effect of a conditioning method on general safety test in guinea pigs. *Lab. Anim. Sci.* 1978; 28:591–593.

Roberts, J. A., Andrews, K. Nonhuman primate quarantine: Its evolution and practice. *ILAR J.* 2008; 49:145–156.

Roughan, J. V., Flecknell, P. A. Behavioural effects of laparotomy and analgesic effects of ketoprofen and carprofen in rats. *Pain* 2000; 90:65–74.

Roughan, J. V., Flecknell, P. A. Behaviour-based assessment of the duration of laparotomy-induced abdominal pain and the analgesic effects of carprofen and buprenorphine in rats. *Behav. Pharmacol.* 2004; 15:461–472.

Roughan, J. V., Flecknell, P. A. Evaluation of a short duration behaviour-based post-operative pain scoring system in rats. *Eur. J. Pain.* 2003; 7:397–406.

Roughan, J. V., Wright-Williams, S. L., Flecknell, P. A. Automated analysis of postoperative behavior: assessment of HomeCageScan as a novel method to rapidly identify pain and analgesic effects in mice. *Lab. Anim.* 2009; 43:17–26.

Ruys, T. *Handbook of facilities planning*. New York: Van Nostrand Reinhold; 1991.

Sanhouri, A. A., Jones, R. S., Dobson, H. The effect of different types of transportation on plasma cortisol and testosterone concentrations in male goats. *Br. Vet. J.* 1989; 145:446–450.

Sneddon, L. U. Ethics and welfare: Pain perception in fish. *Bull. Eur. Assoc. Fish. Pathol.* 2006; 26:6–10.

Toth, L. A., Gardiner, T. W. Food and water restriction protocols: Physiological and behavioral considerations. *Contemp. Top. Anim. Sci.* 2000; 39:9–17.

Tuli, J. S, Smith, J. A., Morton DB. Stress measurements in mice after transportation. *Lab. Anim.* 1995; 29:132–138.

Ward, M. L. Physical examination and clinical techniques. In: Meredith, A., Flecknell, P. A., editor. *BSAVA Manual of Rabbit Medicine and Surgery*. 2nd ed. Gloucester: BSAVA; 2006. p. 18–36.

In: Encyclopedia of Surgery (22 Volume Set)
Editors: Andreas Lehrer and Kristin Mueller
ISBN: 978-1-53618-329-0
© 2020 Nova Science Publishers, Inc.

Chapter 206

FLUID, ELECTROLYTES, AND ACID-BASE BALANCE IN EXPERIMENTAL SURGERY

Kupa Bilolo*, MD
Laboratory of Experimental Surgery, Department of Surgery,
Research Center of Montreal University (CR-CHUM),
University of Montreal, Montreal, Quebec, Canada

ABSTRACT

During surgery, disturbances of body water distribution, electrolyte homeostasis, and acid-base physiology may be secondary to trauma, preexisting medical conditions which alter normal physiology, or the nature of the surgery. Understanding normal physiology and pathophysiology related to these abnormalities is imperatively important in experimental surgery as these parameters are of critical significance for surgical experiment animals.

A normal animal's body weight is composed of about 60% water, which is distributed throughout the intracellular and extracellular compartments. These two major compartments are separated by specialized membranes that are semipermeable to allow water to equilibrate across the membrane according to the osmotic-pressure gradient. Changes in both fluid volume and electrolyte composition, acid-base balance occur preoperatively, intraoperatively, and post operatively, as well as in response to trauma and sepsis. The evaluation of these changes commonly requires a focused history and physical examination, followed by interpretation of biochemical studies of experimental animals.

Fluids are administered to experimental animals to replace fluid losses (e.g., vomiting, blood loss, water loss from the respiratory system) to correct electrolyte abnormalities, promote kidney diuresis, and maintain the tissue or organ perfusion rate before and during surgery or while undergoing anesthesia. Factors considered for fluid therapy are types of surgery and severity of conditions, degree of dehydration, conditions of experiment animals, organic functions of experiment animals and type of electrolyte imbalance.

* Corresponding Author's Email: kbilolo@hotmail.com.

Keywords: acid-base imbalance, electrolytes disorders, fluid therapy, experiment animals

ABBREVIATIONS

ADH	Antidiuretic hormone
ATP	Adenosine triphosphate
BUN	Blood urea nitrogen
D5W	5% Dextrose in water
ECF	Extra cellular fluid
EN	Enteral nutrition
GFR	Glomerular filter rate
GIT	Gastro intestinal tract
HCO_3^-	Ion Bicarbonate
iCa	Ionized calcium
ICF	Intra cellular fluid
LRS	Lactated ringer's solution
mEq/L	Milliequivalents per litre
Pi	Inorganic phosphate
PN	*Parenteral nutrition*
PPN	Partial parenteral nutrition
PTH	Parathyroid hormone
RTA	Renal tubular acidosis
TBF	Total body fluid
TBW	Total body water
UA^-	Unmeasured anions

INTRODUCTION

The organic system and organs take part in harmonizing and regulating fluid, electrolytes and acid-base balance. During surgical procedures, those harmonization and regulation usually go on some changes which can be prevented or corrected so either their effects be minimized during surgical procedures.

In most animals, about 60% to 70% of body weight is water. This is much higher in neonates and can have as much as 80% of their body weight. Aged and obese animals tend to have lower percentage of water (Naylor 1990; Rose 2001). The total body fluid (TBF) is distributed in two major compartments: 55–75% is intracellular fluid (ICF) and 25–45% is extracellular fluid (ECF). The extracellular compartment is further divided into intravascular fluids (blood plasma), extravascular fluids (interstitial fluid, lymph), inaccessible bone fluid (water trapped in deep layers of bone not readily exchangeable) and transcellular fluids (secretions of glandular tissues, gastro-intestinal tract (GIT) fluids, respiratory fluids, aqueous humour, peritoneal fluid, cerebrospinal fluid, etc.) (Constable 2003; Rose 2001; Halperin 1999; Naylor 1990). It has estimated that total body water of a healthy dog, is approximately

534–660 ml/kg; total intravascular fluid volume has been estimated as 80–90ml/kg in dogs and cats.

OSMOLALITY

The intravascular space contains only 8% of total body water (TBW). Water is held in specific fluid compartments by ionic, osmotic, and oncotic particles that are distributed uniquely among these spaces. Serum osmolality is determined by the number of these particles, osmotically active in the solution. The primary extracellular cations, sodium and smaller amounts of other cations (potassium, calcium, magnesium, and other organic cations) with electro neutrally balanced anions (e.g., chloride, bicarbonate, phosphate, sulfate, and other organic anions) plus glucose and urea; generate osmotic forces that maintain fluid in the extracellular space. These extracellular cations, anions, and other osmotic substances result in an extracellular osmolality of 280 to 300mOsm/L. In most animals, it is maintained between 270–310mOsm/L (Oh 1995; Rose 2001). This osmolality can be measured or calculated by following formula:

$$Osmolality\ (mOsm/liter) = 2((Na^{+}) + (K^{+})) + (Glucose)/18 + (BUN)/2.8^{-1}$$

(The glucose and blood urea nitrogen (BUN) are measured in mg/dl rather than in mmol/L, so it must be converted respectively by 18 and 2.8, for the units to be consistent).

The primary intracellular cation, potassium, and smaller amounts of others cations (e.g., sodium, magnesium, calcium) balanced electro neutrally with intracellular anions (i.e., organic phosphates and smaller amounts of ionic proteins, chloride, bicarbonate) create tissue-specific intracellular osmotic forces. Fluids movements between ECF and ICF occur freely across most of cell membranes, keeping the total concentration of the solutes or osmoles in equilibrium (Halperin 1999; Rose 2001).

DEHYDRATION, HYPOVOLEMIA AND HYPERVOLEMIA

In surgical experiment animals, hypotonic fluid loss is characterized by a loss of fluid in excess of solute and can result in a relative increase in serum osmolality. Isotonic fluid loss refers to a loss of fluid that has the same osmolality as plasma, and hypertonic fluid loss occur when solutes are lost from body. Dehydration in experiment animals refers to a decrease in TBW. It depends usually on the type of fluid lost (Rose 2001; Dibartola 2006a). Hypovolemia refers to inadequate circulating volume, usually result in hypovolemic shock from excessive hemorrhage such as that observed with a bleeding splenic mass, arterial laceration, etc. it can also occur due to a severe fluid loss, end-stage renal failure in most surgical experiment animals (Halperin 1999; Rose 2001; Dibartola 2006a). Hypervolemia in surgical experiment animal can be due to heart failure, renal failure, and/or iatrogenic fluid overload. Hypertension is not an indicator of hypervolemia (Halperin 1999; Rose 2001; Dibartola 2006a).

ELECTROLYTES HOMEOSTASIS

Electrolytes are essential cofactors in enzyme mediated biochemical reactions. Differentials electrolyte composition on both inner and outer side of cellular membrane establishes the electrical potentials which make nerve and muscular contraction, and metabolic reactions possible. ECF contains mainly Na+, Cl-, HCO3- & HPO4'2-. ICF contains mainly K+, HCO3-, PO4'3-, SO4'2- and citrate. Kidneys and circulating blood plays a prime importance role in maintaining electrolyte balance. In general, sodium is highly conserved; only very little is excreted in the urine. Substantial quantities of potassium and calcium are excreted on a daily basis, particularly due to the fact that dietary intake of potassium and calcium tends to be high (Halperin 1999; Rose 2001).

WATER BALANCE

The kidneys have also a primary role in water balance through their concentrating and diluting functions. The osmolality of the glomerular filtrate as it gets in the proximal tubule is identical to that of plasma. In this segment of the tubule, the bulk of the urinary solutes (e.g., Na^+ and other electrolytes, amino acids, glucose) and water is reabsorbed isosmotically. As the filtrate traverses the descending limb of the loop of Henle, water diffuses from the tubule lumen to the hypertonic medullary interstitium. The tubular fluid then becomes progressively more dilute as it transits through the ascending limb of the loop of Henle. This diluting process occurs because active Na^+ reabsorption is unaccompanied by water in this segment. The fluid is hypoosmotic to plasma on its arrival in the distal tubule. Antidiuretic hormone (ADH) stimulates reabsorption of sodium chloride in the ascending limb and thus facilitates generation of the renal medullary solute gradient necessary for urinary concentration (Blumenfeld 2002). Hormonal action on the collecting ducts determines the final concentration of urine produced. In a state of antidiuresis, ADH increases water permeability and augments aldosterone-stimulated Na^+ reabsorption, thereby promoting water movement from the tubule lumen to the interstitium for reclamation. In a state of water diuresis, when ADH is not present, the collecting duct remains impermeable to water, and dilute urine is produced. Also, in the distal collecting duct, urea permeability is relatively high and is increased in the presence of ADH; thus, urea moves back into the renal medullary interstitium for maintenance of the medullary gradient (Anderson 1982; Brater 1998; Rose 2001).

The balance between acidity and alkalinity in animal body is referred as acid base balance and it is important homeostatic mechanism determined mainly by H+ ion concentration in various body fluids (Rose 2001).

Disorders of body fluids, electrolytes, and acid-base balance are common in surgical experiment animals; and have frequently occurring etiologies (e.g., vomiting, diarrhea, diabetic ketoacidosis) and infrequently occurring ones (e.g., inorganic acid ingestion, diabetes insipidus, mineralocorticoid excess). These disorders can disrupt cellular and vital organ function in otherwise healthy experiment animals. Theirs evaluation typically requires a focused history and physical examination, followed by interpretation of biochemical factors. A prompt diagnosis and therapeutic interventions are respectively required as well to avoid the consequences of vital organ hypoperfusion and electrolyte imbalance (Halperin 1999).

In this chapter, an overview of fluids, electrolytes and acid-base abnormalities is shortly described. Due to a similarity in physiology among different surgical experiment animals, the extrapolation of this described information should be permissible to most laboratory animal species used in medical research, during and after experimental surgery.

ELECTROLYTES DISORDERS

Disorders of Sodium and Water

Sodium is the major extracellular cation. In humans, normal value of ECF is 140mEq/L, and 10mEq/L in its ICF, approximately. The maintenance of volume and tonicity of body fluids depends on regulation of sodium and water balance (Halperin 1999; DiBartola 2006a). Sodium is regulated by the kidneys in which the volume and constitution of filtrate reaching the collecting ducts is dependent on glomerular filter rate (GFR), sympathetic tone and angiotensin II acting via the effects of ADH and aldosterone to conserve water and sodium. Normothermic extra-renal losses are minimal (±10mmol/day).

Hyonatraemia (Dogs serum conc of Na^+<140mEq/L)

In small animal, the etiology of hyponatraemia is usually caused by hypoadrenocorticism, post obstructive diuresis, diuretic treatment, congestive heart failure, severe liver disease and nephritic syndrome. In Large animal, hyponatraemia is usually caused by acute diarrhea, bladder rupture in new born foals, chronic wasting disease, intrinsic kidney disease and diuresis, gastrointestinal fistula, severe haemorrhage and excessive sweating (Decaux 2003; Wellman2012).

Generally, treatment of this sodium and water disorders include 5% sodium bicarbonate, Lactated Ringers solution as a precursor of bicarbonate, normal 5% saline that could be avoided if acidosis is present. The calculation of Na^+ requirement for replacement therapy in mEq=140 – measured plasma sodium × weight in Kgs (Adrogue 2000a; Rose 2001). The time of development of hyponatremia and the presence of symptoms should dictate the management of hyponatremia. Correction of plasma [Na^+] should be undertaken without delay in symptomatic experiments animals, particularly those experiencing seizures.

In humans, development of hyponatremia in less than 48 hours and the presence of symptoms strongly suggest that the benefit of treating acute cerebral edema outweighs the risk of treatment-associated adverse effects. Hypertonic sodium chloride with or without a loop diuretic is usually started at a rate of 1–2mL/kg/hour to raise sodium concentration by 1–2 mEq/L/hr. This rapid correction of hyponatremia should be limited to the initial phase of management. The overall correction of [Na^+] should not exceed 8–12mEq/L for 24 hours, as the risk of osmotic demyelination rises above this limit (DiBartola 2006a; Fried 1997).

In humans and experiment animal, the rate of correction in chronic hyponatremia has been a major concern. Refers to a guideline in humans, the rate of sodium correction should not exceed 0.5 to 1.0mEqNa^+/L/hour to avoid induction of neurologic disease (Adrogue 1997; Sterns 1990). The optimal period for correction of chronic hyponatremia remains unclear. A period of 72 hours to several days has been proposed refering to some previous studies (Angelos 1999); fluid therapy should be anyway discontinued, and the serum sodium

concentration measured, in case of neurologic signs. In dogs, gradual resolution of neurologic signs has been reported, treatment with nonspecific supportive care (O'Brien 1994).

Hypernatraemia (Dogs Na^+>155mEq/L; Cats Na^+ > 160mEq/L)

In large animals, its etiology includes prolonged exposure to dry heat, respiratory loss with fever, low intake of water, excessive salt intake with adequate water. In small animals, major causes include pure water loss, diabetes insipidus, hypertonic NaHCO3 administration, cardiac arrest, feline urethral obstruction, acute renal failure (Wickstrom 2008; Wellman 2012).

Treatment of different types of hypernatraemia as hypervolaemic, hypovolaemic and isovolaemic include the intake of fresh water in sufficient quantities, 5% dextrose or maintenance fluid intravenously, salt poisoning and loop diuretics (Adrogue 2000b; DiBartola 2006a; Palevsky 1998). In case of acute hypernatremia (<48 hours), it was shown that the brain cells do not develop idiogenic osmoles, that explain the success of a rapid correction of hypernatremia using either isotonic or polyionic fluid therapy; regardless of this, medical and veterinary literature favors a gradual correction of hypernatremia with careful monitoring of neurologic status (Adrogue 2000b; James 2007; Lien 2007). In chronic hypernatremia, the potential exists for ICF of brain cells to contain idiogenic osmoles and increased sodium concentration. Slow correction of hypernatremia is required to avoid brain edema (Angelos 1999).

Disorders of Chloride

Chloride constitutes the major anion filtered by the glomeruli and reabsorbed in the renal tubules. It plays an important role in preserving osmolality and partaking acid-base regulation. Its approximately 2/3 of the anions in plasma (approximately 110mEq/L in dogs and 120mEq/L in cats). Its intracellular concentration is much lower than its plasma concentration and dependent on the resting membrane potential of the cell. It is important in maintaining a normal acid–base state, normal renal tubular function and in the formation of gastric acid. Chloride loss is mainly from the stomach, bile, pancreatic and intestinal secretions (Hobbs 2002; Rose 2001).

Regulation of chloride is quietly related to sodium and inversely related to plasma bicarbonate. In the renal proximal tubule, chloride is excreted with ammonium ions to eliminate hydrogen ions in exchange for sodium and result in the production of acid urine (Yunos 2010).

Hypochloremia

Usually associated with excessive loss of fluids and occurs as a result of an increase in the net loss of electrolyte in the intestinal tract in acute intestinal obstruction, dilatation and impaction and torsion of the abomasum and enteritis. Its symptoms include anorexia, weight loss, lethargy, mild polydipsia and polyurea (Yunos 2010, Rose 2001).

Hyperchloremia

It is defined as a serum level of chloride >117mmol/L in dogs. The Causes of hyperchloremia may include: loss of body fluids from prolonged vomiting, diarrhea, sweating or high fever (dehydration), high levels of blood sodium, kidney failure, or kidney disorders, diabetes insipidus or diabetic coma, drugs such as: androgens, corticosteroids, estrogens, and certain diuretics (Yunos 2010; Rose 2001). Treatment usually requires intravenous fluid therapy, but caution should be exercised to avoid sudden cerebral edema (Piperisova 2009).

Disorders of Potassium

Potassium is the major intracellular cation in mammalian cells. Potassium and sodium have a reversed relationship in ECF and ICF. Serum potassium concentration was shown to be a poor indicator of potassium status in animals. Determination of intracellular potassium concentration in erythrocytes or muscle cells is a more accurate way to assess potassium depletion. In experimental studies of dogs, control values for ICF sodium and potassium concentrations in skeletal muscle were 8.4 to 13.7 and 139 to 142 mEq/L, respectively. In cats, total body potassium is approximately 55mEg/kg body weight and almost all of this potassium is readily exchangeable. In a study of potassium depletion in dogs, the control value for total exchangeable potassium as determined by dilution was 47.1 mEq/kg body weights (range, 39.8 to 61.1mEq/kg) (Wickstrom 2008; Wellman 2012).

Intracellular potassium is important for maintenance of normal cell volume and growth as it is required for the normal function of enzymes responsible for nucleic acid, glycogen, and protein synthesis. Studies also proved that 95% or more of total body potassium is located within cells, with muscle containing 60% to 75% of this potassium. Remaining 5% of the body's potassium is located in the ECF; maintaining the ECF potassium concentration within narrow limits is critical to avoid the life-threatening effects of hyperkalemia on cardiac conduction.

The kidneys are responsible of a mostly amount of potassium's excretion which is stimulated further by aldosterone activity, increased delivery of sodium to aldosterone-sensitive renal reabsorption sites, and high urinary flows. Potassium levels also can be lowered by excretion of smaller amount through the gastrointestinal tract or when moves out of the circulation and into cells, a process that is facilitated by insulin, alkalosis, and beta-adrenergic stimulants.

Hypokalemia (Serum K+ conc < 3.5mEq/L)

It occurs as a result of decreased dietary intake, increased renal excretion, abomasal stasis, intestinal obstruction and enteritis, the prolonged use of potassium-free solutions in fluid therapy for diarrhoeic animals may result in excessive renal excretion of potassium. Hypokalemia effects on myocytes may predispose the animals to atrial and ventricular tachyarrhythmias, atrioventricular dissociation, and ventricular fibrillation. In addition, hypokalemia can predispose the heart to digitalis-induced arrhythmias and cause myocardial cells to be refractory to class I antiarrhythmic drugs.

Treatment of hypokalemia proposes to prevent or correct cardiac electrical disturbances and serious neuromuscular weakness. Usually, this treatment includes potassium chloride

intravenously or orally potassium bicarbonate, potassium citrate orally (Gennari 1998; Mandal 1997). Animals may be refractory to correction of hypokalemia when hypomagnesemia and hypocalcemia exist. It is crucially important to correct all concurrent electrolyte abnormalities to attain normal neuromuscular function. Also, care must be taken not to create hyperkalemia when treating hypokalemia. Frequent monitoring (q6–8hours) of serum potassium concentration is recommended when aggressive replenishment is required. In diabetic patients with hypokalemia, insulin or sodium bicarbonate administration should be delayed until serum potassium concentrations have been replenished. The long-term treatment concerns to return total body potassium to normal levels and identify and correct the primary underlying disease (Halperin 1999; Rose 2001).

Hyperkalemia (Serum K+ conc > 6mEq/L)

Usually, the increase of potassium levels occurs with renal potassium retention, especially with low urine flow or when potassium is extruded from cells during acidosis and alpha-adrenergic activity. Pathologic increases in potassium levels may occur with acute tissue destruction and when the kidney cannot excrete potassium due to acute or chronic renal dysfunction. In small animals rapid infusion of potassium salts, high dose of potassium, penicillin G, oliguric acute renal failure, Terminal stages of chronic renal failure, urethral obstruction, lower urinary tract rupture, metabolic acidosis and hypoadrenocorticism. Hyperkalemia has a profound effect on cardiac function. There is usually marked bradycardia and arrhythmia and sudden cardiac arrest. Changes in the cardiac conduction system are usually evidenced by ECG changes, which may indicate potentially life-threatening arrhythmias. Classic ECG changes include tented T waves, widened QRS complexes, atrio-ventricular conduction blocks, accelerated idio-ventricular rhythm, sino-atrial block, ventricular fibrillation, and asystole.

No absolute level of serum potassium concentration is associated with a particular ECG abnormality; the ECG may be normal with life-threatening hyperkalemia and ECG abnormalities need not be present for emergency treatment of severe hyperkalemia. Bradycardia is commonly seen with hyperkalemia as a result of prolonged de- and repolarization of the myocardial conduction system. Hyperkalemia may also produce mild hyperchloremic metabolic acidosis.

Treatment of hyperkalemia is proposed to prevent adverse cardiac complications, and is aimed at one of following mechanisms: direct antagonism of hyperkalemia on cell membrane polarization, redistribution of extracellular potassium into the intracellular compartment and removal of potassium from the body. Studies shown that acute changes in serum potassium concentrations dispose to produce potentially life-threatening clinical effects than are produced by chronic changes. Animals with acute serum potassium concentrations greater than 6.5 mEq/L or with ECG changes suggestive of hyperkalemia are typically treated. An administration of calcium gluconate is usually given to temporarily alleviate the effects of hyperkalemia on heart. To correct acidosis, an administration of NaHCO3 is given intravenously and shifts K^+ to the intracellular component (Mandal 1997).

Disorders of Calcium

Calcium is required for many vital intracellular and extracellular functions, as well as for skeletal support. Ionized calcium (iCa) is required for enzymatic reactions, membrane transport and stability, blood coagulation, nerve conduction, neuromuscular transmission, muscle contraction, vascular smooth muscle tone, hormone secretion, bone formation and resorption, control of hepatic glycogen metabolism, and cell growth and division (Bushinsky 1998).

Intracellular iCa serves as an ionic messenger, conveying signals received at the cell surface to the inside of the cell. In the extracellular fluid, it regulates cell function in many organs, including the parathyroid gland, kidneys, and thyroid cells by binding to a newly identified cell membrane-bound calcium-sensing receptor. Almost all of the body's calcium is found in bone. A small amount of total bone calcium serves as a dynamic source of calcium resorption and deposition under hormonal control to keep an appropriate physiologic calcium concentration in the intracellular and extracellular fluids.

Hypocalcaemia (Total Serum Ca+<10–11mg/dl Dogs)

It has diverse etiology and can occur immediately after parturition, hypoprotenemia, hypoparathyroid condition and in acute or chronic renal failure, puerperal tetany, ethylene glycol intoxication and inappropriate administration of a hypertonic phosphate enema (Wellman2012). Treatment include Cattle 40% calcium borogluconate intravenously; Calcium chloride/calcium gluconate iv; maintenance dose = 10ml of 10% Ca gluconate added to 500ml of isotonic normal saline 0.9% Nacl solution (Rose 2001; Hobbs 2002).

Hypercalcaemia

Its occurs most frequently as a result of primary hyperparathyroidism, which is an excess production of PTH caused by generalized parathyroid hyperplasia, a solitary parathyroid adenoma, or as a part of multiple endocrine neoplasia type I or IIA. It can also occur when there is malignancy-induced destruction of bone resulting in release of calcium into the circulation, or when a tumor produces a PTH-like substance, most occurs commonly in adenocarcinomas of the kidney, ovary, or endometrium, and in squamous cancers of the lung or head and neck structures. Treatment involves therapy for the hypercalcemia and associated symptoms depending on severity; and the treatment of the underlying cause (Stewart 2005).

Disorders of Phosphorus

Phosphorus plays an important role in metabolic activity such as carbohydrate and energy metabolism that naturally depends on the capacity to phosphorylate intermediate metabolites and to store energy released during oxidation in high-energy phosphate bonds such as ATP or phosphocreatine. Phosphorus is an integral component of 2, 3-DPG, a compound that regulates oxygen discharge from hemoglobin and then it is critical for oxygen delivery to tissues. In the body, phosphorus is present as a stable inorganic phosphate (Pi), an organic phosphate ester, or a phospholipid. The largest fraction of the body phosphorus (~85% of total body phosphorus) is incorporated into bone in an insoluble inorganic phosphate form

(dihydroxyapatite); largely located in ICF (~14%), while <1% of the total body phosphorus is found in ECF, which includes blood serum or plasma. In the ECF, phosphorus is present either as Pi, forming the metabolically relevant fraction, or as phospholipids. The extracellular Pi fraction is largely (~85%) ionized (either $H_2PO_4^-$ or HPO_4^{2-}), while ~10% is protein bound and 5% is complexed with other minerals such as calcium or magnesium. The concentration of Pi in the ECF and thus in serum is dictated by the equilibrium between Pi uptake from the digestive tract; Pi excretion in urine (monogastric species), saliva (ruminants), and milk; the uptake or release of Pi from bone; and compartmental Pi shifts between the ECF and ICF (Tatted 1997).

Hypophosphatemia (Post-Parturient Haemoglobinuria)

In cattle, it occurs in under conditions similar to those of hypocalcaemia such as a decrease in feed intake or alimentary tract stasis. Treatment includes rapid administration of sodium phosphate salt solutions is commonly practiced. Mono- or dibasic phosphate salts (either Na_2HPO_4 or NaH_2PO_4) infused IV rapidly increase the serum Pi concentration. No effective approach to prevent hypophosphatemia and phosphorus depletion at the onset of lactation is known (Wickstrom 2008; Wellman 2012).

Hyperphosphatemia

It is closely associated with a decreased renal phosphate excretion, which occurs with chronic renal failure, hypoparathyroidism and hypomagnesemia. It's also caused by excessive intracellular phosphate movement to the extracellular fluid, as seen in tumor lysis, tumor necrosis, acute hemolysis, and rarely, acute metabolic acidosis due to chronic renal disease. The mainstay of therapy is reduction and restriction of dietary phosphate (Tatted 1997; Wickstrom 2008).

Disorders of Magnesium

Magnesium is distributed intracellularly in bone with smaller amounts found in muscle and other soft tissue (50%–60% of total body Mg are distributed in bone, 40%–50% in soft tissues, and <1% in the extracellular fluid). Intracellular Mg is required for activation of enzymes involving phosphate compounds such as ATPases, kinases, and phosphatases; and for synthesis of RNA, DNA, and protein. Magnesium is a cofactor for >300 enzymatic reactions involving ATP, including glycolysis and oxidative phosphorylation. It is also important in the function of the Na^+/K^+-ATPase pump, membrane stabilization, nerve conduction, ion transportation, and calcium channel activity. It also regulates the movement of calcium into smooth muscle cells, giving it a pivotal role in cardiac contractile strength and peripheral vascular tone. Low ionized Mg concentrations accelerate the transmission of nerve impulses.

Magnesium in bone is not readily available to support intracellular and extracellular phosphate levels, thus making dietary magnesium and renal magnesium reabsorption and excretion an important component of acute magnesium homeostasis. Renal reabsorption of most of the filtered magnesium occurs at the loop of Henle and distal tubular sites, which

makes renal magnesium wasting possible when distal tubule function is disturbed by use of diuretics (Halperin 1999; Rose 2001).

Hypomagnesemia

Magnesium deficit (Plasma Mg++ < 1.5–2.5mEq/l). It due to inadequate energy intake while grazing lush pasture low in magnesium, starvation, anorexia, low dietary content of magnesium, diarrhea and hypothyroidism. Clinical manifestations of severe hypomagnesemia include muscle weakness, muscle fasciculations, ventricular arrhythmias, seizures, ataxia, and coma.

Treatment of hypomagnesemia include magnesium sulphate 10% intravenously, usually concurrent administration of calcium is advisable; magnesium salts may be administered as a 20% solution in 5% dextrose. Less acute and complicated forms of hypomagnesemia can be treated with oral magnesium chloride. Potassium-sparing diuretics are helpful in treating magnesium deficiency created by chronic diuretic use (Rose 2001; Wellman 2012).

Hypermagnesemia

Magnesium excess (plasma Mg concentration >2mg/dL [1.1mmol/L]) is a rare condition reported only in monogastric animals. In normal renal function, hypermagnesemia is an uncommon clinical event because the kidneys efficiently excrete excess magnesium. Hypermagnesemia is most commonly caused by severe renal failure. Other causes of hypermagnesemia include adrenal insufficiency and hypothyroidism. Hypermagnesemia has been reported in cats with renal failure that were receiving IV fluid therapy.

Studies have reported that as plasma Mg concentrations exceed 2.5mmol/L, there may be ECG changes with prolongation of the PR interval; at 5mmol/L, deep tendon reflexes disappear, followed by hypotension and respiratory depression. Cardiac arrest may occur with blood Mg levels >6.0–7.5mmol/L.

The treatment includes avoiding magnesium-containing compounds when the renal function is compromised; in situation with cardiac or respiratory effects of hypermagnesemia, intravenous calcium gluconate should be requiring to antagonize the effect of magnesium (Rose 2001; Wellman 2012).

ACID-BASE DISORDERS

Acid-base homeostasis can be assessing by measuring the bicarbonate (HCO_3^-) concentration and PCO_2, along with the extracellular hydrogen ion concentration (blood pH). Normal ranges for HCO_3^- and PCO_2 are respectively 21 to 30mEq/l and 35 to 45mm Hg. pH is in the normal range of 7.35 to 7.45 when HCO_3^- and PCO_2 are at normal range. Although these values can represent a combination of abnormal acid-base events (Halperin 1999; Gordon 2004).

Acid-base disorders usually begin with an initial respiratory or renal event, altering the PCO_2 or [HCO_3^-], respectively. It is measured by arterial blood gases with pH as the key parameter; plasma pH is deviated out of the normal range (7.35–7.45). Acidosis corresponds to pH of arterial blood <7.35; Alkalosis corresponds to pH of arterial blood >7.45. Both, acidosis and alkalosis refers to the pathophysiologic processes that cause net accumulation of

acid or alkali in the body, whereas acidemia and alkalemia refers specifically to the pH of extracellular fluid. In acidemia, the extracellular fluid pH is less than normal and the $[H^+]$ is higher than normal. In alkalemia, the extracellular fluid pH is higher than normal and the $[H^+]$ is lower than normal. Due to the effectiveness of compensatory mechanisms, animals can have acidosis or alkalosis but not acidemia or alkalemia. i.e., a dog with chronic respiratory alkalosis may have a blood pH that is within the normal range. Such an animal has alkalosis, but does not have alkalemia (DeMorais 2006). The primary acid base disorders are divided into metabolic and respiratory disturbances: metabolic acidosis, metabolic alkalosis, respiratory acidosis, and respiratory alkalosis. The kidneys have been considered responsible for regulation of the metabolic component (blood bicarbonate concentration, $[HCO_3^-]$) and the lungs for regulation of the respiratory component (partial pressure of CO_2, $[pCO_2]$). Each primary (metabolic or respiratory) acid base disturbance is accompanied by a secondary opposing response in the other system (respiratory or metabolic) (Dibartola 2006b). A combined respiratory and metabolic acidosis suggests a mixed acid-base disorder (Hood 1998).

The presence of an acid-base disturbance may also appear as a quantitative alteration in serum chloride and serum bicarbonate concentrations on a basic electrolyte panel. The acid-base-induced changes in serum chloride and bicarbonate concentration are reciprocal and equivalent unless there is an excess of unmeasured anions (i.e, anions other than chloride or bicarbonate). Such unmeasured anions (e.g., beta-hydroxy-butyrate in diabetic ketoacidosis, lactic acid in lactic acidosis, or various toxins) can be detected by calculating the anion gap, which is measured by the following formula: $\{([Na^+] + [K^+]) - ([HCO_3^-] + [Cl^-])\}$ where $[Na^+]$ = sodium concentration; $[K^+]$ = potassium concentration; and $[Cl^-]$ = chloride concentration, for which the normal value is 8 to 16mEq/l. This anion gap can also be measure as $\{([Na^+] - [Cl^-]) + ([HCO_3^-])\}$, for which the normal value is 6 to 12mEq/L. Either way, the presence of an elevated anion gap indicates metabolic acidosis due to an excessive amount of intrinsic or unmeasured anions produced by the addition of extrinsic or the excess production of fixed acids containing anions other than chloride (e.g., ethylene glycol ingestion and lactic acidosis, respectively).

Metabolic Acid-Base Disorders

Metabolic Acidosis

It is the most common acid-base disturbance encountered in sick small animals, horses and camelids. It is identified by a decreased bicarbonate (HCO_3^-) and base excess on a blood gas analysis, and a decreased HCO_3^- on the chemistry panel. Main cause in animals include: an increased accumulation of hydrogen, typically caused by the addition, retention, or excess production of acids. Initially, the excess acid is buffered by bicarbonate content, and eventually, this buffering consumes the bicarbonate reserves and decrease bicarbonate level. Metabolic acidosis also occurs by loss of bicarbonate, leaving the body unable to buffer normally produced acid (Hopper 2012; Constable 2014). Metabolic acidosis can present with a normal or increased anion gap. With high anion gap, the cause typically is addition of an acid, such as beta-hydroxybutyric acid and acetoacetic acid in diabetic ketoacidosis, lactic acid in sepsis, uremic toxin in renal failure, or ingested toxins. In a situation with normal

anion gap, the cause typically is the inability to excrete acid via the kidneys (type 1 renal tubular acidosis), gastrointestinal HCO_3^- loss due to diarrhea, or renal dysfunction in type 2 renal tubular acidosis. Symptoms of metabolic acidosis include diarrhea, polydipsia and polyuria, tinnitus, vision loss, urolithiasis symptoms, etc. (Dubose 1997; Hobbs 2002). To evaluate metabolic acidosis, following tests are useful.

Anion Gap

Occurs when metabolic acidosis is associated with normal anion gap, hypobicarbonatemia and hyperchloremia; usually caused by HCO_3^- loss in diarrhea or renal tubular acidosis (type 2). Also, when metabolic acidosis is accompanied by a high anion gap caused by the addition, retention, or production of fixed acids containing unmeasured anions.

Osmolar Gap

The serum osmolar gap (i.e., the difference between measured and calculated serum osmolality, which is normally less than 10mOsm/kg) is useful in evaluating metabolic acidosis, and should be measured in all cases when the anion gap is large and toxic ingestion is suspected.

Potassium

Metabolic acidosis causes extracellular hyperkalemia. This occurs by removal of hydrogen ions $[H^+]$ from the extracellular fluid into cells, process that results in reciprocal movement of potassium out of cells and into the extracellular fluid. Absence of acidosis-induced hyperkalemia suggests severe total body potassium depletion (Mandal 1997; Lee 2013).

Urine pH and Urinary Anion Gap

Hypokalemic non anion-gap metabolic acidosis with suboptimal urinary acidification (i.e., pH greater than 5) and a positive urinary anion gap ($[U_{Na+} + U_{K+}] - [UCl^-]$) suggests distal renal tubular acidosis (RTA) (type I) caused by decreased renal acid excretion. The same events occur in proximal RTA (type II) when $[HCO_3^-]$ is below the reduced bicarbonate excretion threshold above which bicarbonate is excreted producing a urinary pH greater than 5. A negative urinary anion gap also is consistent with hyperchloremic metabolic acidosis caused by diarrhea, with normal renal $[H^+]$ excretion capacity, produces a urinary pH of less than 5 (Ishihara 1998).

The essential treatment of metabolic acidosis is to stop the excess acid production, addition, or retention or to terminate the bicarbonate loss. Restoration of effective circulating volume is essential to terminating the production of organic acids related to poor perfusion (e.g., lactic acidosis) and to promoting delivery of hydrogen ions to the distal renal tubule for excretion. Hypokalemia also should be corrected to restore renal concentrating capacity and improve urinary acidification ability.

Titration Metabolic Acidosis

Also called high anion gap acidosis is a primary acid-base disorder (i.e., it does not occur in compensation to a primary respiratory acid-base disorder). The titration or consumption of bicarbonate by a non-volatile non-chloride containing acid results in a high anion gap

metabolic acidosis. Main causes of this titration metabolic acidosis in almost species animals include L-lactate, a decreased excretion of normally filtered acids due to kidney. In Small animals, the main causes include ketoacidosis, toxic metabolites (e.g., ethylene glycol, salicylates). In cattle, causes include Ketoacidosis, D-lactate acidosis. In the camelids, ketoacidosis and L-lactate are major causes (Dibartola 2006b; Rose 2001; Constable 2014).

Bicarbonate Loss Metabolic Acidosis

Intestinal loss from secretory diarrhea is the most common cause of this type of primary acid-base disturbance and is the most frequent cause of a bicarbonate loss acidosis in ruminants, particularly calves. In the kidney, loss of bicarbonate is accompanied by retention of hydrogen with chloride in excess of sodium. In this type of acid-base disorder, body maintains electro neutrality by increasing or retaining Cl^-, with hydrogen, since HCO_3^- is an anion. Thus, an acidosis due to HCO_3^- loss is usually accompanied by a corrected hyperchloremia, with a normal anion gap (Rose 2001; Constable 2014).

Gain of a Chloride-Containing Non-Volatile Acid Metabolic Acidosis

This primary hyperchloremic metabolic acidosis occurs with distal renal tubular acidosis, when the proton pump (H-ATPase) in the distal nephron cannot pump out hydrogen with chloride passively following. Thus, hydrogen with chloride is retained resulting in a primary hyperchloremic normal anion gap metabolic acidosis.

In humans, it occurs with inherited defects in the H-ATPase in the distal nephron that causes excretion of hydrogen into the urine. The kidney can create a hyperchloremic normal anion gap metabolic acidosis as compensation for a primary respiratory alkalosis or as correction for a primary metabolic alkalosis, through a decreased ammoniagenesis in the proximal renal tubules primarily so hydrogen is no longer excreted as NH_4Cl, resulting in concomitant loss of bicarbonate; a decreased H-ATPase activity in the collecting tubule primarily, so hydrogen and chloride are retained. Both of these processes results in retention of hydrogen and chloride (in excess of sodium), leading to a compensatory or corrective hyperchloremic normal anion gap metabolic acidosis (Rose 2001; Dibartola 2006b).

Gain of Chloride without Hydrogen as the Proton

In animals, particularly cattle, an acidifying effect can occur and cause urinary acidification as a corrective response, via strong ion principles, when calcium chloride or diets with negative cation are given to anion balance (Constable 2014).

Hyperchloremic Metabolic Acidosis

In animals, the presence of a hyperchloremic normal anion gap metabolic acidosis (low bicarbonate, high Cl^-_{corr}) does not mean the acidosis is a primary disorder. Clinical assessment of animals is required and knowledge of the underlying disease prior to determine whether a hyperchloremic metabolic acidosis is primary or secondary to a respiratory acidosis. In situation of a primary respiratory alkalosis with a compensatory hyperchloremic metabolic acidosis, they should be a presence of a clinical disease or condition causing hyperventilation, the blood pH will be more alkaline than acidic and the pCO_2 will be quite low. Kidney function should also be normal for an animal to be able to compensate for a primary respiratory alkalosis. In small animals, the main causes of hyperchloremic metabolic

acidosis include proximal or distal renal tubular acidosis, vomiting of intestinal contents secretory diarrhea, compensation for a primary respiratory alkalosis, loss of bicarbonate in saliva.

Metabolic Alkalosis

A metabolic alkalosis is identified by an increased HCO_3^- and base excess on a blood gas analysis, and an increased HCO_3^- and/or decreased Cl^-_{corr} on the chemistry panel. Metabolic alkalosis may be caused by Loss of a chloride-containing non-volatile acid (e.g., HCl, NH_4Cl) causes loss of Cl^- without concomitant loss of Na^+. These types of metabolic alkalosis are chloride-responsive. In rare cases, renal losses of hydrogen (e.g., stimulation of the H-ATPase in the collecting tubules) can cause acid loss without much chloride loss, e.g., primary hyperaldosteronism. This latter type of metabolic alkalosis is chloride-unresponsiveness. Metabolic alkalosis may also be caused by a gain of base or bicarbonate; but this is a far less common.

Metabolic Alkalosis Due to Acid Loss

In small and large animals, this type of alkalosis is caused by compensation for a primary respiratory acidosis or correction for a primary metabolic acidosis, vomiting of gastric contents, excessive sweating, sequestration of abomasal contents, etc. This type of alkalosis usually responds to chloride supplementation.

Metabolic Alkalosis Due to Base Gain

This type of metabolic alkalosis is very uncommon and usually iatrogenic. Administration of $NaHCO_3$ (e.g., treatment of metabolic acidosis) or organic anions (which are metabolized to HCO_3^-, e.g., citrate in massive blood transfusions), may cause a metabolic alkalosis, particularly under conditions of volume depletion or renal dysfunction.

The presence of a metabolic alkalosis (high bicarbonate, low Cl^-_{corr}) does not mean the metabolic alkalosis is a primary disorder. Clinical assessment of the patient and knowledge of the underlying disease are required to determine whether a metabolic alkalosis is primary or secondary to a respiratory acidosis (Constable 2014).

Respiratory Acid-Base Disorders

This acidosis is usually due to inefficient ventilation caused by central nervous system respiratory center inhibition, disorders of the respiratory and chest wall muscles, obstruction to ventilation, and pulmonary perfusion and/or diffusion dysfunction. Decreased ventilation leads to hypercapnia (an increased level of $P_{CO2)}$, which stimulates compensatory renal retention of HCO3. Renal compensation HCO_3^- retention is always slow in providing substantial or immediate protection against increasing systemic H^+. It occurs at a rate of 1 mEq/L or 3.5mEq/L for every 10-mm Hg increase in PCO_2, respectively, up to a limit of 30mEq/L for acute respiratory acidosis and 45mEq/L for chronic respiratory acidosis. Symptoms are always due to an underlying pulmonary disease and commonly include shortness of breath. Treatment is directed to the primary cause of poor ventilation to increase the effectiveness of ventilation and pulmonary gas exchange. Oxygen administration may be

essential in case of hypoxemia caused by respiratory depression (Dibartola 2006b, Rose 2001).

Respiratory Acidosis

It is identified by an increased pCO_2 and low pH or tendency towards a low pH on a blood gas analysis. Chemistry panel usually not provide any information on the respiratory component of acid-base status. It is caused by decreased ventilation or gas exchange in the alveoli, which can be secondary to neurologic, musculoskeletal, pulmonary, and cardiac disorders. In animals, most common causes are primary pulmonary disease, ranging from upper airway obstruction to pneumonia. Diseases or drugs that inhibit the medullary respiratory center can also produce a profound respiratory acidosis, e.g., general anesthesia (Rose 2001; Dibartola 2006b).

Respiratory Alkalosis

It is caused by situations or events that increase volume and rate of ventilation, resulting in a reduction in the level of PCO_2, which decreased cellular production and stimulates compensatory renal excretion of HCO_3^-, leading to a compensatory reduction of serum HCO_3^- . The immediate cellular response against decreasing systemic H^+, is usually slow in respiratory alkalosis. In primary acute and chronic respiratory alkalosis, the compensatory serum HCO_3^- reduction occurs at a rate of 2mEq/L or 4mEq/L for every 10-mm Hg decrease in the PCO_2 level, respectively. The limits of the metabolic compensations in acute and chronic respiratory alkalosis are serum HCO_3^- levels of 18mEq/L and 12mEq/L, respectively. If the compensatory HCO_3^- loss is less than or greater than predicted, a mixed acid-base disorder may be present (Hobbs 2002; Laffey 2002).

Respiratory alkalosis is induced by processes that lead to hyperventilation which include pulmonary diseases with hypoxemia; psychogenic disorders, such as anxiety, fever. Symptoms occur with respiratory alkalosis and acute hypocapnia include circumoral and digital paresthesia, light-headedness, carpopedal spasm, and tetany. Treatment is directed to the underlying cause.

Mixed Acid-Base Disorders

It's typically detected when a primary acid-base disturbance is not associated with the expected compensation. This failure of compensation concludes the presence of a respiratory and metabolic acid-base event arising concurrently with the primary event. In animals, it might result from two or rarely three separate primary disturbances present simultaneously. Four disorders cannot coexist in one animal because hyperventilation which refers to respiratory alkalosis and hypoventilation which refers to respiratory acidosis cannot occur at the same time in one animal (Dibartola 2006b). A normal pH with an abnormal serum HCO_3^- and PCO_2 typically also indicates the presence of a mixed acid-base disorder (Hobbs 2002).

In small and large animals, a mixed acid-base disturbance should be suspected in following situations: normal pH normal with an abnormal pCO_2 and/or bicarbonate, when change in pH is greater than can be attributed to one disorder alone, when pCO_2 and HCO_3^-

change is in opposite directions, when the degree of change in acid-base results is not proportional.

Anaesthesia, Surgery and Fluid Balance

During perioperative period, many experiment animals are dehydrated prior surgery by prolonged fasting, use of purgatives or diuretic therapy. In addition, intraoperative losses of body's fluid are frequently underestimated and excess losses, both surgical and third-space losses, persist into the early postoperative period. Consequently, a tendency towards hypovolaemia is usually present leading to thirst and vasopressin secretion. During anaesthesia period, the most important response is sodium and water retention. Number of factors may contribute to this including: the effects of anaesthetic agents on renal blood flow and GFR; effects of intraoperative hypotension or hypovolaemia on renal function; increased sympathetic tone and circulating catecholamines causing renal vasoconstriction; the salt and water retaining effects of increased plasma cortisol and aldosterone levels in response to the stress of surgery; and increased ADH activity which may increase 50–100-fold during surgery and falls at the end of surgery, without return to normal for 3–5 days (similar to the period of post-operative oliguria) (Desborough 2000, Aitkenhead 2001). During surgery, changes also occur in capillary membrane porosity as a result of the cytokine-mediated responses to tissue injury and bacteraemia. Despite a considerable increase in lymphatic drainage, fluid accumulates in previously 'dry' tissues. The situation often exists where circulatory hypovolaemia is significant enough to threaten organ perfusion whilst these 'third-space' tissues are waterlogged. More fluid is usually required in this situation to maintain circulatory volume and adequate organ perfusion (Dobb 1984).

Fluid Therapy for Maintenance and Replacement during Surgery

Fluid therapy serves to correct dehydration, acidosis and alkalosis, electrolyte deficiencies, nutrition and calorie. This therapy should be individualized and fitted to each case and constantly re-evaluated and reformulated according to changes in status (Schott 2006). Fluid selection is prescribed by the animal's needs, including volume, rate, and fluid composition required, as well as location the fluid is needed (interstitial versus intravascular) (Naylor 1990; Kirby 2009). Factors to consider include the following: acute versus chronic conditions, animal pathology (e.g., acid-base balance, oncotic pressure and electrolyte abnormalities), comorbid conditions (DiBartola 2006b; Hallowell 2009).

A variety of conditions can be effectively managed using three types of fluids: a balanced isotonic electrolyte (e.g., a crystalloid such as lactated Ringer's solution (LRS)); a hypotonic solution (e.g., a crystalloid such as 5% dextrose in water (D5W)); and a synthetic colloid (e.g., a hydroxyethyl starch) (Table 1).

Fluid therapy often begins with the maintenance rate, which is the amount of fluid estimated to maintain normal patient fluid balance. This Maintenance fluid therapy is indicated for animals that are not eating or drinking, but do not have volume depletion, hypotension, or ongoing losses. Replacement fluids are proposed to replace lost body fluids and electrolytes (Anderson 1982; Wellman 2012).

Table 1. Available fluids used in experimental surgery

Commercially available fluids	
(Electrolyte Solutions) Isolyte, Premolyte, Dextroselyte	Daily water and electrolyte maintenance and replacement of lose.
Dextrose Solutions	Used in prophylaxis and treatment of ketosis in starvation, diarrhea, vomiting or high fever.
Plasma Volume Expander Dextran in 0.9% Sodium Chloride	Indicated in shock due to decreased effective blood volume, severe dehydration and surgical procedures and anesthesia.

Using replacement solutions for short-term maintenance fluid therapy typically does not alter electrolyte balance; however, electrolyte imbalances can occur in patients with renal disease or in those receiving long-term administration of replacement solutions for maintenance (Hobbs 2002). In most case, isotonic polyionic replacement crystalloid such as LRS is used as either replacement or as maintenance fluids. When it's administering for maintenance, it may predispose the animals to hypernatremia and hypokalemia because this solution contains more sodium (Na) and less potassium (K) than the animals normally loses. Animals with normal renal function and well hydrated are typically able to excrete excess Na and thus do not develop hypernatremia. Animals that receive replacement solutions for maintenance fluid therapy may develop Hypokalemia, in case of anorexia, vomiting or diarrhea because the kidneys do not conserve potassium very well. Monitoring of serum electrolytes is required periodically (e.g., q24h) (Macintire 2004; Schott 2006; Macintire 2012).

Enteral Nutrition

Previous studies reported that in number of animal species, enteral fluids administered alone, or in conjunction with intravenous fluids, are useful for the treatment of dehydration and electrolyte loss associated with diarrhoea (Lopes 2003; Kirby 2009). It's very suitable for treatment of mild to moderately dehydrated animals with some intact intestinal epithelium and motile small intestine. It is contraindicated in animals that are severely dehydrated and /or in hypovolaemic shock when used alone. If used in conjunction with intravenous fluids, enteral nutrition (EN) may ameliorate the effects of villous atrophy and malnutrition (Rainger 2006; Amstrong 1988).

The species of animal, the underlying condition, and the constituents of the fluid, usually influence the choice of the enteral fluid. Available enteral fluids have following components: sodium, chloride and carbohydrates, the amounts of ions and other ingredients such as potassium, alkalising agents, amino acids and short chain fatty acids which may vary (Rainger 2006).

Parenteral Nutrition

It's an important feeding modality for patients unable to receive adequate enteral nutrition. Although, it's effectiveness in animals has not been proven, human studies have shown that using parenteral nutrition (PN) in appropriately selected cases can improve clinical outcome, reduce hospitalization time, and even reduce the overall cost of patient care (Chan 2002; Koneru 2010).

PN formulations for animals are readily available through market, and it involves intravenous administration of nutrients to patients that require nutritional support and are anorectic despite correction of dehydration and other metabolic derangements. PN solutions components are usually mixtures of dextrose solutions, lipid emulsions, and amino acid solutions that variably contain electrolytes, vitamins, and mineral supplements. A mixture of dextrose, lipids, and amino acids together in a PN formulation, resulting in a solution called a three-in-one solution or total nutrient admixture. Three-in-one solution is well tolerated by animals, and easy to administer; it provides a animal's short-term amino acid, glucose, and energy needs in one solution (Rombeau 2001; Hallowell 2009; *Koneru 2010)*. Solution of dextrose and amino acid solutions without lipids is given to animals as well. This solution contains fewer kilocalories per milliliter, require substantially greater volumes of delivery to meet caloric needs, and do not need a daily replacement as with lipid containing admixtures. Its use can help to avoid negative side effects of lipid administration.

An alternative to the total nutrient admixtures with lipids, dextrose, and amino acids is the use of partial parenteral nutrition (PPN) solutions with only amino acids and/or dextrose (Lippert 1989; Plunkett 2002). Available solution such as a mixture of 3% amino acids, glycerol, and electrolytes can be administered continuously for longer than 24 hours because it does not contain lipids, which deteriorate over time.

Careful monitoring of experiment animals receiving PN is important to identify and rectify metabolic abnormalities that may develop (Remillard 1989; Macintire 2005). Vital signs (i.e., temperature, pulse and respiratory rates, animal attitude) should be seriously monitored every 4 to 6 hours for the first 2 to 3 days and at a decreasing frequency thereafter. Body weight should be measured every 12 to 24 hours. Blood and urine glucose should also be evaluated at least every 12 hours for the first 2 to 3 days for evidence of hyperglycemic complications (Pyle 2004; Chan 2002; Amstrong 1988).

PN has a disadvantages to be economically cost, and could induced mechanical complications, metabolic complications and infections which occurs secondary to contamination and growth of bacteria and fungi in a PN bag, nosocomial bacterial or fungal contamination during administration, or bacterial translocation from the animal's own body (specifically the gastrointestinal tract or skin at the catheter site). Contamination of the PN bag during compounding and nosocomial infection introduced during administration can be controlled by careful preparation of PN and aseptic handling of the intravenous tubing *(*Kelly 1996; Koneru 2010).

Refeeding Syndrome

It's usually described as the potentially fatal shifts in fluids and electrolytes that may occur in malnourished patients receiving enterally or parenterally refeeding. These shifts result from hormonal and metabolic changes, caused by rapid initiation of refeeding after a period of undernutrition (Kelly *1996;* Kirby 2009). The hallmark biochemical feature of this syndrome is hypophosphatemia (Marinella 2003*)*. However, the syndrome is complex and may also feature abnormal sodium and fluid balance; changes in glucose, protein, and fat metabolism; thiamine deficiency; hypokalemia; and hypomagnesaemia. Understanding of refeeding syndrome and identification of animals at risk is essentially important as the condition is preventable and the metabolic complications are avoidable. Experiment animals at high risk include undernourished animals and those who have had little or no energy intake

for more than 10 days. Refeeding should be started at a low level of energy replacement. Vitamin supplementation should also be started with refeeding and continued for at least 10 days. The adjustment of electrolyte and fluid imbalances before feeding is not necessary; it should be done in company with feeding (Miller 2000; Bartges 2001; Tsai 2003).

CONCLUSION

Fluid, electrolyte, and acid-base abnormalities can lead to fatal consequences in surgical experiment animals. Understanding of knowledge about fluid and electrolyte homeostasis, acid-base balance and the underlying pathophysiology related to their respective disorders, are of crucial importance to provide optimal management required during and after experiments surgery. In addition, fluid therapy, which is important for many medical conditions in experimental surgery, should be administered depending on experiment animals needs, according to a well-defined fluid administration rates.

REFERENCES

Adrogue HJ, Madias NE. Aiding fluid prescription for dysnatremia. *Intenive Care Med*. 1997; 23:309–316.

Adrogue HJ, Madias NE. Hyponatremia. *N. Engl. J. Med.* 2000a; 342:1581–1589.

Adrogue HJ, Madias NE. Hypernatremia. *N. Engl. J. Med.* 2000b; 342:1493–1489.

Aitkenhead AR, Rowbotham DJ, Smith G. *Textbook of Anaesthesia*, 4th Edn. London: Churchill Livingstone, 2001.

Anderson RR. Water balance in the dog and cat. *J. Small Anim. Pract.* 1982; 23:588.

Angelos SM, Van Metre DC. Treatment of sodium balance disorders. *Vet Clin North Am. Food Pract*. 1999; 15:587–607.

Armstrong PJ, Lippert AC: Enteral and parenteral nutritional support. *Semin. Vet. Med. Surg. (Small Anim).* 1988; 3:216–226.

Bartges JW: Identifying and feeding patients that require nutritional support. *Vet. Med.* 2001; 96:60–73.

Blumenfeld JD, Vaughan ED: Renal physiology and pathophysiology, in Walsh PC, Retik AB, Vaughan ED, Wein AJ (eds): *Campbell's Urology*. Philadelphia, WB Saunders, 2002, pp 169–227.

Bushinsky DA, Monk RD. Electrolyte quintet: Calcium. *Lancet* 1998; 352:306–311. Erratum in: *Lancet* 2002; 359:266.

Brater DC. Diuretic therapy. *N. Engl. J. Med.* 1998; 339:387–395.

Chan DL, Freeman LM, Labato MA: Retrospective evaluation of partial parenteral nutrition in dogs and cats. *J. Vet. Intern. Med*. 2002; 16:440–445.

Constable P. Fluid and electrolyte therapy in ruminants. *Vet. Clin. North Am. Food Anim. Pract.* 2003;19(3):557–597.

Decaux G, Soupart A. Treatment of symptomatic hyponatremia. *Am. J. Med. Sci.* 2003; 326:25–30.

DeMorais HAS and Leisewitz AL: Mixed Acid-base disturbances. In DiBartola SP: *Fluid, Electrolyte, and Acid Base Disorders in Small Animal Practice* (ed. 3), Saunders-Elsevier, St. Louis, 2006.

Desborough JP. The stress response to trauma and surgery. *Br. J. Anaesth*. 2000; 85: 109–117.

DiBartola SP: Disorders of sodium and water: Hypernatremia and hyponatremia, in DiBartola SP (ed): *Fluid, Electrolyte, and Acid-Base Disorders in Small Animal Practice*. St. Louis, Saunders, 2006a, pp 47–79.

DiBartola SP, Bateman S: Introduction to fluid therapy, in DiBartola S (ed): *Fluid, Electrolyte, and Acid-Base Disorders in Small Animal Practice*. St. Louis, Saunders, 2006b, pp 325–344.

Dobb GB. Body water, electrolytes and parenteral fluid therapy. In: Churchill-Davidson HC ed. *A Practice of Anaesthesia*. Chicago: LloydLuke (Medical Books) Ltd, 1984; 568–86.

DuBose TD Jr. Hyperkalemic hyperchloremic metabolic acidosis: pathophysiologic insights. *Kidney Int.* 1997; 51:591–602.

Fried LF, Palevsky PM: Hyponatremia and hypernatremia. *Med. Clin. North Am*. 1997; 81(3):585–609.

Gennari FJ. Hypokalemia. *N. Engl. J. Med.* 1998; 339:451–458.

Gordon S. Sacks. *J. Pediatr. Pharmacol. Ther.* 2004; 9(4): 235–242.

Hallowell GD and Potter TJ. *Intravenous fluid therapy in cattle*. UK Vet: Livestock. 2009; 14(1) 30–34.

Halperin ML, Goldstein MB. *Fluid, Electrolyte, and Acid-Base Physiology: A Problem-Based Approach.* 3rd ed. Philadelphia, PA: WB Saunders; 1999.

Hobbs J. Fluid, electrolyte and acid-base disorders. In: Taylor RB, ed. *Family Medicine Principles and Practice*. 6th ed. New York, NY: Springer-Verlag; 2002:815–832.

Hood VL, Tannen RL. Protection of acid-base balance by pH regulation of acid production. *N. Engl. J. Med.* 1998; 339:819–826.

Hopper K & Epstein SE. Incidence, nature, and etiology of metabolic acidosis in dogs and cats. *J. Vet. Intern. Med.* 2012; 26(5):1107–1114.

Ishihara K, Szerlip HM. Anion gap acidosis. *Semin. Nephrol.* 1998; 18:83–97. Review.

James KM, Lunn KF. An in-depth look: normal and abnormal water balance, hyponatremia and hypernatremia. *Comp. Cont. Ed. Pract. Vet*. 2007; 29: 589–608.

Kelly NC, Wills JM: *BSAVA Manual of Companion Animal Nutrition & Feeding*. Ames, Iowa State University Press, 1996.

Kirby R. *The Physiology of Fluid Therapy Proceedings. 2009; the 15th IVECCS Symposium*. Chicago, Ill.

Koneru VRC, Pothula NR. *Indian J. Anaesth*. 2010 Mar-Apr; 54(2): 95–103.

Laffey JG, Kavanagh BP. Hypocapnia. *N. Engl. J. Med.* 2002; 347:43–53.

Lee HL, Hering-Smith KS, Nakhoul NL. Acid-base and potassium homeostasis. *Semin. Nephrol*. 2013; 33:257.

Lien YH, Shapiro JI. Hyponatremia: clinical diagnosis and management. *Am. J. Med*. 2007; 120:653–658.

Lippert AC, Armstrong PJ: Parenteral nutritional support, in Kirk RW, Bonagura JD (eds): *Current Veterinary Therapy Small Animal Practice X*. Philadelphia, WB Saunders, 1989; pp 25–30.

Lopes MA, Hepburn RJ, McKenzie HC, Sykes BW. Enteral Fluid Therapy for Horses. *Compendium Equine*. 2003; Vol 25(5): 390–397.

Macintire DK, Drobatz KJ, Haskins SC, Saxon WD. *Manual of small animal emergency and critical care medicine*. 1st ed. Philadelphia (PA): Lippincott Williams & Wilkins; 2004:67.

Macintire DK, Drobatz KJ, Haskins SC, Saxon WD. *Manual of Small Animal Emergency and Critical Care Medicine*. Philadelphia, Lippincott Williams & Wilkins; 2005.

Macintire DK, Drobatz KJ, Haskins SC, Saxon WD. *Manual of small animal emergency and critical care medicine*. 2nd ed. Philadelphia (PA): Wiley Blackwell; 2012:69.

Mandal AK. Hypokalemia and hyperkalemia. *Med. Clin. North Am.* 1997; 81:611–639.

Marinella M: The refeeding syndrome and hypophosphatemia. *Nutr. Rev.* 2003; 61:320–323.

Miller CC, Bartges JW: Refeeding syndrome, in Bonagura JD (ed): *Kirk's Current Veterinary Therapy XIII*. Philadelphia, WB Saunders, 2000, pp 87–89.

Naylor JM. Oral fluid therapy in neonatal ruminants and swine. *Vet. Clin. North Am. Food Anim. Pract.* 1990 Mar;6(1):51–67.

O'brien DR, Kroll RA, Johnson GC. Myelinolysis after correction of hyponatremia in two dogs. *J. Vet. Intern. Med.* 1994; 18:40–48.

Oh GS, Carroll HJ: Regulation of intracellular and extracellular volume, in Arieff AI, DeFronzo RA (eds): *Fluid, Electrolyte, and Acid-Base Disorders*. New York, Churchill Livingstone, 1995, pp 1–22.

Palevsky PM. Hypernatremia. *Semin. Nephrol.* 1998; 18:20–30.

Piperisova I. What is your diagnosis? Marked hyperchloremia in a dog. *Vet. Clin. Pathol.* 2009; 38(3):411–414.

Plunkett SJ: *Emergency Procedures for the Small Animal Veterinarian*, ed 2. London, WB Saunders, 2002.

Pyle SC, Marks SL, Kass PH: Evaluation of complications and prognostic factors associated with administration of total parenteral nutrition in cats: 75 cases (1994–2001). *JAVMA* 2004; 225:242–250.

Rainger JE, Dart AJ. Enteral fluid therapy in large animals. *Aust. Vet. J.* 2006 Dec; 84(12):447–451.

Remillard RL, Thatcher CD. Parenteral nutritional support in the small animal patient. *Vet. Clin. North Am. Small Anim. Pract.* 1989; 19:1287–1306.

Rombeau JL, Rolandelli RH: *Clinical Nutrition: Parenteral Nutrition*. Philadelphia, WB Saunders, 2001.

Rose BD, Post TW: *Clinical Physiology of Acid-Base and Electrolyte Disorders.* New York, McGraw-Hill, 2001.

Schott HC. Fluid Therapy: A Primer for Students, Technicians, and Veterinarians, in Equine Practice. Vet Clinics NA, *Equine Practice*. Elsevier, 2006; 22(1) 1–14.

Sterns RH. The treatment of hyponatremia: first do not harm. *Am. J. Med*. 1990;88: 557–560.

Stewart AF. Clinical practice. Hypercalcemia associated with cancer. *N. Engl. J. Med.* 2005; 352:373–379.

Tatted L, Oster JR, Singer I. Review of the literature: severe hyperphosphatemia. *Am. J. Med. Sci.* 1995; 310:167–174. Erratum in *Am. J. Med. Sci.* 1997; 313:158.

Tsai YC, Jeng TS, Jeng CR: Case report: Refeeding syndrome in a cat. *Taiwan Vet. J.* 2003; 29:66–70.

Wellman ML, DiBartola SP, Kohn CW. Applied physiology of body fluids in dogs and cats. In: DiBartola SP, ed. *Fluid, electrolyte, and acid-base disorders in small animal practice*. 4th ed. St. Louis (MO): Elsevier Saunders; 2012:15.

Wickstrom AM. Fluid, Electrolyte, and Acid-Base Disorders in Small Animal Practice, 3rd ed. *The Canadian Veterinary Journal* 2008; 49(5):498.

Yunos NM, Bellomo R, Story D, Kellum J. Bench-to-bedside review: chloride in critical illness. *Crit Care*. 2010; 14: 226.

In: Encyclopedia of Surgery (22 Volume Set)
Editors: Andreas Lehrer and Kristin Mueller
ISBN: 978-1-53618-329-0
© 2020 Nova Science Publishers, Inc.

Chapter 207

IMAGERY TECHNIQUES IN EXPERIMENTAL SURGERY

Junzheng Peng[1,*], MD, PhD and Huifang Chen[2], MD, PhD
[1]Cardiovascular Phenotyping Core Facility, CRCHUM,
University of Montreal, Montreal, Quebec, Canada
[2]Laboratory of Experimental Surgery, Department of Surgery, CRCHUM,
University of Montreal, Montreal, Quebec, Canada

ABSTRACT

Imaging technologies have been widely applied in animal disease models established by experimental surgery. Imaging technologies can be used to explore the mechanism of human diseases at the molecular level and evaluate the effect of new diagnostic and therapeutic agents on human diseases. In this chapter, the updated application of imaging technologies for studying human diseases in animal models will be reviewed.

Keywords: imagery techniques, experimental surgery

ABBREVIATIONS

2D	Two-dimensional
3D	Three-Dimensional
3R	Replacement, reduction and refinement
AD	Alzheimer's disease
ASL	Arterial spin labeling
BLS	Bright-light surgery
BMSCs	Bone mesenchymal stem cells
CAA	Cerebral amyloid angiopathies
CCD	Charged-coupled detector
CEUS	Contrast-enhanced US

* Corresponding Author's Email: pengjunzheng@gmail.com.

CMOS	Complementary metal oxide semiconductor
CZT	Cadmium zinc telluride
DCE–MRI	Dynamic contrast-enhanced imaging
DOT	Diffuse optical tomography
DWI	Diffusion-weighted imaging
EAE	Experimental autoimmune encephalomyelitis
ECG	Electrocardiogram
EDA	Esophagoduodenal anastomosis
EGFR	Epidermal growth factor receptor
EPCs	Endothelial progenitor cells
FDG	Fluoro-2-deoxy-D-glucose
FGS	Fluorescence-guided surgery
FLI	Fluorescence imaging
fMRI	functional MRI
FOV	Field of view
GFP	Green fluorescent protein
GK	Goto-Kakizaki
IVC	Inferior vena cava
LV	Left ventricular
MI	Myocardial infarction
Micro-CT	Micro-computed tomography
Micro-PET	Micro-positron emission tomography
Micro-SPECT	Micro-single photon emission computed tomography
MRA	Magnetic resonance angiography
MRI	Magnetic resonance imaging
MS	Multiple sclerosis
MT.ThC	Medial tibial cartilage thickness
OA	Osteoarthritis
OI	Optical imaging
OPAL	Optical projection of acquired luminescence
PAT	Photo-acoustic tomography
PCXD	Photon counting x-ray detectors
PMT	Photomultiplier tubes
rCBF	Regional cerebral blood flow
ROIs	Regions of interest
SCBF	Spinal cord blood flow
SCI	Spinal cord injury
TEE	Transesophageal echocardiography
TFT	Thin-film transistor
UBM	Ultrasound biomicroscopy
US	Ultrasound
VSI	Vessel size imaging
μMRI	microscopic magnetic resonance imaging

INTRODUCTION

Translational research is changing the medical practice and the way to solve health problems. The application of translational research is the basis for science-based medicine and is the proper future orientation since it benefits from multidisciplinary, multiphase, and multisectorial projects to obtain solutions for health problems (Milne 2009). The application of experimental surgery animal models has an important role in preclinical study. The experimental surgery animal models establish a bridge between molecular discovery and clinical application. The in vitro effect of a molecule needs to be explored *in vivo* for its molecular interactions (Franc 2008). Imaging technologies can be used to explore disease in real time, in a quantitative way and at the molecular level. Disease progression and therapeutic effect can be repeatedly and non-invasively monitored by the imaging technologies (Cunha 2014). The advantages of preclinical imaging methods include 1) the decrease of biological variability; 2) unique information in distinct forms, repeated or modulated as needed; 3) reduction in the number of animals for study (Cunha 2014). The imaging techniques for preclinical study include ultrasound (US), micro-computed tomography (micro-CT), optical imaging (OI), micro-single photon emission computed tomography (micro-SPECT), micro-positron emission tomography (micro-PET) and magnetic resonance imaging (MRI). Each technique has its own advantages and limitations. Multimodality devices are under investigation to overcome the limitations and acquire complementary pathophysiological information.

The combination of high-resolution techniques (micro-CT or MRI) with highly sensitive techniques (micro-PET or micro-SPECT) will expand the horizons of different research fields. It will help to explore the underlying mechanisms of disease and provide efficient and unique tools for assessing new chemical entities and candidate drugs. The added advantage of animal imaging techniques has prompted their growing application. The combination of experimental surgery animal models of disease and highly developed imaging tools can shorten the project length and improve the level of confidence in the obtained results. Moreover, the preclinical validation of drug target is driving the use of animal in vivo imaging technologies for drug development (Franc 2008; Pomper 2005).

This chapter will review the imaging techniques for experimental surgery animal models. The contribution and relative importance of each technique, including its advantages and limitations, is outlined.

IMAGING TECHNIQUES

Imaging techniques are non-invasive which can be used to screen the whole disease process, from disease onset to progression and therapy monitoring. The significant advantages of imaging techniques are the reduction of biological variability and considerable decrease in the number of animals required for a particular study (Zanzonico 2011). Furthermore, the study of complex interactions between the physiological process and biochemical process in biological systems can only be performed with intact animals. It is impossible to fully assess such interactions with cell- or tissue culture-based methods or in *ex*

vivo systems. As most imaging techniques are the same as those used in the clinical setting, results are easily translatable to humans (Zanzonico 2011; Weissleder 2001).

Nevertheless, several challenges need to be resolved when imaging mouse as compared with human. These challenges include the subject size, the total volume, the spatial resolution and the total time spent for images (Weissleder 2001). The crucial challenge is to acquire high signal-to-noise ratio and to localize precisely the imaging probe, while keeping a good temporal resolution with the minimum amount of molecular probe (Massoud 2003).

Nuclear medicine-based techniques (PET and SPECT), OI, CT, MRI and US are the most acceptable for non-invasive in vivo imaging in genomics, proteomics, and nanotechnologies (Grassi 2008). Imaging equipment performance has been improved by the advance of imaging software and hardware (Zanzonico 2011). The existing imaging technologies differ basically in their physical basis and in the type of information provided (Table 1).

Table 1. Summary of general properties of diagnostic imaging techniques

Imaging technique	Physical basis	Information provided
US	Sound reflection of high-frequency	Internal movements and flows,
sound waves	differences of Tissues	
CT	X-rays	Tissue density
OI	Light emissions	Probe uptake
SPECT	Gamma-radiation	Tracer uptake
PET	Gamma-radiation	Tracer uptake
MRI	Magnetic properties	Tissue composition

Adopted from Cunha 2014.

ULTRASOUND (US)

US refers to sound waves with frequencies higher than 20,000 cycles/s (Hz) that are not detectable by the human ear (Liang 2003; Coatney 2001). The principle of US is to produce images by the application of the interaction of sound waves with living tissues/organs (Coatney 2001). Diagnostic US usually utilize frequencies between 2 and 15 MHz (Coatney 2001). Preclinical systems utilize higher frequencies (20–50 MHz) to produce images with higher spatial resolution and a sufficient penetration for anatomical and functional real-time information of the animal models (Tremoleda 2012).

US can provide many specialized imaging formats and techniques that are applied in preclinical study. US biomicroscopy (UBM), transesophageal echocardiography (TEE) and contrast-enhanced imaging are three specialized ultrasound imaging methods for rodents (Coatney 2001). Doppler-based models can detect dynamic and real-time images to decide the speed of a moving tissue and acquire quantitative structural and functional information (Coatney 2001). The effect of Doppler is according to the change of sound-wave frequency when a sound wave is reflected by a moving target. The larger the Doppler shift, the larger the speed of the blood flow (Coatney 2001). Contrast agents with acoustic properties that differ from the target tissues can be used to enhance image quality (Liang 2003). Molecular-targeted contrast agents may be used to estimate biological processes at the molecular level (Deshpande 2010). The most common US contrast agents are microbubbles, which are small

and stabilized gas-encapsulated micro-particles (<10 μm). After intravenous injection, they act comparably to the red blood cells in the circulation and supply a strong reflective blood/gas interface (Greco 2012).

UBM can obtain images using two-dimensional (2D) brightness-mode, pulsed and continuous wave Doppler and color flow Doppler (Comley 2011; Greco 2012). This imaging technique has been applied for the embryonic evaluation and eye development (Golden 2012; Cheung 2007), murine models of myocardial infarction and left ventricular remodeling (Kaufmann 2007), and mouse model of colorectal cancer (Alves 2013). The advantages of US over other imaging techniques include high spatial and temporal resolution, a rapid frame rate, real-time and quantitative imaging, no ionizing radiation, less expensive and extensive availability (Liang 2003; Deshpande 2010). However, US may cause bioeffects such as tissue heating and shock waves (Liang 2003). Skilled operator is needed to acquire accurate, repeatable, and high-quality images (Coatney 2001). US cannot be commonly applied in the brain, spinal cord, and lung due to limitations in imaging bone and gas-filled structures (Greco 2012).

US can be utilized to evaluate muscle atrophy after nerve injury for longitudinal analysis of nerve regeneration in rats (Hundepool 2015). Dynamic contrast-enhanced US (CEUS) changes may supply the angiogenesis and hemodynamic information of rabbit hepatic tumors (Zhou 2015). CEUS was used to evaluate the effects of peripheral sympathetic denervation in common iliac arteries on peripheral microperfusion of the biceps femoris in pigs (Steinberg 2015).

Microbubbles ameliorate the recognition and interpretation of tumor progression, inflammatory processes and cardiovascular diseases. US molecular imaging can be perceived by binding targeted moieties, peptides and antibodies to the surfaces of microbubble due to the excellent sensitivity and specificity. The targets of molecular microbubbles include integrins, selectins, intercellular adhesion molecule 1, vascular cell adhesion molecule 1 and vascular endothelial growth factor receptor-2. These molecular microbubbles were produced and were shown in preclinical experiments to be able to selectively bind to tumor blood vessels and atherosclerotic plaques (Kiessling 2012).

Guided high mechanical index-induced microbubble cavitation from a diagnostic US transducer added to low-dose tissue plasminogen activator (tPA) can quickly ameliorate regional function and decrease infarct size in acute ST segment elevation myocardial infarction (Wu 2015).

Several antibody- or peptide-targeted microbubbles have been favorably evaluated for imaging receptors overexpressed on tumor blood vessels and on atherosclerotic plaques in experimental animal study. The first molecularly targeted microbubble was used in clinical trials to diagnose and localize prostate cancer (Kiessling 2012). Furthermore, microbubbles have been applied for thrombolysis, for increasing drug delivery across biologic barriers, and for integrating disease diagnosis and therapy. Additionally, US with microbubbles supply an adaptable tool for molecular imaging and therapy. Real-time CEUS imaging was used to evaluate post-spinal cord injury (SCI) and spinal cord blood flow (SCBF) changes in a rat contusion model of traumatic spinal cord injury (Dubory 2015). US imaging indicated unequal blood flow along the intact spinal cord in the uninjured animal. Critical ischemia at the level of the epicenter was detected 15 min after SCI. SCBF was not affected in the more remote intact areas. SCBF was markedly decreased in the regions close to the epicenter. The result was similar to the previously reported “ischemic penumbra zone”. This technique is of

great interest for evaluating the treatment effect on limiting ischemia and tissue necrosis subsequent to SCI.

Molecular US imaging was applied to evaluate the early inflammatory effects following 30 min of renal ischemia in animal model (Hoyt 2015). It may determine the extent of injury and observe the tissue throughout disease progression. Molecular US imaging was performed at different time points after carotid artery denudation in atherogenic diet fed mice to monitor accurately the reendothelialization of vessels (Curaj 2015). The results indicate that molecular US imaging is encouraging to evaluate vascular damage and to observe endothelial recovery after arterial interventions. US molecular imaging with a dual P- and E- selectin-targeted contrast agent can accurately detect acute inflammation in a murine model of chronic inflammatory bowel disease (Machtaler 2015). US was used to monitor the improvement of regional and global LV function in rat model of acute myocardial infarction after 5 escalating doses of c-kit (pos) cardiac stem cells were administered (Tang 2015).

US has often been used in the evaluation of venous thrombosis in the clinical setting and can be applied to evaluate thrombus formation and its resolution in the experimental setting. US technique can also be utilized to supply surrogate measures of thrombus composition. This technique has been applied to precisely assess clot age in a rat inferior vena cava (IVC) stasis model (Emelianov 2002). High-frequency US only enabled 2D data acquisition in either length or cross-sectional area for assessments of thrombus size. Three-dimensional (3D) acquisition systems often operated to quantify subcutaneous tumor development could be employed to reconstruct the thrombus and supply a better measure of thrombus burden (Ingram 2013). Fibrin and platelet integrin αIIbβ3 was able to be distinguished by antibody-targeted microbubble contrast agents at sites of arterial thrombus formation in a mouse xenograft model of human pancreatic cancer. These agents could be used for the evaluation of venous thrombosis (Wang 2012). Other agents are available to measure the activation of endothelial cell during atherogenesis (Kaufmann 2010; Weller 2003).

Measurements of blood flow in the vessel lumen have been employed in the evaluation of venous thrombus formation. Blood flow can be measured in the thrombosed segment utilizing an ultrasonic flow probe over a period of 30 to 40 minutes in mouse vascular injury model and mouse xenograft model of human pancreatic cancer (Cardenas 2011; Wang 2012). Time to occlusion of the vessel can be applied as a measurement of thrombus formation. Nevertheless, calculation of time to occlusion may be complicated by residual flow through the thrombosed vessel. Also, blood flow can be measured at fixed time points to monitor the degree of vessel stenosis. The technique has proven powerful to the effects of residual blood flow of the arterial system in murine model of ferric chloride-induced vena cava thrombosis (Wang 2006). Change in blood flow can be used as a measure of vessel stenosis although it cannot provide a direct measure of thrombus size. Ultrasonic blood flow measurement cannot be used in longitudinal studies of the same animal due to the invasive and terminal nature of this model.

MICRO-CT

The application of micro-CT imaging has increased in many preclinical studies over the last decade. The advantages of micro-CT include scanning efficiency, high resolution and

relatively low cost compared to other imaging methods. Micro-CT scanner is according to the same physical principles as a clinical CT scanner and it is produced for higher resolution imaging. Micro-CT usually makes 3D tomographic data at microscopic resolution (voxel size ≤ 100 μm3) by catching several hundred, 2D cone-beam projections from multiple angles around the animal (Holdsworth 2002). The raw projection data are kept on computer before image reconstruction is performed using dark current and flat-field images. Micro-CT is a morphological imaging technique where the differences in tissue densities are measured and compared. It is performed at an almost microscopic level compared to a clinical CT system for human imaging (Cavanaugh 2004). A typical micro-CT system includes an X-ray detector and an X-ray tube assembled in opposing positions in a rotating gantry. Micro-CT requires images with higher resolution although the physical principles are the same for both preclinical and clinical scanners. Special elements had to be presented, such as detectors with small components and X-ray tubes with smaller focal spots, to generate sharp images. Micro-CT supplies 3D tomographic data at microscopic spatial resolution (50 μm) and sub-second temporal resolution (50 ms) (Ritman 2011) of bone structures and soft tissues by catching hundreds of 2D projections from different angles around the animal (Cavanaugh 2004; Badea 2008; de Kemp 2010; Kagadis 2010).

X-Ray Sources

The choice of the X-ray source greatly influences micro-CT system performance. Most x-ray tubes with micro-focus or mini-focus tubes (focal spot diameter < ~50 μm) work with extremely low photon output (on the order of 100-times lower) compared with the high-power tubes of clinical CT scanner due to the tradeoff between thermal loading of the source's metallic anode and focal spot size (Badea 2004). This fact causes a considerable increase in scan time for micro-CT to get within the noise level seen in clinical CT of about 5–10 HU. The most applied X-ray sources for micro-CT are micro-focus, fixed tungsten anode tubes working in continuous mode, with anode currents in the range of 50–1000 μA and voltages in the range of 20–100 kV. *In vivo* micro-CT systems working at low magnification frequently utilize pulsed x-ray sources with wider focal spots and higher power. The application of pulsed X-ray sources is particularly important for prospective electrocardiogram (ECG) gating (Badea 2008). This kind of imaging is also able to be performed with sources operating in continuous mode by utilizing external shutters; nevertheless, the total quantity of photons emitted during each pulse is extremely low when using shutters and the X-ray transmission through the closed shutter should be considered for appropriate raw data calibration. Additional x-ray tube models have been suggested. The application of a compact field-emission micro-focus x-ray source based on carbon nanotubes has been examined (Cao 2010; Cao 2009).

Open-type sources with thin-target spread anodes conquer the restrictions, supplying radiation beams with angular apertures in the range of 140°–160° with the feasibility of positioning the object almost in contact with the focus. However, the back of transmission targets cannot be chilled with liquid, decreasing the maximum possible power per unit area compared to reflection anodes. The spatial resolution available with this kind of source can be < 1 micron, which is similar to synchrotron-based imaging. However, synchrotron-based nano-CT and micro-CT are still superior to laboratory-level micro- and nano-CT systems

concerning signal-to-noise ratio and contrast resolution because synchrotrons supply monochromatic, tunable radiation, avoiding beam hardening artifacts, and much higher photon fluxes, decreasing noise (Stolz 2011).

X-Ray Detectors

The X-ray detector is a crucial part of a micro-CT scanner. Most of micro-CT systems hitherto apply digital flat-surface 2D detectors bringing to a cone beam scanning geometry. High-resolution CT was used to reconstruct a rat kidney from the digitization of multiple film radiographs (Kujoory 1980). Early prototype micro-CT systems used x-ray image intensifiers read by charge-coupled devices (CCDs) (Feldkamp 1989; Holdsworth 1993; Boone 1993). Combined recognition systems including scintillator screens coupled to CCDs via fiber-optic bundles, with various de-magnifying ratios, became the standard for micro-CT imaging (Paulus 2000; Goertzen 2004). More recently, advances in complementary metal oxide semiconductor (CMOS) technology caused to produce large area detectors with high frame rates which are the most broadly utilized systems for animal imaging (Lee 2003; Kalender 2007).

Because of their very low dark noise with respect to flat-panel CMOS detectors, cooled CCDs are still used, especially in applications involving low X-ray fluences. The application of single-pixel or small area detectors operating in photon counting mode (Paulus 2000) and direct conversion detectors coupled to thin-film transistor (TFT) arrays (Goertzen 2004) for animal micro-CT was reported. Energy discerning photon counting X-ray detectors (PCXD) are the subject of concentrated study and pledge to make spectral CT possible. Actually, micro-CT is the experimental stage for spectral CT using PCXD (Taguchi 2013). PCXDs with energy binning can enhance CT performance by counting and binning each X-ray detected into a number of energy bins identical to the number of energy thresholds per pixel. PCXDs enable for the removal of dark noise in the image by refusing all counts under the signal and also enable for spectral segregation. The technology is at its beginning stage and will grow rapidly. Sensor materials for PCXDs comprise silicon, gallium arsenide, and cadmium telluride with pixel sizes as small as 55 μm (Taguchi 2013). The spectral detectors cannot immediately replace the conventional, energy-integrating detectors for biomedical CT applications due to technical limitations (Taguchi 2011).

System Geometry

Two common system geometries for micro-CT are rotating gantry and rotating specimen. The majority of *in vivo* micro-CT systems apply a rotating gantry geometry in which detector and the X-ray tube are assembled in a single gantry. The gantry rotates around a central axis while the specimen or the animal reclines stationary on a table between detector and the tube. Most *ex vivo* micro-CT systems use rotating specimen geometry where the X-ray source and detector are immobile. It is more feasible to modify the position of the specimen and alter magnification for rotating specimen systems than in rotating gantry systems. In producing micro-CT systems with either geometry, a balance must be reached between the required spatial resolution, the system dimensions, the focal spot size of the X-ray source, and the

photon fluence created by the X-ray source. Placing the specimen farther from the detector and closer to the x-ray source increases geometric magnification, enhancing spatial resolution while decreasing the field of view covered by the detector. The magnification can be increased up to the limits established by penumbra blurring or the system dimensions. Penumbra blurring illustrates the X-ray projection blur depending on the finite size of the system configuration and the X-ray tube focal spot (Badea 2008). If source to specimen distance and the specimen to detector distance are similar, as in nearly all of rotating gantry systems, penumbra blurring is comparable to the focal spot size.

To enable the use of a high fluence X-ray source with a large focal spot, the specimen can be put close to the detector, limiting spatial resolution, but allowing extremely short exposures for rodent cardio-respiratory imaging. The configuration has been indicated for dynamic, *in vivo* micro-CT imaging in rotating specimen geometry (Badea 2005). Regardless of system geometry, geometric calibration is an extremely vital need for successful image reconstruction (Johnston 2008). Zoom-in capability and variable geometry is provided in some scanners (Panetta 2012). With such changes, geometric calibration is needed to boost spatial resolution for reconstructed image data. Automated calibration techniques have been established which assess geometric parameters depending on projections of a generic object (Panetta 2008) and by reconstruction-based optimization of image sharpness metrics (Wicklein 2012).

Contrast Agents

The poor contrast sensitivity in biological soft tissue is one of the major challenges for CT imaging. Different staining techniques increased soft tissue contrast for *ex vivo* specimens scanned by micro-CT. Osmium staining has been shown successfully in several micro-CT applications (Johnson 2006). Inorganic iodine and phosphotungstic acid staining are simpler to manipulate with much less toxicity compared to osmium. Inorganic iodine and phosphotungstic acid produce high-contrast X-ray images of many soft tissues (Metscher 2009).

Vascular contrast agents for *in vivo* micro-CT imaging include low molecular weight and blood pool. Iodine-based, low molecular weight contrast agents utilized for clinical CT imaging applications can be applied for preclinical micro-CT in rodents. But such agents remove from mouse vasculature within seconds (Lin 2008). Iodine-based, blood pool contrast agents (e.g., Fenestra from ART, eXIA from Binitio Biomedical) supply stable enhancement over the course of minutes to an hour which facilitates translation of clinical imaging applications to rodent model systems (Ashton 2014). Larger nanoparticle contrast agents dependent on variety of high atomic number elements display great potential for functional and molecular CT imaging applications and supply fine control over vascular half-life. Nanoparticle contrast agents are applied to reduce quick renal clearance (Ashton 2015).

Technological advances in the field of CT have promoted the progress of high-resolution micro-CT imaging platforms suitable for preclinical application. The applications of micro-CT include the assessment of skeletal and lung abnormalities, heart function, and tumor growth. Micro-CT is a powerful technique for the quantitative assessment of angiogenesis related to solid tumors or ischemia (Kagadis 2010, Badea 2008). CT is the favorite technique for lung imaging due to the high contrast yielded by air/tissue differences in the preclinical

situation; imaging of such small and moving structures has been challenging (Badea 2008). Respiratory gating devices were developed recently to reduce breathing motion-related artifacts (de Kemp 2010). Micro-CT was able to dynamically evaluate the topographic distribution and progression of lung fibrosis in small animal models (Zhou 2015). CT is totally dependent on the quantification of X-ray attenuation by the tissues, meaning that fine differences are very hard to differentiate due to almost indistinguishable attenuation characteristics. In an attempt to defeat this limitation, contrast agents might be used to increase CT sensitivity by highlighting either the vascular tree or specific areas of organs or tissues. The most commonly utilized CT contrast agents are iodinated water-soluble compounds (Lee 2013).

Contrast-enhanced micro-CT has been used widely in the study of murine models of cardiovascular diseases, including critical limb ischemia (Takeda 2011), abdominal aortic aneurysms (Nahrendorf 2011), and myocardial infarction (Nahrendorf 2007). Visualization of the vasculature by micro-CT needs intravenous administration of high molecular-weight blood-pool contrast agents (Nebuloni 2013). Contrast-enhanced micro-CT is able to longitudinally measure thrombus resolution as shown in a murine model of IVC stenosis (Grover 2015). Contrast-enhanced micro-CT needs segmentation of thrombus from surrounding tissue for 3D reconstruction and extraction of volumetric data. The strength of this technique is the ability to get high-resolution images with reconstructed voxel dimensions in the range of 20 to 60 μm (Grover 2015). Limitations of this technique for thrombus imaging include the cost of the imaging time, the application of expensive and potentially nephrotoxic contrast agents and the high doses of ionizing radiation needed. Furthermore, contrast-enhanced micro-CT supplies only anatomical data. It cannot provide information on thrombus composition as can be acquired by MRI.

Cardiac Imaging

Micro-CT was used for cardiac morphological and functional imaging in mice and rats (Badea 2007; Nahrendorf 2007; Badea 2008; Detombe 2008). Contrast agents are used to differentiate between the myocardium and blood. Cardiac functional metrics such as cardiac output and ejection fraction was determined by 4D data obtained after blood pool contrast agent is used in most cardiac micro-CT studies. The exactness of these measurements was assessed as a role of contrast agent volume and projections number applied for reconstruction (Badea 2008). Deduction of the volume of contrast agent decreased hypervolemia effects on the hemodynamics and reduction in the number of projections directly reduced radiation dose. The total quantity of contrast agents injected may be further decreased for blood pool contrast agents with higher iodine concentration. eXIA 160 is a contrast agent with a high iodine concentration (160 mg I/ml). The injection quantity was 0.1 ml per 20 gram in a mouse for cardiac micro-CT (Detombe 2012).

Both global cardiac functional metrics (myocardial mass, ejection fraction, cardiac output and stroke volume) and localized dynamic metric (wall mall motion) can be computed using 4D cardiac micro-CT data sets. Numerous software packages (Yushkevich 2006) and algorithmic techniques (Suri 2000; Frangi 2001) are available for semi- and fully-automated cardiac segmentation. Efficient, fully-automated cardiac segmentation is extremely useful for

structural and functional phenotyping practices. Micro-CT was able to illustrate cardiac anatomy and function in a genetic model of dilated cardiomyopathy (Badea 2007).

Micro-CT was first applied for weekly imaging in mouse models of myocardial infarction (MI) to monitor left ventricular (LV) remodeling post-infarction (Detombe 2008). 3D cine micro-CT reliably and rapidly quantified infarct size and evaluated murine anatomy and physiology after coronary ligation using delayed contrast enhancement by combining a low molecular weight contrast agent and the blood pool contrast agent Fenestra VC (Nahrendorf 2007). This efficient imaging tool is a precious supplement to the current phenotyping apparatus and will enable rapid testing of novel drugs and cell-based interventions in murine models. The dose administered to the animal needs to be assessed for in vivo micro-CT. 4D micro-CT techniques with better image reconstruction algorithms have reduced the dose to 0.2 Gy (Badea 2011; Sawall 2011; Armitage 2012) compared to 1 Gy in PG-based cardiac micro-CT (Badea 2005).

Lung Imaging

Micro-CT is very practical for the lung imaging without extra contrast agents due to density difference between soft tissues and air-filled lungs. Although CT is a powerful technique for lung imaging, micro-CT lung imaging in animal models has been challenging because of their small size and rapid respiratory motion. A voxel size on the order of 75 μm is needed to supply anatomic resolution in the mouse similar to that acquired in CT for humans (Ritman 2005). Different gating strategies were performed to obtain each projection at the same point during each respiratory cycle. To control the respiration by mechanical ventilation and intubate the animal is a successful technique of respiratory gating (Hedlund 2002; Namati 2006). Projections can be obtained at precisely identical point in every respiratory cycle (Badea 2004). Micro-CT with respiratory gating has been applied to investigate lots of lung diseases. Micro-CT can be utilized to continuously observe lung metastases in mice (Li 2006) and monitor the lung tumor growth (Hori 2008; Namati 2010; Rudyanto 2013; Li 2013). Micro-CT was used to evaluate the effect of radiation therapy (Kirsch 2010; Perez 2013) or chemotherapy (Ueno 2012) on mice lung tumor model and pulmonary damage caused by radiation therapy (Saito 2012).

Micro-CT can be applied favorably to investigate different *pulmonary* disease animal models, such as emphysema and fibrosis. An emphysema model was induced in mice by using intratracheal instillation of pancreatic elastase and imaged with micro-CT (Postnov 2005). Emphysemic regions have indicated lower HU values compared to the normal lung and the lung volume in emphysemic animals was enlarged. Fibrosis models also have been induced in mice by instillation of bleomycin and monitored longitudinally with micro-CT during disease progression (Shofer 2007). Micro-CT can detect the fibrotic lung regions by the resulting increase in HU. Moreover, micro-CT can evaluate lung compliance in small animals by executing breath-holding over a range of specified pressures and determining lung volumes from the corresponding images to make a pressure-volume curve (Shofer 2007; Guerrero 2006). The loss of pulmonary compliance was evaluated in a study of irradiated mice (Guerrero 2007).

Micro-CT was used to monitor the progression of emphysema in elastase-induced emphysema mice model (Artaechevarria 2011), cigarette smoke-induced pulmonary

inflammation mice model (D'hulst 2005), cigarette smoke-induced emphysema mice model (Shan 2014; Sasaki 2015) and lipopolysaccharide-induced emphysema mice model (Kobayashi 2013; Chen 2016).

Liver Imaging

Micro-CT with liver-specific contrast agent was used to identify liver metastasis in an experimental model of animal pheochromocytoma (Martiniova 2010). Contrast-enhanced micro-CT measurements of hepatic fractional extracellular space and macromolecular contrast material uptake were used to evaluate the degree of early hepatic fibrosis in a rat model (Varenika 2013). Micro-CT was used to evaluate the effect of partial hepatectomy on the hepatic hemodynamics in a rat model (Debbaut 2012). Micro-CT can be used for the first time to observe the liver regeneration of transplanted hepatocytes in a mouse model (Hickey 2015).

Micro-CT with the contrast agent ExiTron nano6000 was used to determine three mouse models of liver injury caused by alcohol, lipopolysaccharide/D-galactosamine and bile duct ligation (Hua 2015). Micro-CT was used to scan isolated rat livers injected with the contrast polymer Microfil (®) which detected hepatic arteriolo-portal venular shunts (Kline 2014). Contrast-enhanced micro-CT was able to precisely observe angiogenesis and antiangiogenic therapy effects in chronic hepatic injury in mice induced by carbon tetrachloride- or bile duct ligation (Ehling 2014).

Bone Imaging

Micro-CT is very useful for high-resolution, non-invasive bone imaging due to the natural contrast between soft tissues and bone. Micro-CT was shown as successful technique for exploring the development of rodent knee longitudinally in a rodent surgical model of osteoarthritis (Appleton 2007; McErlain 2008). Study in critical sized rat calvarial defects suggested that micro-CT was a useful supplement to other techniques for objective assessment of bone tissue engineering and regeneration (Cowan 2007). Micro-CT is able to precisely measure different bone parameters, such as trabecular thickness, cortical thickness, bone mineral density, bone volume, bone surface ratio, and cross-sectional area (Bouxsein 2010). Parameters such as trabecular thickness, bone surface ratio, bone volume ratio and volumetric bone mineral density were measured by micro-CT in the study of bone architecture changes over time (Waarsing 2005). These micro-CT bone structural parameters were applied to quantify the results of stem cell treatments (Lee 2009) and vascular endothelial growth factor (Li 2009) in bone loss, cortical thickening and bone healing in total body irradiation mice with bone marrow transplantation (Dumas 2009).

Micro-CT was used to estimate the short- and long-term effects of estrogen deficiency on trabecular bone of ovariectomized rats (Laib 2001). The calvarial defect animal model is often used to study wound healing and bone regeneration. Micro-CT supplies a precise and rapid method to measure the bone mineral content within calvarial defects in the rat. The advantages of micro-CT analysis comprise highly quantitative measurements, small

coefficient of variation and the ability for serial measurements in the same living animal (Umoh 2009). Micro-CT is very useful to precisely calculate the 3D structure of engineered bone scaffolds, with especial emphasis on connectivity and porosity (Lin 2005; Ho 2006).

Neovascularization is important for the regeneration of fracture bone. First study using micro-CT for microvascular morphology in an osteoporotic critical size defect in the clinically relevant localization of the femur metaphysis was reported (Kampschulte 2015). Neovascularization indicated notably different morphological feature when compared to the non-injured side. The description of microvascularization may be useful for the further assessment of biomaterials and their effect on angiogenesis and their influence on improved bone repair in animal model. Micro-CT scan performed 3 months after vascularized elbow allotransplantation in the rat to verify union in rats treated with cyclosporine and show the joint destruction in the nonimmunosuppressed rats (Tang 2015). Micro-CT was used to monitor the quantification of fracture healing response in a standardized mouse model for combined injury of traumatic brain injury and femoral osteotomy (Tsitsilonis 2015).

Micro-CT supplies a dependable platform for preclinical imaging that is complementary to other animal imaging techniques for many morphological and functional imaging applications. Recently developed contrast agents and innovative acquisition and reconstruction strategies display remarkable promise in overcoming the limitations including low contrast and radiation dose. Combined with powerful new opportunities in spectral and phase contrast imaging, these advances will surely continue to enlarge the applications of micro-CT in experimental surgery.

Vascular Imaging

Micro-CT vascular imaging was performed essentially with blood pool contrast agents. Micro-CT scan was longer than clinical CT scan because of higher resolution need. Low molecular weight contrast agents were not able to be utilized for vascular imaging with early micro-CT scanners due to long scan time. Micro-CT scan can be completed in minutes now. Low molecular weight contrast agents were utilized for vascular imaging of squamous cell carcinomas nude mice model (Kiessling 2004) and mice models of subarachnoid hemorrhage, stroke and cancer (Schambach 2010). But, the contrast agents needed to be continuously or repeatedly provided during the scan to reach a constant level of vascular enhancement. Blood pool contrast agents were very effective for different vascular imaging, such as vascular permeability measurement in rat sepsis model (Langheinrich 2006), vasculature imaging in mice liver metastasis model (Graham 2008), lung vasculature imaging in rats and mice models of pulmonary disease (Johnson, 2007), liver vasculature imaging in mice liver ischemia and reperfusion model (Chouker 2008) and assessments of vascular morphology, diameter, and branching in mouse vascular corrosion cast model (Vandeghinste 2011).

Tumor Imaging

Micro-CT has been confirmed to be functional in tumor perception and tracking, as well as in imaging tumor angiogenesis. Micro-CT was able to detect murine lung nodules with a minimum volume of 0.63 mm3 (Cody 2005). Cancer imaging with micro-CT is closely

connected to the administration of contrast agents. Dynamic micro-CT has been used for the direct measurement of perfusion in tumors following the administration of conventional contrast agent (Kan 2005; Phongkitkarun 2004). The rapid scans frequently need a decrease in spatial resolution in the longitudinal direction to reach sufficient coverage in the longitudinal direction. CT perfusion measurements allow the quantitative assessment of functional parameters, such as permeability-surface area product, blood volume and blood flow. Blood pool and nanoparticle contrast agents are favored for cancer imaging with micro-CT.

Micro-CT with Fenestra VC had the best capability for determining vessel diameter, tortuosity, and density for alveolar rhabdomyosarcomas in a transgenic mouse model. But instrument with a higher resolution was required to visualize tumor capillaries (Kindlmann 2005). Micro-CT scan was used to monitor nude mice bearing STC-1 tumors 15 and 30 days after grafting (Almajdub 2007). Micro-CT scan was performed at 2 and 4 hours after animal received the Fenestra LC injection. Live tumors (0.3–1.5 mm) at day 30 were detected by micro-CT scan with Fenestra LC. Micro-CT scan enabled quantitative follow-up of tumors both in the liver and the spleen up to 15 days after a single Fenestra LC injection.

The main advantages of micro-CT over other imaging modalities are short time required for scanning, detailed morphological information and high spatial resolution images. However, the radiation load related with CT imaging, and the volume of contrast agents (used to enhance the contrast resolution) that may be injected into a single animal, are possible limitations of which researchers should be aware. Normally, based on the desired image contrast and resolution, modern scanners supply short acquisition times with radiation doses in the range of 10–50 mGy and resolution levels are below 100 μm (Kalender 2011). Balance between animal irradiation and image quality needs to be considered in order to avoid unnecessary radiation exposure.

Micro-CT was used to monitor the development of lung tumors in a mouse model of lung adenocarcinoma and dynamic changes in response to treatment. The accuracy of micro-CT was validated with end-point histological quantification (Hegab 2016). Contrast-enhanced micro-CT was used to monitor tumor growth of orthotopic glioblastoma multiforme in nude mice (Yahyanejad 2014). Tumor size detected by micro-CT was well correlated with tumor size acquired by histologic analysis. The precision of micro-CT with contrast agent for mice glioma xenografts was evaluated (Kirschner 2015). Longitudinal micro-CT imaging of brain tumor growth in mice was practicable with high sensitivity and the radiation effects were able to be observed.

The function of macrophages in prostate cancer skeletal metastasis was evaluated by micro-CT in macrophage-ablated mice (Soki 2015). Skeletal tumor growth in macrophage-ablated mice was markedly reduced compared to control mice. Micro-CT results suggested that bone volume was increased in mice treated with clodronate.

Micro-CT with contrast agent exitron nano 12000 enabled automatic analysis of tumor lesions for evaluation of cancer size in mouse hepatocellular carcinoma (Rothe 2015).

Micro-CT localized and determined the volume of liver tumors after intrahepatic or intrasplenic graft of Hep55.1C cells in mice (Bour 2014). The robotized intratumoral injection of low amount of Doxorubicin considerably decreased tumor growth by about 60% after 3 weeks, whereas manual intraperitoneal administration of the same amount of drug had no notable effect on tumor growth.

Brain Imaging

The new Micro-CT blood-brain barrier imaging method with the intra-arterial infusion of iopromide enabled serial quantitative visualization of post-stroke blood-brain barrier dysfunction in mice, with high resolution and in a sensitive manner (Park 2014). Micro-CT with iodine-based contrast was used to differentiate the total differences in the overall mice brain shape caused by experimental treatment (Anderson 2015). Micro-CT was performed to confirm effective blood delivery into the cisterna magna in murine single-blood-injection subarachnoid hemorrhage model (Kamp 2014). Micro-CT was able to recognize most major cerebral vessels and their minor branches in mouse models (Ghanavati 2014).

OI

OI contains different techniques that have in common the application of a set of respective sensing devices and light sources to capture the resulting photon distribution (Bremer 2003). These techniques are classified according to the type of source-detector setting and the contrast mechanism involved. The activity of the chosen molecular targets was able to be measured after targeted fluorescent or activatable probes were developed. Imaging of such probes needs the excitement of the probe at a definite wavelength and identification of the specific signal emission at a significantly different wavelength. The most applicable OI techniques include bioluminescence, fluorescence, and near-infrared fluorescence imaging (Bremer 2003). For image acquisition, the animal needs to be placed in a light-tight imaging enclosure where the emitted light is subsequently caught by a CCD. Extremely sensitive detectors have been made in order to expose visible to near infra-red light emitted from the body. CCD detectors were made of silicon crystals sliced into thin portions for assembly into integrated circuits (Massoud 2003). CCD cameras operated by converting light photons at wavelengths between 400 and 1,000 nm, that strike a CCD pixel with energy of only 2–3 eV (Massoud 2003). The principle of bioluminescence imaging involved the emission of visible photons at specific wavelengths depending on reactions catalyzed by enzymes (luciferases) existing in many organisms as protists, fungi, insects, bacteria, among other species (Wilson 1988). Luciferases activated the oxidation of luciferins (substrate) to generate non-reactive oxyluciferins and release photons of light (Greer 2002). Advances in molecular techniques have caused the isolation of many luciferase genes that have been applied to build DNA vectors (Wilson 1988). The most frequently applied varieties of luciferase–luciferin are the firefly (Fluc) (Greer 2002).

Highly sensitive imaging systems enabled the quantitative identification of small numbers of cells or organisms that expressed luciferase as a transgene (Weissleder 2001). This technique required the target cells to have been previously genetically transduced *ex vivo* in order to express the luciferase gene. The luciferase substrate (luciferin) is then orderly supplied to achieve the target cells. Then it is oxidized by luciferase and emitted photons that are captured by CCD cameras (Bremer 2003).

A bioluminescence image is frequently displayed as a color image that is overlapped on a gray-scale photographic image of the small animal using overlay and image analysis software. To discover very low levels of signal is the main advantage of optical

bioluminescence imaging. The principle of fluorescence imaging is dissimilar to that of bioluminescence. Cells can be either genetically transduced to express a fluorescent probe like a fluorescence-labeled antibody or a fluorescence molecule such as the green fluorescent protein (GFP) (Massoud 2003). In near-infrared fluorescence imaging, light in the 700- to 900-nm range is used to boost tissue penetration and reduce autofluorescence from non-target tissues (Weissleder 2002).

Diffuse optical tomography (DOT) showed better imaging performance as multiple source-detector pairs were applied to build 3D images with good spatial resolution, high sensitivity, accurate quantification and volumetric localization (Culver 2008). However, effective resolution of bioluminescence, fluorescence, or NIR imaging is still substandard and the resulting images are not quantitative. Because factors such as attenuation, the scattering, and dispersion of the emitted light as it penetrates tissue layers mean the captured signal is mostly based on the depth of the tissue of origin (Weissleder 2001). A more recent technique to fluorescence imaging of deeper structures utilized fluorescence mediated tomography (Ntziachristos 2003) and applies multiple projections and quantifies light around the boundaries of the object. Reconstructed images could be acquired with a fluorochrome detection threshold in the nanomolar range and a resolution of 1–2 mm after mathematical processing (Massoud 2003). Contrary to planar images, these 3D images were quantitative, as the signal intensity had direct connection with the local concentration of fluorochrome (Ntziachristos 2003).

The photo-acoustic tomography (PAT) is an imaging technique that benefits from the values of pure OI or ultrasound imaging, without the major disadvantages of each technique. It was performed by illuminating the sample with short pulses of laser beams and collecting the ultrasound waves produced by the photo-acoustic effect. The target tissue absorbed a fraction of incident light pulse energy and converted into heat to cause a rise in the temperature and a thermal expansion of the object. This increase in pressure propagated as a sound wave, which was able to be discovered externally as an acoustic signal (Wang 2012). PAT has achieved enormous development in the past decade and its main preclinical applications include imaging of tumor microenvironments, drug response, angiogenesis, and biomarkers (Wang 2012).

OI established on high-energy beta particle-emitting radionuclides is the more recently discovered variant of this imaging modality (Robertson 2009). It displayed that positron-emitting (β+) radionuclides can supply perceptible light, compatible with Cerenkov radiation, with a continuous spectrum that is weighted towards blue bands of the electromagnetic spectrum and the ultraviolet. Charged particles moving at very high speeds can produce Cerenkov radiation. In certain media, the emission of optical photons can be caught by CCD cameras. Cerenkov radiation is made in a persistent spectrum from the near ultraviolet through the observable spectrum (Robertson 2009). Recent works (Liu 2010; Robertson 2009) showed that images may be produced with ordinary OI equipment by the low-energy window of light (1.2–3.1 eV, 400–1,000 nm) based on beta particle-emitting (β+ and β-) radionuclides. The radionuclide agents that have already been evaluated contain 18F-FDG, Na18F, Na131I, 90YCl3, and several 90Y-labeled peptides. The superiorities of radionuclide OI/Cerenkov imaging over the traditional OI techniques basically associate to the fact that imaging probes are the same as those applied in the clinical context, showing a broad emission spectrum, enabling to track the radioactive probe at different wavelengths without excitation light. Nevertheless, some limitations of this technique, including limited tissue

penetration and comparatively bad quantification ability compared with PET and SPECT are common to other OI techniques (Liu 2010).

The most powerful advantages of OI include the feasibility of simultaneous imaging of six anesthetized mice, determination of physiological and pathophysiological processes at the molecular and cellular level in vivo with high specificity, low cost, short acquisition time, relatively high throughput and the high sensitivity (Massoud 2003; Vooijs 2002). An extra advantage of OI is to produce multichannel imaging using several probes with different spectral characteristics. Fluorescence imaging (FLI) produces high-resolution, real-time mapping with the application of a contrast agent and can considerably intensify intraoperative imaging. Optical projection of acquired luminescence (OPAL) provided increased visualization for lymph nodes from every anatomical location in pigs with intradermal injection of indocyanine green (Ringhausen 2015). FLI was used to evaluate the blood perfusion of the animal with implantation of a bone autograft and a blood-borne fluorescent agent. Bone formation was measured by FLI using a hydroxyapatite-targeted probe and μCT analysis (Cohn Yakubovich 2015).

Combination of bright-light surgery (BLS) and fluorescence-guided surgery (FGS) considerably reduced the residual fibrosarcoma volume and ameliorated disease-free survival in retroperitoneal-implanted human fibrosarcoma nude mice (Uehara 2015). FGS notably decreased recurrence occurring in multiple sites including the lung, liver and other organs compared to BLS in an experimental colorectal liver metastasis nude mouse model. Furthermore, FGS markedly extended disease-free survival and overall survival compared to BLS (Murakami 2015).

MICRO-SPECT

The selection of the collimator for SPECT has an important effect on the resolution and sensitivity of the system (Van Audenhaege 2015). Pinhole collimators are utilized to acquire submillimeter resolution and multiple pinholes are usually integrated to raise sensitivity for small animal imaging. Detectors with better essential spatial resolution and current collimator production methods are improving collimation.

SPECT is based on the tracer principle which requires the injection of tiny amounts of radioactive tracers and the outside evaluation of their bio-distribution by proper detectors. Tracer molecules less than 10^{-10} molar can be discovered by SPECT in vivo with submillimeter (0.5–0.7 mm) resolution, allowing the measurement of the molecular processes in which radioactive tracers are involved (Meikle 2005). The spatial resolution and system sensitivity have been greatly improved after the application of multi-pinhole collimation has become the standard in most preclinical SPECT systems (Peterson 2012). The increase of the number of pinholes and/or the angular sampling for a fixed field of view (FOV) can ameliorate the sensitivity (Kagadis 2010; Khalil 2011). The added pinholes may reduce the sensitivity and reconstruction artifacts may finally appear (Peterson 2012). Thus, the application of a high-sensitivity, non-multiplexing, multi-pinhole approach might be considered a step forward.

Advances in electronics have not only increased sensitivity, but also greatly reduced the whole equipment size and cost (Kagadis 2010; Peterson 2012; Khalil 2011). Some preclinical

SPECT systems included semi-conductor materials, such as cadmium zinc telluride (CZT) or silicon and directly transformed gamma rays to electric signals (Franc 2008; Peterson 2011). These detectors provided excellent spatial resolution as low as 0.38 mm and energy resolution, especially valuable for low-energy radionuclides (as iodine-125) or dual isotope applications (Franc 2008).

The application of scintillation crystals coupled to Photomultiplier tubes (PMT) is very usual. In recent years, position evaluation based on anger logic principles has indicated that hardware progress is the basis of a substantial growth in available computational power. This has enabled the inauguration of more sophisticated algorithms in data processing, basically iterative algorithms, as the maximum-likelihood evaluation and resolution recovery advanced solutions, thus enhancing global performance of systems (Peterson 2012).

SPECT emitters are well-suited for radiolabeling different molecules, including endogenous biomolecules, such as selectins, hormones, peptides and antibodies. These biomolecules are comparatively large and blood clearance is low. This favored the use of radionuclides with longer half-lives in order to widen the temporal window of observation, in contrast to positron emitters (Meikle 2005).

MI could be well imagined using Na [18F] F PET/CT (Han 2015). Na [18F] F uptake was approximately connected with myocardial apoptosis but not with calcification. Na [18F] F PET/CT was positive at the perfusion deficit area in [99mTc] MIBI SPECT/CT and showed almost the same signal distribution with [99mTc] HMDP SPECT/CT. The results suggested that Na [18F] F PET/CT could be a promising hot-spot imaging modality for MI. Na [18F] F PET/CT had few limitations for the early identification of MI, because the highest uptake of Na [18F] F manifested as late as 1 day after MI (Han 2015).

MICRO-PET

PET imaging is dependent on discovering two time-concurring high-energy photons from the emission of a positron emitting radioisotope. The physics of the emission, and the recognition of the concurring photons, yield PET imaging special abilities for both extremely high sensitivity and precise evaluation of the in vivo radiotracer concentration (Vaquero 2015). PET imaging has been broadly applied for clinical neurology, oncology and cardiology investigation. PET imaging has been used as a vital technique in preclinical investigations, especially for evaluating animal models of disease.

PET presents a very important development in the efforts to ameliorate the knowledge of neurodegenerative disorders such as Alzheimer's disease (AD). PET produces the most dependable perceptible biomarkers for the clinical diagnosis (Shimojo 2015). PET is a well-recognized clinical and preclinical imaging technology which depends on the use of compounds labeled with positron-emitting radioisotopes to image and to quantify several biochemical and physiological processes (Phelps 2000). It is widely accepted as a fundamental tool for biomedical research because of its molecular, non-invasive, non-destructive intrinsic nature and the ability to study many biochemical/biological processes in vivo (Phelps 2000). PET is used in different fields from oncology to neurology and cardiology. The most commonly used positron emitters include 18F, 15O, 13N, and 11C, but other isotopes such as 124I, 94mTc, 89Zr, 76Br, 68Ga, 60, 61, 64 Cu are gaining increasing

attention. In fact, peptides labeled with 68Ga have already indicated very promising results in the assessment of neuroendocrine tumors (Kowalski 2003). 89Zr is well-suited for the labeling of monoclonal antibodies due to more time for tumor targeting and optimal biodistribution (Holland 2009). Comparably, 124I has shown higher efficacy in lesion recognition and the ability to supply lesion-specific dosimetry in the context of differentiated thyroid cancer (Basu 2011). These radionuclides are difficult to acquire for many research groups due to their production method, the relative complexity and low yield, although these radionuclides enable the study of many physiological and biochemical processes (Fass 2008). Furthermore, their relatively short physical half-life makes distribution over long distances unfeasible or very expensive. Actually, the application of this imaging technique may need in situ radioisotope production and compound labeling because of the short physical half-lives of most positron emitters. Therefore, the existence at close distance of a multidisciplinary and highly skilled/specialized team is needed.

Actually, lots of radiotracers can only be utilized if they are made locally. So it is now considered ideal for a preclinical facility to be near a radiopharmaceutical production facility. Nevertheless, recent progresses in cyclotron technologies might overcome those aspects in the future. A perfect PET scanner designed for animal imaging would have the following characteristics: high spatial resolution (sub-millimeter range), high sensitivity, detector ring with a FOV optimized to the specific targeted animal size range, good temporal resolution, and multimodality imaging capability (Levin 2007; Yao 2012). Many commercially accessible micro-PET scanners have resulted from previously developed prototypes in academia.

Micro-PET detector blocks include inorganic scintillators, such as lutetium oxyorthosilicate, lutetium-yttrium oxyorthosilicate, or gadolinium orthosilicate, which have substituted the old bismuth germanate scintillators with their more suitable speed, light output, and detection efficiency (Levin 2007; Hutchins 2008). Micro-PET instruments produce much better sensitivity and spatial resolution compared to clinical scanners. These scanners can reach spatial resolution values of around 1.0 mm in reconstructed images, but only conjugating the use of radioisotopes with low energy positrons (from 18F, for instance) with a state-of-the-art equipment that could achieve pixel size less than 1.2 mm and an intrinsic resolution of 0.7 mm (Lecomte 2004). Over the years, PET has been inaugurated as a powerful and reliable instrument for biomedical research. The application of PET is most determined by the presence of an ‘on site solution’ for radiopharmaceutical production.

Micro-PET application has been increasing significantly in industrialized countries, although it has these relevant potential limitations (Comley 2011). (13)N-NH3-micro-PET scan was used to evaluate the cardiac and renal perfusion in myocardial infarction (MI) rats induced by permanent coronary artery ligation. Cardiac perfusion was obviously decreased in MI group, directly associated with ejection fraction and inversely related to MI size. Renal perfusion exhibited non-significant decrease in MI group compared to sham group. (13)N-NH3-microPET could be a potential tool for assessment of cardiac and renal functional and perfusion changes in rat MI models (Juárez-Orozco 2015).

PET detects the tumor according to the metabolism difference between tumor and normal tissue. The metabolism of the transplanted B16 melanoma in the lung of mice was detected by micro PET/CT with [(18) F] fluoro-2-deoxy-D-glucose (FDG). It was difficult to detect the tumor smaller than 1 mm by micro PET/CT. The lung cancer had a notably higher metabolic rate compared with the normal lung tissue (Qiao 2014). Micro-PET with 4-[18F]-ADAM (a

serotonin transporter imaging agent) was able to be applied to detect serotonergic neuron loss, monitor the progress of Parkinson's disease and evaluate the effectiveness of therapy in a Parkinsonian rat model (Weng 2013). PET was a valid method for tracking the inflammatory response in an experimental model of acute lung injury (Zambelli 2012).

Regional cerebral blood flow (rCBF) measurement in rats can obtain the pathophysiologic information of the cerebral circulation. The AV-shunt method enabled less invasive, quantitative and duplicable assessment of rCBF in [15O] H2O PET studies in rats than direct blood sampling and radioassay (Ose 2012).

The esophageal lesions detected by the micro-PET scan with (18) F- FDG were consistent with the changes found in endoscopic observation and histopathology in esophageal mucosa in rat model of esophagoduodenal anastomosis (EDA) (Schiffman 2010). The epidermal growth factor receptor (EGFR) was the target of Erlotinib (Tarceva); Erlotinib was frequently overexpressed in lung cancer and was able to be labeled with [(11) C] by reacting the normethyl precursor with [(11) C]-methyl iodide. Dynamic micro-PET with [11C]-labeled Erlotinib distinguished Erlotinib-sensitive lung cancer in mice with lung tumor xenografts (Memon 2009).

The Goto-Kakizaki (GK) rat, a type 2 diabetic rat model, is preferred for evaluating the surgical effect on diabetes. [11C]-Dihydrotetrabenazine micro-PET scanning is a practicable technique for evaluating the beta-cell mass in GK rodents after metabolic surgical procedures and could prove to be an important modality for assessing beta-cell performance in type 2 diabetes (Inabnet 2009).

MRI

MRI is a non-ionizing 3D imaging technique that employs tissues magnetic properties and their interplays with strong outside magnetic fields. Hydrogen nucleus (1H) from water molecules is most applied in MRI imaging because of its paramagnetic properties and its ubiquitous body distribution. In short, the underlying principle is that, when a specimen in a magnetic field is undergone to a radio-frequency pulse, its protons consume energy and make a measurable signal during the relaxation phase that can be numerically encoded through magnetic field gradients to make digital images. The power of the signal is a function of the number of protons. The dissimilarities of those protons between tissues determine the demonstration of the image (Lewis 2002; Pomper 2005; Dufort 2010; Tremoleda 2011). Water owns a lot of biophysical magnetic signatures in organs and tissues, and the way to achieve goals in different experiments is optimizing experimental parameters and methods in order to increase contrast between normal and abnormal tissue (Lewis 2002).

MRI produces morphological images with excellent contrast and spatial resolution, moreover, information about metabolism, tissue elasticity, tissue composition, oxygenation, perfusion, and identification of molecular probes is obtained in a single acquisition without radiation exposure (Koba 2011). These attributes have increased the widespread utilization of MRI (Comley 2011). Preclinical MRI scanners need a tenfold increase in spatial resolution in each dimension compared with clinical scanners, resulting in signal decreases of at least 1,000. Stronger gradient sets, specific receiver coils, radiofrequency receiver chains, and stronger magnets were established in order to conquer this challenge (Jakob 2011). Animal

MRI scanners should be ideally higher than 7.0 T since the signal-to-noise ratio increases with the magnetic field. Actually, committed small bore MR devices can run between 4.7 and 21 T. If requirements regarding spatial and temporal resolution are not especially strict, clinical scanners may be an acceptable alternative as long as optimized pulse sequences and special radiofrequency coils are used (Jakob 2011; Brockmann 2007).

Several MRI techniques are available for the investigation of many biological processes. Diffusion-weighted imaging (DWI) is able to describe the movement of protons in tissues which are mainly from the water molecule during a period of time. Molecular diffusion is the consequence of the interplay of molecules with different 'barriers' such as fibers, membranes, cellular organelles and other molecules. The information about tissue architecture and cellularity can be obtained by the molecular diffusion patterns. The higher the cell density, the lower the diffusion will be (Leroy-Willig 2007). DWI has been applied for tumor characterization in non-moving structures such as bones and the brain (Weber 2011), being extremely sensitive for the early recognition of brain ischemia (Schaefer 2000).

Functional MRI (fMRI) is new MRI technique which is dependent on the conjunction of both neuronal activity and brain hemodynamics. fMRI basically quantifies changes in blood oxygenation, which translate into changes in the magnetic field. Deoxyhemoglobin and oxyhemoglobin has dissimilar magnetic properties to induce inhomogeneities into the surrounding magnetic field. Deoxyhemoglobin concentration decrease will increase image intensity. fMRI is frequently performed for brain activation studies (Heeger 2002).

Perfusion measurements are possible using two different MRI methods: the dynamic contrast-enhanced imaging (DCE–MRI) with an intravenous bolus injection of a contrast agent during its first passage through the organs and (ii) arterial spin labeling (ASL) with the arterial blood water magnetization as an internal contrast agent (Leroy-Willig 2007). The contrast agent size in DCE–MRI will measure its washout from the vascular space to determine vascular permeability (Leroy-Willig 2007). The ASL technique acts better at high magnetic fields and highly irrigated organs, such as kidneys, muscles, heart and brain. The advantages of ASL technique include no need of contrast injection and repeated measurements (Leroy-Willig 2007; Goetti 2013; Cutajar 2012; Thomas 2011; Kazan 2010).

MRI is now a recognized modality for imaging the cardiovascular system to provide precious information concerning structure, function, and perfusion at cellular/molecular levels in animal models of cardiovascular disease. It is also an important technique for the assessment of new contrast agents and the verification of the cardiovascular phenotypes of genetically modified mice (Tsui 2009; de Kemp 2010). MRI showed high signals of the aortic walls in mice with atherosclerosis confirmed by histology (Qiu 2010). 7T MRI could monitor labeled rat bone mesenchymal stem cells (BMSCs) in injured common carotid artery after allograft transplantation (Cao 2009). New techniques involving casting (*ex vivo*), markers (both *in vivo* and *ex vivo*) and MRI (*ex vivo*; 7 Tesla) were developed that allowed correlation of changes in local and longitudinal wall shear stress with the temporal variations of the diameter and intima-media thickening in the venous segment of arteriovenous fistulas in pig model (Rajabi-Jagahrgh 2014).

In oncology, MRI has been applied widely for tumor growth and development study in a wide variety of animal models. Due to its sensitivity to dynamic processes, it is an outstanding tool to image tumor perfusion/angiogenesis and oxygenation. Moreover, MRI is especially favorable in observing *in vivo* tumor growth and ablation in response to treatment due to the non-invasive and non-destructive nature. It can serially follow individual subjects

of a given cohort for long term (Lewis 2002; Dufort 2010). MRI can explore endothelial progenitor cells (EPCs) involvement in tumor neovasculature due to excellent biocompatibility and sensitivity (Chen 2014).

Micro-MRI has also been successfully used in the evaluation of musculoskeletal tissue structures (Tremoleda 2011). Micro-MRI was applied to evaluate joint inflammation in a rat surgical osteoarthritis (OA) (Jones 2010). Increased and diffuse water signal in the epiphyses of untreated OA rats was detected by micro-MRI 8 weeks after surgery which indicated a bone marrow lesion-like stimulus. Micro-MRI scan was used to quantify wear after tribological simulation of the medial compartmental bovine knee *in vitro*. Knees assessed with the intact meniscus did not reveal change in surface roughness and detectable cartilage loss or deformation. However, the meniscus removal increased contact stress and frictional coefficient which induced immediate surface fibrillation, biomechanical wear and permanent deformation of cartilage (McCann 2009).

Currently X-ray and CT are applied for assessing the spinal fusion process. But both imaging techniques have limitations in discernment of the early stages of this fusion process, because they can only visualize mineralized bone. A practicability study was carried out in a goat spinal fusion model to assess the detection capacity of different tissues with MRI (Uffen 2008). Micro-MRI was used to monitor 6- and 12-months follow-up specimens. The degradable cage material and different types of tissue were determined in the fusion zone and selected as regions of interest (ROIs). Then, the ROIs were ascertained and average signal intensities of every individual ROI were quantified. An outstanding match was found between MRI images and the histological results. Measurable differences were revealed by MRI images in signal intensity between fibrocartilage, fibrous tissue, degradable implant material, bone with hematopoietic marrow and bone with adipose marrow. In time the signal intensity of fibrous tissue, bone with hematopoietic red marrow and bone with adipose marrow stayed comparatively consistent. Additionally, the signal intensity of the degradable implant material and the fibrocartilage modified notably in time and indicated change of structure and composition. MRI supplies detailed information about the early fusion process and enables early diagnosis of non-union (Uffen 2008).

Quantitative 3D high resolution microMRI enabled for non-invasive longitudinal medial tibial cartilage thickness (MT.ThC) assessments in four different locations in both the control and rabbits with anterior cruciate ligament transection. The MT.ThC measurement in the minimum interbone distance area demonstrated the severity of the disease which was the most efficacious to monitor the progress of the medial tibial cartilage destruction (Boulocher 2007). MRI confirmed the phenotypes in rodent models of abdominal wall defects (Carnaghan 2013).

The applications of cryogenic radiofrequency coils MRI in animal models improved image quality and decreased measurement time (Niendorf 2015). MRI is the most sensitive assessment to identify and determine multiple sclerosis (MS) lesions (Milo 2014). Experimental autoimmune encephalomyelitis (EAE) is a MS animal model.

Cryogenically-cooled RF coils to produce microscopic magnetic resonance imaging (μMRI) *in vivo* disclose brain pathology in mice EAE model (Waiczies 2012). The brain inflammation in different areas was detected at the early stage of EAE. μMRI showed obviously the pathology of EAE even without the contrast agent application, and displayed outstanding similarity with conventional histology. High resolution images were obtained

within short scan times. So μMRI can continuously monitor the dynamics and kinetics of immune cell infiltration.

Cerebral amyloid angiopathies (CAA) are neurodegenerative pathologies regarding cerebrovascular dysfunction which constitute a considerable part of the pathophysiology of AD (Biffi 2011). MRI was confirmed to be especially useful for evaluating the effect of amyloid deposition and vascular dysfunction in the pathophysiology and treatment of CAA and AD (Klohs 2014). MRI was able to detect vascular remodeling of hemodynamic alterations which was vital for investigating the consequence of CAA on vascular integrity and function (Salat 2014). Magnetic resonance angiography (MRA) techniques can be utilized to evaluate the cerebral vascular tree. The signal in time-of-flight (TOF)-MRA is determined by the blood flow and is helpful for ascertaining variations of big blood vessels and decreased blood flow in animal models of AD and CAA (Niendorf 2015). The increased resolution of TOF-MRA by cryogenically-cooled coil system is extremely important to ameliorate the recognition of smaller vessel and determine the pathologies associated with neurovascular disease (Niendorf 2015). Contrast-enhanced micro-MRA with cryogenically-cooled coil system and a spatial resolution of (60 × 60 × 61) μm3 was able to detect age-dependent remodeling of the cerebral micro vasculature in CAA mice (Klohs 2012). The periphery vessels were able to be identified by higher spatial resolution contrast-enhanced micro-MRA (Figueiredo 2012).

Cryogenic radiofrequency coils MRI with an in-plane spatial resolution of 51mm was able to detect the tumor borders in an animal model of high grade glioma (Ku 2013; Vinnakota 2013). Glioma mouse model was evaluated by cryogenically-cooled RF coil system combined with vessel size imaging (VSI) and DCE-MRI. A gradient echo spin echo sequence with gadolinium-based contrast agent was used to monitor VSI, vasculature permeability and vasculature perfusion at the same time in a mouse orthotopic glioma model with an antiangiogenic agent treatment (Kording 2014).

EchoMRI™ devices utilize a nuclear magnetic resonance technique to monitor the masses of fat, lean tissues, free water, and total water in a whole body for live animals (Kovner 2010). Fat and lean mass were measured by EchoMRI-700 (Houston, TX) in rat (Ghislain 2016) and mice (Fontés 2015, Plante 2015).

CONCLUSION

Imaging has driven experimental surgery to a higher-level and is believed to be high throughput techniques with immanent enormous advantages over the more conventional *ex vivo* techniques. Its emphasis is on real-time monitoring, being non-destructive and noninvasive. It also allows the provision of multiple time points for longitudinal studies. Multilevel information from cellular/molecular to organ/organism can be acquired. The development and dissemination of animal imaging equipment and techniques have contributed to a very significant decrease in the number of animals needed for preclinical research, fully complying with 3R (Replacement, Reduction and Refinement) policies and strategies. Each imaging technique shows innate advantages and limitations, supplying divergent kinds of information, most often complementary. While nuclear techniques are appropriate for delivering basically molecular and functional information, CTs and MRIs

produce images with excellent spatial resolution. The combination of the functional with morphological imaging modalities has proven very powerful, contributing more precise and practical information. PET and SPECT are by far the most sensitive modality and can detect labeled molecules in picomolar concentrations. Preclinical PET is more often combined with PET-CT and PET-MRI, respectively (Comley 2011). The combination of imaging techniques with high-resolution and highly sensitive techniques will acquire functional information and expand the horizons of research. It will not only enlarge the understanding of the underlying mechanisms of disease, but also supply efficient tools for assessing new therapeutic agents. The added value of multimodality or hybrid imaging techniques has achieved its broad acceptance and widespread application over the last 10 years. New hardware and software will further broaden the range of applications and image quality. The radiolabeling chemistry of SPECT is often simple and easy. The radionuclides have a variety of photonic energies and half-lives. The contemporaneous acquisition of several probes labeled with divergent radionuclides may evaluate the discrete molecular events. The user should strictly comply with the standard operating procedure about biosafety, radiation protection, and animal comfort. Well trained staffs are important to efficiently work with different animal models and the equipment/devices.

REFERENCES

Almajdub M, Nejjari M, Poncet G, Magnier L, Chereul E, Roche C, Janier M. In-vivo high-resolution X-ray microtomography for liver and spleen tumor assessment in mice. *Contrast. Media. Mol. Imaging* 2007; 2(2): 88–93.

Alves KZ, Soletti RC, de Britto MA, de Matos DG, Soldan M, Borges HL, Marchado JC. In Vivo endoluminal ultrasound biomicroscopic imaging in a mouse model of colorectal cancer. *Acad. Radiol*. 2013; 20(1): 90–8.

Anderson R, Maga AM. A Novel Procedure for Rapid Imaging of Adult Mouse Brains with MicroCT Using Iodine-Based Contrast. *PLoS. One.* 2015; 10(11): e0142974.

Appleton CT, McErlain DD, Pitelka V, Schwartz N, Bernier SM, Henry JL, Holdsworth DW, Beier F. Forced mobilization accelerates pathogenesis: characterization of a preclinical surgical model of osteoarthritis. *Arthritis. Res. Ther*. 2007; 9(1): R13.

Armitage SE, Pollmann SI, Detombe SA, Drangova M. Least-error projection sorting to optimize retrospectively gated cardiac micro-CT of free-breathing mice. *Medical. Physics*. 2012; 39(3): 1452–61.

Artaechevarria X, Blanco D, de Biurrun G, Ceresa M, Pérez-Martín D, Bastarrika G, de Torres JP, Zulueta JJ, Montuenga LM, Ortiz-de-Solorzano C, Munoz-Barrutia A. Evaluation of micro-CT for emphysema assessment in mice: comparison with non-radiological techniques. *Eur. Radiol*. 2011; 21(5): 954–62.

Ashton JR, Befera N, Clark D, Qi Y, Mao L, Rockman HA, Johnson GA, Badea CT. Anatomical and functional imaging of myocardial infarction in mice using micro-CT and eXIA 160 contrast agent. *Contrast. Media. Mol. Imaging* 2014; 9(2): 161–8.

Ashton JR, West JL, Badea CT. In vivo small animal micro-CT using nanoparticle contrast agents. *Front. Pharmacol*. 2015; 6: 256.

Badea CT, Hedlund LW, Johnson GA. Micro-CT with respiratory and cardiac gating. *Medical. Physics*. 2004; 31(12): 3324–9.

Badea CT, Fubara B, Hedlund LW, Johnson GA. 4D micro-CT of the mouse heart. *Molecular Imaging* 2005; 4(2):110–16.

Badea CT, Hedlund LW, Mackel JF, Mao L, Rockman HA, Johnson GA. Cardiac Micro-Computed Tomography for Morphological and Functional Phenotyping of Muscle LIM Protein Null Mice. *Mol. Imaging* 2007; 6(4): 261–8.

Badea CT, Wetzel AW, Mistry N, Pomerantz S, Nave D, Johnson GA. Left ventricle volume measurements in cardiac micro-CT: The impact of radiation dose and contrast agent. *Comput. Med. Imaging. Graph*. 2008; 32(3): 239–50.

Badea CT, Schreibmann E, Fox T. A registration-based approach for cardiac micro-CT using combined prospective and retrospective gating. *Medical Physics* 2008; 35(4):1170–9.

Badea CT, Drangova M, Holdsworth DW, Johnson GA. In vivo small-animal imaging using micro-CT and digital subtraction angiography. *Phys. Med. Biol*. 2008; 53(19): R319–50.

Badea CT, Johnston SM, Qi Y, Johnson GA.4D micro-CT for cardiac and perfusion applications with view under sampling. *Phys. Med. Biol*. 2011; 56(11): 3351–69.

Basu S, Urhan M, Rosenbaum J, Alavi A. PET and PET/CT in the management of thyroid cancer. *Method. Mol. Biol*. 2011; 727: 205–24.

Biffi A and Greenberg SM. Cerebral amyloid angiopathy: a systematic review. *J. Clin Neurol.* 2011; 7: 1–9.

Boone JM, Alexander GM, Seibert JA. A fluoroscopy-based computed tomography scanner for small specimen research. *Invest. Radiol*. 1993; 28(6): 539–44.

Boulocher C, Chereul E, Langlois JB, Armenean M, Duclos ME, Viguier E, Roger T, Vignon E. Non-invasive in vivo quantification of the medial tibial cartilage thickness progression in an osteoarthritis rabbit model with quantitative 3D high resolution micro-MRI. *Osteoarthritis Cartilage* 2007; 15(12): 1378–87.

Bour G, Martel F, Goffin L, Bayle B, Gangloff J, Aprahamian M, Marescaux J, Egly JM. Design and development of a robotized system coupled to μCT imaging for intratumoral drug evaluation in a HCC mouse model. *PLoS. One* 2014; 9(9): e106675.

Bouxsein ML, Boyd SK, Christiansen BA, Guldberg RE, Jepsen KJ, Müller R. Guidelines for assessment of bone microstructure in rodents using micro-computed tomography. *J. Bone. Miner. Res*. 2010; 25(7): 1468–86.

Bremer C, Ntziachristos V, Weissleder R. Optical-based molecular imaging: contrast agents and potential medical applications. *Eur. Radiol*. 2003; 13(2): 231–43.

Brockmann MA. Use of clinical MR scanners for small rodent imaging. *Methods* 2007; 43(1):1.

Cao AH, Shi HJ, Zhang Y, Teng GJ. In vivo tracking of dual-labeled mesenchymal stem cells homing into the injured common carotid artery. *Anat. Rec.* (Hoboken). 2009; 292(10): 1677–83.

Cao G, Lee YZ, Peng R, Liu Z, Rajaram R, Calderon-Colon X, An L, Wang P, Phan T, Sultana S, Lalush DS, Lu JP, Zhou O. A dynamic micro-CT scanner based on a carbon nanotube field emission x-ray source. *Physics in Medicine and Biology* 2009; 54(8): 2323.

Cao G, Burk LM, Lee YZ, Calderon-Colon X, Sultana S, Lu J, Zhou O. Prospective-gated cardiac micro-CT imaging of free-breathing mice using carbon nanotube field emission x-ray. *Med. Phys*. 2010; 37(10): 5306–12.

Cardenas JC, Owens AP III, Krishnamurthy J, Sharpless NE, Whinna HC, Church FC. Overexpression of the cell cycle inhibitor p16INK4a promotes a prothrombotic phenotype following vascular injury in mice. *Arterioscler. Thromb. Vasc. Biol*. 2011; 31: 827–33.

Carnaghan H, Roberts T, Savery D, Norris FC, McCann CJ, Copp AJ, Scambler PJ, Lythgoe MF, Greene ND, Decoppi P, Burns AJ, Pierro A, Eaton S. Novel exomphalos genetic mouse model: the importance of accurate phenotypic classification. *J. Pediatr. Surg*. 2013; 48(10): 2036–42.

Cavanaugh D, Johnson E, Price RE, Kurie J, Travis EL, Cody DD. In vivo respiratory-gated micro-CT imaging in small-animal oncology models. *Mol. Imaging*. 2004; 3(1): 55–62.

Chen C, Yu H, Xia R, Wang L, Ai H, Liu S, Xu Z, Xiao X, Gao F. Magnetic resonance tracking of endothelial progenitor cells labeled with alkyl-polyethylenimine 2 kDa/superparamagnetic iron oxide in a mouse lung carcinoma xenograft model. *Mol. Imaging* 2014; 13. doi: 10.2310/7290.2014.00030.

Chen YJ, Chen CM, Wang C, Chou HC. Microcomputed tomography assessment of lipopolysaccharide-induced acute lung injury in rat. *Exp. Lung. Res.* 2016; 42(2): 103−9.

Cheung AM, Brown AS, Cucevic V, Roy M, Needles A, Yang V, et al. Detecting vascular changes in tumour xenografts using micro-ultrasound and micro-CT following treatment with VEGFR-2 blocking antibodies. *Ultrasound Med. Biol*. 2007; 33(8): 1259−68.

Chouker A, Lizak M, Schimel D, Helmberger T, Ward JM, Despres D, Kaufmann I, Bruns C, Löhe F, Ohta A, Sitkovsky MV, Klaunberg B, Thiel M. Comparison of FenestraVC Contrast-enhanced computed tomography imaging with gadopentetate dimeglumine and ferucarbotran magnetic resonance imaging for the in vivo evaluation of murine liver damage after ischemia and reperfusion. *Invest. Radiol.* 2008; 43: 77–91.

Coatney RW. Ultrasound imaging: principles and applications in rodent research. *ILAR. J*. 2001; 42(3): 233–47.

Cody DD, Nelson CL, Bradley WM, Wislez M, Juroske D, Price RE, Zhou X, Bekele BN, Kurie JM. Murine lung tumor measurement using respiratory-gated micro computed tomography. *Invest. Radiol*. 2005; 40(5): 263–9.

Cohn Yakubovich D, Tawackoli W, Sheyn D, Kallai I, Da X, Pelled G, Gazit D, Gazit Z. Computed Tomography and Optical Imaging of Osteogenesis-angiogenesis Coupling to Assess Integration of Cranial Bone Autografts and Allografts. *J. Vis. Exp*. 2015; 106: e53459.

Comley J. In vivo preclinical imaging: an essential tool in translational research. *Drug Discovery World* 2011:58–71.

Cowan CM, Aghaloo T, Chou YF, Walder B, Zhang X, Soo C,Ting K, Wu B. Micro-CT evaluation of three-dimensional mineralization in response to BMP-2 doses in vitro and in critical sized rat calvarial defects. *Tissue Eng*. 2007; 13(3): 501–12.

Culver J, Akers W, Achilefu S. Multimodality molecular imaging with combined optical and SPECT/PET modalities. *J. Nucl. Med*. 2008; 49(2): 169–72.

Cunha L, Horvath I, Ferreira S, Lemos J, Costa P, Vieira D, Veres D, Szigeti D, Summavielle T, Ma´the´ D Metello L. Preclinical Imaging: an Essential Ally in Modern Biosciences. *Mol. Diagn. Ther*. 2014; 18: 153–73.

Curaj A, Wu Z, Fokong S, Liehn EA, Weber C, Burlacu A, Lammers T, van Zandvoort M, Kiessling F. Noninvasive molecular ultrasound monitoring of vessel healing after

intravascular surgical procedures in a preclinical setup. *Arterioscler. Thromb. Vasc. Biol*. 2015; 35(6): 1366–73.

Cutajar M, Thomas DL, Banks T, Clark CA, Golay X, Gordon I. Repeatability of renal arterial spin labelling MRI in healthy subjects. *MAGMA* 2012; 25(2):145–53.

de Kemp RA, Epstein FH, Catana C, Tsui BM, Ritman EL. Small-animal molecular imaging methods. *J. Nucl. Med*. 2010; 1(51 Suppl 1):18S–32S.

de Lin M, Ning L, Badea CT, Mistry NN, Qi Y, Johnson GA. A high precision contrast injector for small animal x-ray digital subtraction angiography. *IEEE Transactions on Biomedical Engineering* 2008; 2008(3): 1082–91.

Debbaut C, De Wilde D, Casteleyn C, Cornillie P, Van Loo D, Van Hoorebeke L, Monbaliu D, Fan YD, Segers P. Modeling the impact of partial hepatectomy on the hepatic hemodynamics using a rat model. *IEEE. Trans. Biomed. Eng.* 2012; 59(12): 3293–303.

Deshpande N, Needles A, Willmann JK. Molecular ultrasound imaging: current status and future directions. *Clin. Radiol*. 2010; 65(7): 567–81.

Detombe SA, Ford NL, Xiang F, Lu X, Feng Q, Drangova M. Longitudinal follow-up of cardiac structure and functional changes in an infarct mouse model using retrospectively gated micro-computed tomography. *Investigative radiology* 2008; 43(7): 520–9.

Detombe SA, Dunmore-Buyze J, Drangova M. Evaluation of eXIA 160 cardiac-related enhancement in C57BL/6 and BALB/c mice using micro-CT. *Contrast Media and Molecular Imaging* 2012; 7(2): 240–6.

D'hulst AI, Vermaelen KY, Brusselle GG, Joos GF, Pauwels RA. Time course of cigarette smoke-induced pulmonary inflammation in mice. *Eur. Respir. J.* 2005; 26: 204–13.

Dubory A, Laemmel E, Badner A, Duranteau J, Vicaut E, Court C, Soubeyrand M. Contrast enhanced ultrasound imaging for assessment of spinal cord blood flow in experimental spinal cord injury. *J. Vis. Exp*. 2015; (99): e52536.

Dufort S, Sancey L, Wenk C, Josserand V, Coll JL. Optical small animal imaging in the drug discovery process. *Biochim. Biophys. Acta*. 2010; 1798(12): 2266–73.

Dumas A, Brigitte M, Moreau MF, Chrétien F, Baslé MF, Chappard D. Bone mass and microarchitecture of irradiated and bone marrow-transplanted mice: Influences of the donor strain. *Osteoporosis International* 2009; 20(3): 435–43.

Ehling J, Bartneck M, Wei X, Gremse F, Fech V, Möckel D, Baeck C, Hittatiya K, Eulberg D, Luedde T, Kiessling F, Trautwein C, Lammers T, Tacke F. CCL2-dependent infiltrating macrophages promote angiogenesis in progressive liver fibrosis. *Gut* 2014; 63(12):1960–71.

Emelianov SY, Chen X, O'Donnell M, Knipp B, Myers D, Wakefield TW, Rubin JM. Triplex ultrasound: elasticity imaging to age deep venous thrombosis. *Ultrasound Med. Biol.* 2002; 28: 757–67.

Fass L. Imaging and cancer: a review. *Mol. Oncol.* 2008; 2(2):115–52.

Feldkamp LA, Goldstein SA, Parfitt AM, Jesion G, Kleerekoper M. The direct examination of three-dimensional bone architecture in vitro by computed tomography. *J. Bone. Miner. Res*. 1989; 4(1): 3–11.

Figueiredo G, Brockmann C, Boll H, Heilmann M, Schambach SJ, Fiebig, T, Kramer M, Groden C, Brockmann MA. Comparison of digital subtraction angiography, micro-computed tomography angiography and magnetic resonance angiography in the assessment of the cerebrovascular system in live mice. *Clin. Neuroradiol.* 2012; 22: 21–8.

Fontés G, Ghislain J, Benterki I, Zarrouki B, Trudel D, Berthiaume Y, Poitout V. The ΔF508 Mutation in the Cystic Fibrosis Transmembrane Conductance Regulator Is Associated with Progressive Insulin Resistance and Decreased Functional β-Cell Mass in Mice. *Diabetes* 2015; 64(12):4112–22.

Franc BL, Acton PD, Mari C, Hasegawa BH. Small-animal SPECT and SPECT/CT: important tools for preclinical investigation. *J. Nucl. Med*. 2008; 49(10): 1651–63.

Frangi AF, Niessen WJ, Viergever MA. Three-dimensional modeling for functional analysis of cardiac images: a review. *IEEE. Trans. Med. Imaging* 2001; 20(1): 2–25.

Ghanavati S, Lerch JP, Sled JG. Automatic anatomical labeling of the complete cerebral vasculature in mouse models. *Neuroimage* 2014; 95:117–28.

Ghislain J, Fontés G, Tremblay C, Kebede MA, Poitout V. Dual-Reporter β-Cell-Specific Male Transgenic Rats for the Analysis of β-Cell Functional Mass and Enrichment by Flow Cytometry. *Endocrinology* 2016; 157(3):1299–306.

Glass R, Kettenmann H. Toll-like receptor2 mediates microglia/brain macrophage MT1-MMP expression and glioma expansion. *Neuro. Oncol.* 2013; 15: 1457–68.

Goertzen AL, Nagarkar V, Street RA, Paulus MJ, Boone JM, Cherry SR.A comparison of x-ray detectors for mouse CT imaging. *Phys. Med. Biol*. 2004; 49(23):5251–65.

Goetti R, O'Gorman R, Khan N, Kellenberger CJ, Scheer I. Arterial spin labelling MRI for assessment of cerebral perfusion in children with moyamoya disease: comparison with dynamic susceptibility contrast MRI. *Neuroradiology* 2013; 55(5):639–47.

Golden HB, Sunder S, Liu Y, Peng X, Dostal DE. In utero assessment of cardiovascular function in the embryonic mouse heart using high-resolution ultrasound biomicroscopy. *Method Mol. Biol*. 2012; 843: 245–63.

Grassi R, Lagalla R, Rotondo A. Genomics, proteomics, MEMS and SAIF: which role for diagnostic imaging? *La Radiologia medica* 2008; 113(6):775–8.

Greco A, Mancini M, Gargiulo S, Gramanzini M, Claudio PP, Brunetti A, Salvatore M. Ultrasound biomicroscopy in small animal research: applications in molecular and preclinical imaging. *J. Biomed. Biotechnol*. 2012; 2012: 519238.

Greer LF III, Szalay AA. Imaging of light emission from the expression of luciferases in living cells and organisms: a review. *Luminescence* 2002; 17(1): 43–74.

Graham KC, Ford NL, Mackenzie LT, Postenka CO, Groom AC, Macdonald IC, Holdsworth DW, Drangova M, Chambers AF. Noninvasive quantification of tumor volume in preclinical liver metastasis models using contrast-enhanced x-ray computed tomography. *Invest. Radiol.* 2008; 43: 92–9.

Grover SP, Saha P, Jenkins J, Mukkavilli A, Lyons OT, Patel AS, Sunassee K, Modarai B, Smith A. Quantification of experimental venous thrombus resolution by longitudinal nanogold-enhanced micro-computed tomography. *Thromb. Res*. 2015. doi: 10.1016/ j.thromres.2015.10.006.

Guerrero T, Castillo R, Sanders K, Price R, Komaki R, Cody D. Novel method to calculate pulmonary compliance images in rodents from computed tomography acquired at constant pressures. *Phys. Med. Biol.* 2006; 51(5):1101–12.

Guerrero T, Castillo R, Noyola-Martinez J, Torres M, Zhou X, Guerra R, Cody D, Komaki R, Travis E. Reduction of pulmonary compliance found with high-resolution computed tomography in irradiated mice. *Int. J. Radiat. Oncol. Biol. Phys*. 2007; 67(3): 879–87.

Han JH, Lim SY, Lee MS, Lee WW. Sodium [^{18}F] fluoride PET/CT in myocardial infarction. *Mol. Imaging. Biol*. 2015; 17(2): 214–21.

Hedlund LW, and Johnson GA. Mechanical ventilation for imaging the small animal lung. *ILAR. J*. 2002; 43: 159–74.

Heeger DJ, Ress D. What does fMRI tell us about neuronal activity? *Nat. Rev. Neurosci*. 2002; 3(2): 142–51.

Hegab AE, Kameyama N, Kuroda A, Kagawa S, Yin Y, Ornitz D, Betsuyaku T. Using Micro-computed Tomography for the Assessment of Tumor Development and Follow-up of Response to Treatment in a Mouse Model of Lung Cancer. *J. Vis. Exp*. 2016 May 20; (111). doi: 10.3791/53904.

Hickey RD, Mao SA, Amiot B, Suksanpaisan L, Miller A, Nace R, Glorioso J, O'Connor MK, Peng KW, Ikeda Y, Russell SJ, Nyberg SL. Noninvasive 3-dimensional imaging of liver regeneration in a mouse model of hereditary tyrosinemia type 1 using the sodium iodide symporter gene. *Liver. Transpl*. 2015; 21(4):442–53.

Ho ST, Hutmacher DW. A comparison of micro CT with other techniques used in the characterization of scaffolds. *Biomaterials* 2006; 27(8):1362–76.

Holdsworth DW, Drangova M, Fenster A. A high-resolution XRII-based quantitative volume CT scanner. *Med. Phys*. 1993; 20(2 Pt 1):449–62.

Holdsworth DW, Thornton M. Micro-CT in small animal and specimen imaging. *Trends in Biotechnology* 2002; 20(8): S34–9.

Holland JP, Sheh Y, Lewis JS. Standardized methods for the production of high specific-activity zirconium-89. *Nucl. Med. Biol*. 2009; 36(7): 729–39.

Hori Y, Takasuka N, Mutoh M, Kitahashi T, Kojima S, Imaida, K., Suzuki M, Kohara K, Yamamoto S, Moriyama N, Sugimura T, Wakabayashi K. Periodic analysis of urethane-induced pulmonary tumors in living A/J mice by respiration-gated X-ray microcomputed tomography. *Cancer. Sci*. 2008; 99: 1774–7.

Hoyt K, Warram JM, Wang D, Ratnayaka S, Traylor A, Agarwal A. Molecular Ultrasound Imaging of Tissue Inflammation Using an Animal Model of Acute Kidney Injury. *Mol. Imaging. Biol*. 2015; 17(6):786–92.

Hua XW, Lu TF, Li DW, Wang WG, Li J, Liu ZZ, Lin WW, Zhang JJ, Xia Q. Contrast-enhanced micro-computed tomography using ExiTron nano6000 for assessment of liver injury. *World. J. Gastroenterol*. 2015; 21(26): 8043–51.

Hundepool CA, Nijhuis TH, Rbia N, Bulstra LF, Selles RW, Hovius SE. Noninvasive Ultrasound of the Tibial Muscle for Longitudinal Analysis of Nerve Regeneration in Rats. *Plast. Reconstr. Surg*. 2015; 136(5): 633e–9e.

Hutchins GD, Miller MA, Soon VC, Receveur T. Small animal PET imaging. *ILAR. J*. 2008; 49(1):54–65.

Inabnet WB 3rd, Milone L, Korner J, Durak E, Ahmed L, Pomrantz J, Harris PE, Bessler M. A rodent model of metabolic surgery for study of type 2 diabetes and positron emission tomography scanning of beta cell mass. *Surg. Obes. Relat. Dis*. 2009; 5(2):212−7

Ingram N, Macnab SA, Marston G, Scott N, Carr IM, Markham AF, Whitehouse A, Coletta PL. The use of high-frequency ultrasound imaging and biofluorescence for in vivo evaluation of gene therapy vectors. *BMC. Med. Imaging* 2013; 13:35

Jakob P. Small animal magnetic resonance imaging: basic principles, instrumentation and practical issues. In: Kiessling F, Pichler BJ, editors. *Small animal imaging—basics and practical guide*. Heidelberg: Springer; 2011. p. 151–164.

Johnson JT, Hansen MS, Wu I, Healy LJ, Johnson CR, Jones GM, Capecchi MR, Keller C. Virtual histology of transgenic mouse embryos for high-throughput phenotyping. *PLoS. Genet*. 2006; 2(4):e61.

Johnson KA. Imaging techniques for small animal imaging models of pulmonary disease: Micro-CT. *Toxicol. Pathol*. 2007; 35: 59–64.

Jones MD, Tran CW, Li G, Maksymowych WP, Zernicke RF, Doschak MR. In vivo microfocal computed tomography and micro-magnetic resonance imaging evaluation of antiresorptive and antiinflammatory drugs as preventive treatments of osteoarthritis in the rat. *Arthritis Rheum*. 2010; 62(9):2726–35.

Johnston SM, Johnson GA, Badea CT. Geometric calibration for a dual tube/detector micro-CT system. *Med. Phys*. 2008; 35(5):1820–9.

Juárez-Orozco LE, Szymanski MK, Hillege HL, Kruizinga S, Noordzij W, Koole M, Tio RA, Alexanderson E, Dierckx RA, Slart RH. Imaging of cardiac and renal perfusion in a rat model with 13N-NH 3 micro-PET. *Int. J. Cardiovasc. Imaging* 2015; 31(1):213–9.

Kagadis GC, Loudos G, Katsanos K, Langer SG, Nikiforidis GC. In vivo small animal imaging: current status and future prospects. *Med. Phys*. 2010; 37(12):6421–42.

Kalender WA, Kyriakou Y. Flat-detector computed tomography (FD-CT). *Eur. Radiol*. 2007; 17(11):2767–79.

Kalender WA, Deak P, Engelke K, Karolczak M. X-ray and X-ray CT. In: Kiessling F, Pichler BJ, editors. *Small animal imaging–basics and practical guide*. Heidelberg: Springer; 2011. p. 125–39.

Kamp MA, Dibué M, Sommer C, Steiger HJ, Schneider T, Hänggi D. Evaluation of a murine single-blood-injection SAH model. *PLoS. One* 2014; 9(12):e114946.

Kampschulte M, Krombach GA, Richards DC, Sender J, Lips KS, Thormann U, El Khassawna T, Ray S, Alt V, Langheinrich AC. Neovascularization of osteoporotic metaphyseal bone defects: A morphometric micro-CT study. *Microvasc. Res*. 2015; 105: 7–14.

Kan Z, Phongkitkarun S, Kobayashi S, Tang Y, Ellis LM, Lee TY, Charnsangavej C. Functional CT for quantifying tumor perfusion in antiangiogenic therapy in a rat model. *Radiology* 2005; 237(1):151–8.

Kaufmann BA, Lankford M, Behm CZ, French BA, Klibanov AL, Xu Y, et al. High-resolution myocardial perfusion imaging in mice with high-frequency echocardiographic detection of a depot contrast agent. *J. Am. Soc. Echocardiogr*. 2007; 20(2): 136–43.

Kaufmann BA, Carr CL, Belcik JT, Xie A, Yue Q, Chadderdon S, Caplan ES, Khangura J, Bullens S, Bunting S, Lindner JR. Molecular imaging of the initial inflammatory response in atherosclerosis: implications for early detection of disease. *Arterioscler. Thromb. Vasc. Biol*. 2010; 30: 54–9.

Kazan SM, Chappell MA, Payne SJ. Modelling the effects of cardiac pulsations in arterial spin labelling. *Phys. Med. Biol*. 2010; 55(3):799–816.

Khalil MM, Tremoleda JL, Bayomy TB, Gsell W. Molecular SPECT imaging: an overview. *Int. J. Mol. Imaging* 2011; 2011:796025.

Kiessling F, Greschus S, Lichy MP, Bock M, Fink C, Vosseler S, Moll J, Mueller MM, Fusenig NE, Traupe H, Semmler W. Volumetric computed tomography (VCT): a new technology for noninvasive, high-resolution monitoring of tumor angiogenesis. *Nat. Med.* 2004; 10: 1133–8.

Kiessling F, Fokong S, Koczera P, Lederle W, Lammers T. Ultrasound microbubbles for molecular diagnosis, therapy, and theranostics. *J. Nucl. Med*. 2012; 53(3):345–8.

Kim H, Furenlid LR, Crawford MJ, Wilson DW, Barber HB, Peterson TE, Hunter WC,

Kindlmann GL, Weinstein DM, Jones GM, Johnson CR, Capecchi MR, Keller C. Practical vessel imaging by computed tomography in live transgenic mouse models for human tumors. *Mol. Imaging* 2005; 4(4):417–24.

Kirsch DG, Grimm J, Guimaraes AR, Wojtkiewicz GR, Perez BA, Santiago PM, Anthony NK, Forbes T, Doppke K, Weissleder R, Jacks T. Imaging primary lung cancers in mice to study radiation biology. *Int. J. Radiat. Oncol. Biol. Phys*. 2010; 76: 973–7.

Kirschner S, Felix MC, Hartmann L, Bierbaum M, Maros ME, Kerl HU, Wenz F,Glatting G, Kramer M, Giordano FA, Brockmann MA. In vivo micro-CT imaging of untreated and irradiated orthotopic glioblastoma xenografts in mice: capabilities, limitations and a comparison with bioluminescence imaging. *J. Neurooncol*. 2015; 122(2): 245–54.

Kline TL, Knudsen BE, Anderson JL, Vercnocke AJ, Jorgensen SM, Ritman EL. Anatomy of hepatic arteriolo-portal venular shunts evaluated by 3D micro-CT imaging. *J. Anat.* 2014; 224(6): 724–31.

Klohs J, Baltes C, Princz-Kranz F, Ratering D, Nitsch RM, Knuesel I, Rudin M. Contrast-enhanced magnetic resonance micro angiography reveals remodeling of the cerebral micro vasculature in transgenic ArcAb mice. *J. Neurosci.* 2012; 32: 1705–13.

Klohs J, Rudin M, Shimshek DR, and Beckmann N. Imaging of cerebro vascular pathology in animal models of Alzheimer's disease. *Front. Aging. Neurosci.* 2014; 6: 32.

Koba W, Kim K, Lipton ML, Jelicks L, Das B, Herbst L, Fine E. Imaging devices for use in small animals. *Semin. Nucl. Med*. 2011; 41(3): 151–65.

Kobayashi S, Fujinawa R, Ota F, Kobayashi S, Angata T, Ueno M, Maeno T, Kitazume S, Yoshida K, Ishii T, Gao C, Ohtsubo K, Yamaguchi Y, Betsuyaku T, Kida K, Taniguchi N. A single dose of lipopolysaccharide into mice with emphysema mimics human chronic obstructive pulmonary disease exacerbation as assessed by micro-computed tomography. *Am. J. Respir. Cell. Mol. Biol*. 2013; 49(6): 971–7.

Kording F, Weidensteiner C, Zwick S, Osterberg N, Weyerbrock A, Staszewski O, von Elverfeldt D, Reichardt W. Simultaneous assessment of vessel size index, relative blood volume, and vessel permeability in a mouse brain tumor model using a combined spin echo gradient echo echo-planar imaging sequence and viable tumor analysis. *J. Magn. Reson. Imaging.* 2014; 40: 1310–18.

Kovner I, Taicher GZ, Mitchell AD. Calibration and validation of EchoMRI™ whole body composition analysis based on chemical analysis of piglets, in comparison with the same for DXA. *Int. J. Body Compos. Res*. 2010; 8(1):17–29.

Kowalski J, Henze M, Schuhmacher J, Macke HR, Hofmann M, Haberkorn U. Evaluation of Positron Emission Tomography Imaging Using [68 Ga]-DOTA-D Phe1-Tyr3-Octreotide in Comparison to [111In]-DTPAOC SPECT. First Results in Patients with Neuroendocrine Tumors. *Mol. Imaging Biol*. 2003; 5(1): 42–8.

Ku MC, Wolf SA, Respondek D, Matyash V, Pohlmann A, Waiczies S. Waiczies H, Niendorf T, Synowitz M, Glass R, Kettenmann H. *Acta. Neuro. pathol.* 2013; 125: 609–20.

Laib A, Kumer JL, Majumdar S, Lane NE. The Temporal Changes of Trabecular Architecture in Ovariectomized Rats Assessed by Micro-CT. *Osteoporosis International* 2001; 12(11): 936–41.

Langheinrich AC, and Ritman EL. Quantitative imaging of microvascular permeability in a rat model of lipopolysaccharide-induced sepsis: evaluation using cryostatic micro-computed tomography. *Invest. Radiol.* 2006; 41: 645–50.

Lecomte R. Technology challenges in small animal PET imaging. *Nucl. Instrum. Methods. Phys. Res. A*. 2004; 527(1–2):157–65.

Lee N, Choi SH, Hyeon T. Nano-sized CT contrast agents. *Adv. Mater*. 2013; 25(19): 2641–60.

Lee SC, Kim HK, Chun IK, Cho MH, Lee SY, Cho MH.. A flat-panel detector based micro-CT system: performance evaluation for small animal imaging. *Phys. Med. Biol*. 2003; 48(24): 4173–85.

Lee SW, Padmanabhan P, Ray P, Gambhir SS, Doyle T, Contag C, Goodman SB, Biswal S. Stem cell-mediated accelerated bone healing observed with in vivo molecular and small animal imaging technologies in a model of skeletal injury. *Journal of Orthopaedic Research* 2009; 27(3): 295–302.

Leroy-Willig A, Geldwerth-Feniger G. Nuclear magnetic resonance imaging and spectroscopy. In: Ntziachristos V, Leroy-Willig A, Tavitian B, editors. *Textbook of in vivo imaging invertebrates*. UK: Wiley; 2007. p. 1–56

Levin CS, Zaidi H. Current trends in preclinical PET system design. *PET. Clin*. 2007; 2(2): 125–60.

Lewis JS, Achilefu S, Garbow JR, Laforest R, Welch MJ. Small animal imaging: current technology and perspectives for oncological imaging. *Eur. J. Cancer* 2002; 38(16): 2173–88.

Li M, Jirapatnakul A, Biancardi A, Riccio ML, Weiss RS, and Reeves AP. Growth pattern analysis of murine lung neoplasms by advanced semi-automated quantification of micro-CT images. *PLoS. On.* 2013; 8: e83806.

Li XF, Zanzonico P, Ling CC, and O'Donoghue J. Visualization of experimental lung and bone metastases in live nude mice by X-ray microcomputed tomography. *Technol. Cancer. Res. Treat.* 2006; 5: 147–55.

Li R, Stewart DJ, von Schroeder HP, Mackinnon ES, Schemitsch EH. Effect of cell-based VEGF gene therapy on healing of a segmental bone defect. *Journal of Orthopaedic Research* 2009; 27(1): 8–14.

Liang HD, Blomley MJ. The role of ultrasound in molecular imaging. *British J. Radiol*. 2003; 76(2): S140–50.

Lin CY, Schek RM, Mistry AS, Shi X, Mikos AG, Krebsbach PH, Hollister SJ. Functional bone engineering using ex vivo gene therapy and topology-optimized, biodegradable polymer composite scaffolds. *Tissue. Eng*. 2005; 11(9–10): 1589–98.

Liu H, Ren G, Miao Z, Zhang X, Tang X, Han P, et al. Molecular optical imaging with radioactive probes. *PloS. One* 2010; 5(3): e9470.

Machtaler S, Knieling F, Luong R, Tian L, Willmann JK. Assessment of Inflammation in an Acute on Chronic Model of Inflammatory Bowel Disease with Ultrasound Molecular Imaging. *Theranostics* 2015; 5(11): 1175–86.

Martiniova L, Schimel D, Lai EW, Limpuangthip A, Kvetnansky R, Pacak K. In vivo micro-CT imaging of liver lesions in small animal models. *Methods* 2010; 50(1): 20–5.

Massoud TF, Gambhir SS. Molecular imaging in living subjects: seeing fundamental biological processes in a new light. *Genes. Dev*. 2003; 17(5): 545–80.

McCann L, Ingham E, Jin Z, Fisher J. Influence of the meniscus on friction and degradation of cartilage in the natural knee joint. *Osteoarthritis Cartilage* 2009; 17(8): 995–1000.

McErlain DD, Appleton CT, Litchfield RB, Pitelka V, Henry JL, Bernier SM, Beier F, Holdsworth DW. Study of subchondral bone adaptations in a rodent surgical model of OA using in vivo micro-computed tomography. *Osteoarthritis Cartilage* 2008; 16(4): 458–69.

Meikle SR, Kench P, Kassiou M, Banati RB. Small animal SPECT and its place in the matrix of molecular imaging technologies. *Phys. Med. Biol*. 2005; 50(22): R45–61.

Memon AA, Jakobsen S, Dagnaes-Hansen F, Sorensen BS, Keiding S, Nexo E. Positron emission tomography (PET) imaging with [11C]-labeled erlotinib: a micro-PET study on mice with lung tumor xenografts. *Cancer. Res*. 2009; 69(3): 873–8.

Metscher BD. MicroCT for developmental biology: a versatile tool for high-contrast 3D imaging at histological resolutions. *Dev. Dyn*. 2009; 238(3): 632–40.

Milne CP, Kaitin KI. Translational medicine: an engine of change for bringing new technology to community health. *Sci. Transl. Med*. 2009; 1(5): 5cm5.

Milo R and Miller A. Revised diagnostic criteria of multiple sclerosis. *Autoimmun. Rev.* 2014; 13: 518–24.

Murakami T, Hiroshima Y, Zhang Y, Bouvet M, Chishima T, Tanaka K, Endo I, Hoffman RM. Improved disease-free survival and overall survival after fluorescence-guided surgery of liver metastasis in an orthotopic nude mouse model. *J. Surg. Oncol.* 2015; 112(2): 119–24.

Nahrendorf M, Badea C, Hedlund LW, Figueiredo JL, Sosnovik DE, Johnson GA, Weissleder R. High-resolution imaging of murine myocardial infarction with delayed enhancement cine micro-CT. *Am. J. Physiol. Heart Circ. Physiol*. 2007; 292(6): H3172–8.

Nahrendorf M, Keliher E, Marinelli B, Leuschner F, Robbins CS, Gerszten RE, Pittet MJ, Swirski FK, Weissleder R. Detection of macrophages in aortic aneurysms by nanoparticle positron emission tomography-computed tomography. *Arterioscler. Thromb. Vasc. Biol*. 2011; 31: 750–7.

Namati E, Chon D, Thiesse J, Hoffman EA, De Ryk J, Ross A, McLennan G. In vivo micro-CT lung imaging via a computer-controlled intermittent iso-pressure breath hold (IIBH) technique. *Phys. Med. Biol.* 2006; 51:6061–75.

Namati E, Thiesse J, Sieren JC, Ross A, Hoffman EA, and Mclennan G. Longitudinal assessment of lung cancer progression in the mouse using in vivo micro-CT imaging. *Med. Phys.* 2010; 37:4793–4805.

Nebuloni L, Kuhn GA, Müller R. A comparative analysis of water-soluble and blood-pool contrast agents for in vivo vascular imaging with micro-CT. *Acad. Radiol*. 2013; 20: 1247–55.

Niendorf T, Pohlmann A, Reimann HM, Waiczies H, Peper E,Huelnhagen T, Seeliger E, Schreiber A, Kettritz R, Strobel K, Ku MC, Waiczies S. Advancing Cardiovascular, Neurovascular, and Renal Magnetic Resonance Imaging in Small Rodents Using Cryogenic Radiofrequency Coil Technology. *Front. Pharmacol*. 2015; 6:255.

Ntziachristos V, Bremer C, Weissleder R. Fluorescence imaging with near-infrared light: new technological advances that enable in vivo molecular imaging. *Eur. Radiol*. 2003; 13(1):195–208.

Ose T, Watabe H, Hayashi T, Kudomi N, Hikake M, Fukuda H, Teramoto N, Watanabe Y, Onoe H, Iida H. Quantification of regional cerebral blood flow in rats using an arteriovenous shunt and micro-PET. *Nucl. Med. Biol*. 2012; 39(5): 730–41.

Panetta D, Belcari N, Del Guerra A, Moehrs S. An optimization-based method for geometrical calibration in cone-beam CT without dedicated phantoms. *Phys. Med. Biol*. 2008; 53(14): 3841–61.

Panetta D, Belcari N, Del Guerra A, Bartolomei A, Salvadori PA. Analysis of image sharpness reproducibility on a novel engineered micro-CT scanner with variable geometry and embedded recalibration software. *Physica. Medica* 2012; 28(2): 166–73.

Park JY, Lee SK, Kim JY, Je KH, Schellingerhout D, Kim DE. A new micro-computed tomography-based high-resolution blood-brain barrier imaging technique to study ischemic stroke. *Stroke* 2014; 45(8): 2480–4.

Paulus MJ, Gleason SS, Kennel SJ, Hunsicker PR, Johnson DK. High resolution X-ray computed tomography: an emerging tool for small animal cancer research. *Neoplasia.* 2000; 2(1–2): 62–70.

Perez BA, Ghafoori AP, Lee CL, Johnston SM, Li Y, Moroshek JG, Ma Y, Mukherjee S, Kim Y, Badea CT, Kirsch DG. Assessing the radiation response of lung cancer with different gene mutations using genetically engineered mice. *Front. Oncol*. 2013; 3: 72.

Peterson TE, Furenlid LR. SPECT detectors: the Anger Camera and beyond. *Phys. Med. Biol*. 2011; 56(17): R145–82.

Peterson TE, Shokouhi S. Advances in preclinical SPECT instrumentation. *J. Nucl. Med*. 2012; 53(6): 841–4.

Phelps ME. Positron emission tomography provides molecular imaging of biological processes. *Proc. Nat. Acad. Sci. USA*. 2000; 97(16): 9226–33.

Phelps ME. PET: the merging of biology and imaging into molecular imaging. *J. Nucl. Med.* 2000; 41(4): 661–81.

Phongkitkarun S, Kobayashi S, Kan Z, Lee TY, Charnsangavej C. Quantification of angiogenesis by functional computed tomography in a Matrigel model in rats. *Acad. Radiol*. 2004; 11(5): 573–582.

Plante E, Menaouar A, Danalache BA, Yip D, Broderick TL, Chiasson JL, Jankowski M, Gutkowska J. Oxytocin treatment prevents the cardiomyopathy observed in obese diabetic male db/db mice. *Endocrinology* 2015; 156(4):1416–1428.

Pomper MG, Lee JS. Small animal imaging in drug development. *Curr. Pharm. Des*. 2005; 11(25): 3247–3272.

Postnov AA, Meurrens K, Weiler H, Van Dyck D, Xu H, Terpstra P, De Clerck NM. In vivo assessment of emphysema in mice by high resolution X-ray microtomography. *J. Microsc*. 2005; 220(Pt 1): 70–5.

Qiao H, Li J, Chen Y, Wang D, Han J, Mei M, Li D. A study of the metabolism of transplanted tumor in the lung by micro PET/CT in mice. *Med. Eng. Phys*. 2014; 36(3): 294–9.

Qiu B, Treuting P, Zhan X, Xie D, Frevert CW, Yang X. Dual transfer of GFP gene and MGd into stem-progenitor cells: toward in vivo MRI of stem cell-mediated gene therapy of atherosclerosis. *Acad. Radiol*. 2010; 17(5): 547–52.

Rajabi-Jagahrgh E, Roy-Chaudhury P, Wang Y, Al-Rjoub M, Campos-Naciff B, Choe A, Dumoulin C, Banerjee RK. New techniques for determining the longitudinal effects of

local hemodynamics on the intima-media thickness in arteriovenous fistulae in an animal model. *Semin. Dial*. 2014; 27(4): 424–35.

Ringhausen E, Wang T, Pitts J, Sarder P, Akers WJ. Evaluation of Dynamic Optical Projection of Acquired Luminescence for Sentinel Lymph Node Biopsy in Large Animals. *Technol. Cancer. Res. Treat*. 2015 Sep 15. pii: 1533034615604978.

Ritman EL. Micro-computed tomography of the lungs and pulmonary-vascular system. *Proc. Am. Thorac. Soc*. 2005; 2(6): 477–80.

Ritman EL. Current status of developments and applications of micro-CT. *Annu. Rev. Biomed. Eng*. 2011; 15(13): 531–52.

Robertson R, Germanos MS, Li C, Mitchell GS, Cherry SR, Silva MD. Optical imaging of Cerenkov light generation from positron-emitting radiotracers. *Phys. Med. Biol*. 2009; 54(16): N355–65.

Rothe JH, Rudolph I, Rohwer N, Kupitz D, Gregor-Mamoudou B, Derlin T, Furth C, Amthauer H, Brenner W, Buchert R, Cramer T, Apostolova I. Time course of contrast enhancement by micro-CT with dedicated contrast agents in normal mice and mice with hepatocellular carcinoma: comparison of one iodinated and two nanoparticle-based agents. *Acad. Radiol*. 2015; 22(2): 169–78.

Rudyanto RD, Bastarrika G, De Biurrun G, Agorreta J, Montuenga LM, Ortiz-De-Solorzano C, Muñoz-Barrutia A. Individual nodule tracking in microCT images of a longitudinal lung cancer mouse model. *Med. Image. Anal*. 2013; 17:1095–105.

Saito S, and Murase K. Detection and early phase assessment of radiation induced lung injury in mice using micro-CT. *PLoS. One* 2012; 7: e45960.

Salat DH. Imaging small vessel-associated white matter changes in aging. *Neuroscience.* 2014; 276: 174–86.

Sasaki M, Chubachi S, Kameyama N, Sato M, Haraguchi M, Miyazaki M, Takahashi S, Betsuyaku T. Evaluation of cigarette smoke-induced emphysema in mice using quantitative micro-computed tomography. *Am. J. Physiol. Lung Cell Mol. Physiol*. 2015; 308(10):L1039-45.

Sawall S, Bergner F, Lapp R, Mronz M, Karolczak M, Hess A, Kachelriess M. Low-dose cardio-respiratory phase-correlated cone-beam micro-CT of small animals. *Medical Physics* 2011; 38(3): 1416–24.

Schaefer PW, Grant PE, Gonzalez RG. Diffusion-weighted MR imaging of the brain. *Radiology* 2000; 217(2):331–45.

Schambach SJ, Bag S, Groden C, Schilling L and Brockmann MA. Vascular imaging in small rodents using micro-CT. *Methods* 2010; 50: 26–35.

Schiffman SC, Li Y, Dryden G, Li X, Martin RC. Positive correlation of image analysis by mini-endoscopy with micro-PET scan and histology in rats after esophagoduodenal anastomosis. *Surg. Endosc.* 2010; 24(11): 2835–41.

Shan M, You R, Yuan X, Frazier MV, Porter P, Seryshev A, Hong JS, Song LZ, Zhang Y, Hilsenbeck S, Whitehead L, Zarinkamar N, Perusich S, Corry DB, Kheradmand F. Agonistic induction of PPARγ reverses cigarette smoke-induced emphysema. *J. Clin. Invest.* 2014; 124(3): 1371–81.

Shimojo M, Higuchi M, Suhara T, Sahara N. Imaging Multimodalities for Dissecting Alzheimer's Disease: Advanced Technologies of Positron Emission Tomography and Fluorescence Imaging. *Front. Neurosci*. 2015; 9: 482.

Shofer S, Badea C, Auerbach S, Schwartz DA, Johnson GA.A micro-computed tomography-based method for the measurement of pulmonary compliance in healthy and bleomycin-exposed mice. *Exp. Lung. Res*. 2007; 33(3–4): 169–83.

Steinberg VA, Mommertz G, Thiesler T, Kristiansen G, Schild H, Naehle CP. Effect of Peripheral Artery Sympathetic Denervation on Muscle Microperfusion and Macroperfusion in an Animal Peripheral Artery Disease Model Using Contrast-Enhanced Ultrasound and Doppler Flow Measurement. *J. Vasc. Interv. Radiol*. 2015; 26(9): 1396–402.e2.

Soki FN, Cho SW, Kim YW, Jones JD, Park SI, Koh AJ, Entezami P, Daignault-Newton S, Pienta KJ, Roca H, McCauley LK. Bone marrow macrophages support prostate cancer growth in bone. *Oncotarget* 2015; 6(34): 35782–96.

Stolz E, Yeniguen M, Kreisel M, Kampschulte M, Doenges S, Sedding D, Ritman EL, Gerriets T, Langheinrich AC. Angioarchitectural changes in subacute cerebral venous thrombosis. A synchrotronbased micro- and nano-CT study. *NeuroImage* 2011; 54(3):1881–1886.

Suri JS. Computer vision, pattern recognition and image processing in left ventricle segmentation: the last 50 years. *Pattern Analysis and Applications* 2000; 3(3): 209–42.

Taguchi K, Xu J, Srivastava S, Tsui BM, Cammin J, Tang Q. Interior region-of-interest reconstruction using a small, nearly piecewise constant subregion. *Med. Phys*. 2011; 38(3):1307–12.

Taguchi K, Iwanczyk JS. Vision 20/20: Single photon counting x-ray detectors in medical imaging. *Med. Phys*. 2013; 40(10):100901.

Tang J, Zhu H, Luo X, Li Q, Levin LS, Tintle SM. A vascularized elbow allotransplantation model in the rat. *J. Shoulder. Elbow. Surg*. 2015; 24(5): 779–86.

Tang XL, Rokosh G, Sanganalmath SK, Tokita Y, Keith MC, Shirk G, Stowers H, Hunt GN, Wu W, Dawn B, Bolli R. Effects of Intracoronary Infusion of Escalating Doses of Cardiac Stem Cells in Rats With Acute Myocardial Infarction. *Circ. Heart. Fail*. 2015; 8(4): 757–65.

Takeda Y, Costa S, Delamarre E, Roncal C, Leite de Oliveira R, Squadrito ML, Finisguerra V, Deschoemaeker S, Bruyère F, Wenes M, Hamm A, Serneels J, Magat J, Bhattacharyya T, Anisimov A, Jordan BF, Alitalo K, Maxwell P, Gallez B, Zhuang ZW, Saito Y, Simons M, De Palma M, Mazzone M. Macrophage skewing by Phd2 haplodeficiency prevents ischaemia by inducing arteriogenesis. *Nature* 2011; 479: 122–6.

Thomas D, Wells J. MR angiography and arterial spin labelling. *Method. Mol. Biol.* 2011; 711: 327–45.

Tremoleda JL, Khalil M, Gompels LL, Wylezinska-Arridge M, Vincent T, Gsell W. Imaging technologies for preclinical models of bone and joint disorders. *EJNMMI. Res*. 2011; 1(1): 11.

Tremoleda JL, Kerton A, Gsell W. Anaesthesia and physiological monitoring during in vivo imaging of laboratory rodents: considerations on experimental outcomes and animal welfare. *EJNMMI. Res*. 2012; 2(1): 44.

Tsitsilonis S, Seemann R, Misch M, Wichlas F, Haas NP, Schmidt-Bleek K, Kleber C, Schaser KD. The effect of traumatic brain injury on bone healing: an experimental study in a novel in vivo animal model. *Injury* 2015; 46(4):661–5.

Tsui BM, Kraitchman DL. Recent advances in small-animal cardiovascular imaging. *J. Nucl. Med*. 2009; 50(5): 667–70.

Uehara F, Hiroshima Y, Miwa S, Tome Y, Yano S, Yamamoto M, Matsumoto Y, Maehara H, Tanaka K, Bouvet M, Kanaya F, Hoffman RM. Fluorescence-guided surgery of retroperitoneal-implanted human fibrosarcoma in nude mice delays or eliminates tumor recurrence and increases survival compared to bright-light surgery. *PLoS. One*. 2015; 10(2): e0116865.

Ueno T, Imaida K, Yoshimoto M, Hayakawa T, Takahashi M, Imai T, Yanaka A, Tsuta K, Komiya M, Wakabayashi K, Mutoh M. Non-invasive X-ray micro-computed tomographic evaluation of indomethacin on urethane-induced lung carcinogenesis in mice. *Anticancer. Res*. 2012; 32: 4773–80.

Uffen MP, Krijnen MR, Hoogendoorn RJ, Strijkers GJ, Everts V, Wuisman PI, Smit TH. Tissue identification with micro-magnetic resonance imaging in a caprine spinal fusion model. *Eur. Spine. J*. 2008; 17(8):1006–11

Umoh JU, Sampaio AV, Welch I, Pitelka V, Goldberg HA, Underhill TM, Holdsworth DW. In vivo micro-CT analysis of bone remodeling in a rat calvarial defect model. *Phys. Med. Biol*. 2009; 54(7): 2147–61.

Van Audenhaege K, Van Holen R, Vandenberghe S, Vanhove C, Metzler SD, Moore SC. Review of SPECT collimator selection, optimization, and fabrication for clinical and preclinical imaging. *Med. Phys*. 2015; 42(8): 4796–813.

Vandeghinste B, Trachet B, Renard M, Casteleyn C, Staelens S, Loeys B, Segers P, Vandenberghe S. Replacing vascular corrosion casting by in vivo micro-CT imaging for building 3D cardiovascular models in mice. *Mol. Imaging. Biol.* 2011; 13: 78–86.

Vaquero JJ, Kinahan P. Positron Emission Tomography: Current Challenges and Opportunities for Technological Advances in Clinical and Preclinical Imaging Systems. *Annu. Rev. Biomed. Eng*. 2015; 17: 385–414.

Varenika V, Fu Y, Maher JJ, Gao D, Kakar S, Cabarrus MC, Yeh BM. Hepatic fibrosis: evaluation with semiquantitative contrast-enhanced CT. *Radiology* 2013; 266(1): 151-8.

Verhaegen F, Vooijs M. Complementary use of bioluminescence imaging and contrast-enhanced micro-computed tomography in an orthotopic brain tumor model. *Mol. Imaging* 2014; 13. doi: 10.2310/7290.2014.00038.

Vinnakota K, Hu F, Ku MC, Georgieva PB, Szulzewsky F, Pohlmann A, Waiczies S, Waiczies H, Niendorf T, Lehnardt S, Hanisch UK, Synowitz M, Markovic D, Wolf SA,

Vooijs M, Jonkers J, Lyons S, Berns A. Noninvasive imaging of spontaneous retinoblastoma pathway-dependent tumors in mice. *Cancer. Res*. 2002; 62(6):1862–7.

Waarsing JH, Day JS, Weinans H. Longitudinal micro-CT scans to evaluate bone architecture. *J. Musculoskelet. Neuronal. Interact*. 2005; 5(4): 310–2

Waiczies H, Millward JM, Lepore S, Infante-Duarte C, Pohlmann A, Niendorf T, Waiczies S. Identification of cellular infiltrates during early stages of brain inflammation with magnetic resonance microscopy. *PLoS. One* 2012; 7: e32796.

Wang JG, Geddings JE, Aleman MM, et al. Tumor-derived tissue factor activates coagulation and enhances thrombosis in a mouse xenograft model of human pancreatic cancer. *Blood* 2012; 119: 5543–52.

Wang LV, Hu S. Photoacoustic tomography: in vivo imaging from organelles to organs. *Science* 2012; 335(6075):1458–62.

Wang X, Smith PL, Hsu MY, Ogletree ML, Schumacher WA. Murine model of ferric chloride-induced vena cava thrombosis: evidence for effect of potato carboxypeptidase inhibitor. *J. Thromb. Haemost*. 2006; 4: 403– 410.

Wang X, Hagemeyer CE, Hohmann JD, Leitner E, Armstrong PC, Jia F, Olschewski M, Needles A, Peter K, Ahrens I. Novel single-chain antibody-targeted microbubbles for molecular ultrasound imaging of thrombosis: validation of a unique noninvasive method for rapid and sensitive detection of thrombi and monitoring of success or failure of thrombolysis in mice. *Circulation* 2012; 125: 3117–26

Weber WA, Kiessling F. Imaging in oncology research. In: Kiessling F, Pichler BJ, editors. *Small animal imaging—basics and practical guide*. Heidelberg: Springer; 2011. p. 543–64.

Weller GE, Lu E, Csikari MM, Klibanov AL, Fischer D, Wagner WR, Villanueva FS. Ultrasound imaging of acute cardiac transplant rejection with microbubbles targeted to intercellular adhesion molecule-1. *Circulation* 2003; 108: 218–224.

Weissleder R, Mahmood U. Molecular imaging. *Radiology* 2001; 219(2):316–33.

Weissleder R. Scaling down imaging: molecular mapping of cancer in mice. *Nat. Rev. Cancer* 2002; 2(1):11–8.

Weng SJ, Shiue CY, Huang WS, Cheng CY, Huang SY, Li IH, Tao CC, Chou TK, Liao MH, Chang YP, Ma KH. PET imaging of serotonin transporters with 4-[18F]-ADAM in a Parkinsonian rat model. *Cell Transplant* 2013; 22(7):1295–305.

Wicklein J, Kunze H, Kalender WA, Kyriakou Y. Image features for misalignment correction in medical flat-detector CT. *Med. Phys.* 2012; 39(8):4918–31.

Wilson T, Hastings J. Bioluminescence. *Annu. Rev. Cell. Dev. Biol.* 1988; 14:197–230.

Wu J, Xie F, Lof J, Sayyed S, Porter TR. Utilization of modified diagnostic ultrasound and microbubbles to reduce myocardial infarct size. *Heart* 2015; 101(18):1468–74.

Yahyanejad S, Granton PV, Lieuwes NG, Gilmour L, Dubois L, Theys J, Chalmers AJ,

Yao R, Lecomte R, Crawford ES. Small-animal PET: what is it, and why do we need it? *J. Nucl. Med. Technol*. 2012; 40(3): 157–65.

Yushkevich PA, Piven J, Hazlett HC, Smith RG, Ho S, Gee JC, Gerig G. User-guided 3D active contour segmentation of anatomical structures: Significantly improved efficiency and reliability. *Neuroimage* 2006; 31(3): 1116–28.

Zambelli V, Di Grigoli G, Scanziani M, Valtorta S, Amigoni M, Belloli S, Messa C, Pesenti A, Fazio F, Bellani G, Moresco RM. Time course of metabolic activity and cellular infiltration in a murine model of acid-induced lung injury. *Intensive Care Med*. 2012; 38(4): 694–701.

Zanzonico P. Noninvasive imaging for supporting basic research. In: Kiessling F, Pichler BJ, editors. *Small animal imaging–basics and practical guide*. Heidelberg: Springer; 2011. p. 3–16.

Zhou Y, Chen H, Ambalavanan N, Liu G, Antony VB, Ding Q, Nath H, Eary JF, Thannickal VJ. Noninvasive imaging of experimental lung fibrosis. *Am. J. Respir. Cell Mol. Biol*. 2015; 53(1): 8–13.

Zhou Y, Gao JB, Xu H, Dong JQ, Wang MY. Evaluation of neovascularization with spectral computed tomography in a rabbit VX2 liver model: a comparison with real-time contrast-enhanced ultrasound and molecular biological findings. *Br. J. Radiol.* 2015; 88(1055): 20140548.

In: Encyclopedia of Surgery (22 Volume Set)
Editors: Andreas Lehrer and Kristin Mueller
ISBN: 978-1-53618-329-0
© 2020 Nova Science Publishers, Inc.

Chapter 208

TELEMETRY APPLICATIONS IN EXPERIMENTAL ANIMALS FOR STUDYING HUMAN DISEASES

Junzheng Peng[1,*], MD, PhD and Huifang Chen[2], MD, PhD
[1]Cardiovascular Phenotyping Core Facility, CRCHUM
University of Montreal, Montreal, Quebec, Canada
[2]Laboratory of Experimental Surgery, Department of Surgery, CRCHUM
University of Montreal, Montreal, Quebec, Canada

ABSTRACT

Radio telemetry technique has considerably improved in the last 15 years and has been applied to monitor different physiological signals in conscious and free moving laboratory animals. Implantable radio telemetry can be used to measure physiological parameters including blood pressure (BP), heart rate (HR), right ventricular pressure (RVP), left ventricular pressure (LVP), electrocardiogram (ECG), respiratory rate (RR), intrapleural pressure (IPP), intra-abdominal pressure (IAP), gastric pH, stomach temperature, gastric slow wave, intestine slow wave, intrauterine pressure (IUP), bladder pressure, renal pelvic pressure (RPP), intra-cavernous pressure (ICP1), intracranial pressure (ICP2), electroencephalogram (EEG), electromyography (EMG), sympathetic nerve activity, single neuron activity, intraocular pressure (IOP), activity, body temperature (BT) and arterial blood glucose. The aim of this chapter is to present an update on the current developments of radio telemetry for studying human diseases in animal models established by experimental surgery.

Keywords: radiotelemetry, physiologic signals, laboratory animals, experimental surgery

* Corresponding Author's Email: pengjunzheng@gmail.com.

ABBREVIATIONS

AAAs	Abdominal aortic aneurysms
BP	Blood pressure
BT	Body temperature
CPEs	Carbon paste electrodes
CSP	Corpus spongiosum of the penis
DSI	Data science international
ECG	Electrocardiogram
EEG	Electroencephalogram
EMG	Electromyography
GI	Gastrointestinal
GRTs	Gastric residence times
HR	Heart rate
IAP	Intraabdominal pressure
ICP1	Intracavernous pressure
ICP2	Intracranial pressure
IM	Intramuscular
IOP	Intraocular pressure
IPP	Intrapleural pressure
ISP	Intraspongiosal pressure
IUP	Intrauterine pressure
IV	Intravenously
IVBG	Intravenous blood glucose
LUTD	Lower urinary tract dysfunction
LV	Left ventricular
LVP	Left ventricular pressure
NHP	Non-human primate
OT	Oxytocin
PA	Pulmonary artery
PAB	Pulmonary artery banding
PH	Pulmonary hypertension
PTL	Preterm labor
PTL	Preterm labor
RPP	Renal pelvic pressure
RR	Respiratory rate
RSNA	Renal sympathetic nerve activity
RV	Right ventricle
RVP	Right ventricular pressure
SCI	Spinal cord injury
TBI	Traumatic brain injury
UI	Urinary incontinence
WMC	Wireless motility capsule
WT	Wild-type

INTRODUCTION

Physiologic signals monitoring of laboratory animals has an important role in modern biomedical research. Telemetry is a promising technology to measure various physiological parameters in conscious and freely moving animals. Telemetry is the transmission of measured physiological parameters to remote receivers via an antenna in conscious and freely moving animals. The receiver transforms the analog frequency signal into a digital signal in a data acquisition system. The quality of physiological signals obtained from conscious, freely moving animals is preferable, because the data are recorded under the normal state of the animals. Telemetry systems are classified as three types including wire telemetry system, radio telemetry system, and fiber-optic telemetry system according to the signal transmission medium. Radio telemetry application has been dramatically increased since the first affordable, reliable, and user friendly commercial telemetry implantable devices for physiological signals measurements from conscious and freely moving animals was developed (Brockway 1993). The components of the radio telemetry system include implantable transmitter, telemetry receiver, data exchange matrix, ambient barometric pressure and data acquisition/analysis system. Radio telemetry unites tiny sensors and transmitters to discover and transmit physiologic signals in animals to telemetry receivers. The receivers are connected to a data exchange matrix that inputs to a software system designed for acquisition and analysis. The implantable transmitter can directly measure the physiologic signals and telemeters it digitally from within the animal. The telemetry receiver converts the analog frequency signal into a digital signal to a computer with data acquisition system. Ambient barometric pressure is also monitored and deducted from the telemetered pressure by data acquisition software to correct changes in atmospheric pressure (Mills 2000). The data acquisition system can keep, handle, format, arrange, and output the data according to the user's instructions.

The advantages of implantable radio telemetry in biomedical research include elimination of artifact from restraint stress, a humane method for monitoring physiologic parameters in conscious animals, reduction of animal use in research, elimination of infection risk from exit sites, automated data collection around-the-clock, unrestricted continuous data collection from days to months, availability for all laboratory species, data quality improvement compared to conventional measurement techniques and utility of implanted animals for successive studies (Kramer 2001; Kramer 2003). The disadvantages of implantable radio telemetry include the cost to acquire the requisite equipment, specialized training/certifications for surgically prepare and study animals, large amounts of data generated by continuous or regular scheduled sampling and dedicated space within the animal facility to conduct studies and possibility of long-term drift (Kramer 2001; Kramer 2003).

Radio telemetry is an important tool for collection of a considerable number of physiological parameters including BP (Mills 2000; Kramer 2001; Kramer 2003; Braga 2009; Sivarajah 2010; Ingram-Ross 2012), HR (Mills 2000; Kramer 2001; Kramer 2003; Braga 2009; Sivarajah 2010; Ingram-Ross 2012), RVP (Oommen 2015; Handoko 2008; Haushalter 2008), LVP (Lujan 2012; Cools 2014; Holdsworth 2014), ECG (Kramer 2001; Kramer 2003; Ingram-Ross 2012), RR (Kramer 2003; Ingram-Ross 2012), IPP (Ednick 2007; Bhatia 2012; Murphy 2001), IAP (Rauch 2012; Goineau 2013), gastric pH (Rauch 2012; Sagawa 2009), stomach temperature (Austin 2006; Sauvé 2014), gastric slow wave (Farajidavar 2012),

intestine slow wave (Woo 2010), IUP (Pierce 2010; Chellman 2004; Rada 2015), bladder pressure (Noël 2013; McCafferty 2009; Djurhuus 1990), RPP (Djurhuus 1990), ICP1 (Bernabé 1999; Bernabé 1995), ICP2 (Guild 2015; Hiploylee 2014; Kawoos 2014; Silasi 2009), EEG (Kramer 2003; Weiergräber 2005; Bassett 2014), EMG (Kramer 2003; Weiergräber 2005; Bassett 2014), sympathetic nerve activity (Stocker 2013; Hamza 2012; Robinson 2015; Burke 2011), single neuron activity (Korshunov 2006; Lei 2004; Roy 2012), IOP (Gouws 2007; Schnell 1996; Dinslage 1998; Downs 2011), activity (Johansson 1997; Hoffmann 2012), BT (Kramer 2001; Johansson 1997; Hoffmann 2012) and arterial blood glucose (Brockway 2015).

Implantable radiotelemetry is now a feasible and commercially available alternative to conventional measurement methods for physiological signals in biomedical research. Implant telemetry devices are available from different manufacturers including Data science international (DSI, St-Paul, MN, USA), *The Millar Telemetry System (*Houston, Texas USA*)*, Stellar Telemetry (Homburg Germany), Emka TECHNOLOGIES (Paris, France) and EndoGear® I (Ithaca, NY USA), Konigsberg Instruments (Pasadena, CA, USA), Mini Mitter (Sunriver, OR, USA); Remo Technologies Ltd (Salisbury, UK); and Telemetronics Biomedical BV (Wageningen, The Netherlands).

TELEMETRY APPLICATIONS IN EXPERIMENTAL SURGERY FOR CARDIOVASCULAR DISEASES

Hypertension is an important contributor to the world disease burden. Lots of evidences demonstrate that hypertension is the main risk factor for cardiovascular mortality and morbidity. Furthermore, it can also cause several illnesses, such as renal failure, stroke, or aneurysm.

It is better to perform the study of cardiovascular physiology and pathophysiology in conscious animals to avoid the complications caused by anesthesia. Anesthesia can desperately inhibit the cardiovascular system and undermine the ability to regulate body temperature. Highly reliable data can be acquired by radio telemetry in animals under physiological conditions. Radio telemetry systems for monitoring cardiovascular parameters, including ECG, HR and BP were originally produced for pharmaceutical companies (Butz 2001; Mills 2000), in response to prerequisites by the FDA to present continuous monitoring of vital functions with each new drug application. Together with BT and activity indices (Mills 2000), they have been the most repeatedly described physiological signals monitored via radio telemetry, especially in rodents.

BP Measurement

BP is usually monitored to evaluate the reactivity of the cardiovascular system to environmental factors (salt, diet or stress) and genetic factors. The techniques for monitoring BP in experimental animals have refined greatly over the past decade, and several techniques are accessible that enable routine measurement of BP during day and night over prolonged periods of time in unrestrained, unstressed and conscious animals. Although indirect

techniques that allow only intermittent recording of BP may be useful for some studies, techniques for directly monitoring BP are normally preferred because of their ability to measure the highly dynamic nature of BP in a comprehensive fashion. The technique selection should eventually be guided by the study objectives to ensure that the technique chosen is suitable for the type of animal experiment.

BP monitoring in animals study is a very practical tool for finding fundamental mechanisms of cardiovascular diseases such as heart failure (Oommen 2015), hypertension (Kramer 2003; Handoko 2008), and pre-eclampsia (Hoffmann 2008; Falcao 2009). Furthermore, BP measurement in experimental animals is often used to investigate the long-term effect of pharmacological agents for treating hypertension.

BP measurement methods for animals include indirect methods and direct methods. The tail-cuff plethysmography is the most frequently used indirect method for BP measurement in animals. American Heart Association recommended the tail-cuff plethysmography for noninvasive measurement of systolic BP changes in large numbers of animals, substantial group differences in systolic BP, substantial changes in systolic BP over time and frank systolic hypertension (Kurtz 2005). The tail-cuff plethysmography is often performed during the day and cannot provide BP information during the night when rodents are more active. The tail-cuff plethysmography measurement of BP in mice and rats induces substantial amounts of thermal and restraint stress which affects BP, heart rate, and stress hormones. BP results measured by indirect methods have displayed poor agreement with BP results simultaneously monitored by direct methods (Reddy 2003; Jamieson 1997). Systolic BP measured by tail-cuff has revealed sizable differences with systolic pressure monitored by direct methods in some cases (Reddy 2003). Furthermore, continuous measurement of BP cannot be performed with the tail-cuff method.

BP can be directly recorded via radio telemetry methods or by indwelling catheters connected to externally mounted transducers. American Heart Association recommended direct BP measurement methods for continuous BP measurement, monitoring BP in free moving animals, studying BP effects of different interventions or variables (drugs, diet, genotype), quantifying relationships between BP and other variables (target organ damage), identifying intermittent or subtle forms of hypertension and quantifying the magnitude of hypertension (Kurtz 2005). 24-hour BP and HR can be measured by indwelling catheters and animals needed to be tethered to an outside transducer (Li 1999).

The use of genetically modified rodent models is increased for investigating the causes of cardiovascular diseases and potential treatments for cardiovascular diseases. Mouse models are frequently used for the study of hypertension, heart failure, atherothrombotic disease and abdominal aortic aneurysms (AAAs) (Zaragoza 2011).

Mice BP Implant Telemetry Surgery

There are two methods for telemetric transmitter implantation including the abdominal aorta implantation and carotid artery implantation.

Abdominal Aorta Implant Telemetry Surgery

Before implantation of the TA11PA-C20 BP device (DSI), the catheters of the probes were filled with an antithrombotic gel. The telemetry probes were calibrated by the data acquisition system and the pressure pre offset was checked. Then the probes were sterilized overnight in 2% glutaraldehyde following instructions provided by the vendor. The transmitters were washed and soaked in sterile 0.9% saline immediately prior to implantation **(**Gross 2000; Carlson 2000). Mice were anaesthetized with a mixture of ketamine/xylacine. The abdominal surgical areas were shaved and denuded by a depilatory cream. The mice were put on a heating pad to maintain body temperature during surgery and in the recovery period. The aorta was separated from the surrounding tissues through abdominal incision. The aorta was separated from the vena cava below the left renal artery and a suture (4–0) was placed around the aorta. The abdominal aorta was rinsed with 2% lidocaine before the transmitter catheter was inserted. The catheter was inserted into the aorta from a 25 gauge needle and advanced 5−6 mm after the aorta was blocked. Subsequently, the catheter was fixed by Vetbond tissue adhesive and the aorta was rinsed with 2% lidocaine to reduce aorta spasms. The incision was closed after transmitter was fixed on the abdominal wall. Lower-extremity paralysis was encountered in a large number of animals which subsequently died or were euthanized (Gross 2000). The success rate was less than 20% (Carlson 2000; Reddy 2003).

Carotid Artery Implant Telemetry Surgery

Abdominal aorta implantation had a high mortality rate and a general inability to perform studies reliably in most transgenic mice. Carotid artery implantation technique was subsequently established (Carlson 2000; Reddy 2003). Radio-telemetry transmitter was prepared according to the method described in mice abdominal aorta implantation. The mice were anesthetized and maintained as described in mice abdominal aorta implantation. Neck was prepared by shaving and a depilatory cream. All surgical procedures were done according to aseptic surgical methods. A vertical incision was then made on the neck and a subcutaneous pouch in the right flank was prepared for implant body placement. The left common carotid artery was separated and ligated with the first suture (7–0 silk) at the site of bifurcation into the internal and external branches (Wu 2012; Luo 2012). The suture was then retracted to the head side. The second suture was put around the common carotid artery about 10 mm below the bifurcation, and blood flow was blocked by retracting this suture to the tail. The tip of the telemetry probe catheter was gently held by vessel cannulation forceps, and the artery lumen was inserted near the carotid bifurcation using a 26-G needle on which the tip had been bent at a 90-degree angle. The tip of the catheter was inserted into the carotid artery lumen and advanced to the point of the occlusion suture by the 26-G needle. The catheter was fixed with suture and a drop of Vetbond. The incision of the neck was closed with suture (6–0 silk). BP was measured after one week of recovery.

The success rate of the carotid artery implantation was more than 90% compared with less than 20% success rate with the abdominal aorta implantation method reported by the same study (Carlson 2000). The carotid placement did not block blood flow to any major area. The results showed that occlusion of the right carotid artery induced only a transient rise in arterial pressure and no significant chronic effect was observed. In contrast, the abdominal aorta implantation considerably blocked blood flow to the hindquarters and caused animal death within 24 to 48 hours. The catheter tip is quite big compared to the abdominal aorta of

the adult mouse and may damage blood flow to the lower extremities causing high rates of morbidity and mortality (Carlson 2000; Butz 2001). Thus, implantation of the catheter into the thoracic aorta via the common carotid artery is an often applied approach in mice, although some investigators have also developed femoral artery implantation method (Vecchione 2002). The carotid artery implantation has been verified to be a very reliable and successful method for acquiring high-fidelity measurements over weeks and months in average size mice (Carlson 2000; Butz 2001; Wu 2012; Luo 2012). Exteriorization of the probe and perturbation of the wound were shown when the transmitter body was placed at mid-scapular position (Carlson 2000; Butz 2001). Keeping the transmitter body subcutaneously along the inner flank of the mouse has proven quite effective. The implants keep relatively undisturbed over the months of implantation because this region is not easily reached by the mouse (Butz 2001). Furthermore, the procedure for this approach is less invasive by avoiding abdominal surgery. Animals generally need at least 7 days to recover before BP is measured after circadian rhythms and basal BP levels return to normal (Butz 2001). The measurement can be either intermittent or continuous according to the purpose of the study.

Mice LVP Implant Telemetry Surgery

The mouse has numerous advantages over other animal models for the molecular study of left ventricular (LV) function. Worldwide efforts are now in the process to knock out specific genes in the offspring of mice and to knock in genes with specific mutations and/or to selectively express or silence gene products in different tissues to understand, prevent, and treat cardiovascular diseases (Manis 2007).

Radio telemetry transmitter was prepared according to the method described in mice abdominal aorta implantation. All surgical procedures were done according to aseptic surgical methods. A ventilator was intubated to support the animal after anesthesia was maintained. A left thoracotomy through the 3rd intercostal space was performed to expose the heart. A loose purse-string 8–0 silk suture was put around the apex after the apex was exposed. The myocardium was inserted by 21-gauge needle in the center of the purse-string suture. The catheter of a telemetry implant TA11PA-C10 (DSI) was routed through the 6th intercostal space and inserted into the LV through the apical stab wound for continuous measurement of LVP in free moving animal. The LVP signal was checked to confirm the proper placement of catheter. The purse string suture was closed after the LVP signal was verified. The chest and the skin were closed. The transmitter body was kept subcutaneously on the left flank (Ishizaka 2004; Joho 2007; Lujan 2012). The animals recovered after at least one week of the surgery.

Mice RVP Implant Telemetry Surgery

Pulmonary hypertension (PH) has a poor prognosis which causes right heart dysfunction, right heart failure and death. It is characterized by abnormal vessel wall cell proliferation and abnormal vascular remodeling and increased pulmonary vascular resistance (Humbert 2004**)**. Mice PH model can be induced by hypoxia (Weissmann 2014) or pulmonary artery banding

(PAB) (Oommen 2015). Radio telemetry transmitter was prepared according to the method described in mice abdominal aorta implantation. All surgical procedures were done according to aseptic surgical methods. The telemetry implant TA11PA-C10 was implanted in PH mice model. The catheter was inserted in the right ventricle (RV) via the jugular vein under ultrasound control. The catheter position was confirmed by displaying the pressure amplitude of the RV on the computer monitor (Weissmann 2014).

Rat BP Implant Telemetry Surgery

Rat Femoral Artery Implant Telemetry Surgery

Radio telemetry transmitter was prepared according to the method described in mice abdominal aorta implantation. All surgical procedures were done according to aseptic surgical methods. The abdominal cavity was opened using the ventral midline incision after anesthesia was induced and maintained. The catheter of radio telemetry transmitter TA11PA-C40 was tunneled through the abdominal wall to the incision of the left femoral artery. Then it was inserted centrally to a distance of 3 cm and secured in place. Five ml sterile saline was supplied by IP injection to each rat to compensate for loss of fluids before the abdominal wound was closed. The transmitter body was then kept in the abdomen and fixed to abdominal muscles (Hill 2002; Dutil 2001). The transmitter body also can be placed subcutaneously along the flank to avoid intraperitoneal invasion (Kramer 2001).

Abdominal Aorta Implant Telemetry Surgery for BP and ECG Measurement

Radio telemetry transmitter TL11M2-C50-PXT (DSI) was prepared according to the method described in mice abdominal aorta implantation. All surgical procedures were done according to aseptic surgical methods. Surgery was performed under isoflurane anesthesia. Carprofen (5 mg/kg, SC) was administered prior to surgery to the anesthetized rats. The descending aorta was carefully isolated by sterile cotton applicators and blunt dissection after an abdominal incision (4–5 cm) was made. A 2–0 occlusion silk was inserted between the aorta and the vena cava to block backflow. The aorta was punctured as the method described in mice using a 21 g needle bent 90° at the beveled end. The tip of the catheter was inserted guided by the needle. Surgical glue Vetbond was applied to the puncture site to secure the catheter. The transmitter was secured in the abdomen and the skin was closed. The rat was allowed to recover on a heating pad before it was returned to the cage (Greene 2007).

Mouse telemetry transmitter TA11PA-C10 can be implanted to rats with reliable blood pressure and heart rate data similar to those acquired by using the rat transmitter TA11PA-C40. Reducing the size of the transmitter with accuracy in data acquisition will enable researchers to acquire reliable cardiovascular data (Braga 2009). The approach of introducing the catheter directly into the aorta of the rat with Vetbond to secure it in place has been mainly replaced by a simpler introduction of the catheter from the femoral artery and positioning of the transmitter body subcutaneously along the flank without intraperitoneal invasion.

Rat RVP Implant Telemetry Surgery

Radio telemetry transmitter TA11PA-C40 was prepared according to the method described in mice abdominal aorta implantation. All surgical procedures were done according to aseptic surgical methods. The pressure was measured continuously during surgery to verify proper position of the tip of the catheter. The trans-thoracic approach and trans-diaphragm approach were reported (Handoko 2008).

Trans-Thoracic Approach

The abdominal cavity was opened by midline laparotomy after anesthesia was induced and maintained. The transmitter was kept in the peritoneal cavity. The heart was exposed by a left thoracotomy conducted at the sixth intercostal space and mid-clavicular line. The catheter of the implant was subsequently tunneled subcutaneously to the thorax cavity. Heart was exposed after the ribs were retracted by small hooks. The pericardium was then opened. A superficial purse string (6–0 Prolene, Ethicon) was put on the RV free wall close to the apex. Through the purse string, a 19 G syringe needle was inserted into the RV in the direction of the RV outflow tract to avoid any coronary vessel. The site was wiped with a sterile cotton stick after the needle was removed. The tip of the catheter was then inserted into the RV by a vessel cannulation forceps. Live pressure waveform trace reaffirmed proper RV catheterization and RV systolic/diastolic pressures are usually about 25/1 mmHg. The pressure catheter was subsequently approached for about 2 cm and the tip of the catheter was left beyond the pulmonary valves. Moreover, live pressure waveform trace verified correct positioning of the pressure catheter in the pulmonary artery where PA systolic/diastolic pressures are commonly about 25/10 mmHg. Eventually, the catheter was secured by the purse string and tissue adhesive Vetbond at the site of insertion. Full expansion of the lungs was promoted by using a small burst of positive pressure (maximally 10 cm H2O for 1 s). A chest tube (18 G) was put as air outlet and was removed after proper thorax excursions were found. The ribs were closed and the chest muscles were laid back in layers. The transmitter was sutured to the abdominal muscle. The abdominal wall was closed. The skin of the chest and abdomen was closed.

Trans-Diaphragm Approach

A 5-cm midline laparotomy was made and the abdominal cavity was exposed by two hooks. The xiphoid process was lifted by a retraction suture to expose the diaphragm during the whole procedure. Wet gazes were used to cover the visceral organs temporarily and a blade holder was applied to push down the liver gently. A small midline incision in the diaphragm was next performed. The heart was well exposed by two retraction sutures in two sides of the diaphragm. The RV catheterization was completed similarly as mentioned above. Blood clots in the thorax were eliminated after catheterization. A running suture (5–0 Vicryl) was used to close the diaphragm. The pressure catheter was protruded the diaphragm at the dorsal end of the incision. The retraction suture from the xiphoid process was discarded. Full expansion of the lungs was performed as described above. The chest tube was put between the sutures of the diaphragm until proper thorax excursions were observed. One drop of Vetbond was used to further fix the closure of the diaphragm. The abdomen was closed after the transmitter was secured to the abdominal wall.

Five ml warm sterile saline was supplied by IP injection to all animals at the end of the procedure. The animals were housed in individual cages for recovery. The animals were monitored and received post-surgical analgesia buprenorphine for the first two days after surgery. Drinking gel pads and softened rat chow were given until animals completely recovered from surgery.

Rat LVP Implant Telemetry Surgery

Radio telemetry transmitter TA11PA-C40 was prepared according to the method described in mice abdominal aorta implantation. All surgical procedures were done according to aseptic surgical methods. After anesthesia was induced and maintained, all animals were intubated and supported on a ventilator. A left thoracotomy through the 4th intercostal space was performed to expose the heart. A loose purse-string suture (6–0 silk) was put around the apex. 18-gauge needle was used to puncture the myocardium in the center of the purse-string suture. Then, the catheter of a telemetry device was inserted into the LV by the 6th intercostal space. The proper placement of pressure catheter was confirmed by LVP measurement. The purse string suture was closed after the proper position was verified. The chest was closed in layers and the skin was closed. The transmitter body was kept in the abdominal cavity **(**Lujan 2012**)**.

Dog BP, LVP and ECG Implant Telemetry Surgery

Assessment of cardiovascular parameters, including ECG and BP, is needed by the regulatory guidelines. Implantable radio telemetry devices are commonly performed chronically in non-rodent species for safety pharmacology studies. High-quality BP and ECGs signals are crucial for the identification of potentially important changes in ECG and hemodynamic parameters. Proper catheter and lead placement are needed to acquire high-quality data. The detailed surgery procedures were described (Takahara 2001). In short, radio telemetry transmitter TL11M3-D70-PCP (DSI) was prepared according to the method described in mice abdominal aorta implantation. All surgical procedures were done according to aseptic surgical methods. Beagle dogs were originally anesthetized with thiopental sodium (30 mg/kg, IV). 1.0% halothane vaporized with 100% oxygen was inhaled with a volume-limited ventilator after intubation with a cuffed endotracheal tube. The chest incision was performed at the 6th intercostal space to expose the heart. A pressure catheter of the implantable transmitter unit was inserted into the LV of the heart through its apex for recording the LVP. Subcutaneous pouch was made in the left flank before closing the chest. The unit's tabs were sutured in the underlying tissue. Another pressure catheter was tunneled subcutaneously from the flank to the groin where the left femoral artery was isolated. The catheter tip was sent to the abdominal aorta from the femoral artery and secured with silk ligature. One lead of ECG was routed under the skin close to the right axilla and the other was fixed in the area of the lower left abdomen to monitor the lead II ECG. All incisions were closed and antibiotic prophylaxis was administered for 10 days. BP was measured 4 weeks after the surgery.

Non-Human Primate (NHP) BP and ECG Implant Telemetry Surgery

NHP is always an important preclinical cardiovascular disease model. The accurate BP measurement in NHP was utilized to evaluate the efficacy of test agents for cardiovascular diseases. Telemetry is becoming more extensively utilized in preclinical testing for large animals. NHP has an important role as a large animal model to assess the cardiovascular efficacy of novel test agents.

Multiple model systems are available to monitor BP in conscious NHP from restrained to telemeterized animals. The affordable commercial telemetry systems have resulted in a significant increase in primate telemetry application.

NHP were anesthetized with an intramuscular (IM) injection of acepromazine (10 mg/ml, 0.14 mg/kg) and ketamine (100 mg/ml, 13.6 mg/kg). 10% lidocaine spray was provided onto the arytenoids prior to endotracheal intubation by laryngoscopy. A sterile ophthalmic ointment was given to both eyes to prevent drying of the cornea. Animals were then kept on a heating pad and inhaled a mixture of 1.0 L/min oxygen (O2) and 2.5% isoflurane. RR was kept between 10 and 12 breaths/min with an inspiratory airway pressure between 18 and 20 cm H2O using a mechanical ventilator. HR and pulsatile hemoglobin saturation in O2 were monitored during anesthesia. Prophylactic antibiotic therapy (Cefazolin injectable, 25 mg/kg) was supplied by IM injection at least 1 h before surgery, at the end of surgery and every 8 h for 24 h after surgery. Analgesic (buprenorphine 0.05 mg/kg) was provided by IM injection upon completion of the surgery and was given every 8 h for 24 h post-surgery. Fluid therapy was administered intravenously (IV) throughout anesthesia using sterile Lactated Ringer's solution at a rate of 10 ml/kg/h. The surgical region was shaved and aseptically prepared using isopropyl alcohol and 4% chlorhexidine gluconate (Authier 2007).

Radio telemetry transmitter D70-PCT™ (DSI) was prepared similarly to the method described in mice abdominal aorta implantation. All surgical procedures were done according to aseptic surgical methods. The transmitter D70-PCT™ (DSI) was inserted between the abdominal internal oblique and the abdominal transverse muscles from a longitudinal abdominal incision. The right inguinal incision was made to expose the right femoral artery. The transmitter catheter was tunneled subcutaneously to the right inguinal incision using a trocar. The catheter was inserted into the femoral artery. Skin incisions were performed on the left lateral aspect of the thorax close to the last rib and on the right side of the thorax in the area of the thoracic inlet to enable ECG lead placement. The skin incisions were closed with interrupted intradermal absorbable sutures (Polyglactin 3-0). All monkeys were equipped with tether system and a jacket after surgery. The monkeys were returned to their cage after the rectal BT reached at least 37.0°C (Authier 2007).

The surgery was conducted using aseptic technique, under general anesthesia with intermittent positive pressure ventilation. A dorsoventral incision through the skin was done on the left flank posterior to the last rib. A pocket was prepared between internal and the external abdominal oblique muscle layers to keep the transmitter body. A left thoracotomy was completed through the 4th intercostal space. The biopotential leads, LV and arterial pressure catheters were entered the thoracic cavity through the intercostal space caudal to the thoracotomy. The LV catheter was put in the apex of the heart through an incision of the left ventricle and fixed with a non-absorbable purse string suture. The positive biopotential electrode was fixed to the apical end of the left ventricle, near the pressure catheter. The negative electrode was put near the base of the heart, cranial to the aortic arch. The arterial

pressure catheter was put in the descending thoracic aorta through a stab incision and secured by a preplaced non absorbable purse string suture. Thoracotomy incision was closed in several layers with absorbable suture. Air was evacuated from the thorax with the lungs fully inflated before final closure. The animals were maintained by the respirator until surgery was finished and then slowly removed the respirator. The animals were observed for normal breathing and monitored for signs of abnormal breathing. Post-operative analgesics were given and the animals recovered from anesthesia. Animals needed at least 4 weeks to recover after surgery.

Subcutaneous Lead Placement via Laparotomy

The surgery was performed with aseptic technique in 8 monkeys, using general anesthesia plus intermittent positive pressure ventilation. A midline laparotomy incision was made to keep the transmitter body inside the abdomen. The arterial pressure catheter was inserted into the femoral artery. The catheter was secured via ligatures around the artery. The biopotential leads were subcutaneously secured in an approximate Lead II configuration. The positive lead was kept on the left side of the caudal thorax. The negative lead was put near the thoracic inlet on the right side of the thorax (Henriques 2010). The study indicated that placing leads directly on the epicardium remarkably decreases signal interruption due to room disruptions and subsequent animal exhilaration. This surgical technique showed adequate sensitivity to monitor changes in ECG parameters, specifically QTc interval prolongation in monkey.

Non-Human Primate (NHP) LVP Implant Telemetry Surgery

ECG leads were placed in a base-apex epicardial arrangement according to a general method previously reported in the non-human primate to optimize the consistency and amplitude of ECG component waveforms (Moddrelle 2012).

A left thoracotomy from the 5th intercostal space was done and the heart cradled in the pericardium. The bio-potential leads were inserted to the 7th intercostal space, entered the thorax, and trimmed and tied to expose a loop of bare wire. The positive biopotential lead was attached to the epicardial surface of the LV near the ventricular apex with non-absorbable suture. The negative bio-potential lead was kept in the neighborhood of pericardial fat tissue near the mediastinal aspect of the heart/base of the right atrium by non-absorbable suture. TL11-M3-D70-PCTP (DSI) LVP catheter was introduced via the LV apex using an intermedullary pin, and secured within the LV using non-absorbable suture. Telemetry (D70-PCTP) signals were continuously evaluated during surgery to confirm functionality of the telemetry probes and optimize the ECG based on lead arrangement. Telemetry data were collected two weeks later. Ventricular rhythm variants was significantly bigger in animals with LV catheters (62/67; 93%) compared to animals with epicardial leads only (21/55; 38.2%) and surgically naïve animals (9/18; 50%) (Holdsworth 2014). The catheter/transducer implantation surgery causes inflammation, damage and cardiac tissue scar in the vicinity of the ventricular apex which is usually for catheterization (Henriques 2010). Myocardial damage caused by acute puncture injury through the ventricular apex and catheter placement was able to induce ventricular arrhythmias (Sarazan 2011; Sarazan 2012), the continued

interaction of the catheter with adjacent transmural and endocardial tissues with potential associated foreign body response (Anderson 2008; Baird 2013).

TELEMETRY APPLICATIONS IN EXPERIMENTAL SURGERY FOR RESPIRATORY DISEASES

Respiration is an important vital sign, especially for patients suffering from sleep apnea syndrome, asthma and chronic obstructive pulmonary disease. Many parameters, such as respiratory CO_2 emission, respiratory airflow, respiratory sounds and the kinematics of chest or abdomen associated with respiratory activity, can be used for respiration monitoring. The respiratory-related chest or abdominal movements are the most common measured parameters.

The mechanical properties of the lung and ventilatory parameters (breathing patterns) are often monitored for evaluating respiratory function. The volume and flow changes associated with breathing patterns can be estimated directly by using a plethysmograph chamber or a pneumotachometer attached to a mask or a tracheal catheter. Changes in lung airflow can also be assessed by measuring thoracic displacement using inductive or impedance pneumography or sonomicrometry. Lots of methods have been adapted for application to conscious animals. IPP needs to be monitored to directly evaluate the mechanical properties of the lung.

IPP Measurements

IPP was monitored chronically in conscious monkeys after the catheter of radiotelemetry transmitter TL11M3-D70-PCP (DSI) was implanted beneath the serosal layer of the esophagus and within the thoracic cavity **(**Murphy 2001). This technique expedited the assessment of the effects of drugs, environmental agents, or disease on respiratory function by repeated measurements of respiratory function in a free moving nonhuman primate.

Flunixin meglumine (1 mg/kg IM) and acetylcholine (0.025 mg/kg IM) were given to monkeys. Anesthesia was induced by ketamine (10 mg/kg IM) and maintained by isoflurane (1–3%) delivered in 100% oxygen. A feeding tube was inserted to the stomach. The telemetry transmitter body was sutured to the abdominal wall after midline laparotomy was performed. Two retracting sutures were positioned in the stomach just below the cardia. The esophagus was found at the point where it enters the diaphragm and a suture was prepared at this site. An incision was performed through the serosal layer of the esophagus. A modified groove director was put between the muscularis and serosal layers and approached cranially through the diaphragm along the dorsolateral aspect of the esophagus guided by the feeding tube. The pressure catheter was advanced to the thoracic cavity. IPP was confirmed and a negative deflection was verified with each respiratory effort. The position of catheter was adjusted until a maximal change in pressure (>4 mmHg) was obtained. The catheter was fixed by the preplaced suture. The position of the catheter was verified by transesophageal ultrasound imaging.

The IPP measured by telemetry in rats was very inconsistent. Excessive struggling during the infusion periods caused the variability (Ewart 2010). Changes in IPP were measured by

pressure sensitive tips of surgically implanted telemetry devices TA11PA-C40. Rats were anaesthetized using 2–4% isoflurane mixed in 3 L/min oxygen and the fur shaved from the inguinal area to the sternum. Rats were prepared under strict aseptic conditions with analgesia (0.01 mg/kg buprenorphine). The surgical area was then disinfected and a central abdominal incision was made. The lobes of the liver were carefully held back by moist cotton swabs and the esophagus was separated about 2 cm below the junction with the diaphragm. A trocar was inserted between the serosal and muscularis layers and tunneled cranially the thoracic cavity from the juncture with the diaphragm. The catheter of the telemetry implant was inserted into the channel after the trocar was removed. The pressure signal was monitored to confirm correct placement of the transmitter. The catheter of the transmitter was fixed in place at the entry point with Vetbond and a cellulose patch (DSI) after a pressure signal of maximal strength (amplitude of at least 20 cm H_2O) was reached. The body of the transmitter was kept in the peritoneal cavity. The wound was closed in layers.

Preclinical respiratory safety pharmacology studies are routinely performed in several animal models including rat, mouse, dog and monkey (Flandre 2003; Schierok 2000; Baldrick 2008; Murphy 2001). A new implantation device for large animals was designed at WIL Research Laboratories, LLC (WIL) in cooperation with DSI (Kearney 2010). The device joins an impedance-based sensor and lead set for the evaluation of respiratory function to the standard cardiovascular telemetry device used in large animals.

Beagle dogs were implanted with a prototype telemetry device similar to the TL11M2-D70-PCT transmitter (DSI), which can collect ECG (lead II configuration), BP, and BT in addition to respiratory data via impedance leads (Kearney 2010). The telemetry implant body was kept in the pleural cavity. Impedance leads were tunneled subcutaneously to a lateral midline incision. Impedance leads were fixed to the intercostal space at this position. Lead position was modified during each surgery in order to improve the signal quality and establish a standard procedure for this new surgery.

The results suggest the feasibility of further validation and application of implantable impedance in safety pharmacology studies, in order to obtain the advantage of chronic, simultaneous (time-matched) collection of cardiovascular and respiratory data in ambulatory setting, with the reduction of animal use and resources (Samson 2011). Identification of drug effectiveness using population based conversion factors promotes the potential application of this tool for fast screening of candidates and decrease of pre study positive control calibrations. Implantable impedance technique may also show advantages over externally placed devices through increased sensitivity and decrease in user error owing to less components. External systems are influenced by variation because of movement of bands following calibrations. No such concern is related to implanted devices, because the position of the impedance sensor should keep steady throughout the duration of the implant.

A new telemetry device was implanted in Göttingen minipigs to monitor transthoracic impedance to approximate respiratory tidal volume and rate (Willens 2014). The telemetry device was kept in a retroperitoneal pocket. Paired biopotential leads were secured intermuscularly at the position of the seventh rib midway between sternums bilaterally and spine to supply substitute data for respiratory function. Multiple cardiopulmonary endpoints were evaluated by telemetry in restrained, conscious rabbits (Horsmon 2016).

Telemetry Applications in Experimental Surgery for Digestive Diseases

Telemetry capsules were provided to monitor temperature, pH or pressure inside the gastrointestinal (GI) tract. These capsules were expected to substitute invasive techniques in the diagnosis of function disorders in the GI tract. Nevertheless, problems such as signal loss and uncertainty of the pills position restrained their application in a clinical setting.

The pH telemetry capsules (Bravo1 capsule) from Medtronic, Inc. (Minneapolis, MN) were calibrated ten minutes before dosing according to manufacturer's instructions (Sagawa 2009). Continuous pH measurements were monitored with Bravo capsules to explore the time course of gastric pH regarding gastric residence times (GRTs) and meals in dogs. Experiments were performed in home cages or study cages, and meals were provided at designated times. The dogs maintained fasted gastric pH acidic in both the study and home cages. The pH was usually increased for dogs in home cages and kept acidic for dogs in study cages when feeding time is close. The gastric pH maintained acidic during meal consumption and for at least 10 h after meals in both home cage and study cage. The GRTs between fasted (25 ± 32 min) and fed (686 ± 352 min) state was notably different with sizable inter- and intra-subject variability. Dogs had similar fasted gastric pH as monkey and human. But gastric pH of dogs remained acidic after meals. Dogs had shorter GRTs in fasted state and longer GRTS under fed conditions compared to humans (Mahar 2012).

A bidirectional telemetry system was designed and validated for measuring gastric slow wave activity (Farajidavar 2012). This device measured slow wave for the first time with an adequately high signal quality for recognizing individual slow wave activation times. The system was displayed to be extremely dependable and power efficient, and its small size made it portable and suitable for implantation.

A telemetry capsule system was produced and applied to record the slow wave activity of the small bowel which is a vital parameter for the diagnosis of gastric diseases (Woo 2010). The slow wave signal from the intraluminal electrodes was increased by the capsule which transferred the digitally sampled data by a radio frequency transmitter. The capsule (11 × 21 mm^2) was smaller than a capsule endoscope, and it kept active for at least 18 h.

An intra-abdominal monitoring implement, with a pressure sensor and electrodes within the gastric wall, enabled the continuous measurement of the intensity and frequency of contractions at the same time with an electromyogram (EMG) (Burger 2006). A representative inter-digestive mobility cycle was duplicatable in fasting dogs. The pressure curve increased considerably within 15 min of feeding and achieved its peak 30-45 min post-prandially. The peak frequency also obviously increased instantly after feeding and achieved the peak of 22 contractions per 5 min. Passive telemetry was confirmed to be an appropriate method for the long-term study of the physiological gastric motility and the effect of food additives in dogs.

For the abdominal implantation of the measurement device, the dogs were provided full anesthesia induced by the IV administration of thiopentone 20 mg/kg body weight. Then endotracheal intubation anesthesia was induced and kept with nitrous oxide and oxygen (2:1) and halothane (1–2%).

The stomach was exteriorized for the placing of the pressure sensor from the abdominal incision. At the caudal side of the stomach, 2–3 cm from the pylorus and half way between the major and the minor curvatures of the stomach, a 1.5 cm long incision was performed through the muscle layer, so that the mucosal layer was protruding through the incision. The

muscle layer was undermined within the submucosa with a forceps and the mushroom-like sensor head was put in this pocket in such a way that its diaphragm was lying on the mucosa and orientated towards the lumen of the stomach. The incision was then closed. The cable was also secured with a 5 cm long suture sling at the corpus area of the stomach to relieve the tension and the suture was 7 cm from the sensor head. The three electrodes were introduced into the muscle layer with a cannula and fixed with single sutures. EMG wires were also fixed with a long suture sling about 4 cm from the implantation site to reduce the tension. Sensor and EMG wires were connected by separate cables to the transponder case which was outside of the omentum major in the abdomen. The ring antenna was fixed onto a ring made of polyvinylchloride.

Continuous intra-abdominal pressure was monitored by a motility capsule in pig (Rauch 2012). The intra-vesical pressure varied from 3 to 15 mmHg recorded through the bladder. The intra-gastric pressure by the capsule fluctuated from 1 to 3 mmHg. Stomach pressure monitored by motility capsule underrated the intra-vesical pressure. Difference between intra-vesical pressure and gastric pressure could be produced by different position of the 2 devices to the zero reference point and gastric dilatation (Rauch 2012).

A new multi-channel wireless mapping system was designed to measure slow wave signals from the porcine gastric and intestinal serosa in vivo (Paskaranandavadivel 2015).

The device obtained high quality signals, and has the possibility to promote chronic measurement studies and clinical translation of spatiotemporal mapping.

The Smart Pill wireless motility capsule (WMC) system was approved by FDA to assess suspected delayed emptying in functional dyspepsia and gastroparesis. The device can monitor transit in the colon, small intestine and stomach by finding characteristic pH transitions, and evaluate pressure waves in each gut region (Hasler 2014). Accumulative benefits of WMC testing in patients with suspected gastroparesis comprise representation of pressure abnormalities, colonic and small intestinal transit delays. The effect of WMC methods in patients with upper gastrointestinal motor disorders and suspected gastroparesis will be validated in multicenter studies.

Telemetry Applications in Experimental Surgery for Obstetrics and Gynecology Diseases

About 20% of pregnant women are at high risk of preterm labor. 12.7% of babies born each year are premature in United States (Center for Disease Control and Prevention and National Center for Health Statistics data for 2005). Preterm labor explains 85% of infant mortality and 50% of infant neurological disorders (Callaghan 2006). The early detection of labor is very important for the treatment of preterm labor. Prediction of labor in normal pregnancies plays a *crucial* role in reducing unnecessary hospitalizations, interventions and expenses. Also, correct diagnosis of preterm labor will permit practitioners to begin therapy early in patients with true labor and avoid unnecessary treatment and hospitalization in patients who are not in true labor. Classification of pregnant patients and correct diagnosis of preterm labor are still crucial challenges in obstetrics. Uterine EMG has demonstrated considerable assurance for surveilling patients during pregnancy.

Genetically modified mouse models have been established to explore the signaling pathways crucial to labor-both preterm and term. Human and mouse are similar regarding

many of the pathways involved to alter pregnancy outcome although there are some differences in parturition between these species (Mitchell 2009). Mouse models of modified parturition comprise those in which abnormal cervical ripening, progesterone withdrawal, myometrial contraction, or the circadian rhythm is affected (Ratajczak 2008). Modifications in individual genes can affect different pathways to parturition and finally cause a change in myometrial contraction. Although measurement of isometric tension can bring characterization of changes in uterine contraction associated with abnormal pregnancy in the mouse, they are limited to one stage of pregnancy rather than providing a comprehensive view of contractile and pressure changes over the course of pregnancy and delivery. Moreover, the animals need to be euthanized in this method. Therefore evaluation of the innate progression of labor or its initiation is impossible.

Rat IUP measurement by radiotelemetry was reported (Mackay 2009; Shi 2008). Telemetry transmitter (c50-pxt, DSI) was fixed to the abdominal wall with two wires placed in the myometrium for recording EMG activity and the catheter was passed into the uterine cavity for IUP measurement during labor. This method was useful for uterine EMG and IUP measurement, without adverse effects on delivery morbidity rates or mortality (Kothari 2008).

Radio telemetry transmitter was prepared according to the method described in mice abdominal aorta implantation. All surgical procedures were performed using aseptic surgical techniques. The abdominal cavity was opened using the ventral midline incision after anesthesia was induced and maintained. The uterus was carefully exposed and the total pups were counted. Catheter was inserted through a small incision at the top of one uterine horn. The pressure catheter was cautiously put in the uterine horn between the uterine wall and fetus by vessel cannulation forceps. The transmitter was carefully put in the lower portion of the abdominal cavity to avoid damage to the liver, and the implanted horn was kept in the body cavity. Soft food was given to animals from after surgery through to post-delivery to ameliorate maternal outcome.

The effect of telemetry was evaluated in both wild-type (WT) mice and defective parturition mice (SK3 channel-overexpressing mice) after telemetry implant was placed in the uterine horn. Uterine contractions were reduced and delivery was delayed in SK3 channel-overexpressing mice (Bond 2000; Pierce 2008). Continuous measurements from day 18 of pregnancy through delivery showed that WT mice usually delivered during the 12-h dark cycle after 19.5 days postcoitum. IUP slowly rose during this cycle to threefold higher than that recorded during the 12-h cycle before delivery in in WT mice. The SK3 channel-overexpressing mice displayed lower intrauterine pressure over the same period. These studies suggest that radiotelemetry can be applied efficiently to investigate uterine contractions, as part of the full characterization of genetic mouse models of disrupted labor.

Preterm labor (PTL) and uterine contractions in pregnant *cynomolgus* monkeys was assessed by a telemetric-based model (Chellman 2004). EMG and IUP were measured continuously as indicators of uterine activity. A pressure sensor was inserted into the amnion of pregnant monkeys on gestational day 120 ± 3 and biopotential sensors were fixed to the uterus. A telemetry transmitter was kept in a subcuticular pocket located in the flank. EMG and/or IUP were measured continuously post-operatively. IUP is a trustworthy parameter for recording intrauterine activity. A close relationship between IUP increase and bursts of activity in the EMG was observed. Basal uterine activity during the day with irregular contractions of <10 mmHg was recorded in animals close to term. In the night, spontaneous contractions (10–40 mmHg) happened every 3–6 min. 5–60 mU oxytocin (OT) per kilogram

per hour infusion caused artificial contractions of 15–40 mmHg that imitated preterm labor. These contractions kept unchanging for up to 14 h of constant infusion of OT and demonstrated a dose-dependent response to OT. Contractions went to baseline within 1 h after OT was removed. No desensitization of oxytocin-triggered contractions was shown when oxytocin was given daily for up to several weeks. This telemetric model typifies uterine contractions in NHP and supplies an outstanding method to assess pharmacological characteristics of drug candidates for PTL treatment (Chellman 2004).

Transgenic and knockout mouse are useful models in the investigation of genes affecting the timing and/or progression of labor contractions. Mice telemetry surgery methods for IUP measurement were shown (Pierce 2010; Rada 2015). IUP monitoring in the mouse from mid-pregnancy until delivery by telemetry was illustrated in detail (Rada 2015). This method may accelerate the development of therapeutics for myometrial disorders during pregnancy, including preterm labor (Rada 2015).

TELEMETRY APPLICATIONS IN EXPERIMENTAL SURGERY FOR UROLOGICAL DISEASES

RPP is important for the regulation of renal functions, such as sodium excretion, renin release and blood flow autoregulation. Different physiological controllers adjust renal function by their direct effects on intrinsic hemodynamics and renal tubular functions within the kidneys as well as indirect effects by amending RPP. Furthermore, many pathogenic factors may cause renal injury also through their direct destructive actions on the kidneys (RPP independent) and indirect destructive actions by modifying RPP that induces renal dysfunction (RPP dependent) (Cupples 2007, Mattson 2003; Mori 2006). To investigate the effect of RPP on renal function and dissect the pressure-independent and -dependent effects of different renal or cardiovascular controllers, an equipment to control the RPP is needed. Various servocontrol systems have been established for application in different animal models (Mori 2004; Nafz 1992). Nevertheless, these servocontrol systems were produced to utilize analog signals of BP acquired from indwelling arterial catheters and are difficult to establish and maintain.

An RPP servocontrol system with telemetry pressure device and LabVIEW computer software (National Instruments) was reported (Xia 2008). Lower abdominal aorta pressure in rats was measured by telemetry which reflected RPP. A computer program (LabVIEW) estimated the RPP data with a predetermined pressure setting and operated a bidirectional syringe pump to manage the inflation of a vascular occluder around the aorta above renal arteries.

The implantable carbon paste electrode (CPE)-telemetry system for PO2 assessment was described in detail (Koeners 2013). Briefly, reference electrodes and carbon paste were put in the renal medulla, while the auxiliary electrode was coiled and positioned on top of the kidney. Electrodes were kept to the renal capsule by a piece of surgical mesh glue and the leads were fixed on the aorta. The telemeter was placed in the abdomen. Each rat was put on a SmartPad that allowed transcutaneous recharging and continuous recording.

Vesico-urethral function can be assessed in animal by cystometry and urethral pressure profilometry or by electromyography under general anesthesia. Anesthesia can reduce bladder

and urethral pressures and inhibit the micturition reflex. Urodynamic telemetry takes noteworthy benefits for urologic research and has been shown in pigs (Mills 2000), dogs (McCafferty 2009; Noël 2013) and monkey (Ghoniem 1996). Urodynamic telemetry can decrease stress to the animals because animal handling or chemical restraint is not needed. Anesthesia and catheters in bladder or urethra are known to change the micturition reflex.

A ventral midline celiotomy was made and the transmitter body was fixed subcutaneously to the left abdominal wall. The leads of the transmitter were entered the abdominal cavity from the abdominal wall. The first pressure catheter of transmitters TL11M3-D70-PCTP (DSI) was placed into the bladder through a hole made in the ventral bladder wall and was fixed to the bladder wall. The second pressure catheter was put free in a posterior intraabdominal position. The two EMG leads were kept in the smooth muscle part of the urethral wall at the level of the cranial third of the urethra, and fixed with simple interrupted sutures. The abdomen was routinely closed.

Long-term study of the lower urinary tract by telemetry should be performed during the night to obtain repeatable recordings due to circadian variations. The investigation of urethral smooth muscle function by EMG needle electrodes seems to be a practicable technique to evaluate the effects of drugs with urethral tropism.

Continuous measurements of pressures in the bulb of the corpus spongiosum of the penis (CSP) in awake, freely moving rats enables for simultaneous recording of erectile and micturition events (Nout 2007). Monitoring of CSP pressures can be conducted 8–12 weeks in conscious animals, and the methods have recently been verified in rats. New method to simultaneously monitor micturition and erections in rats by telemetry in the CSP was established (Nout 2007). The catheter of telemetry pressure implant was placed in the bulb of the CSP. CSP pressure was measured. Micturition was recorded by video to determine *presence and volume* simultaneously. Behavioral tests were performed to determine erection. Micturition duration measured by CSP pressure and volume calculated by urine weight were greatly matched. 100% of visually verified erectile events happened simultaneously with CSP pressure waveforms characteristic of erections during ex copula reflex erection tests. Telemetry found more erections during noncontact erection and mating tests compared to observation alone. Erections were shorter in duration and usually were characterized by a single suprasystolic CSP pressure peak. Quality of measurements kept stable for 8 weeks. Telemetric measurement of CSP pressure supplies a quantitative and qualitative evaluation of penile erections and micturition in freely behaving rats.

The major complications of spinal cord injury (SCI) include disruption of bladder function and sexual reflexes. Telemetric monitoring of CSP pressures was reported to evaluate micturition and erectile events following SCI in rats (Nout 2007). Pressure catheter was implanted in the bulb of the CSP rat. Telemetry measurement of CSP pressures in conscious rats is a precious and dependable technique for evaluating recovery of autonomic function following SCI (Nout 2007).

The advantages of telemetry measurement for intraspongiosal pressure (ISP) and ICP1 were summarized (Shamloul 2008). First, it enables for qualitative and quantitative evaluation of erectile responses in experimental animals which is not possible by other techniques. Second, it also enables for monitoring of "real" ICP1 and ISP changes in conscious animals subjected to different sexual stimuli. Third, telemetric measurement can monitor intrapenile pressure changes at different time points. Thus the data collected are more reliable particularly in behavioral studies. Fourth, this technique takes the advantage of being able to

analyze ICP1 changes in copulating male animals during actual sexual contacts with their females, supplying precious data on physiological changes occurring during mating. Fifth, extensive analysis of ICP1 and ISP changes during reflexive erection, non-contact erection and drug-induced erections can be only performed by telemetric recording. Sixth, ISP telemetry measurement in mice enabled to recognize a series of extended ISP peaks that easily corresponded to ejaculation (Soukhova-O'Hare 2007). Lastly, telemetry technique can be used to set ICP1 cut-off values for full erectile response to solve the issue of partial vs. full erectile response for behavioral evaluation of erectile responses. The application of telemetric measurement of ICP1 and ISP may become the gold standard method for evaluation of erectile responses.

The pressure of CSP was recorded by telemetry (Gulia 2008; Nout 2007; Salas 2007). In brief, the catheter tip of the telemetric transducer (TA11PA-C40 DSI) was inserted into the bulb through a slit made by a needle after the distal portion of the bulb of the CSP was gently exposed. The implant body was secured subcutaneously to the abdominal muscle. The catheter was fixed at entrance of the catheter by biological glue and was sutured to the fascia overlying the shaft of the penis.

Urinary incontinence (UI) is a frequent and disturbing problem which may affect the quality of life in the elderly, diabetics and autistic children. UI may also induce other complications including kidney failure and infections. Bladder sensors are needed for UI patients without sensation after bladder urine volume/pressure is over normal ranges. Pressure variations are recorded by a catheter-based sensor which is kept in bladder from the urethra. Disturbances in catheter lines can influence the accuracy of the measurement. Furthermore, infection can be induced by prolonged use of this method. Implantable telemetry sensors for bladder volume/pressure measurement would enable long-term measurement in the bladder and keeping the quality of life (Dakurah 2015).

A telecystometric implanted minipig model was established which can be used to explore the circadian behavior and physiological and pathological bladder function (Huppertz 2015).

Telemetry was used to monitor the systemic and urodynamic parameters in lower urinary tract dysfunction (LUTD) in rats induced by experimental traumatic brain injury (TBI) (Moody 2014). Telemetry measurement established that moderate TBI was a risk factor for neurogenic bladder disorder.

A new approach to cystometry by telemetry in conscious rats with cyclophosphamide-induced bladder dysfunction was reported (Monjotin 2016). Bladder pressure and voided volume are able to be measured in both anaesthetized and conscious animals by conventional cystometry. In conscious animals, bladder infusion cystometry can be influenced by several experimental biases which include the decreased movements of the animal, an under-estimation of the sensory element for triggering the micturition cycle and the compound of the infusion fluid. Radio-telemetry can continuously measure physiological parameters in fully unrestrained and more physiological conditions. A similar technique was established in beagle dogs (McCafferty 2009) or in minipigs (Huppertz 2015).

PA-C40 (DSI) telemetry implant was kept on the right side of the abdominal cavity and fixed on the abdominal wall in order to avoid contact with the bladder (Monjotin, 2016). The pressure catheter was put in the dome of the urinary bladder and sutured with 6-0 silk. The quality of traces and parameters recording monitored by telemetry were similar to those with conventional cystometry. This telemetry measurement is as precise as conventional cystometry. Compounds for modulating the voiding patterns may be assessed repeatedly by

telemetry. Telemetry can be used to monitor the physiological and pathophysiological functions of the bladder. Telemetry will enable the pharmacological assessment of compounds for bladder function.

Renal sympathetic nerve activity (RSNA) and BP was measured by telemetry in two-kidney, one-clip rat model with renal denervation by cryoablation of the renal nerve to the clipped kidney (Rossi 2016). The catheter of the radio telemetry implant (TA11PA-C40; DSI) was inserted into the femoral artery and then advanced into the abdominal aorta after renal artery clipping was completed (Rossi 2016). The telemetry probe (Telemetry Research TR46S, Auckland, New Zealand), including BP and nerve electrode components, was implanted according to a modification of the technique (Stocker 2013). Briefly, left groin incision and left flank incision were made. A tunnel was made subcutaneously from the femoral area to the flank. The electrode wires from the transmitter were passed through this tunnel for subsequent placement. The catheter with BP telemetry probe was inserted into the left femoral artery and fixed. The left renal nerve was separated under a stereomicroscope. The nerve was carefully put onto the exposed ends of the electrode wires from the transmitter. The silicone casing of the proximal ends of the wires was then stabilized by anchoring it with 6-0 sutures to the adventitia of the aortic wall. The electrodes position and the nerve signal quality were determined by assessing the nerve sound by an audio monitor and confirmed by an oscilloscope. Then, the nerve and electrodes were covered with silicone gel (Kwik-Sil; World Precision Instruments, Sarasota, FL).

TELEMETRY APPLICATIONS IN EXPERIMENTAL SURGERY FOR NEUROLOGICAL DISEASES

Early diagnosis of shunt malfunction is crucial in preventing neurological morbidity and death in patients with hydrocephalus. Diagnostic techniques for shunt malfunction are limited. Implantable ICP2 monitor cannot be used to diagnose shunt malfunction for long term due to limited instrumentation lifespan, marked measurement drift and device complexity. Baric probe was produced to resolve these problems (Limbrick 2012). It includes a subdural fluid bladder and multichannel indicator that traces the location of an air-fluid interface. A handheld ultrasound probe is applied to examine the baric probe *in vivo* for noninvasive ICP2 measurement. Short- and long-term *in vivo* experiments were done in a porcine model with concurrent measurements of ICP2 by a fiber optic monitor. Baric probe, the long-term implantable ICP2 monitor produced to promote the prompt and accurate diagnosis of shunt malfunction. The baric probe demonstrated a constant linear relationship between ICP2 and the device's AFI in short- and long-term *in vivo* models.

Patients with head injury, idiopathic intracranial hypertension and hydrocephalus often need measurement of ICP2 and may require repeated recording for months or years. The gold standard for assessment of ICP2 is the external ventricular catheter. All the ICP2 recording tools in current clinical application need a physical connection between the brain and the external environment. The duration of measurement is limited due to infection. Telemetric recording implements have been produced but remarkable technical problems have prevented their application in routine clinical practice. All available ICP2 detectors are nonpermanent

percutaneous implanted devices. Placement of these devices involved remarkable morbidity, especially infection. Repeated monitoring for patients needs several surgical procedures.

Precise telemetric ICP2 monitoring system can reduce the risk of infection in patients with severe head injury and keep its high reliability for a long time. Several neurosurgical conditions need careful control of ICP2 over several years to assure an acceptable outcome, such as idiopathic intracranial hypertension, hydrocephalus treated by endoscopic third ventriculostomy or a VP shunt. ICP2 is monitored by lumbar puncture tapping or by a ventricular access device for these situations. These invasive procedures, often necessary in children, have a risk of infection. Now ICP monitors display a notable zero drift of the sensor over time which excludes them from long-term use since the sensor of the implant cannot be recalibrated.

An implantable telemetric device would control many of the problems currently related to ICP2 measurement. Telemetry would enable the ICP to be recorded non-invasively at home; symptoms could then be easily assessed and the necessary adjustments to a programmable shunt, when present, could be done and confirmed. A fully implantable ICP2 sensor was designed for long-term use by utilizing micro- and nanotechnologies as well as advanced packaging technologies. The sensor implant includes an absolute capacitive pressure sensor and readout integrated circuit with ultralow power consumption and so an implanted battery does not need a power supply, which would otherwise limit the implant's lifetime. The implant is produced in a way so that it can be inserted as stated in the confirmed minimally invasive procedures known from current ICP monitors. The monitoring tip can be put either in the brain parenchyma or ventricle while the telemetry unit is placed outside the cranial bone directly under the skin for optimal linking to the external unit (Frischholz 2007).

EEG was measured by EEG telemetry transmitters of the 10–20 system in Cynomolgus monkey, Beagle dog and Sprague–Dawley rat (Bassett 2014). Pentylenetetrazol (PTZ) was given intravenously as a positive seizurogenic agent to decide seizure threshold. Premonitory clinical signs usually comprised hypersalivation, ataxia, emesis (except in rats), reduced physical activity, increased physiological tremors, and myoclonus.

The telemetry transmitter was kept between the aponeurosis of the transversus abdominis muscle and the internal abdominal oblique muscle for monkey. EEG electrodes were tunneled subcutaneously to a small skin incision in the neck. EEG leads (TL11M2-D70-EEE, DSI) were fixed on to the skull bones to measure three standard bipolar derivations (C3-O1, C4-O2 and Cz-Oz) by the 10–20 electrode system. A linear groove was performed in the cranial cortical bone to fix the electrodes with surgical glue Vetbond and acrylic. EMG recording was acquired by electrodes fixed to longitudinal muscles in the neck area and measured continuously with the telemetry transmitter. Measurement was performed three weeks after the surgery.

A telemetry transmitter (TL11M2-C50-PXT or F40-EET, DSI) for EEG measurement was used with one standard bipolar derivation (Fz-Oz) in rats. Penicillin G procaine (1.0 mL, 300 000 IU/mL) was given SC once daily for three days beginning on the day of surgery. Buprenorphine (0.04 mL, 0.3 mg/mL) was provided twice daily for three days. Local anesthetics (Bupivacaine, 0.25%, 0.1 mL; Lidocaine, 20 mg/mL, 0.1 mL) were given in 4 SC sites dispersed over the skull surgical site. The animal was put on a heating pad under the anesthesia of isoflurane. The telemetry transmitter was fixed in the abdominal cavity. The electrodes of EEG and EMG were tunneled subcutaneously to the neck skin incision. The abdominal skin incision was closed and the animal was kept in sternal recumbency to uncover

the skull during the surgery. The EEG leads were fixed on the cranial bone to record one bipolar derivation while EMG leads were fixed to muscles of the neck. A linear groove was performed in the cranial cortical bone to fix the electrodes with surgical glue Vetbond and acrylic. Measurement was performed three weeks after the surgery.

Telemetry video-EEG for seizure liability studies was described in rats, dogs and NHP. Rats are a preferred model in seizure liability evaluations. Beagle dogs are commonly connected with overt susceptibility to seizure and are usually utilized in seizure liability investigations only if needed by regulators. NHP is a vital model in seizure liability evaluations, provided similarities to humans and a high translational potential.

A portable measurement system and techniques for acquiring chronic monitoring of single units and tracking rhesus monkey behavior in an open field was reported (Lei 2004). The techniques supply a new way to evaluate correlation between NHP behaviors and single neuron activity, and are also useful to investigate the cellular basis of NHP social behaviors.

Implantation of the device in masticatory muscles was able to evaluate the signals and ascertain the activity levels for daily muscle application (Langenbach 2002). Analysis of the transmitted EMG disclosed that the device can be utilized for prolonged in vivo EMG registration, identification of peak activity levels, and the evaluation of general muscle use by the time spent at different levels of activity.

Video-EEG measurement is a standard diagnostic method in humans. Its application in telemetered freely moving macaque monkeys for safety pharmacology study is limited. Rodents are usually used for proconvulsant risk assessment. NHP was used in toxicology and safety pharmacology. Telemetry implants were instrumented in cynomolgus monkeys (Authier 2009). EEG-video recording can be helpful to characterize neurological unfavorable effects with unforeseeable onset in NHP. Computerized video-EEG analysis was a precious method for safety pharmacology studies including proconvulsant risk evaluation, spectral analysis of frequency bands and sleep stage confirmation.

Pre-clinical animal models of human neurologic diseases can slowly develop the disease and be used to evaluate the interventions at various stages of the disease process. EEG continuous measurement in immature rodents models of seizures and other neurological disorders has a technical challenge due to the small physical size of immature rodents and their dependence on the dam prior to weaning (Zayachkivsky 2015).

The autonomic nervous system supervises involuntary control of different visceral organs such as the heart and blood vessel (Jänig 2006; Robertson 2012). The diagnostic methods for autonomic function evaluation have been established in laboratory animals. The limitations and usefulness of diagnostic methods was reviewed recently (Salman 2015). Telemetry was reported for the first time to simultaneously monitor BP and renal SNA in chronic renal dysfunction rat model (Salman 2015). The surgery details and techniques for monitoring renal, lumbar and splanchnic SNA in conscious rats was reviewed (Stocker 2013). Renal SNA and BP were able to be measured by telemetry in conscious mice (Hamza 2012). Brain tissue oxygen can be measured chronically by telemetry in conscious rats (Russell 2012).

TELEMETRY APPLICATIONS IN EXPERIMENTAL SURGERY FOR GLAUCOMA

Glaucoma is one of the important reasons of blindness in the developed world (Quigley 2006). Ocular hypertension is an important risk factor for glaucoma. To decrease ocular hypertension is the only confirmed-effective therapy for glaucoma. IOP dynamics and its contribution to the disease progression are monitored by the tonometry methods usually used in clinical practice. IOP measurements which are taken at patient visits are not enough to characterize pressure variations due to disease and typical daily pressure variations.

Animal model for glaucoma research needs precise and duplicatable measurements of IOP. The pneumatonometer (PTG) is the typical technique used in pharmacology and eye research. The major disadvantages of this technique are that the animals must be restrained and human intervention is needed. Furthermore, a local anesthesia needs to be topically provided before IOP measurements by PTG are obtained. This may interfere with the absorption pattern or activity of the new drug in experiment. Radio telemetry system was first used in rabbit to characterize IOP in response to pharmacological agents (McLaren 1996). It was also used in rats (Lin 2010), mice (Li 2008), pig (Leonardi 2009) and NHP **(**Downs 2011).

Rabbits were anesthetized with IM ketamine (50 mg/kg) 20 minutes after IM xylazine (10 mg/kg). Anesthesia was maintained by providing additional doses of xylazine (5 mg/kg) or ketamine (50 mg/kg) as required. Animals were prepared according to aseptic surgery method. A 4-cm midline incision was performed on the dorsal neck. Muscle over the vertebral column, between the scapulae and the connective tissue were separated to make a pouch to carry the transducer capsule. The right eye was used in all experiments.

Slight head position changes modify the altitude of the eye relative to the telemetry transducer, which may cause big errors in the IOP measurement for animals with a large head and flexible neck (Downs 2015). IOP transducers should be kept in the orbit or eye to reduce head position artifact for NHPs and other large animals.

Implantation of Transmitters for Measurements of IOP

The pressure transmitters TA11PA-C40 were implanted subcutaneously under aseptic conditions. The rabbits were shaved in the scalp region and put on a warmed sterile operative field after the anesthesia was induced and maintained. A small scalp incision was performed and one subcutaneous air pocket was prepared in the neck region. The transmitter body was sutured in the neck pocket, and its pressure catheter was tunneled subcutaneously to an exit site in the superior conjunctival sac of the implanted eye. The telemetry catheter was subsequently inserted in the midvitreous of the eye which was 3 to 4 mm behind the corneoscleral junction. It was fixed at the site of entry with tissue adhesive Vetbond. The skin incision was closed. IOP, MAP, HR, and motor activity were able to be accurately and reliably measured by telemetry in conscious freely moving rabbits. This technique can be applied to evaluate the effects of drug treatment on the parameters over short or long time in conscious rabbits under physiological conditions.

IOP Telemetry in NHPs

The benefits of the telemetry system from Konigsberg Instruments, Inc. (Pasadena, CA) included continuous measurement of IOP at a 500 Hz measurement frequency for about 24 months, low drift of < 3 mm Hg per month, direct calibration of implants by anterior chamber cannulation and manometry, and the transducer in the orbital wall adjacent to the eye (Downs 2011). The disadvantages of the system are cost, the surgery difficulty, and no replaceable battery (Downs 2011).

The IOP transducers is often kept under the skin in the nape of the neck or between the clavicles for rabbits, rodents, and other small animals whose eyes remain at about the same height as the pressure transducer during daily activity. For NHPs and other large animals, IOP transducers must be placed in the orbit or eye to minimize head position artifact (Downs 2015). IOP changes about 10 mm Hg from day to day and hour to hour in free moving nonhuman primates. It suggests that snapshot IOP recording may be insufficient to catch the true dynamic character of IOP (Downs 2011).

TELEMETRY APPLICATIONS IN EXPERIMENTAL SURGERY FOR ENDOCRINE SYSTEM DISEASES

Continuous blood glucose measurement is important for diabetic management because glycemic control can reduce the risk of diabetic complications such as heart diseases, diabetic retinopathy, stroke, kidney damage, and neuropathy. Various technical and biological challenges have limited chronic continuous glucose measurements for animal. New implantable glucose monitor HD-XG (DSI) was applied for continuous monitoring of plasma glucose levels in the arterial blood of rats (Brockway 2015). The catheter of HD-XG was inserted in abdominal aorta by the method as described for rat aorta BP implantation. Continuous measurements of glucose can last for 75 days or longer. Telemetry contributes significant advantages in the quantity and quality of data that can be obtained relative to existing methods. Telemetry gives the possibility to broaden the understanding of both glucose homeostasis and metabolism to improve treatment and cures for diabetes.

A new telemetry system for real-time simultaneous measurement of biosensor signals (brain glucose and lactate) and motion were reported (Rocchitta 2013). The device includes dual-channel, single-supply miniature potentiostat-I/V converter, a signal transmitter, a miniaturized microvibration sensor and a microcontroller unit. The device was validated and characterized before experiments. The biosensors were kept in the striatum of freely moving animals and the biotelemetric device was secured to the animal's head. The simultaneous monitoring of brain neurochemistry and motion could have an important effect in the study of motion-related disorders such as Parkinson's disease in freely moving animals treated with neurotoxins such as 6-hydroxydopamine, 1-methyl-4-phenyl-1,2,3,6-tetrahydropyridine, and/or rotenone.

The intravenous blood glucose (IVBG) system was used to investigate the accuracy, reliability and safety in 100 patients at 6 US hospitals (Bochicchio 2015). The results suggest that the IVBG system is an automatic and practical glucose monitoring system. It provides accurate and reliable blood glucose measurement which ameliorates the safety and efficacy of

insulin therapy and blood glucose control. Continuous glucose monitoring system can precisely determine blood glucose every few minutes (Joseph 2015).

TELEMETRY APPLICATIONS IN EXPERIMENTAL SURGERY FOR CANCER

Radiotherapy and/or chemotherapy with hyperthermia are encouraging strategies for cancer treatment. The key to success of this treatment is temperature control. Temperature measured by telemetry was valuable biomarker of disease progression in mice with lymphoma and could possibly be utilized more extensively to observe mice with other forms of cancer (Hunter 2014). The effects of therapeutic cancer vaccine CHP-NY-ESO-1 on the cardiovascular system were evaluated in dogs to monitor HR and BP by telemetry (Harada 2008). Cardiovascular system safety pharmacology study for resveratrol with cancer preventive activity was evaluated in dogs by telemetry (Johnson 2011).

In vivo sensors have been used to control the temperature changes in cancer cells during combined treatment (Kamal 2012). A smartphone was designed to manage temperature scheduling in *in vivo* sensors and communicate with local or remote clinicians to keep collaborative efforts for combined therapies against cancer.

Vomiting and nausea are usual side effects of cancer chemotherapy. Abdominal pressure measurement in ferret by telemetry is a trustworthy technique to observe emetic events which may accelerate the progress of anti-emetic treatment and new chemotherapeutic agents (Goineau 2013). Telemetry was used to evaluate the synergistic effects of ondansetron and aprepitant in cisplatin-induced emesis ferret model (Goineau 2014).

TELEMETRY APPLICATIONS IN EXPERIMENTAL SURGERY FOR ORGAN TRANSPLANTATION

Xenotransplantation is evaluated to resolve the crucial shortage of donor's organs with improvement of immunosuppressive strategies and the development of genetically modified organ-source pigs. Cardiac xenograft function assessment is hard and time consuming in a pig-to-baboon xenotransplant model. It has been traditionally achieved by palpation, ultrasound and biopsy. Frequent application of anesthesia to the baboon adds the chance of complications such as bleeding, infection, graft injury, morbidity and mortality rate. The animals can be monitored by radiotelemetry while they move freely within their cages. Telemetry has been reported to assess heterotopic cardiac allograft function (Chen 2000; Pirolo 1992; Groeneveld 1981; Koike 1988).

The reliable assessment of graft function provided clues for infection, rejection or loss of graft function. Frequent anesthesia of recipient baboons was avoided by the radio telemetry system to assess the cardiac function. BP, HR, EKG, activity and BT can be measured at the same time. Also, the radio telemetry system avoided manipulation by the primate recipients which were not able to endure external leads and recording devices well unless the animals were completely sedated or restrained. The technique supplied more humane treatment compared to the traditional methods (Chen 2000). Telemetric monitoring systems allowed

non-invasive, trustworthy and continuous evaluations of cardiac xenograft function and contributed precious information for the improved understanding of transplantation pathophysiology. Importantly, telemetry system avoided repeated anesthesia of the animals and was able to measure without the effects of anesthetics.

The telemetry transmitter (TL11M3-D70-PCTP DSI) has two pressure catheters and two biopotential leads. One pressure catheter was inserted into the xenograft's left ventricle through the apex and fixed by a 6-0 purse-string suture with pledgets. The other pressure catheter was implanted into the aorta. The two biopotential leads were sutured and fixed onto the ventricular epicardium for ECG monitoring. The telemetry transmitter was put in a subcutaneous pocket in the chest wall before the thoracic cavity was closed. The parameters LVPSP, HR, ± dP/dtmax and QRSA recorded by telemetry are reliable indicators of myocardial damage related to graft rejection at an early stage after cardiac xenotransplantation. The application of the telemetry system might help to guide immunosuppressive therapy and further improve graft survival in future experiments (Fan 2013).

The advantages of this implantable telemetry system include the ability to continuously measure transplanted heart function and recipient temperature remotely and supply accurate measurements of graft survival and management of immunosuppression. The loss of graft function was reliably detected by the radio telemetry measurement of LVP. The complications of LVP probe include bleeding from the LVP probe insertion site and LV cavity thrombus formation. Electrical cardioversion for fibrillation was not able to use with telemetry system. Telemetry system needed to be removed if cardioversion was required (Horvath 2010).

Telemetry was reported to measure cardiovascular parameters in rats that performed a T4 spinal cord transection with or without grafting of embryonic brainstem-derived neural stem cells expressing GFP (Hou 2014). In addition, cardiovascular parameters can be compared before and after spinal cord injury in the same rat.

LVP evaluation by telemetry is a useful method to assess transplanted heart function in experimental heterotopic cardiac xenotransplantation (Horvath 2010). The telemetry was also helpful to detect early onset of fever in the recipients, thus intervene early and prevent potentially lethal septic complications. Continuous measurement of several parameters via telemetry enabled identification of changes related to early complications and rejection. Proper intervention and treatment was given to reverse rejection.

Continuous telemetry measurement found increased ventricular arrhythmias in coronary artery ligated rats with transplantation by intramyocardial injection (Narita 2013) and myocardial infarction mice with transplantations of cell-derived cardiomyocytes (Liao 2013).

CONCLUSION

Radio telemetry techniques have been successfully applied in animal models of human diseases from different systems. The physiologic signals can be monitored chronically in conscious animals for a long period of time. The data quality has been ameliorated compared with conventional methods. These techniques will play an important role to prompt the preclinical research for clinical application.

REFERENCES

Anderson JM, Rodriguez A, & Chang DT. Foreign body reaction to biomaterials. *Seminars in Immunology* 2008; 20: 86–100.

Austin D, Bowen WD, McMillan JI, Boness DJ. Stomach temperature telemetry reveals temporal patterns of foraging success in a free-ranging marine mammal. *J. Anim. Ecol.* 2006; 75(2):408−20.

Authier S, Tanguay JF, Gauvin D, Di Fruscia R, Fournier S, Chaurand F, Troncy E. A cardiovascular monitoring system in conscious cynomolgus monkeys for regulatory safety pharmacology. Part 1: Non-pharmacological validation. *J. Pharmacol. Toxicol. Methods*. 2007; 56(2):115−21.

Authier S, Paquette D, Gauvin D, Sammut V, Fournier S, Chaurand F, Troncy E. Video-electroencephalography in conscious non-human primate using radiotelemetry and computerized analysis: refinement of a safety pharmacology model. *J. Pharmacol. Toxicol. Methods* 2009; 60(1):88−93.

Baird TJ, O'Donohue KP, Ward S, Eliel MW, Dalton JA, & Gauvin DV. Comparison of telemetry-derived epicardial and intravascular electrocardiogram signal characteristics in cynomolgus monkeys. *J. Pharmacol. Toxicol. Methods* 2013; 68: e36.

Baldrick P. Safety evaluation to support First-In-Man investigations I: Kinetic and safety pharmacology studies. *Regulatory Toxicology and Pharmacology* 2008; 51(2): 230−6.

Bassett L, Troncy E, Pouliot M, Paquette D, Ascah A, Authier S. Telemetry video-electroencephalography (EEG) in rats, dogs and non-human primates: methods in follow-up safety pharmacology seizure liability assessments. *J. Pharmacol. Toxicol. Methods* 2014; 70(3):230−40.

Bernabé J, Rampin O, Giuliano F, Benoit G. Intracavernous pressure changes during reflexive penile erections in the rat. *Physiol. Behav*. 1995; 57(5):837−41.

Bernabé J, Rampin O, Sachs BD, Giuliano F. Intracavernous pressure during erection in rats: an integrative approach based on telemetric recording. *Am. J. Physiol*. 1999; 276 (2 Pt 2): R441−9.

Bhatia R, Pagala M, Vaynblat M, Marcus M, Kazachkov M. Intrathoracic airway obstruction and gastroesophageal reflux: a canine model. *Pediatr. Pulmonol*. 2012; 47(11):1097−102.

Bochicchio GV, Hipszer BR, Magee MF, Bergenstal RM, Furnary AP, Gulino AM, Higgins MJ, Simpson PC, Joseph JI. Multicenter Observational Study of the First-Generation Intravenous Blood Glucose Monitoring System in Hospitalized Patients. *J. Diabetes. Sci. Technol*. 2015; 9(4):739−50.

Bond CT, Sprengel R, Bissonnette JM, Kaufmann WA, Pribnow D, Neelands T, Storck T, Baetscher M, Jerecic J, Maylie J, Knaus HG, Seeburg PH, Adelman JP. Respiration and parturition affected by conditional overexpression of the $Ca2^{+}$−activated K^{+} channel subunit, SK3. *Science* 2000; 289: 1942–46.

Braga VA, Prabhakar NR. Refinement of telemetry for measuring blood pressure in conscious rats. *J. Am. Assoc. Lab. Anim. Sci*. 2009; 48(3):268−71.

Brockway BP and Hassler CR. 1993. Application of radio telemetry to cardiovascular measurements in pharmacology and toxicology, p. 109–132. In H. Salem and S. I. Baskin (ed.), *New technologies and concepts for reducing drug toxicity*. CRC Press, Boca Raton, Fla.

Brockway R, Tiesma S, Bogie H, White K, Fine M, O'Farrell L, Michael M, Cox A, Coskun T. Fully Implantable Arterial Blood Glucose Device for Metabolic Research Applications in Rats for Two Months. *J. Diabetes. Sci. Technol*. 2015; 9(4):771−81.

Burger DM, Wiestner T, Montavon PM, Kündig H, Hubler M, Binder H, Arnold S. Long-term measurement of gastric motility using passive telemetry and effect of guar and cellulose as food additives in dogs. *J. Vet. Med. A. Physiol. Pathol. Clin. Med*. 2006; 53(2):85−96.

Burke SL, Lambert E, Head GA. New approaches to quantifying sympathetic nerve activity. *Curr. Hypertens. Rep*. 2011; 13(3):249−57.

Butz GM, Davisson RL. Long-term telemetric measurement of cardiovascular parameters in awake mice: a physiological genomics tool. *Physiol. Genomics*. 2001; 5(2):89−97.

Callaghan WM, MacDorman MF, Rasmussen SA, Qin C, Lackritz EM. The contribution of preterm birth to infant mortality rates in the United States. *Pediatrics* 2006; 118: 1566–73.

Carlson SH, Wyss JM. Long-term telemetric recording of arterial pressure and heart rate in mice fed basal and high NaCl diets. *Hypertension* 2000; 35(2):E1−5.

Chellman GJ, Bee WH, Resendez JC, Meyer JK, Bernal J, Moddrelle DS, Haluska GJ, Reinheimer TM. Telemetric uterine contraction model in preterm cynomolgus monkeys. *Reprod. Toxicol.* 2004; 18 (2): 285−93.

Chen RH, Kadner A, Adams DH. Monitoring pig-to-primate cardiac xenografts with live internet images of recipients and xenograft telemetric signals: histologic and immunohistochemical correlations. *J. Heart. Lung. Transplant*. 2000; 19(6):591−7.

Cools F, Dhuyvetter D, Vanlommel A, Janssens S, Borghys H, Geys H, Gallacher DJ. A translational assessment of preclinical versus clinical tools for the measurement of cardiac contractility: comparison of LV dP/dt(max) with echocardiography in telemetry implanted beagle dogs. *J. Pharmacol. Toxicol. Methods*. 2014; 69(1):17−23.

Cupples WA, Braam B. Assessment of renal autoregulation. *Am. J. Physiol. Renal. Physiol*. 2007; 292: F1105–23.

Dakurah MN, Koo C, Choi W, Joung YH. Implantable Bladder Sensors: A Methodological Review. *Int. Neurourol. J*. 2015; 19(3):133−41.

Dinslage S, McLaren J, Brubaker R. Intraocular pressure in rabbits by telemetry II: effects of animal handling and drugs. *Invest. Ophthalmol. Vis. Sci*. 1998; 39(12):2485−9.

Djurhuus JC, Frokjaer J, Munch Jorgensen T, Knudsen L, Pham T, Constantinou CE. Regulation of renal pelvic pressure by diuresis and micturition. *Am. J. Physiol*. 1990; 259(3 Pt 2):R637−44.

Downs JC, Burgoyne CF, Seigfreid WP, Reynaud JF, Strouthidis NG, Sallee V. 24-hour IOP telemetry in the nonhuman primate: implant system performance and initial characterization of IOP at multiple timescales. *Invest. Ophthalmol. Vis. Sci*. 2011; 52(10):7365−75.

Downs JC. IOP telemetry in the nonhuman primate. *Exp. Eye. Res*. 2015; 141:91−8.

Dutil J, Deng AY. Mapping a blood pressure quantitative trait locus to a 5.7-cM region in Dahl salt-sensitive rats. *Mamm. Genome*. 2001; 12(5):362−5.

Ednick MD, Pagala M, Barakat JP, Nino G, Shah P, Cunningham JN Jr, Vaynblat M, Kazachkov M. Telemetric recording of intrapleural pressure. *J. Surg. Res*. 2007; 138(1):10−14.

Ewart LC, Haley M, Bickerton S, Bright J, Elliott K, McCarthy A, Williams L, Ricketts SA, Holland T, Valentin JP. Pharmacological validation of a telemetric model for the measurement of bronchoconstriction in conscious rats. *J. Pharmacol. Toxicol. Methods.* 2010; 61(2):219−29.

Falcao S, Bisotto S, Gutkowska J, Lavoie JL. Hyperhomocysteinemia is not sufficient to cause preeclampsia in an animal model: the importance of folate intake. *Am. J. Obstet. Gynecol*. 2009; 200(2):198.e1−5.

Fan Jianping. *Application of Telemetry System in Xenogeneic Cardiac Transplantation Using a Heterotopic Thoracic Model*. PhD thesis 2013. https://edoc.ub.uni-muenchen.de/15955/.

Farajidavar A, O'Grady G, Rao SM, Cheng LK, Abell T, Chiao JC. A miniature bidirectional telemetry system for in vivo gastric slow wave recordings. *Physiol. Meas.* 2012; 33(6):N29−37.

Flandre TD, Leroy PL, & Desmecht DJ. Effect of somatic growth, strain, and sex on double-chamber plethysmographic respiratory function values in healthy mice. *J. Appl. Physiol (1985).* 2003; 94: 1129−36.

Frischholz M, Sarmento L, Wenzel M, Aquilina K, Edwards R, Coakham HB. Telemetric implantable pressure sensor for short- and long-term monitoring of intracranial pressure. *Conf. Proc. IEEE. Eng. Med. Biol. Soc*. 2007; 2007:514.

Ghoniem GM, Sakr MA, Shabaan AM, Shoukry MS, Aertker MW: Conventional, continuous, and telemetric monitoring of urodynamic parameters in non-human primates: a comparative study. *Neurourol. Urodyn*. 1996; 15:203–14.

Goineau S, Rompion S, Guillaume P, Barrais L, Castagné V. Using telemetry to automate the detection of emesis in the ferret: new vistas for delayed emesis assessment. *J. Pharmacol. Toxicol. Methods*. 2013; 68(1):160−5.

Goineau S, Guillaume P, Barrais L, Castagné V. Automated analysis of delayed emesis in the telemetered ferret: detection of synergistic effects of aprepitant and ondansetron. *Fundam. Clin. Pharmacol*. 2014; 28(6):643−51.

Gouws P, Moss EB, Trope GE, Ethier CR. Continuous intraocular pressure (IOP) measurement during glaucoma drainage device implantation. *J. Glaucoma*. 2007; 16(3):329−33.

Greene AN, Clapp SL, Alper RH. Timecourse of recovery after surgical intraperitoneal implantation of radiotelemetry transmitters in rats. *J. Pharmacol. Toxicol. Methods*. 2007; 56(2):218−22.

Groeneveld WH, Kort WJ. Endpoint detection of heterotopic grafted rat hearts using an implanted transmitter. *J. Surg. Res*. 1981; 31(1):82−6.

Gross V, Milia AF, Plehm R, Inagami T, Luft FC. Long-term blood pressure telemetry in AT2 receptor-disrupted mice. *J. Hypertens*. 2000; 18(7):955−61.

Guild SJ, McBryde FD, Malpas SC. Recording of intracranial pressure in conscious rats via telemetry. *J. Appl. Physiol* (1985). 2015; 119(5):576−81.

Gulia KK, Jodo E, Kawauchi A, Miki T, Kayama Y, Mallick HN, Koyama Y. The septal area, site for the central regulation of penile erection during waking and rapid eyemovement sleep in rats: a stimulation study. *Neuroscience* 2008; 156, 1064–73.

Hamza SM, Hall JE. Direct recording of renal sympathetic nerve activity in unrestrained, conscious mice. *Hypertension* 2012; 60(3):856−64.

Handoko ML, Schalij I, Kramer K, Sebkhi A, Postmus PE, van der Laarse WJ, Paulus WJ, Vonk-Noordegraaf A. A refined radio-telemetry technique to monitor right ventricle or pulmonary artery pressures in rats: a useful tool in pulmonary hypertension research. *Pflugers. Arch*. 2008; 455(5):951−9.

Harada N, Hoshiai K, Takahashi Y, Sakaguchi Y, Kuno T, Hishida T, Shiku H. Preclinical safety pharmacology study of a novel protein-based cancer vaccine CHP-NY-ESO-1. *Kobe. J. Med. Sci*. 2008; 54(1):E23−34.

Hasler WL. The use of Smart Pill for gastric monitoring. *Expert. Rev. Gastroenterol. Hepatol*. 2014; 8(6):587−600.

Haushalter TM, Friedrichs GS, Reynolds DL, Barecki-Roach M, Pastino G, Hayes R, Bass AS. The cardiovascular and pharmacokinetic profile of dofetilide in conscious telemetered beagle dogs and cynomolgus monkeys. *Br. J. Pharmacol*. 2008; 154(7):1457−64.

Henriques TA, Beck TW, Douglas CL, Jones HM, Kremer JJ, Kruzich PJ, Sarazan RD. Left thoracotomy surgical approach for chronic instrumentation in dogs and monkeys providing high-quality electrocardiogram signals. *J. Pharmacol. Toxicol. Methods*. 2010; 62(2):136−42.

Hill C, Lapanowski K, Dunbar JC. The effects of beta-endorphin (beta-END) on cardiovascular and behavioral dynamics in conscious rats. *Brain. Res. Bull*. 2002; 59(1):29−34.

Hiploylee C, Colbourne F. Intracranial pressure measured in freely moving rats for days after intracerebral hemorrhage. *Exp. Neurol*. 2014; 255:49−55.

Hoffmann DS, Weydert CJ, Lazartigues E, Kutschke WJ, Kienzle MF, Leach JE, Sharma JA, Sharma RV & Davisson RL. Chronic tempol prevents hypertension, proteinuria, and poor feto-placental outcomes in BPH/5 mouse model of preeclampsia. *Hypertension* 2008; 51(4): 1058−65.

Hoffmann K, Coolen A, Schlumbohm C, Meerlo P, Fuchs E. Remote long-term registrations of sleep-wake rhythms, core body temperature and activity in marmoset monkeys. *Behav. Brain. Res*. 2012; 235(2):113−23.

Holdsworth DL, O'Donohue KP, Yoder JD, Gesaman JE, Dalton JA, Gauvin DV, Tilley LP, Smith FW Jr, Baird TJ. Effects of telemetric epicardial leads and ventricular catheters on arrhythmia incidence in cynomolgus monkeys. *J. Pharmacol. Toxicol. Methods*. 2014; 69(2):167−76.

Horsmon MS, Vincelli NM, Taylor JT, Kristovich RL. An Impedance-Based Model for the Assessment of Cardiopulmonary Function in Rabbits. *J. Am. Assoc. Lab. Anim. Sci*. 2016; 55(2):213−20.

Horvath KA, Corcoran PC, Singh AK, Hoyt RF, Carrier C, Thomas ML 3rd, Mohiuddin MM. Left ventricular pressure measurement by telemetry is an effective means to evaluate transplanted heart function in experimental heterotopic cardiac xenotransplantation. *Transplant. Proc*. 2010; 42(6):2152−5.

Hou S, Blesch A, Lu P. A radio-telemetric system to monitor cardiovascular function in rats with spinal cord transection and embryonic neural stem cell grafts. *J. Vis. Exp*. 2014; (92):e51914.

Humbert M, Sitbon O, Simonneau G. Treatment of pulmonary arterial hypertension. *N. Engl. J. Med*. 2004; 351:1425–36.

Hunter JE, Butterworth J, Perkins ND, Bateson M, Richardson CA. Using body temperature, food and water consumption as biomarkers of disease progression in mice with Eμ-myc lymphoma. *Br. J. Cancer*. 2014; 110(4):928–34.

Huppertz ND, Kirschner-Hermanns R, Tolba RH, Grosse JO. Telemetric monitoring of bladder function in female Göttingen minipigs. *BJU. Int*. 2015; 116(5):823–32.

Ingram-Ross JL, Curran AK, Miyamoto M, Sheehan J, Thomas G, Verbeeck J, de Waal EJ, Verstynen B, Pugsley MK. Cardiorespiratory safety evaluation in non-human primates. *J. Pharmacol. Toxicol. Methods* 2012; 66(2):114−24.

Ishizaka S, Sievers RE, Zhu BQ, Rodrigo MC, Joho S, Foster E, Simpson PC, Grossman W. New technique for measurement of left ventricular pressure in conscious mice. *Am. J. Physiol. Heart. Circ. Physiol.* 2004; 286:H1208−15.

Jamieson MJ, Gonzales GM, Jackson TI, Koerth SM, Romano WF, Tan DX, Castillon F, III, Skinner MH, Grossmann M, Shepherd AMM. Evaluation of the IITC tail-cuff blood pressure recorder in the rat against intraarterial pressure according to criteria for human devices. *Am. J. Hypertens*. 1997; 10:209−16.

Jänig W. *The autonomic nervous system: functional anatomy and visceral afferents. The integrative action of the autonomic nervous system*. Cambridge University Press; 2006

Johansson C, Thorén P. The effects of triiodothyronine (T3) on heart rate, temperature and ECG measured with telemetry in freely moving mice. *Acta. Physiol. Scand*. 1997; 160(2):133−8.

Johnson WD, Morrissey RL, Usborne AL, Kapetanovic I, Crowell JA, Muzzio M,McCormick DL. Subchronic oral toxicity and cardiovascular safety pharmacology studies of resveratrol, a naturally occurring polyphenol with cancer preventive activity. *Food. Chem. Toxicol*. 2011; 49(12):3319–27.

Joho S, Ishizaka S, Sievers R, Foster E, Simpson PC, Grossman W. Left ventricular pressure-volume relationship in conscious mice. *Am. J. Physiol. Heart. Circ. Physiol.* 2007; 292: H369−77.

Joseph JI, Torjman MC, Strasma PJ. Vascular Glucose Sensor Symposium: Continuous Glucose Monitoring Systems (CGMS) for Hospitalized and Ambulatory Patients at Risk for Hyperglycemia, Hypoglycemia, and Glycemic Variability. *J. Diabetes. Sci. Technol.* 2015; 9(4):725–38.

Kamal R, Hong CS, Lee SG. A telemedicine application to schedule temperature in an in vivo sensor network for cancer treatment. *Telemed. J. E. Health*. 2012; 18(10):760–71.

Kawoos U, Meng X, Huang SM, Rosen A, McCarron RM, Chavko M. Telemetric intracranial pressure monitoring in blast-induced traumatic brain injury. *IEEE. Trans. Biomed. Eng.* 2014; 61(3):841−7.

Kearney K, Metea M, Gleason T, Edwards T, Atterson P. Evaluation of respiratory function in freely moving Beagle dogs using implanted impedance technology. *J. Pharmacol. Toxicol. Methods* 2010; 62(2):119–26.

Koeners MP, Ow CP, Russell DM, Abdelkader A, Eppel GA, Ludbrook J, Malpas SC, Evans RG. Telemetry-based oxygen sensor for continuous monitoring of kidney oxygenation in conscious rats. *Am. J. Physiol. Renal. Physiol*. 2013; 304(12):F1471–80.

Koike K, Hesslein PS, Dasmahapatra HK, Wilson GJ, Finlay CD, David SL, Kielmanowicz S, Coles JG. Telemetric detection of cardiac allograft rejection. Correlation of electrophysiological, histological, and biochemical changes during unmodified rejection. *Circulation* 1988; 78 (3 Pt 2): I106–12.

Korshunov VA. Miniature microdrive-headstage assembly for extracellular recording of neuronal activity with high-impedance electrodes in freely moving mice. *J. Neurosci. Methods* 2006; 158(2):179−85.

Kothari TH, Maner WL, Shi SQ, Garfield RE, Chen JD. Inhibitory effects of electrical stimulation on delivery in pregnant rats. *Eur. J. Obstet. Gynecol. Reprod. Biol*. 2008; 141:18–22.

Kramer K, Kinter L, Brockway BP, Voss HP, Remie R, Van Zutphen BL. The use of radiotelemetry in small laboratory animals: recent advances. *Contemp. Top. Lab. Anim. Sci*. 2001; 40(1):8−16.

Kramer K and Kinter LB. Evaluation and applications of radiotelemetry in small laboratory animals. *Physiol. Genomics.* 2003; 13: 197−205.

Kurtz TW, Griffin KA, Bidani AK, Davisson RL, Hall JE; Subcommittee of Professional and Public Education of the American Heart Association Council on High Blood Pressure Research. Recommendations for blood pressure measurement in humans and experimental animals: part 2: blood pressure measurement in experimental animals: a statement for professionals from the Subcommittee of Professional and Public Education of the American Heart Association Council on High Blood Pressure Research. *Arterioscler. Thromb. Vasc. Biol*. 2005; 25(3):e22−33.

Langenbach GE, van Ruijven LJ, van Eijden TM. A telemetry system to chronically record muscle activity in middle-sized animals. *J. Neurosci. Methods* 2002; 114(2):197–203.

Lei Y, Sun N, Wilson FA, Wang X, Chen N, Yang J, Peng Y, Wang J, Tian S, Wang M, Miao Y, Zhu W, Qi H, Ma Y. Telemetric recordings of single neuron activity and visual scenes in monkeys walking in an open field. *J. Neurosci. Methods* 2004; 135(1-2):35−41.

Leonardi M, Pitchon EM, Bertsch A, Renaud P, Mermoud A. Wireless contact lens sensor for intraocular pressure monitoring: assessment on enucleated pig eyes. *Acta. Ophthalmol*. 2009; 87(4):433–7.

Li P, Sur SH, Mistlberger RE, Morris M. Circadian blood pressure and heart rate rhythms in mice. *Am. J. Physiol*. 1999; 276:R500–4.

Li R, Liu JH. Telemetric monitoring of 24 h intraocular pressure in conscious and freely moving C57BL/6J and CBA/CaJ mice. *Mol. Vis*. 2008; 14:745–9.

Liao SY, Tse HF, Chan YC, Mei-Chu Yip P, Zhang Y, Liu Y, Li RA. Overexpression of Kir2.1 channel in embryonic stem cell-derived cardiomyocytes attenuates post-transplantation proarrhythmic risk in myocardial infarction. *Heart Rhythm* 2013; 10(2):273–82.

Limbrick DD Jr, Lake S, Talcott M, Alexander B, Wight S, Willie JT, Richard WD, Genin GM, Leuthardt EC. The baric probe: a novel long-term implantable intracranial pressure monitor with ultrasound-based interrogation. *J. Neurosurg. Pediatr*. 2012; 10(6):518–24.

Lin JS, Liu JH. Circadian variations in intracranial pressure and translaminar pressure difference in Sprague-Dawley rats. *Invest. Ophthalmol. Vis. Sci*. 2010; 51(11):5739–43.

Lujan HL, Janbaih H, Feng HZ, Jin JP, DiCarlo SE. Ventricular function during exercise in mice and rats. *Am. J. Physiol. Regul. Integr. Comp. Physiol*. 2012; 302(1):R68−74.

Luo H, Wu Z, Tremblay J, Thorin E, Peng J, Lavoie JL, Hu B, Stoyanova E, Cloutier G, Qi S, Wu T, Cameron M, Wu J. Receptor tyrosine kinase Ephb6 regulates vascular smooth muscle contractility and modulates blood pressure in concert with sex hormones. *J. Biol. Chem*. 2012; 287(9):6819−29.

Mackay LB, Shi SQ, Garfield RE, Maner WL. The effect of bilateral pelvic neurectomy on uterine and abdominal electrical and pressure activity, as measured by telemetry in conscious, unrestrained pregnant rats. *J. Perinat. Med.* 2009*;* 37: 313–9.

Mahar KM, Portelli S, Coatney R, Chen EP. Gastric pH and gastric residence time in fasted and fed conscious beagle dogs using the Bravo pH system. *J. Pharm. Sci*. 2012; 101(7):2439–48.

Manis JP. Knock out, knock in, knock down–genetically manipulated mice and the Nobel Prize. *N. Engl. J. Med.* 2007; 357:2426–9.

Mattson DL. Importance of the renal medullary circulation in the control of sodium excretion and blood pressure. *Am. J. Physiol. Regul. Integr. Comp. Physiol* 2003*;* 284: R13–27.

McCafferty GP, Coatney RW, Laping NJ and Thorneloe KS. Urodynamic Measurements by Radiotelemetry in Conscious, Freely Moving Beagle Dogs. *J. Urol*. 2009; 181(3):1444−51.

McLaren JW, Brubaker RF, FitzSimon JS. Continuous measurement of intraocular pressure in rabbits by telemetry. *Invest. Ophthalmol. Vis. Sci.* 1996; 37(6):966–75.

Mills IW, Noble JG, Brading AF: Radiotelemetered cystometry in pigs: validation and comparison of natural filling versus diuresis cystometry. *J. Urol.* 2000, 164:1745–50.

Mills PA, Huetteman DA, Brockway BP, Zwiers LM, Gelsema AJ, Schwartz RS, Kramer K. A new method for measurement of blood pressure, heart rate, and activity in the mouse by radiotelemetry. *J. Appl. Physiol*. 2000; 88(5): 1537−44.

Mitchell BF, Taggart MJ. Are animal models relevant to key aspects of human parturition? *Am. J. Physiol. Regul. Integr. Comp. Physiol*. 2009; 297: R525–45.

Moddrelle DS, Ward J, O'Donohue K, & Baird T. A modified left thoracotomy approach for enhancing ECG P-wave detection in the cynomolgus monkey. *Journal of Pharmacological and Toxicological Methods* 2012; 66: 184.

Monjotin N, Farrié M, Vergnolle N, Le Grand B, Gillespie J, Junquero D. Bladder telemetry: A new approach to evaluate micturition behavior under physiological and inflammatory conditions. *Neurourol. Urodyn*. 2016 Feb 16. doi: 10.1002/nau.22970.

Moody BJ, Liberman C, Zvara P, Smith PP, Freeman K, Zvarova K. Acute lower urinary tract dysfunction (LUTD) following traumatic brain injury(TBI) in rats. *Neurourol.Urodyn*. 2014; 33(7):1159–64.

Mori T, Cowley AW Jr. Role of pressure in angiotensin ii-induced renal injury: chronic servo-control of renal perfusion pressure in rats. *Hypertension* 2004; 43: 752–9.

Mori T, Cowley AW Jr, Ito S. Molecular mechanisms and therapeutic strategies of chronic renal injury: physiological role of angiotensin II-induced oxidative stress in renal medulla. *J. Pharm. Sci*. 2006*;* 100:2–8.

Murphy DJ, Renninger JP, Coatney RW. A novel method for chronic measurement of respiratory function in the conscious monkey. *J. Pharmacol. Toxicol. Methods* 2001; 46(1):13−20.

Nafz B, Persson PB, Ehmke H, Kirchheim HR. A servo-control system for open- and closed-loop blood pressure regulation. *Am. J. Physiol. Renal. Fluid. Electrolyte. Physiol* 1992*;* 262: F320–5.

Narita T, Shintani Y, Ikebe C, Kaneko M, Harada N, Tshuma N, Takahashi K, Campbell NG, Coppen SR, Yashiro K, Sawa Y, Suzuki K. The use of cell-sheet technique eliminates arrhythmogenicity of skeletal myoblast-based therapy to the heart with enhanced therapeutic effects. *Int. J. Cardiol.* 2013; 168(1):261–9.

Noël S, Massart L and Hamaide A. Urodynamic investigation by telemetry in Beagle dogs: validation and effects of oral administration of current urological drugs: a pilot study. *BMC. Vet. Res*. 2013; 9:197–206.

Nout YS, Bresnahan JC, Culp E, Tovar CA, Beattie MS, Schmidt MH. Novel technique for monitoring micturition and sexual function in male rats using telemetry. *Am. J. Physiol. Regul. Integr. Comp. Physiol*. 2007; 292(3):R1359–67.

Oommen S, Yamada S, Cantero Peral S, Campbell KA, Bruinsma ES, Terzic A, Nelson TJ. Human umbilical cord blood-derived mononuclear cells improve murine ventricular function upon intramyocardial delivery in right ventricular chronic pressure overload. *Stem. Cell. Res. Ther*. 2015; 6:50–64.

Paskaranandavadivel N, Wang R, Sathar S, O'Grady G, Cheng LK,Farajidavar A. Multi-channel wireless mapping of gastrointestinal serosal slow wave propagation. *Neurogastroenterol. Motil*. 2015; 27(4):580–5.

Pierce SL, Kresowik JD, Lamping KG, England SK. Overexpression of SK3 channels dampens uterine contractility to prevent preterm labor in mice. *Biol. Reprod*. 2008; 78: 1058–63.

Pierce SL, Kutschke W, Cabeza R, and England SK. In vivo measurement of intrauterine pressure by telemetry: a new approach for studying parturition in mouse models. *Physiol. Genomics*. 2010; 42(2):310−6.

Pirolo JS, Shuman TS, Brunt EM, Liptay MJ, Cox JL, Ferguson TB Jr. Non-invasive detection of cardiac allograft rejection by prospective telemetric monitoring. *J. Thorac. Cardiovasc. Surg*. 1992; 103(5):969–79.

Quigley HA, Broman AT. The number of people with glaucoma worldwide in 2010 and 2020. *Br. J. Ophthalmol*. 2006; 90(3):262–7.

Rada CC, Pierce SL, Grotegut CA, England SK. Intrauterine telemetry to measure mouse contractile pressure in vivo. *J. Vis. Exp*. 2015; (98):e52541.

Ratajczak CK, Muglia LJ. Insights into parturition biology from genetically altered mice. *Pediatr. Res*. 2008*;* 64: 581–9.

Rauch S, Johannes A, Zollhöfer B, Muellenbach RM. Evaluating intra-abdominal pressures in a porcine model of acute lung injury by using a wireless motility capsule. *Med. Sci. Monit*. 2012; 18(5):BR163−6.

Reddy AK, Taffet GE, Madala S, Michael LH, Entman ML, Hartley CJ. Noninvasive blood pressure measurement in mice using pulsed Doppler ultrasound. *Ultrasound. Med. Biol*. 2003; 29:379−85.

Robertson D, Biaggioni I. *Primer on the autonomic nervous system*. San Diego: Academic; 2012.

Robinson EA, Rhee KS, Doytchinova A, Kumar M, Shelton R, Jiang Z, Kamp NJ, Adams D, Wagner D, Shen C, Chen LS, Everett TH, Fishbein MC, Lin SF, Chen PS. Estimating sympathetic tone by recording subcutaneous nerve activity in ambulatory dogs. *J. Cardiovasc. Electrophysiol*. 2015; 26(1):70−8.

Rocchitta G, Secchi O, Alvau MD, Farina D, Bazzu G, Calia G, Migheli R, Desole MS, O'Neill RD, Serra PA. Simultaneous telemetric monitoring of brain glucose and lactate and motion in freely moving rats. *Anal. Chem*. 2013; 85(21):10282–8.

Rossi NF, Pajewski R, Chen H, Littrup PJ, Maliszewska-Scislo M. Hemodynamic and neural responses to renal denervation of the nerve to the clipped kidney by cryoablation in two-

kidney, one-clip hypertensive rats. *Am. J. Physiol. Regul. Integr. Comp. Physiol*. 2016; 310(2):R197–208.

Roy S, Wang X. Wireless multi-channel single unit recording in freely moving and vocalizing primates. *J. Neurosci. Methods* 2012; 203(1): 28−40.

Russell DM, Garry EM, Taberner AJ, Barrett CJ, Paton JF, Budgett DM, Malpas SC. A fully implantable telemetry system for the chronic monitoring of brain tissue oxygen in freely moving rats. *J. Neurosci. Methods* 2012*;* 204: 242–8.

Sagawa K, Li F, Liese R, Sutton SC. Fed and fasted gastric pH and gastric residence time in conscious beagle dogs. *J. Pharm. Sci*. 2009; 98(7):2494−500.

Salas JC, Iwasaki H, Jodo E, Schmidt MH, Kawauchi A, Miki T, Kayama Y, Otsuki M, Koyama Y. Penile erection and micturition events triggered by electrical stimulation of the mesopontine tegmental area. *Am. J. Physiol. Regul. Integr. Comp. Physiol.* 2007; 294: R102–111.

Salman IM, Kandukuri DS, Harrison JL, Hildreth CM, Phillips JK. Direct conscious telemetry recordings demonstrate increased renal sympathetic nerve activity in rats with chronic kidney disease. *Front. Physiol*. 2015; 6. doi:10.3389/fphys.2015.00218.

Salman IM. Current Approaches to Quantifying Tonic and Reflex Autonomic Outflows Controlling Cardiovascular Function in Humans and Experimental Animals. *Curr. Hypertens. Rep*. 2015; 17(11):84.

Samson N, Dumont S, Specq ML, Praud JP. Radio telemetry devices to monitor breathing in non-sedated animals. *Respir. Physiol. Neurobiol.* 2011; 179(2-3):111–8.

Sarazan RD, Mittelstadt S, Guth B, Koerner J, Zhang J, & Pettit S. Cardiovascular function in nonclinical drug safety assessment: Current issues and opportunities. *International Journal of Toxicology* 2011; 30: 272–86.

Sarazan RD, Kroehle JP, & Main BW. Left ventricular pressure, contractility and dP/dtmax in nonclinical drug safety assessment studies. *Journal of Pharmacological and Toxicological Methods* 2012; 66: 71–78.

Sauvé CC, Van de Walle J, Hammill MO, Arnould JP, Beauplet G. Stomach temperature records reveal nursing behaviour and transition to solid food consumption in an unweaned mammal, the harbour seal pup (Phoca vitulina). *PLoS One* 2014; 9(2):e90329.

Schierok H, Markert M, Pairet M, & Guth B. Continuous assessment of multiple vital physiological functions in conscious freely moving rats using telemetry and a plethysmography system. *Journal of Pharmacological and Toxicological Methods* 2000; 43: 211−7.

Schnell CR, Debon C, Percicot CL. Measurement of intraocular pressure by telemetry in conscious, unrestrained rabbits. *Invest. Ophthalmol. Vis. Sci*. 1996; 37(6):958−65.

Shamloul R. Telemetric intracavernosal and intraspongiosal pressure monitoring. *J. Sex. Med*. 2008; 5: 2246–52.

Shi SQ, Maner WL, Mackay LB, Garfield RE. Identification of term and preterm labor in rats using artificial neural networks on uterine electromyography signals. *Am. J. Obstet. Gynecol*. 2008; 198: 235.e231–5.

Silasi G, MacLellan CL, Colbourne F. Use of telemetry blood pressure transmitters to measure intracranial pressure (ICP) in freely moving rats. *Curr. Neurovasc. Res*. 2009; 6(1):62−9.

Sivarajah A, Collins S, Sutton MR, Regan N, West H, Holbrook M, Edmunds N. Cardiovascular safety assessments in the conscious telemetered dog: utilisation of super-intervals to enhance statistical power. *J. Pharmacol. Toxicol. Methods*. 2010; 62(1):12−9.

Soukhova-O'Hare GK, Schmidt MH, Nozdrachev AD, Gozal D. A novel mouse model for assessment of male sexual function. *Physiol. Behav*. 2007; 91(5):535–43.

Stocker SD, Muntzel MS. Recording sympathetic nerve activity chronically in rats: surgery techniques, assessment of nerve activity, and quantification. *Am. J. Physiol. Heart. Circ. Physiol.* 2013; 305(10):H1407–16.

Takahara A, Dohmoto H, Yoshimoto R, Sugiyama A, Hashimoto K. Cardiovascular action of a cardioselective Ca(2+)channel blocker AH-1058 in conscious dogs assessed by telemetry. *Eur. J. Pharmacol*. 2001; 413(1):101−8.

Vecchione C, Fratta L, Rizzoni D, Notte A, Poulet R, Porteri E, Frati G, Guelfi D, Trimarco V, Mulvany MJ, Agabiti-Rosei E, Trimarco B, Cotecchia S, Lembo G. Cardiovascular influences of alpha1b-adrenergic receptor defect in mice. *Circulation* 2002; 105:1700−7.

Weiergräber M, Henry M, Hescheler J, Smyth N, Schneider T. Electrocorticographic and deep intracerebral EEG recording in mice using a telemetry system. *Brain. Res. Brain. Res. Protoc*. 2005; 14(3):154−64.

Weissmann N, Peters DM, Klöpping C, Krüger K, Pilat C, Katta S, Seimetz M, Ghofrani HA, Schermuly RT, Witzenrath M, Seeger W, Grimminger F, Mooren FC. Structural and functional prevention of hypoxia-induced pulmonary hypertension by individualized exercise training in mice. *Am. J. Physiol. Lung. Cell. Mol. Physiol*. 2014; 306(11): L986−95.

Willens S, Cox DM, Braue EH, Myers TM, Wegner MD. *Comp. Med.* 2014; 64(6):464–70.

Woo SH, Cho JH. Telemetry system for slow wave measurement from the small bowel. *Med. Biol. Eng. Comput*. 2010; 48(3):277−83.

Wu Z, Luo H, Thorin E, Tremblay J, Peng J, Lavoie JL, Wang Y, Qi S, Wu T, Wu J. Possible role of Efnb1 protein, a ligand of Eph receptor tyrosine kinases, in modulating blood pressure. *J. Biol. Chem*. 2012; 287(19):15557−69.

Xia M, Li PL, Li N. Telemetric signal-driven servocontrol of renal perfusion pressure in acute and chronic rat experiments. *Am. J. Physiol. Regul. Integr. Comp. Physiol*. 2008; 295(5): R1494–501.

Zaragoza C, Gomez-Guerrero C, Martin-Ventura JL, Blanco-Colio L, Lavin B, Mallavia B, Tarin C, Mas S, Ortiz A, Egido J. Animal models of cardiovascular diseases. *J. Biomed. Biotechnol*. 2011; 2011: Article ID 497841, 13 pages doi:10.1155/2011/497841

Zayachkivsky A, Lehmkuhle MJ, Dudek FE. Long-term Continuous EEG Monitoring in Small Rodent Models of Human Disease Using the Epoch Wireless Transmitter System. *J. Vis. Exp*. 2015; (101):e52554.

In: Encyclopedia of Surgery (22 Volume Set)
Editors: Andreas Lehrer and Kristin Mueller
ISBN: 978-1-53618-329-0
© 2020 Nova Science Publishers, Inc.

Chapter 209

SMALL ANIMALS AS EXPERIMENTAL MODELS

Rebekah Wilson[1,*], MD,
Adrien Kissenpfennig[2,†], PhD
and James McDaid[1,2,‡], MD, PhD
[1]Department Transplant Surgery, City Hospital, Belfast, UK
[2]Centre for Experimental Medicine,
The Wellcome-Wolfson Institute for Experimental Medicine,
Queen's University Belfast, Belfast

ABSTRACT

Animal models can prove invaluable in predicting outcomes of human surgical procedures and medical interventions. Clearly the closer the anatomic and physiological similarity between the studied animal species and human, the more closely the animal model will mirror outcomes in people. Often non-human primates will most closely approximate results in humans. Nonetheless, ethical and economic concerns regarding these large animal models mean that small animal models retain strong utility. Generally speaking, large animal models are reserved for final pre-clinical toxicity and efficacy studies, with all preliminary studies conducted in small animal models. Small animals used in experimental surgery chiefly consist of mammals – rodents (mouse, rat, guinea pig and hamster) and rabbits. Mice are most commonly used because of their economy, rapid breeding cycle, ease of handling, and availability of inbred strains and genetically modified strains. The large animals (chiefly non-human primate, dog and pig) will be covered in next chapter.

The principles of the three R's: refine (less suffering,), reduce (lower animal numbers) and replace (alternative *in vitro* assays) must be applied in all small animal experiments.

Well-designed animal model experiments have allowed us to develop the surgical techniques currently available for treating patients. In this chapter, we examine background to the common small animal models and practical aspects used in

* Corresponding Author's Email: Rebekah.wilson@hotmail.co.uk.
† Corresponding Author's Email: a.kissenpfennig@qub.ac.uk.
‡ Corresponding Author's Email: James.mcdaid@belfasttrust.hscni.net.

experimental surgery. We also look at the utility and limitations of small animal model surgery.

Keywords: animal model, surgery, rodent, mice, rat

INTRODUCTION

Use of animals in experimental surgery began many centuries ago. Galen used live animals in many of his early experiments for understanding anatomy in the second century AD. In 1100s, the Arabic surgeon Avenzoar would experiment on animals before trying new surgical techniques on humans. The Nobel laureate and surgeon Alexis Carrel used animals in his studies of vessel suturing in the 18th – 19th centuries. It was determined by the Nuremberg Code in 1947 that animal experimentation results must be the basis of conducting research on humans. This was later reinforced by the Helsinki declaration in 1975 (Calasans-MaiaI 2009). Animal models have been used extensively in the development of modern surgery and some models mirror specific diseases, such as the lipopolysaccharide (LPS) administration mouse model for septic shock. Animal models have been used to simulate all types of human transplant, common examples being heart and skin transplants (Chong 2013) and in surgical training e.g., pig laparoscopic cholecystectomy and nephrectomy.

HISTORY OF RODENT MODELS

In the early days of experimental animal surgery, the dog and pig models were most commonly used because of the technical ease of performing the larger vascular anastomoses. With the development of microsurgical techniques in the 1960s, rodents became more popular because of simplicity, favourable public and animal protective agencies opinion, and reduced costs (Chong 2013). The Rat genome was sequenced in 2004 and results revealed that the rat genome contains 2.75 billion base pairs (Gibbs 2004). This compares with 2.9 billion in the human genome and 2.6 billion in the mouse. Humans have 23 pairs of chromosomes, compared with 21 in rats and 20 in mice. In spite of this the three species contain overall a very similar number of genes, and most disease-associated genes are highly conserved between the species.

Mice have proven invaluable in the assessment of surgical disease (Chong 2013). They can be purchased inbred, with relatively reproducible characterised response to experimental protocols because of genetic similarity. The widespread availability of genetically modified mice, both transgenic and knockout, has made them invaluable assets in experimental models. Embryonic stem cells have been isolated and genetically manipulated in mice. In rats, eggs are sensitive to activation and do not tolerate genetic modification well, although this has been resolved within the last decade with cloning techniques allowing production of genetically modified rats (Doorschodt 2014). Interestingly, genes involved in detoxification show important differences between humans and rodents. Cytochrome P450 (CYP450) is important in metabolism of calcineurin inhibitors like cyclosporine, among other immunosuppressive drugs. The CYP450 subfamily member CYP2J has a single gene in

humans, but four in rats and eight in mice (Uno 2009). It can be seen that although rodents bear similarities to humans and are vital to examine and test agents, there are important constraints in applicability.

The use of *in vivo* models facilitates the use of various measurements to determine efficacy of drug and others agents. Steroids when given to rabbits give similar results to humans. If dexamethasone is administered, neutrophilia is seen within a day. This is accompanied with lymphopenia. Lymphocyte numbers in the bone marrow are increased. Both lymphocyte and neutrophil function is suppressed, as measured by concanavalin-A proliferation and reactive oxygen species production respectively (Ulich 1988). Understanding of the complex effects that these agents have on the body could not be easily understood with *in vitro* models alone.

ANATOMY AND PHYSIOLOGY

Rodents belong to the order *Rodentia*, characterised by large incisor teeth, which are modified for gnawing. They have a life span of 1−3 years (Animal Care and Use Committee 2 2016; Animal Care and Use Committee 3 2016) and males weigh 300−500 g and females 250−300 g. It is important to note their differences in vitals from humans to ensure appropriate monitoring and treatment. Their heart rate range is 330−480 beats per minute (bpm) and respiratory rate is approximately 85 breaths per minute. Their temperature ranges from 35.9°C and 37.5°C and they are best kept at a room temperature of 18−26°C (Animal Care and Use Committee 1 2016). Male mice weigh 20−30 g and females 18−35 g. Their heart rate range is 310−840 bpm and respiratory rate is approximately 80−230 breaths per minute. Their temperature ranges from 36.5°C and 38°C and they are best kept at a room temperature of 18−26°C(Animal Care and Use Committee 2 2016).

Rat anatomy is similar in many respects to other mammals except that unlike humans they do not have a gall bladder. The circulatory system carries blood from the heart to the lungs, back to the heart and then to the rest of the body through the systemic circulation. The posterior portion of the body drains blood into the inferior vena cava, which delivers it to the sinus venosus, a quadrangular cavity. This is separated from the right atrial wall by a ridge of fibres. The superior vena cava, which also drains into the sinus venosus is made up of the right cranial vena cava, the left cranial vena cava and the two cardiac veins. As in humans, the ventricle walls are thicker and stronger than the atria and the left more so than the right. The average weight of the heart is 0.9−1.0 g in males and 0.67−0.8 g in females (Hu 2013). Due to the small size of the heart a transplant is generally conducted by end to side anastomosis of the thoracic aorta to the recipient's abdominal aorta and the pulmonary Good haemostatic control is key as their circulating volume is 15−35 ml (Animal Care and Use Committee 2 2016).

SURGERY IN RODENT MODELS

Various surgical models are available in rodents, each with their own utility (Russell 1964). In general, mice and rats are the most commonly used species. Guinea pigs and

Hamsters are used in xenotransplant experiments. Requirements for rodent surgery include; an animal preparation area, surgeon preparation area, surgical and recovery area.

In preparation for animal surgery, it is essential to secure prospective approval from the relevant ethical institution. These bodies vary between countries in structure, but all share the aim of eliminating cruelty to animals and ensuring that the 3 "Rs" are fulfilled. In USA, the ethical body is the institutional animal care and use committee (IACUC), which is typically based within each research institution at a local level. In UK in contrast, all animal experiments are approved by the central government (Home Office), which issues both a personal license to researchers and project license to the experiment. In practise this means that paperwork takes considerably longer in the UK, therefore advance planning is essential.

Once ethical approval is secured, animals are purchased. Animals are typically bought from large commercial designated suppliers such as Harlan© and Charles River©. These are typically inbred and genetically characterised. Alternatively, genetically modified bespoke animals may be moved between academic institutions, which may take time to ensure local vet certification for animal health status and exemption from pathogens. A record should be kept for each animal including its medical history, any abnormalities in appearance or behaviour, observations, examinations, tests and procedures.

Surgical instruments can be purchased from a wide variety of retailers, including Roboz©. A minimum set includes toothed and non-toothed forceps (e.g., DeBakey's), suture scissors, dissecting scissors (e.g., Metzenbaum/Iris/McIndoe), needle holder (called needle driver in USA), and diathermy (e.g., battery powered Bovie). For more delicate procedures, a micro needle holder (e.g., Castroviejo), and jeweler's forceps will be necessary. If possible these should be inspected before use with a magnifying lens to inspect for damage (Animal Care and Use Committee 1 2016). For survival procedures, expired items may be used if they are re-sterilized and their function is not compromised. All expired drugs and fluids cannot be used. For non-survival procedures all expired items may be used except for physiologically active drugs e.g., anaesthetics, analgesics (Animal research advisory committee 2015).

PRE-OPERATIVE PREPARATION

Ensure animals are of an appropriate age, weight and sex for the procedure in question. They should be acclimatised to the facility, which typically means they should have arrived at least five days before from the designated vendor or originating academic institution.

The operating area should always be clean and clear of clutter. It is important to be free from distractions, without foot traffic of other staff passing nearby. It should ideally be situated in a laminar flow hood, but in practise often a clean bench top is used for small animal work. The surgical area should be non-porous and durable. The bench top should be cleaned daily before use with disinfectant. Alcohols (70% ethyl alcohol or 85% isopropyl alcohol) should be left to disinfect for 15 minutes. Aldehydes, phenolics and chlorhexidine are other options. Ammonium compounds should be avoided as organic matter rapidly inactivates them (Animal Care and Use Committee 1 2016).

The animal should be anaesthetised and shaved with electric clippers (♯40 blade), depilatory cream or shaved in an area separate from the surgical field. Depilatory creams are safe, effective, non-traumatic and non-toxic. They are also related with a significant reduction

in skin surface bacteria and useful in areas that are difficult to use clippers (Animal Care and Use Committee 4 2016). Shaving is the least preferred method as it can cause microscopic defects, which may pre-dispose to surgical site infections. The prepared area should be approximately three times the size of the proposed incision (Pritchett-Corning 2011). The animal should be placed on a recirculating water heating pad if available (electrical heating pads should not be used during surgery) and sterilised using two or three applications of povidone iodine or chlorhexidine, with or without alcohol (Pritchett-Corning 2011). This should be from the proposed incision area outwards in a circular motion. The animal is then covered with sterile drapes and surgical instruments should be ideally placed in a hot bead steriliser. The drapes serve to improve sterility and minimise loss of heat and moisture. Rodents have a high surface area to mass ratio and rapidly lose heat and moisture. Hypothermia can predispose to complications such as infection and slow emergence from anaesthesia.

The surgeon should prepare by disinfecting the hands using a surgical scrub such as chlorhexidine. The hands are washed three times, and then dried with a sterile towel. A sterile gown and gloves are donned.

Anaesthesia

Starving the animals prior to surgery, as for human surgery, is not necessary because risk of regurgitation is low. Anaesthesia provides freedom from feelings. Analgesia, or freedom from pain, is particularly important, and may require additional drugs.

Stages of anaesthesia in terms of increasing depth are:

- Stage 1 — excitatory, disorientation, vocalization, urination, defecation.
- Stage 2 — loss of consciousness, many reflexes are intact but righting reflex is lost, rapid irregular breathing and rigidity.
- Stage 3 — surgical stage of anaesthesia, with loss of reflexes, muscle relaxation, deep and rhythmic breathing.
- Stage 4 — medullary paralysis with respiratory arrest, hypotension and imminent death. Cardio-pulmonary resuscitation and drugs to reverse anaesthesia must be given or animal will die (Animal Care and Use Committee 1 2016).

The depth of anaesthesia can be monitored using a foot, tail or abdominal skin pinch. There should not be twitching in response to this painful stimulus. In addition, respiratory rate, heart rate and temperature can be monitored. Additional equipment is necessary to monitor oxygen saturations (pulse oximetry) or carbon dioxide (capnometry) (Animal Care and Use Committee 1 2016). After induction of anaesthesia, ophthalmic ointment should be applied to the eyes to avoid corneal drying.

Anaesthesia can be intravenous, intramuscularly, intraperitoneal or inhalational. The dose of anaesthetic drug can be difficult to predict but should be based on the animal's body weight (which should be recorded on the day of the operation). Smaller animals often have a faster metabolic rate, and can often need higher dose per kg than larger animals. Differences in strain, sex, size all can affect amount of anaesthetic required. Hypothermic animals

metabolise drugs more slowly and can need less anaesthetic. Likewise, very young or old animals may require a lower dose.

Table 1. Injectable anaesthetics and adjuncts in laboratory animals adapted by use of materials from (Animal resource program 2016)

Drug(s)	Mouse	Rat	Rabbit	Comments
Ketamine: Xylazine	80−120 mg/kg: 5−10 mg/kg IP	75−100 mg/kg: 5−10mg/kg IP	20−40 mg/kg: 1−3 mg/kg IM	Provides 20−50 minutes of anaesthesia
Ketamine: Xylazine: Acepromazine	80−100 mg/kg IP: 10−20 mg/kg IP: 2−3 mg/kg IP	40 mg/kg: 5 mg/kg: 1 mg/kg IP	35 mg/kg: 5 mg/kg: 0.75 mg/kg IM	Duration of action: 30−45 minutes in rats and 45−75 minutes in rabbits
Ketamine: Diazepam (Valium)			5 mg/kg: 0.25 mg/kg IV	Short duration and light degree of anesthesia
Pentobarbital	40−60 mg/kg IP	40−50 mg/kg IP		Variable anesthetic depth. Duration 20−40 minutes in mice and 20−60 minutes in rats
Tribromoethanol (Avertin)	200−500 mg/kg IP			Duration of action: 15−45 minutes
Atipamezole	mg/kg IP	mg/kg IP	0.1−1.0 mg/kg IM, IP, SC or IV (depends on xylazine dose administered)	Xylazine reversal agent only
Glycopyrronium bromide			mg/kg IM, SC	Adjunct only: Decreases respiratory secretions and prevents bradycardia

IP = intra-peritoneal, S/C = subcutaneous, IM = intramuscular, IV = intravenous.

Hypothermia is a potential form of anaesthesia in neonatal rodents (up to 5 days old) with a similar potency to morphine 10 mg/kg s/c but may only last up to 30 minutes after removal from hypothermia and so is only suitable for short procedures. This can be induced by a cold water swim at 2−3°C or putting the neonate inside a glove finger and place in crushed ice for approximately 5−8 minutes until there is no response to pain. If this method is used, warming should be slow. And heating pads or lamps are avoided (Animal Care and Use Committee 1 2016). It should be noted that neonatal mice only open their eyes 10−12 days after birth (Animal Care and Use Committee 3 2016).

Injectable anaesthetics should be diluted as small volumes are used and if irritant, it should be injected at several sites. Intraperitoneally drugs commonly used are ketamine/xylazine or 1% pentobarbital. Ketamine/Xylazine is safe and efficacious but may cause hypotension, hypothermia and respiratory depression, it can be reversed by an alpha 2 antagonist e.g., yohimbine or atipamezole. Its use is not as reliable in guinea pigs. Phenobarbital is rapid acting and easily injected but is a poor analgesic and progressively decreases blood pressure, heart rate and respiratory rate and causes acidosis, hypoxia and hypercarbia (Animal Care and Use Committee 1 2016). Fentanyl and midazolam may be considered as an adjunct as they provide analgesia, sedation and muscle relaxation.

Neuromuscular agents should not be used alone as a method of anaesthesia (Animal research advisory committee 2016). Details of specific anaesthetic doses can be found in Table 1.

Inhalational anaesthesia allows greater operator control in terms of the depth and duration but risks gases inadvertently affecting the surgeon so a scavenging system should always be used. In rodents only non-rebreathing systems should be used. Isoflurane (Forane) is most commonly used as it permits rapid induction and recovery and minimally affects the cardiovascular and respiratory systems. However, a precision vaporizer is needed and some strains of rats (SHR and WKY) are more sensitive than normotensive (SD) rats. Halothane (Fluothane) is similar to isoflurane but is hepatotoxic and interferes with interferon stimulated natural killer cell activity in mice so is less favourable (Animal Care and Use Committee 1 2016). Ether is irritating to respiratory passages, is explosive and requires an open drop method where the rodent is dropped into a container that contains ether. It is unsafe in guinea pigs but has various complications in other rodents that can be fatal.

Intra-Operative Care

Knowledge of the anatomy dictates the most appropriate incision e.g., a v-shaped incision will open the anterior rib cage for wide exposure, while avoiding the mammary vessels. This is used when harvesting the heart for transplantation (Hu 2013). The operative field should be covered and wet by warm sterile saline.

Meticulous technique is necessary to minimise blood loss given the small circulating volumes of rodents as well as gentle handling of tissues to avoid trauma. Irrigating the surgical field with warm sterile saline will help reduce fluid loss. Instruments should be maintained as sterile as possible, e.g., by storing on the sterile drapes or in a beaker of alcohol. If the hot bead steriliser (260°C) is used, the instrument tips should be allowed to cool before contacting living tissues. Blood and soft tissue should be wiped off surgical instruments before placing in the hot bead sterilizer.

Microsurgery may be practised by suturing an incision on a latex glove under a microscope or on discarded cadavers of rodents. Typically for anastomosis, 8.0 to 10.0 non-cutting or round needle sutures may be used and 4.0 cutting or reverse cutting for abdominal closure for small animals (Hu 2013). Absorbable sutures are suited to soft tissues including blood vessels and non-absorbable should be used for the skin.

POST-OPERATIVE CARE

When the operation is complete the animal should be placed in a cage with a clean absorbent paper base (not husbandry bedding) with half of the animals body on a heating pad. A warming lamp may alternatively be used. They should be observed and turned every 15 minutes until ambulatory, then daily monitoring for one week. Food and water should be easily accessible. Rats consume 10−30 g/day of feed and drink 20−50 ml/day of water (Animal Care and Use Committee 2 2016) whereas mice consume less, 4−5 g/day of feed and 3−5 ml/day of water (Animal Care and Use Committee 3 2016). Antibiotic prophylaxis is not usually necessary. Abdominal wound clips and sutures should be removed 7−10 days post-op.

Fluid loss may be addressed by administration directly to the abdominal cavity or warm subcutaneous saline (Hu 2013) at 3−5% of body weight (Animal Care and Use Committee 1 2016).

Specialised post-operative monitoring after cardiac surgery may use electrocardiogram. This is by using a 4 conductor shielded electrode cable which has hypodermic needles soldered to it. As the electrodes are placed subcutaneously, it is necessary to anaesthetise the animal in the supine position. There is only one precordial lead when investigating small animals. Leads 1, 2, 3, AvR, AvL and AvF will be produced (Hu 2013). As a rough guide of post-operative recovery and physiologic function, urine output in rats is 3.3 ml/100g/day and for mice is 0.5−1.0 ml/day (Animal Care and Use Committee 2 2016; Animal Care and Use Committee 3 2016).

After finishing surgery, all instruments should be thoroughly cleaned with soap, water and a brush. They should then be autoclaved where possible or soaked in disinfectant. Disinfectant should be rinsed off with sterile saline before operating. It is advisable to use a new sterile pack after 5 rodents (Animal Care and Use Committee 1 2016). The same cap and mask may continue to be worn between cases but sterile gloves and disposable gowns should be changed. Accurate records should be kept for surgical procedures. This should include the date, time, DOB, age, gender, name of surgeon, animal ID number, description of the operation, drugs used (name, dose, route) and intraoperative and post operative observations.

It is important to ensure animals are kept comfortable following surgery. Pre-emptive analgesic options are buprenorphine, morphine paracetamol and NSAIDs. Local anaesthetic to the wound site is also an option. Post-operative pain management is an important area to address for the humane treatment of these experimental models and will also aid their recovery.

Signs of pain in rodents include:

- Hunched up posture
- Shivering, blue extremities, hypothermia
- Unkempt, ruffled fur without proper grooming
- Anorexia, not eating and not passing faeces
- Dehydration, not drinking and ability to pinch skin
- Panting, rapid breathing

Both mice and rats have a harderian gland, which is horseshoe-shaped and found within the eyes orbit. It secretes a reddish-brown porphyrin pigment in differing quantities depending on the physiologic state, age, strain and sex of the mouse. During periods of stress i.e., pain or inadequate analgesia secretions increase and appears as ‘red crusts’ around the eyes and nostrils (Animal Care and Use Committee 2 2016; Animal Care and Use Committee 3 2016). If this is observed steps should be taken to address possible causes of stress (Table 2).

Analgesics include opioids, non-steroidal anti-inflammatory drugs (NSAIDs) and paracetamol (acetaminophen). The opioids have an extensive first pass metabolism in the liver in rodents, somewhat limiting oral potency. Examples include morphine, fentanyl, carprofen and buprenorphine. Oxymorphone provides 2−3 hours of analgesia and is available

in the form of duromoroh (Animal Care and Use Committee 1 2016). Pentazocine has similar analgesic effects but is less sedating. Naloxone may be used if necessary.

Table 2. Possible signs associated with pain or distress in mice, rats and rabbits (Animal research advisory committee 2015)

Potential Signs	Mice	Rats	Rabbits
Decreased Food and Water Consumption	X	X	X
Weight loss	X	X	X
Self-imposed isolation/hiding	X	X	X
Self-mutilation, gnawing at limbs	X	X	X
Rapid Breathing	X	X	X
Opened-Mouth Breathing	X	X	X
Abdominal Breathing	X	X	X
Grinding Teeth		X	X
Biting/Growling/Aggression		X	X
Increased/Decreased Movement	X	X	X
Unkempt Appearance (Erected, Matted, or Dull Haircoat)	X	X	X
Abnormal Posture/Positioning (e.g., Head-pressing, Hunched Back)	X	X	X
Restless Sleep			X
Tearing (including Porphyria), Lack of Blinking Reflex		X	X
Dilated Pupils			X
Muscle Rigidity, Lack of Muscle Tone	X	X	X
Dehydration/Skin Tenting/Sunken Eyes	X	X	X
Twitching, trembling, tremor	X	X	X
Vocalization (Rare)	X	X	X
Redness or Swelling Around Surgical Site	X	X	X
Increased Salivation	X	X	X

Table 3. Doses of analgesic drugs for mice, rats and rabbits (Animal resource program 2015)

Drug	Mouse	Rat	Rabbit	Comments
Bupivicaine 0.5% (Local anaesthetic)	Maximum 8 mg/kg S/C	Maximum 8 mg/kg S/C		Injected or dripped onto incision site. Duration 4−8 hours
Buprenorphine	0.05−0.1 mg/kg S/C, IP	0.01−0.05 mg/kg S/C, IP	0.01−0.05 mg/kg S/C, IM or IV	For mild to moderate pain Duration: 8−12 hours in mice and 6−12 hours in rats and rabbits
Butorphanol	1.0−5.0 mg/kg S/C	2.0 mg/kg S/C	0.1−0.5 mg/kg IM / IV	For mild to moderate pain Duration: 4 hours
Carprofen (NSAID)	4−5 mg/kg S/C	5−10 mg/kg S/C, PO	2−4 mg/kg S/C, 1.5mg/kg PO	For mild to moderate pain Duration: 24 hours in mice/rats, 12−24 hours in rabbits
Flunixin meglumine (NSAID)	2.5 mg/kg S/C	2.5 mg/kg S/C	1.1 mg/kg S/C	Duration: 12 hours
Ketoprofen (NSAID)	5 mg/kg S/C	5 mg/kg S/C	3 mg/kg S/C	For mild pain Duration: 12−24 hours
Meloxicam (NSAID)	1−5 mg/kg S/C	1−2 mg/kg S/C, PO	0.2−0.3 mg/kg S/C	For mild pain Duration: 24 hours
Morphine	10 mg/kg S/C	10 mg/kg S/C	2−5 mg/kg S/C	For moderate to severe pain Duration: 2−3 hours in mice and rats, 2−4 hours in rabbits

S/C = subcutaneous, IM = intramuscular, IV = intravenous.

The most commonly used NSAIDs are ketoprofen, caprofen and ibuprofen. They are available in intravenous and intraperitoneal preparations. They are analgesic, anti-inflammatory and anti-pyretic. Paracetamol has limited analgesic properties in rodents, but does not cause intestinal haemorrhage like aspirin can (Table 3).

If the animal is euthanized or dies, their complete medical record should be retained and sent upon request to the IC Animal Program Director. All animal medical records should be kept for 3 years after the conclusion of the study (Animal research advisory committee 2014). The preferred process of euthanasia by veterinarians is sedation followed by injection of a barbiturate, preferably sodium pentobarbital (Calasans-MaiaI 2009).

TRANSPLANT MODELS

The skin transplant was the first model developed and used by Sir Peter Medawar in the 1940s and 50s in seminal experiments, which led to the understanding of self and non-self (Brent 1976). This was the only model to study transplant immunology until the 1960s. The skin transplant model is technically straightforward. It involves excising a small square of full thickness skin from the donor animal and deep fat is dissected off. This is placed on a similar sized defect on the recipient abdominal wall and secured with glue or sutures. The graft is protected for 3−5 days with a dressing. This procedure will induce a rapid tempo of T cell-mediated rejection within 7−12 days for mice different at the major histocompatibility complex (MHC) locus (Mayer 1988).

The first rodent vascularized organ transplants were performed in the rat but now virtually all organ transplants performed in the rat are also performed in mice. Although technically more challenging (due to very small diameter of vessels), mouse models of transplantation have several advantages. First, many congenic, transgenic, and knockout strains are available. There are specific mouse strains available to study specific cell populations. Second, there are more reagents including monoclonal antibodies available for mice. Third, due to small body weight, mice need only about one tenth the quantity of drug that rats consume. The disadvantage of the mouse models is mainly technical, but it has been shown that spontaneous acceptance of both liver and kidney graft occurs more frequently in all mouse strains compared to rat (Qian 1994).

Heart transplants are the most popular vascularised allograft performed. The heart is transplanted in a heterotopic position, with the veins of the heart tied off. The donor aorta is anastomosed to recipient aorta and donor pulmonary artery anastomosed to recipient inferior vena cava. This makes a non-physiological model of circulation, and the heart is subject to a moderate level of chronic ischemia, so histological changes do not exactly mirror those seen in humans (Chong 2013). Graft function is monitored by palpation of heart beating, or by using electrocardiogram (Martins 2008).

Although rodent models of immunosuppression have provided useful data, large animal models mirror much more closely the events in humans. Laboratory mice are typically bred in specific pathogen-free conditions, so their immune systems are relatively naive and have not had alloantigen exposure sufficient to develop significant immunologic memory (Chong 2013). Rodents are also often transplanted very young, in the first few months of life, which

further limits how well experiments can be extrapolated to humans, where recipients are mostly middle-aged.

CONCLUSION

In summary, it can be seen that small animal models provide a useful means of testing surgical techniques and drugs prior to use in humans. Limitations of these studies are an important constraint, and not all animal data can be extrapolated to humans. In particular, differences in the immune system between humans and rodents relate to the older age of human transplant recipients and greater exposure to pathogens. This creates more memory cells and therefore less dependence on co-stimulation and greater resistance to tolerance in humans. Additional differences in physiology and pharmacology limit extrapolation from small animal models to human studies. The small size of rodents creates technical anatomic constraint in developing surgical models. In spite of limitations, animal models remain the most useful predictor of surgical intervention utility.

REFERENCES

Animal Care and Use Committee 1 2016, *Survival Surgery Procedures: Rodents* [Homepage of John Hopkins University], [Online]. Available: http://web.jhu.edu/animalcare/procedures/survival-rodents.html [2016, October 1].

Animal Care and Use Committee 2 2016, *The Rat* [Homepage of John Hopkins University], [Online]. Available: http://web.jhu.edu/animalcare/procedures/rat.html [2016, October 20].

Animal Care and Use Committee 3 2016, *The Mouse* [Homepage of John Hopkins University], [Online]. Available: http://web.jhu.edu/animalcare/procedures/mouse.html#normative [2016, October 20].

Animal Care and Use Committee 4 2016, *Hair removal on rodents* [Homepage of John Hopkins University], [Online]. Available: http://web.jhu.edu/animalcare/policies/Hair%20Removal%20on%20Rodents.pdf [2016, October 20].

Animal research advisory committee 2014, *Guidelines for Animal Medical Record Keeping and Transfer of Records between NIH Intramural Animal Facilities*. Available: https://oacu.oir.nih.gov/sites/default/files/uploads/arac-guidelines/medical_records.pdf [2016, Oct 17].

Animal research advisory committee 2015, *Guidelines for Pain and Distress in Laboratory Animals: Responsibilities, Recognition and Alleviation*. Available: https://oacu.oir.nih.gov/sites/default/files/uploads/arac-guidelines/pain_and_distress.pdf [2016, Oct 17].

Animal research advisory committee 2016, *Rodent Drug Formulary: Quick Reference Guide* [Homepage of John Hopkins University], [Online]. Available: http://web.jhu.edu/animalcare/rdf/index.html [2016, October 20].

Animal resource program, 2015 December 03., *Analgesic Drugs and doses* [Homepage of Penn State University], [Online]. Available: https://www.research.psu.edu/arp/anesthesia/analgesic-drugs-and-delivery.html [2016, October 12].

Animal resource program 2016, *Injectable anesthesia* [Homepage of Penn State University], [Online]. Available: https://www.research.psu.edu/arp/anesthesia/injectable-anesthesia.html [2016, October 12].

Brent L, Brooks CG, Medawar PB & Simpson E, Transplantation tolerance. *British Medical Bulletin*, 1976 vol. 32, pp. 101−106.

Calasans-MaiaI M, MonteiroII M, ÁscoliIII F. & GranjeiroIV J. The rabbit as an animal model for experimental surgery. *Acta Cirurgica Brasileira*, [Online], 2009, vol. 24, no. 4, pp. 18/10/16. Available from: http://www.scielo.br/scielo.php?script=sci_arttext&pid=S0102-86502009000400014.

Chong A, Alegre M, Miller M & Fairchild R. Lessons and limits of mouse models. *Cold Spring Harbor perspectives in medicine* 2013; 3: a015295.

Doorschodt B, Teubner A, Kobayashi E. & Tolba R. Promising future for the transgenic rat in transplantation research. *Transplantation reviews* 2014; 28: 155−162.

Gibbs R, Weinstock G, Metzker M, Muzny D, Sodergren E, Scherer S, Scott G, Steffen D, Worley KC, Burch P, Okwuonu G, Hines S, Lewis L, DeRamo C, Delgado O, Dugan-Rocha S, Miner G, Morgan M, Hawes A, Gill R, Celera R, Adams M, Amanatides P, Baden-Tillson H, Barnstead M, Chin S, Evans C, Ferriera S, Fosler C, Glodek A, Gu Z, Jennings D, Kraft C, Nguyen T, Pfannkoch C, Sitter C, Sutton G, Venter J, Woodage T, Smith D, Lee H, Gustafson E, Cahill P, Kana A, Doucette-Stamm L, Weinstock K, Fechtel K, Weiss R, Dunn D. Green E, Blakesley R, Bouffard G, De Jong P, Osoegawa K, Zhu B, Marra M, Schein J, Bosdet I, Fjell C, Jones S, Krzywinski M, Mathewson C, Siddiqui A, Wye N, McPherson J, Zhao S, Fraser C, Shetty J, Shatsman S, Geer K, Chen Y, Abramzon S, Nierman W, Havlak P, Chen R, Durbin K, Egan A, Ren Y, Song X, Li B, Liu Y, Qin X, Cawley S, Worley K, Cooney A, D'Souza L, Martin K, Wu J, Gonzalez-Garay M, Jackson A, Kalafus K, McLeod M, Milosavljevic A, Virk D, Volkov A, Wheeler D, Zhang Z, Bailey J, Eichler E, Tuzun E, Birney E, Mongin E, Ureta-Vidal A, Woodwark C, Zdobnov E, Bork P, Suyama M, Torrents D, Alexandersson M, Trask B, Young J, Huang H, Wang H, Xing H, Daniels S, Gietzen D, Schmidt J, Stevens K, Vitt U, Wingrove J, Camara F, Mar Alba M, Abril J, Guigo R, Smit A, Dubchak I, Rubin E, Couronne O, Poliakov A, Hubner N, Ganten D, Goesele C, Hummel O, Kreitler T, Lee YA, Monti J, Schulz H, Zimdahl H, Himmelbauer H, Lehrach H, Jacob H, Bromberg S, Gullings-Handley J, Jensen-Seaman M, Kwitek A, Lazar J, Pasko D, Tonellato P, Twigger S, Ponting C, Duarte J, Rice S, Goodstadt L, Beatson S, Emes R, Winter E, Webber C, Brandt P, Nyakatura G, Adetobi M, Chiaromonte F, Elnitski L, Eswara P, Hardison R, Hou M, Kolbe D, Makova K, Miller W, Nekrutenko A, Riemer C, Schwartz S, Taylor J, Yang S, Zhang Y, Lindpaintner K, Andrews T, Caccamo M, Clamp M, Clarke L, Curwen V, Durbin R, Eyras E, Searle S, Cooper G, Batzoglou S, Brudno M, Sidow A, Stone E, Venter J, Payseur B, Bourque G, Lopez-Otin C, Puente X, Chakrabarti K, Chatterji S, Dewey C, Pachter L, Bray N, Yap V, Caspi A, Tesler G, Pevzner P, Haussler D, Roskin K, Baertsch R, Clawson H, Furey T, Hinrichs A, Karolchik D, Kent W, Rosenbloom K, Trumbower H, Weirauch M, Cooper D, Stenson P, Ma B, Brent M, Arumugam M, Shteynberg D, Copley R, Taylor M, Riethman H, Mudunuri U, Peterson J, Guyer M, Felsenfeld A, Old S, Mockrin S & Collins F. Genome sequence of the Brown Norway rat yields insights into mammalian evolution. *Nature* 2004; 428: 493−521.

Hu Y, & Chen H. *Heterotropic heart transplantation in rats*. *Experimental organ transplantation*, eds. H. Chen & S. Qian, 1st edn, Nova Science Publishers, Inc (US), New York, USA, 2013 pp. 133−142.

Martins P. Assessment of graft function in rodent models of heart transplantation. *Microsurgery* 2008; 28: 565−570.

Mayer T, Bhan A & Winn H. Immunohistochemical analyses of skin graft rejection in mice. Kinetics of lymphocyte infiltration in grafts of limited immunogenetic disparity. *Transplantation* 1988; 46: 890−899.

Pritchett-Corning K, Mulder G, Luo Y & White WJ. Principles of Rodent Surgery for the New Surgeon. *Journal of Visualized Experiments* JoVE 2011; 47: 10. 3791−2586.

Qian S, Demetris A, Murase N, Rao A, Fung J & Starzl T. Murine liver allograft transplantation: tolerance and donor cell chimerism. *Hepatology* (Baltimore, Md.) 1994; 19: 916−924.

Russell P & Monaco A. The Biology of Tissue Transplantation. *The New England journal of medicine* 1964; 271: 664−671.

Ulich T, Keys M, Ni R, del Castillo J & Dakay E. The contributions of adrenal hormones, hemodynamic factors, and the endotoxin-related stress reaction to stable prostaglandin analog-induced peripheral lymphopenia and neutrophilia. *Journal of leukocyte biology* 1988; 43: 5−10.

Uno S, Endo K, Ishida Y, Tateno C, Makishima M, Yoshizato K & Nebert D. CYP1A1 and CYP1A2 expression: comparing ‘humanized’ mouse lines and wild-type mice; comparing human and mouse hepatoma-derived cell lines. *Toxicology and applied pharmacology* 2009; 237: 119−126.

In: Encyclopedia of Surgery (22 Volume Set)
Editors: Andreas Lehrer and Kristin Mueller
ISBN: 978-1-53618-329-0
© 2020 Nova Science Publishers, Inc.

Chapter 210

LARGE AND TRANSLATIONAL ANIMAL MODELS IN EXPERIMENTAL SURGERY

Kupa Bilolo*, MD
Laboratory of Experimental Surgery, Department of Surgery
Center of Research of Montreal University (CR-CHUM)
University of Montreal, Montreal, Quebec, Canada

ABSTRACT

In the field of surgery, every discovery for improvement of human health must be translated into practical applications. Such discovery usually begins at "the bench" with basic research and then progresses to the clinical level. In experimental surgery, animal models play a very important role in the evaluation of efficacy and safety of new medical treatment or devices before their use in human clinical studies. Thus, we need an animal model that mimics aspects of human anatomy and physiology more closely, and provides practical and clinically relevant ways to study both the natural history and response to treatment. The development of such animal models require (i) to establish criteria for selection of the species most suitable as a model for the question under investigation; (ii) evaluate and validate standardized phenotyping protocols; (iii) create a database of existing models (v) scientific and ethical evaluation of experiments with large animals. This would help to make data from experimental surgery more reproducible and translatable to the clinic. An overview on a choice, evaluation and validation requirements of large and translational animal models is provided in this chapter, in order to facilitate the translation of experimental surgery to patients.

Keywords: Large animal model, Translational animal model, Translational research

* Corresponding Author's Email: kbilolo@hotmail.com.

ABBREVIATIONS

ACUC	Animal Care and Use Committee
FOSCC	Feline oral squamous cell carcinoma
GLP	Good laboratory practice
HNSCC	Head and neck squamous cell carcinoma
LCL	Lateral Collateral Ligament
NHP	Non-Human Primate
RSV	Respiratory syncytial virus
TCC	Transitional cell carcinoma

INTRODUCTION

Experimental surgery is tightly and viciously associated to animal experimentation in the popular imagination. Previous studies showed that the use of animal as experimental model is essential to the development of new and more effective methods of diagnosis and treatment of human diseases (Zerhouni 2005). Based on medical research literature, rodent models frequently fail to fully mimic clinical signs and significant pathologic hallmarks of human diseases (Boivin 2003; Evans 2015; Flisikowska 2012). In recent decades, interest within the scientific community in developing large animal models that more closely approximate the clinical and pathologic features of human disease has increased (Cibelli 2013).

In surgical research and training, large animal model-based studies remains relevant as well as the development of new surgical procedures are necessary. These models of experimentation have been judged as good surgical training or research models for many reasons. They are biologically similar to humans, therefore susceptible to many of the same health problems as humans (Brandacher 2012; Zerhouni 2005; Lumley 1990); i.e., chimpanzees share more that 99% of DNA with humans (Damy 2010). Additionally, a diversity of these animals provides very useful models for the study of diseases afflicting humans. According to medical literature information, it is estimated that between 25 and 30 million animals are used in medical research each year worldwide. Approximately 95% of these animals are rats and mice specifically bred for research and 4.25% of these animals include rabbits, guinea pigs, sheep, fish, frogs, insects, and other species. Most importantly, only 0.75% of the animals in research are cats, dogs, and primates (Bontrop 2001; Carlsson 2004). This wide range of animal species models gives choice for the most appropriate animal for the study design. Usually, the least phylogenetically developed animals available in sufficient quantity, is a preferred choice (Persidsky 2007; Liebschner 2004).

Experiments and procedures involving these animal models must be designed and performed with specific consideration of their pertinence to human or animal health, for the advancement of knowledge and for the benefit to society (Hassan 2005). Thus choice of an animal model should be phylogenetically similar to human beings to allow achievement of approximate information or result than what can be expected in human beings (Solinas 2014; Fagundes 2014). However, there has been a consistent outcry about unethical practices in the use of animals in biomedical research and training. The use of animal models in Experimental surgery research or training must be based on scientific, ethical, and legal principles (Hassan

2005). The three ethical aspects have to be kept in balance when carrying out surgical procedures to satisfy good quality, control and safety for both the trainees or researchers and the animals. Additionally, all animal research must be described in an Animal Care and Use Committee (ACUC) Protocol Form, which must be approved by the institutional ACUC prior any animal work being carried out.

Surgical animal models are usually divided into following two groups: small animal category requiring local animal ethical committee approval: rats, mice, Guinea pigs, rabbit (National Research Council 2011) and the large animal category requiring central animal ethical committee approval in addition to the local ethical committee: dogs, goats, pigs, primates (National Research Council 2011; Dougherty 2008). Mice, rat, rabbits and guinea pigs are universally accepted and specially bred for scientific research, despite a law governing the prevention of pain and performing euthanasia at the end of the study (Morton 1985). Among large animal models, non-human primates are only approved in special cases where the use of other animals is judged to be unreliable, and also in specific need because of their physiologically and anatomically closer features with man (Sughrue 2009). Species such as dogs and pigs share similar physiological and anatomic features with man and are conditionally approved. The use of ruminants is limited due to their varied and distinct physiology and anatomy structure. Mammals, birds, reptiles, amphibians and fish are used rarely (McGonigle 2014).

The common objective of basic science and biomedical research is to improve the health, although this goal has not been achieved as often as desired or needed (Begley 2011). Previous studies from medical literature have recognized translation as a vital component of research and a necessary process to reach health care improvements from basic science research (Fiscella 2008; Keramaris 2008). This process of translating basic scientific knowledge to patient care has been discussed for decades; its importance and difficulty involves applying insights, ideas, and discoveries generated through basic research for treatments or preventions of human diseases, and also taking insights, ideas, and discoveries from the clinic back to the basic experimental settings to identify underlying mechanisms; and this could be defined as a bridge between bench-to-bedside-and-back (Wolf 1974).

In surgery, translational research can be: studies discovering new therapeutic strategies, studies defining the effects of therapeutics in humans, studies providing basis for improving therapeutics, studies identifying clinically relevant biomarkers, and studies developing new drugs and procedures (Rubio 2010). It plays a critical role in helping to understand the mechanism of disease, to improve methods of early detection, and to identify and investigate potential treatment targets (Sung 2003; Wolf 2008).

The translation of surgical discoveries, particularly new surgical procedures or novel therapies of human diseases, requires development of suitable animal models. A translational animal model aids the translation of findings from basic science to practical applications that improve human health and well-being (Table 1). It supplies practical and clinically pertinent ways to study both the natural history and response to treatment of human diseases (Contopoulos-Ioannidis 2003). This animal model should not only necessitate replicating human diseases in etiopathogenesis and pathobiology but also required biomarkers development and toxicity prediction (van Meer 2015). Adequate design and conduct of experimental surgery research as well as further choice of appropriate animal translational models can offer invaluable information to the knowledge of surgery and medicine in general, including the discovery and development of new drugs (Westfall 2007).

Table 1. Translational Model: From Bench to Bedside

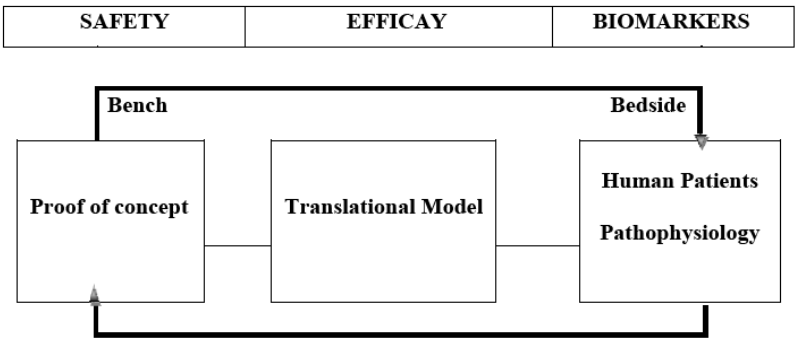

Source: Adapted from Sharing Advances on Large Animal Models. Gene Center, LMU Munich, December 15−17, 2014.

This chapter will help to understand the important role large animal models play in experimental surgery research and the benefits of translational animal models as an important research subject in bench-to-bedside-and-back cycle necessary for the human health care improvements.

Large Animal Models in Experimental Surgery

Historically, large animal models have played a critical role in the exploration and characterization of disease pathophysiology, target identification, and in the *in vivo* evaluation of novel therapeutic agents and treatments. In surgery, they are very advantageous and suitable models for surgical training, development of surgical techniques and research. Most of surgical conditions, specifically for the musculoskeletal, digestive, genitourinary, cardiovascular systems etc. are largely reproducible in the large animals because of their anatomical similarity to humans.

Choice and Experimental Values of Large Animal Models

Whatever the experimental model selected, critical analysis has to be made for the limitations imposed by the physical and anatomical differences from humans and of the pathology, therapies or surgical techniques that can potentially be investigated.

Criteria of large animal models have a different order of preference, according to the purpose of the animal's use. In surgical experiments, anatomic considerations such as size and accessibility of the organs and tissues of interest are the crucial primary determinants for model choice; i.e., for research based on models of human diseases, similarity in biology, both anatomical and physiological, is a primordial criterion of model choice (Al-Rakan 2014; Bugbee 2015); higher mammals, which are closer to humans, like cats, sheep, pigs, dogs and primates etc., which have the identical set of organs (heart, lungs and liver) like humans, constitute a better choice. Different species of large animals fulfil these necessities and offer numerous profitable characteristics (Lu 2014). For example, pigs share many anatomical

structures (proportional organ sizes) (Gonzalez 2015) and physiological similarities (lifestyle: diurnal rhythms, omnivorous habits and propensity to sedentary behaviour) with humans than any other animal species. Therefore, it mimics human condition more accurately than other species, mainly with regards to skin, cardiovascular system, gastrointestinal tract, kidneys and spleen. Also, its convenient size and nature facilitate housing and adequate breeding, and maintenance of strains at any time of the year (early puberty, non-seasonal breeding, short weaning-to-mating interval and high prolificacy). Another outstandingly used model is sheep which is traditionally used as a model in orthopaedics, regenerative medicine, respiratory diseases, reproductive endocrinology and fertility therapies. Its size and temperament are convenient for housing and handling, and also facilitate sequential screening by non-invasive imaging and assessment of hormones and metabolites. It is especially interesting in developmental programming because of singleton pregnancy and similar developmental trajectory to humans; its screening of foetal and early postnatal development is also well-established. Swine also provides breeds and strains fitting for different surgical research objectives and its advantages as a model have been boosted by its availability of porcine genome data, which facilitates genetic modification and creation of genetically engineered strains for specific applications in translational research (Swindle 1994). The cow has proved to be an excellent animal model to investigate human reproduction with a comparable follicular growth length, cycle length and oocytes with the same size. In cows and women, metabolic stress syndromes, characterized by elevated levels of free fatty acids in the blood, have been related with reduced fertility. However, ethical issues prevent a proper experimental design with human reproductive material.

The genetic background such as congenic, isogenic, mutant, recombinant or transgenic characteristics have to be considered, once the experimental model has been chosen. As an example, rabbits (Oryctolagus cuniculus) and pigs (Sus scropha domesticus) breeds should be well defined. The white New Zealand rabbit is the breed most often used in experiments and the pig breeds most used are large white, landrace, Yorkshire, and Hampshire. Also, differences in physiology, genotype, phenotype and maturity at a given weight and age should all be taken into account (Albert 2012; Damy 2010). All animal species should also be sourced from the same supplier throughout an experiment, since even isogenic animals can vary from one animal house to another. Depending on feeding regime, Miniature pigs (usually from Brazil) weigh 0.5 kg at birth, 12−45 kg at 4 months of age and reach 45−100 kg when adults (Tanaka 2006). They should be recommended for longer experiments due to their small size and weight. Traditional pig breeds weight is increased rapidly from 1 kg at birth to 100 kg by 4 months, reaching around 150 kg at 9 months. Consequently, they should mostly be appropriate for acute experiments or experiments lasting a maximum of 3 weeks.

AVAILABLE AND WELL DOCUMENTED LARGE ANIMALS MODELS IN EXPERIMENTAL SURGERY

Porcine

The features of the pig combined with an increasing availability of biological tools and reagents for use to study porcine tissue make the pig arguably the best model available for

translational biomedical research. It is appreciated as a distinctly advantageous model for human beings in numerous fields of science and increasing number of articles and proceedings are being published in biomedical research using pigs (Swindle 2012) The pig has many fundamental anatomic, physiological, genomic, proteomic, immunologic, and nutritional similarities to human beings (Kirk 2003; Swindle 2012; Roura 2016; Rothkotter 2002; Bendixen 2010; Lunney 2007; Hart 2007; Ibrahim 2006) The pig also shows potential for interspecies transplantation work, as well as the ability to fulfill United States Food and Drug Administration requirements for pharmaceutical testing (Gonzalez 2015).

Dogs and Cats

Despite numerous advances in understanding cancer at the molecular level, timely and effective translation to clinical application of novel therapeutics in human cancer patients is lacking; most of failure of cancer therapeutic drugs were found to be closely associated with a result of toxicity or inefficacy not predicted by preclinical animal models (Tobinick 2009; Kola 2008). Dogs and cats as companion animals were found to be biologically relevant translational research model which allows spontaneous disease modeling of human cancer (Gardner 1996). These felines develop an oral squamous cell carcinoma (FOSCC) (Marretta 2015) which shares similar etiopathogenesis (tobacco and papillomavirus exposure) and molecular markers (EGFR, VEGF, and p53) with head and neck squamous cell carcinoma (HNSCC) (Tannehill-Gregg 2006), a common cancer with a poor prognosis and limited clinical advancements in humans. FOSCC and HNSCC share similar tumor biology, clinical outcome, treatment, and prognosis (Martin 2011; Rautava 2012; Bergkvist 2011).

Dog's naturally occurring bladder cancer very closely mimics human invasive bladder cancer, specifically high-grade invasive transitional cell carcinoma (TCC; also referred to as invasive urothelial carcinoma) in cellular and molecular features; biological behavior, including sites and frequency of metastasis and response to therapy (Knapp 2014). This model has been used to help define heritable risks (through very strong breed-associated risk) and environment risks and to evaluate prevention and treatment approaches that benefit humans as well as dogs. The preclinical treatment trials with this model are considered a win-win scenario by clinician scientists in improving detection of TCC and preneoplastic lesions, earlier intervention, better prediction of patient outcome, and more effective TCC management overall.

Caprine and Ovine Models

Previous studies proved caprine (goat) and ovine (sheep) models to be the most appropriate models for large-scale large animal studies in cartilage surface defect repair (Klein 2009; Kon 2010; Milano 2010; Jurgens 2013; Nukavarapu 2013), as the anatomy is closest to humans; they have similar biomechanics of their stifle joint to human knees (Proffen 2012) and they have an adequate cartilage thickness allowing for partial and full thickness defects (Patil 2014). Ovine stifle joint is used in experimental surgery training as device development model (Madry 2015; Ahern 2009; Allen 1998) because it has very similar cruciate ligaments to humans and large menisci as well as a similar lateral collateral

ligament (LCL) complex, popliteus tendon and popliteofibular ligament. However, there are significant differences in their anatomy and biomechanics compared to humans; these differences must be recognised and considered in both study design and in comparing study outcomes, in order to enable the successful translation. For *in vivo* assessment of chondral and osteochondral defect repair (Chevrier 2015), this caprine model represents very a good and feasible option to conduct large animal studies to evaluate biological responses, durability, toxicology, lesion size and location analogous to human studies (Cook 2014).

Nonhuman Primates

Nonhuman primate (NHP) models in transplantation have been used as a variety of species, including baboons, macaques, and, rarely, chimpanzees-which are now eliminated as funded model (Hau 2006; Gluck 2003). NHP models have a high degree of homology with humans, and are predominantly used in highly targeted biologic- and antibody-based therapy studies. NHPs offer a rational basis for the translation of immunosuppressive and tolerance strategies from the bench to the bedside (Douglas 2013). Baboons have commonly been used in xenotransplantation studies, as their relatively large size better accommodates the porcine organs. Macaques (cynomolgus, rhesus, and pigtail) have defined major histocompatibility complex (MHC), and are sufficiently homologous with humans such that most molecular targets will cross-react, with the notable exception of CD3 (Adams 2002; Cendales 2005; Chen 2000). Practically all clinically used standard immunosuppressants have been found to be successful in prolonging graft survival in primate models first, particularly when adjustments for distribution and metabolism have been considered.

Experiments Design Strategy

Experiment protocols are different according to the selected species. In surgical research, a need for biological model, a choice of the species and a relevance of the proposed study have to be determined before deciding to initiate a project with large animals (Abdullahi 2014; Alam 2012). Knowledge of species used, their requirements, management and handling techniques have to be taken in consideration by experimental design to avoid wastage of animal lives.

The use of sensitive techniques for detecting biological differences and appropriate data collection and statistical analysis, are all prerequisites for reducing the number of animals used and for obtaining results with a high degree of acuity, reproducibility and precision (Puopolo 2004). All animal research should be described in an Animal Care and Use Committee Protocol Form, which should be approved by the institutional committee prior to any animal work being performed (Poole 1999).

In surgical research or training, experimental design should greatly consider an anatomic structure such as size of organs, accessibility of the organs and tissues which allow an easy understanding of the various physiological and pathological processes affecting human beings.

The use of large animals in research is exposed to intense societal and philosophical debate because of their psychosocial awareness and privileged status in the human community. Considerations driving species selection usually include scientific, ethical, legal and economic deliberations. Some large research animals such as dogs or non-human primates are highly regulated while others, such as pigs or goats receive less attention. Decisions related to the design and implementations of experiments have to be made in consultation with appropriate review groups such as the institutional animal care and use committee as well as the institution's appointed veterinarians (Kol 2015).

Indeed, ethical use and care of animals including the avoidance or minimization of distress, discomfort and pain have to be rigourously respected by careful protocol design outlining pre- and post-procedural use of analgesics, anesthesia, sedation and euthanasia. The subsequent recovery of animals from procedures must also be monitored to ensure their welfare (Graham 2015).

Welfare, Safety and Management

Regarding environmental standardization, several factors such as temperature, humidity, illumination, light/dark cycles and air quality have to be maintained within the experimental environment by automatic adjustments when housing; since their high variations could influence some metabolic processes, pathological changes and affect some biochemical parameters (Heine 1998). Furthermore, it was proven that good social aspect and environmental enrichment influence animal's physical and psychological welfare. In experimental surgery, individual housing was proven to be unavoidable (Ruys 1991). Specifications for the humane handling, care, treatment and transportation of these large animals have all been described in Animal Welfare Act and Animal Welfare Regulations (USDA 2013). Transportation from the supplier to the research center must be carried out in a manner that preserves both the health and welfare of the animals being transported. Acclimatization of animals to the experimentation area should be observed. Due to bioethical considerations, all procedures with animals should be carried out by trained professionals; they will be responsible for the development and education programs and contribute to the in-depth development of innovative concepts in the humane care and use of laboratory animals. Strict adherence to good laboratory practice (GLP) has to be applied to eliminate many sources of errors and uncertainties. Systematic errors and artifacts could be avoided through the application of technical validity and approved standardized operating procedures. In case of use of genetically-modified organisms, specifics directives have to be set out by technical committee on biosafety.

Challenges in Using Large Animal Model in Experimental Surgery

The practicalities of animal husbandry during treatment can only approximate the care human patients receive. Indwelling catheters and wound care after surgery are often difficult. In conscious animal models, monitoring and vascular access is challenging, often limiting the options for drug delivery and dosing schedules.

In transplantation, the immunologic diversity of large animals can lead to significant differences in outcome via heterologous immune interactions, an experimental parameter that is challenging to quantify and control for. An important issue in transplanted animals is the age of animals and survival time of grafts. For feasible reasons, adolescent animals are often used, and evidence suggests that these young animals, like young humans, have a predominately naïve immune system that will mature toward a memory phenotype as the animal ages (Rodriquez-Carreno 2002; Saalmüller 2002). Regarding graft survival in large animals, convention has established several years as indicative of acceptance. Based on medical literature, no data was supported that graft survival should be interpreted proportionally to lifespan. Data, should be interpreted for what it is, and not extrapolated to indicate longer survival in longer-lived animals (Kirk 2003).

TRANSLATIONAL ANIMAL MODELS IN EXPERIMENTAL SURGERY

Choice of Appropriate Translational Animal Models

Each animal model has specific advantages and disadvantages. The selection of an appropriate pre-clinical *in vivo* model is important in ensuring successful translation to the clinic. In order to choose an appropriate translational model, clinically pertinent question under investigation and hypothesis being tested are seriously important to be considered (Prabhakar 2012; Woolf 2008). Selection of species and strain of translational model has to be carefully made depending on the relevant research interest. The age, gender and health status of the translational animal model should be matched as closely as possible to the clinical condition under investigation; also very special conditions in the design need to be considered, depending on the pathology and the target of interest i.e., in a study with monoclonal antibody TGN1412, the anti T-cell co-stimulatory receptor CD28 antibody TGN1412 caused a severe cytokine storm in its first human volunteer trial (Hansen 2006; Stebbings 2007); but this effect was not observed in animal models using non-human primates during preclinical study. It was found that less activation of memory T-cells in non-human primates than in the human volunteers, despite a near 100% sequence identity of the target, could be the reason that might have afforded this contrariety (Attarwala 2010).

As it has been shown from medical research literature, information gathered from smaller animal translational model is usually less applicable to human. Larger animals offer the advantages of being a good translational animal model because of its closer anatomical similarity to human; easily submitted to some minimally invasive evaluation techniques (i.e., arthroscopy, CT scan, MRI, and biomarkers) without the need for a particular sacrifice (Bouchgua 2009; Hwang 2007; Garner 2011); allowing serial sampling of large amounts of blood and tissues; easy assessment of hormones and metabolites. Only disadvantages include cost and public perception (Mutter 2013; Kirk 2003).

In burn studies research for example, *in vitro* models are limited in their ability to capture all aspects of burn pathophysiology and the complex clinical features of human burn injury; but animal models are still essential for uncovering the molecular (Sayeed 2005; Williams 2009) and cellular (Marshall 2013) aspects that characterize human burn traumas. In clinic, the lack of a suitable animal model that captures all of the prominent features of burn trauma,

is still a major limitation in searching for practical treatment options. Depending on heterogenous nature of burns trauma, specific valuable animal models are needed to uncover the post-burn pathological mechanisms and to test novel therapeutic approaches.

Design and Conduction of Translational Experiments

Numerous factors in designing and conducting translational experiments have to be considered to yield conclusive data (Muschler 2010).

The number of animals to use is usually minimized for ethical and other reasons; this needs to be balanced with the statistical power required generate solid data in order to either verify, or to reject the experimental hypothesis (Feesting 2002).

The time course of therapeutic treatment or to evaluate the outcome should be taken in consideration for the translatability. In preclinical study, it was reported that the benefit of treatments might be greater in animal models because treatment is initiated at the time the injury is induced, before the development of disease, contrary to clinical trials where humans are treated much later in the disease process, normally after onset of symptoms and clear diagnosis.

Since subjective evaluations are generally very efficient way to score behavioral endpoints, it can be easier to create bias. High intra and inter-operator variation of most subjective measures have to be carefully controlled to avoid difficulty in standardization. Safety and quality of life endpoints (e.g., overall activity, body weight, food consumption) in animal efficacy studies should be standard with translational animal model in experimental surgery research.

Reproducibility of experimental animal results with slightly different parameters may produce different results (Crabbe 1999; Richter 2011; Wahlsten 2003). Desire of reporting experimental animal data with a positive or negative result is also inspirited to allow more reproducibility of experiments (Hooijmans 2011; Kilkenny 2010; Kilkenny 2012; Rice 2008).

Validation and prediction of translational animal models: By definition, a translational model is not a perfect replication of the clinical condition (Hackam 2006). Different typical criteria have to be taken in consideration for validation of translational animal model to fit for a specific clinical purpose or situation. Medical literature has shown that not all criteria of validation can be met by a single translational model. However, a combination of different models can eventually come closer to the clinical situation than a single or an even highly sophisticated model. Some authors like, Sams-Dodd (Sams Dodd 2006) has suggested a model validity scoring system in attempt to define an optimal combination of models. This scoring system uses five different important criteria (Table 2).

1. Species: Closer is a species to humans; more likely is the pathophysiology of the disease similar to humans (Akhtar 2015).
2. Complexity: more complex the involved test system is, the more probable that the relevant mechanisms are included; i.e., an *in vitro* ion-channel Test may detect the effect of a test compound on conductance of a cardiac ion-channel whereas an ex vivo or an *in vivo* test system can evaluate its effect on the overall cardiac effect e.g., on contractibility (Suzuki 2009).

3. Disease simulation: Translational animal models use different principles to induce the disease of interest. Simplest models usually do not attempt to induce a disease but easily adapt a measure in healthy individuals; other more complex model use drugs to induce disease symptoms. For many others disorders for which the etiology has not been fully elucidated, it is nearly impossible to truly simulate the disease symptoms. Infectious diseases may be one of the exceptions for the ease of replicating a disease simulation as shown for example by the development of a sophisticated neonatal lamb model for respiratory syncytial virus (RSV) infection (Derscheid 2012; Morton 1999).
4. Predictivity: The model should allow the comparison of different treatments and may help to decide as to whether an experimental treatment has a similar or even superior efficacy to the existing standard of care (Cook 2012).
5. Face validity: This criterion is usually differentiated depending on whether just one symptom of a disease is modeled or a set of symptoms. The scoring system (Table 2) can be used to assemble combination of models altogether for a maximal validity; i.e., the neonatal lamb model for RSV infection scores high for all criteria other than species and could thus be ideally complemented by an ex vivo human cell culture model (Villenave 2012).

Table 2. Proposed validity scoring system

Criterion	Value	Score
Species	Human	4
	Non-human primate	3
	Non-human mammal	2
	Non-mammal	1
Disease simulation	True	4
	Complex	3
	Pharmacological	2
	No	1
Face validity	>1 core symptom	4
	1 core symptom	3
	1 symptom	2
	No 1	1
Complexity	In vivo	4
	Tissue	3
	Cellular	2
	Sub-cellular/molecular	1
Predictivity	Graded for all pharmacology principles	4
	Graded for certain pharmacology principles	3
	All or none for certain pharmacology principles	2
	No or not shown	1

Source: Adapted from T. Denayer et al./New Horizons in Translational Medicine 2014; 2:5–11.

Summarily, following criteria are typically taken in consideration for general validation of translational animal model:

- Similarity in biology and symptoms between translational animal model and the human disease.
- Clinically effective interventions should demonstrate similar effect in the model.

- The target under investigation should have a similar role in the disease models as in the clinical situation; i.e., beta- 3 adrenergic receptor which has an important role in the energy metabolism of rodents but not in humans (Weyer 1999).

Challenges and Limitations of Translational Animal Model

To bridge the translational gap between preclinical animal model and clinical trials, there is a need for making animal model testing more clinical trial-like. Several aspects need to be highlighted for improving the translational value of animal models:

1. Clinical trials endpoints like quality of life are not assessable in animal models. Quality of life is important issue in clinical trials, specifically for a variety of different chronic diseases. This endpoint is usually assessed by questionnaires, a methodology that obviously cannot be used in experimental animals (Kim 2010; Stasiak 2003). However, it was reported in a successful model of human brief pain inventory in canine (dogs) suffering from bone cancer pain (Brown 2009)
2. Requested endpoint is often limited in translational animal models than in clinical trials, some time for ethical reasons; i.e., in oncology, the tumor size is often the primary endpoint of preclinical tumor study models, while overall survival is targeted as endpoint in clinical trials (Marwick 2001).
3. Usefulness of translation and back translation. Back translation from clinical trials to animal models to clinical might help in understanding some clinical data in case of clinical trials failure (Alam 2012); it might be necessary for further improvement of predictive value for future research perspectives; i.e., Importance of this translation and back translation process in proteomics studies in order to improve the patient outcomes (Guest 2013).
4. Improve the quality of translational animal models. This involves following three aspects:
   - Improving the performance quality of existing models. An adequate selection of animal models that fit for research purpose and a better ethical conduction of experiments, taking in consideration all translational study's factors are crucials aspects which could make preclinical data more reproducible and translatable to the clinic (Markides 2015; Mullane 2014).
   - Ameliorate the way animal models are used in the decision making process.
   - Promote the development of more clinically pertinent and predictable and alternative models. Several potential alternatives of animal models have been tested. Three of them are listed here:
     1. Humanized animal model: In this translational animal model, human cells or tissues are engrafted to the model depending on the human disease and question addressed (Ito 2012). This model is extremely useful as it permits functional research studies *in vivo* and hence supports clinical translation. It has helped to improve the clinical translation, especially in oncology and inflammatory diseases (Zhou 2014). Most commonly used are the human tumor xenograft models for study of cancer, and the humanized mouse

models that mimic the human immune system (Siolas 2013; Petersen 2008). An important step will be the creation and use of humanized large animal models such as pigs and nonhuman primates, which will complement mice and may have greater predictive capability (Daadi 2014; Maisano 2015; Matsunari 2009).

2. Use of in silico modeling for reproducing disease mechanisms (Maxwell 2008; Schmidt 2013; Geerts 2013). This approach has been considered as an addition in the translational research armamentarium than a substitute for well-designed animal models.
3. Use of translational animal model in experimental surgery in establishing the safety of stem cell applications is very significant, since the dosages of biologics, the route of administration, treatment outcomes and the development of procedures and techniques, such as surgical and visualization technologies can be extrapolated readily to humans (Hare 2009; Casado 2012; Felfly 2014). Careful and rigorous selection of the best animal models for specific diseases is critical and represents a serious limitation because of the absence of models for disease conditions precisely recapitulating the human phenotype with comparable organ sizes and physiologies. Factors such as the cost, availability of animals and genetic tools, long-term monitoring and appropriate infrastructure may also represent limitation when choosing the optimal model. A need for further development of the regulatory requirements for translational large animal model is a must to ensure efficacy and safety of stem cell-based product applications for human therapeutics (Duda 2014).

CONCLUSION

The use of large animal models in experimental surgery research is scientifically justifiable because of important anatomic and physiological similarities with human beings. These models offer a number of marked translational advantages and play a key role in the development of novel treatments for human disease. Their requirements for larger, more specialized housing and surgical facilities, with higher expenses related to feed, veterinary care, and surgery costs have impeded their widespread use in medical research.

As translational animal models, they are essential to bridge the translational gap between basic research, preclinical research and clinical trials; and reversely, translated back from clinical findings that were not predicted and used to refine the animal models. The selection, evaluation and validation of these animal models should fit the purpose according to stringent criteria and being reproducible. Rational design of experiments should be a part of the translational plan and data from these animal models should be also essential in predicting the clinical outcome for development of specific research issues.

Ethical review, standardization and refinement of animal models by disease expert groups, elaboration of specific good laboratory practice and guidelines were reported to be effective in improving translational potential of these animal models. Acquiescence with high standards of care, refinement of research methodology, and husbandry techniques should be

seriously considered before planning any experiments with these animals; and all of these factors should contribute to build the required safety data package valuable in development of the expected clinical performance of the treatment or others clinical issues.

Continued innovation and refinement in these animal models as well as the need and value of more effective standardization are needed to develop an accurate and optimized guideline for such translational models. This could represent a potentially useful tool in experimental surgery that could help to achieve a greater success rate in translational studies.

ACKNOWLEDGMENT

To Lucile Chambily, an internship student at Experimental Surgery laboratory, CR-CHUM, University of Montreal, Montreal, Quebec, for her contribution to the redaction of this chapter.

REFERENCES

Abdullahi A, Amini-Nik S, Jeschke MG. Animal models in burn research. *Cell. Mol. Life.* Sci. 2014; 71(17):3241–3255.

Adams AB, Shirasugi N, Durham MM, Strobert E, Anderson D, Rees P, Cowan S, Xu H, Blinder Y, Cheung M. Calcineurin inhibitor-free CD28 blockade-based protocol protects allogeneic islets in nonhuman primates. *Diabetes* 2002; 51: 265–270.

Ahern BJ, Parvizi J, Boston R, Schaer TP. Preclinical animal models in single site cartilage defect testing: a systematic review. *Osteoarthritis Cartilage* 2009; 17(6):705–713.

Akhtar A. The Flaws and Human Harms of Animal Experimentation. *Camb Q Healthc Ethics* 2015; 24(4): 407–419.

Alam HB. Translational barriers and opportunities for emergency preservation and resuscitation in severe injuries. *Br. J. Surg*. 2012; 99 Suppl 1:29–39. Review.

Albert FW, Somel M, Carneiro M, et al. A Comparison of Brain Gene Expression Levels in Domesticated and Wild Animals. Akey JM., ed. *PLoS Genetics* 2012; 8(9): e1002962.

Allen MJ, Houlton JE, Adams SB, Rushton N. The surgical anatomy of the stifle joint in sheep. *Vet. Surg.* 1998; 27(6):596–605.

Al-Rakan M, Shores JT, Bonawitz S, Santiago G, Christensen JM, Grant G, Murphy RJ, Basafa E, Armand M, Otovic P, Eller S, Brandacher G, Gordon CR. Ancillary procedures necessary for translational research in experimental craniomaxillofacial surgery. *J. Craniofac. Surg*. 2014; 25(6):2043–2050.

Attarwala H. TGN1412: from discovery to disaster, J. Young. *Pharm*. 2010; 2 (3): 332–336.

Begley S. The Best Medicine. *Scientific American* 2011; 305:50–55.

Bendixen E, Danielsen M, Larsen K. Advances in porcine genomics and proteomics-a toolbox for developing the pig as a model organism for molecular biomedical research. Brief Funct. *Genomics* 2010; 9: 208–219.

Bergkvist GT, Argyle DJ, Pang LY, Muirhead R, and Yool DA. Studies on the inhibition of feline EGFR in squamous cell carcinoma: enhancement of radiosensitivity and rescue of

resistance to small molecule inhibitors. *Cancer Biology and Therapy* 2011; 11(11):927–937.

Boivin GP, Washington K, Yang K. Pathology of mouse models of intestinal cancer: consensus report and recommendations. *Gastroenterology* 2003; 124:762–777.

Bontrop RE. Nonhuman primates: essential partners in biomedical research. *Immunol. Rev.* 2001; 183:5–9.

Bouchgua M, Alexander K, André d'Anjou MA, Girard CA, Carmel EN, Beauchamp G, Richard H, Laverty S. Use of routine clinical multimodality imaging in a rabbit model of osteoarthritis - part I. *Osteoarthritis and Cartilage* 2009;17(2):188–196.

Brandacher G, Grahammer J, Sucher R, Lee WP. Animal models for basic and translational research in reconstructive transplantation. *Birth Defects Res. C. Embryo. Today* 2012;96(1):39–50. Review.

Brown DC, Boston R, Coyne JC, Farrar JT. A novel approach to the use of animals in studies of pain: validation of the canine brief pain inventory in canine bone cancer. *Pain Med.* 2009;10(1): 133–142.

Bugbee WD, Pallante-Kichura AL, Görtz S, Amiel D, Sah R. Osteochondral allograft transplantation in cartilage repair: Graft storage paradigm, translational models, and clinical applications. *J. Orthop. Res*. 2015; 34(1) 31–38.

Carlsson HE, Schapiro SJ, Farah I, Hau J. Use of primates in research: a global overview. *Am. J. Primatol.* 2004; 63:225–237.

Casado JG, Gomez-Mauricio G, Alvarez V, Mijares J, Tarazona R, Bernad A, Sanchez-Margallo FM. Comparative phenotypic and molecular characterization of porcine mesenchymal stem cells from different sources for translational studies in a large animal model. *Vet. Immunol. Immunopathol*. 2012;147(1–2) :104–112.

Cendales LC, Xu H, Bacher J, Eckhaus MA, Kleiner DE, Kirk AD. Composite tissue allotransplantation: Development of a preclinical model in nonhuman primates. *Transplantation* 2005; 80: 1447–1454.

Chen H, Peng J, Luo H, Loubeau M, Wan X, Xu D, Daloze P, Fitzsimmons WE, Bekersky I, Peets J. Compromised kidney graft rejection response in Vervet monkeys after withdrawal of immunosuppressants tacrolimus and sirolimus. *Transplantation* 2000; 69: 1555–1561.

Chevrier A, Kouao AS, Picard G, Hurtig MB, Buschmann MD. Interspecies comparison of subchondral bone properties important for cartilage repair. *J. Orthop. Res*. 2015; 33(1):63–70.

Cibelli J, Emborg ME, Prockop DJ. Strategies for improving animal models for regenerative medicine. *Cell Stem Cell*. 2013; 12:271–274.

Crabbe JC, Wahlsten D, Dudek BC. Genetics of mouse behavior: interactions with laboratory environment. *Science* 1999; 284(5420): 1670–1672.

Contopoulos-Ioannidis DG, Ntzani E, Ioannidis JP. Translation of highly promising basic science research into clinical applications. *Am. J. Med*. 2003; 114:477–484.

Cook JL, Hung CT, Kuroki K, Stoker AM, Cook CR, Pfeiffer FM. Animal models of cartilage repair. *Bone. Joint. Res*. 2014; 3(4):89–94.

Cook N, Jodrell DI, Tuveson DA. Predictive *in vivo* animal models and translation to clinical trials. *Drug Discov Today*. 2012; 17(5–6):253–260.

Daadi MM, Barberi T, Shi Q, Lanford RE. Nonhuman primate models in translational regenerative medicine.*Stem Cells* 2014; 23 Suppl 1:83−87.

Damy SB, Camargo RS, Chammas R, Poli-de-Figueiredo LF. The fundamentals of experiments with animals – Applications in experimental surgery. *Rev. Assoc. Med. Bras*. 2010; 56(1): 103–111.

Derscheid RJ, Ackermann MR. Perinatal lamb model of respiratory syncytial virus (RSV) infection. *Viruses* 2012; 4(10): 2359–2378.

Dougherty D, Conway PH. The ‘‘3T’s’’ road map to transform US health care: the ‘‘how’’ of high-quality care. *JAMA* 2008; 299: 2319–2321.

Douglas J. Anderson and Allan D. Kirk. Primate Models in Organ Transplantation. *Cold Spring Harb Perspect Med.* 2013; 3(9): a015503.

Duda GN, Grainger DW, Frisk ML, Bruckner-Tuderman L, Carr A, Dirnagl U, Einhäupl KM, Gottschalk S, Gruskin E, Huber C, June CH, et al. Changing the Mindset in Life Sciences toward Translation: *A Consensus. Sci. Transl. Med*. 2014; 6 264cm12.

Evans JP, Sutton PA, Winiarski BK, Fenwick SW, Malik HZ, Vimalachandran D, Tweedle EM, costello E, Palmer DH, Park BK, Kitteringham NR. From mice to men: Murine models of colorectal cancer for use in translational research. *Crit. Rev. Oncol. Hematol*. 2015; pii: S1040-8428(15)30058–5.

Fagundes DJ, Taha MO. Animal disease model: Choice´s criteria and current animals specimens. *Acta. Cir. Bras*. 2004; 19:59–65

Felfly H, Haddad GG. Hematopoietic stem cells: potential new applications for translational medicine. *J. Stem. Cells* 2014; 9(3):163–197.

Festing MF, Altman DG. Guidelines for the design and statistical analysis of experiments using laboratory animals. *ILAR J.* 2002; 43: 244–258.

Fiscella K, Bennett NM, Szilagyi PG. Nomenclature in translational research. *JAMA*. 2008; 299(18):2148−2149; author reply 2149−2150.

Flisikowska T, Merkl C, Landmann M. A porcine model of familial adenomatous polyposis. *Gastroenterology* 2012; 143:1173–1175.

Gardner DG. Spontaneous squamous cell carcinomas of the oral region in domestic animals: a review and consideration of their relevance to human research. *Oral Diseases*. 1996; 2(2):148–154.

Garner BC, Stoker AM, Kuroki K, Evans R, Cook CR, Cook JL. Using animal models in osteoarthritis biomarker research. *The Journal of Knee Surgery* 2011; 24(4):251–264.

Geerts H, Spiros A, Roberts P, Carr R. Quantitative systems pharmacologyas an extension of PK/PD modeling in CNS research and development, *J. Pharmacokinet Pharmacodyn*. 2013; 40(3): 257–265.

Gluck JP, Bell J. Ethical issues in the use of animals in biomedical and psycho-pharmacological research. *Psychopharmacology* (Berl) 2003; 171:6–12

Graham ML, Prescott MJ. The multifactorial role of the 3Rs in shifting the harm-benefit analysis in animal models of disease. *Eur. J. Pharmacol*. 2015; 759:19–29.

Green LA, Seifert CM. Translation of research into practice: why we can’t “just do it.” *J. Am. Board Fam. Pract.* 2005; 18:541–545.

Gonzalez LM, Moeser AJ, Blikslager AT. Porcine models of digestive disease: the future of large animal translational research. *Transl. Res*. 2015; 166(1):12–27.

Gould SE, Junttila MR, de Sauvage FJ. Translational value of mouse models in oncology drug development. *Nat. Med.* 2015; 21(5):431–439.

Guest PC, Gottschalk MG, Bahn S. Proteomics: improving biomarker translation to modern medicine? *Genome Med*. 2013; 5 (2):17.

Hackam DG, Reidelmeier DA. Translation of research evidence from animals to humans. *JAMA* 2006; 296:1731–1732.

Hansen S, Leslie RG. TGN1412: Scrutinizing preclinical trials of antibody - based medicines. *Nature* 2006; 441(7091): 282.

Hare JM. Translational development of mesenchymal stem cell therapy for cardiovascular diseases. *Tex. Heart Inst. J.* 2009; 36(2):145–147.

Hart EA, Caccamo M, Harrow JL. Lessons learned from the initial sequencing of the pig genome: comparative analysis of an 8 Mb region of pig chromosome 17. *Genome Biol.* 2007; 8: R168.

Hassan AZ, Kadima KB, Remi-adewumi BD, Awasum CA, Abubakar MT. Animal models in surgical training: Choice and ethics. *Nigerian journal of surgical research.* 2005; 7 (3–4): 260–267.

Hau J, Schapiro SJ. Nonhuman primates in biomedical research. *Scand. J. Lab. Anim. Sci.* 2006; 33:9–12.

Heine WO. *Environmental management in laboratory animal units*. Berlim: Padst Science Publichers; 1998.

Hildebrand F, Andruszkow H, Barkatali BM, Pfeifer R, Lichte P, Kobbe P, Pape HC. Animal models to assess the local and systemic effects of nailing: review of the literature and considerations for future studies. *J. Trauma Acute Care Surg.* 2014; 76(6):1495–1506.

Hooijmans CR, deVries R, Leenaars M, Curfs J, Ritskes-Hoitinga M. Improving planning, design, reporting and scientific quality of animal experiments by using the Gold Standard Publication Checklist, in addition to the ARRIVE guidelines, *Br. J. Pharmacol*. 2011; 162 (6):1259–1260.

Hwang GL, Patel TH, Hofmann LV. Role of image-guided vascular intervention in therapeutic angiogenesis translational research. *Expert. Rev. Cardiovasc. Ther*. 2007; 5(5):903–915. Review.

Ibrahim Z, Busch J, Awwad M. Selected physiologic compatibilities and incompatibilities between human and porcine organ systems. *Xenotransplantation* 2006; 13: 488–499.

Ito R, Takahashi T, Katano I, Ito M. Current advances inhumanized mouse models. *Cell. Mol. Immunol.* 2012; 9 (3): 208–214.

Jurgens WJ, Kroeze RJ, Zandieh-Doulabi B, van Dijk A, Renders GA, Smit TH, van Milligen FJ, Ritt MJ, Helder MN. One-step surgical procedure for the treatment of osteochondral defects with adipose-derived stem cells in a caprine knee defect: a pilot study. *Biores Open Access*. 2013; 2(4):315–325.

Keramaris NC, Kanakaris NK, Tzioupis C, Kontakis G, Giannoudis PV. Translational research: from benchside to bedside. *Injury* 2008; 39(6): 643−50.

Kilkenny C, Browne WJ, Cuthill IC, Emerson M, Altman DG. Improving bioscience research reporting: the ARRIVE guidelines for reporting animal research. *PLoSBiol*.8 (6) (2010) e1000412.

Kilkenny C, Browne WJ, Cuthill IC, Emerson M, Altman DG. Improving bioscience research reporting: the ARRIVE guidelines for reporting animal research, *Osteoarthr. Cartil*.2012; 20 (4): 256–260.

Kim H, Sung B, Mao J. Animal models of acute surgical pain. *Methods Mol. Biol*. 2010; 617:31−39.

Kirk AD. Crossing the bridge: large animal models in translational transplantation research. *Immunol. Rev*. 2003; 196:176–196.

Klein TJ, Malda J, Sah RL, Hutmacher DW. Tissue engineering of articular cartilage with biomimetic zones. *Tissue Eng. B. Rev*. 2009; 15(2):143–157.

Knapp DW, Ramos-Vara JA, Moore GE, Dhawan D, Bonney PL, Young KE. Urinary bladder cancer in dogs, a naturally occurring model for cancer biology and drug development. *ILAR J*. 2014; 55(1):100–118.

Kol A, Arzi B, Athanasiou KA, Farmer DL, Nolta JA, Rebhun RB, Chen X, Griffiths LG, Verstraete FJ, Murphy CJ, Borjesson DL. Companion animals: Translational scientist's new best friends. *Sci. Transl. Med*. 2015; 7(308):308ps21.

Kola I. The state of innovation in drug development. *Clinical Pharmacology and Therapeutics*. 2008; 83(2): 227–230.

Kon E, Delcogliano M, Filardo G, Fini M, Giavaresi G, Francioli S, Martin I, Pressato D, Arcangeli E, Quarto R, Sandri M, Marcacci M. Orderly osteochondral regeneration in a sheep model using a novel nano-composite multilayered biomaterial. *J. Orthop. Res*. 2010; 28(1):116–124.

Liebschner MA. Biomechanical considerations of animal models used in tissue engineering of bone. *Biomaterials* 2004; 25:1697–714.

Lu P, Sodhi CP, Jia H, Shaffiey S, Good M, Branca MF, Hackam DJ. Animal models of gastrointestinal and liver diseases. Animal models of necrotizing enterocolitis: pathophysiology, translational relevance, and challenges. *Am. J. Physiol. Gastrointest. Liver Physiol*. 2014; 306(11): G917–928.

Lumley JSP, Green CJ, Lear P, Angell-Jams JE. *Essentials of experimental surgery*. 1990; - v, 19.

Lunney JK. Advances in swine biomedical model genomics. *Int. J. Biol. Sci*. 2007; 3: 179–184.

Madry H, Ochi M, Cucchiarini M, Pape D, Seil R. Large animal models in experimental knee sports surgery: focus on clinical translation. *J. Exp. Orthop*. 2015; 2(1):9.

Maisano F, Reser D, Pavicevic J, Guidotti A, Denti P, Taramasso M, Addis A, Cesarovic N, Emmert MY, Nietlispach F, Swain J, Falk V, Leon M. A translational "humanised" porcine model for transcatheter mitral valve interventions: the neo inferior vena cava approach. *EuroIntervention* 2015; 11(1):92−95.

Marretta JJ, Garrett LD, and Marretta SM. Feline oral squamous cell carcinoma: an overview. *Veterinary Medicine* 2015; 102(6): 392–406.

Marshall AH, Brooks NC, Hiyama Y, Qa'aty N, Al-Mousawi A, Finnerty CC, Jeschke MG. Hepatic apoptosis postburn is mediated by c-Jun N-terminal kinase 2. *Shock* 2013;39(2):183–188.

Martin CK, Tannehill-Gregg SH, Wolfe TD, and Rosol TJ. Bone-invasive oral squamous cell carcinoma in cats: pathology and expression of parathyroid hormone-related protein. *Veterinary Pathology* 2011; 48 (1): 302–312.

Markides H, McLaren JS, El Haj AJ. Overcoming translational challenges - The delivery of mechanical stimuli *in vivo*. *Int. J. Biochem. Cell Biol.* 2015; 69:162–172.

Marwick C. Scientists recall progress and promise of translational research. *J. Natl. Cancer. Inst.* 2001; 93:13–15.

Matsunari H, Nagashima H. Application of genetically modified and cloned pigs in translational research. *J. Reprod. Dev*. 2009; 55(3):225–230.

Maxwell G, Mackay C. Application of a systems biology approach to skin allergy risk assessment, *Altern. Lab. Anim.* 2008; 36(5) 521–556.

McGonigle P, Ruggeri B. Animal models of human disease: challenges in enabling translation. *Biochem Pharmacol*. 2014; 87(1):162–171.

Milano G, Sanna Passino E, Deriu L, Careddu G, Manunta L, Manunta A, Saccomanno MF, Fabbriciani C. The effect of platelet rich plasma combined with microfractures on the treatment of chondral defects: an experimental study in a sheep model. *Osteoarthritis Cartilage* 2010; 18(7):971–980.

Mullane K, Winquist RJ, Williams M. Translational paradigms in pharmacology and drug discovery. *Biochem. Pharmacol*. 2014; 87(1):189–210.

Muschler GF, Raut VP, Patterson TE, Wenke JC, Hollinger JO. The design and use of animal models for translational research in bone tissue engineering and regenerative medicine. *Tissue Eng. Part B Rev*. 2010; 16(1):123–145.

Mutter D, Dallemagne B, Perretta S, Vix M, Leroy J, Pessaux P, Marescaux J. Innovations in minimally invasive surgery: lessons learned from translational animal models. *Langenbeck's Archives of Surgery* 2013; 398 (7): 919–923.

Morton DB. Ethical aspects of the use of animal models of infection. In: Zak O, Sand MA, editors. *Handbook of animals models of infection*. San Diego: Academic Press; 1999. p. 30–48.

Morton DB and Griffiths. Guidelines on the recognition of pain, distress and discomfort in experimental animals and a hypothesis for assessment. *The Veterinary Record*. 1985, April; pp. 431–436.

National Research Council. *Guide for the care and use of laboratory animals*, 8th ed. The National Academies Press. 2011, Washington, DC.

Nukavarapu SP, Dorcemus DL. Osteochondral tissue engineering: current strategies and challenges. *Biotechnol Adv*. 2013; 31(5):706–721.

Patil S, Steklov N, Song L, Bae WC, D'Lima DD. Comparative biomechanical analysis of human and caprine knee articular cartilage. *Knee* 2014; 21(1):119–125.

Persidsky Y, Fox H. Battle of animal models. *J. Neuroimmune Pharmacol*. 2007; 2:171Y177.

Petersen TK, Sørensen P. Translational dermatology in drug discovery: perspectives for integrating humanized xenograft models and experimental clinical studies. *Drug Discov. Today* 2008; 13(5–6):240–246.

Phillips JB, Westerfield M. Zebrafish models in translational research: tipping the scales toward advancements in human health. *Dis. Model Mech*. 2014; 7(7):739–743.

Poole TB. The UFAW Handbook on the care and management of laboratory animals. London: *Longman Scientific & Technical*; 1999.

Prabhakar S. Translational research challenges: finding the right animal models. *J. Investig Med*. 2012; 60(8):1141–1146.

Proffen BL, McElfresh M, Fleming BC, Murray MM. A comparative anatomical study of the human knee and six animal species. *Knee*. 2012; 19(4):493–499.

Puopolo M. Biostatistical approaches to reducing the number of animals used in biomedical research. *Ann. 1st Super Sanità*. 2004; 40: 157–163.

Rautava R and Syrjanen S. Biology of human papillomavirus infections in head and neck carcinogenesis. *Head and Neck Pathology* 2012; 6(1): S3–S15.

Richter SH, Garner JP, Zipser B, Lewejohann L, Sachser N, Touma C, Schindler B, Chourbaji S, Brandwein C, Gass P. Effect of population heterogenization on the reproducibility of mouse behavior: a multi-laboratory study. *PLoS One* 2011; 6 (1): e16461.

Rice AS, Cimino-Brown D, Eisenach JC, Kontinen VK, Lacroix-Fralish ML, Machin I, Mogil JS, Stohr T. Animal models and the prediction of efficacy in clinical trials of analgesic drugs: a critical appraisal and call for uniform reporting standards. *Pain 2*008; 139 (2):243–247.

Rodriguez-Carreno MP, Lopez-Fuertes L, Revilla C, Ezquerra A, Alonso F, Dominguez J. Phenotypic characterization of porcine IFN-γ-producing lymphocytes by flow cytometry. *J Immunol Methods* 2002; 259: 171–179.

Rothkotter HJ, Sowa E, Pabst R. The pig as a model of developmental immunology. *Hum. Exp. Toxicol*. 2002; 21: 533–536.

Roura E, Koopmans SJ, Lallès JP. Critical review evaluating the pig as a model for human nutritional physiology. *Nutr. Res. Rev*. 2016; 29: 60–90.

Rubio DM, Schoenbaum EE, Lee LS, Schteingart DE, Marantz PR, Anderson KE, Platt LD, Baez A, Esposito K. Defining translational research: implications for training. *Acad. Med.* 2010 Mar; 85(3):470–475.

Ruys T. *Handbook of facilities planning*. New York: Van Nostrand Reinhold; 1991.

Saalmüller A, Werner T, Fachinger V. T-helper cells from naive to committed. *Vet. Immunol. Immunopathol*. 2002; 87:137–145.

Sams-Dodd F. Strategies to optimize the validity of disease models in the drug discovery process. *Drug Discov.Today* 2006; 11 (7–8):355–363.

Sayeed MM. Inflammatory/cardiovascular-metabolic responses in a rat model of burn injury with super imposed infection. *Shock* 2005; 24(Suppl 1):40–44.

Schmidt BJ, Papin JA, Musante CJ. Mechanistic systems modeling to guide drug discovery and development. *Drug Discov. Today* 2013; 18 (3–4):116–127.

Shultz LD, Brehm MA, Garcia-Martinez JV, Greiner DL. Humanized mice for immune system investigation: progress, promise and challenges, *Nat. Rev. Immunol*. 2012; 12(11):786–798.

Siolas D, Hannon GJ. Patient-derived tumor xenografts: transforming clinical samples into mouse models. *Cancer Res.*2013 ; 73(17): 5315–5319.

Solinas P, Isola M, Lilliu MA, Conti G, Civolani A, Demelia L, Loy F, Isola R. Animal models are reliably mimicking human diseases? A morphological study that compares animal with human NAFLD. *Microsc. Res. Tech*. 2014; 77(10):790–796.

Stasiak KL, Maul D, French E, Hellyer PW, Vandewoude S. Species-specific assessment of pain in laboratory animals. *Contemp. Top*. 2003; 42: 13–19.

Stebbings R, Findlay L, Edwards C, Eastwood D, Bird C, North D, Mistry Y, Dilger P, Liefooghe E, Cludts I, et al. "Cytokine storm" in the phaseI trial of monoclonal antibody TGN1412: better understanding the causes to improve preclinical testing of immunotherapeutics. *J. Immunol.* 2007; 179(5): 3325–3331.

Sughrue ME, Mocco J, Mack WJ, Ducruet AF, Komotar RJ, Fischbach RL, Martin TE, Connolly ES Jr. Bioethical considerations in translational research: primate stroke. *Am. J. Bioeth.* 2009;9(5):3–12.

Sung NS, Crowley WF Jr, Genel M. Central challenges facing the national clinical research enterprise. *JAMA* 2003; 289:1278–1287.

Suzuki Y, Yeung AC, Ikeno F. The pre-clinical animal model in the translational research of interventional cardiology. JACC Cardiovasc. *Interv.* 2009; 2(5):373–383.

Swindle MM, Smith AC, Lader-Laird K, Dungan L. Swine in biomedical research: management and models. *ILAR J.* 1994; 36: 39.

Swindle MM, Makin A, Herron AJ. Swine as models in biomedical research and toxicology testing. *Vet. Pathol*. 2012; 49:344–356.

Tanaka H, Kobayashi E. Education and research using experimental pigs in a medical school. *J. Artif. Organs.* 2006; 9(3):136–143.

Tannehill-Gregg S, Levine A, and Rosol T. Feline head and neck squamous cell carcinoma: a natural model for the human disease and development of a mouse model. *Veterinary and Comparative Oncology* 2006; 4(2): 84–97.

Tobinick EL. The value of drug repositioning in the current pharmaceutical market. *Drug News and Perspectives* 2009; 22(2):119–125.

USDA. *Animal welfare act and Animal Welfare Regulations*. November 2013. Available from:https://www.aphis.usda.gov/animalwelfare/downloads/AnimalCareBlueBook-final.pdf

Van Meer PJ, Graham ML, Schuurman HJ. The safety, efficacy and regulatory triangle in drug development: Impact for animal models and the use of animals. *Eur. J. Pharmacol*. 2015; 759:3–13.

Villenave RS. Thavagnanam S, Sarlang S, Parker J, Douglas I, Skibinski G, Heaney LG, McKaigue JP, Coyle PV, Shields MD. *In vitro* modeling of respiratory syncytial virus infection of pediatric bronchial epithelium, the prmary target of infection *in vivo*. *Proc. Natl. Acad. Sci. USA* 2012; 109 (13): 5040–5045.

Wahlsten D, Metten P, Phillips TP, Boehm 2nd SL, Burkhart-Kasch S, Dorow J, Doerksen S, Downing C, Fogarty J, Rodd-Henricks K. Different data from different labs: Lessons from studies of gene environment interaction. *J. Neurobiol*. 2003; 54 (1): 283–311.

Westfall JM, Mold J, Fagnan L. Practice-based research 'blue highways' on the NIH roadmap. *JAMA* 2007; 297:403–406.

Weyer C, Gautier JF, Danforth Jr E. Development of beta 3-adrenoceptor agonists for the treatment of obesity and diabetes – an update. *Diabetes Metab*.1999; 25(1):11–21.

Williams FN, Herndon DN, Jeschke MG. The hypermetabolic response to burn injury and interventions to modify this response. *Clinics in plastic surgery* 2009; 36(4):583–596.

Wolf S. Editorial: the real gap between bench and bedside. *New Engl. J. Med.* 1974; 290:802–803.

Woolf SH. The meaning of translational research and why it matters. *JAMA* 2008; 299:211–213.

Zerhouni EA. US biomedical research: basic, translational, and clinical sciences. *JAMA* 2005; 294:1352–1358.

Zerhouni EA. Translational and clinical science−time for a new vision. *The New Engl. J. Med.* 2005; 353:1621–1623.

Zhou Q, Facciponte J, Jin M, Shen Q, Lin Q. HumanizedNOD-SCIDIL2rg (-/-) mice as a preclinical model for cancer research and its potential use for individualized cancer therapies, *Cancer Lett*. 2014; 344(1):13–19.

In: Encyclopedia of Surgery (22 Volume Set)
Editors: Andreas Lehrer and Kristin Mueller
ISBN: 978-1-53618-329-0
© 2020 Nova Science Publishers, Inc.

Chapter 211

CARDIOVASCULAR BIOMECHANICAL MODELS

Ethan Kung*, PhD
Department of Mechanical Engineering,
Department of Bioengineering,
Clemson University,
Clemson, SC, US

ABSTRACT

Computational and *in vitro* methods offer powerful means to model the cardiovascular system and investigate biomechanics related to blood flow, cardiovascular tissue, and medical devices. These models can be constructed to directly describe human anatomy and physiology, and can be more highly controlled compared to animal models. Low-order models composed of lumped-parameter elements and simplified descriptions of cardiac function can capture the global physiology, while high-order models exhibiting detailed 3D anatomy and dynamics can provide highly realistic replication of biomechanical interactions in a small region of the circulation. Multiscale models offer the freedom to capture biomechanics in different regions at the desired level of details. In this chapter we describe the fundamentals and the current state-of-the-art of model construction both in the computational and *in vitro* approaches. These models have been applied to understand the physiologic impacts of medical device implantations, predict surgical outcomes, and investigate hemodynamics in vascular diseases; we present several illustrative case studies here. Finally we examine the pros and cons of each type of models and discuss the considerations in proper model selection for a research study.

Keywords: lumped-parameter, image-based, patient-specific, CFD, *In Vitro*, multiscale

* Corresponding Author's Email: ekung@clemson.edu.

ABBREVIATIONS

CFD	computational fluid dynamics
LPM	lumped-parameter model
RCR	resistor-capacitor-resistor
VAD	ventricular assist device

INTRODUCTION

Surgical palliation of cardiovascular abnormalities and implementation of cardiovascular medical devices are intended to modify and improve patient hemodynamic parameters such as cardiac output, blood pressure, pulmonary perfusion, and blood flow patterns. Biomechanical parameters in the cardiovascular system such as 3D flow and pressure fields, as well as stress and strain in blood vessels, have direct effects on the progression of cardiovascular diseases (Caro 1971; Glagov 1988; Ku 1985; Malek 1999). The hemodynamic forces within blood vessels directly affect the biological adaptation of vessel diameters and wall thicknesses (Langille 1989; Wolinsky 1967). The design and evaluation of implantable devices require consideration of the interactions between the device and *in vivo* forces and motions. In this chapter we will examine several types of cardiovascular biomechanical models that can account for these important interactions in the investigation of cardiovascular devices and surgical procedures.

There are two inherent limitations to using animal models for studying human biomechanics: 1) the intrinsic variabilities in living organisms make highly controlled experiments difficult and 2) the physiological differences between the model animal and human make the implications of animal study results ambiguous. For these reasons, there is great motivation to employ non-living models that offer simplified, but well-controlled experiments that can be constructed based on human physiology and anatomy. Computational and *in vitro* models are two common approaches to constructing non-living biomechanical models. Models of different orders are used to capture the behavior of the cardiovascular system at different desired levels of details. Low-order models are simplified representations capable of encompassing large regions of the cardiovascular system; and high-order models can provide detailed 3D hemodynamic information for small regions of special interest.

Since the 1960s, lumped-parameter approaches have been used to construct low-order models of the circulatory system (Thiry 1976; Westerhof 2009; Westerhof 1969). While these models do not provide spatial information, they are capable of capturing complex vascular organizations and interactions, and providing realistic estimations of hemodynamics. Starting in the 1990s, the development of high-order models based on 3D medical imaging data allowed for biomechanical models to directly represent a small portion of patient-specific anatomy (Taylor 1998a; Taylor 1998b; Taylor 1999; Milner 1998; Steinman, 2002). Together, the current state-of-the-art involves combining models of different orders and constructing multiscale models to capture the relevant information of interest at the appropriate levels of details (Corsini 2013; Kung 2011b; Kung 2013; Vukicevic 2013; Schiavazzi 2015).

In this chapter, we present the computational and *in vitro* approaches to both low-order and high-order biomechanical models of the cardiovascular system. We will discuss how these models can be coupled together to construct multiscale models; we will also look at several example applications of different model configurations. Lastly we will discuss the considerations for selecting an appropriate model suitable for a research study depending on the relevant physics and the types of parameters to be investigated.

LOW-ORDER MODELS

Low-order models are greatly simplified representations of the cardiovascular system typically used to capture the systemic behaviors of the entire circulation (or a large portion of the circulation). This approach can offer the "bird's eye view" of the system where the congregated behavior of each subcomponent is approximated without great amounts of detail. A very common type of low-order model for the cardiovascular system is the lumped-parameter model (LPM). In this approach, aspects of the cardiovascular system are represented by components analogical to electrical circuit elements. This type of model does not contain spatial information other than the structure of the vascular network represented as the corresponding circuit element organization in the model. Another type of cardiovascular low-order model is one that solves the 1D equations of blood flow (Hughes and Lubliner, 1973). This approach offers spatial information along a single dimension (down the length of blood vessels), and is a slightly more complex and computationally expensive type of low-order model. In this chapter, we will focus on the lumped-parameter approach to the low-order model.

In the vascular system, blood is driven through a vascular bed by arterial blood pressure. The vascular bed is typically considered passive in the sense that it does not generate pressure. The underlying physics governing the blood flow characteristics in a passive vascular bed can be modeled via 3 types of basic elements in the LPM: resistance, capacitance, and inductance. The resistance element describes the viscous dissipation of pressure energy as blood flows through vasculature. The compliance of blood vessels (mostly in large vessels) is modeled by the capacitance element in the LPM, which captures the effects of blood vessel elasticity damping pressure and flow pulsations. Lastly, inductance elements are used in the LPM to describe how the momentum of blood resists changes in flow. This aspect of blood flow is especially important for accurately modeling hemodynamics in regions close to the heart (i.e., flow through the aortic valve, in the abdominal aorta, etc.) where the blood flow pulsation is significant. The capacitance and inductance are non-dissipative elements.

The active components in the LPM generate pressures to drive blood through the passive vascular beds. The main active component is the heart itself; the driving pressure generated by the heart is almost always included in an LPM. Pressures generated by other active components are selectively included in each specific model depending on their relative importance to the topic being investigated. These can include respiration, muscle pumps, and medical devices such as blood pumps.

Computational Representation

Passive Components

The viscous flow resistance is modeled by the equation $P = QR$, where Q is the volumetric flow rate through the resistance, R is the resistance value, and P is the pressure drop across the resistance. In healthy situations, blood flow is laminar in most of the cardiovascular system. Small arterioles with little compliance (and thus little change in diameter over a cardiac cycle) contribute to most of vascular resistance. According to Poiseuille's solution for laminar flow in a tube, the viscous resistance of blood vessels is therefore relatively constant across the cardiac cycle at a given physiologic state. The viscous flow resistance in non-laminar flow regions, such as across heart valves or surgical shunts, are typically represented as flow-dependent resistances. The mathematical relationship between the flow and pressure drop in these elements is typically derived empirically (Migliavacca 2000).

Capacitance is modeled by the equation $Q=C\ dP/dt$, where C is the capacitance value, dP/dt is the time rate of change of the pressure across the capacitor, and Q is the volumetric flow rate into the capacitor. This equation describes the physical scenario where flow into a capacitor "charges up" the capacitor, much like how the internal pressure of an elastic balloon increases when fluid is pumped into the balloon.

Inductance is modeled by the equation $P = L\ dQ/dt$, where L is the inductance value, dQ/dt is the time rate of change of the volumetric flow rate through the inductor, and P is the pressure across the inductor. This relationship stems from Newton's second law and describes the physical scenario where a change in volumetric flow rate (acceleration) requires a pressure difference across the inductor (i.e., force applied to the fluid). A summary of the aforementioned passive components is provided in Figure 1.

Element	Symbol	Computational Model	Experimental Model
Resistance (models viscous dissipation)		P = Q R	Parallel glass capillary tubes
Capacitance (models vessel compliance)		Q = C dP/dt	Trapped air pocket
Inductance (models blood momentum)		P = L dQ/dt	Any tubing segment (parasitic)

Figure 1. Summary of common passive elements in the lumped-parameter model.

Heart Models

There are two common types of heart models for the computational LPM: the elastance function model and the active-passive function model. The first approach utilizes the normalized elastance function to model the ventricle. The elastance "*E*" is defined as the ratio between the pressure and relative volume inside a ventricle, and by the equation $P=E(t)\ (V-Vo)$, where $E(t)$ is the time-varying elastance, V is the blood volume inside the ventricle, Vo is the ventricle's reference volume, and P is the blood pressure in the ventricle. Conceptually, the elastance describes the "stiffness" of a ventricle at any point in time as it contracts and

relaxes. The justification for using the normalized elastance function to model the ventricle is based on previous findings that the shape of the normalized (with respect to amplitude and timing of the peak) elastance waveform is relatively constant across people, and independent of ventricular load, contractile state, and various cardiac diseases (Suga 1973). Since the physiologic basis for the elastance function model is based on studies of the ventricle, this approach is typically not used for modeling the atria. In the implementation workflow, each elastance function model begins with the normalized elastance function (Figure 2a). This function is then "de-normalized" for each specific model simulation. The de-normalization involves stretching or shrinking the function in the x-axis according to the specific heart rate and ventricular activation to be simulated, scaling the function amplitude in the y-axis according to the contractility to be modeled, and offsetting the function in the y-axis to describe the appropriate passive filling characteristics of the ventricle (Kung 2014).

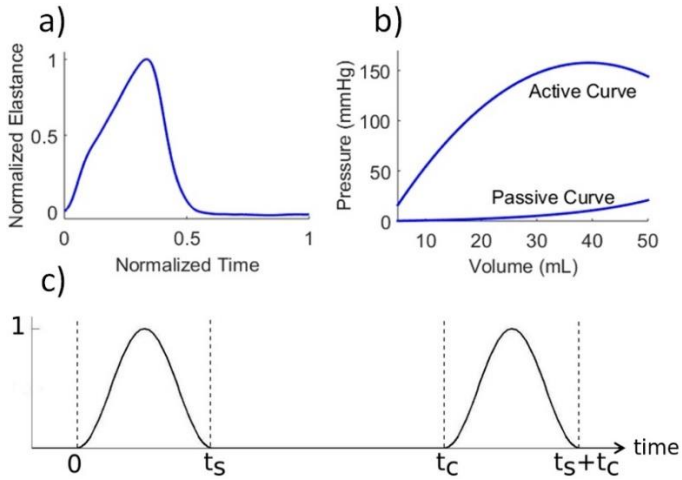

Figure 2. a) The normalized elastance function for modeling the ventricle b) An example active and passive curve for modeling a heart chamber (the ventricle of a pediatric patient is represented in this particular example) c) An example activation function to describe the cardiac contraction of each heartbeat. "tc" is the cardiac period and "ts" is the systolic length.

The active-passive function approach can be used to model both the atrium and ventricle. In the active-passive function model, two pressure-volume relationships (Figure 2b) are used to describe the active and passive behaviors of the heart chamber. The passive curve is defined based on the elastic properties of the chamber during relaxation, and the active curve is defined based on contractile characteristics. An activation function (Figure 2c) is used to describe the timing and duration of active contraction. Different shapes may be chosen for these curves depending on the design of the specific heart model. The pressure inside the heart chamber is then defined as $P=A*P_{act} + P_{pas}$, where A, P_{act}, and P_{pas} is the value of the activation function, active pressure, and passive pressure, respectively (Corsini 2013). Note that A is a function of time, and P_{act} and P_{pas} are functions of the heart chamber volume.

There are advantages and disadvantages to these two different heart modeling approaches. The elastance function approach is empirically-based; the normalized elastance function already encapsulates the congregated underlying mechanisms that result in the observed behavior of the ventricle. This model requires few parameters to be tuned for each modeling scenario, but only offers a somewhat "black box" approach to modeling the heart.

The active-passive approach mathematically describes the underlying properties of heart tissue and contraction characteristics, and offers a lower-level mechanistic approach to capturing heart function. It requires the tuning of more parameters, each needing to be set appropriately in order for the model to accurately describe the specific heart to be simulated.

Other Active Components

Mathematical descriptions of other active components driving blood flow can be constructed and implemented into the computational LPM. Like the heart model, active components are generally implemented as pressure sources. The specific mathematical constructions to describe these components can vary greatly and the discussion is beyond the scope of this chapter. Common active components that are modeled besides the heart include respiration (Kung 2014; Baretta 2012) and ventricular assist devices (Giridharan 2002; Pekkan 2005; Schmidt 2016). Interested readers are encouraged to refer to the cited literature for further details.

Example Implementation

Here we present a simple example to illustrate how to use the various components discussed to perform calculations of pressure, flow, and volumes in a computational LPM. In this exercise we use an active-passive function model to describe an atrium, an elastance function model to describe a ventricle, and a few passive components to describe a simplified vascular bed. Note that the two ideal diodes included in this LPM represent heart valves and allow uni-directional flow with no added resistance (Figure 3).

Assume that based on atrial and ventricular characteristics, we have already defined $E(t)$, $P_{act}(Va)$, $P_{pas}(Va)$, and $A(t)$, which are the de-normalized elastance function of the ventricle, the atrial active and passive pressures as functions of atrial volume, and the activation function of the atrium, respectively. Assume that based on the scenario to be modeled, we have also already determined the resistance, capacitance, and inductance component values, the initial values of differential variables, and the ventricular reference volume "*Vo*." The resulting system of equations describing this LPM is then:

$$Pv = E(t)(Vv - Vo) \quad \text{(Eqn 1)}$$

$$Pa = A(t)P_{act}(Va) + P_{pas}(Va) \quad \text{(Eqn 2)}$$

$$Q_{av} = \begin{cases} \frac{Pa-Pv}{R2} \; for \; Pa \geq Pv \\ 0 \; for \; Pv > Pa \end{cases} \quad \text{(Eqn 3)}$$

$$\frac{dQ_L}{dt} = \begin{cases} 0 \; for \; Q_L \leq 0 \; and \; Pc > Pv \\ \frac{Pv-Pc}{L} \; else \end{cases} \quad \text{(Eqn 4)}$$

$$\frac{dPc}{dt} = \frac{Q_L - (\frac{Pc-Pa}{R1})}{C} \quad \text{(Eqn 5)}$$

$$\frac{dVa}{dt} = \frac{Pc-Pa}{R1} - Q_{av} \quad \text{(Eqn 6)}$$

$$\frac{dVv}{dt} = Q_{av} - Q_L \quad \text{(Eqn 7)}$$

This system of equations can be solved using a numerical time-stepping scheme, such as the 4th order Runge-Kutta method.

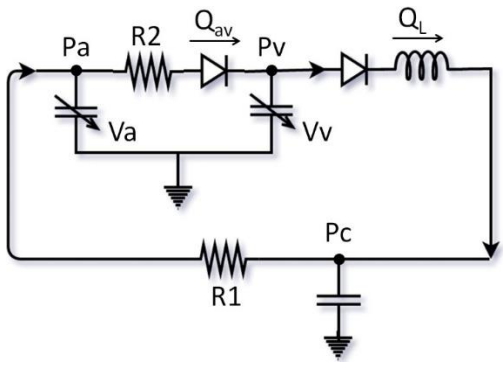

Figure 3. Schematic of the example LPM. "Va" and "Vv" are the atrial and ventricular volumes, respectively.

In vitro Representation

Passive Component: Resistance

According to the Poisuille solution, the viscous resistance of a flow conduit is a function of only the fluid property and the geometry of the conduit as expressed by equation 8. Note that this solution is only valid for laminar flow; in the turbulent flow regime, the resistance is a function of also the flow rate. Due to the fact that blood flow is laminar in the large number of parallel small blood vessels, under normal physiologic conditions the viscous resistance of a vascular bed behaves similar to an ideal resistor that is not a function of flow rate. In order to replicate this vascular resistance behavior, an *in vitro* resistance component should be constructed using a large number of parallel small channels. This is supported by examining the relationship $R \propto N^{3/2}\, Re / Q$ where *R* is the overall resistance of a resistor component, *N* is the number of parallel channels used to create the resistor, *Re* is the Reynolds number in each individual channel, and *Q* is the total flow rate through the resistor (Kung 2011). For a given resistance, in order to accommodate high enough (physiologic) flow rates while maintaining *Re* in the laminar flow regime, a large number of parallel channels should be used (Figure 4). A practical method to construct such a flow resistance component is by placing a number of glass capillary tubes in parallel inside a larger conduit as shown in Figure 1 (Kung 2011). The following equations for calculating the resistance value "R" and maximum laminar flow rate "Q_{max}"of the resistance component are useful for its design and construction:

$$R = \frac{8\,\mu\, l}{N\,\pi\, r^4} \quad \text{(Eqn 8)}$$

$$Q_{max} = 1050\,\pi\,\mu\, r\, N\, /\, \rho \quad \text{(Eqn 9)}$$

μ and ρ are the dynamic viscosity and density of the working fluid. l, r, and N are the length, inner radius, and total number of capillary tubes.

Alternatively, many studies choose to use a simple partially closed ball valve to create flow resistance in an experiment (Figliola 2010; Vukicevic 2013; Khoiy 2016; Timms 2011). This approach results in a resistance that is a direct function of flow rate (Figure 5) (Kung 2011). In experiments where the flow is fairly constant, the simple ball valve resistor may provide a good approximation of the desired resistance. In highly pulsatile flow scenarios, the approximation begins to deteriorate. While the ball valve flow resistor is very simple to construct, it is difficult to tune. Very small adjustments of the valve closure can result in significant changes in the resulting flow resistance. When employing a ball valve resistor in an experiment, it is important to completely avoid physical perturbation of the valve after tuning. Depending on the specific topic of study, the ball valve resistor may be an appropriate option to quickly provide a desired mean resistance.

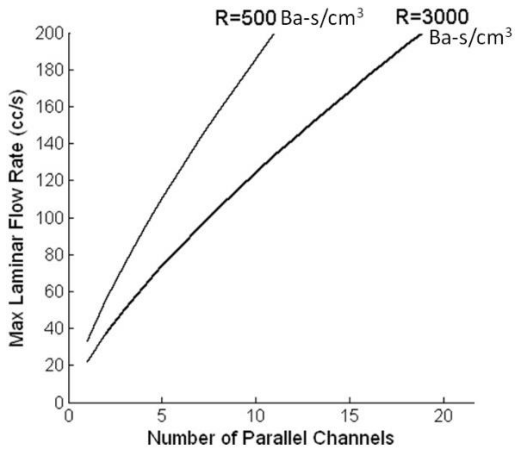

Figure 4. Maximum laminar flow rate versus number of parallel channels for the resistance component. In order to accommodate higher flow rates, a flow resistor needs to be constructed from an increasing number of parallel channels.

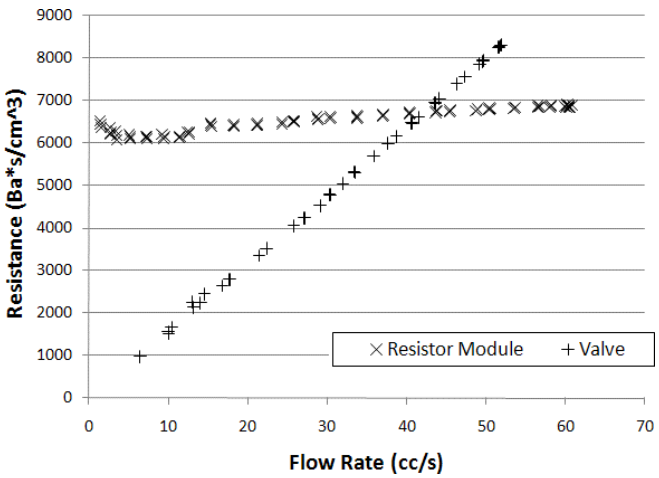

Figure 5. Resistance characteristics of a resistance component made from parallel capillary tubes, versus one made from a partially closed ball valve.

Passive Component: Capacitance

The most common method for constructing a flow capacitance is to use a chamber that traps a pocket of air, where liquid entering the chamber would compress the air pocket (Figure 1). By combining the mathematical definition of the capacitance and Boyle's law, we obtain that the capacitance of an air pocket due to compression is $C_c=V/P$, where V is the volume of the air and P is the absolute pressure of the air. For small perturbations in the air volume and pressure, the capacitance value stays fairly constant. Another contribution of capacitance that is a byproduct of the use of such a chamber is the changing height of the liquid-air interface as liquid enters and leaves the chamber. Using hydrostatic calculations we obtain that this capacitance is $C_h = A / \rho g$, where A is the horizontal cross-sectional area of the chamber, ρ is the density of the liquid, and g is gravity. C_c and C_h are two capacitances in series resulting from this setup. C_h is typically much larger than C_c and thus can be neglected with the two capacitances being in series. In the case where a very large capacitance is desired, a chamber that is open to the atmosphere can be used. In such a construction the capacitance is described by C_h alone (Kung 2011).

Passive Component: Inductance

The flow inductance describes how the acceleration of fluid results in a force which manifests as a pressure differential. Due to the fluid mass in flow conduits, the inductance is often a parasitic parameter in an *in vitro* experiment. The inductance "L" of a flow conduit can be calculated by $L = \rho\ l / A$ where l is the length and A the cross-sectional area of the conduit (Kung 2011). Inductance can be added to a flow system by simply putting in sections of long tubing. However, it is uncommon to insert tubing for the sole purpose of adding inductance, since the inherent inductance of existing connection tubing required in a flow system is often already sufficient or more than the desired vascular inductance to be modeled.

Active Components

The fluid flow in an *in vitro* experiment is typically driven using programmable flow pump. Commercial devices such as the 'Harvard pump' (Harvard Apparatus, Holliston. MA, USA) and the 'SuperPump' (Vivitro Labs, Victoria, BC, Canada) operate on a piston pump principle and are capable of generating outputs that resemble the flow through the aortic valve (containing regions of zero flow). The output of this type of pumps must contain a zero flow region due to the necessity for the piston cylinder to refill in each cardiac cycle. These pumps are relatively simple and inexpensive, and are ideal for *in vitro* experiments replicating flow conditions in regions near the heart. In order to create flow conditions corresponding to those at specific vascular regions further away from the heart, extensive downstream vascular simulator (i.e., an *in vitro* LPM) may be required to provide the necessary impedances (Groves 2014; Pahlevan 2013). The proper construction and tuning of the vascular simulator may be taxing.

A more sophisticated type of programmable flow pump utilizes a gear pump together with a stepper or servo motor to create output flow waveforms of an arbitrary shape. Custom built devices (Mechoor 2016) or commercial devices such as the 'CardioFlow' (Shelley Medical Imaging Technologies, London, ON, Canada) can generate flow waveforms precisely corresponding to those at specific anatomic locations. A feedback mechanism that adjusts motor input signal based on the actual flow output (Mechoor 2016) can be used to

correct any errors in the output flow waveform due to varying downstream loading conditions. This type of programmable flow pump is the best option for re-creating precise flow waveform shapes without the need for complicated vascular simulator setup and tuning.

A programmable flow pump together with real-time pressure measurement feedback can construct an *in vitro* active component that approximates the Frank-Starling behavior of the heart, albeit without highly realistic end-systolic and end-diastolic pressure-volume characteristics and preload sensitivities (Baloa 2001; Gregory 2011; Gwak 2005; Timms 2011; Pantalos 2004; Ferrari 1998).

In the human body, the movement of the diaphragm due to respiration leads to dynamically changing pressures inside the thoracic and abdominal cavities, which then act on the blood vessels in those cavities to affect blood flow. An *in vitro* setup can capture this effect by applying an external pressure, typically by pneumatics, to flexible tubing that represent large blood vessels in those cavities.

Constructing the LPM

A vascular bed can typically be represented as a resistor-capacitor-resistor (RCR) block (Figure 6), with the proximal resistor "*Rp"* representing the combined resistance of the larger arteries, the capacitor "*C"* representing the combined compliance of the elastic vessels, and the distal resistor "*Rd"* representing the combined resistance of the arterioles and capillaries of the vascular bed. An additional capacitor and resistor are sometimes added to the RCR block to describe the venous compliance and resistance. RCR blocks representing different vascular beds are then organized together to represent the circulation to be modeled (Figure 7). Based on the goals of a specific research study and the particular regions of interest, the researcher must determine the appropriate amount of details when constructing different parts of the LPM. Inductors should be added to points of the LPM where flow is highly pulsatile. Active components such as the atria, ventricles, and respiration should be added as pertinent to the study.

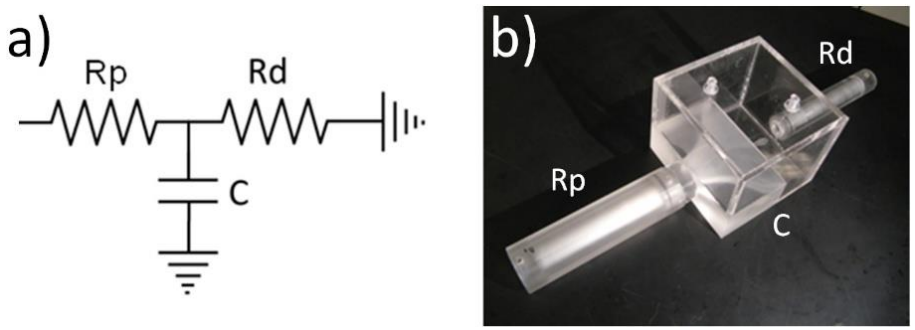

Figure 6. Basic lumped-parameter representation of a vascular bed using the resistor-capacitor- resistor block. a) Symbolic representation; b) *In vitro* physical module.

Once the structure of the LPM is determined, the component values and parameters of the LPM are often tuned based on clinical data acquired from the patients to be modeled. The averaged pressure drop and the flow across a vascular network together determine the total

resistance of the network. The ratio of the proximal to the distal resistance, as well as the value of the capacitance both affect the shape of the flow and pressure waveforms. For example, given a specific inflow waveform to a vascular block, increasing the capacitor component value or decreasing the ratio of the proximal to distal resistance will result in decreased pressure waveform amplitude at the inlet of the block. An iterative process is often used to tune the values of the LPM components, as well as sometimes the structure of the LPM circuit, until the LPM produces hemodynamic conditions that match the corresponding clinical measurements.

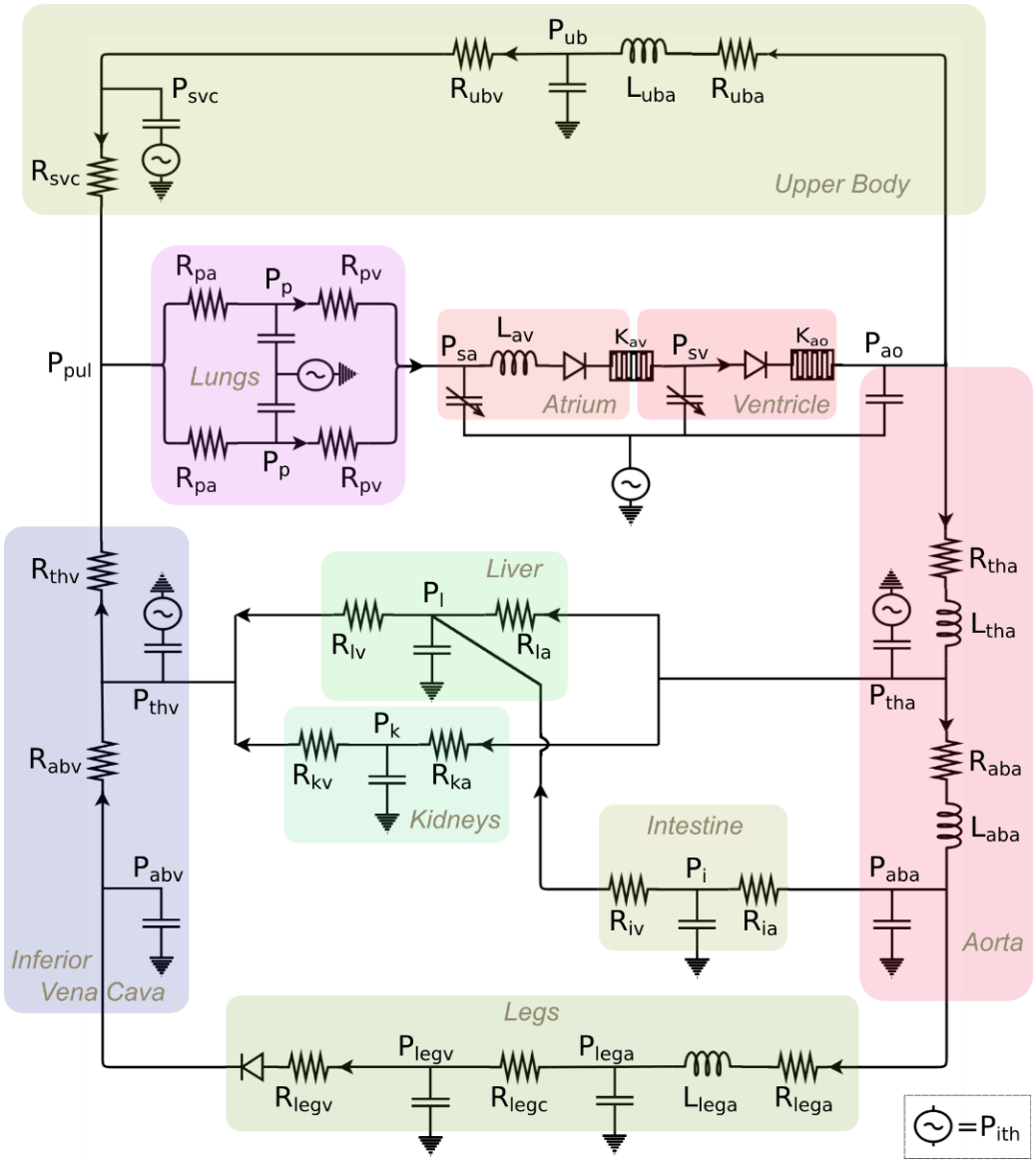

Figure 7. An example LPM describing the single-ventricle circulation. Pith represents the thoracic pressure. (Kung 2014).

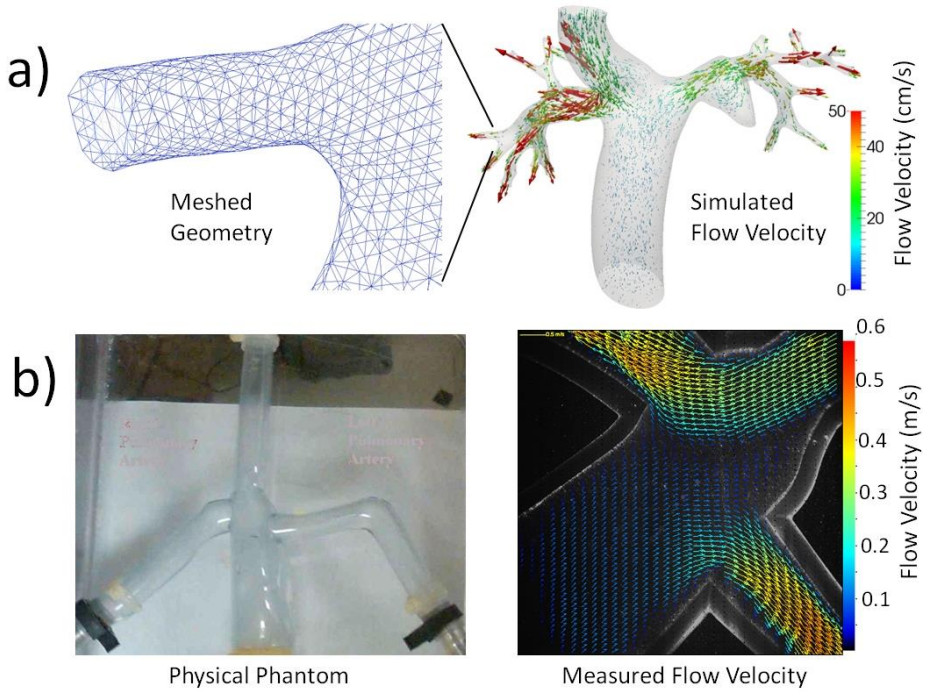

Figure 8. Analysis of blood flow patterns using a a) computational; and b) experimental[1] high-order model.

HIGH-ORDER MODELS

High-order models are capable of capturing detailed 3D dynamics that are dependent on anatomy and geometry (Figure 8). They are useful in situations where the details of these parameters have global effects, or are important to the topic of interest. For example, the design of the propeller in a blood pump or the proper closure of a heart valve has important impacts to the global hemodynamics (such as cardiac output and blood pressure). The blood flow pattern in an aneurysm revealing local areas of recirculation or low vessel wall shear stress may suggest thrombotic risks or biological responses that contribute to aneurysm enlargement. For these types of studies it is often necessary to use high-order models to capture the relevant dynamics.

The scope of high-order models is typically limited to small regions of the circulation, since the complexity and cost of high-order models make it currently impractical to model the entire circulation with them. 3D medical imaging data such as those from computed tomography or magnetic resonance imaging provide the geometrical basis for model construction. 3D segmentation based on image intensity and 2D segmentation along blood vessel centerlines are common methods for reconstructing high-order models that reflect patient-specific anatomy (Soler 2001; Les 2010). Using patient-specific high-order models, different surgical procedures can be attempted and evaluated via computational simulations or *in vitro* experiments. Models of vasculature with deformable walls are also capable of

[1] Courtesy Richard Figliola.

capturing important fluid-structure interactions in the cardiovascular system. Currently, one of the main challenges with utilizing deformable-wall models is the difficulty in prescribing relevant tissue properties, as this information is difficult to obtain from patients non-invasively.

Computational Representation

In a computational high-order model, the relevant geometry is discretized into a large number of entities (elements or control volumes) (Krause 1985; Peskin, 1972) using meshing software. Blood flow velocity and pressure are then computed using finite volume or finite element methods by solving the well-known mass conservation and incompressible Navier-Stokes equations. Newtonian fluid assumption is widely accepted for modeling hemodynamics in large blood vessels (Gijsen 1999). Non-Newtonian shear thinning behavior of blood needs to be considered in modeling scenarios such as capillary flow and flow near blood vessel walls. High-performance parallel computing and significant storage capacity are typically required for running high-order computational models.

To incorporate the effects of blood vessel wall deformation, the coupled momentum method (Figueroa 2006) was developed to be a computationally inexpensive method for capturing fluid-structure interactions. In this approach the blood vessel wall motion is prescribed as a velocity boundary condition to the fluid domain, while the fluid mesh remains fixed. This method is suitable in scenarios where the vessel deformation is small, and has been experimentally validated to produce reasonably accurate results for vessel-wall strains up to ~10% (Kung 2011a). For cases where the geometric deformation is large, the Arbitrary Lagrangian-Eulerian method (Long 2012; Bazilevs 2010) is often employed. In this method, the fluid mesh is moved in each computation step based on vessel wall motion and reconstructed when the geometrical deformation becomes large, resulting in a drastic increase in computational expense.

An alternative approach that does not require mesh reconstruction during large geometric deformation is the immersed boundary method (Peskin 1972; Zheng 2012). In this method the entire fluid domain is represented as a fixed Eulerian mesh with an arbitrary mobile boundary that represents the fluid-structure interface. This approach has been an active area of research especially for simulating heart valves (Griffith 2012; Wu 2016; Watton 2007; Borazjani 2013). One of the main limitations of the immersed boundary method is the lack of mesh density control with respect to the specific geometry to be modeled and thus difficulty in obtaining accurate shear stresses near fluid-structure interfaces.

There are various computational approaches for capturing the fluid-structure interaction involving the active myocardial wall motion. These can include the direct prescription of cardiac wall motion based on time-resolved imaging data (Lee 2013), and electromechanical models that simulate cardiac motion based on myocardial fiber orientation and activation (Trayanova 2011; Bayer 2012).

In vitro Representation

High-order *in vitro* models typically involve a physical replica of the anatomy, geometry, or medical device to be investigated. A physical model of the anatomy with which flow experiments can be performed is referred to as a "phantom." Stereolithography (3D-printing) is a popular method for physically reconstructing patient specific anatomy. Commercial materials such as Somos® WaterShed plastic provide suitable options for 3D-printing rigid phantoms (Kung 2011b). However, there is currently no suitable material option for 3D-printing compliant phantoms with elastic properties that mimic real blood vessels. Rubber-like stereolithography materials such as TangoPlus (Stratasys Inc.) produce homogeneous compliant phantoms that are more visco-elastic than real vascular tissue. Phantoms made with silicon currently have the most realistic compliant properties, but cannot be 3D-printed. Highly uniform and sub-millimeter wall thickness is often desired in a compliant silicon vascular phantom. This can be achieved via a silicon dipping process for a phantom with trivial geometry (Kung 2011a). More complex phantom geometries need to be constructed using a silicon casting process involving an inner and outer mold; however, uniform and sub-millimeter wall thickness is difficult to achieve this way.

The selection of phantom material needs to account for compatibility with the desired mode of *in vitro* measurements. For example, phantoms for flow experiments intended in a particle imaging velocimetry study must have similar index of refraction as the working fluid. Studies employing ultrasound imaging should use phantoms with minimal acoustic attenuation and reflection. Phantoms used in magnetic resonance imaging studies must be made with materials that do not contain metal traces to avoid imaging artifacts.

A popular working fluid for *in vitro* models is 40% glycerol solution. This fluid possesses density and viscosity that are similar to those of blood and hence exhibits realistic fluid dynamic behaviors.

Coupled Multiscale Models

While the isolated use of a low-order model can have practical utilities (Schmidt 2016, Kung 2015), a high-order model is rarely used on its own since it only captures a very small region of the cardiovascular system. Much of the dynamics in a high-order model is determined by its boundary conditions. We can see from the computational simulation results in Figure 9 that the same geometric model with different outlet boundary condition prescriptions exhibits completely different pressure and flow behaviors. Proper boundary condition prescriptions in high-order models are essential for generating the correct flow split between multiple outlets and the proper pressure waveforms for producing accurate tissue movements in deformable models. In order to obtain realistic boundary conditions, a high-order model can be coupled to a low-order model, forming a multiscale model containing different domains. Figure 10 illustrates example multiscale models where a high-order anatomic model is coupled to a low-order LPM in order to reproduce local hemodynamics in a specific anatomic region within the context of the larger circulation.

In a multiscale model, the flow and pressure in each of the domains are coupled in a way such that they directly affect those in the other. The technical implementation of this coupling in the computational model involves passing flow and pressure information between the high-

order and low-order models at each simulation time step. At each interface between the two domains, boundary condition is prescribed to the high-order model as either the Neumann or Dirichlet condition. The Neumann boundary condition is suitable when the most adjacent differential element in the low-order model near the interface is a capacitance. In this type of boundary condition, the low-order model provides pressure information to the high-order model, and the high-order model provides flow rate information to the low-order model. The Dirichlet boundary condition is suitable when the most adjacent differential element in the low-order model near the interface is an inductance. In this case, the low-order and high-order model provides flow and pressure information to the other, respectively. In an *in vitro* multiscale model, the coupling between the high and low order models can occur simply via direct physical connections (Figure 10b).

A coupled multiscale model can be categorized as either open-loop or closed-loop. The differentiation lies in whether the model is designed in a way such that the dynamic response of the heart is reflected. An open-loop model typically prescribes a fixed pressure or flow waveform as the active driver of the system, where a closed-loop model contains a heart model actively responding to factors such as preload and afterload. The open-loop model is simple to set up and suitable for studies focusing on the isolated dynamics of the high-order model. However, when the global physiological response is an important aspect of a study, the closed-loop model should be used.

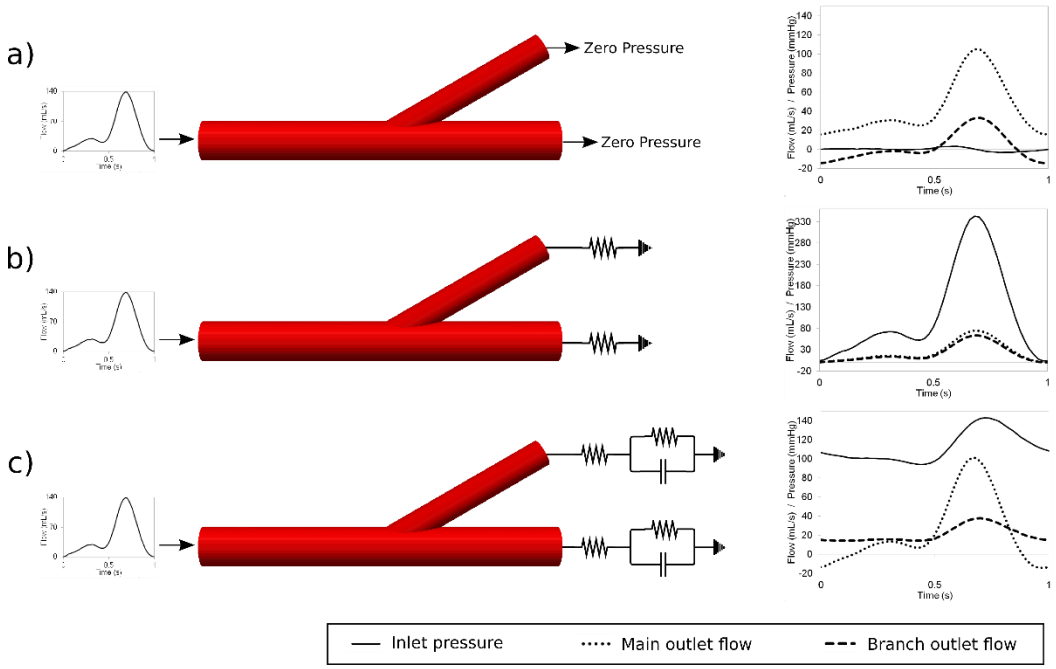

Figure 9. (a) Zero pressure; (b) resistance; and (c) RCR outlet boundary conditions prescribed to the same geometric model show that results in the high-order model are directly dependent on the prescribed boundary conditions. (Marsden 2015).

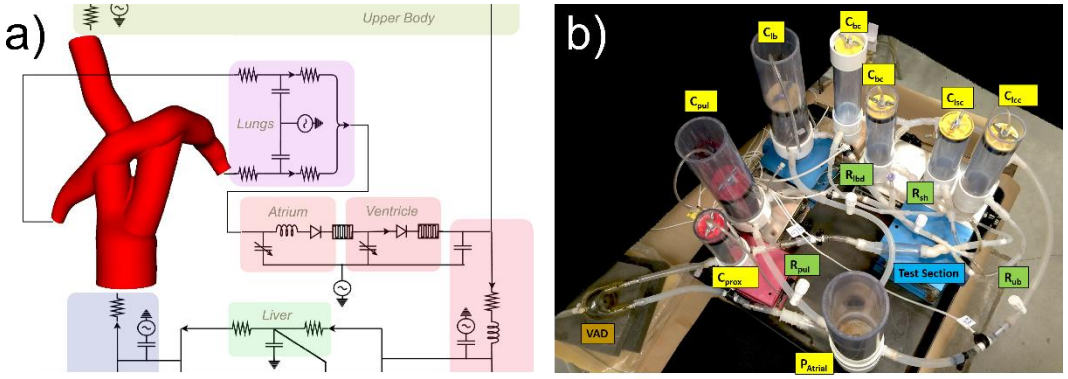

Figure 10. Example multiscale models of the single-ventricle circulation: a) Computational model of the stage 3 circulation with a high-order model representing the Fontan junction; and b) *In vitro* model of the stage 1 circulation with a high-order model representing the aortic arch and pulmonary shunt[a].

EXAMPLE CASE STUDIES:

Ventricular Assist Device Implementation in Single Ventricle Infants: Low-Order Closed-Loop Computational Model

In this case study we examine the use of a low-order closed-loop computational model to investigate the physiologic impacts of ventricular assist device (VAD) implementation in single ventricle infants (Schmidt 2016). We will see how the model delineates mechanisms behind performance differences often observed clinically between steady and pulsatile VADs.

A VAD can be used as mechanical support in heart failure patients either as bridge-to-transplant, bridge-to-recovery, or destination therapy. VADs are used in various types of circulations including single ventricle circulations (Calvaruso 2007; Cardarelli 2009; Chu 2007) and normal bi-ventricular circulations (Hetzer 2006; Stiller 2003; Adachi 2011). The two main categories of these devices are the pulsatile or continuous flow VAD. A Pulsatile flow VAD (such as the Berlin Heart) drives blood via a pneumatically actuated membrane and one-way valves located at the inlet and outlet of the blood chamber, emulating the heart's distinct phases of diastole and systole. Some evidences suggest that pulsatile flow VAD may promote better ventricular unloading and more natural physiology (Cheng 2014; Drews 2008; Klotz 2004). Continuous flow VADs use spinning propellers to produce a pressure rise (Moazami 2013) and often have better reliability and smaller size, providing reduced risk of infection, bleeding, trauma, and thrombus (Cheng 2014; Drews 2008; Feller 2007; Kato 2011).

In this case study we use a closed-loop computational LPM (Figure 11) to investigate the physiologic response of stage 1 single ventricle patients to pulsatile and continuous flow VADs, and to identify mechanistic explanations for the differences in physiologic outcomes. Clinical data from six stage 1 single ventricle patients are used to tune the LPM to create six models each describing a unique patient. Ventricular contractility in each LPM is then diminished to simulate a heart failure condition. The HeartWare VAD and the Berlin Heart EXCOR VAD are each implemented in the LPM to describe the continuous and pulsatile VAD scenario, respectively. As the VAD attempts to draw blood from the ventricle, a

negative ventricular pressure may result which could lead to ventricular tissue being drawn into the cannula and ventricular collapse (Salamonsen 2015). As part of the VAD implementation in the LPM, a ventricular suction equation is developed and incorporated to describe the suction resistance "R_{SUC}" due to ventricular collapse, thereby impeding VAD flow (Schmidt 2016).

The results of this modeling study show that the continuous VAD is capable of providing significantly higher cardiac output in all of the six patient physiologies examined (Table 11). Closer examination of the blood volume inside the pulsatile VAD reveals the underlying mechanism responsible for this difference. For the pulsatile VAD, cardiac output increases are achieved by means of increasing device heart rate or device size (i.e., maximum stroke volume). However, if a large pulsatile VAD is implemented in a stage 1 single ventricle patient, who typically is a small infant, ventricular suction tends to occur and the device is unable to fill completely during diastole as its pump rate increases (Figure 12). The decreased stroke volume at higher pump rates results in the inability to augment cardiac output.

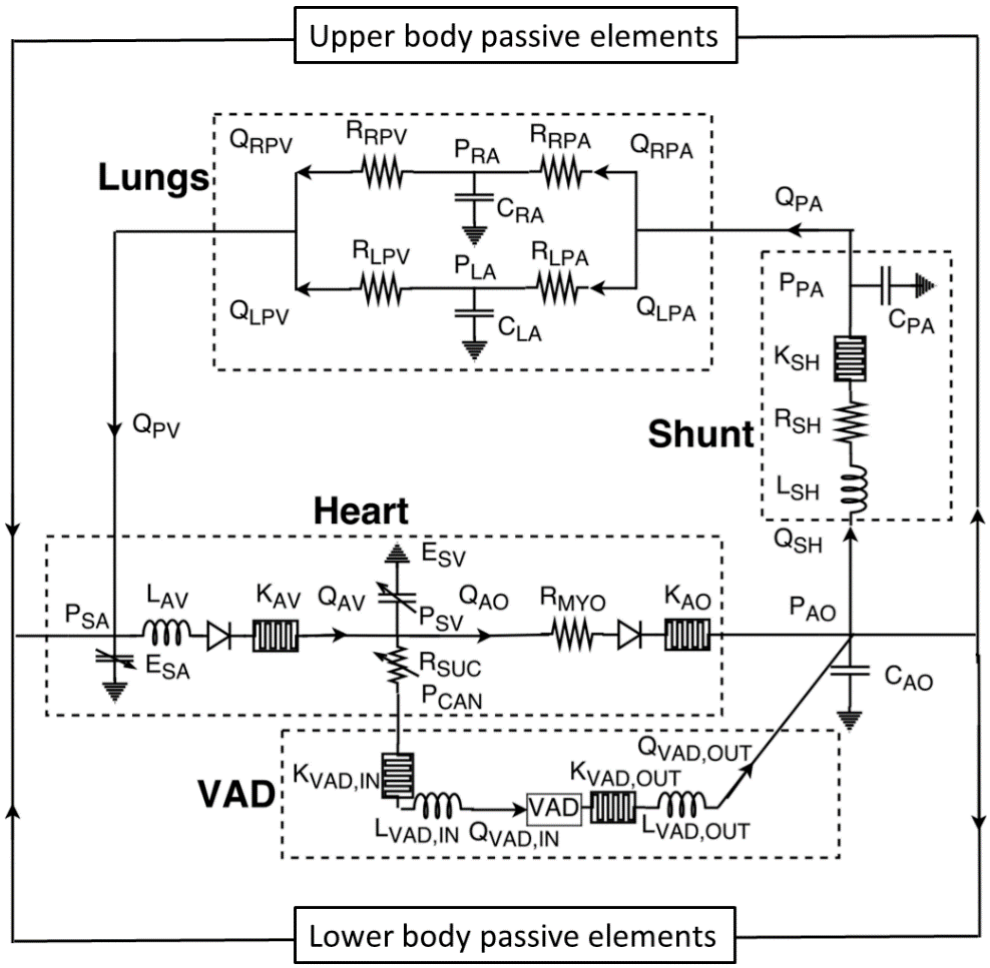

Figure 11. A low-order closed-loop computational model describing a ventricular assist device implemented in the stage 1 single-ventricle circulation.

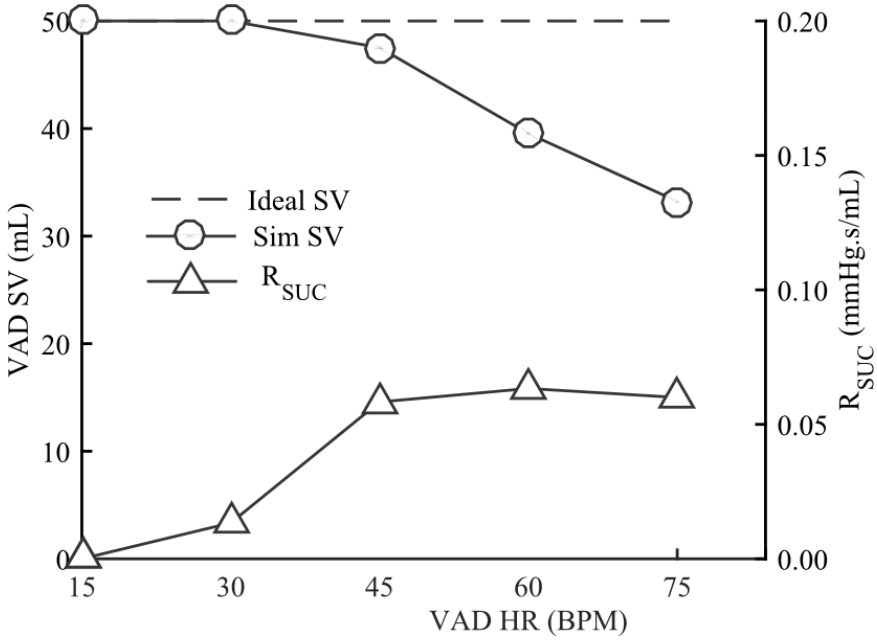

Figure 12. Stroke volume (SV) and suction resistance (R_{SUC}) versus VAD heart rate (HR) for the 50 mL Berlin Heart. Results show that the pulsatile VAD does not maintain the expected cardiac output at higher HR due to reduced SV. Data shown is the cohort mean across 6 patients.

Hemodynamics in an Abdominal Aortic Aneurysm: Multiscale Open-Loop *In vitro* Model

Hemodynamic parameters such as the 3D blood flow and pressure fields have direct effects on the initiation and development of atherosclerosis and aneurysms (Taylor 1971; Glagov 1988; Ku 1985; Malek 1999). Modern imaging techniques such as phase-contrast magnetic resonance imaging can be used in an *in vitro* experiment to perform high-resolution direct measurements of flow velocity patterns in an anatomical phantom. In this case study, we demonstrate an *in vitro* model for studying the blood flow patterns in an abdominal aortic aneurysm (Kung 2011b).

A flow phantom made of MR-compatible resin (WaterShed® XC 11122, DSM Somos®, Elgin, IL) is 3D-printed according to a patient anatomical model constructed from a gadolinium-enhanced magnetic resonance angiography of the patient; anatomy of the abdominal aortic aneurysm and the renal and common iliac arteries are included in the flow phantom (Figure 13). Two RCR blocks are constructed to create downstream vascular impedances for the renal and aortic outlets of the phantom. The values of the resistor and capacitor components are set to produce physiologically realistic pressure and flow split waveforms under a physiologically realistic inlet flow waveform (Table 2). The resistor components are constructed by placing a large number of thin-walled glass capillary tubes (Sutter Instrument, CA) in parallel inside a plexiglass cylinder. The capacitor components have a smooth contour for the inlet in order to minimize flow turbulences and thus avoid parasitic resistances.

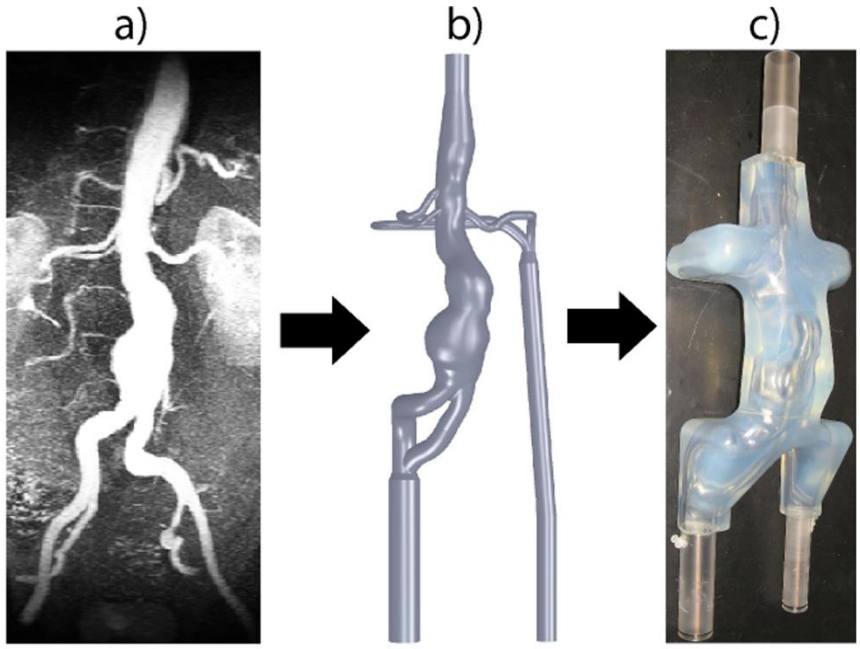

Figure 13. Anatomical phantom construction: a) MR Imaging data from an abdominal aortic aneurysm patient. b) 3D computer model constructed based on patient imaging data. c) Physical phantom constructed from 3D computer model (Kung 2011b).

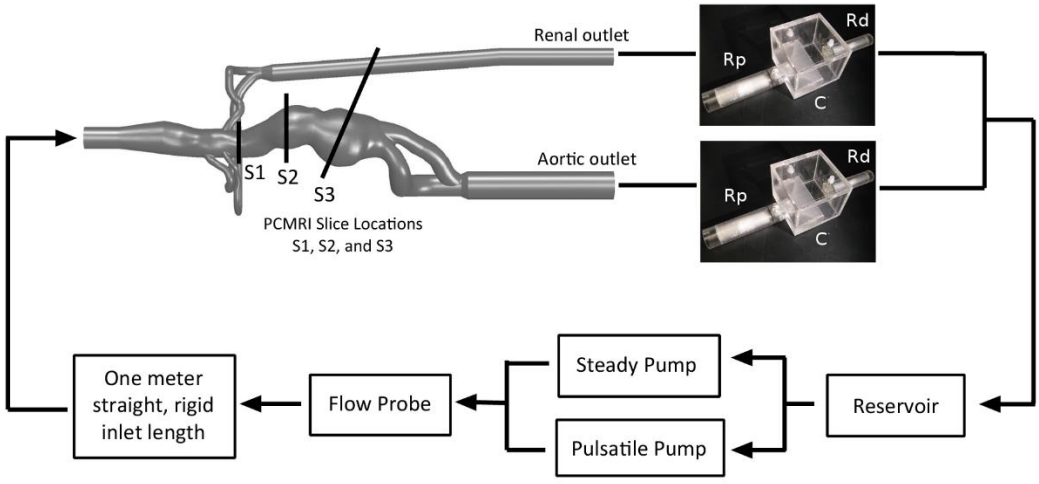

Figure 14. Flow system setup for the abdominal aortic aneurysm *in vitro* model.

Table 1. Maximum cardiac output (L/min) achieved in each patient without VAD, with pulsatile VAD, and with continuous VAD

	Patient A	Patient B	Patient C	Patient D	Patient E	Patient F
Pre-VAD	1.29	1.55	1.42	1.60	1.87	1.75
Pulsatile VAD	1.92	2.30	2.14	2.24	2.21	2.79
Continuous VAD	3.11	3.37	3.36	3.51	3.31	4.09

Table 2. Values of lumped-parameter components in the RCR blocks of the abdominal aortic aneurysm *in vitro* model. Rp, C, and Rd are the proximal resistance, capacitance, and distal resistance, respectively

	Aortic outlet	Renal outlet
Rp (dynes-s/cm^5)	549	3053
C (cm^5/dynes)	3.25e-4	1.64e-4
Rd (dynes-s/cm^5)	7132	5951

We connect the RCR blocks to the anatomic flow phantom and place them in a flow system (Figure 14). Based on the flow waveforms measured in the patient (Bax 2005; Les 2010), we use a custom-built, MR-compatible, and computer-controlled pulsatile pump (Ku 2005) in parallel with a steady flow pump (Model 3-MD-HC, Little Giant Pump Co., OK) to reproduce the supra-renal aortic flow waveforms as the input flow to the phantom. The phantom input flow is monitored using a MR-compatible ultrasonic transit-time flow sensor (8PXL, Transonic Systems, NY).

Using a cardiac-gated 2D 3-component cine PCMRI sequence in a 1.5T GE MR scanner (Signa, GE Medical Systems, Waukesha, WI) and an 8-channel cardiac coil, we acquire flow velocity measurements at different slice locations within the phantom. The slice locations represent the mid-aneurysm location for each lobe of the bilobed aneurysm anatomy and the location directly downstream of the renal branches where flow is likely to be complex. As we examine the velocity imaging results at different time points in the flow cycle (Figure 15), it is easy to see the prominent swirling of blood and the stagnant regions in the large aneurysm. This observed flow pattern may provide information regarding the endothelial health in the aneurysm. Such an *in vitro* setup can also serve as a testbed to investigate the hemodynamic effects of various surgical procedures or vascular device implantations.

Virtual Surgery of the Superior Vena Cava to Pulmonary Artery Anastomosis: Multiscale Closed-Loop Computational Model

In this case study we demonstrate the use of a multiscale closed-loop computational model to predict and compare surgical outcomes of the single ventricle stage 2 palliation procedure. In this surgical procedure, the superior vena cava is connected to the pulmonary artery via two options: the “Glenn” or the “Hemi-Fontan” procedure (Norwood 1991). The Glenn procedure severs the superior vena cava from the right atrium and connects it to the right pulmonary artery, where the Hemi-Fontan procedure connects the top half of the right atrium to the pulmonary artery while leaving the superior vena cava attached to the atrium. Various degrees of left pulmonary stenosis are common among these patients, and part of the consideration of the stage 2 procedure is whether to perform the additional surgical steps to remove the stenosis, if present. Using a multiscale computational model, we investigate the hemodynamic differences between the Glenn and the Hemi-Fontan surgical options, as well as the physiologic impacts of a left pulmonary stenosis.

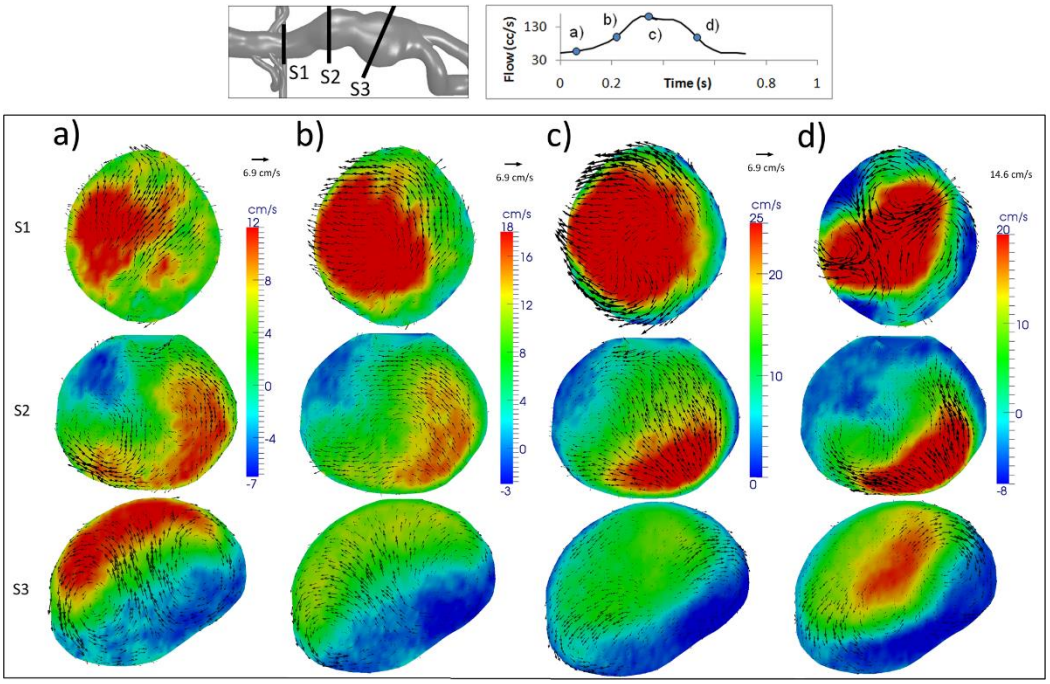

Figure 15. Phase-contrast magnetic resonance imaging measured flow velocities in the abdominal aortic aneurysm *in vitro* phantom experiment.

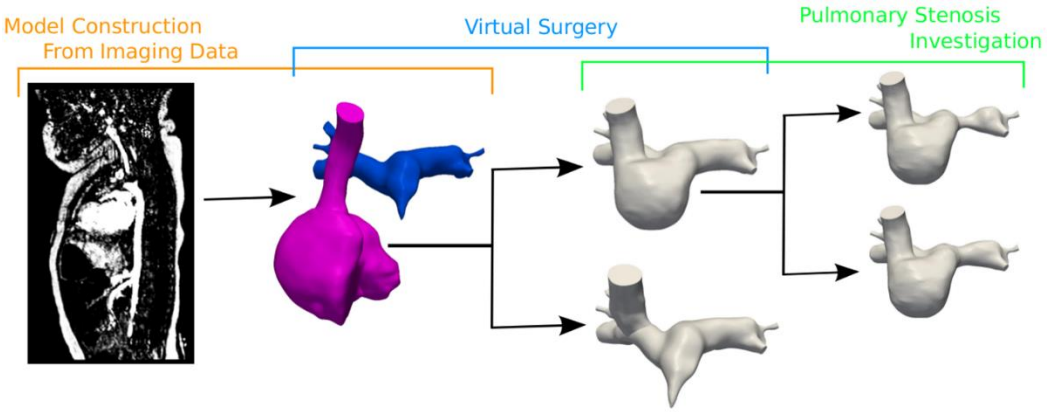

Figure 16. Virtual surgery and virtual pulmonary stenosis investigation from preoperative 3D anatomical model constructed based on patient imaging data. (Marsden 2015).

From 3D imaging data of a patient, we construct a high-order computational model that is a representation of the patient's pre-operative anatomy. We then perform "virtual" Glenn or Hemi-Fontan surgeries and add a "virtual" left pulmonary stenosis of various severities by computationally modifying the pre-operative anatomic geometry (Figure 16). Using the pre-operative clinical data from the same patient, we tune an LPM (the low-order model) to represent the global circulation of the patient and couple the high and low order models to complete a multiscale simulation setup (Figure 17). The coupled multiscale simulation is run using open source software Simvascular (www.simtk.org) on a super computing cluster.

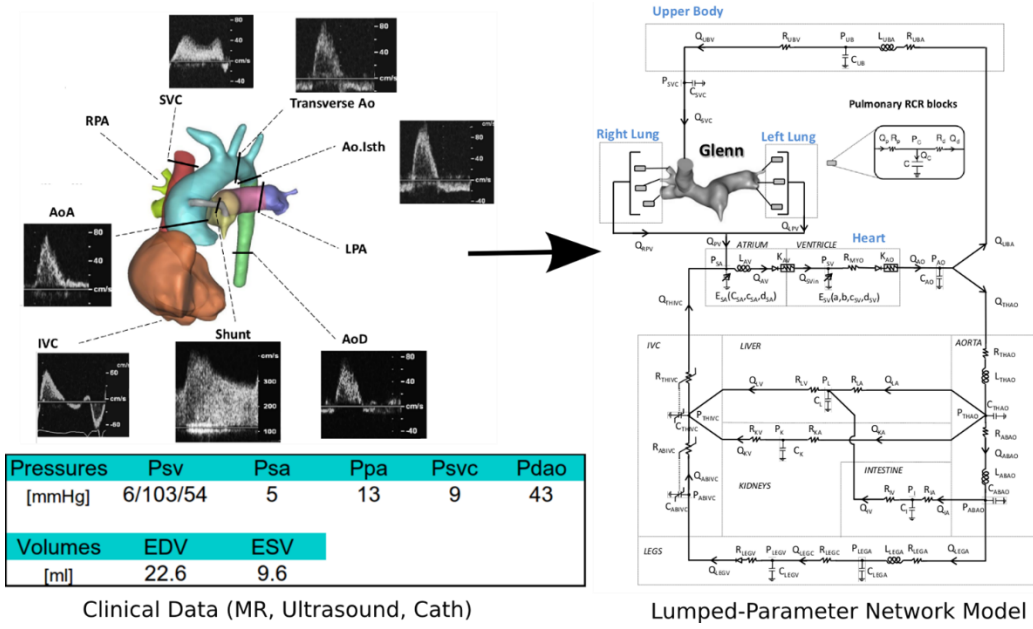

Figure 17. Preoperative clinical data supplies parameter tuning information for the closed-loop multiscale model consisting of a LPM coupled to a 3D anatomical model. (Marsden 2015).

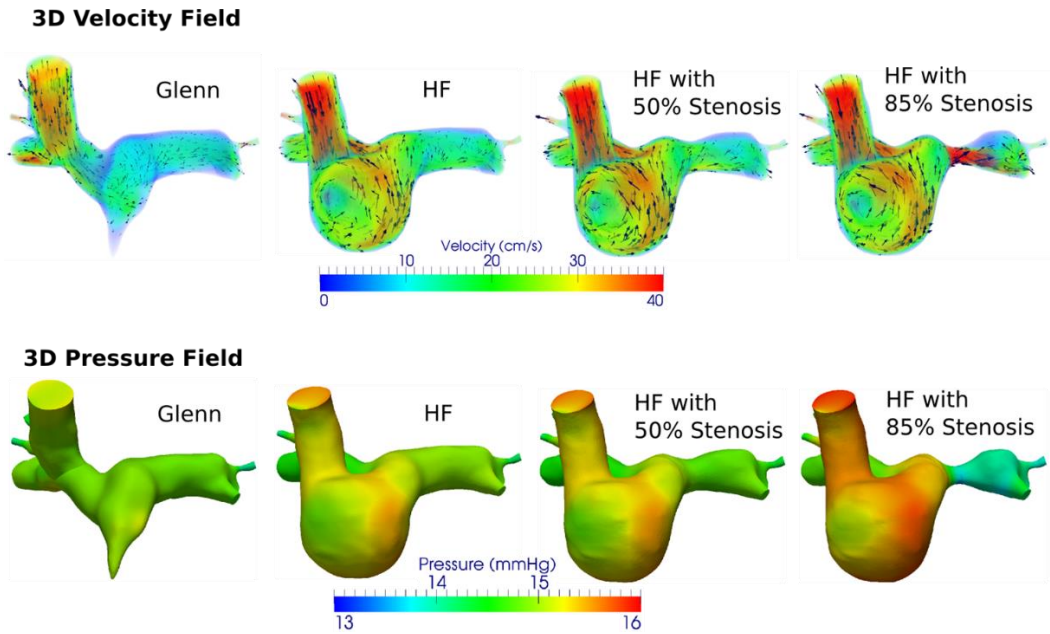

Figure 18. Simulated 3D pressure and flow patterns in the high-order model (Marsden 2015).

Clinically relevant information such as the 3D pressure and flow in the high-order model (Figure 18), time tracings of physiologic parameters in the LPM (Figure 19), and power loss in the surgical junction relative to other systemic powers (Figure 20) can be extracted from the multiscale simulation results. This modeling investigation reveals that while flow patterns within the surgical junction are affected by different surgical options, physiology at the global

level is not. In this particular case study, a 50% or 85% area stenosis also does not produce a significant impact to the global physiology. This is due to the fact that compared to the systemic power losses, the power loss in the surgical junction is relatively small. The differences in the 3D flow patterns between the surgical options, however, may provide information for assessing clinical considerations such as thrombotic risk.

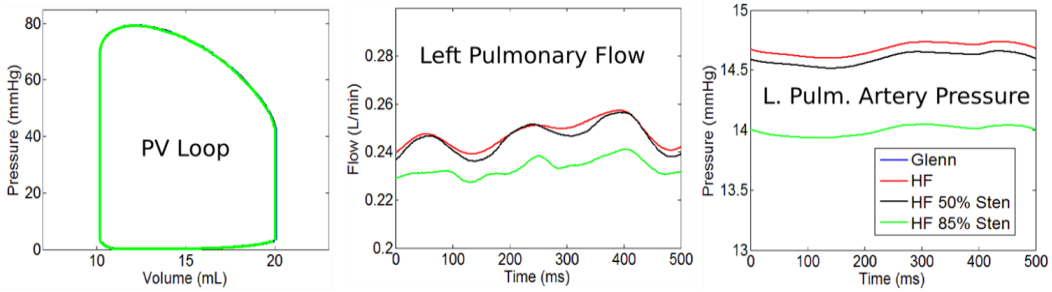

Figure 19. 0D physiologic parameters extracted from the low-order model (Marsden 2015).

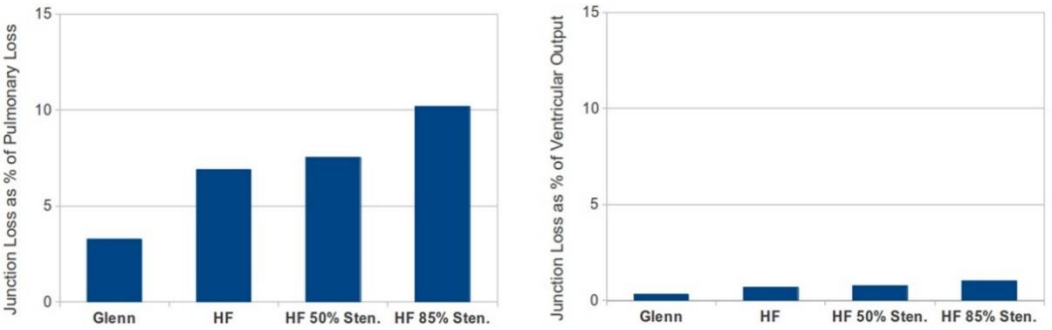

Figure 20. Power loss in the surgical junction as a fraction of other systemic powers (Marsden 2015).

MODEL SELECTION

Designing a cardiovascular model that is appropriate for the topic of study is essential for obtaining meaningful results. The choices between high versus low order models and computational versus *in vitro* models should depend on the input information available, the output information desired, and the aspects of biomechanics important to the study.

Low-Order versus High-Order

The main advantage of low-order models is that they are relatively low-cost to perform. Low-order models are suitable for simulating overall physiology and examining pressure and flow waveforms at different parts of the circulation. Since detailed geometric data is not required for model construction, it is also simpler (compared to high-order models) to create new implementations to describe complex scenarios such as the operation of active medical devices (i.e., the first example case study) as long as enough data is available to construct the

required mathematical descriptions. The limitation of low-order models is their inability to account for or capture 3D parameters; therefore in the cases where the effects of these 3D quantities are important to the topic of study, high-order models should be employed. High-order models require detailed geometric input information and are labour-intensive to construct. Simulations of high-order models are also computationally expensive. In the choice between high or low order models, one should determine whether geometry or 3D dynamics affect the quantities of interest or whether the 3D parameters themselves are the quantities of interest. If the answer is yes to either of these questions, a high-order model is suitable. The use of high-order models should be limited to regions of the circulation that require them. The rest of the circulation should be represented using low-order models in order to achieve the most resource-efficient multiscale modeling approach for a research study.

Computational versus *In vitro*

Computational models are typically less costly and quicker to construct than *in vitro* models. A computational low-order model can be set up within minutes with a few lines of code while an *in vitro* model could require hours of machining and physically connecting several components in a flow loop. In research studies that investigate systematic changes in a model, a computational setup can be automated to require minimal manual involvement. Extraction of output parameters is also more straight-forward in a computational model, as the desired information can be directly accessed from the computation data. In an *in vitro* model, measurements of the desired parameters require different sensor implementations and/or imaging setup and are subject to measurement noise and limited resolution. Measurements in an *in vitro* model with magnetic resonance, ultrasound, or particle imaging velocimetry often bring challenging technical requirements for phantom construction and experiment setup. For example, all of the devices in an *in vitro* setup for magnetic resonance imaging must be MR compatible to ensure safety and to avoid signal interference and imaging artifacts. This often means a large physical setup since long tubing and cables are required to keep the flow pump and pressure measurement equipment at a safe distance from the MR scanner. In an experiment for particle imaging velocimetry, index of refraction must be matched between the phantom and the working fluid, which significantly complicates phantom construction and often results in the necessity of adding corrosive chemicals such as sodium iodide in the working fluid. The strict geometrical setup criteria of particle imaging velocimetry also limit data acquisition to very few imaging planes. Lastly, the ability for *in vitro* models to describe the closed-loop response of the heart to changing preload and afterload is currently primitive, presenting a significant limitation compared to computational models.

On the other hand, computational models may not capture as many aspects of the relevant physics compared to *in vitro* models, especially in the area of fluid-structure interactions. Computational simulations of fluid-structure interactions are technically challenging, and reliable simulation techniques may not exist for the scenarios of interest. For example, current computational capabilities for simulating heart valve dynamics are primitive and very few groups have successfully performed simulations able to model leaflet contact (Wu 2016). Transient analysis of 3D computational models involving rotary blood pumps is extremely computationally expensive, therefore most studies are limited to steady-state analyses without

accounting for realistic pulsatile flow scenarios (Fraser 2011). For the situations where computational methods face significant limitations, an *in vitro* model where the fluid-structure interactions are directly replicated in a physical setup may be more suitable. *In vitro* high-order models are often suitable for medical device studies, since the device to be investigated can be implemented directly into the anatomical phantom under realistic flow and pressure conditions. Measurements of the resulting hemodynamics can reveal detailed 3D mechanical interactions between device operation and patient physiology and anatomy.

CONCLUSION AND FUTURE PERSPECTIVES

Computational and *in vitro* cardiovascular biomechanical models provide highly-controlled approaches for studying the cardiovascular system. This chapter provides an overview of several major types of models, the pros and cons of each, and a few examples of model application. The proper selection of high-order versus low-order and computational versus *in vitro* models for each research topic is important for capturing the relevant dynamics and minimizing resource usage. When employed properly, the types of biomechanical models presented in this chapter can bring significant progress to a research project at lower costs of resource and time compared to the use of animal models.

There are several areas of current development towards broadening the scope and usefulness of cardiovascular biomechanics models. The first is the incorporation of cellular biomechanics and biochemistry to capture the interactions and effects of biological responses at the microscale. Computationally, this would involve coupling cellular kinetics models with macroscale hemodynamic models (i.e., those presented in this chapter). Experimentally, tissue engineered constructs containing live cells can be implemented into an anatomical vascular simulator and allowed to directly interact with the macroscale hemodynamics. Second, there is a need for *in vitro* models to accurately capture closed-loop responses of the cardiovascular system, which is important for accounting for physiologic feedback and assessing physiologic impacts. A method to address this need is currently being developed in the author's research group and referred to as the "Physiology Simulation Coupled Experiment." This approach is similar to the hardware-in-the-loop concept commonly used in the aviation industry and couples a high-order *in vitro* model to a low-order computational physiology model. Finally, there is a pressing need for the validation of model predictions against clinical data. Due to the limitations in clinical data acquisition and lack of clinical database for modeling purposes, reliable large-scale validation of cardiovascular biomechanical models is rare. Close coordination between clinicians and engineers is essential for bridging this gap and bringing the much-needed validation to justify application of these biomechanical models towards clinical use.

REFERENCES

Adachi I, and Fraser CD. Mechanical circulatory support for infants and small children. *Semin. Thorac. Cardiovasc. Surg. Pediatr. Card. Surg. Annu.* 2011; 14(1): 38−44.

Baloa LA, Boston J R, and Antaki J F. Elastance-based control of a mock circulatory system. *Ann Biomed Eng*, 2001;29(3):244−51.

Baretta A, Corsini C, Marsden A L, Vignon-Clementel I E, Hsia TY, Dubini G, Migliavacca F, and Pennati G. (2012) Respiratory effects on hemodynamics in patient-specific CFD models of the Fontan circulation under exercise conditions. *European Journal of Mechanics-B/Fluids* 2012; 35:61−69.

Bax L, Bakker, CJ, Klein WM, Blanken N, Beutler JJ, and Mali WP. Renal blood flow measurements with use of phase-contrast magnetic resonance imaging: normal values and reproducibility. *J. Vasc. Interv. Radiol.* 2005; 16(6):807−14.

Bayer JD, Blake RC, Plank G, and Trayanova NA. A novel rule-based algorithm for assigning myocardial fiber orientation to computational heart models. *Ann. Biomed. Eng.* 2012; 40(10) :2243−54.

Bazilevs Y, Hsu MC, Zhang Y, Wang W, Kvamsdal T, Hentschel S, and Isaksen JG. Computational vascular fluid-structure interaction: methodology and application to cerebral aneurysms. *Biomech. Model. Mechanobiol.* 2010; 9(4):481−98.

Borazjani I. Fluid–structure interaction, immersed boundary-finite element method simulations of bio-prosthetic heart valves. *Computer Methods in Applied Mechanics and Engineering* 2013; 257: 103−116.

Calvaruso DF, Ocello S, Salviato N, Guardì D, Petruccelli DF, Rubino A, Fattouch K, Cipriani A, and Marcelletti CF. Implantation of a Berlin Heart as single ventricle by-pass on Fontan circulation in univentricular heart failure. *ASAIO J.* 2007; 53(6): e1−2.

Cardarelli MG, Salim M, Love J, Simone S, Tumulty J, Conway D, and Griffith B. Berlin heart as a bridge to recovery for a failing Fontan. *Ann. Thorac. Surg.* 2009; 87(3):943−6.

Caro CG, Fitz-Gerald JM, and Schroter RC. Atheroma and arterial wall shear. Observation, correlation and proposal of a shear dependent mass transfer mechanism for atherogenesis. *Proc. R. Soc. Lond. B. Biol. Sci.* 1971;177(46) :109−59.

Cheng A, Williamitis CA, and Slaughter MS. Comparison of continuous-flow and pulsatile-flow left ventricular assist devices: is there an advantage to pulsatility? *Ann. Cardiothorac. Surg.* 2014; 3(6):573−81.

Chu MW, Sharma K, Tchervenkov CI, Jutras LF, Lavoie J, Shemie, SD, Laliberte E, Calaritis C, and Cecere R. Berlin Heart ventricular assist device in a child with hypoplastic left heart syndrome,' *Ann. Thorac. Surg.* 2007; 83(3):1179−81.

Corsini C, Baker C, Kung E, Schievano S, Arbia G, Baretta A, Biglino G, Migliavacca F, Dubini G, Pennati G, Marsden A, Vignon-Clementel I, Taylor A, Hsia TY, Dorfman A, and MOCHA Investigators. An integrated approach to patient-specific predictive modeling for single ventricle heart palliation. *Comput Methods Biomech Biomed Engin*. 2014;17(14):1572–89.

Drews T, Jurmann M, Michael D, Miralem P, Weng Y, and Hetzer R. Differences in pulsatile and non-pulsatile mechanical circulatory support in long-term use,' *J. Heart Lung Transplant.* 2008; 27(10):1096−101.

Feller ED, Sorensen EN, Haddad M, Pierson RN, Johnson FL, Brown JM, and Griffith BP. Clinical outcomes are similar in pulsatile and nonpulsatile left ventricular assist device recipients. *Ann. Thorac. Surg.* 83(3): 1082−8.

Ferrari G, De Lazzari C, Mimmo R, Tosti G, Ambrosi D, and Gorczynska K. A computer controlled mock circulatory system for mono- and biventricular assist device testing. *Int. J. Artif. Organs.* 1998;21(1): 26−36.

Figliola RS, Giardini A, Conover T, Camp TA, Biglino G, Chiulli J, and Hsia TY. In Vitro Simulation and Validation of the Circulation with Congenital Heart Defects. *Prog. Pediatr. Cardiol.* 2010; 30(1−2): 71−80.

Figueroa CA, Vignon-Clementel IE, Jansen KE, Hughes TJR, and Taylor CA. A coupled momentum method for modeling blood flow in three-dimensional deformable arteries. *Computer Methods in Applied Mechanics and Engineering* 2006;195(41−43): 5685−5706.

Fraser KH, Taskin ME, Griffith BP, and Wu ZJ. The use of computational fluid dynamics in the development of ventricular assist devices. *Med. Eng. Phys.* 2011;33(3):263−80.

Gijsen FJ, van de Vosse, FN, and Janssen JD. The influence of the non-Newtonian properties of blood on the flow in large arteries: steady flow in a carotid bifurcation model. *J. Biomech.* 1999;32(6):601−8.

Giridharan GA, Skliar M, Olsen DB, and Pantalos GM. Modeling and control of a brushless DC axial flow ventricular assist device. *ASAIO journal* 2002; 48(3): 272−289.

Glagov S, Zarins C, Giddens DP, and Ku DN. Hemodynamics and atherosclerosis. Insights and perspectives gained from studies of human arteries. *Arch. Pathol. Lab. Med.* 1988;112(10): 1018−31.

Gregory SD, Stevens M, Timms D, and Pearcy M. Replication of the Frank-Starling response in a mock circulation loop. *Conf. Proc. IEEE Eng. Med. Biol. Soc.* 2011:6825−8.

Griffith BE. Immersed boundary model of aortic heart valve dynamics with physiological driving and loading conditions. *Int. J. Numer. Method. Biomed. Eng.* 2012;28(3):317−45.

Groves EM, Falahatpisheh A, Su JL, and Kheradvar A. The effects of positioning of transcatheter aortic valves on fluid dynamics of the aortic root. *ASAIO.* 2014; 60(5):545−52.

Gwak KW, Noh MD, Paden BE, and Antaki J F. Fluidic operational amplifier for mock circulatory systems-simulation and experimental results. *Proceedings of the 2005. American Control Conference*, 2005; *IEEE*. 2005; 3817−3822.

Hetzer R, Potapov EV, Stiller B, Weng Y, Hübler M, Lemmer J, Alexi-Meskishvili V, Redlin M, Merkle F, Kaufmann F, and Hennig E. Improvement in survival after mechanical circulatory support with pneumatic pulsatile ventricular assist devices in pediatric patients. *Ann. Thorac. Surg.* 2006; 82(3): 917−24; discussion 924−5.

Hughes TJ, and Lubliner J. On the one-dimensional theory of blood flow in the larger vessels,' *Mathematical Biosciences*, 1973; 18(1):161−170.

Kato TS, Chokshi A, Singh P, Khawaja T, Cheema F, Akashi H, Shahzad K, Iwata S, Homma S, Takayama H, Naka Y, Jorde U, Farr M, Mancini DM, and Schulze PC. Effects of continuous-flow versus pulsatile-flow left ventricular assist devices on myocardial unloading and remodeling. *Circ. Heart Fail.* 2011; 4(5):546−53.

Khoiy KA, Biswas D, Decker TN, Asgarian KT, Loth F, and Amini R. Surface Strains of Porcine Tricuspid Valve Septal Leaflets Measured in Ex-vivo Beating Hearts. *Journal of Biomechanical Engineering*. 2016;138(11):111006.

Klotz S, Deng MC, Stypmann J, Roetker J, Wilhelm MJ, Hammel D, Scheld HH, and Schmid C. Left ventricular pressure and volume unloading during pulsatile versus nonpulsatile left ventricular assist device support. *Ann. Thorac. Surg.* 2004;77(1):143-9; discussion 149−50.

Krause E. Computational fluid dynamics: its present status and future direction. *Computers & fluids* 1985; 13(3):239−269.

Ku DN, Giddens DP, Zarins CK, and Glagov S. Pulsatile flow and atherosclerosis in the human carotid bifurcation. Positive correlation between plaque location and low oscillating shear stress. *Arteriosclerosis* 1985:5(3):293−302.

Ku JP, Elkins CJ, and Taylor CA. Comparison of CFD and MRI flow and velocities in an in vitro large artery bypass graft model. *Ann. Biomed. Eng.* 2005;33(3): 257−69.

Kung E, Baretta A, Baker C, Arbia G, Biglino G, Corsini C, Schievano S, Vignon-Clementel IE, Dubini G, Pennati G, Taylor A, Dorfman A, Hlavacek AM, Marsden AL, Hsia TY, and Migliavacca F. Predictive modeling of the virtual Hemi-Fontan operation for second stage single ventricle palliation: Two patient-specific cases. *Journal of Biomechanics* 2013; 46(2):423−9.

Kung E, Les A, Figueroa, CA, Medina F, Arcaute K, Wicker R., McConnell M, and Taylor C. In Vitro Validation of Finite Element Analysis of Blood Flow in Deformable Models. *Ann. Biomed. Eng.* 2011a; 39(7): 1947−60.

Kung E, Pennati G, Migliavacca F, Hsia TY, Figliola RS, Marsden A, Giardini A, and MOCHA Investigators. A Simulation Protocol For Exercise Physiology In Fontan Patients Using A Closed-Loop Lumped-Parameter Model,' *J. Biomech. Eng.* 2014; 136(8):81007.

Kung E, and Taylor C. Development of a Physical Windkessel Module to Re-Create In Vivo Vascular Flow Impedance for In Vitro Experiments. *Cardiovascular Engineering and Technology* 2011; 2(1):2−14.

Kung EO, Les AS, Medina F, Wicker RB, McConnell MV, and Taylor CA. In vitro validation of finite-element model of AAA hemodynamics incorporating realistic outlet boundary conditions. *J. Biomech. Eng.* 2011b; 133(4):041003.

Kung E, Perry JC, Davis C, Migliavacca F, Pennati G, Giardini A, Hsia TY, and Marsden A. Computational Modeling of Pathophysiologic Responses to Exercise in Fontan Patients. *Ann. of Biomed. Eng.* 2015; 43:1335–1347.

Langille BL, Bendeck MP, and Keeley FW. Adaptations of carotid arteries of young and mature rabbits to reduced carotid blood flow. *Am. J. Physiol.* 1989; 256(4 Pt 2):H931−9.

Lee J, Moghadam ME, Kung E, Cao H, Beebe T, Miller Y, Roman BL, Lien CL, Chi NC, and Marsden AL. Moving Domain Computational Fluid Dynamics to Interface with an Embryonic Model of Cardiac Morphogenesis. *PloS One* 2013;8(8): e72924.

Les AS, Shadden SC, Figueroa CA, Park JM, Tedesco MM, Herfkens RJ, Dalman RL, and Taylor CA. Quantification of hemodynamics in abdominal aortic aneurysms during rest and exercise using magnetic resonance imaging and computational fluid dynamics. *Ann. Biomed. Eng.* 2010;38(4):1288−1313.

Long CC, Hsu MC, Bazilevs Y, Feinstein JA, and Marsden AL. Fluid-structure interaction simulations of the Fontan procedure using variable wall properties. *Int. J. Numer. Method Biomed. Eng.* 2012; 28(5):513−27.

Malek AM, Alper SL, and Izumo S. Hemodynamic shear stress and its role in atherosclerosis. *JAMA* 1999; 282(21):2035−42.

Marsden A, and Kung E. Multiscale Modeling of Cardiovascular Flows,' *Computational Bioengineering*: CRC Press 2015:163−190.

Mechoor RR, Schmidt T, and Kung E. A Real-Time Programmable Pulsatile Flow Pump For In-Vitro Cardiovascular Experimentation *Journal of Biomechanical Engineering*. 2016;138(11):111002.

Migliavacca F, Dubini G, Pennati G, Pietrabissa R, Fumero R, Hsia TY, and de Leval MR. Computational model of the fluid dynamics in systemic-to-pulmonary shunts. *J. Biomech.* 2000;33(5):549−57.

Milner JS, Moore JA, Rutt BK, and Steinman DA. Hemodynamics of human carotid artery bifurcations: computational studies with models reconstructed from magnetic resonance imaging of normal subjects. *J. Vasc. Surg.* 1998; 28(1):143−56.

Moazami N, Fukamachi K, Kobayashi M, Smedira NG, Hoercher KJ, Massiello A, Lee S, Horvath DJ, and Starling RC. Axial and centrifugal continuous-flow rotary pumps: a translation from pump mechanics to clinical practice. *J. Heart Lung Transplant* 2013; 32(1): 1−11.

Norwood JWI. Hypoplastic left heart syndrome. *The Annals of Thoracic Surgery* 1991; 52(3):688−695.

Pahlevan NM, and Gharib M. In-vitro investigation of a potential wave pumping effect in human aorta. *J. Biomech.* 2013;46(13):2122−9.

Pantalos GM, Koenig SC, Gillars KJ, Giridharan GA, and Ewert DL. Characterization of an adult mock circulation for testing cardiac support devices. *ASAIO J.* 2004; 50(1):37−46.

Pekkan K, Frakes D, De Zelicourt D, Lucas CW, Parks WJ and Yoganathan AP. Coupling pediatric ventricle assist devices to the Fontan circulation: simulations with a lumped-parameter model. *ASAIO J.* 2005; 51(5): 618−28.

Peskin CS. Flow patterns around heart valves: a numerical method. *Journal of computational physics* 1972;10(2) :252−271.

Salamonsen RF, Lim E, Moloney J, Lovell NH, and Rosenfeldt FL. Anatomy and Physiology of Left Ventricular Suction Induced by Rotary Blood Pumps. *Artif. Organs* 2015; 39(8):681−90.

Schiavazzi DE, Kung EO, Marsden AL, Baker C, Pennati G, Hsia TY, Hlavacek A, Dorfman AL, and MOCHA Investigators. Hemodynamic effects of left pulmonary artery stenosis after superior cavopulmonary connection: A patient-specific multiscale modeling study,' *J. Thorac. Cardiovasc. Surg.* 2015; 149(3):689−696.e3.

Schmidt T, Rosenthal D, Reinhartz O, Riemer K, He F, Hsia TY, Marsden A, Kung E. and MOCHA Investigators. Superior performance of continuous over pulsatile flow ventricular assist devices in the single ventricle circulation: A computational study. *J. Biomech.* 2016; 52: 48−54.

Soler L, Delingette H, Malandain G, Montagnat J, Ayache N, Koehl C, Dourthe O, Malassagne B, Smith M, Mutter D, and Marescaux J. Fully automatic anatomical, pathological, and functional segmentation from CT scans for hepatic surgery. *Comput. Aided. Surg.* 2001; 6(3):131−42.

Steinman DA. Image-based computational fluid dynamics modeling in realistic arterial geometries. *Ann. Biomed. Eng.* 2002; 30(4):483−97.

Stiller B, Hetzer R, Weng Y, Hummel M, Hennig E, Nagdyman N, Ewert P, Lehmkuhl H, and Lange PE. Heart transplantation inhildren after mechanical circulatory support with pulsatile pneumatic assist device. *J. Heart Lung Transplant.* 2003;22(11):1201−8.

Suga H, Sagawa K, and Shoukas AA. Load independence of the instantaneous pressure-volume ratio of the canine left ventricle and effects of epinephrine and heart rate on the ratio. *Circulation Research* 1973;32(3): 314−322.

Taylor C, Hughes T, and Zarins C. Finite element modeling of blood flow in arteries. *Computer Methods in Applied Mechanics and Engineering*, 1998a;158(1−2):155−196.

Taylor C, and Steinman D. Image-Based Modeling of Blood Flow and Vessel Wall Dynamics: Applications, Methods and Future Directions: Sixth International Bio-Fluid Mechanics Symposium and Workshop, March 28−30, 2008, Pasadena, California (Position Paper), *Annals of Biomedical Engineering* 2008; 38(3):1188−1203.

Taylor CA, Draney MT, Ku JP, Parker D, Steele BN, Wang K, and Zarins CK. Predictive medicine: computational techniques in therapeutic decision-making. *Comput. Aided Sur.* 1999; 4(5):231−47.

Taylor CA, Hughes TJ, and Zarins CK. Finite element modeling of three-dimensional pulsatile flow in the abdominal aorta: relevance to atherosclerosis. *Ann. Biomed. Eng.* 1998b;26(6): 975−87.

Thiry PS, and Roberge FA. Analogs and models of systemic arterial circulation. *Rev. Can. Biol.* 1976; 35(4):217−38.

Timms DL, Gregory SD, Greatrex NA, Pearcy MJ, Fraser JF, and Steinseifer U. A compact mock circulation loop for the in vitro testing of cardiovascular devices. *Artif. Organs* 1976; 35(4):384−91.

Trayanova NA. Whole-heart modeling: applications to cardiac electrophysiology and electromechanics. *Circ. Res.* 2011; 108(1):113−28.

Vukicevic M, Chiulli JA, Conover T, Pennati G, Hsia TY, Figliola RS, and Network M. Mock circulatory system of the Fontan circulation to study respiration effects on venous flow behavior. *ASAIO J.* 2013; 59(3):253−60.

Watton PN, Luo XY, Wang X, Bernacca GM, Molloy P, and Wheatley DJ. Dynamic modelling of prosthetic chorded mitral valves using the immersed boundary method. *J. Biomech.* 2007; 40(3):613−26.

Westerhof N, Bosman F, De Vries CJ, and Noordergraaf A. Analog studies of the human systemic arterial tree. *J. Biomech.* 1969;2(2):121−43.

Westerhof N, Lankhaar JW, and Westerhof BE. The arterial Windkessel. *Med. Biol. Eng. Comput.* 2009; 47(2):131−41.

Wolinsky H. and Glagov S. A lamellar unit of aortic medial structure and function in mammals. *Circ. Res.* 1967; 20(1), :99-111.

Wu W, Pott D, Mazza B, Sironi T, Dordoni E, Chiastra C, Petrini L, Pennati G, Dubini G, Steinseifer U, Sonntag S, Kuetting M, and Migliavacca F. Fluid-Structure Interaction Model of a Percutaneous Aortic Valve: Comparison with an In Vitro Test and Feasibility Study in a Patient-Specific Case. *Ann. Biomed. Eng.* 2016;44(2):590−603.

Zheng X, Seo J, Vedula V, Abraham T, and Mittal R. Computational modeling and analysis of intracardiac flows in simple models of the left ventricle. *European Journal of Mechanics-B/Fluids.* 2012; 35:31−39.

In: Encyclopedia of Surgery (22 Volume Set)
Editors: Andreas Lehrer and Kristin Mueller
ISBN: 978-1-53618-329-0
© 2020 Nova Science Publishers, Inc.

Chapter 212

ISOLATED KIDNEY PERFUSION MODELS

Isabel M. A. Brüggenwirth[1], Henri G. D. Leuvenink[1], PhD and Paulo N. Martins[2,*], MD, PhD

[1]Department of Surgery, University Medical Center Groningen,
University of Groningen, Groningen, The Netherlands
[2]Department of Surgery, Division of Organ Transplantation
University of Massachusetts, UMass Memorial Medical Center,
Worcester, MA, US

ABSTRACT

The isolated perfused kidney (IPK) model emerged in the 1970s and has since been extensively used to study renal drug disposition. The model allows to elucidate mechanisms of drug excretion, screen for drug-drug interactions, study renal drug metabolism, and to correlate renal drug disposition to kidney function. Over the last decade, IPK has been particularly useful in the development of preservation techniques for deceased donor kidneys before transplantation. To increase the donor pool, kidneys retrieved from extended criteria donors (ECD) and donation after circulatory death (DCD) donors are increasingly utilized. ECD organs might particularly benefit from hypothermic machine perfusion (HMP), which has been hypothesized to protect deceased donor kidneys from ischemia-reperfusion (I/R) injury. Conflicting data exist on the benefit of HMP for DCD kidneys. DCD kidneys are known to suffer extensive ischemic damage and avoidance of cold-induced injury in sub-normothermic machine perfusion (SMP) might be beneficial for these organs. In addition, higher temperatures reduce vascular stiffness resulting in less endothelial and vascular impairment. Normothermic machine perfusion (NMP) mimics the physiological environment and maintains cellular metabolism during preservation. Numerous cold preservation solutions exist and are still being developed, but the University of Wisconsin solution is still the gold standard in renal preservation. Today, most research focuses on *ex-vivo* treatment of grafts before transplantation.

* Corresponding Author's Email: paulo.martins@umassmemorial.org.

Keywords: isolated kidney perfusion, *ex-vivo* perfusion, renal physiology, drug disposition, machine perfusion, solutions, preservation, and kidney transplantation

ABBREVIATIONS

ATC	apricitabine
BPAR	first biopsy proven acute rejection
BSA	bovine serum albumin
CI	confidence interval
CIT	cold ischemia time
COR	controlled oxygenated rewarming
CSA	cyclosporine A
DBD	donation after brain death
DCD	donation after cardiac death
DGF	delayed graft function
DME	dimethylaminoethanol
ECD	extended criteria donors
GFR	glomerular filtration rate
GST	glutathione S-transferase
HES	hydroxyethyl starch
H-FABP	heart-type fatty acid binding protein
HMP	hypothermic machine perfusion
HOC	hyperosmolar citrate
HOPE	hypothermic oxygenated machine perfusion
HTK	histidine-tryptophan-ketoglutarate
I/R	ischemia-reperfusion
IGF	initial graft function
IGL-1	Institut Georges Lopez-1
IPK	Isolated perfused kidney
KHS	Krebs-Henseleit bicarbonate
L-FABP	liver-type fatty acid binding protein
MP	machine perfusion
MSC	mesenchymal stem cell therapy
MTP	metoprolol
MTX	methotrexate
NHB	non-heart beating
NMP	normothermic machine perfusion
NSX	N4-acetylsulfisoxazole
OR	odds ratio
PAH	para-aminohippuric acid
PBS	phosphate-buffered sucrose
PEG	polyethylene glycol
PFC	perfluorcarbon
PHP	pyridoxalated haemoglobin polyoxythylene

Pn	prednisolone
PNF	primary non-function
RCT	randomized controlled trial
RR	renovascular resistance
SA	salicylic acid
SCS	static cold storage
siRNA	small interfering RNA
SMA	superior mesenteric artery
SMP	sub-normothermic machine perfusion
SU	salicyluric acid
SX	sulfisoxazole
UW	University of Wisconsin
WIT	warm ischemia time

INTRODUCTION

The isolated kidney perfusion model (IPK) was first established in 1876, when Bunge and Schmeideberg reported the synthesis of hippurate from glycine and benzoic acid in isolated perfused dog kidneys (Chang 2013). The model was originally used to investigate physiological and biochemical aspects of renal function, but soon became a useful tool in drug disposition studies. In the 1970s, Bowman and Bekersky using a rat model demonstrated the utility of IPK for drug disposition analysis. Hence the model was used to elucidate mechanisms of drug excretion, screen for drug-drug interactions, study renal drug metabolism, and to correlate renal drug disposition to kidney function (Bowman 1975; Bekersky 1984; Bekersky 1983; Bekersky 1980; Bekersky 1980). Over the last decade, *ex-vivo* isolated kidney perfusion has been particularly useful in the establishing of preservation techniques for deceased donor kidneys before transplantation. Although cheaper and more practical, the perfusion of small laboratory animal kidneys has limited value in testing novel preservation techniques since differences in renal function largely differ from humans. Therefore, porcine kidney systems are commonly used to mimic the situation in humans. In this chapter, characteristics of hypo-, normo-, and subnormothermic kidney machine perfusion will be described.

While the potential applications of IPK experimentation are enormous, several disadvantages are encountered with this technique. Abnormalities in renal hemodynamics, urinary concentration and dilution ability, and excretion of fluid and electrolytes are prominent defects of the model. High renal perfusate flow due to perfusates with low-viscosity, and diminished distal tubular functions are the proposed sources of these model flaws. Glomerular and proximal tubular functions are well preserved however. Lastly, the surgical procedure involved in IPK requires considerable training and experience to perfect (David 2004).

THE ISOLATED PERFUSED KIDNEY SYSTEM

Surgical Procedure (Retrieval of the Kidney)

Many different retrieval techniques similar to human nephrectomy could be used. We therefore describe below the preferred technique for explantation of the right kidney from a living donor animal. After the animal is anesthetized a midline incision is made from the bladder to sternum. Major anatomical features (right kidney, right renal artery and vein, aorta, superior mesenteric artery, right ureter) are identified and cleared of overlying connective tissue and fat. First the right ureter is cannulated. Three loose ligatures are made around the right renal artery and proximal and distal superior mesenteric artery, respectively. Prior to insertion of an arterial cannula, the distal ligature on the superior mesenteric artery is tied. This is followed by a small incision made proximal to the tied distal ligature on the mesenteric artery and a cannula is inserted into the artery. The cannula is then threaded across the aorta into the right renal artery. The other ligatures around the mesenteric artery and renal artery are then tied to secure the cannula in place. Finally, the right kidney and its associated vessels and ureter are excised en bloc. Figure 1 shows a schematic drawing of the surgical field for cannulation of the renal artery with major anatomic landmarks and placement of ligatures.

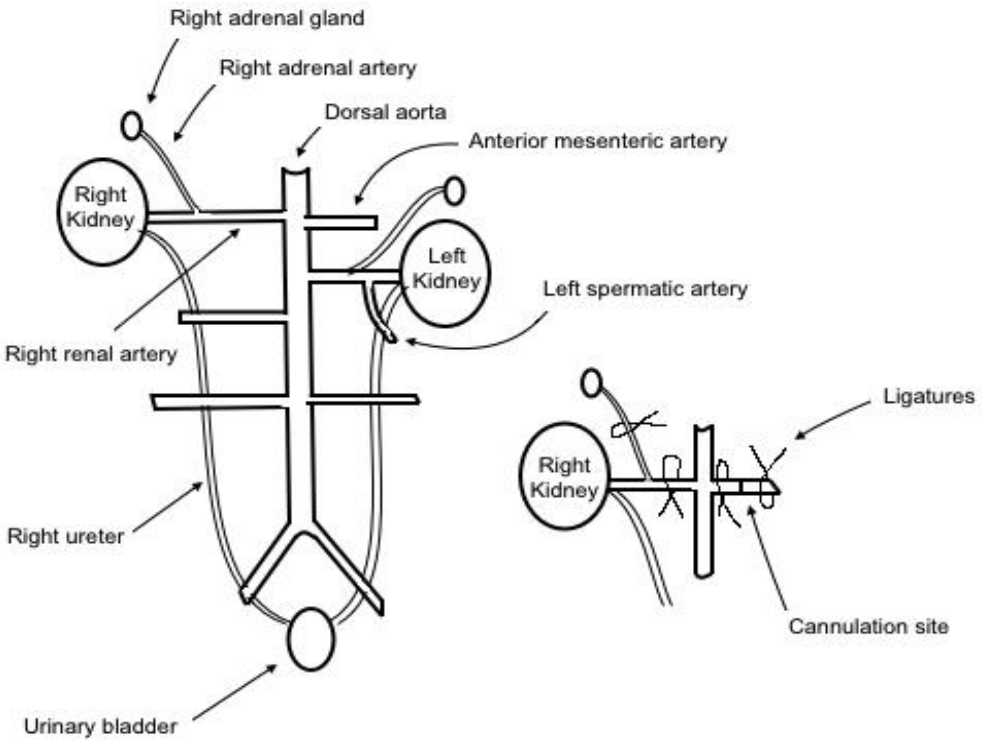

Figure 1. Schematic drawing of the surgical field for cannulation of the renal artery with major landmarks and placement of ligatures.

Perfusion Apparatus

A schematic representation of an experimental IPK model is shown in Figure 2. The perfusion apparatus consists of a pump system to deliver the perfusion solution to the renal artery at variable speeds to achieve the desired arterial pressure. Especially for small animal IPK systems roller pumps are used. The perfusion flow produced by the roller pump is high with values up to 35 ml/min (Wang 2004). The high perfusion flow compared to *in vivo* measurements is due to lower viscosity of the perfusion solution with respect to blood, and it is essential to maintain the adequate oxygenation of renal tissue (Bekersky 1983).

Oxygenation of the perfusate can be achieved by bubbling an oxygen gas mixture directly into the arterial perfusate reservoir through a fine bubble diffuser. Foaming of the perfusate can be avoided by passing the perfusate through a semi-permeable membrane such as thin walled silicone tubing. An experimental IPK set-up is shown in Figure 3.

There are several key indices of kidney function that require close monitoring during isolated perfused kidney experiments. These include glomerular filtration rate (GFR), fractional reabsorption of glucose (to asses proximal tubule function), and fractional reabsorption of sodium ions (to asses distal tubule function). In addition, urine flow rate, urine pH and perfusion pressure are also monitored. Generally, GFR values are lower in IPK compared to in vivo values. A lower GFR leads to a decrease in filtered load and, occasionally, to lower absolute reabsorption with respect to a kidney with normal GFR (Maack 1986). Also, urine is almost isosmolar with the perfusion solution and the renal ability to concentration and dilute is severely interrupted.

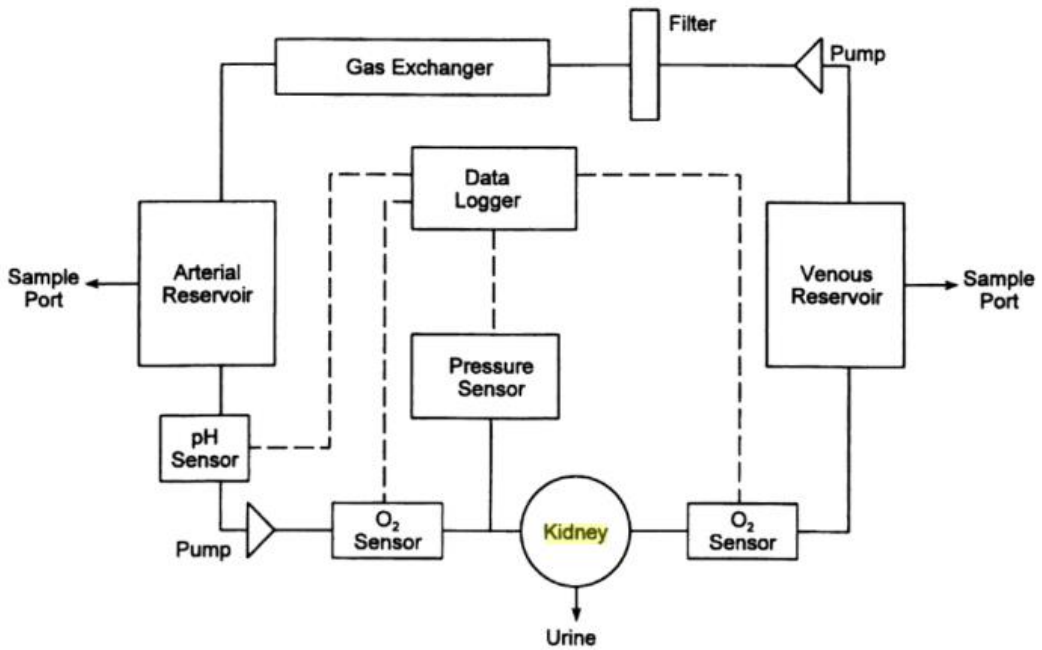

Figure 2. Schematic representation of an experimental isolated perfused kidney model.



Figure 3. Experimental kidney perfusion model.

Perfusion Solutions

The main criteria considered when selecting an artificial perfusate medium, is to make the perfusate analogous to plasma. The basis component of IPK perfusion solution is Krebs-Henseleit bicarbonate (KHS) buffer. KHS solution contains a mixture of amino acids, electrolytes and other salts comparable to those measured in vivo. Glucose is added as an energy source and to support optimal GFR, cellular metabolism, and fractional reabsorption of sodium and potassium ions. Bovine serum albumin (BSA) or dextran is most commonly used as an oncotic agent in the perfusion medium. The oncotic agent generates a 'physiological' coloidosmotic pressure and allows for assessment of the relation between drug-protein binding and renal excretion. During experimental studies, the concentration of BSA can be varied in a controlled manner to allow variations in drug free fraction in the perfusate. When BSA concentration is low (<6%), dextran should be added in order to maintain the necessary oncotic pressure within the renal vasculature (David 2004). Noteworthy, GFR values obtained with BSA as an oncotic agent are lower than those found *in vivo*. In contrast to albumin, dextran does not bind to other compounds, which makes dextran more useful for pharmacokinetic studies. The most commonly used albumin concentration is 60–65 g/l. The molecular weight of dextran must be ranged between 60,000–90,000 Da (Bekersky 1983; Maack 1986).

Renal Disposition of Drugs

The IPK model provides an excellent tool to elucidate more precise information on the underlying mechanisms in pharmacokinetics and renal clearance of a drug. The binding of drugs to plasma proteins can have many effects on the processes that contribute to

metabolism, distribution and excretion of drugs. An extensive list of drug disposition studies using the IPK model can be found in the literature, with Bekersky being one of the pioneers in the research field. An overview of drug disposition studies over the years can be found in Table 1.

Table 1. Drug disposition studies using the IPK model

Researchers	Compound	Findings
(Engbersen et al., 2012)	Sulfonylurea drugs	Sulfonylurea drugs exert differential effects on vascular smooth muscle channels. Glibenclamide and glimepiride will interact with these channels at therapeutic concentrations
(Arnaud-Batista et al., 2012)	Bufadienolides	The study shows direct diuretic, natriuretic, and kaliuretic effects of bufalin in IPK and the relevance of Na^+-K^+-ATPase-mediated signal transduction
(El-Gowilly, 2011)	Metorpolol (MTP) and cyclosporine A (CSA)	MTP abrogates the hypertensive and nephrotoxic effects of CSA
(Wang, Evans, Knights, & Miners, 2011)	4-methylumbelliferone and 4-methylumbelliferyl glucoronide	Data confirmed an important role for the kidney in metabolic clearance of xenobiotics via glucuronidation
(Fonseca-Magalhães et al., 2011)	Sertraline	Sertraline had antispasmodic effects probably caused by a direct action on vascular smooth muscle cells
(Babayeva, Cox, White, & Taft, 2011)	Apricitabine (ATC)	This study showed that IPK is more sensitive to secretory inhibition as compared to in vivo. The study generated important information on renal handling of ATC to support its development and commercialization
(Ajavon, Bonate, & Taft, 2010)	Clofarabine	Clofarabine is a substrate for a cimetidine-sensitive organic cation transporter system in the kidney. The magnitude of cimetidine-clofarabine interaction was similar in vivo and in IPK
(Tamhane, Chakilam, Jayaraj, Thakkar, & Taft, 2010)	VX-702 (a novel p38 MAPK inhibitor) and methotrexate	Drug-drug interaction between VX-702 and methotrexate would be unlikely
(Poola, Kalis, Plakogiannis, & Taft, 2003)	Pentamidine and tetraethylammonium	Potential drug-drug interactions between pentamidine and organic cations exist
(Zarzuelo, Lanao, López, & Sánchez-Navarro, 2002)	Netilmicin	The apparent partition coefficients in renal cortex and medulla show higher values for slower perfusion rates of netilmicin
(Katayama, Yasuhara, & Hori, 1999)	Cefoperazone	Plasma clearance of unbound cefoperazone is decreased in acute renal failure
(Shanahan, Evans, & Nation, 1997)	Morphine	The results suggest that tubular secretion of morphine is not saturated over a wide range of concentrations (0.2–200 microM)
(Masereeuw, Moons, & Russel, 1997)	Hydrochlorothiazide	The diuretic effect of hydrochlorothiazide is restricted by saturable accumulation and secretion
(Kugler, Olson, & Smith, 1995)	Quinapril and quinaprilat	The clearance ratio of quinapril represented extensive tubular secretion. Following quinaprilat administration, a net secretion process for renal elimination was indicated
(Boom, Moons, & Russel, 1994)	Cimetidine	Renal handling of cimetidine in the IPK is concentration-dependant and is determined by glomerular filtration, active tubular secretion, and a substantial flow- and pH-dependent passive reabsorption
(Statkevich, Fournier, & Sweeney, 1993)	Methotrexate, indomethacin and flurbiprofen	The secretory component was significantly inhibited by indomethacin and flurbiprofen after concomitant administration of oncolytic doses of methotrexate

Table 1. (Continued)

Researchers	Compound	Findings
(Redegeld, Hofman, van de Loo, Koster, & Noordhoek, 1991)	2-methyl-1, 4-naphtoquinone (gluthathione conjugate of menadione)	Thiodione-mediated toxicity can be linked to cellular uptake by anionic transport systems and metabolism by gamma-glutamyltranspeptidase
(Cox, Moons, Russel, & van Ginneken, 1990)	Naproxen	Relatively low doses of naproxen exert a specific stereoselective effect on kidney function caused by inhibition of prostaglandin E2 synthesis. High doses exert a non-stereoselective effect on kidney function.
(Lohr & Acara, 1990)	Dimethylaminoethanol (DME) and choline	DME is an effective inhibitor of betaine production and may be an important agent for the study of osmoregulation
(Somogyi, Hovens, Muirhead, & Bochner, 1989)	Amiloride and cimetidine	Cimetidine inhibits renal tubular secretion of amiloride. In humans, gastrointestinal absorption of amiloride and cimetidine appear to be reduced by each other
(Bekersky & Popick, 1986)	Bumetanide and furosemide	Diuresis was produced by both drugs. Furosemide was dependant on high clearance from filtration and secretion. Bumetanide was filtered and partially absorbed.
(Bekersky, Popick, & Colburn, 1984)	Sulfisoxazole (SX) and N4-acetylsulfisoxazole (NSX)	The metabolism od SX to NSX is reversible and influenced by protein binding. Tubular excretion of SX is a function of total drug in the perfusate
(Bekersky, Popick, & Colburn, 1983)	Gentamicin	Addition of gentamicin-specific antiserum decreased renal clearance and tissue accumulation of gentamicin
(Rocci, Szefler, Acara, & Jusko, 1981)	Prednisolone (Pn)	The extent of urinary clearance of Pn and prednisone is related to glomerular filtration and passive tubular reabsorption
(Bekersky, Colburn, Fishman, & Kaplan, 1980)	Salicylic acid (SA) and salicyluric acid (SU)	SA/SU metabolism was found to be reversible and a larger renal contribution to overall salicylate disposition is suggested

During IPK studies, renal excretion mechanisms can be studied by dose-escalation studies or interaction experiments. By comparing renal disposition of a certain drug over a range of doses, nonlinear excretion behavior can be identified. Likewise, the disposition of cimetidine was studied over a range of several doses. The study demonstrated that net tubular secretion was observed at lower doses, progressing to net tubular reabsorption with increasing dose (Boom 1994). In addition, specific mechanisms of renal excretion can be identified through co-administration of known inhibitors of the organic anion and organic cation transport systems. Two commonly used inhibitors are probenecid and cimetidine. Subsequently, probenecid has shown to reduce renal excretion of the anionic compound bumetanide (Bekersky 1986). Cimetidine, a common probe for renal cation transport, has been utilized to study the renal disposition of amiloride (Somogyi 1989). Reduced clearance in the presence of potential interactants demonstrates a role of these transport systems in drug excretion.

Continuous monitoring of kidney function during IPK experiments offers the potential for correlating renal drug excretion with pharmacodynamic effects. This is particularly valuable for diuretic drugs. For example, the IPK model was used to correlate the relationship among perfusate drug concentration, kidney accumulation, and diuretic response following hydrochlorothiazide administration (Masereeuw 1997). The model has also been used to

characterize the renal disposition and pharmacodynamic effects of the diuretic agents bumetanide and furosemide (Bekersky 1986).

In addition to studying pharmacokinetic-pharmacodynamic relationships between drugs, the IPK model has been an effective tool to study mechanisms of nephrotoxicity. In an early study by Bekersky et al., gentamicin appeared to have a significant effect on renal potassium handling making it potentially nephrotoxic (Bekersky 1983). More recently, the anti-fungal agent pentamidine was found to be associated with a high incidence of kidney toxicity (Poola 2003).

Although the liver is the main organ responsible for drug biotransformation, the kidney contains many drug-metabolizing enzymes and contributes to renal metabolism of a number of medications. Biotransformation has been demonstrated in a number of medications in the IPK, like prednisolone, sulfisoxazole and glutathione (Rocci 1981; Bekersky 1984; Redegeld 1991). A distinct advantage of drug metabolism studies in the isolated kidney compared to in vitro experiments is that the overall contributions of transport mechanisms and biotransformation by the kidney can be elucidated. Also, mechanisms of excretion of the formed metabolites can be monitored.

Drug-drug interaction studies are routinely used in IPK studies for two reasons: to determine/confirm pathways contributing to drug excretion and to identify medications that may display clinically significant interactions when co-administered to patients (Taft 2004). Antiviral medications are primarily excreted by renal mechanisms. Since these agents are commonly part of a multi-drug regimen, the potential exists for clinically significant drug interactions to occur. The IPK model allows for assessment of possible drug-drug interactions in a controlled manner. A study affirmed how the interaction between methotrexate (MTX) and non-steroidal anti-inflammatory drugs can be toxic. The kidney is the primary route of excretion for MTX, a dihydrofolate reductase inhibitor used in treatment of cancer, psoriasis, and arthritis. They demonstrated that secretory transport was significantly inhibited by indomethacin and flurbiprofen (Statkevich 1993).

Over the past years, advances in scientific technology have significantly impacted the drug development process. Demonstrated correlations between IPK data and clinical outcomes make the model a potentially useful tool for drug discovery and evaluation in humans.

Other Potential Applications of the IPK Model

Besides studying drug dispositions, the IPK model can be useful in several other areas of interest. There are studies that identify the effect of aging (Savant 2001; Awe 2007) and gender (Taft 2006) on drug disposition. The excretion of para-aminohippuric acid (PAH), an indicator of renal plasma flow, was significantly affected by aging. The study demonstrated an age-dependent reduction in PAH excretion. However, the correlation between PAH clearance and GFR was limited, which contradicts the ‘Whole Nephron Hypothesis’ (each nephron is either a fully functional unit or does not function) (Savant 2001). Ageing was also found to decrease alpha1-adrenoceptor-mediated vasoconstriction of rat kidneys (Awe 2007). The IPK model provided supportive evidence that gender-dependent transport differences exist at the basolateral and luminal membrane of the kidney. Renal clearance of PAH and furosemide was higher in male rat perfusion experiments compared to females. Gender

differences in transporter expression and function may result in differences in systemic exposure of narrow therapeutic range medications and risks to nephrotoxic agents. Therefore, disparities in drug disposition between males and females are an emerging issue for drug development (Taft 2006). Another important and successful application of the IPK model is as a potential preservation technique before kidney transplantation.

THE IPK MODEL AS A PRESERVATION TECHNIQUE

In the 1960s, Belzer et al. started experiments studying hypothermic machine perfusion (HMP) in canine kidneys and the first successful human transplantation of a hypothermically machine perfused kidney took place in 1968 (Belzer 1967). After the definition of irreversible coma in 1968, the concept of brain death became acceptable in the early 1970s. Consequently, the shift to recover organs from heart beating instead of non-heart-beating (NHB), nowadays named donation after circulatory death (DCD) donors, increased success rates and the majority of transplant centers abandoned the practice of DCD donation. Initially, only young and mainly trauma patients were considered suitable for donation and these organs were preserved equally well by either static cold storage (SCS) or HMP. Over the last few decades, more marginal donors, as well as DCD donors are accepted to overcome organ shortage and machine perfusion regained worldwide interest. Substantial experimental work contributed to improved clinical results and a recent randomized controlled trial (RCT) proved clinical efficacy short- (Moers 2009) and long-term (Moers 2012). Therefore, machine perfusion is the present method of choice to obtain good long-term preservation and for preservation of marginal kidneys

In the U.S. by 2008, nearly half of the kidney transplants from extended criteria donors (ECD) and 70% of those from DCD donors were machine perfused indicating the common belief that these organs require better preservation techniques. In other parts of the world machine perfusion is slowly increasing as well. During perfusion after organ retrieval, the preservation is continuously pumped through the organ via the vasculature. A heat exchanger regulates the perfusate temperature at hypothermic (0−4ºC), sub-normothermic (20−30ºC) or normothermic (37ºC) temperatures. If required, the perfusate can be oxygenated via a membrane oxygenator.

Machine perfusion perfuses the organ *ex situ,* after it has been procured, cannulated and connected to a pump (Jochmans 2016). Continuous perfusion (from procurement to implantation) or pre-implantation perfusion (after a period of SCS and just before transplantation) is most commonly used. During perfusion, the kidney can be supplied with nutrients and oxygen, have waste products removed, and drugs or other therapeutic agents supplied as needed. Challenges are however: understanding the metabolic requirement of the *ex vivo* perfused organ, development of viability biomarkers, and maintenance of endothelial cell integrity (Belzer 1980).

Hypothermic Machine Perfusion

HMP is based on a controlled continuous circulation of a cold perfusate (0−4ºC), which has been hypothesized to protect the deceased donor kidneys from injuries related to ischemia and reperfusion. Immediately after procurement, the organ is attached to the perfusion system via the renal artery. Circulation of the perfusate is achieved through a device that generates either a continuous or pulsatile flow by a roller pump or centrifugal pump. The interest in HMP decreased in 1969, after the introduction of SCS by Collins, because this preservation technique was more simple and economic and allowed preservation up to much longer times (>30 hours) (Catena 2013). However, in recent years the interest in HMP regained attention due to the greater number of organs from marginal donors, which are predisposed to primary graft non-function (PNF) and delayed graft function (DGF). HMP maintains the hemodynamic stimulation of the vasculature, which plays a critical role under normal physiologic conditions. Evidence supporting the hypothesis that HMP may reduce ischemia-reperfusion (I/R) injury was published by Wszola et al. Kidneys preserved by SCS showed elevated levels of genes that are correlated with I/R injury compared to hypothermic machine perfused kidneys (Wszola 2014). Zhang et al. observed more apoptotic cells in cold stored kidneys versus HMP kidneys in a canine DCD model. In parallel, phospho-AKT and ezrin expression was induced in the HMP group, implying that cell proliferation, turnover, and renewal are positively influenced when kidneys are subjected to HMP instead of SCS (Zhang 2016). A meta-analysis conducted between 1971 and 2001 showed that HMP is associated with a relative risk of DGF of 0.80 (95%CI = 0.67–0.96) compared to SCS (Jochmans 2015). More recently, a large RCT comparing continuous HMP with SCS of 336 kidney pairs using the LifePort™ pump was conducted in 2009. This MP-trial showed an overall reduced risk of DGF in HMP kidneys compared to SCS kidneys (20.8% vs. 26.5%, p = 0.05). One-year graft survival significantly increased from 90% in SCS kidneys to 94% in HMP kidneys (p = 0.04) (Moers 2009). Also on longer term the protective effects of machine perfusion were evident (Moers 2012)

Figures 4, 5 show machine-perfused kidneys in the clinical setting.

Figure 4. Kidney preservation by machine perfusion.

Figure 5. Inside the kidney preservation machine.

Extended Criteria Donor Kidneys

As mentioned earlier, more marginal, or ECD, kidneys are used to overcome the problem of increasing organ shortage. ECD kidneys might particularly benefit from HMP, since they are more susceptible to preservation-induced injury, DGF and PNF. A study compared ECD kidneys that were cold stored during transport followed by HMP to kidneys that were cold stored throughout the preservation period. The HMP organs showed markedly reduced expression of all analyzed cytokines as well as soluble intracellular adhesion molecular type 1, compared to constant or even elevated levels in the cold stored group (Tozzi 2013). In a study on 91 randomized ECD kidney pairs, HMP significantly reduced the risk of DGF compared to SCS (adjusted odds ratio (OR) = 0.46; 95%CI = 0.21–0.99). Also, PNF was lower and 1-year graft survival was higher in hypothermic machine perfused kidneys (3% vs. 12%, p = 0.04 and 92.3% vs. 80.2%, p = 0.02, respectively) (Treckmann 2011).

One category of ECD donors is the DCD donor (previously referred to as non-heart-beating). In these donors circulatory arrest occurs before organ procurement. DCD kidneys are exposed to a period of warm ischemia during the period of circulatory arrest, which makes these organs particularly vulnerable to the development of DGF. The literature reveals conflicting data on HMP of DCD kidneys. Some studies have suggested that HMP of DCD kidneys leads to better outcomes, but other studies could not find a difference in DGF or graft survival. In the multi-center Machine Perfusion trial in the Eurotransplant region on 82 DCD kidney pairs, continuous HMP showed a reduced risk of DGF compared to SCS kidneys (53.7% vs. 69.5% respectively, p = 0.025) (Jochmans 2010). In 2010, Watson et al. published results on a RCT in the U.K. comparing HMP with SCS for 45 DCD kidney pairs. Their results did not show a beneficial effect on 1- or 3-year graft survival or DGF for hypothermic machine perfused kidneys (Watson 2010). The contradicting outcomes of these currently largest RCTs might be related to the setting in which HMP is performed. Hosgood et al., showed in a porcine kidney transplant model that the beneficial effect of MP disappears when kidneys are not pumped immediately after procurement (Hosgood 2011). Following this, in the Machine Perfusion trial, kidneys were pumped immediately after retrieval at the donor

center, whereas in the U.K. trial kidneys were cold stored during transfer and then HMP was started.

Preservation Solution

Many preservation solutions exist, all with different compositions aimed to prevent I/R injury and maximizing graft survival and function. Early preservation solution consisted of diluted blood and ringers lactate solution. After the introduction of SCS by Collins in 1969, prolonged kidney preservation became feasible. Currently, the most commonly used preservation solutions are University of Wisconsin (UW) and histidine-tryptophan-ketoglurate (HTK) followed by smaller use of Celsior, Institute George-Lopez (IGL-1), Polysol, Euro-Collins, hypertonic citrate or Marshall solution (HOC), and phosphate-buffered sucrose (PBS).

In 1987, Belzer and colleagues developed the University of Wisconsin (UW) solution (also known as Belzer's solution and produced by Organ Recovery Systems as KPS-1) and this has become the gold standard among organ preservation solutions today. In the European Multicenter Trial the use of UW versus EuroCollins solution significantly reduced the rate of DGF (10% vs. 23%) (Ploeg 1992). UW shows good outcome of short and long-term kidney preservation, but the main disadvantage is its high viscosity mainly due to hydroxyl ethyl starch (HES) (Catena 2013). For HMP, UW-G is used, in which a more extracellular solution is achieved through replacing lactobionate by gluconate and reducing the potassium level (Catena 2013). Although UW solution is considered the ideal solution for kidney preservation, it does not completely prevent I/R induced injury.

Some institutions favor the low-viscosity HTK solution to preserve DCD kidneys as opposed to the assumed less favorable washout facilitated with the high-viscosity UW solution. HTK was introduced in 1980 by Bretschneider and is may be used in HMP at low pressures and high perfusion volumes. More recently, Rauen and De Groot developed Custodiol-N solution as improved modification of the former HTK solution. The solution is particularly suitable, because the iron chelators inhibit cold-induced free radical mediated injury and have already shown to be effective to protect isolated rat livers during HMP (Stegemann 2010). Minor et al. using a porcine transplant model provided *in vivo* evidence for the sustainability of Custodiol-N as an effective perfusate for renal machine perfusion. HMP with Custodiol-N resulted in less acute tubular injury and lower serum creatinine levels compared to KPS-1. Also, lower expression of endothelin-1 and of Toll-like receptor 4, suggests less endothelial stress in the Custodiol-N perfused kidneys (Minor 2015).

Developed in 1994, Celsior solution is a colloid and combines the osmotic efficacy of UW (lactobionate and mannitol) with the potent buffering ability of HTK (histidine). It is particularly beneficial to prevent tissue edema caused by hydrostatic pressure of HMP, because Celsior contains macromolecules that do not pass the cellular membrane (Catena 2013).

The fairly new preservation solution IGL-1 combines the advantages of UW and Celsior and is characterized by high sodium concentration and polyethylene glycol (PEG, 35 kDa), substituting HES. A non-randomized prospective multi-center study showed the same effectiveness for IGL-1 versus UW solution, but lower costs for the former (Codas 2009). Polysol, a new low-viscosity preservation solution, is introduced to facilitate transplantation of ischemically damaged organs. Amino acids, vitamins, potent buffers, and anti-oxidants

have been added to support metabolism during HMP (Bessems 2005). One of the main components is PEG 35, a low-molecular-weight colloid that does not increase viscosity as seen with HES-containing solutions. Polysol is currently used in experimental settings only, but recent reports seem promising. A study in a porcine auto-transplant model reports better preservation of microcirculation and renal function after 20-hour SCS preservation compared to UW (Schreinemachers 2009).

HOC or Marshall's solution is extensively used for clinical transplantation in the U.K. and Australia. HOC is an intracellular solution with high potassium content, mannitol as the impermanent ion, and citrate as its buffer. The hypertonic character of HOC prevents entry of fluid into the cells and has shown to be effective for 72-hour canine kidney preservation (Kay 2009; Hosgood 2009; Bagul 2009; Nicholson 2009).

Role of Oxygenation

In HMP oxygenation plays a central role of importance for reconditioning after ischemic storage. Lack of oxygen leads to ATP decrease, which can be as large as 80% for kidneys (Jassem 2004). Ischemic damage can be minimized by various preservation solutions. In some settings, perfusion per se was not sufficient to protect the organ from injury and failed to provide functional improvement upon reperfusion. Continuous oxygenation might be useful to support the remaining metabolic demand of the organ during preservation. On the other hand, high concentrations of oxygen are believed to favor the production of oxygen free radicals, thus promoting adverse effects on tissue during long-term oxygenated preservation (Stegemann 2010; Rauen 2004). However, several studies strongly suggest oxygen to be a constitutive adjunct in organ preservation by HMP, improving functional outcome of the graft. Hoyer and colleagues showed that HMP with 100% oxygen results in higher flow and lower renal resistance (RR) during perfusion. In addition, kidneys that were exposed to 100% oxygen during perfusion had a significantly higher graft function than kidneys that did not receive any oxygen during HMP (Hoyer 2014). The positive results after HMP with oxygen were confirmed by studies with a 3-month post-transplant follow-up by Thuillier et al. Oxygenated kidneys had lower serum creatinine peak and significantly lower levels of several injury markers. The positive short-term effects were followed by lower serum creatinine, less proteinuria and less chronic kidney fibrosis post-transplant (Thuillier 2013). The efficacy of oxygenation in DCD kidneys is currently investigated in a RCT executed in Europe (www.cope.eu).

Kron et al. investigated the effects of 1-hour hypothermic oxygenated perfusion (HOPE) before transplantation after kidneys were cold stored. HOPE-treated DCD kidneys showed dramatically better function after transplantation compared to SCS grafts in terms of nuclear injury, macrophage activation, endothelium activation, tubulus damage, and graft function (Kron 2016). Grafts that have been exposed to a period of warm ischemia seem to particularly benefit from oxygenated perfusion. A study by Buchs et al. found that levels of ATP were restored in DCD porcine kidneys, but no added benefit of oxygenation was found in kidneys without injury (Buchs 2011).

Perfusion Parameters

Machine perfusion provides the opportunity to determine perfusion parameters including perfusion pressure, perfusion flow, and renovascular resistance. Flow and resistance are often

used to assess suitability for transplantation. Kidneys with low flow (<100 mL/min) and high RR (>0.4 mmHg/mL/min) are believed to be higher-risk organs (Mozes 2005). However, the literature is inconsistent. Several studies proposed that there is no significant relation between low flows during preservation and post-transplant outcomes. Mozes et al. analyzed 336 ECD kidneys and showed similar outcomes between 'poor' (RR 0.4–0.6 mmHg/mL/min) perfusion parameters and 'good' perfusion parameters (Mozes 2005). Likewise, acceptable short- and long-term results were reported in a small series of deceased donor kidneys with 'poor' perfusion parameters (flow <80 mL/min and RR >0.4 mmHg/mL/min) (Guarrera 2010). On the contrary, Jochmans et al., showed in a multivariate analysis of 302 kidneys that RR at the end of HMP was an independent risk factor for the development of DGF and 1-year graft failure (Jochmans 2011). Matsuno and colleagues found that MP flow is a reliable indicator of graft viability based on the rate of PNF and immediate renal allograft function, especially in marginal donors. The highest rate of PNF (25.7%) was found in kidneys that were perfused with a flow of 0.45–0.65 mL/min/g, compared to 0% in kidneys that were preserved with a flow of >0.9 mL/min/g (Matsuno 2006). In a large database study, pumped ECD kidneys (n = 2,351) with high resistance at the end of MP (>0.25 mmHg/ml/min) were associated with higher odds of discard. ECD kidneys with low resistance (<0.25 mmHg/mL/min) were discarded 14.0% of the time and kidneys with high pressure (>0.25 mmHg/mL/min) had a discard rate of 25.7%. Those with resistances >0.38 mmHg/mL/min even had a discard rate of 53.1% ($p < 0.0001$) (Sung 2008). This suggests that RR is an important tool to be used in kidney graft quality assessment and can be helpful for clinicians in the postoperative management of recipients of these organs. Nevertheless, it cannot be used as a stand-alone viability parameter to accept or discard a given kidney.

The average flow rate for a kidney is achieved at a mean of 2 hours, but the organ does not seem to be much affected by longer pump times (>24 hours) (Patel 2012). A study on 339 deceased donor recipients showed that DGF rates were unaffected by length of pump time, short (<24 hours) or long (>24 hours) (Ciancio 2010). There are also studies that favor a longer pump time. It has been suggested that a significantly lower rate of first biopsy proven acute rejection (BPAR) was seen among recipients with longer pump times, even though there was no trend found for improved graft survival (Ciancio 2010). A study on 66 pairs of recipients showed that longer pump times were not associated with any unfavorable effect on DGF, graft and patient survival, or impaired renal function. In fact, they offered a significantly favorable protection from BPAR with pump time >24 hours (Ciancio 2012). An explanation for the favorable effect of MP on rejection is currently unknown. One theory is a better flushing of immunogenic cells (passenger leukocytes) from the deceased kidney. Surprisingly, BPAR occurrence is known to be associated with an increased risk of graft failure, but no associations between longer pump times and decreased rates of graft failure were found. More recently, a large registry analysis (90,000 kidneys) has shown that HMP reduced the risk of DGF compared with SCS, regardless of very short or very long cold ischemia time (CIT) (Gill, Dong, Eng, Landsberg, & Gill, 2014). Nevertheless, because CIT is a well-established predictor of DGF, a balance between minimizing CIT and any potential benefits of HMP is required and the ideal pumping time has not been established yet.

Viability Assessment

One key question during organ preservation is whether the likelihood of a renal graft to resume function can be predicted. Accurate evaluation of graft function is essential to prevent unnecessary discard and to plan appropriate postoperative care. Machine perfusion offers the possibility to assess organ quality during perfusion and identify differences in metabolomic profile between immediate or delayed graft function. The assessment of organ viability is especially important in marginal kidneys with their increased risk of developing DGF and PNF. Perfusate biomarkers are promising tools to accept or discard kidneys for transplantation. However, the value of perfusate biomarkers to predict organ viability is not or hardly known. Overall, the literature remains mixed about the predictive utility of these physical measurements with regard to kidney viability and allograft outcomes.

One of the most promising biomarkers and frequently used for viability testing is glutathione S-transferase (GST), an enzyme localized in the renal tubulus. Warm ischemia predominantly damages proximal tubule cells; therefore, the appearance of GST in the perfusate may reflect the number of proximal tubule cells that are damaged (Daemen 1997). Several studies demonstrated that αGST strongly correlates with warm ischemia time (WIT) and is hence able to discriminate viable from non-viable DCD kidneys (Daemen 1997; Kievit 1997). In a subset of 111 kidneys from the Machine Perfusion trial, GST levels at the end of HMP were higher in kidneys that developed DGF, but not after multivariable adjustment (Kozaki 2000). Hoogland et al. analyzed perfusate samples of 335 DCD kidneys and found that total GST, heart-type fatty acid binding protein (H-FABP), redox-active iron and neutrophil gelatinase-associated lipocalin (NGAL) were not associated with PNF or 1-year graft failure. They did show an association of LDH and IL-18 concentrations with PNF (OR = 1.001; 95%CI = 1.000–1.002). The association might be more apparent in DCD kidneys compared to DBD donors. The reason behind this is as follows; LDH measured in machine perfusate is released either by the perfused kidney or by hemolytic erythrocytes from the capillaries (Cohen 1998); DCD kidneys sustain a period of warm ischemia with stasis of blood on the organs and therefore, may have a relatively high concentration of erythrocytes and blood clots in the capillaries after poor initial flush out after cardiac arrest (Hoogland 2013).

Redox-active iron is released during I/R injury and is believed to catalyze the formation of oxygen-free radicals, which are known to induce apoptotic and necrotic cell death and subsequent inflammatory responses (de Vries 2004). Also, cold ischemia has been indicated to induce tissue accumulation of redox-active iron, which is considered a critical step in cold storage-induced injury. A study by de Vries et al. showed that redox-active iron concentrations were significantly higher in ischemically injured NHB donor kidneys compared to heart beating donor kidneys that were not subjected to warm ischemia (3.9 ± 1.1 vs. 2.8 ± 1.0 μmol/L, p = 0.001) (de Vries 2006). Moreover, redox-active iron concentration was an independent predictor of post-transplant graft viability (OR 1.68, $p = 0.01$).

IL-18 is a proinflammatory cytokine produced by macrophages and other cell types present in the kidney during I/R injury and contributes to inflammatory reactions. IL-18 was shown to be significantly associated with PNF in multivariate analysis on 335 transplanted DCD donor kidneys (OR 1.001; 95% CI 1.000−1.002, p = 0.003) (Hoogland 2013). Parikh et al. found higher IL-18 values at the end of perfusion in DGF kidneys (13.4 pg/mL vs. 11.8 pg/mL, p = 0.005) (Parikh 2015).

In addition, significantly lower levels of glucose in DGF kidneys compared to immediate graft function (IGF) organs (7.78 vs. 9.46, p = 0.006) were observed by Guy et al. The same group observed significantly different concentrations of inosine and leucine (0.002 vs. 0.013 mM, p = 0.009 and 0.011 vs. 0.006 mM, p = 0.036), as well as gluconate levels (49.10 vs. 59.51, p = 0.009) (Guy 2015).

Currently, NGAL and liver-type fatty acid-binding protein (L-FABP) are approved biomarkers of kidney injury in Europe and clinically used in Japan. Nonetheless, a recent study in 671 recipients by Parikh et al. only found modest associations for perfusate NGAL and L-FABP at the end of HMP with allograft function, indicating that these biomarkers have poor prognostic utility (Parikh 2016). Median perfusate concentrations of NGAL, kidney injury molecule 1, IL-18 and L-FABP were either lower or not significantly different in discarded kidneys compared to transplanted kidneys. Notably, recipients of transplanted kidneys with 'undesirable' biomarker levels experienced acceptable 6-month allograft function, suggesting that these characteristics should not be used in isolation for discard decisions. Additional studies must confirm the utility of biomarkers to assess kidney quality.

Devices

As HMP is gaining recognition, more perfusion machines are becoming available (Figure 13.6). The most commonly used device is the pressure-driven LifePort Kidney Transporter (Organ Recovery Systems, Itasca, IL, USA). Another commonly used device is the flow-driven Waters Medical RM3 (Birmingham, AL, USA). In both systems, the operator can modify the systolic perfusion pressure, with flow and resistance recorded over time. Relevant differences between the systems are related to the way both devices generate and control flow and pressure. The RM3 uses a flow-driven system, which requires 50% higher systolic pressures (45 vs. 30 mmHg) to obtain similar flow rates. A comparative study on both systems demonstrated minimal differences in early kidney recovery, but significantly higher levels of post-transplant fibrosis in kidneys preserved by RM3 compared to LifePort (Wszola 2013). Another study showed favorable results for the LifePort device compared to RM3 with shorter duration of DGF after transplant, lower incidences of interstitial fibrosis and tubular atrophy in biopsies taken within 1-year post transplant, and lower renal resistance during perfusion (Wszola 2013). Other devices currently on the market are the oxygenated MP system from Organ-Assist bv and the Waves machine (Waters).

Figure 13.6. Kidney machine perfusion devices. A: Waters Medical RM3, B: LifePort Kidney Transporter, C: Kidney Assist Transporter.

SUB-NORMOTHERMIC MACHINE PERFUSION

The interest in sub-normothermic machine perfusion (SMP) has increased after more became known on hypothermia-induced organ injury caused by organ cooling during preservation. Avoidance of cold-induced injury might be particularly favorable for DCD organs, which are known to suffer extensive ischemic damage. In a porcine model of renal I/R injury, oxygenated SMP demonstrated better protection of the organ compared to cold storage. SMP grafts showed nearly twofold better values of creatinine clearances compared to oxygenated HMP (Hoyer 2014). Another benefit is that SMP allows higher pressures to be used without risk of endothelial and vascular impairment as higher temperature reduces vascular stiffness (Hoyer 2014). Higher temperatures also lead to higher metabolic demands requiring active oxygenation and sufficient perfusion flow. Clinical use of SMP in clinical kidney transplantation has not yet been reported.

GRADUAL REWARMING

One cause of ischemic damage could be the abrupt temperature shift from hypo- to normothermia, leading to mitochondrial dysfunction and proapoptotic signal transduction (Minor 2013). Therefore, recent studies have investigated the effect of the promising new aspect of controlled oxygenated rewarming (COR). The protective effect of controlled tissue rewarming after cold storage was first shown in a pig liver perfusion model, where end-ischemic MP with gradual rewarming resulted in superior functional recovery compared to hypo- or subnormothermic perfusion prior to reperfusion (Minor 2013). Recently, this evidence was supported in a pig liver perfusion model comparing COR up to sub-normothermic temperatures to NMP. COR resulted in lower mitochondrial caspase-9-activity. Significantly lower enzyme leakage and higher bile production were also observed during reperfusion (Hoyer 2016). Schopp et al. reported a nearly twofold increase in renal clearances of creatinine and urea after COR of pig kidneys compared to controls. This was accompanied by significantly improved renal oxygen consumption and less cellular apoptosis (Schopp 2015). Similarly, Mahboub et al. demonstrated less renal parenchymal injury, tubular injury and better endothelial preservation in the gradual rewarming groups versus the control group. Perfusate AST and LDH were less increased in the gradual rewarmed kidneys and sodium re-absorption was improved. Heat shock protein 70, intracellular adhesion molecule 1 and vascular cell adhesion molecule 1 mRNA expressions were decreased in gradually rewarmed kidneys (Mahboub 2015). These data suggest that a gradual increase in temperature results in better energetic recovery, less cellular injury, and ultimately superior function of kidneys subjected to COR. The first clinical application of COR has recently been applied in a first clinical series of 6 liver transplant patients. All treated recipients had normal liver function after 6-month follow-up (Hoyer 2016).

NORMOTHERMIC MACHINE PERFUSION

In contrast to cold preservation, the concept of NMP is to replicate the physiological environment and maintain cellular metabolism during preservation. Aerobic metabolism can be restored allowing the kidney to regain function; this can minimize or avoid the cold ischemic insult and is particularly beneficial for DCD and ECD kidneys. The mechanistic effect of *ex vivo* NMP has not yet been thoroughly investigated. Nonetheless, in addition to replenishing ATP, studies have shown that repair mechanisms are up regulated during NMP. The expression of heat shock protein 70 has been shown to increase after NMP, which ensures effective recovery and prevents oxidative damage (Hosgood 2013). On the contrary, the act of rewarming may aggravate inflammatory processes and increase graft injury. Proinflammatory cytokines, such as IL-6, are upregulated in response to ischemic injury and were released in the kidney during reperfusion after NMP (Hosgood 2013). However, IL-6 can also have anti-inflammatory properties and is capable of resolving the tissue damage after its initial inflammatory response (Nechemia-Arbely 2008).

Ex vivo NMP can be used throughout the preservation interval or for shorter periods. The most practical approach is to combine normothermic and hypothermic techniques. Subsequently, 1- or 2-hour periods of NMP have been performed to restore function and replenish ATP after warm and cold ischemic injury in porcine kidneys (Bagul 2008; Hosgood 2013; Hosgood 2011). The kidneys had less tubular injury, improved blood flow and oxygenation and were metabolically more stable than the cold stored kidneys. In 2011, Hosgood et al. reported the first case of successful kidney transplantation in man after the organ was cold stored for 11 hours, followed by 35 min of *ex vivo* NMP. The 55-year old recipient had slow graft function, but the patient remained dialysis independent (Hosgood 2011). A pilot clinical study compared 18 ECD kidneys that received 1 hour of pre-implantation blood-based NMP with 47 matched SCS controls. Significantly lower DGF rates were observed with pre-implantation NMP (5.6% vs. 36.2%, $p = 0.014$) (Nicholson 2013).

Since DCD and ECD organs poorly tolerate the effects of hypothermia in SCS, a more novel approach of NMP totally avoids storage in hypothermic conditions. A study by Kaths et al. demonstrated that NMP with an erythrocyte-based solution could replace hypothermic storage techniques and thus avoid its harmful effects. NMP kidneys showed similar serum creatinine levels and creatinine clearance post-transplant compared to SCS grafts. After 10 days follow-up, NMP animals had serum creatinine and blood urea nitrogen values comparable to basal levels, whereas SCS grafts showed elevated values (Kaths 2016). Recently, Hosgood et al. reported the successful transplantation of a pair of human kidneys that were deemed unsuitable for transplantation due to inadequate perfusion, but subsequently transplanted after perfusion and assessment using *ex vivo* NMP (Hosgood 2016).

Preservation Solution

Continuous perfusion with an oxygenated solution to support aerobic metabolism is key under normothermic conditions. During NMP the perfusate can be based on either a natural oxygen carrier such as blood or an artificial-based medium. Early preservation solutions consisted of diluted blood and Ringers lactate solution. From 1985 until 1993 Collins or

Euro-Collins solution was the common used solution, and from 1993 onwards this shifted to UW, which is still the gold standard for abdominal organ preservation today (Wight 2003).

Brasile et al. were the first to develop an acellular normothermic solution based on perfluorocarbon (PFC) emulsion and enriched tissue culture-like medium containing essential and non-essential amino acids, lipids and carbohydrates (Brasile 1994). PFCs are inert solutions that have a high capacity for dissolving oxygen. New, more stable, PFCs are now being developed mainly as blood substitutes. Humphreys et al. recently used a commercially made PFC to provide oxygenation and reduce ischemic injury to the kidney during warm ischemia by retrograde infusion through the urinary system (Humphreys 2006). These new generation PFCs could potentially be developed as normothermic preservation solutions. However, due to complexity of manufacturing they are very expensive. A more stable pyridoxalated haemoglobin polyoxyethylene (PHP) solution has proven to be more successful and Brasile et al. have since replaced the PFC with this solution (Stubenitsky 2000). Other solutions such as Lifor (an artificial preservation medium containing a non-protein oxygen carrier, nutrients and a growth factors) have also been used during NMP. Some studies have shown higher flow rates in Lifor perfused kidneys compared to UW (Gage 2009; Olschewski 2010). The most newly reported acellular solution is Hemarina-M101, extracellular hemoglobin derived from a marine invertebrate. It has been formulated into an oxygen carrier mainly as a blood substitute. M101 has been used in SCS to deliver oxygen with favorable results and functions over a wide range of temperatures (4−37°C) (Thuillier 2011).

A blood-based solution during NMP was previously considered to have their limitations because of hemolysis, platelet activation, detoriation in the oxygen-carrying capacity of red blood cells, high intra-renal resistance and tissue edema (Thiara 2007). However, much has been learnt and they provide a more natural environment for the kidney compared with artificial-based solutions. The early results of an isolated perfusion system that perfused kidneys with one unit of compatible packed red blood cells mixed with a similar priming solution with added protective agents are promising. In a series of 18 ECD kidneys DGF was 5.6% compared to 36% in similarly matched recipients of a kidney undergoing SCS (Nicholson 2013). The exact composition of the perfusion solution will be subject to investigation.

Viability Assessment

In contrast to HMP, kidney function can be evaluated during NMP by assessing macroscopic appearance of blood perfusion, renal blood flow and urine output. Recently, Hosgood et al. used ex vivo NMP to develop a novel scoring system for pre-transplant assessment of marginal kidneys (Table 2) (Hosgood 2015). Based on assessment scores from their clinical series, it became clear that kidneys with a score of 1 to 4 could be transplanted successfully. Kidneys with a score of 5 would be considered very high-risk and unlikely to be suitable for transplantation. In their study on 36 kidneys, grafts with an assessment score of 3 had a significantly higher incidence of DGF (38%) compared to kidneys with a score of 1 (6%) or 2 (0%) ($p = 0.024$).

Table 2. *Ex vivo* normothermic perfusion assessment score (Hosgood 2015)

	Score
Macroscopic assessment	
Grade I: excellent perfusion (global pink appearance)	1
Grade II: moderate perfusion (patchy appearance)	2
Grade III: poor perfusion (global mottled and purple/black appearance)	3
Renal blood flow (ml per min per 100g)	
Threshold ≥ 50	0
Threshold <50	1
Total urine output	
Threshold ≥ 43	0
Threshold <43	1

Therapies

Preventing I/R injury is an ultimate goal for researchers and extensive research is currently carried out to find ways of preventing ischemic injury and improving renal function during machine perfusion. NMP also provides the opportunity to add therapies to a functioning organ to directly manipulate and improve its condition. One way of achieving this is through recently developed gene therapies. During NMP, genes are administered with a viral, non-viral or cell based vector. RNA interference uses small interfering RNA (siRNA) to modulate and protect the kidney. A study by Zheng et al. observed reduced levels of blood urea nitrogen, serum creatinine, cell apoptosis, histological changes and expression of proinflammatory cytokines after administration of a siRNA solution. They also reported prolonged graft survival compared to control groups (Zheng 2016). Gene silencing through siRNA injection can be of great potential in clinical organ transplantation.

The administration of gaseous molecules, such as nitric oxide in the form of soluble carbon monoxide-releasing molecules enhances renal blood flow and has been shown to be protective against reperfusion injury in porcine kidneys (Hosgood 2008). Over the last decade, mesenchymal stem cell therapy (MSC) has emerged as a potential therapeutic strategy. The ability of stem cells to differentiate and self-renew make them ideally suited for cellular therapy. Not everything is known about the mechanism of MSC therapy, but most likely the paracrine effect of the secreted growth factor re-established kidney tissue leading to clinical improvement (Wang 2013). Vascular endothelial growth factor was a critical factor in MSCs induced renoprotection in a rat model of ischemia-reperfusion injury (Tögel 2005). To date, the mechanism of MSC is understood as follows: therapeutic infusion of MSCs into an impaired kidney with existing host cells; engraftment and differentiation of MSCs into the host tissue or organ, followed by release of paracrine and/or endocrine signals. NMP can facilitate MSC delivery directly to the kidney. MSCs have appeared to stimulate renal recovery through engraftment and differentiation into renal cells among several kinds of acute kidney diseases (Wang 2013). These constantly developing therapies provide enormous scope in the treatment of reperfusion injury, rejection or to prolong graft survival.

CONCLUSION

The IPK model is an effective tool to study renal drug disposition. When the experimental design is appropriate and the results are sensibly interpreted, it can be utilized as an important experimental tool in the study of renal physiology and pathophysiology. More recently, kidney machine perfusion has emerged as a successful method for organ preservation before transplantation. Hypothermic, normothermic and sub-normothermic machine perfusion preservations are all potential methods to increase the exsisting donor pool. The ability to recover marginal kidneys can be particularly beneficial.

CONFLICT OF INTEREST

The authors of this chapter have no conflicts of interest to declare with any machine perfusion device.

REFERENCES

Ajavon AD, Bonate PL, & Taft DR. Renal excretion of clofarabine: assessment of dose-linearity and role of renal transport systems on drug excretion. *Eur. J. Pharm. Sci.* 2010; *40*(3): 209–16.

Arnaud-Batista FJ, Costa GT, Oliveira IMB, de Costa PPC, Santos CF, Fonteles MC, Uchôa DE, Silveira ER, Cardi BA, Carvalho KM, Amaral LS, Pôças ES C, Quintas LEM, Noël F, & Nascimento NRF. Natriuretic effect of bufalin in isolated rat kidneys involves activation of the Na+-K+-ATPase-Src kinase pathway. *Am. J. Physiol. Renal. Physiol.* 2012; *302*(8): F959-66.

Awe SO, & Adeagbo ASO. Vascular alpha1-adrenoceptors in isolated perfused rat kidney: influence of ageing. *Auton. Autacoid. Pharmacol.* 2007; *27*(1): 19–26.

Bagul A, Hosgood SA, Kaushik M, Kay MD, Waller HL, & Nicholson ML. Experimental renal preservation by normothermic resuscitation perfusion with autologous blood. *Br. J. Surg.* 2008; *95*(1): 111–8.

Babayeva M, Cox S, White MP, & Taft DR. Renal excretion of apricitabine in rats: ex vivo and in vivo studies. *Eur. J. Drug Metab. and Pharmacokinet.* 2011; *36*(3): 141–50.

Bekersky I. Use of the isolated perfused kidney as a tool in drug disposition studies. *Drug Metab. Rev.* 1983; *14*(5): 931–60.

Bekersky I, & Colburn WA. Acetylation of sulfisoxazole by isolated perfused rat kidney. *J. Pharm. Sci.* 1980; *69*(11): 1359.

Bekersky I, Colburn WA, Fishman L, & Kaplan SA. Metabolism of salicylic acid in the isolated perfused rat kidney. Interconversion of salicyluric and salicyclic acids. *Drug Metab. Dispos.* 1980; *8*(5):319–24.

Bekersky I, & Popick AC. Disposition of bumetanide in the isolated perfused rat kidney: effects of probenecid and dose response. *Am. J. Cardiol.* 1986; *57*(2): 33A–37A.

Bekersky I, Popick AC, & Colburn WA. Gentamicin-specific antiserum alters the disposition of gentamicin by the isolated perfused rat kidney. *J. Lab. Clin. Med.* 1983; *102*(2): 205–12.

Bekersky I, Popick AC, & Colburn WA. Influence of protein binding and metabolic interconversion on the disposition of sulfisoxazole and its N4-acetyl metabolite by the isolated perfused rat kidney. *Drug Metab. Dispos.* 1984; *12*(5): 607–13.

Bekersky I, Poynor WJ, & Colburn WA. Pharmacokinetics of saccharin in the rat. Renal clearance in vivo and in the isolated perfused kidney. *Drug Metab. Dispos.* 1980; *8*(2): 64–7.

Belzer FO, Ashby BS, & Dunphy JE. 24-hour and 72-hour preservation of canine kidneys. *Lancet.* 1967; *2*(7515): 536–8.

Belzer FO, & Southard JH. The future of kidney preservation. *Transplantation* 1980; *30*(3): 161–5.

Bessems M, Doorschodt BM, van Marle J, Vreeling H, Meijer AJ, & van Gulik TM. Improved machine perfusion preservation of the non-heart-beating donor rat liver using Polysol: a new machine perfusion preservation solution. *Liver Transpl.* 2005; *11*(11): 1379–88.

Boom SP, Moons MM, & Russel FG. Renal tubular transport of cimetidine in the isolated perfused kidney of the rat. *Drug Metabolism Dispos.* 1994; *22*(1): 148–53.

Bowman RH. The perfused rat kidney. *Methods Enzymol.* 1975; *39*: 3–11.

Brasile L, DelVecchio P, Amyot K, Haisch C, & Clarke J. Organ preservation without extreme hypothermia using an Oxygen supplemented perfusate. *Artif. Cell Blood Substit Immob. Biotechnol.* 1994; *22*(4): 1463–8.

Buchs J-B, Lazeyras F, Ruttimann R, Nastasi A, & Morel P. Oxygenated hypothermic pulsatile perfusion versus cold static storage for kidneys from non heart-beating donors tested by in-line ATP resynthesis to establish a strategy of preservation. *Perfusion* 2011; *26*(2): 159–65.

Catena F, Coccolini F, Montori G, Vallicelli C, Amaduzzi A, Ercolani G, Ravaioli M, Del Gaudio M, Schiavina R, Brunocilla E, Liviano G, Feliciangeli G, & Pinna AD. Kidney preservation: review of present and future perspective. *Transplant. Proc.* 2013; *45*(9): 3170–7.

Chang HH, Choong B, Phillips A, & Loomes KM. Isolated perfused rat kidney: a technical update. *Exp. Anim.* 2013; *62*(1): 19–23.

Ciancio G, Gaynor JJ, Sageshima J, Chen L, Roth D, Kupin W, Guerra G, Tueros L, Zarak A, Hanson L, Ganz S, Ruiz P, O'Neill WW, Livingstone AS, & Burke GW. Favorable outcomes with machine perfusion and longer pump times in kidney transplantation: a single-center, observational study. *Transplantation* 2010; *90*(8): 882–90.

Ciancio G, Gaynor JJ, Sageshima J, Roth D, Kupin W, Guerra G, Tueros L, Zarak A, Hanson L, Ganz S, Chen L, Ruiz P, Livingstone AS, & Burke GW. Machine perfusion following static cold storage preservation in kidney transplantation: donor-matched pair analysis of the prognostic impact of longer pump time. *Transpl. Int.* 2012; *25*(1): 34–40.

Codas R, Petruzzo P, Morelon E, Lefrançois N, Danjou F, Berthillot C, Contu P, Espa M, Martin X, & Badet, L. IGL-1 solution in kidney transplantation: first multi-center study. *Clin. Transplant.* 209; *23*(3):337–42.

Cohen JA, Brecher ME, & Bandarenko N. Cellular source of serum lactate dehydrogenase elevation in patients with thrombotic thrombocytopenic purpura. *J. Clin. Apher.* 1998; *13*(1): 16–9.

Cox PG, Moons WM, Russel FG, & van Ginneken CA. Renal disposition and effects of naproxen and its l-enantiomer in the isolated perfused rat kidney. *J. Pharmacol. Exp. Ther.* 1990; *255*(2): 491–6.

Daemen JW, Oomen AP, Janssen MA, van de Schoot L, van Kreel BK, Heineman E, & Kootstra G. Glutathione S-transferase as predictor of functional outcome in transplantation of machine-preserved non-heart-beating donor kidneys. *Transplantation* 1997; *63*(1): 89–93.

de Vries B, Snoeijs MGJ, von Bonsdorff L, Ernest van Heurn LW, Parkkinen J, & Buurman, WA. Redox-active iron released during machine perfusion predicts viability of ischemically injured deceased donor kidneys. *Am. J. Transplant.* 2006; *6*(11):2686–93.

de Vries B, Walter SJ, von Bonsdorff L, Wolfs TGAM, van Heurn LWE, Parkkinen J, & Buurman WA. Reduction of circulating redox-active iron by apotransferrin protects against renal ischemia-reperfusion injury. *Transplantation* 2004; *77*(5): 669–75.

El-Gowilly SM. Metoprolol ameliorates cyclosporine a-induced hypertension and nephrotoxicity in rats. *J. Cardiol. Pharmacol.* 2011; *58*(6): 639–46.

Engbersen R, Masereeuw R, van Gestel MA, Siero HLM, Moons MM, Smits P, & Russel FGM. Differential effects of sulfonylurea derivatives on vascular ATP-sensitive potassium channels. *Eur. J. Pharmacol.* 2012; *681*(1–3):75–9.

Fonseca-Magalhães PA, Sousa DF, de Siqueira RJB, Jorge RJB, Meneses GC, Alves RS, Monteiro HSA, Magalhães PJC, & Martins AMC. Inhibitory effects of sertraline in rat isolated perfused kidneys and in isolated ring preparations of rat arteries. *J. Pharm. Pharmacol.* 2011; *63*(9):1186–94.

Gage F, Leeser DB, Porterfield NK, Graybill JC, Gillern S, Hawksworth JS, Jindal RM, Thai N, Falta EM, Tadaki DK, Brown TS, & Elster EA. Room temperature pulsatile perfusion of renal allografts with Lifor compared with hypothermic machine pump solution. *Transplant. Proc.* 2009; *41*(9): 3571–4.

Gill J, Dong J, Eng M, Landsberg D, & Gill JS. Pulsatile perfusion reduces the risk of delayed graft function in deceased donor kidney transplants, irrespective of donor type and cold ischemic time. *Transplantation* 2014; *97*(6): 668–74.

Guarrera JV, Goldstein MJ, Samstein B, Henry S, Reverte C, Arrington B, Brown T, Coleman TK, Mattei G, Mendez N, Kelly J, & Ratner LE. "When good kidneys pump badly": outcomes of deceased donor renal allografts with poor pulsatile perfusion characteristics. *Transpl. Int.* 2010; *23*(4): 444–6.

Guy AJ, Nath J, Cobbold M, Ludwig C, Tennant DA, Inston NG, & Ready AR. Metabolomic analysis of perfusate during hypothermic machine perfusion of human cadaveric kidneys. *Transplantation* 2015; *99*(4): 754–9.

Hoogland ERP, de Vries EE, Christiaans MHL, Winkens B, Snoeijs MGJ, & van Heurn LWE. The value of machine perfusion biomarker concentration in DCD kidney transplantations. *Transplantation* 2013; *95*(4): 603–10.

Hosgood SA, Bagul A, Kaushik M, Rimoldi J, Gadepalli RS, & Nicholson ML. Application of nitric oxide and carbon monoxide in a model of renal preservation. *Br. J. Surg.* 2008; *95*(8): 1060–7.

Hosgood SA, Barlow AD, Hunter JP, & Nicholson ML. Ex vivo normothermic perfusion for quality assessment of marginal donor kidney transplants. *Br. J. Surg.* 2015; *102*(11):1433–40.

Hosgood SA, Barlow AD, Yates PJ, Snoeijs MGJ, van Heurn ELW, & Nicholson MLA pilot study assessing the feasibility of a short period of normothermic preservation in an experimental model of non heart beating donor kidneys. *J. Surg. Res.* 2011; *171*(1): 283–90.

Hosgood SA, Mohamed IH, Bagul A, & Nicholson ML. Hypothermic machine perfusion after static cold storage does not improve the preservation condition in an experimental porcine kidney model. *Br. J. Surg.* 2011; *98*(7):943–50.

Hosgood SA, & Nicholson ML. First in man renal transplantation after ex vivo normothermic perfusion. *Transplantation* 2011; *92*(7): 735–8.

Hosgood SA, Patel M, & Nicholson ML. The conditioning effect of ex vivo normothermic perfusion in an experimental kidney model. *J. Surg. Res.* 2013; *182*(1):153–60.

Hosgood SA, Saeb-Parsy K, Hamed MO, & Nicholson ML. Successful Transplantation of Human Kidneys Deemed Untransplantable but Resuscitated by Ex Vivo Normothermic Machine Perfusion. *Am. J. Transplant.* 2016; 16(11): 3282–3285.

Hoyer DP, Gallinat A, Swoboda S, Wohlschlaeger J, Rauen U, Paul A, & Minor T. Influence of oxygen concentration during hypothermic machine perfusion on porcine kidneys from donation after circulatory death. *Transplantation* 2014; *98*(9): 944–50.

Hoyer DP, Gallinat A, Swoboda S, Wohlschläger J, Rauen U, Paul A, & Minor T. Subnormothermic machine perfusion for preservation of porcine kidneys in a donation after circulatory death model. *Transp Int.* 2014; *27*(10): 1097–106.

Hoyer DP, Mathé Z, Gallinat A, Canbay AC, Treckmann JW, Rauen U, Paul A, & Minor T. Controlled Oxygenated Rewarming of Cold Stored Livers Prior to Transplantation: First Clinical Application of a New Concept. *Transplantation* 2016; *100*(1): 147–52.

Hoyer DP, Paul A, Luer S, Reis H, Efferz P, & Minor T. End-ischemic reconditioning of liver allografts: Controlling the rewarming. *Liver Transpl.* 2016; *22*(9): 1223–30.

Humphreys MR, Ereth MH, Sebo TJ, Slezak JM, Dong Y, Blute ML, & Gettman MT. Can the kidney function as a lung? Systemic oxygenation and renal preservation during retrograde perfusion of the ischaemic kidney in rabbits. *BJU Int.* 2006; *98*(3): 674–9.

Jassem W, & Heaton ND. The role of mitochondria in ischemia/reperfusion injury in organ transplantation. *Kidney Int.* 2004; *66*(2):514–7.

Jochmans I, Akhtar MZ, Nasralla D, Kocabayoglu P, Boffa C, Kaisar M, Brat A, O'Callaghan J, Pengel LHM, Knight S, & Ploeg R. Past, present and future of dynamic kidney and liver preservation and resuscitation. *Am. J. Transplant.* 2016; 16(9): 2545–2555.

Jochmans I, Moers C, Smits JM, Leuvenink HGD, Treckmann J, Paul A, Rahmel A, Squifflet JP, van Heurn E, Monbaliu D, Ploeg RJ, & Pirenne J. Machine perfusion versus cold storage for the preservation of kidneys donated after cardiac death: a multicenter, randomized, controlled trial. *Ann. Surg.* 2010; *252*(5): 756–764.

Jochmans I, Moers C, Smits JM, Leuvenink HGD, Treckmann J, Paul A, Rahmel A, Squifflet JP, van Heurn E, Monbaliu D, Ploeg RJ, & Pirenne J. The prognostic value of renal resistance during hypothermic machine perfusion of deceased donor kidneys. *Am. J. Transplant.* 2011; *11*(10):2214–20.

Jochmans I, O'Callaghan JM, Pirenne J, & Ploeg RJ. Hypothermic machine perfusion of kidneys retrieved from standard and high-risk donors. *Transpl. Int.* 2015; *28*(6): 665–676.

Kaths JM, Echeverri J, Goldaracena N, Louis KS, Chun YM, Linares I, Wiebe A, Foltys DB, Yip PM, John R, Mucsi I, Ghanekar A, Bagli DJ, Grant DR, Robinson LA, & Selzner M. Eight-Hour Continuous Normothermic Ex Vivo Kidney Perfusion Is a Safe Preservation Technique for Kidney Transplantation: A New Opportunity for the Storage, Assessment, and Repair of Kidney Grafts. *Transplantation* 2016; *100*(9): 1862–70.

Katayama H, Yasuhara M, & Hori R. Effect of acute renal failure on the disposition of cefoperazone. *J. Pharm. Pharmacol.* 1999; *51*(3): 361–6.

Kay MD, Hosgood SA, Bagul A, & Nicholson ML. Comparison of preservation solutions in an experimental model of organ cooling in kidney transplantation. *Br. J. Surg.* 2009; *96*(10), 1215–21.

Kievit JK, Nederstigt AP, Oomen AP, Janssen MA, Schoot L, & Kootstra G. Release of alpha-glutathione S-transferase (alpha GST) and pi-glutathione S-transferase (pi GST) from ischemic damaged kidneys into the machine perfusate--relevance to viability assessment. *Transplant. Proc.* 1997; *29*(8):3591–3.

Kievit JK, Oomen AP, Janssen MA, van Kreel BK, Heineman E, & Kootstra G. Viability assessment of non-heart-beating donor kidneys by alpha glutathione S-transferase in the machine perfusate. *Transplant. Proc.* 1997; *29*(1–2): 1381–3.

Kozaki K, Sakurai E, Kubota K, Iwamoto H, Hama K, Narumi Y, Uchiyama M, Kikuchi K, Degawa H, Matsuno N, Kozaki M, & Nagao T. Prediction of kidney nonfunction after transplantation with machine perfusion preservation. *Transplantat. Proc.* 2000; *32*(2): 275–6.

Kron P, Schlegel A, de Rougemont O, Oberkofler CE, Clavien PA, & Dutkowski P. Short Cool, and Well Oxygenated - HOPE for Kidney Transplantation in a Rodent Model. *Ann. Surg.* 2016; 264:815–822.

Kugler AR, Olson SC, & Smith DE. Disposition of quinapril and quinaprilat in the isolated perfused rat kidney. *J. Pharmacokinet Biopharm.* 1995; *23*(3): 287–305.

Lohr J, & Acara M. Effect of dimethylaminoethanol, an inhibitor of betaine production, on the disposition of choline in the rat kidney. *J. Pharmacol. Exp. Ther.* 1990; *252*(1):154–8

Maack T. Renal clearance and isolated kidney perfusion techniques. *Kidney Int.* 1986; *30*(2): 142–51.

Mahboub P, Ottens P, Seelen M, 't Hart N, t Hart N, Van Goor H, Ploeg R, Martins PN, Martins P, & Leuvenink H. Gradual Rewarming with Gradual Increase in Pressure during Machine Perfusion after Cold Static Preservation Reduces Kidney Ischemia Reperfusion Injury. *PloS One*. 2015; *10*(12): e0143859.

Masereeuw R, Moons WM, & Russel FG. Saturable accumulation and diuretic activity of hydrochlorothiazide in the isolated perfused rat kidney. *Pharmacol.* 1997; *54*(1): 33–42.

Matsuno N, Konno O, Mejit A, Jyojima Y, Akashi I, Nakamura Y, Iwamoto H, Hama K, Iwahori T, Ashizawa T, & Nagao T. Application of machine perfusion preservation as a viability test for marginal kidney graft. *Transplantation* 2006; *82*(11): 1425–8.

Minor T, Efferz P, Fox M, Wohlschlaeger J, & Lüer B. Controlled oxygenated rewarming of cold stored liver grafts by thermally graduated machine perfusion prior to reperfusion. *Am. J. Transplant.* 2013; *13*(6):1450–60.

Minor, T., Paul, A., Efferz, P., Wohlschlaeger, J., Rauen, U., & Gallinat, A. Kidney transplantation after oxygenated machine perfusion preservation with Custodiol-N solution. *Transpl. Int.* 2015; *28*(9): 1102–8.

Moers C, Smits JM, Maathuis MHJ, Treckmann J, van Gelder F, Napieralski BP, van Kasterop-Kutz M, van der Heide JJH, Squifflet JP, van Heurn E, Kirste GR, Rahmel A, Leuvenink HGD, Paul A, Pirenne J, & Ploeg RJ. Machine perfusion or cold storage in deceased-donor kidney transplantation. *N. Engl. J. Med.* 2009; *360*(1): 7–19.

Mozes MF, Skolek RB, & Korf BC. Use of perfusion parameters in predicting outcomes of machine-preserved kidneys. *Transplan Proc.* 2005; *37*(1): 350–1.

Nechemia-Arbely Y, Barkan D, Pizov G, Shriki A, Rose-John S, Galun E, & Axelrod JH. IL-6/IL-6R axis plays a critical role in acute kidney injury. *J. Am. Soc. Nephrol.* 2008; *19*(6): 1106–15.

Nicholson ML, & Hosgood SA. Renal transplantation after ex vivo normothermic perfusion: the first clinical study. *Am. J. Transplant.* 2013; *13*(5): 1246–52.

Olschewski P, Gass P, Ariyakhagorn V, Jasse K, Hunold G, Menzel M, Schöning W, Schmitz V, Neuhaus P, & Puhl G. The influence of storage temperature during machine perfusion on preservation quality of marginal donor livers. *Cryobiology*. 2010; *60*(3): 337–43.

Parikh CR, Hall IE, Bhangoo RS, Ficek J, Abt PL, Thiessen-Philbrook H, Lin H, Bimali M, Murray PT, Rao V, Schröppel B, Doshi MD, Weng FL, & Reese PP. Associations of perfusate biomarkers and pump parameters with delayed graft function and deceased-donor kidney allograft function. *Am. J. Transplant.* 2015

Parikh CR, Hall IE, Bhangoo RS, Ficek J, Abt PL, Thiessen-Philbrook H, Lin H, Bimali M, Murray PT, Rao V, Schröppel B, Doshi MD, Weng FL, & Reese PP. Associations of Perfusate Biomarkers and Pump Parameters With Delayed Graft Function and Deceased Donor Kidney Allograft Function. *Am. J. Transplant.* 2016; *16*(5): 1526–39.

Patel SK, Pankewycz OG, Nader ND, Zachariah M, Kohli R, & Laftavi MR. Prognostic utility of hypothermic machine perfusion in deceased donor renal transplantation. *Transplantat. Proc.* 2012; *44*(7): 2207–12.

Ploeg RJ, van Bockel JH, Langendijk PT, Groenewegen M, van der Woude FJ, Persijn GG, Thorogood J, & Hermans J. Effect of preservation solution on results of cadaveric kidney transplantation. The European Multicentre Study Group. *Lancet* 1992; *340*(8812):129–37.

Poola NR, Kalis M, Plakogiannis FM, & Taft DR. Characterization of pentamidine excretion in the isolated perfused rat kidney. *The J. Antimicrob. Chemother.* 2003; *52*(3): 397–404.

Rauen U, & de Groot H. New insights into the cellular and molecular mechanisms of cold storage injury. *J. Investig. Med.* 2004; *52*(5): 299–309.

Redegeld FA, Hofman GA, van de Loo PG, Koster AS, & Noordhoek J. Nephrotoxicity of the glutathione conjugate of menadione (2-methyl-1, 4-naphthoquinone) in the isolated perfused rat kidney. Role of metabolism by gamma-glutamyltranspeptidase and probenecid-sensitive transport. *J. Pharmacol. Exp. Ther.* 1991; *256*(2): 665–9.

Rocci ML, Szefler SJ, Acara M, & Jusko WJ. Prednisolone metabolism and excretion in the isolated perfused rat kidney. *Drug Metab. Dispos.* 1981; *9*(3): 177–82.

Savant IA, Kalis M, Almoazen H, Ortiz SR, AbuTarif M, & Taft DR. Alternative high-performance liquid chromatographic assay for p-aminohippuric acid (PAH): effect of aging on PAH excretion in the isolated perfused rat kidney. *J. Pharm. Biomed. Anal.* 2001; *26*(5–6), 687–99.

Schopp I, Reissberg E, Lüer B, Efferz P, & Minor T. Controlled Rewarming after Hypothermia: Adding a New Principle to Renal Preservation. *Clin. Trans. Sci.* 2015; *8*(5): 475–8.

Schreinemachers MCJM, Doorschodt BM, Florquin S, Idu MM, Tolba RH, & van Gulik T. M. Improved renal function of warm ischemically damaged kidneys using Polysol. *Transplant. Proc.* 2009; *41*(1): 32–5.

Shanahan KM, Evans AM, & Nation RL. Disposition of morphine in the rat isolated perfused kidney: concentration ranging studies. *J. Pharmacol. Exp. Ther*. 1997; (3): 1518–25.

Somogyi AA, Hovens CM, Muirhead MR, & Bochner F. Renal tubular secretion of amiloride and its inhibition by cimetidine in humans and in an animal model. *Drug Metabolism Dispos.* 1989; *17*(2): 190–6.

Statkevich P, Fournier DJ, & Sweeney KR. Characterization of methotrexate elimination and interaction with indomethacin and flurbiprofen in the isolated perfused rat kidney. *J. Pharmacol. Exp. Ther.* 1993; *265*(3): 1118–24.

Stegemann J, Hirner A, Rauen U, & Minor T. Use of a new modified HTK solution for machine preservation of marginal liver grafts. *J. Surg. Res.* 2010; *160*(1): 155–62.

Stubenitsky BM, Booster MH, Brasile L, Araneda D, Haisch CE, & Kootstra G. Exsanguinous metabolic support perfusion−a new strategy to improve graft function after kidney transplantation. *Transplantation* 2000; *70*(8): 1254–8.

Sung RS, Christensen LL, Leichtman AB, Greenstein SM, Distant DA, Wynn JJ, Stegall MD., Delmonico FL, & Port FK. Determinants of discard of expanded criteria donor kidneys: impact of biopsy and machine perfusion. *Am. J. Transplant.* 2008; *8*(4):783–92.

Taft DR. The isolated perfused rat kidney model: a useful tool for drug discovery and development. *Curr. Drug Disco.c Technol.* 2004; *1*(1): 97–111.

Taft DR, Dontabhaktuni A, Babayeva M, Nakatani-Freshwater T, & Savant I. A. Application of the isolated perfused rat kidney model to assess gender effects on drug excretion. *Drug Dev. Ind. Pharm.* 2006; *32*(8): 919–28.

Tamhane M, Chakilam AR, Jayaraj A, Thakkar V, & Taft DR. Comparative renal excretion of VX-702, a novel p38 MAPK inhibitor, and methotrexate in the perfused rat kidney model. *Drug Dev. Ind. Pharm.* 2010; *36*(3): 315–22.

Thiara APS, Hoel TN, Kristiansen F, Karlsen HM, Fiane AE, & Svennevig JL. Evaluation of oxygenators and centrifugal pumps for long-term pediatric extracorporeal membrane oxygenation. *Perfusion* 2007; *22*(5): 323–6.

Thuillier R, Allain G, Celhay O, Hebrard W, Barrou B, Badet L, Leuvenink H, & Hauet T. Benefits of active oxygenation during hypothermic machine perfusion of kidneys in a preclinical model of deceased after cardiac death donors. *J. Surg. Res.* 2013; *184*(2): 1174–81.

Thuillier R, Dutheil D, Trieu MTN, Mallet V, Allain G, Rousselot M, Denizot M, Goujon JM, Zal, F., & Hauet T. Supplementation with a new therapeutic oxygen carrier reduces chronic fibrosis and organ dysfunction in kidney static preservation. *Am. J. Transplant.* 2011; *11*(9): 1845–60.

Tögel F, Hu Z, Weiss K, Isaac J, Lange C, & Westenfelder C. Administered mesenchymal stem cells protect against ischemic acute renal failure through differentiation-independent mechanisms. *Am. J. Physiol. Renal. Physiol.* 2005; *289*(1): F31-42.

Tozzi M, Franchin M, Soldini G, Ietto G, Chiappa C, Maritan E, Villa F, Carcano G, & Dionigi R. Impact of static cold storage VS hypothermic machine preservation on

ischemic kidney graft: inflammatory cytokines and adhesion molecules as markers of ischemia/reperfusion tissue damage. Our preliminary results. *Int. J. Surg.* 2013; *11 Suppl 1*: S110-4.

Treckmann J, Moers C, Smits JM, Gallinat A, Maathuis MHJ, van Kasterop-Kutz M, Jochmans I, Homan van der Heide JJ, Squifflet JP, van Heurn E, Kirste GR, Rahmel A, Leuvenink HGD, Pirenne J, Ploeg RJ, & Paul A. Machine perfusion versus cold storage for preservation of kidneys from expanded criteria donors after brain death. *Transp Int.* 2011; *24*(6): 548–54.

Wang J, Nation RL, Evans AM, & Cox S. Isolated rat kidney perfused with dextran and bovine serum albumin: a stable model for investigating renal drug handling. *J. Pharmacol. Toxicol. Methods.* 2004; *49*(2): 105–13.

Wang Y, He J, Pei X, & Zhao W. Systematic review and meta-analysis of mesenchymal stem/stromal cells therapy for impaired renal function in small animal models. *Nephrology* 2013; *18*(3): 201–8.

Wang J, Evans A. M, Knights KM, & Miners JO. Differential disposition of intra-renal generated and preformed glucuronides: studies with 4-methylumbelliferone and 4-methylumbelliferyl glucuronide in the filtering and nonfiltering isolated perfused rat kidney. *J. Pharm. Pharmacol.* 2011; *63*(4): 507–14.

Watson CJE, Wells AC, Roberts RJ, Akoh JA, Friend PJ, Akyol M, Calder FR, Allen JE, Jones MN, Collett D, & Bradley JA. Cold machine perfusion versus static cold storage of kidneys donated after cardiac death: a UK multicenter randomized controlled trial. *Am J. Transplant.* 2010; *10*(9): 1991–9.

Wight JP, Chilcott JB, Holmes MW, & Brewer N. Pulsatile machine perfusion vs. cold storage of kidneys for transplantation: a rapid and systematic review. *Clin. Transplant.* 2003; *17*(4): 293–307.

Wszola M, Kwiatkowski A, Diuwe P, Domagała P, Górski L, Kieszek R, Berman A, Perkowska-Ptasińska A, Durlik M, Pączek L, & Chmura A. One-year results of a prospective, randomized trial comparing two machine perfusion devices used for kidney preservation. *Transp Int.* 2013; *26*(11): 1088–96.

Wszola M, Kwiatkowski A, Domagala P, Wirkowska A, Bieniasz M, Diuwe P, Rafał K, Durlik M, & Chmura A. Preservation of kidneys by machine perfusion influences gene expression and may limit ischemia/reperfusion injury. *Prog. Transplant.* 2014; *24*(1): 19–26.

Zarzuelo A, Lanao JM, López FG, & Sánchez-Navarro A. Influence of the infusion rate on disposition of netilmicin in the isolated rat perfused kidney. *Eur. J. Pharm. Sci.* 2002; *16*(3), 133–41.

Zhang Y, Fu Z, Zhong Z, Wang R, Hu L, Xiong Y, Wang Y, & Ye Q. Hypothermic Machine Perfusion Decreases Renal Cell Apoptosis During Ischemia/Reperfusion Injury via the Ezrin/AKT Pathway. *Artif. Organs* 2016; *40*(2): 129–35.

Zheng X, Zang G, Jiang J, He W, Johnston NJ, Ling H, Chen R, Zhang X, Liu Y, Haig A, Luke P, Jevnikar AM, & Min WP. Attenuating Ischemia-Reperfusion Injury in Kidney Transplantation by Perfusing Donor Organs With siRNA Cocktail Solution. *Transplantation* 2016; *100*(4): 743–52.

In: Encyclopedia of Surgery (22 Volume Set)
Editors: Andreas Lehrer and Kristin Mueller
ISBN: 978-1-53618-329-0
© 2020 Nova Science Publishers, Inc.

Chapter 213

ISOLATED LIVER PERFUSION SYSTEMS

Isabel Brüggenwirth[1,2], Hazel Marecki[2], MD and Paulo N. Martins[2,*], MD, PhD

[1]Surgical Research Laboratory, Department of Surgery,
University Medical Center Groningen, University of Groningen,
Groningen, The Netherlands
[2]Department of Surgery, Division of Organ Transplantation,
UMass Memorial Medical Center, Worcester, MA, US

ABSTRACT

The *ex-vivo* liver perfusion model was first described in the 1850s. Over the years isolated hepatic perfusion (IHP) has been used to investigate hepatobiliary function, toxicity due to drug-drug interactions, to treat malignancies, and as a potential method of organ preservation for transplantation. The liver is frequently targeted by primary cancer and is often affected by metastases from various malignancies. The unique hepatic vascular anatomy allows vascular isolation of the liver to deliver high doses of cytotoxic agents with minimal system toxicity. This way, hepatic metastases can be treated using the IHP technique. More recently, IHP emerged as a promising technique to increase the organ donor pool, particularly for livers retrieved from extended criteria donors (ECD) and donation after circulatory death (DCD) donors. Hypothermic machine perfusion (HMP) is currently the simplest approach of liver machine perfusion, and therefore with high practicability and relatively low costs. It is an attractive method to avoid further warm ischemic injury and minimize graft metabolic requirements, while providing oxygenation and metabolic support. Numerous ex vivo HMP experiments have been published in the last 2 decades and they demonstrated beneficial results compared to static cold storage (SCS). On the contrary, it has been hypothesized that a more gradual rewarming course may relieve the cold ischemic insult by employing a stepwise normalization of temperature and metabolic demand. Recent studies have shown promising effects of the new aspect of controlled oxygenated rewarming (COR). Normothermic machine perfusion (NMP) enables prolonged preservation without time-dependent damage that is caused by cold preservation, the ability of the organ to recover

* Corresponding Author's Email: paulo.martins@umassmemorial.org.

from injury, and the opportunity to measure the function of the organ during preservation in order to predict post-transplant outcomes. Following kidney preservation, liver machine perfusion is close to becoming standard clinical practice.

Keywords: isolated perfusion, malignancies, drug disposition, machine perfusion, DCD

ABBREVIATIONS

ADP	adenosine diphosphate
ALT	alanine aminotransferase
AST	aspartate aminotransferase
ATP	adenosine triphosphate
BCKA	branched-chain keto acids
COR	controlled oxygenated rewarming
CS	cold storage
CyA	cyclosporine A
DBD	donation after brain death
DCD	donation after circulatory death
DGF	delayed graft function
ECD	extended criteria donor
HAT	hepatic artery thrombosis
HMP	hypothermic machine perfusion
HOPE	hypothermic oxygenated machine perfusion
HTK	histidine-tryptophan-ketoglurate
I/R	ischemia-reperfusion
IGL	Institut George Lopez
IHP	isolated hepatic perfusion
ITBL	ischemic-type biliary lesions
IVC	inferior vena cava
KPS-1	kidney machine perfusion 1
LDH	lactate dehydrogenase
NMP	normothermic machine perfusion
PNF	primary non-function
PVP	peribiliary vascular plexus
SCS	static cold storage
SMP	subnormothermic machine perfusion
TNFα	tumor necrosis factor alpha
UW	University of Wisconsin
VAS	Vasosol

INTRODUCTION

In the 1850s, Claude Bernard was the first to describe an ex-vivo liver perfusion model. Shortly after, an isolated hepatic perfusion (IHP) model perfused with blood was used to

identify the role of the liver in synthesis of plasma proteins (Miller 1951). Over the years IHP has been used to investigate hepatobiliary function, toxicity due to drug-drug interactions, to treat malignancies, and as a potential method to preserve organs for transplantation.

A significant advantage of the IHP system is that hepatobiliary function can be assessed in the absence of extrahepatic factors, such as circulating hormones and changes in cardiovascular function. Furthermore, extrahepatic clearance of biomarkers is eliminated and experimental conditions are carefully controlled. By measuring influent and effluent concentrations of biomarker compounds infused into the portal vein as well as biliary concentrations, rates of hepatocellular uptake in addition to biliary excretion can be determined. In addition, accurate determinations of the rate of bile acid-dependent and -independent bile flow are possible in the isolated perfused liver (Chazouillères 1991). Since the IHP model avoids neural and hormonal interferences and excludes influences from absorption and non-hepatic elimination routes, it also provides a relatively clean hepatic system to study drug-drug interactions and pharmacokinetics.

The liver is frequently affected by cancer. Primary liver cancer is the sixth most common cancer in the world and also the third cause of cancer-related death. Surgical resection offers the best chance on long-term survival, but for 80% of patients with liver metastases this is not feasible due to the extent or location of the disease (Tzeng 2013). Liver malignancies have a dominant or exclusive vascular supply from the hepatic artery, whereas the majority of the blood supply of non-tumorous liver parenchyma is derived from the portal vein (Breedis 1954). The unique hepatic anatomy allows vascular isolation of the liver to deliver high doses of cytotoxic agents with minimal system toxicity. This way, various malignancies with metastases to the liver can be treated using the IHP technique. This section will describe the surgical procedure of IHP and an overview of malignancies treated with IHP.

Currently the fastest developing use of IHP is as a potential method to recover marginal organs for transplantation. Ever since Thomas Starz performed the first human liver transplant in 1963, liver transplantation is now fully established as the standard treatment for patients with end-stage liver failure. Since the early days of transplantation, static cold storage (SCS) (a bag inside an ice bucket) has been the standard preservation of organs. In the early era of transplantation there were attempts to preserve livers with machine perfusion. However, after the first unsuccessful attempts of hypothermic perfusion (HMP) of human livers, the clinical use and development of human liver perfusion devices did not move forward.

Unfortunately, the current disparity between supply and demand of liver grafts has dramatically increased the waiting time and mortality on patients in the waiting list. Consequently, there has been an increase in the use of marginal, or so-called extended criteria donor (ECD) grafts over the past decades. In particular, donation after circulatory death (DCD) liver grafts has become increasingly important as these grafts make up an increasing portion of the donor pool. DCD grafts are known to be more susceptible to ischemia-reperfusion (I/R) injury, leading to higher rates of delayed graft function (DGF), primary non-function (PNF) and biliary complications post-transplant (Pezzati 2015; Attia 2008). Biliary complications in DCD organs are a major source of morbidity, graft loss, and even mortality long-term after liver transplantation. They are much more common in DCD grafts compared to livers from brain dead donors (20–40% vs. 5% respectively). The most troublesome biliary complication is the ischemic-type biliary lesions (ITBL), also called ischemic cholangiopathy. The risk of ischemic cholangiopathy is 10 times higher in DCD donors compared to brain

dead donors (Jay 2011). Machine perfusion allows the opportunity to repair damage of warm ischemia and cold storage, reawaken liver metabolic function, and measure viability of a liver graft prior to transplantation. However, the simplicity and lower costs of traditional SCS have kept this method as the gold standard for transplantation centers today. Growing data supports the use of machine perfusion preservation, but the variability of systems, techniques, settings, and costs have interfered with standardization and global use. Many innovative approaches have been developed to improve the quality of preservation, assess the quality of the organ during preservation and even allow repair injury of the donor organ prior to transplantation. In this context, machine perfusion of the liver at various temperatures has emerged as a prominent method to achieve these goals. Characteristics of machine perfusion at different temperatures will be discussed later in this chapter.

PHARMACOKINETIC AND PHARMACODYNAMIC STUDIES USING THE ISOLATED HEPATIC PERFUSION

Hepatobiliary function is complex and numerous techniques have been developed to evaluate the hepatic physiology and effect of toxic substances on hepatobiliary function. In 1951, Miller et al. described an isolated perfused liver model to identify roles of the liver in synthesis of plasma proteins. It was not until the 1960s however, that this technique was applied to study metabolism and pharmacokinetics (Liu 2004). For decades researchers have studied cultured isolated cells, but it has become clear that the spatiotemporal organization of different cell types in a tissue requires studies using models of the intact organ or tissue. This applies particularly to the liver as the major organ of metabolic transformation and activity. A 3-hour perfusion period has usually been applied to study hepatic clearance and metabolism, but the perfused liver can be viable up to 8 hours. Based on the amounts of dose recovered in perfusate, bile, and liver, the drug distribution and mass balance can be accurately calculated. In addition, the IHP allows for plasma and bile samples to be easily collected for identification of metabolites (Liu 2004).

Many compounds are present in blood as a plasma protein bound form, but only the unbound fractions are believed to be taken up and cleared by the liver. The extent of plasma protein binding may have a major impact on the rate at which a compound is cleared from plasma and enters the hepatocytes. The IHP model provides an excellent tool to study the effect of plasma protein binding on hepatic uptake and clearance. Subsequently, a study showed that defenestration of the liver sinusoidal endothelium in old age results in reduced hepatic extraction of highly protein-bound drugs, like diazepam (Mitchell 2012). The difference in hepatic clearance and the presence and absence of plasma proteins simply determines the effect of plasma protein binding.

Drug Disposition Studies

The IHP has been extensively used as an intact organ model for determining hepatic clearance and drug metabolism. Since IHP avoids neural and hormonal interferences and excludes influences from absorption and non-hepatic elimination routes, it provides a

relatively clean hepatic system to study metabolism and pharmacokinetics. Table 1 provides an overview of drug disposition studies that have been done using the IHP model.

Table 1. Drug disposition studies using the isolated hepatic perfusion model

Researchers	Compound	Findings
Khezrian 2015	Etoposide and cyclosporine A	It was proven that CyA led to significant in hepatic excretion, hepatic clearance, and half-life of etoposide in a dose-dependent manner.
Pfeifer 2013	Rosuvastatin (RSV)	The data confirmed the significant role of basolateral efflux clearance (CLBL) in RSV hepatic elimination, and demonstrated that both CLBL and RSV biliary clearance influence RSV hepatic and systemic exposure.
Lavasani 2013	Tramadol	The pharmacokinetic of tramadol and its three metabolites are influenced by diabetes.
Zhang 2012	Piper methysticum (kavalactone)	Liver macrophages may be a factor in liver injury induced by Piper methysticum. Characterization and modulation of the liver macrophage response may enable the development of strategies to avoid these hepatic side effects.
Mitchell 2012	Diazepam	The results highlight the importance of the liver sinusoidal endothelium in the ultrafiltration of highly protein-bound drugs, and may also provide an additional mechanism for reduced hepatic clearance of diazepam in conditions associated with defenestration.
Mitchell 2011	Paracetamol	Poloxamer 407 treatment resulted in increased recovery and decreased permeability-surface area product of paracetamol following a single pass through the isolated perfused liver.
Miranda 2008	Silymarin	The data indicate a primary role for multidrug resistance-associated protein 2 in the biliary elimination of silymarin flavonolignan conjugates.
Mehvar 2004	Cyclosporine A	The tissue binding of cyclosporine A is substantial, slowly reversible, and gender-dependent in isolated perfused rat livers.
Holecek 2003	Glutamine	Decreased delivery of glutamine to hepatic tissue activates glutamine synthesis, decreases resynthesis of essential branched-chain amino acid from branched-chain keto acids (BCKA), increases catabolism of BCKA, and has a significant effect on protein turnover in hepatic tissue.
Dewar 2002	Nicotine	The data support the hypothesis that inhibition of glycolysis by nicotine increases oxygen uptake due to an ADP-dependent increase in mitochondrial respiration.
Farabos 2001	Irinotecan	The data indicate that the hepatic disposition of irinotecan may vary at high dose, both at the level of biliary excretion and of activation to the antineoplastic drug SN-38.
Beaufort 2001	Vecuronium	Hypothermia significantly and reversibly reduced the net uptake up vecuronium.
Roumi 1997	Hexarelin (HEX)	Hepatic extraction of HEX is low, allowing researchers to predict that its hepatic clearance may be limited upon HEX protein binding.
Wilhelm 1996	Aluminum	It was concluded that by using the isolated perfused rat changes of liver functions occur only at very high aluminum concentrations in the perfusate and that only negligible amounts of aluminum are eliminated by the liver.
Takakura 1996	Oligonucleotides	The hepatic uptake process of phosphodiester oligonucleotides greatly depends on their types.
Chou 1993	Barbituric acids	The similarity between the dispersion number for different barbiturates and that for reference markers suggests that the relative axial spreading of these barbiturates is determined primarily by the heterogeneity of the hepatic vasculatory system.
Mets 1993	Lidocaine	Lidocaine metabolism may be an early indicator of severe hepatic hypoxia.

Table 1. (Continued)

Researchers	Compound	Findings
Hussein 1993	Diclofenac	Additional parameters influence the relationship between availability and fraction unbound for diclofenac.
Díaz-García 1992	Diazepam	The dispersion of diazepam in the perfused rat liver is determined primarily by the architecture of the hepatic microvasculature.
Mol 1992	Steroidal muscle relaxants	Results indicate that the pharmacokinetic analysis of the hepatic disposition of steroidal muscle relaxants may be used to evaluate actual transport phenomena participating in the hepatic disposition of these drugs.
Lenzen 1991	Antiarrhythmic drugs	The present results indicate that antiarrhythmic drugs produce cholestasis in the isolated perfused rat liver independently of their adverse effect on hepatic hemodynamics.
De Bandt 1990	Norepinephrine	The results suggest that norepinephrine modulates hepatic protein balance.
Ballet 1987	Doxorubicin (DX)	In the isolated perfused rat liver, DX~~C~~ has a low extraction ratio, is poorly metabolized and extensively excreted into bile.
Jones 1984	Propranolol	The data confirm precisely to the predictions of the venous equilibrium model and are incompatible with the sinusoidal model. The apparently 'unphysiological' venous equilibrium model represents a valid description of the hepatic elimination of propranolol.
Avner 1982	Protoporphyrin	It may be inferred that if plasma protoporphyrin concentration is in excess of that predicted from total protoporphyrin excretion, a defect in hepatic protoporphyrin clearance exists.
Meijer 1976	d-tubocurarine (d-TC)	The results support the idea that the balance of hydrophilic and hydrophobic properties is an important factor determining hepatic transport of organic compounds.

Drug transporters play a significant role in drug disposition and response. Considering the function of efflux transporters, the inhibition of these drug transporters by inhibitors like cyclosporine A (CyA), may lead to better responses after drug treatment (Khezrian 2015). There have been several studies focusing on the effect of CyA on pharmacokinetic behavior of etoposide (an anticancer agent). However, hepatic clearance has thus far not been described. The IHP model makes it possible to evaluate the etoposide interactions with different transporters and its hepatic disposition during co-administration with different doses of CyA. Subsequently, it was proven that CyA led to significant changes in hepatic excretion, hepatic clearance, and half-life of etoposide in a dose-dependent manner (Khezrian 2015). In addition, the tissue binding of CyA was shown to be substantial, slowly reversible, and gender-dependent in isolated perfused rat livers (Mehvar 2004).

In addition, the IHP is an effective tool to study liver toxicity. Hepatic toxicity is observed as a side effect in some herbal treatments, including the anxiolytic crop Piper methysticum. Extensive damage to the hepatic sinusoids was displayed after IHP with Piper methysticum (Zhang 2012). Exposure of the isolated liver to aluminum can accumulate this metal in the organ, which can be toxic to the hepatic tissue at high concentrations. By isolated perfused rat livers, changes of liver function were shown to occur only at high aluminum concentrations in the perfusate and only negligible amounts of aluminum were eliminated by the liver (Wilhelm 1996).

Hepatic biotransformation of pharmaceutical agents may be altered by different physical states. An isolated perfusion model using diabetic rat livers showed that the pharmacokinetic effect of tramadol (a pain reliever) was influenced by diabetes (Lavasani 2013). Pharmacodynamics of muscle relaxants may be influenced by hypothermia. A study showed

that hypothermia reduced hepatic net uptake and hepatic metabolism of vecoronium. The IHP model allowed the researchers to study the influence of hypothermia on just the liver, because other organs that are important for the distribution or elimination of vecoronium are absent (Beaufort 2001). Likewise, glutamine deficiency, a common finding in severe illness, has a negative influence on hepatic metabolism. This evidence was supported using an isolated perfused rat liver, which showed that decreased delivery of glutamine to hepatic tissue activates glutamine synthesis, decreases resynthesis of essential branched-chain amino acid from branched-chain keto acids (BCKA), increases catabolism of BCKA, and has a significant effect on protein turnover in hepatic tissue (Holecek 2003).

The enzyme glycyrrhizinate was shown to reduce portal hypertension in isolated perfused rat livers with chronic hepatitis (Zhao 2013). Xu et al. showed how glycyrrhizin increases hepatic glutathione content possibly through inhibition of multidrug resistance associated protein-2, which then reduced the biliary excretion of glutathione (Xu 2012).

Gene Therapy

The liver is one of the major target organs for gene therapy of inherited metabolic disorders. The objective of *in vivo* gene delivery is to achieve genetic modification of the target organ. A major concern here is that the vector spreads to other areas than the target organ and insufficient transduction efficacy *in vivo* can be a reason for treatment failure. IHP allows for specific *in vivo* gene delivery and local administration of the vector or the tissue of interest (Kinoshita 2010; de Roos 1997). It has been demonstrated that *in vivo* IHP is effective for targeted delivery of a transgene to the liver with recombinant adenoviruses (de Roos 1997). Toxic effects related to the exposure of hepatocytes to the adenoviruses were not observed and this procedure resulted in a significantly higher expression of the marker gene compared to infusion of the vector into the portal vein. Shigeo et al. described a procedure for IHP that enables reproducible and tissue-specific gene delivery by Sendai virus vectors. Direct intravenous injection of Sendai virus vectors is otherwise not feasible because of their hemagglutinating and hemolytic activities. Marker genes were expressed in most parenchymal hepatocytes and undetectable in non-hepatic tissues, indicating that this approach offers good clinical potential for human gene therapy (Fujita 2006). Moreover, van Etten et al. performed IHP in rats with a recombinant adenoviral vector and demonstrated a decreased neutralizing antibody formation and high transduction efficacy compared to systemic intravenous treatment (van Etten 2004).

Figure 1 shows a schematic representation of an experimental liver machine perfusion set-up. The rat liver is placed in an organ chamber (A) after which tubes enabled perfusion fluid to flow to the arterial and portal side. Two tubular membrane oxygenators provide oxygen to the perfusion solution, as well as removal of CO_2 (B). Roller pumps on both sides provide a continuous flow to the portal vein and a pulsatile or continuous flow to the hepatic artery (C). Elastic tubing and a bubble trapper (E) allow elimination of the pulses in the portal flow. For the hepatic artery, the bubble trapper can be removed for a pulsatile flow and replaced to create a continuous flow (E). The temperature of the perfusion solution can be manually maintained by 2 heat exchangers connected to water baths (D). Two inline sensors are used to measure temperature (F). Flow and pressure (G) are detected by in-line sensors, and data is analyzed and displayed in real time on a computer. Several bubble traps can be

used to eliminate air bubbles in the perfusion solution (H). Bile is collected in Eppendorf tubes (I).

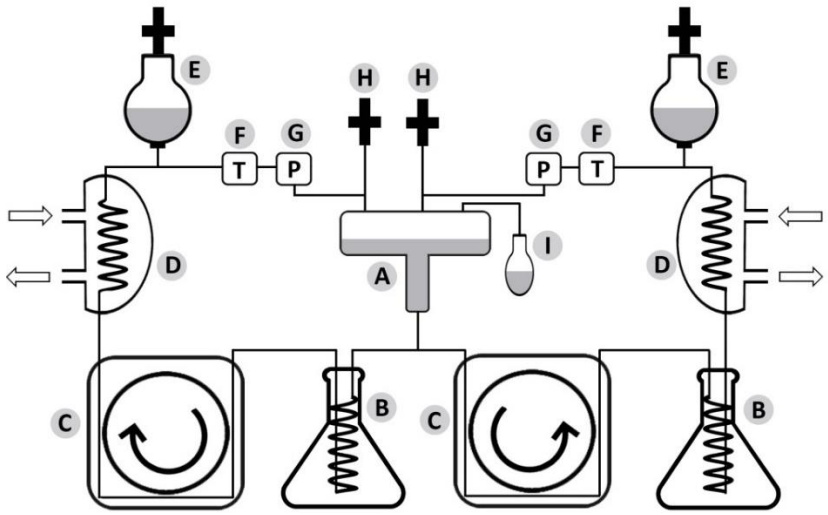

Figure 1. Schematic set-up of a liver machine perfusion system.

ISOLATED LIVER PERFUSION AS A TREATMENT FOR MALIGNANCIES

For several decades, hepatic perfusion via the operative (isolated hepatic perfusion) or percutaneous (percutaneous hepatic perfusion) technique has been tested clinically in patients with diffuse isolated liver metastases from various solid organ cancers. Dr. Robert Ausman was the first to describe IHP to treat malignancies over 50 years ago. The technique was first refined in a canine model and later he reported outcomes of 5 patients treated with 60-minute IHP. Toxicity was considerable and there was no long-term follow up, but there was evidence of antitumor activity in 2 out of 5 of his patients, so a therapeutic effect of IHP was possible (Ausman, 1961). Two decades thereafter, there were scattered reports from several centers around the world describing IHP in small numbers of patients. The procedure was generally felt to be risky and thus far no clear benefits had been shown. However, in 1992, the IHP model regained interest after Drs. Lienard and Lejeune reported a 90% complete response rate in 29 patients with a high-grade unresectable extremity sarcoma or in-transit melanoma (Lienard 1992). They combined chemotherapy with the toxic tumor necrosis factor alpha (TNFα), which placed emphasis on ensuring complete vascular liver isolation to make sure that no systemic leaks occurred during perfusion.

One of the more important aspects of IHP treatment is monitoring for perfusate leaks during perfusion. A significant leak into the systemic circulation of a patient can be fatal depending on the regimen used. Inadequate ligation of the small IVC vessels is a typical predisposition for systemic leaks. To monitor intraoperative leaking, a system has been designed using human serum albumin labeled with ‘I’ (iodine-131). A 10 times smaller amount of I is injected into the systemic circulation compared to the perfusion circuit. A gamma-counter is placed over the centrifugal pump housing to monitor for radioactivity in

the systemic circulation. A 10% leak would result in a doubling of the radioactive counts in the systemic circulation. Leaks will be detected immediately and the perfusion can be stopped (Boone 2012).

Surgical Procedure

The unique hepatic anatomy allows vascular isolation of the liver to deliver high doses of cytotoxic agents with minimal system toxicity (Burgmans 2016). After induction of general anesthesia, a laparotomy is performed. The inferior vena cava (IVC) is exposed by performing a generous Kocher maneuver of the duodenum. Then, ligation of all venous tributaries to the IVC is performed. Following heparinization, the portal vein structures are isolated and the arterial cannula is placed into the proper hepatic artery via the gastroduodenal artery. Venous cannulas are placed in the saphenous, portal and axillary veins and the patient is placed on veno-veno bypass to maintain systemic venous return. Hereafter, the IVC is clamped with supra- and infra-hepatic clamps, while a retrohepatic cannula is inserted to collect the venous outflow (Figure 2). The drug is infused via the arterial cannula. Upon completion of the infusion, the liver is flushed and venotomies are repaired. Physiologic hepatic blood flow can then be promptly restored (Yamamoto 2014; Reddy 2014).

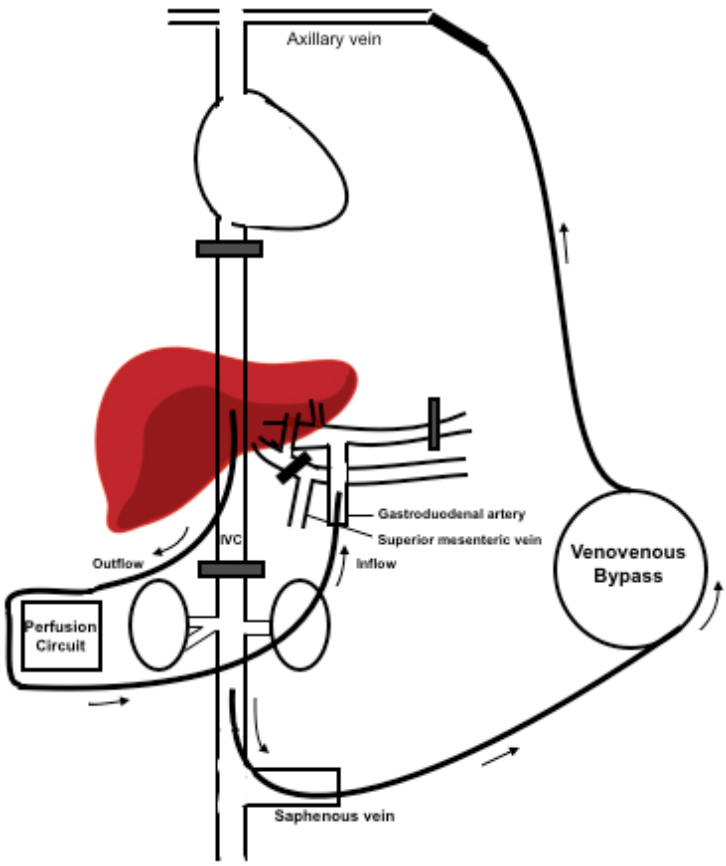

Figure 2. Illustration showing the isolated hepatic perfusion circuit.

Uveal Melanoma Liver Metastases

Approximately one third of patients with uveal melanoma develop liver metastases. The prognosis is poor with a median survival of 6 months (Diener-West 2005). For these patients IHP offers an aggressive regional therapy to control disease progression in the liver. Several studies showed response rates between 30–60% with a median survival of 10–12 months when treating their patients with IHP (Table 2). The results of IHP are better than those obtained with systemic therapy alone and a research group in Sweden reported a 14-month survival benefit with IHP versus the treatment administered to the longest surviving patients with uveal melanoma (Olofsson 2014). Recently, the same group described 68 patients treated with IHP for uveal melanoma metastases and they reported an overall response rate of 67% (Ben-Shabat 2016). Median survival was 22 months and 20% of the patients had a complete response. In addition to cancer treatment, IHP offers a unique possibility to study exosomes from the liver of patients with uveal melanoma liver metastases. Eldh et al. showed that specific melanoma signatures could be seen in circulating exosomes from patients with advanced melanoma. They also showed that the amount of protein per exosomes increased with the disease, which indicates a potential role of exosomes as diagnostic markers (Eldh 2014).

Table 2. Isolated hepatic perfusion for uveal melanoma liver metastases

Author	Year	*N*	Mortality *n (%)*	Median survival (mo)	Median progression (mo)
Ben-Shabat 2016	2016	68	5 (7%)	22	10
Rizell 2008	2008	20 (+ 7 cutaneous and anal melanoma)	6 (22%)	12.6	-
van Iersel 2007	2008	12	0 (0%)	10	6.6
van Etten 2009	2003	8	0 (0%)	11	6
Noter 2004	2003	8	0 (0%)	9.9	6.7
Alexander 2003	2003	29	0 (0%)	12.1	8
Alexander 2000	2000	22	1 (5%)	11	9

Colorectal Cancer Liver Metastases

For colorectal cancer liver metastases, second-line chemotherapy response rates are less than 25% and median survival is less than 15 months (Giantonio 2007; Reddy 2014). IHP treatment in colorectal cancer patients has shown to be controversial. In a case-control study, van Iersel and colleagues showed no beneficial effect when comparing IHP with melphalan (n = 99) to systemic chemotherapy (n = 111) in patients with unresectable colorectal cancer liver metastases. Median overall survival was 25.0 months for IHP and 21.7 months for systemic treatment. Treatment-related mortality was 2% for systemic treatment and 6% for IHP (van Iersel 2010). One of the major drawbacks is its hepatoxicity with associated morbidity, mainly attributable to veno-occlusive disease (van Iersel 2007). Impressive response rates for systemic chemotherapy may render IHP unjustifiable as a first-line therapy, but it could be reserved as a second-line therapy. Table 3 lists data from prospective Phase I/II clinical trials of IHP for colorectal cancer liver metastases.

Current research focuses on additional chemotherapeutic agents that can be used to improve response rates in IHP. Also, identification of the ideal patient population, perfusate, and combination of regional-systemic therapy will be important in defining the role of IHP and its acceptance as a recognized modality in the treatment of patients with unresectable metastatic solid tumors.

Table 3. Isolated hepatic perfusion for colorectal liver metastases

Author	Year	*N*	Mortality n (%)	Median survival (mo)	Median progression (mo)	Radiographic response	Complete response
Zeh 2009	2009	13	1 (8%)	25	15	66%	8%
van Iersel 2007	2007	30	1 (3%)	16.9	11.5	41%	0%
Rothbarth 2003	2003	73	4 (6%)	28.8	7.7	59%	5%
Bartlett 2001	2000	51	1 (2%)	16	8.5	76%	0%
Vahrmeijer 2000	2000	24	2 (8%)	19		29%	6%

MACHINE PERFUSION FOR LIVER PRESERVATION

Donor shortage has led to increased mortality rates of patients on the waiting list. To expand the donor pool of suitable organs for transplantation, there is an increased interest in utilizing ECD organs. These organs comprise, for example, livers with varying degrees of steatosis and livers that were retrieved after circulatory arrest of the donor (the so-called DCD donors). ECD livers have a greater susceptibility to ischemia reperfusion injury and a higher risk of poor post-transplant outcomes. *Ex vivo* machine perfusion has shown to be a promising new modality in the organ preservation field to reduce I/R injury and recover ECD liver grafts. In addition, the model allows assessment of viability and function of grafts prior



Figure 3. Human liver in a closed perfusion circuit.

to transplantation. Based on different perfusion temperatures, three machine perfusion variants are currently explored: hypothermic machine perfusion (HMP) (temperatures around 5°C), sub-normothermic machine perfusion (SMP) (20–30°C), and normothermic machine perfusion (NMP) (35–37°C).

Figure 3 shows a human liver in a closed perfusion circuit. The liver is placed in the chamber with a blood-based solution. The organ is perfused through both the portal vein and hepatic artery. Circulation of the perfusion fluid is driven by the two roller pumps on the floor. Lastly, two bubble trappers make sure no air bubbles circulate in the perfusion system.

Devices

To date, no liver machine perfusion devices have been approved by the Food and Drug Administration. Four devices are currently used in clinical trials: OrganOx *metra*® Liver Assist, TransMedics OCS™ Liver, LifePort Liver Transporter (Figure 4).

Hypothermic Machine Perfusion

Since the early days of preservation, SCS has been the standard preservation of organs (Figure 5). In the early era of transplantation there were attempts to preserve livers with machine perfusion. However, after the first unsuccessful attempts of HMP of human livers by Starzl et al. in 1967, the clinical use and development of human liver perfusion devices did not move forward (Starzl 1967). After a landmark paper was published in 2009 on the improved preservation of human kidney grafts with machine preservation, it has become a very hot topic with great clinical relevance for transplantation of all organs (Moers 2009). The first successful experiments using HMP were documented by the Wisconsin group in 1985, first by D'Alessandro et al. (D'Alessandro 1986) and later by Pienaar et al. (Pienaar 1990). Both managed to preserve and transplant good-quality canine livers after 72-hr HMP in a canine model. HMP is currently the simplest approach of liver machine perfusion, with therefore high practicability and at relatively low costs. It is an attractive method to avoid further warm ischemic injury and minimize graft metabolic requirements, while providing oxygenation and metabolic support. Numerous *ex vivo* liver HMP experiments have been published in the last 2 decades and they demonstrated beneficial results compared to SCS. Guarerra et al. were the first to report on hypothermic dual (portal vein and hepatic artery) perfusion applied after SCS. The twenty patients that received machine-perfused livers showed significantly less peak enzyme release and a shorter hospital stay, as well as less early graft dysfunction compared to the control group (Guarrera 2010). In 2015, the same group showed less biliary complications after application of hypothermic perfusion to 31 ECD organs that were declined by the originating United Network for Organ Sharing region (Guarrera 2015). The Groningen group applied end-ischemic hypothermic oxygenated machine perfusion (HOPE) in DCD livers. The results confirm a greater than 10-fold adenosine triphosphate (ATP) increases by HOPE and less non-anastomotic biliary strictures in transplant recipients (Westerkamp 2015). Recently, the same group applied 2 hrs of HOPE after traditional cold storage and showed a great than 15-fold increase in ATP levels compared to livers that were normothermically perfused after SCS. Cumulative bile

production and biliary secretion of bilirubin and bicarbonate were significantly higher after HOPE, but no differences in hepatobiliary injury markers were found (Westerkamp 2016). Dutkowski et al. were the first to compare between standard-preserved (n = 50) and HOPE-treated (n = 25) DCD liver transplants, demonstrating important benefits in favor of the HOPE approach. Their study showed less I/R injury and better graft function with a lower incidence of later intrahepatic biliary complications. Most importantly, overall and cholangiopathy-free graft survival after 1-year post transplant was 90% in HOPE-treated livers compared to 69% in unperfused organs (Dutkowski 2015). The full potential of end-ischemic HOPE should be discovered in the upcoming years.

Figure 4. Liver machine perfusion devices currently used in clinical trials. A: OrganOx *metra*®, B: Liver Assist, C: TransMedics OCS™ Liver, D: LifePort Liver Transporter.

Figure 5. Liver prepared for static cold storage.

Perfusion Solution for Machine Preservation

The most commonly used perfusion medium during HMP is the original or modified University of Wisconsin (UW) solution or UW machine perfusion (UW-MP) solution. In addition, studies have used Institut George Lopez (IGL), Celsior or Histidine-Tryptophan-Ketoglurate (HTK) solutions. Polysol is a more recently developed preservation solution and was shown to decrease aminotransferases compared to the modified UW solution in rat livers. Also, machine perfusion using Polysol resulted in increased perfusate flow, bile production, and ammonia clearance (Bessems 2005).

The new generation solution Vasosol (VAS) is a machine perfusion solution based on Organ Recovery Systems kidney machine perfusion solution 1 (KPS-1) that is enhanced with antioxidants, metabolic intermediates and vasodilators. The solution has been shown to decrease transaminases and proinflammatory cytokines, and shortened hospital stays in human liver transplant recipients (Bae 2014). With the addition of a-tocopherol, the benefits can be further improved. Bae et al. found a reduced level of alanine aminotransferase (ALT), as well as reduced levels of inflammatory cytokines during reperfusion in a DCD rodent liver model (Bae 2014). Human application of HMP is currently done using Belzer's machine perfusate or its modifications, including ketoglutarate, nitroglycerine, i-arginine, n-acetylcysteine, and prostaglandin E1. A low potassium concentration decreases vascular resistance in hypothermic conditions and the presence of starch increases viscosity. Therefore, solutions with low potassium and without starch appear advantageous (Schlegel 2015). However, unlike the UW solution in kidney perfusion, no gold standard has yet emerged for liver preservation.

Is Oxygenation Necessary during HMP?

Oxygenation of the preservation solution has been a neglected aspect of HMP. However, attention is desired since oxygen is necessary for ATP synthesis, but could also result in an increase of toxic reactive oxygen species. Previous studies have shown successful HMP of livers without any additional oxygenation (Guarrera 2005). On the other hand, the efficiency of HMP to preserve functional and structural liver integrity may be markedly increased by additional oxygenation of the perfusate during machine perfusion. 't Hart et al. showed significantly higher ATP content in 21% and 95% oxygen saturation groups compared to non-oxygenated livers. In addition, livers preserved without additional oxygen showed significantly higher aspartate aminotransferase (AST), ALT and lactate dehydrogenase (LDH) levels probably related to a decreased energy state preventing homeostasis of the cell. In the 0% and 95% oxygenated groups an increase of reactive-oxygen species was found after cold storage in UW-MP solution. Therefore, saturation of UW-MP with 21% oxygen may provide optimal preservation results ('t Hart 2005). Contrary to this, Lüer et al. demonstrated efficient HMP by addition of 100% oxygen. HMP with 100% oxygen resulted in reduced oxygen free radical-mediated lipid peroxidation after reperfusion compared to livers oxygenated with air (20% oxygen). Also, a nearly 2-fold increase in bile production was observed in 100% oxygenated perfused livers compared to 20% or 0% oxygenated organs ($p < 0.05$) (Lüer 2010).

Perfusion Pressure and Flow

In contrast to kidney preservation, data on HMP of livers are scarce and there is still controversy when it comes to ideal parameters and settings during machine preservation. Various perfusion pressure and flow settings have been used in different studies, all aimed to minimize ischemic injury and recover the organ before transplantation. HMP settings are by definition not particularly physiologic with perfusate temperatures most commonly defined as 4°C. A critical target of injury by hypothermic preservation is the sinusoidal endothelial cell. ‘t Hart et al. found that increased perfusion pressures during HMP in rats resulted in more complete perfusion, but increased endothelial damage. They concluded that 25% of the physiological perfusion pressure gave the best results (‘t Hart 2007). In line with this, high flow rates in pigs were shown to induce detrimental effects due to sinusoidal endothelial injury through over-expression of von Willebrand factor and TNF with subsequent activation of Kupffer- and endothelial cells (Fondevila 2012). Also, dilation of the sinusoids appears to be more pronounced in livers perfused with high flows. Excessive dilation may lead to shear stress, endothelial cell lining disruption, and eventually suboptimal parenchymal preservation (Vekemans 2007). A human study by Dutkowski et al. confirmed that a low portal perfusion pressure of 3 mmHg results in complete perfusion without evidence of sinusoidal impairment (Dutkowski 2014). Generally, most studies prefer low portal vein (3−5 mmHg) and arterial (20−30 mmHg) pressures.

Is Portal Perfusion Alone Effective in Hypothermic Conditions?

Several different perfusion routes have been advocated for machine liver perfusion and the best perfusion method has been discussed widely. Perfusion through the portal vein alone is commonly used in rat liver perfusion experiments. Arguments for perfusion of the hepatic artery include perhaps superior oxygen supply to the peribiliary vascular plexus (PVP) (Brüggenwirth 2016). Slieker has shown that the biliary tree receives blood supply from the portal vein (Slieker 2012). However, the biliary tract is mainly supplied with arterial blood through the PVP and therefore, any injury to the PVP may contribute the ischemic death of biliary epithelial cells after transplantation (Nishida 2006). The importance of hepatic artery perfusion is also illustrated by the high incidence of biliary necrosis and strictures after hepatic artery thrombosis (HAT) in patients after transplantation (Mourad 2014). Additionally, during early reperfusion the oxygen delivery is heavily dependent on arterial flow and as a result, Foley et al. showed superior bile production and output of phospholipid, cholesterol and bilirubin in dual perfused livers (Foley 1999). Combined arterial and portal machine perfusion of DCD porcine livers also results in less arteriolonecrosis and better preservation of the PVP (Op den Dries 2014). On the contrary, single portal vein perfusion adds simplicity to liver machine perfusion and authors have described portal perfusion to be sufficient to prevent I/R injury of the large bile ducts (Schlegel 2016). Hepatic artery perfusion alone seems to be less beneficial than single portal vein or dual perfusion (Compagnon 2001). Figures 6 and 7 show an experimental set-up of a dual perfused rat liver.



Figure 6. Dual perfused rat liver.

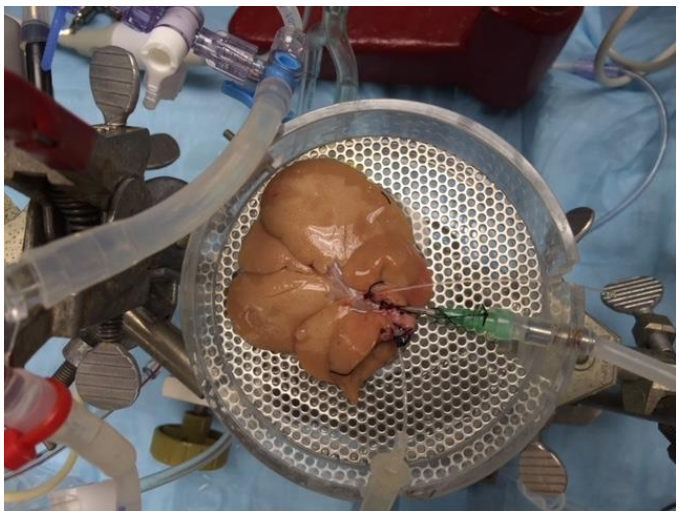

Figure 7. Dual perfused rat liver close-up.

Sub-Normothermic Machine Perfusion

Warm perfused organ preservation regained interest after more became known about the detrimental effects of hypothermic storage, particularly for ECD livers. It has been hypothesized that a more gradual rewarming course may relieve the cold ischemic insult by employing a stepwise normalization of temperature and metabolic demand. SMP systems have been investigated and might benefit from a lower metabolic demand compared to NMP, while still maintaining sufficient metabolism for viability testing and improvement of graft function. Bruinsma et al. showed a considerable recovery of energy metabolism during SMP. Most notable were an increase in ATP and other adenine nucleotide ratios (Bruinsma 2016). The same study showed great promise for the use of metabolomic analysis during machine perfusion of the liver. Severely ischemic and steatotic DCD livers had a significantly higher release of injury markers. Subsequently, metabolic profiling was able to cluster livers with similar metabolomic patterns based on the degree of injury. Moreover, perfusion parameters

combined with differences in metabolic factors suggest variable mechanisms that result in poor energy recovery in injured livers (Bruinsma 2016). The clinical application of metabolomics remains underexplored, but emerging techniques such as rapid evaporative ionization mass spectrometry will enable near-real-time metabolic profiling in the future.

Recently, Bruinsma and colleagues applied 3 hours of oxygenated SMP to human livers that were discarded for transplantation. Beneficial results were observed regarding improved oxygen uptake, lactate levels, and ATP content, as well as increased bile production (Bruinsma 2014). This evidence is proven by previous experiments using an SMP model in animal experiments. Vairretti et al. showed improved cell survival and hepatic preservation of normal and steatotic livers that were machine perfused at 20 degrees compared to SCS livers (Vairetti 2009; Vairetti 2007). Likewise, Berendsen et al. were able to effectively regenerate ischemically damaged rat livers using 3 hr SMP without oxygen carriers (Berendsen 2012). Lastly, Gringeri et al. confirmed that SMP was able to resuscitate liver grafts from DCD pig livers. The SMP group showed better histopathologic results with significantly less hepatic damage compared to SCS livers (Gringeri 2012). Unfortunately, no clinically controlled studies have been executed to date and future studies are required to determine whether SMP translates to better post-transplant outcomes.

Controlled Oxygenated Rewarming

One cause of ischemic damage could be the abrupt temperature shift from hypo- to normothermia, leading to mitochondrial dysfunction and proapoptotic signal transduction. Therefore, recent studies have investigated the effect of the promising new aspect of controlled oxygenated rewarming (COR). The protective effect of controlled tissue rewarming after cold storage was first shown in a pig model, where end-ischemic MP with gradual rewarming resulted in superior functional recovery compared to hypo- or subnormothermic perfusion prior to reperfusion (Minor 013). Hoyer et al. supported this evidence in a porcine model comparing COR up to sub-normothermic temperatures to NMP. COR resulted in lower mitochondrial caspase-9-activity. Significantly lower enzyme leakage and higher bile production were observed during reperfusion (Hoyer 2016). The same group was the first to successfully apply COR in a clinical series of 6 patients. Graft survival rates after 6 months were 100% in the COR group and 80.9% in matched controls ($p = 0.24$). This first clinical application suggests that controlled graft rewarming after cold storage is a feasible and safe method in clinical practice and might become an adjunct in organ preservation (Hoyer 2016).

Normothermic Machine Perfusion

The concept underlying NMP is the recreation of a physiological environment during preservation. NMP enables prolonged preservation without time-dependent damage that is caused by cold preservation, the ability of the organ to recover from injury, and the opportunity to measure the function of the organ during preservation in order to predict post-transplant outcomes. NMP was first described in the 1930s, by Alexis Carrel and Charles Lindbergh (Carrel 1935). Several animal experiments followed, but with marginal results

(Kestens 1966; Brettschneider 1968; Brettschneider 1968) Later, Brettschneider et al. were able to preserve 7 human livers for 4–7 hours and all recipients survived the first postoperative week. The introduction of Collins solution shortly after, and the ease of SCS moved the emphasis away from machine perfusion (Collins 1969). However, the increasing pressure to expand the donor pool with high-risk organs leads to regained interest in machine perfusion. A landmark paper by Schön et al. in 2001 demonstrated in a porcine model that NMP is a feasible preservation method and enabled successful transplantation of donor livers that had been subjected to warm ischemia (Schön 2001). Around the same time, the potential benefits of NMP regarding synthetic and metabolic function were demonstrated (Friend 2001; Imber 2002). There has been ongoing debate on whether the benefits of NMP can be delivered by a brief period of perfusion after SCS, or requires complete avoidance of cooling. The Oxford group investigated the effect of 5 hours and 20 hours preservation times in a DBD and DCD porcine liver transplantation model. They showed no difference between SCS and NMP in the 5 hours preserved DBD livers. However, in the 20 hours preserved DBD livers 6 out of 7 normothermically perfused livers survived compared to 2 out of 7 SCS transplants. In the DCD group, none of the SCS transplanted animals survived compared to 4 out of 5 NMP transplanted livers. This suggests that NMP might be able to resuscitate livers that experienced warm ischemic injury prior to retrieval that would otherwise not have been viable with cold preservation alone (Brockmann 2009). With promising results from large animal models, NMP moved into discarded human liver experiments. Op den Dries et al. have reported results on 4 discarded DCD human liver grafts after 6 hr of NMP using the Liver Assist (OrganAssist) followed by cold preservation. This demonstrated feasibility of NMP in human livers with well-perfused livers, continuous bile production, reduced lactate levels and preservation of liver histology and histological examination (op den Dries 2013). Recently, Mergental et al. transplanted 4 DCD livers that were rejected due to prolonged warm ischemic times, and 1 liver from a DBD donor that was declined for high liver function tests. All livers were exposed to a variable period of SCS prior to commencing NMP. The transplant procedure was uneventful in every recipient and all grafts showed immediate graft function (Mergental 2016).

In addition, it has been hypothesized that NMP might be beneficial for the recovery of steatotic livers since cooling of these organs considerably alters the compliance of hepatic tissue. Also, NMP reduces I/R injury for which steatotic livers are particularly sensitive, and allows mobilization and reduction of intracellular fat (Jamieson 2011). NMP is of great potential to increase to existing donor pool available for liver transplantation. The ability of this new technology to push back boundaries of organ acceptance is paramount. If NMP is to succeed, its value will need to be shown in the context of improved outcomes of ECD livers.

Viability Assessment

Several groups have demonstrated that NMP provides a tool to assess organ viability pre-transplantation as the liver is maintained in a physiological metabolic state (op den Dries 2013; Adham 1997). Sutton et al. recently suggested that bile output and other metabolic parameters may differentiate viable from non-viable livers (Sutton 2014). The same group demonstrated that a rising bicarbonate level in the perfusate indicated a viable liver. In addition, the ability of the liver to maintain acid-base homeostasis has been demonstrated to

be good predictor of post-operative outcome (St Peter 2003). When comparing SCS to NMP preserved porcine livers, the latter group was able to correct the pH, while SCS livers were unable to reverse the acidosis (St Peter 2003). Lastly, non-viable grafts were noted to have portal pressures significantly greater than those that functioned, with portal pressures maintained at physiological values (Brockmann 2009).

CONCLUSION

The IHP model is an effective tool to study pharmacokinetic and pharmacodynamic effects on the liver. Besides, IHP allows clinicians to administer chemotherapeutic agents to treat various malignancies with hepatic metastases. The technique is still developing to yield the improved response rates in the future. Over the last decades, a lot of research has focused on liver machine perfusion as a preservation technique prior to transplantation. It has not been implemented as the gold standard for liver preservation today, but hypothermic-, normothermic- and sub-normothermic machine perfusion preservations are all potential methods to increase the existing donor pool.

REFERENCES

't Hart, NA; der van Plaats, A; Leuvenink, HGD; van Goor, H; Wiersema-Buist, J; Verkerke, GJ; Rakhorst, G; Ploeg, RJ. Determination of an adequate perfusion pressure for continuous dual vessel hypothermic machine perfusion of the rat liver. *Transpl. Int.*, 2007, 20(4), 343−52.

't Hart, NA; van der Plaats, A; Faber, A; Leuvenink, HGD; Olinga, P; Wiersema-Buist, J; Verkerke, GJ; Rakhorst, G; Ploeg, RJ. Oxygenation during hypothermic rat liver preservation: An *in vitro* slice study to demonstrate beneficial or toxic oxygenation effects. *Liver Transpl.*, 2005, 11(11), 1403−1411.

Adham, M; Peyrol, S; Chevallier, M; Ducerf, C; Vernet, M; Barakat, C; De La Roche, E; Taibi, A; Bizollon, T; Rigal, D; Pouyet, M; Baulieux, J. The isolated perfused porcine liver: assessment of viability during and after six hours of perfusion. *Transplant. Int.*, 1997, 10(4), 299–311.

Alexander, HR; Libutti, SK; Bartlett, DL; Puhlmann, M; Fraker, DL; Bachenheimer, LC. A phase I-II study of isolated hepatic perfusion using melphalan with or without tumor necrosis factor for patients with ocular melanoma metastatic to liver. *Clin. Cancer Res.*, 2000, 6(8), 3062–70.

Alexander, HR; Libutti, SK; Pingpank, JF; Steinberg, SM; Bartlett, DL; Helsabeck, C; Beresneva, T. Hyperthermic isolated hepatic perfusion using melphalan for patients with ocular melanoma metastatic to liver. *Clin. Cancer Res.*, 2003, 9(17), 6343–9.

Atti, M; Silva, MA; Mirza, DF. The marginal liver donor--an update. *Transplant. Int.*, 2008, 21(8), 713–24.

Ausman, RK. Development of a technic for isolated perfusion of the liver. *N. Y. State J. Med.*, 1961, 61, 3993–7.

Avner, DL; Berenson, MM. Hepatic clearance and biliary secretion of protoporphyrin in the isolated, in situ-perfused rat liver. *J. Lab. Clin. Med.*, 1982, 99(6), 885–94.

Bae, C; Pichardo, EM; Huang, H; Henry, SD; Guarrera, JV. The benefits of hypothermic machine perfusion are enhanced with Vasosol and α-tocopherol in rodent donation after cardiac death livers. *Transplant. Proc.*, 2014, 46(5), 1560–6.

Bartlett, DL; Libutti, SK; Figg, WD; Fraker, DL; Alexander, HR. Isolated hepatic perfusion for unresectable hepatic metastases from colorectal cancer. *Surgery*, 2001, 129(2), 176–87.

Ballet, F; Vrignaud, P; Robert, J; Rey, C; Poupon, R. Hepatic extraction, metabolism and biliary excretion of doxorubicin in the isolated perfused rat liver. *Cancer Chemother. Pharmacol.*, 1987, 19(3), 240–5.

Beaufort, TM; Proost, JH; Maring, J; Scheffer, ER; Wierda, JK; Meijer, DK. Effect of hypothermia on the hepatic uptake and biliary excretion of vecuronium in the isolated perfused rat liver. *Anesthesiology*, 2001, 94(2), 270–9.

Ben-Shabat, I; Belgrano, V; Ny, L; Nilsson, J; Lindnér, P; Olofsson Bagge, R. Long-Term Follow-Up Evaluation of 68 Patients with Uveal Melanoma Liver Metastases Treated with Isolated Hepatic Perfusion. *Ann. Surg. Oncol.*, 2016, 23(4), 1327–34.

Berendsen, TA; Bruinsma, BG; Lee, J; D'Andrea, V; Liu, Q; Izamis, ML; Uygun, K; Yarmush, ML. A simplified subnormothermic machine perfusion system restores ischemically damaged liver grafts in a rat model of orthotopic liver transplantation. *Transplant. Res.*, 2012, 1(1), 6.

Bessems, M; Doorschodt, BM; van Marle, J; Vreeling, H; Meijer, AJ; van Gulik, TM. Improved machine perfusion preservation of the non-heart-beating donor rat liver using Polysol: a new machine perfusion preservation solution. *Liver Transp.*, 2005, 11(11), 1379–88.

Boone, BA; Bartlett, DL; Zureikat, AH. Isolated hepatic perfusion for the treatment of liver metastases. *Curr. Probl. Cancer.*, 2012, 36(2), 27–76.

Breedis, C; Young, G. The blood supply of neoplasms in the liver. *Am. J. Pathol.*, 1954, 30(5), 969–77.

Brettschneider, L; Daloze, PM; Huguet, C; Porter, KA; Groth, CG; Kashiwagi, N; Hutchison, DE; Starzl, TE. The use of combined preservation techniques for extended storage of orthotopic liver homografts. *Surg. Gynecol. Obstet.*, 1968, 126(2), 263–274.

Brettschneider, L; Kolff, J; Smith, GV; Martin, AJ; Taylor, P; Starzl, TE. An evaluation of perfusion constituents in liver preservation. *Surg. Forum.*, 1968, 19, 354–6.

Brockmann, J; Reddy, S; Coussios, C; Pigott, D; Guirriero, D; Hughes, D; Morovat, A; Roy, D; Winter, L; Friend, PJ. Normothermic perfusion: a new paradigm for organ preservation. *Ann. Surg.*, 2009, 250(1), 1–6.

Brüggenwirth, IMA; Burlage, LC; Porte, RJ; Martins, PN. Is single portal vein perfusion the best approach for machine preservation of liver grafts? *J. Hepatol.*, 2016, 64(5), 1194–5.

Bruinsma, BG; Sridharan, GV; Weeder, PD; Avruch, JH; Saeidi, N; Özer, S; Geerts, S; Porte, RJ; Heger, M; van Gulik, TM; Martins, PN; Markmann, JF; Yeh, H; Uygun, K. Metabolic profiling during ex vivo machine perfusion of the human liver. *Sc Rep.*, 2016, 6, 22415.

Bruinsma, BG; Sridharan, GV; Weeder, PD; Avruch, JH; Saeidi, N; Özer, S; Geerts, S; Porte, RJ; Heger, M; van Gulik, TM; Martins, PN; Markmann, JF; Yeh, H; Uygun, K.

Metabolic profiling during ex vivo machine perfusion of the human liver. *Sci. Rep.*, 2016, 6, 22415.

Bruinsma, BG; Yeh, H; Ozer, S; Martins, PN; Farmer, A; Wu, W; Saeidi, N; Op den Dries, S; Berendsen, TA; Smith, RN; Markmann, JF; Porte, RJ; Yarmush, ML; Uygun, K; Izamis, ML. Subnormothermic machine perfusion for ex vivo preservation and recovery of the human liver for transplantation. *Am. J. Transplant.*, 2014, 14(6), 1400–9.

Burgmans, MC; de Leede, EM; Martini, CH; Kapiteijn, E; Vahrmeijer, AL; van Erkel, AR. Percutaneous Isolated Hepatic Perfusion for the Treatment of Unresectable Liver Malignancies. *Cardiovas Intervent. Radiol.*, 2016, 39(6), 801–14.

Carrel, A; Lindbergh, CA. The culture of whole organs. *Science*, 1935, 81(2112), 621–3.

Chazouillères, O; Ballet, F; Legendre, C; Bonnefis, MT; Rey, C; Chrétien, Y; Poupon, R. Effect of bile acids on ischemia-reperfusion liver injury. *J. Hepatol.*, 1991, 13(3), 318–22.

Chou, CH; Evans, AM; Fornasini, G; Rowland, M. Relationship between lipophilicity and hepatic dispersion and distribution for a homologous series of barbiturates in the isolated perfused in situ rat liver. *Drug Metab. Dispos.*, 1993, 21(5), 933–8.

Collins, GM; Bravo-Shugarman, M; Terasaki, PI. Kidney preservation for transportation. Initial perfusion and 30 hours' ice storage. *Lancet*, 1969, 2(7632), 1219–22.

Compagnon, P; Clément, B; Campion, JP; Boudjema, K. Effects of hypothermic machine perfusion on rat liver function depending on the route of perfusion. *Transplantation*, 2001, 72(4), 606–14.

D'Alessandro, A; Southard, JH; Kalayoglu, M; Belzer, FO. Comparison of cold storage and perfusion of dog livers on function of tissue slices. *Cryobiology*, 1986, 23(2), 161–167.

De Bandt, JP; Ballet, F; Cynober, L; Rey, C; Coudray-Lucas, C; Giboudeau, J. Effects of norepinephrine on hepatic amino acid metabolism in isolated perfused rat liver. *Nutrition*, 1990, 6(5), 363–6.

de Roos, WK; Fallaux, FJ; Marinelli, AW; Lazaris-Karatzas, A; von Geusau, AB; van der Eb, MM; Cramer, SJ; Terpstra, OT; Hoeben, RC. Isolated-organ perfusion for local gene delivery: efficient adenovirus-mediated gene transfer into the liver. *Gene Ther.*, 1997, 4(1), 55–62.

Dewar, BJ; Bradford, BU; Thurman, RG. Nicotine increases hepatic oxygen uptake in the isolated perfused rat liver by inhibiting glycolysis. *J. Pharmacol. Exp. Ther.*, 2002, 301(3), 930–7.

Díaz-García, JM; Evans, AM; Rowland, M. Application of the axial dispersion model of hepatic drug elimination to the kinetics of diazepam in the isolated perfused rat liver. *J. Pharmacokinet Biopharm.*, 1992, 20(2), 171–93.

Diener-West, M; Reynolds, SM; Agugliaro, DJ; Caldwell, R; Cumming, K; Earle, JD; Hawkins, BS; Hayman, JA; Jaiyesimi, I; Jampol, LM; Kirkwood, JM; Koh, WJ; Robertson, DM; Shaw, JM; Straatsma, BR; Thoma, J. Development of metastatic disease after enrollment in the COMS trials for treatment of choroidal melanoma: Collaborative Ocular Melanoma Study Group Report No. 26. *Arch. Ophthalmol.*, 2005, 123(12), 1639–43.

Dutkowski, P; Polak, WG; Muiesan, P; Schlegel, A; Verhoeven, CJ; Scalera, I; DeOliveira, ML; Kron, P; Clavien, PA. First Comparison of Hypothermic Oxygenated PErfusion Versus Static Cold Storage of Human Donation After Cardiac Death Liver Transplants: An International-matched Case Analysis. *Ann. Surg.*, 2015, 262(5), 764-70–1.

Dutkowski, P; Schlegel, A; de Oliveira, M; Müllhaupt, B; Neff, F; Clavien, PA. HOPE for human liver grafts obtained from donors after cardiac death. *J. Hepatol.*, 2014, 60(4), 765–72.

Eldh, M; Olofsson Bagge, R; Lässer, C; Svanvik, J; Sjöstrand, M; Mattsson, J; Lindnér, P; Choi, DS; Gho, YS; Lötvall, J. MicroRNA in exosomes isolated directly from the liver circulation in patients with metastatic uveal melanoma. *BMC Cancer*, 2014, 14, 962.

Farabos, C; Haaz, MC; Gires, P; Robert, J. Hepatic extraction, metabolism, and biliary excretion of irinotecan in the isolated perfused rat liver. *J. Pharm. Sci.*, 2001, 90(6), 722–31.

Foley, DP; Vittimberga, FJ; Quarfordt, SH; Donohue, SE; Traylor, AN; MacPhee, J; McLaughlin, T; Ricciardi, R; Callery, MP; Meyers, WC. Biliary secretion of extracorporeal porcine livers with single and dual vessel perfusion. *Transplantation*, 1999, 68(3), 362–8.

Fondevila, C; Hessheimer, AJ; Maathuis, MHJ; Muñoz, J; Taurá, P; Calatayud, D; Leuvenink, H; Rimola, A; García-Valdecasas, JC; Ploeg, RJ. Hypothermic oxygenated machine perfusion in porcine donation after circulatory determination of death liver transplant. *Transplantation*, 2012, 94(1), 22–9.

Friend, PJ; Imber, C; St Peter, S; Lopez, I; Butler, AJ; Rees, MA. Normothermic perfusion of the isolated liver. *Transplant. Proc.*, 2001, 33(7–8), 3436–8.

Fujita, S; Eguchi, A; Okabe, J; Harada, A; Sasaki, K; Ogiwara, N; Inoue, Y; Ito, T; Matsuda, H; Kataoka, K; Kato, A; Hasegawa, M; Nakanishi, M. Sendai virus-mediated gene delivery into hepatocytes via isolated hepatic perfusion. *Biol. Pharm. Bull.*, 2006, 29(8), 1728–34.

Giantonio, BJ; Catalano, PJ; Meropol, NJ; O'Dwyer, PJ; Mitchell, EP; Alberts, SR; Schwartz, MA; Benson, AB. Bevacizumab in combination with oxaliplatin, fluorouracil, and leucovorin (FOLFOX4) for previously treated metastatic colorectal cancer: results from the Eastern Cooperative Oncology Group Study E3200. *J. Clin. Oncol.*, 2007, 25(12), 1539–44.

Gringeri, E; Bonsignore, P; Bassi, D; D'Amico, FE; Mescoli, C; Polacco, M; Buggio, M; Luisetto, R; Boetto, R; Noaro, G; Ferrigno, A; Boncompagni, E; Freitas, I; Vairetti, MP; Carraro, A; Neri, D; Cillo, U. Subnormothermic machine perfusion for non-heart-beating donor liver grafts preservation in a Swine model: a new strategy to increase the donor pool? *Transplant. Proc.*, 2012, 44(7), 2026–8.

Guarrera, JV; Henry, SD; Samstein, B; Reznik, E; Musat, C; Lukose, TI; Ratner, LE; Brown, RS; Kato, T; Emond, JC. Hypothermic Machine Preservation Facilitates Successful Transplantation of "Orphan" Extended Criteria Donor Livers. *Am. J. Transplant.*, 2015, 15(1), 161–169.

Guarrera, JV; Estevez, J; Boykin, J; Boyce, R; Rashid, J; Sun, S; Arrington, B. Hypothermic machine perfusion of liver grafts for transplantation: technical development in human discard and miniature swine models. *Transplant. Proc.*, 2005, 37(1), 323–5.

Guarrera, JV; Henry SD; Samstein B; Odeh-Ramadan R; Kinkhabwala M; Goldstein MJ; Ratner, LE; Renz, JF; Lee, HT; Brown, RS; Emond, JC. Hypothermic machine preservation in human liver transplantation: the first clinical series. *Am. J. Transplant.*, 2010, 10(2), 372–81.

Holecek, M; Rysava, R; Safranek, R; Kadlcikova, J; Sprongl, L. Acute effects of decreased glutamine supply on protein and amino acid metabolism in hepatic tissue: a study using isolated perfused rat liver. *Metabolism.*, 2003, 52(8), 1062–7.

Hoyer, DP; Mathé, Z; Gallinat, A; Canbay, AC; Treckmann, JW; Rauen, U; Paul, A; Minor, T. Controlled Oxygenated Rewarming of Cold Stored Livers Prior to Transplantation: First Clinical Application of a New Concept. *Transplantation*, 2016, 100(1), 147–52.

Hoyer, DP; Paul, A; Luer, S; Reis, H; Efferz, P; Minor, T. End-ischemic reconditioning of liver allografts, Controlling the rewarming. *Liver Transpl.*, 2016, 22(9), 1223–30.

Hussein, Z; Evans, AM; Rowland, M. Physiologic models of hepatic drug clearance: influence of altered protein binding on the elimination of diclofenac in the isolated perfused rat liver. *J. Pharm. Sci.*, 1993, 82(9), 880–5.

Imber, CJ; St Peter, SD; Lopez de Cenarruzabeitia, I; Pigott, D; James, T; Taylor, R; McGuire, J; Hughes, D; Butler, A; Rees, M; Friend, PJ. Advantages of normothermic perfusion over cold storage in liver preservation. *Transplantation*, 2002, 73(5), 701–9.

Jamieson, RW; Zilvetti, M; Roy, D; Hughes, D; Morovat, A; Coussios, CC; Friend, PJ. Hepatic steatosis and normothermic perfusion-preliminary experiments in a porcine model. *Transplantation*, 2011, 92(3), 289–95.

Jay, CL; Lyuksemburg, V; Ladner, DP; Wang, E; Caicedo, JC; Holl, JL; Abecassis, MM; Skaro, AI. Ischemic cholangiopathy after controlled donation after cardiac death liver transplantation: a meta-analysis. *Ann. Surg.*, 2011, 253(2), 259–64.

Jones, DB; Morgan, DJ; Mihaly, GW; Webster, LK; Smallwood, RA. Discrimination between the venous equilibrium and sinusoidal models of hepatic drug elimination in the isolated perfused rat liver by perturbation of propranolol protein binding. *J. Pharmacol .Exp. Ther.*, 1984, 229(2), 522–6.

Kestens, PJ; Mikaeloff, P; Haxhe, JJ; Dureau, G; Alexandre, G; Rassat, JP; Cuilleret, J; Hassoun, A; Dubernard, M; Descotes, J; Morelle, J. Homotransplantation of the canine liver after hypothermic perfusion of long duration. *Bull. Soc. Int. Chir.*, 1996, 25(6), 647–59.

Khezrian, M; Sheikholeslami, B; Dadashzadeh, S; Lavasani, H; Rouini, M. Effects of cyclosporine A on the hepatobiliary disposition and hepatic uptake of etoposide in an isolated perfused rat liver model. *Cancer Chemother. Pharmacol.*, 2015, 75(5), 961–8.

Kinoshita, H; Watanabe, A; Hisayasu, S; Suzuki, S; Shimada, T. Targeted gene delivery to selected liver segments via isolated hepatic perfusion. *J. Surg. Res.*, 2010, 160(1), 47–51.

Lavasani, H; Sheikholeslami, B; Ardakani, YH; Abdollahi, M; Hakemi, L; Rouini, MR. Study of the pharmacokinetic changes of Tramadol in diabetic rats. *Daru.*, 2013, 21(1), 17.

Lenzen, R; Stremmel, W; Strohmeyer, G. Antiarrhythmic drugs impair hepatic uptake and secretory function by different mechanisms in the isolated perfused rat liver. *Biochim. Biophys. Acta.*, 1992, 1074(3), 406–12.

Lienard, D; Ewalenko, P; Delmotte, JJ; Renard, N; Lejeune, FJ. High-dose recombinant tumor necrosis factor alpha in combination with interferon gamma and melphalan in isolation perfusion of the limbs for melanoma and sarcoma. *J. Clin. Oncol.*, 1992, 10(1), 52–60.

Liu, Y; Weber, SJ; Onua, ET. Hepatic clearance and drug metabolism using isolated perfused rat liver. *Curr. Protoc. Pharmacol.*, 2004, Chapter 7, Unit 7.9.

Lüer, B; Koetting, M; Efferz, P; Minor, T. Role of oxygen during hypothermic machine perfusion preservation of the liver. *Transpl. Int.*, 2010, 23(9), 944–50.

Mehvar, R; Chimalakonda, AP. Hepatic disposition of cyclosporine A in isolated perfused rat livers. *J. Pharm. Pharm. Sci.*, 2004, 7(1), 47–54.

Meijer, DK; Weitering, JG; Vonk, RJ. Hepatic uptake and biliary excretion of d-tubocurarine and trimethyltubocurarine in the rat *in vivo* and in isolated perfused rat livers. *J. Pharmacol. Exp. Ther*., 1976, 198(1), 229–39.

Mergental, H; Perera, MTPR; Laing, RW; Muiesan, P; Isaac, JR; Smith, A; Stephenson, BTF; Cilliers, H; Neil, DAH; Hübscher, SG; Afford, SC; Mirza, DF. Transplantation of Declined Liver Allografts Following Normothermic Ex-Situ Evaluation. *Am. J. Transplant.*, 2016, 16(11), 3235–3245.

Mets, B; Hickman, R; Allin, R; Van Dyk, J; Lotz, Z. Effect of hypoxia on the hepatic metabolism of lidocaine in the isolated perfused pig liver. *Hepatology.*, 1993, 17(4), 668–76.

Miller, LL; Bly, CG; Watson, ML; Bale, WF. The dominant role of the liver in plasma protein synthesis; a direct study of the isolated perfused rat liver with the aid of lysine-epsilon-C14. *J. Exp. Med.*, 1951, 94(5), 431–53.

Minor, T; Efferz, P; Fox, M; Wohlschlaeger, J; Lüer, B. Controlled oxygenated rewarming of cold stored liver grafts by thermally graduated machine perfusion prior to reperfusion. *Am. J. Transplant.*, 2013, 13(6), 1450–60.

Miranda, SR; Lee, JK; Brouwer, KLR; Wen, Z; Smith, PC; Hawke, RL. Hepatic metabolism and biliary excretion of silymarin flavonolignans in isolated perfused rat livers: role of multidrug resistance-associated protein 2 (Abcc2). *Drug Metabol. Dispos.*, 2008, 36(11), 2219–26.

Mitchell, SJ; Huizer-Pajkos, A; Cogger, VC; McLachlan, AJ; Le Couteur, DG; Hilmer, SN. Poloxamer 407 increases the recovery of paracetamol in the isolated perfused rat liver. *J. Pharm. Sci.*, 2011, 100(1), 334–40.

Mitchell, SJ; Huizer-Pajkos, A; Cogger, VC; McLachlan, AJ; Le Couteur, DG; Jones, B; de Cabo R; Hilmer, SN. The influence of old age and poloxamer-407 on the hepatic disposition of diazepam in the isolated perfused rat liver. *Pharmacology*., 2012, 90(5–6), 233–41.

Moers, C; Smits, JM; Maathuis, MHJ; Treckmann, J; van Gelder, F; Napieralski, BP; van Kasterop-Kutz, M; van der Heide, JJH; Squifflet, JP; van Heurn, E; Kirste, GR; Rahmel, A; Leuvenink, HGD; Paul, A; Pirenne, J; Ploeg, RJ. Machine perfusion or cold storage in deceased-donor kidney transplantation. *N. Engl. J. Med.*, 2009, 360(1), 7–19.

Mol, WE; Rombout, F; Paanakker, JE; Oosting, R; Scaf, AH; Meijer, DK. Pharmacokinetics of steroidal muscle relaxants in isolated perfused rat liver. *Biochem. Pharmacol.*, 1992, 44(7), 1453–9.

Mourad, MM; Liossis, C; Gunson, BK; Mergental, H; Isaac, J; Muiesan, P; Mirza, DF; Perera, MTPR; Bramhall, SR. Etiology and management of hepatic artery thrombosis after adult liver transplantation. *Liver Transpl.*, 2014, 20(6), 713–23.

Nishida, S; Nakamura, N; Kadono, J; Komokata, T; Sakata, R; Madariaga, JR; Tzakis, AG. Intrahepatic biliary strictures after liver transplantation. *J. Hepatobiliary Pancreat. Surg.* 2006, 13(6), 511–6.

Noter, SL; Rothbarth, J; Pijl, MEJ; Keunen, JEE; Hartgrink, HH; Tijl, FGJ; Kuppen, PJK; van de Velde, CJH; Tollenaar RAEM. Isolated hepatic perfusion with high-dose

melphalan for the treatment of uveal melanoma metastases confined to the liver. *Melanoma. Res.*, 2004, 14(1), 67–72.

Olofsson, R; Cahlin, C; All-Ericsson, C; Hashimi, F; Mattsson, J; Rizell, M; Lindnér, P. Isolated hepatic perfusion for ocular melanoma metastasis: registry data suggests a survival benefit. *Ann. Surg. Oncol.*, 2014, 21(2), 466–72.

Op den Dries, S; Karimian, N; Sutton, ME; Westerkamp, AC; Nijsten, MWN; Gouw, ASH; Wiersema-Buist, J; Lisman, T; Leuvenink, HGD; Porte, RJ. *Ex vivo* Normothermic Machine Perfusion and Viability Testing of Discarded Human Donor Livers. *Am. J. Transplant.*, 2013, 13(5), 1327–1335.

Op den Dries, S; Sutton, ME; Karimian, N; de Boer, MT; Wiersema-Buist, J; Gouw, ASH; Leuvenink, HGD; Lisman, T; Porte, RJ. Hypothermic oxygenated machine perfusion prevents arteriolonecrosis of the peribiliary plexus in pig livers donated after circulatory death. *PloS. One*, 2014, 9(2), e88521.

Pezzati, D; Ghinolfi, D; De Simone, P; Balzano, E; Filipponi, F. Strategies to optimize the use of marginal donors in liver transplantation. *World J. Hepatol.*, 2015, 7(26), 2636–47.

Pfeifer, ND; Bridges, AS; Ferslew, BC; Hardwick, RN; Brouwer, KLR. Hepatic basolateral efflux contributes significantly to rosuvastatin disposition II: characterization of hepatic elimination by basolateral, biliary, and metabolic clearance pathways in rat isolated perfused liver. *J. Pharmacol. Exp. Ther.*, 2013, 347(3), 737–45.

Pienaar, BH; Lindell, SL; Van Gulik, T; Southard, JH; Belzer, FO. Seventy-two-hour preservation of the canine liver by machine perfusion. *Transplantation*, 1990, 49(2), 258–60.

Reddy, SK; Kesmodel, SB; Alexander, HR. Isolated hepatic perfusion for patients with liver metastases. *Ther. Adv. Med. Oncol.*, 2014, 6(4), 180–94.

Rizell, M; Mattson, J; Cahlin, C; Hafström, L; Lindner, P; Olausson, M. Isolated hepatic perfusion for liver metastases of malignant melanoma. *Melanom. Res.*, 2008, 18(2), 120–6.

Rothbarth, J; Pijl, MEJ; Vahrmeijer, AL; Hartgrink, HH; Tijl, FGJ; Kuppen, PJK; Tollenaar, RAEM; van de Velde, CJH. Isolated hepatic perfusion with high-dose melphalan for the treatment of colorectal metastasis confined to the liver. *Br. J. Surg.*, 2003, 90(11), 1391–7.

Roumi, M; Marleau, S; Boghen, M; Nilsson, M; Du Souich, P; Ong, H. Hepatic extraction of hexarelin, a new peptidic GH secretagogue, in the isolated perfused rat liver. *Pharm. Res.*, 1997, 14(8), 1008–13.

Schlegel, A; Kron, P; De Oliveira, ML; Clavien, PA; Dutkowski, P. Is single portal vein approach sufficient for hypothermic machine perfusion of DCD liver grafts? *J. Hepatol.*, 2016, 64(1), 239–41.

Schlegel, A; Kron, P; Dutkowski, P. Hypothermic Oxygenated Liver Perfusion: Basic Mechanisms and Clinical Application. *Curr. Transplant. Rep.*, 2015, 2(1), 52–62.

Schön, MR; Kollmar, O; Wolf, S; Schrem, H; Matthes, M; Akkoc, N; Schnoy, NC; Neuhaus, P. Liver transplantation after organ preservation with normothermic extracorporeal perfusion. *Ann. Surg.*, 2001, 233(1), 114–23.

Slieker, JC; Farid, WRR; van Eijck, CHJ; Lange, JF; van Bommel, J; Metselaar, HJ; de Jonge, J; Kazemier, G. Significant contribution of the portal vein to blood flow through the common bile duct. *Ann. Surg.*, 2012, 255(3), 523–7.

St Peter, SD; Imber, CJ; Kay, J; James, T; Friend, PJ; Peter, SD. Hepatic control of perfusate homeostasis during normothermic extrocorporeal preservation. *Transplant. Proc.*, 2003, 35(4), 1587–90.

Starzl, TE; Brettschneider, L; Groth, CG. Liver transplantation. *Bull. Soc. Int. Chir.*, 1967, 26(5), 474–88.

Sutton, ME; op den Dries, S; Karimian, N; Weeder, PD; de Boer, MT; Wiersema-Buist, J; Gouw, ASH; Leuvenink, HGD; Lisman, T; Porte, RJ. Criteria for viability assessment of discarded human donor livers during ex vivo normothermic machine perfusion. *PloS. One*, 2014, 9(11), e110642.

Takakura, Y; Mahato, RI; Yoshida, M; Kanamaru, T; Hashida, M. Uptake characteristics of oligonucleotides in the isolated rat liver perfusion system. *Antisense & Nucleic Acid Drug Dev.*, 1996, 6(3), 177–83.

Tzeng, CWD; Aloia, TA. Colorectal liver metastases. *J. Gastrointest. Surg.*, 2013, 17(1), 195−202.

Vahrmeijer, AL; van Dierendonck, JH; Keizer, HJ; Beijnen, JH; Tollenaar, RA; Pijl, ME; Marinelli, A; Kuppen, PJ; van Bockel, JH; Mulder, GJ; van de Velde, CJ. Increased local cytostatic drug exposure by isolated hepatic perfusion: a phase I clinical and pharmacological evaluation of treatment with high dose melphalan in patients with colorectal cancer confined to the liver. *Br J Cancer.*, 2000, 82(9), 1539–46.

Vairetti, M; Ferrigno, A; Carlucci, F; Tabucchi, A; Rizzo, V; Boncompagni, E; Neri, D; Gringeri, E; Freitas, I; Cillo, U. Subnormothermic machine perfusion protects steatotic livers against preservation injury: a potential for donor pool increase? *Liver Transpl.*, 2009, 15(1), 20–9.

Vairetti, M; Ferrigno, A; Rizzo, V; Richelmi, P; Boncompagni, E; Neri, D; Freitas, I; Cillo, U. Subnormothermic machine perfusion protects against rat liver preservation injury: a comparative evaluation with conventional cold storage. *Transplant. Proc.*, 2007, 39(6), 1765–7.

van Etten, B; Eggermont, AMM; Ambagtsheer, G; van Tiel, ST; ten Hagen, TLM. Impaired neutralising antibody formation and high transduction efficacy after isolated hepatic perfusion with adenoviral vectors. *Br. J. Cancer.*, 2004, 91(8), 1610–3.

van Iersel, LBJ; Koopman, M; van de Velde, CJH; Mol, L; van Persijn van Meerten, EL; Hartgrink, HH; Kuppen, PJK; Vahrmeijer, AL; Nortier, JWR; Tollenaar, RAEM; Punt, C; Gelderblom, H. Management of isolated nonresectable liver metastases in colorectal cancer patients: a case-control study of isolated hepatic perfusion with melphalan versus systemic chemotherapy. *Ann. Oncol.*, 2010, 21(8), 1662–7.

van Iersel, LB; Verlaan, MR; Vahrmeijer, AL; van Persijn van Meerten, EL; Tijl, FGJ; Sparidans, RW; Gelderblom, H; Kuppen, PJK; Tollenaar, RAEM; van de Velde, CJ. H. Hepatic artery infusion of high-dose melphalan at reduced flow during isolated hepatic perfusion for the treatment of colorectal metastases confined to the liver: a clinical and pharmacologic evaluation. *Eur. J. Surg. Oncol.*, 2007, 33(7), 874–81.

Vekemans, K; Liu, Q; Brassil, J; Komuta, M; Pirenne, J; Monbaliu, D. Influence of flow and addition of oxygen during porcine liver hypothermic machine perfusion. *Transplant. Proc.*, 2007, 39(8), 2647–51.

Westerkamp, AC; Karimian, N; Matton, APM; Mahboub, P; van Rijn, R; Wiersema-Buist, J; de Boer, MT; Leuvenink, HGD; Gouw, ASH; Lisman, T; Porte, RJ. Oxygenated

Hypothermic Machine Perfusion After Static Cold Storage Improves Hepatobiliary Function of Extended Criteria Donor Livers. *Transplantation*, 2016, 100(4), 825–35.

Westerkamp, AC; Mahboub, P; Meyer, SL; Hottenrott, M; Ottens, PJ; Wiersema-Buist, J; Gouw, ASH; Lisman, T; Leuvenink, HGD; Porte, RJ. End-ischemic machine perfusion reduces bile duct injury in donation after circulatory death rat donor livers independent of the machine perfusion temperature. *Liver Transpl.*, 2015, 21(10), 1300–11.

Wilhelm, M; Jaeger, DE; Schüll-Cablitz, H; Hafner, D; Idel, H. Hepatic clearance and retention of aluminium: studies in the isolated perfused rat liver. *Toxicol. Lett.*, 1996, 89(3), 257–63.

Xu, R; Zhang, X; Yang, J; Liu, X; Davey, AK; Wang, J. Effects of glycyrrhizin on biliary transport and hepatic levels of glutathione in rats. *Biopharm. Drug Dispos.*, 2012, 33(5), 235–45.

Yamamoto, M; Zager, JS. Isolated hepatic perfusion for metastatic melanoma. *J. Surg. Oncol.*, 2014, 109(4), 383–8.

Zhang, L; Rowe, A; Braet, F; Ramzan, I. Macrophage depletion ameliorates kavalactone damage in the isolated perfused rat liver. *J. Toxicol. Sci.*, 2012, 37(2), 447–53.

Zhao, X; Deng, B; Xu, XY; Yang, SJ; Zhang, T; Song, YJ; Liu, XT; Wang, YQ; Cai, DY. Glycyrrhizinate reduces portal hypertension in isolated perfused rat livers with chronic hepatitis. *World J. Gastroenterol.*, 2013, 19(36), 6069–76.

In: Encyclopedia of Surgery (22 Volume Set)
Editors: Andreas Lehrer and Kristin Mueller
ISBN: 978-1-53618-329-0
© 2020 Nova Science Publishers, Inc.

Chapter 214

EXPERIMENTAL MODELS OF CARTILAGE REPAIR

Jakub Zafar Qazi[1], Huifang Chen[2], MD, PhD and Muhammad Zafarullah[3,*], PhD

[1]Anatomy and Cell Biology, McGill University, Montreal, Quebec, Canada
[2]Department of Surgery, CRCHUM, Montreal, Quebec, Canada
[3]Department of Medicine, Université de Montréal, Montreal, Quebec, Canada

ABSTRACT

Cartilage focal injuries resulting from trauma and sports can lead to disability and osteoarthritis (OA). The World Health Organization estimates that 9.6% of the male and 18% of the female population over 60 suffers from OA worldwide. Chronic OA greatly limits movement and day-to-day activities. The progressive degeneration of hyaline cartilage is caused by physical stress and its inability to regenerate spontaneously due to its avascular nature and hypocellularity. It is, therefore, necessary to develop and test new surgical and pharmacological cartilage repair methods and materials in animal models mimicking clinical scenarios. Rodents, rabbit, dog, pig, Göttingen minipig, horse, cow, nonhuman primates (NHPs) and human cartilage have been utilized to model *in vitro* (monolayer-, suspension-, pellet-, micromass cultures), *ex vivo* (explants) and *in vivo* repair after cartilage loss. Current surgical cartilage repair approaches involve bone marrow stimulation by microfracturing, mosaicplasty, autologous chondrocyte implantation (ACI) and allograft transplantation. Chondrocyte or chondrogenic stem cell (adult, reprogrammed iPSCs) therapy with scaffolds has been especially promising for cartilage repair owing to the regenerative, anti-inflammatory and immunomodulatory properties of stem cells. It is also possible to conduct selective differentiation into only articular chondrocytes. The quality of repaired cartilage can be analyzed by micro-CT, MRI and immunohistochemical techniques using various (OARSI, ICRS) scoring systems. Furthermore, the development of new delivery systems for both the pharmacological (chondrogenic growth factors, small molecules, chondroprotective agents) and cell-based therapies is also essential to their proper translation in clinic. Despite these hurdles, this field warrants the attention of surgeons, researchers and the public due to the prevalence of individuals afflicted with cartilage injuries, chronic

* Corresponding Author's Email: Muhammad.Zafarullah@umontreal.ca.

rheumatic conditions, ageing populations and the advent of many novel treatment options.

Keywords: cartilage, chondrocytes, mesenchymal stem cells, growth factors, scaffolds

ABBREVIATIONS

ACI	Autologous chondrocyte implantation
ADSCs	Adipose-derived stem cells
BMP	Bone morphogenetic protein
BMSCs	Bone marrow-derived mesenchymal stem cells
COX2	Cyclooxygenase-2
DMM	Destabilization of medial meniscus
ECM	Extracellular matrix
FGF	Fibroblast growth factor
GDF	Growth differentiation factor
HA	Hyaluronic acid
ICRS	International Cartilage Repair Society
IGF	Insulin-like growth factor
iPSCs	Induced pluripotent stem cells
MMPs	Matrix metalloproteinases
MRI	Magnetic resonance imaging
MSCs	Mesenchymal stem cells
NHPs	Nonhuman primates
NSAIDs	Non-steroidal anti-inflammatory drugs
OA	Osteoarthritis
OARSI	Osteoarthritis Research Society International
PBMCs	Peripheral blood mononuclear cells
PRP	Platelet-rich plasma
Rac1	Ras-related C3 botulinum toxin substrate 1
Sox9	SRY (sex determining region Y)-box 9
TGF-β	Transforming growth factor beta

INTRODUCTION

Animals contain different types of cartilage tissues. Some examples include the hyaline cartilage of the nasal septum, tracheal rings, ribs, the elastic cartilages of the ear and epiglottis and the fibrocartilages of the intervertebral discs, temporomandibular joint disc, and knee meniscus (Huey 2012). Articular cartilage is an important joint tissue that provides a friction-free gliding surface, absorbs shocks and distributes weight, thus enabling diverse and complex human movements. Hyaline cartilage includes articular cartilage which consists of distinct superficial, transitional, radial and calcified zones. However, cartilage is frequently injured by traumatic work- and sports-related activities creating focal chondral or

osteochondral injuries/defects which lead to common joint degenerative disease, osteoarthritis (OA) over the long term, causing a great amount of pain (Blaney Davidson 2017), disability and an economic burden. Disc herniation and ruptured annulus fibrosus is frequent cause of back pain requiring lumber discectomy (Guterl 2013). Although mostly associated with older people, increasing physical inactivity and obesity also alter weight-bearing abilities of joints and constitute OA risk factors for younger individuals (Gabay 2008).

Degradation of cartilage extracellular matrix (ECM) in OA occurs by proinflammatory cytokines-instigated matrix metalloproteinases (MMPs) and aggrecanases which is a shared feature of rheumatoid arthritis (RA) and OA, the most common arthritic diseases. In contrast with repairable bone fractures, adult human cartilage has limited capacity to regenerate due to its avascularity, hypocellularity, chondrocyte senescence and hyporesponsiveness to chondrogenic/anabolic growth factors such as transforming growth factor beta (TGF-β) superfamily members. When all the physical (exercise, weight loss), pharmacological (analgesics, hyaluronic acid, NSAIDs, COX2 inhibitors, corticosteroids treatment) and surgical approaches (such as lavage and debridement) fail to manage symptoms of OA (pain) and cartilage has been damaged beyond repair, joint (knee, hip) replacement surgery (arthroplasty) is performed, which also lasts for about 10–12 years and, then, fails. Thus, it is important to prevent cartilage injuries and repair cartilage at a much earlier stage.

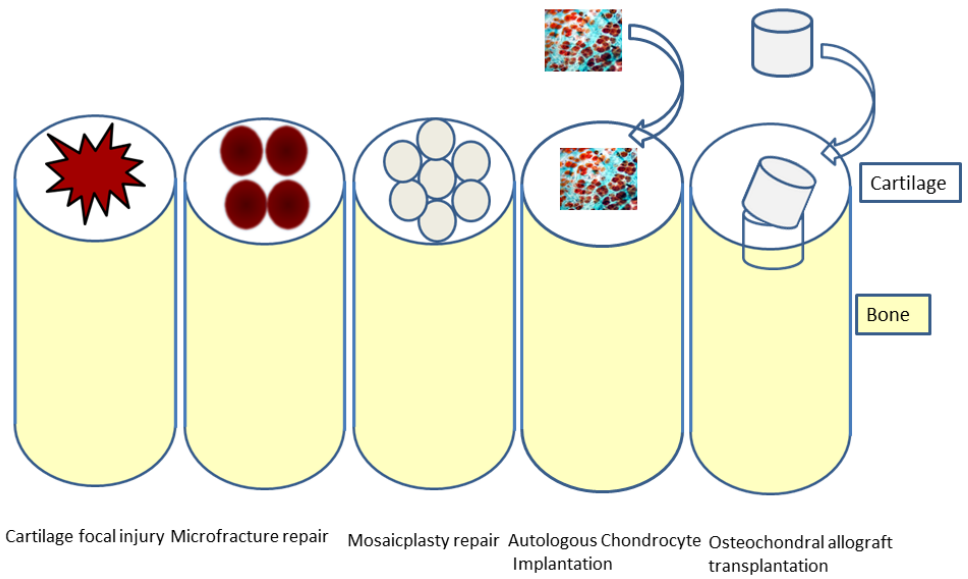

Figure 1. Schematic representations of surgical techniques for repairing cartilage. Cartilage focal injury can be repaired by: removing loose pieces of cartilage (debridement) and drilling holes until bone marrow and formation of blood clot which leads to repair (microfracturing); by removing circular pieces from non-weight bearing areas and their implantation as a mosaic (mosaiplasty); biopsy of cartilage, growth and multiplication of chondrocytes and injection of chondrocytes at the lesion site under a periosteal flap (Autologous Chondrocyte Implantation); removal of osteochondral graft from cadaver or patient and insertion of the graft of the size matching with lesion with a pin (osteochondral allograft transplantation). Normal cartilage (white) and bone (light brown) are also indicated (inspired from and based on: https://cartilage.org/patient/about-cartilage/cartilage-repair/.

Surgical focal cartilage repair approaches involve debridement (removal of loose non-functional pieces of cartilage), bone marrow stimulation by microfracturing (microdrilling until subchondral bone and bone marrow, from where new cartilage develops), mosaicplasty (an autograft of healthy circular osteochondral tissues from non-weight bearing regions of the knee into drilled tunnels in a mosaic pattern within sections of defective cartilage), autologous chondrocyte implantation (ACI-for younger patients) and allograft or xenograft (for lesions greater than 2 cm) transplantation (Figure 1) (Clouet 2009; Katz 2010). However, bone marrow stimulation leads to substandard fibrocartilage, autografts do not integrate well as shown in a sheep model (Gelse 2015) and allografts may bring infections to the host and loss of cell viability. The problems of tissue regeneration technology include a limited availability of donor cells for transplantation, the formation of fibrocartilage of poor biomechanical quality, chondrocyte necrosis, chondrocyte dedifferentiation and poor integration with the native cartilage (Umlauf 2010).

Thus, there is an urgent need to develop and evaluate effective and durable new treatments for cartilage trauma and joint diseases-associated lesions by using a variety of experimental repair models. Here, we discuss various components of cartilage regeneration and recent developments in the field using specific examples.

CHONDROGENESIS

Cartilage originates from the mesoderm of the implanted embryo and constitutes one of the earlier steps of bone development. Fibroblast Growth Factor 2 (FGF2) primes mesenchymal stem cells (MSCs) by condensation for chondrogenesis causing them to express and deposit collagens type I, III and IV. This is followed by stimulation of chondrocyte progenitor cells with TGF-β to start differentiation into prechondrocytes, early chondroblasts, columnar chondroblasts, pre-hypertrophic chondrocytes (all expressing type II, IX and XI collagens, aggrecan), hypertrophic chondrocytes (expressing type X collagen) and calcified terminal hypertrophic chondrocytes (Goldring 2012). Overall, the chondrocyte differentiation steps are promoted by, amongst others, the SOX9 and RUNX2/3 master genes and antagonized by TWIST1, SOX5/6, and MEF2C/D through their inhibition of the 2 master factors (Liu 2017) which may provide interesting therapeutic targets for the treatment of OA. During OA, the aforementioned hypertrophic differentiation and calcification undergone by articular chondrocytes coincides with the expression of the hypertrophic chondrocyte markers, collagen type X and matrix metalloproteinase 13 (MMP-13) putatively regulated by growth arrest and DNA-damage-inducible protein beta (GADD45β). The changes in the expression profile of these differentiating cells in addition to the ensuing ECM remodelling leads to their eventual ossification (Goldring 2006).

In contrast with growth plate chondrogenesis where chondrocytes at the end of bones progressively undergo osteochondral ossification, for articular chondrocyte differentiation, MSCs lead to prechondrocytes, early chondroblasts and articular chondrocytes; the latter normally never undergo hypertrophic differentiation, thereby constituting the permanent articular cartilage. However, during OA, articular chondrocyte may undergo abnormal hypertrophic differentiation (Pitsillides 2011). The biological and biochemical agents which promote articular cartilage formation and prevent terminal differentiation may be of

therapeutic value for permanent cartilage repair and regeneration. For instance, Triiodothyronine may prevent terminal hypertrophic differentiation.

Nonetheless, the current inability to stunt the maturation of grafted cells before reaching a fibrocartilaginous state (an intermediate of hypertrophic differentiation characterized by the co-expression of type I and II collagens and loss of tissue elasticity) constitutes one of the greatest hurdles of cartilage regenerative therapy. This challenge stems from the irreversible changes to the ECM upon exposure to chronic physical stress which, in part, drives the aberrant expression of genes responsible for the pathogenesis of joint-related degeneration.

IN VITRO AND *EX VIVO* MODELS OF CARTILAGE REPAIR

Various types of cultures such as 2-D monolayer-cultured cells, suspension, micromass as well as pellet cultures of articular chondrocytes representing different cell compactions with variable densities of chondrocytes have been used as *in vitro* models to test cartilage regenerative molecules and growth factors. For this purpose, rat, rabbit, bovine, equine, porcine, dog and human chondrocytes are used. Upon subculturing, monolayer chondrocyte cultures progressively lose their cartilage phenotype (Sox9, aggrecan and collagen 2A1 expression) as demonstrated by a loss of cartilage-specific Alcian Blue and Safranin-O (glycosaminoglycan)/fast green staining. Attempts are continuously being made to maintain the chondrocyte phenotype by growing them at high density and in 3-D cultures in agarose and alginate beads. Treatment with recombinant acid ceramidase (rAC; which maintains bioactive lipids such as ceramide) resulted in improved phenotype in rat, horse and human chondrocytes. Furthermore, the addition of rAC to feline, equine and rat bone marrow resulted in a 2-fold enrichment of MSCs and their chondrogenic differentiation (Simonaro 2013). Such approaches may improve cartilage repair technology. Because of its large size and easy accessibility, the bovine femur is a popular cartilage source and a repair model. In a study, a trephine drill head was used to explant an osteochondrol tissue from femoral condyle and used to punch defects as an *ex vivo* model maintaining the native cartilage matrix environment (de Vries-van Melle 2012). Pellet cultures were found superior to monolayer and suspension culture in repairing defects in such explants (Schmutzer 2017). Porcine femoral condyles have been used to generate osteochondral test tissue cylinders to evaluate adhesive properties of fibrin (Dehne 2012). Chondrogenesis-stimulating growth factors such as TGF-β1 and BMP-2 also enhanced cartilage repair in such models.

ANIMAL MODELS TO STUDY OSTEOARTHRITIS AND CARTILAGE REPAIR

Mature axolotl salamander diarthrodial joints are phenotypically similar to the developing synovial joints in mammals and have the remarkable and exceptional ability to regenerate its amputated limbs due to blastema, limb bud-like structures (Mitogawa 2015). Thus, they have been projected as vertebrate models for studying joint development and repair (Cosden-Decker 2012).

Small animal models used for inducing OA-related cartilage loss are mice, rats, guinea pigs and rabbits (Little 2012). The surgical destabilization of medial meniscus (DMM) or anterior cruciate ligament (ACL) transaction leads to OA which can be used to study disease progression and therapies for preventing cartilage degradation (Culley 2015). The injection of type II collagen antibodies in mouse paws induces cartilage loss without causing inflammation which can be used to study cartilage protective therapies (Croxford 2013). The commonly used mouse strain for genetic modification, C57Bl/6 has been developed as articular cartilage repair model by full-length injuries to patellar groove of 3-weeks (young), 4-weeks (juvenile) and 8-weeks old (adult) mice with a 27G needle followed by studying repair. Young and juvenile animals showed superior repair after 8 weeks (Matsuoka 2015). Transgenic mouse strains overexpressing human MMP-13 in joints lead to cartilage loss and can be used as repair therapy models. There are numerous other enzymatically- and chemically-induced and genetically modified models causing OA-like cartilage loss or protecting against cartilage degradation.

Among large animals, goat, sheep, minipigs such as Göttingen minipig (Christensen 2016) and horses are well suited to induce chondral defects (Madry 2015). ACL and DMM models of cartilage loss can also be developed in large animals such as dog. The number of osteochondral defect research animals can be reduced if both joints are used, as observed in a rabbit model (Orth 2013). Further, bone marrow stimulation in rabbit trochlear groove appears to induce more chondrogenesis compared to medial femoral condyle (Chen 2013).

Due to the close genetic proximity of primates, the *Cynomolgus* monkey model may be highly pertinent to conduct preclinical cartilage repair research and ultimately translate these findings to clinic. We achieved high-quality repair in microfracture and collagenase-induced cartilage injury models with chondrogenic bone marrow-derived mesenchymal stem cells (BMSCs) delivered by acellular dermal matrix scaffold (Jiang 2014, Ma 2013). Earlier, osteochondral defects were treated for 6−12 weeks by microfracture-based bone marrow stimulation in *Cynomolgus* monkeys (Gill 2005). However, the long-term properties of the repaired cartilage (fibrocartilage formation and eventual degeneration) are not known. Use of nonhuman primates and dogs for cartilage research may be troubling due to ethical unacceptability by the society.

GROWTH FACTORS THAT PROMOTE ARTICULAR CARTILAGE FORMATION

The same growth factors responsible for embryonic cartilage development may also play a role in adult cartilage repair. TGF-β signalling is required for limb regeneration in Axolotls (Lévesque 2007) and for the formation of joints, as TGF-β type II receptor gene knockout mice lack interphalangeal joints (Spagnoli 2007). Human OA cartilage responds poorly to TGF-β due to IL-1β-mediated decreased receptor II and due to up-regulation of inhibitory Smad7 (Verdier 2005). It is a major growth factor for repairing joint injuries and for preventing cartilage degradation. Cartilage regenerative factors include TGF-β1/BMP, FGF and Wnt family members. TGF-β1, TGF-β3 plus dynamic compression could promote cartilage formation with compressive properties closer to those of native cartilage. FGF-18 promotes cartilage growth and prevents degradation (Huey 2012). Recombinant human FGF-

18 treatment in the sheep chondral defect microfracture model displayed increased cartilage-specific type II collagen staining and improved cartilage repair scores (Howard 2015). Treatment of monkey bone marrow-derived MSCs with BMPs, BMP-2, BMP-4, BMP-7, BMP-9, growth differentiation factor 5 (GDF-5), TGF-β and IGF-1 in different combinations may extend the differentiated chondrocyte phenotype, upregulate chondrocyte gene expression and result in better-quality and longer-lasting cartilage. BMPs induce chondrogenesis and cartilage repair (Reddi 2003). BMP-7 and GDF-5 expression levels are reduced in murine arthritic cartilage, indicating impaired repair during the pathogenesis (Bobacz 2008). BMP-7 was also shown to protect cartilage in a rabbit OA model (Badlani 2008). TGF-β1 and BMP-7 induced chondrogenesis in human embryonic stem cells, but these articular chondrocytes did not express lubricin or proteoglycan-4 with lubricative properties (Nakagawa 2009). Overexpression of BMP-2, BMP-4 or TGF-β1 genes also induced chondrogenesis in human MSCs, but, subsequently, led to hypertrophic differentiation (Steinert 2009; Pagnotto 2007). BMP-4 can induce redifferentiation of rabbit chondrocytes *in vitro* and *in vivo* (Lin 2007). Low-level of combined BMP-2, TGF-β1 and IGF-1 expression resulted in larger cartilage aggregates (Steinert 2009a). IGF-1 and BMP-7 synergized to enhance human OA chondrocyte survival and increased bovine spine disc (nucleus pulposus) regeneration (Kim 2010). Adenoviral-based or plasmid-based IGF-1-expressing chondrocytes (gene therapy) improved early cartilage healing in horses and rabbits (Goodrich 2007; Ortved 2015; Madry 2013) (Table 1).

Table 1. Some of the different approaches of cartilage repair; please see text for details and references

Cartilage Repair Approaches (partial list)	
Types of cartilage repair	Procedures/factors/molecules
Surgical	Debridement and microfracturing, mosaicplasty, autologous chondrocyte implantation, osteochondral allograft transplantation
Cell Therapy	Chondrocytes (autologous-, allogeneic- and xenogeneic) Chondrogenic stem cells (embryonic, adult, reprogrammed or induced pluripotent cells), bone marrow-derived stem cells, umbilical cord-derived stem cells, human Wharton's jelly MSCs, peripheral blood mononuclear cells
Pharmacological small molecules (chondrogenic)	Kartogenin, Triiodothyronine, TGF-β+Rac1 inhibitor, TD-198946, RNA interference, microRNAs
Chondrogenic growth factors	Fibroblast growth factor, Fibroblast growth factor-18, Growth differentiation factor, Bone morphogenetic protein, Transforming growth factor beta, Insulin-like growth factor
Scaffolds for cartilage repair	Extracellular matrix, Platelet-rich plasma, Chitosan, Autologous platelet-enriched fibrin, Hyaluronic acid
Inhibitors of cartilage degradation	Doxycycline, FGFR1 inhibitor (G141), Trichostatin A, Tissue inhibitors of metalloproteinases or TIMPs, Synthetic matrix metalloproteinase (MMP) and aggrecanase (ADAMTS) inhibitors, RNA interference, microRNAs

CELLS USED TO REGENERATE AND REPAIR CARTILAGE

Neither MSCs, nor chondrocytes have been effective in generating proper quality of cartilage. MSCs can differentiate into chondrocytes, fibroblast-like chondrocytes and hypertrophic chondrocytes (expressing type X collagen and MMP-13) which produce a

mixture of fibrocartilage and hypertrophic cartilage that eventually fails as a tissue due to its poor biomechanical quality. The microfracture surgery technique also results in fibrocartilage. Delivery of *in vitro* differentiated chondrocytes also does not maintain the proper chondrocyte phenotype, and hyaline cartilage markers such as type II collagen and SOX9 gradually decline. Thus, any therapeutic cells which besides generating hyaline cartilage also produce fibrocartilage and hypertrophic cartilage result in organ failure.

Autologous chondrocytes implantation requires harvesting cartilage and, then, implanting them in a different tissue of the same individual. To increase their number by expansion, if chondrocytes are cultured as monolayer, they dedifferentiate into fibroblasts and start expressing type I and III collagens; implantation of such cells result in fibrocartilage formation. Attempts to redifferentiate such cells into chondrocytes are being made by using various culture conditions and stimuli (Huey 2012). Bianchi et al. have grown high density passage 2 human chondrocytes on a membrane in 3-D system in serum-free redifferentiation medium with TGF-β3 which resulted in a continuous layer of articular cartilage-like tissue without a scaffold (Bianchi 2017). Allogeneic (from same animal species) and xenogeneic (from different animal species) chondrocyte transplantation result in immunological rejection and may also bring infections to the host. Nevertheless, conditions for acquisition, preservation and storage of osteochondral allografts have been established by using human and goat knee experimental models (Bugbee 2016). Platelets have been shown to promote chondrocyte proliferation *in vitro* and cartilage repair in rat OA model by increasing adenosine diphosphate (ADP) and BMP-7 (Zhou 2016). Human peripheral blood mononuclear cells (PBMC) and derived MSC-like adherent (1:20 and 1:2 ratios) cells under hypoxic conditions were used with a collagen-glycosaminoglycan (GAG)-scaffold to treat mountain sheep osteochondral defects and were found to regenerate cartilage, suggesting easily accessible PBMCs as a new source of cartilage repairing cells (Hopper 2015). The lifespan of older rabbit chondrocytes could be increased by transfecting with human telomerase reverse transcriptase (hTERT) and glucose-regulated protein 78 genes suggesting that older chondrocytes may also be useful for repair (Sato 2012).

USE OF MSCS TO REPAIR CARTILAGE

Embryonic, adult and induced pluripotent stem cells (iPSCs) are potentially attractive sources for articular cartilage regeneration (Sakata 2015). Sources of adult MSCs include synovial membranes, synovial fluid, bone marrow and adipose tissue among others (Mazor 2014). Bone marrow is a rich source of multipotential cells (Jones 2002; Sekiya 2002). Other sources include muscle and periosteum (De Bari 2001). Co-expression of TGF-β and cartilage-specific transcription factor, SOX9, by gene transfer in BMSCs resulted in chondrogenic markers expression for 21 days and reduced hypertrophic differentiation (Tao 2016). Intraarticular injection of mouse synovial MSCs from C57BL6 and MRL/MpJ "super-healer" strains lead to increased cartilage repair in a mouse joint injury model after 4 weeks (Mak 2016; reviewed in Rai 2014). Adipose tissue contains directly usable stromal vascular fraction (SVF) or their adherent derivatives for cartilage repair (De Francesco 2015). Among adipose-derived MSCs (ADSCs) and differentiated chondrocytes in a rat OA model, the latter were more effective in regenerating cartilage defect as measured by various cartilage markers

(Latief 2016). However, the testing of different types of MSCs in rodent models gave inconsistent results; most studies showing a statistically significant positive score in arthritis improvement while other showing statistically significant deterioration in arthritis score or no impact (reviewed in Hynes 2016). Both autologous chondrocytes and allogenic MSCs introduced in rabbit osteochondral defect for 6 months had similar regenerative capacities (Tay 2012).

As a new source of adult MSCs, human Wharton's jelly MSCs (hWJMSCs) were used to repair a rabbit femur patellar groove full-length defect for 16 months that was not rejected and yielded properly structured hyaline cartilage (Liu 2017). Delivery of umbilical cord blood-derived mesenchymal stem cells (hUCB-MSCs) with a hyaluronic acid (HA) hydrogel composite resulted in trochlear groove osteochondroal defect (5 mm wide-10 mm deep) repair with superior hyaline cartilage in minipig models after 12 weeks (Ha 2015). hUCB-MSCs with 4% HA hydrogel gave best results in a rat model (Park 2015).

TGFβ3 and Rac1 inhibitor (NSC23766) treatments were able to commit ADSCs to chondro-lineage differentiation mostly into articular chondrocytes (Zhu 2014). Activation of TGF-β signaling pathway in human pluripotent stem cells-derived chondrogenic progenitors leads to articular chondrocytes which produce stable articular cartilage *in vitro* and *in vivo*. In contrast, treatment of the same cells with BMP-4 leads to hypertrophic chondrocytes which start endochondral ossification *in vivo* (Craft 2015). A small thienoindazole derivative compound, TD-198946 regulating Runx1 could induce chondrogenic differentiation and prevent hypertrophy in metatarsal organ culture in addition to preventing and repairing OA in surgically-induced mouse model (Yano 2013). Kartogenin is a powerful inducer of differentiation of MSCs into chondrocytes, is chondroprotective *in vitro* and in two OA animal models (Johnson 2012). Kartogenin conjugated with chitosan nanoparticles and microparticles were retained in rat joints longer and were more preventive of degeneration (Kang 2014). TGF-β treatment *in vitro* could induce condensation of human MSCs into mesenchymal cell bodies (recapitulating cartilage development) followed by chondrogenic differentiation into clinically-relevant and mechanically functional pieces of articular cartilage, with the ability to repair *in vitro* cartilage defect (Bhumiratana 2014). Thus, these promising studies suggest that it may be possible to conduct selective differentiation into only articular chondrocytes. It remains to be seen if these approaches can be translated to human cartilage repair in clinic.

Due to the scarcity of chondrogenic cells, other sources of such cells are being sought. Many adult cells such as keratinocytes, fibroblasts, synovial cells and blood cells can be reprogrammed by transfecting with factors such as Oct4, Sox2; K, Klf4, c-Myc, Nanog and Lin28 into iPSCs and then into chondrocytes which, in turn, can be potentially useful for cartilage regenerative medicine (Liu 2016). Human iPSCs could be 3D bioprinted into cartilage mimics with a nanofibrillated cellulose (NFC) composite bioink and co-printed with irradiated human chondrocytes (Nguyen 2017). However, safety issues such as host immune reactions, genetic aberrations and teratoma formation need to be addressed before their application in clinic (Lietman 2016) (Table 1).

SCAFFOLDS TO DELIVER CELLS AND FACTORS FOR CARTILAGE REPAIR

Current tissue engineering strategies to repair cartilage involve autologous cells in resorbable delivery biomaterials or scaffolds; they provide mechanical stability, 3-D cell distribution and improved differentiation. Such systems deliver stem cells, growth factors and chondrogenic genes (Sittinger 2004). Scaffolds designed for cartilage repair should have the following properties: an ability to match growth and degradation rates, to remove scaffold degradation by-products and harsh chemicals, to maintain round chondrocyte morphology and phenotype and to match compressive properties of native cartilage in addition to having sufficient surface and tensile abilities (reviewed in Huey 2012). Scaffolds with nanomaterials, functional mechanocompatible scaffolds, multilayered scaffolds, and extracellular matrix scaffolds for articular cartilage surface regeneration have been developed (Sakata 2015; Benders 2013). The following approaches are used to introduce these biomaterials into host tissue: i) implantation of engineered constructs of MSC-seeded scaffolds, and (ii) direct delivery of an appropriate population of MSCs by intra-articular injection. Platelet-rich plasma (PRP)-augmented scaffolds prepared and administered with variable methods showed improved outcomes in some animal models or had negative effects or no impact relative to controls (reviewed in Sermer 2015). PRP containing BMSCs were able to significantly regenerate early-stage degenerated rabbit intervertebral disc (a cartilage-like tissue) (Wang 2016). RPR and autologous BMSCs (undifferentiated and differentiated into chondrocytes) promoted repair of articular cartilage in a collagenase-degenerated OA rabbit model (Hermeto 2016). Chitosan implantation (which coagulates in situ at body temperature) in microdrilled defects suppressed fibrocartilage scar tissue formation in rabbits promoting bone remodeling and blood vessel migration in cartilage lesion (Mathieu 2013). Chitostan-PRP hybrids displayed greater cell recruitment and regenerative capacity than PRP only (Chevrier 2017). Bone marrow stimulation with an ultrapurified alginate gel in rabbit patellar groove resulted in more hyaline-like cartilage compared to untreated defect and bone marrow-stimulated defect (Baba 2015). Autologous platelet-enriched fibrin (APEF) scaffold alone without BM-MSCs has generated thick cartilage tissue in a 15 mm chondral defect in horses (Goodrich 2016). In the same model, autologous progenitor cells and fibrin gave a better cartilage repair score than allogenic cells with fibrin (Frisbie 2015). A collagen sponge vehicle was used to conduct a matrix-assisted (autologous) chondrocyte implantation (MACI) in horses, which after 53 weeks resulted in a cartilage with compressive and frictional properties similar to native tissue, but with inferior shear abilities (Griffin 2015; Nixon 2015). A scaffold using pig peritoneum-derive acellular matrix conjugated with BM-MSC affinity peptide (E7) able to recruit MSCs was used to repair rabbit femoral cartilage microfracture defects resulting in a lack of transplant rejection and stable hyaline cartilage generation as analyzed by histological assessment, synovial fluid analysis, magnetic resonance imaging (MRI) and nanomechanical methods (Meng 2017). Furthermore, gellan-gellan-sulfate sponge-soaked with tenascin-C was proven to be an effective method to repair rabbit patellar groove osteochondral defect (Ikemura 2015). Despite many trials of scaffolds, no material matches the compressive, friction and tensile (value of 5–25 MPa) properties of natural cartilage which confer the tissue its ability to withstand various deformations and motions. Recently, soft hydrogel scaffolds have been reinforced by 3-D printed high-porosity microfibre networks. The stiffness and

elasticity of these composite scaffolds was similar to that of articular cartilage enabling chondrocytes to maintain their innate morphology and phenotype (Visser 2015). Scaffold-free technologies have also been developed, which recapitulate native cartilage without scaffold (reviewed in Lee 2017) (Table 1).

INTEGRATION OF ENGINEERED CARTILAGE INTO NATIVE TISSUE

The proper integration of repaired cartilage in surrounding tissue is essential for biological fixation, load distribution and biomechanical signal transmission. Both vertical and lateral integration of the engineered or transplanted tissue is required for successful functioning of cartilage. The neocartilage may appear histologically integrated, but may not be functionally integrated. The non-integration is due to cell death at the edges of the tissue and the non-adhesive properties of cartilage ECM; these issues can be dealt with by treatment with anti-apoptotic agents and ECM degrading enzyme (reviewed in Huey 2012).

PROMOTING CARTILAGE REPAIR BY INHIBITING CARTILAGE DEGRADATION

Traumatic injuries and aging may lead to cartilage degeneration. Additionally, surgically grafted cartilage may also degenerate with time. Therefore prevention of such degradation may promote repair. Cartilage degradation can be induced in mice by destabilization of medial meniscus (DMM). Within this model, the degradation can be reduced by the deletion of fibroblast growth factor receptor 1 (FGFR1) and a novel non-ATP-competitive FGFR1 inhibitor, G141. The same was shown in chondrocytes and human cartilage explants (Xu 2016). A carbohydrate-based drug candidate, tri-butanoylated N-acetyl-D-galactosamine analog (3, 4, 6-O-Bu3GalNAc) promoted cartilage production *in vitro* in MSCs and reduced OA in rat OA model (Kim 2016). Cell therapy of intervertebral disc nucleus pulposus with BM-MSCs increased TGF-β, which inhibited IκB phosphorylation and NF-κB activation and suppressed disc degeneration (Yang 2015). PRP injection in rabbit discs also prevented degeneration (Gui 2015). Trichostatin A was shown to prevent the degradation of transplanted autologous osteochondral tissue in the rabbit model (Hou 2015). Doxycycline, an antibiotic shown to inhibit MMP-13-mediated cartilage degradation in pellet cultures and in rats, induced chondrogenesis in hBM-MSCs and promoted osteochondral defect repair in Sprague-Dawley rats (Lee 2013). Other agents capable of preventing cartilage degradation include, synthetic MMP/aggrecanase inhibitors, endogenous tissue inhibitors of metalloproteinases (TIMPs), cytokine antagonists (IL-1 receptor anatagonist, soluble IL1R, sTNFR), apoptosis inhibitors (Bcl-2). Such strategies can prolong the survival of engineered or repaired cartilage.

ASSESSING THE QUALITY OF CARTILAGE REPAIR

Various methods can be used to evaluate the quality of the repaired cartilage. These include macroscopic evaluation, non-destructive structure evaluation by high field (9.4 Tesla) magnetic resonance imaging (MRI) (Goebel 2015) and micro-computed tomography (micro CT), biochemical, biomechanical and molecular biological, histological and immunohistochemical methods for which scoring systems such as those of International Cartilage Repair Society (ICRS), modified O'Driscoll Scores and Osteoarthritis Research Society International (OARSI) can be applied (Madry 2015; Orth 2012). MRI is also being adapted for smaller murine models of cartilage defect repair (Mak 2015).

CONCLUSION

The current problems of cartilage tissue repair/regeneration technology include a limited number of donor cells for surgical transplantation, the formation of fibrocartilage of poor biomechanical quality, chondrocyte necrosis, chondrocyte dedifferentiation into fibroblasts and poor integration of new cartilage with the native cartilage. The resulting tissue, thus, lacks the elasticity to efficiently protect joints. Currently, surgical research has produced various treatments such as bone marrow stimulation by microfracturing, mosaicplasty, autograft and allograft transplantation using small and large animal models of cartilage loss (DMM model) and repair. Similarly, biomedical research strategies involve stimulation of chondrogenesis particularly towards articular cartilage phenotype (by Triiodothyronine, recombinant acid ceramidase, different combinations of TGF-β1 and BMPs, FGF-18, GDF-5, IGF-1, TGFβ3 plus Rac1 inhibitor-NSC23766, TD-198946, Kartogenin), cell therapy with autogenic, allogenic and xenogeneic chondrocytes, platelets, PBMCs, embryonic and adult MSCs and reprogrammed iPSCs. For the efficient delivery of chondrogenic cells, genes and molecules into defect sites, various kinds of scaffold systems such as ECM-based, acellular matrix, platelet-rich plasma-enriched, alginate, chitosan, fibrin, etc. as well as nanomaterials and 3-D printing in various combinations are being used (Table 1). Proper integration of implanted or engineered cartilage can be achieved with limited enzymatic treatments at the edges. All these strategies may be effective in the short-term. However, the issue of further differentiation of the inoculated cells into a state favoring further degeneration still needs to be addressed. This may have to do with the innate differences between the microenvironment of the pathological and healthy joint which may affect the outcome of treatments. To this end, numerous inhibitors of cartilage degradation and chondroprotective agents may be useful. So what still remains to be determined is how one may stunt this process at the right stage of chondrogenesis (articular cartilage) without allowing for further differentiation into the later stages and their analogues (fibrocartilage). In the future, it will be possible to selectively silence antichondrogenic factors/genes by RNA interference (RNAi) and promote cartilage repair due to injuries, disease and aging as recently reported (Lolli 2017). Furthermore, this new repertoire of treatment options also requires a matching set of non-invasive diagnostic and surveillance tools to monitor the progression of disease and the effectiveness of treatment as well as improve the success of prophylactic treatment from lifestyle changes to proper rehabilitation at trauma sites. With regards to this, resources must also be allocated to the

development of new clinically-relevant biomarkers specific to OA (as opposed to generalized inflammatory markers). Although we haven't addressed this, great strides have been made in this regard with the avenue of various cartilage synthesis and degradation serum-, urine-synovial fluid-borne biomarkers, (such as aggrecan/collagen II neoepitopes). From both diagnostic and therapeutic viewpoints, the many challenges underlying cartilage repair do not outweigh the field's potential for growth. In the future, only a treatment inducing durable cartilage tissue repair that is not subject to degradation and which can closely mimic the native cartilage tissue has a chance of meeting FDA approval.

REFERENCES

Baba R, Onodera T, Momma D, Matsuoka M, Hontani K, Elmorsy S, Endo K, Todoh M, Tadano S, Iwasaki N. A novel bone marrow stimulation technique augmented by administration of ultrapurified alginate gel enhances osteochondral repair in a rabbit model. *Tissue Eng. Part C. Methods* 2015; 21(12):1263−1273.

Badlani N, Inoue A, Healey R, Coutts R, Amiel D. The protective effect of OP-1 on articular cartilage in the development of osteoarthritis. *Osteoarthritis Cartilage* 2008; 16(5):600−606.

Benders KE, van Weeren PR, Badylak SF, Saris DB, Dhert WJ, Malda J. Extracellular matrix scaffolds for cartilage and bone regeneration. *Trends Biotechnol.* 2013; 31(3):169−176.

Bhumiratana S, Eton RE, Oungoulian SR, Wan LQ, Ateshian GA, Vunjak-Novakovic G. Large, stratified, and mechanically functional human cartilage grown in vitro by mesenchymal condensation. *Proc. Natl. Acad. Sci. U S A.* 2014; 111(19):6940−6945.

Bianchi VJ, Weber JF, Waldman SD, Backstein D, Kandel RA. Formation of hyaline cartilage tissue by passaged human osteoarthritic chondrocytes. *Tissue Eng. Part. A.* 2017; 23(3-4):156−165.

Blaney Davidson EN, van Caam AP, van der Kraan PM. Osteoarthritis year in review 2016: biology. *Osteoarthritis. Cartilage.* 2017; 25(2):175−180.

Bobacz K, Sunk IG, Hayer S, Amoyo L, Tohidast-Akrad M, Kollias G, Smolen JS, Schett G. Differentially regulated expression of growth differentiation factor 5 and bone morphogenetic protein 7 in articular cartilage and synovium in murine chronic arthritis: potential importance for cartilage breakdown and synovial hypertrophy. *Arthritis Rheum.* 2008; 58(1):109−118.

Bugbee WD, Pallante-Kichura AL, Gortz S, Amiel D, Sah R. Osteochondral allograft transplantation in cartilage repair: Graft storage paradigm, translational models, and clinical applications. *J. Orthop. Res.* 2016; 34(1):31−38.

Chen H, Chevrier A, Hoemann CD, Sun J, Lascau-Coman V, Buschmann MD. Bone marrow stimulation induces greater chondrogenesis in trochlear vs condylar cartilage defects in skeletally mature rabbits. *Osteoarthritis Cartilage* 2013; 21(7):999−1007.

Chevrier A, Darras V, Picard G, Nelea M, Veilleux D, Lavertu M, Hoemann CD, Buschmann MD. Injectable chitosan-platelet-rich plasma (PRP) implants to promote tissue regeneration: In vitro properties, in vivo residence, degradation, cell recruitment and vascularization. *J. Tissue Eng. Regen. Med.* 2017. doi: 10.1002/term.2403.

Christensen BB. Autologous tissue transplantations for osteochondral repair. *Dan. Med. J.* 2016; 63(4): pii: B5236

Clouet J, Vinatier C, Merceron C, Pot-vaucel M, Maugars Y, Weiss P, Grimandi G, Guicheux J. From osteoarthritis treatments to future regenerative therapies for cartilage. *Drug Discov. Today* 2009; 14(19-20):913−925.

Cosden-Decker RS, Bickett MM, Lattermann C, MacLeod JN. Structural and functional analysis of intra-articular interzone tissue in axolotl salamanders. *Osteoarthritis Cartilage* 2012; 20(11):1347−1356.

Craft AM, Rockel JS, Nartiss Y, Kandel RA, Alman BA, Keller GM. Generation of articular chondrocytes from human pluripotent stem cells. *Nat. Biotechnol.* 2015; 33(6):638−645.

Croxford AM, Whittingham S, McNaughton D, Nandakumar KS, Holmdahl R, Rowley MJ. Type II collagen-specific antibodies induce cartilage damage in mice independent of inflammation. *Arthritis Rheum.* 2013; 65(3):650−659.

Culley KL, Dragomir CL, Chang J, Wondimu EB, Coico J, Plumb DA, Otero M, Goldring MB. Mouse models of osteoarthritis: surgical model of posttraumatic osteoarthritis induced by destabilization of the medial meniscus. *Methods Mol. Biol.* 2015; 1226:143−173.

de Vries-van Melle ML, Mandl EW, Kops N, Koevoet WJ, Verhaar JA, van Osch GJ. An osteochondral culture model to study mechanisms involved in articular cartilage repair. *Tissue Eng. Part C. Methods* 2012; 18(1):45−53.

De BC, Dell'Accio F, Luyten FP. Human periosteum-derived cells maintain phenotypic stability and chondrogenic potential throughout expansion regardless of donor age. *Arthritis Rheum.* 2001; 44(1):85−95.

De FF, Ricci G, D'Andrea F, Nicoletti GF, Ferraro GA. Human adipose stem cells: from bench to bedside. *Tissue Eng. Part B Rev.* 2015; 21(6):572−584.

Dehne T, Zehbe R, Kruger JP, Petrova A, Valbuena R, Sittinger M, Schubert H, Ringe J. A method to screen and evaluate tissue adhesives for joint repair applications. *BMC. Musculoskelet. Disord.* 2012; 13:175.

Frisbie DD, McCarthy HE, Archer CW, Barrett MF, McIlwraith CW. Evaluation of articular cartilage progenitor cells for the repair of articular defects in an equine model. *J. Bone Joint Surg. Am.* 2015; 97(6):484−493.

Gabay O, Hall DJ, Berenbaum F, Henrotin Y, Sanchez C. Osteoarthritis and obesity: experimental models. *Joint Bone Spine* 2008; 75(6):675−679.

Gelse K, Riedel D, Pachowsky M, Hennig FF, Trattnig S, Welsch GH. Limited integrative repair capacity of native cartilage autografts within cartilage defects in a sheep model. *J. Orthop. Res.* 2015; 33(3):390−397.

Gill TJ, McCulloch PC, Glasson SS, Blanchet T, Morris EA. Chondral defect repair after the microfracture procedure: a nonhuman primate model. *Am. J. Sports Med.* 2005; 33(5):680−685.

Goebel L, Muller A, Bucker A, Madry H. High resolution MRI imaging at 9.4 Tesla of the osteochondral unit in a translational model of articular cartilage repair. *BMC. Musculoskelet. Disord.* 2015; 16:91.

Goldring MB. Chondrogenesis, chondrocyte differentiation, and articular cartilage metabolism in health and osteoarthritis. *Ther. Adv. Musculoskelet. Dis*. 2012; 4(4):269−285.

Goldring MB, Tsuchimochi K, Ijiri K. The control of chondrogenesis. *J. Cell. Biochem.* 2006; 97(1):33−44.

Goodrich LR, Hidaka C, Robbins PD, Evans CH, Nixon AJ. Genetic modification of chondrocytes with insulin-like growth factor-1 enhances cartilage healing in an equine model. *J. Bone Joint Surg. Br.* 2007; 89(5):672−685.

Goodrich LR, Chen AC, Werpy NM, Williams AA, Kisiday JD, Su AW, Cory E, Morley PS, McIlwraith CW, Sah RL, Chu CR. Addition of mesenchymal stem cells to autologous platelet-enhanced fibrin scaffolds in chondral defects: does it enhance repair? *J. Bone Joint Surg. Am.* 2016; 98(1):23−34.

Griffin DJ, Bonnevie ED, Lachowsky DJ, Hart JC, Sparks HD, Moran N, Matthews G, Nixon AJ, Cohen I, Bonassar LJ. Mechanical characterization of matrix-induced autologous chondrocyte implantation (MACI (R)) grafts in an equine model at 53 weeks. *J. Biomech.* 2015; 48(10):1944−1949.

Gui K, Ren W, Yu Y, Li X, Dong J, Yin W. Inhibitory effects of platelet-rich plasma on intervertebral disc degeneration: a preclinical study in a rabbit model. *Med. Sci. Monit.* 2015; 21:1368−1375.

Guterl CC, See EY, Blanquer SB, Pandit A, Ferguson SJ, Benneker LM, Grijpma DW, Sakai D, Eglin D, Alini M, Iatridis JC, Grad S. Challenges and strategies in the repair of ruptured annulus fibrosus. *Eur. Cell Mater.* 2013; 25:1−21.

Ha CW, Park YB, Chung JY, Park YG. Cartilage Repair Using Composites of Human Umbilical Cord Blood-Derived Mesenchymal Stem Cells and Hyaluronic Acid Hydrogel in a Minipig Model. *Stem Cells Transl. Med.* 2015; 4(9):1044−1051.

Hermeto LC, DeRossi R, Oliveira RJ, Pesarini JR, Antoniolli-Silva AC, Jardim PH, Santana AE, Deffune E, Rinaldi JC, Justulin LA. Effects of intra-articular injection of mesenchymal stem cells associated with platelet-rich plasma in a rabbit model of osteoarthritis. *Genet. Mol. Res.* 2016; 15(3). doi:10.4238/gmr.15038569.

Hopper N, Wardale J, Brooks R, Power J, Rushton N, Henson F. Peripheral blood mononuclear cells enhance cartilage repair in in vivo osteochondral defect model. *PLoS. One.* 2015; 10(8):e0133937.

Hou H, Zheng K, Wang G, Ikegawa S, Zheng M, Gao X, Qin J, Teng H, Jiang Q. Influence of intra-articular administration of trichostatin a on autologous osteochondral transplantation in a rabbit model. *Biomed. Res. Int.* 2015; 470934.

Howard D, Wardale J, Guehring H, Henson F. Delivering rhFGF-18 via a bilayer collagen membrane to enhance microfracture treatment of chondral defects in a large animal model. *J. Orthop. Res.* 2015; 33(8):1120−1127.

Huey DJ, Hu JC, Athanasiou KA. Unlike bone, cartilage regeneration remains elusive. *Science* 2012; 338(6109):917−921.

Hynes K, Bright R, Proudman S, Haynes D, Gronthos S, Bartold M. Immunomodulatory properties of mesenchymal stem cell in experimental arthritis in rat and mouse models: A systematic review. *Semin. Arthritis Rheum.* 2016; 46(1):1−19.

Ikemura S, Hasegawa M, Iino T, Miyamoto K, Imanaka-Yoshida K, Yoshida T, Sudo A. Effect of tenascin-C on the repair of full-thickness osteochondral defects of articular cartilage in rabbits. *J. Orthop. Res.* 2015; 33(4):563−571.

Jiang L, Ma A, Song L, Hu Y, Dun H, Daloze P Yu Y, Jiang J, Zafarullah M, Chen H. Cartilage regeneration by selected chondrogenic clonal mesenchymal stem cells in the

collagenase-induced monkey osteoarthritis model. *J. Tissue Eng. Regen. Med.* 2014; 8(11):896−905.

Johnson K, Zhu S, Tremblay MS, Payette JN, Wang J, Bouchez LC, Meeusen S, Althage A, Cho CY, Wu X, Schultz PG. A stem cell-based approach to cartilage repair. *Science* 2012; 336(6082):717−721.

Jones EA, Kinsey SE, English A, Jones RA, Straszynski L, Meredith DM, Markham AF, Jack A, Emery P, McGonagle D. Isolation and characterization of bone marrow multipotential mesenchymal progenitor cells. *Arthritis Rheum.* 2002; 46(12):3349−3360.

Kang ML, Ko JY, Kim JE, Im GI. Intra-articular delivery of kartogenin-conjugated chitosan nano/microparticles for cartilage regeneration. *Biomaterials* 2014; 35(37):9984−9994.

Katz JN, Earp BE, Gomoll AH. Surgical management of osteoarthritis. *Arthritis Care Res. (Hoboken.)* 2010; 62(9):1220−1228.

Kim C, Jeon OH, Kim dH, Chae JJ, Shores L, Bernstein N, Bhattacharya R, Coburn JM, Yarema KJ, Elisseeff JH. Local delivery of a carbohydrate analog for reducing arthritic inflammation and rebuilding cartilage. *Biomaterials* 2016; 83:93−101.

Kim JS, Ellman MB, An HS, van Wijnen AJ, Borgia JA, Im HJ. Insulin-like growth factor 1 synergizes with bone morphogenetic protein 7-mediated anabolism in bovine intervertebral disc cells. *Arthritis Rheum.* 2010; 62(12):3706−3715.

Latief N, Raza FA, Bhatti FU, Tarar MN, Khan SN, Riazuddin S. Adipose stem cells differentiated chondrocytes regenerate damaged cartilage in rat model of osteoarthritis. *Cell Biol. Int.* 2016; 40(5):579−588.

Lee HH, O'Malley MJ, Friel NA, Chu CR. Effects of doxycycline on mesenchymal stem cell chondrogenesis and cartilage repair. *Osteoarthritis. Cartilage.* 2013; 21(2):385−393.

Lee JK, Link JM, Hu JC, Athanasiou KA. The self-assembling process and applications in tissue engineering. *Cold Spring Harb. Perspect. Med.* 2017 doi: 10.1101/cshperspect.a025668.

Levesque M, Gatien S, Finnson K, Desmeules S, Villiard E, Pilote M, Philip A, Roy S. Transforming growth factor: beta signaling is essential for limb regeneration in axolotls. *PLoS. One* 2007; 2(11):e1227.

Lietman SA. Induced pluripotent stem cells in cartilage repair. *World J. Orthop.* 2016; 7(3):149−155.

Lin L, Zhou C, Wei X, Hou Y, Zhao L, Fu X, Zhang J, Yu C. Articular cartilage repair using dedifferentiated articular chondrocytes and bone morphogenetic protein 4 in a rabbit model of articular cartilage defects. *Arthritis Rheum.* 2008; 58(4):1067−1075.

Little CB, Zaki S. What constitutes an "animal model of osteoarthritis" - the need for consensus? *Osteoarthritis. Cartilage.* 2012; 20(4):261−267.

Liu CF, Samsa WE, Zhou G, Lefebvre V. Transcriptional control of chondrocyte specification and differentiation. *Semin. Cell Dev. Biol.* 2017; 62:34−49.

Liu H, Yang L, Yu FF, Wang S, Wu C, Qu C, Lammi MJ, Guo X. The potential of induced pluripotent stem cells as a tool to study skeletal dysplasias and cartilage-related pathologic conditions. *Osteoarthritis Cartilage* 2016; 25(5):616−624.

Liu S, Jia Y, Yuan M, Guo W, Huang J, Zhao B, Peng J, Xu W, Lu S, Guo Q. Repair of osteochondral defects using human umbilical cord wharton's jelly-derived mesenchymal stem cells in a rabbit model. *Biomed. Res. Int.* 2017; 2017:8760383.

Lolli A, Penolazzi L, Narcisi R, van Osch GJVM, Piva R. Emerging potential of gene silencing approaches targeting anti-chondrogenic factors for cell-based cartilage repair. *Cell Mol Life Sci.* 2017. doi: 10.1007/s00018-017-2531-z.

Ma A, Jiang L, Song L, Hu Y, Dun H, Daloze P, Yu Y, Jiang J, Zafarullah M, Chen H. Reconstruction of cartilage with clonal mesenchymal stem cell-acellular dermal matrix in cartilage defect model in nonhuman primates. *Int. Immunopharmacol.* 2013; 16(3):399−408.

Madry H, Kaul G, Zurakowski D, Vunjak-Novakovic G, Cucchiarini M. Cartilage constructs engineered from chondrocytes overexpressing IGF-I improve the repair of osteochondral defects in a rabbit model. *Eur. Cell Mater.* 2013; 25:229−247.

Madry H, Ochi M, Cucchiarini M, Pape D, Seil R. Large animal models in experimental knee sports surgery: focus on clinical translation. *J. Exp. Orthop.* 2015; 2(1):9.

Mak J, Leonard C, Foniok T, Rushforth D, Dunn JF, Krawetz R. Evaluating endogenous repair of focal cartilage defects in C57BL/6 and MRL/MpJ mice using 9.4T magnetic resonance imaging: A pilot study. *Magn Reson. Imaging* 2015; 33(5):690−694.

Mak J, Jablonski CL, Leonard CA, Dunn JF, Raharjo E, Matyas JR, Biernaskie J, Krawetz RJ. Intra-articular injection of synovial mesenchymal stem cells improves cartilage repair in a mouse injury model. *Sci. Rep.* 2016; 6:23076.

Mathieu C, Chevrier A, Lascau-Coman V, Rivard GE, Hoemann CD. Stereological analysis of subchondral angiogenesis induced by chitosan and coagulation factors in microdrilled articular cartilage defects. *Osteoarthritis Cartilage* 2013; 21(6):849−859.

Matsuoka M, Onodera T, Sasazawa F, Momma D, Baba R, Hontani K, Iwasaki N. An articular cartilage repair model in common C57Bl/6 mice. *Tissue Eng. Part C. Methods* 2015; 21(8):767−772.

Mazor M, Lespessailles E, Coursier R, Daniellou R, Best TM, Toumi H. Mesenchymal stem-cell potential in cartilage repair: an update. *J. Cell Mol. Med.* 2014; 18(12):2340−2350.

Meng Q, Hu X, Huang H, Liu Z, Yuan L, Shao Z, Jiang Y, Zhang J, Fu X, Duan X, Ao Y. Microfracture combined with functional pig peritoneum-derived acellular matrix for cartilage repair in rabbit models. *Acta Biomater.* 2017; 53:279−292.

Mitogawa K, Makanae A, Satoh A, Satoh A. Comparative analysis of cartilage marker gene expression patterns during axolotl and xenopus limb regeneration. *PLoS. One.* 2015; 10(7):e0133375.

Nakagawa T, Lee SY, Reddi AH. Induction of chondrogenesis from human embryonic stem cells without embryoid body formation by bone morphogenetic protein 7 and transforming growth factor beta1. *Arthritis Rheum.* 2009; 60(12):3686−3692.

Nguyen D, Hagg DA, Forsman A, Ekholm J, Nimkingratana P, Brantsing C, Kalogeropoulos T, Zaunz S, Concaro S, Brittberg M, Lindahl A, Gatenholm P, Enejder A, Simonsson S. Cartilage tissue engineering by the 3d bioprinting of IPS cells in a nanocellulose/alginate bioink. *Sci. Rep.* 2017; 7(1):658.

Nixon AJ, Rickey E, Butler TJ, Scimeca MS, Moran N, Matthews GL. A chondrocyte infiltrated collagen type I/III membrane (MACI(R) implant) improves cartilage healing in the equine patellofemoral joint model. *Osteoarthritis Cartilage* 2015; 23(4):648−660.

Orth P, Zurakowski D, Wincheringer D, Madry H. Reliability, reproducibility, and validation of five major histological scoring systems for experimental articular cartilage repair in the rabbit model. *Tissue Eng. Part C. Methods* 2012; 18(5):329−339.

Orth P, Zurakowski D, Alini M, Cucchiarini M, Madry H. Reduction of sample size requirements by bilateral versus unilateral research designs in animal models for cartilage tissue engineering. *Tissue Eng. Part C. Methods* 2013; 19(11):885−891.

Ortved KF, Begum L, Mohammed HO, Nixon AJ. Implantation of rAAV5-IGF-I transduced autologous chondrocytes improves cartilage repair in full-thickness defects in the equine model. *Mol. Ther.* 2015; 23(2):363−373.

Pagnotto MR, Wang Z, Karpie JC, Ferretti M, Xiao X, Chu CR. Adeno-associated viral gene transfer of transforming growth factor-beta1 to human mesenchymal stem cells improves cartilage repair. *Gene Ther.* 2007; 14(10):804−813.

Park YB, Song M, Lee CH, Kim JA, Ha CW. Cartilage repair by human umbilical cord blood-derived mesenchymal stem cells with different hydrogels in a rat model. *J. Orthop. Res.* 2015; 33(11):1580−1586.

Pitsillides AA, Beier F. Cartilage biology in osteoarthritis--lessons from developmental biology. *Nat. Rev. Rheumatol.* 2011; 7(11):654−663.

Rai MF, Sandell LJ. Regeneration of articular cartilage in healer and non-healer mice. *Matrix Biol.* 2014; 39:50−55.

Reddi AH. Cartilage morphogenetic proteins: role in joint development, homoeostasis, and regeneration. *Ann. Rheum. Dis.* 2003; 62 Suppl 2: ii73−ii78.

Sakata R, Iwakura T, Reddi AH. Regeneration of articular cartilage surface: morphogens, cells, and extracellular matrix scaffolds. *Tissue Eng. Part B Rev.* 2015; 21(5):461−473.

Sato M, Shin-ya K, Lee JI, Ishihara M, Nagai T, Kaneshiro N, Mitani G, Tahara H, Mochida J. Human telomerase reverse transcriptase and glucose-regulated protein 78 increase the life span of articular chondrocytes and their repair potential. *BMC. Musculoskelet. Disord.* 2012; 13:51.

Schmutzer M, Aszodi A. Cell compaction influences the regenerative potential of passaged bovine articular chondrocytes in an ex vivo cartilage defect model. *J. Biosci. Bioeng.* 2017; 123(4):512−522.

Sekiya I, Vuoristo JT, Larson BL, Prockop DJ. In vitro cartilage formation by human adult stem cells from bone marrow stroma defines the sequence of cellular and molecular events during chondrogenesis. *Proc. Natl. Acad. Sci. U. S. A.* 2002; 99(7):4397−4402.

Sermer C, Devitt B, Chahal J, Kandel R, Theodoropoulos J. The addition of platelet-rich plasma to scaffolds used for cartilage repair: a review of human and animal studies. *Arthroscopy* 2015; 31(8):1607−1625.

Simonaro CM, Sachot S, Ge Y, He X, Deangelis VA, Eliyahu E, Leong DJ, Sun HB, Mason JB, Haskins ME, Richardson DW, Schuchman EH. Acid ceramidase maintains the chondrogenic phenotype of expanded primary chondrocytes and improves the chondrogenic differentiation of bone marrow-derived mesenchymal stem cells. *PLoS. One* 2013; 8(4):e62715.

Sittinger M, Hutmacher DW, Risbud MV. Current strategies for cell delivery in cartilage and bone regeneration. *Curr. Opin. Biotechnol.* 2004; 15(5):411−418.

Spagnoli A, O'Rear L, Chandler RL, Granero-Molto F, Mortlock DP, Gorska AE, Weis JA, Longobardi L, Chytil A, Shimer K, Moses HL. TGF-beta signaling is essential for joint morphogenesis. *J. Cell Biol.* 2007; 177(6):1105−1117.

Steinert AF, Proffen B, Kunz M, Hendrich C, Ghivizzani SC, Noth U, Rethwilm A, Eulert J, Evans CH. Hypertrophy is induced during the in vitro chondrogenic differentiation of

human mesenchymal stem cells by bone morphogenetic protein-2 and bone morphogenetic protein-4 gene transfer. *Arthritis Res. Ther.* 2009; 11(5):R148.

Steinert AF, Palmer GD, Pilapil C, Noth U, Evans CH, Ghivizzani SC. Enhanced in vitro chondrogenesis of primary mesenchymal stem cells by combined gene transfer. *Tissue Eng. Part A* 2009a; 15(5):1127−1139.

Tao K, Frisch J, Rey-Rico A, Venkatesan JK, Schmitt G, Madry H, Lin J, Cucchiarini M. Co-overexpression of TGF-beta and SOX9 via rAAV gene transfer modulates the metabolic and chondrogenic activities of human bone marrow-derived mesenchymal stem cells. *Stem Cell Res. Ther.* 2016; 7:20.

Tay LX, Ahmad RE, Dashtdar H, Tay KW, Masjuddin T, Ab-Rahim S, Chong PP, Selvaratnam L, Kamarul T. Treatment outcomes of alginate-embedded allogenic mesenchymal stem cells versus autologous chondrocytes for the repair of focal articular cartilage defects in a rabbit model. *Am. J. Sports Med.* 2012; 40(1):83−90.

Umlauf D, Frank S, Pap T, Bertrand J. Cartilage biology, pathology, and repair. *Cell Mol. Life Sci.* 2010; 67(24):4197−4211.

Verdier MP, Seite S, Guntzer K, Pujol JP, Boumediene K. Immunohistochemical analysis of transforming growth factor beta isoforms and their receptors in human cartilage from normal and osteoarthritic femoral heads. *Rheumatol. Int.* 2005; 25(2):118−124.

Visser J, Melchels FP, Jeon JE, van Bussel EM, Kimpton LS, Byrne HM, Dhert WJ, Dalton PD, Hutmacher DW, Malda J. Reinforcement of hydrogels using three-dimensionally printed microfibres. *Nat. Commun.* 2015; 6:6933.

Wang SZ, Jin JY, Guo YD, Ma LY, Chang Q, Peng XG, Guo FF, Zhang HX, Hu XF, Wang C. Intervertebral disc regeneration using plateletrich plasmacontaining bone marrow derived mesenchymal stem cells: A preliminary investigation. *Mol. Med. Rep.* 2016; 13(4):3475−3481.

Xu W, Xie Y, Wang Q, Wang X, Luo F, Zhou S, Wang Z, Huang J, Tan Q, Jin M, Qi H, Tang J, Chen L, Du X, Zhao C, Liang G, Chen L. A novel fibroblast growth factor receptor 1 inhibitor protects against cartilage degradation in a murine model of osteoarthritis. *Sci. Rep.* 2016; 6:24042.

Yang H, Cao C, Wu C, Yuan C, Gu Q, Shi Q Zou J. TGF-betal suppresses inflammation in cell therapy for intervertebral disc degeneration. *Sci. Rep.* 2015; 5:13254.

Yano F, Hojo H, Ohba S, Fukai A, Hosaka Y, Ikeda T, Saito T, Hirata M, Chikuda H, Takato T, Kawaguchi H, Chung UI. A novel disease-modifying osteoarthritis drug candidate targeting Runx1. *Ann. Rheum. Dis.* 2013; 72(5):748−753.

Zhou Q, Xu C, Cheng X, Liu Y, Yue M, Hu M, Luo D, Niu Y, Ouyang H, Ji J, Hu H. Platelets promote cartilage repair and chondrocyte proliferation via ADP in a rodent model of osteoarthritis. *Platelets* 2016; 27(3):212−222.

Zhu S, Chen P, Wu Y, Xiong S, Sun H, Xia Q, Shi L, Liu H, Ouyang HW. Programmed application of transforming growth factor beta3 and Rac1 inhibitor NSC23766 committed hyaline cartilage differentiation of adipose-derived stem cells for osteochondral defect repair. *Stem Cells Transl. Med.* 2014; 3(10):1242−1251.

In: Encyclopedia of Surgery (22 Volume Set)
Editors: Andreas Lehrer and Kristin Mueller
ISBN: 978-1-53618-329-0
© 2020 Nova Science Publishers, Inc.

Chapter 215

EXPERIMENTAL MODELS OF FRACTURE REPAIR

Jakub Zafar Qazi[1], Huifang Chen[2], MD, PhD and Muhammad Zafarullah[3,*], PhD

[1]Anatomy and Cell Biology, McGill University, Montreal, Quebec, Canada
[2]Department of Surgery, CRCHUM, Montreal, Quebec, Canada
[3]Department of Medicine, Université de Montréal, Montreal, Quebec, Canada

ABSTRACT

Orthopaedic trauma causes major morbidity and mortality around the world. Bone fractures are caused by trauma, diabetes and osteoporosis, whereas their complications frequently cause long-term disability and, even, death in the elderly. Various *in vitro*, *in silico* and *in vivo* models have been developed to mimic the pathogenesis of various human diseases and biological processes as well as study potential treatment options. Animals such as mice, rat, rabbit, Yucatan mini-pig, goat, sheep, pig, dog and non-human primates (NHPs) are used to study methods of accelerating fracture healing by surgical, biomechanical, biological, engineering and cell therapy approaches. Many models are designed to mimic compromised human bone repair and microbial infections. The quality of fracture repair is analyzed by radiography, micro-computed tomography, histology, histochemistry, immunohistochemistry and molecular biology techniques. Biomechanical testing such as torsion and bending is performed to assess the strength of repaired bones. We discuss various approaches that promote healing of fractures using different models. The findings may be applicable to bone repair in human trauma-, osteoporosis-, and diabetes-associated fractures.

Keywords: bone, fracture, repair, models, *in vivo*

[*] Corresponding Author's Email: Muhammad.Zafarullah@umontreal.ca.

ABBREVIATIONS

BMP2	Bone morphogenic protein 2
BMSCs	Bone marrow-derived mesenchymal stem cells
CCL2	Chemokine (C-C motif) ligand 2
COX-2	Cyclooxygenase-2
DBM	Demineralized bone matrix or decalcified bone matrix
FGF	Fibroblast growth factor
GDF	Growth and differentiation factor
HA	Hyaluronic acid or hydroxyapatite
HSCs	Hematopoietic stem cells
IGF-1	Insulin-like growth factor
IL-6	Interleulin-6
iPSCs	Induced pluripotent stem cells
k-wire	Kirschner wire
LIPUS	Low-intensity pulsed ultrasound
MCP-1	Monocyte chemoattractant protein-1
Micro/μ-CT	Microcomputed tomography
NHPs	Non-human primates
NSAIDs	Non-steroidal anti-inflammatory drugs
OI	Osteogenesis imperfecta
PDGF	Platelet-derived growth factor
PTH	Parathyroid hormone
RA	Rheumatoid arthritis
SA	Staphylococcus aureus
SD	Sprague Dawley
T2DM	Type 2 Diabetes mellitus
TGF-β	Transforming growth factor beta
VEGF	Vascular endothelial growth actor

INTRODUCTION

Bone is made up of several cell types which are responsible for its remodeling and resorption. Bone cells originate from mesenchymal stem cells (MSCs) and hematopoietic stem cells (HSCs). MSCs lead to undifferentiated mesenchymal stem cells or preosteoblasts which differentiate into osteoblasts. Single-nucleated preosteoblasts are found in canals, endosteum, periosteum, and marrow and play an important role in fracture healing by differentiating into osteoblasts. Bone lining cells originate from osteoblasts and remove organic components of mineralized matrix in response to parathyroid hormone secretion whose action is offset by calcitonin. Osteocytes result from the final differentiation of osteoblasts surrounded by matrix and are found abundantly in mature bone to form a cell network. Osteoclasts are multinucleated (3–20, when active) lysosome-rich, mitochondria-harboring cells which result from the differentiation of hematopoietic stem cells. These cells

are involved in bone demineralization and resorption during bone repair to subsequently recruit bone-forming osteoblasts (Alghazali 2015).

Various traumatic injuries (such as sports-related and work place-related injuries, combat casualties and motor vehicle accidents among others), bone tumor removal, infections, osteoporosis and diabetes cause bone fractures in humans. Fractures occur when the load forces such as bending, tension, compression, shear, and torsion exceeds the elastic limit of the bone. In return, these fractures may cause four major types of bone defects: calvarial (skull) defect**s**, long bone or segmental defect**s**, cortical defect**s** and cancellous bone defect**s**. Fracture repair is a complex process which involves an initial inflammatory response, revascularization, soft and hard callus formation, initial bony union and slow bone remodeling (reviewed in Claes 2012). While bones have enormous regenerative and healing capacity, some fractures are subject to delayed union or nonunion, in which case bones have failed to heal. Standard bone fracture regeneration involves biomechanical support by a cast and with devices such as braces, nails, screws and plates promoting revascularization (blood supply) at the trauma site. The outcome of fracture repair depends upon the severity of trauma, the quality of realignment, stabilization techniques and the onset of infection or chronic pathogenic inflammation (reviewed in Claes 2012).

Bone grafting is a very common surgical procedure to repair fractures performed in instances of delayed unions, nonunions, osteotomies, arthrodesis and multi-fractures in addition to replacing bone due to cancer and cyst removal. Critical-size defects constituting the minimum length of fractures that do not heal spontaneously within a defined time period, are commonly used to model nonunion. They may be used to study defective fracture healing caused by diabetes, sepsis, rheumatoid arthritis (RA), osteoporosis and several other conditions. This process may also be impaired with aging and after cancer radiation therapy (Giganti 2014; Inyang 2014). Additionally, a variety of cellular mechanisms underlie fracture repair. Central to this process is osteogenesis, the differentiation of donor endogenous osteoprogenitor cells into osteoblasts and osteocytes. Another crucial mechanism, osteoinduction, involves the stimulation of host MSCs primarily with transforming growth factor beta (TGF-β) superfamily members or recruitment of circulating osteoprogenitors into graft site to differentiate into osteoblasts. Moreover, osteoconduction is a property that enables the growth of new blood vessels and bone using the graft as a scaffold. This scaffold serves to fill the bone defect, an area lacking bone, with cells, growth factors and vessels, thereby enabling healing.

The artificial scaffold should preferably be porous, sterilisable, degradable and compatible with the structure of the target bone defect, the ultimate goal being its replacement with natural bone. The materials such as hydroxyapatite, demineralized bone matrix (DBM) and ceramics have osteoconductive properties; DBM is a source of TGF-β, insulin-like growth factor (IGF-1) and fibroblast growth factor (FGF) which lead to chondroblastic differentiation of mesenchymal cells followed by bone generation through osteochondral osteogenesis. Finally, osteointegration is the proper integration of graft into host bone tissue. The initial phase of fracture healing resembles that of inflammation, but the magnitude and duration of this phase is not known (reviewed in Giannoudis 2015). The current gold standard for fracture repair is by autogenous bone graft where bone tissue harvested from the same individual (in areas such as iliac crest, fibula and scapula in humans) is implanted into a different bone of the same person (autograft). Although it is a painful and invasive procedure, this prevents infections and immune reaction against exogenous elements, enabling optimal

healing. However, the extraction of autograft from iliac crest may lead to blood loss, nerve injury, hernia, infection, arterial or urethral injuries, pelvic instability, fracture and pain. Similarly, allografts (from donor of the same species) and xenografts (graft from a donor of different species) may lead to viral infections and rejection by host immune system necessitating the use of *in vitro*, *in silico* and animal models to develop new approaches and materials (biomolecules, cell therapies and biomaterials) to repair fractures. Excellent reviews have been written for the appropriate use of rodent and other animal models for mimicking human bone fracture healing and regeneration (Garcia 2013; Peric 2015; Bigham-Sadegh 2015). Here we focus on the recent developments over the last 5 years in the field.

PHASES OF FRACTURE REPAIR AND BASIC MECHANISMS OF OSTEOGENESIS

Stages of fracture healing have been best studied in rat and essentially consist of four phases: hematoma formation and inflammation, soft callus formation, hard callus formation and bone remodeling (reviewed in Alghazali 2015) (Figure 1). After fracture and rupture of blood supply, the initial acute inflammatory phase is started in the surrounding soft tissue. Plasma and leukocytes exudate and bone ends die off. At the gap, fibrinogen is converted into fibrin, leading to fracture *hematoma formation* (sealed blood clot) which contains platelets, macrophages, osteoclasts, and various inflammatory cells, such as granulocytes, lymphocytes, and monocytes, proinflammatory and anti-inflammatory cytokines. The hematoma acts as scaffold to attract polymorphonuclear neutrophils (PMNs) which release macrophage-attracting chemokines such as CCL2 (chemokine (C-C motif) ligand 2) and IL-6 (interleulin-6). The dead cells and debris are cleared from hematoma. Afterwards, lymphocytes migrate to the site of injury and start an adaptive immune response. Inflammatory cytokines such as IL-1, IL-6, TNF-α, receptor activator of nuclear factor κB ligand (RANKL), macrophage colony-stimulating factor 1 (MCSF1) as well as bone morphogenetic proteins (BMP 2, BMP 4, BMP 5 and BMP 6) are released. Subsequently, angiogenic factors (first, angiopoetin-1, and, then, vascular endothelial growth factor, VEGF) are released due to the hypoxic microenvironment of the fracture site. Endothelial cells migrate from periosteal vessels into the hematoma and initiate neovascularization; the new vessels providing osteoprogenitor cells. Fibroblasts synthesize collagen and the hematoma is transformed into a tissue mass rich in collagen, cells and capillaries. In rats, this phase lasts 7 days and promotes angiogenesis and differentiation of MSCs. Antiinflammatory drugs such as cyclooxygenase-2 (COX-2) inhibitors impair this phase.

The type of repair depends upon biomechanical conditions and the degree of movement at the site of fracture. Under low interfragmentary movements, direct primary bone repair takes place by normal bone remodeling. During this process, osteoclasts originating from hematopoietic stem cells resorb bone and create tunnels where blood vessels are formed which recruit progenitor cells (undifferentiated mesenchymal cells) to differentiate into bone-forming osteoblasts (which synthesize type 1 collagen, osteocalcin and osteopontin) ultimately connecting bone fragments. Under more movement of fracture site, indirect secondary bone healing process takes place resulting in soft callus and, then, into bony callus. This phase partially overlaps with the inflammatory phase. In 3–7 days, osteoblasts

originating from periosteal precursor cells contribute to bone formation. The undifferentiated pluripotent cells (such as bone marrow) are recruited and could be differentiated with growth factors-promoted differentiation of mesenchymal cells into chondrogenesis or cartilage formation resulting in *soft callus*. In 7–10 days, callus formation is driven by chondrocytes and cartilaginous tissue formation which progresses to the fracture site reaching to maximum size by 14 days. Fibroblasts synthesize fibrous tissue which also contributes to fibrocartilage formation that holds fracture fragments together. During *hard callus* formation, after 10–14 days, proliferating chondrocytes become hypertrophic, deposit collagen, release calcium (mineralization) and undergo apoptosis in a manner similar to growth plate endochondral ossification. The mineralized cartilage tissue is invaded by blood vessels. Vasculature and increased oxygen promote osteoblast differentiation. The blood vessels enable the recruitment of MSCs and monocytes; the latter differentiate into osteoclast-like cells, which resorb the calcified cartilage and MSCs differentiate into osteoblasts which fill the lacunae with new woven bone and bridge the gap. The osteoblasts mature into osteocytes and establish new osteons called secondary osteons. Bony bridging is regarded as successful repair.

In the final stage, *bone remodeling* occurs by resorption of the periosteal callus by osteoclasts, thereby creating channels for osteoblast recruitment. The cells later mature into osteocytes that form secondary osteons resulting in the restoration of original bone shape, structure and strength. Irregularly woven bone is converted into lamellar bone. Vascularization and proinflammatory cytokines are reduced during this phase and takes 5–8 weeks in rats (reviewed by Claes 2012) (Figure 1). In other mature animals, all these phases may take from 3 (mice) to 24 weeks (NHPs) (reviewed in Peric 2015). The integrity of bone tissue is maintained by a continuous balance between synthesis by osteoblasts and resorption by osteoclasts in response to hormones and local growth factors such as bone morphogenetic protein (BMP), transforming growth factor beta (TGF-β), platelet-derived growth factor (PDGF), epidermal growth factor (EGF), fibroblast growth factor (FGF) and insulin-like growth factor (IGF). These factors, particularly BMPs are important drivers of bone fracture repair.

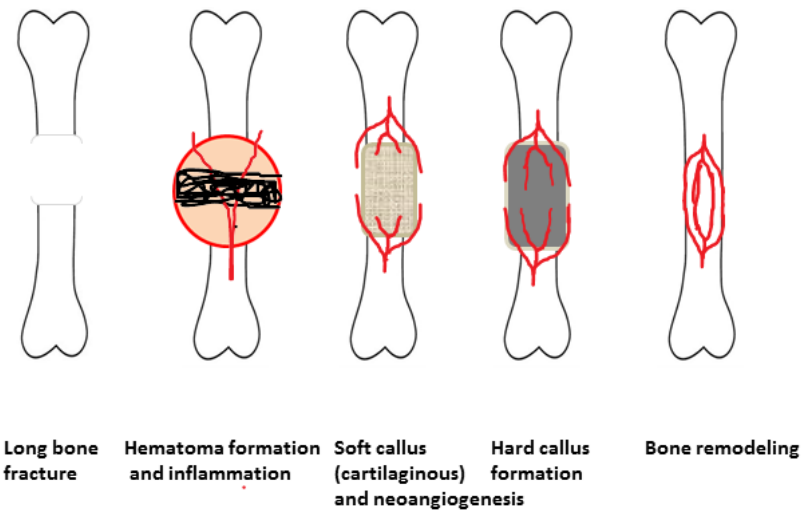

Figure 1. Depiction of four essential stages of bone fracture healing/repair. Please see text for details and references.

BONE REPAIR MODELS

In vitro and *In silico* Models

Development of *in vitro* and *in silico* models including computer simulation of fracture surgeries and repair could help patient recovery and facilitate compliance with the guiding principles of 3Rs (replacement, reduction, refinement) for ethical utilization of animals. An *in vitro* fracture (wound) healing assay was developed on the microgrooved polycaprolactone substrates to study the effect of microgroove widths and depths on the osteoblast-like cell (MG-63) migration and fracture healing (Zhang 2015). For bone repair and regeneration via drug delivery, a biomineralized (calcium phosphate), temperature-responsive and injectable hydrogel system containing hyaluronic acid (HA) and poloxamer was developed (Huh 2015). Vertebral bodies from fresh-frozen cadaveric thoracolumbar spines were used to study the ability of a novel biodegradable copolymer, poly (propylene fumarate-co-caprolactone) [P(PF-co-CL)] to repair vertebral lytic defects (Fang 2014). Since angiogenesis plays an important role in fracture repair, a computer-based multiscale model of osteogenesis and sprouting angiogenesis, incorporating lateral inhibition of endothelial cells (MOSAIC) has been developed and tested (Carlier 2012).

In vivo Models

Just as in any other branch of the health sciences, animal models should have clear endpoints and reflect real clinical situations such as: normal fracture repair (healing without delay), delayed union (repair after fracture or osteotomy in a prolonged fashion), established hypertrophic non-union (abundant callus made up of fibrocartilage that does not bridge the fracture), established atrophic non-union (fractures that do not show any signs of repair including lack of callus formation in a defined time frame; 16 weeks in small animals), fractures with a segmental defect and fractures at risk of delayed or non-union (such as non-healing, critical size defects, open and infected fractures from compromised patients) (Mills 2012). The goal of animal models is to study the efficacy and safety of the surgical procedures, drugs, bioactive molecules or cell therapy approaches. For certain clinical situations, appropriate animal models may not be generated due to major differences between animals and humans.

There are quite a few examples of this distinction. One of the most common differences involves bone healing being faster in small animals relative to large animals and humans. Additionally, in contrast to mammals, teleosts can regenerate the amputated bony fin rays. However, a better model was developed by introducing bone crush injury in adult caudal fin of zebrafish to closely mimic fracture bone repair in mammals (Sousa 2012). Less invasive ectopic bone models such as intraperitoneal, intramuscular and subcutaneous locations of animals (mostly in rodents) can be used to evaluate or screen the bone-generating capacity of implanted stem cells, growth factors and osteoinductive materials (scaffolds) within a period of 3 to 24 weeks. However, the ectopic models have limitations such as eventual reabsorption of newly formed bone and the lack of mechanical stimulus required for proper bone remodelling. Orthotopic models deal with bone directly or area around it.

As animals have different life expectancy, and older animals may have impaired quality and repair capacity, the age of the animal must be taken into account when choosing a model. Similarly, hormonal cycles in female animals may affect bone repair and turnover, therefore choice of the appropriate gender is also required. For instance, older thyroparathyroidectomized and ovariectomized rats have delayed healing of femoral fractures and reduced bone mineral density and could serve as models of osteoporosis fractures in postmenopausal women.

Several animal models such as rats (36% of models used), mice (26%), rabbits (13%), dogs (9%), non-human primates (3%) and sheep, pigs and cats (2%) have been used to study fracture repair. They differ widely among themselves and relative to humans (particularly rodents) in terms of biochemistry, biomechanics and anatomy of normal bone and healing processes (reviewed in Mills 2012). Smaller animals (rodents, rabbit-used in 80% of studies) may cost less while pigs, sheep and dogs (20% of studies) may have higher maintenance (feeding, housing etc.) costs. Dogs and non-human primates (NHPs), though closer to humans, are used as a last resort due to the ethical concerns of general public. Rat and rabbit models are generally used for calvarial defects and rabbits and dogs for segmental defects. Due to the short duration of bone maturation, rabbits are popular for bone healing studies such as testing of growth factors, biomaterials and stem cells. For creating calvarial defect in rabbits, an anteroposterior midline 4–5 cm skin incision is made over the cranial vault and the periosteum is elevated and retracted to expose the cranial bone to make a 15 mm defect using a trephine. For segmental defects, rabbit radius offers several advantages (Bigham-Sadegh 2015). Different type of bones and their defects may have different rates of regeneration.

RODENTS

Due to their small bone size, mice are not ideal for bone fracture repair studies, but are preferred due to low cost, ease of handling and the availability of biomarkers and genetically modified lines; nevertheless, segmental defects and fracture stabilization have been performed in this model (Clough 2015). Due to the similarity of human and rat receptors, rat osteoblasts, osteocytes and osteoclasts respond to drugs similarly to those of human bones. However, rodents lack the Haversian system and have permanently open growth plates. In mice models, bone healing was found to be delayed in open femur osteotomies relative to open fractures after stabilization with intramedullary screws (Klein 2015). For studying atrophic non-union fractures, a rat model was developed where osteotomy of the femur diaphysis, removal of periosteum and endosteum, isolation of the fracture site using a latex artefact (Penrose drain tube) and reduction of the fracture using an intramedullary pin was performed, removal of the latex and repair followed after 125 days (Roberto-Rodrigues 2015). To develop reliable nonreunion murine models, 10 months old Col1/ColII double transgenic mice were subjected to femur fractures of 0.6 mm (sub-critical) and 1.6 mm length (critical) and stabilized with plates and screws. Subcritical fractures completely healed in 5 weeks while critical fracture did not heal when analyzed by histology or micro-CT and, thus, could serve as non-union models to test therapeutic interventions (Chaubey 2013). A poly (2-hydroxyethyl methacrylate)-nanocrystalline hydroxyapatite (pHEMA-nHA)-vancomycin synthetic bone graft preabsorbed with 3μg rhBMP-2, promoted repair of critical-size (5 mm)

infection-prone rat femoral segmental defects (Skelly 2014). A rodent closed fracture model was developed that involved creation of a medial parapatellar incision, dislocation of the patella, boring an 18 gauge hole through the center of the femur, delivery of an adjunct (if applicable), fixation of the k-wire in the greater trochanter of the femur, suturing of muscle and skin, and finally, creation of the mid-diaphyseal fracture with a three-point bending fracture device (Drissi 2015). To study mechanisms of intramembranous bone regeneration, fully stabilized, single-cortex defects in mouse femurs were developed (McGee-Lawrence 2015). To investigate the occurrence of non-unions of fractures, an integrative *in vivo* and *in silico* approach enabling possible treatment strategies was developed. In these models, the dynamics of blood vessel formation, oxygen supply, growth factor production and cell proliferation and the interactions thereof with the host environment were taken into account (Carlier 2014). A geriatric fracture model was generated by using 25-months old C57BL/6 mice (equivalent to 70–85 years old humans) through creation of transverse, traumatic tibial diaphyseal fractures. A 40-day analysis revealed that their molecular program was intact, but with a reduced callus expansion and bone volume (Lopas 2014).

SHEEP

Due to the similar weight, size, bone structure, and bone remodeling process, sheep could be analogous to humans. To develop a nonunion process in a noncritical segmental tibial defect in sheep, in Group 1 (experimental), a defect was created by surgically stripping the periosteum from the edges of a distal tibial osteotomy, keeping the edges 5 mm apart, and placing an incomplete O-shaped silicone ring in the gap. In group 2, control sheep, a simple fracture at the distal end of the tibia was created followed by fixation with interlocking nails in both groups. After 8 weeks, the control group depicted typical repair process while experimental group showed a fracture line with rounded edges and a scarce callus formation mostly consisting of fibrous tissue (Lozada-Gallegos 2013). Sheep model was also used to assess spinal fusion status after anterior cervical discectomy and fusion (ACDF) procedure which demonstrated that cyclic arginine-glycine-aspartic (cRGD) and mineralized collagen matrix were the superior promoters of spinal fusion compared to the collagen matrix alone and cRGD was as effective as rhBMP-2 to increase the incidence of fusion events (Scholz 2013).

PIGS AND NON-HUMAN PRIMATES

Anatomy, microstructure and remodeling of pig bones resemble those of humans. The skeleton, posture, structure, composition and remodeling pattern of non-human primate bones is also similar to humans, but their use is constrained due to limited availability, high cost and ethical reasons. Adult common marmoset monkeys (*Callithrix jacchus*) have been suggested as models due to anatomical characteristics similar to those of humans including absence of growth plates, the presence of a Haversian system and true remodeling of cancellous and cortical bone.

Overall, rats have been proposed to be a first line of small models, followed by primates, pig and dog, while rabbit and marmoset could serve as intermediate models. European Medicines Agency (EMA) suggests that primates, sheep and pigs are the ideal animal models for testing new drugs prior to clinical trials in humans (Peric 2015).

COMPROMISED BONE REPAIR AND RELATED MODELS

As previously stated, there are several clinical situations where endogenous bone fracture repair is impaired. These may include Type 2 Diabetes mellitus (T2DM), rheumatoid arthritis (RA), lupus, hypothyroidism, malnutrition, alcoholism, smoking, infection of the fracture site, radiation use and non-steroidal anti-inflammatory drugs (NSAIDs) therapy (Table 1). In systemic chronic inflammatory diseases such as RA and type II diabetes, there is bone loss and osteoporosis, ultimately leading to fracture risk. This is mainly due to stimulation of osteoclastogenesis by proinflammatory cytokines resulting in an imbalance between bone formation and bone resorption. Acute inflammatory conditions such as sepsis and polytrauma also impair fracture healing in patients and animals due to a systemic increase of inflammation (Claes 2012). Generally, the ageing world population may explain the increasing incidence of cases of impaired bone regeneration.

Fracture healing is impaired in diabetes partly through plasminogen activator inhibitor-1 (PAI-1) whose deficiency partly restored healing by increasing alkaline phosphatase-positive cells (Mao 2014). Type 2 Diabetes (T2DM) models were generated by placing male C57BL/6J mice at 5 weeks of age on high-fat diet. Tibial fractures were introduced at 17 weeks. These mice had delayed fracture healing and weakened biomechanical properties with callus adiposity rather than osteoblast lineage (Brown 2014). In the same diabetic mouse model, skeletal repair was found to be impaired by increased levels of TNF-α-driven suppression of Indian Hedgehog (Ihh) expression which could be rescued by delivery of purified Ihh via slow release hydrogel to the fracture site (Tevlin 2017). In another T2DM model, subcritical femoral defects were created in diabetic fa/fa and nondiabetic +/+ Zucker Diabetic Fatty (ZDF) rats and internally stabilized. Vehicle or 75 μg/kg/d parathyroid hormone (PTH 1−84) was injected for 12 weeks. Skeletal effects were evaluated by μCT (micro computed tomography), biomechanical testing, histomorphometry and biochemical markers, and defect regeneration was analyzed by μCT. PTH was able to partially reverse adverse skeletal effects more effectively in normal rats compared to diabetic animals (Hamann 2014). Obese diabetic mice lacking leptin receptor (db/db) could also serve as model as they are deficient in postnatal regenerative osteogenesis in ectopic osteogenesis and fracture healing models (Roszer 2014). Compared to control (C57BL/6) mice, leptin-deficient obese ob/ob mice showed increased fracture callus volume and delayed callus maturation; such impaired healing could be reversed by local application of leptin (Khan 2013). Similarly, treatment of Sprague Dawley (SD) rats with recombinant leptin presented better femoral fracture healing and biomechanical properties than control rats (Liu 2017). Intramedullary delivery of Ultralente insulin, a form of insulin which can last up to 36 hours, in femoral fractures of non-diabetic Wistar rats contributed to early-stage fracture healing by increasing osteogenic markers expression, subperiosteal angiogenesis, and mineralized tissue formation (Paglia 2013).

Table 1. Diverse approaches which promote bone fracture repair by different mechanisms. We also list certain conditions and factors which either cause fractures or impair their repair. Please see text for references

Inducers and Inhibitors of Bone Fracture Repair	
Types of fracture repair	Procedure/factors/molecules
Surgical	Immobilization/stabilization and realignment by cast and braces, nails, screws, K-wire and plates Bone grafting (autografts, allografts and xenografts) for delayed unions, nonunions, osteotomies, arthrodesis and multi-fractures
Biological, Pharmacological	Osteogenesis-inducing agents Osteoinduction by transforming growth factor beta (TGF-β) superfamily including bone morphogenetic proteins (BMP-2), growth and differentiation factor-5, Insulin, Insulin-like growth factor (IGF-1), Fibroblast growth factor (FGF), Platelet-derived growth factor, Epidermal growth factor Osteoconduction by growth of new blood vessels (angiopoetin‑1 and vascular endothelial growth actor) on graft scaffolds Osteointegration Strontium ranelate, Statins (Simvastatin, Lovastatin), Parathyroid hormone-related peptide, Stromal-derived factor, sclerostin antibody Low-intensity pulsed ultrasound (LIPUS)
Cell therapy	Bone marrow-derived mesenchymal stem cells, Bone marrow-derived mononuclear cells, Osteogenic cells from adipose tissue, muscle, umbilical cord blood, peripheral blood, dental pulp Induced pluripotent stem cells Endothelial progenitor cells (through angiogenic factors) Fat tissue pericytes
Biomaterials/Scaffolds/ Bioengineering (for osteogenic cell, molecule, factor delivery)	Scaffolds: Bioactive inorganic materials: Tricalcium phosphate and Hydroxyapatite Biological polymers: Collagen, decalcified bone matrix (DBM), Collagen-glycosaminoglycan, fibrin (promotes wound healing, cell attachment and proliferation), Chitosan (a polysaccharide), Hyaluronic acid (HA), platelet-rich plasma (PRP) Synthetic polymers: Polyfumarates, polyurethane, poly (glycolic-co-lactic acid) (PLA), polyglycolic acid (PGA), copolymers of PLA and PGA (PLGA) and polycaprolactone Inorganic-organic composites such as collagen-hydroxyapatite
Inhibitors of fracture repair or compromised fracture repair	Diabetes, Osteoporosis, Sepsis, Rheumatoid arthritis, Lupus, Infections (causing osteomyelitis), Aging, Cancer radiation therapy, Hypothyroidism, Malnutrition, Alcoholism, Smoking, Use of non-steroidal anti-inflammatory drugs (NSAIDs) and Cyclooxygenase-2 inhibitors, TNF-α, Corticosteroids

Osteoporosis is a major factor causing fractures in elderly patients. Bone mineral density is a major predictor of osteoporotic fractures, which is controlled by genetic factors. Loss of EN1, a non-coding variant, leads to bone loss (Zeng 2015). As a model of osteoporosis, mice were ovariectomized at 9 weeks of age and subjected to drill-hole surgery in the right tibial diaphysis at 11 weeks (Matsumoto 2016). 12 week post op ovariectomized rats were subjected to unilateral transverse osteotomy on the proximal tibiae and effectiveness of semaphorin 3A (Sema3A) to enhance callus volume and density at 4 weeks post-fracture and ossification at 8 weeks was shown (Li 2015). In a mouse femoral osteotomy model, ovariectomy-induced osteopenia (reduced bone density) impaired the middle and late stages of bone healing (Pang 2015). Strontium ranelate (SR) was shown to be beneficial in osteoporotic bone healing in rats even when applied after fracture (Komrakova 2015). Simvastatin at 20 mg dose was shown to stimulate repair in osteoporotic female rat femur fractures stabilized with k-wire (Issa 2015). Leptin receptor null Lepr(-/-) mice have been used as a model of diabetic osteoporotic fractures to demonstrate parathyroid hormone-related

peptide (PTHrP)-driven stimulation of fracture repair by increasing osteoblast gene expression and bone formation (Liu 2015). Concerns have been raised about many of the osteoporotic models as they do not exactly imitate human postmenopausal and senile osteoporosis or secondary osteoporosis (reviewed in Simpson 2015).

Osteogenesis imperfecta (OI) is a human genetic disorder characterized by multiple fractures due to a mutation in the collagen type I gene. *Oim* mice (B6C3fe-a/a-*oim*) constitute a model of severe OI and have a guanine deletion at nucleotide 3,983 in *COL1A2* resulting in the absence of normal heterotrimeric collagen $\alpha1(I)_2\alpha2(I)_1$, replaced by homotrimeric $\alpha1(I)_3$, which accumulates in the extracellular matrix. The homozygous *oim* animals have brittle bones, multiple fractures, and skeletal deformities (Chipman 1993). Additionally, Brtl/+ mice constitute a heterozygous model of OI containing a Gly349Cys substitution in one COL1A1 allele, and displaying a low ductility phenotype. At 8 weeks of age, Brtl/+ has an increased osteoclast number, which mimics the upregulated bone turnover of OI patients (Davis 2012). Primed human first trimester fetal blood mesenchymal stem cells (hfMSCs) treated with SDF1 (stromal-derived factor) upregulated CXCR4 and enhanced engraftment *in vivo* in both *oim* and wild-type bone and bone marrow (Jones 2012).

Use of knockout and genetically defective animals (mostly mice) may serve as models of compromised situations. Fracture healing was impaired in NOD/scid-IL2Rγcnull immunodeficient mice due to delayed endochondral ossification and decreased osteoclast activity suggesting the requirement of an intact immune system for bone healing (Rapp 2016). Dystrophin-utophin double knockout mice are potential models of Duchenne muscular dystrophy (DMD; where patients exhibit lack of dystrophin expression, osteopenia, fragility fractures, and scoliosis) and display a reduced bone healing in addition to abnormalities in skeletal muscle, cartilage and intervertebral discs (Isaac 2013).

MODELS OF BONE REPAIR UNDER INFECTIONS

In humans, bone allograft transplantation can transmit bacterial (such as *Clostridium* species and *Treponema pallidum*-causing syphilis) and viral diseases such as HIV, Hepatitis B and C. Bacterial infections may cause septic arthritis, delayed union and osteomyelitis. Therefore, it is necessary to study bone repair under infection situations in animal models. Some examples are presented here. Skeletally mature C57bl/6 mice were subjected to a transverse osteotomy of the femur, which was treated with titanium fracture fixation plates and screws to keep in position. This model could then be infected with *Staphylococcus aureus (SA)* to study the immune response of the fracture (Rochford 2016). A similar model using Balb/c mice was developed to investigate a low grade acute SA osteitis by femoral defects stabilized by titanium locking plate and, then, infecting with SA. After debridement at 7 and 14 days, mice were sacrificed at 28 days and displayed delayed healing (Windolf 2013). In mice, a novel clinically-relevant model was established utilizing a locking fracture fixation plate to enable debridement of a bioluminescent *Staphylococcus aureus*-infected segmental bone defect during a revision surgery to study the therapeutic effects of placing a vancomycin-laden spacer in the defect, which reduced infection and osteolysis (Inzana 2015). A rabbit humerus model was developed using plating and nails to study prevention of implant-related bone infection and osteomyelitis (Arens 2015). Retaining an implant in the

presence of a *Staphylococcus aureus* infection without antibiotic leads to a weaker callus and impedes callus maturation relative to noninfected controls in a Sprague-Dawley rat model (Bilqili 2015). A novel broad-spectrum antibiotic CSA-90 (cationic steroid antibiotic-90) and rhBMP-2 were found to promote osteogenesis *in vitro* and in a rat open fracture model infected with *S. aureus* (Schindeler 2015). Many factors such as bacterial (*Staphylococcus epidermidis*) infections cause osteomyelitis and could prevent fracture repair and induce non-unions as demonstrated in a recently developed pre-clinical *in vivo* rat femur osteotomy model (Lovati 2016).

BIOLOGICAL AND BIOCHEMICAL AGENTS AFFECTING FRACTURE REPAIR RESPONSE

Biological molecules enhancing repair include growth factors (mainly BMPs), vascularization-promoting angiogenic factors (such as VEGF, FGF, PDGF, IGF), immunomodulatory cytokines, anti-cytokines, corticosteroids, parathyroid hormone, growth hormone, steroids, calcitonin and vitamin D. Different combinations of the factors may stimulate osteogenesis, osteoblast differentiation and angiogenesis. BMPs are already in clinical use, but have several side effects (Peric 2015). Tibial bone defects in male Wistar albino rats were used to demonstrate effectiveness of *Potentilla fulgens* extract to enhance trabecular bone formation as measured by osteonectin and osteopontin expression in osteoblasts and osteocytes (Koparal 2016). In a rat calvarial defect (5 mm) model, collagen sponge and fibrin glue were shown to promote new bone formation over 4–8 weeks period, the latter being better than the former (Santos 2015). Analysis by radiography and micro-CT revealed that platelet-rich plasma increases bone formation, bone area and torsional stiffness in animal long bone defect models (reviewed in Gianakos 2015). Blockade of a Wnt signalling pathway inhibitor, sclerostin, by injection with its associated antibody in a mouse tibial midshaft osteotomy model resulted in earlier healing of the fracture (Alzahrani 2016). Similar results were obtained by systemic sclerostin mAb (monoclonal antibody) administration in a rat femoral osteotomy model (Feng 2015). In rheumatoid arthritis-like collagen-induced arthritis (CIA), in male DBA/1 mice, sclerostin antibody prevented or reversed the decrease in axial and appendicular bone mass, but did not prevent or repair local bone erosion (Marenzana 2013). Lovastatin and tocotrienol were shown to upregulate the expression of genes related to tibial fracture healing in ovariectomized Sprague-Dawley female rats, an osteoporosis-like model (Ibrahim 2015). In metaphyseal small plug defects and diaphyseal segmental bone defects in rat femora, injectable lovastatin microparticles with biodegradable polyurethane (PUR) scaffolds resulted in increased new bone formation and bridging (Yoshii 2014). Vitamin C, an antioxidant and cofactor, improves bone health and could potentially prevent osteoporotic bone fractures (Aghajanian 2015). However, in a human clinical trial, no benefit for fracture repair was found (Ekrol 2014). Nutritional supplementation of mice subjected to closed tibial transverse fractures with basic milk protein displayed a larger and harder callus with increased chondrogenesis- and osteogenesis-associated gene expression and biomechanical properties (Yoneme 2015). In a murine tibial fracture or fragility fracture model, low-dose recombinant human TNF-α treatment within 24 h of injury increased fracture repair, which works through the recruitment of neutrophils and

monocytes by increasing CCL2 (Chan 2015). In contrast, high levels of TNF-α in transgenic mice (hTNFtg mice) had a negative impact on fracture healing in that the mice displayed more soft calluses and decreased biomechanical stability while TNF-α inhibition by Infliximab reversed these effects without interfering with fracture healing (Timmen 2014). It was recently shown that, after fracture, a C-X-C motif-ligand-12 (CXCL12) (+)-BMP2 (+) perivascular cell population is recruited along the endosteum, followed by a timely increase of BMP2 leading to downregulation of CXCL12 that determines the fate of the CXCL12(+)-BMP2(+) to osteogenesis instead of their role to angiogenesis. These results may lead to novel pharmacological and cell therapy approaches for fracture repair (Myers 2015). Delivery of BMP-2 by nanofiber mesh-alginate (NMA-rhBMP-2) in rat femoral large defect improved bone formation and biomechanical function compared to the gold standard of autograft treatment (Krishnan 2015). Delivery of adenovirus-mediated BMP2-expressing allogenic cells encapsulated in poly (ethylene glycol) diacrylate (PEGDA) hydrogel in a 5 mm rat femoral defect lead to more rapid healing (in 3 weeks) compared to high dose rhBMP2 (2-3 months) (Sonnet 2013). Basic fibroblast-derived growth factor containing a polycystic kidney disease (PKD) domain and collagen-binding domain (CBD) and demineralized bone matrix (DBM) increased callus formation and bone mineral density in a mouse femur fracture model (Saito 2015). In critical-sized 15-mm rabbit, radius defects treated with a growth factor (BMP2, GDF-5; growth and differentiation factor-5 and swap mutant GDF-5V453/V456 or BB-1)-loaded collagen carrier resulted in strong angiogenicity and osteogenicity; BB1 being the most osteogenic, as shown by micro-CT and immunohistochemistry analysis (Kleinschmidt 2014). Treatment of transversely cut rat femur at the midsection with a nonselective endothelin 1 receptor blocker, bosentan (100 mg/Kg) resulted in better radiographic healing score and callus/new bones formation relative to control group (Aydin 2015). BMP2 and debridement promoted repair in rat femur non-union fractures (Schützenberger 2014). In the germline, neuropeptide Y knockout mice, closed tibial fracture repair was delayed due to decrease in bone callus volume and strength (Sousa 2013). Monocyte chemoattractant protein-1 (MCP-1) is expressed in osteoblasts of ulnar stress fracture model and may have an important role in the early phase repair and activated remodeling (Wu 2013). Delivery of VEGF in hydroxyapatite-containing gelatin scaffold yielded favorable results in critical size rabbit tibial defect repair (Ozturk 2013). AAV-DJ harbored COX-2 vector gene therapy led to a ~5-fold increase in infectivity in MSCs, which enhanced COX-2 expression and significantly promoted fracture union in mice at 21 days by inducing osteoblastic differentiation of MSCs (Lakhan 2015). Lentivirus-mediated Wnt10b gene overexpression in rat femur non-union fracture model enhanced BMP2 expression, bone mass density and bone mineral density in callus leading to complete healing by 8 weeks (Gao 2015).

UTILIZATION OF STEM CELLS AND CELL THERAPY IN FRACTURE REPAIR

Stem cells are undifferentiated cells which can proliferate and self-renew themselves, that originate from the ectoderm, mesoderm and endoderm of the implanted embryo. Multipotent cell can differentiate into different cell-types of a particular germ layer. For instance, bone

marrow-derived multipotent stem cells (MSCs) can be differentiated under appropriate conditions into osteogenic, chondrogenic and adipogenic lineage and, therefore, can be used for cell therapy approaches to repair bone fractures. Besides the bone marrow, other sources of osteogenic multipotent cells include adipose tissue, muscle, umbilical cord blood, peripheral blood, dental pulp, etc., from humans, pigs, rodents, rabbits, dogs, cats, small ruminants, and horses which may differ from the bone marrow in terms of phenotype, morphology, proliferation and osteogenic potential. Induced pluripotent stem cells (iPSCs) are generated by reprograming adult cells such as fibroblasts to express embryonic stem cell characteristics (reviewed in Alghazali 2015). Other than being a source of osteogenic cells, transplanted MSCs contribute to repair by excreting various cytokines and growth factors. For cell therapy, autologous MSCs can be first differentiated into osteogenic cells, and then transplanted at the fracture site. Endothelial progenitor cells can also be used to release osteogenic and angiogenic factors leading to neovascularization and repair at the site of fracture. In all MSC-based repairs, the properties and fate of these cells should be monitored with appropriate markers. Cell therapy and tissue engineering approaches have been combined to include growth factors, scaffolds and osteogenic cells to enhance regeneration (Peric 2015). The role of MSCs in bone repair has been investigated in several animal models. To investigate the intrinsic progenitor cells in non-union fractures, Wistar rats were subjected to an atrophic nonunion at the tibial midshaft by stripping the periosteum and endosteum as well as creating a 1.0 mm noncritical gap. The fracture was subsequently stabilized. The ensuing results revealed that despite the systemic increase in bone marrow-derived mesenchymal stem cells (BMSCs), an impaired local response at non-union fractures was observed, but the cells could be differentiated under osteogenic and chondrogenic conditions, but not under adipogenic conditions (Tawonsawatruk 2014). In a mouse model of segmental bone defect, the combination of IGF1 and CXCR4 antagonist, AMD3100, was able to stimulate mobilization of BMSCs to the fracture site and increase bone growth and healing through Akt, ERK and Smad signaling pathways (Kumar 2012). As stated above, diabetes impairs bone formation and fracture healing. In a streptozotocin-induced diabetes type I mouse model, increased TNF-α reduced mesenchymal stem cell (MSC) number by decreasing proliferation and increasing apoptosis in the repair area, thus reducing regenerative potential (Ko 2015). Enriched $CD146^{+}NG^{2+}CD45^{-}$ cells from mouse fat tissue pericytes could be differentiated into osteoblasts in vitro, and could colonize cancellous bone scaffolds and contribute to regeneration of large bone defects *in vivo* (Konig 2016). Low-intensity pulsed ultrasound (LIPUS) and bone mesenchymal stem cells C3H10T1/2 promoted femoral bone-defect healing after 4 weeks in Sprague-Dawley rats by increasing proliferation *in vitro* and *in vivo* (He 2015). LIPUS also promoted osteogenesis, neovascularisation and repair in steroid (lipopolysaccharide and methylprednisolone)-induced femoral osteonecrosis rabbit model (Zhu 2015). In an ovariectomized rabbit (osteoporosis-like conditions), allogenic fetal BMSCs and decalcified bone matrix scaffolds were seeded in osteogenic media and transplanted into fracture defect which resulted in more bone tissue after 3 months compared to tissue engineering with BMSCs or scaffold alone (Wang 2015). Osteogenic cell sheets made from rat BMSCs containing osteoblasts and extracellular matrix and inserted in a critical fracture healing model of Fischer 344 inbred rats revealed enhanced bone regeneration and maximum bending load as determined by biomechanical testing relative to controls (Shimizu 2015). In ovariectomized osteoporotic mice, the implantation of mouse MSC-derived osteoblasts loaded in 3-D collagen I gel resulted in increased trabecular bone volume

relative to matrix alone suggesting usefulness of stem cell therapy for bone (Taiani 2014). Endothelial progenitor cells (EPCs) from the bone marrow of syngeneic rats loaded in a gelfoam scaffold introduced in bone defect were able to heal the fracture after 10 weeks by increasing BMP2 and promoting angiogenesis (Li 2014). Intravenous injection of CD271-selected human bone marrow MSCs and labelled with infrared fluorochrome, cypate, resulted in homing of BMSCs at mouse femur fracture site (Dreger 2014). In a murine transverse femoral fracture model, injection of AMD3100, an antagonist of the chemokine receptor 4 (CXCR4) lead to mobilization of endogenous circulating mesenchymal stromal cells, hematopoietic stem cells and endothelial progenitor cells and a larger fracture callus and better regeneration (Toupadakis 2013). In a dog femoral neck fracture model, delivery of autologous uncultured bone marrow-derived mononuclear cells (BMMNCs) through fibrin glue and a modified cannulated screw resulted in effective fracture healing (Licheng 2013).

BIOMECHANICAL APPROACHES TO REPAIR FRACTURES

The purpose of fracture fixation is to align the fracture fragments to enable healing. Stabilization with an intramedullary nail may enhance indirect repair in most models. Low interfragmentary movement leads to direct conversion of mesenchymal cells into bone, moderate movement enables cartilage matrix conversion to callus/bone (endochondral ossification) and high movement inhibits bone repair. These goals can be achieved with external splinting (with plaster casts or braces) or internal splinting (intramedullary nails and plates). Such techniques affect the quality of revascularization, an essential step for repair (Claes 2012). For direct repair, plating may lead to repair, but may leave weakness due to the required screw holes. In an ovine osteotomy model, active locking plates were shown to stimulate circumferential callus and yield faster and stronger healing compared to standard plates (Bottlang 2016). Stabilization of CD1 mouse femur midshaft fractures with screws lead to faster bone repair compared to delayed non-stabilized fractures (Histing 2016). In ovariectomized mice subjected to drill-hole surgery in tibia, noise-like whole-body vibration and intermittent administration of parathyroid hormone enhanced osteoporotic bone healing (Matsumoto 2016). The fixation method of fracture could also impact healing. In a numerical predictive model and its testing in an ovine long bone transversal fracture model, an optimized, moderate axial stiffness together with certain shear stiffness was shown to enhance fracture healing (Steiner 2014). In a critical size rat femur defect model, initial low-stiffness fixation of the defect, followed by high-stiffness fixation during the healing process (termed reverse dynamization) with rhBMP-2 on collagen sponge accelerated healing (Glatt 2012). Similarly in a critical size (6 mm) defect in rat femora receiving rhBMP-2 in alginate hydrogel, compliant fixation plate samples adapted to more efficiently distribute loads in the defects (Boerckel 2012). There are now numerous computational analysis approaches available to predict and monitor fracture repair (reviewed in Anderson 2014).

USE OF BIOMATERIALS TO REPAIR BONE FRACTURES

Fracture repair may be impaired because of interruption in blood supply, inflammation and infections. Thus, various biomaterials and scaffolds are used to give a template for mechanical support for cells and tissues and guide them for regeneration, deliver repair-promoting drugs and thereby enhance bone repair. The ideal biomaterials should have osteoinductive, osteoconductive and osteointegrative properties so that the need for autologous grafts or allografts is eliminated due to abovementioned complications (infections, rejection). Over time, such materials should be resorbed and replaced with natural regenerated bone tissue. A bone tissue engineering system should have following properties: a) enable cell adhesion and growth; b) degradation products of its scaffold should not cause inflammation and toxicity; c) provide mechanical support and strength for cells; d) be porous to enable cells and molecules to circulate efficiently; e) its degradation products should be fully absorbable f) there should be balance between resorption and regeneration (Alghazali 2015). Biomaterials used for scaffolds may be classified as bioactive ceramics, bioactive glasses, biological or synthetic polymers and their composite materials. Bioactive inorganic materials include tricalcium phosphate and hydroxyapatite (HA) which mimic the mineral phase of bone and can help in osteointegration. Biological polymers include collagen, decalcified bone matrix (DBM), fibrin (promotes wound healing, cell attachment and proliferation), chitosan (a polysaccharide) and hydrogel containing hyaluronic acid (HA). Examples of synthetic polymers are polyfumarates, polyurethane, poly (glycolic-co-lactic acid) (PLA), polyglycolic acid (PGA), copolymers of PLA and PGA (PLGA) and polycaprolactone. Moreover, nano-hydroxyapatite/collagen constitutes an example of inorganic-organic composite that is similar to real bone. Synthetic extracellular matrix-like materials such as hydrogels contribute to repair by their immunomodulatory properties. The third-generation biomaterials are both bioactive and degradable as they contain both cells and molecules (antimicrobials, pharmaceuticals, growth promoters) along with a scaffold (Peric 2015; Alghazali 2015). Scaffolds may be classified as hydrogel, porous and fibrous (mimicking collagen architecture), polymer-bioceramic composite scaffolds, nature/biological-inspired scaffolds and hybrid scaffolds (reviewed in Alghazali 2015).

Here are some examples of the use of different scaffolds in animal models. Three rat models closely mimicking human fractures were developed. In the first model, for a healing control group, the right tibia were fractured and stabilized with a PDLLA (poly DL-lactide)-coated k-wire. In the second, hypertrophic rats were subjected to an open osteotomy and stabilized like the previous. Finally, rats of the atrophy group were also osteotomized and treated with Fumagillin locally via the coating system of the k-wire. Fracture repair was followed by radiography, micro-CT and osteogenic gene expression for 3, 7, 14, 21 and 42 days. At the end of 42-days, only the first model displayed fracture gap, but not the others (Minkwitz 2015). Human scaphoid fracture non-union was modeled in Yucatan mini-pigs by performing a 3 mm osteotomy of the radiocarpal bone followed by immediate fixation or filling with a dense collagen gel and delayed fixation (Behrends 2015). In one study, dogs were subjected to an osteotomy in the mandibular body, which was fixed with a device manufactured with biodegradable poly-L-DL-lactic acid (70:30). The dogs were euthanized at 2 and 18 weeks and bone repair at the osteotomy site was observed (Sverzut 2015). Implantation of Beta-tricalcium phosphate (β-TCP) bone substituted with 75% porosity in a

subchondral bone plate of pigs was the most effective material in repairing cancellous bone after 3 months (Matsuo 2015). In rabbit radius osteotomy defect model with positive (autogenous bone graft) and negative (empty sham) controls, it was concluded that the collagen-glycosaminoglycan scaffold could be useful for a low load-bearing defect. The rhBMP-2 containing collagen-glycosaminoglycan and collagen-hydroxyapatite scaffolds may be suitable for established nonunion defects (Lyons 2014). The use of standardized animal models such as rat, rabbit and sheep to test new materials and for simulation of patient fractures has been suggested (Reifenrath 2014).

MEASURING THE STRENGTH OF REPAIRED BONE FRACTURE TISSUE

Techniques to verify the quality of repair tissue can be non-invasive or invasive. Non-invasive methods comprise of physical examination and activity testing the weight-bearing ability of repaired tissue, imaging technologies such as plain radiography, contrast radiography, magnetic resonance imaging, quantitative computed tomography (qCT), peripheral quantitative CT (pQCT), and micro CT (μCT) and plain and color Doppler ultrasonography. These techniques assess bone geometry, mass and structure. X-ray with or without pQCT is the method of choice for *in vivo* follow-up due to its good correlation with the mechanical testing of bone strength (Peric 2015). Micro-CT offers advantages of rapid 3-D analysis of trabecular morphology without destroying the sample and its usage for other analyses. The invasive approaches comprise of microscopic techniques (transmission electron microscopy, scanning electron microscopy, phase contrast microscopy, laser microscopy and immuno-florescent microscopy), biomechanical testing (using special apparatus and criteria such as stress, strain, load, deflection, force, displacement, ultimate strength, fracture stiffness), biochemistry and molecular biology methods (measuring various, serum and urine biomarkers, proteins, DNA, RNA markers). The strength of callus and bone can be measured *ex vivo* by 3-point or 4-point bending and correlated with radiological assessment. Several stains and histopathological techniques can be used to measure specific components of bone (for example: alkaline phosphatase for osteoblast, Tartrate Resistant Acid Phosphatase or TRAP for osteoclasts, Von Kossa and counterstaining with toluidine blue for mineralized bone and cartilage in callus, calcein, tetracycline and alizarin for labeling mineralizing bone surfaces among others). There are numerous scoring systems for each method of evaluation for bone healing (reviewed in Bigham-Sadegh 2015). By comparing the sensitivities of different methods it was discovered that whole-bone stiffness is of limited reliability to assess the healing quality particularly at the late stages of the healing of long bones (Chen 2015). The comparison of ultrasonometric (ultrasound propagation velocity or UV) and computed-tomographic imaging techniques to study bone healing using sheep tibiae revealed that both methods are similarly effective in monitoring the post-operative healing status after a regular and resection osteotomy (Barbieri 2012). Methods have been developed to measure mouse femoral bone fracture toughness during crack initiation and propagation (Carriero 2014).

CONCLUSION

Considering the increasing population of aged people in the world, cases of bone fractures and compromised bone repair are also likely to increase. As currently used repair approaches such as autografts, allografts, xenografts and tissue engineering have several caveats, efforts are being made to repair fractures by tissue engineering using growth factors, nanostructured scaffolds and biomaterials and stem cells. Hypertrophic cartilage, which has all the signals for bone tissue formation, vascularization, remodeling and functional bone marrow development, may accurately model bone tissue through endochondral ossification. Techniques such as 3-D printing may also have enhanced repair potential in the future.

Through multidisciplinary technologies and approaches, numerous animal models are available to create and repair diverse types of bone fractures. However, experimental animal models should reflect the human fracture scenarios as closely as possible. Therefore, such models should be carefully selected to test the aforementioned materials and surgical methods which could benefit human patients as the ultimate goal is to improve their quality of life.

REFERENCES

Aghajanian P, Hall S, Wongworawat MD, Mohan S. The roles and mechanisms of actions of vitamin C in bone: new developments. *J. Bone Miner. Res.* 2015; 30(11):1945−1955.

Alghazali KM, Nima ZA, Hamzah RN, Dhar MS, Anderson DE, Biris AS. Bone-tissue engineering: complex tunable structural and biological responses to injury, drug delivery, and cell-based therapies. *Drug Metab Rev.* 2015; 47(4):431−454.

Alzahrani MM, Rauch F, Hamdy RC. Does sclerostin depletion stimulate fracture healing in a mouse model? *Clin. Orthop. Relat Res.* 2016; 474(5):1294−1302.

Anderson DD, Thomas TP, Campos MA, Elkins JM, Lack WD, Lacroix D. Computational techniques for the assessment of fracture repair. *Injury* 2014; 45 Suppl 2:S23−S31.

Arens D, Wilke M, Calabro L, Hackl S, Zeiter S, Zderic I, Richards RG, Moriarty TF. A rabbit humerus model of plating and nailing osteosynthesis with and without Staphylococcus aureus osteomyelitis. *Eur. Cell Mater.* 2015; 30:148−161.

Aydin A, Halici Z, Akpinar E, Aksakal AM, Saritemur M, Yayla M, Kunak CS, Cadirci E, Atmaca HT, Karcioglu SS. What is the role of bosentan in healing of femur fractures in a rat model? *J. Bone Miner. Metab* 2015; 33(5):496−506.

Barbieri G, Mazzer N, Ribeiro EA, Nogueira-Barbosa MH, Barbieri CH. A comparative analysis between ultrasonometry and computer-aided tomography to evaluate bone healing. *J. Orthop. Res.* 2012; 30(7):1076−1082.

Behrends DA, Khendek L, Gao C, Zayed N, Henderson JE, Martineau PA. Characterization of a pre-clinical mini-pig model of scaphoid non-union. *J. Funct. Biomater.* 2015; 6(2):407−421.

Bigham-Sadegh A, Oryan A. Selection of animal models for pre-clinical strategies in evaluating the fracture healing, bone graft substitutes and bone tissue regeneration and engineering. *Connect. Tissue Res.* 2015; 56(3):175−194.

Bilgili F, Balci HI, Karaytug K, Sariyilmaz K, Atalar AC, Bozdag E, Tuna M, Bilgic B, Gurler N. Can normal fracture healing be achieved when the implant is retained on the

basis of infection? An Experimental Animal Model. *Clin. Orthop. Relat Res.* 2015; 473(10):3190−3196.

Boerckel JD, Kolambkar YM, Stevens HY, Lin AS, Dupont KM, Guldberg RE. Effects of in vivo mechanical loading on large bone defect regeneration. *J. Orthop. Res.* 2012; 30(7):1067−1075.

Bottlang M, Tsai S, Bliven EK, von RB, Klein K, Augat P, Henschel J, Fitzpatrick DC, Madey SM. Dynamic stabilization with active locking plates delivers faster, stronger, and more symmetric fracture-healing. *J. Bone Joint Surg. Am.* 2016; 98(6):466−474.

Brown ML, Yukata K, Farnsworth CW, Chen DG, Awad H, Hilton MJ, O'Keefe RJ, Xing L, Mooney RA, Zuscik MJ. Delayed fracture healing and increased callus adiposity in a C57BL/6J murine model of obesity-associated type 2 diabetes mellitus. *PLoS. One* 2014; 9(6):e99656.

Carlier A, Geris L, Bentley K, Carmeliet G, Carmeliet P, Van OH. MOSAIC: a multiscale model of osteogenesis and sprouting angiogenesis with lateral inhibition of endothelial cells. *PLoS. Comput. Biol.* 2012; 8(10):e1002724.

Carlier A, van GN, Geris L, Carmeliet G, Van OH. Size does matter: an integrative in vivo-in silico approach for the treatment of critical size bone defects. *PLoS. Comput. Biol.* 2014; 10(11):e1003888.

Carriero A, Zimmermann EA, Shefelbine SJ, Ritchie RO. A methodology for the investigation of toughness and crack propagation in mouse bone. *J. Mech. Behav. Biomed. Mater.* 2014; 39:38−47.

Chan JK, Glass GE, Ersek A, Freidin A, Williams GA, Gowers K, Espirito Santo AI, Jeffery R, Otto WR, Poulsom R, Feldmann M, Rankin SM. Low-dose TNF augments fracture healing in normal and osteoporotic bone by up-regulating the innate immune response. *EMBO Mol. Med.* 2015; 7(5):547−561.

Chaubey A, Grawe B, Meganck JA, Dyment N, Inzana J, Jiang X, Connolley C, Awad H, Rowe D, Kenter K, Goldstein SA, Butler D. Structural and biomechanical responses of osseous healing: a novel murine nonunion model. *J. Orthop. Traumatol.* 2013; 14(4):247−257.

Chen G, Wu FY, Zhang JQ, Zhong GQ, Liu F. Sensitivities of biomechanical assessment methods for fracture healing of long bones. *Med. Eng. Phys.* 2015; 37(7):650−656.

Chipman SD, Sweet HO, McBride DJ, Jr., Davisson MT, Marks SC, Jr., Shuldiner AR, Wenstrup RJ, Rowe DW, Shapiro JR. Defective pro alpha 2(I) collagen synthesis in a recessive mutation in mice: a model of human osteogenesis imperfecta. *Proc. Natl. Acad. Sci. U. S. A* 1993; 90(5):1701−1705.

Claes L, Recknagel S, Ignatius A. Fracture healing under healthy and inflammatory conditions. *Nat. Rev. Rheumatol.* 2012; 8(3):133−143.

Clough BH, McCarley MR, Gregory CA. A simple critical-sized femoral defect model in mice. *J. Vis. Exp.* 2015; (97) doi: 10.3791/52368.

Davis MS, Kovacic BL, Marini JC, Shih AJ, Kozloff KM. Increased susceptibility to microdamage in Brtl/+ mouse model for osteogenesis imperfecta. *Bone* 2012; 50(3):784−791.

Dreger T, Watson JT, Akers W, Molligan J, Achilefu S, Schon LC, Zhang Z. Intravenous application of CD271-selected mesenchymal stem cells during fracture healing. *J. Orthop. Trauma* 2014; 28 Suppl 1:S15−S19.

Drissi H, Paglia DN. Surgical procedures and experimental outcomes of closed fractures in rodent models. *Methods Mol. Biol.* 2015; 1226:193−211.

Ekrol I, Duckworth AD, Ralston SH, Court-Brown CM, McQueen MM. The influence of vitamin C on the outcome of distal radial fractures: a double-blind, randomized controlled trial. *J. Bone Joint Surg. Am.* 2014; 96(17):1451−1459.

Fang Z, Giambini H, Zeng H, Camp JJ, Dadsetan M, Robb RA, An KN, Yaszemski MJ, Lu L. Biomechanical evaluation of an injectable and biodegradable copolymer P(PF-co-CL) in a cadaveric vertebral body defect model. *Tissue Eng. Part A* 2014; 20(5-6):1096−1102.

Feng G, Chang-Qing Z, Yi-Min C, Xiao-Lin L. Systemic administration of sclerostin monoclonal antibody accelerates fracture healing in the femoral osteotomy model of young rats. *Int. Immunopharmacol.* 2015; 24(1):7−13.

Gao F, Zhang CQ, Chai YM, Li XL. Lentivirus-mediated Wnt10b overexpression enhances fracture healing in a rat atrophic non-union model. *Biotechnol. Lett.* 2015; 37(3):733−739.

Garcia P, Histing T, Holstein JH, Klein M, Laschke MW, Matthys R, Ignatius A, Wildemann B, Lienau J, Peters A, Willie B, Duda G. Rodent animal models of delayed bone healing and non-union formation: a comprehensive review. *Eur. Cell Mater.* 2013; 26:1−12.

Gee-Lawrence ME, Razidlo DF. Induction of fully stabilized cortical bone defects to study intramembranous bone regeneration. *Methods Mol. Biol.* 2015; 1226:183−192.

Gianakos A, Zambrana L, Savage-Elliott I, Lane JM, Kennedy JG. Platelet-rich plasma in the animal long-bone model: an analysis of basic science evidence. *Orthopedics* 2015; 38(12):e1079−e1090.

Giannoudis PV, Hak D, Sanders D, Donohoe E, Tosounidis T, Bahney C. Inflammation, bone healing, and anti-inflammatory drugs: an update. *J. Orthop. Trauma* 2015; 29 Suppl 12:S6−S9.

Giganti MG, Tresoldi I, Masuelli L, Modesti A, Grosso G, Liuni FM, Celi M, Rao C, Gasbarra E, Bei R, Tarantino U. Fracture healing: from basic science to role of nutrition. *Front Biosci. (Landmark. Ed)* 2014; 19:1162−1175.

Glatt V, Miller M, Ivkovic A, Liu F, Parry N, Griffin D, Vrahas M, Evans C. Improved healing of large segmental defects in the rat femur by reverse dynamization in the presence of bone morphogenetic protein-2. *J. Bone Joint Surg. Am.* 2012; 94(22): 2063−2073.

Hamann C, Picke AK, Campbell GM, Balyura M, Rauner M, Bernhardt R, Huber G, Morlock MM, Gunther KP, Bornstein SR, Gluer CC, Ludwig B. Effects of parathyroid hormone on bone mass, bone strength, and bone regeneration in male rats with type 2 diabetes mellitus. *Endocrinology* 2014; 155(4):1197−1206.

He R, Zhou W, Zhang Y, Hu S, Yu H, Luo Y, Liu B, Ran J, Wu J, Wang Y, Chen W. Combination of low-intensity pulsed ultrasound and C3H10T1/2 cells promotes bone-defect healing. *Int. Orthop.* 2015; 39(11):2181−2189.

Histing T, Heerschop K, Klein M, Scheuer C, Stenger D, Holstein JH, Pohlemann T, Menger MD. Characterization of the healing process in non-stabilized and stabilized femur fractures in mice. *Arch. Orthop. Trauma Surg.* 2016; 136(2):203−211.

Huh HW, Zhao L, Kim SY. Biomineralized biomimetic organic/inorganic hybrid hydrogels based on hyaluronic acid and poloxamer. *Carbohydr. Polym.* 2015; 126:130−140.

Ibrahim N,' Mohamed N, Soelaiman IN, Shuid AN. The Effects of targeted deliveries of lovastatin and tocotrienol on ossification-related gene expressions in fracture healing in

an osteoporosis rat model. *Int. J. Environ. Res. Public Health* 2015; 12(10): 12958−12976.

Inyang AF, Tchanque-Fossuo CN, Merati M, Radzolsky ER, Buchman SR. Microdensitometric and microarchitectural alterations in irradiated mandibular fracture repair. *J. Craniofac. Surg.* 2014; 25(6):2022−2026.

Inzana JA, Schwarz EM, Kates SL, Awad HA. A novel murine model of established Staphylococcal bone infection in the presence of a fracture fixation plate to study therapies utilizing antibiotic-laden spacers after revision surgery. *Bone* 2015; 72:128−136.

Isaac C, Wright A, Usas A, Li H, Tang Y, Mu X, Greco N, Dong Q, Vo N, Kang J, Wang B, Huard J. Dystrophin and utrophin "double knockout" dystrophic mice exhibit a spectrum of degenerative musculoskeletal abnormalities. *J. Orthop. Res.* 2013; 31(3):343−349.

Issa JP, Ingraci de LC, Dos Santos Kotake BG, Goncalves GM, Tocchini de Figueiredo FA, Mizusaki ID, Macedo AP, Ervolino E. The effect of simvastatin treatment on bone repair of femoral fracture in animal model. *Growth Factors* 2015; 33(2):139−148.

Jones GN, Moschidou D, Lay K, Abdulrazzak H, Vanleene M, Shefelbine SJ, Polak J, de CP, Fisk NM, Guillot PV. Upregulating CXCR4 in human fetal mesenchymal stem cells enhances engraftment and bone mechanics in a mouse model of osteogenesis imperfecta. *Stem Cells Transl. Med.* 2012; 1(1):70−78.

Khan SN, DuRaine G, Virk SS, Fung J, Rowland DJ, Reddi AH, Lee MA. The temporal role of leptin within fracture healing and the effect of local application of recombinant leptin on fracture healing. *J. Orthop. Trauma* 2013; 27(11):656−662.

Klein M, Stieger A, Stenger D, Scheuer C, Holstein JH, Pohlemann T, Menger MD, Histing T. Comparison of healing process in open osteotomy model and open fracture model: Delayed healing of osteotomies after intramedullary screw fixation. *J. Orthop. Res.* 2015; 33(7):971−978.

Kleinschmidt K, Wagner-Ecker M, Bartek B, Holschbach J, Richter W. Superior angiogenic potential of GDF-5 and GDF-5(V453/V456) compared with BMP-2 in a rabbit long-bone defect model. *J. Bone Joint Surg. Am.* 2014; 96(20):1699−1707.

Ko KI, Coimbra LS, Tian C, Alblowi J, Kayal RA, Einhorn TA, Gerstenfeld LC, Pignolo RJ, Graves DT. Diabetes reduces mesenchymal stem cells in fracture healing through a TNFalpha-mediated mechanism. *Diabetologia* 2015; 58(3):633−642.

Komrakova M, Weidemann A, Dullin C, Ebert J, Tezval M, Stuermer KM, Sehmisch S. The impact of strontium ranelate on metaphyseal bone healing in ovariectomized rats. *Calcif. Tissue Int.* 2015; 97(4):391−401.

Konig MA, Canepa DD, Cadosch D, Casanova E, Heinzelmann M, Rittirsch D, Plecko M, Hemmi S, Simmen HP, Cinelli P, Wanner GA. Direct transplantation of native pericytes from adipose tissue: A new perspective to stimulate healing in critical size bone defects. *Cytotherapy.* 2016; 18(1):41−52.

Koparal M, Irtegun S, Alan H, Deveci E, Gulsun B, Seker U. Effects of Potentilla fulgens as a prophylactic agent in tibial defects in rats. *Anal. Quant. Cytopathol. Histpathol.* 2016; 38(2):111−116.

Krishnan L, Priddy LB, Esancy C, Li MT, Stevens HY, Jiang X, Tran L, Rowe DW, Guldberg RE. Hydrogel-based delivery of rhBMP-2 improves healing of large bone defects compared with autograft. *Clin. Orthop. Relat Res.* 2015; 473(9):2885−2897.

Kumar S, Ponnazhagan S. Mobilization of bone marrow mesenchymal stem cells in vivo augments bone healing in a mouse model of segmental bone defect. *Bone* 2012; 50(4):1012−1018.

Lakhan R, Baylink DJ, Lau KH, Tang X, Sheng MH, Rundle CH, Qin X. Local administration of AAV-DJ pseudoserotype expressing COX2 provided early onset of transgene expression and promoted bone fracture healing in mice. *Gene Ther.* 2015; 22(9):721−728.

Li R, Nauth A, Gandhi R, Syed K, Schemitsch EH. BMP-2 mRNA expression after endothelial progenitor cell therapy for fracture healing. *J. Orthop. Trauma* 2014; 28 Suppl 1:S24−S27.

Li Y, Yang L, He S, Hu J. The effect of semaphorin 3A on fracture healing in osteoporotic rats. *J. Orthop. Sci.* 2015; 20(6):1114−1121.

Licheng Z, Lihai Z, Meng X, Qi Y, Peifu T. Autologous uncultured bone marrow-derived mononuclear cells and modified cannulated screw in repair of femoral neck fracture. *J. Orthop. Res.* 2013; 31(8):1302−1307.

Liu A, Li Y, Wang Y, Liu L, Shi H, Qiu Y. Exogenous parathyroid hormone-related peptide promotes fracture healing in Lepr(-/-) mice. *Calcif. Tissue Int.* 2015; 97(6):581−591.

Liu P, Cai M. Leptin influences healing in the Sprague Dawley rat fracture model. *Med. Sci. Monit.* 2017; 23:258−265.

Lopas LA, Belkin NS, Mutyaba PL, Gray CF, Hankenson KD, Ahn J. Fractures in geriatric mice show decreased callus expansion and bone volume. *Clin. Orthop. Relat Res.* 2014; 472(11):3523−3532.

Lovati AB, Romano CL, Bottagisio M, Monti L, De VE, Previdi S, Accetta R, Drago L. Modeling Staphylococcus epidermidis-induced non-unions: subclinical and clinical evidence in rats. *PLoS. One* 2016; 11(1):e0147447.

Lozada-Gallegos AR, Letechipia-Moreno J, Palma-Lara I, Montero AA, Rodriguez G, Castro-Munozledo F, Cornejo-Cortes MA, Juarez-Mosqueda ML. Development of a bone nonunion in a noncritical segmental tibia defect model in sheep utilizing interlocking nail as an internal fixation system. *J. Surg. Res.* 2013; 183(2):620−628.

Lyons FG, Gleeson JP, Partap S, Coghlan K, O'Brien FJ. Novel microhydroxyapatite particles in a collagen scaffold: a bioactive bone void filler? *Clin. Orthop. Relat Res.* 2014; 472(4):1318−1328.

Mao L, Kawao N, Tamura Y, Okumoto K, Okada K, Yano M, Matsuo O, Kaji H. Plasminogen activator inhibitor-1 is involved in impaired bone repair associated with diabetes in female mice. *PLoS. One.* 2014; 9(3):e92686.

Marenzana M, Vugler A, Moore A, Robinson M. Effect of sclerostin-neutralising antibody on periarticular and systemic bone in a murine model of rheumatoid arthritis: a microCT study. *Arthritis Res. Ther.* 2013; 15(5):R125.

Matsumoto T, Sato D, Hashimoto Y. Individual and combined effects of noise-like whole-body vibration and parathyroid hormone treatment on bone defect repair in ovariectomized mice. *Proc. Inst. Mech. Eng. H.* 2016; 230(1):30−38.

Matsuo T, Kita K, Mae T, Yonetani Y, Miyamoto S, Yoshikawa H, Nakata K. Bone substitutes and implantation depths for subchondral bone repair in osteochondral defects of porcine knee joints. *Knee. Surg. Sports Traumatol. Arthrosc.* 2015; 23(5):1401−1409.

Mills LA, Simpson AH. In vivo models of bone repair. *J. Bone Joint Surg. Br.* 2012; 94(7):865−874.

Minkwitz S, Fassbender M, Kronbach Z, Wildemann B. Longitudinal analysis of osteogenic and angiogenic signaling factors in healing models mimicking atrophic and hypertrophic non-unions in rats. *PLoS. One.* 2015; 10(4):e0124217.

Myers TJ, Longobardi L, Willcockson H, Temple JD, Tagliafierro L, Ye P, Li T, Esposito A, Moats-Staats BM, Spagnoli A. BMP2 Regulation of CXCL12 cellular, temporal, and spatial expression is essential during fracture repair. *J. Bone Miner. Res.* 2015; 30(11):2014−2027.

Ozturk BY, Inci I, Egri S, Ozturk AM, Yetkin H, Goktas G, Elmas C, Piskin E, Erdogan D. The treatment of segmental bone defects in rabbit tibiae with vascular endothelial growth factor (VEGF)-loaded gelatin/hydroxyapatite "cryogel" scaffold. *Eur. J. Orthop. Surg. Traumatol.* 2013; 23(7):767−774.

Paglia DN, Wey A, Breitbart EA, Faiwiszewski J, Mehta SK, Al-Zube L, Vaidya S, Cottrell JA, Graves D, Benevenia J, O'Connor JP, Lin SS. Effects of local insulin delivery on subperiosteal angiogenesis and mineralized tissue formation during fracture healing. *J. Orthop. Res.* 2013; 31(5):783−791.

Pang J, Ye M, Gu X, Cao Y, Zheng Y, Guo H, Zhao Y, Zhan H, Shi Y. Ovariectomy-induced osteopenia influences the middle and late periods of bone healing in a mouse femoral osteotomy model. *Rejuvenation. Res.* 2015; 18(4):356−365.

Peric M, Dumic-Cule I, Grcevic D, Matijasic M, Verbanac D, Paul R, Grgurevic L, Trkulja V, Bagi CM, Vukicevic S. The rational use of animal models in the evaluation of novel bone regenerative therapies. *Bone* 2015; 70:73−86.

Rapp AE, Bindl R, Recknagel S, Erbacher A, Muller I, Schrezenmeier H, Ehrnthaller C, Gebhard F, Ignatius A. Fracture healing is delayed in immunodeficient NOD/scidIL2Rgammacnull mice. *PLoS. One.* 2016; 11(2):e0147465.

Reifenrath J, Angrisani N, Lalk M, Besdo S. Replacement, refinement, and reduction: necessity of standardization and computational models for long bone fracture repair in animals. *J. Biomed. Mater. Res. A* 2014; 102(8):2884−2900.

Roberto-Rodrigues M, Fernandes RM, Senos R, Scoralick AC, Bastos AL, Santos TM, Viana LP, Lima I, Guzman-Silva MA, Kfoury-Junior JR. Novel rat model of nonunion fracture with vascular deficit. *Injury* 2015; 46(4):649−654.

Rochford ET, Sabate BM, Zeiter S, Kluge K, Poulsson A, Ziegler M, Richards RG, O'Mahony L, Moriarty TF. Monitoring immune responses in a mouse model of fracture fixation with and without Staphylococcus aureus osteomyelitis. *Bone* 2016; 83:82−92.

Roszer T, Jozsa T, Kiss-Toth ED, De CN, Balogh L. Leptin receptor deficient diabetic (db/db) mice are compromised in postnatal bone regeneration. *Cell Tissue Res.* 2014; 356(1):195−206.

Saito W, Uchida K, Matsushita O, Inoue G, Sekiguchi H, Aikawa J, Fujimaki H, Takaso M. Acceleration of callus formation during fracture healing using basic fibroblast growth factor-kidney disease domain-collagen-binding domain fusion protein combined with allogenic demineralized bone powder. *J. Orthop. Surg. Res.* 2015; 10:59 doi: 10.1186/s13018-015-0201-0.

Santos TS, Abuna RP, Almeida AL, Beloti MM, Rosa AL. Effect of collagen sponge and fibrin glue on bone repair. *J. Appl. Oral Sci.* 2015; 23(6):623−628.

Schindeler A, Yu NY, Cheng TL, Sullivan K, Mikulec K, Peacock L, Matthews R, Little DG. Local delivery of the cationic steroid antibiotic CSA-90 enables osseous union in a rat

open fracture model of Staphylococcus aureus infection. *J. Bone Joint Surg. Am.* 2015; 97(4):302−309.

Scholz M, Schleicher P, Sewing A, Gelinsky M, Kandziora F. Cyclic-RGD is as effective as rhBMP-2 in anterior interbody fusion of the sheep cervical spine. *Spine (Phila Pa 1976.)* 2013; 38(2):E59−E65.

Schutzenberger S, Kaipel M, Schultz A, Nau T, Redl H, Hausner T. Non-union site debridement increased the efficacy of rhBMP-2 in a rodent model. *Injury* 2014; 45(8):1165−1170.

Shimizu T, Akahane M, Morita Y, Omokawa S, Nakano K, Kira T, Onishi T, Inagaki Y, Okuda A, Kawate K, Tanaka Y. The regeneration and augmentation of bone with injectable osteogenic cell sheet in a rat critical fracture healing model. *Injury* 2015; 46(8):1457−1464.

Simpson AH, Murray IR. Osteoporotic fracture models. *Curr. Osteoporos. Rep.* 2015; 13(1):9−15.

Skelly JD, Lange J, Filion TM, Li X, Ayers DC, Song J. Vancomycin-bearing synthetic bone graft delivers rhBMP-2 and promotes healing of critical rat femoral segmental defects. *Clin. Orthop. Relat Res.* 2014; 472(12):4015−4023.

Sonnet C, Simpson CL, Olabisi RM, Sullivan K, Lazard Z, Gugala Z, Peroni JF, Weh JM, Davis AR, West JL, Olmsted-Davis EA. Rapid healing of femoral defects in rats with low dose sustained BMP2 expression from PEGDA hydrogel microspheres. *J. Orthop. Res.* 2013; 31(10):1597−1604.

Sousa DM, McDonald MM, Mikulec K, Peacock L, Herzog H, Lamghari M, Little DG, Baldock PA. Neuropeptide Y modulates fracture healing through Y1 receptor signaling. *J. Orthop. Res.* 2013; 31(10):1570−1578.

Sousa S, Valerio F, Jacinto A. A new zebrafish bone crush injury model. *Biol. Open.* 2012; 1(9):915−921.

Steiner M, Claes L, Ignatius A, Simon U, Wehner T. Numerical simulation of callus healing for optimization of fracture fixation stiffness. *PLoS. One.* 2014; 9(7):e101370.

Sverzut CE, de Matos FP, Trivellato AE, Kato RB, Sverzut AT, Taba JM, de Rezende Duek EA, de Oliveira PT. Histologic and histometric analysis of bone repair at the site of mandibular body osteotomy and at the bone-screw interface after using a biodegradable 2.0-mm internal fixation system. *J. Craniofac. Surg.* 2015; 26(4):1214−1219.

Taiani JT, Buie HR, Campbell GM, Manske SL, Krawetz RJ, Rancourt DE, Boyd SK, Matyas JR. Embryonic stem cell therapy improves bone quality in a model of impaired fracture healing in the mouse; tracked temporally using in vivo micro-CT. *Bone* 2014; 64:263−272.

Tawonsawatruk T, Kelly M, Simpson H. Evaluation of native mesenchymal stem cells from bone marrow and local tissue in an atrophic nonunion model. *Tissue Eng. Part C. Methods* 2014; 20(6):524−532.

Tevlin R, Seo EY, Marecic O, McArdle A, Tong X, Zimdahl B, Malkovskiy A, Sinha R, Gulati G, Li X, Wearda T, Morganti R. Pharmacological rescue of diabetic skeletal stem cell niches. *Sci. Transl. Med.* 2017; 9(372) doi: 10.1126/scitranslmed.aag2809.

Timmen M, Hidding H, Wieskotter B, Baum W, Pap T, Raschke MJ, Schett G, Zwerina J, Stange R. Influence of antiTNF-alpha antibody treatment on fracture healing under chronic inflammation. *BMC. Musculoskelet. Disord.* 2014; 15:184.

Toupadakis CA, Granick JL, Sagy M, Wong A, Ghassemi E, Chung DJ, Borjesson DL, Yellowley CE. Mobilization of endogenous stem cell populations enhances fracture healing in a murine femoral fracture model. *Cytotherapy*. 2013; 15(9):1136−1147.

Wang ZX, Chen C, Zhou Q, Wang XS, Zhou G, Liu W, Zhang ZY, Cao Y, Zhang WJ. The treatment efficacy of bone tissue engineering strategy for repairing segmental bone defects under osteoporotic conditions. *Tissue Eng. Part A* 2015; 21(17-18):2346−2355.

Windolf CD, Meng W, Logters TT, MacKenzie CR, Windolf J, Flohe S. Implant-associated localized osteitis in murine femur fracture by biofilm forming Staphylococcus aureus: a novel experimental model. *J. Orthop. Res.* 2013; 31(12):2013−2020.

Wu AC, Morrison NA, Kelly WL, Forwood MR. MCP-1 expression is specifically regulated during activation of skeletal repair and remodeling. *Calcif. Tissue Int.* 2013; 92(6):566−575.

Yoneme H, Hatakeyama J, Danjo A, Oida H, Yoshinari M, Aijima R, Murata N, Watanabe T, Oki Y, Kido MA. Milk basic protein supplementation enhances fracture healing in mice. *Nutrition* 2015; 31(2):399−405.

Yoshii T, Hafeman AE, Esparza JM, Okawa A, Gutierrez G, Guelcher SA. Local injection of lovastatin in biodegradable polyurethane scaffolds enhances bone regeneration in a critical-sized segmental defect in rat femora. *J. Tissue Eng. Regen. Med.* 2014; 8(8): 589−595.

Zhang Q, Dong H, Li Y, Zhu Y, Zeng L, Gao H, Yuan B, Chen X, Mao C. Microgrooved polymer substrates promote collective cell migration to accelerate fracture healing in an in vitro model. *ACS Appl. Mater. Interfaces* 2015; 7(41):23336−23345.

Zheng HF, Forgetta V, Hsu YH, Estrada K, Rosello-Diez A, Leo PJ, Dahia CL, Park-Min KH, Tobias JH, Kooperberg C, Kleinman A, Styrkarsdottir U. Whole-genome sequencing identifies EN1 as a determinant of bone density and fracture. *Nature* 2015; 526(7571):112−117.

Zhu H, Cai X, Lin T, Shi Z, Yan S. Low-intensity pulsed ultrasound enhances bone repair in a rabbit model of steroid-associated osteonecrosis. *Clin. Orthop. Relat Res.* 2015; 473(5):1830−1839.

In: Encyclopedia of Surgery (22 Volume Set)
Editors: Andreas Lehrer and Kristin Mueller
ISBN: 978-1-53618-329-0
© 2020 Nova Science Publishers, Inc.

Chapter 216

EXPERIMENTAL SOLID ORGAN TRANSPLANTATION IN SMALL ANIMALS

Hao Dun*, MD
Laboratory of Experimental Surgery, Department of Surgery, CRCHUM,
University of Montreal, Montreal, Quebec, Canada

ABSTRACT

Clinical organ transplantation for patients with end-stage organ failure has become an acceptable choice of treatment. Experimental solid organ transplantation modes in small animals have offered a unique advantage for addressing mechanistic questions of transplant rejection. In particular, rodents (rats/mice) are frequently selected to achieve experimental conclusions that probably can form the basis of clinical strategies, because their anatomical, physiological and immunological characteristics are similar to those of humans. Therefore, currently most of research projects are still performed in rodents. Nowadays, multiple organ transplant models in small animals have been developed and extensively used in transplantation research, based on their technical feasibilities. Of note, patterns of allograft rejection or tolerance vary between donor and recipient strain combinations, and among different transplanted organs. This raises concerns about the selection of an ideal model when using small animals as solid organ transplantation models. In this chapter, we will briefly review several most commonly used vascularized solid organ transplantation models in rodents, and hope that it may provide a better understanding and useful choices for certain organ transplants in small animal models.

Keywords: experimental model, solid organ, transplantation, rodent, microsurgery

* Corresponding Author's Email: dunhao64@yahoo.com.

ABBREVIATIONS

ALT	Alanine aminotransferase
APCs	Antigen presenting cells
AST	Aspartate aminotransferase
BUN	Blood urea nitrogen
CAN	Chronic allograft nephropathy
CAV	Cardiac allograft vasculopathy
CCA	Common carotid artery
Clcr	Creatinine clearance
ECG	Echocardiography
EJV	External jugular vein
EKG	Electrocardiography
IVC	Inferior vena cava
LA	Left atrium
LV	Left ventricle
MHC	Major histocompatibility complex
MRI	Magnetic resonance imaging
MST	Median survival time
PET	Positron emission tomography
RA	Right atrium
RV	Right ventricle
SCr	Serum creatinine
SMA	Superior mesenteric artery
SVC	Superior vena cava
UBM	Ultrasound biomicroscopy

INTRODUCTION

Life-saving solid organ transplantation is one of the most remarkable therapeutic successes in modern medicine. It has progressed initially from early stage of animal experiment to routine, reliable and effective clinical practice during the past 70 years. In the early days of experimental organ transplantation, big animal models were most commonly used, because anastomotic techniques were relatively easier with larger vassals. The most important development in this filed was from late 19th into early 20th century while French surgeon Alexis Carrel first used sutures to anastomose blood vessels in animals (Doyle 2004). Subsequently, his anastomotic techniques were adopted by other surgeons and became the basis for the standard vascular anastomotic techniques used today. In the early 1900s, Dr. Carrel performed kidney transplantation into the neck of the same dog, which allowed this animal to survive for several years and have offspring (Carrel 1905). A few years later, he also successfully performed kidney transplantation between different dogs. Due to his pioneering vascular suturing techniques, he received a Nobel Prize in 1912 in Physiology or Medicine.

In parallel to advances of microsurgical techniques and instrumentation, experimental organ transplantations in small animals were also being conducted from the 1960s, and became preferred models. Compared with big animals, the disadvantage of small animal is their smaller size for performing microsurgery. Thus, a higher level of microsurgical technical skill is demanded to achieve microsurgery in small animals. However, small animals, such as rodent models offer certain advantages over big animal models owing to the relative ease and comparative low cost of breeding. Moreover, there has been an increased availability of genetically, both transgenic and knockout, well-characterized strains of rodents. Nowadays embryonic stem cells have been isolated and genetically manipulated in mice, rather than in other mammalian animals (Niwa 2001). For immunology research, the mouse immune system indeed represents the ideal platform, and provides sufficient homology for pathway determinations and mechanistic studies (Anderson 2013). In addition, there have been a large number of specific monoclonal antibodies and immunological reagents available for rodents. These facts make the rodent models invaluable in transplant research.

Nevertheless, there are several potential limitations in rodent models. Unlike other large animal models, mice do not constitutively express class II antigens on vascular endothelium (Pescovitz 1984; Choo 1997). Methods of tolerance induction in mice have been limited by inability to repeat with large animals, especially in nonhuman primates and humans (Sachs 2003; Kirk 2003). In addition, allograft survival in rodent models varies depending on specific transplanted organs and donor-recipient strain combinations. Zhang et al. (Zhang 1996) demonstrated that all mouse intestinal allografts were rapidly rejected, and heart allografts also developed acute rejection without spontaneous acceptance, whereas kidney grafts showed both spontaneous acceptance and rejection depending on donor-recipient strain combinations. In contrast, the majority of liver allografts were spontaneously accepted despite fully major histocompatibility complex (MHC)-mismatched strain combinations (Zhang 1996). The rejection pattern of the mouse uterus grafts is similar to that of heart transplants (El-Akouri 2006). In general, the allograft rejection in mice appears less severe, compared to that in rat models (Zhang 1996). Clearly, further studies are warranted to determine values and limitations of rodent transplantation models, and identify physiological barriers to tolerance induction.

To date, more than 95% of organ transplantation studies are performed in rodents in research projects (Wang 2012). With state-of-the-art microsurgical technique, solid organ transplants in rodents including heterotopic heart, kidney, liver, small bowel, lung and uterus can be performed with a high success rate. All of these organ transplantation models are useful tools in fundamental organ transplantation research. However, each organ graft has a unique rejection pattern, and therefore its application varies depending on the specific need of research. In this chapter we will focus on the heterotopic heart, kidney, liver, small bowel and lung transplantation models in rodents (mice/rats), as these methods have become the predominant models used owing to their technical feasibilities, and the most needs for preclinical research when assaying transplantation immunity and developing novel therapeutic approaches that prevent allograft rejection.

HETEROTOPIC HEART TRANSPLANTATION IN MICE

The heterotopic heart transplantation in mice nowadays is one of the most frequently applied transplant models. It was described for the first time by Corry in 1973 (Corry 1973). The surgical procedure was comparable to the heart transplantation in rats as performed by Ono et al. in 1969 (Ono 1969). The technique involves end-to-side anastomoses of the donor ascending aorta and pulmonary artery to the recipient abdominal aorta and inferior vena cava (IVC), respectively. After grafting, the heart graft quickly starts contracting. This leads to a retrograde blood flow from the recipient abdominal aorta via the donor ascending aorta directly into the coronary arteries, thus irrigating the myocardium by capillary bed. Then, blood flow is drained from coronary circulation back into the coronary veins, coronary sinus, the right atrium (RA) and the right ventricle (RV), and finally reaches the recipient IVC via the main pulmonary trunk. Hence, the presented model is associated with a non-functional heart graft because it does not pump blood maintaining physiological blood pressure despite heart graft contractions.

Since the model was introduced in 1973, *many modified methods* have subsequently been reported to continuously improve and refine techniques (Gu 2007; Wang 2006; Wang 2003; Li 2004). Basically, two different sites, abdominal or cervical, can be experimentally used for the fully vascularized heterotopic heart transplantation in mice. A suture technique of the cervical heterotopic heart transplantation was first performed in 1991, with the anastomoses of the donor innominate artery and pulmonary artery to the recipient common carotid artery (CCA) and external jugular vein (EJV), respectively (Chen 1991). Because of the small size in diameter of cervical vessels, this alternative technique is technically more difficult to perform vascular anastomoses with the sutures, and in general, more frequently produces complications. Subsequently, cuff techniques, instead of sutures for the vascular anastomoses, were established by several authors (Matsuura 1991; Tomita 1997; Wang 2005; Feng 2005; Gu 2007). Indeed, in the cervical model, the cuff technique is preferred over the suture technique in terms of revascularization, due to its lower technical requirement and higher surgical success rate (Zhou 2010). However, regarding the abdominal model, vascular sutures cannot be substituted by cuff techniques, due to its exclusive fashion of end-to-side anastomosis in revascularization of the graft. Since the vascular suture method is much more frequently associated with anastomotic complications than the cuff technique, the abdominal model has even been considered to be replaced by the cervical model with cuff techniques (Wang 2007). However, the carotid artery is much smaller in diameter than the ascending aorta of the donor, so that anastomoses are not easier to perform (Doenst 2001) in the cervical site, despite the introduction of cuffs. Moreover, the transplanted heart graft positioned in the abdominal cavity is likely self-guided and less twisted (Doenst 2001). Therefore, most of researchers still prefer the abdominal model based on their experiences and abilities with this method to produce reliable results with limited experimental variables (Hasegawa 2007). Nevertheless, the cervical model as a second-choice site provides the possibility for the heart re-transplantation or the second graft transplant for the purpose of testing donor-type organ-specific tolerance, when the abdominal site has been occupied by a transplanted heart graft (Chen 1991).

The function of the transplanted heart is evaluated by palpating the heartbeat of the graft in recipients. This sensitive diagnostic method is easy, effective and reliable for monitoring

transplant rejection. Such advantages of the immediate vascularization and the ease of monitoring rejection noninvasively make the model excellent, and popular to study alloreactivity that results in acute rejection. In addition, several alternative means, with advantages and limitations, have been employed for graft rejection evaluations, such as electrocardiography (EKG) (Superina 1986; Mottram 1988), ultrasound biomicroscopy (UBM) (Zhou 2007), echocardiography (ECG) (Książek 2016; Scherrer-Crosbie 2008), and magnetic resonance imaging (MRI) (Figueiredo 2009). However, the most simple and reliable form of assessing rejection is still the direct abdominal palpation of the graft (Zhang 1996).

Donor MHC antigens elicit graft rejection by interacting directly with recipient T cells, or indirectly as donor MHC–derived peptides expressed on recipient MHC molecules (Felix 2000). Fully MHC-mismatched (both class I and class II MHC allelic differences) heart allografts are quickly rejected within 7–10 days (Qian 1996; Chong 2013; Schenk 2008; Kwun 2011; Corry 1973). The survival times of heart grafts from MHC class I or class II-deficient mice are significantly prolonged to 30–40 days in fully MHC-mismatched hosts (Qian 1996). Moreover, single class I or class II MHC-mismatched heart allografts or MHC-matched/multiple minor histocompatibility antigen-mismatched allografts can generally take a considerable amount of time to be rejected, and can survive for more than 60 days (Hattori 2012; Schenk 2005). This lack of acute rejection is probably because of $CD25^+$ regulatory T cell mediated-inhibition of alloreactive T cells, which play a dominant role in mediating acute graft rejection (Schenk 2005).

The orthotopic heart transplantation in mice is technically challenging, and to our knowledge, is currently unavailable (Figueiredo 2009). Instead, the heterotopic heart transplant model in mice has been extensively used to address basic immunologic questions of rejection and tolerance. To date, this technique is considered to be the best model in transplantation study. However, the retrogradely perfused, beating but nonfunctional graft, with a total mechanical unloading of left ventricle (LV), is the shortcomings of the model, which leads to mural thrombi form in the LV and progressive atrophy of the transplanted graft (Baldwin 2014). To address this issue, Figueiredo et al. (Figueiredo 2009) established the partial LV loading model in mice by heterotopic combined heart/lung transplantation. However, whether the volume-loaded heterotopic heart transplantation is superior to the classical myocardial unloading model in rodents remains controversial (Didié 2013; Tang-Quan 2010; Liu 2015).

HETEROTOPIC HEART TRANSPLANTATION IN RATS

The heterotopic abdominal heart transplantation model in rats, anastomosing donor ascending aorta and pulmonary artery to the recipient abdominal aorta and IVC, respectively, by an end-to-end fashion, was first described in 1964 by Abbott et al. (Abbott 1964). This technique opened a new avenue in terms of establishing fully vascularized organ transplantation models in small animals. However, the end-to-end anastomosis procedure completely shunted the blood flow of the recipient lower extremities to the heart graft, leading to severe complications of paraparesis and paraplegia, consequently restricting the recipient survival. Subsequently, Ono and Lindsey (Ono 1969) modified the model with end-to-side anastomoses for both the donor ascending aorta to the recipient abdominal aorta and

the donor pulmonary artery to the recipient IVC, allowing an adequate blood flow to and from the lower extremities of the recipient. As a result, the refined technique achieved a 90% graft and recipient survival. Since then, the classical Ono and Lindsey model of the rat heterotopic heart transplantation has been widely used in research. Over the last 4 decades, there have been numerous modifications reported for simplifying the technique and improving reliability of the model. Nowadays, the rat heart transplantation models used for locating a heart graft involve cervical, femoral, or abdominal sites in recipients. Each site has inherent advantages and disadvantages. The model should be selected cautiously, depending on the specific needs of research. The abdominal site model using the end-to-side anastomosis of relatively larger vessels likely is performed easily, with a higher success rate. Thus, the abdominal site model is still the most preferred option for the rat heterotopic heart transplantation in many centers, because the required microsurgical suturing technique is technically less challenging. As compared to abdominal site model, the principal drawback of the cervical and femoral site models is that vessel diameters are smaller (Fensterer 2014), making anastomoses more challenging, which may lead to an increased failure rate. However, Ma et al. (Ma 2011) carried out a study to compare two models of cervical and abdominal heart transplantation in rats, and concluded that two models are comparable in terms of both achievement of success rate and the histologic features of acute allogeneic rejection. Moreover, due to the feasibility of the end-to-end fashion of the arterial and venous anastomoses, the cervical site model provides the possibility for using cuff techniques for the rat heart transplantation (Gu 2007; Xiu 2001; Matsuura 1991). The cuff technique is favored, because it reduces the graft ischemic time and enhances the operative success rate of the small vessel anastomosis procedure when performed by surgeons without a high level of microsurgical skills (Zhou 2010). Overall, the femoral site model is technically *difficult* because of vessels at the femoral site are very thin and the operative space is narrow, consequently lengthening the procedure time and increasing the ischemic time of grafts (Gordon 2007a; Gordon 2007b). However, the femoral site model enables easier handling of grafts, and allows more precise evaluation of the rejection endpoint through using the ECG (Gordon 2007a). On the other hand, cervical and femoral models may provide more possibilities for the re-transplanting of the second or third heart grafts, in the transplantation studies.

The graft function in terms of heartbeat is monitored by direct abdominal palpation that provides immediate, accurate evaluations with non-invasiveness. In addition, ECG (Voiglio 1995), EKG (Wada 1999) and fluorescence-based surveillance (Morgan 1999) have been reported for monitoring transplant rejection with limited predictive accuracy or practicability.

Fully MHC-mismatched rat heart allografts, such as Dark Agouti (DA; $RT1^{av1}$) donor to Wistar Furth (WF; $RT1^{u}$) recipient (Syrjälä 2014), DA donor to Lewis (LEW; $RT1^{l}$) recipient (Ma 2011), Brown-Norway (BN) donor to LEW recipient (Wada 1999), LEW.1W ($RT1.A^{u}$ B^{u} D^{u}) donor to LEW.1A ($RT1.A^{a}$ B^{a} D^{a}) recipient (Pêche 2006), RA ($RT1^{p}$) donor to PVG ($RT1^{c}$) recipient (Koshiba 2003), and LEW or ACI ($RT1^{a}$) donor to Buffalo ($RT1^{b}$) recipient (Goss 1993) are rejected within 10 days. Partially MHC-mismatched rat heart allografts of LEW donor to F-344 recipient with certain immunosuppressive drugs showing a chronic heart graft rejection, have been used to study cardiac allograft vasculopathy (CAV) (Hölschermann 2000; Suzuki 1999; Fujino 2012).

In the classical Ono and Lindsey model of the heterotopic abdominal heart transplantation in rats, blood from the recipient abdominal aorta via the donor ascending aorta enters the coronary circulation. Due to the closed aortic valve, the LV is unloaded in this

model. Thus, this technique is a less adequate model for the hemodynamic or function study, because its total mechanical unloading LV of the transplanted heart leads to substantial cardiac atrophy and functional deterioration. To circumvent these limitations, several alternative surgical techniques in order to partially load the LV have been proposed (Asfour 1999; Klein 1991). Asfour et al. (Asfour 1999) developed a volume-loaded heterotopic heart transplantation model via the anastomosis of donor pulmonary artery to left atrium (LA). In addition, the donor ascending aorta and superior vena cava (SVC) is end-to-side anastomosed to the recipient abdominal aorta and IVC, respectively. In this model, some of the coronary circulation blood flow return to the LV via the additional anastomoses, thus allowing for a partial loading of the LV. Comparing the partial volume-loaded and classical volume-unloaded models, Didié et al. (Didié 2013) concluded that the partial volume-loaded model shows superior morphological as well as functional preservation. However, there are *controversies* surrounding this topic. The extra surgical procedures required in the partial volume-loaded model result in longer ischemic time of the heart graft. And moreover, the mixture of deoxygenated blood returning to arterial coronary circulation may cause the myocardial chronic ischemic injury and dysfunction (Tang-Quan 2010). In this regard, it was argued that the classical non-loaded heterotopic heart transplantation in rats remains a more practical model relevant to preclinical transplant studies (Tang-Quan 2010).

KIDNEY TRANSPLANTATION IN MICE

The first kidney transplantation in mice was performed by Skoskiewicz et al. in 1973 (Skoskiewicz 1973). The technique they reported was similar to the model in rats described by Fisher et al. in 1960s (Lee 1967). Because of the small size of vessels (less than 0.4 mm in the diameter of the mouse renal artery), the technique is extremely difficult in vascular anastomoses with much higher incidences of surgical complication, an almost 30−50% mortality rate, so that its wide use was limited over next twenty years. Since 1990s, several modified techniques have been reported to overcome the small size of the vessels in using the donor aorta (Kalina 1993) rather than the base of renal artery to form the arterial anastomosis. Such a refinement significantly improved the technique, making it more practical and reliable for studying immunological mechanisms of transplant rejection. Nevertheless, to date, the kidney transplantation in mice is still highly challenging, and can be performed only in a few transplant research centers in the world.

Since the model established, there have been many modified techniques reported (Kalina 1993; Zhang 1995; Han 1999), thus greatly contributing to the development of the model. Similar to clinical renal transplantation, basally, a functioning kidney transplant requires establishment of vascular flow through arterial and venous anastomoses between donor and recipient vessels, and the connection of the donor ureter into recipient bladder. To date, the most commonly used experimental kidney transplantation method in mice is a heterotopic rather than orthotopic model, which creates an arterial anastomosis by the end-to-side anastomosis of the donor suprarenal (Kalina 1993) or infrarenal (Zhang 1995) aorta to the recipient abdominal aorta, such that the donor aorta acts as a conduit to the renal artery. The donor renal vein can be connected to the recipient IVC by an end-to-side anastomosis, or connected to the recipient renal vein by a cuff technique (Chen 2013). The urinary tract

reconstruction can be performed by anastomosis between the donor and recipient bladder patch (Kalina 1993; Zhang 1995; Chen 2013) or direct insertion of the donor ureter into the recipient bladder (Han 1999). Although many researchers currently still prefer the *bladder patch*-to-*bladder anastomosis technique* for restoration of urinary tract continuity (Kalina 1993), it has been suggested that direct implantation of the donor ureter into the recipient bladder is a quicker and easier procedure, which is associated with reduced surgical complications (Han 1999).

Unlike the model of the heterotopic heart transplantation, the kidney transplantation can be as an ideal life-supporting model, when both native nephrectomies are performed in the recipient, since its survival is dependent on the viability of the graft. To create a truly transplant dependent model, the second native nephrectomy can be immediately performed after grafting. Alternatively, some researchers preferred removing the second native kidney on the 4th−7th postoperative day to avoid an initial period of acute renal failure caused by surgical procedures (Skoskiewicz 1973; Chen 2013; Russell 1978; Benson 1985; Pratt 2002). Nevertheless, in many cases, for example, for short-term immunological and histological assessments, the recipient native kidney has been left *in situ*, so that the recipient mouse is not dependent on the transplanted graft for survival (Wang 2004; Inoue 1991; Wyburn 2006). Such an advantage of the mouse undergoing a limited surgical procedure reduces the surgical mortality, and prevents animals from the adverse effects of the gradual renal failure.

The function of the kidney graft in the nephrectomized recipient is assessed by the quantification of serum creatinine (SCr) and blood urea nitrogen (BUN), as well as creatinine clearance (Clcr) (Wang 2010), similar to clinical renal transplantation. Using the I-Stat portable clinical analyzer (Heska Corp., Fort Collins, CO), the SCr can be sequentially monitored with less than 0.2 ml whole blood sample from the retro-orbital sinus or lateral tail veins without sacrificing recipients (Bickerstaff 2008).

The kidney transplantation in mice has provided a potential model for studying acute and chronic graft rejection that is clinically more relevant. Several different combinations of inbred mouse strains have been used in kidney transplantation studies with varying progression and pattern of kidney allograft rejection. Acute allograft rejection can be observed in some strains of fully MHC-mismatched combinations, including C57BL/6 recipients of BALB/c or B10.BR allografts (Qi 1999; Brown 2007). Generally, kidney allografts with either a single class I or Class II MHC-mismatched strain combinations can survive for a long period without immunosuppression (Skoskiewicz 1973; Russell 1978). However, even with the fully MHC-mismatched combination such as C57BL/6 recipients of DBA/2 allografts, the majority of kidney grafts are accepted (Brown 2007), whereas heart grafts are usually rejected in this strain combination. Underlying mechanisms remain to be further elucidated. Of note, survival results vary among different research groups. For example, BALB/C allografts in C57/BL6 recipients have been reported with a survival time as low as 8 days (Qi 1999), versus that over 100 days in the other study (Lutz 2007). Mechanisms contributing to the discrepancy in allograft survival time observed in different groups remain unclear. Some authors were concerned that surgical factors may be involved (Tse 2013). Overall, the kidney transplantation model in mice is technically more demanding to perform reliable surgical procedures, and it is difficult to monitor allograft rejection as well, compared with the heterotopic heart transplantation model, while limiting its wide use.

KIDNEY TRANSPLANTATION IN RATS

The first report of the rat kidney transplantation was presented at the American College of Surgeons Meeting in Chicago in 1961 by Bernard Fisher and Sun Lee (Shrestha 2014), and subsequently published in the middle of the 1960s (Fisher 1965; Lee 1967). Initially, the kidney graft was transplanted into the recipient in an orthotopic position. End-to-end anastomoses were performed with the donor renal artery and vein to the remains of the recipient renal artery and vain after nephrectomy. The urinary tract was also reconstituted by an end-to-end anastomosis between the donor and the recipient ureters. Since then, several modified microsurgical techniques with respect to improving surgical procedures have been reported over the last four decades. Each of them with certain advantages and disadvantages has contributed to the development of the model.

Currently, commonly used microvascular surgical techniques include (1) the end-to-end anastomosis of the donor renal artery and vein to the recipient renal artery and vein; (2) the end-to-side anastomosis of the donor renal artery and vein to the recipient abdominal aorta and IVC; and (3) the sleeve technique for the renal artery and the cuff procedure for the renal vein (Schumacher 2003; Lopez-Neblina 1994; Zhang 1991; Zhu 2009). In the end-to-side anastomosis fashion, the graft vessels should have a patch to increase the size of vessels, making anastomoses easier. In addition, Zhu et al. (Zhu 2009) described a cervical heterotopic kidney transplantation technique in rats, where the donor renal artery and vein were end-to-end anastomosed to the recipient left CCA using a sleeve anastomosis, and to the recipient EJV with a cuff technique, respectively. The donor bladder patch was exteriorized to form a cervical cutaneous stoma. Vascular conduits from the donor abdominal aorta and IVC in continuity to the transplanted organ vessels are often employed in other organ transplantation models, such as the small bowel transplantation in rats (Wasserberg 2004; Santiago 1992; Bakonyi Neto 1999; Wasserberg 2003). Based on this technique, Karatzas et al. (Karatzas 2007) used vascular conduits from donor abdominal aorta and IVC in continuity to renal vessels, to perform arterial and venous end-to-side anastomoses to the recipient abdominal aorta and IVC, respectively. This method is similar to the procedure of the kidney transplantation in mice. Although the extra procedures are required for harvesting the donor abdominal aorta and IVC, the technique likely makes vascular anastomoses easier. There are several procedures available to restore the continuity of the urinary tract, including the anastomosis of (1) the donor bladder patch to the recipient bladder, (2) the donor ureter to the recipient ureter with or without a ureteral stent, and (3) a direct insertion of the donor ureter into the recipient bladder.

Specific technical factors may affect outcomes of the graft function and survival. Spanjol et al. (Spanjol 2011) showed that the end-to-end vascular anastomosis has a better result with respect to the transplanted renal graft survival compared to the end-to-side fashion. Schumacher et al. (Schumacher 2003) argued that the end-to-end or end-to-side vascular anastomoses are preferable to the sleeve technique, because the latter in small arteries may cause the reduced blood flow, and subsequently result in a higher incidence of stenosis. Regarding urinary reconstruction, due to inadequate blood supply to the distal ureter and bladder of the donor, the anastomosis of the donor bladder to recipient bladder is associated with ischemia and necrosis at the anastomotic site, leading to urine leakage with fatal consequences. A ureteral stent is often adopted in the clinical kidney transplantation to reduce

the incidence of urine leaks and ureteric stenosis (Wilson 2013; Gomes 2013). However, the placement of a stent within a ureter, which may be associated with the calculi formation and obstruction of the urinary tract, should be avoided (Martins 2003). Overall, direct implantation of the donor ureter into recipient bladder is an easier and more reliable procedure, which should be recommended for the urinary reconstruction in the model.

Basically, post-transplanted renal grafts are monitored by renal retention parameters, such as SCr and BUN. Xue et al. (Xue 2016) showed that the increasing levels of serum hepcidin and SCr were significantly correlated with impairment of renal function with the progression of chronic allograft nephropathy (CAN), suggesting that hepcidin may be a potential biomarker for monitoring the impaired renal functions after kidney transplantation. Moreover, Reuter et al. (Reuter 2009) proposed a non-invasive, entirely image-based method for assessment of renal allograft rejection in the rat model, based on high-resolution whole body small animal positron emission tomography (PET), following injection of ^{18}F-fluorodeoxyglucose. In addition, non-specific symptoms frequently presenting in acute or chronic rejection, such as proteinuria, oliguria, hypertension, graft tenderness and peripheral edema, should be observed.

Acute renal allograft rejection commonly occurs in fully MHC-mismatched rat strain combinations, such as WF to LEW (Li L 2016; Yang 2015), LEW-BN to LEW (Grabner 2013; Reuter 2009) and DA to LEW (Grau 2011) rat combinations. For example, without immunosuppression, DA grafts in LEW recipients lead to death of recipients from acute rejection around 7 days after kidney transplantation (Grau 2011).

Despite dramatic improvements in developing new immunosuppressant therapies, late graft loss after kidney transplantation remains an unsolved problem (Jevnikar 2008; Xue 2016). The CAN is the leading cause of late allograft loss. The kidney transplantation model in rats has provided an important tool for understanding the pathogenesis and molecular biology, and identifying potential treatment of the CAN (Shrestha 2014). The rat CAN model was first established by White et al. in 1969 (White 1969), using the F344 rat as the donor and the LEW rat as the recipient without immunosuppression to produce chronic allograft rejection. In such a rat CAN model, impairment of renal function and pathogenesis are similar to that occurred in clinical human transplantation. Therefore, this model is regarded as a standard model, and most commonly used to study the CAN (Shrestha 2014). The F344-to-LEW model can be employed to induce CAN because the rat strains differ partially at MHC (class I and class II) and various non-MHC loci, thereby allowing transplant without immunosuppression, which cannot be done in other fully MHC-mismatched rat strain combinations. However, with use of certain immunosuppressive agents, other combinations, such as DA-to-BN, DA-to-WF, DA-to-LEW, SD-to-WF, and LEW-to-BN have also been used to induce the CAN, depending on the aim of the individual study (Shrestha 2014).

LIVER TRANSPLANTATION IN MICE

Based on the technique of the orthotopic liver transplantation in rats (Lee 1973; Zimmermann 1978; Kamada 1979), the orthotopic liver transplantation model in mice was established by Qian et al. in 1991 (Qian 1991). In the model, the suprahepatic inferior vena cava of the donor and recipient was end-to-end anastomosed with a continuous suture

method, and then cuff techniques were used for anastomoses of the portal vein and the infrahepatic vena cava, respectively. Biliary continuity was restored by tying the ducts over a tube stent. It was suggested that the anhepatic time should be limited to less than 20 min (Qian 1991). In this model, hepatic rearterialization of liver graft with reconstitution of the hepatic artery was not included. Therefore, it is not physiologically accurate, which was considered as a shortage of the model. However, due to the technical simplicity, it remains popular today at many research centers (John 2007; Conzelmann 2003; Nakagawa 2012; Que 2004; Li 2008; Birsner 2004). Later, Tian et al. (Tian 2002) developed an arterialized liver transplantation model in mice, where an arterial segment consisting of the hepatic, celiac and aorta from the graft was end-to-side anastomosed to the recipient abdominal aorta. The data demonstrated that arterialization of liver transplants in mice results in an improved function compared with grafts without hepatic artery (Tian 2002). Consistent with this study, Shen et al. (Shen 2005) showed that arterialized mouse liver transplants have tremendous benefits compared with non-arterialized grafts regarding ischemia injury and recipient survival after a prolonged cold ischemia (24 h). These findings suggested that arterial reconstruction might be a necessary procedure for consistent animal survival and reduced liver injury, and thus provide a superior and physiologically relevant model for liver transplantation research. Based on the previous technologies, Tian et al. (Tian 2003) established arterialized partial (50% and 30%) mouse liver transplantation model. The surgical procedure is similar to the standard model, but partial hepatectomy is achieved by removal of relevant lobes on the donor liver. The result indicated that the partial liver transplantation between a graft volume of 30% and 45% is feasible in the mouse model, which is similar to clinical patients (Tian 2003).

After transplants, the liver graft function is monitored by determination of the serum alanine aminotransferase (ALT) and aspartate aminotransferase (AST) levels as markers of hepatocyte injury (Iu 1987), and alkaline phosphatase levels served as a marker of bile duct injury (Tian 2002). In addition, other biochemical determinations, such as bilirubin, total protein, and albumin are often included (Qian 1991).

In mice, liver allografts are accepted across MHC barriers without requirement for immunosuppressive therapy (Qian 1994; Jiang 2006). For example, liver grafts can be permanently accepted with a median survival time (MST) >100 days in the strain combination of the C57BL/10 (B10; H2b) to C3H (H2k) mouse. In the same strain combination, heart grafts are quickly rejected with an MST of 10 days (Qian 1994). The underlying mechanisms are still unknown. There have been many proposed mechanisms regarding the ability of the transplanted liver to be accepted by the recipient. Dahmen et al. (Dahmen 1994) found that cells isolated from the recipient spleen and liver graft-infiltrating cells exhibit a strong donor and third-party alloreactivity *in vitro*, though hyporesponsive *in vivo*. This phenomenon has been named as "split tolerance." Findings have suggested that restoration of apoptotic activity of liver graft-infiltrating cells and recipient spleen cells, especially $CD8^+$ T cells, is critical for the development of liver transplant survival and tolerance (Qian 1997; Li 20011a; Li 2001b). Li et al. (Li 2008) showed that $Foxp3^+CD25^+CD4^+$ regulatory T cells were increased within liver grafts and recipient spleens. Depletion of recipient $CD25^+CD4^+$ T cells increased proliferative response of $CD4^+$ T cells and cytotoxic T lymphocyte induction of $CD8^+$ T, and induced acute liver allograft rejection (Li 2008; Jiang 2006). Similarly, blockade of CTLA4, an effector molecule of $Foxp3^+CD25^+CD4^+$ regulatory T cells, protects allo-reactive T cells from apoptotic death,

leading to liver graft rejection (Li 2005). These findings suggest that Treg-mediated immune suppression may play an important role in the induction of liver transplant tolerance. However, why this occurs only in liver grafts, but not in other organ grafts, remains to be elucidated.

LIVER TRANSPLANTATION IN RATS

The orthotopic liver transplantation in rats was pioneered by Lee et al. in 1973 (Lee 1973), in which all anastomoses were performed using hand-suture techniques. Due to relatively longer operative time, an extracorporeal portosystemic shunt was used in the model. Later, the technique was simplified by elimination of the hepatic artery anastomosis and the extracorporeal portosystemic shunt (Lee 1975). However, because of technical demand and long operative time, this model has not been widely used (Ishii 2013). Since the introduction of the cuff technique making a vital improvement of the model in 1979 by Kamada et al. (Kamada 1979), the method has remained the gold standard, and became one of most commonly used model worldwide. In this model, the suprahepatic inferior vena cava is end-to-end anastomosed with a running suture technique, and the portal vein, the infrahepatic vena cava and the bile duct are reconstructed using cuff method. This technique has significantly simplified microvascular anastomoses and shortened the operation and especially anhepatic time in the recipient, thus enabling higher success rates of the long-term survival. However, hepatic artery reconstruction of the graft is not included, although it is routinely performed in clinical transplantation. Engerman et al. (Engemann 1982) argued that rearterialization of the liver graft was necessary, and established an end-to-side anastomosis between the donor aortic segment and the recipient infrarenal aorta to reconstruct hepatic artery. Later, Howden et al. (Howden 1989) developed an end-to-end sleeve anastomosis between the donor celiac axis and the recipient right renal artery. However, in his technique, an extra surgical procedure of right nephrectomy is required, making the method less optimal. Hereafter, there have been numerous techniques reported to establish hepatic rearterialization, greatly contributing to the development of the rat liver transplantation (Gao 1993; Huang 2011; Hasuike 1988; Steffen 1989; Howden 1989; Li 2002; Lehmann 2005; Liu 2015; Tan 2005).

Hepatic artery reconstruction is considered as an important step in human and large animal liver transplantations (Uchiyama 2002). However, it remains controversial in the rat liver transplantation. Some studies showed that there were neither significant improvement in recipient survival, nor histologic differences in hepatocyte or bile duct architecture between arterialized and non-arterialized grafts, suggesting that arterial reconstruction might be an unnecessary procedure of the operation (Kamada 1992; Kamada 1983). Thus, arterialization does not have a major contribution to the outcome of the rat liver transplantation. Therefore, biliary complications are more likely to be technique-related rather than the result of ischemia associated with the non-arterialized method (Kamada 1992). On the contrary, Nosaka et al. (Nosaka 1999) reported that the non-arterialized model is associated with higher rates of biliary complications and liver defects. Moreover, several studies showed that the arterialized model of liver transplantation in rats has benefits over nonarterialized transplants in many respects, such as improvement of the recipient survival after prolonged cold ischemia (Gao

1993), antigen presentation (Engemann 1982), microvascular perfusion and graft function (Post 1992). Clearly, *further studies are warranted* for eliciting this issue, especially to exclude surgical technical factors that may markedly influence the outcome of the survival.

The bowel infarction, as a consequence of a long period of portal triad clamping, may cause recipient early deaths within the first three hours after reperfusion (Oldani 2012). Therefore, the ideal anhepatic phase should be limited within 20 minutes. The acceptable ischemia time was considered to be up to 24 hours (Oldani 2012).

In many species, the acceptance or *mild rejection of* liver allografts *are often observed*, whereas their skin, heart and kidney allografts undergo acute rejection. *In* particular, in rats without immunosuppressive treatment, liver allografts can be permanently accepted between certain strain combinations (Houssin 1979). For example, a fully MHC-mismatched combination of organ transplants between PVG donors and DA recipients, hearts or kidneys are rejected by <10 days, while livers survive >100 days (Ganbold 2012). Furthermore, PVG rats grafted with a DA liver have been shown to be systemically tolerant with the permanent acceptance of a simultaneous or subsequent graft of DA heart, kidney or skin (Kamada 1980; 1984; 1985). Overall, liver graft has a unique ability to be accepted, and can protect other simultaneously transplanted organs against rejection. This was of particular interest for the clinical setting. However, the underlying mechanism of the phenomenon of non-rejection that is only restricted to liver, but not other organs, is still unclear. In short, due to its technical feasibility, the rat liver transplantation has become a reliable and practical model for studying transplantation immunity, regarding mechanisms of graft rejection, tolerance, and preservation-induced injury in liver transplantation. Nevertheless, its technique is still challenging with a steep learning curve (Hori 2010).

SMALL BOWEL TRANSPLANTATION IN MICE

The small bowel transplantation in mice was first reported by Squiers et al. in 1992 (Squiers 1992). They described a heterotopic technique including end-to-side anastomoses of the donor superior mesenteric artery (SMA) with a Carrell patch to the recipient abdominal aorta, and the donor portal vein to the recipient IVC, respectively. After vascular reperfusion of the graft, ends of the grafted bowel are brought out as stomata and secured to the skin on the abdominal wall. Using this technique, Zhong et al. (Zhong 1993) performed a large number of 247 cases of the small bowel transplantation in mice, with a 13% and 87% success rate for their first 132 cases and last 30 cases, respectively. This report indicated that this procedure is technically difficult and the microsurgical expertise is required for achieving consistent results. Later, He et al. (He 1998) developed a paratopic model of the small bowel transplantation in mice. The primary difference from the previous heterotopic model is that the distal end of the donor small bowel is end-to-side anastomosed to the recipient jejunem, while the proximal end of the small bowel is still brought out as a stoma. More recently, Liu et al. (Liu 2005) described an orthotopic technique for the small bowel transplantation in mice. The vascular anastomosis is similar to the manner as described for the previous heterotopic method. Differently, the entire recipient small bowel is removed, leaving approximately 1.0 cm on each end of the recipient jejunum and ileum, which then are end-to-end anastomosed to the end of the donor jejunum and ileum, respectively.

Because the small bowel is the most immunogenic organ among all the solid organs (Zhang 1996b), its transplantation has been still unsatisfactory compared to other organs in clinical and experimental transplantation studies. A possible explanation for the high incidence of its rejection over other organs, such as kidney and liver, is that the small bowel consists of a large number of lymphoid organs, such as lymph nodes and Peyer's patches, as well as massive antigen presenting cells (APCs). However, the unique pattern of the alloimmune response to a small bowel allograft remains to be elucidated. In the mouse model, small bowel grafts with MHC-mismatched strain combination are rapidly rejected without any cases of spontaneous acceptance (Zhang 1996b). Moreover, some immunosuppressive agents can effectively prevent rejection of other organs, such as kidney and heart, but not small bowel grafts (Zhang 1996a). Overall, the small bowel transplantation model in mice offers a useful method to study immunology and physiology of the gut transplantation, as well as to investigate immunosuppressive agents. However, this model is limited to use due to extremely technical challenges (Liu 2007).

SMALL BOWEL TRANSPLANTATION IN RATS

The first heterotopic small bowel transplantation model in rats was described by Monchik et al. in 1971 (Monchik 1971). Later, Kort et al. (Kort 1973) developed the model of the orthotopic small bowel transplantation in rats. In both methods, the small bowel is transplanted into the recipient by end-to-side anastomoses of the donor aortic segment to the recipient infrarenal aorta, and the donor portal vein to the recipient IVC, respectively. In the orthotopic model, the recipient native small bowel is removed, and it is replaced by the transplanted small bowel graft in continuity. In contrast, in the heterotopic model, the recipient small bowel is kept intact, so that the small bowel graft is not functionally involved in the continuity of the recipient digestive tract. In general, two different methods have been used for heterotopically locating small bowel grafts (Zhong 1991). In the first one, both ends of the graft are placed as stomata (ileostoma and duodenostoma) in the abdominal wall of the recipient. In the second one, the distal end of the graft is end-to-side anastomosed to the terminal ileum of the recipient, while the proximal end of the graft is exteriorized and sutured to the abdominal wall as a stoma (Nakao 2002). In addition, instead of sutures, the cuff methods have been reported for vascular anastomoses in the model, where the recipient left renal vessels were dissected and the left native kidney was removed, and then the small bowel graft was connected to the recipient renal vessels by a cuff technique (Wallander 1988). Moreover, the rat small bowel can be transplanted in the cervical area with the connections of the donor SMA to the recipient CCA and the donor superior mesenteric vein or portal vein to the recipient EJV, respectively, using the suture (Sonnino 1990) or the artery sleeve and venous cuff (Zhu 2008) techniques.

The well-established rat small bowel transplantation model has been extensively used for investigating various reactions related to the small bowel transplantation. Compared with the orthotopic model, the heterotopic model involves relatively simple techniques, and therefore has a higher survival rate (Nakao 2002). Furthermore, the heterotopic model is available for endoscopic evaluation and biopsy through the stoma (Toyama 1995; Nakao 2001). In fact, the heterotopic model has been the commonly employed model for studying immunological

reactions of the small bowel transplantation and evaluation of immunosuppressive strategies, although it does not represent a physiologic state of the small bowel. In contrast, the small bowel grafted in the orthotopic model is under physiologic conditions, making it more clinically relevant and suitable for studies of the graft function. Overall, both heterotopic and orthotopic models have advantages and shortcomings. The selection of an appropriate model is important for achieving a specific research goal.

ORTHOTROPIC LUNG TRANSPLANTATION IN MICE

Until 2007, the orthotropic lung transplantation in mice has been first developed by Okazaki et al. (Okazaki 2007). Of note, unlike other solid organ transplantation model, which can be anastomosed directly by sutures, the bronchial and vascular anastomoses required for the lung transplantation in mice are all performed using cuff techniques. This technique involves pulling the donor pulmonary artery, pulmonary vein and bronchus through a Teflon Catheter Cuff (24G, 20G and 20G, respectively). Then, vessels and the bronchus are folded over the cuff in order to expose the endothelial surface of vessels or epithelial surface of the bronchus, which is secured with a 10-0 nylon tie. Subsequently, the lung is transplanted by inserting cuff-equipped donor pulmonary artery, vein and bronchus into the respective structures of the recipient, which is also secured with a 10-0 nylon tie.

Clinical lung transplantation is far worse than other solid organ transplantations for long-term survival outcomes (Trulock 2006), mainly due to bronchiolitis obliterans syndrome that is considered as a manifestation of chronic allograft rejection (Chan 2004). The underlying mechanisms are not clearly known. To this end, the heterotopic tracheal transplantation model in mice has been developed to study lung transplantation biology (Hertz 1993). Due to the technical simplicity of this model, it has been widely used for studying immunological mechanisms of lung transplantation leading to obliterative airway diseases (Maruyama 2005; Higuchi 2005). However, the heterotopic tracheal transplantation model in mice lacking vascularization and aeration makes it difficult to draw conclusions about changes that can be only observed in whole lung transplantation. Thus, orthotropic lung transplantation in mice offers a physiological model of lung transplantation for investigating non-immunologic and immunologic mechanisms that contribute to lung allograft injury, despite its technical challenge.

ORTHOTOPIC LUNG TRANSPLANTATION IN RATS

The orthotopic lung transplantation in rats was first reported by Asimacopoulos et al. in 1971 (Asimacopoulos 1971). It was performed with sutures to anastomose the pulmonary artery, the pulmonary vein and the bronchus between the donor and recipient. Because of technical difficulties of the model in the vascular and bronchial anastomoses, its wide use as a standard experimental model of the lung transplantation was limited for more than ten years. In 1989, Mizuta et al. (Mizuta 1989) introduced the cuff technique, instead of sutures for anastomoses of vessels, making the model technically simpler, and more attractive. Later, they also applied the cuff technique in the bronchial anastomosis (Mizuta 1991). Since then,

this method has become the standard experimental model of the lung transplantation in rats, owing to its technical feasibility and reliability. Subsequently, based on Mizuta's model, several modifications have been reported to simplify the surgical procedure and enhance the quality of the model (Goto 2012; Reis 1995; Sánchez 2007; Santana Rodríguez 2004). Of note, Goto et al. (Goto 2012) introduced cuffs to all of vessels and bronchi in both donor and recipient sides, and then connected them by interposing pieces of the donor descending aortas. This technique provides the possibility of using donor aorta in other organ transplantations.

Lung transplantation has been optioned for patients with end-stage lung disease. However, its outcomes have been greatly limited by the primary graft dysfunction and the bronchiolitis obliterance syndrome (Christie 2010). Experimental animal models of orthotopic lung transplantation have provided a useful physiological model for investigating mechanisms leading to lung allograft injuries from acute or chronic rejection. Because of its low cost, availability of inbred strains, and technical feasibility and reliability, the rat lung transplantation has been considered to be one of the best models, offering a valid alternative for those performed in large animals. However, despite the introduction of cuff methods, its surgical technique is still complex, and therefore it requires a long-term learning process for surgeons to achieve reliable results (Santana Rodríguez 2004).

CONCLUSION

Small animal models of solid organ transplantation provide unique tools for gaining insights into mechanisms of organ transplant rejection, and for developing novel therapeutic approaches that prevent rejection and induce transplantation tolerance. Rodent models of transplantation have become the first choice for fundamental transplantation research, due to their technical feasibility, the availability of numerous well-established transgenic and knockout inbred strains, low costs and simple handling. Nevertheless, there are limitations when translating information obtained from these models to clinic, due to certain inherent differences between rodents and humans in the genetics, physiology and immunology. These limitations can be overcome by using large animals, such as nonhuman primates, which are more close to human being in many ways. Finally, small animal solid organ transplantation models will continue to be important and remain indispensable tools for basic transplantation research.

REFERENCES

Abbott CP, Lindsey ES, Creech O Jr, Dewitt CW. A technique for heart transplantation in the rat. *Arch. Surg.* 1964; 89: 645−652.

Anderson DJ, Kirk AD. Primate models in organ transplantation. *Cold Spring Harb. Perspect. Med.* 2013; 3(9): a015503.

Asfour B, Hare JM, Kohl T, Baba HA, Kass DA, Chen K, Tjan TD, Hammel D, Weyand M, Hruban RH, Scheld HH, Byrne BJ. A simple new model of physiologically working

heterotopic rat heart transplantation provides hemodynamic performance equivalent to that of an orthotopic heart. *J. Heart Lung Transplant.* 1999; 18(10): 927−936.

Asimacopoulos PJ, Molokhia FA, Pegg CA, Norman JC. Lung transplantation in the rat. *Transplant. Proc.* 1971; 3(1): 583−585.

Bakonyi Neto A, Ricordi C, Feo CF, Porcu A, Misiakos EP, Gandia C, Ruiz P, Bertho M, Carreno M, Esquenazi V, Miller J, Tzakis AG. Correlation between allograft survival and chimeric state after bone marrow infusion in rat small bowel transplantation. *Pediatr. Transplant.* 1999; 3(1): 67−73.

Baldwin WM 3rd, Su CA, Shroka TM, Fairchild RL. Experimental models of cardiac transplantation: design determines relevance. *Curr. Opin. Organ Transplant.* 2014; 19(5): 525−530.

Benson EM, Colvin RB, Russell PS. Induction of IA antigens in murine renal transplants. *J. Immunol.* 1985; 134(1): 7−9.

Bickerstaff A, Pelletier R, Wang JJ, Nadasdy G, DiPaola N, Orosz C, Satoskar A, Hadley G, Nadasdy T. An experimental model of acute humoral rejection of renal allografts associated with concomitant cellular rejection. *Am. J. Pathol.* 2008; 173(2): 347−357.

Birsner JH, Wan C, Cheng G, Evans ZP, Polito CC, Fiorini RN, Gilbert G, Haines JK, Schmidt MG, Chavin KD. Steatotic liver transplantation in the mouse: a model of primary nonfunction. *J. Surg. Res.* 2004; 120(1): 97−101.

Brown K, Moxham V, Karegli J, Phillips R, Sacks SH, Wong W. Ultra-localization of Foxp3+ T cells within renal allografts shows infiltration of tubules mimicking rejection. *Am. J. Pathol.* 2007; 171(6): 1915−1922.

Carrel A, Guthrie CC. Functions of a transplanted kidney. *Science* 1905; 22(563): 473.

Chan A, Allen R. Bronchiolitis obliterans: an update. *Curr. Opin. Pulm. Med.* 2004; 10(2): 133−141.

Chen H, Zhang Y, Zheng D, Praseedom RK, Dong J. Orthotopic kidney transplantation in mice: technique using cuff for renal vein anastomosis. *PLoS One* 2013; 8(10): e77278.

Chen ZH. A technique of cervical heterotopic heart transplantation in mice. *Transplantation* 1991; 52(6): 1099−1101.

Chong AS, Alegre ML, Miller ML, Fairchild RL. Lessons and limits of mouse models. *Cold Spring Harb. Perspect. Med.* 2013; 3(12): a015495.

Choo JK, Seebach JD, Nickeleit V, Shimizu A, Lei H, Sachs DH, Madsen JC. Species differences in the expression of major histocompatibility complex class II antigens on coronary artery endothelium: implications for cell-mediated xenoreactivity. *Transplantation* 1997; 64(9): 1315−1322.

Christie JD, Edwards LB, Kucheryavaya AY, Aurora P, Dobbels F, Kirk R, Rahmel AO, Stehlik J, Hertz MI. The Registry of the International Society for Heart and Lung Transplantation: twenty-seventh official adult lung and heart-lung transplant report--2010. *J. Heart Lung Transplant.* 2010; 29(10): 1104−1118.

Conzelmann LO, Zhong Z, Bunzendahl H, Wheeler MD, Lemasters JJ. Reduced-size liver transplantation in the mouse. *Transplantation* 2003; 76(3): 496−501.

Corry RJ, Winn HJ, Russell PS. Primarily vascularized allografts of hearts in mice. The role of H-2D, H-2K, and non-H-2 antigens in rejection. *Transplantation* 1973; 16(4): 343−350.

Dahmen U, Qian S, Rao AS, Demetris AJ, Fu F, Sun H, Gao L, Fung JJ, Starzl TE. Split tolerance induced by orthotopic liver transplantation in mice. *Transplantation* 1994; 58(1): 1−8.

Dennis MJ, Beckingham IJ, Blamey RW. Evaluation of animal models of chronic vascular rejection. *Transplant. Proc.* 1993; 25(2): 2102.

Didié M, Biermann D, Buchert R, Hess A, Wittköpper K, Christalla P, Döker S, Jebran F, Schöndube F, Reichenspurner H, El-Armouche A, Zimmermann WH. Preservation of left ventricular function and morphology in volume-loaded versus volume-unloaded heterotopic heart transplants. *Am. J. Physiol. Heart Circ. Physiol.* 2013; 305(4): H533−541.

Doenst T, Schlensak C, Kobba JL, Beyersdorf F. A technique of heterotopic, infrarenal heart transplantation with double anastomosis in mice. *J. Heart Lung Transplant.* 2001; 20(7): 762−765.

Doyle AM, Lechler RI, Turka LA. Organ transplantation: halfway through the first century. *J. Am. Soc. Nephrol.* 2004; 15(12): 2965−2971.

El-Akouri RR, Mölne J, Groth K, Kurlberg G, Brännström M. Rejection patterns in allogeneic uterus transplantation in the mouse. *Hum. Reprod.* 2006; 21(2): 436−442.

Engemann R, Ulrichs K, Thiede A, Müller-Ruchholtz W, Hamelmann H. Value of a physiological liver transplant model in rats. Induction of specific graft tolerance in a fully allogeneic strain combination. *Transplantation* 1982; 33(5): 566−568.

Felix NJ, Brickey WJ, Griffiths R, Zhang J, Van Kaer L, Coffman T, Ting J. H2-DMalpha (-/-) mice show the importance of major histocompatibility complex-bound peptide in cardiac allograft rejection. *J. Exp. Med.* 2000; 192(1): 31−40.

Feng JE, Sun ZQ. A mouse cervical heart transplantation model using a cuff technique. *Chin. J. Exp. Surg.* 2005; 22: 1576–1577.

Fensterer TF, Miller CJ, Perez-Abadia G, Maldonado C. Novel cuff design to facilitate anastomosis of small vessels during cervical heterotopic heart transplantation in rats. *Comp. Med.* 2014; 64(4): 293−299.

Figueiredo JL, Nahrendorf M, Sosnovik DE, Weissleder R. MRI of a novel murine working heart transplant model. *Circ. Heart Fail.* 2009; 2(3):272−274.

Fisher B, Lee S. Microvascular surgical techniques in research, with special reference to renal transplantation in rat. *Surgery* 1965; 58(5): 904–914.

Fujino Y, Kamoda Y, Tanioka Y, Sakai T, Kuroda Y. Prevention of intimal hyperplasia employing the cavitary two-layer method in allogeneic rat heart transplantation. *J. Surg. Res.* 2012; 176(1): 275−280.

Ganbold A, Andersen S, Tay SS, Cunningham E, Ilie V, Krishnan S, Wang C, McCaughan GW, Sharland AF, Bishop GA. Expression of common gamma chain signalling cytokines and their receptors distinguishes rejection from tolerance in a rat organ transplant model. *Transpl. Immunol.* 2012; 27(2−3): 89−94.

Gao W, Lemasters JJ, Thurman RG. Development of a new method for hepatic rearterialization in rat orthotopic liver transplantation. Reduction of liver injury and improvement of surgical outcome by arterialization. *Transplantation* 1993; 56(1): 19−24.

Gomes G, Nunes P, Castelo D, Parada B, Patrão R, Bastos C, Roseiro A, Mota A. Ureteric stent in renal transplantation. *Transplant. Proc.* 2013; 45(3): 1099−1101.

Gordon CR, Lefebvre DR, Matthews MS, Strande LF, Marra SW, Guglielmi M, Skaf J, Hollenberg SM, Hewitt CW. Pulse doppler and M-mode to assess viability of cardiac

allografts using heterotopic femoral heart transplantation in rats. *Microsurgery* 2007a; 27(4): 240−244.

Gordon CR, Matthews MS, Lefebvre DR, Strande LF, Marra SW, Guglielmi M, Hollenberg SM, Hewitt CW. A new modified technique for heterotopic femoral heart transplantation in rats. *J. Surg. Res.* 2007b; 139(2): 157−163.

Goss JA, Nakafusa Y, Yu S, Flye MW. Intrathymic injection of donor alloantigens induces specific tolerance to cardiac allografts. *Transplantation* 1993; 56(1): 166−173.

Goto T, Kohno M, Anraku M, Ohtsuka T, Izumi Y, Nomori H. Simplified rat lung transplantation using a new cuff technique. *Ann. Thorac. Surg.* 2012; 93(6): 2078−2080.

Grabner A, Kentrup D, Edemir B, Sirin Y, Pavenstädt H, Schlatter E, Schober O, Schäfers M, Schnöckel U, Reuter S. PET with 18F-FDG-labeled T lymphocytes for diagnosis of acute rat renal allograft rejection. *J. Nucl. Med.* 2013; 54(7): 1147−1153.

Grau V, Fuchs-Moll G, Wilker S, Weimer R, Padberg W. Proliferation of CD8-positive T cells in blood vessels of rat renal allografts. *Am. J. Transplant.* 2011; 11(9): 1979−1985.

Gu X, Xiang J, Zhou Y, Qian S, Chen Z. Improved cuff technique for cervical heart transplantation in mice. *Microsurgery* 2007; 27(4): 317−319.

Han WR, Murray-Segal LJ, Mottram PL. Modified technique for kidney transplantation in mice. *Microsurgery* 1999; 19(6): 272−274.

Hanaoka K, Kawato Y, Kubo K, Nakanishi T, Maeda M, Nakamura K, Hirose J, Noto T, Fukahori H, Fujikawa A, Miyoshi S, Takakura S, Morokata T, Higashi Y. A chronic renal rejection model with a fully MHC-mismatched rat strain combination under immunosuppressive therapy. *Transpl. Immunol.* 2016; 38: 19−26.

Hasegawa T, Visovatti SH, Hyman MC, Hayasaki T, Pinsky DJ. Heterotopic vascularized murine cardiac transplantation to study graft arteriopathy. *Nat. Protoc.* 2007; 2(3): 471−480.

Hasuike Y, Monden M, Valdivia LA, Kubota N, Gotoh M, Nakano Y, Okamura J, Mori. A simple method for orthotopic liver transplantation with arterial reconstruction in rats. *Transplantation* 1988; 45(4): 830−832.

Hattori Y, Bucy RP, Kubota Y, Baldwin WM 3rd, Fairchild RL. Antibody-mediated rejection of single class I MHC-disparate cardiac allografts. *Am. J. Transplant.* 2012; 12(8): 2017−2028.

He G, Hart J, Thistlethwaite JR Jr, Newell KA. Modified surgical model of paratopic small bowel transplantation in mice. *J. Surg. Res.* 1998; 80(2): 188−193.

Hertz MI, Jessurun J, King MB, Savik SK, Murray JJ. Reproduction of the obliterative bronchiolitis lesion after heterotopic transplantation of mouse airways. *Am. J. Pathol.* 1993; 142(6): 1945−1951.

Higuchi T, Maruyama T, Jaramillo A, Mohanakumar T. Induction of obliterative airway disease in murine tracheal allografts by CD8+ CTLs recognizing a single minor histocompatibility antigen. *J. Immunol.* 2005; 174(4): 1871−1878.

Hori T, Nguyen JH, Zhao X, Ogura Y, Hata T, Yagi S, Chen F, Baine AM, Ohashi N, Eckman CB, Herdt AR, Egawa H, Takada Y, Oike F, Sakamoto S, Kasahara M, Ogawa K, Hata K, Iida T, Yonekawa Y, Sibulesky L, Kuribayashi K, Kato T, Saito K, Wang L, Torii M, Sahara N, Kamo N, Sahara T, Yasutomi M, Uemoto S. Comprehensive and innovative techniques for liver transplantation in rats: a surgical guide. *World J. Gastroenterol.* 2010; 16(25): 3120−3132.

Houssin D, Gigou M, Franco D, Szekely AM, Bismuth H. Spontaneous long-term survival of liver allograft in inbred rats. *Transplant. Proc.* 1979; 11(1): 567−570.

Howden B, Jablonski P, Grossman H, Marshall VC. The importance of the hepatic artery in rat liver transplantation. *Transplantation* 1989; 47(3): 428−431.

Huang H, Deng M, Jin H, Liu A, Dirsch O, Dahmen U. A novel end-to-side anastomosis technique for hepatic rearterialization in rat orthotopic liver transplantation to accommodate size mismatches between vessels. *Eur. Surg. Res.* 2011; 47(2): 53−62.

Hölschermann H, Bohle RM, Schmidt H, Zeller H, Fink L, Stahl U, Grimm H, Tillmanns H, Haberbosch W. Hirudin reduces tissue factor expression and attenuates graft arteriosclerosis in rat cardiac allografts. *Circulation* 2000; 102(3): 357−363.

Inoue K, Niesen N, Albini B, Milgrom F. Studies on immunological tolerance induced in mice by kidney allografts. *Int. Arch. Allergy Appl. Immunol.* 1991; 96(4): 358−361.

Ishii E, Shimizu A, Takahashi M, Terasaki M, Kunugi S, Nagasaka S, Terasaki Y, Ohashi R, Masuda Y, Fukuda Y. Surgical technique of orthotopic liver transplantation in rats: the Kamada technique and a new splint technique for hepatic artery reconstruction. *J. Nippon Med. Sch.* 2013; 80(1): 4−15.

Iu S, Harvey PR, Makowka L, Petrunka CN, Ilson RG, Strasberg SM. Markers of allograft viability in the rat. Relationship between transplantation viability and liver function in the isolated perfused liver. *Transplantation* 1987; 44(4): 562−569.

Jevnikar AM, Mannon RB. Late kidney allograft loss: what we know about it, and what we can do about it. *Clin. J. Am. Soc. Nephrol.* 2008; 3 Suppl 2: S56−67.

Jiang X, Morita M, Sugioka A, Harada M, Kojo S, Wakao H, Watarai H, Ohkohchi N, Taniguchi M, Seino K. The importance of CD25+ CD4+ regulatory T cells in mouse hepatic allograft tolerance. *Liver Transpl.* 2006; 12(7): 1112−1118.

John B, Klein I, Crispe IN. Immune role of hepatic TLR-4 revealed by orthotopic mouse liver transplantation. *Hepatology* 2007; 45(1): 178−186.

Kalina SL, Mottram PL. A microsurgical technique for renal transplantation in mice. *Aust. N. Z. J. Surg.* 1993; 63(3): 213−216.

Kamada N. The immunology of experimental liver transplantation in the rat. *Immunology* 1985; 55(3): 369−389.

Kamada N, Brons G, Davies HS. Fully allogeneic liver grafting in rats induces a state of systemic nonreactivity to donor transplantation antigens. *Transplantation* 1980; 29(5): 429−431.

Kamada N, Calne RY. A surgical experience with five hundred thirty liver transplants in the rat. *Surgery* 1983; 93(1 Pt 1): 64−69.

Kamada N, Calne RY. Orthotopic liver transplantation in the rat. Technique using cuff for portal vein anastomosis and biliary drainage. *Transplantation* 1979; 28(1): 47−50.

Kamada N, Sumimoto R, Kaneda K. The value of hepatic artery reconstruction as a technique in rat liver transplantation. *Surgery* 1992; 111(2): 195−200.

Kamada N, Wight DG. Antigen-specific immunosuppression induced by liver transplantation in the rat. *Transplantation* 1984; 38(3): 217−221.

Karatzas T, Santiago S, Xanthos T, de Faria W, Gandia C, Kostakis A. An easy and safe model of kidney transplantation in rats. *Microsurgery* 2007; 27(8): 668−672.

Kirk AD. Crossing the bridge: large animal models in translational transplantation research. *Immunol. Rev.* 2003; 196: 176−196.

Klein I, Hong C, Schreiber SS**.** Isovolumic loading prevents atrophy of the heterotopically transplanted rat heart. *Circ. Res.* 1991; 69(5): 1421–1425.

Kort WJ, Westbroek DL, MacDicken I, Lameijer LD. Orthotopic total small bowel transplantation in the rat. *Eur. Surg. Res.* 1973; 5(2): 81–89.

Koshiba T, Van Damme B, Ji P, Sefrioui H, Rutgeerts O, Waer M, Pirenne J. The effect of FTY 720 on engraftment in a model of spontaneous allograft acceptance. *Transpl. Int.* 2003; 16(6): 383–390.

Krupnick AS, Lin X, Li W, Okazaki M, Lai J, Sugimoto S, Richardson SB, Kornfeld CG, Garbow JR, Patterson GA, Gelman AE, Kreisel D. Orthotopic mouse lung transplantation as experimental methodology to study transplant and tumor biology. *Nat. Protoc.* 2009; 4(1): 86–93.

Książek AA, Mitchell KJ, Morax L, Schwarzwald CC, Hoerstrup SP, Weber B Hemodynamic Assessment of a Murine Heterotopic Biventricularly Loaded Cardiac Transplant in vivo Model. *Eur. Surg. Res.* 2016; 57(3–4): 171–185.

Kwun J, Malarkannan S, Burlingham WJ, Knechtle SJ. Primary vascularization of the graft determines the immunodominance of murine minor H antigens during organ transplantation. *J. Immunol.* 2011; 187(8): 3997–4006.

Lee S. An improved technique of renal transplantation in the rat. *Surgery* 1967; 61(5): 771–773.

Lee S, Charters AC, Chandler JG, Orloff MJ. A technique for orthotopic liver transplantation in the rat. *Transplantation* 1973; 16(6): 664–669.

Lee S, Charters AC 3rd, Orloff MJ. Simplified technic for orthotopic liver transplantation in the rat. *Am. J. Surg.* 1975; 130(1): 38–40.

Lehmann TG, Bunzendahl H, Langrehr JM, Neuhaus P. Arterial reconstruction in rat liver transplantation--development of a new tubing technique of the common hepatic artery. *Transpl. Int.* 2005; 18(1): 56–64.

Li J, Dahmen U, Dirsch O, Shen K, Gu Y, Broelsch CE. Modified sleeve anastomosis for reconstruction of the hepatic artery in rat liver transplantation. *Microsurgery* 2002; 22(2): 62–68.

Li L, Zhang Y, Xu M, Rong R, Wang J, Zhu T. Inhibition of histone methyltransferase EZH2 ameliorates early acute renal allograft rejection in rats. *BMC Immunol.* 2016; 17(1): 41.

Li Q, Wang Y, Yi T, Chalasani G, Dai Z, Lorber MI, Tellides G, Lakkis FG. Technique for retransplanting heterotopic heart grafts in mice. *Microsurgery* 2004; 24(6): 465–467.

Li W, Kuhr CS, Zheng XX, Carper K, Thomson AW, Reyes JD, Perkins JD. New insights into mechanisms of spontaneous liver transplant tolerance: the role of Foxp3-expressing CD25+CD4+ regulatory T cells. *Am. J. Transplant.* 2008; 8(8): 1639–1651.

Li W, Lu L, Wang Z, Wang L, Fung JJ, Thomson AW, Qian S. Costimulation blockade promotes the apoptotic death of graft-infiltrating T cells and prolongs survival of hepatic allografts from FLT3L-treated donors. *Transplantation* 2001a; 72(8): 1423–1432.

Li W, Lu L, Wang Z, Wang L, Fung JJ, Thomson AW, Qian S. Il-12 antagonism enhances apoptotic death of T cells within hepatic allografts from Flt3 ligand-treated donors and promotes graft acceptance. *J. Immunol.* 2001b; 166(9): 5619–5628.

Li W, Zheng XX, Kuhr CS, Perkins JD. CTLA4 engagement is required for induction of murine liver transplant spontaneous tolerance. *Am. J. Transplant.* 2005; 5(5): 978–986.

Liu F, Kang SM. Small bowel transplantation in mice. *J. Vis. Exp.* 2007; (7): 258.

Liu J, Fishbein TM, Bromberg JS, Boros P. Orthotopic small bowel transplantation in mice. *Transplantation* 2005; 79(8): 973–976.

Liu X, He C, Huang T, Gu J. Development of a New Technique for Reconstruction of Hepatic Artery during Liver Transplantation in Sprague-Dawley Rat. *PLoS One* 2015; 10(12): e0145662.

Liu Y, Maureira P, Gauchotte G, Falanga A, Marie V, Olivier A, Groubatch F, Gu C, Marie PY, Tran N. Effect of chronic left ventricular unloading on myocardial remodeling: Multimodal assessment of two heterotopic heart transplantation techniques. *J. Heart Lung Transplant.* 2015; 34(4): 594–603.

Lopez-Neblina F, Toledo-Pereyra LH, Suzuki S. Ultrarapid orthotopic technique for renal transplantation in the rat. *Microsurgery* 1994; 15(4): 274–278.

Lutz J, Lu R, Strobl M, Huang H, Deng M, Wang M, Ouyang N, Heemann U. ICOS/B7RP-1 interference in mouse kidney transplantation. *Transplantation* 2007; 84(2): 223–230.

Ma Y, Wang G. Comparison of 2 heterotopic heart transplant techniques in rats: cervical and abdominal heart. *Exp. Clin. Transplant.* 2011; 9(2): 128–133.

Martins PNA, Filatenkov A. Microsurgical techniques for experimental kidney transplantation and general guidelines to establish studies about transplantation immunology. *Acta Cir Bras* [serial online] 2003 Jul-Aug; 18(4). Available from URL: http://www.scielo.br/acb.

Maruyama T, Jaramillo A, Narayanan K, Higuchi T, Mohanakumar T. Induction of obliterative airway disease by anti-HLA class I antibodies. *Am. J. Transplant.* 2005; 5(9): 2126–2134.

Matsuura A, Abe T, Yasuura K. Simplified mouse cervical heart transplantation using a cuff technique. *Transplantation* 1991; 51(4): 896–898.

Mizuta T, Kawaguchi A, Nakahara K, Kawashima Y. Simplified rat lung transplantation using a cuff technique. *J. Thorac. Cardiovasc. Surg.* 1989; 97(4): 578–581.

Mizuta T, Nakahara K, Shirakura R, Fujii Y, Kawaguchi A, Minami M, Kawashima Y. Total nonmicrosuture technique for rat lung transplantation. *J. Thorac. Cardiovasc. Surg.* 1991; 102(1): 159–160.

Monchik GJ, Russell PS. Transplantation of small bowel in the rat: technical and immunological considerations. *Surgery* 1971; 70(5): 693–702.

Morgan DC, Wilson JE, MacAulay CE, MacKinnon NB, Kenyon JA, Gerla PS, Dong C, Zeng H, Whitehead PD, Thompson CR, McManus BM. New method for detection of heart allograft rejection: validation of sensitivity and reliability in a rat heterotopic allograft model. *Circulation* 1999; 100(11): 1236–1241.

Mottram PL, Smith JA, Mason A, Mirisklavos A, Dumble LJ, Clunie GJ. Electrocardiographic monitoring of cardiac transplants in mice. *Cardiovasc. Res.* 1988; 22(5): 315–321.

Nakagawa K, Tanaka N, Morita M, Sugioka A, Miyagawa S, Gonzalez FJ, Aoyama T. PPARα is down-regulated following liver transplantation in mice. *J. Hepatol.* 2012; 56(3): 586–594.

Nakao A, Ogino Y, Tahara K, Uchida H, Kobayashi E. Orthotopic intestinal transplantation using the cuff method in rats: a histopathological evaluation of the anastomosis. *Microsurgery* 2001; 21(1): 12–15.

Nakao A, Tahara K, Inoue S, Tanaka N, Kobayashi E. Experimental models of small intestinal transplantation in rats: orthotopic versus heterotopic model. *Acta Med. Okayama* 2002; 56(2): 69–74.

Niwa H. Molecular mechanism to maintain stem cell renewal of ES cells. *Cell Struct. Funct.* 2001; 26(3): 137–148.

Nosaka T, Bowers JL, Cay O, Clouse ME. Biliary complications after orthotopic liver transplantation in rats. *Surg. Today* 1999; 29(9): 963–965.

Okazaki M, Krupnick AS, Kornfeld CG, Lai JM, Ritter JH, Richardson SB, Huang HJ, Das NA, Patterson GA, Gelman AE, Kreisel D. A mouse model of orthotopic vascularized aerated lung transplantation. *Am. J. Transplant.* 2007; 7(6): 1672–1679.

Oldani G, Lacotte S, Morel P, Mentha G, Toso C. Orthotopic liver transplantation in rats. *J. Vis. Exp.* 2012; (65): 4143.

Ono K, Lindsey ES. Improved technique of heart transplantation in rats. *J. Thorac. Cardiovasc. Surg.* 1969; 57(2): 225–229.

Pescovitz MD, Thistlethwaite JR Jr, Auchincloss H Jr, Ildstad ST, Sharp TG, Terrill R, Sachs DH. Effect of class II antigen matching on renal allograft survival in miniature swine. *J. Exp. Med.* 1984; 160(5): 1495–1508.

Pêche H, Renaudin K, Beriou G, Merieau E, Amigorena S, Cuturi MC. Induction of tolerance by exosomes and short-term immunosuppression in a fully MHC-mismatched rat cardiac allograft model. *Am. J. Transplant.* 2006; 6(7): 1541–1550.

Post S, Menger MD, Rentsch M, Gonzalez AP, Herfarth C, Messmer K. The impact of arterialization on hepatic microcirculation and leukocyte accumulation after liver transplantation in the rat. *Transplantation* 1992; 54(5): 789–794.

Pratt JR, Basheer SA, Sacks SH. Local synthesis of complement component C3 regulates acute renal transplant rejection. *Nat. Med.* 2002; 8(6): 582–587.

Qi S, Xu D, Peng J, Liu D, Chen H. Synergistic effect of rapamycin and cyclosporine in prevention of acute kidney allograft rejection in the mouse. *Microsurgery* 1999; 19(7): 344–347.

Qian S, Demetris AJ, Murase N, Rao AS, Fung JJ, Starzl TE. Murine liver allograft transplantation: Tolerance and donor cell chimerism. *Hepatology* 1994; 19(4): 916–924.

Qian S, Fu F, Li Y, Lu L, Rao AS, Starzl TE, Thomson AW, Fung JJ. Impact of donor MHC class I or class II antigen deficiency on first- and second-set rejection of mouse heart or liver allografts. *Immunology* 1996; 88(1): 124–129.

Qian S, Lu L, Fu F, Li Y, Li W, Starzl TE, Fung JJ, Thomson AW. Apoptosis within spontaneously accepted mouse liver allografts: evidence for deletion of cytotoxic T cells and implications for tolerance induction. *J. Immunol.* 1997; 158(10): 4654–4661.

Qian SG, Fung JJ, Demetris AV, Ildstad ST, Starzl TE. Orthotopic liver transplantation in the mouse. *Transplantation* 1991; 52(3): 562–564.

Que X, Debonera F, Xie J, Furth EE, Aldeguer X, Gelman AE, Olthoff KM. Pattern of ischemia reperfusion injury in a mouse orthotopic liver transplant model. *J. Surg. Res.* 2004; 116(2): 262–268.

Reis A, Giaid A, Serrick C, Shennib H. Improved outcome of rat lung transplantation with modification of the nonsuture external cuff technique. *J. Heart Lung Transplant.* 1995; 14(2): 274–279.

Reuter S, Schnöckel U, Schröter R, Schober O, Pavenstädt H, Schäfers M, Gabriëls G, Schlatter E. Non-invasive imaging of acute renal allograft rejection in rats using small animal F-FDG-PET. *PLoS One* 2009; 4(4): e5296.

Russell PS, Chase CM, Colvin RB, Plate JM. Induced immune destruction of long-surviving, H-2 incompatible kidney transplants in mice. *J. Exp. Med.* 1978; 147(5): 1469–1486.

Russell PS, Chase CM, Colvin RB, Plate JM. Kidney transplants in mice. An analysis of the immune status of mice bearing long-term, H-2 incompatible transplants. *J. Exp. Med.* 1978; 147(5): 1449–1468.

Sachs DH. Tolerance: of mice and men. *J. Clin. Invest.* 2003; 111(12): 1819–1821.

Sánchez PG, Martins LK, Martins FK, Schimer R, Cardoso PF, Andrade CF. Technical modification of unilateral lung transplantation in rats. *J. Bras. Pneumol.* 2007; 33(4): 448–453.

Santana Rodríguez N, Martín Barrasa JL, López García A, Rodríguez Suárez P, Ponce González M, Freixinet Gilart J. Lung transplantation in rats: a viable experimental model. *Arch. Bronconeumol.* 2004; 40(10): 438–442.

Santiago SF, Fukuzawa M, Azuma T, Okada A. Effect of short-term immunosuppressive therapy with FK-506 or CsA on the donor in small intestine allotransplantation in rats. *Transplant. Proc.*1992; 24(3): 1189.

Schenk AD, Nozaki T, Rabant M, Valujskikh A, Fairchild RL. Donor-reactive CD8 memory T cells infiltrate cardiac allografts within 24-h posttransplant in naive recipients. *Am. J. Transplant.* 2008; 8(8): 1652–1661.

Schenk S, Kish DD, He C, El-Sawy T, Chiffoleau E, Chen C, Wu Z, Sandner S, Gorbachev AV, Fukamachi K, Heeger PS, Sayegh MH, Turka LA, Fairchild RL. Alloreactive T cell responses and acute rejection of single class II MHC-disparate heart allografts are under strict regulation by CD4+ CD25+ T cells. *J. Immunol.* 2005; 174(6): 3741–3748.

Scherrer-Crosbie M, Thibault HB. Echocardiography in translational research: of mice and men. *J. Am. Soc. Echocardiogr.* 2008; 21(10): 1083–1092.

Schumacher M, Van Vliet BN, Ferrari P. Kidney transplantation in rats: an appraisal of surgical techniques and outcome. *Microsurgery* 2003; 23(4): 387–394.

Shan J, Huang Y, Feng L, Luo L, Li C, Ke N, Zhang C, Li Y. A modified technique for heterotopic heart transplantation in rats. *J. Surg. Res.* 2010; 164(1): 155–161.

Shen XD, Gao F, Ke B, Zhai Y, Lassman CR, Tsuchihashi S, Farmer DG, Busuttil RW, Kupiec-Weglinski JW. Inflammatory responses in a new mouse model of prolonged hepatic cold ischemia followed by arterialized orthotopic liver transplantation. *Liver Transpl.* 2005; 11(10): 1273–1281.

Shrestha B, Haylor J. Experimental rat models of chronic allograft nephropathy: a review. *Int. J. Nephrol. Renovasc. Dis.* 2014; 7: 315–322.

Skoskiewicz M, Chase C, Winn HJ, Russell PS. Kidney transplants between mice of graded immunogenetic diversity. *Transplant. Proc.* 1973; 5(1): 721–725.

Sonnino RE, Teitelbaum DH, Harmel RP Jr. Cervical small bowel transplantation in the rat: a useful tool. *Microsurgery* 1990; 11(4): 309–313.

Spanjol J, Celić T, Jakljević T, Ivancić A, Markić D. Surgical technique in the rat model of kidney transplantation. *Coll. Antropol.* 2011; 35 Suppl 2: 87–90.

Squiers EC, Kelley SE, West JC. Small bowel transplantation in the mouse: development of a model. *Microsurgery* 1992; 13(6): 345–347.

Steffen R, Ferguson DM, Krom RA. A new method for orthotopic rat liver transplantation with arterial cuff anastomosis to the recipient common hepatic artery. *Transplantation* 1989; 48(1): 166–168.

Superina RA, Peugh WN, Wood KJ, Morris PJ. Assessment of primarily vascularized cardiac allografts in mice. *Transplantation* 1986; 42(2): 226–227.

Suzuki K, Hamano K, Ito H, Fujimura Y, Esato K. The detection of chronic heart graft rejection by 31P NMR spectroscopy. *Surg. Today* 1999; 29(2): 143–148.

Syrjälä SO, Tuuminen R, Nykänen AI, Raissadati A, Dashkevich A, Keränen MA, Arnaudova R, Krebs R, Leow CC, Saharinen P, Alitalo K, Lemström KB. Angiopoietin-2 inhibition prevents transplant ischemia-reperfusion injury and chronic rejection in rat cardiac allografts. *Am. J. Transplant.* 2014; 14(5): 1096–1108.

Tan F, Chen Z, Zhao Y, Liang T, Li J, Wei J. Novel technique for suprahepatic vena cava reconstruction in rat orthotopic liver transplantation. *Microsurgery* 2005; 25(7): 556–560.

Tian Y, Graf R, Jochum W, Clavien PA. Arterialized partial orthotopic liver transplantation in the mouse: a new model and evaluation of the critical liver mass. *Liver Transpl.* 2003; 9(8): 789–795.

Tian Y, Rüdiger HA, Jochum W, Clavien PA. Comparison of arterialized and nonarterialized orthotopic liver transplantation in mice: prowess or relevant model? *Transplantation* 2002; 74(9): 1242–1246.

Tang-Quan KR, Bartos J, Deuse T, Churchill E, Schäfer H, Reichenspurner H, Mochly-Rosen D, Robbins RC, Schrepfer S. Non-volume-loaded heart provides a more relevant heterotopic transplantation model. *Transpl. Immunol.* 2010; 23(1–2): 65–70.

Tomita Y, Zhang QW, Yoshikawa M, Uchida T, Nomoto K, Yasui H. Improved technique of heterotopic cervical heart transplantation in mice. *Transplantation* 1997; 64(11): 1598–1601.

Toyama N, Kobayashi E, Yamada S, Enosawa S, Miyata M. Fulminant second-set allograft rejection and endoscopic findings following small bowel transplantation in the rat. *J. Gastroenterol.* 1995; 30(4): 465–471.

Trulock EP, Edwards LB, Taylor DO, Boucek MM, Keck BM, Hertz MI; International Society for Heart and Lung Transplantation. Registry of the International Society for Heart and Lung Transplantation: twenty-third official adult lung and heart-lung transplantation report--2006. *J. Heart Lung Transplant.* 2006; 25(8): 880–892.

Tse GH, Hughes J, Marson LP. Systematic review of mouse kidney transplantation. *Transpl. Int.* 2013; 26(12): 1149–1160.

Uchiyama H, Hashimoto K, Hiroshige S, Harada N, Soejima Y, Nishizaki T, Shimada M, Suehiro T. Hepatic artery reconstruction in living-donor liver transplantation: a review of its techniques and complications. *Surgery* 2002; 131(1 Suppl): S200–4.

Voiglio E, Desseigne P, Tourniaire F, Margonari J, De Lorgeril M, Tabib A. Echocardiography is not a good way of monitoring cardiac grafts after abdominal heterotopic transplantation in the rat. *Transplant. Proc.* 1995; 27(2): 1690.

Wada T, Ono K, Hadama T, Uchida Y, Shimada T, Arita M. Detection of acute cardiac rejection by analysis of heart rate variability in heterotopically transplanted rats. *J. Heart Lung Transplant.* 1999; 18(6): 499–509.

Wallander J, Holtz A, Larsson E, Gerdin B, Läckgren G, Tufveson G. Small-bowel transplantation in the rat with a nonsuture cuff technique. Technical and immunological considerations. *Transpl. Int.* 1988; 1(3): 135–139.

Wang D, Li HA, Wang J, Klest C, Schnotz J. A simplified technique for heart transplantation in mice: modified venous anastomosis. *J. Heart Lung Transplant.* 2007; 26(6): 665–666.

Wang D, Yuan R, Feng Y, El-Asady R, Farber DL, Gress RE, Lucas PJ, Hadley GA. Regulation of CD103 expression by CD8+ T cells responding to renal allografts. *J. Immunol.* 2004; 172(1): 214–221.

Wang H. Small animal models of xenotransplantation. *Methods Mol. Biol.* 2012; 885: 125–153.

Wang K, Zhang N, Li H. Improved technique of mouse heterotopic heart graft retransplantation. *Microsurgery* 2006; 26(3): 200–202.

Wang M, Bai J, Baumann M, Heemann U. New model for simultaneous heart and kidney transplantation in mice. *Microsurgery* 2003; 23(2): 164–168.

Wang Q, Liu Y, Li XK. Simplified technique for heterotopic vascularized cervical heart transplantation in mice. *Microsurgery* 2005; 25(1): 76–79.

Wang S, Schmaderer C, Kiss E, Schmidt C, Bonrouhi M, Porubsky S, Gretz N, Schaefer L, Kirschning CJ, Popovic ZV, Gröne HJ. Recipient Toll-like receptors contribute to chronic graft dysfunction by both MyD88- and TRIF-dependent signaling. *Dis. Model Mech.* 2010; 3(1–2): 92–103.

Wasserberg N, Salgar S, Yang D, Santiago S, Ruiz P, Niv Y, Ho S,Mor E, Tzakis A. Tacrolimus does not upregulate mucin geneexpression after small bowel transplantation in rats. *Transplant. Proc.* 2003; 35(2): 670–671.

Wasserberg N, Tzakis AG, Santiago SF, Ruiz P, Salgar SK. Anastomotic healing in a small bowel transplantation model in the rat. *World J. Surg.* 2004; 28(1): 69–73.

Wen P, Wang X, Wang J, Zhang B, Qiu G, Fan Y, Xu Y, Tang H, Sun X, Peng Z. A simple technique for a new working heterotopic heart transplantation model in rats. *Transplant. Proc.* 2013; 45(6): 2522–2526.

White E, Hildemann WH, Mullen Y. Chronic kidney allograft reactions in rats. *Transplantation* 1969; 8(5): 602–617.

Wilson CH, Rix DA, Manas DM. Routine intraoperative ureteric stenting for kidney transplant recipients. *Cochrane Database Syst. Rev.* 2013; (6):CD004925.

Wyburn K, Wu H, Chen G, Yin J, Eris J, Chadban S. Interleukin-18 affects local cytokine expression but does not impact on the development of kidney allograft rejection. *Am. J. Transplant.* 2006; 6(11): 2612–2621.

Xiu D, Uchida H, To H, Sugimoto K, Kasahara K, Nagai H, Fujimura A, Kobayashi E. Simplified method of heterotopic rat heart transplantation using the cuff technique: application to sublethal dose protocol of methotrexate on allograft survival. *Microsurgery* 2001; 21(1): 16–21.

Xue D, Zhou C, Shi Y, Lu H1, He X. Hepcidin as a Biomarker of Impaired Renal Function in Rat Models for Chronic Allograft Nephropathy. *Med. Sci. Monit.* 2016; 22: 608–616.

Yang C, Zhang Y, Wang J, Li L, Wang L, Hu M, Xu M, Long Y, Rong R, Zhu T. A novel cyclic helix B peptide inhibits dendritic cell maturation during amelioration of acute kidney graft rejection through Jak-2/STAT3/SOCS1. *Cell Death Dis.* 2015; 6: e1993.

Zhang L, Tuchler RE, Shaw WW, Siebert JW. A new technique for microvascular sleeve anastomosis. *Microsurgery* 1991; 12(5): 321–325.

Zhang Z, Lazarovits A, Grant D, Garcia B, Stiller C, Zhong R. CD45RB monoclonal antibody induces tolerance in the mouse kidney graft, but fails to prevent small bowel graft rejection. *Transplant. Proc.* 1996a; 28(5): 2514.

Zhang Z, Schlachta C, Duff J, Stiller C, Grant D, Zhong R. Improved techniques for kidney transplantation in mice. *Microsurgery* 1995; 16(2): 103–109.

Zhang Z, Zhu L, Quan D, Garcia B, Ozcay N, Duff J, Stiller C, Lazarovits A, Grant D, Zhong R. Pattern of liver, kidney, heart, and intestine allograft rejection in different mouse strain combinations. *Transplantation* 1996b; 62(9): 1267–1272.

Zhong R, Grant D, Sutherland F, Wang PZ, Chen HF, Lo S, Stiller C, Duff J. Refined technique for intestinal transplantation in the rat. *Microsurgery* 1991; 12(4): 268–274.

Zhong R, Zhang Z, Quan D, Duff J, Stiller C, Grant D. Development of a mouse intestinal transplantation model. *Microsurgery* 1993; 14(2): 141–145.

Zhou Y, Gu X, Xiang J, Qian S, Chen Z. A comparative study on suture versus cuff anastomosis in mouse cervical cardiac transplant. *Exp. Clin. Transplant.* 2010; 8(3): 245–249.

Zhou YQ, Bishay R, Feintuch A, Tao K, Golding F, Zhu W, West LJ, Henkelman RM. Morphological and functional evaluation of murine heterotopic cardiac grafts using ultrasound biomicroscopy. *Ultrasound Med. Biol.* 2007; 33(6): 870–879.

Zhu L, Gong D, Zou Y, Li Y, Wu Y, Guan L, Wu Q, Yuan B, Wang L, Luo F. Cervical heterotopic kidney transplantation in rats using non-suturing and preserving-bag techniques. *Nephrol. Dial. Transplant.* 2009; 24(9): 2708–2713.

Zhu L, Gong D, Zou Y, Li Y, Wu Y, Yuan B, Guan L, Wu Q. Cervical heterotopic small intestinal transplantation in rats using artery sleeve anastomosis. *Transplant. Proc.* 2008; 40(5): 1645–1649.

Zimmermann FA, Butcher GW, Davies HS, Brons G, Kamada N, Türel O. Techniques for orthotopic liver transplantation in the rat and some studies of the immunologic responses to fully allogeneic liver grafts. *Transplant. Proc.* 1979; 11(1): 571–577.

In: Encyclopedia of Surgery (22 Volume Set)
Editors: Andreas Lehrer and Kristin Mueller
ISBN: 978-1-53618-329-0
© 2020 Nova Science Publishers, Inc.

Chapter 217

LARGE ANIMAL MODELS IN ORGAN TRANSPLANTATION

Babak Movahedi[1], MD, PhD, Maria Lucia Madariaga[2], MD, Sebastian Michel[3], MD, Adel Bozorgzadeh[1], MD and Paulo N. Martins[1,*], MD, PhD

[1]Division of Organ Transplantation, Department of Surgery,
UMass Memorial Medical Center,
University of Massachusetts Medical School, Worcester, MA, US
[2]Massachusetts General Hospital, Boston, MA, US
[3]Ludwig Maximilian University of Munich, Munich, Germany

ABSTRACT

Large animal models have been and continue to be an essential link in development of clinical protocols in treatment of patients with end stage organ disease through organ transplantation. Rodent models are often the first step in testing hypotheses or assessing new therapies. Rodent models are however often not representative for clinical scenario and the large animals are indispensable in evaluating safety and efficacy of new techniques, treatment protocols or drug candidates. Porcine models are extremely valuable in testing, validating and fine-tuning organ procurement, preservation, and implantation techniques and protocols prior to clinical implementation. Safety and efficacy of immunosuppressive agents and immunomodulation protocols such as costimulation blockade and immune tolerance will ubiquitously have to be tested in large animals such as non-human primates prior to clinical trials. Furthermore, innovative approaches such as xenotransplantation are first developed in porcine to primate models before human trials. This chapter provides an overview of the current state of large animal models in transplantation research. Additionally, porcine models for kidney, liver, heart and lung transplantation are discussed and detailed protocols are provided.

* Corresponding Author's Email: paulo.martins@umassmemorial.org.

Keywords: large animal, transplantation, liver, kidney, heart, lung, porcine, non-human primate, immunosuppression, donor, recipient

ABBREVIATIONS

ABG	arterial blood gas
CBD	common bile duct
DCD	donation after cardiac death
DIC	disseminated intravascular coagulation
ECMO	extracorporeal membrane oxygenation
Gal	galactose-a-1, 3 galactose
GDA	gastroduodenal artery
HA	hepatic artery
ICA	internal carotid artery
IJV	internal jugular vein
INR	international normalized ratio
IVC	inferior vena cava
MHC	major histocompatibility complex
NHP	non- human primates
PVR	pulmonary vascular resistance
SLA	swine leukocyte antigen
SVC	superior vena cava
TRAIL	tumor necrosis factor-alpha-related apoptosis-inducing ligand
vWF	Von Willebrand factor

INTRODUCTION

Large animal research plays a crucial role in moving a therapy into a more complex *in vivo* system and evaluating the feasibility of a therapy. As therapies are developed for clinical application, they require validation in models that are reasonably predictive of their performance in humans. Large animal models have been used to study the safety and the efficacy of proposed transplant protocols, prior to moving forward with clinical trials. Large animal models have proven to be indispensable to design practical therapeutic protocols and validating mechanistic pathways originating from *ex vivo* and rodent studies (Kirk 2003). In this chapter, we describe why large animal models are needed to advance transplant science in humans. Kidney, liver, and heart-lung models in pigs are further described in detail.

WHY ARE LARGE ANIMAL MODELS NEEDED?

Immunosuppressive drugs and biologicals have a narrow therapeutic-toxic range and their efficacy and side effects in humans cannot necessarily be extrapolated from rodent studies. Large animal models have been instrumental in predicting efficacy and toxicity of

new agents and in developing clinical protocols. Chronic immunosuppression is associated with significant morbidity and many short-term and long-term complications such as infections, diabetes and malignancies. There has been an ongoing quest for immunosuppression-free transplantation through induction of immunologic tolerance towards the graft, while maintaining an otherwise intact immune response. In small animals, tolerance has been successfully achieved. Unfortunately, those strategies have proven to be less successful in humans (Levin 1985; Buhler 2002; Millan 2002; Oura 2015). Small animal models might therefore not be adequate in representing the complex human immune network associated with a longer lifespan and much broader exposure to variety of pathogens.

Currently, the shortage of donor organs is the single foremost challenge in the care of patients with end stage organ disease awaiting transplantation. By the end of 2015, nationwide (USA) over 60,000 patients were waiting for a kidney transplant, 14,000 were on liver transplant waiting list and 400 patients on the heart list. During that year, 7,125 liver transplants were performed, while full third of patients died or were removed due to being too sick to undergo transplant. The wait list mortality rate has been increasing during the last several years and reached a new high at 12.1% in 2014. It is clear that shortage of organs is having a detrimental effect on chances of survival for patients in need of a lifesaving transplant. Many approaches have been studied to increase the donor pool. Use of marginal and extended criteria organs has slightly increased overall access to transplant but the general picture has not changed. If successful, use of animal organs for human transplantation could change the current dire situation. Experimental xenotransplantation has come a long way and large animal studies have been paving the road towards clinical trials.

The most commonly used large animals for transplantation studies are dogs, pigs and non- human primates (NHP). Each specific large animal model has its advantages but also its limitations.

Dogs were the animal model of choice in early transplant experiments. Initial successful studies using azathioprine and 6-mercaptopurine were done in dogs (Calne 1982). Over time, canine studies have significantly decreased as social status of dogs has evolved.

NHP models are mostly used in studies evaluating biologics and antibodies, as there is a high degree of interspecies cross-reactivity in targets of monoclonal antibodies. Furthermore, NHPs are the recipient of choice for xenotransplantation studies, using porcine organs (Cooper 2014).

Pigs have been used extensively as they have several benefits. Their use has been more socially accepted as they are used for human consumption. Additionally, pigs have been amenable to genetic modifications. This has opened a window of opportunity to develop organs and tissues that are protected against human immune system. Although this goal has not been reached, major progress has been made in preclinical studies using NHPs as recipient of genetically modified pig organs (Ekser 2012; Cooper 2014). The first genetically altered pig models were those expressing human complement regulatory proteins such as CD59 and CD55 (Fodor 1994; Cozzi 1995). Since then, several other targets have been explored including transgenic expression of human tumor necrosis factor-alpha-related apoptosis-inducing ligand (TRAIL) to control cellular rejection (Klose 2005), human Fas ligand to protect porcine cells from human CD8+ T cells and natural killer cells (Lee 2014), and many other targets. However, the main hurdle in using porcine organs in primates has been hyper-acute rejection caused by the presence of preformed antibodies against galactose-α-1, 3 galactose (Gal). Similar to ABO antibodies, this antibody – antigen interaction causes

acute endothelial injury, activation of platelets and coagulation cascade and subsequent organ thrombosis and failure. Pigs with reduced or complete deletion of Gal antigen expression were available at the turn of the century (Costa 1999; Phelps 2003). As expected, organs from Gal knock-out pigs were less prone to hyper-acute rejection (Kuwaki 2005; Yamada 2005). With lack of hyper-acute rejection and proper immunosuppression controlling cellular and antibody-mediated rejection, the main hurdle to long term graft survival has been coagulation incompatibility between the host and the donor and development of thrombotic microangiopathy of the pig heart heterotopically transplanted in a baboon (Houser 2004). For unclear reasons, the problem of coagulation incompatibility is more pronounced for kidney transplantation. The host develops consumptive coagulopathy with thrombocytopenia, reduced fibrinogen levels and an increased international normalized ratio (INR) and fibrin degradation products (Ierino 1998; Buhler 2000; Cozzi 2004; Lin 2010). Efforts made to address the coagulation incompatibilities include recombinant expression of membrane-tethered anticoagulants antagonizing tissue factor (Chen 2004), inhibiting platelet activation by Von Willebrand factor (vWF) deletion (Cantu 2007), or protein C activation by transgenic expression of human thrombomodulin (Petersen 2009). In a recent study using Gal knock-out / human CD55 transgenic pig donors, bilaterally nephrectomized baboons survived for over 4 months. Researchers selected NHPs with low anti-porcine antibody levels. Hosts were induced with T-cell depletion and received maintenance treatment with co-stimulation blockade (Higginbotham 2015).

PIG MAJOR HISTOCOMPATIBILITY COMPLEX (MHC)

In swine, the major histocompatibility complex (MHC) is called the swine leukocyte antigen (SLA). It is located in chromosome 7, and most of its class I and II regions have been sequenced. It was first described in commercial breeds, and subsequently, MHC inbred miniature pig lines were established at the National Institutes of Health and the University of Oklahoma (Chardon 1999; Pedersen 2011). The NIH inbred miniature swine MHC (SLA) genotypes (Homozygous AA, CC, and DD herds) were selectively bred from the original breeding pair designated AB and CD. The B allele was lost in the initial breeding (Sachs 1976; Flye 1999). Availability of genetically defined large animal model benefits the studies of transplant immunobiology, and also provides source of homozygous antisera for chemical characterization of MHC products (Sachs 1976).

Pig Kidney Transplant Model

For many reasons outlined above, pigs are the most widely used animals in preclinical kidney transplant studies. Here, we describe a porcine auto-transplant model. Depending on the scope of the study, timing of the donor and recipient surgeries are critical. Several factors need to be taken into consideration and the logistics will be different for autologous transplant versus allo- or xeno-transplant, short versus long preservation times, etc. For the purpose of this work, a heterotopic autologous porcine kidney transplant model will be described. This

protocol is partially based on the work of Kaths et al. (Kaths 2016). Preoperative and anesthesia management is described elsewhere in this chapter (Porcine liver transplant).

Donor Surgery

The animal is placed in supine position. Depending on the scope of the study, central or peripheral venous access has to be established. For central access, the internal jugular vein can be catheterized. Alternatively, an angiocatheter can be inserted into an ear vein for peripheral venous access. A combination of metronidazole 500 mg and Cefazolin 1 g is used for perioperative antibiotic prophylaxis.

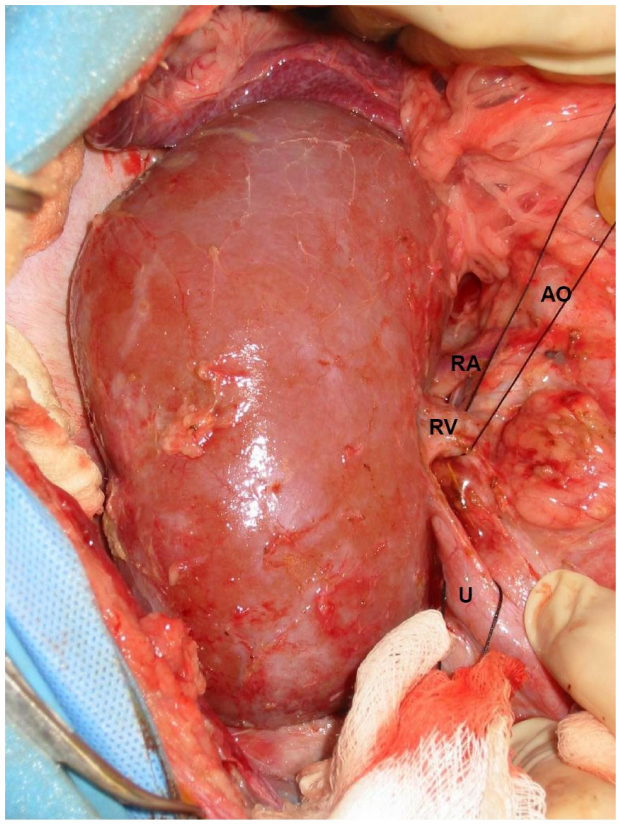

Figure 1. Right kidney in donor's abdomen. Renal artery, vein and ureter have been dissected free. Kidney has been completely mobilized. AO: aorta, RA: renal artery, RV: renal vein, U: ureter.

Abdomen and pelvis are prepped and draped in a sterile fashion. The abdomen is entered through a midline laparotomy and a retractor is needed for adequate exposure. The right kidney is approached by moving the bowls to the animal's left. A sterile surgical towel is helpful to keep the bowl out of the surgical field. The right ureter is then identified and encircled with a vessel loop. The ureter is then dissected free from surrounding tissues using electro cautery. Care needs to be taken to leave sufficient tissue around the ureter in order not to devascularize it. Next, the renal vein and artery are dissected free, all the way to their

origin at the level inferior vena cava (IVC) and the aorta (Figure 1). The renal artery is prone to spasm which if occurs will reduces the blood flow to the organ. The degree of spasm can be reduced by minimizing direct manipulation of the artery itself and by topical application of papaverine directly over the artery. The kidney itself is further dissected free and lifted form its bed.

Once the kidney including the renal vessels and ureter is completely mobilized, the distal ureter is ligated using (2/0) silk tie and transected proximal to the tie. Heparin is given intravenously (100 U/kg body weight) and 5 minutes are allowed for circulation. Using a vascular clamp, the renal artery is clamped at its origin close to the aorta. Next, the renal vein is clamped at the level of the IVC. The vessels are then transected using a surgical blade or a sharp pair of scissors leaving just enough tissue to safely oversew the stumps. The retrieved kidney is then immediately transferred to a sterile bag resting on an ice basin. Through an arterial cannula inserted in the renal artery, the kidney is flushed with cold preservation solution (e.g., Histidine-tryptophan-ketoglutarate) until clear and at least 500 ml. Depending on the protocol, the kidney can be preserved using static cold storage surrounded by preservation solution or pumped until transplanted. In the donor, the renal artery and vein stumps are over sewn using non-absorbable suture (6/0 Prolene). After adequate hemostasis, bowls are placed in their natural position and fascia is closed using a monofilament (number 1 PDS) running suture, followed by skin closure.

Recipient Surgery

When the focus of the study is on variables that will affect intrinsic graft features such as preservation and ischemia reperfusion, often an auto-transplant model is most appropriate. On the other hand, when investigating rejection, tolerance and other aspects of immune response, an allo- or xenotransplant model will be better suited. In either case, the recipient usually undergoes native nephrectomy at the time of transplant to allow for a precise post-transplant measurement of the graft function. Here, we will describe an auto-transplant case where contralateral nephrectomy is performed during the transplant operation, just prior to the graft implantation. In case of an allotransplant, bilateral nephrectomies will be required.

Preparation for the procedure, anesthesia and antibiotic prophylaxis is similar to the donor procedure as described above. Animal is placed in supine position and the abdomen and pelvis are prepped and draped in sterile fashion. Abdomen is reopened through the previous incision and retractor is assembled for adequate exposure. Right nephrectomy is then performed by dissecting free the renal vessels and the ureter, ligating and transecting them and removing the kidney similar to the graft nephrectomy described above. The bowl is moved to the left of the abdomen to expose the infrarenal aorta and IVC. The distal portions of both vessels are then cleared off the overlaying neuro-lymphatic tissue to accept the renal vessels. The lymphatic channels should be left intact as much as possible or ligated when transected. Care should also be taken not to avulse the posterior lumbar branches. Enough length is dissected free to accept the vascular clamps. After meticulous hemostasis, heparin (100 IU / kg body weight) is administered intravenously.

Venous anastomosis: Implantation is started by clamping the IVC with a side biting vascular clamp such as a Satinsky clamp. A longitudinal venotomy is performed using a surgical blade (Number 11) and extended with scissors to match the width of the renal vein.

Four 6-0 prolene sutures are placed in the four quadrants of the venotomy. The kidney is wrapped in a surgical sponge submerged in sterile slush and brought into the field. The four quadrant stiches are placed in the renal vein. The upper corner suture is tied down and anastomosis is performed using running suture. Once one side of the vein is anastomosed, kidney is flipped to the other side and the other wall is anastomosed with the same suture to a few mm to the first corner. Through the small remaining opening, a Marks needle connected to a syringe containing heparinized saline is inserted and a few cc's is injected to distend the vein and safely place the last few stiches to complete the anastomosis. The two lateral stay sutures are very helpful as they keep the vein laterally open. They can be removed once the anastomosis is completed. Alternatively, one can suture the back wall from inside, then bring the needle out and suture the front wall from outside, without moving the kidney.

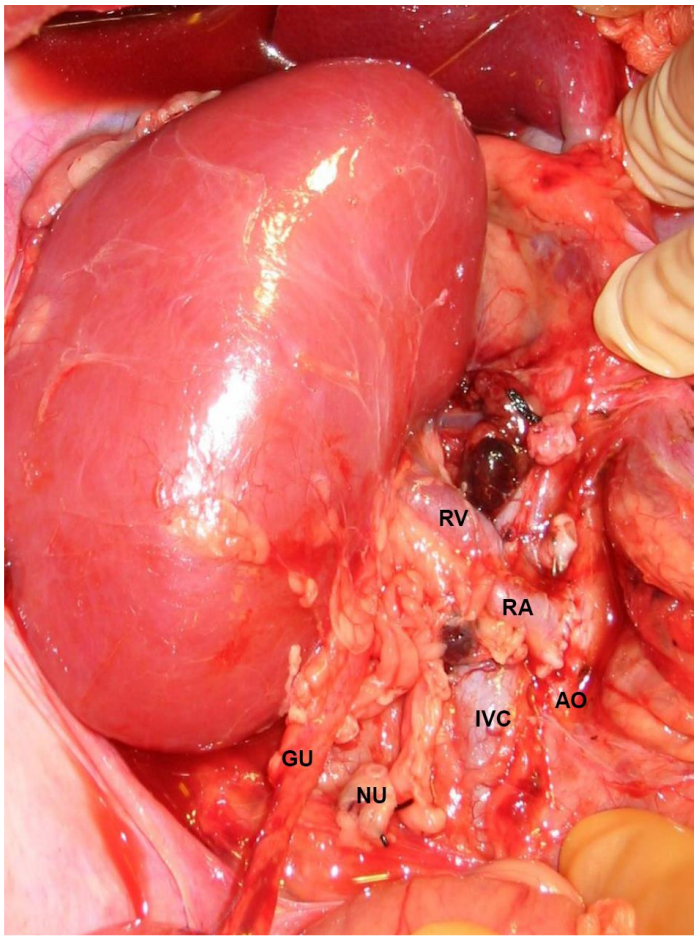

Figure 2. Kidney graft anastomosed to the aorta and the IVC after reperfusion. Note that ureter anastomosis has not been done yet. AO: aorta, RA: renal artery, RV: renal vein, GU: graft ureter.

Arterial anastomosis: Aorta is clamped using similar side biting vascular clamp. An arteriotomy is made using a number 11 scalpel and enlarged using an aortic punch (3.5 or 4 mm) to match the size of the artery. Two 6-0 Prolene sutures are placed proximally and distally in both the aorta and renal artery. One is tied down and used to make the anastomosis

in a running fashion. It is extremely important to include all the layers of the vessel wall with each stich, to avoid dissection after reperfusion. Gentle bulldog clamps are placed on both the renal artery and vein. Subsequently, the aortic and caval clamps are removed and any anastomotic bleeding is addressed prior to removing the bulldog clamps. It is important to maintain adequate blood pressure (above 100 mm Hg) to assure optimal perfusion of the graft. Additional IV fluid or vasopressors (norepinephrine drip) may be necessary to maintain arterial pressure. The wrapping around the kidney is removed. Topical Papaverine is applied to the renal artery to avoid potential spasm. The venous bulldog is removed first, followed by the arterial one. Irrigation of the abdominal cavity with warm sterile normal saline helps warming up the organ faster, and improves the blood flow (Figure 2).

Ureteral anastomosis: The graft's and recipient's ureters are trimmed to appropriate length enabling a comfortable anastomosis without tension or redundancy. Both ureters are then spatulated on opposite sides. This reduces the risk of anastomotic stricture. The ureter anastomosis is then performed using 6-0 PDS in a running fashion.

The bowel is then placed back in its original position. The fascia is closed using number 1 PDS in a running fashion. Skin is closed using non-absorbable suture (silk or nylon). Animal is kept warm, analgesia provided and blood pressure is closely monitored and until complete recovery. After extubation and recovery from general anesthesia, animal is returned to separate housing. Analgesia is administered routinely for the first few days and IV fluids as needed if oral intake is insufficient. Site of surgery is monitored closely for signs of infection. Surgical site infection can be treated with intravenous cefazolin and metronidazole.

Liver Transplantation in Pigs

The physiological and anatomical characteristics of the pig closely resemble those of humans in many ways, and pigs are cheaper and their use is more acceptable from the public's perspectives than non-human primates. In addition, in contrast with non-human primate species, inbred (genetically defined) lines of pigs are available, and different from mice, pigs constitutively express class II antigens on the vascular endothelium (Oike 2000), and the immunosuppressive drug metabolism is more similar to humans than rodents (Tata 2009). All of these characteristics facilitate the study of rejection and tolerance immunology. As a result, the pig has been extensively used in transplant immunobiology (Flye 1992). The early era of clinical liver transplantation and transplant research was based on dog experiments (Goodrich 1956; Moore 1959; Starlz 1960; Todo 1985) including the first successful liver transplant by Welch in 1955 (Goodrich 1956). Later, with more animal research restriction and animal protection activists' protest, experiments in dogs became less acceptable. Another reason is that unlike dogs, pigs more closely resemble the man in that they appear to have no hepatic vein sphincters and therefore do not manifest hepatic outflow block after liver transplantation, a frequent problem with dog liver transplants (Starlz 1960; Memsic 1986). Thus, the pig became the most used large animal model of liver transplantation and has been important for the development of clinical transplantation. The pig liver transplant model has been instrumental to train transplant surgeons; to test new surgical techniques; and to investigate organ preservation, organ rejection, and immunological tolerance (Steinig 1990; Gianello 1993; Oldhafer 1993; Hertl 1999; Hojo 2003). Arguably, the most attractive use of the porcine model however, is as a potential

source of xenogenic cells and organs for human use (Ekser 2011; Elliott 2011). The production of transgenic pig lines that express human molecules which control host complement reactions against pig tissues, or lines which express a decreased amount of the Gal (α 1, 3) epitope, constitutes the first significant step towards the use of pig tissues in humans (Chardon 1999; Ekser 2011). This section reviews the techniques used for liver transplantation in pigs as well as pre- and post-operative management.

Pig Liver Anatomy

The pig liver can be divided into eight segments in a similar way to those described in the human liver by Couinaud, with the exception of segment I, or caudate lobe, which is adjacent to the visceral surface of the right lateral lobe and contains the cava within the parenchyma. Each segment is separated by the others by prominent fissures and has its own arterial supply, venous and biliary drainage. The left lateral lobe can be divided into segments II and III, and the right lateral lobe into segments VI, VII and I. The left medial lobe consists of segment IV, and the right medial lobe can be divided into segments V and VIII (Court 2003) (Figure 3).

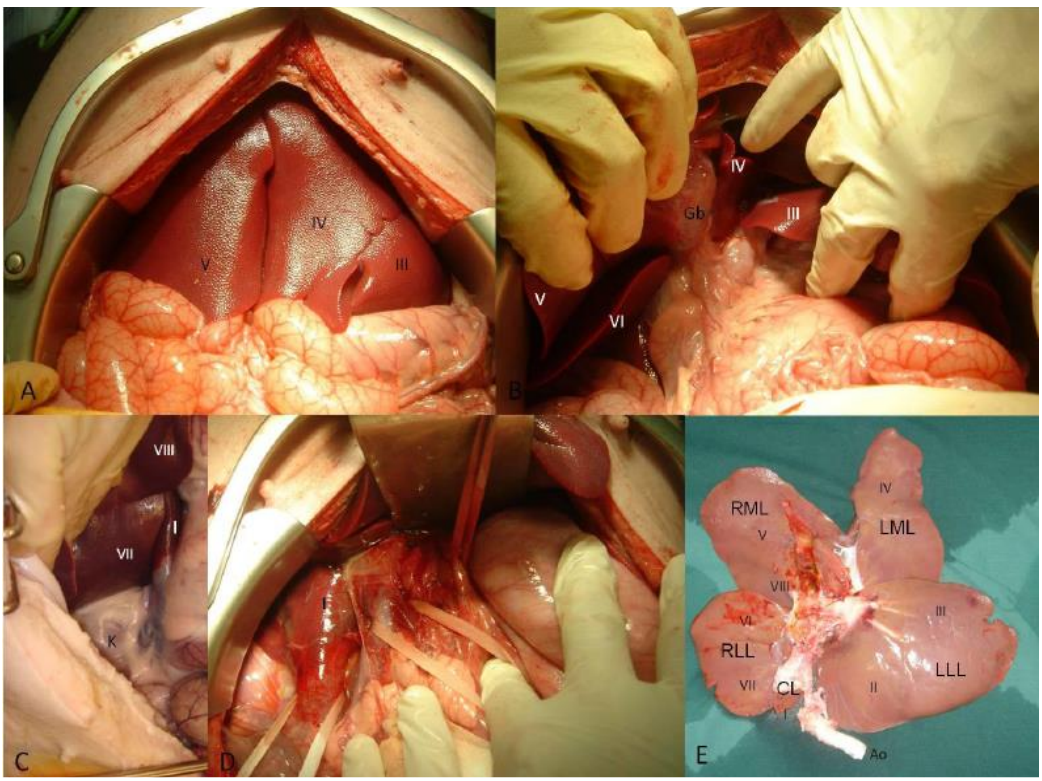

Figure 3. Anatomy of the pig liver. A) anterior view, B) visceral aspect without dissection, C) Infra-hepatic IVC, D) IVC, Portal vein and hepatic artery are isolated; E) Visceral aspect of the graft (gallbladder was removed). Segments of the liver. CL (segment I), RLL (segments VI and VII), RML (segments V and VIII), LML (segment IV), LLL (segments II and III). Gb: Gallbladder, K: kidney, RLL: right liver lobe, CL: caudate lobe, RML: right medial lobe, LML: left medial lobe, LLL: left lateral lobe. Ao: aorta.

The portal vein has two main branches, which divide at the hilum very close to the liver parenchyma. There are commonly one or even two communicating branches of the portal vein, which traverse the fissure between the right lateral and right median lobes of the liver. There are no communicating branches between the right and left median lobes, thus allowing complete division of right and left hemi-livers (Court 2003). The hepatic vein has four main branches coming directly from the IVC and draining the left lateral, left medial, right medial and right lateral lobes, respectively. Segment I drains directly into the IVC. In the pig, the retrohepatic IVC and the hepatic vein confluence are entirely intrahepatic (Court 2003). The main hepatic artery (HA) splits into a variable number of branches, but most commonly there are three branches visible anterior to the portal trunk. Usually the HA gives off one or two branches to the right lobe, a branch to the right medial lobe, a branch to the left lateral and left medial lobes.

The right and left hepatic biliary ducts generally drain their respective hemi-livers before joining into the common hepatic duct. The segmental distribution of the biliary ducts follows that of the portal vein as they lie together within the Glissonian sheaths. The left hepatic duct is generally of much larger caliber than the right, and drains both the left median and left lateral lobes. The right hemi-liver is drained by two separate hepatic ducts, similar to the arrangement in the human liver (Court 2003).

PRE-OPERATIVE MANAGEMENT

Most investigators relied on miniature pigs, 25–35 kg, as both donors and recipients. The dissection of anatomical structures is more difficult in older and heavier animals due to intra-abdominal fat accumulation. To facilitate exposure and to avoid abdomen compartment syndrome donor weight should preferably be lower than recipient weight. The animals are transported to the laboratory at least 2 days prior to the surgery to minimize stress. The pigs are housed in temperature and light-controlled cages on a 12–12 h light-dark cycle and provided with food and water *ad libitum*. The animals are fasted at least 12h before the procedure. Unless it is relevant for the research objectives, animals do not need immunological matching, nor preoperative cross-matching. All surgical procedures are performed in a sterile fashion.

ANESTHESIA MANAGEMENT

Anesthesia is of crucial importance for achieving success in liver transplantation (de Lange 1984; Eisele 1986; Kaiser 2006). Animals receive 30 mg/kg ketamine intramuscularly. We use a heating pad and warm IV fluids to prevent hypothermia (body temperature is maintained at 39°C). An angio-catheter is inserted into an ear vein for IV access. For anesthesia induction, the pig receives 0.0035 mg/kg fentanyl and isoflurane 3% through face mask. After pre-oxygenation with 100% oxygen, it is intubated with an appropriate size cuffed cannula (7 mm endotracheal tube for a 30 kg animal) using an extra-long straight Miller laryngoscope. Intubation of the pig may be difficult because of long snout, copious oral secretions, tortuous larynx, and long epiglottis. Very often the epiglottis needs to be

placed to the side just before advancing the tube. If intubation is not possible, ventilation can be achieved through a tracheostomy. After endotracheal intubation, maintenance of anesthesia is provided by a mixture of nitrous oxide (50%) and oxygen combined with isoflurane at 1−2%. The Tidal volume is 10 ml/kg and a rate of 15 breaths/min. Pancuronium 0.10 mg/kg is given to provide muscle relaxation and repeated at regular intervals as needed. Cefazolin 20 mg/kg IV is given before incision. An orogastric tube is placed to decompress the stomach and improve operative exposure. The left carotid artery is cannulated for continuous arterial pressure measurement and to collect arterial blood gases (ABGs), and the jugular vein is cannulated for central vein pressure measurement and for rapid infusion of fluids intra-op, and kept for daily blood checks. Urethral catheterization is done for continuous assessment of urine output. Arterial blood gases and blood glucose measurements are obtained during the case. If glucose is below than 70 mg/dl, dextrose 50% is administered. Low-dose dopamine infusion is started if necessary to keep mean arterial pressure above 70 mm/Hg (Eisele 1986). We keep IV fluids at about 20 ml/kg/h to provide around 10 ml/kg of urine per hour (Kaiser 2006). During the anhepatic phase, the level of anesthesia should be decreased to prevent hypotension; also during this phase, the animal receives blood, bolus of albumin or saline, and a dopamine drip to keep the blood pressure at normal levels. Calcium chloride and sodium bicarbonate are used after reperfusion. Sodium bicarbonate is given at 5 mEq/10 kg of body weight or more based on ABG results. Eisele showed that the average amount of sodium bicarbonate during a liver transplant and shortly after was 85 mEq (Eisele 1986). Frequently, after reperfusion, dextrose boluses are also required. Regarding blood transfusion, it is advised to use blood compatible products. Hemolytic transfusion reactions in previously untransfused pigs was believed to occur only rarely; however, there have been reports that the use of A–O incompatible transfusions in pigs undergoing liver transplants resulted in adverse reactions. Hunfeld showed that pigs that received A–O incompatible transfusions developed pulmonary hypertension and disseminated intravascular coagulation. Eight of 15 pigs died during or shortly after surgery due to hemorrhage and four pigs died due to severe bronchospasm (Hunfeld 1984). Sheil reported that two pigs that received A–O incompatible blood transfusions during liver transplants died due to disseminated intravascular coagulation (DIC), bleeding and progressive hypotension (Sheil 1972). Thus, it seems that it would be prudent either to use packed red blood cells, with a minimum volume of plasma, or to use A–O compatible blood for transfusion (Sheil 1972; Hunfeld 1984; Smith 2006).

DONOR OPERATION

The donor operation should be timed so that the recipient is ready to receive the liver to minimize the period of organ ischemia, ideally using two surgical teams. The pig liver has a tolerance to ischemia similar or inferior to the human liver. Some animals start dying when cold ischemia is longer than 16 hours. Monbaliu showed that livers exposed to 15 minutes of warm ischemia function normally after transplantation, whereas all livers submitted to 60 minutes of warm ischemia display primary nonfunction and cause recipient death. Graft function and survival are occasionally observed after 30 and 45 minutes of warm ischemia (Monbaliu 2005). The abdomen is prepped and draped from above the xiphoid to the pelvis and a midline incision is made from the xiphoid to the pubis. In the lower abdomen, care is

taken in the male pig by diverting the incision to the right to avoid the penis and the periurethral vascular plexus. A large Balfour retractor is placed and the abdominal wall retracted. First, the colon is mobilized, and the intestines covered with moist towels are hand retracted to expose the distal aorta, which is dissected and encircled. The left and right triangular ligaments are divided. The hepatic hilum is dissected and the hepatic artery, portal vein and common bile duct isolated. The common bile duct is isolated, ligated as low as possible, and divided. The gallbladder is incised and flushed with saline to remove sludge. The diaphragm pillars are divided, exposing the supra-celiac aorta for cross-clamping. Further dissection of the liver hilum can be done either before (warm dissection) or after (cold dissection) cold flushing. We prefer to do it after cold flushing to avoid vasospasm. Heparin is given (300 U/kg IV). After 5 min, the abdominal aorta is ligated distally and an 18-Fr cannula introduced and secured just above the aortic bifurcation. After cannulation, we collect 500 ml of blood into a bag containing citrate to use during or after the recipient operation. In addition to the aorta cannula, some groups place a cannula into the portal vein/splenic vein for in-situ flushing (Oike 2001). We prefer to flush the portal vein on the back-table. Next, the supraceliac aorta is cross-clamped, and cold flushing is initiated using 3L of Ringer lactate connected to a bladder irrigation tubing system. At the same time, either the suprahepatic or infrahepatic IVC is vented to allow venous drainage. At this point, the abdominal cavity is filled with slush. Next, attention is turned to the portal triad structures in the hepatoduodenal ligament, which are dissected as close to the duodenum as possible (Fondevila 2011). The gastroduodenal artery (GDA) is dissected and cut, the portal vein exposed and cut at the level of superior mesenteric vein and splenic vein. The proximal hepatic artery is skeletonized, the splenic artery and the left gastric artery are ligated and divided. The dissection is then carried to the origin of the celiac artery, and a segment of the aorta is removed with the graft. The suprahepatic IVC is cut with a cuff of diaphragm and the infra-hepatic IVC cut just above the renal veins. After hepatectomy, the portal vein, hepatic artery and bile duct are flushed with 1L of cold UW solution on the back table. On the back-table, excess of diaphragm is removed, the liver vessels are cleaned and branches are tied off; and the suprahepatic vena cava is trimmed to keep a short cuff (Heuer 2010) (Figure 4).

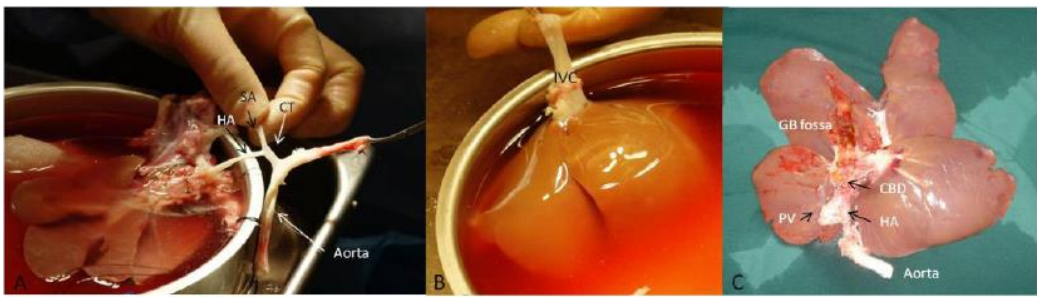

Figure 4. A–C. Back-table preparation on the liver graft. After donor hepatectomy the graft is placed on a basin with cold preservation solution. HA: hepatic artery, CT: celiac trunk, SA: splenic artery, PV: portal vein, CBD: common bile duct, GB: gallbladder.

LIVER TRANSPLANTATION TECHNIQUE

In the early reports of pig liver transplantation the recipient operative and perioperative mortality was very high, often approaching 50% (Calne 1968; Terblanche 1968; Chalstrey 1971; de Lange 1984). The learning curve is slow; de Lange showed that in the first series of 53 transplants the peri-operative mortality was 49%, and in a second series of 50 transplants the preoperative mortality was 20% (de Lange 1984). More recently, with advanced anesthesia and surgical techniques, the results are much improved. Fondevila found that with recipients of standard, whole-liver grafts, the 5-day survival rate was 100%; for the recipients of donation after cardiac death (DCD) grafts, the 5-day survival rate was 59%; and for the recipients of small-for-size grafts, the 5-day survival rate was 35% (Fondevila 2011). The time to perform the transplant procedure is in general less than 3 hours.

Various techniques of orthotopic porcine liver transplantation have previously been reported (Calne 1968; Terblanche 1968; Chalstrey 1971; Barron 1975; Woodle 1985; Filipponi 1989; Tanaka 1994; Flye 1999; Gruttadauria 2001; Oike 2001; Fondevila 2011). However, the main difference pertains to the use of veno-venous bypass. Because the pig retrohepatic IVC is entirely intrahepatic and unable to be separated from the surrounding hepatic parenchyma; liver transplant with retrohepatic caval preservation, the ‘‘piggyback’’ technique, is not able to be performed in the porcine model. Therefore, caval clamping during the anhepatic phase is unavoidable in pig liver transplantation (Fondevila 2011) and most groups use an external veno–venous bypass in order to minimize the adverse effects of portal and caval clamping (Calne 1968; Woodle 1985; Memsic 1986; Flye 1999). Another suggested approach is a side-to-side portocaval shunt with passive caval-jugular shunt (Gruttadauria 2001). However, some groups propose a simplified technique without the use of veno-venous bypass by showing that the severe hemodynamic alterations can be avoided, and the survival rates can be similar when the anhepatic phase is kept short (below 30 min) (Oike 2000; Ai 2007; Fondevila 2011). Both Oike and Fondevila showed that without bypass 87% and 100% of animals survived more than 1 week, respectively (Oike 2000; Fondevila 2011). Motsch also reported that there were no differences in operative mortality and the postoperative survival rate between the non-shunted and shunted groups despite a more pronounced but retrievable change in hemodynamics and acid-base equilibrium (Motsch 1987).

Besides orthotopic whole liver transplantation, other models: auto-transplantation (Gruttadauria 2001), partial or split transplantation (Kamimura 1997; Hayashi 1998; Hayashi 1998; Hayashi 1998; Hojo 2003; Kelly 2004), auxiliary transplantation (Hagihara 1975; Ducerf 1995; Hayashi 1998; Fukueda 2006), small for size models (Yanaga 1995; Fu 2011; Hessheimer 2011), non-heart beating (DCD) models (Tabet 1997; Garcia-Valdecasas 1999) multi-visceral (Alessiani 1998; Yagi 1998; Ai 2007) have been described using the pig model.

Step-by-Step Orthotopic Liver Transplant Technique

After induction of general anesthesia, the animal is placed on its back on a heated electric blanket and secured to the operating table with restraining ropes. Then, the animal is intubated, and the cervical and abdominal areas are shaved and prepped. A paratracheal

incision of about 10 cm is made on the right side of the neck, parallel to the trachea, and the internal jugular vein (IJV) and internal carotid artery (ICA) are dissected. A triple-lumen catheter is placed in the IJV for drug and fluid administration, with one port connected to a pressure transducer for venous pressure monitoring. A single-lumen catheter is placed in the ICA and connected to a pressure transducer for arterial pressure and heart rate monitoring. The large external jugular vein is found, isolated and prepared for later placement of the venous-venous shunt (Woodle 1985). At the end of the transplant procedure in the recipient, the neck incision is closed, and a Witzel tunnel is created to fix the venous catheter to the back of the neck. Permanent venous access is essential for frequent post-op and daily blood sampling.

The abdomen is opened via a midline incision and a large Balfour or Bookwalter retractor is placed (Figure 5). Then the liver is mobilized, first by dividing the left and right triangular ligaments. The terminal branches of the hepatic artery are ligated and divided as high as possible. The bile duct is doubly ligated and divided as high as possible (Figure 5). Once the liver is attached only to the IVC and portal vein, the veno-venous bypass can be initiated. The portal vein, infrahepatic IVC, and suprahepatic IVC are then clamped sequentially in that order. Next, the liver is excised leaving long segments of vena cava, portal vein, hepatic artery and bile duct with the recipient (Figure 6). The suprahepatic IVC is prepared by uniting the hepatic vein orifices, creating a common lumen on a large IVC cuff. The suprahepatic IVC anastomosis is performed end-to-end to the suprahepatic IVC of the graft with a running everting 4-0 polypropylene suture (Figure 7). After the suprahepatic IVC anastomosis, the liver is flushed with 1L of cold ringer lactate to wash out potassium rich solution from the liver while keeping it cold (If crystalloid flushing of the liver is not used, before opening the supra-hepatic IVC clamp the liver should be reperfused and 200 ml of blood released through the infrahepatic IVC or bypass tubing). The infra-hepatic IVC anastomosis is performed with a running 4-0 polypropylene suture in a similar way. Portal veno-venous bypass is discontinued (IVC to SVC bypass can be maintained). Then, recipient and donor portal veins are trimmed to avoid redundancy and kinking, and the anastomosis is performed with a running 6-0 polypropylene suture, leaving a growth factor of about 1 cm to prevent stenosis. The clamp on the suprahepatic IVC is released and we check for bleeding. After that, we release the infra-hepatic clamp, and check again for bleeding. Next, the portal vein clamp is released and the liver is reperfused (Heuer 2010; Fondevila 2011). After checking for hemostasis, we next dissect the hepatic artery, and a vascular clamp is placed proximal to the GDA. The donor common hepatic artery (with the GDA or splenic artery branch patch) or celiac artery is anastomosed to the recipient common hepatic artery (with a GDA branch patch) in an end-to-end fashion using polypropylene 7-0 running suture (Fondevila 2011). In the early reported series, the arterial reconstruction was performed by anastomosis of the long aorta segment attached to the graft to the infra-renal aorta (Terblanche 1968), or the aortic Carrel patch to the aorta (Calne 1968). After confirming stable hemodynamics, veno-venous bypass is interrupted. After arterial reperfusion, the gallbladder is removed (if not removed at the back-table). The distal common bile duct (CBD) of donor and recipient are trimmed to remove ischemic tissue and anastomosis is performed in an end-to-end fashion with PDS 6-0 suture in an interrupted fashion.

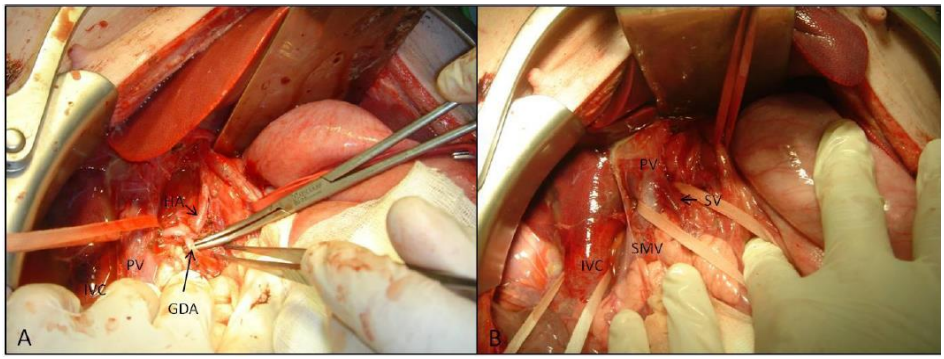

Figure 5. Liver pedicle after dissection of the hepatogastroduodenal ligament. HA: hepatic artery, PV: portal vein, GDA: gastroduodenal artery, SMV: superior mesenteric vein, SV: splenic vein.

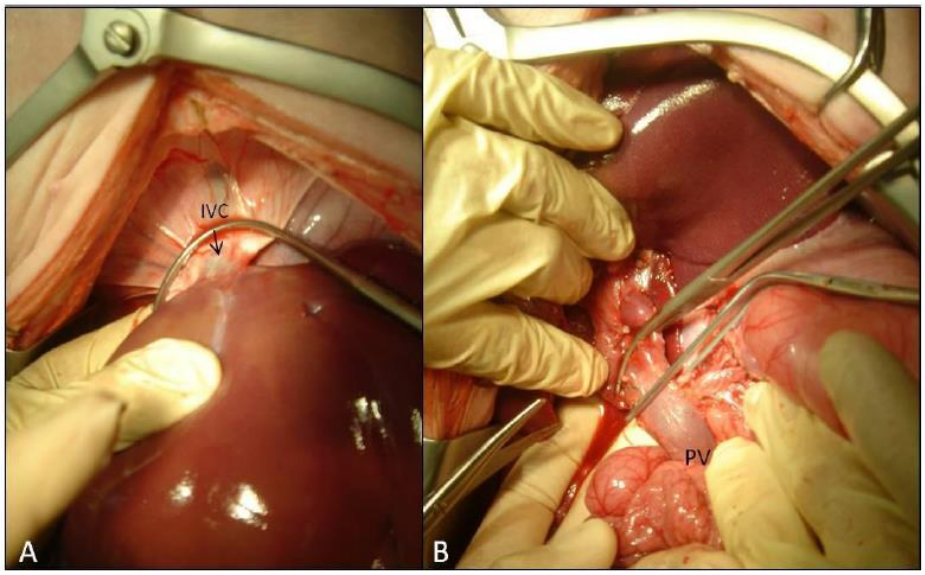

Figure 6. Recipient hepatectomy. A) A vascular clamp is placed on the supra-hepatic IVC taking a cuff of the diaphragm; B) The portal vein is clamped and cut as high as possible.

Veno-venous bypass is initiated usually just before completion of recipient hepatectomy. The bypass tube, primed with heparinized saline, is inserted through the external jugular vein (18−20 Fr cannula), and tightly secured. The infrahepatic vena cava is closed using a vascular clamp, and a bypass tube (24 Fr cannula) is inserted. The portal vein is ligated close to the liver at the level of its bifurcation. If we insert the bypass cannula directly into the portal vein instead of using the splenic vein, first the portal vein is clamped, a partial venotomy close to this ligature is performed, the tourniquet is loosened and the portal bypass tube (18−20 Fr cannula) is inserted for about 4 cm into the proximal portal vein and secured with a tourniquet. The portal vein venotomy is completed (above the cannula). At this point, the bypass circulation can be initiated (Heuer 2010). The porto-jugular bypass is interrupted just shortly before the portal vein anastomosis. When the shunt is removed, the splenic vein is ligated and the spleen can be either left in place (Flye 1999; Oike 2001) or removed (Stevens 1994). The external jugular vein is ligated cranially with a 3-0 silk ligature.

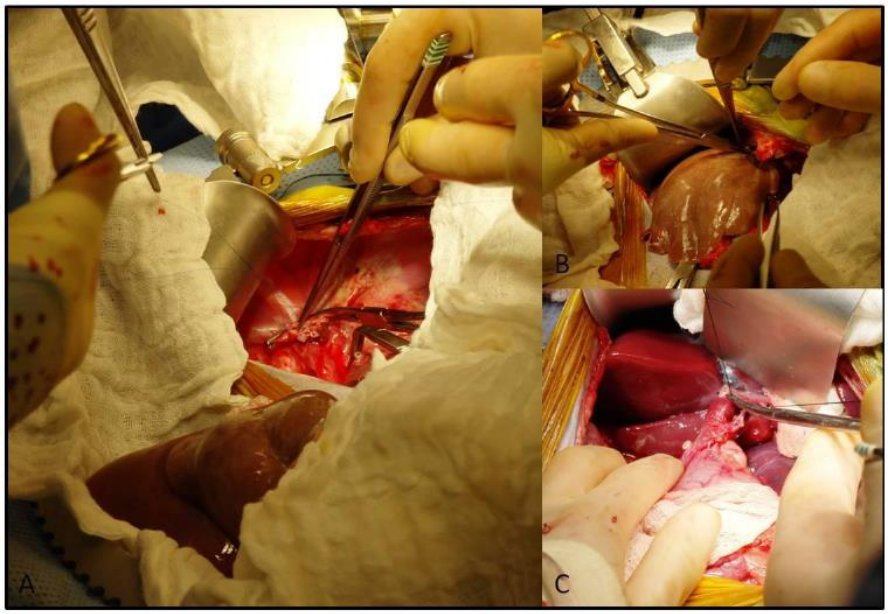

Figure 7. A) After recipient hepatectomy, the hepatic veins are opened to form a single IVC opening. The vascular clamp on the supra-hepatic IVC should have a cuff of diaphragm to increase the size of the venous cuff; B) The graft is placed in orthotopic position; C) Liver graft after portal reperfusion.

Memsic showed that pump-assisted veno-venous bypass is superior to passive bypass achieving an operative survival of 94%. He showed that pump-assisted veno-venous bypass had statistically significant improvements in portal decompression and hemodynamic stabilization. The intestines are less congested in the pump-assisted shunted animals compared to those with the passive shunt. The pump has the added advantage of a heat exchanger which, when used, can maintain the pig's body temperature (Memsic 1986). Motsch did not show differences in survival but confirmed better hemodynamics with bypass (Motsch 1987).

POST-OPERATIVE MANAGEMENT

Postoperatively, animals return to warmed individual cages and are given free access to water and food. Venous blood samples are obtained frequently for acid-base balance and glucose measurements; and sodium bicarbonate or glucose is given if necessary. Animals are administered 250–500 mL of dextrose 5% + normal saline solution IV Q8 h, for the first 24–48 h. If the animal is not doing well, CVP measurement can guide fluid replacement. A cage that allows collection of urine also helps with fluid management. In addition, animals receive a Fentanyl patch on the skin for analgesia (alternatively, buprenorphin 0.1 mg IM Q8 h can be used for the first 48 h and thereafter as needed), antibiotics (Amoxicillin 15 mg/kg/day), proton-pump inhibitors (omeprazol 20 mg/daily) to prevent gastrointestinal bleeding, and immunosuppression according to protocols. Blood samples are obtained daily. The venous line is cleaned with antiseptics and flushed daily with heparinized saline to maintain patency. Aseptic technique to manipulate lines is extremely recommended in animals on long-term

follow-up. If the white blood count increases, blood cultures should be drawn, and targeted antibiotic therapy should be continued until the end of the observation time. If follow-up is long or if animals become septic, IV lines need to be removed.

SPONTANEOUS TOLERANCE, REJECTION, AND IMMUNOSUPPRESSION

Calne and others showed that rejection of liver grafts in pigs were less frequent than in the dog (Calne 1967; Calne 1968; Terblanche 1968; Calne 1969; Dent 1971; Battersby 1974; Bockhorn 1981; Filipponi 1992). Calne found that without immunosuppression 23% of 55 outbred pigs lived more than 2 months (Calne 1967). Flye and colleagues showed that the median survival of technically successful liver allografts between pairs of outbred pigs (n=20) was 38 days (mean 145.7 ± 53.4 days), and between partially inbred swine matched at the SLA locus (n=17) was 79 days. Interestingly, mixed leukocyte reaction responsiveness did not correlate with the development of rejection. Five of 20 (25%) outbred pigs and 6 of 17 (35%) MHC-matched inbred miniature swine survived more than 100 days. On the other hand, all SLA-mismatched inbred recipients (n=26) died rapidly from massive liver rejection, with a median survival time of 9 days (Flye 1999).

There is no standard immunosuppression for pig liver transplantation. It depends on the goal of the experiment and planned follow-up period. In a MHC mismatch combination, it was shown that when cyclosporine at a dose of 20 mg/kg was given intramuscularly for a period of 21 days beginning on the day before the transplant, only one out of ten pigs had graft rejection while the others developed long-term acceptance (Bom-van Noorloos 1984). Oike showed that spontaneous tolerance to one haplotype-identical liver allograft [donor SLAdd class Id/d, class IId/d, and recipient SLAcd (class Ic/d, class IIc/d)] did not occur. All untreated animals (n=8) rejected their allograft and died within 28.1 ± 9.5 days. On the other hand, all tacrolimus treated animals developed a specific anti-donor unresponsiveness, and five (out of 14) survived long-term (112, 154, 406, 413, and 440 days), whereas several pigs died with a normal allograft function from either over-immunosuppression or other complications. Tacrolimus was given for 12 days through daily intramuscular injection at 0.1–0.4 mg/kg, in order to reach daily trough levels between 7 and 20 ng/ml (Oike 2000). Ducerf kept immunosuppression for the whole observation period. Initially, 500 mg of methylprednisolone IV is given. Then, cyclosporine (15 mg/kg) is given daily through gastrostomy tube for the first 10 days, and then mixed with food thereafter (Ducerf 1995). In his series, Fondevilla, gave immunosuppression for 4 days (tacrolimus 0.04 mg/kg IV Q24 h, methylprednisolone 125-100-75-50 mg IV Q24 h) even when the follow-up period was only 5 days (Fondevila 2011).

HEART AND LUNG TRANSPLANTATION

Development of Heart Transplantation Animal Models

Heterotopic abdominal heart transplantation is the most important model to study immunosuppressive protocols or tolerance approaches in large animals. The heart is placed in

a non-life supporting position, and even life-threatening complications like ventricular fibrillation of a rejecting heart do not automatically terminate the experiment. Other advantages over the orthotopic model in animal research are easy access for biopsies and technical simplicity in general. The technique is well established both in pig and NHP models. It was developed at the beginning of the 20th century by Carrel and Guthrie when they anastomosed the heart of a puppy to the neck vessels of an adult dog. In 1969, Ono and Lindsey described the first heterotopic heart transplant in the abdominal position which is the favored technique today (Ono 1969). There is extensive experience with heterotopic pig-to-baboon heart xenotransplantation at the Mayo clinic and at the National Institutes of Health. Using genetically modified pigs, heart graft survival in the xenotransplantation model is now greater than 1 year (Mohiuddin 2014; Mohiuddin 2015).

Combined Organ Transplants with Abdominal Heterotopic Heart Transplantation for Tolerance Induction

To study tolerance, heterotopic heart-kidney (Madariaga 2013; Madariaga 2015) and heart-lung transplants (Madariaga 2016) in major histocompatibility complex (MHC)-inbred miniature swine are used with 12 days of high-dose calcineurin inhibition. Heart-thymus and heart-kidney transplants in monkeys with a mixed-chimerism is yet another approach to study functional tolerance (Kawai 2011). We found that after kidney co-transplantation, stable long-term tolerance is induced without rejection of either organ after all immunosuppression is weaned. However, lung co-transplantation was unable to confer tolerance to the heart (Madariaga 2016).

Orthotopic Heart Transplantation in Pig-to-Baboon Xenotransplantation

The technique of orthotopic heart transplantation was developed by Lower and Shumway in Stanford (Lower 1960). In the 1960s they used dogs to develop the biatrial technique, where a donor cuff of right and left atrium is sewn to recipient cuffs of right and left atrium. These experiments led to the first human heart transplant performed by Barnard in 1967. Recently, this technique was changed to the bicaval technique where superior vena cava (SVC) and IVC are anastomosed separately, which seems to preserve the sinoatrial node and tricuspid valve function better. A meta-analysis of 41 papers comparing the two techniques found significant early advantages for the bicaval technique in terms of tricuspid valve regurgitation, sinus rhythm vs necessity of permanent pacemaker implantation, and even perioperative mortality. Long-term outcomes, however, were similar (Jacob 2009).

Today, only very few groups (University of Munich, Mayo Clinic) use orthotopic heart transplantation in a large animal model. Due to the necessity of cardiopulmonary bypass, full heparinization and the life-supporting position of the heart (in contrast to heterotopic abdominal heart transplant), this is a very complex procedure to perform in a preclinical animal setting. It is mostly used in pig-to-baboon xenotransplantation. The easier biatrial technique is used in Munich because we believe it suits better to the preclinical setting where bypass and operation times should be kept as short as possible as there is no ICU available postoperatively, and the baboon needs to be extubated shortly after the procedure.

Heterotopic Intrathoracic Heart Transplantation in Pig-to-Baboon Xenotransplantation

In this model, the original heart of the recipient is left in place and is supported by the new donor heart. Both hearts beat together as "one." Heterotopic thoracic cardiac transplantation was originally developed by Barnard in Cape Town in the 1970s because preservation techniques and immunosuppression were imperfect (cyclosporine A was not yet available), and there was always a high risk of primary graft failure (Barnard 1977). The native recipient organ in place served as a hemodynamic backup in case the new heart would fail. Barnard also tried this technique as a life-saving procedure in cardiogenic shock after cardiopulmonary bypass (Barnard 1977). Today, the indication for heterotopic heart transplant is heart failure with irreversibly elevated pulmonary vascular resistance (PVR > 6 Wood units). The only alternative approach in such a clinical situation would be combined heart lung transplantation which is not ideal due to the shortage of lung donors. Recently, it has been shown that the implantation of a left ventricular assist device can reduce PVR into ranges where the patient then becomes a candidate for a normal orthotopic heart transplantation. This development is probably the end of *clinical* heterotopic HTx.

The concept of having a back-up heart, however, was shown to be very helpful in *preclinical* pig-to-baboon xenotransplantation. Bruno Reichart´s group in Munich used this technique and performed 21 heterotopic intrathoracic transplantations to test different immunosuppressive regimens and tried to achieve long-term survival (Abicht 2015). They concluded that this technique could be helpful when xenogeneic heart transplantation first comes to the clinic because the back-up function of the recipient´s native heart could replace extracorporeal membrane oxygenation (ECMO) in case of primary graft failure (Abicht 2015).

Development of Lung Transplantation Models

The first successful large animal model of lung transplantation was developed by a Russian physiologist with transplantation of individual canine pulmonary lobes in 1947. This was shortly followed by several groups successfully performing single canine lung transplant in the 1950s with the technical addition of using the bronchial artery to provide systemic blood supply to the airway and using a left atrial cuff for the pulmonary vein anastomosis instead of anastomosing individual pulmonary veins (Hardin 1954). Further development of the large animal lung transplantation model was limited until the 1960s when the use of postoperative immunosuppression (azathioprine and high-dose prednisone) increased postoperative survival as demonstrated in the experience of Hardy et al. with over 400 canine lung transplants (Hardy 1964; Alican 1971).

Following this extensive experimental experience, the first human lung transplantation was attempted by Hardy in 1963 (Hardy 1963); however, the patient died on postoperative day 18 from renal failure. For the next decade, several groups attempted lung or lobar transplants around the world with limited success (Cooper 2016). The main obstacle was dehiscence of the bronchial anastomosis. Further research in the canine model determined that use of high-dose prednisone prevented healing at the bronchial anastomosis (Lima 1981) and subsequently the initial immunosuppression regimen was changed to azathioprine and

cyclosporine-A, with later introduction of prednisone. In addition, omentopexy was performed at the bronchial anastomosis to encourage collateralization and avoid anastomotic stricture (Dubois 1984).

The first successful human heart-lung transplantation program was started in 1981 with Shumway at Stanford (Reitz 1982), followed by a successful program of human lung transplantation by the Toronto Lung Transplant Group in 1983 (1986). Rapid advancements in survival outcomes ensued.

Currently, the main limitation to lung transplantation is the problem of chronic rejection. To further study chronic rejection, a large animal model of chronic lung rejection was developed using MHC-inbred miniature swine. Using MHC-inbred miniature swine allows transplants to be performed across reproducible MHC barriers (Sachs 1976). In this model, pigs received 12-day course of high-dose calcineurin inhibitor (Allan 2002) or cyclosporine, prednisone, and azathioprine (al-Dossari 1994) and were then followed by cellular immune assays and biopsies. All grafts survived for at least 5 months and developed manifestations of chronic rejections such as bronchiolitis obliterans, interstitial fibrosis and occlusive vasculopathy (al-Dossari 1994; Allan 2002).

PREOPERATIVE CARE AND ANESTHESIA

In the following section, we mainly present the protocols that are in use at the Center for Transplantation Sciences at MGH.

Animals are without food but with free access to water for 12 hours prior to the scheduled operation. Approximately 1 hour prior to the operation, the animal is sedated using ketamine analogue Telazol (1.4 mg/kg IM or IV, single dose, onset of action 15 minutes, duration of effect 90 minutes); glycopyrrolate (0.01 mg/kg IM or IV, single dose, onset of action 15 minutes, duration of effect 60 minutes); and xylazine (2 mg/kg IM or IV, single dose, onset of action 15 minutes, duration of effect 60 minutes). Within 1 hour of incision the animal is given cefazolin (1 g IV or IM, single dose).

Inhalational anesthesia is used (isoflurane). Pancuronium is administered (0.1 mg/kg) if paralysis is required (useful for lung transplantation).

For postoperative pain control in pigs, animals are given buprenorphine (0.03 mg IM or IV, single dose, onset of action 1−2 h after administration, duration of action 8−12 h) and a fentanyl patch (1−4 mcg/kg/h TD, applied on the day of surgery, onset of action 3−4 h after application, duration of action 72 h continuous while patch is in place).

For postoperative pain control in NHP, animals are given buprenorphine (0.01 mg/kg IM or IV every 10–14 h) on a scheduled basis for the first three postoperative days and as needed thereafter. NHP recipients also receive ketorolac (3mg daily IM) as an anti-platelet agent for the first five postoperative days.

CENTRAL LINE INSERTION

Central lines are useful for administration of drugs and fluid as well as for frequent blood draws to monitor drug levels and laboratory values. Central lines are generally kept in place

for no longer than 60 consecutive days due to risk of systemic infection. Central line care involves sterile technique in accessing the lines and keeping the central line entry site clean. Central lines are flushed at least twice daily with heparinized saline (100 units/mL) to maintain patency. Jackets are placed on the animals to prevent damage or inadvertent line dislodgement.

The preferred central line accesses in pigs are internal and external jugular veins in the neck. The animal is placed supine and a 5 cm incision is made about one fingerbreadth lateral to the trachea. After exposing the internal jugular and the external jugular veins, 0-silk is used to ligate the vein in the cephalad direction. Gentle retraction is placed in the caudal direction and a small venotomy is made. The central line is tunneled through the skin with an entry point as far dorsal as possible to avoid trauma to the line when the animal is awake. The central line is then inserted into the venotomy and inserted so that its tip would rest in the SVC. The line is tested and then secured. The incision is closed in layers.

HEART TRANSPLANTATION: DONOR HEART HARVEST

After induction of general anesthesia, the animal is prepped and draped in the usual sterile fashion. The chest is opened via median sternotomy. The superior vena cava, inferior vena cava, pulmonary artery, and aorta are isolated with 0-silk sutures. Heparin 200 units/kg is administered. A purse string suture is placed in the ascending aorta with 5-0 Prolene and the aorta is cannulated with an 18 gauge angiocatheter or needle vent. The azygos vein is tied off and divided. In pigs, it is also critical to tie off and divide the hemiazygos vein to avoid bleeding in the recipient. The SVC and IVC are tied off and the aorta is cross-clamped. The heart is vented through the IVC and the pulmonary veins (when an isolated heart is transplanted) or left atrial appendage (when the lung is also harvested). Cardioplegia (e.g., 1L of Plegisol) is administered through the aortic cannula to arrest the heart. For topical cooling, iced saline is placed in the chest. The heart is transected and excised beginning at the IVC and SVC, pulmonary veins, then aorta and pulmonary artery. When the lungs are also used, the heart-lung block is excised *in toto* and heart and lungs are divided at the back table (Figures 8−10).

In heterotopic heart and orthotopic lung transplantation, a cuff of left atrium is created for the lung, and the left atrium of the heart is closed with a 4-0 Prolene suture in a running fashion (Figure 11).

During back table dissection for isolated heterotopic abdominal heart transplant all pulmonary veins as well as the SVC and the IVC are tied off with 0-silk. We also create a 3 mm atrial septal defect in pigs to avoid thrombosis in the atria after heterotopic heart transplant.

For orthotopic heart transplant, a left atrial cuff is created by cutting open the pulmonary veins and a right atrial cuff is created by cutting open the IVC in the direction of the right atrial appendage (the SVC is tied off).

Figure 8. Heart and lung en bloc. Heart and lung are removed from the donor animal en bloc. Left clamp occluding the trachea. Middle forceps showing the aorta. Right clamp on the pulmonary artery.

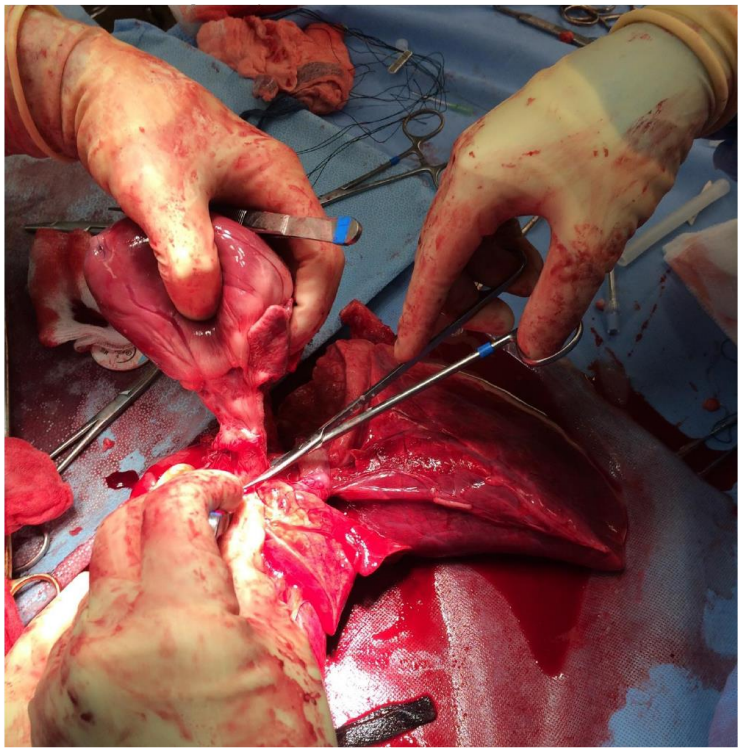

Figure 9. Separation of the heart and lung. The heart and lung are separated at the left atrium, leaving a left atrial cuff around the pulmonary veins.

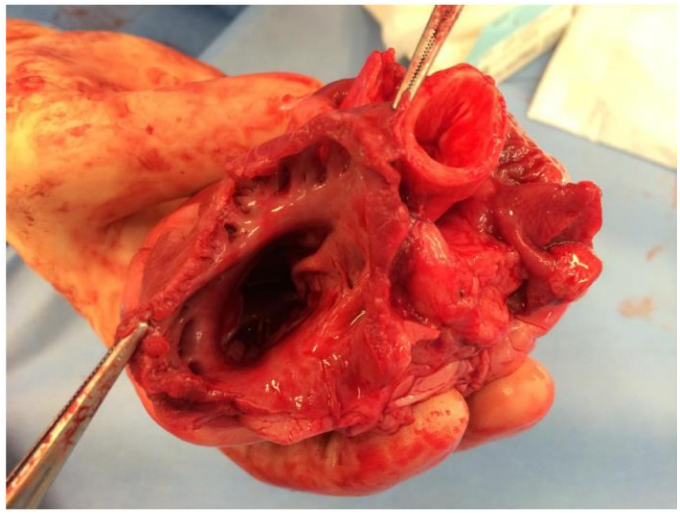

Figure 10. Heart alone with left atrium opened.

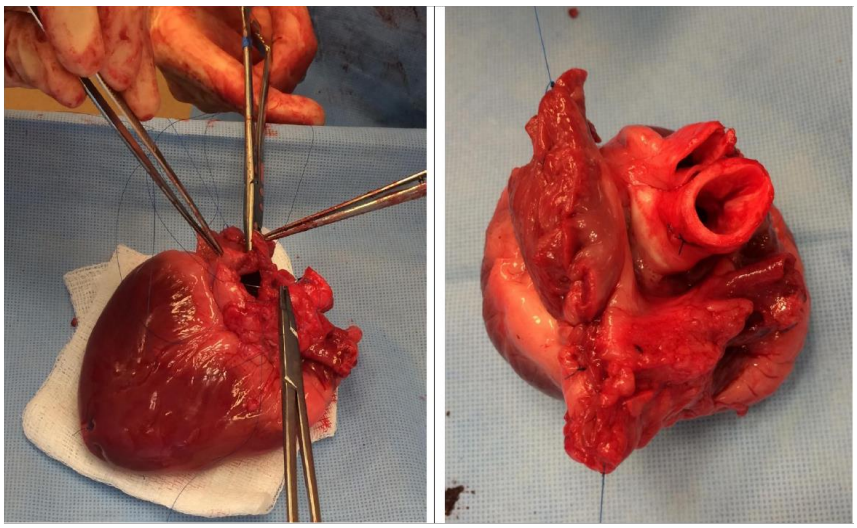

Figure 11. Closing the left atrium. The left atrium is closed with running 4-0 prolene suture. When the heart is harvested alone for solitary heart transplant, the pulmonary veins are divided and ligated.

Heterotopic Abdominal Heart Transplantation

After a midline laparotomy the viscera are retracted to expose the aorta and inferior vena cava which are dissected free. The heart graft is transplanted into the right side of the animal (Figure 12). Heparin is administered (200 units/kg IV). After partial clamping using a Satinsky clamp, the IVC is opened longitudinally with a blade and Potts scissors. An end-to-side anastomosis between the donor pulmonary artery and the recipient IVC is performed with 6-0 Prolene in a running fashion. After that, the abdominal aorta is partially clamped and opened longitudinally and the donor aorta is anastomosed to the recipient aorta using 6-0 Prolene in a running fashion. Before tying the knots and removing the clamps, de-airing with

saline is performed. If the graft initially fibrillates, it is defibrillated to attain normal sinus rhythm. The animal´s abdomen is then closed in three layers: peritoneum with running 3-0 Vicryl, fascia with running 2-0 PDS, and subcutaneous with 3-0 Vicryl. The skin is stapled (in pigs) or sutured with monocryl (in NHP).

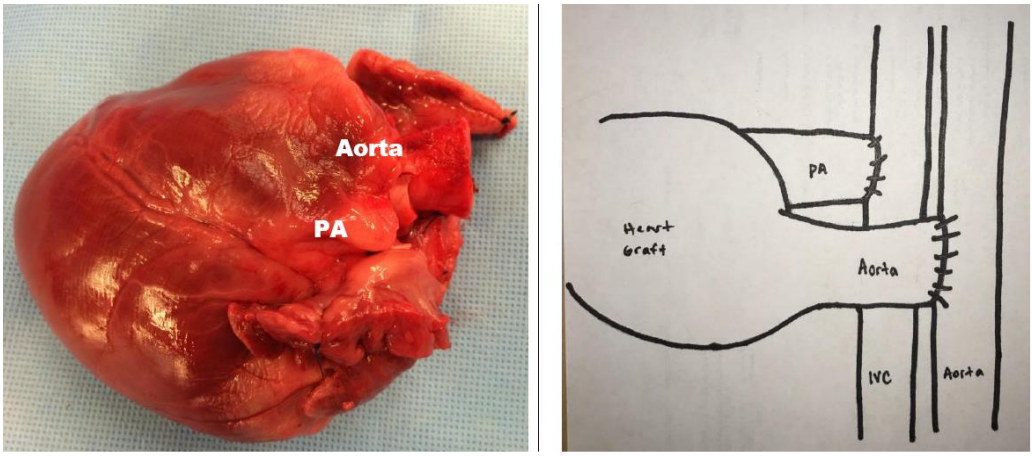

Figure 12. Prepared heart graft. Heart donor organ ready for heterotopic abdominal transplantation.

Orthotopic Heart Transplantation (Pig-to-Baboon, Munich Protocol)

After a median sternotomy, the pericardium is opened. Heparin is administered (400 units/kg IV), the aorta and both venae cavae are cannulated and total cardiopulmonary bypass is established. The animal is cooled to 30°C. Recipient cardiectomy is performed leaving cuffs of left and right atrium in place. Implantation of the donor heart is begun with the left atrial anastomosis (5-0 Prolene in a running fashion), followed by the right atrial anastomosis (5-0), the pulmonary artery (6-0) and the aorta (5-0). A needle vent is placed in the ascending aorta and the apex is punctured for de-airing before reperfusion. The heart is reperfused for 60 minutes, and the animal is rewarmed. Immunosuppression starts before reperfusion. Pacemaker wires are placed and cardiopulmonary bypass is weaned after 60 minutes of reperfusion. Protamine is given. Hemostasis is secured and a Blake drain is placed in the pericardium. The sternum is closed with wires, and the wound is closed in layers. Drains are removed and a jacket is put on before the baboon is wakened, extubated and put in the cage.

Heterotopic Intrathoracic Heart Transplantation (Pig-to-Baboon, Munich Protocol)

The right-sided pulmonary veins are ligated, and the openings of the left pulmonary veins are transected to form the left atrial cuff. The right atrial cuff is created as usual. Management of cardiopulmonary bypass is identical to orthotopic heart transplant. After cross-clamping the aorta, Bretschneider cardioplegia is administered through the aortic root. The donor heart is put into the right side of the chest. Both atria are anastomosed with 5-0 Prolene in a running

fashion (diamond-shaped for large opening). The aorta and pulmonary artery are anastomosed end-to-side, for the latter, an interposition with a vascular graft is necessary (for a more detailed description and pictures see Abicht et al. (Abicht 2015).

HEART BIOPSY AFTER HETEROTOPIC HEART TRANSPLANT

After induction of general anesthesia, the animal is placed in the left lateral decubitus position. An 8 cm incision is made in the right flank overlying the visibly beating heart graft. After the subcutaneous tissue and muscle are divided, the retroperitoneum is entered and the heart graft is exposed. A 4-0 prolene suture is used to make a pursestring stitch at the apex of the left ventricle, taking care to avoid any coronary arteries. A Tru-cut core biopsy needle is deployed through the apex into the septum and then withdrawn. After sufficient tissue is obtained, the pursestring stitch is tied and an additional mattress stitch using 4-0 prolene can be placed to achieve hemostasis. The incision is then closed in layers.

Lung Transplantation

Donor Lung Harvest

After induction of general anesthesia, the chest is entered through a median sternotomy. The SVC and IVC are encircled. The hemi-azygous and azygous veins are ligated. The space between the aorta and pulmonary artery is dissected and the aorta surrounded with umbilical tape to assist with later cross clamping. Heparin 200 units/kg IV is administered. A 4-0 prolene purse string sutures is placed in the pulmonary artery. An arteriotomy is made and the pulmonary artery is cannulated with cystoscopy tubing. The SVC and IVC are ligated. The aorta is cross-clamped, and cold preservative solution (e.g., Perfadex, XVIVO Perfusion; Englewood, CO) containing Alprostadil (prostaglandin E1, 500ug/L) is perfused into both lungs through the pulmonary artery cannula. Alprostadil can also be administered directly into the pulmonary artery. The heart is vented by incising the left atrial appendage. Iced saline is placed in the chest and then the lungs and heart are removed *en bloc* for back table dissection.

During back table dissection, the left lung is separated from the heart by isolating the pulmonary artery, the left main stem bronchus and creating a left atrial cuff for the pulmonary vein (Figures 13 and 14).

Recipient Lung Transplantation

The animal is placed in the right lateral decubitus position to expose the left chest. A posterolateral incision is made just below the left scapula. In the pig, rib 4 or 5 is exposed by resecting a small portion of the cartilage of the scapula. The rib is then cut with bone cutters and removed to optimize exposure. A rib spreader is inserted.

Upon gaining entry to the chest, the inferior pulmonary ligament is sharply incised. The left hilum was dissected. The superior pulmonary vein is usually small and can be ligated with suture. The inferior pulmonary vein is isolated. The left pulmonary artery is isolated. The left main bronchus is isolated. After the donor organ is ready, the recipient is

systemically heparinized with 200 units/kg of heparin the pulmonary vein and the pulmonary artery are clamped with Satinsky clamps and then cut distally. The bronchus is cut and the left recipient lung is removed from the field.

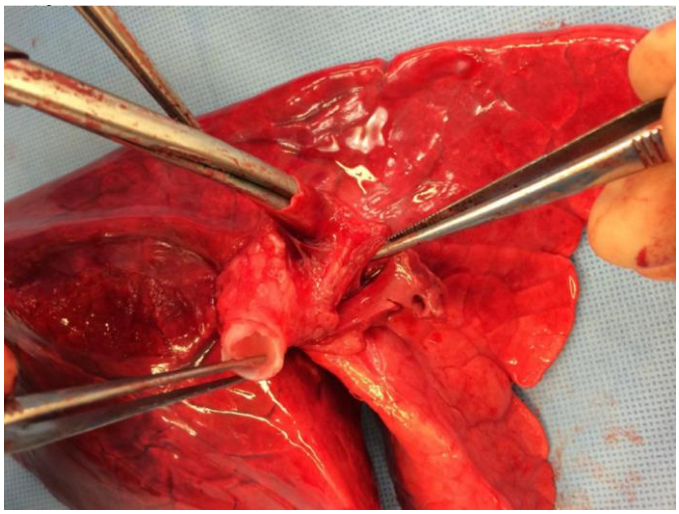

Figure 13. Lung preparation. L main bronchus (left), left pulmonary artery (middle) and left atrial cuff (right).

Figure 14. Prepared lung graft. Lung donor organ ready for transplantation.

We generally do not use bronchial blockers. Instead we have found it simpler to sew during periods of apnea and occlude the bronchus periodically to allow for ventilation.

The bronchial anastomosis is performed with 8 to 10 interrupted 4-0 vicryl stitches. The sutures are placed in an organized fashion. The donor bronchus is then telescoped down into the recipient bronchus and then the sutures are tied.

The recipient pulmonary vein to donor left atrial cuff anastomosis is then performed with running 5-0 prolene suture. The pulmonary artery anastomosis is also performed with running 5-0 prolene suture.

If there is significant size discrepancy between the donor and the recipient, a donor left upper lobectomy can be performed before implanting the lung.

After hemostasis is achieved, a Blake drain connected to bulb suction is tunneled through the skin and placed inside the chest. The thoracostomy drain is removed on postoperative day 2. The thoracotomy is closed with figure-of-eight #2 vicryl sutures to approximate the ribs and the muscle and subcutaneous tissues are closed in layers. The skin is stapled and interrupted #2 nylon retention sutures are placed. Sterile dressing with antibiotic ointment is then applied. A protective jacket is placed over the incision that also covers the central lines in the neck.

Lung Biopsy

After induction of general anesthesia, the animal is placed in the right lateral decubitus position. A 10 cm curvilinear incision is then made about 2 cm below the previous thoracotomy incision. The incision is carried down to a rib. The rib is isolated and shingled. After the pleural space is entered, the lung is examined. Biopsy can be performed sharply or with a stapler to wedge a piece of lung. If the biopsy is performed sharply, hemostasis can be achieved by using direct pressure and surgicell. The incision is then closed in layers. If the lung is densely adherent to the chest wall, a pleural catheter is not needed to evacuate air. If the lung is free of adhesions, a small Blake drain can be placed to evacuate air and removed on postoperative day 2.

COMBINED HEART AND LUNG TRANSPLANTATION

Our group at Massachusetts General Hospital used a swine model of combined heterotopic heart and orthotopic left lung transplant to see whether a lung can confer tolerance to a heart the way a kidney does (Madariaga 2016). These experiments were carried out without cardiopulmonary bypass, which enabled a survival rate of almost 100% in a preclinical setting.

The recipients first underwent left orthotopic lung transplantation before heterotopic abdominal heart transplantation as described above. Heart grafts were placed on ice while lung transplantation was performed.

POSTOPERATIVE CARE AND MONITORING AFTER HETEROTOPIC HEART TRANSPLANT AND LUNG TRANSPLANT IN SWINE

Immunosuppression with calcineurin inhibitors (Cyclosporine A or FK506) is started in the OR and continued for 12 days. Trough levels are measured daily and doses adapted accordingly.

Heart function is monitored by daily palpation and electrocardiogram (ECG) using the AliveCor Veterinary Heart Monitor (AliveCor, Inc., San Francisco, CA). Routine biopsies after heterotopic abdominal HTx are performed via flank incisions at predetermined time

intervals (POD 20−30, 50−60, 90−100) or whenever a decrease in palpation or QRS-wave amplitude occurs. Cardiac allograft rejection (heart survival time) was defined by either loss of a ventricular impulse on palpation, and/or QRS-wave amplitude of less than 0.3 mV, and/or the lack of ventricular contraction on echocardiography (Avitall 1988).

Lung function is monitored by clinical examination of breath sounds and weekly chest radiographs. Routine biopsies are performed on all transplant recipients via mini-thoracotomies at predetermined time intervals (POD 20−30, 50−60, 90−100) or whenever there was clinical suspicion for rejection.

CONCLUSION

Swine and primates have been extensively used in biomedical research, including transplant immunobiology (Swindle 1988; Swindle 1998; Critser 2009). Large animal transplant models have served a valuable role to train transplant surgeons; to test new surgical techniques; and to study the immunobiology of transplantation. Transplantation experiments in the large animals are complex, costly, and require adequate facilities and team-work. The learning curve is very steep, and the surgeon needs to be aware of technical modifications, and best model for the particular experiment. In addition, optimal anesthesia and post-operative care are essential to obtain good results. In the future, genetically modified pigs may provide a source of cells or organ grafts for clinical transplantation (Critser 2009; Sachs 2009; Elliott 2011; Gock 2011).

REFERENCES

Abicht JM, Mayr T, Reichart B, Buchholz S, Werner F, Lutzmann I, Schmoeckel M, Bauer A, Thormann M, Langenmayer M, Herbach N, Pohla H, Herzog R, McGregor CG, Ayares D, Wolf E, Klymiuk N, Baehr A, Kind A, Hagl C, Ganswindt U, Belka C, Guethoff S, Brenner P. Pre-clinical heterotopic intrathoracic heart xenotransplantation: a possibly useful clinical technique. *Xenotransplantation* 2015; 22(6): 427−442.

Ai LM, Peng CH, Wu YL, Cao LP, Fang HQ, Liu YB, Peng SY. Orthotopic abdominal multivisceral transplantation without venovenous bypass in pigs. *Transplant. Proc.* 2007; 39(1): 273−277.

al-Dossari GA, Kshettry VR, Jessurun J, Bolman RM, 3rd. Experimental large-animal model of obliterative bronchiolitis after lung transplantation. *Ann. Thorac. Surg.* 1994; 58(1): 34−39; discussion 39−40.

Alessiani M, Spada M, Vaccarisi S, Fayer F, Puletti G, Ruggiero R, Bellinzona G, Noli S, Scandone M, Maestri M, Dionigi P, Zonta A. Multivisceral transplantation in pigs: technical aspects. *Transplant. Proc.* 1998; 30(6): 2627−2628.

Alican F, Cayirli M, Isin E, Hardy JD. One-stage replantation of both lungs in the dog. *JAMA* 1971; 215(8): 101−106.

Allan JS, Wain JC, Schwarze ML, Houser SL, Benjamin LC, Madsen JC, Sachs DH. Modeling chronic lung allograft rejection in miniature swine. *Transplantation* 2002; 73(3): 447−453.

Avitall B, Payne DD, Connolly RJ, Levine HJ, Dawson PJ, Isner JM, Salem DN, Cleveland RJ. Heterotopic heart transplantation: electrophysiologic changes during acute rejection. *J. Heart. Transplant.* 1988; 7(3): 176−182.

Barnard CN, Losman JG, Curcio CA, Sanchez HE, Wolpowitz A, Barnard MS. The advantage of heterotopic cardiac transplantation over orthotopic cardiac transplantation in the management of severe acute rejection. *J. Thorac. Cardiovasc. Surg.* 1977; 74(6): 918−924.

Barnard CN, Wolpowitz A, Losman JG. Heterotopic cardiac transplantation with a xenograft for assistance of the left heart in cardiogenic shock after cardiopulmonary bypass. *S. Afr. Med. J.* 1977; 52(26): 1035−1038.

Barron PT, Vogelfanger IJ, Waddell WG. Orthotopic liver transplantation utilizing a vascular stapling instrument. *Br. J. Surg.* 1975; 62(6): 438−440.

Battersby C, Egerton WS, Balderson G, Kerr JF, Burnett W. Another look at rejection in pig liver homografts. *Surgery* 1974; 76(4): 617−623.

Bockhorn H. [The allogeneic liver transplantation. II. Immunological examinations in pigs (author's transl)]. *Res. Exp. Med. (Berl)* 1981; 178(3): 177−199.

Bom-van Noorloos AA, Visser JJ, Drexhage HA, Meijer S, Hoitsma HF. Cyclosporin A in orthotopic porcine liver transplantation. Long-term survival after short-term treatment. *Eur. Surg. Res.* 1984; 16(6): 329−335.

Buhler L, Basker M, Alwayn IP, Goepfert C, Kitamura H, Kawai T, Gojo S, Kozlowski T, Ierino F L, Awwad M, Sachs DH, Sackstein R, Robson SC, Cooper DK. Coagulation and thrombotic disorders associated with pig organ and hematopoietic cell transplantation in nonhuman primates. *Transplantation* 2000; 70(9): 1323−1331.

Buhler LH, Spitzer TR, Sykes M, Sachs DH, Delmonico FL, Tolkoff-Rubin N, Saidman SL, Sackstein R, McAfee S, Dey B, Colby C, Cosimi AB. Induction of kidney allograft tolerance after transient lymphohematopoietic chimerism in patients with multiple myeloma and end-stage renal disease. *Transplantation* 2002; 74(10): 1405−1409.

Calne RY, Sells RA, Pena JR, Davis DR, Millard PR, Herbertson BM, Binns RM, Davies DA. Induction of immunological tolerance by porcine liver allografts. *Nature* 1969; 223(5205): 472−476.

Calne RY, White HJ, Yoffa DE, Maginn RR, Binns RM, Samuel JR, Molina VP. Observations of orthotopic liver transplantation in the pig. *Br. Med. J.* 1967; 2(5550): 478−480.

Calne RY, Yoffa DE, White HJ, Maginn RR. A technique of orthotopic liver translantation in the pig. *Br. J. Surg.* 1968; 55(3): 203−206.

Calne RY. The initial study of the immunosuppressive effects of 6-mercaptopurine and azathioprine in organ transplantation and a few words on cyclosporin A. *World J. Surg.* 1982; 6(5): 637−640.

Cantu E, Balsara KR, Li B, Lau C, Gibson S, Wyse A, Baig K, Gaca J, Gonzalez-Stawinski GV, Nichols T, Parker W, Davis RD. Prolonged function of macrophage, von Willebrand factor-deficient porcine pulmonary xenografts. *Am. J. Transplant.* 2007; 7(1): 66−75.

Chalstrey LJ, Parbhoo SP, Tappin A, Baker GJ, Gracey LR, Mullen PA, Lester R. Technique of orthotopic liver transplantation in the pig. *Br. J. Surg.* 1971; 58(8): 585−588.

Chardon P, Renard C, Vaiman M. The major histocompatibility complex in swine. *Immunol. Rev.* 1999; 167: 179−192.

Chen D, Weber M, McVey JH, Kemball-Cook G, Tuddenham EG, Lechler RI, Dorling A. Complete inhibition of acute humoral rejection using regulated expression of membrane-tethered anticoagulants on xenograft endothelium. *Am. J. Transplant.* 2004; 4(12): 1958−1963.

Cooper DK, Satyananda V, Ekser B, van der Windt DJ, Hara H, Ezzelarab MB, Schuurman HJ. Progress in pig-to-non-human primate transplantation models (1998-2013): a comprehensive review of the literature. *Xenotransplantation* 2014; 21(5): 397−419.

Cooper JD. Surgery of the airway: historic notes. *J. Thorac. Dis.* 2016; 8(Suppl 2): S113-120.

Costa C, Zhao L, Burton WV, Bondioli K R, Williams BL, Hoagland TA, Ditullio PA, Ebert KM, Fodor WL. Expression of the human alpha1,2-fucosyltransferase in transgenic pigs modifies the cell surface carbohydrate phenotype and confers resistance to human serum-mediated cytolysis. *FASEB J.* 1999; 13(13): 1762−1773.

Court FG, Wemyss-Holden SA, Morrison CP, Teague BD, Laws PE, Kew J, Dennison AR, Maddern GJ. Segmental nature of the porcine liver and its potential as a model for experimental partial hepatectomy. *Br. J. Surg.* 2003; 90(4): 440−444.

Cozzi E, Simioni P, Boldrin M, Seveso M, Calabrese F, Baldan N, Castagnaro M, Gavasso S, Fadin M, Zerbinati P, Tormene D, Tognin G, Thiene G, Pagnan A, Ancona E. Alterations in the coagulation profile in renal pig-to-monkey xenotransplantation. *Am. J. Transplant.* 2004; 4(3): 335−345.

Cozzi E, White DJ. The generation of transgenic pigs as potential organ donors for humans. *Nat. Med.* 1995; 1(9): 964−966.

Critser JK, Laughlin MH, Prather RS, Riley LK. Proceedings of the Conference on Swine in Biomedical Research. *ILAR J.* 2009; 50(1): 89−94.

de Lange JJ, Hoitsma HF, Meijer S. Anaesthetic management in experimental orthotopic liver transplantation in the pig. *Eur. Surg. Res.* 1984; 16(6): 360−365.

Dent DM, Hickman R, Uys CJ, Saunders S, Terblanche J. The natural history of liver alloone and autotransplantation in the pig. *Br. J. Surg.* 1971; 58(6): 407−413.

Dubois P, Choiniere L, Cooper JD. Bronchial omentopexy in canine lung allotransplantation. *Ann. Thorac. Surg.* 1984; 38(3): 211−214.

Ducerf C, Malaise J, Caillon P, Margotton J, Gonnet E, Pouyet M. Auxiliary heterotopic liver graft using splenopancreatic venous blood flow in pig. *J. Surg. Res.* 1995; 58(4): 401-406.

Eisele PH, Woodle ES, Hunter GC, Talken L, Ward RE. Anesthetic, preoperative and postoperative considerations for liver transplantation in swine. *Lab. Anim. Sci.* 1986; 36(4): 402−405.

Ekser B, Ezzelarab M, Hara H, van der Windt DJ, Wijkstrom M, Bottino R, Trucco M, Cooper D K. Clinical xenotransplantation: the next medical revolution? *Lancet* 2012; 379(9816): 672−683.

Ekser B, Gridelli B, Veroux M, Cooper DK. Clinical pig liver xenotransplantation: how far do we have to go? *Xenotransplantation* 2011; 18(3): 158−167.

Elliott RB, Living Cell T. Towards xenotransplantation of pig islets in the clinic. *Curr. Opin. Organ Transplant.* 2011; 16(2): 195−200.

Filipponi F, Fabbri LP, Elbetti C, Falcini F, Rontini M. Orthotopic liver transplantation in the pig: a surgical experience with 124 liver transplants. *G. Chir.* 1992; 13(3): 101−105.

Filipponi F, Falcini F, Benassai C, Martini E. [Orthotopic liver transplant in pigs: several variations of the surgical technic]. *G. Chir.* 1989; 10(7-8): 374−378.

Flye MW (1992). *Swine as Models in biomedical research*, Iowa State University Press**:** 44−56.

Flye MW, Pennington L, Kirkman R, Weber B, Sindelar W, Sachs DH. Spontaneous acceptance or rejection of orthotopic liver transplants in outbred and partially inbred miniature swine. *Transplantation* 1999; 68(5): 599−607.

Fodor WL, Williams BL, Matis LA, Madri J A, Rollins SA, Knight JW, Velander W, Squinto SP. Expression of a functional human complement inhibitor in a transgenic pig as a model for the prevention of xenogeneic hyperacute organ rejection. *Proc. Natl. Acad. Sci. USA* 1994; 91(23): 11153−11157.

Fondevila C, Hessheimer AJ, Flores E, Vendrell M, Munoz J, Escobar B, Calatayud D, Taura P, Fuster J, Garcia-Valdecasas JC. Step-by-step guide for a simplified model of porcine orthotopic liver transplant. *J. Surg. Res.* 2011; 167(1): e39−45.

Fu Y, Zhang HB, Yang N, Zhu N, Si-Ma H, Chen W, Zhao WC, Yang GS. Porcine partial liver transplantation without veno-venous bypass: an effective model for small-for-size liver graft injury. *Transplant. Proc.* 2011; 43(5): 1953−1961.

Fukueda M, Ishizaki N, Hamada N, Kadono J, Kaieda M, Nakamura N, Komokata T, Sakata R. Porcine model of auxiliary partial orthotopic liver transplantation for acute liver failure. *Transplantation* 2006; 82(10): 1312−1318.

Garcia-Valdecasas JC, Tabet J, Valero R, Deulofeu R, Taura P, Rull R, Capdevila L, Cifuentes A, Gonzalez FX, Net M, Beltran J, Lopez-Boado MA, Palacin J, Garcia F, Visa J. Evaluation of ischemic injury during liver procurement from non-heart-beating donors. *Eur. Surg. Res.* 1999; 31(6): 447−456.

Gianello P, Fishbein JM, Sachs DH. Tolerance to primarily vascularized allografts in miniature swine. *Immunol. Rev.* 1993; 133: 19−44.

Gock H, Nottle M, Lew AM, d'Apice AJ, Cowan P. Genetic modification of pigs for solid organ xenotransplantation. *Transplant. Rev. (Orlando)* 2011; 25(1): 9−20.

Goodrich EO, Jr., Welch HF, Nelson JA, Beecher TS, Welch CS. Homotransplantation of the canine liver. *Surgery* 1956; 39(2): 244−251.

Gruttadauria S, Marino G, Catalano F, Sgroi AV, Di Mauro GL, Basile F. Porcine orthotopic liver autotransplantation: facilitated technique. *J. Invest. Surg.* 2001; 14(2): 79−82.

Hagihara PF, Griffen WO, Jr. Homologous heterotopic porcine liver transplantation. *J. Surg. Res.* 1975; 19(2): 89−97.

Hardin CA, Kittle CF. Experiences with transplantation of the lung. *Science* 1954; 119(3081): 97−98.

Hardy JD, Eraslan S, Webb WR. Transplantation of the Lung. *Ann. Surg.* 1964; 160: 440-448.

Hardy JD, Webb WR, Dalton ML, Jr., Walker GR, Jr. Lung Homotransplantation in Man. *JAMA* 1963; 186: 1065−1074.

Hayashi S, Lin MG, Katayama A, Namii Y, Nagasaka T, Koike C, Negita M, Kobayashi T, Yokoyama I, Takagi H. Auxiliary orthotopic xenogeneic liver transplantation using pigs for fulminant hepatic failure: with special reference to the technique and immunosuppression. *Transplant. Proc.* 1998; 30(7): 3836.

Hayashi S, Nagasaka T, Kojima T, Namii Y, Katayama A, Kobayashi T, Yokoyama I, Takagi H. Combination splitting using both in situ and ex situ techniques in triple split liver transplantation in pigs. *Transpl. Int.* 1998; 11(6): 408−412.

Hayashi S, Namii Y, Nagasaka T, Kozima T, Katayama A, Kobayashi T, Yokoyama I, Takagi H. Technique of triple split-liver transplantation in pigs using inferior vena cava reconstruction and intraoperative intrahepatic portosystemic shunt. *Transplant. Proc.* 1998; 30(7): 3229−3231.

Hertl M, Hertl MC, Kunkel P, Schilling S, Prevot B, Kluth D, Malago M, Broelsch C E. Tauroursodeoxycholate ameliorates reperfusion injury after pig liver transplantation. *Transpl. Int.* 1999; 12(6): 454−462.

Hessheimer AJ, Fondevila C, Taura P, Munoz J, Sanchez O, Fuster J, Rimola A, Garcia-Valdecasas JC. Decompression of the portal bed and twice-baseline portal inflow are necessary for the functional recovery of a "small-for-size" graft. *Ann. Surg.* 2011; 253(6): 1201−1210.

Heuer M, Reinhardt R, Kneiseler G, Wurzinger P, Zou X, Hua F, Jian F, Paul A, Kaiser GM. Liver transplantation in swine without venovenous bypass. *Eur. Surg. Res.* 2010; 45(1): 20−25.

Higginbotham L, Mathews D, Breeden CA, Song M, Farris AB, 3rd, Larsen CP, Ford ML, Lutz A J, Tector M, Newell KA, Tector AJ, Adams AB. Pre-transplant antibody screening and anti-CD154 costimulation blockade promote long-term xenograft survival in a pig-to-primate kidney transplant model. *Xenotransplantation* 2015; 22(3): 221−230.

Hojo N, Ishibashi T, Yasuda T, Sakuma Y, Fujiwara T, Kawarasaki H, Nagai H. Porcine model for surgical training of living related liver transplantation. *Transplant. Proc.* 2003; 35(1): 82−84.

Houser SL, Kuwaki K, Knosalla C, Dor F J, Gollackner B, Cheng J, Shimizu A, Schuurman HJ, Cooper DK. Thrombotic microangiopathy and graft arteriopathy in pig hearts following transplantation into baboons. *Xenotransplantation* 2004; 11(5): 416−425.

Hunfeld MA, Hoitsma HF, Meijer S, van Haeringen H, Rietveld FW. The role of A-O-incompatible blood transfusions in porcine orthotopic liver transplantations. *Eur. Surg. Res.* 1984; 16(6): 354−359.

Ierino FL, Kozlowski T, Siegel JB, Shimizu A, Colvin RB, Banerjee PT, Cooper DK, Cosimi AB, Bach FH, Sachs DH, Robson SC. Disseminated intravascular coagulation in association with the delayed rejection of pig-to-baboon renal xenografts. *Transplantation* 1998; 66(11): 1439−1450.

Jacob S, Sellke F. Is bicaval orthotopic heart transplantation superior to the biatrial technique? *Interact. Cardiovasc. Thorac. Surg.* 2009; 9(2): 333−342.

Kaiser GM, Heuer MM, Fruhauf NR, Kuhne CA, Broelsch CE. General handling and anesthesia for experimental surgery in pigs. *J. Surg. Res.* 2006; 130(1): 73−79.

Kamimura R, Ishizaki N, Suzuki S, Tanaka K, Taira A. Division of donor liver for successful split-liver transplantation in pigs. *Exp. Anim.* 1997; 46(4): 315−317.

Kaths JM, Echeverri J, Goldaracena N, Louis KS, Yip P, John R, Mucsi I, Ghanekar A, Bagli D, Selzner M, Robinson LA. Heterotopic Renal Autotransplantation in a Porcine Model: A Step-by-Step Protocol. *J. Vis. Exp.* 2016; (108): 53765.

Kawai T, Cosimi AB, Sachs DH. Preclinical and clinical studies on the induction of renal allograft tolerance through transient mixed chimerism. *Curr. Opin. Organ Transplant.* 2011; 16(4): 366−371.

Kelly DM, Demetris AJ, Fung JJ, Marcos A, Zhu Y, Subbotin V, Yin L, Totsuka E, Ishii T, Lee MC, Gutierrez J, Costa G, Venkataraman R, Madariaga JR. Porcine partial liver

transplantation: a novel model of the "small-for-size" liver graft. *Liver Transpl.* 2004; 10(2): 253−263.

Kirk AD. Crossing the bridge: large animal models in translational transplantation research. *Immunol. Rev.* 2003; 196: 176−196.

Klose R, Kemter E, Bedke T, Bittmann I, Kelsser B, Endres R, Pfeffer K, Schwinzer R, Wolf E. Expression of biologically active human TRAIL in transgenic pigs. *Transplantation* 2005; 80(2): 222−230.

Kuwaki K, Tseng YL, Dor FJ, Shimizu A, Houser SL, Sanderson TM, Lancos CJ, Prabharasuth DD, Cheng J, Moran K, Hisashi Y, Mueller N, Yamada K, Greenstein JL, Hawley RJ, Patience C, Awwad M, Fishman JA, Robson SC, Schuurman HJ, Sachs DH, Cooper DK. Heart transplantation in baboons using alpha1,3-galactosyltransferase gene-knockout pigs as donors: initial experience. *Nat. Med.* 2005; 11(1): 29−31.

Lee IK, Son YM, Ju YJ, Song SK, Gu M, Song KD, Lee HC, Woo JS, Seol JG, Park SM, Han SH, Yun CH. Survival of porcine fibroblasts enhanced by human FasL and dexamethasone-treated human dendritic cells in vitro. *Transpl. Immunol.* 2014; 30(2-3): 99−106.

Levin B, Hoppe RT, Collins G, Miller E, Waer M, Bieber C, Girinsky T, Strober S. Treatment of cadaveric renal transplant recipients with total lymphoid irradiation, antithymocyte globulin, and low-dose prednisone. *Lancet* 1985; 2(8468): 1321−1325.

Lima O, Cooper JD, Peters WJ, Ayabe H, Townsend E, Luk SC, Goldberg M. Effects of methylprednisolone and azathioprine on bronchial healing following lung autotransplantation. *J. Thorac. Cardiovasc. Surg.* 1981; 82(2): 211−215.

Lin CC, Ezzelarab M, Shapiro R, Ekser B, Long C, Hara H, Echeverri G, Torres C, Watanabe H, Ayares D, Dorling A, Cooper DK. Recipient tissue factor expression is associated with consumptive coagulopathy in pig-to-primate kidney xenotransplantation. *Am. J. Transplant.* 2010; 10(7): 1556−1568.

Lower RR, Shumway N E. Studies on orthotopic homotransplantation of the canine heart. *Surg. Forum.* 1960; 11: 18−19.

Madariaga ML, Michel SG, La Muraglia GM, 2nd, Sekijima M, Villani V, Leonard DA, Powell HJ, Kurtz JM, Farkash EA, Colvin RB, Allan JS, Cetrulo CL, Jr., Huang CA, Sachs DH, Yamada K, Madsen JC. Kidney-induced cardiac allograft tolerance in miniature swine is dependent on MHC-matching of donor cardiac and renal parenchyma. *Am. J. Transplant.* 2015; 15(6): 1580−1590.

Madariaga ML, Michel SG, Tasaki M, Villani V, La Muraglia GM, 2nd, Sihag S, Gottschall J, Farkash EA, Shimizu A, Allan JS, Sachs DH, Yamada K, Madsen JC. Induction of cardiac allograft tolerance across a full MHC barrier in miniature swine by donor kidney cotransplantation. *Am. J. Transplant.* 2013; 13(10): 2558−2566.

Madariaga ML, Spencer PJ, Michel SG, La Muraglia GM, 2nd, O'Neil MJ, Mannon EC, Leblang C, Rosales IA, Colvin RB, Sachs DH, Allan JS, Madsen JC. Effects of Lung Cotransplantation on Cardiac Allograft Tolerance Across a Full Major Histocompatibility Complex Barrier in Miniature Swine. *Am. J. Transplant.* 2016; 16(3): 979−986.

Memsic L, Quinones-Baldrich W, Kaufman R, Rasool I, Busuttil RW. A comparison of porcine orthotopic liver transplantation using a venous-venous bypass with and without a nonpulsatile perfusion pump. *J. Surg. Res.* 1986; 41(1): 33−40.

Millan MT, Shizuru JA, Hoffmann P, Dejbakhsh-Jones S, Scandling JD, Grumet FC, Tan JC, Salvatierra O, Hoppe RT, Strober S. Mixed chimerism and immunosuppressive drug

withdrawal after HLA-mismatched kidney and hematopoietic progenitor transplantation. *Transplantation* 2002; 73(9): 1386−1391.

Mohiuddin MM, Reichart B, Byrne GW, McGregor CG. Current status of pig heart xenotransplantation. *Int. J. Surg.* 2015; 23(Pt B): 234−239.

Mohiuddin MM, Singh AK, Corcoran PC, Hoyt RF, Thomas ML, 3rd, Ayares D, Horvath KA. Genetically engineered pigs and target-specific immunomodulation provide significant graft survival and hope for clinical cardiac xenotransplantation. *J. Thorac. Cardiovasc. Surg.* 2014; 148(3): 1106−1113; discussion 1113−1104.

Monbaliu D, Crabbe T, Roskams T, Fevery J, Verwaest C, Pirenne J. Livers from non-heart-beating donors tolerate short periods of warm ischemia. *Transplantation* 2005; 79(9): 1226−1230.

Moore F D, Smith L L, Burnap T K, Dallenbach F D, Dammin G J, Gruber U F, Shoemaker W C, Steenburg R W, Ball M R, Belko J S. One-stage homotransplantation of the liver following total hepatectomy in dogs. *Transplant. Bull.* 1959; 6(1): 103−107.

Motsch J, Zimmermann FA. Effects of a passive venous bypass on cardiovascular and acid-base balance variables during liver transplantations in pigs. *J. Cardiothorac. Anesth.* 1987; 1(6): 535−542.

Oike F, Talpe S, Otsuka M, Dehoux JP, Lerut J, Otte JB, Gianello P. A 12-day course of FK506 allows long-term acceptance of semi-identical liver allograft in inbred miniature swine. *Transplantation* 2000; 69(11): 2304−2314.

Oike F, Uryuhara K, Otsuka M, Dehoux JP, Otte JB, Lerut J, Gianello P. Simplified technique of orthotopic liver transplantation in pigs. *Transplantation* 2001; 71(2): 328−331.

Oldhafer KJ, Hauss J, Gubernatis G, Pichlmayr R, Spiegel HU. Liver transplantation in pigs: a model for studying reperfusion injury. *J. Invest. Surg.* 1993; 6(5): 439−450.

Ono K, Lindsey ES. Improved technique of heart transplantation in rats. *J. Thorac. Cardiovasc. Surg.* 1969; 57(2): 225−229.

Oura T, Hotta K, Cosimi AB, Kawai T. Transient mixed chimerism for allograft tolerance. *Chimerism* 2015; 6(1−2): 21−26.

Pedersen LE, Harndahl M, Rasmussen M, Lamberth K, Golde WT, Lund O, Nielsen M, Buus S. Porcine major histocompatibility complex (MHC) class I molecules and analysis of their peptide-binding specificities. *Immunogenetics* 2011; 63(12): 821−834.

Petersen B, Ramackers W, Tiede A, Lucas-Hahn A, Herrmann D, Barg-Kues B, Schuettler W, Friedrich L, Schwinzer R, Winkler M, Niemann H. Pigs transgenic for human thrombomodulin have elevated production of activated protein C. *Xenotransplantation* 2009; 16(6): 486−495.

Phelps CJ, Koike C, Vaught TD, Boone J, Wells KD, Chen SH, Ball S, Specht SM, Polejaeva IA, Monahan JA, Jobst PM, Sharma SB, Lamborn AE, Garst AS, Moore M, Demetris AJ, Rudert WA, Bottino R, Bertera S, Trucco M, Starzl TE, Dai Y, Ayares DL. Production of alpha 1,3-galactosyltransferase-deficient pigs. *Science* 2003; 299(5605): 411−414.

Reitz BA, Wallwork JL, Hunt SA, Pennock JL, Billingham ME, Oyer PE, Stinson EB, Shumway N E. Heart-lung transplantation: successful therapy for patients with pulmonary vascular disease. *N. Engl. J. Med.* 1982; 306(10): 557−564.

Sachs DH, Leight G, Cone J, Schwarz S, Stuart L, Rosenberg S. Transplantation in miniature swine. I. Fixation of the major histocompatibility complex. *Transplantation* 1976; 22(6): 559−567.

Sachs DH, Sykes M, Yamada K. Achieving tolerance in pig-to-primate xenotransplantation: reality or fantasy. *Transpl. Immunol.* 2009; 21(2): 101−105.

Sheil AG, Halliday JP, Drummond JM, Bookallil MJ, Gaudry PL, Yezerski SD. A modified technique for orthotopic liver transplantation. *Arch. Surg.* 1972; 104(5): 720−724.

Smith DM, Newhouse M, Naziruddin B, Kresie L. Blood groups and transfusions in pigs. *Xenotransplantation* 2006; 13(3): 186−194.

Starlz TE, Kaupp HA, Jr., Brock DR, Lazarus RE, Johnson RV. Reconstructive problems in canine liver homotransplantation with special reference to the postoperative role of hepatic venous flow. *Surg. Gynecol. Obstet.* 1960; 111: 733−743.

Steinig D, Mentha G, Lecoultre C, Pittet JF, Jeanjacquot A, Huber O, Meyer P, Rohner A. Experimental porcine orthotopic liver transplantation: a training protocol for transplantation in humans. *Helv. Chir. Acta.* 1990; 57(1): 177−186.

Stevens LHP, JB., Broelsch, CE., (1994). Liver transplantation in the dog. *Handbook of Animal Models in Transplantation Research,* CRC press**:** 53−72.

Swindle MM, Smith AC, Hepburn BJ. Swine as models in experimental surgery. *J. Invest. Surg.* 1988; 1(1): 65−79.

Swindle MMS, A.C. Comparative anatomy and physiology of the pig. *Scand. J. Lab. Anim. Sci.* 1998; 25: 11−21.

Tabet J, Garcia-Valdecasas JC, Rull R, Valero R, Angas J, Gonzalez FX, Cifuentes A, Garcia F, Beltran J, Ordi J, Deulofeu R, Elena M, Cabrer C, Visa J. Non-heart-beating donor pigs: the feasibility of liver donation. *Transplant. Proc.* 1997; 29(1-2): 1374−1375.

Tanaka K, Nishimura A, Ogata S, Yoshimine M, Ikoma A, Taira A. A simple method for orthotopic liver transplantation in pigs--a new cuff technique using expanded polytetrafluoroethylene vascular grafts for portal and vena caval anastomosis. *Transplantation* 1994; 58(10): 1139−1142.

Tata P N, Subbotina N, Burckart G J, Muddiman D C, Gusev A I, Hercules D M, Starzl T E, Venkataramanan R. Species-dependent hepatic metabolism of immunosuppressive agent tacrolimus (FK-506). *Xenobiotica* 2009; 39(10): 757−765.

Terblanche J, Peacock JH, Bowes J, Hobbs KE. The technique of orthotopic liver homotransplantation in the pig. *J. Surg. Res.* 1968; 8(4): 151−160.

Todo S, Kam I, Lynch S, Starzl TE. Animal research in liver transplantation with special reference to the dog. *Semin. Liver. Dis.* 1985; 5(4): 309−317.

Toronto Lung Transplant Group. Unilateral lung transplantation for pulmonary fibrosis. *N. Engl. J. Med.* 1986; 314(18): 1140−1145.

Woodle ES, Hunter GC, Eisele P, Talken L, Ward RE. Orthotopic porcine liver transplantation: operative technique. *J. Surg. Res.* 1985; 39(6): 483−488.

Yagi T, Oishi M, Mitsuoka S, Endo A, Okada Y, Matsuda H, Fujisawa K, Ishido N, Ishikawa T, Matsuno T, Tanaka N. Splanchnic jump graft technique with passive venovenous bypass improves survival of multivisceral transplantation in a pig model. *Transplant. Proc.* 1998; 30(6): 2620−2621.

Yamada K, Yazawa K, Shimizu A, Iwanaga T, Hisashi Y, Nuhn M, O'Malley P, Nobori S, Vagefi P A, Patience C, Fishman J, Cooper DK, Hawley RJ, Greenstein J, Schuurman HJ, Awwad M, Sykes M, Sachs DH. Marked prolongation of porcine renal xenograft survival in baboons through the use of alpha1,3-galactosyltransferase gene-knockout donors and the cotransplantation of vascularized thymic tissue. *Nat. Med.* 2005; 11(1): 32−34.

Yanaga K, Kishikawa K, Suehiro T, Nishizaki T, Shimada M, Itasaka H, Nomoto K, Kakizoe S, Sugimachi K. Partial hepatic grafting: porcine study on critical volume reduction. *Surgery* 1995; 118(3): 486−492.

In: Encyclopedia of Surgery (22 Volume Set)
Editors: Andreas Lehrer and Kristin Mueller
ISBN: 978-1-53618-329-0
© 2020 Nova Science Publishers, Inc.

Chapter 218

EXPERIMENTAL COMPOSITE TISSUES AND SOFT TISSUES TRANSPLANTATION

Hao Wang*, MD, PhD
Department of General Surgery, Tianjin Medical University General Hospital,
Tianjin General Surgery Institute, Tianjin, China

ABSTRACT

Composite tissue allotransplantation (CTA) is the transplantation of body structures which include tissues from both ectoderm and mesoderm. Different from life-saving solid organ transplantation (SOT), the purpose of CTA is commonly to maintain appearance and function integrity of the recipient. There are some body structures that have been transplanted successfully around the world. Among them, the numbers of hand and facial experimental research transplantations and clinical cases are much more than that of other organs/tissues. In this article, firstly, we review the history and development of CTA. As these transplanted structures contain tissues with different degrees of immunogenicity, therefore, the immunogenicity of the whole composite tissue is complex. The history of CTA is also accompanied with the development of immunosuppressive therapy. Thus, we introduce the immunosuppressive treatments used in the experimental and clinical studies which mainly include immunosuppressive drugs, polyclonal or monoclonal antibodies and chimerism. Through the application of immunosuppressive therapies, the primary goal of CTA is to ensure the successful graft survived, and the final goals are to induce donor-specific immune tolerance and to further reduce the complications of immunosuppressive drugs. Secondly, two of the most commonly used research models, hand and facial transplantation are introduced using both experimental and clinical research situations. Finally, a brief introduction to several other transplantations, such as abdominal wall, larynx and penis allotransplantation is provided. Based on all those studies, we believe that with the advances in technology and immunosuppressive therapy, it can be expected that CTA will be beneficial to more and more patients.

Keywords: composite tissue, allotransplantation, immunosuppression, review

* Corresponding Author's Email: hwangca272@hotmail.com.

ABBREVIATIONS

AD-MSCs	adipose-derived mesenchymal stromal cells
ALG	antilymphocyte globulin
ALS	antilymphocyte serum
ATG	antithymocyte globulin
AZA	azathioprine
BM-MSCs	bone marrow-derived mesenchymal stromal cells
BMT	bone-marrow transplantation
CIPS	calcineurininhibitor-induced pain syndrome
CNI	calcineurin inhibitor
CS	corticosteroid
CsA	cyclosporine A
CTA	composite tissue allotransplantation
CTLA4Ig	cytotoxic T-lymphocyte antigen 4 immunoglobulin
GVHD	graft-versus-host disease
IDO	indoleamine 2,3-dioxygenase
IL	interleukin
LBN	Lewis-Brown Norway
LEW	Lewis
LF	LF 15-0195
MLR	mixed lymphocyte reaction
MMF	mycophenolate mofetil
MSCs	mesenchymal stromal cells
mTOR	mammalian target of rapamycin
NFAT	nuclear factor of activated T-cells
NFAT-P	phosphorylated nuclear factor of activated T-cells
NF-κB	nuclear factor-kappa B
PBMC	peripheral blood mononuclear cell
RAPA	rapamycin
SOT	solid organ transplantation
SRL	sirolimus
TAC	tacrolimus
TGF- β	transforming growth factor-β
WF	Wistar Furth
αβ-TCR	αβ–T-cell receptor

INTRODUCTION

Composite tissue allotransplantation (CTA) is the transplantation of body structures which include the tissues originated from both ectoderm and mesoderm, such as skin, subcutaneous tissue, muscle, tendon, nerve, vessel, cartilage, bone and bone marrow. Around the world, several different body structures have been transplanted, mainly including hand, face, larynx, abdominal wall, tendon, knee, tongue and penis. The reasons for the damage or

deficiency of these tissues are plenty, such as malignancy, electrical injuries, war damages, fire burns and animal bites. Compared to lifesaving solid organ transplantation (SOT), the purpose of CTA is more likely to maintain appearance and functional integrity.

HISTORY

The history of CTA is extremely long. The hypothetical proposition of replacing the incomplete or injured tissues can be traced back to a very long time ago. It begins with a legend back to the year 348AD, when a church sacristan got cancer which led to gaseous gangrene on one of his legs, and a healthy leg from a recently dead Ethiopian Moor was grafted to the sacristan by twin brothers, Cosmas and Damien (Kahan 1983). This seems to be the earliest record of CTA, although the final results of this story became a mystery. After that, not until the 16th century, a man's nose was sliced off in swordplay, and Gaspare Tagliacozzi, who is supposed to be the Father of Plastic Surgery, used a flap from the arm donated by a slave to repair it. Surprisingly, the nose lived for 3 years before a sudden rejection (Kahan 1983). In modern times, CTA was first proposed by Kleinert and Peacock with a digital flexor mechanism transplantation in 1957 (Peacock 1960).

With the development of transplantation, it was recognized gradually that not only microsurgery but also immunity plays an important role in CTA. In World War II, some British seamen and pilots were suffering from painful burns in U-boat attacks. When doctors carried out allogeneic tissue transplantation to the injured soldiers, the complications resulting from the immune rejection could not be ignored. Tom Gibson and Peter Medawar began the experimental research on tissue immunology; they were first to describe the rejection process, and for this contribution to the research, Peter Medawar received the Nobel Prize in 1960 (Tobin 2007).

Accordingly, with the in-depth studies, the role of immune system played in CTA cannot be ignored. The history of CTA is also accompanied with the development of immunosuppression therapy.

IMMUNOSUPPRESSION IN CTA

CTA is different from SOT as the transplanted tissues contain skin, subcutaneous tissue, muscle, tendon, fascia, nerve, blood vessel and so on. Their immunogenicity is discrepant. A research study performed by Murray investigated the antigenic strength of different tissues and organs, and it showed that the skin was the most antigenic tissue (Murray 1971). Subsequent research showed that followed by the skin, the muscle presented as medium antigenic, bone and cartilage were further alleviative and least antigenic (Buttemeyer 1996). Therefore, the degree of immunogenicity of the composite tissues seems to be a complex question. Is it higher than any one of the tissues, or equal to the highest antigenicity tissue, or lower than the highest antigenicity tissue? The research carried out by Lee may provide some answers. During the research, they tested and compared the antigenicity of each individual tissue (skin, subcutaneous tissue, muscle, bone, and blood vessel) of a limb through a vascularized limb transplantation in rat and further compared the antigenicity with the whole

limb transplantation. The result showed that the antigenicity of the whole limb is less than some of the individual tissue, and the severity of cellular and humoral immune responses was also different for different tissues (Lee 1991). This study shows the complexity of the immune response in CTA.

Because the immunosuppressive effect induced by the same immunosuppressive therapy was discrepant due to the different immunogenicity of different transplanted tissues, the researchers proposed split tolerance. This phenomenon was discovered earlier (Lustgraaf 1996; Heslop 1962). Generally, as the skin immune system has strong immunogenicity, skin is usually rejected first (Bos 2009). The immune system of skin is also complex; it contains immune cells of both innate and adaptive immunity such as macrophages, endothelial cells, dendritic cells, T cells and B cells (Bos 2009), and these immune cells could further secrete cytokines (Pidwell 2007). It has been reported that in a continuous experimental study, a musculoskeletal allograft was carried out in a minor histocompatibility mismatch swine modeland, the graft achieved a long-term survival with a short-course use of cyclosporine A (CsA) as the immunosuppressive drug (Lee 1998). However, in the skin transplantation from the same donor later, half of the recipients rejected it (Bourget 2001). Further studies showed that the dermis survived, but the epidermis was rejected (Mathes 2003). Another study had shown rejection of the same donor's skin in a bone marrow chimerical model but no rejection of successive heart transplantation (Fuchimoto 2001).

Similar to other organ transplantations, without the development of immunosuppression drugs and therapy, it is hard for CTA to achieve long-term survival. Therefore, it is necessary to introduce the immunosuppressive therapy in induction and maintenance of immunosuppression. It mainly consists of one or more agents from the following categories: immunosuppressive drugs, polyclonal or monoclonal antibodies and chimerism.

IMMUNOSUPPRESSIVE DRUGS

There are four main types of immunosuppressive drugs, corticosteroids (CS), calcineurin inhibitors (CNI) (CsA or tacrolimus (TAC)), antimetabolites [azathioprine (AZA) or mycophenolate mofetil (MMF)], and mammalian target of rapamycin (mTOR) inhibitor [sirolimus (SRL)] (Söderlund 2015). They can be used in both induction and maintenance therapy after transplantation.

CS has the anti-inflammation and immunosuppression effects with complex mechanisms. They can enter the cell directly through cell membrane and regulate the transcription of DNA mainly through inhibiting activator protein-1 and nuclear factor-kappa B (NF-κB) to affect the number and function of leukocytes in both innate and adaptive immune system (Auphan 1995). They play an important role in immunosuppression after CTA. However, the side effects of CS are obvious, for example, moon face, buffalo hump, hypertension, gastric ulcer, poor wound healing, water-sodium retention, osteoporosis and chronic adrenal suppression after long-term use of CS.

CNI is widely used for immunosuppression after CTA and the effects of preventing the proliferation and differentiation of T cells are obvious. Representative of CNI, CsA and TAC can enter the cell through diffusion or by combining with immunophilines. They then inhibit the calcineurin to dephosphorylate the phosphorylated nuclear factor of activated T-cells

(NFAT-P). The dephosphorylated nuclear factor of activated T-cells (NFAT) could enter nucleus to promote the transcription of some cytokines such as interleukin (IL)-2, which could promote the occurrence of rejection. Therefore, the main mechanism of CNIs is to inhibit the secretion of cytokines including IL-2 (Reem 1992). A study had shown that the levels of CsA in skin in the first week after transplantation played important roles in the graft survival; when it reached the therapeutic levels in the first postoperative week, the allograft could have a greater possibility to achieve rejection-free status (Swearingen 2008). TAC also plays an important role in inhibiting rejection. In a Wistar Furth to Lweis (LEW) rats' limb allograft transplantation model, a combination therapy with CsA, ALS and TAC was used and as a result, the allografts survived well. More importantly, the levels of TAC in skin were 100-fold higher than that of other tissues such as blood and muscle. This study revealed that TAC had the function of immunosuppression and especially could inhibit the function of immune cells in skin (Solari 2009). The main side effect of CNIs is nephrotoxicity. It could present as acute and chronic disease with continuity in pathology from dose-related and reversible to irreversible symptoms with the vasoconstriction of renal afferent arterioles, leading to the occurrence of tubular atrophy and interstitial fibrosis (Pallet 2011). Other side effects include drug to drug interactions, neurotoxicity, hypertension, dyslipidemia, cholestasis, cholelithiasisand calcineurin-inhibitor induced pain syndrome (CIPS) (Söderlund 2015; Lindenfeld 2004; Grotz 2001).

As the representatives of antimetabolite drugs, the function of both AZA and MMF is to inhibit the replication of DNA and to affect the proliferation of both T and B cells through different mechanisms. When AZA enters the plasma, it converts to 6-mercaptopurine rapidly, then to thio-inosinemonophosphate, and further to a purine analog, which is the active metabolite of AZA (Elion 1993). MMF is the non-competitive inhibitor of inosine monophosphate dehydrogenase, which is important for the guanine nucleotides synthesis, and further for the replication of DNA (Ensley 1993). The side effect of AZA is mainly myelosuppression, and the side effects of MMF are leukopenia, nausea, vomiting and diarrhea.

SRL, also known as rapamycin (RAPA), which is a macrolide antifungal antibiotic secreted by *Streptomyces hygroscopicus* and found from the Easter Island in 1975 (Vezina 1975). It was first used as an immunosuppressive drug after transplantation in 1989 (Calne 1989). It targets and inhibits the enzyme mTOR, and further influence the proliferation of both T and B cells (Brown 1994; Waldner 2016). The side effects of SRL are drug to drug interaction, dyslipidemia, pancytopenia, delayed wound healing, oral ulcers and thrombocytopenia (Söderlund 2015; Lindenfeld 2004). However, there is a study which showed that the continuous use of SRL as maintenance therapy did not affect the follow-up operation and bone healing (Cavadas 2011).

ANTIBODIES

Antibody products are commonly used to induce immune tolerance. The main antibodies used in CTA are antilymphocyte serum (ALS)/antilymphocyte globulin (ALG)/antithymocute globulin (ATG), IL-2 receptor antagonists (basiliximab or daclizumab) and monoclonal antibodies targeting the co-stimulator of T cells.

ALS/ALG/ATG contain non-selective polyclonal antibodies, which can interact with the antigens of T and B cells and cause the complement-mediated lysis, eventually leading to the reduction of T and B cells. Their side effects are mainly thrombocytopenia, leukopenia, cytokine release syndrome and serum sickness (Siemionow 2002).

In the process of immune rejection, IL-2 secreted by T cells can promote the activation, proliferation and differentiation of T cells (Söderlund 2015). Therefore, inhibition of IL-2 can delay the occurrence of rejection. There are some monoclonal antibodies such as basiliximab and daclizumab which work through inhibiting the IL-2 receptor. Additionally, no serious side effects of these antibodies have been reported.

As we know, T cells play an important role in immune rejection; therefore, by inhibiting the effect of T cells, we could partly reduce immune rejection after transplantation. Some antibodies could target the co-stimulator on the surface of T cells and further affect the downstream signaling pathway. The CD40-CD154 and CD28-CD80/CD86 co-stimulatory pathways could be blocked by different monotherapies (Bartlett 2002; Siemionow 2010; Tung 2008).Anti-CD3, anti-CD52 monoclonal antibody and cytotoxic T-lymphocyte antigen 4 immunoglobulin (CTLA4Ig) could also block the function of T cells (Strome 2001; Wekerle 2000).

CHIMERISM

The final goal of immunosuppression is to induce donor-specific and immunosuppressive drugs-free immune tolerance. In order to achieve this goal, chimerism is widely used in CTA. Chimerism was first described by Owen in bovine biovular twins where each of them contains the blood cells of the other one without rejection (Owen 1945). This is thought to be a natural hematopoietic stem cell chimerism. In 1955, skin homograft transplantation achieved success by chimerism (Main 1955). Then, it was utilized successfully in allogenic skin transplantation in 1984 (Ildstad 1984).

There are two types of chimerism: microchimerism and macrochimerism. Microchimerism is transplantation of passenger leukocytes such as immature dendritic cells to the lymphoid organs of recipient. The recipient does not require pretreatment in this method. Macrochimerismis transplantation of bone marrow cells from donors; these stem cells could migrate to the bone marrow, thymus and other lymphoid organs of recipient and lead to the decrease of recipient T cells. But, this requires pretreatment in recipients; usually it is done through bone marrow irradiation to clear recipient hematopoietic cells in order to facilitate the donor hematopoietic system in the recipient. This method can induce donor-specific immune tolerance and prolong graft survival.

Chimerism is effective to induce and maintain long-term tolerance to CTA, however, some side effects of chimerism are lethal such as graft-versus-host disease (GVHD). It was first described by Vos in 1956 in the mice receiving total body irradiation, which upon receiving allogeneic bone marrow died 20 days after irradiation. The histological analysis showed that the mice died from multiple organ failure, and they called it secondary syndrome (Vos 1956).The reason for GVHD is that T cells from donor attack the tissues of recipient such as skin, intestinal mucosa, bile ducts and lymph nodes (Vriesendorp 2016). Therefore, it is important to achieve a balance between long-term survival and occurrence of GVHD. A

study had been carried out with limb transplantation in MHC-mismatched rats and the results showed that the 20%−50% chimerism level is ideal which resulted in CTA survival of 100% and occurrence of GVHD reduced to 0% (Lin 2012).

Another cell-type used in inducing immune suppression is mesenchymal stromal cells (MSCs). MSCs are adult stromal cells with potential of self-renewal and multilineage differentiation. MSCs can be separated and obtained from bone marrow, adipose tissue and cord blood. In 2006, the international association for cell therapy had confirmed the identification criteria of MSCs such as plastic-adherence, expression of CD105, CD73 and CD90, and ability to differentiate into adipocytes, osteoblasts and chondroblasts (Dominici 2006). As the development of stem cell treatment in the induction of immunotolerance progressed and the MSCs appeared as perfect therapeutic candidates, their effect was also studied in CTA. MSCs could induce immune tolerance through cell-to-cell contact and cytokines secretion (Fryer 2015). Donor-derived MSCs could induce chimerism in the recipient resulting in no- or gentle GVHD. The side effects of MSCs are invasive recovery and delivery methods and related complications and their limited proliferation capacity (Meng 2007).

EXPERIMENTAL AND CLINICAL STUDY OF CTA

The successful clinical application of research is closely related to the results from animal experiments. Animal models, thus, play an important role in CTA research. Different models of functional studies and transplantation immunization studies have been explored. Also, for this purpose, several types of animals have been used. They range from the rodents (mouse and rat) to the dog (Lapchinsky 1973; Zhao 2016; Goldwyn 1966) and swine (Hettiaratchy 2004; Kuo 2009), and further to the nonhuman primate models (Hovius 1992; Stark 1987). In this part, we will address some animal models and related clinical advances. As limb and facial transplantation are more commonly done, and due to their better knowledge in both experimental research and clinical practice, we will focus on them in the following section.

LIMB COMPOSITE TISSUE ALLOTRANSPLANTATION

Limb transplantation is the most used animal CTA model. The limb mainly consists of tissues like skin, subcutaneous tissue, muscle, tendon, blood vessel, fat, nerves, cartilage and bone. Limb transplantation model is divided into functional and non-functional, or orthotopic and heterotopic models according to the different research priorities, such as immune-suppression or function.

The research of experimental limb transplantation was started in 1907 when Carrel had described leg transplantation between dogs (Carrel 1908). Although the issue of immune rejection was not raised at the time, the issues of postoperative nerve regeneration and limb function recovery had been considered. This was supposed to be the first animal model of limb transplantation in modern medicine. In 1936, both orthotopic and heterotopic limb transplantation was performed between young albino rat by Schwind, and with the connection of muscles and nerves, the transplanted limbs achieved muscular control and lived longer than

3 months (Schwind 1936). 26 years later, Schwind found that limb transplantation between non-inbred genetic background rat aged no more than two weeks, could achieve immune tolerance induced by immature immune system (Schwind 1962).

With the discovery and usage of immunosuppressive drugs, the study of CTA came to a new stage. By the time, some immunosuppressive drugs were used in limb transplantation, representative drugs like CSs (Lance 1971), CsA, AZA and 6-mercaptopurine (Goldwyn 1966) could prolong survival time of grafts. In 1984, a study with the application of CsA in the orthotopic limb transplantation between BUF (H-1^b, Ag-B6) and LEW(H-1^l, Ag-B1) rats was performed; the limb allograft survived with a continuous dose of CsA (10 mg/kg/day), however, about one week after CsA was stopped, the allograft was rejected (Kim 1984). Right after that in 1985, Black reported that they achieved allograft tolerance in limb transplantation between Lewis-Brown Norway hybrid (LBN) (Rt-1^{l+n}) and LEW rats through using CsA 8 mg/kg/day for 20 days for induction treatment and 8 mg/kg/day twice weekly for maintenance treatment (Black 1985). At the same time, the inhibitory effects of different single immunosuppressive drugs on immunological rejection in limb transplantation were compared in another study. The effect of CsA (25 mg/kg), TAC (2 mg/kg) and MMF (30 mg/kg) on immunosuppression of limb transplantation in ACI to LEW rats were compared. The drugs were all used daily for 14 days as induction therapy, and then twice a week as maintenance therapy. The result showed that only TAC could maintain immunosuppression without signs of rejection, however, the rats died of bacterial pneumonia with mean survival time of 296.11 ± 29.78 days (Jones 2001). The first trial of limb osteomyocutaneous flap transplantation in large animals was done in pigs in 1998. With the combination use of CsA, MMF and prednisone, the survival time was prolonged. More important point is that the immunosuppressive therapy could be used in large animal CTA, bringing it close to the next step in its application to the human (Ustuner 1998).

With the extensive application of immunosuppressive drugs, the side effects are gradually emerging, such as lifelong use of anti-rejection drugs, infection, malignancy and organ toxicity. At the same time, researchers are trying to find other ways to induce lifelong and donor-specific tolerance. In addition to the use of immunosuppressive drugs, other treatments have also been explored. Poole described immunological effects of renal transplantation on limb transplantation. The researchers injected AS rat anti-August antiserum to AS rat at first, then the kidney of (AS × August) F1 rat was transplanted to AS rat, 156 days later, a limb was transplanted from (AS × August) F1 rat to AS rat. At last, the result showed that the two transplanted limbs survived for 92 and 207 days respectively, which means that long-term renal transplantation plays a role in the maintenance of immune tolerance in the later limb transplantation (Poole 1976). In 2003, Ozer demonstrated that combined use of CsA and ALS for 21 days could achieve donor-specific tolerance in semi-allogeneic rats' limb transplantation checked by donor and third-party skins; the donor skins were accepted and the third-party skins were rejected. In the peripheral blood, there were 35% to 42% donor-specific chimerism. This study in fact explored inducing donor-specific transplantation by chimerism (Ozer 2003). The same result was found in fully MHC-mismatched rats' limb transplantation later (Ozer 2003).

The study carried out by Foster showed that mixed chimerism induced by total-body irradiation and T-cell-depleted bone-marrow transplantation (BMT) in combination with CD28 blockade by CTLA4-Ig, could also induce donor-specific tolerance in rat limb transplantation models from ACI (RT1A^a) to Wistar Furth (WF) rats (Foster 2003). Another

study was designed to observe the effect of combination of αβ–T-cell receptor (TCR) monoclonal antibody and CsA (αβ-TCR-CsA) treatment on reducing immune rejection. The results showed that by using αβ-TCR-CsA therapy for 7 days, could induce donor-specific tolerance as determined by skin transplantation *in vivo* and mixed lymphocyte reaction (MLR) *ex vivo* (Siemionow 2003). After that, they also demonstrated that thymus played an important role in this treatment for the induction of donor-specific tolerance (Siemionow 2006). In addition, subsequent study found that $CD4^+CD25^+Foxp3^+$Treg cells were important in the immune tolerance maintaining in CTA (Bozulic 2011). We had also reported an immunosuppressive protocol in mice vascularized limb transplant model. The combined use of anti-CD45RB monoclonal antibody (mAb) (3 mg/kg/day), LF 15-0195 (LF)(2 mg/kg/day) and RAPA(2 mg/kg/day) for 14 days right after the transplantation could achieve a long-term survival in mice limb allograft transplantation (Wang 2013). At the same time, in a recent study, Jindal used a human IL-2 fusion protein to react with IL-2 to further block its function. In combination use of ALS and CsA, in a rat limb CTA model, the allograft achieved long-term survival by suppressing effector T cells and by increasing the proliferation of Tregs (Jindal 2015). In order to study the influence on the expression of cell surface molecules during the process of rejection, pathological examination was performed on the skin from hand or forearm of patients with rejection. At different stages of rejection, some markers were expressed at higher levels, such as CD3, CD68, Foxp3, indoleamine 2,3-dioxygenase (IDO), intercellular adhesion molecule-1 (ICAM-1), E-selectin and P-selectin. When some of these markers were inhibited, the allografts could survive longer, and upon blocking E-selectin and P-selectin in the skin, the survival time of limb allograft in rat was significantly longer (Hautz 2010).

By infusing donor DCs to the recipient could induce microchimerism as introduced above. Dendritic cells (DCs), as an important antigen presenting cell in innate immune system, play an irreplaceable role in mediating immune rejection. But the immature DCs could induce immune tolerance to self-antigen. Thus, the immature DCs can be inducted into immune tolerance to the allogeneic graft antigens. In a rat limb transplantation model, DCs from recipient bone marrow were pretreated with alloantigen lysate and then applied the treatment combination of CsA and ALS. The results showed that they together prolonged the survival time of allograft and increased the percentage of $CD4^+CD25^+$ T cells (Kuo 2009).

Along with the discovery and research of MSCs in other SOT researches, they have also been used in the study of CTA. A combination therapy with ALS, RAPA, MSCs and BMT after body irradiation was carried out in a rat limb allotransplantation model. The combination use of MSCs was helpful for the induction of a stable chimerism without GVHD happening compared with other BMT treatment group alone (Pan 2010). Similar experiment was carried out in a swine limb transplantation model with the combined therapy of MSCs, BMT and CsA, and result showed that the therapy could prolong the survival time of allografts, and MSCs could also prevent the occurrence of GVHD led by BMT (Kuo 2009). The mechanism may be related to increasing $CD4^+CD25^+Foxp3^+$Treg cells both in peripheral blood circulation and skin of transplanted tissues, decreasing $CD3^+$T cell population and increasing the anti-inflammatory cytokines such as transforming growth factor-β (TGF- β) and IL-10 (Kuo 2011). In another study, the author compared the function of adipose-derived mesenchymal stromal cells (AD-MSCs) and bone marrow-derived mesenchymal stromal cells (BM-MSCs) in rat limb transplantation. The result showed that both AD-MSCs and BM-MSCs together with tacrolimus for 21 days could achieve long-term immune tolerance in

vascularized composite allotransplantation. However, the chimerism induced by both of them was temporary for only 4 weeks (Plock 2015).

For the human hand transplantation, the first attempt was performed in 1964 by Ecuador when a bilateral amputee accepted a single hand transplantation and the immunosuppressive drugs given were AZA and steroids; unfortunately, after 2 weeks' treatment, the hand was rejected (Bozulic 2011). In 1998, a really successful hand transplantation was performed in France, where the induction therapies for immunosuppressive treatment were ALG, TAC, MMF and steroidsand maintenance therapies were TAC, MMF and prednisone (Dubernard 1999). Since then, with the development of immunosuppressive therapy, hand transplantation has been gradually well-developed around the world.

Facial and Scalp Composite Tissue Allotransplantation

Face contains the tissues of skin, muscle, bone, cartilage, nerve and vessel. In general, the purpose of facial transplantation is to repair the lesion and improve the appearance. However, skin is the largest part of face which has strong allogenicity. On the other hand, nerve regeneration is also an important part of facial transplantation, which is the basis of facial sensation and motor recovery. Neuroendocrine facial tissues contain fibroblasts, macrophages, mast cells, vessels and other immunogenic components which play an import role in local immune response.

The research of facial transplantation was carried out later than that of limb transplantation. However, with the guidance of the experience from the SOT and limb transplantation, it is developing faster. The rat model of facial transplantation is the commonly used model. Ulusal demonstrated that in a rat facial and scalp transplantation model between LBN rats ($RT1^{l/n}$) and LEW rats ($RT1^{l}$), the mono-treatment therapy of CsA for both induction (16 mg/kg/day) and maintenance (2 mg/kg/day) therapy induced the immunosuppression for more than 170 days (Ulusal 2003). At the same time, another rat hemifacial allograft transplant model was used to explore the immunotolerance and function recovery after transplantation with the same drug therapy, and the result showed that both donor-specific chimerism and functional tolerance were achieved (Demir 2004). Subsequently, an osteomusculocutaneous hemiface/calvaria flap model from LBN rats to LEW rats was performed, with CsA monotherapy for both induction and maintenance immunosuppressive therapy; the graft survived well and the average survival time was 154 days (Yazici 2006). However, most studies are hemiface transplantation, and compared to those, the whole face and scalp transplantation may have a more stringent demand for the vessels. In another face transplantation study, the authors confirmed that without vascular anastomosis, the large skin graft cannot survive. Furthermore, vascularized facial transplantation with CsA monotherapy could achieve better survival of allograft (Siemionow 2003).

Rat is a rodent and has a large evolutionary difference from human. Therefore, the orthotopichemiface/calvaria transplantation was studied in the rabbits transplanted from Dutch to Japanese White strains. The immunosuppressive drugs were CsA and prednisone, and composite tissues survived well without rejection. This was a trial of hemiface/calvaria transplantation in larger animals (Nie 2008). Similarly, another study was performed on the miniature swine to make a hemiface transplantation model; the transplant tissues included ear

cartilage, nerve, parotid gland, lymphoid tissue, muscle and skin, using immunosuppressive treatment of CsA for only 4 weeks. Results showed that the allograft was rejected at 38−49 days, longer than that of untreated group. The skin and parotid gland could be used to monitor the rejection (Kuo 2009).

For the human facial transplantation, the first successful case was performed in France in 2005 when a 38 years old woman had a central and lower face transplantation from a brain-dead woman with distal nose, both lips, chin and cheeks. The immunosuppressive therapy was the combination of thymoglobulin, TAC, MMF, prednisone and infusions of donor bone marrow cells. The grafts survived well at least for 4 months after transplantation (Devauchelle 2005). Subsequently, 37 facial transplantations have been carried out in eight countries by the end of 2015, with 17 full face and 20 partial face transplantation. Five of them died because of different reasons such as sepsis, cancer, lymphoma, respiratory failure or suicide. Most of them had suffered acute rejection but the incidence of chronic rejection was low (Sosin 2016).

OTHER COMPOSITE TISSUE ALLOTRANSPLANTATION

In addition to the above two types of CTA, attempts have also been made to perform other CTAs. As the immunosuppressive therapies are usually similar with hand or facial transplantation, the following is a brief introduction to other CTAs.

Abdominal Wall Composite Tissue Allotransplantation

Abdominal wall allotransplantation is also conducted together with or after the intestinal, liver, or multivisceral transplantation, for the closure of the abdomen. Because the sizes of transplanted organs between donor and recipient are different, intestines get edema after reperfusion. It is important to maintain tension-free closure. It is also helpful to closely observe the occurrence of rejection (Gerlach 2016). Some different techniques are used in such cases. The types of transplanted abdominal wall usually are of full or partial thickness. According to the need for vascular reconstruction, it can be divided into vascularized or nonvascularized transplantation. Some animal models have been used for the research of abdominal wall transplantation (Ramirez 2014; Quigley 2013).

For the human, since the first abdominal wall transplantation was performed in USA in 2003 (Levi 2003), there were about 61 cases reported until the end of 2015. The most widely used method of transplantation is the full-thickness vascularized abdominal wall allotransplantation, and the major complications are delayed closure, wound infection, rejection and sepsis (Giele 2016).

LARYNGEAL COMPOSITE TISSUE ALLOTRANSPLANTATION

Laryngeal transplantation is suitable for the treatment of larynx irreversible trauma or low-grade malignant tumor with total laryngectomy. The goal of laryngeal transplantation is to make larynx functional, such as breathing, swallowing and voice. The animal models used

for laryngeal transplantation mainly include rats and pigs. For the human, the first one was performed by Cleveland Clinic in 1998 where the transplanted tissue included the entire larynx, thyroid and parathyroid. The immunosuppressive drugs included anti-CD3 antibodies, CsA, MMF and methylprednisolone; the CsA was changed to TAC when a mild rejection happened 15 months after the transplantation. Subsequently, laryngeal function was recovered well (Strome 2001). After that, Duque reported 13 cases of laryngeal transplantation with 2-year graft survival rate of 90% (Duque 2007).

PENILE COMPOSITE TISSUE ALLOTRANSPLANTATION

Penis contains tissues with different antigenic properties; they are mainly skin, muscle, fascia, sponge, nerve, neurofilm and blood vessels. In addition to the prevention of rejection, for the penile allotransplantation, it is more important to maintain the function of urination and erection. At the same time, it also involves complex ethical problems (Zhang 2010; Calne 2016). The experimental studies on penile transplantation are relatively few. Koga carried out early experimental penile transplantation in fully allogenic rats with TAC as the immunosuppressive drug, and achieved success in short-term survival (Koga 2003). Then a vascularized penile transplantation model was presented by Sonmez; with the treatment of CsA, the allografts survived longer than 200 days (Sonmez 2009). In another *ex vivo* experiment, the penile tissue from penile prosthesis surgery was co-cultured with allogenic or autologous peripheral blood mononuclear cells (PBMCs). The activation of PBMCs prompts rejection. This model could be used to evaluate the effect of different immunosuppressive therapies on the inhibition of rejection (Sopko 2016). At the same time, a penile transplantation model was established in Beagle dogs to research the blood supply recovery and tissue architecture changes (Zhao 2016).

The world's first penile transplantation was performed in China; however, the transplanted penis was removed 14 days after the operation because of the psychological problems but without the occurrence of rejection (Hu 2006). Subsequently not until 2015, a surgical team in Tygerberg hospital performed a successful penis transplantation (Bateman 2015).

CONCLUSION

In summary, compared with life-saving SOT, the purpose of CTA is to improve the life quality of the patients. With the development of medical technology and improvements in immunosuppressive treatments, both experimental and clinical CTAs are constantly developing. However, it still needs constant effort to achieve a balance between long-term allograft survival and low immunosuppressive side effects. At the same time, the ethical problems should also be considered. We believe that with the continuous technological development and maturity of CTA, it will benefit more patients in the future.

REFERENCES

Auphan N, DiDonato JA, Rosette C, Helmberg A, Karin M. Immunosuppression by glucocorticoids: inhibition of NF-kappa B activity through induction of I kappa B synthesis. *Science* 1995; 270(5234):286−290.

Bartlett AS, McCall JL, Ameratunga R, Yeong ML, Benjamin CD, Peach R, Munn SR. Prolongation of fully allogeneic skin graft survival in the rat by combined administration of costimulatory blockade and sirolimus. *Transplant. Proc*. 2002; 34(4):1127−1129.

Bateman C. World's first successful penis transplant at Tygerberg Hospital. *S. Afr. Med. J*. 2015; 105(4):251−252.

Black KS, Hewitt CW, Fraser LA, Howard EB, Martin DC, Achauer BM, et al. Composite tissue (limb) allografts in rats. II. Indefinite survival using low-dose cyclosporine. *Transplantation* 1985; 39(4):365−368.

Bos JD, Luiten RM. Skin immune system. *Cancer Treat. Res*. 2009; 146(4):45−62.

Bourget JL, Mathes DW, Nielsen GP, Randolph MA, Tanabe YN, Ferrara VR, Wu A, Arn S, Sachs DH, Lee WP. Tolerance to musculoskeletal allografts with transient lymphocyte chimerism in miniature swine. *Transplantation* 2001; 71(7):851−856.

Bozulic LD, Wen Y, Xu H, Ildstad ST. Evidence that FoxP3+ regulatory T cells may play a role in promoting long-term acceptance of composite tissue allotransplants. *Transplantation* 2011; 91(8):908−915.

Brown EJ, Albers MW, Shin TB, Ichikawa K, Keith CT, Lane WS, Schreiber SL. A mammalian protein targeted by G1-arresting rapamycin-receptor complex. *Nature* 1994; 369(6483):756−758.

Buttemeyer R, Jones NF, Min Z, Rao U. Rejection of the component tissues of limb allografts in rats immunosuppressed with FK-506 and cyclosporine. *Plast.Reconstr. Surg*. 1996; 97(1):139−151.

Calne RY, Collier DS, Lim S, Pollard SG, Samaan A, White DJ, Thiru S. Rapamycin for immunosuppression in organ allografting. *Lancet* 1989; 2(8656):227.

Caplan AL, Kimberly LL, Parent B, Sosin M, Rodriguez ED. The Ethics of Penile Transplantation: Preliminary Recommendations. *Transplantation* 2017; 101(6): 1200−1205.

Carrel A. Results of the transplantation of blood vessels, organs and limbs. *JAMA* 1908; 51:1662−1667.

Cavadas PC, Hernan I, Landin L, Thione A. Bone healing after secondary surgery on hand allografts under sirolimus-based maintenance immunosuppression. *Ann. Plast. Surg*. 2011; 66(6):667−669.

Demir Y, Ozmen S, Klimczak A, Mukherjee AL, Siemionow M. Tolerance induction in composite facial allograft transplantation in the rat model. *Plast. Reconstr. Surg*. 2004; 114(7):1790−1801.

Devauchelle B, Badet L, Lengele B, Morelon E, Testelin S, Michallet M, D'Hauthuille C, Dubernard JM. First human face allograft: early report. *Lancet* 2006; 368(9531): 203−209.

Dominici M, Le Blanc K, Mueller I, Slaper-Cortenbach I, Marini F, Krause D, Deans R, Keating A, Prockop D, Horwitz E. Minimal criteria for defining multipotent

mesenchymal stromal cells. The International Society for Cellular Therapy position statement. *Cytotherapy* 2006; 8(4):315−317.

Dubernard JM, Owen E, Herzberg G, Lanzetta M, Martin X, Kapila H, et al. Human hand allograft: report on first 6 months. *Lancet*. 1999; 353(9161):1315−1320.

Duque E, Duque J, Nieves M, Mejia G, Lopez B, Tintinago L. Management of larynx and trachea donors. *Transplant. Proc*. 2007; 39(7):2076−2078.

Elion GB. The George Hitchings and Gertrude Elion Lecture. The pharmacology of azathioprine. *Ann. N. Y. Acad. Sci*. 1993; 685:400−407.

Ensley RD, Bristow MR, Olsen SL, Taylor DO, Hammond EH, O'Connell JB, Dunn D, Osburn L, Jones KW, Kauffman RS, Gay WA, DG R. The use of mycophenolate mofetil (RS-61443) in human heart transplant recipients. *Transplantation* 1993; 56:75−82.

Foster RD, Pham S, Li S, Aitouche A. Long-term acceptance of composite tissue allografts through mixed chimerism and CD28 blockade. *Transplantation* 2003; 76(6):988−994.

Fryer M, Grahammer J, Khalifian S, Furtmuller GJ, Lee WP, Raimondi G, Brandacher G. Exploring cell-based tolerance strategies for hand and face transplantation. *Expert. Rev. ClinImmunol*. 2015; 11(11):1189−1204.

Fuchimoto Y, Gleit ZL, Huang CA, Kitamura H, Schwarze ML, Menard MT, Mawulawde K, Madsen JC, Sachs DH. Skin-specific alloantigens in miniature swine. *Transplantation* 2001; 72(1):122−126.

Gerlach UA, Vrakas G, Sawitzki B, Macedo R, Reddy S, Friend PJ, Giele H, Vaidya A. Abdominal Wall Transplantation: Skin as a Sentinel Marker for Rejection. *Am. J. Transplant*. 2016; 16(6):1892−1900.

Giele H, Vaidya A, Reddy S, Vrakas G, Friend P. Current state of abdominal wall transplantation. *Curr. Opin. Organ Transplant*. 2016; 21(2):159−164.

Goldwyn RM, Beach PM, Feldman D, Wilson RE. Canine limb homotransplantation. *Plast. Reconstr. Surg*. 1966; 37(3):184−195.

Grotz WH, Breitenfeldt MK, Braune SW, Allmann KH, Krause TM, Rump JA, Schollmeyer PJ. Calcineurin-inhibitor induced pain syndrome (CIPS): a severe disabling complication after organ transplantation. *Transpl. Int*. 2001; 14(1):16−23.

Hautz T, Zelger B, Grahammer J, Krapf C, Amberger A, Brandacher G, Landin L, Muller H, Schon MP, Cavadas P, Lee AW, Pratschke J, Margreiter R, Schneeberger S. Molecular markers and targeted therapy of skin rejection in composite tissue allotransplantation. *Am. J. Transplant*. 2010; 10(5):1200−1209.

Heslop BF, Nisbet NW. Split tolerance in inbred rats. *Transplant. Bull*. 1962; 29:99−101.

Hettiaratchy S, Melendy E, Randolph MA, et al. Tolerance to composite tissue allografts across a major histocompatibility barrier in miniature swine. *Transplantation* 2004; 77(4):514−521.

Hovius SE, Stevens HP, van Nierop PW, et al. Allogeneic transplantation of the radial side of the hand in the rhesus monkey: I. Technical aspects. *Plast. Reconstr. Surg*. 1992; 89(4):700−709.

Hu W, Lu J, Zhang L, Wu W, Nie H, Zhu Y, Deng Z, Zhao Y, Sheng W, Chao Q, Qiu X, Yang J, Bai Y. A preliminary report of penile transplantation. *Eur. Urol*. 2006; 50(4):851−853.

Ildstad ST, Sachs DH. Reconstitution with syngeneic plus allogeneic or xenogeneic bone marrow leads to specific acceptance of allografts or xenografts. *Nature* 1984; 307(5947):168−170.

Jindal R, Unadkat J, Zhang W, Zhang D, Ng TW, Wang Y, Jiang J, Lakkis F, Rubin P, Lee WP, Gorantla VS, Zheng XX. Spontaneous resolution of acute rejection and tolerance induction with IL-2 fusion protein in vascularized composite allotransplantation. *Am. J. Transplant*. 2015; 15(5):1231−1240.

Jones NF, Hebebrand D, Buttemeyer R, Zhao M, Benhaim P, Rao U. Comparison of long-term immunosuppression for limb transplantation using cyclosporine, tacrolimus, and mycophenolate mofetil: implications for clinical composite tissue transplantation. *Plast. Reconstr. Surg*. 2001; 107(3):777−784.

Kahan BD. Cosmas and Damian revisited. *Transplant. Proc*. 1983; 15(4 Suppl 1−2):2211−2216.

Kann BR, Furnas DW, Hewitt CW. Past, present, and future research in the field of composite tissue allotransplantation. *Microsurgery* 2000; 20(8):393−399.

Kim SK, Aziz S, Oyer P, Hentz VR. Use of cyclosporinA in allotransplantation of rat limbs. *Ann. Plast. Surg*. 1984; 12(3):249−255.

Koga H, Yamataka A, Wang K, Kato Y, Lane GJ, Kobayashi H, Sueyoshi N, Miyano T. Experimental allogenic penile transplantation. *J. Pediatr. Surg*. 2003; 38(12):1802−1805.

Kuo YR, Chen CC, Shih HS, Goto S, Huang CW, Wang CT, Chen CL, Wei FC. Prolongation of composite tissue allotransplant survival by treatment with bone marrow mesenchymal stem cells is correlated with T-cell regulation in a swine hind-limb model. *Plast. Reconstr. Surg*. 2011; 127(2):569−579.

Kuo YR, Goto S, Shih HS, Wang FS, Lin CC, Wang CT, Huang EY, Chen CL, Wei FC, Zheng XX, Lee WP. Mesenchymal stem cells prolong composite tissue allotransplant survival in a swine model. *Transplantation* 2009; 87(12):1769−1777.

Kuo YR, Huang CW, Goto S, Wang CT, Hsu LW, Lin YC, Yang KD, Chen CL, Lee WP. Alloantigen-pulsed host dendritic cells induce T-cell regulation and prolong allograft survival in a rat model of hindlimballotransplantation. *J. Surg. Res*. 2009; 153(2):317−325.

Kuo YR, Shih HS, Lin CC, Huang CC, Yang JC, Wu WS, Goto S, Chen CL, Lee WP. Swine hemi-facial composite tissue allotransplantation: a model to study immune rejection. *J. Surg. Res*. 2009; 153(2):268−273.

Lance EM, Inglis AE, Figarola F, Veith FJ. Transplantation of the canine hind limb.Surgical technique and methods of immunosuppression for allotransplantation.A preliminary report. *J. Bone. Joint. Surg. Am*. 1971; 53(6):1137−1149.

Lapchinsky AG, Eingorn AG, Uratkov EF. Homotransplantation of extremities in tolerant dogs observed up to seven years. *Transplant. Proc*. 1973; 5(1):773−779.

Lee WP, Rubin JP, Cober S, Ierino F, Randolph MA, Sachs Dh. Use of swine model in transplantation of vascularized skeletal tissue allografts. *Transplant. Proc*. 1998; 30(6):2743−2745.

Lee WP, Yaremchuk MJ, Pan YC, Randolph MA, Tan CM, Weiland AJ. Relative antigenicity of components of a vascularized limb allograft. *Plast Reconstr. Surg*. 1991; 87(3):401−411.

Levi DM, Tzakis AG, Kato T, Madariaga J, Mittal NK, Nery J, Nishida S, Ruiz P. Transplantation of the abdominal wall. *Lancet* 2003; 361(9376):2173−2176.

Lin JY, Tsai FC, Wallace CG, Huang WC, Wei FC, Liao SK. Optimizing chimerism level through bone marrow transplantation and irradiation to induce long-term tolerance to composite tissue allotransplantation. *J. Surg. Res*. 2012; 178(1):487−493.

Lindenfeld J, Miller GG, Shakar SF, Zolty R, Lowes BD, Wolfel EE, Mestroni L, Page RL, 2nd, Kobashigawa J. Drug therapy in the heart transplant recipient: part II: immunosuppressive drugs. *Circulation* 2004; 110(25):3858−3865.

Lustgraaf EC, Fuson RB, Eichwald EJ. Sex tolerance and split tolerance. *Transplant. Bull*. 1960; 26:145−150.

Main JM, Prehn RT. Successful skin homografts after the administration of high dosage X radiation and homologous bone marrow. *J. Natl. Cancer Inst*. 1955; 15(4):1023−1029.

Mathes DW, Randolph MA, Solari MG, Nazzal JA, Nielsen GP, Arn JS, Sachs DH, Lee WP. Split tolerance to a composite tissue allograft in a swine model. *Transplantation* 2003; 75(1):25−31.

Meng XL, Ichim TE, Zhong J, Rogers A, Yin ZL, Jackson J, et al. Endometrial regenerative cells: A novel stem cell population. *J. Transl. Med*. 2007; 5(1): 57.

Murray JE.Organ transplantation (skin, kidney, heart) and the plastic surgeon. *Plast. Reconstr. Surg*. 1971; 47(5):425−431.

Nie C, Yang D, Li N, Liu G, Guo T. Establishing a new orthotopic composite hemiface/calvaria transplantation model in rabbits. *Plast. Reconstr. Surg*. 2008; 122(2): 410−418.

Owen RD. Immunogenetic Consequences of Vascular Anastomoses between Bovine Twins. *Science* 1945; 102(2651):400−401.

Ozer K, Gurunluoglu R, Zielinski M, Izycki D, Unsal M, Siemionow M. Extension of composite tissue allograft survival across major histocompatibility barrier under short course of anti-lymphocyte serum and cyclosporine a therapy. *J. Reconstr. Microsurg*. 2003; 19(4):249−256.

Ozer K, Oke R, Gurunluoglu R, Zielinski M, Izycki D, Prajapati R, et al. Induction of tolerance to hind limb allografts in rats receiving cyclosporine A and antilymphocyte serum: effect of duration of the treatment. *Transplantation* 2003; 75(1): 31−36.

Pallet N, Djamali A, Legendre C. Challenges in diagnosing acute calcineurin-inhibitor induced nephrotoxicity: from toxicogenomics to emerging biomarkers. *Pharmacol. Res*. 2011; 64(1):25−30.

Pan H, Zhao K, Wang L, Zheng Y, Zhang G, Mai H, Han Y, Yang L, Guo S. Mesenchymal stem cells enhance the induction of mixed chimerism and tolerance to rat hind-limb allografts after bone marrow transplantation. *J. Surg. Res*. 2010; 160(2):315−324.

Peacock EE, Jr. Homologous composite tissue grafts of the digital flexor mechanism in human beings. *Transplant. Bull.*1960; 7:418−421.

Pidwell DJ, Burns C. The immunology of composite tissue transplantation. *Clin Plast. Surg*. 2007; 34(2):303−317.

Plock JA, Schnider JT, Zhang W, Schweizer R, Tsuji W, Kostereva N, Fanzio PM, Ravuri S, Solari MG, Cheng HY, Rubin PJ, Marra KG, Gorantla VS. Adipose- and Bone Marrow-Derived Mesenchymal Stem Cells Prolong Graft Survival in Vascularized Composite Allotransplantation. *Transplantation* 2015; 99(9):1765−1773.

Poole M, Bowen JE, Batchelor JR. Prolonged survival of rat leg allografts due to immunological enhancement. *Transplantation* 1976; 22(2):108−111.

Quigley MA, Fletcher DR, Zhang W, Nguyen VT. Development of a reliable model of total abdominal wall transplantation. *Plast Reconstr. Surg*. 2013; 132(4):988−994.

Ramirez AE, Cheng HY, Lao WW, Wang YL, Wen CJ, Wallace CG, Lin CF, Shih LY, Chuang SH, Wei FC. A novel rat full-thickness hemi-abdominal wall/

hindlimbosteomyocutaneous combined flap: influence of allograft mass and vascularized bone marrow content on vascularized composite allograft survival. *Transpl. Int*. 2014; 27(9):977−986.

Reem GH. Molecular mode of action of cyclosporine and FK506 in human thymocytes. *J. Autoimmun*. 1992; 5(suppl A):159-165.

Schwind JV. Homotransplantation of extremities by parabiosis. *Ann. N. Y. Acad. Sci.*1962; 99:933−942.

Schwind JV. Successful Transplantation of a Leg in Albino Rats with Reestablishment of Muscular Control. *Science* 1936; 84(2181):355.

Siemionow M, Gozel-Ulusal B, EnginUlusal A, Ozmen S, Izycki D, Zins JE. Functional tolerance following face transplantation in the rat. *Transplantation* 2003; 75(9): 1607−1609.

Siemionow M, Izycki D, Ozer K, Ozmen S, Klimczak A. Role of thymus in operational tolerance induction in limb allograft transplant model. *Transplantation* 2006; 81(11):1568−1576.

Siemionow M, Klimczak A. Advances in the development of experimental composite tissue transplantation models. *Transpl. Int*. 2010; 23(1):2−13.

Siemionow M, Ozer K. Advances in composite tissue allograft transplantation as related to the hand and upper extremity. *J. Hand Surg. Am*. 2002; 27(4):565−580.

Siemionow M, Izycki D, Zielinski M. Donor-specific tolerance in fully major histocompatibility major histocompatibility complex-mismatched limb allograft transplants under an anti-alphabeta T-cell receptor monoclonal antibody and cyclosporine A protocol. *Transplantation* 2003; 76(12):1662−1668.

Söderlund C, Rådegran G. Immunosuppressive therapies after heart transplantation - The balance between under- and over-immunosuppression. *Transplant Rev. (Orlando)*. 2015; 29:181−189.

Solari MG, Washington KM, Sacks JM, Hautz T, Unadkat JV, Horibe EK, Venkataramanan R, Larregina AT, Thomson AW, Lee WP. Daily topical tacrolimus therapy prevents skin rejection in a rodent hind limb allograft model. *Plast. Reconstr. Surg*. 2009; 123(2 Suppl):17S−25S.

Sonmez E, Nasir S, Siemionow M. Penis allotransplantation model in the rat. *Ann. Plast. Surg*. 2009; 62(3):304−310.

Sopko NA, Matsui H, Lough DM, Miller D, Harris K, Kates M, Liu X, Billups K, Redett R, Burnett AL, Brandacher G, Bivalacqua TJ. Ex Vivo Model of Human Penile Transplantation and Rejection: Implications for Erectile Tissue Physiology. *Eur. Urol*. 2017; 71(4):584-593.

Sosin M, Rodriguez ED. The Face Transplantation Update: 2016. *Plast. Reconstr. Surg*. 2016; 137(6):1841−1850.

Stark GB, Swartz WM, Narayanan K, et al. Hand transplantation in baboons. *Transplant. Proc*. 1987; 19(5):3968−3971.

Strome M, Stein J, Esclamado R, Hicks D, Lorenz RR, Braun W, Yetman R, Eliachar I, Mayes J. Laryngeal transplantation and 40-month follow-up. *N. Engl. J. Med*. 2001; 344(22):1676−1679.

Swearingen B, Ravindra K, Xu H, Wu S, Breidenbach WC, Ildstad ST. Science of composite tissue allotransplantation. *Transplantation* 2008; 86(5):627−635.

Tobin GR, Breidenbach WC, 3rd, Pidwell DJ, Ildstad ST, Ravindra KV. Transplantation of the hand, face, and composite structures: evolution and current status. *Clin. Plast. Surg*. 2007; 34(2):271−278, ix-x.

Tung TH, Mackinnon SE, Mohanakumar T. Costimulation blockade of CD40 and CD28 pathways in limb transplantation. *Transplant. Proc*. 2008; 40(10):3723−3724.

Ulusal BG, Ulusal AE, Ozmen S, Zins JE, Siemionow MZ. A new composite facial and scalp transplantation model in rats. *Plast. Reconstr. Surg*. 2003; 112(5):1302−1311.

Ustuner ET, Zdichavsky M, Ren X, Edelstein J, Maldonado C, Ray M, Jevans AW, Breidenbach WC, Gruber SA, Barker JH, Jones JW. Long-term composite tissue allograft survival in a porcine model with cyclosporine/mycophenolate mofetil therapy. *Transplantation* 1998; 66(12):1581−1587.

Vezina C, Kudelski A, Sehgal SN. Rapamycin (AY-22,989), a new antifungal antibiotic. I. Taxonomy of the producing streptomycete and isolation of the active principle. *J. Antibiot (Tokyo)*. 1975; 28(10):721−726.

Vos O, Davids JA, Weyzen WW, Van Bekkum DW. Evidence for the cellular hypothesis in radiation protection by bone marrow cells. *Acta. Physiol. Pharmacol. Neerl*. 1956; 4(4):482−486.

Vriesendorp HM, Heidt PJ. History of graft-versus-host disease. *Exp. Hematol*. 2016; 44(8):674−688.

Waldner M, Fantus D, Solari M, Thomson AW. New perspectives on mTOR inhibitors (rapamycin, rapalogs and TORKinibs) in transplantation. *Br. J. Clin. Pharmacol*. 2016; 82(5):1158−1170.

Wang H. Limb Transplantation in Mice – Induction of Limb Allograft Tolerance in Mice: Clinical Course and Pathology Studies. In: Huifang Chen and Shiguang Qian, eds. *Experimental Organ Transplantation. USA: Nova Science Publishers*, 2013.

Wekerle T, Kurtz J, Ito H, Ronquillo JV, Dong V, Zhao G, Shaffer J, Sayegh MH, Sykes M. Allogeneic bone marrow transplantation with co-stimulatory blockade induces macrochimerism and tolerance without cytoreductive host treatment. *Nat. Med*. 2000; 6(4):464−469.

Yazici I, Unal S, Siemionow M. Composite hemiface/calvaria transplantation model in rats. *Plast. Reconstr. Surg*. 2006; 118(6):1321−1327.

Zhang LC, Zhao YB, Hu WL. Ethical issues in penile transplantation. *Asian. J. Androl*. 2010; 12(6): 795−800.

Zhao Y, Hu W, Zhang L, Guo F, Wang W, Wang B, Zhang C. Penis Allotransplantation in Beagle Dog. *Biomed. Res. Int*. 2016; 2016:1489204.

In: Encyclopedia of Surgery (22 Volume Set)
Editors: Andreas Lehrer and Kristin Mueller
ISBN: 978-1-53618-329-0
© 2020 Nova Science Publishers, Inc.

Chapter 219

ISCHEMIA-REPERFUSION INJURY ANIMAL MODELS

Junzheng Peng[1,*], MD, PhD and Huifang Chen[2], MD, PhD
[1]Cardiovascular Phenotyping Core Facility, CRCHUM,
University of Montreal, Montreal, Quebec, Canada
[2]Lab of Experimental Surgery, CRCHUM,
University of Montreal, Montreal, Quebec, Canada

ABSTRACT

Ischaemia-reperfusion injury (IRI) is the principal pathological mechanism causing numerous widespread diseases. The complications induced by IRI including cardiovascular disease and cerebrovascular disease are a major reason of death in developed countries. IRI of native and transplant organs is an important cause of acute organ injury and a vital determinant of long-term organ dysfunction. The animal models of organ IRI are vital for understanding the underlying processes of IRI and development of efficacious treatment. Ischemic preconditioning (IPC) is a situation where preconditioning an organ with a sub-lethal/mild ischemic injury of short period can induce the organ's transient adaptive resistance to a lethal ischemic injury. Remote ischemic preconditioning (RIPC) is the phenomenon where a short sub-lethal ischemia and reperfusion in remote organs can induce ischemic tolerance in target organ. Ischemic postconditioning (IPoC) is a protective approach in which repeated brief IR is performed in the early phase of reperfusion after ischemia. The IRI animal models and different ischemic conditioning strategies in preclinical and available clinical application are reviewed in this chapter.

Keywords: ischemia-reperfusion injury, animal models, ischemic preconditioning, remote ischemic preconditioning, ischemic postconditioning

* Corresponding Author's Email: pengjunzheng@gmail.com.

ABBREVIATIONS

AKI	Acute kidney injury
ALI	Acute lung injury
AMI	Acute mesenteric ischemia
ARDS	Acute respiratory distress syndrome
ARF	Acute renal failure
BBB	Blood-brain barriers
BUN	Blood urea nitrogen
CABG	Coronary artery bypass grafting
CBF	Cerebral blood flow
CP	Cerebral palsy
CR	Controlled reperfusion
CTT	Controlled tension tourniquet
DTI	Diffusion tensor imaging
ECG	Electrocardiography
FGR	Fetal growth restriction
HF	Heart failure
HI	Hypoxic-ischemic
HIE	Hypoxic-Ischemic Encephalopathy
ICH	Intracerebral hemorrhage
IOP	Intraocular pressure
IPC	Ischemic preconditioning
IPoC	Ischemic postconditioning
IR	Ischemia-reperfusion
IRI	Ischemia-reperfusion injury
IVH	Intraventricular hemorrhage
LAD	Left anterior descending coronary artery
LCA	Left coronary artery
LV	Left ventricular
MCA	Middle cerebral artery
MHL	McGivney hemorrhoidal ligator band
MI	Myocardial infarction
MPTP	Mitochondrial permeability transition pore
ORB	Orthodontic rubber bands
PCI	Percutaneous coronary intervention
PSS	Portasystemic shunt
PTCA	Percutaneous transluminal coronary angiography
PVL	Periventricular leukomalacia
RIPC	Remote ischemic preconditioning
ROS	Reactive oxygen species
RVM	Rice-Vannucci model
SCI	Spinal cord injury
SMA	Superior mesenteric artery
STEMI	ST-elevation myocardial infarction

tMCAO	temporary MCA occlusion
UCO	Umbilical cord occlusion
WMI	White matter injury

INTRODUCTION

Ischemia-reperfusion (IR) is a well-known pathological situation that is characterized by an early occlusion of blood supply to an organ or area followed by later vascular restoration and associated reoxygenation of downstream tissue (Eltzschig 2011). The restoration of blood supply to the affected organ/ tissue produces remarkable organ/tissue injury which is known as IRI. IRI can develop as a consequence of trauma, hypertension, shock, sepsis, organ transplantation, or bypass surgery leading to end-organ failure such as acute renal tubular necrosis, bowel infarct, and liver failure. Furthermore, IRI can happen under different complications of vascular diseases such as myocardial infarction and stroke (Eltzschig 2011; Duehrkop 2014). IRI causes morbidity and mortality in extensive pathologies, including circulatory arrest, trauma, ischemic stroke, myocardial infarction, acute kidney injury, sickle cell disease and sleep apnea. Moreover, IRI is a great challenge during cardiothoracic, vascular and general surgery and organ transplantation. An imbalance in demand within the ischemic organ and metabolic supply induces extensive tissue hypoxia and microvascular dysfunction. Later reperfusion further increases the activation of innate and adaptive immune responses and cell death programs.

IRI is unavoidable in clinical transplantation. IRI-related impairment can be reduced by keeping the organ in a cold solution. But it is not possible to totally prevent such injury. Furthermore, IRI can cause delayed graft function which may affect the organ function and survival in short-term and long-term (Ponticelli 2015).

Acute IRI causes cell injury and death in lots of clinical conditions and in different tissues and organs including the brain, lung, heart, liver, spine cord, kidneys, stomach, intestine, pancreas, uterus and ovaries.

Ischemia conditioning is one strategy to improve IRI. IPC is a situation where preconditioning an organ with a sub-lethal/mild ischemic injury of short period can induce the organ's adaptive transient resistance to a lethal ischemic injury. IPC was first reported in dog heart study which showed that induction of mild ischemia followed by a period of reperfusion made the heart more resistant to a subsequent, ordinarily lethal ischemic insult (Murry 1986). Then the protective effect of IPC was verified in different animal models and in humans (Kloner 1998). IPC has been confirmed to be a potent method to induce tolerance to ischemic insults in most organs investigated and has been replicated in many laboratories around the world. IPC can decrease reperfusion injury and its systemic consequences. The main disadvantage of IPC is mechanical trauma to major vessels and direct stress to the target organ. So its clinical application is restricted.

RIPC is the phenomenon where a short sub-lethal ischemia and reperfusion in remote organs can induce ischemic tolerance in target organ. RIPC is a new approach where ischemia followed by reperfusion of one organ is thought to preserve remote organs (Tapuria 2008). RIPC was first described in 1993 and ischemia in the kidney followed by reperfusion decreased myocardial infarct size after ischemia (McClanahan 1993). Brief IR of the limb,

gut, mesenteric, or kidney reduced myocardial infarct size in animal models (McClanahan 1993; Gho 1996; Birnbaum 1997). In humans, skeletal preconditioning has been used for myocardial protection with the beneficial effect being attributed to regulation of endothelial protection. The protective mechanisms of RIPC may involve adjustment of neurogenic pathways, elaboration of endogenous mediators, deduction of inflammatory cytokine production including tumor necrosis factor-α, and debilitation of IR-caused endothelial dysfunction (Meldrum 1998; Kharbanda 2002; Tapuria 2008). The mechanisms of RIPC's protective effect have yet to be explained. Investigations suggested that humoral and neural signalling pathways might be involved. More detailed information is available in some excellent reviews on the subject (Hausenloy 2013; Przyklenk 2013; Sluijter 2014).

Ischemic postconditioning (IPoC) is a protective approach in which repeated brief IR are performed in the early phase of reperfusion after ischemia. It was first reported in the dog heart (Zhao 2003). The protective effect of IPoC on IRI has been confirmed in different organs and animal species. IPoC is efficacious when it is performed in a remote organ or the target organ (Kerendi 2005; Zhao 2010). IPoC decreased myocardial infarct size by about 40% in animal models and in humans. IPoC has shown its clinical potential by decreasing IRI in different organs in several animal models. The strategies to reduce IRI such as IPC, RIPC and IPoC are safe, simple to perform and reproducible in human clinical trials.

RENAL IRI ANIMAL MODELS

Acute kidney injury (AKI) is a major kidney disease related to high mortality in patients. Clinically, ischemia is an important cause of AKI and can be induced by renal vascular occlusion, kidney transplantation or decreased cardiac output. IRI-induced acute renal failure (ARF) imitates the hemodynamic alterations-caused changes in renal function.

Different renal IRI animal models have been established and evaluated. Two types of warm renal IRI models are commonly applied: 1) bilateral renal IRI (Altmann 2012; Celie 2012; Zager 2012); and 2) unilateral renal IRI (Matsuda 2011; Tremblay 2002; Kitada 2002, Lee 2010, Yang 2016). The unilateral renal IRI model includes unilateral IRI without contralateral nephrectomy (Alikhan 2011; Godwin 2010) and unilateral IRI with contralateral nephrectomy (Matsuda 2011; Tremblay 2002; Kitada 2002, Lee 2010, Yang 2016). The bilateral renal IRI model is commonly used because it is considered more relevant to human pathological conditions where blood supply is normally affected in both kidneys (Altmann 2012; Lan 2012; Zager 2012). In the bilateral renal IRI model, decapsulation was carried out before renal ischemia (Megyesi 2002; Li 2009) which was shown to have renoprotective effects (Stone 1977). But, decapsulation was not performed in the majority of published studies of bilateral renal IRI. Renal IRI models were well established in large animals (Crane 2013; Lee 2006; Espinosa 1996). Rat IRI models then became the most popular animal model. The investigation with mouse renal IRI model has been extensively applied using genetically modified mouse since it was first developed in 1990 (Shoskes 1990). The mouse model of warm renal IR has crucial similarities with human IRI. The genetically modified mouse strains are very useful in investigating the molecular and cellular biology of IRI. The main disadvantage of renal IRI is the absence of cold ischemia. Usually, longer ischemia time

is required to induce the same IRI effect on an organ for larger animals. Moreover, females seem to be more resistant to ischemia than males (Kennedy 2008).

Porcine Renal IRI Model

The left kidney was exposed through midline abdominal incision after the anesthesia was induced and maintained (Crane 2013). The left renal artery was occluded by vessel loops after intravenous heparin (50 units⁄kg) and mannitol (350 mg⁄kg) were given. Pigs were subjected to hypothermic (5°C) or normothermic (33°C) ischemia. Sterile ice slush was filled in the abdomen cavity to produce hypothermic ischemia and ice slush was removed before reperfusion.

Canine Renal IRI Model

The kidney and renal hilum were exposed by laparotomy. The renal artery and vein were blocked by Satinsky clamps to induce normothermic renal ischemia (Crane 2013). The left kidney was exposed from the peripheral tissue and fat through median laparatomy. The left renal artery and vein were occluded by an atraumatic vascular clamp. The clamp was removed after 30 min of normothermic ischemia and then the right nephrectomy was done. Blood urea nitrogen (BUN) levels were significantly increased 14 days after reperfusion compared to before IRI. Blood BUN levels were significantly increased on 4 days after 90 minutes of warm unilateral renal ischemia with contralateral nephrectomy in dog (Sekhon 2003). ARF was developed within 3 h by clamping the left renal artery for 1 h followed by reperfusion in uninephrectomized dogs (Yatsu 1998).

Bilateral Renal IRI Mice Model

The anesthesia is induced and maintained by isoflurane. The mouse is put on the homeothermic blanket of a homeothermic monitor system and covered by sterile surgical drape after the skin preparation (Wei 2012). The left kidney was exposed through left flank incision. The left kidney was gently pushed out of body cavity with cotton swabs to expose the renal pedicle. The pedicle was clamped by a microaneurysm. Sympathetic nerve damage may happen during the isolation of the renal artery in mice. Complete ischemia is confirmed by color change of the kidney from red to dark purple in a few seconds. Then, the left kidney was returned to the abdomenal cavity. Then the right kidney was exposed through the right flank incision and the renal pedicle was clamped using the same method. 22 and 35 minutes of ischaemia has been used for bilateral mouse renal IRI in most published studies. After the ischemia, the micro-aneurysm clip was removed for each kidney to start the reperfusion (Wei 2012).

Unilateral Renal IRI Mice Model

The left kidney and renal vessels were exposed via a dorsal incision after the anesthesia was induced and maintained by isoflurane. The left renal artery was clamped with a small vascular clamp for 50 minutes and released. Occlusion was confirmed visually by a change in kidney color, and reperfusion was confirmed by appearance of the original color. Then, the right kidney was nephrectomized via a dorsal incision. During surgery, body temperature was kept by putting the mice on a 38°C heating pad. Fifty minutes of ischemia and contralateral nephrectomy caused severe tubular damage that resulted in renal dysfunction in mice. Mortality occurred between 24 and 72 hours after IRI. The survival rate 7 days after IRI was 25% (Matsuda 2011). The left kidney and renal vessels were exposed by the abdominal incision after the anesthesia was induced and maintained by isoflurane (Yang 2016). The left renal artery was clamped with a small vascular clamp for 30 minutes. The right kidney was nephrectomized after the left kidney ischemia was finished.

Unilateral Renal IRI Rat Model

The right kidney was removed under light flurane anesthesia through a mid-abdominal incision. The left kidney was subjected to transient ischemia by occlusion of the left renal artery and vein using a micro-clip (Tremblay 2002). The surgical wound was temporarily closed, and the rats were placed on a heating pad kept at a temperature of 37°C for either 45 or 60 minutes of occlusion. The clip was then removed and the wound closed with a 3–0 suture. A 25% survival rate was observed 8 days after 60-minute renal ischemia.

Morphological studies have demonstrated that ischemia caused irreversible damages to the distal segments of the proximal tubules whereas more proximal segments suffer reversible injury after a short period (30 min) of normothermic ischemia (Shanley 1986).

Ischemic Conditioning Application in Renal IRI Animal Model

Contrast-induced AKI is a common and life-threatening complication after cardiac catheterization and no successful prophylactic treatment is available. IRI is certain to happen during transplantation.

RIPC by brief hind limb ischaemia had protective effect on renal IRI in rats (Wever 2011). Unilateral or bilateral RIPC were performed in rats. After 24 hours of reperfusion, Kidney function was ameliorated in both the bilateral RIPC group and unilateral group. Bilateral RIPC had better effect compared to unilateral RIPC (Wever 2011). RIPC by brief small intestinal ischemia reduced renal IRI in rats (Song 2007). RIPC was performed by three cycles of 8-minute ischemia and 5-minute reperfusion of the small intestine. Left renal ischemia was caused by a 45-minute renal artery blockage and reperfusion for 2 or 24 hours with right nephrectomy. Renal ischemic impairment was significantly improved. RIPC by 10 min of brief hepatic ischemia was shown to have protective effect on 45 min renal ischemia in

rats (Atesx 2002). Repeated RIPC did not provide stronger protection against renal IRI compared to single dose RIPC in rats (Menting 2017).

IPoC was first reported to prevent mice ischemic ARF in 2007 (Szwarc 2007). IPoC ameliorated renal function after IRI in dog (Jiang 2010; Jiang 2012) and rats (Chen H 2008; Serviddio 2008; Eldaif 2010; Yun 2009; Zhang 2011; Miklos 2012). Renal injury parameters were remarkably reduced in IPoC compared with IRI only. IPoC prevented reactive oxygen species (ROS) production and prompted antioxidant activity which prevented cellular injury (Yun 2009). Moreover, mitochondria were more resistant to injury by IPoC, causing less apoptosis by up-regulation of antiapoptotic proteins as well as reduction of proapoptotic gene expression (Zhang 2011).

RIPC induced by three 5-min cycles of brief repetitive IR by clamping the exposed external iliac artery improved the early recovery of renal function in patients after kidney transplantation (Wu 2014). RIPC is a potential method to reduce transplantation-related IRI. RIPC induced by 4 cycles of 5 min lower limb ischemia and 5 min reperfusion using an arterial tourniquet cuff did not ameliorate renal function after live donor kidney transplantation in a double blind randomized clinical trial (Nicholson 2015).

The clinical protection effect of RIPC was demonstrated in a large-scale, multi-centre, multinational phase III renal transplantation with 406 live donor-recipient pairs (MacAllister 2015). Both recipients and donors received simultaneously the RIPC induced by four cycles of 5-min upper arm ischemia. Early RIPC was performed immediately before surgery and late RIPC was carried out 24 h before surgery. Early RIPC seems to provide renoprotection that potentially extend allograft lifespan by 2–3 years.

A multicentre, randomized controlled clinical trial is undergoing to evaluate whether RPIC of the leg of the patient ameliorates short and long-term graft function after kidney transplantation (Krogstrup 2015). RIPC reduced the renal damage in 42 patients with elective abdominal aortic aneurysm repair (Ali 2007).

CARDIAC IRI ANIMAL MODELS

The incidence of myocardial infarction is about one million people per year in the United States. Cardiac IRI is the typical pathophysiological characteristic for patients with the partial or complete arrest of cardiac circulation (Turer 2010). The first cardiac IRI model was developed in dog (Jennings 1960). The histological results suggested that 30–60 minutes of IRI in dog were comparable to the degree of necrosis usually observed after 24 hours of permanent coronary occlusion in human.

Myocardial ischemia is a usual clinical symptom characterized by low oxygen, low pH values, and high extracellular potassium concentration, which may trigger arrhythmias, myocardial infarction (MI), cardiac dysfunction and sudden death (Jennings 2013; Heusch 2014). Later reperfusion may repair the impaired myocardial structure and reduce heart function caused by ischemia. The effect of reperfusion is determined by the length and severity of prior ischemia (Lee 2012). Nonetheless, cardiac reperfusion could further initiate a complex inflammatory response, which may eventually cause cardiac IRI (Fauconnier 2011).

Different experimental models, including MI and cardiac IRI were developed depending on the the duration and extent of coronary blood flow impairment and cardiac ischemic damage.

MI Animal Models

MI can be induced by different techniques of coronary arteries occlusions. These approaches were often applied to completely or partially block coronary artery branches in larger animals which were appropriate to generate MI and heart failure (HF) (Roth 1987; Harada 1994). Left anterolateral thoracotomy was carried out for occlude implantation after anesthesia was induced and maintained. A branch of the left coronary artery (LCA) was separated and the hydraulic occluder was put around the vessel. It was then inflated to cause incomplete constriction or full obstruction. An ameroid constrictor was implanted in a similar fashion but obstruction was reached by a dissimilar mechanism. The ring around the artery shrinks slowly due to the hygroscopic property of the casein plastic material. MI-induced HF model was produced by the hydraulic occluder or the ameroid constrictor in big animals (Harada 1994; Roth 1987).

HF model was first developed by coronary artery ligation in dog (Hood 1967). Proximal left anterior descending coronary artery (LAD) was ligated to induce MI after orotracheal intubation and left thoracotomy was performed. The mortality of this model was more than 50% because of malignant ventricular tachycardias in the acute phase. Moreover, the average infarction size was 21% of the left ventricle and slight haemodynamic abnormalities were detected (Hood 1967). Additionally, the model is laborious and costly. But, this technique used in the pig induced a mortality of only 20%, mainly because of ventricular fibrillation and acute ventricular tachycardias (Iwanaga 2004).

Rat left ventricular (LV) MI model was first developed in 1979 (Pfeffer 1979). In short, orotracheal intubation and thoracotomy was performed after the anesthesia was induced and maintained. LCA was ligated in the proximal segment after the heart was exposed. Rats with small (4–30%) MI had no detectable damage in either baseline hemodynamics or peak indices of pumping and pressure-generating ability when compared to the sham-operated and noninfarcted rats. Rats with moderate (31–46%) MI had normal baseline hemodynamics but decreased peak flow indices and developed pressure. Congestive HF was developed when infarction was more than 46% at 21 days with elevated filling pressures, reduced cardiac output, and a minimal capacity to respond to pre- and after-load stress.

The degree of impairment of LV function is directly associated to the extent of myocardial loss (Pfeffer 1979). The mortality is strain-dependent. The mortality of Sprague-Dawley rats was 36% and Lewis inbred rats was 16% (Liu 1997).

The mouse is often used to characterise MI induced by coronary artery ligation. The surgical procedure to induce MI in the mouse is similar to the rat model (Gao 2000). But, a microscope is needed to precisely expose and ligate the relatively small LCA of the mouse. Mortality of MI mice is about 37–50% (Gehrmann 2001; Kuhlmann 2006). Most mice died within 1 h after ligation because of ventricular fibrillation and severe acute HF.

Myocardial IRI Model

Cardiac dysfunction induced by myocardial IRI is an important issue to be solved after percutaneous transluminal coronary angiography (PTCA) and thrombolysis are widely performed for acute MI therapy in human. Further, cardiac dysfunction induced by myocardial IRI usually happens in cardiac surgery because reperfusion is inevitable during surgery with cardioplegia techniques and extracorporal circulation. Myocardial IRI animal models are well established. The duration of coronary artery occlusion affects the MI.

Regional myocardial IRI animal model is the classic model. The coronary artery is ligated with thread for small animals and a strip of moistened umbilical tape for big animals. However, a small plastic tube is put between the ligated vessel and the node in order to easily remove the occlusion.

Ischemia can be confirmed by the rapid regional whiteness of the myocardium andelectrocardiography (ECG) modifications. Reperfusion is confirmed by the occurrence of hyperaemia in the previously white region. Myocardial IRI animal model causes a higher infiltration of inflammatory cells, impaired fibrotic remodelling and increased neovascularisation in the area of infarction compared to the permanent occlusion model (Vandervelde 2006).

Myocardial IRI model was first developed in large animals. But rodent myocardial IRI models were often performed over the last decades. Myocardial IRI model in the closed-chest mouse was established to reduce inflammatory effects caused by surgery (Nossuli 2000). A thin suture was put under the LAD and the ends of the suture were threaded through a 0.5-mm piece of PE-10 tubing causing a loose snare around the LAD after thoracotomy was performed. The ends of the suture were externalized through each side of the chest wall, the chest was secured and ultimately the suture ends were hidden under the skin. The final IRI experiment was carried out a few days later after inflammatory cytokines levels returned to baseline. The LAD was obstructed by extracting the free suture ends in opposite directions and reperfusion was started by releasing them.

ISCHEMIC CONDITIONING APPLICATION IN CARDIAC IRI ANIMAL MODEL

Cardioprotection evoked by IPC is one of the most potent treatments for reducing infarct size after acute cardiac IRI. Mitochondria may play important roles in the protective effect of IPC. Signaling ROS are released by mitochondria in response to IPC and then suppress the mitochondrial permeability transition pore (MPTP) to reduce cardiac reperfusion injury and limit infarct size (Ferdinandy 2014). One considerable limitation of IPC is to perform the therapeutic intervention before myocardial ischemia. However, the beginning of myocardial ischemia is unforeseeable in MI patients.

IPoC by several cycles of short period ischemia has defeated this limitation (Zhao 2003).

The protection effect of IPoC has been verified in different species including man although the underlying mechanisms and signal transduction have not been yet understood (Skyschally 2009). Many of the signaling pathways underlying IPoC, but not all, are shared with IPC (Heusch 2006). The considerable disadvantage of IPC and IPoC as treatment for

reducing cardiacl IRI is that both methods need to be performed directly to the heart. So the clinical application is limited.

RIPC was first described in 1993 and ischemia in the kidney followed by reperfusion decreased myocardial infarct size after ischemia (McClanahan 1993). RIPC by muscle stimulation with reduction of femoral arterial blood flow decreased myocardial infarct size in rabbit after 30 minutes of coronary artery occlusion and 4 hours of reperfusion (Birnbaum 1997). RIPC by 10 minutes limb ischemia significantly reduced reperfusion arrhythmias after 30 minutes left descending coronary artery occlusion in rats (Oxman 1997). RIPC by four 5-minute cycles of lower limb ischemia decreased myocardial infarct size after 40 minutes of balloon occlusion of the left anterior descending artery in pigs (Kharbanda 2002).

RIPC by later non-invasive hind limb ischemia significantly decreased myocardial injury, infarct size, and incidence of ventricular arrhythmias after 30 minutes of left anterior descending coronary artery occlusion and 120 min of reperfusion in rats (Li 2010). RIPC by 15 minutes occlusion of the anterior mesenteric artery protected myocardium against infarction induced by 60 minutes oronary artery occlusion in rats (Gho 1996).

RICP by 10 minutes left renal artery occlusion in rabbit reduced myocardial infarct sizes induced by 30 minutes occlusion of left coronary artery and 2h reperfusion (Pell 1998).

RIPC induced by six cycles of 5min limb occlusion and 15min limb reperfusion considerably decreased heart IRI in rat caused by acute left anterior descending artery occlusion (60 min ligation and 180 min reperfusion). Furthermore, RIPC in bilateral upper and lower limbs showed a better effect in decreasing infarct size than RIPC in bilateral upper-limb and in bilateral lower-limb (Wu 2016).

RIPC performed by three 5-minute cycles of ischemia of the contralateral limb prevented endothelial IRI caused by 20 minutes of upper limb ischemia (inflation of a blood pressure cuff to 200 mm Hg) and reperfusion in humans (Kharbanda 2002). RIPC by two time periods of 3 min of ischaemia and 2 min of reperfusion around the right upper extremity with a tourniquet protected myocardium in patients undergoing coronary artery surgery by increasing anaerobic glycolysis (Günaydin 2000).

RIPC can provide cardioprotection at different time points of acute cardiac IRI. RIPC can be performed before myocardial ischemia (Przyklenk 1993); after the beginning of myocardial ischemia but before reperfusion (Schmidt 2007); at the beginning of myocardial reperfusion (Andreka 2007). RIPC was produced by 15 min obstruction of femoral arteries and provided a similar degree of cardioprotection when performed 25 min before MI, 10 or 25 min after the begining of MI and 10 min after the begining of reperfusion in in rat myocardial IRI (30 min of left coronary artery occlusion and 120 min of reperfusion) (Basalay 2012). Repeated daily RIPC for 28 days after MI reduces adverse LV remodeling and improves survival in a rat cardiac IRI (Wei 2011).

RIPC decreased myocardial damage in 42 patients with elective abdominal aortic aneurysm repair (Ali 2007). RIPC significantly decreased total serum troponin-T release at 6, 12, 24, and 48 h in 57 patients after elective coronary artery bypass grafting (CABG) and decreased 43% of troponin T area under the curve (Hausenloy 2007). Meta-analysis suggested that RIPC had an overall beneficial effect on cardiac damage biomarkers in 891 patients with CABG from13 trials (Yetgin 2012).

RIPC produced perioperative cardiac protection and ameliorated the prognosis in 329 patients with elective CABG surgery (Thielmann 2013). A meta-analysis of 8 randomized

controlled trials suggested that RIPC did not ameliorate the all-cause mortality at 30 days in patients with CABG surgery (Zhang 2014).

RPIC decreased MI size of ST-elevation MI (STEMI) patients with urgent revascularization by percutaneous coronary intervention (PCI) in five randomized trials (Rentoukas 2010). RIPC performed during ambulance transport increased median salvage index at 30 days in 333 patients with acute MI (Botker 2010). IPoC performed in the first minutes of reperfusion, decreased infarct size by 20% in 100 patients with primary PCI for anterior STEMI (Crimi 2013). RIPC decreased 30% concentration of biomarker released in STEMI patients. IPoC did not provide additional benefit (Prunier 2014). The protective effect of RIPC was verified in 197 STEMI patients by reducing 27% of MI size (White 2015). However, several large, multicentre, randomized, controlled clinical trials on cardioprotection have emphasized the challenges of translating ischemic conditioning cardioprotection strategies into patient benefit (Hausenloy 2016).

LUNG IRI ANIMAL MODELS

Lung IRI happens after lung transplantation, pulmonary thromboembolectomy, or cardiopulmonary bypass. Acute lung injury (ALI) causes the most serious symptom, the acute respiratory distress syndrome (ARDS) which is a clinical syndrome characterized by acute hypoxemic respiratory failure, bilateral pulmonary infiltrates consistent with edema, and normal cardiac filling pressures (Ware 2000).

Lung ischemia up to several hours is certain to happen during lung transplantation. Reperfusion of the transplanted lung can induce nonspecific pulmonary edema, alveolar damage and hypoxemia within 72 h after lung transplantation. 15% of the patients with lung transplantation encounter graft complications owing to lung IRI (de Perrot 2003).

IRI is a versatile pathological process that complicates the perioperative treatment of patients with lung transplantation. The most severe type can cause primary graft failure and is an important reason of morbidity and mortality after lung transplantation. Lung IRI generally shows quick damage in lung function after transplantation accompanied by fast progress of pulmonary edema, augmented pulmonary vascular resistance, and reduced airway compliance (Lee 2010). Lung IRI causes systemic effects in heart and liver and is distinguished by neutrophil sequestration and increased ROS in the circulation (Esme 2006; McMillen 1993).

Animal models can establish a bridge between clinical study and the preclinical investigation. Hypotheses produced in clinical investigations can be examined directly in animal models, and the results from in vitro investigations can be determined in animal models to evaluate their relevance in entire living systems. It is impossible to verify clinical hypotheses produced in clinical investigations and confirm the value of in vitro findings without animal models.

ALI animal models should replicate the mechanisms and consequences of ALI in humans, including the physiological adaptation and pathological alteration (Matute-Bello 2008). Single animal model cannot replicate all the features of human ALI/ARDS. Most of the animal models are associated with restricted features of human ALI/ARDS (Matute-Bello 2008).

ANIMAL MODELS OF LUNG IRI

Lung IRI models mainly include ventilated ischemia and anoxic ischemia. The most extensively applied models of lung ischemia are occlusion of the pulmonary artery, which keeps the venous return and bronchial circulation *intact,* and blockage of the hilum, which induces full ischemia and anoxia. The factors affecting the lung IRI models include animal species, desuflation vs. insuflation of the lung, the type of ischemia (hilum, pulmonary artery, venous return), experimental preparation (*in vivo* vs. isolated perfused lungs) and the length of both ischemia and reperfusion (Matute-Bello 2008). The lungs are perfused by two different vascular systems, the bronchial circulation and the pulmonary circulation. Ischemia can be induced by blocking the pulmonary artery, which maintains the bronchial circulation, or by occluding the hilum, which ceases all circulation.

Lung IRI induced by 2 h of ischemia and 2 h of reperfusion of the left lower lobe in cats triggered lung damage typified by the presence of neutrophils, macrophages, and RBCs in alveoli and alveolar edema (Neely 1995). Blockage of the pulmonary artery only causes less damage than obstruction of both the bronchial circulation and the pulmonary artery (Hamvas 1994; Pearse 1994). Reverse pulmonary venous circulation from the left atrium can happen if the hilum is not occluded, causing milder damage than full closure of the hilum (Hamvas 1992; Obermiller 1991). The degree of ischemia is also influenced by whether oxygenated air continues to ventilate the lungs while the circulation is occluded.

Ischemia without reperfusion in rabbit may or may not cause damage which is determined by the degree of inflation of the ischemic bed (Bishop 1994). When the reperfusion time remains persistent, such longer ischemic time induces worse lung damage in rats (Waddell 1996) and rabbits (Sakuma 1999). When the ischemic time is unchanging, the severity of damage increases with longer reperfusion time in cats (Neely 1995) and in rats (Khimenko 1996). So, ischemia and reperfusion times both influence extent of the following damage.

IRI can be performed either in vivo or in isolated lung preparations, and the experimental method does not seem to affect the development of injury. *In vivo* models enable the investigation of consequential alterations in the contralateral lung. Lung IRI results differ among species. Rabbits have been most extensively utilized in lung IRI models. In the dog, pulmonary postcapillary resistance was significantly increased after lung reperfusion (Jackson 1992). In rats, the permeability of the postalveolar venules was increased to cause lung edema *(*Khimenko 1999*)*. Lung IRI-induced lung damage is distinguished by raised pulmonary vascular permeability and edema, hemorrhage and PMN infiltration. The degree of damage is worse when the lungs keep deflated during the ischemic period and when the pulmonary and bronchial circulations are blocked simultaneously.

Nonpulmonary IRI

Nonpulmonary IRI was induced by occlusion of blood supply except the bronchial circulation and the pulmonary circulation. The nonpulmonary IRI models were reported mostly in mice and rats. Models varied according to the ischemic anatomic area, the ischemic time, and the reperfusion time. The severity of lung damage is often associated to the volume

of ischemic tissue than to the time of ischemia. Nonpulmonary IRI is usually reached by separating and blocking a specific artery for certain time and then starting perfusion. The superior mesenteric artery is the frequently utilized vascular bed in large animals (Fullerton 1996; Koike 1992; Koike 1995). Hindlimb ischemia was more commonly used in mice (Engles 1997; Welborn 1996). For example, 45 min of superior mesenteric artery occlusion induced moderate ^{125}I-albumin lung leak at 6 hr of reperfusion which was reversed at 18 hr in rats (Koike 1992).

ISCHEMIC CONDITIONING APPLICATION IN LUNG IRI ANIMAL MODEL

IPC induced by 10 min IR remarkably decreased the injured alveoli to 23 +/- 13% which was caused by 2 h ischemia and 2 h reperfusion which was similar to 2 h ischemia and 1 h reperfusion in cat (Neely 1995). IPC induced by one cycle of 5 min of IR prevented the vascular and biochemical alterations in response to lung IRI caused by 2 h of normothermic ischemia in rat (Yildiz 2007). RIPC induced by three cycles of 5 min bilateral hind-limb IR significantly reduced pulmonary edema and respiratory failure in pig acute lung IRI (2 h ischemia/2.5 h reperfusion) (Harkin 2002). RIPC by three cycles of 5 min left common femoral artery IR protected against acute lung IRI and pulmonary hypertension in pig acute IRI (1.5 h ischemia/5 h reperfusion) (Waldow 2005). Intestinal RIPC improved the lung IRI by decreasing myeloperoxidase, malondialdehyde, TNF-α, and interleukin-1 levels in the serum and lung tissue and by increasing the NO level in the serum and lung tissue in rats (Wang 2015). Intestinal RIPC improved the function of anti-oxygen free radical, suppressed the release of pro-inflammatory cytokines and reduced apoptosis in lung IRI in rats.

IPoC by three successive cycles of 30-s reperfusion per 30-s occlusion before restoring full perfusion reduced pulmonary neutrophil accumulation/activation and lung IRI (40 min of left-lung ischemia and 120 min of reperfusion) and decreased systemic inflammatory responses (Xu 2011). IPoC induced by three cycles of 30 sec reperfusion and 30 sec reocclusion at the onset of reperfusion improved acute lung IRI which was comparable to IPC in rat (Liu 2009). IPC was induced by 10 min Superior mesenteric artery (SMA) occlusion and 10 min reperfusion before prolonged occlusion. Delayed IPoC did not have the protective effect.

Three cycles of lower limb RIPC before allograft reperfusion were performed in the recipients. RIPC did not significantly improve partial pressure of arterial oxygen/fraction of inspired oxygen ratio in a randomized controlled trial of 60 patients with bilateral sequential lung transplantation (Lin 2014). RIPC-treated group had less primary graft dysfunction and acute rejection. Anyway, the results in this small study warrant a large multicenter trial of RIPC in lung transplantation. RIPC provided pulmonary protection in 62 patients after elective open infrarenal abdominal aortic aneurysm repair (Li 2013).

LIVER IRI ANIMAL MODELS

Liver IRI is a main reason of liver impairment during liver transplantation and liver resection (Fondevila 2003; de Rougemont 2010). During liver resection, in-flow vascular occlusion for reducing intraoperative blood loss may induce warm liver IRI. In orthotopic liver transplantation, the liver undergoes cold–rewarming IRI when the donor liver is reperfused in the recipient (de Rougemont 2010).

Animals from pigs to mice can be used to investigate the complex biological processes of hepatic IRI and evaluate the protective effect of treatment agents. The animal studies can be used as a reference for human study with some limitations. The limitations include anatomical differences of the livers of various species and subspecies, the differences in hypothermia and ischemia tolerance and the experimental models differences. So, it is extremely vital to select the appropriate animal species and experimental model and to standardize the protocol according to the study.

The advantages of mice and rats include minimal logistical, financial or ethical problems, and availability for genetic alterations studies. Nevertheless, the disadvantage is that the results obtained from small animals are of restricted relevance to human beings because of their variable size and anatomy of the liver and their faster metabolism (Abdo 2003). The age and sex of the animals need to be considered. Remarkable variations in hepatic microcirculation were observed between young and older rats (Yahanda 1990).

14–16 weeks old rats are the most appropriate for liver IRI study. The younger rats may have technical problems and the older rats are more susceptible to fat accumulation and respiratory infections. Gender also influences experimental results. Hormone levels in female animals are dependent on the estrous cycle which definitely changes the ischemia tolerance of the liver. The male rats were less sensitive to IRI than female rats after normothermic liver ischemia (Gasbarrini 2001).

Partial Liver IRI

Partial hepatic IR I was developed by occlusion of the hepatic artery, the portal vein and the bile duct of the left and median lobes for 60–120 min and 24 hr reperfusion in rats (Yamauchi 1982). This 70% partial ischemia model has been generally used for hepatic IRI study (Massip-Salcedo 2008, Casillas-Ramirez 2008). Furthermore, a 30% partial liver ischemia model has been established to block the blood supply to the right lobe of the liver by occlusion of the hepatic artery and portal vein (Peralta 2000).

Partial hepatectomy under IR is usually performed to control bleeding during parenchymal dissection in clinical practice. Hepatic regeneration and IRI animal model is utilized to imitate the clinical situation of selective or hemihepatic vascular occlusion for liver resections. The portal triad supplying the median lobe is blocked by microvascular clamp after resection of left hepatic lobe in animal model. The congestion of the bowel can be avoided during the ischemic period by maintaining the portal flow through the right and caudate lobes. The right lobe and caudate lobes are removed at the end of ischemia. Reperfusion of the median lobe is achieved after the clamp is removed. This model does not

need any portal decompression and also achieves some major standard such as good duplicability, reversibility, and easy operation (Selzner 1999, Ramalho 2009).

Total Hepatic IRI with Portocaval Decompression

Total hepatic IRI with portal decompression closely imitates the clinical situation of warm ischemia after the Pringle maneuver for liver resection and liver transplantation. The portacaval shunts for portal hypertension was first developed in rats (Blakemore 1945). Then a simple technique for portocaval shunt in the rat was reported (Bernstein 1959). Portosystemic shunt transferred the portal blood to the iliac vein after functional hepatectomy. The splenocaval shunt was developed in rat (Spiegel 1995). A portofemorojugular bypass was used in pigs (Uhlmann 2003).

Total Hepatic IRI with Spleen Transposition

Total hepatic ischemia with spleen transposition was first established in rats for the surgical treatment of portal hypertension (Bengmark 1970). The spleen was relocated to a subcutaneous pouch. Acceptable portosystemic anastomoses was performed 2–3 weeks later. The spleen transposition produced reversal of blood flow in the splenic vein and triggered angiogenesis. An easy and simple experimental rat model of total hepatectomy, hepatic ischemia and extrahepatic portal obstruction was established in rat (Omokawa 1991). The spleen with its scarified capsule was firstly relocated to a subcutaneous pouch to perform portasystemic anastomosis. Total hepatectomy was easily carried out in a lobe-by-lobe fashion 2 weeks later. Anhepatic rats with a glucose infusion survived for 10 hours and all died of acute hepatic failure. Sixty minutes of hepatic ischemia was done in rats with a spleen transposition for a portasystemic shunt (PSS). The long time interval (3 weeks) for the establishment of satisfactory portosystemic collaterals is the disadvantage of this model. Total hepatic IRI with PSS using a 1-mm inner diameter tube was strongly comparable to partial hepatic ischemia in the pathophysiological profile during hepatic ischemia in rats. Rats without PSS badly endured 30 min of total hepatic ischemia. Rats with PSS or partial hepatic ischemia survived 60 min of total hepatic ischemia (Suzuki 1998).

Total hepatic ischemia in the mouse was first established by partial hepatectomy with clamping of the remnant liver (Yadav 1998). A partial (30%) hepatectomy was carried out with resection of the caudate, right lateral, and quadrate lobes and papillary process. The pedicles of the median and left lateral lobe at the level of the hilum were blocked by vascular microclamps to reach total ischemia. Spontaneous portocaval shunts through caudate branches and collateral vessels prevented mesenteric congestion. All animals survived 60 min of ischemia. However all animals died after 90 min of ischemia.

Different factors need to be considered before the selection of an experimental model of hepatic IRI. The severity of hepatic IRI is decided by the ischemia time (González-Flecha 1993). It is better to utilize an ischemia time with high survival for investigating the hepatic IRI mechanisms or the protective mechanisms of an agent. The ischemia time with low survival is more suitable for the relevance study of a drug in hepatic IRI. 60 min of warm ischemia caused reversible cell injury. Liver oxygen consumption recovered to control levels

after reperfusion. 120–180 min warm ischemia induced irreversible cell damage after reperfusion. 90 min of ischemia was the cellular endpoint for hepatocytes (González-Flecha 1993).

ISCHEMIC CONDITIONING APPLICATION IN LIVER IRI ANIMAL MODEL

IPC was induced by 10 minutes ischemia and 10 minutes reperfusion prior to 60 minutes of ischemia in rat and mice model of hepatic IRI. IPC reduced liver IRI, as shown by lower hepatic inflammatory cytokines, lower serum aminotransferase levels, and less severe IR-related histopathologic alterations (Liu 2014). IPC protected against hepatic IRI, at least in part, by heme oxygenase-1-mediated autophagy. The proof from systematic review demonstrated that IPC conferred a protective impact in experimental steatotic livers with IRI which improved the survival and reduced histological injury (Chu 2015).

RIPC as a liver protective approach was first reported in rat left lobe of liver IRI (45 min ischemia/240 min reperfusion) (Lai 2006). RIPC by four 10-min cycles of IR to hind limb significantly reduced plasma alanine aminotransferase which was related to the induction of hemeoxygenase-1 (Lai 2006). Different RIPC protocols were used to verify the protective effects of limb RIPC against acute liver IRI in the rat, rabbit and mouse (Tapuria 2009; Kanoria 2006; Abu-Amara 2012). RIPC by four cycles of 4 min hind limb IR significantly increased sinusoidal flow, sinusoidal perfusion, red blood cell velocity, and reduced neutrophil adhesion and cell death in rat partial hepatic ischemia IRI (45 min ischemia/3 h reperfusion) (Tapuria 2009). Hemeoxygenase-1 had an important role in regulating hepatic microcirculation and endothelial function.

Liver IRI (25 min ischemia/120 min reperfusion) in rabbits increased serum aminotransferases and decreased mean arterial blood pressure, hepatic blood flow and peripheral oxygen saturation (Kanoria 2006). RIPC by three cycles of 10 min hind limb IR significantly improved these parameters and considerably increased hepatic venous nitrate/nitrite. RIPC by six cycles of 4 min hind limb IR significantly increased hepatic microcirculatory blood flow and reduced plasma transaminases in mice partial liver IRI (40 min ischemia/120 min reperfusion) (Abu-Amara 2012). The hepatic soluble guanylyl cyclase-cyclic GMP pathway was needed for mediating the protective effects of hind limb RIPC on hepatic microcirculatory blood flow in mice liver IRI.

In rat liver IRI model (30 min ischemia and 30 min reperfusion), 172 genes were found as the most highly affected, and these genes demonstrated similar patterns regarding the up- and down-regulated expression levels among IPC, IPoC, and IPC + IPoC groups (Knudsen 2012). IPC, IPoC, and IPC + IPoC demonstrated significant impacts on the expression levels of a large number of genes during early reperfusion. IPC, IPoC, and IPC + IPoC seem to effectuate their protective effects by adjusting the same genes and genetic networks (Knudsen 2012). These recognized networks are involved in keeping cellular homeostasis.

PANCREASE IRI ANIMAL MODELS

Pancreas transplantation is the most effective long-term treatment for insulin-dependent diabetes mellitus. However, long-term pancreas survivals are remarkably lower compared to other whole organ allografts. Increased sensitivity to IRI may, in part, be responsible for this clinical difference by direct damage to the allograft. IRI is the original stimulus for organ injury after transplantation. Tissues are susceptible to cold and warm ischemic injury before transplantation. Also damaged cells then are potent stimuli for the innate immune system which may induce the activation and maturation of alloreactive T and B cells and destroy the allograft damage (Brennan 2010). IRI may finally trigger acute rejection of the transplanted organ.

A mouse pancreatic IRI model was developed for the first time to distinguish the histologic and biochemical impairment related to IRI and to estimate the immunologic markers of ischemic injury to the pancreas in 2013 (Lunsford 2013). Total pancreatic ischemia induced by occlusion of the superior pancreaticoduodenal artery, inferior pancreaticoduodenal artery, and lieno-pancreatic artery for 10 minutes caused high mortality. Distal pancreatic ischemia induced by occlusion of the lieno-pancreatic artery and the lienal artery for 30 minutes caused time-limited and reversible pancreatic inflammatory process. Perceptible ischemic changes reversed after reperfusion. Serum amylase and lactate dehydrogenase reached the peak at 6 hour and returned to normal range by 120 hour after IRI. Biochemical evidence of inflammation was detected. Noticeable inflammation was observed by histologic scoring. Time-limited pancreatic inflammation and damage was detected by histologic and biochemical indices in this new mouse distal pancreatic IRI model.

Complete pancreas IRI rat model was first developed by occlusion of the four blood-supplying arteries (left gastric artery, gastroduodenal artery, splenic artery, and caudal pancreaticoduodenal artery) to the pancreas in 1995 (Hoffmann 1995). The complete pancreas IR caused pancreatic microvascular failure. The severity of changes was determined by duration of ischemia and duration of reperfusion. The morphological and biochemical changes showed that IR induced an inflammatory reaction similar to that of acute pancreatitis.

The whole rat pancreas ischemia was induced by occlusion of the left gastric artery, gastroduodenal artery, splenic artery and caudal pancreaticoduodenal artery with microvascular clip for 1 or 2 hours (Neeff 2012). The pancreas is highly susceptible to ischemic damage. IR of the pancreas caused acute pancreatitis in rats (Dobschuetz 2008; Lo 2009). IR induced an inflammatory reaction similar to acute pancreatitis. The rat pancreas IRI was induced by occlusion of the splenic and the gastroduodenal artery for 2 hours followed by reperfusion for 6 hours (Lo 2009). The superior and inferior pancreaticoduodenal arteries with vessels of the splenic artery were occluded using microvascular clamps for 30 minutes in rabbits. The reperfusion period was 30 minutes (Apostolidis 2012).

ISCHEMIC CONDITIONING APPLICATION IN PANCREAS IRI ANIMAL MODEL

Combined pancreas–kidney transplantation has been successfully implemented for patients with type 1 diabetes and end-stage renal failure (Wynn 2004). This operation can be

complicated by graft pancreatitis, a contributing factor for which is acute IRI, resulting in graft loss (Büsing 1993). RIPC by 15 min of infrarenal aortic ischemia and reperfusion could protect the pancreas against acute IRI as evidenced by improved circulation, reduced inflammatory tissue response and histological damage (Oehmann 2007). RIPC could be one approach to ameliorate organ procurement in pancreas transplantation.

RIPC-mediated protection against acute pancreatic IRI has been confirmed by a subsequent study (Nikeghbalian 2009). RIPC of liver was performed by first clamping of the hepatic pedicle for 10 minutes in rats. Following this, IR of the pancreas was induced by first clamping the inferior splenic artery for 30 minutes, followed by reperfusion for one hour. RIPC of the liver decreased the severity of IR-induced pancreatitis (Nikeghbalian 2009). These effects were partly associated with the decrease of pro-inflammatory interleukin-1 beta. However, the protective effect of RIPC was not observed in rats (Warzecha 2008). RIPC was carried out by occlusion of femoral or renal artery twice for 5 min with 5 min interval. RIPC had no effect on pancreatic exocrine secretion and did not decrease the severity of IR-induced pancreatitis in rats (Warzecha 2008).

GASTRIC IRI ANIMAL MODELS

Stomach is one of the most vulnerable organ systems to ischemia. Gastric IRI is a major and usual clinical situation which could cause mucosal injury. Gastric IRI was induced by different clinical situations which included hemorrhagic shock, peptic ulcer bleeding, ischemia gastrointestinal disease and vascular rupture or surgery (Guo 2014). Gastric IRI is a quite common condition causing mucosal damage and may influence mucosal repair by regulating the gene expression of growth factors. Thus, accurate comprehension of the molecular mechanism of IRI may help to explore new mucosal protective agents.

The gastric IRI rat model was developed. The celiac artery was exposed through abdominal midline incision and clamped for 80 min (Mogami 2012) or 30 min (Kyoi 2004) in rat. Reperfusion was initiated for 12 h or 48 h after 80 min ischemia (Mogami 2012). The gastric IRI mice model was also established. Gastric IRI was induced in mice by 30 min celiac artery clamping and 60 min reperfusion. Macroscopically visible injuries were constantly found in the stomach 60 min after the inception of reperfusion following ischemia for 30 min (Nakamori 2010).

ISCHEMIC CONDITIONING APPLICATION IN GASTRIC IRI ANIMAL MODEL

IPC was produced by two 5 min episodes of celiac artery occlusion and 10 min reperfusion. IPC increased plasma corticosterone and reduced the gastric damages caused by prolonged gastric IR (30 min occlusion of celiac artery and 3 h of reperfusion) in rats (Bobryshev 2009). RIPC by two cycles of 5 min myocardial or hepatic IR was first reported to protect gastric mucosa against severe gastric IRI (3h ischemia/3h reperfusion) as efficiently as gastric preconditioning (Brzozowski 2004A; Brzozowski 2004B) in rat.

Gastric IRI was induced by putting an elastic rubber band on the proximal part of the bilateral lower limb for ligature for 3 h and reperfusion for different period in rats (Wang 2011, Wang 2014). IPoC by three cycles of 30-s reperfusion and 30-s femoral aortic reocclusion were performed before reperfusion. IPoC decreased post-ischemic oxidative stress (Wang 2011). RIPC was carried out by three cycles of 30 s of reperfusion and 30 s of reocclusion of the femoral aortic immediately after gastric IR and before reperfusion for up to 24 h. RIPC provided effective functional protection and prevented gastric IRI by anti-inflammatory and antioxidant actions (Wang 2014).

INTESTINE IRI ANIMAL MODELS

The survival rate of patients with ischemic intestinal damage is usually less than 50% (Gregory 2011; Yasuhara 2005). Intestinal ischemia is related to different clinical conditions including hemorrhagic shock (Corcos 2013; Fishman 2014), trauma (Corcos 2013), cardiopulmonary disease (Sastry 2014), acute mesenteric ischemia (Yasuhara 2005), neonatal necrotizing enterocolitis (Nankervis 2008), volvulus (Schwartz 2013) and intestinal transplant rejection (Mallick 2004). Different intestine IRI animal models are decribed below.

Complete Vascular Occlusion

Intestinal IRI model is usually produced by temporary vascular occlusion of the SMA with atraumatic vascular clamps or permanent vascular ligation of SMA. The SMA is exposed through a midline incision and blocked for a period of time (Ikeda 1998). Heparin is administered intravenously to prevent thrombus formation within the SMA and the circulation is reestablished after the atraumatic vascular clamps are released. SMA occlusion only was not reliable in inducing consistent and reproducible injury. SMA occlusion combined with ligation of collateral arcades caused a higher degree of injury and a greater but consistent level of mortality in the animals (Megison 1990). SMA blockage caused blood flow decrease of 63% in the proximal colon, 71% in the jejunum and ileum, 61% in the distal duodenum and 35% in the proximal duodenum. Blood flow decrease was not found in the mid and distal colon (Premen 1987). So the effect of SMA blockage is mainly dependent on the intestinal segment. The intestine segments may have different sensitivity to ischemic injury. The colon was more resistant to ischemia injury compared to intestine in rats (Leung 1992). The advantages of SMA ligation animal model are representation of occlusive causes of ischemia and easy to establish surgical model. The main disadvantages of SMA ligation animal model include 1) intestine segments resist differently to ischemic injury (Robinson 1981; Leung 1992; Chen 2013) and 2) undependable to produce constant damage and high mortality rate (Megison 1990).

SMA Embolization

A complete irreversible ischemia was reported in a porcine model by SMA embolization. The SMA was approached either by endovascular catheterization (Acosta 2007; Rosow 2005) or via percutaneously (Klein 1996). These models are especially helpful for imaging investigations to improve diagnosis in patients suspected of acute mesenteric ischemia (AMI). AMI is a complex of diseases and includes occlusive AMI or nonocclusive AMI. Occlusive AMI can be separated to acute or chronic and whether veins or arteries are influenced. Nonocclusive AMI damages all types of mesenteric ischemia with patent mesenteric arteries. It is usually related to patients over 50 years of age with aortic insufficiency, congestive heart failure myocardial infarction, renal disease, hepatic disease or undergoing cardiac surgery (Trompeter 2002). Nonocclusive AMI composes 20−30% of AMI with a mortality rate of 50%.

The advantages of SMA embolization animal model include representation of occlusive causes of ischemia, non-manipulation of intestinal tract (Acosta 2007, Block 2011) and perfection for diagnostic imaging studies. The disadvantages of SMA embolization animal model include only arterial supply blocked, poor model of chronic ischemia, need for advanced surgical technique, requirement of large animal and irreversible ischemia, prohibiting study of reperfusion.

Low-Flow Ischemia

Most of the original low-flow ischemia investigations were carried out in cats (Granger 1986; Kubes 1992; Nilsson 1994; Acosta 2007). This model well represents the type of intestinal injury induced by hemorrhagic shock or other events that greatly decrease‐blood supply to an intestinal segment. In the low-flow ischemia model, blood flow is decreased to 20% of baseline levels (25–35 mmHg). A segment of ileum is typically separated by a midline incision. An arterial route is produced between the superior mesenteric and femoral arteries and pressure cannulas are utilized for vascular pressure measurement. Reduced blood pressure within the SMA (25–30 mmHg) is reached by application of an adjustable vascular clamp. Most damage related to this model has been attributed to reperfusion as a result of elevation in xanthine oxidase and neutrophil activation. It may not sufficiently represent clinical scenarios, in which injury induced by ischemia may be so severe that reperfusion injury is of limited significance.

The advantages of low-flow ischemia animal model include representation of nonocclusive causes of ischemia and ameliorated model of reperfusion injury. The disadvantages of low-flow ischemia animal model include increased difficulty of surgery and minimal ischemic injury.

Segmental Mesenteric Vascular Occlusion

Intestine ischemia model can be induced by segmental mesenteric vascular occlusion in which the blood flow within a discrete loop of intestine is interrupted by clamping the local mesenteric vascular supply and cross-clamping the bowel. In one animal, multiple loops can

be undertaken to different lengths of ischemia with or without reperfusion, thus quantifing the degree of injury within each loop. It is not difficult to establish this model in pigs and in rodents (Grootjans 2013a; Grootjans 2013b). The advantage of this model is to provide multiple treatment groups and controls within a single animal. But, this model of strangulating obstruction depends on full occlusion of the arterial and venous blood supply. In clinical situation, the venous circulation is usually damaged before the arterial blood supply due to differences in vessel wall thickness and compliance (Park 1990). The animal species utilized may contribute remarkably to the outcome. Variations of the mucosal vascular supply in the small intestine exist among species. The pig and human villus microvascular architecture are extremely comparable (Bellamy 1973, Casley-Smith 1984). The mesenteric vascular differences may affect the physiological function of the intestinal mucosa among species and likely their sensitivity to injury. Intestinal permeability studies have shown remarkable differences between rodents and humans and considerable correlation between pigs and humans (Delahunty 1987; Bijlsma 1995).

The advantages of segmental mesenteric vascular occlusion animal model include representation of occlusive causes of ischemia and establishment of multiple loops of different duration of ischemia in one animal. The disadvantage of segmental mesenteric vascular occlusion animal model includes ligation of venous and arterial supply. Appropriate experimental design and data interpretation can be achieved according to the advantages and disadvantages of each model.

ISCHEMIC CONDITIONING APPLICATION IN INTESTINE IRI ANIMAL MODEL

RIPC of the rabbit heart was the first report to have the protective effect on jejunal intestinal contractile function in a model of sustained (1 h) simulated ischemia in isolated, spontaneously contracting rabbit jejunum (Dickson 2002). RIPC by 15-min infrarenal aortic occlusion and reflow could protect against intestinal IRI in rats receiving small bowel transplantation as effective as IPC (Saeki 2011).

Surgery for the abdominal aorta disease induced intense and unexpected hemodynamic modifications caused by aortic clamping and unclamping (Eide 2005). The IRI of the splanchnic organs is the major complication of abdominal aorta occlusion (Cornet 2009). The intestine is very susceptible to IRI which is important in the induction of systemic inflammation response syndrome and multiple organ dysfunction syndrome (de Arruda 2006; Zanoni 2009). It is the important reason of morbidity in patients with major aortic repair (Back 2005). Supraceliac aortic occlusion reduced intestinal mucosal length by decreasing villous height and increased serum lactic dehydrogenase and lactate levels in rats. Both IPC and RIPC alleviated these histopathological and laboratory changes in rats (Erling Junior 2013). RIPC provided intestine protection in 62 patients after elective open infrarenal abdominal aortic aneurysm repair (Li 2013).

SPINE CORD IRI ANIMAL MODELS

The neurological function after spinal cord IRI could not be ameliorated, and the irreversible and delayed death of spinal neurons happened (Weir 2002). Spinal cord IRI is a usual problem after thoracic or thoracoabdominal aortic surgery (Kuniyoshi 2003). 400,000 spinal cord injury (SCI) patients in the United States and 14,000 new cases every year were reported (Sekhon 2001). Spinal cord IRI patients have a poor prognosis, usually resulting in severe paralysis or mortality (Sinha 2010).

Experimental work can improve the understanding of spinal cord ischemia and develop new methods to protect spinal cord during extensive aortic surgery. The consequence of spinal cord injury during and after aortic surgery is determined by the duration and degree of ischemia, failure to reestablish blood flow to the spinal cord after repair and biochemically-mediated reperfusion injury (Svensson 1997). Spinal cord IRI animal models have been established to explore the mechanisms involved in rat (Taira 1996), rabbit (Naslund 1992), pig (Qayumi 1997) and mice (Lang-Lazdunski 2000).

Rat Spinal Cord IRI Model

An aortic cross-clamping technique was utilized to produce the rat spinal cord IRI model (Lang-Lazdunski 2000). A longitudinal incision was performed along the left vertex of the sternum to the third rib. The aortic arch was isolated from the left common carotid and subclavian arteries. Attention was paid to avoid the left internal mammary artery, the left superior vena cava and the left recurrent laryngeal nerve. Heparin (100 UI/kg) was given intravenously 10 min before aortic clamping. The left subclavian artery and aortic arch were blocked simultaneously by micro-artery clamps. The artery clamps were removed after 14 min for reperfusion.

Mice Spinal Cord IRI Model

The application of genetically modified mice promotes understanding of pathological mechanisms in many diseases and improves therapy development. It is now possible to evaluate the effects of spinal cord IRI on specific genes and molecular signaling pathways.

The first spinal cord mice IRI model was established in 2000 (Lang-Lazdunski 2000). The anesthesia was induced and maintained by 2% isoflurane. A cervicothoracic procedure was utilized to isolate the aortic arch. The aortic arch was clamped between the left subclavian artery and the left common carotid artery. An additional clamp was put on the left subclavian artery (Lang-Lazdunski 2000). The clamps were removed 5 minutes after ischemia. This model was used infrequently because the surgical technique was difficult and mortality after surgery was high. Survival is limited to less than 1 week and paralysis happens often immediately. In order to control consistently different outcomes of spinal cord IRI model, a simple and reproducible mouse model of spinal cord IRI was developed by transient cross-clamp of the descending aorta through a lateral thoracotomy (Awad 2010).

The beginning and extent of paralysis is decided by aortic cross-clamp time and the intraoperative core temperature that was kept during the period of ischemia. By modifying these parameters, mice can be consistently stratified into two groups: 1) immediate and severe paralysis; and 2) delayed paralysis which mimicks the phenomenon of humans undergoing similar surgery (Awad 2010). This new model will enable the screening of neuroprotective therapeutics and will help disclose basic mechanisms of post IR pathology and functional impairment induced by aortic cross-clamp (Awad 2010).

Transient Cross-Clamp at the Descending Aorta (Awad 2010)

Intubated mice were put on their right side and the left forelimb was placed and fixed laterally beneath the mandible. The rib cage is exposed by a transverse incision performed below the left forelimb and shoulder. Muscle between the 2nd and 3rd rib was cut to fully expose the inferior vena cava, descending aorta, thymus and left atrium. The descending aorta was separated and blocked by a small aneurysm clip across the vessel. Aortic cross-clamp was kept for 3–11 minutes.

A simplified mouse spinal cord IRI model was reported recently (Wang 2010). Mice were anesthetized with isoflurane and endotracheally intubated. The middle segment of the thoracic aorta was blocked by cross-clamping for 0, 8, 10 or 12 min via left lateral thoracotomy. 90% blood flow reduction was detected in the lumbar spinal cord. Neuronal cell death and neurological deficit were related to the ischemia time. 80% of mice with 10 min aortic clamping survived for 28 days and had significant neurological deficit.

ISCHEMIC CONDITIONING APPLICATION IN SPINE CORD IRI ANIMAL MODEL

The incidence of temporary or permanent spinal cord injury still fluctuates between 3% and 20% after extensive thoracoabdominal aneurysm repair (Murana 2015). Paraparesis and paraplegia still happen after the surgery. The beneficial effect of RIPC was shown in rabbit spinal cord IRI (Sapmaz 2015). RIPC and IPoC remarkably ameliorated the neurological outcomes in rabbit spinal cord IRI (Sapmaz 2015). RIPC and IPoC significantly reduced percentage of apoptosis and intracellular edema. Hind limb RIPC preserved spinal cord function after left subclavian artery and segmental artery occlusion in a porcine model, as indicated by the motor-evoked potential amplitudes (Haapanen 2016).

CEREBRAL IRI ANIMAL MODELS

Cerebral IRI causes wide-ranging damage and is associated with morbidity and mortality. Stroke and cardiac arrest are the main reason for cerebral IRI in adults. Cerebral IRI is induced by complications during labor and delivery which may cause neonatal hypoxic-ischemic encephalopathy in infants.

Stroke is the third most important cause of disability and death in USA (Lloyd-Jones 2010). Strokes are most frequently ischemic in origin, induced by vascular blockage in the cerebral circulation. Stroke causes a focal brain injury.

Another important cause of Cerebral IRI is cardiac arrest followed by resuscitation. Cardiac arrest induces full ischemia in the whole brain. 70,000 patients are resuscitated from cardiac arrest each year and 10–35% of resuscitated patients survive to hospital discharge with the severe brain damage induced by cerebral IRI (Bloom 2007; Nichol 2008).

Animal Models of Localized Hypoxic-Ischemic (HI) Injury and Stroke

The complex cascade of events after global and focal HI brain injury shares certain similarities to the development of injury. The difference is depending on brain regions affected. It is not easy to translate the animal results to clinical practice. Neonatal stroke is a complicated pathophysiologic process that is inadequately understood and difficult to study.

Rice-Vannucci model (RVM) is the most frequently used model to investigate HI injury in the newborn. Unilateral carotid ligation was performed in the postnatal day 7 rat with exposure to 8% hypoxia for approximately 1.5 hours results in a reproducible area of hemispheric ischemic injury (Rice 1981). The rat brain at the postnatal day 7 is histologically similar to a 32- to 34-week gestation human fetus or newborn infant (Vannucci 1997). This method was applied to explore neonatal asphyxia in rat pups, piglets, dogs and kittens (Roohey 1997). A model of neonatal stroke was established by 4 hours middle cerebral artery occlusion and 24 h reperfusion without craniectomy in rat pups (Ashwal 1995). The advantage of this model is relatively noninvasive, focal brain hypoxia and temporary occlusion.

The most frequent types of ischemia-related injuries in preterm human babies (23–32 weeks of gestation) include periventricular white matter injury (WMI), periventricular leukomalacia (PVL), intracerebral hemorrhage (ICH) and intraventricular hemorrhage (IVH) (Volpe 2009). Ischemic injury at-term brain is different from those in preterm newborns. The injury at-term brain is displayed focally in gray matter regions (Kirton 2011).

Perinatal arterial ischemic stroke happens between 20 weeks of gestation to 28 days postnatal. The incidence is 1 in 2300 live infant births. Perinatal arterial ischemic stroke causes remarkable morbidity and severe lasting cognitive and neurological adeficits including neurodevelopmental disabilities, epilepsy, cerebral palsy, impaired vision and language function (Nelson 2007).

Animal Models for Ischemia-Related Preterm and Term Injury

Different models of hypoxia-ischemia, hypoxia, IVH and focal stroke have been established in small and large animals to imitate ischemic injuries observed in the human infant.

Large Animal Models

A birth asphyxia model was established in non-human primates by 15-18 min of umbilical cord occlusion (UCO) prior to birth (Traudt 2013). UCO caused death or moderate-severe cerebral palsy in 43% of animals. UCO animals showed poor weight gain, poor cerebellar growth, behavioral impairment and abnormal brain diffusion tensor imaging (DTI) (Traudt 2013). But the cost limited the use of non-human primate model.

The most frequently applied large mammal species to produce HI in the premature brain are pigs, sheep and rabbits. These mammal species have a white/grey matter ratio similar to the human brain.

Cerebral ischemia models in fetal sheep were first established in the near term fetus by bilateral transient occlusion of the carotid arteries (Williams 1992). The intrauterine pathophysiology and the contribution of other organs on the brain could be investigated in fetal sheep UCO model. WMI and deep grey matter injury was more observed in the preterm fetuses of these models (Mallard 1994). However, fetal models are complicated by maternal/placenta metabolism, which is not present in the human situation of hypoxic-ischemic encephalopathy (HIE). Newborn pigs with different combinations of hypoxia and ischemia demonstrated alterations in metabolism and cerebral blood flow (CBF) comparable to that detected in human infants with HIE (Laptook 1988). The HI models induced by temporary common carotid arteries occlusion/hypoxemia in newborn pigs (Thoresen 1995) and 30 min of cerebral ischemia in fetal sheep (Gunn 1997) have been involved in development of therapeutic hypothermia for term infants with HIE.

A majority of cerebral palsy cases are induced by prenatal HI. Rabbits have many advantages compared to other animal species; mainly, their motor development is in the perinatal period, similar to humans. Intrauterine ischemia is caused at 22 days gestation in rabbits as equivalent to the preterm, and at 29 days gestation to simulate at-term injury (Derrick 2007). HI in preterm rabbits causes impairment predominantly in subcortical areas, such as thalamus and basal ganglia ((Derrick 2007). This model has shown a correlation between abnormalities on neuropathology and cerebral palsy-like hypertonic motor deficits and MRI in the newborn pups.

Rodent Models

Much rodent brain development happens after birth as in human. Different regions of the rodent brain mature at a dissimilar pace. It is not easy to follow a single postnatal day as a complete presentation of brain development in human. Comparative studies between rodents and humans have shown that the rodent brain at postnatal day 1 – day 5 is equivalent to 23–32 weeks of gestation in the humans which is appropriate for investigation of preterm injury. The rodent brain at postnatal day 7 – day10 is equivalent to 36–40 weeks of gestation in humans which is acceptable in brain injury investigation at term (Semple 2013). WMI models established included unilateral common carotid artery ligation and hypoxia in postnatal day 1 – day3 rat, (Sheldon 1996; Back 2002), prolonged low grade gestational hypoxia (Baud 2004) and ibotenate injection in postnatal day 5 rats (Gressens 1996). HI model was established in postnatal day 7 rats (Rice 1981) and postnatal day 7–9 mice (Ek 2015) which was able to

mimic HIE in the at-term human infant and acquire information about the pathophysiology of the disease.

HI increased blood-brain barriers (BBB) permeability to small and large molecules within hours after the HI (Ek 2015). Brain pathology was closely associated with decreases in regional CBF during the hypoxia. HI caused inflammation which contributed to the development of injury in the newborn brain (Doverhag 2010).

Genetic background (Sheldon 1998) and sex may impact mechanisms of neuronal cell death and damage severity (Johnston 2007). Various models have been developed to investigate the underlying mechanisms of perinatal arterial stroke, including models of irreversible middle cerebral artery (MCA) ligation (Renolleau 1998) and temporary MCA occlusion (tMCAO) in postnatal day 7–10 rats (Derugin 1998; Mu 2003) and postnatal day 9 mice (Woo 2012). Different severity of damage can be induced by the varied length of tMCAO (Woo 2012). The presence of recirculation in the tMCAO model (Fernandez 2012) imitates reperfusion, which often happens in arterial stroke in term infants.

Large animal cerebral ischemia models would be very appropriate in translational research because the white/grey matter ratio is comparable to the human brain and the brains are gyrencephalic. In neonatal models, newborn pigs are most suitable because their general brain and organ maturation at term are alike to that of humans. Global models combined with global hypoxia and hypotension have been established which cause permanent brain injury, organ failure, post-hypoxic seizures and abnormal neurology, alike to humans on survival. But, maintenance cost and long-term neurorehabilitation have greatly restricted the application of larger animals.

Rodents are not gyrencephalic species and their physiology, CBF regulation and white/gray matter ratios are extremely dissimilar from those in humans. These differences between rodents and human limit the translatability of investigations in rodents.

Cerebral palsy (CP) is a complicated multifactorial disease which influences about 2.5–3/1000 live term births and 22/1000 prematurely born babies. CP is associated with damage to the developing brain experienced before, during, or after birth. Spastic CP, the most frequent type, is mainly connected to damage of the cerebral cortex and subcortical white matter and the deep gray matter. HI during the last third of pregnancy and around birth age is the main etiological factors of spastic CP.

The rodent HI model is the most appropriate, cost-effective, and extensively utilized animal model and has provided considerable knowledge on CP pathophysiology. But, investigation in large animals with greater similarity to humans was provoked due to the shortcomings of the rodent HI model. In the fetal instrumented sheep model, preterm fetus (95 days of gestation) was similar to 24–28 gestational weeks in humans which showed cerebral hemodynamics comparable to that in the human fetus, both in normal conditions (Papile 1985; Helou 1994) and in response to HI (Mallard 1992; Bennet 1998). Furthermore, the gyrencephalic structure of the sheep brain cerebrum and the important stages of neurodevelopment are equivalent to those in humans (Cook 1987). Long-term monitoring of the fetus and pertinent clinical interventions was established in large sheep according to that model (Gunn 1997).

The main disadvantage of the instrumented fetal sheep model is inability to investigate motor deficiencies, especially dexterity movements, related to HI injury (Back 2012). A non-human primate model established in baboons at 125 days of gestation, comparable to 26 weeks of gestation in human, has demonstrated equivalences with human preterm infants in

the pattern of white matter damage (Griffith 2012). A HI model in a newborn piglet has shown neuropathological and electro-physiological disturbances comparable to those in the asphyxiated term human infant (Thoresen 1996). The model can imitate similar alterations in brain white matter to a human newborn (Kyng 2015). But, high mortality and differences in protocols cause instability in the extent of brain damage. The firm conclusions are difficult to make.

Ischemia-related damage to prenatal or early postnatal brain affects many critical neurodevelopmental processes that experience maturation alterations during these time frames, causing different structural-functional abnormalities later in life. Application of several IRI models from small and big animals allows the improved understanding of brain pathology and development of novel therapies for the immature brain because no single animal model can entirely summarize the complexity of the human condition.

Neurological injury after global brain ischaemia is still problematic. However, sudden death models bring undesirable factors for investigating the brain due to multiple organ injury. A new minimally invasive large animal model of isolated global brain ischaemia was developed by carotid and vertebral arteries occlusion for 30 min of normothermic ischemia in pigs (Allen 2012). Cardiac or pulmonary function was not affected. Multiple post-reperfusion seizures, post-brain oedema and extensive cerebral infarctions were found in this model.

ISCHEMIC CONDITIONING APPLICATION IN CEREBRAL IRI ANIMAL MODEL

IPC is really the best known strategy to prevent or reverse neurodegeneration (Lehotský 2009). IPC has confirmed so far to be one of the most successful infarct-limiting strategies available. IPC is an innovative strategy for cerebral ischemia therapy and protective effect has been confirmed in large and small animal models of focal and global cerebral ischemia (Koch 2013). IPC in brain includes an early and a late period, during which different neuroprotective responses are evoked in specific time windows (time interval between sublethal injury and lethal injury). There is a rapid period for which the cumulative protective effect of released factors is maximal if the window between sublethal injury and lethal injury is about 1 h in duration (Perez-Pinzon 1996; Perez-Pinzon 1997). Delayed preconditioning evokes maximum protection if the window is expanded to several days after the preconditioning injury (Kato 1992a; Kato 1992b) and has been demonstrated to supply stronger and longer lasting neuroprotection than the early period.

RIPC is the preferred method which overcomes some of the limitations of IPC (Dezfulian 2013). However, it still must be provided before the onset of ischemia. Thus, the application of IPC and RIPC for acute stoke therapy is mostly limited owing to the unpredictability of acute stroke onset. RIPC by transient limb ischemia significantly reduced brain infarct size in a rat transient middle cerebral artery occlusion model of acute stroke (Hahn 2011). RIPC produced by tightening the upper two-thirds of both hind limbs for 15 or 30 min was first shown to have neuroprotection in a rat model of asphyxial cardiac arrest (Dave 2006). Rapid RIPC with three cycles of 15 min unilateral limb occlusion just before stroke decreased infarct size in rats. Stroke was induced by a permanent occlusion of the left distal middle cerebral artery and a 30 min occlusion of the bilateral common carotid arteries (Ren 2008).

Delayed preconditioning with three cycles of 15 min limb occlusion 2 days before stroke also decreased infarct size. 4 cycles of 5 minutes of ischemia of the hind limb protected the brain injury induced by 60 minutes hypothermic circulatory arrest in piglets (Jensen 2011).

Neuroprotection has been reported in both rapid (0 –1 h after RIPC) and delayed (24 h) temporal windows as well as treatment after the ischemic event (Pignataro 2013; Sun 2012). RIPC by 20 min of femoral artery occlusion reduced 50% infarct size caused by 100 min of middle cerebral artery occlusion which was performed 10 minutes after RIPC (Pignataro 2013). Delayed RIPC induced by five cycles of 5 min limb occlusion 24 hrs before global ischemia did not prevent hippocampal CA1 neuronal death at 7 days after transient global cerebral ischemia. Global ischemia was induced by bilateral common carotid artery occlusion and hypotension (35 and 40 mmHg) (Saxena 2009).

IPoC decreased 50% infarct size *in vivo* and about 30% *in vitro* (Pignataro 2008). IPoC induced by 10 min ischemia and 10 mins reperfusion was demonstrated to be the most effective both *in vivo* and *in vitro*. IPoC has equivalent neuroprotection as IPC. IPoC considerably prevented global cerebral IR-caused behavioral deficits by activation of phosphoinositide 3-kinase-linked pathway (Rehni 2007). Global cerebral IR was induced by 10 min bilateral carotid artery occlusion and 24 h reperfusion. IPoC was produced by three cycles of 10 s carotid artery occlusion and 10 s reperfusion. IPoC remarkably decreased infarct volume at 48 hours and ameliorated functional outcomes at 4 weeks after neonatal HI brain injury in rat pups by opioid receptor/Akt pathway (Zhou 2011). HI was produced in postnatal Day 10 rat pups by unilateral carotid ligation plus 2 hours of hypoxia. IPoC was produced by 4 cycles of 10 minutes of IR on both hind limbs just after HI.

LIMB IRI ANIMAL MODELS

Lower extremity ischemia may happen because of traumatic or embolic/thrombotic vascular obstruction, or alternately owing to tourniquet utilization during surgical procedure. Reperfusion of the ischemic extremity is critical for tissue survival. But reperfusion may initiate complex inflammatory cascades which can provoke ischemic tissue damage and cause local and systemic inflammatory reaction. Locally, lower extremity IRI induces rigidity, muscle edema formation, loss of muscle viability, apoptosis and necrosis. Furthermore, lower limb IRI can cause multiple organ dysfunction (Yassin 2002).

Acute limb IRI is widespread clinical problem and is widely investigated in pig (Harkin 2002), canine (Belkin 1990), rabbit (Summers 1995), rat (Sternbergh 1994) and mouse (Kyriakides 2001) models. Limb IRI is induced by a tourniquet or an elastic rubber band on the proximal part of the limb, clamping the femoral artery or iliac artery, or the infrarenal aorta (Bonheur 2004; Dick 2008; Lundberg 2003). But, ischemia induction methods, ischemia time and reperfusion time are different. The ischemia time varies from 2 h to 4 h in acute model rats. The reperfusion time differs from 1 h to 24 h (Dick 2008; Hosseinzadeh 2009; Chen 2009).

Unilateral Hind Limb IRI

The femoral artery and vein were exposed by a groin incision after the anesthesia was induced and maintained. A tourniquet (standardized weight of 450 g) was put below the femoral vessels to occlude collateral circulation (Dick 2008). The femoral artery was obstructed for 3 h using two microvascular clamps. The rat hind limbs were not exsanguinated, but venous return was allowed during the whole period of ischemia in order to avoid venous congestion and other injury through microcirculatory impairment, which would not present the clinical condition. Reperfusion was started after 3h ischemia.

An acute rat unilateral hind limb IRI model with 2 h of reperfusion is adequate to evaluate basic parameters of IR and it may be acceptable for a first screening of drug candidates. 24 h of reperfusion will be needed for in-depth analysis of mechanisms of actions, muscle viability and distant organ damage (Duehrkop 2014).

Tourniquet-caused hind limb IRI mice model was induced by the McGivney hemorrhoidal ligator band (MHL) (Kyriakides 2001). Tourniquet models are commonly utilized for murine investigation of IRI models. Occlusion of several branches of the femoral and iliac arteries is needed to reach dependable limb ischemia in angiogenesis mice model. The rich collateral blood supply surrounding the murine pelvic girdle supplies considerable collateral flow often from iliac and tail branches.

The disadvantage of MHL model is to cause nonspecific neuromuscular injury because of the crushing force of the rubber band on the underlying tissue. The controlled tension tourniquet (CTT) enabled utilization of minimal amounts of reproducible circumferential tension to induce full hind limb ischemia. Reperfusion could also be easily reached by releasing the tightness on the winch (Bonheur 2004, Conrad 2005). Orthodontic rubber bands (ORB) induced similar tissue ischemia compared with MHL in murine models of limb IRI with less neuromuscular dysfunction. ORB may be the preferred model for selected studies of limb IRI (Crawford 2007).

RETINAL IRI ANIMAL MODEL

Retinal IRI is a general clinical situation and is related to the neurons loss, the retina degeneration, retinal function loss, and finally vision loss (Cho 2009; Kim 2013). Retinal IRI induces the pathologic processes of some retinal diseases such as retinopathy of prematurity, acute glaucoma, diabetic retinopathy and central retinal artery occlusion (Andreeva 2014; Sun 2010). Retina is more susceptible to ischemic damage since it has very high oxygen consumption. Retina as an extension of central nervous system is a perfect model system to investigate the pathophysiology of IRI and evaluate various treatment agents in animal models (London 2013).

Rat Retinal IRI Animal Model

The rat pressure-induced retinal IRI model was generated in 1991 **(**Büchi 1991). Anesthesia was induced and maintained with isoflurane/O2. A 30-gauge needle was

cannulated to the anterior chamber of left eye and was connected to a reservoir with 0.9% NaCl. The intraocular pressure was raised to 120 mm Hg for 30, 45, or 90 min. Retinal ischemia was verified by retinal edema and stasis in retinal arteries **(**Joachim 2012). The needle was removed at the end of ischemia and intraocular pressure (IOP) was returned to normal pressure. Reperfusion was verified with observation of episcleral veins.

Mice Retinal IRI Animal Model (Kim 2013; Silverman 2016)

Mice were kept on a heating pad to avoid hypothermia during the anesthesia. The left eye was dilated with 2.5% Phenylephrine HCl after the anesthesia was induced and maintained. A 30-gauge needle attached to sterile saline or PBS reservoir was inserted into the anterior chamber of left eye. The reservoir was elevated to produce an IOP of 120 mmHg for 1 h to cause retinal ischemia. Retinal ischemia was verified by blanching of the retina using an ophthalmoscope. The right eye was used as controls. The needle was removed after 60 minutes and reperfusion for the retina was started.

Pig Retinal IRI Animal Model (Gesslein 2010)

Endotracheal tubes were orally intubated for animals after the anesthesia was induced and maintained. Mechanical ventilation was maintained in the volume-controlled mode and regulated to acquire normocapnia. The animals were ventilated with a mixture of oxygen (70%) and dinitrous oxide (30%). A 30-gauge needle was cannulated into the posterior chamber of one eye. The IOP was raised to 80 mmHg by continuous infusion of a balanced salt solution for ophthalmic irrigation. The IOP was confirmed by a Tono-Pen®XL tonometer. The other eye was used as a control, and the same surgical procedure was carried out except for increase of the IOP. The cannulation needles were removed 1h after ischemia. Reperfusion of the retinal vasculature was started for 5 or 12 h during anesthesia. Ischemia was verified by indirect ophthalmoscopic examination and fundus imaging.

ISCHEMIC CONDITIONING APPLICATION IN RETINAL IRI ANIMAL MODEL

RIPC by tightening a tourniquet around the upper thigh and releasing for three cycles improved retinal IRI induced by right middle cerebral artery occlusion and pterygopalatine artery occlusion for 60 min through the upregulation of antioxidative stress proteins (Zhang 2014). Retinal ganglion cells damaged by optic nerve transection caused extensive cell death. IPoC induced by several mild IR to the hind limb at 10 min or 6 h after optic nerve cut improved ganglion cell survival at 7 days post-injury. 10 min IPoC still had protection at 14 days post-injury (Liu 2013).

IPoC induced by seven cycles of 1 min/1 min IR reduced glial fibrillary acidic protein levels of Müller cells at 3 and 7 days post-ischemia and provided protection against rat rential IRI (Fernandez 2009). IPoC can effectively prevent injury after retinal ischemia when it was

performed early (within 1 h) in the post-ischemic period (Fernandez 2009; Dreixler 2010). The rential protective effect of IPoC depends upon the ischemia time. IPoC has no synergistic effect with IPC. IPoC works, in part, by preventing apoptotic injury to the inner retina. IPoC has considerable promise for clinical translation to eye diseases that cause blindness by ischemia (Dreixler 2010). Indeed, delayed IPoC (24h after prolonged ischemia) significantly improved the rential ischemia in rats (Dreixler 2011).

UTERINE IRI MODEL

Uterine transplantation is a treatment option for patients with unmanageable uterine factor infertility. Uterine transplantation has been well performed in mice (Racho El-Akouri 2003), sheep (Ramirez 2011) and rats (Wranning 2011). However, uterine IRI affected the success of uterine transplantation. Intraoperative treatment IRI decreased the incidence of acute rejection and ameliorated the long-term graft outcome (Land 2005). Tacrolimus reduced oxidative damage and protected tissue damage in rat uterine IRI caused by distal abdominal aortic occlusion (Sahin 2014).

Uterine IRI was induced in rats by occlusion of ovarian arteries and the lower abdominal aorta for 30 min in rat (Sahin Ersoy 2017). Unilateral uterine IRI was produced by occlusion of the uterine and ovarian arteries of the right uterine horn for 30 minutes in rats on day 17 of gestation which was effective for inducing fetal growth restriction (FGR) (Thaete 2006). This rat model was helpful because it imitated the imbalance of supply/demand for blood perfusion in gestational tissue. On the 15th day of gestation, unilateral mice uterine IR model was established by occlusion of the uterine and ovarian arteries to the right horn of the uterus for 30 minutes (Thaete 2013). Fetal and placental weights were decreased after IR which suggested that IR caused FGR as it did in rats. This mouse model is very important because it allows the investigation of IR-related developmental pathology at the molecular level in genetically modified mice.

The uterine IRI in cynomolgus monkey was induced by occlusion of the bilateral uterine and ovarian vessels for 0.5, 1, 2, 4, 8 h and then 3 h reperfusion. No abnormality was detected by both light and electron microscopy after 2 h ischemia and 3 h reperfusion (Adachi 2016). No noticeable change was found after 4 h ischemia. However, rough endoplasmic reticulum swelling and dilated nuclear pores were detected after 3 h reperfusion. The uterus of the cynomolgus monkey could tolerate 4h warm ischemia.

OVARY IRI ANIMAL MODEL

IRI is a noteworthy problem following reperfusion treatment for ovarian torsion. Ovarian torsion is a rare but significant gynecologic surgical emergency that can affect women of all ages (Houry 2001). It is originally related with decreased venous ovarian blood flow, and ischemia and infarction can happen due to restriction of arterial blood flow (Wilkinson 2012; Sasaki 2014).

Rat ovary IRI model is often used which is induced by 360° ovary torsion and detorsion (Caglayan 2014; Celik 2014; Sak 2013; Yaman 2016). In the rat ovarian IRI model, the

adnexa including ovarian tissues and the tube were rotated 360c clockwise and then secured to the abdominal wall (Sak 2013; Yaman 2016). Period of ischemia was 2−3 h and bilateral adnexal detorsion (reperfusion) was 2−3h.

Ischemia was induced by the lower part of the right ovary occlusion with vascular clips in rats (Ingec 2011; Kumbasar 2016). 1 h controlled reperfusion (CR) (on-off method: controlled reperfusion by opening and closing the clips (on/off) in 10-second intervals, for 5 times for a total of 100 seconds) was performed. CR improved ovarian IRI. CR decreased sterility and ovarian oxidative stress induced by IRI in a rat model of ovarian IRI with unilateral oophorectomy (Aksoy 2015).

Ovarian autotransplantation is a more utilized approach for preserving fertility in women with cytotoxic treatment for immunosuppressive disorders or cancer, which eventually provoke early ovary failure (Donnez 2005; Mhatre 2005). It was found in 34% of women receiving chemotherapy and 92% of patients having radiotherapy or chemotherapy for bone marrow transplantation (Meirow 1999). IRI of the graft ovary is one of the important factors affecting the graft revascularization and success of ovarian transplantation (Liu 2002).

ISCHEMIC CONDITIONING APPLICATION IN OVARY IRI ANIMAL MODEL

RIPC by 15 min iliac artery occlusion was found the best timing to reach functional support and preserve more viable ovarian follicles in rats with bilateral oophorectomy and ovarian transplantation (Damous 2008). RIPC group showed greater amounts of viable ovarian follicles and raised vascularization and vasodilatation than the control group. RIPC by the common iliac artery occlusion for a 15 min ischemia and 15 min reperfusion before ovarian transplantation significantly increased the estradiol levels in autologous ovarian transplants. Better graft morphology and more mature follicles were observed (Damous 2009).

CONCLUSION

IRI animal models from small animals to big animals have been established in different organs. IRI animal models can establish a bridge between clinical study and the preclinical in vitro investigations. Hypotheses produced in clinical investigations can be examined directly in animal models, and the results from *in vitro* investigations can be determined in animal models to evaluate their relevance in entire living systems. The animal models of of organ IRI are very important for understanding the underlying processes of IRI and development of efficacious treatment. Animal investigations suggest that IPC, RIPC and IPoC contribute to protection against IRI in different organs.

RIPC definitely has a reasonable prospect for ischemic protection of the heart and other organs (Heusch 2013). RIPC may protect against acute IRI in various noncardiac organs and tissues including the lungs, liver, kidneys, ovaries, pancreas, stomach and intestine in animal models (Candillo 2013). The main restriction in clinical translation of IPC is to block the blood supply of the target organ or tissue. Translation of IPC, RIPC and IPoC strategies from

successful preclinical investigations to the clinical study has been relatively discouraging (Ferdinandy 2014). Ischemic conditioning cardioprotection strategies verified in animal heart IRI model have been evaluated in patients with acute MI or CABG surgery. Some large, multicentre, randomized, controlled clinical trials on cardioprotection have emphasized the challenges of translating ischemic conditioning cardioprotection strategies into patient benefit (Hausenloy 2016). Ischemic conditioning showed protective effects on kidney, lung and intestine in some single centers with small number of patients. Multicentre, randomized controlled clinical trials will be needed to evaluate whether ischemic conditioning has protective effects on IRI of different organs.

REFERENCES

Abdo EE, Cunha JE, Deluca P, Coelho AM, Bacchella T, Machado MC. Protective effect of N2-mercaptopropionylglycine on rats and dogs liver during ischemia/reperfusion process. *Arq. Gastroenterol*. 2003; 40(3):177–80.

Abu-Amara M, Yang SY, Quaglia A, Rowley P, Tapuria N, Fuller B, Davidson B, Seifalian A. The hepatic soluble guanylyl cyclase-cyclic guanosine monophosphate pathway mediates the protection of remote ischemic preconditioning on the microcirculation in liver ischemia-reperfusion injury. *Transplantation* 2012; 93(9):880–6.

Acosta S, Nilsson TK, Malina J, Malina M. L-lactate after embolization of the superior mesenteric artery. *J. Surg. Res.* 2007; 143: 320–28.

Adachi M, Kisu I, Nagai T, Emoto K, Banno K, Umene K, Nogami Y, Tsuchiya H, Itagaki I, Kawamoto I, Nakagawa T, Ogasawara K, Aoki D. Evaluation of allowable time and histopathological changes in warm ischemia of the uterus in cynomolgus monkey as a model for uterus transplantation. *Acta. Obstet. Gynecol. Scand*. 2016; 95(9):991–8.

Aksoy AN, Aydın F, Topdagı Yılmaz EP, Batmaz G, Suleyman B. The Effect of Controlled Reperfusion in the Prevention of Infertility Caused by Ischemia Induced in the Contralateral Ovary in Rats with Unilateral Ovariectomy. *Gynecol. Obstet. Invest*. 2015; 80(3):199–205.

Ali ZA, Callaghan CJ, Lim E, Ali AA, Nouraei SA, Akthar AM, Boyle JR, Varty K, Kharbanda RK, Dutka DP, Gaunt ME. Remote ischemic preconditioning reduces myocardial and renal injury after elective abdominal aortic aneurysm repair: a randomized controlled trial. *Circulation* 2007; 116:I98–105.

Alikhan MA, Jones CV, Williams TM, Beckhouse AG, Fletcher AL, Kett MM, Sakkal S, Samuel CS, Ramsay RG, Deane JA, Wells CA, Little MH, Hume DA, Ricardo SD. Colony-stimulating factor-1 promotes kidney growth and repair via alteration of macrophage responses. *Am. J. Pathol.* 2011; 179:1243–56.

Allen BS, Ko Y, Buckberg GD, Sakhai S, Tan Z. Studies of isolated global brain ischaemia: I. A new large animal model of global brain ischaemia and its baseline perfusion studies. *Eur. J. Cardiothorac. Surg*. 2012; 41(5):1138–46.

Altmann C, Andres-Hernando A, McMahan RH, Ahuja N, He Z, Rivard CJ, Edelstein CL, Barthel L, Janssen WJ, Faubel S. Macrophages mediate lung inflammation in a mouse model of ischemic acute kidney injury. *Am. J. Physiol. Renal. Physiol.* 2012; 302: F421–32.

Andreeva K, Zhang M, Fan W, Li X, Chen Y, Rebolledo-Mendez JD, Cooper NG. Time-dependent Gene Profiling Indicates the Presence of Different Phases for Ischemia/Reperfusion Injury in Retina. *Ophthalmol. Eye. Dis*. 2014; 6: 43–54.

Andreka G, Vertesaljai M, Szantho G, Font G, Piroth Z, Fontos G, Juhasz ED, Szekely L, Szelid Z, Turner MS, Ashrafian H, Frenneaux MP, Andreka P. Remote ischaemic postconditioning protects the heart during acute myocardial infarction in pigs. *Heart* 2007; 93(6):749–52.

Apostolidis D, Ntinas A, Kardassis D, Koulouris N, Thomareis O, Karayannopoulou G, Vrochides D. Nimesulide may be more efficient than allopurinol in protecting pancreas from acute ischemia/reperfusion injury in an animal model. *Vasc. Endovascular. Surg*. 2012; 46(8):654–63.

Ashwal S, Cole DJ, Osborne S, Osborne TN, Pearce WJ. A new model of neonatal stroke: reversible middle cerebral artery occlusion in the rat pup. *Pediatr. Neurol*. 1995; 12(3):191–6.

Atesx E, Genç E, Erkasap N, Erkasap S, Akman S, Firat P, Emre S, Kiper H: Renal protection by brief liver ischemia in rats. *Transplantation* 2002; 74: 1247–51.

Awad H, Ankeny DP, Guan Z, Wei P, McTigue DM, Popovich PG. A mouse model of ischemic spinal cord injury with delayed paralysis caused by aortic cross-clamping. *Anesthesiology* 2010; 113(4):880–91.

Back MR, Bandyk M, Bradner M, Cuthbertson D, Johnson BL, Shames ML, Bandyk DF. Critical analysis of outcome determinants affecting repair of intact aneurysms involving the visceral aorta. *Ann. Vasc. Surg*. 2005; 19(5):648–56.

Back SA, Han BH, Luo NL, Chricton CA, Xanthoudakis S, Tam J, Arvin KL, Holtzman DM. Selective vulnerability of late oligodendrocyte progenitors to hypoxia-ischemia. *J. Neurosci.* 2002; 22:455–63.

Back SA, Riddle A, Dean J, Hohimer AR. The instrumented fetal sheep as a model of cerebral white matter injury in the premature infant. *Neurotherapeutics* 2012; 9:359–70.

Basalay M, Barsukevich V, Mastitskaya S, Mrochek A, Pernow J, Sjöquist PO, Ackland GL, Gourine AV, Gourine A. Remote ischaemic pre- and delayed postconditioning - similar degree of cardioprotection but distinct mechanisms. *Exp. Physiol*. 2012; 97(8):908–17.

Baud O, Daire JL, Dalmaz Y, Fontaine RH, Krueger RC, Sebag G, et al. Gestational hypoxia induces white matter damage in neonatal rats: A new model of periventricular leukomalacia. *Brain. Pathol*. 2004; 14:1–10.

Belkin M, Wright JG, Hobson RW 2nd. Iloprost infusion decreases skeletal muscle ischemia-reperfusion injury. *J. Vasc. Surg*. 1990; 11(1):77–82.

Bellamy JE, Latshaw WK, Nielsen NO. The vascular architecture of the porcine small intestine. *Can. J. Comp. Med.* 1973; 37: 56–62.

Bengmark S, Börjesson B, Olin T, Sakuma S, Vosmic J. Subcutaneous transposition of the spleen--an experimental study in the rat. *Scand. J. Gastroenterol. Suppl*. 1970; 7: 175–9.

Bennet L, Peebles DM, Edwards AD, Rios A, Hanson MA. The cerebral hemodynamic response to asphyxia and hypoxia in the near-term fetal sheep as measured by near infrared spectroscopy. *Pediatr. Res.* 1998; 44:951–7.

Bernstein D and Cheiker S. Simple technique for portocaval shunt in the rat. *Journal of Applied Physiology* 1959; 14(3): 467–70.

Bijlsma PB, Peeters RA, Groot JA, Dekker PR, Taminiau JAJM, Van Der Meer R. Differential in vivo and in vitro intestinal permeability to lactulose and mannitol in animals and humans: a hypothesis. *Gastroenterology* 1995; 108: 687–96.

Birnbaum Y, Hale SL, Kloner RA. Ischemic preconditioning at a distance: reduction of myocardial infarct size by partial reduction of blood supply combined with rapid stimulation of the gastrocnemius muscle in the rabbit. *Circulation* 1997; 96:1641.

Bishop MJ, Holman RG, Guidotti SM, Alberts MK, Chi EY. Pulmonary artery occlusion and lung collapse depletes rabbit lung adenosine triphosphate. *Anesthesiology* 1994; 80: 611–17.

Blakemore A, Lord J. The technic of using vitallium tubes in establishing portacaval shunts for portal hypertension. *Annals of Surgery* 1945; 122(4):449–475.

Block T, Isaksson HS, Acosta S, Bjorck M, Brodin D, Nilsson TK. Altered mRNA expression due to acute mesenteric ischaemia in a porcine model. *Eur. J. Vasc. Endovasc. Surg.* 2011; 41: 281–287.

Bloom HL, Shukrullah I, Cuellar JR, Lloyd MS, Dudley SC Jr, Zafari AM. Long-term survival after successful inhospital cardiac arrest resuscitation. *Am. Heart. J*. 2007; 153(5):831–6.

Bobryshev P, Bagaeva T, Filaretova L. Ischemic preconditioning attenuates gastric ischemia-reperfusion injury through involvement of glucocorticoids. *J. Physiol. Pharmacol*. 2009; 60 Suppl 7:155–60.

Bonheur JA, Albadawi H, Patton GM, Watkins MT. A noninvasive murine model of hind limb ischemia-reperfusion injury. *J. Surg. Res.* 2004; 116:55–63.

Botker HE, Kharbanda R, Schmidt MR, Bottcher M, Kaltoft AK, Terkelsen CJ, Munk K, Andersen NH, Hansen TM, Trautner S, Lassen JF, Christiansen EH, Krusell LR, Kristensen SD, Thuesen L, Nielsen SS, Rehling M, Sørensen HT, Redington AN, Nielsen TT. Remote ischemic conditioning before hospital admission, as a complement to angioplasty, and effect on myocardial salvage in patients with acute myocardial infarction: a randomised trial. *Lancet* 2010; 375:727–34.

Brennan TV, Lunsford KE, Kuo PC. Innate pathways of immune activation in transplantation. *J. Transplant*. 2010 2010. pii: 826240. doi: 10.1155/2010/826240.

Brzozowski T, Konturek PC, Pajdo R, Kwiecień S, Sliwowski Z, Drozdowicz D,Ptak-Belowska A, Pawlik M, Konturek SJ, Pawlik WW, Hahn GG. Importance of brain-gut axis in the gastroprotection induced by gastric and remote preconditioning. *J. Physiol. Pharmacol.* 2004; 55(1 Pt 2):165–77.

Brzozowski T, Konturek PC, Konturek SJ, Pajdo R, Kwiecien S, Pawlik M, Drozdowicz D, Sliwowski Z, Pawlik WW. Ischemic preconditioning of remote organs attenuates gastric ischemia-reperfusion injury through involvement of prostaglandins and sensory nerves. *Eur. J. Pharmacol*. 2004; 499(1-2):201–13.

Büchi ER, Suivaizdis I, Fu J. Pressure-induced retinal ischemia in rats: an experimental model for quantitative study. *Ophthalmologica* 1991; 203(3):138–47.

Büsing M, Hopt UT, Quacken M, Becker HD, Morgenroth K. Morphological studies of graft pancreatitis following pancreas transplantation. *Br. J. Surg*. 1993; 80(9):1170–3.

Caglayan EK, Caglayan K, Göcmen AY, Cinar H, Seckin L, Seckin S, Güngör B, Polat MF. Protective effect of ethyl pyruvate on ischemia-reperfusion injury in rat ovary: biochemical and histopathological evaluation. *Eur. J. Obstet. Gynecol. Reprod. Biol*. 2014; 182:154–9.

Candillo L, Malik A, Hausenloy DJ. Protection of organs other than the heart by remote ischemic conditioning. *J. Cardiovasc. Med* (Hagerstown). 2013; 14:193–205.

Casillas-Ramirez A, Amine-Zaouali M, Massip-Salcedo M, Padrissa-Altés S, Bintanel-Morcillo M, Ramalho F, Serafín A, Rimola A, Arroyo V, Rodés J, Roselló-Catafau J, Peralta C. Inhibition of angiotensin II action protects rat steatotic livers against ischemia-reperfusion injury. *Crit. Care. Med*. 2008; 36(4):1256–66.

Casley-Smith JR, Gannon BJ. Intestinal microcirculation: spatial organization and fine structure. In: *Physiology of the Intestinal Circulation*, edited by Granger DN and Shepherd AP. New York: Raven, 1984, p.9–31.

Celie JW, Katta KK, Adepu S, Melenhorst WB, Reijmers RM, Slot EM, Beelen RH, Spaargaren M, Ploeg RJ, Navis G, van der Heide JJ, van Dijk MC, van Goor H, van den Born J. Tubular epithelial syndecan-1 maintains renal function in murine ischemia/reperfusion and human transplantation. *Kidney. Int.* 2012; 81: 651–61.

Celik M, Aksoy AN, Aksoy H, Aksoy Y, Halici Z. Sildenafil reduces ischemia-reperfusion injury in rat ovary: biochemical and histopathological evaluation. *Gynecol. Obstet. Invest.* 2014; 78(3):162–7.

Chen H, Xing B, Liu X, Liu X, Zhan B, Zhou J, Zhu H, Chen Z. Ischemic postconditioning inhibits apoptosis after renal ischemia/reperfusion injury in rat. *Transpl. Int.* 2008; 21: 364.

Chen HY, Hung YC, Lee EJ, Chen TY, Chuang IC and Wu TS. The protective efficacy of magnolol in hind limb ischemia-reperfusion injury. *Phytomedicine* 2009; 16: 976–81.

Chen SH, Tang YB, Chen HC. Survival of transferred ileum after ischemia time longer than 1 hour: a clinical result different from animal studies. *J. Am. Coll. Surg.* 2013*;* 217: 300–5.

Cho JH, Mu X, Wang SW, Klein WH. Retinal ganglion cell death and optic nerve degeneration by genetic ablation in adult mice. *Exp. Eye. Res*. 2009; 88(3):542–52.

Chu MJ, Vather R, Hickey AJ, Phillips AR, Bartlett AS. Impact of ischaemic preconditioning on experimental steatotic livers following hepatic ischaemia-reperfusion injury: a systematic review. *HPB* (Oxford). 2015; 17(1):1–10.

Conrad MF, Stone DH, Albadawi H, Hua HT, Entabi F, Stoner MC, Watkins MT. Local inflammatory and thrombotic responses differ in a murine model of partial and complete hindlimb ischemia/reperfusion. *Surgery* 2005; 138: 375–81.

Cook CJ, Williams C, Gluckman PD. Brainstem auditory evoked potentials in the fetal sheep, in utero. *J. Dev. Physiol.* 1987; 9:429–39.

Corcos O, Nuzzo A. Gastro-intestinal vascular emergencies. *Best. Pract. Res. Clin. Gastroenterol.* 2013; 27: 709–25.

Cornet AD, Kingma SD, Trof RJ, Wisselink W, Groeneveld AB. Hepatosplanchnic ischemia/reperfusion is a major determinant of lung vascular injury after aortic surgery. *J. Surg. Res*. 2009; 157(1):48–54.

Crane NJ, Huffman SW, Alemozaffar M, Gage FA, Levin IW, Elster EA. Evidence of a heterogeneous tissue oxygenation: renal ischemia/reperfusion injury in a large animal model. *J. Biomed. Opt*. 2013; 18(3):035001.

Crawford RS, Hashmi FF, Jones JE, Albadawi H, McCormack M, Eberlin K, Entabi F, Atkins MD, Conrad MF, Austen WG Jr, Watkins MT. A novel model of acute murine hindlimb ischemia. *Am. J. Physiol. Heart Circ. Physiol*. 2007; 292(2):H830–7.

Crimi G, Pica S, Raineri C, Bramucci E, De Ferrari GM, Klersy C, Ferlini M, Marinoni B, Repetto A, Romeo M, Rosti V, Massa M, Raisaro A, Leonardi S, Rubartelli P, et al.

Remote ischemic post-conditioning of the lower limb during primary percutaneous coronary intervention safely reduces enzymatic infarct size in anterior myocardial infarction: a randomized controlled trial. *JACC. Cardiovasc. Interv.* 2013; 6:1055–63.

Damous LL, Silva SM, Simões RS, Morello RJ, Carbonel AP, Simões MJ, Montero EF. Remote ischemic preconditioning on neovascularization and follicle viability on ovary autotransplantation in rats. *Transplant. Proc*. 2008; 40(3):861–4.

Damous LL, Silva SM, Carbonel AP, Simões RS, Simões MJ, Montero EF. Effect of remote ischemic preconditioning on rat estradiol serum levels and follicular development after ovarian transplantation. *Transplant. Proc*. 2009; 41(3):830–3.

Dave KR, Saul I, Prado R, Busto R, Perez-Pinzon MA. Remote organ ischemic preconditioning protects brain from ischemic damage following asphyxial cardiac arrest. *Neurosci. Lett*. 2006; 404(1-2):170–5.

de Arruda MJ, Poggetti RS, Fontes B, Younes RN, Souza AL Jr, Birolini D. Intestinal ischemia/reperfusion induces bronchial hyperreactivity and increases serum TNF-alpha in rats. *Clinics (Sao Paulo)* 2006; 61(1):21–8.

de Perrot M, Liu M, Waddell TK, Keshavjee S. Ischemia-reperfusion induced lung injury. *Am. J. Respir. Crit. Care. Med.* 2003; 167: 490–511.

de Rougemont O, Dutkowski P, Clavien PA. Biological modulation of liver ischemia–reperfusion injury. *Curr. Opin. Organ. Transplant*. 2010; 15:183–9.

Delahunty T, Hollander D. A comparison of intestinal permeability between humans and three common laboratory animals. *Comp. Biochem. Physiol. A. Comp. Physiol.* 1987; 86: 565–67.

Derrick M, Drobyshevsky A, Ji X, Tan S. A model of cerebral palsy from fetal hypoxia-ischemia. *Stroke* 2007; 38:731–5.

Derugin N, Ferriero DM, Vexler ZS. Neonatal reversible focal cerebral ischemia: A new model. *Neurosci. Res.* 1998; 32:349–53.

Dezfulian C, Garrett M, Gonzalez NR. Clinical application of preconditioning and postconditioning to achieve neuroprotection. *Translational stroke research* 2013; 4:19–24.

Dick F, Li J, Giraud MN, Kalka C, Schmidli J and Tevaearai H. Basic control of reperfusion effectively protects against reperfusion injury in a realistic rodent model of acute limb ischemia. *Circulation* 2008; 118: 1920–8.

Dickson EW, Tubbs RJ, Porcaro WA, Lee WJ, Blehar DJ, Carraway RE, Darling CE, Przyklenk K. Myocardial preconditioning factors evoke mesenteric ischemic tolerance via opioid receptors and K(ATP) channels. *Am. J. Physiol. Heart Circ. Physiol*. 2002; 283(1):H22–8.

Dobschuetz Von, Schmidt R, ScholtesM, Thomusch O, Schwer CI, Geiger KK,Hopt UT, Pannen BH. Protective role of heme oxygenase-1 in pancreatic microcirculatory dysfunction after ischemia/reperfusion in rats. *Pancreas* 2008; 36(4):377–84.

Donnez J, Squifflet J, Dolmans MM, Martinez-Madrid B, Jadoul P, Van Langendonckt A. Orthotopic transplantation of fresh ovarian cortex: a report of two cases. *Fertil Steril* 2005; 84(4):1018.

Doverhag C, Hedtjarn M, Poirier F, Mallard C, Hagberg H, Karlsson A, Sävman K. Galectin-3 contributes to neonatal hypoxic-ischemic brain injury. *Neurobiol. Dis*. 2010; 38:36–46.

Dreixler JC, Shaikh AR, Alexander M, Savoie B, Roth S. Post-ischemic conditioning in the rat retina is dependent upon ischemia duration and is not additive with ischemic pre-conditioning. *Exp. Eye. Res*. 2010; 91(6):844–52.

Dreixler JC, Poston JN, Shaikh AR, Alexander M, Tupper KY, Marcet MM, Bernaudin M, Roth S. Delayed post-ischemic conditioning significantly improves the outcome after retinal ischemia. *Exp. Eye. Res*. 2011; 92(6):521–7.

Duehrkop C, Rieben R. Refinement of tourniquet-induced peripheral ischemia/reperfusion injury in rats: comparison of 2 h vs 24 h reperfusion. *Lab. Anim*. 2014; 48(2):143–54.

Duehrkop C, Rieben R. Ischemia/reperfusion injury: effect of simultaneous inhibition of plasma cascade systems versus specific complement inhibition. *Biochem. Pharmacol*. 2014; 88(1):12–22.

Eide TO, Aasland J, Romundstad P, Stenseth R, Saether OD, Aadahl P, Myhre HO. Changes in hemodynamics and acid-base balance during cross-clamping of the descending thoracic aorta. A study in patients operated on for thoracic and thoracoabdominal aortic aneurysm. *Eur. Surg. Res*. 2005; 37(6):330–4.

Ek CJ, D'Angelo B, Baburamani AA, Lehner C, Leverin AL, Smith PL, Nilsson H, Svedin P, Hagberg H, Mallard C. Brain barrier properties and cerebral blood flow in neonatal mice exposed to cerebral hypoxia-ischemia. *J. Cereb. Blood Flow. Metab.* 2015; 35:818–27.

Eldaif SM, Deneve JA, Wang NP, Jiang R, Mosunjac M, Mutrie CJ, Guyton RA, Zhao ZQ, Vinten-Johansen J. Attenuation of renal ischemia-reperfusion injury by postconditioning involves adenosine receptor and protein kinase C activation. *Transpl. Int.* 2010; 23: 217.

Eltzschig HK, Eckle T. Ischemia and reperfusion--from mechanism to translation. *Nat. Med*. 2011; 17(11):1391–401.

Engles RE, Huber TS, Zander DS, Hess PJ, Welborn MB, Moldawer LL, Seeger JM. Exogenous human recombinant interleukin-10 attenuates hindlimb ischemia-reperfusion injury. *J. Surg. Res.* 1997; 69: 425–8.

Erling Junior N, Montero EF, Sannomiya P, Poli-de-Figueiredo LF. Local and remote ischemic preconditioning protect against intestinal ischemic/reperfusion injury after supraceliac aortic clamping. *Clinics (Sao Paulo)* 2013; 68(12):1548–54.

Esme H, Fidan H, Koken T, Solak O. Effect of lung ischemia--reperfusion on oxidative stress parameters of remote tissues. *Eur. J. Cardiothorac. Surg*. 2006; 29(3):294–8.

Espinosa G, López Farré A, Cernadas MR, Manzarbeitia F, Tan D, Digiuni E, Mosquera JR, Montón M, Millás I, Hernando L, Casado S, Caramelo C. Role of endothelin in the pathophysiology of renal ischemia-reperfusion in normal rabbits. *Kidney Int*. 1996; 50(3):776–82.

Fauconnier J, Meli AC, Thireau J, Roberge S, Shan J, Sassi Y, Reiken SR, Rauzier JM, Marchand A, Chauvier D, Cassan C, Crozier C, Bideaux P, Lompré AM, Jacotot E, Marks AR, Lacampagne A. Ryanodine receptor leak mediated by caspase-8 activation leads to left ventricular injury after myocardial ischemia-reperfusion. *Proc. Natl. Acad. Sci. USA*. 2011; 108(32):13258–63.

Ferdinandy P, Hausenloy DJ, Heusch G, Baxter GF, Schulz R. Interaction of risk factors, comorbidities, and comedications with ischemia/reperfusion injury and cardioprotection by preconditioning, postconditioning, and remote conditioning. *Pharmacol. Rev*. 2014; 66(4):1142–74.

Fernandez DC, Chianelli MS, Rosenstein RE. Involvement of glutamate in retinal protection against ischemia/reperfusion damage induced by post-conditioning. *J. Neurochem.* 2009; 111(2):488–98.

Fernandez Lopez D, Faustino J, Daneman R, Zhou L, Lee SY, Derugin N, Wendland MF, Vexler ZS. Blood-brain barrier permeability is increased after acute adult stroke but not neonatal stroke in the rat. *J. Neurosci.* 2012; 32:9588–600.

Fishman JE, Sheth SU, Levy G, Alli V, Lu Q, Xu D, Qin Y, Qin X, Deitch EA. Intraluminal nonbacterial intestinal components control gut and lung injury after trauma hemorrhagic shock. *Ann. Surg.* 2014; 260: 1112–20.

Fondevila C, Busuttil RW, Kupiec-Weglinski JW. Hepatic ischemia/reperfusion injury a fresh look. *Exp. Mol. Pathol.* 2003; 74:86–93.

Fullerton DA, Eisenach JH, Friese RS, Agrafojo J, Sheridan BC, McIntyre RC Jr. Impairment of endothelial-dependent pulmonary vasorelaxation after mesenteric ischemia/ reperfusion. *Surgery* 1996; 120: 879–84.

Gao XM, Dart AM, Dewar E, Jennings G, Du XJ. Serial echocardiographic assessment of left ventricular dimensions and function after myocardial infarction in mice. *Cardiovasc. Res.* 2000; 45:330–8.

Gasbarrini A, Addolorato G, Di Campli C, Simoncini M, Montemagno S, Castagneto M, Padalino C, Pola P, Gasbarrini G. Gender affects reperfusion injury in rat liver. *Dig. Dis. Sci.* 2001; 46(6):1305–12.

Gehrmann J, Frantz S, Maguire CT, Vargas M, Ducharme A,Wakimoto H, Lee RT, Berul CI.. Electrophysiological characterization of murine myocardial ischemia and infarction. *Basic. Res. Cardiol.* 2001; 96:237–50.

Gesslein B, Håkansson G, Gustafsson L, Ekström P, Malmsjö M. Tumor necrosis factor and its receptors in the neuroretina and retinal vasculature after ischemia-reperfusion injury in the pig retina. *Mol. Vis.* 2010; 16:2317–27.

Gho BC, Schoemaker RG, van den Doel MA, Duncker DJ, Verdouw PD. Myocardial protection by brief ischemia in noncardiac tissue. *Circulation* 1996; 94: 2193–200.

Godwin JG, Ge X, Stephan K, Jurisch A, Tullius SG, Iacomini J. Identification of a microRNA signature of renal ischemia reperfusion injury. *Proc. Natl. Acad. Sci. USA.* 2010; 107: 14339–44.

González-Flecha B, Cutrin JC, Boveris A. Time course and mechanism of oxidative stress and tissue damage in rat liver subjected to in vivo ischemia-reperfusion. *J. Clin. Invest.* 1993; 91(2):456–64.

Granger DN, McCord JM, Parks DA, Hollwarth ME. Xanthine oxidase inhibitors attenuate ischemia-induced vascular permeability changes in the cat intestine. *Gastroenterology* 1986; 90: 80–4.

Gregory KE, Deforge CE, Natale KM, Phillips M, Van Marter LJ. Necrotizing enterocolitis in the premature infant: neonatal nursing assessment, disease pathogenesis, and clinical presentation. *Adv. Neonatal. Care.* 2011; 11: 155–64.

Gressens P, Marret S, Evrard P. Developmental spectrum of the excitotoxic cascade induced by ibotenate: A model of hypoxic insults in fetuses and neonates. *Neuropathol. Appl. Neurobiol.* 1996; 22:498–502.

Griffith JL, Shimony JS, Cousins SA, Rees SE, Mccurnin DC, Inder TE, Neil JJ. MR imaging correlates of white-matter pathology in a preterm baboon model. *Pediatr. Res.* 2012; 71:185–91.

Grootjans J, Hundscheid IH, Buurman WA. Goblet cell compound exocytosis in the defense against bacterial invasion in the colon exposed to ischemia-reperfusion. *Gut Microbes* 2013; 4: 232–5.

Grootjans J, Hundscheid IH, Lenaerts K, Boonen B, Renes IB, Verheyen FK, Dejong CH, von Meyenfeldt MF, Beets GL, Buurman WA. Ischaemia-induced mucus barrier loss and bacterial penetration are rapidly counteracted by increased goblet cell secretory activity in human and rat colon. *Gut* 2013; 62: 250–8.

Gunn AJ, Gunn TR, De Haan HH, Williams CE, Gluckman PD. Dramatic neuronal rescue with prolonged selective head cooling after ischemia in fetal lambs. *J. Clin. Invest.* 1997; 99:248–56.

Guo C, Liang F, Shah Masood W, Yan X. Hydrogen sulfide protected gastric epithelial cell from ischemia/reperfusion injury by Keap1 s-sulfhydration, MAPK dependent anti-apoptosis and NF-κB dependent anti-inflammation pathway. *Eur. J. Pharmacol*. 2014; 725:70–8.

Günaydin B, Cakici I, Soncul H, Kalaycioglu S, Cevik C, Sancak B, Kanzik I, Karadenizli Y. Does remote organ ischaemia trigger cardiac preconditioning during coronary artery surgery? *Pharmacol. Res*. 2000; 41(4):493–6.

Haapanen H, Heraj€arvi J, Arvola O, Anttila T, Starck T, Kallio M, Anttila V, Tuominen H, Kiviluoma K, Juvonen T. Remote ischemic preconditioning protects the spinal cord against ischemic insult: an experimental study in a porcine model. *J. Thorac. Cardiovasc. Surg*. 2016; 151:777–85.

Hahn CD, Manlhiot C, Schmidt MR, Nielsen TT, Redington AN. Remote ischemic per-conditioning: a novel therapy for acute stroke? *Stroke* 2011; 42:2960–2.

Hamvas A, Park CK, Palazzo R, Liptay M, Cooper J, Schuster DP. Modifying pulmonary ischemia-reperfusion injury by altering ventilator strategies during ischemia. *J. Appl. Physiol.* 1992; 73: 2112–9.

Hamvas A, Schuster DP. Bronchial and reverse pulmonary venous blood flow protects the lung from ischemia-reperfusion injury. *J. Appl. Physiol.* 1994; 77: 731–6.

Harada K,GrossmanW, Friedman M, Edelman ER, Prasad PV,Keighley CS, Manning WJ, Sellke FW, Simons M. Basic fibroblast growth factor improves myocardial function in chronically ischemic porcine hearts. *J. Clin. Invest.* 1994; 94:623–30.

Harkin DW, Barros D'Sa AA, McCallion K, Hoper M, Campbell FC. Ischemic preconditioning before lower limb ischemia--reperfusion protects against acute lung injury. *J. Vasc. Surg.* 2002; 35(6):1264–73.

Hausenloy DJ, Mwamure PK, Venugopal V, Harris J, Barnard M, Grundy E, Ashley E, Vichare S, Di Salvo C, Kolvekar S, Hayward M, Keogh B, MacAllister RJ, Yellon DM. Effect of remote ischaemic preconditioning on myocardial injury in patients undergoing coronary artery bypass graft surgery: a randomised controlled trial. *Lancet* 2007; 370:575–9.

Hausenloy D. Cardioprotection Techniques: Preconditioning, Postconditioning and Remote Con-ditioning (Basic Science). *Curr. Pharm. Des.* 2013; 19 (25): 4544–63.

Hausenloy DJ, Yellon DM. Ischaemic conditioning and reperfusion injury. *Nat. Rev. Cardiol.* 2016; 13(4):193–209.

Heusch G. Remote conditioning: the future of cardioprotection? *J. Cardiovasc. Med* (Hagerstown). 2013; 14:176–9.

Helou S, Koehler RC, Gleason CA, Jones MD Jr, Traystman RJ. Cerebrovascular autoregulation during fetal development in sheep. *Am. J. Physiol.* 1994; 266:H1069–74.

Heusch G, Libby P, Gersh B, Yellon D, Böhm M, Lopaschuk G, Opie L. Cardiovascular remodelling in coronary artery disease and heart failure. *Lancet* 2014; 383(9932):1933–43.

Hoffmann TF, Leiderer R, Waldner H, Arbogast S, Messmer K. Ischemia reperfusion of the pancreas: a new in vivo model for acute pancreatitis in rats. *Res. Exp. Med (Berl).* 1995; 195(3):125–44.

Hood Jr WB, McCarthy B, Lown B. Myocardial infarction following coronary ligation in dogs. Hemodynamic effects of isoproterenol and acetylstrophanthidin. *Circ. Res.* 1967; 21:191–9.

Hosseinzadeh H, Modaghegh MH and Saffari Z. Crocus sativus L. (Saffron) extract and its active constituents (crocin and safranal) on ischemia-reperfusion in rat skeletal muscle. *Evid. Based. Complement. Alternat. Med.* 2009; 6: 343–50.

Houry D, Abbott JT. Ovarian torsion: a fifteen-year review. *Ann. Emerg. Med*. 2001; 38:156–9.

Ikeda H, Suzuki Y, Suzuki M, Koike M, Tamura J, Tong J, Nomura M, Itoh G. Apoptosis is a major mode of cell death caused by ischaemia and ischaemia/reperfusion injury to the rat intestinal epithelium. *Gut* 1998; 42:530–7.

Ingec M, Isaoglu U, Yilmaz M, Calik M, Polat B, Alp HH, Kurt A, Gundogdu C, Suleyman H. Prevention of ischemia-reperfusion injury in rat ovarian tissue with the on-off method. *J. Physiol. Pharmacol*. 2011; 62(5):575–82.

Iwanaga K, Takano H, Ohtsuka M, Hasegawa H, Zou Y, Qin Y, Odaka K, Hiroshima K, Tadokoro H, Komuro I. Effects of G-CSF on cardiac remodeling after acute myocardial infarction in swine. *Biochem. Biophys. Res. Commun*. 2004; 325:1353–9.

Jackson RM, Russell WJ, Veal CF. Endogenous and exogenous catalase in reoxygenation lung injury. *J. Appl. Physiol* (1985). 1992; 72(3):858–64.

Jennings RB, Sommers HM, Smyth GA, Flack HA, Linn H. Myocardial necrosis induced by temporary occlusion of a coronary artery in the dog. *Arch. Pathol*. 1960; 70:68–78.

Jennings RB. Historical perspective on the pathology of myocardial ischemia/reperfusion injury. *Circ. Res*. 2013; 113(4):428–38.

Jensen HA, Loukogeorgakis S, Yannopoulos F, Rimpiläinen E, Petzold A, Tuominen H, Lepola P, Macallister RJ, Deanfield JE, Mäkelä T, Alestalo K, Kiviluoma K, Anttila V, Tsang V, Juvonen T. Remote ischemic preconditioning protects the brain against injury after hypothermic circulatory arrest. *Circulation* 2011; 123(7):714–21.

Jiang B, Liu X, Chen H, Liu D, Kuang Y, Xing B, Chen Z. Ischemic postconditioning attenuates renal ischemic/reperfusion injury in mongrel dogs. *Urology* 2010; 76: 1519 e1.

Jiang B, Chen Q, Liu X, Kong D, Kuang Y, Weng X, Chen H. Ischemic postconditioning protects renal function after 24 hours of cold preservation in a canine autotransplantation model. *Transplant. Proc*. 2012; 44: 1776.

Joachim SC, Jehle T, Boehm N, Gramlich OW, Lagreze WA, Pfeiffer N, Grus FH. Effect of ischemia duration on autoantibody response in rats undergoing retinal ischemia-reperfusion. *Ophthalmic. Res*. 2012; 48(2):67–74.

Johnston MV, Hagberg H. Sex and the pathogenesis of cerebral palsy. *Dev. Med. Child Neurol.* 2007; 49:74–8.

Kanoria S, Jalan R, Davies NA, Seifalian AM, Williams R, Davidson BR. Remote ischaemic preconditioning of the hind limb reduces experimental liver warm ischaemia-reperfusion injury. *Br. J. Surg*. 2006; 93(6):762–8.

Kato H, Araki T, Kogure K. Preserved neurotransmitter receptor binding following ischemia in preconditioned gerbil brain. *Brain. Res. Bull*. 1992; 29:395–400.

Kato H, Araki T, Murase K, Kogure K. Induction of tolerance to ischemia: alterations in secondmessenger systems in the gerbil hippocampus. *Brain. Res. Bull*. 1992; 29:559–65.

Kennedy SE, Erlich JH. Murine renal ischaemia-reperfusion injury. *Nephrology (Carlton)* 2008; 13: 390.

Kerendi F, Kin H, Halkos ME, Jiang R, Zatta AJ, Zhao ZQ, Guyton RA,Vinten-Johansen J. Remote postconditioning. Brief renal ischemia and reperfusion applied before coronary artery reperfusion reduces myocardial infarct size via endogenous activation of adenosine receptors. *Basic. Res. Cardiol*. 2005; 100: 404–12.

Kharbanda RK, Mortensen UM, White PA, Kristiansen SB, Schmidt MR, Hoschtitzky JA, Vogel M, Sorensen K, Redington AN, MacAllister R. Transient limb ischemia induces remote ischemic preconditioning in vivo. *Circulation* 2002; 106(23):2881–3.

Khimenko PL, Moore TM, Taylor AE. Blocked ETA receptors prevent ischemia and reperfusion injury in rat lungs. *J. Appl. Physiol.* 1996; 80: 203–7.

Khimenko PL, Taylor AE. Segmental microvascular permeability in ischemia-reperfusion injury in rat lung. *Am. J. Physiol*. 1999; 276(6 Pt 1):L958–60.

Kim BJ, Braun TA, Wordinger RJ, Clark AF. Progressive morphological changes and impaired retinal function associated with temporal regulation of gene expression after retinal ischemia/reperfusion injury in mice. *Mol. Neurodegener*. 2013; 8:21.

Kirton A, Armstrong-Wells J, Chang T, Deveber G, Rivkin MJ, Hernandez M, Carpenter J, Yager JY, Lynch JK, Ferriero DM; International Pediatric Stroke Study Investigators. Symptomatic neonatal arterial ischemic stroke: The international pediatric stroke study. *Pediatrics* 2011; 128:e1402–10.

Kitada H, Sugitani A, Yamamoto H, Otomo N, Okabe Y, Inoue S, Nishiyama K,Morisaki T, Tanaka M. Attenuation of renal ischemia-reperfusion injury by FR167653 in dogs. *Surgery* 2002; 131(6):654–62.

Klein HM, Klosterhalfen B, Kinzel S, Jansen A, Seggewiss C, Weghaus P, Kamp M, Tons C, Gunther RW. CT and MRI of experimentally induced mesenteric ischemia in a porcine model. *J. Comput. Assist. Tomogr*. 1996; 20: 254–61.

Kloner RA, Bolli R, Marban E, Reinlib L, Braunwald E. Medical and cellular implications of stunning, hibernation, and preconditioning: an NHLBI workshop. *Circulation* 1998; 97:1848–67.

Knudsen AR, Kannerup AS, Dich R, Funch-Jensen P, Grønbaek H, Kruhøffer M, Mortensen FV. Ischemic pre- and postconditioning has pronounced effects on gene expression profiles in the rat liver after ischemia/reperfusion. *Am. J. Physiol. Gastrointest. Liver. Physiol.* 2012; 303(4):G482–9.

Koch S, Perez-Pinzon MA. Proceedings of the 2nd translational preconditioning meeting Miami. *Transl. Stroke. Res*. 2013; 4(1):1–2.

Koike K, Moore FA, Moore EE, Poggetti RS, Tuder RM, Banerjee A. Endotoxin after gut ischemia/reperfusion causes irreversible lung injury. *J Surg Res*. 1992; 52(6):656-62.

Koike K, Moore EE, Moore FA, Kim FJW, Carl VS, Banerjee A. Gut phospholipase A2 mediates neutrophil priming and lung injury after mesenteric ischemia-reperfusion. *Am. J. Physiol. Gastrointest. Liver. Physiol.* 1995; 268: G397–G403.

Krogstrup NV, Oltean M, Bibby BM, Nieuwenhuijs-Moeke GJ, Dor FJ, Birn H, Jespersen B. Remote ischaemic conditioning on recipients of deceased renal transplants, effect on immediate and extended kidney graft function: a multicentre, randomized controlled trial protocol (CONTEXT). *BMJ. Open*. 2015; 5(8):e007941.

Kubes P, Hunter J, Granger DN. Ischemia/reperfusion-induced feline intestinal dysfunction: importance of granulocyte recruitment. *Gastroenterology* 1992; 103: 807–12.

Kuhlmann MT, Kirchhof P, Klocke R, Hasib L, Stypmann J, Fabritz L, Stelljes M,Tian W, Zwiener M, Mueller M, Kienast J, Breithardt G, Nikol S.G-CSF/SCF reduces inducible arrhythmias in the infarcted heart potentially via increased connexin43 expression and arteriogenesis. *J. Exp. Med*. 2006; 203:87–97.

Kumbasar S, Salman S, Al RA, Ozturk C, Yarali O, Alp HH, Altuner D, Suleyman B. The effect of metamizole on ischemia/reperfusion injury in the rat ovary: An analysis of biochemistry, molecular gene expression, and histopathology. *Indian. J. Pharmacol*. 2016; 48(1):32–6.

Kuniyoshi Y, Koja K, Miyagi K, Shimoji M, Uezu T, Arakaki K, Yamashiro S, Mabuni K, Senaha S, Nakasone Y. Prevention of postoperative paraplegia during thoracoabdominal aortic surgery. *Ann. Thorac. Surg*. 2003; 76:1477–84.

Kyng KJ, Skajaa T, Kerrn-Jespersen S, Andreassen CS, Bennedsgaard K, Henriksen TB. A Piglet model of neonatal hypoxic-ischemic encephalopathy. *J. Vis. Exp.* 2015; 99:e52454.

Kyoi T, Kitazawa S, Tajima K, Zhang X, Ukai Y. Phosphodiesterase type IV inhibitors prevent ischemia-reperfusion-induced gastric injury in rats. *J. Pharmacol. Sci*. 2004; 95(3):321–8.

Kyriakides C, Favuzza J, Wang Y, Austen WG Jr, Moore FD Jr, Hechtman HB. Recombinant soluble P-selectin glycoprotein ligand 1 moderates local and remote injuries following experimental lower-torso ischaemia. *Br. J. Surg*. 2001; 88(6):825–30.

Lai IR, Chang KJ, Chen CF, Tsai HW. Transient limb ischemia induces remote preconditioning in liver among rats: the protective role of heme oxygenase-1. *Transplantation* 2006; 81(9):1311–7.

Lan R, Geng H, Polichnowski AJ, Singha PK, Saikumar P, McEwen DG, Griffin KA, Koesters R, Weinberg JM, Bidani AK, Kriz W, Venkatachalam MA. PTEN loss defines a TGF_induced tubule phenotypeof failed differentiation and JNK signaling during renal fibrosis. *Am. J. Physiol. Renal. Physiol.* 2012; 302: F1210–23.

Land WG. The role of postischemic reperfusion injury and other nonantigen-dependent inflammatory pathways in transplantation. *Transplantation* 2005; 79(5):505–14.

Lang-Lazdunski L, Heurteaux C, Mignon A, Mantz J, Widmann C, Desmonts J, Lazdunski M. Ischemic spinal cord injury induced by aortic cross-clamping: Prevention by riluzole. *Eur. J. Cardiothorac. Surg*. 2000; 18:174–81.

Lang-Lazdunski L, Matsushita K, Hirt L, Waeber C, Vonsattel JP, Moskowitz MA, Dietrich WD. Spinal cord ischemia. Development of a model in the mouse. *Stroke* 2000; 31:208–13.

Laptook AR, Hassan A, Peterson J, Corbett RJ, Nunnally RL. Effects of repeated ischemia on cerebral blood flow and brain energy metabolism. *NMR. Biomed*. 1988; 1:74–79.

Lee GJ, Kim SK, Kang SW, Kim OK, Chae SJ, Choi S, Shin JH, Park HK, Chung JH. Real time measurement of myocardial oxygen dynamics during cardiac ischemia-reperfusion of rats. *Analyst* 2012; 137(22):5312–9.

Lee JC, Christie JD, Keshavjee S. Primary graft dysfunction: definition, risk factors, short- and long-term outcomes. *Semin. Respir. Crit. Care. Med.* 2010; 31:161–71.

Lee JI, Kim MJ, Park CS, Kim MC. Influence of ascorbic acid on BUN, creatinine, resistive index in canine renal ischemia-reperfusion injury. *J. Vet. Sci*. 2006; 7(1):79–81.

Lee JY, Kim HS, Park CS, Kim MC. Erdosteine in renal ischemia-reperfusion injury: an experimental study in pigs. *J. Vet. Med. Sci.* 2010; 72(1):127–30.

Lehotský J, Burda J, Danielisová V, Gottlieb M, Kaplán P, Saniová B. Ischemic tolerance: the mechanisms of neuroprotective strategy. *Anat. Rec.* (Hoboken). 2009; 292(12):2002–12.

Leung FW, Su KC, Passaro E Jr, Guth PH. Regional differences in gut blood flow and mucosal damage in response to ischemia and reperfusion. *Am. J. Physiol. Gastrointest. Liver. Physiol*. 1992; 263: G301–5.

Li C, Li YS, Xu M, Wen SH, Yao X, Wu Y, Huang CY, Huang WQ, Liu KX. Limb remote ischemic preconditioning for intestinal and pulmonary protection during elective open infrarenal abdominal aortic aneurysm repair: a randomized controlled trial. *Anesthesiology* 2013; 118:842–52.

Li S, Nagothu KK, Desai V, Lee T, Branham W, Moland C, Megyesi JK, Crew MD, Portilla D. Transgenic expression of proximal tubule peroxisome proliferator-activated receptor-alpha in mice confers protection during acute kidney injury. *Kidney Int.* 2009; 76: 1049–62.

Li SJ, Wu YN, Kang Y, Yin YQ, Gao WZ, Liu YX, Lou JS. Noninvasive limb ischemic preconditioning protects against myocardial I/R injury in rats. *J. Surg. Res*. 2010; 164(1):162–8.

Lin E, Snell GI, Levvey BJ, Mifsud N, Paul M, Buckland MR, Gooi J, Marasco S, Sharland AF, Myles PS. Safety, feasibility, and effect of remote ischemic conditioning in patients undergoing lung transplantation. *J. Heart. Lung. Transplant*. 2014; 33(11):1139–48.

Liu A, Fang H, Wei W, Dirsch O, Dahmen U. Ischemic preconditioning protects against liver ischemia/reperfusion injury via heme oxygenase-1-mediated autophagy. *Crit. Care. Med*. 2014; 42(12):e762–71.

Liu J, Van der Elst J, Van den Broecke R, Dhont M. Early massive follicle loss and apoptosis in heterotopically grafted newborn mouse ovaries. *Hum. Reprod*. 2002; 17(3):605–11.

Liu KX, Li YS, Huang WQ, Li C, Liu JX, Li Y. Immediate but not delayed postconditioning during reperfusion attenuates acute lung injury induced by intestinal ischemia/reperfusion in rats: comparison with ischemic preconditioning. *J. Surg. Res*. 2009; 157(1):e55–62.

Liu X, Sha O, Cho EY. Remote ischemic postconditioning promotes the survival of retinal ganglion cells after optic nerve injury. *J. Mol. Neurosci*. 2013; 51(3):639–46.

Liu YH, Yang XP, Nass O, Sabbah HN, Peterson E, Carretero OA. Chronic heart failure induced by coronary artery ligation in Lewis inbred rats. *Am. J. Physiol*. 1997; 272:H722–7.

Lloyd-Jones D, Adams RJ, Brown TM, Carnethon M, Dai S, De Simone G, Ferguson TB, Ford E, Furie K, Gillespie C, Go A, Greenlund K, Haase N, Hailpern S, Ho PM, Howard V, Kissela B, Kittner S, Lackland D, Lisabeth L, Marelli A, McDermott MM, Meigs J, Mozaffarian D, Mussolino M, Nichol G, Roger VL, Rosamond W, Sacco R, Sorlie P,

Roger VL, Thom T, Wasserthiel-Smoller S, Wong ND, Wylie-Rosett J; American Heart Association Statistics Committee and Stroke Statistics Subcommittee. Heart disease and stroke statistics--2010 update: a report from the American Heart Association. *Circulation* 2010; 121(7):e46–e215.

Lo HA, Sun LN, Chen CF, Wang D, Zhang HP. Ischemiareperfusion of the pancreas induced hyperresponsiveness of the airways in rats. *Transplant. Proc.* 2009; 41(1):63–6.

London A, Benhar I, Schwartz M. The retina as a window to the brain – from eye research to CNS disorders. *Nat. Rev. Neurol.* 2013; 9(1):44–53.

Lundberg G, Luo F, Blegen H, Kalin B and Wahlberg E. A rat model for severe limb ischemia at rest. *Eur. Surg. Res*. 2003; 35: 430–8.

Lunsford KE, Baird BJ, Sempowski GD, Cardona DM, Li Z, Weinhold KJ, Sudan DL, Brennan TV. Upregulation of IL-1β, IL-6, and CCL-2 by a novel mouse model of pancreatic ischemia-reperfusion injury. *Transplantation* 2013; 95(8):1000–7.

MacAllister R, Clayton T, Knight R, Robertson S, Nicholas J, Motwani M, Veighey K. Remote preconditioning for Protection against Ischaemia–Reperfusion in renal transplantation (REPAIR): a multicentre, multinational, double-blind, factorial designed randomised controlled trial. Southampton (UK): *NIHR Journals Library*, 2015.

Mallard EC, Gunn AJ, Williams CE, Johnston BM, Gluckman PD. Transient umbilical cord occlusion causes hippocampal damage in the fetal sheep. *Am. J. Obstet. Gynecol.* 1992; 167:1423–30.

Mallard EC, Williams CE, Johnston BM, Gluckman PD. Increased vulnerability to neuronal damage after umbilical cord occlusion in fetal sheep with advancing gestation. *Am. J. Obstet. Gynecol.* 1994; 170:206–14.

Mallick IH, Yang W, Winslet MC, Seifalian AM. Ischemia-reperfusion injury of the intestine and protective strategies against injury. *Dig. Dis. Sci.* 2004; 49: 1359–77.

Massip-Salcedo M, Zaouali MA, Padrissa-Altés S, Casillas-Ramirez A, Rodés J, Roselló-Catafau J, Peralta C. Activation of peroxisome proliferator-activated receptor-alpha inhibits the injurious effects of adiponectin in rat steatotic liver undergoing ischemia-reperfusion. *Hepatology* 2008; 47(2):461–72.

Matsuda H, Lavoie JL, Gaboury L, Hamet P, Tremblay J. HCaRG accelerates tubular repair after ischemic kidney injury. *J. Am. Soc. Nephrol*. 2011; 22(11):2077–89.

Matute-Bello G, Frevert CW, Martin TR. Animal models of acute lung injury. *Am. J. Physiol. Lung. Cell. Mol. Physiol.* 2008; 295: L379–99.

McClanahan TB, Nao BS, Wolke LJ. Brief renal occlusion and reperfusion reduces myocardial infarct size in rabbits. *FASEB. J*. 1993; 7 [abstract].

McMillen MA, Huribal M, Sumpio B. Common pathway of endothelial-leukocyte interaction in shock, ischemia, and reperfusion. *Am. J. Surg*. 1993; 166(5):557–62.

Megison SM, Horton JW, Chao H, Walker PB. A new model for intestinal ischemia in the rat. *J. Surg. Res.* 1990; 49: 168–73.

Megyesi J, Andrade L, Vieira JM Jr, Safirstein RL, and Price PM. Coordination of the cell cycle is an important determinant of the syndrome of acute renal failure. *Am. J. Physiol. Renal. Physiol.* 2002; 283: F810–6.

Meirow D, Fasouliotis SJ, Nugent D, Schenker JG, Gosden RG, Rutherford AJ. A laparoscopic technique for obtaining ovarian cortical biopsy specimens for fertility conservation in patients with cancer. *Fertil Steril* 1999; 71(5):948–51.

Meldrum DR, Dinarello CA, Shames BD, Cleveland JC Jr, Cain BS, Banerjee A, Meng X, Harken AH. Ischemic preconditioning decreases postischemic myocardial tumor necrosis factor-alpha production. Potential ultimate effector mechanism of preconditioning. *Circulation* 1998; 98:1214.

Menting TP, Ergun M, Bruintjes MH, Wever KE, Lomme RM, van Goor H, Warlé MC. Repeated remote ischemic preconditioning and isoflurane anesthesia in an experimental model of renal ischemia-reperfusion injury. *BMC. Anesthesiol*. 2017; 17(1):14.

Mhatre P, Mhatre J, Magotra R. Ovarian transplant: a new frontier. *Transplant. Proc*. 2005; 37(2):1396–8.

Miklos Z, Kurthy M, Degrell P, Ranczinger E, Vida M, Lantos J, Arató E, Sínay L, Hardi P, Balatonyi B, Ferencz S, Jávor S, Kovács V, Borsiczky B, Wéber G, Rőth E, Jancsó G. Ischaemic postconditioning reduces serum and tubular TNF-alpha expression in ischaemic-reperfused kidney in healthy rats. *Clin. Hemorheol. Microcirc.* 2012; 50: 167.

Mogami S, Suzuki H, Fukuhara S, Matsuzaki J, Kangawa K, Hibi T. Reduced ghrelin production induced anorexia after rat gastric ischemia and reperfusion. *Am. J. Physiol. Gastrointest. Liver. Physiol.* 2012; 302(3):G359–64.

Mu D, Jiang X, Sheldon RA, Fox CK, Hamrick SE, Vexler ZS, Ferriero DM. Regulation of hypoxia-inducible factor 1alpha and induction of vascular endothelial growth factor in a rat neonatal stroke model. *Neurobiol. Dis.* 2003; 14:524–34.

Murana G, Castrovinci S, Kloppenburg G, Yousif A, Kelder H, Schepens M, de Maat G, Sonker U, Morshuis W, Heijmen R. Open thoracoabdominal aortic aneurysm repair in the modern era: results from a 20-year single-centre experience. *Eur. J. Cardiothorac. Surg*. 2015; 49:1374–81.

Murry CE, Jennings RB, Reimer KA. Preconditioning with ischemia: a delay of lethal cell injury in ischemic myocardium. *Circulation* 1986; 74:1124–36.

Nakamori Y, Komatsu Y, Kotani T, Kojima S, Takeuchi K. Pathogenic importance of cysteinyl leukotrienes in development of gastric lesions induced by ischemia/reperfusion in mice. *J. Pharmacol. Exp. Ther*. 2010; 333(1):91–8.

Nankervis CA, Giannone PJ, Reber KM. The neonatal intestinal vasculature: contributing factors to necrotizing enterocolitis. *Semin. Perinatol.* 2008; 32: 83–91.

Naslund TC, Hollier LH, Money SR, Facundus EC, Skenderis BS. Protecting the ischemic spinal cord during aortic clamping. The influence of anesthetics and hypothermia, *Ann. Surg.* 1992*;* 215, 409–515.

Neeff HP, Sommer O, Meyer S, Tinelli A, Scholtes M, Hopt UT, Drognitz O, von Dobschuetz E. Blood modulates the kinetics of reactive oxygen release in pancreatic ischemia-reperfusion injury. *Pancreas* 2012; 41(7):1105–11.

Neely CF, Keith IM. A1 adenosine receptor antagonists block ischemia-reperfusion injury of the lung. *Am. J. Physiol*. 1995; 268(6 Pt 1): L1036–46.

Nelson KB. Perinatal ischemic stroke. *Stroke* 2007; 38:742–5.

Nichol G, Thomas E, Callaway CW, Hedges J, Powell JL, Aufderheide TP, Rea T, Lowe R, Brown T, Dreyer J, Davis D, Idris A, Stiell I; Resuscitation Outcomes Consortium Investigators. Regional variation in out-of-hospital cardiac arrest incidence and outcome. *JAMA*. 2008; 300(12):1423–31.

Nicholson ML, Pattenden CJ, Barlow AD, Hunter JP, Lee G, Hosgood SA. A Double Blind Randomized Clinical Trial of Remote Ischemic Conditioning in Live Donor Renal Transplantation. *Medicine (Baltimore)* 2015; 94(31):e1316.

Nikeghbalian S, Mansoorian MR, Hosseini SM, Mardani P, Geramizadeh B, Hosseini SA. Reduction of the severity of ischemia reperfusion-induced pancreatitis by ischemic preconditioning of the liver. *Saudi. J. Kidney. Dis. Transpl*. 2009; 20(6):1010–4.

Nilsson UA, Schoenberg MH, Aneman A, Poch B, Magadum S, Beger HG, Lundgren O. Free radicals and pathogenesis during ischemia and reperfusion of the cat small intestine. *Gastroenterology* 1994; 106: 629–36.

Nossuli TO, Lakshminarayanan V, Baumgarten G, Taffet GE, Ballantyne CM, Michael LH, Entman ML. A chronic mouse model of myocardial ischemia-reperfusion: essential in cytokine studies. *Am. J. Physiol. Heart. Circ. Physiol*. 2000; 278:H1049–55.

Obermiller T, Lakshminarayan S, Willoughby S, Mendenhall J, Butler J. Influence of lung volume and left atrial pressure on reverse pulmonary venous blood flow. *J. Appl. Physiol.* 1991; 70: 447–53.

Oehmann C, Benz S, Drognitz O, Pisarski P, Hopt UT, Obermaier R. Remote preconditioning reduces microcirculatory disorders in pancreatic ischemia/reperfusion injury. *Pancreas* 2007; 35(4):e45–50.

Omokawa S, Arai Y, Saito H, Furuya T, Sato T, Sato T, Shirayama K, Ito M, Asanuma Y, Koyama K. A simple experimental model of total hepatectomy, hepatic ischemia and extrahepatic portal obstruction in rats using splenic transposition. *Jpn. J. Surg*. 1991; 21(1):50–6.

Oxman T, Arad M, Klein R, Avazov N, Rabinowitz B. Limb ischemia preconditions the heart against reperfusion tachyarrhythmia. *Am. J. Physiol*. 1997; 273(4 Pt 2):H1707–12.

Papile LA, Rudolph AM, Heymann MA. Autoregulation of cerebral blood flow in the preterm fetal lamb. *Pediatr. Res.* 1985; 19:159–61.

Park PO, Haglund U, Bulkley GB, Falt K. The sequence of development of intestinal tissue injury after strangulation ischemia and reperfusion. *Surgery* 1990; 107: 574–80.

Pearse DB, Wagner EM. Role of the bronchial circulation in ischemia reperfusion lung injury. *J. Appl. Physiol.* 1994; 76: 259–65.

Pell TJ, Baxter GF, Yellon DM, Drew GM. Renal ischemia preconditions myocardium: role of adenosine receptors and ATP-sensitive potassium channels. *Am. J. Physiol*. 1998; 275(5 Pt 2):H1542–7.

Peralta C, Bartrons R, Riera L, Manzano A, Xaus C, Gelpí E, Roselló-Catafau J. Hepatic preconditioning preserves energy metabolism during sustained ischemia. *Am. J. Physiol. Gastrointest. Liver. Physiol.* 2000; 279(1):G163–71.

Perez-Pinzon MA, Mumford PL, Rosenthal M, Sick TJ. Anoxic preconditioning in hippocampal slices: role of adenosine. *Neuroscience* 1996; 75:687–94.

Perez-Pinzon MA, Xu GP, Dietrich WD, Rosenthal M, Sick TJ. Rapid preconditioning protects rats against ischemic neuronal damage after 3 but not 7 days of reperfusion following global cerebral ischemia. *J. Cereb. Blood. Flow. Metab.* 1997; 17:175–82.

Pfeffer MA, Pfeffer JM, Fishbein MC, Fletcher PJ, Spadaro J, Kloner RA, Braunwald E. Myocardial infarct size and ventricular function in rats. *Circ. Res*. 1979; 44:503–12.

Pignataro G, Meller R, Inoue K, Ordonez AN, Ashley MD, Xiong Z, Gala R, Simon RP. In vivo and in vitro characterization of a novel neuroprotective strategy for stroke: ischemic postconditioning. *J. Cereb. Blood. Flow. Metab.* 2008; 28(2):232–41.

Pignataro G, Esposito E, Sirabella R, Vinciguerra A, Cuomo O, Di Renzo G,Annunziato L. nNOS and p-ERK involvement in the neuroprotection exerted by remote

postconditioning in rats subjected to transient middle cerebral artery occlusion. *Neurobiol. Dis*. 2013; 54:105–14.

Ponticelli CE. The impact of cold ischemia time on renal transplant outcome. *Kidney. Int*. 2015; 87(2):272–5.

Prunier F, Angoulvant D, Saint Etienne C, Vermes E, Gilard M, Piot C, Roubille F, Elbaz M, Ovize M, Bie` re L, Jeanneteau J, Dele´pine S, Benard T, Abi-Khalil W, Furber A. The RIPOST-MI study, assessing remote ischemic perconditioning alone or in combination with local ischemic postconditioning in ST-segment elevation myocardial infarction. *Basic. Res. Cardiol.* 2014; 109:400.

Przyklenk K, Bauer B, Ovize M, Kloner RA, Whittaker P. Regional ischemic 'preconditioning' protects remote virgin myocardium from subsequent sustained coronary occlusion. *Circulation* 1993; 87(3):893–9.

Przyklenk K, Whittaker P. Genesis of remote conditioning. *J. Cardiovasc. Med.* 2013; 14 (3): 180–6.

Qayumi AK, Janusz MT, Lyster DM, Gillespie KD. Animal model for investigation of spinal cord injury caused by aortic cross-clamping. *J. Invest. Surg. 1997;* 10:47–52.

Racho El-Akouri R, Wranning CA, Molne J, Kurlberg G, Brannstrom M. Pregnancy in transplanted mouse uterus after long-term cold ischaemic preservation. *Hum. Reprod*. 2003; 18(10):2024–30.

Ramalho FS, Alfany-Fernandez I, Casillas-Ramirez A, Massip-Salcedo M, Serafín A, Rimola A, Arroyo V, Rodés J, Roselló-Catafau J, Peralta C. Are angiotensin II receptor antagonists useful strategies in steatotic and nonsteatotic livers in conditions of partial hepatectomy under ischemia-reperfusion? *J. Pharmacol. Exp. Ther*. 2009; 329(1):130–40.

Ramirez ER, Ramirez Nessetti DK, Nessetti MB, Khatamee M, Wolfson MR, Shaffer TH, Ramirez VZ, Ramirez HA. Pregnancy and outcome of uterine allotransplantation and assisted reproduction in sheep. *J. Minim. Invasive. Gynecol*. 2011; 18(2):238–45.

Rehni AK, Singh N. Role of phosphoinositide 3-kinase in ischemic postconditioning-induced attenuation of cerebral ischemia-evoked behavioral deficits in mice. *Pharmacol. Rep*. 2007; 59(2):192–8.

Ren C, Gao X, Steinberg GK, Zhao H. Limb remote-preconditioning protects against focal ischemia in rats and contradicts the dogma of therapeutic time windows for preconditioning. *Neuroscience* 2008; 151(4):1099–103.

Renolleau S, Aggoun-Zouaoui D, Ben-Ari Y, Charriaut-Marlangue C. A model of transient unilateral focal ischemia with reperfusion in the p7 neonatal rat: Morphological changes indicative of apoptosis. *Stroke* 1998; 29:1454–60.

Rentoukas I, Giannopoulos G, Kaoukis A, Kossyvakis C, Raisakis K, Driva M, Panagopoulou V, Tsarouchas K, Vavetsi S, Pyrgakis V, Deftereos S. Cardioprotective role of remote ischemic periconditioning in primary percutaneous coronary intervention: enhancement by opioid action. *JACC. Cardiovasc. Interv.* 2010; 3:49–55.

Rice J, Vannucci R, Brierly J. The influence of immaturity on hypoxia-ischemic brain damage in the rat. *Ann. Neurol*. 1981; 9:131–41.

Robinson JW, Mirkovitch V, Winistorfer B, Saegesser F. Response of the intestinal mucosa to ischaemia. *Gut* 1981; 22: 512–27.

Roohey T, Raju TN, Moustogiannis AN: Animal models for the study of perinatal hypoxic-ischemic encephalopathy: a critical analysis. *Early. Hum. Dev.* 1997; 47: 115–46.

Rosow DE, Sahani D, Strobel O, Kalva S, Mino-Kenudson M, Holalkere NS, Alsfasser G, Saini S, Lee SI, Mueller PR, Fernandezdel Castillo C, Warshaw AL, Thayer SP. Imaging of acute mesenteric ischemia using multidetector CT and CT angiography in a porcine model. *J. Gastrointest. Surg.* 2005*;* 9: 1262–74.

Roth DM, White FC, Mathieu-Costello O, Guth BD, Heusch G, Bloor CM, Longhurst JC. Effects of left circumflexAmeroid constrictor placement on adrenergic innervation of myocardium. *Am. J. Physiol*. 1987; 253:H1425–34.

Saeki I, Matsuura T, Hayashida M, Taguchi T. Ischemic preconditioning and remote ischemic preconditioning have protective effect against cold ischemia-reperfusion injury of rat small intestine. *Pediatr. Surg. Int*. 2011; 27(8):857–62.

Sahin S, Ozakpinar OB, Ak K, Eroglu M, Acikel M, Tetik S, Uras F, Cetinel S. The protective effects of tacrolimus on rat uteri exposed to ischemia-reperfusion injury: a biochemical and histopathologic evaluation. *Fertil Steril* 2014; 101(4):1176–82.

Sahin Ersoy G, Kurek Eken M, Cevik O, Cilingir OT, Tal R. Mycophenolate mofetil attenuates uterine ischaemia/reperfusion injury in a rat model. *Reprod. Biomed. Online*. 2017; 34(2):115–23.

Sak ME, Soydinc HE, Sak S, Evsen MS, Alabalik U, Akdemir F, Gul T. The protective effect of curcumin on ischemia-reperfusion injury in rat ovary. *Int. J. Surg*. 2013; 11(9):967–70.

Sakuma T, Takahashi K, Ohya N, Kajikawa O, Martin TR, Albertine KH, Matthay MA. Ischemia-reperfusion lung injury in rabbits: mechanisms of injury and protection. *Am. J. Physiol. Lung. Cell. Mol. Physiol.* 1999; 276: L137–45.

Sapmaz A, Ulus AT, Turan NN, Kaymaz FF, Yazıcıoğlu H, Ersöz S, Simsek E, Köksoy C. Which type of conditioning method protects the spinal cord from the ischemia-reperfusion injury in 24 hours? *Vascular* 2015; 23: 614–21.

Sasaki KJ and Miller CE: Adnexal torsion: Review of the literature. *J. Minim. Invasive. Gynecol.* 2014; 21: 196–202.

Sastry P, Hardman G, Page A, Parker R, Goddard M, Large S, Jenkins DP. Mesenteric ischaemia following cardiac surgery: the influence of intraoperative perfusion parameters. *Interact. Cardiovasc. Thorac. Surg.* 2014; 19: 419–24.

Saxena P, Bala A, Campbell K, Meloni B, d'Udekem Y, Konstantinov IE. Does remote ischemic preconditioning prevent delayed hippocampal neuronal death following transient global cerebral ischemia in rats? *Perfusion* 2009; 24(3):207–11.

Schmidt MR, Smerup M, Konstantinov IE, Shimizu M, Li J, Cheung M, White PA, Kristiansen SB, Sorensen K, Dzavik V, Redington AN, Kharbanda RK. Intermittent peripheral tissue ischemia during coronary ischemia reduces myocardial infarction through a KATP-dependent mechanism: first demonstration of remote ischemic perconditioning. *Am. J. Physiol. Heart. Circ. Physiol*. 2007; 292(4):H1883–90.

Schwartz MZ. Novel therapies for the management of short bowel syndrome in children. *Pediatr. Surg. Int.* 2013; 29: 967–74.

Sekhon CS, Sekhon BK, Singh I, Orak JK, Singh AK. Attenuation of renal ischemia/reperfusion injury by a triple drug combination therapy. *J. Nephrol*. 2003; 16(1):63–74.

Sekhon LH, Fehlings MG. Epidemiology, demographics, and pathophysiology of acute spinal cord injury. *Spine (Phila Pa 1976)* 2001; 26:S2–S12.

Selzner M, Camargo CA, Clavien PA. Ischemia impairs liver regeneration after major tissue loss in rodents: protective effects of interleukin-6. *Hepatology* 1999; 30(2):469–75.

Semple BD, Blomgren K, Gimlin K, Ferriero DM, Noble-Haeusslein LJ. Brain development in rodents and humans: Identifying benchmarks of maturation and vulnerability to injury across species. *Prog. Neurobiol.* 2013; 106–107:1–16.

Serviddio G, Romano AD, Gesualdo L, Tamborra R, Di Palma AM, Rollo T, Altomare E, Vendemiale G. Postconditioning is an effective strategy to reduce renal ischaemia/reperfusion injury. *Nephrol. Dial. Transplant.* 2008; 23: 1504.

Shanley PF, Rosen MD, Brezis M, Silva P, Epstein FH, Rosen S. Topography of focal proximal tubular necrosis after ischemia with reflow in the rat kidney. *Am. J. Pathol.* 1986; 122: 462–8.

Sheldon RA, Chuai J, Ferriero DM. A rat model for hypoxic-ischemic brain damage in very premature infants. *Biol. Neonate.*1996; 69:327–41.

Sheldon RA, Sedik C, Ferriero DM. Strain-related brain injury in neonatal mice subjected to hypoxia- ischemia. *Brain. Res.*1998; 810:114–22.

Sheldon RA, Jiang X, Francisco C, Christen S, Vexler ZS, Tauber MG, Ferriero DM. Manipulation of antioxidant pathways in neonatal murine brain. *Pediatr. Res.* 2004; 56:656–62.

Shoskes DA, Parfrey NA, Halloran PF. Increased major histocompatibility complex antigen expression in unilateral ischemic acute tubular necrosis in the mouse. *Transplantation* 1990; 49: 201–7.

Silverman SM, Kim BJ, Howell GR, Miller J, John SW, Wordinger RJ, Clark AF. C1q propagates microglial activation and neurodegeneration in the visual axis following retinal ischemia/reperfusion injury. *Mol. Neurodegener*. 2016; 11:24.

Sinha AC, Cheung AT. Spinal cord protection and thoracic aortic surgery. *Curr. Opin. Anaesthesiol.* 2010; 23:95–102.

Skyschally A, van Caster P, Iliodromitis EK, Schulz R, Kremastinos DT, Heusch G. Ischemic postconditioning: experimental models and protocol algorithms. *Basic. Res. Cardiol.* 2009; 104(5):469–83.

Sluijter J, Condorelli G, Davidson S Engel FB, Ferdinandy P, Hausenloy DJ, Lecour S, Madonna R, Ovize M, Ruiz-Meana M, Schulz R, Van Laake LW; Nucleus of the European Society of Cardiology Working Group Cellular Biology of the Heart. Novel therapeutic strategies for cardioprotection. *Pharmacol. Ther.* 2014; 144 (1): 60–70.

Song T, Peng YF, Guo SY, Liu YH, Liu LY: Brief small intestinal ischemia lessens renal ischemia-reperfusion injury in rats. *Comp. Med.* 2007; 57: 200–5.

Spiegel HU, Bremer C, Boin C, and Langer M. Reduction of hepatic reperfusion injury by indomethacin-mediated vasoconstriction: a rat model with temporary splenocaval shunt. *J. Invest. Surg.*1995; 8(5): 363–9.

Sternbergh WC 3rd, Tuttle TM, Makhoul RG, Bear HD, Sobel M, Fowler AA 3rd. Postischemic extremities exhibit immediate release of tumor necrosis factor. *J. Vasc. Surg*. 1994; 20(3):474–81.

Stone HH, Fulenwider JT. Renal decapsulation in the prevention of post-ischemic oliguria. *Ann. Surg.* 1977; 186: 343–55.

Summers ST, Konishi GP, Freischlag JA. No contralateral neutrophil (PMN) stimulation after rabbit hindlimb ischemia/reperfusion. *Ann. Vasc. Surg*. 1995; 9(3):261–5.

Sun J, Tong L, Luan Q, Deng J, Li Y, Li Z, Dong H, Xiong L. Protective effect of delayed remote limb ischemic postconditioning: role of mitochondrial K (ATP) channels in a rat

model of focal cerebral ischemic reperfusion injury. *J. Cereb. Blood. Flow. Metab.* 2012; 32(5):851–9.

Sun MH, Pang JH, Chen SL, Han WH, Ho TC, Chen KJ, Kao LY, Lin KK, Tsao YP. Retinal protection from acute glaucoma-induced ischemia-reperfusion injury through pharmacologic induction of heme oxygenase-1. *Invest. Ophthalmol. Vis. Sci*. 2010; 51(9):4798–808.

Suzuki S, Nakamura S, Sakaguchi T, Mitsuoka H, Tsuchiya Y, Kojima Y, Konno H, Baba S. Pathophysiological appraisal of a rat model of total hepatic ischemia with an extracorporeal portosystemic shunt. *J. Surg. Res*. 1998; 80(1):22–7.

Svensson LG. New and future approaches for spinal cord protection. *Semin. Thorac. Cardiovasc. Surg.* 1997; 9(3):206–21.

Szwarc I, Soullier S, Gayrard N, Mejean C, Mourad G, Argiles A. Ischemic postconditioning prevents ischemic acute renal failure. *Transplant. Proc*. 2007; 39: 2554.

Taira Y, Marsala M. Effect of proximal arterial perfusion pressure on function, spinal cord blood flow, and histopathologic changes after increasing intervals of aortic occlusion in the rat. *Stroke* 1996*;* 27: 1850–8.

Tapuria N, Kumar Y, Habib MM, Abu Amara M, Seifalian AM, Davidson BR. Remote ischemic preconditioning: a novel protective method from ischemia reperfusion injury--a review. *J. Surg. Res*. 2008; 150:304–30.

Tapuria N, Junnarkar SP, Dutt N, Abu-Amara M, Fuller B, Seifalian AM, Davidson BR. Effect of remote ischemic preconditioning on hepatic microcirculation and function in a rat model of hepatic ischemia reperfusion injury. *HPB* 2009; 11(2):108–17.

Thaete LG, Neerhof MG. Endothelin and platelet-activating factor: significance in the pathophysiology of ischemia/reperfusion-induced fetal growth restriction in the rat. *Am. J. Obstet. Gynecol.* 2006; 194(5):1377–83.

Thaete LG, Qu XW, Jilling T, Crawford SE, Fitchev P, Hirsch E, Khan S, Neerhof MG. Impact of toll-like receptor 4 deficiency on the response to uterine ischemia/reperfusion in mice. *Reproduction* 2013; 145(5):517–26.

Thielmann M, Kottenberg E, Kleinbongard P, Wendt D, Gedik N, Pasa S, Price V, Tsagakis K, Neuha¨user M, Peters J, Jakob H, Heusch G. Cardioprotective and prognostic effects of remote ischaemic preconditioning in patients undergoing coronary artery bypass surgery: a single-centre randomised, double-blind, controlled trial. *Lancet* 2013; 382:597–604.

Thoresen M, Penrice J, Lorek A, Cady EB, Wylezinska M, Kirkbride V, Cooper CE,Brown GC, Edwards AD, Wyatt JS, et al. Mild hypothermia after severe transient hypoxia-ischemia ameliorates delayed cerebral energy failure in the newborn piglet. *Pediatr. Res.* 1995; 37:667–70.

Thoresen M, Haaland K, Loberg EM, Whitelaw A, Apricena F, Hanko E, Hankø E, Steen PA. A piglet survival model of posthypoxic encephalopathy. *Pediatr. Res.* 1996; 40:738–48.

Traudt CM, McPherson RJ, Bauer LA, Richards TL, Burbacher TM, McAdams RM, Juul SE. Concurrent erythropoietin and hypothermia treatment improve outcomes in a term nonhuman primate model of perinatal asphyxia. *Dev. Neurosci*. 2013; 35(6):491–503.

Tremblay J, Chen H, Peng J, Kunes J, Vu MD, Der Sarkissian S, deBlois D, Bolton AE, Gaboury L, Marshansky V, Gouadon E, Hamet P. Renal ischemia-reperfusion injury in the rat is prevented by a novel immune modulation therapy. *Transplantation* 2002; 74(10):1425–33.

Trompeter M, Brazda T, Remy CT, Vestring T, Reimer P. Nonocclusive mesenteric ischemia: etiology, diagnosis, and interventional therapy. *Eur. Radiol.* 2002; 12: 1179–87.

Turer AT, Hill JA. Pathogenesis of myocardial ischemia-reperfusion injury and rationale for therapy. *Am. J. Cardiol*. 2010; 106:360–8.

Uhlmann D, Armann B, Gaebel G, Ludwig S, Hess J, Pietsch UC, Escher E, Fiedler M, Tannapfel A, Hauss J, Witzigmann H. Endothelin A receptor blockade reduces hepatic ischemia/reperfusion injury after warm ischemia in a pig model. *J. Gastrointest. Surg*. 2003; 7(3):331–9.

Vandervelde S, van Amerongen MJ, Tio RA, Petersen AH, van Luyn MJ, Harmsen MC. Increased inflammatory response and neovascularization in reperfused vs. non-reperfused murine myocardial infarction. *Cardiovasc. Pathol*. 2006; 15:83–90.

Vannucci RC, Vannucci SJ: A model of perinatal hypoxic-ischemic brain damage. *Ann. NY. Acad. Sci.* 1997; 835:234–49.

Volpe JJ. The encephalopathy of prematurity--brain injury and impaired brain development inextricably intertwined. *Semin. Pediatr. Neurol*. 2009; 16:167–78.

Waddell TK, Gorczynski RM, DeCampos KN, Patterson GA, Slutsky AS. Major histocompatibility complex expression and lung ischemia-reperfusion in rats. *Ann. Thorac. Surg.* 1996; 62: 866–72.

Waldow T, Alexiou K, Witt W, Albrecht S, Wagner F, Knaut M, Matschke K. Protection against acute porcine lung ischemia/reperfusion injury by systemic preconditioning via hind limb ischemia. *Transpl. Int*. 2005; 18(2):198–205.

Wang Z, Yang W, Britz GW, Lombard FW, Warner DS, Sheng H. Development of a simplified spinal cord ischemia model in mice. *J. Neurosci. Methods.* 2010; 189(2):246–51.

Wang T, Leng YF, Zhang Y, Xue X, Kang YQ, Zhang Y. Oxidative stress and hypoxia-induced factor 1α expression in gastric ischemia. *World J. Gastroenterol*. 2011; 17(14):1915–22.

Wang T, Zhou YT, Chen XN, Zhu AX, Wu BH. Remote ischemic postconditioning protects against gastric mucosal lesions in rats. *World J. Gastroenterol*. 2014; 20(28):9519–27.

Wang Z, Ji Y, Wang S, Wang R, Li Z, Kang A, Xu H, Shi M, Zhao M. Protective effect of intestinal ischemic preconditioning on ischemia reperfusion-caused lung injury in rats. *Inflammation* 2015; 38(1):424–32.

Ware LB, Matthay MA. The acute respiratory distress syndrome. *N. Engl. J. Med.* 2000; 342: 1334–49.

Warzecha Z, Dembiński A, Ceranowicz P, Cieszkowski J, Konturek SJ, Dembiński M, Kuśnierz-Cabala B, Tomaszewska R, Pawlik WW. Ischemic preconditioning of the hindlimb or kidney does not attenuate the severity of acute ischemia/reperfusion-induced pancreatitis in rats. *J. Physiol. Pharmacol*. 2008; 59(2):337–52.

Wei M, Xin P, Li S, Tao J, Li Y, Li J, Liu M, Li J, Zhu W, Redington AN. Repeated remote ischemic postconditioning protects against adverse left ventricular remodeling and improves survival in a rat model of myocardial infarction. *Circ. Res*. 2011; 108(10):1220–5.

Wei Q, Dong Z. Mouse model of ischemic acute kidney injury: technical notes and tricks. *Am. J. Physiol. Renal. Physiol*. 2012; 303(11):F1487–94.

Weir CJ, Zivin JA, Lyden PD. Inter-relationships between spinal cord blood flow, neuronal death and neurological function in rabbit spinal cord ischemia. *Brain. Res*. 2002; 946:43–51.

Welborn MB 3rd, Douglas WG, Abouhamze Z, Auffenburg T, Abouhamze AS, Baumhofer J, Seeger JM, Pruitt JH, Edwards PD, Chizzonite R, Martin D, Moldawer LL, Harward TR. Visceral ischemia-reperfusion injury promotes tumor necrosis factor (TNF) and interleukin-1 (IL-1) dependent organ injury in the mouse. *Shock* 1996; 6: 171–6.

Wever KE, Warlé MC, Wagener FA, van der Hoorn JW, Masereeuw R, van der Vliet JA, Rongen GA: Remote ischaemic preconditioning by brief hind limb ischaemia protects against renal ischaemia-reperfusion injury: The role of adenosine. *Nephrol. Dial. Transplant.* 2011; 26: 3108–17.

White SK, Frohlich GM, Sado DM, Maestrini V, Fontana M, Treibel TA, Tehrani S, Flett AS, Meier P, Ariti C, Davies JR, Moon JC, Yellon DM, Hausenloy DJ. Remote ischemic conditioning reduces myocardial infarct size and edema in patients with ST-segment elevation myocardial infarction. *JACC. Cardiovasc. Interv.* 2015; 8(1PB):178–88.

Wilkinson C and Sanderson A: Adnexal torsion - a multimodality imaging review. *Clin. Radiol.* 2012; 67:476–83.

Williams CE, Gunn AJ, Mallard C, Gluckman PD. Outcome after ischemia in the developing sheep brain: an electroencephalographic and histological study. *Ann. Neurol.* 1992; 31(1):14–21.

Woo MS, Wang X, Faustino J, Derugin N, Wendland MF, Zhou P, Iadecola C, Vexler ZS. Genetic deletion of cd36 enhances injury after acute neonatal stroke. *Ann. Neurol*. 2012; 72:961–70.

Wranning CA, Akhi SN, Diaz-Garcia C, Brannstrom M. Pregnancy after syngeneic uterus transplantation and spontaneous mating in the rat. *Hum. Reprod*. 2011; 26(3):553–8.

Wu J, Feng X, Huang H, Shou Z, Zhang X, Wang R, Chen Y, Chen J. Remote ischemic conditioning enhanced the early recovery of renal function in recipients after kidney transplantation: a randomized controlled trial. *J. Surg. Res*. 2014; 188(1):303–8.

Wu Y, Hong X, Wang A, Wei D, Wang X, Liang K, Kou J. Effects of Different Limb Remote Ischaemic Preconditioning on Ischaemia Reperfusion Injury in an Acute Left Anterior Descending Artery Occlusion Rat Model. *Heart. Lung. Circ*. 2016; 25(7):719–24.

Wynn JJ, Distant DA, Pirsch JD, Norman D, Gaber AO, Ashby VB, Leichtman AB. Kidney and pancreas transplantation. *Am. J. Transplant*. 2004; 4 Suppl 9:72–80.

Xu B, Gao X, Xu J, Lei S, Xia ZY, Xu Y, Xia Z. Ischemic postconditioning attenuates lung reperfusion injury and reduces systemic proinflammatory cytokine release via heme oxygenase 1. *J. Surg. Res*. 2011; 166(2):e157–64.

Yadav SS, Gao W, Harland RC, Clavien PA. A new and simple technique of total hepatic ischemia in the mouse. *Transplantation* 1998; 65(11):1433–6.

Yahanda AM, Paidas CN, Clemens MG. Susceptibility of hepatic microcirculation to reperfusion injury: a comparison of adult and suckling rats. *J. Pediatr. Surg*. 1990; 25(2):208–13.

Yaman Tunc S, Agacayak E, Goruk NY, Icen MS, Turgut A, Alabalik U, Togrul C, Ekinci C, Ekinci A, Gul T. Protective effects of honokiol on ischemia/reperfusion injury of rat ovary: an experimental study. *Drug. Des. Devel. Ther*. 2016; 10:1077–83.

Yamauchi H, Baca I, Mittmann U, Geisen HP, Salzer M. Postischemic liver damage in rats: effect of some therapeutic interventions on survival rate. *Tohoku. J. Exp. Med*. 1982; 138(1):63–70.

Yang B, Dieudé M, Hamelin K, Hénault-Rondeau M, Patey N, Turgeon J, Lan S, Pomerleau L, Quesnel M, Peng J, Tremblay J, Shi Y, Chan JS, Hébert MJ, Cardinal H. Anti-LG3 Antibodies Aggravate Renal Ischemia-Reperfusion Injury and Long-Term Renal Allograft Dysfunction. *Am. J. Transplant.* 2016 May 12. doi: 10.1111/ajt.13866.

Yassin MM, Harkin DW, Barros D'Sa AA, Halliday MI, Rowlands BJ. Lower limb ischemia-reperfusion injury triggers a systemic inflammatory response and multiple organ dysfunction. *World J. Surg*. 2002; 26(1):115–21.

Yasuhara H. Acute mesenteric ischemia: the challenge of gastroenterology. *Surg. Today.* 2005; 35: 185–95.

Yatsu T, Arai Y, Takizawa K, Kasai-Nakagawa C, Takanashi M, Uchida W, Inagaki O, Tanaka A, Takenaka T. Effect of YM435, a Dopamine DA1 receptor agonist, in a canine model of ischemic acute renal failure. *Gen. Pharmacol*. 1998; 31:803–7.

Yetgin T, Manintveld OC, Boersma E, Kappetein AP, van Geuns RJ, Zijlstra F, Duncker DJ, van der Giessen WJ. Remote ischemic conditioning in percutaneous coronary intervention and coronary artery bypass grafting. *Circ. J.* 2012; 76:2392–404.

Yildiz G, Demiryürek AT, Gümüşel B, Lippton H. Ischemic preconditioning modulates ischemia-reperfusion injury in the rat lung: role of adenosine receptors. *Eur. J. Pharmacol*. 2007; 556(1-3):144–50.

Yun Y, Duan WG, Chen P, Wu HX, Shen ZQ, Qian ZY, Wang DH. Ischemic postconditioning modified renal oxidative stress and lipid peroxidation caused by ischemic reperfusion injury in rats. *Transplant. Proc.* 2009; 41: 3597.

Zager RA, Vijayan A, Johnson AC. Proximal tubule haptoglobin gene activation is an integral component of the acute kidney injury "stress response." *Am. J. Physiol. Renal. Physiol.* 2012; 303: F139–48.

Zanoni FL, Benabou S, Greco KV, Moreno AC, Cruz JW, Filgueira FP, Martinez MB, Figueiredo LF, Silva MR, Sannomiya P. Mesenteric microcirculatory dysfunctions and translocation of indigenous bacteria in a rat model of strangulated small bowel obstruction. *Clinics (Sao Paulo)* 2009; 64(9):911–9.

Zhang B, Zhou J, Li H, Zhou M, Chen A, Zhao Q. Remote ischemic preconditioning does not improve the clinical outcomes in patients undergoing coronary artery bypass grafting: a meta-analysis of randomized controlled trials. *Int. J. Cardiol.* 2014; 172:e36–8.

Zhang WL, Zhao YL, Liu XM, et al. Protective role of mitochondrial K-ATP channel and mitochondrial membrane transport pore in rat kidney ischemic postconditioning. *Chin. Med. J (Engl).* 2011; 124:2191.

Zhang X, Jizhang Y, Xu X, Kwiecien TD, Li N, Zhang Y, Ji X, Ren C, Ding Y. Protective effects of remote ischemic conditioning against ischemia/reperfusion-induced retinal injury in rats. *Vis. Neurosci*. 2014; 31(3):245–52.

Zhao ZQ, Corvera JS, Halkos ME, Kerendi F, Wang NP, Guyton RA, Vinten-Johansen J. Inhibition of myocardial injury by ischemic postconditioning during reperfusion: comparison with ischemic preconditioning. *Am. J. Physiol. Heart. Circ. Physiol.* 2003; 285: H579–88.

Zhao ZQ. Postconditioning in reperfusion injury: a status report. *Cardiovasc. Drugs. Ther.* 2010; 24:265–79.

Zhou Y, Fathali N, Lekic T, Ostrowski RP, Chen C, Martin RD, Tang J, Zhang JH. Remote limb ischemic postconditioning protects against neonatal hypoxic-ischemic brain injury in rat pups by the opioid receptor/Akt pathway. *Stroke* 2011; 42(2):439–44.

In: Encyclopedia of Surgery (22 Volume Set)
Editors: Andreas Lehrer and Kristin Mueller
ISBN: 978-1-53618-329-0
© 2020 Nova Science Publishers, Inc.

Chapter 220

ENCAPSULATED ISLET TRANSPLANTATION: FROM ALLOGENEIC TO XENOGENEIC TRANSPLANTATION

Kun Ho Yoon[1,*], Eun Young Lee[1], Jun-Seop Shin[2,3,4,5], Byoung-Hoon Min[2,3,5], Jong-Min Kim[2,3,4,5] and Chung-Gyu Park[2,3,5,6,7]

[1]Division of Endocrinology and Metabolism, Department of Internal Medicine,
Seoul St. Mary's Hospital, College of Medicine,
The Catholic University of Korea, Seoul, Korea
[2]Xenotransplantation Research Center
[3]Department of Microbiology and Immunology
[4]Institute of Endemic Diseases
[5]Cancer Research Institute
[6]Department of Biomedical Sciences, and
[7]Biomedical Research Institute, Seoul National University College of Medicine,
Seoul, Korea

ABSTRACT

Islet transplantation is considered an ultimate modality for patients with diabetes mellitus. After adoption of the Edmonton protocol in 2000, clinical islet transplantation has increased the duration of insulin independence up to 5 years post-transplant. However, two major challenges limit the broad clinical application of islet transplantation: a shortage of organ donors and the need for immunosuppression. Islet encapsulation, a method of encasing islets in a semipermeable matrix to provide a physical immune barrier, is one of the strategies for overcoming these limitations. Islet encapsulation blocks immune-regulating cells with high molecular weights, while still allowing oxygen, insulin, and nutrients with low molecular weights to pass through the barrier. Currently, a number of encapsulation methods are being investigated in

* Corresponding Author's Email: yoonk@catholic.ac.kr.

preclinical and clinical trials, including macroencapsulation, microencapsulation, conformal coating, and nanoencapsulation. Because of the shortage of pancreas donors, a xenogeneic pancreas may be considered as an alternate source for islet transplantation. In this chapter, we review the basic concepts of islet encapsulation and islet transplantation from allogeneic and xenogeneic sources.

Keywords: diabetes mellitus, islet transplantation, encapsulation, allogeneic, xenogeneic

ABBREVIATIONS

FACS	fluorescence-activated cell sorting
IEQ	islet equivalent
IXA	international xenotransplantation association
NHP	non-human primate
PEG	polyethylene glycol
SNU	Seoul national university
SPF	specific-pathogen-free

INTRODUCTION

Islet transplantation is considered to be both a treatment and a cure for diabetes mellitus (Figure 1). The first attempted islet transplantation was reported by Watson-Williams and Harshant in 1893, which predated the discovery of insulin (Srinivasan 2007). Watson-Williams and Harshant transplanted the minced pancreas of sheep to patients with diabetic ketoacidosis; however, their attempt failed after transient improvement of glycosuria for 24 h. In 2000, a landmark study on islet transplantation, the Edmonton protocol, revolutionized the field of islet transplantation (Shapiro 2000). Since then, many promising results in human islet transplantation have been reported with the use of immunosuppressive agents, including low doses of tacrolimus, sirolimus, and daclizumab (Shapiro 2006). In the late 2000s, the results of clinical islet transplantation showed marked improvement, with patients showing normal C-peptide levels, reduced HbA1c, and decreased islet reinfusion rates (Barton 2012). According to the Collaborative Islet Transplant Registry, the islet graft survival rate at 3 years post-transplant was 44% during the period 2007–2010, which was significantly improved compared with the rate of 27% in 1999–2002 (Barton 2012). This success may be partly attributed to changes in immunosuppression strategies.

Despite these improvements in islet transplantation, two major barriers—a shortage of human pancreas donors and the need for immunosuppression—still limit the widespread clinical application of islet transplantation (Frank 2004). The current protocol for islet transplantation requires at least two donor pancreases for successful islet transplantation, which increases the shortage of organ donors. Moreover, the use of immunosuppressants for preventing transplant rejection is toxic to islets as well as transplant recipients. In this regard, islet encapsulation could be an immune isolation tool that addresses these challenges (Figure 2).

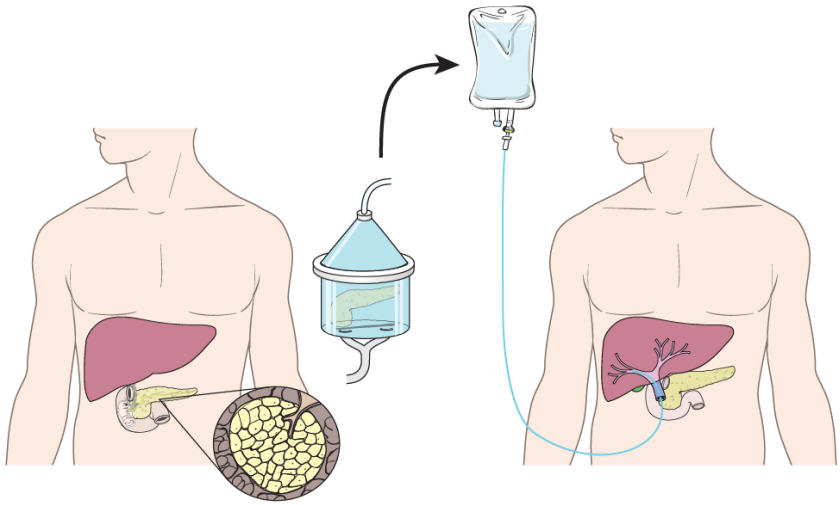

Figure 1. Conventional islet transplantation.

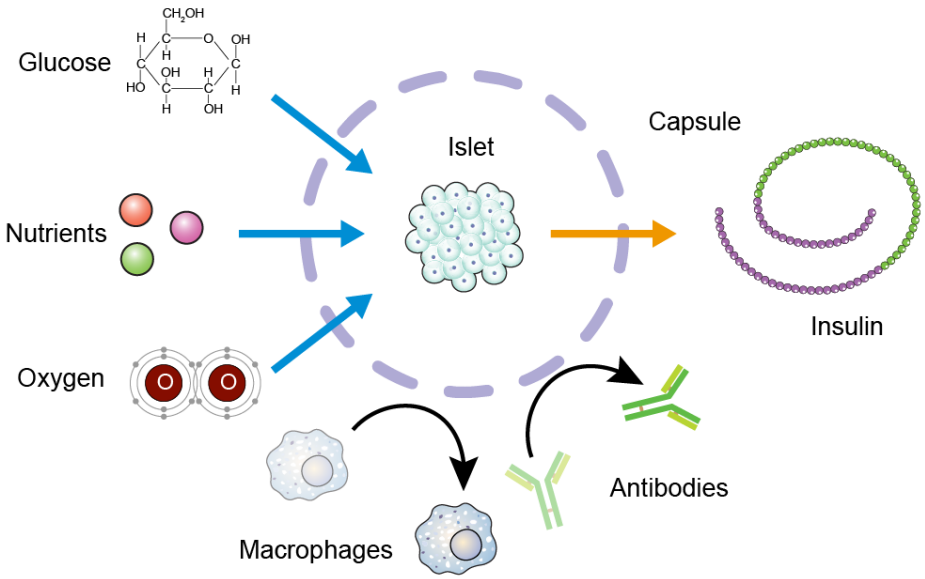

Figure 2. The principles of encapsulation technology.

By using an encapsulation technique, immune system components with high molecular weights, such as immune cells (7 μm) and antibodies (~150–900 kDa), can be blocked. Meanwhile, substances with low molecular weights, such as oxygen, insulin (~6 kDa), nutrients, and hormones, can pass through the barrier (Dufrane 2012). Therefore, islet encapsulation could prevent immune rejection, although protection from chemokines and cytokines with lower molecular weights is inadequate. Xenogeneic islets are one of the avenues to address the shortage of human pancreas donors. In this chapter, we describe experimental islet transplantation, including islet encapsulation and graft islet sources.

STRUCTURAL APPROACHES FOR ISLET ENCAPSULATION

Structurally, islet encapsulation can be divided into four groups (Figure 3): 1) macroencapsulation; 2) microencapsulation; 3) conformal coatings; and 4) nanoencapsulation or layer-by-layer coating. The latter two types are cell surface modifications.

Macroencapsulation

In macroencapsulation, a large mass of islets is encapsulated in one or several large capsules. There are two main types of macrocapsules: intravascular and extravascular.

Intravascular Macrocapsules

In an intravascular macrocapsule, the islets are located in a hollow semi-permeable membrane containing many artificial capillaries. Using vascular anastomoses with an intravascular shunt, the device is directly connected to the host's systemic circulation; thus, it allows blood flow into the hollow fibers (Monaco 1991). The major advantage of this device is its proximity to the blood stream of the recipient. Islets are located near the fibers and can directly receive oxygen and nutrients from the blood stream, therefore improving graft survival and glucose-stimulated insulin secretion. In addition, the islets are protected from immune cells by the fiber membrane.

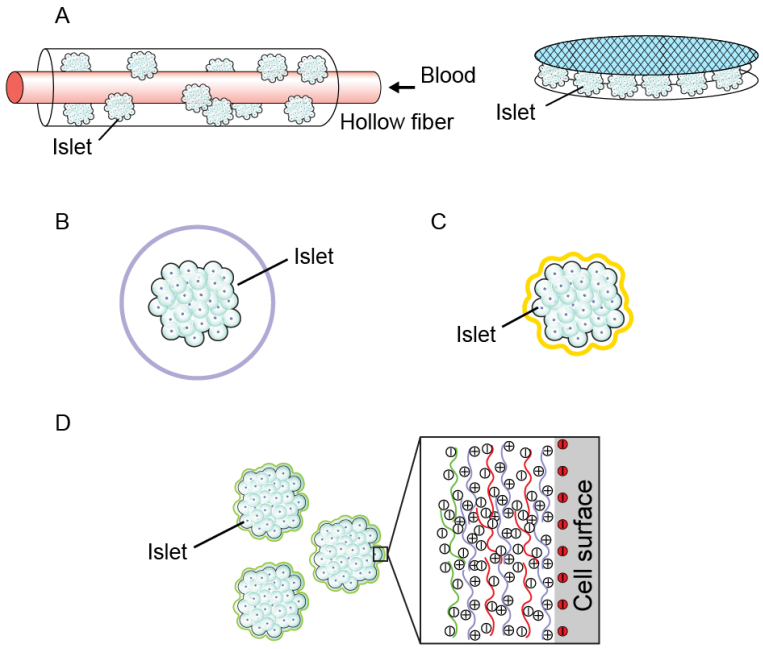

Figure 3. Structural approaches to islet encapsulation: macroencapsulation (A), microencapsulation (B), conformal coating (C), and nanoencapsulation (D).

Researchers have demonstrated long-term islet function with these devices in a canine xenograft model without immunosuppression (Sullivan 1992). However, despite successful animal studies, embolization and thrombus formation within the lumen or at the anastomotic sites have been severe problems that required intense anticoagulation therapy (Vaithilingam 2011). The risks associated with vascular prosthetic procedures, such as bleeding, also make intravascular devices unsuitable for clinical applications. For example, the failure of carotid artery device connections resulted in the sudden death of a canine during long-term follow-up (Scharp 2014). For these reasons, the US Food and Drug Administration has not approved clinical trials of this hybrid artificial pancreas.

Extravascular Macrocapsules

Extravascular macrocapsules do not require intravascular shunts because they are based on the principle of simple diffusion chambers. A major advantage of these devices is the ease of retrieval or reloading. Other advantages include minimal surgical risk, no risk of thrombosis, the ability to transplant into different sites, and the ability to keep graft cells within the device (Schulz 2012). Macrocapsules also have greater mechanical strength than microcapsules. However, a major disadvantage is the relatively low ratio of surface area to graft islet volume. This interferes with oxygen diffusion and nutrient transport, leading to compromised islet viability and function. A low surface-to-volume ratio also slows the exchange of glucose and insulin (Pareta 2012). Packing density is another critical issue for clinical application. The islet density in the device has to be less than 5%–10% to maintain an adequate supply of oxygen and nutrients. Therefore, macrocapsules may be somewhat impractical: the relatively large devices need to be implanted to provide sufficient islet masses and cannot be placed at conventional transplantation sites (Van Suylichem 1992).

The macrocapsular devices have been tested in tubular and planar chambers (Figure 3A). The tubular devices are typically made of copolymers (including polyacrylonitrile and polyvinylchloride) and have a smooth or fenestrated surface (Colton 1995). Both the cylindrical shape and smooth surface contribute to greatly improved biocompatibility, thus preventing fibrosis. These devices showed successful results in a rodent model (Lacy 1991). In clinical setting, excellent graft survival at 2 weeks post-transplantation was reported in patients with type 1 and type 2 diabetes (Scharp 1994). However, there are two major disadvantages of tubular chambers: a susceptibility to rupture and the need for a large number of islets because of their low islet seeding density (Colton1995).

The planar diffusion chamber is made up of two flat sheets attached to a ring support, giving it a flat configuration. These chambers are more stable than tubular chambers and can supply oxygen to the whole graft. However, initial studies using this device failed because of pericapsular fibrosis (Brauker 1996; Scharp 1984). Several bilayer planar devices have been developed to improve vascularization and consequently provide effective immune isolation (Brauker 1995; Geller 1997). In the 1990s, Baxter Healthcare (Deerfield, IL, USA) developed a planar device with two composite membranes and a loading port. This macrocapsule, which was later named the TheraCyte® Implant System, was 4 cm long and teabag shaped, with a bilayered polytetrafluoroethylene membrane. Xenotransplantation studies using this device allowed neonatal pig islets to survive in diabetic mice for up to 16 weeks and in nondiabetic cynomolgus monkeys for up to 8 weeks (Elliott 2005). Preimplantation of TheraCyte devices

has improved vascularization and reduced the islet doses required to normalize blood glucose levels in diabetic rodents (Sörenby 2008). Moreover, human fetal pancreatic tissue within TheraCyte devices differentiated into insulin-producing cells in a rodent model, although they were not fully mature (Lee 2009). Currently, several organizations (e.g., Betalogics of Janssen Pharmaceuticals, ViaCyte) and other academic investigators are conducting further investigations and testing various modifications to create a clinically applicable device (Scharp 2014).

An islet sheet is another type of planar flat-sheet device, which was developed in the late 1990s. In a pancreatectomized beagle model, euglycemia was maintained for 84 days after the implantation of islet sheets containing 75,000 islet equivalents (IEQs) of islets into the omentum (Storrs 2001). Later, human islets transplanted into the subcutaneous space of rats using islet sheets demonstrated islet survival after explantation (Lamb 2011). More recently, Krishnan et al. proposed a model using islet sheets and dorsal window chambers to monitor the microvascular environment around biomaterial implants (Krishnan 2014). They observed significant changes in blood flow, hemoglobin oxygen saturation, and vascular density within the first 2 weeks after transplantation of islet sheet devices.

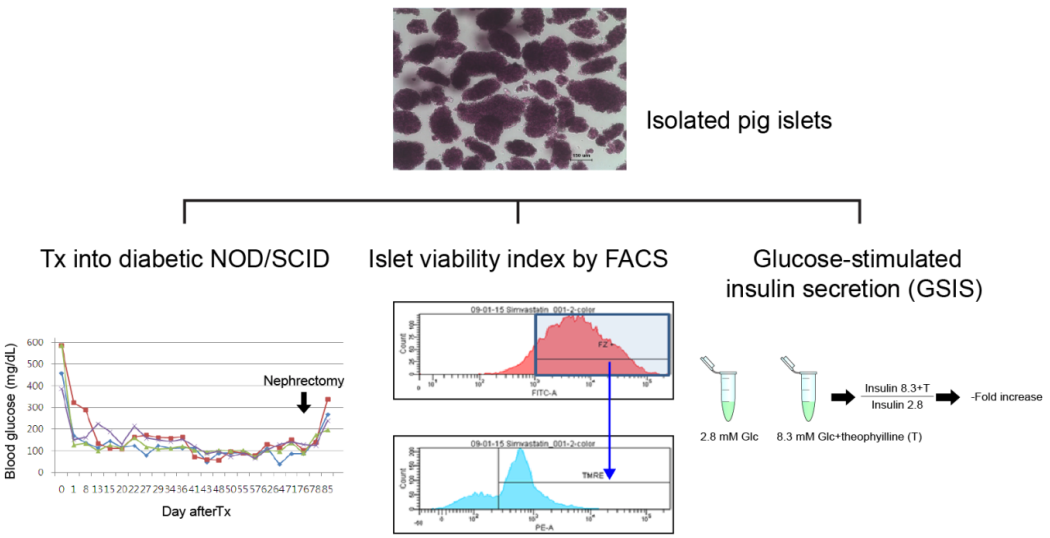

Figure 4. Quality control of the isolated pig islets. Portions of the isolated pig islets were tested for potency using three independent assays: NOD/SCID bioassay (*), FACS index (+), and glucose-stimulated insulin secretion (#). For the NOD/SCID bioassay, four animals were rendered diabetic by injecting streptozotocin (200 mg/kg). Blood glucose levels were followed after pig islet transplantation (marginal mass: 2,500 IEQ) into subcapsules of the kidney. For the FACS index, pig islets were dissociated into single cells and were stained with fluozin-3 and TMRE for measuring β-cells and mitochondrial potential, respectively. Then, the stained cells were analyzed by FACS. The FACS index was calculated by the fluozin-3-positive (β-cells) × TMRE-positive cell fraction. For the glucose-stimulated insulin secretion, a small portion of the final preparation of the pig islets (100 IEQ, in triplicate) before transplantation was sequentially incubated in Kreb's HEPES buffer containing 2.8 mM glucose and then 8.3 mM plus theophylline for 1 hr, respectively. The secreted insulin was measured by enzyme-linked immunosorbent assay.

An oxygen-refueled macrochamber device (called βAir) was developed by Beta-O2 Technologies Ltd. This device has two main compartments: an immune-protected compartment and an oxygen supply compartment. In this device, islets are immobilized in alginate, shielded from the immune system by three layers (a thin hydrophilized Teflon membrane, an alginate layer, and an alginate matrix with high guluronic acid), and supplied with oxygen by daily refueling through the subcutaneous port (Ludwig 2010). Animal studies using this device have shown positive results in rodents (Ludwig 2012) and pigs (Neufeld 2013).

Another sheet-type macroencapsular device was introduced in 2004 by Qi et al. (Qi 2004). This device used polyvinyl alcohol (PVA) hydrogel and was prepared by using a freezing and thawing technique. Xenogeneic transplantation using this hydrogel sheet demonstrated improved glycemic status and renal dysfunction in rodents (Sakata 2006). Furthermore, cryopreservation of islets using the PVA macroencapsulation method was reported to be effective up to 30 days (Qi 2010). Rodent models also showed insulin-positive islets at 24 weeks after allogeneic transplantation (Qi 2012). This device has not yet been part of a clinical trial, but it has unique characteristics and potential utility for the cryopreservation of graft islets.

A monolayer cellular device has a collagen matrix covered with gelled alginate on both sides (Dufrane 2010). In this system, the interaction of islets with the biological membrane is enhanced and the islet concentration per unit surface area is increased as the islets are placed in a monolayer on the collagen matrix (Dufrane 2012). In primates, subcutaneous implantation of this monolayer cellular device resulted in significant improvements in hyperglycemia (HbA1c < 7%) for 6 months without immunosuppression (Dufrane 2010).

All of the previously mentioned studies indicate that extravascular macrocapsular devices are attractive candidates for clinical applications. However, low graft survival rates have hampered their clinical use.

Microencapsulation

Microcapsules are smaller than macrocapsules. They contain one or a few islets in a spherical semipermeable microcapsule (Figure 3B). Generally, the size of microcapsules is less than 1,000 μm in diameter (Jain 1999; O'Sullivan 2011; Scharp 2014). Microcapsules have many advantages over macrocapsules (Table 1). They are not only very simple to construct but are also mechanically stable. The simplicity of the manufacturing process allows for easy changes to key parameters, such as pore size, thickness, and permeability. The higher surface-to-volume ratio of their spherical configuration results in better diffusion rates (Van Schilfgaarde 1999). Finally, the transplantation of microcapsules is a simple procedure that does not require major surgery. Therefore, microencapsulated islets are currently the preferred system for approaching a bioartificial pancreas (De Vos 2002; Kizilel 2005; O'Sullivan 2011; Scharp 2014).

However, some disadvantages of the microencapsulation technique need to be addressed. The difficulty of retrieving implanted islets from the recipient is a major challenge. Early pericapsular fibrosis causes a foreign body reaction and negatively affects graft islet function (Gotfredsen 1990). Almost 10% of the capsules have shown fibroblast and macrophage

overgrowth (Fritschy 1994). Insufficient biocompatibility of the capsules also can affect the function of encapsulated islets (Gotfredsen 1990; Tuch 2009).

Table 1. Comparison between macroencapsulation and microencapsulation

	Macrocapsule	Microcapsule
Encapsulation material	Alginate Polytetrafluoroethylene Acrylic copolymer Agarose Polysulfone Amphiphilic conetwork membrane	Alginate Poly-L-lysin Poly-L-ornithine Agarose Sodium cellulose sulfate
Site for transplantation	Peritoneum Subcutaneous adipose tissue	Peritoneal cavity Renal capsule Subcutaneous adipose tissue
Advantages	Use of allogeneic and xenogeneic islets without immunosuppression Easy implantation Easy retrieval Mechanically stable	Use of allogeneic and xenogeneic islets without immunosuppression Better oxygen and nutrient transport Easy implantation
Disadvantages	Higher dose of islets Risk of capsular rupture Inadequate graft oxygenation	Difficult to retrieve Capsule clumping in peritoneum Mechanically and chemically fragile

In general, microcapsules are produced from polymers that form hydrogels under certain conditions. They are derived from either natural or synthetic routes. To improve biocompatibility, researchers have investigated various materials, including alginate, chitosan, methacrylic acid, methyl methacrylate, polyethylene glycol, 2-hydroxyethyl methacrylate, polycations and anions, agarose, collagen, silica, and dexamethasone (De Vos 2010; O'Sullivan 2011). In islet transplantation, alginate has been the most widely used hydrogel; it can be produced under physiological conditions for physiological pH, isotonic solutions, and room or body temperature (Ménard 2010; Sandler 1997). Alginate-based microcapsules do not interfere with islet function (Jain 1999; Opara 2010) and provide a microenvironment that promotes the functional survival of islets, presumably due to the mechanical support of the islets and the conservation of their structures. Because alginate molecules are negatively charged like the cellular surface, the binding of immune cells to alginate microcapsules is limited. Therefore, alginate is considered to be highly biocompatible. The long-term survival of islets and well-preserved graft function after transplantation have been demonstrated in both animals and humans (Jain 1999; Vaithilingam 2011). The first transplantation with alginate microcapsules was performed by Lim and Sun in 1980. Since then, many studies in rodent, pig, and canine models of diabetes have reported successful transplantation with microcapsules. However, in nonhuman primates (NHPs), only two groups have shown successful results (Elliott 2005; Sun 1996).

Alginate molecules are anionic copolymers of β-D-mannuronic (M) and α-L-guluronic acids (G), which readily form a gel in the presence of divalent cations such as Ca2+, Ba2+, or strontium (De Vos 2002; Kizilel 2005; O'Sullivan 2011; Opara 2010; Scharp 2014). The commercially available alginates originate from seaweed. Adequate purification of these natural compounds is necessary to maximize biocompatibility and islet viability while also minimizing immunogenicity. Alginates are polysaccharides composed of M and G linked together; the composition and ratio of G: M varies depending on the source. When dissolved,

alginate forms a highly viscous solution. An air-driven droplet generator creates small droplets, namely microcapsules. The droplets are stabilized by immersion in a solution of divalent cations such as Ca2+ or Ba2+, which form strong cross-links with G and M monomers (De Vos 2009). Various factors (e.g., G and M composition, concentration, viscosity, gel homogeneity, capsule size) determine the characteristics of the capsules, including their strength, flexibility, durability, and permselectivity. Because divalent cations bind more strongly to G components than to M or MG components, microcapsules with a high content of G alginate tend to be more rigid and stable than those with a high content of M alginate (Mørch 2006). Microcapsules with high M alginate content tend to increase swelling, resulting in inadequately encapsulated islets. However, a study suggested that a high content of M alginate is more favorable than a high content of G alginate in terms of encapsulated islet survival (King 2003). Traditionally, calcium is one of the most commonly used cross-linking cations. The introduction of barium in microcapsules decreased the capsule size and reduced permeability to immunoglobulin G. Compared with calcium and barium, strontium shows immediate binding affinity when a high content of G alginates is used and an equivalent effect when a high content of M alginate is used.

One study suggested that the type of polyamine (poly-L-lysine, poly-D-lysine, or poly-L-ornithine) rather than the type of alginate (high-G or high-M) matters in immune response (Ponce 2006). A three-layer coating of alginate-polyamine-alginate creates a permeability barrier, which provides immune isolation for the microcapsules. The thickness of this barrier varies with incubation time and concentration (Jain 1999). Poly-L-lysine was the first permselective biomaterial used to create this barrier and is the most widely used (Lim 1980). Poly-L-lysine showed the least reactivity to the host compared with poly-D-lysine or poly-L-ornithine (Ponce 2006). However, a poly-L-ornithine coating was shown to mechanically support the microcapsules and markedly reduce immune response (Darrabie 2005; Tam 2011). More recently, a method incorporating CXCL12 chemokines in alginate microcapsules was introduced in an attempt to modulate the immune environment surrounding the islet graft (Chen 2015). Microencapsulation of islets using this method demonstrated a long-term (>300 days) immunoprotective effect in allogeneic and xenogeneic transplantation and a selective increase in intragraft regulatory T cells.

Conformal Coating

Traditional methods for microencapsulation produce beads of a consistent size. However, because islets vary in shape and size, these traditional methods can produce much larger sized capsules than the islet itself. The empty space inside the capsule results in core hypoxia and delayed insulin secretion in response to glucose (Yang 2015). This may, in part, contribute to the death and dysfunction of transplanted islets. Conformal coating is one of the technologies to overcome this problem. In conformal coating, the coating conforms to each islet's individual shape through a polymer bath (Figure 3C). This gives each islet a tight coating with very little additional space, which allows the islet to keep its own shape (Benchley 2013). Compared to conventional microcapsules, this technique greatly reduces the size and total volume of the islets for transplantation. Therefore, intraportal transplantation of conformally coated islets is possible.

The most common material used for the conformal coating of islets is a hydrogel polymer of polyethylene glycol (PEG). When exposed to photoinitiators such as ultraviolet or visible light, PEG can form a cross-linking covalently and polymerize (Shen 2005). Because the photoinitiator is bound to the surface of the islet, the polymerization can propagate outward at a controlled distance. Conformal coating produces thicker cross-linked hydrogels (50 to 70 μm) than nanotechnology, which is discussed later (Scharp 2014).

In 1997, Neocrin Inc. demonstrated successful xenogeneic transplantation of conformally coated porcine islets into diabetic rodents without immunosuppression (Hill 1997). However, the company failed to conduct further studies in larger animal models, presumably because of an aggressive reaction to the PEG coatings and xenograft tissue. Novocell then modified PEG triacrylate to improve the binding ability to photoinitiators and reactivity in large animals (Scharp 2014). An animal model with diabetic baboons demonstrated survival of allograft islets with minimal immune reactions up to 20 months (Scharp 2014). However, a clinical trial of two recipients with type 1 diabetes of 25–30 years failed to achieve insulin independence after transplantation. The longer duration of insulin use in humans was suggested as a possible reason for the different results between baboons and humans, with a reduced release of insulin and poor survival of the grafted islets (Scharp 2014). More recently, a computationally optimized method was introduced for conformal coatings (Tomei 2014). With this method, the islets can be completely encapsulated with a thin continuous layer of hydrogel. In diabetic mice, allogeneic transplantation of conformally coated islets resulted in euglycemia for more than 100 days with no foreign body reaction and normal revascularization.

Nanoencapsulation or Layer-by-Layer Coating

Nanoencapsulation is a more recently developed technique (Tendulkar 2013). Nanomedicine—the medical application of nanotechnology—is associated with tiny measurements at the level of 1–100 nanometers (nm). Nanoencapsulation encapsulates islets by alternating positively and negatively charged polymers on the surface of the cell aggregates (Figure 3D); it is also referred to as layer-by-layer coating when limited to the nanoencapsulation of islets for the treatment of diabetes (Wilson 2008). This approach was developed because of the reality of standard cell aggregate hydrogel coatings (that may leave openings in the coating) and, the diffusional concerns of hydrogel microcapsules (that may reduce the responsiveness of encapsulated islets to glucose changes). With nano-encapsulation, capsule thickness can be significantly minimized, which improves glucose-dependent insulin release as well as the diffusion of nutrients and waste products. In addition, a variety of agents also can be integrated to improve the survival and function of encapsulated islets.

Krol et al. coated islet surfaces with polyelectrolytes of poly (allylamine hydrochloride) and polystyrene sulfonate layers (Krol 2006). Wilson et al. demonstrated nanoencapsulated islet function both *in vitro* and *in vivo* using a PEG coating combined with biotin-PEG peptide conjugates with streptavidin (Wilson 2008). Furthermore, nanoencapsulation using biotin-PEG-GLP-1 was found to promote islet viability and insulin secretory capability in response to glucose (Kizilel 2010). More recently, nanoencapsulated islets coated with polylysine and polyglutamic acid effectively reversed hyperglycemia after allogeneic

transplantation in diabetic mice for a month (Zhi 2012). Also in 2012, Dong et al. demonstrated that a nanoencapsulation technique induced normoglycemia for more than 3 months, even in major histocompatibility complex mismatched diabetic mice. They also demonstrated the longer survival of pegylated islets with nanoparticles containing leukemia inhibitory factor versus pegylated islets with empty nanoparticles or uncoated islets (Dong 2012).

SOURCE OF GRAFT ISLETS

Allogeneic Islets

Allogeneic islets are the most widely used source for islet transplantation. As in other organ transplantation, a major barrier in allogeneic islet transplantation is host immunity. Both the innate (within the first 2–3 days) and adaptive immune systems respond to destroy the graft after islet transplantation into the recipient (Gibly 2011). The autoimmune process and alloimmunity have been suggested to influence islet survival after allotransplantation in patients with type 1 diabetes (Harlan 2009; Hilbrands 2009). Islet encapsulation has been shown to protect allografts in experimental models. In addition, encouraging results have been obtained both in preclinical and initial human allograft studies, as discussed previously (Calafiore 2006; De Vos 2010; O'Sullivan 2011; Vaithilingam 2011). Encapsulation may protect islets from autoimmunity (Kobayashi 2006; Vaithilingam 2011) and allograft rejection in immunized hosts (Kumagai Braesch 2013). Although there has been much research on how to prevent an immune response in allogeneic islet transplantation, the availability of organ donors is still a major hurdle for human islet transplantation. The demand for donors far exceeds the supply.

Xenogeneic Islets

As in allogeneic transplantation, host immunity is a critical issue in xenogeneic transplantation. However, xenogeneic transplantation has an advantage by overcoming the shortage of organ donors. Many studies have investigated its clinical applications.

Guidelines for Clinical Islet Xenotransplantation

In 1994, Groth et al. first transplanted fetal pig islet-like cell clusters into 10 diabetic kidney-transplant patients. Porcine C-peptide was detected in the urine of four patients for ~200–400 days after transplantation (Groth 1994). In Mexico, Valés-Gonzaléz et al. co-transplanted pig islets and Sertoli cells placed in a stainless steel chamber under the skin in pediatric patients with diabetes (Valdes-Gonzalez 2005). In China, Wang et al. transplanted neonatal pig islets into the arterial veins of the liver in 25 patients with type 1 diabetes using clinically available immunosuppression (Wang 2011). However, these early clinical trials showed an absence of clinical benefits to the patients who received porcine islet

transplantation, as well as insufficient regulatory oversight: appropriate peer review of the protocol, efficacy, and safety of preclinical studies in NHPs should be guaranteed before clinical trials.

In 2008, key members of the International Xenotransplantation Association (IXA) and World Health Organization gathered in Changsha, China to develop principles and guidance for clinical islet xenotransplantation, referred to as the *Changsha Communiqué* ("First WHO Global Consultation on Regulatory Requirements for Xenotransplantation Clinical Trials: Changsha, China, 19-21 November 2008. The Changsha Communique," 2009). Since then, IXA has published consensus statements on clinical trial protocols for porcine islet products in type 1 diabetes (Hering 2009). This document describes several key issues, such as the ethical requirements and progress of an internationally regulatory framework, source pigs, pig islet product manufacturing and release testing, preclinical efficacy and complication data required to justify a clinical trial, strategies to prevent the transmission of porcine endogenous retroviruses, patient selection for pilot clinical trials of islet xenotransplantation, and informed consent in xenotransplantation clinical trials. In 2016, IXA updated this consensus statement (Hering 2016).

Clinical trials of porcine islet xenotransplantation should be conducted under appropriate regulatory oversight based on the guidance provided in the IXA consensus statement, which protects the patients from potential risks of infection and advises the investigators on obtaining public consensus on the safety of xenotransplantation. This point needs to be emphasized because islet xenotransplantation may be the key to the clinical realization of xenotransplantation. In this sense, NHP preclinical studies showing the efficacy and safety of the protocol should be a prerequisite. Matsumoto et al. reported that a clinical trial of encapsulated porcine islets in eight patients under regulation of the authority in Argentina could lead to a significant improvement of HbA1c and reduction of hypoglycemic unawareness events with an improved transplant estimated function (Matsumoto 2016).

Management of the Pigs and Islet Isolation

Our group acquired a specific-pathogen-free (SPF) miniature pig strain from the University of Chicago in 2004. Since then, we have been breeding and maintaining a closed herd in an SPF barrier facility. The characteristics of this Seoul National University (SNU) miniature pig, including microbiological monitoring, islet isolation, and the predictive parameters for high islet yield, have been reported elsewhere (Jin 2010; Jin 2011; Kim 2009). In microbiological monitoring, 41 viral pathogens, 35 bacterial pathogens, 2 fungal pathogens, and 25 parasites were screened for and confirmed to be negative, indicating that this closed herd has achieved designated-pathogen-free status. In addition, all SNU miniature pigs have been tested for the presence of porcine endogenous retrovirus (PERV) by reverse transcription-polymerase chain reaction. The results showed that PERV types A, B, and C were present in the genome. However, no reverse transcription activity of PERV (as assessed by *in vitro* reverse transcriptase assay) was observed in more than 50 monkeys that underwent pig islet transplantation. This observation is supported by the gene sequence data of PERV in SNU miniature pigs, which showed that most PERV genes were integrated into the chromosome as defective forms (data not shown).

The SNU miniature pigs also produced a higher yield of islets compared with other strains of pigs (~9,600 IEQs per gram of pancreas)—the highest value that has been reported worldwide to date (Kim 2007). The characteristics of the pig contributed to this extremely high islet yield, including strain specificity, age, gender, pregnancy experience in female, as did the techniques of islet isolation and maintenance, including an efficient pancreas procurement procedure with no warm ischemia time, less than 20 min of cold ischemia time, and a good degree of pancreas distension by collagenase infusion. The selection of a high-yield pig using the parameters for successful islet isolation prediction contributed to a consistently high yield of islets (Kim 2009). Implementation of all of these procedures allowed our group to achieve consistent glycemic control in long-term (>6 months) in diabetic NHPs using pig islet transplantation (Shin 2015; Shin 2016).

Quality Control of Isolated Pig Islets

To achieve consistent glycemic control after the transplantation of porcine islets in NHPs, quality control of isolated islets is important. Table 2 lists the assays that can be used to determine the quality of isolated islets. In our pig-to-NHP islet xenotransplantation experiments (Shin 2015; Shin 2016), we performed three independent assays: 1) an islet cell viability test using a β-cell-specific fluorescent dye (Fluozin-3), a mitochondrial activity indicator (tetramethylrhodamine, ethyl ester [TMRE]), and a fluorescence-activated cell sorting (FACS) machine; 2) glucose-stimulated insulin secretion (GSIS); and 3) a nondiabetic obese severe combined immunodeficiency (NOD/SCID) mouse bioassay. Four streptozotocin-induced diabetic mice were transplanted with 2,500 IEQ pig islets under kidney subcapsules. Their blood glucose levels were monitored 2–3 times per week for at least 2 months (Figure 4). Our study showed that the isolated pig islets were >90% pure by dithizone staining, with >80% healthy β-cells by FACS and >60% diabetes correction capacity by the NOD/SCID bioassay (Shin 2015). Although the increase of insulin upon the glucose stimulation of pig islets overall exceeded one-fold, the results from the GSIS assay were highly variable and do not reflect the potency of the isolated pig islets, unlike those from other species (data not shown).

Table 2. Assays to determine the quality of isolated pig islets

Test	Method	Advantages and disadvantages
Viability	β-cell viability by FACS using β-cell-specific fluorescent dye	Relatively easy to perform, but cell dissociation procedure may yield an artifact
Glucose-stimulated insulin secretion (GSIS)	Insulin-secreting capacity upon a glucose stimulus	Relatively easy to perform, but the results are highly variable and not correlated to transplantation outcome
Oxygen consumption rate (OCR)/DNA	Oxygen consumption rate by normal cellular metabolism; fractional cell viability	Relatively easy to perform, and the results are relatively well correlated to transplantation outcome
Mouse bioassay	Diabetes reversal capacity in vivo; golden standard	Most difficult and requires a long time, but the results are well correlated to transplantation outcome
ADP/ATP	ADP/ATP ratio by normal cellular metabolism	Relatively easy to perform, but the results are variable

TRANSPLANTATION SITES

Determining the optimal site for encapsulated islet transplantation requires intense research. Several factors should be taken into consideration for future studies, including biocompatibility, revascularization, mechanical resistance, and retrieval of graft islets.

Generally, macrocapsules have been transplanted into the subcutaneous space. The major advantage of this location is its easy accessibility, which provides potential for biopsy access and retrieval. However, the poor vascular supply of the subcutaneous space may compromise islet function and engraftment. Because the macrocapsules are not permeable to vascular ingrowth, they may need a mechanism to enhance oxygen supply. Pretreatment with fibroblast growth factors in macroencapsulated islets demonstrated the beneficial effects of neovascularization and normoglycemia up to 3 months in rodents (Wang 2002). Implantation in prevascularized subcutaneous sites also showed long-term survival of graft islets without immunosuppression in rodents (Luan 2014). Several other sites have been suggested for islet transplantation, such as the pancreas, skeletal muscles, gastrointestinal tract, bone marrow, lymph nodes, spleen, and immune-privileged sites (thymus, testis, and anterior chamber of eyes) (Yang 2015). However, these sites have not been evaluated in encapsulated islet transplantation thus far.

The intraperitoneal space has been the most commonly investigated site for the transplantation of microencapsulated islets. The technical ease of accessibility and its capacity to accommodate a relatively large volume of transplanted material are major advantages of the intraperitoneal space. Although the intraperitoneal space has been used in most studies of encapsulated islets, the optimal site for encapsulated islet transplantation has not yet been elucidated. Difficulty in vascular network and retrieval of transplanted capsules are disadvantages of the peritoneal cavity. The clumping of capsules in biped humans and NHPs by gravity should also be solved for the clinical application of transplantation. It is generally accepted that vascularized sites would be better locations than the intraperitoneal space in terms of oxygen supply. Therefore, researchers have been investigating other transplant sites, such as the kidney capsule, subcutaneous space, and omentum.

Capsules implanted subcutaneously or under the kidney capsules showed increased viability and insulin secretion rates, as well as lower immune responses, compared with those implanted intraperitoneally (Dufrane 2006). However, these sites have a limitation of restricted volume. The implantation of encapsulated islets into the omentum via the omental pouch also showed successful results in rodent models of diabetes (Pareta 2014). The omental pouch has several advantages, such as unlimited space for islet transplantation, relatively easier retrieval of graft islets, improved proximity to vessels, and delivery of insulin to the portal circulation. Taken together, these observations support the previous suggestion that research should be focused on finding or creating a transplantation site to allow close contact between the vasculature and encapsulated islets rather than the unmodified peritoneal cavity (De Vos 1999).

INSULIN RELEASE FROM ENCAPSULATED ISLETS

Because macrocapsules have generally thicker walls and larger diameters than microcapsules, an impaired diffusion of nutrients and oxygen can threaten the viability of the islets and slow the kinetic release of insulin. As discussed previously, to guarantee an adequate supply for the cells, the islet density in the macrocapsules should be kept quite low (< 5−10%). Consequently, large devices are required to provide sufficient masses of islets (Lanza 2011). A capsule's components can also affect glucose-stimulated insulin secretion. For example, hydroxyl methylation of polysulphone permitted for efficient insulin release from the macroencapsulated islets (Lembert 2001), whereas blending polysulphone with polyvinyl pyrrolidone or sodium dodecyl sulfate did not show glucose-induced insulin release (Orive 2003). Although several *in vivo* and *in vitro* studies have shown maintenance of long-term normoglycemia and insulin release after retrieval of macroencapsulated islets (Kessler 1997; King 2001; Lembert 2001), the relatively large surface-to-volume ratio may slow the exchange rate of glucose and insulin, leading to inadequate regulation of glucose levels.

In this regard, microencapsulation may provide some advantages. However, the kinetics of insulin release from microencapsulated islets has been reported to be delayed in previous studies, which seems to be related to microcapsule volume (De Vos 2002; De Vos 2010; O'Sullivan 2011; Orive 2003). *In vitro*, insulin release usually peaks 10–15 minutes later in microencapsulated islets compared to naked islets. A similar delay in insulin release from microencapsulated islets was observed when glucose concentration decreased (Wang 1997). *In vivo*, intraperitoneal transplantation of microencapsulated islets cured diabetic mice in the long term, but with a delay of C-peptide release from the graft islets.

An intraperitoneal location may affect the kinetics of insulin release from microencapsulated islets. There are two time-dependent steps: the elevation of glucose levels in intraperitoneal spaces (which stimulates the graft islets to release insulin) and entrance of the secreted insulin from capsulated islets into systemic circulation. Intraperitoneal glucose concentration in rats has been shown to follow blood glucose levels with a delay of 5 minutes and a reduction of up to 80% of blood glucose levels (Velho 1989). Consequently, the signal for insulin release is delayed and reduced in intraperitoneal transplantation. There is also a delay before insulin in the peritoneal space is absorbed into the venous system (De Vos 1996). Previous studies suggest that absorption of insulin administered intraperitoneally is dependent on volume, concentration, and time (Schade 1981). The kinetics of insulin release may be further affected by other variables, such as the clumping of capsules, pericapsular cellular attachment, or modification of the peritoneal cavity. This may be further complicated after meals or during exercise, when there is a need to halt insulin secretion to prevent hypoglycemia (Omer 2004).

Islet cell aggregates can provide additional benefits in terms of insulin secretion and beta cell survival after microencapsulation, probably because of improved oxygenation (Zhi 2013). Islet cell aggregates are usually obtained by dispersing islets into single cells and allowing them to reaggregate in culture. By using this approach with rat islets, glucose-stimulated insulin release was improved *in vitro* compared with whole islets (Zhi 2013). In nanoencapsulation, the kinetics of insulin release may be improved due to the absence of dead space around the islets. However, studies regarding insulin secretion kinetics of nanoencapsulated islets are still scarce. Coating materials may also affect the kinetics of

insulin secretion. The nanocoating of human islets with poly-(diallyldimethylammonium chloride) showed blunted insulin release (Krol 2006), whereas conformal nanothin PEG coatings of islets via layer-by-layer self-assembly of poly (L-lysine)-g-poly(ethyleneglycol)(biotin) and streptavidin demonstrated better insulin secretory function (Wilson 2008). More studies are needed to identify the factors regulating the kinetics of insulin release from nanoencapsulated islets.

TRACKING MICROENCAPSULATED ISLET TRANSPLANTS

Currently, the only way to evaluate the functional status of implanted microcapsules is invasive recovery surgery. There is a growing interest in improving the ability to monitor implanted cell-loaded devices. As an attempt to resolve this need, Barnett et al. developed radiopaque alginate-based microcapsules using either barium sulfate or bismuth sulfate, which can be monitored by X-ray (Barnett 2006). Another group successfully tracked microcapsules in real time with a bioluminescence approach (Tiernan 2014). Further research is needed to determine whether these emerging techniques could be applied to the clinical transplantation of microencapsulated islets.

CONCLUSION

The efficacy of encapsulated islet transplantation has been demonstrated in diabetic animal models. Although several techniques for islet encapsulation have been extensively investigated, the problems of biocompatibility and long-term survival of graft islets still need to be solved. In addition, other limitations exist, such as the detrimental effects of cytokines, delayed insulin secretion from encapsulated islets, choice of transplantation sites, and need to track microcapsules. Furthermore, even though technical success has been achieved in animal models, the shortage of organ donors has to be addressed prior to clinical application. Xenotransplantation with pig islets is a potential alternative source of islets, as discussed in this chapter. Induced pluripotent stem cells (Alipio 2010) and human embryonic stem cells (Motté 2014) also have been suggested as alternative sources of islets. The creation of guidelines and consensus statements on encapsulated islet transplantation from various sources may also affect the field of encapsulated islet transplantation. In the future, further extensive research is needed to address the unresolved factors in islet transplantation.

ACKNOWLEDGMENTS

This work was supported by a grant from the Korea Healthcare Technology R&D Project through the Korea Health Industry Development Institute (KHIDI), funded by the Ministry for Health and Welfare, Republic of Korea (Grant No. HI13C0954). The authors thank S. K. Park, J. W. Choi, and S. Y. Kim for isolating pig islets.

REFERENCES

Alipio, Z; Liao, W; Roemer, E; Waner, M; Fink, L; Ward, D; Ma, Y. Reversal of hyperglycemia in diabetic mouse models using induced-pluripotent stem (iPS)-derived pancreatic beta-like cells. *Proc. Natl. Acad. Sci. U. S. A.* 2010, 107(30), 13426−13431.

Barnett, B; Kraitchman, D; Lauzon, C; Magee, C; Walczak, P; Gilson, W; Arepally, A; Bulte, J. Radiopaque alginate microcapsules for X-ray visualization and immunoprotection of cellular therapeutics. *Mol. Pharm.*, 2006, 3(5), 531−538.

Barton, F; Rickels, M; Alejandro, R; Hering, B; Wease, S; Naziruddin, B; Oberholzer, J; Odorico, J; Garfinkel, M; Levy, M; Pattou, F; Berney, T; Secchi, A; Messinger, S; Senior, P; Maffi, P; Posselt, A; Stock, P; Kaufman, D; Luo, X; Kandeel, F; Cagliero, E; Turgeon, N; Witkowski, P; Naji, A; O'Connell, P; Greenbaum, C; Kudva, Y; Brayman, K; Aull, M; Larsen, C; Kay, TWH; Fernandez, L; Vantyghem, MC; Bellin, M; Shapiro, AMJ. Improvement in outcomes of clinical islet transplantation: 1999-2010. *Diabetes Care*, 2012, *35*(7), 1436−1445.

Benchley, B. (2013). *Insulin Nation*. 2013, from http://insulinnation.com/.

Brauker, J; Martinson, LA; Young, SK; Johnson, RC. Local inflammatory response around diffusion chambers containing xenografts. Nonspecific destruction of tissues and decreased local vascularization. *Transplantation*, 1996, 61(12), 1671−1677.

Brauker, JH; Carr Brendel, VE; Martinson, LA; Crudele, J; Johnston, WD; Johnson, RC. Neovascularization of synthetic membranes directed by membrane microarchitecture. *J. Biomed. Mater. Res.*, 1995, 29(12), 1517−1524.

Calafiore, R; Basta, G; Luca, G; Lemmi, A; Racanicchi, L; Mancuso, F; Montanucci, MP; Brunetti, P. Standard technical procedures for microencapsulation of human islets for graft into nonimmunosuppressed patients with type 1 diabetes mellitus. *Transplant. Proc.*, 2006, 38(4), 1156−1157.

Chen, T; Yuan, J; Duncanson, S; Hibert, ML; Kodish, BC; Mylavaganam, G; Maker, M; Li, H; Sremac, M; Santosuosso, M; Forbes, B; Kashiwagi, S; Cao, J; Lei, J; Thomas, M; Hartono, C; Sachs, D; Markmann, J; Sambanis, A; Poznansky, MC. Alginate encapsulant incorporating CXCL12 supports long-term allo- and xenoislet transplantation without systemic immune suppression. *Am. J. Transplantation*, 2015, 15(3), 618−627.

Colton, CK. Implantable biohybrid artificial organs. *Cell Transplant.*, 1995, 4(4), 415−436.

Darrabie, M; Kendall, W; Opara, E. Characteristics of Poly-L-Ornithine-coated alginate microcapsules. *Biomaterials*, 2005, 26(34), 6846−6852.

De Vos, P; Bucko, M; Gemeiner, P; Navrátil, M; Svitel, J; Faas, M; Strand, B; Skjak Braek, G; Morch, Y; Vikartovská, A; Lacík, I; Kolláriková, G; Orive, G; Poncelet, D; Pedraz, J; Ansorge Schumacher, M. Multiscale requirements for bioencapsulation in medicine and biotechnology. *Biomaterials*, 2009, 30(13), 2559−2570.

De Vos, P; Hamel, A; Tatarkiewicz, K. Considerations for successful transplantation of encapsulated pancreatic islets. *Diabetologia*, 2002, 45(2), 159−173.

De Vos, P; Marchetti, P. Encapsulation of pancreatic islets for transplantation in diabetes: the untouchable islets. *Trends Mol. Med.*, 2002, 8(8), 363−366.

De Vos, P; Spasojevic, M; Faas, MM. (2010). Treatment of diabetes with encapsulated islets *Therapeutic Applications of Cell Microencapsulation*, (pp. 38−53), Springer.

De Vos, P; Van Straaten, JF; Nieuwenhuizen, AG; de Groot, M; Ploeg, RJ; De Haan, BJ; Van Schilfgaarde, R. Why do microencapsulated islet grafts fail in the absence of fibrotic overgrowth? *Diabetes*, 1999, 48(7), 1381−1388.

De Vos, P; Vegter, D; De Haan, BJ; Strubbe, JH; Bruggink, JE; Van Schilfgaarde, R. Kinetics of intraperitoneally infused insulin in rats. Functional implications for the bioartificial pancreas. *Diabetes*, 1996, 45(8), 1102−1107.

Dong, H; Fahmy, T; Metcalfe, S; Morton, S; Dong, X; Inverardi, L; Adams, D; Gao, W; Wang, H. Immuno-isolation of pancreatic islet allografts using pegylated nanotherapy leads to long-term normoglycemia in full MHC mismatch recipient mice. *PLoS One*, 2012, 7(12), e50265−e50265.

Dufrane, D; Gianello, P. Macro- or microencapsulation of pig islets to cure type 1 diabetes. *World J. Gastroenterol.*, 2012, 18(47), 6885−6893.

Dufrane, D; Goebbels, RM; Gianello, P. Alginate macroencapsulation of pig islets allows correction of streptozotocin-induced diabetes in primates up to 6 months without immunosuppression. *Transplantation*, 2010, 90(10), 1054−1062.

Dufrane, D; van Steenberghe, M; Goebbels, RM; Saliez, A; Guiot, Y; Gianello, P. The influence of implantation site on the biocompatibility and survival of alginate encapsulated pig islets in rats. *Biomaterials*, 2006, 27(17), 3201−3208.

Elliott, RB; Escobar, L; Calafiore, R; Basta, G; Garkavenko, O; Vasconcellos, A; Bambra, C. Transplantation of micro- and macroencapsulated piglet islets into mice and monkeys. *Transplant. Proc.*, 2005, 37(1), 466−469.

First WHO Global Consultation on Regulatory Requirements for Xenotransplantation Clinical Trials: Changsha, China, 19-21 November 2008. The Changsha Communique. *Xenotransplantation*, 2009, 16(2), 61−63.

Frank, A; Deng, S; Huang, X; Velidedeoglu, E; Bae, YS; Liu, C; Abt, P; Stephenson, R; Mohiuddin, M; Thambipillai, T; Markmann, E; Palanjian, M; Sellers, M; Naji, A; Barker, C; Markmann, J. Transplantation for type I diabetes: comparison of vascularized whole-organ pancreas with isolated pancreatic islets. *Ann. Surg.*, 2004, 240(4), 631−640, discussion 640.

Fritschy, WM; de Vos, P; Groen, H; Klatter, FA; Pasma, A; Wolters, GH; van Schilfgaarde, R. The capsular overgrowth on microencapsulated pancreatic islet grafts in streptozotocin and autoimmune diabetic rats. *Transplant Int.*, 1994, 7(4), 264−271.

Geller, RL; Loudovaris, T; Neuenfeldt, S; Johnson, RC; Brauker, JH. Use of an immunoisolation device for cell transplantation and tumor immunotherapy. *Ann. N. Y. Acad. Sci.*, 1997, 831(1), 438−451.

Gibly, RF; Graham, JG; Luo, X; Lowe, WL; Hering, BJ; Shea, LD. Advancing islet transplantation: from engraftment to the immune response. *Diabetologia*, 2011, 54(10), 2494−2505.

Gotfredsen, CF; Stewart, MG; O'Shea, GM; Vose, JR; Horn, T; Moody, AJ. The fate of transplanted encapsulated islets in spontaneously diabetic BB/Wor rats. *Diabetes Res.*, 1990, 15(4), 157−163.

Groth, CG; Korsgren, O; Tibell, A; Tollemar, J; Moller, E; Bolinder, J; Ostman, J; Reinholt, FP; Hellerstrom, C; Andersson, A. Transplantation of porcine fetal pancreas to diabetic patients. *Lancet*, 1994, 344(8934), 1402−1404.

Harlan, D; Kenyon, N; Korsgren, O; Roep, B. Current advances and travails in islet transplantation. *Diabetes*, 2009, 58(10), 2175−2184.

Hering, BJ; Cooper, DK; Cozzi, E; Schuurman, HJ; Korbutt, GS; Denner, J; O'Connell, PJ; Vanderpool, HY; Pierson, RN. 3rd. The International Xenotransplantation Association consensus statement on conditions for undertaking clinical trials of porcine islet products in type 1 diabetes-- executive summary. *Xenotransplantation*, 2009, 16(4), 196−202.

Hering, BJ; Cozzi, E; Spizzo, T; Cowan, PJ; Rayat, GR; Cooper, DK; Denner, J. First update of the International Xenotransplantation Association consensus statement on conditions for undertaking clinical trials of porcine islet products in type 1 diabetes−Executive summary. *Xenotransplantation*, 2016, 23(1), 3−13.

Hilbrands, R; Huurman, VAL; Gillard, P; Velthuis, JHL; De Waele, M; Mathieu, C; Kaufman, L; Pipeleers Marichal, M; Ling, Z; Movahedi, B; Jacobs-Tulleneers-Thevissen, D; Monbaliu, D; Ysebaert, D; Gorus, F; Roep, B; Pipeleers, D; Keymeulen, B. Differences in baseline lymphocyte counts and autoreactivity are associated with differences in outcome of islet cell transplantation in type 1 diabetic patients. *Diabetes*, 2009, 58(10), 2267−2276.

Hill, RS; Cruise, GM; Hager, SR; Lamberti, FV; Yu, X; Garufis, CL; Yu, Y; Mundwiler, KE; Cole, JF; Hubbell, JA. Immunoisolation of adult porcine islets for the treatment of diabetes mellitus. *Ann. N. Y. Acad. Sci.*, 1997, 831(1), 332−343.

Jain, K; Asina, S; Yang, H; Blount, ED; Smith, BH; Diehl, CH; Rubin, AL. Glucose control and long-term survival in biobreeding/Worcester rats after intraperitoneal implantation of hydrophilic macrobeads containing porcine islets without immunosuppression. *Transplantation*, 1999, 68(11), 1693−1700.

Jin, SM; Kim, KS; Lee, SY; Gong, CH; Park, SK; Yu, JE; Yeom, SC; Yoon, TW; Ha, J; Park, CG; Kim, SJ. Enhanced prediction of porcine islet yield and posttransplant outcome using a combination of quantitative histomorphometric parameters and flow cytometry. *Cell Transplant.*, 2010, 19(3), 299-311.

Jin, SM; Shin, JS; Kim, KS; Gong, CH; Park, SK; Kim, JS; Yeom, SC; Hwang, ES; Lee, CT; Kim, SJ; Park, CG. Islet isolation from adult designated pathogen-free pigs, use of the newer bovine nervous tissue-free enzymes and a revised donor selection strategy would improve the islet graft function. *Xenotransplantation*, 2011, 18(6), 369−379.

Kessler, L; Legeay, G; West, R; Belcourt, A; Pinget, M. Physicochemical and biological studies of corona-treated artificial membranes used for pancreatic islets encapsulation: Mechanism of diffusion and interface modification. *Journal of Biomedical Materials Research Part A*, 1997, 34(2), 235−245.

Kim, HI; Lee, SY; Jin, SM; Kim, KS; Yu, JE; Yeom, SC; Yoon, TW; Kim, JH; Ha, J; Park, CG; Kim, SJ. Parameters for successful pig islet isolation as determined using 68 specific-pathogen-free miniature pigs. *Xenotransplantation*, 2009, 16(1), 11−18.

Kim, JH; Kim, HI; Lee, KW; Yu, JE; Kim, SH; Park, HS; Park, CG; Ihm, SH; Ha, J; Kim, SJ; Lee, HK; Ahn, C; Park, KS. Influence of strain and age differences on the yields of porcine islet isolation: extremely high islet yields from SPF CMS miniature pigs. *Xenotransplantation*, 2007, 14(1), 60−66.

King, A; Lau, J; Nordin, A; Sandler, S; Andersson, A. The effect of capsule composition in the reversal of hyperglycemia in diabetic mice transplanted with microencapsulated allogeneic islets. *Diabetes Technol. Ther.*, 2003, 5(4), 653−663.

King, SR; Dorian, R; Storrs, RW. Requirements for encapsulation technology and the challenges for transplantation of islets of Langerhans. *Graft*, 2001, 4(7), 491.

Kizilel, S; Garfinkel, M; Opara, E. The bioartificial pancreas: progress and challenges. *Diabetes Technol. Ther.*, 2005, 7(6), 968−985.

Kizilel, S; Scavone, A; Liu, X; Nothias, JM; Ostrega, D; Witkowski, P; Millis, M. Encapsulation of pancreatic islets within nano-thin functional polyethylene glycol coatings for enhanced insulin secretion. *Tissue Engineering Part A*, 2010, 16(7), 2217−2228.

Kobayashi, T; Aomatsu, Y; Iwata, H; Kin, T; Kanehiro, H; Hisanga, M; Ko, S; Nagao, M; Harb, G; Nakajima, Y. Survival of microencapsulated islets at 400 days posttransplantation in the omental pouch of NOD mice. *Cell Transplant.*, 2006, 15(4), 359−365.

Krishnan, R; Arora, R; Alexander, M; White, S; Lamb, M; Foster, C; Choi, B; Lakey, JRT. Noninvasive evaluation of the vascular response to transplantation of alginate encapsulated islets using the dorsal skin-fold model. *Biomaterials*, 2014, 35(3), 891−898.

Krol, S; del Guerra, S; Grupillo, M; Diaspro, A; Gliozzi, A; Marchetti, P. Multilayer nanoencapsulation. New approach for immune protection of human pancreatic islets. *Nano Lett.*, 2006, 6(9), 1933−1939.

Kumagai Braesch, M; Jacobson, S; Mori, H; Jia, X; Takahashi, T; Wernerson, A; Flodström, Tullberg, M; Tibell, A. The TheraCyte™ device protects against islet allograft rejection in immunized hosts. *Cell Transplant.*, 2013, 22(7), 1137−1146.

Lacy, PE; Hegre, OD; Gerasimidi Vazeou, A; Gentile, FT; Dionne, KE. Maintenance of normoglycemia in diabetic mice by subcutaneous xenografts of encapsulated islets. *Science*, 1991, 254(5039), 1782−1784.

Lamb, M; Storrs, R; Li, S; Liang, O; Laugenour, K; Dorian, R; Chapman, D; Ichii, H; Imagawa, D; Foster, C; King, S; Lakey, JRT. Function and viability of human islets encapsulated in alginate sheets: *in vitro* and *in vivo* culture. *Transplant. Proc.*, 2011, 43(9), 3265−3266.

Lanza, R; Langer, R; Vacanti, JP. (2011). *Principles of tissue engineering*, Academic press.

Lee, SH; Hao, E; Savinov, A; Geron, I; Strongin, A; Itkin Ansari, P. Human beta-cell precursors mature into functional insulin-producing cells in an immunoisolation device: implications for diabetes cell therapies. *Transplantation*, 2009, 87(7), 983−991.

Lembert, N; Wesche, J; Petersen, P; Zschocke, P; Enderle, A; Planck, H; Ammon, H. Macroencapsulation of rat islets without alteration of insulin secretion kinetics. *Experimental and clinical endocrinology & diabetes*, 2001, 109(02), 116−119.

Lim, F; Sun, AM. Microencapsulated islets as bioartificial endocrine pancreas. *Science* 1980, 210(4472), 908−910.

Luan, NM; Iwata, H. Long-term allogeneic islet graft survival in prevascularized subcutaneous sites without immunosuppressive treatment. *Am. J. Transplantation*, 2014, 14(7), 1533−1542.

Ludwig, B; Rotem, A; Schmid, J; Weir, G; Colton, C; Brendel, M; Neufeld, T; Block, N; Yavriyants, K; Steffen, A; Ludwig, S; Chavakis, T; Reichel, A; Azarov, D; Zimermann, B; Maimon, S; Balyura, M; Rozenshtein, T; Shabtay, N; Vardi, P; Bloch, K; de Vos, P; Schally, A; Bornstein, S; Barkai, U. Improvement of islet function in a bioartificial pancreas by enhanced oxygen supply and growth hormone releasing hormone agonist. *Proc. Natl. Acad. Sci. U. S. A.*, 2012, 109(13), 5022−5027.

Ludwig, B; Zimerman, B; Steffen, A; Yavriants, K; Azarov, D; Reichel, A; Vardi, P; German, T; Shabtay, N; Rotem, A; Evron, Y; Neufeld, T; Mimon, S; Ludwig, S; Brendel,

MD; Bornstein, SR; Barkai, U. A novel device for islet transplantation providing immune protection and oxygen supply. *Horm. Metab. Res.*, 2010, 42(13), 918−922.

Ménard, M; Dusseault, J; Langlois, G; Baille, W; Tam, S; Yahia, LH; Zhu, XX; Hallé, JP. Role of protein contaminants in the immunogenicity of alginates. *Journal of biomedical materials research. Part B, Applied biomaterials*, 2010, 93(2), 333−340.

Mørch, Y; Donati, I; Strand, B; Skjåk Braek, G. Effect of Ca2+, Ba2+, and Sr2+ on alginate microbeads. *Biomacromolecules*, 2006, 7(5), 1471-1480.

Matsumoto, S; Abalovich, A; Wechsler, C; Wynyard, S; Elliott, RB. Clinical Benefit of Islet Xenotransplantation for the Treatment of Type 1 Diabetes. *EBioMedicine*, 2016, 12, 255−262.

Monaco, AP; Maki, T; Ozato, H; Carretta, M; Sullivan, SJ; Borland, KM; Mahoney, MD; Chick, WL; Muller, TE; Wolfrum, J. Transplantation of islet allografts and xenografts in totally pancreatectomized diabetic dogs using the hybrid artificial pancreas. *Ann. Surg.*, 1991, 214(3), 339−360, discussion 361.

Motté, E; Szepessy, E; Suenens, K; Stangé, G; Bomans, M; Jacobs-Tulleneers-Thevissen, D; Ling, Z; Kroon, E; Pipeleers, D. Composition and function of macroencapsulated human embryonic stem cell-derived implants: comparison with clinical human islet cell grafts. *Am. J. Physiol. Endocrinol. Metabol.*, 2014, 307(9), E838−E846.

Neufeld, T; Ludwig, B; Barkai, U; Weir, G; Colton, C; Evron, Y; Balyura, M; Yavriyants, K; Zimermann, B; Azarov, D; Maimon, S; Shabtay, N; Rozenshtein, T; Lorber, D; Steffen, A; Willenz, U; Bloch, K; Vardi, P; Taube, R; de Vos, P; Lewis, E; Bornstein, S; Rotem, A. The efficacy of an immunoisolating membrane system for islet xenotransplantation in minipigs. *PLoS One*, 2013, 8(8), e70150−e70150.

O'Sullivan, E; Vegas, A; Anderson, D; Weir, G. Islets transplanted in immunoisolation devices: a review of the progress and the challenges that remain. *Endocr. Rev.*, 2011, 32(6), 827−844.

Omer, A; Duvivier Kali, V; Aschenbach, W; Tchipashvili, V; Goodyear, L; Weir, G. Exercise induces hypoglycemia in rats with islet transplantation. *Diabetes*, 2004, 53(2), 360−365.

Opara, E; Mirmalek Sani, SH; Khanna, O; Moya, M; Brey, E. Design of a bioartificial pancreas(+). *J. Investig. Med.*, 2010, 58(7), 831−837.

Orive, G; Hernández, RM; Gascón, AR; Calafiore, R; Chang, TM; De Vos, P; Hortelano, G; Hunkeler, D; Lacík, I; Shapiro, AJ. Cell encapsulation: promise and progress. *Nat. Med.*, 2003, 9(1), 104−107.

Pareta, R; Farney, AC; Opara, EC; McQuilling, JP. (2012). *Bioartificial pancreas: evaluation of crucial barriers to clinical application*: INTECH Open Access Publisher. Page 239 − 266.

Pareta, R; McQuilling, J; Sittadjody, S; Jenkins, R; Bowden, S; Orlando, G; Farney, A; Brey, E; Opara, E. Long-term function of islets encapsulated in a redesigned alginate microcapsule construct in omentum pouches of immune-competent diabetic rats. *Pancreas*, 2014, 43(4), 605−613.

Ponce, S; Orive, G; Hernández, R; Gascón, A; Pedraz, J; de Haan, B; Faas, M; Mathieu, HJ; de Vos, P. Chemistry and the biological response against immunoisolating alginate-polycation capsules of different composition. *Biomaterials*, 2006, 27(28), 4831−4839.

Qi, M; Gu, Y; Sakata, N; Kim, D; Shirouzu, Y; Yamamoto, C; Hiura, A; Sumi, S; Inoue, K. PVA hydrogel sheet macroencapsulation for the bioartificial pancreas. *Biomaterials*, 2004, 25(27), 5885-5892.

Qi, Z; Shen, Y; Yanai, G; Yang, K; Shirouzu, Y; Hiura, A; Sumi, S. The *in vivo* performance of polyvinyl alcohol macro-encapsulated islets. *Biomaterials*, 2010, 31(14), 4026−4031.

Qi, Z; Yamamoto, C; Imori, N; Kinukawa, A; Yang, Kc; Yanai, G; Ikenoue, E; Shen, Y; Shirouzu, Y; Hiura, A; Inoue, K; Sumi, S. Immunoisolation effect of polyvinyl alcohol (PVA) macroencapsulated islets in type 1 diabetes therapy. *Cell Transplant.*, 2012, 21(2-3), 525−534.

Sörenby, A; Kumagai Braesch, M; Sharma, A; Hultenby, K; Wernerson, A; Tibell, A. Preimplantation of an immunoprotective device can lower the curative dose of islets to that of free islet transplantation: studies in a rodent model. *Transplantation*, 2008, 86(2), 364−366.

Sakata, N; Gu, Y; Qi, M; Yamamoto, C; Hiura, A; Sumi, S; Sunamura, M; Matsuno, S; Inoue, K. Effect of rat-to-mouse bioartificial pancreas xenotransplantation on diabetic renal damage and survival. *Pancreas*, 2006, 32(3), 249−257.

Sandler, S; Andersson, A; Eizirik, DL; Hellerström, C; Espevik, T; Kulseng, B; Thu, B; Pipeleers, DG; Skjåk Braek, G. Assessment of insulin secretion *in vitro* from microencapsulated fetal porcine islet-like cell clusters and rat, mouse, and human pancreatic islets. *Transplantation*, 1997, 63(12), 1712−1718.

Schade, DS; Eaton, RP; Davis, T; Akiya, F; Phinney, E; Kubica, R; Vaughn, EA; Day, PW. The kinetics of peritoneal insulin absorption. *Metabolism; clinical and experimental*, 1981, 30(2), 149-155.

Scharp, DW; Marchetti, P. Encapsulated islets for diabetes therapy: history, current progress, and critical issues requiring solution. *Adv. Drug Del. Rev.*, 2014, 67, 35−73.

Scharp, DW; Mason, NS; Sparks, RE. Islet immuno-isolation: the use of hybrid artificial organs to prevent islet tissue rejection. *World J. Surg.*, 1984, 8(2), 221−229.

Scharp, DW; Swanson, CJ; Olack, BJ; Latta, PP; Hegre, OD; Doherty, EJ; Gentile, FT; Flavin, KS; Ansara, MF; Lacy, PE. Protection of encapsulated human islets implanted without immunosuppression in patients with type I or type II diabetes and in nondiabetic control subjects. *Diabetes*, 1994, 43(9), 1167−1170.

Schulz, T; Young, H; Agulnick, A; Babin, MJ; Baetge, E; Bang, A; Bhoumik, A; Cepa, I; Cesario, R; Haakmeester, C; Kadoya, K; Kelly, J; Kerr, J; Martinson, L; McLean, A; Moorman, M; Payne, J; Richardson, M; Ross, K; Sherrer E; Song, X; Wilson, A; Brandon, E; Green, C; Kroon, E; Kelly, O; D'Amour, K; Robins, A. A scalable system for production of functional pancreatic progenitors from human embryonic stem cells. *PLoS One*, 2012, 7(5), e37004−e37004.

Shapiro, AM; Lakey, JR; Ryan, EA; Korbutt, GS; Toth, E; Warnock, GL; Kneteman, NM; Rajotte, RV. Islet transplantation in seven patients with type 1 diabetes mellitus using a glucocorticoid-free immunosuppressive regimen. *The New England Journal of Medicine*, 2000, 343(4), 230−238.

Shapiro, AMJ; Ricordi, C; Hering, B; Auchincloss, H; Lindblad, R; Robertson, RP; Secchi, A; Brendel, M; Berney, T; Brennan, D; Cagliero, E; Alejandro, R; Ryan, E; DiMercurio, B; Morel, P; Polonsky, K; Reems, JA; Bretzel, R; Bertuzzi, F; Froud, T; Kandaswamy, R; Sutherland, DER; Eisenbarth, G; Segal, M; Preiksaitis, J; Korbutt, G; Barton, F; Viviano, L; Seyfert Margolis, V; Bluestone, J; Lakey, JRT. International trial of the Edmonton protocol for islet transplantation. *The New England Journal of Medicine*, 2006, 355(13), 1318−1330.

Shen, F; Li, A; Cornelius, R; Cirone, P; Childs, R; Brash, J; Chang, P. Biological properties of photocrosslinked alginate microcapsules. *Journal of biomedical materials research. Part B, Applied biomaterials*, 2005, 75(2), 425−434.

Shin, JS; Kim, JM; Kim, JS; Min, BH; Kim, YH; Kim, HJ; Jang, JY; Yoon, IH; Kang, HJ; Kim, J; Hwang, ES; Lim, DG; Lee, WW; Ha, J; Jung, KC; Park, SH; Kim, SJ; Park, CG. Long-term control of diabetes in immunosuppressed nonhuman primates (NHP) by the transplantation of adult porcine islets. *Am. J. Transplant.*, 2015, 15(11), 2837−2850.

Shin, JS; Min, BH; Kim, JM; Kim, JS; Yoon, IH; Kim, HJ; Kim, YH; Jang, JY; Kang, HJ; Lim, DG; Ha, J; Kim, SJ; Park, CG. Failure of transplantation tolerance induction by autologous regulatory T cells in the pig-to-non-human primate islet xenotransplantation model. *Xenotransplantation*, 2016, 23(4), 300−309.

Srinivasan, P; Huang, GC; Amiel, SA; Heaton, ND. Islet cell transplantation. *Postgrad. Med. J.*, 2007, 83(978), 224−229.

Storrs, R; Dorian, R; King, SR; Lakey, J; Rilo, H. Preclinical development of the Islet Sheet. *Ann. N. Y. Acad. Sci.*, 2001, 944(1), 252−266.

Sullivan, SJ; Maki, T; Carretta, M; Ozato, H; Borland, K; Mahoney, MD; Muller, TE; Solomon, BA; Monaco, AP; Chick, WL. Evaluation of the hybrid artificial pancreas in diabetic dogs. *ASAIO J.*, 1992, 38(1), 29−33.

Sun, Y; Ma, X; Zhou, D; Vacek, I; Sun, AM. Normalization of diabetes in spontaneously diabetic cynomologus monkeys by xenografts of microencapsulated porcine islets without immunosuppression. *J. Clin. Invest.*, 1996, 98(6), 1417.

Tam, SK; Bilodeau, S; Dusseault, J; Langlois, G; Hallé, JP; Yahia, LH. Biocompatibility and physicochemical characteristics of alginate-polycation microcapsules. *Acta Biomater.*, 2011, 7(4), 1683-1692.

Tendulkar, S; Ramasubramanian, KM; Opara, CE. Microencapsulation: The emerging role of microfluidics. *Micro and Nanosystems* 2013, 5(3), 194−208.

Tiernan, AR; Sambanis, A. Bioluminescence tracking of alginate micro-encapsulated cell transplants. *J. Tissue Eng. Regen. Med.*, 2014.

Tomei, A; Manzoli, V; Fraker, C; Giraldo, J; Velluto, D; Najjar, M; Pileggi, A; Molano, RD; Ricordi, C; Stabler, C; Hubbell, J. Device design and materials optimization of conformal coating for islets of Langerhans. *Proc. Natl. Acad. Sci. U. S. A.*, 2014, 111(29), 10514−10519.

Tuch, B; Keogh, G; Williams, L; Wu, W; Foster, J; Vaithilingam, V; Philips, R. Safety and viability of microencapsulated human islets transplanted into diabetic humans. *Diabetes Care*, 2009, 32(10), 1887−1889.

Vaithilingam, V; Tuch, B. Islet transplantation and encapsulation: an update on recent developments. *The review of diabetic studies*, 2011, 8(1), 51−67.

Valdes-Gonzalez, RA; Dorantes, LM; Garibay, GN; Bracho-Blanchet, E; Mendez, AJ; Davila-Perez, R; Elliott, RB; Teran, L; White, DJ. Xenotransplantation of porcine neonatal islets of Langerhans and Sertoli cells: a 4-year study. *Eur. J. Endocrinol.*, 2005, 153(3), 419−427.

Van Schilfgaarde, R; de Vos, P. Factors influencing the properties and performance of microcapsules for immunoprotection of pancreatic islets. *J. Mol. Med.*, 1999, 77(1), 199−205.

Van Suylichem, PT; Strubbe, JH; Houwing, H; Wolters, GH; van Schilfgaarde, R. Insulin secretion by rat islet isografts of a defined endocrine volume after transplantation to three different sites. *Diabetologia*, 1992, 35(10), 917−923.

Velho, G; Froguel, P; Reach, G. Determination of peritoneal glucose kinetics in rats, implications for the peritoneal implantation of closed-loop insulin delivery systems. *Diabetologia*, 1989, 32(6), 331−336.

Wang, T; Lacík, I; Brissová, M; Anilkumar, AV; Prokop, A; Hunkeler, D; Green, R; Shahrokhi, K; Powers, AC. An encapsulation system for the immunoisolation of pancreatic islets. *Nat. Biotechnol.*, 1997, 15(4), 358−362.

Wang, W; Gu, Y; Tabata, Y; Miyamoto, M; Hori, H; Nagata, N; Touma, M; Balamurugan, AN; Kawakami, Y; Nozawa, M; Inoue, K. Reversal of diabetes in mice by xenotransplantation of a bioartificial pancreas in a prevascularized subcutaneous site. *Transplantation*, 2002, 73(1), 122−129.

Wang, W; Mo, Z; Ye, B; Hu, P; Liu, S; Yi, S. A clinical trial of xenotransplantation of neonatal pig islets for diabetic patients. *Zhong Nan Da Xue Xue Bao Yi Xue Ban*, 2011, 36(12), 1134−1140.

Wilson, J; Cui, W; Chaikof, E. Layer-by-layer assembly of a conformal nanothin PEG coating for intraportal islet transplantation. *Nano Lett.*, 2008, 8(7), 1940−1948.

Yang, H; Yoon, KH. Current status of encapsulated islet transplantation. *J. Diabetes Complications*, 2015, 29(5), 737−743.

Zhi, ZL; Khan, F; Pickup, JC. Multilayer nanoencapsulation: a nanomedicine technology for diabetes research and management. *Diabetes Res. Clin. Pract.*, 2013, 100(2), 162−169.

Zhi, ZL; Kerby, A; King, AJF; Jones, PM; Pickup, JC. Nano-scale encapsulation enhances allograft survival and function of islets transplanted in a mouse model of diabetes. *Diabetologia*, 2012, 55(4), 1081−1090.

In: Encyclopedia of Surgery (22 Volume Set)
Editors: Andreas Lehrer and Kristin Mueller
ISBN: 978-1-53618-329-0
© 2020 Nova Science Publishers, Inc.

Chapter 221

HEPATOCYTE TRANSPLANTATION

Nalu Navarro Alvarez[1,*], MD, PhD
and Paulo Martins[2], MD, PhD
[1]Center for Transplantation Sciences (CTS), Massachusetts General Hospital,
Harvard Medical School, Boston, MA, US
[2]Department of Surgery, Transplant Division, UMass Memorial Medical Center,
University of Massachusetts. Boston, MA, US

ABSTRACT

Hepatocyte transplantation has been investigated as an alternative therapeutic modality to orthotopic liver transplantation in patients with liver disease. Since the implementation of a reliable isolation method for hepatocytes, several experimental animal models of induced or inherited liver failure have been developed to test their potential. So far, the transplantation of hepatocytes has been shown to be effective in restoring biochemical function in animal models of liver-based metabolic disease, to improve the survival of animals with experimentally-induced acute and chronic liver failure and to engraft and proliferate when the host conditions allow for growth advantage of the transplanted hepatocytes. Lessons learned from the experimental animal models have been translated into clinical attempts in patients with liver diseases. While some efficacy has been demonstrated, most patients eventually need a whole liver transplant due to the lack of long-term engraftment and functionality of hepatocytes. Therefore, before this procedure becomes a routine, we must overcome these obstacles for which further research will be needed.

Here we discuss the advances and hurdles of hepatocyte transplantation and describe some animal models used to study this promising alternative therapy.

Keywords: liver, hepatocyte, transplantation

[*] Corresponding Author's Email: nnavarro-alvarez@mgh.harvard.edu.

ABBREVIATIONS

ACLF	Acute on Chronic Liver Failure
AILF	Acetaminophen Induced Liver Failure
ALF	Acute Liver Failure
apo	apolipoprotein
BDL	Surgical bile duct ligation
CCL4	Carbon tetrachloride
CN1	Crigler-Najjar type 1 disease
DAMPs	Danger-associated molecular patterns
DSAs	Donor Specific Antibodies
EDTA	Ethylenediaminetetraacetic acid
FAH	furamylacetoacetate hydrolase
GMP	Good Manufacturing Practices
HBSS	Hank's Balanced Salt Solution
HCC	hepatocellular carcinoma
HT1	Human Hereditary tyrosinemia type 1
HTx	Hepatocyte transplantation
KC	Kupffer cells
LDL	low density lipoprotein
LFT	Liver Failure Tests
LSEC	Liver sinusoidal endothelial cells
NAC	N -acetylcysteine
NASH	nonalcoholic steatohepatitis
OLT	Orthotopic liver transplantation
OTC	Ornithine transcarbamylase deficiency
PMN	Polymorphonuclear cells
UGT1	hepatic UDP-glucuronosyl transferase

INTRODUCTION

Hepatocyte transplantation is an experimental procedure that has been widely used not only to improve the quality of life of patients awaiting for an OLT (Orthotopic Liver Transplantation), but also as a treatment for patients with end stage or genetic metabolic liver diseases by providing the metabolic and synthetic support that they need.

The first description that lead to the surge of hepatocyte transplantation dates back to 1898, where Ribbert et al. (Ribbert 1898) attempted to place small fragments of liver into the lymph nodes of rabbits and guinea pigs. He observed the animals for 4−5 weeks and found that hepatocytes and ducts were nearly normal for 1−2 weeks. However, after 2−3 weeks there was a gradual atrophy and bile ducts were necrotic or proliferated to form adenoma-like nodules.

A year later (1899), Lubarsch et al. intravenously injected hepatocytes in the pulmonary veins of rabbits, but they were degenerated in 3−4 weeks (Lubarsch 1899). While no evidence of function was observed in any of these attempts, it paved the way for other investigators to

explore alternate sites to heterotopically graft minute amounts of liver tissue, such as subcutaneous tissue (Herxheimer 1926), peritoneal cavity, anterior chamber of the eye, kidney, small intestine, and stomach among others (Grisham 1964). Unfortunately, survival of hepatic tissue depended upon the development of collateral circulation, which did not occur and engrafted tissue either underwent total necrosis, or resulted in complete loss of hepatocytes.

Back in the days, there was no specific isolation technique to get hepatocytes; it was not until the mid-1960s, when Howard et al. (Howard 1967) used the combination of a mechanical and enzymatic digestion technique to isolate rat hepatocytes. Later, this technique was modified in 1969 by Berry and Friend, who described for the first time the successful preparation of isolated rat liver parenchymal cells using a collagenase perfusion method (Berry 1969). This method has been refined and optimized not only to achieve better yield (Seglen 1976) but to use the isolated hepatocytes clinically (Gramignoli 2015).

Since then, laboratory animal studies and some clinical trials have demonstrated that hepatocyte transplantation (HTx) can be used for the treatment of liver failure and inborn errors of liver metabolism (Dhawan 2015; Jorns 2016; Coppin 2017). This procedure has several advantages over OLT: it involves a simple technique, where implantation of hepatocytes into the recipient is usually done by infusion into the portal vein, or the splenic artery (Strom 1997; Fox 1998), although some other places have been also tested. The infusion can be performed on a scheduled basis, hepatocytes can be cryopreserved to be used in the future, and more importantly, one donor can be used for multiple patients (Mitry 2004).

From the immunological perspective, if hepatocytes are lost, they do so in a less severe manner than whole liver. These characteristics make hepatocyte transplantation an attractive alternative therapy for the treatment of patients waiting for a liver by improving their quality of life while the organ becomes available or by providing the necessary metabolic and synthetic support while the native liver regenerates.

This book chapter will describe the advances and hurdles of hepatocyte transplantation as an experimental technique in animal models and in clinical settings.

MICROSCOPIC ANATOMY OF THE LIVER

The liver is the largest organ in the body representing approximately 2.5% of the total body weight of an adult. In a resting state, 25% of the total cardiac output gets into the liver through the hepatic portal vein and the hepatic artery. The liver has regulatory, secreting, synthetic, metabolic and excretory functions. The principal cell performing all these functions is the “Hepatocyte” which accounts for roughly 80% of the liver mass (Rhoades 2009).

Hepatocytes are arranged in plates separated by capillary networks called sinusoids. The polygonal shape of the cells allows them for one side (basal membrane side) to be in contact with the sinusoids from where they receive nutrients and oxygen, and on the other side (apical side) with their neighboring hepatocytes, with whom they form bile canaliculi (Gissen 2015) (Figure 1).

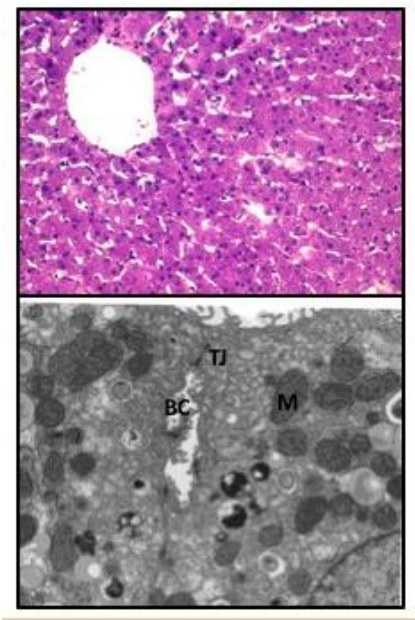

Figure 1. Microscopic anatomy of the liver. H&E (upper panel) and Transmission Electron Microscope picture of polarized hepatocytes (TJ: Tight Junction; BC: bile canaliculi; M: mitochondria).

Unfortunately, following isolation, hepatocytes lose their polarity which is extremely important when cells are transplanted, since for cells to function, they need to follow a similar arrangement in the organ they allocate. Defects in hepatocyte polarization lead to major pathophysiological consequences (Gissen 2015) including graft failure.

HEPATOCYTE ISOLATION

Hepatocyte transplantation encompasses 3 steps: The isolation of hepatocytes, the preparation of cell suspensions and its implantation in the recipient. Diverse methods have been recently described for the isolation of different sources of hepatocytes; while all of them are founded on the same concept, they varied based on the technique and the type of enzymes used. Regardless of the species, when hepatocyte isolation is performed from a whole organ, the general technique involves liver perfusion through the existing vasculature; and by injecting the solutions directly into the parenchyma when isolation is from small liver biopsies.

Human Hepatocyte Isolation

In the case of human hepatocytes, the main issue facing is the lack of adequate sources to get viable cells. Hepatocytes are generally obtained from discarded organs due to steatosis greater than 40−50% (Strom 1997), prolonged ischemia time (Muraca 2002), traumatic graft injury, capsular tear (Bilir 2000; Alexandrova 2005), blood group incompatibility (Fox 1998) as well as donor livers after the portion used for transplantation has been removed (Mitry

2002; Mitry 2004). Other proposed sources are hepatic tissue from liver resections due to benign disease or after resection of a colorectal tumor (Gunasegaram 2008).

The isolation is performed using a two-step Ethylenediaminetetraacetic acid (EDTA) or EGTA/collagenase enzymatic perfusion technique. First, cannulation of the hepatic artery and the portal vein from discarded hepatic tissue is performed (Figure 2). The enzymatic digestion consists of two stages: a first stage of non-recirculating perfusion of the hepatic tissue with a HEPES-buffer free of calcium and containing EDTA to wash out the blood and weaken intercellular junctions; the second stage is a recirculating perfusion step where the same previous solution is used with the addition of $CaCl_2$ and collagenase to achieve complete digestion of the hepatic tissue. Both stages are performed at 37ºC. The tissue is then mechanically disaggregated, filtered and washed to obtain a hepatocyte suspension (Figure 2), which will then be used for transplantation. While experimentally hepatocytes have been placed in culture for a few days allowing time for hepatocytes to recover from the harsh enzymatic treatment, clinically, this is not routinely performed.

Figure 2. Procedure for the isolation of human hepatocytes comprising: Liver cannulation and perfusion with digestive enzymes, mechanical dispersion of the liver, to obtain single cell suspension.

While most of the protocols are based on the use of Collagenase Type 1: 0.05% (Alexandrova 2005; Hughes 2006; Dhawan 2015), there have been some protocols using different collagenase and slightly different concentrations (Cho 2004). One of the most recent modifications to the protocol was the use of Liberase (a blend of collagenase I and collagenase II and dispase or thermolysin) and addition of the antioxidant *N* -acetylcysteine (NAC) (Bartlett 2014) with an overall 70% success rate for isolations from normal and diseased livers.

The yield and the viability of hepatocyte following the isolation will vary depending on the conditions of the tissue. Lower yields and viabilities have been observed when hepatocytes are isolated from fibrotic or steatotic livers, or with an increased gamma-glutamyltranspeptidase or aspartate aminotransferase activity and bilirubin content. Cold ischemia times and weight of the perfused livers also influence yield. Interestingly, yield is significantly increased by chemotherapy treatment (Lee 2014). Therefore, the number of hepatocytes obtained ranges from $2.0 \times 10^{(6)}$–$1.8 \times 10^{(10)}$ cells (Mitry 2003; Lee 2014).

Mouse Hepatocyte Isolation

Hepatocytes are isolated by the same enzymatic digestion technique developed by Berry and Friend (Berry 1969) as an in situ two-step collagenase perfusion technique and as modified by Seglen (Seglen 1976).

Independently of the mouse or rat strained used, the following procedures are usually performed:

In general, all solutions should be prepared just before isolation and pre-warmed at 37−40°C. The isolation involves an in vivo perfusion, where a cannula is inserted in either the portal vein (Berthiaume 1999; Li 2010) or into the vena cava through the right atrium of the animal while the animal's heart is still beating (Severgnini 2012). The liver is then perfused with a solution that is usually Hank's Balanced Salt Solution (HBSS) containing EDTA to wash out blood, followed by a collagenase perfusion with concentrations that vary from as low as 0.03% to as high as 0.2% (Chung 2010; Sewing 2016). Several collagenases have been used, including collagenases type I, type II, Type III and Type IV. In some protocols, the addition of Elastase has been tested (Oliva 2008). After the perfusion is terminated, the surface of the liver sac is cut to release the hepatocytes, which are then collected and passed through a cells strainer, followed by a round of centrifugations and washes that will yield single isolated hepatocytes.

Several protocols use the additional step of cell purification through gradient centrifugation with Ficoll or Percoll. To avoid the manipulation of the cells which unfortunately results in a reduced cell number and viability, investigators have used a protocol that reduces the need for the gradient centrifugation purification step and results in high yields of viable and functional cells (Severgnini 2012).

Porcine Hepatocyte Isolation

The isolation for porcine hepatocytes resembles pretty much the human procedure (Figure 2). The differences lie on the concentration and type of collagenase used, and the addition of other enzymes to the perfusate to achieve better yield and viability.

The collagenase that is more commonly used in this species is type I and IV, and the concentrations range from 0.02% to 0.8% (Gerlach 1996). The addition of Neutral Protease and Deoxyribonuclease I have been also tested (Meng 2010). And so, does the use of Dispase and a four-step retrograde perfusion combining both dispase and collagenase (Maruyama 2003).

HEPATOCYTE TRANSPLANTATION

Since more than 40 years ago, the potential of Hepatocyte transplantation (HTX) has been investigated in different animal models of induced acute liver failure (Chen 2005; Tanaka 2006; Totsugawa 2007; Yamamoto 2010; Navarro-Alvarez 2010), chronic liver failure (Nagata 2003; Nakamura 2014); (Kobayashi 2000) and hereditary liver disorders (Matas 1976; Yoshida 1996).

While a significant improvement of liver function and survival has been observed experimentally, unfortunately the outcome of hepatocyte transplantation in patients with liver failure has been disappointing, except when used as bridge to liver transplantation.

One cannot directly extrapolate the techniques and approaches used in these models to the clinical scenario, and individual case by case factors need to be taken into consideration. Among those, some important factors that need special attention when transplanting hepatocytes clinically are: the route of administration and the number of infusions and cells administered on each infusion, as the efficiency of the transplanted cells depends on those conditions. The administration of too many cells imposes a risk to the donor, by increasing the portal pressure (Dhawan 2015).

The average adult liver contains 2.8×10^{11} hepatocytes (Fitzpatrick 2009; Dhawan 2015). Therefore, it has been anticipated that in total, approximately 5−10% of the recipient's estimated liver cell mass, should be infused (Fox 1998) (Jorns 2012) (Muraca 2002). The final cell dose is usually adjusted based on the patient's body weight and clinical situation, but as a rule, 1%−2% of liver mass may be the upper limit of hepatocytes that can be safely infused in each infusion (Horslen 2003; Dhawan 2015). To deliver the total dose required, multiple infusions will need to be done, separated by hours, or even days, with a careful monitoring of portal pressure which should not increase by more than 12 mm Hg to avoid significant portal hypertension.

Route of Hepatocyte Infusion

The infusion of hepatocytes experimentally and clinically is currently done by a slow infusion through the portal vein, the splenic vein or in the intraperitoneal cavity. The portal vein route has been generally used when attempting to transplant hepatocytes with the goal of correcting inborn errors of metabolism, which is usually done by catheterization via an ultrasound-guided approach of the portal or inferior mesenteric vein or by laparoscopic surgery (Fox 1998) (Figure 3). Using this route generates the advantage of having hepatocytes in their natural microenvironment right away, where they can respond to local growth factors and cytokines. Hepatocytes rapidly integrate in the liver parenchyma and start replacing missing liver functions; they can undergo proliferation and repopulation of the host liver, causing minimal stress when compared with whole liver transplantation (Figure 4).

On the other hand, in patients where the parenchyma is not intact, such as in the case of cirrhosis, the splenic arterial route has been mostly used, which is accessed through a catheter inserted in the femoral artery for implantation in the spleen. This organ is considered to be very attractive and convenient; its location makes it easy to access, its structure can accommodate a relatively large number of cells, and since it is a non-vital organ, it could be easily removed without fatal consequences if graft rejection ensues. Nevertheless, it is recommended that after each cell infusion a repeated Doppler ultrasound is performed to rule out the formation of thrombosis.

This route has been tested in patients suffering from ALF (acute liver failure) (Bilir 2000) or ACLF (acute on chronic liver failure) (Wang 2014). Direct intrasplenic injection has been experimentally proved to produce an engraftment far superior to that obtained using splenic artery infusion (Nagata 2003a; Nakamura 2014; Nagata 2003b; Ito 2007).

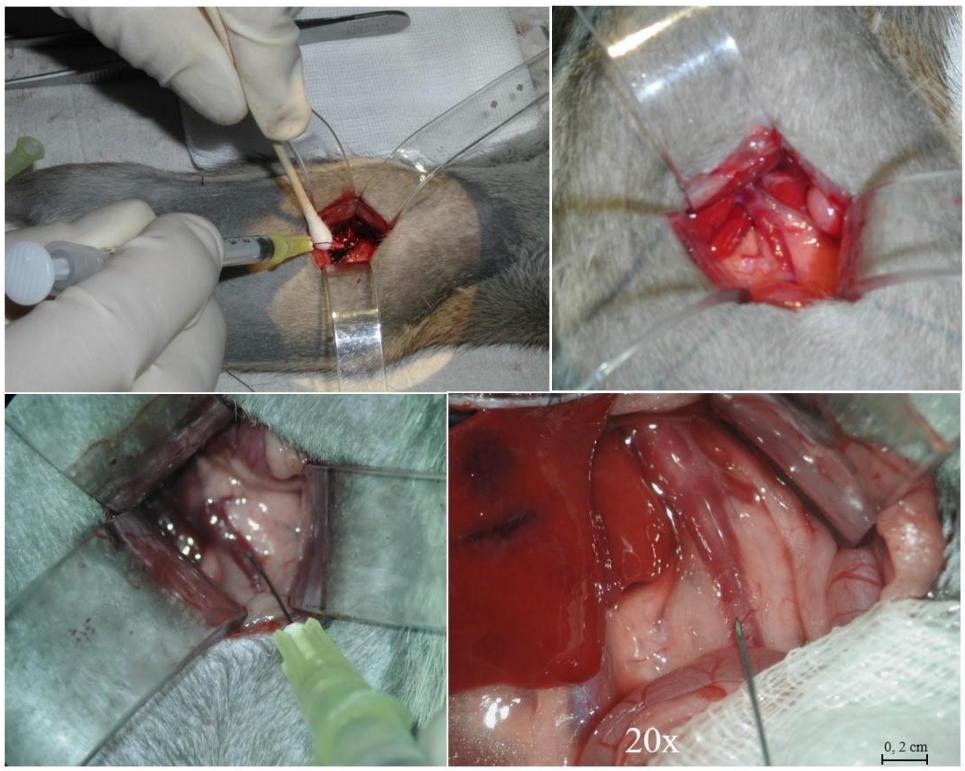

Figure 3. Injection of hepatocytes into the portal vein.

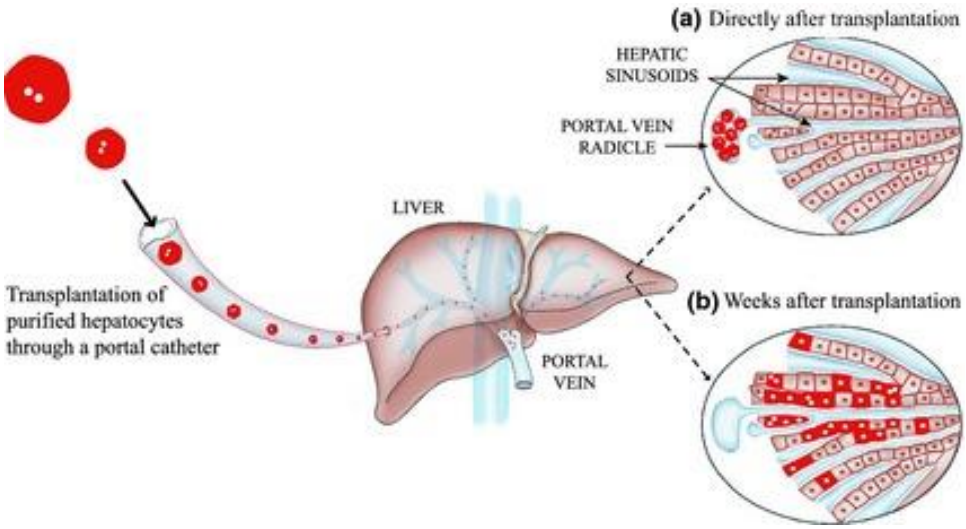

Figure 4. Integration of hepatocytes following injection.

An additional site that has been proposed especially for patients with acute liver failure, is the intraperitoneal cavity (Habibullah 1994). Usually these patients have severe coagulopathy and liver inflammation, which makes access to the portal system very

challenging due to the higher risk of possible systemic embolization or portal vein thrombosis that can result from hepatocyte transplantation. Therefore, the peritoneal cavity is an alternative site for hepatocyte transplantation (Dhawan 2015). In order to avoid the host immune response, hepatocytes have been encapsulated in alginate microspheres. This allows short-term support, while providing time for the native liver to regenerate (Jitraruch 2014; Jitraruch 2017; Sgroi 2011). An optimized protocol to produce (Good Manufacturing Practices) GMP grade alginate-encapsulated human hepatocytes has been established and could be soon used in clinical transplantation (Jitraruch 2014).

INDICATIONS

Metabolic Liver Disorders

These disorders are characterized by inherited alterations in either hepatic enzymes or proteins with metabolic functions. In this situation, the liver parenchyma is usually intact, and the rest of the liver functions are normal.

The information regarding the potential of hepatocyte transplantation in these disorders comes mainly from animal models that have attempted to mimic human genetic liver diseases. These models have provided valuable insight into the physiological, biochemical and molecular mechanism underlying each disease.

1) Model for Human Crigler–Najjar syndrome type I: Crigler-Najjar type 1 disease (CN1) is a rare inherited metabolic disease characterized by complete absence of hepatic UDP-glucuronosyl transferase (UGT1), resulting in high levels of unconjugated bilirubin.
   The Gunn rat is a natural model for CN1 that allows us to study the mechanism of bilirubin conjugation and deposition in order to understand its toxicity. This rat lacks hepatic bilirubin UDP-glucuronosyl transferase activity (UGT1A1), thus resembling Crigler-Najjar syndrome Type I. In this rat model, transplantation of normal hepatocytes resulted in the production of bilirubin glucuronides in the bile with a concomitant decrease in their serum bilirubin levels (Rugstad 1970; Polgar 2017).
2) Model for Human Hereditary tyrosinemia type 1 (HT1): This is a recessive liver disease caused by deficiency of the enzyme furamylacetoacetate hydrolase (FAH), which is responsible for the last step in the tyrosine catabolism. Accumulation of fumarylacetoacetate, the substrate for FAH, and its precursor, maleylacetoacetate, are thought to be hepatotoxic. HT1 affects mainly the liver and the kidney where FAH is most expressed (St-Louis 1997). Patients with HT1 either develop acute fatal liver failure in infancy or can progress to cirrhosis and hepatocellular carcinoma (HCC) early in childhood (Gokay 2016). If not treated, patients die of acute and severe hepatorenal failure in the early infancy. There are several animal models that are useful to study this lethal disease; a mouse (Aponte 2001), a rat (Zhang 2016) and a porcine model (Hickey 2011), which are deficient in FAH. Fah-deficient mice and pigs are usually maintained using 2-(2-Nitro-4-trifluoromethylbenzoyl)-1, 3-cyclohexanedione (NTBC), which is an inhibitor of 4-hydroxyphenylpyruvate

dioxygenase that blocks the accumulation of toxic metabolites such as fumarylacetoacetate and maleylacetoacetate. If NTBC is withdrawn, usually these animals develop progressive liver failure and renal tubular dysfunction. Hepatocyte transplantation into these species can rescue these animals demonstrating complete liver repopulation by the transplanted hepatocytes (Zhang 2016).

3) Model of Human familial hypercholesterolemia: This is an autosomal dominant disorder characterized by premature atherosclerosis, cardiovascular disease with markedly elevated plasma levels of LDL cholesterol and apolipoprotein (apo) B100 due to mutations in the low density lipoprotein (LDL) receptor gene. Several species have been used to develop experimental models for the study of this disease: In mice, the Ldlr-/- mice have high LDL cholesterol and apoB100 levels and developed extensive atherosclerosis on a chow diet (Powell-Braxton 1998). In rabbits, the Watanabe Heritable Hyperlipidemic rabbit also presents with elevated serum LDL cholesterol levels and early atherosclerosis. In these models, autologous hepatocyte transplantation of genetically corrected ex vivo with recombinant retroviruses demonstrated a significant and persistent decrease in total serum cholesterol (Chowdhury 1991).

Given the lower surgical risk and fewer consequences of graft loss when compared with LT, hepatocyte transplantation is a good alternative therapy for these patients, where replacement of the defective hepatocytes can be achieved through hepatocyte injection. In fact, hepatocyte transplantation has been performed in more than 30 children with inborn errors of metabolism including urea cycle defects, Crigler-Najjar Type I (Fox 1998), Type I Glycogenosis, tyrosinaemia type I, Ornithine transcarbamylase deficiency (OTC) (Ribes-Koninckx 2012), Factor VII deficiency, Refsum's disease, Familial Hypercholesterolemia (Grossman 1995) to name a few. An initial partial correction of the defect is expected by the transplantation of hepatocytes which significantly reflects in the improved clinical outcome of the disease. It is estimated that for children with metabolic disorders, engrafted cells representing 5% of the native liver would suffice to reconstitute an enzymatic defect. However, the outcome unfortunately doesn't last long, and it is thought to be due to a low initial engraftment and an insufficient proliferation of the transplanted cells, for which investigators have been looking at different approaches to improve engraftment and repopulation of hepatocytes such as host conditioning by radiation therapy (Soltys 2016).

Acute Liver Failure

Acute liver failure (ALF) is a clinical syndrome caused by liver damage by a large number of noxious agents which is unfortunately associated with a high mortality rate. There have been several animal experimental models of acute liver failure ranging from surgical models to drug models.

1. Surgical models of induced acute liver failure:
    a) The most widely used model is the 90% hepatectomy. This model leads to a 100% mortality in mice within 3−5 days (Navarro-Alvarez 2010). The animals die of liver failure with elevation of liver enzymes, hyperbilirubinemia, ascites

and encephalopathy, thus recapitulating the clinical picture of acute liver failure observed in patients. The transplantation of isolated hepatocytes can improve the survival of the recipients in this model of ALF. Several sources of hepatocytes have been used such as syngeneic hepatocytes, xenogeneic hepatocytes (Tanaka 2006; Soto-Gutierrez 2007; Yamamoto 2010), stem cell-derived hepatocytes (Soto-Gutiérrez 2006) and immortalized human hepatocytes (Kobayashi 2000b). All of them consistently have demonstrated promising results.

2. Drug-induced liver failure: Several drugs have been used to induce acute liver failure:
    a) Acetaminophen: Acetaminophen hepatotoxicity is due to its toxic metabolite, *N*-acetyl-*p*-benzo- quinoneimine (NAPQI), which is produced by the cytochrome P450 system when alternative detoxification pathways are saturated. The main underlying mechanism of Acetaminophen Induced Liver Failure (AILF) is the massive necrosis of hepatocytes which leads to the release of danger-associated molecular patterns (DAMPs) and formation of the inflammasome complex in various cells such as Kupffer cells (KC). This activates innate immune cells creating a sterile inflammation which will further contribute to the necrosis of more hepatocytes (Jaeschke 2014). Several models of AILF have been created. The most studied animals are the mice. There have been several issues when developing this model, for instance, it is well known that gender makes a difference; female mice usually develop less necrosis in the liver than male mice, independent of their genetic background (Mohar 2014). However, the differences in their genetic background require dose adjustments for reproducible results, because they develop more or less injury (Masubuchi 2009). Acetaminophen is usually administered by a single intra-peritoneal dose in doses that typically ranged from 250 mg/kg to as high as 600 mg/kg (Navarro-Alvarez 2010; Mossanen 2015). The transplantation of hepatocytes in this model has significantly extended the survival of these animals (Tanaka 2006; Yamamoto 2010).
    b) D-Galactosamine: It is an amino sugar metabolized via the galactose pathways in the liver. It is used in experimental animals to induce acute or fulminant liver failure. D-Galactosamine leads to the depletion of uridine moieties within the liver, therefore altering the hepatocyte RNA metabolism, and resulting in massive hepatic necrosis (Bélanger 2005). Animals develop biochemical changes consistent with ALF, encephalopathy, hypoglycemia and coma, resulting in a high mortality if not treated. When used in large animals such as pigs, the dose has been typically 0.5 g/kg of D-Gal given via the jugular route 24 h prior to cell transplantation. Investigators have used this model to test the feasiblity of hepatocyte transplantation. In this model, Totsugawa et al. tested primary and immortalized human hepatocytes injected intraportaly at a dose of 1x10^9 representing the 5% mass of the pig liver. The transplantation of hepatocytes significantly improved the survival and the clinical parameters of the animals (Totsugawa 2007).
3. Combined surgery and drug induced liver failure:
    a) Retrorsine + 70% hepatectomy: In this model retrorsine, a pyrrolizidine alkaloid that inhibits hepatocyte proliferation is used, followed by 70% hepatectomy which is usually performed 4 weeks later. Because retrorsine inhibits

regeneration of the liver after resection, animals cannot recover from the loss of hepatocyte mass. The model produces the clinical picture of liver failure including high LFTs, hyperammonemia-induced hepatic encephalopathy, and hypoglycemia (Navarro-Alvarez 2010). This model is widely used to evaluate the repopulation of transplanted cells, since it allows a selective long-term survival and repopulation advantage to the engrafted donor hepatocytes (Liu 2012; Navarro-Alvarez 2014).

b) Carbon tetrachloride (CCL_4) + Ischemia: Although carbon tetrachloride is used mainly to induce chronic liver failure, there have been models that have used it for the creation of fulminant liver failure. In a large animal model using pigs, Yuasa et al. investigated different doses of CCL4 administered through the portal vein combined with 30 mins ischemia by occlusion of the portal vein. He demonstrated that the use of 7.5 ml, of CCL_4 plus 30 mins of ischemia, represented the most reliable and reproducible model of fulminant liver failure, recapitulating the biochemical, hemodynamic and pathological findings found in patients undergoing this dreadful complication (Yuasa 2008). These parameters make this a great model to study the effect of hepatocyte transplantation.

In all these models, the transplantation of hepatocytes has been shown to improve the survival and clinical parameters of the animals undergoing acute liver failure (Tanaka 2006; Totsugawa 2007; Yamamoto 2010; Navarro-Alvarez 2010) and to prevent the development of intracranial hypertension in preclinical studies using large animals with acute ischemic liver failure (Arkadopoulos 1998).

Hepatocyte transplantation performed on patients with liver failure aims at sustaining liver functions to serve as a bridge to OLT while improving the quality of life of the patient, or where possible, until liver regeneration is achieved (Strom 1999; Dhawan 2015; Gramignoli 2015). In this context, usually patients with severe ALF, grade III to IV encephalopathy and those who were not candidates for OLT are selected to undergo this experimental treatment. Significant clinical improvement has been observed, however, they are not stable enough in some cases and patients eventually died if they did not receive an organ on time. Following transplantation, there is usually 48- to 72-hour delay in functioning of the transplanted hepatocytes which might represent a recovery or engraftment period. The transplanted hepatocytes have been easily identified both on transjugular biopsy and on autopsy in the spleen and liver by light microscopy and fluorescent in situ hybridization (FISH) in some of the transplanted patients (Bilir 2000; Gramignoli 2015).

Chronic Liver Failure and Acute-on-Chronic Liver Failure (ACLF)

Defined as an acute deterioration of an existing chronic liver disease, which could be a known compensated disease or an asymptomatic undiagnosed chronic hepatitis, nonalcoholic steatohepatitis (NASH) or cirrhosis.

1) Drug induced: The most used animal model to study chronic liver failure is the CCL4- induced cirrhosis alone or combined with phenobarbital. It is widely studied in small animals such as mice (Navarro-Alvarez 2010) and rats (Kobayashi 2000b).

The principle established is the same across species when using small animals and consists of giving a mixture of CCl4 and mineral oil diluted 1:9 by intraperitoneal injection twice a week for 6 weeks which can be extended up to 10 weeks depending on the progression of the disease. Protocols usually start at a dose of 0.20 ml, where the percentage of CCl4 in the mineral oil (v/v) is adjusted weekly based on changes in body weight. Animals in this protocol clearly recapitulate the clinical picture of patients with cirrhosis. They develop increased LFTs, hyperbilirubinemia, coagulation dysregulations, and clinically proven ascites. The transplantation of hepatocytes in this model has contributed to an improvement of biochemical parameters and survival.

2) Surgical: Surgical bile duct ligation (BDL) is the most common, quick and reproducible model of obstructive cholestatic liver injury in mice and rats. This model intends to reproduce the fibrosis and cirrhosis observed in the patient liver cirrhosis induced by hepatotoxins. Mice and rats in this model present with severe jaundice 21 to 28 days after the ligation (Kountouras 1984).

Despite these diverse models showing-significant benefit of hepatocyte transplantation in chronic diseases, clinically, OLT is the only cure for these patients. But, there have been some promising results indicating that HTx could be used as an alternative treatment (Pareja 2013; Wang 2014). Improvement of clinical parameters and liver function has been observed and in some cases of patients, has served as a bridge to liver transplantation (Pareja 2013; Gramignoli 2015).

IMMUNOSUPPRESION

Hepatocytes are subjected to a cell-mediated immune rejection; therefore an immunosuppresion protocol must be in place when performing hepatocyte transplantation. The first thing to consider is the ABO compatibility.

Following transplantation, the surviving allogeneic cells in humans have to overcome the adaptive immune system which might contribute to the gradual loss of graft function. Although the exact mechanisms by which hepatocytes are rejected are not very well understood; it is known that hepatocytes stimulate a cell-mediated immune response induced by both CD4 and CD8 T cells (Han 2009). Therefore, patients usually undergo an immunosuppression protocol consisting of the administration of a bolus of corticosteroids prior to hepatocyte infusion followed by double therapy with corticosteroids and calcineurin inhibitors such as cyclosporine or tacrolimus (Fox 1998; Dhawan 2010; Dhawan 2015; Gramignoli 2015; Khan 2017).

Although previously not considered, it has been recently demonstrated that hepatocyte transplantation is associated with the formation of *de novo* DSA antibodies, therefore it would be wise to reconsider the immunosuppression protocols currently used in order to take this factor into account (Jorns 2016). Further studies are required to better understand the immune mechanisms involved in graft loss after HT and to improve the current immunosuppressive protocols.

ENGRAFTMENT IMPROVEMENT

Following transplantation, there is an inflammatory response mediated by innate immune cells, which accounts for the early clearance (80–90%) of the transplanted cells (Viswanathan 2014). Cells not only need to overcome this response, but they have to find their way to integrate into the hepatic parenchyma, which they achieve by disrupting the endothelial barrier. Therefore, to get the most beneficial effect from the transplanted cells, several attempts have been made towards decreasing that initial inflammatory response, and aid in the integration of hepatocytes in the liver.

Several drugs aiming at the same outcome of improving cell engraftment and liver repopulation have been tested in preclinical animal models. In an experimental setting, pretreatment of the recipient with Thalidomide has demonstrated a significant reduction in the hepatic recruitment of PMN and KC, with the concomitant decrease of the inflammatory responses mediated by cytokine and chemokines (Viswanathan 2016) whereas the use of etanercept (ETN) successfully neutralized TNF-α expressed by neutrophils (PMN) or Kupffer cells (KC) (Viswanathan 2014).

Thalidomide also demonstrated positive effects on endothelial injury and increased engraftment of transplanted cells (Viswanathan 2016). Additional attempts such as vasodilation of the hepatic sinusoids with ET-1 receptor blockers (Bahde 2014) or induction of injury to Liver Sinuoidal Endothelial Cells (LSEC) with cyclophosphamide or doxorubicin improved engraftment (Malhi 2002; Kim 2005).

Once cells are in the hepatic parenchyma, they would need to repopulate the liver. Therefore, scientists have worked towards ways to create growth advantage for the transplanted cells to enhance the engraftment and/or proliferation of donor cells. Among those, preconditioning of the liver before transplantation with either hepatic irradiation, portal vein embolization, or hepatectomy have been proposed. Some of which have already been tested clinically and have yielded superior liver repopulation (Soltys 2016).

CONCLUSION

Hepatocyte transplantation for the treatment of liver diseases has dramatically increased over the years. Although considerable progress has been made, especially for inborn errors of metabolism, its full potential has not proven successful in the treatment of acute and chronic liver failure which has been hampered by lack of long-term hepatocyte functionality. Established and newly developed models of liver failure have been so far an excellent working tool to investigate the effects of hepatocyte transplantation and will continue to improve our understanding of this alternative therapy in the years to come.

REFERENCES

Alexandrova K, Griesel C, Barthold M. Large-scale isolation of human hepatocytes for therapeutic application. *Cell transplantation* 2005; 14:845–53.

Aponte JL, Sega GA, Hauser LJ. Point mutations in the murine fumarylacetoacetate hydrolase gene: Animal models for the human genetic disorder hereditary tyrosinemia type 1. *Proc. Natl. Acad. Sci. USA* 2001; 98:641–5.

Arkadopoulos, Chen, Khalili. Transplantation of hepatocytes for prevention of intracranial hypertension in pigs with ischemic liver failure. *Cell Transplant*. 1998; 7:357–63.

Bahde R, Kapoor S, Viswanathan P. Endothelin-1 receptor A blocker darusentan decreases hepatic changes and improves liver repopulation after cell transplantation in rats. *Hepatology* 2014; 59:1107–17.

Bartlett D, Hodson J, Bhogal R. Combined use of N-acetylcysteine and Liberase improves the viability and metabolic function of human hepatocytes isolated from human liver. *Cytotherapy* 2014; 16:800–9.

Bélanger M, Butterworth RF. Acute liver failure: a critical appraisal of available animal models. *Metab. Brain Dis.* 2005; 20:409–23.

Berry MN, Friend DS. High-yield preparation of isolated rat liver parenchymal cells: a biochemical and fine structural study. *J. Cell. Biol.* 1969; 43:506–20.

Berthiaume, Tompkins, Yarmush. Isolation and long-term maintenance of adult rat hepatocytes in culture. *Methods in molecular medicine* 1999; 18:447–56.

Bilir BM, Guinette D, Karrer F. Hepatocyte transplantation in acute liver failure. *Liver Transpl.* 2000; 6:32–40.

Chen Y, Kobayashi N, Suzuki S. Transplantation of human hepatocytes cultured with deleted variant of hepatocyte growth factor prolongs the survival of mice with acute liver failure. *Transplantation* 2005; 79:1378–85.

Cho J-J, Joseph B, Sappal B. Analysis of the functional integrity of cryopreserved human liver cells including xenografting in immunodeficient mice to address suitability for clinical applications. *Liver international* 2004; 24:361–70.

Chowdhury JR, Grossman M, Gupta S. Long-term improvement of hypercholesterolemia after ex vivo gene therapy in LDLR-deficient rabbits. *Science* 1991; 254:1802–5.

Chung S, Timmins J, Duong M. Targeted deletion of hepatocyte ABCA1 leads to very low density lipoprotein triglyceride overproduction and low density lipoprotein hypercatabolism. *The Journal of biological chemistry* 2010; 285:12197–209.

Coppin L, Sokal E, Stephenne X. Hepatocyte Transplantation in Children. *Methods Mol. Biol.* 2017; 1506:295-315.

Dhawan A. Clinical human hepatocyte transplantation: Current status and challenges. *Liver transplantation* 2015; 21 (Suppl 1):S39–44.

Dhawan A, Puppi J, Hughes R, Mitry R. Human hepatocyte transplantation: current experience and future challenges. *Nature reviews Gastroenterology & hepatology* 2010; 7:288–98.

Fitzpatrick, Mitry, Dhawan. Human hepatocyte transplantation: state of the art. *Journal of internal medicine* 2009; 266:339–57.

Fox IJ, Chowdhury JR, Kaufman SS. Treatment of the Crigler-Najjar syndrome type I with hepatocyte transplantation. *N. Engl. J. Med*. 1998; 338:1422–6.

Gerlach, Brombacher, Smith, Neuhaus. High yield hepatocyte isolation from pig livers for investigation of hybrid liver support systems: influence of collagenase concentration and body weight. *The Journal of surgical research* 1996; 62:85–9.

Gissen P, Arias I. Structural and functional hepatocyte polarity and liver disease. *Journal of hepatology* 2015; 63:1023–37.

Gokay S, Ustkoyuncu PS, Kardas F, Kendirci M. The outcome of seven patients with hereditary tyrosinemia type 1. *J. Pediat.r Endocrinol. Metab*. 2016; 29:1151–1157.

Gramignoli R, Vosough M, Kannisto K. Clinical hepatocyte transplantation: practical limits and possible solutions. *Eur. Surg. Res.* 2015; 54:162–77.

Grisham JW, Leong GF, Hole BV. Heterotopic partial autotransplantation of rat liver: technic and demonstration of structure and function of the graft. *Cancer res.* 1964; 24:1474–95.

Grossman M, Rader DJ, Muller DW. A pilot study of ex vivo gene therapy for homozygous familial hypercholesterolaemia. *Nat. Med*. 1995; 1:1148–54.

Gunasegaram A, Akhter J, Yao P. Hepatocytes isolated from neoplastic liver-immunomagnetic purging as a new source for transplantation. *World journal of gastroenterology* 2008; 14:5025–31.

Habibullah, Syed, Qamar, Taher-Uz. Human fetal hepatocyte transplantation in patients with fulminant hepatic failure. *Transplantation* 1994; 58:951–2.

Han B, Lu Y, Meng B, Qu B. Cellular Loss after allogenic hepatocyte transplantation. *Transplantation* 2009; 87:1.

Herxheimer G. Uber Pigmentbildung und Regeneration in Lebertransplantaten. *Beitr. Pathol. Anat.* 1926; 75:157–80.

Hickey RD, Lillegard JB, Fisher JE. Efficient production of Fah-null heterozygote pigs by chimeric adeno-associated virus-mediated gene knockout and somatic cell nuclear transfer. *Hepatology* 2011; 54:1351–9.

Horslen S, McCowan T, Goertzen T. Isolated hepatocyte transplantation in an infant with a severe urea cycle disorder. *Pediatrics* 2003; 111:1262–7.

Howard RB, Christensen AK, Gibbs FA, Pesch LA. The enzymatic preparation of isolated intact parenchymal cells from rat liver. *J. Cell Biol*. 1967; 35:675–84.

Hughes R, Mitry R, Dhawan A. Isolation of hepatocytes from livers from non-heart-beating donors for cell transplantation. *Liver transplantation* 2006; 12:713–7.

Ito M, Nagata H, Yamamoto T. Intrasplenic hepatocyte transplantation prolonged the survival in Nagase analbuminemic rats with liver failure induced by common bile duct ligation. *Cell transplantation* 2007; 16:547–53.

Jaeschke H, Xie Y, McGill MR. Acetaminophen-induced Liver Injury: from Animal Models to Humans. *J. Clin. Transl. Hepatol.* 2014; 2:153–61.

Jitraruch S, Dhawan A, Hughes R. Alginate microencapsulated hepatocytes optimised for transplantation in acute liver failure. *PloS one* 2014; 9:113609.

Jitraruch S, Dhawan A, Hughes RD. Cryopreservation of Hepatocyte Microbeads for Clinical Transplantation. *Cell Transplant.* 2017; Jan 20 [Epub ahead of print].

Jorns, Ellis, Nowak. Hepatocyte transplantation for inherited metabolic diseases of the liver. *Journal of internal medicine* 2012; 272:201–23.

Jorns, Nowak, Nemeth. De Novo Donor-Specific HLA Antibody Formation in Two Patients With Crigler-Najjar Syndrome Type I Following Human Hepatocyte Transplantation With Partial Hepatectomy Preconditioning. *American Journal of Transplantation* 2016; 16:1021–30.

Khan Z, Strom SC, Hepatocyte Transplantation in Special Populations: Clinical Use in Children. *Methods Mol. Biol*. 2017; 1506:3–16.

Kim K, Joseph B, Inada M, Gupta S. Regulation of hepatocyte engraftment and proliferation after cytotoxic drug-induced perturbation of the rat liver. *Transplantation* 2005; 80:653–9.

Kobayashi, Fujiwara, Westerman. Prevention of acute liver failure in rats with reversibly immortalized human hepatocytes. *Science* 2000a; 287:1258–62.

Kobayashi N, Ito M, Nakamura J. Hepatocyte transplantation in rats with decompensated cirrhosis. *Hepatology* 2000b; 31:851–857.

Kountouras, Billing, Scheuer. Prolonged bile duct obstruction: a new experimental model for cirrhosis in the rat. *British journal of experimental pathology* 1984; 65:305–11.

Lee S, Schelcher C, Laubender R. An algorithm that predicts the viability and the yield of human hepatocytes isolated from remnant liver pieces obtained from liver resections. *PloS one* 2014; 9:e107567.

Li W-C, Ralphs K, Tosh D. Isolation and culture of adult mouse hepatocytes. *Methods Mol. Biol*. 2010; 633:185−96.

Liu L, Yannam GR, Nishikawa T. The microenvironment in hepatocyte regeneration and function in rats with advanced cirrhosis. *Hepatology* 2012; 55:1529–39.

Lubarsch D. Ueber Gewebsembolieen und Gewebsverlagerun gen. *Verhandi Deutsch Pathol Gesell.* 1899; 1:97–103.

Malhi H, Annamaneni P, Slehria S. Cyclophosphamide disrupts hepatic sinusoidal endothelium and improves transplanted cell engraftment in rat liver. *Hepatology* 2002; 36:112–21.

Maruyama M, Totsugawa T, Kunieda T. Hepatocyte isolation and transplantation in the pig. *Cell Transplant*. 2003; 12:593–8.

Masubuchi Y, Sugiyama S, Horie T. Th1/Th2 cytokine balance as a determinant of acetaminophen-induced liver injury. *Chem. Biol. Interact*. 2009; 179:273–9.

Matas, Sutherland, Steffes. Hepatocellular transplantation for metabolic deficiencies: decrease of plasms bilirubin in Gunn rats. *Sci. New York N Y*. 1976; 192:892–4.

Meng F, Chen Z, Han M. Porcine hepatocyte isolation and reversible immortalization mediated by retroviral transfer and site-specific recombination. *World Journal of Gastroenterology* 2010; 16:1660–4.

Mitry R, Dhawan A, Hughes R. One liver, three recipients: segment IV from split-liver procedures as a source of hepatocytes for cell transplantation. *Transplantation* 2004; 77:1614–6.

Mitry R, Hughes R, Aw M. Human hepatocyte isolation and relationship of cell viability to early graft function. *Cell transplantation* 2003; 12:69–74.

Mitry R, Hughes R, Dhawan A. Progress in human hepatocytes: isolation, culture & cryopreservation. *Seminars in cell & developmental biology* 2002; 13:463–7.

Mohar I, Stamper BD, Rademacher PM. Acetaminophen-induced liver damage in mice is associated with gender-specific adduction of peroxiredoxin-6. *Redox Biol*. 2014; 2:377–87.

Mossanen JC, Tacke F. Acetaminophen-induced acute liver injury in mice. *Lab Anim*. 2015; 49:30–6.

Muraca M, Gerunda G, Neri D. Hepatocyte transplantation as a treatment for glycogen storage disease type 1a. *Lancet* 2002; 359:317–8.

Nagata H, Ito M, Cai J. Treatment of cirrhosis and liver failure in rats by hepatocyte xenotransplantation. *Gastroenterology* 2003a; 124:422–31.

Nagata H, Ito M, Shirota C. Route of hepatocyte delivery affects hepatocyte engraftment in the spleen1. *Transplantation* 2003b; 76:732.

Nakamura Y, Mizuguchi T, Tanimizu N. Preoperative hepatocyte transplantation improves the survival of rats with nonalcoholic steatohepatitis-related cirrhosis after partial hepatectomy. *Cell Transplant*. 2014; 23:1243–54.

Navarro-Alvarez N, Soto-Gutierrez A, Chen Y. Intramuscular transplantation of engineered hepatic tissue constructs corrects acute and chronic liver failure in mice. *J. Hepatol.* 2010; 52:211–9.

Navarro-Alvarez N, Yang Yongguang. Lack of CD47 on donor hepatocytes promotes innate immune cell activation and graft loss: a potential barrier to hepatocyte xenotransplantation. *Cell Transplant*. 2014; 23:345–54.

Oliva J, Bardag-Gorce F, French B. Fat10 is an epigenetic marker for liver preneoplasia in a drug-primed mouse model of tumorigenesis. *Experimental and molecular pathology* 2008; 84:102–12.

Pareja, Gomez-Lechon MJ, Cortes. Human Hepatocyte Transplantation in Patients with Hepatic Failure Awaiting a Graft. *Eur. Surg. Res*. 2013; 50:273–281.

Polgar Z, Li Y, Wang X Li. Gunn Rats as a Surrogate Model for Evaluation of Hepatocyte Transplantation-Based Therapies of Crigler-Najjar Syndrome Type 1. *Methods Mol. Biol*. 2017; 1506:131–147.

Powell-Braxton L, Véniant M, Latvala RD. A mouse model of human familial hypercholesterolemia: markedly elevated low density lipoprotein cholesterol levels and severe atherosclerosis on a low-fat chow diet. *Nat. Med*. 1998; 4:934–8.

Ribbert H. Uber Veranderungen transplantirten Gewebe. *Arch Entwickl. Mech. Organ*. 1898; 6:131–147.

Rhoades RA, Bell DR. *Medical Physiology Principles for Clinical Medicine* 2009; 3rd ed. Wolters Kluwer Lippincott Williams & Wilkins.

Ribes-Koninckx C, Ibars E, Agrasot M. Clinical outcome of hepatocyte transplantation in four pediatric patients with inherited metabolic diseases. *Cell transplantation* 2012; 21:2267–82.

Rugstad, Robinson, Yannoni, Tashjian. Transfer of bilirubin uridine diphosphate-glucuronyltransferase to enzyme-deficient rats. *Science* 1970; 170:553–5.

Seglen PO. Preparation of isolated rat liver cells. *Methods Cell Biol.* 1976; 13:29–83.

Severgnini M, Sherman J, Sehgal A. A rapid two-step method for isolation of functional primary mouse hepatocytes: cell characterization and asialoglycoprotein receptor based assay development. *Cytotechnology* 2012; 64:187–95.

Sewing S, Boess F, Moisan A. Establishment of a Predictive In Vitro Assay for Assessment of the Hepatotoxic Potential of Oligonucleotide Drugs. *PloS one* 2016; 11:e0159431.

Sgroi A, Mai G, Morel P. Transplantation of Encapsulated Hepatocytes During Acute Liver Failure Improves Survival Without Stimulating Native Liver Regeneration. *Cell Transplant.* 2011*;* 20:1791–1803(13).

Soltys KA, Setoyama K, Tafaleng EN. Host conditioning and rejection monitoring in hepatocyte transplantation in humans. *J. Hepatol.* 2017; 66(5):987−1000.

Soto-Gutiérrez A, Kobayashi N, Rivas-Carrillo JD. Reversal of mouse hepatic failure using an implanted liver-assist device containing ES cell-derived hepatocytes. *Nat. Biotechnol*. 2006; 24:1412–9.

Soto-Gutierrez A, Navarro-Alvarez N, Rivas-Carrillo JD. Construction and transplantation of an engineered hepatic tissue using a polyaminourethane-coated nonwoven polytetrafluoroethylene fabric. *Transplantation* 2007; 83:129–37.

St-Louis M, Tanguay RM. Mutations in the fumarylacetoacetate hydrolase gene causing hereditary tyrosinemia type I: overview. *Hum. Mutat.* 1997; 9:291–9.

Strom SC, Chowdhury JR, Fox IJ. Hepatocyte transplantation for the treatment of human disease. *Semin. Liver Dis.* 1999; 19:39–48.

Strom SC, Fisher RA, Thompson MT. Hepatocyte transplantation as a bridge to orthotopic liver transplantation in terminal liver failure. *Transplantation* 1997; 63:559–69.

Tanaka K, Kobayashi N, Gutierrez AS. Prolonged survival of mice with acute liver failure with transplantation of monkey hepatocytes cultured with an antiapoptotic pentapeptide V5. *Transplantation* 2006; 81:427–37.

Totsugawa T, Yong C, Rivas-Carrillo JD. Survival of liver failure pigs by transplantation of reversibly immortalized human hepatocytes with Tamoxifen-mediated self-recombination. *J Hepatol.* 2007; 47:74–82.

Viswanathan P, Gupta P, Kapoor S, Gupta S. Thalidomide promotes transplanted cell engraftment in the rat liver by modulating inflammation and endothelial integrity. *Journal of hepatology* 2016; 65:1171–1178.

Viswanathan P, Kapoor S, Kumaran V. Etanercept blocks inflammatory responses orchestrated by TNF-α to promote transplanted cell engraftment and proliferation in rat liver. *Hepatology* 2014; 60:1378–88.

Wang F, Zhou L, Ma X. Monitoring of intrasplenic hepatocyte transplantation for acute-on-chronic liver failure: a prospective five-year follow-up study. *Transplant Proc*. 2014; 46:192–8.

Yamamoto T, Navarro-Alvarez N, Soto-Gutierrez A. Treatment of acute liver failure in mice by hepatocyte xenotransplantation. *Cell Transplant*. 2010; 19:799–806.

Yoshida, Tokusashi, Lee, Ogawa. Intrahepatic transplantation of normal hepatocytes prevents Wilson's disease in Long-Evans cinnamon rats. *Gastroenterology* 1996; 111:1654–60.

Yuasa T, Yamamoto T, Rivas-Carrillo J. Laparoscopy-assisted creation of a liver failure model in pigs. *Cell transplantation* 2008; 17:187–93.

Zhang L, Shao Y, Li L. Efficient liver repopulation of transplanted hepatocyte prevents cirrhosis in a rat model of hereditary tyrosinemia type I. *Sci. Rep*. 2016; 6:31460.

In: Encyclopedia of Surgery (22 Volume Set)
Editors: Andreas Lehrer and Kristin Mueller
ISBN: 978-1-53618-329-0
© 2020 Nova Science Publishers, Inc.

Chapter 222

PRECLINICAL MODELS OF DECOMPRESSIVE CRANIECTOMY: LESSONS FROM EXPERIMENTAL TRAUMATIC BRAIN INJURY AND OTHER DISEASE MODELS

E. G. Hayman, M. J. Kole and J. M. Simard*
Department of Neurosurgery, University of Maryland Medical Center,
Baltimore, MD, US

ABSTRACT

Decompressive craniectomy represents an important surgical option to control intractable intracranial hypertension not responsive to maximal medical management, as recommended by the Guidelines for the Management of Severe Traumatic Brain Injury. Despite its technical simplicity, decompressive craniectomy initiates a wide variety of physiologic and histologic changes in the brain that remain poorly understood. Animal models of decompressive craniectomy have the potential to provide insight into the procedure. This chapter provides a critical overview of animal models of decompressive craniectomy in TBI and other conditions, highlighting several methodologic issues limiting animal studies of decompressive craniectomy in TBI in the current literature. In the context of these limitations, this chapter then discusses insights from animal models of craniectomy in TBI with regard to histologic and physiologic changes in the central nervous system.

Keywords: animal model, decompressive craniectomy, traumatic brain injury, edema

INTRODUCTION

Severe traumatic brain injury (TBI) encompasses a wide variety of pathological processes often progressing to the same end, namely elevation of intracranial pressure (ICP), and

* Corresponding Author's Email: msimard@som.umaryland.edu.

potentially herniation and death. Although a variety of medical therapies to control ICP exist, in cases of severe head injury, medical management may prove inadequate, leaving decompressive craniectomy (DC) as a therapeutic option of last resort [1]. Removing a large portion of the skull (but never half, as suggested by the misnomer "hemicraniectomy") and expanding the dura transforms the intracranial compartment from a closed anatomical space into an open one, preventing brainstem compression and allowing for survival. However, DC represents a major surgical intervention, with all the attendant risks and complications [1, 2]. Furthermore, craniectomy mandates a second surgery in survivors, cranioplasty, to restore an intact skull. Finally, the effects of DC following TBI remain poorly understood, and DC may initiate secondary pathologic processes, such as contusion expansion, which worsens outcome [1, 3].

Recent clinical work in DC in TBI emphasizes the shortcomings in our understanding of the physiological consequences of the procedure. Although one recent randomized controlled trial of DC for intracranial hypertension "refractory" to conventional therapies (RESCUEicp) demonstrated improved survival with DC, DC achieved this improved survival at the cost of increasing the number of vegetative and severely disabled patients [4]. Similarly, another trial of DC performed with a less stringent definition of "refractory" (DECRA) demonstrated *worse* neurological outcomes in patients [5]. The results of these trials suggest that: (a) DC as currently employed in the management of TBI has a relatively narrow therapeutic index; (b) the harms resulting from DC may reduce or counteract its benefits. If the latter were true, this would indicate that improvements in operative technique, perioperative management, and adjuvant therapies might expand its therapeutic benefits. As such, experimental models of DC represent a valuable adjunct for improving the care of patients with TBI. Unfortunately, despite the use of robust models of DC in animal studies of stroke, technical aspects of DC vary widely in animal studies of TBI. Besides these technical differences, studies of DC use time points and indications that may be irrelevant to clinical practice. As such, effective experimental study of DC for TBI is both needed and lacking. This review will attempt to summarize various animal models of DC in the literature, both in the context of TBI and more generally. Following this overview, the review will critically examine experimental conclusions regarding DC derived from animal models of TBI and other conditions.

MECHANISMS OF BRAIN SWELLING IN TBI

Although a full treatment of brain swelling following TBI extends well beyond the scope of this article, any discussion of DC in TBI merits at least brief discussion of the pathophysiology responsible for its need. For a full discussion of edema formation following brain injury, excellent reviews exist [6-8]. Several processes initiate brain swelling following TBI. Widespread metabolic failure and cell death can lead to ion channel dysfunction with cell swelling and, secondary to fluid and ion depletion from the interstitial space, creation of an ionic gradient with net fluid transfer from the intravascular to the interstitial compartments, a phenomenon termed *ionic edema*. Loss of blood-brain barrier (BBB) function may allow intravascular fluid to move along its hydrostatic gradient, resulting in so-called *vasogenic edema*. In an edema-independent context, loss of cerebrovascular autoregulation may induce widespread hyperemia and brain swelling prior to significant edema formation, a

phenomenon noted in severe pediatric TBI [9]. Although conceptually distinct, these processes likely occur concurrently after sufficiently severe brain injury.

TBI initiates widespread cell death and injury throughout the CNS through a variety of mechanisms, with the consequences of early cell swelling and ionic edema formation [10]. *In vitro* models of TBI demonstrate that mechanical stretch itself induces injury to cells of the CNS independent of other factors such as ischemia or hemorrhage [11, 12]. Following TBI, release of excitatory molecules such as glutamate results in neuronal excitotoxicity and cell death [13]. The hemorrhages resulting from trauma can yield a variety of toxic breakdown products, which injure surrounding cells [14]. TBI results in the accumulation of multiple cytotoxic pro-oxidant species, such as peroxynitrite [15]. TBI also induces a profound and long-lasting inflammatory response in the brain, serving to augment the secondary injury process [16]. Although neurons represent arguably the most well-studied CNS component vulnerable to injury following trauma, glial cells generally and astrocytes in particular form the cellular bulk of the CNS and may be the principal agents responsible for ionic edema following TBI [12]. Various studies implicate a number of pathologic channels in cytotoxic astrocyte swelling following TBI, including aquaporin-4 [17], the SUR1-TRPM4 non-specific cation channel [18, 19], and the sodium-potassium channel NKCC1 [20]. Ionic edema therefore represents a complex and multifactorial process following TBI.

A number of factors responsible for glial and neuronal injury following TBI also injure the endothelium. While injured astrocytes and neurons drive ionic edema following TBI, endothelial injury also contributes to ionic as well as vasogenic edema formation. Rapid and progressive BBB breakdown represents a common feature of a variety of experimental TBI models [21-24]. Aside from the cytotoxic processes discussed above, which mediate BBB disruption through endothelial cell death and swelling, other mechanisms unique to the endothelium mediate vasogenic edema formation. One notable mechanism, the downregulation of the tight junction proteins between endothelial cells, mediates BBB disruption in a variety of experimental TBI models [22, 25]. Inflammation, aside from direct effects on endothelial cells, also induces upregulation of proteinases such as matrix metalloproteinase 9 (MMP-9), leading to direct degradation of these tight junction proteins following TBI [26, 27]. Hemorrhagic progression of contusion, a common process following TBI, represents an extreme form of BBB disruption, wherein the same processes that undermine capillary integrity following TBI subsequently lead to disruption of the capillary itself with frank hemorrhage [28]. Although the pathologic channels previously discussed play a role in vasogenic edema formation as well as cytotoxic edema formation, these roles are not necessarily identical. Aquaporin-4, for example, mediates both ionic edema formation as well as clearance of vasogenic edema [29, 30].

Although edema and brain swelling are used interchangeably in clinical practice, compromise of autoregulation with concurrent hyperemia may result in significant brain swelling without edema formation [31, 32]. Moreover, failed autoregulation exacerbates vasogenic edema formation in the context of failed BBB due to a pathologic increase of intravascular hydrostatic pressure. As is characteristic of TBI, mechanisms for post-TBI hyperemia are diverse. Increased production of the vasodilator nitric oxide causes significant vasodilation of cerebral arteries and arterioles following TBI [33, 34]. Oxidative injury to vascular smooth muscle cells can lead to loss of gap junction function, with defective contractile responses [35]. Mechanical stretching of the vasculature itself can induce smooth muscle dysfunction and reduced contractility, a phenomenon that is dependent on purinergic

receptors [36]. While vasodilation and hyperemia may mediate brain swelling, this response is not always maladaptive, as the increased blood flow may also aid perfusion of ischemic brain following TBI, as evidenced by the neuroprotective effects of inhaled nitric oxide in murine TBI [37].

SURGICAL TECHNIQUE IN DECOMPRESSIVE CRANIECTOMY

Although a nuanced discussion of DC in humans lies beyond the scope of this chapter, several points related to the technique merit review to contextualize work with animal models. Broadly speaking, DC describes not one, but two procedures. Unilateral DC describes a large, usually 15x12 cm in diameter, opening centered over the frontoparietotemporal bones, with additional bone removal to decompress the middle cranial fossa. Bifrontal DC refers to a family of techniques whereby a surgeon removes a large portion of the bone overlying both frontal and temporal lobes, usually with removal of bone overlying the superior sagittal sinus, the latter at the surgeon's discretion. A dural opening (durotomy) typically accompanies craniectomy, as surgical relaxation of the dura accounts for a significant proportion of ICP reduction [38]. Although underemphasized, the wide middle fossa decompression accounts for a significant component of the decompression [39]. *Primary DC* refers to the use of DC as an adjunct to a primary procedure (such as subdural hematoma evacuation) and, in the case of TBI, usually occurs shortly after the initial injury. *Secondary DC*, in contrast, occurs in a delayed fashion to reduce elevated ICP refractory to medical management. Although surgeons employ both procedures in the management of TBI, only secondary DC has been the subject of high-quality randomized controlled trials [4, 5, 40].

ANIMAL MODELS OF DECOMPRESSIVE CRANIECTOMY: A CRITICAL OVERVIEW

Investigators have used several species to study DC, including cats, dogs, rats, and mice. Although studies of DC generally employ rat models, studies of DC in TBI frequently use mice; as such, a similar number of studies of DC in TBI exist for rats and mice. Although studies of DC in cats and dogs exist, their primary use has been the study of the physiologic effects of DC on normal brain [41-44]. The following section provides an overview of animal models of TBI from a critical perspective, specifically, how well they model the phenomenon they aim to study.

Rat Models of Decompressive Craniectomy

The rat has a number of advantages as an experimental model in neurosurgical research. While sufficiently insentient to avoid the ethical concerns that affect experiments on higher mammals, the rat is large enough to easily permit a number of surgical interventions and is of sufficient complexity to allow for relatively sophisticated neurobehavioral studies. Unsurprisingly, rat models of DC predominate in the experimental literature on DC. Although

one rat study evaluating the treatment of cerebral edema in fulminant hepatitis via DC describes a model with bifrontal DC [45], virtually all of the rat models of DC describe a unilateral approach. The majority of studies on DC in rats are in the context of stroke, usually some variant of middle cerebral artery occlusion [46-58]. Almost all of these stroke studies utilize a similar unilateral craniectomy size of ~50–60 mm^2 with additional temporal bone removal down to the middle fossa floor, followed by a cruciate durotomy without subsequent duraplasty. Although technically more complex than a simple craniectomy, these procedures accurately recapitulate the steps undertaken in DC in humans (Figure 1A).

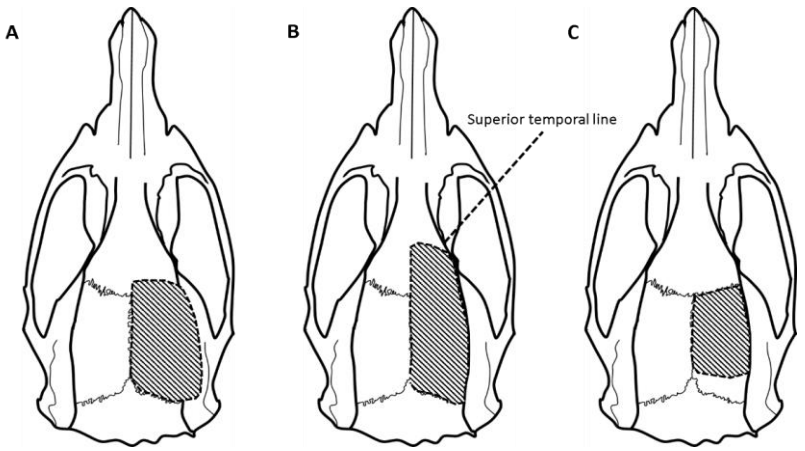

Figure 1. Decompressive craniectomy variations in rodent models. Three different models of rodent decompressive craniectomy as described in the literature. Dashed outlines depict borders of craniectomy. (A) Large craniectomy incorporating bone removal past the superior temporal line up to the middle cranial fossa, mimicking the procedure in humans [58]. (B) Large craniectomy incorporating ample bone removal, but without middle fossa decompression [64]. (C) Smaller craniectomy without significant bone removal or middle fossa decompression [80]. (Courtesy of J Marc Simard, University of Maryland).

Rat models for DC in TBI use variable craniectomies (Figure 1B–C) of slightly smaller dimensions (~40–55 mm^2), but strikingly, none of the models incorporate durotomy or middle fossa decompression, a significant deviation from both standard surgical practice and other disease models using DC in rats. While stroke models evaluate DC at a variety of time points, ranging from one hour to one day [50, 58], TBI models usually perform decompression within twenty minutes of injury, a time unlikely to be achieved in clinical practice short of a patient sustaining head trauma *en route* to the operating room. As such, experimental models of DC for the management of TBI in rats universally fail to evaluate clinically relevant scenarios with regard to both technique and timing, limiting the external validity of their results.

Mouse Models of Decompressive Craniectomy

Given the logistical advantages of a smaller mammal and the large number of transgenic variants, studies of DC underutilize mice. Nevertheless, in contrast to rat studies, the majority of murine models of DC focus on TBI. Furthermore, a significant proportion of these studies

incorporate both techniques and time points that more accurately mimic clinical applications of DC, although tremendous variation still exists. Although two murine studies of DC in TBI incorporate both temporal decompression and durotomy [59, 60], the remaining studies of TBI employ neither of these techniques [61, 62], with one study attempting to model DC via failure to replace a small craniectomy flap [62]. Similarly, time points of decompression vary among studies, with several murine studies incorporating clinically relevant, albeit early, time points [59-61]. The incorporation of clinically relevant timepoints and decompressive techniques in some murine studies increases their external validity, although, like rats, widespread variation of DC technique exists in murine TBI studies.

Higher Mammal Models of Decompressive Craniectomy

In contrast to rat and mouse studies of DC, no formal study of DC for TBI exists in higher order mammals. Two studies of DC in cats both examined the effects of DC on uninjured brain [43, 44]. Of note, both of these studies incorporated temporal decompression but avoided durotomy, limiting the clinical validity of these studies. Similarly, although studies of DC in dogs subjected to non-traumatic injury routinely employ durotomy [42, 63], the relative sizes of craniectomy employed may not accurately mimic DC in humans. Both the technical issues with the technique of DC itself and the absence of experimental studies of TBI in these models limit their applicability towards understanding the effects of DC on human TBI.

Animal Models of Decompressive Craniectomy in TBI: Experimental Results

Edema Formation

Cerebral edema formation is a pernicious secondary effect of brain injury due to trauma. DC potentially modulates edema formation through a variety of mechanisms. By increasing perfusion via a reduction in tissue pressure, DC may alleviate edema formation via reduced cell death, with a corresponding decrease in cellular swelling and ionic edema formation. Conversely, in the context of a failed BBB, DC may exacerbate edema formation by increasing the hydrostatic gradient between the vasculature and the parenchyma. Despite anecdotal clinical experience that occasionally supports the latter interpretation, several rodent studies suggest that the effects of DC on edema formation following TBI may be beneficial. One preclinical study employing a controlled cortical impact injury in rats found that DC shortly after injury reduced edema formation compared to rats undergoing closure of their defect, possibly due to a reduction in contusion volume in decompressed rats [64]. Another study employing a similar rat decompression model found both decreased expression of aquaporin-4, a molecule relevant to both edema formation and resolution, as well as decreased edema at 48 hours following injury [65]. Finally, a murine model of DC performed at different times following TBI found early, but not late, DC reduced edema formation following cortical impact injury [61]. Although these results suggest an anti-edema effect of

DC following TBI, all of these studies failed to use models of DC resembling actual surgical technique with regard to both subtemporal decompression and durotomy, while only one employed time points of DC of potential clinical relevance [61]. In contrast to the above studies, and in keeping with occasional anecdotal clinical experiences, two murine studies evaluating a clinically accurate model of DC at a clinically feasible, albeit very early, time both demonstrate worsening of edema with DC [59, 60]. Given the divergent effects of craniectomy without and with duraplasty on edema formation, one could speculate that the greater degree of decompression afforded by duraplasty exacerbates edema formation, perhaps through reduction of brain interstitial pressure and subsequent elevation of the vascular-interstitial hydrostatic pressure gradient. The absence of consistent ICP monitoring in the aforementioned studies precludes a firm conclusion. A direct evaluation of durotomy following craniectomy and its role in edema formation represents an intriguing and clinically relevant experimental question.

Hydrocephalus

Hydrocephalus can accompany DC, in both TBI and other conditions [66, 67]. Whether this relationship is causal remains unclear, as TBI can cause both ventriculomegaly and hydrocephalus without DC. As such, the occurrence of hydrocephalus following DC may reflect the severity of the initial injury, rather than a direct sequel of decompression [3]. Although animal studies provide an avenue to address this question, only one study to date does so. Employing a rat model of TBI, investigators evaluated the effect of DC on ventricular volume [68]. At one month following injury, the ventricular volumes of animals that underwent DC and their non-decompressed counterparts were equivalent. This relationship proved true for both sham and injured animals. Compellingly, all injured rats, regardless of decompression status, developed ventriculomegaly, suggesting that TBI itself mediates the observed hydrocephalus, rather than DC.

Contusion Volume

Traumatic contusions initiate complex molecular cascades ending with microvascular failure. They are prone to expansion and hemorrhagic progression, hence the term hemorrhagic progression of a contusion (HPC) [69]. In clinical practice, neurosurgeons express concern that the intentional reduction in tissue pressure induced by DC will predispose to HPC [70]. Whether the phenomenon of HPC occurs following DC is still a matter of debate, but several animal studies attempted to address this question. A single study in rats found that DC reduces contusion volume in animals injured by controlled cortical impact when performed twenty minutes after injury [64]. Another study employing mice noted a similar reduction in contusion expansion with DC following controlled cortical impact, although their DC method, consisting of a large bone flap created prior to injury followed by immediate replacement of the flap following injury in controls, raises concerns about the external validity of their results [71]. However, a separate evaluation by the same group found that craniectomy performed one and three hours after controlled cortical impact significantly reduced the contusion area; delay of craniectomy to eight hours significantly

attenuated this salutary effect [61]. None of these studies included formal durotomy as part of the experimental procedures. In contrast, a single TBI study in mice provides evidence that craniectomy causes increased contusion volume [60]. Notably, the authors performed DC with durotomy one hour following injury, with emphasis on decompression to the floor of the middle fossa, closely approximating early decompression in human patients. Although animal studies demonstrate conflicting results regarding the effect of DC on contusion volume, the negative effects of DC in the most clinically relevant model mandates further experimental work.

Effects of DC on Neuronal Injury in TBI

In murine TBI, craniectomy immediately prior to controlled cortical contusion without replacement of the bone flap resulted in less neuronal loss in pericontusional white matter and the CA3 region of the hippocampus one week after initial injury, when compared to replacement of the bone flap [62]. A second mouse study, using time points and techniques more analogous to human injury, showed opposite results. Animals subjected to closed head injury subsequently underwent decompression one hour after injury. One day after injury, animals in the DC group had gross necrosis of the hippocampus and additional new areas of hemorrhage remote from the injury, findings not observed in mice without DC [60]. As previously discussed, timing and technique may underlie these divergent results. Given that both increased edema and worse hemorrhage were concurrent findings in the latter study, DC may cause the observed increase in histologic injury by exacerbating failure of the BBB, although this mechanism remains speculative.

Animal Models of Decompressive Craniectomy in Other Disease Conditions

Ischemic Stroke

Outside of craniectomy for TBI, DC for large hemispheric infarction represents the most widely recognized indication for DC. Several studies have evaluated DC in various rat models of stroke. In contrast to TBI, the decompressive craniectomies used in rat stroke models consistently employ a large bone flap with subtemporal decompression and durotomy. Virtually all studies employing DC show a benefit with regard to survival and improved outcome in rats undergoing DC following large hemispheric infarction induced via middle cerebral artery or internal carotid artery occlusion, either with [49, 53] or without [50, 51, 55, 57, 58] subsequent reperfusion. Although prevention of brain injury secondary to herniation undoubtedly drives a large degree of the observed benefit, numerous experimental studies suggest that DC reduces infarct size following experimental stroke [53-55, 57, 58]. This neuroprotective aspect of DC in hemispheric infarction appears to be time dependent, with some studies suggesting that delay in decompression either attenuates [47] or eliminates [54] DC's ability to reduce infarct volumes. Mechanisms invoked to explain this observation include improved perfusion of the peri-infarct ischemic penumbra [53, 56], as well as

preservation of BBB integrity [47, 48]. Of note, DC does not seem to provide neuroprotective benefits in milder forms of stroke, as DC in smaller thromboembolic stroke fails to improve infarct volume [52], suggesting that DC prevents secondary compromise of blood flow due to brain swelling. In preclinical models evaluating DC in the context of other therapies, DC both proves superior to [48] and synergizes with [51] therapeutic hypothermia, a common neuroprotective modality. However, DC demonstrates inferior neuroprotective effects compared to glyburide [49], a promising anti-edema agent under current clinical evaluation in ischemic stroke [72]. In contrast to experimental TBI, rodent models of DC in stroke consistently demonstrate significant benefits to DC for space-occupying infarct while suggesting that, when warranted, early DC may potentially prevent secondary injury in the ischemic penumbra. As alternative therapies for post-ischemic swelling come into clinical use, future experimental work should focus on the precise role DC should play in an evolving clinical landscape.

Hemorrhagic Stroke

Compared to ischemic stroke, hemorrhagic stroke remains less studied from the standpoint of DC, reflecting perhaps the relative rarity of hemorrhagic stroke in humans, and the absent clinical consensus on the utility of DC in these conditions. Nevertheless, existing experimental studies of DC in hemorrhagic conditions provide several intriguing insights. Two studies to date evaluate DC in parenchymal intracerebral hemorrhage (ICH). One study evaluated DC with durotomy at various time points following autologous blood injection within the basal ganglia in rats to model the effects of DC on mortality and recovery following ICH [73]. Several insights emerge from this study. Perhaps least surprising, decompression reduced mortality and improved behavioral outcomes, consistent with the high rate of death due to herniation in the untreated rats in this model. More compelling, DC resulted in a reduction in final hematoma volume in surviving rats compared to non-decompressed controls. Although a theoretical risk of DC for ICH is loss of tamponade and hematoma expansion, these results argue against this hypothesis or at least argue that loss of tamponade matters less than the deleterious effects of localized edema and elevated intracranial pressure with regard to hematoma growth and reabsorption. Evaluation of edema in this model did note worsening hemispheric expansion following DC, although the high mortality in rats not undergoing DC undoubtedly confounds these results, as DC allows rats with significant swelling to survive an otherwise fatal event. A similar study evaluating DC shortly after collagenase-induced ICH in mice reported similar findings, with a significant reduction in mortality without a significant effect on hematoma volume in the craniectomy group [74].

In contrast to intraparenchymal hemorrhage, the admittedly limited experimental literature argues against early DC in subarachnoid hemorrhage (SAH), with only a single study to date evaluating its effects [75]. Using a murine endovascular perforation model, the authors performed DC either immediately prior to or immediately after induction of hemorrhage. Several compelling results emerge from their study. Although DC reduces ICP following SAH, these improvements in pressure do not yield improved cerebral blood flow, suggesting that microvascular failure, rather than elevated ICP, underlies post-hemorrhage hypoperfusion. Furthermore, elevated ICP apparently exerts a beneficial effect in this model

secondary to pseudo-aneurysm tamponade and prevention of rebleeding events, which frequently occurred in the pre-hemorrhage DC cohort. Consistent with an absence of beneficial effects in this model, surviving mice exposed to DC demonstrated worse behavioral and survival outcomes, especially those undergoing DC prior to SAH-induction. Finally, consistent with other studies, DC did not appear to induce ventriculomegaly. Although several case series argue for the beneficial effects of DC in SAH [76, 77], the existing experimental data suggest a cautious interpretation of these results.

Other Models of Brain Edema

Several animal models of DC have studied the procedure in the context of experimental cerebral edema outside of traditional neurosurgical conditions, whether in models of purely experimental edema such as cryoischemia or medical conditions such as acute liver failure. One study of bilateral DC in experimental galactosamine-induced liver failure found a significant survival benefit to DC versus non-operative management or cerebrospinal fluid drainage, suggesting that DC may serve as a bridge to transplant in liver failure patients [45]. While the aforementioned study provided little insight into the effects of DC, several animal models using highly artificial or, in some cases, no brain injury nevertheless provide important insight into the effects of DC. In larger animals, several studies suggest that DC either fails to improve or exacerbates underlying brain injury. An early study comparing DC to necrotic tissue resection in a cat model of cryoischemia-induced brain edema found that only resection of edematous tissue halted the progression of edema and subsequent metabolic evidence of brain injury [78]. A similar model in rabbits confirmed that DC had little effect on edema progression but did demonstrate a benefit with regard to brain perfusion [79]. In contrast, a study of DC following cryoischemia in dogs noted a nearly seven-fold increase in edema because of decompression, suggesting that DC can potentially worsen brain injury [41]. Furthermore, studies of DC in uninjured cats suggest a paradoxical reduction in brain perfusion following DC [43]. Although these studies rely on highly artificial experimental models, they nevertheless suggest that DC has important pathophysiological consequences that might escape notice in routine clinical practice.

CONCLUSION

The paucity and inconsistency of DC as used in rodent models of TBI reflects an important experimental gap in the scientific literature. Although certain studies do demonstrate functional and histologic benefits to DC following experimental TBI, both important technical variations from clinical practice and use of clinically unachievable time points for DC limit generalization of these conclusions. Future research in the field of DC should focus on its effects using clinically relevant DC techniques and time points, as is the case with experimental work on DC in stroke. Given both the apparent narrow therapeutic index of DC and the profound physiologic changes it induces, a better understanding of its effects on the pathophysiology of TBI may greatly augment its utility.

REFERENCES

[1] Aarabi B, Hesdorffer DC, Ahn ES, Aresco C, Scalea TM, Eisenberg HM. Outcome following decompressive craniectomy for malignant swelling due to severe head injury. *J Neurosurg*. 2006;104(4):469-79.

[2] Kurland DB, Khaladj-Ghom A, Stokum JA, Carusillo B, Karimy JK, Gerzanich V, et al. Complications associated with decompressive craniectomy: a systematic review. *Neurocrit Care*. 2015;23(2):292-304.

[3] Hayman EG, Kurland DB, Grunwald Z, Urday S, Sheth KN, Simard JM. Decompressive Craniectomy in Neurocritical Care. *Semin Neurol*. 2016;36(6):508-19.

[4] Hutchinson PJ, Kolias AG, Timofeev IS, Corteen EA, Czosnyka M, Timothy J, et al. Trial of decompressive craniectomy for traumatic intracranial hypertension. *N Engl J Med.* 2016;375(12):1119-30.

[5] Cooper DJ, Rosenfeld JV, Murray L, Arabi YM, Davies AR, D'Urso P, et al. Decompressive craniectomy in diffuse traumatic brain injury. *N Engl J Med.* 2011;364(16):1493-502.

[6] Stokum JA, Gerzanich V, Simard JM. Molecular pathophysiology of cerebral edema. *J Cereb Blood Flow Metab*. 2016;36(3):513-38.

[7] Simard JM, Kahle KT, Gerzanich V. Molecular mechanisms of microvascular failure in central nervous system injury--synergistic roles of NKCC1 and SUR1/TRPM4. *J Neurosurg*. 2010;113(3):622-9.

[8] Simard JM, Kent TA, Chen M, Tarasov KV, Gerzanich V. Brain oedema in focal ischaemia: molecular pathophysiology and theoretical implications. *Lancet Neurol.* 2007;6(3):258-68.

[9] Bruce DA, Alavi A, Bilaniuk L, Dolinskas C, Obrist W, Uzzell B. Diffuse cerebral swelling following head injuries in children: the syndrome of "malignant brain edema." *J Neurosurg*. 1981;54(2):170-8.

[10] Marmarou A, Signoretti S, Fatouros PP, Portella G, Aygok GA, Bullock MR. Predominance of cellular edema in traumatic brain swelling in patients with severe head injuries. *J Neurosurg*. 2006;104(5):720-30.

[11] Morrison B, 3rd, Cater HL, Benham CD, Sundstrom LE. An in vitro model of traumatic brain injury utilising two-dimensional stretch of organotypic hippocampal slice cultures. *J Neurosci Methods.* 2006;150(2):192-201.

[12] Jayakumar AR, Tong XY, Ruiz-Cordero R, Bregy A, Bethea JR, Bramlett HM, et al. Activation of NF-kappaB mediates astrocyte swelling and brain edema in traumatic brain injury. *J Neurotrauma*. 2014;31(14):1249-57.

[13] Gao Y, Xu S, Cui Z, Zhang M, Lin Y, Cai L, et al. Mice lacking glutamate carboxypeptidase II develop normally, but are less susceptible to traumatic brain injury. *J Neurochem*. 2015;134(2):340-53.

[14] Okubo S, Xi G, Keep RF, Muraszko KM, Hua Y. Cerebral hemorrhage, brain edema, and heme oxygenase-1 expression after experimental traumatic brain injury. *Acta Neurochir Suppl*. 2013;118:83-7.

[15] Khan M, Dhammu TS, Matsuda F, Annamalai B, Dhindsa TS, Singh I, et al. Targeting the nNOS/peroxynitrite/calpain system to confer neuroprotection and aid functional recovery in a mouse model of TBI. *Brain Res*. 2016;1630:159-70.

[16] Loane DJ, Kumar A, Stoica BA, Cabatbat R, Faden AI. Progressive neurodegeneration after experimental brain trauma: association with chronic microglial activation. *J Neuropathol Exp Neurol*. 2014;73(1):14-29.

[17] Yao X, Uchida K, Papadopoulos MC, Zador Z, Manley GT, Verkman AS. Mildly reduced brain swelling and improved neurological outcome in aquaporin-4 knockout mice following controlled cortical impact brain injury. *J Neurotrauma.* 2015;32(19):1458-64.

[18] Chen M, Dong Y, Simard JM. Functional coupling between sulfonylurea receptor type 1 and a nonselective cation channel in reactive astrocytes from adult rat brain. *J Neurosci.* 2003;23(24):8568-77.

[19] Zweckberger K, Hackenberg K, Jung CS, Hertle DN, Kiening KL, Unterberg AW, et al. Glibenclamide reduces secondary brain damage after experimental traumatic brain injury. *Neuroscience.* 2014;272:199-206.

[20] Jayakumar AR, Panickar KS, Curtis KM, Tong XY, Moriyama M, Norenberg MD. Na-K-Cl cotransporter-1 in the mechanism of cell swelling in cultured astrocytes after fluid percussion injury. *J Neurochem.* 2011;117(3):437-48.

[21] Dash PK, Zhao J, Kobori N, Redell JB, Hylin MJ, Hood KN, et al. Activation of alpha 7 cholinergic nicotinic receptors reduce blood-brain barrier permeability following experimental traumatic brain injury. *J Neurosci.* 2016;36(9):2809-18.

[22] Lucke-Wold BP, Logsdon AF, Smith KE, Turner RC, Alkon DL, Tan Z, et al. Bryostatin-1 restores blood brain barrier integrity following blast-induced traumatic brain injury. *Mol Neurobiol*. 2015;52(3):1119-34.

[23] Gao W, Zhao Z, Yu G, Zhou Z, Zhou Y, Hu T, et al. VEGI attenuates the inflammatory injury and disruption of blood-brain barrier partly by suppressing the TLR4/NF-kappaB signaling pathway in experimental traumatic brain injury. *Brain Res.* 2015;1622:230-9.

[24] Rossi JL, Todd T, Daniels Z, Bazan NG, Belayev L. Interferon-stimulated gene 15 upregulation precedes the development of blood-brain barrier disruption and cerebral edema after traumatic brain injury in young mice. *J Neurotrauma.* 2015;32(14):1101-8.

[25] Thal SC, Luh C, Schaible EV, Timaru-Kast R, Hedrich J, Luhmann HJ, et al. Volatile anesthetics influence blood-brain barrier integrity by modulation of tight junction protein expression in traumatic brain injury. *PLoS One*. 2012;7(12):e50752.

[26] Cao F, Jiang Y, Wu Y, Zhong J, Liu J, Qin X, et al. Apolipoprotein E-mimetic COG1410 reduces acute vasogenic edema following traumatic brain injury. *J Neurotrauma.* 2016;33(2):175-82.

[27] Muradashvili N, Benton RL, Saatman KE, Tyagi SC, Lominadze D. Ablation of matrix metalloproteinase-9 gene decreases cerebrovascular permeability and fibrinogen deposition post traumatic brain injury in mice. *Metab Brain Dis.* 2015;30(2):411-26.

[28] Simard JM, Kilbourne M, Tsymbalyuk O, Tosun C, Caridi J, Ivanova S, et al. Key role of sulfonylurea receptor 1 in progressive secondary hemorrhage after brain contusion. *J Neurotrauma*. 2009;26(12):2257-67.

[29] Verkman AS, Binder DK, Bloch O, Auguste K, Papadopoulos MC. Three distinct roles of aquaporin-4 in brain function revealed by knockout mice. *Biochim Biophys Acta.* 2006;1758(8):1085-93.

[30] Zhang C, Chen J, Lu H. Expression of aquaporin-4 and pathological characteristics of brain injury in a rat model of traumatic brain injury. *Mol Med Rep.* 2015;12(5):7351-7.

[31] Martin NA, Patwardhan RV, Alexander MJ, Africk CZ, Lee JH, Shalmon E, et al. Characterization of cerebral hemodynamic phases following severe head trauma: hypoperfusion, hyperemia, and vasospasm. *J Neurosurg.* 1997;87(1):9-19.

[32] Kelly DF, Kordestani RK, Martin NA, Nguyen T, Hovda DA, Bergsneider M, et al. Hyperemia following traumatic brain injury: relationship to intracranial hypertension and outcome. *J Neurosurg*. 1996;85(5):762-71.

[33] Golding EM, Steenberg ML, Cherian L, Marrelli SP, Robertson CS, Bryan RM, Jr. Endothelial-mediated dilations following severe controlled cortical impact injury in the rat middle cerebral artery. *J Neurotrauma*. 1998;15(8):635-44.

[34] Villalba N, Sonkusare SK, Longden TA, Tran TL, Sackheim AM, Nelson MT, et al. Traumatic brain injury disrupts cerebrovascular tone through endothelial inducible nitric oxide synthase expression and nitric oxide gain of function. *J Am Heart Assoc.* 2014;3(6):e001474.

[35] Yu GX, Mueller M, Hawkins BE, Mathew BP, Parsley MA, Vergara LA, et al. Traumatic brain injury in vivo and in vitro contributes to cerebral vascular dysfunction through impaired gap junction communication between vascular smooth muscle cells. *J Neurotrauma.* 2014;31(8):739-48.

[36] Luo W, Guth CM, Jolayemi O, Duvall CL, Brophy CM, Cheung-Flynn J. Subfailure Overstretch Injury Leads to Reversible Functional Impairment and Purinergic P2X7 Receptor Activation in Intact Vascular Tissue. *Front Bioeng Biotechnol*. 2016;4:75.

[37] Terpolilli NA, Kim SW, Thal SC, Kuebler WM, Plesnila N. Inhaled nitric oxide reduces secondary brain damage after traumatic brain injury in mice. *J Cereb Blood Flow Metab*. 2013;33(2):311-8.

[38] Burger R, Duncker D, Uzma N, Rohde V. Decompressive craniotomy: durotomy instead of duroplasty to reduce prolonged ICP elevation. *Acta Neurochir Suppl*. 2008;102:93-7.

[39] Munch E, Horn P, Schurer L, Piepgras A, Paul T, Schmiedek P. Management of severe traumatic brain injury by decompressive craniectomy. *Neurosurgery.* 2000;47(2):315-22; discussion 22-3.

[40] Taylor A, Butt W, Rosenfeld J, Shann F, Ditchfield M, Lewis E, et al. A randomized trial of very early decompressive craniectomy in children with traumatic brain injury and sustained intracranial hypertension. *Childs Nerv Syst*. 2001;17(3):154-62.

[41] Cooper PR, Hagler H, Clark WK, Barnett P. Enhancement of experimental cerebral edema after decompressive craniectomy: implications for the management of severe head injuries. *Neurosurgery*. 1979;4(4):296-300.

[42] Bagley RS, Harrington ML, Pluhar GE, Keegan RD, Greene SA, Moore MP, et al. Effect of craniectomy/durotomy alone and in combination with hyperventilation, diuretics, and corticosteroids on intracranial pressure in clinically normal dogs. *Am J Vet Res.* 1996;57(1):116-9.

[43] Schaller B, Graf R, Sanada Y, Wienhard K, Heiss WD. Decompressive hemicraniectomy in a new cat model. Methodological description of the PET study protocol. *Brain Res Brain Res Protoc*. 2004;12(3):125-31.

[44] Schaller B, Graf R, Sanada Y, Rosner G, Wienhard K, Heiss WD. Hemodynamic and metabolic effects of decompressive hemicraniectomy in normal brain. An experimental PET-study in cats. *Brain Res*. 2003;982(1):31-7.

[45] Yamamoto S, Steers JL, Wharen RE, Jr., Eckman CB, Nguyen JH. Cerebrospinal fluid drainage and cranial decompression prolong survival in rats with fulminant hepatic failure. *Transpl Int.* 2006;19(8):675-82.

[46] Calikoglu C, Akgul MH, Akgul O, Karatas A. Effects of decompressive craniectomy, hypertonic saline solution and mannitol on an experimental model of cerebral ischemia. *Ulus Travma Acil Cerrahi Derg*. 2015;21(6):425-31.

[47] Altintas O, Antar V, Baran O, Karatas E, Altintas MO, Kesgin S, et al. Neuroprotective effects of hemicraniectomy in malign middle cerebral artery infarctions: experimental study. *J Neurosurg Sci.* 2015.

[48] Allahtavakoli M, Kahnouei MH, Rezazadeh H, Roohbakhsh A, Mahmoodi MH, Moghadam-Ahmadi A, et al. Delayed combination therapy of local brain hypothermia and decompressive craniectomy on acute stroke outcome in rat. *Iran J Basic Med Sci*. 2014;17(7):476-82.

[49] Simard JM, Tsymbalyuk N, Tsymbalyuk O, Ivanova S, Yurovsky V, Gerzanich V. Glibenclamide is superior to decompressive craniectomy in a rat model of malignant stroke. *Stroke*. 2010;41(3):531-7.

[50] Zhao Z, Yu J, Liao S, Xiong L, Liang Z, Ling L, et al. Delayed decompressive craniectomy improves the long-term outcomes in hypertensive rats with space-occupying cerebral infarction. *Neurocrit Care.* 2007;7(3):263-9.

[51] Jieyong B, Zhong W, Shiming Z, Dai Z, Kato Y, Kanno T, et al. Decompressive craniectomy and mild hypothermia reduces infarction size and counterregulates Bax and Bcl-2 expression after permanent focal ischemia in rats. *Neurosurg Rev*. 2006;29(2):168-72.

[52] Engelhorn T, Heiland S, Schabitz WR, Schwab S, Busch E, Forsting M, et al. Decompressive craniectomy in acute cerebral ischemia in rats. Is there any benefit in smaller thromboembolic infarcts? *Neurosci Lett.* 2004;370(2-3):85-90.

[53] Engelhorn T, Doerfler A, de Crespigny A, Beaulieu C, Forsting M, Moseley ME. Multilocal magnetic resonance perfusion mapping comparing the cerebral hemodynamic effects of decompressive craniectomy versus reperfusion in experimental acute hemispheric stroke in rats. *Neurosci Lett*. 2003;344(2):127-31.

[54] Doerfler A, Engelhorn T, Heiland S, Benner T, Forsting M. Perfusion- and diffusion-weighted magnetic resonance imaging for monitoring decompressive craniectomy in animals with experimental hemispheric stroke. *J Neurosurg*. 2002;96(5):933-40.

[55] Doerfler A, Schwab S, Hoffmann TT, Engelhorn T, Forsting M. Combination of decompressive craniectomy and mild hypothermia ameliorates infarction volume after permanent focal ischemia in rats. *Stroke.* 2001;32(11):2675-81.

[56] Engelhorn T, Doerfler A, Kastrup A, Beaulieu C, de Crespigny A, Forsting M, et al. Decompressive craniectomy, reperfusion, or a combination for early treatment of acute “malignant” cerebral hemispheric stroke in rats? Potential mechanisms studied by MRI. *Stroke*. 1999;30(7):1456-63.

[57] Doerfler A, Forsting M, Reith W, Staff C, Heiland S, Schabitz WR, et al. Decompressive craniectomy in a rat model of "malignant" cerebral hemispheric stroke: experimental support for an aggressive therapeutic approach. *J Neurosurg.* 1996;85(5):853-9.

[58] Forsting M, Reith W, Schabitz WR, Heiland S, von Kummer R, Hacke W, et al. Decompressive craniectomy for cerebral infarction. An experimental study in rats. *Stroke*. 1995;26(2):259-64.

[59] Szczygielski J, Mautes AE, Schwerdtfeger K, Steudel WI. The effects of selective brain hypothermia and decompressive craniectomy on brain edema after closed head injury in mice. *Acta Neurochir Suppl*. 2010;106:225-9.

[60] Szczygielski J, Mautes AE, Muller A, Sippl C, Glameanu C, Schwerdtfeger K, et al. Decompressive craniectomy increases brain lesion volume and exacerbates functional impairment in closed head injury in mice. *J Neurotrauma*. 2016;33(1):122-31.

[61] Zweckberger K, Eros C, Zimmermann R, Kim SW, Engel D, Plesnila N. Effect of early and delayed decompressive craniectomy on secondary brain damage after controlled cortical impact in mice. *J Neurotrauma.* 2006;23(7):1083-93.

[62] Friess SH, Lapidus JB, Brody DL. Decompressive craniectomy reduces white matter injury after controlled cortical impact in mice. *J Neurotrauma.* 2015;32(11):791-800.

[63] Salvatore C, Fabrice V, Marco M, Leonardo T, Thomas L, Benoit L, et al. The "Skull Flap" a new conceived device for decompressive craniectomy experimental study on dogs to evaluate the safety and efficacy in reducing intracranial pressure and subsequent impact on brain perfusion. *J Neurosci Rural Pract.* 2013;4(4):421-6.

[64] Tian R, Han L, Hou Z, Hao S, Mao X, Zhu Z, et al. Neuroprotective efficacy of decompressive craniectomy after controlled cortical impact injury in rats: An MRI study. *Brain Res*. 2015;1622:339-49.

[65] Tomura S, Nawashiro H, Otani N, Uozumi Y, Toyooka T, Ohsumi A, et al. Effect of decompressive craniectomy on aquaporin-4 expression after lateral fluid percussion injury in rats. *J Neurotrauma*. 2011;28(2):237-43.

[66] Waziri A, Fusco D, Mayer SA, McKhann GM, 2nd, Connolly ES, Jr. Postoperative hydrocephalus in patients undergoing decompressive hemicraniectomy for ischemic or hemorrhagic stroke. *Neurosurgery*. 2007;61(3):489-93; discussion 93-4.

[67] De Bonis P, Pompucci A, Mangiola A, Rigante L, Anile C. Post-traumatic hydrocephalus after decompressive craniectomy: an underestimated risk factor. *J Neurotrauma.* 2010;27(11):1965-70.

[68] Takeuchi S, Nagatani K, Wada K, Nawashiro H, Otani N, Osada H, et al. Is decompressive craniectomy a risk factor for ventriculomegaly? *Acta Neurochir* Suppl. 2013;118:281-3.

[69] Kurland D, Hong C, Aarabi B, Gerzanich V, Simard JM. Hemorrhagic progression of a contusion after traumatic brain injury: a review. *J Neurotrauma*. 2012;29 (1):19-31.

[70] Flint AC, Manley GT, Gean AD, Hemphill JC, 3rd, Rosenthal G. Post-operative expansion of hemorrhagic contusions after unilateral decompressive hemicraniectomy in severe traumatic brain injury. *J Neurotrauma*. 2008;25(5):503-12.

[71] Zweckberger K, Stoffel M, Baethmann A, Plesnila N. Effect of decompression craniotomy on increase of contusion volume and functional outcome after controlled cortical impact in mice. *J Neurotrauma*. 2003;20(12):1307-14.

[72] Sheth KN, Elm JJ, Molyneaux BJ, Hinson H, Beslow LA, Sze GK, et al. Safety and efficacy of intravenous glyburide on brain swelling after large hemispheric infarction (GAMES-RP): a randomised, double-blind, placebo-controlled phase 2 trial. *Lancet Neurol*. 2016;15(11):1160-9.

[73] Marinkovic I, Strbian D, Pedrono E, Vekovischeva OY, Shekhar S, Durukan A, et al. Decompressive craniectomy for intracerebral hemorrhage. *Neurosurgery*. 2009;65(4):780-6, 1 p following 6; discussion 6.

[74] Omary R, Chernoguz D, Lasri V, Leker RR. Decompressive hemicraniectomy reduces mortality in an animal model of intracerebral hemorrhage. *J Mol Neurosci.* 2013;49 (1):157-61.

[75] Buhler D, Azghandi S, Schuller K, Plesnila N. Effect of decompressive craniectomy on outcome following subarachnoid hemorrhage in mice. *Stroke.* 2015;46(3):819-26.

[76] Guresir E, Schuss P, Vatter H, Raabe A, Seifert V, Beck J. Decompressive craniectomy in subarachnoid hemorrhage. *Neurosurg Focus*. 2009;26(6):E4.

[77] Otani N, Takasato Y, Masaoka H, Hayakawa T, Yoshino Y, Yatsushige H, et al. Surgical outcome following decompressive craniectomy for poor-grade aneurysmal subarachnoid hemorrhage in patients with associated massive intracerebral or Sylvian hematomas. *Cerebrovasc Dis*. 2008;26(6):612-7.

[78] Gaab M, Knoblich OE, Fuhrmeister U, Pflughaupt KW, Dietrich K. Comparison of the effects of surgical decompression and resection of local edema in the therapy of experimental brain trauma. Investigation of ICP, EEG and cerebral metabolism in cats. *Childs Brain.* 1979;5(5):484-98.

[79] Rinaldi A, Mangiola A, Anile C, Maira G, Amante P, Ferraresi A. Hemodynamic effects of decompressive craniectomy in cold induced brain oedema. *Acta Neurochir Suppl* (Wien). 1990;51:394-6.

[80] Wu JC, Chen KY, Yo YW, Huang SW, Shih HM, Chiu WT, et al. Different sham procedures for rats in traumatic brain injury experiments induce corresponding increases in levels of trauma markers. *J Surg Res*. 2013;179(1):138-44.

In: Encyclopedia of Surgery (22 Volume Set)
Editors: Andreas Lehrer and Kristin Mueller
ISBN: 978-1-53618-329-0
© 2020 Nova Science Publishers, Inc.

Chapter 223

IMPAIRED CEREBRAL ENERGY METABOLISM FOLLOWING TRAUMATIC BRAIN INJURY CONTRIBUTES TO POOR OUTCOMES AND LIMITS THE EFFECTIVENESS OF DECOMPRESSIVE CRANIECTOMY

Courtney L. Robertson[1], MD and Gary M. Fiskum[2,*], PhD
[1]Department of Anesthesiology and Critical Care Medicine,
Johns Hopkins University School of Medicine, Baltimore, MD, US
[2]Department of Anesthesiology, University of Maryland School of Medicine,
Baltimore, MD, US

ABSTRACT

When therapeutically effective, decompressive craniectomy typically reduces intracerebral pressure, improves cerebral blood flow and tissue oxygenation, and increases aerobic cerebral energy metabolism. The efficacy of craniectomy following traumatic brain injury may at times be limited by damage to mitochondrial oxidative phosphorylation proteins that occurs prior to surgery. Moreover, when the craniectomy stimulates reperfusion following even partial ischemia, secondary mechanisms of injury to metabolism and other activities may be activated, thereby defeating the purpose. This chapter reviews the evidence for a causative role of mitochondrial and metabolic dysfunction in poor outcomes following traumatic brain injury. An appraisal of the literature devoted to decompressive craniectomy reveals a scarcity of studies that assess the role of cerebral energy metabolism in the success or failure of craniectomies. A case is made for much more research testing combinations of decompressive craniectomy with other neuroprotective interventions, particularly those that improve brain energy metabolism and are effective in animal models of cerebral ischemia/reperfusion.

Keywords: mitochondria, calcium, ischemia, reperfusion, oxidative stress, edema

[*] Corresponding Author's Email: gfiskum@som.umaryland.edu.

INTRODUCTION

The normal adult human brain consumes up to 20% of all energy produced by the body. A large portion of this energy (~50%) is used for synaptic activity, with the rest of the energy directed at maintaining ionic gradients and biosynthesis, as reviewed in [1]. Neurons consume the vast majority of energy, with glial cells accounting for only ~10% of consumed energy [2]. The obligate fuel source for the brain is glucose, with a normal brain consuming ~120 g/day. However, in special circumstances, e.g., starvation, the brain can utilize alternative fuels, such as ketone bodies [1].

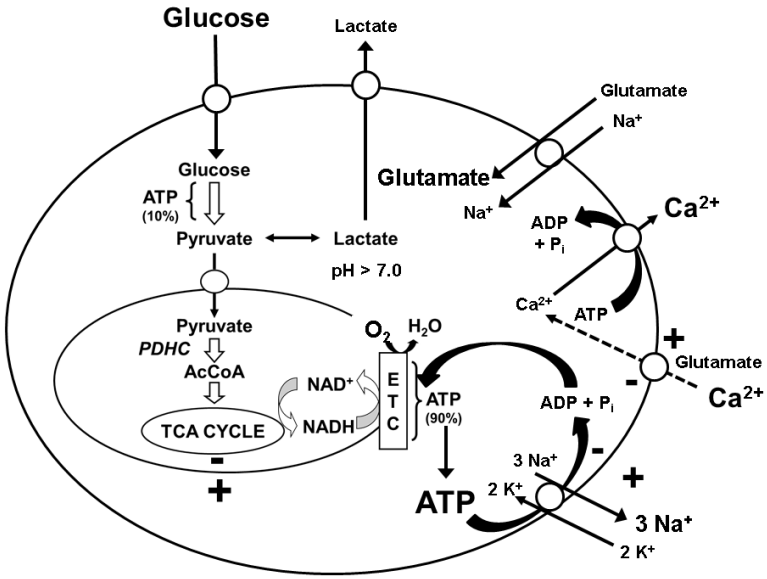

Figure 1. Normal neuronal energy metabolism and transmembrane ionic fluxes. Approximately 90% of ATP production by healthy neurons is generated by mitochondrial oxidative phosphorylation compared to 10% by glycolysis. Lactate is higher in the brain than most other tissues and can be both produced and utilized by neurons. Oxidative phosphorylation requires the continuous availability of oxidizable substrates, e.g., pyruvate, proper functioning of the pyruvate dehydrogenase complex (PDHC), the tricarboxylic acid (TCA) cycle, the electron transport chain (ETC), and the ATP synthase (not shown). ATP is used for many energy-requiring activities, including the plasma membrane sodium/potassium ATPase, which is necessary to maintain the cellular membrane potential and the sodium gradient, which provides the driving force for the uptake of glucose and for glutamate through sodium cotransporters. ATP is also necessary to actively pump calcium out of the cell, which allows for physiologic intracellular calcium signaling when calcium enters the cell through both voltage dependent and ligand gated calcium channels (dashed line).

Glucose is transported across the blood brain barrier and into cells via the GLUT transporters, where it then undergoes glycolysis, ending in the production of pyruvate. Pyruvate is then converted into acetyl-CoA by the mitochondrial enzyme, pyruvate dehydrogenase complex (PDHC). Therefore, PDHC is the important bridge between anaerobic (glycolysis) and aerobic (Krebs cycle) metabolism (Figure 1). In the presence of mitochondrial dysfunction, such as due to reduced PDHC activity, the production of lactate from pyruvate is accelerated, while conversion to acetyl-CoA is depressed. Acetyl-CoA brings acetyl units into the Krebs cycle, where they are oxidized into CO_2, with electrons

transferred to NAD^+ and FAD, forming NADH and $FADH_2$. The electrons from NADH and $FADH_2$ are then transferred to molecular oxygen, through a series of electron carriers in the mitochondrial electron transport chain. Ultimately, the energy produced by this process is used to make ATP by the process known as oxidative phosphorylation. Specifically, the movement of electrons down the electron transport chain pumps protons out of the mitochondrial matrix, creating a proton gradient. Protons then flow back into the mitochondrial matrix through the FoF1 ATP synthase complex, and ATP is generated.

After traumatic brain injury (TBI), many of these pathways can become disrupted or inhibited, resulting in altered cerebral energy metabolism. Lactate production can increase significantly after TBI, even in the presence of normal cerebral blood flow (CBF) and oxygenation [3, 4]. This tissue lactic acidosis is primarily due to mitochondrial dysfunction, and has been demonstrated in multiple animal studies and in humans [5]. The following sections summarize alterations in cerebral energy metabolism and mitochondrial function that occur after TBI.

TRAUMATIC BRAIN INJURY AND CEREBRAL ENERGY METABOLISM

Severe TBI stimulates many pathologic cascades in the injured brain, ultimately leading to cell death. One of the key cascades involves alterations in cerebral energy metabolism, which can begin very early after injury (minutes) and persist for days or weeks [6]. Altered brain metabolism has been identified in both animal models and clinical studies of TBI. Initial experimental work in the fluid percussion model of TBI used [^{14}C]2-deoxy-D-glucose autoradiography to demonstrate early (<1 hour) increases in glycolysis, followed by longer periods (hours to days) of metabolic depression [6-8]. These post-injury alterations in cerebral metabolism may be age-dependent. Studies in adult rats showed that the period of posttraumatic metabolic depression lasted 2 to 4 weeks [7], while correlative studies in pediatric models, using immature rats (postnatal day [PND] 17), showed a much shorter period of metabolic depression, with local cerebral metabolic rate for glucose (CMRglc) recovering by 3 days after injury [9]. Importantly, using the fluid percussion injury model of TBI in immature (PND 17, PND 28) and adult rats, investigators found that the temporal pattern of learning deficits closely mirrored the temporal pattern of depressed brain metabolism [10]. Details of the complex neurochemistry and metabolism following TBI are summarized in a review by Hovda et al. [6].

Clinical studies have shown similar posttraumatic alterations in cerebral metabolism [11]. Early studies used fluorodeoxyglucose positron emission tomography (FDG-PET) imaging to evaluate cerebral hyperglycolysis in 28 severely head-injured adults [12]. They found that 56% of these TBI patients had evidence of cerebral hyperglycolysis in the first week after injury [12]. Other groups have used FDG-PET and brain microdialysis to confirm this early increase in brain glucose utilization [13]. Also, similar to experimental studies, this period of early increases in glucose metabolism is quickly followed by a more prolonged period of metabolic depression that may last for weeks to months [14].

Studies using other measurements of cerebral metabolism, such as microdialysis and magnetic resonance spectroscopy (MRS) have supported these initial clinical findings. Studies in adult TBI have demonstrated a significant relationship between abnormalities in

microdialysis neurochemical markers and clinical outcomes [15]. For example, the Cambridge group used microdialysis in a series of 232 severe TBI patients to show marked alterations in neurochemistry following injury. They found a positive correlation between high glutamate and lactate to pyruvate (L/P) ratios and mortality or unfavorable outcomes [16]. Furthermore, glucose and L/P ratios were independent positive predictors of mortality, while pyruvate level was a negative predictor of mortality in a multivariate logistic model [16].

An important pattern seen in these studies is that markers of metabolic crisis can be detected even without significant elevations in intracranial pressure (ICP) or reductions in cerebral perfusion pressure. Stein et al. evaluated a series of 89 patients with severe TBI and showed that 76% had low glucose and 93% had increased L/P ratios in the first 72 hours after injury, despite having adequate post-injury resuscitation and controlled ICP [17]. Furthermore, metabolic crisis detected by microdialysis was a strong predictor of poor outcome at 6 months after TBI in these patients [8]. One important aspect of metabolic alterations in microdialysis markers is that they can potentially occur before changes in ICP or cerebral profusion pressure are detected. Studies have shown increases in L/P ratios and other neurochemical markers up to several hours prior to the detection of intracranial hypertension [1, 19].

The use of microdialysis to monitor neurochemical changes after severe TBI in children is much more limited [20], with one study from the United Kingdom reporting <1% of pediatric severe TBI patients being monitored with microdialysis [21]. Limited pediatric microdialysis studies do suggest that glutamate metabolism may play an even more important role in the pathophysiology of TBI in the developing brain [22, 23]. Despite the limited clinical data, studies in a piglet model of severe pediatric TBI have demonstrated marked increases in L/P ratios following injury, with improvements in markers of metabolic crisis being seen with neuroprotective approaches and vasoactive infusions to support CBF [24-26]. Importantly, neurochemical markers had a strong correlation with total injury volume in this piglet model of diffuse TBI [27].

In addition to microdialysis studies, proton magnetic resonance spectroscopy (^{1}H MRS) has been used to characterize metabolic alterations after TBI. Injury induces increases in lactate/creatine ratios, with concurrent decreases in N-acetylasparate (NAA)/creatine ratios. In clinical studies in adults, these ^{1}H-MRS metabolic markers correlate with initial Glasgow Coma Scale score, and with clinical outcomes [28, 29]. Information from ^{1}H-MRS in pediatric TBI is relatively strong, with a large series of studies conducted by investigators at Loma Linda University. In an initial study of 26 infants (1–18 months) and 27 children (>18 months), MRS voxels placed in remote occipital gray matter demonstrated significant lactate peaks in 91% of infants and 80% of children with poor outcomes, while none of the patients with good outcome had detectable lactate peaks [30]. Ongoing studies by this group confirmed an association between abnormal neurochemical markers using ^{1}H-MRS and long-term outcomes following pediatric TBI [31-33]. Specifically, in infants suffering abusive head trauma, ^{1}H-MRS showed elevated lactate and decreased NAA in multiple brain regions, which were associated with poor clinical outcomes [34].

Preclinical studies using ^{1}H-MRS have been able to better define the time course of metabolic alterations following severe TBI [35]. These studies have utilized multiple models of focal and diffuse TBI, and have shown very early increases in lactate and decreases of NAA, within minutes after injury [36, 37] with a persistent production of lactate even in areas

remote from the site of injury [38]. Furthermore, reductions in NAA correlate with severity of injury [39]. In a preclinical study of pediatric TBI, immature rats had early increases in lactate/creatine (4 hours and 24 hours) and late decreases in NAA/creatine (24 hours and 7 days), with significant decreases in the NAA/lactate ratio at all times studied over the first week after severe TBI [40].

TRAUMATIC BRAIN INJURY AND MITOCHONDRIAL DYSFUNCTION

A primary cause of altered cerebral energy metabolism after TBI is mitochondrial dysfunction in the posttraumatic period [41, 42]. Robust preclinical evidence demonstrates this. An early report in a fluid percussion model of TBI showed modest reductions in the active, ATP synthesizing (State 3) rate of mitochondrial respiration at 4 hours after injury [43]. Subsequently, a series of studies revealed marked perturbations in mitochondrial respiration in the ipsilateral hemisphere after focal TBI in rats [44]. Reductions in the State 3 rate of mitochondrial respiration began early after injury (1 hour) and persisted to 14 days [44], with correlative alterations in mitochondrial calcium homeostasis. Furthermore, agents that targeted mitochondrial dysfunction, such as calcium channel blockers and antioxidants, could prevent mitochondrial alterations, and were neuroprotective after TBI [45, 46]. Similar methods were used to isolate brain mitochondria from resected pericontusional tissue in patients after severe TBI. Results obtained from these human mitochondria demonstrated severely impaired mitochondrial respiration and ATP synthesis, similar to the findings obtained after TBI in rats [46].

Other investigators have also demonstrated early (30 minutes) alterations in mitochondrial respiration and coupling, with persistent deficits in mitochondrial respiratory control ratios out to 72 hours in hippocampus and cortex after TBI in adult mice [47]. These mitochondrial respiratory changes were accompanied by significant structural changes in brain mitochondria, with swelling and rupture of outer mitochondrial membranes [47]. In addition, there was evidence for posttraumatic reactive oxygen and nitrogen species playing a role in mitochondrial damage, with increases in oxidative lipid and protein damage in mitochondrial isolates, and mitochondrial protection was achieved with antioxidant strategies, such as penacillamine and tempol [48]. There is also evidence for the opening of the mitochondrial permeability transition pore after TBI, with subsequent alterations in mitochondrial respiration and calcium buffering capacity, leading to marked mitochondrial swelling [47, 49, 50]. Agents that block mitochondrial permeability transition pore formation after TBI were able to rescue mitochondrial function and were neuroprotective [51, 52].

Experimental studies in pediatric TBI have also described significant alterations in mitochondrial energy metabolism. In experiments using the controlled cortical impact (CCI) model in immature rats (PND 17), mitochondria had significant respiratory alterations, with increases in the resting (State 4) respiratory rates at 1 hour, and decreases in the State 3 respiratory rate by 4 hours after CCI [53]. Isolated mitochondria also had decreased activity of PDHC. Using gel-based proteomics, other investigators have shown loss of PDHC subunit expression that lasted at least 2 weeks after TBI in immature rats [54]. Since pyruvate dehydrogenase is the critical enzymatic link between glycolysis and the tricarboxylic acid

(TCA) cycle, loss of PDHC activity after TBI could have major implications for posttraumatic brain energy metabolism.

Direct evidence for mitochondrial dysfunction after human TBI is more limited. A recent clinical study evaluated resected tissue from contusion and pericontusional regions in adults after severe TBI [55]. There was evidence for altered metabolism, with elevated L/P and ADP/ATP ratios found in both tissue regions. In addition, more direct evidence for mitochondrial dysfunction was seen by marked decreases in mitochondrial electron transport chain complex I activity levels in both synaptosomes and non-synaptosomal mitochondria, as well as decreases in activity of other mitochondrial enzymes, such as succinate dehydrogenase and malate dehydrogenase [55]. Proteomics and western blot studies also showed decreases in key mitochondrial proteins [41]. Human studies have also shown marked alterations in mitochondrial morphology following severe TBI [37]. In a study of 22 adults with severe TBI, mitochondria were examined using electron microscopy on resected brain tissue. Mitochondria demonstrated very diverse morphological changes after TBI, from normal to end-stage, degenerating mitochondria. Furthermore, there was a correlation between mitochondrial phenotypes and injury severity, with the most severely injured patients (Glasgow Coma Scale 3-5) showing primarily end stage degenerating profiles. There were also time- and region-dependent changes in mitochondrial morphology [56].

Additional clinical studies have provided supportive evidence for mitochondrial dysfunction after TBI. For example, Pineda et al. used arterial spin labelling MRI to measure CBF and oxygenation extraction fraction, and used these measurements to calculate the oxygen metabolic index (OMI) [57]. OMI was decreased in all TBI patients at both times studied, potentially representing metabolic crisis and mitochondrial dysfunction after injury. In another study of 50 adults with severe TBI, investigators used microdialysis to evaluate changes in neurochemistry after treatment with cyclosporin A (CsA), a drug targeting mitochondrial rescue [58]. CsA treatment decreased glutamate and L/P ratio and increased glucose levels in brain tissue, demonstrating potentially neuroprotective effects on brain metabolism [39]. Finally, cerebrospinal fluid (CSF) measurements in clinical studies have supported a role for mitochondrial dysfunction, with increases in mitochondrial markers after TBI, including cytochrome c, caspase-9, heat shock protein 60, and α-synuclein [59-63]. Furthermore, CSF mitochondrial markers were associated with outcome and mechanism of injury, with the highest levels seen in those with the poorest Glasgow Outcome Scale, and in victims of abusive head trauma [59, 61, 63].

In summary, numerous preclinical and clinical studies have demonstrated evidence for marked alterations in cerebral energy metabolism after TBI. These alterations can occur very early after injury, and can be sustained for days to weeks. Importantly, metabolic changes can occur in the presence of normal CBF with adequate substrate (oxygen and glucose) delivery. This would suggest that primary mitochondrial damage and dysfunction are major contributors to secondary injury after TBI. This is especially important when considering neuroprotective approaches, such as decompressive craniectomy, that primarily target improvements in CBF and oxygen/glucose delivery. These approaches may therefore need to be combined with agents that target mitochondrial protection and limit ongoing mitochondrial damage.

METABOLIC LIMITATIONS OF IMPROVING NEUROLOGIC OUTCOMES FOLLOWING DECOMPRESSIVE CRANIECTOMY

The primary justification for utilizing decompressive craniectomy (DC) following severe, edematous brain injury is to allow the brain to expand with reduced resistance, thereby relieving the intracranial pressure and its deleterious effects on the brain. This release can, but not always, improve CBF, allowing for delivery of the relatively very high levels of oxygen and glucose that are necessary for aerobic energy metabolism [64; 65]. Aerobic brain energy metabolism is essential for maintaining the level of ATP in neurons and other brain cells at the levels necessary for normal integrative cell function and the level necessary for preserving neuronal viability. This scenario is therefore closely related to other examples of cerebral ischemia and reperfusion, such as what occurs spontaneously or via administration of thromboembolytic drugs following ischemic stroke, or what transpires during resuscitation following cardiac arrest. In each of these cases, reperfusion following partial or complete ischemia is necessary to minimize acute, necrotic cell death. However, the effectiveness of reperfusion is limited by the extent of ischemic brain injury that occurs prior to improved blood flow, by the extent to which oxygen and glucose are delivered during reperfusion, and by the various pathological mechanisms that are ignited during brain perfusion after ischemia. The following discussion summarizes the molecular pathophysiology of both cerebral ischemia and reperfusion, culminating in suggestions for avenues of neuroprotection research that could potentially be translated into improved effectiveness of DC.

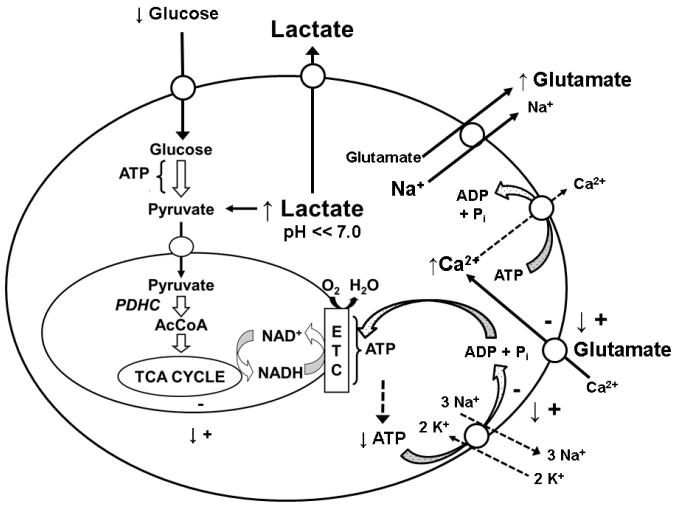

Figure 2. Alterations in neuronal energy metabolism and transmembrane ion fluxes during cerebral ischemia, such as what occurs during pathologically high intracranial pressure following traumatic brain injury. Reduced cerebral blood flow results in hypoxia where the intracellular oxygen concentration falls below the level necessary for sustaining the electron transport chain and therefore aerobic energy metabolism. These conditions result in increased anaerobic glycolysis and lactate production, causing an acid shift in intracellular pH. Anaerobic glycolysis is incapable of maintaining normal ATP levels, particularly in response to ischemia which reduces glucose availability. The subsequent fall in ATP causes inhibition of ATP-driven ion pumps, leading to membrane depolarization, abnormal activation of voltage-gated ion channels, and a dramatic increase in intracellular sodium and calcium. The rise in sodium can cause reversal of the sodium/glutamate co-transporter and a supranormal elevation of extracellular glutamate. Prolonged saturation of glutamate receptors, e.g., the NMDA receptor, contributes to the rise in intracellular calcium and also sodium (not shown).

Ischemic injury to cells and particularly to neurons is initiated when the rate of ATP generation by oxidative phosphorylation falls below the level of ATP utilization, resulting in a net reduction in the cytosolic ATP concentration. For example, following complete ischemia, brain ATP levels can fall by >90% within 2 minutes (66). During this decay, the activities of ATP-driven ion transporters, e.g., the plasma membrane sodium/potassium ATPase and the calcium ATPase, also decline, resulting in collapse of transmembrane ion gradients and depolarization of the plasma membrane (Figures 1 and 2) [67]. Following even a partial decline in membrane potential, a variety of voltage-gated and ligand-gated ion channels open, further stimulating membrane depolarization, accompanied by a massive increase in the intracellular concentrations of sodium and calcium. Perhaps the most important of these channels is the N-methyl-D-aspartate receptor (also known as the NMDA receptor or NMDAR). This receptor, which binds to, and is activated by, the neurotransmitter glutamate, is a major contributor to the influx of calcium and sodium and the "excitotoxicity" that ensues if the ion channel remains open for even a few minutes [68]. The rise in intracellular sodium results in the release of glutamate due to reversal of the sodium/glutamate co-transporter, which is normally responsible for active uptake of glutamate [69].

During the first few minutes following the onset of cerebral ischemia, changes in ion flux also occur across intracellular membranes. In particular, the mitochondrial inner membrane rapidly depolarizes owing to the lack of delivery of energy metabolite precursors, e.g., glucose, and the lack of oxygen necessary to utilize these metabolites as fuel for the process of oxidative phosphorylation (Figure 2). The mitochondrial membrane potential, which is generated by a proton gradient driven by the energy transduced by the mitochondrial electron transport chain, is normally primarily responsible for oxidative phosphorylation but can also normally be used to drive the influx of calcium ions (Ca^{2+}) through the inner membrane into the mitochondrial matrix (not shown). The mitochondrial depolarization that occurs during ischemia eliminates the ability of mitochondria to buffer changes in cytosolic Ca^{2+}, which can rise from a resting ionized concentration of approximately 0.1 μM to over 30 μM within a few minutes [70]. Since the cytosolic concentration of Ca^{2+} normally varies only between 0.1 and 1.0 μM, it is not surprising that the abnormally very high Ca^{2+} concentration that exists in the cytosol during cerebral ischemia is responsible for many of the molecular alterations that ultimately result in cell death either during or after cerebral ischemia. Examples of such alterations include Ca^{2+}-activated proteolysis by enzymes, e.g., calpains [71], and phospholipid hydrolysis by Ca^{2+}-activated phospholipases, e.g., phospholipase A2 [72]. Periods of complete ischemia in excess of 30 minutes will cause acute, irreversible damage to selectively vulnerable neurons and other brain cells, primarily due to Ca^{2+}-dependent degradation of cell membranes, proteins, and other molecules. The extent and time-course of cell death during incomplete ischemia depends, of course, on the degree to which the partial ischemia results in cellular de-energization and associated excitotoxicity and associated necrosis.

Reperfusion of ischemic brain tissue caused either by impaired systemic blood flow, thromboembolic or hemorrhagic stroke, or excessive cerebral edema and elevated ICP is absolutely necessary to terminate the cell destruction caused by inadequate blood flow. However, reperfusion is associated with a variety of additional molecular mechanisms of cell damage and death that must be considered in the effort to optimize neurologic outcomes. One of these mechanisms is impaired cerebral energy metabolism (Figure 3). One study compared

the cerebral metabolic rate of oxygen (CMRO2) for severe TBI patients who underwent DC to that of non-operated TBI patients and found that the aerobic energy metabolism was actually lower in the patients who underwent craniectomy [64]. In general, good functional outcome was strongly associated with higher CMRO2 but not with higher CBF. These findings suggest that more research is needed to understand why cerebral aerobic energy metabolism is not necessarily improved by DC and to identify additional metabolic interventions that could be used together with craniectomy to improve neurologic outcomes.

Normally, over 90% of the energy (ATP) generated in the brain results from aerobic energy metabolism, which is completely dependent on mitochondrial oxidative phosphorylation. Remarkably, no published clinical or animal studies have focused on the effects of post-TBI DC on brain mitochondrial function. One clinical study focused on bedside diagnosis of mitochondrial dysfunction after malignant middle cerebral artery infarction [73]. The authors of that study used bilateral microdialysis and found the lactate/pyruvate ratio and lactate levels were significantly higher in the infarcted tissue than the contralateral hemisphere. These differences are likely due to an impaired flux of carbon through the mitochondrial tricarboxylic acid cycle, inhibition of the electron transport chain, or inhibition of the mitochondrial ATP synthase. The connection between CMRO2, but not CBF, and neurologic outcomes mentioned above is further evidence indicating that the rate of mitochondrial oxidative phosphorylation may be the limiting factor in improvement of cerebral energy metabolism during DC.

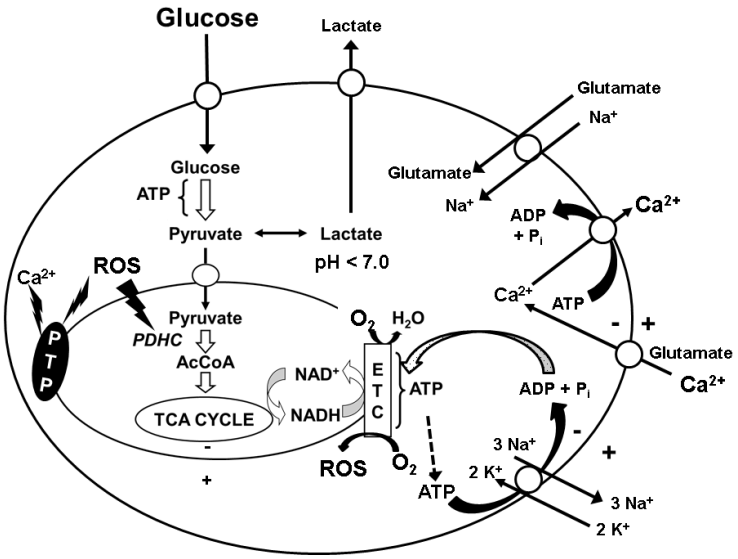

Figure 3. Decompressive craniectomy-relevant reperfusion effects on cellular bioenergetics and oxidative stress. The rise in intracellular oxygen and glucose that can occur during increased cerebral blood flow brought about by decompressive craniectomy has the potential for improving cell energy metabolism, thereby reducing cerebral edema and neuronal death. However, the conditions that exist during reperfusion can limit the effectiveness of decompressive craniectomy. For example, reperfusion often results in a rise in the net production of reactive oxygen species (ROS) owing to a combination of damage to the electron transport chain, high intracellular calcium, and low intracellular pH. Reactive oxygen and nitrogen molecules can directly inactivate a number of key metabolic proteins, e.g., the pyruvate dehydrogenase complex (PDHC), and proteins present in the electron transport chain (ETC). The combination of high intracellular calcium plus ROS can activate the mitochondrial inner membrane permeability transition pore (PTP), resulting in osmotic swelling of mitochondria, membrane depolarization, and secondary metabolic failure.

Figure 3 presents a few mechanisms of reperfusion-induced mitochondrial bioenergetics dysfunction that are likely applicable to the use of DC following elevations of ICP known to cause cerebral ischemia. Post-ischemic reperfusion of the brain is associated with an increase in the levels of reactive oxygen and nitrogen species, e.g., superoxide, hydrogen peroxide, nitric oxide, and peroxynitrite. Some studies indicate that mitochondria are the source of these toxic metabolites [74; 75]; however, no studies have tested this hypothesis following DC. Reactive oxygen species (ROS) produced by mitochondria or other sources, e.g., the NADPH oxidase [76], can disrupt mitochondrial energy transduction and ATP formation in numerous ways. There are several metabolic enzymes that are sensitive to inactivation by ROS, including aconitase in the TCA cycle, the pyruvate dehydrogenase complex (Figure 3), and several proteins present in the electron transport chain. In addition, the combination of ROS and high intracellular calcium potently activates the mitochondrial permeability transition pore (PTP) (Figure 3) [77]. When the PTP is open for a few minutes or even less, irreversible mitochondrial membrane depolarization occurs and is followed by release of intramitochondrial cofactors, e.g., NAD(H) and glutathione, from the mitochondrial matrix into the cytosol. Ultimately, unchecked PTP opening results in osmotic mitochondrial lysis and irreversible inhibition of oxidative phosphorylation, which is strongly implicated in the pathogenesis of neuronal death caused by TBI [78]. As with the other reperfusion-initiated mitochondrial damage mechanisms, the role that PTP opening plays in the limitation of DC to improve cerebral energy metabolism and reduce neurologic injury has not been studied.

Despite the widespread use of DC for TBI patients exhibiting potentially lethal elevation of ICP, no studies, including those with animals, have been published that test for agents or conditions in combination with DC that could compensate for the failure of DC to completely improve cerebral energy metabolism. Examples of conditions that could be tested together with DC include hypothermia and hyperoxia. Mild hypothermia in the range of 32–35°C is neuroprotective in animal models of TBI [79] Hypothermia during DC was recently shown to lower intracranial hypertension and to improve survival when combined with DC, in comparison to outcomes following normothermic DC [80]. Both normobaric and hyperbaric hyperoxia have been used for TBI but not specifically during DC [81]. While the use of supplemental oxygen to avoid brain hypoxia is absolutely necessary, caution should be used to avoid tissue hyperoxia. In one retrospective study, both elevated arterial oxygen levels (PaO_2 >200 mm Hg) and low PaO_2 (<100 mm Hg) present within 24 hours after hospital admittance were found to be equally detrimental to short-term outcomes in patients with TBI [82]. In contrast, in another study performed with 68 severe TBI patients, 6-month outcomes were better in patients ventilated on 80% oxygen for the first 6 hours than in those ventilated on 50% oxygen [83]. As with mild hypothermia, no studies have tested different inspired oxygen levels specifically during DC. As mentioned earlier, damage to the metabolic enzymes and other molecules that occur following TBI may limit aerobic cerebral energy metabolism rather than the brain tissue oxygen tension. Therefore, consideration should be given to the administration of agents that can either counteract this damage or protect against further, reperfusion-induced injury.

As noted earlier, inhibition of brain PDHC activity within hours following TBI has been shown in animal models by several different laboratories. One compensatory approach to loss of PDHC activity is the administration of alternative biofuels that can substitute for pyruvate utilization. Both molecules are rapidly metabolized to form acetyl-CoA, which is the product of PDHC and provides most of the carbon to the TCA cycle in the adult human brain (see

Figure 1). Administration of either ketone bodies (or ketogenic diet) or acetyl-L-carnitine protects against brain mitochondrial respiratory inhibition and provides neuroprotection in rodent TBI models [84, 85]. The use of these natural metabolic intermediates together with DC could be particularly effective since they exhibit almost no toxicity and can therefore be used at relatively high doses.

As shown in Figure 3, opening of the mitochondrial inner membrane PTP is one molecular mechanism of mitochondrial dysfunction that can have catastrophic effects on brain energy metabolism. The immunosuppressive drug cyclosporin A is a potent inhibitor of PTP opening and has exhibited neuroprotection in a number of rodent TBI models [86, 87]. Nevertheless, clinical trials using cyclosporin A for TBI have been unsuccessful [42]. Since PTP opening is often associated with mitochondrial uptake of calcium and the oxidative stress that accompanies reperfusion, cyclosporin might be more effective when administered together with DC.

There is compelling evidence from both preclinical and clinical studies that oxidative stress and the oxidative modification of proteins, lipids, and DNA contribute to the pathophysiology of TBI [88]. While no one antioxidant has demonstrated TBI neuroprotection in clinical studies, a meta-analysis of six separate antioxidant trials resulted in the conclusion that the "overall trend of using antioxidant therapies to improve the clinical outcomes of TBI was positive" [89]. Considering the fact that oxidative stress is a major contributor to reperfusion brain injury, research testing the effects of antioxidants administered before and during DC should be a high priority.

One drawback of the use of most antioxidants is that they typically target only one or a few of the many reactive oxygen and nitrogen species that are responsible for oxidative damage to brain energy metabolism and many other cell activities. A potentially more effective approach is the administration of agents that act indirectly as antioxidants by increasing the expression of many different antioxidant-related proteins. A well-established example of this genomic post-conditioning response is what occurs following exposure to chemicals that directly or indirectly cause oxidation of the protein KEAP. The ensuing change in protein structure triggers the release of the protein Nrf2 from KEAP. Following Nrf2 phosphorylation, Nrf2 enters the nucleus and binds to antioxidant response elements on the promoter region of many different genes that code for antioxidant proteins [90]. These genes evolved both to directly detoxify ROS and to maintain a relatively reduced intracellular and intramitochondrial redox state, which is necessary for ROS detoxification and repair of oxidatively modified molecules.

An increasing number of agents that activate the Nrf2 pathway of gene expression have exhibited neuroprotection in animal models of TBI. One of the best studied of these molecules is sulforaphane, which is an isothiocyanate found in cruciferous vegetables, e.g., broccoli. In addition to its increasing the levels of antioxidant proteins in cells and within mitochondria, administration of sulforaphane to animals increases the resistance to PTP opening in both brain and liver mitochondria [91, 92]. Most importantly, it provides neuroprotection when given to rats or mice intraperitoneally shortly after TBI [93, 94]. Other agents that provide neuroprotection following acute CNS injuries in animal studies include the drug dimethylfumarate (Tecfidera) [95], carnosic acid [96], melatonin [97], and progesterone [98]. Like most of the other neuroprotective approaches covered in this chapter, none of these agents have been studied when combined with DC.

CONCLUSION

The application of microdialysis, magnetic resonance spectroscopy, and many other technologies to preclinical and clinical research has provided convincing evidence that abnormal cerebral energy metabolism is one of the main causes of both acute and chronic neurodegeneration following TBI. A few of the many specific molecular mechanisms that underlie this causal relationship include impairment of mitochondrial enzymes, e.g., the PDHC, and mitochondrial osmotic swelling induced by activation of the permeability transition pore. Almost all of the studies that constructed these pathophysiologic models of TBI have used animals or patients who did not undergo decompressive craniectomy. Given this limitation, it is very difficult to identify the factors that limit the effectiveness of DC. However, the use of DC following TBI shares many common physiologic factors with brain ischemia and reperfusion, e.g., fluctuations in cerebral blood flow and tissue oxygenation. It therefore follows that at least some of the mechanisms responsible for isolated ischemia/reperfusion brain injury are likely to apply to TBI followed by DC.

Considerably more attention should be given to animal models of TBI/DC to elucidate the most likely targets of intervention that would improve the therapeutic efficacy of DC. Based on ischemia/reperfusion research, these targets probably include oxidative stress and impaired aerobic energy metabolism. Verification of these and other targets requires both a surge of support for animal models of TBI/DC that utilize clinically translatable *in vivo* imaging, neurochemical measurements, and the combination of DC with drugs that have proven effective in models of cerebral ischemia and reperfusion..

REFERENCES

[1] Verweij BH, Amelink GJ, Muizelaar JP. Current concepts of cerebral oxygen transport and energy metabolism after severe traumatic brain injury. *Prog. Brain Res* 2007;161:111-24.

[2] Siesjo BK. Cerebral circulation and metabolism. *J Neurosurg*. 1984 60(5):883-908.

[3] Zauner A, Doppenberg EM, Woodward JJ, Choi SC, Young HF, Bullock R. Continuous monitoring of cerebral substrate delivery and clearance: initial experience in 24 patients with severe acute brain injuries. *Neurosurgery* 1997 41(5):1082-91.

[4] De Salles AA, Muizelaar JP, Young HF. Hyperglycemia, cerebrospinal fluid lactic acidosis, and cerebral blood flow in severely head-injured patients. *Neurosurgery* 1987 21(1):45-50.

[5] Dienel GA. Lactate shuttling and lactate use as fuel after traumatic brain injury: metabolic considerations. *J Cereb Blood Flow Metab.* 2014 34(11):1736-48.

[6] Hovda DA, Lee SM, Smith ML, Von SS, Bergsneider M, Kelly D, et al. The neurochemical and metabolic cascade following brain injury: moving from animal models to man. *J Neurotrauma* 1995 12(5):903-6.

[7] Yoshino A, Hovda DA, Kawamata T, Katayama Y, Becker DP. Dynamic changes in local cerebral glucose utilization following cerebral conclusion in rats: evidence of a hyper- and subsequent hypometabolic state. *Brain Res*. 1991 561(1):106-19.

[8] Kawamata T, Katayama Y, Hovda DA, Yoshino A, Becker DP. Administration of excitatory amino acid antagonists via microdialysis attenuates the increase in glucose utilization seen following concussive brain injury. *J Cereb Blood Flow Metab.* 1992 12(1):12-24.

[9] Thomas S, Prins ML, Samii M, Hovda DA. Cerebral metabolic response to traumatic brain injury sustained early in development: a 2-deoxy-D-glucose autoradiographic study. *J Neurotrauma* 2000 17(8):649-65.

[10] Prins ML, Hovda DA. Mapping cerebral glucose metabolism during spatial learning: interactions of development and traumatic brain injury. *J Neurotrauma* 2001 18(1):31-46.

[11] Buitrago Blanco MM, Prashant GN, Vespa PM. Cerebral Metabolism and the role of glucose control in acute traumatic brain injury. *Neurosurg Clin N Am*. 2016 27(4):453-63.

[12] Bergsneider M, Hovda DA, Shalmon E, Kelly DF, Vespa PM, Martin NA, et al. Cerebral hyperglycolysis following severe traumatic brain injury in humans: a positron emission tomography study. *J Neurosurg.* 1997 86(2):241-51.

[13] O'Connell MT, Seal A, Nortje J, Al-Rawi PG, Coles JP, Fryer TD, et al. Glucose metabolism in traumatic brain injury: a combined microdialysis and [18F]-2-fluoro-2-deoxy-D-glucose-positron emission tomography (FDG-PET) study. *Acta Neurochir Suppl.* 2005 95:165-8.

[14] Bergsneider M, Hovda DA, McArthur DL, Etchepare M, Huang SC, Sehati N, et al. Metabolic recovery following human traumatic brain injury based on FDG-PET: time course and relationship to neurological disability. *J Head Trauma Rehabil*. 2001 16(2):135-48.

[15] Hutchinson P, O'Phelan K. International multidisciplinary consensus conference on multimodality monitoring: cerebral metabolism. *Neurocrit Care* 2014 21: Suppl 2:S148-S158.

[16] Timofeev I, Carpenter KL, Nortje J, Al-Rawi PG, O'Connell MT, Czosnyka M, et al. Cerebral extracellular chemistry and outcome following traumatic brain injury: a microdialysis study of 223 patients. *Brain* 2011 134(Pt 2):484-94.

[17] Stein NR, McArthur DL, Etchepare M, Vespa PM. Early cerebral metabolic crisis after TBI influences outcome despite adequate hemodynamic resuscitation. *Neurocrit Care* 2012 17(1):49-57.

[18] Belli A, Sen J, Petzold A, Russo S, Kitchen N, Smith M. Metabolic failure precedes intracranial pressure rises in traumatic brain injury: a microdialysis study. *Acta Neurochir*. (Wien) 2008 150(5):461-9.

[19] Adamides AA, Rosenfeldt FL, Winter CD, Pratt NM, Tippett NJ, Lewis PM, et al. Brain tissue lactate elevations predict episodes of intracranial hypertension in patients with traumatic brain injury. *J Am Coll Surg*. 2009 209(4):531-9.

[20] Charalambides C, Sgouros S, Sakas D. Intracerebral microdialysis in children *Childs Nerv Syst* 2010 26(2): 215-20.

[21] Morris KP, Forsyth RJ, Parslow RC, Tasker RC, Hawley CA; UK Paediatric Traumatic Brain Injury Study Group; Paediatric Intensive Care Society Study Group. Intracranial pressure complicating severe traumatic brain injury in children: monitoring and management. *Intensive Care Med*. 2006 32(10): 1606-12.Tolias CM, Richards DA,

Bowery NG, Sgouros S. Extracellular glutamate in the brains of children with severe head injuries: a pilot microdialysis study. *Childs Nerv Syst.* 2002 18(8):368-74.

[22] Richards DA, Tolias CM, Sgouros S, Bowery NG. Extracellular glutamine to glutamate ratio may predict outcome in the injured brain: a clinical microdialysis study in children. *Pharmacol Res.* 2003 48(1):101-9.

[23] Friess SH, Smith C, Kilbaugh TJ, Frangos SG, Ralston J, Helfaer MA, et al. Early cerebral perfusion pressure augmentation with phenylephrine after traumatic brain injury may be neuroprotective in a pediatric swine model. *Crit Care Med*. 2012 40(8):2400-6.

[24] Friess SH, Bruins B, Kilbaugh TJ, Smith C, Margulies SS. Differing effects when using phenylephrine and norepinephrine to augment cerebral blood flow after traumatic brain injury in the immature brain. *J Neurotrauma* 2015 15;32(4):237-43.

[25] Kilbaugh TJ, Bhandare S, Lorom DH, Saraswati M, Robertson CL, Margulies SS. Cyclosporin A Preserves Mitochondrial function after traumatic brain injury in the immature rat and piglet. *J Neurotrauma* 2011 28(5):763-74.

[26] Friess SH, Ralston J, Eucker SA, Helfaer MA, Smith C, Margulies SS. Neurocritical care monitoring correlates with neuropathology in a swine model of pediatric traumatic brain injury. *Neurosurgery* 2011 69(5):1139-47.

[27] Du Y, Li Y, Lan Q. 1H-Magnetic resonance spectroscopy correlates with injury severity and can predict coma duration in patients following severe traumatic brain injury. *Neurol India* 2011 59(5):679-84.

[28] Tollard E, Galanaud D, Perlbarg V, Sanchez-Pena P, Le FY, Abdennour L, et al. Experience of diffusion tensor imaging and 1H spectroscopy for outcome prediction in severe traumatic brain injury: Preliminary results. *Crit Care Med.* 2009 37(4):1448-55.

[29] Ashwal S, Holshouser BA, Shu SK, Simmons PL, Perkin RM, Tomasi LG, et al. Predictive value of proton magnetic resonance spectroscopy in pediatric closed head injury. *Pediatr Neurol*. 2000 23(2):114-25.

[30] Babikian T, Freier MC, Ashwal S, Riggs ML, Burley T, Holshouser BA. MR spectroscopy: predicting long-term neuropsychological outcome following pediatric TBI. *J Magn Reson Imaging* 2006 24(4):801-11.

[31] Ashwal S, Holshouser B, Tong K, Serna T, Osterdock R, Gross M, et al. Proton MR spectroscopy detected glutamate/glutamine is increased in children with traumatic brain injury. *J Neurotrauma* 2004 21(11):1539-52.

[32] Ashwal S, Babikian T, Gardner-Nichols J, Freier MC, Tong KA, Holshouser BA. Susceptibility-weighted imaging and proton magnetic resonance spectroscopy in assessment of outcome after pediatric traumatic brain injury. *Arch Phys Med Rehabil.* 2006 87(12 Suppl 2):S50-S58.

[33] Aaen GS, Holshouser BA, Sheridan C, Colbert C, McKenney M, Kido D, et al. Magnetic resonance spectroscopy predicts outcomes for children with nonaccidental trauma. *Pediatrics* 2010 125(2):295-303.

[34] .Marino S, Ciurleo R, Bramanti P, Federico A, De Stefano N. 1H-MR spectroscopy in traumatic brain injury. *Neurocrit Care* 2011 14(1): 127-33.

[35] Berry I, Moseley M, Germano IM, Ishige N, Nishimura MC, Bartkowski HM, et al. Combined magnetic resonance imaging and spectroscopy in experimental regional injury of the brain. Ischemia and impact trauma. *Acta Radiol Suppl*. 1986 369: 338-49.

[36] McIntosh TK, Faden AI, Bendall MR, Vink R. Traumatic brain injury in the rat: alterations in brain lactate and pH as characterized by 1H and 31P nuclear magnetic resonance. *J Neurochem*. 1987 49(5):1530-40.

[37] Cohen Y, Sanada T, Pitts LH, Chang LH, Nishimura MC, Weinstein PR, et al. Surface coil spectroscopic imaging: time and spatial evolution of lactate production following fluid percussion brain injury. *Magn Reson Med*. 1991 17(1):225-36.

[38] Signoretti S, Marmarou A, Tavazzi B, Lazzarino G, Beaumont A, Vagnozzi R. N-Acetylaspartate reduction as a measure of injury severity and mitochondrial dysfunction following diffuse traumatic brain injury. *J Neurotrauma* 2001 18(10):977-91.

[39] Casey PA, McKenna MC, Fiskum G, Saraswati M, Robertson CL. Early and sustained alterations in cerebral metabolism after traumatic brain injury in immature rats. *J Neurotrauma* 2008 25(6):603-14.

[40] Robertson CL, Scafidi S, McKenna MC, Fiskum G. Mitochondrial mechanisms of cell death and neuroprotection in pediatric ischemic and traumatic brain injury. *Exp Neurol.* 2009 218(2):371-80.

[41] Gajavelli S, Sinha VK, Mazzeo AT, Spurlock MS, Lee SW, Ahmed AI, et al. Evidence to support mitochondrial neuroprotection, in severe traumatic brain injury. *J Bioenerg Biomembr*. 2015 47(1-2):133-48.

[42] Vink R, Head VA, Rogers PJ, McIntosh TK, Faden AI. Mitochondrial metabolism following traumatic brain injury in rats. *J Neurotrauma* 1990 7(1):21-7.

[43] Xiong Y, Gu Q, Peterson PL, Muizelaar JP, Lee CP. Mitochondrial dysfunction and calcium perturbation induced by traumatic brain injury. *J Neurotrauma* 1997 14(1):23-34.

[44] Xiong Y, Peterson PL, Muizelaar JP, Lee CP. Amelioration of mitochondrial function by a novel antioxidant U-101033E following traumatic brain injury in rats. *J Neurotrauma* 1997 14(12):907-17.

[45] Verweij BH, Muizelaar JP, Vinas FC, Peterson PL, Xiong Y, Lee CP. Mitochondrial dysfunction after experimental and human brain injury and its possible reversal with a selective N-type calcium channel antagonist (SNX-111). *Neurol Res*. 1997 19(3):334-9.

[46] Singh IN, Sullivan PG, Deng Y, Mbye LH, Hall ED. Time course of post-traumatic mitochondrial oxidative damage and dysfunction in a mouse model of focal traumatic brain injury: implications for neuroprotective therapy. *J Cereb Blood Flow Metab* 2006 26(11):1407-18.

[47] Singh IN, Sullivan PG, Hall ED. Peroxynitrite-mediated oxidative damage to brain mitochondria: Protective effects of peroxynitrite scavengers. *J Neurosci Res*. 2007 85(10):2216-23.

[48] Sullivan PG, Rabchevsky AG, Waldmeier PC, Springer JE. Mitochondrial permeability transition in CNS trauma: cause or effect of neuronal cell death*? J Neurosci Res.* 2005 79(1-2):231-9.

[49] Readnower RD, Pandya JD, McEwen ML, Pauly JR, Springer JE, Sullivan PG. Post-injury administration of the mitochondrial permeability transition pore inhibitor, NIM811, is neuroprotective and improves cognition after traumatic brain injury in rats. *J Neurotrauma* 2011 28(9):1845-53.

[50] Mbye LH, Singh IN, Sullivan PG, Springer JE, Hall ED. Attenuation of acute mitochondrial dysfunction after traumatic brain injury in mice by NIM811, a non-immunosuppressive cyclosporin A analog. *Exp Neurol*. 2008 209(1):243-53.

[51] Sullivan PG, Thompson MB, Scheff SW. Cyclosporin A attenuates acute mitochondrial dysfunction following traumatic brain injury. *Exp Neurol*. 1999 160(1):226-34.

[52] Robertson CL, Saraswati M, Fiskum G. Mitochondrial dysfunction early after traumatic brain injury in immature rats. *J Neurochem*. 2007 101(5):1248-57.

[53] Kochanek AR, Kline AE, Gao WM, Chadha M, Lai Y, Clark RS, et al. Gel-based hippocampal proteomic analysis 2 weeks following traumatic brain injury to immature rats using controlled cortical impact. *Dev Neurosci*. 2006 28(4-5):410-9.

[54] Harish G, Mahadevan A, Pruthi N, Sreenivasamurthy SK, Puttamallesh VN, Keshava Prasad TS, et al. Characterization of traumatic brain injury in human brains reveals distinct cellular and molecular changes in contusion and pericontusion. *J Neurochem.* 2015 134(1):156-72.

[55] Balan IS, Saladino AJ, Aarabi B, Castellani RJ, Wade C, Stein DM, et al. Cellular alterations in human traumatic brain injury: changes in mitochondrial morphology reflect regional levels of injury severity. *J Neurotrauma* 2013 30(5):367-81.

[56] Ragan DK, McKinstry R, Benzinger T, Leonard JR, Pineda JA. Alterations in cerebral oxygen metabolism after traumatic brain injury in children. *J Cereb Blood Flow Metab.* 2013 33(1):48-52.

[57] Mazzeo AT, Alves OL, Gilman CB, Hayes RL, Tolias C, Niki KK, et al. Brain metabolic and hemodynamic effects of cyclosporin A after human severe traumatic brain injury: a microdialysis study. *Acta Neurochir*. (Wien) 2008 150(10):1019-31.

[58] Satchell MA, Lai Y, Kochanek PM, Wisniewski SR, Fink EL, Siedberg NA, et al. Cytochrome c, a biomarker of apoptosis, is increased in cerebrospinal fluid from infants with inflicted brain injury from child abuse. *J Cereb Blood Flow Metab*. 2005 25(7):919-27.

[59] Lai Y, Stange C, Wisniewski SR, Adelson PD, Janesko-Feldman KL, Brown DS, et al. Mitochondrial heat shock protein 60 is increased in cerebrospinal fluid following pediatric traumatic brain injury. *Dev Neurosci*. 2006 28(4-5):336-41.

[60] Darwish RS, Amiridze NS. Detectable levels of cytochrome C and activated caspase-9 in cerebrospinal fluid after human traumatic brain injury. *Neurocrit Care* 2010 12(3):337-41.

[61] Su E, Bell MJ, Wisniewski SR, Adelson PD, Janesko-Feldman KL, Salonia R, et al. alpha-Synuclein levels are elevated in cerebrospinal fluid following traumatic brain injury in infants and children: the effect of therapeutic hypothermia. *Dev Neurosci*. 2010 32(5-6):385-95.

[62] Au AK, Aneja RK, Bell MJ, Bayir H, Feldman K, Adelson PD, et al. Cerebrospinal fluid levels of high-mobility group box 1 and cytochrome C predict outcome after pediatric traumatic brain injury. *J Neurotrauma* 2012 29(11):2013-21.

[63] Soustiel JF, Sviri GE, Mahamid E, Shik V, Abeshaus S, Zaaroor M. Cerebral blood flow and metabolism following decompressive craniectomy for control of increased intracranial pressure. *Neurosurgery* 2010 67(1):65-72.

[64] Bor-Seng-Shu E, Figueiredo EG, Fonoff ET, Fujimoto Y, Panerai RB, Teixeira MJ. Decompressive craniectomy and head injury: brain morphometry, ICP, cerebral hemodynamics, cerebral microvascular reactivity, and neurochemistry. *Neurosurg* Rev. 2013 36(3):361-70.

[65] Wagner SR, Lanier WL. Metabolism of glucose, glycogen, and high-energy phosphates during complete cerebral ischemia. A comparison of normoglycemic, chronically

hyperglycemic diabetic, and acutely hyperglycemic nondiabetic rats. *Anesthesiology* 1994 81(6):1516-26.

[66] Katsura K, Kristian T, Siesjo BK. Energy metabolism, ion homeostasis, and cell damage in the brain. *Biochem Soc Trans*. 1994 22(4):991-6.

[67] Johnston MV. Excitotoxicity in perinatal brain injury. *Brain Pathol*. 2005 15(3):234-40.

[68] Grewer C, Gameiro A, Zhang Z, Tao Z, Braams S, Rauen T. Glutamate forward and reverse transport: from molecular mechanism to transporter-mediated release after ischemia. *IUBMB Life* 2008 60(9):609-19.

[69] Silver IA, Erecinska M. Intracellular and extracellular changes of [Ca^{2+}] in hypoxia and ischemia in rat brain in vivo. *J Gen Physiol*. 1990 95:837-66.

[70] Curcio M, Salazar IL, Mele M, Canzoniero LM, Duarte CB. Calpains and neuronal damage in the ischemic brain: The swiss knife in synaptic injury. *Prog Neurobiol.* 2016 143:1-35.

[71] Farooqui AA, Ong WY, Horrocks LA. Inhibitors of brain phospholipase A2 activity: their neuropharmacological effects and therapeutic importance for the treatment of neurologic disorders. *Pharmacol Rev.* 2006 58(3):591-620.

[72] Nielsen TH, Schalen W, Stahl N, Toft P, Reinstrup P, Nordstrom CH. Bedside diagnosis of mitochondrial dysfunction after malignant middle cerebral artery infarction. *Neurocrit Care* 2014 21(1):35-42.

[73] Matsuura TR, Bartos JA, Tsangaris A, Shekar KC, Olson MD, Riess ML, et al. Early effects of prolonged cardiac arrest and ischemic postconditioning during cardiopulmonary resuscitation on cardiac and brain mitochondrial function in pigs. *Resuscitation* 2017 116:8-15.

[74] Dezfulian C, Kenny E, Lamade A, Misse A, Krehel N, St CC, et al. Mechanistic characterization of nitrite-mediated neuroprotection after experimental cardiac arrest. *J Neurochem*. 2016 139(3):419-31.

[75] von Leden RE, Yauger YJ, Khayrullina G, Byrnes KR. Central nervous system injury and nicotinamide adenine dinucleotide phosphate oxidase: Oxidative stress and therapeutic targets. *J Neurotrauma* 2017 15;34(4):755-64.

[76] Perez-Pinzon MA, Stetler RA, Fiskum G. Novel mitochondrial targets for neuroprotection. *J Cereb Blood Flow Metab*. 2012 32(7):1362-76.

[77] Mazzeo AT, Beat A, Singh A, Bullock MR. The role of mitochondrial transition pore, and its modulation, in traumatic brain injury and delayed neurodegeneration after TBI. *Exp Neurol*. 2009 218(2):363-70.

[78] Dietrich WD, Bramlett HM. The evidence for hypothermia as a neuroprotectant in traumatic brain injury. *Neurotherapeutics* 2010 7(1):43-50.

[79] Tang C, Bao Y, Qi M, Zhou L, Liu F, Mao J, et al. Mild induced hypothermia for patients with severe traumatic brain injury after decompressive craniectomy. *J Crit Care* 2017 39:267-70.

[80] Beynon C, Sun L, Marti HH, Heiland S, Veltkamp R. Delayed hyperbaric oxygenation is more effective than early prolonged normobaric hyperoxia in experimental focal cerebral ischemia. *Neurosci Lett*. 2007 2;425(3):141-5.

[81] Brenner M, Stein D, Hu P, Kufera J, Wooford M, Scalea T. Association between early hyperoxia and worse outcomes after traumatic brain injury. *Arch Surg*. 2012 147(11):1042-6.

[82] Taher A, Pilehvari Z, Poorolajal J, Aghajanloo M. Effects of Normobaric Hyperoxia in Traumatic Brain Injury: A Randomized Controlled Clinical Trial. *Trauma Mon.* 2016 21(1):e26772.

[83] Scafidi S, Racz J, Hazelton J, McKenna MC, Fiskum G. Neuroprotection by acetyl-L-carnitine after traumatic injury to the immature rat brain. *Dev Neurosci*. 2011 32(5-6):480-7.

[84] Scafidi S, Fiskum G, Lindauer SL, Bamford P, Shi D, Hopkins I, et al. Metabolism of acetyl-L-carnitine for energy and neurotransmitter synthesis in the immature rat brain. *J Neurochem*. 2010 114(3):820-31.

[85] Lulic D, Burns J, Bae EC, van LH, Borlongan CV. A review of laboratory and clinical data supporting the safety and efficacy of cyclosporin A in traumatic brain injury. *Neurosurgery* 2011 68(5):1172-85.

[86] Yokobori S, Mazzeo AT, Gajavelli S, Bullock MR. Mitochondrial neuroprotection in traumatic brain injury: rationale and therapeutic strategies. *CNS Neurol Disord Drug Targets* 2014 13(4):606-19.

[87] Bains M, Hall ED. Antioxidant therapies in traumatic brain and spinal cord injury. *Biochim Biophys Acta* 2012 1822(5):675-84.

[88] Shen Q, Hiebert JB, Hartwell J, Thimmesch AR, Pierce JD. Systematic review of traumatic brain injury and the impact of antioxidant therapy on clinical outcomes. *Worldviews Evid Based Nurs.* 2016 13(5):380-9.

[89] Zhang L, Wang H. Targeting the NF-E2-Related Factor 2 Pathway: a novel strategy for traumatic brain injury. *Mol Neurobiol*. 2017 Epub Feb 21.

[90] Greco T, Fiskum G. Brain mitochondria from rats treated with sulforaphane are resistant to redox-regulated permeability transition. *J Bioenerg Biomembr*. 2010 42(6):491-7.

[91] Greco T, Shafer J, Fiskum G. Sulforaphane inhibits mitochondrial permeability transition and oxidative stress. *Free Rad Biol Med*. 2011 12:2164-71.

[92] Dash PK, Zhao J, Orsi SA, Zhang M, Moore AN. Sulforaphane improves cognitive function administered following traumatic brain injury. *Neurosci Lett*. 2009 460(2):103-7.

[93] Hong Y, Yan W, Chen S, Sun CR, Zhang JM. The role of Nrf2 signaling in the regulation of antioxidants and detoxifying enzymes after traumatic brain injury in rats and mice. *Acta Pharmacol Sin*. 2010 31(11):1421-30.

[94] Cordaro M, Casili G, Paterniti I, Cuzzocrea S, Esposito E. Fumaric Acid Esters Attenuate Secondary Degeneration after Spinal Cord Injury. *J Neurotrauma* 2017 Epub Jul 5.

[95] Miller DM, Singh IN, Wang JA, Hall ED. Nrf2-ARE activator carnosic acid decreases mitochondrial dysfunction, oxidative damage and neuronal cytoskeletal degradation following traumatic brain injury in mice. *Exp Neurol*. 2015 264:103-10.

[96] Ding K, Wang H, Xu J, Li T, Zhang L, Ding Y, et al. Melatonin stimulates antioxidant enzymes and reduces oxidative stress in experimental traumatic brain injury: the Nrf2-ARE signaling pathway as a potential mechanism. *Free Radic Biol Med.* 2014 73:1-11.

[97] Zhang M, Wu J, Ding H, Wu W, Xiao G. Progesterone Provides the Pleiotropic Neuroprotective Effect on Traumatic Brain Injury Through the Nrf2/ARE Signaling Pathway. *Neurocrit Care* 2017 26(2):292-300.

In: Encyclopedia of Surgery (22 Volume Set)
Editors: Andreas Lehrer and Kristin Mueller
ISBN: 978-1-53618-329-0
© 2020 Nova Science Publishers, Inc.

Chapter 224

MULTIMODAL MONITORING IN DECOMPRESSIVE CRANIECTOMY FOR TRAUMATIC BRAIN INJURY AND STROKE

Masoom Desai, MD, Corey Lewis and Neeraj Badjatia*, MD
Section of Neurocritical Care, Program in Trauma
University of Maryland School of Medicine
Baltimore, MD, US

ABSTRACT

The popularity of multimodal monitoring (MMM) in guiding treatment has grown over the past decade, despite slight evidence to support its use. Clarity is lacking about the indications for MMM, when it should be instituted, and how the collected data should be interpreted. Also in question are which MMM physiologic variables are most clinically pertinent and whether a monitoring-targeted approach improves outcomes. Although the contemporary concept of individualizing treatment based on patient-specific physiologic variables has gained increasing favor, few clinical data support this approach. Relying on therapy guided by monitoring of intracranial pressure and cerebral perfusion pressure is proving to be insufficient in addressing the pathophysiology of critical neurologic conditions. Understanding the limitations and challenges of MMM is crucial to interpretation of the data. Moreover, integration of the continuously monitored data and defining the phenotype of brain injury by a cumulative analysis are essential. The integration of MMM into clinical practice is evolving. Recently, several computational systems allowing the integration of the data into electronic medical records have been developed. The concept of individualizing physiologic parameter thresholds and regimen needs further prospective clinical validation.

Keywords: multimodal monitoring, traumatic brain injury, stroke, individualized treatment, data integration, limitations of multimodal monitoring, indications of multimodal monitoring, multimodal monitoring and clinical outcomes

* Corresponding Author's Email: nbadjatia@umm.edu.

INTRODUCTION

Care of patients undergoing decompressive craniectomy for traumatic brain injury or stroke lies in preventing and mitigating secondary brain injury through timely intervention, thus improving outcomes. To achieve the best outcome, appropriate physiological variables such as ICP, CPP, PRx, blood flow velocity, PbtO2, lactate/pyruvate ratio are monitored and any significant changes are managed accordingly. Appropriate decision making is hindered when insufficient data are obtained from the neurological exam and neuroimaging. These static measures do not provide sufficient information on the dynamic pathophysiology that drives secondary brain injury. Data acquisition using several tools such as the neurological exam, neuroimaging, and systemic and neurophysiological parameters, i.e., multimodal monitoring (MMM), can guide individualized care. This approach is promising in detection of early changes before irreversible damage ensues. In this chapter, we discuss the different parameters for MMM, their integration in decision making, and the challenges and limitations they present to those using them.

INTRACRANIAL PRESSURE AND CEREBRAL PERFUSION PRESSURE

Some fundamental concepts undergird our understanding of the dynamic relationship between intracranial pressure (ICP) and cerebral perfusion pressure (CPP). The Monro-Kellie doctrine, for example, provides the conceptual basis for treating elevated ICP. Human intracranial volume is constant and is a sum of the volumes of cerebrospinal fluid, brain, blood, and mass lesion. An increase in the volume of any one of these components beyond the compliance of the brain inevitably leads to elevated ICP. Lundberg [1] introduced the concept of slow waves of ICP and interpretation of pathologic waveforms. Later, Langfitt et al. [2] and Lofgren and Zwetnow [3] introduced the pressure–volume curve and the term *compensatory reserve*.

ICP Wave Forms

The ICP wave form comprises three prominent components: pulse wave form, respiratory wave form, and slow waves. These components overlap in the time domain but can be separated in the frequency domain. The pulse wave form has several components of which the fundamental component correlates with heart rate and represents the mean ICP. The amplitude of this component is valuable in extracting various indices. ICP wave has pulsatile quality at two different frequencies, one synchronous with the arterial pulse and the other synchronous with the respiration. The respiratory waveform is related to the frequency of the respiratory cycle (8–20 cycles per minute). Slow waves commonly are not as explicit as in the original Lundberg thesis [1]. The cerebrospinal fluid pulse waveform is depicted in Figure 1. The three classically described patterns of ICP fluctuation reported by Lundberg are known as A, B, and C waves. Figures 2 and 3 depict Lundberg type A and B waveforms. C waveforms are not thought to have pathophysiological importance.

Pressure Volume Compensatory Reserve

The brain has a compensatory mechanism when there is an increase in one of the compartments with volume changes in the others. This compensatory mechanism defines the compliance of the brain. When these compensatory mechanisms fail, a small volume change can cause a significant ICP increase or even herniation. Compliance is vital since a patient with poor compliance is at a greater risk than one with good compliance, even if that patient's ICP is normal. The compensatory reserve can be plotted by defining the relationship between the mean ICP and changes in volume of the intracerebral space, known as the pressure–volume curve. This index is called the RAP [4], i.e., the correlation coefficient [R] between the amplitude [A] and the mean pressure [P]. An interpretation of RAP as an index delineates where the cerebrospinal system "working" point rests on the pressure–volume curve. An RAP coefficient nearing 0 signifies a lack of synchronization between changes in the amplitude of the fundamental component and the mean ICP. This represents a good pressure–volume compensatory reserve at low ICP, where a change in volume produces no or very minor change of the pressure. On the other hand, when RAP increases to +1, the amplitude of the fundamental component varies proportionally to the ICP. The curve of intracranial space shifts toward the right, toward the steep part of the pressure–volume curve. In this phase, the compensatory reserve is low and thus any additional increase in the volume will lead to a sharp
rise in ICP.

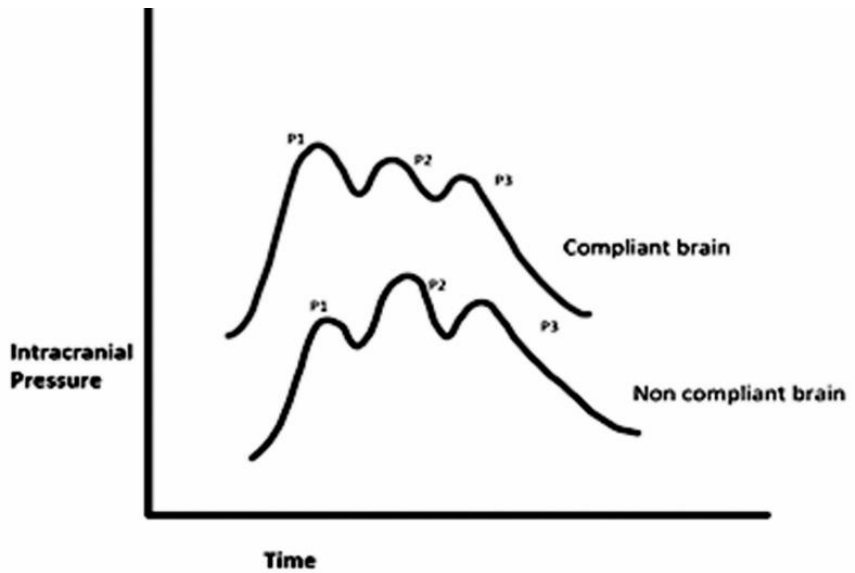

Figure 1. Sketch indicating the three components of ICP monitoring tracing, (1): percussion wave (P1), tidal wave (P2), and dicrotic wave (P3). The percussion wave correlates with the arterial pulse transmitted through the choroid plexus into the cerebrospinal fluid, and via a column of fluid into the external ventricular drain (EVD) transducer. The tidal wave represents the cerebral compliance. The amplitude of P2 generally increases as compliance decreases, and when the P2 exceeds the P1 waveform, a marked decrease in cerebral compliance exists. The dicrotic wave correlates with the closure of the aortic valve, which makes the trough prior to P3 the equivalent of the dicrotic notch. (Courtesy of N Badjatia, University of Maryland).

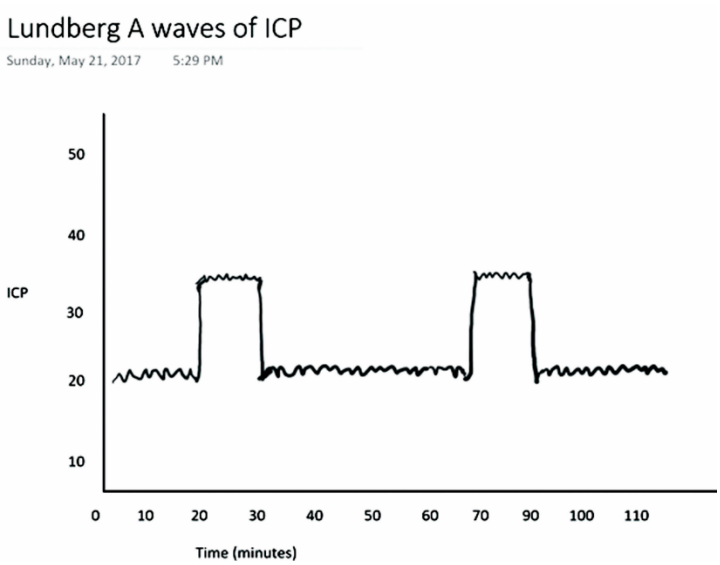

Figure 2. Sketch indicates 2 classic Lundberg type A waves. These are steep rises in ICP to a plateau of 40 mm Hg or higher and are sustained for 5 to 20 minutes before falling rapidly. They represent a critical reduction in intracranial compliance. Plateau waves are associated with working cerebrovascular reactivity and low cerebrospinal compensatory reserve (Courtesy of N Badjatia, University of Maryland).

METHODS OF ICP MONITORING

ICP monitoring and treatment are best performed through a multimodal approach that encompasses clinical examination and imaging modalities. The intraparenchymal and intraventricular catheters are two preferred techniques in widespread use for ICP monitoring. Both are invasive devices and carry minimal risk of infection and bleeding when placed by skilled operators [5]. The intraventricular catheter is considered a gold standard and represents a global ICP assessment in comparison to the intraparenchymal monitor. In addition, it aids in cerebrospinal fluid diversion into the external ventricular drainage (EVD) and hence is an important resuscitation tool, especially in cases of acute hydrocephalus. It may have additional benefits with lower rates of refractory ICP and improved outcomes over intraparenchymal monitors [6]. The intraventricular catheter can also assist in delivering intraventricular drugs such as a thrombolytic for clearance of intraventricular hemorrhage [7]. Intraparenchymal monitors are relatively easier to place than intraventricular catheters. A major downside of intraparenchymal monitors is that they can give an inaccurate reading in cases where there is focal pathology leading to compartmentalization of ICP due to cerebral hemispheric and tentorial boundaries [8].

A change in baseline ICP readings, called a zero drift, associated with microtransducer systems in the intraparenchymal probes can result in measurement error over a certain period. In addition, parenchymal devices have limitations regarding recalibration in vivo and durability [9]. A recent meta-analysis showed both types of monitors yield similar average values, but interval values could differ [10]. Choice of which method to use is decided on an individualized basis and factors such as the etiology of the brain injury, coagulopathy,

accuracy, reliability, complication rates, and the cost associated with the devices [11]. With transition to electronic charting, a new paradigm of automated data collection allows for more accurate recording of data and holds intriguing future applications. Manual recording of ICP is not an accurate representation of the true pattern of unstable ICP in patients with traumatic brain injury (TBI) [12]. Automated continuous dynamic monitoring of mean arterial pressure (MAP) and ICP allows accurate prediction of episodes of intracranial hypertension and long-term outcomes in the neurosurgical intensive care unit [13].

Noninvasive Modalities for ICP Monitoring

Noninvasive techniques such as transcranial Doppler (TCD) and optic nerve sheath diameter (ONSD) have been utilized for ICP monitoring, especially when an invasive modality is contraindicated, not clearly indicated, or not available. TCDs can assess ICP through several methods including pulsatility index, noninvasive assessment of CPP, and several mathematical models. Depending on the method, there is considerable intra- and inter-group variability in reporting accuracy. Using the pulsatility index, Bellner and colleagues demonstrated encouraging results [14]. They cited a robust relationship between the pulsatility index and ICP with a correlation coefficient of $R = 0.94$ ($P < 0.05$). However, other studies have reported a weaker correlation between the pulsatility index and ICP [15, 16]. Studies have reported a similar variance in accuracy of monitoring ICP when using CPP estimation with TCDs. Czosnyka et al. estimated CPP using flow velocity and arterial blood pressure and reported a correlation coefficient of $R = 0.73$ between noninvasive CPP measurements and CPP measured through a parenchymal monitor. The estimation error was less than 15 mm Hg in up to 84% of cases [17]. TCD, however, is insensitive in cases where the elevation of ICP is not vasogenic in origin [18]. There can be technical difficulties in cases where an adequate acoustic window for artery insonation is not present. Precision of the tool is also dependent on operator skills. Despite of these limitations, TCD is good screening tool for ICP. ONSD can be measured using an ultrasound, and a 4.5- to 5.5-mm ONSD roughly correlates to an ICP of 20 mm Hg [19, 20]. ONSD has been shown to be much more predictive of ICP than computed tomography (CT) features in severe TBI patients [21]. The robust data on ONSD reported by Rajajee et al. [19] suggested an ONSD >4.8 mm correlated to an ICP >20 mm Hg with a sensitivity of 96% and a specificity of 94%. Other studies have reported a lower sensitivity and specificity [22]. Although ONSD is a quick tool to assess ICP, it provides only a snapshot of information. ONSD varies with individual factors such as age and underlying pathology, making it difficult to create a threshold for ICP treatment. This tool has good utility as a screening tool and in places lacking resources for continuous ICP monitoring. Another noninvasive approach of ICP measurement is an automated Neurological Pupil index obtained using a pupilometer. All of the above techniques have limitations, such as lacking the capability of continuous detection of changes, and need further clinical validation. Still, they serve as good screening tools and provide easy means of performing repeated assessments.

Indications for ICP Monitoring

The Brain Trauma Foundation (BTF) "Guidelines for the Management of Severe Traumatic Brain Injury" advocates monitoring ICP in all salvageable patients with a severe TBI (Glasgow Coma Score [GCS] 3–8 after resuscitation) and an abnormal CT scan (revealing hematomas, contusions, swelling, herniation, or compressed basal cisterns). This position was supported by Level IIB evidence [23]. ICP monitoring should be established in patients with severe TBI with a normal CT scan if two or more of the following features are noted at admission—age over 40 years, unilateral or bilateral motor posturing, or systolic blood pressure <90 mm Hg. The reason is that the incidence of intracranial hypertension was almost 60% when at least two of these features were present [24].

The consensus conference of recognized experts on ICP monitoring in TBI has made several additional recommendations [25]:

- Monitoring the ICP of comatose TBI patients with a normal initial head CT is generally not recommended. Repeat CT is recommended to rule out any new abnormalities after an early initial CT. Patients with new or worsening CT findings should be monitored.
- ICP monitoring is recommended following a secondary decompressive craniectomy to assess its effectiveness in controlling ICPs and to guide further therapy.
- ICP monitoring after evacuation of an acute supratentorial intracranial hematoma should be considered for salvageable patients with features associated with an increased risk of elevated ICPs. The following are the pre-operative and intra-operative clinical findings warranting ICP monitoring in supratentorial lesions: a GCS motor score ≤ 5 (the risk was felt to be even higher if ≤ 4); pupillary abnormalities (anisocoria or bilateral mydriasis); prolonged/severe hypoxia and/or hypotension; compressed or obliterated basal cisterns; midline shift exceeds 5 mm; midline shift exceeds thickness of an extra-axial clot; additional extra-axial hematomas, parenchymal injuries (such as contusions) or swelling and evidence of intraoperative brain swelling.
- Comatose patients with an initial CT scan demonstrating diffuse injury with signs of brain swelling (e.g., compressed/absent basal cisterns) should have ICP monitoring.
- Comatose patients with traumatic brain contusions, in whom the interruption of sedation to check the neurological status is considered dangerous or when the clinical examination is not completely reliable, should be subjected to ICP monitoring.
- Primary decompressive craniectomy (i.e., absence of bone flap) is not a sufficient reason for not monitoring the ICP in the postoperative period if any indications for ICP monitoring are present.

ICP Monitoring in Traumatic Brain Injury and Outcomes

CPP optimization and control of raised ICP are fundamental in addressing the primary and secondary pathophysiologic processes in TBI. ICP is an important marker of injury severity in TBI [26]. Increased ICP is associated with mortality and poor outcomes [26-30]. Even transient episodes of ICP elevation are associated with poor outcomes [30]. In addition,

the pattern and duration of rise and the total dose of ICP are consequential in defining outcomes [27, 31, 32]. ICP treatment responsiveness or refractoriness also affects outcomes [26, 33].

As indicated by the BTF guidelines, moderate quality data exist from multiple observational studies demonstrating benefits of treatment guided by ICP monitoring in the form of decreased in-hospital and 2-week post-injury mortality [34-37]. Aggressive ICP-guided care has also been shown to be more cost effective than routine care [38]. The consensus summary statement of the International Multidisciplinary Consensus Conference on Multimodality Monitoring in Neurocritical Care mandates ICP monitoring when other intracranial monitors are used, to provide a framework for optimal interpretation [11]. Retrospective studies [39, 40] emphasize the importance of monitoring ICP post-decompressive craniectomy, having found better outcomes in the group where the management strategy was based on ICP monitoring.

The Benchmark Evidence from South American Trials: Treatment of Intracranial Pressure (BEST TRIP) showed no superiority of treatment based on ICP monitoring versus intervention based on protocolized neurological exam and imaging [41]. ICP-guided treatment was, nonetheless, more efficient in treating ICPs than the other approach. BEST TRIP, however, was not a trial of ICP monitoring or the efficacy of ICP monitoring, but rather a study of two methods of severe TBI management. The results were informative on the need for further study on selection of patients for ICP monitoring, determination of patient-specific ICP thresholds, and development of treatment protocols and strategies [42].

The recent RESCUEicp trial (Randomised Evaluation of Surgery with Craniectomy for Uncontrollable Elevation of ICP) [43] addressed some of the key limitations of the DECRA (Decompressive Craniectomy) trial evaluating the role of decompressive craniectomy for management of refractory ICP [44]. The RESCUEicp trial compared last-tier secondary decompressive craniectomy with continued medical management in patients with a higher ICP threshold (25 mm Hg for 1 to 12 hours) despite maximal medical treatment except for barbiturates. The study showed benefit in the surgical arm in terms of lower mortality, but a higher number of patients in a vegetative state or with severe disability. The RESCUEicp trial was effective in reducing refractory ICPs, but provided no benefits to the pathophysiology of primary neurologic insult.

Despite current recommendations and clinical practice, Level 1 evidence is lacking on whether therapy guided by ICP monitoring makes a difference in clinical outcome. There is no randomized control trial (RCT) addressing treatment threshold in TBI. The data on target ICP number are derived from several observational studies [23, 24, 45]. An increase in ICP above 22 mm Hg is associated with unfavorable outcomes [46], and is currently the treatment threshold in the BTF guidelines as a Level 2B recommendation [23].

Although CPP can be derived by monitoring ICP, the adequacy of cerebral perfusion cannot be reliably determined by an ICP number. Secondary brain injury can occur even with normal ICP and CPP numbers [47]. Bouzart et al. [48] made this point emphatically by showing that MMM incorporating brain tissue partial pressure of oxygen monitoring in addition to ICP can identify cerebral hypoperfusion more reliably than ICP monitoring alone.

The ICP value is dependent on the interplay of several factors, including cerebral compliance, perfusion, oxygenation, and cellular functioning, that vary in different pathophysiological states. In addition, the intensity of the treatment is driven by patient's response/resistance to treatment, which predicts the severity of the insult in several disease

states but does not alter the underlying pathology. Hence, targeting isolated CPP/ICP addresses the supply to brain without considering the underlying cerebral metabolism.

Treatment decisions regarding ICP tend to focus on individualizing thresholds based on patient characteristics, cerebral physiology, and risk–benefit considerations. The approach of treating ICP thresholds is not pathophysiology-specific and is a generalized measure. Hence, the approach to ICP treatment is more phenomenological than mechanistic. It does not allow individualizing therapy and is more reactive than proactive. This underlines the significance of MMM to intervene appropriately on pathophysiological states and individualizing care rather than merely treating an ICP number.

CEREBRAL BLOOD FLOW, CEREBRAL PERFUSION PRESSURE, AND ISCHEMIA

Hypotension significantly impacts outcomes after TBI [49, 50]. Adequate perfusion to the brain is essential in preventing secondary brain injury driven by hypoxia, ischemia, and cerebral metabolism.

Cerebral Blood Flow

Cerebral blood flow (CBF) is regulated and affected by several varied factors such as arterial blood pressure, intracranial pressure, venous outflow, blood viscosity, partial pressure of carbon dioxide or oxygen in arterial blood (PaCO2 and PaO2, respectively), collateral flow, vasoreactivity, and the status of cerebral autoregulation. Alterations in the PaCO2 exert a profound influence on CBF, with an approximately 4% change in CBF for every 1-mm Hg change in PaCO2 in either direction. This arteriolar response is mediated by a local effect of H+ ions or pH fluctuations in the extracellular fluid surrounding vessels in the brain [51]. The PaO2 in the normal physiological range does not affect CBF, but when PaO2 falls below 50 mm Hg, CBF increases dramatically. CBF can be measured both directly and indirectly; however, direct measurement is challenging. For this reason, surrogate variables have been used to monitor and treat patients with TBI and stroke. CBF can be directly measured using a thermal diffusion probe (Hemedex) inserted into brain parenchyma. The probe measures the thermal gradient between the distal thermistor and the proximal temperature sensor, providing a regional CBF measured in milliliters/100 grams brain tissue/minute. Normal CBF in humans varies widely depending on tissue demands and age, but averages around 50 mL/100g/minute. Irreversible neuronal damage occurs in a time-dependent manner when CBF is below 10–15 mL/100 g/minute, whereas reversible neuronal dysfunction has been noted at a CBF between 15 and 20 mL/100 g/minute.

TCD is a well-studied, noninvasive, and easily reproducible tool for estimating CBF. TCDs provide an indirect estimate of CBF based on flow velocity through a cerebral vessel. A linear relationship exists between CBF and middle cerebral artery flow velocity if the cross-sectional area and angle of insonation are constant. The Lindegaard ratio [52], the ratio of the middle cerebral artery velocity to the internal carotid velocity, can signify if the increase in the middle cerebral artery (MCA) velocity is related to vessel narrowing.

The strategy of hyperventilation is often used in the acute setting of TBI and elevated ICP. Excessive hyperventilation in TBI can result in ischemia and is associated with poor outcomes [53, 54]. An end tidal CO_2-guided hyperventilation strategy and assessment of CBF can therefore be crucial in these patients. In addition, CBF assessment is also crucial in patients requiring sedation and paralysis with mechanical ventilation. TCDs can help estimate CBF at bedside under these circumstances.

Although positron emission tomography (PET) is the accepted gold standard for assessment of CBF and brain metabolism, its prohibitive cost and limited accessibility in many trauma centers have restricted the widespread clinical use of PET in the acute setting. As an alternative, xenon-enhanced CT has been validated as a method for measuring CBF and guiding management in TBI [55-57]. Xenon-enhanced CT provides a measurement of the CBF. Ischemia within 6–12 hours following trauma as detected by xenon CT studies in TBI patients has been associated with adverse long-term outcome [58].

Arterial spin labeling (ASL) is a magnetic resonance imaging (MRI) technique that enables the measurement of brain perfusion noninvasively at the tissue level. ASL works on the principle of magnetically labeled blood obviating the need of contrast. ASL is a sensitive modality to detect structural brain damage and outcome in mild TBI [59]. Application of ASL depicts mismatch perfusion in acute stroke and helps identify tissue at risk in chronic cerebrovascular disease. ASL can be used to estimate the cerebrovascular reserve and future risk of cerebrovascular events [60].

Cerebral Perfusion Pressure

CPP is defined as the difference between the MAP and the ICP. This represents the pressure gradient driving CBF and hence oxygen and metabolite delivery. The current BTF guidelines on CPP recommend a threshold of 60–70 mm Hg in TBI patients [23]. Different strategies to optimize CPP in TBI patients have been studied [61, 62]. Patients who have an impaired autoregulatory status will have increased cerebral blood volume and increased risk of secondary brain injury with higher CPPs due to elevated ICPs and hyperemia [63]. Loss of autoregulation puts the patient at risk of secondary brain injury via ischemia with hypotensive episodes. On the other hand, patients with intact autoregulatory status would be better served with higher CPPs. Depletion of the cerebrovascular reserve and impaired autoregulation leads to direct dependence of CBF on CPP; hence the CBF may still be suboptimal despite the CPP being within normal range [64]. The adequacy of the CBF and CPP is also dependent on the cerebral metabolic oxygen consumption. Despite decreased CBF, there would be no ischemia if the cerebral metabolic rate of oxygen (CMRO2) is decreased (e.g., in sedation). To the contrary, when CBF reduction is greater than the CMRO2, ischemia and eventually secondary brain injury ensue. The ultimate goal for CPP depends on the autoregulatory status of the patient. Optimal CPP, i.e., the range of CPP at which the autoregulatory status is intact, can be calculated using the pressure reactivity index (PRx). Several studies have assessed the relationship between optimal CPP, neurologic outcomes (65-68), and physiologic outcomes [64] in TBI. Jaeger et al. demonstrated that CPP above optimal has no benefit on brain tissue oxygenation after TBI [64]. Large deviations from CPP above optimal on either side are associated with poor outcomes [68]. CPP augmentation puts patients at risk for systemic complications (e.g., ARDS), for demand ischemia in other organs, and for poor outcomes [62,

69]. Targeting optimal CPP can be much more effective than having a range of CPP thresholds in preventing secondary brain injury and complications. However, there still is not enough evidence to incorporate a single number for CPP into clinical practice [70].

Cerebral Autoregulation

Under normal physiological conditions, cerebral autoregulation is a complex process that is a byproduct of the interplay between myogenic, neurogenic, and metabolic mechanisms. Cerebral autoregulation is a protective hemodynamic mechanism developed to protect the brain from changes in CPP causing either hypoperfusion or hyperperfusion. Autoregulation normally maintains MAP between ~ 50 and 150 mm Hg. Normal CBF in humans varies widely depending on tissue demands and age but averages around 50 mL/100 g brain tissue/minute. Acute brain injury, however, often leads to dysfunctional autoregulatory mechanisms lasting up to 2 weeks [71]. The assessment of pressure autoregulation can be classified as static or dynamic [72]. Static assessment illustrates changes in the CBF measures due to fluctuations in MAP. Dynamic assessment takes into account the time factor when looking at changes in CBF in response to MAP. There are two fundamental approaches to optimizing therapy and treating patients with TBI. One approach is the Lund concept [73, 74] that is based on managing increased ICP and regulating cerebral volume. The other is an aggressive CPP management [61] to prevent ischemia and secondary brain injury. Howells et al. [75] suggested that the most appropriate of the two approaches for individual patients may depend on the state of cerebrovascular PRx. PRx is a dynamic assessment of autoregulation.

Pressure Reactivity Index

Cerebrovascular pressure reactivity is the ability of vascular smooth muscle to respond to changes in transmural pressure. As described by Czosnyka and colleagues, PRx is a computer-aided method of calculating a correlation coefficient between 40 past consecutive 5-second averages of ICP and arterial blood pressure (ABP); computations were repeated with a moving window every 5 seconds [76]. Current standards for computing PRx in monitoring are modified to a moving correlation coefficient between 30 values of consecutive 10-second ABP and ICP averages. If pressure reactivity is intact, a rise in MAP will lead within 5–15 seconds to vasoconstriction with reduction in cerebral blood volume, and thus will lower ICP. If there is dysregulation in pressure reactivity, cerebral blood volume will increase passively, and ICP will rise. When there is a reduction in MAP, the opposite takes place. This technology has been used to develop individualized thresholds for ICP and CPP above optimal. Information on pressure reactivity can potentially guide treatment decisions for intracranial hypertension based on the cerebral physiology.

A positive PRx suggests a positive association of ABP and ICP, reflecting a passive non-reactive vascular bed (Figure 4). A negative value of PRx reflects a normally reactive vascular bed, representing an inverse association between ABP and ICP. Patients can have impaired autoregulation even with mild TBI, making them more susceptible to hypotension. Impaired cerebral autoregulation will lead to sudden increases in MAP being easily transmitted into the microcirculation and can contribute to secondary brain injury in the form

of ischemia/ infarction, hyperemia, cerebral edema, or cerebral hypoxia [63]. Furthermore, cerebral autoregulation determines the response to the treatment administered to a patient with severe TBI, including hyperosmolar therapy and vasopressors. A positive PRx correlates significantly with high ICP, low admission GCS score, and poor outcome at 6 months after injury [76]. PRx correlates well with cerebral autoregulation flow velocity in TCD ultrasonography, static rate of autoregulation based on TCD.

The PRx has been validated against a PET-derived static rate of autoregulation based on PET and oxygen extraction fraction [77]. Patient-specific ICP thresholds calculated based on PRx and the total ICP dose were shown to be more robust predictors of 6-month clinical status and mortality than the conventional thresholds of 20 and 25 mm Hg [78]. In patients after decompressive craniectomy, PRx might not be as useful unless clearly positive, because of the considerably high compliance of intracranial cavity after skull opening. Limitations of the PRx lie in measuring accurate MAPs and CPP calculations, which can have significant implications for treatment based on them [79]. Despite optimal CPP/ICP numbers, cerebral hypoxia can still occur [80, 81]. Studies assessing the interplay between cerebral microdialysis, PET imaging, and brain tissue oxygen tension (PbtO2) monitoring have demonstrated that despite normal ICP/CPP parameters, cerebral hypoxia and secondary brain injury can occur [47, 82-84]. A CPP/ICP-targeted approach might therefore be suboptimal in TBI patients. For this reason, there has been a recent emphasis on characterizing the cerebral physiology and metabolism and on individualizing treatment based on the patient's clinical profile. This approach could offer an edge in guiding therapy and preventing potential deleterious side effects of the treatment strategies (Figure 5).

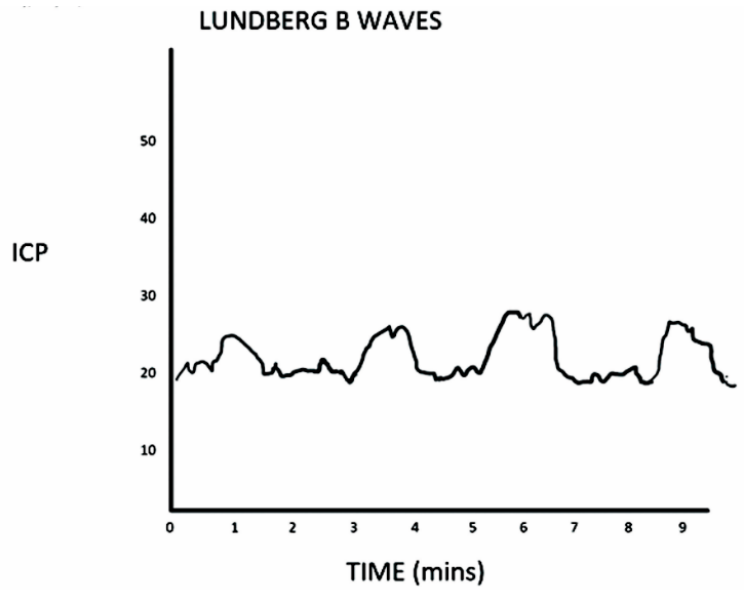

Figure 3. Sketch indicates Lundberg type B waves. Lundberg type B waves occur with a frequency of 0.5 to 2 Hz and are rhythmic oscillations to 20–30 mm Hg above the baseline but without a sustained period of intracranial hypertension (Figure 3) (Courtesy of N Badjatia, University of Maryland).

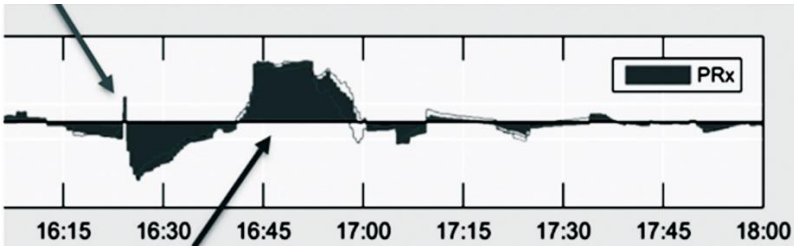

Figure 4. Sketch indicating a positive correlation coefficient (pointed out by the long arrow at 16:45) between changes in mean ICP and MAP (PRx) which signifies poor pressure-reactivity of cerebral arterioles (Courtesy of N Badjatia, University of Maryland).

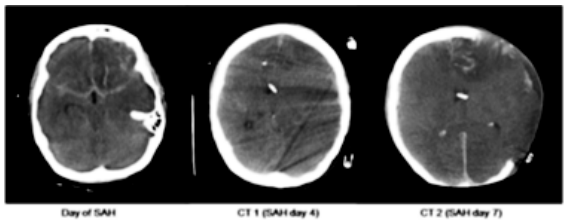

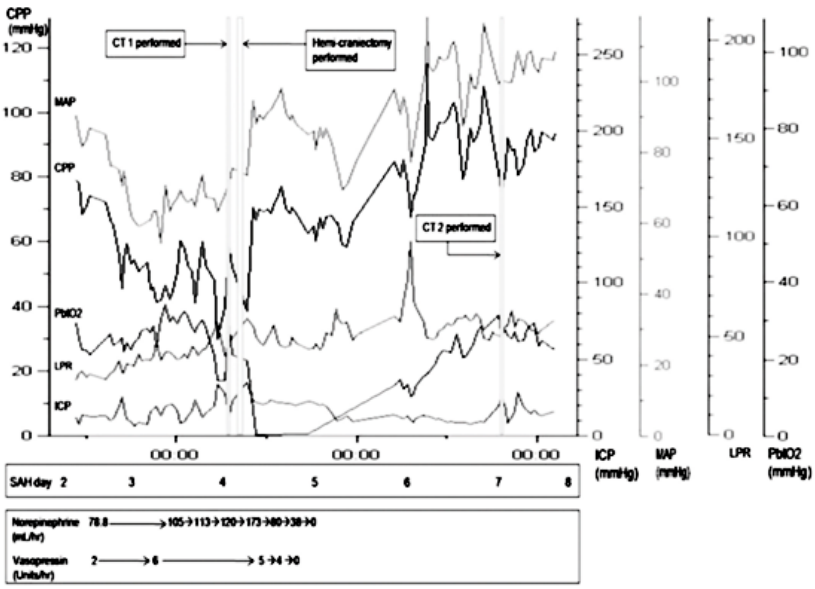

Figure 5. Example of MMM changes preceding hemicraniectomy in a subarachnoid hemorrhage patient (reference: Stuart et al. Neurocrit Care (2011) 15:146–150). Intracranial pressure (ICP), cerebral perfusion pressure (CPP), mean arterial pressure (MAP), lactate: pyruvate ratio (LPR), and brain tissue oxygen tension (PbtO2) trends for post-bleed days (SAH days) 2–8. Infusion rates of norepinephrine and vasopressin are also displayed, as well as timing of head CT's. Before craniectomy, note the decrease in CPP and MAP despite increasing rates of norepinephrine and vasopressin, as well as the early rise in LPR >40, decrease in CPP < 40 mm Hg, and late decrease in PbtO2 < 25 mm Hg. In the hours immediately preceding hemicraniectomy, the LPR was actually greater than the CPP. After craniectomy, ICP was maintained <25 mm Hg and CPP > 60 mm Hg, and all pressors were weaned to off within hours. The PbtO2 probe malfunctioned immediately post-surgery (Courtesy of N Badjatia, University of Maryland).

Brain Oxygenation

While PET is considered the gold standard in monitoring brain tissue oxygenation, other modalities include jugular venous oxygen saturation (SjVO2), brain tissue oxygenation (PbtO2), oxygen reactivity index (ORx), near-infrared spectroscopy (NIRS), and MR spectroscopy. Imaging modalities provide snapshots of information versus dynamic information obtained through continuous modalities. BTF guidelines recommend placement of a brain oxygenation monitoring device when hyperventilation strategies are employed. More recent MMM guidelines recommend placement of a PbtO2 device in patients at risk for ischemia [11, 23].

SjVO2

Oxygenation of cerebral venous outflow has been utilized as a neuromonitoring modality for several decades [85, 86]. SjVO2 provides an estimate of global cerebral oxygenation status and adequacy of the CBF. The jugular bulb, the dilated portion of the jugular vein just below the base of the skull, is the preferred site for blood sampling. Even though the jugular bulb drains bilateral hemispheres, usually the right internal jugular vein is the dominant side of drainage, making it the preferred side for insertion in diffuse disease processes. In cases of a focal brain injury, it is controversial whether the catheter insertion site should be ipsilateral to the brain injury side or on the dominant side, if a difference exists. There is significant disparity between two jugular vein oxygen saturation measurements [87]. Needle puncture, retrograde central venous catheter into the jugular vein, or insertion of a fiber optic catheter all allow for a continuous SjVO2 monitoring. Skull x-ray can be used to confirm placement. On a lateral neck radiograph, the catheter tip should be at the level of and just medial to the mastoid process.

Important formulas related to the physiology of brain oxygenation and utilization are as follows:

$$DO2 = CBF \times CaO2$$
$$CMRO2 = CBF\ (CaO2 - CjvO2)$$
$$AjvDO2 = CMRO2 \div CBF$$
$$CBF = \underline{\Delta}P\ \pi\ r\ 4 \div 8ZL$$
$$\text{Arterial Oxygen content} = (1.34 \times Hgb \times PaO2) + (0.0031 \times PaO2)$$

where DO2 = delivery of oxygen, CBF = cerebral blood flow, CaO2 = arterial oxygen content, CMRO2 = cerebral metabolic rate of oxygen, CjVO2 = jugular venous oxygen content, Hgb = hemoglobin, SjVO2 = jugular venous oxygen saturation, AjvDO2 = difference in oxygen content between arterial and jugular venous blood, PaO2 = arterial oxygen saturation, r = radius, P = pressure, Z = viscosity, and L = length. CBF is governed by Pouiselle's law.

Normal SjVO2 ranges from 55% to 75%. SjVO2 is an indirect assessment of cerebral oxygen consumption. When demand exceeds supply, the brain extracts greater oxygen, resulting in decreased jugular bulb oxygen saturation. If CBF decreases, eventually the compensatory mechanism of increased oxygen extraction in response to decreased CBF will

fail and result in anaerobic metabolism with lactate production. When cerebral oxygen supply exceeds demand, SjVO2 is elevated.

SjVO2 monitoring has numerous clinical implications. For one, it promptly diagnoses ischemia resulting from either cerebral or systemic causes [88-92]. SjVO2 < 55% suggests ischemia or increased metabolism and oxygen extraction, whereas SjvO2 > 75% indicates hyperemia and decreased metabolic demand. Low values are associated with poor outcomes especially in the setting of no improvement with CPP augmentation [93]. SjVO2 can guide treatment decisions regarding fluid strategy, optimization of CPP and oxygenation [11, 23, 89], and detecting arteriovenous fistulas [94]. ICP management, including utility of barbiturates [95] for suppressing cerebral metabolism, is also guided by SjVO2 monitoring [11, 23].

Complications associated with SjVO2 include carotid artery puncture, pneumothorax, injury of cranial nerves IX and X, infection, and thrombosis. Appropriate placement of the catheter in the jugular bulb is crucial to avoid extracranial contamination and inaccurate information. The interpretation of SjVO2 and CBF can be challenging by itself, since the assumption is that the CMRO2 remains constant. In addition, SjVO2 can be insensitive to focal ischemia. High SjvO2 values can be falsely reassuring because they may, in fact, be associated with pathologic arteriovenous shunting, brain death, or cerebral infarction.

PbtO2

PbtO2 has become the gold standard for monitoring brain oxygenation. The limitations of CPP/ICP monitoring to detect ischemia/hypoxia are avoided by PbtO2 monitoring [48]. It assists in better understanding the underlying pathophysiology of secondary brain injury. PbtO2 is affected by oxygen demand and supply including perfusion and oxygenation [96-99]. However, several factors such as relative proportion of arterial and venous supply in the region of interest (shunting) and diffusion barriers (interstitial/cellular edema) [100], cerebral metabolism (fever, seizures, shivering), and systemic factors like PaCO2, PaO2 [101-104] affect PbtO2. Hence, PbtO2 is more of a marker of cellular and mitochondrial functioning. Rosenthal et al. showed that a PbtO2 number is the result of CBF and the arteriovenous oxygen tension difference rather than being a surrogate of cerebral metabolism and oxygen delivery [105]. That PbtO2 can be low despite a normal CBF suggests microcirculatory collapse and edema [100]. This can be clinically significant when assessing MMM data to guide treatment.

Normal PbtO2 ranges from 25 to 35 mm Hg [106-108], with the most recent MMM guidelines suggesting 20 mm Hg as the treatment threshold [11]. Ischemic thresholds have ranged between 10 and 19 mm Hg in the literature [109-111]. PbtO2 <5 mm is associated with cell death [112-114]. The clinical significance of the PbtO2 number varies based on the probe placement [109]. When the probe is placed in the normal tissue and autoregulation is intact, PbtO2 has a good correlation with CPP. In penumbral tissue, the correlation with CPP can be inconsistent. When placed in dead tissue, there is no correlation with CBF/CPP.

PbtO2 has various methods of measurement. Biomedical engineering includes optical luminescent and polarographic methods. The polarographic method is much more common, and has been used in the development of the LICOX® (Integra Neurosciences, Plainsboro, NJ) brain tissue monitoring system, commonly used in clinical practice. The NEUROVENT®-PTO (Raumedic Co., Mills River, NC) multimodal catheter uses optical

luminescence methodology. The LICOX monitor is inserted into the brain parenchyma like a fiber optic ICP monitor, generally 3.5 cm below the dura in the frontal white matter. It measures the partial pressure of oxygen around the catheter insertion site, which measures about 17 mm^3 of brain tissue around the distal end. In TBI, the monitor is usually inserted into the normal brain tissue in the frontal lobe ipsilateral to the severely injured brain. In cases of diffuse injury, the monitor is usually inserted into the non-dominant hemisphere.

PbtO2 monitoring has numerous clinical implications. In TBI, several observational studies have reported the effect of brain hypoxia on outcome. The presence of cerebral hypoxia has been associated with unfavorable outcomes at 6 months and increased mortality [47, 115-117]. Increasing duration of hypoxia [111] and early hypoxia within the first 72 hours after brain injury [118] have been shown to predict mortality. The duration and burden of brain tissue hypoxia have also been associated with worse outcome at 30 days [47, 84]. PbtO2 has been established as an independent predictor of outcomes. Low PbtO2 is not specific for simple perfusion failure. Factors such as PCO2, PaO2, and hypermetabolic states can all affect PbtO2. PbtO2 number signifies a balance between supply, which is dependent on perfusion, and demand, which is the magnitude of oxygenation and extraction. Although a PbtO2-guided intervention strategy in TBI has been studied, the data on outcome benefits are still unclear [119-122]. The BTF guidelines recommend PbtO2 monitoring in patients with severe TBI to complement ICP/CPP monitoring [23]. PbtO2 monitoring can be used to individualize thresholds for CPP in conjunction with ICP monitoring [123].

ORx

The oxygen reactivity index (ORx) is a surrogate of pressure autoregulation and has some prognostic value. The potential to improve PbtO2 using vasopressors by increasing the MAPs and CPP is dependent on the status of cerebral autoregulation. When the autoregulation is intact, increasing the CPP usually has a negligible effect on the PbtO2, and compensatory vasoconstriction leads to the CBF and oxygen delivery remaining constant. In the event of the autoregulation being impaired or when the CPP is outside the autoregulatory range, either too low or too high, CBF and brain PbtO2 correlate directly with CPP augmentation, leading to elevation in brain PbtO2. The ORx is calculated as the moving linear (Pearson) correlation coefficient between PbtO2 and CPP and ranges from +1 to -1. When autoregulation is intact, ORx is near 0 or negative. When autoregulation is impaired, PbtO2 passively follows CPP, and ORx is positive. Recent studies, however, have refuted the relationships between PRx and ORx and between ORx and PbtO2 [124].

ORx has the advantage of being one of the most effective real time bedside monitoring tools available for detecting focal ischemia. It provides focal monitoring for tissue at risk of secondary brain injury, and it is a relatively safe modality. But its use does have limitations. Because it is a focal invasive monitor, ORx can miss distant changes in the tissues. It can have sensitivity drift requiring recalibration. There is a “run in” period immediately after the probe insertion, when the readings are inaccurate. “Oxygen challenge” should be performed daily post insertion to verify accurate functioning of the probe. Placing the probe into the precise location is challenging, and the probe can give an inaccurate assessment if it is inserted into the lesion instead of viable tissue. Critical thresholds have been ascertained through patient outcomes in small studies rather than pathophysiologic evidence of ischemic damage at the cellular level.

NIRS

Near-infrared spectroscopy (NIRS) in the TBI population is best applied in detection of mass lesions, midline shift, and cerebral edema because of high sensitivity [125]. NIRS is most suitable for use in the outpatient setting for early detection, resuscitation, and quick transfer of patients to well-equipped tertiary centers. Use of NIRS to detect intracranial pathology in the inpatient setting is not widespread owing to readily available CT scan and imaging modalities.

Although the application of NIRS in monitoring ICP has been studied, the exact relationship between information obtained from NIRS and severity of ICP is not quite clear [126, 127]. In addition, there is no convincing evidence that NIRS can be reliably combined with any other invasive monitoring modality (ICP, tissue oxygen tension, jugular bulb saturation), and NIRS cannot be used in place of these modalities when they are indicated. The correlation of PbtO2, SjvO2, and microdialysis with the information obtained from NIRS data is inconclusive. The use of NIRS in TBI is therefore not widespread, owing to concerns about extracranial tissue and lesions interfering with the modality. Current devices monitor change in brain oxygenation. Another limitation of NIRS is that the thresholds for ischemia/hypoxia are not well determined.

Systemic Oxygenation

Systemic venous oxygenation is not a surrogate of SjVO2. The brain receives approximately 15% to 25% of the total cardiac output and has a high extraction capacity and a low oxygenation reserve compared to other organs. Brain PbtO2 correlates with systemic oxygenation and PaO2. For example, acute lung disease will lead to a lower brain PbtO2, independent of cerebral and systemic injuries [128]. The ratio of the change in PbtO2 to the change in PaO2 is described as the tissue oxygen response. The brain responds to hyperoxia in the form of cerebral vasoconstriction [129, 130], thus reducing CBF, a brain protective mechanism related to oxygen toxicity. The tissue oxygen response is another marker of cerebral autoregulation, like PRx and ORx.

Cerebral Metabolism and Microdialysis

Cerebral metabolism, which is significantly altered in acute brain injury, is roughly divided into three phases after brain injury: hypermetabolism lasting hours to days, hypometabolism lasting days to weeks, and transition into normal metabolism lasting weeks to months (this third phase is less well established) [131]. MMM guidelines recommend cerebral microdialysis as a clinical tool in patients with or at risk of cerebral ischemia, hypoxia, energy failure, and glucose deprivation [11].

Cerebral microdialysis requires that a specialized catheter with a semipermeable dialysis membrane be placed into the brain parenchyma through a burr hole and secured by a cranial bolt. The catheter is perfused with a cerebrospinal fluid-like solution, and sampling of brain extracellular fluid is conducted periodically to assess concentrations of lactate and pyruvate, ischemic metabolites, glucose, glycerol, markers of cell membrane damage, glutamate, and

excitatory amino acid. The best of these biomarkers is the lactate/pyruvate (L/P) ratio, which implies a shift from aerobic to anaerobic metabolism and has prognostic significance [11]. L/P ratios >25 have been suggested as critical thresholds for metabolic crisis [132, 133]. Metabolic crisis can occur despite normal ICPs [132] and is associated with poor outcomes. Energy crisis has been found to occur, characterized by normal PbtO2 and elevated lactate with normal/low pyruvate levels, without evidence of ischemia or defect in oxygen delivery related to mitochondrial dysfunction [82]. In addition, L/P ratio has been associated with several causes such as low CPP [134] and thresholds of hemoglobin [135]. Hence, the L/P ratio can have significant clinical implications when using strategies to maximize perfusion.

Several diverse types of brain tissue hypoxias and neuromonitoring profiles have been described in the literature ([136, 137] Table 1). PET studies have found a variable relationship between cerebral metabolic rate for oxygen, L/P ratio, and oxygen extraction fraction depending on the location of the probe, timing of monitoring, and thresholds for ischemia [82, 138]. The type of hypoxia defines the relationship between L/P ratio and oxygen extraction fraction [139]. Interpretation of dialysate components might be confounded by drugs, nonconvulsive status epilepticus, and enzyme deficiencies (140). A reduced brain/serum glucose ratio [141] signifies metabolic crisis and can help differentiate other confounders causing high L/P ratio. In defining critical causes of cerebral perfusion, Bouzat et al. [48] defined a better role for PbtO2 and cerebral microdialysis than ICP monitoring alone. The safety profile of cerebral microdialysis used to determine L/P ratio is similar to any other probe in MMM. Because it provides a focal measurement, its limitations lie in the metabolic collection assessment based on the location between injured and preserved brain. Cerebral microdialysis is a cumbersome technique and metabolite collection occurs over time. Hence, the data interpretation and usage can be delayed. Moreover, the benefits of targeting L/P ratio thresholds in terms of outcomes are unclear. The ideal location for regional monitors of MMM has not been identified. Conventional practice is placement in brain parenchyma at the greatest risk for secondary injury. For focal injury, such as ischemic stroke or traumatic intracerebral hemorrhage or contusion, that location is directly adjacent to the damaged area. In global injury, the non-dominant frontal cortex is used.

Table 1. Neuromonitoring profiles and treatment approaches, by category of brain tissue hypoxia

Category of hypoxia	Neuromonitoring profile	Treatment approach
Ischemic	↓CBF, ↓ CPP ⌣ ICP ↓ PbtO2↑LPR	CPP augmentation with fluid and/or vasopressors Improve oxygen delivery
Hypermetabolic (Demand supply mismatch)	↑CBF, ↑ CPP ⌣ ICP ↑PbtO2↑LPR	Evaluate and treat for causes such as fever, shivering, ictal-interictal EEG patterns

Electrophysiology

Electroencephalography (EEG) is a noninvasive, continuous modality utilized in detecting seizures, ischemic changes, new structural lesions, and recovery of altered mental status following TBI or stroke. EEG provides information on global and regional cerebral

functioning. The rationale for long-term EEG monitoring lies in detecting subclinical seizures as an etiology for altered mental status or coma. In addition, it is hoped that early detection and suppression of seizures, either convulsive or nonconvulsive, would translate into improved outcomes [11, 142, 143]. Incidence of nonconvulsive seizures in TBI has been reported to be up to 22% (144), whereas the incidence of early seizures in acute stroke ranges from 3% to 33%, with 50% to 78% of the seizures occurring within the first 24 hours [145]. Occurrence of seizures within 24 hours of stroke is associated with higher 30-day mortality [145]. Vespa et al. [146] demonstrated a high incidence of nonconvulsive status epilepticus and a relationship between acute posttraumatic nonconvulsive status epilepticus and disproportionate long-term hippocampal atrophy.

Fluctuations in CBF have been linked to changes on the EEG [147], (Figures 5 and 6) and different cellular responses. When CBF drops to 25–35 mL/100 g/minute, the EEG first loses faster frequencies due to anaerobic metabolism and glutamate release at a cellular level. As CBF continues to plummet to about 17–18 mL/100 g/minute, slower frequencies increase, with generation of lactic acidosis and depletion of ATP at the cellular stage. This represents an ischemic threshold (reversible). As CBF declines to 10–12 mL/100 g/minute and lower, sodium-potassium pump failure, an increase in cellular water content, and eventually cell death take place. Cell death is marked by severe suppression on continuous EEG. Diffusion-weighted imaging (DWI) is capable of detecting ischemic changes in stroke at CBF 35–40 mL/100 g/minute within 30 minutes [148]. In comparison, continuous EEG can detect ischemic changes within seconds and provide a window of opportunity to intervene, especially in the case of a mismatch between DWI-identified lesions and clinical assessment.

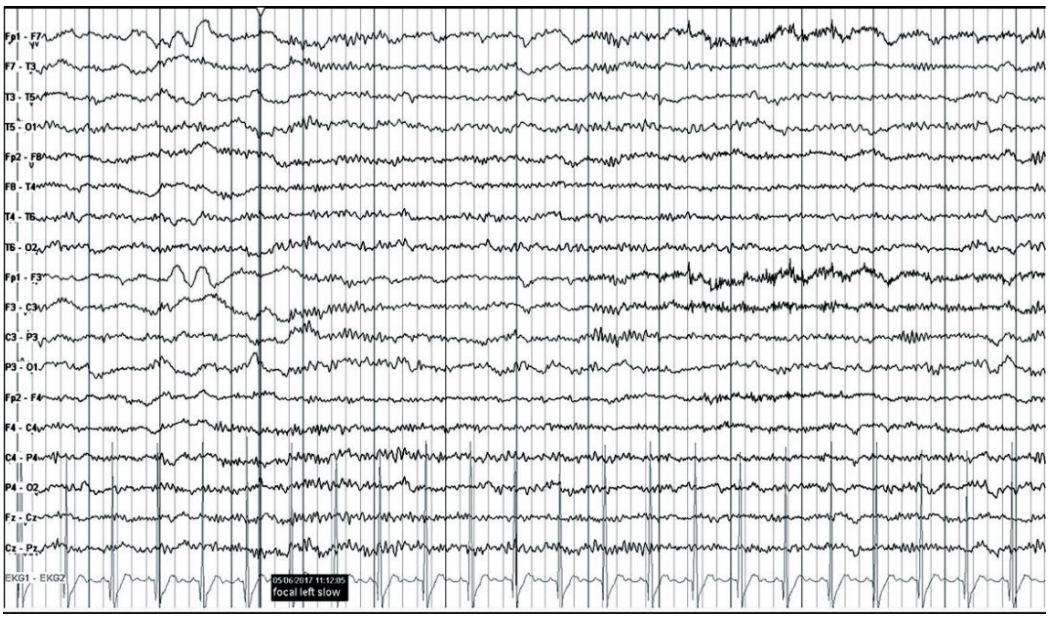

Figure 6. A short strip EEG belonging to a subject following TBI manifesting radiographic evidence of left internal carotid artery (ICA) vasospasm due to post traumatic subarachnoid hemorrhage. There is evidence of slowing of electrical waves over the left hemisphere (Leads with odd numbers) (Courtesy of N Badjatia, University of Maryland).

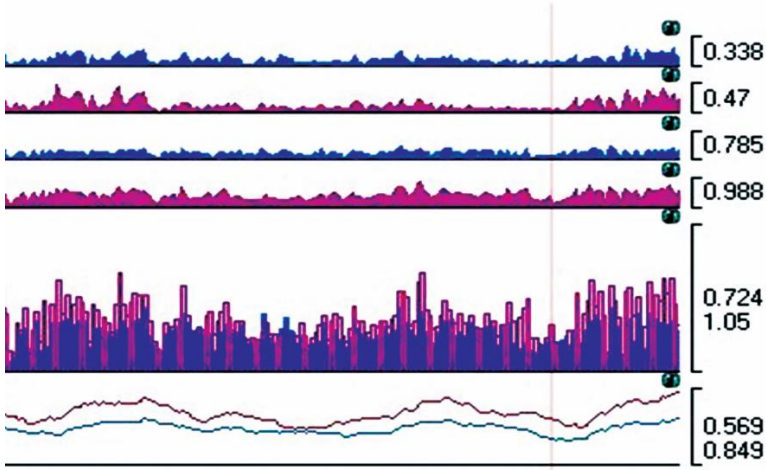

Figure 7. Quantitative analysis of EEG belonging to a subject following TBI manifesting radiographic evidence of left internal carotid artery (ICA) vasospasm due to post traumatic subarachnoid hemorrhage. There is evidence of difference in the Alpha Delta Ratio (ADR) between the left (0.569) and right hemisphere (0.872) (Courtesy of N Badjatia, University of Maryland).

EEG can assist in guiding treatment with either tissue plasminogen activator [149, 150] or augmentation of blood pressure or CBF after an acute ischemic stroke [151]. Quantitative EEG limits subjectivity in EEG interpretation, obviating the need for trained personnel to interpret EEG in the intensive care unit. With Fourier transformation, EEG can be quantified in terms of its amplitude, power, frequency, and rhythmicity, and numerical values, ratios, or percentages can be obtained. When applying quantitative EEG in acute ischemic stroke, the hemispheric relative delta percentage and the overall mean frequency correlate well with CBF [152]. Increase or decrease in the power of slower and faster frequencies varies with the changes in the cerebral metabolism [153]. Continuous EEG can be used to monitor neuropathological mechanisms and to detect markers of secondary brain injury [154] (Figures 6 and 7). These markers are manifested as periods of isolated or continuous depression in the form of high amplitude delta activity induced by spreading cortical depolarization, a feature of all acute brain injury. There are some data on the role of EEG in prognostication in patients with acute brain injury (TBI/stroke). Loss of reactivity [155] and lack of sleep-wake cycles [156] may portend poor prognosis (and indicate possible brainstem involvement). On the other hand, the presence of faster frequencies within 24 hours is consistent with a good outcome [157].

Glucose and Nutrition

Early sympathetic surge related to brain injury can cause dysfunction of glucose control. Hyperglycemia not only is a marker of disease severity in TBI but also can worsen secondary injury. In a study conducted on 59 patients with moderate and severe brain injuries, serum glucose levels >200 mg/dL in the first 24 hours after hospital admission were associated with worse neurologic outcome at hospital discharge, 3 months, and 1 year following trauma [158]. Cerebral microdialysis holds great promise in helping to understand the

pathophysiology of metabolic demand after brain injury and thereby providing an individualized goal. Studies using microdialysis have shown that tight glucose control can exacerbate brain metabolic crisis [159]. In ischemic brain injury, hyperglycemia has been associated with worse outcomes [160]. The Stroke Hyperglycemia Insulin Network Effort trial [161] will be informative in terms of the range of blood glucose to target in acute ischemic stroke.

Temperature and Inflammation

Target temperature management in TBI has been studied under two hypotheses. The first concerns mitigating secondary brain damage caused by ischemia/reperfusion injury and inflammation. The second is based on the role of hypothermia in ICP management. The National Acute Brain Injury Study: Hypothermia (NABIS:H) found no evidence of improved outcomes (Glasgow Outcome Scale at 6 months) in patients who were maintained on a hypothermia regimen for 48 hours after injury [162]. In a later report, NABIS:H II did not show any beneficial effect on morbidity or mortality for patients with severe brain injury [163]. However, subanalyses of RCTs and some animal data suggest a benefit of early, preoperative hypothermia in patients with focal brain lesion [164]. An international multicenter RCT (HOPES trial) is underway assessing the role of hypothermia in acute subdural hemorrhage. More recently, a multicenter RCT to examine the efficacy and safety of long-term mild hypothermia in severe TBI is planned in China (the LTH-1 trial).

The Eurotherm3235 [165] trial was a multicenter RCT assessing hypothermia as a second-tier treatment strategy along with standard medical management versus only medical management with an ICP threshold of 20 mm Hg. The study was stopped prematurely owing to safety concerns, but the results suggest that outcomes were worse with hypothermia than with standard care alone. Several questions have been raised about the trial concerning the timing of hypothermia in general practice and the treatment threshold of ICP used in the study. In a case control study, maintaining normothermia reduced the number of ICP spikes greater than 25 mm Hg, leading the authors to recommend fever avoidance in TBI patients [166]. Currently, the role of hypothermia in TBI is unclear.

Acute Stroke and the Role of Multimodal Monitoring

The use of MMM in acute stroke is far less common than in TBI. Still, the indications for MMM in acute ischemic/hemorrhagic stroke are like those discussed in the section on TBI above. The International Multidisciplinary Consensus Conference on Multimodality Monitoring has made recommendations regarding which non-TBI patients are suitable for ICP and CPP monitoring [167]:

1. Stroke patients with poor neurological exam either before or after decompressive hemicraniectomy.
2. Patients at risk for elevated intracranial pressure/hydrocephalus
3. Patients with supratentorial large hemispheric lesions or large infratentorial lesions

4. Patients with intraventricular hemorrhage with a GCS <8 (poor neurological exam) should be considered for an EVD and ICP and CPP monitoring
5. Patients with deep ischemic/hemorrhagic stroke (at risk for obstructive hydrocephalus) with imaging and clinical exam mismatch should be considered for MMM

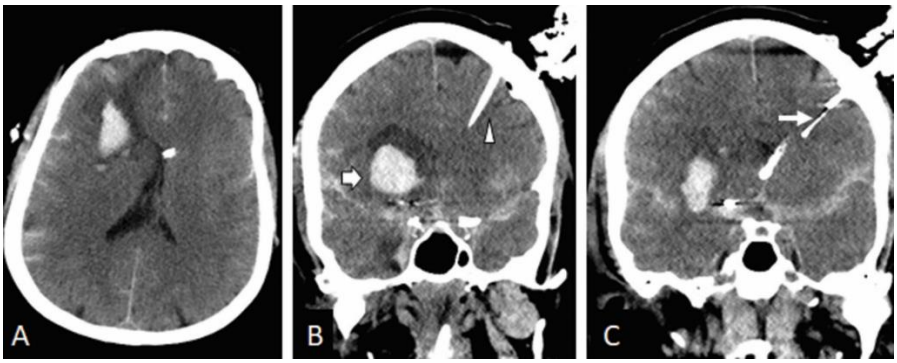

Figure 8. CT images of the head showing diffuse subarachnoid hemorrhage and a frontal parenchymal hematoma with surrounding edema and midline shift. The tip of the EVD is seen in the left lateral ventricle on the axial imaging (Plate A). Coronal sections (Plates B and C) indicate the tip of the Licox probe placed into the normal brain parenchyma (Courtesy of N Badjatia, University of Maryland).

Location of Monitoring

There is no consensus on the ideal location of the MMM probe and the EVD site in the stroke population. The location of the probe should be in the area at highest risk of secondary injury. Thus, in stroke patients the best location is in the penumbra or perihematomal area [168] (Figure 8). However, in cases of severe unilateral damage or if the patient has already undergone a hemicraniectomy, the monitors are inserted into the contralateral areas near the side of lesion. There is also a concern for compartmentalization of elevated ICP in focal brain lesions at a deep or infratentorial location. Because of these limitations, the ICP numbers can be inaccurate and cerebral herniation can ensue without a rise in ICP [169].

ICP and CPP Monitoring in Stroke

When elevated ICP is a concern in management of stroke due to either intraventricular hemorrhage or cerebral edema, EVD is considered the gold standard for monitoring ICP [170, 171]. If intraparenchymal probes are used, the ICP sensor placed contralateral to the ischemic hemisphere can lead to an inaccurate estimation of ICP. Few, if any, studies have shown benefit with therapy guided by ICP monitoring in stroke care. American Heart Association/American Stroke Association guidelines recommend that patients with a GCS ≤8, those with clinical evidence of transtentorial herniation, and those with significant intraventricular hemorrhage or hydrocephalus might be considered for ICP monitoring and treatment. A CPP of 50 to 70 mm Hg has been recommended depending on the state of cerebral autoregulation [170, 171]. Regardless of the underlying physiologic differences in

ICP elevation, maintaining proper CPP before initiating ICP-lowering treatments is of utmost importance. ICP monitoring can give us an understanding of autoregulation and cerebral physiology in stroke. Optimal CPP targets can be delineated for individual patients, and thus assist in pathophysiological goal-directed therapy. A single center using MMM consisting of ICP probe, PbtO2 monitor, and cerebral microdialysis in intracerebral hemorrhage showed the risk of brain tissue hypoxia was higher with CPP <80 mm Hg than CPP >100 mm Hg [172]. In addition, survivors in the study had consistently lower elevations in their L/P ratio and PRx, showing intact cerebral autoregulation compared to those with fatal outcomes. One retrospective observational study utilizing ICP monitoring-based treatment in patients with stroke after decompressive hemicraniectomy showed effective treatment of ICP, but no studies have addressed differences in outcome with such treatment [173].

Cerebral Blood Flow in Stroke

TCDs can be used as a modality for estimating CBF. TCD is less accurate than CT angiography and MR angiography for steno-occlusive disease, with a sensitivity and specificity of 55% to 90% and 90% to 95%, respectively [170]. TCD usage is limited by the skills of the interpreter and the patient's vascular anatomy. Moreover, TCD is not applicable for posterior circulation strokes.

Cerebral Microdialysis in Stroke

In a small prospective clinical study of patients with malignant space-occupying infarction, monitoring showed a substantial increase in concentrations of glutamate and lactate and in the L/P ratio [174]. Overall, the data on cerebral microdialysis are limited in stroke. Data on PbtO2 and SjvO2 are obtained from the TBI studies, and very few studies have looked into their roles in the stroke population [175].

Monitoring of Cerebral Edema in Stroke

Malignant MCA stroke represents 2% to 8% of all hospitalized ischemic stroke cases, and MCA territory ischemic stroke accounts for 10% to 15% of patients hospitalized for stroke [176]. Clinical examination, cortical signs, NIH Stroke Scale, early pupillary abnormalities, and level of consciousness have been associated with malignant MCA and cerebral edema [176]. Neurological deterioration can occur within 72 to 96 hours, and sometimes up to day 10. In the cerebellar strokes, compression of brainstem structures and development of obstructive hydrocephalus will manifest as decline in consciousness with cranial nerve abnormalities [176]. CT is a readily available, safe first-line test that can be used to assess cerebral edema. Several CT findings have been shown to predict development of malignant edema and poor prognosis: hypodensity involving >50% MCA territory on CT within 6 hours, involvement of a third or more of the MCA, and a midline shift ≥5 mm within 2 days [176]. MRI is not as widely available and thus might not be suitable for every patient. The data on MRI to predict development of malignant edema suggest a superiority of MRI over CT. Two studies evaluating MRI within 6 hours found similar cutoffs for DWI volume,

around 80 mL, to be highly predictive, with specificities of 50% to 95%, but sensitivities of 50% to 85%. A DWI volume cutoff of >145 mL for an MRI done in 14 hours achieved a 100% sensitivity and 94% specificity [176, 177].

Limitations of Multimodal Monitoring

MMM is limited in the following ways:

1. It is resource intensive and cumbersome.
2. It requires expertise in interpreting the complex data sets.
3. There is a lack of evidence on improved outcomes using this treatment strategy.
4. Data can be inaccurate depending on the limitations of the modalities and the factors affecting them.

Beyond the obvious challenges of expense, large number of human and technological resources needed, and requirement for expertise in interpreting data, some other problems are less obvious. Chief among these are acquisition, integration, and synchronization of MMM data. Electronic medical records have eased recordkeeping through automated data collection, and they provide more reliable documentation. Unfortunately, many monitors do not interface with electronic medical records. As a result, the data are being captured continuously, but recorded only intermittently. Clearly, further development of continuous data integration into electronic medical records with a user-friendly interface is required. This will help clinicians simultaneously visualize all of the data at any given time, interpret it, and then apply that knowledge to patient care.

CONCLUSION

The integration of MMM in the field of neurointensive care holds great promise for early recognition of worsening brain injury and improving the efficacy of treatment strategies. It is a powerful monitoring tool in cases where the neurologic exam is limited. MMM allows for individualized care rather than a general approach based on the collected continuous data. It helps us detect changes in cerebral physiologic and metabolic states. In addition, the effect of treatment strategy can be observed in real time and the approach can be tailored accordingly. Interpreting and acting on the different physiologic variables can be challenging and have several limitations. The accuracy of several probes and devices can vary based on several factors. Because clinical data on improved outcomes based on treatment guided by MMM are limited, further studies analyzing the application of MMM in improving patient outcomes are required.

REFERENCES

[1] Lundberg N. Continuous recording and control of ventricular fluid pressure in neurosurgical practice. *Acta Psychiatr Scand Suppl*. 1960;36(149):1-193.

[2] Langfitt TW, Weinstein JD, Kassell NF, Gagliardi LJ. Transmission of increased intracranial pressure II. within the supratentorial space. *J Neurosurg*. 1964;21:998-1005.

[3] Lofgren J, von Essen C, Zwetnow NN. The pressure-volume curve of the cerebrospinal fluid space in dogs. *Acta Neurol Scand*. 1973;49(5):557-74.

[4] Czosnyka M, Smielewski P, Timofeev I, Lavinio A, Guazzo E, Hutchinson P, et al. Intracranial pressure: more than a number. *Neurosurg Focus*. 2007;22(5):E10.

[5] Bauer DF, Razdan SN, Bartolucci AA, Markert JM. Meta-analysis of hemorrhagic complications from ventriculostomy placement by neurosurgeons. *Neurosurgery*. 2011;69(2):255-60.

[6] Liu H, Wang W, Cheng F, Yuan Q, Yang J, Hu J, et al. External Ventricular Drains versus Intraparenchymal Intracranial Pressure Monitors in Traumatic Brain Injury: A Prospective Observational Study. *World Neurosurg*. 2015;83(5):794-800.

[7] Webb AJ, Ullman NL, Mann S, Muschelli J, Awad IA, Hanley DF. Resolution of intraventricular hemorrhage varies by ventricular region and dose of intraventricular thrombolytic: the Clot Lysis: Evaluating Accelerated Resolution of IVH (CLEAR IVH) program. *Stroke*. 2012;43(6):1666-8.

[8] Sahuquillo J, Poca MA, Arribas M, Garnacho A, Rubio E. Interhemispheric supratentorial intracranial pressure gradients in head-injured patients: are they clinically important? *J Neurosurg.* 1999;90(1):16-26.

[9] Bekar A, Dogan S, Abas F, Caner B, Korfali G, Kocaeli H, et al. Risk factors and complications of intracranial pressure monitoring with a fiberoptic device. *J Clin Neurosci*. 2009;16(2):236-40.

[10] Zacchetti L, Magnoni S, Di Corte F, Zanier ER, Stocchetti N. Accuracy of intracranial pressure monitoring: systematic review and meta-analysis. *Critical Care.* 2015;19(1):420.

[11] Le Roux P, Menon DK, Citerio G, Vespa P, Bader MK, Brophy GM, et al. Consensus summary statement of the International Multidisciplinary Consensus Conference on Multimodality Monitoring in Neurocritical Care: a statement for healthcare professionals from the Neurocritical Care Society and the European Society of Intensive Care Medicine. *Neurocrit Care.* 2014;21 Suppl 2:S1-26.

[12] Zanier ER, Ortolano F, Ghisoni L, Colombo A, Losappio S, Stocchetti N. Intracranial pressure monitoring in intensive care: clinical advantages of a computerized system over manual recording. *Critical Care*. 2007;11(1):R7-R.

[13] Guiza F, Depreitere B, Piper I, Van den Berghe G, Meyfroidt G. Novel methods to predict increased intracranial pressure during intensive care and long-term neurologic outcome after traumatic brain injury: development and validation in a multicenter dataset. *Crit Care Med*. 2013;41(2):554-64.

[14] Bellner J, Romner B, Reinstrup P, Kristiansson KA, Ryding E, Brandt L. Transcranial Doppler sonography pulsatility index (PI) reflects intracranial pressure (ICP). *Surg Neurol*. 2004;62(1):45-51; discussion

[15] Zweifel C, Czosnyka M, Carrera E, de Riva N, Pickard JD, Smielewski P. Reliability of the blood flow velocity pulsatility index for assessment of intracranial and cerebral perfusion pressures in head-injured patients. *Neurosurgery.* 2012;71(4):853-61.

[16] Voulgaris SG, Partheni M, Kaliora H, Haftouras N, Pessach IS, Polyzoidis KS. Early cerebral monitoring using the transcranial Doppler pulsatility index in patients with severe brain trauma. *Med Sci Monit.* 2005;11(2):CR49-52.

[17] Czosnyka M, Matta BF, Smielewski P, Kirkpatrick PJ, Pickard JD. Cerebral perfusion pressure in head-injured patients: a noninvasive assessment using transcranial Doppler ultrasonography. *J Neurosurg.* 1998;88(5):802-8.

[18] Sloan MA, Alexandrov AV, Tegeler CH, Spencer MP, Caplan LR, Feldmann E, et al. Assessment: transcranial Doppler ultrasonography: report of the Therapeutics and Technology Assessment Subcommittee of the American Academy of Neurology. *Neurology*. 2004;62(9):1468-81.

[19] Rajajee V, Vanaman M, Fletcher JJ, Jacobs TL. Optic nerve ultrasound for the detection of raised intracranial pressure. *Neurocrit Care.* 2011;15(3):506-15.

[20] Cammarata G, Ristagno G, Cammarata A, Mannanici G, Denaro C, Gullo A. Ocular ultrasound to detect intracranial hypertension in trauma patients. *J Trauma.* 2011;71(3):779-81.

[21] Sekhon MS, Griesdale DE, Robba C, McGlashan N, Needham E, Walland K, et al. Optic nerve sheath diameter on computed tomography is correlated with simultaneously measured intracranial pressure in patients with severe traumatic brain injury. *Intensive Care Med.* 2014;40(9):1267-74.

[22] Strumwasser A, Kwan RO, Yeung L, Miraflor E, Ereso A, Castro-Moure F, et al. Sonographic optic nerve sheath diameter as an estimate of intracranial pressure in adult trauma. *J Surg Res*. 2011;170(2):265-71.

[23] Carney N, Totten AM, O'Reilly C, Ullman JS, Hawryluk GW, Bell MJ, et al. Guidelines for the Management of Severe Traumatic Brain Injury, Fourth Edition. *Neurosurgery*. 2016.

[24] Narayan RK, Kishore PR, Becker DP, Ward JD, Enas GG, Greenberg RP, et al. Intracranial pressure: to monitor or not to monitor? A review of our experience with severe head injury. *J Neurosurg*. 1982;56(5):650-9.

[25] Stocchetti N, Picetti E, Berardino M, Buki A, Chesnut RM, Fountas KN, et al. Clinical applications of intracranial pressure monitoring in traumatic brain injury : report of the Milan consensus conference. *Acta Neurochir* (Wien). 2014;156(8):1615-22.

[26] Treggiari MM, Schutz N, Yanez ND, Romand JA. Role of intracranial pressure values and patterns in predicting outcome in traumatic brain injury: a systematic review. *Neurocrit Care*. 2007;6(2):104-12.

[27] Sheth KN, Stein DM, Aarabi B, Hu P, Kufera JA, Scalea TM, et al. Intracranial pressure dose and outcome in traumatic brain injury. *Neurocrit Care.* 2013;18(1):26-32.

[28] Badri S, Chen J, Barber J, Temkin NR, Dikmen SS, Chesnut RM, et al. Mortality and long-term functional outcome associated with intracranial pressure after traumatic brain injury. *Intensive Care Med*. 2012;38(11):1800-9.

[29] Bremmer R, de Jong BM, Wagemakers M, Regtien JG, van der Naalt J. The course of intracranial pressure in traumatic brain injury: relation with outcome and CT-characteristics. *Neurocrit Care*. 2010;12(3):362-8.

[30] Stein DM, Hu PF, Brenner M, Sheth KN, Liu KH, Xiong W, et al. Brief episodes of intracranial hypertension and cerebral hypoperfusion are associated with poor

functional outcome after severe traumatic brain injury. *J Trauma*. 2011;71(2):364-73; discussion 73-4.

[31] Stein DM, Brenner M, Hu PF, Yang S, Hall EC, Stansbury LG, et al. Timing of intracranial hypertension following severe traumatic brain injury. *Neurocrit Care.* 2013;18(3):332-40.

[32] Majdan M, Mauritz W, Wilbacher I, Brazinova A, Rusnak M, Leitgeb J. Timing and duration of intracranial hypertension versus outcomes after severe traumatic brain injury. *Minerva Anestesiol*. 2014;80(12):1261-72.

[33] Colton K, Yang S, Hu PF, Chen HH, Stansbury LG, Scalea TM, et al. Responsiveness to therapy for increased intracranial pressure in traumatic brain injury is associated with neurological outcome. *Injury.* 2014;45(12):2084-8.

[34] Alali AS, Fowler RA, Mainprize TG, Scales DC, Kiss A, de Mestral C, et al. Intracranial pressure monitoring in severe traumatic brain injury: results from the American College of Surgeons Trauma Quality Improvement Program. *J Neurotrauma.* 2013;30(20):1737-46.

[35] Farahvar A, Gerber LM, Chiu YL, Carney N, Hartl R, Ghajar J. Increased mortality in patients with severe traumatic brain injury treated without intracranial pressure monitoring. *J Neurosurg*. 2012;117(4):729-34.

[36] Gerber LM. Marked reduction in mortality in patients with severe traumatic brain injury. *J Neurosurg*. 2013;119(6):1583-90.

[37] Talving P, Karamanos E, Teixeira PG, Skiada D, Lam L, Belzberg H, et al. Intracranial pressure monitoring in severe head injury: compliance with Brain Trauma Foundation guidelines and effect on outcomes: a prospective study. *J Neurosurg.* 2013;119(5):1248-54.

[38] Whitmore RG, Thawani JP, Grady MS, Levine JM, Sanborn MR, Stein SC. Is aggressive treatment of traumatic brain injury cost-effective? *J Neurosurg.* 2012;116 (5):1106-13.

[39] Picetti E, Caspani ML, Iaccarino C, Pastorello G, Salsi P, Viaroli E, et al. Intracranial pressure monitoring after primary decompressive craniectomy in traumatic brain injury: a clinical study. *Acta Neurochir* (Wien). 2017;159(4):615-22.

[40] Huang YH, Ou CY. Prognostic Impact of Intracranial Pressure Monitoring After Primary Decompressive Craniectomy for Traumatic Brain Injury. *World Neurosurg.* 2016;88:59-63.

[41] Chesnut RM, Temkin N, Carney N, Dikmen S, Rondina C, Videtta W, et al. A Trial of Intracranial-Pressure Monitoring in Traumatic Brain Injury. *New England Journal of Medicine.* 2012;367(26):2471-81.

[42] Chesnut RM, Bleck TP, Citerio G, Classen J, Cooper DJ, Coplin WM, et al. A Consensus-Based Interpretation of the Benchmark Evidence from South American Trials: Treatment of Intracranial Pressure Trial. *J Neurotrauma*. 2015;32(22):1722-4.

[43] Hutchinson PJ, Kolias AG, Timofeev IS, Corteen EA, Czosnyka M, Timothy J, et al. Trial of Decompressive Craniectomy for Traumatic Intracranial Hypertension. *New England Journal of Medicine.* 2016;375(12):1119-30.

[44] Cooper DJ, Rosenfeld JV, Murray L, Arabi YM, Davies AR, D'Urso P, et al. Decompressive Craniectomy in Diffuse Traumatic Brain Injury. *New England Journal of Medicine. 2011*;364(16):1493-502.

[45] Ratanalert S, Phuenpathom N, Saeheng S, Oearsakul T, Sripairojkul B, Hirunpat S. ICP threshold in CPP management of severe head injury patients. *Surg Neurol*. 2004;61(5):429-34; discussion 34-5.

[46] Sorrentino E, Diedler J, Kasprowicz M, Budohoski KP, Haubrich C, Smielewski P, et al. Critical thresholds for cerebrovascular reactivity after traumatic brain injury. *Neurocrit Care*. 2012;16(2):258-66.

[47] Oddo M, Levine JM, Mackenzie L, Frangos S, Feihl F, Kasner SE, et al. Brain hypoxia is associated with short-term outcome after severe traumatic brain injury independently of intracranial hypertension and low cerebral perfusion pressure. *Neurosurgery*. 2011;69(5):1037-45; discussion 45.

[48] Bouzat P, Sala N, Payen J-F, Oddo M. Beyond intracranial pressure: optimization of cerebral blood flow, oxygen, and substrate delivery after traumatic brain injury. *Annals of Intensive Care*. 2013;3:23-.

[49] Jeremitsky E, Omert L, Dunham CM, Protetch J, Rodriguez A. Harbingers of poor outcome the day after severe brain injury: hypothermia, hypoxia, and hypoperfusion. *J Trauma*. 2003;54(2):312-9.

[50] Chesnut RM, Marshall LF, Klauber MR, Blunt BA, Baldwin N, Eisenberg HM, et al. The role of secondary brain injury in determining outcome from severe head injury. *J Trauma*. 1993;34(2):216-22.

[51] Pannier JL, Weyne J, Leusen I. Effects of changes in acid-base composition in the cerebral ventricles on local and general cerebral blood flow. *Eur Neurol*. 1971;6(1):123-6.

[52] Lindegaard K-F, Nornes H, Bakke SJ, Sorteberg W, Nakstad P. Cerebral vasospasm diagnosis by means of angiography and blood velocity measurements. *Acta Neurochir* (Wien). 1989;100(1):12-24.

[53] Coles JP, Fryer TD, Coleman MR, Smielewski P, Gupta AK, Minhas PS, et al. Hyperventilation following head injury: effect on ischemic burden and cerebral oxidative metabolism. *Crit Care Med*. 2007;35(2):568-78.

[54] Dumont TM, Visioni AJ, Rughani AI, Tranmer BI, Crookes B. Inappropriate prehospital ventilation in severe traumatic brain injury increases in-hospital mortality. *J Neurotrauma.* 2010;27(7):1233-41.

[55] Kelcz F, Hilal SK, Hartwell P, Joseph PM. Computed tomographic measurement of the xenon brain-blood partition coefficient and implications for regional cerebral blood flow: a preliminary report. *Radiology*. 1978;127(2):385-92.

[56] Ultra-early evaluation of regional cerebral blood flow in severely head-injured patients using xenon-enhanced computerized tomography. *J Neurosurg*. 1992;77(3):360-8.

[57] Latchaw RE, Yonas H, Darby JM, Gur D, Pentheny SL. Xenon/CT cerebral blood flow determination following cranial trauma. *Acta Radiol Suppl*. 1986;369:370-3.

[58] Kaloostian P, Robertson C, Gopinath SP, Stippler M, King CC, Qualls C, et al. Outcome prediction within twelve hours after severe traumatic brain injury by quantitative cerebral blood flow. *J Neurotrauma*. 2012;29(5):727-34.

[59] Grossman EJ, Jensen JH, Babb JS, Chen Q, Tabesh A, Fieremans E, et al. Cognitive impairment in mild traumatic brain injury: a longitudinal diffusional kurtosis and perfusion imaging study. *AJNR Am J Neuroradiol*. 2013;34(5):951-7, s1-3.

[60] Gupta A, Chazen JL, Hartman M, Delgado D, Anumula N, Shao H, et al. Cerebrovascular reserve and stroke risk in patients with carotid stenosis or occlusion: a systematic review and meta-analysis. *Stroke*. 2012;43(11):2884-91.

[61] Rosner MJ, Rosner SD, Johnson AH. Cerebral perfusion pressure: management protocol and clinical results. *J Neurosurg.* 1995;83(6):949-62.

[62] Robertson CS, Valadka AB, Hannay HJ, Contant CF, Gopinath SP, Cormio M, et al. Prevention of secondary ischemic insults after severe head injury. *Crit Care Med.* 1999;27(10):2086-95.

[63] Simard JM, Bellefleur M. Systemic arterial hypertension in head trauma. *Am J Cardiol*. 1989;63(6):32c-5c.

[64] Jaeger M, Dengl M, Meixensberger J, Schuhmann MU. Effects of cerebrovascular pressure reactivity-guided optimization of cerebral perfusion pressure on brain tissue oxygenation after traumatic brain injury. *Crit Care Med*. 2010;38(5):1343-7.

[65] Aries MJ, Czosnyka M, Budohoski KP, Steiner LA, Lavinio A, Kolias AG, et al. Continuous determination of optimal cerebral perfusion pressure in traumatic brain injury. *Crit Care Med.* 2012;40(8):2456-63.

[66] Pressure autoregulation monitoring and cerebral perfusion pressure target recommendation in patients with severe traumatic brain injury based on minute-by-minute monitoring data. *J Neurosurg.* 2014;120(6):1451-7.

[67] Steiner LA, Czosnyka M, Piechnik SK, Smielewski P, Chatfield D, Menon DK, et al. Continuous monitoring of cerebrovascular pressure reactivity allows determination of optimal cerebral perfusion pressure in patients with traumatic brain injury. *Crit Care Med*. 2002;30(4):733-8.

[68] Dias C, Silva MJ, Pereira E, Monteiro E, Maia I, Barbosa S, et al. Optimal Cerebral Perfusion Pressure Management at Bedside: A Single-Center Pilot Study. *Neurocrit Care.* 2015;23(1):92-102.

[69] Contant CF, Valadka AB, Gopinath SP, Hannay HJ, Robertson CS. Adult respiratory distress syndrome: a complication of induced hypertension after severe head injury. *J Neurosurg*. 2001;95(4):560-8.

[70] Needham E, McFadyen C, Newcombe V, Synnot AJ, Czosnyka M, Menon D. Cerebral Perfusion Pressure Targets Individualized to Pressure-Reactivity Index in Moderate to Severe Traumatic Brain Injury: A Systematic Review. *J Neurotrauma*. 2016.

[71] Sviri GE, Aaslid R, Douville CM, Moore A, Newell DW. Time course for autoregulation recovery following severe traumatic brain injury. *J Neurosurg.* 2009;111(4):695-700.

[72] Panerai RB. Assessment of cerebral pressure autoregulation in humans--a review of measurement methods. *Physiol Meas*. 1998;19(3):305-38.

[73] Grände P-O. The “Lund Concept” for the treatment of severe head trauma – physiological principles and clinical application. *Intensive Care Medicine*. 2006;32(10):1475-84.

[74] Asgeirsson B, Grande PO, Nordstrom CH. A new therapy of post-trauma brain oedema based on haemodynamic principles for brain volume regulation. *Intensive Care Med*. 1994;20(4):260-7.

[75] Howells T, Elf K, Jones PA, Ronne-Engstrom E, Piper I, Nilsson P, et al. Pressure reactivity as a guide in the treatment of cerebral perfusion pressure in patients with brain trauma. *J Neurosurg.* 2005;102(2):311-7.

[76] Czosnyka M, Smielewski P, Kirkpatrick P, Laing RJ, Menon D, Pickard JD. Continuous assessment of the cerebral vasomotor reactivity in head injury. *Neurosurgery.* 1997;41(1):11-7; discussion 7-9.

[77] Steiner LA, Coles JP, Johnston AJ, Chatfield DA, Smielewski P, Fryer TD, et al. Assessment of cerebrovascular autoregulation in head-injured patients: a validation study. *Stroke.* 2003;34(10):2404-9.

[78] Lazaridis C, Smielewski P, Menon DK, Hutchinson P, Pickard JD, Czosnyka M. Patient-Specific Thresholds and Doses of Intracranial Hypertension in Severe Traumatic Brain Injury. *Acta Neurochir Suppl*. 2016;122:117-20.

[79] Kosty JA, Leroux PD, Levine J, Park S, Kumar MA, Frangos S, et al. Brief report: a comparison of clinical and research practices in measuring cerebral perfusion pressure: a literature review and practitioner survey. *Anesth Analg*. 2013;117(3):694-8.

[80] Longhi L, Pagan F, Valeriani V, Magnoni S, Zanier ER, Conte V, et al. Monitoring brain tissue oxygen tension in brain-injured patients reveals hypoxic episodes in normal-appearing and in peri-focal tissue. *Intensive Care Med*. 2007;33(12):2136-42.

[81] Stiefel MF, Udoetuk JD, Spiotta AM, Gracias VH, Goldberg A, Maloney-Wilensky E, et al. Conventional neurocritical care and cerebral oxygenation after traumatic brain injury. *J Neurosurg.* 2006;105(4):568-75.

[82] Vespa P, Bergsneider M, Hattori N, Wu H-M, Huang S-C, Martin NA, et al. Metabolic crisis without brain ischemia is common after traumatic brain injury: a combined microdialysis and positron emission tomography study. *Journal of cerebral blood flow and metabolism : official journal of the International Society of Cerebral Blood Flow and Metabolism.* 2005;25(6):763-74.

[83] Wintermark M, Chiolero R, van Melle G, Revelly JP, Porchet F, Regli L, et al. Relationship between brain perfusion computed tomography variables and cerebral perfusion pressure in severe head trauma patients. *Crit Care Med*. 2004;32(7):1579-87.

[84] Chang JJ, Youn TS, Benson D, Mattick H, Andrade N, Harper CR, et al. Physiologic and functional outcome correlates of brain tissue hypoxia in traumatic brain injury. *Crit Care Med.* 2009;37(1):283-90.

[85] Ferris EB, Engel GL, et al. The validity of internal jugular venous blood in studies of cerebral metabolism and blood flow in man. *Am J Physiol*. 1946;147(3):517-21.

[86] Lennox WG, Gibbs FA, Gibbs EL. Relationship of unconsciousness to cerebral blood flow and to anoxemia. *Archives of Neurology & Psychiatry*. 1935;34(5):1001-13.

[87] Stocchetti N, Paparella A, Bridelli F, Bacchi M, Piazza P, Zuccoli P. Cerebral venous oxygen saturation studied with bilateral samples in the internal jugular veins. *Neurosurgery*. 1994;34(1):38-43; discussion -4.

[88] Gupta AK, Hutchinson PJ, Al-Rawi P, Gupta S, Swart M, Kirkpatrick PJ, et al. Measuring brain tissue oxygenation compared with jugular venous oxygen saturation for monitoring cerebral oxygenation after traumatic brain injury. *Anesth Analg*. 1999;88(3):549-53.

[89] Thiagarajan A, Goverdhan PD, Chari P, Somasunderam K. The effect of hyperventilation and hyperoxia on cerebral venous oxygen saturation in patients with traumatic brain injury. *Anesth Analg*. 1998;87(4):850-3.

[90] Chan KH, Dearden NM, Miller JD, Andrews PJ, Midgley S. Multimodality monitoring as a guide to treatment of intracranial hypertension after severe brain injury. *Neurosurgery.* 1993;32(4):547-52; discussion 52-3.

[91] Fortune JB, Feustel PJ, Graca L, Hasselbarth J, Kuehler DH. Effect of hyperventilation, mannitol, and ventriculostomy drainage on cerebral blood flow after head injury. *J Trauma*. 1995;39(6):1091-7; discussion 7-9.

[92] Murr R, Schurer L. Correlation of jugular venous oxygen saturation to spontaneous fluctuations of cerebral perfusion pressure in patients with severe head injury. *Neurol Res*. 1995;17(5):329-33.

[93] Le Roux PD, Newell DW, Lam AM, Grady MS, Winn HR. Cerebral arteriovenous oxygen difference: a predictor of cerebral infarction and outcome in patients with severe head injury. *J Neurosurg*. 1997;87(1):1-8.

[94] Calon B, Freys G, Launoy A, Boyer P, Tongio J, Pottecher T. Early discovery of a traumatic carotid-cavernous sinus fistula by jugular venous oxygen saturation monitoring. *Case report. J Neurosurg*. 1995;83(5):910-1.

[95] Cruz J. Adverse effects of pentobarbital on cerebral venous oxygenation of comatose patients with acute traumatic brain swelling: relationship to outcome. *J Neurosurg.* 1996;85(5):758-61.

[96] Radolovich DK, Czosnyka M, Timofeev I, Lavinio A, Kim DJ, Jaeger M, et al. Transient changes in brain tissue oxygen in response to modifications of cerebral perfusion pressure: an observational study. *Anesth Analg.* 2010;110(1):165-73.

[97] Stocchetti N, Chieregato A, De Marchi M, Croci M, Benti R, Grimoldi N. High cerebral perfusion pressure improves low values of local brain tissue O2 tension (PtiO2) in focal lesions. *Acta Neurochir Suppl*. 1998;71:162-5.

[98] Valadka AB, Hlatky R, Furuya Y, Robertson CS. Brain tissue PO2: correlation with cerebral blood flow. *Acta Neurochir Suppl*. 2002;81:299-301.

[99] Doppenberg EMRMD, Zauner AMD, Bullock RMD, Ph.D, Ward JDMD, Fatouros PPPD, et al. Correlations Between Brain Tissue Oxygen Tension, Carbon Dioxide Tension, pH, and Cerebral Blood Flow—A Better Way of Monitoring The Severely Injured Brain? *Surgical Neurology*.49(6):650-4.

[100] Menon DK, Coles JP, Gupta AK, Fryer TD, Smielewski P, Chatfield DA, et al. Diffusion limited oxygen delivery following head injury. *Crit Care* Med. 2004;32 (6):1384-90.

[101] Wolf S, Plev DV, Trost HA, Lumenta CB. Open lung ventilation in neurosurgery: an update on brain tissue oxygenation. *Acta Neurochir Suppl*. 2005;95:103-5.

[102] Stocchetti N, Protti A, Lattuada M, Magnoni S, Longhi L, Ghisoni L, et al. Impact of pyrexia on neurochemistry and cerebral oxygenation after acute brain injury. *Journal of Neurology, Neurosurgery, and Psychiatry*. 2005;76(8):1135-9.

[103] Oddo M, Frangos S, Maloney-Wilensky E, Andrew Kofke W, Le Roux PD, Levine JM. Effect of shivering on brain tissue oxygenation during induced normothermia in patients with severe brain injury. *Neurocrit Care*. 2010;12(1):10-6.

[104] Rosenthal G, Hemphill JC, Sorani M, Martin C, Morabito D, Meeker M, et al. The role of lung function in brain tissue oxygenation following traumatic brain injury. *J Neurosurg.* 2008;108(1):59-65.

[105] Rosenthal G, Hemphill JC, 3rd, Sorani M, Martin C, Morabito D, Obrist WD, et al. Brain tissue oxygen tension is more indicative of oxygen diffusion than oxygen delivery and metabolism in patients with traumatic brain injury. *Crit Care Med*. 2008;36(6):1917-24.

[106] Maas AI, Fleckenstein W, de Jong DA, van Santbrink H. Monitoring cerebral oxygenation: experimental studies and preliminary clinical results of continuous monitoring of cerebrospinal fluid and brain tissue oxygen tension. *Acta Neurochir Suppl (*Wien). 1993;59:50-7.

[107] Zauner A, Bullock R, Di X, Young HF. Brain oxygen, CO2, pH, and temperature monitoring: evaluation in the feline brain. *Neurosurgery.* 1995;37(6):1168-76; discussion 76-7.

[108] Meixensberger J, Dings J, Kuhnigk H, Roosen K. Studies of tissue PO2 in normal and pathological human brain cortex. *Acta Neurochir Suppl* (Wien). 1993;59:58-63.

[109] Sarrafzadeh AS, Kiening KL, Bardt TF, Schneider G-H, Unterberg AW, Lanksch WR. Cerebral Oxygenation in Contusioned vs. Nonlesioned Brain Tissue: Moniting of PtiO2 with Licox and Paratrend. In: Marmarou A, Bullock R, Avezaat C, Baethmann A, Becker D, Brock M, et al., editors. Intracranial Pressure and Neuromonitoring in Brain Injury: *Proceedings of the Tenth International ICP Symposium*, Williamsburg, Virginia, May 25–29, 1997. Vienna: Springer Vienna; 1998. p. 186-9.

[110] Doppenberg EM, Zauner A, Watson JC, Bullock R. Determination of the ischemic threshold for brain oxygen tension. *Acta Neurochir Suppl*. 1998;71:166-9.

[111] Valadka AB, Gopinath SP, Contant CF, Uzura M, Robertson CS. Relationship of brain tissue PO2 to outcome after severe head injury. *Crit Care Med*. 1998;26(9):1576-81.

[112] Scheufler KM, Lehnert A, Rohrborn HJ, Nadstawek J, Thees C. Individual value of brain tissue oxygen pressure, microvascular oxygen saturation, cytochrome redox level, and energy metabolites in detecting critically reduced cerebral energy state during acute changes in global cerebral perfusion. *J Neurosurg Anesthesiol*. 2004;16(3):210-9.

[113] Valadka AB, Goodman JC, Gopinath SP, Uzura M, Robertson CS. Comparison of brain tissue oxygen tension to microdialysis-based measures of cerebral ischemia in fatally head-injured humans. *J Neurotrauma.* 1998;15(7):509-19.

[114] Meixensberger J, Kunze E, Barcsay E, Vaeth A, Roosen K. Clinical cerebral microdialysis: brain metabolism and brain tissue oxygenation after acute brain injury. *Neurol Res*. 2001;23(8):801-6.

[115] Bardt TF, Unterberg AW, Hartl R, Kiening KL, Schneider GH, Lanksch WR. Monitoring of brain tissue PO2 in traumatic brain injury: effect of cerebral hypoxia on outcome. *Acta Neurochir Suppl*. 1998;71:153-6.

[116] Kiening KL, Hartl R, Unterberg AW, Schneider GH, Bardt T, Lanksch WR. Brain tissue pO2-monitoring in comatose patients: implications for therapy. *Neurol Res*. 1997;19(3):233-40.

[117] van den Brink WA, van Santbrink H, Steyerberg EW, Avezaat CJ, Suazo JA, Hogesteeger C, et al. Brain oxygen tension in severe head injury. *Neurosurgery.* 2000;46(4):868-76; discussion 76-8.

[118] Eriksson EA, Barletta JF, Figueroa BE, Bonnell BW, Sloffer CA, Vanderkolk WE, et al. The first 72 hours of brain tissue oxygenation predicts patient survival with traumatic brain injury. *J Trauma Acute Care Surg*. 2012;72(5):1345-9.

[119] Spiotta AM, Stiefel MF, Gracias VH, Garuffe AM, Kofke WA, Maloney-Wilensky E, et al. Brain tissue oxygen-directed management and outcome in patients with severe traumatic brain injury. *J Neurosurg.* 2010;113(3):571-80.

[120] Narotam PK, Morrison JF, Nathoo N. Brain tissue oxygen monitoring in traumatic brain injury and major trauma: outcome analysis of a brain tissue oxygen-directed therapy. *J Neurosurg.* 2009;111(4):672-82.

[121] Green JA, Pellegrini DC, Vanderkolk WE, Figueroa BE, Eriksson EA. Goal Directed Brain Tissue Oxygen Monitoring Versus Conventional Management in Traumatic Brain Injury: An Analysis of In Hospital Recovery. *Neurocrit Care*. 2013;18(1):20-5.

[122] Pascual JL, Georgoff P, Maloney-Wilensky E, Sims C, Sarani B, Stiefel MF, et al. Reduced brain tissue oxygen in traumatic brain injury: are most commonly used interventions successful*? J Trauma.* 2011;70(3):535-46.

[123] Oddo M, Bösel J. Monitoring of Brain and Systemic Oxygenation in Neurocritical Care Patients. *Neurocrit Care*. 2014;21(2):103-20.

[124] Radolovich DK, Czosnyka M, Timofeev I, Lavinio A, Hutchinson P, Gupta A, et al. Reactivity of brain tissue oxygen to change in cerebral perfusion pressure in head injured patients. *Neurocrit Care*. 2009;10(3):274-9.

[125] Robertson CS, Gopinath S, Chance B. Use of near infrared spectroscopy to identify traumatic intracranial hemotomas. *Journal of Biomedical Optics*. 1997;2(1):31-41.

[126] Weerakkody RA, Czosnyka M, Zweifel C, Castellani G, Smielewski P, Brady K, et al. Near infrared spectroscopy as possible non-invasive monitor of slow vasogenic ICP waves. *Acta Neurochir Suppl*. 2012;114:181-5.

[127] Budohoski KP, Czosnyka M, de Riva N, Smielewski P, Pickard JD, Menon DK, et al. The relationship between cerebral blood flow autoregulation and cerebrovascular pressure reactivity after traumatic brain injury. *Neurosurgery.* 2012;71(3):652-60; discussion 60-1.

[128] Oddo M, Nduom E, Frangos S, MacKenzie L, Chen I, Maloney-Wilensky E, et al. Acute lung injury is an independent risk factor for brain hypoxia after severe traumatic brain injury. *Neurosurgery.* 2010;67(2):338-44.

[129] Floyd TF, Clark JM, Gelfand R, Detre JA, Ratcliffe S, Guvakov D, et al. Independent cerebral vasoconstrictive effects of hyperoxia and accompanying arterial hypocapnia at 1 ATA. *J Appl Physiol* (1985). 2003;95(6):2453-61.

[130] Nakajima S, Meyer J, Amano T, Shaw T, Okabe T, Mortel KF. Cerebral vasomotor responsiveness during 100% oxygen inhalation in cerebral ischemia. *Archives of Neurology.* 1983;40(5):271-6.

[131] Bergsneider M, Hovda DA, McArthur DL, Etchepare M, Huang SC, Sehati N, et al. Metabolic recovery following human traumatic brain injury based on FDG-PET: time course and relationship to neurological disability. *J Head Trauma Rehabil*. 2001;16(2):135-48.

[132] Stein NR, McArthur DL, Etchepare M, Vespa PM. Early cerebral metabolic crisis after TBI influences outcome despite adequate hemodynamic resuscitation. *Neurocrit Care*. 2012;17(1):49-57.

[133] Timofeev I, Carpenter KLH, Nortje J, Al-Rawi PG, O'Connell MT, Czosnyka M, et al. Cerebral extracellular chemistry and outcome following traumatic brain injury: a microdialysis study of 223 patients. *Brain.* 2011;134(2):484-94.

[134] Nordström MDPDC-H, Reinstrup MDPDP, Xu MDW, Gärdenfors MDA, Ungerstedt MDPDU. Assessment of the Lower Limit for Cerebral Perfusion Pressure in Severe Head Injuries by Bedside Monitoring of Regional Energy Metabolism. *Anesthesiology.* 2003;98(4):809-14.

[135] Oddo M, Milby A, Chen I, Frangos S, MacMurtrie E, Maloney-Wilensky E, et al. Hemoglobin concentration and cerebral metabolism in patients with aneurysmal subarachnoid hemorrhage. *Stroke.* 2009;40(4):1275-81.

[136] Haitsma IK, Maas AI. Advanced monitoring in the intensive care unit: brain tissue oxygen tension. *Curr Opin Crit Care*. 2002;8(2):115-20.

[137] Lazaridis C, Robertson CS. The Role of Multimodal Invasive Monitoring in Acute Traumatic Brain Injury. *Neurosurg Clin N Am*. 2016;27(4):509-17.

[138] Hutchinson PJ, Gupta AK, Fryer TF, Al-Rawi PG, Chatfield DA, Coles JP, et al. Correlation between cerebral blood flow, substrate delivery, and metabolism in head injury: a combined microdialysis and triple oxygen positron emission tomography study. *J Cereb Blood Flow Metab*. 2002;22(6):735-45.

[139] Larach DB, Kofke WA, Le Roux P. Potential non-hypoxic/ischemic causes of increased cerebral interstitial fluid lactate/pyruvate ratio: a review of available literature. *Neurocrit Care.* 2011;15(3):609-22.

[140] Larach DB, Kofke WA, Le Roux P. Potential Non-Hypoxic/Ischemic Causes of Increased Cerebral Interstitial Fluid Lactate/Pyruvate Ratio: A Review of Available Literature. *Neurocritical Care*. 2011;15(3):609-22.

[141] Kurtz P, Claassen J, Schmidt JM, Helbok R, Hanafy KA, Presciutti M, et al. Reduced brain/serum glucose ratios predict cerebral metabolic distress and mortality after severe brain injury. *Neurocrit Care*. 2013;19(3):311-9.

[142] Vespa P. Continuous EEG monitoring for the detection of seizures in traumatic brain injury, infarction, and intracerebral hemorrhage:"to detect and protect". *Journal of clinical neurophysiology.* 2005;22(2):99-106.

[143] Vespa PM, Miller C, McArthur D, Eliseo M, Etchepare M, Hirt D, et al. Nonconvulsive electrographic seizures after traumatic brain injury result in a delayed, prolonged increase in intracranial pressure and metabolic crisis. *Crit Care Med.* 2007;35(12):2830-6.

[144] Vespa PM, Nuwer MR, Nenov V, Ronne-Engstrom E, Hovda DA, Bergsneider M, et al. Increased incidence and impact of nonconvulsive and convulsive seizures after traumatic brain injury as detected by continuous electroencephalographic monitoring. *J Neurosurg.* 1999;91(5):750-60.

[145] Camilo O, Goldstein LB. Seizures and Epilepsy After Ischemic Stroke. *Stroke.* 2004;35(7):1769.

[146] Vespa PM, McArthur DL, Xu Y, Eliseo M, Etchepare M, Dinov I, et al. Nonconvulsive seizures after traumatic brain injury are associated with hippocampal atrophy. *Neurology.* 2010;75(9):792-8.

[147] Sharbrough FW, Messick JM, Sundt TM. Correlation of continuous electroencephalograms with cerebral blood flow measurements during carotid endarterectomy. *Stroke*. 1973;4(4):674-83.

[148] Kohno K, Hoehn-Berlage M, Mies G, Back T, Hossmann K-A. Relationship between diffusion-weighted MR images, cerebral blood flow, and energy state in experimental brain infarction. *Magnetic resonance imaging*. 1995;13(1):73-80.

[149] de Vos CC, van Maarseveen SM, Brouwers PJ, van Putten MJ. Continuous EEG monitoring during thrombolysis in acute hemispheric stroke patients using the brain symmetry index. *Journal of clinical neurophysiology.* 2008;25(2):77-82.

[150] Finnigan SP, Rose SE, Chalk JB. Rapid EEG changes indicate reperfusion after tissue plasminogen activator injection in acute ischaemic stroke. *Clinical Neurophysiology.* 2006;117(10):2338-9.

[151] Wood JH, Polyzoidis KS, Epstein CM, Gibby GL, Tindall GT. Quantitative EEG alterations after isovolernic-hemodilutional augmenhtion of cerebral perfhion in stroke patients. *Neurology*. 1984;34(6):764-.

[152] Tolonen U, Sulg I. Comparison of quantitative EEG parameters from four different analysis techniques in evaluation of relationships between EEG and CBF in brain infarction. *Electroencephalography and clinical neurophysiology*. 1981;51(2):177-85.

[153] Nagata K, Tagawa K, Hiroi S, Shishido F, Uemura K. Electroencephalographic correlates of blood flow and oxygen metabolism provided by positron emission tomography in patients with cerebral infarction. *Electroencephalography and clinical neurophysiology.* 1989;72(1):16-30.

[154] Hartings JA, Wilson JA, Hinzman JM, Pollandt S, Dreier JP, DiNapoli V, et al. Spreading depression in continuous electroencephalography of brain trauma. *Ann Neurol*. 2014;76(5):681-94.

[155] Bricolo A, Turazzi S, Faccioli F, editors. Combined clinical and EEG examinations for assessment of severity of acute head injuries. *Proceedings of the 6th European Congress of Neurosurgery; 1979*: Springer.

[156] Bergamasco B, Bergamini L, Doriguzzi T, Sacerdote I. The sleep cycle in coma: prognostic value. *Electroencephalography and clinical neurophysiology*. 1968;25 (1):87-.

[157] Burghaus L, Hilker R, Dohmen C, Bosche B, Winhuisen L, Galldiks N, et al. Early electroencephalography in acute ischemic stroke: prediction of a malignant course? *Clinical neurology and neurosurgery*. 2007;109(1):45-9.

[158] Young B, Ott L, Dempsey R, Haack D, Tibbs P. Relationship between admission hyperglycemia and neurologic outcome of severely brain-injured patients. *Annals of Surgery.* 1989;210(4):466-73.

[159] Marion DW. Optimum serum glucose levels for patients with severe traumatic brain injury. *F1000 Med Rep.* 2009;1.

[160] Bruno A, Levine SR, Frankel MR, Brott TG, Lin Y, Tilley BC, et al. Admission glucose level and clinical outcomes in the NINDS rt-PA Stroke Trial. *Neurology.* 2002;59(5):669-74.

[161] Bruno A, Durkalski VL, Hall CE, Juneja R, Barsan WG, Janis S, et al. The Stroke Hyperglycemia Insulin Network Effort (SHINE) trial protocol: a randomized, blinded, efficacy trial of standard vs. intensive hyperglycemia management in acute stroke. *Int J Stroke.* 2014;9(2):246-51.

[162] Clifton GL, Miller ER, Choi SC, Levin HS, McCauley S, Smith KR, Jr., et al. Lack of effect of induction of hypothermia after acute brain injury. *N Engl J Med.* 2001;344(8):556-63.

[163] Clifton GL, Drever P, Valadka A, Zygun D, Okonkwo D. Multicenter Trial of Early Hypothermia in Severe Brain Injury. *J Neurotrauma.* 2009;26(3):393-7.

[164] Yokobori S, Frantzen J, Bullock R, Gajavelli S, Burks S, Bramlett H, et al. The Use of Hypothermia Therapy in Traumatic Ischemic/Reperfusional Brain Injury: Review of the Literatures. *Therapeutic Hypothermia and Temperature Management.* 2011;1(4): 185-92.

[165] Andrews PJD, Sinclair HL, Rodriguez A, Harris BA, Battison CG, Rhodes JKJ, et al. Hypothermia for Intracranial Hypertension after Traumatic Brain Injury. *New England Journal of Medicine.* 2015;373(25):2403-12.

[166] Puccio AM, Fischer MR, Jankowitz BT, Yonas H, Darby JM, Okonkwo DO. Induced Normothermia Attenuates Intracranial Hypertension and Reduces Fever Burden after Severe Traumatic Brain Injury. *Neurocrit Care*. 2009;11(1):82.

[167] Helbok R, Olson DM, Le Roux PD, Vespa P. Intracranial Pressure and Cerebral Perfusion Pressure Monitoring in Non-TBI Patients: Special Considerations. *Neurocrit Care*. 2014;21(2):85-94.

[168] Stuart RM, Schmidt M, Kurtz P, Waziri A, Helbok R, Mayer SA, et al. Intracranial multimodal monitoring for acute brain injury: a single institution review of current practices. *Neurocrit Care*. 2010;12(2):188-98.

[169] Poca MA, Benejam B, Sahuquillo J, Riveiro M, Frascheri L, Merino MA, et al. Monitoring intracranial pressure in patients with malignant middle cerebral artery infarction: is it useful? *J Neurosurg*. 2010;112(3):648-57.

[170] Jauch EC, Saver JL, Adams HP, Jr., Bruno A, Connors JJ, Demaerschalk BM, et al. Guidelines for the early management of patients with acute ischemic stroke: a guideline for healthcare professionals from the American Heart Association/American Stroke Association. *Stroke*. 2013;44(3):870-947.

[171] Hemphill JC, 3rd, Greenberg SM, Anderson CS, Becker K, Bendok BR, Cushman M, et al. Guidelines for the Management of Spontaneous Intracerebral Hemorrhage: A Guideline for Healthcare Professionals From the American Heart Association/ American Stroke Association. *Stroke*. 2015;46(7):2032-60.

[172] Ko S-B, Choi HA, Parikh G, Helbok R, Schmidt JM, Lee K, et al. Multimodality Monitoring for Cerebral Perfusion Pressure Optimization in Comatose Patients With Intracerebral Hemorrhage. *Stroke.* 2011;42(11):3087-92.

[173] Paldor I, Rosenthal G, Cohen JE, Leker R, Harnof S, Shoshan Y, et al. Intracranial pressure monitoring following decompressive hemicraniectomy for malignant cerebral infarction. *J Clin Neurosci*. 2015;22(1):79-82.

[174] Schneweis S, Grond M, Staub F, Brinker G, Neveling M, Dohmen C, et al. Predictive value of neurochemical monitoring in large middle cerebral artery infarction. *Stroke.* 2001;32(8):1863-7.

[175] Steiner T, Pilz J, Schellinger P, Wirtz R, Friederichs V, Aschoff A, et al. Multimodal online monitoring in middle cerebral artery territory stroke. *Stroke.* 2001;32(11):2500-6.

[176] Wijdicks EF, Sheth KN, Carter BS, Greer DM, Kasner SE, Kimberly WT, et al. Recommendations for the management of cerebral and cerebellar infarction with swelling: a statement for healthcare professionals from the American Heart Association/American Stroke Association. *Stroke.* 2014;45(4):1222-38.

[177] Thomalla G, Hartmann F, Juettler E, Singer OC, Lehnhardt FG, Kohrmann M, et al. Prediction of malignant middle cerebral artery infarction by magnetic resonance imaging within 6 hours of symptom onset: A prospective multicenter observational study. *Ann Neurol*. 2010;68(4):435-45.

In: Encyclopedia of Surgery (22 Volume Set)
Editors: Andreas Lehrer and Kristin Mueller
ISBN: 978-1-53618-329-0
© 2020 Nova Science Publishers, Inc.

Chapter 225

DECOMPRESSIVE CRANIECTOMY: THE EFFECTS ON NEUROCHEMISTRY AND BRAIN OXYGEN DELIVERY

Anna Teresa Mazzeo[1], Ashley Ralston[2], Deepak Gupta[3] and Ross Bullock[2,*]

[1]Department of Anesthesia and Intensive Care, University of Torino, Torino, Italy
[2]Department of Neurosurgery, University of Miami, Miami, FL, US
[3]Neurosciences Centre and JPN Apex Trauma Centre,
All India Institute of Medical Sciences, New Delhi, India

ABSTRACT

Intracranial hypertension refractory to maximal medical treatment is a nightmare for both neurointensivists and neurosurgeons caring for patients with severe traumatic brain injury (TBI). Decompressive craniectomy represents one of the most powerful weapons to potentially interrupt deleterious cerebral events responsible for secondary brain damage and death after TBI. Neuromonitoring tools, such as cerebral microdialysis, may contribute to understanding the pathomechanisms of acute brain injury, provide an early warning of secondary cerebral deterioration, and help in selecting the patients most suitable to benefit from this very invasive surgical rescue therapy. Furthermore, neuromonitoring can be used as a measure of the effect of decompressive craniectomy on neurochemistry derangement and brain energy crisis jeopardizing the injured brain. In this chapter, we discuss experimental and human data on the role of brain metabolism monitoring to detect the effect of decompressive craniectomy on brain energy metabolism after severe TBI.

Keywords: decompressive craniectomy, intracranial hypertension, cerebral microdialysis, neurobiochemistry, energy metabolism

* Corresponding Author E-mail: rbullock@med.miami.edu.

INTRODUCTION

Traumatic brain injury (TBI) has the capacity to transform human life more than almost any other event, and brain herniation, due to an intracranial mass lesion or edema, is the most dramatic and feared sequela of TBI. Occasionally, even mild or moderate TBI can result in death, or persistent vegetative state due to herniation. Intracranial pressure (ICP) monitoring, and the therapies that comprise neurocritical care are directed primarily at preventing herniation and the less dramatic forms of secondary brain damage after TBI. Decompressive craniectomy (DC), the focus of this book, is emerging as one of the most potent, though highly invasive, forms of therapy to prevent secondary brain damage and herniation, but has not yet been accepted as "the standard of care" by many experts in the field. Of the many therapeutic maneuvers available after severe TBI, DC may be the most controversial. DC as a treatment of intracranial hypertension refractory to conventional treatments represents a challenge, for both the neurosurgeon and the neurointensivist, owing to the controversies regarding optimal patient selection, timing, and perioperative management. The purpose of this chapter is to briefly review some of the most important mechanisms of secondary brain damage after severe TBI, and discuss how DC may ameliorate these. We review the limited human data available demonstrating how DC influences or mitigates these damage mechanisms. Clearly much more mechanistic research, in both animal TBI models and the injured human brain in the neurosurgical intensive care unit, is needed to open new avenues of therapy for the future.

NEUROBIOCHEMISTRY IN SEVERE TBI

Various factors, such as injury severity, presenting Glasgow Coma Scale (GCS) score, age, early hypoxia, and hypotension are the most important prognostic markers after severe TBI [1]. While the primary insult cannot be prevented except by "social engineering and environmental modifications," secondary insults and resuscitation are the major targets of therapeutic intervention [2]. Well understood is the fact that both ischemic and non-ischemic metabolic disturbances lead to ongoing insult in the injured brain, which is far more vulnerable than in normal parenchyma because of impaired cerebrovascular autoregulation, metabolic impairment, and release of numerous harmful cellular mediators. New robust mechanisms that are capable of harming the injured brain after TBI are discovered every year, and the possibility of discovering new therapeutics for TBI such as small molecule drugs, monoclonal antibodies, and gene therapies is the major impetus for TBI research. However, before these mechanisms can be accepted, they should be validated in the injured human brain after TBI.

A few methods exist to evaluate this in the living brain, such as MRI, MR spectroscopy, *in vivo* microdialysis, and *ex vivo* analysis of cerebrospinal fluid and blood biomarkers.

Microdialysis

Intracerebral microdialysis is one such technique that detects ongoing biochemical changes at bedside in near real time. Depending on the availability of an appropriate

analytical assay, virtually any soluble molecule in the interstitial fluid can be measured by microdialysis. A perfusate solution that does not contain the analyte of interest is passed through a microdialysis probe inserted into the relevant area. These probes have a semipermeable membrane, through which diffusion of the analyte occurs along a concentration gradient. These molecules are then recovered and analyzed. We must understand that the measured values for interstitial products using microdialysis vary with perfusion rates since that affects the relative recovery of the molecule. Normative data for microdialysis are dependent on several technical factors, including the perfusion rate, microdialysis membrane, and duration of perfusion. With reduction in the perfusion rate to 0.3 µL/minute, the *in vivo* recovery increases. Reinstrup et al. have defined the reference baseline values at 0.3 µL/minute. The common variables studied include glucose, lactate, pyruvate, glutamate, and glycerol [3].

Most commonly, microdialysis catheter probes (molecular weight cutoff of 20 kDa, 10-mm membrane) are placed in the perilesional tissue. The probes are perfused with CNS perfusion fluid at 0.3 µL/minute and samples collected for intracerebral glycerol and lactate/pyruvate (L/P) ratio every hour. Concentrations of glucose, lactate, pyruvate, glutamate, and glycerol in the microdialysate are analyzed using the microdialysis analyzer. Data that can be recorded at each hour for each individual include hourly microdialysis values, in addition to such neurophysiological parameters as ICP, cerebral perfusion pressure (CPP), mean arterial pressure (MAP), and plasma glucose (see Figure 1).

Under normal aerobic conditions, glucose is converted to pyruvate by glycolysis and taken up in the citric acid cycle and the mitochondrial respiratory chain. In TBI, shear forces and the release of free radicals and intracellular calcium lead to inactivation of mitochondrial respiration and the stages of the Krebs cycle. Conversion of pyruvate to large amounts of lactate occurs as a result of anaerobic metabolism. The use of microdialysis in severe TBI has primarily been used to evaluate small molecule fluxes that are the manifestation of this "energy crisis," including the delivery of glucose and its conversion to pyruvate by glycolysis. Normally, the pyruvate would then be used in the tricarboxylic acid (Krebs) cycle. As one of many manifestations of this mitochondrial dysfunction, pyruvate is metabolized to lactate by anaerobic metabolism (Figure 2). Mitochondrial swelling is easily seen, by electron microscopy, from the injured human brain, and is the structural correlate of these metabolic derangements (Figure 3). The L/P ratio is therefore used as a marker of anaerobic metabolism and has been well correlated with dynamic measurements of impaired aerobic metabolism on positron emission tomography scanning after human TBI [4-7].

Glutamate is another small molecule easily measured by microdialysis that may be used as a marker of excitotoxicity, and has been seen to be elevated 100- to 200-fold in severe primary human TBI, and in very severe secondary insults; it is correlated with herniation, hypoxia/ischemia, and poor outcome [4, 8, 9].

Glycerol is a less widely reported, but well validated marker of free radical generation, bimolecular leaflet cell membrane damage, phospholipid breakdown, and consequent free fatty acid release. This results from hypoxic/ischemic events, as well as calcium release into neurons and astrocytes, via the inactivation of protective enzymes such as peroxidase and superoxide dismutase, among others [4, 10-12].

During this TBI-induced mitochondrial dysfunction, the biochemical pattern is characterized by an elevated L/P ratio (L/P ratio >25) with a pronounced increase in lactate concentration at a normal or increased pyruvate level, also known as type II elevation of the

L/P ratio. This pattern contrasts with the condition during "pure" cerebral ischemia (e.g., stroke) where the pyruvate level is very low (pyruvate <70), known as type I elevation of the L/P ratio [13-16].

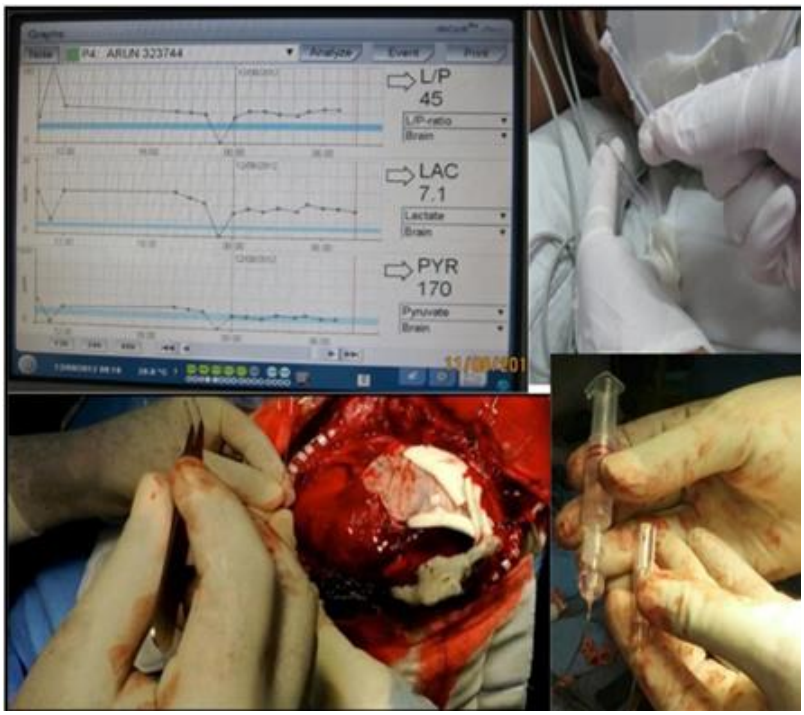

Figure 1. Clockwise from left: ICU pilot software showing time traces of two analytes, lactate/pyruvate ratio, lactate and pyruvate; microvials with collected cerebral dialysate; perfusion fluid attached to the microcatheter; insertion of microdialysis catheter at the time of decompressive craniectomy.

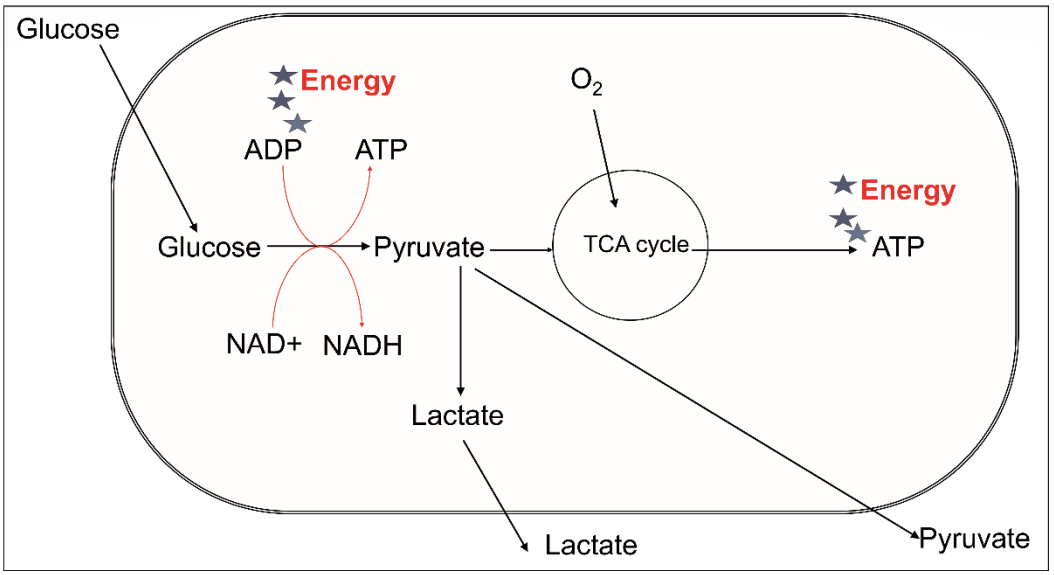

Figure 2. Glycolytic pathway: generation of lactate occurs during anaerobic metabolism.

RATIONALE OF MONITORING NEUROCHEMISTRY AND BRAIN OXYGEN DELIVERY IN PATIENTS WHO MAY REQUIRE DC

Maintenance of adequate cerebral tissue oxygenation is a primary goal in the care of neurological critically ill patients. Because brain ischemia and hypoxia are central causes of brain damage, prompt detection and correction of any event jeopardizing oxygen supply and utilization is fundamental in neurocritical care [17]. In particular, TBI is a dynamic and heterogeneous disease in which the activation and interaction of multiple pathophysiological cascades, such as neuroinflammation, oxidative stress, excitotoxic damage, mitochondrial dysfunction, and cerebral blood flow alterations, contribute to brain damage and to worsened neurological outcome. Furthermore, several potentially brain damaging events, known as secondary insults (e.g., hypotension, hypoxia, high ICP, low CPP, hyperthermia, and seizures, among others) may occur after TBI and contribute to worsened neurological outcome depending on the severity, duration, and number of insults [18]. Therefore, the prevention of secondary brain injury is recognized as a cornerstone in the treatment of severe TBI and has improved neurological outcomes over decades. Because of the complexity of these secondary neurochemical events after severe TBI and the inability to detect them by imaging, neuromonitoring techniques have been advocated and attempted in patients in the neurointensive care unit.

In this complex scenario, the use of neuromonitoring tools may provide clinicians with essential information that could be helpful to optimize clinical decision making. Various monitoring techniques each offer a slightly different perspective on brain pathophysiology. For example, cerebral metabolism, oxygenation, electrophysiology by electro-encephalography and electrocorticography and blood flow and neurochemistry by microdialysis have been evaluated together and separately in TBI patients, and there is a growing belief that such "multimodal monitoring" may provide a more accurate overall picture.

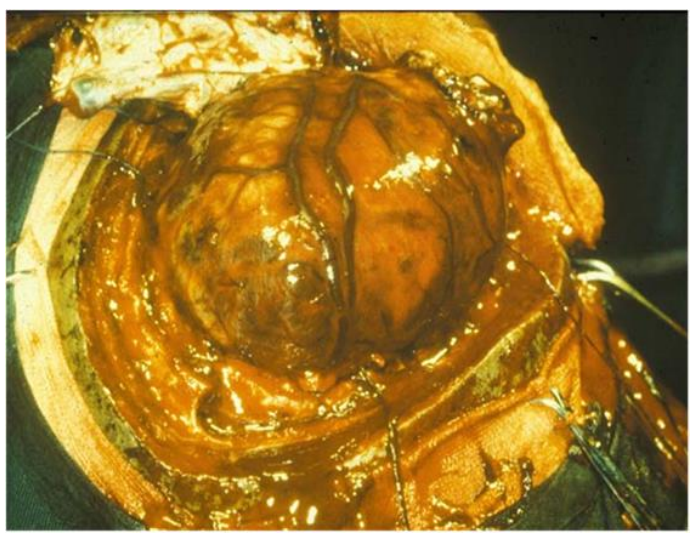

Figure 3A. Massive intra-operative brain swelling with hyperemia and "metabolic crisis" leading to herniation.

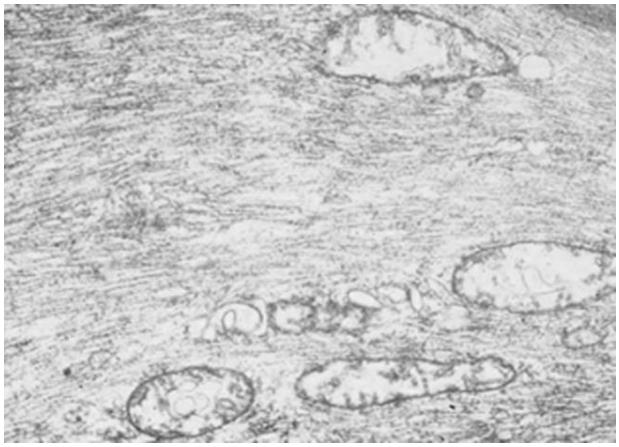

Figure 3B. Electron microscopy to demonstrate swollen mitochondria 30 minutes after severe TBI.

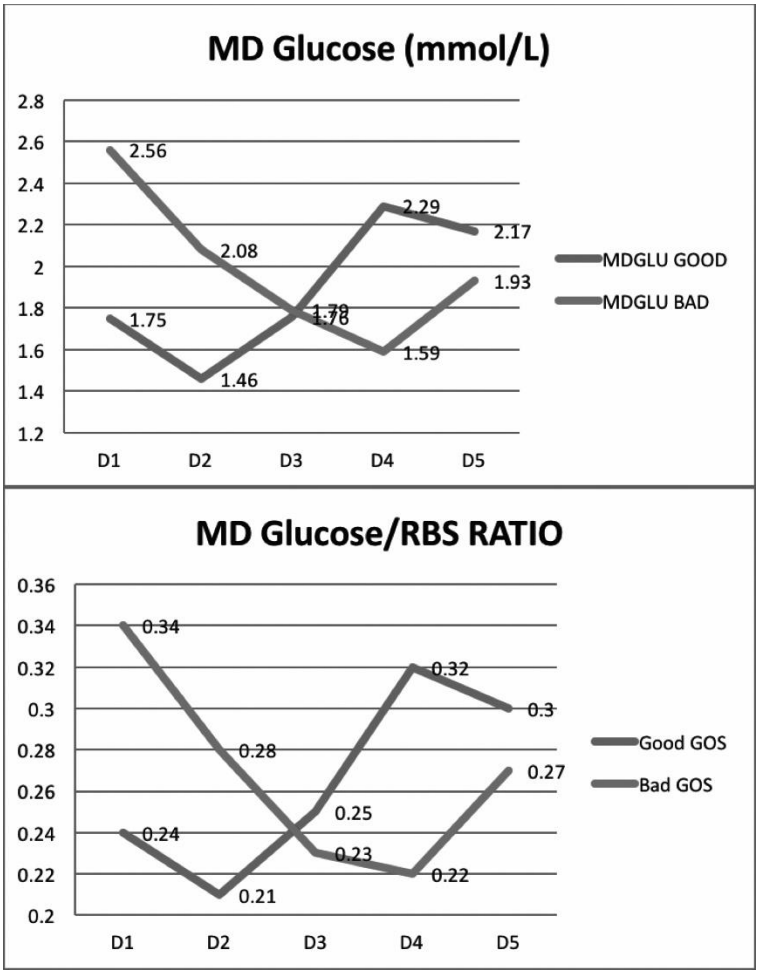

Figure 4. Over 5 days of intracerebral microdialysis (MD) monitoring, the good Glasgow Outcome Scale (GOS) outcome group showed a rising cerebral glucose and cerebral glucose/blood glucose (RBS) ratios.

Some of these new cerebral monitoring techniques have corroborated the existence of mechanisms of potential damage after TBI, such as mitochondrial failure, spreading depolarizations, non-convulsive seizures, glutamate excitotoxicity, and low brain oxygen tension. However, questions remain. Can these techniques guide therapy in the ICU, as ICP monitoring has done historically? Can detection of these events before a rise in ICP be used to focus a "targeted therapy," thus preventing high ICP and, potentially, reducing the need for DC? If clinically applicable, this could be a true "holy grail" for neurocritical care.

The TBI literature reports DC cases where the decision has been guided by neuromonitoring after TBI [19-24], subarachnoid hemorrhage [25-27], meningitis [28], and large middle cerebral artery infarcts [29, 30].

In this complex arena, monitoring neurochemistry and brain oxygen delivery by microdialysis and brain tissue oxygenation techniques can possibly provide clinicians with additional information in several related aspects of management. Robust neurochemical changes and alteration in brain tissue oxygenation have been detected in response to clinical pathophysiological events after an acute brain injury, so that the specific effect of DC on the different pathomechanisms of injury can be difficult to isolate from primary injury and other therapies using these neuromonitoring tools. Below, we review the studies supporting the hypothesis that neuromonitoring can provide additional information regarding the effects of DC on neurochemistry.

RESULTS FROM PRECLINICAL STUDIES

Whether DC may interrupt the vicious circle of events responsible for failure of brain energy metabolism and cellular damage caused by refractory intracranial hypertension has been debated. Nevertheless, in the more homogeneous and controlled condition represented by experimental animal models of acute brain injury, researchers have tried to answer several issues concerning the role of DC in this setting.

One study investigated the neuroprotective effect of DC on lateral controlled cortical impact in rat models at 3 hours, 1, 2, 3, and 7 days after TBI. Using magnetic resonance imaging and concomitant proton magnetic resonance spectroscopy to characterize the metabolic response after acute brain injury, the authors found that DC could reduce brain edema [31]. In particular, they observed that animals undergoing DC exhibited reduced apparent diffusion coefficient (a marker of brain edema severity), reduced contusion volume, decreased lactate/creatinine ratio, and higher N-acetylaspartate/creatinine and choline/creatinine ratios versus animals without DC. Decreasing N-acetylaspartate (a marker of mitochondrial damage), increased lactate (a marker of hypoxia), and decreased choline (a marker of membrane breakdown) were all observed and support a neuroprotective role for DC in experimental models of cortical impact injury. Furthermore, the demonstrated beneficial effects and improved mitochondrial dysfunction after DC were sustained up to 7 days after injury [31].

Another study investigating the role of DC on brain edema formation after lateral fluid percussion injury in rats found that at 48 hours after TBI, aquaporin-4 expression in the animals with DC was significantly decreased compared with the animals without DC, as an expression of a reduction of cerebral edema formation [32]. Other authors had previously

evaluated the hemodynamic and metabolic effects of experimental DC, using positron emission tomography in the early phase after experimental DC in the normal brain tissue in cats. Schaller et al. demonstrated that cerebral blood flow was significantly decreased and the oxygen extraction ratio significantly increased after DC, and that in regions with the most severe cerebral blood flow reduction, metabolism was also reduced [33].

Furthermore, using beta amyloid precursor protein and neurofilament-200 as histopathological markers of axonal injury, Friess et al. saw reduced pericontusional axonal injury at 7 days post injury [34]. This interesting finding suggests that DC in this animal model may actually reverse axonal destruction due to traumatic or diffuse axonal injury induced by the impact. Moreover, after controlled cortical impact in mice, early craniectomy was able to prevent secondary brain damage as shown by a more than 50% decrease in the amount of brain edema formation and no lesion expansion in craniectomized mice within the first 24 hours after trauma [35]. More recently, in a model of controlled cortical impact in mice, to test the hypothesis that reduction in ICP induced by DC would result in decreased axonal injury and white matter atrophy, investigators found that closed cranial animals (those that underwent replacement of the previously removed bone flap) had increased white matter atrophy, with smaller corpus callosum and external capsule volumes than did open cranial animals (bone left out) [34].

CLINICAL MICRODIALYSIS AS A TOOL TO UNDERSTAND THE EFFECTS OF DC

Neuromonitoring can be a measure of the effect of treatment (i.e., DC) on cerebral ischemia and hypoxia, as it relates to neurologic outcomes. The results of neuromonitoring can offer clinicians a perspective on the appropriate time-window for the investigated rescue treatment [34-36].

Guidance of critical care management after DC, especially in those cases characterized by occurrence of a hyperemic response after the procedure, may be an important next step. In fact, postoperative derangement in cerebrovascular pressure reactivity may be present after DC and could cause malignant cerebral hyperemia, as may be seen in the operating, room (Figure 3A) in the case of very high CPP [37]. Failure of restoration of brain energy metabolism resulting from a persistent energy metabolic crisis may occur, demonstrated by mitochondrial dysfunction or signs of cerebral ischemia, and clearly needs further evaluation [37].

Overall, the evaluation of the effects of DC on neurochemistry and brain oxygen delivery may contribute to a better understanding of the role of this procedure in the treatment of intracranial hypertension.

Gupta et al. [24, 38] studied a cohort of 41 patients with severe TBI undergoing DC. The group had a mean age of 33.42 years (standard deviation [SD] 13.55), range 18–85. The median post-resuscitation GCS score for the study group was 7 (range 4–7). Twenty-six patients (63.4%) had a favorable outcome (Glasgow Outcome Scale score 4 or 5) and 15 patients (36.6%) had an unfavorable outcome (Glasgow Outcome Scale score 1–3) at 6 months' follow-up. See Table 1.

All patients were managed in the neurointensive care unit with multimodality monitoring over a course of 5 days following DC. A total of 3813 hours of monitoring values of various microdialysis variables were obtained. There were no episodes of catheter insertion-induced hematoma or meningitis.

Table 1. Demographics of patients who underwent DC [38]

	Total	Good Glasgow Outcome Scale score	Bad Glasgow Outcome Scale score	P
N	41	26 (63.4%)	15 (36.6%)	
Mean age (standard deviation), years	33.41 (13.55)	36.40 (17.5)	31.54 (10.85)	0.28
Median Glasgow Coma Scale score	7	7	5	0.12

BIOCHEMICAL MEASUREMENTS

In our series of 41 cases, 25 in the original publication and 16 we have added since then for continued monitoring, we made the following observations regarding various biochemical parameters [24, 38].

Glucose

There was no significant difference in mean random blood sugar (RBS) ($P = 0.166$) (7.26 mmol/L versus 7.61 mmol/L) and mean cerebral glucose ($P = 0.221$) (1.84 mmol/L versus 1.95 mmol/L) values among the good or bad outcome groups, respectively. A poor correlation between plasma and cerebral glucose for the entire cohort (Pearson's correlation coefficient 0.01 with $P = 0.642$) was noted. This suggests that brain microdialysis glucose values are not always reflective of changes in systemic glucose. A significant difference was noted in the incidence of hyperglycemia (RBS >10 mmol/L) and hypoglycemia (RBS <5 mmol/L) between the two groups ($P < 0.0001$). The microdialysis glucose values during the episodes of hyperglycemia or hypoglycemia did not show a significant difference between the two groups ($P = 0.86$ and $P = 0.46$). However, we noticed that microdialysis glucose values showed a rising trend over the course of 5 days of monitoring in the good outcome group. Similarly, the good outcome group showed rising microdialysis glucose to blood glucose ratios. This indicates a recovering metabolic state in the brain tissue that may indicate a good outcome [24, 38].

We noted that the difference between the two groups, comparing episodes of cerebral hypoglycemia during systemic hypoglycemic episodes (RBS <5 mmol/L) was significant ($P = 0.0026$). This probably reflects increased susceptibility of brain tissue to hypoglycemia, related to impaired autoregulation, in the poorer outcome group. The previous assumption that cerebral extracellular glucose concentration would change in parallel with blood glucose values may be an oversimplification [39]. An increased metabolism of intracerebral glucose may lead to lower microdialysis glucose values following head injury [40]. Similarly, poor correlation has been noted between blood and extracellular brain glucose in patient with

subarachnoid hemorrhage [41]. Abate and colleagues attributed poor control of microdialysis glucose based on blood glucose values secondary to the metabolic heterogeneity that may be expected in TBI patients [42]. In our study, we also found poor correlation between microdialysis glucose and blood glucose values ($R^2 = 0.01$, $P = 0.64$) [38].

Lactate/Pyruvate Ratio

The mean L/P ratio was significantly higher in the poor outcome group than the good outcome group (mean 80.2 [SD 320.3] versus 45.8 [SD 169.8], $P < 0.01$). CPP had an inverse correlation to the L/P ratio for the whole cohort as would be expected with increased perfusion ($R^2 = 0.04$, $P = 0.03$). An inverse correlation was also seen in the unfavorable outcome group ($R^2 = 0.14$, $P < 0.01$). Taking both L/P ratio <45 and CPP 70 mm Hg together as cutoffs, we found a statistical significance in predicting outcome ($P = 0.03$).

Nikaina et al. showed that CPP and L/P ratio have significant effects on the long-term outcome prognosis after a spontaneous cerebral hematoma [43]. They proposed a cutoff CPP of ≥75 mm Hg and L/P ratio ≤36. Parafarou et al. suggested a CPP cutoff >75 mm Hg, L/P ratio <37, and glycerol <72 micromoles/L as markers of good outcome [44]. Our study shows somewhat similar results (L/P ratio <45 and CPP ≥70 mm Hg).

In the event of TBI, ischemia and decreased cerebral blood flow can occur even with CPP ≈ 65– 75 mm Hg [45]. Therefore, CPP alone is not a reliable indicator to assess adequacy of the cerebral blood flow in such patients. There is, however, no consensus for the ideal CPP values in severe TBI. Some authors have warned about a higher risk of acute respiratory distress syndrome with a CPP above 70 mm Hg, with no additional benefit to outcome [18]. A lower CPP goal of 60 mm Hg has been endorsed by the American Association of Neurological Surgeons, and recently the Brain Trauma Foundation suggested a general threshold in the area of 50–70 mm Hg [46]. An elevated L/P ratio can have various causes such as ischemia, hyperglycolysis, and mitochondrial dysfunction [6, 47, 48]. The key to finding the appropriate cutoff for CPP may depend on keeping a favorable metabolic profile, as indicated by low L/P ratios.

Glutamate

Increased levels of extracellular glutamate have been reported in human TBI, with persistent glutamate elevation seen in the post-injury period. In ischemic models, levels have been seen to rise from 2 μmol/L to >20 μmol/L. In our study, levels of glutamate were significantly higher in the bad outcome group than the good outcome group: 40.31 μmol/L (SD 67.24) versus 21.68 μmol/L (SD 38.31), $P < 0.01$ [24]. Recovering trends of glutamate values were seen in the good outcome group over a period of 5 days, consistent with our previous studies [15]. This suggests that glutamate could be a useful prognostic marker in TBI.

Mitochondrial Dysfunction and Ischemia

Brain Trauma Foundation guidelines recommend a target CPP value between 60 and 70 mm Hg to avoid ischemia for survival and favorable outcomes; however, attempts to maintain CPP >70 mm Hg with fluids and pressors should be avoided because of the risk of acute respiratory distress syndrome. As mentioned earlier, the L/P ratio elevation has been seen to occur in conditions of ischemia (with a fall in pyruvate) and also in mitochondrial dysfunction (with a near normal pyruvate level). Gupta et al. noted the unfavorable outcome group showed significantly higher episodes of both mitochondrial dysfunction and ischemia than the favorable GOS group: 65.9% versus 55.9% ($P < 0.0001$) and 13.9% versus 7.24% ($P < 0.001$), respectively [24, 38]. These changes were more pronounced with pericontusional catheter placement. We compared the results for the time spent in each category, post-resuscitation GCS and age to the Glasgow Outcome Scale score at last follow-up (GOS 1-5). For most patients being monitored for a period of 3 to 5 days, this meant that even a 10% increase in ischemia (8-10 hours) as shown by microdialysis, doubled their odds of progressing to a worse outcome group. Similarly, for mitochondrial dysfunction, the odds ratio was 1.475 (95% confidence interval: 1.066–2.040) ($P = 0.019$). During episodes of ischemia, the ICP was significantly higher and the CPP significantly lower [48]. In view of the odds of worsening outcome with each episode of ischemia, close control of CPP should be maintained.

Ischemia and mitochondrial dysfunction require different therapies. If a condition is characterized as ischemic based on microdialysis values of the L/P ratio and pyruvate levels, therapy is indicated to increase CPP or to pharmacologically improve microcirculation. On the other hand, bedside detection of non-ischemic mitochondrial dysfunction should lead to consideration of novel therapies targeting mitochondrial function, such as hyperbaric oxygen [48].

LITERATURE REVIEW

A recently held consensus meeting by the International Microdialysis Forum, led by P. J. Hutchinson, combined literature review with expert opinion to produce practical guidance for the use of cerebral microdialysis (see Table 2) [49]. The authors noted that the correlation between cerebral and serum glucose was weak; however, the trend of values for cerebral hypoglycemia, L/P ratio, and CPP correlated well with outcomes in the majority of cases of severe TBI [26].

CONCLUSION

Scholars have compared the complexity of the brain and its cellular function and arrangements to the cosmos, and TBI has been termed the most complex disease, affecting the most complex structure known to man. With advancements in technology, pre-hospital care, resuscitation and targeted management in a dedicated neurointensive care unit, the prognosis has improved for severe TBI from ~80% mortality in the 1950s to ~20% in the current

decade, with well-resourced neurosurgical intensive care units and dedicated care teams [50]. In the future, new monitoring techniques and therapies will make DC a crude, obsolete, archaeological relic, but our challenge is to use the methods available now to better understand the events that make DC necessary, and to prevent worse secondary disability, after TBI. Although cerebral microdialysis and other types of multimodal monitoring have been in use for almost two decades, their potential is huge for the future.

Table 2. Summary of the consensus statements and recommendations regarding cerebral microdialysis

	Consensus Statement 2015	Recommendation	Evidence
Methodology of microdialysis	20 kDa catheters for small molecules and 100 kDA for large molecules.	Flow rate of 0.3 µL/min with hourly sampling recommended.	
Reference values	Glucose (Tier 1 intervention)	<0.2 mmol/L <0.8 mmol/L	Low glucose associated with poor outcome.
	L/P ratio (Tier 1 intervention)	>40 >25	High L/P ratio associated with poor outcome.
	Lactate	>4 mmol/L	L/P ratio better than lactate
	Glutamate (Tier 2)	Raised in ischemia	May be useful in prognostication.
	Glycerol (Tier 3)	Limited specificity	No definitive evidence.
Management guidelines	Glucose	Raise RBS if low. Treat perfusion, if low CPP.	
	L/P ratio	If ischemia, raise CPP. If low PbtO2, improve oxygenation.	
Catheter placement	Focal injury	Ipsilateral In normal brain	Multiple catheters may be used.
	Diffuse injury	Right frontal lobe	
Monitoring	Trend is more important than absolute point values.		

REFERENCES

[1] Murray GD, Butcher I, McHugh GS, Lu J, Mushkudiani NA, Maas AI, et al. Multivariable prognostic analysis in traumatic brain injury: results from the IMPACT study. *J Neurotrauma*. 2007;24(2):329-37. doi: 10.1089/neu.2006.0035. PubMed PMID: 17375997.

[2] McHugh GS, Engel DC, Butcher I, Steyerberg EW, Lu J, Mushkudiani N, et al. Prognostic value of secondary insults in traumatic brain injury: results from the IMPACT study. *J Neurotrauma*. 2007;24(2):287-93. doi: 10.1089/neu.2006.0031. PubMed PMID: 17375993.

[3] Reinstrup P, Stahl N, Mellergard P, Uski T, Ungerstedt U, Nordstrom CH. Intracerebral microdialysis in clinical practice: baseline values for chemical markers during wakefulness, anesthesia, and neurosurgery. *Neurosurgery*. 2000;47(3):701-9; discussion 9-10. PubMed PMID: 10981758.

[4] Hlatky R, Valadka AB, Goodman JC, Contant CF, Robertson CS. Patterns of energy substrates during ischemia measured in the brain by microdialysis. *J Neurotrauma*. 2004;21(7):894-906. doi: 10.1089/0897715041526195. PubMed PMID: 15307902.

[5] Tisdall MM, Smith M. Cerebral microdialysis: research technique or clinical tool. *Br J Anaesth*. 2006;97(1):18-25. doi: 10.1093/bja/ael109. PubMed PMID: 16698861.

[6] Vespa P, Bergsneider M, Hattori N, Wu HM, Huang SC, Martin NA, et al. Metabolic crisis without brain ischemia is common after traumatic brain injury: a combined microdialysis and positron emission tomography study. *J Cereb Blood Flow Metab*. 2005;25(6):763-74. doi: 10.1038/sj.jcbfm.9600073. PubMed PMID: 15716852; PubMed Central PMCID: PMCPMC4347944.

[7] Giza CC, Hovda DA. The New Neurometabolic Cascade of Concussion. *Neurosurgery*. 2014;75(suppl_4):S24-S33. doi: 10.1227/NEU.0000000000000505. PubMed PMID: 28173540.

[8] Hutchinson PJ, Gupta AK, Fryer TF, Al-Rawi PG, Chatfield DA, Coles JP, et al. Correlation between cerebral blood flow, substrate delivery, and metabolism in head injury: a combined microdialysis and triple oxygen positron emission tomography study. *J Cereb Blood Flow Metab*. 2002;22(6):735-45. doi: 10.1097/00004647-200206000-00012. PubMed PMID: 12045672.

[9] Menzel M, Doppenberg EM, Zauner A, Soukup J, Reinert MM, Bullock R. Increased inspired oxygen concentration as a factor in improved brain tissue oxygenation and tissue lactate levels after severe human head injury. *J Neurosurg.* 1999;91(1):1-10. doi: 10.3171/jns.1999.91.1.0001. PubMed PMID: 10389873.

[10] Marklund N, Salci K, Lewen A, Hillered L. Glycerol as a marker for post-traumatic membrane phospholipid degradation in rat brain. *Neuroreport.* 1997;8(6):1457-61. PubMed PMID: 9172153.

[11] Hillered L, Valtysson J, Enblad P, Persson L. Interstitial glycerol as a marker for membrane phospholipid degradation in the acutely injured human brain. *J Neurol Neurosurg Psychiatry*. 1998;64(4):486-91. PubMed PMID: 9576540; PubMed Central PMCID: PMCPMC2170060.

[12] Merenda A, Gugliotta M, Holloway R, Levasseur JE, Alessandri B, Sun D, et al. Validation of brain extracellular glycerol as an indicator of cellular membrane damage due to free radical activity after traumatic brain injury. *J Neurotrauma.* 2008;25(5):527-37. doi: 10.1089/neu.2007.0359. PubMed PMID: 18363507.

[13] Stahl N, Mellergard P, Hallstrom A, Ungerstedt U, Nordstrom CH. Intracerebral microdialysis and bedside biochemical analysis in patients with fatal traumatic brain lesions. *Acta Anaesthesiol Scand*. 2001;45(8):977-85. PubMed PMID: 11576049.

[14] Nordstrom CH, Siesjo BK. Effects of phenobarbital in cerebral ischemia. Part I: cerebral energy metabolism during pronounced incomplete ischemia. *Stroke.* 1978;9(4):327-35. PubMed PMID: 27884.

[15] Bullock R, Zauner A, Woodward JJ, Myseros J, Choi SC, Ward JD, et al. Factors affecting excitatory amino acid release following severe human head injury. *J Neurosurg.* 1998;89(4):507-18. doi: 10.3171/jns.1998.89.4.0507. PubMed PMID: 9761042.

[16] Bullock R, Zauner A, Woodward J, Young HF. Massive persistent release of excitatory amino acids following human occlusive stroke. *Stroke.* 1995;26(11):2187-9. PubMed PMID: 7482671.

[17] Mazzeo AT, Bullock R. Monitoring brain tissue oxymetry: will it change management of critically ill neurologic patients? *J Neurol Sci*. 2007;261(1-2):1-9. doi: 10.1016/j.jns.2007.04.026. PubMed PMID: 17537460.

[18] Robertson CS, Valadka AB, Hannay HJ, Contant CF, Gopinath SP, Cormio M, et al. Prevention of secondary ischemic insults after severe head injury. *Crit Care Med.* 1999; 27(10):2086-95. PubMed PMID: 10548187.

[19] Ho CL, Wang CM, Lee KK, Ng I, Ang BT. Cerebral oxygenation, vascular reactivity, and neurochemistry following decompressive craniectomy for severe traumatic brain injury. *J Neurosurg.* 2008;108(5):943-9. doi: 10.3171/JNS/2008/108/5/0943. PubMed PMID: 18447711.

[20] Figaji AA, Fieggen AG, Argent AC, Le Roux PD, Peter JC. Intracranial pressure and cerebral oxygenation changes after decompressive craniectomy in children with severe traumatic brain injury. *Acta neurochirurgica Supplement*. 2008;102:77-80. Epub 2008/01/01. PubMed PMID: 19388292.

[21] Weiner GM, Lacey MR, Mackenzie L, Shah DP, Frangos SG, Grady MS, et al. Decompressive craniectomy for elevated intracranial pressure and its effect on the cumulative ischemic burden and therapeutic intensity levels after severe traumatic brain injury. *Neurosurgery.* 2010;66(6):1111-8; discussion 8-9. doi: 10.1227/01.NEU.0000369607.71913.3E. PubMed PMID: 20386136.

[22] Winkler PA, Stummer W, Linke R, Krishnan KG, Tatsch K. Influence of cranioplasty on postural blood flow regulation, cerebrovascular reserve capacity, and cerebral glucose metabolism. *J Neurosurg*. 2000;93(1):53-61. doi: 10.3171/jns.2000.93.1.0053. PubMed PMID: 10883905.

[23] Soustiel JF, Sviri GE, Mahamid E, Shik V, Abeshaus S, Zaaroor M. Cerebral blood flow and metabolism following decompressive craniectomy for control of increased intracranial pressure. *Neurosurgery*. 2010;67(1):65-72; discussion doi: 10.1227/01.NEU.0000370604.30037.F5. PubMed PMID: 20559092.

[24] Gupta DK, Singla R, Kale SS, Sharma BS. Intracerebral hypoglycemia and its clinical relevance as a prognostic indicator in severe traumatic brain injury: A cerebral microdialysis study from India. *Neurol India.* 2016;64(2):259-64. doi: 10.4103/0028-3886.177617. PubMed PMID: 26954803.

[25] Strege RJ, Lang EW, Stark AM, Scheffner H, Fritsch MJ, Barth H, et al. Cerebral edema leading to decompressive craniectomy: an assessment of the preceding clinical and neuromonitoring trends. *Neurol Res*. 2003;25(5):510-5. doi: 10.1179/016164103101201742. PubMed PMID: 12866200.

[26] Nagel A, Graetz D, Vajkoczy P, Sarrafzadeh AS. Decompressive craniectomy in aneurysmal subarachnoid hemorrhage: relation to cerebral perfusion pressure and metabolism. *Neurocrit Care*. 2009;11(3):384-94. doi: 10.1007/s12028-009-9269-x. PubMed PMID: 19714498.

[27] Stuart RM, Claassen J, Schmidt M, Helbok R, Kurtz P, Fernandez L, et al. Multimodality neuromonitoring and decompressive hemicraniectomy after subarachnoid hemorrhage. *Neurocrit Care*. 2011;15(1):146-50. doi: 10.1007/s12028-009-9264-2. PubMed PMID: 19669604.

[28] Bordes J, Boret H, Lacroix G, Prunet B, Meaudre E, Kaiser E. Decompressive craniectomy guided by cerebral microdialysis and brain tissue oxygenation in a patient

with meningitis. *Acta Anaesthesiol Scand*. 2011;55(1):130-3. doi: 10.1111/j.1399-6576.2010.02355.x. PubMed PMID: 21058942.

[29] Nielsen TH, Schalen W, Stahl N, Toft P, Reinstrup P, Nordstrom CH. Bedside diagnosis of mitochondrial dysfunction after malignant middle cerebral artery infarction. *Neurocrit Care*. 2014;21(1):35-42. doi: 10.1007/s12028-013-9875-5. PubMed PMID: 23860668.

[30] Altintas O, Antar V, Baran O, Karatas E, Altintas MO, Kesgin S, et al. Neuroprotective effects of hemicraniectomy in malign middle cerebral artery infarctions: experimental study. *J Neurosurg Sci*. 2015. PubMed PMID: 26439453.

[31] Tian R, Han L, Hou Z, Hao S, Mao X, Zhu Z, et al. Neuroprotective efficacy of decompressive craniectomy after controlled cortical impact injury in rats: An MRI study. *Brain research.* 2015;1622:339-49. Epub 2015/07/15. doi: 10.1016/j.brainres.2015.06.039. PubMed PMID: 26168891.

[32] Tomura S, Nawashiro H, Otani N, Uozumi Y, Toyooka T, Ohsumi A, et al. Effect of decompressive craniectomy on aquaporin-4 expression after lateral fluid percussion injury in rats. *Journal of neurotrauma*. 2011;28(2):237-43. Epub 2010/11/19. doi: 10.1089/neu.2010.1443. PubMed PMID: 21083433.

[33] Schaller B, Graf R, Sanada Y, Rosner G, Wienhard K, Heiss WD. Hemodynamic and metabolic effects of decompressive hemicraniectomy in normal brain. An experimental PET-study in cats. *Brain Res.* 2003;982(1):31-7. PubMed PMID: 12915237.

[34] Friess SH, Lapidus JB, Brody DL. Decompressive craniectomy reduces white matter injury after controlled cortical impact in mice. *Journal of neurotrauma*. 2015;32(11):791-800. Epub 2015/01/06. doi: 10.1089/neu.2014.3564. PubMed PMID: 25557588; PubMed Central PMCID: PMCPMC4449625.

[35] Zweckberger K, Eros C, Zimmermann R, Kim SW, Engel D, Plesnila N. Effect of early and delayed decompressive craniectomy on secondary brain damage after controlled cortical impact in mice. *J Neurotrauma*. 2006;23(7):1083-93. doi: 10.1089/neu.2006.23.1083. PubMed PMID: 16866621.

[36] Plesnila N. Decompression craniectomy after traumatic brain injury: recent experimental results. *Progress in brain research*. 2007;161:393-400. Epub 2007/07/10. doi: 10.1016/s0079-6123(06)61028-5. PubMed PMID: 17618993.

[37] Bor-Seng-Shu E, Figueiredo EG, Fonoff ET, Fujimoto Y, Panerai RB, Teixeira MJ. Decompressive craniectomy and head injury: brain morphometry, ICP, cerebral hemodynamics, cerebral microvascular reactivity, and neurochemistry. *Neurosurgical review*. 2013;36(3):361-70. Epub 2013/02/07. doi: 10.1007/s10143-013-0453-2. PubMed PMID: 23385739.

[38] Singla Raghav GD, Borkar Sachin, Suri Ashish, Kale Shashank S, Sharma BS. Cerebral Perfusion Pressure in Severe Traumatic Brain Injury and Its Relation to MicrodialysisAssessed Interstitial Brain Glycerol and Lactate Pyruvate Ratio. Indian *Journal of Neurotrauma*. 2016;13(2):59-65. Epub April 19, 2016. doi: http://dx.doi.org/10.1055/s-0036-1585092.

[39] Choi IY, Lee SP, Kim SG, Gruetter R. *In vivo* measurements of brain glucose transport using the reversible Michaelis-Menten model and simultaneous measurements of cerebral blood flow changes during hypoglycemia. *J Cereb Blood* Flow Metab. 2001;21(6):653-63. doi: 10.1097/00004647-200106000-00003. PubMed PMID: 11488534.

[40] Vespa PM, McArthur D, O'Phelan K, Glenn T, Etchepare M, Kelly D, et al. Persistently low extracellular glucose correlates with poor outcome 6 months after human traumatic brain injury despite a lack of increased lactate: a microdialysis study. *J Cereb Blood Flow Metab*. 2003;23(7):865-77. doi: 10.1097/01.WCB.0000076701.45782.EF. PubMed PMID: 12843790.

[41] Schlenk F, Nagel A, Graetz D, Sarrafzadeh AS. Hyperglycemia and cerebral glucose in aneurysmal subarachnoid hemorrhage. *Intensive Care Med*. 2008;34(7):1200-7. doi: 10.1007/s00134-008-1044-5. PubMed PMID: 18320167.

[42] Abate MG, Trivedi M, Fryer TD, Smielewski P, Chatfield DA, Williams GB, et al. Early derangements in oxygen and glucose metabolism following head injury: the ischemic penumbra and pathophysiological heterogeneity. *Neurocrit Care.* 2008;9(3):319-25. doi: 10.1007/s12028-008-9119-2. PubMed PMID: 18563636.

[43] Nikaina I, Paterakis K, Paraforos G, Dardiotis E, Chovas A, Papadopoulos D, et al. Cerebral perfusion pressure, microdialysis biochemistry, and clinical outcome in patients with spontaneous intracerebral hematomas. *J Crit Care*. 2012;27(1):83-8. doi: 10.1016/j.jcrc.2011.04.004. PubMed PMID: 21703812.

[44] Paraforou T, Paterakis K, Fountas K, Paraforos G, Chovas A, Tasiou A, et al. Cerebral perfusion pressure, microdialysis biochemistry and clinical outcome in patients with traumatic brain injury. *BMC Res Notes*. 2011;4:540. doi: 10.1186/1756-0500-4-540. PubMed PMID: 22168902; PubMed Central PMCID: PMCPMC3275520.

[45] Coles JP, Steiner LA, Johnston AJ, Fryer TD, Coleman MR, Smieleweski P, et al. Does induced hypertension reduce cerebral ischaemia within the traumatized human brain? *Brain.* 2004;127(Pt 11):2479-90. doi: 10.1093/brain/awh268. PubMed PMID: 15456706.

[46] Brain Trauma F, American Association of Neurological S, Congress of Neurological S. Guidelines for the management of severe traumatic brain injury. *J Neurotrauma*. 2007;24 Suppl 1:S1-106. doi: 10.1089/neu.2007.9999. PubMed PMID: 17511534.

[47] Oddo M, Levine JM, Frangos S, Maloney-Wilensky E, Carrera E, Daniel RT, et al. Brain lactate metabolism in humans with subarachnoid hemorrhage. *Stroke.* 2012;43(5):1418-21. doi: 10.1161/STROKEAHA.111.648568. PubMed PMID: 22343642.

[48] Yokobori S, Mazzeo AT, Gajavelli S, Bullock MR. Mitochondrial neuroprotection in traumatic brain injury: rationale and therapeutic strategies. *CNS Neurol Disord Drug Targets*. 2014;13(4):606-19. PubMed PMID: 24168363.

[49] Hutchinson PJ, Jalloh I, Helmy A, Carpenter KL, Rostami E, Bellander BM, et al. Consensus statement from the 2014 International Microdialysis Forum. *Intensive Care Med*. 2015;41(9):1517-28. doi: 10.1007/s00134-015-3930-y. PubMed PMID: 26194024; PubMed Central PMCID: PMCPMC4550654.

[50] Maas AI, Steyerberg EW, Butcher I, Dammers R, Lu J, Marmarou A, et al. Prognostic value of computerized tomography scan characteristics in traumatic brain injury: results from the IMPACT study. *J Neurotrauma.* 2007;24(2):303-14. doi: 10.1089/neu.2006.0033. PubMed PMID: 17375995.

In: Encyclopedia of Surgery (22 Volume Set)
Editors: Andreas Lehrer and Kristin Mueller
ISBN: 978-1-53618-329-0
© 2020 Nova Science Publishers, Inc.

Chapter 226

MEDICAL MANAGEMENT OF INTRACRANIAL HYPERTENSION AND INDICATIONS FOR SECONDARY DECOMPRESSIVE CRANIECTOMY

G. Schwartzbauer[1,*] and D. Stein[2]
[1]Department of Neurosurgery,
[2]Department of Surgery,
[1,2]R Adams Cowley Shock Trauma Center,
University of Maryland Medical Center, Baltimore, MD, US

"Pressure can burst a pipe, or pressure can make a diamond."—
Robert Horry, retired basketball player

ABSTRACT

Intracranial hypertension (ICHTN) can result from several medical conditions, including metabolic syndromes, brain tumors, ischemic or hemorrhagic strokes, or traumatic brain injury. The importance of ICHTN and raised intracranial pressure (ICP), put simply, relates to the blood's inability to perfuse the brain adequately. This, in turn, is ultimately responsible for impaired neurologic function resulting from homeostatic changes affecting ICP, cerebral perfusion pressure (CPP), mean arterial pressure (MAP), and metabolic state. Medical optimization of neurologic function and outcome through careful observtion of the patient in an intensive care unit and use of neurologic vital signs such as ICP, CPP, MAP, pressure reactivity index, and mixed venous oxygen staturation has made some progress in recent years, yet certain patients remain with intractable ICHTN. For these patients who fail an established stepwise medical escalation in care, decompressive craniectomy is often the only option to lower ICP.

Keywords: intracranial hypertension, cerebral perfusion pressure, intracranial pressure, traumatic brain injury, edema

[*] Corresponding Author's Email: gschwartzbauer@som.umaryland.edu.

INTRODUCTION

For a meaningful discussion and ultimately a critically defensible treatment protocol for intracranial hypertension (ICHTN), we first need to define ICHTN. Over the years ICHTN has usually meant an intracranial pressure (ICP) greater than 20 mm Hg in the setting of some clinically relevant disease state. For example, in a healthy person a simple Valsalva maneuver can transiently raise ICP above that threshold, but it rapidly returns to baseline without obvious consequence. However, following a traumatic brain injury (TBI), for example, several now classic studies have shown that patient outcomes are better in those patients who had ICP controllable to less than 20 mm Hg [1-3]. A slightly higher threshold of 22 mm Hg was found in a larger retrospective cohort study by Sorrentino [4]. It is important to note that herniation can occur below this threshold and often depends on lesion location in TBI [5]. Also cerebral perfusion pressure (CPP) by definition is affected by ICP, i.e., CPP = mean arterial pressure (MAP) minus ICP, and, and goals for optimal CPP have also been established. Yet even this straightforward number may have to be tailored to the individual patient's needs depending on the presence of intact cerebral autoregulation [6].

All of these numbers, these neurologic vital signs, help guide therapy for the brain-injured patient, especially in the deeply comatose patient where that may be all we have, but for all other patients any definition of ICHTN must include the medical first principle of 'how is the patient doing?' Close observation for changes in neurologic exam along with radiographic imaging has proved to be perhaps as powerful a tool as ICP monitoring [7]. Thus as care is delivered to improve numbers, it is important to remember that each patient may ultimately have a unique set of optimal parameters that leads to the best outcome.

CAUSES OF INTRACRANIAL HYPERTENSION

From the microscopic to the macroscopic, raised ICP can result from several causes, and can lead to life-threatening underperfusion of the brain or even herniation. Macroscopically, ICHTN generally results from three broad mechanisms—either trapped cerebral spinal fluid (CSF; hydrocephalus), mass lesion (tumor or blood), or brain swelling. Although medical management certainly plays a role in patients with hydrocephalus and mass lesions, a majority of this chapter will deal with the medical management of patients with ICHTN predominately driven by brain swelling. Although discussed in greater detail in other chapters of this volume, a brief review of microscopic processes leading to brain swelling, such as vasogenic edema, is necessary to understand current medical treatment modalities.

Normally, ICP is between 10 and 15 mm Hg, fluctuating with the cardiac and respiratory cycles. As mentioned, transient spikes may occur with Valsalva maneuvers such as coughing, but a sustained pressure above 20 mm Hg is generally accepted as a reason to intervene [8]. Macroscopically, ICP is driven by the Monro-Kellie doctrine relating to the fixed volume of the cranial vault, and the contents of blood, brain tissue, and CSF that occupy that space. Under normal circumstances the volume of these compartments is tightly regulated, and perturbation in one compartment can lead to a compensatory response in another; for example, brain swelling can lead to displacement of CSF to the spine. However, the capacity

to buffer large changes in intracranial volumes is limited, and soon small incremental changes in volume lead to exponential changes in ICP.

Multiple primary injuries can lead to raised ICP, and these primary injuries may lead to a complex array of secondary injuries. For example, TBI may result in an acute subdural hematoma, brain contusion, seizure, and hypoxemia as primary insults leading to both generalized and focal increases in ICP through mechanical and secondary swelling through cytotoxic and vasogenic edema. Each of these insults as well as the secondary injuries may have an idealized treatment algorithm, thus contributing to potential complexity. Stepwise escalation of medical intervention leading ultimately to decompressive craniectomy (DC), if all else fails, has become standard of care. However, it is worth discussing each cause of ICHTN to perhaps parse out areas for further inquiry.

ETIOLOGIES AND TREATMENT OF INTRACRANIAL HYPERTENSION

Traumatic Brain Injury

TBI is perhaps the best-studied cause of increased ICP, and this has resulted in a fairly protocolized treatment algorithm. Yet outcomes over the past few decades have not improved much, indicating the need for more work to be done. TBI is the leading cause of death and disability between the ages of 1 and 44 years old. TBI represents a substantial health burden, and in the United States alone over 1.7 million new cases are diagnosed each year, contributing to 50% of trauma deaths (braintrauma.org). In emerging economies the increased use of motor vehicles supports a rise in young male TBI [9], and in more mature states TBI from falls in an aging population has countered a fall in motor vehicle-related TBI owing to seatbelts and speed limits [10].

Trauma has the potential to set in motion the most complex causes of raised ICP. Mass lesions including subdural hematoma, epidural hematoma, intraventricular hematoma, and contusion can all increase intracranial volume, thus leading to increased ICP. Significant focal lesions can be managed surgically, but of particular concern is expansion of hemorrhagic contusions. Indeed, some preclinical and clinical data suggest that DC itself may contribute to hemorrhagic progression of contusion through a proposed release of an initial tamponade [11, 12]. And even without DC, some studies show up to 50% of hemorrhagic contusions can progress over the acute period, thus affecting focal if not global ICP [13]. Altered coagulation, as determined by partial thromboplastin time (PTT), prothrombin time (PT), and platelet number, may play a role in the severity of progression, yet in roughly 50% of hemorrhagic progression of contusion, this is not the case, implicating alternative mechanisms of capillary breakdown separate from the primary injury [13]. Preclinical studies by Simard et al. [14] suggest a novel mechanism whereby trauma causes the upregulation and expression of the Sur1-Trpm4 ion channel in the brain that then acts as an end executioner to kill capillary endothelial cells, causing fragmentation and contusion expansion. Interestingly, the Sur1-Trpm4 ion channel can be blocked by low amounts of the sulfonylurea glibenclamide to prevent hemorrhage expansion in animal models and thus may one day be of use following TBI (see Chapter 1).

Brain swelling and cerebral edema following TBI is the most serious challenge to managing ICP, and is thought to contribute to over 50% of TBI mortality [15]. In order to treat cerebral edema and brain swelling, first we need to understand some basic concepts and mechanisms of cerebral edema. Cerebral edema itself is a pathological process involving increased fluid and water mass contained in the brain interstitial space. Thus various components of brain swelling and cerebral edema that have been classically defined, including cytotoxic edema, ionic edema, and vasogenic edema, refer to different processes and indeed perhaps different stages of this pathological state. Cytotoxic edema can be thought of more as a premorbid state since cytotoxic toxic edema does not lead to brain tissue swelling but merely the swelling of brain cells whether that be neurons, support cells, or endothelial cells [16]. Ionic edema and vasogenic edema are two processes that involve transvascular flow of ions, water, and proteinaceous material. Cytotoxic edema is the influx of osmolytes into cells, particularly astrocytes, often in a damage-control response to injury or toxins. Cellular influx of osmolytes is often due to primary active transport or secondary transport. Primary transport is ATP dependent, while secondary transport relies on already established gradients. A common mechanism in astrocytes relies on collapse of the extracellular Na+ gradient following injury, with Cl- and water following secondarily. Triggers for this process include altered K+, low pH, and high glutamate concentration [17]. Transmembrane flow of water can be by diffusion, co-transport, or channels such as aquaporin-4. Cytotoxic edema generates a gradient between the brain interstitial fluid and the vascular fluid. Thus the next phase of brain swelling, ionic edema, constitutes transport of ions and eventually water to follow across the endothelial membranes on the luminal side as well as the abdominal side to the brain interstitial fluid. This is an ionic process the next phase of which depends to a large degree on blood brain barrier breakdown to allow large macromolecules to flow from the vascular department into the interstitial fluid, thus constituting vasogenic edema. It is important to note that during the cytotoxic edema and ionic edema phases, only ion gradients contribute to brain swelling, but during vasogenic edema both ionic *and* hydrostatic forces are at work. Thus one can predict during the vasogenic stages of cerebral edema that it is possible to actually exacerbate edema by driving the mean arterial pressure too high. In preclinical and clinical studies, the Sur1-Trpm4 ion channel has been shown to play a central role in cytotoxic edema and vasogenic edema and may constitute an important therapeutic target in future trials (see Chapter 1).

ICP monitoring of the severely brain-injured patient has become customary in the modern intensive care unit (ICU). Perhaps surprisingly, the data to support this practice come mostly from observational studies, and this has led to a standard of care based on the fact that significantly raised ICP is associated with poorer outcomes [1-3]. Thus the current Brain Trauma Foundation (BTF) guidelines have softened the recommendation for monitoring in severe TBI patients to simply “reduce in-hospital and 2 week post injury mortality” [8]. What remains to be determined is exactly what patient population needs to be monitored, for how long, and in what manner. Prior BTF guidelines suggested that TBI patients with a post-resuscitated Glasgow Coma Scale (GCS) of 3–8 and abnormal computed tomography (CT), or normal CT and age >40 years, or abnormal posturing, or systolic blood pressure (SBP) <90 mm Hg should have an ICP monitor. A good quality randomized controlled trial (RCT) conducted in Bolivia and Ecuador by Chesnut et al. [7] showed no difference between patients having an ICP monitor and those managed by clinical exam and radiographic

findings. Various lower quality studies have been conducted that show increased mortality with monitoring [18], no difference [19-21], or improved outcomes [22-24].

Studies have compared management based on ICP versus CPP, and tried to determine an optimal CPP. If one assumes in the most basic sense that the greater the CPP is, then perhaps the better the outcome will be, as long as cerebral autoregulation is intact and CPP is within the autoregulatory window. However, studies have found conflicting minimum values for CPP, either 60 mm Hg or 70 mm Hg, and thus the current BTF recommendation is for between 60 and 70 mm Hg, with pressure above 70 mm Hg possibly leading to pulmonary failure [4, 25, 26]. When ICP optimization was compared to CPP management, Huang et al. [27] found a lower favorable outcome in the ICP than the CPP targeted group ($P<0.04$). The optimal CPP may rely on intact cerebral autoregulation with a better tolerance for a higher CPP as compared to those with disrupted autoregulation who are more appropriately managed by ICP control [28].

To help find an optimal CPP, the cerebral pressure reactivity index (PRx) can be determined. In the normal range of intact autoregulation, blood pressure and ICP are negatively correlated. That is, an increase in cerebral blood flow is followed by cerebral vasoconstriction that decreases the volume of the intracranial blood compartment, thereby decreasing the ICP. With the PRx, clinicians can identify the individualized blood pressure range in which autoregulation is intact, thereby preserving CPP [29]. The individual patient's optimal CPP (CPPopt) is the CPP at which the PRx is most negative, that is, when autoregulation is most appropriately responsive. Aries et al. [30] showed in a large retrospective cohort of severe TBI patients requiring neurocritical care that 6-month Glasgow Outcome Scores (GOS) were better in patients whose CPP was maintained within 5 mm Hg of their CPPopt. Mortality was greatly increased in patients whose CPP was more than 5 mm Hg below their CPPopt [30]. Drawbacks include the need for the specialized software ICM+ (University of Cambridge) to calculate the Pearson correlation coefficient between mean ICP and mean BP, and determination of CPPopt may not be possible for some patients [31].

Although determination of brain tissue oxygenation (PbtO2) has fallen out of favor recently since better quality studies have shown equivocal benefit in TBI patients [32, 33]. In certain patients determination of mixed venous jugular bulb oxygen saturation and arteriovenous oxygen difference (AVDO2) may be useful. Le Roux et al. [34] found that AVDO2 that remained elevated after maximal treatment (by craniotomy or mannitol) had an increased risk of unfavorable outcome, while patients with increasing desaturation episodes had increased risk of mortality [35].

Although continuous drainage of CSF for ICHTN was shown to lower the burden of time spent at pressures above 20 cm H_2O better than intermittent drainage for pressure spikes, but it had no effect on patients' 6-month survival or GOS [36]. Interestingly, another retrospective study found higher mortality in patients with an external ventricular drain (EVD) and presenting GCS ≥ 6 [37].

Current standard of care is to monitor severe TBI patients in the setting of a modern ICU and to treat according to both clinical exam and ICP recordings. If local care options do not allow for readily available ICP monitoring, then careful attention to clinical exam along with imaging seems to be an effective alternative [7]. We usually place an ICP monitor in patients with CT findings (contusions, cerebral edema, shift, effaced cisterns) and a GCS motor score <6 as long as the patient does not have auditory verbal agnosia and the scoring is not related to external factors such as drugs and alcohol.

At the R Adams Cowley Shock Trauma Center, we routinely critically evaluate and update a generalized treatment algorithm for TBI that is broadly based on the BTF Guidelines, best available evidence, and clinical experience (Figure 1A and Figure 1B). Medical management begins in the field and continues on arrival to the Trauma Resuscitation Unit. There after evaluating the patient, resuscitation, stabilization, and advanced imaging may show the need for an operative intervention by neurosurgery (and others). During this time airway and breathing assessment is rapidly done to ensure SpO_2 (peripheral oxygen saturation) >94% with protection of an airway, hemodynamic stabilization for SBP >100 mm Hg, and international normalized ratio (INR) and platelet counts corrected to <1.5k and >80k, respectively. If signs of herniation are present, e.g., pupillary dilation, then 500 mL of 3% hypertonic saline are delivered, and as soon as possible a head CT is obtained. Assuming there is no mass lesion with shift or malignant edema (Marshall Diffuse Injury IV; [38]) requiring immediate operative intervention, an EVD is usually placed in patients with a GCS motor score <6 not explained by reasons other than TBI.

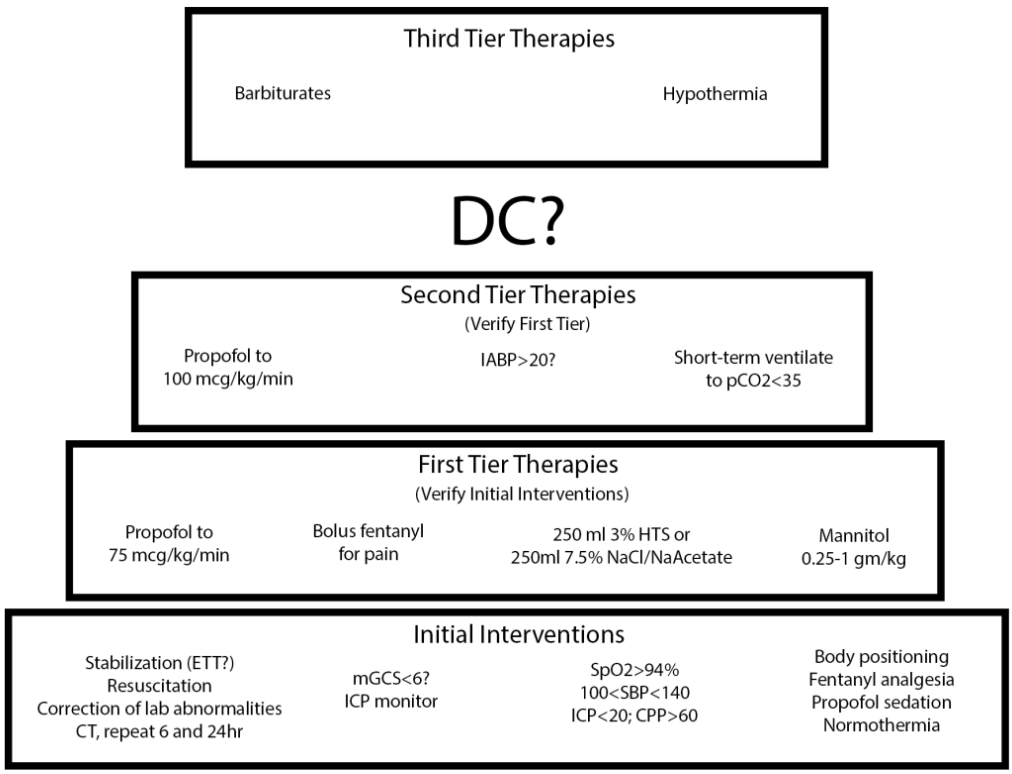

Figure 1A. Summarized medical management of intracranial hypertension (Courtesy of D Stein, University of Maryland).

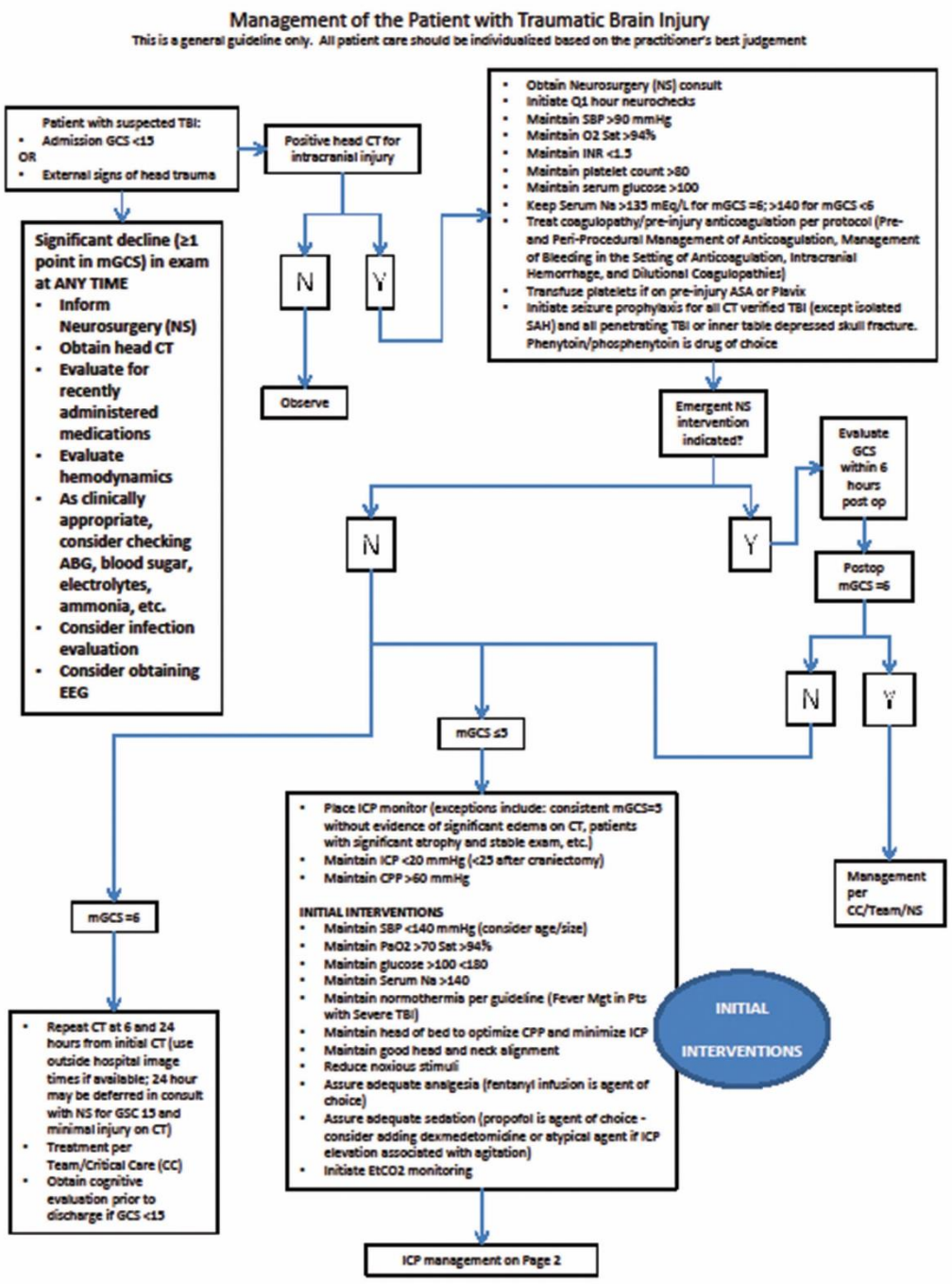

Figure 1B. (Continued).

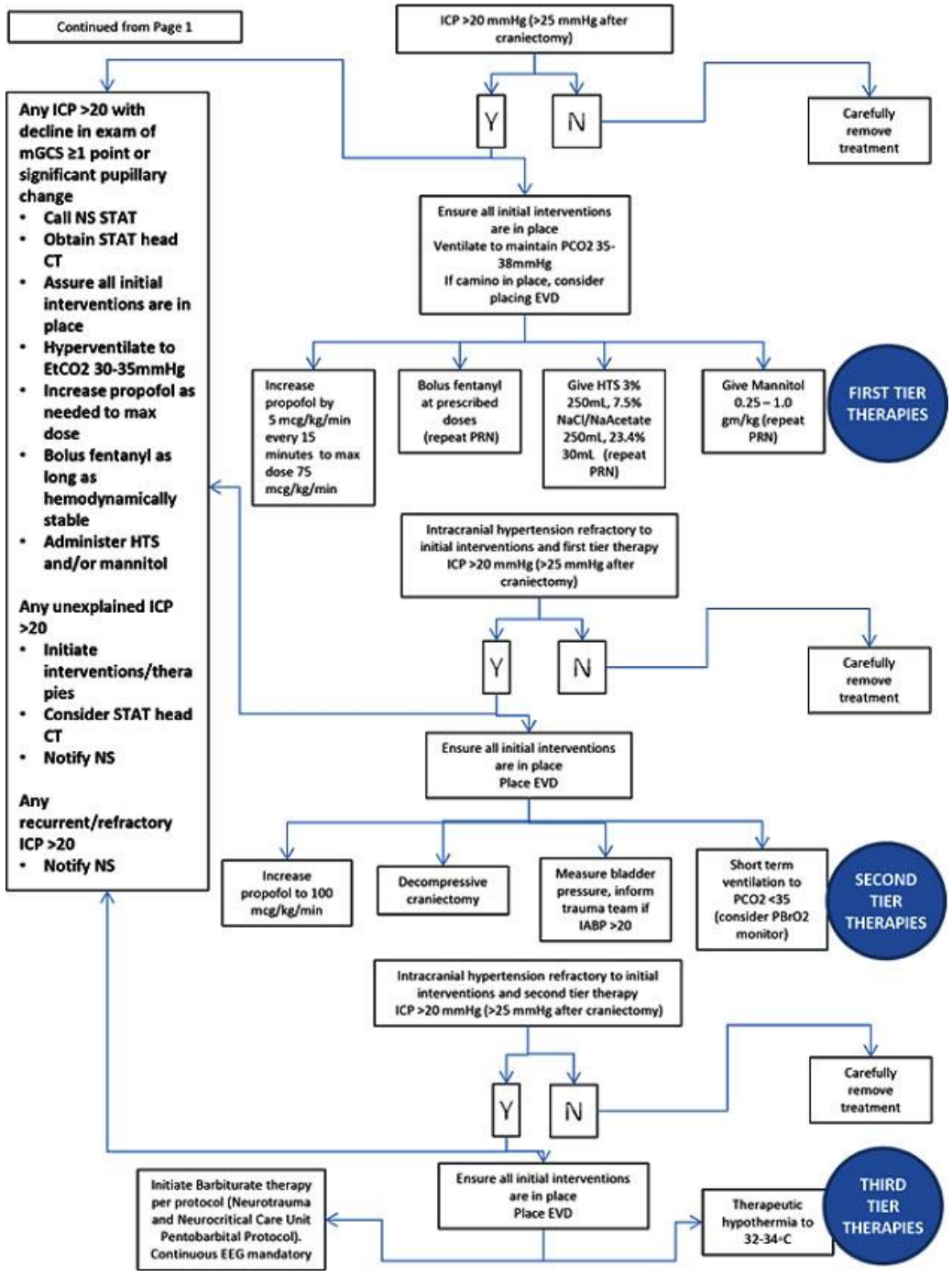

Figure 1B. Detailed medical management of intracranial hypertension based on 3 tiers of brain trauma foundation (BTF) (Courtesy of D Stein, University of Maryland).

Initial Interventions

From this point, the patients are generally managed in a critical care unit with hourly neurologic checks and ICP recordings. Initial intervention is aimed at relative homeostasis with ICP <20 mm Hg (<25 mm Hg post-craniectomy), CPP >60 mm Hg, SBP between 100 and 140 mm Hg, SpO_2 >94%, serum Na+ >140, and normothermia. If the patient is intubated, end tidal CO_2 monitoring is standard and correlated to $PaCO_2$ (partial pressure of carbon dioxide in arterial blood) and targeted within a normal range (~40 mm Hg). These laboratory values, in addition to head of bed maintained at 30 degrees, head and neck aligned, and an appropriate level of analgesia (fentanyl) and sedation with propofol (maximum 75 mcg/kg/min, measure daily myoglobin), are what we consider 'initial interventions.' CT scans are obtained again at 6 hours and 24 hours after the initial abnormal CT to test for stability. If propofol infusion syndrome or ICP control is needed for more than 7 days, then consider switching to midazolam infusion or dexmedetomidine if ICP is due to agitation [39]. Patients are at increased risk for propofol infusion syndrome if the dosage is more than 4 mg/kg/hour or is administered longer than 48 hours. The patient's condition should be carefully monitored for acidosis, rhabdomyolysis, hyperkalemia, hyperlipidemia, renal failure, and hypotension which might result in sudden cardiac arrest and death.

First Tier Therapies

If at any time ICP is greater than 20 mm Hg (or 25 mm Hg post-DC), neurosurgery is notified, initial interventions are verified, and if verification is made then the patient is ventilated to target $PaCO_2$ to 35 – 38 mm Hg, propofol can be raised by 5 mcg/kg/min to a maximum 75 mcg/kg/min, small fentanyl bolus can be given for pain, and if the ICP is still elevated 250 mL of 3% hypertonic saline (or 7.5% NaCl or Na acetate if hyperchloremic). Alternatively, mannitol 0.25 – 1 gm/kg can be given in a resuscitated patient. The relative merits of hypertonic saline versus mannitol for ICP lowering beyond the overall volume status of the patient are not well defined. However, at least one small RCT and a recent retrospective study have suggested that hypertonic saline may lead to more durable ICP-lowering effects following treatment as a percentage of time spent above 20 mm Hg; however, no advantage to GOS or mortality was seen [40, 41].

If the ICP is >20 mm Hg *and* motor GCS declines by 1 point or more at any time, also order a stat CT to evaluate for evolving brain injury.

Second Tier Therapies

If ICP still remains elevated above 20 mm Hg after first tier therapies, propofol is increased to a maximum 100 mcg/kg/min, bladder pressure is measured to determine if abdominal compartment syndrome is contributing to ICP, and, as a short-term bridge to the operating room, hyperventilate the patient to $PaCO_2$ <35 mm Hg. Recent studies suggest that hyperventilation be used only as a temporizing measure, as prolonged exposure can lead to significant ischemic problems in TBI patients [42].

If these interventions fail to reduce ICP, then according to the wishes of the family and in consultation with neurosurgery and critical care, the patient may be taken for DC.

Indication for DC, meaning what is the advantage of DC over any other treatment reasonably available to the patient, is still under investigation. Only two high quality RCTs have been published, the DECRA and the RESCUEicp trials, which are discussed at length

elsewhere in this book [43, 44]. Because the interpretation of these studies directly affects indications for DC, some salient points bear mentioning here. In the DECRA (Decompressive Craniectomy) study, a relatively early randomization to DC at 15 minutes of ICP >20 mm Hg after first tier therapy and an aggressive bifrontal DC may have contributed to worse outcomes at 6 months in the DC group than the medical management group [43]. When random selection bias for pupil reactivity was addressed in a post hoc analysis, DC still appeared at best no better than medical management alone. Since ICP was shown to be acutely reduced by DC, other factors including bifrontal DC and second tier use of DC may have confounded the results. For these and other reasons, the BTF does not recommend DC under these conditions. However, the question raised by this study was whether TBI patients with pure ICHTN refractory to medical treatment might be salvageable? The RESCUEicp (Randomized Evaluation of Surgery with Craniectomy for Uncontrollable Elevation of Intracranial Pressure) study was performed in a significantly different manner, including surgeon's choice of unilateral or bifrontal DC and use of DC as a 'last-tier' intervention after 1 to 12 hours of ICP >25 mm Hg despite maximal medical management excluding barbiturates [44]. The results of this RCT were more in line with other RCTs conducted for DC utility following malignant cerebral ischemia (please see Chapter 9 "Decompressive Craniectomy in Ischemic Stroke"), in that DC seems to save lives but at the cost of existing in a severely disabled state.

Thus a discussion with the family should address the possibility that although DC may save the patient's life, there is a significantly increased risk of severe disability or vegetative state by the time DC is typically considered. Advance directives should be part of the conversation.

Third Tier Therapies

If after second tier therapies the ICP is still elevated, the patient can be treated with barbiturate and/or with induced hypothermia. Neither intervention has led to improved outcome in most studies, yet both are powerful means to lower ICP. Although the study of Eisenberg and colleagues [1] showed that TBI patients who responded to barbiturates to lower ICP had lower mortality (92% versus 17%), the crossover design made this difference disappear when only non-crossover patients were considered. More recent studies by Majdan et al. [45] and Perez-Barcena et al. [46] highlight the fact that although barbiturates effectively lower ICP in TBI patients, other severe side effects such as hypotension offset any positive effect on outcomes. Interestingly, the medical arm of the RESCUEicp trial had a relatively high mortality rate of 48.9% where 87.2% of these patients received barbiturates versus only 9.4% in the DC group (Hutchinson et al. [44]. Patients must be intubated and have continuous ECG and EEG monitoring, along with ICP monitoring and invasive or non-invasive cardiac output monitoring. It is essential that the patient is adequately resuscitated and that fluid bolus and/or vasopressors are ready at the bedside during the typical bolus infusion of pentobarbital given the possible severe depression of cardiac output. Pentobarbital is given 1 – 5 mg/kg intravenously at a maximum rate of 50 mg/min, and can be repeated every 15 minutes until the ICP lowers or up to a maximum dose of 1000 mg or 20 mg/kg is delivered (whichever is lower). If burst suppression on EEG is reached prior to lowering ICP, it our experience that further pentobarbital doses will only add to side effects and not affect ICP. In addition to cardiopulmonary depression, patients lose gag and cough, and often suffer

from ileus, and so should be positioned on their side and should feeding through a post-pyloric feeding tube. Motility agents such as erythromycin or metoclopramide and/or trickle feeding may be necessary.

The use of prophylactic hypothermia for TBI has been controversial as the data for universal employment have been inconclusive. Several randomized trials have utilized various cooling strategies, including timing, patient population, and head-only cooling. The most recent BTF guidelines based on a meta-analysis of seven RCTs of hypothermia versus normothermia (one Class 1, six class 2) found only low-quality evidence to suggest a benefit in outcome and thus could not recommend this for general practice. Studies exploring timing and head-only cooling remain sparse and of poor quality. However, of note in the only Class 1 RCT of Clifton et al. [47] comparing outcomes of patients with severe brain injury randomly assigned to hypothermia (cooled to 33 ℃ for 48 hours and then rewarmed before treatment) or normothermia groups, there was no statistically meaningful difference in outcomes between the groups as a whole, but those with craniotomy for evacuation of hematoma apparently did have better outcomes (33% versus 69%, $p = 0.02$). Follow-up post hoc analysis by this same group that included data from an earlier study in 2001 similarly showed that craniotomy patients cooled within 1.5 hours of surgery had fewer poor outcomes than those cooled slowly or kept normothermic (41% versus 62%, $p = 0.009$) [48]. Thus, even though hypothermia may present no apparent benefit for diffuse TBI other than short-term ICP reduction, certain patient subpopulations such as those with evacuated mass lesions may ultimately benefit. However, more rigorous testing of this hypothesis awaits clinical trials before widespread implementation.

Intracranial Hemorrhage

The most common non-traumatic hemorrhages within the cranial vault are intracerebral hemorrhage (ICH), intraventricular hemorrhage (IVH), and aneurysmal subarachnoid hemorrhage (SAH), all of which can lead to increased ICP. Because ICH is focal in nature, global changes in ICP tend to be less of an issue than mass effect or midline shift. However, pending any surgical intervention meeting the latest guidelines that rely heavily on the STICH trials [49, 50], medical management is focused on management of SBP to prevent further hemorrhage, correction of any coagulation abnormalities, hyperosmolar therapy with hypertonic saline or mannitol if there is a symptomatic shift or impending herniation, and use of an EVD if there is intraventricular extension or large shift of the ICH [51]. IVH can lead to hydrocephalus and the requirement of an EVD and/or hyperosmolar treatment. SAH can lead to diffuse cerebral edema as well as acute hydrocephalus that may need to be treated and monitored by EVD. The overall management of SAH and other spontaneous brain hemorrhages, beyond management of ICP, is outside the scope of this chapter.

Intracerebral hemorrhage (ICH) for the purposes of this chapter will include bleeds within the cerebral hemispheres as well as the cerebellum. Once an underlying vascular lesion or hemorrhagic mass is excluded by advanced imaging, e.g., CT angiogram, digital subtraction angiogram, and/or contrasted magnetic resonance imaging (MRI), opinion is mixed on the benefit of any craniotomy or craniectomy for supratentorial ICH. Results of the two largest trials show a small but non-significant survival benefit for early clot evacuation that may be relevant only when the prognosis is poor for declining patients with a lobar ICH

[49, 51]. Thus current guidelines recommend ICH clot evacuation in a deteriorating patient as a life-saving measure only, whose benefits to outcome are currently unclear. For a declining patient with a cerebellar ICH, the patient should be taken to the operating room immediately once any bleeding disorder is corrected and in accordance with family wishes.

Patients should be evaluated as soon as possible, and may present with any number of symptoms resembling ischemic stroke. A clinical scale such as the NIH Stroke Scale regarding ischemic stroke and ICH-specific tools such as the ICH score and FUNC score are used [52, 53]. Rapid imaging by CT is critical, as is blood pressure control (SBP <140 mm Hg once ICH diagnosis is made). Laboratory tests, especially coagulation and complete blood count studies, as well as patient history for any anticoagulants or antiplatelet agents in use are key. Any coagulopathies should be corrected according to American Heart Association Stroke Council guidelines [51]. Coagulation parameters should be corrected to an INR <1.4, platelets to >100k, or if the patient is on NSAIDS, then one six-pack of platelets should be given. If the patient is deteriorating, and following evidence of a worsening CT scan, a discussion should occur with neurosurgery and the family to determine if it is consistent with the known wishes of the patient to consider a possible life-sparing surgery that will have an unclear impact on overall outcome. This includes ICH patients with lobar, surface (<1 cm), or cerebellar ICH only. Patients with deep basal ganglia hemorrhages are generally not amenable to open craniotomy evacuation, but may benefit from a clinical trial of catheter evacuation at tertiary centers, e.g., Minimally Invasive Surgery Plus rt-PA for Intracerebral Hemorrhage Evacuation (MISTIE) trial [54]. Patients with IVH extension of ICH or large shift may develop hydrocephalus requiring EVD placement. The most recent guidelines do not recommend prophylactic antiepileptics [51].

In the ICU, standard critical care protocols for homeostasis are carried out to maintain oxygenation, blood pressure, and hemostatic, metabolic, and nutritional goals. Hourly neurologic assessment is crucial in the first 24 hours. Repeat non-contrast CT scans should occur at 6 hours and at 24 hours for stability, and neurosurgical staff should made aware of any clinical or CT changes. Neurologic decline at any time should warrant emergent call to neurosurgery and trigger a stat CT scan.

Patients with IVH may present in a number of ways depending on whether the IVH is accompanied by an ICH. The most common complaint is headache, but severe IVH can lead to acute hydrocephalus, loss of consciousness, and death, making timely evaluation and management critical. As with ICH, rapid assessment of the patient's neurologic exam, CT scan, laboratory values with particular attention to complete blood count and coagulation parameters, and history of antiplatelet or anticoagulant use is essential. If known baseline measures have declined and evidence of hydrocephalus is present, the patient will likely need an EVD as long as blood clotting is normal and placement of the drain is consistent with known patient wishes. In general, there is little role for craniotomy or craniectomy for IVH.

Infarction

A more thorough description of the disease and a detailed analysis of the clinical data regarding DC for infarction, including the DESTINY, DECIMAL, and HAMLET trials among others, appear elsewhere in this volume. Here we summarize indications and ICU care.

A large cerebral ischemic stroke (>80 cm^3) in the internal carotid artery, middle cerebral artery (MCA) territory, or cerebellar hemisphere warrants special attention. Ischemic cerebral stroke above 145 cm^3 by MRI at 14 hours has been shown to pose a risk for herniation and death [55], while those >80 cm^3 at 6 hours may benefit from early decompression [56]. Clinical features are specific to the area affected, but even hemispheric strokes may exhibit little change to arousal. To date, no specific clinical feature has been found to track with level of consciousness; thus a thorough baseline exam is essential for further treatment. A standardized scale, such as the National Institutes of Health Stroke Scale (NIHSS) score, should be used to convey consistent patient information. Once baseline patient data have been established, changes to level of consciousness can be recorded in an ICU setting. There are no definitive criteria for DC, but it has been suggested from several prospective clinical trials that those younger than 60 years and within 48 hours of cerebral stroke may show a lower mortality if decompressed than medically managed patients; however, no patient was left without significant neurologic deficit in these trials [57]. A more recent meta-analysis of seven RCTs by Alexander et al. [58] showed that the benefit of decompression may also extend to patients older than 60. Various aspects of neurologic decline are possible in cerebral infarction, including worsening motor function, ipsilateral pupillary dysfunction, mydriasis, and adductor difficulty. Cerebellar infarct can lead to brain stem findings (pinpoint pupils, irregular breathing) and acute hydrocephalus (and death). Thus timely, accurate, and ongoing assessment is critical to patient outcomes.

On arrival to the emergency department, patients should be evaluated as soon as possible by neurological staff for initial treatment with standard of care according to the AHA Stroke Council guidelines [57]. Once diagnosed with a large cerebral or cerebellar stroke, the patient should be transferred to the ICU. Patients rarely require DC in less than 24 hours after a stroke, but if internal carotid artery stroke volume is >145 cc, an early neurosurgical consult may be warranted. Blood pressure management is initially guided by whether the patient is a candidate for thrombolytic therapy. If the patient is a candidate, then the recommendation is for SBP ≤185 mm Hg and diastolic blood pressure (DBP) ≤110 mm Hg with maintenance at ≤180/105 for 24 hours after treatment. If no thrombolytic treatment is needed, the blood pressure can left alone, only correcting for SBP >220 mm Hg or DBP >120 mm Hg.

In the ICU, neurological assessment is required once an hour with maintenance of homeostasis maintaining normoxia, controlling excessive hypertension or hyperglycemia according to American Heart Association Stroke Council guidelines [57, 58]. Key to patient management in this setting is recognition of cognitive decline attributable to the stroke. ICP monitoring is not required in this setting and in fact may be misleading [59]. If an EVD is placed into a patient with large cerebellar stroke who is developing signs and symptoms of hydrocephalus, it should be only a temporizing measure until the patient can be taken to the operating room for suboccipital decompression [60].

For patients with malignant hemispheric infarctions, decisions regarding DC need, above all, to take into account family and patient wishes based on a through discussion including reasonable expectations for outcome. Mortality as high as 78% has been reported without decompression, although perhaps confounded by withdrawal of care [61]. In years past, preference was given to those younger than 60 years and having a non-dominant hemisphere stroke given the fear of an aphasic patient, yet many people view hemiplegia as at least as bad if not worse than aphasia alone—or even death [62]. Additionally, many aphasic patients show improvement over time [63]. Stroke of the non-dominant hemisphere can also lead to

severe deficits such as abulia, neglect, and depression; thus, sidedness has become less of an issue.

Predicting which patients may progress to a malignant swelling in the 10% of patients with ischemic strokes has been associated with an NIHSS >18, early CT with infarction of >50% of the MCA territory, young age, hypertension, heart failure, and female sex [64]. Other modalities may help prognosis in the future such as serum biomarkers, CT perfusion, and cerebral microdialysis as more studies are performed to define relevant parameters.

No absolute selection criteria exist for when DC becomes necessary, but in general based on the available RCT data, patients to be considered are those having an NIHSS >16 (including altered level of consciousness on NIHSS question 1a), age younger than 60 years, less than 48 hours since onset stroke, either >50% MCA on CT or >145 cc on MRI infarcted, no surgical contraindications (coagulopathy, hemodynamically unstable), fixed dilated pupils, large hemorrhagic transformation, or limited life expectancy. Those older than 60 or at more than 48 hours can be considered on a case by case basis [65].

Cerebral venous thrombosis (CVT) is a relatively uncommon disorder accounting for <1% of all strokes [66]. Risk factors include thrombophilias, pregnancy, oral contraceptive use, infection, and malignancy. Predictors of mortality at 30 days includes depressed consciousness, hemorrhagic lesions, and deep venous thrombosis. Up to 5% of patients die in the acute phase, mainly due to large hemorrhagic lesions and diffuse cerebral edema [67, 68]. Up to 40% of CVT patients can have ICHTN [69]. Treatment is centered on anticoagulation, and data suggest that low-molecular-weight heparin may be more effective without increased risk of hemorrhage than unfractionated heparin [70]. If the patient is unstable or may have an upcoming procedure, then heparin should be used. Endovascular treatment for patients unresponsive to anticoagulation has been used with variable success, and there seems to be no advantage for patients with large hemorrhagic lesions or impending herniation [71].

DC in patients with intractable ICP and CVT has been shown to be of benefit, especially in those patients without hemorrhagic transformation or deep cerebral venous involvement [72]. There have been no RCTs for this condition, but the roughly ten published small studies have reported 0% – 30% mortality and 57% – 100% favorable outcome [73]. Even for those with hemorrhage, it can be a life-saving intervention.

Intracranial Mass

The medical management of intra- and extra-axial brain masses is subject to the properties of the focal lesion(s). If significant midline shift or posterior fossa swelling is present, then surgical debulking should certainly enter into consideration. For tumors, maintenance of eunatremia, euvolemia, and normoxia remain the underlying goals, and for lesions with significant mass effect and/or swelling, high-dose steroids such as dexamethasone 4 mg every 6 hours can be used [73]. For abscesses, use of appropriate antimicrobials remains the first line, but a large mass effect may need stereotactic drainage or debridement, or ventricular entrapment may require an EVD for CSF diversion. In case of either a mass or an abscess, the mainstays of treatment are prevention of hyponatremia or hypotension, CSF diversion if needed, hyperosmolar therapy for raised ICP or impending herniation, and medication targeted therapy to the lesion. DC in either case is not the usual standard of care, unless evacuating a large epidural empyema with contamination of the bone

flap that necessitates disposal. Conversely, DC for tumor debulking may result in fungation of the tumor [74].

Meningitis

Patients with meningitis can develop significant ICHTN, and along with antimicrobial treatment, they may require hyperosmolar treatment and/or CSF diversion through an EVD or serial lumbar puncture, if theirs is a non-obstructive presentation. Overall, dose escalation treatment of ICHTN is similar to that used for TBI, and there have been several scattered case reports of DC for intractable ICHTN over the years [75].

Idiopathic Intracranial Hypertension

Idiopathic intracranial hypertension (IIH) is a disorder of unknown etiology predominantly affecting obese women of childbearing age. The primary problem is chronically elevated ICP, and the most important neurologic manifestation is secondary progressive optic atrophy, visual loss, and possible blindness. Signs and symptoms include headaches, visual loss, diplopia, tinnitus, and radicular pain in the arms. Diagnosis is made by ophthalmologic exam looking for papilledema, MRI/venography with gadolinium to rule out sinus thrombosis or mass lesions, and lumbar puncture. Treatment is aimed at preserving optic nerve function and vision. Medical therapy includes acetazolamide for ICP lowering and headache control through amitriptyline or another migraine prophylaxis agent. Surgical intervention includes optic nerve fenestration, ventriculoperitoneal shunt, or venous sinus stenting if visual function deteriorates. DC is not appropriate treatment for this condition [76].

Hepatic Encephalopathy

Hepatic encephalopathy in cirrhosis patients is characterized by personality changes, sexual impairment, and a depressed level of consciousness. The underlying mechanism is pollution of the systemic circulation with neurotoxic substances through patent portosystemic collateral vessels. Thirty to forty-five percent of cirrhosis patients will show signs and symptoms of encephalopathy as will 24% to 53% of patients who undergo portosystemic shunt surgery [77]. By the time patients are ill enough to be admitted to hospital the 3-year survival rate is a grim 23% [78]. Approximately 30% of patients dying of end-stage liver disease experience significant encephalopathy approaching coma. This is a hallmark of acute liver failure (ALF) [79]. Encephalopathy from cirrhosis and ALF share many of the same pathogenic mechanisms.

ALF is a rapid deterioration of liver function resulting in coagulopathy, with the INR >1.5, and altered mental status in a previously healthy individual. Cerebral edema, jaundice, ascites, tenderness, hematemesis, and hypotension are some of the presenting symptoms, and the critical step in treatment is the identification of a cause that will guide further treatment. For example, acetaminophen may lead to liver failure as a result of intentional or accidental overdose. In the US Acute Liver Failure study, unintentional acetaminophen use accounted

for 48% of cases, whereas 44% of cases were due to intentional use [80]. Chronic alcohol use may greatly increase susceptibility to hepatotoxicity from acetaminophen because of depleted glutathione stores. Prompt treatment with N-acetylcysteine is essential especially when patients present within 8 hours of acetaminophen ingestion; treatment with N-acetylcysteine combined with activated charcoal is effective when they present within 4 hours [81].

These patients may progress to multiorgan failure, vasoplegia mimicking septic shock, and hemorrhage, but the development of cerebral edema is the major cause of morbidity and mortality. Cerebral edema resulting from hepatic encephalopathy involves both cytotoxic and vasogenic components [82]. Elevated levels of inflammatory cytokines are often found, but hyperammonemia may be the dominant cause. Astrocytes act to detoxify the brain, converting ammonia to glutamine by glutamine synthetase, and accumulation of glutamine leads to astrocyte swelling. Release of systemic nitric oxide leads to disruption of cerebral autoregulation, increasing blood flow to the brain and also raising ICP.

Reducing elevated ammonia levels via enteral administration of lactulose might help prevent or treat cerebral edema. The occurrence of cerebral edema and ICHTN in patients with ALF is related to the severity of encephalopathy [83]. Cerebral edema is seldom observed in patients with grades I – II encephalopathy that is characterized by lethargy, slowed responses, loss of inhibition, asterixis, and ataxia at worst. The risk of edema rises to 25% – 35% with progression to grade III (somnolence, aggression, Babinski, rigidity) and increases to 65% – 75% (or more) in patients reaching grade IV coma. The primary purpose of ICP monitoring is to detect elevations in ICP and reductions in CPP so that interventions can be made to prevent herniation while preserving brain perfusion. The ultimate goal of such measures is to maintain neurologic integrity and to prolong survival while awaiting the receipt of a donor organ or recovery of sufficient functioning hepatocyte mass. Additionally, refractory ICP and/or decreased CPP are considered contraindications to liver transplantation in many centers. ICP is managed initially with the use of mannitol, and it is effective in the short term to decrease cerebral edema. The dose may be repeated once or twice, as needed, provided that serum osmolality has not exceeded 320 mOsm/L. Volume overload is a risk with mannitol use in patients with renal impairment and may necessitate the use of dialysis to remove excess fluid.

If life-threatening ICP is not controlled with mannitol infusion and other general management as outlined above, hyperventilation may be instituted temporarily in an attempt to acutely lower the ICP and to prevent impending herniation. Hyperventilation to reduce the PaCO2 to 25 to 30 mm Hg can quickly lower ICP via vasoconstriction, causing decreased cerebral blood flow, but this effect is short-lived.

Other therapies used to decrease ICP, but not routinely recommended, may be considered in refractory ICH. These include hypertonic saline, barbiturates, and hypothermia.

In the absence of bleeding, it is usually not necessary to correct clotting abnormalities with fresh frozen plasma (FFP). The exception is when an invasive procedure is planned or in the presence of profound coagulopathy (INR >7). Bleeding abnormalities can occur when coagulation factors are less than 17% and may have to be corrected with a 15 mL/kg FFP infusion. Low levels of fibrinogen (80 mg/dL) may need to be corrected with cryoprecipitate, and for platelet levels between 10k and 80k, six to eight donor units of platelets are infused before or upon start of an urgent procedure. In certain cases of excessive bleeding or anticipated procedure, recombinant factor VII (4 mcg/kg) may need to be used in patients refractory to FFP alone.

DC in general is not considered in this patient population because of the usual accompanying coagulopathy. Neurosurgery staff are generally consulted to place ICP monitors for the management of cerebral edema and to aid triage to liver transplant when indicated. Although opinion is mixed on the utility of ICP monitors in ALF patients as no effect on long-term outcome has been seen in retrospective studies, such monitoring may aid in selection for transplantation [84].

CONCLUSION

Medical management of ICHTN should be carried out in an ICU setting, where close clinical assessment of the patient and careful attention to traditional and neurologic vital signs can take place. Surprisingly few high-quality RCTs have been done to directly address some of the most important questions, such as optimal ICP thresholds for treatment, optimal hyperosmolar therapy, and timing of DC. Most clinical decisions are based on smaller lower-quality trials and case series, as well as local clinical experience. Future care of these patients may very well rely on an individualized treatment algorithm to optimize neurologic vital signs, where a rigid 'one size fits all' protocol is no longer sufficient to improve outcomes. International collaborative efforts underway, such as Center-TBI (http://www.center-tbi.eu) and TRACK-TBI (https://tracktbi.ucsf.edu), may ultimately prove necessary to analyze 'Big Data' sets across the spectrum of TBI patients to help form more customized treatment.

REFERENCES

[1] Eisenberg HM, Frankowski RF, Contant CF, Marshall LF, Walker MD. High-dose barbiturate control of elevated intracranial pressure in patients with severe head injury. *Journal of neurosurgery.* 1988;69(1):15-23.

[2] Marmarou A, Anderson RL, Ward JD, Choi SC, Young HF. Impact of ICP instability and hypotension on outcome in patients with severe head trauma. *Journal of neurosurgery.* 1991;75:S59-S66.

[3] Narayan RK, Kishore PR, Becker DP, Ward JD, Enas GG, Greenberg RP, et al. Intracranial pressure: to monitor or not to monitor? A review of our experience with severe head injury. *Journal of neurosurgery.* 1982;56(5):650-9.

[4] Sorrentino E, Diedler J, Kasprowicz M, Budohoski KP, Haubrich C, Smielewski P, et al. Critical thresholds for cerebrovascular reactivity after traumatic brain injury. *Neurocritical care.* 2012;16(2):258-66.

[5] Andrews BT, Chiles BW, 3rd, Olsen WL, Pitts LH. The effect of intracerebral hematoma location on the risk of brain-stem compression and on clinical outcome. *Journal of neurosurgery.* 1988;69(4):518-22.

[6] Howells T, Elf K, Jones PA, Ronne-Engstrom E, Piper I, Nilsson P, et al. Pressure reactivity as a guide in the treatment of cerebral perfusion pressure in patients with brain trauma. *Journal of neurosurgery.* 2005;102(2):311-7.

[7] Chesnut RM, Temkin N, Carney N, Dikmen S, Rondina C, Videtta W, et al. A trial of intracranial-pressure monitoring in traumatic brain injury. *The New England journal of medicine.* 2012;367(26):2471-81.

[8] Carney N, Totten AM, O'Reilly C, Ullman JS, Hawryluk GW, Bell MJ, et al. *Guidelines for the Management of Severe Traumatic Brain Injury,* Fourth Edition. Neurosurgery. 2017;80(1):6-15.

[9] Khan A, Prince M, Brayne C, Prina AM. Lifetime Prevalence and Factors Associated with Head Injury among Older People in Low and Middle Income Countries: A 10/66 Study. *PloS one.* 2015;10(7):e0132229.

[10] Sarmiento K, Langlois JA, Mitchko J. "Help seniors live better, longer: prevent brain injury": an overview of CDC's education initiative to prevent fall-related TBI among older adults. *The Journal of head trauma rehabilitation.* 2008;23(3):164-7.

[11] Cepeda S, Gomez PA, Castano-Leon AM, Martinez-Perez R, Munarriz PM, Lagares A. Traumatic Intracerebral Hemorrhage: Risk Factors Associated with Progression. *Journal of neurotrauma.* 2015;32(16):1246-53.

[12] Flint AC, Manley GT, Gean AD, Hemphill JC, 3rd, Rosenthal G. Post-operative expansion of hemorrhagic contusions after unilateral decompressive hemicraniectomy in severe traumatic brain injury. *Journal of neurotrauma.* 2008;25(5):503-12.

[13] Kurland D, Hong C, Aarabi B, Gerzanich V, Simard JM. Hemorrhagic progression of a contusion after traumatic brain injury: a review. *Journal of neurotrauma.* 2012;29(1):19-31.

[14] Simard JM, Kilbourne M, Tsymbalyuk O, Tosun C, Caridi J, Ivanova S, et al. Key role of sulfonylurea receptor 1 in progressive secondary hemorrhage after brain contusion. *Journal of neurotrauma.* 2009;26(12):2257-67.

[15] Donkin JJ, Vink R. Mechanisms of cerebral edema in traumatic brain injury: therapeutic developments. *Current opinion in neurology.* 2010;23(3):293-9.

[16] Stokum JA, Gerzanich V, Simard JM. Molecular pathophysiology of cerebral edema. Journal of cerebral blood flow and metabolism: *Official journal of the International Society of Cerebral Blood Flow and Metabolism.* 2016;36(3):513-38.

[17] Stokum JA, Kurland DB, Gerzanich V, Simard JM. Mechanisms of astrocyte-mediated cerebral edema. *Neurochemical research.* 2015;40(2):317-28.

[18] Shafi S, Diaz-Arrastia R, Madden C, Gentilello L. Intracranial pressure monitoring in brain-injured patients is associated with worsening of survival. *The Journal of trauma.* 2008;64(2):335-40.

[19] Haddad S, Aldawood AS, Alferayan A, Russell NA, Tamim HM, Arabi YM. Relationship between intracranial pressure monitoring and outcomes in severe traumatic brain injury patients. *Anaesthesia and intensive care.* 2011;39(6):1043-50.

[20] Kostic A, Stefanovic I, Novak V, Veselinovic D, Ivanov G, Veselinovic A. Prognostic significance of intracranial pressure monitoring and intracranial hypertension in severe brain trauma patients. *Medicinski pregled.* 2011;64(9-10):461-5.

[21] Mauritz W, Steltzer H, Bauer P, Dolanski-Aghamanoukjan L, Metnitz P. Monitoring of intracranial pressure in patients with severe traumatic brain injury: an Austrian prospective multicenter study. *Intensive care medicine.* 2008;34(7):1208-15.

[22] Fakhry SM, Trask AL, Waller MA, Watts DD. Management of brain-injured patients by an evidence-based medicine protocol improves outcomes and decreases hospital charges. *The Journal of trauma.* 2004;56(3):492-9; discussion 9-500.

[23] Lane PL, Skoretz TG, Doig G, Girotti MJ. Intracranial pressure monitoring and outcomes after traumatic brain injury. *Canadian journal of surgery. Journal canadien de chirurgie*. 2000;43(6):442-8.

[24] Patel HC, Menon DK, Tebbs S, Hawker R, Hutchinson PJ, Kirkpatrick PJ. Specialist neurocritical care and outcome from head injury. *Intensive care medicine.* 2002;28(5):547-53.

[25] Allen BB, Chiu YL, Gerber LM, Ghajar J, Greenfield JP. Age-specific cerebral perfusion pressure thresholds and survival in children and adolescents with severe traumatic brain injury*. Pediatric critical care medicine: *A journal of the Society of Critical Care Medicine and the World Federation of Pediatric Intensive and Critical Care Societies.* 2014;15(1):62-70.

[26] Clifton GL, Miller ER, Choi SC, Levin HS. Fluid thresholds and outcome from severe brain injury. *Critical care medicine.* 2002;30(4):739-45.

[27] Huang SJ, Chen YS, Hong WC, Chang L, Han YY, Kao MC, et al. Clinical experience of hydroxyethyl starch (10% HES 200/0.5) in cerebral perfusion pressure protocol for severe head injury. *Surgical neurology.* 2006;66 Suppl 2:S26-31.

[28] Johnson U, Nilsson P, Ronne-Engstrom E, Howells T, Enblad P. Favorable outcome in traumatic brain injury patients with impaired cerebral pressure autoregulation when treated at low cerebral perfusion pressure levels. *Neurosurgery.* 2011;68(3):714-21; discussion 21-2.

[29] Zweifel C, Lavinio A, Steiner LA, Radolovich D, Smielewski P, Timofeev I, et al. Continuous monitoring of cerebrovascular pressure reactivity in patients with head injury. *Neurosurgical focus.* 2008;25(4):E2.

[30] Aries MJ, Czosnyka M, Budohoski KP, Steiner LA, Lavinio A, Kolias AG, et al. Continuous determination of optimal cerebral perfusion pressure in traumatic brain injury. *Critical care medicine.* 2012;40(8):2456-63.

[31] Dias C, Silva MJ, Pereira E, Monteiro E, Maia I, Barbosa S, et al. Optimal Cerebral Perfusion Pressure Management at Bedside: A Single-Center Pilot Study. *Neurocritical care.* 2015;23(1):92-102.

[32] Martini RP, Deem S, Yanez ND, Chesnut RM, Weiss NS, Daniel S, et al. Management guided by brain tissue oxygen monitoring and outcome following severe traumatic brain injury. *Journal of neurosurgery.* 2009;111(4):644-9.

[33] Meixensberger J, Jager A, Dings J, Baunach S, Roosen K. Multimodal hemodynamic neuromonitoring--quality and consequences for therapy of severely head injured patients. *Acta neurochirurgica Supplement.* 1998;71:260-2.

[34] Le Roux PD, Newell DW, Lam AM, Grady MS, Winn HR. Cerebral arteriovenous oxygen difference: a predictor of cerebral infarction and outcome in patients with severe head injury. *Journal of neurosurgery.* 1997;87(1):1-8.

[35] Robertson C. Desaturation episodes after severe head injury: influence on outcome. *Acta neurochirurgica Supplementum.* 1993;59:98-101.

[36] Nwachuku EL, Puccio AM, Fetzick A, Scruggs B, Chang YF, Shutter LA, et al. Intermittent versus continuous cerebrospinal fluid drainage management in adult severe traumatic brain injury: assessment of intracranial pressure burden. *Neurocritical care.* 2014;20(1):49-53.

[37] Griesdale DE, McEwen J, Kurth T, Chittock DR. External ventricular drains and mortality in patients with severe *traumatic brain injury. The Canadian journal of*

neurological sciences Le journal canadien des sciences neurologiques. 2010;37(1):43-8.

[38] Marshall LF, Marshall SB, Klauber MR, Van Berkum Clark M, Eisenberg H, Jane JA, et al. The diagnosis of head injury requires a classification based on computed axial tomography. *Journal of neurotrauma.* 1992;9 Suppl 1:S287-92.

[39] Ghori KA, Harmon DC, Elashaal A, Butler M, Walsh F, O'Sullivan MG, et al. Effect of midazolam versus propofol sedation on markers of neurological injury and outcome after isolated severe head injury: a pilot study. Critical care and resuscitation: *Journal of the Australasian Academy of Critical Care Medicine.* 2007;9(2):166-71.

[40] Mangat HS, Chiu YL, Gerber LM, Alimi M, Ghajar J, Hartl R. Hypertonic saline reduces cumulative and daily intracranial pressure burdens after severe traumatic brain injury. *Journal of neurosurgery.* 2015;122(1):202-10.

[41] Cottenceau V, Masson F, Mahamid E, Petit L, Shik V, Sztark F, et al. Comparison of effects of equiosmolar doses of mannitol and hypertonic saline on cerebral blood flow and metabolism in traumatic brain injury. *Journal of neurotrauma.* 2011;28(10):2003-12.

[42] Soustiel JF, Mahamid E, Chistyakov A, Shik V, Benenson R, Zaaroor M. Comparison of moderate hyperventilation and mannitol for control of intracranial pressure control in patients with severe traumatic brain injury--a study of cerebral blood flow and metabolism. *Acta neurochirurgica.* 2006;148(8):845-51; discussion 51.

[43] Cooper DJ, Rosenfeld JV, Murray L, Arabi YM, Davies AR, D'Urso P, et al. Decompressive craniectomy in diffuse traumatic brain injury. *The New England journal of medicine.* 2011;364(16):1493-502.

[44] Hutchinson PJ, Kolias AG, Timofeev IS, Corteen EA, Czosnyka M, Timothy J, et al. Trial of Decompressive Craniectomy for Traumatic Intracranial Hypertension. *The New England journal of medicine.* 2016;375(12):1119-30.

[45] Majdan M, Mauritz W, Wilbacher I, Brazinova A, Rusnak M, Leitgeb J. Barbiturates use and its effects in patients with severe traumatic brain injury in five European countries. *Journal of neurotrauma.* 2013;30(1):23-9.

[46] Perez-Barcena J, Llompart-Pou JA, Homar J, Abadal JM, Raurich JM, Frontera G, et al. Pentobarbital versus thiopental in the treatment of refractory intracranial hypertension in patients with traumatic brain injury: a randomized controlled trial. *Critical care* (London, England). 2008;12(4):R112.

[47] Clifton GL, Valadka A, Zygun D, Coffey CS, Drever P, Fourwinds S, et al. Very early hypothermia induction in patients with severe brain injury (the National Acute Brain Injury Study: Hypothermia II): a randomised trial. *The Lancet Neurology.* 2011;10(2):131-9.

[48] Clifton GL, Coffey CS, Fourwinds S, Zygun D, Valadka A, Smith KR, Jr., et al. Early induction of hypothermia for evacuated intracranial hematomas: a post hoc analysis of two clinical trials. *Journal of neurosurgery.* 2012;117(4):714-20.

[49] Mendelow AD, Gregson BA, Rowan EN, Murray GD, Gholkar A, Mitchell PM. Early surgery versus initial conservative treatment in patients with spontaneous supratentorial lobar intracerebral haematomas (STICH II): a randomised trial. *Lancet* (London, England). 2013;382(9890):397-408.

[50] Mendelow AD, Gregson BA, Fernandes HM, Murray GD, Teasdale GM, Hope DT, et al. Early surgery versus initial conservative treatment in patients with spontaneous

supratentorial intracerebral haematomas in the International Surgical Trial in Intracerebral Haemorrhage (STICH): a randomised trial. *Lancet* (London, England). 2005;365(9457):387-97.

[51] Hemphill JC, 3rd, Greenberg SM, Anderson CS, Becker K, Bendok BR, Cushman M, et al. Guidelines for the Management of Spontaneous Intracerebral Hemorrhage: A Guideline for Healthcare Professionals From the American Heart Association/American Stroke Association. *Stroke.* 2015;46(7):2032-60.

[52] Hemphill JC, 3rd, Bonovich DC, Besmertis L, Manley GT, Johnston SC. The ICH score: a simple, reliable grading scale for intracerebral hemorrhage. *Stroke.* 2001;32(4):891-7.

[53] Rost NS, Smith EE, Chang Y, Snider RW, Chanderraj R, Schwab K, et al. Prediction of functional outcome in patients with primary intracerebral hemorrhage: the FUNC score. *Stroke.* 2008;39(8):2304-9.

[54] Barnes B, Hanley DF, Carhuapoma JR. Minimally invasive surgery for intracerebral haemorrhage. *Current opinion in critical care.* 2014;20(2):148-52.

[55] Oppenheim C, Samson Y, Manai R, Lalam T, Vandamme X, Crozier S, et al. Prediction of malignant middle cerebral artery infarction by diffusion-weighted imaging. *Stroke.* 2000;31(9):2175-81.

[56] Mlynash M, Lansberg MG, De Silva DA, Lee J, Christensen S, Straka M, et al. Refining the definition of the malignant profile: insights from the DEFUSE-EPITHET pooled data set. *Stroke.* 2011;42(5):1270-5.

[57] Wijdicks EF, Sheth KN, Carter BS, Greer DM, Kasner SE, Kimberly WT, et al. Recommendations for the management of cerebral and cerebellar infarction with swelling: a statement for healthcare professionals from the American Heart Association/American Stroke Association. *Stroke.* 2014;45(4):1222-38.

[58] Alexander P, Heels-Ansdell D, Siemieniuk R, Bhatnagar N, Chang Y, Fei Y, et al. Hemicraniectomy versus medical treatment with large MCA infarct: a review and meta-analysis. *BMJ open.* 2016;6(11):e014390.

[59] Poca MA, Benejam B, Sahuquillo J, Riveiro M, Frascheri L, Merino MA, et al. Monitoring intracranial pressure in patients with malignant middle cerebral artery infarction: is it useful? *Journal of neurosurgery.* 2010;112(3):648-57.

[60] Raco A, Caroli E, Isidori A, Salvati M. Management of acute cerebellar infarction: one institution's experience. *Neurosurgery.* 2003;53(5):1061-5; discussion 5-6.

[61] Zahuranec DB, Gonzales NR, Brown DL, Lisabeth LD, Longwell PJ, Eden SV, et al. Presentation of intracerebral haemorrhage in a community. *Journal of neurology, neurosurgery, and psychiatry.* 2006;77(3):340-4.

[62] Solomon NA, Glick HA, Russo CJ, Lee J, Schulman KA. Patient preferences for stroke outcomes. *Stroke.* 1994;25(9):1721-5.

[63] Sul B, Kim JS, Hong BY, Lee KB, Hwang WS, Kim YK, et al. The Prognosis and Recovery of Aphasia Related to Stroke Lesion. *Annals of rehabilitation medicine.* 2016;40(5):786-93.

[64] Staykov D, Gupta R. Hemicraniectomy in malignant middle cerebral artery infarction. *Stroke.* 2011;42(2):513-6.

[65] Juttler E, Unterberg A, Woitzik J, Bosel J, Amiri H, Sakowitz OW, et al. Hemicraniectomy in older patients with extensive middle-cerebral-artery stroke. *The New England journal of medicine.* 2014;370(12):1091-100.

[66] Ameri A, Bousser MG. Cerebral venous thrombosis. *Neurologic clinics.* 1992;10(1):87-111.

[67] Canhao P, Ferro JM, Lindgren AG, Bousser MG, Stam J, Barinagarrementeria F. Causes and predictors of death in cerebral venous thrombosis. *Stroke.* 2005;36(8):1720-5.

[68] Diaz JM, Schiffman JS, Urban ES, Maccario M. Superior sagittal sinus thrombosis and pulmonary embolism: a syndrome rediscovered. *Acta neurologica Scandinavica.* 1992;86(4):390-6.

[69] Saposnik G, Barinagarrementeria F, Brown RD, Jr., Bushnell CD, Cucchiara B, Cushman M, et al. Diagnosis and management of cerebral venous thrombosis: a statement for healthcare professionals from the American Heart Association/American Stroke Association. *Stroke.* 2011;42(4):1158-92.

[70] Coutinho JM, Ferro JM, Canhao P, Barinagarrementeria F, Bousser MG, Stam J. Unfractionated or low-molecular weight heparin for the treatment of cerebral venous thrombosis. *Stroke.* 2010;41(11):2575-80.

[71] Stam J, Majoie CB, van Delden OM, van Lienden KP, Reekers JA. Endovascular thrombectomy and thrombolysis for severe cerebral sinus thrombosis: a prospective study. *Stroke.* 2008;39(5):1487-90.

[72] Zhang S, Zhao H, Li H, You C, Hui X. Decompressive craniectomy in hemorrhagic cerebral venous thrombosis: clinicoradiological features and risk factors. *Journal of neurosurgery.* 2016:1-7.

[73] Ryken TC, McDermott M, Robinson PD, Ammirati M, Andrews DW, Asher AL, et al. The role of steroids in the management of brain metastases: a systematic review and evidence-based clinical practice guideline. *Journal of neuro-oncology.* 2010;96(1):103-14.

[74] Verma SK, Kumar A, Singh PK, Bindra A, Sagar S, Sharma BS. Glioblastoma multiforme presenting as a fungating mass extending through previous craniotomy site. *Neurology India.* 2013;61(3):325-6.

[75] Hoehne J, Friedrich M, Brawanski A, Melter M, Schebesch KM. Decompressive craniectomy and early cranioplasty in a 15-year-old boy with N. meningitidis meningitis. *Surgical neurology international.* 2015;6:58.

[76] Chan JW. Current concepts and strategies in the diagnosis and management of idiopathic intracranial hypertension in adults. *Journal of neurology.* 2017.

[77] Poordad FF. Review article: the burden of hepatic encephalopathy. *Alimentary pharmacology & therapeutics.* 2007;25 Suppl 1:3-9.

[78] Bustamante J, Rimola A, Ventura PJ, Navasa M, Cirera I, Reggiardo V, et al. Prognostic significance of hepatic encephalopathy in patients with cirrhosis. *Journal of hepatology.* 1999;30(5):890-5.

[79] Bernal W, Wendon J. Acute liver failure. *The New England journal of medicine.* 2013;369(26):2525-34.

[80] Larson AM, Polson J, Fontana RJ, Davern TJ, Lalani E, Hynan LS, et al. Acetaminophen-induced acute liver failure: results of a United States multicenter, prospective study. *Hepatology* (Baltimore, Md). 2005;42(6):1364-72.

[81] Green JL, Heard KJ, Reynolds KM, Albert D. Oral and Intravenous Acetylcysteine for Treatment of Acetaminophen Toxicity: A Systematic Review and Meta-analysis. *The western journal of emergency medicine.* 2013;14(3):218-26.

[82] Butterworth RF. Pathogenesis of hepatic encephalopathy and brain edema in acute liver failure. *Journal of clinical and experimental hepatology.* 2015;5(Suppl 1):S96-s103.

[83] Blei AT, Cordoba J. Hepatic Encephalopathy. *The American journal of gastroenterology.* 2001;96(7):1968-76.

[84] Karvellas CJ, Fix OK, Battenhouse H, Durkalski V, Sanders C, Lee WM. Outcomes and complications of intracranial pressure monitoring in acute liver failure: a retrospective cohort study. *Critical care medicine.* 2014;42(5):1157-67.

In: Encyclopedia of Surgery (22 Volume Set)
Editors: Andreas Lehrer and Kristin Mueller
ISBN: 978-1-53618-329-0
© 2020 Nova Science Publishers, Inc.

Chapter 227

PREOPERATIVE AND POSTOPERATIVE NURSING CARE OF PATIENTS UNDERGOING DECOMPRESSIVE CRANIECTOMY

Karen A. McQuillan [*] ***and Tya Schoppe*** [†]
R. Adams Cowley Shock Trauma Center, University of Maryland Medical Center, Baltimore, MD, US

ABSTRACT

Nurses are vital members of the health care team that cares for patients with severe traumatic brain injury before and after decompressive craniectomy. To achieve optimal outcomes for these patients, the team is focused on avoiding secondary brain injury, preventing and treating potential complications, and enhancing emotional, cognitive, and psychosocial aspects. This calls for nurses to recognize and interpret changes in the patient's clinical status and alterations in monitored variables, prompting notification of the provider and timely intervention. Nurses must be knowledgeable about the desired therapeutic endpoints, nursing implications, and potential complications associated with medically prescribed treatments and nursing care used to treat patients with severe traumatic brain injury through resuscitation, critical care, and as the patient transitions from acute care or progresses to brain death. Communication about the patient's response to interventions is essential to guide sound clinical decision making aimed at achievement of optimal patient and family outcomes.

Keywords: nursing care, brain injury, decompressive craniectomy

[*] Corresponding Author's Email: Karen A. McQuillan, RN, CNS-BC, CCRN, CNRN, FAAN-Kmcquill@umm.edu.
[†] Tya Schoppe, RN, BSN.

INTRODUCTION

Nurses are an integral part of the health care team caring for patients before and after decompressive craniectomy (DC). The nurse must draw on a strong knowledge base and highly developed critical thinking skills to perform astute patient assessments that identify detrimental trends in monitored parameters and subtle changes in the patient's clinical examination findings. Once identified, the nurse must react swiftly to the unfavorable findings and work collaboratively with other members of the health care team so that appropriate interventions are instituted. In addition, nursing care is essential to prevent, quickly recognize, and appropriately intervene to treat potential complications that can occur in patients with severe brain injury.

GOALS OF CARE

Following brain injury a principal goal of nurses together with others on the interdisciplinary health care team is to prevent secondary injury. Unlike primary brain injury that occurs immediately upon impact and for which there is no direct treatment, secondary brain injury can evolve or occur hours to days after the primary injury and may be preventable. Factors that exacerbate progression of the intracellular pathologic cascade of events leading to delayed cell death such as hypoxia, hypotension [1, 2, 3, 4], intracranial hypertension [1, 5, 6, 7], hyper- or hypo-capnea [1], fluid and electrolyte imbalance, coagulopathy [8, 9], hyper- or hypo-glycemia [10, 11], hyperthermia [3, 7, 12], seizures [1], anemia [13, 14], and ischemia may be prevented to avoid secondary brain injury [15]. Some neurons are compromised functionally, but not disrupted mechanically following primary brain injury. If given an optimal environment for survival, these neurons may recover. These same neurons are particularly vulnerable to secondary brain injury, especially when exposed to factors that make delayed cell death more likely. For this reason, a primary aim in the management of brain injury is prevention of secondary injury [15, 16].

Nurses and the rest of the health care team also strive to prevent, quickly recognize, and appropriately treat potential complications that may exacerbate secondary brain injury and can increase mortality and morbidity. Finally, the health care team aims to sustain and enhance the emotional, cognitive, and psychosocial aspects of patients with brain injury. Attainment of these goals fosters achievement of optimal patient outcomes.

PREOPERATIVE NURSING CARE OF PATIENTS UNDERGOING DECOMPRESSIVE CRANIECTOMY

Clinical Assessment

After initial resuscitation interventions to ensure a patent airway, effective ventilation, and sufficient circulation, attention is then given to obtaining a neurologic assessment. Neurologic assessment should include a baseline clinical examination followed by serial reassessments to identify changes in the patient's condition. The baseline neurologic

evaluation should include information about the mechanism of brain injury and the prehospital course, including the examination findings and interventions initiated prior to hospitalization. As soon as a knowledgeable family member or significant other is contacted, a health history should be obtained to determine any premorbid conditions and medications taken before the injury that could affect treatment decisions.

Clinical examination, while a seemingly basic neurologic assessment strategy, constitutes an important aspect of assessing function of the injured brain. Nurses play a key role in performing a comprehensive initial neurologic examination and ongoing serial reassessments that allow detection and, when appropriate, communication to the provider of changes in the patient's condition. Major components of the clinical neurologic examination include assessment of the following: level of consciousness, motor and sensory function, eye and pupil signs, other key reflexes assessing cranial nerve function, and vital signs.

Level of consciousness assessment includes evaluation of arousal and awareness or cognition. The least noxious stimulus needed to elicit a response from the patient determines arousal. The patient may be alert and respond when approached or may require a stimulus, such as voice, shaking, peripheral pain, or deep central pain to elicit a response. If the patient is arousable, attempts can be made to evaluate awareness by assessing various cerebral cortical functions (e.g., affect, orientation, memory, intellectual ability).

Motor function is first evaluated by noting the patient's response to the stimuli applied when assessing arousal. The best possible response is the ability of the patient to consistently follow commands (e.g., protrude the tongue or hold up two fingers). Some patients may not follow commands but can localize to a stimulus, and others with an even lower level of consciousness may withdraw or have a normal flexor movement. Even worse motor responses include abnormal flexion (i.e., decorticate posturing), abnormal extension (i.e., decerebrate posturing), or no motor response. Also symmetry of motor strength, as well as muscle tone and any abnormal movements (i.e., seizures, tics, or tremors) should be noted. In patients who are alert and able to follow commands, more thorough assessment of awareness, sensation, cerebellar function, and the cranial nerves can be performed.

Generally, in minimally responsive patients receiving sedative or analgesic infusions, the nurse momentarily halts those agents known to suppress the neurologic status in order to obtain an optimal neurologic assessment. If the patient does not tolerate stopping these drugs as evidenced by monitored neurologic (e.g., intracranial pressure), hemodynamic, and/or respiratory parameters exceeding acceptable thresholds, this should be communicated to the provider. A determination can be made whether, at least temporarily, these drugs should not be discontinued before attempting a neurologic examination. After the examination is complete, the neurologic findings should be well documented so that other health care team members can accurately determine any changes in the patient's condition. To avoid confusion, vague terminology to describe responsiveness, such as lethargic, obtunded, and semi-comatose, should be avoided. Instead, what should be recorded is a clear description of both the stimulus needed to elicit a response and the motor response to the stimulus. Because assessment findings may be interpreted differently by various nurses and other health care team members, it is best that when handoffs occur between shifts and when transitioning between care areas, a neurologic assessment be done with the off-going and oncoming nurses present.

Cranial nerve motor/sensory function can be assessed by evaluating the direct and consensual light reflex, corneal reflex, facial grimace, gag reflex, and cough reflex. Absence

of the corneal reflex triggers the nurse to take care to protect the cornea by instillation of prescribed ophthalmic lubricants, taping the eyelid closed, or use of an eye shield. An impaired gag or cough reflex alerts the nurse to increased risk for patient aspiration.

Abnormal eye and pupil findings can be ominous signs of neurologic deterioration, especially when accompanied with other evidence of worsening neurologic examination. Change in pupil shape from a round to an oval or irregular shape can signify impending transtentorial herniation causing third cranial nerve compression. Likewise, a delayed or sluggish pupil response to light is an early warning sign that the pupil may soon become nonreactive to light. Nurse recognition and provider notification of these subtle early pupil signs are important so that interventions intended to halt further brain damage can be promptly administered.

Manual evaluation of pupil size and reactivity to light is plagued by inconsistencies within and between those performing assessments and by errors in detecting the light reflex in certain conditions [17, 18]. Therefore, some institutions have adopted use of a handheld automated pupillometer to provide objective measures of pupil size and reactivity to light. Meeker and colleagues [17] determined in a trial of 20 patients that the pupillometer was more reliable and accurate than manual pupil checks to measure pupil size and reactivity. The pupillometer compares the patient's measures of pupil maximal size, latency, average and maximum constriction, and dilatation velocity to a multidimensional normative model and reports this value as the neuropupillary index (NPi) [19]. Normal NPi is $\geq$3.0. An NPi score <3.0 is abnormal and may reflect intracranial pressure elevations and so should be reported to the provider [19].

Regardless of the method used to evaluation pupil size and reactivity, nurses and other clinicians need to remain cognizant of the effects that other premorbid conditions, drugs, and associated injuries may have on pupil size and reactivity. For example, alcohol use, opiate administration, and instillation of ophthalmic miotic drugs may cause pupil constriction, whereas amphetamine use, atropine administration, and instillation of cycloplegic agents are associated with pupil dilation. Knowledge of drugs the patient may have taken prior to admission or that have been administered to the patient should be well documented and communicated to other clinicians before they perform their neurologic exam.

Vital signs, including heart rate and rhythm, blood pressure, respiratory rate, as well as, pulse oximetry (SpO_2), and end tidal carbon dioxide ($ETCO_2$) are typically monitored continuously in critically ill patients with severe brain injury. This enables rapid detection of deterioration in these parameters. Efforts to quickly intervene to remedy any detrimental alterations are essential to prevent or treat hypoxia, hypercapnea, and poor perfusion, all of which increase secondary brain injury.

Core body temperature and, if available, brain temperature should also be monitored at frequent intervals or, ideally, continuously. The inflammatory response to injury, presence of blood in the brain, and damage to the temperature-regulating hypothalamus can trigger fever or hyperthermia in the brain-injured patient [12]. Reportedly, core body temperature is 0.39°C to 2.5°C less than the temperature measured in the brain [20]. The most accurate methods for measuring core body temperature are with a intravascular (e.g., pulmonary artery catheter), bladder, esophageal, or rectal sensor [21]. Regardless of the method used, the nurse must confirm proper temperature sensor placement and function to ensure accurate measures.

Standardized assessment tools that use neurologic clinical examination findings to quantify the severity of injury or neurologic disability are often employed with brain injured

patients. The internationally recognized Glasgow Coma Scale (GCS) is the most commonly used tool to score and communicate the severity of brain injury or degree of consciousness [22, 23]. A decline in the GCS score should trigger notification of the provider to determine if additional interventions are warranted. Even those who created the GCS suggest that in the acute phase, pupil and eye movement and cerebral and brain stem function should be used in addition to the GCS to evaluate overall neurologic function [23]. Some have proposed use of alternative scales to evaluate consciousness, such as the Full Outline of UnResponsiveness (FOUR) Score. The FOUR score incorporates brainstem reflexes, breathing patterns, and a variation on measures related to motor and eye response, and it eliminates a verbal response score [24]. Serial scores can indicate the patient's response to therapy as well as signal whether the overall neurologic status is improving or worsening over time. Consideration should always be given to factors that can confound an accurate score, such as administration of analgesics, sedatives, paralytics, or anesthetics, endotracheal intubation, aphasia, language incomprehension, inability to hear, periorbital edema, drug intoxication, injury to the eye, face, cranial nerves or spinal cord, dementia, developmental impairments, psychiatric disorders, and inability to speak [25]. Presence of such variables should be well documented with the score.

In addition, the nurse must remain vigilant in recognizing and responding to other intracranial and extracranial complications or associated injuries that threaten to promote secondary brain injury or that could adversely affect the neurologic examination. For example, pulmonary complications; hemodynamic instability, coagulopathy, anemia, fluid and electrolyte imbalance, elevated or reduced glycemic states, infection, and seizures should raise concern. To reduce risk of secondary brain injury, when these complications are recognized, they should be reported to the provider and interventions to remedy them should be promptly initiated.

Neurodiagnostics and Monitoring

Clinical neurologic assessment findings raising concern for brain injury typically prompt providers to order diagnostic studies. Generally, a computerized tomography (CT) scan of the brain without contrast is the imaging modality of choice in the resuscitation phase of trauma care. The CT scan generally identifies most brain pathology, particularly that which may require medical or surgical intervention, such as hemorrhage, contusion, cerebral edema, pneumocephalus, or brain herniation. Additional follow-up CT scans may be prescribed as well to follow the progression of brain injury or to investigate the cause of neurologic deterioration. An angiography, CT angiography, or magnetic resonance angiography may be prescribed when vascular injuries are suspected. When the CT scan does not demonstrate findings that explain the patient's poor neurologic status, magnetic resonance imaging (MRI) may be requested to better visualize areas of the brain (e.g., the brainstem, base of the brain) and injuries (e.g., microhemorrhages accompanying diffuse axonal injury, nonhemorrhagic lesions of the parenchyma, acute infarction, subacute or chronic hemorrhage) not seen as well on CT [26].

The nurse generally coordinates the transport of the patient for diagnostic studies. Before leaving the unit with the patient, the nurse should verify the test to be done and the readiness of the personnel to perform the study. It is also vital that the nurse ensure the patient can

safely tolerate the travel and the diagnostic procedure. If the patient has significant hemodynamic or respiratory instability, it is best to stabilize the patient prior to transport. Also, the nurse needs to be sure the patient will tolerate being supine and flat for the duration of the study. Placing the patient in this position and evaluating the effect on hemodynamic, respiratory, and, if available, intracranial monitored parameters best assesses this readiness prior to transport. If going for MRI, typically a checklist is completed to assess if the patient has any contraindications for the study and to insure the test can be safely performed. All members of the health care team who will accompany the patient on the transport, required equipment, and prescribed medications needed during the trip should be assembled. The nurse should closely monitor the patient throughout the transport and for the duration of the study.

Based on clinical examination and neurodiagnostic findings, the provider may decide to place an intracranial pressure (ICP) monitor. A fundamental aspect of care for patients with severe traumatic brain injury (TBI) in developed countries has been to monitor ICP and intervene to reduce intracranial hypertension. Because a number of studies have shown that intracranial hypertension causes secondary brain injury, prompt recognition of it and intervention to alleviate it are important to promote optimal neurologic outcomes for patients [1, 5, 6, 7]. Controversy still surrounds use of ICP monitoring following TBI. While some studies demonstrated a survival advantage when ICP monitoring is used [27, 28], others have not [29, 30]. A trial done by Chesnut and colleagues [29], known as the BEST-TRIP trial, randomized patients with severe TBI in South America to receive treatment for intracranial hypertension based on monitored ICP or on imaging and clinical examination findings. Results showed no significant difference in outcomes between the two groups although the number of brain-specific treatments was significantly greater in the imaging/clinical examination group [29]. A follow-up consensus-based interpretation of the BEST-TRIP study stressed that this research compared two ICP treatment protocols, not ICP monitoring and noted the results should not change practice of those currently monitoring ICP. These findings highlight the need for further research on use of ICP monitoring [31].

The most recent evidence-based Guidelines for Management of Severe Traumatic Brain Injury, 4th edition, recommend (Level IIB) that ICP monitoring be used to manage severe TBI to decrease mortality in-hospital and 2 weeks after injury [1]. While lacking the evidence to support a formal recommendation in the 4th edition of the Guidelines, the recommendations for when ICP monitoring is indicated were carried over from the 3rd edition. These recommendations are that ICP monitoring is indicated in all salvageable patients with a GCS score of ≤8 and an abnormal CT scan (i.e., contusions, hematoma, swelling, compressed basal cisterns, or brain herniation); and in patients with a GCS score of ≤8 with a normal CT scan when at least two of three findings are noted at admission: (1) older than 40 years of age; (2) abnormal posturing on one or both sides; (3) systolic blood pressure below 90 mm Hg [1, 32]. An ICP monitor may also be placed at the physician's discretion (e.g., when the patient has a GCS of 9 but there is concern about increased intracranial hemorrhage or swelling and a prolonged surgical intervention is planned).

Currently there are four types of transducers that can transmit pressure data from inside the cranium to an outside monitor: the fluid-filled or hydraulic, fiber optic, miniature strain gauge, and pneumatic transducer systems. Each type of transducer has specific nurse and provider implications to consider during insertion and maintenance [33–36] (see Table 1).

Table 1. Description, advantages, disadvantages and implications of using different intracranial pressure monitor transducers. References [33, 34, 35, 36]

Type of transducer description	Advantages	Disadvantages	Implications for insertion and maintenance
Fluid filled or Hydraulic system Uses static fluid column to transmit pressure from within the cranium to an external strain gauge transducer	• Inexpensive • Can be re-zeroed after insertion by turning the system stopcocks to close the transducer to the patient and opening the transducer to atmospheric air then zeroing the monitor	• Air bubbles, blood, brain tissue and other debris may get into the fluid column or transducer or the system may have loose connections or be kinked dampening the ICP waveform and causing inaccurate measures • Requires the external transducer be leveled with the external anatomic reference point corresponding to the distal tip of the fluid filled system • Risk for introduction of infectious organisms into fluid filled system causing device related intracranial infection	• Prior to attaching to the patient ensure system is primed with sterile preservative-free normal saline using syringe no larger than 30 ml, ensuring all air is expelled from the tubing and transducer. Use a flushless transducer and never use a flush solution or pressure bag which causes risk for inadvertent intracranial infusion of fluid • Reassess frequently to ensure transducer is leveled with a consistently used external anatomic landmark. When used with intraventricular placement the Foramen of Monroe is the zero reference level and the tragus of ear or outer canthus of the eye is typically selected as the consistent external landmark for leveling. Use a carpenter's level or laser to ensure accuracy of the transducer placement with the landmark. • Re-zero the transducer each shift, after temporarily disconnecting the patient from the monitor and when troubleshooting questionable readings. • Inspect the system for kinks, leaks, and the presence of air bubbles, blood or debris that may skew accuracy of measures. • Avoid introducing infection by employing strict sterile technique during insertion and manipulation of the system, ensuring snug connections, using dead-enders over any openings and minimizing system interruptions • If a deadender is removed from an opening (i.e., during re-zeroing), sterile gloves should be worn and a new sterile dead ender should be applied. [33, 34]

Table 1. (Continued)

Type of transducer description	Advantages	Disadvantages	Implications for insertion and maintenance
Implantable Transducer Catheter Systems A. Fiberoptic Transducer Tipped Monitoring System Uses fiberoptics to transmit pressure from a transducer embedded at the tip of the intracranially placed catheter to a bedside monitor B. Miniature Strain-Gauge Transducer-tipped System ICP is transmitted electronically from a miniature strain-gauge pressure sensor at the end of the catheter to an external bedside monitor	• Eliminates complications inherent in the fluid filled system • Closed system may reduce risk of intracranial infection • No leveling of transducer required • Can be placed in brain parenchyma	• Unable to re-zero after insertion • Drift in measured pressures over time • Catheter can become dislodged, damaged or have technical malfunction	• Must be zeroed prior to insertion • Secure the catheter to patient to prevent dislodgement • Avoid kinking to prevent catheter breakage
Air-pouch (Pneumatic) Sensor ICP is transmitted thought the walls of a small air filled pouch at the tip of the catheter that is then converted to an electrical signal by a transducer in the connected ICP monitor.	• Eliminates complications inherent in the fluid filled system • Closed system may reduce risk of intracranial infection • No leveling of transducer required • Automatically re-zeros at regular intervals • Can be placed in brain parenchyma • Also measures brain compliance	• One study comparing the air-pouch sensor to the fluid filled showed a trend toward lower readings with the air-pouch sensor as ICP increased [35] • Violation of the air bladder can occur [36]	• Secure sensor to prevent dislodgement or damage

Intracranial pressure monitors may be placed in the ventricle, brain parenchyma, subdural/subarachnoid space, or epidural space. Intraventricular catheters (IVC), typically placed in the anterior horn of a lateral ventricle, are considered the gold standard for measurement of ICP [16, 36]. When the IVC is placed in this location, ICP can be monitored and cerebrospinal fluid (CSF) can be drained to reduce intracranial hypertension. Placement of an IVC may be difficult if the patient's ventricles have shifted or are compressed, and each attempt at insertion increases the risk for intracerebral hemorrhage or additional tissue injury. This location for ICP monitor placement also carries a high risk for intracranial infection [1, 16, 33, 37]. Intraparenchymal placement of a fiber optic or micro-strain gauge sensor is suggested to be second only to intraventricular devices with regard to accuracy, reliability, and cost [32]. Monitors placed in the brain parenchyma tend to be quick and easy to insert even when the ventricles are compressed. Although less so than the more invasive IVC, the intraparenchymal monitors carry risk for intracranial infection and for hemorrhage at the site of insertion. The greatest disadvantage to ICP monitor placement in the brain tissue is the inability to drain CSF. Typically, subdural/subarachnoid and epidural locations for monitoring ICP are less attractive options since they tend to be less accurate than intraventricular location [32]. Nurses assisting with the ICP monitor insertion and caring for the patient after placement should be aware of the possible complications so they can take appropriate actions to minimize risks and can remain vigilant for evidence of these problems.

Prior to ICP monitor insertion, the nurse should ensure any abnormal patient coagulation parameters are reported to the provider. Depending on the degree of coagulopathy, there may be a need to correct coagulation before ICP monitor insertion to prevent triggering intracranial hemorrhage. In non-emergent cases, consent for monitor insertion should be obtained from the legally authorized representative, and a time out should always be performed. The nurse can assist with positioning the patient for the procedure and provide prescribed medications. It is important that a baseline neurologic examination be completed before and then after placement of the ICP monitor. Ideally, a protocol that reflects best practices to avoid complications related to the insertion and maintenance of the ICP monitor should be developed and routinely used. Hepburn-Smith and colleagues [37] found that although there was variability between protocols used for insertion and maintenance of external ventricular drains (EVD) to monitor ICP at ten different facilities, each site reported a significant reduction in EVD-related infections after protocol implementation. All protocols included a number of interventions to reduce risk of infection and addressed identified deficiencies in their prior practice [37].

Table 2 lists recommended best practices for insertion and maintenance of EVDs [1, 33, 34, 37, 38, 39]. Some organizations have found use of checklists; intervention bundles, and EVD supply carts that can be moved near the bedside helpful in achieving compliance with best practice protocols. Adherence to the established protocols can be promoted by engaging the entire multidisciplinary team in infection reduction efforts such as developing the protocol, providing regular staff education, validating staff competency, and monitoring protocol compliance- and EVD-related complications [37].

Table 2. Recommended best practices for insertion and maintenance of external ventricular drains. References [1, 33, 34, 37, 38, 39]

Recommendations for Insertion
• Prior to the procedure evaluate coagulation parameters and notify the provider of abnormalities
• Consider use of an antimicrobial-impregnated catheter for EVD to prevent catheter related infection (level III recommendation in the Guidelines for Management of Severe Traumatic Brain Injury)
• Position patient with head up 30-45 degrees, head midline and immobilized
• Administer any prescribed antibiotics, analgesic and sedatives
• Monitor vital signs including heart rate and rhythm, respiratory rate, blood pressure, pulse oximetery and end tidal CO_2 throughout and after the procedure
• Assess neurologic examination before, as able during, and hourly or as prescribed after the procedure. Notify the provider if deterioration in the exam findings are noted
• Perform a time out
• Ensure adherence to strict sterile technique and maximal barrier precautions during insertion – When possible close the doors and limit personnel in the room where the procedure is taking place – All staff in the room should perform hand hygiene and wear a hat, eye protection and mask – Provider placing the device and anyone assisting should have a gown, hat, mask, eye protection, and sterile gloves – Clip hair around the EVD – Scrub surgical site with antimicrobial solution. Chlorhexidine is a recommended option. – Use a broad sterile drape around the protected surgical site
• Use an EVD insertion checklist
• Typically the IVC is tunneled under the scalp away from the insertion site to reduce infection risk
• Use a chlorhexidine impregnated patch and bio-occlusive dressing at the insertion site and have competent personnel change dressing weekly or when non-adherent
• A CT scan may be ordered following the procedure to verify placement and assess for any complications
Rec Recommendations for Maintenance
• Ensure stopcocks are properly positioned for prescribed drainage
• Ensure the transducer and zero point of the drainage system are leveled at the external anatomic landmark for the Foramen of Monroe using a level or laser.
• Hourly or as prescribed assess and record the ICP, CPP, neurologic status, drainage amount and character. Notify the provider of sustained ICP elevations, CPP persistently outside desired range, or unexpected change in neurologic status, CSF drainage or character
• Clearly mark the EVD tubing so medications are not mistakenly administered into the drain
• Ensure drainage system is properly positioned and secured to prevent over drainage. Explain to visitors and other healthcare personnel not to change the height of the bed without assistance to re-level the EVD.
• Minimize risk for infection – Adhere to strict aseptic technique with any manipulation of the EVD – Minimize accessing or manipulating the EVD system and the length of time the EVD is in place – Assess the drainage system to ensure connections are snug and there are no leaks – Ensure insertion site dressing is dry and intact and changed per institutional policy. Observe insertion site for infection or CSF leak and if noted, notify the provider – Only change the drainage bag when nearly full – Obtain CSF samples only when indicated from the distal port of the EVD
• The EVD or the drainage system should not be changed at any regular interval but a change in the drainage system is indicated if it becomes inadvertently disconnected
• Provide ongoing staff education
• Regularly assess compliance with EVD maintenance
• Monitor EVD related infection rates

After placement of an IVC, CSF can be drained continuously or intermittently. The 4th edition of the Guidelines for Management of Severe Traumatic Brain Injury provides a Level III recommendation that continuous drainage of CSF with an EVD system zeroed at the

midbrain may lower the ICP burden better than when drainage is performed only intermittently [1]. When continuous drainage is prescribed, stopcocks of the EVD are positioned to keep the drain open, and CSF automatically empties into the drip chamber once ICP exceeds a predetermined level. The provider should specify the desired level at which the air–fluid interface of the CSF drip chamber should be positioned above the designated external landmark for the foramen of Monro (e.g., tragus, outer canthus of the eye). CSF drainage should be temporarily stopped to obtain an accurate measure and waveform. When intermittent CSF drainage is prescribed, the system is kept closed to drain and the transducer is kept open to the patient to enable continuous ICP monitoring. The provider's orders should specify the ICP value that should prompt drainage, as well as how long the system should remain open or how much CSF should be drained before reclosing the system. The nurse needs to closely monitor and record the amount and character of CSF drained and should notify the provider if the character of the drainage changes (e.g., more bloody or cloudy), if drainage stops, or if there is an abrupt increase.

Once in place, the ICP monitor provides data that can help detect worsening brain pathology (e.g., cerebral edema or hematoma expansion) and guides treatment. It is vital that the nurse know how to interpret the data and how to react to abnormal findings. A numeric ICP value is displayed as well as an ICP waveform. To acquire an accurate ICP pressure measure and waveform with an IVC, the stopcocks in the system must be positioned to have the drain off and the transducer open to the patient. Generally, the ICP is recorded hourly or as prescribed. If the patient has a sustained ICP elevation above 20 mm Hg, the provider should be notified and the numeric value should be recorded at more frequent intervals, such as every 15 minutes [33]. The Guidelines for Management of Severe TBI, 4th edition, recommend that 22 mm Hg serve as the threshold for initiating treatment to reduce intracranial hypertension since ICP values above this level are associated with higher morality [1]. When interpreting numeric ICP and collaborating with the provider to make treatment decisions, the patient's clinical examination and CT scan findings should be taken into consideration [1]. The nurse can determine if a recent event such as suctioning or turning may have contributed to a transient ICP elevation that will likely return to normal in a short while. Attempts should be made to reduce ICP with simple interventions like better positioning the patient or reducing noxious stimuli to effectively normalize the ICP. It is important the nurse keep the provider informed of sustained intracranial hypertension or a persistent inability to provide essential care (e.g., pulmonary hygiene) to the patient because of ICP elevations.

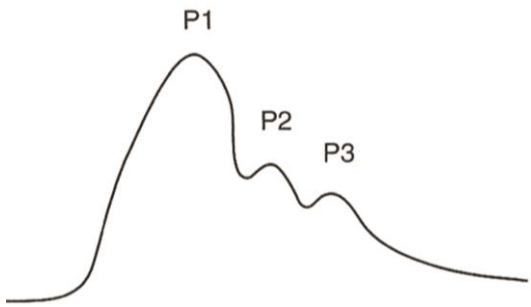

Figure 1. ICP wave form, please see text. (Used with permission from McQuillan KA, Thurman PT. Traumatic Brain Injury. In: McQuillan KA, Makic MBF, Whalen E, editors. Trauma Nursing: From *Resuscitation Through Rehabilitation*. 4th ed. St. Louis, Saunders Elsevier; 2009. p. 481.)

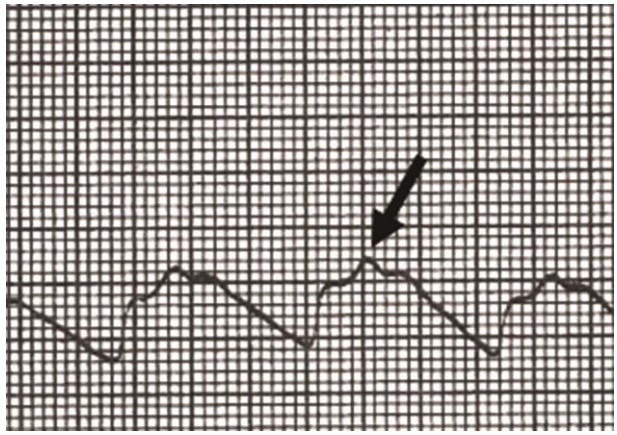

Figure 2. ICP waveform with reduced compliance, please see text. (Used with permission from McQuillan KA, Thurman PT. Traumatic Brain Injury. In: McQuillan KA, Makic MBF, Whalen E, editors. Trauma Nursing: From *Resuscitation Through Rehabilitation*. 4th ed. St. Louis, Saunders Elsevier; c2009. p. 481.)

The ICP waveform should also be carefully assessed and considered when making decisions about care. (Figure 1) These waves correlate with cardiac systole and diastole and originate from pulsations of the cerebral vasculature . Normally each ICP waveform has three peaks. The first peak, P1, is the percussion wave that has fairly consistent amplitude. The second peak, P2, is the tidal wave, which normally has lower amplitude than P1, but the height of the peak can be more variable depending on brain compliance. The third peak, P3, is the dicrotic wave that occurs with closure of the aortic valve, and this wave typically tapers back to baseline [33]. The amplitudes of the waves rise in response to elevations in ICP. As brain compliance decreases, the amplitude of P2 exceeds that of P1 or P3, making the ICP waveform appear more rounded [33, 40] (Figure 2). When the ICP waveform configuration shows P2 equal to or greater than P1, the nurse should suspect that the patient's compliance or brain compensatory capacity is low, suggesting the patient may have sustained ICP elevations as a result of interventions likely to increase ICP (e.g., putting the head down, suctioning).

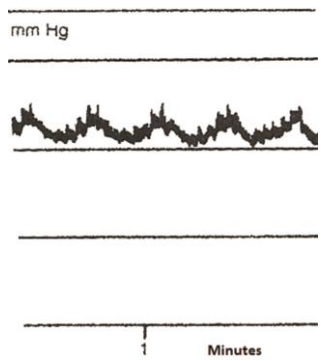

Figure 3. Lundberg type C waves, please see text. (Used with permission from McQuillan KA, Thurman PT. Traumatic Brain Injury. In: McQuillan KA, Makic MBF, Whalen E, editors. Trauma Nursing: From *Resuscitation Through Rehabilitation*. 4th ed. St. Louis, Saunders Elsevier; c2009. p. 482.)

In addition to analyzing the configuration of individual ICP waves, observing trends in ICP can also be val for figure captionsuable. C waves are rhythmic fast waves that correspond with blood pressure changes and are believed to have no clinical significance (Figure 3). B waves are sudden elevations in ICP up to 20 to 50 mm Hg for a few seconds that occur every 30 seconds to 2 minutes (Figure 4). They may signify poor brain compliance and precede the more pathologic A waves. A waves are characterized by ICP elevations as high as 50 to 100 mm Hg for 5 to 20 minutes (Figure 5). During these high plateaus, CPP is compromised and immediate intervention to reduce ICP is necessary.

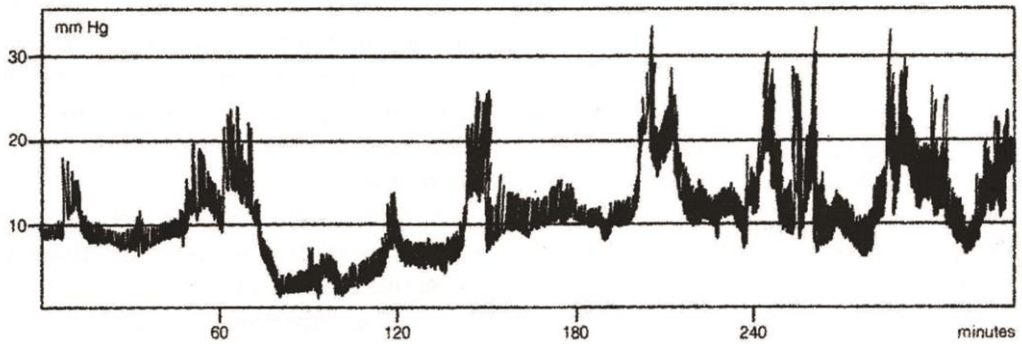

Figure 4. Lundberg type B waves, please see text. (Used with permission from McQuillan KA, Thurman PT. Traumatic Brain Injury. In: McQuillan KA, Makic MBF, Whalen E, editors. Trauma Nursing: From *Resuscitation Through Rehabilitation*. 4th ed. St. Louis, Saunders Elsevier; c2009. p. 482.)

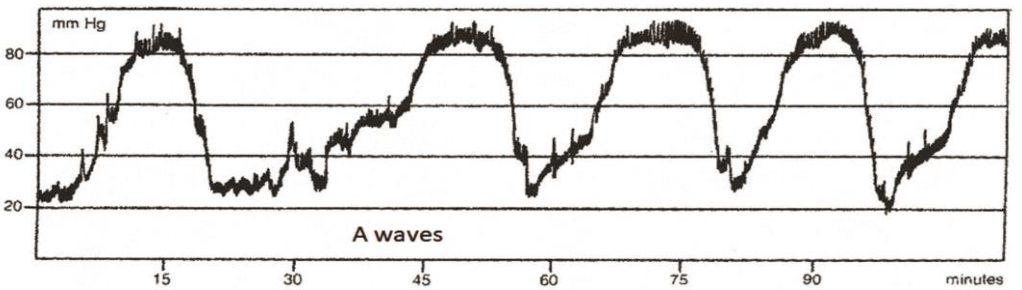

Figure 5. Lundberg type A waves, please see text. (Used with permission from McQuillan KA, Thurman PT. Traumatic Brain Injury. In: McQuillan KA, Makic MBF, Whalen E, editors. Trauma Nursing: From *Resuscitation Through Rehabilitation*. 4th ed. St. Louis, Saunders Elsevier; c2009. p. 482.)

A dampened ICP waveform, while not unusual after DC, prior to this intervention suggests a dysfunction of the monitoring system. The nurse should troubleshoot the system methodically looking for evidence of leak, kinks, or of air, blood or debris in the fluid-filled set up. Also consider malfunction of the pressure cables or monitor. If no problem is found and after re-zeroing the external transducer the problem is not alleviated, the provider should be notified. The accuracy of the numeric value should be questioned while the waveform is dampened.

Monitoring ICP also offers the ability to quickly calculate cerebral perfusion pressure (CPP) by taking the mean arterial blood pressure (MABP) and subtracting the mean ICP from it. CPP is the pressure gradient needed to drive blood and the essential nutrients it carries to

the brain. In healthy individuals who have intact pressure autoregulation, the cerebral blood vessels are able to autoregulate their diameter to maintain a constant cerebral blood flow despite fluctuations in pressure as long as the CPP is maintained at 50 to 150 mm Hg. Brain injury disrupts normal cerebral autoregulation, at times causing a direct correlation between pressure changes and alterations in cerebral blood flow. The Guidelines for Management of Severe TBI recommend (Level IIB) maintaining a CPP range of 60 to 70 mm Hg for survival and optimal outcomes [1]. Minimal optimal CPP for a patient is not clear but likely depends on the autoregulatory status of the brain-injured individual [1]. When CPP is insufficient due to low blood pressure and/or high ICP, perfusion to the brain is compromised and ischemia can occur causing secondary brain injury. Extremely high CPP can also be detrimental to outcomes. Aggressive efforts to elevate CPP above 70 mm Hg have been shown to cause greater incidence of adult respiratory distress syndrome (ARDS) and is therefore not recommended [1, 41]. When CPP fails to remain at the desired therapeutic level, the nurse should promptly notify the provider to take actions that lower ICP and/or raise MABP to achieve sufficient perfusion pressure.

Optimal CPP may vary among patients and fluctuate over time, suggesting the need to individualize desired CPP thresholds [15, 42]. Again the autoregulation status of the patient is another likely determinant of the optimal CPP level [1]. Therefore, other measures such as the cerebral oxygenation, cerebral blood flow, or pressure reactivity index (PRx) may be helpful in determining the best CPP for a specific patient [42].

Multiple monitoring tools may be used simultaneously to provide better insight into the injured brain's physiology so that treatment can be targeted to correct alterations quickly before significant secondary injury occurs [15]. Table 3 highlights various monitoring tools that may be used for multimodal monitoring and some key advantages and disadvantages of each [43]. Additional research is still warranted to close knowledge gaps related to exact treatment thresholds and how to best integrate and use the data provided from some technologies [1]. The reader is encouraged to refer to the chapter on Multimodality Monitoring in Decompressive Craniectomy for Traumatic Brain Injury and Stroke for more detail about various monitoring strategies that may be used together to monitor and guide treatment of brain-injured patients.

The nurse must be knowledgeable about any monitor used in a patient for whom they are caring. This includes understanding the purpose, limitations, and function of the device. The nurse needs to be able to interpret the numeric and any waveform data provided and appreciate the implications of these findings on functionality of the monitoring device and the care needed by the patient. To ensure that accurate measures are obtained, the nurse should properly level, zero, and/or calibrate the monitoring devices as needed according to the manufacturer's recommendations. Also the nurse should be well informed of any factors that may skew monitor accuracy or confound measures. When there is concern about the monitor's proper functioning and data accuracy, the nurse should be proficient in troubleshooting the device and know when to notify the provider about possible problems. Being well apprised of the desired therapeutic endpoints for any monitored parameters enables the nurse to guide nursing interventions and prescribed therapy to best reach preferred goals and to recognize when a provider-ordered change in treatment might be necessary.

Table 3. Techniques for brain monitoring

Technique	Detail	Advantages	Disadvantages
Neurologic examination	Global assessment of consciousness, sensory and motor responses, cranial nerve assessment, and ancillary tests	Can be used in all patients; findings can direct additional confirmatory testing or imaging	Affected by sedation, fever, seizures; in severely injured, exam may be static despite dynamic neurologic injury
Intracranial pressure (ICP) monitor	Typically monitored by a probe placed in the ventricle or parenchyma	Well established in traumatic brain injury; Ventricular drain allows removal of cerebrospinal fluid for ICP therapy/ labs; Enables cerebral perfusion pressure (CPP) calculation	Invasive monitor, potential risk for infection, hardware malfunction
Pressure reactivity index (PRx)	Algorithm relates changes in blood pressure to ICP to determine measure of autoregulation	Individualized measure of autoregulation and goal directed CPP therapy	Requires concurrent ICP monitor; an optimal CPP not always able to be calculated; software malfunction may occur
Cerebral microdialysis	Intraparenchymal probe obtains dialysate for lab assays	Informative of cerebral microenvironment and metabolic state; special lab assays possible	Invasive monitor, potential risk of infection, hardware malfunction; results potentially not reflective of entire brain
Jugular venous oxygen saturation ($SjvO_2$)	Catheter placed in jugular bulb of internal jugular vein measures hemoglobin oxygen saturation	Allows for assessment of global cerebral oxygen supply and demand balance; guides therapy to promote adequate oxygen supply to meet metabolic need of the brain	Potential risk for infection, vascular injury or thrombosis; catheter malposition, damage or fibrin clot on the tip can cause inaccurate measures; regional brain ischemia may be underestimated or undetected especially in unmeasured hemisphere
Partial pressure of brain tissue oxygen ($PbtO_2$)	Intraparenchymal probe measures partial pressure of oxygen	Enables targeted therapy	Invasive monitor, potential risk of infection, hardware malfunction; results potentially not reflective of regional oxygenation changes in other areas of the brain
Near-infrared spectroscopy/ diffuse correlation spectroscopy	Optical probes placed on the scalp. Measures cerebral oxygenation (NIS) and cerebral blood flow (DCS)	Noninvasive, cerebral oxygenation and extraction related to metabolism, cerebral blood flow, continuous monitoring possible	Assess brain tissue to a depth of 2-3 cm, typically frontal lobes
Continuous cerebral blood flow	Laser doppler flowmetry or thermal diffusion sensors placed on or in the brain cortex	Provide continuous measure of regional cerebral blood flow; allows for assessment of autoregulation	Invasive monitor, potential risk for infection, hardware malfunction; results potentially not reflective of other areas of the brain
Continuous electroencephalography	Assess brain electrical activity through scalp electrodes	Cerebral metabolic rate is related to brain activity; Can identify seizure activity	May be affected by sedation, intracranial mass lesions, presence of other intracranial monitors; inherently subjective interpretation; hardware malfunction; continuous monitoring not widely available
Serum markers	Measures of proteins indicative of neuronal injury	Non-invasive prognosticator of outcome	Not “real-time”. Affected by extracranial trauma and timing of injury. Subject to differences in specimen handling, hemolysis and differences between laboratory assays

Adapted from: Techniques for Brain Monitoring in Jones S, Schwartzbauer G, Jia, X. Brain monitoring in critically neurologically impaired patients. Int J Mol Sci. 2017;18(43):page 3.

Nursing Interventions

Initial Resuscitation

Initial priorities in resuscitation of the trauma patient are to ensure a patent airway, sufficient ventilation, and control of hemorrhage with sufficient circulation [44]. These top three priorities are fitting for the trauma patient with brain injury since accomplishing these goals is essential to prevent hypoxia, hypercapnea, and hypotension – all key factors that can exacerbate secondary brain injury. Only after these concerns are addressed will attention focus on TBI-specific interventions.

Airway obstruction is not uncommon after TBI owing to the relaxation of the upper airway and backward prolapse of the tongue associated with unconsciousness, loss of protective airway reflexes (e.g., cough, gag), risk for vomiting and aspiration, and possible associated facial injury. Patients with TBI may have an associated spinal cord injury, and so consideration needs to be given to ensure spinal precautions when establishing the airway. Use of the chin lift or jaw thrust maneuver taking care to avoid neck extension is recommended to initially open the airway [44]. In the presence of obstruction or in patients with a GCS score ≤8, endotracheal intubation is likely needed. The nurse can prepare the equipment and prescribed medications in anticipation of rapid sequence intubation and, if possible, obtain a neurologic examination before administration of these pharmacologic agents. Manual immobilization of the cervical spine and head should be maintained during intubation [44, 45]. If the provider is unable to secure an airway with an endotracheal tube, a surgical airway may need to be established. Once the tracheal tube is in place, the nurse should always make sure it is well secured to prevent inadvertent tube removal that could cause hypoxia and hypercapnea with devastating effects on neurologic outcome. Placement of an orogastric tube to decompress the stomach further assists in preventing aspiration.

Once the airway is established, ensuring adequate ventilation with sufficient respiratory gas exchange is important. The airway must remain clear, typically with endotracheal suctioning and in some cases a need for bronchoscopy. The nurse's careful assessment of the patient's breath sounds and respiratory pattern and effort helps to identify when the airway is congested and requires additional hygiene. The nurse and other members of the health care team should also assess for other associated life-threatening chest injuries (i.e., massive hemothorax, tension pneumothorax, open pneumothorax, flail chest with pulmonary contusion, cardiac tamponade) that require urgent intervention.

Continuous SpO_2 and $ETCO_2$ monitoring should be initiated to enable rapid recognition of deficient oxygenation and excessive or insufficient carbon dioxide. Typically, the desire is to keep the PaO_2 well above 60 mm Hg. In some institutions the PaO_2 goal is >70 mm Hg, and in others even higher thresholds are established. SpO_2 is usually targeted well above 90%, preferably >94%. Supplemental oxygen is typically administered to achieve these oxygenation goals. When the patient has no evidence of brain herniation, the aim for carbon dioxide levels is the normal 35 – 45 mm Hg range [1]. It is important to avoid both hypocapnea, which causes cerebral vasoconstriction and possibly ischemia, and hypercapnea, which produces cerebral vasodilatation and may result in increased cerebral blood flow and intracranial hypertension [1].

In patients with severe TBI, ineffective respiratory patterns and medications that cause respiratory depression may contribute to insufficient ventilation [45]. Initially, manual use of

a bag valve mask at a rate that keeps $ETCO_2$ within the desired range can be employed, but mechanical ventilation is generally called for to support effective ventilation in this acute phase. The 4th edition of the Guidelines for Management of Severe TBI restate recommendations from the 3rd edition that hyperventilation should be avoided within 24 hours following TBI because of decreased cerebral blood flow at this time. Hyperventilation should be considered as a temporizing measure to reduce intracranial hypertension [1, 32].

Systemic hypotension in the trauma patient is likely from hemorrhage due to extracranial injury although medullary compression and impending brain death can also cause circulatory instability. Also associated cardiac dysrhythmias, myocardial dysfunction, pericardial tamponade or pneumothorax may cause hypotension and should be quickly corrected. Hemorrhage control and repletion of intravascular volume are important to regain hemodynamic stability. Generally isotonic crystalloids are infused and, if necessary, blood products to achieve euvolemia. Hypotonic solutions are avoided to prevent lowering intravascular osmolality, which can encourage fluid extravasation outside the blood vessels, thereby exacerbating cerebral edema. The patient's hemodynamic parameters and indicators of tissue perfusion (e.g., lactate, base excess) are used to guide fluid resuscitation so that excessive volume is not administered. Once euvolemia is achieved, use of vasoactive and inotropic agents may be prescribed to support the patient's cardiovascular status so that sufficient blood pressure and cerebral perfusion pressure is achieved.

As the airway, ventilation, and circulation are reestablished and cerebral perfusion and oxygenation are presumably better, level of consciousness may be noted to improve. Other etiologies for altered mental status may include drugs taken prior to or administered during hospitalization or hypoglycemia. It is important the patient's altered level of consciousness never be attributed solely to these or other conditions until brain injury is ruled out [44]. Timely clear communication to others on the resuscitation team about assessment findings is important so confounding factors that may impact the patient's neurologic condition are either ruled out or recognized and corrected.

A CT scan of the brain performed as soon as possible will assist in determining if there is brain injury and if so whether there is an urgent need for surgical intervention or indication for intracranial monitor placement. Extracranial injuries may also require immediate surgery, which may be done alone or together with any needed intracranial procedure. If indicated, the nurse quickly prepares the patient for operative intervention.

To ensure a thorough assessment, patients must be completely disrobed, which exposes them to the risk of hypothermia. Open wounds and administration of cold intravenous fluids add to the probability of lowered body temperature, which could increase the likelihood of coagulopathy and suppressed immune function [1]. While early prophylactic hypothermia has been suggested to be beneficial in lowering the cerebral metabolic rate, decreasing ICP, and reducing processes causing secondary brain injury, clinical trials have yielded conflicting results [1, 46–50]. The Guidelines for Management of Severe TBI provide only one recommendation (Level IIB) that states, in patients with diffuse brain injury, prophylactic hypothermia provided early, within the first 2.5 hours, for 48 hours post-injury is not recommended to improve outcomes [1]. Typically the goal is to maintain normothermia. It is important for the nurse to closely monitor the patient's temperature and use warmed blankets and intravenous fluids to prevent or treat hypothermia. In more severe cases, an automated blanket or endovascular temperature regulation device may be used to achieve normothermia. Hyperthermia, known to be a factor that aggravates secondary brain injury and worsens

patient outcomes, should be avoided, but should it occur, it demands prompt intervention to bring the temperature back to normal [3, 7, 12].

Nurses play an integral role in the resuscitation effort, working together with other members of the health care team to achieve the goals of initial resuscitation. Typically, during resuscitation each member of the health care team has clear responsibilities. Ongoing nurse assessment and vigilant monitoring of the patient helps identify areas of concern, evaluates the effect of interventions, and determines if the patient's condition is improving or deteriorating.

Nurses are responsible for implementing numerous prescribed and protocolized interventions, assisting the provider with procedures, and ensuring documentation of the care provided. Development of interdisciplinary protocols based on the best available evidence that clearly state desired therapeutic endpoints and interventions to achieve those goals can assist with decision making when monitored parameters fall outside the preferred range. Creation of provider order sets that include evidence-based best practices (e.g., deep vein thrombosis [DVT] and seizure prophylaxis) ensures important interventions are not inadvertently overlooked. These orders can also enable nurses to take specific actions when monitored parameters fall outside an acceptable range, ensuring a quick response to remedy the problem. The reader is referred to the chapter in this volume on Medical Management of Intracranial Hypertension and Indications for Secondary Decompressive Craniectomy for more detailed information on the medical management of patients with severe TBI.

It is important to treat pain and agitation to minimize cerebral metabolic rate, control possible intracranial hypertension, achieve patient comfort, and enable the patient to safely tolerate various diagnostic and therapeutic interventions. Analgesics and sedatives should be given with the knowledge that they will likely, at least temporarily, obscure the patient's clinical neurologic examination, hence the preferred use of short-acting or easily reversible agents such as fentanyl for pain or propofol for sedation. The nurse is responsible for administering these agents as prescribed and for pausing the medications when appropriate and as tolerated by the patient to obtain a neurologic examination. The nurse should always consider possible extracranial causes for agitation (e.g., hypoxia) that may require an intervention other than sedation to correct. Caution must be exercised whenever providing sedation or analgesia to a patient who is not supported on mechanical ventilation since any respiratory suppression could cause detrimental hypoxia and hypercapnea. Likewise, use of these agents can lower blood pressure, thus compromising CPP and increasing the likelihood of brain ischemia. Care should always be taken to avoid excessive administration of medication to prevent respiratory compromise or hypotension that may contribute to secondary brain injury and if noted they should be quickly corrected.

In addition, nurses offer information and support to the patient and family during this time of crisis. The patient may be unaware of or confused about his or her environment, and so the nurse should explain what is happening, reorient the patient frequently, and offer reassurance. It is likely the family will require repeated information about the patient's condition. When available, the assistance of pastoral care services and/or social work to assess and encourage use of effective coping mechanisms and supports can be helpful.

After initial resuscitation is complete, the patient with severe TBI is transferred to a critical care unit. The resuscitation nurse must provide a thorough handoff to the critical care nurse taking over the care of the patient. It is important that the transition report include the patient's assessment and changes that have occurred over time. It is ideal that the sending and

receiving nurses perform a neurologic assessment together to ensure there is good inter-rater reliability in how they are interpreting findings. Verification of the patient's identity and review of his/her history, mechanism of injury, diagnostic findings, infusions, tubes, drains, and family situation are important points to cover in the handoff report. Interventions that have been administered and the patient's response should also be reported, as well as any pending orders and the ongoing plan for care.

Ongoing Critical Care Management Prior to Decompressive Craniectomy

After initial resuscitation, the focus of care remains on prevention of secondary brain injury. Critical care nurses collaborate with others on the health care team to prevent, identify, and quickly intervene to remedy potential intracranial and extracranial complications associated with TBI. This requires nurses to provide frequent comprehensive clinical assessments while meticulously monitoring potentially numerous intracranial parameters as well as many measures that assess other body systems. All of these variables must be considered together with the desired therapeutic endpoints established for the patient when making treatment decisions. Again, institution protocols and order sets that define desired therapeutic endpoints and appropriate interventions are helpful in guiding clinical decisions about care. Daily multidisciplinary patient rounds and use of goals sheets that clarify individualized patient therapeutic goals each day can enhance effective communication and collaborative decision making with all members of the health care team.

Ensuring adequate respiratory gas exchange to prevent hypoxia or hypercapnea remains a priority. This can be challenging because of the prevalence of pulmonary complications, such as airway obstruction, atelectasis, pulmonary infection, pulmonary emboli, neurogenic pulmonary edema, and ARDS in patients with severe TBI. Both continuous monitoring of the patient's SpO_2 and $ETCO_2$ and regular assessment of respiratory status remain important so the nurse can readily detect hypoxia, hypercapnea, or evidence of pulmonary complications, thus allowing for prompt intervention to resolve these problems. Typically, the goals remain to maintain SpO_2 above 90%, preferably >94%, and the $PaCO_2$ in the normal range. When ICP becomes less responsive to initial interventions, the patient's $PaCO_2$ may be maintained more in the low normal range (35 – 38 mm Hg).

The nurse must continue to take precautions to ensure a patent airway. The endotracheal tube or tracheostomy tube must remain well secured, protected from inadvertent removal, and kept clear of secretions. Pulmonary hygiene, including suctioning and possibly chest physiotherapy, is important for secretion removal from the airway to prevent impediment to adequate respiratory gas exchange. These pulmonary hygiene interventions, while helpful in promoting airway patency, can raise ICP and compromise CPP and perhaps other monitored intracranial parameters [51, 52]. Use of evidence-based suctioning protocols for patients with severe TBI can be helpful to minimize any detrimental impact while employing this intervention [51–54] (see Table 4).

While performing these interventions, the nurse must carefully monitor the effect on the patient's neurologic function, including ICP, CPP, and when present other intracranial measures. Hygiene measure may need to be aborted if monitored parameters are sustained outside of the desired range. Pre-medicating the patient with a prescribed sedative and ensuring good body alignment may aid in the patient's ability to tolerate such pulmonary hygiene interventions [55]. It is important that the nurse keep the critical care and

neurosurgical teams informed of the patient's inability to tolerate these interventions so that this is considered when deciding on the plan for the patient's care.

Table 4. Research based recommendations for suctioning patients with traumatic brain injury. References [51 – 54]

• Pass the suction catheter for no longer than 10 seconds. • Limit the catheter suction passes, preferably to no more than two passes per suction episode. • Hyperoxygenation the patient before each passage of the suction catheter but avoid hyperventilation • Minimize airway stimulation (i.e., stabilize the endotracheal tube; avoid passing the suction catheter all the way to the carina). • Use of a closed suction catheter versus an open catheter may be preferable to minimize ICP elevations and PaO_2 reductions

Adapted from: McQuillan KA, Thurman PT. Traumatic Brain Injury. In: McQuillan KA, Makic MBF, Whalen E, editors. Trauma Nursing: From Resuscitation Through Rehabilitation. 4th ed. St. Louis, Sounders Elsevier; c2009. P. 491. Table 20-8.

Use of mechanical ventilation is likely in the critical care setting. The nurse needs to be aware of the effect that ventilator settings have not only on the patient's respiratory status but also on cerebrovascular status. As airway pressures rise, intrathoracic pressure can increase, thereby impeding cerebrovenous outflow and raising ICP. Venous return may also be impaired with high intrathoracic pressure possibly compromising blood pressure and cerebral perfusion pressure. Ventilation strategies that have been used effectively in other patient populations, such as permissive hypercapnea and use of high airway pressures in an attempt to recruit collapsed alveoli, will not likely be well tolerated in patients with severe TBI and poor intracranial compliance [45]. Both nurses and respiratory therapists need to remain cognizant of the impact mechanical ventilation settings have not only on respiratory measures but also on intracranial parameters and should notify the provider of any detrimental effect of mechanical ventilator setting changes.

Maintenance of an adequate blood pressure and myocardial performance to promote sufficient brain perfusion remains essential. A euvolemic state is desired and isotonic crystalloids remain the fluid typically administered. In patients at risk for high ICP, it is desirable to have a high normal or slightly increased serum sodium and osmolality so that fluid does not extravasate from the intravascular space and exacerbate brain edema. Red blood cells may be prescribed to treat anemia, and when a patient has undergone transfusion, the nurse should be alert for potential complications related to blood administration (e.g., transfusion reaction, transfusion related lung injury, transfusion associated circulatory overload). Other blood products (e.g., fresh frozen plasma, platelets, cryoprecipitates) and blood product derivatives (e.g., Factor VIIa, prothrombin complex concentrates) may be prescribed to prevent or correct coagulopathy commonly seen in patient with severe TBI [8, 9]. Failure to resolve coagulopathy can increase risk of intracranial bleed or re-bleed and is associated with higher mortality and unfavorable outcome following TBI [8, 9]. Patients' hemodynamic status, clinical assessment, and indicators of tissue perfusion help indicate when intravascular volume is sufficient. Vasoactive and inotropic agents are then titrated as prescribed to optimize cardiac performance and support an adequate blood pressure.

If other sources of hypotension or fluid and electrolyte imbalance are suspected, they should be investigated so the cause can be clarified and appropriate treatment to correct the imbalance can be initiated. Diuretic administration, surgical procedures, extracranial injuries,

diuresis from diabetes insipidus, and movement of fluid to the interstitial space due to inflammation can be sources of intravascular fluid loss. Hypertonic saline administration may also cause electrolyte and fluid disequilibrium. Water and sodium retention may result from stress-induced release of adrenocorticotropic hormone (ACTH) and aldosterone, which causes antidiuretic hormone (ADH) release adding to water retention. Brain injury impacting the hypothalamic/ posterior pituitary system may result in insufficient ADH release causing neurogenic diabetes insipidus. Excessive ADH release, however, results in the syndrome of inappropriate ADH. Both of these ADH imbalances can cause substantial fluid and electrolyte alterations. Cerebral salt wasting, also triggered by brain injury, can cause salt and water loss, thus creating an imbalance. Acute adrenal insufficiency, which is present in a number of patients with TBI, can also lower blood pressure. Sedation and analgesic agents can pose a risk for hypotension and require careful blood pressure monitoring during and after administration. The risk of these imbalances and the threat they pose to the patient's hemodynamic and neurologic status reinforce the need for nurses to closely monitor intake and output, serum and, when ordered, urine electrolytes, and osmolarity, as well as hemodynamic parameters and indicators of tissue perfusion.

Excessive hypertension could also prove detrimental due to venous engorgement and subsequent intracranial hypertension, although treatment is controversial. Some patients, such as those with brain ischemia, vasospasm, or history of chronic systemic hypertension, may benefit from a higher blood pressure. Brainstem compression can cause a compensatory elevation in blood pressure, so if the patient demonstrates other symptoms synonymous with this phenomenon, the nurse should immediately inform the provider so that interventions can address ICP reduction. If prescribed, antihypertensives should be administered with extreme caution so as to prevent detrimental systemic hypotension.

Prevention and management of intracranial hypertension is typically a focus in the critical care phase. When ICP exceeds the prescribed therapeutic threshold the nurse should ensure oxygenation, carbon dioxide levels, blood pressure, and fluid and electrolyte status are within the desired range. These therapeutic endpoints should be well communicated, and, as in the resuscitation phase, this is often best done with evidence-based protocols and order sets. Nurses caring for patients with severe TBI should be well educated on these protocols and seek clarification from the provider if unsure about the directions provided. In addition to ensuring sufficient respiratory gas exchange and desired fluid and electrolyte status, there are a number of nurse-driven interventions that may be effective in lowering ICP before resorting to additional medical or surgical interventions. These include patient positioning, maintaining normothermia, and employing patient care interventions as best tolerated by the patient.

Patient position can significantly affect ICP, CPP, and other intracranial parameters, as well as respiratory and hemodynamic measures. Evidence suggests a number of positioning techniques that can minimize ICP. It is important to maintain good head and neck alignment, avoiding head rotation and neck flexion or compression (e.g., from a cervical collar) to avoid impediment of cerebrovenous outflow, which increases intracranial volume and can elevate ICP [56, 57]. Avoid sharp hip flexion that may also aggravate increases in ICP. Altering the patient's position may cause a transient or sustained ICP elevation or may lower the ICP depending on the patient and position change selected. Turning should be done after first explaining the anticipated action to the individual and then gradually moving the patient while continuously monitoring the impact on intracranial, hemodynamic, and respiratory parameters. There are times when patients with intracranial hypertension and poor brain

compliance simply do not tolerate turning without having substantial ICP elevations, detrimental reductions in CPP, and/or perhaps adverse effect on other measured intracranial parameters.

In studies of patients with brain injury, a 30 degree head elevation yielded a lower ICP in most, a better or unchanged CPP, and no significant alterations in cerebral oxygenation versus when the head of the bed was flat [58]. When a number of head of bed positions were compared, the 30 degree elevation was optimal for controlling ICP and CPP in most subjects, but no single body position was identified that could reliably reduce ICP and increase CPP and brain oxygenation [59]. These results, together with findings from other studies of patients with severe TBI, suggest the head of bed position that best minimizes ICP and optimizes CPP and other cerebral parameters should be selected based on the patient's individualized response [59, 60].

Prone positioning has been advocated for improving oxygenation in patients with ARDS. A number of small studies exploring the effects of prone positioning in brain-injured patients with ARDS found that although ICP can increase with use of this position, CPP may remain sufficient and oxygenation improves [61, 62]. These findings suggest that the benefits of prone positioning may be achieved as long as cerebral parameters are closely monitored to detect unacceptable changes that warrant aborting this intervention. Prior to DC when ICP elevations may be refractory to initial interventions, prone positioning may not be well tolerated. The inability to provide this and other interventions to improve respiratory failure should be communicated to the critical care and neurosurgical providers so it is considered when deciding on escalation of treatment for intracranial hypertension.

In the patient with severe TBI, it remains important to maintain normothermia typically for the first 7 days after injury [63]. Ideally, a protocol and order set are established that prescribe appropriate interventions the nurse can use to reduce hyperthermia, which is prevalent after severe TBI. The nurse should continuously, or at least hourly, monitor the patient's temperature, but also note frequently the fluid temperature of any cooling blanket or endovascular catheter. If the temperature of the fluidized cooling system is dropping in an effort to maintain the patient's body temperature at normal, that suggests the patient may be trying to mount a fever or may be seizing or shivering. This provides indication for assessing other signs and symptoms of infection, including evaluation for the need to send cultures. Other extracranial etiologies of temperature elevation, such as blood or drug reaction, thromboembolism, or atelectasis, should be considered and treated appropriately. Seizures should be appropriately managed with prescribed anticonvulsants. Severity of shivering should be assessed and documented hourly by the nurse using the Bedside Shivering Assessment (BSA) scale [64]. Shivering may be less problematic when body temperature is reduced slowly and skin counterwarming (warming the face, hands, and feet to reduce the perception of cold) is used. When shivering exceeds a score of 0 on the BSA scale, additional anti-shivering interventions (e.g., buspirone, maintaining higher magnesium levels, additional sedation, analgesia, paralytics) are warranted and should be employed as ordered [65]. Failure to control shivering will make it difficult if not impossible to achieve and maintain normothermia.

The nurse must remain vigilant about the individualized effect that various stimuli (e.g., pain, familiar or unfamiliar voice, music) and nursing care interventions have on the patient. Nurses need to use sound judgment to determine the risk and benefits of each intervention. Nurses can anticipate that some care may not be well tolerated when brain compliance is low.

Poor brain compliance is suspected when the P2 segment of the ICP waveform is ≥P1 or ICP elevations are sustained at rest or in response to interventions. Nyholm and colleagues [55] looked at brain compliance using amplitudes in the ICP curve (≥6 mm Hg), pressure autoregulation (PRx ≥0.3), and baseline ICP ≥15 mm Hg as predictors of sustained ICP elevations (>20 mm Hg for 5 minutes or longer) associated with nursing interventions and found that baseline ICP ≥15 mm Hg was most important in determining risk of ICP elevations. When interventions that may cause ICP elevation or impose detrimental effects on other intracranial parameters must be carried out, the intervention should be well planned and done using a technique that minimizes adverse effects [55]. It can be determined if providing rest periods between activities or if providing added prescribed sedation or analgesia prior to performing interventions assists in helping the patient better tolerate the activity. Reducing unnecessary noxious stimuli and ensuring optimal patient positioning during the procedure also may foster tolerance of the interventions [55].

Sustained ICP elevations above the desired threshold together with a decline in the GCS score or pupillary changes call for prompt notification of the critical care and neurosurgery providers. A thorough assessment is needed to ensure all initial interventions remain in place and no other factor is taking place that could alter neurologic status or aggravate ICP elevation (e.g., hypercapnea, hypoxia, glycemic or electrolyte imbalance, infection, seizures). A repeat stat head CT scan is often prescribed and the nurse coordinates the needed members of the health care team for timely transport of the patient for the study. The nurse should assess the patient's ability to tolerate the flat position prior to leaving the unit and should anticipate the possible need for additional medical intervention (e.g., hyperosmolar therapy, sedative, analgesia) before lowering the head of the bed for the diagnostic test. When transporting the patient with an IVC, it is typically closed to avoid over drainage. Once in the procedural area if intracranial hypertension is a concern, the drainage system can be properly leveled, and if continuous drainage is prescribed, it can remain open for drainage during the procedure [66].

If an intraparenchymal ICP monitor is being employed and intracranial hypertension exceeds the therapeutic threshold, placement of an IVC may be considered. The IVC will provide the benefit of external ventricular drainage of CSF to treat elevated ICP. As described earlier, the nurse assists with the insertion and then manages the CSF drainage as prescribed.

Nurses are responsible for administering prescribed medical interventions to reduce or prevent intracranial hypertension. Details on these medical interventions are described in another chapter of this text on medical management of intracranial hypertension. Analgesia and sedation typically initiated in the resuscitation phase are generally continued in critical care to treat pain and agitation, thereby reducing ICP. A need for increased doses of sedative and analgesic agents is likely if intracranial hypertension persists. Nurses must anticipate that the neurologic examination will be obscured. It is important to watch intently for detrimental hypotension and other drug-specific complications that may be associated with administration of these agents. For example, when administering propofol, particularly at high doses (over 5 mg/kg/hour) or for prolonged periods (more than 48 hours), the nurse should closely monitor laboratory and physical assessment findings that may suggest onset of propofol infusion syndrome, such as elevated myoglobin, hyperkalemia, lipemia, metabolic acidosis, cardiac dysrhythmias, and evidence of renal or myocardial failure [1]. Early identification of these findings should be reported immediately so the propofol can be discontinued and another sedative selected.

Hyperosmolar therapy, another first-line intervention often used to control intracranial hypertension, entails administration of prescribed mannitol and/or hypertonic saline. Prior to administering mannitol, it is important to ensure the patient is adequately hydrated to reduce risk of systemic hypotension or renal failure that can result from use of this osmotic diuretic. Because mannitol can precipitate, a filtered needle should be used to administer the drug, preferably through a central line, to minimize risk of extravasation of this hypertonic solution into the tissues. Hypertonic saline may also be used instead of or in addition to mannitol. While 3% saline can be administered through a peripheral intravenous catheter, use of a central line for repeated doses is preferable. Central venous access should be used to infuse higher concentrations of hypertonic saline to avoid extravasation and subsequent tissue injury. Prior to hypertonic saline administration, hyponatremia, especially persistent hyponatremia, should be ruled out to avoid risk of causing osmotic myelinolysis. The nurse should remain vigilant for these and other potential complications associated with hypertonic saline use, including volume overload, hypernatremia, hemolysis, acid-base imbalance, and coagulopathies. Suggested use of sodium acetate rather than sodium chloride can minimize problems with metabolic acidosis. Use of either mannitol or hypertonic saline requires the nurse to closely monitor the patient's fluid and electrolyte balance, hemodynamic status, and effect on the patient's neurologic parameters.

Paralytics may be used in patients with TBI for rapid sequence intubation, to prevent movement so diagnostics and treatments can be safely performed, to control shivering associated with targeted temperature management, and to foster synchrony with mechanical ventilation. In some institutions, neuromuscular blocking agents are administered to stop movement (e.g., posturing) and reflexive responses to airway stimulation to control intracranial hypertension that requires treatment escalation. Early regular use of paralytics for ICP control was not found to improve overall outcomes and might prolong length of stay in the intensive care unit (ICU) and increase incidence of pneumonia and sepsis, therefore such use is typically not indicated [67]. When paralytics are used, the nurse should ensure adequate analgesia and sedation to block the perception of pain and control anxiety. The patient's neurological examination will be obscured except that pupil reaction typically remains present and should continue to be regularly assessed. Because movements associated with seizure activity will be concealed with paralytics, the nurse should be vigilant for unexplained elevations in heart rate, blood pressure, and ICP that may signal an underlying seizure that could be confirmed with an EEG.

The patient's individualized response and development of potential adverse reactions to each intervention should be noted by the nurse and communicated to the provider. Communication of persistent intracranial hypertension, detrimental alterations in other measured intracranial parameters, and/or inability of patient to tolerate potentially life-saving care (e.g., pulmonary hygiene) is essential for the health care team to make the best decisions on what additional interventions may be most appropriate. Intracranial hypertension refractory to initial interventions may be treated with an increased dose of sedation or added doses of hyperosmolar agents. Often multiple interventions are used together in an effort to reduce intracranial hypertension. Persistent intracranial hypertension despite initial interventions can lead to consideration of additional interventions more likely to have detrimental consequences, such as high dose sedatives, therapeutic hyperventilation, DC, high dose barbiturates, or hypothermia. The patient's condition as well as the risks and benefits of

each treatment option must to be considered by the health care team when deciding on which option will be selected.

While preferably not used within the first 24 hours after injury when cerebral blood flow is decreased, hyperventilation may be selected as a temporizing measure to lower intracranial hypertension [1, 32]. When hyperventilation is used, the nurse needs to closely monitor the patient's $ETCO_2$ to avoid lengthy prophylactic reductions in $PaCO_2$ ≤25 mm Hg [1]. It is recommended that a measure of cerebral oxygenation (e.g., jugular venous oxygen saturation, brain tissue partial pressure of oxygen) be monitored during use of hyperventilation so that inadequate cerebral oxygen delivery is quickly recognized and $PaCO_2$ levels can be appropriately adjusted [1, 32]. If hyperventilation is used, particularly when used for prolonged periods, the $PaCO_2$ should be gradually normalized to prevent a rebound increase in cerebral blood flow with a subsequent rise in ICP.

High dose barbiturates may be considered to treat intracranial hypertension refractory to conventional medical and surgical interventions in patients who are hemodynamically stable [1]. A loading dose followed by maintenance infusion is typically prescribed with the goal of controlling intracranial hypertension while ensuring sufficient CPP. The drug's effectiveness is considered optimized once there is burst suppression on the EEG. A number of detrimental side effects associated with high dose barbiturates can be life threatening to the patient and have significant implications for nursing care of the patient. Perhaps most worrisome is the myocardial depression and hypotension induced by the barbiturates that can cause an undesirable reduction in CPP and cerebral blood flow. Vigilant monitoring of the patient's hemodynamic status (e.g., continuous arterial blood pressure monitoring, cardiac output monitoring) is important to quickly recognize and act when hypotension or myocardial depression become evident. Vasoactive and inotropic agents may be needed to support cardiovascular function to ensure adequate brain perfusion. The patient's neurologic examination will be obscured, with many aspects of the assessment suppressed including level of consciousness, motor response, and many reflexes. Protection of the eyes is important to prevent corneal damage resulting from the suppression of the corneal reflex. Also, immunosuppression typically occurs and makes the patient vulnerable to infection, which may go unnoticed due to barbiturate-induced cardiovascular effects and lower body temperature. Gastrointestinal motility also may be reduced, which can affect the patient's ability to tolerate enteral nutrition.

Some institutions employ hypothermia to control refractory intracranial hypertension. Andrews and colleagues [68] conducted a randomized controlled trial in which adult TBI patients with ICP >20 mm Hg for 5 minutes without reversible cause were randomized to receive either standard care (the control group) or standard care plus hypothermia (32ºC – 35ºC for at least 48 hours or until ICP was controlled) as a primary intervention. Recruitment for the study was halted due to safety concerns including more favorable outcomes, lower risk of death, and fewer adverse events seen in the control group. Despite these findings, others have suggested therapeutic hypothermia should still be considered for use in patients with refractory intracranial hypertension [69]. If hypothermia is used, the nurse needs to be well aware of its potential complications, including immunosuppression, fluid and electrolyte imbalance, coagulopathy, arrhythmias, hyperglycemia, and shivering, so that these adverse effects can be promptly recognized and treated appropriately. Shivering can be prevented and treated via prescribed anti-shivering interventions. It is important to ensure gradual rewarming.

DC is yet another intervention to be considered to treat refractory intracranial hypertension. Indications for DC, surgical technique, controversial aspects of this intervention, and potential complications are detailed elsewhere in this book. Once a decision to proceed with a DC has been made, the nurse makes preparations for the patient to go for the procedure. As time permits, this preparation includes ensuring the family has been informed about the procedure and its complications and has provided consent; administering any prescribed preoperative medications; halting any enteral feedings, removing any dentures, glasses, hearing aids, or prostheses; sending and checking results of prescribed lab work including a current blood type and cross match; making sure the ordered blood products are available; and verifying the appropriate patient and procedure. The nurse should provide a thorough handoff to the perioperative team ensuring the proper patient identity and reviewing the patient's history, all infusions, tubes, drains, monitored parameters, response to interventions, current assessment, and family contact information. The nurse and perioperative team coordinate preparation for transport and movement of the patient to the operating room.

When multimodal monitoring is used, other measured variables (see Table 3) in addition to ICP and CPP may influence clinical decisions about which interventions are selected to best manage the patient. Alterations in these additional intracranial parameters may precede changes in ICP and CPP, prompting diagnostic studies or specific interventions. For example, parameters that evaluate cerebral oxygenation may be helpful in decisions about ICP and CPP management, especially in selecting optimal CPP or guiding use of hyperventilation. Measures below the desired threshold may also prompt interventions that optimize oxygen delivery to the brain, focusing not only on optimizing CPP but also on the patient's oxygenation, respiratory function (e.g., ensure patent airway, pulmonary hygiene, and sufficient ventilation) and cardiovascular status (e.g., ensure adequate myocardial function, intravascular volume, blood pressure, and hemoglobin). Recognition and timely intervention to treat fever or seizures, which increase oxygen utilization, will be a priority to optimize cerebral oxygenation, reduce ICP, and prevent secondary injury.

Nurses must remain vigilant in preventing, recognizing, and treating a host of potential complications associated with severe TBI that can all trigger secondary brain injury. The neurologic injury, resulting deficits that occur, dysregulation of the coagulation system, injury-induced inflammatory response, or interventions used to manage TBI can instigate these complications. Astute ongoing assessment of the patient's clinical examination, monitored parameters, and diagnostic results allow for timely recognition of neurologic deterioration which may indicate delayed or expansion of cerebral hemorrhage, increased cerebral edema, or onset of posttraumatic hydrocephalus. These complications are often the triggers for intracranial hypertension.

Other worrisome potential neurologic complications include cerebral vasospasm, intracranial infection, and seizures. In the comatose patient, cerebral vasospasms can go undetected, but if suspected, a vascular study (transcranial Doppler, angiography) may be prescribed to diagnose or rule out this complication. Intracranial infection is more likely in those patients with open head injury or those requiring intracranial operative intervention or placement of invasive brain monitors. As previously noted, nurses play a vital role in ensuring strict sterile techniques are used during placement and manipulation of any intracranial monitor. The nurse also administers antibiotics prescribed prophylactically or for a known

infection. Attention to clinical evidence of infection or change in neurologic status by nurses is important so that timely intervention to treat this complication can be initiated.

Although the rate of clinical seizures after severe TBI is reported to be as much as 12%, the rate of subclinical seizures evident on EEG is double that at 20% to 25% [1]. Anticonvulsants that may have been initiated prophylactically for evidence of brain injury on the CT scan during resuscitation are generally continued for 7 days. The Guidelines for Management of Severe Traumatic Brain Injury recommend that when benefits outweigh the possible adverse effects of the drug, phenytoin should be administered to prevent seizures for the first 7 days (early seizures) after TBI [1]. While some institutions use levetiracetam for anticonvulsant prophylaxis, no evidence shows it is more efficacious than phenytoin [1, 70]. Administration of phenytoin starts with a loading dose followed by maintenance doses of the drug. Routine drug levels are generally prescribed to ensure the phenytoin levels are within the desired therapeutic range. All patients should have seizure precautions in place, and if a seizure occurs, the nurse should take note of the seizure characteristics and promptly notify the provider so that appropriate anticonvulsant therapy can be prescribed.

Not unlike the care of other critically ill patients, the nurse plays a vital role in preventing hospital-acquired infections in those with severe TBI. Risk of pulmonary infection is reduced by providing good mouth care; unless contraindicated, keeping the head of bed elevated at least 30 degrees; and preventing and routinely assessing for gastric distention [71]. Studies evaluating the effect of mouth care on ICP found clinically insignificant elevations occurred during the procedure and suggest oral hygiene is safe in patients with normal ICP. The effect in patients with intracranial hypertension requires further study [72]. Risk of central line associated bloodstream infections (CLABSI) is minimized by ensuring that best aseptic practices are used when inserting and maintaining central lines and that removal is timely. The Centers for Disease Control provides a Checklist for Prevention of Central Line Associated Blood Stream Infections that lists recommended best practices to prevent CLABSI [73]. Likewise, bladder catheter associated urinary tract infections (CAUTI) are avoided by inserting catheters using sterile technique and adhering to best practices for their maintenance and removal. A thorough review of evidence-based best practices for CAUTI prevention is described elsewhere [74].

Increased pressure within the abdominal cavity is transmitted to the thorax, which can then impede cerebral venous outflow and aggravate intracranial hypertension. Therefore, it is important for the nurse to routinely assess the patient for evidence of intra-abdominal hypertension and if suspected obtain intra-abdominal pressure measures. If intra-abdominal hypertension is present, decompressive laparotomy may be considered [75] Placement of an indwelling bladder catheter and gastric tube for drainage typically done during resuscitation can reduce the distention that contributes to intra-abdominal hypertension. For more on this topic, the reader is referred to another chapter in this volume, Decompressive Laparotomy to Treat Intracranial Hypertension and Multiple Compartment Syndrome.

Patients with severe TBI generally become hypermetabolic, which can rapidly lead to protein-calorie malnutrition if nutrition is not initiated in a timely fashion. Ideally, collaboration with a dietitian to recommend needed nutritional support is helpful. The Guidelines for the Management of Severe Traumatic Brain Injury recommend providing nutrition so that the patient's basal caloric replacement is achieved by day 5 or day 7 at the latest to reduce mortality [1]. Nurses often have responsibility to place the enteral feeding tube and, once proper placement is confirmed, initiate prescribed feedings. A bowel regimen

should also be initiated to avoid constipation. The patient's tolerance of the nutritional support should also be evaluated and the provider notified if the feedings are not tolerated. Even before initiating feedings, the nurse should be closely monitoring glucose levels to avoid hyperglycemia and hypoglycemia, factors that can exacerbate secondary brain injury. Tight glucose control protocols may increase the risk of detrimental hypoglycemia. Therefore, treatment thresholds that maintain serum glucose >100 and <180 may be sufficient to prevent hyperglycemia and avoid low glucose levels [76].

Nurses must take action to reduce complications related to immobility caused by neurologic deficits as well as interventions (e.g., sedation, analgesics) used to treat TBI. Turning and range of motion should be attempted as tolerated. Patients who have poor brain compliance may not tolerate changes in position well. In this situation, a specialty bed or surface that reduces pressure is ideal for minimizing risk for a hospital-acquired pressure ulcer. Other pressure relieving measures (e.g., padded cervical collars, heel protectors) that protect boney prominences vulnerable to skin breakdown should also be used. Regular assessment of the skin, particularly under cooling pads and removable immobilization devices, is essential to identify any disruption in skin integrity.

Immobility as well as the hypercoaguable state following brain injury puts the patient at high risk for DVT. Pneumatic compression devices or compression stockings should be used. Pharmacologic anticoagulation (i.e., low molecular weight heparin or low dose unfractionated heparin) can be used together with the compression devices or stockings; however, because this risks further intracranial bleeding, it is not typically prescribed until the benefits outweigh the risk. The Guidelines for the Management of Severe Traumatic Brain Injury note that there is not ample evidence to recommend a preferred anticoagulant, dose, or timing of initiation for DVT prophylaxis [1]. In patients with refractory intracranial hypertension where DC is planned, pharmacologic prophylaxis will typically be held.

During this critical care phase when the patient's condition is tenuous, the patient's family will need frequent communication and support. When the family is present at the bedside, the nurse has an opportunity to use oral and written strategies, to explain what is happening with the patient and to teach them how to best interact with their loved one. Interdisciplinary family conferences where all providers and the family members meet to discuss the patient's plan of care offer an opportunity for the family to ask questions and participate in decision making. Social workers, pastoral care, and, when available, family navigators can be used as needed and desired by the family to provide much needed support [77].

POSTOPERATIVE NURSING CARE OF PATIENTS UNDERGOING DECOMPRESSIVE CRANIECTOMY

Postoperative interventions to maintain the desired therapeutic endpoints for patients with severe TBI after DC are very similar to preoperative interventions, which attempt to prevent secondary brain injury. Continued use of protocols and order sets based on the best available evidence to guide practice and clinical decision-making are helpful. Effective strategies to communicate the plan of care between practitioners remain essential in this postoperative

phase. The nurse remains a vital member of the health care team and a key coordinator for the complex care needed by patients and their family after DC.

Continued Close Assessment and Monitoring for Intracranial and Extracranial Complications

Postoperative nursing care of patients who have undergone DC continues to be extremely important, especially when considering the many serious potential complications of this procedure. These include wound break down, contralateral hygroma and hematomas, hydrocephalus, ipsilateral and interhemispheric subdural or subgaleal hygromas, seizures, cerebrospinal fluid leakage, hemorrhagic progression of contusions, persistent intracranial hypertension, brain herniation through small craniectomies, and subgaleal, superficial, and deep CNS infections [78]. Patients who have undergone DC are also at higher risk for injury related to compromised skull integrity. Honeybul and Kwok completed a retrospective analysis of 164 patients who required DC for severe head injury, during which 81 of those patients (55.5%) had at least one complication after surgery. These complications were often associated with prolonged stays in both hospitals and rehabilitation centers [79].

Development of a subdural or epidural hematoma on the opposite side of the craniectomy site (contralateral hematoma) is a serious complication after DC. A study by Su and colleagues found that patients with contralateral hematomas often present with postoperative pupillary abnormalities, acute neurological decline, and increased ICP that becomes unmanageable, causing severe consequences for the patient [80]. Hydrocephalus is a more frequent complication of DC following TBI and may lead to clinical decline and poor patient outcomes if not recognized and treated with therapeutic diversion of CSF to normalize ICP [81]. Subdural or subgaleal hygromas are other well-known complications of DC that result from collections of CSF. Aarabi and colleagues found, in 39 patients who developed a subdural hygroma (SDG) after DC and survived >30 days, that SDG was evident on CT scan during the first postoperative week. Volume of the SDG peaked at 3 to 4 weeks after DC and then gradually resolved around week 17 [82]. Approximately 2 months after injury, nearly 8% of the SDGs transformed into subdural hematomas [82]. According to Honeybul and Ho, patients with SDGs were more likely to have longer hospital stays and take more time in rehabilitation with poorer neurological outcomes at 18 months after surgery than patients without hygromas [83].

Due to concerns about post-DC complications, as well as the continued worry about exposure to factors that could exacerbate secondary brain injury, postoperative management routinely occurs initially in the ICU where ICP continues to be monitored. Nurses with astute assessment skills who are knowledgeable about signs and symptoms of possible complications have the potential to recognize these intracranial complications early, promptly notify the provider, and initiate interventions to thwart further secondary brain injury. This requires performing frequent and thorough neurological assessments. Attention should be given to fluctuations in neurological status, detection of personality changes, as well as neurologic changes associated with patient positioning [78]. Also important is the continued monitoring of CSF drainage, ICP, CPP, and any additional brain parameters. In monitoring ICP after DC, it is important to note that the waveform may be dampened and a higher threshold for intervention may be prescribed.

Hospital-acquired infections including postoperative surgical site infections (SSIs) are also considered serious complications that often result in higher costs of health care, longer hospital stay for patients, and increased morbidity and mortality [84]. In patients with brain injury, infection can also prompt fever and secondary brain injury causing worse neurologic outcome. In order to help prevent these infections, nurses should be knowledgeable about the evidence-based best practices for prevention and management of SSIs. Together with other members of the interdisciplinary health care team, nurses can lead performance improvement initiatives that ensure best practices are consistently implemented and SSIs are reduced, thereby optimizing patient outcomes after DC. A wide variety of guidelines are available to assist nurses in this endeavor, including the Department of Health's Care Bundle to Prevent Surgical Site Infection, SSI quality standards from the National Institute of Health and Care Excellence, and the World Health Organization's Surgical Safety Checklist [85]. These guidelines and checklists recommend specific interventions to be utilized by nurses and other members of the health care team, such as diligent hand hygiene, surveillance of SSIs, patient education, and wound care practices.

Aspiration frequently occurs in brain-injured patients because of neurologic impairment that causes disturbances in oral, pharyngeal, and esophageal functions, sometimes including loss of protective airway reflexes. Also, patients may have disruptions in cognitive function and behavioral processes that interfere with normal swallowing mechanisms [86]. Most patients who have undergone a DC have been subjected to prolonged intubation and mechanical ventilation, typically longer than 48 hours, which is also thought to contribute to swallowing dysfunction through factors such as alterations of glottic anatomy, atrophy of skeletal muscles of the larynx related to inactivity, and suppressed level of consciousness [87]. Swallowing dysfunction can lead to aspiration and aspiration pneumonia, which are preventable with proper nursing care.

Aspiration pneumonia is often associated with dysphagia and ineffective cough. Following brain injury the hypoxia, hypercapnea, and fever from respiratory infections can be particularly detrimental owing to their threat to exacerbate secondary brain injury. Mortality rates for aspiration pneumonia range from 20% to 65%, and diagnosis is often predictive of hospital readmissions [88]. These statistics clearly support the importance of nursing interventions to avoid aspiration and aspiration pneumonia. While the patient is intubated, nursing care continues to include keeping the head of the bed elevated 30 degrees or higher if not otherwise contraindicated, providing good mouth care, and implementing interventions to facilitate ventilator weaning and safe extubation of the patient [71]. A swallow evaluation should be completed prior to beginning oral intake of fluids or food. Hospitals have implemented various guidelines and dysphagia screening tools to help nurses adequately assess swallowing in specific patient populations, including those with altered mental status, seizures, and post-airway extubation. For example, the University of Maryland Medical System utilizes a Registered Nurse Dysphagia Screening Algorithm with specific interventions to assist nurses when screening these high-risk patients. Prior to a patient's oral intake of fluid, foods, or medications, nurses answer several yes or no questions to assess that person's alertness, breathing, coughing, speech, and voice quality. Once the questions are answered, nurses will either administer water and perform a bedside swallow evaluation, or notify the provider and request a formal swallow evaluation from speech-language pathology. The nursing bedside swallow screen involves administering small amounts of water while carefully observing the patient for signs of aspiration. Reportable conditions that are

considered signs of aspiration include respiratory distress, coughing, choking, throat clearing, or change in vocal quality either during or after the screening.

After DC, the patient is at high risk for secondary brain injury from any impact to the head where there is compromised skull bone integrity. Because a portion of the skull is removed, standard nursing care should involve fitting the patient for a protective helmet. The helmet helps to prevent additional brain injury from events like falls by providing padding over the skin and open cerebrum [78]. Single case reports have shown that a fall after DC can cause catastrophic consequences, which provides justification for the routine use of a cranial helmet during mobilization after craniectomy [89].

Progress to Recovery

Overall, patient outcomes after DC may vary significantly, but generally fall into the two separate categories of recovery or death. The term *recovery* is used broadly in view of the fact that some patients recover full function and may return to their previous level of independence (i.e., to school, work, and other prior responsibilities), while others suffer serious long-term cognitive and other neurologic deficits that forever impede their ability to live independently [90]. During recovery, nurses should assess patients for frequently reported physical, emotional, cognitive, sensory, or sleep symptoms that may be related to the brain injury itself, or may be caused by other factors such as anxiety, depression, chronic headaches, bodily pain, posttraumatic stress, psychosocial factors, or personality changes [91]. During the first few weeks up to several months after DC, it is important for nurses to carefully monitor patients and seek feedback from family to identify apparent personality changes or decreased level of consciousness that could indicate development of late-onset seizures, hydrocephalus, or syndrome of the trephined [78]. Syndrome of the trephined is a rare, but important complication of craniectomy, characterized by neurological dysfunction with varied symptoms including cognitive, motor, and language defects that improve after cranioplasty [92]. Nurses should coordinate care with the medical and neurosurgical teams to help identify the ideal timing for bone flap replacement.

Nurses should also monitor for other complications after cranioplasty including surgical site infection, discussed previously, and bone flap resorption. Bone flap resorption is reported in 2% to 32% of patients who have had a cranioplasty and results in cosmetic flaws, as well as increased risk of brain injury. This complication often requires further surgical interventions and replacement of the bone flap with other foreign materials [93].

Major depression is frequently recognized as a significant comorbid condition associated with TBI and is associated with adverse outcomes including lower quality of life, greater physical disability, poor psychosocial functioning and community participation, and suicidal ideation [94]. Evidence-based tools should be used to assess patients for the presence of depression, which DC patients are at high risk for developing [78]. The Patient Health Questionnaire 9 (PHQ-9) is one of the most widely used depression screening tools developed to assist providers in working with various types of clinical populations and settings. The questionnaire is brief and can be used to assess for the presence and severity of depression in the previous 2 weeks. Patients are asked a series of nine simple questions about feeling down or depressed, difficulty sleeping, eating habits, energy levels, ability to concentrate, level of

interest in doing things, and thoughts of suicide. Prior evidence has been gathered verifying the validity of using the PHQ-9 in patients with mild to severe TBI [95].

Cognitive Therapy

As previously mentioned, patients with brain injuries can suffer from long-term cognitive deficits that interfere with return to independent living. Cognitive therapy can help them gain more independence, with the possibility of returning to their prior living situations and responsibilities [90]. Patients with severe injuries are more difficult to treat because they suffer persistent adverse consequences that affect their general quality of life [96]. Therapy teams consist of physical, occupational, and speech language therapists (SLPs) who are responsible for evaluating and treating these patients once they are stabilized after surgery. Nurses should ensure consultations for these therapies are requested and then may coordinate timing of these evaluations. SLPs perform thorough initial cognitive assessments that are used to determine therapy needs and patient disposition after discharge from the hospital. This assessment is also used throughout the course of patients' recovery, either during inpatient rehabilitation or outpatient therapy. Many patients receive cognitive therapy from nurses or therapists who focus on improvement of attention, learning, and memory in hopes of an eventual safe return home. A literature review by Stephens et al. [97] identifies and summarizes evidence-based recommendations focused on cognitive rehabilitation for adult patients with brain injuries. These recommendations include promoting self-awareness, encouraging learning and memory, developing executive function, and improving overall cognitive function, also known as daily cognition [97].

Deficits in self-awareness and subjective well-being impair motivation to participate in therapy activities because the patient deems them unnecessary. Nurses and therapists can help the patient to first recognize their deficits, which eventually leads to improving them. Difficulty with learning and memory causes patients to experience encoding deficits and struggle with being active participants in their own recovery. Strategies to promote deeper memory encoding and facilitate learning include self-generation, which asks patients to create their own examples for understanding new material and spacing out information, which facilitates learning by providing small amounts of new information over relatively short periods of time. Deficit in executive functioning, which is the ability to plan, organize, strategize, and focus attention, can be profound and debilitating, and have the strongest effect on functional outcomes. Providers can improve deficits in executive functioning by encouraging patients to use metacognition, which is the ability to recognize their own cognitive capacity and seek other methods to enhance functioning. For instance, patients who have difficulty understanding and remembering orally presented information can use the metacognitive strategy of requesting written or other visual information, which nurses and therapists can utilize for learning assessments and patient education. Finally, the literature review examined methods to improve overall cognitive function, also known as daily cognition. These methods include using different forms of technology to assist patients with learning skills needed for daily functioning, as well as providing therapy in the patient's natural environment or a virtual reality environment, which supports the concept that relearning daily tasks in a natural setting leads to greater functional gains [97].

Preparation for Transition from Acute Care

Patients recovering from DC eventually transition from the acute care setting to inpatient rehabilitation centers or skilled nursing facilities, depending on their required level of care. In the past several years, enactment of the Affordable Care Act in the United States, reimbursement based on pay-for-performance models, and implementation of readmission penalties for preventable diagnoses have required health care organizations to focus more on transitional care, as well as care coordination. Following a brain injury and DC procedure, patients commonly require and receive follow-up treatment in various settings, including inpatient rehabilitation. Nurses have a responsibility to help these patients successfully transition from acute care to rehabilitation facilities, which also helps to prevent unplanned readmissions, increased health care costs, and other complications or medical errors. The appropriate type of discharge facility is decided upon by a multidisciplinary team of health care providers, including physicians, advanced practice registered nurses (APRNs), physical, occupational, and speech therapists, case managers, and social workers. Team members complete an array of diagnostic tests, assessments, and evaluations in order to determine the level of care and rehabilitation required by each patient. Patient needs, patient/family preference, and insurance coverage or payment methods then help determine the selection.

Nurses should strive for successful patient transitions from acute care to rehabilitation facilities by providing adequate patient and family education, promoting independence, assisting with and encouraging early mobilization, and ensuring patients are adequately prepared to participate in rehabilitation and cognitive therapy. Patients and families should have a complete understanding of the diagnosis and possible complications. Providing adequate patient and family education involves teaching about important safety issues such as fall prevention and the use of protective helmets, medications and possible side effects with medication changes, as well as, surgical site monitoring and interventions to prevent infections. They should be fully informed regarding follow-up needs, future appointments, and whom to contact with questions, concerns, or problems after discharge. Patient and family education is fundamental for successful outcomes after discharge. Clinical nurses play a vital role in the delivery of this education and have the unique opportunity to have an impact on these outcomes.

Nurses should also promote early independence, which better prepares patients for rehabilitation, where they relearn activities of daily living, including self-care tasks such as bathing/showering, toileting, personal hygiene and grooming, dressing, self-feeding, and functional mobility or transferring. Encouraging patients to independently perform these activities while in the acute care setting allows for better outcomes and shorter lengths of stay in rehabilitation facilities. The standard of care for DC patients in the ICU includes several days or even weeks of mechanical ventilation, which often includes deep sedation and prolonged immobility. Critically ill patients who are not mobilized during early phases of hospitalization experience deconditioning, persistent weakness, alterations in neuro-psychological function, and decreased quality of life. Once DC is performed and the patient's condition stabilizes enabling safe movement out of bed, early mobilization should be initiated. Early mobilization protocols used by nurses, who are key providers of mobility for these patients, can improve a number of patient outcomes including reduced duration of mechanical ventilation and overall length of stay in the ICU [98].

Finally, patients must be adequately prepared to participate in rehabilitation and cognitive therapy. Symptoms of brain injury may include agitation, hostility, anxiety, fatigability, and depressive mood, which can impede patients' ability to participate in these activities [99]. Because nurses spend the most time with patients, they can help other members of the interdisciplinary health care team determine whether patients are prepared for the transition from acute care to inpatient rehabilitation.

Brain Death

Unfortunately, not all patients recover, and some will suffer from refractory intracranial hypertension, cerebral ischemia, and eventually brain death. Brain death is considered irreversible and is defined by The American Association of Neurology (AAN) based on three cardinal signs: coma or unresponsiveness, apnea, and cessation of the functions of the brain including the brain stem [100]. Nurses are often present and may be required to assist physicians by monitoring the patient during clinical testing used to diagnose brain death. Nurses can help to ensure patients are normothermic, hemodynamically stable, and free from sedative and paralytic drugs when physicians are performing the brain death examinations. Coma is diagnosed when patients become unresponsive to deep central pain such as sternal rub or supraorbital pressure. Nurses also assist physicians to assess the cessation of brain functions during formal evaluations of brain stem reflexes (e.g., corneal reflex, pupil light reflex, gag, cough, occulovestibular reflex, and if the cervical spine is cleared, the occulocephalic reflex); these are clinical tests that must all be negative to diagnose brain death. Finally, an apnea test is done to determine there is no function of the brain stem respiratory center by verifying the patient has no spontaneous respirations when carbon dioxide levels are elevated [100].

After the diagnosis of brain death is made, nurses are responsible for patient monitoring, clinical management, and, most importantly, patient advocacy and family care. Many patients complete documentation that expresses their wishes regarding donation of their organs (e.g., advanced directives, organ donation registration), and nurses should help advocate for their patients' preferences. A 2013 article in *Critical Care Nurse* [101] highlighted several recommendations to assist nurses in providing family members with the best possible nursing care during this stressful and difficult time. Nurses are pivotal in establishing trust while helping the family to understand a continuous stream of complicated medical information from the interdisciplinary team of health care providers. The nurse is often able to reinforce information to provide the family with a better understanding of brain injury, as well as the progression of the injury to brain death. When formal brain death testing is completed, nurses should allow family members the time and opportunity to process their experience and express their emotions. Resources such as chaplains or other spiritual support that take into account the families' cultural and religious preferences can be very helpful in providing the family support. Religious issues are of extreme importance when discussing brain death with family members, and understanding these issues can better assist with the difficult discussion of organ donation. Finally, before discussing organ donation nurses should use consistent terminology and definitions to ensure the family understands brain death.

CONCLUSION

Nurses are essential members of the health care team striving to achieve optimal outcomes for patients with severe TBI before and after DC. Their role requires compassion, strong critical thinking skills, and a sound knowledge base. They have the responsibility to interpret clinical examination findings and monitored parameters to determine appropriate interventions. Nurses communicate vital information about the patient's condition and response to interventions to other health care colleagues, thereby promoting well-informed collaborative decision making. Participation in decisions about the plan of care demands nursing awareness of the desired therapeutic endpoints for the patient and the expected effects, potential complications, and implications of each medically prescribed and nursing intervention. Nurses use interventions effective in reducing secondary brain injury, preventing and treating complications, and enhancing psychosocial, emotional, and cognitive aspects of the patient before and after DC to realize optimal outcomes for patients and their families.

REFERENCES

[1] Carney N, Totten AM, O'Reilly C, Ullman JS, Hawryluk GWJ, Bell MJ, et al. Guidelines for the Management of Severe Traumatic Brain Injury, 4th ed. *Neurosurgery*. 2016;80(1):1-243.

[2] Chesnut RM, Marshall LF, Klauber MR, Blunt BA, Baldwin N, Eisenberg HM, et al. The role of secondary brain injury in determining outcome from severe head injury. *J Trauma.* 1993;34(2):216-222.

[3] Jones PA, Andrews PJ, Midgley S, Anderson SI, Piper IR, Tocher JL, et al. Measuring the burden of secondary insults in head-injured patients during intensive care. *J Neurosurg Anesthesiol.* 1994;6(1):4-14.

[4] Spaite DW, Hu C, Bobrow BJ, Chikani V, Barnhart B, Gaither JB, et al. Emergency medical services/original research: The effect of combined out-of-hospital hypotension and hypoxia on mortality in major traumatic brain injury. *Ann Emerg Med.* 2017;69:62-72.

[5] Balestreri M, Czosnyka M, Hutchinson P, Steiner LA, Hiler M, Smielewski P, et al. Impact of intracranial pressure and cerebral perfusion pressure on severe disability and mortality after head injury. *Neurocrit Care.* 2006;4(1):8-13.

[6] Juul N, Morris GF, Marshall SB, Marshall LF. Intracranial hypertension and cerebral perfusion pressure: Influence on neurological deterioration and outcome in severe head injury. The Executive Committee of the International Selfotel Trial. *J Neurosurg.* 2000;92(1):1-6.

[7] Bonds BW, Hu P, Li Y, Yang S, Colton K, Gonchigar A, et al. Predictive value of hyperthermia and intracranial hypertension on neurological outcomes in patients with severe traumatic brain injury. *Brain Injury.* 2015;29(13):1642-1647.

[8] Epstein DS, Mitra B, O'Reilly G, Rosenfeld JV, Cameron PA. Acute traumatic coagulopathy in the setting of isolated traumatic brain injury: A systematic review and meta-analysis. *Injury.* 2014;45(5):819-824.

[9] Abdelmalik P, Boorman D, Tracy J, Jallo J, Rincon F. Acute traumatic coagulopathy accompanying isolated traumatic brain injury is associated with worse long-term functional and cognitive outcomes. *Neurocrit Care.* 2016;24(3):361-370.

[10] Jeremitsky E, Omert LA, Dunham CM, Wilberger J, Rodriguez A. The impact of hyperglycemia on patients with severe brain injury. *J Trauma.* 2005;58(1):47-50.

[11] Kobata H, Sugie A, Suehiro E, Dohi K, Kaneko T, Fujita M, et al. Association between blood glucose levels the day after targeted temperature initiation and outcome in traumatic brain injury: a post-hoc analysis of the B-HYPO study. *J Neurotrauma.* 2017;34(5):987-995.

[12] Madden LK, DeVon HA. A systematic review of the effects of body temperature on outcome after adult traumatic brain injury. *J Neurosci Nurs.* 2015;47(4):190-203.

[13] Robertson CS, Hannay HJ, Yamal J, Gopinath S, Goodman JC, Tilley BC. Effect of erythropoietin and transfusion threshold on neurological recovery after traumatic brain injury: A randomized clinical trial. *JAMA.* 2014;312(1):36-47.

[14] Al-Dorzi H, Al-Humaid W, Tamim HM, Haddad S, Aljabbary A, Arifi A, et al. Anemia and blood transfusion in patients with isolated traumatic brain injury. *Crit Care Res & Pract.* 2015:2015:1-7.

[15] Korbakis G, Vespa PM. Multimodal neurologic monitoring. *Handb Clin Neurol.* 2017;140:91-105.

[16] Reddy GD, Gopinath S, Robertson C. Critical care management of the patient with traumatic brain injury. *Semin Neurol.* 2016;36(6):570-576.

[17] Meeker M, Du R, Bacchetti P, Privitera CM, Larson MD, Holland MC, et al. Pupil examination: validity and clinical utility of an automated pupillometer. *J Neurosci Nurs.* 2005;37(1):34-40.

[18] Zafar SF, Suarez JI. Automated pupillometer for monitoring the critically ill patient: A critical appraisal. *J Crit Care.* 2014;29:599-603.

[19] Olson DM, Bazil JC. Pupillometer. In: Wiegand DL, editor. *AACN procedure manual for high acuity, progressive, and critical care.* 7th ed. St. Louis: Elsevier; 2017. p. 880-884.

[20] Mcilvoy L. Comparison of brain temperature to core temperature: A review of the literature. *J Neurosci Nurs.* 2004;36(1):23-31.

[21] O'Grady NP, Barie PS, Bartlett JG, Bleck T, Carroll K, Kalil AC, et al. Guidelines for evaluation of new fever in critically ill adult patients: 2008 update from the American College of Critical Care Medicine and the Infectious Diseases Society of America. *Crit Care Med.* 2008;36(4):1330-1349.

[22] Teasdale G, Jennett B. Assessment of coma and impaired consciousness. A practical scale. *Lancet* 1974;2:81-84.

[23] Teasdale G, Maas A, Lecky F, Manley G, Stocchetti N, Murray G. The Glasgow Coma Scale at 40 years: Standing the test of time. *Lancet Neurol.* 2014;13(8):844-854.

[24] Wijdicks EFM, Bamlet WR, Maramattom BV, Manno EM, McClelland RL. Validation of a new coma scale: The FOUR score. *Ann Neurol.* 2005;58(4):585-593.

[25] Middleton PM. Literature review: Practical use of the Glasgow Coma Scale; a comprehensive narrative review of GCS methodology. *Australas Emerg Nurs J.* 2012;15:170-183.

[26] Currie S, Saleem N, Straiton JA, Macmullen-Price J, Warren DJ, Craven IJ. Imaging assessment of traumatic brain injury. *Postgrad Med J.* 2016;92(1083):41-50.

[27] MacLaughlin BW, Plurad DS, Sheppard W, Bricker S, Bongard F, Neville A, et al. The impact of intracranial pressure monitoring on mortality after severe traumatic brain injury. *Am J Surg.* 2015;210(6):1082-1086.

[28] Dawes AJ, Sacks GD, Cryer HG, Gruen JP, Preston C, Gorospe D, et al. Intracranial pressure monitoring and inpatient mortality in severe traumatic brain injury: A propensity score-matched analysis. *J Trauma Acute Care Surg.* 2015;78(3):492-501.

[29] Chesnut RM, Temkin N, Carney N, Dikmen S, Rondina C, Videtta W, et al. A trial of intracranial-pressure monitoring in traumatic brain injury. *N Engl J Med.* 2012;367(26):2471-2481.

[30] Tang A, Pandit V, Fennell V, Jones T, Joseph B, O'Keeffe T, et al. Intracranial pressure monitor in patients with traumatic brain injury. *J Surg Res.* 2015;194(2):565-570.

[31] Chesnut RM, Bleck TP, Citerio G, Classen J, Cooper DJ, Coplin WM, et al. A consensus-based interpretation of the benchmark evidence from South American trials: Treatment of intracranial pressure trial. *J Neurotrauma.* 2015;32(22):1722-1724.

[32] Bratton SL, Chestnut RM, Ghajar J, McConnell Hammond F,F., Harris OA, Hartl R, et al. Guidelines for the management of severe traumatic brain injury. VII. Intracranial pressure monitoring technology. *J Neurotrauma.* 2007;24 Suppl 1:S45-S54.

[33] Slazinski T, Anderson TA, Cattell E, Eigsti JE, Heimsoth S, Holleman J, et al. Care of the patient undergoing intracranial pressure monitoring/extraventricular drainage or lumbar drainage. In: Thompson HJ, ed. *AANN clinical practice guideline series*. 3rd ed. Glenview: American Association of Neuroscience Nurses; 2012. p. 1-36.

[34] Cox S. Intraventricular catheter with external transducer for cerebrospinal fluid drainage and intracranial pressure monitoring. In: Wiegand DL, ed. *AACN procedure manual for high acuity, progressive, and critical care.* 7th ed. St. Louis: Elsevier; 2017. p. 842-855.

[35] Lang J, Beck J, Zimmermann M, Seifert V, Raabe A. Clinical evaluation of intraparenchymal Spiegelberg pressure sensor. *Neurosurgery.* 2003;52(6):1455-1459.

[36] Akbik OS, Carlson AP, Yonas H. The roles of ventricular and parenchymal intracranial pressure monitoring. *Curr Neurobiol.* 2016;7(1):1-6.

[37] Hepburn-Smith M, Dynkevich I, Spektor M, Lord A, Czeisler B, Lewis A. Establishment of an external ventricular drain best practice guideline: The quest for a comprehensive, universal standard for external ventricular drain care. *J Neurosci Nurs.* 2016;48(1):54-65.

[38] Slazinski T. Intraventricular/fiberoptic catheter insertion (assist), monitoring, nursing care, troubleshooting, and removal. In: Wiegand DL, ed. *AACN procedure manual for high acuity, progressive, and critical care.* 7th ed. St. Louis: Elsevier;2017. p. 835-841.

[39] Fried HI, Nathan BR, Rowe AS, Zabramski JM, Andaluz N, Bhimraj A, et al. The insertion and management of external ventricular drains: An evidence-based consensus statement:A statement for healthcare professionals from the Neurocritical Care Society. *Neurocrit Care.* 2016;24(1):61-81.

[40] Kirkness CJ, Mitchell PH, Burr RL, March KS, Newell DW. Intracranial pressure waveform analysis: Clinical and research implications. *J Neurosci Nurs.* 2000;32 (5):271-277.

[41] Robertson CS, Valadka AB, Hannay HJ, Contant CF, Gopinath SP, Cormio M, et al. Prevention of secondary ischemic insults after severe head injury. *Crit Care Med.* 1999;27(10):2086-2095.

[42] Czosnyka M, Miller C. Monitoring of cerebral autoregulation. *Neurocrit Care.* 2014;21:95-102.

[43] Jones S, Schwartzbauer G, Jia X. Brain monitoring in critically neurologically impaired patients. *Int J Mol Sci.* 2016;18(1):1-17.

[44] American College of Surgeons Committee on Trauma. *Advanced trauma life support student course manual.* 9th ed. Chicago: American College of Surgeons Committee on Trauma;2012.

[45] Seder DB, Bösel J. Chapter 2: Airway management and mechanical ventilation in acute brain injury. *Handb Clin Neurol.* 2017;140:15-32.

[46] Marion DW, Penrod LE, Kelsey SF, Obrist WD, Kochanek PM, Palmer AM, et al. Treatment of traumatic brain injury with moderate hypothermia. *N Engl J Med.* 1997;336(8):540-546.

[47] Jiang J, Yu M, Zhu C. Effect of long-term mild hypothermia therapy in patients with severe traumatic brain injury: 1-year follow-up review of 87 cases. *J Neurosurg.* 2000;93(4):546-549.

[48] Clifton GL, Miller ER, Choi SC, Levin HS, McCauley S, Jr SK, et al. Lack of effect of induction of hypothermia after acute brain injury. *N Engl J Med.* 2001;344(8):556-563.

[49] Clifton GL, Valadka A, Zygun D, Coffey CS, Drever P, Fourwinds S, et al. Very early hypothermia induction in patients with severe brain injury (the National Acute Brain Injury Study: Hypothermia II): A randomised trial. *Lancet Neurol.* 2011;10(2):131-139.

[50] Shaefi S, Mittel AM, Hyam JA, Boone MD, Chen CC, Kasper EM. Hypothermia for severe traumatic brain injury in adults: Recent lessons from randomized controlled trials. *Surg Neurol Int.* 2016;7:103.

[51] Brucia J, Rudy E. The effect of suction catheter insertion and tracheal stimulation in adults with severe brain injury. *Heart Lung.* 1996;25(4):295-303.

[52] McNett MM, Olson DM. Evidence to guide nursing interventions for critically ill neurologically impaired patients with ICP monitoring. *J Neurosci Nurs.* 2013;45 (3):120-123.

[53] Kerr ME, Rudy EB, Brucia J, Stone KS. Head-injured adults: Recommendations for endotracheal suctioning. *J Neurosci Nurs.* 1993;25(2):86-91.

[54] Ugras GA, Aksoy G. The effects of open and closed endotracheal suctioning on intracranial pressure and cerebral perfusion pressure: A crossover, single-blind clinical trial. *J Neurosci Nurs.* 2012;44(6):E1-8.

[55] Nyholm L, Howells T, Enblad P. Predictive factors that may contribute to secondary insults with nursing interventions in adults with traumatic brain injury. *J Neurosci Nurs.* 2017;49(1):49-55.

[56] Williams A, Coyne SM. Effects of neck position on intracranial pressure. *Am J Crit Care.* 1993;2(1):68-71.

[57] Sullivan J. Positioning of patients with severe traumatic brain injury: Research-based practice. *J Neurosurg Nurs.* 2000;32(4):204-209.

[58] Fan J. Effect of backrest position on intracranial pressure and cerebral perfusion pressure in individuals with brain injury: A systematic review. *J Neurosci Nurs.* 2004;36(5):278-288.

[59] Ledwith MB, Bloom S, Maloney-Wilensky E, Coyle B, Polomano RC, Le Roux PD. Effect of body position on cerebral oxygenation and physiologic parameters in patients with acute neurological conditions. *J Neurosci Nurs.* 2010;42(5):280-287.

[60] Agbeko RS, Pearson S, Peters MJ, McNames J, Goldstein B. Intracranial pressure and cerebral perfusion pressure responses to head elevation changes in pediatric traumatic brain injury. *Pediatr Crit Care Med.* 2012;13(1):e39-e47.

[61] Thelandersson A, Å. Cider, Nellgård B. Prone position in mechanically ventilated patients with reduced intracranial compliance. *Acta Anaesthesiol Scand.* 2006;50(8):937-941.

[62] Nekludov M, Bellander B-, Mure M. Oxygenation and cerebral perfusion pressure improved in the prone position. *Acta Anaesthesiol Scand.* 2006;50(8):932-936.

[63] Badjatia N. Fever control in the neuro-ICU: Why, who, and when? *Curr Opin Crit Care* 2009;15(2):79-82.

[64] Badjatia N, Strongilis E, Gordon E, Prescutti M, Fernandez L, Fernandez A, et al. Metabolic impact of shivering during therapeutic temperature modulation the Bedside Shivering Assessment Scale. *Stroke.* 2008;39(12):3242-3247.

[65] Presciutti M, Bader MK, Hepburn M. Shivering management during therapeutic temperature modulation: Nurses' perspective. *Crit Care Nurse.* 2012;32(1):33-42.

[66] Chaikittisilpa N, Lele AV, Lyons VH, Nair BG, Newman S, Blissitt PA, et al. Risks of routinely clamping external ventricular drains for intrahospital transport in neurocritically ill cerebrovascular patients. *Neurocrit Care.* 2016 10/18.

[67] Hsiang JK, Chesnut RM, Crisp CB, Klauber MR, Blunt BA, Marshall LF. Early, routine paralysis for intracranial pressure control in severe head injury: Is it necessary? *Crit Care Med.* 1994;22(9):1471-1476.

[68] Andrews PJD, Sinclair HL, Rodriguez A, Harris BA, Battison CG, Rhodes JKJ, et al. Hypothermia for intracranial hypertension after traumatic brain injury. *N Engl J Med.* 2015;373(25):2403-2412.

[69] O'Leary R, Hutchinson PJA, Menon D, Andrews PJD, Harris BA, Murray GD. Hypothermia for intracranial hypertension after traumatic brain injury. *N Engl J Med* 2016 04/07;374(25):1383-1384.

[70] Inaba K, Menaker J, Branco BC, Gooch J, Okoye OT, Herrold J, et al. A prospective multicenter comparison of levetiracetam versus phenytoin for early posttraumatic seizure prophylaxis. *J Trauma Acute Care Surg.* 2013;74(3):766-771.

[71] Munro N, Ruggiero M. Ventilator-Associated Pneumonia Bundle. *AACN Adv Crit Care.* 2014;25(2):163-175.

[72] Szabo CM, Grap MJ, Munro CL, Starkweather A, Merchant RE. The effect of oral care on intracranial pressure in critically ill adults. *J Neurosc Nurse.* 2014;46(6):321-329.

[73] Centers for Disease Control and Prevention. *Checklist for prevention of central line associated blood stream infections*. Available at: https://www-cdc-gov.proxy-hs.researchport.umd.edu/hai/pdfs/bsi/checklist-for-CLABSI.pdf. Accessed May 28, 2017.

[74] Centers for Disease Control and Prevention. *Catheter-associated urinary tract infections (CAUTI)*. 2017; Available at: https://www-cdc-gov.proxy-hs.researchport.umd.edu/infectioncontrol/guidelines/cauti/index.html. Accessed May 28, 2017.

[75] Joseph DK, Dutton RP, Aarabi B, Scalea TM. Decompressive laparotomy to treat intractable intracranial hypertension after traumatic brain injury. *J Trauma.* 2004; 57(4):687-695.

[76] Jacobi J, Bircher N, Krinsley J, Agus M, Braithwaite SS, Deutschman C, et al. Guidelines for the use of an insulin infusion for the management of hyperglycemia in critically ill patients. *Crit Care Med.* 2012;40(12):3251-3276.

[77] Davidson JE, Aslakson RA, Long AC, Puntillo KA, Kross EK, Hart J, et al. Guidelines for family-centered care in the neonatal, pediatric, and adult ICU. *Crit Care Med.* 2017;45(1):103-128.

[78] Livesay S, Moser H. Evidence-based nursing review of craniectomy care. *Stroke.* 2014;45(11):e217-e219.

[79] Honeybul S, Ho KM. Long-term complications of decompressive craniectomy for head injury. *J Neurotrauma* 2011;28(6):929-935.

[80] Su T, Lan C, Lee T, Hsu S, Lu C. Risk factors for the development of contralateral epidural hematoma following decompressive craniectomy in patients with calvarial skull fracture contralateral to the craniectomy site. *World Neurosurg.* 2016;89:223-229.

[81] Kammersgaard LP, Linnemann M, Tibæk M. Hydrocephalus following severe traumatic brain injury in adults. Incidence, timing, and clinical predictors during rehabilitation. *NeuroRehabilitation.* 2013;33(3):473-480.

[82] Aarabi B, Chesler D, Maulucci C, Blacklock T, Alexander M. Dynamics of subdural hygroma following decompressive craniectomy: A comparative study. *Neurosurg Focus.* 2009;26(6):1-12.

[83] Honeybul S, Ho KM. Incidence and risk factors for post-traumatic hydrocephalus following decompressive craniectomy for intractable intracranial hypertension and evacuation of mass lesions. *J Neurotrauma.* 2012;29(10):1872-1878.

[84] Cassir N, Rosa DL, Melot A, Touta A, Troude L, Loundou A, et al. Risk factors for surgical site infections after neurosurgery: A focus on the postoperative period. *Am J Infect Control.* 2015;43(12):1288-1291.

[85] Harrington P. Prevention of surgical site infection. *Nurs Stand* 2014;28(48):50-58.

[86] Schurr MJ, Ebner KA, Maser AL, Sperling KB, Helgerson RB, Harms B. Formal swallowing evaluation and therapy after traumatic brain injury improves dysphagia outcomes. *J Trauma.* 1999;46(5):817-823.

[87] Brown CVR, Hejl K, Mandaville AD, Chaney PE, Stevenson G, Smith C. Swallowing dysfunction after mechanical ventilation in trauma patients. *J Crit Care.* 2011;26: 108.e9-108.e13.

[88] Eisenstadt ES. Dysphagia and aspiration pneumonia in older adults. *J Am Acad Nurse Pract.* 2010;22(1):17-22.

[89] Honeybul S. Decompressive craniectomy: A new complication. *J Clin Neurosci.* 2009;16(5):727-729.

[90] Kushner DS, Johnson-Greene D. Changes in cognition and continence as predictors of rehabilitation outcomes in individuals with severe traumatic brain injury. *J Rehabil Res Dev.* 2014;51(7):1057-1068.

[91] Lippa SM, Lange RT, Bailie JM, Kennedy JE, Brickell TA, French LM. Utility of the Validity-10 scale across the recovery trajectory following traumatic brain injury. *J Rehabil Res Dev.* 2016;53(3):379-390.

[92] Ashayeri K, Jackson EM, Huang J, Brem H, Gordon CR. Syndrome of the trephined: A systematic review. *Neurosurgery.* 2016;79(4):525-534.

[93] Daou B, Zanaty M, Chalouhi N, Dalyai R, Jabbour P, Yang S, et al. Low incidence of bone flap resorption after native bone cranioplasty in adults. *World Neurosurg.* 2016;92:89-94.

[94] Bombardier CH, Hoekstra T, Dikmen S, Fann JR. Depression trajectories during the first year after traumatic brain injury. *J Neurotrauma.* 2016;33(23):2115-2124.

[95] Cook KF, Bombardier CH, Bamer AM, Choi SW, Kroenke K, Fann JR. Do somatic and cognitive symptoms of traumatic brain injury confound depression screening? *Arch Phys Med Rehabil.* 2011;92(5):818-823.

[96] Kline AE, Leary JB, Radabaugh HL, Cheng JP, Bondi CO. Combination therapies for neurobehavioral and cognitive recovery after experimental traumatic brain injury: Is more better? *Prog Neurobiol.* 2016;142:45-67.

[97] Stephens JA, Williamson KC, Berryhill ME. Cognitive rehabilitation after traumatic brain injury: A reference for occupational therapists. *OTJR.* 2015;35(1):5-22.

[98] Castro E, Turcinovic M, Platz J, Law I. Early mobilization: Changing the mindset. *Crit Care Nurse* 2015;35(4):e1-7.

[99] Lauterbach MD, Notarangelo PL, Nichols SJ, Lane KS, Koliatsos VE. Diagnostic and treatment challenges in traumatic brain injury patients with severe neuropsychiatric symptoms: Insights into psychiatric practice. *Neuropsychiatr Dis Treat.* 2015;2015:1601-1607.

[100] Kumar L. Brain death and care of the organ donor. *J Anaesthesiol Clin Pharmacol*. 2016;32(2):146-152.

[101] Arbour RB. Brain death: Assessment, controversy, and confounding factors. *Crit Care Nurse*. 2013;33(6):27-46.

In: Encyclopedia of Surgery (22 Volume Set)
Editors: Andreas Lehrer and Kristin Mueller
ISBN: 978-1-53618-329-0
© 2020 Nova Science Publishers, Inc.

Chapter 228

DECOMPRESSIVE LAPAROTOMY TO TREAT INTRACRANIAL HYPERTENSION AND MULTIPLE COMPARTMENT SYNDROME

Margaret H. Lauerman*, MD and Thomas M. Scalea, MD
Department of Trauma/Critical Care, R. Adams Cowley Shock Trauma Center,
University of Maryland Medical Center, Baltimore, MD, US

ABSTRACT

Multiple compartment syndrome (MCS) encompasses the interconnected physiology between the abdominal cavity, thoracic cavity, and cranial vault. The cranial vault cannot be considered in isolation, and elevated pressure in one of these compartments can affect pressure in another compartment. Elevations in intra-abdominal pressure must especially be considered in patients with MCS since relief of elevated intracranial pressure (ICP) in MCS often requires decompressive laparotomy for its decrease in addition to the usual therapy aimed at lessening cerebral edema and intracranial hemorrhage. Without identification of MCS in patients with elevated ICP and decompressive laparotomy, elevation in ICP will persist.

Keywords: decompressive laparotomy, open abdomen, multiple compartment syndrome, intraabdominal pressure

INTRODUCTION

The brain does not exist in isolation but in fact interacts with other organs outside of the central nervous system (CNS). The cranial vault sits on top of a series of compartments that include the thorax and the abdomen. Pressures in one compartment can be transmitted to an

* Corresponding Author's Email: mlauerman@umm.edu.

adjacent compartment. For instance, intra-abdominal pressure (IAP) can be transmitted to the thorax and then even to the brain.

Therapies commonly used to reduce excessive pressure in extracranial compartments may then similarly affect the brain. Something as simple as a ventilator manipulation in acute respiratory failure or fluid resuscitation for hemorrhagic shock may have an unintended secondary effect on the brain by raising intracranial pressure (ICP). While therapies for elevations in ICP are generally intended to affect the brain directly, these relationships raise the possibility that ICP can be modulated by altering pressures outside of the cranial vault. Clinicians must have an intimate knowledge of these relationships in order to care for multiply injured patients with severe brain injury.

Principles of Compartment Syndrome

Compartment syndrome, defined as an elevation in pressure that decreases perfusion within a confined body cavity, is induced by a variety of causes including trauma, immobilization, rhabdomyolysis, thermal injuries, coagulopathy, and infection [1]. While compartment syndrome can develop in many different body compartments, it is most commonly thought of as taking place in the extremities. Within the extremities, compartment syndrome most often occurs in the lower extremities but can also occur in the hand, arm, foot, or gluteus. However, compartment syndrome can also take place outside of the extremities. Abdominal, thoracic, and ocular compartment syndromes are uncommon, but do happen [2-4].

The extremity compartments are surrounded by a fascial layer, which is a relatively inflexible tissue that does not easily stretch [1]. The abdominal cavity is similarly surrounded by fascia. Regardless of the cause, as the pressure within a compartment increases, the fascia does not allow compartmental volume to expand. Instead, the fascia restricts the compartment's volume, and swelling within the compartment increases pressure rather than volume. In addition to the physical constriction of the fascia, molecular mechanisms are thought to play a role in development of compartment syndrome, including hypoxemia, hypoglycemia, and sodium-potassium channel dysfunction [1].

Because presenting findings for compartment syndrome vary depending on the body cavity involved (Table 1), the physical examination is commonly used to screen for compartment syndrome. Depending on the affected body compartment, invasive testing is used to measure compartment pressures and diagnose compartment syndrome (Table 2). Early diagnosis of compartment syndrome is crucial in that time to decompression is associated with the return of neurologic and muscular function in the extremities [5]. The mainstay of therapy for compartment syndrome is fasciotomy to release the pressure in the affected compartment and restore perfusion, with fascial release performed emergently to prevent further physiologic decline and tissue necrosis. The same principles are relevant in compartment syndrome regardless of the location.

Table 1. Findings concerning for elevated compartment pressures in multiple compartment syndrome

Concerning Findings For Elevated Compartment Pressure in Multiple Compartment Syndrome
Thoracic Cavity
High ventilator driving pressure
High peak airway pressure
Abdominal Cavity
Abdominal distention
Abdominal tenderness
Tense abdominal exam
Decreased urine output
Hypotension
Elevated peak airway pressures
Cranial Vault
Diminished Glasgow Coma Scale score
Pupillary abnormality
Neurologic deficit

Table 2. Methods of compartment pressure measurement

Modern Methods of Measuring Compartment Pressure
Extremity
Stryker® needle
Thoracic Cavity
High peak airway pressure (Inferred to be elevated)
High ventilator driving pressure (Inferred to be elevated)
Abdominal Cavity
Bladder pressure
Cranial Vault
Intraventricular catheter
Subarachnoid bolt

As pressure in a compartment rises, it can quickly exceed venous pressure. With initial elevation in pressure within the compartment, arterial inflow is maintained but blood cannot exit the compartment because of the increases in the pressure within the compartment. As the compartment pressure continues to rise, it ultimately exceeds perfusion pressure, resulting in ischemia. Within the extremities, myonecrosis takes place. Within the abdomen, organ dysfunction happens first, followed by tissue infarction.

Elevated ICP can correctly be considered "brain compartment syndrome." In patients with traumatic brain injury (TBI), cerebral edema or hemorrhage can increase the pressure within the cranial vault. The rigid skull, much like the fascia that surrounds many extra-CNS compartments, prevents expansion of the cranial vault volume and thus the ICP increases. These increased ICP levels can produce cerebral hypoperfusion, much as hypoperfusion occurs in extra-CNS compartments with increasing compartment pressures. Ultimately, the brain herniates.

ABDOMINAL COMPARTMENT SYNDROME

Diagnosis and Monitoring

The first screening tool for abdominal compartment syndrome (ACS) is a high-quality physical examination. The abdomen should be visually inspected, auscultated, and palpated. Because the normal abdomen should appear flat and non-distended, any abdominal distention or a tense appearance should raise concern for elevated IAP. A tender abdomen on palpation should raise a similar concern. Physical examination in obese patients or non-responsive patients can be difficult, which is likely one reason that physical exam has not been shown to be universally effective for diagnosing elevated IAP [6, 7]. While physical exam is a costless bedside screen for ACS, given its limitations it should not be the definitive test.

When concern exists for elevation in IAP, measurement is the next step. IAP measurement is done by indirectly measuring a bladder pressure, which transduces the IAP across the bladder wall [4]. Previous measurement techniques using rectal, uterine, inferior vena cava, and gastric pressures, while possible, are no longer commonly performed [8]. To perform a bladder pressure, 25 cc of sterile saline is instilled into the bladder through a Foley catheter [4, 9], with a pressure then transduced. The gauge should be set at the level of the pelvis. For ideal measurement of a bladder pressure, the patient should be supine and paralyzed to prevent patient abdominal wall tension causing false elevations in pressure. Bladder pressures, although not a direct measure of IAP, have been shown to correlate well with actual IAP when created with laparoscopic insufflation [10]. The bladder pressure is not just a one-time measurement, and in patients for whom ACS is a concern serial bladder pressure measurements can be performed.

Normal IAP usually ranges from 5 to 7 mm Hg in critically ill patients, with elevated IAP defined as an abdominal pressure greater than 12 mm Hg [4]. Elevated IAP is a common finding in critically ill patients in the intensive care unit (ICU), with 32% of ICU patients showing evidence of such. Given the common occurrence of elevated IAP in critically ill patients, discerning a pathologic elevation from a non-significant elevation in IAP can be difficult [11]. ACS has classically been defined as an IAP measurement greater than 20 mm Hg with evidence of organ dysfunction [4]. Common clinical symptoms of organ dysfunction in ACS include hypotension, renal dysfunction with oliguria, or elevation in peak airway ventilator pressures.

Physiology

ACS, with its multitude of physiologic causes, can be divided into primary, secondary, and tertiary ACS. Primary ACS is caused by an intra-abdominal pathology, such as acute pancreatitis, intra-abdominal hemorrhage, or mesenteric ischemia. Intra-abdominal pressure rises either directly from the intra-abdominal pathology, such as in bleeding, or from secondary inflammation. Secondary ACS is caused by an extra-abdominal pathology such as large volume resuscitation for sepsis [4]. While resuscitation is often required for extra-abdominal pathology, the resulting visceral edema, edema of the abdominal wall, and

retroperitoneal edema can combine to elevate IAP [12]. Tertiary ACS is recurrent ACS after initial treatment of the disorder, and can be seen with premature abdominal wall closure [13].

Oliguria is one of the common signs of organ dysfunction in ACS. This decrease in urine output often occurs despite ongoing resuscitation [13]. However, the exact mechanism of oliguria and renal failure with elevated IAP is unknown. Diminished renal arterial blood flow, increased renal venous resistance, and decreased cardiac output are all proposed mechanisms of oliguria in ACS, with decrease in renal blood flow seeming to occur in animal models when IAP is between 20 and 30 mm Hg [14-16]. Alterations in levels of aldosterone, cortisol, and adrenaline may also induce renal vasoconstriction [16].

Cardiac failure manifested as hypotension also occurs with ACS. This organ dysfunction in ACS is mediated through the cardiovascular system even with primary intra-abdominal pathology. Hypotension in ACS is likely caused by both decreased preload and increased afterload with increased levels of IAP [17, 18]. With these changes to preload and afterload, cardiac output decreases, and hypotension then occurs [13].

The third commonly seen organ dysfunction in ACS is elevation in peak airway pressures on the ventilator, indicating worsening pulmonary dysfunction and increased intrathoracic pressure (ITP). In patients with elevated IAP, the diaphragm is pushed upward from the abdominal cavity against the thoracic cavity. Total lung capacity is decreased with this upward compression of the diaphragm, and functional residual capacity decreases as well [13]. Pulmonary compliance decreases and the chest wall stiffens [19], both of which contribute to increased peak airway pressures.

If left untreated, ACS can progress to intestinal ischemia. Superior mesentery artery (SMA) flow is shown to decrease with IAP as low as 3 mm Hg, and is 65% of normal SMA flow at an IAP of 40 mm Hg [20, 21]. The mesenteric veins, which have lower wall strength than the mesenteric arteries, are similarly compressed by elevations in IAP, reducing venous outflow from the intestines and contributing to visceral edema. This obstruction can initiate a cycle of worsening IAP, whereby venous outflow obstruction causes visceral edema, which elevates IAP, which worsens the venous obstruction, and onward in a self-perpetuating cycle [22].

EFFECT OF INTRATHORACIC AND INTRA-ABDOMINAL PRESSURES ON INTRACRANIAL PRESSURE

Intrathoracic Pressure

ITP can influence ICP via multiple pathways, all of which are through the cardiovascular system. Elevated ITP may impair cranial vault venous outflow through the internal jugular veins into the mediastinum. Venous return from the cranial vault into the central circulation is driven by a differential in pressure between the cranial vault and mediastinum [23]. When ITP is elevated, the pressure differential between the cranial vault and thoracic cavity can decrease, which can subsequently lessen cranial venous outflow. The resulting increased venous volume within the cranial vault can elevate ICP (Figure 1).

Increases in ITP can decrease cardiac output, in turn decreasing cerebral arterial blood flow. This lowered cerebral blood flow causes a reactive cerebral arterial vasodilation, which

increases the volume of blood within the cerebral circulation despite the decrease in blood flow. With the increased volume of arterial blood within the cerebral vault, ICP can rise [23].

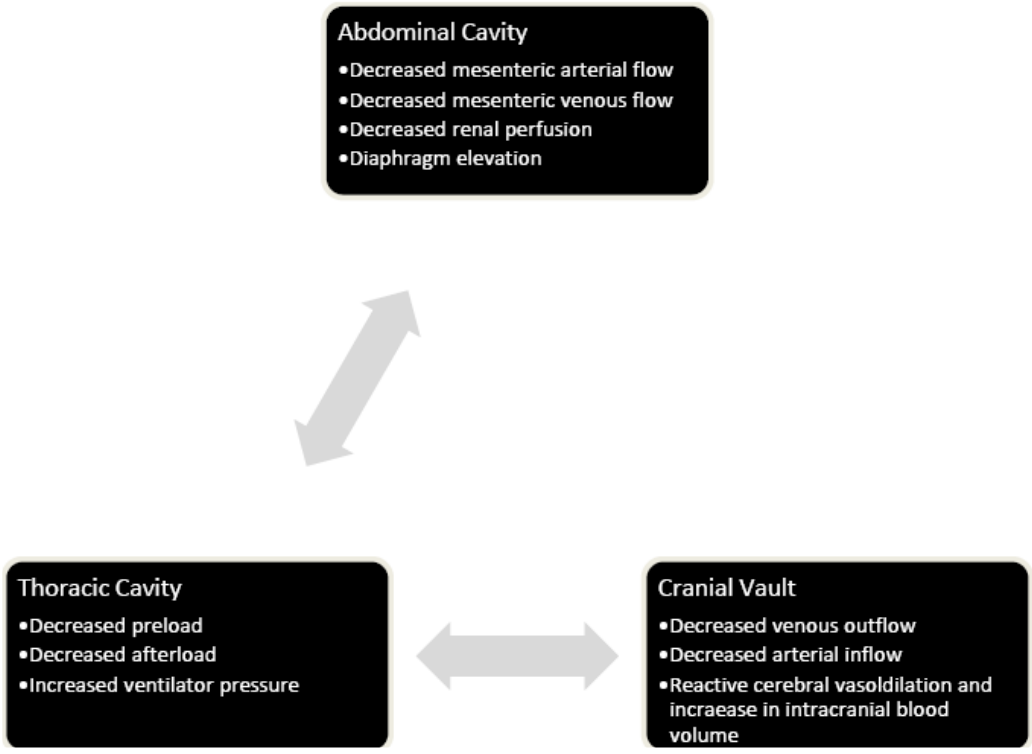

Figure 1. Relationship between elevated pressure in the thoracic cavity, abdominal cavity, and cranial vault in multiple compartment syndrome.

Multiple maneuvers in the care of patients with TBI assist with optimizing the gradient for venous outflow from the cranial vault as well, and must be undertaken in concert with minimizing ITP. Jugular venous obstruction should be avoided given the variations in anatomy of the venous outflow of the cranial vault [24]. Additionally, the patient's head should be in a straight-forward position, as venous outflow can similarly become obstructed if the head is turned [25]. Cervical collars should be well-fitting and without excess pressure, as should any ties securing endotracheal tubes or tracheostomy tubes.

In general, for patients with an isolated TBI, the ventilator can be set without increasing ITP. However, in patients with TBI and concurrent pulmonary pathology, such as acute respiratory distress syndrome or pneumonia, a high ITP may be required to treat the pulmonary pathology. A balancing of increased ITP to prevent hypoxemia or hypercarbia and minimizing of ITP in light of the TBI must be undertaken. While it is known that patients with TBI and acute lung injury have worse outcomes, the ideal ventilator management strategy is unknown [26].

Intra-Abdominal Pressure

Elevated IAP is also associated with elevation in ICP. In an animal model in which elevated IAP was created by directly infusing solution into the abdominal cavity, when IAP was increased, ICP significantly increased, and when the abdomen was decompressed by removing the infused fluid, the ICP decreased [27], demonstrating a direct relationship between IAP and ICP.

In humans this association between IAP and ICP is similar. When a 15-pound water bag was placed onto the abdomen of patients with TBI, a significant increase in both in ICP and IAP was seen. The increase in ICP occurred soon after the increase in IAP. Notably, the initial ICP did not influence the amount of ICP increase following the creation of elevated IAP [28].

DECOMPRESSIVE LAPAROTOMY FOR ELEVATED INTRA-ABDOMINAL AND INTRACRANIAL PRESSURES

The relationship between ICP an IAP has been known for some time. However, manipulating it for patient care is recent. The first person for whom we used decompressive laparotomy to treat elevated ICP was a police officer who was injured in a high speed motorcycle crash. After evacuation of a subdural hematoma, he developed refractory elevations of his ICP, up to 45 mm Hg despite maximal medical therapy. His abdomen was distended with an IAP of 25 mm Hg. While his IAP was not as markedly elevated, abdominal decompression seemed our last possible option. He responded beautifully, required little in the way of additional therapy for his ICP, and made a complete neurological recovery. Several weeks later, we had another patient who also responded to abdominal decompression. This soon became part of our armamentarium for difficult to control ICP.

The first series of seventeen patients undergoing this procedure was from our institution and was reported in 2004. In that series, reductions in ICP were seen following abdominal decompression [29]. Patients who sustained drops in central venous pressure seemed to have the best neurologic outcomes. Today, decompressive laparotomy remains an important tool to treat refractory intracranial hypertension, particularly in multiply injured patients with TBI. This is true regardless of whether they have abdominal trauma. Even in the absence of direct injury to the abdomen, resuscitation needs for extra-abdominal injuries often can raise IAP and secondarily raise ICP. In our opinion, practitioners of all specialties who care for these patients must be cognizant of these relationships and options for therapy.

Technique of Decompressive Laparotomy

Treatment of elevated IAP should proceed according to the World Society for Intra-abdominal Hypertension guidelines. Medical treatment options for elevated IAP include gastric decompression, rectal decompression, diuresis, drainage of abdominal fluid, increased sedation, and paralysis [4]. However, with the development of ACS in any patient, or in TBI

patients with elevated IAP and intractable elevation in ICP, decompressive laparotomy should be performed.

A decompressive laparotomy is usually performed in the operating room. Critically ill patients, however, may not tolerate transport to the operating room, and the decompressive laparotomy can be performed in the ICU with the operating room team brought to the bedside of selected patients. While bedside laparotomy is feasible and can be life-saving, mortality risk is very high [30, 31].

Patients undergoing decompressive laparotomy are most often in the supine position, which starkly contrasts with the head of bed elevation used in patients with TBI. Of particular concern are the large increases in ICP that can occur when patients with TBI are laid flat [32]. Still, laparotomy can be performed in patients with elevated ICP who do not tolerate lying flat by positioning the patient in the reverse Trendelenburg position.

To perform the decompressive laparotomy, a vertical midline incision is made down through all the abdominal wall layers from the xiphoid process superiorly to the pubis inferiorly. This allows for the widest possible opening of the abdominal cavity. Full incision of the abdominal wall releases the abdominal contents that were under pressure. When ACS is present, the abdominal viscera will often eviscerate beyond the level of the abdominal wall, and not be completely reducible back into the abdominal cavity. The surgeon should explore the abdominal cavity to evaluate for any primary abdominal causes of elevated IAP, though in MCS this elevation is often the result of fluid resuscitation and not a primary intra-abdominal cause.

Managing the Open Abdomen

After the initial decompressive laparotomy has been performed, the abdominal wall is not closed. Instead, all the layers of the abdominal wall are left open to minimize the chance of recurrence of the elevated IAP. The abdomen is then covered with a temporary negative pressure suction dressing. Either a proprietary suction dressing attached to a portable suction machine or a homemade abdominal dressing attached to a wall suction container can be used as temporary abdominal coverage. Both dressings will remove fluid from the abdominal cavity, keep the intra-abdominal contents sterile, and cover the viscera while the patient recovers in the ICU.

Patients who are being managed with an open abdomen after decompressive laparotomy should undergo re-exploration every 2 to 4 days, and at each exploration the patient should be evaluated for definitive closure of the abdominal wall. Closure of the abdominal wall is usually not attempted if the patient still has persistently elevated ICP to avoid recurrent ACS. At abdominal re-exploration, if the fascia can be approximated and the tidal volumes do not worsen, the abdominal wall is closed. Decreases in tidal volumes with fascial closure are an indication of recurrent elevation in IAP inducing elevation in ITP. If the fascia cannot be reapproximated, the dressing is replaced over the abdominal wall.

Fluid status management in patients with an open abdomen can be difficult. Fluid output from the open abdominal cavity can be multiple liters per day, especially in patients who have undergone a substantial fluid resuscitation. However, a negative fluid balance in patients with an open abdomen can aid abdominal wall closure by decreasing visceral edema and increasing abdominal wall mobility. Achieving a negative fluid balance can be difficult in

patients with TBI where intravascular volume depletion can cause hypotension and a subsequent decrease in cerebral blood flow.

In patients who are unable to undergo abdominal wall closure after decompressive laparotomy, the abdominal wall is left open. Granulation tissue is allowed to form over top of the viscera in lieu of abdominal wall closure. Often an absorbable mesh is placed above the viscera to provide coverage. Once the granulation tissue has formed, the patient can undergo split thickness skin grafting to cover the wound and provide a permanent coverage over the viscera. Abdominal wall reconstruction is performed a minimum of 6 months later.

Because decompressive laparotomy has many potential complications, it is performed only in patients with a diagnosis of ACS or elevated IAP and intractable ICP elevations. Given that the cause of elevated IAP in ACS is often visceral edema, many patients undergoing decompressive laparotomy do not ultimately achieve abdominal wall closure [29]. Inability to close the abdominal wall exposes the underlying stomach, small bowel, and large bowel to potential enterocutaneous fistula formation, and the patient to higher rates of renal dysfunction [33]. Patients managed with an open abdomen who do not undergo fascial closure are left with a planned ventral hernia, and face future procedures to repair this hernia in an elective fashion after the acute illness has resolved [34].

MULTIPLE COMPARTMENT SYNDROME IN TRAUMATIC BRAIN INJURY

Overview

MCS was first described in trauma patients when it was noted that severely injured patients with TBI often developed elevated IAP and/or elevated ITP at the same time as elevated ICP. They seemed to have simultaneously developed compartment syndrome in multiple places, hence the term MCS. In the ICU, these changes can be insidious and extreme vigilance is required to recognize MCS when it is first developing. Commonly, the sequence of events of MCS development is as follows. A patient requires increased ventilator support. As ITP increases, cardiac output falls along with blood pressure. Typically, fluid is used to support the cardiovascular system, which may increase interstitial edema in the lung, prompting more support from the ventilator, and may increase visceral edema. As respiratory function worsens and ventilator needs increase, the ability to do positional therapy often decreases. Increases in ITP produce increases in IAP. Increases in ICP are treated with increased sedation and/or hyperosmolar agents that may then decrease intravascular volume. This cycle progresses, then repeats, and produces MCS.

Both decompressive craniectomy and decompressive laparotomy can decrease ICP in patients with MCS, whether used alone or in sequence. After decompressive craniectomy, patients with MCS had an improvement in ICP to below 20 mm Hg, with an 18 mm Hg mean decrease in ICP with decompressive craniectomy. After decompressive laparotomy, patients with MCS also had a significant decrease in ICP of 9 mm Hg, again to levels less than 20 mm Hg. When used in sequence, the order of decompressive laparotomy and decompressive craniectomy did not significantly affect mean ICP [35]. Therefore, surgeons should perform the procedures in the order deemed clinically necessary for the individual patient.

Multiple risk factors are associated with MCS development, although the amount of fluid resuscitation is likely the inciting factor. Patients with MCS had a drastically higher fluid administration, with 23 liters more given over the initial 7 days of the hospitalization, than patients who did not develop MCS [35]. Often in patients with MCS, ascites and liver congestion were noted at the time of laparotomy, confirming the substantial degree of fluid resuscitation administered in patients with MCS [29]. More critically injured patients with higher Injury Severity Scores were also more likely to develop MCS [35].

Outcomes in patients with MCS are worse than in patients with an isolated TBI without MCS. Mortality is higher in patients with MCS than in patients only requiring decompressive craniectomy. Patients with MCS have a 12% higher mortality than patients with elevated ICP requiring decompressive craniectomy without concurrent elevation in IAP [35]. Overall survival rates in series of patients with MCS range from 58% to 65%, with younger age being the only predictor of survival in MCS [29, 35]. Length of stay for patients with MCS was unsurprisingly higher as well [35]. Given these worse outcomes in patients with MCS, fortunately the development of MCS is rare, with only 2% of patients with a TBI developing MCS [35].

However, these risk factors do not completely explain the pathophysiology of MCS given the anatomic separation between the cranial vault and the abdominal cavity, and the connection between ICP and IAP is more complex than just an association between ICP and IAP. The relationship is likely mediated through the thoracic cavity, which separates the cranial vault and abdominal cavity, and involves relationships between ICP and ITP, and between ITP and IAP, with these complex relationships comprising the physiology of MCS explained below.

Physiology of Multiple Compartment Syndrome

The abdomen and the cranial vault are separated by the thoracic cavity, and in view of the known association of both ITP and IAP with ICP, the effect of IAP on ICP is likely transmitted through the thoracic cavity. Multiple animal models have demonstrated an active association between elevated ICP, IAP, and ITP. In an animal model of cardiopulmonary resuscitation (CPR), chest compressions during CPR induced a rise in both ITP and ICP. With abdominal binding, the increase in ITP with CPR produced a larger increase in ICP. This is likely due to the preferential transmission of pressure into the cranial vault given the restriction of the abdominal cavity with the abdominal binder [36].

In another animal model where IAP was elevated by inflating an intra-abdominal balloon, both ITP and ICP increased. With this increase in IAP, significant increases in peak airway pressures and central venous pressures were also noted, as was a decrease in cardiac index. However, in this animal model of intra-abdominal balloon insufflation, when a sternotomy and a pleuropericardotomy were performed to release the thoracic cavity as well, the increase in ICP was no longer seen with increasing levels of IAP, although the significant increase in peak airway pressure and the significant decrease in cardiac index were maintained [37]. This animal model affirms that the thoracic compartment is the connection between elevated IAP and ICP in MCS.

In humans, relief of MCS has proved the relationship between ICP, ITP, and IAP. When patients with MCS underwent decompressive laparotomy, mean ventilator airway pressure

had a significant decrease after 24 hours and ICP also showed a significant reduction [29, 35], likely indicating that decompressive laparotomy had lowered IAP, ITP, and ICP.

CONCLUSION

The cranial vault does not exist in isolation, as demonstrated by the interplay between ICP, ITP, and IAP. Elevated ICP in patients with TBI mainly requires treatment aimed at reducing cerebral edema and intracranial contents, but in patients with MCS it may require treatment aimed at extra-CNS sources. Volume of fluid resuscitation likely plays a role in the development of MCS, and fluid resuscitation in patients with TBI should be judicious given the potential development of MCS yet balanced against the need to maintain cerebral perfusion and prevent secondary brain injury. All patients with elevated ICP should be screened for a concurrent elevation in IAP, as ICP management in patients with MCS will be unsuccessful without decompressive laparotomy.

The realization that injuries could affect physiology and different body compartments gave rise to the recognition of multiple compartment syndrome. In fact, multiply injured patients may develop compartment syndrome in more than one body cavity, either from the direct effects of injury, such as severe TBI and intra-abdominal hemorrhage, or from the therapy of those injuries, such as large volume resuscitation in a patient with severe TBI and elevated ICP.

REFERENCES

[1] von Keudell AG, Weaver MJ, Appleton PT, Bae DS, Dyer GS, Heng M, et al. Diagnosis and treatment of acute extremity compartment syndrome. *Lancet.* 2015;386(10000):1299-1310.

[2] Wandling MW, An GC. A case report of thoracic compartment syndrome in the setting of penetrating chest trauma and review of the literature. *World J Emerg Surg.* 2010;5:22. doi: 10.1186/1749-7922-5-22.

[3] Lima V, Burt B, Leibovitch I, Prabhakaran V, Goldberg RA, Selva D. Orbital compartment syndrome: The ophthalmic surgical emergency. *Surv Ophthalmol.* 2009;54(4):441-9.

[4] Kirkpatrick AW, Roberts DJ, De Waele J, Jaeschke J, Malbrain ML, De Keulenaer B, et al. Intra-abdominal hypertension and the abdominal compartment syndrome: Updated consensus definitions and clinical practice guidelines from the world society of the abdominal compartment syndrome. *Intensive Care Med.* 2013;39(7):1190-1206.

[5] Rorabeck CH, Clarke KM. The pathophysiology of the anterior tibial compartment syndrome: An experimental investigation. *J Trauma.* 1978;18(5):299-304.

[6] Kirkpatrick AW, Brenneman FD, McLean RF, Rapanos T, Boulanger BR. Is clinical examination an accurate indicator of raised intra-abdominal pressure in critically injured patients? *Can J Surg.* 2000;43(3):207-11.

[7] Sugrue M, Bauman A, Jones F, Bishop G, Flabouris A, Parr M, et al. Clinical examination is an inaccurate predictor of intraabdominal pressure. *World J Surg*. 2002;26(12):1428-31.

[8] Malbrain ML. Different techniques to measure intra-abdominal pressure (IAP): Time for a critical re-appraisal. *Intensive Care Med*. 2004;30(3):357-71.

[9] Malbrain ML, Cheatham ML, Kirkpatrick A, Sugrue M, Parr M, De Waele J, et al. Results from the international conference of experts on intra-abdominal hypertension and abdominal compartment syndrome. I. definitions. *Intensive Care Med.* 2006;32(11):1722-32.

[10] Fusco MA, Martin RS, Chang MC. Estimation of intra-abdominal pressure by bladder pressure measurement: Validity and methodology. *J Trauma*. 2001;50(2):297-302.

[11] Malbrain ML, Chiumello D, Pelosi P, Bihari D, Innes R, Ranieri VM, et al. Incidence and prognosis of intraabdominal hypertension in a mixed population of critically ill patients: A multiple-center epidemiological study. *Crit Care Med*. 2005;33(2):315-22.

[12] Ball CG, Kirkpatrick AW, McBeth P. The secondary abdominal compartment syndrome: Not just another post-traumatic complication. *Can J Surg*. 2008;51(5):399-405.

[13] Carr JA. Abdominal compartment syndrome: A decade of progress. *J Am Coll* Surg. 2013;216(1):135-46.

[14] Barnes GE, Laine GA, Giam PY, Smith EE, Granger HJ. Cardiovascular responses to elevation of intra-abdominal hydrostatic pressure. *Am J Physiol*. 1985;248(2 Pt 2):R208-13.

[15] Harman PK, Kron IL, McLachlan HD, Freedlender AE, Nolan SP. Elevated intra-abdominal pressure and renal function. *Ann Surg*. 1982;196(5):594-97.

[16] Gudmundsson FF, Gislason HG, Myking OL, Viste A, Grong K, Svanes K. Hormonal changes related to reduced renal blood flow and low urine output under prolonged increased intra-abdominal pressure in pigs. *Eur J Surg*. 2002;168(3):178-86.

[17] Vivier E, Metton O, Piriou V, Lhuillier F, Cottet-Emard JM, Branche P, et al. Effects of increased intra-abdominal pressure on central circulation. *Br J Anaesth.* 2006;96(6): 701-7.

[18] Mertens zur Borg IR, Lim A, Verbrugge SJ, IJzermans JN, Klein J. Effect of intraabdominal pressure elevation and positioning on hemodynamic responses during carbon dioxide pneumoperitoneum for laparoscopic donor nephrectomy: A prospective controlled clinical study. *Surg Endosc*. 2004;18(6):919-23.

[19] Mutoh T, Lamm WJ, Embree LJ, Hildebrandt J, Albert RK. Abdominal distension alters regional pleural pressures and chest wall mechanics in pigs in vivo. *J Appl Physiol* (1985). 1991;70(6):2611-18.

[20] Friedlander MH, Simon RJ, Ivatury R, DiRaimo R, Machiedo GW. Effect of hemorrhage on superior mesenteric artery flow during increased intra-abdominal pressures. *J Trauma*. 1998;45(3):433-89.

[21] Mogilner J, Sukhotnik I, Brod V, Hayari L, Coran AG, Shiloni E, et al. Effect of elevated intra-abdominal pressure on portal vein and superior mesenteric artery blood flow in a rat. J Laparoendosc *Adv Surg Tech A*. 2009;19 Suppl 1:S59-62.

[22] Cheatham ML. Abdominal compartment syndrome: Pathophysiology and definitions. *Scand J Trauma Resusc Emerg Med*. 2009;17:10. doi: 10.1186/1757-7241-17-10.

[23] Ngubane T. Mechanical ventilation and the injured brain. *Southern African Journal of Anaesthesia and Analgesia*. 2014;17(1):76-80.

[24] Gokce E, Pinarbasili T, Acu B, Firat MM, Erkorkmaz U. Torcular herophili classification and evaluation of dural venous sinus variations using digital subtraction angiography and magnetic resonance venographies. *Surg Radiol Anat.* 2014;36(6):527-36.

[25] Gooding CA, Stimac GK. Jugular vein obstruction caused by turning of the head. *AJR Am J Roentgenol*. 1984;142(2):403-6.

[26] Holland MC, Mackersie RC, Morabito D, Campbell AR, Kivett VA, Patel R, et al. The development of acute lung injury is associated with worse neurologic outcome in patients with severe traumatic brain injury. *J Trauma*. 2003;55(1):106-11.

[27] Saggi BH, Bloomfield GL, Sugerman HJ, Blocher CR, Hull JP, Marmarou AP, et al. Treatment of intracranial hypertension using nonsurgical abdominal decompression. *J Trauma*. 1999;46(4):646-51.

[28] Citerio G, Vascotto E, Villa F, Celotti S, Pesenti A. Induced abdominal compartment syndrome increases intracranial pressure in neurotrauma patients: A prospective study. *Crit Care Med*. 2001;29(7):1466-71.

[29] Joseph DK, Dutton RP, Aarabi B, Scalea TM. Decompressive laparotomy to treat intractable intracranial hypertension after traumatic brain injury. *J Trauma.* 2004;57(4): 687-93; discussion 693-5.

[30] Schreiber J, Nierhaus A, Vettorazzi E, Braune SA, Frings DP, Vashist Y, et al. Rescue bedside laparotomy in the intensive care unit in patients too unstable for transport to the operating room. *Crit Care*. 2014;18(3):R123. doi: 10.1186/cc13925.

[31] Diaz JJ,Jr, Mejia V, Subhawong AP, Subawong T, Miller RS, O'Neill PJ, et al. Protocol for bedside laparotomy in trauma and emergency general surgery: A low return to the operating room. *Am Surg*. 2005;71(11):986-91.

[32] Feldman Z, Kanter MJ, Robertson CS, Contant CF, Hayes C, Sheinberg MA, et al. Effect of head elevation on intracranial pressure, cerebral perfusion pressure, and cerebral blood flow in head-injured patients. *J Neurosurg*. 1992;76(2):207-11.

[33] Dubose JJ, Scalea TM, Holcomb JB, Shrestha B, Okoye O, Inaba K, et al. Open abdominal management after damage-control laparotomy for trauma: A prospective observational american association for the surgery of trauma multicenter study. *J Trauma Acute Care Surg*. 2013;74(1):113-20; discussion 1120-2.

[34] Brenner M, Bochicchio G, Bochicchio K, Ilahi O, Rodriguez E, Henry S, et al. Long-term impact of damage control laparotomy: A prospective study. *Arch Surg.* 2011;146(4):395-99.

[35] Scalea TM, Bochicchio GV, Habashi N, McCunn M, Shih D, McQuillan K, et al. Increased intra-abdominal, intrathoracic, and intracranial pressure after severe brain injury: Multiple compartment syndrome. *J Trauma*. 2007;62(3):647-56; discussion 656.

[36] Guerci AD, Shi AY, Levin H, Tsitlik J, Weisfeldt ML, Chandra N. Transmission of intrathoracic pressure to the intracranial space during cardiopulmonary resuscitation in dogs. *Circ Res*. 1985;56(1):20-30.

[37] Bloomfield GL, Ridings PC, Blocher CR, Marmarou A, Sugerman HJ. A proposed relationship between increased intra-abdominal, intrathoracic, and intracranial pressure. *Crit Care Med*. 1997;25(3):496-503.

In: Encyclopedia of Surgery (22 Volume Set)
Editors: Andreas Lehrer and Kristin Mueller
ISBN: 978-1-53618-329-0
© 2020 Nova Science Publishers, Inc.

Chapter 229

DECOMPRESSIVE CRANIECTOMY IN ISCHEMIC STROKE

Matthew Jaffa*, DO, Carolyn A. Cronin, MD, PhD and Barney J. Stern, MD
Department of Neurology, University of Maryland School of Medicine, Baltimore, MD, US

ABSTRACT

Few stroke syndromes have as high a risk of mortality or severe disability as does the "malignant" middle cerebral artery infarction seen in the setting of large artery occlusions. Malignant stroke syndromes are relatively rare; however, when present they are associated with a close to 80% mortality rate. The management of these patients is controversial and presents a major challenge for the neurologists, neurosurgeons, and neurointensivists caring for them. Many studies have assessed the benefits and risks of decompressive craniotomy versus optimal medical management, with the goal of improving not only survival but also survival with good functional outcomes. The conclusions of these studies remain mixed, and practice patterns vary widely. We review the landmark trials of decompressive surgery in ischemic stroke as well as the pooled analyses and those addressing quality of life to improve our understanding of this complicated syndrome in which the optimal management strategy may vary depending on a patient's values and preferences.

Keywords: malignant stroke, decompressive craniotomy, large artery occlusion, quality of life, functional outcomes

INTRODUCTION

Stroke is defined as the sudden onset of neurologic disability caused by neuronal death due to blockage or severely reduced blood flow or hemorrhage within the brain parenchyma.

* Corresponding Author's Email: matthewjaffa@umm.edu.

Currently, stroke is the world's second leading cause of mortality and third for disability [1]. In the United States, stroke is now the fifth leading cause of death, is one of the top causes of long-term disability, and costs the nation nearly 33 billion dollars annually [1]. Larger territories of parenchymal damage typically equate to higher levels of morbidity and mortality. In this chapter we discuss the definition of malignant cerebral infarction and the role of decompressive craniectomy in the treatment of stroke and prevention of both morbidity and mortality.

In the United States, more than 80% of strokes are ischemic. Ischemic infarctions result from three main mechanisms: thrombosis, embolism, and cerebral hypoperfusion. Thrombosis typically is the result of disease of the arterial wall such as atherosclerotic plaque, whereas embolism is the result of vessel occlusion by blood clot or other material dislodged from a more proximal site such as a larger diameter vessel or a chamber of the heart. Thrombosis and embolism may lead to occlusion of vessels anywhere from the more proximal internal carotid artery (ICA) to the most distal branches of the intracerebral vasculature. Branches of the middle cerebral artery (MCA) are denoted with a number for each more distal branching point from M1 to M4. Each succession of branching vessels leads ultimately to an individual area of brain tissue perfused by the most distal vessels. Therefore, the more proximal a site of blockage is, the greater the amount of the parenchyma at risk for infarction. Systemic hypotension can lead to a more global process of damage with the greatest source of ischemic damage being in the areas of distal vessel overlap known as the "watershed zones" or "border zones" between the anterior cerebral artery (ACA), MCA, and posterior cerebral artery (PCA).

While a strategically placed stroke in the cerebral hemispheres or brainstem may lead to profound neurologic disability including loss of language abilities, alteration in personality, visual loss, and hemiplegia, few infarctions are associated with as high a likelihood of mortality or severe morbidity as are large artery occlusions that result in an infarction involving a large volume of brain. The "malignant" MCA syndrome is one of these infarctions, and typically is the result of occlusion of the distal ICA or proximal MCA [2]. Hacke introduced the term "malignant MCA syndrome" in 1996. It describes the small subset of stroke victims with severe hemiparesis and sensory loss, horizontal gaze deviation, and global aphasia (when the dominant hemisphere is involved) that progress to deterioration of their mental and respiratory status within the first 24 to 48 hours of symptom onset [2-5]. Death from cerebral edema and herniation leading to compression of the brainstem commonly occurs in the first 2 to 5 days following infarction [2, 3]. The malignant MCA syndrome is associated with a greater than 80% mortality [2, 6]. Fortunately, these infarctions are relatively rare, encountered in only about 10% of all patients with ischemic strokes [4]. Each year approximately 70,000 patients are at risk for the malignant MCA syndrome in the United States alone.

Predicting which patients will develop such severe stroke syndromes and their impending rates of death and disability is a source of great interest. Higher National Institutes of Health Stroke Scale (NIHSS) scores have a high sensitivity (96%) but a low specificity (72%) for those patients with scores greater than 19 in the prediction of the development of malignant stroke syndromes, while identification on magnetic resonance angiography of an internal carotid artery "T-lesion" has a lower sensitivity of 64% but greater specificity of 85%, making neither a perfect predictor [7]. Imaging findings have been found to have the strongest predictive value. Early work by von Kummer et al. showed that early computed

tomography (CT) hypodensity representing greater than 50% of the MCA territory within 5 hours of stroke onset was predictive of fatal outcomes in 85% of cases [8]. Later magnetic resonance imaging studies showed a 100% sensitivity and 94% specificity for predicting malignant MCA syndrome in patients with a diffusion-weighted imaging lesion greater than 145 mL up to 14 hours after symptom onset [3, 9]. Thomalla et al. demonstrated that more rapid completion of magnetic resonance imaging within 6 hours could be predictive of malignant MCA syndrome with changes in apparent diffusion coefficient volume greater than 82 mL [3, 7].

ACUTE MANAGEMENT OF ISCHEMIC STROKE

Time is of the essence in the acute management of ischemic infarction. Longer duration of ischemia leads to increasing neuronal death and likelihood of permanent damage. Treatment with intravenous tissue plasminogen activator (IV tPA) within 3 hours from the time of symptom onset has been shown to reduce morbidity at 3 months compared to placebo in the National Institute of Neurological Disorders and Stroke (NINDS) trial and then later with an extension of the time frame to 4.5 hours in the European Cooperative Acute Stroke Study 3 (ECASS III) [10, 11]. Data consistently demonstrate that for every 15-minute shortening in time to treatment there is a mortality and morbidity benefit [12]. The time standard of care for reperfusion treatment has been expanding since the positive results of trials for endovascular therapy were published beginning with the Multicenter Randomized Clinical Trial of Endovascular Treatment for Acute Ischemic Stroke in the Netherlands (MR CLEAN) [13] in January 2015. With the completion of additional trials, namely, Endovascular Treatment for Small Core and Anterior Circulation Proximal Occlusion with Emphasis on Minimizing CT to Recanalization Times (ESCAPE) [14], Extending the Time for Thrombolysis in Emergency Neurological Deficits - Intra-Arterial (EXTEND-IA) [15], Solitaire with the Intention for Thrombectomy as Primary Endovascular Treatment (SWIFT-PRIME) [16], and Randomized Trial of Revascularization with Solitaire FR Device versus Best Medical Therapy in the Treatment of Acute Stroke Due to Anterior Circulation Large Vessel Occlusion Presenting within Eight Hours of Symptom Onset (REVASCAT) [17], the American Heart Association/American Stroke Association (AHA/ASA) updated its acute stroke management guidelines to include use of endovascular therapy with stent retrievers for large artery occlusions (i.e., ICA and M1) for patients up to 6 hours from their last known normal time [18].

Ultimately, the goal of these interventions is recanalization of the occluded vessel to restore blood flow to distal ischemic tissue. Rha and Savers' meta-analysis of 53 studies examining recanalization reported that recanalization was achieved 24.1% of the time spontaneously, 46.2% with IV tPA, and 83.6% with mechanical thrombectomy [19]. Recanalization is determined by several factors, the most important of which are length and location of the thrombus. In MCA thrombosis there is a high likelihood of recanalization following IV tPA for clots less than 5 mm in length as compared to a less than 1% chance for clots longer than 8 mm [20]. Recanalization of the ICA has the lowest success rate at 49% across all methodologies, with IV thrombolysis yielding the lowest rate of 13% [19]. Even with the success of early recanalization, studies have shown that the final infarct volume, not

recanalization, is what drives outcomes [21, 22]. Thus, mitigation of the morbidity and mortality associated with these infarctions depends not only on recanalization success but also on the subsequent management of patients at high risk for malignant cerebral infarctions.

STUDIES OF DECOMPRESSIVE CRANIECTOMY

After the emergent management and stabilization of acute stroke patients, including patients treated with IV tPA or endovascular recanalization, the patient is typically observed in a critical care or stroke unit. Patients thought to be at risk for development of the malignant MCA syndrome are usually observed in a critical care unit.

The studies discussed here were all designed to answer the question of the role of decompressive craniectomy in the treatment of malignant cerebral edema following ischemic infarction. Trials looked at the outcomes of mortality as well as modified Rankin Scale (mRS) scores [23] to quantify long-term disability, as described in Table 1. On this non-linear scale, 0 indicates no symptoms while 6 indicates death. The differences between scores of 3 and 4 are related to the ability to ambulate and attend to one's bodily needs without assistance. These scores, which were found to have a significant relationship with discharge to institutional care in the large Nationwide Inpatient Sample data pool, are an active area of debate and discussion about how to judge the impact of the intervention [24, 25]. All trials were stopped early because of poor/slow enrollment and the desire to pool data for meta-analyses. These three trials form the basis of all the meta-analyses that will be reviewed later.

Table 1. Modified Rankin Scale scoring description

Modified Rankin Scale (MRS)
0 No symptoms
1 No significant disability, despite symptoms; able to perform all usual duties and activities
2 Slight disability; unable to perform all previous activities but able to look after own affairs without assistance
3 Moderate disability; requires some help, but able to walk without assistance
4 Moderately severe disability; unable to walk without assistance and unable to attend to own bodily needs without assistance
5 Severe disability; bedridden, incontinent, and requires constant nursing care and attention
6 Death

DECIMAL [26]

The decompressive craniectomy in malignant MCA infarction (DECIMAL) trial was completed at 13 stroke centers in France from December 2001 through November 2005. The trial enrolled patients between the ages of 18 and 55 within 24 hours of an acute ischemic stroke that met criteria suggestive of the patient's being at high risk for a malignant MCA

syndrome. Patients were enrolled if they had an NIHSS score of greater than 16, CT of the head with hypodensity in more than 50% of the MCA territory, and a DWI stroke volume of greater than 145 mL. Thirty-eight patients were enrolled and randomized to receive either decompressive craniectomy within 6 hours of randomization or 30 hours following symptom onset versus maximal medical therapy which included preventing hyperthermia or hyperglycemia, maintaining the head of the bed to an elevation greater than 30°, intravenous hydration, and the use of intravenous mannitol in patients with rapidly progressing symptoms due to edema.

The results of this first study demonstrated a life-saving effect with respect to craniectomy. Those in the surgical arm had an almost 53% absolute reduction in death. Follow-up for patients was reported at 6 months and 1 year after enrollment. At both time points, a greater proportion of patients had a mRS of less than or equal to 3 in the surgical treatment group than the medical group. At 6 months the difference was 25% versus 5.6%, and at 1 year those percentages increased to 50% and 22.2% for surgical and medical therapy, respectively, as depicted in Figure 1; the P values for these data points were not statistically significant. When using mRS of less than or equal to 4 as the outcome measure, the difference at 1 year increased to 75% in the surgical arm versus 22.2% for the medical arm (P = 0.0029).

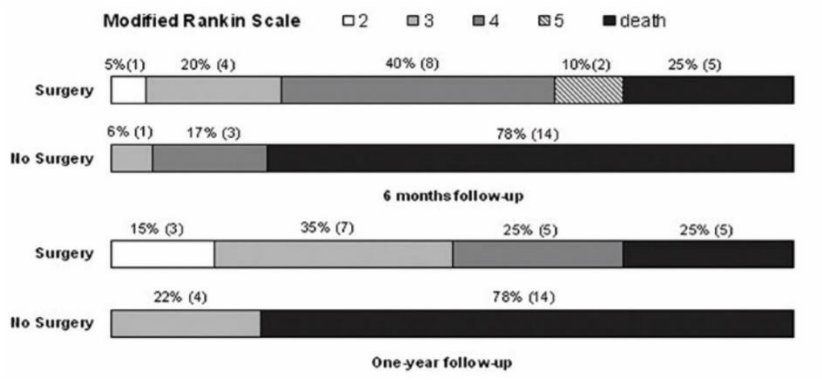

Figure 1. DECIMAL trial patient outcomes (Reprinted from Stroke, 38(9), Vahedi et al. Sequential-design, multicenter, randomized, controlled trial of early decompressive craniectomy in malignant middle cerebral artery infarction (DECIMAL Trial), Pg 2511, 2007, with permission from Elsevier).

The DECIMAL trial brought to light the idea that while survival was significantly improved by surgical intervention, the two treatment arms had no statistically significant difference in survivors with good outcomes (mRS less than or equal to 3). However, because the trial was stopped early, it likely did not have power to show a statistically significant difference.

DESTINY [27]

This trial of decompressive surgery for the treatment of malignant infarction in the MCA territory enrolled 32 patients across six study sites in Germany from February 2004 through October 2005. Inclusion criteria for this study included subjects aged 18–60 years, NIHSS score >18 in patients with non-dominant hemisphere infarcts and >20 when in the dominant

hemisphere, and CT imaging findings demonstrating infarction of greater than two thirds of the MCA territory including part of the basal ganglia. Patients were randomized either to conservative therapy, which allowed for the use of osmotic therapy for any signs of increasing edema, intubation and hyperventilation, sedation, ICP monitoring, and maintenance of normothermia and euglycemia, or to surgical decompression within 36 hours of symptom onset.

Randomization groups were fairly evenly matched, though it was noted that because of more patients with dominant hemisphere strokes in the control group, the NIHSS score was modestly higher at time of entry to the study in this group. Patients were predominantly screened and treated at one center. End points for the study included the 30-day survival reported as 88% in the surgical arm versus 47% in the conservatively managed group. The trial was designed to evaluate not only the mortality associated with malignant infarctions but also the functional outcomes at 6 months and 1 year, as represented in Figure 2. Again, the study results were dichotomized at a mRS score of less than or equal to 3, with 47% of patients achieving this in the surgical group and only 27% in those conservatively managed. These results again trended positive but were not statistically significant, whereas when the good outcomes score is expanded to mRS less than or equal to 4 there is a significant improvement based on surgical intervention.

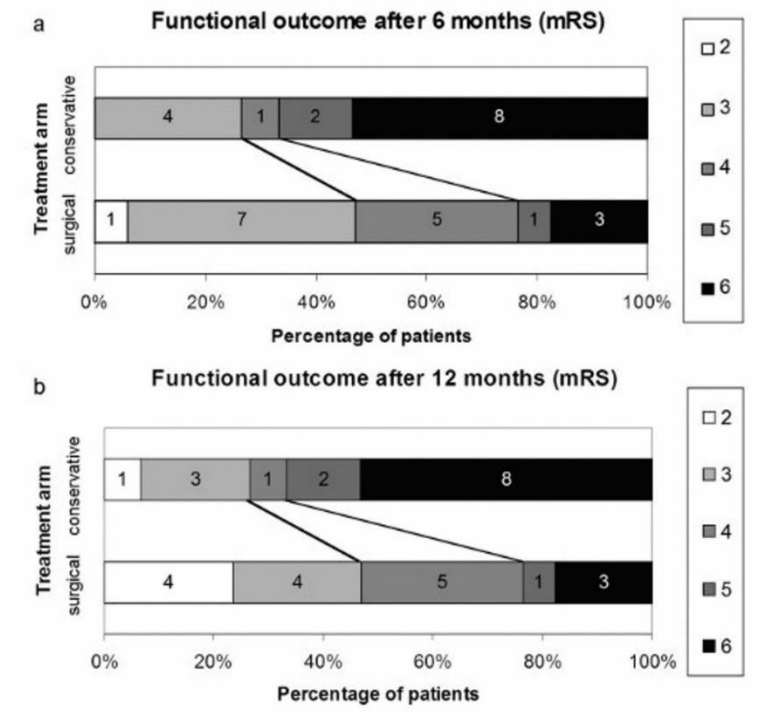

Figure 2. DESTINY trial patient outcomes (Reprinted from Stroke, 38(9), Juttler et al. Decompressive Surgery for the Treatment of Malignant Infarction of the Middle Cerebral Artery (DESTINY): a randomized, controlled trial, Pg 2523, 2007, with permission from Elsevier).

HAMLET [24, 28]

The Hemicraniectomy After MCA infarction with Life threatening Edema Trial (HAMLET) was completed at six centers in the Netherlands from November 2002 through October of 2007 and enrolled 64 patients. Patients aged 18 to 60 years were randomized to surgical decompression or medical therapy within 96 hours of symptom onset. The inclusion time of up to 96 hours from symptom onset was a major difference between HAMLET and the other trials (24 hours for DECIMAL and 36 hours for DESTINY). Inclusion criteria included a NIHSS score of >16 in right hemispheric stroke patients and >21 for left hemispheric stroke patients as well as hypodensity covering at least two thirds of the MCA territory on CT imaging.

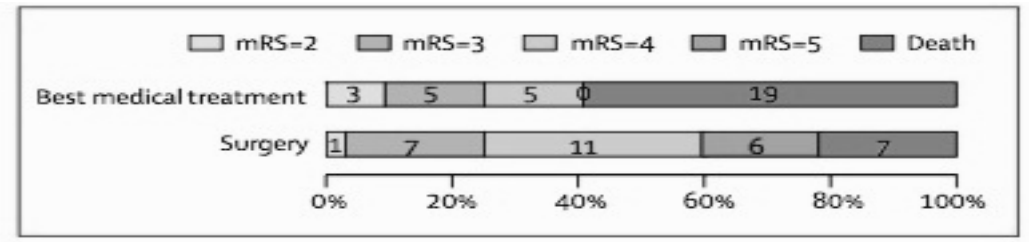

Figure 3. HAMLET trial patient outcomes (1 year) (Reprinted from The Lancet, 8(4), Hofmeijer et al. Surgical decompression for space-occupying cerebral infarction (the Hemicraniectomy After Middle Cerebral Artery infarction with Life-threatening Edema Trial [HAMLET]): a multicentre, open, randomised trial, Pg 329, 2009, with permission from Elsevier).

In this study, the only endpoint that was shown to have a significant reduction with hemicraniectomy was the likelihood of death, with an absolute risk reduction of 38%. The primary outcome of mRS dichotomized between 0–3 and 4–6 at 1 year had an absolute risk reduction (ARR) of 0%, though when extended to 0–4 versus 5–6 there was a trend toward benefit with surgical decompression and an ARR of 19%, as depicted in Figure 3.

Meta-Analyses

DECIMAL and DESTINY were halted prematurely in 2006 to combine the data for a meta-analysis. Each of the three trials had a similar protocol and outcome parameters allowing for relative ease of pooling patient data. Given the differences in eligibility criteria between studies, subjects were only included in the combined analysis with ages between 18 and 60, an NIHSS score >15, and a CT scan demonstrating infarction of at least 50% of the MCA territory or DWI infarct volume >145 mL. From these three studies, 93 patients were included who had been randomized within 45 hours of symptom onset [29]. In this data set, a primary outcome of mRS 0–4 was chosen to define favorable outcome, with secondary analyses using mortality at 1 year and favorable outcome of mRS 0–3.

The pooled analysis demonstrated the positive effects of decompressive craniectomy with an ARR of 51.2% when comparing patients with mRS 0–4 versus 5–6 at 12 months [29]. Craniectomy reduced rates of death from 71% to 21.5%, as seen in Figure 4, essentially inverting the historical mortality rate for malignant MCA infarctions. In addition, when

dichotomized for mRS 0–3 versus 4–6 there was still a significant ARR of 22.7% (P = 0.014). These data suggested that the previous concern that decompressive craniectomy improves survival while leaving the majority of patients in a severely debilitated state (i.e., mRS = 5) was false and that, in fact, the likelihood of this was nearly unchanged.

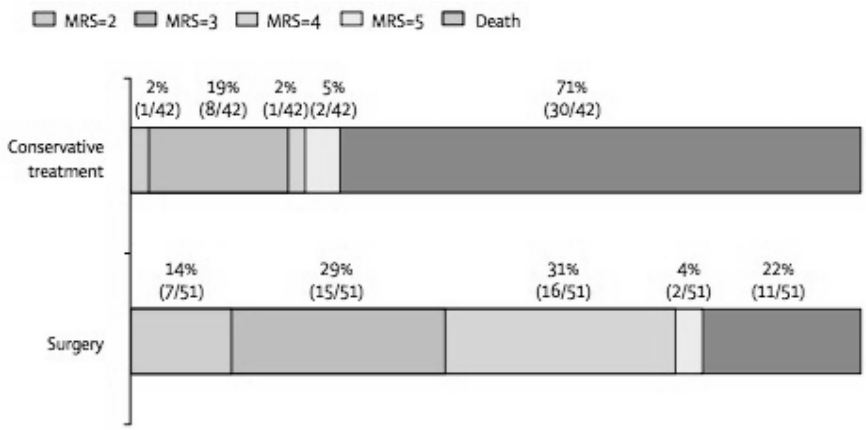

Figure 4. Pooled Analysis of DECIMAL, DESTINY, and HAMLET (1 year patient outcomes) (Reprinted from The Lancet, 6(3), Vahedi et al. Early decompressive surgery in malignant infarction of the middle cerebral artery: a pooled analysis of three randomised controlled trials, Pg 218, 2007, with permission from Elsevier).

In the years since this first meta-analysis and the results of the individual trials were published (2007–2009), several additional groups have looked at the data for hemicraniectomy in malignant cerebral edema related to MCA infarction. These studies again highlight the long debated question of the utility of surgical treatment in malignant stroke when the risk of severe disability is weighed against death and how severe disability should be defined.

Back et al. reviewed six studies in 2015 that included the three previously described studies as well as three more recently completed studies [30]. DESTINY2 [31], the follow-up to DESTINY, examined the effect of surgical decompression in patients older than 61 years. The Hemicraniectomy and Durotomy Upon Deterioration From Infarction-Related Swelling Trial (HeADDFIRST) [32] standardized the medical therapy provided to patients in neurologic intensive care units, including waiting until clinical deterioration before proceeding to decompression. Zhao et al. studied patients randomized up to the age of 80 in China [33]. To compare the 317 patients from these six studies, the researchers utilized odds ratios (OR) to assess the likelihood of each individual mRS outcome with respect to medical management versus surgery. They found that, as in each individual study, an mRS of 6 (death) was significantly reduced with surgical decompression with an OR = 0.19 and 0.17 at 6 and 12 months, respectively [30]. While the number of patients with mRS scores of 3 and 5 were increased at 6 and 12 months in the patients randomized to surgery, these did not reach statistical significance. The authors did find a significant increase in patients with mRS of 2 at 12 months (OR = 4.51). However, at both follow-up time points, surgical patients also had a statistically significantly higher likelihood of having an mRS of 4 with OR = 3.29 and 4.43 for 6 and 12 months, respectively [30].

Table 2. Likelihood of different outcomes based on meta-analysis of 6 trials [35]

	All patients		Patients >60 years	
	ARI	NNT	ARI	NNT
Excellent Functional Outcome (mRS 0-2)	6.6%	15.2	*	n/a
Favorable Outcome (mRS 0-3)	15.0%	6.7	4.0%	25.0
Unfavorable Functional Outcome (mRS 4-5)	29.5%	3.4	32.5%	3.1
*No patients > 60 with mRS 0-2				

ARI = Absolute Risk Increase; NNT = Number Needed to Treat.

Two additional meta-analyses have been performed by Yang et al. and Streib et al. utilizing five of the same six studies, but replacing the HeADDFIRST data with that from the preliminary results of a Croatian study by Slezins et al. [34, 35]. In the review by Yang et al. mortality was significantly decreased in the setting of early craniectomy (OR = 0.19, 95% confidence interval [CI]: 0.12–0.30; P < 0.00001), though the number of patients surviving with an mRS outcome of 4–5 was not statistically different for craniectomy or best medical therapy (pooled OR = 1.71, 95% CI: 0.78–3.74; P = 0.18) [34]. Both demonstrated that regardless of age the results were consistent, although in patients older than age 60 the likelihood of achieving survival with an mRS of less than 3 was zero regardless of treatment arm, and only 7% had a score of 3 after surgery compared to 3% in the medical arm [35]. In their primary analysis, Streib et al.'s meta-analysis evaluated the absolute risk increase for undergoing early craniectomy and therefore number needed to treat to meet defined functional outcome categories. Table 2 shows likely outcomes based on data from Streib et al. [35].

More recently, Dasenbrock et al. analyzed data from the National Inpatient Sample database to assess the predictors and association of time to decompressive craniectomy with outcomes. The review of approximately 1300 inpatient admissions evaluated the outcomes of discharge to institutional care (i.e., nursing facility, extended care facility, or hospice, but excluding rehabilitation or other acute care facility) and poor outcome (defined by death, tracheostomy and gastrostomy, or discharge to institutional care) based on time to surgery both on a continuous scale as well as dichotomously. Greater delay in surgery was associated with greater likelihood of discharge to institutional care with an OR = 1.17 (95% CI: 1.05–1.31; P = 0.005) and poor outcome with an OR = 1.12 (95% CI: 1.02–1.23; P = 0.02) (25). In the dichotomous analysis there was no difference in outcomes within 24 or 48 hours but increased odds of poor outcome after 72 hours (OR = 1.52, 95% CI: 1.07–2.16; P = 0.02). Discussion of the predictors for surgery concluded that craniectomy before herniation might be a more important factor, especially in patients who do not have significant decompensation prior to 48 hours from stroke onset [25]. Of course, this study also must be looked at with a cautious eye as the data collected were based on diagnostic coding as opposed to the more traditionally utilized data including NIHSS score, premorbid mRS, and distribution or size of infarct area. Still, the most interesting finding was that practices for timing of craniectomy did not seem to have any relationship to the year of operation as one might predict if the previously discussed clinical trial data were being utilized as recommendations for changing clinical practice [25].

POSTERIOR CIRCULATION INFARCTIONS AND DECOMPRESSION

While a great deal of research has been directed toward determining the benefits of decompressive surgery in malignant MCA infarctions, there are limited data regarding aggressive treatment of patients with edema from cerebellar infarctions. Possibly more menacing than even large hemispheric strokes, those in the posterior circulation and affecting the cerebellum can lead to life-threatening upward herniation with only small increases in swelling due to the limited space in the posterior fossa. Suboccipital decompression (SDC) has been performed in the setting of brainstem compression and obstructive hydrocephalus as a life-saving therapy. Unfortunately, there have been no randomized controlled studies to suggest the actual benefit of this procedure nor research into which patients would likely benefit the most.

From March of 2007 until September of 2015, records of 1162 patients admitted to one of five hospitals in Korea for cerebellar infarction were reviewed and selected for a case-control study of SDC versus medical management. Twenty-eight patients who had undergone SDC and 56 who had not were reviewed and assessed using multiple logistic regression propensity score matching based on having had a cerebellar infarction volume ratio between 25% and 33% with a Glasgow Coma Scale score greater than or equal to 9 and no clinical deterioration prior to 72 hours from symptom onset. Insertion of an external ventricular device for cerebrospinal fluid drainage as treatment for hydrocephalus was performed in patients with findings of significant hydrocephalus, including 50% of those patients who underwent preventive SDC and 90.6% of those requiring emergent intervention [36]. At follow-up 1 year after the infarction, 66.7% of those receiving SDC had a favorable outcome ($P = 0.030$), defined as mRS of 0–2, versus 51% of those who had not undergone SDC ($P = 0.030$) [36]. The results from this case-control series indicate that *preventive* SDC prior to signs of brainstem compression or obstructive hydrocephalus in patients with an infarct volume ratio of 0.25–0.33 may be beneficial.

Even with the results of this study, there is still a great need for further research into the characteristics of those patients who have suffered a cerebellar infarction and will have overwhelming cerebellar edema leading to increased morbidity and mortality associated with brainstem compression or infarction. While not the main focus of this chapter, it certainly is an important area for future research.

QUALITY OF LIFE

Ultimately, each of these individual studies and meta-analyses demonstrates that while neurosurgical intervention has a clear survival benefit in nearly all patients with malignant MCA syndrome, the evidence of a beneficial difference in morbidity depends on the authors' definition of "good" outcome. Similar to the opinions espoused in the discussions of the more recent meta-analyses, we feel very strongly that a patient's individual beliefs and goals of care need to be weighed when deciding to move forward with surgical decompression in the setting of malignant edema. The data suggest a trend toward an increased representation of patients with outcomes that would allow for a life at home, albeit many will require significant help from family members. Review of those same studies shows a statistically

significant increase in the number of patients who survive with an mRS of 4 that would almost certainly mean a life relegated to living with dependence on others for all of their needs.

Quality of life (QoL) data were collected in most of these trials either prospectively or retrospectively and reveal that relatively few patients or family members regret the decision to undergo surgery despite the ultimate level of dependency [26, 37]. A review of seventeen studies of craniectomy in malignant edema reported outcomes for QoL with data available for six of those trials that looked at scores of overall QoL. Patient QoL measures were in a range of 60% to 67% (an outlier in the DESTINY study of 46% was noted) as compared to best possible QoL [38]. Depression among patients has been reported as mild to moderate in almost 50% of survivors and severe in 15% [38]. While these values may appear to be relatively high, in view of the fact that patients with more severe disability were also included in these analyses, it suggests that patient perception of disability may change or be different at baseline than previously believed [39]. This divide in the acceptability of outcome can be demonstrated when neurologists, neurointensivists, and neurosurgeons were polled: only 38% believed an mRS of 4 to be a favorable outcome [40]. Do patients simply adapt to a disability and life they never before would have accepted?

The answer to that question is exceedingly complex and requires an intimate knowledge of the patient's previous insights and life goals. As would seem obvious, most of the patients who present with a massive ischemic infarct were not expecting or planning for this abrupt change in their lives. Further complicating the situation is that many individuals have neither had a conversation with their legally authorized representatives nor documented their wishes in an advance directive. Even if a person had indicated their general wishes, the circumstances surrounding malignant brain infarction are unique enough that patients and family will need to extrapolate from their prior constructs to the specifics of their current medical condition. Moreover, the physicians caring for them did not have a prior relationship with the patient or their loved ones, though their primary care providers might be able to provide insight into the patient's wishes. It is our practice to look at each individual patient and discuss with the family and patient, if possible, the wide array of outcomes that may occur in the setting of potential malignant brain infarction. This conversation unfortunately relies on a great many unknowns and can be easily directed by the framework in which it is presented.

OPINIONS FROM EXPERIENCE

Reviewing the data from these trials suggests that in patients under age 60 decompressive craniectomy has both mortality and morbidity benefits, though the morbidity must be carefully defined as including the possibility of need for around the clock care. While none of the previously discussed studies analyzed data dichotomized by early versus later surgery, a study from China looked at "ultra-early" surgical decompression in those with an NIHSS score greater than 20 and imaging suggestive of impending herniation syndromes at an inflection point of 6 hours. This study found a statistically significant reduction in mortality in surgically treated patients as well as compromised function as based on Glasgow Coma Outcome scores, with no increase in surgical complications if operated on before or after 6

hours from time of stroke onset [41]. Thus, we believe, pending new research findings, that patients requiring hemicraniectomy should be treated within 48 hours of symptom onset, and not after the patient begins to demonstrate findings of progression from malignant edema. That being said, we appreciate that the glyburide treatment studies published to date, GAMES and GAMES-RP, recommended decompressive craniotomy only after the patient exhibited symptoms and signs of deterioration (defined as Glasgow Coma Scale score ≤8, increase of ≥1 on item 1a of the NIHSS score, new pupillary abnormalities, or less brisk response to pain) to have time to determine the efficacy of medical therapy alone prior to surgery [42, 43].

In our own experience, we find hemicraniectomy to be infrequently advised within an early timeframe in the hope that optimal medical therapy will allow some patients with large MCA territory infarcts to "sneak by" without surgery. Often, surgical options are explored only after it is thought that medical optimization has taken the patient as far as it can and by this point there are signs of impending or active herniation (i.e., decrease in consciousness, pupillary changes, or evidence of vascular compromise of the non-infarcted hemisphere). Does holding off on surgery lead to irreversible damage that ultimately leaves the patient with increased disability and a higher likelihood of being classified as an mRS 4 instead of a 3? Might earlier surgery spare brain tissue at risk for infarction or anatomical distortion as suggested by observations in study patients treated with glyburide for prevention of brain swelling as well as laboratory observations in rats [44-46]?

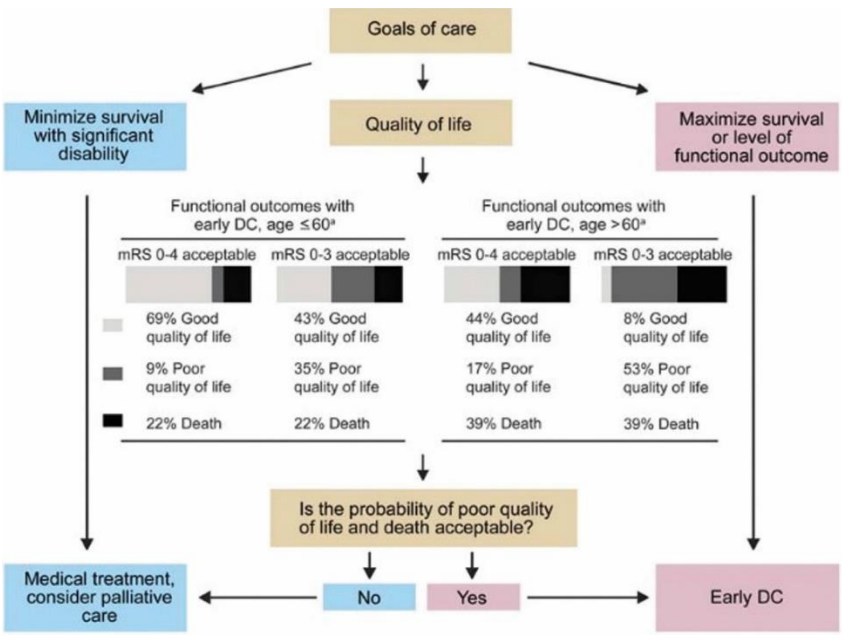

Figure 5: Algorithm for Hemicraniectomy Decision in Malignant Cerebral Infarction as developed by Streib et al. [35] (Reprinted from Neurology Clinical Practice, 6(5), Streib et al, Early decompressive craniectomy for malignant cerebral infarction: Meta-analysis and clinical decision algorithm, Pg 440, 2016, with permission from Elsevier).

There is an important role for early patient and family (or legally authorized representative) discussions to be conducted for patients at high risk for malignant infarction. To determine the most appropriate direction of care, a good understanding is necessary of

what a patient may consider to be a reasonable outcome and in turn the care provider should describe the most objective outcome probabilities based on the data available. Streib et al. created a clinical decision algorithm that dichotomizes decisions based on whether a patient would find a life dependent on others acceptable. In their estimations for patients under the age of 60, when an mRS of 3 is considered acceptable QoL, there is a 35% likelihood of poor QoL with only a 43% likelihood of good QoL, whereas when an mRS of 4 is defined as acceptable, then those likelihoods are 9% and 69%, respectively [35]. For patients older than age 60, the likelihood of good outcomes is more restricted, as represented in Figure 5.

FUTURE DIRECTIONS

The meta-analyses discussed here are not the final statement for the care of patients with malignant MCA infarctions. The protocols demonstrate regional and individual physician treatment preferences, especially for medical management. In fact, there are now American Heart Association/American Stroke Association guidelines for medical management for patients at risk for severe brain swelling following stroke, though many of the interventions have not been critically evaluated [47].

Further research on and discussion of the ethics of decompressive surgery should acknowledge that decisions are often made within the context of time constraints and the stress of critical illness and are deserving of further exploration. The collaboration of stroke neurologists, neurointensivists, neurosurgeons, patients, and their families is paramount to the improvement in outcomes for patients with malignant edema from ischemic infarction. Ideally, an institutional protocol for directing conversation between disciplines should be developed and implemented, thus creating a pathway for this decision making process.

CONCLUSION

Large territory, "malignant," ischemic infarcts are associated with exceedingly high morbidity and mortality. In the past 20 years, multiple studies [24, 26, 27, 29, 32, 33] have been undertaken to establish the benefits of surgical decompressive craniotomy. Results have been mixed demonstrating a paradoxical improvement in mortality and good outcomes, but at the cost of an increase in poor outcomes. Currently, there is no consensus with regard to the timing of surgical intervention and which patients will benefit. Review of the available literature [25, 29, 30, 34, 35, 37] suggests that surgery continues to be an individually applied treatment, though likely with the greatest positive impact on patients under the age of 60 and those who have decompressive surgery within the first 48 hours from symptom onset. Continued collaboration between neurologists, neurosurgeons, neurointensivists, and patients and their families to identify the patients whose clinical presentation and goals of care align with intensive therapy, including early surgery, is vital to providing the best chance for each patient to achieve a desirable outcome. Finally, should new brain anti-swelling drugs become available, the concepts outlined will need to be re-examined within a new management context.

REFERENCES

[1] Mozaffarian D, Benjamin EJ, Go AS, Arnett DK, Blaha MJ, Cushman M, et al. Heart disease and stroke statistics-2016 update: a report from the American Heart Association. *Circulation*. 2016;133(4):e38-360.

[2] Hacke W, Schwab S, Horn M, Spranger M, De Georgia M, von Kummer R. 'Malignant' middle cerebral artery territory infarction: clinical course and prognostic signs. *Arch Neurol*. 1996;53(4):309-15.

[3] Hofmeijer J, Algra A, Kappelle LJ, van der Worp HB. Predictors of life-threatening brain edema in middle cerebral artery infarction. *Cerebrovasc Dis*. 2008;25(1-2):176-84.

[4] Huttner HB, Schwab S. Malignant middle cerebral artery infarction: clinical characteristics, treatment strategies, and future perspectives. *Lancet Neurol*. 2009;8(10):949-58.

[5] Treadwell SD, Thanvi B. Malignant middle cerebral artery (MCA) infarction: pathophysiology, diagnosis and management. *Postgrad Med J*. 2010;86(1014): 235-42.

[6] Berrouschot J, Sterker M, Bettin S, Köster J, Schneider D. Mortality of space-occupying ('malignant') middle cerebral artery infarction under conservative intensive care. *Intensive Care Med.* 1998;24(6):620-3.

[7] Thomalla GJ, Kucinski T, Schoder V, Fiehler J, Knab R, Zeumer H, et al. Prediction of malignant middle cerebral artery infarction by early perfusion- and diffusion-weighted magnetic resonance imaging. *Stroke*. 2003;34(8):1892-900.

[8] von Kummer R, Meyding-Lamade U, Forsting M, Rosin L, Rieke K, Hacke W, et al. Sensitivity and prognostic value of early CT in occlusion of the middle cerebral artery trunk. *AJNR Am J Neuroradiol*. 1994;15(1):9-15.

[9] Oppenheim C, Samson Y, Manai R, Lala T, Vandamme X, Crozier S, et al. Prediction of malignant middle cerebral artery infarction by diffusion-weighted imaging. *Stroke.* 2000;31(9):2175-81.

[10] Disorders TNIoN, Group Sr-PSS. Tissue plasminogen activator for acute ischemic stroke. *N Engl J Med*. 1995;333(24):1581-8.

[11] Hacke W, Kaste M, Bluhmki E, Brozman M, Dávalos A, Guidetti D, et al. Thrombolysis with alteplase 3 to 4.5 hours after acute ischemic stroke. *N Engl J Med*. 2008;359(13):1317-29.

[12] Saver JL, Fonarow GC, Smith EE, Reeves MJ, Grau-Sepulveda MV, Pan W, et al. Time to treatment with intravenous tissue plasminogen activator and outcome from acute ischemic stroke. *JAMA.* 2013;309(23):2480-8.

[13] Berkhemer OA, Fransen PSS, Beumer D, van den Berg LA, Lingsma HF, Yoo AJ, et al. A randomized trial of intraarterial treatment for acute ischemic stroke. *N Engl J Med*. 2015;372(1):11-20.

[14] Goyal M, Demchuk AM, Menon BK, Eesa M, Rempel JL, Thornton J, et al. Randomized assessment of rapid endovascular treatment of ischemic stroke. *N Engl J Med.* 2015;372(11):1019-30.

[15] Campbell BCV, Mitchell PJ, Kleinig TJ, Dewey HM, Churilov L, Yassi N, et al. Endovascular therapy for ischemic stroke with perfusion-imaging selection. *N Engl J Med*. 2015;372(11):1009-18.

[16] Saver JL, Goyal M, Bonafe A, Diener H-C, Levy EI, Pereira VM, et al. Stent-retriever thrombectomy after intravenous t-PA vs. t-PA alone in stroke. *N Engl J Med.* 2015;372(24):2285-95.

[17] Jovin TG, Chamorro A, Cobo E, de Miquel MA, Molina CA, Rovira A, et al. Thrombectomy within 8 hours after symptom onset in ischemic stroke. *N Engl J Med.* 2015;372(24):2296-306.

[18] Powers WJ, Derdeyn CP, Biller J, Coffey CS, Hoh BL, Jauch EC, et al. 2015 AHA/ASA focused update of the 2013 guidelines for the early management of patients with acute ischemic stroke regarding endovascular treatment. *Stroke.* 2015;46(10):3020-35.

[19] Rha J-H, Saver JL. The impact of recanalization on ischemic stroke outcome: a meta analysis. *Stroke.* 2007;38(3):967-73.

[20] Riedel CH, Zimmermann P, Jensen-Kondering U, Stingele R, Deuschl G, Jansen O. The importance of size: successful recanalization by intravenous thrombolysis in acute anterior stroke depends on thrombus length. *Stroke.* 2011;42(6):1775-7.

[21] Zaidi SF, Aghaebrahim A, Urra X, Jumaa MA, Jankowitz B, Hammer M, et al. Final infarct volume is a stronger predictor of outcome than recanalization in patients with proximal middle cerebral artery occlusion treated with endovascular therapy. *Stroke.* 2012;43(12):3238-44.

[22] Flores A, Rubiera M, Ribó M, Pagola J, Rodriguez-Luna D, Muchada M, et al. Poor collateral circulation assessed by multiphase computed tomographic angiography predicts malignant middle cerebral artery evolution after reperfusion therapies. *Stroke.* 2015;46(11):3149-53.

[23] Banks JL, Marotta CA. Outcomes validity and reliability of the modified rankin scale: implications for stroke clinical trials. *Stroke.* 2007;38(3):1091.

[24] Hofmeijer J, Kappelle LJ, Algra A, Amelink GJ, van Gijn J, van der Worp HB. Surgical decompression for space-occupying cerebral infarction (the hemicraniectomy after middle cerebral artery infarction with life-threatening edema trial [HAMLET]): a multicentre, open, randomised trial. *Lancet Neurol*. 2009;8(4):326-33.

[25] Dasenbrock HH, Robertson FC, Vaitkevicius H, Aziz-Sultan MA, Guttieres D, Dunn IF, et al. Timing of decompressive hemicraniectomy for stroke: a nationwide inpatient sample analysis. *Stroke.* 2017;48(3):704-11.

[26] Vahedi K, Vicaut E, Mateo J, Kurtz A, Orabi M, Guichard JP, et al. Sequential-design, multicenter, randomized, controlled trial of early decompressive craniectomy in malignant middle cerebral artery infarction (DECIMAL Trial). *Stroke.* 2007;38(9):2506-17.

[27] Juttler E, Schwab S, Schmiedek P, Unterberg A, Hennerici M, Woitzik J, et al. Decompressive surgery for the treatment of malignant infarction of the middle cerebral artery (DESTINY): a randomized, controlled trial. *Stroke.* 2007;38(9):2518-25.

[28] Hofmeijer J, Amelink GJ, Algra A, van Gijn J, Macleod MR, Kappelle LJ, van der Worp HB. Hemicraniectomy after middle cerebral artery infarction with life-threatening Edema trial (HAMLET). Protocol for a randomised controlled trial of decompressive surgery in space-occupying hemispheric infarction. *Trials.* 2006;7:29.

[29] Vahedi K, Hofmeijer J, Juettler E, Vicaut E, Georde B, Algra A, et al. Early decompressive surgery in malignant infarction of the middle cerebral artery: a pooled analysis of three randomised controlled trials. *Lancet Neurol*. 2007;6(3):215-22.

[30] Back L, Nagaraja V, Kapur A, Eslick GD. Role of decompressive hemicraniectomy in extensive middle cerebral artery strokes: a meta-analysis of randomised trials. *Internal Medicine Journal*. 2015;45(7):711-7.

[31] Juttler E, Bosel J, Amiri H, Schiller P, Limprecht R, Hacke W, et al. DESTINY II: decompressive surgery for the treatment of malignant infarction of the middle cerebral artery II. *Int J Stroke*. 2011;6(1):79-86.

[32] Frank JI, Schumm LP, Wroblewski K, Chyatte D, Rosengart AJ, Kordeck C, et al. Hemicraniectomy and durotomy upon deterioration from infarction-related swelling trial randomized pilot clinical trial. *Stroke.* 2014;45(3):781-94.

[33] Zhao J, Su YY, Zhang Y, Zhang YZ, Zhao R, Wang L, et al. Decompressive hemicraniectomy in malignant middle cerebral artery infarct: a randomized controlled trial enrolling patients up to 80 years old. *Neurocrit Care.* 2012;17(2):161-71.

[34] Yang MH, Lin HY, Fu J, Roodrajeetsing G, Shi SL, Xiao SW. Decompressive hemicraniectomy in patients with malignant middle cerebral artery infarction: A systematic review and meta-analysis. *Surgeon*. 2015;13(4):230-40.

[35] Streib CD, Hartman LM, Molyneaux BJ. Early decompressive craniectomy for malignant cerebral infarction Meta-analysis and clinical decision algorithm. *Neurol Clin Pract.* 2016;6(5):433-43.

[36] Kim MJ, Park SK, Song J, Oh SY, Lim YC, Sim SY, et al. Preventive suboccipital decompressive craniectomy for cerebellar infarction: a retrospective-matched case-control study. *Stroke*. 2016;47(10):2565-73.

[37] Jüttler E, Unterberg A, Woitzik J, Bösel J, Amiri H, Sakowitz OW, et al. Hemicraniectomy in older patients with extensive middle-cerebral-artery stroke. *N Engl J Med*. 2014;370(12):1091-100.

[38] van Middelaar T, Nederkoorn PJ, van der Worp HB, Stam J, Richard E. Quality of life after surgical decompression for space-occupying middle cerebral artery infarction: systematic review. *Int J Stroke*. 2015;10(2):170-6.

[39] Vahedi K, Benoist L, Kurtz A, Mateo J, Blanquet A, Rossignol M, et al. Quality of life after decompressive craniectomy for malignant middle cerebral artery infarction. *J Neurol Neurosurg Psychiatry*. 2005;76(8):1181-2.

[40] Neugebauer H, Creutzfeldt CJ, Hemphill JC, Heuschmann PU, Jüttler E. DESTINY-S: attitudes of physicians toward disability and treatment in malignant MCA infarction. *Neurocrit Care.* 2014;21(2):27-34.

[41] Cho DY, Chen TC, Lee HC. Ultra-early decompressive craniectomy for malignant middle cerebral artery infarction. *Surg Neurol*. 2003;60(3):227-32.

[42] Kimberly WT, Battey TW, Pham L, Wu O, Yoo AJ, Furie KL, et al. Glyburide is associated with attenuated vasogenic edema in stroke patients. *Neurocrit Care.* 2014;20(2):193-201.

[43] Sheth KN, Elm JJ, Beslow LA, Sze GK, Kimberly WT. Glyburide advantage in malignant edema and stroke (GAMES-RP) trial: rationale and design. *Neurocrit Care.* 2016;24(1):132-9.

[44] Engelhorn T, Doerfler A, Kastrup A, Beaulieu C, Alexander de Crespigny, Forsting M, et al. Decompressive craniectomy, reperfusion, or a combination for early treatment of

acute “malignant” cerebral hemispheric stroke in rats? *Potential mechanisms studied by MRI*. 1999;30(7):1456-63.

[45] Simard JM, Chen M, Tarasov KV, Bhatta S, Ivanova S, Melnitchenko L, et al. Newly expressed SUR1-regulated NC(Ca-ATP) channel mediates cerebral edema after ischemic stroke. *Nat Med*. 2006;12(4):433-40.

[46] Simard JM, Geng Z, Silver FL, Sheth KN, Kimberly WT, Stern BJ, et al. Does inhibiting Sur1 complement rt-PA in cerebral ischemia? *Ann NY Acad Sci.* 2012;1268:95-107.

[47] Wijdicks EFM, Sheth KN, Carter BS, Greer DM, Kasner SE, Kimberly WT, et al. Recommendations for the management of cerebral and cerebellar infarction with swelling. *A statement for healthcare professionals from the American Heart Association/American Stroke Association.* 2014;45(4):1222-38.

In: Encyclopedia of Surgery (22 Volume Set)
Editors: Andreas Lehrer and Kristin Mueller
ISBN: 978-1-53618-329-0
© 2020 Nova Science Publishers, Inc.

Chapter 230

DECOMPRESSIVE CRANIECTOMY IN DIFFUSE INJURY: INTERPRETATION AND IMPLICATIONS OF THE INTERNATIONAL DECRA RANDOMIZED TRIAL

D. J. Cooper*, A. Udy, A. Nichol, J. V. Rosenfeld and M. Hunn
Monash University Australia, Australia

ABSTRACT

The Decompressive Craniectomy in diffuse traumatic brain injury (DECRA) randomized trial unexpectedly found that decompressive craniectomy (DC) surgery effectively controlled ICP but increased the proportion of vegetative survivors, and decreased the proportion of independent functioning survivors. The results led to a reconsideration of the indications for DC surgery after severe TBI, and to an understanding that complications of DC surgery likely outweigh benefits for many diffuse injury patients.

Keywords: DECRA, head injury, outcome, decompressive craniectomy

INTRODUCTION

Intracranial pressure (ICP) monitoring and maintaining control of ICP below agreed limits are fundamental to intensive care therapy for traumatic brain injury (TBI) patients [1]. Increased ICP is associated with worse functional outcomes following TBI, in part because increased ICP is a marker of brain injury severity and in part because increased ICP may further worsen secondary brain injury. Which of these two factors is the most dominant in contributing to worse functional outcomes is unknown. However, although the initiation and

* Corresponding Author's Email: jamie.cooper@monash.edu.

intensity of many therapies depend on it, ICP monitoring and control have not been demonstrated in randomized trials to improve TBI patient outcomes [2].

In patients with refractory intracranial hypertension, decompressive craniectomy was known to control ICP, even though DC surgery did not influence the brain swelling underlying the increased ICP. A randomized trial of DC might therefore test not only the efficacy of DC surgery itself to improve patient outcomes, but might also test the construct that improved ICP control alone should, of itself, decrease the cascade of increased ICP insults, decrease secondary brain injury, and be better for patients' outcomes. In other words, a randomized trial of DC surgery might be one way to objectively test the real benefit of tighter ICP control for reducing secondary brain injuries and improving outcomes.

A small randomized trial in pediatric TBI suggested that DC led to better ICP control and improved outcomes in children [3]. However, larger, randomized trials in adults were required to balance the many potential confounders and establish whether the theoretical benefits of DC for improved long-term functional outcomes were real.

Prior to 2000-2002, when randomized trials of decompressive craniectomy were planned, the use of DC surgery was increasing in both civilian and military TBI patients, and in some settings, even prior to ICP monitoring [4]. Uncontrolled and controlled case-series suggested DC was a highly effective method of ICP control, and better patient outcomes seemed likely. DC surgery was also being increasingly discussed for low and middle-income country applications, where modern intensive care was unavailable but neurosurgery was potentially feasible.

DECOMPRESSIVE CRANIECTOMY (DECRA) TRIAL

The Decompressive Craniectomy in diffuse traumatic brain injury (DECRA) randomized trial [5] enrolled patients with severe TBI when their ICP became refractory to all standard intensive care therapies (sedation, osmotherapy, paralysis, and repeated extraventricular drainage [EVD] of cerebrospinal fluid), but before use of "second tier therapies," i.e., hypothermia and barbiturates. To be designated *refractory*, ICP elevation was sustained longer than 15 minutes in the absence of any patient stimulation. DECRA employed the accepted standard ICP upper limit (>20 mm Hg) to trigger all clinical ICP therapies and also for the trial randomization. DECRA addressed the question which of two alternative "second tier" therapies, DC surgery or optimized medical therapy with barbiturates, would best improve the ICP of patients with severe TBI and their long-term functional neurological outcomes. The ICP randomization trigger of consistently greater than 20 mm Hg was chosen because international guidelines at the time used 20 mm Hg to initiate all therapies for intracranial hypertension, and it seemed likely that requiring longer periods before randomization, by setting a higher ICP threshold to be reached (such as 25 or 30 mm Hg), might increase secondary brain injury during the intervening period, impair outcomes, and decrease the potential to determine a benefit from DC, if one existed. Of note, after the DECRA publication, the fourth edition of the Brain Trauma Foundation Guidelines raised its recommended ICP threshold for usual therapies to 22 mm Hg [1].

The DECRA trial, therefore, assessed a specific surgical procedure (DC) compared to a common medical alternative. It also provided a unique opportunity to learn more about the

fundamental construct underlying many therapies for severe TBI patients, namely, that better ICP control below accepted targets will reduce secondary brain injury and improve outcomes. Nevertheless, this opportunity to learn would require an understanding that all therapies may have undesirable complications, and DC surgery would be no exception.

EXCLUSION OF PATIENTS WITH FOCAL MASS LESIONS

The issues of concern to the DECRA investigators are equally important for all types of patients with severe TBI. However, fundamental differences in the management of patients with diffuse injury versus those with focal mass lesions led the DECRA investigators to exclude mass-lesion patients from this high quality randomized trial. In the presence of mass lesions (hematomas and large contusions), neurosurgical equipoise is less widespread. Surgeons differ on leaving the bone out after an initial mass lesion evacuation and also on indications for a second craniectomy. Furthermore, other recent randomized trials of ICP therapies in TBI patients [6] have suggested that these two distinct patient cohorts (diffuse injury versus mass-lesion) may respond to ICP therapies in opposite directions, and this might confound an ability to detect the real outcome differences. Because of the heterogeneity of the surgical and medical groups, interpreting results would have been difficult if DECRA included both patients with diffuse injury and those with focal mass lesions. Seeking a definitive trial design and clear results that might translate to patient care, DECRA chose to study diffuse injury TBI patients only.

RANDOMIZATION AND TREATMENT OF PATIENTS WITH DIFFUSE INJURY

In DECRA, patients were randomized *after* optimized sedation, positioning, ventilation, osmotherapy, paralysis and intermittent cerebrospinal fluid drainage via an EVD, but *before* the three therapies often described as se*cond tier* – hypothermia, barbiturates, or DC. These were all untested in randomized trials, and so DECRA compared two of them – DC versus optimized medical therapy usually with barbiturates. Induced hypothermia was avoided. Late "rescue" craniectomy after 72 hours was permitted in the control group of medical-therapy patients for ethical reasons.

DECRA did not include hypothermia therapy as a treatment option. During trial design it was considered that all the three second-tier therapies were equally untested, and that hypothermia for early refractory ICP was being examined in a different randomized trial [7]. Including hypothermia as an option in either the control medical therapy or DC study groups may also have confounded detection of real outcome differences between the DC surgery and barbiturate coma. In time, the *Eurotherm* trial was published and suggested that induced hypothermia in a similar setting controlled ICP but was detrimental to patient outcomes; therefore, the decision reached during design of DECRA was found to be advantageous in retrospect.

Although several different technical variations of bilateral DC surgery exist, DECRA pragmatically tested the procedure that was most accepted by neurosurgeons in the

Australia/New Zealand region, and felt to be associated with the lowest rate of surgical complications. Bilateral craniectomy was chosen because trial patients had bilateral diffuse injury, and the surgical technique was based on the only published series to have reported improved patient outcomes compared to a (retrospective) control group [8]. The DECRA surgery included wide bi-fronto-temporo-parietal craniectomy to minimize injury to the brain on the edge of the craniectomy during swelling beyond the skull margins, avoidance of damage to the sagittal sinus by not dividing the falx cerebri, and bilateral dural openings to maximize pressure reduction. Cranioplasty was conducted months later, in a second surgery procedure.

The DECRA trial randomized 155 adults over 7 years starting in 2002. Eligible patients were younger than 60 years old with diffuse severe TBI, and had intracranial hypertension refractory to first tier therapies. Patients were recruited in Australia, New Zealand, and Saudi Arabia. Patients with bilateral unreactive pupils were excluded, owing to their poor prognosis. To maximize potential benefits and to avoid secondary brain injury from persistent intracranial hypertension, patients were enrolled after all first tier therapies including EVD drainage had been optimized, and for whom, in the absence of patient stimulation, ICP remained above 20 mm Hg for more than 15 minutes. An automated system was used to conceal allocation to treatment group, and patients were balanced between sites and for use of EVD drainage. Physicians and nurses in hospitals were not blinded, but the primary outcome assessors were centralized and blind to treatment allocation. Patients in both groups were well balanced with respect to age, motor score, injury severity score, secondary insults, and computed tomography grading of injury severity. By design, no patient had dilated pupils, but by chance there were more patients with unreactive small pupils in the craniectomy group.

RESULTS

In this trial, DC surgery was clearly more effective to control intracranial hypertension than optimized medical therapy. DC surgery also decreased time on the ventilator and time in the Intensive Care Unit. However, neurological outcomes at 6 months did not favor DC surgery. Compared to optimized medical therapy, DC did not change mortality (18% vs. 19%). DC surgery was associated with an increased proportion of vegetative survivors (12% vs. 2%) and of all non-independent survivors (51% vs. 33%). The proportion of good outcome survivors was halved (4% vs. 9%). The unadjusted overall measure of neurological function used in the trial was significantly worse after DC, as was the same measure after the preplanned adjustment for key variables. After post-hoc adjustment for the only unbalanced baseline measure (pupils), the trend to worse long-term outcomes remained clear, but no longer significant. At the same time, DC surgery had a higher complication rate than medical therapy. Specifically, there was a 10% rate of hydrocephalus requiring a shunt compared to just 1% in medical patients.

The DECRA trial informed clinicians that in patients with severe diffuse TBI, DC surgery after carefully optimized first-tier therapies more effectively controls ICP but does not improve patient outcomes. Further, DC surgery increased the proportion of vegetative and severely disabled survivors, and did not increase the rate of good outcome among survivors.

The DECRA trial results were unexpected, concerning, and controversial. Given the intense focus of clinicians worldwide on meticulous ICP control in severe TBI patients to minimize secondary brain injury, the finding that using surgery to achieve better ICP control not only failed to improve patient outcomes, but led instead to worse outcomes overall and to more severely disabled survivors, was disturbing.

LESSONS FOR CLINICIANS

We believe that the primary lesson from DECRA for clinicians is that before considering DC surgery in diffuse TBI patients with ICP consistently above 20 mm Hg, first tier therapies including EVD drainage and paralysis and then medical therapy including barbiturates should be optimized. It is unknown whether DC surgery would be effective to improve patient outcomes when restricted to use after barbiturates have failed in the ICP therapy cascade. However, no signals from DECRA support this suggestion. DECRA did not address the question of DC surgery after higher ICP thresholds (25 or 30 mm Hg) are exceeded.

The DECRA findings were likely correct because the trial design was rigorous and the patient groups were well matched for all variables other than small pupil reactivity. The chance difference in pupil reactivity has been much discussed, but in the context of excellent baseline matching for age, Glasgow Coma Scale motor score, and computed tomography score, and given that small pupils may be unreactive early in TBI due to drugs and/or external trauma, it seems highly unlikely that this single difference in one baseline characteristic could account for the overall DECRA trial conclusions.

INTERPRETATION AND IMPLICATIONS OF UNEXPECTED FINDINGS

Why then would a randomized trial deliver findings so different from those expected? The most likely explanation is that early after severe TBI, the negative impact of DC surgery and its complications outweighed potential benefits, and exceeded those of barbiturate coma therapy when supported by modern intensive care. Although the surgical complication rate in DECRA was less than previously reported for DC surgery, hydrocephalus requiring a shunt occurred ten times more frequently in the DC treatment patient group. Post-operative hydrocephalus may impair long-term neurological function. DC surgery also brought with it a need for transport to the operating room at a time when patients were maximally unstable after TBI. It also required a second surgery – the delayed cranioplasty, which may have its own complications including infection. The two surgical procedures and the surgical complications were all avoided in the medical therapy control patients.

Another possible explanation of the unexpected findings is that the negative impact of DC surgery is in part related to brain shift and herniation leading to direct injury or ischemia at the edges of the craniectomy due to cortex herniation through the surgical site, or to stretching or shearing of deep white matter axons during herniation. High-resolution multi-modal magnetic resonance imaging in survivors may provide future insights into these possibilities. Disturbances of autoregulation and of cerebral blood flow are also likely after craniectomy and may have contributed. Finally, the unusual but debilitating “syndrome of the

trephined" [9] after craniectomy, and prior to cranioplasty, likely contributed to negative outcomes in some DC surgery patients.

Another important consideration is that in the context of modern intensive care as practiced in the three countries participating in DECRA, optimized medical treatment including barbiturate coma therapy has become a relatively safe treatment option for intracranial hypertension. Barbiturate therapy has been associated with immune suppression, infectious complications, and cardiac depression [10], but these complications were infrequent in DECRA and likely easily managed without adverse effects on patient outcomes. Further, the significantly longer period of intensive care support, which was mandated by the mechanical ventilation support for long-acting barbiturate therapy, may have been beneficial for the early recovery of the swollen TBI brain. The effective and immediate ICP control experienced by DC surgery patients occurred even though the underlying brain swelling was usually continuing at this early time after injury.

A major implication of the DECRA findings derives from the fact that the purpose of DC surgery is control of ICP, but not control of the brain swelling, which underlies rising brain pressure. After DC surgery including removal of both skull bone and dural opening, post-traumatic brain edema must continue its natural course, even though ICP measurements are no longer a valid indicator of the edema severity. Further, DECRA reported shortened ventilator and Intensive Care Unit times after DC surgery, which likely occurred because clinicians acted upon the lower ICP measurements and withdrew sedation and osmotherapy earlier after DC, than they did in the medical therapy patients. After DECRA it seems likely that best long-term outcomes after severe TBI will be achieved by continuing mechanical ventilation support and the brain swelling therapies until brain edema and brain swelling has visibly subsided. Following DC surgery, ICP below conventional pressure thresholds is clearly no longer a useful indicator of brain swelling, and perhaps should now be supplanted by either much lower ICP thresholds [11] or other means (e.g., visual assessment of brain herniation) of assessing ongoing brain edema.

The DECRA trial findings suggest that the ICP threshold for targeting intensive therapy below 20 mm Hg may be too low. Complications from DC surgery may have outweighed benefits in patients with an ICP of 20 mm Hg, but perhaps not at an ICP of 30 mm Hg. A rising ICP may eventually cause death from brain herniation, and DC surgery would likely prevent this outcome. The optimal ICP pressure thresholds for different medical and surgical interventions may not all be the same, and should be carefully reconsidered.

Two interventions, DECRA [5] and rescue hypothermia [7] for early refractory ICP have now been tested in randomized trials and found to improve ICP control but concurrently to increase patients' long-term functional disability. These findings do not mean that other interventions intended to reduce brain swelling from occurring might not be beneficial. For example, prophylactic hypothermia might slow the development of brain swelling with all its implications at an early stage after injury, and thereby both decrease ICP and improve patient outcomes. The ongoing POLAR randomized trial [12] addresses this question.

Finally, it is important to consider the likelihood of bias in a randomized surgical trial where double blinding was impossible. DECRA eliminated bias at randomization by allocation concealment, and at also outcome assessment by blinding, but could not blind clinicians during the intensive hospital period. It is therefore possible that unconscious bias may have led to treatment withdrawal less frequently in the surgical patients. This potential bias cannot be measured, but may in part explain the greatly increased frequency of

vegetative survivors after DC compared to medical management. The trial, however, likely mimics the real world, and such an effect of DC, if true, likely also occurs in usual patient care – to the detriment of patients and families.

Many of the DECRA trial findings were supported by the second large randomized trial of DC surgery for severe TBI. The Randomised Evaluation of Surgery with Craniectomy for Uncontrollable Elevation of Intracranial Pressure **(**RESCUEicp) [13] studied a mixed group of severe TBI patients with both mass lesions and diffuse injury, randomized at a later time point after injury – following hypothermia, and at a higher ICP threshold of 25 mm Hg. In this setting, RESCUEicp found improved patient survival, but at the cost of more vegetative and severe disability survivors. Neither trial had an increase in fully functionally independent survivors, who are usually described as "favorable outcomes." A subgroup analysis from RESCUEicp separating mass lesion and diffuse TBI patients is awaited and may assist further understanding of both of these randomized trials. Meanwhile, the key findings that dependent poor-outcome survivors were increased, whether DC surgery was conducted earlier [5] or later [13] in the time course of severe TBI, should lead to a complete reconsideration of the indications for DC surgery in all severe TBI patients.

The DECRA trial results were specific for patients with diffuse injury and bilateral swelling. They do not exclude the potential for DC surgery being a reasonable management option for selected TBI patients. DECRA assessed a single procedure (bi-frontal DC) in a specific context (diffuse TBI). It is possible that a lifesaving DC procedure might be a reasonable choice when the mechanisms of injury, clinical course, and radiology together suggest that the patient has sustained a predominantly focal brain injury. In that context, DC surgery might save a life with potential for an independent outcome. In the future, large comparative effectiveness trials [14] may also enable better outcome prediction and improved selection of patients who might benefit from better targeted DC surgery.

CONCLUSION

After DECRA, when DC surgery is being considered and discussed with families, expectations must be realistic and information about the high potential for a vegetative or a dependent, severe disability outcome should be provided. In the context of treatment options, families should be made aware that, instead of DC, for many patients optimized medical therapy may lead to a longer period in intensive care but also to a smaller chance of a vegetative outcome, and a greater chance of independent survival.

REFERENCES

[1] Carney, N., Totten, A. M., O'Reilly, C., Ullman, J. S., Hawryluk, G. W., Bell, M. J., et al. Guidelines for the management of severe traumatic brain injury, Fourth Edition. *Neurosurgery*. 2017; 80(1):6-15.

[2] Chesnut, R. M., Temkin, N., Carney, N., Dikmen, S., Rondina, C., Videtta, W., et al. A trial of intracranial-pressure monitoring in traumatic brain injury. *N. Engl. J. Med.* 2012; 367(26):2471-81.

[3] Taylor, A., Butt, W., Rosenfeld, J., Shann, F., Ditchfield, M., Lewis, E., et al. A randomized trial of very early decompressive craniectomy in children with traumatic brain injury and sustained intracranial hypertension. *Childs Nerv. Syst.* 2001; 17(3):154-62.

[4] Demetriades, D., Kuncir, E., Brown, C. V., Martin, M., Salim, A., Rhee, P., et al. Early prediction of mortality in isolated head injury patients: a new predictive model. *J. Trauma.* 2006; 1(4):868-72.

[5] Cooper, D. J., Rosenfeld, J. V., Murray, L., Arabi, Y. M., Davies, A. R., D'Urso, P., et al. Decompressive craniectomy in diffuse traumatic brain injury. *N. Engl. J. Med.* 2011; 364(16):1493-502.

[6] Clifton, G. L., Valadka, A., Zygun, D., Coffey, C. S., Drever, P., Fourwinds, S., et al. Very early hypothermia induction in patients with severe brain injury (the National Acute Brain Injury Study: Hypothermia II): a randomised trial. *Lancet Neurol.* 2011; 10(2):131-9.

[7] Andrews, P. J., Sinclair, H. L., Rodriguez, A., Harris, B. A., Battison, C. G., Rhodes, J. K., et al. Hypothermia for intracranial hypertension after traumatic brain injury. *N. Engl. J. Med.* 2015; 373(25):2403-12.

[8] Polin, R. S., Shaffrey, M. E., Bogaev, C. A., Tisdale, N., Germanson, T., Bocchicchio, B., et al. Decompressive bifrontal craniectomy in the treatment of severe refractory posttraumatic cerebral edema. *Neurosurgery*. 1997; 41(1):84-92; discussion -4.

[9] Ashayeri, K., Jackson, E. M., Huang, J., Brem, H., Gordon, C. R. Syndrome of the trephined: a systematic review. *Neurosurgery*. 2016; 79(4):525-34.

[10] Schalen, W., Messeter, K., Nordstrom, C. H. Complications and side effects during thiopentone therapy in patients with severe head injuries. *Acta Anaesthesiol. Scand.* 1992; 36(4):369-77.

[11] Sauvigny, T., Gottsche, J., Czorlich, P., Vettorazzi, E., Westphal, M., Regelsberger, J. Intracranial pressure in patients undergoing decompressive craniectomy: new perspective on thresholds. *J. Neurosurg.* 2017; Published online April 14, 2017; DOI: 10.3171/2016.11.JNS162263.

[12] Haines, S. J. Efficacy of antibiotic prophylaxis in clean neurosurgical operations. *Neurosurgery*. 1989; 24(3):401-5.

[13] Hutchinson, P. J., Kolias, A. G., Timofeev, I. S., Corteen, E. A., Czosnyka, M., Timothy, J., et al. Trial of decompressive craniectomy for traumatic intracranial hypertension. *N. Engl. J. Med.* 2016; 375(12):1119-30.

[14] Maas, A. I., Menon, D. K., Steyerberg, E. W., Citerio, G., Lecky, F., Manley, G. T., et al. Collaborative European NeuroTrauma Effectiveness Research in Traumatic Brain Injury (CENTER-TBI): a prospective longitudinal observational study. *Neurosurgery*. 2015; 76(1):67-80.

In: Encyclopedia of Surgery (22 Volume Set)
Editors: Andreas Lehrer and Kristin Mueller
ISBN: 978-1-53618-329-0
© 2020 Nova Science Publishers, Inc.

Chapter 231

DECOMPRESSIVE CRANIECTOMY FOR REFRACTORY POSTTRAUMATIC INTRACRANIAL HYPERTENSION: INTERPRETATION AND IMPLICATIONS OF THE INTERNATIONAL RESCUEICP RANDOMIZED TRIAL*

Tamara Tajsic, MD, PhD, Angelos G. Kolias, PhD, Hadie Adams, MD, Ivan Timofeev, PhD, David K. Menon† and Peter J. Hutchinson‡, PhD
Division of Neurosurgery
University of Cambridge and Addenbrooke's Hospital
Cambridge Biomedical Campus,
Cambridge, UK

ABSTRACT

Although decompressive craniectomy has been used for more than 100 years in neurosurgery, uncertainties still remain regarding the indications, optimal timing, and effects of decompressive craniectomy on the functional outcome of head-injured patients. In this chapter we discuss the role of decompressive craniectomy for refractory intracranial hypertension following severe traumatic brain injury.

Keywords: decompressive craniectomy, traumatic brain injury, refractory intracranial hypertension, RESCUEicp

* This chapter is partly based on the NEJM publication and subsequent correspondence (references [46, 47, 49]).

† David K. Menon, FMedSci.
‡ Corresponding Author's Email: pjah2@cam.ac.uk.

INTRODUCTION

One of the major determinants of outcome after traumatic brain injury (TBI) is the severity of the primary injury, which is irreversible. Primary injury, however, invariably leads to the activation of cellular and molecular processes, which mediate further (secondary) injury over the ensuing hours and days [1] and are therefore amenable to therapeutic intervention. These molecular cascades can lead to brain swelling within the confines of a fixed intracranial compartment, leading to increased intracranial pressure (ICP). This can, in turn, compromise the cerebral perfusion pressure (CPP), cerebral blood flow (CBF), and brain oxygenation [2, 3]. Ischemia and cell damage can exacerbate the swelling, forming part of a vicious circle that can lead to life-threatening brain herniation. TBI is associated with extracranial injuries in at least 35% of the cases, and these can further increase the risk of secondary injury due to hypotension, hypoxemia, hypercarbia, pyrexia, and/or coagulopathy [4, 5]. A considerable body of evidence links posttraumatic intracranial hypertension at levels above 20 to 25 mm Hg with excess mortality and worse functional outcomes [6-11]. Similar findings have been shown for reduced CPP at levels below 50 to 55 mm Hg [6, 7, 11].

The control of ICP and preservation of CPP has therefore been the mainstay of neuro-intensive care management of TBI for several decades. Tier-based protocols employing neuroprotective measures such as sedation, controlled hyperventilation, therapeutic hypothermia, hyperosmolar therapies, barbiturate coma, and ventricular drainage have been recommended and are widely used in intensive care units to control intracranial hypertension and facilitate cerebral perfusion and oxygenation [12, 13]. Measures such as hyperventilation, therapeutic hypothermia, and barbiturate-induced coma have been found to be effective in reducing ICP; however, subsequent clinical studies have failed to demonstrate clinical benefit, and in certain instances these therapies may have even caused harm [14-18], possibly due to unfavorable effects on cerebral perfusion [19, 20] or adverse extracranial effects [17].

DECOMPRESSIVE CRANIECTOMY

Decompressive craniectomy (DC) is an operative procedure whereby a large segment of skull (bone flap) is removed; the underlying dura is then opened and left unsutured or a wide nonconstricting duraplasty is performed. This procedure can reduce ICP and maintain or improve cerebral compliance [21, 22]. In the context of TBI, DC can be used as the primary or a secondary procedure. Primary DC refers to leaving a bone flap out after evacuating an intracranial hematoma (mass lesion) in the early phase after the head injury either because of evident brain swelling (brain protruding beyond the margins of the inner table of the skull) or because there is a concern of impending brain swelling in the next few hours to days [23-26]. A secondary DC is performed as part of tiered therapeutic protocols, which aim to control intracranial hypertension. The operation can be undertaken as last-tier (life-saving) therapy when all other measures have failed to reduce ICP to levels below 25–35 mm Hg. Alternatively, it can be performed as a second-tier therapy in patients with less pronounced elevation of ICP (e.g., 20 mm Hg); this can be viewed as a neuroprotective measure [25].

From a physiological viewpoint, DC provides additional space for the swollen brain to decompress with beneficial effects on ICP [21]. The procedure was described by Theodor

Kocher in 1901 [26]. Following his description, Harvey Cushing presented a case series of patients with head injury treated with subtemporal decompression [27]. Cushing reported a surgery-associated reduction in mortality from 50% to less than 15% and concluded that the brain edema and swelling that accompany severe cerebral contusions were best managed with a subtemporal DC. Renewed interest in DC emerged in the late 1960s and early 1970s in the context of TBI as well as ischemic stroke [28-30]. However, its utility was questioned in the late 1970s owing to the reports on poor clinical outcomes [31, 32] as well as animal studies that seemed to suggest that decompression may worsen cerebral edema [33]. With the significant improvements in the prehospital and neurointensive care management of TBI in the past 30 years, along with the widespread adoption of ICP monitoring and tier-based therapeutic protocols, the role of DC was re-examined. A resurgence of interest was seen throughout the 1980s and 1990s with a progressive increase in the number of publications describing its use in TBI as well as in other pathologies causing life-threatening intracranial hypertension [34, 35]. Although there were reports of the survival benefit of DC [35, 36], those studies were largely observational/uncontrolled, and the optimal timing and functional outcome of patients remained unclear.

The 2006 Cochrane Database Systematic Review on the use of DC for the treatment of refractory high ICP in TBI [22] identified only one randomized controlled trial [37]. In that study, 27 children (median age, 120.9 months; range, 13.6–176.4 months) with head injuries were randomly assigned to receive medical management alone or medical management plus bi-temporal DC (removal of a disc of temporal bone measuring about 3–4 cm, with extension of the craniectomy to the floor of the middle cranial fossa; dura mater was not opened). The study showed that DC was associated with a risk ratio of 0.54 (95% confidence interval, 0.29–1.01) for unfavorable outcome (death, vegetative status, or severe disability) at 6 months after injury (non-significant trend) [37].

With the continued dearth of good quality data from randomized controlled trials, questions about the utility of DC persisted, and DC did not feature in the 2007 Brain Trauma Foundation Guidelines for the Management of Severe Traumatic Brain Injury (3rd edition) [12]. Several reports have emerged in the past 10 years addressing differences in TBI surgical techniques, timing of DC, and patient populations [37-41]. While DECRA [42] examined the efficacy of early DC in patients with diffuse injury with an ICP threshold of 20 mm Hg for 15 minutes within 72 hours of injury, the role of DC in the treatment of raised and refractory intracranial hypertension was examined solely in observational studies [43, 44].

RESCUEICP TRIAL

The need for a good quality randomized controlled trial to examine the role of DC in the treatment of intracranial hypertension (> 25 mm Hg for 1–12 hours) refractory to medical treatment was widely recognized, and the RESCUEicp trial was launched in 2004 [45, 46]. This international, multicenter, parallel-group, superiority, randomized trial [46], compared last-tier secondary DC with continued medical management for refractory intracranial hypertension after TBI. The trial included patients with TBI aged between 10 and 65 years, with an abnormal computed tomography scan of the brain, an ICP monitor in place, and raised ICP of more than 25 mm Hg for 1 to 12 hours, despite applying stage 1 and 2 measures

of the ICP protocol. All patients were treated in intensive care according to a stratified protocol (see Figure 1 in [46]) aimed at maintaining an ICP of 25 mm Hg or less. If, despite these measures, the ICP remained above 25 mm Hg for 1 to 12 hours, then at stage 3 of the protocol, patients were randomized to DC with medical therapy or to continued medical therapy with an option to use barbiturates to reduce the ICP.

The surgical treatment was either large unilateral frontotemporoparietal craniectomy (hemicraniectomy) or bifrontal craniectomy [46]. The primary outcome measure was the Extended Glasgow Outcome Scale (GOS-E) at 6 months after randomization. Table 1 lists the secondary outcome measures.

Four hundred and eight patients were recruited to this trial: 206 were randomized to the surgical and 202 to the medical group. No significant between-group variability was observed in terms of baseline characteristics and medical or surgical treatment given prior to randomization [46]. Looking at the primary outcome measure (GOS-E at 6 months), the surgical (DC) group had a significantly lower mortality rate than the medical group (26.9% versus 49.9%). Surgery was found to be associated with higher rates of vegetative state, lower severe disability, and upper severe disability than was medical management, but the rates of moderate disability and good recovery were similar between the groups (see Table 3 and Figure 2 in [46]). The trial pre-specified favorable outcome as upper severe disability or better on the GOS-E and with such prespecified sensitivity analysis, 42.8% of surgical patients had a favorable outcome compared to 34.6% of medical patients (P = 0.12) [46]. Using the same prespecified sensitivity analysis at 12 months showed that 45.4% of surgical patients had a favorable outcome compared to 32.4% of medical patients (P = 0.01) (see Figure 2 in [46]).

Table 1. RESCUEicp trial outcome measures. GOSE-Extended Glasgow Outcome Scale; GCS- Glasgow Coma Scale; ICU- Intensive Care Unit

Primary outcome measure
• Extended Glasgow Outcome Scale (GOSE) at 6 months
Secondary outcome measure
• GOSE at 12 and 24 months • Mortality at 6, 12 and 24 months • Quality of life at 6, 12 and 24 months • GCS at time of discharge from ICU • Assessment of intracranial pressure control • Time to discharge or death in ICU • Economic evaluation

The trial also showed that the control of ICP was better in the surgical than the medical group. It is therefore not surprising that 37.2% of patients in the medical group eventually underwent a craniectomy and only 9.4% of patients in the surgical group required barbiturates as the failure to control ICP was greater in the medical group [46].

In contrast to the RESCUEicp trial, the DECRA trial [42] showed that patients undergoing craniectomy had worse ratings on the 6-month GOS-E than those receiving standard care (P = 0.03) with similar rates of death at 6 months (19% versus 18%). As we

discussed in our correspondence that followed publication of the initial paper in the *New England Journal of Medicine* [47]:

> The contrasting results of the DECRA and RESCUEicp trials are due to different hypotheses, inclusion criteria, and therapeutic protocols. The DECRA trial, as compared with the RESCUEicp trial, enrolled patients with a lower intracranial-pressure threshold (20 mm Hg vs. 25 mm Hg) for shorter intervals (15 minutes vs. 1 to 12 hours), after lower intensities of therapy (stage 1 interventions vs. stage 1 and 2 interventions), and within a shorter interval after injury (all patients enrolled within 72 hours after injury vs. 44% of patients enrolled >72 hours after injury). Patients with intracranial hematomas were enrolled in the RESCUEicp trial, but they were not enrolled in the DECRA trial. At enrollment, the populations also differed with respect to expected outcome; the requirement for stage 2 interventions increases the relative risk of death by 60%. Hence, at 6 months, the pooled mortality of 37.5% in the RESCUEicp trial versus 18.7% in the DECRA trial is unsurprising. In addition, our primary analysis showed a significant between-group difference in the GOS-E distribution and a substantial reduction in mortality with surgery; this finding differed from that of the DECRA trial, in which mortality was similar in the two groups. The severity of injury in the RESCUEicp trial underpinned dichotomization in the prespecified sensitivity analysis at upper severe disability (independent at home) or better. Given the high expectation of a poor outcome, the use of a "conventional" dichotomy would be as inappropriate as the use of it in populations with mild TBI (in whom disability-free survival is often attainable).

The survival advantage of DC in the RESCUEicp trial was translated to both dependent and independent living, and this is something that clinicians and family members will need to be aware of when making decisions regarding treatment [46]. It is important to appreciate that the perspectives of patients and their families need to be respected when determining the degree of "acceptable" disability and subsequently whether a craniectomy should be considered. We believe that the concept of shared decision making can play a fundamental role to this end [11, 48].

CONCLUSION

Improved control of ICP with surgery may have accounted for mortality that was lower than that observed with medical management. With a large body of evidence showing that it drives mortality, the treatment of intracranial hypertension will remain important [43, 44]. Future research should also focus on cranial reconstruction and the role of primary craniectomy for acute subdural hematomas, which is the topic of the ongoing RESCUE-ASDH trial (rescueasdh.org). To close, we would like to quote an excerpt from our recently published correspondence in the *British Journal of Anaesthesia* [49]:

> In the past, we never advocated for an indiscriminate use of craniectomy, and we are not doing so after the publication of the trial results. However, we believe that the RESCUEicp results have shown that craniectomy can be useful, as long as a thoughtful approach is adopted with involvement of the multidisciplinary clinical team and family members in the decision-making process.

REFERENCES

[1] Masel, B. E., DeWitt, D. S. Traumatic brain injury: a disease process, not an event. *Journal of neurotrauma.* 2010; 27(8):1529-40.

[2] Werner, C., Engelhard, K. Pathophysiology of traumatic brain injury. *British journal of anaesthesia*. 2007; 99(1):4-9.

[3] Unterberg, A. W., Stover, J., Kress, B., Kiening, K. L. Edema and brain trauma. *Neuroscience*. 2004; 129(4):1021-9.

[4] Maas, A. I., Stocchetti, N., Bullock, R. Moderate and severe traumatic brain injury in adults. *The Lancet Neurology*. 2008; 7(8):728-41.

[5] Gennarelli, T. A., Champion, H. R., Sacco, W. J., Copes, W. S., Alves, W. M. Mortality of patients with head injury and extracranial injury treated in trauma centers. *The Journal of trauma.* 1989; 29(9):1193-201; discussion 201-2.

[6] Chambers, I. R., Treadwell, L., Mendelow, A. D. Determination of threshold levels of cerebral perfusion pressure and intracranial pressure in severe head injury by using receiver-operating characteristic curves: an observational study in 291 patients. *Journal of neurosurgery*. 2001; 94(3):412-6.

[7] Balestreri, M., Czosnyka, M., Hutchinson, P., Steiner, L. A., Hiler, M., Smielewski, P., et al. Impact of intracranial pressure and cerebral perfusion pressure on severe disability and mortality after head injury. *Neurocritical care*. 2006; 4(1):8-13.

[8] Vik, A., Nag, T., Fredriksli, O. A., Skandsen, T., Moen, K. G., Schirmer-Mikalsen, K., et al. Relationship of "dose" of intracranial hypertension to outcome in severe traumatic brain injury. *Journal of neurosurgery.* 2008; 109(4):678-84.

[9] Farahvar, A., Gerber, L. M., Chiu, Y. L., Hartl, R., Froelich, M., Carney, N., et al. Response to intracranial hypertension treatment as a predictor of death in patients with severe traumatic brain injury. *Journal of neurosurgery*. 2011; 114(5):1471-8.

[10] Badri, S., Chen, J., Barber, J., Temkin, N. R., Dikmen, S. S., Chesnut, R. M., et al. Mortality and long-term functional outcome associated with intracranial pressure after traumatic brain injury. *Intensive care medicine.* 2012; 38(11):1800-9.

[11] Guiza, F., Depreitere, B., Piper, I., Citerio, G., Chambers, I., Jones, P. A., et al. Visualizing the pressure and time burden of intracranial hypertension in adult and paediatric traumatic brain injury. *Intensive care medicine*. 2015; 41(6):1067-76.

[12] Bratton, S. L., Chestnut, R. M., Ghajar, J., McConnell Hammond, F. F., Harris, O. A., Hartl, R., et al. Guidelines for the management of severe traumatic brain injury (3rd Edition). *Journal of neurotrauma.* 2007; 24 Suppl 1:S1-106.

[13] Carney, N., Totten, A. M., O'Reilly, C., Ullman, J. S., Hawryluk, G. W., Bell, M. J., et al. Guidelines for the Management of Severe Traumatic Brain Injury, Fourth Edition. *Neurosurgery*. 2017; 80(1):6-15.

[14] Curley, G., Kavanagh, B. P., Laffey, J. G. Hypocapnia and the injured brain: more harm than benefit. *Critical care medicine*. 2010; 38(5):1348-59.

[15] Eisenberg, H. M., Frankowski, R. F., Contant, C. F., Marshall, L. F., Walker, M. D. High-dose barbiturate control of elevated intracranial pressure in patients with severe head injury. *Journal of neurosurgery.* 1988; 69(1):15-23.

[16] Andrews, P. J., Sinclair, H. L., Rodriguez, A., Harris, B. A., Battison, C. G., Rhodes, J. K., et al. Hypothermia for Intracranial Hypertension after Traumatic Brain Injury. *The New England journal of medicine*. 2015; 373(25):2403-12.

[17] Muizelaar, J. P., Marmarou, A., Ward, J. D., Kontos, H. A., Choi, S. C., Becker, D. P., et al. Adverse effects of prolonged hyperventilation in patients with severe head injury: a randomized clinical trial. *Journal of neurosurgery*. 1991; 75(5):731-9.

[18] Ward, J. D., Becker, D. P., Miller, J. D., Choi, S. C., Marmarou, A., Wood, C., et al. Failure of prophylactic barbiturate coma in the treatment of severe head injury. *Journal of neurosurgery*. 1985; 62(3):383-8.

[19] Sakoh, M., Gjedde, A. Neuroprotection in hypothermia linked to redistribution of oxygen in brain. *American journal of physiology, Heart and circulatory physiology*. 2003; 285(1):H17-25.

[20] Yundt, K. D., Diringer, M. N. The use of hyperventilation and its impact on cerebral ischemia in the treatment of traumatic brain injury. *Critical care clinics*. 1997; 13(1):163-84.

[21] Timofeev, I., Czosnyka, M., Nortje, J., Smielewski, P., Kirkpatrick, P., Gupta, A., et al. Effect of decompressive craniectomy on intracranial pressure and cerebrospinal compensation following traumatic brain injury. *Journal of neurosurgery*. 2008; 108(1):66-73.

[22] Sahuquillo, J., Arikan, F. Decompressive craniectomy for the treatment of refractory high intracranial pressure in traumatic brain injury. *The Cochrane database of systematic reviews*. 2006(1):Cd003983.

[23] Bullock, M. R., Chesnut, R. Fau – Ghajar, J., Ghajar, J. Fau – Gordon, D., Gordon, D. Fau – Hartl, R., Hartl, R. Fau – Newell, D. W., Newell, Dw. Fau – Servadei, F., et al. *Surgical management of acute subdural hematomas*. 2006(1524-4040 (Electronic)).

[24] Timofeev, I., Santarius, T., Kolias, A. G., Hutchinson, P. J. Decompressive craniectomy - operative technique and perioperative care. *Advances and technical standards in neurosurgery*. 2012; 38:115-36.

[25] Kolias, A. G., Adams, H., Timofeev, I., Czosnyka, M., Corteen, E. A., Pickard, J. D., et al. Decompressive craniectomy following traumatic brain injury: developing the evidence base. *British journal of neurosurgery*. 2016; 30(2):246-50.

[26] Kocher, T. Hirnerschtterung, Hirndruck und chirurgische Eingriffe bei Hirnkrankheitende. *Die Therapie des Hirndruckes*. Vienna: A, H'Ider.; 1901:262-66.

[27] Cushing, H. Subtemporal Decompressive Operations for the Intracranial Complications Associated with Bursting Fractures of the Skull. *Annals of surgery*. 1908; 47(5):641-4.1.

[28] Ransohoff, J., Benjamin, V. Hemicraniectomy in the treatment of acute subdural haematoma. *Journal of neurology, neurosurgery, and psychiatry*. 1971; 34(1):106.

[29] Kjellberg, R. N., Prieto, A., Jr. Bifrontal decompressive craniotomy for massive cerebral edema. *Journal of neurosurgery*. 1971; 34(4):488-93.

[30] Greenwood, J., Jr. Acute brain infarctions with high intracranial pressure: surgical indications. *The Johns Hopkins medical journal*. 1968; 122(5):254-60.

[31] Cooper, P. R., Rovit, R. L., Ransohoff, J. Hemicraniectomy in the treatment of acute subdural hematoma: a re-appraisal. *Surgical neurology*. 1976; 5(1):25-8.

[32] Venes, J. L., Collins, W. F. Bifrontal decompressive craniectomy in the management of head trauma. *Journal of neurosurgery*. 1975; 42(4):429-33.

[33] Cooper, P. R., Hagler, H., Clark, W. K., Barnett, P. Enhancement of experimental cerebral edema after decompressive craniectomy: implications for the management of severe head injuries. *Neurosurgery*. 1979; 4(4):296-300.

[34] Gaab, M. R., Rittierodt, M., Lorenz, M., Heissler, H. E. Traumatic brain swelling and operative decompression: a prospective investigation. *Acta neurochirurgica Supplementum*. 1990; 51:326-8.

[35] Polin, R. S., Shaffrey, M. E., Bogaev, C. A., Tisdale, N., Germanson, T., Bocchicchio, B., et al. Decompressive bifrontal craniectomy in the treatment of severe refractory posttraumatic cerebral edema. *Neurosurgery*. 1997; 41(1):84-92; discussion -4.

[36] Whitfield, P. C., Patel, H., Hutchinson, P. J., Czosnyka, M., Parry, D., Menon, D., et al. Bifrontal decompressive craniectomy in the management of posttraumatic intracranial hypertension. *British journal of neurosurgery*. 2001; 15(6):500-7.

[37] Taylor, A., Butt, W., Rosenfeld, J., Shann, F., Ditchfield, M., Lewis, E., et al. A randomized trial of very early decompressive craniectomy in children with traumatic brain injury and sustained intracranial hypertension. Child's nervous system: ChNS: *official journal of the International Society for Pediatric Neurosurgery*. 2001; 17(3):154-62.

[38] Bohman, L. E., Schuster, J. M. Decompressive craniectomy for management of traumatic brain injury: an update. *Current neurology and neuroscience reports.* 2013; 13(11):392.

[39] Huang, X., Wen, L. Technical considerations in decompressive craniectomy in the treatment of traumatic brain injury. *International journal of medical sciences*. 2010; 7(6):385-90.

[40] Ragel, B. T., Klimo, P., Jr., Martin, J. E., Teff, R. J., Bakken, H. E., Armonda, R. A. Wartime decompressive craniectomy: technique and lessons learned. *Neurosurgical focus.* 2010; 28(5):E2.

[41] Quinn, T. M., Taylor, J. J., Magarik, J. A., Vought, E., Kindy, M. S., Ellegala, D. B. Decompressive craniectomy: technical note. *Acta neurologica Scandinavica.* 2011; 123(4):239-44.

[42] Cooper, D. J., Rosenfeld, J. V., Murray, L., Arabi, Y. M., Davies, A. R., D'Urso, P., et al. Decompressive craniectomy in diffuse traumatic brain injury. *The New England journal of medicine*. 2011; 364(16):1493-502.

[43] Bor-Seng-Shu, E., Figueiredo, E. G., Amorim, R. L., Teixeira, M. J., Valbuza, J. S., de Oliveira, M. M., et al. Decompressive craniectomy: a meta-analysis of influences on intracranial pressure and cerebral perfusion pressure in the treatment of traumatic brain injury. *Journal of neurosurgery*. 2012; 117(3):589-96.

[44] Timofeev, I., Hutchinson, P. J. Outcome after surgical decompression of severe traumatic brain injury. *Injury*. 2006; 37(12):1125-32.

[45] Hutchinson, P. J., Corteen, E., Czosnyka, M., Mendelow, A. D., Menon, D. K., Mitchell, P., et al. Decompressive craniectomy in traumatic brain injury: the randomized multicenter RESCUEicp study (www.RESCUEicp.com). *Acta neurochirurgica Supplement.* 2006; 96:17-20.

[46] Hutchinson, P. J., Kolias, A. G., Timofeev, I. S., Corteen, E. A., Czosnyka, M., Timothy, J., et al. Trial of Decompressive Craniectomy for Traumatic Intracranial Hypertension. *The New England journal of medicine*. 2016; 375(12):1119-30.

[47] Hutchinson, P. J., Kolias, A. G., Menon, D. K. Craniectomy for Traumatic Intracranial Hypertension. *The New England journal of medicine.* 2016; 375(24):2403-4.

[48] Muehlschlegel, S., Shutter, L., Col, N., Goldberg, R. Decision Aids and Shared Decision-Making in Neurocritical Care: An Unmet Need in Our NeuroICUs. *Neurocritical care.* 2015; 23(1):127-30.

[49] Menon, D. K., Kolias, A. G., Servadei, F., Hutchinson, P. J. Survival with disability. Whose life is it, anyway? *British journal of anaesthesia.* 2017; 119(5):1062-3.

In: Encyclopedia of Surgery (22 Volume Set)
Editors: Andreas Lehrer and Kristin Mueller
ISBN: 978-1-53618-329-0
© 2020 Nova Science Publishers, Inc.

Chapter 232

OUTCOME FOLLOWING DECOMPRESSIVE CRANIECTOMY FOR MANAGING HIGH INTRACRANIAL PRESSURE IN TRAUMATIC BRAIN INJURY PATIENTS: A SYSTEMATIC REVIEW

Juan Sahuquillo[1,*] and Jane A. Dennis[2]

[1]Department of Neurosurgery, Neurotraumatology and Neurosurgery Research Unit (UNINN), Vall d'Hebron University Hospital, Universitat Autònoma de Barcelona, Paseo Vall d'Hebron 119-129, 08035 Barcelona, Spain.

[2]Musculoskeletal Research Unit, School of Clinical Sciences, University of Bristol, Bristol, UK

"For those who survive,…focusing on a person's strengths and abilities rather than their disabilities may help relieve some of the isolation often felt by patients and their families on the long road to recovery."

Honeybul et al., 2016 [2]

ABSTRACT

High intracranial pressure (ICP) is the most frequent cause of death and disability after a severe traumatic brain injury (TBI). High ICP is usually treated with general maneuvers (normothermia, sedation, etc.) and a set of first-tier therapeutic measures (moderate hypocapnia, mannitol, etc.). When these measures fail to control high ICP, second-tier therapies are initiated, such as barbiturates, hyperventilation, moderate hypothermia, or removal of a variable amount of skull bone (decompressive craniectomy, DC).

Objectives. To assess the effects of secondary DC on outcomes and quality of life for patients with severe TBI in whom conventional medical therapeutic measures have failed to control a raised ICP.

Search methods. We searched the Cochrane Central Register of Controlled Trials, Ovid MEDLINE, Embase, and ISI Web of Science. We also searched clinical trials registries and contacted experts.

* Corresponding author: Email: sahuquillo@neurotrauma.net.

Selection criteria and data collection. Randomized or quasi-randomized studies assessing patients over the age of 12 months with severe TBI who underwent DC to control ICP refractory to conventional medical treatments. The search results were examined and potentially relevant trials were retrieved in full, data extraction performed, and studies assessed for risk of bias.

Main results. Three trials were identified. One involved 27 pediatric patients; the DECRA trial was conducted in three countries and recruited 155 adult patients; the RESCUEicp trial was conducted in 24 countries and recruited 408 participants (both adolescents and adults). Each study compared DC combined with standard care (which might include induced coma and/or cooling of the brain) to standard care alone.

Conclusions and recommendations. 1. In the pediatric population (patients ≤18 years old), decompressive surgery reduces the risk of death and other unfavorable outcomes (vegetative status and severe disability) in patients with ICP refractory to medical treatment (low quality evidence). 2. In adult patients with severe TBI, DC in those with refractory moderate high ICP (>20 mm Hg threshold) does not reduce mortality or decrease the risk of an unfavorable outcome (moderate quality evidence). In adult patients with severe TBI and high ICP (≥25 mm Hg) refractory to conventional medical treatment, DC has a strong effect in reducing mortality at 6 months (ARR: 19.8%) and 12 months (ARR: 21.5%) after injury. The evidence supporting this conclusion is of high quality. The fact that DC improves the chance for survival but with significant disability needs to be conveyed to the patient's family or legal representatives before DC is conducted.

Keywords: decompressive craniectomy, severe traumatic brain injury, cerebral edema, systematic review, Glasgow Outcome Scale, increased intracranial pressure

INTRODUCTION

Traumatic brain injury (TBI), a major health problem worldwide, has its greatest burden in low- and middle-income countries where 85% of the world's population lives [3]. In the past 2 decades, multiple military conflicts have significantly changed the spectrum of TBI. Motor vehicle crashes and falls are the most frequent causes of civilian TBI-related death, while blast-induced TBI is the most frequent in members of the military [4]. Most victims of TBI, both civilian and military, are young male adults, and because of the long-term disabilities sustained by survivors, severe TBI is a challenge to health systems and a burden on families and the community in terms of monetary cost, suffering, and disability [5].

Despite a much better understanding of the pathophysiology and neurochemical cascades triggered by mechanical trauma as well as technical advances in neuromonitoring, the outcomes of patients with severe TBI seem to have reached a plateau. Clinical trial drugs that were promising in preclinical studies yielded disappointing results when tested in multicenter randomized controlled trials (RCTs) [6]. This failure may reveal that experimental models do not have the ability to accurately simulate human TBI, selection of target populations is inaccurate, studies are underpowered and have low probabilities of detecting clinically relevant effects, or knowledge of the optimal therapeutic windows for the drugs is insufficient. Further reasons could be a lack of penetration of the neuroprotective drugs in the brain, insensitivity of the outcome scales currently available to discriminate the potential benefits of a new treatment, or the intrinsic heterogeneity of TBI. An additional hypothesis is

that severe primary brain damage may be present in some of the patients and that such damage cannot be modified by any available treatments [7].

Decompressive Craniectomy

In recent decades, neurosurgeons and intensivists have shown renewed interest in decompressive craniectomy (DC) for the management of high intracranial pressure (ICP) that is refractory to first- or second-level therapeutic measures. These patients have a dismal outcome if ICP is not controlled quickly. Furthermore, highly favorable patient outcomes have been reported after surgical decompression in small-series retrospective cohort studies and prospective non-randomized studies. However, owing to the weak methodological design of these studies, these favorable outcomes do not prove the effectiveness of this dramatic therapy, and many neurosurgeons are still reluctant to use it. Skepticism about the benefits of this procedure is influenced by the notion— shared by many neurosurgeons— that even if DC does reduce ICP, the functional outcome of the survivors is not improved. Additionally, DC has potential adverse effects such as increased brain edema, subdural collections, hydrocephalus, and brain infarctions. A previous version of this review [8] closed with words from the seminal paper by Kjellberg and Prieto, "We have presented our appraisal of the case material (bifrontal decompressive craniectomy), not so much as proof of its superiority over other methods, but rather as provocation for further critical appraisal of its use" [9]. Now that the majority of results of two long-anticipated randomized clinical trials – DECRA and RESCUEicp — are published [10, 11], we hope to shed light on this issue. This systematic review is focused on closed TBI but excludes all military injuries including blast injuries.

Raised Intracranial Pressure in TBI

High ICP is usually defined as ICP >20 mm Hg when measured within the subdural, intraventricular, or intraparenchymal compartments. In the early 1990s, this was considered the most frequent cause of death and disability after severe TBI [12], and high ICP still remains a frequent cause of such. Juul et al., in a *post hoc* analysis of data from the international multicenter trial of the N-methyl-D-aspartate antagonist Selfotel, showed that the most powerful predictor of neurological worsening was the presence of ICP ≥ 20 mm Hg [13]. Traditionally, it was considered that approximately 50% of severe TBIs with abnormal computed tomography (CT) scans had high ICP [12, 14]. However, this incidence has changed significantly in studies published in the past 2 decades. In the dexanabinol multicenter study, only 10% of patients had ICPs above 25 mm Hg [15], while in the Traumatic Coma Data Bank (TCDB) published in 1991, 72% of the patients had ICPs above 20 mm Hg [12]. A possible reason for this fairly large difference is that half the patients in the dexanabinol study had diffuse brain injuries type II, but only 24% of patients were classified in this category in the TCDB [12]. This lower incidence of high ICP is consistent with the DECRA (Decompressive Craniectomy in Diffuse Traumatic Brain Injury) study, which included only 155 of the 3,478 patients screened for eligibility (4.5%) [11]. Reasons for the lower incidence of high ICP in DECRA may be better resuscitation strategies, better and faster transport to referral centers, and much more aggressive treatments of the mass lesions.

Management of High ICP

In most centers worldwide, the treatment of high ICP is based on the recommendations of the "Guidelines for the Management of Severe Traumatic Brain Injury" developed by the Brain Trauma Foundation (BTF). These guidelines are endorsed by most scientific societies worldwide, and they have been translated into many languages and define the core principles for managing severe TBI. These guidelines have been periodically updated since the first version was published in 1996 [16]; the latest version was published in 2016 [17]. The sequence of steps for treating high ICP recommended in the BTF guidelines was based on an algorithm that was published in the first and second versions but was withdrawn in the 2007 version [18]. However, because the terminology (first- and second-tier maneuvers) used in the 1996 algorithm is familiar to clinicians and firmly ingrained in the TBI literature, we have used it in this review. In brief, when ICP is above 20 mm Hg, a set of general maneuvers is recommended (head elevation, normothermia, volume resuscitation, sedation, etc.). If these general maneuvers fail, a set of first-tier therapeutic measures is started. These measures include cerebrospinal fluid (CSF) drainage, moderate hypocapnia (pCO_2 30 to 35 mm Hg), and mannitol administration. When first-tier measures fail to control ICP, only a few therapeutic options (second-tier therapies) are available unless potentially evacuable mass lesions are detected in the CT scan. Suggested second-tier measures are high-dose barbiturates, intense hyperventilation (pCO_2 < 30 mmHg), increasing mean arterial blood pressure, mild or moderate hypothermia, and DC. Of these, only the use of barbiturates has reached a Level II recommendation (based on Class II evidence) to treat high ICP; other medical and surgical therapies have failed to do so [18].

Despite the recommendations of the BTF guidelines on the use of barbiturates, a Cochrane systematic review did not find evidence that the use of barbiturates improves the outcome in severe TBI [19]. Although barbiturates may reduce ICP, this reduction is not associated with lower mortality or improved outcomes in survivors [19]. Barbiturates lower blood pressure in one of four patients, and this hypotensive effect may offset the beneficial effect of lowering ICP [19]. Because of this lack of effective therapeutic measures, alternatives to barbiturates and in particular DC have been reconsidered in the treatment of high ICP.

DECOMPRESSIVE CRANIECTOMY IN THE MANAGEMENT OF TBI

Historically, removal of different parts and quantities of the skull, with or without opening the duramater or augmentative duraplasty, has been performed in TBI. Kocher was the first to propose DC in patients with clinical symptoms of elevated ICP [20]. Later, in 1905, Cushing made a detailed report on a subtemporal and suboccipital decompression procedure to relieve high ICP in patients with inoperable brain tumors [21]. Decompressive surgery for refractory intracranial hypertension is directed toward improving cerebral perfusion, preventing ischemic damage, and avoiding mechanical compression of the brain (brain herniations), and its rationale is based on the Monro-Kellie doctrine [22]. According to this hypothesis, intracranial volume should remain constant and volumetric compensations should be achieved by shifts in CSF, cerebral blood volume, or brain herniations. Removing a

variable amount of bone, with or without leaving the dura mater open or augmented by a duraplasty, is a fast and effective means of increasing intracranial volume, reducing elevated ICP, and increasing the compliance of the intracranial space [23].

Although DC has no proven effect on the primary brain injury, it could reduce damage caused by secondary lesions such as brain herniations and high ICP. As a consequence of the experience gathered in military conflicts, in which neurosurgeons used DC as a strategy of damage control in the battlefield, it has also been used in civilian penetrating (missile) brain injuries. Intracranial gunshot wound injuries are common in some countries and have a dismal prognosis. The assassination attempt against Congresswoman Gabrielle Giffords in the USA in 2011 involved a shot to the head that was managed with early DC, resulting in an unexpected good outcome. This brought the procedure to the attention of international media [24]. This systematic review is an update of a previous review [8] focused exclusively on closed TBI and therefore excludes any study or report published in the field of civilian or military penetrating gunshot wound injuries.

Types of Surgical Decompression

Decompressive craniectomy can be performed in two very different clinical scenarios. The first option, prophylactic decompression or primary-DC (P-DC), is defined as any bone decompression performed in patients undergoing surgery for the evacuation of any intradural lesion [8] with the aim of preventing expected postsurgical increases in ICP. In these procedures the decision is taken by the surgeon and is usually based on the CT scan or intraoperative surgical findings (brain swelling, a "tight" brain, or difficulties in repositioning the bone flap), or both. Some authors have also proposed the use of P-DC as a therapeutic strategy in the management of some types of brain contusions [25], as a damage control procedure in patients with acute subdural hematomas, or for severe brain swelling in countries with low resources and limited availability of intensive care facilities [26]. For the purposes of this review, all these procedures are considered P-DC. The second option, secondary-DC (S-DC), was defined in the first version of this review as a procedure performed on patients with continuous ICP monitoring to control high ICP that is refractory to first- or second-tier medical treatments [8]. This therapeutic option is used in some centers after first- or second-tier therapeutic measures have failed to control ICP over a predefined threshold. In the category of S-DC, we also included patients who underwent a first surgical procedure to evacuate a space-occupying lesion and who had later developed delayed massive unilateral or bilateral brain swelling, when the purpose of DC was to control delayed high ICP [27].

Surgical Technique

Wide variability in surgical procedures for performing DC has been reported. These variations include small to massive amounts of bone removal, unilateral or bilateral bone decompression, scarifying the dura mater to decrease its rigidity, opening the dura mater or leaving it closed, and sectioning the falx, among others. Localization of bone removal can be unilateral, bilateral, bifrontal, or subtemporal, or it can be expanded to what has been called "circumferential decompression" [27-30]. The closing of the dura mater is also highly

variable and the type of grafts used to augment decompression can be autologous, synthetic, or biological [31].

SYSTEMATIC REVIEW METHODOLOGY

Objective

The main objective of this review was to assess the effects of S-DC on mortality, functional outcomes, and, when possible, quality of life in patients with TBI for whom medical treatment has failed to control high ICP. All randomized or quasi-randomized controlled trials in any language were eligible for inclusion. Quasi-randomized controlled trials were defined according to the *Cochrane Handbook for Systematic Reviews of Interventions* as those trials in which quasi-random methods of assignment were used, i.e., alternation, date of birth, medical record number, etc. [32] Trials not fulfilling these basic criteria were reviewed but excluded from the analysis.

Participants

Included in this review were patients over the age of 12 months with a severe traumatic brain injury and in a coma (post-resuscitation Glasgow Coma Scale score below or equal to 8 points) and who underwent S-DC to control raised ICP that was refractory to medical treatment (analgesia, sedation, muscular paralysis, hyperosmolar solutions, hyperventilation, barbiturates, etc.). As in the previous version of this review [8], only those studies that defined the lesion using a CT scan and monitored ICP were included.

Interventions

In this systematic review, S-DC is defined as bone decompression with the dura mater closed, scarified, left open, or opened and augmented by duraplasty. However, the importance of opening the dura mater in any decompressive procedure was clearly stated by Cushing in 1905: *"*The mere removal of bone alone does not usually answer as a palliative measure, for, owing to the inelasticity of the dura, sufficient decompression will not ensue until this membrane has been freely incised or removed" [21]. Because several experimental and clinical studies have confirmed this point, studies that performed large bone decompression without opening the dura mater have been included in this review, but considered suboptimal. We excluded all studies in which P-DC was conducted.

Comparisons

Patients receiving any standard medical treatment (regardless of level of intensity) were considered the control group. Standard medical treatment is defined as non-surgical therapy used to control ICP, i.e., hyperosmolar solutions, sedation and paralysis, hyperventilation,

barbiturates, and/or moderate hypothermia. CSF drainage for lowering ICP was also considered non-surgical therapy.

Outcomes

The primary outcome for this systematic review was neurological outcome at 6 or 12 months evaluated with the dichotomized Glasgow Outcome Scale (GOS) [33] or the extended GOS (GOS-E) and categorized into "good" or "bad" outcomes. The GOS-E scale splits each of the original severe disability, moderate disability, and good recovery categories into lower and upper categories and extends the five original GOS categories into eight [34, 35]. The GOS-E increases the sensitivity of the original GOS, but it also decreases the interobserver agreement and, therefore, increases the risk of misclassification in untrained evaluators [36]. Patients with a good recovery or moderate disability according to either the GOS or GOS-E were included in the good outcome group while those who were severely disabled, remained in a vegetative state, or died were included in the bad outcome group. We continued to do so despite the presentation of data in one study [10] with a less traditional dichotomization that involved grouping those with "upper severe disability" of the GOS-E into the category of good outcome [10]. In addition to the original good-bad outcome analysis described in the original protocol, and because this is an arbitrary dichotomization that generates controversies, we have conducted a new analysis including death/vegetative versus alive. We believe that death and survival in a vegetative status are considered bad outcomes, without generating controversy [37]. This way, the interpretation of the results is easier for clinicians, and stands apart from the controversy about at which particular point of the GOS-E the threshold should be placed to define a bad/unfavorable or good/favorable outcome. In the opinion of many, the cutoff to define bad and good outcomes is an arbitrary threshold the definition of which should be left to the patients and caregivers and not to the health providers.

Search Methods for Identification of Studies

In order to reduce publication and retrieval bias, we did not restrict our search by language, date, or publication status. The search was conducted by the Cochrane Injuries Group Trials Search Coordinator. The searched databases, search strategies, keyword searching, and hand searching are described extensively in the complete review published in the Cochrane Library [1]. Both reviewers examined titles, abstracts, and keywords of citations from electronic databases for eligibility. The full texts of all relevant records were obtained and assessed to see whether the record met the pre-defined inclusion criteria. When in doubt, we requested advice from the editorial team of the Cochrane Injuries Group.

Risk of Bias Tool

The risk of bias tool recommended by Higgins and Altman was used [32]. This scale is a domain-based evaluation in which critical assessments are made separately for six different

domains (sequence generation, allocation concealment, blinding, incomplete outcome data, selective outcome reporting, and "other"). Naturally, because of the nature of the intervention in this review, clinicians could not be blinded to the type of treatment to which the patient was allocated; however, the domain of blinding was assessed in such a way that information on blinding of the outcome evaluator could examined separately.

Measures of Treatment Effect and Data Synthesis

We calculated unadjusted treatment effects using the Cochrane Collaboration's Review Manager (RevMan v5.3) software where possible [38]. Risk ratios and 95% confidence intervals (CIs) were calculated for dichotomous outcomes. In this review, we have also added the absolute risk reduction (ARR) and the number needed to treat (NNT) to avoid the outcome of interest. For calculating ARR and NNT we have used the online calculator available at (http://ebm-tools.knowledgetranslation.net/calculator/prospective).

RESULTS

For this review the combined search strategy identified 184 published and unpublished studies, but only three fulfilled the eligibility criteria [10, 11, 39]. All three were prospective parallel RCTs. Investigators from one trial randomized patients in blocks of four [39]. In the other two, the unit of analysis was the individual [10, 11]. Sample size at randomization varied from 27 participants in the study conducted by Taylor et al. [39] to 155 in DECRA [11] and to 408 in the RESCUEicp trial [10]. For a comprehensive review of the characteristics of these studies, the reader is referred to the full Cochrane review [1].

Overall, evidence in this review was produced from trials undertaken in intensive care units at hospitals in 25 countries. Recruitment was conducted between 1991 and 2014. The study by Taylor et al. was conducted at a single site in Australia, with a recruitment period covering 1991 to 1998 [39]. The DECRA study was conducted at sites in Australia, New Zealand, and Saudi Arabia, recruiting between 2002 and 2010 [11]. The RESCUEicp was conducted within 73 centers across 24 countries, but the majority of participants (325) were recruited in either the UK (291) or continental Europe (34) [10].

Age, Gender, and Cause of Injury

The study by Taylor et al. focused solely on children aged 1 to 14 years [39]. The DECRA study included participants aged 15 to 59; the median age was 23.7 years in the intervention group and 24.6 years in the control group [11]. The RESCUEicp study had the oldest participants overall, with a mean age in the intervention group of 32.3 years and a mean of 34.8 years in the control group [10]. Males made up the majority of participants within the review (77% in DECRA and 81% in RESCUEicp). Gender of child participants was not reported in the study conducted by Taylor et al. nor was the cause of injury [39]. In DECRA, 85% of participants had suffered motor vehicle accidents, with the rest of injuries largely being related to bicycle or pedestrian accidents. The RESCUEicp reported a diverse

range of causes of head injury, including motor vehicle accidents (35%), falls (32%), assaults (13%), pedestrian accidents (11%), and other/unknown (9%).

Severity at Baseline

All three studies shared the aim of controlling ICP before considering DC, and each refers to detailed protocols for stages or tiers of ICP-reducing treatment. All of them followed the recommendations given by the different versions of the BTF guidelines [16, 17]. As the question of whether DC is being used to treat early and/or moderate increases in ICP or only to treat ICP refractory to all conventional medical treatment, the threshold used in the different studies was a critically important aspect of eligibility criteria [40]. In the Taylor et al. study, investigators first established a threshold of ICP ≤ 20 mm Hg with an adequate cerebral perfusion pressure [39]. This was defined initially as a cerebral perfusion pressure > 50 mm Hg, but 2 years into the study (1993), parameters for an adequate cerebral perfusion pressure were then adjusted for age: ≥ 35 mm Hg (1–4 years); ≥ 40 mm Hg (5–8 years); ≥ 45 mm Hg (9–12 years); and ≥ 50 mm Hg (>12 years). Later, in 1997, a final definition for adequate cerebral perfusion pressure was then implemented: ≥ 50 mm Hg (1–4 years); ≥ 60 mm Hg (5–8 years); and ≥ 70 mm Hg (>8 years) [39]. In the DECRA study, treatment threshold for ICP was defined as a 20 mm Hg threshold for more than 15 minutes (continuously or intermittently) within a 1-hour period. In the RESCUEicp, the objective was to maintain an ICP of < 25 mm Hg, to be followed by randomization if this was exceeded in any participant for a period of 1 to 12 hours [10].

Interventions and Comparator Groups

In the Taylor et al. study, children receiving DC underwent a bi-temporal craniectomy in addition to standard care as received by the control group. The intervention involved a 3- to 4-cm disc of temporal bone being removed by extending the opening down to the floor of the middle cranial fossa. The dura mater was left intact and, in a few cases, scarified. According to our protocol, this was considered a suboptimal surgical procedure. Randomization reportedly took place at a median of 16 hours after injury, and in the intervention group, DC was performed at a median of 19.2 hours from the time of injury [39]. No child crossed over between treatment arms. In the DECRA, a bi-frontotemporoparietal DC –without sagittal sinus and falx cerebri division— was performed in adult patients in whom first-tier intensive care therapies did not control ICP. In this study, the mean time from injury to randomization was 35.2 hours in the intervention group and 34.8 hours in the control.

The RESCUEicp trial involved a standard protocol to manage participants with the objective of maintaining ICP < 20 mm Hg. DC itself included two options: (a) a large unilateral frontotemporoparietal craniectomy for patients with unilateral hemisphere swelling or (b) a large bilateral frontotemporoparietal craniectomy from the frontal sinus anteriorly to the coronal suture posteriorly and the pterion laterally with a wide dural opening with the option of division of the falx anteriorly for patients with bilateral diffuse brain swelling [10]. The median time for the 92% of participants who underwent DC was 2.2 hours. In this study,

the protocol permitted DC surgery to be performed later at the clinician's discretion if the patient subsequently deteriorated.

The comparator group in all three studies was medical management, variously described between studies as maximal medical treatment, medical treatment, standard care, and/or continued medical management. In the Taylor et al. study, this involved barbiturate-induced coma and moderate hypothermia in all cases [39]. In DECRA, second-tier options for refractory ICP included mild hypothermia, barbiturates or both [11]. In the RESCUEicp, the comparator group was defined as a continuation of standard care, i.e., medical treatment per two predefined stages. Stage 1 procedures might include sedation, analgesia, and ventilation; stage 2 might involve more advanced treatment measures including draining CSF, mannitol, inotropes, moderate hyperventilation, hypertonic saline, moderate hypothermia (35–36°C), diuretics, and steroids. Barbiturates were not included as part of either stage, but were reserved as part of continued medical treatment following randomization. Among the 87% of those allocated to continued medical management, the median time until barbiturate infusion was 1.5 hours and the median duration of this therapy was 52 hours [10].

RISK OF BIAS IN INCLUDED STUDIES

The risk of bias assessments for the three included studies are presented narratively below and graphically in Figure 1.



Figure 1. Risk of bias summary. This figure illustrates the authors' judgments about each domain for each included study. The + sign and green color denote low risk of bias; the - sign and red color denote high risk of bias; the question mark and amber/yellow color denote unclear risk of bias.

Sequence Generation

Two studies were assessed as being at low risk of bias for sequence generation. In DECRA, investigators used a stratified procedure and patients were randomized in blocks of two to four according to both the particular center and the technique used to measure ICP; an automated telephone service was used to convey information to centers. In RESCUEicp, a central telephone randomization service was used, and participants were allocated in permuted blocks of random sizes with stratification according to trial site. In the Taylor et al. study, bias was rated as "high" [39]. This is because, after two allocations of four blocks of children each, investigators apparently changed to using the Zelen method of randomization [41], which requires informed consent after generation of sequence.

Allocation Concealment

Both DECRA and RESCUEicp met criteria for low risk of bias. In DECRA, allocation was performed by independent researchers and conveyed by telephone [11]; in RESCUEicp, concealment was assured because the service employed by the trialists did not release the randomization code until a participant had reached the third stage of the treatment protocol, at which point the decision to perform DC or not was carried out [10]. In the Taylor et al. trial, allocation concealment was initially done using sealed opaque envelopes [39], but this trial has nevertheless been rated as being at a high risk of bias because this method only applied to the first two blocks randomized (8 children), after which Zelen randomization was used and allocation could not be concealed.

Blinding of Participants, Personnel, and Outcome Assessors

Lack of concealment of treatment status is an intrinsic limitation of any decompressive study. All three studies were necessarily judged at high risk of bias for blinding of participants and personnel. Outcome assessors were kept blind to treatment status in all three studies, leading to uniform assessments of low risk of bias for this domain.

Incomplete Outcome Data (Attrition Bias)

Both Taylor et al. and DECRA were assessed as being at low risk of bias for this domain. Taylor et al. investigators planned to conduct analyses by intention-to-treat, but were not required to do so as no participant crossed over and no participant who survived the first week was later lost to follow-up [39]. In the RESCUEicp trial, incomplete data were few and 93% [373/398] of the sample were evaluated at 12 months. Missing outcome data were not imputed, but the investigators performed a sensitivity analysis for the primary-outcome measure in the per-protocol population. The risk of bias for the DECRA study was assessed as unclear for this domain. No patients were lost to follow-up; however, "fifteen patients (18%) in the control group underwent delayed decompressive craniectomy as a lifesaving

intervention, according to the protocol" [11]. Of these, four patients in the standard care group, received DC "less than 72 hours after admission, contrary to protocol" [11]. Investigators reported conducting all analyses according to the intention-to-treat principle; however, the change in the primary outcome on the basis of interim analysis, combined with the fact that so many patients in the control group underwent DC, makes the intention-to-treat analysis of unclear utility.

Selective Reporting (Reporting Bias)

The DECRA was assessed to be at low risk of bias for this category [11] despite the change in the primary outcome noted elsewhere in this review. The RESCUEicp was also considered to be at low risk of bias. In the trial conducted by Taylor et al., all expected outcomes were reported, but in the absence of access to a protocol for this trial, we decided to assess it as being at unclear risk of bias [39].

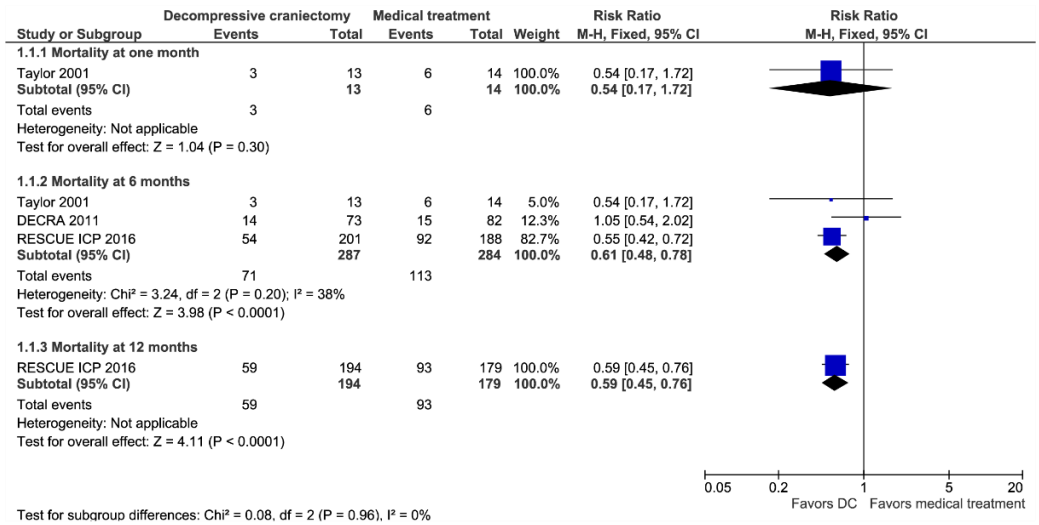

Figure 2. Forest plots summarize the effect of decompressive craniectomy (DC) on mortality. DC (intervention) versus medical treatment (control). M-H: Mantel-Haenszel. In this chapter we discuss only 6-month mortality. However, the 30-day and 12-month mortality are also included in the full version of this review.

Baseline Imbalances

In the Taylor et al. study, both the control and the treatment groups were well balanced in significant covariates such as age, Glasgow Coma Scale score at randomization, pupillary reactivity, and ICP at baseline [39]. In the DECRA study, randomization did not achieve balanced groups in one of the most significant covariates, pupillary reactivity. Bilateral unreactive pupils were present at baseline in 27% of the patients in the DC arm but only in 12% of patients in the control group [11]. In the RESCUEicp study, both groups were quite

similar at randomization apart from history of drug and alcohol use, and therefore no significant bias was introduced because of the differences of the patients at baseline [10].

EFFECTS OF INTERVENTIONS

Mortality at 6 Months after Injury

All included studies [10, 11, 39] reported results for the 6-month outcome, as summarized in Figure 2. In the pediatric study [39], DC reduced the ARR for death by 19.8% (95% CI: -15 to 48.5%, NNT = 5). In adults, the RESCUEicp trial showed that DC achieved a 22.1% ARR (95% CI: 13 to 31%, NNT = 5). In the DECRA study (lower ICP threshold), no significant difference in the ARR was found. Pooled results for the three studies did indicate that the risk of death at 6 months following injury was lower with DC than medical treatment (RR 0.61, 95% CI: 0.48 to 0.78; participants = 571; I^2 = 38%).

Death/Vegetative versus Alive at 6 Months

Two of the included studies [10, 11] reported these results for the 6-month outcome (n = 544). We could not get the results of the Taylor et al. study for this combined outcome. In the DECRA study (lower ICP threshold), an increase in the risk of death/vegetative state was found for this combined outcome. In the RESCUEicp, however, a 15.7% ARR in this outcome was observed (95% CI: 6 to 25%), and the NNT to avoid this combined outcome was seven patients. Pooled results for the two studies did indicate that the combined risk of death and vegetative status at 6 months following injury was decreased by DC versus medical treatment (RR 0.82, 95% CI: 0.66 to 1.02; participants = 544).

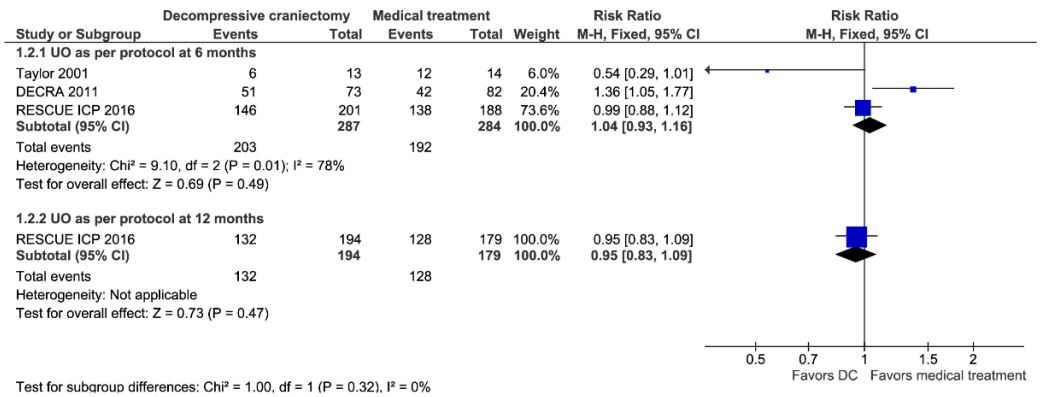

Figure 3. Forest plots summarize the effect of decompressive craniectomy (DC) on unfavorable outcome (UO) as defined in the original Cochrane protocol. DC (intervention) versus medical treatment (control). The primary outcomes for this systematic review were neurological outcome at 6 or 12 months, evaluated with the traditional dichotomized Glasgow Outcome Scale (GOS) or the extended GOS (GOS-E). This outcome is analyzed by dichotomizing the GOS/GOS-E into the categories of bad/unfavorable outcome (death, vegetative state, or severe disability) and good/favorable outcome (moderate disability or good recovery).

Six-Month Outcome Categorized as Good or Bad

All three studies reported results for the 6-month outcome (n = 571) [10, 11, 39]. Forest plots for this outcome summarize these results in Figure 3.

In the pediatric study, DC reduced the ARR for a bad outcome by 39% (95% CI, 39 to 65%) [39]. The NNT to avoid an unfavorable outcome (death, vegetative status, and severe disability) was three children. In adults, the RESCUEicp trial did show that DC did not reduce the ARR of an unfavorable outcome when compared with medical treatment [10]. In the DECRA (lower ICP threshold), the ARR for a bad outcome significantly increased in the DC group when compared to the standard treatment. The ARR was -19% (95% CI: -3 to -33%) [11]. However, this difference was in part justified by the imbalance between baseline characteristics of the control and treatment groups, as remarked by the authors and also discussed elsewhere [11, 42].

Pooled results indicate no significant difference between DC and medical treatment regarding the risk of an unfavorable outcome at 6 months following injury between groups (RR 1.08, 95% CI: 0.93 to 1.20; participants = 579; studies = 3) albeit heterogeneity was very high, $I^2 = 78\%$.

ICP Reduction

Pooled results for the Taylor et al. and DECRA studies, which reported data in a format suitable for meta-analysis, indicate that DC was superior to medical treatment in achieving a 5-mm-Hg reduction within 48 hours [11, 39]. ICP data from the RESCUEicp could not be pooled, as ICP changes were calculated in multiple ways. Results are consistent, however, with the findings of the meta-analysis and show a positive effect for the outcome of ICP control, manifestly in excess of the goal of a 5 mm Hg reduction following intervention.

DISCUSSION

Since the first version of this systematic review was published in 2006, views on DC in patients with acute neurological injuries have changed significantly. The major shift has been in perceptions of the medical community about the role of DC in the management of acute brain injuries. For most surgeons and intensivists, DC was long considered a “primitive” and “obsolete” surgical procedure for managing refractory increases in ICP. However, multiple retrospective and prospective but non-randomized clinical trials have shown that DC is effective in reducing the risk of death in TBI patients with high ICP and in managing swelling-induced brain herniation in patients with large ischemic stroke or acute spontaneous intracerebral hemorrhages [43-46]. Another reason that explains why DC is on the rise is the influence of the use of DC by military neurosurgeons in war-related head injuries [47]. In addition, robust evidence obtained from multicenter RCTs shows that DC significantly reduces mortality and improves functional neurological outcome in patients with large middle cerebral artery ischemic stroke and brain edema at any age [45, 48-50].

Since our first review was published in 2006, not only the incidence of high ICP but also its definition and evaluation have significantly changed in closed TBI because of the experience in the analysis of many multicenter drug studies funded by the pharmaceutical industry. In the analyses of these trials, two points have been raised: first, different methods were used to define high ICP and to evaluate its burden and the effectiveness of different drug and non-drug therapies in controlling it; second, the number of patients with increased ICP was significantly lower than in studies conducted in the 1990s, as already discussed in the Introduction of this review. The different studies conducted so far have used a wide variety of methods to record ICP data (nurse's end-hour ICP, hourly recordings, minute-by-minute digitally recorded data, etc.), introducing wide variability in the methodology to present the data and summarize it. As a consequence, the summary measures and the methods to analyze ICP are still widely heterogeneous. The mean ICP, the time or the percentage of time above a certain ICP threshold (usually above 20 mm Hg), the standardized area under the curve, or the percentage of patients requiring second-tier therapeutic measures are among these. Thus, the true incidence of high ICP in severe TBI is unreliable, and the effectiveness of different treatments to maintain ICP under control is difficult to determine.

Recently, the "dose of ICP" concept has been proposed and used as the best measure to summarize the burden of ICP [51, 52]. The dose of ICP is defined as the area under the curve above the threshold of 20 mm Hg [51] calculated by using high-resolution ICP recording – ranging from a measure every 6 seconds to minute-by-minute. This methodology allows for calculation of the ICP dose and considers all intensity thresholds above 10 mm Hg, not just the traditional 20 mm Hg threshold [51]. By using this approach, Güiza et al. have been able to show that moderate ICP increases of between 15 and 20 mm Hg are, if sustained, related to unfavorable neurological outcomes [51]. It has been shown that the critical ICP threshold for causing brain damage in TBI patients cannot be generalized and that this threshold is patient-dependent. The ICP cutoff, at which the brain suffers secondary damage, depends on the localization of the brain lesion and its characteristics (focal or diffuse lesion), the insult duration or "dose," age, cerebral perfusion pressure, and the autoregulatory status of the patient. It has been suggested that "pressure times time dose" expressed in mm Hg/hour is a much better measure of the burden of ICP than calculations of frequency or duration of episodes of high ICP [52].

Because of this relatively new information and because we believe this variable was difficult to compare among included studies, we changed the way outcomes in ICP have been evaluated and reported in this review upgrade. In addition, most neurosurgeons and intensivists agree that DC, when appropriately performed, significantly reduces ICP in most patients. In a systematic review on the effect of DC on postoperative ICP, Bor-Seng-Shu et al. showed that DC significantly decreases ICP and increases cerebral perfusion pressure in TBI patients with refractory high ICP [53]. However, the main disagreement and lack of evidence concern whether this ICP reduction is translated to reduced mortality and to a better neurological outcome for the survivors.

SUMMARY OF THE MAIN RESULTS

Mortality at 6 Months

All included studies presented data for the traditional 6-month mortality. In the two studies in which the ICP threshold was the most widely accepted (≥25 mm Hg), the ARR for death was significantly reduced. In the pediatric study, DC reduced the ARR for death by 19.8% (95% CI: -15 to 48.5%) [39]. In RESCUEicp, in which the majority of participants were adults, the results showed that DC had an ARR for death of 22.1% (NNT = 5) [10]. In the DECRA study (lower ICP threshold), no statistically significant difference in the ARR for death at 6 months was found between the intervention and the control groups [11]. Pooled results for the three studies did indicate that the risk of death at 6 months following injury was lower for DC than medical treatment (RR 0.61, 95% CI: 0.48 to 0.78). In the two studies in which the conventional ICP threshold was used, the ARR for death at 6 months was significantly reduced, although the risk of bias and the low sample size in Taylor's study made these results statistically non-significant. However, in the DECRA study, DC did not change the ARR for mortality at 6 months [11]. Only the RESCUEicp reported the mortality at 12 months [10]. Again, the ARR for death at this time point was significantly modified by DC compared to medical treatment only. ARR for death at 12 months was 21.5% (NNT = 5) (Figure 2).

In summary, all studies but DECRA showed a very significant reduction in mortality at any time point when DC was used to control refractory high ICP. The characteristics of and caveats about the DECRA study regarding the low ICP threshold to indicate DC and the suboptimal surgical technique have been summarized in this review and discussed in detail elsewhere [42]. The DECRA study showed that when the trigger to define refractory ICP is set low (20 mm Hg), DC is not superior to the standard of care in the management of patients with severe TBI [11].

Death/Vegetative versus Alive Outcome at 6 Months

The evidence that DC improves 6-month mortality in patients with ICP ≥25 mm Hg is of high quality for adults but low quality for children. However, similar to the results of DC in malignant infarction, there are concerns that DC may prolong poor quality life by increasing the number of survivors with major disability [45, 48]. The Glasgow Outcome Scale (GOS) is a global scale originally described by Jennet and Bond in 1975 for evaluating TBI outcome [33]. The GOS scale rates a patient's status into one of five ordered categories: dead, vegetative state, severe disability, moderate disability, or good recovery. The lack of positive results in all phase III RCTs led some authors to question the sensitivity of the GOS to detect small but clinically relevant treatment effects [34]. Because of this, the extended GOS (GOS-E) introduced by Jennett et al. in 1981 [35] was the scale recommended by the IMPACT group (International Mission for Prognosis and Analysis of Clinical Trials in TBI) as the optimal outcome scale.

Traditionally, TBI trials have been analyzed by dichotomizing the GOS into the categories of bad/unfavorable outcome (death, vegetative state, or severe disability) and

good/favorable outcome (moderate disability or good recovery). This was essentially an arbitrary decision based on the tradition of considering any type of dependence for activities of daily life as a bad outcome. In the RESCUEicp trial, the authors decided to include patients in the "upper severe disability" category, i.e., patients independent at home, in the favorable outcome group [10]. However, the only justification for this new cutoff that the authors gave to support this decision was that "it was agreed a priori by the trial team and the steering committee that the upper severe-disability category would be included in the definition of favorable outcome" [10]. Therefore, this was another arbitrary cutoff that introduced bias into the interpretation of the outcome results. In addition, Wilson et al. remarked that the highest level of interobserver disagreement when using the GOSE-E was found specifically in scoring this "upper severe disability" category [36].

Because of this, and with all the caveats to be discussed later, for this review we decided to use the conventional dichotomy and then added to the analysis another option, which was to group together dead and vegetative state and compare this outcome with the number of patients who were alive. This is another option available to interpret outcome data in TBI trials, one justified by the fact remarked upon by Weir et al. that any patient in a vegetative state could never be regarded as experiencing a favorable outcome, even if the baseline prognosis is strongly adverse [34]. However, the use of the degree of dependency for the daily life activities to define an unfavorable/bad outcome and who should define this — patients versus health-care providers — are still a matter of debate.

Conventional Dichotomized Neurological Outcome at 6 Months

As described previously, in this analysis we used the conventional cutoff for favorable (good recovery and moderate disability) and unfavorable (death, vegetative state, and severe disability) outcomes. All three studies reported results for this outcome at 6 months [10, 11, 39]. In the pediatric study [39], DC significantly reduced the ARR for a bad outcome by 39% (NNT = 3). In adults, the RESCUEicp showed that DC did not reduce the ARR of an unfavorable outcome when compared with medical treatment [10]. In the DECRA study the ARR for a bad outcome significantly increased in the DC group when compared to the standard treatment [11] (Figure 3). However, this difference was in part accounted for by the imbalance between baseline characteristics of the control and treatment groups [11, 42].

Completeness and Applicability of Evidence

We included three studies, all of which sought to address the questions relevant to this review. Regarding ICP control, the results are quite convincing and in line with most previous non-randomized clinical trials showing that ICP was significantly reduced after DC [53]. Regarding mortality in children, although the results are clear regarding the ARR for death, the results were not statistically significant owing to the small number of patients enrolled. Because of this, the evidence should be considered of "low quality" according to the GRADE guidelines [54]. A rough estimate of the number of children needed to enroll in an RCT to show a significant difference as high as 20%, as shown in the Taylor et al. study, would be 188 patients (94 per arm in a 1/1 allocation ratio) for a power of 80% and an alpha error of

0.05. The results of Taylor et al. in children and of the RESCUEicp for adults make it unlikely that any internal review board would grant ethical approval to enroll patients in a new trial. This is one of the cases in which, although an additional trial could upgrade the degree of evidence, the clinical equipoise for raising the evidence bar could be difficult to achieve or might even be ethically questionable.

All three studies included managed severe TBI patients with high ICP according to some iteration of the BTF guidelines; therefore, the treatments used are consistent with the management that many patients receive in some high-income countries. However, the external validity of the recommendations established here are limited for low- and middle-income countries. This is because the main cornerstone of managing high ICP in all versions of the BTF guidelines is the monitoring of ICP, which is generally available only in high-income countries. Indeed, a major limitation of the current version of this review is that the question of how and when to decide to conduct DC in patients without ICP monitoring cannot be answered. Therefore, clinicians reading this review should not draw any conclusions regarding whether the recommendations given here can be extrapolated to patients managed without any ICP probe implanted. Indeed, the data presented here cannot be integrated to any patient management protocol when any surrogate measures of high ICP, such as the status of the basal cisterns or midline shift in the CT scan, are used. Therefore, the results and recommendations of this review are not applicable outside those institutions in high-income countries where ICP is routinely monitored.

Our review did not allow for in-depth consideration of the complications of DC and the required mandatory second surgery to repair the iatrogenic skull defect in survivors (cranioplasty or bone flap reposition). Early complications of DC have been recorded in most trials, but no trial has documented the complications related to bone replacement or cranioplasty in survivors. Cranioplasty is usually deferred a variable time after DC in different institutions. In addition, the primary endpoint of all three included studies was the 6-month outcome. Some of the early or late surgically related complications of DC are, among others, expansion of preexistent hemorrhagic contusions, development of new ipsilateral or contralateral hematomas (subdural or intracerebral), seizures, CSF leaks, subdural hygroma or brain herniations through the craniectomy defect, posttraumatic hydrocephalus, or the syndrome of the trephined [55, 56]. Kurland et al. conducted a systematic review on the short- and medium-term intracranial complications of DC. In their review they included not only RCTs but all types of studies [56]. This review identified many DC-related complications of three major types: hemorrhagic, infectious/inflammatory, and disturbances of the CSF compartment. Kurland et al. reported that the frequency of complications after DC was 13.4%. On average, 6.4% of the patients presented complications related to bone replacement or cranioplasty [56].

CONCLUSION

- In the pediatric population (patients ≤ 18 years old), decompressive surgery reduces the risk of death and other unfavorable outcomes (vegetative status and severe disability) in patients with ICP refractory to medical treatment. However, the quality of evidence to support this is low and is based on a single-center randomized trial

that showed that DC, even without opening the dura mater, is effective in reducing ICP and mortality, and in improving functional outcome. However, leaving the dura mater intact should be considered a suboptimal procedure, even in a pediatric population. In addition, this study was very small and was assessed to have a high risk of bias on important domains, and so the results must be interpreted with caution. Although ideally these results should be replicated in a larger clinical trial, it is unlikely that any ethical review board would approve a second trial in children on the basis of scientific reasons alone. Because of this, DC is a reasonable treatment to include as a last step in children with high ICP refractory to all conventional medical options. We need to wait for the publication of the RESCUEicp results in children (n = 56) to see whether adding new data may improve the quality of evidence for DC in the pediatric population.

- In adult patients (> 18 years old) with severe TBI, DC in those with refractory moderate high ICP (> 20 mm Hg threshold) does not reduce mortality or decrease the risk of an unfavorable outcome (evidence of moderate quality). This conclusion is based on the results of the DECRA study and therefore should be interpreted with caution because of the high risk of bias of the study, the imbalance in the baseline characteristics of the patients, and the suboptimal surgical procedure that was used in this trial. Whether further studies with the same inclusion criteria but different surgical technique will change this conclusion cannot be predicted. In addition, the lack of clinical equipoise to conduct new trials at this lower ICP threshold makes it very difficult to change our certainty in the quality of evidence.
- In adult patients with severe TBI and high ICP (≥ 25 mm Hg) refractory to conventional medical treatment based on the BTF guidelines, DC has a strong effect in reducing mortality at 6 months (ARR: 19.8%) and 12-months (ARR: 21.5%) after injury. The evidence supporting this conclusion is of high-quality and is based on the results of the RESCUEicp trial.
- In adult patients with severe TBI and high ICP (≥ 25 mm Hg) refractory to conventional medical treatment, DC significantly reduces mortality at 6 and 12 months after injury but does not decrease the risk of an unfavorable outcome measured in the traditional way of dichotomizing either the GOS or GOS-E into favorable or unfavorable outcome (death, vegetative state, and severe disability). This conclusion is of high quality and is based on the results of the RESCUEicp. Therefore, increased survival may occur at the expense of surviving with a more or less severe degree of disability. Nevertheless, the degree of disability that should be considered a bad outcome is a matter of considerable debate, and is a variable that should be self-reported by patients and caregivers and not by health professionals who are usually highly biased. In most Western cultures, individuals, if they are able to consent, or their legal representatives, if they are not, are the target of the informed consent. However, in other cultures such as Asian cultures [57], even if the patients are competent, the families have the obligation to protect the common interests of the whole family and therefore they take a very active role in the medical decision process. Therefore, the fact that DC improves the chance for survival but with significant disability needs to be conveyed to the patient's family or legal representatives before DC is conducted. This way, they will have all the information

needed to participate in the medical decision process and take a decision that respects the patient's preferences, expectations, and values.

- An unavoidable major limitation of this review is that how and when to decide to conduct DC in patients without ICP monitoring cannot be answered. Therefore, clinicians reading this review should not draw any conclusions regarding whether the recommendations given here can be extrapolated to patients managed without ICP monitoring. The relatively high cost of ICP monitoring and the lack of robust evidence of its usefulness will probably limit its implementation in low- and middle-income countries in the short-term future. In high-income countries, ICP monitoring is now routinely conducted in many centers managing severe TBI. Therefore, the results and recommendations of this review are not applicable outside those centers where ICP is routinely monitored.

To refine the role of secondary DC in the management of high ICP in patients for whom conventional measures have failed and to increase the level and quality of the available evidence, new clinical studies are still needed, especially in the pediatric population. However, the difficulties in designing, implementing, and funding adequately powered RCTs are considerable. Considering the size of the strong effect that DC has in reducing mortality in adults shown by the RESCUEicp, new trials in adults should focus on identifying the best biomarkers to define survival with an acceptable quality of life, the best timing for DC, the most appropriate surgical technique, and whether some synergistic treatments—hypothermia, barbiturates, or any other neuroprotective drugs—used together with DC may improve the functional outcome and the quality of life of survivors. The better understanding of the pathophysiology of TBI gathered in the past decade, the data obtained from multimodal neuromonitoring, and some of the lessons learned in previous clinical trials should be taken into consideration and applied to any new controlled study.

ACKNOWLEDGMENTS

We gratefully acknowledge the assistance of the following people during the writing of the final report over many versions: Katharine Ker, Review Group Co-ordinator of The Cochrane Injuries Group, for continuous help throughout the writing of the review; Karen Blackhall and Deirdre Beecher, Trials Search Coordinators, for helping us to conduct the electronic searches for this study and in obtaining papers that were difficult to locate; and Paola Tejada, Fundacion MEDITECH, Centro Adherente Cochrane, Universidad Surcolombiana Neiva (Colombia), for providing an independent evaluation of the DECRA study.

REFERENCES

[1] Sahuquillo, J; Dennis, JA. Decompressive craniectomy for the treatment of high intracranial pressure in closed traumatic brain injury. *The Cochrane database of systematic reviews*. 2017.

[2] Honeybul, S; Gillett, GR; Ho, KM; Janzen, C; Kruger, K. Is life worth living? Decompressive craniectomy and the disability paradox. *Journal of neurosurgery*., 2016, 125(3), 775-8.

[3] De, Silva, MJ; Roberts, I; Perel, P; Edwards, P; Kenward, MG; Fernandes, J; et al. Patient outcome after traumatic brain injury in high-, middle- and low-income countries: analysis of data on 8927 patients in 46 countries. *International journal of epidemiology*., 2009, 38(2), 452-8.

[4] Meaney, DF; Morrison, B; Dale, Bass, C. The mechanics of traumatic brain injury: a review of what we know and what we need to know for reducing its societal burden. *Journal of biomechanical engineering*., 2014, 136(2), 021008.

[5] Fearnside, DF; Simpson, DA. Epidemiology. In: Reilly P, Bullock MR, editors. *Head Injury Pathophysiology and Management of Severe Closed Injury*. London, UK: Chapman and Hall, 1997, 3-23.

[6] Maas, AI; Steyerberg, EW; Murray, GD; Bullock, R; Baethmann, A; Marshall, LF; et al. Why have recent trials of neuroprotective agents in head injury failed to show convincing efficacy? A pragmatic analysis and theoretical considerations. *Neurosurgery*., 1999, 44(6), 1286-98.

[7] Sahuquillo, J; Poca, MA. Diffuse Axonal Injury after Head Trauma. A Review. In: Pickard J, Dolenc VV, Lobo-Antunes J, Reulen HJ, Sindou M, Strong AJ, et al., editors. *Advances and Technical Standards in Neurosurgery* Vol 27., 27. Wien, Springer-Verlag, 2002, 23-86.

[8] Sahuquillo, J; Arikan, F. Decompressive craniectomy for the treatment of refractory high intracranial pressure in traumatic brain injury. *The Cochrane database of systematic reviews*., 2006(1), Cd003983.

[9] Kjellberg, RN; Prieto, A; Jr. Bifrontal decompressive craniotomy for massive cerebral edema. *Journal of neurosurgery*., 1971, 34(4), 488-93.

[10] Hutchinson, PJ; Kolias, AG; Timofeev, IS; Corteen, EA; Czosnyka, M; Timothy, J; et al. Trial of Decompressive Craniectomy for Traumatic Intracranial Hypertension. *The New England journal of medicine*., 2016, 375(12), 1119-30.

[11] Cooper, DJ; Rosenfeld, JV; Murray, L; Arabi, YM; Davies, AR; D'Urso, P; et al. Decompressive craniectomy in diffuse traumatic brain injury. *The New England journal of medicine.*, 2011, 364(16), 1493-502.

[12] Marmarou, A; Anderson, RL; Ward, JD; Choi, SC; Young, HF. Impact of ICP instability and hypotension on outcome in patients with severe head trauma. *Journal of neurosurgery*., 1991, 75, S59-S66.

[13] Juul, N; Morris, GF; Marshall, SB; Marshall, LF. Intracranial hypertension and cerebral perfusion pressure: influence on neurological deterioration and outcome in severe head injury. The Executive Committee of the International Selfotel Trial. *Journal of neurosurgery*., 2000, 92(1), 1-6.

[14] Narayan, RK; Kishore, PR; Becker, DP; Ward, JD; Enas, GG; Greenberg, RP; et al. Intracranial pressure: to monitor or not to monitor? A review of our experience with severe head injury. *Journal of neurosurgery*., 1982, 56(5), 650-9.

[15] Maas, AI; Murray, G; Henney, H; 3rd; Kassem, N; Legrand, V; Mangelus, M; et al. Efficacy and safety of dexanabinol in severe traumatic brain injury: results of a phase III randomised, placebo-controlled, clinical trial. *The Lancet Neurology*., 2006, 5(1), 38-45.

[16] Bullock, MR; Chesnut, RM; Clifton, G; Ghajar, J; Marion, D; Narayan, R; et al. Guidelines for the management of severe head injury. Brain Trauma Foundation, American Association of Neurological Surgeons, Joint Section on Neurotrauma and Critical Care. *J of Neurotrauma*., 1996, 13(11), 641-734.

[17] BTF. [Available from: https: //braintrauma.org/uploads/03/12/Guidelines_for_ Management_of_Severe_TBI_4th_Edition.pdf.

[18] Bratton, SL; Chestnut, RM; Ghajar, J; McConnell, Hammond, FF; Harris, OA; Hartl, R; et al. Guidelines for the management of severe traumatic brain injury (3rd Edition). *Journal of neurotrauma*., 2007, 24 Suppl 1, S1-106.

[19] Roberts, I; Sydenham, E. Barbiturates for acute traumatic brain injury. *Cochrane Database of Systematic Reviews*. UK: John Wiley & Sons Ltd: 2012.

[20] Kocher, T. Hirnerschtterung, Hirndruck und chirurgische Eingriffe bei Hirnkrankheitende. *Die Therapie des Hirndruckes*. Vienna: A, H"Ider., 1901, 262-66.

[21] Cushing, H. The establishment of cerebral hernia as a decompressive measure for inaccessible brain tumor: With the description of intramuscular methods of making the bone defect in temporal and occipital regions. *Gynecology and Obstetrics*., 1905, 1, 297-314.

[22] Wilson, MH. Monro-Kellie 2.0: The dynamic vascular and venous pathophysiological components of intracranial pressure. *Journal of cerebral blood flow and metabolism: official journal of the International Society of Cerebral Blood Flow and Metabolism*., 2016, 36(8), 1338-50.

[23] Aarabi, B; Hesdorffer, DC; Ahn, ES; Aresco, C; Scalea, TM; Eisenberg, HM. Outcome following decompressive craniectomy for malignant swelling due to severe head injury. *Journal of neurosurgery*., 2006, 104(4), 469-79.

[24] Lin, DJ; Lam, FC; Siracuse, JJ; Thomas, A; Kasper, EM. "Time is brain" the Gifford factor – or: Why do some civilian gunshot wounds to the head do unexpectedly well? A case series with outcomes analysis and a management guide. *Surgical neurology international*. 2012, 3, 98.

[25] Qiu, B; Xu, S; Fang, L; Chotai, S; Li, W; Qi, S. Surgical strategies for neurological function preservation in severe brain contusion. *Turkish neurosurgery*., 2012, 22(3), 329-35.

[26] Rubiano, AM; Villarreal, W; Hakim, EJ; Aristizabal, J; Hakim, F; Diez, JC; et al. Early decompressive craniectomy for neurotrauma: an institutional experience. *Ulusal travma ve acil cerrahi dergisi = Turkish journal of trauma & emergency surgery: TJTES*., 2009, 15(1), 28-38.

[27] Guerra, WK; Piek, J; Gaab, MR. Decompressive craniectomy to treat intracranial hypertension in head injury patients. *Intensive care medicine*., 1999, 25(11), 1327-9.

[28] Clark, K; Nash, TM; Hutchison, GC. The failure of circumferential craniotomy in acute traumatic cerebral swelling. *Journal of neurosurgery*., 1968, 29(4), 367-71.

[29] Munch, E; Horn, P; Schurer, L; Piepgras, A; Paul, T; Schmiedek, P. Management of severe traumatic brain injury by decompressive craniectomy. *Neurosurgery*., 2000, 47(2), 315-22, discussion 22-3.

[30] Ruf, B; Heckmann, M; Schroth, I; Hugens-Penzel, M; Reiss, I; Borkhardt, A; et al. Early decompressive craniectomy and duraplasty for refractory intracranial hypertension in children: results of a pilot study. *Critical care* (London, England). 2003, 7(6), R133-8.

[31] Huang, X; Wen, L. Technical considerations in decompressive craniectomy in the treatment of traumatic brain injury. *International journal of medical sciences*., 2010, 7(6), 385-90.

[32] Higgins, JPT; Green, S. *Cochrane Reviewers' Handbook* 5.1.02011.

[33] Jennett, B; Bond, M. Assessment of outcome after severe brain damage. *Lancet (London, England)*., 1975, 1(7905), 480-4.

[34] Weir, J; Steyerberg, EW; Butcher, I; Lu, J; Lingsma, HF; McHugh, GS; et al. Does the extended Glasgow Outcome Scale add value to the conventional Glasgow Outcome Scale? *Journal of neurotrauma*., 2012, 29(1), 53-8.

[35] Jennett, B; Snoek, J; Bond, MR; Brooks, N. Disability after severe head injury: observations on the use of the Glasgow Outcome Scale. *Journal of neurology, neurosurgery, and psychiatry*., 1981, 44(4), 285-93.

[36] Wilson, JT; Slieker, FJ; Legrand, V; Murray, G; Stocchetti, N; Maas, AI. Observer variation in the assessment of outcome in traumatic brain injury: experience from a multicenter, international randomized clinical trial. *Neurosurgery*., 2007, 61(1), 123-8, discussion 8-9.

[37] Honeybul, S; Ho, KM; Lind, CRP; Gillett, GR. The current role of decompressive craniectomy for severe traumatic brain injury. *Journal of clinical neuroscience, official journal of the Neurosurgical Society of Australasia*., 2017, 43, 11-5.

[38] *Review Manager* (Rev Man) Version 5.3 [program]. Copenhagen: The Nordic Cochrane Center, 2014.

[39] Taylor, A; Butt, W; Rosenfeld, J; Shann, F; Ditchfield, M; Lewis, E; et al. A randomized trial of very early decompressive craniectomy in children with traumatic brain injury and sustained intracranial hypertension. *Child's nervous system: ChNS: official journal of the International Society for Pediatric Neurosurgery*., 2001, 17(3), 154-62.

[40] Servadei, F. Clinical value of decompressive craniectomy. *The New England journal of medicine*., 2011, 364(16), 1558-9.

[41] Zelen, M. A new design for randomized clinical trials. *The New England journal of medicine*., 1979, 300(22), 1242-5.

[42] Sahuquillo, J; Martinez-Ricarte, F; Poca, MA. Decompressive craniectomy in traumatic brain injury after the DECRA trial. Where do we stand? *Current opinion in critical care*., 2013, 19(2), 101-6.

[43] Mitchell, P; Gregson, BA; Vindlacheruvu, RR; Mendelow, AD. Surgical options in ICH including decompressive craniectomy. *Journal of the neurological sciences*., 2007, 261(1-2), 89-98.

[44] Moussa, WM; Khedr, W. Decompressive craniectomy and expansive duraplasty with evacuation of hypertensive intracerebral hematoma, a randomized controlled trial. *Neurosurgical review*., 2017, 40(1), 115-27.

[45] Mohan, Rajwani, K; Crocker, M; Moynihan, B. Decompressive craniectomy for the treatment of malignant middle cerebral artery infarction. *British journal of neurosurgery*., 2017, 1-9.

[46] Simard, JM; Sahuquillo, J; Sheth, KN; Kahle, KT; Walcott, BP. Managing malignant cerebral infarction. *Current treatment options in neurology*., 2011, 13(2), 217-29.

[47] Ecker, RD; Mulligan, LP; Dirks, M; Bell, RS; Severson, MA; Howard, RS; et al. Outcomes of 33 patients from the wars in Iraq and Afghanistan undergoing bilateral or bicompartmental craniectomy. *Journal of neurosurgery*., 2011, 115(1), 124-9.

[48] Cruz-Flores, S; Berge, E; Whittle, IR. Surgical decompression for cerebral oedema in acute ischaemic stroke. *The Cochrane database of systematic reviews*., 2012, 1, Cd003435.

[49] Juttler, E; Unterberg, A; Woitzik, J; Bosel, J; Amiri, H; Sakowitz, OW; et al. Hemicraniectomy in older patients with extensive middle-cerebral-artery stroke. *The New England journal of medicine.*, 2014, 370(12), 1091-100.

[50] Juttler, E; Schwab, S; Schmiedek, P; Unterberg, A; Hennerici, M; Woitzik, J; et al. Decompressive Surgery for the Treatment of Malignant Infarction of the Middle Cerebral Artery (DESTINY): a randomized, controlled trial. *Stroke*., 2007, 38(9), 2518-25.

[51] Guiza, F; Depreitere, B; Piper, I; Citerio, G; Chambers, I; Jones, PA; et al. Visualizing the pressure and time burden of intracranial hypertension in adult and paediatric traumatic brain injury. *Intensive care medicine*., 2015, 41(6), 1067-76.

[52] Kahraman, S; Dutton, RP; Hu, P; Xiao, Y; Aarabi, B; Stein, DM; et al. Automated measurement of "pressure times time dose" of intracranial hypertension best predicts outcome after severe traumatic brain injury. *The Journal of trauma*., 2010, 69(1), 110-8.

[53] Bor-Seng-Shu, E; Figueiredo, EG; Amorim, RL; Teixeira, MJ; Valbuza, JS; de, Oliveira, MM; et al. Decompressive craniectomy: a meta-analysis of influences on intracranial pressure and cerebral perfusion pressure in the treatment of traumatic brain injury. *Journal of neurosurgery*., 2012, 117(3), 589-96.

[54] Guyatt, G; Eikelboom, JW; Akl, EA; Crowther, M; Gutterman, D; Kahn, SR; et al. A guide to GRADE guidelines for the readers of JTH. *Journal of thrombosis and haemostasis: JTH*. 2013, 11(8), 1603-8.

[55] Alvis-Miranda, H; Castellar-Leones, SM; Moscote-Salazar, LR. Decompressive Craniectomy and Traumatic Brain Injury: A Review. *Bulletin of emergency and trauma*., 2013, 1(2), 60-8.

[56] Kurland, DB; Khaladj-Ghom, A; Stokum, JA; Carusillo, B; Karimy, JK; Gerzanich, V; et al. Complications Associated with Decompressive Craniectomy: A Systematic Review. *Neurocritical care*., 2015, 23(2), 292-304.

[57] Lin, ML; Kan, WM; Chen, CH. Patients' perceptions and expectations of family participation in the informed consent process of elective surgery in taiwan. *Asian Nurs Res (Korean Soc Nurs Sci)*., 2012, 6(2), 55-9.

In: Encyclopedia of Surgery (22 Volume Set)
Editors: Andreas Lehrer and Kristin Mueller
ISBN: 978-1-53618-329-0
© 2020 Nova Science Publishers, Inc.

Chapter 233

DECOMPRESSIVE CRANIECTOMY IN PEDIATRIC TBI

David S. Hersh, MD and Mari L. A. Groves*, MD
Department of Neurosurgery, University of Maryland, Baltimore, MD, US
Division of Pediatric Neurosurgery, Department of Neurosurgery,
Johns Hopkins University, Baltimore, MD, US

ABSTRACT

Traumatic brain injury (TBI) is the leading cause of death and disability in children older than age 1, adolescents, and young adults. Pediatric patients have unique anatomical and physiological features that influence their susceptibility to both primary and secondary injury. Although the management of pediatric TBI patients previously had been extrapolated from the adult literature, the importance of research studies and practice protocols that are specific to the pediatric population is becoming increasingly recognized. In particular, the indications, outcomes, and complications of decompressive craniectomy in pediatric TBI patients have been reported by various groups. As a result, decompressive craniectomy has been incorporated into the Guidelines for the Acute Medical Management of Severe Traumatic Brain Injury in Infants, Children, and Adolescents, which recommend that surgery may be considered for pediatric TBI patients who are showing early signs of neurologic deterioration or herniation or are developing intracranial hypertension refractory to medical management during the early stages of their treatment. However, further work is necessary to identify patients who are suitable candidates for decompression, in the ongoing effort to optimize the outcomes of pediatric patients following TBI.

Keywords: pediatric, traumatic brain injury, decompressive craniectomy, cranioplasty

* Corresponding Author Email: MGroves@som.umaryland.edu.

INTRODUCTION

Unique Considerations

Although the literature tends to focus on the use of decompressive craniectomy in the adult population, the procedure is frequently performed in pediatric patients as well. Pediatric patients may undergo a decompressive craniectomy to treat malignant cerebral edema in the setting of a large stroke [1], or rarely severe encephalitis [2, 3]. Most commonly, though, decompressive craniectomy is discussed in the context of patients with severe traumatic brain injury (TBI). This is particularly relevant to the pediatric population, as each year approximately 475,000 children experience TBI, resulting in close to 40,000 hospitalizations annually [4]. Trauma can be particularly injurious to the developing brain, resulting in lifelong neurological, cognitive, emotional, and behavioral deficits [5]. TBI is therefore widely recognized as the leading cause of death and disability in children older than 1 year of age, adolescents, and young adults [6-8].

A number of unique features distinguish pediatric TBI patients from their adult counterparts. In particular, anatomical differences in the size, shape, and consistency of the skull have important biomechanical implications. On the one hand, children have smaller brains than adults and are therefore less susceptible to whiplash injuries caused by angular acceleration [9]. On the other hand, children's heads are large and heavy relative to the rest of their body, while their neck muscles are relatively weak. Additionally, until the skull is fully calcified, it remains relatively soft and pliable, but less able to withstand a bending load or distribute pressure. Biomechanical studies demonstrated that the adult skull can withstand an impact that has eleven times the force relative to a neonate [10]. The compressibility of the soft pediatric skull results in a higher percentage of diffuse axonal "shear" injuries that ultimately produce diffuse swelling and intracranial hypertension, in contrast to adults who are more commonly affected by focal mass lesions [11-13].

While these anatomical features affect the primary injury that follows a trauma, pediatric patients also demonstrate unique physiological features that influence the subsequent secondary injury. In particular, children have an immature cerebral vasculature compared to their adult counterparts, and a long-standing hypothesis has been that cerebral autoregulation is impaired in pediatric patients following a severe injury, resulting in vasodilation and diffuse cerebral hyperemia. The subsequent increase in cerebral blood flow (CBF) and cerebral blood volume (CBV) ultimately produces diffuse cerebral edema and elevated intracranial pressure (ICP) [12-16]. Interestingly, some studies have disputed the concept of hyperemia following TBI, instead reporting that cerebral hyperemia is uncommon in pediatric TBI patients and that CBF values are typically within normal limits [17-21]. Ongoing research is therefore needed to clarify the pathophysiological processes that take place in pediatric TBI patients.

Given the possibility that CBF, CBV, and cerebral metabolism are intrinsically different in pediatric patients and adults, some have questioned whether the definition of intracranial hypertension that is used in adults (i.e., greater than 20 mm Hg) can be applied to the

pediatric population as well. There is some evidence that "normal" ICP ranges are age-dependent, with infants tending to have ICPs in the 2–4 mm Hg range, while older children and adolescents tend to have ICPs in the 5–15 mm Hg range [22, 23]. Infants and young children also tend to have lower cerebral perfusion pressures (CPPs) than adults; one group established a "minimum CPP" of 30 mm Hg in neonates, 40 mm Hg in infants aged 1 month to 1 year, 50 mm Hg in 1- to 4-year-olds, 60 mm Hg in 5- to 8-year-olds, and 70 mm Hg in children older than 8 years [24]. A more recent study examined slightly different age groups, establishing a minimum CPP of 48 mm Hg in 2- to 6-year-olds, 54 mm Hg in 7- to 10-year-olds, and 64 mm Hg in 11- to 15-year-olds [25].

These values become relevant in the setting of TBI, where decreases in CPP can result in cerebral ischemia, a critical mechanism of secondary injury. Given the definition of the CPP as the difference between the mean arterial pressure and the ICP, intracranial hypertension translates into reduced cerebral perfusion, thereby limiting the delivery of oxygen to the injured brain. As a result, it is now common (though not universal) practice to monitor the ICP in severe TBI patients and initiate therapies that lower the ICP once it has surpassed a certain threshold [26-28]. Numerous studies support this practice, having established that sustained intracranial hypertension is associated with poor outcome in pediatric TBI patients [29-33]. However, high-quality evidence for specific ICP thresholds at which to initiate treatment remains limited. The second edition of the Guidelines for the Acute Medical Management of Severe Traumatic Brain Injury in Infants, Children, and Adolescents, which was published in 2012, provided a Level III recommendation to initiate treatment of sustained intracranial hypertension at a threshold of 20 mm Hg, the same cutoff as in adult patients [34]. The authors of the guidelines pointed out, however, that a lower ICP threshold, as low as 15 mm Hg, may be more appropriate in infants and young children, and that further studies are necessary in order to determine age-specific thresholds.

Indications and Technical Considerations

Regardless of which ICP threshold is used, a number of options are available to lower the ICP once the decision has been made to initiate treatment. Many pediatric trauma centers have specific protocols in place for treating intracranial hypertension and tend to parallel those used for adult TBI patients. First-tier therapies include head of bed elevation, mild hyperventilation, hyperosmolar therapy, cerebral spinal fluid (CSF) diversion, sedation, and paralytics (see Figure 1). Second-tier options for pediatric patients with refractory intracranial hypertension include hypothermia, barbiturate-induced coma, and decompressive craniectomy (see Figure 2) [8, 35, 36]. In this setting, decompressive craniectomy is typically performed in a delayed manner, after ICP-directed therapies have been attempted and failed. This is classified as a secondary decompressive craniectomy. Alternatively, decompression may be performed early in the patient's hospitalization, when it is most commonly combined with removal of a mass lesion such as a subdural hematoma or a contusion. In this setting, the procedure is classified as a primary decompressive craniectomy (see Figure 3).

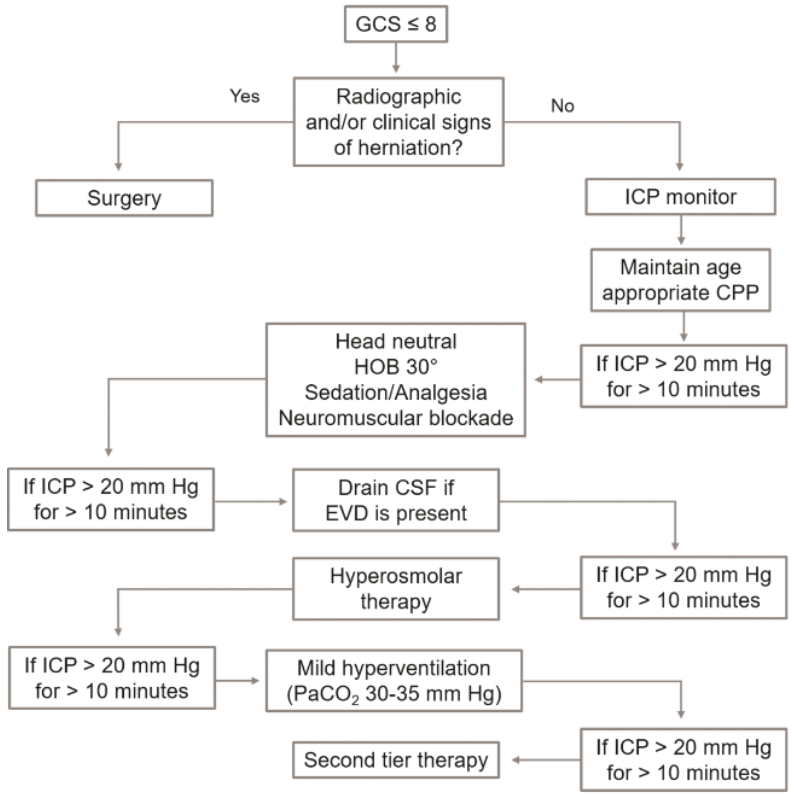

Figure 1. A flowchart demonstrating first-tier therapies for the management of intracranial hypertension in pediatric patients (adapted from the institutional protocol of a local Level 1 pediatric trauma center) (Courtesy of M Groves, University of Maryland).

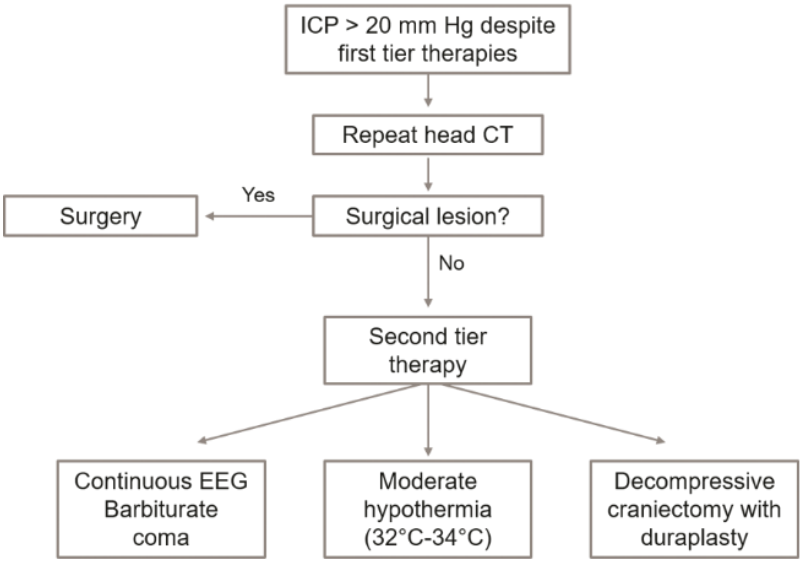

Figure 2. A flowchart demonstrating second-tier therapies for the management of intracranial hypertension in pediatric patients (adapted from the institutional protocol of a local Level 1 pediatric trauma center) (Courtesy of M Groves, University of Maryland).

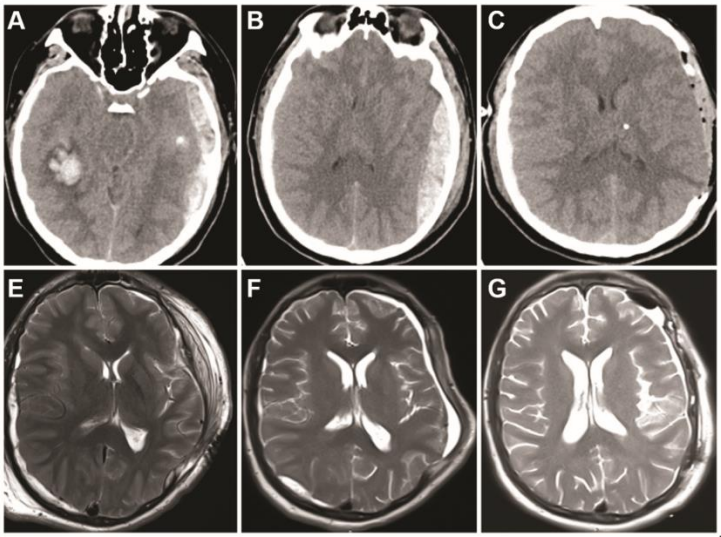

Figure 3. A 14-year-old boy was struck in the head by a falling tree branch and underwent primary decompressive craniectomy. The initial head CT (A, B) demonstrated a right temporal contusion as well as a 2-cm left extra-axial hematoma with 4 mm of midline shift. The patient was taken for urgent decompressive hemicraniectomy and expansile duraplasty with evacuation of the extra-axial hematoma (C). Postoperative MRI (D) was completed 4 days following decompression, and a subsequent MRI (E) demonstrated ex-vacuo changes with mild enlargement of the ventricles. A cranioplasty was performed (F) and the patient made a full clinical recovery. He has returned to school and is neurologically at his baseline (Courtesy of M Groves, University of Maryland).

A variety of surgical procedures may be performed to lower the ICP, and while they are all classified as "decompressive craniectomies," each one involves a varying degree of bony removal and/or dural opening. A large, unilateral frontoparietotemporal craniectomy is performed in patients with focal pathology and unilateral swelling and is particularly useful in patients with mass lesions [37]. In patients with diffuse pathology and bilateral swelling, some practitioners continue to perform a unilateral fronto-parietotemporal craniectomy, but other options include bilateral frontoparietotemporal craniectomies or a large bifrontal craniectomy with or without ligation of the anterior sagittal sinus and splitting of the falx [38-41]. The options for dural opening include leaving the dura intact, scoring the dura, or opening it with or without an expansile duraplasty. Wide dural opening has the advantage of reducing the ICP even further than bony decompression alone [42]. At our institution, wide dural opening is always accompanied by an expansile duraplasty using alloderm to graft the dura. A less aggressive option involves unilateral or bilateral removal of the temporal bone in order to prevent uncal herniation [43].

OUTCOMES FOLLOWING DECOMPRESSIVE CRANIECTOMY IN PEDIATRICS: 20 YEARS OF EXPERIENCE

Early reports of decompressive craniectomy in pediatric TBI patients demonstrated mixed results [38, 39]. More optimistic reports began to emerge in the 1990s. A case-controlled study performed by Cho et al. [44] examined twenty-three patients younger than 2

years of age with non-accidental trauma and ICPs greater than 30 mm Hg. Five patients underwent unilateral frontoparietotemporal craniectomy and duraplasty, while five patients underwent bifrontal craniectomy and duraplasty; they were compared to a matched group of thirteen children who were treated medically. The authors found that decompressive craniectomy resulted in a significant reduction in ICP and improved Children's Outcome Scale scores at a mean follow-up of 3.2 years. Similarly, Dam Hieu et al. [45] reported two 8-year-old patients who underwent decompressive craniectomy within 12 hours of presentation after the patients developed intracranial hypertension and clinically decompensated, developing first a unilateral fixed/dilated pupil and then bilateral dilated pupils, despite medical management. The authors documented successive decreases in ICP with craniectomy, dural opening, and debridement of contused tissue. Although the decompression had been performed as a "salvage" procedure, both patients were ambulating and one had returned to normal speech and behavior while the other had returned to school after 6–10 months of follow-up.

A subsequent retrospective case-control study by Polin et al. [40] compared thirty-five severe TBI patients (eighteen pediatric patients and seventeen adults) who underwent bifrontal craniectomies to a cohort of ninety-two matched patients from the Traumatic Coma Databank who were managed medically. The study group was limited to patients who underwent bifrontal craniectomies for diffuse cerebral edema. Patients who underwent decompressive craniectomy in association with the evacuation of a mass lesion were excluded. Bifrontal craniectomy successfully reduced the average ICP from 34.9 to 21.6 mm Hg, while medical management only reduced the average ICP from 33.2 to 29.4 mm Hg. Decompressive craniectomy also had a significant influence on clinical outcomes, with medical management alone having a nearly four-times greater risk of an unfavorable outcome. Subgroup analyses revealed that 44% of the pediatric patients had a favorable outcome, defined as a Glasgow Outcome Scale (GOS) score of 4 or 5, after decompressive craniectomy, compared to only 29% of the adult patients. Additionally, patients who underwent decompressive craniectomy within 48 hours and did not exhibit sustained ICPs greater than 40 mm Hg were more likely to have favorable outcomes. Pediatric patients who met these criteria and underwent decompressive craniectomy had favorable outcomes in 80% of cases, compared to only 24% of the pediatric patients who were managed medically ($P = 0.002$). Nevertheless, the conclusions of the study were tempered by the methodological challenges of using an appropriately matched historical control group, and the need for a prospective, randomized trial became clear.

To date, the only prospective, randomized clinical trial to focus exclusively on decompressive craniectomy in pediatric TBI patients was completed at the Royal Children's Hospital in Melbourne, Australia, and was reported in 2001 [46]. The investigators included all pediatric TBI patients older than 12 months of age who had an intraventricular catheter and demonstrated either intracranial hypertension or clinical signs of herniation during the first hospital day. Intracranial hypertension was defined as an ICP of 20–24 mm Hg for at least 30 minutes, 25-29 mm Hg for at least 10 minutes, or greater than or equal to 30 mm Hg for at least 1 minute, while clinical herniation was defined as unilateral pupillary dilation or bradycardia. During the 7 years of the trial, fourteen patients were randomized to medical management alone and thirteen patients were randomized to a bitemporal 3- to 4-cm craniectomy with occasional scarification of the dura (in addition to medical management). Decompressive craniectomy was effective in decreasing the ICP in 92% of cases, resulting in

a mean ICP of 17.4 mm Hg. In contrast, medical management alone was effective only 71% of the time, resulting in a mean ICP of 21.9 mm Hg. At 6 months, 54% of the patients who had undergone decompressive craniectomy achieved favorable outcomes (defined as a modified GOS reflecting children who were normal, functionally normal, or mildly disabled but independent, as well as a "good" Health State Utility index of 1.00–0.7), compared to only 14% of the patients who were managed medically. These results prompted the authors of the study to recommend early surgical decompression in cases of intracranial hypertension and/or herniation, rather than reserving surgery as a last resort after medical management has failed. However, their results should be interpreted cautiously, given the small sample size, long duration, and short follow-up period of only 6 months. Above all, the bitemporal craniectomies performed by the authors are inherently different from the frontoparietotemporal craniectomies and bifrontal craniectomies that are more commonly performed in pediatric patients undergoing a decompression, making it difficult to generalize their findings.

A number of subsequent case series continued to explore the role of early surgical decompression, but focused on the early use of larger, unilateral decompressive craniectomies. One series of seven pediatric patients who presented with decerebrate posturing and diffuse cerebral edema found that a unilateral frontotemporal craniectomy (the parietal and occipital regions were left intact) and duraplasty performed within 6 hours of the trauma decreased the ICP from over 45 mm Hg to less than 20 mm Hg in all cases and resulted in complete recovery within 5 weeks [47]. Another series of five children with severe TBI and diffuse cerebral edema described the use of a unilateral frontoparietotemporal decompressive craniectomy and duraplasty for clinical and radiographic deterioration within 48 hours of the trauma [48]. (Two patients underwent a true craniectomy, whereas the remaining three patients underwent a "floating" craniotomy.) At follow-up (ranging from 14 to 42 months), all five patients had a favorable outcome, defined as a GOS score of 4 or 5.

Other studies have instead included patients with bilateral decompressive craniectomies. A prospective, observational pilot study by Ruf et al. [49] followed six children with "refractory" intracranial hypertension, defined as an ICP greater than 20 mm Hg for more than 30 minutes despite first-tier therapies and a single dose of barbiturates and mannitol. Three patients underwent bilateral frontoparietotemporal craniectomies, two patients underwent unilateral craniectomies, and one patient underwent a suboccipital craniectomy. The ICPs normalized in five of the six patients, and the authors reported that three of the six patients (including two of the three patients who underwent bilateral craniectomies) were neurologically "normal" after 6 months. The authors therefore promoted the early use of decompressive craniectomy soon after refractory intracranial hypertension has been diagnosed. Similarly, Rutigliano et al. [50] reported thirty adolescents with severe TBI and ICPs greater than 30 mm Hg for an unspecified duration. Six patients did not respond to medical therapy and underwent bifrontal and biparietal craniectomies with a bifrontal duraplasty, ranging from 2 to 26 hours after intracranial hypertension first developed. Of the six patients, five had normal ICPs following the decompression, and five were independent or required minimal assistance upon discharge from rehab. The authors concluded that once intracranial hypertension develops, decompressive craniectomy should be performed as early as possible.

Outcomes following primary versus secondary decompressive craniectomy were further investigated by Kan et al. [36], who retrospectively reviewed fifty-one children with a mean

age of 6.6 years who presented with severe TBI and underwent a large unilateral decompressive craniectomy. A primary decompression was performed in forty-five patients, in whom the craniectomy was performed in conjunction with removal of a mass lesion, while six patients underwent a secondary decompressive craniectomy due to ICPs that remained greater than 25 mm Hg despite medical therapy. Postoperatively, there was a substantial difference in outcome between the two groups. Patients who underwent a secondary decompressive craniectomy had a high mortality rate, with five of these six patients (83%) dying, in contrast to eleven of the forty-five patients (24%) who underwent a primary decompression with evacuation of a mass lesion. However, the survivors in the primary decompression group had a high rate of posttraumatic shunt-dependent hydrocephalus (40% of patients) and posttraumatic epilepsy (20% of patients). Nevertheless, at a mean follow-up of 18.6 months, thirty of the survivors had a favorable outcome as determined by a King's Outcome Scale for Closed Head Injury (KOSCHI) score of 4 or 5 [51]. The authors therefore concluded that they would not recommend a decompressive craniectomy in pediatric patients without a mass lesion. However, the six patients who were included in this category were severely injured, with a pre-operative Glasgow Coma Scale (GCS) score of 3–5, pre-operative ICPs >40 mm Hg, and fixed pupils.

In contrast, other surgical series have produced more promising results. In a retrospective review of twelve pediatric patients with severe TBI and refractory intracranial hypertension (defined as ICPs greater than 20 mm Hg for more than 20 minutes), six patients underwent a unilateral or bilateral frontoparietotemporal craniectomy without duraplasty, while six patients were treated with hypothermia and/or barbiturates [35]. The patients in the surgical cohort underwent decompressive craniectomy an average of 7 hours (range 2–18 hours) after the ICPs had become elevated. All six patients experienced normal ICPs postoperatively, and all had good outcomes at 1-year follow-up. In contrast, despite having less severe imaging findings, the six patients in the non-operative cohort had worse outcomes: two patients died, one patient had a GOS score of 3, and only three patients had a favorable outcome at 1 year. In another retrospective review of eighteen patients with a mean age of 7.8 years who underwent decompressive craniectomy for severe TBI, the median ICP improved from 40 mm Hg to 16 mm Hg and brain tissue oxygenation ($PbtO_2$) improved from 17.4 to 43.4 mm Hg pre- and post-decompression, respectively [52]. Favorable outcomes were achieved by 78% of the patients, despite having a high rate of pupillary abnormalities and a low GCS score pre-operatively.

Jagannathan et al. [53] were among the first to explore long-term outcomes following decompressive craniectomy in pediatric TBI patients. The authors reported a group of twenty-three children with a mean age of 11.9 years who presented with severe TBI over a 10-year period and underwent decompressive craniectomy for refractory intracranial hypertension (defined as ICPs > 20 mm Hg). Eight patients with mass lesions underwent a unilateral frontoparietotemporal craniectomy with duraplasty, while fifteen patients with diffuse swelling underwent a bifrontal craniectomy with duraplasty and sectioning of the falx. Overall, 65% of the patients in the series had favorable outcomes 2 years later, with 82% of the survivors demonstrating good functional outcomes, suggesting that decompressive craniectomy improves not only the survival of pediatric TBI patients, but also functional outcomes. The authors identified several predictors of outcome, finding that patients with a concomitant vascular injury and/or ICPs greater than 20 mm Hg following surgical decompression had a higher risk of mortality. Additionally, patients who underwent surgery

due to pupillary changes suggestive of impending herniation, rather than refractory intracranial hypertension, had worse outcomes. The patients spanned a wide spectrum, with an average time to surgery of 68 hours following the trauma, but with some undergoing early decompression while others presented with intracranial hypertension in a more delayed fashion. However, the authors did not identify an association between the time to surgery and survival. They concluded that the timing of surgery should be decided on an individualized basis – patients with early hypoxia and ischemia, reduced CBF, and cytotoxic edema may benefit from an early decompressive craniectomy, while those who develop reduced carbon dioxide responsivity and increased CBF 3 to 5 days after the trauma may benefit from a late decompressive craniectomy.

A more recent retrospective case-control study by Mhanna et al. [54] also explored long-term outcomes, following patients for a median of 4 years post-decompression. They reported seventeen pediatric patients with severe TBI who underwent decompressive craniectomy (all were unilateral except for one), as well as seventeen contemporarily matched patients who were managed medically. Surgery was performed a median of 2 hours after admission. In this series, decompressive craniectomy did not appear to significantly improve survival, although there was a significant effect on morbidity – the only patients to achieve a GOS score of 5 at the most recent follow-up had undergone an early decompressive craniectomy.

While many of the prior studies used survival, the GOS score, or the KOSCHI score as their primary outcome measures, the importance of quality of life (QOL), particularly with regard to neurocognitive developmental delays, has been recently emphasized. Jacob et al. [55] performed a meta-analysis of seventeen prior studies in addition to their own series of eleven patients, identifying a total of 193 pediatric trauma patients who underwent decompressive craniectomy and had at least 6 months of follow-up. The authors converted the GOS scores at 6 months to parametric measures of utility or health-related QOL. They found a pooled mean mortality at 6 months of 20.3%. However, the pooled mean QOL among those who survived was 0.723, which translates into a QOL that is 72% of the value of a normal state of health. Sixty percent of all of the included patients had a favorable outcome at 6 months; when only those patients who survived were considered, 78% had a favorable outcome. The authors therefore concluded that despite a mortality rate of 20%, children who survive 6 months following a decompressive craniectomy for refractory intracranial hypertension can be expected to function independently.

In another retrospective review, Pérez Suárez et al. [56] placed a particular emphasis on psychiatric disorders and academic performance following decompressive craniectomy. They reported fourteen patients with a mean age of 5.5 years, four of whom underwent decompressive craniectomy due to refractory intracranial hypertension, while ten underwent early surgery due to clinical and radiographic findings that were compatible with herniation. Twelve of the patients underwent unilateral parietotemporal hemicraniectomy and duraplasty, while two patients underwent bifrontal craniectomy with bilateral duraplasty. Two patients (14%) died, but all of the survivors had functional independence (GOS of 4 or 5) after 2 years of follow-up. Nevertheless, many of the patients experienced psychiatric and/or academic complications. At a mean follow-up of 3.2 years, two patients were diagnosed with attention-deficit/hyperactivity disorder, three had issues with aggressiveness, one had oppositional defiant disorder, and three required psychiatric care. Four patients had good academic performance, six patients had acceptable performance but required support, and an additional two patients needed to have their curriculum adapted because of a low intelligence quotient.

Academic performance following decompressive craniectomy was also explored by Güresir et al. [57]. Among a series of thirty-four pediatric patients who underwent a decompressive craniectomy, twenty-three were TBI patients, all of whom presented with a GCS score of 3 and were taken to the operating room immediately. Within the TBI cohort, 30% of the patients did not graduate from school, but one patient achieved a 9th grade education, five achieved a 10th grade education, and one patient became eligible for university. In an attempt to identify predictors of outcome, the authors performed a systematic review of 172 pediatric patients who underwent decompressive craniectomy. Overall, 62% of the patients had a favorable outcome after at least 6 months (69% in the non-trauma cohort versus 60% in the trauma cohort). There was no relationship between age or timing of surgery and outcome, and while unilateral and particularly bilateral mydriasis seemed to predict a poorer outcome, the differences did not reach statistical significance. In fact, a multivariate regression analysis found that a non-traumatic indication for decompression was the only variable that was significantly associated with a favorable outcome.

COMPLICATIONS OF DECOMPRESSIVE CRANIECTOMY IN THE PEDIATRIC POPULATION

Among pediatric patients, decompressive craniectomy is associated with many of the same complications as in adults, although the prevalence varies based on age. Hydrocephalus and subdural hygromas are the most common complications, with clinical series finding an incidence of post-surgical hygroma as high as 62% to 83% [56, 58]. Infants, in particular, have been hypothesized to have a higher rate of subdural collections following trauma due to the presence of a permeable dural venous plexus, which is thought to have a role in CSF resorption until the arachnoid granulations mature. According to this hypothesis, a large duraplasty using an allogenic graft impairs the ability of the native dura to resorb CSF, and subsequently allows CSF to collect in the subdural space. Posttraumatic hydrocephalus can further exacerbate the subdural collection by "feeding" it through a posttraumatic or post-surgical arachnoidal tear [59]. Alternatively, blood-brain barrier disruption and/or abnormal CSF flow dynamics may occur after trauma, surgery, or both, contributing to the pathophysiology of both hygroma and hydrocephalus [58].

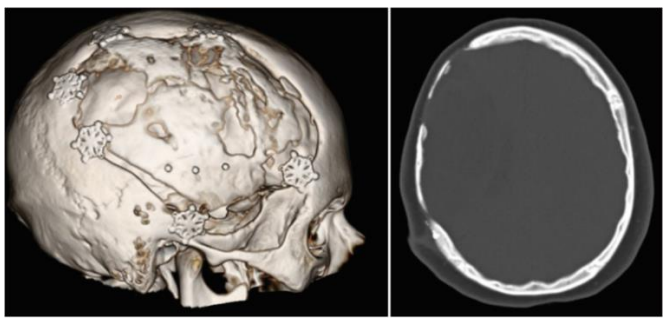

Figure 4. A lateral 3D reconstruction (left) and an axial bone window (right) of a CT scan demonstrating bone flap resorption in a 17-year-old boy with a right MCA infarct who underwent decompressive craniectomy and subsequent cranioplasty 2 months later. (Courtesy of M Groves, University of Maryland).

Bone flap resorption following cranioplasty is another significant issue seen in pediatric patients undergoing decompressive craniectomy, occurring at much higher rates than in adults (see Figure 4). Particularly in pediatric patients, replacement of the original bone that was removed during the decompression has typically been advocated in order to allow the bone to become reintegrated and grow with the patient, as well as to avoid the introduction of a foreign body [60]. The bone flap is routinely cryopreserved; although subcutaneous storage of the bone in an abdominal pocket is an option for adults, it is typically not recommended in pediatric patients, particularly infants and young children, given the large head-to-body ratio and the surgical trauma that would be required to create an adequate abdominal pocket [59]. Unfortunately, upon replacement of the bone flap, many pediatric patients experience resorption of the bone over time, with Piedra et al. [61], Gruber et al. [62], Grant et al. [60], and Bowers et al. [63] reporting resorption rates of 29.5%, 33.3%, 50%, and 50%, respectively. These rates are higher than those reported for other elective pediatric cranial procedures [64].

There are various explanations for the high rate of bone resorption in pediatric patients undergoing decompressive craniectomy and subsequent cranioplasty. Successful reintegration of an autologous cranioplasty requires bone revascularization, osteoconduction, osteoinduction, and osteogenesis [59]. Freezing the bone flap was originally thought to contribute to the risk of resorption, as the cryopreservation process was thought to impact the osteoconductive potential of the bone [65, 66]. However, the results of more recent studies seem to suggest otherwise [67]. Additionally, this would not explain the higher rate of bone resorption in pediatric patients relative to adults. Intrinsic anatomical and physiological features of pediatric patients, however, may also play a role. In particular, children have inherently thinner skulls and undergo naturally high rates of bone turnover, potentially contributing to the incidence of bone resorption [60, 67, 68]. Moreover, preclinical data suggest that the growing brain places mechanical, tensile strain on the overlying immature dura, which induces the secretion of growth factors that contribute to osteogenesis, particularly during the first 2 years of life [59, 69, 70]. Expansile duraplasty, in which a large segment of the brain is covered with an artificial dural replacement, may interrupt the physiological interactions between the brain, the native dura, and the overlying bone, and the subsequent lack of growth factor secretion may contribute to bone flap resorption. Similarly, the presence of a ventriculoperitoneal shunt may also blunt the natural ICP fluctuations that contribute to skull growth, resulting in a higher rate of resorption in shunted patients [63].

Several groups have identified specific risk factors for bone flap resorption in pediatric patients. Grant et al. [60] found that the size of the craniectomy was a significant factor, concluding that bone flaps larger than 75 cm^2 were more likely to undergo resorption (60% versus 0%). Piedra et al. [61], on the other hand, identified a freezer time of more than 6 weeks as the only significant risk factor for resorption (42% versus 14.3%). In a study of fifty-four patients who underwent cranioplasty following decompressive craniectomy for TBI, Bowers et al. [63] found that 50% of the patients experienced bone flap resorption at an average of 4.8 months following replacement. They identified several independent risk factors for resorption, including underlying contusion, a permanent ventriculoperitoneal shunt, and age less than or equal to 2.5 years. In general, revision cranioplasties were quite successful with close to an 85% success rate, although synthetic bone flap replacements (including polyetheretherketone synthetic flaps) were found to be more successful than autologous split-thickness bone grafts.

GUIDELINES FOR THE ACUTE MEDICAL MANAGEMENT OF SEVERE TRAUMATIC BRAIN INJURY IN INFANTS, CHILDREN, AND ADOLESCENTS: THE ROLE OF DECOMPRESSIVE CRANIECTOMY

Given the variable practices, outcomes, and complication rates reported in the literature, over the years the need for evidence-based guidelines became clear. The first edition of the "Guidelines for the Management of Severe Head Injury" was published in 1996 and represented an effort by the Brain Trauma Foundation, the American Association of Neurological Surgeons, and the Congress of Neurological Surgeons to collate the existing literature and develop evidence-based recommendations for the management of adults with severe TBI [24]. Unfortunately, the guidelines did not specifically address pediatric patients. Therefore, participants of the 5th Annual Aspen Neurobehavioral Conference in March 2000 initiated a multidisciplinary task force to adapt the adult guidelines, developing a set of key topics pertaining to the management of patients younger than 18 years old with severe TBI. Classifying the evidence as Class I (randomized controlled trials), Class II (prospective studies or retrospective studies based on reliable data), or Class III (retrospective data in the form of clinical series, case reports, or expert opinion), the authors developed a set of standards (high degree of clinical certainty), guidelines (moderate degree of clinical certainty), and options (unclear clinical certainty), which were published in 2003 as the "Guidelines for the Acute Medical Management of Severe Traumatic Brain Injury in Infants, Children, and Adolescents" [71].

Upon reviewing the literature from 1966-2001, the authors determined that none of the topics had sufficient evidence to support a standard. However, a number of guidelines and options were promoted, and a critical pathway for the treatment of established intracranial hypertension was developed by committee consensus. In particular, ICP monitoring was determined to be an option in infants and children with a GCS score less than or equal to 8, regardless of whether the fontanelles and sutures are open. ICP monitoring may also be considered in patients with mild or moderate TBI who have mass lesions, or in patients who cannot undergo serial neurological examinations because of sedation. Furthermore, the panel determined that an option for the treatment of intracranial hypertension is to initiate treatment at an ICP greater than or equal to 20 mm Hg, although they noted that this should be considered within the context of the neurological exam, other physiologic parameters, and imaging findings. A number of treatments for intracranial hypertension were explored, including decompressive craniectomy. The authors presented decompressive craniectomy as an option for the treatment of pediatric patients with severe TBI, diffuse cerebral swelling, and refractory intracranial hypertension, particularly in patients who presented with abusive head trauma. Patients with "potentially recoverable" injuries who developed a secondary clinical deterioration and/or an evolving cerebral herniation syndrome within the first 48 hours following the trauma were promoted as a particularly favorable group. In contrast, patients whose GCS score was never better than 3 and those with sustained ICPs greater than 40 mm Hg prior to surgery were felt to be poor candidates for decompression.

These guidelines were updated in a second edition that was published in 2012 (see Table) [34]. The panel identified twenty-seven new studies that had been published since 2003 and utilized more rigorous inclusion criteria, resulting in the exclusion of twenty-five publications that had been included in the initial set of guidelines. Furthermore, the recommendations in

the second edition of the guidelines were presented as Level I, II, and III recommendations, rather than standards, guidelines, and options. The authors provided Level III recommendations simply stating that the "use of ICP monitoring may be considered in infants and children with severe TBI" and that treatment of ICP may be considered at a threshold of 20 mm Hg. However, the authors admitted that treatment may need to be individualized in certain circumstances, and that in particular the need for age-adjusted ICP thresholds requires further investigation. Unlike the first edition of the guidelines, the authors of the second edition concluded that there was insufficient evidence to determine patient characteristics that are predictors of outcome following decompressive craniectomy. Instead, the panel provided a Level III recommendation that "decompressive craniectomy with duraplasty, leaving the bone flap out, may be considered for pediatric patients with TBI who are showing early signs of neurologic deterioration or herniation or are developing intracranial hypertension refractory to medical management during the early stages of their treatment" [34].

The first and second editions of the Guidelines for the Acute Medical Management of Severe Traumatic Brain Injury in Infants, Children, and Adolescents provided an evidence-based framework for the management of pediatric patients with severe TBI, and recent literature has established that the guidelines are effective. A retrospective study performed at five regional pediatric trauma centers confirmed that a set of sixteen acute care clinical indicators of adherence to the 2003 guidelines during the first 72 hours following admission resulted in improved survival at discharge and improved neurological outcome on follow-up [72]. Unfortunately, though, many of the recommendations in the guidelines were at the "option" or "Level III" level, and there has been substantial variability in institutional adherence to the guidelines. An analysis of the American College of Surgeons National Trauma Databank from 2002 –2008 identified 7,140 pediatric patients with moderate or severe TBI who were hospitalized at 156 individual hospitals and found significant patient, hospital, and regional variability with regard to the decision to perform ICP monitoring and/or decompressive craniectomy [73]. The Pediatric Guideline Adherence and Outcomes (PEGASUS) project has attempted to track and study these variations in adherence to the evidence-based guidelines [74]. With an improved understanding as to what drives adoption of the guidelines, the investigators of the PEGASUS project hope to ultimately improve adherence and thereby optimize patient outcomes.

Table 1. Summary of 2012 guidelines for the use of decompressive craniectomy in the management of pediatric TBI patients

Topic	Level III Guideline
Indications for ICP monitoring	• Consider in pediatric patients with severe TBI
Threshold for treatment of ICP	• Consider treatment at a threshold of 20 mm Hg
CPP thresholds	• Minimum CPP 40 mm Hg in children with TBI • Consider a threshold of 40-50 mm Hg • There may be age-specific thresholds
Decompressive craniectomy	• Decompressive craniectomy with duraplasty, leaving the bone flap out, may be considered for: o Early signs of neurologic deterioration or herniation o Refractory intracranial hypertension during early stages of treatment

FUTURE DIRECTIONS

While the publication of the Guidelines for the Acute Medical Management of Severe Traumatic Brain Injury in Infants, Children, and Adolescents represented a significant step in formulating evidence-based recommendations for the management of this complex patient population, the guidelines have also highlighted how much work is still left to be done. In particular, further studies are needed to determine whether age-specific guidelines are necessary, especially with regard to the use of age-dependent ICP thresholds. Additionally, to date a prospective randomized trial has not been performed to evaluate the more common decompression techniques, i.e., unilateral fronto-parietotemporal craniectomy and duraplasty or bifrontal craniectomy and duraplasty, specifically in pediatric patients. Nevertheless, the recently published RESCUEicp trial included patients as young as 10 years of age, and a subgroup analysis of the pediatric patients would be valuable [75].

Moving forward, a primary challenge for TBI researchers and clinicians remains the relatively low numbers of pediatric patients who present to individual centers with severe TBI. Consequently, there is now a growing recognition that in order to analyze a large enough sample size, multi-center collaborations are critical. A second option involves the use of prospective pediatric TBI databases and registries, which would allow the statistical analysis of observational data involving large cohorts. To this end, the National Institute of Neurological Disorders and Stroke has completed a comprehensive effort to develop "common data elements" for pediatric TBI [76, 77]. These data elements will allow more uniform data to be collected across centers, enabling data from different studies to be compared more effectively or combined in meta-analyses. While there are still many unanswered questions, future studies with expanded datasets may ultimately lead to more nuanced management guidelines and higher levels of evidence for the use of decompressive craniectomy in pediatric TBI patients.

REFERENCES

[1] Smith SE, Kirkham FJ, Deveber G, Millman G, Dirks PB, Wirrell E, et al. Outcome following decompressive craniectomy for malignant middle cerebral artery infarction in children. *Dev Med Child Neurol*. 2011;53(1):29-33.

[2] Bayram N, Ciftdogan DY, Karapinar B, Ozgiray E, Polat M, Cagliyan E, et al. A case of herpes simplex encephalitis revealed by decompressive craniectomy. *Eur J Pediatr*. 2008;167(7):821-2.

[3] Singhi P, Saini AG, Sahu JK, Kumar N, Vyas S, Vasishta RK, et al. Unusual Clinical Presentation and Role of Decompressive Craniectomy in Herpes Simplex Encephalitis. *J Child Neurol*. 2015;30(9):1204-7.

[4] Langlois JA, Rutland-Brown W, Thomas KE. The incidence of traumatic brain injury among children in the United States: differences by race. *J Head Trauma Rehabil.* 2005;20(3):229-38.

[5] Madikians A, Giza CC. Treatment of traumatic brain injury in pediatrics. *Curr Treat Options Neurol*. 2009;11(6):393-404.

[6] Keenan HT, Bratton SL. Epidemiology and outcomes of pediatric traumatic brain injury. *Dev Neurosci.* 2006;28(4-5):256-63.

[7] Murgio A, Andrade FA, Sanchez Munoz MA, Boetto S, Leung KM. International Multicenter Study of Head Injury in Children. ISHIP Group. *Childs Nerv Syst*. 1999;15(6-7):318-21.

[8] Appelboom G, Zoller SD, Piazza MA, Szpalski C, Bruce SS, McDowell MM, et al. Traumatic brain injury in pediatric patients: evidence for the effectiveness of decompressive surgery. *Neurosurg Focus*. 2011;31(5):E5.

[9] Ommaya AK, Hirsch AE. Tolerances for cerebral concussion from head impact and whiplash in primates. *J Biomech*. 1971;4(1):13-21.

[10] Ommaya AK, Goldsmith W, Thibault L. Biomechanics and neuropathology of adult and paediatric head injury. *Br J Neurosurg*. 2002;16(3):220-42.

[11] Zimmerman RA, Bilaniuk LT. Pediatric head trauma. *Neuroimaging Clin N Am*. 1994;4(2):349-66.

[12] Aldrich EF, Eisenberg HM, Saydjari C, Luerssen TG, Foulkes MA, Jane JA, et al. Diffuse brain swelling in severely head-injured children. A report from the NIH Traumatic Coma Data Bank. *J Neurosurg*. 1992;76(3):450-4.

[13] Bruce DA. Head injuries in the pediatric population. *Curr Probl Pediatr*. 1990;20(2):61-107.

[14] Kimelberg HK. Current concepts of brain edema. Review of laboratory investigations. *J Neurosurg*. 1995;83(6):1051-9.

[15] Shulman K. Late complications of head injuries in children. *Clin Neurosurg*. 1972;19:371-80.

[16] Zimmerman RA, Bilaniuk LT. Computed tomography in pediatric head trauma. *J Neuroradiol.* 1981;8(3):257-71.

[17] Muizelaar JP, Ward JD, Marmarou A, Newlon PG, Wachi A. Cerebral blood flow and metabolism in severely head-injured children. Part 2: Autoregulation. *J Neurosurg.* 1989;71(1):72-6.

[18] Muizelaar JP, Marmarou A, DeSalles AA, Ward JD, Zimmerman RS, Li Z, et al. Cerebral blood flow and metabolism in severely head-injured children. Part 1: Relationship with GCS score, outcome, ICP, and PVI. *J Neurosurg.* 1989;71(1): 63-71.

[19] Sharples PM, Matthews DS, Eyre JA. Cerebral blood flow and metabolism in children with severe head injuries. Part 2: Cerebrovascular resistance and its determinants. *J Neurol Neurosurg Psychiatry*. 1995;58(2):153-9.

[20] Sharples PM, Stuart AG, Matthews DS, Aynsley-Green A, Eyre JA. Cerebral blood flow and metabolism in children with severe head injury. Part 1: Relation to age, Glasgow coma score, outcome, intracranial pressure, and time after injury. *J Neurol Neurosurg Psychiatry*. 1995;58(2):145-52.

[21] Adelson PD, Srinivas R, Chang Y, Bell M, Kochanek PM. Cerebrovascular response in children following severe traumatic brain injury. *Childs Nerv Syst.* 2011;27(9):1465-76.

[22] Adelson PD, Bratton SL, Carney NA, Chesnut RM, du Coudray HE, Goldstein B, et al. Guidelines for the acute medical management of severe traumatic brain injury in infants, children, and adolescents. Chapter 6. Threshold for treatment of intracranial hypertension. *Pediatr Crit Care Med*. 2003;4(3 Suppl):S25-7.

[23] Giza CC, Mink RB, Madikians A. Pediatric traumatic brain injury: not just little adults. *Curr Opin Crit Care*. 2007;13(2):143-52.
[24] Bullock R, Chesnut RM, Clifton G, Ghajar J, Marion DW, Narayan RK, et al. Guidelines for the management of severe head injury. Brain Trauma Foundation. *Eur J Emerg Med*. 1996;3(2):109-27.
[25] Chambers IR, Jones PA, Lo TY, Forsyth RJ, Fulton B, Andrews PJ, et al. Critical thresholds of intracranial pressure and cerebral perfusion pressure related to age in paediatric head injury. *J Neurol Neurosurg Psychiatry*. 2006;77(2):234-40.
[26] Tilford JM, Simpson PM, Yeh TS, Lensing S, Aitken ME, Green JW, et al. Variation in therapy and outcome for pediatric head trauma patients. *Crit Care Med*. 2001;29(5):1056-61.
[27] Keenan HT, Nocera M, Bratton SL. Frequency of intracranial pressure monitoring in infants and young toddlers with traumatic brain injury. *Pediatr Crit Care Med.* 2005;6(5):537-41.
[28] Morris KP, Forsyth RJ, Parslow RC, Tasker RC, Hawley CA, Group UKPTBIS, et al. Intracranial pressure complicating severe traumatic brain injury in children: monitoring and management. *Intensive Care Med.* 2006;32(10):1606-12.
[29] Esparza J, J MP, Sarabia M, Yuste JA, Roger R, Lamas E. Outcome in children with severe head injuries. *Childs Nerv Syst*. 1985;1(2):109-14.
[30] Pfenninger J, Kaiser G, Lutschg J, Sutter M. Treatment and outcome of the severely head injured child. *Intensive Care Med*. 1983;9(1):13-6.
[31] Downard C, Hulka F, Mullins RJ, Piatt J, Chesnut R, Quint P, et al. Relationship of cerebral perfusion pressure and survival in pediatric brain-injured patients. *J Trauma.* 2000;49(4):654-8; discussion 8-9.
[32] Adelson PD, Ragheb J, Kanev P, Brockmeyer D, Beers SR, Brown SD, et al. Phase II clinical trial of moderate hypothermia after severe traumatic brain injury in children. *Neurosurgery.* 2005;56(4):740-54; discussion -54.
[33] White JR, Farukhi Z, Bull C, Christensen J, Gordon T, Paidas C, et al. Predictors of outcome in severely head-injured children. *Crit Care Med.* 2001;29(3):534-40.
[34] Kochanek PM, Carney N, Adelson PD, Ashwal S, Bell MJ, Bratton S, et al. Guidelines for the acute medical management of severe traumatic brain injury in infants, children, and adolescents--second edition. *Pediatr Crit Care Med*. 2012;13 Suppl 1:S1-82.
[35] Josan VA, Sgouros S. Early decompressive craniectomy may be effective in the treatment of refractory intracranial hypertension after traumatic brain injury. *Childs Nerv Syst.* 2006;22(10):1268-74.
[36] Kan P, Amini A, Hansen K, White GL, Jr., Brockmeyer DL, Walker ML, et al. Outcomes after decompressive craniectomy for severe traumatic brain injury in children. *J Neurosurg*. 2006;105(5 Suppl):337-42.
[37] Coplin WM, Cullen NK, Policherla PN, Vinas FC, Wilseck JM, Zafonte RD, et al. Safety and feasibility of craniectomy with duraplasty as the initial surgical intervention for severe traumatic brain injury. *J Trauma.* 2001;50(6):1050-9.
[38] Kjellberg RN, Prieto A, Jr. Bifrontal decompressive craniotomy for massive cerebral edema. *J Neurosurg*. 1971;34(4):488-93.
[39] Venes JL, Collins WF. Bifrontal decompressive craniectomy in the management of head trauma. *J Neurosurg*. 1975;42(4):429-33.

[40] Polin RS, Shaffrey ME, Bogaev CA, Tisdale N, Germanson T, Bocchicchio B, et al. Decompressive bifrontal craniectomy in the treatment of severe refractory posttraumatic cerebral edema. *Neurosurgery*. 1997;41(1):84-92; discussion -4.

[41] Whitfield PC, Patel H, Hutchinson PJ, Czosnyka M, Parry D, Menon D, et al. Bifrontal decompressive craniectomy in the management of posttraumatic intracranial hypertension. *Br J Neurosurg*. 2001;15(6):500-7.

[42] Yoo DS, Kim DS, Cho KS, Huh PW, Park CK, Kang JK. Ventricular pressure monitoring during bilateral decompression with dural expansion. *J Neurosurg*. 1999;91(6):953-9.

[43] Gower DJ, Lee KS, McWhorter JM. Role of subtemporal decompression in severe closed head injury. *Neurosurgery.* 1988;23(4):417-22.

[44] Cho DY, Wang YC, Chi CS. Decompressive craniotomy for acute shaken/impact baby syndrome. *Pediatr Neurosurg*. 1995;23(4):192-8.

[45] Dam Hieu P, Sizun J, Person H, Besson G. The place of decompressive surgery in the treatment of uncontrollable post-traumatic intracranial hypertension in children. *Childs Nerv Syst*. 1996;12(5):270-5.

[46] Taylor A, Butt W, Rosenfeld J, Shann F, Ditchfield M, Lewis E, et al. A randomized trial of very early decompressive craniectomy in children with traumatic brain injury and sustained intracranial hypertension. *Childs Nerv Syst.* 2001;17(3):154-62.

[47] Hejazi N, Witzmann A, Fae P. Unilateral decompressive craniectomy for children with severe brain injury. Report of seven cases and review of the relevant literature. *Eur J Pediatr*. 2002;161(2):99-104.

[48] Figaji AA, Fieggen AG, Peter JC. Early decompressive craniotomy in children with severe traumatic brain injury. *Childs Nerv Syst*. 2003;19(9):666-73.

[49] Ruf B, Heckmann M, Schroth I, Hugens-Penzel M, Reiss I, Borkhardt A, et al. Early decompressive craniectomy and duraplasty for refractory intracranial hypertension in children: results of a pilot study. *Crit Care*. 2003;7(6):R133-8.

[50] Rutigliano D, Egnor MR, Priebe CJ, McCormack JE, Strong N, Scriven RJ, et al. Decompressive craniectomy in pediatric patients with traumatic brain injury with intractable elevated intracranial pressure. *J Pediatr Surg*. 2006;41(1):83-7; discussion -7.

[51] Crouchman M, Rossiter L, Colaco T, Forsyth R. A practical outcome scale for paediatric head injury. *Arch Dis Child*. 2001;84(2):120-4.

[52] Figaji AA, Fieggen AG, Argent AC, Le Roux PD, Peter JC. Intracranial pressure and cerebral oxygenation changes after decompressive craniectomy in children with severe traumatic brain injury. *Acta Neurochir Suppl*. 2008;102:77-80.

[53] Jagannathan J, Okonkwo DO, Dumont AS, Ahmed H, Bahari A, Prevedello DM, et al. Outcome following decompressive craniectomy in children with severe traumatic brain injury: a 10-year single-center experience with long-term follow up. *J Neurosurg*. 2007;106(4 Suppl):268-75.

[54] Mhanna MJ, Mallah WE, Verrees M, Shah R, Super DM. Outcome of children with severe traumatic brain injury who are treated with decompressive craniectomy. *J Neurosurg Pediatr*. 2015:1-7.

[55] Jacob AT, Heuer GG, Grant R, Georgoff P, Danish SF, Storm PB, et al. Decompressive hemicraniectomy for pediatric traumatic brain injury: long-term outcome based on quality of life. *Pediatr Neurosurg.* 2011;47(2):81-6.

[56] Perez Suarez E, Serrano Gonzalez A, Perez Diaz C, Garcia Salido A, Martinez de Azagra Garde A, Casado Flores J. Decompressive craniectomy in 14 children with severe head injury: clinical results with long-term follow-up and review of the literature. *J Trauma*. 2011;71(1):133-40.

[57] Guresir E, Schuss P, Seifert V, Vatter H. Decompressive craniectomy in children: single-center series and systematic review. *Neurosurgery*. 2012;70(4):881-8; discussion 8-9.

[58] Pechmann A, Anastasopoulos C, Korinthenberg R, van Velthoven-Wurster V, Kirschner J. Decompressive craniectomy after severe traumatic brain injury in children: complications and outcome. *Neuropediatrics*. 2015;46(1):5-12.

[59] Frassanito P, Massimi L, Caldarelli M, Tamburrini G, Di Rocco C. Complications of delayed cranial repair after decompressive craniectomy in children less than 1 year old. *Acta Neurochir* (Wien). 2012;154(5):927-33.

[60] Grant GA, Jolley M, Ellenbogen RG, Roberts TS, Gruss JR, Loeser JD. Failure of autologous bone-assisted cranioplasty following decompressive craniectomy in children and adolescents. *J Neurosurg*. 2004;100(2 Suppl Pediatrics):163-8.

[61] Piedra MP, Thompson EM, Selden NR, Ragel BT, Guillaume DJ. Optimal timing of autologous cranioplasty after decompressive craniectomy in children. *J Neurosurg Pediatr*. 2012;10(4):268-72.

[62] Gruber R, Peter R, Hora J. The prognosis of cranioplasty following large craniectomy in children. *Z Kinderchir*. 1988;43(6):375-83.

[63] Bowers CA, Riva-Cambrin J, Hertzler DA, 2nd, Walker ML. Risk factors and rates of bone flap resorption in pediatric patients after decompressive craniectomy for traumatic brain injury. *J Neurosurg Pediatr*. 2013;11(5):526-32.

[64] Posnick JC, Goldstein JA, Armstrong D, Rutka JT. Reconstruction of skull defects in children and adolescents by the use of fixed cranial bone grafts: long-term results. *Neurosurgery*. 1993;32(5):785-91; discussion 91.

[65] Oklund SA, Prolo DJ, Gutierrez RV, King SE. Quantitative comparisons of healing in cranial fresh autografts, frozen autografts and processed autografts, and allografts in canine skull defects. *Clin Orthop Relat Res*. 1986(205):269-91.

[66] Prolo DJ, Burres KP, McLaughlin WT, Christensen AH. Autogenous skull cranioplasty: fresh and preserved (frozen), with consideration of the cellular response. *Neurosurgery*. 1979;4(1):18-29.

[67] Iwama T, Yamada J, Imai S, Shinoda J, Funakoshi T, Sakai N. The use of frozen autogenous bone flaps in delayed cranioplasty revisited. *Neurosurgery*. 2003;52(3):591-6; discussion 5-6.

[68] Rocque BG, Amancherla K, Lew SM, Lam S. Outcomes of cranioplasty following decompressive craniectomy in the pediatric population. *J Neurosurg Pediatr*. 2013;12(2):120-5.

[69] Fong KD, Warren SM, Loboa EG, Henderson JH, Fang TD, Cowan CM, et al. Mechanical strain affects dura mater biological processes: implications for immature calvarial healing. *Plast Reconstr Surg*. 2003;112(5):1312-27.

[70] Greenwald JA, Mehrara BJ, Spector JA, Chin GS, Steinbrech DS, Saadeh PB, et al. Biomolecular mechanisms of calvarial bone induction: immature versus mature dura mater. *Plast Reconstr Surg*. 2000;105(4):1382-92.

[71] Carney NA, Chesnut R, Kochanek PM, American Association for Surgery of T, Child Neurology S, International Society for Pediatric N, et al. Guidelines for the acute medical management of severe traumatic brain injury in infants, children, and adolescents. *Pediatr Crit Care Med*. 2003;4(3 Suppl):S1.

[72] Vavilala MS, Kernic MA, Wang J, Kannan N, Mink RB, Wainwright MS, et al. Acute care clinical indicators associated with discharge outcomes in children with severe traumatic brain injury. *Crit Care Med*. 2014;42(10):2258-66.

[73] Van Cleve W, Kernic MA, Ellenbogen RG, Wang J, Zatzick DF, Bell MJ, et al. National variability in intracranial pressure monitoring and craniotomy for children with moderate to severe traumatic brain injury. *Neurosurgery*. 2013;73(5):746-52; discussion 52; quiz 52.

[74] Brolliar SM, Moore M, Thompson HJ, Whiteside LK, Mink RB, Wainwright MS, et al. A qualitative study exploring factors associated with provider adherence to severe pediatric traumatic brain injury guidelines. *J Neurotrauma*. 2016;33(16):1554-60.

[75] Hutchinson PJ, Kolias AG, Timofeev IS, Corteen EA, Czosnyka M, Timothy J et al. RESCUEicp Trial Collaborators. Trial of decompressive craniectomy for traumatic intracranial hypertension. *N Engl J Med*. 2016;375(12):1119-1130.

[76] Bell MJ, Kochanek PM. Pediatric traumatic brain injury in 2012: the year with new guidelines and common data elements. *Crit Care Clin*. 2013;29(2):223-38.

[77] Miller AC, Odenkirchen J, Duhaime AC, Hicks R. Common data elements for research on traumatic brain injury: pediatric considerations. *J Neurotrauma*. 2012;29(4):634-8.

In: Encyclopedia of Surgery (22 Volume Set)
Editors: Andreas Lehrer and Kristin Mueller
ISBN: 978-1-53618-329-0
© 2020 Nova Science Publishers, Inc.

Chapter 234

EARLY DECOMPRESSIVE CRANIECTOMY FOR BLAST AND PENETRATING BRAIN INJURY IN WAR: LESSONS FOR CIVILIAN SURGEONS

***Jeffrey V. Rosenfeld*[1,2,4,*], *Randy S. Bell*[3,4] *and Rocco Armonda*[5,6]**

[1]Department of Neurosurgery, Alfred Hospital, Melbourne Australia
[2]Department of Surgery, Monash University, Melbourne Australia
[3]Department of Neurosurgery, Walter Reed National Military Hospital, Bethesda, MD, US
[4]Department of Surgery, F. Edward Hébert School of Medicine, Uniformed University of the Health Sciences, Bethesda, MD, US
[5]Georgetown University Hospital, Washington, DC, US
[6]MedStar Washington Hospital Center, Washington, DC, US

ABSTRACT

Bomb blast causes severe multiple trauma and distinctive patterns of head and neck injury. Brain swelling, hemorrhage, and penetrating metal and bone fragments with intracranial air are typical, resulting in severe intracranial hypertension. Decompressive craniectomy has become a mainstay of treatment for blast and missile penetrating injuries of the brain occurring in modern warfare. The clinical management and the surgical techniques for these injuries are directly transferable to the management of civilians injured by bomb blast during terrorist attacks in countries where wars are not being fought. We therefore strongly recommend that civilian neurosurgeons become familiar with the resuscitation, assessment, investigation, and surgery required to treat these injuries.

Keywords: decompressive craniectomy, blast injury, penetrating brain injury, military surgery, gunshot wound

* Corresponding Author's Email: Jeffrey.rosenfeld@monash.edu.

INTRODUCTION

The wars on terror in Iraq and Afghanistan (Operation Iraqi Freedom [OIF] and Operation Enduring Freedom [OEF], respectively) followed the horrendous terrorist attacks on the United States of America on September 11, 2001. The improvised explosive device (IED) became the weapon of choice for the enemy fighters and terrorists (including suicide bombers) in Iraq and Afghanistan. Bomb blasts have caused many military and civilian casualties in these wars and in terror attacks on civilians around the world [1-3]. Casualties with extensive multisystem injuries, called "polytrauma", have resulted. The four main types of trauma caused by these bomb blasts have been extensively reviewed and consist of combinations of primary blast injury, fragmentation injury, displacement injury from persons or objects being thrown by the blast, and miscellaneous injury including burns that may affect the face, scalp, and respiratory tract [4, 5].

Trauma to the head and neck has been a common site for injury following exposure to bomb blast [6, 7]. After the terrorist bombing in Madrid in 2004, 52% of victims sustained head trauma [2]. In terror-related incidents, secondary fragments injured the face in 49.5% of casualties, the head in 33.7, and the neck in 13% [3].

Military neurosurgeons have treated many victims of bomb blast in the past 15 years and have gained much experience in how best to treat these complex injuries [5, 6, 8, 9]. These bomb blast injuries are frequently associated with gross brain swelling, hemorrhage, and raised intracranial pressure. Penetration of bomb fragments into the brain adds further complexity to these injuries.

Penetrating brain injuries due to high-velocity military rounds have also been frequently encountered in modern war zones. These missiles also cause extensive trauma with hemorrhage and gross brain swelling. The management of these injuries frequently requires decompressive craniectomy [10]. Gunshot wounds to the head are also frequently encountered by neurosurgeons in civilian hospitals [11].

Early extensive decompressive craniectomy has become a mainstay of treatment for soldiers thus injured and has also been of advantage for the safe evacuation of the casualty to more advanced levels of care. Decompressive craniectomy allows for maximal intracranial pressure (ICP) control during long medical flights to more advanced care [12]. Tension aerocele is also prevented in flight. Injured in-country personnel or civilians who have had decompressive craniectomy can then be transferred to the local health facilities, which may lack the expertise or equipment to manage elevated ICP [12].

Although more extensive debridement for the management of ballistic head trauma was performed by some neurosurgeons in the Vietnam war [13] and the Iran/Iraq war [14], other neurosurgeons in the Israel/Lebanon war [15] and the Iran/Iraq war [16] have advocated less extensive debridement. The surgical management of blast and missile penetrating head trauma in OIF/OEF has become more extensive than in previous wars. This more recent trend for more extensive surgery has resulted, first, from the substantial injury caused by close exposure to the bomb blast versus more focal shrapnel or bullet injury; second, from high quality prehospital care that results in survivors with more severe injuries; and third, from the proximity of neurosurgeons to the battle zone.

Unfortunately, terrorist attacks resulting in mass casualties due to bomb blast have become more common throughout the world [17]. We strongly recommend civilian

neurosurgeons become familiar with the management of blast and penetrating injuries including the surgical techniques for decompressive craniectomy. Extensive decompressive craniectomies have become standard practice for these injuries.

The decompressive craniectomy randomized clinical trial for diffuse brain injury with intracranial hypertension (DECRA) was conducted on a select group of patients with blunt traumatic injuries and diffuse symmetrical swelling of the hemispheres without intracranial hemorrhage [18]. This trial and the subsequent RESCUEicp trial [19] do not apply to the management of military neurotrauma due to bomb blast or penetrating injury to the head. The pathophysiology of blast injury and penetrating injury (see below) is different from blunt injury and diffuse axonal injury caused by deceleration in motor vehicle accidents, falls, sport injuries, and assaults. Patients with blast and penetrating injury were not included in these two trials.

HISTORY OF CRANIOTOMY/CRANIECTOMY FOR PENETRATING AND BLAST INJURY

The history of military cranial surgery for penetrating injury has been extensively reviewed [20]. In 1908 Cushing described subtemporal decompression for the intracranial complications associated with bursting fractures of the skull [21]. Cushing advanced military neurosurgery during his service on the Western Front in the first World War (WWI). He advocated en bloc removal of involved bone, aggressive debridement of the brain, and extraction of bone fragments [20, 22]. Both Cushing and Horrax emphasized additional perioperative procedures including shaving the scalp, patient positioning, and overall aseptic technique [20]. Cushing also advocated water-tight closure of the scalp, a procedure that was not universally practiced during WWI [23]. Cushing was influenced by the previous experience of other surgeons in WWI [23].

Advances in resuscitation, anesthesia, surgical technique, antibiotics and infection treatment, seizure prophylaxis and management in subsequent wars informed civilian practice [20, 24-27]. The US Army Medical Service *Neurological Surgery of Trauma* published in 1965 recommended exposure of 4 cm of bone around a fracture site and en bloc excision of the fracture and removal of in-driven bone fragments [28]. However, extensive decompressive craniectomy for blast and penetrating brain injuries was not a feature of surgery in WWI or the second World War (WWII). Casualties received early neurosurgery in forward hospitals in WWI, WWII, and the Korean War [20, 27, 29]. Early evacuation by helicopter in the Vietnam War enabled casualties to receive early neurosurgery. Rish et al. advocated craniotomy as a debridement technique for penetrating cranial trauma in Vietnam [30].

Less extensive surgery was practiced in the Israel-Lebanon war, informed by early computed tomography (CT) scan for the first time in modern warfare [15]. No attempt was made to remove in-driven fragments of bone or metal. Minimal debridement was also practiced in the Iran-Iraq War [16]. These injuries tended to be low velocity fragment injuries rather than the diffuse blast seen in OIF/OEF. Also, CT was able to identify those with hematomas or later infection who needed more extensive surgery. CT brain scans were also used to help guide surgery in Operation Desert Storm in 1991 [31].

Kjellberg and Prieto described bifrontal decompressive craniotomy for massive cerebral edema in 1971 [32], and Polin et al. described decompressive bifrontal craniectomy for severe refractory posttraumatic cerebral edema in 1997 [33]. Decompressive craniectomy became extensively used in severe blunt traumatic brain injury (TBI) in the 1980s and 1990s to treat brain swelling, acute subdural hematoma, and intracranial hypertension. Unilateral craniectomy was most often used. Hemicraniectomy was also found to be of benefit for malignant middle cerebral artery territory infarction [34, 35]. This experience from civilian neurosurgery influenced the practice of military neurosurgery for blast injury.

From the Iraq and Afghanistan wars of the 1990s to the present, use of more powerful bombs and IEDs has increased with soldiers frequently being close to the epicenter of the blast, either mounted in vehicles or dismounted on patrol. The basic science and pathophysiology of blast and penetrating injuries was better understood than in previous wars. Survival from these severe blast injuries has improved because of immediate resuscitation by skilled combat medics in the field, rapid evacuation to far-forward combat support hospitals for further resuscitation and initial wound surgery, and early evacuation to in-theater advanced field hospitals where neurosurgery and other specialty surgery is performed. More extensive craniofacial injuries due to bomb blast were also encountered by military neurosurgeons in OIF/OEF. A more aggressive approach to the head and neck injury and the other extensive injuries was required to save lives and obtain the best outcomes. All of this civilian and military surgery experience combined to encourage neurosurgeons in OIF and OEF to perform more extensive decompressive craniectomy in the acute military setting [8, 9].

Figure 1. Axial CT brain scan of a bomb blast injury showing multiple fragments of metal that have entered from the left parietal region, associated generalized brain swelling, patchy small hemorrhages, and bubbles of air. Note the fractures in the skull on the left side and the gross scalp hematoma/swelling. (Courtesy of J Rosenfeld, Monash University).

Figure 2. Axial CT brain scan of a bomb blast injury showing basal subarachnoid hemorrhage. Note the two metal fragments on the right side in relation to the circle of Willis. The patient requires an angiogram (CT or digital subtraction angiogram if available). (Courtesy of J Rosenfeld, Monash University).

From 2007 to 2009, two hundred ten neurosurgical procedures were performed at the US Hospital at Bagram, Afghanistan. Ninety were craniotomies for wartime trauma including twenty-eight decompressive craniectomies (31% of craniotomies) in twenty-seven patients. Twenty-four of twenty-eight (86%) were unilateral frontotemporal, seven of twenty-eight (25%) were bifrontal, and two of twenty-eight (7%) were suboccipital. Nineteen of these were performed for penetrating injury (gunshot wound = 13; explosions = 6) and nine for severe closed head injury (explosions = 6; motor vehicle crash = 2; fall = 1) [12].

PATHOPHYSIOLOGY OF BLAST INJURY TO THE BRAIN

The wide spectrum of injury to the brain, head, and neck caused by bomb blast ranges from mild concussion to severe life-threatening or non-survivable trauma [36, 37]. The extent of injury depends on the distance of the victim from the epicenter of the blast, whether the victim is in an enclosed or open space, whether the victim is wearing head protection with a helmet and ballistic eye protection, and the position and body disposition of the victim (standing or horizontal). The pathophysiology of blast injury to the head has been studied extensively in rodent and pig models [38].

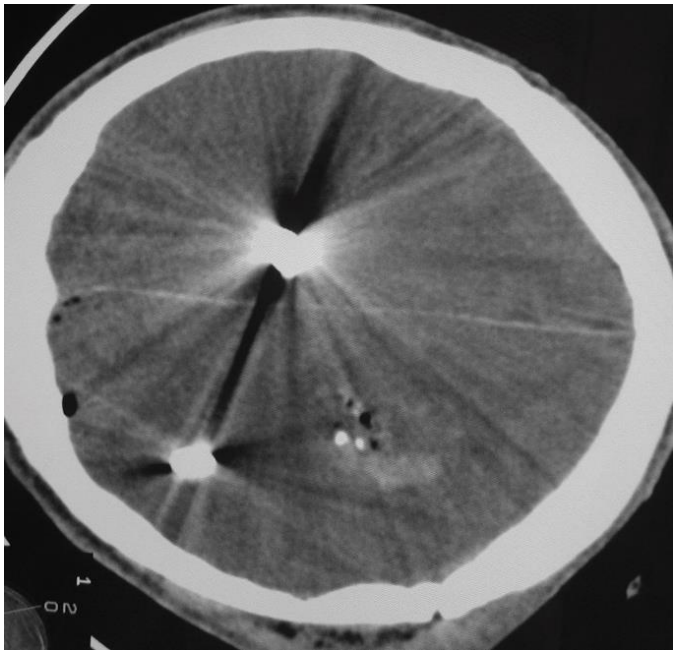

Figure 3. Axial CT brain scan of a bomb blast injury showing multiple fragments of metal, intracerebral hemorrhage, and generalized brain swelling. (Courtesy of J Rosenfeld, Monash University).

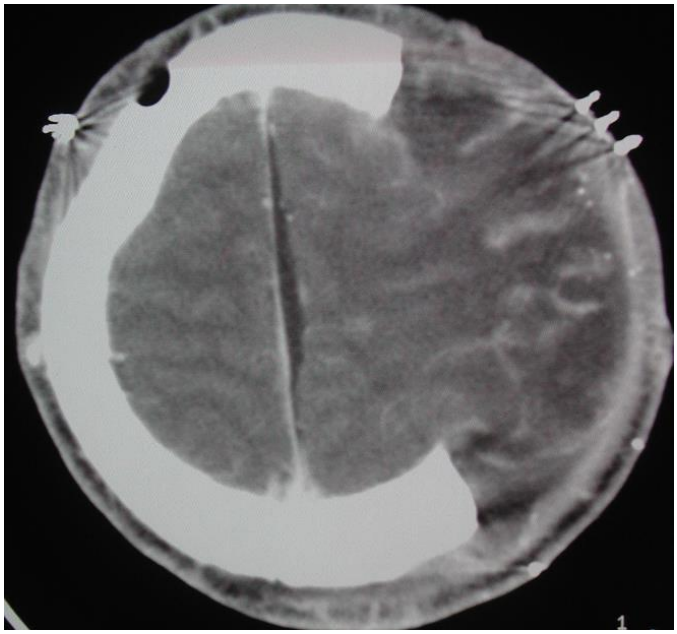

Figure 4. Axial CT brain scan of a bomb blast injury following decompressive craniectomy showing brain edema and herniation at the craniectomy site. (Courtesy of J Rosenfeld, Monash University).

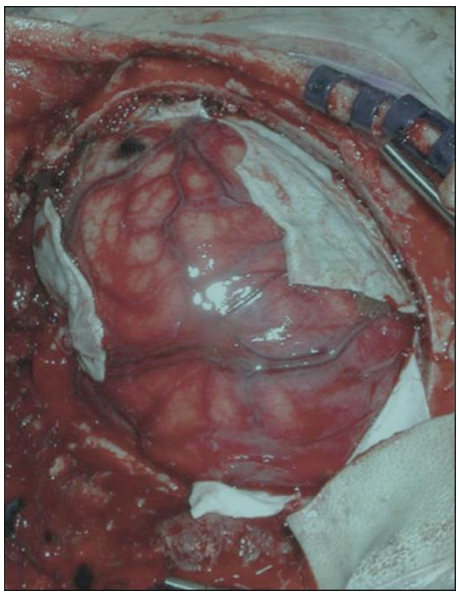

Figure 5. Operative photograph showing the gross brain swelling and vascular engorgement caused by bomb blast. (Courtesy of J Rosenfeld, Monash University).

The over-pressure waves generated from the bomb blast epicenter result in shock waves that pass through the skull, skull orifices, and brain and reflect off the inside of the skull to magnify the effect. The physics of blast injury is complex and multifaceted [6]. There is diffuse brain swelling, diffuse axonal injury, and combinations of intracranial hemorrhage including epidural, subdural, subarachnoid, intracerebral, and intraventricular. The brain edema is often severe and results in life-threatening intracranial hypertension. See Figures 1–5.

This pathology is compounded by penetrating metal fragments of bomb and skull bone fragments, often with dirt, fragments of clothing, skin, and hair entering the brain in addition to the metal. These penetrating wounds are heavily contaminated. The trajectory of fragments may pass from below through the facial skeleton, orbits, or posterior fossa or lower temporal zone into the brain. Complex calvarial compound depressed fractures and basal fractures with cerebrospinal fluid (CSF) leaks result [5, 6, 10]. Pseudoaneurysms and vasospasm develop in a significant number of severe blast TBI victims and may cause delayed deterioration [39, 40]. The eyes and ear drums, ossicles, cochlea, and vestibular organs may also be injured. The structures in the neck are also vulnerable, namely, the pharynx, larynx, carotid and vertebral arteries, spine, and spinal cord.

Facial and/or orbital injuries may extend to skull base fractures. Extension into the sphenoid wing or body is not uncommon. When these skull base fractures occur, there is a higher likelihood of carotid artery injury, with pseudoaneurysm, dissection, and carotid cavernous fistula. Other injuries are CSF fistula through fractures in the frontal, sphenoid, and/or ethmoid sinuses with delayed meningitis, cranial nerve palsies (I, II, III, IV, V, VI), and frontal encephaloceles through defects in the skull base. Both carotid cavernous fistula and encephalocele can result in pulsatile proptosis. The extension of facial/orbital injuries into the sphenoid bone can be identified on bone windows of the CT scan and proximal carotid injury can be identified on CT angiogram.

Paradoxical brain herniation could occur following a decompressive craniectomy if there is ongoing CSF leak through the skull base fractures. This creates a downward pressure gradient with atmospheric pressure acting on the brain from above and the CSF leak lowering the intracranial pressure from below.

High velocity missile or projectile penetrating injury involves direct pressure effects of the projectile, and cavitation of surrounding brain with resultant intracerebral hemorrhage and brain swelling are both quite different from blunt injury and diffuse axonal injury caused by deceleration [10, 41].

ACUTE MANAGEMENT

We have previously described the management of penetrating injury to the head including blast injury [5, 10]. The early surgery for severe trauma should follow the principles of "damage control surgery" with vigorous resuscitation, rapid access to the operating room, abbreviated surgery, and continued correction of physiological derangement to prevent the lethal triad of acidosis, coagulopathy, and hypothermia. The term *abbreviated surgery* was originally used to describe trauma laparotomy with rapid control of bleeding and hollow viscus contamination of the peritoneal cavity. "Damage control" principles also apply to emergency neurosurgery where emergency decompressive craniectomy has a role in the management of blast injury to the brain [42]. Importantly, "abbreviated" in the context of neurosurgery indicates being time efficient, but does not mean insufficient. Taking short-cuts, such as leaving the dura open, may result in serious preventable morbidity. Neurosurgery can be both meticulous and abbreviated.

Battlefield resuscitation has advanced considerably in the past decade and has been informed by a growing evidence base [43]. A highly efficient military trauma system that delivers early advanced care to the injured soldier has saved many lives and has been translated to the civilian trauma system. Evidence has been generated from extensive battlefield experience and collated and analyzed from the Joint Theater Trauma Registry of the US military. Guidelines have been prepared and published in the *Journal of Trauma* and online [44-48].

Triage and Initial Resuscitation

The casualty should be rapidly triaged by an experienced trauma specialist. Decisions are made to provide immediate, urgent, or delayed treatment.

The principles of resuscitation are to stop hemorrhage, prevent hypoxia and hypercapnia, and correct shock/hypotension. The principles of "damage control resuscitation" follow from these goals [43]. Blood is cross-matched and blood clotting checked. A well-prepared trauma team carries out "horizontal" simultaneous procedures and treatments rather than a "vertical" step-by-step protocol. Major bleeding is controlled with tourniquets to the limbs and/or direct pressure dressings and manual compression. An airway is rapidly secured. A brief neurological assessment is made, including Glasgow Coma Scale (GCS) score, pupil size and reactivity, and weakness in the limbs (hemiparesis, quadriparesis, or paraparesis before the

patient is sedated or anesthetized). If the GCS score is <9, an endotracheal tube should be placed using a crash induction technique to prevent laryngeal spasm, straining, coughing, and jaw clamping, which will cause secondary rises in intracranial pressure. If there is severe facial trauma or facial /respiratory tract burns, the casualty will require an urgent endotracheal tube before swelling and/or hemorrhage compromises the visualization of the larynx. For those with severe facial trauma or facial burns, the endotracheal tube is converted to a tracheotomy at the commencement of the operating room procedures.

For patients with severe TBI and polytrauma, resuscitation should be directed at achieving adequate cerebral perfusion and correcting coagulopathy and other physiological derangements. A target systolic blood pressure should be based on that required to achieve adequate cerebral perfusion pressure. Blood component replacement (hemostatic resuscitation) should be started early, especially when there is severe cranial penetrating injury. A 1:1:1 ratio of plasma, platelets, and red cells is an effective strategy to correcting coagulopathy of trauma [49]. The casualty should be kept warm with a thermal blanket to prevent hypothermia.

Medication

Prophylactic broad spectrum antibiotics and tetanus prophylaxis are administered [47]. We currently recommend intravenous vancomycin and meropenem prophylaxis for blast and penetrating cranial trauma in war zones because of the heavy contamination of these wounds. Prophylactic anticonvulsants are administered with an intravenous loading dose of phenytoin or levitiracetam. Intravenous mannitol or hypertonic saline may be administered as a temporizing measure if there are signs of deteriorating neurological status while the casualty is awaiting surgery. Steroids are not indicated.

Imaging

There is almost always time to get a CT of the head and neck prior to surgery unless the patient is exsanguinating. In that case, the patient should be taken straight to the operating room. With penetrating injury to the brain or concern about a possible vascular injury, a CT angiogram should be obtained at the time of the CT. An urgent chest radiograph is obtained in the emergency room by mobile x-ray machine. The neurosurgeon should identify injuries to facial skeleton, orbits, sinuses, and skull base. These injuries will need attention during the first operation. The general surgeon may require CT of chest and abdomen with or without pelvis, and the orthopedic surgeon may require some limb radiographs. The time taken to get images should be kept to a minimum.

When a casualty has polytrauma, combined simultaneous surgery may be required to achieve the goals of rapid damage control surgery. For example, the orthopedic and vascular surgeons are debriding and stabilizing a penetrating limb wound with compound fracture and vascular injury, the general surgeon is performing a laparotomy, and the neurosurgeon is performing a decompressive craniectomy. This scenario has been common in military settings but should also be adopted in the civilian setting [50]. The decompressive craniectomy should

not wait until the end of a laparotomy because the brain may suffer ongoing injury from continuing intracranial hypertension during this time.

Acute Management of Accompanying Injuries

The patient's eyes are closely inspected for globe penetration or hyphema before the lids become difficult to open due to swelling. A lateral canthotomy may be required to relieve gross orbital swelling. Fragments of metal in the eyes can be identified on the CT head scan. The external auditory canals are inspected for drum perforation and the presence of blood/CSF in the canals. Severe penetrating injury to the face and sinuses causes profuse hemorrhage and rapid swelling of the tissues. Local packing is placed to quell the hemorrhage until repair is undertaken. Facial and sinus injuries should be addressed early if the surgeon has the skill and resources (see below).

INDICATIONS FOR DECOMPRESSIVE CRANIECTOMY

A serious blast injury to the head will result in significant brain swelling and intracranial hypertension. Decompressive craniectomy is indicated for this injury. There are three types of decompressive craniectomy and the indications for each type depend on the pattern of injury.

Unilateral Decompressive Craniectomy (Hemicraniectomy)

The blast or missile penetrating injury is predominantly on one side of the brain with unilateral hemisphere swelling and midline shift to the opposite side. This is frequently accompanied by acute subdural or epidural hematoma. Penetrating injury may also be present on that side.

Bifrontotemporal Decompressive Craniectomy

The indications are bilateral symmetrical hemisphere swelling/contusion, bifrontal injury, transventricular fragment or missile trajectories. This approach also gives access to the floor of the anterior cranial fossa if there are complex anterior skull base fractures over the orbits and ethmoid and frontal sinuses.

Posterior Fossa (Suboccipital) Decompressive Craniectomy

Indications are penetrating injury to the posterior fossa with extra-axial hemorrhage or hemorrhage/swelling in the cerebellum. If the brain stem is involved in the trajectory of a fragment or bullet, the prognosis may be very poor and decompression is not likely to improve outcome [10].

Penetrating injury across the area of brain 4 cm above the dorsum sellae or "zona fatalis" (midline skull base, thalamus, brainstem) is usually fatal and decompressive surgery is not performed [51].

OPERATIVE SURGERY

The principles developed in OIF/OEF have combined minimal debridement with maximal bone removal [12]. The key objective with any decompressive craniectomy for trauma, especially blast injury, is to make it as large as possible. If the craniectomy is too small, the swollen brain herniates over the bone at the edges and lacerates or strangulates, becoming ischemic or infarcted. The surgical technique for unilateral and bilateral decompressive craniectomy has been well described [12, 52].

Scalp

The scalp should be completely shaved. The three-pin neurosurgery operating table head clamp is applied if available, otherwise the head is placed on the horseshoe rest. Care is taken to place the pins away from where the scalp incision will be made. The ipsilateral shoulder is raised if the head is in a lateral position. The head of the table is elevated 10 degrees.

Three types of scalp incision can be used when performing DC for military trauma:

1. A midline sagittal incision with a "T-bar" incision was described by Ludwig G. Kempe for hemispherectomy [53]. The midline incision extends from the hairline to the inion. The T-bar incision starts 1 to 2 cm anterior to the tragus at the root of the zygoma and extends superiorly to meet the midline incision just behind the coronal suture. This incision preserves the superficial temporal artery and occipital artery angiosomes. The disadvantage is the tripod created at the junction of the two incisions that may necrose. The junction must be handled and sutured very carefully to avoid this problem.
2. The large reverse question mark incision starts at the root of the zygoma, posterior to the superficial temporal artery (STA), back toward the asterion, and then curves around the parietal eminence to the midline and forward to the hairline. The scalp is reflected as a myocutaneous flap with the temporalis muscle. The STA should at least be palpated and marked. A Doppler device can be used to exactly locate the STA, and the incision is kept behind the STA, which is usually 10 to 15 mm in front of the tragus.

   A variation on the standard frontotemporal scalp incision is a large curvilinear C-shaped incision extending from the mastoid region behind the ear up to the midline and carried forward to the hairline if the injury has avulsed the scalp or temporalis muscle over the temporal fossa. This incision is thus separate from potentially devitalized scalp.
3. Bicoronal incision for the bifrontal craniectomy extends from the root of the zygoma, 1 to 2 cm anterior to the tragus, extending up to the midline just behind the coronal

suture and across to the other side. The surgeon should ensure that the bi-coronal incision at the vertex is at the level of the coronal suture behind the hairline. This decompresses the frontal region to the level of the coronal suture.

Late breakdown of posterior wound margins has been seen with the reverse question mark incision. This was related to compromise of the superficial temporal or occipital arteries, to the patient lying directly on the flap, and to complex scalp lacerations incorporated in the scalp flap. For this reason, surgeons in OIF/OEF tended to favor the T-shaped scalp incision, particularly when there were complex scalp lacerations [12].

Skull

The size of the initial craniectomy is of critical importance and should be carefully planned. We have seen patients for whom the extent of the injury was underestimated and the size of the decompressive craniectomy was too small.

The Guidelines for the Management of Severe Traumatic Brain Injury, Fourth Edition, recommend that unilateral frontoparietotemporal decompressive craniectomy in the civilian context be 12 cm x 15 cm diameter [54]. On the basis of their military experience, Bell et al. recommend that a hemicraniectomy for frontoparietotemporal decompression have the dimensions of at least 14 cm anteroposterior by 12 cm superoinferior [9]. The surgeon should mark the midline and the line of the transverse sinus carefully so that the bone cuts avoid the venous sinuses. The posterior bone cut should be at least 2 cm above the asterion and lambdoid suture. The craniotome is taken as low as it will go in the middle fossa, but it is important for the surgeon to use rongeurs to remove the remaining squamous temporal bone and greater wing of the sphenoid down to the floor of the middle fossa. This will decompress the temporal lobe and upper brainstem. Air cells in the sphenoid or mastoid bone must be plugged with bone wax.

For bifrontal decompressive craniectomy, burr holes are placed on either side of the sagittal sinus as well as at the pterion and at the root of the zygoma just below the superior temporal line. The posterior edge of the bone cut can extend just behind the coronal suture and extend vertically downwards to decompress the frontal and temporal lobes. The temporal bone is removed with rongeurs below the inferior cut as described in the preceding paragraph. A strip of bone can be left over the sagittal sinus to protect it. To avoid entering the frontal sinus and thus creating further potential morbidity with CSF leaks and infection, the lower bone cut can pass just above these air sinuses. This can be judged on the scout view of the CT scan or a plain radiograph if no CT is available. Cranialization of the frontal sinus will be required if the sinus is breached.

Dura

The dura should be widely opened to optimize relief of intracranial hypertension and to allow for exposure and treatment of the hematomas/penetrating injury.

For unilateral decompressive craniectomy, the dura is opened in a C shape with multiple relieving spoke-wheel cuts. The dura is cut no closer than 2 cm from the superior sagittal

sinus to avoid trauma to the sinus and bridging veins. Dural tack-up sutures are used to avoid postoperative hematomas beneath the bone edge. For bifrontal decompressive craniectomy, the dura can be opened with cuts parallel to the sagittal sinus and the posterior bone margin or with a stellate opening. Some neurosurgeons have also divided the sagittal sinus inferiorly and released the falx.

The basal dura needs to be repaired if it is lacerated. The use of a vascularized pericranial flap is preferred. This is also used to cover the cranialized frontal sinus. Tensor fascia lata can also be used. These grafts should be tacked down and can also be secured with tissue glue. Onlay graft material such as DuraGen (Integra Life Sciences Corporation, Plainsboro, New Jersey, USA) may not be sufficient for the skull base repair.

Dural expansion should be the goal for repair of the convexity dura. A duroplasty is performed with patches sewn in to create a watertight closure. In an emergency situation, however, a dural substitute such as DuraGen is laid over the dural openings. This does not require suturing and is quickly applied. In blast and penetrating injuries, a watertight scalp closure is critically important to prevent CSF leak and ensure primary healing.

Bone Flap Management

For bone flap management, surgeons have the following four options:

1. In Afghanistan and Iraq because of the high levels of contamination of the bone encountered in the complex penetrating trauma and the high risk of sepsis if the bone was replaced at a later date, the practice was to discard the bone and repair the skull with CT-derived custom-made titanium implants or 3D printed prosthetic materials such a methyl methacrylate. Bell et al. found that just over half of the military patients with severe injury to the central nervous system had concomitant systemic infections. The fluid collection around the abdominal bone implant could not be excluded as the source. The bone was discarded in almost all of these cases [8].
2. The bone can be cleaned, then washed with bacitracin or gentamicin solution, placed in a sterile plastic bag, and cryopreserved at -70°C.
3. The bone is cleaned and washed as above and placed in a subcutaneous pocket in the left lower quadrant so that the scar is not confused with an appendectomy scar in the future.
4. Hinge craniectomy can be considered, particularly in remote locations or war zones where further neurosurgery and eventual cranial reconstruction is not an option [55].

PRINCIPLES OF SURGERY FOR BLAST INJURY TO THE BRAIN

The surgery for blast injury to the brain should be rapid, but with control maintained. Large hematomas are evacuated. Devitalized tissue is debrided. Superficial debridement and irrigation of brain wounds is carried out without overly aggressive searching for deep fragments of metal or bone. Hemostasis is completed. A parenchymal ICP monitor is placed and, preferably, a ventriculostomy is also placed so that CSF can be vented to help control

ICP. The surgeon should consider removing the anterior segment of a grossly swollen damaged temporal lobe to decompress the upper brainstem. In war zones the trauma team and the neurosurgeon should also be aware of the possibility of penetrating small arms ammunition being unexploded ordnance. Special precautions will need to be taken [56].

A head and neck team consisting of neurosurgeon, maxillofacial surgeon, otorhinolaryngologist, ophthalmologist, and plastic surgeon, if available, work together to repair complex craniofacial injuries. Nasal and facial wound packing may be required to control severe hemorrhage. Although the repair of facial injuries should follow abbreviated damage control principles with limited fixation of facial fractures in the first operation, we strongly advocate adequate repair of sinus and skull base injuries at the first operation. More definitive reconstruction of the facial injuries can be pursued further during second- and third-stage surgery once the swelling has subsided.

Careful attention needs to be paid to the repair of the dura over the floor of the anterior fossa as it is frequently lacerated in these injuries. The frontal sinus requires exenteration if it is breached by the injury or by the surgeon during the opening. We recommend using pericranial vascularized flaps and autologous split thickness calvarial autograft to repair these defects. Failure to repair the skull base and sinus injuries at the first operation results in brain hernias, CSF leak, and infection. We strongly recommend against using titanium mesh for skull base repair because the mesh may eventually erode the dura and penetrate the brain or may erode the roof of the nasopharynx. Revisional surgery is rendered very challenging. The fronto-orbital bandeau is restored with autologous bone fragments, titanium miniplates, and elongated plates. This prevents brain herniation or ptosis and provides a cosmetic reconstruction of the facial contour [12]. Following the decompressive craniectomy, the scalp is closed primarily in two layers. Rotational scalp flaps may be required, if there is scalp loss, to avoid closure under tension.

CARE AFTER DECOMPRESSIVE CRANIECTOMY

Intensive Care Management

The details of intensive care management are beyond the scope of this chapter. The patient remains intubated and sedated in the intensive care unit until the ICPs are normal and the brain swelling is subsiding. This may take 7 to 10 days. The head of the bed is elevated to help control ICP. The aim is for normal physiology to be restored as quickly as possible. Rewarming continues to normothermia. Abnormal acid/base balance, coagulation, electrolytes, and hemoglobin are corrected. Early enteral feeding is commenced.

In the military setting, the casualty is evacuated by air from the frontline hospital after 24 to 48 hours and returned back to their nation by 3 to 4 days from the time of the injury [12]. The US Air Force has developed ongoing intensive care management in fixed wing transport aircraft for intercontinental aeromedical evacuation [57].

EARLY COMPLICATIONS

Postoperative hemorrhage is not uncommon and results from ongoing coagulopathy or failure to secure hemostasis at the first operation. This hemorrhage may result in an epidural, subdural, or intracerebral hematoma. A repeat scan the day after surgery or earlier if there is clinical deterioration will pick this up. Inadequate size of craniectomy will result in poor control of ICP and brain herniation with secondary injury to this extruded brain tissue. Wound ischemia or breakdown may require wound revision and avoidance of pressure on this area of scalp.

CSF leak from calvarial wounds should be prevented with dural patching and watertight scalp closure in two layers. CSF leak is not uncommon with complex skull base fractures and dural tears. CSF leak increases the risk of early and late meningitis. Revision surgery may be required to repair the leak. Lumbar drainage may be required when brain swelling subsides in order to stop the CSF leak while the tissues are healing.

Infection is a delayed complication and may require reoperation to drain subdural empyema or brain abscess. Hydrocephalus and the "syndrome of the trephined" are delayed complications that will be described in other chapters.

PROGNOSIS AFTER DECOMPRESSIVE CRANIECTOMY

The prognosis of blast and penetrating injury to the head should not be extrapolated directly from figures derived from series of patients with closed head injury, nor should the computer models of prognosis such as CRASH or IMPACT be relied upon. The outcomes of a military population with severe blast or penetrating TBI have been compared with those of a matched civilian population [10, 58].

Weisbrod et al. reported 32% of those in a combat population presenting with a GCS of 3–5 and 63% of those with GCS 6–8 achieved functional independence 2 years following severe blast of penetrating injury [59]. Bell et al. performed a retrospective study on 480 patients with head injury who presented at far-forward Combat Support Hospitals in OIF/OEF. In this population 188 decompressive craniectomies were performed: 154 for penetrating head injury, 22 for closed injury, and 12 unknown classification. Those who underwent decompressive craniectomy tended to have worse injuries with lower GCS and higher Injury Severity Score than those who did not. Glasgow Outcome Score tended to be higher in the non-craniectomy group, but those with craniectomy improved over time. At 1 year 83% had achieved a Glasgow Outcome Score greater than 3. Those with bilateral injury also on average recovered to participate in rehabilitation at 6 to 12 months [9]. Many of these soldiers would likely have died or been worse off without the decompressive craniectomy. It should also be appreciated that significant improvements in these patients may occur over 2 years, particularly with active therapy and rehabilitation.

RECOMMENDATIONS FOR TRAINING AND SIMULATION

Preparation of military surgeons and trauma teams for neurosurgical decision making and to perform selected surgical techniques including decompressive craniectomy is valuable prior to deployment [60]. Civilian general surgeons are taught the basic steps of burr hole and craniectomy/craniotomy in the Definitive Surgery for Trauma Course and practice this on cadavers, but this does not prepare these surgeons for performing extensive decompressive craniectomy.

Neurosurgeons in training would benefit from exposure to simulation models for craniectomy. Virtual reality-based simulation systems that include haptic feedback have been developed for burr holes and are being extended to intracranial hematoma craniotomy simulations [61, 62]. We await further improvements in 3D polymer printing to produce more life-like cranial simulations than those currently available. These would have all the normal layers present to give the trainee surgeon a more realistic simulation model for practice.

CONCLUSION

In wars and military conflicts, early extensive decompressive craniectomy should be considered in almost all penetrating injuries and severe closed head injuries due to bomb blast and military grade weapons. This also applies to blast injury in the civilian population resulting from terrorist attacks. Civilian neurosurgeons should become familiar with the management of bomb blast injuries.

Illustrative Case

A 16-year-old boy presented with a gunshot wound to the brain from point-blank range. There was a high left parietal entry with an anterior trajectory that carried the missile through the Sylvian fissure and exited through the frontal sinus region. The patient arrived with GCS 6T, with active brain extravasation from the exit wound. CT head scan revealed the extent of damage including significant parenchymal, probable cortical arterial, and anterior skull base, left frontal bone and frontal sinus disruption (Figure 6a, b). The key to this case was the immediate resuscitation that began upon the patient's arrival to the emergency room with 1:1:1 ratio of packed red blood cells, fresh frozen plasma, and platelets. The patient was transported to the operating room where an immediate frontoparietotemporal decompressive craniectomy was performed (minimum 15 x 12 cm) with removal of the multiple skull fracture fragments, clip occlusion of multiple bleeding middle cerebral artery vessels, exenteration and cranialization of the frontal sinus, and dural onlay with DuraGen and watertight dural closure (Figure 6c). A ventriculostomy was placed postoperatively. Early postoperative CT scans revealed the extent of initial damage and subsequent decompression (Figure 6d). Delayed CT scan revealed the residual left-sided cortical damage (Figure 6e). The patient survived, and with rehabilitation was able to ambulate and speak at the time of cranioplasty 6 months later.

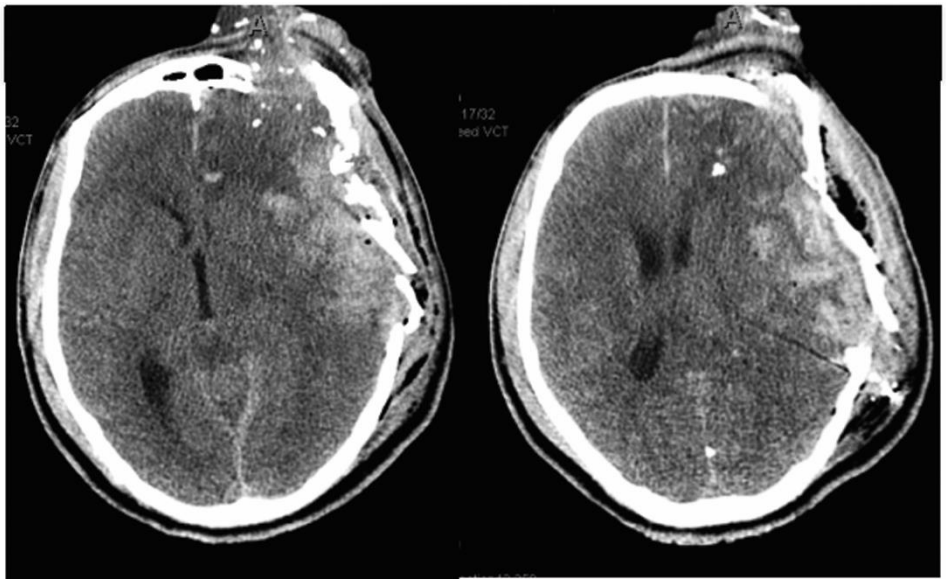

Figure 6a. CT head scan showing the extent of damage from a gunshot injury to the left parietal and frontal region including significant parenchymal and intracerebral hematoma metal fragments in the brain and left hemisphere swelling. (Courtesy of R. Bell, Walter Reed National Military Hospital).

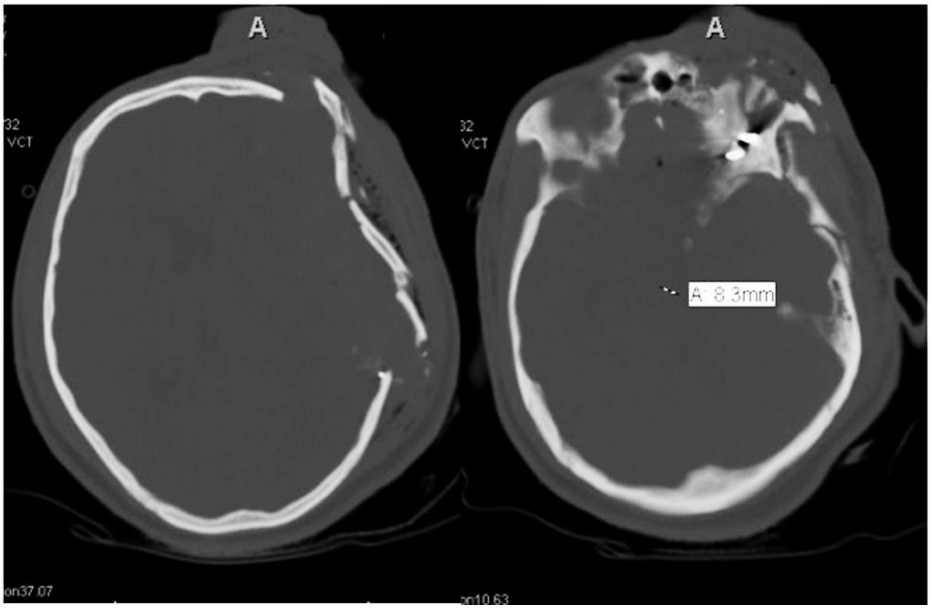

Figure 6b. CT scan with bone windows showing extensive fractures on the left side of the skull, with anterior skull base and frontal sinus disruption. Note the two metal fragments lodged in the left anterior skull base. (Courtesy of R. Bell, Walter Reed National Military Hospital).

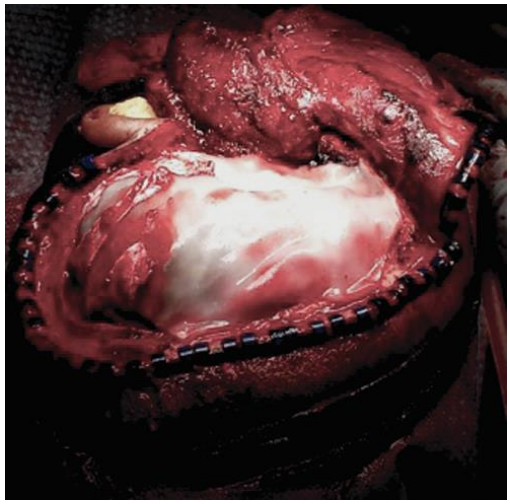

Figure 6c. Operative photo showing dural onlay graft with DuraGen and a watertight dural closure. (Courtesy of R. Bell, Walter Reed National Military Hospital).

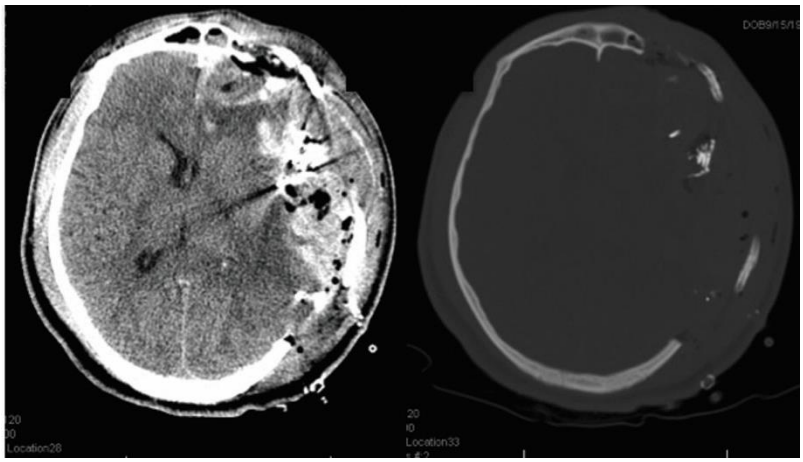

Figure 6d. Early postoperative CT scan reveals the extent of initial damage and subsequent decompression. (Courtesy of R. Bell, Walter Reed National Military Hospital).

REFERENCES

[1] Lakstein, D; Blumenfeld, A. Israeli Army casualties in the second Palestinian uprising. *Mil Med.*, 2005, 170(5), 427-30.

[2] Gutierrez, de, Ceballos, JP; Turegano, Fuentes, F; Perez, Diaz, D; Sanz, Sanchez, M; Martin, Llorente, C; Guerrero, Sanz, JE. Casualties treated at the closest hospital in the Madrid, March 11, terrorist bombings. *Critical care medicine*., 2005, 33(1 Suppl), S107-12.

[3] Sheffy, N; Mintz, Y; Rivkind, AI; Shapira, SC. Terror-related injuries: a comparison of gunshot wounds versus secondary-fragments-induced injuries from explosives. *J Am Coll Surg.*, 2006, 203(3), 297-303.

[4] Neuhaus, SJ; Sharwood, PF; Rosenfeld, JV. Terrorism and blast explosions: lessons for the Australian surgical community. *ANZ J Surg*., 2006, 76(7), 637-44.

[5] Rosenfeld, J. Neurosurgical injuries related to terror. Chapter 19 in *Essentials of Terror Medicine*. Shapira S HJ, Cole LA., editor. New York: Springer Verlag., 2009.

[6] Rosenfeld, JV; McFarlane, AC; Bragge, P; Armonda, RA; Grimes, JB; Ling, GS. Blast-related traumatic brain injury. *Lancet neurol*., 2013, 12(9), 882-93.

[7] Almogy, G; Luria, T; Richter, E; Pizov, R; Bdolah-Abram, T; Mintz, Y; et al. Can external signs of trauma guide management?: Lessons learned from suicide bombing attacks in Israel. *Arch Surg.*, 2005, 140(4), 390-3.

[8] Bell, RS; Vo, AH; Neal, CJ; Tigno, J; Roberts, R; Mossop, C; et al. Military traumatic brain and spinal column injury: a 5-year study of the impact blast and other military grade weaponry on the central nervous system. *The Journal of trauma.*, 2009, 66(4 Suppl), S104-11.

[9] Bell, RS; Mossop, CM; Dirks, MS; Stephens, FL; Mulligan, L; Ecker, R; et al. Early decompressive craniectomy for severe penetrating and closed head injury during wartime. *Neurosurg*., 2010, 28(5), E1.

[10] Rosenfeld, JV; Bell, RS; Armonda, R. Current concepts in penetrating and blast injury to the central nervous system. *World J Surg*., 2015, 39(6), 1352-62.

[11] Aarabi, B; Tofighi, B; Kufera, JA; Hadley, J; Ahn, ES; Cooper, C; et al. Predictors of outcome in civilian gunshot wounds to the head. *J Neurosurg*., 2014, 120, 1138-46.

[12] Ragel, BT; Klimo, P; Jr.; Martin, JE; Teff, RJ; Bakken, HE; Armonda, RA. Wartime decompressive craniectomy: technique and lessons learned. *Neurosurg*., 2010, 28(5), E2.

[13] Carey, ME; Young, HF; Mathis, JL. The neurosurgical treatment of craniocerebral missile wounds in Vietnam. *Surg Gynecol Obstet*., 1972, 135(3), 386-9.

[14] Aarabi, B. Comparative study of bacteriological contamination between primary and secondary exploration of missile head wounds. *Neurosurgery*., 1987, 20(4), 610-6.

[15] Brandvold, B; Levi, L; Feinsod, M; George, ED. Penetrating craniocerebral injuries in the Israeli involvement in the Lebanese conflict, 1982-1985. Analysis of a less aggressive surgical approach. *J Neurosurg*., 1990, 72(1), 15-21.

[16] Amirjamshidi, A; Abbassioun, K; Rahmat, H. Minimal debridement or simple wound closure as the only surgical treatment in war victims with low-velocity penetrating head injuries. Indications and management protocol based upon more than 8 years follow-up of 99 cases from Iran-Iraq conflict. *Surg Neurol*., 2003, 60(2), 105-10, discussion 10-1.

[17] Institute for Economics and Peace. *Global Terrorism Index* 2016 University of Maryland, USA.2016 [Available from: http: //visionofhumanity.org/app/uploads/ 2017/02/Global-Terrorism-Index-2016.pdf.] Accessed May 2017.

[18] Cooper, DJ; Rosenfeld, JV; Murray, L; Arabi, YM; Davies, AR; D'Urso, P; et al. Decompressive craniectomy in diffuse traumatic brain injury. *The New England journal of medicine*., 2011, 364(16), 1493-502.

[19] Hutchinson, PJ; Kolias, AG; Timofeev, IS; Corteen, EA; Czosnyka, M; Timothy, J; et al. Trial of Decompressive Craniectomy for Traumatic Intracranial Hypertension. *The New England journal of medicine*., 2016, 375(12), 1119-30.

[20] Agarwalla, PK; Dunn, GP; Laws, ER. An historical context of modern principles in the management of intracranial injury from projectiles. *Neurosurg*., 2010, 28(5), E23.

[21] Cushing, HI. Subtemporal decompressive 0perations for the intracranial complications associated with bursting fractures of the skull. *Ann Surg.*, 1908, 47(5), 641-4 1.
[22] Cushing, H. A study of a series of wounds involving the brain and its enveloping structures. *Br J Surgery*., 1918, 5, 558-684.
[23] Carey, ME. Cushing and the treatment of brain wounds during World War I. *J Neurosurg*., 2011, 114(6), 1495-501.
[24] Rish, BL; Caveness, WF. Relation of prophylactic medication to the occurrence of early seizures following craniocerebral trauma. *J Neurosurg.*, 1973, 38(2), 155-8.
[25] Meirowsky, AM. Neurological surgery in warfare. *Mil Med*., 1962, 127, 639-46.
[26] Ascroft, P. Treatment of head wounds due to missiles. Analysis of 500 cases. *Lancet*., 1943, 2(August 21), 211-8.
[27] Cairns, H. Neurosurgery in the British Army, 1939-1945. *Br J Surg*., 1947, 55(Suppl 1), 9-26.
[28] US Army Medical Service. *Neurological surgery of trauma*. Washington, DC, Department of the Army, 1965.
[29] Eden, K. Mobile neurosurgery in warfare. Experience in the Eighth Army's campaign in Cyrenaica, Tripolitania and Tunisia. *Lancet*., 1943, 2(December 4), 689-92.
[30] Rish, BL; Dillon, JD; Caveness, WF; Mohr, JP; Kistler, JP; Weiss, GH. Evolution of craniotomy as a debridement technique for penetrating craniocerebral injuries. *J Neurosurg*., 1980, 53(6), 772-5.
[31] Carey, ME; Joseph, AS; Morris, WJ; McDonnell, DE; Rengachary, SS; Smythies, C; et al. Brain wounds and their treatment in VII Corps during Operation Desert Storm, February 20 to April 15, 1991. *Mil Med*., 1998, 163(9), 581-6.
[32] Kjellberg, RN; Prieto, A; Jr. Bifrontal decompressive craniotomy for massive cerebral edema. *J Neurosurg*., 1971, 34(4), 488-93.
[33] Polin, RS; Shaffrey, ME; Bogaev, CA; Tisdale, N; Germanson, T; Bocchicchio, B; et al. Decompressive bifrontal craniectomy in the treatment of severe refractory posttraumatic cerebral edema. *Neurosurgery*., 1997, 41(1), 84-92, discussion -4.
[34] Carter, BS; Ogilvy, CS; Candia, GJ; Rosas, HD; Buonanno, F. One-year outcome after decompressive surgery for massive nondominant hemispheric infarction. *Neurosurgery*., 1997, 40(6), 1168-75, discussion 75-6.
[35] Schwab, S; Steiner, T; Aschoff, A; Schwarz, S; Steiner, HH; Jansen, O; et al. Early hemicraniectomy in patients with complete middle cerebral artery infarction. *Stroke*., 1998, 29(9), 1888-93.
[36] Ling, G; Ecklund, JM; Bandak, FA. Brain injury from explosive blast: description and clinical management. *Handb. Clin. Neurol.*, 2015, 127, 173-80.
[37] Bandak, FA; Ling, G; Bandak, A; De, Lanerolle, NC. Injury biomechanics, neuropathology, and simplified physics of explosive blast and impact mild traumatic brain injury. *Handb. Clin. Neurol.*, 2015, 127, 89-104.
[38] Bauman, RA; Ling, G; Tong, L; Januszkiewicz, A; Agoston, D; Delanerolle, N; et al. An introductory characterization of a combat-casualty-care relevant swine model of closed head injury resulting from exposure to explosive blast. *Journal of neurotrauma*., 2009, 26(6), 841-60.
[39] Ling, G; Bandak, F; Armonda, R; Grant, G; Ecklund, J. Explosive blast neurotrauma. *Journal of neurotrauma*., 2009, 26(6), 815-25.

[40] Bell, RS; Ecker, RD; Severson, MA; 3rd. Wanebo, JE; Crandall, B; Armonda, RA. The evolution of the treatment of traumatic cerebrovascular injury during wartime. *Neurosurg*., 2010, 28(5), E5.

[41] Rosenfeld, JV. Gunshot injury to the head and spine. *J Clin Neurosci*., 2002, 9(1), 9-16.

[42] Rosenfeld, JV. Damage control neurosurgery. *Injury*., 2004, 35(7), 655-60.

[43] Dawes, R; Thomas, GO. Battlefield resuscitation. *Curr Opin Crit Care*., 2009, 15(6), 527-35.

[44] Part 1: Guidelines for the management of penetrating brain injury. Introduction and methodology. *The Journal of trauma*., 2001a, 51(2 Suppl), S3-6.

[45] Surgical management of penetrating brain injury. *The Journal of trauma*., 2001b, 51(2 Suppl), S16-25.

[46] Management of cerebrospinal fluid leaks. *The Journal of trauma*., 2001c, 51(2 Suppl), S29-33.

[47] Antibiotic prophylaxis for penetrating brain injury. *The Journal of trauma*., 2001d, 51(2 Suppl), S34-40.

[48] Neurosurgical management. Joint Theatre Trauma System Clinical Practice Guideline, 2012. 2012 [Available from: http: //www.usaisr.amedd.army.mil/assets/ cpgs/ Neurosurgical_Management_7_Mar_12.pdf.

[49] Holcomb, JB; Tilley, BC; Baraniuk, S; Fox, EE; Wade, CE; Podbielski, JM; et al. Transfusion of plasma, platelets, and red blood cells in a 1: 1: 1 vs a 1: 1: 2 ratio and mortality in patients with severe trauma: the PROPPR randomized clinical trial. *JAMA*., 2015, 313(5), 471-82.

[50] Moore, JM; Thomas, PA; Gruen, RL; Chan, P; Rosenfled, JV. Simultaneous multisystem surgery: An important capability for the civilian trauma hospital. *Clinical neurology and neurosurgery*., 2016, 148, 13-6.

[51] Kim, KA; Wang, MY; McNatt, SA; Pinsky, G; Liu, CY; Giannotta, SL; et al. Vector analysis correlating bullet trajectory to outcome after civilian through-and-through gunshot wound to the head: using imaging cues to predict fatal outcome. *Neurosurgery*., 2005, 57(4), 737-47, discussion -47.

[52] Quinn, TM; Taylor, JJ; Magarik, JA; Vought, E; Kindy, MS; Ellegala, DB. Decompressive craniectomy: technical note. *Acta neurologica Scandinavica*., 2011, 123(4), 239-44.

[53] Kempe, L. *Hemispherectomy, in Operative Neurosurgery*. New York: Springer-Verlag, 1968.

[54] Carney, N; Totten, AM; O'Reilly, C; Ullman, JS; Hawryluk, GW; Bell, MJ; et al. Guidelines for the Management of Severe Traumatic Brain Injury, Fourth Edition. *Neurosurgery*. 2016.

[55] Schmidt, JH; 3rd; Reyes, BJ; Fischer, R; Flaherty, SK. Use of hinge craniotomy for cerebral decompression. Technical note. *J Neurosurg*., 2007, 107(3), 678-82.

[56] Forbes, JA; Laughlin, I; Newberry, S; Ryhn, M; Pasley, J; Newberry, T. Stratification of risk to the surgical team in removal of small arms ammunition implanted in the craniofacial region: case report. *J Neurosurg*., 2016, 125(3), 661-6.

[57] Fang, R; Dorlac, GR; Allan, PF; Dorlac, WC. Intercontinental aeromedical evacuation of patients with traumatic brain injuries during Operations Iraqi Freedom and Enduring Freedom. *Neurosurg*., 2010, 28(5), E11.

[58] Dubose, JJ; Barmparas, G; Inaba, K; Stein, DM; Scalea, T; Cancio, LC; et al. Isolated severe traumatic brain injuries sustained during combat operations: Demographics, mortality outcomes, and lessons to be learned from contrasts to civilian counterparts. *Journal of Trauma - Injury, Infection and Critical Care*., 2011, 70(1), 11-8.

[59] Weisbrod, AB; Rodriguez, C; Bell, R; Neal, C; Armonda, R; Dorlac, W; et al. Long-term outcomes of combat casualties sustaining penetrating traumatic brain injury. *Journal of Trauma and Acute Care Surgery*., 2012, 73(6), 1525-30.

[60] Teff, RJ. Use of neurosurgical decision-making and damage-control neurosurgery courses in the Iraq and Afghanistan conflicts: a surgeon's experience. *Neurosurg.*, 2010, 28(5), E9.

[61] Acosta, E; Liu, A; Armonda, R; Fiorill, M; Haluck, R; Lake, C; et al. Burrhole simulation for an intracranial hematoma simulator. *Studies in health technology and informatics*. 2007, 125, 1-6.

[62] Lobel, DA; Elder, JB; Schirmer, CM; Bowyer, MW; Rezai, AR. A novel craniotomy simulator provides a validated method to enhance education in the management of traumatic brain injury. *Neurosurgery*., 2013, 73 Suppl 1, 57-65.

In: Encyclopedia of Surgery (22 Volume Set)
Editors: Andreas Lehrer and Kristin Mueller
ISBN: 978-1-53618-329-0
© 2020 Nova Science Publishers, Inc.

Chapter 235

DECOMPRESSIVE CRANIECTOMY IN CASUALTIES FROM OIF AND OEF: MANAGEMENT AFTER EVACUATION FROM THE WAR ZONE

Chris J. Neal[1], MD, Randy S. Bell[1], MD,
Nicholas Szuflita[1], MD and Rocco Armonda[2], MD
[1]Division of Neurosurgery, Walter Reed National Military Medical Center, Bethesda, MD, US
[2]Department of Neurosurgery, Georgetown University Hospital, MedStar, Washington, DC, US

ABSTRACT

Care for the severe TBI patient who has undergone a decompressive craniectomy in a war zone does not end downrange. This life saving procedure is utilized to create a window of time that will allow relatively safe transport to higher echelons of care, where further treatment, complication management, and ultimately cranial reconstruction can take place. This chapter outlines the evacuation process and highlights management issues that have been seen when treating patients that were injured during Operation Iraqi Freedom and Operation Enduring Freedom.

Keywords: decompressive craniectomy, war, Iraq, Afghanistan, military, neurosurgery

INTRODUCTION

Consideration for immediate decompressive craniectomy versus a delayed decompression depends on the early radiographic findings, mechanism of injury, patient's exam and the

1 The views expressed in this presentation do not represent the official policy or opinion of the United States Navy, United States Army, the Defense Health Agency, the Department of Defense, or the United States Government.

environmental considerations for where the injury has occurred. In a patient subjected to a violent blast injury in an austere environment with a poor exam and radiographic evidence of diffuse edema, early decompression has been a game-changer [1]. The ability to decompress the injured hemisphere allows for a more neurologically stable patient who can then better tolerate a prolonged medical evacuation process.

This practice involves a series of carefully orchestrated events that allows a critically ill patient to be transferred along escalating levels of care. Each stage of the transfer and recovery process offers its own challenges that must be met to maximize a patient's neurological recovery. From continuing ICP management, re-exploration, vascular injury studies, hydrocephalus, infection, and ultimately cranioplasty, patients who suffer severe TBI from blast or high velocity munitions in a wartime environment are unique from their civilian counterparts [2-6]. Not necessarily in the types of issues encountered, but the degree in which they are seen.

EVACUATION OF A DECOMPRESSIVE CRANIECTOMY FROM THEATER

Once the craniectomy patient has undergone their initial medical and surgical treatment, the next question revolves around their stability to be evacuated from the theater of war. Not only does this take into account the medical/neurological status of the patient, but also the logistics of having the transport vehicle, the proper equipment, the weather, battlefield conditions, and an appropriate medical team to manage the patient during the transport process.

Depending on the location of the injury and site of initial treatment, this can involve transport by ground, helicopter, or fixed wing aircraft to higher echelons of care, ultimately back to the Continental United States (CONUS). During Operation Iraqi Freedom (OIF) and Operation Enduring Freedom (OEF), evacuation out of theater often meant stopping at Landstuhl Regional Medical Center in Germany prior to CONUS transport. At every stop along the evacuation route, Advanced Trauma Life Support (ATLS) protocols are followed in addition to Joint Theater Trauma System (JTTS) clinical practice guidelines, which look to build upon the management of severe head injury by applying the unique lessons learned over the years of caring for patients suffering a head injury while in a theater of war [7, 8].

During each leg of the evacuation, an Air Force Critical Care Aeromedical Transport Team (CCATT), is assigned to the craniectomy patient [9]. Developed to meet the needs of the battle-injured patient, CCATT allows en route, critical care to be delivered throughout the transport process. The average time for evacuation from the point of injury to arriving at a CONUS facility, with stops at higher echelons of care along the way, was 4-5 days during the height of OIF/OEF [9-11]. Prior to aeromedical evacuation, a unique concern that needs to be discussed with the CCATT team is the potential risk of expansion of post-operative pneumocephalus secondary to altitude. While less of a concern in a craniectomy patient given the disruption of the cranium from surgery, precautions should still be discussed [12].

Resuscitation and treatment of the patient does not stop during transport. The critical care management of a severe TBI patient, extensively defined elsewhere, is continued by the CCATT en route.[7, 8] For this patient population, given the physiological stress associated aeromedical evacuation such as hypobaric hypoxia, vibration, temperature, noise, and

altitude, a goal SaO2 and PaO2 of >93-95 and >80, respectively, has been set [8, 9]. Frequent documentation of the neurological exam is critical as there are multiple hand-offs by transport teams along the evacuation route.

During transport, the continuous monitoring and treatment of intracranial hypertension is critical. These patients are often intubated/sedated so an exam can be difficult to obtain. It is paramount that a working ICP monitor, preferably a ventriculostomy, is in place prior to transport, because placing or trouble-shooting an ICP monitor in flight is challenging and often the expertise is not available. Along these lines, it is better to have a monitor in place than remove it just before transport, even if ICP's have been well controlled [8]. The same logic applies to surgical drains. Medical management of intracranial hypertension in a trauma patient is maximized with the use of hypertonic agents such as 3% Saline or mannitol, head of bed elevation, sedation, paralysis, and pain control using short acting agents. An additional consideration in this patient population is to load these patients last and to off-load first, with the patient head first into the aircraft to help ameliorate the affects of relative trendelenberg position for both the take off and landing on intracranial pressure [13].

There may be times that the safest course of action for a patient with significant cerebral edema or increased ICP, despite a decompressive craniectomy, is to not evacuate them until their ICP is better controlled. As noted, there are limited treatments and few resources once the patient is en route and diverting a flight may not be an option. Given the timing of peak swelling (48-72 hours) after a head injury, it is best to do the initial decompression and transport them to LRMC or CONUS prior to this time point. Sometimes, there are patients with tenuous ICP after early decompression where a direct "tail to tail" movement is preferred, meaning they are transported directly from the theater of war to a CONUS location.

MANAGEMENT OF ICP

Classically a stepwise approach is advocated for ICP management. This includes early intubation with CO2 control, hypertonic saline, HOB elevation, and avoiding jugular compression. If ICP remains elevated the use of a ventriculostomy is advised and could be considered if the ventricles are normal or enlarged. In those cases with slit-ventricles it may not prove worth the attempt. A ventriculostomy should be considered early unless the patient is immediately undergoing a decompressive craniectomy. Ideally decompressive craniectomy should resolve an ICP crisis. In most cases this is true, with early decompression the management of a patient's ICP is more easily controlled. The onset of delayed swelling, edema and resulting ICP elevation should be avoided with a properly performed operation. This assumes that the decompression is done in a timely manner and is large enough. A critical element is that it extends to the floor of the middle cranial fossa, and includes a large duraplasty. In those cases in which the decompression is inadequate increased ICP, cortical spreading depression and brain "fungation" out of the defect will result in further neurologic deterioration and long-term poorer outcomes [14]. Despite it being done in a timely fashion and of an appropriate size, those cases with a persistent increased ICP are usually associated with additional neurovascular injuries. Such an example includes patients with an associated thrombosis of a major dural venous sinus with inadequate collateral venous outflow. Additional examples include patient's with a markedly altered autoregulation with a passive reflection of ICP related directly to the systemic blood pressure [15]. These patients would

benefit from additional neuro-monitoring to include ICP, TCDs, Brain PbO2, and CBF monitoring. An autoregulation response curve can then be produced that evaluates CBF/MAP and ICP over a range of values and in response to various CO2 values. In those rare cases in which ICP is persistently elevated due to a major cortical vein thrombosis or a dural sinus thrombosis then other strategies should be employed. If the patient has already undergone a decompressive craniectomy then consider the role for a neurointerventional thromboaspiration of the occluded sinus. In the face of a decompressive craniotomy with normal venous outflow and persistently elevated ICP consider the additional use of induced hypothermia and/or pentobarbital coma or in rare cases both. The temporary use of these adjuncts will allow for the re-establishment of autoregulation, controllable ICP management.

DELAYED MANAGEMENT: HYDROCEPHALUS/ SYNDROME OF THE TREPHINE

Once patients have undergone decompressive craniectomy they are vulnerable to a variety of CSF and pressure disturbances. These include delayed hydrocephalus, “sinking scalp syndrome”, and external hydrocephalus/hygromas [16-19]. It is unclear which patient’s are likely to develop which complication, as it is a matter of time, size of decompression and volume of underlying brain injury. Different theories exist to explain CSF disturbance but remain conjecture as proving the etiology in-vivo is clouded by multiple variables. One of the strongest theories places the development of hydrocephalus as a compensation for the collapse of the subarachnoid spaces and atmospheric pressure displaced on the dural venous sinus and large cortical veins. The resulting effect is postulated to be an increased “windkessel” effect from the arterial pulse-pressure displaced to the brain [20]. As a result the anterior choroidal artery and the choroid plexus has increased amplitude of pulsations. These pulsations are then dampened by the expansion of the ventricles as atmospheric pressure effects on the open hemicranium usually collapse the subarachnoid space. In some of these cases reconstructive cranioplasty alone without shunting resolves the hydrocephalus. However, in those with significant volume loss from underlying brain injury shunting is required. In such a case the combination of shunting with a hemicraniectomy results a significant exacerbation of the syndrome of the trephine. Collapse of the cortical mantle, overlying scalp and ventricular system may exacerbate the underlying neurologic dysfunction with a paradoxical mid-line shift, and downward herniation of the diencephalon. It has been our experience that the use of programmable valves, anti-siphon devices, abdominal binders, trendelenburg position, and hydration help to mitigate this effect [21]. Typically, the symptoms are improved only after reconstruction of the cranial vault. Restoring normal physiology with a closed cranial vault allows the cortical mantle to re-expand, subarachnoid space to be restored and its damping effect of the CSF to occur.

DELAYED MANAGEMENT: CEREBROSPINAL FLUID LEAK

Severe blast and ballistic injuries can affect the skull base and lead to sub-acute or delayed CSF leaks, encephaloceles, and possible brain abscess, or meningitis. The loss of

anatomic continuity from the anterior or middle cranial fossa with the orbit, sphenoid sinus, or nasopharynx is a common pattern seen in sub-acute or delayed CSF leaks. Many of these leaks are sub-acute or delayed and noticed only after the period of acute cerebral edema. Once the brain has relaxed and retracted from the underlying skull base defect the disrupted dural can no longer contain the CSF [22, 23]. This becomes a two-way tract for microbes and CSF leakage. CSF can leak via the skin, the eustachian tube, sphenoid sinus, orbit, ethmoids, petrous bone, mastoid air cells, or even from the posterior fossa via the clivus. Identification of the CSF can be performed with a combination of CT-metrizimide, fluorescein, and nuclear medicine plegett studies [24]. Having a high likelihood of suspicion and early detection and intervention helps prevent life-threatening complications. A combination of skull base injury, hemicraniectomy, and CSF leakage can create a lethal triad leading to "paradoxical" herniation [25]. Those defects in the midline are best treated endoscopically while those more laterally placed are best treated with an open reconstructive ablative approach. The defects involving the frontal sinuses and orbital region require the use of bony reconstruction, soft-tissue reconstruction, multi-layer closure, and frontal sinus exenteration with obstruction of the nasofrontal duct. The concept of orbitofrontal reconstruction early allows a reference point of registration for future cranial reconstruction and maintenance of the facial proportions [26]. These steps are intimately related with early orbital-facial reconstruction tied to skull base reconstruction decreasing the risk for CSF leakage and both functional and aesthetic skeletal restoration.

DELAYED MANAGEMENT: TRAUMATIC VASOSPASM AND ANEURYSMS

Traumatic cerebral vasospasm, or a reduction in the caliber of cerebral arteries in response to some external stress, is a condition that has frequently complicated critical care management in patients with severe closed and penetrating head injury from the conflicts in Iraq and Afghanistan [4, 5]. Vasospasm, in general, can result in a reduction in blood flow to whatever organ is subserved by the effected artery. In the case of cerebral vasospasm, the clinical consequence can be delayed ischemic neurologic deficits and stroke. In a study of 119 military patients who suffered blast injury over a two-year period, many of whom required decompressive craniectomy at the time of initial management, 47% had concomitant cerebral vasospasm. The presence of vasospasm in this population was predicted by the extent of brain injury and the presence of traumatic aneurysms, and portended a worse early clinical outcome [4, 5]. Like vasospasm that follows subarachnoid hemorrhage, the vasospasm seen in the setting of blast induced head injury was reliably followed by transcranial Doppler ultrasonography, and was safely treated with balloon angioplasty [5].

In general, there should be a high index of suspicion for the presence of vasospasm and traumatic aneurysms in patients with blast induced closed and penetrating brain injury with or without decompressive craniectomy. Patients, especially those with penetrating injury, should receive a routine diagnostic cerebral angiogram during their early hospital stay and should be followed with daily transcranial Doppler ultrasonography. (FIGURE 1) Traumatic aneurysms should be treated at the time of diagnosis secondary to the risk of delayed rupture [4]. Treatment strategies in this setting can include open surgical resection, clipping, endovascular

coil occlusion, or a combination of both [2, 3]. Those with worsening vasospasm on TCD's and a poor baseline neurologic examination may benefit from multi-modal monitoring strategies that can help guide critical care management, including brain tissue oxygen monitoring and quantitative pupillometry. Critical care management strategies should at a baseline include maintenance of adequate mean arterial pressure, adequate circulating blood volume, normothermia, and maintenance of normal intracranial pressure. With respect to cerebral vasospasm, continued increase in mean flow velocities and worsening clinical status should prompt repeat cerebral angiogram and possible endovascular intervention (balloon angioplasty, spasmolytics) if indicated [5].

DELAYED MANAGEMENT: ENLARGING CRANIECTOMY

There are few circumstances that are more frustrating than the management of patients who have received inadequate craniectomy during their initial surgical management. While there may be many explanations for why this might occur, in almost every circumstance it relates to a lack of recognition or understanding of the extent of injury by the initial operating neurosurgeon. (FIGURE 2) With respect to the management of severe closed head injury, the Brain Trauma Foundation recently recommended that the size of a frontotemporoparietal decompressive craniectomy be "not less than 12 x 15 cm or 15 cm in diameter"[7]. Evidence that the decompression is too small may include fungating herniation of both normal and injured brain through the decompression. Should a diagnosis of inadequate decompressive craniectomy be made during the course of critical care management, every effort should be made to enlarge the craniectomy if there is persistent elevation in intracranial pressure or fungating brain from the cranial defect. Alternatively, bilateral or bi-compartmental craniectomy has been reported. In 2011, Ecker et al. reported on 33 patients from OIF/OEF undergoing such procedures. While 7 (23%) had died from their injury, 18 (60%) had a Glasgow Outcome Score (GOS) of 4 or 5 [27]. While this is a very select population, it is an option to be considered (Figure 3).

DELAYED MANAGEMENT: THE EFFECT OF POLYTRAUMA ON PATIENTS WITH A DECOMPRESSIVE CRANIECTOMY

Initial management of the polytrauma patient is appropriately dictated by ATLS principles. The presence of concomitant severe brain injury requiring decompressive craniectomy and polytrauma can complicate follow on critical care management significantly. The possible management scenarios are numerous and beyond the scope of this chapter. Needless to say, polytrauma often requires balance so that all organ systems may function and heal. This may include permissive hypercapnia or prone positioning in the scenario of severe acute respiratory distress syndrome (ARDS) or elevated positive end expiratory pressure (PEEP) more so than is normally allowed. Conversely, other services may need to change positioning standards in the operating room to accommodate the need for head positioning, such as when working on an extremity. Polytrauma in a patient with a decompressive craniectomy requires frequent communication based on a multidisciplinary team approach.

For the neurosurgeon, it is imperative to understand the implications of other procedures and therapies on the injured brain.

There is one particular issue that remains controversial and for which there are limited data to guide practice- the appropriate timing and agent for chemical deep vein thrombosis prophylaxis in the setting of severe traumatic brain injury. It is well known that severe systemic trauma can increase the risk for the formation of deep vein thrombosis (DVT), that the presence of DVT's increases the risk of pulmonary embolism, and that pulmonary embolism can worsen outcomes in trauma by a full order of magnitude compared to those without [28, 29]. Additionally, there is a well-known and particular association between TBI and hypercoagulability [30-32]. In a study of 408 severe TBI patients from the first 5 years of OIF, there was a 7% incidence of pulmonary embolism [6]. Despite the known association, neurosurgeons in particular have been reluctant to treat with chemical prophylaxis secondary to the possible risk of delayed cerebral hemorrhage expansion. The reluctance to treat has in part resulted from a relative paucity of supporting clinical and basic science research [33-36]. There is so much ambiguity in this area that while the 4th Edition of the TBI guidelines supports a level 3 recommendation for the use of low molecular weight heparin or unfractionated heparin, there are insufficient data to recommend preferred agent, dose or timing of pharmacologic prophylaxis [7].

Still, because of the disturbingly high association between severe military TBI and venous thromboembolic events, a strategy of early chemoprophylaxis (24 hours from injury) was instituted. A study was recently conducted to assess the safety and efficacy of this practice in the most severely injured patients: those with penetrating brain injury [37]. A total of 65 patients with penetrating brain injury from OEF were evaluated over a three-year period. Roughly half the patients received chemical DVT prophylaxis within 24 hours of injury. The study revealed a venous thromboembolism rate of 15%. Overall, there was no increased risk of hemorrhagic expansion in those who received early chemical DVT prophylaxis, and there was a trend towards a reduction in DVT and PE. What remains clear is that further research in this area is clearly needed to guide care.

DELAYED MANAGEMENT: CRANIOPLASTY

Cranioplasty is often considered the more straightforward aspect of the care for a patient with a decompressive craniectomy. As noted throughout this chapter, the care for service members that require a decompressive craniectomy secondary to military munitions are far from straightforward. Traditional military munitions tend to involve higher velocity rounds, resulting in greater dissipation of kinetic energy to the surrounding brain in penetrating head injury. Additionally, blast related trauma involves multiple mechanisms of injury not often seen in civilian settings [38].

In 2010, Stephens et al. detailed complications related to cranioplasty in 108 military service members injured during OIF/OEF, finding an overall complication rate of 24% with one death [39]. Twelve patients (11%) required prosthesis removal for extra-axial hematoma or infection. Timing of cranioplasty is balanced between infectious issues, the presence of other polytrauma injuries, and the stage of recovery/rehabilitation. To help avoid implant failure, patients with a transfrontal, transorbital, or transfascial trajectory of their initial injury

need to have their frontal-orbital bar evaluated and reconstructed prior to cranioplasty if there is an anticipated two centimeter or greater gap from the dura to the cranial reconstruction [26, 40]. Given the polytrauma nature of many of these patients, it is recommended that the calvarial bone is discarded at the time of the decompressive and therefore, not available for reconstruction [8].

CONCLUSION

The management of a severe traumatic brain injury who has undergone a decompressive craniectomy in a theater of war does not stop after the initial surgery. The collective experience from OIF and OEF has taught us valuable lessons in the follow on care and complication management of these patients. Many of these issues require vigilance and an index of suspicion, allowing early treatment. While outcome data is relatively limited, decompressive craniectomy allows for the safe transport of head injured patients out of theater and to advanced levels of care.

REFERENCES

[1] Bell RS, Mossop CM, Dirks MS, Stephens FL, Mulligan L, Ecker R, et al. Early decompressive craniectomy for severe penetrating and closed head injury during wartime. *Neurosurgical focus.* 2010;28(5):E1. Epub 2010/06/24. doi: 10.3171/2010.2.focus1022. PubMed PMID: 20568925.

[2] Aarabi B. Traumatic aneurysms of brain due to high velocity missile head wounds. *Neurosurgery.* 1988;22(6 Pt 1):1056-63. Epub 1988/06/01. PubMed PMID: 3419568.

[3] Aarabi B. Management of traumatic aneurysms caused by high-velocity missile head wounds. *Neurosurgery clinics of North America*. 1995;6(4):775-97. Epub 1995/10/01. PubMed PMID: 8527918.

[4] Bell RS, Vo AH, Roberts R, Wanebo J, Armonda RA. Wartime traumatic aneurysms: acute presentation, diagnosis, and multimodal treatment of 64 craniocervical arterial injuries. *Neurosurgery*. 2010;66(1):66-79; discussion Epub 2009/12/22. doi: 10.1227/01.neu.0000361285.50218.a8. PubMed PMID: 20023539.

[5] Armonda RA, Bell RS, Vo AH, Ling G, DeGraba TJ, Crandall B, et al. Wartime traumatic cerebral vasospasm: recent review of combat casualties. *Neurosurgery*. 2006;59(6):1215-25; discussion 25. Epub 2007/02/06. doi: 10.1227/01.neu.0000249190.46033.94. PubMed PMID: 17277684.

[6] Bell RS, Vo AH, Neal CJ, Tigno J, Roberts R, Mossop C, et al. Military traumatic brain and spinal column injury: a 5-year study of the impact blast and other military grade weaponry on the central nervous system. *The Journal of trauma.* 2009;66 (4 Suppl):S104-11. Epub 2009/06/12. doi: 10.1097/TA. 0b013e31819d88c8. PubMed PMID: 19359953.

[7] Carney N, Totten AM, O'Reilly C, Ullman JS, Hawryluk GW, Bell MJ, et al. Guidelines for the Management of Severe Traumatic Brain Injury, Fourth Edition.

Neurosurgery. 2016. doi: 10.1227/NEU.0000000000001432. PubMed PMID: 27654000.

[8] McCafferty RR, Neal CJ, Marshall SA, Pamplin JC, Bell RA, Rivet D, et al. Neurosurgery and Severe Head injury. *Joint Trauma System Clinical Practice Guideline* 2017 [updated 3/2/20173/10/2017]. 3/2/2017: [Available from: http://www.usaisr.amedd.army.mil/cpgs/Neurosurgery_Severe_Head_Injury_02Mar2017.pdf.

[9] Goodman MD, Makley AT, Lentsch AB, Barnes SL, Dorlac GR, Dorlac WC, et al. Traumatic brain injury and aeromedical evacuation: when is the brain fit to fly? *J Surg Res.* 2010;164(2):286-93. doi: 10.1016/j.jss.2009.07.040. PubMed PMID: 20006349; PubMed Central PMCID: PMCPMC4612614.

[10] Gawande A. Casualties of war--military care for the wounded from Iraq and Afghanistan. *N Engl J Med.* 2004;351(24):2471-5. doi: 10.1056/NEJMp048317. PubMed PMID: 15590948.

[11] Ingalls N, Zonies D, Bailey JA, Martin KD, Iddins BO, Carlton PK, et al. A review of the first 10 years of critical care aeromedical transport during operation iraqi freedom and operation enduring freedom: the importance of evacuation timing. *JAMA Surg.* 2014;149(8):807-13. doi: 10.1001/jamasurg.2014.621. PubMed PMID: 25074327.

[12] Donovan DJ, Iskandar JI, Dunn CJ, King JA. Aeromedical evacuation of patients with pneumocephalus: outcomes in 21 cases. *Aviation, space, and environmental medicine.* 2008;79(1):30-5. Epub 2008/01/30. PubMed PMID: 18225775.

[13] Johannigman JA, Zonies D, Dubose J, Blakeman TC, Hanseman D, Branson RD. Reducing secondary insults in traumatic brain injury. *Mil Med.* 2015;180(3 Suppl):50-5. doi: 10.7205/MILMED-D-14-00381. PubMed PMID: 25747631.

[14] Hartings JA, Vidgeon S, Strong AJ, Zacko C, Vagal A, Andaluz N, et al. Surgical management of traumatic brain injury: a comparative-effectiveness study of 2 centers. *J Neurosurg.* 2014;120(2):434-46. doi: 10.3171/2013.9.JNS13581. PubMed PMID: 24180566.

[15] Preiksaitis A, Krakauskaite S, Petkus V, Rocka S, Chomskis R, Dagi TF, et al. Association of Severe Traumatic Brain Injury Patient Outcomes With Duration of Cerebrovascular Autoregulation Impairment Events. *Neurosurgery.* 2016;79(1):75-82. doi: 10.1227/NEU.0000000000001192. PubMed PMID: 26695090.

[16] Ashayeri K, E MJ, Huang J, Brem H, C RG. Syndrome of the Trephined: A Systematic Review. *Neurosurgery.* 2016;79(4):525-34. doi: 10.1227/NEU. 0000000000001366. PubMed PMID: 27489166.

[17] Dujovny M, Fernandez P, Alperin N, Betz W, Misra M, Mafee M. Post-cranioplasty cerebrospinal fluid hydrodynamic changes: magnetic resonance imaging quantitative analysis. *Neurol Res.* 1997;19(3):311-6. PubMed PMID: 9192385.

[18] Fodstad H, Love JA, Ekstedt J, Friden H, Liliequist B. Effect of cranioplasty on cerebrospinal fluid hydrodynamics in patients with the syndrome of the trephined. *Acta Neurochir* (Wien). 1984;70(1-2):21-30. PubMed PMID: 6741628.

[19] Paredes I, Cicuendez M, Delgado MA, Martinez-Perez R, Munarriz PM, Lagares A. Normal pressure subdural hygroma with mass effect as a complication of decompressive craniectomy. *Surg Neurol Int.* 2011;2:88. doi: 10.4103/2152-7806.82370. PubMed PMID: 21748040; PubMed Central PMCID: PMCPMC3130440.

[20] Wagshul ME, Kelly EJ, Yu HJ, Garlick B, Zimmerman T, Egnor MR. Resonant and notch behavior in intracranial pressure dynamics. *J Neurosurg Pediatr.* 2009;3(5):354-64. doi: 10.3171/2009.1.PEDS08109. PubMed PMID: 19409013.

[21] Pang D, Altschuler E. Low-pressure hydrocephalic state and viscoelastic alterations in the brain. *Neurosurgery.* 1994;35(4):643-55; discussion 55-6. PubMed PMID: 7808607.

[22] Aarabi B, Taghipour M, Alibaii E, Kamgarpour A. Central nervous system infections after military missile head wounds. *Neurosurgery.* 1998;42(3):500-7; discussion 7-9. Epub 1998/04/04. PubMed PMID: 9526984.

[23] Meirowsky AM, Caveness WF, Dillon JD, Rish BL, Mohr JP, Kistler JP, et al. Cerebrospinal fluid fistulas complicating missile wounds of the brain. *J Neurosurg.* 1981;54(1):44-8. doi: 10.3171/jns.1981.54.1.0044. PubMed PMID: 7463119.

[24] Sherif C, Di Ieva A, Gibson D, Pakrah-Bodingbauer B, Widhalm G, Krusche-Mandl I, et al. A management algorithm for cerebrospinal fluid leak associated with anterior skull base fractures: detailed clinical and radiological follow-up. *Neurosurg Rev.* 2012;35(2):227-37; discussion 37-8. doi: 10.1007/s10143-011-0352-3. PubMed PMID: 21947554.

[25] Choi JJ, Cirivello MJ, Neal CJ, Armonda RA. Paradoxical herniation in wartime penetrating brain injury with concomitant skull-base trauma. *The Journal of craniofacial surgery.* 2011;22(6):2163-7. Epub 2011/11/15. doi: 10.1097/SCS.0b013e3182323fd5. PubMed PMID: 22075814.

[26] Tantawi D, Armonda R, Valerio I, Kumar AR. Management of decompressive craniectomy defects: modern military treatment strategies. *The Journal of craniofacial surgery.* 2012;23(7 Suppl 1):2042-5. Epub 2012/11/21. doi: 10.1097/SCS.0b013e318258ba36. PubMed PMID: 23154344.

[27] Ecker RD, Mulligan LP, Dirks M, Bell RS, Severson MA, Howard RS, et al. Outcomes of 33 patients from the wars in Iraq and Afghanistan undergoing bilateral or bicompartmental craniectomy. *Journal of neurosurgery.* 2011;115(1):124-9. Epub 2011/03/29. doi: 10.3171/2011.2.jns101490. PubMed PMID: 21438659.

[28] Gudipati S, Fragkakis EM, Ciriello V, Harrison SJ, Stavrou PZ, Kanakaris NK, et al. A cohort study on the incidence and outcome of pulmonary embolism in trauma and orthopedic patients. *BMC Med.* 2014;12:39. doi: 10.1186/1741-7015-12-39. PubMed PMID: 24589368; PubMed Central PMCID: PMCPMC3996019.

[29] Knudson MM, Ikossi DG, Khaw L, Morabito D, Speetzen LS. Thromboembolism after trauma: an analysis of 1602 episodes from the American College of Surgeons National Trauma Data Bank. *Ann Surg.* 2004;240(3):490-6; discussion 6-8. PubMed PMID: 15319720; PubMed Central PMCID: PMCPMC1356439.

[30] Reiff DA, Haricharan RN, Bullington NM, Griffin RL, McGwin G, Jr., Rue LW, 3rd. Traumatic brain injury is associated with the development of deep vein thrombosis independent of pharmacological prophylaxis. *J Trauma.* 2009;66(5):1436-40. doi: 10.1097/TA.0b013e31817fdf1c. PubMed PMID: 19430251.

[31] Denson K, Morgan D, Cunningham R, Nigliazzo A, Brackett D, Lane M, et al. Incidence of venous thromboembolism in patients with traumatic brain injury. *Am J Surg.* 2007;193(3):380-3; discussion 3-4. doi: 10.1016/j.amjsurg.2006.12.004. PubMed PMID: 17320539.

[32] Ekeh AP, Dominguez KM, Markert RJ, McCarthy MC. Incidence and risk factors for deep venous thrombosis after moderate and severe brain injury. *J Trauma.* 2010;68(4):912-5. doi: 10.1097/TA.0b013e3181b21cad. PubMed PMID: 19996795.

[33] Farooqui A, Hiser B, Barnes SL, Litofsky NS. Safety and efficacy of early thromboembolism chemoprophylaxis after intracranial hemorrhage from traumatic brain injury. *J Neurosurg.* 2013;119(6):1576-82. doi: 10.3171/2013.8.JNS13424. PubMed PMID: 24053504.

[34] Scudday T, Brasel K, Webb T, Codner P, Somberg L, Weigelt J, et al. Safety and efficacy of prophylactic anticoagulation in patients with traumatic brain injury. *J Am Coll Surg.* 2011;213(1):148-53; discussion 53-4. doi: 10.1016/ j.jamcollsurg. 2011.02.027. PubMed PMID: 21459632.

[35] Phelan HA, Wolf SE, Norwood SH, Aldy K, Brakenridge SC, Eastman AL, et al. A randomized, double-blinded, placebo-controlled pilot trial of anticoagulation in low-risk traumatic brain injury: The Delayed Versus Early Enoxaparin Prophylaxis I (DEEP I) study. *J Trauma Acute Care Surg.* 2012;73(6):1434-41. doi: 10.1097/TA. 0b013e31825ac49e. PubMed PMID: 22914079.

[36] Shen X, Dutcher SK, Palmer J, Liu X, Kiptanui Z, Khokhar B, et al. A Systematic Review of the Benefits and Risks of Anticoagulation Following Traumatic Brain Injury. *J Head Trauma Rehabil.* 2015;30(4):E29-37. doi: 10.1097/HTR. 0000000000000077. PubMed PMID: 24992639; PubMed Central PMCID: PMCPMC4282634.

[37] Meyer RM, Larkin MB, Szuflita NS, Neal CJ, Tomlin JM, Armonda RA, et al. Early venous thromboembolism chemoprophylaxis in combat-related penetrating brain injury. *Journal of neurosurgery.* 2016:1-9. Epub 2016/06/18. doi: 10.3171/2016.4.jns16101. PubMed PMID: 27315028.

[38] Wolf SJ, Bebarta VS, Bonnett CJ, Pons PT, Cantrill SV. *Blast injuries. Lancet.* 2009;374(9687):405-15. doi: 10.1016/S0140-6736(09)60257-9. PubMed PMID: 19631372.

[39] Stephens FL, Mossop CM, Bell RS, Tigno T, Jr., Rosner MK, Kumar A, et al. Cranioplasty complications following wartime decompressive craniectomy. *Neurosurgical focus.* 2010;28(5):E3. Epub 2010/06/24. doi: 10.3171/ 2010.2.focus 1026. PubMed PMID: 20568943.

[40] Kumar AR, Tantawi D, Armonda R, Valerio I. Advanced cranial reconstruction using intracranial free flaps and cranial bone grafts: an algorithmic approach developed from the modern battlefield. *Plast Reconstr Surg.* 2012;130(5):1101-9. doi: 10.1097/ PRS.0b013e318267d5cb. PubMed PMID: 23096610.

In: Encyclopedia of Surgery (22 Volume Set)
Editors: Andreas Lehrer and Kristin Mueller
ISBN: 978-1-53618-329-0
© 2020 Nova Science Publishers, Inc.

Chapter 236

GUIDELINES FOR THE MANAGEMENT OF SEVERE TRAUMATIC BRAIN INJURY: RECOMMENDATIONS FROM THE 2017 FOURTH EDITION

Kevin Kwan[1], MD, Jamie S. Ullman[1], MD, Julia Schneider[1], Gregory W. J. Hawryluk[2], MD, PhD, Annette Totten[3], PhD and Jamshid Ghajar[4,*], MD, PhD

[1]Department of Neurosurgery, Donald and Barbara Zucker School of Medicine at Hofstra/Northwell, Hempstead, New York, US
[2]Department of Neurosurgery, University of Utah, Salt Lake City, UT, US
[3]Department of Medical Informatics and Clinical Epidemiology, Oregon Health and Science University, Portland, OR, US
[4]Department of Neurosurgery, Stanford University, Stanford, CA, US

ABSTRACT

Cerebral edema and intracranial hypertension can occur through impaired autoregulation following traumatic brain injury (TBI). The role of decompressive craniectomy (DC) in severe TBI remains controversial owing to conflicting data, particularly from randomized controlled trials. Some argue that DC may simply increase the number of patients who survive but remain in a vegetative state. There are also differences in opinion regarding optimal surgical technique. This chapter summarizes the published evidenced-based guidelines on the utilization of DC for the treatment of severe TBI.

Keywords: guidelines, traumatic brain injury, outcome, decompressive craniectomy

∗ Corresponding Author's Email: jullman1@northwell.edu.

INTRODUCTION

Preventing cerebral hypoxia and hypotension and resultant secondary injury is the main goal of treatment following severe traumatic brain injury (TBI). Cerebral edema can occur through impaired autoregulation after injury leading to disruption of the normal homeostatic mechanisms [1] and resulting in a vicious cycle of increased intracranial hypertension, reduced cerebral blood flow, and metabolic dysfunction [2, 3]. As pressure within the skull increases, brain tissue displacement can lead to cerebral herniation, culminating in significant morbidity or mortality [4-6].

Decompressive craniectomy (DC), the surgical removal of a portion of the cranium, has been performed for many years in patients with TBI [7]. In patients with elevated intracranial pressure (ICP), DC has been reported to improve cerebral perfusion and oxygenation, with outcome improvement in posttraumatic patients with intractable intracranial hypertension [8, 9]. Primary DC is accomplished when the bone flap is not replaced after evacuation of an intracranial hematoma in the early phases of TBI, whereas secondary DC is employed when the cranium is removed after failure to control intracranial hypertension by other methods [10, 11].

The pivotal issue of managing ICP increases in TBI patients is comparable to what is seen in compartment syndromes. For example, in abdominal compartment syndrome, as intra-abdominal pressure rises, splanchnic blood flow declines. Subsequently, this can potentiate a sequelae of progressively adverse effects on cardiac, pulmonary, and renal systems. When intra-abdominal pressure reaches critical levels, abdominal fascial release through open laparotomy is the standard of care [12].

The controversy surrounding the role of DC in severe TBI results from conflicting data, particularly from randomized controlled trials (RCTs), assessing both primary and secondary DC [10, 13-15]. Controversy still exists on whether DC may simply increase the number of patients who survive but remain in a vegetative state [11, 15]. Additionally, opinion varies widely regarding the specific surgical technique utilized in patients undergoing DC. Over the past three decades, numerous clinical trials and observational studies have tried to address these variations including investigating craniectomy dimensions, craniectomy versus craniotomy, and timing of surgery [16-20]. In general, most of the evidence surrounding DC in trauma is based on low-quality RCTs, moderate- to low-quality cohort or case control studies, case series, and other non-comparative designs. Consequently owing to inconsistent clinical data, the level of confidence for treatment efficacy has been reduced.

METHODS

The Brain Trauma Foundation's Guidelines for the Management of Severe Traumatic Brain Injury, 4th edition, most recently updated in January 2017 [21], developed evidence-based recommendations based on research studies categorized as Class 1, 2, or 3 that constituted high, moderate, or low confidence, respectively. The class assignments were made on the basis of the extent to which the evidence reflected the true effect based on a combination of study design and how the risk of bias was addressed. Specifically, Class 1, the highest assignment, is limited to good-quality randomized trials. Class 2 includes moderate-

quality randomized controlled trials and good-quality cohort or case-control studies. Class 3, the lowest assignment, is given to low-quality randomized controlled trials, moderate- to low-quality cohort or case control studies, and case series and other non-comparative designs [21]. Levels of recommendations were based on the strength of the body of evidence, and recommendations were divided into Level I (low risk of bias RCTs), Level IIA and II B, and Level III recommendations, which constituted high-, moderate-, and low-quality evidence, respectively [21].

The 4th edition included the results from the Decompressive Craniectomy Trial (DECRA) in diffuse TBI (22), but it went to press shortly before the initial advanced publication of the largest multinational RCT, the Randomized Evaluation of Surgery with Craniectomy for Uncontrollable Elevation of Intracranial Pressure (RESCUEicp) trial, which pragmatically evaluated the role of DC in the management of refractory cerebral hypertension [15]. The current guidelines analyzed 31 potentially relevant studies and excluded 21 studies not meeting inclusion criteria. The ten remaining studies included one Class 1 study [22], two Class 2 studies [23, 24], and seven Class 3 studies [16-20, 25, 26].

Class 1 Study: DC versus Initial Medical Management

The DECRA trial is an RCT that compared bifrontotemporoparietal DC to initial medical management for refractory intracranial hypertension, with refractory ICP defined as >20 mm Hg for 15 minutes within a 1-hour period. The investigators recruited patients in fifteen tertiary care hospitals in three countries between 2002 and 2010 [22]. The Brain Trauma Foundation characterized this study's evidence as Class 1. The DC group included 73 patients and the medical management group included 82. The study found worse Extended Glasgow Outcome Scale (GOS-E) scores for patients in the DC group than those in standard care at 6 months post-injury although DC patients had lower ICP and fewer ICU days. Mortality at 6 months was 19% in the DC group versus 18% in the medical management groups (not statistically significant). Interestingly, the proportion of patients in the DC group with reactivity in neither pupil on admission was higher (27% versus 12%, P = 0.04) than in controls. Adjustment for pupil reactivity after post hoc analysis revealed the between-group differences were no longer significant for the score on the GOS-E (adjusted odds ratio, 1.53; 95% confidence interval [CI]: 0.86 to 2.73; P = 0.15) or for the risk of an unfavorable outcome (adjusted odds ratio, 1.90; 95% CI: 0.95 to 3.79; P = 0.07), although a suggestion of harm remained. The Guidelines Panel concluded that, although the study was of high quality, it was ultimately a single study, and replication was needed for higher confidence in the results [21].

Class 2 Study: Size of DC

The Guidelines classified two studies as Class 2 that evaluated the role of differently sized craniectomy bone flaps and their effect on patient mortality and functional outcomes. These studies did not include a non-decompressed comparison group. The quality of the body of evidence was deemed to be moderate.

Jiang et al. [23] conducted a multi-institutional RCT comparing the influence of unilateral frontoparietal (12 x 15 cm) versus a smaller temporoparietal (6 x 8 cm) DC on patient outcomes. This study was conducted at five medical centers in China. Inclusion criteria consisted of patients with refractory intracranial hypertension. The larger-sized craniectomy group included 245 patients and the smaller-sized craniectomy group included 241 patients. Larger craniectomies were associated with better GOS-E scores than smaller craniectomies, with GOS-E scores of 4 or 5 (39.8% versus 28.6%), GOS-E scores of 2 or 3 (34% versus 36.3%), and GOS-E scores of 1 (26.2% versus 35.1%), respectively [23].

Qiu et al. (24) conducted a RCT comparing the influence of unilateral 15-cm craniectomy versus routine temporoparietal craniectomy on patient outcomes. This study was conducted at only a single site. The inclusion criteria necessitated computed tomography (CT) evidence showing intracranial swelling. The larger DC group included 37 patients and the routine DC group also included 37 patients. GOS-E scores of 4 or 5 for the larger DC group versus the smaller DC group at 1 year were 56.8% versus 32.4%, and mortality was 27% versus 57% ($P = 0.010$), respectively. There was also evidence of increased rates of complications for the larger DC group [24]. In both Class 2 studies, the Guidelines' authors expressed concern regarding baseline differences in patients, procedures, and treatment and the lack of adjustment for any covariates in both studies.

Class 3 Study

Class 3 studies were not integrated into the recommendations. The body of evidence was rated as insufficient, primarily because the results were inconsistent, and it was not feasible to resolve these differing results given the quality of the studies. Following is a summary of the seven Class 3 studies.

DC versus Medical Management

Olivecrona et al. utilized a retrospective cohort study comparing DC (N = 21) with medical management (N = 72). The results did not show any significant differences in mortality: 14.4% versus 14.1% in the DC and medical management groups, respectively; GOS-E score 5-4 was 71% versus 61%; GOS-E score 3 was 9.6% versus 21.1%; and GOS-E score 2 was 4.8% versus 4.2%. Of note, the reduction of ICP was statistically significant in the DC group 72 hours post-procedure [25].

Soustiel et al. conducted a prospective cohort study comparing DC (N = 36) with medical management (N = 86). Mortality and GOS-E score were adjusted for age, CT scan, Glasgow Coma Score (GCS) at admission, ICP, cerebral blood flow, and cerebral metabolic rate of oxygen. The results did not show any significant differences in mortality (odds ratio 0.8, $P = 0.4185$), but there was significantly improved functional outcome at 6 months (odds ratio 0.14, $P \leq 0.05$) [26].

DC versus Craniotomy

Huang et al. compared DC with duraplasty (N = 38) to craniotomy (N = 16) in a retrospective cohort study of the treatment of hemorrhagic cerebral contusion. Their results showed no significant differences in mortality (13.2% versus 25%) but lower re-operative

rates (7.9% versus 37.5%) and better GOS-E scores (5.55 versus 3.25) in the DC group versus the craniotomy group [16].

Soukiaasian et al. compared DC (N = 24) to craniotomy (N = 96) in a retrospective cohort study that evaluated mortality, TBI, and complications. The results again showed no difference in mortality and no difference in survival between groups, 52% versus 79%, in DC versus craniotomy. Complications included collapse of basilar cisterns (30.4% versus 4.3%) and herniation (17.4% versus 5.4%) in DC versus craniotomy [17].

Large versus Small DC

Lu et al. compared large (N = 115) versus small (N = 115) DC in an observational study and measured mortality, GOS-E scores, and complications. In their comparison, there was a significant difference in mortality (41.7% versus 57.7%), but no difference in GOS-E scores for good outcomes (25% versus 18.3%) or GOS-E scores for severe disability/vegetative survival (34.8% versus 24.3%). This Class 3 study's conclusions are similar to those of a higher quality Class 2 study [20].

Earlier versus Later DC

Akyuz et al. compared DC as a second-tier (N = 36) versus first-tier (N = 40) treatment for severe TBI in an observational study and evaluated mortality, GOS-E scores, ICP, and complications. First-tier or early DC was performed for patients with an opening ICP above 25 mm Hg. There was a significant difference in mortality, 44.4% versus 12.5% (P = 0.0018), but no difference in GOS-E scores 4 and 5, 27.8% versus 50% (P = 0.047), in second-tier versus first-tier treatments. This Class 3 study suggested that early DC resulted in better outcomes [18]. Wen et al. compared early DC (N = 25) versus late DC (N = 19) in a prospective cohort and evaluated mortality, GOS-E scores, and complications. This study found no difference in outcomes between the groups in terms of mortality or GOS-E scores [19].

APPLICABILITY OF STUDIES

The assessment of applicability differed across the studies and topics. Of note, the one Class 1 RCT was conducted over an 8-year period and was multinational [22]. Although the variety in patient selection may have limited the ability to detect an effect, it could increase the applicability of the study. The applicability of the two Class 2 RCTs comparing large versus small DC may be limited as they were both conducted in a single country (China), which may differ in important ways that could not be controlled for in the analysis [23, 24].

SUMMARY OF THE RECOMMENDATIONS REGARDING DC FROM THE 4TH EDITION

There were insufficient data to support a Level I (highest level representing high quality, strong evidence) recommendation for utilizing DC for the management of intracranial hypertension secondary to severe TBI (21). One Level IIA recommendation is that "bifrontal

DC is not recommended to improve outcomes as measured by GOS-E scores at 6 months post-injury in severe TBI patients with diffuse injury (without mass lesions) and with ICP elevations to values >20 mm Hg for more than 15 minutes within a 1-hour period that are refractory to first-tier therapies. However, it [DC] was demonstrated to reduce ICP and to minimize days in the intensive care unit" [22]. Another Level IIA recommendation is that "large frontotemporoparietal DC (not less than 12 x 15 cm or 15 cm in diameter) is recommended over a small frontotemporoparietal DC for reduced mortality and improved neurologic outcomes in patients with severe TBI" [23, 24].

PREVIOUS PUBLISHED GUIDELINES

DC was initially addressed in three articles among several published in 2006 as the Guidelines for the Surgical Management of Traumatic Brain Injury. For acute subdural hematomas, the recommended method for surgical evacuation was craniotomy with or without bone flap removal and duraplasty [27]. In regard to traumatic parenchymal lesions for patients with diffuse, medically refractory posttraumatic cerebral edema and resultant intracranial hypertension, a bifrontal DC within 48 hours was recommended. Moreover, for patients with refractory intracranial hypertension and diffuse parenchymal injury with clinical and radiographic evidence for impending transtentorial herniation, utilization of decompressive procedures, including subtemporal decompression, temporal lobectomy, and hemispheric decompressive craniectomy, were advocated [28]. Additionally, suboccipital craniectomy was recommended for significant traumatic posterior fossa mass lesions [29].

The second edition of The Guidelines for the Acute Medical Management of Severe Traumatic Brain Injury in Infants, Children, and Adolescents, published in 2012 [30], featured a new chapter on DC for the treatment of intracranial hypertension. The lowest of three levels of recommendation, based on the quality of evidence, is as follows: "DC with duraplasty, leaving the bone flap out, may be considered for pediatric patients with TBI who are showing early signs of neurologic deterioration or herniation or are developing intracranial hypertension refractory to medical management during the early stages of their treatment" [30]. Furthermore, the included studies were mostly retrospective case series, with the exception of one study that used a prospectively collected database [31]. There were no internal or matched external controls, and no RCTs were included. Notably, a RCT conducted by Taylor et al. in 2001 on early DC in children with TBI and sustained intracranial hypertension was excluded from the guidelines because of prolonged patient accrual time, utilization of an unusual bilateral mid-temporal craniectomy technique, and the inclusion of patients with a GCS >8 [32]. The authors of the Guidelines concluded that it was impossible to accurately compare the cohorts between these various studies given the scarcity of descriptive statistics [30].

NEW EVIDENCE

The RESCUEicp trial is an RCT that aimed to evaluate the effectiveness of DC offered as late-tier treatment for patients with TBI and refractory intracranial hypertension (>25 mm

Hg). This pragmatic study randomized 402 patients, aged 10 to 65 years, in 52 centers and twenty countries between 2004 and 2014. The DC group included 206 patients, and the medical management group included 196 patients. Patients had to be between 10 and 65 years of age, have a TBI with an abnormal computed tomographic scan of the brain, have an ICP monitor in place, and have refractory ICP (>25 mm Hg for 1 to 12 hours) despite maximum treatment measures (with the exclusion of barbiturate utilization). Patients who had undergone an immediate operation for evacuation of an intracranial hematoma could be included as long as the operation was not a craniectomy. Patients were excluded if they had bilateral fixed and dilated pupils, bleeding diathesis, or an injury that was deemed to be incompatible with life [15].

The GOS-E scores at 6 months were: death, 26.9% among patients in the surgical group versus 48.9% among patients in the medical group; vegetative state, 8.5% versus 2.1%; lower severe disability (reliant on others for care), 21.9% versus 14.4%; upper severe disability (autonomous at home), 15.4% versus 8.0%; moderate disability, 23.4% versus 19.7%; and good recovery, 4.0% versus 6.9%. The GOS-E scores at 12 months were: death, 30.4% versus 52.0%; vegetative state, 6.2% versus 1.7%; lower severe disability, 18.0% versus 14.0%; upper severe disability, 13.4% versus 3.9%; moderate disability, 22.2% versus 20.1%; and good recovery, 9.8% versus 8.4%. Surgical patients had a higher rate of adverse events (16.3% versus. 9.2%, $P = 0.03$) but fewer hours than medical patients with ICP above 25 mm Hg (median, 5.0 versus 17.0 hours; $P < 0.001$) [15].

The study concluded that, at 6 months, "decompressive craniectomy in patients with TBI and refractory intracranial hypertension resulted in lower mortality and higher rates of vegetative state, lower severe disability, and upper severe disability than medical care." The two groups did not differ in regard to the rates of moderate disability or good recovery [15].

CONCLUSION

Despite the completion of the two largest RCTs comparing the efficacy of DC versus medical management for patients with TBI, the protocol for the management of refractory hypertension remains highly controversial. The DECRA study showed no advantage from early bifrontal surgical DC to reduce ICP in diffuse TBI, although the reliability of the results was arguable owing to the restrictive inclusion criteria. The RESCUEicp trial brought a new perspective to these issues by including more frequently encountered patient conditions and by refining the description of refractory intracranial hypertension (>25 mm Hg for 1 to 12 hours). The RESCUEicp trial showed that DC in patients who failed initial treatment measures was associated with lower mortality than in patients who underwent medical management. However, more survivors in the surgical group than those in the medical group were in a vegetative state or reliant on others for activities of daily living.

While these results may underscore the age-old belief that improvements in mortality from emergent lifesaving procedures do not necessarily correlate with enhancements in quality of life, there is concern for relying on 6-month outcome measures to define the treatment's effectiveness for a condition (severe TBI) that demonstrates ongoing recovery for 12 to 24 months, or longer. Careful evaluation of the 12-month outcome for RESCUEicp suggests improvement in the DC cohort given that the upper severe disability group, by

definition, had partial independence at home. Twenty-four month follow-up is expected to be published after the data are analyzed. However, the conclusions thus far argue for greater scrutiny in selecting patients for DC and for improvement in our diagnosis and treatment through further research and technological innovation. For patients who sustain severe TBI, it is necessary to have early, comprehensive discussions with families regarding the risks/benefits of treatment and the potential prognosis for recovery.

REFERENCES

[1] Kakar V, Nagaria J, John Kirkpatrick P. The current status of decompressive craniectomy. *British journal of neurosurgery*. 2009;23(2):147-57.

[2] Xi G, Keep RF, Hoff JT. Pathophysiology of brain edema formation. *Neurosurgery clinics of North America*. 2002;13(3):371-83.

[3] Stocchetti N, Maas AI. Traumatic intracranial hypertension. *The New England journal of medicine*. 2014;371(10):972.

[4] Dunn LT. Raised intracranial pressure. *Journal of neurology, neurosurgery, and psychiatry.* 2002;73 Suppl 1:i23-7.

[5] Farahvar A, Gerber LM, Chiu YL, Hartl R, Froelich M, Carney N, et al. Response to intracranial hypertension treatment as a predictor of death in patients with severe traumatic brain injury. *Journal of neurosurgery.* 2011;114(5):1471-8.

[6] Vik A, Nag T, Fredriksli OA, Skandsen T, Moen KG, Schirmer-Mikalsen K, et al. Relationship of "dose" of intracranial hypertension to outcome in severe traumatic brain injury. *Journal of neurosurgery*. 2008;109(4):678-84.

[7] Guerra WK, Gaab MR, Dietz H, Mueller JU, Piek J, Fritsch MJ. Surgical decompression for traumatic brain swelling: indications and results. *Journal of neurosurgery.* 1999;90(2):187-96.

[8] Bor-Seng-Shu E, Figueiredo EG, Amorim RL, Teixeira MJ, Valbuza JS, de Oliveira MM, et al. Decompressive craniectomy: a meta-analysis of influences on intracranial pressure and cerebral perfusion pressure in the treatment of traumatic brain injury. *Journal of neurosurgery.* 2012;117(3):589-96.

[9] Eberle BM, Schnuriger B, Inaba K, Gruen JP, Demetriades D, Belzberg H. Decompressive craniectomy: surgical control of traumatic intracranial hypertension may improve outcome. *Injury.* 2010;41(9):894-8.

[10] Sahuquillo J, Arikan F. Decompressive craniectomy for the treatment of refractory high intracranial pressure in traumatic brain injury. *The Cochrane database of systematic reviews.* 2006(1):Cd003983.

[11] Kolias AG, Kirkpatrick PJ, Hutchinson PJ. Decompressive craniectomy: past, present and future. *Nature reviews Neurology*. 2013;9(7):405-15.

[12] Scalea TM, Bochicchio GV, Habashi N, McCunn M, Shih D, McQuillan K, et al. Increased intra-abdominal, intrathoracic, and intracranial pressure after severe brain injury: multiple compartment syndrome. *The Journal of trauma*. 2007;62(3):647-56; discussion 56.

[13] Bohman LE, Schuster JM. Decompressive craniectomy for management of traumatic brain injury: an update. *Current neurology and neuroscience reports.* 2013;13(11):392.

[14] Huang X, Wen L. Technical considerations in decompressive craniectomy in the treatment of traumatic brain injury. *International journal of medical sciences*. 2010;7(6):385-90.

[15] Hutchinson PJ, Kolias AG, Timofeev IS, Corteen EA, Czosnyka M, Timothy J, et al. Trial of Decompressive Craniectomy for Traumatic Intracranial Hypertension. *The New England journal of medicine*. 2016;375(12):1119-30.

[16] Huang AP, Tu YK, Tsai YH, Chen YS, Hong WC, Yang CC, et al. Decompressive craniectomy as the primary surgical intervention for hemorrhagic contusion. *Journal of neurotrauma*. 2008;25(11):1347-54.

[17] Soukiasian HJ, Hui T, Avital I, Eby J, Thompson R, Kleisli T, et al. Decompressive craniectomy in trauma patients with severe brain injury. *The American surgeon*. 2002;68(12):1066-71.

[18] Akyuz M, Ucar T, Acikbas C, Kazan S, Yilmaz M, Tuncer R. Effect of early bilateral decompressive craniectomy on outcome for severe traumatic brain injury. *Turkish neurosurgery*. 2010;20(3):382-9.

[19] Wen L, Wang H, Wang F, Gong JB, Li G, Huang X, et al. A prospective study of early versus late craniectomy after traumatic brain injury. *Brain injury*. 2011;25(13-14):1318-24.

[20] Lu LQ, Jiang JY, Yu MK, Hou LJ, Chen ZG, Zhang GJ, et al. Standard large trauma craniotomy for severe traumatic brain injury. Chinese journal of traumatology = Zhonghua chuang shang za zhi/*Chinese Medical Association*. 2003;6(5):302-4.

[21] Carney N, Totten AM, O'Reilly C, Ullman JS, Hawryluk GW, Bell MJ, et al. Guidelines for the Management of Severe Traumatic Brain Injury, Fourth Edition. *Neurosurgery*. 2017;80(1):6-15.

[22] Cooper DJ, Rosenfeld JV, Murray L, Arabi YM, Davies AR, D'Urso P, et al. Decompressive craniectomy in diffuse traumatic brain injury. *The New England journal of medicine*. 2011;364(16):1493-502.

[23] Jiang JY, Xu W, Li WP, Xu WH, Zhang J, Bao YH, et al. Efficacy of standard trauma craniectomy for refractory intracranial hypertension with severe traumatic brain injury: a multicenter, prospective, randomized controlled study. *Journal of neurotrauma*. 2005;22(6):623-8.

[24] Qiu W, Guo C, Shen H, Chen K, Wen L, Huang H, et al. Effects of unilateral decompressive craniectomy on patients with unilateral acute post-traumatic brain swelling after severe traumatic brain injury. *Critical care* (London, England). 2009;13(6):R185.

[25] Olivecrona M, Rodling-Wahlstrom M, Naredi S, Koskinen LO. Effective ICP reduction by decompressive craniectomy in patients with severe traumatic brain injury treated by an ICP-targeted therapy. *Journal of neurotrauma*. 2007;24(6):927-35.

[26] Soustiel JF, Sviri GE, Mahamid E, Shik V, Abeshaus S, Zaaroor M. Cerebral blood flow and metabolism following decompressive craniectomy for control of increased intracranial pressure. *Neurosurgery*. 2010;67(1):65-72; discussion

[27] Bullock MR, Chesnut R, Ghajar J, Gordon D, Hartl R, Newell DW, et al. Surgical management of acute subdural hematomas. *Neurosurgery*. 2006;58(3 Suppl):S16-24; discussion Si-iv.

[28] Bullock MR, Chesnut R, Ghajar J, Gordon D, Hartl R, Newell DW, et al. Surgical management of traumatic parenchymal lesions. *Neurosurgery*. 2006;58(3 Suppl):S25-46; discussion Si-iv.

[29] Bullock MR, Chesnut R, Ghajar J, Gordon D, Hartl R, Newell DW, et al. Surgical management of posterior fossa mass lesions. *Neurosurgery*. 2006;58(3 Suppl):S47-55; discussion Si-iv.

[30] Kochanek PM, Carney N, Adelson PD, Ashwal S, Bell MJ, Bratton S, et al. Guidelines for the acute medical management of severe traumatic brain injury in infants, children, and adolescents--second edition. *Pediatric critical care medicine : a journal of the Society of Critical Care Medicine and the World Federation of Pediatric Intensive and Critical Care Societies*. 2012;13 Suppl 1:S1-82.

[31] Rutigliano D, Egnor MR, Priebe CJ, McCormack JE, Strong N, Scriven RJ, et al. Decompressive craniectomy in pediatric patients with traumatic brain injury with intractable elevated intracranial pressure. *Journal of pediatric surgery*. 2006;41(1):83-7; discussion -7.

[32] Taylor A, Butt W, Rosenfeld J, Shann F, Ditchfield M, Lewis E, et al. A randomized trial of very early decompressive craniectomy in children with traumatic brain injury and sustained intracranial hypertension. *Child's nervous system: ChNS: official journal of the International Society for Pediatric Neurosurgery*. 2001;17(3):154-62.

In: Encyclopedia of Surgery (22 Volume Set)
Editors: Andreas Lehrer and Kristin Mueller
ISBN: 978-1-53618-329-0
© 2020 Nova Science Publishers, Inc.

Chapter 237

DECOMPRESSIVE CRANIECTOMY: SURGICAL INDICATIONS IN DEVELOPED VERSUS DEVELOPING COUNTRIES

Franco Servadei[1,*], Corrado Iaccarino[2], Edoardo Picetti[3], Davide Nasi[1] and Stephen Honeybul[4]

[1]Department of Neurosurgery, Humanitas University, Milano, Italy
[2]Department of Neurosurgery, University Hospital of Parma, Parma, Italy
[3]Department of Anesthesia and Intensive Care,
University Hospital of Parma, Parma, Italy
[4]Sir Charles Gairdner Hospital Queen Elizabeth II Medical Center, Perth, Australia

ABSTRACT

There continues to be a debate regarding the role of decompressive craniectomy in the management of neurological crises. There is now clear evidence from recent randomized controlled trials that surgical decompression reduces mortality. However, in most of the trials this reduction in mortality was almost directly translatable into an increase in the number of survivors with either severe disability or in a vegetative state. The implications that these findings have for the ongoing use of the procedure in high income countries are significant given the socioeconomic implications of converting death into survival with complete dependency. However, there are limitations when applying the results of these trials to patients who require surgical intervention in low and middle income countries. There are significant and evolving differences in terms of global epidemiological disease patterns, prehospital care, in-hospital diagnostic facilities and rehabilitation facilities. The implications of performing "life-saving" surgery differ depending on the resources available and the application of outcome data from well-funded trials and the impact that use of such surgical techniques has on health care resources will vary markedly.

* Corresponding Author's Email: franco.servadei@gmail.com.

Keywords: decompressive craniectomy, floating craniotomies, developing countries, traumatic brain injury management, intracranial pressure, prehospital care

INTRODUCTION

The role of decompressive craniectomy (DC) in the management of neurological crises is the subject of considerable debate. Evidence from randomized controlled trials (RCTs) in the context of ischemic stroke [1-3] and severe traumatic brain injury (TBI) [4, 5] has been added to numerous retrospective studies reporting use of the procedure in other conditions such as subarachnoid hemorrhage [6, 7], infection [8, 9], venous sinus thrombosis [10, 11], and in certain inflammatory conditions [12, 13]. DC can be performed as either a primary or secondary procedure. A primary procedure is performed when the brain is determined to be swollen following evacuation of a mass lesion such an acute subdural hematoma in the context of severe TBI or following removal of a lesion such as a tumor or abscess. A secondary procedure is performed for refractory intracranial hypertension despite maximal medical therapy. This can be in the context of intracranial pressure (ICP) monitoring following severe TBI or following clinical deterioration in the context of ischemic stroke or infection [14].

A growing body of evidence has provided support for the use of DC as a life-saving intervention and recent RCTs demonstrated that a significant reduction in mortality can be achieved [1-5]. However, evidence that surgical intervention improves clinical outcome has been less forthcoming. Indeed, evidence from these trials has demonstrated that the reduction in mortality led to an almost direct increase in the number of survivors with severe disability [15, 16].

The socioeconomic implications of this outcome will not be insignificant given the health care requirements of these survivors, especially for those patients in lower and middle income countries (LMICs) where resources can be limited. Further limitations must also be acknowledged when applying evidence obtained from trials conducted in high income countries (HICs) to LMICs because of the disproportionately high incidence of pathologies such as stroke and trauma in LMICs and the fewer available health care resources. This shortfall in resources applies to all aspects of surgical intervention ranging from prehospital care, in-hospital diagnostic facilities, monitoring, and therapeutic resources, through to rehabilitation and nursing home facilities.

The aim of this chapter is to examine the impact that the mismatch between the epidemiology of pathology and the availability of resources can have on the management of patients who may require DC.

DECOMPRESSIVE CRANIECTOMY – EVOLVING EPIDEMIOLOGY

The global epidemiological patterns for many of the conditions that require consideration for DC have changed considerably over recent years. In the context of severe TBI, motor vehicle accidents have always contributed significantly to the global burden of disease. However, in HICs the number of total TBI events has been decreasing, and the main cause of

severe TBI is now falls in elderly patients [17, 18]. Probably, no single reason accounts for this change, and several interrelated factors may be responsible, for example, improvements in car design, the introduction of air bags, preventative legislation such as the compulsory wearing of seat belts and motor cycle helmets, the need to adhere to strict speed limits, and drink drive laws. Improved control of cardiovascular disease has led to a longer life expectancy with the attendant increase in risk for falls among the elderly.

In LMICs, while the use of motor vehicles and motor cycles has increased, it has not been accompanied by improvement in laws to prevent unsafe driving habits. Similarly, traffic safety education remains lacking in this setting. Given these problems it is probably unsurprising that although only 54% of the world's registered vehicles are in LMICs, 90% of the deaths attributable to road traffic accidents occur in LMICs. Furthermore, because of limited reporting systems (i.e., trauma registries) in LMICs, this is likely to be an underestimation [18, 19]. Finally, the type of head injuries may differ between patients considered for DC in HICs and LMICs because most patients with TBI in LMICs are pedestrians, cyclists, and motorcyclists who often have no helmet protection. In addition, in certain regions where the prevalence of armed violence is high (Central America, the Middle East, and Central Africa), assault and gunshot injuries are important causes of TBI, which may further contribute to the difference in injury patterns in patients who present for treatment [18].

In the context of ischemic stroke, there are similar differences between the types of patients who are considered for DC in HICs and LMICs. In HICs age standardized stroke mortality and morbidity rates have steadily decreased over recent years with subsequent declines in absolute stroke mortality and morbidity [20]. A good example of this reduction can be seen in data from the United States where, for many years, stroke was the third most common cause of death. In 2008, however, it dropped to fourth place and 5 years later to fifth place [21]. Other HICs have similar findings, and mortality rates are likely to improve further with the introduction of endovascular techniques using either intra-arterial therapy or mechanical thrombectomy [22-24]. Findings in LMICs, however, show that stroke remains the third most common cause of death and disability. Many factors contribute to this, not the least of which are the worldwide prevalence of hypertension and an increase in other risk factors such as high fasting blood glucose, high total cholesterol, and tobacco smoking, all of which have historically been more prevalent in HICs [25].

The data are less robust on the epidemiology of other conditions for which patients present and are subsequently considered for DC. Even so, it must be acknowledged that the manner in which patients present and their disease severity may vary between HICs and LMICs. These differences may be further compounded by the health care resources available for prehospital, in-hospital, and rehabilitative care.

DECOMPRESSIVE CRANIECTOMY – PREHOSPITAL CARE

The aims of prehospital care for patients who may require DC are early diagnosis and resuscitation, avoidance of secondary insults such as hypoxia and hypotension, and rapid transport of patients to an appropriate health care facility. In the context of trauma, most HICs have well-organized trauma systems with highly trained paramedical staff, critical to the

management of TBI patients [26]. Prehospital management is directed toward preventing secondary brain injury while facilitating rapid transport to a facility that can provide neurocritical care. Initial management includes the assessment of respiratory and cardiovascular systems, consciousness level, and examination of the pupillary reactivity. In many HICs, the increasing use of prehospital intubation and ventilation has benefited survival when applied efficaciously [27, 28].

In the context of ischemic stroke, the need for a rapid diagnosis, resuscitation, and transport has increased following the development and subsequent proven efficacy of endovascular techniques such as intra-arterial therapy or mechanical thrombectomy [21-23]. This has also led to the development of well-integrated stroke response teams aimed at reducing the so-called "door to needle" time in order to initiate these time-critical endovascular therapies.

In LMICs, available prehospital resources vary greatly. Nielsen et al. performed a survey to determine the status of prehospital care in a wide range of LMICs [29]. They found that a substantial number of critically ill patients are transported by commercial and private vehicles with very limited life support capabilities. Similarly, Smart et al. reported that in Mwanza, the second most populated area in Tanzania, the majority of patients are transported to hospital in private vehicles including taxis [30].

Obviously, in these circumstances the drivers and prehospital care providers will have very limited, if any, paramedical training, and it is therefore remarkable that hypotension and hypoxia on hospital arrival did not seem to be associated with poor outcome [29]. Although this finding seems counterintuitive, it serves to emphasize the self-selecting aspect of limited prehospital care. It is highly likely that given the often-long distances involved, those patients in LMICs with either a very severe TBI or stroke will not survive the journey to hospital, and those who do survive may have a different injury pattern and severity than patients who present in HICs. This again serves to emphasize the inherent difficulties in comparing data from different health care regions.

DECOMPRESSIVE CRANIECTOMY – NEUROCRITICAL CARE

Over recent years the medical management of patients in the intensive neurocritical care setting in HICs has become increasingly specialized. Management is targeted at optimizing cerebral perfusion and oxygenation with a view to minimizing secondary insults. A number of studies have demonstrated that specialist protocol-driven management can improve long-term clinical outcome, especially in the context of severe TBI [31-33]. Sedation and ventilation allow full control of cerebral perfusion and oxygenation, prevent agitation due to pain and distress, and facilitate ICP monitoring in order to identify those patients who develop either surgical lesions requiring evacuation or progressive cerebral swelling that would preclude early weaning [34-37]. This ICP-targeted approach aims to maintain the pressure below a certain threshold via interventions introduced in a stepwise protocol-driven manner [38]. These include head elevation, further sedation and paralysis, cerebrospinal fluid (CSF) drainage, osmotherapy, barbiturate therapy, and more recently, hypothermia and surgical decompression. Rapid access to neuroimaging is critical in this regard since it can differentiate between those patients who develop a mass lesion that requires evacuation and

those patients who develop diffuse swelling and may therefore be a candidate for surgical decompression.

In addition to these therapeutic options, multimodal monitoring techniques have been developed so that it is now possible to obtain continuous data on a number of physiological and biochemical parameters [36]. The aim of these monitors is to gather as much information as possible in order to limit the progression of the primary brain injury and accurately assess the development and severity of secondary injuries so that appropriate treatment can be instigated. Considerable debate, however, continues about the benefit provided by data that may merely reflect the severity of the injury rather than provide information that may guide therapy. Indeed, it has even been suggested that invasive monitoring merely increases the number of medical and surgical interventions and may actually worsen outcome [39, 40]. However, adopting this position fails to recognize that it is not the monitoring that harms the patient but is instead the clinicians' interpretation of the information gained and the appropriateness of the clinical response [41].

In LMICs, the extent to which neurocritical resources are available varies widely [42 - 45]. Often, there are few or no intensive care facilities and only limited access to mechanical ventilation or neurocritical monitoring [44]. Such restrictive conditions can lead to innovative practices, as described by Gupta et al. who recently published a study describing the use of resterilized intraparenchymal strain gauge catheters. Sixty-six consecutive patients with severe TBI were monitored using catheters that had been resterilized with ethylene oxide. No increase in meningitis was observed. These catheters, after sterilization, could be reused two to four times and reliably recorded the ICP with insignificant drift [45].

Such significant differences in neurocritical care settings in HICs and LMICs must be taken into account when considering patient selection for surgical decompression.

PATIENT SELECTION

In HICs with advanced neurocritical care and monitoring facilities, the use of ICP monitoring in severe TBI has become routine and plays an important role in patient selection for surgical decompression [34 -36]. In general, an ICP of 20 mm Hg has been used as the threshold at which to instigate medical therapies aimed at maintaining cerebral perfusion. This practice is based on the observation of a strong correlation between outcome and the number of hours the ICP remains above 20 mm Hg [47, 48]. It has also been demonstrated that patients whose ICP can be satisfactorily controlled below this level have a better outcome than those with intractably raised ICP [49, 50]. Still, debate continues about the precise threshold ICP at which surgical intervention should be initiated because it is becoming increasingly apparent that the reduction in ICP achieved by surgical decompression is not necessarily converted into an improvement in outcome. This was clearly demonstrated by the Decompressive Craniectomy (DECRA) study in which patients randomized to the surgical arm of the trial had significantly lower ICPs and spent less time in intensive care. However, at 6 months follow-up their outcomes were worse than those of patients randomized to medical therapy [4].

These findings serve to highlight not only the morbidity of the procedure but also the limitations of interpreting outcome data from LMICs where patient selection is less specific.

Adeleye reported a good example of this practice in a Nigerian neurosurgical unit, where the only monitoring available was the clinical examination. Based on the observation that young patients with mild or moderate head injury often die suddenly a few days after admission from what appears to be an intracranial event following evacuation of hematoma, Adeleye performed DC not only for severe TBI but also for mild and moderate TBI in order to "prevent" clinical deterioration [51]. This type of practice can be justified if there is limited access to postoperative imaging following a primary decompressive procedure; however, it again serves to emphasize the inherent difficulties in comparing outcome studies in HICs versus LMICs.

Similar difficulties arise with other neurological pathologies such as stroke and subarachnoid hemorrhage. Given the limitations of using the ICP as a marker of injury severity, determination of severity relies largely on radiological findings, which are readily available in HICs but obviously far less so in LMICs, which will again skew any comparison of outcomes.

SURGICAL TECHNIQUE

In HICs with well-organized neurosurgical services, the technical requirements of the surgical procedure are relatively straightforward. A large scalp flap is reflected, which usually covers as wide an area as possible within the confines of patient positioning. A large bone flap, either bifrontal or unilateral, is removed, the dura is opened, and a duraplasty is often performed with a dural substitute. Depending on institutional practices, the bone flap is either discarded or stored in a refrigerator. Once the patient has recovered from the neurological crisis that necessitated the decompressive procedure, a cranioplasty procedure is performed with either the autologous bone or a suitable substitute material.

Until recently, both the decompressive procedure and cranioplasty were perceived to be relatively straightforward; however, it is becoming increasingly apparent that both procedures are associated with significant morbidity [52]. The impact that this has in HICs the economic impact of increased morbidity is likely to be relatively small in the context of the overall health care budget, but in LMICs where economic resources are limited, these costs present a major health care problem [44].

Another problem that needs special consideration in LMICs is the reconstructive cranioplasty, which requires that the autologous bone flap be stored for a period of time in a designated refrigerator at a specific temperature. Such storage presents not only financial difficulties but also logistical problems related to long-term follow-up. Several solutions to this problem have been suggested. One of the most common solutions is to store the bone flap in the anterior abdomen. Although some suggest that this method of preservation is associated with an increased complication rate, a recent meta-analysis found no difference in complications between subcutaneous abdominal implantation and cryopreserved bone flaps [53]. Notwithstanding these findings, it is still necessary that the patient be appropriately followed up, which does present logistical problems in many LMICs.

Other technical modifications of decompressive surgery have been suggested. One modification is that the floating bone flap after craniotomy is not removed but rather left to either freely float over the skull defect or be held loosely in place with sutures. Mezue et al.

report this technique and emphasize the need for a large bone flap to be reflected [54]. They report a mortality of 21%, which is consistent with DC results in HICs. It is yet to be determined whether this procedure always provides adequate decompression; however, the avoidance of the need for a second surgical procedure makes economic sense.

Adeleye describes a hinge decompressive craniectomy (hDC) in which the frontotemporoparietal skull flap is hinged on the temporal muscle [42]. The advantage of this technique is that it too eliminates the need for the subsequent cranioplasty, and the authors report 40 consecutive cases without apparent complications. Peethambaran et al. describe a four-quadrant osteoplastic DC that avoids cranioplasty [55, 56]. These authors of both studies emphasize that the main advantage of these procedures is avoidance of the need for a second procedure to replace the bone flap. However, it should be noted that in both studies the mortality rate was extremely high. This may of course be a reflection of injury severity however, caution must always be exercised when a new procedure appears to be associated with a very poor outcome (Table 2).

A final surgical technique that requires consideration is that of cisternotomy. In this procedure the basal cisterns are systematically opened in order to drain CSF and reduce the ICP [57, 58]. Although the authors describe the backflow of the CSF that can be achieved through the Virchow-Robin spaces with subsequent decrease in ICP, the clinical evidence supporting these assertions is limited.

OUTCOME

Despite the problems associated with the selection of patients for decompressive craniectomy in LMICs, an even greater challenge faces those patients who survive the surgery. Highly problematic in LMICs are both long-term outcome and the resources available to care for those who survive with severe disability.

These difficulties are compounded by the lack of outcome studies for patients in LMICs. Published reports have documented only outcome at discharge (Table 1). Comparing these limited data with fuller outcome data from HICs is problematic and for this reason, any application of the results from the recent RCTs to clinical practice in LMICs requires caution.

The pooled analysis of the three European stroke studies clearly demonstrated a significant reduction in mortality from 71% in those patients randomized to standard medical therapy to 22% in those patients randomized to surgery [59]. However, this reduction in mortality was achieved primarily because of an increase in the number of patients who survived with a modified Rankin score of 4 (2% in those patients randomized to the standard medical therapy versus 31% in those patients randomized to surgical decompression). In the Decompressive Surgery for the Treatment of malignant infarction of the middle cerebral artery II (DESTINY II) study that investigated hemicraniectomy in patients over 60 years of age, the conversion of death into survival with dependency was even more striking [60]. Mortality was reduced from 70% to 33%, but among the twenty-seven patients who were randomized to surgery and survived, most were fully dependent with severe aphasia or neuropsychological deficits [61].

Table 1. Mortality and Good Outcome (GOSE 4-5) in main consecutive series of patients underwent DC for TBI reported in last five years. In the LMI countries the follow-up is mostly reported at discharge

Country	World Bank Country Classification	Author	Mortality	Good Outcome (GOS 4-5)
India	LMI	Bhat AR	37,3% (IH)	68,6% (D)
India	LMI	Agrawal D	54% (IH)	22% (D)
India	LMI	Peethambaran AK	60% (IH)	NA
Nigeria	LMI	Adeleye AO	Moderate TBI 2% (IH) Severe TBI 83,3% (IH)	Mild TBI 100% (D) Moderate TBI 83,3% (D) Severe TBI 33,3% (D)
Nigeria	LMI	Mezue WC	21,3% (IH)	47,3%
Pakistan	LMI	Waqas M	23,2% (IH)	46,3% (6m FU)
China	UMI	Yuan Q	22% (IH)	42%
Iran	UMI	Khalili H	21,5% (6m FU)	47,3% (6m FU)
Australia	HI	Nambiar M	47% (IH)	26,3% (6m FU)
Australia	HI	Honeybul S	16,7% (18m FU)	62,2% (18m FU)
Germany	HI	Sauvigny T	NA	52,55 (NA)
Italy	HI	Tagliaferri F	NA	26% (6m FU)
Japan	HI	Takeuchi S	27,5%	40,2% (NA)
Taiwan	HI	Huang YH	32,3% (42m FU)	38,5%(42m FU)
Uruguay	HI	Grille P	43% (IH)	34% (IH)

Legend: LMI: Lower middle income, UMI: Upper middle income, HI: High income, IH: In-Hospital, D: Discharge, FU: Follow-Up, m: months; NA : Not Available

Findings related to severe TBI have been similar. The DECRA study demonstrated that early surgical intervention provided no improvement in outcome, highlighting that surgical intervention is not without morbidity [4]. While the trial prompted some criticism, its findings certainly support caution when considering the approach by Adeleye because operating early will not necessarily improve outcome [51]. More recently, the Randomised Evaluation of Surgery with Elevation of Intracranial Pressure (RESCUEicp) trial confirmed a survival benefit, but again this came about only as a result of an increased number of dependent survivors [5, 62].

It is difficult to determine the impact that these findings should have on clinical practice in LMICs as only patients in HICs were studied and any therapeutic implications arising from these results should be applied with caution. Still, a number of issues are noteworthy. First, the trials have clearly established that surgical intervention does not reverse the effects of the pathology that precipitated the neurological crisis. Second, while surgical decompression reduces mortality, this procedure leads to an almost direct conversion into survival with severe disability and dependency. In HICs the financial manpower impact that this increase in the number of severely disabled survivors has on health care resources is significant but probably sustainable by most healthcare institutions, especially in the context of a well-funded RCT.

Table 2. Main consecutive series of patients underwent DC for TBI reported in last five years. The number of surgery and the mean age of patients is different related to the countries

Country	World Bank Country Classification	Author	Type of study	Number of center	Period of study	Number of DC/month (AVG)	Mean Age (y)
India	LMI	Bhat AR	Prospective	Single	Jun 2006 Jun 2011	3.7	NA
India	LMI	Agrawal D	Retrospective	Single	Jan 2009 Dec 2009	22,7	34,3
India	LMI	Salunke P	Retrospective	Single	Aug 2012 May 2013	26,6	40
Nigeria	LMI	Adeleye AO	Prospecctive	Single	40 months	1	38,4
Nigeria	LMI	Mezue WC	Retrospective	Single	Aug 2002 May 2010	0,4	36
Pakistan	LMI	Waqas M	Retrospective	Single	Jan 2009 Mar 2013	3,5	31,4
China	UMI	Yuan Q	Retrospective	Single	Jan 2005 Dec 2009	3,4	48
Iran	UMI	Khalili H	Retrospective	Single	Mar 2012 Apr 2013	7,1	35,1
Australia	HI	Nambiar M	Retrospective	Single	Jan 2005 Jun2011	0,7	30
Australia	HI	Honeybul S	Prospective	Two	Jan 2004 Dec 2012	2,8	30
Germany	HI	Sauvigny T	Retrospective	Single	Dec 2007 May 2014	0,5	52,8
Italy	HI	Tagliaferri F	Retrospective	Seven	Jan 2005 Dec 2008	8,4	49,6
Japan	HI	Takeuchi S	Retrospective	Single	7 years	1,3	50,3
Taiwan	HI	Huang YH	Retrospective	Single	Jan 2006 Dec 2008	8,3	46,2
Uruguay	HI	Grille P	Retrospective	Single	Jan 2003 Dec 2012	0,5	31

Legend: LMI: Lower middle income, UMI: Upper middle income, HI: High income

Cost effectiveness in itself should not be the overriding factor when considering the value of a therapeutic intervention, especially a definitive life-saving procedure. There is, nevertheless, a strong ethical imperative to consider the impact that any one particular procedure has on health care resources. Hofmeijer et al., recently reported the incremental costs per quality-adjusted life year gained after hemicraniectomy in young patients with malignant stroke [63]. They demonstrated that the costing represented approximately eleven times the gross domestic cost per capita for an LMIC such as Mexico [64]. Similar studies have been done in the context of severe TBI [65].

In most LMICs the health care resource implications of survival with severe disability are unknown, and this leads to the important issue of long-term outcome data collection. Given the limited funding available in LMICs, health care resources must be allocated appropriately. Proper collection of data on management and outcomes in LMICs is extremely important, and a prospective project funded by Western national or international agencies may help. Possibly, decompressive surgery provides benefit to patients in LMICs since they present in quite different circumstances from those of HICs. Alternatively, decompressive surgery in this setting may mainly convert death into survival with severe disability and dependency, thereby placing an unacceptable and unsustainable burden on scarce health care resources. The absence of robust databases allowing accurate statistical analysis impedes government efforts to adjust and apportion health care budgets appropriately.

CONCLUSION

Regarding the question "Do the indications for decompressive craniectomy change according to the available resources?", the available data are probably insufficient for an objective assessment. What is certain is that the implications of performing "life-saving" surgery are very different for HICs and LHICs. Application of outcome data from well-funded RCTs in HICs to the patient populations in LMICs has major limitations given the different and evolving epidemiology and the surgical resources available in these two groups. In addition, the impact that use of such surgical techniques has on health care resources will vary markedly between HICs and LMICs.

If use of these procedures is to continue in LMICs, more active data collection is required in order to carry out robust cost-effectiveness analyses so that scarce resources can be applied appropriately and equitably.

REFERENCES

[1] Jüttler, E; Schwab, S; Schmiedek, P; Unterberg, A; Hennerici, M; Woitzik, J; et al., DESTINY Study Group. Decompressive Surgery for the Treatment of Malignant Infarction of the Middle Cerebral Artery (DESTINY): a randomized, controlled trial. *Stroke*., 2007, 38(9), 2518-25.

[2] Vahedi, K; Vicaut, E; Mateo, J; Kurtz, A; Orabi, M; Guichard, JP; et al., DECIMAL Investigators. Sequential-design, multicenter, randomized, controlled trial of early

decompressive craniectomy in malignant middle cerebral artery infarction (DECIMAL Trial). *Stroke*., 2007, 38(9), 2506-17.

[3] Hofmeijer, J; Kappelle, LJ; Algra, A; Amelink, GJ; van, Gijn, J; van, der, Worp; et al., HAMLET investigators. Surgical decompression for space-occupying cerebral infarction (the Hemicraniectomy After Middle Cerebral Artery infarction with Life-threatening Edema Trial [HAMLET]): a multicentre, open, randomised trial. *Lancet Neurol*., 2009, 8(4), 326-33.

[4] Cooper, DJ; Rosenfeld, JV; Murray, L; Arabi, YM; Davies, AR; D'Urso, P; et al., DECRA Trial Investigators.; Australian and New Zealand Intensive Care Society Clinical Trials Group. Decompressive craniectomy in diffuse traumatic brain injury. *N Engl J Med*., 2011, 364(16), 1493-502.

[5] Hutchinson, PJ; Kolias, AG; Timofeev, IS; Corteen, EA; Czosnyka, M; Timothy, J; et al., RESCUEicp Trial Collaborators. Trial of Decompressive Craniectomy for Traumatic Intracranial Hypertension. *N Engl J Med*., 2016, 375(12), 1119-30.

[6] Fisher, CM; Ojemann, RG. Bilateral decompressive craniectomy for worsening coma in acute subarachnoid hemorrhage. Observations in support of the procedure. *Surg Neurol*., 1994, 41(1), 65-74.

[7] Smith, ER; Carter, BS; Ogilvy, CS. Proposed use of prophylactic decompressive craniectomy in poor-grade aneurysmal subarachnoid hemorrhage patients presenting with associated large sylvian hematomas. *Neurosurgery*., 2002, 51(1), 117-24.

[8] Baussart, B; Cheisson, G; Compain, M; Leblanc, PE; Tadie, M; Benhamou, D ; et al. Multimodal cerebral monitoring and decompressive surgery for the treatment of severe bacterial meningitis with increased intracranial pressure. *Acta Anaesthesiol Scand*., 2006, 50(6), 762-65.

[9] Perin, A; Nascimben, E; Longatti, P. Decompressive craniectomy in a case of intractable intracranial hypertension due to pneumococcal meningitis. *Acta Neurochir (Wien)*., 2008, 150(8), 837-42.

[10] Coutinho, JM; Majoie, CB; Coert, BA; Stam, J. Decompressive hemicraniectomy in cerebral sinus thrombosis: consecutive case series and review of the literature. *Stroke*., 2009, 40(6), 2233-5.

[11] Ferro, JM; Crassard, I; Coutinho, JM; Canhão, P; Barinagarrementeria, F; Cucchiara, B; et al., Second International Study on Cerebral Vein and Dural Sinus Thrombosis (ISCVT 2) Investigators. Decompressive surgery in cerebrovenous thrombosis: a multicenter registry and a systematic review of individual patient data. *Stroke*., 2011, 42(10), 2825-31.

[12] Ahmed, AI; Eynon, CA; Kinton, L; Nicoll, JA; Belli, A. Decompressive craniectomy for acute disseminated encephalomyelitis. *Neurocrit Care*., 2010, 13(3), 393-5.

[13] Dombrowski, KE; Mehta, AI; Turner, DA; McDonagh, DL. Life-saving hemicraniectomy for fulminant acute disseminated encephalomyelitis. *Br J Neurosurg.*, 2011, 25(2), 249-52.

[14] Kolias, AG; Kirkpatrick, PJ; Hutchinson, PJ. Decompressive craniectomy: past, present and future. *Nat Rev Neurol*., 2013, 9(7), 405–15.

[15] Puetz, V; Campos, CR; Eliasziw, M; Hill, MD; Demchuk, AM. Calgary Stroke Program. Assessing the benefits of hemicraniectomy: what is a favourable outcome? *Lancet Neurol*., 2007, 6(7), 580-81.

[16] Honeybul, S. Decompressive craniectomy for severe traumatic brain injury reduces mortality but increases survival with severe disability. *Evid Based Med*., 2017, 22(2), 61.

[17] Brazinova, A; Rehorcikova, V; Taylor, MS; Buckova, V; Majdan, M; Psota, M; et al. Epidemiology of Traumatic Brain Injury in Europe: A Living Systematic Review. *J Neurotrauma*., 2016, Aug 25. doi, 10.1089/neu.2015.4126.

[18] Rubiano, AM; Carney, N; Chesnut, R; Puyana, JC. Global neurotrauma research challenges and opportunities. *Nature*., 2015, 527(7578), S193-S97.

[19] Roozenbeek, B; Maas, AI; Menon, DK. Changing patterns in the epidemiology of traumatic brain injury. *Nat Rev Neurol*., 2013, 9(4), 231-36.

[20] Feigin, VL; Forouzanfar, MH; Krishnamurthi, R; Mensah, GA; Connor, M; Bennett, DA; et al. Global and regional burden of stroke during 1990-2010: findings from the Global Burden of Disease Study 2010. Global Burden of Diseases, Injuries, and Risk Factors Study 2010 (GBD 2010) and the GBD Stroke Experts Group. *Lancet*., 2014, 383(9913), 245-54.

[21] Kim, AS; Cahill, E; Cheng, NT. Global Stroke Belt: Geographic Variation in Stroke Burden Worldwide. *Stroke*., 2015, 46(12), 3564-70.

[22] Al-Ajlan, FS; Goyal, M; Demchuk, AM; Minhas, P; Sabiq, F; Assis, Z; et al., ESCAPE Trial Investigators. Intra-Arterial Therapy and Post-Treatment Infarct Volumes: Insights From the ESCAPE Randomized Controlled Trial. *Stroke*., 2016, 47(3), 777-81.

[23] Berkhemer, OA; Fransen, PS; Beumer, D; van, den, Berg, LA; Lingsma, HF; Yoo, AJ; et al., MR CLEAN Investigators. A randomized trial of intraarterial treatment for acute ischemic stroke Investigators. *N Engl J Med*., 2015, 372(1), 11-20.

[24] Goyal, M; Demchuk, AM; Menon, BK; Eesa, M; Rempel, JL; Thornton, J; et al., ESCAPE Trial Investigators. Randomized assessment of rapid endovascular treatment of ischemic stroke. *N Engl J Med.*, 2015, 372(11), 1019-30.

[25] Johnston, SC; Mendis, S; Mathers, CD. Global variation in stroke burden and mortality: estimates from monitoring, surveillance, and modelling. *Lancet Neurol*., 2009, 8(4), 345-54.

[26] Minardi, J; Crocco, TJ. Management of traumatic brain injury: first link in chain of survival. *Mt Sinai J Med*., 2009, 76(2), 138-44.

[27] Rudehill, A; Bellander, BM; Weitzberg, E; Bredbacka, S; Backheden, M; Gordon, E. Outcome of traumatic brain injuries in 1,508 patients: impact of prehospital care. *J Neurotrauma.*, 2002, 19(7), 855-68.

[28] Winchell, RJ; Hoyt, DB. Endotracheal intubation in the field improves survival in patients with severe head injury. Trauma Research and Education Foundation of San Diego. *Arch Surg*., 1997, 132(6), 592-97.

[29] Nielsen, K; Mock, C; Joshipura, M; Rubiano, AM; Zakariah, A; Rivara, F. Assessment of the status of prehospital care in 13 low- and middle-income countries. *Prehosp Emerg Care*., 2012, 16(3), 381-89.

[30] Smart, LR; Mangat, HS; Issarow, B; McClelland, P; Mayaya, G; Kanumba, E; et al. Severe Traumatic Brain Injury at a Tertiary Referral Center in Tanzania: Epidemiology and Adherence to Brain Trauma Foundation Guidelines. *World Neurosurg* 2017. In press.

[31] Elf, K; Nilsson, P; Enblad, P. Outcome after traumatic brain injury improved by an organized secondary insult program and standardized neurointensive care. *Crit Care Med.*, 2002, 30(9), 2129-34.

[32] Patel, HC; Menon, DK; Tebbs, S; Hawker, R; Hutchinson, PJ; Kirkpatrick, PJ. Specialist neurocritical care and outcome from head injury. *Intensive Care Med*., 2002, 28(5), 547-53.

[33] Patel, HC; Bouamra, O; Woodford, M; King, AT; Yates, DW; Lecky, FE. Trends in head injury outcome from 1989 to 2003 and the effect of neurosurgical care: an observational study. *Lancet*., 2005, 366(9496), 1538-44.

[34] Servadei, F; Picetti, E. Intracranial pressure monitoring and outcome in traumatic brain injury: the probe does matter? *World Neurosurg*., 2015, 83(5), 732-33.

[35] Chesnut, RM; Bleck, TP; Citerio, G; Classen, J; Cooper, DJ; Coplin, WM; et al. A Consensus-Based Interpretation of the Benchmark Evidence from South American Trials: Treatment of Intracranial Pressure Trial. *J Neurotrauma*., 2015, 32(22), 1722-24.

[36] Chesnut, R; Videtta, W; Vespa, P; Le, Roux, P. Participants in the International Multidisciplinary Consensus Conference on Multimodality Monitoring. Intracranial pressure monitoring: fundamental considerations and rationale for monitoring. *Neurocrit Care*., 2014, 21Suppl2, S64-S84.

[37] Stocchetti, N; Picetti, E; Berardino, M; Buki, A; Chesnut, RM; Fountas, KN; et al. Clinical applications of intracranial pressure monitoring in traumatic brain injury: report of the Milan consensus conference. *Acta Neurochir (Wien)*., 2014, 156(8), 1615-22.

[38] Bratton, SL; Chestnut, RM; Ghajar, J; McConnell, Hammond, FF; Harris, OA; et al., Brain Trauma Foundation; American Association of Neurological Surgeons, Congress of Neurological Surgeons; Joint Section on Neurotrauma and Critical Care, AANS/CNS. Guidelines for the management of severe traumatic brain injury. *J Neurotrauma*., 2007, 24, suppl1.

[39] Akopian, G; Gaspard, DJ; Alexander, M. Outcomes of blunt head trauma without intracranial pressure monitoring. *Am Surg*., 2007, 73(5), 447-50.

[40] Shafi, S; Diaz-Arrastia, R; Madden, C; Gentilello, L. Intracranial pressure monitoring in brain-injured patients is associated with worsening of survival. *J Trauma*., 2008, 64(2), 335-40.

[41] Servadei, F; Compagnone, C; Sahuquillo, J. The role of surgery in traumatic brain injury. *Curr Opin Crit Care*., 2007, 13(2), 163–68.

[42] Adeleye, AO. Clinical and Radiologic Outcome of a Less Invasive, Low-Cost Surgical Technique of Osteoplastic Decompressive Craniectomy. *J Neurol Surg A Cent Eur Neurosurg*., 2016, 77(2), 167-75.

[43] Mateen, FJ. Neurocritical care in developing countries. *Neurocrit Care*., 2011, 15(3), 593-98.

[44] Rubiano, AM; Puyana, JC; Mock, CN; Bullock, MR; Adelson, PD. Strengthening neurotrauma care systems in low and middle income countries. *Brain Inj*., 2013, 27(3), 262-72.

[45] Güiza, F; Depreitere, B; Piper, I; Citerio, G; Chambers, I; Jones, PA; et al. Visualizing the pressure and time burden of intracranial hypertension in adult and paediatric traumatic brain injury. *Intensive Care Med*., 2015, 41(6), 1067-76.

[46] Gupta, DK; Bisht, A; Batra, P; Mathur, P; Mahapatra, AK. A cost effectiveness based safety and efficacy study of resterilized intra-parenchymal catheter based intracranial pressure monitoring in developing world. *Asian J Neurosurg*., 2016, 11(4), 416-20.

[47] Juul, N; Morris, GF; Marshall, SB; Marshall, LF. Intracranial hypertension and cerebral perfusion pressure: influence on neurological deterioration and outcome in severe head injury. The Executive Committee of the International Selfotel Trial. *J Neurosurg*., 2000, 92(1), 1-6.

[48] Marmarou, A; Anderson, R; Ward, JD. Impact of ICP instability and hypotension on outcome in patients with severe head trauma. *J Neurosurg*., 1991, 75, s59-s66.

[49] Ratanalert, S; Phuenpathom, N; Saeheng, S; Oearsakul, T; Sripairojkul, B; Hirunpat, S. ICP threshold in CPP management of severe head injury patients. *Surg Neurol*., 2004, 61(5), 429-34.

[50] Saul, TG; Ducker, TB. Effect of intracranial pressure monitoring and aggressive treatment on mortality in severe head injury. *J Neurosurg*., 1982, 56(4), 498-503.

[51] Adeleye, AO. Decompressive craniectomy for traumatic brain injury in a developing country: an initial observational study. *Indian Journal of Neurotrauma*., 2010, 7(1), 41-6.

[52] Honeybul, S; Ho, KM. Long-term complications of decompressive craniectomy for head injury. *J Neurotrauma*., 2011, 28(6), 929-35

[53] Corliss, B; Gooldy, T; Vaziri, S; Kubilis, P; Murad, G; Fargen, K. Complications After In Vivo and Ex Vivo Autologous Bone Flap Storage for Cranioplasty: A Comparative Analysis of the Literature. *World Neurosurg*., 2016, 96, 510-15.

[54] Mezue, WC; Ndubuisi, C; Ohaegbulam, SC; Chikani, M; Erechukwu, U. Cranial bony decompressions in the management of head injuries: decompressive craniotomy or craniectomy? *Niger J Clin Pract*., 2013, 16(3), 343-47.

[55] Peethambaran, AK; Gopal, VV; Valsalamony, J. Four-quadrant osteoplastic decompressive craniotomy: A novel technique for refractory intracranial hypertension - A pilot study. *Neurol India*., 2015, 63(6), 895-902.

[56] Peethambaran, AK; Valsalmony, J. Four-quadrant osteoplastic decompressive craniotomy: a novel technique for decompressive craniectomy avoiding revision cranioplasty after surgery. *Neurol India*., 2012, 60(6), 672-4.

[57] Cherian, I; Bernardo, A; Grasso, G. Cisternostomy for Traumatic Brain Injury: Pathophysiologic Mechanisms and Surgical Technical Notes. *World Neurosurg*., 2016, 89, 51-7

[58] Cherian, I; Yi, G; Munakomi, S. Cisternostomy: replacing the age old decompressive hemicraniectomy? *Asian J Neurosurg*., 2013, 8(3), 132-8.

[59] Vahedi, K1; Hofmeijer, J; Juettler, E; Vicaut, E; George, B; Algra, A; et al., DECIMAL, DESTINY, and HAMLET investigators. Early decompressive surgery in malignant infarction of the middle cerebral artery: a pooled analysis of three randomised controlled trials. *Lancet Neurol*., 2007, 6(3), 215-22.

[60] Jüttler, E; Unterberg, A; Woitzik, J; Bösel, J; Amiri, H; Sakowitz, OW; et al., DESTINY II Investigators. Hemicraniectomy in older patients with extensive middle-cerebral-artery stroke. *N Engl J Med*., 2014, 370(12), 1091-100.

[61] Honeybul, S; Ho, KM; Gillett, G. Outcome Following Decompressive Hemicraniectomy for Malignant Cerebral Infarction: Ethical Considerations. *Stroke*., 2015, 46(9), 2695-98

[62] Honeybul, S. Decompressive craniectomy for severe traumatic brain injury reduces mortality but increases survival with severe disability. *Evid Based Med*., 2017, 22(2), 61.

[63] Hofmeijer, J; van, der, Worp, HB; Kappelle, LJ; Eshuis, S; Algra, A; Greving, JP. HAMLET Steering Committee. Cost-effectiveness of surgical decompression for space-occupying hemispheric infarction. *Stroke*., 2013, 44(10), 2923-5.

[64] López-Ortega, M; García-Peña, C; Granados-García, V; García-González, JJ; Pérez-Zepeda, MU. Economic burden to primary informal caregivers of hospitalized older adults in Mexico: a cohort study. *BMC Health Serv Res*., 2013, 13, 51.

[65] Ho, KM; Honeybul, S; Lind, CR; Gillett, GR; Litton, E. Cost-effectiveness of decompressive craniectomy as a lifesaving rescue procedure for patients with severe traumatic brain injury. *J Trauma*., 2011, 71(6), 1637-44.

In: Encyclopedia of Surgery (22 Volume Set)
Editors: Andreas Lehrer and Kristin Mueller
ISBN: 978-1-53618-329-0
© 2020 Nova Science Publishers, Inc.

Chapter 238

TIMING AND TECHNIQUE OF CRANIOPLASTY

Gabriel F. Santiago[1,2], MD, Judy Huang[2], MD and Chad R. Gordon[1,2,*], DO

[1]Department of Plastic and Reconstructive Surgery,
Johns Hopkins University School of Medicine,
Baltimore, MD, US
[2]Johns Hopkins Multidisciplinary Adult Cranioplasty Center (MACC),
Department of Neurosurgery,
Johns Hopkins University School of Medicine,
Baltimore, MD, US

ABSTRACT

Cranial defects requiring cranioplasty reconstruction can result from a variety of etiologies that require neurosurgical intervention for intracranial pathology. The goals of craniofacial reconstruction are to restore skull continuity for cerebral protection, restore craniofacial contour and symmetry, and reverse associated neurological deficits. Techniques and timing of cranioplasty reconstruction to optimize outcomes are presented and how to address accompanying bone flap defects is discussed.

Keywords: traumatic brain injury, decompressive craniectomy, cranioplasty

INTRODUCTION

Cranial defects requiring cranioplasty reconstruction can result from a variety of etiologies that require neurosurgical intervention for intracranial pathology. These include decompressive craniectomy to control acutely elevated intracranial pressure from intractable cerebral edema caused by ischemic stroke or cerebrovascular accident, traumatic brain injury, and aneurysmal subarachnoid hemorrhage. Other indications include bone flap infections and

* Corresponding Author's Email: cgordon@jhmi.edu.

resorption, and tumor involvement of the calvarium [1, 2]. Options for cranial reconstruction include autogenous bone flap replacement and/or bone allograft, bridging with titanium mesh, and other customized implants made of various synthetic biomaterials. In cases of craniectomy performed for cranial tumors, postoperative radiation and susceptibility to infection from immunosuppression may result in permanent bone flap removal and loss [1]. The principal goals of craniofacial reconstruction are to protect the underlying brain, restore symmetrical craniofacial contour, and prevent neurological dysfunction associated with the absence of bone flaps, such as "sinking skin flap syndrome" or "syndrome of the trephined". The headaches and neurological deficits associated with Syndrome of the Trephined are postulated to result from four mechanisms: craniocaudal cerebrospinal fluid (CSF) flow inhibition, venous congestion, atmospheric pressure effects, and alterations in various cellular mechanisms [3]. Therefore, post-craniectomy CSF circulation abnormalities may be symptomatic, as described below [1-9].

TIMING OF CRANIOPLASTY

The timing of cranioplasty largely depends on the factors that led to initial craniectomy. The reasons for craniectomy can be classified into four categories:

1. Craniectomy required for the purposes of increasing the available space for brain expansion, e.g., following trauma or cerebrovascular accident.
2. Craniectomy required as a result of neurosurgical intervention to address brain or skull pathology.
3. Craniectomy required as a result of infection, including bone flap osteomyelitis.
4. Craniectomy required due to resorption of a patient's native bone flap without evidence of infection or bone flap osteomyelitis.

In cases of trauma, decisions regarding the timing of cranioplasty should be guided by the amount of residual brain edema as determined by both clinical and radiographic examinations [10, 11].

With respect to "early" versus "late" cranioplasty, several studies have described the risks and benefits of each approach [12-15]. In cases of patients undergoing craniectomy for reasons other than surgical site infection, multiple studies have found that "early" cranioplasty (in some cases during the same admission) has several beneficial effects. Among these are provision of brain protection, improved vascular and CSF circulation, improved appearance, and the potential avoidance and/or reversal of complications such as Syndrome of the Trephined, which is marked by a significant deterioration of neurologic function after craniectomy that subsequently improves following cranioplasty [3, 12-16].

In a 10-year retrospective study of 157 patients comparing early (<12 weeks) versus late (>12 weeks) cranioplasty in the setting of trauma, the infection rate was lower (7.7% vs. 14%, respectively) in the early cranioplasty cohort. Bone graft resorption was also lower in the early cranioplasty cohort (15% early vs. 19% late), while complications such as hydrocephalus (7.7% early vs. 1.3% late) and postoperative hematoma (3.9% early vs. 1.3% late) were higher in the early group [14].

These differences, however, were not found to be statistically significant, and an overall complication rate of 35% was found in both early and late cranioplasty cohorts [14].

In another study comparing early versus late cranioplasty in the setting of craniectomy following hemorrhagic stroke, the overall complication rate was higher in the early cohort (22% vs. 16%), but this difference was not statistically significant (P = 0.5541) [15]. The early cohort in this study had a higher, but not statistically significant, rate of postoperative infection.

For cranioplasty performed in the setting of prior infection, the timing of reconstruction should be delayed until a full course of the appropriate, culture-directed intravenous antibiotics has been completed and all clinical signs of infection have resolved.

Typically, a waiting period of 3 to 12 months has been advocated before attempting cranioplasty in the setting of prior infection or bone flap osteomyelitis, depending on the isolated bacteria and/or fungus [17, 18]. A retrospective study by Lopez et al. looking at time-interval reduction for delayed implant-based cranioplasty found that the overall infection rate (4%) was similar in the early (< 90 – 179 days) and late (> 180 days) cranioplasty groups; with only one infection occurring in the late cranioplasty group out of a total cohort of 25 patients [17]. It is important to note, however, that microbial profiles, treatment, and resistance patterns may be hospital specific, and certain infections may require a longer (6 to 12 months) waiting period before implant-based cranioplasty is safely attempted.

Overall, early cranioplasty seems to have several benefits with little or no increase in complications according to published data [3, 14-16, 19]. For this reason, we concur that cranioplasty should be performed as early as possible once brain edema has resolved and it is safe to proceed, for the benefits described above. Furthermore, timely cranioplasty serves to avoid the contracted sunken scalp that may be problematic from a reconstructive standpoint in the event of delay.

However, the newly developed "pericranial-onlay technique," as described by our group, mitigates this problem by providing additional scalp laxity and multilayer component release [20, 21].

CRANIOPLASTY TECHNIQUE

The initial approach to cranial reconstruction starts with a physical examination. It is important to thoroughly assess for scalp irregularities, open wounds with scabs, areas of alopecia, and previous surgical incisions. Fine-cut computed tomography (CT) of the cranial defect is necessary to assess the underlying skull defect **(**Figure 1**)** and potential for co-existing soft tissue atrophy [22]. If the patient's own bone is unsuitable for use because of a history of infection, damage secondary to trauma or tumor, resorption, or a long time-lag between craniotomy and cranioplasty, a computer-designed customized cranial implant can be made of either poly-methylmethacrylate, porous polyethylene, or polyether ether ketone, the common materials of choice.

By utilizing 3-D printing technology and a revised algorithm described by Zhong et al. [22], the implants can be fashioned to match the exact dimensions of the pre-operative skeletal defect, as well as the accompanying temporal soft tissue atrophy including muscle

and/or fat. The next step would be to call on a vendor who can reliably design and fabricate a customized cranial implant using CAD/CAM technology [1].

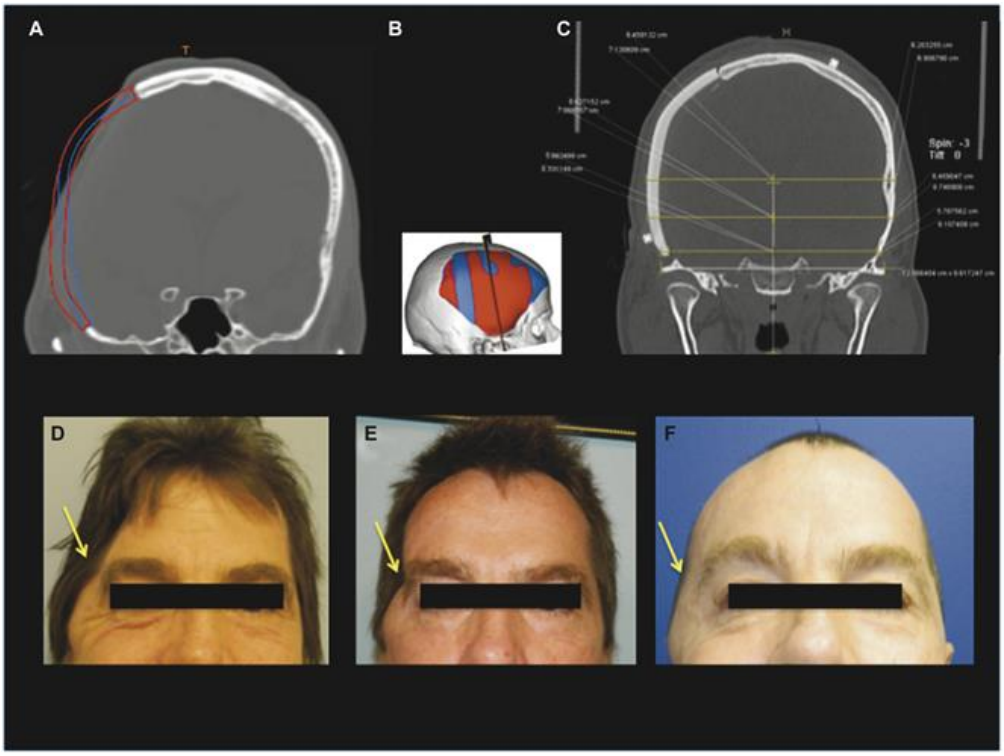

Source: Quantitative Analysis of Dual-Purpose, Patient-Specific Craniofacial Implants for Correction of Temporal Deformity. Used with permission from Oper Neurosurg (Hagerstown). 2015;11(2):205-212. doi:10.1227/NEU.0000000000000679. Oper. Neurosurg. (Hagerstown) | Copyright © 2015 by the Congress of Neurological Surgeons.

Figure 1. A, preoperative CT analysis in red for modified implant shape vs blue outline replicating CCI designed to match the skull. B, virtual 3-D modeling with 2 overlapping designs. C, postoperative CT 2-D analysis showing modified implant in correct position. D, preoperative photograph right pterional craniectomy defect (arrow). E, 3 months after standard CCI cranioplasty showing severe persistent temporal hollowing (arrow). F, 3 months after modified CCI cranioplasty showing ideal cranial contour without temporal deformity (arrow). CCI, customized craniofacial implant.

In addition to providing the missing skull component, compensating for the amount of soft tissue loss in the temporal region is crucial, as cranial implants designed without accounting for temporalis muscle and fat pad atrophy will result in an obvious visual deformity known as “temporal hollowing” or “temporal wasting” [22]. In fact, some authors have reported an incidence of post-neurosurgical temporal hollowing that approaches 50% [23]. The visible asymmetry caused by temporal hollowing is commonly noticed by patients following craniotomy [22].

Obtaining a history of prior infection, radiation, or multiple surgeries should be performed as this can affect the quality of soft tissue coverage of the skull, and may require additional surgical planning with regard to implementation of component separation and/or rotational flap(s) to ensure a tension-free scalp closure with healthy tissue over the planned

reconstruction [21]. Tension-free closure is essential to a durable closure. The physical exam should also assess the quality of the scalp and nearby tissue, and try to determine whether there are any open wounds or scalp defects that may require scalp debridement and/or replacement, with delayed cranioplasty reconstruction to follow.

Preparation of the Surgical Site

Given the high morbidity associated with surgical site infections of the scalp and cranium, it is the practice of the senior author (C.G.) to be present for, and to directly participate in, surgical site sterilization and draping. While these tasks could be delegated to operating room staff or surgical trainees, techniques and consistency with respect to the task of surgical site sterilization may vary greatly, and thus it is in the surgeon's best interest to ensure that this crucial step of the procedure is performed judiciously.

Before surgery, the patient is informed that the majority, if not all, of the hair may require shaving in order to precisely determine the exact location of prior incisions. After shaving, the scalp is scrubbed with iodine solution. This is followed by a wet iodine-based surgical prep; and after demarcation of the surgical site with sterile towels, one last surgical site preparation is performed.

After preparation, all prior incisions are marked with a surgical marker and the bony defect is demarcated using hash marks (Figure 2). A 50:50 mixture of 1% lidocaine with epinephrine and sterile saline is injected into the scalp outside the confines of the cranial defect with care taken to inject away from the cranial defect and underlying brain.

Source: Multidisciplinary Approach for Improved Outcomes in Secondary Cranial Reconstruction: Introducing the Pericranial-Onlay Cranioplasty TechniqueUsed with permission from Oper. Neurosurg. (Hagerstown). 2014;10(0 2):179-190. doi:10.1227/NEU.0000000000000296. Oper. Neurosurg. (Hagerstown) | Copyright © 2014 by the Congress of Neurological Surgeons.

Figure 2. Skin markings used to denote the previous neurosurgical incision (solid line) and the large calvarial defect (dotted line) after infected bone flap removal.

Once the local anesthetic has had a chance to take effect, a #15 blade is used to make a partial thickness incision, just deep to the dermis and bulbs of the hair follicles, along the patient's prior incision. Needlepoint cautery is then used to complete the incision. Wide undermining of the entire scalp is then performed with a periosteal elevator to ensure scalp mobility and a tension-free closure. Once the incision has been opened and the scalp fully mobilized over the skull, the scalp overlying the brain is carefully dissected in a subgaleal plane with care to leave the pericranial tissue on the brain (avoiding the epidural plane) dura, as we previously described elsewhere [20]. When performing this step, it is important to remain in the proper dissection plane to avoid durotomy and brain injury by deviating too deeply and/or to compromise scalp perfusion by dissecting too superficially into the scalp's subdermal plexus.

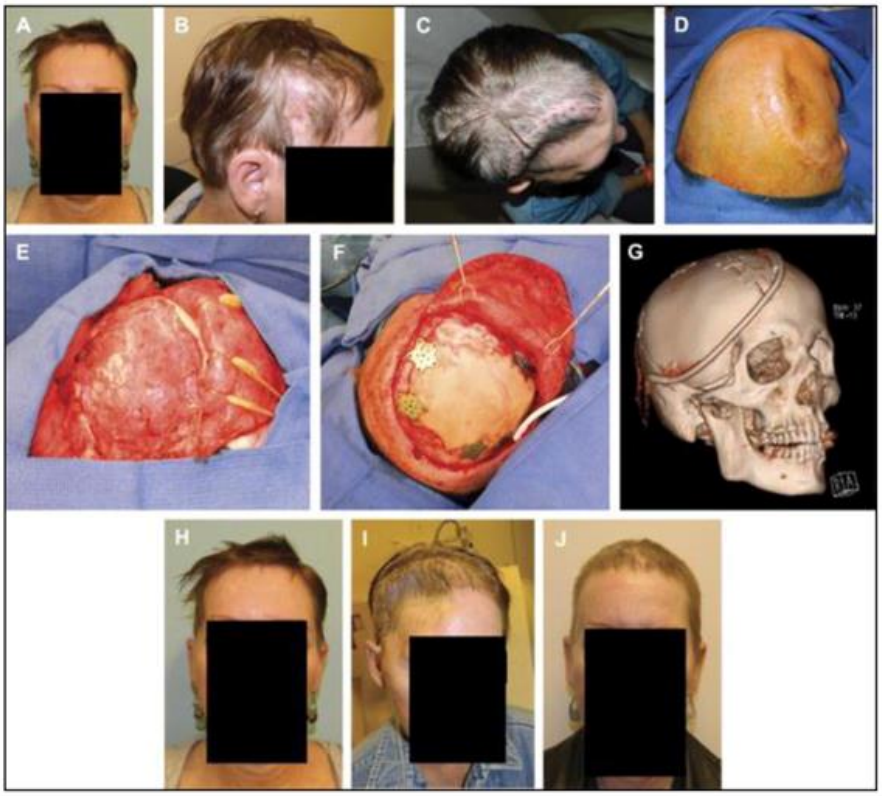

Source: Multidisciplinary Approach for Improved Outcomes in Secondary Cranial Reconstruction: Introducing the Pericranial-Onlay Cranioplasty Technique. Used with permission from Oper. Neurosurg. (Hagerstown). 2014;10(0 2):179-190. doi:10.1227/NEU.0000000000000296. Oper. Neurosurg. (Hagerstown) | Copyright © 2014 by the Congress of Neurological Surgeons.

Figure 3. Frontal view (A) and right profile view (B) of the original presentation with bone flap osteomyelitis. Aerial view (C) of the patient two weeks after removal of infected bone flap. Cephalad (D) on-table view before secondary cranial reconstruction 4 months after the bone flap removal. Photograph of vascularized pericranial-onlay dissection covering the dura (E) before insetting of the custom cranial implant with plates and screws (F). Postoperative 3-dimensional computed tomographic scan demonstrating the relative size of the implant, drain placement, and large amount of accompanying soft tissue reconstruction required with temporalis reinsertion (G). Frontal view photographs at the time of bone flap infection (H), at 3 months after bone flap removal (I), and at 6 months after reconstruction demonstrating acceptable contour and temporal symmetry (J).

These techniques should produce very little blood loss, and transfusions are almost never required for extradural cranial reconstruction.

Implant Placement

After the scalp has been elevated over the brain, the borders of the cranial defect are more clearly defined by removing scar tissue from the edges with electrocautery and periosteal elevators. The customized cranial implant is then checked to ensure proper fit, and it is customized on a side table if necessary prior to rigid fixation. Once the fit has been refined, the implant is fixed in place with titanium hardware (Figure 3). Suction drains are then placed and the scalp is closed in three layers with the galeal and subcutaneous layers closed with 3-0 absorbable suture, and the skin closed in interrupted fashion with nylon suture. A head wrap is then placed and remains in place for 2 to 3 days. Suction drains are monitored for output and removed at an appropriate time. A CT of the head and face is obtained the night of surgery to assess for significant brain edema, hematoma, or pneumocephalus since rare cases of "malignant cerebral edema" following cranioplasty have been reported [10, 11].

POSTOPERATIVE CARE

Following cranioplasty, admission to the intensive care unit is often unnecessary if the dura has not been violated, although this decision can vary greatly by institution based on the familiarity of the nursing staff with the care of cranioplasty patients. Patients typically are discharged on postoperative day 3 and return for suture removal after 3 to 4 weeks to allow time for healing of the thick scalp tissue. Sutures may remain in longer if the patient has other factors that could impair wound healing such as multiple prior surgeries, systemic illness, or history of radiation.

REFERENCES

[1] Huang, G. J., Zhong, S., Susarla, S. M., Swanson, E. W., Huang, J., Gordon, C. R. Craniofacial reconstruction with poly(methyl methacrylate) customized cranial implants. *The Journal of craniofacial surgery*, 2015; 26(1):64-70.

[2] Klinger, D. R., Madden, C., Beshay, J., White, J., Gambrell, K., Rickert, K. Autologous and acrylic cranioplasty: a review of 10 years and 258 cases. *World neurosurgery*, 2014; 82(3-4):e525-30.

[3] Ashayeri, K., E, M. J., Huang, J., Brem, H., C, R. G. Syndrome of the Trephined: A Systematic Review. *Neurosurgery*, 2016; 79(4):525-34.

[4] Dujovny, M., Aviles, A., Agner, C., Fernandez, P., Charbel, F. T. Cranioplasty: cosmetic or therapeutic? *Surgical neurology*, 1997; 47(3):238-41.

[5] Isago, T., Nozaki, M., Kikuchi, Y., Honda, T., Nakazawa, H. Sinking skin flap syndrome: a case of improved cerebral blood flow after cranioplasty. *Annals of plastic surgery*, 2004; 53(3):288-92.

[6] Krause-Titz, U. R., Warneke, N., Freitag-Wolf, S., Barth, H., Mehdorn, H. M. Factors influencing the outcome (GOS) in reconstructive cranioplasty. *Neurosurgical review*, 2016; 39(1):133-9.

[7] Kuo, J. R., Wang, C. C., Chio, C. C., Cheng, T. J. Neurological improvement after cranioplasty - analysis by transcranial doppler ultrasonography. *Journal of clinical neuroscience: official journal of the Neurosurgical Society of Australasia*, 2004; 11(5):486-9.

[8] Sanan, A., Haines, S. J. Repairing holes in the head: a history of cranioplasty. *Neurosurgery*, 1997; 40(3):588-603.

[9] Segal, D. H., Oppenheim, J. S., Murovic, J. A. Neurological recovery after cranioplasty. *Neurosurgery*, 1994; 34(4):729-31; discussion 31.

[10] Honeybul, S., Damodaran, O., Lind, C. R., Lee, G. Malignant cerebral swelling following cranioplasty. *Journal of clinical neuroscience: official journal of the Neurosurgical Society of Australasia*, 2016; 29:3-6.

[11] Hassaneen, W., Germanwala, A., Tsimpas, A. Malignant cerebral edema following cranioplasty. *Journal of clinical neuroscience: official journal of the Neurosurgical Society of Australasia*, 2016; 25:130-2.

[12] Chun, H. J., Yi, H. J. Efficacy and safety of early cranioplasty, at least within 1 month. *The Journal of craniofacial surgery*, 2011; 22(1):203-7.

[13] Schuss, P., Vatter, H., Marquardt, G., Imohl, L., Ulrich, C. T., Seifert, V., et al. Cranioplasty after decompressive craniectomy: the effect of timing on postoperative complications. *Journal of neurotrauma*, 2012; 29(6):1090-5.

[14] Piedra, M. P., Nemecek, A. N., Ragel, B. T. Timing of cranioplasty after decompressive craniectomy for trauma. *Surgical neurology international*, 2014; 5:25.

[15] Piedra, M. P., Ragel, B. T., Dogan, A., Coppa, N. D., Delashaw, J. B. Timing of cranioplasty after decompressive craniectomy for ischemic or hemorrhagic stroke. *Journal of neurosurgery*, 2013; 118(1):109-14.

[16] Quah, B. L., Low, H. L., Wilson, M. H., Bimpis, A., Nga, V. D., Lwin, S., et al. Is There An Optimal Time for Performing Cranioplasties? Results from a Prospective Multinational Study. *World neurosurgery*, 2016; 94:13-7.

[17] Lopez, J., Zhong, S. S., Sankey, E. W., Swanson, E. W., Susarla, H., Jusue-Torres, I., et al. Time Interval Reduction for Delayed Implant-Based Cranioplasty Reconstruction in the Setting of Previous Bone Flap Osteomyelitis. *Plastic and reconstructive surgery*, 2016; 137(2):394e-404e.

[18] Chiang, H. Y., Kamath, A. S., Pottinger, J. M., Greenlee, J. D., Howard, M. A., 3rd, Cavanaugh, J. E., et al. Risk factors and outcomes associated with surgical site infections after craniotomy or craniectomy. *Journal of neurosurgery*, 2014; 120 (2):509-21.

[19] Schuss, P., Vatter, H., Oszvald, A., Marquardt, G., Imohl, L., Seifert, V., et al. Bone flap resorption: risk factors for the development of a long-term complication following cranioplasty after decompressive craniectomy. *Journal of neurotrauma*, 2013; 30(2):91-5.

[20] Gordon, C. R., Fisher, M., Liauw, J., Lina, I., Puvanesarajah, V., Susarla, S., et al. Multidisciplinary approach for improved outcomes in secondary cranial reconstruction: introducing the pericranial-onlay cranioplasty technique. *Neurosurgery*, 2014; 10 Suppl 2:179-89; discussion 89-90.

[21] Ibrahim, Z., Santiago, G. F., Huang, J., Manson, P. N., Gordon, C. R. Algorithmic Approach to Overcome Scalp Deficiency in the Setting of Secondary Cranial Reconstruction. *The Journal of craniofacial surgery*, 2016; 27(1):229-33.

[22] Zhong, S., Huang, G. J., Susarla, S. M., Swanson, E. W., Huang, J., Gordon, C. R. Quantitative analysis of dual-purpose, patient-specific craniofacial implants for correction of temporal deformity. *Neurosurgery,* 2015; 11 Suppl. 2:220-9; discussion 9.

[23] Wachter, D., Reineke, K., Behm, T., Rohde, V. Cranioplasty after decompressive hemicraniectomy: underestimated surgery-associated complications? *Clinical neurology and neurosurgery*, 2013; 115(8):1293-7.

In: Encyclopedia of Surgery (22 Volume Set)
Editors: Andreas Lehrer and Kristin Mueller
ISBN: 978-1-53618-329-0
© 2020 Nova Science Publishers, Inc.

Chapter 239

COMPLICATIONS OF DECOMPRESSIVE CRANIECTOMY

M. J. Kole[1], D. S. Hersh[1] and G. Schwartzbauer[1,2,*]
[1]Department of Neurosurgery,
[2]R Adams Cowley Shock Trauma Center,
University of Maryland Medical Center, Baltimore, MD, US

ABSTRACT

Decompressive craniectomy (DC) can be a life-preserving procedure, but it is not without risk. Some complications develop during the immediate postoperative period, while others characteristically occur remote from surgery. Overall, complications of the initial craniectomy, as well as the cranioplasty that routinely follows, occur in approximately 20% of patients undergoing DC [1]. This chapter provides a synopsis of the common complications that follow DC, as well as the expected incidence, time course, and possible interventions.

Keywords: complication, decompressive craniectomy, traumatic brain injury, hygroma, resorption

INTRODUCTION

Decompressive craniectomy (DC), as described in other chapters of this volume, can be performed for a variety of indications including brain swelling resulting from traumatic brain injury (TBI), malignant cerebral infarction, and infection. DC remains the most effective, albeit drastic, means of reducing intracranial pressure (ICP) and alleviating midline shift [2], but depending on the patient, it may precipitate unique perioperative complications, including expansion of existing hemorrhage(s), severe alteration in cerebrospinal fluid (CSF) dynamics, or infection [3-6]. Some of these occur almost immediately. The important potential

* Corresponding Author's Email: gschwartzbauer@som.umaryland.edu.

complication burden of DC should be kept in mind when discussing patient care with family members as well as other health care providers. In this chapter, we provide a description of the common complications following DC, with an emphasis on those that are relatively unique to this surgery and may require further surgical intervention.

MECHANICAL EFFECTS OF DC

A common complication of DC results from the mechanical effect of decompression on the brain itself. Following DC, the edematous brain often herniates through the craniectomy defect, leading to neuronal stretch injury as well as compression of cortical vessels, which in turn can produce a secondary ischemic insult [3, 7]. Performing a decompression that is at least 12-cm wide may limit this process, though it is still frequently observed [3]. Brain herniation through the craniectomy defect has been proposed as one of the explanations why a randomized trial of bifrontal DC failed to show benefit [8].

In a series of 108 patients who underwent DC for TBI, nearly 28% demonstrated brain herniation through the craniectomy site [6]. This process may play a major role in the mixed outcomes that follow DC, as the ipsilateral hemisphere may experience up to 120% strain, with the brain tissue stretched by a factor of 2.2 times its resting length [7]. Interestingly, the contralateral hemisphere also shows evidence of significant strain. Rapid stretching of neurons to a strain of even 10% has been shown to induce neuronal damage, though the effects on individual neurons in the setting of DC remain unclear. A large part of this herniation event is thought to be driven by edema, and both clinical and preclinical studies suggest a large increase in brain water content at the DC site [7, 9]. Regional edema may be explained by the fact that microvascular dysregulation is present for several hours following a craniectomy. Cerebrovascular pressure reactivity (PRx), which is a correlation coefficient showing the relationship between ICP and mean arterial blood pressure (MAP), remains positive for hours postoperatively, reflecting impaired cerebral autoregulation and resulting in hyperemia and increased swelling [10, 11].

HEMORRHAGE

Blood products are toxic to brain tissue [12]. Unfortunately, intracerebral hemorrhage, including progressive secondary hemorrhage, may occur following DC. The mechanisms that underlie this phenomenon remain incompletely understood. Current management is preventive and consists of correcting coagulopathy and controlling blood pressure. Physicians must be aware of the potential for this complication, as intracerebral hemorrhage may bring about a return to the operating room for evacuation, particularly if the lesion compresses the basal cisterns or causes significant midline shift [3].

DEVELOPMENT OF IPSILATERAL OR CONTRALATERAL HEMORRHAGE

One of the most common complications following DC involves hemorrhage that is either ipsilateral to the DC or alternatively in a remote or contralateral location. Kurland et al., found that over 10% of patients who undergo DC develop new ipsilateral blood in some form, whether it is epidural, subdural, or intracerebral [1]. TBI patients have the highest likelihood of ipsilateral hemorrhage following DC, perhaps indicating underlying trauma-related coagulopathies, disrupted vessels, or contusion expansion. Thus once the swollen brain has been decompressed, meticulous attention to wound hemostasis is essential. These bleeds can result in a high rate of immediate reoperation [13].

Contralateral or remote hemorrhage (Figure 1) following DC remains one of the most vexing problems facing the surgeon and patient. The majority of these tend to occur in TBI patients, and are thought to reflect the release of a tamponade effect on injured vessels that may not be apparent on initial imaging. This mechanism results in an early rebleed pattern, and warrants close-interval radiographic follow-up after DC [1, 3].

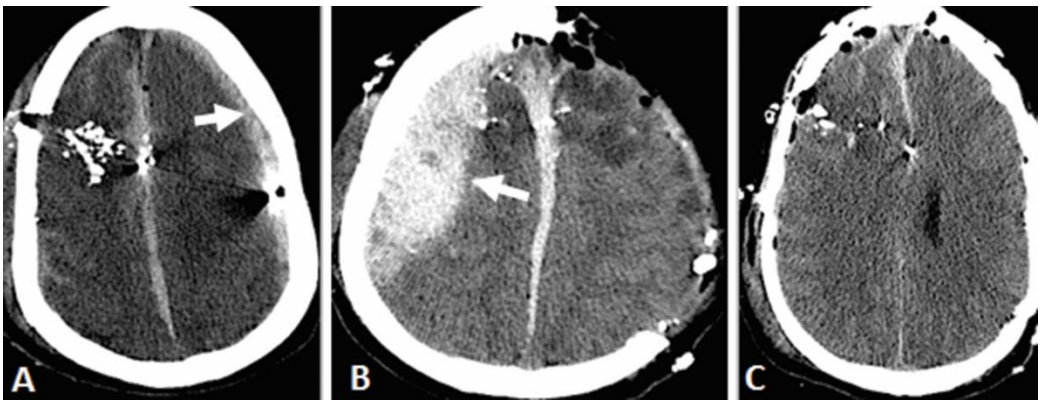

Figure 1. A 29-year-old victim of civilian gunshot wound to the head was admitted to the Trauma Resuscitation Unit stuporous, a GCS motor score of 4 and reactive pupils. CT scan of head (plate A) revealed a perforating injury of right frontal bone and evidence of left sided subdural hematoma. The patient had an urgent DC following evacuation of the SDH. Postoperative CT scan (plate B) revealed a large epidural hematoma which was evacuated in association with debridement of the entrance wound. The patient remained moderately disabled. Plate C indicates cranioplasty 3 months following original DC (Courtesy of G Schwartzbauer, University of Maryland).

DC is also associated with the risk of progressive enlargement of hemorrhagic cerebral contusions, a process commonly referred to as progressive secondary hemorrhage or hemorrhagic progression of a contusion (HPC) [14]. This finding occurs in 13% of patients undergoing decompression [1]. While there are proposed molecular mechanisms that contribute to delayed HPC [15], it is thought that immediate HPC in the setting of DC, especially of large lesions, results from the removal of the tamponade force supplied by the skull. The resulting decrease in tissue pressure is hypothesized to allow for expansion of the volume of hemorrhage. Notably, while TBI patients on anticoagulants or antiplatelet agents requiring DC may be at increased risk of HPC, not all of these patients progress, and in some

studies no association has been shown [14]. Thus, often delayed contusion expansion may be the result of an orchestrated breakdown of vessels within the sphere of traumatic injury, and not simply leakage resulting from primary vascular rents. One promising molecular mechanism involves the activation of the Sur1-Trpm4 ion channel that leads to capillary fragmentation over several hours (see Chapter 1 by Simard and colleagues, for example).

HEMORRHAGIC TRANSFORMATION OF AN ISCHEMIC STROKE

Following DC for malignant MCA infarction, some patients experience hemorrhage into the ischemic stroke bed. Based on a recent review of the literature, the incidence appears to be approximately 24% [1]. The high rate of hemorrhagic transformation in DC patients likely reflects the known association between infarct size and hemorrhagic transformation [16], and a prospective study of 1125 consecutive ischemic stroke patients found an approximately 9% rate of transformation [17]. The clinical significance of hemorrhagic transformation remains controversial, potentially because of inter-study variability in the definition of hemorrhagic transformation [18]. Regardless, increased vigilance for postoperative hemorrhagic transformation should be maintained.

HYGROMA

Approximately 1 week after DC, some patients begin to develop subdural hygromas [19]. Subdural hygromas may form in as many as 30% to 50% of patients undergoing DC for severe TBI [19, 20]. In nearly 90% of cases, hygromas form on the side that is ipsilateral to the craniectomy (Figure 2); however, contralateral hygromas are also observed in a minority of patients [19]. The underlying mechanism of hygroma formation remains under investigation, but hygromas may result from aberrations in CSF flow that result from either the initial injury, the craniectomy, or both. The incidence of subdural hygroma formation peaks at 3 to 4 weeks, and then begins to decline, with ultimate resolution by 4 to 5 months postoperatively [19]. Aarabi et al., (2009) found that approximately 10% of patients with hygromas required a surgical intervention in the form of drainage. Therefore, close observation is warranted, though the vast majority of hygromas are benign collections that are self-limited.

Hygromas have also been documented in the setting of DC for stroke, occurring in approximately 12% of patients [1], though some studies report significantly higher numbers [21]. In one series, these collections were noted within 3 to 5 days following surgery, and disappeared within approximately 8 weeks. None of the patients in this series required surgical intervention for drainage of these collections [22]. However, the time course of subdural hygroma formation and resolution is not as thoroughly characterized in the stroke literature as in the trauma literature.

While most hygromas are benign, conversion to a subdural hematoma has been documented in some cases, which can require surgical intervention [19]. Thus, interval imaging should be obtained to verify resolution of the hygroma.

HYDROCEPHALUS

Patients commonly experience aberrant flow of CSF following DC, resulting in hydrocephalus in some. The incidence appears to be 15% of patients undergoing decompression for TBI and 26% of patients undergoing decompression for ischemic stroke [1]. These numbers are difficult to interpret, however, as authors do not always use consistent criteria to define hydrocephalus. In the case of decompression for stroke, in particular, post-decompressive hydrocephalus remains controversial. Many published series are plagued by small case numbers, making it difficult to draw generalizable conclusions [23, 24]. Compounding this difficulty, many authors often use only radiographic criteria, such as progressive enlargement of the ventricles and effacement of CSF spaces on head computed tomography, to diagnose hydrocephalus, particularly in patients who are neurologically devastated [24-26].

Opinion varies regarding the root cause of this complication. Some investigators have found that more severe brain injuries are associated with an increased risk of hydrocephalus [26]. Others have noted that the development of subdural hygromas in the postoperative period may predict the development of hydrocephalus [26, 27]. Still others have found that large bone flap margins that closely approximate the midline of the cranial vault also raise the risk of hydrocephalus [25, 27, 28].

Of note, ventriculomegaly secondary to cerebral atrophy (also known as hydrocephalus ex vacuo) is common in both trauma and stroke and likely results from the loss of neuronal substrate that follows both pathologies. This may result in enlargement of the lateral ventricle ipsilateral to the injury, with contralateral, third and fourth ventricles that are normal in size [24]. Hydrocephalus ex vacuo does not benefit from surgical intervention. In contrast, true hydrocephalus is both a radiographic and a clinical diagnosis, one component of which is ventriculomegaly. The diagnosis, however, should also include some constellation of progressive enlargement of the ventricular system, neurological decline/arrest of improvement, documentation of an elevated opening pressure by lumbar puncture, and improvement in neurological function following removal/diversion of CSF.

In patients requiring a cranioplasty and permanent CSF diversion (e.g., via a ventriculoperitoneal shunt), our own institutional practice is to perform the cranioplasty first. A ventricular tap may be performed intraoperatively as needed to replace the bone flap. We feel that placing a shunt at the time of the cranioplasty encourages the formation of a potential space between the bone and dura which could fill with blood or fluid. Allowing permissive hydrocephalus in the immediate postoperative period seems to alleviate this problem. Patients are then monitored closely for ventricular enlargement prior to discharge, and again at a follow-up appointment 2 to 6 weeks after the cranioplasty. As above, ventricular enlargement, particularly in the presence of neurological decline, is regarded as an indication for placement of a shunt. Staging these procedures has resulted in decreased rates of complications [29].

SYNDROME OF THE TREPHINED

The syndrome of the trephined was first described in 1939 by Grant and Norcross in their publication regarding the history and indications for cranioplasty [30]. The symptoms they

cited included headache, dizziness, fatigue, discomfort at the craniectomy site, general feelings of anxiety, depression, and "intolerance to vibration." Other authors have added to the list of symptoms, which has become so extensive that some have argued that the syndrome should encompass any neurological symptom that improves rapidly following cranioplasty [31].

Syndrome of the trephined can be most consisely defined as the symptomatic deformation of brain tissue owing to its exposure to atmospheric pressure. Symptoms are most commonly present when the patient is in the upright position and are alleviated when the patient is supine or in a Trendelenberg position. The sunken flap overlying the cortex can compress the brain tissue and cause neurological deficits [32, 33] due to either direct compression or a decrease in cerebral blood flow secondary to compression [34]. Additionally, ICP may be paradoxically elevated in the upright position. In patients with an intact skull, the ICP should decrease when they are sitting upright; in patients with a craniectomy, the ICP will equalize with atmospheric pressure, thus producing an increase in ICP in the upright position [31]. Treatment of syndrome of the trephined involves replacement of the bone flap.

BONE FLAP RESORPTION

Most patients undergoing DC are expected eventually to undergo cranioplasty. This is commonly performed with autologous bone, which can be stored in the patient's abdomen or in a freezer, depending on the institutional practice where the index procedure was performed. While not strictly a complication of DC itself, bone flap resorption is common and costly, and results in repeat presentations following decompression.

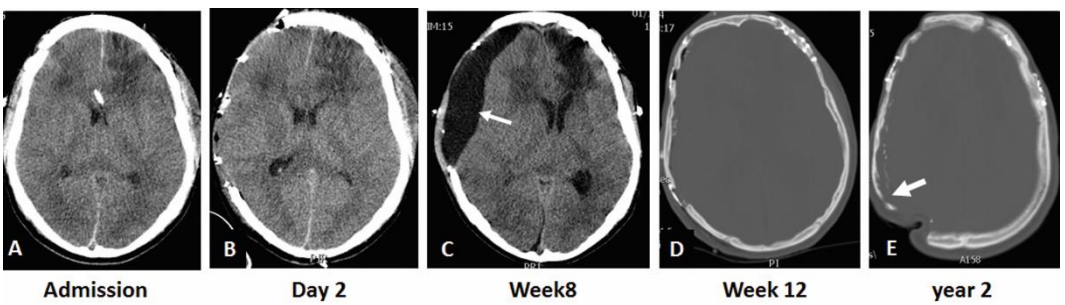

Figure 2. 21-m was admitted to the STC following MVC with a GCS of 7, abnormal pupillary response on the right side and a CT scan of head which was compatible with diffuse injury III (plate A). Medical management for control of ICPs failed 2 days later, therefore he had decompressive craniectomy (plate B). Eight weeks following craniectomy he manifested a large right sided subdural hygroma which was treated conservatively (plate C). Twelve weeks following trauma he had cranioplasty (plate D) and new CT scan bone windows two years following cranioplasty (plate E) shows extensive resorption of right parietal bone. The patient's clinical outcome was severe disability. The patient was able to follow simple commands. (From Aarabi et al, Unpublished data). (Courtesy of G Schwartzbauer, University of Maryland).

Bone resorption following cranioplasty occurs in approximately 16% of cases [1] (Figure 2). Resorption appears to be more common in younger patients [35-37]. The need for shunt placement secondary to hydrocephalus and fragmentation of the bone flap into multiple pieces have also been identified as risk factors for bone resorption [36, 37]. Some authors have gone so far as to suggest that artificial graft material should be used for all patients under 30 years old, as well as older patients with compound fractures and/or hydrocephalus [37].

Several synthetic materials are available as an alternative source for cranioplasty, with options including polymethylmethacrylate (PMMA), polyethyl-ethyl-ketone (PEEK), and titanium. These materials have inherent advantages and disadvantages, which are beyond the scope of this chapter. Often, the material used is based on surgeon familiarity and preference. Future directions of research in this field will likely include a cost analysis of proceeding directly to synthetic implantation in patients at high risk for resorption.

CSF LEAKAGE, WOUND HEALING, INFECTION

A variety of complications that are noted following cranial procedures in general are of particular concern following DC. Leakage of CSF can lead to meningitis and may require CSF diversion in order to facilitate wound healing [1, 38, 39]. In addition, wound healing itself is a common complication of DC. This likely results from the use of a relatively large scalp flap in the presence of a relatively small vascular pedicle. Furthermore, the superficial temporal artery is often ligated during surgical exposure, further compromising the blood supply to the scalp flap [40].

While superficial infections, i.e., those involving the skin superficial to the galea, can often be treated with local wound care with or without a short course of antibiotics, infections involving the intracranial compartment result in significantly more morbidity. Deep infections reportedly occur in 2% to 6% of cases, depending on the indication for decompression [1]. Deep infections typically require surgical intervention in order to obtain cultures, wash out the infectious material, and achieve local source control.

CONCLUSION

Were one to compare DC with any number of elective neurosurgical procedures, the complication profile would likely be deemed unacceptable. However, DC is often the final option for preserving life in patients with large hemorrhagic or ischemic strokes, or in those with severe TBI and refractory intracranial hypertension. For this reason, a risk/benefit analysis by the clinician will often favor performing surgery despite the significant complication profile. That said, patients' medical decision makers must be made to understand the complications of DC since their risk/benefit analysis may differ from the clinician's. In addition, research must continue into the pathophysiology of hemorrhagic transformation or expansion, CSF flow abnormalities, and bone flap resorption, as these can be particularly morbid and possibly require further surgical intervention. While promising

medical therapies are under investigation that may reduce the need for DC, surgery and its attendant complications will persist for the foreseeable future.

REFERENCES

[1] Kurland, D. B., Khaladj-Ghom, A., Stokum, J. A., Carusillo, B., Karimy, J. K., Gerzanich, V., et al. Complications Associated with Decompressive Craniectomy: A Systematic Review. *Neurocrit. Care*. 2015; 23(2):292-304.

[2] Aarabi, B., Hesdorffer, D. C., Ahn, E. S., Aresco, C., Scalea, T. M., Eisenberg, H. M. Outcome following decompressive craniectomy for malignant swelling due to severe head injury. *J. Neurosurg.* 2006; 104(4):469-79.

[3] Ban, S. P., Son, Y. J., Yang, H. J., Chung, Y. S., Lee, S. H., Han, D. H. Analysis of complications following decompressive craniectomy for traumatic brain injury. *J. Korean Neurosurg. Soc.* 2010; 48(3):244-50.

[4] De Bonis, P., Mangiola, A., Pompucci, A., Anile, C. Decompressive craniectomy and hydrocephalus. *Neurosurgery*. 2011; 68(6):E1777-8; author reply E8-9.

[5] Honeybul, S. Complications of decompressive craniectomy for head injury. *J. Clin. Neurosci.* 2010; 17(4):430-5.

[6] Yang, X. F., Wen, L., Shen, F., Li, G., Lou, R., Liu, W. G., et al. Surgical complications secondary to decompressive craniectomy in patients with a head injury: a series of 108 consecutive cases. *Acta Neurochir.* (Wien). 2008; 150(12):1241-7; discussion 8.

[7] von Holst, H., Li, X., Kleiven, S. Increased strain levels and water content in brain tissue after decompressive craniotomy. *Acta Neurochir.* (Wien). 2012; 154(9):1583-93.

[8] Cooper, D. J., Rosenfeld, J. V., Murray, L., Arabi, Y. M., Davies, A. R., D'Urso, P., et al. Decompressive craniectomy in diffuse traumatic brain injury. *N. Engl. J. Med.* 2011; 364(16):1493-502.

[9] Szczygielski, J., Mautes, A. E., Müller, A., Sippl, C., Glameanu, C., Schwerdtfeger, K., et al. Decompressive Craniectomy Increases Brain Lesion Volume and Exacerbates Functional Impairment in Closed Head Injury in Mice. *J. Neurotrauma.* 2016; 33(1):122-31.

[10] Timofeev, I., Czosnyka, M., Nortje, J., Smielewski, P., Kirkpatrick, P., Gupta, A., et al. Effect of decompressive craniectomy on intracranial pressure and cerebrospinal compensation following traumatic brain injury. *J. Neurosurg*. 2008; 108(1):66-73.

[11] Wang, E. C., Ang, B. T., Wong, J., Lim, J., Ng, I. Characterization of cerebrovascular reactivity after craniectomy for acute brain injury. *Br. J. Neurosurg.* 2006; 20(1):24-30.

[12] Aronowski, J., Zhao, X. Molecular pathophysiology of cerebral hemorrhage: secondary brain injury. *Stroke.* 2011; 42(6):1781-6.

[13] Qiu, W., Guo, C., Shen, H., Chen, K., Wen, L., Huang, H., et al. Effects of unilateral decompressive craniectomy on patients with unilateral acute post-traumatic brain swelling after severe traumatic brain injury. *Crit. Care*. 2009; 13(6):R185.

[14] Kurland, D., Hong, C., Aarabi, B., Gerzanich, V., Simard, J. M. Hemorrhagic progression of a contusion after traumatic brain injury: a review. *J. Neurotrauma.* 2012; 29(1):19-31.

[15] Simard, J. M., Kilbourne, M., Tsymbalyuk, O., Tosun, C., Caridi, J., Ivanova, S., et al. Key role of sulfonylurea receptor 1 in progressive secondary hemorrhage after brain contusion. *J. Neurotrauma.* 2009; 26(12):2257-67.

[16] Lodder, J. CT-detected hemorrhagic infarction; relation with the size of the infarct, and the presence of midline shift. *Acta Neurol. Scand.* 1984; 70(5):329-35.

[17] Paciaroni, M., Agnelli, G., Corea, F., Ageno, W., Alberti, A., Lanari, A., et al. Early hemorrhagic transformation of brain infarction: rate, predictive factors, and influence on clinical outcome: results of a prospective multicenter study. *Stroke.* 2008; 39(8):2249-56.

[18] Al-Jehani, H., Petrecca, K., Martel, P., Sinclair, D., Sirhan, D. Decompressive Craniectomy for Ischemic Stroke: Effect of Hemorrhagic Transformation on Outcome. *J. Stroke Cerebrovasc. Dis*. 2016; 25(9):2177-83.

[19] Aarabi, B., Chesler, D., Maulucci, C., Blacklock, T., Alexander, M. Dynamics of subdural hygroma following decompressive craniectomy: a comparative study. *Neurosurg. Focus*. 2009; 26(6):E8.

[20] Yuan, Q., Wu, X., Yu, J., Sun, Y., Li, Z., Du, Z., et al. Subdural hygroma following decompressive craniectomy or non-decompressive craniectomy in patients with traumatic brain injury: Clinical features and risk factors. *Brain Inj*. 2015; 29(7-8):971-80.

[21] Kenning, T. J., Gooch, M. R., Gandhi, R. H., Shaikh, M. P., Boulos, A. S., German, J. W. Cranial decompression for the treatment of malignant intracranial hypertension after ischemic cerebral infarction: decompressive craniectomy and hinge craniotomy. *J. Neurosurg*. 2012; 116(6):1289-98.

[22] Ropper, A. E., Nalbach, S. V., Lin, N., Dunn, I. F., Gormley, W. B. Resolution of extra-axial collections after decompressive craniectomy for ischemic stroke. *J. Clin. Neurosci.* 2012; 19(2):231-4.

[23] Santana-Cabrera, L., Pérez, J. O., Escot, C. R., Rodríguez, M. G. Hydrocephalus after decompressive craniectomy for malignant cerebral infarction. *Clin. Neurol. Neurosur*g. 2015; 133:104-5.

[24] Lee, M. H., Yang, J. T., Weng, H. H., Cheng, Y. K., Lin, M. H., Su, C. H., et al. Hydrocephalus following decompressive craniectomy for malignant middle cerebral artery infarction. *Clin. Neurol. Neurosurg.* 2012; 114(6):555-9.

[25] De Bonis, P., Pompucci, A., Mangiola, A., Rigante, L., Anile, C. Post-traumatic hydrocephalus after decompressive craniectomy: an underestimated risk factor. *J. Neurotrauma.* 2010; 27(11):1965-70.

[26] Honeybul, S., Ho, K. M. Incidence and risk factors for post-traumatic hydrocephalus following decompressive craniectomy for intractable intracranial hypertension and evacuation of mass lesions. *J. Neurotrauma.* 2012; 29(10):1872-8.

[27] De Bonis, P., Sturiale, C. L., Anile, C., Gaudino, S., Mangiola, A., Martucci, M., et al. Decompressive craniectomy, interhemispheric hygroma and hydrocephalus: a timeline of events? *Clin. Neurol. Neurosurg*. 2013; 115(8):1308-12.

[28] Fotakopoulos, G., Tsianaka, E., Siasios, G., Vagkopoulos, K., Fountas, K. Posttraumatic Hydrocephalus after Decompressive Craniectomy in 126 Patients with Severe Traumatic Brain Injury. *J. Neurol. Surg. A Cent. Eur. Neurosurg*. 2016; 77(2):88-92.

[29] Schuss, P., Borger, V., Güresir, Á., Vatter, H., Güresir, E. Cranioplasty and Ventriculoperitoneal Shunt Placement after Decompressive Craniectomy: Staged Surgery Is Associated with Fewer Postoperative Complications. *World Neurosurg.* 2015; 84(4):1051-4.

[30] Grant, F. C., Norcross, N. C. Repair of Cranial Defects by Cranioplasty. *Ann. Surg*. 1939; 110(4):488-512.

[31] Fodstad, H., Love, J. A., Ekstedt, J., Fridén, H., Liliequist, B. Effect of cranioplasty on cerebrospinal fluid hydrodynamics in patients with the syndrome of the trephined. *Acta Neurochir.* (Wien). 1984; 70(1-2):21-30.

[32] Nakamura, T., Takashima, T., Isobe, K., Yamaura, A. Rapid neurological alteration associated with concave deformity of the skin flap in a craniectomized patient. Case report. *Neurol. Med. Chir.* (Tokyo). 1980; 20(1):89-93.

[33] Yamaura, A., Makino, H. Neurological deficits in the presence of the sinking skin flap following decompressive craniectomy. *Neurol. Med. Chir*. (Tokyo). 1977; 17(1 Pt 1):43-53.

[34] Sakamoto, S., Eguchi, K., Kiura, Y., Arita, K., Kurisu, K. CT perfusion imaging in the syndrome of the sinking skin flap before and after cranioplasty. *Clin. Neurol. Neurosurg*. 2006; 108(6):583-5.

[35] Brommeland, T., Rydning, P. N., Pripp, A. H., Helseth, E. Cranioplasty complications and risk factors associated with bone flap resorption. *Scand. J. Trauma Resusc. Emerg. Med.* 2015; 23:75.

[36] Schuss, P., Vatter, H., Oszvald, A., Marquardt, G., Imöhl, L., Seifert, V., et al. Bone flap resorption: risk factors for the development of a long-term complication following cranioplasty after decompressive craniectomy. *J. Neurotrauma.* 2013; 30(2):91-5.

[37] Schwarz, F., Dünisch, P., Walter, J., Sakr, Y., Kalff, R., Ewald, C. Cranioplasty after decompressive craniectomy: is there a rationale for an initial artificial bone-substitute implant? A single-center experience after 631 procedures. *J. Neurosurg.* 2016; 124(3):710-5.

[38] Jiang, J. Y., Xu, W., Li, W. P., Xu, W. H., Zhang, J., Bao, Y. H., et al. Efficacy of standard trauma craniectomy for refractory intracranial hypertension with severe traumatic brain injury: a multicenter, prospective, randomized controlled study. *J. Neurotrauma.* 2005; 22(6):623-8.

[39] Polin, R. S., Shaffrey, M. E., Bogaev, C. A., Tisdale, N., Germanson, T., Bocchicchio, B., et al. Decompressive bifrontal craniectomy in the treatment of severe refractory posttraumatic cerebral edema. *Neurosurgery.* 1997; 41(1):84-92; discussion -4.

[40] Stiver, S. I. Complications of decompressive craniectomy for traumatic brain injury. *Neurosurg. Focus*. 2009; 26(6):E7.

In: Encyclopedia of Surgery (22 Volume Set)
Editors: Andreas Lehrer and Kristin Mueller
ISBN: 978-1-53618-329-0
© 2020 Nova Science Publishers, Inc.

Chapter 240

DECOMPRESSIVE CRANIECTOMY: PROGNOSIS AND COMMUNICATION WITH PATIENT FAMILIES

O. Ugochukwu[1], D. Stein[1,*] and S. Honeybul[2]
[1]Department of Surgery, University of Maryland, Baltimore, MD, US
[2]Department of Neurosurgery, Sir Charles Gairdner Hospital
and Royal Perth Hospital, Western Australia

ABSTRACT

The need to consider prognosis is important in all aspects of modern medicine, especially when there is a possibility that the eventual outcome may leave patients in a condition that they and their families may feel to be unacceptable. Decompressive craniectomy in the context of a neurological catastrophe represents a contemporary example of the clinical and ethical issues that can arise in these circumstances. Although surgical decompression can reduce mortality, it will not reverse the effects of the pathology that precipitated the neurological crisis, and the severity of the initial insult may be such that the most likely outcome is survival with severe disability. Since outcome prediction is necessarily limited, debate about the acceptability or otherwise of survival with severe disability is inevitable. However, discussions with family members cannot dichotomize outcome into life or death because to do so would fail to recognize that in certain circumstances the most likely outcome would be deemed unacceptable to the person on whom the procedure is being performed. The recently introduced ethical concepts of "substantive benefit" and the "risk of unacceptable badness" ("the RUB") may be useful when considering a patient-centered decision regarding realistic outcome expectations.

Keywords: craniectomy, neurosurgery, prognosis, Glasgow Outcome Score, communication

* Corresponding Author's Email: dstein@umm.edu.

INTRODUCTION

The need to consider prognosis is important in all aspects of modern medicine as progressively more complex decisions are required when considering increasingly sophisticated diagnostic and therapeutic interventions. However, despite these advances, there will always come a time when a disease has progressed to such an extent that either further therapy may be deemed overly burdensome or the eventual outcome may leave patients in a condition that they and their families may feel to be unacceptable. Decompressive craniectomy in the context of a neurological catastrophe such as severe traumatic brain injury (TBI) or malignant middle cerebral infarction represents a contemporary example of the clinical and ethical issues that can arise in these circumstances [1, 2]. Surgical intervention can undoubtedly reduce mortality, and numerous cohort studies have reported using the procedure, not only in the context of severe TBI [3-6] and stroke [7-10], but also, more recently, following subarachnoid hemorrhage [11, 12], intracerebral infection [13-15], venous sinus thrombosis [16, 17], and certain inflammatory conditions [18, 19]. However, evidence that functional outcome can be improved has been less forthcoming. This is probably because surgical intervention will not reverse the effects of the primary pathology that precipitated the neurological deterioration. For many years, the concern has been that any reduction in mortality will come as a result of an increase in the number of dependent survivors, some of whom may find this dependence to be an unacceptable outcome [20]. To address this issue, a number of randomized controlled trials were carried out in the past decade comparing surgical decompression with standard medical therapy, initially in the context of ischemic stroke [21-23] and more recently in the context of severe TBI [24, 25].

EVIDENCE FOR EFFICACY OF DECOMPRESSIVE CRANIECTOMY

The pooled analysis of the three European stroke trials published in 2007 established that in patients younger than 60 years, those having decompressive hemicraniectomy had significantly lower mortality than patients who received standard medical therapy [26]. The investigators also concluded that surgical decompression "increases the number of survivors with a favorable functional outcome." However, reaching this conclusion was only possible by redefining the favorable outcome category to include patients with a modified Rankin score (mRS) of 4 [26, 27]. Indeed, the reduction in mortality came about as an almost direct increase in the number of patients with an mRS of 4, thereby confirming that surgical decompression increased the number of dependent survivors [27, 28].

These findings were further confirmed by the DESTINY (Decompressive Surgery for the Treatment of Malignant Infarction of the Middle Cerebral Artery) II trial that investigated decompressive hemicraniectomy in patients older than 60 years [29]. Among the twenty-five survivors in patients randomized to surgery, most were either mRS 4 or 5, and sixteen of these survivors had such severe aphasia or neuropsychological deficits that they were unable to answer a question about retrospective consent [28].

These ethically problematic findings have been confirmed by recent studies investigating decompressive craniectomy in the context of severe TBI [24, 25]. The Decompressive Craniectomy (DECRA) study confirmed the morbidity of the procedure by demonstrating that

despite reducing the intracranial pressure (ICP) and reducing time in intensive care, outcomes were worse in patients who underwent early surgical decompression. More recently, the findings of the RESCUEicp (Randomised Evaluation of Surgery with Craniectomy for Uncontrollable Elevation of ICP) trial were consistent with the stroke trials in that the reduction came about by an almost direct increase in the number of survivors either in a vegetative state or with lower or upper severe disability [25].

There will always be debate about the definition of favorable outcome and the degree to which survivors can learn to live with severe disability [30, 31]. However, a time may come when the degree of neurological injury is such that the potential for functional recovery is limited and the most likely outcome, if the patient survives, is severe neurocognitive disability. In these circumstances, it is reasonable to consider withholding a "lifesaving" intervention because this is an outcome that most individuals would consider unacceptable. However, before this viewpoint can be adopted, several issues require consideration.

ETHICAL ISSUES RELATED TO THE POSSIBILITY OF CONVERTING DEATH INTO SURVIVAL WITH SEVERE DISABILITY

One of the first ethical issues related to lifesaving intervention is the difficulty in accurately assessing the severity of the pathological condition and thereby accurately predicting prognosis in those patients who require either a primary or secondary surgical decompression. Second, although most people may feel that survival with disability would be unacceptable, this is by no means always the case. Some individuals may feel that life is worth preserving at any cost, while others may be willing to risk severe disability in the hope that they may either eventually recover or perhaps learn to adapt and live with a level of disability that they might previously have thought to be unacceptable.

A third issue relates to consent and the role of surrogate decision makers. In most circumstances when consideration is being given to surgical intervention, because of the very nature of the pathological process, patients would have an impaired level of consciousness and would therefore have no competency to participate in decisions about their health care preferences. In these circumstances, relatives are often called upon to provide either known wishes or substituted judgment, which could raise further issues.

ASSESSING INJURY SEVERITY AND CONSIDERING PROGNOSIS IN TRAUMATIC BRAIN INJURY

For many years, the severity of the primary brain injury as adjudged by various clinical and radiological features has been recognized to have prognostic significance. Accordingly, ICP has been used to assess the developing secondary brain injury. However, the ICP has increasingly been acknowledged as a marker of end organ injury, and manipulation of the ICP is not necessarily converted into clinical benefit. Attempts have been made to develop other methods of monitoring secondary brain injury, but their clinical application in general neurotrauma practice has been relatively limited.

Assessment of the Primary Brain Injury

Traditionally, the Glasgow Coma Scale (GCS) has been used as a relatively reliable indicator of the severity of the primary injury as adjudged by the level of consciousness, and it is doubtless a robust assessment scale that has withstood the test of time. However, with the increasing use of prehospital intubation and ventilation [32, 33], its accuracy and reliability have been somewhat reduced [34, 35]. Other parameters having prognostic significance are age, pupillary reaction, presence of extracranial injuries, and certain radiological features on the initial computed tomography scan [4, 6, 36-38]. Although numerous prediction models have been developed that combine the predictive value of these clinical and radiological variables, most have been based on relatively small numbers with limited follow up and have tended to focus on survival as the primary outcome measure [39].

More recently, the availability of increasing amounts of accurate baseline data, combined with advances in statistical analysis, has enabled development of sophisticated Web-based prediction models that provide an accurate mathematical calculation of a prognostic risk [40, 41]. These models, based on large patient samples, have been both internally and externally validated. The CRASH (Corticosteroid Randomization after Significant Head Injury) collaborators' model was developed from the data collected on the 10,000 patients in the CRASH trial that investigated whether steroids were beneficial following TBI, and included mild, moderate, and severe TBI [42]. The clinical predictive variables required for the CRASH model are age, post resuscitation GCS score, pupillary response, and presence of a major extracranial injury. The radiological predictive variables are the presence of petechial hemorrhage, subarachnoid blood, midline shift, unevacuated hematoma, and obliteration of the basal cisterns.

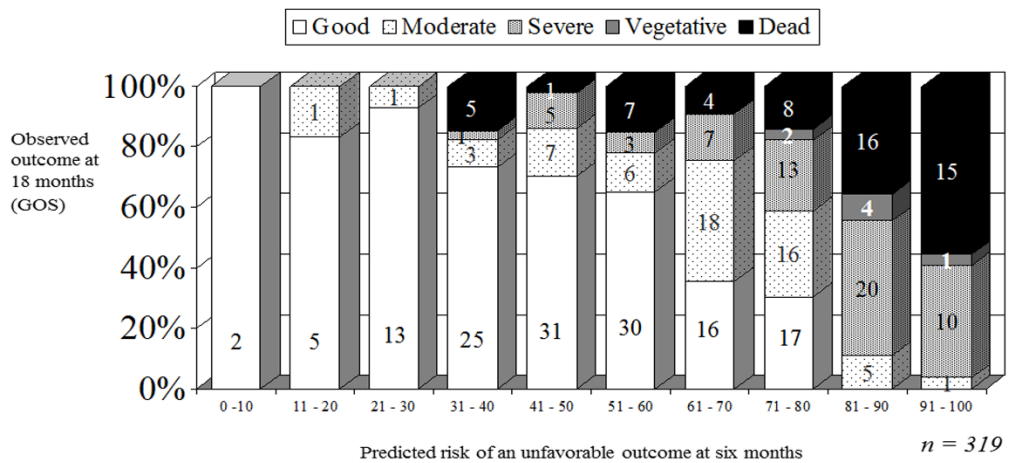

Figure 1. The CRASH collaborators prediction model. The prediction of an unfavorable outcome at 6 months (x axis) and the observed outcome at 18 months among the 319 patients on whom 18-month follow-up was available. Numbers within the bar chart represent absolute patient numbers. (Reproduced with kind permission by Elsevier.)

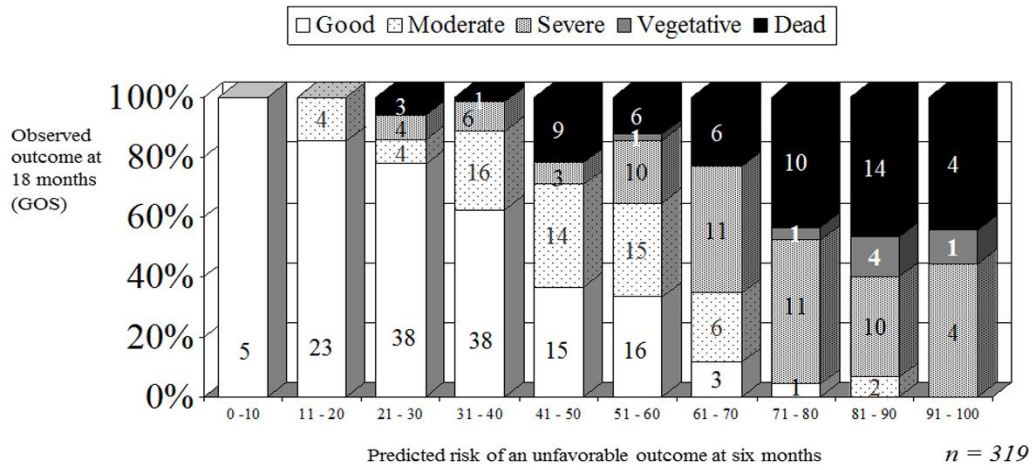

Figure 2. The IMPACT investigators model. The prediction of an unfavorable outcome at 6 months (x axis) and the observed outcome at 18 months among the 319 patients on whom 18-month follow-up was available. Numbers within the bar chart represent absolute patient numbers. (Reproduced with kind permission by Elsevier.)

The IMPACT (International Mission for Prognosis and Clinical Trial) model was developed from 8509 patients and focused on patients with moderate and severe TBI [41]. The baseline presentation data differ slightly from that of the CRASH model. Only the motor function of the GCS is required, hypoxia and hypotension are recorded separately, and epidural mass is recorded as a separate radiological finding. The model also uses the Marshall radiological classification and incorporates the prognostic significance of presentation blood glucose and hemoglobin levels.

Both models are Web based and user friendly, and they provide a percentage risk of unfavorable outcome at 6 months (Figures 1 and 2). Unfavorable outcome is defined by the Glasgow Outcome Score (GOS) of severely disabled, vegetative, or dead [43]. Several studies have demonstrated how the prediction of an unfavorable outcome may be used as a surrogate index of injury severity with which patients can be stratified according to injury severity [44, 46]. Comparing the predicted risk with the observed long-term outcome can provide an objective measure of the most likely clinical outcome in those patients who require either a primary or secondary decompressive craniectomy. While the authors of both models emphasize that the information provided should only be used to support and not replace clinical judgment, the data certainly provide an objective assessment of the most likely outcome for those patients who require surgical intervention.

Assessment of Secondary Brain Injury via ICP

Use of ICP monitoring has become widespread over recent years as it provides important prognostic information. Studies have shown a strong correlation between outcome and the number of hours the ICP remains above 20 mm Hg, and this has been used as a threshold at which medical therapies are introduced in a stepwise protocol-driven manner [47-49]. These therapies include measures such as head elevation, further sedation and paralysis, drainage of

cerebrospinal fluid, and osmotherapy, followed by the judicious use of hyperventilation, barbiturate therapy, and hypothermia [49].

Despite this prognostic significance, one of the fundamental challenges in neurotrauma has been the inability to demonstrate that the reduction in ICP brought about by many of these therapies is necessarily translated into an improvement in clinical outcome [50-55].

For many years patients were routinely hyperventilated, placed in a barbiturate coma, or more recently rendered hypothermic. The rationale was that lowering the ICP improved clinical outcome. However, numerous clinical studies failed to demonstrate that these therapies achieve this objective and may, in certain circumstance, cause harm [53, 56]. On face value, these findings would appear counterintuitive; however, studies investigating the effect that these three therapies have on cerebral blood flow indicate a probable reason. Almost certainly, barbiturates and hypothermia have the potential to be neuroprotective owing to their influence on many aspects of the cellular response to injury, including calcium-mediated toxicity, glutamate excitotoxicity, free radical peroxidation, and cellular apoptosis [57, 59]. However, the mechanism by which these three therapies produce the often rapid fall in ICP that occurs after their application is predominantly a result of cerebral vasoconstriction, and the subsequent reduction in cerebral blood flow has been clearly demonstrated by a number of studies [60-62].

As demonstrated by the underlying pathophysiology and the compensatory mechanisms that occur when the brain swells, the last thing the swollen injured brain needs is less blood, and contemporary medical management aims to optimize cerebral perfusion and avoid secondary brain injury [49]. Currently, therapies such as hyperventilation, barbiturate coma, and hypothermia are generally reserved for intractable intracranial hypertension that is unresponsive to the aforementioned medical therapies.

In these circumstances, consideration is often given to decompressive surgery as it has also been shown consistently to reduce the ICP. Still, as with previous ICP-lowering measures, the results of recent studies have failed to demonstrate that the reduction is necessarily converted into clinical benefit. The DECRA study demonstrated that at the ICP threshold at which patients were enrolled (greater than 20 mm Hg for 15 minutes in an hour) there was insufficient ongoing secondary brain injury and therefore, notwithstanding the reduction in ICP that was observed in the patients randomized to surgery, any potential benefit in terms of improved cerebral perfusion was offset by surgical morbidity [24]. Given the ICP threshold, the absence of survival benefit in the patients in the surgical arm of the trial was unsurprising. The RESCUEicp trial demonstrated a clear survival benefit in those patients randomized to surgery at the higher ICP enrollment threshold; however, the reduction in mortality was consistent with the stroke studies in that this came about as an almost direct translation into survivors in either a vegetative state or with upper or lower severe disability [25].

These results would seem to confirm the limitations in using the ICP as a marker of injury severity in that it really represents a marker of end organ injury. Notwithstanding the prognostic significance of intractable intracranial hypertension, reducing the absolute number by either medical or surgical means will not reverse the effects of the pathology that precipitated the rise in ICP.

What is really needed is a more acute marker of the developing secondary brain injury, and a number of multimodal monitoring techniques have been developed in an attempt to address this issue. These modalities include microdialysis, monitoring brain oxygenation

either indirectly (as with jugular venous bulb monitoring) or directly (as with brain tissue oxygenation monitors), sophisticated bedside measures of autoregulation such as the pressure reactivity index or the mean index, and continuous electroencephalography monitoring [63].

Overall, despite significant developments in the availability and use of these techniques, the clinical significance of many of the recorded events remains undetermined. What is becoming increasingly apparent is that information obtained from a single modality that is interpreted independent from other physiological and metabolic parameters is unlikely to provide clinical benefit. In the same way that the CRASH and IMPACT models have combined individual prognostic indicators, what is now required are advances in real-time, user-friendly data analysis and presentation that can be used to guide appropriately targeted therapeutic management strategies. In addition, while the increasing complexity of monitoring technology must be matched with the appropriate clinical skills required to interpret the information gained, this is unlikely to improve outcome unless accompanied by new or improved therapies.

Predicting Long-Term Outcome in Ischemic Stroke

No such prognostic models are currently available for patients with other neurological pathologies. In the context of ischemic stroke, however, the DESTINY II trial confirmed the prognostic significance of age. Surgical decompression for those patients over 60 years of age is most likely to leave survivors fully dependent with severe neurocognitive deficits, and this outcome must be discussed with surrogate decision makers [29].

Other studies have demonstrated the prognostic significance of GCS on admission, involvement of territories other than the middle cerebral artery region, anisocoria, early clinical deterioration, coronary artery disease, and internal carotid artery occlusion and midline shift. Given the amount of outcome information available, possibly in the future similar prediction models may become available not only in the context of ischemic stroke but also for other pathologies, and while they should not replace clinical judgment, this type of methodology may help support discussions with family members.

COMMUNICATION WITH FAMILIES

Everyone has the right to make decisions regarding their health care preferences, and these decisions can differ substantially between different individuals based on personal, cultural, or religious values. Respect for these preferences is reflected in the importance placed on the need for informed consent prior to any medical or surgical intervention. This requires that individuals have a clear understanding of the facts, implications, and future consequences of an action and have sufficient reasoning faculties so that they are competent to make decisions [64-66].

When decompressive surgery for a neurological catastrophe is under consideration, these principles are challenged because the patients themselves will be in no position to participate in any discussion of treatment options. In these circumstances, family members are often called upon to assist in the decision making processes, and this can be ethically challenging. It

can place an enormous emotional burden on individuals whose competency to make decisions may already be compromised by emotional distress. The timing and manner in which these types of discussion take place may vary due to time constraints, situational circumstances, and available personnel, and there will never be a "one size fits all" approach. However, two key issues must be clearly established when communicating with families. First, the role of families in the decision making process must be clearly defined. Second, based on the aforementioned prognostic information, every attempt must be made to provide patients with an outcome that they would feel to be acceptable as opposed to overly burdensome.

THE ROLE OF FAMILIES IN THE DECISION MAKING PROCESS

Most discussions in the acute care setting are fraught with emotion and commonly result in statements such as "The family wants everything done." However, adopting this position and acting accordingly can be ethically problematic because what is really being asked is whether the injured party would provide consent if it were possible to discuss the goals, risks, and outcome of the procedure. In addition, abandoning family members to make such a challenging decision in isolation is unfair. What is really required is a patient-centered discussion that guides family members through the decision making process and focuses on the *most likely* outcome after surgical intervention. These discussions must be based on either a patient's known wishes (either documented or clearly stated) or substituted judgment regarding the acceptability or otherwise of that outcome, based on the individual's personal values and preferences. If these are not known or if key stakeholders disagree, then discussions may focus on best interests. In these circumstances it may be possible to consider outcome using the recently introduced concepts of "substantial benefit" and the "risk of unacceptable badness" (RUB) in order to explore a more patient-centered view of the utility or indeed futility of surgical intervention based on an individual's preferences.

"Substantial benefit" describes an outcome that the patient now or in the future would regard as worthwhile, recognizing that patients may adapt to a level of disability that they previously might have deemed unacceptable [67]. This observation is reinforced by the concept of the disability paradox that reflects the observation that many people with serious and persistent disabilities report a good or excellent quality of life when to most observers they would appear to live in a very undesirable state [68]. The counterpart of this condition is that of the RUB, which reflects the probability that a patient will end up living in a state that they would describe as intolerable [69].

The literary source of this term comes from Shakespeare's character Hamlet who contemplates: "To sleep, perchance to dream, Aye, there's the rub." In the play, he has been told by a ghost that his uncle (who has since married his mother) murdered his father. Hamlet is considering revenge, but he realizes that if he acts on demonic information and commits a mortal sin, he will be damned. However, if he fails to avenge his father, he cannot live with himself. He then considers suicide and the release of eternal sleep, but he also contemplates the possibility that in death one dreams. The prospect of spending eternity dead, and therefore impotent, but wracked with the moral torments, is to him an unacceptably bad prospect. He therefore faces the RUB, the risk of falling into this unacceptably bad state [69].

In the context of decompressive craniectomy, these ethical concepts may be useful because notwithstanding the disability paradox, surgical intervention considerably increases the risk of survival within a state that fails to provide a person with substantive benefit and may be deemed unacceptable.

PROVIDING AN ACCEPTABLE OUTCOME

Before any decision is reached, acknowledgement should be made of the uncertainties in all fields of medicine and the grey areas in clinical decision making and health care preferences. Still, the actual decision to intervene surgically is a black and white choice, and the time comes when a decision has to be made.

Overall, three main categories of decisions require consideration: patients who have either stated, or for whom it was felt, that survival with severe disability would be unacceptable; patients for whom life is sacrosanct and worth preserving at any cost; and patients who have neither stated nor intimated their preferences or for whom there is disagreement or conflict among surrogate decision makers

Survival with Disability is Unacceptable

Somewhat abstract statements such as "I would rather die than live with severe disability" may or may not reflect a person's thinking when actually faced with the possibility of disabling surgical sequelae. People have a right to make decisions about their health care preferences while competent to do so, and this forms the basis of advance directives, or living wills. These views must be respected and, whenever possible, acted upon. Surgeons may not reasonably assume that they have obtained consent to proceed with surgery if a person has previously documented, or stated, that he or she would not want to live with disability. Likewise, when relatives are asked "Knowing your relative as you did, would he or she be satisfied with survival with a serious disability?" and they state that their relative would find this to be unacceptable, then surgery should not be performed. This position is reinforced in the context of ischemic stroke for patients over 60 years of age or in the context of traumatic brain injury when the prediction of unfavorable outcome is greater than 80%. In these circumstances, the *most likely* outcome is severe disability. This must be fully reflected in discussions with family members who should not be made to feel that they are in any way burdened with making a decision; instead, the information should be provided so that the surgical team can act on a properly considered assessment of the wishes of the patient.

Survival with Severe Disability is Acceptable

Certain individuals may feel that life is sacrosanct and worth preserving at any cost, even if it means that they remain disabled and dependent. They would not view this outcome as unacceptably bad, but instead would feel that they would derive substantive benefit merely by being alive. This outlook may depend on a number of personal, cultural, or religious values,

and while it may not represent the majority view, whenever possible these values must be respected. When discussing these issues with families, care must be taken to determine that this is the viewpoint of the individual concerned and not the possibly unrealistic expectations of the family members who are hoping for a miracle cure. Similarly, while certain individuals may feel survival with severe disability to be unacceptable, they may be willing to take the risk of that outcome in the hope that they would either improve over time or adapt to a level of disability that they previously might have deemed unacceptable. It is in this regard that the data presented in Figures 1 and 2 may be useful for guiding discussions with family members.

The limitations of applying statistics obtained from large data sets to individual cases must be acknowledged. However, when considering a decompressive craniectomy in the context of acute neurotrauma, if the prediction of unfavorable outcome is less than 60%, it is unlikely (but not impossible) that the patient will be left severely disabled. Similarly, if this prediction is greater than 80%, the most likely outcome is either death or survival with either severe disability or in a vegetative state. If the prediction is between 60% and 80%, the outcome is truly uncertain, and this prognostic uncertainty must be a part of discussions about realistic outcome expectations.

Unknown Whether Survival with Severe Disability Would Be Acceptable

The largest and most challenging group of patients are those whose views on survival with severe disability are unknown. Most such patients are young and unlikely to have considered the possibility of themselves having to make such a decision about their preferences were such a neurological catastrophe to occur. Realistically, it would be very difficult not to proceed with surgical intervention for a young person in the context of ischemic stroke or severe TBI even if their prior wishes were not known and there was at least some chance of "substantive benefit" for that person. In talking with family members, the patient's risk of survival with severe disability must be acknowledged and the acceptability or otherwise of this outcome must be directly confronted. Time constraints can make it difficult to fully explore alternative possibilities. Family members may be resentful if they are made to feel that the outcome of surgery was dichotomized into life or death with no mention of the possibility of survival with disability, especially if this is the eventual outcome. Similarly, if risk of an unacceptable outcome was acknowledged and accepted by those making the decision, surgical intervention can be justified even if the eventual outcome is indeed unacceptable. Clearly, the inevitable risks and uncertainties in all fields of medicine must be recognized by all those involved, especially those burdened with the decision making.

Decompressive craniectomy for the management of intracranial hypertension has been shown to increase survival in patients who have suffered catastrophic neurologic brain injuries. Whether the survival benefit translates into improved functional outcome is a matter of ongoing debate that continues to influence the application of this therapeutic option. In circumstances where a patient who has suffered a catastrophic brain injury has an advanced directive, goals of care are usually well defined with little room for ambiguity. Because of the acute and abrupt nature of these injuries, patients often do not have well-defined medical directives, thus requiring family members to provide substituted judgment on behalf of their loved ones. It is in these circumstances that we explore whether the acceptability of survival

with severe disability is indeed to the benefit of the patient within the context of overall quality of life. As we continue to expand our research into the field of therapeutic management of catastrophic neurologic trauma, it is important that we also strive to reconcile the need to increase survival in this patient population with the quality of life that the patients themselves would expect or desire.

REFERENCES

[1] Honeybul S, Gillett GR, Ho K. Futility in neurosurgery: a patient-centered approach. *Neurosurgery.* 2013;73(6):917-22.

[2] Gillett GR, Honeybul S, Ho KM, Lind CR. Neurotrauma and the RUB: where tragedy meets ethics and science. *J Med Ethics.* 2010;36(12):727-30.

[3] Albanèse J, Leone M, Alliez JR, Kaya JM, Antonini F, Alliez B et al. Decompressive craniectomy for severe traumatic brain injury: Evaluation of the effects at one year. *Crit Care Med.* 2003;31(10):2535-2538.

[4] Guerra WK, Gaab MR, Dietz H, Mueller JU, Piek J, Fritsch MJ.. Surgical decompression for traumatic brain swelling: indications and results. *J Neurosurg.* 1999;90(2):187-196.

[5] Polin RS, Shaffrey ME, Bogaev CA, Tisdale N, Germanson T, Bocchicchio B et al.. Decompressive bifrontal craniectomy in the treatment of severe refractory posttraumatic cerebral edema. *Neurosurgery.* 1997;41(1):84-94.

[6] Aarabi B, Hesdorffer DC, Ahn ES, Aresco C, Scalea TM, Eisenberg HM. Outcome following decompressive craniectomy for malignant swelling due to severe head injury. *J Neurosurg.* 2006;104(4):469-479.

[7] Delashaw JB, Broaddus WC, Kassell NF, Haley EC, Pendleton GA, Vollmer DG et al. Treatment of right hemispheric cerebral infarction by hemicraniectomy. *Stroke.* 1990;21(6):874-881.

[8] Rieke K, Schwab S, Krieger D, von Kummer R, Aschoff A, Schuchardt V et al.. Decompressive surgery in space-occupying hemispheric infarction: results of an open, prospective trial. *Crit Care Med.* 1995;23(9):1576-1587.

[9] Carter BS, Ogilvy CS, Candia GJ, Rosas HD, Buonanno F.. One-year outcome after decompressive surgery for massive nondominant hemispheric infarction. *Neurosurgery.* 1997;40(6):1168-1175.

[10] Schwab S, Steiner T, Aschoff A, Schwarz S, Steiner HH, Jansen O et al.. Early hemicraniectomy in patients with complete middle cerebral artery infarction. *Stroke.* 1998;29(9):1888-1893.

[11] Fisher CM, Ojemann RG.. Bilateral decompressive craniectomy for worsening coma in acute subarachnoid hemorrhage. Observations in support of the procedure. *Surg Neurol.* 1994;41(1):65-74.

[12] Smith ER, Carter BS, Ogilvy CS. Proposed use of prophylactic decompressive craniectomy in poor-grade aneurysmal subarachnoid hemorrhage patients presenting with associated large sylvian hematomas. *Neurosurgery.* 2002;51(1):117-124.

[13] Baussart B, Cheisson G, Compain M, Leblanc PE, Tadie M, Benhamou D et al. Multimodal cerebral monitoring and decompressive surgery for the treatment of severe

bacterial meningitis with increased intracranial pressure. *Acta Anaesthesiol Scand.* 2006;50(6):762-765.

[14] Perin A, Nascimben E, Longatti P.. Decompressive craniectomy in a case of intractable intracranial hypertension due to pneumococcal meningitis. *Acta Neurochir (Wien).* 2008;150(8):837-842.

[15] González Rabelino GA, Fons C, Rey A, Roussos I, Campistol J. Craniectomy in herpetic encephalitis. *Pediatr Neurol.* 2008;39(3):201-203.

[16] Coutinho JM, Majoie CB, Coert BA, Stam J. Decompressive hemicraniectomy in cerebral sinus thrombosis: consecutive case series and review of the literature. *Stroke.* 2009;40(6):2233-5.

[17] Ferro JM, Crassard I, Coutinho JM, Canhão P, Barinagarrementeria F, Cucchiara B, et al. Second International Study on Cerebral Vein and Dural Sinus Thrombosis (ISCVT 2) Investigators. Decompressive surgery in cerebrovenous thrombosis: a multicenter registry and a systematic review of individual patient data. *Stroke.* 2011;42(10):2825-31.

[18] Ahmed AI, Eynon CA, Kinton L, Nicoll JA, Belli A. Decompressive craniectomy for acute disseminated encephalomyelitis. *Neurocrit Care.* 2010;13(3):393-5.

[19] Dombrowski KE, Mehta AI, Turner DA, McDonagh DL. Life-saving hemicraniectomy for fulminant acute disseminated encephalomyelitis. *Br J Neurosurg.* 2011;25(2):249-52.

[20] Cooper PR, Rovit RL, Ransohoff J. Hemicraniectomy in the treatment of acute subdural hematoma: a re-appraisal. *Surg Neurol.* 1976;5(1):25-28.

[21] Jüttler, E., Schwab, S, Schmiedek P, Unterberg A, Hennerici M, Woitzik J et al. DESTINY Study Group. Decompressive Surgery for the Treatment of Malignant Infarction of the Middle Cerebral Artery (DESTINY): a randomized, controlled trial. *Stroke.* 2007;38(9):2518-2525.

[22] Vahedi K, Vicaut E, Mateo J, Kurtz A, Orabi M, Guichard JP et al. DECIMAL Investigators. Sequential-design, multicenter, randomized, controlled trial of early decompressive craniectomy in malignant middle cerebral artery infarction (DECIMAL Trial). *Stroke.* 2007;38(9):2506-2517.

[23] Hofmeijer J, Kappelle LJ, Algra A, Amelink GJ, van Gijn J, van der Worp et al. HAMLET investigators. Surgical decompression for space-occupying cerebral infarction (the Hemicraniectomy After Middle Cerebral Artery infarction with Life-threatening Edema Trial [HAMLET]): a multicentre, open, randomised trial. *Lancet Neurol.* 2009;8(4):326-333.

[24] Cooper DJ, Rosenfeld JV, Murray L, Arabi YM, Davies AR, D'Urso P et al. Decompressive craniectomy in diffuse traumatic brain injury. the DECRA Trial Investigators and the Australian and New Zealand Intensive Care Society Clinical Trials Group. *N Engl J Med.* 2011;364(16):1493-1502.

[25] Hutchinson PJ, Kolias AG, Timofeev IS, Corteen EA, Czosnyka M, Timothy J et al. RESCUEicp Trial Collaborators.. Trial of Decompressive Craniectomy for Traumatic Intracranial Hypertension. *N Engl J Med.* 2016;375(12):1119-1130.

[26] Vahedi K1, Hofmeijer J, Juettler E, Vicaut E, George B, Algra A et al. DECIMAL, DESTINY, and HAMLET investigators. Early decompressive surgery in malignant infarction of the middle cerebral artery: a pooled analysis of three randomised controlled trials. *Lancet Neurol.* 2007;6(3):215-222.

[27] Puetz V, Campos CR, Eliasziw M, Hill MD, Demchuk AM; Calgary Stroke Program. Assessing the benefits of hemicraniectomy: what is a favourable outcome? *Lancet Neurol.* 2007;6(7):580-581.

[28] Honeybul S, Ho KM, Gillett G. Outcome Following Decompressive Hemicraniectomy for Malignant Cerebral Infarction: Ethical Considerations. *Stroke* 2015;46(9):2695-2698.

[29] Jüttler E, Unterberg A, Woitzik J, Bösel J, Amiri H, Sakowitz OW, et al; DESTINY II Investigators. Hemicraniectomy in older patients with extensive middle-cerebral-artery stroke. *N Engl J Med.* 2014;370(12):1091-1100.

[30] Larach DR, Larach DB, Larach MG. A life worth living: seven years after craniectomy. *Neurocrit Care.* 2009;11(1):106-111.

[31] Honeybul S, Gillett GR, Ho KM, Janzen C, Kruger K. Is life worth living? Decompressive craniectomy and the disability paradox. *J Neurosurg.* 2016;125(3):775-778.

[32] Winchell RJ, Hoyt DB. Endotracheal intubation in the field improves survival in patients with severe head injury. Trauma Research and Education Foundation of San Diego. *Arch Surg.* 1997;132(6):592-597.

[33] Rudehill A, Bellander BM, Weitzberg E, Bredbacka S, Backheden M, Gordon E. Outcome of traumatic brain injuries in 1,508 patients: impact of prehospital care. *J Neurotrauma.* 2002;19(7):855-868.

[34] Stocchetti N, Pagan F, Calappi E, Canavesi K, Beretta L, Citerio G, et al. Inaccurate early assessment of neurological severity in head injury. *J Neurotrauma.* 2004;21(9):1131-1140.

[35] Balestreri M, Czosnyka M, Chatfield DA, Steiner LA, Schmidt EA, Smielewski P, Matta B, Pickard JD. Predictive value of Glasgow Coma Scale after brain trauma: change in trend over the past ten years. *J Neurol Neurosurg Psychiatry.* 2004;75(1):161-2.

[36] Cremer OL, Moons KG, van Dijk GW, van Balen P, Kalkman CJ. Prognosis following severe head injury: Development and validation of a model for prediction of death, disability, and functional recovery. *J Trauma.* 2006;61(6):1484-1491.

[37] Howard JL, Cipolle MD, Anderson M, Sabella V, Shollenberger D, Li PM, et al. Outcome after decompressive craniectomy for the treatment of severe traumatic brain injury. *J Trauma.* 2008;65(2):380-385.

[38] Meier U, Gräwe A, König A. The importance of major extracranial injuries by the decompressive craniectomy in severe head injuries. *Acta Neurochir Suppl.* 2005;95:55-7.

[39] Perel P, Edwards P, Wentz R, Roberts I: Systematic review of prognostic models in traumatic brain injury. *BMC Med Inform Decis Mak.* 2006;6:38.

[40] Perel P, Arango M, Clayton T, Edwards P, Komolafe E, Poccock S. Predicting outcome after brain injury: Practical prognostic models based on a large cohort of international patients. *BMJ.* 2008;336(7641):425-429.

[41] Murray GD, Butcher I, McHugh GS, Lu J, Mushkudiani NA, Maas AI, Marmarou A, Steyerberg EW. Multivariable prognostic analysis in traumatic brain injury: results from the IMPACT study. *J Neurotrauma* 2007;24:329-337.

[42] Roberts I, Yates D, Sandercock P, Farrell B, Wasserberg J, Lomas G et al. CRASH trial collaborators. Effect of intravenous corticosteroids on death within 14 days in 10008

adults with clinically significant head injury (MRC CRASH trial): randomised placebo-controlled trial. *Lancet* 2004;364(9442):1321-1328.

[43] Jennett B, Bond M Assessment of outcome after severe brain damage. *Lancet.* 1975;1(7905):480-484.

[44] Honeybul S, Ho KM, Lind CRP, Gillett GR. The retrospective application of a prediction model to patients who have had a decompressive craniectomy for trauma. *J Neurotrauma.* 2009;26(12):2179-2183.

[45] Honeybul S, Ho KM, Lind CRP, Gillett GR. Observed versus predicted outcome for decompressive craniectomy: A population based study. *J Neurotrauma.* 2010;27 (7):1225-1232.

[46] Honeybul S, Ho KM. Predicting long-term neurological outcomes after severe traumatic brain injury requiring decompressive craniectomy: A comparison of the CRASH and IMPACT prognostic models. *Injury.* 2016;47(9):1886-1892.

[47] Juul N, Morris GF, Marshall SB, Marshall LF. Intracranial hypertension and cerebral perfusion pressure: influence on neurological deterioration and outcome in severe head injury. The Executive Committee of the International Selfotel Trial. *J Neurosurg* 2000;92(1):1-6.

[48] Marmarou A, Anderson R, Ward JD. Impact of ICP instability and hypotension on outcome in patients with severe head trauma. *J Neurosurg* 1991;75:s59-s66.

[49] Bratton SL, Chestnut RM, Ghajar J, McConnell Hammond FF, Harris OA et al. Brain Trauma Foundation; American Association of Neurological Surgeons; Congress of Neurological Surgeons; Joint Section on Neurotrauma and Critical Care, AANS/CNS. Guidelines for the management of severe traumatic brain injury. *J Neurotrauma* 2007;24, suppl 1s.

[50] Clifton GL, Miller ER, Choi SC, Levin HS, McCauley S, Smith KR Jr, et al. Lack of effect of induction of hypothermia after acute brain injury. *N Engl J Med* 2001;344(8):556-63.

[51] Clifton GL, Valadka A, Zygun D, Coffey CS, Drever P, Fourwinds S, et al. Very early hypothermia induction in patients with severe brain injury (the National Acute Brain Injury Study: Hypothermia II): a randomised trial. *Lancet Neurol* 2011;10(2):131-9.

[52] Eisenberg HM, Frankowski RF, Contant CF, Marshall LF, Walker MD. High-dose barbiturate control of elevated intracranial pressure in patients with severe head injury. *J Neurosurg* 1988;69(1):15-23.

[53] Hutchison JS, Ward RE, Lacroix J, Hébert PC, Barnes MA, Bohn DJ. Hypothermia Pediatric Head Injury Trial Investigators and the Canadian Critical Care Trials Group. Hypothermia therapy after traumatic brain injury in children. *N Engl J Med* 2008;358(23):2447-2456.

[54] Muizelaar JP, Marmarou A, Ward JD, Kontos HA, Choi SC, Becker DP, et al. Adverse effects of prolonged hyperventilation in patients with severe head injury: a randomized clinical trial. *J Neurosurg* 1991;75(5):731-739.

[55] Ward JD, Becker DP, Miller JD, Choi SC, Marmarou A, Wood C, et al. Failure of prophylactic barbiturate coma in the treatment of severe head injury. *J Neurosurg* 1985;62(3):383-388.

[56] Curley G, Kavanagh BP, Laffey JG. Hypocapnia and the injured brain: more harm than benefit. *Crit Care Med* 2010;38(5):1348-1359.

[57] Koerner IP, Brambrink AM. Brain protection by anesthetic agents. *Curr Opin Anaesthesiol* 2006;19(5):481-486.

[58] Koizumi H, Povlishock JT. Posttraumatic hypothermia in the treatment of axonal damage in an animal model of traumatic axonal injury. *J Neurosurg* 1998;89(2):303-309.

[59] Sutcliffe IT, Smith HA, Stanimirovic D, Hutchison JS. Effects of moderate hypothermia on IL-1 beta-induced leukocyte rolling and adhesion in pial microcirculation of mice and on proinflammatory gene expression in human cerebral endothelial cells. *J Cereb Blood Flow Metab* 2001;21(11):1310-9.

[60] Rosomoff HL, Holaday DA. Cerebral Blood Flow and Cerebral Oxygen Consumption During Hypothermia. *Am J Physiol* 1954;179(1):85-8.

[61] Nordström CH, Messeter K, Sundbärg G, Schalén W, Werner M, Ryding E. Cerebral blood flow, vasoreactivity, and oxygen consumption during barbiturate therapy in severe traumatic brain lesions. *J Neurosurg* 1988;68(3):424-431.

[62] Yundt KD, Diringer MN. The use of hyperventilation and its impact on cerebral ischemia in the treatment of traumatic brain injury. *Crit Care Clin* 1997;13(1):163-184.

[63] Honeybul S. An update on the management of traumatic brain injury. *J Neurosurg Sci.* 2011;55(4):343-55.

[64] Druml C.. Informed consent of incapable (ICU) patients in Europe: existing laws and the EU Directive, *Curr Opin Crit Care.* 2004;10(6):570-3.

[65] Beauchamp TL, Childress JF. The meaning and justification of informed consent In: *Principles of Biomedical Ethics*. 5th ed. New York: Oxford University Press 2001;77-98.

[66] Dunn LB, Nowrangi MA, Palmer BW, Jeste DV, Saks ER. Assessing decisional capacity for clinical research or treatment: A review of instruments. *Am J Psychiatry.* 2006;163(8):1323-1334.

[67] Gillett G. Minimally conscious states, deep brain stimulation, and what is worse than futility. *Journal of Bioethical Inquiry.* 2011;8.2:145-150.

[68] Ubel PA, Loewenstein G, Schwarz N, Smith D. Misimagining the unimaginable: the disability paradox and health care decision making. *Health Psychol,* 24 (4S):S57-6, 2005.

[69] Gillett GR. The RUB. The risk of unacceptable badness. *N Z Med J.* 2001;27:188-189.

In: Encyclopedia of Surgery (22 Volume Set)
Editors: Andreas Lehrer and Kristin Mueller
ISBN: 978-1-53618-329-0
© 2020 Nova Science Publishers, Inc.

Chapter 241

ETHICAL CONSIDERATIONS IN DECOMPRESSIVE CRANIECTOMY

Stephen Honeybul[1,*], Franco Servadei[2], Kwok Ming Ho[3], Luca Longhi[4] and Grant Gillett[5]

[1]Department of Neurosurgery, Sir Charles Gairdner Hospital and Royal Perth Hospital, Western Australia
[2]Department of Neurosurgery, Humanitas University and Institute Milano, Italy
[3]Department of Intensive Care Medicine and School of Population Health, University of Western Australia
[4]Neurosurgical Intensive Care Unit, Department of Anaesthesia and Critical Care Medicine, ASST-Papa Giovanni XXIII, Bergamo, Italy
[5]Dunedin Hospital and Otago Bioethics Centre, University of Otago, Dunedin, New Zealand

ABSTRACT

The use of decompressive craniectomy for neurological emergencies continues to attract considerable interest, and evidence indicates that surgical intervention can reduce mortality. However, surgery will not reverse the effects of the pathological condition that precipitated the clinical deterioration. A concern has always been that many survivors will be left with severe disability and dependency, and some patients may consider this possibility unacceptable. A number of randomized controlled trials have attempted to address this issue, but their results have in many ways made the decision-making paradigm more difficult. They have confirmed unequivocally that mortality can be reduced; however, this has come at an *almost* direct translation into survival with severe disability. This finding raises several ethical issues regarding the definition of favorable outcome, the acceptability or otherwise of survival with severe disability, and wider issues regarding the allocation of health care resources.

Keywords: severe traumatic brain injury, futility, ethics

* Corresponding Author's Email: stephen.honeybul@health.wa.gov.au.

INTRODUCTION

Over the past three decades, interest in decompressive craniectomy has been considerable with numerous studies reporting its use, most commonly following severe traumatic brain injury [1–4] and ischemic stroke [5–8]. More recently, further cohort studies have reported use of the procedure in the context of subarachnoid hemorrhage [9, 10], intracranial infection [11, 12], and inflammatory conditions [13].

Overall, there appears to be little doubt that surgical intervention can lower the intracranial pressure and reduce mortality; however, it will not reverse the effects of the pathological condition that precipitated the clinical deterioration. For many years, the concern has been that many survivors will be left with a level of disability and dependency that they and their families may find unacceptable [14].

In an attempt to address this issue over the past decade, a number of prospective, multicenter, randomized controlled trials have investigated the efficacy of decompressive surgery, initially in the context of ischemic stroke [15–17] and more recently in the context of severe traumatic brain injury [18, 19]. The results of these trials have provided good evidence on which to base clinical practice; however, they have in some ways made the clinical decision-making paradigm more difficult, given the ethical issues that have arisen regarding long-term outcome and the acceptability or otherwise of survival with severe disability and dependency.

RESULTS OF THE RANDOMIZED CONTROLLED TRIALS

Decompressive Hemicraniectomy for Ischemic Stroke

In the early 2000s, three major trials conducted in Europe compared decompressive hemicraniectomy with standard medical therapy for patients under 60 years of age, who clinically deteriorated following the development of “malignant” middle cerebral infarction [15–17]. None of these trials were fully completed owing to difficulties with slow recruitment; however, each trial independently demonstrated that surgical decompression reduced mortality. Thereafter, a pooled analysis of the three trials found an “increase in the number patients with a favorable functional outcome” [20]. This finding appeared to provide unequivocal support for ongoing use of the procedure. Yet, closer examination of the study design raised concerns about a redefining of favorable outcome.

Traditionally, outcome following stroke has been assessed using the modified Rankin Scale (mRS), and favorable outcome has been defined as an mRS of 0–3. The implication of this definition seems to be that most people who recover want to have some degree of independence [21]. However, in the pooled analysis the favorable outcome category was changed to include patients with an mRS of 4. Favorable outcome therefore included patients who were highly dependent in that they could not walk unaided and could not attend to their bodily needs, an outcome that most investigators have previously deemed unfavorable [22, 23]. To justify this change, investigators asked patients who survived with severe disability whether they regretted having had surgery and whether they would have provided consent if

they had known their eventual outcome [15–17]. The relatively high levels of so-called "retrospective consent" were taken as justification for the recategorization.

An alternative interpretation of these positive responses, however, is that patients may have adapted to a level of neurological disability or recalibrated their preferences such that they now accept a level of disability that they might previously have deemed unacceptable. This phenomenon has previously been observed in the context of both stroke and severe traumatic brain injury, and it is certainly a testament to the human ability to survive and adapt to difficult circumstances [24, 25]. Still, we would contend that to accept this as a variation of the consent process and thereby validation of the surgical intervention is ethically problematic.

Informed consent, a fundamental tenet of modern medicine, requires that patients have a clear understanding of the facts, implications, and future consequences of an action *prior to* that action being performed [26, 27]. Furthermore, it requires that the patient be competent to make that judgment [28, 29]. While it must be acknowledged that there are significant limitations when a person makes somewhat abstract statements such as "I would rather die than survive with severe disability," such assessments form the basis of documentation such as living wills and advance directives, and these views must be respected.

The finding that surgical intervention translates death into survival with full dependency was even more pronounced in the DESTINY II trial that investigated decompressive hemicraniectomy in patients over 60 years of age [30]. The trial confirmed that mortality was reduced from 70% at 6 months in those patients randomized to medical treatment down to 33% in those patients randomized to surgical decompression. However, the conclusion that "hemicraniectomy increased survival without severe disability" requires clarification given that only two patients (among the twenty-seven patients who survived following decompressive hemicraniectomy) achieved an mRS score of 3. The remaining twenty-five survivors were equally distributed between an mRS of 4 and 5. Furthermore, sixteen of these survivors had such severe aphasia or neuropsychological deficits that they were unable to answer a relatively simple question about retrospective consent [22].

Overall, the evidence is unequivocal that decompressive hemicraniectomy in the context of ischemic stroke almost uniformly translates deaths into increased numbers of survivors with severe disability and dependency. This must be thoroughly discussed with key stakeholders prior to considering surgical intervention. Similarly, evidence for this ethically problematic choice is now found in the context of severe traumatic brain injury.

Decompressive Craniectomy for Severe Traumatic Brain Injury

Numerous observational cohort studies have demonstrated that decompressive surgery can be used to control severe intractable intracranial hypertension in the context of severe traumatic brain injury [1–4]. Furthermore, two large multicenter randomized controlled trials have compared surgical decompression with standard medical therapy [18, 19]. The DECRA study investigated the role of early bifrontal decompressive craniectomy in the context of diffuse cerebral swelling. The hypothesis on which the trial was based was that early decompression would optimize cerebral perfusion and improve clinical outcome by reducing secondary insults. To examine this hypothesis, patients were randomized at the relatively low intracranial pressure (ICP) threshold of greater than 20 mm Hg for more than fifteen minutes

in the hour after first-tier medical therapy. Given this threshold, it was unsurprising that there was no survival benefit in those patients randomized to the surgical arm of the trial compared to those patients randomized to standard medical therapy. What was unexpected, however, was that despite consistently lower ICP and less time spent in intensive care, neurological outcomes at 6 months were worse in patients who had been randomized to surgery. The results of the study provoked considerable debate. One of the key criticisms was that the ICP threshold at which patients were randomized was not representative of current clinical practice (which is to intervene at higher ICP thresholds) [31]. With the benefit of hindsight, this is a valid observation, but if the trial had shown benefit, these patients would have come to represent the *clinical practice of the future*, which would have had a significant impact on neurosurgical practice, especially if survival (regardless of quality of life) were the only valued outcome [32].

The DECRA trial clearly, unequivocally demonstrated that, at that particular ICP enrollment threshold, the ongoing secondary brain injury was insufficient to justify surgical intervention and that any potential benefit obtained from improved cerebral perfusion was offset by the increasingly appreciated morbidity of the procedure [33]. Prior to these findings, it was almost assumed that lowering the ICP would be beneficial; however, in many ways these results have highlighted the need for more considered judgment when making surgical decisions [34].

The results of the RESCUEicp trial have provided even more evidence to inform the ethical debate [19]. The higher ICP enrollment threshold led to a significant survival benefit in those patients randomized to the surgical arm of the trial, and these results were consistent with the stroke trials. There were further similarities in that this reduction in mortality came as an almost direct result of an increase in the number of survivors either in a vegetative state or with severe disability. At 12-month follow up, there was a small increase, albeit statistically insignificant, in the percentage of patients with a favorable outcome—from 34.6% in the medical arm of the trial to 42% ($P = 0.12$) in the surgical arm of the trial. However, this small increase was only seen when the Extended Glasgow Outcome Scale category was changed to include upper levels of severe disability as favorable, in a similar fashion to the stroke trials that deemed an mRS of 4 as favorable. Without this recategorization, the percentage of patients who survived with lower moderate disability or better (traditionally regarded as a genuinely favorable outcome) was very similar (32% favorable in the surgical arm of the trial and 28.5% favorable in the medical arm). Furthermore, and perhaps of greatest concern, the number of survivors in a vegetative state increased. At 6 months, the number of vegetative survivors increased from 4 out of 188 patients (2.1%) randomized to the medical arm of the trial, to 17 out of 201 patients (8.5%) randomized to the surgical arm. This finding is even more ethically problematic when considering outcome findings at 12 months because apparently six of these patients who were in a vegetative state at 6 months subsequently died (five patients in the surgical arm and one patient in the medical arm). The psychological distress for families involved in these circumstances and the enormous financial costs to society should be balanced against the benefits for the patients surviving with lesser degrees of disability.

DECOMPRESSIVE CRANIECTOMY – RESULTS ANALYSIS

Compelling evidence now supports the ethically challenging conclusion that surgical intervention reduces mortality at the expense of an increase in survivors either with severe disability or in a vegetative state. These findings must be reflected in discussions regarding outcome following decompressive craniectomy because long-term outcome cannot be dichotomized into life or death. Indeed, to do so would fail to recognize that surgical intervention increases the likelihood of exposing patients to an outcome that they and their families may consider unacceptable. In addition, the time may have come for a more nuanced ethical examination regarding the ongoing use of a procedure that in a small but significant number of cases increases short-term survival in a fully dependent state at a considerable financial and psychological cost to society.

Overall, the results of the randomized controlled trials have provided good evidence on which to base clinical management; however, they have in many ways emphasized the need for more considered judgment to be exercised when making decisions regarding surgical intervention.

DECOMPRESSIVE CRANIECTOMY – FUTURE CONSIDERATIONS

Despite the evidence from the randomized controlled trials, certain individuals who undergo surgical decompression undoubtedly survive a life-threatening neurological catastrophe and either go on to make a good neurological recovery or adapt to a level of disability that they may previously have deemed unacceptable. The difficulty remains identifying those individuals who are most likely to derive clinical benefit. In the context of ischemic stroke, age is obviously an important factor, and it would seem reasonable to consider surgical intervention for young people, especially if their prior wishes are unknown, because they may learn to adapt to a level of disability that they may previously have thought to be unacceptable [24, 25].

This viewpoint is further supported by the ethical concept of the "rule of rescue" that describes the powerful human proclivity to rescue identified endangered lives, regardless of cost or risk [35]. Furthermore, people obtain considerable social utility and a feeling of security from knowing they live in a compassionate society that cares for the needs of each constituent member and where those in most desperate need will not be ignored or abandoned merely on the basis of resource allocation. However, this security can be threatened if the rescue system is seen to be a juggernaut that is insensitive to the way people actually value their lives. The DESTINY II trial clearly demonstrated the difficulty in invoking the rule of rescue for patients over 60 years of age given that most survivors will be immobile, unable to communicate, and fully dependent on nursing care.

In the context of severe traumatic brain injury, while age is an acknowledged important prognostic factor, several other clinical and radiological parameters have also been shown to significantly affect prognosis. Recent improvements in data collection and statistical analysis have enabled researchers to develop sophisticated Web-based outcome prediction models that provide a percentage prediction of unfavorable outcome at 6 months (defined by the Glasgow Outcome Scale as severe disability, vegetative, or dead) [36, 37]. The CRASH model

(Corticosteroid Randomisation after Significant Head Injury) uses the clinically predictive variables of age, post-resuscitation Glasgow Coma Scale (GCS), pupillary response, and presence of a major extracranial injury. The radiological predictive variables used are the presence of petechial hemorrhage, subarachnoid blood, midline shift, unevacuated hematoma, and obliteration of the basal cisterns. The baseline presentation data required for the IMPACT (International Mission for Prognosis and Clinical Trial) model differs slightly from that of the CRASH model. Only the motor function of the GCS is required, hypoxia and hypotension are recorded separately, and epidural mass is recorded as a separate radiological finding. In addition, the Marshall radiological classification is used, and the final part of the model incorporates the prognostic significance of presentation blood glucose and hemoglobin levels.

A number of studies have used the percentage prediction to stratify patients according to injury severity and compared the *prediction* of unfavorable outcome with the *observed* long-term outcome [38–40]. Presenting data in this manner provides an objective assessment of the *most likely* outcome following surgical intervention and can perhaps form the basis of a more rational and informed discussion among stakeholders when considering decompressive surgery (Figures 1 and 2).

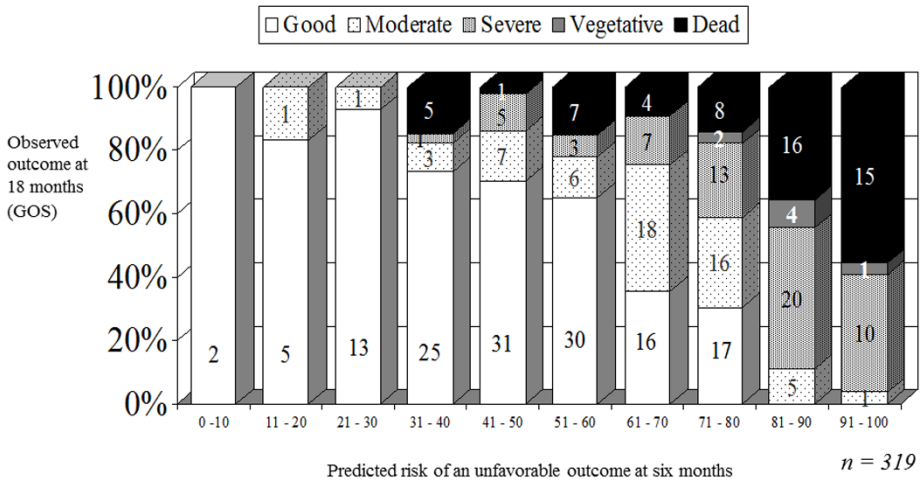

Figure 1. The CRASH collaborators prediction model. The prediction of an unfavorable outcome at 6 months (x axis) and the observed outcome at 18 months among the 319 patients on whom 18-month follow-up was available. Numbers within the bar chart represent absolute patient numbers. (Reproduced with kind permission by Elsevier).

The decision to offer or undertake decompressive surgery, however, cannot rest solely on the preferences of the patients or their next of kin because of the important resource allocation issues related to long-term care for those who survive with dependency. It must, of course, be acknowledged there will always be limitations when attempting to predict long-term outcome, and from a purist's perspective, prognostic models should never be used to guide medical decision-making for individual patients. In addition, there will always be those patients who defy the odds and make a miraculous recovery despite seemingly desperate circumstances.

Inevitably, a time comes when these issues must be considered, as in the case of patients over 60 years of age with ischemic stroke or patients with a severe traumatic brain injury and a prediction of unfavorable outcome greater than 80%. In these ethically challenging

circumstances, the most likely outcome for survivors is either severe disability or survival in a vegetative state. The surgeon, therefore, has an obligation, both professionally and ethically, to establish whether this outcome would be acceptable for that individual. In addition, the larger community has to determine the value placed on a single individual's life at any and all (financial and non-financial) cost. The considerations here are not only financial but also personal and ethical, and they require us to exercise well-considered judgment about our actions.

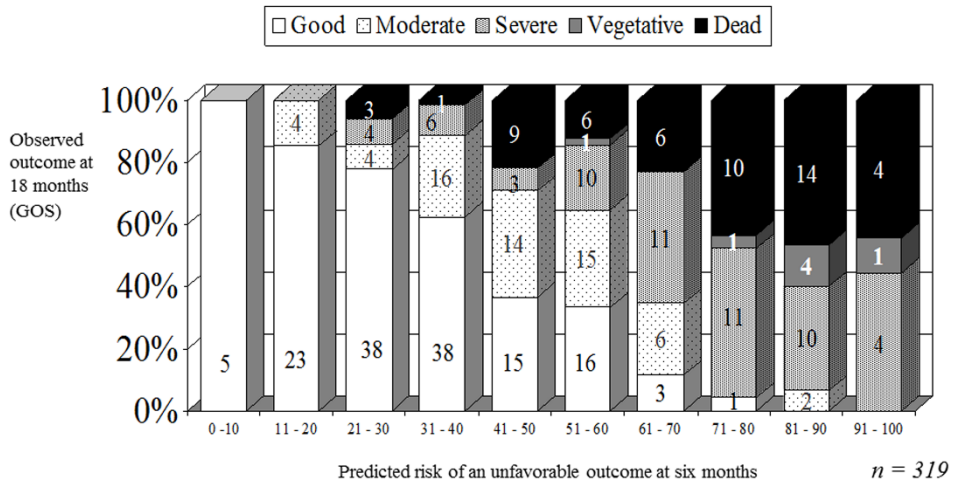

Figure 2. The IMPACT investigators model. The prediction of an unfavorable outcome at 6 months (x axis) and the observed outcome at 18 months among the 319 patients on whom 18-month follow-up was available. Numbers within the bar chart represent absolute patient numbers. (Reproduced with kind permission by Elsevier).

In the fraught setting of an acute neurological deterioration, neurosurgeons are often called on late in the clinical scenario to perform lifesaving surgery, often with insufficient time for detailed discussion of realistic outcome expectations. In addition, families will often have compromised capacity (caused by emotional distress) to really consider the true implications of survival with severe disability, and their hopes for a miracle cure may be at odds with likely outcomes. Before approaching families to discuss the potential benefit or burden of surgical intervention, all medical and surgical stakeholders must reach a clear consensus. Such clarity will help ease the family's difficult decision-making regarding surgery.

Finally, given available evidence, the time may have come for policy makers and society as a whole to be more explicit regarding resource allocation and perhaps more openly discuss the limitations of our modern health care systems and the need to spend resources wisely [41].

CONCLUSION

In reality, the decision to perform decompressive craniectomy will always be challenging. There is now clear evidence that mortality can be reduced but that this reduction comes at the cost of an outcome some individuals consider unacceptable. In the context of

severe traumatic brain injury, the ongoing use and further refinement of high-quality outcome prediction models may provide an objective assessment of the most likely outcome following surgical intervention. No such models exist for decompressive hemicraniectomy in the context of ischemic stroke or other neurological catastrophes; however, given the amount of data available, this would not appear to be a particularly difficult undertaking.

It must be acknowledged that there will always be limitations when using population-based data on individual cases, but the objective assessment that they can provide may help prompt appropriate patient-centered discussions regarding realistic outcome expectations. Further work may be required to establish the role of decompressive craniectomy in other neurological emergencies. Given the evidence now available, however, a broader debate is needed on the use of a medical intervention that increases the number of survivors with either severe disability or in a vegetative state, survival that comes at what may be a considerable psychological stress to their families and financial burden to the society.

REFERENCES

[1] Albanèse, J; Leone, M; Alliez, JR; Kaya, JM; Antonini, F; Alliez, B; et al. Decompressive craniectomy for severe traumatic brain injury: Evaluation of the effects at one year. *Crit Care Med*., 2003, 31(10), 2535-8.

[2] Guerra, WK; Gaab, MR; Dietz, H; Mueller, JU; Piek, J; Fritsch, MJ. Surgical decompression for traumatic brain swelling: indications and results. *J Neurosurg*., 1999, 90(2), 187-96.

[3] Polin, RS; Shaffrey, ME; Bogaev, CA; Tisdale, N; Germanson, T; Bocchicchio, B; et al. Decompressive bifrontal craniectomy in the treatment of severe refractory posttraumatic cerebral edema. *Neurosurgery*., 1997, 41(1), 84-94.

[4] Aarabi, B; Hesdorffer, DC; Ahn, ES; Aresco, C; Scalea, TM; Eisenberg, HM. Outcome following decompressive craniectomy for malignant swelling due to severe head injury. *J Neurosurg*., 2006, 104(4), 469-79.

[5] Delashaw, JB; Broaddus, WC; Kassell, NF; Haley, EC; Pendleton, GA; Vollmer, DG; et al. Treatment of right hemispheric cerebral infarction by hemicraniectomy. *Stroke*., 1990, 21(6), 874-81.

[6] Rieke, K; Schwab, S; Krieger, D; von, Kummer, R; Aschoff, A; Schuchardt, V; et al. Decompressive surgery in space-occupying hemispheric infarction: results of an open, prospective trial. *Crit Care Med.*, 1995, 23(9), 1576-87.

[7] Carter, BS; Ogilvy, CS; Candia, GJ; Rosas, HD; Buonanno, F. One-year outcome after decompressive surgery for massive nondominant hemispheric infarction. *Neurosurgery*., 1997, 40(6), 1168-75.

[8] Schwab, S; Steiner, T; Aschoff, A; Schwarz, S; Steiner, HH; Jansen, O; et al. Early hemicraniectomy in patients with complete middle cerebral artery infarction. *Stroke*., 1998, 29(9), 1888-93.

[9] Fisher, CM; Ojemann, RG. Bilateral decompressive craniectomy for worsening coma in acute subarachnoid hemorrhage. Observations in support of the procedure. *Surg Neurol*., 1994, 41(1), 65-74.

[10] Smith, ER; Carter, BS; Ogilvy, CS. Proposed use of prophylactic decompressive craniectomy in poor-grade aneurysmal subarachnoid hemorrhage patients presenting with associated large sylvian hematomas. *Neurosurgery*., 2002, 51(1), 117-24.

[11] Baussart, B; Cheisson, G; Compain, M; Leblanc, PE; Tadie, M; Benhamou, D; et al. Multimodal cerebral monitoring and decompressive surgery for the treatment of severe bacterial meningitis with increased intracranial pressure. *Acta Anaesthesiol Scand*., 2006, 50(6), 762-5.

[12] Perin, A; Nascimben, E; Longatti, P. Decompressive craniectomy in a case of intractable intracranial hypertension due to pneumococcal meningitis. *Acta Neurochir (Wien)*. 2008, 150(8), 837-42.

[13] González, Rabelino, GA; Fons, C; Rey, A; Roussos, I; Campistol, J. Craniectomy in herpetic encephalitis. *Pediatr Neurol*., 2008, 39(3), 201-3.

[14] Cooper, PR; Rovit, RL; Ransohoff, J. Hemicraniectomy in the treatment of acute subdural hematoma: a re-appraisal. *Surg Neurol*., 1976, 5(1), 25-28.

[15] Jüttler; E.; Schwab; S; Schmiedek, P; Unterberg, A; Hennerici, M; Woitzik, J; et al., DESTINY Study Group. Decompressive Surgery for the Treatment of Malignant Infarction of the Middle Cerebral Artery (DESTINY): a randomized, controlled trial. *Stroke*., 2007, 38(9), 2518-25.

[16] Vahedi, K; Vicaut, E; Mateo, J; Kurtz, A; Orabi, M; Guichard, JP; et al., DECIMAL Investigators. Sequential-design, multicenter, randomized, controlled trial of early decompressive craniectomy in malignant middle cerebral artery infarction (DECIMAL Trial). *Stroke*., 2007, 38(9), 2506-17.

[17] Hofmeijer, J; Kappelle, LJ; Algra, A; Amelink, GJ; van, Gijn, J; van, der, Worp, HB; et al., HAMLET investigators. Surgical decompression for space-occupying cerebral infarction (the Hemicraniectomy After Middle Cerebral Artery infarction with Life-threatening Edema Trial [HAMLET]): a multicentre, open, randomised trial. *Lancet Neurol*., 2009, 8(4), 326-33.

[18] Cooper, DJ; Rosenfeld, JV; Murray, L; Arabi, YM; Davies, AR; D'Urso, P; et al., the DECRA Trial Investigators and the Australian and New Zealand Intensive Care Society Clinical Trials Group. Decompressive craniectomy in diffuse traumatic brain injury. *N Engl J Med*., 2011, 364(16), 1493-1502.

[19] Hutchinson, PJ; Kolias, AG; Timofeev, IS; Corteen, EA; Czosnyka, M; Timothy, J; et al., RESCUEicp Trial Collaborators. Trial of Decompressive Craniectomy for Traumatic Intracranial Hypertension. *N Engl J Med*., 2016, 375(12), 1119-30.

[20] Vahedi, K1; Hofmeijer, J; Juettler, E; Vicaut, E; George, B; Algra, A; et al., DECIMAL, DESTINY, and HAMLET investigators. Early decompressive surgery in malignant infarction of the middle cerebral artery: a pooled analysis of three randomised controlled trials. *Lancet Neurol.*, 2007, 6(3), 215-22.

[21] Honeybul, S; Ho, KM; Blacker, DW. ORACLE Stroke Study: opinion regarding acceptable outcome following decompressive hemicraniectomy for ischemic stroke. *Neurosurgery*., 2016, 79(2), 231-6.

[22] Puetz, V; Campos, CR; Eliasziw, M; Hill, MD; Demchuk, AM. Calgary Stroke Program. Assessing the benefits of hemicraniectomy: what is a favourable outcome? *Lancet Neurol*., 2007, 6(7), 580-1.

[23] Honeybul, S; Ho, KM; Gillett, G. Outcome following decompressive hemicraniectomy for malignant cerebral infarction: ethical considerations. *Stroke*, 2015, 46(9), 2695-8.

[24] Larach, DR; Larach, DB; Larach, MG. A life worth living: seven years after craniectomy. *Neurocrit Care*., 2009, 11(1), 106-11.

[25] Honeybul, S; Gillett, GR; Ho, KM; Janzen, C; Kruger, K. Is life worth living? Decompressive craniectomy and the disability paradox. *J Neurosurg*., 2016, 125(3), 775-8.

[26] Druml, C. Informed consent of incapable (ICU) patients in Europe: existing laws and the EU Directive. *Curr Opin Crit Care*., 2004, 10(6), 570-3.

[27] Beauchamp, TL; Childress, JF. The meaning and justification of informed consent. In: *Principles of biomedical ethics*. 5th ed. New York: Oxford University Press, 2001. p. 77-98.

[28] Dunn, LB; Nowrangi, MA; Palmer, BW; Jeste, DV; Saks, ER. Assessing decisional capacity for clinical research or treatment: a review of instruments. *Am J Psychiatry*., 2006, 163(8), 1323-34.

[29] Beauchamp, TL; Childress, JF. The meaning and justification of informed consent. In: *Principles of biomedical ethics*. 5th ed. New York: Oxford University Press, 2001. p. 69-77.

[30] Jüttler, E; Unterberg, A; Woitzik, J; Bösel, J; Amiri, H; Sakowitz, OW; et al., DESTINY II Investigators. Hemicraniectomy in older patients with extensive middle-cerebral-artery stroke. *N Engl J Med*., 2014, 370(12), 1091-100.

[31] Timmons, SD; Ullman, JS. Eisenberg HM. Craniectomy in diffuse traumatic brain injury. *N Engl J Med*., 2011, 365(4), 373.

[32] Honeybul, S; Ho, KM; Lind, CR. What can be learned from the DECRA study. *World Neurosurg*., 2013, 79(1), 159-61.

[33] Honeybul, S; Ho, KM. Long term complications of decompressive craniectomy for head injury. *J Neurotrauma*., 2011, 28, 929-35.

[34] Honeybul, S; Ho, KM. The surgical management of intracranial hypertension following traumatic brain injury. *Anaesth Intensive Care*., 2012, 40(3), 558-9.

[35] Jonsen, AR. Bentham in a box: technology assessment and health care allocation. *Law Med Health Care*., 1986, 14, 172-4.

[36] Perel, P; Arango, M; Claydon, T; Edwards, P; Komolafe, E; Poccock, S; et al., MRC CRASH Trial Collaborators. Predicting outcome after brain injury: practical prognostic models based on a large cohort of international patients. *BMJ*., 2008, 336(7641), 425-9.

[37] Steyerberg, EW; Mushkudiani, N; Perel, P; Butcher, I; Lu, J; McHugh, GS; et al. Predicting outcome after traumatic brain injury: development and international validation of prognostic scores based on admission characteristics. *PLoS Med*., 2008, 5(8), e165.

[38] Honeybul, S; Ho, KM; Lind, CRP; Gillett, GR. The retrospective application of a prediction model to patients who have had a decompressive craniectomy for trauma. *J Neurotrauma*., 2009, 26(12), 2179-83.

[39] Honeybul, S; Ho, KM; Lind, CRP; Gillett, GR. Observed versus predicted outcome for decompressive craniectomy: a population based study. *J Neurotrauma*., 2010, 27(7), 1225-32.

[40] Honeybul, S; Ho, KM. Predicting long-term neurological outcomes after severe traumatic brain injury requiring decompressive craniectomy: a comparison of the CRASH and IMPACT prognostic models. *Injury*., 2016, 47(9), 1886-92.

[41] Ho, KM; Honeybul, S; Lind, CR; Gillett, GR; Litton, E. Cost-effectiveness of decompressive craniectomy as a lifesaving rescue procedure for patients with severe traumatic brain injury. *J Trauma.*, 2011, 71(6), 1637-44.

[42] Honeybul, S; Ho, KM; Lind, CR; Gillett, GR. Decompressive craniectomy for neurotrauma: the limitations of applying an outcome prediction model. *Acta Neurochir (Wien).*, 2010, 152(6), 959-64.

[43] Honeybul, S; Gillett, GR; Ho, K. Futility in neurosurgery: a patient-centered approach. *Neurosurgery.*, 2013, 73(6), 917-22.

[44] Honeybul, S; Gillett, GR; Ho, KM; Lind, CR. Neurotrauma and the rule of rescue. *J Med Ethics.*, 2011, 37(12), 707-10.

[45] Honeybul, S; Gillett, G; Ho, K; Lind, CR. Ethical considerations for performing decompressive craniectomy as a life-saving intervention for severe traumatic brain injury. *J Med Ethics.*, 2012, 38(11), 657-61.

In: Encyclopedia of Surgery (22 Volume Set)
Editors: Andreas Lehrer and Kristin Mueller
ISBN: 978-1-53618-329-0
© 2020 Nova Science Publishers, Inc.

Chapter 242

THE PROGNOSTIC VALUE OF TRAUMATIC BRAINSTEM INJURY ON MAGNETIC RESONANCE IMAGING: A SYSTEMATIC REVIEW

B. Aarabi[1,*], A. Wessell[1], N. Pratt[1], T. Chryssikos[1], M. Scarboro[2], C. Diaz Lomangino[2] and C. Aresco[2]

[1]Department of Neurosurgery, University of Maryland, Baltimore, MD, US
[2]Department of Surgery, Shock Trauma Center,
University of Maryland, Baltimore, MD, US

ABSTRACT

On October 9, 2017, in an open scientific session of the Congress of Neurological Surgeons on "Neurotrauma and Critical Care," Drs. Shelly Timmons (Pennsylvania State University) and Martina Stippler (Harvard University) presented a lively debate *for* and *against* decompressive craniectomy.* In this session, Dr. Stippler presented the following scenario to the audience: "When the ICP threshold is alarming and life-threatening, who would proceed with decompressive craniectomy for severe traumatic brain injury?" The show of hands overwhelmingly supported decompressive craniectomy.

This systematic review appraises the existing body of literature, and focuses specifically on the prognostic value of traumatic brainstem injury (TBSI) on magnetic resonance imaging (MRI) studies in this clinical setting. Does MRI add to the predictive significance of the existing prognostic models? And should it therefore influence decision-making regarding decompressive craniectomy? In the following chapter, we review what has been conclusively written about the role of MRI in predicting neurologic outcome following traumatic injury to the central nervous system and provide a case report of our own.

A computerized search of the National Library of Medicine PubMed database of literature, applying multiple medical subject headings, yielded 734 citations addressing MRI and traumatic brain injury. Nine articles specifically reported the prognostic significance of TBSI and long-term outcome. Level II and III evidence indicated that the presence of TBSI on MRI was usually an indication of extensive rostral-caudal traumatic

* Corresponding Author's Email: baarabi@som.umaryland.edu.

axonal injury and signified unfavorable outcome. In one Level II study, inclusion of MRI variables in the core model (age, pupillary dilatation, and GCS score) of Area Under the Receiver Operating Characteristics (AUROC)+ CT Rotterdam covariates increased the prognostic significance (GOSE ≤6 at 12 months) from 0.8287 to 0.8763.

Keywords: MRI, TBI, brainstem, outcome, decompressive craniectomy, GOSE

INTRODUCTION

Over the past 40 years histopathological and preclinical studies [2-6] have indicated that the translation of kinetic energy (stress/strain) following mechanical injury to the brain transpires in less than 200 milliseconds and disrupts the structure and function of the central nervous system in a centripetal fashion [2-16]. The Ommaya-Gennarelli hypothesis of diffuse brain injury, first reported in 1974 [6] in primate models of traumatic brain injury (TBI), articulated the principle that energy dispersion following trauma spreads from the cortex into the subcortical white, central gray, corpus callosum, mesencephalic-diencephalic junction, and brain stem in a graded rostral-caudal fashion. Less severe energy dispersion over the superficial cortex produced concussion; however, more extensive strain/sprain spread during angular acceleration/deceleration injuries resulted in coma or death [17, 18]. In a 1988 report, Levin et al. studied the magnetic resonance imaging (MRI) results of 94 patients with closed head injuries of varying severity and found that the depth of the lesions correlated positively with the degree and duration of altered consciousness, independently of secondary influences such as intracranial pressure and size of the lesion, thereby lending support to Ommaya and Gennarelli's original hypothesis [19]. This concept supports the notion that any evidence of traumatic brainstem injury (TBSI) on imaging studies may be an indication of more severe diffuse injury capable of substantial disruption of structure and function.

With the advent of computed tomography (CT) in 1976, Merino and Taveras reported visual representation of intracranial hematomas, brain swelling, and evidence of midline shift due to hematomas or brain swelling [20]. Marshall et al., in 1997, and Maas et al., in 2007, introduced CT classifications of severe TBI [21, 22] with high internal validity: area under the curve (AUC) = 0.77 [22, 23]. Approximately half of patients with severe head injury show evidence of intracranial mass lesions and the other half show indications of diffuse injury 1-4 on the Marshall Classification [24, 25]. Nevertheless, -because of bone artefact (low signal-to-noise ratio) and inadequate contrast and resolution, CT scan is weak in discriminating posterior fossa microhemorrhages or TBSI [25, 26].

In a prospective study of 40 patients with blunt TBI and a Glasgow Coma Scale (GCS) score ranging from 3 to 14, Gentry et al. found higher sensitivity of magnetic resonance imaging (MRI) in detecting focal and diffuse brainstem lesions with precise anatomical localization: superficial versus deep, dorsal versus ventral, and midbrain versus pons versus medulla oblongata [26]. While CT detected only 9.1% of TBSIs, the detection rate was 81.8% on T1 and 72.7% on T2 MRI. The superiority of MRI in detecting brainstem injuries has been recorded by other investigators [27-30]. MRI clearly depicts microhemorrhages on SWI (Susceptibility Weighted Image) and T2*GRE (Star Gradient Echo), diffuse injuries on FLAIR (Fluid Attenuated Inversion Recovery) and T2WI (T2 Weighted Image), and evidence of ischemic damage on DWI/ADC (Diffusion Weighted Image/Apparent Diffusion

Coefficient) sequences. Collectively, these represent the pathological hallmarks of traumatic injuries to central nervous system [28, 29, 31, 32]. Only two subjects in Mannion's cohort of 46 ventilated patients with severe head injury showed CT evidence of TBSI while MRI was capable of revealing evidence of TBSI in 13 patients [25]. In a prospective study by Lagares et al., only three of 100 patients had CT evidence of TBSI while MRI showed 33 patients with significant injury to the mesencephalon, pons, and medulla [33]. The incidence of TBSI on MRI of patients with severe TBI has ranged from 25% to 50% [25, 30, 34-37].

Acquisition of early multi-sequence MRI in a patient with severe TBI under controlled ventilation in the intensive care unit is often not feasible. Availability, cost, compatibility of life-support equipment, and safety of transportation are some of the hurdles to acquiring MRI studies for the purposes of TBSI evaluation [25]. In addition, inadequate support for the strength of association between TBSI and outcome and the time window available to complete the study make this imaging modality risky and impractical in some cases.

In this chapter, we questioned the level of evidence in previous studies on the role of MRI in predicting neurologic outcome in traumatic brain injury in order to further clarify the strength by which MRI might be recommended for evaluation of these patients. Specifically, we address the hypothesis that MRI enhances the predictive value of existing models for TBI and TBSI, and we conclude with a case report that address the prognostic capabilities of this modality and its role in the decision to pursue decompressive craniectomy in the setting of TBI/TBSI.

REVIEW OF THE LITERATURE

Search Criteria

To identify pertinent evidence, we performed a computerized search of the National Library of Medicine (NLM) literature database (PubMed) from 1990-2017, using the following medical subject headings:

1) "MRI AND TBI" — 734 citations.
2) "MRI AND TBI AND prognosis" — 156 citations.
3) "MRI AND prognosis after severe head injury" — 151 citations.
4) "MRI AND brainstem AND prognosis AND TBI" — 71 citations.

An additional search of the reference lists of identified publications yielded another 21 citations.

From these search results, we selected nine publications for this Systematic Review that offer the best evidence [25, 30-33, 36, 38-40].

Methodology

Figure 1 illustrates our methodology. Three reviewers independently read all the titles and abstracts of the 734 published articles identified in our original search. Then applying our

inclusion and exclusion criteria, they excluded 725, leaving nine studies. Full texts of these nine articles were appraised by the three reviewers for precision of the study design and directness of methodology; robustness of the data; details of the results; extent of statistical analysis; risks of bias; and interpretation of the results (Figure 1, Table 1).

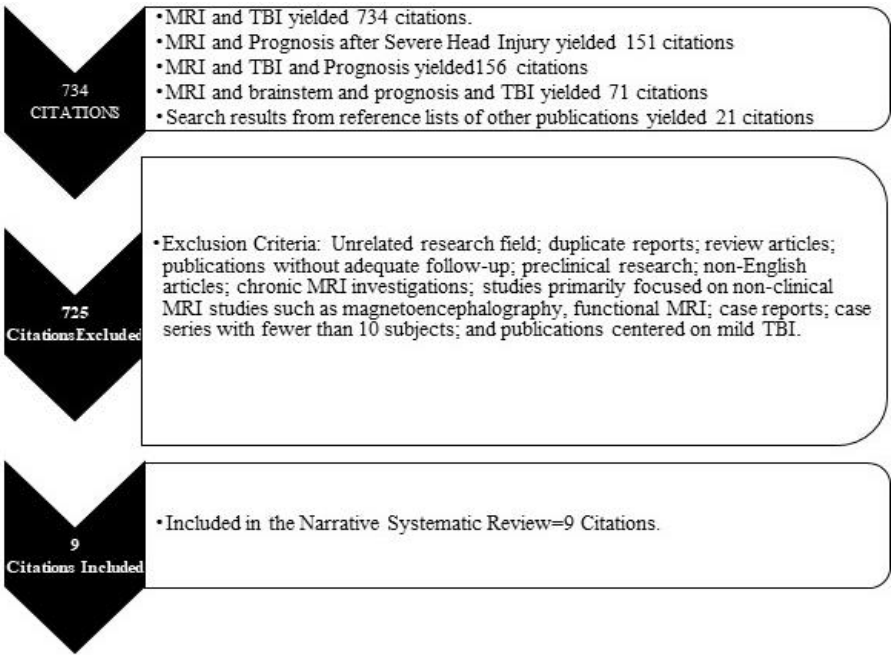

Figure 1. Flow diagram indicating computerized search of National Library of Medicine (NLM) PubMed literature database from 1990-2017. (Courtesy of B Aarabi, University of Maryland).

DISCUSSION

Three Level II and six level III evidence citations from this Systematic Review bring several important concepts into focus:

1) Primary TBSI is distinguished from Secondary TBSI, the latter of which is thought to be due mainly from brainstem compression. Primary TBSI almost always is part of a more extensive traumatic process involving centripetal kinetic energy dispersion and parenchymal stress/strain. The neuropathological studies of Adams et al. and the primate models of diffuse axonal injury (DAI) reported by Ommaya and Gennarelli arrived at this conclusion decades ago [6, 12-14, 17, 18, 41, 42]. Since CT imaging is rather insensitive in imaging traumatic axonal injury (TAI), Compared with CT, MRI provides high spatial resolution with high signal-to-noise ratio, and at present remains the gold standard modality for detecting and characterizing traumatic axonal injury (TAI) involving the cerebrum and brainstem tegmentum [43-48].
2) In patients with severe head injury, functional outcome is dictated by the collective lesion load (volume and location) spread across the cerebral cortex, subcortical white, central gray, corpus callosum, and brainstem [32, 40].

Table 1. Strength of evidence

<table>
<tr><th>Study</th><th>Level</th><th>Years of Study</th><th>Patients</th><th>Level of Consciousness</th><th>Intervention</th><th>Outcome</th></tr>
<tr><td>Smitherman E J Neurotrauma 2016 [32] University Texas Southwestern USA</td><td>III (R)</td><td>2005-2012</td><td>63</td><td>Glasgow Coma Scale (GCS) <12 (5.6±3.9)</td><td>The researchers studied prognostic value of FLAIR hyperintense lesion load and location on the Pediatric Glasgow Outcome Scale – Extended (GOS-E Peds) outcome 13.5 months after trauma (favorable GOS-E Peds 1-4 and unfavorable GOS-E Peds 5-8). MRI field strength 1.5 or 3T). Hyperintense Lesion Volume Index (HLVI) was calculated for lesions involving cortex, central gray, and brain stem. Mean age was 9.9 (0-17) and the studies were performed a mean of 6.2 days following trauma (0-22 days).
HLVI = HLV / total brain volume×100</td><td>Distribution of FLAIR hyperintense lesions (FHLs) was in 3 zones: A=superficial cortex; B=corpus callosum, basal ganglia, and thalamus; and C=brainstem. Distribution of FHLs was in 3 patterns: A: superficial; A+B: superficial and deep lesions; and A+B+C: lesions in all 3 zones. Fifteen of 63 (24%) patients had TBSI, 14 of which were associated with more superficial lesions. Total FLAIR HLVI (P = 0.02) and brainstem HLVI (P = 0.024) predicted favorable and unfavorable outcomes, respectively. In adolescents, total FLAIR lesion volume correlated best with outcome; in children <13 y, deep lesion volume correlated best with outcome.
Compared to patterns A and A+B, logistic regression testing of all injury patterns indicated that the A+B+C injury pattern was significantly predictive of unfavorable outcome (OR 4.38, 95% CI 1.19-16.0) P = 0.03. In addition to injury pattern A+B+C, HLVI-total (P <0.0001) was related to unfavorable outcome.
The Relationship Between HLVI and Outcome (GOSE-Peds)
<table>
<tr><td>Hyperintensity Lesion Volume Zones</td><td></td></tr>
<tr><td>HLVI Zone A (cortical structures)</td><td>r = 0.31, P <0.02</td></tr>
<tr><td>HLVI Zone B (basal ganglia, corpus callosum, internal capsule, and thalamus)</td><td>r = 0.35, P = 0.004</td></tr>
<tr><td>HLVI Zone C (brainstem)</td><td>r = 0.5, P = 0.007</td></tr>
<tr><td>HLVI-Total</td><td>r = 0.39, P = 0.002</td></tr>
</table>
</td></tr>
</table>

Table 1. (Continued)

<table>
<tr><th>Study</th><th>Level</th><th>Years of Study</th><th>Patients</th><th>Level of Consciousness</th><th>Intervention</th><th>Outcome</th></tr>
<tr><td>Moen KG J Neurotrauma 2014 Norwegian and St Olay Universities, Norway [40]</td><td>II (P)</td><td>2004-2009</td><td>128</td><td>GCS 3-12</td><td>FLAIR, DWI, and T2*GRE MRI sequences were used to measure the prognostic value of traumatic axonal injury (TAI) lesion loads in corpus callosum, thalamus, and brainstem and relate that to GOSE outcome at 12 months. The studies were within 8 days of trauma (0-28 days). The cohort’s mean age was 33.9 years.</td><td>Among the severe head injury (SHI) patients, 19 (30%) had TBSI. After adjustment for age, GCS, and pupillary reaction, the TAI lesion load was an independent prognostic factor in patients with severe TBI (OR = 1.3-6.9, P <0.001)

Multivariate Logistic Regression Models Predicting Outcome (GOSE)

<table>
<tr><th>Region</th><th>OR (95% CI)</th><th>P</th></tr>
<tr><td>FLAIR (volume)</td><td></td><td></td></tr>
<tr><td>Whole brain</td><td>1.15 (1.06-1.25)</td><td>0.001</td></tr>
<tr><td>Corpus callosum</td><td>1.27 (1.08-1.49)</td><td>0.004</td></tr>
<tr><td>Brainstem</td><td>1.37 (1.06-1.77)</td><td>0.017</td></tr>
<tr><td>Thalamus</td><td>1.70 (1.22-2.36)</td><td>0.002</td></tr>
<tr><td>DWI (number)</td><td></td><td></td></tr>
<tr><td>Whole brain</td><td>1.10 (1.01-1.20)</td><td>0.25</td></tr>
<tr><td>Corpus callosum</td><td>2.67 (1.57-4.55)</td><td><0.001</td></tr>
<tr><td>Brainstem</td><td>3.06 (1.31-7.14)</td><td>0.010</td></tr>
<tr><td>Thalamus</td><td>6.87 (1.95-24.2</td><td>0.003</td></tr>
<tr><td>T2*GRE (number)</td><td></td><td></td></tr>
<tr><td>Whole brain</td><td>1.02 (1.00-1.05)</td><td>0.055</td></tr>
<tr><td>Corpus callosum</td><td>1.01 (1.00-1.03)</td><td>0.16</td></tr>
<tr><td>Brainstem</td><td>1.01 (0.99-1.04)</td><td>0.36</td></tr>
<tr><td>Thalamus</td><td>1.17 (0.99-1.38)</td><td>0.07</td></tr>
<tr><td>Rotterdam CT score</td><td>1.47 (0.94-2.29</td><td>0.88</td></tr>
</table>
</td></tr>
</table>

<table>
<tr><th>Study</th><th>Level</th><th>Years of Study</th><th>Patients</th><th>Level of Consciousness</th><th>Intervention</th><th>Outcome</th></tr>
<tr><td>Hilario A AJNR 2012 Hospital 12 de Octubre, Madrid, Spain [31]</td><td>III (R)</td><td>2002-2011</td><td>108</td><td>GCS <8</td><td>Geographic location (anterior, posterior, unilateral, and bilateral) of TBSI lesions and their association with GOSE 6 months following severe head injury were studied a mean of 17 days after trauma. The age of patients was 15–75 years. MRI field strength was 1.5 T; sequences were T1WI, T2WI, FLAIR, and T2*GRE.</td><td>Fifty-one of 108 (47%) patients had TBSI. Depth of lesion analysis indicated that subcortical lesions were present in 92% and injury to corpus callosum in 71% of patients with TBSI. Among patients with TBSI 66% had poor outcome. Bilateral (P <0.05), posterior (OR 6.8, CI 1.8-25, sensitivity 68%, specificity 76%) and hemorrhagic lesions had better discriminatory capacity for outcome than anterior, nonhemorrhagic, and unilateral lesions (P <0.05, OR 5.9, CI 1.6-22). A posterior, bilateral, and hemorrhagic lesion had the worst prognostic significance. On the other hand, nonhemorrhagic, unilateral and anterior lesions had the highest discriminatory capacity for good outcome.
MRI FEATURES OF TBSI IN 51 PATIENTS WITH SEVERE TBI
<table><tr><th>MRI FINDINGS</th><th>N(%)</th></tr><tr><td>Mesencephalon</td><td>43 (84)</td></tr><tr><td>Pons</td><td>2 (4)</td></tr><tr><td>Medulla</td><td>3 (6)</td></tr><tr><td>More than one</td><td>3 (6)</td></tr><tr><td>Posterior location</td><td>27 (63)</td></tr><tr><td>Anterior location</td><td>24 (47)</td></tr><tr><td>Bilateral</td><td>13 (26)</td></tr></table></td></tr>
<tr><td>Chew BG J Neurosurg 2012 Alleghany General Hospital Pittsburgh, PA USA(39)</td><td>III (R)</td><td>2004-2012</td><td>36</td><td>GCS <8 in 24 patients</td><td>Early MRI (median 1 and range 0-35 days, Field Strength 1.5 T and sequences T1WI, T2WI, T2*GRE, FLAIR, DWI and ADC) were performed aimed at defining the prognostic value of MRI and traumatic lesion load at the brainstem. Mean age of the cohort was 45.5 years.</td><td>Nineteen (53%) patients had poor outcome, including 17 patients who died. Twenty-two TBSIs were at the level of midbrain, 17 at the level of pons, and two at the level of medulla. Lesion loads crossing the midline at the level of medulla or pons were associated with higher proportions of patients dead or in a vegetative state (P = 0.0156, OR 0.075). None of the 15 patients with brainstem lesions crossing the midline and a GCS motor score of ≤4 recovered. When MRI findings were coupled with GCS motor score, there was a strong correlation with poor outcome.</td></tr>
</table>

Table 1. (Continued)

<table>
<tr><th>Study</th><th>Level</th><th>Years of Study</th><th>Patients</th><th>Level of Consciousness</th><th>Intervention</th><th>Outcome</th></tr>
<tr><td></td><td></td><td></td><td></td><td></td><td>Prognosis was dichotomized into dead/vegetative vs. severe disability and above at 6 months.</td><td>In the logistic regression model this combination was associated with a C-statistics of 0.913, suggesting that over 90% of the variability in the outcome is explained by those two factors.
Functional recovery and its relationship with TBSI

<table><tr><th>GCS MOTOR SUB-SCORE</th><th>TBSI CROSSED</th><th>TBSI DID NOT CROSS</th><th></th><th></th><th></th></tr><tr><td>1</td><td>0/5</td><td>2/3</td><td></td><td></td><td></td></tr><tr><td>2</td><td>0/5</td><td>-</td><td></td><td></td><td></td></tr><tr><td>3</td><td>0/2</td><td>1/1</td><td></td><td></td><td></td></tr><tr><td>4</td><td>0/3</td><td>2/2</td><td></td><td></td><td></td></tr><tr><td>5</td><td>2/3</td><td>4/4</td><td></td><td></td><td></td></tr><tr><td>6</td><td>4/4</td><td>4/4</td><td></td><td></td><td></td></tr></table></td></tr>
<tr><td>Skandsen T J Neurotrauma 2011 Norwegian and Trondheim Universities, Norway [38]</td><td>III (P)</td><td>2004-2008</td><td>106</td><td>GCS <12 (Moderate 57 and severe 49)</td><td>MRI (field strength 1.5 Tesla, sequences T2WI, FLAIR,T2*GRE, T1WI, and DWI) was performed within 4 weeks (median 8 days) of trauma in moderate and severe head injury patients (mean age 28 years, range 5–65). Outcome was assessed using GOSE in 6 months.</td><td>The investigators tried to relate the depth of injury in severe head injury and outcome.

<table><tr><th>Hemisphere</th><th>Lobar Cortex and White Matter</th></tr><tr><td>Central</td><td>Corpus callosum, basal ganglia, thalamus</td></tr><tr><td>Unilateral TBSI</td><td>Unilateral brainstem injury</td></tr><tr><td>Bilateral TBSI</td><td>Bilateral brainstem injury</td></tr></table>
Brainstem lesions were seen in 22 (45%) patients with severe head injury. Compared to unilateral TBSI, bilateral TBSI had good discriminative ability as a predictor of poor outcome (positive predictive value and negative predictive value were 0.86 and 0.88, sensitivity of 0.75 and specificity of 0.94, respectively).</td></tr>
</table>

<table>
<tr><th>Study</th><th>Level</th><th>Years of Study</th><th>Patients</th><th>Level of Consciousness</th><th>Intervention</th><th>Outcome</th></tr>
<tr><td>Lagares A Acta Neurochir 2009 Hospital 12 de Octubre, Madrid, Spain [33]</td><td>II (P)</td><td>2001-2004</td><td>100</td><td>GCS ≤12</td><td>Patients (age = 15-75) were prospectively enrolled in this study. Subjects with head injury had MRI (FLAIR, T2WI, T2*GRE) within 30 days (inter-quartile range 6-20 days) of trauma. Outcome was determined at 6 months using the GOSE instrument.</td><td>The investigators modeled their Diffuse Axonal Injury (DAI) Classification on the MRI after Adams et al. study [15]. Depth of lesion was classified into Grades 1-3. The depth of lesion was associated with poor outcome.

<table><tr><th>Grade</th><th>Description</th><th>Patients</th></tr><tr><td>1</td><td>Subcortical White</td><td>65</td></tr><tr><td>2</td><td>Corpus Callosum</td><td>36</td></tr><tr><td>3</td><td>Brainstem</td><td>33</td></tr></table>
Ninety-seven percent of patients with injuries to corpus callosum, and 94% of patients with TBSI also had injuries to subcortical white matter. In a multivariate logistic regression analysis model, Grade 3 DAI was significantly associated with unfavorable (GOSE) outcome (P <0.05). In addition, area under the curve (AUC) for receiver operating characteristics (ROC) assessing the role of MRI, GCS, and unfavorable outcome, there was a significant relationship when GCS motor subscore at admission was ≤4 [[33] Figure 2 from Springer with permission].</td></tr>
<tr><td>Mannion RJ J Neurotrauma 2007 Wolfson Brain Injury Unit, Cambridge, UK [25]</td><td>II (P)</td><td>2002-2005</td><td>46</td><td>GCS <8</td><td>This study aimed at finding the relationship between brainstem and supratentorial lesions in patients (mean age 34) with severe head injury and in need of ventilator support. The study was prospective, MRI field strength 3 Tesla, data acquisition within 3 days of trauma, and outcome evaluation at 6 months (GOS).</td><td>TBSIs were detected in 13 patients (28.2%). Computed tomography was positive for TBSI in only 2 (4.3%) patients. TBSI was in association with DAI in 6 patients, secondary to focal compression following herniation in 5 and with no evidence of supratentorial DAI in 2. Overall unfavorable outcome in this study was 61%. Eleven of 13 patients with TBSI (85%) had unfavorable outcome, including 5 who died (P <0.05). Outcome was favorable in 2 patients with TBSI and no evidence of global DAI. Poor outcome was more prevalent in TBSI associated with large supratentorial masses (5 patients) and diffuse injury (6 patients).</td></tr>
</table>

Table 1. (Continued)

<table>
<tr><th>Study</th><th>Level</th><th>Years of Study</th><th>Patients</th><th>Level of Consciousness</th><th>Intervention</th><th>Outcome</th></tr>
<tr><td></td><td></td><td></td><td></td><td></td><td>Methodology required brainstem lesion on at least 2 MRI sequences (e.g., SWI and FLAIR).</td><td></td></tr>
<tr><td>Woischneck D Childs Nerv Syst 2003 Otto von-Guericke University, Magdeburg, Germany [30]</td><td>III (R)</td><td>Not Mentioned</td><td>30</td><td>Severe GCS <8</td><td>Children <18 years of age who were comatose and needed respiratory support had MRI within a mean of 3.5 days (10 hours – 8 days) of trauma. T1 and T2 WI sequences were obtained. Field strength was 1.5 T. Subjects were followed from 3 months - 2.5 years to determine GOS outcome.</td><td>None of the 30 patients had evidence of TBSI on CT scan. TBSIs were noticed in 60% of children and were significantly associated with GOS score. BSI was secondary in 2 patients and primary in 16. Caudal pontine and medullary lesions were fatal.</td></tr>
<tr><td>Firsching R Neurological Research 2002 Klinik fur Neurochirurgie der Universitat Leipzigerstr, Magdeburg, Germany [36]</td><td>III (P)</td><td>Not Mentioned</td><td>102</td><td>Severe GCS <8</td><td>From 102 patients (mean age 36 years) 37 had mass lesions (11 EDH, 22 SDH, and 4 ICH). Twenty-four patients had decompressive craniectomy. Consecutive T1 and T2 MRI (field strength 1.5) study of patients was performed within 8 hours of injury. Neither SWI nor T2*GRE nor DWI was procured.</td><td>MRI Lesion Location
<table>
<tr><th>Lesion</th><th>Grade</th><th>#</th><th>Unfavorable Outcome %</th><th>Mortality %</th><th>P Value</th></tr>
<tr><td>Hemispheres</td><td>I</td><td>44</td><td>5</td><td>14</td><td><0.001</td></tr>
<tr><td>Unilateral TBSI</td><td>II</td><td>22</td><td>13</td><td>23</td><td>Not Significant</td></tr>
<tr><td>Bilateral Midbrain</td><td>III</td><td>17</td><td>56</td><td>24</td><td>Not Significant</td></tr>
<tr><td>Bilateral Pons</td><td>IV</td><td>19</td><td>-</td><td>100</td><td><0.001</td></tr>
<tr><td>Total</td><td>NA</td><td>102</td><td>15</td><td>33</td><td>NA</td></tr>
</table></td></tr>
</table>

Study	Level	Years of Study	Patients	Level of Consciousness	Intervention	Outcome
					Lesion location was classified and outcome (GOS) was determined a mean of 22 months.	Nearly 57% of the cohort had some kind of brainstem and hemispheric injury with a mortality of 49%, almost 3 times the patients with only supratentorial lesions (hemispheres, corpus callosum, and central gray). CT identified only 3 of 68 cases with TBSI lesion on MRI. It is hard to estimate the proportions of diffuse injury, evacuated mass, and nonevacuated mass in this study or what proportion of TBSI was primary and what proportion secondary due to herniation

Abbreviations: ADC=Apparent Diffusion Coefficient, AUC=Area Under the Curve, AUROC=Area Under the Receiver Operating Characteristics, CI=Confidence Interval, DAI=Diffuse Axonal Injury, DWI=Diffusion Weighted Image, EDH=Epidural Hematoma, FHL=FLAIR Hyperintense Lesion, FLAIR=Fluid Attenuated Inversion Recovery, GCS=Glasgow Coma Scale, GOS-E=Glasgow Outcome Score Extended, HLVI=Hyperintensity Lesion Volume Index, OR=Odds Ratio, P=Prospective, Peds=Pediatrics, R=Retrospective, ROC=Receiver Operating Characteristics, SDH=Subdural Hematoma, SHI=Severe Head Injury, T1WI=T1 Weighted Image Sequence, T2*GRE=T2* Gradient Echo, TAI=Traumatic Axonal Injury, TBSI=Traumatic Brainstem Injury.

3) Bilateral and posterior TBSIs at the level of the pons and mesencephlon are devastating and have unfavorable outcome [31, 34-36].
4) Addition of MRI variables to the core AUROC model and Rotterdam CT independent variables increases the discriminative power of prognostic models by improving the AUROC [33, 40].

In 2001, Firsching et al. from the Otto-von-Guericke University (Magdeburg, Germany) [36] prospectively investigated the prognostic value of TBSI seen on MRI in 102 patients (mean age: 36; range: 2-86) with severe TBI (GCS <8) who had MRI within 8 days of trauma. We downgraded this investigation to Level III because of minor weaknesses in the study design, precision, and methodology. MRI sequences were restricted to T1 and T2 WI, and there was no segregation of the TBSI into primary or secondary. Thirty-seven of 102 patients had surgery for a mass lesion including 24 who had decompressive craniectomy. Although the investigators precisely defined the location of the parenchymal lesions, no information was provided defining the lesion volume. The investigators classified TBSI into four grades Table 2:

TBSI was discovered in 58 patients. Patients with no evidence of TBSI had significantly less mortality (P <0.001) than patients with TBSI, and bilateral pontine lesions were specifically catastrophic and 100% fatal (P <0.001). In this study, with the exception of three patients, all patients with any evidence of TBSI also had supratentorial lesions. Patients with Grade I lesions had significantly better outcome than patients in Grade II and III categories. Good outcome was noted in 37% of Grade I patients in no Grade III patients.

Table 2. Grade of injury

Diagnostic groups of lesions based on MRI after severe head injury [36]			
Parenchymal Injury	Grade	Injury	No.
Supratentorial lesions only	Grade I	No TBSI	44
TBSI with or without supratentorial lesions	Grade II	Unilateral TBSI at any level	22
	Grade III	Bilateral midbrain TBSI	17
	Grade IV	Bilateral pontine TBSI	19

In a 3.5-year prospective MRI study of 30 children with severe head injury within 8 days of trauma, Woischneck et al. (Magdeburg, Germany, 2003) looked for evidence of TBSI [30]. It is likely that some of the investigated patients were among the 102 patients reported in 2001 by Firsching et al. Of note, the investigators took P = 0.08 as the level of statistical significance, and the minimum follow-up was 3 months using the GOS scale. None of the 30 patients had CT evidence of TBSI. Only two of 30 patients had secondary TBSI and 13 had primary. One hundred percent of patients with TBSI also had evidence of injury to supratentorial structures. Mortality in this series was 23%. Evidence of traumatic injury on MRI was seen primarily in the supratentorial structures in 12 patients (40%), and in 18 patients the brainstem was involved in addition to supratentorial structures. Death, persistent vegetative state, and severe disability were primarily concentrated in patients with TBSI.

Mannion et al. (2007, Cambridge), in a 37-month prospective study, investigated the relationship between TBSI and outcome in 46 patients who sustained severe head injury [25]. The investigators applied multiple MRI sequences using a 3 Tesla field-strength magnet,

acquired MRI within 3 days of trauma, and described the findings according to the Firsching Classification [36]. Thirteen of these patients (28.3%) had evidence of TBSI. TBSI in five patients was located dorsolateral to the mesencephalon most likely secondary to uncal herniation. In six patients BSI was "primary" and part of a more centripetal widespread diffuse axonal injury that involved subcortical white, central gray, and corpus callosum in addition to the brainstem. TBSI in two patients was isolated without DAI above the posterior fossa. Primary and secondary TBSI had an 85% chance of unfavorable outcome. Thirty-three of 46 patients had no evidence of TBSI with an unfavorable outcome of slightly more than 50% ($P = 0.05$). The results of this study indicated that a significant number of patients with severe TBI requiring ventilator support had brainstem injury that was not seen on CT. According to the authors, TBSIs in themselves were not predictive of outcome compared with TBSIs associated with more extensive DAI. Ommaya-Gennarelli's hypothesis [6] of acceleration/deceleration/shear centripetal DAI therefore remains consistent with this study's findings.

In a 5-year prospective prognostic study of 100 patients with moderate and severe TBI, Lagares et al. [33] classified MRI (median of 15 days following trauma) morphological pattern of injury (T2*GRE, T2WI, and FLAIR) based on Adams et al.'s centripetal distribution of histopathological findings. The cohort's mean age was 33 and post-resuscitation GCS score in 63 patients was ≤7 Table 3.

Table 3. Patterns of rostral-caudal injury

Pattern I	Lesions confined to the subcortical white matter of frontal and temporal lobes
Pattern II	Lesions in subcortical white and corpus callosum
Pattern III	Lesions in dorsolateral mesencephalon and pons

Based on the Marshall et al. CT Classification, 72 patients in the Lagares et al. cohort had diffuse 1-3 injuries, 35 had mass lesions, but only four had evidence of brainstem damage. In this clinical investigation thirty patients had an unfavorable outcome, including five who died. MRI evidence of TBSI in 33 patients primarily involved the midbrain. There was a statistically significant relationship between unfavorable outcome and TBSI seen on MRI in this series. Based on the AUROC the prognostic model significantly improved when the core model GCS motor subscore was added to MRI covariates (Figure 2) [33].

In a 2011 study from Norway, Skandsen et al. assessed the predictive value of MRI on long-term outcome in 106 patients [38]. The cohort was a combined pediatric and adult (mean age: 28 years) and a mixture of moderately and severely disabled patients. From the 48 patients with severe head injury, 46% had TBSI. Bilateral TBSI was significantly associated with unfavorable outcome as measured by the Extended Glasgow Outcome Scale (GOSE) (Table 4).

In 2012, Chew et al. retrospectively analyzed a T2WI and T2*GRE volumetric analysis of TBSI in 36 patients [39]. Mean age was 45.5 years, and either subdural hematoma or epidural hematoma EDH was present in 21 patients. At 6-month follow-up 19 patients had poor outcome (17 died and two were in a persistent vegetative state). The mean volume of TBSI was 1.76 cm^3 in patients who recovered and 6.13 cm^3 in those who did not. TBSI involved midbrain in 22 (61%), pons in 17 (47%), and medulla in two (6%). The likelihood of TBSI crossing the midline increased as the lesion extended from the mesencephalon to the

medulla oblongata. T2WI sequence was a better indicator of volume of injury in TBSI. Stepwise logistic regression of all the variables indicated that lesions crossing the midline (P = 0.0156, OR = 0.075) and with a 24-hour motor score of ≤4 (P = 0.045, OR = 2.25) had the highest chance of poor outcome (C-statistic = 0.913).

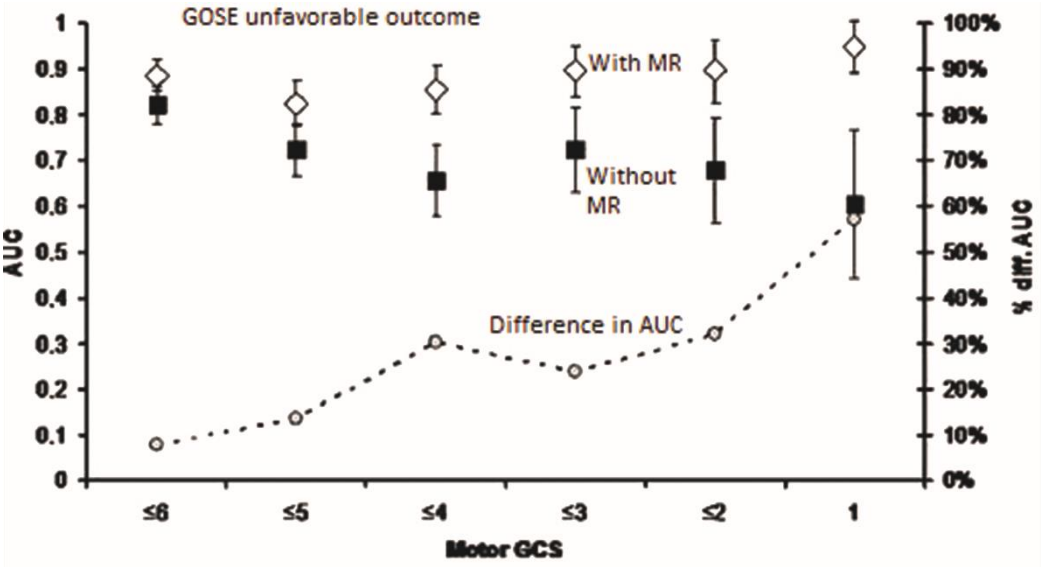

Figure 2. AUROC indicating improvement in predictive significance of the prognostic model when motor sub-score and MRI variables are included in the statistical analysis. (From Lagares et al, Acta Neurochirurgica with permission.

Table 4. Prognostic factors and outcome in severe head injury, ordinal logistic regression

Depth	N	Good Recovery	Moderate Disability	Dead or Severe Disability	O R (95% CI) adjusted for age	P value
Hemisphere	12	8 (67)	4 (32)	0	Reference	-
Central Core	14	5 (38)	7 (56)	2 (14)	6.5 (2.2-38.7)	0.04
TBSI Unilateral	8	4 (50)	2 (25)	2 (25)	7.9 (1.0-62.4)	0.05
TBSI Bilateral	14	1 (7)	1 (7)	12 (86)	181.6 (16.5-2000)	<0.001

Hilario et al. [31] investigated the relationship between geographic location of TBSI on MRI (anterior, posterior, unilateral, bilateral, rostral, and caudal) and GOSE outcome in 108 patients (2012). Sixty-six percent of the patients had an unfavorable outcome. The investigators discovered that all patients with TBSI also had subcortical (47 of 51 patients, or 92%) or corpus callosal (36 of 51, or 71%) injuries. Eighty-four percent of patients had involvement of mesencephalon, 6% medulla oblongata and 4% pons. In 6% of patients TBSI involved multiple spots on the brainstem. The discriminatory strength of morphology of TBSI is indicated in the following Table 5.

AUROC = area under the receiver operating characteristics. CI = confidence interval. OR = odds ratio.

Table 5. Discriminatory strength of morphology of TBSI on outcome [Ref. 31]

MRI Findings	Good Outcome Present	Good Outcome Absent	P value	OR (95% CI)	AUROC
Nonhemorrhagic	58	19	<0.01	5.9 (1.6-22)	0.71
Unilateral	33	0	<0.05	-	0.69
Anterior	54	15	<0.05	6.8 (1.8-25)	0.72
Anterior+nonhemorrhagic	50	10	<0.01	9.5 (1.8-48)	0.82
Anterior+nonhemorrhagic+ unilateral	60	8	<0.01	18 (3.5-93)	0.79

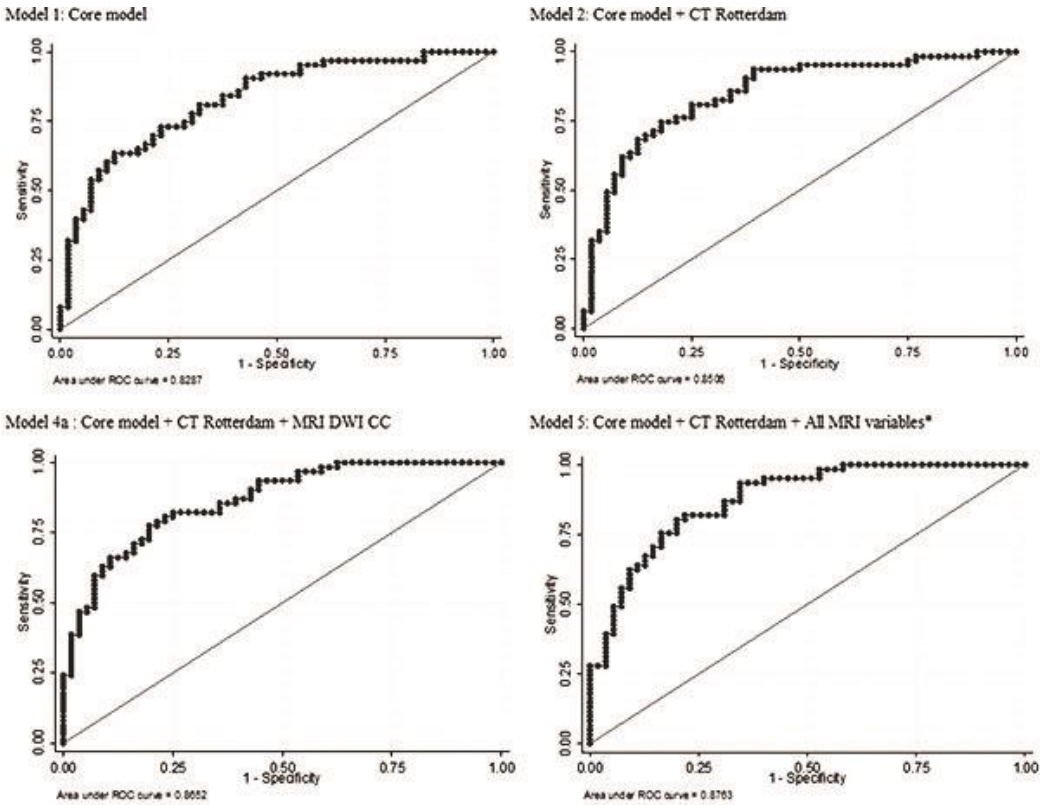

Figure 3. AUROC indicating progressive improvement in the discriminative power of the prognostic model when MRI values are added to the core and Rotterdam CT variables. (From Moen et al. with permission from J Neruotrauma [40]).

Moen et al. (2014, Norway) investigated the extent of diffuse axonal injury (volume and number of lesions) across the neuraxis on MRI and its effect on long-term functional outcome. In this prospective observational case control study, a cohort of moderate (n = 64) and severe (n = 64) patients had MRI within 8 days of trauma [40]. The subjects were followed for at least 12 months to determine their outcome on the GOSE scale. The anatomical distribution of the amount (based on DWI) and volume (based on FLAIR) of DAI as seen on MRI following trauma was classified into three stages: Stage 1 - involvement of the hemispheres, Stage 2 - involvement of the corpus callosum, and Stage 3 - involvement of the brainstem. Nearly 30% of patients with severe TBI and 20% of patients with moderate

TBI had TBSI. The MRI covariates were included in a prognostic model that also included the core model and Rotterdam CT variables. Using this prognostic model, the AUROC had a much improved discriminating power in predicting outcome in comatose patients with TBSI (Figure 3) [40].

In a retrospective clinical investigation, Smitherman et al. [32] volumetrically analyzed FLAIR hyperintense lesions (FHL) in 63 children with moderate and severe head injury. This research project confirmed the rostral-caudal neuraxis dispersion of kinetic energy following trauma and validated the Ommaya-Gennarelli centripetal pathological distribution of lesions along the neuraxis. The investigators defined the Hyperintensity Lesion Volume Index (HLVI) as the FHL volume in one zone/whole brain volume×100. Three zones were defined: Zone A was cortical, Zone B was central core (basal ganglia, thalamus, corpus callosum), and Zone C was brainstem. Ninety-three percent of patients in Zone C also had lesions in Zones A and B. In a logistic regression analysis, compared to patients with injuries in Zone A and Zone B, patients with lesions in all three zones had a significantly higher chance of unfavorable outcome (OR = 4.38 and 95% CI = 1.19-16). In addition, HLVI in Zone C by itself predicted poor outcome (Table 6).

Table 6. Functional outcome in different zones of injury (Ref. [32] Smitherman)

Pattern*	Number (%)	Favorable Number (%)	Unfavorable Number (%)
Zone A	19 (33)	16 (84)	3 (16)
Zones A+B	24 (42)	19 (79)	5 (21)
Zones A+B+C	14 (25)	7 (50)	7 (50)
Total	57	42 (74)	15 (26)

*In one patient FHLs were seen only in Zone C.

IMPLICATIONS OF THIS SYSTEMATIC REVIEW IN DECOMPRESSIVE CRANIECTOMY

We present an unpublished case report as a potential case for decompressive craniectomy (DC). A 26-year-old non-restrained female passenger was transferred to the Trauma Resuscitation Unit (TRU) at the University of Maryland R Adams Cowley Shock Trauma Center following a motor vehicle accident with a post-resuscitation GCS motor subscore of 4. Emergency Medical Technician records indicated respiratory arrest at the scene of accident. In the TRU she was already intubated when first evaluated by the neurosurgical service. The patient's GCS motor subscore was 4 and CT scan was consistent with DI2/DI3. Medical management was successful in maintaining acceptable intracranial pressure (ICP) and cerebral perfusion pressure (CPP) values (Figure 4) during her entire 7 days of hospitalization, after which time the family withdrew support. Admission CT scan (Figure 5, row A) of the head indicated minor intraventricular bleeding (arrow) and no significant finding at the level of the brainstem. FLAIR, SWI, and DWI sequences of her MRI on day 5 of admission was indicative of a centripetal injury to subcortical white, central core, corpus callosum, and brainstem (Rows B-D).

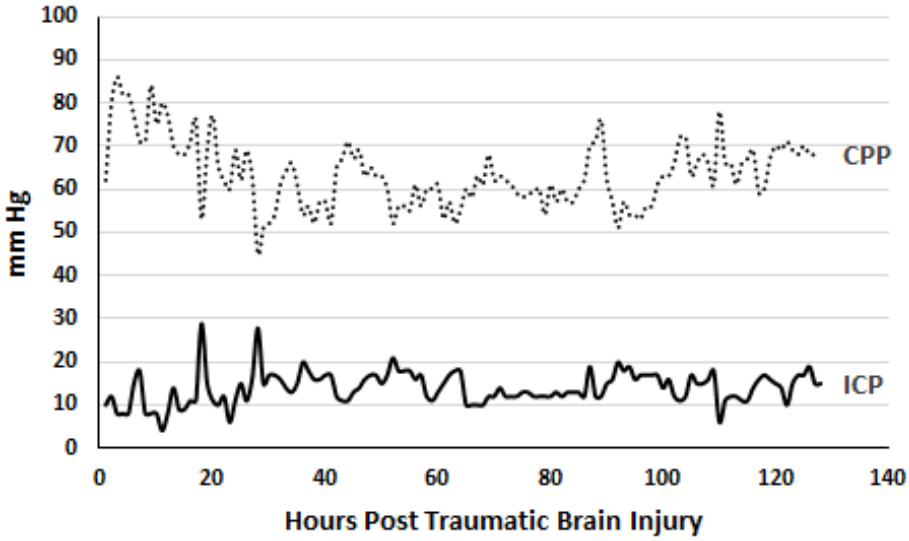

Figure 4. Post-resuscitation hourly ICP and CPP measures during the first 5 days of hospitalization indicating adequate medical management. (Courtesy of B Aarabi, University of Maryland).

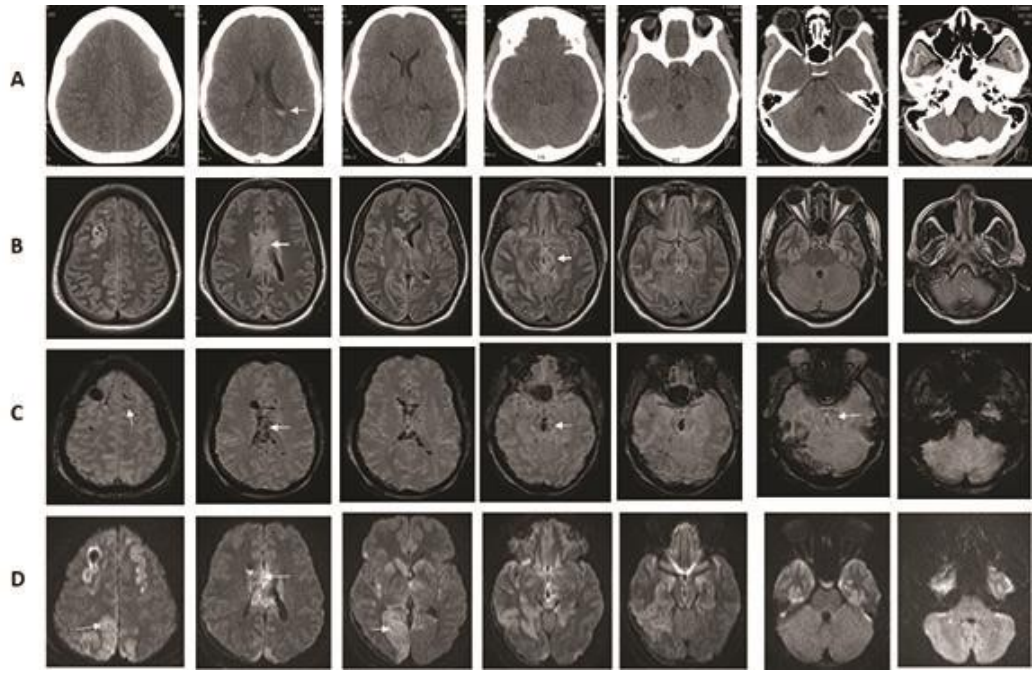

Figure 5. Computed tomography (CT) of head at admission and magnetic resonance imaging (MRI) on day 5 of injury. Row A: Computed tomography views indicating evidence of intraventricular bleed (arrow). Row B: Fluid Attenuation Inversion Recovery (FLAIR) MRI views of brain indicating hyperintense subcortical, corpus callosum, central core and brainstem (mainly mesencephalon) injuries (arrows). Row C: Susceptibility Weighted Images (SWI) of brain indicating hemorrhagic subcortical, corpus callosum, central core, mesencephalon and pontine injuries. Row D: Diffusion weighted Images (DWI) views of brain indicating restricted diffusion in parasagittal and occipital cortices, central gray, corpus callosum and midbrain (arrows), (Courtesy of B Aarabi, University of Maryland).

Prior to the acquisition of an MRI study in this patient, and despite successful efforts to medically manage the patient's intracranial pressure, both the critical care and neurosurgery services braced for the possible need to carry out a decompressive craniectomy procedure for this patient. We know that intractable intracranial hypertension following trauma is deadly [49-53]; however, we also know that the majority of trauma patients respond to medical management [54]. Only 5% to 10% of patients with severe TBI need DC [24, 55-57]. For example, in the DECRA Trial, only 155 of 3478 (4.4%) patients, whereas in RESCUEicp, 206 of 2008 patients (10%) with severe head injury were eligible and enrolled in the randomized controlled trials [56, 57]. In one uncontrolled cohort study, only 50 of 967 (5.2%) patients needed DC for diffuse swelling [24]. In this case, the issue of possibly taking the patient to the operating room did not arise as the patient's ICP remained below the typically concerning threshold of 20-25 mm Hg throughout the hospitalization, with the exception of two temporary "spikes."

We argue that decompressive craniectomy would have led to unnecessary morbidity in this patient. Had the MRI study demonstrating the severity of this patient's injury not been acquired, and given that her diffuse injury was under-appreciated on her initial CT scan, we argue, she might very well have been taken for decompressive surgery in the event of a sustained ICP crisis. The MR images of this case clearly demonstrate the classic pattern of centripetally-directed injury as originally described by Ommaya and Gennarelli, proceeding from the subcortical white matter to the central core, corpus callosum, and brain stem. In the absence of the MRI study, the chances of devastating TBSI would have instead been reported for purposes of prognosis as anywhere from 25% to 50% [25, 31, 33, 34, 36, 39, 40, 58].

As presented in this review, the evidence provided from other groups and a case report from our own experience leads to the conclusion that the acquisition of FLAIR and possibly SWI MRI sequences may be useful before proceeding with decompressive craniectomy, in that it may foretell a grim prognosis and therefore prevent placing patients destined for a poor clinical outcome under unnecessary morbidity associated with the procedure. In otherwords, the families of patients with hyperintense or hemorrhagic TBSI lesions seen on MRI, in the setting of GCS motor subscore is ≤ 4, should be counseled regarding future expectations and end-of-life decision making prior to undertaking this invasive surgical procedure.

REFERENCES

[1] Stippler M, Timmons SD, editors. Debate: Decompressive Craniectomy: Is it Over? *Annual Meeting, Congress of Neurological Surgeons*; 2017; Boston, Massachusetts, USA: Congress of Neurological Surgeons.

[2] Graham DI, Adams JH, Gennarelli TA. Mechanisms of non-penetrating head injury. *Progress in clinical and biological research.* 1988;264:159-68.

[3] Graham DI, Adams JH, Nicoll JA, Maxwell WL, Gennarelli TA. The nature, distribution and causes of traumatic brain injury. *Brain pathology* (Zurich, Switzerland). 1995;5(4):397-406.

[4] Graham DI, Clark JC, Adams JH, Gennarelli TA. Diffuse axonal injury caused by assault. *Journal of clinical pathology.* 1992;45(9):840-1.

[5] Graham DI, Gennarelli TA, and, McIntosh TK, (2002). Trauma in: *Greenfield's Neuropathology*, 7th ed. D.I. Graham and P.L. Lantos (eds), Arnold Press. London, New York, New Delhi. p. 823-98.

[6] Ommaya AK, Gennarelli TA. Cerebral concussion and traumatic unconsciousness. Correlation of experimental and clinical observations of blunt head injuries. *Brain: a journal of neurology*. 1974;97(4):633-54.

[7] Graham DI, Adams JH, Doyle D, Ford I, Gennarelli TA, Lawrence AE, et al. Quantification of primary and secondary lesions in severe head injury. *Acta neurochirurgica Supplementum*. 1993;57:41-8.

[8] Graham DI, Ford I, Adams JH, Doyle D, Lawrence AE, McLellan DR, et al. Fatal head injury in children. *Journal of clinical pathology*. 1989;42(1):18-22.

[9] Adams H, Mitchell DE, Graham DI, Doyle D. Diffuse brain damage of immediate impact type. Its relationship to 'primary brain-stem damage' in head injury. *Brain: a journal of neurology*. 1977;100(3):489-502.

[10] Adams JH, Doyle D, Ford I, Gennarelli TA, Graham DI, McLellan DR. Diffuse axonal injury in head injury: definition, diagnosis and grading. *Histopathology*. 1989;15(1):49-59.

[11] Adams JH, Doyle D, Ford I, Graham DI, McGee M, McLellan DR. Brain damage in fatal non-missile head injury in relation to age and type of injury. *Scottish medical journal*. 1989;34(1):399-401.

[12] Adams JH, Graham DI, Gennarelli TA. Acceleration induced head injury in the monkey. II. *Neuropathology. Acta neuropathologica Supplementum*. 1981;7:26-8.

[13] Adams JH, Graham DI, Gennarelli TA. Head injury in man and experimental animals: neuropathology. *Acta neurochirurgica Supplementum*. 1983;32:15-30.

[14] Adams JH, Graham DI, Gennarelli TA, Maxwell WL. Diffuse axonal injury in non-missile head injury. *Journal of neurology, neurosurgery, and psychiatry*. 1991;54(6):481-3.

[15] Adams JH, Graham DI, Murray LS, Scott G. Diffuse axonal injury due to nonmissile head injury in humans: an analysis of 45 cases. *Annals of neurology*. 1982;12(6):557-63.

[16] Adams JH, Jennett B, Murray LS, Teasdale GM, Gennarelli TA, Graham DI. Neuropathological findings in disabled survivors of a head injury. *Journal of neurotrauma*. 2011;28(5):701-9.

[17] Gennarelli TA. Mechanisms of brain injury. *The Journal of emergency medicine*. 1993;11 Suppl 1:5-11.

[18] Gennarelli TA, Adams JH, Graham DI. Acceleration induced head injury in the monkey.I. The model, its mechanical and physiological correlates. *Acta neuropathologica Supplementum*. 1981;7:23-5.

[19] Levin HS, Williams D, Crofford MJ, High WM, Jr., Eisenberg HM, Amparo EG, et al. Relationship of depth of brain lesions to consciousness and outcome after closed head injury. *Journal of neurosurgery*. 1988;69(6):861-6.

[20] Merino-deVillasante J, Taveras JM. Computerized tomography (CT) in acute head trauma. *AJR American journal of roentgenology*. 1976;126(4):765-78.

[21] Marshall LF, Marshall SB, Klauber MR, van Berkum Clark M, Eisenberg HM, Jane JA, et al. A new classification of head injury based on computerized tomography. *Journal of neurosurgery*. 1991;75 (Suppl):S14-S20.

[22] Maas AI, Steyerberg EW, Butcher I, Dammers R, Lu J, Marmarou A, et al. Prognostic value of computerized tomography scan characteristics in traumatic brain injury: results from the IMPACT study. *Journal of neurotrauma.* 2007;24(2):303-14.

[23] Maas AI, Hukkelhoven CW, Marshall LF, Steyerberg EW. Prediction of outcome in traumatic brain injury with computed tomographic characteristics: a comparison between the computed tomographic classification and combinations of computed tomographic predictors. *Neurosurgery.* 2005;57(6):1173-82; discussion -82.

[24] Aarabi B, Hesdorffer DC, Ahn ES, Aresco C, Scalea TM, Eisenberg HM. Outcome following decompressive craniectomy for malignant swelling due to severe head injury. *Journal of neurosurgery.* 2006;104(4):469-79.

[25] Mannion RJ, Cross J, Bradley P, Coles JP, Chatfield D, Carpenter A, et al. Mechanism-based MRI classification of traumatic brainstem injury and its relationship to outcome. *Journal of neurotrauma.* 2007;24(1):128-35.

[26] Gentry LR, Godersky JC, Thompson B, Dunn VD. Prospective comparative study of intermediate-field MR and CT in the evaluation of closed head trauma. *AJR American journal of roentgenology.* 1988;150(3):673-82.

[27] Beauchamp MH, Beare R, Ditchfield M, Coleman L, Babl FE, Kean M, et al. Susceptibility weighted imaging and its relationship to outcome after pediatric traumatic brain injury. *Cortex; a journal devoted to the study of the nervous system and behavior.* 2013;49(2):591-8.

[28] Geurts BH, Andriessen TM, Goraj BM, Vos PE. The reliability of magnetic resonance imaging in traumatic brain injury lesion detection. *Brain injury.* 2012;26(12):1439-50.

[29] Spitz G, Maller JJ, Ng A, O'Sullivan R, Ferris NJ, Ponsford JL. Detecting lesions after traumatic brain injury using susceptibility weighted imaging: a comparison with fluid-attenuated inversion recovery and correlation with clinical outcome. *Journal of neurotrauma.* 2013;30(24):2038-50.

[30] Woischneck D, Klein S, Reissberg S, Peters B, Avenarius S, Gunther G, et al. Prognosis of brain stem lesion in children with head injury. *Child's nervous system: ChNS: official journal of the International Society for Pediatric Neurosurgery.* 2003;19(3):174-8.

[31] Hilario A, Ramos A, Millan JM, Salvador E, Gomez PA, Cicuendez M, et al. Severe traumatic head injury: prognostic value of brain stem injuries detected at MRI. *AJNR American journal of neuroradiology.* 2012;33(10):1925-31.

[32] Smitherman E, Hernandez A, Stavinoha PL, Huang R, Kernie SG, Diaz-Arrastia R, et al. Predicting Outcome after Pediatric Traumatic Brain Injury by Early Magnetic Resonance Imaging Lesion Location and Volume. *Journal of neurotrauma.* 2016;33(1):35-48.

[33] Lagares A, Ramos A, Perez-Nunez A, Ballenilla F, Alday R, Gomez PA, et al. The role of MR imaging in assessing prognosis after severe and moderate head injury. *Acta neurochirurgica.* 2009;151(4):341-56.

[34] Firsching R, Woischneck D, Diedrich M, Klein S, Ruckert A, Wittig H, et al. Early magnetic resonance imaging of brainstem lesions after severe head injury. *Journal of neurosurgery.* 1998;89(5):707-12.

[35] Firsching R, Woischneck D, Klein S, Ludwig K, Dohring W. Brain stem lesions after head injury. *Neurological research.* 2002;24(2):145-6.

[36] Firsching R, Woischneck D, Klein S, Reissberg S, Dohring W, Peters B. Classification of severe head injury based on magnetic resonance imaging. *Acta neurochirurgica.* 2001;143(3):263-71.

[37] Woischneck D, Kapapa T, Grimm C, Skalej M, Schmitz B, Blumstein N, et al. [Injuries to the upper cervical medulla in severe brain injuries]. *Zeitschrift fur Orthopadie und Unfallchirurgie.* 2011;149(5):541-5.

[38] Skandsen T, Kvistad KA, Solheim O, Lydersen S, Strand IH, Vik A. Prognostic value of magnetic resonance imaging in moderate and severe head injury: a prospective study of early MRI findings and one-year outcome. *Journal of neurotrauma.* 2011;28(5):691-9.

[39] Chew BG, Spearman CM, Quigley MR, Wilberger JE. The prognostic significance of traumatic brainstem injury detected on T2-weighted MRI. *Journal of neurosurgery.* 2012;117(4):722-8.

[40] Moen KG, Brezova V, Skandsen T, Haberg AK, Folvik M, Vik A. Traumatic axonal injury: the prognostic value of lesion load in corpus callosum, brain stem, and thalamus in different magnetic resonance imaging sequences. *Journal of neurotrauma.* 2014;31(17):1486-96.

[41] Gennarelli TA, Thibault LE, Adams JH, Graham DI, Thompson CJ, Marcincin RP. Diffuse axonal injury and traumatic coma in the primate. *Annals of neurology.* 1982;12(6):564-74.

[42] Gennarelli TA, Tipperman R, Maxwell WL, Graham DI, Adams JH, Irvine A. Traumatic damage to the nodal axolemma: an early, secondary injury. *Acta neurochirurgica Supplementum.* 1993;57:49-52.

[43] Kandel ER, Kupfermann I, Iversen S. Learning and Memory, in *Principles of Neural Science*, in Kandel ER, Schwartz JH, Jessell TM (eds). Fourth ed. New York: McGraw-Hill; 2000.

[44] Posner JB, Saper CB, Schiff ND, Plum F. *Plum and Posner's Diagnosis of Stupor and Coma*. 4th ed. New York New York USA: Oxford University Press; 2007.

[45] Irimia A, Wang B, Aylward SR, Prastawa MW, Pace DF, Gerig G, et al. Neuroimaging of structural pathology and connectomics in traumatic brain injury: Toward personalized outcome prediction. *NeuroImage Clinical.* 2012;1(1):1-17.

[46] Wu X, Zou Q, Hu J, Tang W, Mao Y, Gao L, et al. Intrinsic Functional Connectivity Patterns Predict Consciousness Level and Recovery Outcome in Acquired Brain Injury. *The Journal of neuroscience: the official journal of the Society for Neuroscience.* 2015;35(37):12932-46.

[47] Huntenburg JM, Bazin PL, Goulas A, Tardif CL, Villringer A, Margulies DS. A Systematic Relationship between Functional Connectivity and Intracortical Myelin in the Human Cerebral Cortex. *Cerebral cortex* (New York, NY: 1991). 2017;27(2):981-97.

[48] Xu W, Kaur H, Wang X, Li H. The Role of Magnetic Resonance Imaging in the Prediction of Minimally Conscious State after Traumatic Brain Injury. *World neurosurgery.* 2016;94:167-73.

[49] Miller JD, Becker DP, Ward JD, Sullivan HG, Adams WE, Rosner MJ. Significance of intracranial hypertension in severe head injury. *Journal of neurosurgery.* 1977;47(4):503-16.

[50] Marshall LF. Head injury: recent past, present, and future. *Neurosurgery*. 2000;47(3):546-61.
[51] Marshall LF, Gautille T, Klauber MR, Eisenberg HM, Jane JA, Luerssen TG, et al. The outcome of severe closed head injury. *Journal of neurosurgery*. 1991;75:S28-S36.
[52] Marmarou A, Anderson RL, Ward JD, Choi SC, Young HF. Impact of ICP instability and hypotension on outcome in patients with severe head trauma. *Journal of neurosurgery*. 1991;75:S59-S66.
[53] Clifton GL, Coffey CS, Fourwinds S, Zygun D, Valadka A, Smith KR, Jr., et al. Early induction of hypothermia for evacuated intracranial hematomas: a post hoc analysis of two clinical trials. *Journal of neurosurgery*. 2012;117(4):714-20.
[54] Carney N, Totten AM, O'Reilly C, Ullman JS, Hawryluk GW, Bell MJ, et al. Guidelines for the Management of Severe Traumatic Brain Injury, Fourth Edition. *Neurosurgery*. 2017;80(1):6-15.
[55] Barthelemy EJ, Melis M, Gordon E, Ullman JS, Germano IM. Decompressive Craniectomy for Severe Traumatic Brain Injury: A Systematic Review. *World neurosurgery*. 2016;88:411-20.
[56] Cooper DJ, Rosenfeld JV, Murray L, Arabi YM, Davies AR, D'Urso P, et al. Decompressive craniectomy in diffuse traumatic brain injury. *The New England journal of medicine*. 2011;364(16):1493-502.
[57] Hutchinson PJ, Kolias AG, Timofeev IS, Corteen EA, Czosnyka M, Timothy J, et al. Trial of Decompressive Craniectomy for Traumatic Intracranial Hypertension. *The New England journal of medicine*. 2016;375(12):1119-30.
[58] Moen KG, Skandsen T, Folvik M, Brezova V, Kvistad KA, Rydland J, et al. A longitudinal MRI study of traumatic axonal injury in patients with moderate and severe traumatic brain injury. *Journal of neurology, neurosurgery, and psychiatry*. 2012;83(12):1193-200.

In: Encyclopedia of Surgery (22 Volume Set)
Editors: Andreas Lehrer and Kristin Mueller
ISBN: 978-1-53618-329-0
© 2020 Nova Science Publishers, Inc.

Chapter 243

ROBOTIC PORTAL LUNG RESECTION

Roman V. Petro, Charles T. Bakhos and Abbas E. Abbas
Department of Thoracic Medicine and Surgery,
Lewis Katz School of Medicine at Temple University, Philadelphia, PA, US

INTRODUCTION

Alone or in combination with other modalities, surgical resection of lung cancer is the cornerstone of curative treatment for this devastating disease. This fact has remained true ever since the first oncologic lung resection, left pneumonectomy, was performed by Dr. Evarts Graham almost a century ago [1]. Resection of the cancer with an adequate margin along with the anatomical unit of lung in which reside lymphatics, vessels and parenchyma remains the gold standard of care, against which other ablative modalities must be judged. Whether this "anatomical unit" is a lobe, two lobes, one or more segments, or even a whole lung depends on both patient and tumor factors such as pulmonary functional status, comorbidities, location of tumor, size and histology. Increasing evidence is emerging of the oncologic equivalence of sublobar resection to lobectomy, especially for small or subsolid tumors [2, 3].

Safe surgical technique in the chest demands meticulous finesse in the hilar dissection of bronchovascular structures. This has traditionally required thoracotomy, a rib-spreading incision, big enough to accommodate surgeon's hands to allow free bimanual dissection and assistance. This approach is still the most common access for lobectomy, as it provides excellent exposure of the hilum and pleural cavity. Unfortunately, this incision is also quite painful, and may be associated with higher morbidity, including chronic pain and impaired respiratory mechanics, leading to atelectasis and pneumonia. For this reason there has been a quest by thoracic surgeons to find a less invasive alternative.

Non-rib spreading video assisted thoracoscopic surgery (VATS) for lung resection has been the main approach for minimally invasive lung resection, providing better short-term outcomes in numerous studies [4-8]. However, VATS lobectomy is quite different from thoracotomy. The viewing angle is anterior, not superior, necessitating an anterior to posterior hilar dissection with division of the fissure last. With VATS approach posterior dissection, which is sometimes necessary, is quite difficult. The main VATS dissection technique is a

single rigid instrument, performing either a lift and burn or a push and spread of tissue instead of the time-honored surgical rules of bimanual traction and countertraction, with careful alternation of both blunt and sharp dissection. Despite these drawbacks, experienced surgeons have described use of VATS for advanced cases, including uniportal VATS sleeve lobectomies and pneumonectomies. However, VATS can only be safely recommended for small peripheral tumors that are not associated with significant hilar adenopathy [8].

As opposed to traditional VATS, robotic surgery allows the surgeon to manipulate the pulmonary hilar structures and mediastinal lymph nodes with excellent 3-dimensional visualization, facilitating the conduct of the operation. The wristed instruments allow unimpeded manipulation of the tissues and the ability to perform fine sharp dissection as we were taught in the open surgery, facilitating dissection of hilar structures and lymphadenectomy. In fact, robotic portal thoracoscopy has been likened to an open procedure done through the ports, or a "virtual thoracotomy" [9]. It gives the surgeon visual illusion of looking at the lung through an open chest and of being able to address the anatomy in a natural bimanual wristed technique.

By the early 2000's, the first reports had appeared of *robotic-assisted thoracic surgery* (RATS) [10], described initially as an approach to patients with early-stage lung cancer. Since then, it has been consistently applied for more advanced cases such as segmentectomy, bilobectomy, pneumonectomy, sleeve resections and chest wall involvement (Figures 1-7), situations, where most VATS surgeons would otherwise opt (perhaps wisely) for thoracotomy [11].

Another important advantage of the robotic platform is the unique applicability to teaching and training. A double console (Figure 8) allows two surgeons to operate simultaneously and to switch control at any time. Attending surgeon with the use of telestration is able to direct trainee to perform increasingly complex tasks, while maintaining full visual control of the situation. In addition, surgical simulators have been developed that greatly enhance the ability of trainees to learn this new technology.

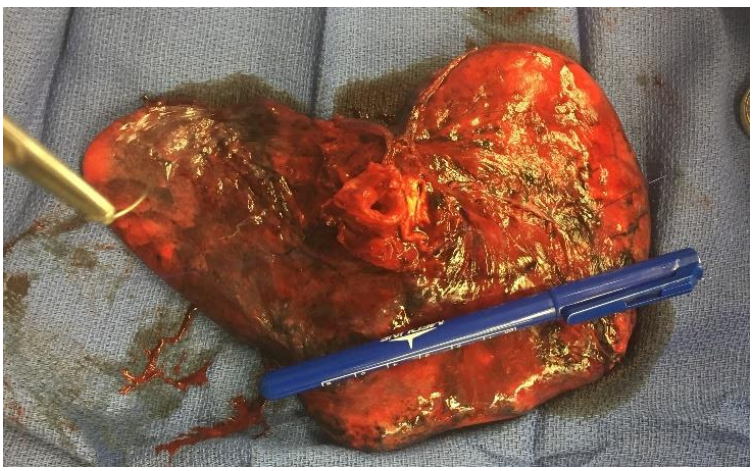

Figure 1. Sleeve right upper lobectomy specimen.

Figure 2. Left pneumonectomy specimen with large hilar tumor.

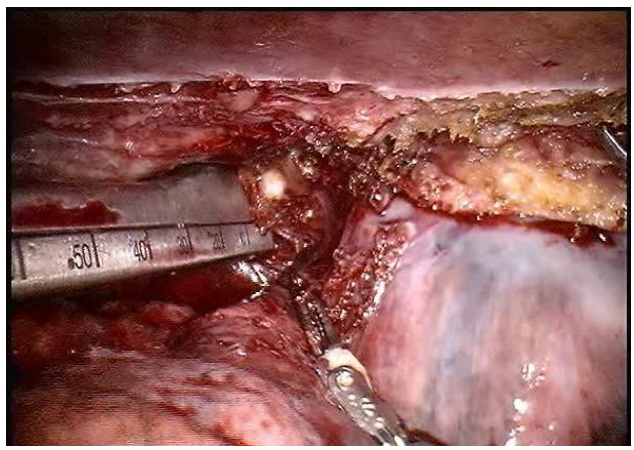

Figure 3. Use of dennis rib cutter in left upper lobectomy with en-bloc chest wall resection.

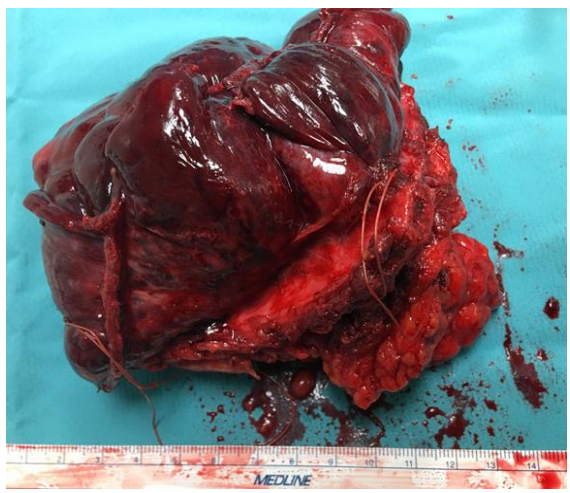

Figure 4. Right middle and lower bilobectomy with en-bloc chest wall resection specimen.

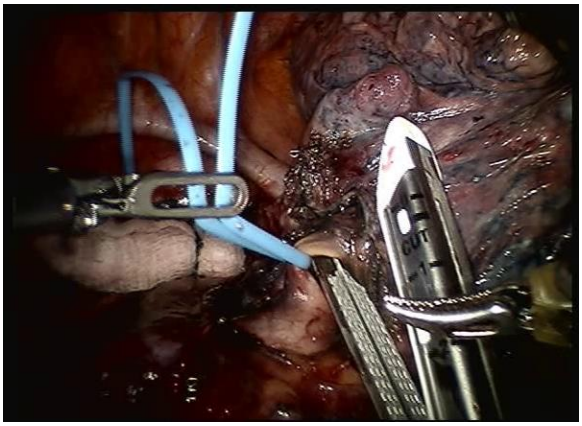

Figure 5. Division of the posterior ascending artery in posterior segmentectomy of the right upper lobe.

Figure 6. Right main bronchus stump during right pneumonectomy.

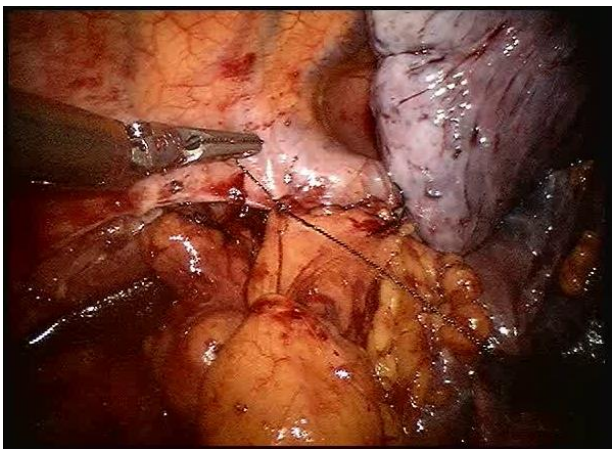

Figure 7. Reinforcement of the right bronchial stump with thymic flap.

Figure 8. Teaching capabilities of double console.

COMPARISON OF ROBOTIC SURGERY WITH OTHER MODALITIES

No prospective randomized trials have compared the clinical outcomes of robotic surgery to other surgical approaches for lung cancer. However, numerous retrospective studies have reported on the benefits of robotic lung resection.

Although not the only criterion of the radicality of a cancer operation, studies have shown that the number of lymph nodes removed is equivalent in both robotic and open procedures [11] In addition, studies have reported an upstaging frequency (i.e., ability to detect unexpected nodal metastasis) of 10-13% for robotic lobectomy which compares favorably with that of open lobectomy and is superior to VATS [12, 13].

When comparing to open thoracotomy, one study of a cohort of 168 patients showed that those, undergoing robotic lobectomy, suffered less perioperative morbidity (27% vs. 38%), had shorter chest tube drainage (1.5 vs. 3 days) and required shorter hospital stay (2 vs. 4 days) [11]. Another study showed less postoperative pain and shorter hospital stay in patients who underwent robotic compared to open lobectomy [14].

Studies have also compared RATS to VATS lung resection. One retrospective case-control analysis, comparing RATS with VATS in two matched groups, found that RATS patients received less narcotic analgesia and resumed their normal activities sooner [15]. As part of a large database study of 33,095 cases of lobectomy and segmentectomy between 2008 and 2010, RATS, when compared to VATS, was associated with lesser mortality (0.2% vs. 1.1%), shorter hospital stays (5.9 days vs. 6.3 days), and lower complication rates (43.8% vs. 45.3%), although these differences did not reach statistical significance [16].

Far fewer studies have reported on the long-term survival after robotic lobectomy for lung cancer. One of these is a retrospective study of stage-specific survival for 325 consecutive patients, who underwent robotic lobectomy for NSCLC at three centers (two in Italy, one in the USA) over an 8-year period from 2002 to 2010. Median follow-up was 27

months and overall 5-year survival were 80%: 91% for stage IA, 88% for stage IB, and 49% for stage II. Three-year survival for stage IIIA patients was 43%. These results are at least equivalent for those expected after VATS or thoracotomy [13].

Table 1. Robotic preprocedural emergency conversion timeout drill

Role	What to do
Anesthesiologist	Call for additional anesthesia support Avoid inflation of the lung
Circulating Nurse	If thoracotomy instruments not already open do that first. Call for additional help Deliver blood to anesthesia team Notify blood bank to prepare for more units
Scrub nurse or technician	Leave gown and glove on side of cart for surgeon to self-gown Do not remove or switch off camera Undock only the arms that the console surgeon specifies. Have thoracotomy instruments open Have bedside instrument-release wrench available
Bedside surgeon	Depends on the situation: If holding pressure on a bleeding vessel then continue to do that and do not assist in the undocking process If control is lost then make an emergent thoracotomy (at 5th intercostal space)
Console surgeon	Scrub, gown and glove oneself Call a colleague to assist Keep calm and carry on

Despite these potential benefits of robotic surgery some valid concerns still exist. A frequent criticism of RATS is limitations in the event of uncontrollable hemorrhage. The primary surgeon is not even at the bedside, is not sterile, and there is a heavy machine on top of the patient. Converting the case to open thoracotomy necessitates removing the instruments and ports, undocking the robot, sterilely scrubbing the surgeon and rapidly gaining an open access to the chest. This exercise can be accomplished in seconds if the team is familiar with the logistics of this critical process. For these purposes it is important to frequently review this emergency scenario as a drill with the entire surgical team so when the crisis strikes, each individual in the room knows exactly what his or her role is. These authors routinely announce a preprocedural "timeout," reviewing the role of each person in the room; the anesthesiologist to call for assistance, the circulating nurse to call for blood, the scrub nurse to start the undocking procedure and the assistant to perform whatever is necessary at the time (e.g., holding pressure on a bleeding vessel or making a thoracotomy; Table 1). VATS and thoracotomy instruments should be immediately available. Although the need for conversion will diminish with experience, bleeding emergency should be an expectation not a surprise in any busy thoracic program, especially as surgeons undertake increasingly complex cases [9].

Perhaps the biggest drawback of robotic surgery is the hefty price tag, which makes it not affordable to the vast majority of surgeons and their patients in the world. In the future this price will likely to diminish as we see more competition amongst manufacturers and academic institutions. Furthermore, robotic surgery may actually be more profitable when it leads to better outcomes, shorter hospital stays and faster returns to work. It should therefore be preferentially selected for cases with high acuity such as thoracic procedures where these

benefits will make the most difference. Using it for simple outpatient procedures on the other hand may not be cost-effective at present [17].

TECHNIQUE

We have previously described our technique for robotic lobectomy using da Vinci Xi Surgical System (Intuitive Surgical, Inc., Sunnyvale, CA) and a four-arm, totally portal approach [18]. We do not employ a utility incision and all assistance is accomplished through the assistant port. Extraction of the specimen is done trans-diaphragmatically through a subcostal incision rather than the more common approach of intercostal extraction employed by other surgeons. It is the authors' opinion that this is the only really portal based procedure since removing a large specimen through an intercostal space will inevitably cause a degree of rib-spreading.

After induction of general anesthesia, lung isolation is achieved by either a bronchial blocker or a double lumen tube. We prefer the bronchial blocker for several reasons. First, its smaller profile allows safer and easier dissection around the airway. Second, larger inner diameter of the single lumen endotracheal tube allows toilet bronchoscopy at the end of the procedure by simply removing the blocker. Finally, if the patient cannot be extubated immediately after completion of the procedure, it obviates the need for a potentially dangerous exchange of the double lumen tube. Next, the patient is moved into the lateral decubitus position, and the bed is flexed to 150 degrees at the level of the 8th intercostal space (ICS). The robot is positioned behind the patient's head.

Five ports are then inserted (Figure 9). Care is taken to position these ports approximately 10 cm apart (about a hand's breadth) in order to avoid external collisions between the arms. We attempt to place all 4 ports in the 8th intercostal space. The first port of entry is at the posterior axillary line (PAL). We then place a camera endoscope, start carbon dioxide insufflation at a pressure of 10 mm Hg and confirm the placement of the other ports. Three other robotic ports are placed in the 8th intercostal space at the midclavicular line (MCL) (12mm), anterior axillary line (AAL) (8mm) and paraspinal line (PSL) (8mm). We ensure that this last posterior port is at least 5 cm from the lateral border of the spine in order to avoid injury of the intercostal bundle in the narrow posterior aspect of the intercostal space. These ports are placed in the same locations for both left and right sided procedures. An assistant port (15mm) is then placed subcostally near the tip of the 11th rib and through the insertion of the diaphragm. Using this technique, our port locations have been the same for all past and current da Vinci robot models. The robot is then docked from the head of the table, and the surgeon takes position at the console. Camera is placed in the anterior axillary line port and working instruments include Bipolar Maryland Forceps in the most medial port, Cadiere Forceps or Fenestrated Bipolar Forceps in posterior axillary line port and Tip Up Fenestrated Grasper or Double Fenestrated Grasper in the most posterior port.

After initial inspection to rule out pleural metastatic disease, we begin by mobilizing the hilum. For dissection and tissue division we prefer bipolar energy technique. The other surgeons hand assist in manipulating the lung, providing exposure. Arm in the paraspinal port serves as a static retractor. Bedside assistant, utilizing 15 mm subcostal port, passes gauze

rolls, vessel loops, retrieves specimens, provides suction for clearance of the blood and operates endostaplers if robotic stapling is unavailable.

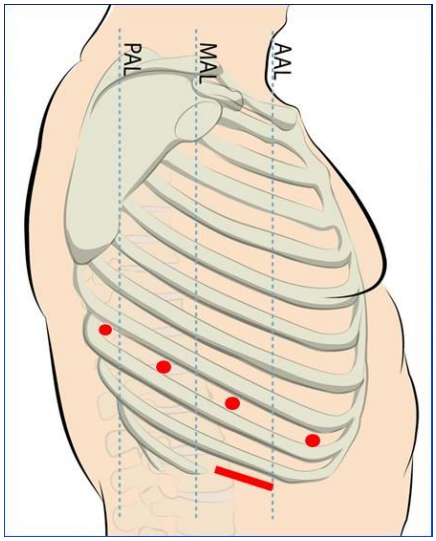

Figure 9. Diagram of robotic ports location.

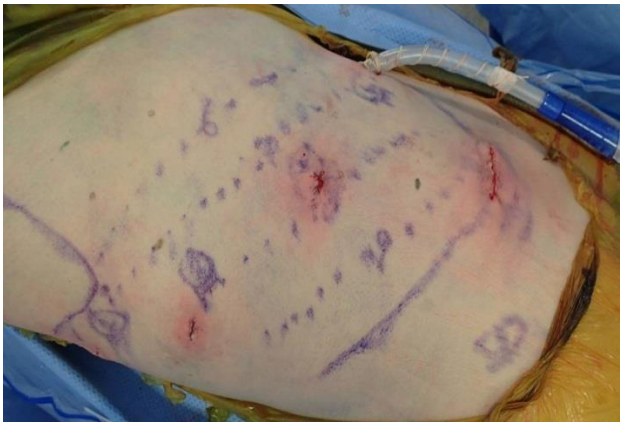

Figure 10. Completion of the robotic lung surgery. Note same interspace location of ports and subcostal location of the extraction incision.

Initially, the inferior pulmonary ligament is divided followed by the mediastinal pleura circumferentially around the hilum. In the process, the mediastinal lymph node dissection is completed before division of any bronchovascular structures and all nodes are removed in a protective bag to avoid spillage. Completing the nodal dissection first facilitates the exposure of the hilar structures and allows frozen section exam of any suspicious findings.

Following this, the lobar vein, artery and bronchus are divided according to the individual patient anatomy and surgeon preference as opposed to VATS where anterior to posterior approach (vein to artery to bronchus) is almost mandatory. The vascular structures are divided with the robotic 30mm curved vascular load, while the green load is used for the bronchus (30 mm) and parenchyma (45 mm). At the end, the specimen is placed in the retrieval bag and the

robot is undocked. The assistant port incision is then extended to about 3-4cm and the specimen is removed. A chest tube is placed through the anterior port site followed by closure of the incisions in the standard fashion (Figure 10). Care is taken to use permanent suture for reinsertion of the edge of the diaphragm to the 10th rib.

Bimanual wristed motion of the robotic instruments provides unique opportunity for finesse tissue management, allowing advanced minimally invasive resection in complex locally advanced situations or sublobar resections. For sleeve bronchial resection, once bronchus is divided, continuous absorbable 3-0 V-loc suture (Medtronic, Minneapolis, MN)) is used for bronchial anastomosis. In cases of pulmonary artery sleeve resection proximal and distal vascular control is achieved by application of laparoscopic bulldog clamps. We prefer 25 mm curved bulldog clamps.

In cases of chest wall invasion, attachment of the lung to the chest wall frequently provides excellent retraction for hilar dissection and whenever possible we approach the hilum first. However, when visualization is impaired by the fixed lung, resection of chest wall can be accomplished as an initial step. At least two to three-centimeter resection margin is required in these cases. Hot Shears is an excellent instrument for the dissection and division of the intercostal muscles. Whenever angle is appropriate, we use Dennis Rib Cutter (Figure 3; Scanlan International, Saint Paul, MN), advanced through the assistant incision after removal of the port for rib resection. When invasion is in the apical aspect of the chest, with limited reach of the Rib Cutter, a fragment of Gigli saw is passed around the rib and is used to divide the bone with both robotic arms. Finally, in difficult angles when none of these techniques work, Gigli saw can be brought outside with Carter-Thomason (CooperSurgical, Inc., Trumbull, CT) device through two stab skin incisions around the rib and can be used externally by bedside assistant for rib division.

FUTURE DIRECTIONS

Robotic technology continues to evolve with new and exciting advances on the horizon. One of these promising approaches is a navigational technology, i.e., the ability to direct the surgeon to a target that is too small or deep to localize. A recent publication by this author's group describes electromagnetic navigational bronchoscopic localization of small, deep or subsolid nodules and injecting them with Indocyanine Green (ICG). Using near infrared laser emission by specially equipped robotic cameras allows easy identification of the autofluorescent nodules [19]. Further developments may allow navigational technology to direct the robot itself to the target nodule. Yet another important area of innovation in robotics is virtual haptic feedback, which would allow the surgeon to palpate and feel the consistency of tissue. Additional potentially revolutionary innovation would be the ability to intermittently overlay a reconstructed 3-dimensional study (e.g., CT scan or MRI) over the real time video image. This would enable the surgeon to more easily identify hidden structures such as the pulmonary vessels or difficult nodules.

REFERENCES

[1] Horn L, Johnson DH. Evarts A. Graham and the first pneumonectomy for lung cancer. *J Clin Oncol*. 2008 Jul 1;26(19):3268-75.

[2] Cao C, Chandrakumar D, Gupta S, Yan TD, Tian DH. Could less be more?-A systematic review and meta-analysis of sublobar resections versus lobectomy for non-small cell lung cancer according to patient selection. *Lung Cancer*. 2015 Aug;89(2):121-32.

[3] Sakurai H, Asamura H. Sublobar resection for early-stage lung cancer. *Transl Lung Cancer R*es. 2014 Jun;3(3):164-72.

[4] Landreneau RJ, Hazelrigg SR, Mack MJ, Dowling RD, Burke D, Gavlick J, et al. Postoperative pain-related morbidity: video-assisted thoracic surgery versus thoracotomy. *Ann Thorac Surg*. 1993 Dec;56(6):1285-9.

[5] Jaklitsch MT, DeCamp MM, Jr, Liptay MJ, Harpole DH, Jr, Swanson SJ, Mentzer SJ, et al. Video-assisted thoracic surgery in the elderly. A review of 307 cases. *Chest*. 1996 Sep;110(3):751-8.

[6] Demmy TL, Curtis JJ. Minimally invasive lobectomy directed toward frail and high-risk patients: a case-control study. *Ann Thorac Surg*. 1999 Jul;68(1):194-200.

[7] Kaseda S, Aoki T, Hangai N, Shimizu K. Better pulmonary function and prognosis with video-assisted thoracic surgery than with thoracotomy. *Ann Thorac Surg*. 2000 Nov;70(5):1644-6.

[8] McKenna RJ, Jr, Houck W, Fuller CB. Video-assisted thoracic surgery lobectomy: experience with 1,100 cases. *Ann Thorac Surg*. 2006 Feb;81(2):421,5; discussion 425-6.

[9] Abbas AE. Robotic portal lobectomy, surgery through a virtual thoracotomy. *J Thorac Dis*. 2017 Sep;9(9):2871-5.

[10] Melfi FM, Menconi GF, Mariani AM, Angeletti CA. Early experience with robotic technology for thoracoscopic surgery. *Eur J Cardiothorac Surg*. 2002 May; 21(5): 864-8.

[11] Cerfolio RJ, Bryant AS, Skylizard L, Minnich DJ. Initial consecutive experience of completely portal robotic pulmonary resection with 4 arms. *J Thorac Cardiovasc Surg*. 2011 Oct;142(4):740-6.

[12] Wilson JL, Louie BE, Cerfolio RJ, Park BJ, Vallieres E, Aye RW, et al. The prevalence of nodal upstaging during robotic lung resection in early stage non-small cell lung cancer. *Ann Thorac Surg*. 2014 Jun;97(6):1901,6; discussion 1906-7.

[13] Park BJ, Melfi F, Mussi A, Maisonneuve P, Spaggiari L, Da Silva RK, et al. Robotic lobectomy for non-small cell lung cancer (NSCLC): long-term oncologic results. *J Thorac Cardiovasc Surg*. 2012 Feb;143(2):383-9.

[14] Darr C, Cheufou D, Weinreich G, Hachenberg T, Aigner C, Kampe S. Robotic thoracic surgery results in shorter hospital stay and lower postoperative pain compared to open thoracotomy: a matched pairs analysis. *Surg Endosc*. 2017 Oct;31(10):4126-30.

[15] Louie BE, Farivar AS, Aye RW, Vallieres E. Early experience with robotic lung resection results in similar operative outcomes and morbidity when compared with matched video-assisted thoracoscopic surgery cases. *Ann Thorac Surg*. 2012 May;93(5):1598, 604; discussion 1604-5.

[16] Kent M, Wang T, Whyte R, Curran T, Flores R, Gangadharan S. Open, video-assisted thoracic surgery, and robotic lobectomy: review of a national database. *Ann Thorac Surg*. 2014 Jan;97(1):236, 42; discussion 242-4.

[17] Shen J. Prof. Abbas E. Abbas: a robotic thoracic practice can provide both clinical and financial benefits for an academic institution. *J Thorac Dis*. 2017 Jun;9(6):E573-5.

[18] Shulman, R. M. & Abbas, A. ES. The state of the art and future directions of robotic-assisted thoracic surgery. *Indian J Thorac Cardiovasc Surg*. 2018;Supl 1(34):40-6.

[19] Abbas A, Kadakia S, Ambur V, Muro K, Kaiser L. Intraoperative electromagnetic navigational bronchoscopic localization of small, deep, or subsolid pulmonary nodules. *J Thorac Cardiovasc Surg*. 2017 Jun;153(6):1581-90.

In: Encyclopedia of Surgery (22 Volume Set)
Editors: Andreas Lehrer and Kristin Mueller
ISBN: 978-1-53618-329-0
© 2020 Nova Science Publishers, Inc.

Chapter 244

ROBOTIC-ASSISTED MEDIASTINAL MASS RESECTION

Wissam Raad[1], MD and Faiz Bhora[2], MD
[1]Department of Thoracic Surgery, Icahn School of Medicine at Mount Sinai, Mount Sinai Health System, New York, NY, US
[2]Department of Thoracic Surgery at MSW/MSSL, Icahn School of Medicine at Mount Sinai, Mount Sinai Health System, New York, NY, US

INTRODUCTION

The Robotic-assisted technique for resection of mediastinal masses has been adopted for almost two decades. From its initial adoption, case reports, series, and retrospective studies demonstrated the safety and efficacy of this approach. More importantly, they demonstrated the ability to replicate an open procedure through minimal access incisions [1-3]. This chapter focuses on the indication for robotic assisted resection of mediastinal masses, preoperative work-up, operative technique, and the advantages of utilizing the robotic approach.

INDICATION FOR ROBOTIC-ASSISTED MEDIASTINAL MASS RESECTION

We do not alter our work up or management based on our preferred surgical approach when evaluating mediastinal masses for resection. The same guidelines applied for open surgical resection should also be followed when considering a robotic approach. In general, a resectable thymic mass, teratoma, residual germ cell tumor despite adjuvant therapy, neurogenic tumors, and symptomatic bronchogenic or pericardial cysts are all common indications for surgical resection. Regardless of the type of tumor, a thorough work up of the mediastinal mass is performed prior to surgical management in order to achieve good outcomes. This includes a multidisciplinary team approach, the consideration for a preoperative biopsy, or potential neoadjuvant therapy when indicated. We favor imaging with a contrast CT and/or MRI of the chest to evaluate the vascular anatomy and the extent of structural invasion if present. Pulmonary Function Testing (PFTs) is also checked.

ROBOTIC CREDENTIALING AND ACCREDITATION

Prior to embracing robotic assisted surgery for mediastinal mass resection, we recommend that the thoracic surgeon achieves the appropriate level of competency as outlined in his or her institutional credentialing bylaws. A combination of an online practical introduction, a cadaveric workshop, case observations, and performing the first few cases with proctor supervision is recommended prior to independent utilization of the system. In our experience, this stepwise fashion aids to cultivate the required skills allowing the surgeon to adapt to the 3-dimensional (3D) vision thus compensating for the lack of haptic feedback on the robotic platform [4].

OPERATIVE TECHNIQUE

A. Anesthesia:
   General anesthesia with double lumen intubation or a bronchial blocker. An arterial line is placed for continuous blood pressure monitoring.
B. Positioning:
   For anterior mediastinal tumors, the patient is placed in a partial lateral decubitus position. The right chest is our preferred site of surgery. However, if the dominant portion of the mass is on the left side, we approach it from the left. For posterior and middle mediastinum, full lateral decubitus position is preferred. The table is flexed right above the level of the hip, and a reverse Trendelenburg position is obtained to level the thoracic cavity.The ipsilateral arm is rotated anteromedially and supported with an arm stand as shown in Figure 1.

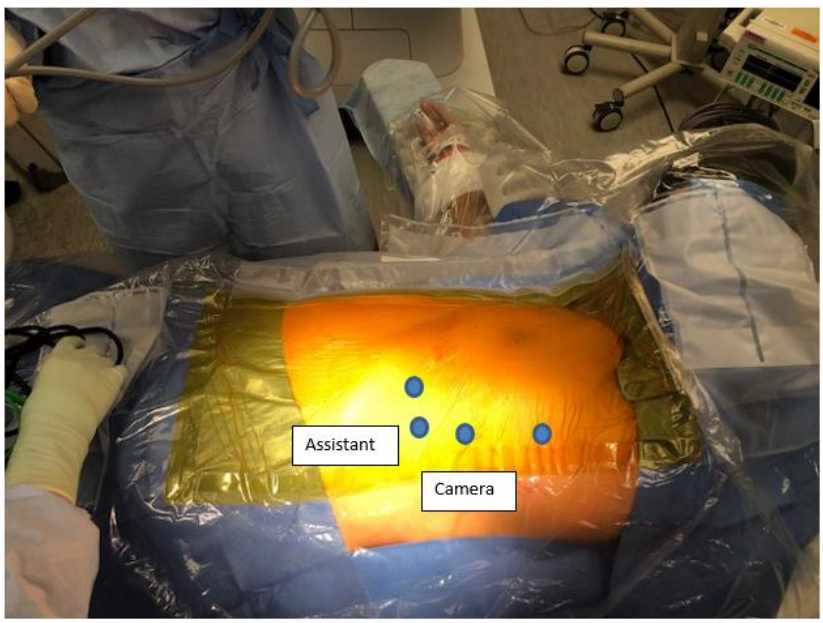

Figure 1. Positioning: Patient in in partial right lateral decubitus in a left sided approach with left arm supported with an arm stand. Port positioning is as shown for both Xi and Si.

Figure 2. The robot is placed to the patient's right. And docked straight in with an Si or an Xi.

A. Port placement: (Both Xi and Si)
We utilize 3 robotic ports (8mm) and 1 assistant port (12mm), for retraction and passing sponges if needed. We start by entering the chest under thoracoscopic or direct vision for safe entry at the level of the 6th intercostal space, mid-axillary line.

1. We recommend the use of local anesthesia and a multilevel intercostal block during the process of port placement or at the completion of the procedure to assist in postoperative pain control.
2. Camera port: The 6th intercostal space mid-axillary line entry site is used as the camera port. Usually this is 8mm or 12mm in size for the Xi or Si respectively.
3. The remaining two robotic 8mm ports are placed 5 fingerbreadths away from the camera port; one to its left, and another to its right.
4. The left 8mm port is placed in the 3rd intercostal space at the level of the mid-posterior axillary line to prevent the need for acute angulation of the wrists of the instrument while dissecting deep in the mediastinum. In such circumstances, the wrist can rub on the chest wall and/or internal thoracic vessels.
5. The right 8mm port is placed in the 5th intercostal space, anterior-midaxillary line.
6. An assistant port is then placed under direct vision in the same rib space or one space lower than the inferior robotic arm, along the mid clavicular line or a fire centimeters lateral to it. The robot is docked from the patient's right side as shown in figure 2. We tend to use the assistant port as an accessory robotic arm to make use of the added benefit of having a grasper in one hand, a dissector in another hand, and the vessel sealer in the third hand. This allows for a totally robotic procedure and helps significantly in maintaining precise retraction and exposure.

B. Essential Instruments:

1. Fenestrated bipolar
2. Robotic sealer (The vessel sealer has an excellent geometrical shape with smooth edges making it ideal for blunt dissection around the innominate vein and other delicate areas)
3. Long tip bipolar dissector

C. Intrathoracic Steps:

1. CO2 insufflation is used to assist in exposure and dissection.
2. No touch technique.(Avoid touching the actual tumor)
3. Circumferential dissection with acceptable margins is performed starting inferiorly and working our way up seperiorly.
4. Critical structures are identified and protected. This may include the phrenic nerve, the SVC, and the recurrent laryngeal nerve. It is important to remain cognizant of the robotic instruments' wrists while operating to avoid accidental traction or injury to these critical structures. Depending on the extent of resection, one may need to identify the contralateral phrenic nerve. In such cases, utilizing a 30 degrees scope might be helpful.
5. Hemostasis is achieved by using bipolar dissection. Larger vessels are divided with the vessel sealer.
6. The specimen is retrieved in a sterile bag through the assistant's port.
7. A channel drain is placed through lowest port and placed across the mediastinum
8. The chest tube is removed and the patient is discharge on postoperative day 1.

DISCUSSION

We believe that the robotic platform is ideal for access and resection of mediastinal masses. It provides excellent exposure and easy maneuvarability in this tight area. We do acknowledge that a median sternotomy is still preferred by some surgeons for resection of larger anterior mediastinal masses. This is mainly due to the excellent exposure it provides to the mediastinum and the ability to extend the incision to a hemi- or full clamshell for more exposure when needed [5]. However, the robotic 3D camera provides excellent visibility and exposure. Recent data supports robotic assisted resection of large mediastinal tumors up to 12.5cm in size [6]. Therefore, we do not feel that the large tumor size per se warrants an open approach. We use our judgment based on the level of invasion to surrounding structures if present, and on the consideration of a potential need for mediastinal node assessment as is the case in staging for thymus malignancy [7]. In the latter situation, we feel that a robotic technique is favorable since the aortopulmonary window and paratracheal lymph nodes are difficult to reach via sternotomy. The primary goal when approaching mediastinal tumors should be the ability to safely achieve negative margins. The advantage of the robotic platform in this regard includes the wrist movements feature, targeted precision and the

elimination of operator's tremor, reproducibility of the procedure, and the enhanced 3D camera visibility. These added benefits, as opposed to the 2D camera and the lack of articulating instruments with VATS, provide the robotic approach with the capability to replicate the steps of an open sternotomy approach, but of course with smaller incisions.

There are no randomized controlled trials to date comparing the robotic approach to the gold standard open approach. However, retrospective data demonstrate feasibility in terms of safety, achieving negative margins, decreasing the hospital length of stay, and providing an acceptable rate of complications. Radkani et al. reported there results on 49 patients who underwent robotic mediastinal mass resection over a 4-year period. Their study demonstrated the ability to access tumors in various locations of the mediastinum [6]. Moreover, a propensity-matched analysis comparing 100 patients in each group who underwent robotic or trans-sternal thymectomy demonstrated comparable long term outcomes. Based on these results, the authors concluded that robotic thymectomy should be considered an alternative surgical option for treating anterior mediastinal masses [8]. In addition, a study by Raad et al showed that robotic access is associated with lower narcotic requirements when compared to sternotomy [9]. Finally, a propensity-matched analysis by Seong et al comparing 37 robotic to 145 open resections demonstrated lesser tube drainage, lower blood loss, shorter tube days and length of hospital stay without any postoperative complications in the robotic group [10].

In conclusion, Robotic-assisted mediastinal mass resection is a feasible, safe, and reproducible approach. It should be attempted as the first line approach for mediastinal mass resections. A gradual and systematic methodology for credentialing and accreditation on the robotic platform is advised prior to embracing this advanced operative technique.

REFERENCES

[1] Bacchetta, M. D., Korst, R. J., Altorki, N. K., Port, J. L., Isom, O. W., Mack, C. A. Resection of a symptomatic pericardial cyst using the computer-enhanced da Vinci Surgical System. *Ann. Thorac. Surg.*, 2003 Jun.; 75(6):1953 - 5.

[2] Bodner, J., Wykypiel, H., Wetscher, G., Schmid, T. First experiences with the da Vinci operating robot in thoracic surgery. *Eur. J. Cardiothorac. Surg.*, 2004 May; 25(5):844 - 51.

[3] Bodner, J., Wykypiel, H., Greiner, A., Kirchmayr, W., Freund, M. C., Margreiter, R., Schmid, T. Early experience with robot-assisted surgery for mediastinal masses. *Ann. Thorac. Surg.*, 2004 Jul.; 78(1):259 - 65; discussion 265 - 6.

[4] Bhora, F. Y., Al-Ayoubi, A. M., Rehmani, S. S., Forleiter, C. M., Raad, W. N., Belsley, S. G. Robotically Assisted Thoracic Surgery: Proposed Guidelines for Privileging and Credentialing. *Innovations (Phila)*, 2016 Nov./Dec.; 11(6):386 - 389.

[5] Wilson, W. L. Li, Wim Jan, P. van Boven, Jouke, T. Annema, Susanne Eberl, Houke, M. Klomp, Bas, A. J. M. de Mol. Management of large mediastinal masses: surgical and anesthesiological considerations. *J. Thorac. Dis.*, 2016 Mar.; 8(3): E175–E184.

[6] Radkani, P., Joshi, D., Barot, T., Williams, R. Robotic video-assisted thoracoscopy: minimally invasive approach for management of mediastinal tumors. *J. Robot Surg.*, 2017 Mar. 23. doi: 10.1007/s11701-017-0692-2.

[7] Bhora, F. Y., Chen, D. J., Detterbeck, F. C., Asamura, H., Falkson, C., Filosso, P. L., Giaccone, G., Huang, J., Kim, J., Kondo, K., Lucchi, M., Marino, M., Marom, E. M., Nicholson, A. G., Okumura, M., Ruffini, E., Van Schil, P. The ITMIG/IASLC Thymic Epithelial Tumors Staging Project: A Proposed Lymph Node Map for Thymic Epithelial Tumors in the Forthcoming 8th Edition of the TNM Classification of Malignant Tumors. Staging and Prognostic Factors Committee; Advisory Boards. *J. Thorac. Oncol.*, 2014 Sep.; 9(9 Suppl 2):S88-96.

[8] Kang, C. H., Hwang, Y., Lee, H. J., Park, I. K., Kim, Y. T. Robotic Thymectomy in Anterior Mediastinal Mass: Propensity Score Matching Study With Transsternal Thymectomy. *Ann. Thorac. Surg.*, 2016 Sep.; 102(3):895 – 901.

[9] Raad, W. N., Forest, S., Follis, M., Friedmann, P., DeRose, J. J. The Impact of Robotic Versus Conventional Coronary Artery Bypass Grafting on In-Hospital Narcotic Use: A Propensity-Matched Analysis. *Innovations (Phila)*, 2016 Mar.-Apr.; 11(2):112 - 5.

[10] Seong, Y. W., Kang, C. H., Choi, J. W., Kim, H. S., Jeon, J. H., Park, I. K., Kim, Y. T. Early clinical outcomes of robot-assisted surgery for anterior mediastinal mass: its superiority over a conventional sternotomy approach evaluated by propensity score matching. *Eur. J. Cardiothorac. Surg.*, 2014 Mar.; 45(3):e68-73; discussion e73.

In: Encyclopedia of Surgery (22 Volume Set)
Editors: Andreas Lehrer and Kristin Mueller
ISBN: 978-1-53618-329-0
© 2020 Nova Science Publishers, Inc.

Chapter 245

ROBOTIC ASSISTED MINIMALLY INVASIVE ESOPHAGECTOMY FOR ESOPHAGEAL CANCER

Matthew C. Black, MD, James D. Luketich*, MD and Inderpal S. Sarkaria†, MD
Department of Cardiothoracic Surgery, The University of Pittsburgh School of Medicine and the University of Pittsburgh Medical Center, Pittsburgh, PA, US

INTRODUCTION

Esophageal cancer remains a prevalent problem both worldwide and in the United States. It is the eighth most common malignancy across the globe with nearly half a million people affected, the majority of which are in Southeast Asia [1]. In the United States, the estimated incidence in 2017 is 16,940. Of these, nearly 15,690 people will succumb to this disease. Despite these daunting statistics, the outcomes for esophageal cancer are steadily improving. In the 1950s, 5-year survival rates were around 4%, compared to 9% in the late 1980s [2]. Today, survival rates have doubled to 18% [3]. The improvements can be attributed to advances in multimodal therapy as well as refinements in surgical technique.

While the best approach to surgical resection remains controversial, a number of techniques have been described, with variations on these methods being developed as technology has advanced. Prior to laparoscopy, three main approaches had been utilized [4]. The choice of operation was based on tumor location and/or surgeon preference. The location and histology have seen a shift in recent decades in Western nations, with increased prevalence of adenocarcinoma of the gastroesophageal junction and lower third of the esophagus over squamous cell carcinoma of the mid and upper esophagus [5]. The traditional operative approached to these malignancies include transhiatal (laparotomy with cervical neck anastomosis), Ivor-Lewis (laparotomy and thoracotomy with thoracic anastomosis) and McKeown, or three-hole, approach (thoracotomy and laparotomy with cervical neck anastomosis) [4]. As thoracic surgeons have become more facile with laparoscopy and

* Henry T. Bahnson Professor and Chair, Department of Cardiothoracic Surgery.
† Vice Chair, Clinical Affairs & Director, Robotic Thoracic Surgery.

thoracoscopy, minimally invasive esophaectomy (MIE), in various forms, has developed and gained a significant degree of prominence worldwide. Similarly, with the introduction of advanced robotic minimally invasive technologies over recent decades, robotic assisted minimally invasive esophagectomy (RAMIE) has also developed as an alternative approach to standard laparoscopic and thoracoscopic MIE.

The indications for resection of esophageal cancer by RAMIE are essentially the same for MIE. Endoscopic biopsy establishes the pathologic diagnosis of esophageal cancer as well as delineates the extent of proximal and distal disease. The depth of intraluminal invasion or local spread to lymph nodes is determined by endoscopic ultrasound (EUS). A staging CT scan of the chest, abdomen, and pelvis is utilized, often with fluorodeoxyglucose-18 positron emission tomography as an adjunct, to evaluate the primary tumor and identify metastatic sites of disease, as well as monitor response to induction therapies [6]. Bronchoscopy is utilized for assessment of invasive airway involvement, in particular with middle and upper esophageal tumors. Staging laparoscopy may allow for assessment of bulky gastric tumors and adenopathy, and occult intraperitoneal metastases [7]. Patients with T3 (or greater) disease or those with suspected or confirmed lymph node involvement (N1 disease) by EUS are referred for neoadjuvant chemotherapy or chemoradiation followed by surgical resection. Those with T1-2 disease are considered for upfront surgical resection [4]. Patients considered unfit for surgical resection are referred for definitive chemoradiation.

Robotic technology builds on the advantages of standard minimally invasive surgery. These added benefits include magnified stereoscopic and central optics, articulation of instrument arms with superior freedom of motion, an additional surgeon arm to allow self-assistance, and direct control of all these components under the primary surgeon, in comparison to standard laparoscopic/thoracoscopic approaches [8]. Similar to MIE, reports of RAMIE have demonstrated oncologic outcomes similar to MIE and open operations, without compromising patient safety. Given the highly complex technical aspects of an MIE, the technology of robotic surgery may demonstrate a facilitated learning curve as systematic approaches are developed [9, 10]. At this time, RAMIE, when performed in high volume centers, demonstrates equipoise compared to standard MIE as a viable option for the surgical treatment of esophageal cancer [8, 11].

HISTORY AND DEVELOPMENT

Similar to the development of other robotic surgical approaches, the RAMIE lagged behind the laparoscopic MIE by about a decade. Horgan et al. described the first robotic esophagectomy as a transhiatal approach in 2003, utilizing a gastric conduit with a cervical incision and neck anastomosis [12]. Kernstine et al. published the first series of robotic transthoracic esophagectomy via a McKeown approach. This series consisted of 14 patients, with progression throughout the series from a hybrid (robotic assisted thoracoscopic with laparoscopic abdomen) approach to the last eight being completely robotic chest and abdominal operations [13]. This series demonstrated initial feasibility of transthoracic robotic esophagectomy.

APPROACH

Most initial reports included a three-hole approach with variation among how the abdominal dissection was completed. While Kernstine et al. shifted toward both a robotic transthoracic and abdominal approach, Boone et al. published a series of 47 patients with a robotic chest portion, but still utilized laparotomy or laparoscopy to complete the gastric and transhiatal dissection [14]. Putambeker et al. described the transthoracic three-hole approach in a series of patients that were placed in the prone position to perform the thoracic esophageal dissection. The setup included a 12 mm port placed just off the inferior border of the scapula in the 5th or 6th interspace, two 8 mm ports placed 5 cm apart in the 3rd and 8th interspace, and a fourth 10 mm assistant port placed between the left arm and the camera port. The authors felt the prone positioning allowed the esophagus to fall anteriorly, providing tension and simplifying the dissection, which was started just inferiorly to the azygous vein. The anterior three-fourths dissection was completed and then the aortic plane was dissected last. Complete thoracic dissection was carried caudally to the hiatus to above the azygous vein, keeping it preserved [15].

Dunn et al. expounded on the initial approach described by Horgan. This approach mimics the open transhiatal approach utilizing a robotic abdominal portion to perform the paraesophageal dissection with an open cervical incision and anastomosis. A camera port is placed to the left of the umbilicus. The two robotic working ports are then placed 8 cm to both sides of this port and 4 cm above. Additional ports are placed for the liver retractor and an assistant port. In this series, the intraabdominal portion is completed laparoscopically including mobilization of the stomach, dissection of the hiatus, dividing the short gastrics, mobilizing the duodenum, and dividing the left gastric as well as the lymphadenectomy. The robotic dock is the brought into place and the mediastinal lymphadenectomy and esophageal mobilization was then completed. The robot was then undocked and the gastric conduit was created, followed by cervical dissection and anastomosis in the standard fashion [16].

Sarkaria et al. described the first total robotic Ivor Lewis approach, initially in 21 patients, and in a subsequent report including 100 patients from Memorial Sloan Kettering Cancer Center [10, 17, 18]. The initial experience was performed using the Da Vinci Si (Intuitive Surgical Inc, Sunnyvale, CA), with a more recent transition to the Da Vinci Xi platform. The newer platform allows refinements in ease of positioning and technique, but the essentials of the operation are unchanged [19]. For the abdominal portion, the patient is placed in the supine position on the right edge of the operating room table to maximize utility of the liver retractor. The right arm is abducted 45° and the left arm may be tucked to the patient's side or left out. A footboard allows placement in steep reverse Trendellenburg position. For the thoracic portion, the patient is placed in standard left lateral decubitus position on a bean-bag with the left arm slight flexed on an armboard and the right arm suspended. Slight modification to a lower and more cranial position of this arm may facilitate working in the axillae (Figure 1) [19].

The abdominal approach utilizes a 12 mm Hasson cutdown port which will be used for a 10mm, 30-degree camera. The remaining ports placed under direct visualization include left sided 5 mm subcostal and 8 mm midclavicular ports, a 5 mm right subcostal port used for a liver retractor and an 8 mm right subcostal working port. A 12 mm assistant port is placed periumbilical. For the thoracic portion, a Veress needle is utilized to gain access to the chest

with insufflation of gas. A 12 mm port is placed in the 8th interspace in the mid axillary line. Additional 5 mm and 8 mm ports are placed in the 3rd and 5th interspace of the anterior axillary line, respectively. An 8 mm working port is placed in the 9th interspace off of the scapular tip. A 12 mm assistant port is placed between the camera port and the left 8 mm working port in the 10th interspace (Figure 2) [19]. Standard instrument setup includes a fenestrated bipolar in the robotic left hand and robotic ultrasonic shears in the right hand. The fourth arm is utilized as a retracting arm usually with a Shertl atraumatic grasper. The dissection in both the abdomen and chest mimics the MIE dissection as developed and described at the University of Pittsburgh, including lymphadenectomy, creation of gastric conduit and esophageal mobilization [20]. Okusanya et al. described the first early series of RAMIE at the University of Pittsburgh, which identified excellent perioperative outcomes similar to the institution's extensive MIE experience, and with a higher median number of lymph nodes harvested [8, 21].

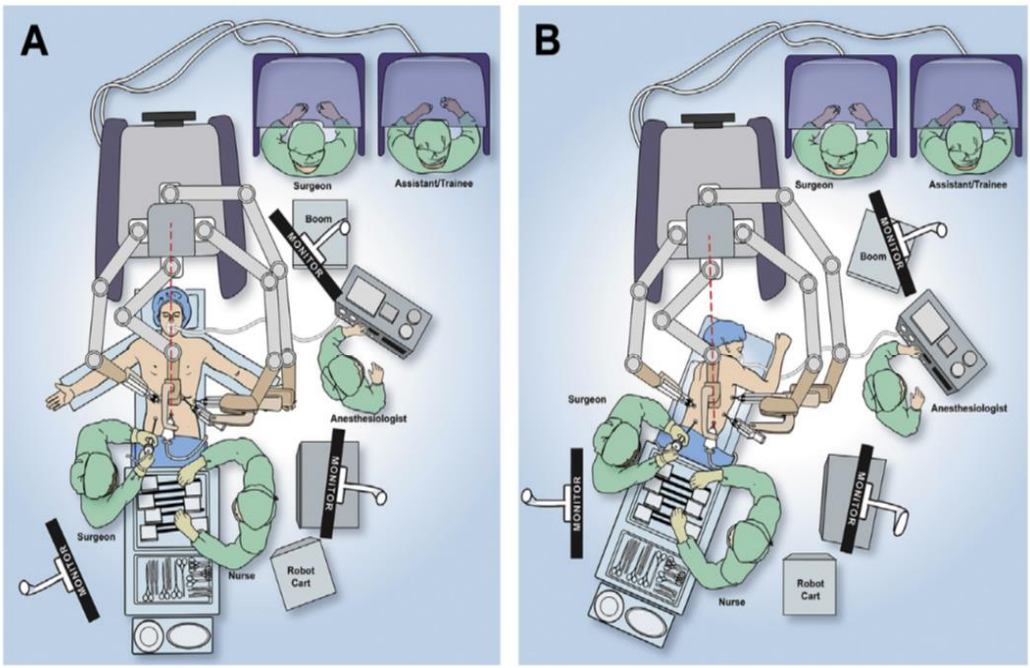

Figure 1. Robotic-assisted minimally insasive esophagectomy (RAMIE) operating room setup for the abdominal (A) and thoracic (B) phases. (Courtesy of Memorial Sloan-Kettering Cancer Center, New York, NT; with permission).

As an adjunct to our operative technique, we have instituted using near infrared imaging (NIFI) for confirmation of critical vascular structures and conduit perfusion assessment. In a prospective observation trial, thirty patients were assessed by a single dose indocyanine green (ICG) injection prior to conduit creation during RAMIE. The median time to fluorescence was only 37.5 seconds and identification was successful in all cases. Given that this technology is already available in the robotic platform and a short duration to fluorescence there is little downside to performing a confirmatory test to provide safe mobilization of the gastric conduit as well as determine the terminus of the right gastroepiploic arcade [22].

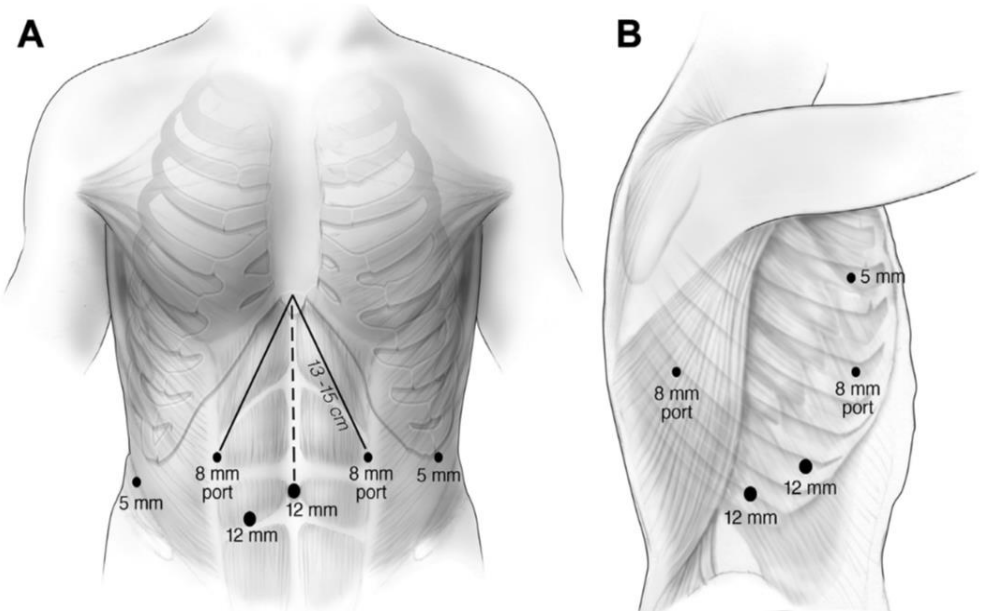

Figure 2. RAMIE port placement for the abdominal (A) and thoracic (B) phases (Courtesy of Memorial Sloan-Kettering Cancer Center, New York, NT; with permission).

ANASTOMOSIS

The techniques utilized for esophageal anastomoses are based upon techniques demonstrated with open techniques. The initial series with robotic three-hole esophagectomy and robotic transhiatal approaches both utilized open cervical incisions [14, 15]. For this reason, they will not be covered in detail.

Similar to the initial hesitancy for a thoracic anastomosis in MIE, the same concerns exist when considering an Ivor-Lewis RAMIE. Hess et al. describe an EEA stapled anastomosis similar to that described by Luketich et al. with non-robotic MIE [20]. The esophageal anastomosis is created using a stapled end to side technique with our preference being a 28 mm EEA stapler. However, if the esophagus is small, a 25 mm EEA stapler has been used on occasion. To accommodate specimen removal and introduction of the EEA stapler, an access incision is created below the posterior 8 mm port and extends 4 cm in length. The anvil is inserted and placed in the open end of the esophagus after placement of a running "baseball stitch" suture. The suture is then snugged and secured and a second superficial pursestring suture reinforces the anvil. Anvil insertion is performed using Cadiere forceps given the stronger grip strength compared to the fenestrated bipolar forceps. A gastrotomy is made in the proximal conduit to accommodate the stapler, with the gastrotomy to be closed after completion of the EEA anastomosis [8]. The docking of the spike into the anvil and stapler deployment is similar to open or minimally invasive techniques [19].

Leak rates using this method have been reported in the 4%-7% range and are similar to those reported for MIE [8, 10, 18, 20].

Hodari et al, described a hybrid stapled and sewn technique in a cohort of 54 patients published in 2015 [23]. The posterior layer was completed with a linear stapler after the esophagus and conduit were oriented similarly to that described by Orringer [24]. The anterior layer was completed in a 2-layer sewn anastomosis. Three patients (5.4%) experienced anastomotic leaks. This series utilized indocyanine green and near infrared imaging to assess conduit perfusion at the time of anastomotic completion [23].

Cerfolio et al. described their early progression from a stapled to a fully hand-sewn robotic anastomosis [25]. In this series of 22 patients, the first six were performed by a hybrid stapled and sewn anastomosis, as described above. However, this was abandoned due to five major conduit/anastomotic morbidities early in this experience. A 2-layer completely sewn anastomosis was adopted, despite the increase in operative time. The posterior layer is composed of interrupted silk suture approximating the posterior muscular layer of the esophagus to the serosa of the stomach. A running PDS suture constructs the inner layer and the anterior layer is completed in a series of Lembert sutures with the knots secured extraluminally. With this technique, the authors reported no major anastomotic related morbidities in the last 16 patients of the cohort.

NODAL DISSECTION

A thorough examination of an adequate number of lymph nodes provides for accurate staging, prognostic data, and potentially improved survival [26, 27].

The initial robotic experience has demonstrated equipoise in performing an adequate lymph node dissection. In the 2 largest series utilizing the three-hole technique, Boone et al had a median of 29 lymph nodes, while Putambekar et al. harvested 18 [14, 28]. Weksler et al. compared 11 patients undergoing RAMIE to 26 patients undergoing MIE within a single institution and there was no difference between lymph node yield, 19 vs 20.5, respectively [29]. Using a transhiatal approach, Dunn et al. reported a median of 20 lymph nodes obtained but only a median of 4 within the mediastinum ranging from 0-12 [16]. Coker et al. obtained a median of 15 lymph nodes (range, 5-29) [30]. The Ivor-Lewis RAMIE demonstrated consistent median lymph node harvests between 18-26 lymph nodes at their respective institutions [8, 18, 25, 31].

ONCOLOGIC OUTCOMES

In Boone's series of 47 patients undergoing a three-hole esophagectomy, R0 resection was achieved in 76.6% of patients, and Putambekar reported a 97.6% rate [14, 28]. The transhiatal approach was able to obtain a 94% rate of R0 resection despite no transthoracic dissection [16]. The Ivor-Lewis RAMIE approach also provides adequate resection, with rates of complete resection reported from 90%-100%, similar to those reported for MIE [8, 10, 18, 20, 23].

Little 5-year oncologic data had been published regarding RAMIE being a viable oncologic operation to rival an open esophagectomy or MIE. Van der Sluis et al published a series of 108 patients, followed for at least 29 months and with some up to 5 years. This

cohort underwent a thoraco-laparoscopic RAMIE (prone chest) with a two-field lymphadenectomy and cervical anastomosis (ROBOT trial). Most patients were clinically stage T3 of higher (78%) with and over two-thirds had clinical lymph node involvement (68%). The patient cohort mirrored the shift to patients predominantly presenting with adenocarcinomas (78%). In 65% of the patients, neoadjuvant therapy was administered and an R0 resection was achieved in 95% [32].

Median follow up was 58 months with none lost to follow up. The 5-year survival for this cohort was 42%. Consistent with previously published data, ten patients (14%) had a pathologic complete response [33]. Median disease free survival was 21 months. In patients with recurrent disease, only 6% had isolated locoregional disease, demonstrating a viable oncologic operation. Recurrence rates in this series were also consistent with published data on recurrent disease after open esophagectomy [34].

SAFETY

In high volume centers, operative mortality for RAMIE is low, similar to trends seen with open esophagectomy [11, 18]. Mortality in Boone et al.'s cohort of three-hole esophagectomy was 6.3% with three in-hospital deaths, while Putambekar et al. reported no 30-day operative mortality [14, 28]. Dunn et al.'s cohort of transhiatal robotic esophagectomies reported a mortality rate of 2.5% [16]. With experience and a dedicated team approach specific to the RAMIE Ivor Lewis operation, Sarkaria et al. and Okusanya et al. have reported 90-day mortality rates of 1% and 0%, from MSKCC and UPMC respectively[8, 10].

Pulmonary complications, including pneumonia and respiratory failure, remain a major cause of morbidity with esophagectomy. While data specifically regarding RAMIE is accruing, standard MIE has shown a significant decrease in pulmonary related morbidity compared to open procedures in a randomized controlled study [35]. Importantly, with both RAMIE and MIE, specific care must be taken to avoid direct airway injury and subsequent formation of conduit-airway fistulas. These complications, often under-reported, are technical in nature, and can be avoided with meticulous avoidance of direct thermal insult to the airway during peri-tracheal esophageal mobilization and lymphadenectomy [17].

LEARNING CURVE

The MIE operation remains a highly complex laparoscopic and thoracoscopic procedure, and complete inexperience with minimally invasive skills can be expected to lengthen the learning process. However, due to the sophistication of the robotic technology, the surgeon learning curve may be attenuated, although a direct measure of this supposition is difficult to attain [8, 36]. In 2013, Hernandez attempted to define when proficiency is achieved in robotic esophagectomies by evaluating a 52-patient cohort divided into increments of ten. Then, operating times, conversion to open operations, and post op complications were examined. Near proficiency was observed around 20 cases. Following completion of 20 esophagectomies, operating time decreased from 514 to 397 minutes ($p < 0.005$). No significant differences in complications were identified in any 10 patient section [9].

From a posterior approach, Kim et al. studied a surgical oncologist with no prior thoracoscopic experience performing the chest dissection with console times being halved from the first six patients to the next fifteen [37]. Similar conclusions can be drawn from Putambekar et al.'s updated cohort where proficiency was likely achieved early on. The total operative time for the first 32 patients was 210 minutes with the average only decreasing to 204 minutes when an additional 51 patients were included [28].

The most robust experience regarding the learning curve in completely robotic RAMIE includes a cohort of 100 patients from Memorial Sloane Kettering. The study design ensured a dedicated operating room team remained constant including 2 attending surgeons and specific anesthiologists and operating room staff that were familiar with the operation. Median operative time decreased from 447 minutes to 357 minutes between the two fifty case cohorts. Median operative time decreased to 370 minutes between cases 30-45 with the nadir between cases 40-45, likely representing the point of proficiency. 30-day mortality was 0% and 90-day mortality was 1%. Conversion rates decreased from 13 in the first 50 cases to two in the last 50 cases. Estimated blood loss and overall complications also decreased. The number of lymph nodes harvested also increased but this did not reach statistical significance. The authors advocated that excellent outcomes can be achieved by adhering to key programmatic principles including a consistent operative team, pre-execution planning and ongoing critique of outcomes and refinements in technique [10].

CONCLUSION

In summary, RAMIE has been performed by multiple approaches and, like open esophagectomy, the most efficacious method remains a matter of some equipoise. From single institution studies, surgeons have shown the RAMIE operation can be performed safely with low mortality. The morbidity mimics those complications seen with the previously described minimally invasive or open operations. The data published demonstrates that a sound index oncologic operation can be performed. Data regarding long-term survival is still accruing, given the relative infancy of these procedures. As a final, but equally important and often neglected consideration, significant data is lacking in the utility of the ergonomically superior robotic technology to decrease work-place related injuries and enhance the health and lengthen the career of operating surgeons.

REFERENCES

[1] Ferlay J, S. I., Ervik M., Dikshit R., Eser S., Mathers C., Rebelo M., Parkin D. M., Forman D, Bray, F. Globocan 2012: *Estimated Cancer Incidence, Mortality and Prevalence Worldwide in 2012*. 2013 5/9/2017 08/15/2017]; Available from: http://globocan.iarc.fr/Pages/fact_sheets_cancer.aspx.

[2] Howlader N., N. A., Krapcho M., Miller D., Bishop K., Kosary C. L., Yu M., Ruhl J., Tatalovich Z., Mariotto A., Lewis D. R., Chen H. S., Feuer E. J., Cronin K. A. S*EER Cancer Statistics Review*, 1975-2014. 2017 April 2017 08/15/2017]; Available from: https://seer.cancer.gov/statfacts/html/esoph.html.

[3] Board, C. N. E. *Esophageal Cancer-Statistics*. 2012 June 25, 2012 08/15/2017].

[4] D'Amico, T. A., Outcomes after surgery for esophageal cancer. *Gastrointest Cancer Res*, 2007. **1**(5): p. 188-96.

[5] Hur, C., Miller, M., Kong, C. Y., Dowling, E. C., Nattinger, K. J. et al., Trends in esophageal adenocarcinoma incidence and mortality. *Cancer*, 2013. **119**(6): p. 1149-58.

[6] Napier, K. J., Scheerer, M. and Misra, S. Esophageal cancer: A Review of epidemiology, pathogenesis, staging workup and treatment modalities. *World J Gastrointest Oncol*, 2014. **6**(5): p. 112-20.

[7] Varghese, T. K., Jr., Hofstetter, W. L., Rizk, N. P., Low, D. E., Darling, G. E. et al., The society of thoracic surgeons guidelines on the diagnosis and staging of patients with esophageal cancer. *Ann Thorac Surg*, 2013. **96**(1): p. 346-56.

[8] Okusanya, O. T., Sarkaria, I. S., Hess, N. R., Nason, K. S., Sanchez, M. V. et al., Robotic assisted minimally invasive esophagectomy (RAMIE): the University of Pittsburgh Medical Center initial experience. *Ann Cardiothorac Surg*, 2017. **6**(2): p. 179-185.

[9] Hernandez, J. M., Dimou, F., Weber, J., Almhanna, K., Hoffe, S. et al., Defining the learning curve for robotic-assisted esophagogastrectomy. *J Gastrointest Surg*, 2013. **17**(8): p. 1346-51.

[10] Sarkaria, I. S., Rizk, N. P., Grosser, R., Goldman, D., Finley, D. J. et al., Attaining Proficiency in Robotic-Assisted Minimally Invasive Esophagectomy While Maximizing Safety During Procedure Development. *Innovations* (Phila), 2016. **11**(4): p. 268-73.

[11] Ruurda, J. P., van der Sluis, P. C., van der Horst, S. and van Hilllegersberg, R, Robot-assisted minimally invasive esophagectomy for esophageal cancer: A systematic review. *J Surg Oncol*, 2015. **112**(3): p. 257-65.

[12] Horgan, S., Berger, R. A., Elli, E. F. and Espat, N. J. Robotic-assisted minimally invasive transhiatal esophagectomy. *Am Surg*, 2003. **69**(7): p. 624-6.

[13] Kernstine, K. H., DeArmond, D. T., Shamoun, D. M. and Campos, J. H. The first series of completely robotic esophagectomies with three-field lymphadenectomy: initial experience. *Surg Endosc*, 2007. **21**(12): p. 2285-92.

[14] Boone, J., Schipper, M. E.,. Moojen, W. A., Borel Rinkes, I. H., Cromheecke, G. J. et al., Robot-assisted thoracoscopic oesophagectomy for cancer. *Br J Surg*, 2009. **96**(8): p. 878-86.

[15] Puntambekar, S. P., Rayate, N., Joshi, S. and Agarwal, G. Robotic transthoracic esophagectomy in the prone position: experience with 32 patients with esophageal cancer. *J Thorac Cardiovasc Surg*, 2011. **142**(5): p. 1283-4.

[16] Dunn, D. H., Johnson, E. M., Morphew, J. A., Dilworth, H. P., Krueger, J. L. et al., Robot-assisted transhiatal esophagectomy: a 3-year single-center experience. *Dis Esophagus*, 2013. **26**(2): p. 159-66.

[17] Sarkaria, I. S., Rizk, N. P., Finley, D. J., Bains, M. S., Adusumilli, P. S. et al., Combined thoracoscopic and laparoscopic robotic-assisted minimally invasive esophagectomy using a four-arm platform: experience, technique and cautions during early procedure development. *Eur J Cardiothorac Surg*, 2013. **43**(5): p. e107-15.

[18] Sarkaria, I. S. and Rizk, N. P. Robotic-assisted minimally invasive esophagectomy: the Ivor Lewis approach. *Thorac Surg Clin*, 2014. **24**(2): p. 211-22, vii.

[19] Hess, N. O., O.; Sarkaria, I., Operative Technique of Robotic-Assisted Minimally Invasive Esophagectomy (RAMIE). *Scientific American*, 2017.

[20] Luketich, J. D., Pennathur, A., Awais, O., Levy, R. M., Keeley, S. et al., Outcomes after minimally invasive esophagectomy: review of over 1000 patients. *Ann Surg*, 2012. **256**(1): p. 95-103.

[21] Okusanya, O. T., Hess, N. R., Luketich, J. D. and Sarkaria, I. S. Technique of robotic assisted minimally invasive esophagectomy (RAMIE). *J Vis Surg*, 2017. **3**: p. 116.

[22] Sarkaria, I. S., Bains, M. S., Finley, D. J., Adusumilli, P. S., Huang, J. et al., Intraoperative near-infrared fluorescence imaging as an adjunct to robotic-assisted minimally invasive esophagectomy. *Innovations* (Phila), 2014. **9**(5): p. 391-3.

[23] Hodari, A., Park, K. U., Lace, B., Tsiouris, A. and Hammoud, Z. Robot-Assisted Minimally Invasive Ivor Lewis Esophagectomy With Real-Time Perfusion Assessment. *Ann Thorac Surg*, 2015. **100**(3): p. 947-52.

[24] Orringer, M. B., Transhiatal esophagectomy without thoracotomy for carcinoma of the thoracic esophagus. *Ann Surg*, 1984. **200**(3): p. 282-8.

[25] Cerfolio, R. J., Bryant, A. S. and Hawn, M. T. Technical aspects and early results of robotic esophagectomy with chest anastomosis. *J Thorac Cardiovasc Surg*, 2013. **145**(1): p. 90-6.

[26] Herrera, L. J., Extent of lymphadenectomy in esophageal cancer: how many lymph nodes is enough? *Ann Surg Oncol*, 2010. **17**(3): p. 676-8.

[27] Rizk, N. P., Ishwaran, H., Rice, T. W., Chen, L. Q., Schipper, P. H. et al., Optimum lymphadenectomy for esophageal cancer. *Ann Surg*, 2010. **251**(1): p. 46-50.

[28] Puntambekar, S., Kenawadekar, R., Kumar, S., Joshi, S., Agarwal, G. et al., Robotic transthoracic esophagectomy. *BMC Surg*, 2015. **15**: p. 47.

[29] Weksler, B., Sharma, P., Moudgill, N., Chojnacki, K. A. and Rosato, E. L. Robot-assisted minimally invasive esophagectomy is equivalent to thoracoscopic minimally invasive esophagectomy. *Dis Esophagus*, 2012. **25**(5): p. 403-9.

[30] Coker, A. M., Barajas-Gamboa, J. S., Cheverie, J., Jacobsen, G. R., Sandler, B. J. et al., Outcomes of robotic-assisted transhiatal esophagectomy for esophageal cancer after neoadjuvant chemoradiation. *J Laparoendosc Adv Surg Tech A*, 2014. **24**(2): p. 89-94.

[31] de la Fuente, S. G., Weber, J., Hoffe, S. E., Shridhar, R., Karl, R. et al., Initial experience from a large referral center with robotic-assisted Ivor Lewis esophagogastrectomy for oncologic purposes. *Surg Endosc*, 2013. **27**(9): p. 3339-47.

[32] van der Sluis, P. C., Ruurda, J. P., Verhage, R. J., van der Horst, S., Haverkamp, L. et al., Oncologic Long-Term Results of Robot-Assisted Minimally Invasive Thoraco-Laparoscopic Esophagectomy with Two-Field Lymphadenectomy for Esophageal Cancer. *Ann Surg Oncol*, 2015. **22 Suppl 3**: p. S1350-6.

[33] Donahue, J. M., Nichols, F. C., Li, Z., Schomas, D. A., Allen, M. S. et al., Complete pathologic response after neoadjuvant chemoradiotherapy for esophageal cancer is associated with enhanced survival. *Ann Thorac Surg*, 2009. **87**(2): p. 392-8; discussion 398-9.

[34] van Hagen, P., Wijnhoven, B. P., Nafteux, P., Moons, J., Haustermans, K. et al., Recurrence pattern in patients with a pathologically complete response after neoadjuvant chemoradiotherapy and surgery for oesophageal cancer. *Br J Surg*, 2013. **100**(2): p. 267-73.

[35] Biere, S .S., van Berge Henegouwen, M. I., Maas, K. W., Bonavina, L., Rosman, C. et al., Minimally invasive versus open oesophagectomy for patients with oesophageal cancer: a multicentre, open-label, randomised controlled trial. *Lancet*, 2012. **379**(9829): p. 1887-92.

[36] Kumar, A. and Asaf, B. B. Robotic thoracic surgery: The state of the art. *J Minim Access Surg*, 2015. **11**(1): p. 60-7.

[37] Kim, D. J., Hyung, W. J., Lee, C. Y., Lee, J. G., Haam, S. J. et al., Thoracoscopic esophagectomy for esophageal cancer: feasibility and safety of robotic assistance in the prone position. *J Thorac Cardiovasc Surg*, 2010. **139**(1): p. 53-59 e1.

In: Encyclopedia of Surgery (22 Volume Set)
Editors: Andreas Lehrer and Kristin Mueller
ISBN: 978-1-53618-329-0
© 2020 Nova Science Publishers, Inc.

Chapter 246

FUNDAMENTAL APPROACHES AND CHALLENGES TO BENIGN ESOPHAGEAL ROBOTIC SURGERY

Caitlin Wahl[1], MD and John F. Lazar[2], MD
[1]Department of General Surgery, MedStar Washington Hospital Center, Washington, DC, US
[2]Division of Thoracic Surgery, Georgetown University School of Medicine, Director Thoracic Robotics, MedStar Washington Hospital Center, Washington, DC, US

INTRODUCTION

Surgical management of esophageal disease represents a unique challenge for physicians. The esophagus abuts many vital organs as it travels from the neck, through the chest, and down into the abdomen. Surgeons must therefore have a high degree of comfort operating in three distinct anatomic compartments using a wide variety of operative techniques and approaches. As the field of minimally invasive esophageal surgery grows, safer and more efficient techniques have made care of this complicated organ easier. Robotic surgery is the newest development in this progression, and its use is becoming increasingly more common in the treatment of a variety of esophageal conditions. Rather than highlight the indications for surgery, which for the most part is currently well established with minimal controversy, this chapter will focus on the surgical management and challenges of benign esophageal diseases, specifically that of achalasia, paraesophageal hernia, gastroesophageal reflux disease (GERD), and esophageal diverticula.

Achalasia

Achalasia is a fairly uncommon condition that affects approximately 1 in 100,000 adults annually [1]. Surgeons first became involved in the management of this debilitating disease in 1913 when Ernest Heller developed the technique of performing a transabdominal myotomy of the distal esophagus. Subsequent developments led to development of an open transthoracic approach. The first foray into minimally invasive management of achalasia

came in 1992 when Pellegrini et al. published a case series of 17 patients treated by either thoracoscopic or laparoscopic approach [2]. As the field of minimally invasive surgery has grown, laparoscopic Heller myotomy has become the mainstay of surgical management for achalasia. The laparoscopic approach has been shown to have equal rates of efficacy at reducing symptoms of dysphagia when compared to the open approach, with the added advantages of shorter hospital stay, less post-operative pain, and decreased hospital costs [3-6]. In the early 2000s, the first robotic Heller myotomies were performed [7]. The robotic platform allows for better visualization of the hiatus as well as the transecting of muscle fibers during myotomy to avoid injury to the mucosa. The increased range of motion of the robotic arms and wrists facilitates a greater degree of ease for the dissection of the muscle and mediastinum [8]. There have been several small studies comparing the safety and efficacy of robotic versus laparoscopic approach. Maseo et al. published a meta-analysis which included more than 2,100 patients and found that while the efficacy of the two techniques was similar, with robotic Heller myotomy had a decreased rate of esophageal perforation when compared to laparoscopic surgery (0% vs. 11%) [9]. These findings have been corroborated by several other studies [10, 11] and suggest that a robotic approach to achalasia will become increasingly popular.

Gastroesophageal Reflux

Surgical management of GERD via fundoplication is a safe and effective way of treating those patients whose symptoms are refractory to medical management. Historically, this surgery was performed open either via abdominal, transabdominal or thoracic open approach, until in 1991 when Dallemagne et al. reported a case series of 12 laparoscopic Nissen fundoplications. He concluded that a minimally invasive approach was both safe and effective at managing patient symptoms [12]. These findings have been supported by subsequent studies that have compared minimally invasive techniques to open surgeries. In one randomized trial that followed 148 patients over 10 years, the authors found that laparoscopic techniques are equally effective at managing patient symptoms and improving quality of life, with the added advantage of fewer reoperations [13]. Other studies have also noted that laparoscopic surgeries result in shorter hospital stays, faster recovery, and better pain control [14]. More recently, robotic systems have been used to perform anti-reflux procedures. To date there are few studies directly comparing robotic versus laparoscopic techniques, but the few trials that do exist show similar rates of efficacy and complications between the two approaches [15-16]. Robotics did have an advantage over laparoscopy in anti-reflux reoperations with fewer conversions to open, recurrences, and shorter operative times [17, 18].

Paraesophageal Hernia

Hiatal or paraesophageal hernias are fairly common findings and may cause a significant amount of morbidity for patients. Traditional repair of this condition was done by an open, typically thoracic or transabdominal, approach. However, as with other fields of esophageal surgery, a minimally invasive approach to the treatment of paraesophageal hernias has

become increasingly popular since the first laparoscopic repair was performed by Cuschieri in 1992. He documented a case series of 8 patients successfully treated via a minimally invasive approach [19]. Since then, there have been many studies comparing the two techniques. While symptomatic relief and patient satisfaction have been shown to be equivalent between laparoscopic and open approaches [20, 21], minimally invasive surgery has thus far proven superior in terms of patient safety and complication rates. Scholttman's review of the National Inpatient Sample database reviewed more than 60,000 patients undergoing paraesophageal hernia repair (PEHR). He found that patients undergoing minimally invasive surgery were less likely to experience post-operative bleeding, infection, organ failure, and mortality while also having shorter hospital stays [22]. Mungo et al. found similar results evaluating more over 8,000 patients in the National Surgical Quality Improvement Program (NSQIP) database. Their data showed that 30 day mortality for laparoscopic repair is almost 3 times lower than open approach, and rates of respiratory, cardiac, and infectious complications similarly favored laparoscopic repair [23]. There has been some concern about the durability of laparoscopic repair when compared to open due to several studies showing higher rates of radiographic recurrence in laparoscopic compared to open techniques. Despite this finding, patients do not report any difference in clinical symptoms or overall satisfaction, suggesting this finding may not be clinically significant and should not deter surgeons from a minimally invasive approach [24, 25]. There is little data currently that compares laparoscopic to robotic outcomes. The limited data that does exist indicates similar rates of success and complications between robotic and laparoscopic techniques [26]. With greater adoption of robotic technique for this procedure, both by thoracic and general surgeons, we should expect answers to this question to be answered via large databases in the near future.

Esophageal Diverticula

Diverticula of the esophagus are quite rare, appearing in less than 1% of upper GI studies [27]. They may occur anywhere along the esophagus, requiring a variety of approaches to management depending upon their location. Excluding proximal diverticula, the traditional open approach via either an abdominal or thoracic incision has lost favor in comparison with minimally invasive techniques, beginning with the first laparoscopic diverticulectomy in 1998 [28]. Because of the uncommon nature of this disease, data comparing different surgical approaches is somewhat limited. However, the studies that do currently exist show significant reduction in mortality (1.6% vs 6%) as well as leak rate (7% vs 10%) with a laparoscopic compared to open approach [27]. There is minimal data on the use of the robotic platform in treatment of esophageal diverticula, mostly single center retrospective reports, but the robot appears to offer superior visibility and ease of dissection compared to laparoscopic surgery, with similar patient outcomes [29].

OPERATIVE TECHNIQUE

Both the Xi and Si da Vinci robotic system (Intuitive Surgical, Sunnyvale, CA) will be discussed for set up and port placement. The operations themselves are essentially identical for either system.

Pre-Operative Planning and Testing

The pre-operative planning for any of the four benign esophageal processes to be discussed in this (achalasia, GERD, paraesophageal hernias, diverticula) should follow the same planning that goes into an open or laparoscopic procedure as robotics should essentially be considered as another mode of minimally invasive surgery.

Room and Robotic Set Up

Our room is fitted with a TruSystem 7000dV operating table (Trumpf Medical, Saalfeld, Germany) which allows for synchronized movement between the Xi and the table while the robot is docked. The patient is then induced and intubated with a single lumen endotracheal tube. Two large bore IV's are placed, foley, intermittent pneumatic compression devices of the lower extremity are placed, subcutaneous heparin, and pre-operative antibiotics are given. A foot plate is placed on the bed, pillow placed under the knees, and a strap is placed over the thighs. A Bair Hugger (3M, Maplewood, MN) is placed over the over the lower legs.

If the patient needs a pre-procedural esophagogastroduodenoscopy (EGD) then we usually do it at this time, but is not often the case. If an EGD is performed pre-incision then we may leave it in the esophagus and place the umbilical cord under the pillow. If not, than an orogastric tube is often placed for decompression.

Si Port Placement and Docking

Once the patient is prepped and draped we usually use a Hassan open technique for gaining access to the abdomen placed just left of the umbilicus. This 10-12 mm port will then serve as our assistant's access port. It is perfectly reasonable to use other access techniques (e.g., Veress needle or optical ports with separate 5mm camera) based either on surgeon preference or patient characteristics (e.g., prior surgery). Before insufflation, we visually confirm trocar placement within the abdominal cavity. Once correct placement is ensured, we insufflate to 15 mmHg, and further port placement is performed under direct visualization.

A 5 mm trocar is placed laterally on the patient's right below the liver and medial to the bowel for the articulating liver retractor. A 10-12 mm blunt tip disposable trocar is placed midline two-thirds of the way down from the xiphoid for the 12 mm Si camera. Two 8 mm metal da Vinci ports are placed a hands breadth left and to the right of the camera port (approximately 10 cm). A third 8 mm port is placed a hand's breadth away from the right port (patient's left) (See Figure 1).

The liver retractor is placed and held in place by articulating arm attached to the bed. The patient is placed in steep reverse Trendelenburg. (Some surgeons prefer to bring the robot in first and then place the robot in reverse trendelenburg. The key is to do it before docking as you cannot change the angle of the bed while the robotic arms are docked on the Si.) The robot is then brought in over the patient's head and docked (See Figure 2). The docking for the Si makes it more difficult for anesthesia to access the patient, especially if you will need accesses to the mouth later in the case (i.e., to place a bougie, nasogastric tube, or perform an EGD).

Special consideration for port placement should be considered for two specific groups of patients: those with narrow waists and redo surgery. The former can be very difficult for port placement as ideally the Si ports/arms need approximately 10 cm of space (hence a hand's breadth), but this is not always feasible in very narrow patients. The surgeon will need to adapt to the anatomy. As for redo surgery, port entry and placement may be the most difficult aspect of the case. Initial entry to the abdomen and subsequent lysis of adhesions may be required. Be prepared and be patient, as this may require a significant amount of time to accomplish. The reward for your diligence is the ability to complete the case robotically and perform a high quality procedure.

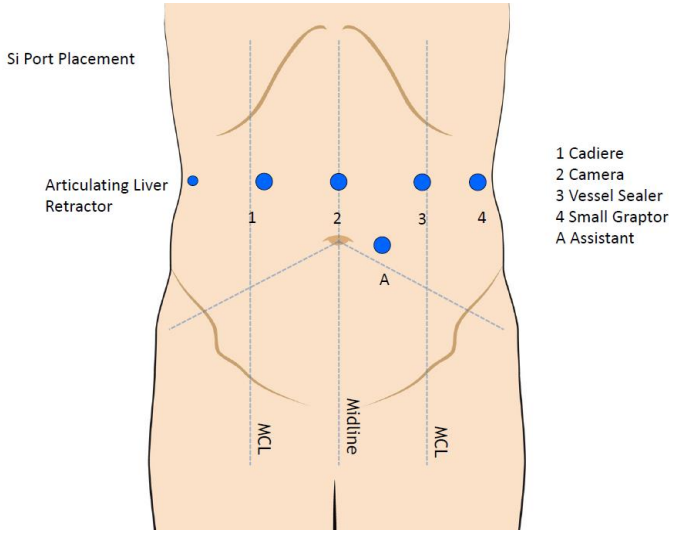

Figure 1. Si port placement.

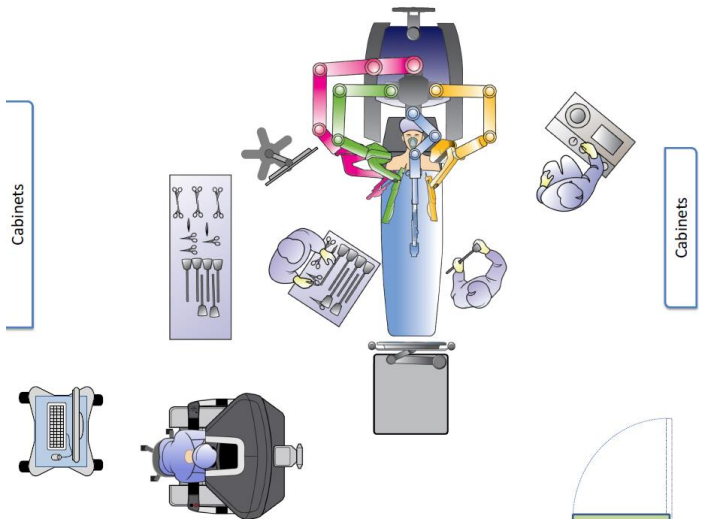

Figure 2. Si docking configuration.

Xi Port Placement and Docking

There are some significant docking differences between the Si and Xi. Firstly, we place all the ports at the level of the umbilicus except for the 5 mm liver retractor (See Figure 3). The Xi instruments are longer than the Si and to accommodate we lower the placement. In theory, we like to keep the working instruments a good deal below the targeted anatomy. We apply this to all the robotic surgery we perform, and it has been very helpful. The arm ports so close to the assistant port makes it a little harder for the assistant port, but we have learned to work around this- some surgeons don't use it at all. Secondly, the camera port is replaced with an 8 mm da Vinci metallic port. Thirdly, we use a 12 mm da Vinci port for Endowrist stapler instead of an 8 mm port just to the right of the camera port (patient's let) for paraesophageal hernia repairs (PEHR) in case they need a lengthening procedure. Fourthly, the docking of the Xi can occur on either side of the patient due to the rotating boom that allows greater freedom and oral access to the anesthesiologist. Finally, we do not use the targeting feature of the Xi because we feel that we are able to control exactly where we want to be manually (See Figure 4).

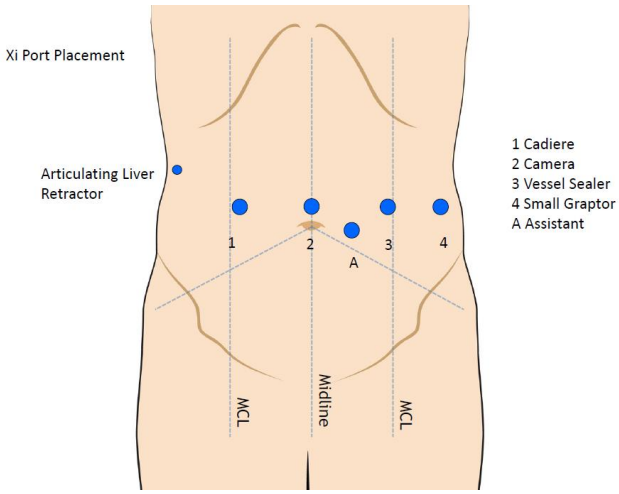

Figure 3. Xi port placement.

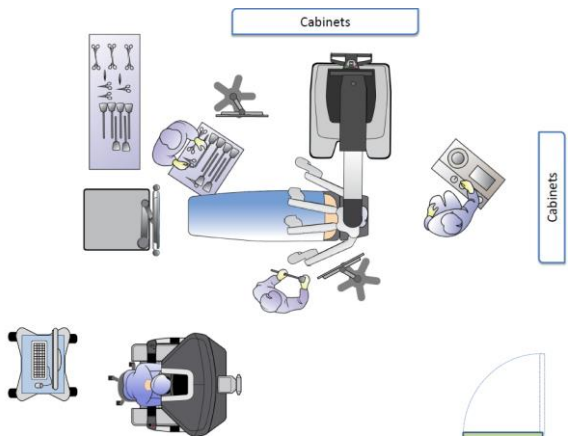

Figure 4. Xi docking configuration.

ACHALASIA

Once the robot is docked, regardless of system, the same instruments are placed: cadiere forcep in the surgeon's left "hand", curved bipolar in right and small graptor in right lateral arm. (A vessel sealer or harmonic can also be used.) The pars flaccida is opened first which allows perfect access to right crus and the hiatus. We continue our dissection by taking down the thin veil of tissue between the right crus and esophagus making sure to not damage the right crus fascia. This dissection is carried superiorly and is continued laterally to the left lateral aspects of the hiatus also making sure not to damage the fascia along the left crus.

Throughout the dissection the 4th arm, which is controlling the small graptor, has a rolled up gauze sponge and is being used as a passive retractor. We make a concerted effort to avoid grasping the tissue for traction and instead rely almost entirely on passive traction.

There are a few ways to approach the myotomy and fundoplication. Our preference is to use the bipolar and cadiere to create a window between the esophagus and the mediastinum for the intra-thoracic esophagus in order to create the myotomy. If not, then we prefer to use the vessel sealer. (This can also be used later to take down the short gastrics if so desired for the partial fundoplication.) It is important to ensure one has enough visible esophagus in the chest by dissecting out approximately 5-8 cm above the hiatus before starting the myotomy. We do not routinely dissect out the posterior aspect of the hiatus, but if there is a concomitant hernia this may be necessary.

Once the dissection has been completed, our tool of choice is the hook cautery which is also used in the right arm replacing the bipolar. The myotomy can be performed a myriad of ways; just as long as it is effective and safe (e.g., cold scissors, harmonic scalpel, etc). Some surgeons like to use a bougie while doing the myotomy; we routinely use 50 French, which is placed by anesthesia and confirmed as it is placed under direct visualization with the robotic camera.

We begin the myotomy usually at the gastroesophageal junction (GEJ) and work proximally along the esophagus. Both the right and left graspers/forceps are used to help facilitate the dissection by gently pulling the muscle laterally. We generally perform approximately 5-7 cm myotomy vertically along the esophagus and then open the proximal stomach another 2-3 cm. The fundamental aspect of this part of the procedure is preventing an enterotomy. The best way to do this is through a meticulous dissection with your instrument and avoiding any inadvertent contact, blind dissection, or a delayed heat injury. If you do see an enterotomy, repair it immediately with an absorbable suture. If you are still very worried an anterior fundoplication can help buttress an intra-abdominal injury.

What separates a surgical Heller myotomy from an endoscopic procedure (i.e., *P*eroral *E*ndoscopic *M*yotomy aka POEM) is the ability to perform a fundoplication. The most common fundoplication after myotomy is an anterior 180 degree (Dor) fundoplication that lies on top of the myotomy. We do not recommend leaving the Heller without any fundoplication as there can be significant associated reflux afterwards.

An EGD can be performed at this time to ensure that there is adequate length to the myotomy, but this is not always necessary. We keep the EGD cart in the room in every procedure just in case.

Once the myotomy is completed, we close the crura with interrupted 0 silk stitches so that it is closed but not too tight. To accomplish this, we use the mega suture cut needle driver in

the right hand. The key to a good closure is ensuring that the crura fascia remains intact during dissection as this is the aspect of the muscle that provides crural integrity.

There are several keys to performing a good fundoplication: 1) taking enough short gastrics so that the wrap lays tension free behind the esophagus once pulled through; 2) a meticulous posterior dissection so the wrap pulls through easily if it is a 270 degree posterior fundoplication; 3) identification of the anterior and posterior vagus nerve and avoiding them; 4) making sure that you are able to visualize the fundus and the esophagus while sewing. The last point is where many surgeons' wraps fail because the stomach has not been secured appropriately thus potentially herniating/slipping through the plication.

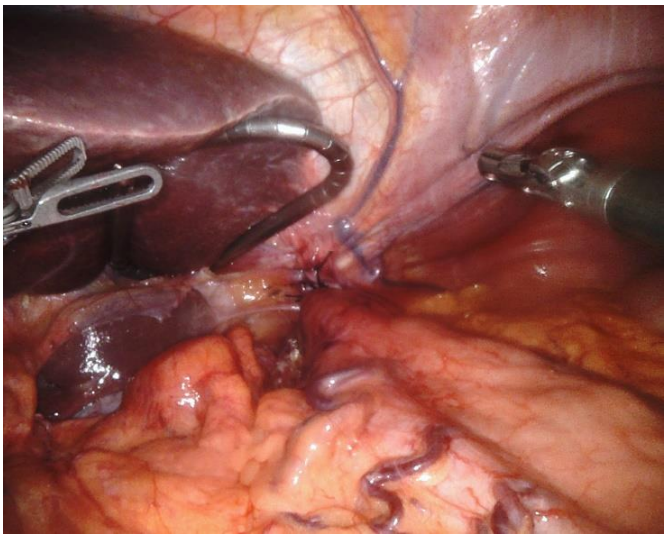

Figure 5. Anterior fundoplication.

An anterior fundoplication is very easy to perform and requires only a few stitches. Many times it does not require taking the short gastrics, but it should lay tension free. If it does not then we recommend dissecting enough of the lateral attachments of the stomach until it does so. To secure the wrap we place the first stitch at the 3 or 4 o'clock position along the left crus with one bite along the left crus and another into the fundus using a 2-0 silk stitch. We then place another two to four 2-0 silk interrupted stitches in the same manner working counter clockwise to the base of the right crus (Figure 5).

Again, some surgeons like to perform an EGD at this point before closing to ensure the myotomy is wide open. At this point the procedure is completed and closing is performed in the usual manner. Generally speaking, 8 mm port sites do not require facial closure.

ESOPHAGEAL DIVERTICULA

The three areas of the esophagus that can develop diverticula (proximal, medial and distal) each represent a different disease process with different approaches to repairing normal esophageal luminal flow. At this time there is no robotic approach for the proximal diverticula which is a result of a hypertensive cricopharyngeal muscle. The mid esophagus

diverticulum are usually caused by an issue with a malignant or infected mediastinal lymph node and is a true diverticulum. This chapter will focus only on the lower esophageal diverticula which are usually secondary to an underlying abnormality of the lower esophageal sphincter (LES; i.e., secondary to achalasia). In such cases, the underlying esophageal pathology (e.g., Heller myotomy in the case of achalasia) must be addressed at the time of the diverticulectomy.

Regardless of robotic system, Xi or Si, the approach to a diverticulectomy is similar as the initial aspects of a Heller myotomy just discussed except we recommend a complete dissection around the esophagus so that it is fully visualized. Once the entire esophagus has been dissected and cleared of the crura the diverticula should be visualized. The muscle fibers of the esophagus are spread in order to visualize the entire neck of the diverticula. A bougie can be placed carefully by anesthesia to ensure that the esophageal lumen is not narrowed during stapling (approximately 50 French). At this point the diverticula can be stapled with any laparoscopic stapler through the assistant port or the da Vinci Endowrist stapler (blue load) depending on the technology available. (A 12 mm da Vinci metallic port is required for the Xi stapler.) The specimen is then removed in a sterile bag through the assistant port.

As most distal diverticula are secondary to achalasia, a myotomy and fundoplication as discussed in the prior section would need to be performed. The myotomy should be approximately 180 degrees from the staple line.

ANTI-REFLUX PROCEDURES

The room and port set up for a robotic fundoplication procedure is exactly the same as was described for achalasia. The one major difference is that we do like to place a bougie, at least 54 French, before closing the crura and doing the fundoplication. The additional crucial aspect to consider before performing an anti-reflux procedure is that the patient absolutely will benefit from it. This can be confirmed by the appropriate tests pre-operatively. There is nothing worse than having to re-operate on someone because the proper procedure was not done initially.

In the proceeding section, the anterior (Dor) fundoplications was discussed. A posterior or 270 (Toupet) fundoplication offers greater anti-reflux relief than an anterior fundoplication without some of the associated issues of a complete wrap. The value of these procedures over a complete 360 degree fundoplication (Nissen) for reflux should be performed based on surgeon preference and patient characteristics.

As stated before, the critical aspects of performing a technically sound fundoplication is: 1) making sure there is not a sliding or paraesophageal component to the reflux, and if there is, then it must fixed appropriately; 2) mobilizing fundus by taking enough short gastrics so that the wrap lays tension free behind the esophagus once pulled through; 3) a meticulous posterior dissection so the wrap pulls through easily; 4) identification of the anterior and posterior vagus nerves and avoiding them; 5) making sure that you are clearly able to visualize the fundus and the esophagus while sewing. This last point is where the wrap fails because the incorrect tissues have been sutured leading to the stomach to herniate/slip through the plication due to approximating fatty tissue to the esophagus rather than the fundus. Many

times this is avoided by taking the fat pad along the lesser curve/GEJ, which we do on every case. This can also provide some additional esophageal length if that is an issue.

For either the complete or posterior fundoplication, we mobilize the short gastrics by placing the vessel sealer in the right hand which replaces the bipolar. There are multitudes of ways to take down the short gastrics we like the vessel sealer for its ability to reliably ligate vessels/tissues and that it can act like as an additional grasper and dissector. This can be very helpful while completing the last of the dissection along the left crus and the decussation if there are adhesions.

We then slide the fundus behind the esophagus and it should slide easily through. There are many different ways to perform a 270 degree fundoplication, but our preference is to place a 2-0 silk from the superior aspect of the fundus into the lateral aspect of the esophagus. We start on the patient's left and then do the same thing on the right. Once completed, we move about a cm below and place another row of 2-0 silk stitches starting on the patient's left fundus to the lateral edge of the esophagus, and repeat on the patient's right. A third and final row is placed just distally to the second. We secure the fundoplication to each of the crus with 2-0 silk (See Figure 6). The entire length of the fundoplication should be approximately 2-3 cm.

For a 360 degree fundoplication the fundus is brought along behind the esophagus, like the 270-degree posterior wrap, and should lay tension free behind the GEJ. An interrupted 2-0 silk superiorly is placed between the two edges of the fundus. Another interrupted 2-0 silk is placed between the fundus and the esophagus and through the esophagus opposite fundus. A third interrupted is placed inferiorly between the fundus edges. The stitches are then tied down. A crus stitch is placed laterally to the fundus as a securing stitch on either side. The bougie is removed (See Figure 7).

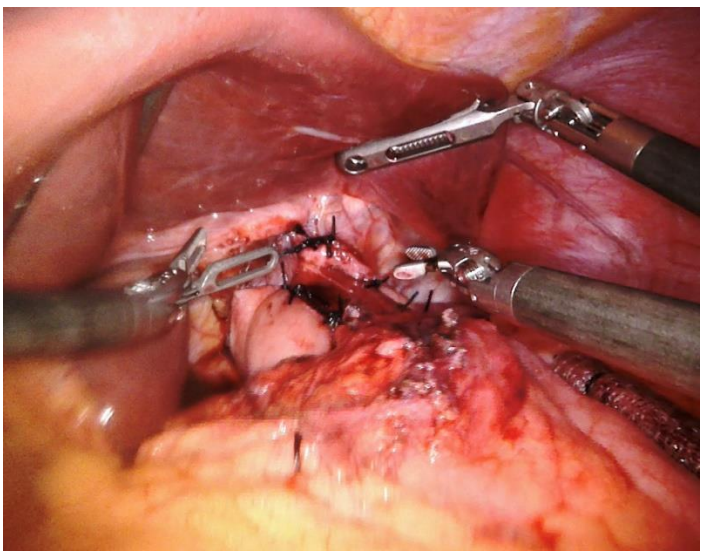

Figure 6. Posterior fundoplication (Toupet).

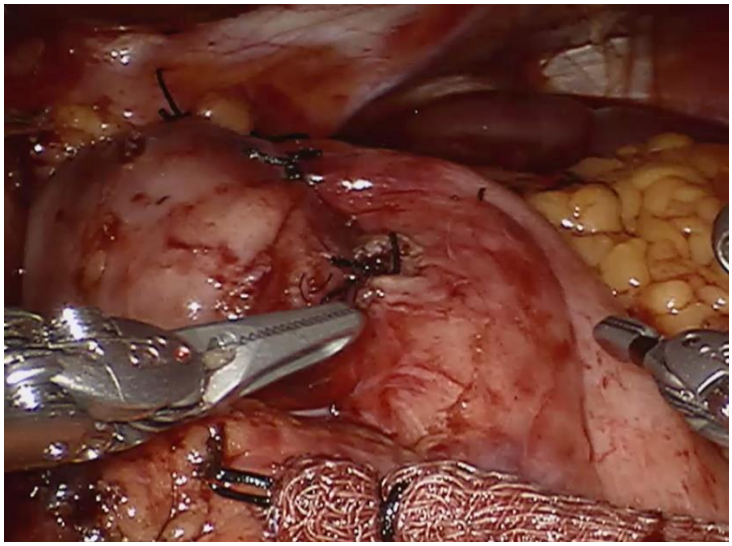

Figure 7. Complete fundoplication (Nissen).

PARAESOPHAGEAL HERNIA

PEHR is a complex multi-step operation with each part being performed fastidiously to prevent recurrence. Most recurrences are a result of either missing or skipping any of these steps. There are currently some controversies surrounding PEHR: type of fundoplication, use of biologic mesh to close hiatus, lengthening procedure, optimal time to repair. The described procedure is what we feel to be best practice based on the most current literature and on years of evidence in both open and laparoscopic PEHR- not just robotics.

Each surgeon will have their own style and preference, but overall should adhere to following principles: 1) surgically remove the entire sac; 2) preservation of both vagal nerves; 3) ensuring crura fascia integrity is maintained; 4) 2-3 cm of intra-abdominal esophageal length once stomach is delivered from chest; 5) ligating the short gastrics so that there is a tension free mobilization of the fundus for potential fundoplication.

Patient position, port placement (including the 12 mm da Vinci port for Endowrist stapler if you think you may need a gasatroplasty) is as discussed in prior sections.

The pars flaccida is opened initially with the energy source of choice (we prefer the curved bipolar to start) working to dissect out the right crus. As the tissue thickens we move to the vessel sealer as we like the wristed forceps and grasper capabilities in addition to its ligating energy. We separate the sac from the right crus making sure not to damage the integrity of the fascia while working our way into the intra-thoracic component of the hernia. As we peel the sac back we try not to enter the pleura. Sometimes this is unavoidable due to adhesions and a simple stitch or cautery can seal it back up. (Hardly ever is a chest tube required intra-operatively.) Moving in a clockwise fashion from the patient's right to the superior/anterior aspect, the sac is dissected while also working your way to the posterior. Usually it is initially very challenging to remove the sac along the 5 or 6 o'clock part of the sac along the base of the left crus.

At this point we usually transition to taking the short gastrics and the lateral attachments. We start inferiorly and work superiorly along the greater curve. By approaching it this way you are eventually able to complete the dissection posteriorly along the decussation and left crus safely from the greater curve.

Once this is completed we usually measure how much intra-abdominal esophageal length we have. Almost always, we have to go back and dissect more of the proximal esophagus. Our routine is to always take the dissection to the inferior pulmonary veins in order to get enough length.

If after this maneuver there is still not enough intra-abdominal length several surgeons have advocated for the use of wedge gastroplasty using the several fires of the green da Vinci Endowrist stapler. In our own practice we have liberally employed a gastroplasty and have had no complications in our limited series (7 patients). To perform the gastroplasty, we then have anesthesia place between a 51-60 French Savory bougie down the esophagus. (Ensure there is no orogastric or nasogastric tube before stapling.) We usually start the stapling at the more distal aspect of the wedge along the greater curve holding it up with the cadiere in our left hand using a green load (See Figure 8). The first fire is perpendicular to the bougie and the second, and third if necessary, is parallel to the bougie (See Figure 8 A - D). Once completed, it is removed via the assistant port in a sterile bag.

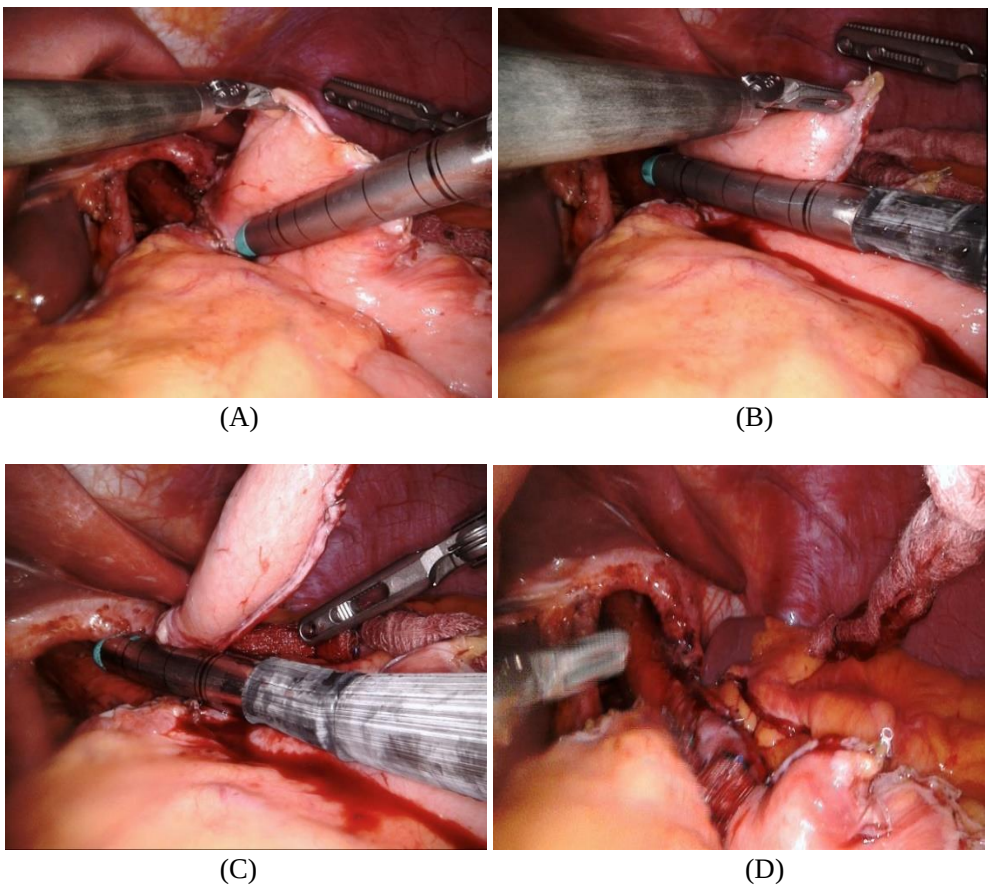

Figure 8. Creating gastroplasty. (A) First Staple bit; (B) Second Staple Bite; (C) Third Bite; (D) Final Gastroplasty.

The fat pad along the lesser curve is excised along with any excess sac that would make a fundoplication difficult. Be sure to avoid injuring the vagus nerve during the dissection. Closure of hiatal crura is as discussed in prior section with interrupted 0 silks and mega suture needle driver. If you are unable to bring the crura together we advocate initially reducing insufflation pressure. If that does not work a relaxing incision can be made parallel to the left crus along the lateral diaphragm and patched at the end of the case with mesh (we recommend vicryl due to low cost). We do not advocate using biological mesh to close the gap in the hiatus although many surgeons/authors espouse this technique. As thoracic surgeons we see many complications from this technique and have found that closing it primarily is usually feasible. In very difficult cases where relaxing incision does not help to close the crura we have employed the COR-KNOT system (LSI Solutions, Rochester, NY) with great results.

Once this is all completed, we advocate employing a fundoplication; our preference is a posterior wrap, but we leave this up to surgical discretion. The robot is then undocked. We only close the 12 mm port under direct visualization using a Carter Thomason guide (Cooper Surgical, Trumbull, CT) and a suture passer.

CONCLUSION

As stated at the beginning of the chapter there are few studies that compare robotic benign esophageal foregut surgery to the other modalities. Almost all are retrospective and are not propensity matched. We do know from these studies that the outcomes are safe and for the most part equivalent. Increased cost is an issue usually in regards to operative time, but judicial use of resources and improved operative time can usually overcome these issues. The big gain in robotic benign esophageal surgery for surgeons is the ability to be minimally invasive and perform a high end operation due to the multiple advantages the robot brings. We look forward to single site surgery, perhaps randomized control studies, as well as new technology from new partnerships. Regardless, robotic surgery's future looks very bright.

REFERENCES

[1] Abir F, Modlin IM, Kidd M, Bell R. Surgical Treatment of Achalasia: Current Status and Controversies. *Dig Surg.* 2004;21(3):165-76. Epub 2004 Jun 24.

[2] Allaix ME, Ramirez M, Patti MG. Heller Myotomy for Achalasia. From the Thoracoscopic to the Laparoscopic Approach. *World J Surg*. 2015 Jul;39(7): 1603-7.

[3] Bencini L, Moraldi L, Bartolini I, Coratti A. Esophageal Surgery in the Minimally Invasive Era. *World J Gastrointest Surg.* 2016 Jan 27;8(1):52-64.

[4] Bello B. Impact of minimally invasive surgery on the treatment of benign esophageal disorders. *World J Gastrointest Surg.* 2012;18(46):6764.

[5] Harold KL, Matthews BD, Kercher KW, Sing RF, Heniford BT. Surgical Treatment of Achalasia in the 21st Century. *South Med J.* 2004;97(1):7-10.

[6] Campos GM, Vittinghoff E, Rabl C, Takata M. Endoscopic and surgical treatments for achalasia: a systematic review and meta-analysis. *Ann Surg.* 2009 Jan;249(1):45-57.

[7] Hanna JM, Onaitis MW. Robotic Benign Esophageal Procedures. *Thorac Surg Clin.* 2014;24(2):223-229.

[8] Finnerty BM, Afaneh C, Zarnegar R. Laparoscopic Treatment of Esophageal Motility Disorders. In: *Current Surgical Therapy*. 12th ed. Elsevier; 2017:1538-1545.

[9] Maeso S, Reza M, Mayol JA, et al. Efficacy of the Da Vinci Surgical System in Abdominal Surgery Compared With That of Laparoscopy. *Ann Surg.* 2010;252(2):254-62.

[10] Horgan S, Galvani C, Gorodner M, et al. Robotic-Assisted Heller Myotomy Versus Laparoscopic Heller Myotomy for the Treatment of Esophageal Achalasia: Multicenter Study. *J Gastrointest Surg.* 2005;9(8):1020-1030.

[11] Stefanidis D, Richardson W, Farrell TM, Kohn GP, Augenstein V, Fanelli RD. SAGES guidelines for the surgical treatment of esophageal achalasia. *Surg Laparosc Endosc.* 2011;26(2):296-311.

[12] Dallemagne B, Weerts JM, Jehaes C, Markiewicz S, Lombard R. Laparoscopic Nissen fundoplication: preliminary report. *Surg Laparosc Endosc*. 1991;1(3):138-143.

[13] Broeders JA, Jong HGR-D, Draaisma WA, Broeders I, Smout A, Gooszen HG. Ten-Year Outcome of Laparoscopic and Conventional Nissen Fundoplication: Randomized Clinical Trial. *Ann Surg.* 2009;250(5):698-706.

[14] Majeed AW, Johnson AG. Randomized clinical trial of laparoscopic versus open fundoplication: blind evaluation of recovery and discharge period. *Br J Surg.* 2000;87(12):1732-1737.

[15] Stefanidis D, Hope WW, Kohn GP, et al. Guidelines for Surgical Treatment of Gastroesophadeal Reflux Disease. *Surg Endosc.* 2010;24(11):2647-2669.

[16] Draaisma WA, Ruurda JP, Scheffer RCH, et al. Randomized clinical trial of standard laparoscopic versus robot-assisted laparoscopic Nissen fundoplication for gastro-oesophageal reflux disease. *Bri J Surg.* 2006;93(11):1351-1359.

[17] Ceccarelli G, Patriti A, Biancafarina A, et al. Intraoperative and Postoperative Outcome of Robot-Assisted and Traditional Laparoscopic Nissen Fundoplication. *Eur Surg Res.* 2009;43(2):198-203.

[18] Tolboom RC, Draaisma WA, Broeders IAMJ. Evaluation of conventional laparoscopic versus robot-assisted laparoscopic redo hiatal hernia and antireflux surgery: a cohort study. *J Robot Surg.* 2016;10(1):33-39.

[19] Cuschieri A, Shimi S, Nathanson LK. Laparoscopic reduction, crural repair, and fundoplication of large hiatal hernia. *Am J Surg.* 1992;163(4):425-430.

[20] Schlottmann F, Strassle PD, Farrell TM, Patti MG. Minimally Invasive Surgery Should Be the Standard of Care for Paraesophageal Hernia Repair. *J Gastrointest Surg.* 2017;21(5):778-784.

[21] Mattar SG, Bowers SP, Galloway KD, Hunter JG, Smith CD. Long-term outcome of laparoscopic repair of paraesophageal hernia. *Surg Endosc.* 2002 May;16(5):745-9.

[22] Peters JH. SAGES guidelines for the management of hiatal hernia. *Surg Endosc.* 2013;27(12):4407-8.

[23] Mungo B, Molena D, Stem M, Feinberg RL, Lidor AO. Thirty-Day Outcomes of Paraesophageal Hernia Repair Using the NSQIP Database: Should Laparoscopy Be the Standard of Care? *J Am Coll Surg.* 2014;219(2):229-236.

[24] Andujar JJ, Papasavas PK, Birdas T, et al. Laparoscopic repair of large paraesophageal hernia is associated with a low incidence of recurrence and reoperation. *Surg Endosc.* 2004;18(3):444-7.

[25] Dallemagne B, Kohnen L, Perretta S, Weerts J, Markiewicz S, Jehaes C. Laparoscopic repair of paraesophageal hernia: long-term follow-up reveals good clinical outcome despite high radiological recurrence rate. *Ann Surg.* 2011;253(2):291-6.

[26] Vasudevan V, Reusche R, Nelson E, Kaza S. Robotic paraesophageal hernia repair: a single-center experience and systematic review. *J Robot Surg.* 2017;12(1):81-86.

[27] Macke RA, Luketich JD, Pennathur A, et al. Thoracic Esophageal Diverticula: A 15-Year Experience of Minimally Invasive Surgical Management. *Ann Thorac Surg.* 2015;100(5):1795-1802.

[28] Brandeis AE, Singhal S, Lee TH, Mittal SK. Surgical management of epiphrenic diverticulum: A single-center experience and brief review of literature. *Am J Surg.* 2017 Jul 19. pii: S0002-9610(17)30826-7.

[29] Hukkeri VS, Jindal S, Qaleem M, Tandon V, Govil D. Robotic transhiatal excision of epiphrenic diverticula. *J Robot Surg.* 2016;10(4):365-368.

In: Encyclopedia of Surgery (22 Volume Set)
Editors: Andreas Lehrer and Kristin Mueller
ISBN: 978-1-53618-329-0
© 2020 Nova Science Publishers, Inc.

Chapter 247

ROBOTIC MITRAL VALVE REPLACEMENT AND REPAIR

T. Sloane Guy[1], MD, Lucas B. Ohmes[2], MD and Ahmed A. Abouarab[3], MD

[1]Cardiothoracic Surgery, Director of Robotic Cardiac Surgery, Department of Cardiothoracic Surgery, Weill Cornell Medicine, New York, NY, US
[2]Department of General Surgery, Rutgers University, Newark, NJ, US
[3]Department of Cardiothoracic Surgery, Weill Cornell Medicine, New York, NY, US

INTRODUCTION

Robotically-assisted mitral valve procedures (RMVP) represent a major advancement in the field of minimally invasive surgery, which is the blueprint of the current surgical era. It is the most common type of robotically-assisted cardiac surgeries practiced today. These procedures involve both mitral valve repair and replacement with or without additional procedures such as the Maze procedure for atrial fibrillation. Similar to other minimally invasive surgeries, the main goal is to lessen the operative trauma and postoperative pain that patients have to endure. Thus, instead of the conventional sternotomy incision, this procedure is performed via five smaller intercostal incisions without rib-spreading. The procedure can be done totally endoscopically. This means that no portion of the operation is done by looking directly into the chest, due to the small port size, and all visualization is with the robotic camera.

Other benefits associated with minimally invasive cardiac surgeries include; better cosmetic results with minimal scarring, less amount of bleeding, lower risk of infection, as well as shorter hospital stay and recovery periods. Despite being a controversial issue, a cost-effectiveness benefit has also been reported, attributed to shorter hospital stay and minimal use of pain and antibiotic medications.

Since the first RMVP in 1998, [1] the procedure has endured many challenges, uncertainties and discredit. Through the process of continuous modulation, the current technique practiced today has evolved. Multiple stages of modification and testing were

required to optimize the conduct of this procedure, involving; robotic equipment, surgical instruments, surgical technique, health-care team organization and preoperative assessment and planning. Reproduction of experiences of different surgical teams has also contributed to identifying standard patient selection criteria.

This chapter will discuss the current indications, contraindications, advantages, disadvantages, preoperative preparation, operative technique and complications of RMVP, along with tips to improve outcomes [2].

INDICATIONS FOR MITRAL VALVE REPAIR

The American Heart Association (AHA) and the American College of Cardiology (ACC) 2014 guidelines for the management of patients with valvular heart disease have categorized patients into five groups based on their level of degenerative mitral regurgitation (MR) (See Table 1). In general, for primary MR patients surgical repair should be done in those with stage D and C2 disease, Class I recommendation. Other Class I recommendations for primary MR intervention are those patients with posterior leaflet disease, those with anterior leaflet disease or bileaflet disease and successful repair is deemed possible, and when a concomitant surgery is planned. The evidence for secondary MR is less robust, however the AHA/ACC recommend that surgical interventions is warranted in patients with stage D or C who are undergoing either CABG or AVR (Class IIa), those with stage D disease with poor functional status NYHA class III/IV, and those with stage B disease who are undergoing any other cardiac surgery (Class IIb for both).

Table 1. Stages of mitral regurgitation for both secondary and primary causes

Grade	Definition
A	At risk for development of MR
B	Diagnosed MR with disease progression
C1	Severe disease in asymptomatic with preserved left ventricular function (EF > 60%)
C2	Severe disease in asymptomatic patient with early-reduced left ventricular function (EF < 60%)
D	Severe MR and symptomatic

PATIENT SELECTION FOR ROBOTIC MITRAL VALVE SURGERY

Patients are candidates for robotic mitral valve surgery if they meet the criteria set forth by the AHA/ACC guidelines. The robotic approach is done through the right chest, thus any thoracic pathology in the region may be a contraindication. While general contraindications to cardiac surgery also apply to robotic surgery, lists of specific absolute and relative contraindications to the robotic approach are outlined in Table 2. In our experience, 98% of isolated mitral valve procedures can be done robotically. The 2% consists of high-risk patients unsuitable for any type surgery, severe mitral annular calcification, severe peripheral vascular disease, ascending aortic aneurysm >40mm, and severe adhesions in the right pleural space. All of these are relative not absolute contraindications. Different surgical groups have different philosophies on this with some groups being more selective for extremely low risk

patients and including other exclusions such as redo surgery. We have not found redo surgery to be a problem and in fact, it can be easier than a redo sternotomy if there are limited adhesions in the right pleural space.

Table 2. Absolute and relative contraindications for robotic mitral valve surgery

Absolute	
Previous right thoracic surgery	Coronary artery disease requiring CABG
Severe peripheral vascular disease	Dilation of the aortic root or ascending aorta
Mild to moderate aortic valve insufficiency	Calcifications of the mitral annulus
Moderate to severe aortic root or ascending aorta calcification	Severe chronic pulmonary disease
Relative	
Previous sternotomy	Mild to moderate peripheral vascular disease
Chest deformities	Mild to moderate aortic valvular disease either insufficiency or stenosis
Additional valvular pathology involving other heart valves	Moderate chronic pulmonary disease

PREOPERATIVE WORK-UP

Patient work up should always begin with a thorough and in-depth history and physical. Those patients who meet the AHA/ACC criteria for surgical intervention and have no contraindications to robotic surgery found on history and physical are then progressed to preoperative imaging [3]. Computed tomography (CT) of the chest, abdomen and pelvis with intravenous contrast is required. This allows for imaging of the vasculature for possible bypass cannulation sites, assessment of the aorta for dilation or excessive calcifications, and any anatomical abnormalities not seen on physical exam. One of the most important things to look for is the presence of intraluminal thrombus. Such thrombus can cause strokes if retrograde femoral arterial perfusion is used. Patients with suspected or at risk for coronary artery disease and men >40 and women >50 years of age may undergo either traditional cardiac catheterization or CT coronary angiogram. Those with significant pulmonary disease or concern for severe pulmonary hypertension on echocardiogram may undergo right heart catheterization as well. A high quality (usually 3D) transesophageal echocardiogram is optional preoperatively but is extremely helpful in preoperative planning. A preoperative risk stratification assessment such as the Society of Thoracic Surgeons (STS) score should also be calculated to aid the surgeon in preoperative planning and for patient education.

OPERATIVE TECHNIQUE FOR TOTALLY ENDOSCOPIC ROBOTIC MITRAL VALVE REPAIR

The technique used by the author is described below in general terms to present an overview of the operation. Specific pitfalls and troubleshooting are described later. See Table 3 for brief overview.

1. Patients are placed supine on the operating table, general anesthesia is inducted and the patient is intubated with a left angled double-lumen endotracheal tube to allow for deflation of the right lung during the initial portions of the procedure and at the end of the procedure. Some groups use a single lumen tube with or with a bronchial blocker instead.
2. Anesthesia routinely places bilateral arterial lines. We prefer bilateral brachial arterial lines so that we can be certain of the relative pressures of the right and left arms during the procedure. Also placed is a right single-lumen internal jugular central line for later use by the surgeon for bicaval cannulation, a percutaneous coronary sinus catheter for cardioplegia, and a percutaneous pulmonary artery vent both of which are placed under fluoroscopy and transesophageal echocardiogram guidance. Foley bladder catheter for monitoring of body temperature and urine output is also placed at this time.
3. The right chest is bumped up to an angle of 15 degrees. The neck, chest, abdomen, pelvis, and legs are prepped and draped.
4. Depending on preoperative imaging a right or left groin cut-down is done and the vessels are assessed for possible cannulation. If the vessels are suitable for access, a purse string suture is placed in the femoral vein for later use. Axillary artery cannulation is an alternative in patients with descending thoracic aortic intra-lumenal thrombus as this reduces the incidence of stroke. This strategy could include the use of a transthoracic aortic cross clamp or placement of the endoballoon via the femoral artery or in selected cases, through the axillary artery as well.
5. Right lung isolation is initiated at this point and four 8mm robotic ports are placed in the right chest with one 12mm working port placed in the 4th or 5th intercostal space in the anterior axillary line. Figure 1
6. Three 14 gauge angiocatheters (5 ½ inches long) are placed in the right lateral chest with 0 silk suture loops to be used later as retraction sutures.
7. A 12-french peel-away sheath along with a 12-french sump drain are placed into the right chest for later use.
8. Venous cannulation is performed next. This is done using a 22 or 24-french multi-stage Edwards Lifesciences (Irvine, CA) venous cannula into the common femoral vein that had been previously exposed via a cut down. The Seldinger technique is used and under echocardiogram guidance the tip is placed in the superior vena cava. The cannula was then attached to the cardiopulmonary bypass circuit.
9. The femoral artery is cannulated with an Edwards Endoreturn 21 or 23F cannula via Seldinger technique and under echocardiogram guidance to ensure the wire is in the aortic lumen. A 4-0 Prolene (Ethicon, Inc., Somerville, NJ) purse-string is used. We routinely place a 6F or 7F wire wrapped sheath in the distal femoral artery in an antegrade fashion as a distal limb perfusion technique. We connect the side port of the sheath to a branch off the arterial line to ensure limb perfusion. Many groups use these selectively or not at all. We also use distal limb oximetry to monitor limb oxygen saturation throughout the case. Figure 1B.
10. At this point the right single-lumen internal jugular catheter that had been previously placed was exchanged over a wire to a 16-french superior vena caval drainage catheter. This was done to achieve bicaval drainage.
11. The robot is then docked. Figure 2

12. The tendon of the right hemidiaphragm is tented up with a robotic long tipped forceps and a CV2 (Gore Medical, Flagstaff, AZ) pledgeted mattress suture is placed, tied down, and exteriorized via the most inferior lateral chest wall angio-catheter. This is done to improve exposure and protect the diaphragm and liver from injury.
13. Next the pericardium is opened from the inferior vena cava over to the aorta. Once this has been done and adequate exposure is achieved, cardiopulmonary bypass is initiated. If exposure is challenging, the surgeon can go on bypass prior to opening the pericardium.

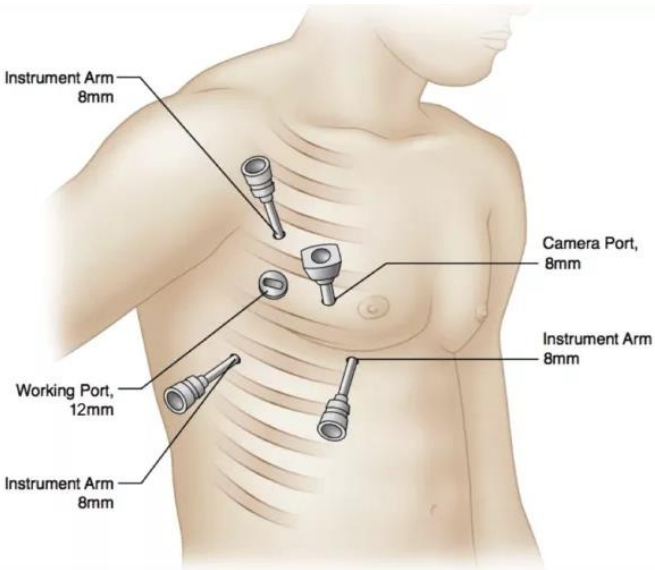

(A)

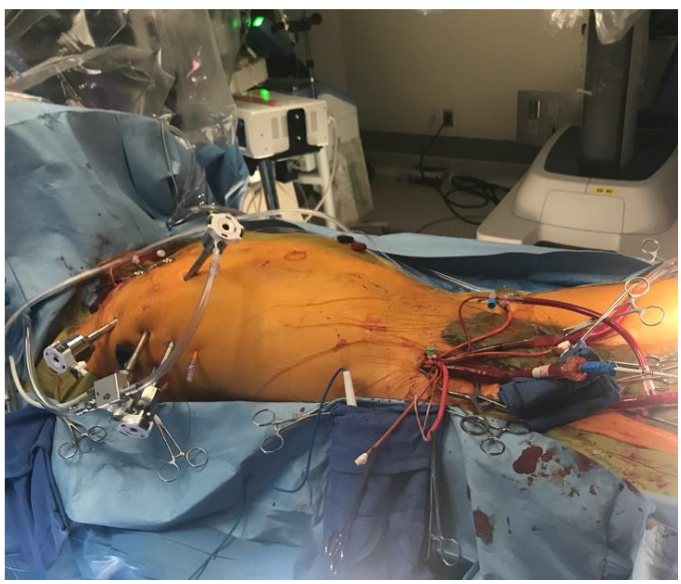

(B)

Figure 1. A.) Robotic port placement in right chest. B.) Port placement and groin cannulation.

Table 3. Brief outline of robotic mitral valve surgery

Nerve block, patient to room
Double Lumen ETT, foley, bilat brachial a-lines
RIJ SLC, proplege, PA vent (TEE+Fluoro)
Fem expose, lung down, ports, 14GX3, LA sump
Heparin-Fem V, leg shunt, FA, endoballoon, SVC
Dock bot, diaphragm suture, open pericardium
Pericardial retraction, CPB, checklist, arrest
Atrial Entry, LA retraction stitch, LAA closure
Valve analysis, repair, static test
Close LA, pacer wire, blake in pericardium
De-air, tie LA suture, remove instruments
Gradual lung re-inflation, wean off CPB, TEE
Decannulate, Protamine, RVATS
Close, remove PA vent, proplege, SL ETT, ICU

Figure 2. Docking of the robotic arms and camera.

14. Pericardial retraction sutures are placed and exteriorized through the angio catheters by using the previously placed silk suture loops to grab the retraction sutures and exteriorize them outside the body. They are then affixed with a hemostat.
15. At this point the heart is arrested with the endo balloon in the ascending aorta. The author uses 30mg of adenosine followed by 1 liter of antegrade high potassium, cold, del Nido cardioplegia given into the ascending aorta. Then 500 milliliters of

retrograde cardioplegia is given as well. If at 1 hour cross-clamp things are going well or the repair is completed, no further cardioplegia is given. If it appears the procedure may be prolonged beyond 90 minutes cross-clamp time, a second dose is given of 750 cc retrograde cardioplegia.

16. After adequate arrest of the heart, the left atrium is opened. This is done through the oblique sinus behind the inferior vena cava in Waterston groove.
17. The intracardiac sump drain is placed into the left pulmonary veins.
18. The author routinely closes the left atrial appendage, which is done at this point of the operation. This is performed using a CV4 Gore-Tex (CV2 (Gore Medical, Flagstaff, AZ) suture in a double layered fashion. In part we do this to improve exposure of the P1 region and the left commissural area. We also place a retraction suture to retract the posterior left atrium down to the pericardium to improve exposure of the posterior P2/P3 portion of the valve.
19. The valve is inspected at this point and static tested to evaluate how best to repair the valve. We use the da Vinci Xi suction irrigator to perform the static test as this allows for very precise testing.
20. Once the area of pathology is identified, a strategy is developed which might include either resectional or non-resectional approaches. In most cases of prolapse, we use neochords (NeoChord, St. Louis Park, MN) more and more. All the neochords are places without tying them (two passes of each needle) and placed on a hemostat outside the body. We then static test again and perform dynamic adjustment of the chord length for each Neochord. We then grab the sutures with a robotic debakey and have the bedside assistant place 12 knots on each.
21. The annulus is sized next. The appropriately sized flexible band is then placed and sutured with a CV4 mattressed suture, one at each trigone. A running horizontal mattress suture is also placed. Alternatively, in the case of functional mitral regurgitation or ischemic mitral regurgitation, we will use a semi-rigid complete ring with interrupted 2-0 ethibond sutures secured with Cor-Knots (LSI, Inc., Rochester, NY).
22. The valve is then again static tested for compliance and a left ventricular sump drain was placed across the valve.
23. Atrial retraction sutures are removed and the left atriotomy is closed with a CV4 Gore tex suture.
24. The aorta is de-aired the endo balloon is deflated ending the crossclamp time.
25. A single pacing wire is placed into the right ventricle and a 24 French Blake drain is placed behind the inferior vena cava into the oblique sinus and into the pericardium. Many groups do not place a pacing wire or use a pacing Swan Ganz catheter, but we have been very happy with routine pacing wires as this provides us with a margin of safety when managing the heart rate and is the same as for open surgery which makes ICU management more similar to other cases.
26. De-airing is undertaken and reperfusion of the heart for a period of time. Then the ventricular sump drain is removed and the suture line is tied down and bolstered with pledgeted CV4 Gore-Tex mattress sutures.
27. The pericardium is then loosely approximated with two sutures of 2-0 Ethibond (Ethicon, Inc., Somerville, NJ).

Figure 3. Robotic mitral valve procedure incisions.

28. Before removal, all robotic port sites are inspected for bleeding. Ports are then removed, CO2 gas is evacuated, and both lungs are gradually reinflated. Gradual reinflation is an important part of the prevention of unilateral pulmonary edema. As part of this strategy we routinely cool the patient to 30 degrees Celcius to protect the lung.
29. Cardiopulmonary bypass is gradually weaned, rewarming is accomplished, and the patient is separated from bypass.
30. A completion echocardiogram is done at this point to assess the newly repaired valve.
31. If the repair is satisfactory, the robot is undocked, the pericardial retraction sutures are removed, and the diaphragm stitch is cut.
32. The endo balloon is removed followed by the venous cannula, the aterial perfusion cannula, and the distal limb perfusion cannula. The pursestrings are all tied down. If there is a concern for hemostasis of the artery or narrowing of the artery, clamps are applied and a more formal repair performed but this is not commonly required.
33. Once the cannulas are removed protamine is given for heparin reversal.
34. The right lung is then again deflated and re-exploration of the right chest is done with video thorascopy to ensure adequate hemostasis.
35. A 24 French Blake drain is placed through the right robotic arm in the right chest apex. All port sites are closed ending the procedure. (Figure 3)

OPERATIVE TECHNIQUE FOR TOTALLY ENDOSCOPIC ROBOTIC MITRAL VALVE REPLACEMENT

The technique used by the author is described below in general terms to present an overview of the operation. Specific pitfalls and troubleshooting are described later. The initial steps for mitral valve replacement are similar to those described above for repair. The steps only differ once the valve is encountered and are described as follows:

1. The anterior leaflet of the valve is often removed with a combination of robotic scissors and electrocautery. Care is taken to not damage the annulus or surrounding structures.

2. The valve is then sized and then a series of 2-0 Ethibond pledgeted sutures are placed robotically with a large robotic needle driver around the annulus with the pledgets on the ventricular side. These are kept in proper order by exteriorizing the sutures and placing them in a suture guide outside the patient in specific order.
3. At this point the assistant or the surgeon places the sutures through the valve ring, detaches the valve from the holder and lowers the valve in the patient within view of the robotic camera. In the case of a tissue valve, a "cinch" suture of 2-0 Prolene is used to temporarily guard against struts being caught by the sutures. This will later be removed.
4. The valve is then seated robotically while the assistant helps with tightening the sutures.
5. Once properly seated the sutures are tied down with Cor-Knot. In the case of a tissue valve, the "cinch" suture is cut and removed.
6. The valve is then static tested to evaluate for perivalvular leaks and rule out strut impingement.

PITFALLS AND TROUBLESHOOTING

In addition to the complications that may occur with any cardiac or conventional mitral valve procedure, there are a few complications related the robotic technique pertaining mainly to perioperative perfusion, ventilation or access establishment. Unlike its previous versions, the current daVinci Robotic System (XI) has not yet reported to cause any additional complications. Table 4 summarizes the complications that have been reported so far, along with tips to improve outcomes and for effective prevention and management of such complications.

Table 4. Pitfalls and troubleshooting

Pitfalls	Troubleshooting
I- Retrograde Perfusion related complications	
Embolic Strokes Vena Caval Injury Dissections (Femoral and Aortic)	Entire body vascular CT scanning to anticipate such complications pre-operatively. Modifying management plan accordingly.
Lower Limb Ischemia	Close monitoring of lower limbs' oxygen saturation and perfusing the femoral artery distally as needed using a shunt.
Right Ventricular Dysfunction and Air Embolism	Attention should be given to proper de-airing technique. Avoidance of the right 30 degree-up position. (risk of air embolism)
II- Ventilation related Complications	
Pulmonary Edema	Proper ventilation pressure (Low positive pressure during bypass is believed to be of benefit). Minimal lung deflation and perfusion times. Judicious blood product transfusions.
III- Surgical Technique and Iatrogenic Injuries	
Cross Clamp Injuries (The right pulmonary artery, left main coronary and atrium are at risk of injury by the posterior jaw)	Proper inspection of the clamp placement field.
Phrenic Nerve Injury (This injury can be caused by aggressive myocardial manipulation, cautery, or instruments)	Meticulous surgical technique and field anatomy identification are essential. Patients with poor pre-operative pulmonary function should be properly prepared for RVMP.

Eventually, it is imperative to emphasize that conventional sternomtoy or at least videoscopic conversion are available options to consider when appropriate and confident RVMP cannot be conducted.

RESULTS AND DISCUSSION

Robotic mitral valve procedures have been shown to be as effective as conventional sternotomy mitral valve surgeries [4]. Similarly, the accuracy of repair or replacement relies largely on appropriate patient selection and surgical technique. Despite that its safety was put into question in a previous study, those findings failed to be generalized on the larger population of RMVP due to heterogeneity of the tested population and other factors [5]. This was followed by many successful reports from large institutions [6–10]. Mortality and stroke risks were found to be generally less than 1%, and a consensus has been reached regarding the most important factors for those results. Essentially, proper patient selection and pro-operative assessment.

These concepts have been practiced in cardiac surgery, and in other surgical disciplines, since its birth in the past century. Other factors that warrants proper assessment are that concomitant cardiac pathologies could potentially affect the outcomes of RVMP, such as the case in concomitant aortic regurgitations. Regarding applicability, with the exception of mitral annular calcifications, RMVP could potentially be applied on any mitral pathology. Some of the obstacles against wide application include the additional complexity added to cardiac surgeries especially regarding perfusion technique and the need for optimal port placement. This also brings into picture the learning curve required for surgeons practicing such procedures. Ideally, a surgeon would require training in conventionally cardiac surgery, in addition to training in robotic surgery concepts. Such a long training curve takes into consideration the long training curve for cardiac surgeons. However, the commencement of this technique is much better than that of other minimally invasive surgical procedures, which are the standard of care today. Another issue regarding RMVP is cost-effectiveness. The increased cost of equipment and preoperative assessment still exceeds the benefit from shorter hospital stay and time to return to regular activity. However, it is believed that this would improve with time and experience to levels similar to that of conventional surgery [11].

COMBINED PROCEDURES

While mitral valve surgery remains the dominate use for robotic cardiac surgery, combined or concomitant procedures have not been well described. The first was done by Carpentier when he reported results of for patients treated with ring annuloplasty, one of which had a combined atrial septal defect closure [12]. Despite this initial combined procedure the use of robotics in cardiac surgery has mainly been limited to single procedure. However, more recent literature is showing that robotics can in fact be used for combined procedures. Certainly, concomitant procedures that are relatively easy to perform include: appendage closure, patent foramen ovales or atrial septal defect closure, tricuspid valve

repair, MAZE procedures, or tumor removal from the left atrium, right atrium, or left ventricle.

Hybrid CABG with PCI

Hybrid coronary revascularization combines the advantages of minimally invasive robotic coronary revascularization with percutaneous coronary stenting. One of the largest studies on the subject by Bonatti and colleges reported results on 226 patients who underwent hybrid coronary revascularization [13]. The majority (65.0%) of patients underwent a single bypass graft with surgery being done first in 70.8%, percutaneous intervention in 16.8% and a combined procedure in 12.4% of patients. Hospital mortality was 1.3% with an average length of stay of 6 days. Five-year survival was 92.9% and freedom from major adverse cardiac or cerebral event was 75.2%. The authors conclude that the hybrid technique provides a minimally traumatic cardiac intervention with shortened recovery time and outcomes comparable with standard cardiac surgery.

Hybrid strategies for patients with mitral disease and concomitant coronary artery disease include:

1. Changing to a traditional open coronary bypass and mitral procedure
2. Robotic mitral valve repair plus stents to a coronary (either before or after depending on the anatomy). We generally prefer after unless a critical lesion given need for anti-platelet agents with stent placement.
3. Robotic mitral valve repair and medical management of residual coronary disease (for example a moderate lesion in right coronary artery that is asymptomatic).

Although there have been anecdotal reports of combined robotic mitral repair and either robotic TECAB (totally endoscopic coronary artery bypass) or robotic MIDCAB (minimally invasive direct coronary artery bypass with robotic internal mammary artery harvest followed by hand-sewn anastomosis to the left anterior descending via a left anterior thoracotomy), the experience with this approach has been limited and very uncommon. We do not favor this approach given the added complexity and time required. Alternatively, we favor a hybrid approach when appropriate or conversion an open sternotomy strategy.

Other Minimally Invasive Procedures [14]

Similarly, minimally invasive mitral valve procedures are either to repair the native valve or to implant a new valve. These techniques have enabled the management of mitral valve lesions safely in high-risk patients for surgery. However, these techniques face many challenges and their true benefits are yet to be assessed.

For years, many surgeons have performed minimally invasive mitral surgery via several techniques. Both upper and lower mini-sternotomies have been used. Also a right “mini” thoracotomy or “port access” approaches have been popular. The advantage of such approaches over robotic endoscopic techniques is simplicity. The disadvantages are numerous including the need to spread the ribs (which often leads to more pain than even a sternotomy),

difficulty using long straight-shafted instruments with less degrees of freedom than those offered by the robotic instruments, the need for a larger incision to work through, and lack of an easily maneuverable 3D high definition camera to visualize the valve. Some surgeons do use a camera with a fixed arm but even this is not as versatile as the robotic option.

Another evolving option is trans-catheter mitral valve repair and replacement. Mitral valve lesions usually consists of multiple complex lesions. Based on this fact, surgical management is tailored to the complexity of the mitral valve pathology. In order to have outcomes comparable to surgery, transcatheter repair needs to take into consideration: appropriate selection of patients, designs for transcatheter mitral valves and stents, different anchoring methods and delivery modes, as well as valve materials. Any single design would inevitably affect other functioning parts of the mitral valve.

For trans-catheter mitral valve implantation, proper anchoring technique of the prosthesis is essential considering the imposed ventricular load. Anatomically, the mitral annulus is not perfectly circular, but rather saddle-shaped, and highly dynamic. The trigones of the mitral valve are continuous with the fibrous skeleton. Other areas of the annulus also can have variable degrees of compliance (annular calcification). The annulus is close to the coronary sinus and circumflex artery, imposing a potential for impingement. Other patients may also present with myxomatous degeneration with disjunction at the site of leaflet insertion.

Ideally, these prostheses must be multiplanar to avoid the risk of paravalvular leak. Perfecting the sealing area is crucial. Another issue is that the device must minimize interference with the outflow tract. Echocardiography and contrast-computed tomography techniques continue to be assessed in order to accurately predict this factor.

The placement of ventricular leads for cardiac resynchronization therapy is routinely done via an endovascular approach through the coronary sinus. When this is not possible or fails epicardial placement through a left sided mini-thoracotomy with robotic assistance has been described. This was first described in 2002 in Frankfurt, Germany by Kleine and colleges who reported left ventricular lead placement during biventricular defibrillator implantation [15]. This has shown to be a durable option for patients with favorable and stable pacing thresholds and lead impedance at 44 months [16].

Robotic cardiac surgery for the treatment of congenital heart defects, atrial fibrillation ablation procedures, myxoma resections, and aortic graft suturing have all be described in the literature [17]. However, these operations are limited to highly specialized centers and large case numbers have not been reported.

Due to the limited volume of studies and low number of patients the only procedures that meet criteria for randomized control trials are robotic mitral valve repair, hybrid coronary revascularization, and catheter ablation for atrial fibrillation.

REFERENCES

[1] Carpentier A, Loulmet D, Aupècle B, Kieffer JP, Tournay D, Guibourt P, et al. Computer assisted open heart surgery. First case operated on with success. *C R Acad Sci III.* 1998 May;321(5):437–42.

[2] Bush B, Nifong LW, Alwair H, Chitwood WR. Robotic mitral valve surgery—current status and future directions. *Ann Cardiothorac Surg*. 2013 Nov;2(6):814–7.

[3] Nishimura RA, Otto CM, Bonow RO, Carabello BA, Erwin JP, Guyton RA, et al. 2014 AHA/ACC Guideline for the Management of Patients With Valvular Heart Disease: executive summary: a report of the American College of Cardiology/American Heart Association Task Force on Practice Guidelines. *Circulation*. 2014 Jun 10;129(23): 2440–92.

[4] Gammie JS, Zhao Y, Peterson ED, O'Brien SM, Rankin JS, Griffith BP. J. Maxwell Chamberlain Memorial Paper for adult cardiac surgery. Less-invasive mitral valve operations: trends and outcomes from the Society of Thoracic Surgeons Adult Cardiac Surgery Database. *Ann Thorac Surg*. 2010 Nov;90(5):1401–8, 1410.e1; discussion 1408-1410.

[5] Mihaljevic T, Jarrett CM, Gillinov AM, Williams SJ, DeVilliers PA, Stewart WJ, et al. Robotic repair of posterior mitral valve prolapse versus conventional approaches: potential realized. *J Thorac Cardiovasc Surg*. 2011 Jan;141(1):72-80.e1-4.

[6] Suri RM, Burkhart HM, Daly RC, Dearani JA, Park SJ, Sundt TM, et al. Robotic mitral valve repair for all prolapse subsets using techniques identical to open valvuloplasty: Establishing the benchmark against which percutaneous interventions should be judged. *J Thorac Cardiovasc Surg.* 2011 Nov 1;142(5):970–9.

[7] Nifong LW, Rodriguez E, Chitwood WR. 540 consecutive robotic mitral valve repairs including concomitant atrial fibrillation cryoablation. *Ann Thorac Surg.* 2012 Jul;94(1): 38–42; discussion 43.

[8] Murphy DA, Moss E, Binongo J, Miller JS, Macheers SK, Sarin EL, et al. The Expanding Role of Endoscopic Robotics in Mitral Valve Surgery: 1,257 Consecutive Procedures. *Ann Thorac Surg*. 2015 Nov;100(5):1675–81; discussion 1681-1682.

[9] Ramzy D, Trento A, Cheng W, De Robertis MA, Mirocha J, Ruzza A, et al. Three hundred robotic-assisted mitral valve repairs: the Cedars-Sinai experience. *J Thorac Cardiovasc Surg*. 2014 Jan;147(1):228–35.

[10] Suri RM, Taggarse A, Burkhart HM, Daly RC, Mauermann W, Nishimura RA, et al. Robotic Mitral Valve Repair for Simple and Complex Degenerative Disease: Midterm Clinical and Echocardiographic Quality Outcomes. *Circulation*. 2015 Nov 24;132(21):1961–8.

[11] Suri RM, Thompson JE, Burkhart HM, Huebner M, Borah BJ, Li Z, et al. Improving affordability through innovation in the surgical treatment of mitral valve disease. *Mayo Clin Proc*. 2013 Oct;88(10):1075–84.

[12] Pettinari M, Navarra E, Noirhomme P, Gutermann H. The state of robotic cardiac surgery in Europe. *Ann Cardiothorac Surg*. 2017 Jan;6(1):1–8.

[13] Bonatti JO, Zimrin D, Lehr EJ, Vesely M, Kon ZN, Wehman B, et al. Hybrid coronary revascularization using robotic totally endoscopic surgery: perioperative outcomes and 5-year results. *Ann Thorac Surg*. 2012 Dec;94(6):1920–6; discussion 1926.

[14] Sorajja P, Leon MB, Adams DH, Webb JG, Farivar RS. Transcatheter Therapy for Mitral Regurgitation Clinical Challenges and Potential Solutions. *Circulation*. 2017 Jul 25;136(4):404–17.

[15] Kleine P, Grönefeld G, Dogan S, Hohnloser SH, Moritz A, Wimmer-Greinecker G. Robotically enhanced placement of left ventricular epicardial electrodes during implantation of a biventricular implantable cardioverter defibrillator system. *Pacing Clin Electrophysiol PACE*. 2002 Jun;25(6):989–91.

[16] Kamath GS, Balaram S, Choi A, Kuteyeva O, Garikipati NV, Steinberg JS, et al. Long-term outcome of leads and patients following robotic epicardial left ventricular lead placement for cardiac resynchronization therapy. *Pacing Clin Electrophysiol PACE*. 2011 Feb;34(2):235–40.

[17] Bonatti J, Vetrovec G, Riga C, Wazni O, Stadler P. Robotic technology in cardiovascular medicine. *Nat Rev Cardiol*. 2014 May;11(5):266–75.

In: Encyclopedia of Surgery (22 Volume Set)
Editors: Andreas Lehrer and Kristin Mueller
ISBN: 978-1-53618-329-0
© 2020 Nova Science Publishers, Inc.

Chapter 248

ROBOTIC CORONARY REVASCULARIZATION

Philip Erwin[1], DO, Sharon Ben-Or[2], MD and Eric J. Lehr[3], MD, PhD

[1]Greenville Memorial Hospital, Greenville, SC, US
[2]University of South Carolina at Greenville, Greenville, SC, US
[3]Robotic and Minimally Invasive Cardiac Surgery, Cardiac Surgery Research and Education, Swedish Heart and Vascular Institute, Seattle, WA, US

ABSTRACT

Coronary artery bypass grafting (CABG) has been long been established as an effective method of restoring blood flow to the myocardium in the setting of advanced coronary artery disease. Grafting the left internal mammary artery (LIMA) to the left anterior descending coronary artery (LAD) improves long-term survival and multi-arterial grafting likely provides additional long-term benefits. Many patients do not receive the benefit of IMA revascularization due to the morbidity associated with CABG. Consequently, cardiac surgeons in the 1990s developed less invasive methods of myocardial revascularization from which spawned the development of robotic coronary artery bypass grafting procedures.

Minimally invasive direct coronary artery bypass grafting (MIDCAB) was independently described by Dr. Valavanur Subramanian and Dr. Federico Benetti in 1994 at the International Workshop on Arterial Conduits for Myocardial Revascularization and led to the presentation of a multi-center trial of 168 patients presented at the Annual Meeting of the American Heart Association in 1995. As MIDCAB was adopted by numerous surgeons, its challenges were identified including difficulty harvesting the entire length of the LIMA, limited access to the right internal mammary artery (RIMA), IMA rotation, target vessel identification, suturing through a small incision. Endoscopic techniques for IMA harvesting and anastomotic suturing were also developed, but proved to be very challenging and did not gain widespread adoption.

In the late 1990s, robotic technology became available, providing superior visualization of the entire thorax and improved intra-thoracic ergonomic motion for complex intra-thoracic procedures. This technology provided solutions for the challenges associated with endoscopic and limited access coronary artery bypass grafting by allowing ease of access to all intrathoracic regions from single sided ports allowing full

dissection of bilateral internal mammary arteries (BIMAs), target vessel identification, access to all regions of the myocardium and more facile anastomoses. Consequently, robotic assisted CABG became a reality and was adopted by a number of highly dedicated centers, where outcomes have been favorable. The procedure has evolved to the point where quadruple vessel CABG has become feasible. Procedures can be performed on the arrested and beating heart. This approach can be extended to approximately one-third of CABG patients when coronary anatomy is carefully assessed, usually in the context of a heart-team, and the treatment of each lesion is considered.

ARRESTED HEART TECAB

Totally endoscopic robotic coronary artery bypass (TECAB) grafting was first performed using cardiopulmonary bypass and cardioplegic arrest. This method provides several advantages over beating heart versions. Importantly, anastomoses are constructed on a still heart. With deflated lung and an empty heart, there is increased working space [1]. It is easier to manage technical challenges including bleeding, intramyocardial vessels, myocardial perforation, myocardial ischemia and hemodynamic instability.

ANESTHETIC CONSIDERATIONS

For the standard procedure, patients are positioned supine, elevating the left hemi-thorax 30 degrees. Defibrillator pads are placed out of the surgical area and optimally, leaving room for sternotomy in the event that conversion is required. Typically one pad is placed over the right pectoralis area and another posteriorly on the left. Lung isolation is usually achieved with a double lumen endotracheal tube, although a bronchial blocker can also be used. Standard invasive monitoring devices are utilized including arterial lines, central lines and transesophageal echocardiography. Myocardial protection can be augmented with a percutaneous retrograde coronary sinus cardioplegia catheter (Figure 1). A pressurized capnothorax is induced and may impact the hemodynamic status requiring interventions including fluid resuscitation, vasopressors and inotropes or a reduction in the insufflation pressure [2].

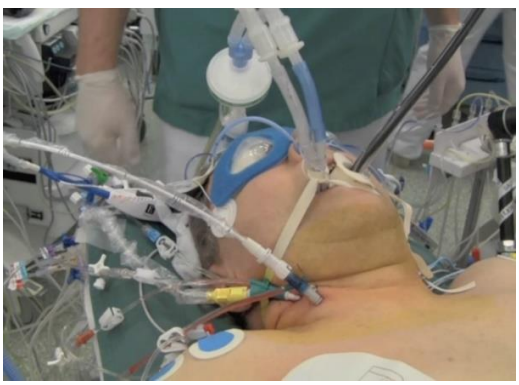

Figure 1. Anesthesia setup demonstrating the double lumen endotracheal tube, right internal jugular double stick for the retrograde coronary sinus cardioplegia catheter and central line with pulmonary artery catheter.

CARDIOPULMONARY BYPASS AND MYOCARDIAL PROTECTION

Cardiopulmonary bypass is achieved by peripheral cannulation. Preoperative computed tomographic angiography of the chest, abdomen and pelvis is performed to assess the vasculature [3]. A small incision is made typically over the right groin and the dissection is carried down to the anterior surface of the common femoral artery and vein. Double purse-string sutures are placed in each and after heparinization, both are cannulated using a modified Seldinger technique. A 6F sheath can be placed antegrade first after gaining access through a separate pursestring suture using a micropuncture kit for distal limb perfusion as a fairly large cannula is preferred when using an endoaortic occlusion balloon. Guidewire and cannula placement are confirmed with transesophageal echocardiography. Arterial cannulation is best performed with a perfusion cannula with a side arm through which an endoaortic occlusion balloon is passed over a guidewire into the aortic root. These maneuvers can be performed by the tableside surgeon, while the console surgeon is harvesting the internal mammary arteries.

Cardiopulmonary bypass is slowly initiated while being alert to high perfusion line pressure, which may signal a retrograde aortic dissection. Once stable flows have been established, the endoaortic occlusion balloon is inflated, its position confirmed between the sinotubular junction and the innominate artery with confirmation by transesophageal echocardiography. Cardioplegia is then administered to arrest the heart. A percutaneous pulmonary artery vent can assist in providing a dry operative field and a percutaneous retrograde coronary sinus catheter can be considered to augment myocardial protection.

SURGICAL PROCEDURE

Accurate port placement is an important consideration for a success procedure. The sternum is marked. Locations for the camera, right, and left arms of the robot as well as the subxiphoid port are marked (Figure 2). The camera port is placed first, lateral of the midpoint of the sternum where the chest begins to roll posteriorly, typically a centimeter (cm) or two posterior to the anterior axillary line. Caution must be undertaken when placing this port as it is typically done in a blind fashion. A pressurized capnothorax is induced at approximately 7 mmHg, watching that the hemodynamic profile of the patient remains stable. Under endoscopic vision, right and left arm ports are placed 7-8 cm cranial and caudal and 2 cm medial to the camera port.

After docking the robot, the IMAs are harvested. This is initiated by opening the endothoracic fascia and dissected away from the LIMA, working cranially and then caudally. Next, the IMA is gently teased from the loose connective tissue attachments to its venae comitantes. Low power cautery can be used to divide most branches while only the larger branches are double clipped and divided with Potts scissors. The LIMA is harvested from near its midpoint cranially to the phrenic nerve and then caudally to its bifurcation. After heparinization, it is clipped and divided distally. If bilateral IMAs are to be used, the retrosternal attachments are divided with electrocautery and long-tipped forceps. The RIMA is harvested first to avoid inadvertent injury to the LIMA after it is harvested as it could be out of the field of vision while harvesting the RIMA. The right pleural space is opened widely

creating a right pressurized capnothorax and maintaining the right lung out of the surgical field. The RIMA is harvested in the same manner as the LIMA. After the IMAs have been divided, hemostasis of the harvest site is ensured and an 8 mm assistant port is placed through the LIMA harvest site to bring additional supplies into and out of the thorax.

Figure 2. The endoscope is placed in the midpoint between the sternal notch and the tip of the xiphoid and laterally where the thumbs meet when placing the 5th fingers at the previous landmarks.

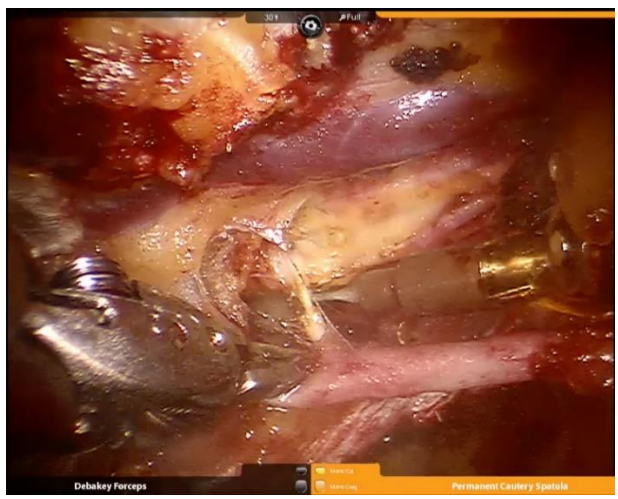

Figure 3. Right internal mammary artery harvest is carried out before the left using a skeletonized technique. Low power electrocautery is used to control most branches.

Cardiopulmonary bypass is established as described above. A stabilizer port is now placed by the tableside surgeon in the midclavicular line, about 2 cm caudal to the costal margin. Kelly forceps are used to dissect under the costal margin, scraping the posterior costal margin to avoid entering the peritoneum. Once the path is developed, the port is positioned and the third robotic arm is docked and the stabilizer is brought into the chest, ensuring that there are no external arm conflicts.

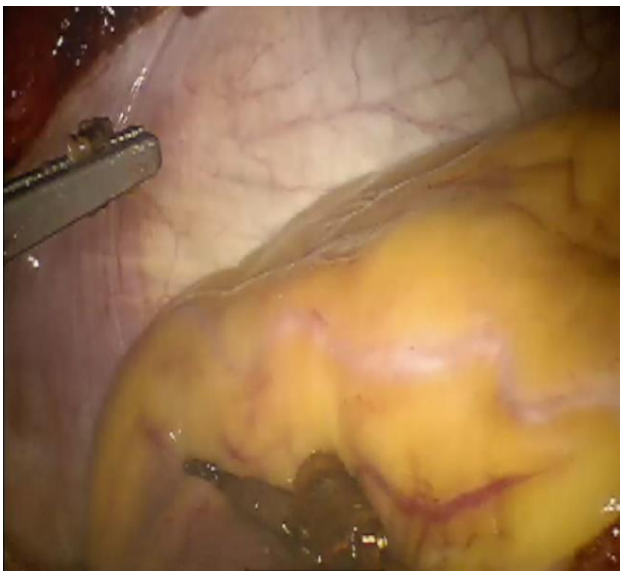

Figure 4. Target vessel identification is critical. The left anterior descending artery is seen coursing towards the apex of the left ventricle, usually appearing horizontal across the screen, or slightly upwards towards the left upper corner.

During the procedure, blood may collect in the pericardium and obscure the operative field. A small window is made in the pericardium posterior to the left phrenic nerve using long-tipped forceps and electrocautery. After arresting the heart as above, the pericardial fat pad is dissected from the lateral cranial aspect medially and then caudally towards the diaphragm. It is allowed to hang laterally which will assist in holding the pericardium out of the operative area. A pericardiotomy is then made in a similar fashion as the dissection of the fat pad, taking care to avoid the phrenic nerve and the left atrial appendage.

Identification of the target vessels is carried out by introducing the stabilizer and rotating the heart to see the appropriate coronary arteries. Typically, the LAD runs horizontally across the screen and even slightly upwards as one looks leftwards along the screen, whereas diagonal vessels tend to head towards the left bottom coroner of the screen (Figure 4). Other vessels are identified by noting their position and characteristic features such a curves and branches. The vessels on the heart can be compared to the angiogram in the operating room, and potentially even viewed picture-in-picture on the robotic console. Grafting should obviously not be undertaken until one is confident that the intended target vessels have been identified.

Grafting is then undertaken. Typically, order of grafting proceeds first with right coronary artery targets followed by the left coronary artery vessels, working laterally towards the LAD. If sequential grafts are performed, usually the distal anastomosis is completed first.

The epicardium is dissected from the vessel using Potts scissors and a lancet blade is used to create an arteriotomy that is extended again using the Potts scissors. A small bulldog clamp is applied to the IMAs and the distal end is excised on an angle and extended. Flow through the graft is confirmed. Using a 7 cm 8-0 Pronova (Ethicon, Somerville, NJ) suture, the anastomosis begins at the 10 o'clock position of the target vessel driving the needle from inside to out and parking the needle in the epicardium. The second needle is passed through the graft from inside out and from outside in on the target, moving in a clockwise position

along the back wall of the anastomosis. After 3 bites, the graft is brought down by pulling up on both ends of the suture. Suturing continues along the back wall of the anastomosis in a similar fashion, coming around the heel to the 5 o'clock position and the needle is parked in the epicardium. The first needle is taken up and suturing now continues counterclockwise around the toe working from outside in on the graft and inside out on the coronary artery.

Patency of the heel and toe is confirmed by probing with a closed black diamond microforceps. After deairing, the suture ends are cut and pulled up and the anastomosis is inspected for loose bites, which can be tightened by using a needle as a nerve hook. An instrument tie completes the anastomosis and the suture ends are broken off with the microforceps (Figure 5). Hemostasis of the anastomosis is assessed by releasing the bulldog and patency is evaluated by visualization filling of the proximal and distal coronary artery, contraction of the area supplied by the graft and watching the myocardium turn pink. Graft flow is measured with a Doppler flow probe once the endoaortic occlusion balloon is released and contractions begin.

As the heart is reperfusing, all foreign materials are removed from the chest with help from the tableside assistant. Vasodilators can be sprayed on the grafts and anastomoses by the tableside assistant and guidance from the console surgeon. Graft lie and length is assessed while the patient is weaned from cardiopulmonary bypass. Transesophageal echocardiography is used to confirm appropriate wall motion and the patient is decannulated. Protamine is administered and hemostasis of the surgical sites is confirmed with careful attention to the mammary artery beds and each port site. After the robot is undocked, port sites are again inspected using the robotic endoscope and the ports are packed with a topical hemostatic agent. The lungs should be reinflated under direct visualization and the port sites closed. Long-acting local anesthetic is infiltrated around the port sites and intercostal blocks can be placed.

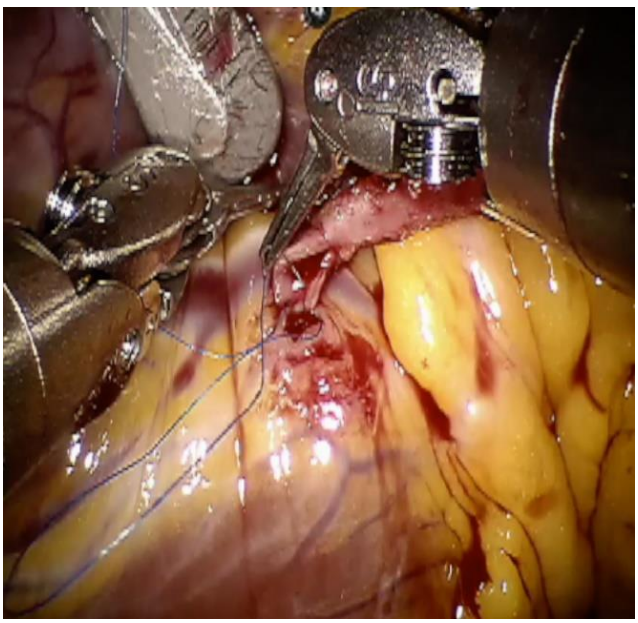

Figure 5. Suturing the left internal mammary artery to an obtuse marginal branch is very comfortable with the robot, which provides excellent magnification and visualization.

Multi-arterial coronary artery grafting can be undertaken using a combination of bilateral internal mammary artery, radial artery and saphenous vein grafts in single, sequential and Y-graft configurations. Typically, Y-grafts are constructed in the thorax prior to opening the pericardium. The endostabilizer can be used to provide a stable platform to complete the Y anastomosis. Vein grafts can be attached to the left subclavian artery [4] and brought through the chest wall. These techniques have allowed for triple [5] and even quadruple [6] coronary artery bypass procedures.

BEATING HEART TECAB – SUTURE TECHNIQUE

TECAB can also be performed on the beating heart. With the heart full and beating and without the safety net of cardiopulmonary bypass, additional considerations are important. Positive airway pressure on the deflated lung may enhance oxygenation. An experienced anesthesiologist is important to assist in managing hemodynamic derangements from a pressurized capnothorax and clear communication between the surgeon and anesthesiologist are important as changes in physiology and ventilation parameters can lead to cardiac trauma. Transthoracic echocardiography is important to monitor the heart during the procedure. Careful administration of pharmacologic support can minimize changes in contractility and heart rate, which can make suturing on the beating heart more challenging. Lidocaine is infused intravenously during the procedure to stabilize ventricular arrhythmias.

Patient positioning and port placement is the same as arrested heart TECAB. IMAs are harvested as required, preferably in a skeletonized fashion, but the graft should be left attached to the chest wall in several locations. With the endoscope looking down, the pericardial fat pad is resected and the pericardium opened. Short bursts of cautery should be used to minimize the risk of ventricular arrhythmias.

Once the target vessel is identified, the endostabilizer is introduced and heparin is administered to maintain an activated clotting time greater than 300 seconds. Papaverine is sprayed onto the graft. All devices for completing the anastomosis are now brought into the operative field and secured, including two locking silastic and a soft-tipped bulldogs. After placing two clips on the distal IMA and the bulldog proximally, it is partially divided and spatulated. A 7-0 double-armed Pronova suture is placed at the heel and toe and the IMA transection is completed. Once the endostabilizer is positioned, the epicardium is dissected away with a robotic beaver knife and the edges can be clipped to the adjacent epicardium to aid with exposure. A clip is used to hold the graft near the target vessel. Locking silastic loops are now secured proximally and distally around the target vessel and secured. An arteriotomy is made with an endoscopic lancet knife and extended approximately 4 mm as appropriate with Potts scissors. The Pronova sutures are brought through the heel and toe of the target vessel, the graft is lowered into position and three instrument throws are placed. Completion of the anastomosis is carried out along the back wall from heel to toe, placing sutures inside out in the target and outside in on the graft. Once the toe is reached the suture is tied to one arm of the toe stitch. Switching back to the heel, the remaining suture is brought towards the toe, suturing outside in on the graft and inside out on the vessel up to the midpoint of the front wall of the anastomosis. Finally, the remaining arm is brought counterclockwise along the front wall of the anastomosis to meet the heel stitch at the midpoint. Once the anastomosis is

tied, hemostasis is confirmed and graft flow is assessed with transit time Doppler [7,8]. Additional grafts are completed in a similar fashion and the operation completed as described above for arrested heart TECAB.

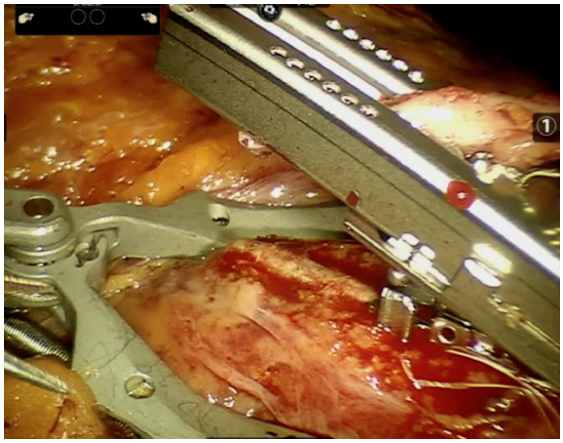

(A)

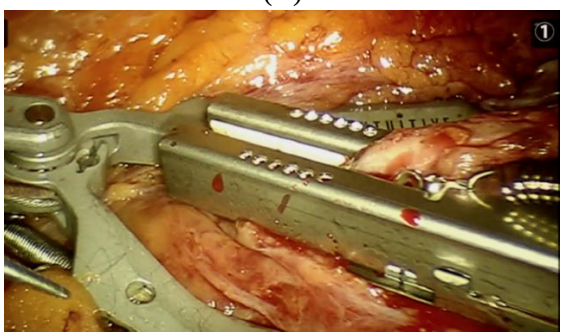

(B)

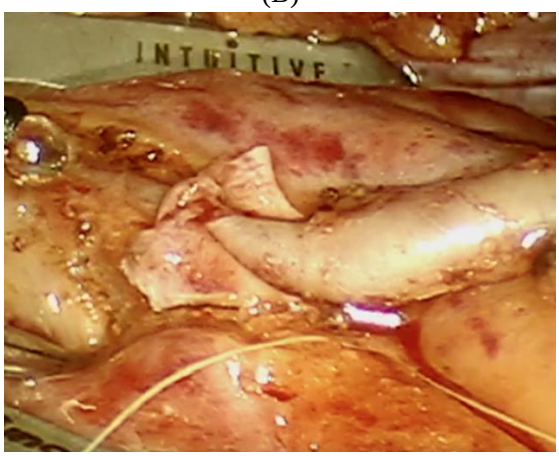

(C)

Figure 6. (A) LIMA graft is loaded on the anastomotic device. The anvil is inserted into the target vessel parallel to its long axis. (B) After insertion to the tissue stop, the tableside surgeon fires the anastomotic device. (C) A completed anastomosis with a plump hood and no bleeding. (Courtesy of Dr. Husam Balkhy, The University of Chicago).

BEATING HEART TECAB – USING AN ANASTOMOTIC DEVICE

Anastomotic connectors have been developed to facilitate reproducible anastomoses [9]. Although these have not been taken up for routine CABG surgery via sternotomy, they have advantages in TECAB and can potentially simplify the operation. Setup for the procedure is similar as for sutured beating heart TECAB procedures. A skeletonized IMA is preferred especially if a Y-graft is to be constructed and simplifies intrathoracic manipulation of the graft. Once the IMAs are harvested, the stabilizer port is placed and the 4th arm is docked. The coronary artery target is stabilized with the robotic stabilizer and the coronary artery is prepared. Once the epicardium is dissected, a silastic snare is placed around the artery and a polytetrafluoroethylene CV8 (Gore Medical, Flagstaff, AZ) horizontal mattress adventitial stitch is taken a few millimeters proximal to the anastomotic site. Heparin is administered to achieve a target activated clotting time of 300 – 350 seconds. Partial transection of the IMA provides access to insert a small catheter to instill papaverine.

The Flex A (Dextera Surgical, Inc., Redwood City, CA) device is positioned through a 15 mm port in the second left intercostal space in the midclavicular line with the cartridge and anvil gently approximated. All robotic instruments are removed from ports prior to inserting the device as the reduction of capnothorax may allow the heart and lung to move towards the chest wall, which could cause injury. While grasping the one of the heel tabs of the Flex A device with a Debakey forceps or heavy needle driver, the Flex A device cables are aligned with anvil facing the heart and the device is then rotated counter-clockwise towards the sternum with the tip angled towards the camera port. The IMA graft is rotated and aligned with the anastomotic device and is spatulated for a length of approximately 8-9 mm. Grasping the adventitia on either side of the heel, the graft is loaded onto the heel clip of the device and the tableside surgeon activates the piercer. To ensure an appropriate hood size and to protect the graft during the arteriotomy, the graft shield is then deployed onto the hood of the graft. Subsequently, the graft edges are draped over the device and the right-wing guard is lowered by the tableside surgeon who then removes the piercer and deploys the left-wing guard. Once the stabilizer is introduced and the target vessel is again exposed and stabilized, a 1 mm arteriotomy is made in the target vessel at the location of the previously placed stitch. While holding the device by a tab, the anvil is very carefully inserted into the target vessel at a 45-degree angle, and then orienting the anvil parallel to the target. It is critical that the anvil is confirmed to be intraluminal (Figure 6a). Once the device has been advanced to the tissue stop, the tableside surgeon fires the connector (Figure 6b). Care must be taken to avoid disrupting the anastomosis while removing the device. The anvil stitch is then tied and the anastomosis is inspected (Figure 6c). If there are signs of coronary ischemia, a shut can be used. Additional grafts are then constructed. Y-grafts can be completed in a similar fashion. Side-to-side anastomoses are typically completed after the distal anastomoses to avoid damaging the more proximal anastomosis while manipulating the conduit for the distal anastomosis. Completion of the procedure is carried out as with other TECAB operations described above [10].

ROBOTIC-ASSISTED MIDCAB

Many surgeons find the leap from open to endoscopic robotic coronary surgery very daunting. One method to bridge this gap and an excellent sternal sparing procedure that can be simpler is the robotic-assisted minimally invasive direct coronary artery bypass (RA-MIDCAB). This procedure offers the patients the benefits of minimally invasive coronary surgery, while avoiding the complexities of completing an intrathoracic anastomosis yet overcomes many of the limitations of a conventional MIDCAB operation. In the standard MIDCAB procedure, it can be challenging to harvest the entire length of the LIMA and is very challenging to take down the RIMA, leading to concerns regarding graft length. With robotic assistance, BIMAs can be harvesting in their entirety and the anastomosis is completed with standard hand-sewn beating heart techniques through a very small left thoracotomy.

Preoperative work-up anesthetic considerations and patient positioning are similar to other robotic coronary procedures. At the crux of a successful RA-MIDCAB is the perfect positioning of the endoscopic port, as this incision will be extended to complete the anastomosis. Consequently, it is important to mark the location of the midline of the sternum, and the locations of the LIMA and diaphragm. Plain posteroanterior and lateral chest x-rays are valuable in determining the optimal location of the endoscope port. First, the midpoint of longitudinal axis of the sternum is located. Second, the medial-lateral orientation of the endoscope port is gained by noting how lateral the apex of the heart is on the posteroanterior x-ray and matching its position externally on the left hemithorax. Finally, consideration is placed on whether the anticipated anastomotic location on the LAD is more proximal or distal and the port is moved one interspace more cranially or caudally as required.

Once the endoscope port is positioned and a capnothorax is induced, right and left arm ports are installed and can be lifted to enhance intrathoracic working space. One or both IMAs are now harvested as above. It is helpful to make a small pericardial window posterior to the left phrenic nerve to avoid buildup of fluid that can impede visualization of the anastomosis. After the pericardial fat pad is retracted laterally the pericardium is opened widely, but not beyond the apex.

One of the major benefits of RA-MIDCAB over tradition MIDCAB is localization of the LAD and the ideal location for the anastomosis. Inspection of the LAD is carried out and the ideal location for the anastomosis is marked with several hemoclips so that if one falls off, the preferred location of the anastomosis can still be identified. Orientation of the LIMA is maintained by placing a stitch in the adventitia and epicardium or pericardium near the target area.

After the robot is undocked, the anastomotic site is identified through the endoscope port site and enlarged in an appropriate direction. A soft tissue retractor is position, taking care to avoid trapping the LIMA graft. The suction tubing of the stabilizer is brought from the minithoracotomy through the inferior robotic port and the stabilizer is placed in the incision and is connected to the stabilizer pole which is inserted through the inferior robotic port. Positioning of the heart can be enhanced with tractions sutures on the pericardium. A standard hand-sewn anastomosis is now undertaken after placing a silastic loop around the target vessel

HYBRID REVASCULARIZATION

Another aspect in the evolution of TECAB and robotic coronary surgery is the development of hybrid procedures. Hybrid coronary revascularization (HCR) is the combination of coronary artery bypass with the use robotic assistance in addition to percutaneous coronary intervention (PCI) to treat remaining diseased coronary vessels. Approaches using the combination of TECAB and PCI as well as robotic-assisted CABG and PCI are in practice today. This can include treating one or more vessels endoscopically and either followed by, or preceded by PCI. In some institutions with access to hybrid operating rooms, PCI is able to immediately follow bypass during the same operation. This offers intervention to all of the diseased vessels in a single setting and also allows immediate evaluation of the LIMA-LAD patency. Other programs are performing surgery prior to PCI; whether PCI was followed within the same week or was months later tended to vary. Many practices prefer surgery before PCI as patients are not yet on dual antiplatelet therapy [11]. The remaining option is to perform PCI prior to surgery, a situation preferred if the culprit lesion or vessel with most severe stenosis would be approached via PCI.

Drug-eluding stents (DES) were most commonly used. A meta-analysis reports DES were used nearly 90% of the time. Cases in which DES were not used, utilized bare metal stents, angioplasty and thrombo-aspiration [12].

Outcomes of hybrid revascularization techniques prove that these procedures can accomplish good results with low morbidity and mortality. Bonaros et al reported a 0% mortality, 3% rate of myocardial infarction (MI), and a less than 1% rate of stroke. This study found no difference regarding the sequence of the interventions, whether PCI was performed before, during, or after the bypass [13]. Bonatti and colleagues also observed a 0% mortality rate in a study including 140 hybrid procedures. Follow-up at 5 years revealed a freedom from bypass re-intervention rate of 97.3% and a freedom from PCI re-intervention rate of 85.8% [14]. A meta-analysis by Harskamp et al did not identify a difference in the rates of death, MI, stroke in the short term post-op period, but did note higher rates of repeat revascularization in the hybrid group compared to the conventional CABG group. This study was also able to show that HCR was associated with less frequent blood transfusions, shorter hospital length of stay, and a faster return to work [15].

In addition to endoscopic bypass of LAD to LIMA, hybrid approaches may also include multi-vessel bypass to accompany PCI. After analysis of hybrid procedures involving single vessel versus multi-vessel bypass, outcomes were no different. This finding, in addition to understanding that coronary bypass is superior to PCI alone, emphasizes that LAD-LIMA bypass is the key component to successful outcomes. Taking this into consideration, determining the best approach to revascularization of the remaining diseased vessels must be established. As stent technology improves, compelling evidence exists supporting DES being superior to vein grafts as they have been shown to have patency rates higher than that of vein grafts. This argues that a single vessel TECAB in combination with PCI may generate best long-term results.

When comparing hybrid techniques to conventional approaches, it is important to keep in mind that patient risk factors and comorbidities are known to be greater in those undergoing open procedures. With appropriate patient selection, hybrid coronary revascularization offers

the gold standard of bypass to the LAD with a new approach to the treatment of multi-vessel disease.

LEARNING CURVE

As with any new surgical procedure, TECAB is a complex operation with a steep learning curve and challenges along the way. Overcoming the learning curve requires direction. Purposeful steps should be taken to ensure safe and successful integration of robotics into a cardiac surgery practice. Several studies have shown that it is feasible to obtain outcomes comparable to that of traditional open bypass procedures or other minimally invasive techniques. Many have compared their outcomes over time and have shown that with the proper preparation and patient selection, TECAB can be successfully performed and provide an equally efficacious surgical option.

To successfully initiate a robotics program, many have adopted a stepwise approach: starting with LIMA harvesting, then moving to pericardiotomy, and eventually adding anastomosis to LAD. Once successful single vessel TECAB has been accomplished, more complex procedures can be performed, including bilateral internal thoracic artery harvest, hybrid coronary revascularization procedures, and multi-vessel TECAB.

As previously stated, implementation of robotic assistance generally starts with harvesting of the LIMA. This can be done with complete or incomplete skeletonization of the graft. Overcoming the learning curve for this can be accomplished after approximately twenty cases [16, 17, 18]. Operative times shorten, conversion rates decrease and blood transfusions decrease once this threshold is reached. Many programs have chosen to routinely perform robotic assisted coronary artery bypass by harvesting the LIMA endoscopically and performing the remainder of the case via mini-thoracotomy. This has been proven advantageous to increase conduit length while also using a technique that limits trauma to the chest wall, thus causing less post-operative pain [19]. Surgeons then move on to perform subsequent portions of the operation robotically with planned conversions at various steps in the operation or after a various amount of time has passed, as it has been proven operative time plays an important role in clinical outcomes.

A critical factor in developing a successful endoscopic cardiac program is proper patient selection. Exclusion criteria vary, but typically include patients with a low ejection fraction (<30%), distal coronary target vessel smaller than 1.5 mm in diameter, a history of left lung trauma, previous left lung surgery or even sternotomy, patients requiring emergency bypass and patients with significant lung disease with an inability to tolerate single lung ventilation. Others simply exclude patients with any significant medical comorbidities that may deem the patient to have less biological reserve [18]. Rates of successful TECAB completion have proven higher with a strict criterion for patient selection, leading to lower morbidity and mortality.

Although many of these potentially limiting factors can be determined pre-operatively, other factors that reduce success rates are not found until entry into the thoracic cavity. It is important to recognize these limitations and understand when to convert to an alternative minimally invasive or open technique to complete the operation. While no absolute criteria

exist for operative conversion of the procedure, many factors have proven to portend worse outcomes if encountered.

One anatomic limitation includes dense pleural adhesions that inhibit viewing the anatomy and limiting working space in a closed chest. Another limiting factor based on the patient's anatomy is an intramuscular target vessel that was not identified on preoperative imaging. The tenuous dissection is such that it is unlikely to be performed successfully endoscopically, and an approach with direct visualization and higher familiarity should be chosen. Another reason to convert to a different approach specific to this operation include injury to the graft during LIMA dissection. If the graft is unable to be salvaged, a separate graft needs to be determined and the procedure should be converted to a technique that is amenable to usage of other types of conduits. If the LIMA is able to be safely dissected and harvested, but the anastomosis is unsatisfactory, many centers are suggesting conversion at this time to ensure adequate patency upon conclusion of the operation, rather than endoscopic revision. This is undoubtedly surgeon and case dependent.

Also, it is understood with any new approach to an operation that times may be longer than standard approaches. This is no different when performing a TECAB. Although operative times continue to decrease, TECAB times remain longer than most open/minimally invasive bypass operations performed without the use of endoscopy. Given the benefits of TECAB, longer operative times are an acceptable outcome; however, this should be limited. Several studies have shown as operative time increases, CPB time increases, as does single lung ventilation, causing longer ventilator times post-operatively, longer intensive care unit (ICU) and hospital stays, as well as increased morbidity and mortality. It is important to have a threshold to convert from an endoscopic technique when that threshold is met [18]. Studies have shown that worse outcomes occur once eight hours is exceeded, thus the procedure should be converted when nearing this point [20].

Other factors that Bonatti et al. studied and determined to positively impact the learning curve included the use of a consistent operative team, using fibrin glue at the anastomosis, and adding a fourth endoscopic port for a tableside surgeon to assist. Operative times, which some use to measure overcoming the learning curve, were found to improve with each additional modification [17, 18, 21].

OUTCOMES

The use of robotics in coronary bypass continues to evolve and improve. Utility ranges from harvesting the LIMA robotically before subsequently performing the anastomosis and completing the operation through a non-robotic technique, to a totally endoscopic coronary artery bypass (TECAB), performed either on or off pump, as well as with single or multiple grafts. Feasibility alone has been proven for quite some time now, dating back to the first reported TECAB twenty years ago [22]. However, safety and efficacy continue to be closely monitored to ensure adequate outcomes.

Intra-operative conversion rates continue to decline, and many recent studies have shown a conversion rate of less than 10% [23,24]. Several reasons are attributed to the need to convert to an open procedure. LIMA injuries typically account for 2% or less, which is around 1% in an open bypass technique. Poor graft flow after anastomosis and bleeding at the

anastomosis site are also reasons endoscopic cases require conversion, although typically only 1-2% of the time [24]. Other conversions can be attributed to adhesions precluding visualization, patient intolerance, or immediate graft dysfunction being identified. It has been noted that the need for return to the operating room for immediate complication tends to occur 1-2% of the time as well, but this seems comparable to conventional approaches to coronary bypass and is generally secondary to bleeding [1]. Cardiopulmonary bypass time has been reported to average between 110-120 minutes for TECAB, compared to conventional cases, which average just over half that time. Similarly, cross-clamp times are nearly twice as long in some reports for robotic procedures [25].

Post-operative results prove TECAB to be a safe procedure with satisfactory results. Rates of myocardial infarction, stroke and mortality have also been evaluated, which reveal no difference in the two groups [23]. Argenziano et al. reported an MI rate of 1.2% and a mortality rate of 0% in a prospective study evaluating outcomes of single-vessel TECAB [24]. Bonatti et al. observed a 0.7% mortality rate in a study of over 400 TECAB patients. This study also reported a significantly lower heart failure rate (1.2% in the TECAB group, and 8.6% in the conventional open group) and a lower new onset atrial fibrillation rate (1.2% vs. 16.8%) [26]. Length of stay in the ICU and in the hospital are comparable to conventional approaches when evaluated in a propensity score match comparison [25]. However, a prospective study by Leyvi et al. showed that discharge to an acute care facility was significantly lower in the TECAB group when compared to the conventional group (16.0% vs. 25.83%, p=0.008) [27].

Graft patency rates have consistently been described to be 95% or greater, even after three-year follow-up. In 2015, Yang et al. reported graft patency of 240 consecutive patients who underwent off-pump coronary bypass with robotic assistance, 100 TECAB and 140 mini-thoracotomy coronary artery bypass (MINICAB). Graft patency was evaluated with either coronary angiography or computed tomographic angiography. The IMA graft patency was 97.1% in TECAB and 96.4% in the MINICAB group over three years post-operatively [1]. In a study by Argenziano et al, three-month angiography was performed on 76 patients, which identified graft occlusion in two cases and significant anastomotic stenosis in four cases, in addition to one case that required re-intervention on post-operative day one for graft occlusion. Of the six that were observed at three month follow-up, only one patient was symptomatic and required re-intervention, yielding a high freedom from graft failure rate [24]. It has been reported that there is no increased rate of re-do operations or need for percutaneous interventions of those undergoing TECAB [1].

Although CPB and total operative time remains longer than conventional CABG approaches, TECAB has proven a safe and efficacious operation. As surgeons continue to employ this technique, proficiency continues to improve. Prospective randomized trials are currently not available for comparison between techniques and may not ever be. Current studies that attempt to compare all patients undergoing CABG are including patients who tend to have more co-morbidities and higher rates of urgently performed operations. The literature that does exist for TECAB proves that with proper patient selection, this is an operation with great outcomes.

REFERENCES

[1] Bonatti J, Schachner T, Bonaros N, Lehr EJ, Zimrin D, Griffith B. Robotically assisted totally endoscopic coronary bypass surgery. *Circulation* 2011; 124:236–44. doi:10.1161/CIRCULATIONAHA.110.985267.

[2] Vassiliades TA. The cardiopulmonary effects of single-lung ventilation and carbon dioxide insufflation during thoracoscopic internal mammary artery harvesting. *Heart Surg Forum* 2002; 5:22–4.

[3] Youssef SJ, Millan JA, Youssef GM, Earnheart A, Lehr EJ, Barnhart GR. The Role of Computed Tomography Angiography in Patients Undergoing Evaluation for Minimally Invasive Cardiac Surgery: An Early Program Experience. *Innovations: Technology and Techniques in Cardiothoracic and Vascular Surgery* 2015; 10:33–8. doi:10.1097/IMI.0000000000000126.

[4] Lehr EJ, Zimrin D, Vesely M, Odonkor P, Griffith B, Bonatti J. Axillary-coronary sequential vein graft for total endoscopic triple coronary artery bypass. *Ann Thorac Surg* 2010; 90:e79-81. doi:10.1016/j.athoracsur.2010.08.051.

[5] Bonatti J, Rehman A, Schwartz K, Deshpande S, Kon Z, Lehr E, et al. Robotic totally endoscopic triple coronary artery bypass grafting on the arrested heart: report of the first successful clinical case. *Heart Surg Forum* 2010; 13:E394-396. doi:10.1532/HSF98.20101143.

[6] Bonatti J, Wehman B, de Biasi AR, Jeudy J, Griffith B, Lehr EJ. Totally Endoscopic Quadruple Coronary Artery Bypass Grafting Is Feasible Using Robotic Technology. *The Annals of Thoracic Surgery* 2012; 93:e111–2. doi: 10.1016/j.athoracsur.2011.11.049.

[7] Srivastava S, Barrera R, Quismundo S. One Hundred Sixty-Four Consecutive Beating Heart Totally Endoscopic Coronary Artery Bypass Cases without Intraoperative Conversion. *The Annals of Thoracic Surgery* 2012; 94:1463–8. doi:10.1016/j.athoracsur.2012.05.028.

[8] Srivastava S, Gadasalli S, Agusala M, Kolluru R, Barrera R, Quismundo S, et al. Beating Heart Totally Endoscopic Coronary Artery Bypass. *The Annals of Thoracic Surgery* 2010; 89:1873–80. doi:10.1016/j.athoracsur.2010.03.014.

[9] Matschke KE, Gummert JF, Demertzis S, Kappert U, Anssar MB, Siclari F, et al. The Cardica C-Port System: clinical and angiographic evaluation of a new device for automated, compliant distal anastomoses in coronary artery bypass grafting surgery--a multicenter prospective clinical trial. *J Thorac Cardiovasc Surg* 2005; 130:1645–52. doi:10.1016/j.jtcvs.2005.08.033.

[10] Balkhy HH, Wann LS, Krienbring D, Arnsdorf SE. Integrating Coronary Anastomotic Connectors and Robotics Toward a Totally Endoscopic Beating Heart Approach: Review of 120 Cases. *The Annals of Thoracic Surgery* 2011; 92:821–7. doi:10.1016/j.athoracsur.2011.04.103.

[11] Giambruno V, Hafiz A, Fox SA, Jeanmart H, Cook RC, Khaliel FH, et al. Is the Future of Coronary Arterial Revascularization a Hybrid Approach?: The Canadian Experience Across Three Centers. *Innovations (Phila)* 2017; 12:82–6. doi:10.1097/IMI.0000000000000355.

[12] Giambruno V, Jones P, Khaliel F, Chu MW, Teefy P, Sridhar K, et al. Hybrid Coronary Revascularization Versus On-Pump Coronary Artery Bypass Grafting. *Ann Thorac Surg* 2018; 105:1330–5. doi:10.1016/j.athoracsur.2017.11.019.

[13] Bonaros N, Schachner T, Kofler M, Lehr E, Lee J, Vesely M, et al. Advanced hybrid closed chest revascularization: an innovative strategy for the treatment of multivessel coronary artery disease *Eur J Cardiothorac Surg* 2014; 46:e94-102; discussion e102. doi:10.1093/ejcts/ezu357.

[14] Bonatti JO, Zimrin D, Lehr EJ, Vesely M, Kon ZN, Wehman B, et al. Hybrid Coronary Revascularization Using Robotic Totally Endoscopic Surgery: Perioperative Outcomes and 5-Year Results. *Ann Thorac* Surg 2012. doi:10.1016/j.athoracsur.2012.05.041.

[15] Harskamp RE, Bagai A, Halkos ME, Rao SV, Bachinsky WB, Patel MR, et al. Clinical outcomes after hybrid coronary revascularization versus coronary artery bypass surgery: a meta-analysis of 1,190 patients. *Am Heart J* 2014; 167:585–92. doi:10.1016/ j.ahj.2014.01.006.

[16] Bonaros N, Schachner T, Lehr E, Kofler M, Wiedemann D, Hong P, et al. Five hundred cases of robotic totally endoscopic coronary artery bypass grafting: predictors of success and safety. *Ann Thorac Surg* 2013; 95:803–12. doi:10.1016/ j.athoracsur. 2012.09.071.

[17] Cheng N, Gao C, Yang M, Wu Y, Wang G, Xiao C. Analysis of the learning curve for beating heart, totally endoscopic, coronary artery bypass grafting. *J Thorac Cardiovasc Surg* 2014; 148:1832–6. doi:10.1016/j.jtcvs.2014.02.002.

[18] Novick RJ, Fox SA, Kiaii BB, Stitt LW, Rayman R, Kodera K, et al. Analysis of the learning curve in telerobotic, beating heart coronary artery bypass grafting: a 90 patient experience. *Ann Thorac Surg* 2003; 76:749–53.

[19] Bonatti J, Schachner T, Bernecker O, Chevtchik O, Bonaros N, Ott H, et al. Robotic totally endoscopic coronary artery bypass: program development and learning curve issues. *J Thorac Cardiovasc Surg* 2004; 127:504–10.

[20] Wiedemann D, Bonaros N, Schachner T, Weidinger F, Lehr EJ, Vesely M, et al. Surgical problems and complex procedures: issues for operative time in robotic totally endoscopic coronary artery bypass grafting. *J Thorac Cardiovasc Surg* 2012; 143:639-647.e2. doi:10.1016/j.jtcvs.2011.04.039.

[21] Bonatti J, Schachner T, Bonaros N, Oehlinger A, Ruetzler E, Friedrich G, et al. How to improve performance of robotic totally endoscopic coronary artery bypass grafting. *Am J Surg* 2008; 195:711–6. doi:10.1016/j.amjsurg.2007.11.010.

[22] Loulmet D, Carpentier A, d'Attellis N, Berrebi A, Cardon C, Ponzio O, et al. Endoscopic coronary artery bypass grafting with the aid of robotic assisted instruments. *J Thorac Cardiovasc Surg* 1999; 118:4–10. doi:10.1016/S0022-5223(99)70133-9.

[23] Halkos ME, Liberman HA, Devireddy C, Walker P, Finn AV, Jaber W, et al. Early clinical and angiographic outcomes after robotic-assisted coronary artery bypass surgery. *The Journal of Thoracic and Cardiovascular Surgery* 2014; 147:179–85. doi:10.1016/j.jtcvs.2013.09.010.

[24] Argenziano M, Katz M, Bonatti J, Srivastava S, Murphy D, Poirier R, et al. Results of the prospective multicenter trial of robotically assisted totally endoscopic coronary artery bypass grafting. *Ann Thorac Surg 2006*; 81:1666–74.

[25] Yang M, Wu Y, Wang G, Xiao C, Zhang H, Gao C. Robotic Total Arterial Off-Pump Coronary Artery Bypass Grafting: Seven-Year Single-Center Experience and Long-

Term Follow-Up of Graft Patency. *The Annals of Thoracic Surgery* 2015; 100:1367–73. doi:10.1016/j.athoracsur.2015.04.054.

[26] Kofler M, Stastny L, Reinstadler SJ, Dumfarth J, Kilo J, Friedrich G, et al. Robotic Versus Conventional Coronary Artery Bypass Grafting: Direct Comparison of Long-Term Clinical Outcome. *Innovations: Technology and Techniques in Cardiothoracic and Vascular Surgery* 2017; 12:239–46. doi:10.1097/IMI. 0000000000000393.

[27] Leyvi G, Forest SJ, Srinivas VS, Greenberg M, Wang N, Mais A, et al. Robotic coronary artery bypass grafting decreases 30-day complication rate, length of stay, and acute care facility discharge rate compared with conventional surgery. *Innovations (Phila)* 2014; 9:361–7; discussion 367. doi:10.1097/IMI. 0000000000000095.

In: Encyclopedia of Surgery (22 Volume Set)
Editors: Andreas Lehrer and Kristin Mueller
ISBN: 978-1-53618-329-0
© 2020 Nova Science Publishers, Inc.

Chapter 249

ROBOTIC APPROACHES FOR RECTAL CANCER

Kevin T. Behm and David W. Larson*
Division of Colon and Rectal Surgery, Mayo Clinic, Rochester, MN, US

INTRODUCTION

Minimally invasive techniques have revolutionized the field of colon and rectal surgery since their inception in 1991 by Jacobs et al. [1]. Through the years multiple landmark randomized controlled clinical trials including the COST, COLOR, CLASICC, and Barcelona study not only demonstrated equivalent oncologic outcomes, but also proved the superiority of laparoscopic surgery over standard open technique with respect to short term outcomes [2-10]. Despite this data laparoscopic techniques have been challenged by slow adoption. As of 2011 only 42.2% of colon resections are being performed laparoscopically at academic centers and conversion rates remain high at 15.8% [11]. While diffusion of laparoscopic colectomy for cancer continues unabated, total mesorectal excision (TME) for rectal cancer remains controversial.

Major randomized control trials including the MRC CLASSIC, COREAN, and COLOR II have compared open to laparoscopic TME (LTEM). Concerns were raised initially in the CLASSIC trial with high rates of circumferential radial margin positivity (CRM+) at 12% and high rates of conversion to open surgery at 34%. While the COLOR II trial showed significantly lower rates of positive CRM+ (5.0%) rates of conversion remained high (16%) confirming the technical expertise required for LTME. To date however, these trials have demonstrated no difference in oncologic outcomes with improved short-term outcomes for those with rectal cancer [6-8, 12-14].

In the US, Australia, and New Zealand controversy over LTME remained. In response to these concerns two large multicenter, randomized, non-inferiority trials (ACOSOG Z6051 and ALaCaRT) were established to determine whether LTME was non-inferior to OTME for the management of locally advanced rectal cancer. Successful resection was determined in each trial by a composite of three surrogates and included circumferential radial margin (CRM) greater than 1 mm/CRM ≥ 1 mm, distal margin without tumor/ distal resection margin

* Corresponding Author's Email: Larson.David2@mayo.edu.

≥ 1 mm, and completeness of TME respectively. The ACOSOG trial demonstrated successful resection in 81.7% of laparoscopic resection cases and 86.9% of open resection cases which did not support noninferiority (difference, − 5.3%; 1-sided 95% CI, − 10.8% to ∞; P for noninferiority = .41) [15]. Conversion rate was 11.3%. The ALaCaRT trial reported similar results with successful resection in 82% of the laparoscopic group and 89% in the open surgery group (risk difference of − 7.0% [95% CI, − 12.4% to ∞]; P = .38 for noninferiority). Conversion rate from laparoscopic to open surgery was 9% [16]. Both studies are examples of excellent quality amongst both surgical arms, but the findings did not provide sufficient evidence for the routine use of laparoscopic surgery for the treatment of rectal cancer until long term outcomes could be confirmed. At present the oncologic impact of these preselected surrogates for successful resection has not yet been determined.

Beyond the controversy of current literature and research are the operative issue of pelvic surgery. The challenges of pelvic dissection include difficult operating angles, narrow working space, and proximity to surrounding structures. The robotic surgical platform has significant technical advantages over traditional open or laparoscopic surgery including a stable surgeon controlled 3D image, finer dissection with articulated instruments, the addition of a third surgeon controlled arm, and dramatically improved surgeon ergonomics. These advantages have the potential to improve multiple aspects of care. Current and future research will be needed to identify the impacts to learning curve, complication rates, conversion, and oncological outcomes. This chapter will focus on operative technique and outcomes from current published work comparing robotic approaches to lower anterior resection and abdominoperineal resection for the management of rectal cancer using the da Vinci robotic system (Intuitive Surgical Inc., Sunnyvale, CA, USA).

INDICATIONS FOR ROBOTIC APPROACH

The robotic platform is used for the treatment of both benign and malignant diseases encompassing the entire field of colon and rectal surgery. Robotic colon and rectal procedures continue to increase annually as surgeons expand this MIS practice. Our chapter's focus will be on the use of robotics in the pelvis, as this represents the most technically demanding application of the platform and the area of greatest research. Despite the significant increase in the number of robotic colon and rectal procedures, quality data remains limited. The available data consists mostly of single-center experiences and small prospective studies. Despite limited data, the findings have consistently shown the safety and feasibility of robotic approaches across a breadth of procedures [17-22]. As a critical adjunct to the technical aspects of surgery we acknowledge and recommend care process models including enhanced recovery pathway (ERP) principles within a robotic surgical practice. Enhanced recovery pathways include multi-modal pre-, intra-, and post-operative elements in an attempt to operate in a physiologically normal state, optimize post-operative pain control, manage post-operative nausea, limit fluids, and allow for institution of a general diet [23-24]. Together these techniques and care processes will help to shape the future of pelvic surgery.

OPERATIVE TECHNIQUE

Initial Approach

The ultimate docking position of the robot is dependent upon the surgical approach being undertaken. For a patient undergoing rectal resection, a modified lithotomy position is chosen to provide access to the perineum. Abdominal access can be obtained by a variety of methods. We prefer the use of a modified open technique, utilizing an Optiview trocar (Ethicon Endo-Surgery, Inc., Summerville, NJ) placed under direct visualization a few centimeters to the right of the midline just superior to the umbilicus. The Optiview trocar has particular benefit in an obese patient in which a traditional open technique is difficult secondary to poor visualization. Ideally the camera port should be 15-20 cm from the target anatomy. Pneumoperitoneum is established, and the abdomen is explored to ensure there is no evidence of metastatic disease.

The additional trocar sites are then measured out and marked ensuring 6-8 cm between each robotic cannula to avoid external or internal collisions. We generally place two additional 8 mm robotic trocars, one 12 mm robotic trocar, [Figure 1] and one assist port. The 8 mm robotic trocars are placed in the left lower quadrant, approximately at the mid-clavicular line and in the left lateral abdomen cranial to the anterior superior iliac spine (Arms 1 and 2, respectively). The 12-mm robotic stapler port is placed in the right lower quadrant in the mid-clavicular line (Arm 4). The 5-mm assist port is placed in the right upper quadrant. This is positioned to allow the assistant to avoid colliding with the robotic arms while allowing appropriate access to the deep pelvis. This port is a 5 mm Airseal port that utilizes Airseal System (ConMed, Utica, NY) to allow for stable pneumoperitoneum and continuous smoke evacuation for improved visualization during deep pelvic dissection.

Precise trocar placement is critical when performing robotic proctectomy. If inappropriate trocar sites are selected the boney aspects of the pelvic sidewall and sacral promontory can create significant impedance to safe surgical dissection. Trocars placed too far cephalad in a patient with a long torso will make the presacral dissection towards the pelvic floor difficult secondary to reach. Trocars placed too far laterally (particularly in a male patient) will make the low pelvic dissection difficult secondary to collisions with the lateral pelvic sidewall.

With the trocars in appropriate position the patient is placed in steep Trendelenburg allowing the small bowel to fall out of the pelvis. The robot is then docked over the left hemiabdomen aligning the targeting icon directly over Arm 3. With the arms docked the 30-degree camera is placed in Arm 3 and the targeting technology is utilized to align the robotic arms for pelvic dissection. The Small Grapter is placed in Arm 1, the fenestrated bipolar forceps in Arm 2, and the monopolar-curved scissors in Arm 4.

In addition, the Xi platform can be paired with the Trumpf Medical TruSystem 7000dV table (Trumpf Medical, Saalfeld, Germany) allowing the surgeon to use Table Motion technology. This innovation allows the patient to be repositioned throughout the operation without undocking the robotic arms. This provides further flexibility when performing multiquadrant operations or when operating on patients with severe visceral obesity.

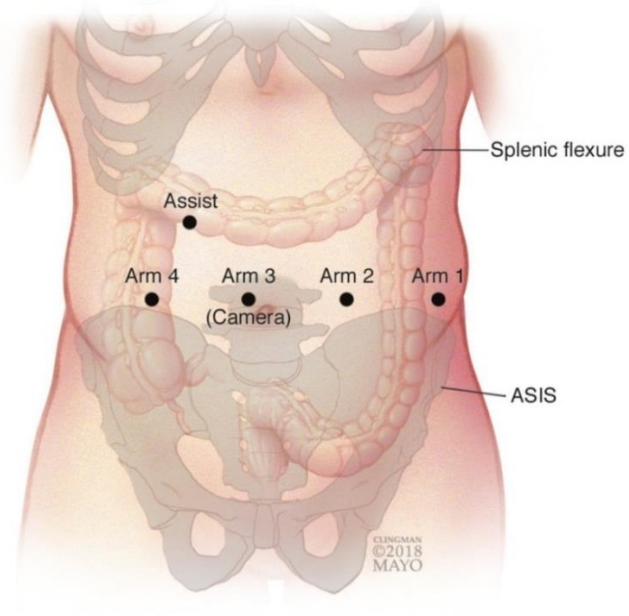

Figure 1. Trocar positions for pelvic dissection.

OPERATIVE STEPS

Step 1 – Exposure

Using Arm 1, the rectosigmoid junction or its mesentery is grasped and the rectum is placed on tension proximally, pulling it out of the pelvis. Alternatively, an assistant may grasp this area, allowing Arm 1 to grasp more distally on the rectum to provide additional traction, placing the rectosigmoid mesocolon and mesorectum on tension. It is critical that the upper rectum be elevated in such a way as to stretch the peritoneum overlying the right pelvic gutter, as well as the superior rectal artery to help separate the vessels from the sacral promontory. In a female patient, it may be necessary to suspend the uterus to obtain an unobstructed view of the pelvis. We place a suture trans-abdominally around the round ligaments to suspend the uterus anteriorly.

Step 2 – Control of the Inferior Mesenteric Artery (IMA) and Inferior Mesenteric Vein (IMV)

The monopolar shears are utilized to incise the peritoneum along the right side of the rectum, caudal to the sacral promontory. This technique exposes and opens the presacral space [Figure 2A/B]. Dissection is carried cephalad along the posterior aspect of the mesorectum towards the IMA [Figure 3A], taking care not to breach the fascia propria of the rectum and avoiding injury to the superior hypogastric nerves. Injury to the nervous structures

around the IMA may result in retrograde ejaculation and/or bladder dysfunction. As one dissects directly below the superior rectal artery and above the retroperitoneal fascial planes, the left ureter and gonadal vessels should be identified just above the pelvic brim. As the dissection continues in this plane, the vessel is elevated from the retroperitoneum and the ureter and gonadal vessels can be easily swept bluntly posteriorly to maintain their position within the retroperitoneum, posterior and lateral to the IMA [Figure 3B].

Dissection is carried along the IMA until the origin is reached in order to perform a complete D3 lymphadenectomy. The IMA is skeletonized with the monopolar shears, ligated utilizing three da Vinci robotic clips (two proximal and one distal), and divided sharply [Figure 4A/B/C]. The decision to ligate the IMA proximal or distal to the left colic artery is determined by the need for colonic length. If a low pelvic anastomosis is required the IMA is divided proximal to the left colic artery, while a more proximal anastomosis will allow preservation of the left colic branch.

Once the IMA is ligated and divided the colonic mesentery can now be elevated off the retroperitoneum proximally and laterally. The extent of dissection extends to the inferior border of the pancreas and laterally overlying Gerota's fascia. The cut edge of the colonic mesentery can continue to be transected superiorly, lateral to the duodenum and medial to IMV. The IMV is traced proximal to the inferior border of the pancreas where it is isolated and divided with the da Vinci Vessel Sealer.

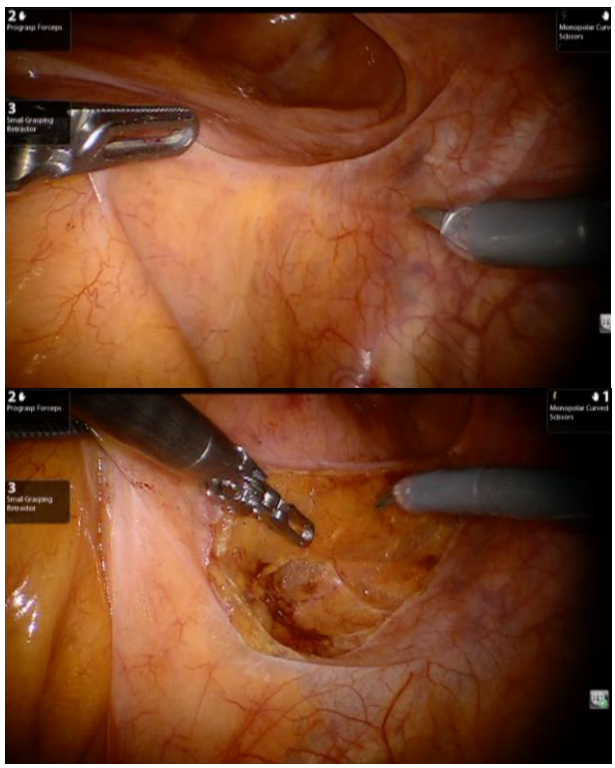

Figure 2A/B. An unobstructed view of the pelvis is obtained. The rectum is retracted cephalad and to the left using Arm 1. The rectum must be elevated to stretch the peritoneum and raise the superior rectal artery anteriorly to separate the vessels from the sacral promontory. Electrocautery is then used to incise the peritoneum along the right side of the rectum, caudal to the sacral promontory.

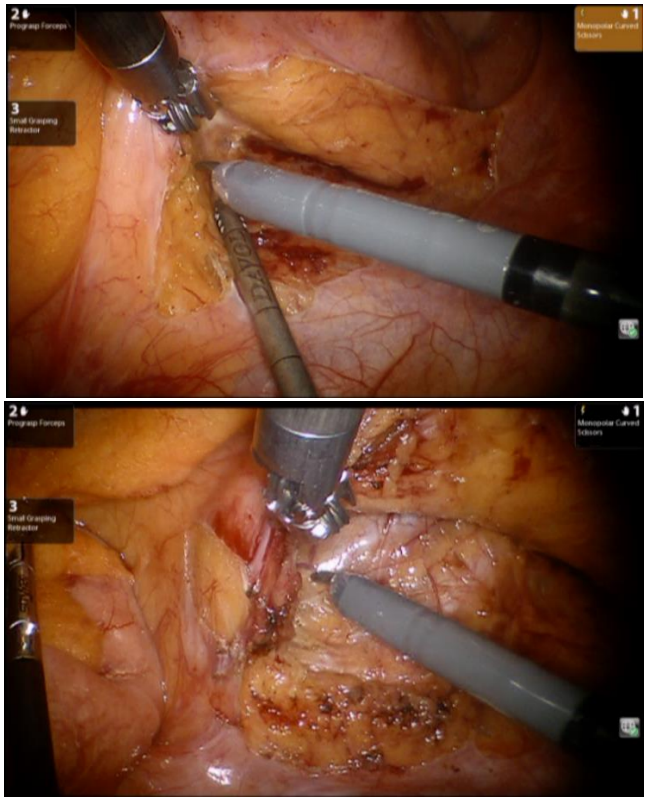

Figure 3A/B. Identifying and isolating the inferior mesenteric artery - dissection is carried cephalad along the posterior aspect of the mesorectum towards the IMA. Arm 2 (LLQ) is placed posterior to the vascular bundle and mesorectum and retracted anteriorly. The assistant may place counter traction using either a laparoscopic grasper or suction device to aid the dissection. The vessel is elevated from the retroperitoneum and the gonadal vessels and ureter should be identified within the retroperitoneum, just above the pelvic brim, posterior and lateral to the IMA.

Our typical approach at this point includes taking the colonic mesentery just proximal to the pedicle of the IMA to the edge of the junction of the sigmoid/descending colon. This allows for complete vascular isolation of the target anatomy. and provides an estimate as to the proximal area for anastomosis. Once the mesentery has been divided we do not divide the bowel as it provides a fantastic opportunity for retraction during the pelvic dissection.

Step 3 – Rectal Dissection

The proximal rectum is grasped with the Small Grapter utilizing Arm 1 and the rectum is retracted out of the pelvis. Arm 2 is placed posterior to the mesorectum and elevated anteriorly opening the presacral plane while the monopolar shears in arm 3 perform the sharp dissection. This dissection is carried as far to the left pelvic sidewall as possible to decrease the amount of dissection necessary from the patients left side [Figure 5A/B]. The posterior dissection is continued distally, including the lateral stalks, which are taken with monopolar cautery. If a middle rectal vessel is present within the lateral stalks and not controlled with

cautery, this may be controlled with either bipolar or the robotic vessel sealer. The instrumentation in Arms 4 and 2 may be exchanged in order to complete the dissection along the left side of the rectum. Dissection that is too lateral in the region of the lateral stalks places the nervi erigentes at risk for injury, which can lead to erectile dysfunction.

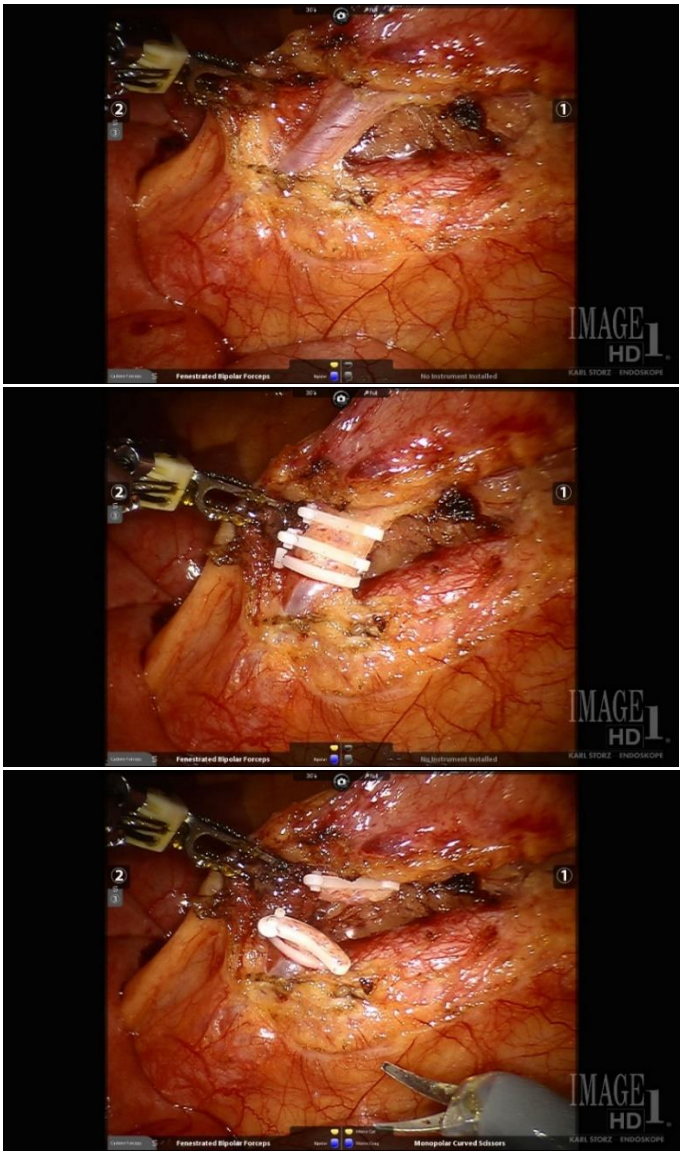

Figure 4 A/B/C. Ligation of the IMA is shown. The pedicle is completely cleared utilizing the monopolar shears. Prior to ligation, this retroperitoneal plane should be developed such that the empty space between the IMA and left colic artery in the colonic mesentery is visualized. Arm 1 continues to retract the rectum out of the pelvis and places the IMA on a near vertical orientation. Arm 2 can be used to grasp the peritoneum overlying the vessel (as shown), or the vessel itself, distal to the transection point. The IMA is ligated utilizing three da Vinci® robotic clips (two proximal and one distal), and divided sharply.

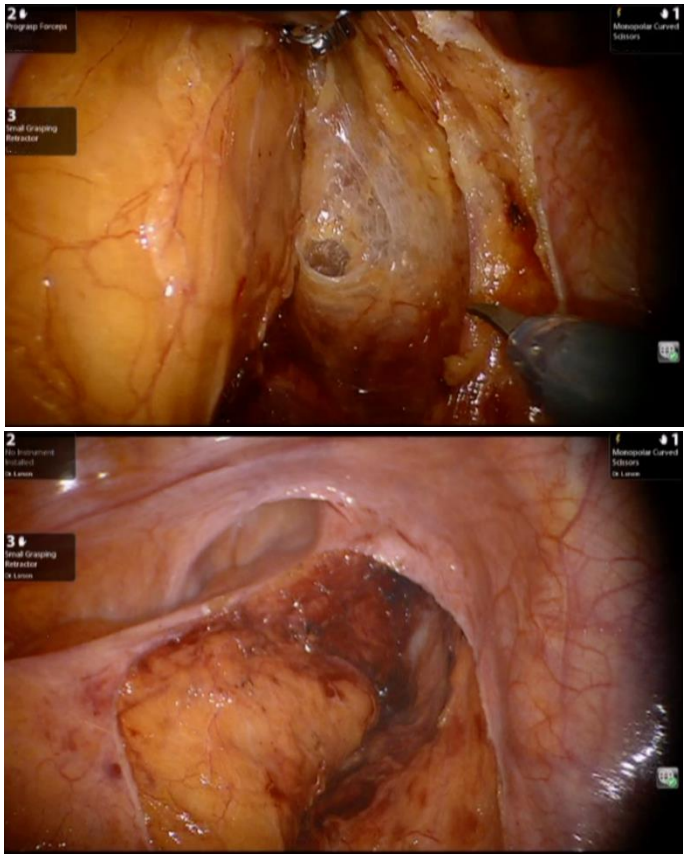

Figure 5A/B. We typically start the presacral dissection along the posterior, right side and proceed caudally – Arm 1 maintains traction on the rectum in a cephalad direction, out of the pelvis, Arm 2 retracts the mesorectum toward the patient's left side and Arm 4 is used to perform the dissection. This dissection is carried as far to the left pelvic sidewall as possible to decrease the amount of dissection necessary from the patients left side.

The anterior dissection is then undertaken. Initially Arm 1 is used to pull the rectum out of the pelvis in a posterior vector to provide proper tension on the anterior structures. The assistant aids the dissection by placing a suction device or grasper anterior at the level of the seminal vesicle or posterior vagina and lifting anteriorly [Figure 6]. As the anterior dissection proceeds distally the Small Grapter in Arm 1 is left in an open position and used to provide strong anterior counter retraction while Arm 2 places gentle traction on the rectum in a posterior vector. This allows the dissection to progress down to the pelvic floor. This is particularly useful in a deep narrow male pelvis. In patients with an anterior tumor, our dissection plane is always anterior to Denonvillier's Fascia. With posterior based tumors, our dissection plane is just posterior. The peri-prostatic nerve plexus carries mixed sympathetic and parasympathetic fibers and may be injured during this phase of the dissection.

A total mesorectal excision is completed circumferentially to the pelvic floor for patients undergoing coloanal anastomosis. For more proximal tumors, the dissection proceeds to a level that includes a 5cm distal mesorectal margin. In this case, the mesorectum at the distal transection point is ligated using the robotic vessel sealer in order to isolate the rectum and

prepare it for transection ensuring a tumor-specific mesorectal excision. The rectum is then divided with the robotic green load stapler completing the pelvic dissection [Figure 7].

In patients undergoing abdominoperineal resection (APR), the rectal dissection proceeds robotically to the pelvic floor in a cylindrical manner. The bare area of the rectum distal to the mesorectum must not be unroofed. In this scenario, the pelvic floor musculature can even be incised from the pelvis and the ischioanal space entered, exposing the ischioanal fat. The perineal portion of the resection is then conducted in the usual open fashion and the rectum is extracted through the perineum. Finally, the abdomen is insufflated after closure of the perineal incision and the end-colostomy is identified and matured usually in the left lower quadrant.

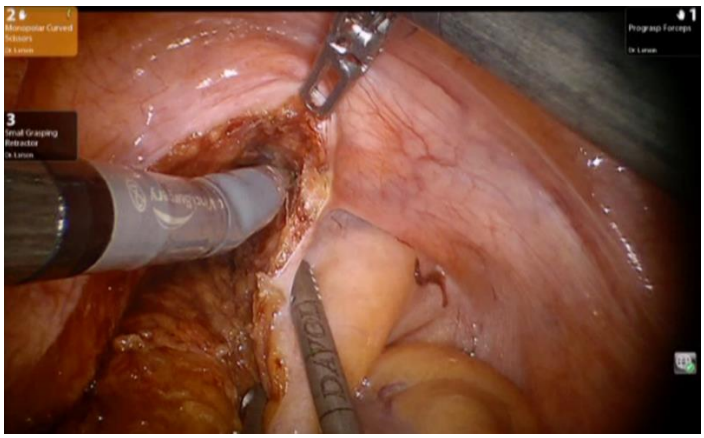

Figure 6. The anterior dissection, either anterior or posterior to Denonvillier's fascia (dependent upon tumor location), is performed by placing the rectum on tension in a posterior and cephalad direction (Arm 1). Arm 2 retracts anteriorly, and Arm 4 is performing the dissection (these may be interchanged). Additional counter traction can be obtained by having the assistant either retract posteriorly (as shown) or anteriorly.

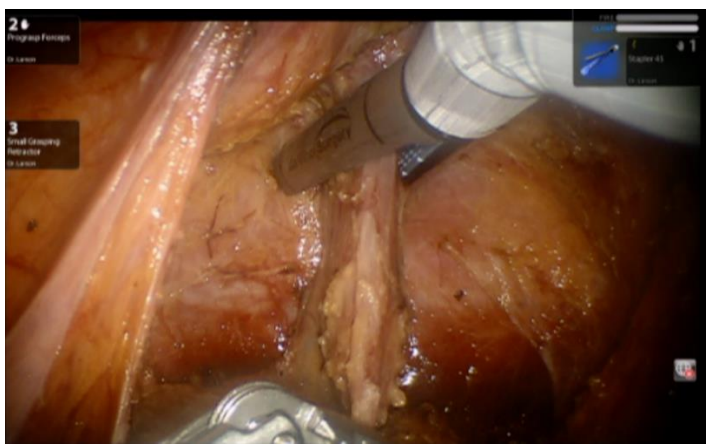

Figure 7. The robotic stapler is utilized to transect the rectum (here for an LAR). The mesorectum has already been cleared with the robotic vessel sealer.

Step 4 – Medial-to-Lateral and Splenic Flexure Mobilization

At this point the robot is undocked and the boom is reversed with the splenic flexure selected as the new target anatomy. The patient is placed in reverse Trendelenburg and right side down. The camera is moved to Arm 2, the Small Graptor is placed in Arm 1, and the monopolar shears are placed in Arm 3. Arm 4 is undocked and utilized by the assistant to aid in retraction [Figure 8]. Arm 1 and the assistant elevate the descending colon mesentery and the previous medial dissection plane is identified. Utilizing a combination of monopolar and blunt dissection the embryologic planes are carefully separated. It is imperative to ensure that Toldt's fascia is preserved and the retroperitoneum is not violated – doing so places the retroperitoneal structures (kidney, ureter, and gonadal vessels) at risk of injury. This dissection is complete when all that remains of the colonic attachments are the lateral peritoneal attachments and filmy attachments to the splenic flexure. These attachments are divided with the monopolar shears completing the mobilization of the left colon. At this point 3 cc of Indocyamine Green (ICG) are injected intravenously and the Intuitive Surgical Firefly Fluorescence Imaging is utilized to evaluate the blood supply of the descending colon [Figure 9A/B] and rectal stump.

If an APR is to be performed, it is not necessary to mobilize the splenic flexure. The colonic mesentery is instead transected with the vessel sealer to the border of the sigmoid colon and the colon is divided with the robotic blue load stapler.

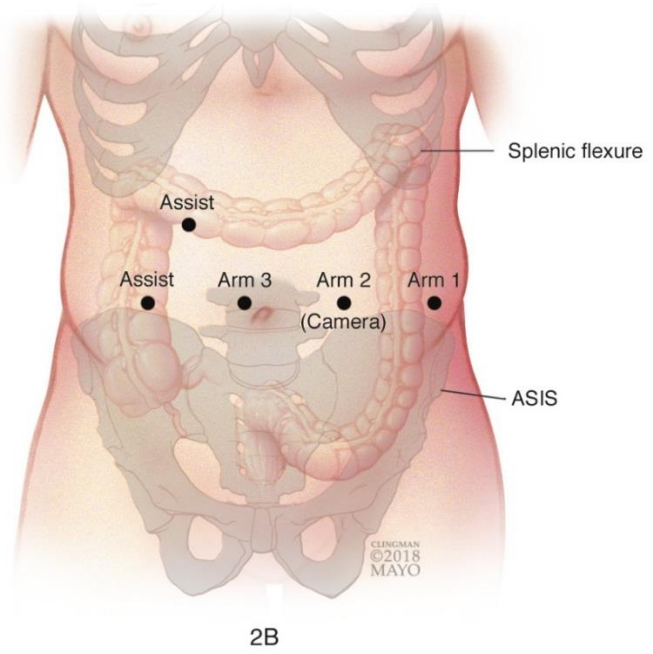

Figure 8. Trocar positions for splenic flexure mobilization.

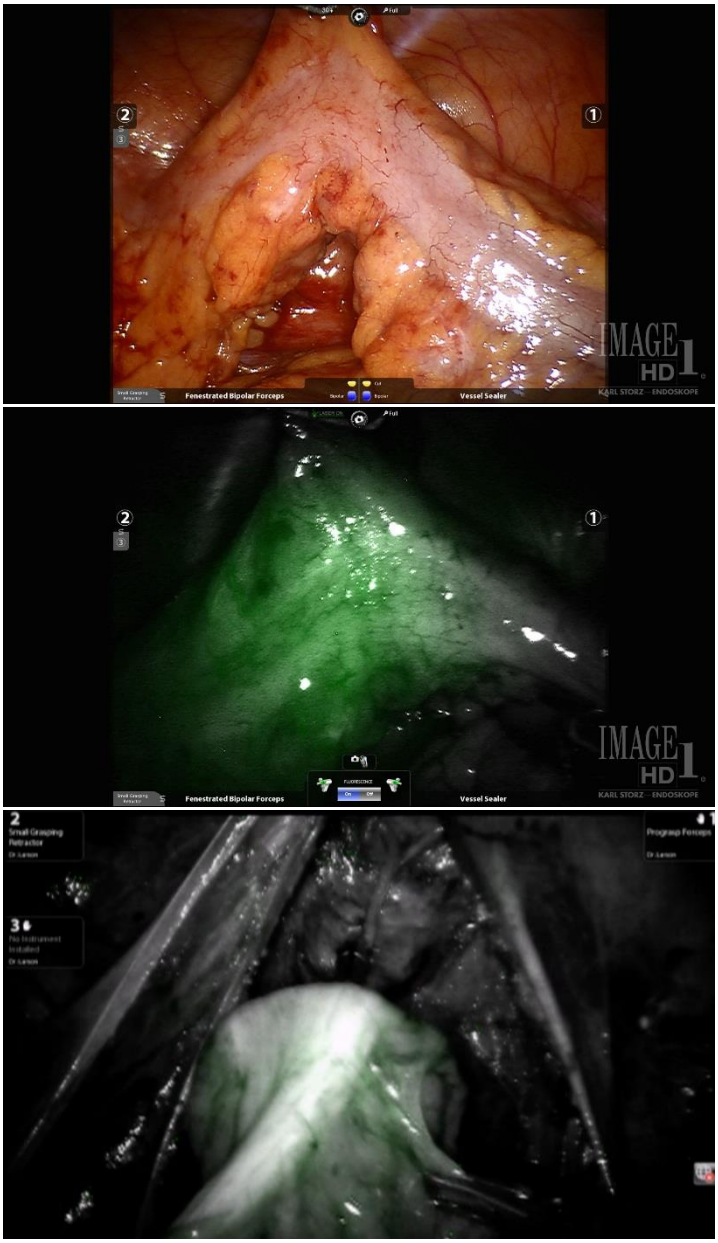

Figure 9 A/B/C. Fluorescence angiographic imaging evaluates the blood supply of the bowel prior transection and to performing an anastomosis.

Step 5 – Anastomotic Technique

The robot is again undocked and restored to the initial setup with the patient back in Trendelenburg position. A 5 cm Pfannenstiel incision is made and a small Alexis (Applied Medical, Rancho Santa Margarita, CA) wound retractor is utilized. The rectum and left colon are removed from the abdomen. The bowel is divided sharply at the previously marked point

of transection and a 29 mm EEA anvil is secured utilizing a 2-0 Prolene suture. The left colon is returned to the abdomen and the Alexis wound retractor is sealed with a laparotomy pad. Once pneumoperitoneum is restored a standard stapled end- to-end anastomosis is performed under direct robotic visualization. ICG and Firefly are again utilized to ensure excellent perfusion to the anastomosis [Figure 9C]. A standard leak test is then performed.

For those patients with a low rectal tumor and undergoing a handsewn coloanal anastomosis, a mucosectomy is completed just proximal to the dentate line. Placement of a Lone Star retractor (CooperSurgical, Trumbull, CT) generally provides adequate visualization. The mucosectomy is carried proximally to just above the anorectal ring. The pelvis is then entered from the perineal side just anterior to the coccyx. A finger placed into the pelvis, transanally, is then utilized to identify the correct plane of dissection to free the rectum circumferentially with electrocautery. When performing this dissection anteriorly, one must take care not to injure the urethra in males or the vagina in females. Once completely mobilized, the rectum may be extracted transanally and divided at the previously identified proximal transection point on the descending colon. A single layer hand-sewn coloanal anastomosis is then fashioned with interrupted absorbable sutures placed circumferentially.

A diverting loop ileostomy is routinely used in patients with low (below the anterior peritoneal reflection) anastomoses, or those patients who received pre-operative radiation therapy. Consideration for ileostomy reversal occurs 3 months after the index operation, or once any potential adjuvant therapy is completed.

RESULTS

Once the safety and feasibility of LTME for the management of rectal was proven data was needed to ensure equivalent long term oncologic outcomes to traditional open TME (OTEM). This evidence was provided by three major randomized control trials including the MRC CLASSIC, COREAN, and COLOR II. In each of these trials the 3 and 5 years data revealed no statistically significant differences between LTME and OTME in terms of overall survival, disease-free survival, and local and distant recurrence [7, 8, 12, 14]. With the already proven short-term benefits of LTME many authors believed MIS for rectal cancer was the superior technique. Due to the complex nature of rectal cancer there was a call for additional large multicenter randomized trials. The ACOSOG Z6051 and ALaCaRT were two large non-inferiority trials performed to compare LTME to OTME. The results of both trials showed excellent quality amongst both surgical arms, but LTME failed to meet the criterion for noninferiority for pathologic outcomes when compared to OTME. These findings could not support routine use of LTME for rectal cancer until long term outcomes could be confirmed [15, 16]. Robotic TME (RTME) offered the potential for non-inferiority based upon the known technical advantages of the robotic platform over standard laparoscopic techniques.

The first robotic colorectal surgery was performed by Ballantyne et al. in 2001 utilizing the da Vinci robotic system as a potential solution to the pitfalls of laparoscopic colectomy [26]. Then in 2006 Pigazzi et al. developed the concept of RTME for rectal cancer. Their study compared short-term outcomes between RTME and LTME and showed the safety and feasibility of RTME [27]. Despite the technique of RTME being around for greater than a

decade, the available data primarily consists of single-center experiences and a few small prospective studies.

Although the data is limited the results have consistently shown that RTME is safe, feasible, and offers excellent short term and long-term outcomes [17, 18, 28-33]. In addition, these limited series on RTME have suggested other potential areas of improved outcomes including decreased intra operative blood loss, higher lymph node harvest, shorter length of stay, and improved surgical margins when compared to LTME. Although these particular findings remain inconsistent RTME has consistently shown improved genitourinary function and lower conversions rates [17, 32, 34-39]. Additionally the robotic platform allows for the use of Firefly Fluorescence Imaging in conjunction with ICG. In a large prospective database study 436 consecutive patients underwent robotic assisted sphincter sparing surgery for rectal cancer. The authors showed a 10.6% change in operative decision which correlated to a decrease in anastomotic leak rate between the control and ICG group of 5.4% and 0.8% respectively ($p = 0.031$) [40].

There are however, important potential negatives of RTME which must be mentioned. The two most significant disadvantages include short term operational and inventory cost and increased operative times [17, 31, 33, 36, 37]. These negative findings have been a major barrier to more widespread adoption of robotic colon and rectal surgery. With increasing surgeon experience and the Xi robotic platform current data has shown decreased operative times and near equivalent costs when accounting for conversion rates and high volume robotic surgeons [41-43].

With limited quality data available on RTME there was a need for a large randomized trial. In response to this the ROLARR Trial was designed. This trial was a large international, multicenter, randomized, unblinded, parallel group trial that was designed to provide quality data on the safety and efficacy of RTME for the treatment of rectal cancer. 471 total patients were randomized to robotic-assisted or conventional laparoscopic surgery. The overall conversion rate to open laparotomy was 10.1% with 12.2% in the conventional laparoscopic group and 8.1% in the robotic assisted group ($p = 0.16$). Unfortunately, the study was dramatically underpowered due to poor study design and allowed surgeons with limited robotics experience (10 or more robotic procedures) to participate. Despite these limitations there was a significant difference noted in conversion rates for male patients (16.4% vs 8.7%, $p = 0.04$). In addition the robotic arm had a rate of CRM+ of 5.1% which is the lowest CRM+ rate when compared to COLOR II, MRC CLASSIC, ALACART, and ACOSOG Z6051. There were otherwise no significant differences identified in any of the secondary outcomes including intraoperative complications, postoperative complications, mortality, resection margin positivity, bladder dysfunction, and sexual function. Although this trial failed to demonstrate improved conversion rates with RTME it did confirm that RTME is safe and feasible in the largest robotic randomized trial to date [44].

CONCLUSION

Robotic rectal resection is both safe and feasible. Not unlike laparoscopic rectal resection the results of robotics appear to be in line with these historical works within MIS. As adoption of new MIS technique like RTME for rectal cancer expand it will be critical that

new research be engaged to demonstrate the value and challenges of this new technology. To date however, RTME has demonstrated itself to be a uniquely adaptable platform with outcomes equal to those of other forms of MIS. The future will help us demonstrate if the current outstanding short-term outcomes will translate into long-term improvements in morbidity and oncologic quality.

REFERENCES

[1] Jacobs, M; Verdeja, JC; Goldstein, HS. "Minimally invasive colon resection (laparoscopic colectomy)," *Surgical Laparoscopic and Endoscopy*, vol. *1*, no. 3, pp. 144-150, 1991.

[2] Clinical Outcomes of Surgical Therapy Study Group: A comparison of laparoscopically assisted and open colectomy for colon cancer. *N Engl J Med*, 2004, 350(20), 2050–2059.

[3] Fleshman, J; Sargent, DJ; Green, E; Anvari, M; Stryker, SJ; et al., Laparoscopic colectomy for cancer is not inferior to open surgery based on 5-year data from the COST study group trial. *Ann Surg*, 2007, 246(4), 655–664.

[4] Veldkamp, R; Kuhry, E; Hop, WC; Jeekel, J; Kazemier, G; et al., Laparoscopic surgery versus open surgery for colon cancer: short-term outcomes of a randomized trial. *Lancet Oncol*, 2005, 6(7), 477–484.

[5] Colon Cancer Laparoscopic or Open Resection Study Group, et al., Survival after laparoscopic surgery versus open surgery for colon cancer: long-term outcome of a randomized clinical trial. *Lancet Oncol*, 2009, 10(1), 44–52.

[6] Guillou, PJ; Quirke, P; Thorpe, H; Walker, J; Jayne, DG; et al., Short-term endpoints of conventional versus laparoscopicassisted surgery in patients with colorectal cancer (MRC CLASICC trial): multicenter, randomized controlled trial. *Lancet*, 2005, 365(9472), 1718–1726.

[7] Jayne, DG; Guillou, PJ; Thorpe, H; Quirke, P; Copeland, J; et al., Randomized trial of laparoscopic-assisted resection of colorectal carcinoma: 3-year results of the UK MRC CLASICC trial group. *J Clin Oncol*, 2007, 25(21), 3061–3068.

[8] Jayne, DG; Thorpe, HC; Copeland, J; Quirke, P; Brown, JM; et al., Five-year follow-up of the Medical Research Council CLASICC trial of laparoscopically assisted versus open surgery for colorectal cancer. *Br J Surg*, 2010, 97(11), 1638–1645.

[9] Lacy, AM; Garcia-Valdecasa, JC; Delgado, S; Castells, A; Taura, P; et al., Laparoscopy-assisted colectomy versus open colectomy for treatment of non-metastatic colon cancer: a randomized trial. *Lancet*, 2002, 359(9325), 2224–2229.

[10] Lacy, AM; Delgado, S; Castells, A; Prins, HA; Arroyo, V; et al., The long-term results of a randomized clinical trial of laparoscopyassisted versus open surgery for colon cancer. *Ann Surg*, 2008, 248(1), 1–77.

[11] Simorov, A; Shaligra, A; Shostrom, V; Boilesen, E; Thompson, J; et al., Laparoscopic colon resection trends in utilization and rate of conversion to open procedure: a national database reivew of academic centers. *Ann Surg.*, 2012, 256(3), 462-8.

[12] Kang, SB; Park, JW; Jeong, SY; Nam, BH; Choi, HS; et al., Open versus laparoscopic surgery for mid or low rectal cancer after neoadjuvant chemoradiotherapy (COREAN trial). *Lancet Oncol*, 2010, 11(7), 637–645.

[13] COLOR II Study Group, Buunen, M; Bonjer, HJ; Hop, WC; Haglind, E; et al., COLOR II: A randomized clinical trial comparing laparoscopic and open surgery for rectal cancer. *Dan Med Bull*, 2009, 56(2), 89–91.

[14] Baik, SH; Gincherman, M; Mutch, MG; Birnbaum, EH; Fleshman, J. Laparoscopic vs open resection for patients with rectal cancer: comparison of perioperative outcomes and long-term survival. *Dis Colon Rectum*, 2011, 54(1), 6–14.

[15] Fleshman, J; Branda, M; Sargent, DJ; et al., Effect of Laparoscopic-Assisted Resection vs Open Resection of Stage II or III Rectal Cancer on Pathologic Outcomes; The ACOSOG Z6051 Randomized Clinical Trial. *JAMA*., 2015, 314(13), 1346-1355.

[16] Andrew, RL; Stevenson, MB; Solomon, MJ; Lumley, JW; et al., Effect of Laparoscopic-Assisted Resection vs Open Resection on Pathological Outcomes in Rectal Cancer; The ALaCaRT Randomized Clinical Trial. *JAMA*., 2015, 314(13), 1356-1363.

[17] Memon, S; Heriot, AG; Murphy, DG; Bressel, M; Lynch, AC. Robotic versus laparoscopic proctectomy for rectal cancer: a meta-analysis. *Annals of surgical oncology*., 2012 Jul, 19(7), 2095-101.

[18] Park, EJ; Cho, MS; Baek, SJ; Hur, H; Min, BS; Baik, SH; et al. Long-term Oncologic Outcomes of Robotic Low Anterior Resection for Rectal Cancer: A Comparative Study With Laparoscopic Surgery. *Annals of surgery*., 2015 Jan, 261(1), 129-37.

[19] Miller, PE; Dao, H; Paluvoi, N; Bailey, M; Margolin, D; Shah, N; Vargas, HD. Comparison of 30-Day Postoperative Outcomes after Laparoscopic vs Robotic Colectomy. *J Am Coll Surg*., 2016 Aug, 223(2), 369-73.

[20] Bhama, AR; Obias, V; Welch, KB; Vandewarker, JF; Cleary, RK. A comparison of laparoscopic and robotic colorectal surgery outcomes using the American College of Surgeons National Surgical Quality Improvement Program (ACS NSQIP) database. *Surg Endosc*., 2016 Apr, 30(4), 1576-84.

[21] Dolejs, SC1; Waters, JA2; Ceppa, EP2; Zarzaur, BL2. Laparoscopic versus robotic colectomy: a national surgical quality improvement project analysis. *Surg Endosc*., 2017 Jun, 31(6), 2387-2396.

[22] Van Iersel, JJ1; Formijne Jonkers, HA; Paulides, TJC; Verheijen, PM; Draaisma, WA; Consten, ECJ; Broeders, IAMJ. Robot-Assisted Ventral Mesh Rectopexy for Rectal Prolapse: A 5-Year Experience at a Tertiary Referral Center. *Dis Colon Rectum.*, 2017 Nov, 60(11), 1215-1223.

[23] Khreiss, W; Huebner, M; Cima, RR; Dozois, ER; Chua, HK; Pemberton, JH; et al. Improving conventional recovery with enhed recovery in minimally invasive surgery for rectal cancer. *Diseases of the colon and rectum.*, 2014 May, 57(5), 557-63.

[24] Lovely, JK; Maxson, PM; Jacob, AK; Cima, RR; Horlocker, TT; Hebl, JR; et al. Case-matched series of enhanced versus standard recovery pathway in minimally invasive colorectal surgery. *The British journal of surgery*., 2012 Jan, 99(1), 120-6.

[25] Hubner, M; Lovely, JK; Huebner, M; Slettedahl, SW; Jacob, AK; Larson, DW. Intrathecal analgesia and restrictive perioperative fluid management within enhanced recovery pathway: hemodynamic implications. *Journal of the American College of Surgeons.*, 2013 Jun, 216(6), 1124-34.

[26] Ballantyne, GH; Merola, P; Weber, A; Wasielewski, A. Robotic solutions to the pitfalls of laparoscopic colectomy. *Osp Ital Chir.*, 2001, 7, 405–412.

[27] Pigazzi, A; Ellenhorn, JD; Ballantyne, GH; Paz, IB. Robotic-assisted laparoscopic low anterior resection with total mesorectal excision for rectal cancer. *Surg Endosc.*, 2006, 20, 1521–1525.

[28] Kim, J; Baek, SJ; Kang, DW; Roh, YE; Lee, JW; Kwak, HD; Kwak, JM; Kim, SH. Robotic Resection is a Good Prognostic Factor in Rectal Cancer Compared with Laparoscopic Resection: Long-term Survival Analysis Using Propensity Score Matching. *Dis Colon Rectum.*, 2017 Mar, 60(3), 266-273.

[29] Lim, DR; Bae, SU; Hur, H; Min, BS; Baik, SH; Lee, KY; Kim, NK. Long-term oncological outcomes of robotic versus laparoscopic total mesorectal excision of mid-low rectal cancer following neoadjuvant chemoradiation therapy. *Surg Endosc.*, 2017 Apr, 31(4), 1728-1737.

[30] Gómez Ruiz, M; Alonso Martin, J; Cagigas Fernández, C; Martín Parra, JI; Real Noval, H; et al. Short- and mid-term outcomes of robotic-assisted total mesorectal excision for the treatment of rectal cancer. Our experience after 198 consecutive cases. *Eur J Surg Oncol.*, 2016 Jun, 42(6), 848-54.

[31] Feroci, F; Vannucchi, A; Bianchi, PP; Cantafio, S; Garzi, A; et al. Total mesorectal excision for mid and low rectal cancer: Laparoscopic vs robotic surgery. *World J Gastroenterol.*, 2016, Apr 7, 22(13), 3602-10.

[32] Sun, Y; Xu, H; Li, Z; Han, J; Song, W; et al. Robotic versus laparoscopic low anterior resection for rectal cancer: a meta-analysis. *World J Surg Oncol.*, 2016, Mar 1, 14, 61.

[33] Pai, A; Marecik, SJ; Park, JJ; Melich, G; Sulo, S; et al. Oncologic and Clinicopathologic Outcomes of Robot-Assisted Total Mesorectal Excision for Rectal Cancer. *Dis Colon Rectum.*, 2015 Jul, 58(7), 659-67.

[34] Wang, G; Wang, Z; Jiang, Z; Liu, J; Zhao, J; et al. Male urinary and sexual function after robotic pelvic autonomic nerve-preserving surgery for rectal cancer. *Int J Med Robot.*, 2017 Mar, 13(1).

[35] Panteleimonitis, S; Ahmed, J; Ramachandra, M; Farooq, M; Harper, M; et al. Urogenital function in robotic vs laparoscopic rectal cancer surgery: a comparative study. *Int J Colorectal Dis.*, 2017 Feb, 32(2), 241-248.

[36] Moghadamyeghaneh, Z; Phelan, M; Smith, BR; Stamos, MJ. Outcomes of Open, Laparoscopic, and Robotic Abdominoperineal Resections in Patients With Rectal Cancer. *Dis Colon Rectum*., 2015 Dec, 58(12), 1123-9.

[37] Li, X; Wang, T; Yao, L; Hu, L; Jin, P; et al. The safety and effectiveness of robot-assisted versus laparoscopic TME in patients with rectal cancer: A meta-analysis and systematic review. *Medicine (Baltimore).*, 2017 Jul, 96(29), e7585.

[38] Speicher, PJ; Englum, BR; Ganapathi, AM; Nussbaum, DP; Mantyh, CR; et al. Robotic Low Anterior Resection for Rectal Cancer: A National Perspective on Short-term Oncologic Outcomes. *Ann Surg.*, 2015 Dec, 262(6), 1040-5.

[39] Wang, Y1; Zhao, GH; Yang, H; Lin, J. A Pooled Analysis of Robotic Versus Laparoscopic Surgery for Total Mesorectal Excision for Rectal Cancer. *Surg Laparosc Endosc Percutan Tech.*, 2016 Jun, 26(3), 259-64.

[40] Kim, JC; Lee, JL; Yoon, YS; Alotaibi, AM; Kim, J. Utility of indocyanine-green fluorescent imaging during robot-assisted sphincter-saving surgery on rectal cancer patients. *Int J Med Robot.*, 2016 Dec, 12(4), 710-717.

[41] Rashidi, L; Neighorn, C; Bastawrous, A. Outcome comparisons between high-volume robotic and laparoscopic surgeons in a large healthcare system. *Am J Surg.*, 2017 May, 213(5), 901-905.

[42] Cleary, RK; Mullard, AJ; Ferraro, J; Regenbogen, SE. The cost of conversion in robotic and laparoscopic colorectal surgery. *Surg Endosc.*, 2017, Sep 15. doi: 10.1007/s00464-017-5839-8. [Epub ahead of print].

[43] Ozben, V; Cengiz, T; Atasoy, D; Bayraktar, O; Aghayeva, A; et al., Is da Vinci Xi Better than da Vinci Si in Robotic Rectal Cancer Surgery? Comparison of the 2 Generations of da Vinci Systems. *Surg Laparosc Endosc Percutan Tech.*, 2016 Oct, 26(5), 417-423.

[44] Jayne, D; Pigazzi, A; Marshall, H; Croft, J; Corrigan, N; et al. Effect of Robotic-Assisted vs Conventional Laparoscopic Surgery on Risk of Conversion to Open Laparotomy Among Patients Undergoing Resection for Rectal Cancer: The ROLARR Randomized Clinical Trial. *JAMA.*, 2017, Oct 24, 318(16), 1569-1580.

In: Encyclopedia of Surgery (22 Volume Set)
Editors: Andreas Lehrer and Kristin Mueller
ISBN: 978-1-53618-329-0
© 2020 Nova Science Publishers, Inc.

Chapter 250

ROBOTIC-ASSISTED ABDOMINAL WALL HERNIA REPAIR

Paul A. R. Del Prado, MD and James G. Bittner IV, MD
[1]Robotic Surgery Program, University of Arizona School of Medicine,
Department of Surgery, Maricopa Medical Center, Phoenix, AZ, US
[2]Sentara RMH Medical Center, Harrisonburg, VA, US

INTRODUCTION

A hernia is defined as an anatomical part which protrudes through an opening, tear, or weakness of the abdominal wall [1]. This defect may be congenital or acquired; due to muscle weakness or previous incision. Hernias are classified by type (primary or incisional), location, and size. While most abdominal wall hernias are congenital, a large proportion (42%) are acquired [2]. Incisional hernia occurs frequently (11-20%) following midline laparotomy [3]. Up to 5 million open abdominal operations are performed annually in the United States so the number of people likely to develop incisional hernia is quite high. An estimated 350,000 to 500,000 abdominal wall hernias then may be repaired annually in the United States.

Groin hernias are comprised of inguinal (96.3%), femoral (3%), and obturator hernias (0.7%). They have a bimodal distribution with a higher lifetime risk among men (27%) than women (3%). Up to 750,000 groin hernia repairs are performed annually in the United States and most are repaired using an open approach [4, 5]. Despite evidence demonstrating the benefits of a minimally invasive approach to groin hernias including low rate of surgical site infection, minimal postoperative pain, and early return to activity, the frequency of laparoscopic and/or robot-assisted groin hernia repair is relatively low (4-30% of all repairs). Recent research supports the use of minimally invasive groin hernia repair with equivalent rates of recurrence compared to open tension-free mesh repairs [6, 7]. The limited adoption of minimally invasive techniques may be due to lack of surgeon training, experience, and/or equipment as well as cost [8].

With the introduction of surgical robotic platforms, a growing number of groin hernias are now repaired using a minimally invasive approach. In 2016, the proportion of groin hernias repaired using a robot-assisted technique approached 20% of all repairs in the United

States. Most of these cases represent a shift from an open to minimally invasive approach, thereby increasing the total proportion of patients who benefited from a minimally invasive approach to groin hernia repair. The reason for this trend is multifactorial but certainly benefits offered by the surgical robotic platform play a role. Advantages of a robotic surgical platform include but are not limited to superior 3-dimensional visualization, stability of the platform, articulating instrumentation, and ergonomic benefits to the operating surgeon. Potential technical benefits related to visualization and stability of the surgical robotics platform include ease of enterolysis, dissection of the hernia sac and contents, approximation of fascia (and diastasis recti), and fixation of mesh [9]. There is also improved ergonomics for the operating surgeon, especially with angulation of instruments to perform dissection in various directions along the abdominal wall [7]. Theoretically, less trauma and pain may occur at trocar sites as the fulcrum for angulation is shifted from the abdominal wall (for laparoscopy) to the instrument (for robotics).

The robotic surgical platform facilitates various approaches to ventral and incisional hernias compared to the traditional laparoscopic intraperitoneal onlay mesh (IPOM) repair. These additional robotic-assisted techniques include transabdominal pre-peritoneal (TAPP) repair, Rives-Stoppa procedure, and posterior component separation (PCS) technique. With more options the surgeon can safely and effectively repair increasingly complex and larger defects previously repair using an open approach.

BACKGROUND

Hernia repair can be traced back to the early Egyptians as described by Georg Moritz Eber's ancient papyrus dated 3,000 to 2,500 B.C. [10]. Since then, hernia management has shifted from non-operative to operative strategies as people developed an understanding of the abdominal wall and groin anatomy. An initial operative technique was described by Lucas-Championneire, who included excision of the hernia sac and closure of the defect as key components of hernia repair [11]. William Mayo proposed the "pants over vest" technique [12]. Recurrence was a persistent problem until the introduction of knitted polypropylene mesh in the early 1950s [13]. Utilization of mesh allowed surgeons to decrease recurrence rates from 24-54% to 10-20%.

The first laparoscopic inguinal hernia repair (IHR) was performed by Ralph Ger in 1982 wherein he used metallic clips to close the hernia sac without mesh [14]. Ten years later a prosthetic mesh was utilized in conjunction with laparoscopic inguinal hernia repair [15]. Complications of IPOM include adhesions and bowel erosion, prompting surgeons to vary mesh placement based on anatomical locations. Access to the preperitoneal space was described either through the transabdominal preperitoneal (TAPP) approach or the totally extraperitoneal (TEP) approach, in which an endoscopic hernioplasty is performed by dissecting the myopectineal orifice without entering the peritoneal cavity [15, 16]. Subsequently, LeBlanc and Booth published the first laparoscopic ventral hernia repair (VHR) which involved intraperitoneal onlay mesh (IPOM) secured with staples [17].

The United States Food and Drug Administration approved the first robotic surgical platform in 2000. Ballantyne et al. published the first series of robotic-assisted VHR in 2003 [18]. The robotic surgical platform allowed for easier primary closure of the defect because of

wristed instruments [18-20]. A decade after, utilization of the robotic surgical platform for hernia repair has increased as various open techniques were adapted to a minimally invasive approach. This allowed for repair of more complex and larger hernia defects, decreased length of stay with decreased pain scores and decreased morbidity from large incisions.

OPERATIVE TECHNIQUE – VENTRAL/INCISIONAL HERNIA

The advantages of minimally invasive hernia repair are well described; however, certain barriers limit its widespread adoption. These potential barriers include the need for laparoscopic equipment, the technical difficulty, and the associated learning curve, especially in dissection and suturing of the anterior abdominal wall [7, 9]. The robotic surgical platform facilitates dissection of preperitoneal and retromuscular planes, closure of defects in typical and atypical locations, separation of components as needed, and placement of mesh in locations other than the peritoneal cavity. While not necessary in every situation, restoration of the lineal alba during VHR improves isokinetic and isometric measurements of the rectus abdominis muscle specifically and abdominal wall functionality and quality-of-life generally [21].

Patient Selection

The first phase in selecting patients for robotic-assisted ventral hernia repair (RVHR) is prehabilitiation. The second phase is choosing an appropriate operative approach. Before selecting a robotic-assisted approach, the operating surgeon must consider the medical and surgical history, hernia characteristics, as well as individual training and experience. When these two phases are combined, the correct patient is matched to the correct operative approach.

In general, patients should be smoke-free for at least 4 weeks preoperatively to minimize the risk for surgical site infection (SSI). Patients with body mass index (BMI) of 35 to 39 kg/m^2 with co-morbidities and those with BMI of 40 kg/m^2 or greater who wish to undergo RVHR should be counseled about and in some cases required to participate in either medically supervised weight loss or surgical weight loss before VHR. Surgeons must not miss a critical opportunity to offer appropriate counseling and referral of patients with obesity to physicians and/or surgeons who specialize in weight loss. Besides smoking cessation and weight loss, patients are assessed for diabetes mellitus and history of wound infection. Patients with elevated hemoglobin A1c (>8%) are referred for better blood glucose control. Those with a history of SSI, especially with methicillin-resistant *Staphylococcus aureus* (MRSA), may benefit from MRSA eradication and/or antibiotic treatment. Consider the patients' nutritional status before undertaking RVHR. Patients are at risk of SSI and/or poor outcomes when nutritional status is poor.

Room Setup

Operating room setup is important to allow appropriate patient positioning and safety. The orientation of the operating table within the operating theater may vary depending on the model and mobility of robotic equipment as well as room size. Assuming a square-shaped operating room, the operating table is placed in the middle of the room. As routine, anesthesia personnel and equipment are located at the patient's head. The robotic platform can be positioned perpendicular to the operating table from the patient's left or right side (side-docking). If the hernia defect is off midline, the robotic platform should be docked from the ipsilateral side.

When setting up the operating room for RVHR, consider positioning the robotic equipment cart in a location where the cords do not compromise the safety of operating room personnel, ensuring the surgical assistant or technologist has unrestricted access to the patient, and the surgeon console is located away from the sterile field. Closed loop communication among operating room personnel is critical when the operating surgeon is physically separated from the patient (Figure 1).

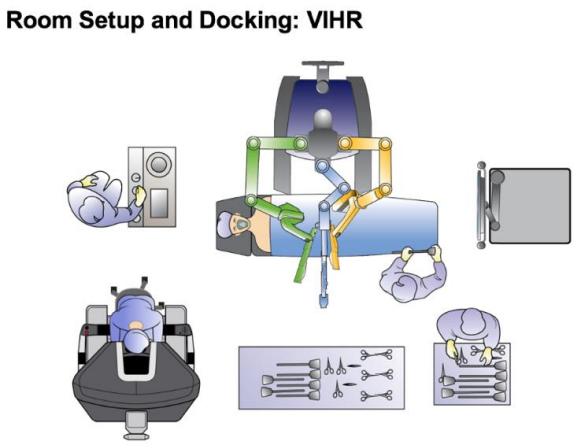

Figure 1. Operating room setup, patient positioning, and platform (da Vinci Si, X, and Xi, Intuitive Surgical, Inc.) docking are important for robotic-assisted ventral/incisional hernia repair.

Patient Positioning

Patients are positioned supine on the operating table with bilateral lower extremity sequential compression devices. The patient should be situated such that the mid abdomen overlies a flex joint in the operating table. In most cases, the patient's arms are tucked with care to protect intravenous access and provide padding of pressure points. One tip is to avoid bulky anterior and medial padding of the arms, as this may limit access to the lateral abdominal wall (or flank), a region commonly chosen for trocar placement. Very thin patients, especially those with medium-sized ventral hernias requiring a lateral trocar position, can be positioned off-center on the operating table with both arms tucked. This off-center positioning minimizes the risk for collision of the robotic arms against the operating table once docked. For patients with a short torso, it may be beneficial to flex the operating

table and elongate the torso slightly. In some patients, the leg ipsilateral to the operative site may impede a robotic arm. By pushing both legs together away from the operative site, a greater angle at the hips allows for more mobility of the inferior robotic arm (Figure 1).

Trocar Placement

Several factors influence the type, number, and location of trocars placed for RVHR. The type and size of trocars may vary by robotic surgical platform, diameter of camera lens, and availability of instruments. At least 3 robotic trocars are required for RVHR.

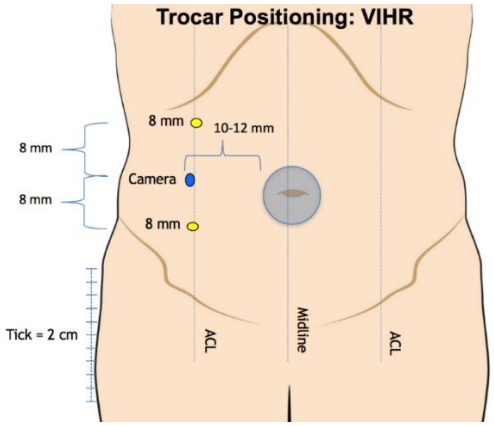

Figure 2. Robotic trocar location varies based on patient surgical history, body habitus, torso length, and hernia size and location. Most commonly, these trocars are placed in a staggered fashion along an anterior axillary line.

Most often these trocars are placed along the anterior axillary line in a staggered fashion, with the camera trocar most posterior. A general rule is to space these trocars 6-8 cm from one another. When using the da Vinci Si or X (Intuitive Surgical Inc., Sunnyvale, CA), the trocars should be spaced 8 cm apart in the vertical plane to prevent robotic arm collisions. Give the advanced patient clearance feature, trocars can be placed only 6 cm apart in the vertical plane when using the da Vinci Xi (Intuitive Surgical, Inc., Sunnyvale, CA). A disposable laparoscopic trocar (assist port) can be placed opposite the robotic trocars when necessary for passage of large or heavyweight mesh, removal of foreign body mesh, or other assistance. Trocar location may vary based on patient surgical history, body habitus, torso length, and hernia size and location (Figure 2). Long robotic trocars (8 mm x 160 mm) can be helpful during RVHR by increasing robotic arm clearance and facilitating deeper dissection. Peritoneal access can be obtained at the surgeon's discretion.

Docking

Docking position depends on the platform model, correct room setup, and hernia characteristics. Some platforms may need to be arranged in the operating room on the side opposite the desired location for trocar placement. Specifically, the da Vinci Si and X

platforms are docked on the side opposite the robotic trocars while the da Vinci Xi platform can be docked on either side of the patient regardless of robotic trocar location (Figure 1). This simple docking strategy is effective for midline ventral and incisional hernias, but defects located in more challenging locations (flank, subxyphoid, suprapubic) may require alternative docking strategies. For repair of defects larger than 5 cm, double docking may be required and the patient is turned 180 degrees after completion of one side of dissection. A mirror image of trocar placement on the opposite side is replicated.

In certain situations, parallel docking or alternate-site docking may facilitate repair of hernias in difficult anatomic positions. For subxyphoid location, RVHR can be performed with trocars placed in the hypogastrium. In that case, docking (Si and X models) over the patient's left or right shoulder may facilitate in-line visualization and dissection as well as minimize robotic arm collisions. For suprapubic location, RVHR can be performed through trocars placed in the subcostal region. If trocars are placed in the subcostal area, the robotic surgical platform (Si and X models) can be docked diagonally from the hip or low lithotomy position. Use of the patient clearance feature available on the newest robotic surgical platform (Xi model) allows for improved range regardless of docking strategy and hernia location.

Dissection

After correct patient positioning, trocar placement, and docking, RVHR is dependent on careful enterolysis and reduction of hernia content. The 12 mm, 30 degree (up) endoscope is placed through the middle trocar. Robotic instruments are inserted under direct visualization. Most commonly an atraumatic grasper and curved scissors are used (Figure 3). One tip to reduce issues with dissection and eventual mesh placement is "ranging the robot," which entails inserting all instruments and moving both instruments as far cephalad and caudad on the ipsilateral side of the camera as possible. The point of "ranging the robot" is to assure that the surgeon will be able to use both instruments to secure a sufficiently large mesh to the anterior abdominal wall.

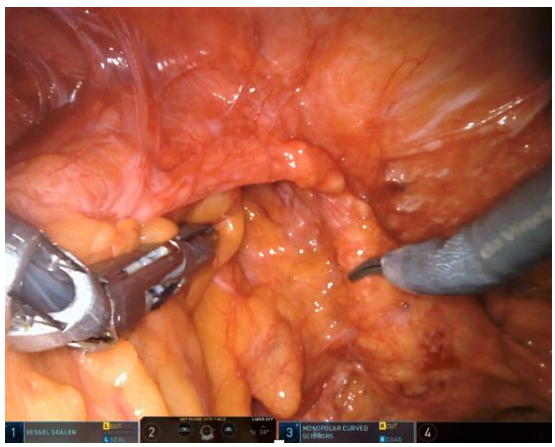

Figure 3. Enterolysis is accomplished with a combination of gentle blunt dissection with atraumatic graspers and careful electrosurgery using robotic shears. In more difficult situations, enterolysis can be facilitated by selecting the robotic vessel sealer (which also serves as an atraumatic grasper) and robotic shears.

Use of 'cut' current at low voltage is preferred compared to 'coagulation' current for dissection. During dissection, care is taken to avoid disrupting the posterior fascia. The hernia sac may either be excised or plicated, to decrease rate of seroma formation. The operating surgeon may choose to dissect and reduce the hernia sac, though this is not required. It is the opinion of the authors that any surgeon who attempts more advanced approaches such as robotic transabdominal preperitoneal (TAPP) VHR or posterior component separation must be proficient with RVHR plus IPOM.

Defect Closure

Once enterolysis, reduction of hernia contents, and control of the sac are complete, the next step is defect closure. It is the opinion of the authors that diastasis recti should be addressed with VHR to improve postoperative cosmesis and abdominal wall function, and lower risk of hernia recurrence.

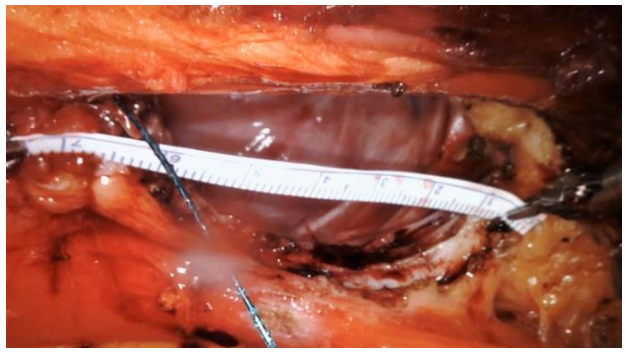

Figure 4. Measuring the length and width of the hernia defect before closure is critical to selecting an appropriate mesh size regardless of the robotic-assisted ventral/incisional hernia repair technique.

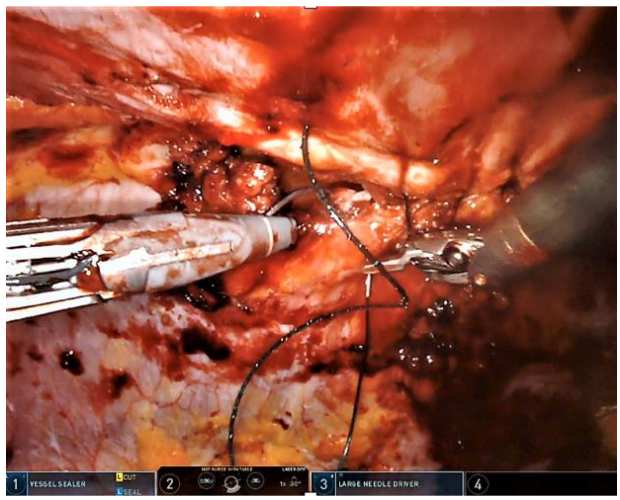

Figure 5. Closure of the ventral/incisional hernia defect is important to reestablish a more functional abdominal wall as well as prevent hernia recurrence.

After measuring the defect to determine appropriate mesh size, plication of diastasis recti and defect closure follows (Figure 4). The authors choose slowly absorbable barbed suture (#0 V-Loc™ 180 Wound Closure Device, Medtronic Inc., Minneapolis, MN) on a GS-21 needle measuring 30 – 45 cm for defect closure. Tips to facilitate proper fascial approximation include decreasing the pneumoperitoneum to 8-10 mmHg, ensuring adequate visualization with each stitch, and adhering to the short stitch technique (Figure 5).

Mesh Placement and Fixation – IPOM

After fascia approximation, mesh implantation is next. The authors prefer a barrier-coated permanent synthetic mesh (medium- or heavyweight polypropylene) for most defects. Mesh size is determined by hernia defect length and width prior to defect closure. Mesh location is centered about the defect by marking the center of the mesh, as well as the long axis such that both are identifiable. This assures mesh is not secured to the abdominal wall in an off-center location.

The mesh is secured to the anterior abdominal wall using one of several fixation strategies including suture fixation with interrupted transfascial stitches, circumferential fascial stitches, and/or tacks. The authors choose circumferential fascial stitches without tacks. If the mesh is larger than 10 x 15 cm in size, the authors use additional fixation in the form of a midline running stitch that secures the long-axis of the mesh to the linea alba. This tightens the mesh against the anterior abdominal wall and may decrease the space available for accumulation of seroma (Figure 6). Pitfalls to consider include ensuring enough working space by proper lateral trocar placement to minimize the difficulty of suturing the mesh on the ipsilateral side of the camera.

Figure 6. Robotic-assisted ventral/incisional hernia repair with intraperitoneal mesh (IPOM) is useful for smaller defects and those in atypical locations.

Once mesh is implanted, it is important to inspect for gaps around the perimeter of the mesh. If there are gaps (≥2 cm) between stitches, additional stitches are warranted to minimize risk for herniation of visceral contents. The authors recommend closure of all fascial defects (>1 cm), including all 10-12 mm trocar sites; however, there may be reasons to close 8 mm trocar sites at the discretion of the operating surgeon.

Compared to conventional laparoscopic IPOM, various modifications have been considered to evaluate possible differences in outcomes related to post-operative pain [22]. Circumferential suturing of the mesh has been described by Allison et al. as an alternative to trans-fascial suture placement and tackers which may be a source of post-operative pain [23]. In 13 patients with up to a 23 month follow up, these authors reported no chronic suture pain or discomfort in their patient cohort [23].

In a study by Rosen and colleagues, patients from the American Hernia Society Quality Collaborative database who underwent either laparoscopic IPOM or robotic-assisted IPOM were propensity-matched and compared for hospital length of stay and surgical site occurrence at 30 days postoperatively [24]. After propensity matching, 454 patients in the laparoscopic IPOM cohort were compared to 177 patients who underwent robotic-assisted IPOM. The results confirmed a shorter median length of stay (0 vs 1 days; $P < 0.001$) and lower rate of surgical site occurrence (5 vs 14%; $P = 0.001$) among patients who had robotic-assisted IPOM repair. However, operative times of greater than 2 hours were more frequent for robotic-assisted IPOM repair, which may be related to surgeon's learning curve, docking and instrument exchanges [24].

Mesh Placement and Fixation – TAPP

The preperitoneal space is useful to avoid direct contact of mesh on viscera, reported to cause increased number and density of adhesions, bowel erosions, and mesh-related infections. The preperitoneal plane allows utilization of less expensive non barrier-coated synthetic mesh. It has also lead to the discovery of occult hernias not evident in preoperative assessment or imaging nor during diagnostic laparoscopy. Missed hernia defects may account for a proportion of recurrences which could have been addressed during the initial VHR.

Sarli et al. compared TAPP to IPOM and showed similar complication rates but lower recurrences after robotic-assisted TAPP repair [25]. The robotic-assisted TAPP repair should be considered when hernia defects can be closed primarily without the need for component separation. Feasibility of this technique was reported by Sugiyama et al. who described better ergonomics with wristed instrumentation compared to standard laparoscopic instruments when creating and closing peritoneal flaps [26]. The preperitoneal plane may provide a better environment for mesh isolation and integration.

After operating room setup, patient positioning, trocar placement, and docking as described above, the next step is dissection which varies compared to IPOM. Dissection begins with "ranging the robot" and ensuring sufficient distance of the camera from the hernia defect to allow adequate dissection and closure of the peritoneal flap. The dissection is initiated by incising the peritoneal flap at least 3 cm away from the camera tip (Figure 7). It is continued until at least a 5 cm overlap in all directions of the hernia defect is obtained. The sac is completely reduced and may be excised. Tears in the peritoneal flap must be closed preferably using rapidly absorbable braided suture in a figure-of-eight fashion to prevent

intraparietal hernia. The defect is closed and mesh is selected based on original defect size to provide adequate overlap. The mesh may be secured per surgeon preference using self-adhesive mesh, fibrin sealant, sutures, or in rare instances, tacks (Figure 8). The peritoneal flap is then closed using a running 2-0 barbed slowly absorbable suture in a running fashion. Should the peritoneum tear beyond repair or fail to dissect off the posterior rectus sheath, the surgeon should consider an IPOM as described previously.

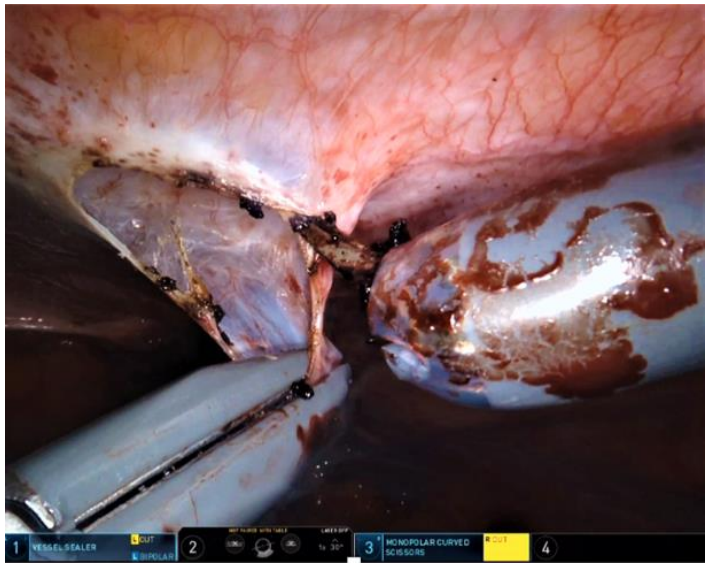

Figure 7. Robotic-assisted ventral/incisional hernia repair with preperitoneal mesh (TAPP) is useful for smaller to medium-sized hernia defects. The procedure begins with "ranging the robot" then initial dissection of the peritoneal flap.

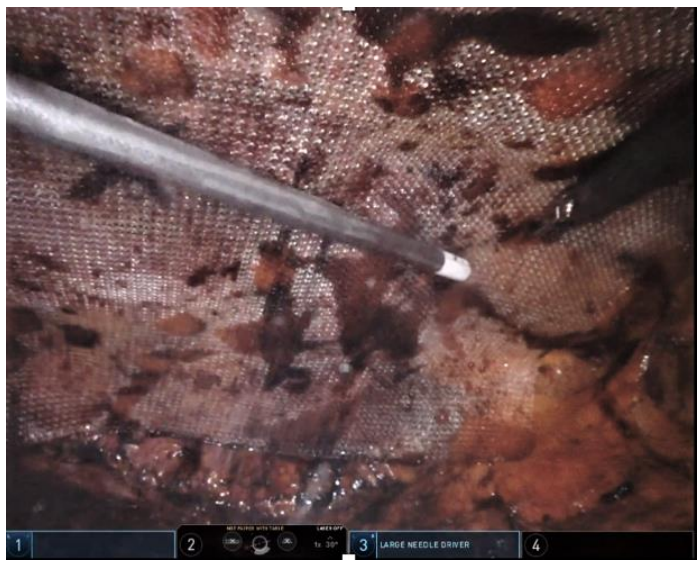

Figure 8. Robotic-assisted ventral/incisional hernia repair with preperitoneal mesh (TAPP) is useful for smaller to medium-sized hernia defects. The procedure includes defect closure and implantation of mesh in the preperitoneal space.

Mesh Placement and Fixation – Retrorectus

The original procedure which revolutionized hernia repair was initially described by Jean Rives and Rene Stoppa in France in the 1960s. They described restoration of the linea alba and reinforcement with prosthetic mesh, which was placed in a sublay position eliminating morbidity associated with mesh against viscera and the creation of subcutaneous flaps. Overall recurrence rates at long-term follow-up ranged from 3.9% to 10.9%. Wound morbidity is up to 13% with surgical site and mesh infection rate at 4%; seroma and hematoma formation at 4% [30-34].

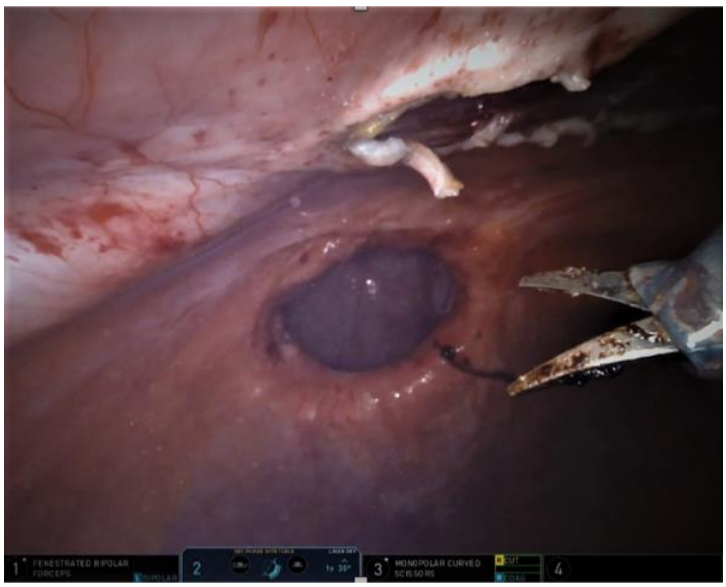

Figure 9. Robotic-assisted ventral/incisional hernia repair with retromuscular mesh (Rives-Stoppa) begins with incising the posterior rectus sheath using robotic shears.

The operation begins with correct operating room setup, patient positioning, trocar placement, and docking as described above. As with other repair techniques, dissection begins with "ranging the robot," enterolysis, and reduction of hernia contents. At a location approximately 2 cm medial to the linea semilunaris, the posterior sheath is incised vertically using robotic scissors with monopolar electrosurgery to expose rectus abdominis muscle fibers (Figure 9). Care should be taken during cephalad and caudad incision of the posterior rectus sheath to ensure the line of division remains medial to the linea semilunaris. The curvilinear incision of the posterior rectus sheath should extend at least 5 cm cephalad and caudad to the respective edges of the defect. Dissection proceeds from lateral to medial until the linea alba is reached (Figure 10). It is important to remain in the preperitoneal plane when crossing the linea alba as there is risk of incising the linea alba itself. During this crossover, the hernia sac is reduced from the subcutaneous tissue. Once across the linea alba, the contralateral posterior rectus sheath is incised vertically to enter the retromuscular space. Dissection proceeds from medial to lateral as far as the linea semilunaris. Care is taken to avoid injury to the neurovascular bundles. This will result in a large flap of posterior rectus sheath separated in the midline by peritoneum. Any peritoneal defects should be closed using

rapidly absorbable braided suture in a figure-of-eight fashion before the next step. Once the retrorectus space is dissected adequately, the hernia defect and resultant space are measured to choose the mesh of correct size and shape. The anterior fascial defect is then closed using a slowly absorbable barbed suture in a running fashion with short-stitch technique. Next, non-barrier-coated synthetic mesh is placed and secured within the retrorectus space. Finally, the posterior rectus sheath is approximated using absorbable barbed suture in a running fashion (Figure 11). It is critical to use a short-stitch technique to minimize the risk of acute intraparietal hernia postoperatively.

Posterior Component Separation

The transversus abdominis release (TAR) was described initially by Novitsky and colleagues [35]. In all, 428 patients underwent open TAR from 2006 to December 2014, with mean hernia defect area of 606 cm^2 and mesh area of 1220 cm^2. Of the 81% with at least one year follow-up, the rates of hernia recurrence, surgical site occurrence, and surgical site infection were 3.7%, 18.7%, and 9.1%, respectively [35]. These early data demonstrated the feasibility, safety, and short-term efficacy of TAR.

TAR as a technique has increased worldwide, with a growing number of TAR cases performed using minimally invasive techniques. Two recent studies demonstrated the potential benefits of robotic-assisted TAR for complex ventral and incisional hernia.

Bittner et al. conducted a single-center review of patients who underwent open or robotic-assisted TAR from 2015 to 2016 [36]. In total, 102 patients were analyzed (76 open TAR and 26 robotic-assisted TAR). Patients were comparable regarding age, gender, body mass index, and the presence of co-morbidities. Most hernia defects were midline (89.5 vs. 83%, $P = 0.47$) and recurrent (52.6 vs. 58.3%, $P = 0.65$). Hernia characteristics were similar regarding mean defect area (260 ± 209 vs. 235 ± 107 cm^2, $P = 0.55$), mesh removal, and type/size mesh implanted. Robotic-assisted TAR took longer to perform but trended toward lower morbidity (39.2 vs. 19.2%, $P = 0.09$), less severe complications, and similar rates of surgical site events and readmission (6.6 vs. 7.7%, $P = 1.00$) compared to open TAR. In addition, robotic-assisted TAR resulted in a significantly shorter median hospital length of stay compared to open TAR (6 days, 95% CI 5.9–8.3 vs. 3 days, 95% CI 3.2–4.3). The authors concluded that in select patients, the robotic surgical platform facilitates a safe, minimally invasive approach to complex abdominal wall reconstruction, specifically TAR. It also offers the short-term benefits of low morbidity and decreased hospital length of stay compared to open TAR [36].

Novitsky et al. compared 38 consecutive patients who underwent robotic-assisted TAR to 76 patients who had open TAR [37]. Patients who underwent robotic-assisted TAR experienced less intraoperative blood loss (49 ± 60 vs. 139 ± 149 mL, $P < 0.001$) and systemic complications (0 vs. 17.1%, $P = 0.026$) as well as shorter mean hospital length of stay (1.3 ± 1.3 vs. 6.0 ± 3.4 days, $P < 0.001$) compared to those who had open TAR. Surgical site events and infection were similar, but wound morbidity was lower after robotic-assisted TAR [37].

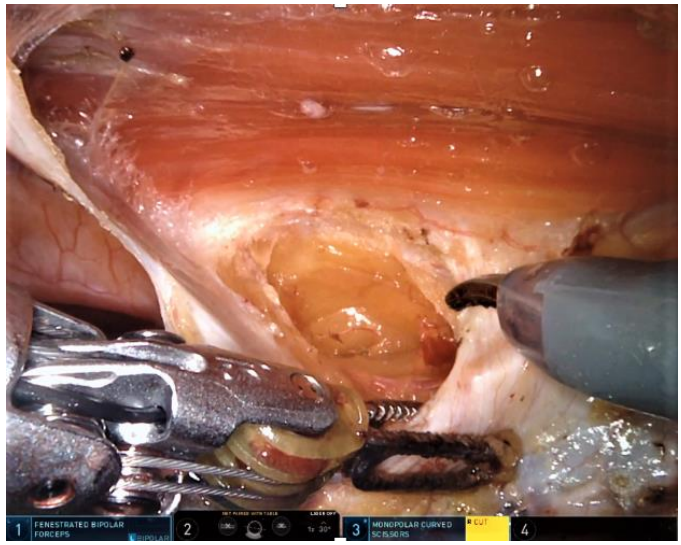

Figure 10. Robotic-assisted ventral/incisional hernia repair with retromuscular mesh (Rives-Stoppa) continues by crossing the linea alba to enter the contralateral retromuscular space.

Figure 11. Robotic-assisted ventral/incisional hernia repair with retromuscular mesh (Rives-Stoppa) concludes by approximation of the posterior rectus sheath using slowly absorbable barbed suture.

Regarding the technique for robotic-assisted TAR, the operation begins with correct operating room setup, patient positioning, trocar placement, and docking as described above. As with other repair techniques, dissection begins with "ranging the robot," enterolysis, and reduction of hernia contents. It is important to note during operating room setup that this procedure requires docking the robot from both right and left sides of the patient (double docking). The next step is dissection of the posterior rectus sheath to the linea semilunaris followed by incision of the posterior lamina of the internal oblique fascia approximately 2 cm medial to the linea semilunaris and neurovascular bundles (Figure 12). This reveals transversus abdominis muscle, which is then transected in its entirety (Figure 13). The next

step is dissection of the transversus abdominis muscle off the transversalis fascia (posterior component separation), and separation of the peritoneum from overlying fascia extending from the diaphragm to space of Retzius and laterally to the retroperitoneum and psoas muscle (Figure 14). In addition, dissection of the myopectineal orifice assures identification and reduction of groin hernia or cord lipoma when present. Next, the posterior rectus sheath is approximated in a running fashion. A large-sheet mesh is placed in the retromuscular/preperitoneal position and secured using either transfascial sutures and/or fibrin sealant (Figure 15). Finally, the anterior rectus sheath is approximated using a 4:1 suture-to-wound-length ratio and short-stitch technique with slowly absorbable barbed suture [36].

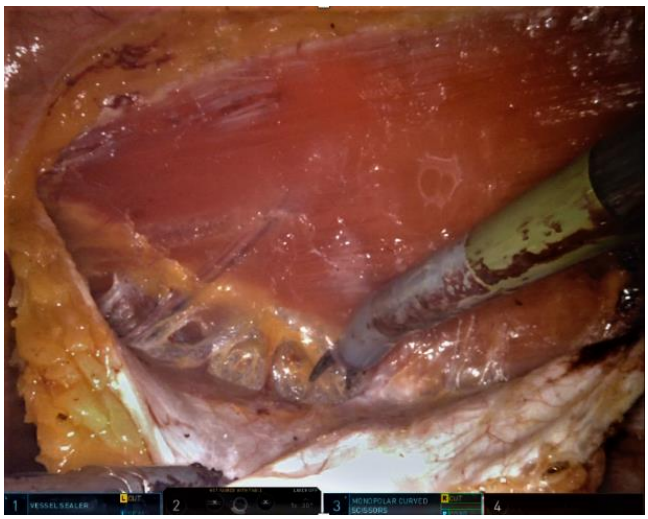

Figure 12. Robotic-assisted ventral/incisional hernia repair with transversus abdominis release (TAR) constitutes an advanced robotic operation. Key anatomic structures include the linea semilunaris and the neurovascular bundles.

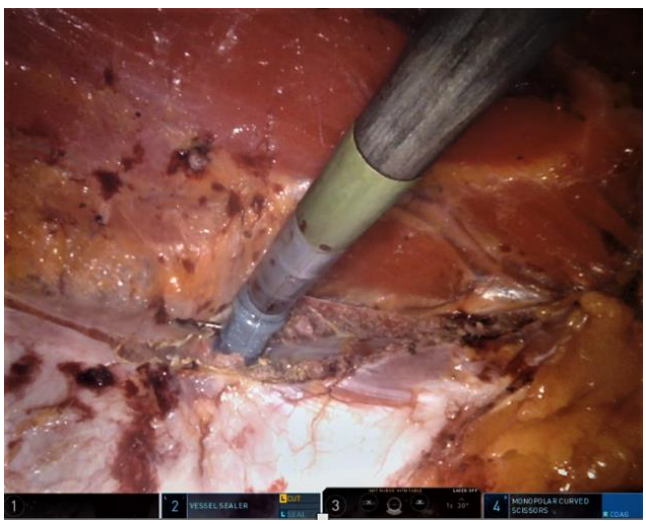

Figure 13. Robotic-assisted ventral/incisional hernia repair with transversus abdominis release (TAR) proceeds with identification and complete transection of the transversus abdominis muscle to reveal the transversalis fascia.

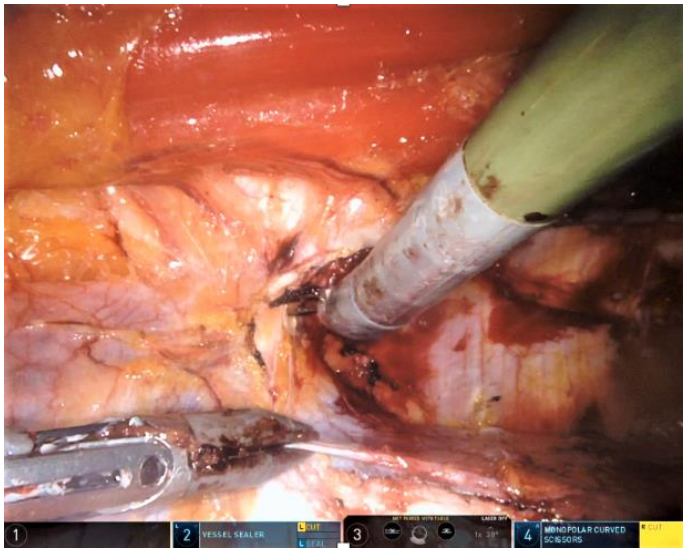

Figure 14. Robotic-assisted ventral/incisional hernia repair with transversus abdominis release (TAR) continues with lateral dissection of the peritoneum off the internal oblique muscle and transversalis fascia.



Figure 15. Robotic-assisted ventral/incisional hernia repair with transversus abdominis release (TAR) concludes with implantation of large, flat sheet mesh secured with either sutures or fibrin sealant.

Diastasis Recti

We recommend repair of diastasis recti associated with midline ventral hernia defects to allow for proper restoration of the linea alba and improve the biomechanics of the abdominal wall. This can be done using a permanent barbed suture in a running fashion to plicate edges of the rectus abdominis muscle to restore the linea alba in conjunction with the hernia repair.

Recurrent Ventral/Incisional Hernia

Selecting the appropriate patient for robotic assisted hernia repair is of paramount importance. This include pre-operative planning to optimize glucose control, weight and ensuring adequate nutritional status. Obtaining a pre-operative CT scan to evaluate the actual size of the hernia defect and its precise location must be considered in order to plan for appropriate technique utilized. Patient's with loss of domain, those with fistulas or ongoing mesh infection should be avoided.

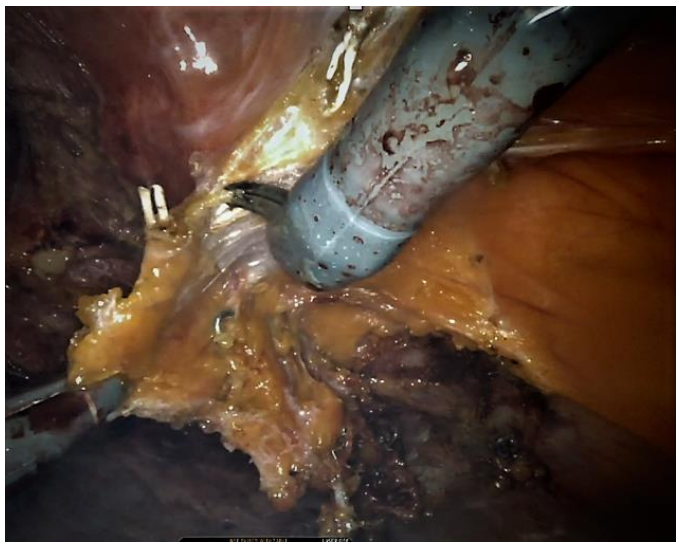

Figure 16. Recurrent ventral/incisional hernia repair may require removal of foreign body including sutures, tacks, and mesh.

The positioning, and docking are similar for midline incisional hernias. Technical aspects will include lysis of adhesions to the posterior abdominal wall and explant of existing mesh which at times may be difficult with adherence to either bowel, or within the posterior sheath (Figure 16). This may be performed sharply using scissors or with electrocautery. This will then dictate the plane available for mesh placement and the need for posterior separation of components to achieve primary closure.

OPERATIVE TECHNIQUE – GROIN HERNIA

The advantages of minimally invasive compared to open inguinal hernia repair (IHR) include lower rates of surgical site infection and acute postoperative groin pain and earlier return to work [6, 7]. Robotic-assisted repair of groin hernia employs a TAPP technique. Published data demonstrates its feasibility and safety with similar recurrence rates and post-operative pain. Studies describe advantages including ease of dissection and suturing due to improved dexterity [39].

Bittner and colleagues compared patients' perceptions of acute postoperative groin pain, activity limitation, and overall satisfaction after robotic-assisted-, laparoscopic, or open

IHR [40]. Random samples of patients from two web-based research panels and surgical practices were screened for patients who underwent IHR between 2015 and 2016. Qualified patients were surveyed to assess perceived acute postoperative groin pain at 1 week postoperatively, activity disruption, and overall satisfaction. Three cohorts based on operative approach were compared. Propensity scoring resulted in 83 robotic-assisted IHR matched to 83 laparoscopic IHR respondents, while 85 robotic-assisted IHR matched with 85 open IHR respondents. The robotic-assisted IHR respondents recalled less acute postoperative groin pain compared to respondents who had open IHR (4.1 ± 0.3 vs 5.6 ± 0.3, $P < 0.01$) but similar pain compared to laparoscopic IHR (4.0 ± 0.3 vs 4.4 ± 0.3, $P = 0.37$). Respondents recalled less activity disruption 1 week postoperatively after robotic-assisted IHR versus open IHR (6.1 ± 0.3 vs. 7.3 ± 0.2, $P < 0.01$) but similar levels of activity disruption after laparoscopic IHR (6.0 ± 0.3 vs. 6.6 ± 0.27, $P = 0.32$). At the time of the survey, respondents perceived less physical activity disruption after robotic-assisted compared to open IHR (1.4 ± 0.2 vs. 2.8 ± 0.4, $P < 0.01$) but similar to laparoscopic IHR (1.3 ± 0.2 vs 1.2 ± 0.2, $P = 0.94$). The authors concluded that patient perceptions of pain and activity disruption differ by approach, suggesting a potential advantage of a minimally invasive technique over open for IHR [40].

PATIENT POSITIONING, TROCAR PLACEMENT, AND DOCKING

Patients are positioned supine on the operating table with bilateral lower extremity sequential compression devices. In most cases, the patient's arms are tucked with care to protect intravenous access and provide padding of pressure points. For patients with a short torso, it may be beneficial to flex the operating table and elongate the torso slightly. Ultimately, the operating table is moved to a Trendelenberg position to permit better visualization of the myopectineal orifice.

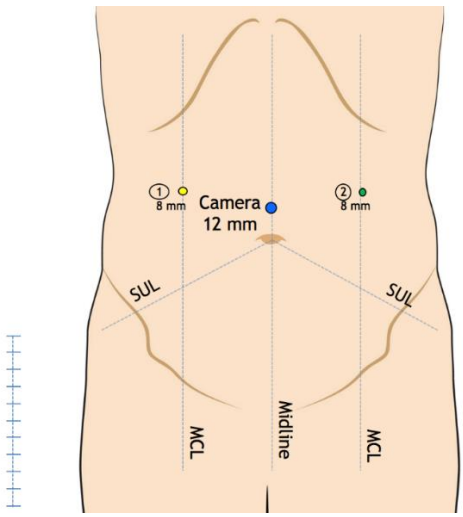

Figure 17. Robotic-assisted inguinal hernia repair begins with proper trocar placement in a staggered fashion, with the camera trocar positioned at or cephalad to the umbilicus and 1-2 cm lateral to midline. A general rule is to space these trocars 6-8 cm from one another.

Several factors influence the type, number, and location of trocars placed for robotic-assisted repair of groin hernia. The type and size of trocars may vary by robotic surgical platform, diameter of camera lens, and availability of instruments. At least 3 robotic trocars (8 mm) are required. Most often these trocars are placed in the epigastrium in a staggered fashion, with the camera trocar positioned at or cephalad to the umbilicus and 1-2 cm lateral to midline. A general rule is to space these trocars 6-8 cm from one another. A disposable laparoscopic trocar (assist port) can be placed when necessary for passage of large or heavyweight mesh, removal of foreign body mesh, or other assistance. Peritoneal access can be obtained at the surgeon's discretion (Figures 17).

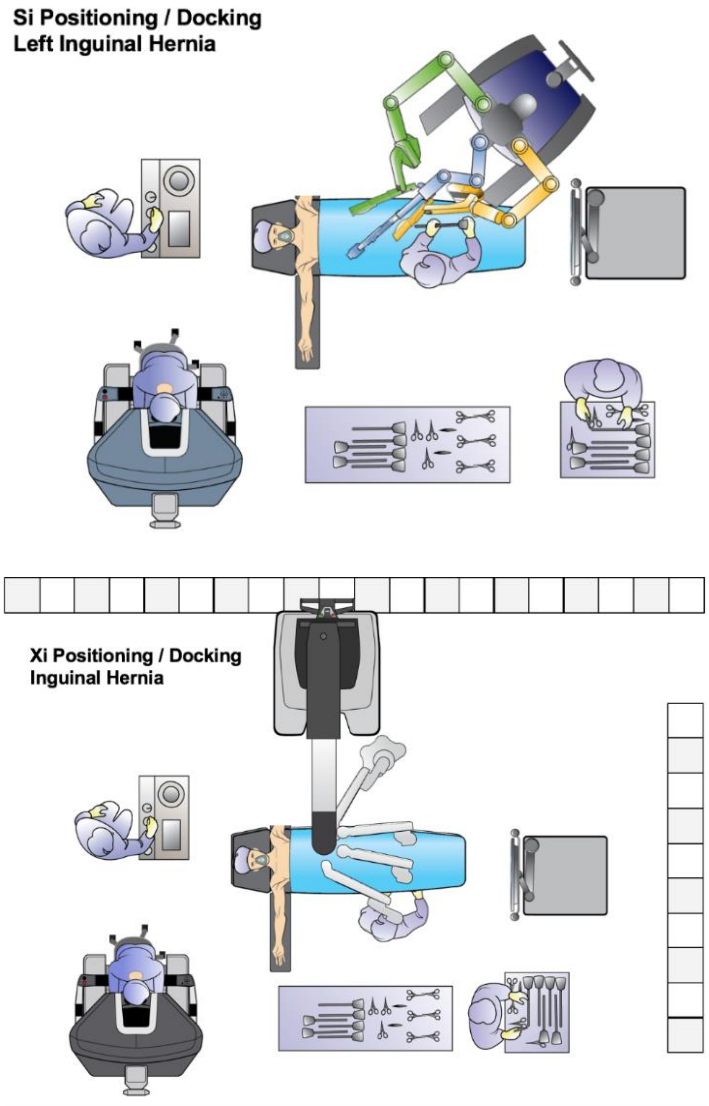

Figures 18-19. Robotic-assisted inguinal hernia repair proceeds with docking, which can vary depending on the robotic surgical platform. The da Vinci Si and X platforms are most often docked at an angle while the da Vinci Xi platform may be side-docked in all situations (Intuitive Surgical Inc., Sunnyvale, CA).

Docking position depends on the platform model and correct room setup. Most often side-docking or angled docking suffice, but in certain situations parallel docking or alternate-site docking may facilitate repair of hernias. If trocars are placed in the subcostal area (epigastrium), the robotic surgical platform can be docked diagonally from the hip or low lithotomy position. Use of the patient clearance feature available on newer robotic surgical platforms allows for improved robotic arm range (Figures 18 and 19).

Dissection

After identifying landmarks including the median umbilical ligaments, anterior superior iliac spine, and inguinal canal, a peritoneal flap is created using robotic shears and monopolar electrosurgery. It is important to identify the transversalis fascia and keep dissection posterior to protect the lateral femoral cutaneous nerve and genitofemoral nerve. Goals during lateral dissection of the myopectineal orifice is to avoid exposure of nerves, expose the psoas muscle, and minimize the use of monopolar electrosurgery to prevent postoperative groin pain. Dissection medial to the inguinal canal proceeds by developing the space of Retzius to expose the pubic tubercle and Cooper's ligament, the direct inguinal space, and to define the obturator canal, femoral canal, and medial border of the external iliac vein. The inferior epigastric is identified and serves to delineate a direct inguinal hernia located medially from an indirect hernia. Any content or fat located in Hesselbach's triangle should be reduced.

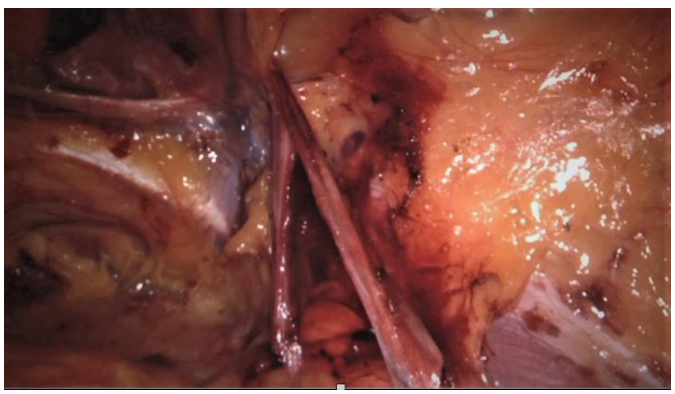

Figure 20. Robotic-assisted inguinal hernia repair must achieve the critical view of the myopectineal orifice, which includes obturator canal, femoral canal, and direct and indirect inguinal region, and result in complete reduction of hernia content and sac(s).

Complete dissection medial and lateral to the inguinal canal results in the critical view of the myopectineal orifice, which is bounded superiorly by the internal oblique and transversus abdominis muscles, medially by the rectus abdominis muscle, laterally by the iliopsoas muscle, and inferiorly by the pubis (Figure 20). Finally, dissection of the inguinal canal includes complete reduction of any indirect hernia sac, isolation of the vas deferens and spermatic vessels or round ligament, and dissection and posterior reduction of the peritoneum off the spermatic cord or round ligament. Care should be taken to avoid grasping the vas deferens or the spermatic vessels directly; rather, grasping the surrounding tissue is preferred. The round ligament can be divided at the surgeon's discretion, preferably close to the

peritoneum rather than close to the internal inguinal ring to avoid injury to the genital branch of the genitofemoral nerve. The critical view of the myopectineal orifice is established in this manner [41].

Dissection must be completed in between the spermatic cord elements to avoid missing attachments of the sac. The femoral canal located medial to the femoral vein, lateral to the lacunar ligament and bounded superiorly by Cooper's ligament is evaluated for the presence of a femoral hernia. The peritoneum must be dissected lateral to the cord structures past the anterior superior iliac spine to allow at least a 10 x 15 cm mesh [41]

Mesh Placement and Fixation

The mesh is laid flat covering the myopectineal orifice with appropriate overlap to prevent a recurrence. Various flat sheet and anatomical mesh options are available (Figure 21). If fixation is deemed necessary, mesh may be secured with suture, fibrin sealant, or a self-fixating mesh may be utilized. The peritoneal flap is closed using either a 3-0 short-term absorbable barbed suture in a running fashion (Figure 22). It is important to close the flap or any other defect completely to prevent occurrence of an inter-parietal hernia.

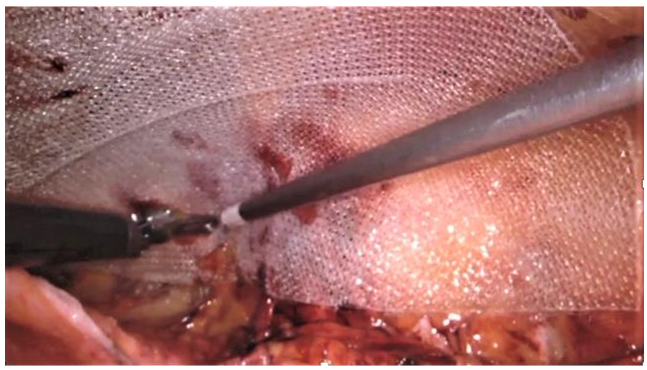

Figure 21. Robotic-assisted inguinal hernia repair requires implantation of preformed polypropylene mesh to cover the entire myopectineal orifice. Fixation strategies may include no fixation, sutures, tacks, fibrin sealant, and/or self-fixating mesh.

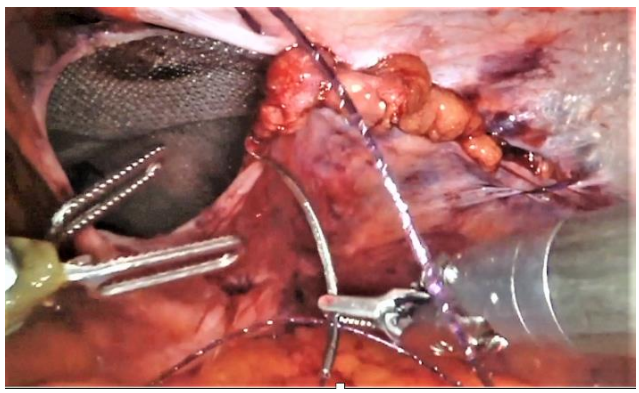

Figure 22. Robotic-assisted inguinal hernia repair concludes with closure of the peritoneal flap using absorbable suture.

CONCLUSION

A robotic surgical platform facilitates a safe, minimally invasive approach to ventral/incisional hernia repair, with known benefits for complex abdominal wall reconstruction. Evidence shows that in the hands of experienced hernia surgeons, robotic-assisted ventral/incisional hernia repair with transversus abdominis release offers the short-term benefits of low morbidity, decreased hospital length of stay, and lower total costs compared to an open approach in select patients [36, 37]. These outcomes translate to value in the delivery of care for patients with ventral/incisional hernia. Similarly, a robotic surgical platform can yield improved short-term outcomes regarding acute postoperative groin pain and activity disruption in select patients with groin hernia [40]. As options for minimally invasive repair of ventral/incisional and inguinal hernia continue to grow, it is ultimately patients that will benefit.

REFERENCES

[1] *Merriam-Webster*. 2017. "abdominal hernia." Accessed December 17. https://www.merriam-webster.com/medical/abdominal%20hernia.

[2] Shah, Priti PraSad, Shaikh, Shama, and Panchabhai, Sunil. 2016. "Prevalence of Anterior Abdominal Wall Hernia and its Associated Risk Factors." *International Journal of Anatomy, Radiology and Surgery* 5(3). Accessed February 21, 2018. http://www.ijars.net/back_issues.asp?issn=2277-8543&year=2016&month=July&volume=5&issue=3&page=-&id=2179.

[3] Le Huu Nho, R., Mege, D., Ouaïssi, M., Sielezneff, I., Sastre, B. 2012. "Incidence and Prevention of Ventral Incisional Hernia." *Journal of Visceral Surgery* 149(5):e3-e14.

[4] Society of American Gastrointestinal and Endoscopic Surgeons. 2018. "*Laparoscopic Ventral Hernia Repair Patient Information from SAGES*." Accessed February 21. http://www.sages.org/publications/patient-information/patient-information-for-laparoscopic-ventral-hernia-repair-from-sages/.

[5] Ruhl, Constance E., Everhart, James E. 2007. "Risk Factors for Inguinal Hernia among Adults in the US Population." *American Journal of Epidemiology* 165(10):1154–61.

[6] Atabek, U., Spence, RK., Pello, M., Alexander, J., Story, L., Camishion, RC. 1994. "A Survey of Preferred Approach to Inguinal Hernia Repair: Laparoscopic or Inguinal Incision?" *American Surgeon* 60:255–8.

[7] Misiakos, Evangelos P., Patapis, Paul, Zavras, Nick, Tzanetis, Panagiotis, Machairas, Anastasios. 2015. "Current Trends in Laparoscopic Ventral Hernia Repair." *Journal of the Society of Laparoendoscopic Surgeons* 19(3):e2015.00048. Accessed February 21, 2018. doi:10.4293%2FJSLS.2015.00048.

[8] Neumayer, Leigh A., Gawande, Atul A., Wang, Jia, Giobbie-Hurder, Anita, Itani, Kamal M. F., Fitzgibbons, Robert J., Reda, Domenic, Jonasson, Olga. 2005. "Proficiency of Surgeons in Inguinal Hernia Repair: Effect of Experience and Age." *Annals of Surgery* 242(3):344-8.

[9] Society of American Gastrointestinal and Endoscopic Surgeons. 2018. "*A Consensus Document on Robotic Surgery*." Accessed February 21. http://SAGES.org/publications/guidelines/consensus-document-robotic-surgery.

[10] Nunn, John F. 1996. *Ancient Egyptian Medicine*. Norman: University of Oklahoma Press.

[11] Keetley, CB. 1888. "The Radical Cure of Hernia." *Annals of Surgery* 8(1):5-23.

[12] Winslow, K. 1904. "The Aponeuroses the Supporting Structures of the Abdominal Wall: Their Approximation for the Prevention and Cure of Hernia." *Annals of Surgery* 39(2):245-55.

[13] Usher, FC. 1963. "Hernia Repair with Knitted Polypropylene Mesh." *Surgery, Gynecology & Obstetrics* 117:239-40.

[14] Pallati, Pradeep. 2018. "*Laparoscopic Inguinal Hernia Repair*." Accessed on February 21. https://www.sages.org/wiki/laparoscopic-inguinal-hernia-repair/.

[15] Arregui, Maurice E., Davis, CJ, Yucel, O., Nagan, RF. 1992. "Laparoscopic Mesh Repair of Inguinal Hernia Using a Preperitoneal Approach: A Preliminary Report." *Surgical Laparoscopy and Endoscopy* 2:53-8.

[16] McKernan, JB., Laws, HL. 1993. "Laparoscopic Repair of Inguinal Hernias Using a Totally Extraperitoneal Prosthetic Approach." *Surgical Endoscopy* 7(1):26-8.

[17] LeBlanc, Karl A., Booth, WV. 1993. "Laparoscopic Repair of Incisional Abdominal Hernias Using Expanded Polytetrafluoroethylene: Preliminary Findings." *Surgical Laparoscopy and Endoscopy* 3(1):39-41.

[18] Ballantyne, Garth H., Hourmont, K., Wasielewski, A. 2003. "Telerobotic Laparoscopic Repair of Incisional Ventral Hernias Using Intraperitoneal Prosthetic Mesh." *Journal of the Society of Laparoendoscopic Surgeons* 7(1):7-14.

[19] Gonzalez, Anthony, Escobar, Ernesto, Romero, Rey, Walker, Gail, Mejias, Jacqueline, Gallas, Michelle, Dickens, Eugene O., Johnson, Christopher J., Rabaza, Jorge, Kudsi, Omar Y. 2017. "Robotic-Assisted Ventral Hernia Repair: A Multicenter Evaluation of Clinical Outcomes*." Surgical Endoscopy* 31(3):1342-9.

[20] Gonzalez, Anthony M., Romero, Rey J., Seetharamaiah, Rupa, Gallas, Michelle, Lamoureux, Julie, Rabaza, Jorge R. 2015. "Laparoscopic Ventral Hernia Repair with Primary Closure versus No Primary Closure of the Defect: Potential Benefits of the Robotic Technology." *International Journal of Medical Robotics and Computer-Assisted Surgery 1*1(2):120-5.

[21] Criss, Cory N., Petro, Clayton C., Krpata, David M., Seafler, Christina M., Lai, Nicola, Fiutem Justin, Novitsky, Yuri W., Rosen, Michael J. 2014. "Functional Abdominal Wall Reconstruction Improves Core Physiology and Quality-of-Life." *Surgery* 156(1):176-82.

[22] Beldi, Guido. "Technical Feasibility of a Robotic-Assisted Ventral Hernia Repair." 2012. *World Journal of Surgery* 36(2):453-4.

[23] Allison, Nathan, Tieu, Ken, Snyder, Brad, Pigazzi, Alessio, Wilson, Erik. "Technical Feasibility of a Robotic-Assisted Ventral Hernia Repair." 2012. *World Journal of Surgery* 36(2):447-52.

[24] Prabhu, Ajita S., Dickens, Eugene O., Copper, Chad M., Mann, John W., Yunis, Jonathan P., Phillips, Sharon, Huang, Li-Ching, Poulose, Benjamin K., Rosen, Michael J. 2017. "*Laparoscopic vs Robotic Intraperitoneal Mesh Repair for Incisional Hernia:*

An Americas Hernia Society Quality Collaborative Analysis." Journal of the American College of Surgeons 225(2):285-93.

[25] Sarli, L., Pietra, N., Choua, O., Costi, R., Cattaneo, G. 1997. "Laparoscopic Hernia Repair: A Prospective Comparison of TAPP and IPOM Techniques." *Surgical Laparoscopy and Endoscopy* 7(6):472-6.

[26] Sugiyama, G, Chivukula S, Chung PJ, Alfonso A. 2015. "Robot-Assisted Transabdominal Preperitoneal Ventral Hernia Repair." *Journal of the Society of Laparoendoscopic Surgeons* 19(4):e2015.00092. Accessed February 21, 2018. doi:10.4293/JSLS.2015.00092.

[27] Beldi, Guido. "Technical Feasibility of a Robotic-Assisted Ventral Hernia Repair." 2012. *World Journal of Surgery* 36(2):453-4.

[28] Allison, Nathan, Tieu, Ken, Snyder, Brad, Pigazzi, Alessio, Wilson, Erik. "Technical Feasibility of a Robotic-Assisted Ventral Hernia Repair." 2012. *World Journal of Surgery* 36(2):447-52.

[29] Prabhu, Ajita S., Dickens, Eugene O., Copper, Chad M., Mann, John W., Yunis, Jonathan P., Phillips, Sharon, Huang, Li-Ching, Poulose, Benjamin K., Rosen, Michael J. 2017. "*Laparoscopic vs Robotic Intraperitoneal Mesh Repair for Incisional Hernia: An Americas Hernia Society Quality Collaborative Analysis." Journal of the American College of Surgeons* 225(2):285-93.

[30] Rogmark, Peder, Smedberg, Sam, Montgomery, Agneta. 2017. "Long-Term Follow-Up of Retromuscular Incisional Hernia Repairs: Recurrence and Quality of Life." *World Journal of Surgery*. Accessed February 21, 2018. doi:10.1007/s0026.

[31] Oprea, Valentin, Matei, O., Leucă, D., Gheorghescu, D., Mic, A., Buia, F., Gavrilaş, F. 2013. "Late Results and Quality of Life After Rives-Stoppa Repair for Incisional Hernias: A Prospective Clinical Study." *Chirurgia* 108(5):679-83.

[32] Forte, Angelo, Zullino, Antonio, Manfredelli, Simone, Montalto, Gioacchino, Covotta, Francesco, Pastore, Piergiorgio, Bezzi, Marcello. 2011. "Rives Technique is the Gold Standard for Incisional Hernioplasty: An Institutional Experience." *Annali Italiani Chirurgia* 2011 82(4):313-7.

[33] Iqbal, Corey W., Pham, Tuan H., Joseph, Anthony, Mai, Jane, Thompson, Geoffrey B., Sarr, Michael G. 2007. "Long-Term Outcome of 254 Complex Incisional Hernia Repairs Using the Modified Rives-Stoppa Technique." *World Journal of Surgery* 31(12):2398-404.

[34] Notash, Yaghoobi A., Notash Jr., Yaghoobi A., Farshi, Seied J., Amoli, Ahmadi H., Salimi, J., Mamarabadi, M. 2007. "Outcomes of the Rives-Stoppa Technique in Incisional Hernia Repair: Ten Years of Experience." *Hernia* 11(1):25-9.

[35] Novitsky, Yuri W., Elliott, Heidi L., Orenstein, Sean B., Rosen, Michael J. 2012. "Transversus Abdominis Muscle Release: A Novel Approach to Posterior Component Separation During Complex Abdominal Wall Reconstruction." *American Journal of Surgery* 204(5):709-16.

[36] Bittner 4th, James G., Alrefai, Sameer, Vy, Michelle, Mabe, Micah, Del Prado, Paul AR., Clingempeel, Natasha L. 2018. "Comparative Analysis of Open and Robotic Transversus Abdominis Release for Ventral Hernia Repair." *Surgical Endoscopy* 32(2):727-34.

[37] Martin-Del-Campo, Luis A., Weltz, Adam S., Belyansky, Igor, Novitsky, Yuri W. 2018. "Comparative Analysis of Perioperative Outcomes of Robotic Versus Open Transversus Abdominis Release." *Surgical Endoscopy* 32(2):840-5.

[38] Iraniha, Andrew, Peloquin, Joshua. 2017. "Long-Term Quality of Life and Outcomes Following Robotic-Assisted TAPP Inguinal Hernia Repair." *Journal of Robotic Surgery*. Accessed February 21, 2018. doi:10.1007/s11701-017-0727-8.

[39] Arcerito, Massimo, Changchien, Eric, Bernal, Oscar, Konkoly-Thege, Adam, Moon, John. 2016. "Robotic Inguinal Hernia Repair: Technique and Early Experience." *American Surgeon* 82(10):1014-7.

[40] Bittner 4th, James G., Cesnik, Lawrence W., Kirwan, Thomas, Wolf, Laurie, Guo, Dongjing. 2018. 'Patient Perceptions of Acute Pain and Activity Disruption Following Inguinal Hernia Repair : A Propensity-Matched Comparison of Robotic-Assisted, Laparoscopic, and Open Approaches.' *Journal of Robotic Surgery*. Accessed February 21, 2018. doi:10.1007/s11701-018-0790-9.

[41] Daes, Jorge, Felix, Edward. 2017. "Critical View of the Myopectineal Orifice." *Annals of Surgery* 266(1):e1-e2. Accessed February 21, 2018. doi:10.1097/SLA.0000000000002104.

In: Encyclopedia of Surgery (22 Volume Set)
Editors: Andreas Lehrer and Kristin Mueller
ISBN: 978-1-53618-329-0
© 2020 Nova Science Publishers, Inc.

Chapter 251

ROBOTIC HEPATOBILIARY AND PANCREATIC SURGERY

Sushruta S. Nagarkatti[1], MD and John B. Martinie[2], MD
[1]Division of Hepatobiliary and Pancreatic Surgery,
Department of Surgery, Carolinas Medical Center, Charlotte, NC, US
[2]Division of Hepatobiliary and Pancreatic Surgery, Department of Surgery,
Carolinas Medical Center, Charlotte, NC, US

INTRODUCTION

Hepatobiliary (HPB) surgery encompasses a complex group of procedures that are performed for a variety of benign and malignant indications.

The morbidity and mortality associated with HPB surgery has decreased over the last several decades due to advances in anesthesia, critical care and other aspects of peri-operative care. Improvement in surgical technique and instrumentation as well as regionalization of care to high volume centers has also led to improvement in outcomes.

The robotic platform provides significant advantages over standard laparoscopy enabling complex HPB procedures to be performed in a minimally invasive fashion. One of these is procedures is the pancreaticoduodenectomy (PD) which is a complex procedure involving the resection of the pancreatic head, uncinate process and duodenum followed by a complex reconstruction with three anastomoses in order to achieve physiologic continuity of the gastrointestinal tract.

The robotic platform provides improved optics with three-dimensional vision through a binocular scope, resulting in improved depth perception, higher magnification, and a stable camera image. Adjuncts such as built in fluorescence imaging and TilePro (Intuitive Surgical, Sunnyvale, CA) picture overlay while performing intra operative ultrasound (US) add to operative efficiency and improve outcomes. As a result of a surgeon controlled stapling device and a fully articulating, bipolar vessel sealing device, a single operating surgeon is able to perform procedures without the need for an assistant surgeon at bedside.

The ability to use fine suture to approximate small structures as part of a complex reconstruction is made possible by the ability to perform supra physiological movements with

the robotic needle drivers. This level of articulation is not possible with standard laparoscopic instruments. The robotic console also provides an ergonomic advantage, allowing a single surgeon to control three operative robotic arms while seated at the console eliminating the "stress" of the arm and hand movements as well as any tremor. The robotic platform therefore provides the tools required to perform complex HPB operations such as a PD in a minimally invasive fashion.

In this chapter, we describe the technical aspects of performing a robotic PD, distal pancreatectomy with splenectomy, and right hepatectomy. We also discuss the outcomes of robotic PD, in order to determine its safety and feasibility.

PATIENT SELECTION

Proper patient selection for robotic assisted HPB surgery cannot be overemphasized. This applies most during the early learning curve. More specifically, deciding whether to offer a patient a robotic assisted procedure depends on the indication for the procedure, individual patient factors, and where the surgeon is in his/her learning curve. Patient selection for both robotic hepatic resections and pancreatic resections are based on similar principles.

Indications for the Procedure and Technical Factors

Tumor pathology and its location is an important factor in determining whether a robotic approach is feasible. When evaluating patients for pancreatic disease, pre-operative pancreatic protocol CT scan and endoscopic ultrasound (EUS) are both commonly used to assess the size, location, and resectability of the tumor. The proximity to and possible involvement of vascular structures must be noted and considered prior to deciding whether to proceed with a robotic approach. In addition, a CT of the chest and abdomen must be performed to evaluate the lungs and liver for distant metastatic disease.

Large pancreatic tumors, those that are borderline resectable, or require concomitant vascular or multi visceral resection are not well suited for the robotic approach and should be avoided. A National Surgical Quality Improvement Program (NSQIP) study examining 30 day outcomes in laparoscopic and robotic PD patients found a higher overall complication rate and a higher conversion rate to an open procedure when it was associated with vascular reconstruction or multi visceral resection [1].

Similarly when planning a robotic hepatic resection, technical factors such as tumor size, and proximity to critical vascular structures determine feasibility of the robotic approach. These patients are evaluated with a triple phase CT scan of the liver. Tumors greater than six cm and those involving the inferior vena cava and/or portal vein bifurcation require maximal exposure best achieved with an open approach.

Learning Curve

During the initial learning curve associated with robotic HPB procedures, we recommended selecting relatively straightforward cases. These include but are not limited to cholecystectomy, distal pancreatectomy with splenectomy (DPS), and straightforward liver procedures. As experience and familiarity with the robotic platform increases, he or she may perform more complex cases such as PD.

During the initial experience with robotic PD, we recommend selecting patients with chronic pancreatitis, neuroendocrine tumors, cystic neoplasms, ampullary cancers and distal cholangiocarcinomas.

Increasing comfort with robotic HPB is reflected by a decrease in operative times and conversion rates to open thus allowing selection of more complex cases. During our initial experience, the ratio of conversion to open for robotic HPB cases was one in every four cases. This decreased significantly to one in every 32 cases later in our series. Simultaneously, operative times also decreased with the number of cases performed [2]. Over a two year period, the operative time in our series for a robotic PD decreased by 30 minutes [2].

This is similar to the data Boone et al. published regarding their learning curve for robotic PD [3]. They demonstrated that estimated blood loss (EBL) and conversion to an open procedure decreased significantly after the first 20 cases. Clinically relevant Grade B/C pancreatic fistulas (POPF) decreased by half after 40 cases with a significant decrease in operative times after 80 cases.

Patient Factors

Body habitus and co morbidities of the individual patient must be taken into consideration prior to proceeding with a robotic approach. Patients with pre operative dyspnea are associated with higher conversion rates to an open procedure [1]. Therefore, patients with high body mass index (BMI), and significant pre-operative cardiopulmonary disease should not be selected for the robotic approach. It is also prudent to avoid elderly frail patients, those with multiple prior abdominal surgeries (ventral hernia repairs with mesh) and patients with very low BMI's or petite body habitus.

OPERATIVE TECHNIQUE

Equipment

The da Vinci Surgical System Si or the Xi (Intuitive Surgical, Sunnyvale, CA) with the associated instrumentation is used. The Prograsp forceps, a fenestrated bipolar and mono-polar scissors are used to perform most robotic assisted HPB cases. In addition, a robotic vessel sealer is key in facilitating dissection while achieving adequate hemostasis.

Table 1. Equipment for robotic HPB procedures

Items	Details (n: number required, if greater than 2)
Robotic system	Da Vinci™ Xi or Si system
Robotic instruments	30-degree camera Prograsp™ Fenestrated Bipolar Mono-polar scissors (2) Large and diamond needle drivers Bipolar vessel sealing device Large clip applier Robotic bulldog clamps Ultrasound probe
Ports	(2) 12 mm assistant trocars (3-4) 8 mm robotic trocars
Basic laparoscopic tray	Veress needle Suction – irrigation Needle drivers Stapling devices on standby
Suture	0 Vicryl suture 4-0 V-lock 4–0 Monocryl, cut to 12 cm 5-0 Monocryl, cut to 12 cm 6-0 Monocryl, cut to 12 cm
Specimen bags	Cook LapSac™ – 5 x 8, 8 x 10 (inches)
Drains	19 French Blake drain
Retractor	Nathanson retractor



Figure 1. Needles used for robotic HPB procedures.

Locking plastic clips (Hemalok, Weck) are used prior to division of larger vessels while micro clips are used for smaller vessels. The operating surgeon using a robotic clip applier fires the clips.

Large and diamond needle drivers are required and used for placement of sutures during the complex reconstructions. A wide range of sutures and needle sizes may be used with the robotic platform. Commonly used suture for our robotic procedures are barbed monofilament suture and monocryl (Ethicon, Inc., Somerville, NJ). Equipment and sutures are listed in Table 1 with needle sizes shown in Figure 1.

ROOM SET-UP AND PATIENT POSITIONING

Most operating rooms have designated robot OR suites where robot assisted procedures are performed. In order to optimize efficiency the OR suite must be set up based on the individual surgeons preferences, ahead of time. This requires determining appropriate placement of the robotic cart, console(s), and AV towers in relation to the scrub table and anesthesia. Movement of equipment on the morning of surgery should be avoided.

The set up varies depending on whether Si or Xi system is used. When using the Si system, following intubation, the patient table is placed at 90 degrees to anesthesia team. The patient in placed in supine position with slight flexion. The left arm is out while the right arm is tucked and they are placed in slight reverse Trendelenberg position as shown in Figure 2. The AV tower is placed at the foot of the bed and the robot cart docks directly above the head of the patient.

For the Xi system, following intubation, the patient table is placed at 45 degrees to the anesthesia team. Both arms are out and wrapped with the patient in supine position, slight flexion and slight reverse Trendelenberg. The robot cart docks to the right of the patient table.

Figure 2. Patient positioning for the Si system. The anesthesia team is to the left of the patient. The robot docks at the head of the patient.

Most robotic HPB procedures are performed with the patient positioning described above. Exceptions to this are right posterior sectionectomy without hilar dissection and non-anatomic segment 6 and 7 resections. These procedures require the patient to be placed in a left lateral decubitus right side up position.

ENTRY AND PORT PLACEMENT

A preferred reliable technique for access to the abdomen should be established. Access is obtained by making a one cm infra umbilical incision and the abdomen is insufflated using a Veress needle following which a 12mm bladeless trocar is used to obtain entry. Alternately, the Hassan technique may be used to gain access. In patients with a prior midline incision, insufflation may be obtained by placing a Veress needle in the left subcostal region in the mid clavicular line followed by entry with a 12mm bladeless trocar.

The robotic camera is used for initial diagnostic laparoscopy as well as for lysis of adhesions. This helps increase to efficiency and minimize cost by avoiding the need to open laparoscopy equipment.

Robotic HPB procedures require the use of three robotic working arms, a robotic camera port and an assistant port. The scrub technician uses the assistant port to suction and exchange sutures.

When using the Si system, the camera port is placed in the infra umbilical position approximately 16-20 cm from target anatomy and adjusted based on body habitus. In patients with a long torso, obesity or a low umbilicus, the camera port may be moved cephalad to a supra umbilical position. The robotic working ports are placed along a semi-circular line directed towards the target anatomy. The distance between each port is approximately eight to ten cm while maintaining at least a three cm distance from surrounding bony structures. If space is limited due to the patient's body habitus, the distance of the working ports from the camera port may be decreased.

The two main working ports are placed along the semi circular line, one on the left and the other on the right side. The robotic "third arm" is placed on the patient's left side as shown in Figure 3. The 12 mm assistant port is placed below the semi-circular line, outside of the ergonomic triangle in order to minimize collisions with the robotic ports. It should be at least 150 mm in length, and should be a balloon trocar if shorter.

Figure 3. Port placement with the Si system. Ports are placed along a semi-circular line 16-20 cm from target anatomy.



Figure 4. The infra umbilical 12 mm assistant port may serve as a robotic port for portions of the procedure.

When using the Xi system, the 12mm umbilical port is used as the assistant port during most of the procedure. This may also serve as a camera or robotic working port if needed, as shown in Figure 4. The robotic ports are placed along a straight line at variable distance from target anatomy depending on the patient's body habitus (Figure 5). The robotic camera is placed in the right mid clavicular line. Two working ports are placed on the left, with one on the right at distance of six to eight cm between each port.

Figure 5. Port placement for the Xi system. The ports are placed along a straight line. The camera port is placed on the patient's right in the mid-clavicular line.

With respect to closure of port site, it is out preference to close only 12 mm trocar sites with 0 vicryl (Ethicon, Inc., Somerville, NJ) using a suture passer. We do not routine close the 5 mm and 8 mm trocar sites. One of the 8 mm trocar sites is used for drain placement.

SINGLE SURGEON ROBOT ASSISTED PANCREATICODUODENECTOMY

Resection

We begin the procedure by inspecting the abdomen to rule out evidence of metastatic disease. It is our practice to use the falciform ligament as a vascularized pedicled flap. We therefore take down the ligament and preserve it (leaving it attached to the liver) to be used at the end of the case.

Retraction is then set up to expose the hilum. This is based on whether the patient has had a prior cholecystectomy. If the gallbladder is present, a stitch is placed securing it to the anterior abdominal wall (Figure 6). However, in the absence of the gallbladder, a Nathanson retractor is used (Figure 7).

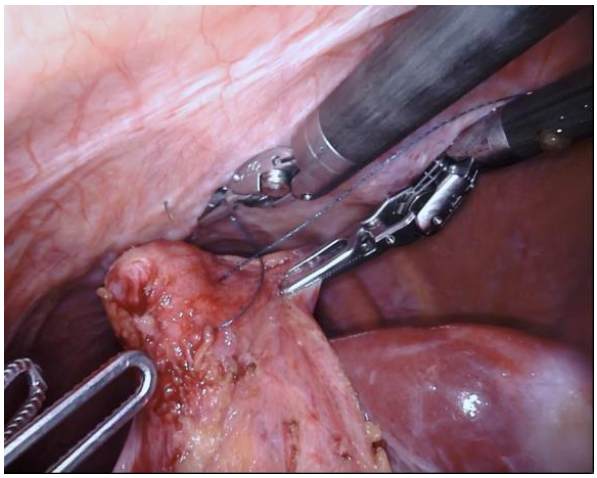

Figure 6. Placement of a gallbladder stitch suspending it to the abdominal wall.

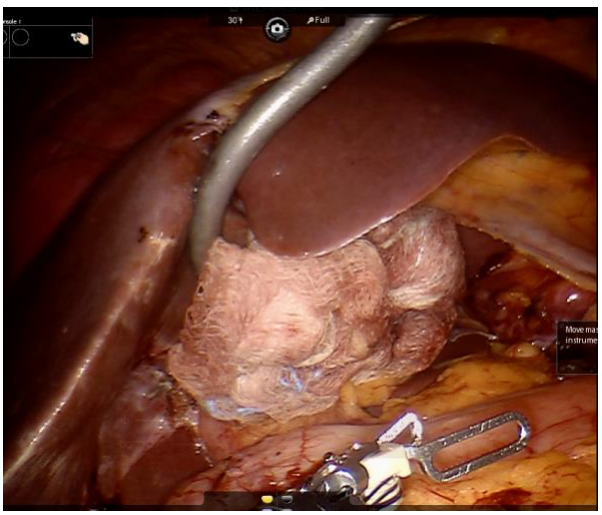

Figure 7. Using a Nathanson retractor for exposure of the hilum. This patient had a prior cholecystectomy.

The gastrocolic ligament is opened in an avascular plane using the monopolar scissors and taken down with the robotic vessel sealer as shown in Figure 8. The posterior stomach is then mobilized off the pancreas.

We then dissect and mobilize the distal gastric antrum and proximal duodenum using the robotic vessel sealer. During this dissection, the right gastro epiploic and right gastric vessels are identified, dissected and divided following the application of Hemalock clips (Figure 9). The hepatic flexure of the colon is then taken down using the robotic vessel sealer.

Our preference is to perform a pylorus preserving procedure. We therefore divide the proximal duodenum just distal to the pylorus using a 60 mm robotic stapler (Figure 10). The duodenum is then Kocherized using the robotic vessel sealer as shown in Figure 11.

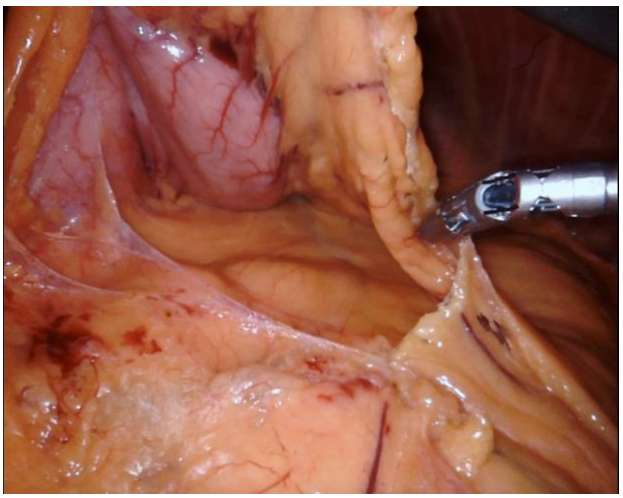

Figure 8. Using the robotic vessel sealer to take down the gastrocolic ligament.

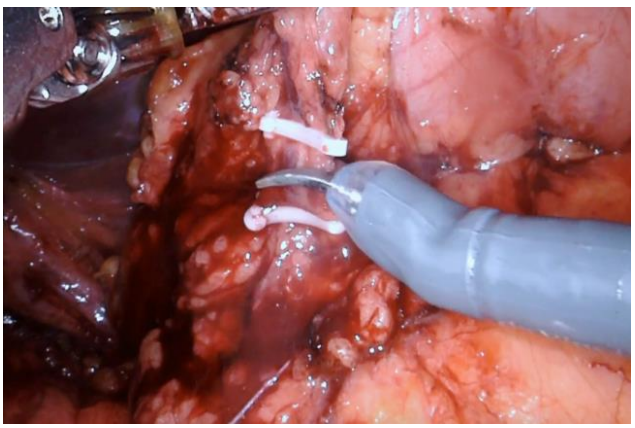

Figure 9. Division of the right gastro epiploic vein after placement of locking clips.

Using the monopolar scissors the hepatic artery is dissected and a portal and celiac lymphadenectomy is performed (Figures 12 and 13). The gastroduodenal artery is then identified, ligated and then clipped with Hemalock clips following which it is divided (Figure 14).

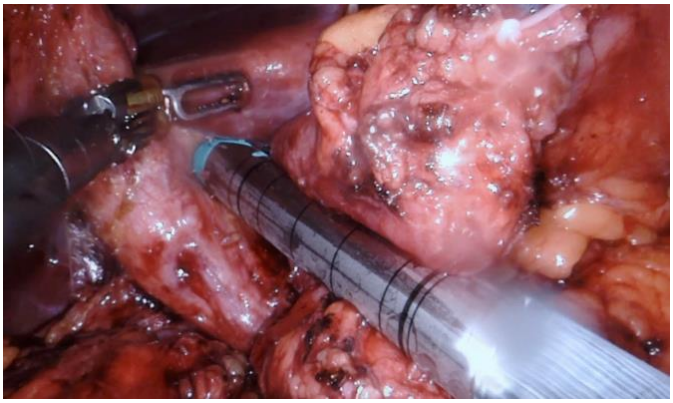

Figure 10. The robotic stapler is used to divide the duodenum just distal to the pylorus.

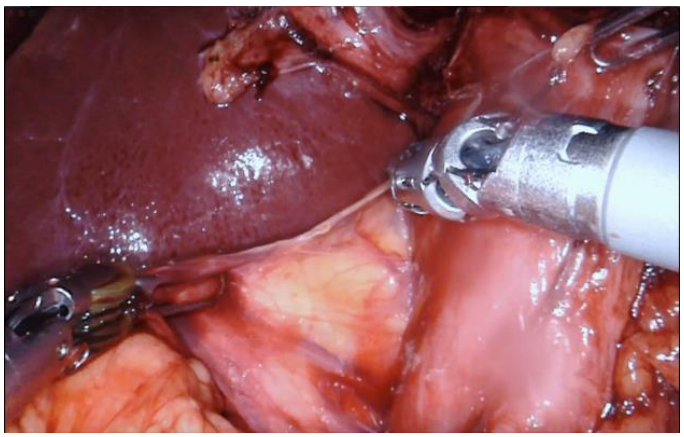

Figure 11. Kocherization of the duodenum.

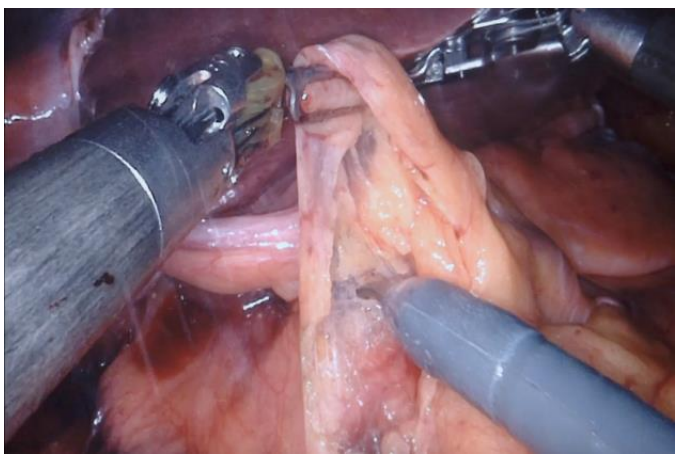

Figure 12. Dissection of the porta hepatis.

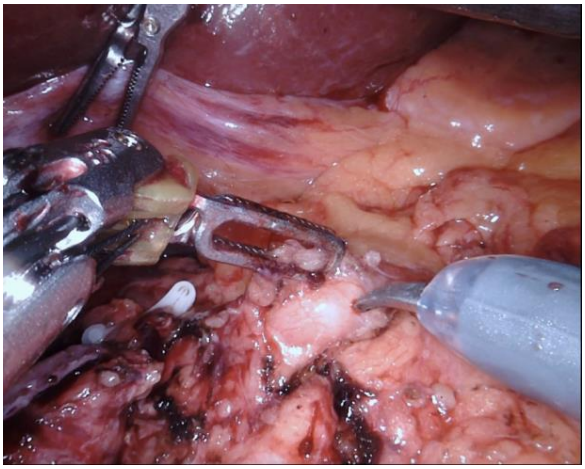

Figure 13. Dissection of celiac lymph nodes and hepatic artery.

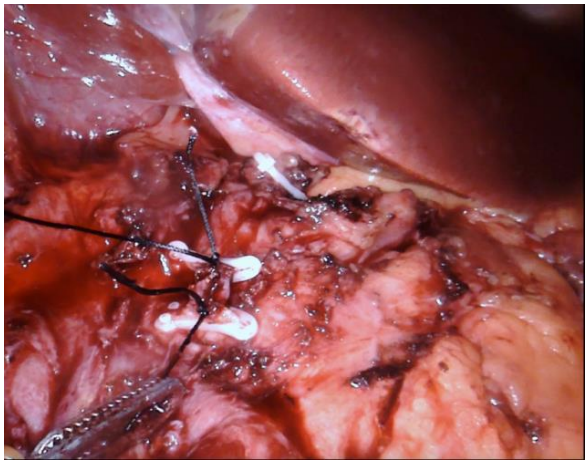

Figure 14. Ligation and clipping of the gastroduodenal artery.

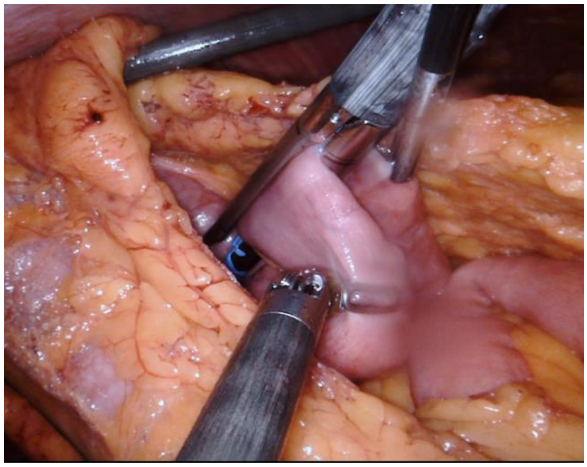

Figure 15. Division of the jejunum 20 cm from the Ligament of Treitz.

The jejunum is divided approximately 20 cm distal to the ligament of Treitz using the robotic stapler as shown in Figure 15. The robotic vessel sealer is then used to seal the mesentery up towards the base of the uncinate process (Figure 16).

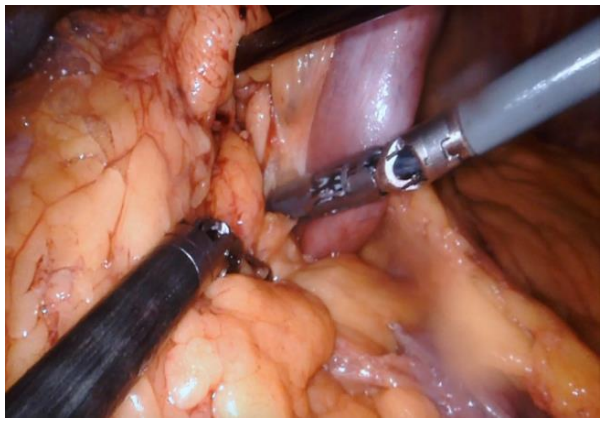

Figure 16. Division of the mesentery with the robotic vessel sealer.

The peritoneum overlying the inferior border of the pancreas is incised and the uncinate process is dissected using the monopolar scissors. Once they have been dissected and mobilized, a tunnel is created above the superior mesenteric vein and portal vein under the neck of and up to the superior border of the pancreas. An umbilical tape is then passed through this tunnel and approximated with a clip in order to facilitate pancreatic neck transection (Figure 17). The neck of the pancreas is transected using the monopolar scissors coupled with saline irrigation.

Following division of the pancreas, the uncinate process is dissected off the superior mesenteric vessels using a combination of the robotic vessel sealer and monopolar scissors (Figure 18). Venous branches draining the head of the pancreas and uncinate process are clipped with locking clips and divided during this dissection.

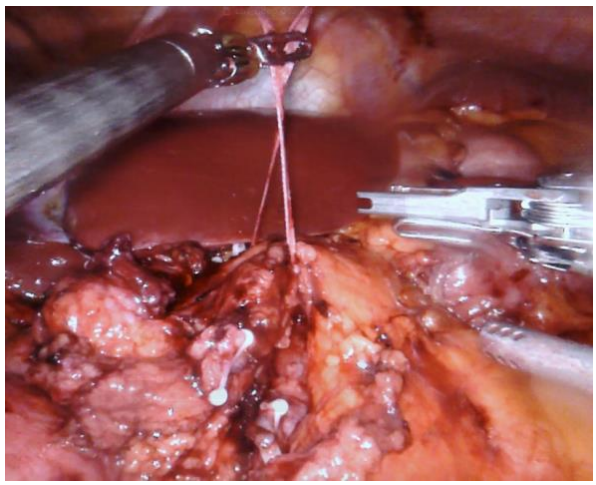

Figure 17. An umbilical tape is placed around the neck of the pancreas and a clip applied. This facilitates transection of the pancreas.

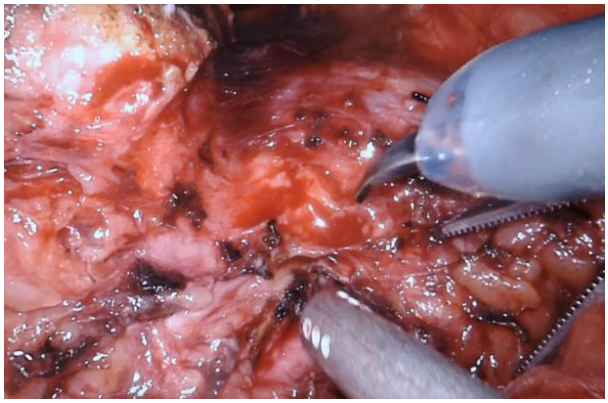

Figure 18. The uncinate process is dissected off the superior mesenteric vessels.

The cystic artery and duct are dissected, clipped with locking clips and divided. The common hepatic duct is then divided using the mono polar scissors just above the take off of the cystic duct (Figure 19). If a stent has been placed previously, it is removed and the specimen is placed in a retrieval bag for removal.

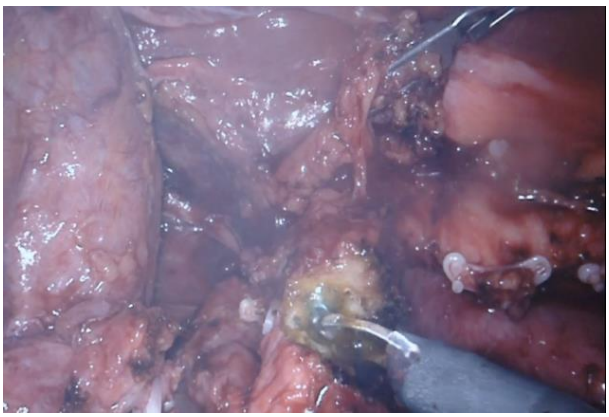

Figure 19. Division of the bile duct containing a stent.

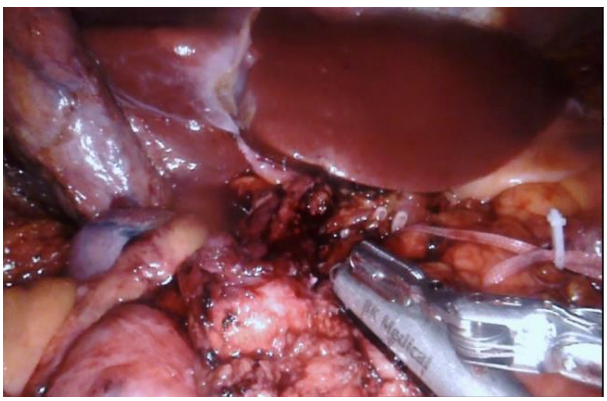

Figure 20. Using intra operative US to visualize tumor location and the superior mesenteric vessels.

Intra operative robotic ultrasound is used throughout the procedure in order to identify and evaluate the vasculature prior to dissection and division of vessels (Figure 20).

Specimen extraction is done through the umbilical port. The port is enlarged to facilitate removal of the specimen bag. Following removal, the space is partially closed, allowing placement of a 12 mm trocar. The robotic camera is then switched to this port for the reconstruction phase of the procedure.

Reconstruction

A window is created in an avascular area of the transverse colon mesentery through which the previously stapled end of the jejunum is brought up to the vicinity of the pancreas for the reconstruction. The pancreaticojejunostomy is performed as a two layer, end to side anastomosis. A 5-0 monofilament suture is used to create the posterior layer of the anastomosis (Figure 21). The capsule of the pancreas and the seromuscular layer of the jejunum are approximated in running fashion.

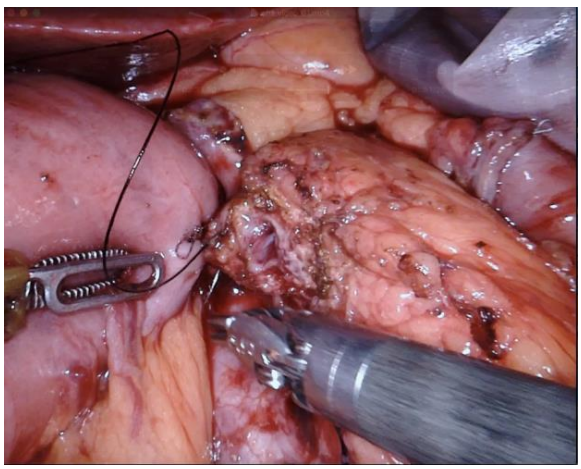

Figure 21. Posterior capsule of the pancreaticojejunostomy. 5-0 mono filament suture is used in running fashion.

Using the mono polar scissors, a small enterotomy is made in the jejunum matching the diameter of the pancreatic duct. Using 6-0 monofilament sutures, a duct to mucosa anastomosis is performed in interrupted fashion (Figure 22). Stents are used variably depending on the diameter of the pancreatic duct. When used, the anastomosis is performed over a 5 or 8 French pediatric feeding tube or stent. The previously fashioned round ligament flap is then wrapped around the anastomosis.

The hepaticojejunostomy is performed approximately 10-15 cm downstream from the pancreatic anastomosis. Whether the anastomosis is performed in running or interrupted fashion depends on the size of the bile duct. When bile duct is small, the anastomosis is performed using a 4-0 or 5-0 monofilament suture in interrupted fashion. This is done to prevent possible stenosis of smaller bile ducts. Larger diameter bile ducts allow the anastomosis to be performed in running fashion with a 4-0 barbed suture, although care must be taken to avoid purse stringing and possible stenosis (Figure 23).

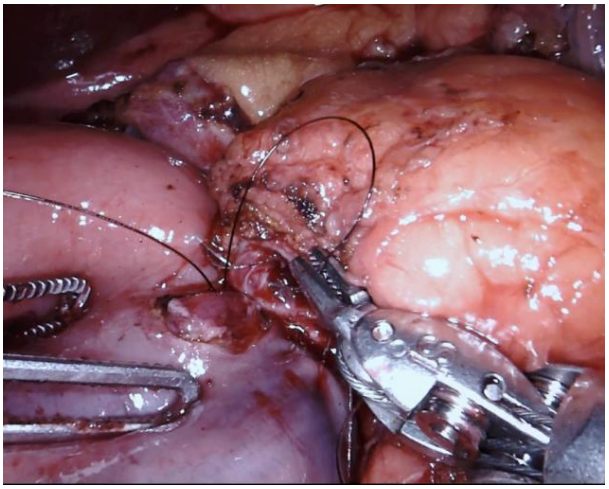

Figure 22. Duct to mucosa pancreaticojejunostomy using 6-0 monofilament suture in interrupted fashion.

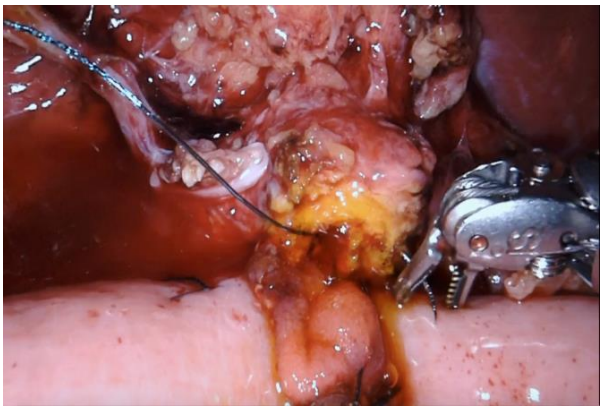

Figure 23. Hepaticojejunostomy performed with 4-0 barbed suture in running fashion.

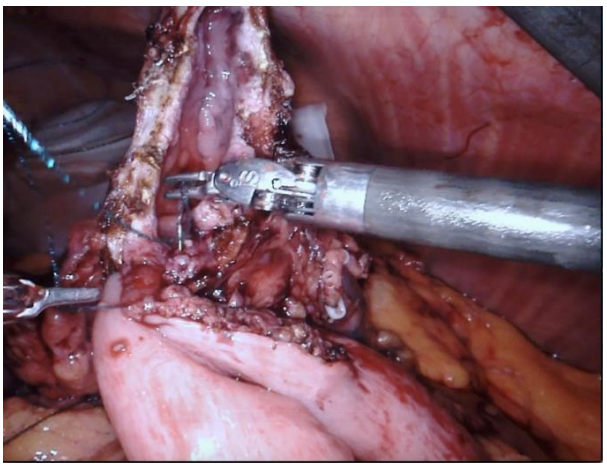

Figure 24. Ante colic duodenojejunostomy performed in running single layer fashion.

Our preference is to perform an ante colic duodenojejunostomy. A loop of the jejunal limb is brought up in ante colic fashion approximately 50 cm from the biliary anastomosis to the vicinity of the duodenal staple line. Once this is done without any tension, an enterotomy is made on the anti mesenteric border corresponding to the length of the duodenal staple line. The duodenal staple line is resected and the anastomosis is performed in single layer fashion. A barbed absorbable monofilament suture is used to take seromuscular bites in running fashion (Figure 24).

We place a single 19 French Blake drain in the vicinity of the pancreatic and biliary anastomosis. TISSEEL (Baxter Healthcare Corp., Deerfield, IL) is sprayed on all three anastomosis upon completion of the procedure.

DISTAL PANCREATECTOMY AND SPLENECTOMY

Exposure of the Pancreas

A ProGrasp forcep and fenestrated bipolar forcep are used to identify a relatively avascular plane in the gastrocolic ligament below the greater curve of the stomach. The robotic vessel sealer is then used to make a window in the ligament and gain entry into the lesser sac. The dissection is carried laterally to divide the splenocolic ligament. Medially, it is carried out up to the gastroepiploic vascular pedicle.

The posterior stomach is mobilized from the anterior pancreas by using the vessel sealer to take down any avascular congenital adhesions or adhesions from endoscopic ultrasound (EUS) biopsy. To facilitate exposure, the stomach is subsequently suspended to the anterior abdominal wall with a running barbed suture (Figure 25).

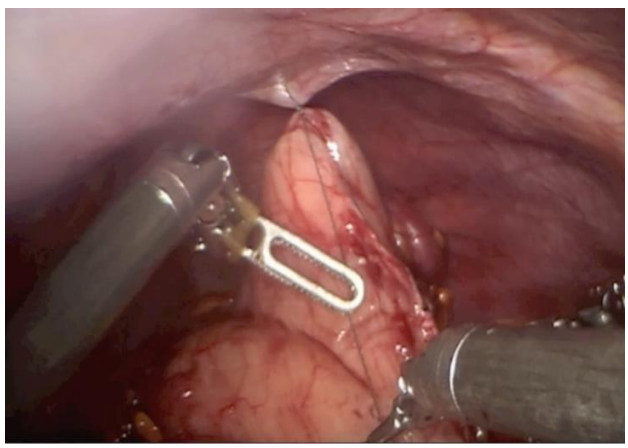

Figure 25. Suturing the stomach to the anterior abdominal wall to facilitate exposure.

Intra Operative Ultrasound

The location of the tumor and its relationship to key vascular structures are confirmed using an intra-operative ultrasound (Figure 26). In particular, the line of pancreatic transection

in relation to the portosplenic confluence and the location of the common hepatic artery are noted. The TilePro picture overlay function on the robotic platform enables simultaneous visualization of the ultrasound images and the operative field.

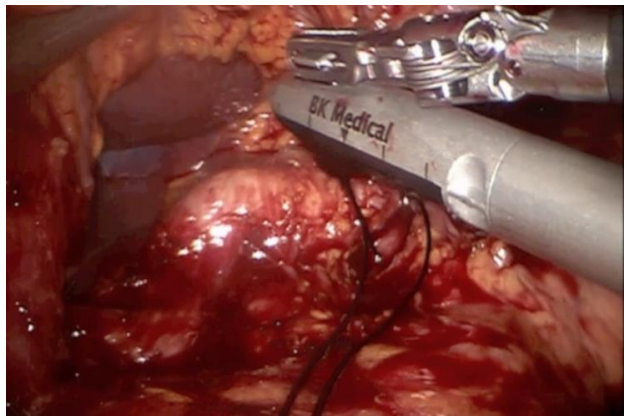

Figure 26. Intra operative US to localize the tumor and relationship to vasculature.

Dissection of the Pancreas and the Splenic Vessels

The peritoneum overlying the inferior border of the pancreas is incised with a monopolar scissor. Dissection is then carried out in the plane between the posterior pancreas and the retroperitoneum from medial to lateral. A combination of the fenestrated bipolar and monopolar scissors are used for dissection with the third robotic arm providing gentle anterior retraction of the pancreas. At the portosplenic confluence the dissection continues in this plane toward the superior border of the pancreas (Figure 27). Micro-clips are used to clip small venous branches draining the pancreas into the splenic vein.

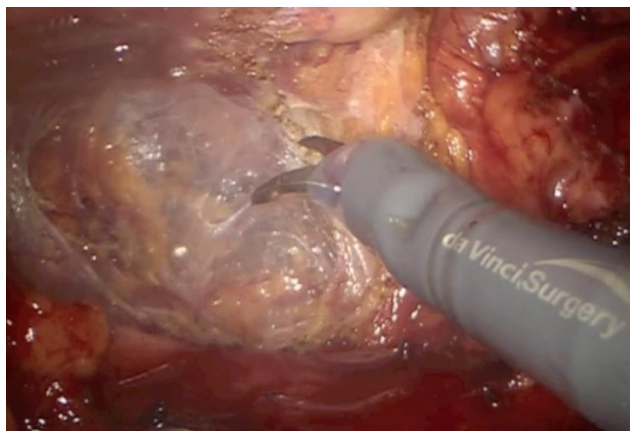

Figure 27. The pancreas is gently retracted superiorly. Dissection in the avascular plane between the pancreas and retroperitoneum.

The peritoneum at the superior border of the pancreas is incised in similar fashion (Figure 28). The splenic artery is then identified and skeletonized close to its take off from the celiac axis by dissecting the surrounding lymphatic tissue (Figure 29). Intra operative ultrasound is again used to confirm isolation of the splenic artery to prevent inadvertent division of the common hepatic artery or celiac trunk. The artery can then be divided with a vascular load using the robotic stapler or endovascular stapler, depending on surgeon preference and availability of a bedside assistant (Figure 30). Alternately, locking plastic clips may be used, which is the author's preference in an effort to minimize the cost of the stapler.

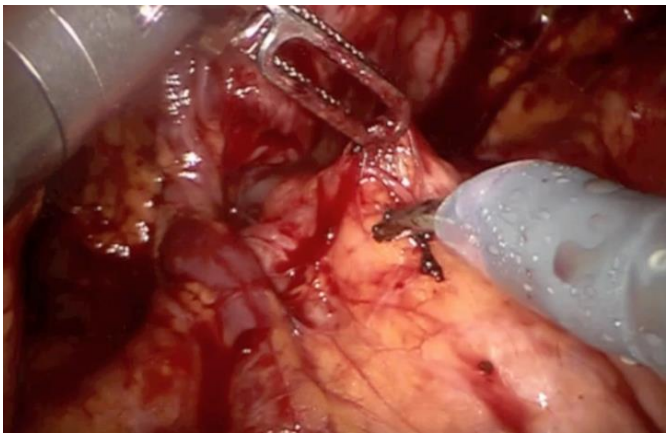

Figure 28. Incision of the peritoneum overlying the superior border of the pancreas.

The tunnel from inferior to superior border of the pancreas is completed, following which the neck of the pancreas is encircled with a Dacron tape. The pancreas is then divided using a stapling device, which again, may either be a robotic or endovascular stapler.

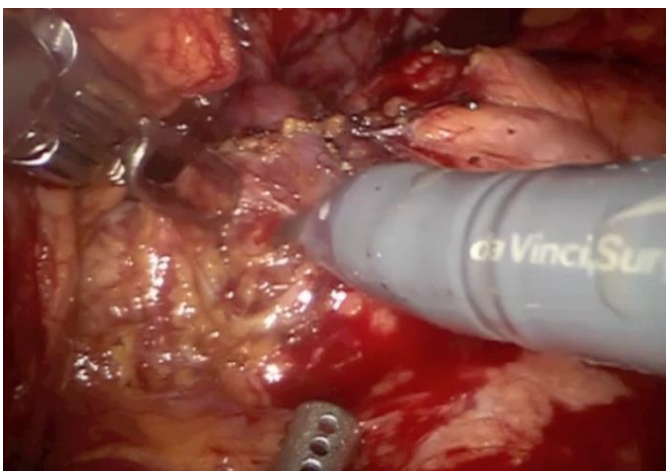

Figure 29. Dissection of the lymphatic tissue around the celiac axis at the superior border of the pancreas.

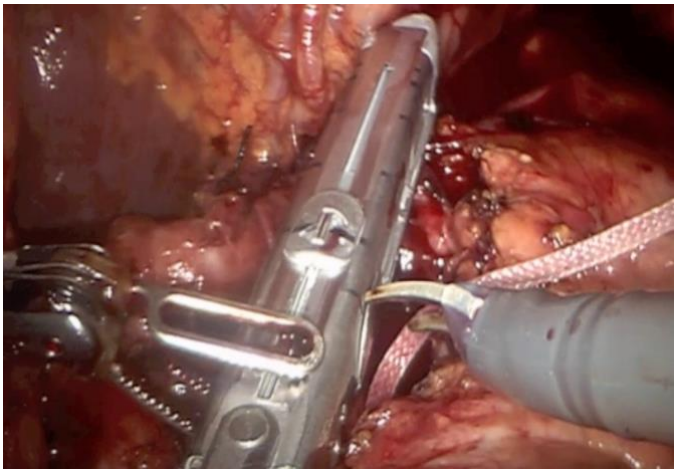

Figure 30. Stapling the splenic artery.

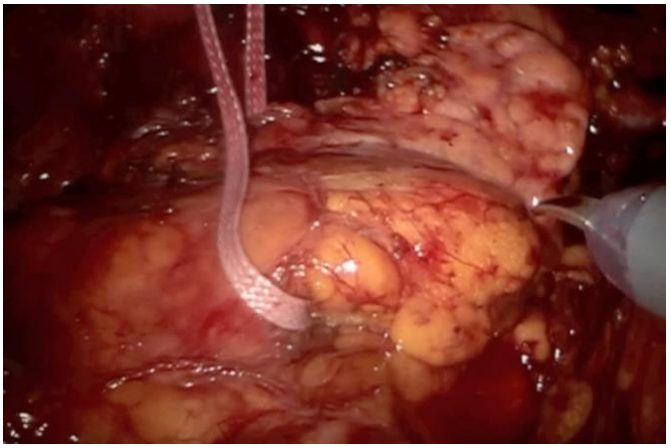

Figure 31. Upon completion of the tunnel a Dacron tape is placed around the pancreas.

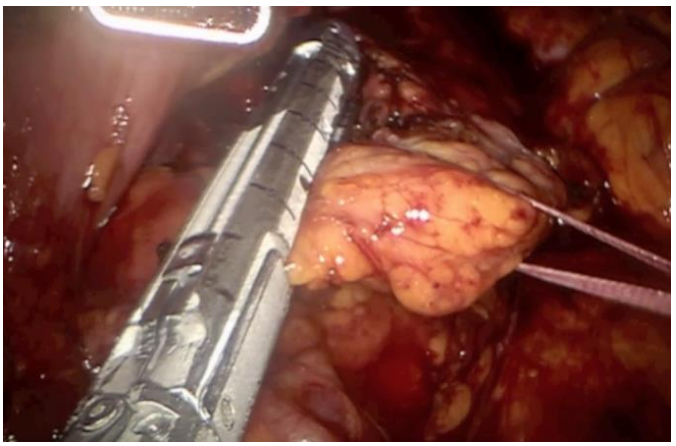

Figure 32. Stapling across the pancreatic neck.

The splenic vein is isolated (Figure 33) and divided distal to the portosplenic confluence and this again may be performed using a vascular cartridge on the stapler, or locking plastic clips (Figure 34). The pancreas is then dissected off the retroperitoneum with mono-polar scissors and a fenestrated bi-polar in a medial to lateral direction.

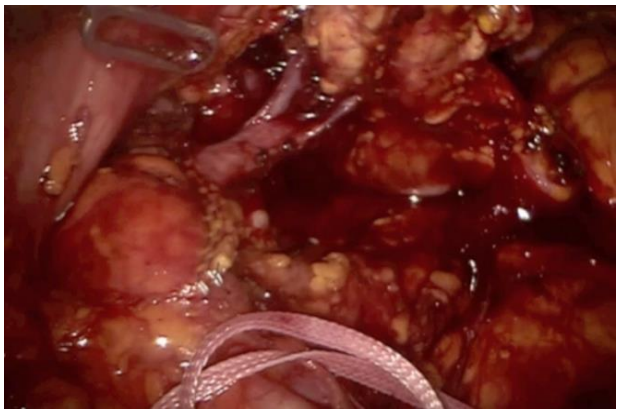

Figure 33. Exposure of the splenic vein following division of the pancreas.

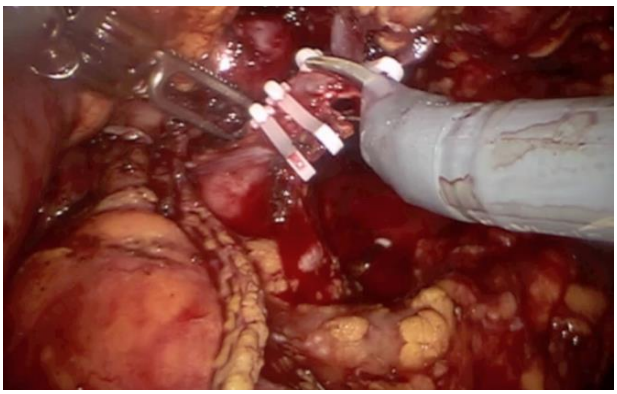

Figure 34. Division of the splenic vein after clipping with plastic locking clips.

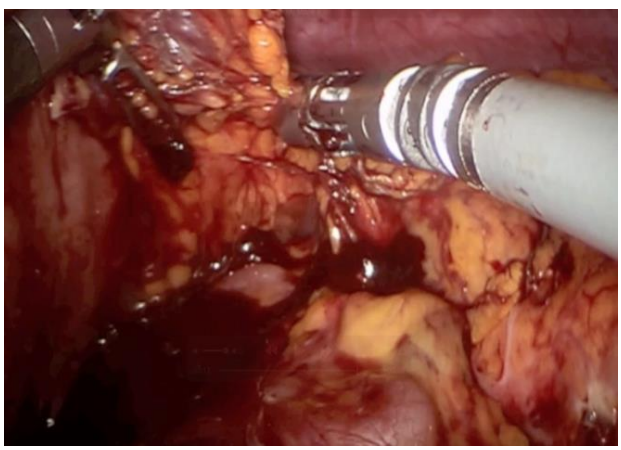

Figure 35. Taking down the short gastric vessels with the robotic vessel sealer.

Dissection of the Spleen and Specimen Extraction

The remaining attachments of the spleen and the short gastric vessels are divided with the vessel sealer (Figure 35). The specimen is placed in the retrieval bag and removed through the umbilical port. This port may be enlarged to permit specimen extraction. Ports and skin are closed as previously described.

ROBOTIC RIGHT HEPATECTOMY

Exposure and Ultrasound

Initial survey of the abdomen and lysis of adhesions is performed robotically eliminating the need for any laparoscopy. Ultrasound is used to delineate tumor location and anatomy.

Exposure of the porta hepatis may be obtained by placing a robotic arm below segment 4B in order to elevate it. Alternately, the gallbladder may be used for retraction once the cystic artery and duct are divided as shown previously.

Porta Hepatis Dissection

Ultrasound is used to identify the structures in the porta hepatis and aberrant anatomy, if present (Figure 36).

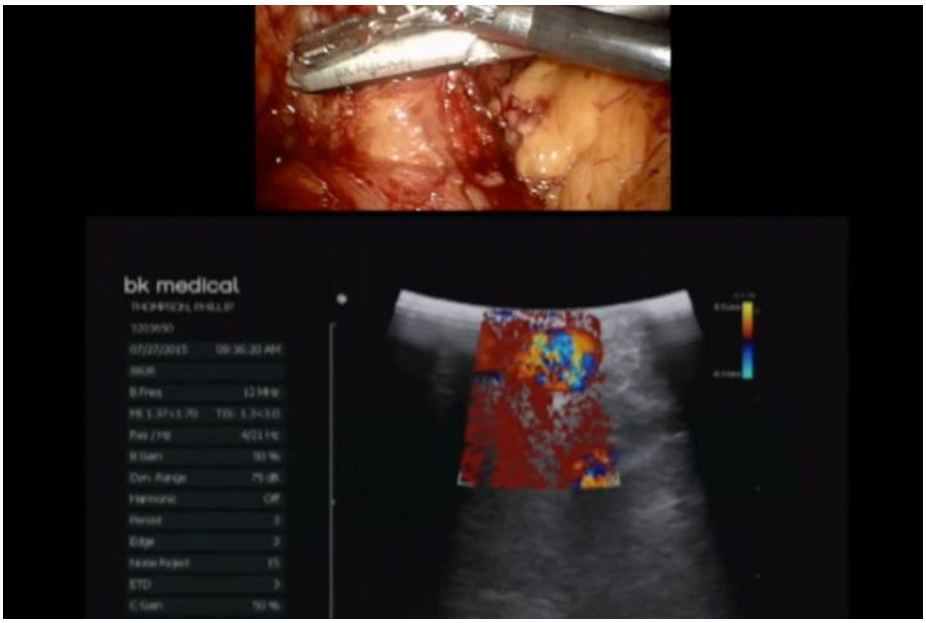

Figure 36. Intra operative US of the porta hepatis using the Tile Pro function.

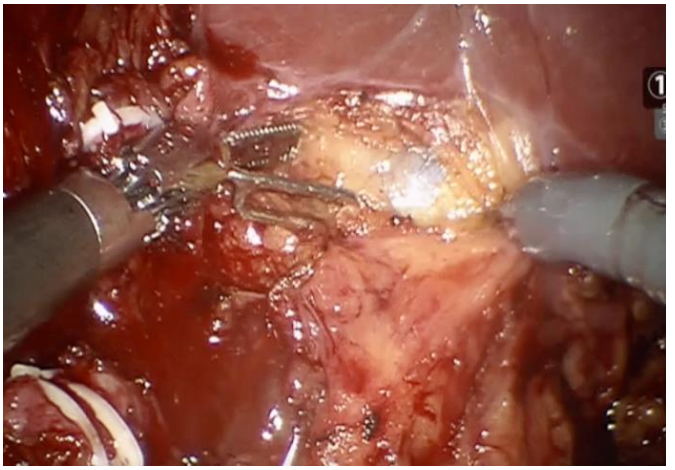

Figure 37. Dissection of the right porta using a fenestrated grasper and monopolar scissors.

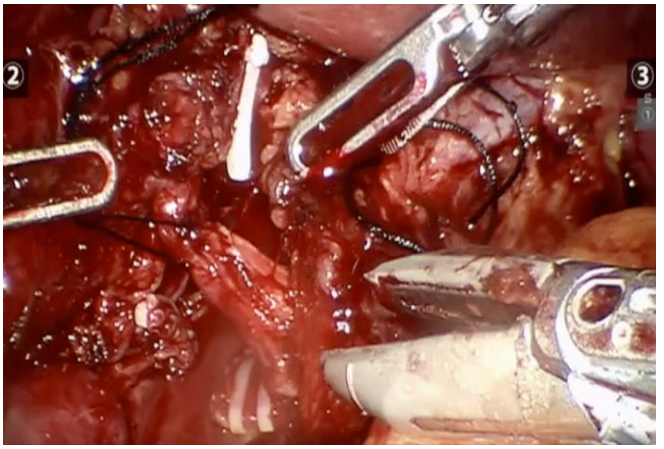

Figure 38. Encircling the right hepatic artery with a silk tie to facilitate exposure.

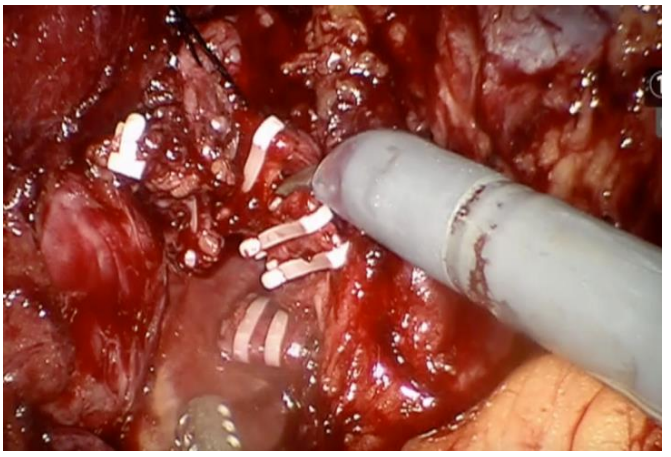

Figure 39. Clipping and division of the anterior branch right hepatic artery.

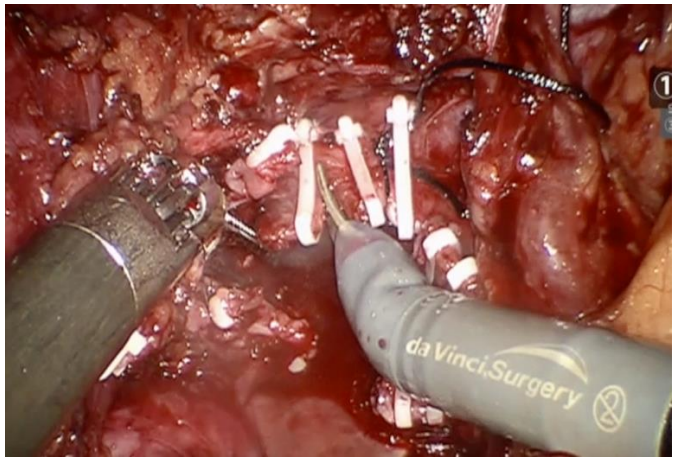

Figure 40. Clipping and division of the right portal vein.

The right portal pedicle is dissected in extra hepatic fashion using the mono polar scissors and fenestrated grasper (Figure 37). Once the right hepatic artery and right hepatic duct have been identified, they are encircled with 2-0 silk ties. The ties allow adequate exposure and control for clip placement and division (Figure 38). Prior to clip placement, the right hepatic artery is clamped with a bulldog clamp and ultrasound is used to confirm flow within the left hepatic artery to the left lobe. The right hepatic artery is then clipped with locking clips and divided (Figure 39).

The dissection in the porta hepatis is then continued with a fenestrated grasper and vessel sealer to identify the right portal vein. An umbilical tape is then placed around the portal vein in order to facilitate exposure. Placement of a silk tie followed by locking clips and division of the right portal vein is performed as is done for the artery (Figure 40).

The liver parenchyma is then examined for demarcation.

Parenchymal Division

Once the inflow to the right lobe has been divided, the line of parenchymal demarcation is identified. If this is not easily apparent, ultrasound may be used to identify the border between segment 4 and the right anterior sector in order to guide division.

Parenchymal division is performed using the robotic vessel sealer (Figure 41). As vessels/pedicles are identified, they are skeletonized, clipped with locking clips and divided (Figure 42). Larger branches may be stapled with a vascular load of the robotic stapler.

Hepatic Vein Division

Once a portion of parenchymal dissection has been done, the right liver is retracted medially to expose the suspensory ligaments. These are then taken down with the vessel sealer. The right coronary and triangular ligaments are taken down and the right hepatic vein

carefully dissected out. This is then encircled with a Dacron tape (Figure 43) following which it is divided with a robotic stapling device. The parenchymal dissection is then completed.

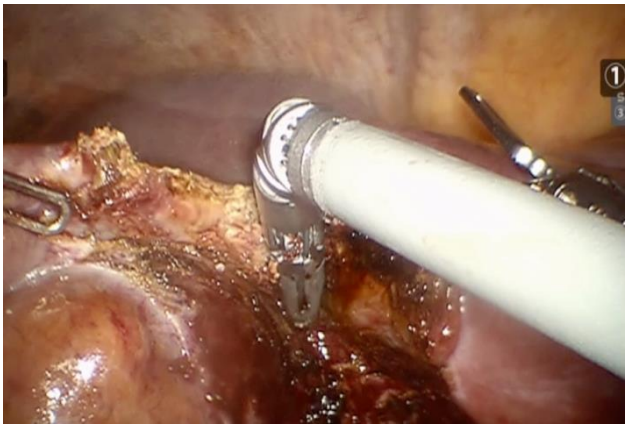

Figure 41. Parenchymal division using the robotic vessel sealer.

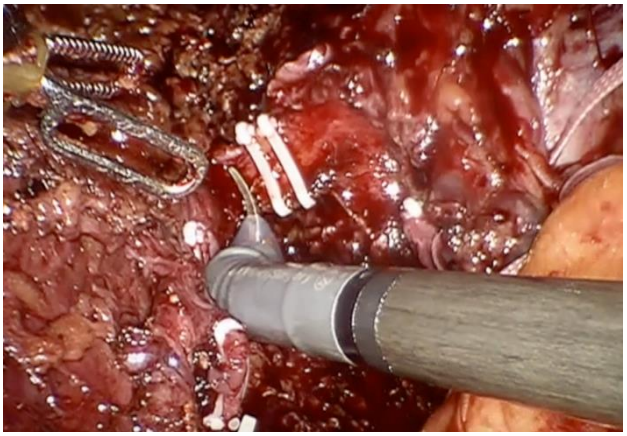

Figure 42. Skeletonization, clipping and division of pedicles during parenchymal transection.

Figure 43. Isolation of the right hepatic vein with Dacron tape.

Hemostasis and Specimen Removal

The cut edge of the liver is evaluated for residual bleeding and leaking biliary radicles. Biliary leakage or arterial bleeding is controlled using 4-0 monocryl. Venous oozing is controlled using a lap sponge to apply pressure followed by the application of hemostatic agents such as SurgiFlo (Ethicon, Inc. Somerville, NJ) Figure 44).

A LapSac Surgical Tissue Pouch (Cook Medical, Bloomington, IN) is introduced through the 12mm umbilical port and opened with its closed end directed towards the diaphragm. The specimen is placed within the bag and secured with a clip (Figure 45). The robot is then undocked prior to specimen removal. If the operation was performed for benign disease, the specimen may be morcellated and extracted through the umbilical port. For malignant disease the umbilical incision may be enlarged approximately 6cm in order to remove the bag with an intact specimen (Figure 46). Port sites and skin are closed as described above.

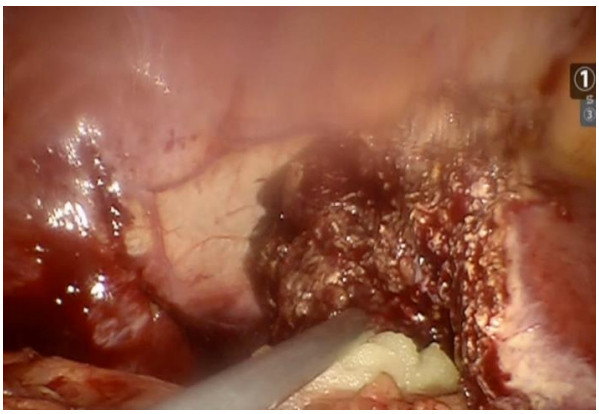

Figure 44. Application of hemostatic agents on the cut edge of the left liver.

ROBOTIC CHOLECYSTECTOMY

Adhesions are taken down by a combination of sharp and blunt dissection using the mono-polar scissors and fenestrated forceps. The liver is retracted superiorly with a Nathanson retractor. A “top-down” approach is used to dissect the gallbladder off the cystic plate. The fundus of the gallbladder or the gallbladder remnant is grasped with the fenestrated grasper and dissection carried out with a mono-polar scissor towards the neck of the gallbladder. The cystic duct and artery are then dissected, clipped with locking clips and divided. The gallbladder and any stones are placed in a robotic specimen retrieval bag and extracted through the 12 mm umbilical port. Port closure is performed as described for the other procedures.

OUTCOMES

Currently, randomized control trials (RCT) comparing robot assisted pancreatic and liver resections with laparoscopic or open resections do not exist. However, there are multiple

single or multi institutional retrospective studies, some using propensity score matching to compare specific outcomes between robotic and open approaches.

Figure 45. Placement of the right liver specimen into the specimen bag.

Figure 46. Removal of the specimen through an enlarged umbilical incision.

ROBOTIC PANCREATICODUODENECTOMY OUTCOMES

A large systematic review examined data from 13 retrospective series [4]. It compared the outcomes of 738 patients who underwent robotic and open PDs between 2000 and 2016. The data showed that a robotic approach was associated with longer intra operative times but lower estimated blood loss (EBL). The learning curve to decrease rates of conversion to an open procedure was found to be 20 robotic PD's.

Overall morbidity rates were comparable between the robot and open groups in most studies. Mortality rates also did not differ between the two approaches and ranged between 1-

12.5%. Pancreatic fistula, post-operative hemorrhage and bile leak rates were not significantly different between the two groups. Delayed gastric emptying (DGE) was however, found to be lower with the robotic approach in most studies. Short-term oncologic outcomes between the two groups showed no difference in the number of lymph nodes harvested or positive margins.

A large multicenter study compared the outcomes of 211 patients from two high volume robotic PD centers and 817 patients from six high volume open PD centers [5]. This study demonstrated that the rate of clinically relevant Grade B/C pancreatic fistulas (CR-POPF) did not differ between the open (9.1%) and the robotic (13.7%) groups. Similar to most other studies, operative times were higher but EBL was lower with the robotic approach.

Other outcomes such as short-term oncologic outcomes, morbidity, 90 day mortality, length of stay and readmission rates did not differ between either operative approach.

A propensity score matched analysis to determine the effect of the robotic or open approach on the incidence of CR-POPF was published by the University of Pittsburgh.[6] The study showed non-inferiority of the robotic to the open approach in terms of CR-POPF. Robotic PD patients had a 6.6% CR-POPF rate compared to the 11.2% fistula rate for the open PD patients. There was also no difference in 90 day mortality, 30 day readmission rates or overall complication rate between the two groups.

Outcomes have also been examined in certain specific patient populations such as those with a high BMI [7]. The robotic approach was found to be protective against CR-POPF in obese patients (classified as those with BMI > 30) undergoing PD. Obese patients who underwent a robotic PD were found to have a lower clinically relevant fistula rate of 13% compared to a 28% fistula rate in obese patients that had an open PD. Another interesting finding was that a robotic approach was protective of wound infections in morbidly obese patients undergoing robotic PD. Morbidly obese patients had a 19% wound infection rate with the robotic approach compared to 44% in those that had an open PD. There was also no difference in the mortality and Clavien 3 or greater morbidity rates between robotic and open approaches for obese patients. However, it must be noted that all the patients in this retrospective study underwent robotic PDs performed by surgeons who had surpassed the learning curve of greater than 80 cases [7].

There is a paucity of data comparing the robotic and laparoscopic approaches to PD. An NSQIP study comparing 30 day outcomes between laparoscopic and robotic PDs found that there was no difference in the 30 day morbidity or mortality between either approach [1]. However, they did find that the rates of conversion to an open procedure were higher for patients undergoing laparoscopic PD. Robotic PD was converted to an open procedure 11.3% of the time compared to a conversion rate of 26% for the laparoscopic approach. These findings are likely due to the technical advantages that the robotic platform provides over conventional laparoscopy.

Retrospective review of our experience with robotic PD at Carolinas Medical Center showed longer operative times of approximately 136 mins when compared with our open PD cohort [8]. As expected EBL was approximately 400mL lower with the robotic approach. Overall, with the robotic approach, patients had lower wound infection rates, and shorter ICU as well as hospital length of stays. The fistula rate was 7.4% for the robotic vs. 12% for the open group. This translated to an overall similar cost between the robotic and open procedures.

The total cost of robotic and open PDs at our institution were broken up into operative cost, in hospital cost and follow up charges. We found that although the operative cost was higher for the robotic approach, the shorter hospital stays associated with a minimally invasive approach and lower complication rate led to a similar overall cost when compared to an open PD.

CONCLUSION

Robot assisted surgery is a safe minimally invasive option for a complex oncologic HPB procedures. The combination of superior articulation, better optics and elimination of tremor provides technical and ergonomic advantages over conventional laparoscopy. These enable the surgeon to perform a safe resection and when required, a complex reconstruction with lower rates of conversion to an open procedure when compared to laparoscopy [1]. At high volume centers, once the learning curve has been surpassed, complex robotic HPB procedures such as robotic PD has been shown to be non-inferior to open PD in terms of POPF development and other peri-operative outcomes [3, 5, 8]. The higher operative cost of the procedure may be offset by lower hospital length of stays associated with a minimally invasive approach. However, more robust data in the form of a randomized controlled trial and other cost benefit studies are warranted.

REFERENCES

[1] Nassour I, Wang SC, Porembka MR et al. Robotic Versus Laparoscopic Pancreaticoduodenectomy a NSQIP Analysis. *J Gastrointest Surg.* 2017 Nov;21(11): 1784-1792.

[2] Sastry AV, Siddiqui I, Cochran A et al. Robotic Hepatobiliary and Pancreatic Surgery: Lessons learned from a 10 - year Experience. Manuscript in preparation.

[3] Boone BA, Zenati M, Hogg ME et al. Assesment of Quality Outcomes of Robotic Pancreaticoduodenectomy. *JAMA Surg.* 2015;150(5):416-422.

[4] Komaropoulos M, Moris D, Beal E et al. Total robotic pancreaticoduodenectomy: a systematic review of the literature. *Surg Endosc.* 2017 Nov;31(11):4382-4392.

[5] Zureikat AH, Postlewait LM, Liu Y et al. A Multi-institutional Comparison of Perioperative Outcomes of Robotic and Open Pancreaticoduodenectomy. *Ann Surg.* 2016; 264: 640-649.

[6] McMillian MT, Zureikat AH, Hogg ME, Kowalsky SJ, Zeh HJ et al. Propensity Score-Matched Analysis of Robotic vs Open Pancreaticoduodenectomy on Incidence of Pancreatic Fistula. *JAMA Surg.* 2017; 152(4):327-335.

[7] Girgis MD, Zenati MS, Steve J, Bartlett DL et al. Robotic approach mitigates perioperative morbidity in obese patients following Pancreaticoduodenectomy. *HPB.* 2016; 19:93-98.

[8] Baker EH, Ross SW, Seshadri R et al. Robotic Pancreaticoduodenectomy for pancreatic adenocarcinoma: Role in 2014 and beyond. *J Gastrointest Oncol.* 2015 Aug;6(4):396-405.

[9] Baker EH, Ross SW, Seshadri R et al. Robotic Pancreaticoduodenectomy: comparison of complications and cost to the open approach. *Int J Med Robot.* 2016 Sept;12(3):554-60.

In: Encyclopedia of Surgery (22 Volume Set)
Editors: Andreas Lehrer and Kristin Mueller
ISBN: 978-1-53618-329-0
© 2020 Nova Science Publishers, Inc.

Chapter 252

ROBOTIC-ASSISTED BARIATRIC SURGERY

Matthew Sharbaugh, MD and Christopher You, MD
[1]MedStar Washington Hospital Center, Washington, DC, US
[2]Minimally Invasive and Bariatric Surgery, Robotic Surgery Program,
MedStar Franklin Square Medical Center, Baltimore, MD, US

INTRODUCTION

Robotic surgery combines the best of open surgery and laparoscopic surgery. With open surgery, the surgeon utilizes the dexterity of one's hands. With laparoscopic surgery, the surgeon takes advantage of the improved vision and magnification. Robotic surgery, in its present form, brings this dexterity and vision together in a way that mitigates the loss of the advantages of open and/or laparoscopic approaches, such as tactile sensation, by providing 3D vision, enhanced vision through fluorescence imaging, and superior ergonomics. Robotic surgery also provides a platform to take surgery even further with computer-assisted surgery that will incorporate enhanced information overlays, real-time remote collaborative surgery, and new paradigms to dissect and reconstruct.

Bariatric surgery adopted laparoscopic techniques and saw dramatic improvements in patient outcomes. Advances in energy devices for dissection and stapling platforms for reconstruction has made laparoscopic surgery the de facto choice for a majority of bariatric surgeons today. They have also prevented bariatric surgeons from adopting robotic surgery because of nascent robotic energy and stapling devices. However, energy and stapling from the current robotic platform is improving and it is expected that an emerging competitive robotic stapling platform will rival the current laparoscopic endostapling companies. Robotic energy devices will also continue to advance next generation devices in development. In addition, companies with expertise in energy and stapling for laparoscopic surgery will be developing computer-assisted surgical platforms within the next several years.

With the advent of a robotic platform with viable energy and stapling devices, increased competition within the robotic surgery space, and the continuing evolution of bariatric surgical procedures that require energy, stapling, and suturing, bariatric surgeons are looking to the robotic platform with increasing interest. However, because of the excellent outcomes

already achieved, how much can be improved by robotic surgery? The rationale for robotic surgery as it "comes of age" for bariatric surgery is not just an outcomes issue, but a cost issue as well. And the cost equation must not only include supply costs but also additional costs due to complications, costs due to time off work for patients, costs due to workplace injury for surgeons, and even costs due to loss and recruitment of surgeons. Further, increasing competition within the industry should help advance instrumentation and reduce costs. We are confident when all these factors are taken into account, robotic surgery will become the dominant approach.

GENERAL CONSIDERATIONS

Preoperative Planning

In preparing patients for robotic surgery, there are no special considerations to prepare a patient for robotic bariatric surgery that is any different from laparoscopic bariatric surgery.

Peripheral IV Access

When we initially started doing gastric bypass on the Si system (Da Vinci, Intuitive Surgical, Sunnyvale, CA), a standard practice for us was to place an IV in each upper extremity. This was because the Si patient cart column would be at the head of the OR table impeding access to the head and to the opposite arm. Since switching to the Xi system (Da Vinci, Intuitive Surgical, Sunnyvale, CA), this practice has continued but is really a vestige of the days we used the Si. While less necessary, with a mixed platform hospital such as ours with Si and Xi systems, it is better to continue this practice for patients undergoing procedures with both Si and Xi.

Robotic System Component Positioning

In regards to the Xi system, positioning the system in relation to the patient is very easy. The Xi patient cart stays in the same place relative to the operating table. It is on the patient's left, backed to the wall. Whether the procedure is bariatric, general surgery, urogynecology, colorectal, or gynecologic oncology, the robot stays in the same place and is wheeled in from the patient's left. The vision cart is placed on the left side of the patient, far enough past the feet to allow for the scrubbed personnel to pass between the vision cart and the patient cart without the risk of contamination. The surgeon console is placed in the corner of the room away from traffic. Access to the patient's upper body and head is not compromised with the Xi system (Figure 1).

Figure 1. Intuitive Surgical da Vinci Xi robot showing access to the patient's upper body for anesthesia.

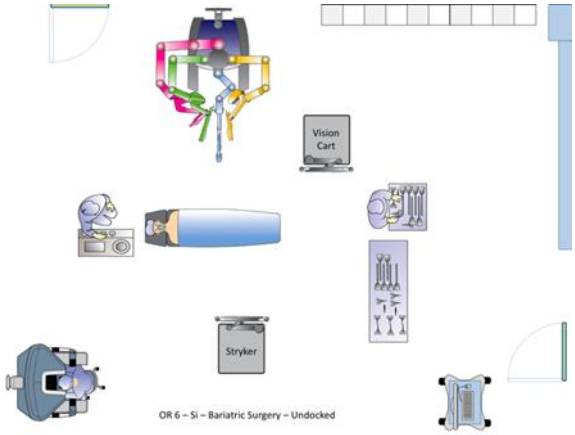

Figure 2. Si system undocked.

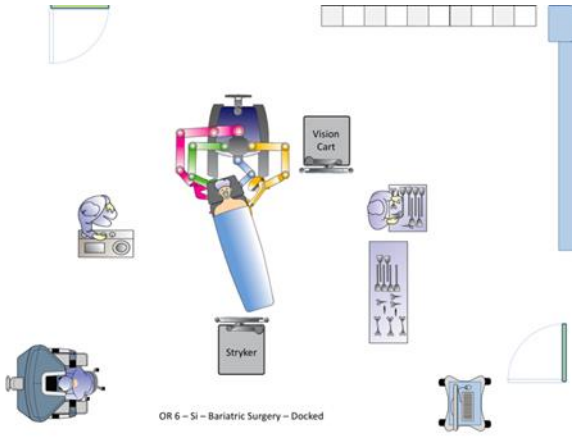

Figure 3. Si system docked.

With the Si system, positioning of the system is more difficult because of the way that the patient cart has to be moved when docking. We have laminated cards in the room to delineate placement of the patient cart, vision cart, and surgeon console for the undocked and docked states (Figures 2 & 3). Additional room cards have been made for the different surgical disciplines.

Patient Positioning

We current utilize a Skytron bed (Skytron, LLC., Grand Rapids, MI) with the split leg attachment and the ability to slide, in addition to the standard bed functions. Gel padding is utilized for areas prone to pressure sores. A hover mat is in place prior to the patient laying down to assist in patient transfer after surgery is complete. A foot plate is placed on the bed and a strap is placed over the thighs.

A Bair Hugger (3M, Mapplewood, MN) can be placed over the upper chest and arms or over the lower legs.

For induction, anesthesia often uses a ramp to elevate the upper torso. This ***must*** be removed prior to operating and the arms should not be hyperextended to prevent a brachial plexus injury. In addition, the ramp decreases the working space in the upper abdomen which may make cases with copious visceral fat very difficult. We typically have the arms out at 45-60 degrees in relation to the abdomen.

Figure 4. Port placement for robotic gastric bypass (Xi).

For liver retraction, a Nathanson liver retractor is attached to an Iron Intern that is attached to the bedrail just under the patient's right arm. A critical detail to avoid collisions

with the robotic arms is to angle the vertical pole towards the head. When the patient is in reverse Trendelenberg, the vertical portion of the Iron Intern is then perpendicular to the floor. In addition, the horizontal portion of the vertical pole should be as close to the patient's body as possible with putting any pressure on the patient's body (Figure 4).

Reverse Trendelenberg is steep for sleeve gastrectomy but for gastric bypass, the amount of reverse Trendelenberg is less than what we do for laparoscopic gastric bypass.

ROBOTIC GASTRIC BYPASS

Technique

There are several salient features of this procedure that must be considered. First, gastric bypass is multi-quadrant surgery, especially when additional procedures must be performed, such as adhesiolysis in the lower abdomen and pelvis, cholecystectomy, ventral hernia repair, and hiatal hernia repair. An analysis of procedures that we have performed showed that one-third of our bariatric surgeries required at least one of these additional procedures. The robot lends itself very well to these situations.

Second, energy is a vital tool in the deconstruction of anatomy. The best energy tool will be able to incorporate the ability to dissect, retract, and seal. It will also have maximum mobility, including reach and wristed motion. For instance, the vessel sealer on the Xi platform is very good at dissecting the tissue layers at the left crus while at the same time using the shaft of the instrument proximal to the point of flexion to retract fat away from the area of dissection. While this may often be momentary retraction before the fat slips back into view, there is often enough time to accomplish the maneuver.

Figure 5. Xi robot docked for gastric bypass.

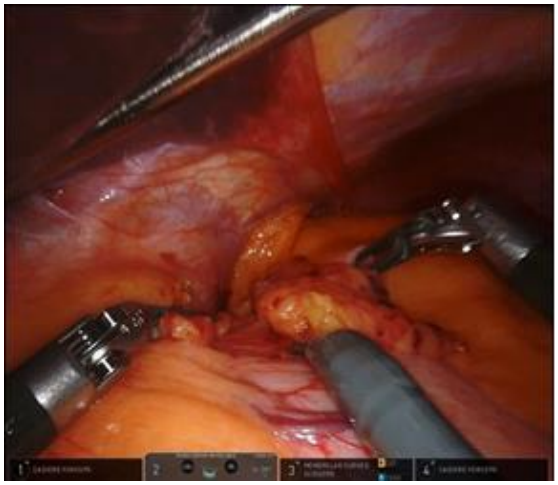

Figure 6. Division of the epiphrenic fat pad.

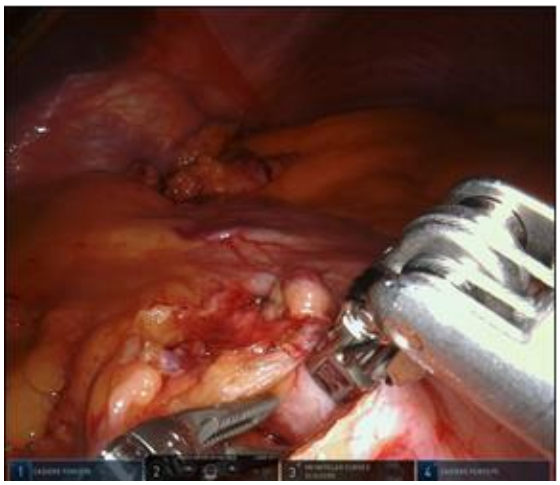

Figure 7. Lesser curve dissection.

Finally, formation and reconstruction are key aspects of the gastric bypass—formation of the gastric pouch and reconstruction of gastric continuity through the gastrojejunostomy and the jejunojejunostomy. The main techniques at our disposal are suturing and stapling. Robotics allows us to take an uncompromising approach, optimizing the use of suturing and stapling to minimize complications.

There is no doubt that formation of the gastric pouch is best done with endostapling. Currently, we utilize the Endowrist robotic stapling platform on the Xi. To create the gastric pouch, we first divide the epiphrenic fat pad to clearly identify the angle of His (Figure 6). The stomach is partially dissected off the left crus as well. We then measure a point 6 cm below the GE junction along the lesser curve. We preserve the lesser curve vessels and vagus nerves by dissecting along the stomach wall into the lesser sac (Figure 7). Sometimes we will have to open pars flaccida to introduce air into the lesser sac which aids in identification of the correct dissection plane. Robotics provides superior visualization and manipulation of tissue to minimize the dissection area and control for bleeding. For the horizontal staple line

from the lesser curve, we use a green 45 mm staple load with Peri-Strips (Figure 8; Ethicon, Inc., Somerville, NJ). The Peri-Strips serve as an anchor for the posterior layer of sutures for the gastrojejunostomy. After completing this staple line, we then dissect any adhesions posterior to the stomach wall towards the angle of His. We will dissect posterior to the stomach all the way to the left crus and find the dissection plane we established from the anterior approach. In dissecting this space, we rarely have to take down vessels to the stomach. There is a distinct plane that is easily seen with 3D visualization between the vessels to the stomach and the peripancreatic fat that opens up to reveal more of the left crus. A vertical staple line using blue loads without buttressing is then created from the end of the horizontal staple line up to the angle of His. This is loosely formed around a 32 French Ewald tube. The ability of the robotic stapler to move left to right in a 108 degree arc and up and down in a 54 degree arc allows one to place the stapler to the tissue rather than distorting the tissue towards the stapler. This is especially useful when creating the vertical staple line near the left crus (Figure 9). If the patient has a history of anticoagulation use, then we will use green loads with Peri-Strips for the vertical staple lines of the pouch.

Figure 8. Gastric pouch horizontal staple line.

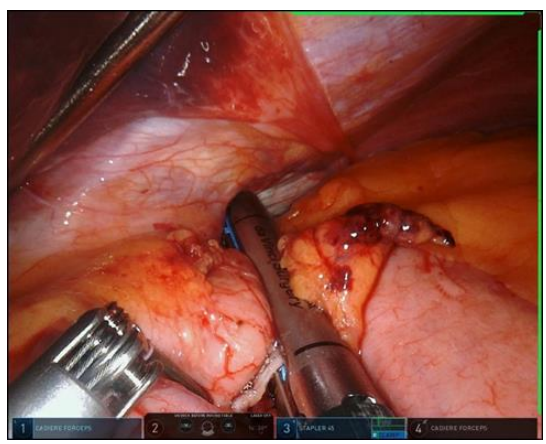

Figure 9. Vertical staple line of gastric pouch.

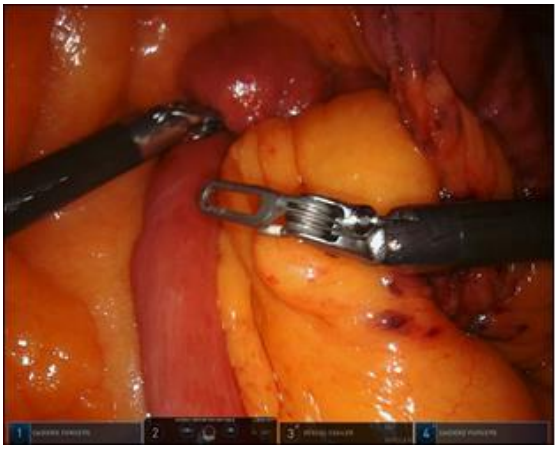

Figure 10. Small bowel management.

Figure 11. Transecting jejunum.

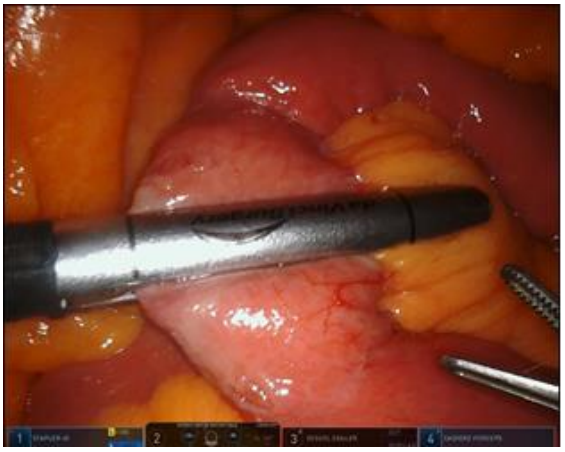

Figure 12. Dividing jejunal arcade.

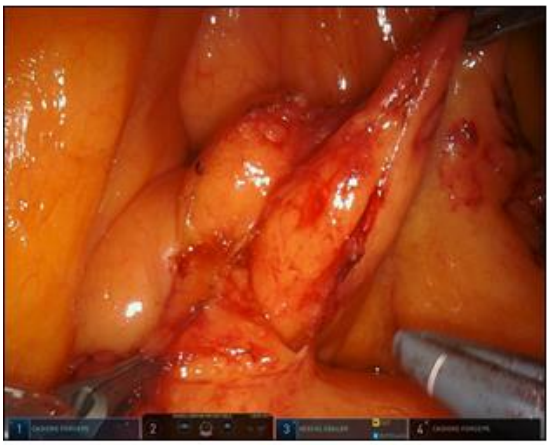

Figure 13. Mesenteric dissection plane.

In reconstructing gastric continuity, the jejunojejunostomy is constructed on the left side of the mesenteric axis in an anti-peristaltic fashion. The biliopancreatic limb is 60 cm long from the ligament of Treitz. A crucial skill when performing a robotic gastric bypass, without the interconnected bed to change the angle of the bed and arms while docked, is managing the bowel. When counting off the biliopancreatic limb, the proximal bowel is pushed towards the patient's left (Figure 10). The transection point of the bowel is positioned towards the patient's right in a gentle loop. A single firing of the Endowrist 45 mm white load from the patient's right is used to divide the bowel at this point (Figure 11). We then carefully divide the mesentery towards the root being careful not to divide the jejunal or straight arteries, and dividing the arcade as needed to ensure adequate length of the Roux limb to reach the gastric pouch (Figure 12). A distinct plane can be developed in the mesenteric fat between the jejunal arteries which is quite remarkable to note under 3D vision that cannot be appreciated via open or laparoscopic approaches (Figure 13). The end of the biliopancreatic limb is lifted towards the abdominal wall and then the Roux limb is tucked above the end of the biliopancreatic limb and to the patient's left as it is counted off to 150 cm. After the appropriate point for the jejunojejunostomy is identified and placed next to the biliopancreatic limb, the small bowel is "unwound" from its position behind the end of the biliopancreatic limb. Enterotomies are made by using the closed Monopolar Curved Scissors using the Cut function (Setting on Dry Cut, Effect Level 2). The openings are kept as small as possible. One of the benefits of the Endowrist stapler, especially on the cartridge side, is that tissue does not snag against the stapler when inserting the anvil or cartridge. A white cartridge on the Endowrist 45 mm stapler is inserted from the patient's right. The anvil is passed first and goes in the Roux/Common channel side. The anvil goes through the enterotomy and points distally in relation to the small bowel. The cartridge side is passed through the enterotomy on the end of the biliopancreatic limb and points proximally, or retrograde. The bowel is positioned parallel to each other according to the "grain" of the bowel which is easily seen with 3D vision. The stapler is closed and fired (Figure 14). The common enterotomy is closed in a single running layer of 2-0 Vicryl (Ethicon, Inc., Somerville, NJ) sutures. We take care to make sure that the ends of the staple lines on either side of the common enterotomy are buried with the 2-0 Vicryl running suture as a single layer (Figure 15). In fact, the ends of the staple line actually lie below the suture line and isn't incorporated into the sutures. To date, we have not had an

obstruction or leak using this technique. Furthermore, when we have returned to the abdomen of a patient we performed a gastric bypass, we do not see dilation of the jejunojejunostomy that is seen with the triple-plus staple technique. The mesenteric defect is closed using 2-0 Ethibond (Ethicon, Inc., Somerville, NJ) in running fashion (Figure 16). Here, we have found that when placing sutures on the side where the mesentery is continuous (Roux limb/common channel), suturing with the needle parallel to the vessels going from the bowel towards the root of the mesentery results in the least chance of bleeding. When suturing on the cut end of the mesentery (biliopancreatic limb), we suture perpendicular to the vessels taking the peritoneum on either side of the mesentery without actually going through the mesentery.

Figure 14. Stapling to create the jejunojejunostomy.

Figure 15. Burying staple line corner on jejunojejunostomy.

The Roux limb is brought up to the gastric pouch in an antecolic fashion. There is a space where bowel can herniate between the transverse colon mesentery and the small bowel mesentery and we close this space with a running 2-0 Vicryl to induce some scarring. When lifting up the transverse colon mesentery up and down away from the small bowel mesentery, one can see the inflection point between the two sides. This is the starting point for our suture. We then let go of the transverse colon and wherever the underside of the transverse colon

mesentery opposes the root of the mesentery of the Roux limb marks the end point of our suture. We then lift the transverse colon mesentery back up and start placing the running suture. As we run the suture and tighten it, we lower the transverse colon to allow the two mesenteries to come together (Figure 17).

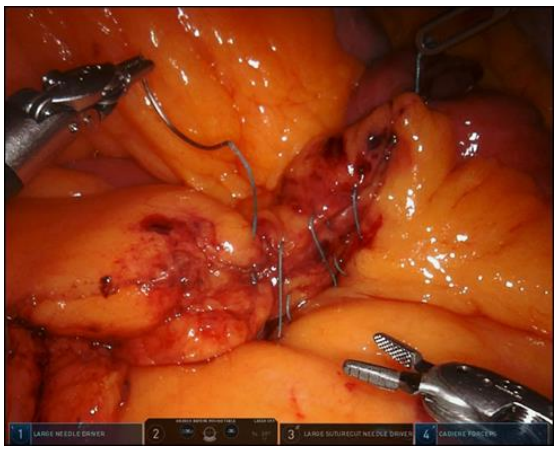

Figure 16. Mesenteric closure.

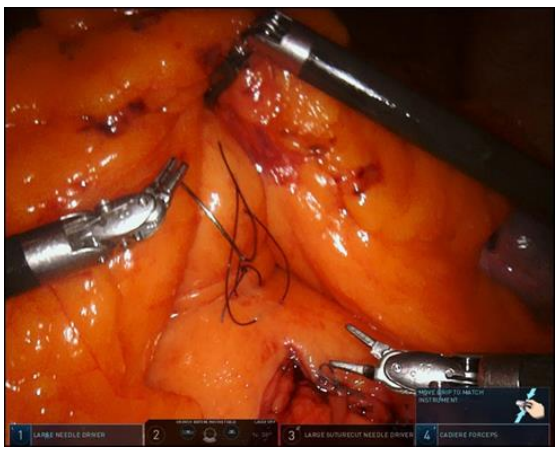

Figure 17. Closing the retro Roux space.

In bringing up the Roux limb, the end points towards the left of the patient. In other words, the Roux limb is oriented in a counter-clockwise fashion when looking down at the patient. Care is taken to make sure that the Roux limb is not twisted around the mesentery. The debate continues about whether a circular-stapled, linear-stapled, or hand-sewn anastomosis is superior for the gastrojejunostomy. Leak rates, structure rates, ulcer rates, and other complications can vary from one method to another depending on the study. Perhaps more than which method is better, the better question is what rate for each complication is the benchmark we should hope to attain with whichever method we adopt. Maybe the best outcomes are by matching a particular surgeon with a particular methodology, mostly by the strengths and weaknesses of the surgeon. Perhaps we will find that the robotic platform will allow for more surgeons to have lower complication rates. With more than 600 robotic gastric

bypasses, our leak rate is zero, stricture rate is less than 1%, and ulcer rate is less than 2%. For us, we feel that the robotic approach allows us to achieve the best outcomes we possibly can. Constant evaluation and assessment allows us to connect our methodology to our outcomes as individual surgeons. In other words, intentional experience gets to a point where we can predict the complications based on patient factors, what we saw during surgery, and how we did in surgery.

After orienting the end of the Roux limb to the horizontal staple line of the gastric pouch, we use an undyed 2-0 Vicryl on an SH needle cut to 8 inches to first get a bite through the stapled corner of the gastric pouch, through the Peri-Strip. Using the left hand, we then suture a couple centimeters away from the end of the Roux limb about 5 mm posterior to the anti-mesenteric border. A surgeon's knot is formed and when cinching down this knot, we make sure that the Roux limb is on the anterior aspect of the staple line. We put a total of four square knots, leaving the free end of the suture a couple centimeters long, and then run the 2-0 Vicryl, advancing 5 mm and starting about 5 mm away from the staple line on the anterior side of the pouch. The needle is brought out through the Peri-Strip on the posterior side between the two staple lines. Every suture through the gastric pouch is done with the right hand while every suture through the Roux limb is done with the left hand. When cinching down this suture line, we make sure the bowel is anterior to the staple line. Once we reach the medial aspect of the gastric pouch, the suture is tied to itself using four square knots (Figure 18).

To make the gastrotomy and the enterotomy, we use the Monopolar Curved Scissors and the "Cut" function (Setting on Dry Cut, Effect Level 2). We open the scissors and using cautery mark out where our gastrotomy will be on the serosa. The "Cut" function is used to go through the layers but if a vessel is seen, then switch to the "Coag" function to control the vessel and go back to the "Cut" function. Once we reach the stomach mucosa from the outside, we make a final small hole using cautery to get into the lumen and then use the scissors to actually open this layer to the extent of the gastrotomy. Opening the mucosa should be bloodless if the vessels outside of the mucosal layers have been controlled. The resulting opening is about 12 mm across (Figure 19).

For the enterotomy, the process is similar, however, the mucosal layer is more folded, due to the plicae circulares. You have to make sure that the entire mucosal layer is divided for the extent of the enterotomy. A double-armed suture is fashioned by taking two 2-0 dyed Vicryl sutures on SH needles cut to seven inches and taking the free ends to make a two-strand overhand knot. We then backhand the first bite through the small bowel side in the middle of the upper side of the opening. We then take the next bite with this suture through the middle of the stomach on the lower side of the opening. Continue running this suture to the left (patient's right). The key here is to advance the suture sufficiently. To ensure this, we simply place the next suture between the corner of the opening and the middle of the opening, again backhanding this through the small bowel and then the stomach. Pass the suture two more times, on either side of the corner of the opening. This suture is cinched down; then take the other end of the double arm and run it to the right in a forehand direction using the left hand, making sure that we advance far enough with each bite using the same technique. After the posterior row of this inner layer is complete (Figure 20), continue the anterior row by advancing the sutures on either side toward the middle. Before cinching down these sutures together which should now be on opposing sides of the opening, the anesthetist will advance

the 32 French Ewald tube gently through the gastrojejunostomy. The suture is snugged up around the Ewald and then tied down (Figure 21).

For the outer anterior layer, run an undyed Vicryl on an SH needle cut to eight inches from the medial aspect of the gastrojejunostomy and tie it to the free end of the posterior outer row that was left long. This completes the gastrojejunostomy (Figure 22). The end of the Ewald tube is drawn back into the pouch and with the small bowel compressed just distal to the gastrojejunostomy, 30 cc of a methylene blue/saline mixture is injected under direct visualization.

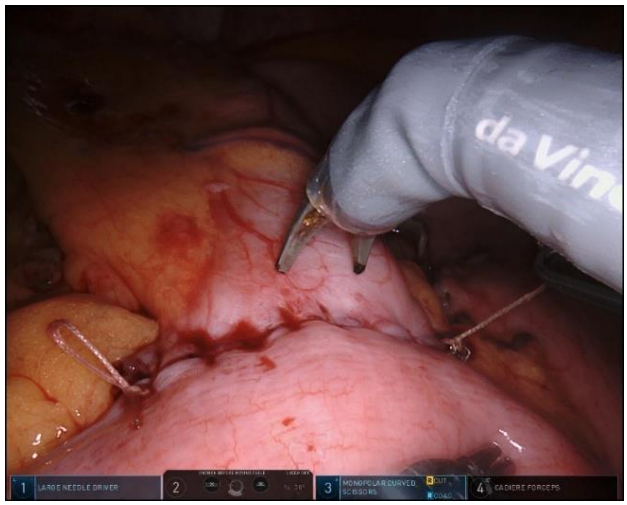

Figure 18. Posterior outer suture line of the gastrojejunostomy.

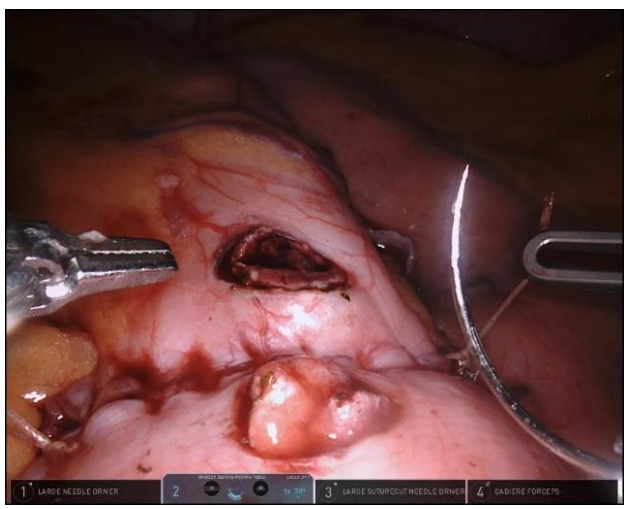

Figure 19. Gastrotomy and enterotomy.

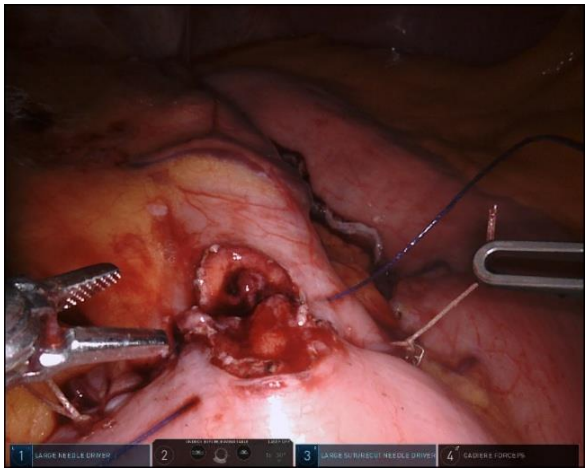

Figure 20. Posterior inner suture line.

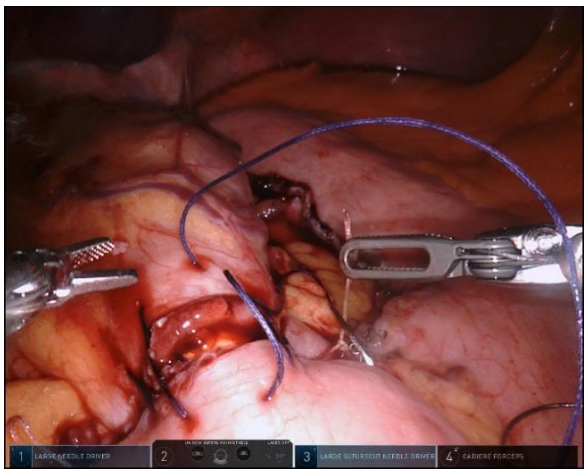

Figure 21. Anterior inner suture line.

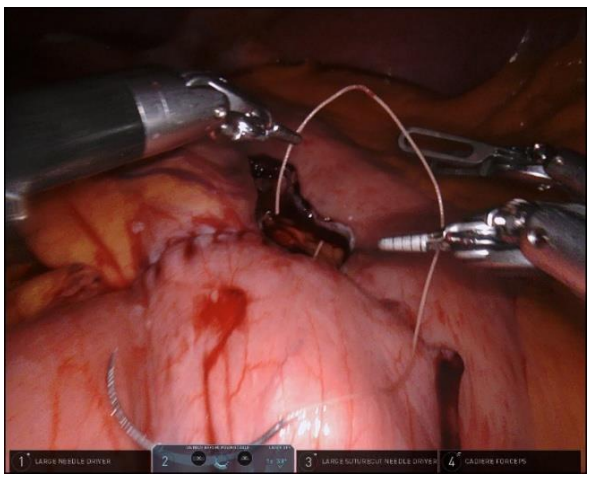

Figure 22. Completed gastrojejunostomy.

Outcomes

Robotic assisted surgery was FDA approved in 2000 and the first robotic assisted Roux-en-Y Gastric Bypass (RYGB) was reported in the literature in 2003 [1]. Since that time the robotic platform has seen increasing use in all aspects of bariatric surgery, from the vertical sleeve gastrectomy (VSG) to revisional bariatric surgery. The most common robotic surgery described in the literature is the RYGB. The reported techniques used in the RYBG vary widely across the literature. The technique described most often is the robotic assisted RYGB, were the stapling is done laparoscopically though an assistant port. The totally robotic RYGB is gaining popularity. The approach creates the gastrojejunostomy via a hand-sewn two layer closure.

Anastomotic leak is rare after gastric bypass surgery but remains the most feared complication as it can be fatal. The robotic platform allows for more accurate suture placement with improved visualization and handling leading to a lower leak rate. A study by Snyder et al. showed a significant reduction in leak rate when using the robotic platform [2]. There were no mortalities in this study. In another study by Buchs et al., 777 patients were reviewed. Those patients undergoing robotic gastric bypass surgery had a significantly lower leak rate of 0.3% when compared to a similar laparoscopic cohort (3.6%) [3]. There are data to the contrary. A report published by Benizri showed a higher leak rate in robotic gastric bypass compared to a laparoscopic cohort (3% vs 0%) [4]. A larger review study encompassing 19 studies did not show an overall difference in leak rate between robotic and laparoscopic gastric bypass. It did, however, support a lower anastomotic leak rate in totally robotic gastric bypass surgery (OR 0.22) when compared to laparoscopic stapled gastric bypass [5]. The robotic RYGB decreases leak rate, the most morbid of post-operative complications.

Anastomotic stricture can present with nausea, pain, and dysphagia. These symptoms are debilitating as patients cannot tolerate oral intake. Strictures require endoscopy and balloon dilation to abate these symptoms. There has been much debate comparing technique and stricture rate in gastric bypass surgery. Maker et al. published a pooled analysis of 1686 patients and found that there was a statistically significant reduction in anastomotic stricture rate in robotic RYGB when compared to the laparoscopic approach [6]. Benizri found the opposite. In this study a 7% stricture rate was noted in RYGB surgeries performed robotically when compared to 0% when done laparoscopically. In a series of 143 patients, Hagen et al. confirmed similar findings to Maker [7]. They reported a 6.8% stricture rate when RGBP was done laparoscopically and 0% rate when done robotically. Li's meta-analysis showed a trend toward lower stricture rates (OR 0.8) favoring the robotic approach; however, this was not statistically significant [5]. Economopoulos' review did not find an overall difference in anastomotic stricture rate but did show a statistically lower stricture rate in robotic RYGB surgery where the gastrojejunostomy was hand sewn [8]. The robotic hand sewn RYGB decreases stricture rate and the associated morbidity.

Traditional length of stay after bariatric surgery is relatively short. The majority of patients are discharged within a few days. The robotic approach aids in decreasing this already short length of stay. The robotic trocar is designed to work as a fulcrum which decreases torque, stress, and strain on the abdominal wall and creates less pain. Less pain can lead to earlier mobilization and oral intake. Ayloo's robotic RYGB patients left the hospital on average one day before a similar laparoscopic cohort of patients [9]. A larger review by

Economopoulos did not show an overall difference in length of stay when comparing robotic and laparoscopic RYGB but subgroup analysis did favor shorter length of stay in the robotically assisted gastric bypass patients [8].

Conversion to open operation is rare in bariatric surgery. Difficult anatomy, poor visualization and dense intra-abdominal adhesions are potential reasons for conversion to open operation. There is no higher likelihood of conversion to open procedure when the robotic technique is used for gastric bypass surgery [5]. Economopoulos' review did not find an overall difference in rates of conversion to open surgery. Subgroup analysis did however find a subset of patients who underwent robotically assisted gastric bypass that had slightly lower reoperation rates [8].

A reported disadvantage to robotic surgery is an increased operating time and the associated costs. The increase in operating room time is contributed to time spent docking and undocking the robotic console and an increase in the use of hand sewn techniques. The hand sewn techniques may take longer than stapled techniques. The tradeoff for increased operative time is decreased complication rates. Not all studies show a longer operating time for robotic surgery, however. Ayloo published a study that showed robotic surgery was actually 27 minutes faster when comparing robotic and laparoscopic RYGB [9]. Fourman, in contrast, found that the laparoscopic technique was 19 minutes faster than robotic RYGB [10]. Economopoulos' meta-analysis did not find a significant difference in overall operating time but subgroup analysis favored the stapled laparoscopic technique [8].

The Intuitive Surgical da Vinci robotic surgical system requires a large upfront investment of up to two million dollars [7]. In addition there is a substantial cost to yearly maintenance. In today's cost conscious environment this large investment has led many to publish negative reviews on the increased cost of robotic surgery. Much of this data was written about hybrid operations where the anastomosis is still done with a laparoscopic stapler. The laparoscopic staplers and cartridge reloads greatly increase the cost of bariatric operations. Hagen showed similar operating room costs when the anastomosis is created with a hand sewn technique and not the stapler [7]. In addition there is a growing body of evidence that the improved optics and maneuverability in a tight space of the robotic platform can lead to lower leak rates [2]. One anastomotic leak is estimated to cost 400,000 dollars if the patient requires ICU admission for sepsis [11]. The reduction of stapler costs and decreased leak rate make the robotic RYGB with a hand-sewn gastrojejunostomy cost effective.

ROBOTIC VERTICAL SLEEVE GASTRECTOMY

Technique

Our current sleeve technique utilizes the Standard Clamp by Standard Bariatrics (Figure 23; Blue Ash, OH). We use four ports with a fifth incision for the Nathanson liver retractor.

The idea behind the Standard Clamp is to employ a laparoscopic device designed to clamp the entire length of the stomach thereby enabling surgeons to plan and hold the staple line prior to division. IT also protects key areas such as the gastroesophageal junction, incisura angularis, and pylorus. The surgeon can create a predictable size, shape, and volume sleeve each and every time."

After positioning the patient as described earlier in the chapter, we access the abdomen using an optical eight mm robotic trocar on the patient's left side along the left anterior axillary line about 22 cm away from the midline. Another eight mm robotic trocar for the camera is placed along the left mid-clavicular line, 12 cm away from midline. The 12 mm robotic staple port is placed at the midline or to the left of midline depending on the location of the pylorus. Before placing the last trocar, a 12 mm non-robotic trocar, a line from the angle of His through a point on the greater curve five cm from the pylorus is projected onto the abdominal wall. This point on the abdominal wall is where the Standard Clamp will go through. Because the Standard Clamp is straight without any flexion points, it is important to have a location through the abdominal wall that will then allow for aligning the clamp to the appropriate landmarks of the stomach, i.e., angle of His, incisura, and five cm from the pylorus. A 12 mm laparoscopic port is placed here. An eight mm robotic trocar is then telescoped within this 12 mm laparoscopic port until the Standard Clamp is needed. The implication of this port placement is to have two instruments for the left hand since stapling is performed with the left hand. We have found this to be the optimal configuration. Finally, a Nathanson liver retractor is placed through the abdominal wall just below the xiphoid process.

To begin the dissection, we choose a point about two-thirds distal on the greater curve from the angle of His. We elevate this portion of the stomach and then bluntly dissect just medial (or superior) to the fat over what appears to be the stomach. Careful and repeated spreading of the vessel sealer allows one to enter the lesser sac without blood loss (Figure 24). Because the vessel sealer is wristed, it is easy to take this dissection distally towards the pylorus and proximally towards the spleen and angle of His.

Figure 23. Standard clamp.

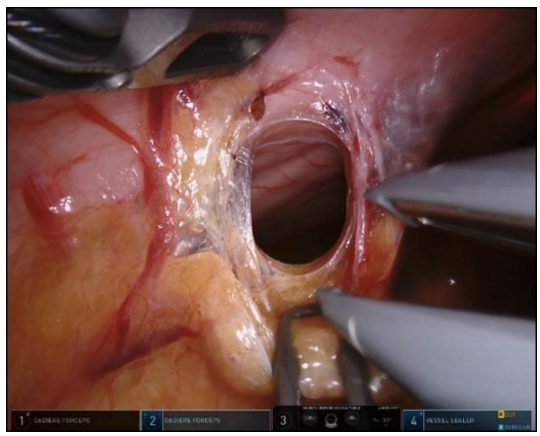

Figure 24. Beginning the greater curve dissection.

When taking this dissection distally, it is important to take down the adhesions and attachments behind the antrum and lesser curve of the stomach (Figure 25). The lesser curve

of the stomach can be mobilized off the pancreas all the up to the left gastric artery. There should be no significant vessels to mobilize the stomach, otherwise the correct plane has not been found.

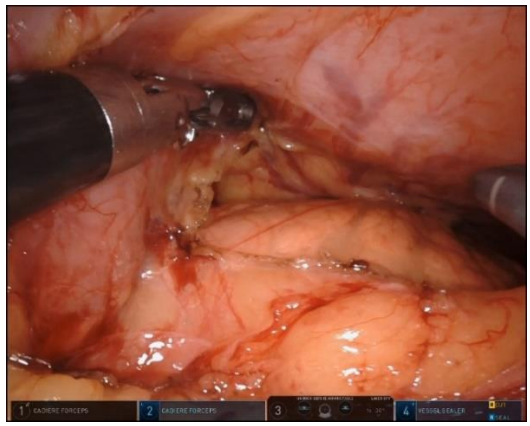

Figure 25. Distal extent of posterior stomach dissection.

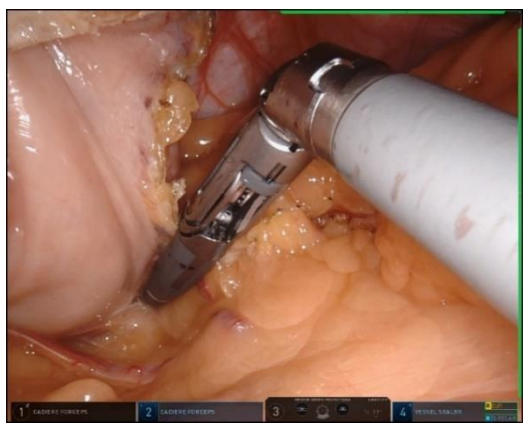

Figure 26. Dissecting the fundus from a posterior approach.

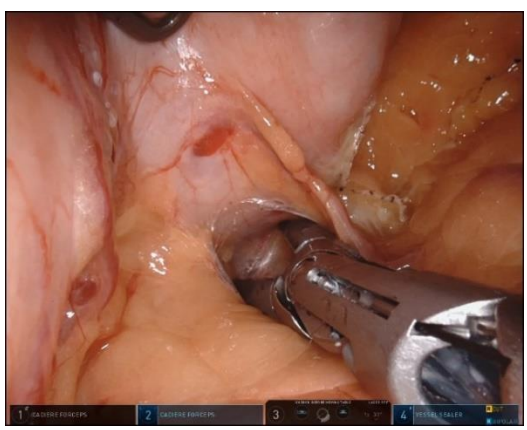

Figure 27. Dissecting the fundus from a medial approach.

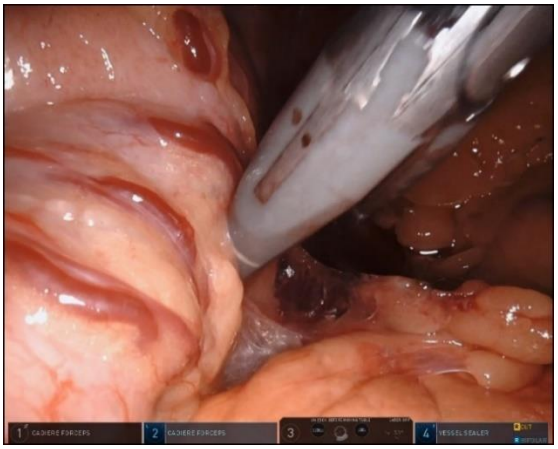

Figure 28. Dissecting between the stomach and pancreas.

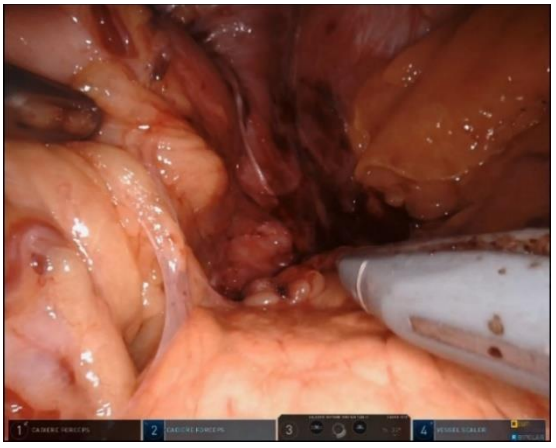

Figure 29. Stomach dissected off of left crus.

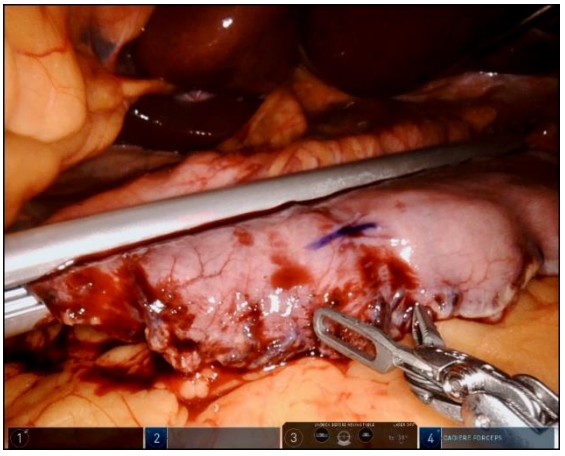

Figure 30. Standard clamp in place.

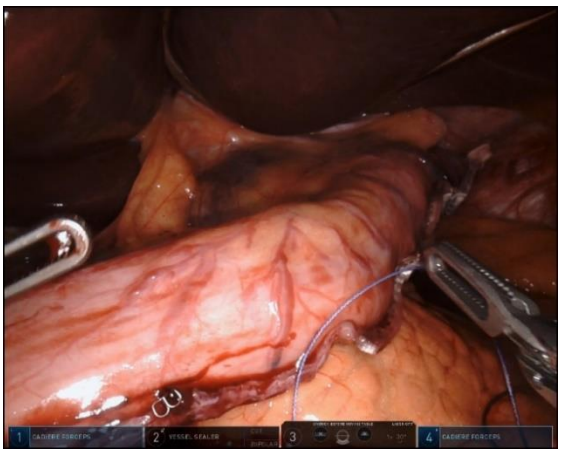

Figure 31. Completed sleeve.

Taking the dissection proximally, when we get to the apex of the fundus, we lift the fundus upwards and laterally (Figure 26). Dissection of the medial aspect of the fundus back down to the angle of His is done from *behind* (i.e., posterior to) the stomach. In some instances, instead of continuing from a lateral approach, dissect from a medial approach starting over the left crus (Figure 27). After the greater curve is completely dissected, we expose more of the left crus inferiorly. This is where the robotic system shines because you can see the distinct plane between the fat and vessels of the stomach on the medial aspect of the left crus compared to the peripancreatic fat on the lateral aspect of the left crus (Figure 28). By exposing the left crus in this plane, very few if any vessels need to be crossed and there is better mobilization of the stomach (Figure 29). When the dissection is complete, the lesser curve vessels are intact, the lateral stomach is completely mobilized with the left crus exposed, and the only point of attachment on the greater curve is the gastrocolic ligament for the last five cm of the stomach.

With the dissection complete, the 18 French orogastric tube is placed along the lesser curve. One must take into account the width of the Standard Clamp and the fact that stapling occurs lateral to the "clamp". Together, the 18 French orogastric tube and the one cm wide Standard Clamp results in a sleeve that is about 40 to 44 Fr. The greater curve is marked one centimeter from the angle of His. A mark is placed perpendicular to the lesser curve three cm away. Finally, a mark is placed six cm away from the pylorus. The number 1 robotic arm is undocked, the eight mm robotic trocar is removed from the 12 mm laparoscopic port and the Standard Clamp is introduced. The two Cadiere graspers are in robotic arms 1 and 4. The Standard Clamp is opened, and the stomach is then placed between the jaws of the standard clamp. The stomach is retracted laterally and once the mark at the angle of His is seen and the clamp is snug against the orogastric tube, the Standard Clamp is closed until the first click is heard. The stomach is worked through the Standard Clamp towards the incisura and once the mark at the incisura is visualized and the clamp is snug against the orogastric tube, the Standard Clamp is closed until the second click is heard. Finally, once the third and final mark on the greater curve is visualized, the Standard Clamp is closed (Figure 30).

Utilizing the SureForm 60 mm stapler, stapling occurs lateral to the Standard Clamp. Currently, the first cartridge of the stapler is a green load. The last three cartridges are

usually blue loads. Occasionally, the last cartridge is a white cartridge. Other times, a fifth cartridge is required to complete the sleeve (Figure 31).

There are multiple benefits to the Standard Clamp. First, a reproducible sleeve is possible using the anatomic landmarks. It does require a more precise dissection along the medial and posterior aspects of the stomach, especially between the fundus and the left crus as well as between the antrum and the transverse colon mesentery and pancreas. Second, fewer staple loads are used. Using the Standard Clamp has resulted in three to four less loads per case of the SureForm 60 mm compared to the Endowrist 45. Finally, because there is less extrusion of the tissues when clamping and firing the stapler, the staple line is straighter. Along with the benefit of consistent placement and straighter staple lines, we have abandoned using Peri-Strips on the first three fires of the stapler. These changes have resulted in a cost per case that is competitive with non-robotic endostaplers.

Outcomes

There is a paucity of data on the robotic sleeve gastrectomy compared to robotic RYGB. The data available to date supports the robotic platform as feasible and safe. One reported advantage of using the robot for vertical sleeve gastrectomy is to oversew the staple line. This technique is surgeon-dependent. The wristed instruments and 3-D magnification make this step more feasible and accurate. However, the benefit of staple line reinforcement leads to longer operating room times and remains a highly debated topic today. The most recent American Society for Metabolic and Bariatric Surgery (ASMBS) data on staple line reinforcement in laparoscopic VSG suggests staple line reinforcement of any kind leads to higher leak rate [12].

Leak and bleeding are the two major causes of morbidity and mortality after sleeve gastrectomy. The leak and bleeding rates are not significantly different between robotic and laparoscopic surgery. Ayloo did not have any patients with staple like leak in a study of 69 patients [13]. Magouliotis' meta-analysis of 16 studies also found no significant difference in leak rate between laparoscopic and robotic techniques [14]. Postoperative bleeding was not statistically different in either study [13, 14].

The VSG operation is designed in a way to limit oral intake. The nature of this restrictive operation lends itself to a very real complication of post-operative stricture. As in RYGB stricturing of the gastric sleeve leads to debilitating oral intolerance and repeated dilations. Romero compared 134 robotic sleeve gastrectomies to a similar laparoscopic cohort and found no difference in stricture rate between the two techniques [15].

Most surgeons observe VSG patients one night in the hospital. These patients need hydration and confirmation that they can tolerate oral intake of liquids. The length of stay is very short. However, in the review article by Magouliotis, length of stay was significantly longer in the robotic VSG group [14]. Data to the contrary was published by Elli where robotic VSG patients had a length of stay 0.5 days shorter [16]. It is unclear why there would be a difference in the length of stay after VSG based on operative technique.

The robotic and laparoscopic RYGB have both excellent and durable long term weight loss. The mean decrease in BMI at one year is 16 [13]. There is no difference between robotic and laparoscopic VSG in excess weight lost at 12 months. Both techniques had considerable

excess weight loss of up to 68% [14] and should be considered when offering surgery to combat medically complicated obesity.

Magouliotis and Ayloo showed a longer operating time for patients undergoing a robotic sleeve gastrectomy when compared to laparoscopic surgery by 20 minutes [13, 14]. Oversewing the staple line is likely to contribute to this difference [13] in some series and in others the docking time made the significant difference [17]. Romero found the operating time to be 12 minutes longer for robotic sleeve gastrectomy when compared to laparoscopic [15]. In contrast, there is a subset of super obese patients with a BMI > 50 where operative time is significantly shorter for robotic sleeve gastrectomy [16]. The large fatty sheet of greater omentum and a smaller working space can limit access to the hiatus and left crus causing difficulty during laparoscopic VSG. The robotic platform allows improved visualization and maneuverability in this area which decreases operative time in the super obese cohort.

A reported disadvantage of robotic VSG is overall cost. As in robotic RYGB, there is a substantial cost to purchasing the robotic platform and yearly maintenance fee. There are few studies reporting the cost of robotic VSG. Magouliotis et al. found increased costs in four out of five studies in their review. Yet they were unable to perform a meta-analysis due to lack of consistent data present in the literature [14]. Diamantis suggested the robotic approach is approximately 400 Euros more expensive [17].

The above data shows the robotic VSG is safe and feasible and provides durable weight loss. The robotic approach is durable and leads to excellent weight loss that is comparable to the laparoscopic approach. The benefits of reduction in anastomotic leak, seen with robotic RYGB, are not present in robotic VSG but the subset of super morbidly obese patients have a shorter length of stay and mean operating room time but at a higher cost. Both of these advantages are likely due to the ease of operating around the diaphragmatic hiatus on the robotic platform.

ROBOTIC REVISIONAL SURGERY

Technique

Because of the varying circumstances for revision, anatomy, deconstruction and reconstruction, it is hard to provide a step-by-step guide to how to perform revisional surgery. Suffice it to say that there is no better way to do revisional surgery than with the robot. The ability to find or make planes, delineate anatomy, and evaluate tissue viability make revisions a pleasant challenge.

One of the first challenges for revisional surgery is getting access to the peritoneal cavity. We perform the minimum amount of adhesiolysis to get at least three robotic trocars into the abdominal cavity. Once this is achieved, then the rest of the adhesiolysis can be performed robotically which can save more time and result in a less bloody field than trying to continue laparoscopically or convert to open. We dissect sharply as much as possible which requires taking the time to find the right planes. Vessels that will bleed when cut are taken care of with cautery before transection, whenever possible, unless they are adjacent or near to bowel. Bipolar energy can be used in these cases if necessary. Additional trocars are placed as

allowable. Liver retractors may not always be needed as scarring often keeps the left lateral segment of the liver elevated off the stomach, especially when adhesions between the liver and stomach are taken down.

After most of the adhesiolysis is done, the next step is to identify the right crus. Access to the left crus is often impeded by scarring so the better landmark to approach first is the right crus. Pars flaccida may already be opened up but in other cases it is necessary to open up pars flaccida. Once the right crus has been identified, one can proceed with dissecting out the hiatus for a hiatal hernia. Alternatively, one can dissect below the level of the left gastric artery posterior to the stomach which can be helpful when forming the gastric pouch. This maneuver may also be helpful to getting around the stomach from behind on a previous sleeve to dissect out an obscured staple line.

During the dissection, care has to be taken to minimize compromising any vessels until the full anatomy is known. In the case of previous vertical banded gastroplasty or non-divided gastric bypass, it is also important to know where the previous staple lines are and make sure they are accounted for appropriately with subsequent firings of the endostapler. It is always prudent to perform a new lateral vertical staple line that is medial to the old staples lines whenever possible. Firefly imaging can be used as an adjunct in these cases to make sure the blood flow to the gastric pouch has not been compromised.

In performing a revision of the gastrojejunostomy due to ulceration, most cases are associated with a gastric pouch that is too large. In these instances, it is straightforward for the horizontal staple line to be above the gastrojejunostomy without fear of making the gastric pouch too small. However, there have been a couple occasions where the gastric pouch was a perfect size and using an endostapler above the gastrojejunostomy would have made the gastric pouch too small. In this situation, devasculariz the small bowel segment that will be coming out first. With blood flow stopped to this portion of the small bowel, a demarcation line will promptly appear between the stomach and the small bowel. Sharp dissection and cautery are then used to divide the gastrojejunostomy at the demarcation line. Subsequently, proceed with the gastrojejunostomy as described in the gastric bypass section.

Outcomes

Surgery is the most effective treatment for obesity. There is a small subset of patients that do not lose the expected weight, have weight regain, or chronic symptomatology that requires revisional surgery. The benefits of operating on the robotic system have led to increased enthusiasm for revisional robotic bariatric surgery. Snyder et al. reviewed 99 patients undergoing revisional bariatric surgery performed on the Intuitive da Vinci robotic surgical system [22]. The revisions were durable leading to a decrease in average BMI from 44 to 29 kg/m^2 at three years. This patient population had a high complication rate (24%) and elevated readmission rate (17%) which is similar to laparoscopic revisional surgery [23]. Buchs et al. compared robotic to laparoscopic revisional bariatric procedures [24]. They found fewer complications in the robotic group. In addition they showed a shorter length of stay but increased operating time. At the present time the robotic platform has a role in these complex reoperative bariatric surgeries but the data remains limited.

DUODENAL SWITCH

The authors currently do not perform duodenal switch (DS) procedures. In the near future, we will begin performing the loop DS. The loop DS is a modification of the DS which only requires one anastomosis between the duodenum and the ileum, in an end-to-side fashion. While currently not on the approved procedures list of ASMBS and not covered by insurance, studies show increased weight loss without the morbidity of traditional duodenal switch. Loop DS lends itself particularly well to a robotic approach due to patient factors such as high BMI, the multi-quadrant nature of the procedure, and the benefits of using a hand-sewn technique for the duodeno-ileostomy. The loop DS will provide the benefits of a bypass type operation, preservation of the pylorus, and increased weight loss, while also decreasing the complexity of surgery compared to procedures requiring two anastomoses. Additional benefits include the ability to use NSAIDS after surgery and less reservations to provide a bypass-type operation for patients at high-risk of nicotine recidivism.

Duodenal switch represents only a small minority of operations performed today for obesity (<1%) [18]. Recently, there has been a renewed interest in the DS with the advent of the robotic surgery platform. Sudan et al. reviewed 59 patients who underwent robotic DS. No patients in their series had an anastomotic leak or bleeding complication (21). There were no mortalities and the complication rate was low. The operative time was on average 306 minutes. The DS is technically challenging but may have a role in the super obese. The robotic approach is safe and feasible but more data is needed for further review of the role of robotic assisted DS.

CONCLUSION

As surgeons, we need to evaluate not only clinical factors but also financial factors. In considering financial factors, we should not just listen to what administrators say, but see for ourselves what the true cost of surgery is. That is, we need to account for costs not only for the clinical care of the patient, but also costs due to patients being out of work, costs due to workplace injury for surgeons, the cost of a surgeon having to retire earlier than expected, and the cost to recruit and replace surgeons.

When considering clinical factors, the potential for technology to make us better surgeons is here and will continue to improve. Surgeons need to critically evaluate for themselves the different tools and techniques available along with an assessment of their own strengths and weaknesses to decide how to approach each case in their surgical repertoire. Fortunately with the Metabolic and Bariatric Surgery Accreditation and Quality Improvement Program, bariatric surgeons can constantly evaluate and improve based on their own clinical data. Finally, increasing competition and continuing development of computer-assisted surgery should help accelerate the field over the next decade.

REFERENCES

[1] Talamini, Mark A., S. Chapman, S. Horgan, and William Scott Melvin. "A prospective analysis of 211 robotic-assisted surgical procedures." *Surgical Endoscopy and Other Interventional Techniques* 17, no. 10 (2003): 1521-1524.

[2] Snyder, Brad Elliott, Todd Wilson, Benjamin Y. Leong, Connie Klein, and Erik B. Wilson. "Robotic-assisted Roux-en-Y gastric bypass: minimizing morbidity and mortality." *Obesity surgery* 20, no. 3 (2010): 265-270.

[3] Buchs, Nicolas C., Philippe Morel, Dan E. Azagury, Minoa Jung, Gilles Chassot, Olivier Huber, Monika E. Hagen, and François Pugin. "Laparoscopic versus robotic Roux-en-Y gastric bypass: lessons and long-term follow-up learned from a large prospective monocentric study." *Obesity surgery* 24, no. 12 (2014): 2031-2039.

[4] Benizri, Emmanuel I., Myriam Renaud, Nicolas Reibel, Adeline Germain, Olivier Ziegler, Rasa Zarnegar, Ahmet Ayav, Laurent Bresler, and Laurent Brunaud. "Perioperative outcomes after totally robotic gastric bypass: a prospective nonrandomized controlled study." *The American Journal of Surgery* 206, no. 2 (2013): 145-151.

[5] Li, Kun, Jianan Zou, Jianxiong Tang, Jianzhong Di, Xiaodong Han, and Pin Zhang. "Robotic versus laparoscopic bariatric surgery: a systematic review and meta-analysis." *Obesity surgery* 26, no. 12 (2016): 3031-3044.

[6] Markar, S. R., A. P. Karthikesalingam, V. Venkat-Ramen, J. Kinross, and P. Ziprin. "Robotic vs. laparoscopic Roux-en-Y gastric bypass in morbidly obese patients: systematic review and pooled analysis." *The International Journal of Medical Robotics and Computer Assisted Surgery* 7, no. 4 (2011): 393-400.

[7] Hagen, Monika E., Francois Pugin, Gilles Chassot, Olivier Huber, Nicolas Buchs, Pouya Iranmanesh, and Philippe Morel. "Reducing cost of surgery by avoiding complications: the model of robotic Roux-en-Y gastric bypass." *Obesity surgery* 22, no. 1 (2012): 52-61.

[8] Economopoulos, Konstantinos P., Vasileios Theocharidis, Travis J. McKenzie, Theodoros N. Sergentanis, and Theodora Psaltopoulou. "Robotic vs. laparoscopic Roux-En-Y gastric bypass: a systematic review and meta-analysis." *Obesity surgery* 25, no. 11 (2015): 2180-2189.

[9] Ayloo, Subhashini M., Pietro Addeo, Nicolas Christian Buchs, Galaxy Shah, and Pier Cristoforo Giulianotti. "Robot-assisted versus laparoscopic Roux-en-Y gastric bypass: is there a difference in outcomes?." *World journal of surgery* 35, no. 3 (2011): 637-642.

[10] Fourman, Matthew M., and Alan A. Saber. "Robotic bariatric surgery: a systematic review." *Surgery for Obesity and Related Diseases* 8, no. 4 (2012): 483-488.

[11] Zambelli-Weiner, A., E. Brooks, and R. Brolin. "Total charges for post-operative leak following laparoscopic sleeve gastrectomy." *Paper Presentation at Obesity Week* (2013).

[12] Berger, Elizabeth R., Ronald H. Clements, John M. Morton, Kristopher M. Huffman, Bruce M. Wolfe, Ninh T. Nguyen, Clifford Y. Ko, and Matthew M. Hutter. "The impact of different surgical techniques on outcomes in laparoscopic sleeve gastrectomies: the first report from the metabolic and bariatric surgery accreditation and

quality improvement program (MBSAQIP)." *Annals of surgery* 264, no. 3 (2016): 464-473.

[13] Ayloo, Subhashini, Nicolas C. Buchs, Pietro Addeo, Francesco M. Bianco, and Pier C. Giulianotti. "Robot-assisted sleeve gastrectomy for super-morbidly obese patients." *Journal of Laparoendoscopic & Advanced Surgical Techniques* 21, no. 4 (2011): 295-299.

[14] Magouliotis, Dimitrios E., Vasiliki S. Tasiopoulou, Eleni Sioka, and Dimitrios Zacharoulis. "Robotic versus laparoscopic sleeve gastrectomy for morbid obesity: a systematic review and meta-analysis." *Obesity surgery* 27, no. 1 (2017): 245-253.

[15] Romero, Rey Jesús, Radomir Kosanovic, Jorge Rafael Rabaza, Rupa Seetharamaiah, Charan Donkor, Michelle Gallas, and Anthony Michael Gonzalez. "Robotic sleeve gastrectomy: experience of 134 cases and comparison with a systematic review of the laparoscopic approach." *Obesity surgery* 23, no. 11 (2013): 1743-1752.

[16] Elli, Enrique, Raquel Gonzalez-Heredia, Shravan Sarvepalli, and Mario Masrur. "Laparoscopic and robotic sleeve gastrectomy: short-and long-term results." *Obesity surgery* 25, no. 6 (2015): 967-974.

[17] Diamantis, Theodoros, Andreas Alexandrou, Nikolaos Nikiteas, Athanasios Giannopoulos, and Eustathios Papalambros. "Initial experience with robotic sleeve gastrectomy for morbid obesity." *Obesity surgery* 21, no. 8 (2011): 1172-1179.

[18] American Society of Metabolic and Bariatric Surgery. July 2016. *Estiamte of Bariatric Surgery Numbers 2011-2016*. Accessed March 25, 2018. https://asmbs.org/resources/estimate-of-bariatric-surgery-numbers

[19] Cadiere, G. B., Jacques Himpens, Marc Vertruyen, and Franco Favretti. "The world's first obesity surgery performed by a surgeon at a distance." *Obesity surgery* 9, no. 2 (1999): 206-209.

[20] Edelson, Paula K., Kristoffel R. Dumon, Seema S. Sonnad, Bilal M. Shafi, and Noel N. Williams. "Robotic vs. conventional laparoscopic gastric banding: a comparison of 407 cases." *Surgical endoscopy* 25, no. 5 (2011): 1402-1408.

[21] Sudan, R., V. Puri, and D. Sudan. "Robotically assisted biliary pancreatic diversion with a duodenal switch: a new technique." *Surgical endoscopy* 21, no. 5 (2007): 729-733.

[22] Snyder, Brad, Todd Wilson, Vicky Woodruff, and Erik Wilson. "Robotically assisted revision of bariatric surgeries is safe and effective to achieve further weight loss." *World journal of surgery* 37, no. 11 (2013): 2569-2573.

[23] Park, Young Suk, Sang Hoon Ahn, Do Joong Park, and Hyung-Ho Kim. "Bariatric and revisional robotic surgery." *Translational Gastrointestinal Cancer* 5, no. 1 (2016): 1-7.

[24] Buchs, Nicolas C., François Pugin, Dan E. Azagury, Olivier Huber, Gilles Chassot, and Philippe Morel. "Robotic revisional bariatric surgery: a comparative study with laparoscopic and open surgery." *The International Journal of Medical Robotics and Computer Assisted Surgery* 10, no. 2 (2014): 213-217.

In: Encyclopedia of Surgery (22 Volume Set)
Editors: Andreas Lehrer and Kristin Mueller
ISBN: 978-1-53618-329-0
© 2020 Nova Science Publishers, Inc.

Chapter 253

ROBOTIC UROLOGIC SURGERY FOR BENIGN DISEASE

Aryeh Keehn[1] and Daniel Eun[2]
[1]Lewis Katz School of Medicine at Temple University, Philadelphia, PA, US
[2]Robotic Surgical Services, Minimally Invasive Robotic Urologic,
Oncology and Reconstructive Surgery, Robotic Urologic Surgery Fellowship,
Lewis Katz School of Medicine at Temple University, Philadelphia, PA, US

INTRODUCTION

Although initially engineered for cardiac surgery, surgical robotics has been dominated by urological interventions over the past two decades. The advantages of the robotic surgery platform have been well documented in over 10,000 peer reviewed publications, and include enhanced 3-D visualization, precision in movement, and accessibility to confined anatomical spaces. In fact, use of the robot has increased roughly 10 percent annually since the year 2000 despite significant concerns of cost sustainability.

One reason for the continued increase in numbers is the integration of the robot into abdominal, pelvic, thoracic and even head and neck surgery. A second reason is that after roughly twenty years of high volume use, urologists have expanded utilization of the robot outside the confines of oncology. Both upper and lower urinary tract reconstruction as well as benign disease have come into vogue for the practicing robotic surgeon. These procedures include simple prostatectomy for BPH, simple nephrectomy, cystectomy for the bladder cripple and urinary diversion. Additionally, the gamut of ureteral reconstruction including pyeloplasty, uretero-ureterostomy, ureteral re-implantation, psoas hitch and boari flap have been reported in multiple series. Finally, advanced ureteral reconstructive cases including revisional surgery after prior repair, ileal ureter, buccal mucosal grafting, appendiceal interposition and kidney auto-transplantation have all been attempted successfully at select centers of excellence.

This chapter will concentrate on the use of the robot for the above benign and reconstructive interventions and is intended as an overview for current practices in non-

oncologic robotic surgery. Particular focus will be paid to indications, technique with commentary from the author's surgical experience, and the most current literature.

ROBOTIC ASSISTED LAPAROSCOPIC SIMPLE NEPHRECTOMY

Simple nephrectomy refers to removal of the kidney itself, while leaving the adrenal gland, lymphatic tissue with the option to leave some or all of Gerota's fascia intact. Indications for the procedure include atrophy from recurrent infections or obstruction, non-function, nephrolithiasis, pain, trauma, familial or acquired cystic disease, and rarely, tuberculosis. Since the first simple nephrectomy performed by Gilmore in 1870, the procedure has undergone significant technical advancement with the popularization of laparoscopy, and then more recently, with the introduction of the robotic surgical platform [1]. In fact, the use of the robot in simple nephrectomy can be extremely beneficial as it is often more challenging than radical nephrectomy secondary to inflammatory processes that obliterate planes and mediate significant fibrosis [2].

Although several large series exist demonstrating the feasibility and utility of robotic assisted radical nephrectomy, there are no dedicated publications to robotic assisted simple nephrectomy. As these procedures are virtually the same, Table 1 details the most recent robotic radical nephrectomy series, some of which include simple nephrectomy within their cohorts.

Table 1. Recent series for robotic assisted radical nephrectomy

Author	Patient	OT (min)	EBL (ml)	HS (d)	Significant Complications
Nazemi et al. 2006	6	345	125	3	Renal vein bleeding from stapler malfunction
Rogers et al. 2008	35	291	221	2.5	None
Rogers et al. 2009	18	224 with 4th arm, 322 without	Not reported	Not reported	4 wound dehiscence
Hemal et al. 2009	15	221	210	3.5	2 vascular complications, 2 ileus, 1 wound incision site infection
Lorenzo et al. 2011	38	127.8	273.6	4.3	Transfusion required in 8%
Dogra et al. 2012	23	132.7	270	3	1 hilar bleed

Preoperative Considerations, Equipment, and Set Up

Although this section deals with nephrectomy, the following technical points are common to all urological robotic cases, and are generalizable to the forthcoming sections in this chapter. At our institution we use both the Si and Xi robotic systems. All port placements are the same for both systems across all interventions. A single notable difference is the 8mm camera port for the Xi versus the 12mm camera port for the Si.

All patients are examined on the morning of surgery, their charts and imaging meticulously reviewed and proper laterality marked. Patients should be evaluated by a dedicated robotic anesthesia team who are well versed in the physiology and potential complications of robotic surgery. For all benign and reconstructive urologic robotic cases, 5000 units of sub-cutaneous heparin are administered alongside sequential compression devices and proper antibiotic coverage. All members of the team should be familiar and proactive in optimizing patient positioning and padding. Finally, the operating room should be large enough to accommodate the robot, surgical equipment, and the entire surgical team. Should an emergency conversion to open be indicated, quick access to open instrument trays and easy movement in and about the operating room can be lifesaving.

Surgical Technique and Outcomes

The technique for robotic nephrectomy mirrors the laparoscopic approach and has been well defined in the literature. The first robotic nephrectomy was actually performed for benign pathology and was described by Guillonneau in 2001 [3]. They reported on a non-functioning, hydronephrotic kidney secondary to UPJ obstruction that was successfully removed using an early robotic technology, the Zeus Robotic Surgical System (Computer Motion Goleta, CA). Thereafter in 2002, Horgan et al. reported on a cohort of 10 patients who had undergone robotic assisted laparoscopic donor nephrectomy [4]. The mean operative time (OT) and estimated blood loss (EBL) was 166 minutes and 68ml respectively. There were no intraoperative complications and no open conversions in this initial group. Interestingly, over the course of only ten cases the authors operative time considerably improved from 210 min for the first case to 140 min for the last, highlighting the ease at which the robotic platform was integrated into their surgical routine. Finally, Rogers et al. reported on a series of 42 patients, 7 of who underwent simple robotic nephrectomy and the remaining radical [5]. The mean operative console time was 158 min, mean EBL 223 mL and no intervention required open conversion. Taken together it is clear that robotic nephrectomy is feasible and reproducible.

Comments

There is significant variability in how robotic nephrectomies are approached in terms of access (transperitoneal vs retroperitoneal), port placement, patient positioning (flank, modified flank), and arm positioning (taped across the chest, anatomic position, Krause arm-rest, elevated over the head). Many surgeons draw from pure laparoscopic experience in defining their preferred approach. After 2500 robotic cases, we have optimized our technique specifically for a robotic approach and to make for an easily reproducible setup that minimizes complications and robotic arm interference. The configuration is detailed below and is used for all adrenal, kidney and upper ureteral procedures.

The patient is rolled into a near-full flank position with the iliac crest positioned just below the break of table. Rather than use individual pillows, blankets or bolsters to maintain the flank position, a single large roll, or “Hoagie Roll” as we term it, is placed posterior to the patient (Figure 1) and buttressed in position using two orthopedic hip positioners that are

clamped to the table. In this fashion, we are able to rapidly but gently place the patient in flank position and maintain the flank position without worrying about the patient slumping back after draping. The downside arm is supported with an axillary roll and secured to a perpendicular arm board in the usual fashion. We prefer to place the upside arm, however, in an anatomical position along the lateral aspect of the hip, taped loosely from posteriorly to prevent the arm from falling into the surgical field.

A 12 mm assistant port is placed peri-umbilically and the camera is placed through this port initially to facilitate further port placement. A straight line from the ribs at the mid-clavicular line down toward the lateral pubis is drawn out. Starting 2cm off the ribs, four 8mm ports are placed with one hand breadth between each along the previously marked line. (Figure 2) The robot is docked over the flank. This port configuration and robot docking methodology is the same for both Si and Xi robotic systems. Of note, the forth arm of the robot is intentionally left undocked for the initial portions of the case as it is not needed and allows for unhindered movement during bowel medialization. The 4th arm is docked after the ureter is identified and the kidney is ready for lateral retraction for access to the hilum.

Figure 1. Rather than use individual pillows, blankets or bolsters to maintain the flank position, a single large roll is placed posterior to the patient

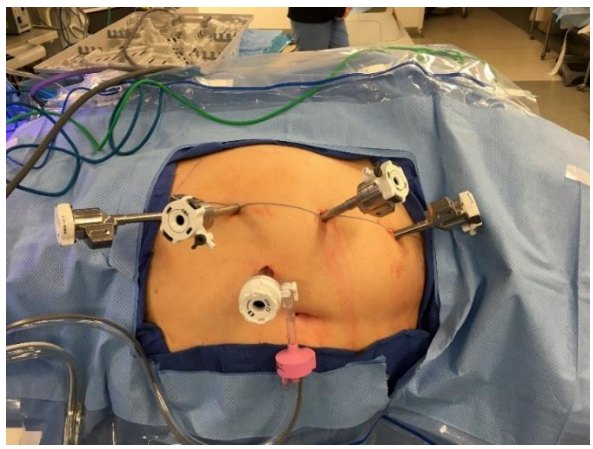

Figure 2. Port placement for renal and upper urinary tract access. Note that the straight line makes access simple and reproducible.

There are several advantages to the above robotic set up for kidney surgery. Firstly, the lateralized placement of the camera significantly decreases obstruction from, and need to medialize, the bowel structures. The lateral camera position also facilitates an easier access line for the assistant. A zero degree lens with the camera port pulled back as much as possible enables a wide viewing angle to help mitigate what might be an altered view for some surgeons. Finally, this setup standardizes port placement in a way that reliably avoids robotic arm clashing and is easily reproducible by all members of the robotic team.

SIMPLE PROSTATECTOMY

Unlike simple nephrectomy, robotic assisted simple prostatectomy (RASP) is becoming well documented in the literature as the technique gains significant momentum in the urologic world. Interestingly, the current EUA and AUA guidelines still describe RASP as investigational secondary to lack of sufficient studies demonstrating value [6-7]. Yet, for glands that are not amenable to standard endoscopic management such as trans urethral resection, robotic simple prostatectomy is an excellent minimally invasive option that significantly enhances voiding parameters while preserving erectile and sexual function. Several approaches have been described and are outlined with peri-operative parameters in Table 2.

Table 2. Recent series of robotic simple prostatectomy with peri-operative parameters

Publication	Cohort size	Technique	IPSS pre-op	IPSS post-op	Pre-op Qmax (Ml/s)	Post-op Qmax (Ml/s)	Mean Operative time in minutes	Hospitalization Time in Days	Catheter time in Days
Pokorny 2015	67	Drop bladder, vertical cystotomy just above prostate-vesical junction, prostatic fossa is then retrigonized using a double-layer 3-0 V-Loc running suture.	25	3	7	23	97	4	3
Autorino 2015	487	Various trans-capsular and trans-vesicle approaches reported.	23	7	8	25	145	2	7
Banapour 2014	16	Horizontal cystotomy proximal to the vesicoprostatic junction, no bladder neck reconstruction	22	7	Not Reported	Not Reported	228	1.3	8
Leslie 2014	25	Vertical incision in dome without dropping bladder. No bladder neck reconstruction	24	3.6	11.3	20	214	4	9
Matei 2012	35	Bladder dropped, horizontal cystotomy proximal to vesico-prostatic junction, Bladder trigonized by suturing posterior edge of bladder neck to posterior urethra	28	7	6.6	19	180	3.2	7.4

Surgical Technique and Outcomes

Patient positioning and port placement follows standard configuration for prostrate interventions with the patient in lithotomy and steep Trendelenburg. There are several technical aspects of the procedure that vary based on surgeon preference. These include a transvesicle or extravesicle approach, the decision to drop the bladder or not, and the performance of a bladder advancement anastomoses. Since the robotic procedure is still in its infancy without comparative studies, there is no consensus as to which techniques is best.

Single institution series for RASP are still relatively small with the largest experience capping out at 67 patients [8]. In that series, Pokorny et al retrospectively analyzed their experience with RASP and reported a median OT of 97 min (IQR 80 – 127), median EBL at 200 ml (IQR 115 – 360), median catheterization time of 3 d (IQR 2 – 4) and the median length of stay (LOS) of 4 d (IQR 3 – 5). More importantly at 6 months follow up the median IPSS score was 3 (IQR 0 – 8), with a median post void residual (PVR) of 0 ml (IQR 0–36). The postoperative complication rate was 30%, including three cases (4.5%) with grade 3b complications (major bleeding requiring cystoscopy and coagulation). A multi-institutional consortium reported similar results from 487 RASP procedures utilizing various approaches with a roughly 16% complication rate of which only 12 were above Clavein 2 [9]. OT was reported at 154.5min (100 – 180), EBL of 200cc (100 – 400), and LOS was 2 days (1 – 4).

Comments

At our institution, we have stopped mimicking the open approaches such as the traditional retropubic or suprapubic techniques. Instead, we use a retzius sparing, posterior transvesical approach for simple prostatectomy. The bladder is left in-situ and not dropped. Instead, a generous, vertical cystotomy is made at the midline from the dome to the floor of the bladder. Keith needles are passed through the lateral abdominal walls, bilaterally, to provide static retraction at the bladder incision. The adenoma is accessed and resected through this posterior cystotomy incision. Using a combination of monopolar cautery and blunt dissection, the adenoma plane is followed, taking care to avoid the capsular plane. After the adenoma is resected, the bladder mucosa is circumferentially advanced and anastomosed to the urethra using a running 12 inch 3 - 0 VLOC barbed suture. Prior to closing the bladder, 10 cc of Floseal (Baxter) is then injected into the prostatic fossa after the anastomosis.

The main advantage to our technique is twofold. The 360-degree bladder neck anastomosis to the prostatic urethra provides complete urothelium to urothelium approximation, resulting in a reliable resolution of postoperative hematuria, obviating the need for continuous bladder irrigation and allowing for an 18 French 2-way catheter postoperatively. Secondly, since the bladder is not dropped, the prostatic dissection is extraperitoneal.

Simple Cystectomy

Simple cystectomy is a rare procedure in current urological practice with published data limited to small, single center, case series. Indications for simple cystectomy are primarily for

severe refractory voiding dysfunction, recurrent inflammation or infection, and life-threatening hematuria, with some reports of other more esoteric indications published as single case reports. A recent analysis of all cystectomies performed in the US from 2005-2014 found that out of roughly 5000 cystectomies, only 8% were performed for benign indications [10]. The rarity of this procedure is likely multifactorial, however, the known morbidity of cystectomy and subsequent urinary diversion is, in all likelihood, the major deterrent in performing this procedure.

For those individuals whose risk of intervention is outweighed by the morbidity of their condition, robotic cystectomy is feasible, and is supported by numerous series from the oncological literature. The approach to robotic simple cystectomy and urinary diversion is similar to radical cystectomy with the exception of sparing all Wollfian and Mullerian structures that would normally be excised in the radical procedure. Lymphadenectomy is also usually skipped and not needed unless intraoperative findings warrant it. There are no published series of robotic simple cystectomy with intracorporeal diversion.

Surgical Technique and Outcomes

Port placement and positioning follows standard configuration for robotic pelvic interventions, and for most, the procedure begins with ureteral identification and transection. Thereafter, several techniques have been described for bladder mobilization, reservoir creation, and ureteral implantation. In 2014 Abreu et al. reported on a large cohort of completely robotic cystectomy and urinary diversion with 57 patients undergoing intracorpreal ilial conduit and 46 with intracorporeal orthotopic neobladder [11]. The authors report a mean OR time of 420 min, EBL of 200 mL, average LOS of 7 days, and a 30-day Clavien 1-2 and 3-5 complication rate of 42% and 17% respectively. The study demonstrated, among other things, the feasibility and reproducibility of both intracorporeal ileal conduit and neobladder procedures. Intracorporeal continent urinary diversion has also been described. Desai et al. reported on a cohort of 10 patients, who underwent intrcorporeal Indiana pouch creation in conjunction with cystectomy [12]. They reported similar operative time to ileal conduit creation, no intraoperative complications, and no transfusion requirements. In both the above studies, malignancy was the indication for the procedures and OT and EBL may be skewed secondary to extensive node dissections that may be skipped in the setting benign indications.

In 2017 Aisen et al. explored patient characteristics and complications of simple cystectomy [13]. Drawing on patients from the National Surgical Quality Improvement Program, they reported no significant difference in complication rates between radical and simple cystectomy (60.4% vs. 57.7%, $p = 0.3$). They did however, identify a significant increase in rate of infection in the benign cohort (31.1% vs 25.1%, $p = 0.009$). This could be secondary to the fact the recurrent cystitis is a common indication for simple cystectomy.

RECONSTRUCTION

Upper urinary tract reconstruction is a complicated field associated with considerable morbidity, and has classically been managed in an open fashion because of significant fibrosis and poor surgical planes [14-15]. Use of the robot in this area of urology has only recently become popular with experienced robotic surgeons. Literature pertaining to robotic upper tract reconstruction is sparse with few publications reporting on small cohorts. Despite this, the topic is of considerable importance as management of ureteral defects can be exceptionally frustrating to both patient and clinician.

Ureteral defects are most often caused by trauma/surgical injury, urolithiasis, radiation, malignancy and even infection such as tuberculosis [16-19]. Ureteral reflux, although not technically a defect in the ureter itself, is also a common cause for reconstructive surgical intervention. Management of these pathologies, includes pyeloplasty, uretero-ureterostomy (UU), ureteral reimplant (UR) with or without psoas hitch, boari flap, and ileal ureter- all of which have been described robotically. The choice of reconstructive technique hinges on several components such as length of defect and the segment of ureter involved. Additionally, the use of appendix and buccal mucosa for ureteral reconstruction has recently been reported. Each of these surgical techniques will be considered in this section.

Prior to this discussion, it is worthy to mention Indocyanine green (ICG) and its important adjunctive tool in the field of robotic ureteral reconstruction. ICG is a cyanine dye, that that when injected intravenously, can be visualized as bright green under near-infrared fluorescence (NIRF), a visual setting that can be turned on and off on the robotic platform. The dye is an ideal intraoperative contrast agent because it has a high signal-to-noise ratio, and an excellent safety profile [20]. Within urologic surgery, the dye was initially proposed for to assist in margin identification during partial nephrectomy. It gained popularity when it was used *intravenously* to aid in selective arterial clamping in partial nephrectomy [21]. In ureteral reconstruction, intravenous ICG can be used to define the vascular supply of the ureter prior to anastomoses or re-implantation with the hope of avoiding anastomotic breakdown or repair failure [22]. It can also be used to assess the vascular supply to an omental flap for interposition [22]. Even more recently, *intraureteral* ICG, an off-label use of the dye, has demonstrated itself to be an invaluable tool in identifying the ureter and site of injury in hostile fibrotic environments [23]. The dye comes in 25mg vials that is mixed in 10cc of water and can be injected antegrade down a nephrostomy tube or retrograde via a ureteral catheter prior to robotic intervention. The ureter then fluoresces within the dense fibrotic tissue aiding in ureteral identification. In this setting, the dye can also identify strictures and poorly perfused ureteral tissue thus helping to identify areas where intervention is needed. In 2013, Lee et all reported on their use of intraureteral ICG on a series of 7 UU repairs [23]. ICG was injected both retrograde and antegrade to both define the ureter and pinpoint the ureteral defect. In 2015, the same authors reported their use of the dye in a cohort of 25 patients undergoing robotic ureteral reconstruction [24]. The results confirmed the feasibility, utility and safety of intraureteral ICG in cases of ureteral reconstruction.

At our institution, ICG and NIRF is used in variable ways depending on the clinical scenario. We outline three different ways that NIRF can be used in complex ureteral reconstructive cases. ICG is a distinctive benefit of the robotic platform since the NIRF setting can be easily toggled on and off at the push of a button. In practice, intraureteral ICG

can be used when faced with severe retroperitoneal fibrosis where significant amount of time can be wasted in identifying the ureter and there may be a real concern for a vascular injury. 5cc of ICG can be placed into the ureter via a 5 French retrocatheter or down a percutaneous nephrostomy tube. This use of ICG is off label and should be discussed with the patient. However, once the labeled urine is spilled, the ICG stains the entire operative field and renders an intravenous application useless. Alternatively, an intravenous approach can be used if the surgeon hasn't applied ICG into the ureter. Once the ureter is identified, 2-3 cc of intravenous ICG can be given to help delineate vascular perfusion of the ureter, bladder and even omentum. In cases where there is a concern of ureteral ischemia (i.e., radiated ureter, pyeloplasty failure, reoperation on a ureter) an intravenous application of ICG can be very helpful in guiding your dissection and deciding where to excise and reanastomose. Intravenous ICG washes out, so intravenous ICG doses can be repeated every 20 minutes to reassess tissue perfusion and vascular integrity of your repair. Lastly, NIRF mode can be used in conjunction with conventional scopes with white light, without the use of ICG. For example, a ureteroscope in the ureter can be used to identify the specific location of the ureteral stricture. With the endoscopic white light turned on, the NIRF mode can be turned on and the white light will be seen as a green fluorescent signal. When using NIRF in this fashion, you can reserve use of the ICG for later in the case to help delineate perfusion information. Make sure the endoscopic light source is turned off promptly to avoid inadvertent thermal injury.

PYELOPLASTY

Robotic assisted laparoscopic pyeloplasty for uretero-pelvic junction obstruction (UPJO) represents one of the most common robotic non-oncological procedures performed by urologists. Although generally associated with the pediatric population, adult UPJO requiring pyeloplasty has a prevalence of roughly 1/1500 adults, and can be secondary to nephrolithiasis, ureteral manipulation, crossing vessels, outlet obstruction, and even idiopathic causes [25].

Table 3. Recent series for robot-assisted laparoscopic pyeloplasty in adults

Study	Cases	Approach	Operative Time minutes	Conversion rate, %	Complication rate, %	Hospitalization time in days	Success rate as a %
Sivaraman et al.	168	Trans	134.9	0	6.6	1.5	97.6
Minnillo et al.	155	Trans	198.5	0	11	1.95	96
Olsen et al.	67	Retro	146	1.5	17.9	2 †	94
Mufarrij et al.	140	Trans	217	0	10	2.1	95.7
Schwentner et al.	92	Trans	108	0	Not Reported	4.6	96.7
Etafy et al.	61	Trans	335	0	11.4	2	81
Gupta et al.	86	Trans	121	2.3	9.3	2.5	97
Cestari et al.	55	Retro and Trans	138.5	0	1.8	3.6	96

The first robotic pyeloplasty series was reported in 2002 by Gettman et al. [26], and since then, its use has steadily increased in popularity representing less than 10% of pyeloplasties in 2006, to 33% in 2007, to more than 80% in 2008 [27-28]. Since then, multiple large series have been reported in the adult population and are summarized with peri-operative parameters in Table 3. One of the largest reported series of 169 patients is reported by Sivaraman et al., who pooled data from three US institutions and confirmed that robotic Pyeloplasty represents a feasible, efficacious, and reproducible intervention for UPJO with high success rates and minimal complications [29].

Technical Considerations

Surgical Approach

Several surgical approaches, including retro-colic, trans-mesocolic and retroperitoneal methodologies have all been reported for robotic pyeloplasty [30]. Shadpour et al. was the first to compare minimally invasive trans-mesocolic pyeloplasty with the standard retrocolic approach in a prospective randomized fashion [31]. They analyzed 64 patients randomized between retrocolic and trans-mesocolic groups with each cohort consisting of 32 patients matched for gender, age, BMI and renal function. Results showcased a marked decrease in time from port placement to UPJ transection translating into a roughly 23% decrease in overall operative time. Although success rates were similar at 97%, length of stay in the trans-mesocolic group was significantly shorter (mean: 2.9 vs 3.6 $p < 0.001$). Gupta et al. reported the outcomes of 24 trans-mesocolic robotic pyeloplasties with mean operative times reported at 125 min, and a 43 minute anastomoses time [32]. LOS was an average of 2.5 days, and a 100% success rate as defined by radiographic evidence of obstruction.

More recently, accessing the UPJ from a retroperitoneal approach has become popular following data reported from robotic retroperitoneal partial nephrectomy series. [33]. The advantages of retroperitoneal access include rapid access to the renal pelvis, elimination of urine spillage into the abdomen, and prevention of injury to the intra-peritoneal structures. Yet, concerns surrounding anatomic orientation, and restricted work space represent universally recognized limitations. Several retroperitoneal series for both adult and pediatric populations have been reported. A recent meta-analysis addressing retroperitoneal versus trans-mesocolic approaches did not demonstrate significant differences in success rates, complications or length of stay [34]. Significant differences were, however, reported favoring the trans-mesocolic approach, in operative time (mean reduction 44.9 min) and risk of conversion to open (RR 0.4). The above meta-analysis included a single prospective randomized trial.

Surgical Technique

Aside from the Anderson-Hynes dismembered pyeloplasty, several other robotic techniques have been reported, including the Fenger, Y-V plasty, spiral flap, and several variations of each [35-38]. The Fenger reduces operative time with short stenotic segments by simply making a longitudinal incision followed by a transverse suture line. The Y-V plasty is ideal for ureters with high insertion into the UPJ, and the spiral can reduce the size of a dilated renal pelvis. Despite these reports, however, there is no level one evidence suggesting

superiority of one technique over another for any given population. A final alternate technique is the vascular hitch procedure which entails transposing aberrant lower pole renal vasculature, and is a method for addressing UPJO without re-anastomosis of the upper urinary tract [39]. Various studies have demonstrated efficacy in carefully selected patients, and the procedure should be utilized on a case by case basis until stronger evidence of its durability is published. [39-40].

Comments

Refining the technique of pyeloplasty remains an extremely active area of research. Each case is unique and the repair considerations need to be adjusted on a case by case basis. Understanding and addressing the cause and extent of the obstruction remains the greatest challenge for the pyeloplasty surgeon. Minimizing direct handling of the ureter, avoiding over dissection of the ureter and consideration of the vascular blood supply are all challenging technical aspects of robotic pyeloplasty. In addition, a number of methods for starting the ureteropelvic anastomosis prior to completing transection have recently been proposed with comparable results to the standard technique [41]. Utmost care must be taken when anastomosing the apex of spatulation and typically we take two throws in the corner for extra support. At our institution, we utilize a 5-0 monocryl suture (Ethicon) on a tapered TF needle, cut to 6 inches for the anastomosis. We typically will perform a running anastomosis on one

side, followed by deploying a double J stent placement and finally, running another 5-0 monocryl suture on the remaining side. Reduction of the renal pelvis should be considered in cases where the renal pelvis is excessively capacious.

URETEROURETEROSTOMY (UU)

UU technically represents one of the more straightforward ureteral reconstructive procedures with an excision and primary anastomoses of the ureteral defect. In practice, UU can be extremely challenging due to mechanism of injury and periureteral tissue quality and fibrosis. The technique presumes that no tissue interposition is required to bridge the gap in the ureter generated by the defect, and is generally utilized in the mid to upper sections of the ureter. Work by De Cicco et al. in a review of all published UU series from 1990-2006 established the feasibility of minimally invasive UU [42]. Since that time, only scant literature has surfaced on robotic UU.

Surgical Technique and Outcomes

Port placement and positioning for UU follows configuration for kidney work with the patient in flank/modified flank and the table flexed. In 2010, Hemal et al. reported on seven proximal robotic UU repairs for benign strictures [43]. Cases began with medializing the colon and varying degrees of ureterolysis depending on the particular pathology. Mean OR

time was reported at 110 minutes (range 85 – 140), with an average EBL of 50 cc (range < 50 – 75), and a mean LOS of 3 days (range 2 – 6). There were no reported complications and at 28 months all patients were symptom free. In 2013 Lee et al. reported on a series of 13 UU repairs spanning from proximal to distal defects [44]. Port placement and patient configuration was flank for proximal and mid ureteral inventions, and lithotomy with pelvic ports for distal repairs. Additionally, downward nephropexy was performed concurrently in all proximal/mid ureteral repairs to ensure tension free and watertight anastomoses. They reported mean operative room time of 190 minutes (range 104 – 354), EBL of 181cc (range 50 – 400), and mean LOS of 1.4 days (range 1 – 5). Although there was one intraoperative complication involving injury to the gallbladder secondary to trocar placement, there were no postoperative complications and at 10 months all patient except one were symptom free. Finally, in 2014 Fifer et all reported on 5 robotic UU repairs within a larger series of 55 patients who underwent robotic repair of ureteral defects from below the UPJ to the uretero-vesicle junction [45]. Although only composite results are tabulated without breakdown of perioperative parameters by type of repair, none of the 5 patients who underwent robotic UU had any form of complication and at a mean follow up of 6 months.

Comments

Traditionally, definitive surgical management for distal ureteral defects has been ureteroneocystotomy with surgeons shying away from performing UU in distal injuries. The support for this trend originates from reports touting that distal UU is accompanied by a higher failure rate secondary to disruption of the delicate plexiform vessels that supply the distal ureter and the difficulty of operating in the deep pelvis [46-47]. Yet avoiding re-implant comes with significant benefits including preservation of bladder integrity and the natural anti-reflux mechanism. In a retrospective report of nine open UU repairs, Paick et al. demonstrated the feasibility and durability of UU in the distal ureter for select patients with non-complex, short, distal ureteral injuries [48]. Our experience with robotic distal UU underscores these findings with 7 patients undergoing successful distal UU repair without intra/postoperative complication and 100% success rate to date [49]. In general, we perform distal UU when the ureteral stricture is short (< 2cm), when the stricture location is > 2 cm from the ureteral insertion and if we can attain a tension free watertight anastomoses. When performing UU in the distal ureter, it is important to try and preserve the distal ureteral blood supply coming from the internal iliac artery whenever feasible. We utilize a 5-o monocryl suture (Ethicon) on a tapered TF needle, cut to 6 inches for the anastomosis. Once on half of the anastomosis is completed, a double J stent is left across the repair before running another 5-0 monocryl suture on the remaining side. At the end of the case, we cystoscopically confirm that the distal stent is properly located in the bladder.

ILEAL URETER (IU)

Interposition of bowel into the upper urinary tract is indicated in the repair of complex and lengthy ureteral strictures and was initially described by Shoemaker in 1909. Although

significant morbidity accompanies it, modern series have established the efficacy of the IU with regards to preservation of renal function [50-55]. The surgical technique has been performed robotically, in limited series, with the most recent reports being summarized in Table 4.

Table 4. Summary of most recent series for minimally invasive ileal interposition

Study (Year)	No. of patients	Ileo-vesical anastomosis	Median operative time minutes (range)	Median EBL (mL) (range)	Perioperative complications (Clavien grade)	Median hospital stay (days) (range)
Wagner et al. (2008)	1	Robotic	720	Minimal	None	5
Brandao et al. (2014)	1	Robotic	420	50	None	4
Sim et al. (2014)	5[a]	Laparoscopic	250 (150 - 320)	100 (50 - 200)	Migrated stent (3b), Fever (2)	8 (6 - 10)
Chopra et al. (2016)	3	Robotic	450 (420 - 540)	100 (50 - 200)	Small bowel necrosis (4a)	9 (2 - 12)
Urbig et al. (2017)	7	Robotic	328 (261 - 394)	100 (50 - 200)	Anastomotic urine leak (3b)	25 (6 - 79)

[a] four cases were laparoscopic, one was robotic.

Surgical Technique and Outcomes

The surgical technique for ileal ureter closely follows that for the open procedure and has been previously described [56]. Robotically, port placement and positioning are challenging to work concomitantly on the upper and lower tract with bowel interposition and proper patient position and port configuration are critical for success. Brandao et al. reported their technique for robotic ileal urter in 2014 on a single patient utilizing a three-arm approach [57]. Patient positioning started in modified flank, transitioned to lithotomy and was then repositioned back into modified flank for the final anastomoses. OT was reported at 420 minutes, EBL was 50cc, foley removal after cystogram on post op day 12, and at two years follow up the patient had stable renal function. A recent report of robotic ileal ureters from Chopra et al. in 2016 describes a 4 arm approach where the operation begins in flank position for bowel mobilization, transitions to lithotomy for lower tract/bladder access and bowel harvesting, and finally repositions back into flank for the final anastomoses of the bowel to the upper tract [58]. They reported their outcomes on a cohort of three with median OT at 450 minutes (range 420 - 540). EBL of 150cc (range 50 - 200). Two out of the three reported good outcomes without the need for further surgical intervention while one patient developed volvulus and subsequently required a takedown of the ileal ureter.

Comments

Interposition of bowel into the urinary tract stands as a last resort in cases where there is an extensive ureteral defect. We typically place the patient in modified flank position with a 4-arm approach and repositioning is not usually necessary. The ports are placed linearly along

the mid-clavicular line and the most caudad port is used as the daVinci stapler port. We use the robotic 45mm blue load staples to perform the ileal transection and bowel re-anastomosis. It is important to remember that on the left side, the entire ileal segment needs to be delivered under the IMA and sigmoid colon mesentery. Although a single dock approach is feasible on the Si platform, the Xi platform has made this procedure much easier with less external collisions due to is lower profile and less bulky arm design.

BOARI FLAP

For distal ureteral strictures not amenable to re-implant (4 - 5cm) or re-implant with psoas hitch (6 - 10cm), a boari flap is an acceptable alternative with acceptable success rates well documented in the literature [59]. As with other open procedures, the transition to minimally invasive approaches started with laparoscopy [60] and transitioned to robotics more recently. Table 5 documents the few known series of robotic ureteral re-implants with Boari Flap.

Table 5. Summary of the current literature on robot-assisted ureteral reimplantation with Boari flap

Report	Diagnosis	Number of renal units	Boari flap renal units	Other procedures	Operative time for Boari flap Minutes	Complications in Boari flap cases
Schimpf and Wagner 2009	Benign strictures, lymphoma, diverticulum, urothelial carcinoma	11	2	9 reimplantations (3 cases with psoas hitch)	150, 188 (robotic time)	External iliac vein injury (robotic repair) x 1 case Ileus x 1 case
Kozinn et al. 2012	Benign strictures	10	2	8 reimplantations (4 cases with psoas hitch)	Not reported	Not reported
Musch et al. 2013	Benign strictures, megaureter, urothelial carcinoma	18 (2 bilateral cases)	2	14 reimplantations (4 cases with psoas hitch), 1 end-to-end anastomosis, 1 ureterolysis and omentum wrap	230 - 320	Prolonged anastomotic leakage x1, bladder wall insufficiency x1, urinary tract infection x 2
Stolzenburg et al. 2016	Benign and malignant ureteral stricture, iatrogenic injury	11	11	Not Reported	166 (115 - 240)	Prolonged anastomotic leakage x 1

Surgical Technique

Surgical technique for robotic ureteral re-implant with boari flap mirrors the open procedure which has been well described previously [59]. In 2014 Do et al. reported on their series of 8 patients who underwent robotic ureteral re-implant with Boari flap [61]. Patient

positioning and trocar placement was similar to standard pelvic interventions with the patient in lithotomy and steep Trendelenburg. The bladder flap was created with a 2:1 length to width ratio and hitched to the psoas muscle prior to ureteral tunneled re-implantation as described by Leadbeter and Politano [62]. Results demonstrated average OT of 172 minutes [115 - 240], EBL of 161 [50 - 250] catheterization time of 7 days [6-12], and 12 month follow up with no significant complications associated with the procedure. In 2016 Stolzenberg et all reported on their series of 11 patients utilizing the same technique for robotic re-implant and Boari flap [63]. They reported an operative time of 167 min (Range: 115 - 240) EBL of 155cc [50 - 250], catheterization time of 6.7 days [6-12], and recurrence free follow up of 15 months [6-24].

Comments

We recommend performing a cystogram or videourodynamics during the surgical planning phase to ensure patient has a minimum of 400 cc bladder capacity. The patients should be counseled that their bladder capacity may be decreased and may impact their postop urinary symptoms. A patient with significant bladder instability or a patient with prior pelvic radiation is not a good candidate for a Boari flap. It is important to make sure a wide based flap is taken to ensure that the apex of the flap has adequate blood supply. We recommend using intravenous ICG and NIRF to assess real-time blood supply of the bladder and flap prior to committing with ureteral anastomosis.

URETERAL RE-IMPLANT

The distal third of the ureter is one of the most common sites requiring reconstructive intervention. Aside from being susceptible to general pathology that effects the ureters, the distal ureter courses in close proximity to the female reproductive organs, thus at increased risk for injury during gynecologic surgery. The rate of ureteral injury in gynecologic surgery ranges from 0.03% to 1.3% with laparoscopic and robotic procedures being greater risk factors for ureteral injury [64]. In reality, however, the rate of ureteral injury in pelvic surgery is commensurate with experience, and at some hospitals, can be significantly higher. Short defects arising from non-malignant disease is usually managed by ureteral re-implant, and is a common reconstructive urological intervention. Majority of the literature pertaining to robotic ureteral re-implantation emanates from the pediatric population where it is used to definitively treat vesico-ureteral reflux. A recent multi-institutional study published in 2017 by Boysen et all reported on a cohort of 363 ureters that were robotically re-implanted in the pediatric population [65]. They reported a roughly 90% success rate defined radiographically with only 25 overall complications majority of which were clavien 1-2. In the adult population, a handful of series report on their experience with robotic ureteral re-implant for benign disease and they are presented in Table 6.

Table 6. Recent series for robotic assisted ureteral re-implant

Reference	Patients	Procedure	Operative time (minutes)	Estimated blood loss (mL)	Length of stay (days)	Complications	Follow-up (months)	Outcomes
Yang et al. 2011	2	1 Reimplant with Boari flap, 1 with psoas hitch	Not Reported	75	5	None	2 years 1 patient	One patient with no hydronephrosis; 1 lost to follow-up
Kozinn et al. 2012	9	6 Reimplants 3 with psoas hitch 1 Boari flap	307	30.6	2.4	None	Up to 24 months	No hydronephorsis
Isac et al. 2013	25	11 Reimplants 4 with psoas hitch, 10 with with Boari flap	279	100	3	2/25 (7.9%): required reoperation	11.6	Two failures requiring further surgical intervention
Musch et al. 2013	9	5 Reimplants 2 with psoas hitch 2 with Boari Flap	271 (153 - 460)	Not Reported	12 (5 - 35)	5/9 (55.5%): 2 Clavien 3b 1 Clavien 4a	11 (4 - 18.2)	1 patient with persistent hydronephrosis
Wason et al. 2015	13	6 primary UNC, 8 UNC with psoas hitch	282 (174 - 418)	123 (20 - 600)	2.5 (1 - 8)	3/13 (23%): 2 Clavien 3b	9.8 (2.3 - 20)	No hydronephrosis

Surgical Technique and Outcomes

Patil et al. were the first to report robotic experience with benign ureteral disease and ureteral reimplantation in 12 patients from a multinational institutional dataset [66]. Patient positioning and port placement followed standard protocol for pelvic interventions with the patient in lithotomy and steep Trendelenburg. The procedures began with mobilization of the colon followed by ureteral identification and ureterolysis to varying degrees. In all cases a stent was left across the anastomoses. Significant findings included a decrease in blood loss and hospital stay in comparison to the open technique on top no reported complications, and no evidence of recurrence at 15 months follow up. Isac et al. retrospectively reviewed and compared their series of 25 patients who underwent robotic re-implant with 41 patients who had open re-implants [67]. Significant results demonstrated lower EBL (100cc VS 150cc p< 0.05) shorter hospital stays (median, 3 versus 5 days p< 0.05), less narcotic use (104.6mg versus 290mg Morphine p< 0.05) and no significant difference in the rate of re-operation (2/25 (7.6%) VS 4/41 (9.7%) p< 0.05). The robotic approach did, however, log longer OT (Avg 200 VS 279 p< 0.05). More recently in 2015 Wason et al. reported on their series of 13 patients involving 14 re-implants, one of the largest single institution series for ureteral re-implantation for benign pathology [68]. Mean overall OT was 282 min (range, 174 – 418), and EBL was a mean of 123cc (range, 20 – 600). Patients spent an average of 2.5 in

the hospital (median, 2; range, 1 – 8), and mean follow-up was roughly 10 months (range, 2.3 – 20). All patients were reported asymptomatic at the time of publication. A standard Bricker refluxing anastomoses was utilized in this series, and although non refluxing re-implants have been described depending on surgical indication, use of a refluxing anastomoses more avidly prevents re-stenosis than does a non-refluxing.

Comments

Except for intervention to prevent refluxing ureter pathology, most indications allow for a non-tunneled, refluxing ureteroneocystostomy. For the anastomosis, a running 4-0 or 5-0 Monocryl (Ethicon, Sommerville, NJ) suture on a TF or RB-1 needle is recommended. Except for the most distal ureteral injuries or obstructions, most ureteral reimplantations, including most resulting from gynecologic complications, will require a psoas hitch to produce a tensionless anastomosis. It is important to completely free the bladder from the space of Rezius to enable maximal bladder mobility. Dividing the contralateral superior vesical artery can offer a modest improvement in bladder mobility. It is important to clean off the psoas fascia before performing the hitch stitch to avoid inadvertent entrapment of the genitofemoral nerve and ensuring that psoas tendon is well identified. In some cases, a psoas tendon is absent and psoas fascia will have to suffice. We recommend that at least 3 point of suture fixation are taken to secure the hitch. Since tying tensioned sutures can be challenging, we prefer using an absorbable Laproclip (Medtronic) to perform a sliding clip maneuver on an 0 VLOC suture with a GS-21 needle as the hitch stitch. The sliding clip technique has been popularized for renorrhaphy during partial nephrectomy and enables a uni-directional ratcheting mechanism so that the hitch can be gradually tensioned without the need to tie a knot.

BUCCAL MUCOSA ONLAY GRAFTS

Ureteral defects of the mid to upper ureter where a tension free anastomoses is unattainable even after downward nephropexy are a unique challenge to the reconstructive urologist. With classic treatment options warranting bowel interposition or nephrectomy, it was clear that a better option was needed to bridge gaps in the ureter that fell just short of successful UU. With established animal models in baboons touting encouraging results, in 1999 Naude reported the first buccal graft ureteroplasties on a cohort of 6 patients [69]. Performed in the open technique, the author reported no complications and patent ureters on retrograde pyelograms at 3 months post operatively. Since his initial report, several small series have been reported in the open surgical literature [70-71].

Surgical Technique and Outcomes

The first report of robotic buccal mucosa ureteroplasty was in a cohort of 4 patients by Zhou et al. in 2015 [72]. Patient positioning was flank and similar to robotic kidney

interventions with the table flexed at the hip. Mean stricture length was 3cm with two patients undergoing posterior onlay, one patients undergoing anterior onlay, and one patient with augmented anterior onlay anastomoses. Oral mucosa was harvested by an otolaryngologist at a length that was pre-defined based on the length of the stricture after ureterolysis and the boarders of pathology clearly defined. They reported no intraoperative complications, average EBL of 75cc, average operative time at 298 min, and no evidence of reoccurrence at 15 months. More recently, Lee et al. presented a cohort of 12 patients that underwent buccal ureteroplasty for a mean stricture length of 3cm [73]. With similar patient positioning they reported on two methodologies of ureteral reconstruction: longitudinal incision of the anterior stricture with subsequent buccal onlay graft, and complete stricture excision with posterior primary repair and anterior augmented buccal graft anastomosis. In the case of total stricture excision, the procedure involved downward nephropexy to shorten the overall ureteral defect. The Oral mucosa was harvested by a reconstructive urologist at a predefined length based on the identified ureteral defect. After the reconstruction, all patients received an omental wrap to protect the anastomoses and nurture the graft. Results included no reported intraoperative complications, mean operative time of 217min, average EBL of 100cc, and at a mean follow up of 13 months 10/12 patients were symptom free.

The largest buccal graft series to date was recently published in late 2017 by Zhao et al. from a multi institutional data set [74]. Incorporating 19 patients, the augmented anastomotic repair was utilized in ~ 20% of patients while the remaining patients underwent an anastomotic repair. The median stricture length was 4.0cm (2.0 - 8.0), operative time was 200min (136 - 397), estimated blood loss was 95cc (25 - 420), and length of stay was 2 d (1 - 15). No intraoperative complications were reported and at median follow-up of 26 months, success rates were reported at ~ 90%. Of note, more than 50% of these interventions were redo procedures after failed non buccal repairs.

Comments

The use of buccal mucosa to reconstruction of the upper tract ureter has revolutionized the management of an exquisitely difficult to treat patient population. Furthermore, the application of this technology to the minimally invasive robotic platform has made this treatment option more accessible to patients given all the technical advantages provided by the robot not available to the few skilled reconstructive urologists who perform these procedures open. One unique aspect of this operation is that since dissection is only localized to the stricture site, failure of this procedure doesn't preclude the more traditional options such as ileal ureter or Boari flap. In addition, since it is meant to minimize disruption of blood supply, it is well suited to revision of a pyeloplasty, unlike a spiral flap. In contrast, blood supply is brought in via omental flap. There are several intrinsic characteristics of BM that make it well suited for incorporation into the urinary system. Firstly, the oral cavity is a hairless, aqueous environment as is the urinary tract. Secondly, exposure of BM to urine does not mediate an inflammatory response which would put the graft in danger for rejection as does keratinized epithelial grafts [75]. Finally, the thick epithelium, thin lamina propria, and matured vascular plexus of BM allow the graft to take exceedingly well [76].

At our institution, intravenous or intraureteral ICG and NIRF is routinely used for these types of cases due the significant amount of peritureteral fibrosis and variable blood supply to

the area of pathology. Using these adjuncts has helped to cut down on excessive ureteral dissection and OR time. Additionally it is helpful to define vascular supply to the ureteral defect which affects the type of repair utilized. If the entire defect has no blood supply, the segment of ureter is excised, a posterior ureteral plate is approximated, and the graft is then onlayed to create an augmented anastomosis. Alternatively, if the strictured segment has adequate blood supply and there is a usable lumen, the anterior wall of the stricture can be sharply incised longitudinally and repaired with an anterior onlay graft.

Suturing your graft is easiest if the ureterotomy is made antero-medially and not posteriorly. In all of our cases, we utilize omentum to deliver blood supply to our graft, therefore the anastomosis is easiest antero-medially. In the rare case that omentum is not available, the ureter may need to be opened posteriorly to gain blood supply directly from the psoas muscle. In these cases, the BMG should be sutured directly into the psoas muscle bed making ureteral anastomosis much more technically challenging. Regarding buccal graft harvesting, we always advise measuring your ureteral defect intracorporeally prior to harvesting the graft. To avoid aneurismal dilation of the BMG, we advise fitting the graft to size and not oversizing it. We use 5-0 moncryl suture on a TF needle, cut to six inches for each half of the anastomosis. 6 French double J stent is usually placed halfway through the completion of the ureteral repair.

APPENDICEAL INTERPOSITION

For ureteral defects that are too long for buccal grafts and would otherwise be amenable to ileal ureter, use of the appendix interposed in the urinary tract stands as a new and attractive option. Originally described in 1912 [77]. Only few reports of this technique have been published and almost all describe use of the appendix as an onlay graft similar to buccal mucosa [78-79].

A recent report from Kavoussi and colleagues in 2015 described 6 laparoscopic appenaceal onlay reconstructions for ureteral stricture disease [80]. They reported feasibility with only a single patient requiring subsequent nephroureterectomy for reasons unrelated to the graft.

Surgical Technique and Outcomes

Although we are aware of several institutions that have performed robotic appendiceal interposition, only a single robotic appendiceal interposition publication exists out of the university of Alabama at Birmingham [81]. In this case report, they describe a patient with a 5cm right sided stricture that was successfully treated with a robotic appendiceal interposition. Operative time was roughly 6 hours with 100cc of blood loss, LOS of 2 days, and at 10 months there was full resolution to hydronephrosis and no clinical symptoms of obstruction.

The full surgical procedure is fully described in the publication. Briefly, a mesenteric window is created in the mesoappendix, with subsequent ligation of the appendix off the cecum. Both the proximal (opposite the cecal end) and distal appendiceal ends ware

spatulated on the antimesenteric side and residual fecal matter is removed. The proximal and distal ends of the ureter are then spatulated on the contralateral side of the appendiceal spatulation and anastomosed. After stent placement, the cecum and right colon are tacked to the abdominal sidewall to relieve possible vascular on the repair.

Comments

The most important advice is to ask your patient preoperatively in the office if the patient has ever had an appendectomy. For complex ureteral reconstructive cases, it is imperative that the surgeon goes into surgery with a well laid out plan. Usually, the appendix is best suited for right sided strictures, as tunneling the appendix under the sigmoid mesentery to reach the left ureter is unlikely. As long as the mesoappendix is well preserved, the appendix can serve as either a tubular ureteral replacement or as an onlay. For longer strictures that require more tissue than buccal mucosa can provide, use of the appendix has several benefits over the standard ileal ureter. Firstly, the caliber of the appendix more closely approximates that of the ureter making the anastomoses less cumbersome. Secondly, the small diameter limits the contact urine has with the intestinal tract and thus protects against metabolic imbalances. Finally, it does not require a bowel anastomoses which stands as a well known source of post operative complications. It is worthy to mention as well that appendicieal interposition does not preclude the patient from future ileal ureter should it fail.

CONCLUSION

Robotic urologic surgery is an ever progressing field with our ability to push boundaries aided by consistently advancing technologies Robotic laparoendoscopic single-site technique (R-LESS), is a technology on the horizon that was first explored in 2005 with the idea of a single port in which several robotic arms and instruments can be passed. Since then, several recent reports have demonstrated its feasibility in urologic surgery. Benefits to this technology include enhanced optics and ergonomics with improved cosmesis and a decrease in incisional hernias and post-operative complications. Yet, the technology has not been perfected with user complaints related to poor triangulation, difficulty with retraction and arm clashing, and decreased assistant access. In response to these concerns, the da Vinci SP 1098 was designed by Intuitive Surgical as a platform designated specifically for R-LESS surgery. The system is still in preclinical phase, however, users report enhanced triangulation and arm clashing. The role of this robotic platform in the armamentarium of the practicing urologist has not yet been defined.

In sum, robotics has revolutionized urologic surgery both by refining current surgical techniques, as well as allowing urologists to tackle more complicated interventions that would otherwise be addressed in the classic open fashion. As more medical specialties adopt the robotic platform, the benefits of this technology will only continue to grow in the coming years.

REFERENCES

[1] Poletajew, Slawomir., Artur, A. Antoniewicz. & Andrzej, Borówka. (2010). "Kidney removal the past, presence, and perspectives a historical review." *Urology Journal*, *7*(4), 215–23.

[2] Abbaza, Ronney. (2013). "*Robotic Renal Surgery, Benign and Cancer Surgery for the Kidneys and Ureters*." New York. Springer.

[3] Guillonneau, Bertrand., Christian, Jayet., Ashutosh, Tewari. & Guy, Vallancien. (2001). "Robot assisted laparoscopic nephrectomy." *The Journal of Urology*, *166*(1), 200-201. doi:10.1016/S0022-5347(05)66111-3.

[4] Horgan, Santiago., Daniel, Vanuno. & Enrico, Benedetti. (2002). "Early experience with robotically assisted laparoscopic donor nephrectomy." *Surgical Laparoscopy Endoscopy Percutananeous Techniques*, *12*(1), 64-70.

[5] Rogers, Craig., Rajesh, Laungani., Louis, Spencer Krane., Akshay, Bhandari., Mahendra, Bhandari. & Mani, Menon. (2008). "Robotic nephrectomy for the treatment of benign and malignant disease." *BJU International*, *102*(11), 1660-1665. doi: 10.1111/j.1464-410X.2008.07895.

[6] McVary, Kevin. T., Claus, Roehrborn., Andrew, L. Avins., Michael, J. Barry., Reginald, C. Bruskewitz., Robert, F. Donnell., Harris, E. Foster., Jr. Chris, M. Gonzalez., Steven, A. Kaplan., David, F. Penson., James, C. Ulchaker. & John, T. Wei. (2011). "Update on AUA guideline on the management of benign prostatic hyperplasia." *The Journal of Urology*, *185*(5), 1793-1803. doi: 10.1016/ J.JURO.2011.01.074.

[7] Oelke, Matthias., Alexander, Bachmann., Aurelien, Descazeaud., Mark, Emberton., Stavros, Gravas., Martin, C. Michel., James, N'Dow., Jorgen, Nordling. & Jean, J. de la Rosette. (2013). "EAU guidelines on the treatment and follow-up of non-neurogenic male lower urinary tract symptoms including benign prostatic obstruction." *European Urology*, *64*, 118-140.

[8] Pokorny, Morgan., Giacomo, Novara., Nicolas, Geurts., Zach, Dovey., Ruben, De GrooteAchilles Ploumidis., Peter, Schatteman., Geert, de Naeyer. & Alexandre, Mottrie. (2015). "Robot-assisted simple prostatectomy for treatment of lower urinary tract symptoms secondary to benign prostatic enlargement: surgical technique and outcomes in a high-volume robotic centre." *European Urology*, *68*(3), 451-457. doi: 10.1016/j.eururo.2015.03.003.

[9] Autorino, R., Zargar, H., Mariano, M. B., et al. "Perioperative Outcomes of Robotic and Laparoscopic Simple Prostatectomy: A European-American Multi-institutional Analysis." *European Urology.*, *68*(1), 86-94. doi: 10.1016/j.eururo.2014.11.044.

[10] Chong, J. T., Dolat, M. T., Klausner, A. P., Dragoescu, E. & Hampton, L. J. (2014). "The role of cystectomy for non-malignant bladder conditions: a review." *Canadian Journal or Urology.*, 2014, 21(5), 7433-41. doi.

[11] Abreu, Andre Luis de Castro., Sameer, Chopra., Raed, A Azhar., Andre, K Berger., Gus, Miranda., Jie, Cai., Inderbir, S Gil., Monish, Aron. & Mihir, M Desai. (2014). "Robotic radical cystectomy and intracorporeal urinary diversion: The USC technique." *Indian Journal of Urology*, *30*(3), 300-6. doi: 10.4103/0970-1591. 135673.

[12] Desai, Mihir M., Giuseppe, Simone., Andre, Luis de Castro Abreu., Sameer, Chopra., Mariaconsiglia, Ferriero., Salvatore, Guaglianone., Francesco, Minisola., Daniel, Park., Rene, Sotelo., Michele, Gallucci. & Inderbir, S. Gill Monish Aron. (2017). "Robotic Intracorporeal Continent Cutaneous Diversion." *The Journal of Urology*, *198*(2), 436-444. doi: 10.1016/j.juro.2017.01.091.

[13] Aisen, Carrie M., Michael, J Lipsky., Henry, Tran. & Doreen, E. Chung. (2017). "Understanding Simple Cystectomy for Benign Disease: A Unique Patient Cohort With Significant Risks." *Urology*, *110*, 239-243. doi: 10.1016/j.urology.2017.07. 002.

[14] Engel, Oliver., Michael, Rink. & Margit, Fisch. (2015). "Management of iatrogenic ureteral injury and techniques for ureteral reconstruction." *Current Opinion in Urology*, *25*(4), 331-335. doi: 10.1097/MOU.0000000000000175.

[15] Knight Richard, B., Steven, J. Hudak. & Allen, F. Morey. (2013). "Strategies for open reconstruction of upper ureteral strictures." *Urologic Clinics of North America*, *40*(3), 351-61. doi: 10.1016/j.ucl.2013.04.005.

[16] Tyritzis, Stavros. & Wiklund, Nils Peter. (2015). "Ureteral strictures revisited…trying to see the light at the end of the tunnel: a comprehensive review." *Journal of Endourology*, *29*, 124–36. doi: 10.1089/end.2014.0522.

[17] Hafez, Khaled., & Stuart, WolfJr. J. (2003). "Update on minimally invasive management of ureteral strictures." *Journal of Endourology*, *17*(7), 453–464. doi: 10.1089/089277903769013586.

[18] Khalaf, Ismail., Ahmed, Shokeir. & Mohamed, Shalaby. (2012). "Urologic complications of genitourinary schistosomiasis." *World Journal of Urology*, *30*, 31–38. doi: 10.1007/s00345-011-0751-7.

[19] Wise Gilbert, J. & Alex, Shteynshlyuger. (2008). "An update on lower urinary tract tuberculosis." *Current Prostate Reports*, *5*, 87-95.

[20] Alander Jarmo, T., Ilkka, Kaartinen., Aki, Laakso., Tommi, Patila., Thomas, Spillman., Valery, V. Tuchin., Maarit, Venermo. & Petri, Valisuo. (2012). "A review of indocyanine green fluorescent imaging in surgery." *International Journal of Biomedical Imaging*, 2012, 940585-940611. doi: 10.1155/2012/940585.

[21] Tobis, Scott., Joy, K. Knopf., Christopher, Silvers., Edward, Messing., Jorge, Yao., Hani, Rashid., Guan, Wu. & Dragan, Golijanin. (2012). "Robot-assisted and laparoscopic partial nephrectomy with near infrared fluorescence imaging." *Journal of Endourology*, *26*(7), 797-802.

[22] Goonewardene, Sanchia. & Alsheikh, M. (2017). "Tips and tricks for robotic urology using ICG." *World Journal of Urology*, *36*(3), 497-498. doi: 10.1007/ s00345-017-2157-7.

[23] Lee, Ziho., Blake, Moore., Laura, Giusto L. & Daniel, D. Eun. (2015). "Use of indocyanine green during robot-assisted ureteral reconstructions." *European Urology*, (2), 291-298. doi: 10.1016/j.eururo.2014.08.057.

[24] Lee, Ziho., Jay, Simhan., Daniel, C. Parker., Christopher, Reilly., Elton, Llukani., David, I. Lee., Jack, H. Mydlo. & Daniel, D. Eun. (2013). "Novel use of indocyanine green for intraoperative, real-time localization of ureteral stenosis during robot-assisted ureteroureterostomy." *Urology*, *82*(3), 729-33. doi: 10.1016/j.urology.2013.05.032.

[25] Khan, Fahd., Kamran, Ahmed., Nikiesha, Lee., Ben, Challacombe B., Mohammad, S. Khan. & Prokar, Dasgupta P. (2014). "Management of ureteropelvic junction

obstruction in adults." *Nature Reviews Urology*, *11*(11), 629-638. doi: 10.1038/nrurol.2014.240.

[26] Gettman, Matthew T., Richard, Neururer., George, Bartsch. & Reinhard, Peschel. (2002). "Anderson-Hynes dismembered pyeloplasty performed using the da Vinci robotic system." *Urology*, *60*, 509–513. doi: http://doi.org/10/1016/S0090-4295(02)01761.

[27] Oberlin Daniel, T., Barry, B. Mcguire., Matthew, Pilecki., Aksharanananda, Rambachan., John, Y. Kim., Kent, T. Perry. & Robert, B. Nadler. "Contemporary national surgical outcomes in the treatment of ureteropelvic junction obstruction." *Urology*, *85*(2), 363–7. 9. doi :10.1016/j.urology.2014.07.068.

[28] Monn, M. Franchesca., Clinton, D. Bahler., Eric, B. Schneider. & Chandru, Sundaram. (2013). "Emerging trends in robotic pyeloplasty for the management of ureteropelvic junction obstruction in adults." *The Journal of Urology*, *189*(4), 1352–1357. doi: 10.1016/j.juro.2012.10.001.

[29] Sivaraman, Ananthakrishnan., Raymond, J. Leveillee., Manoj, B. Patel., Sanket, Chauhan., Jorge, E. Bracho II., Charles, R. Moore., Rafael, F. Coelho., Kenneth, J. Palmar., Oscar, Schatloff., Vincent, G. Bird., Ravi, Munver. & Vipul, R. Patel. (2012). "Robot-assisted laparoscopic dismembered pyeloplasty for ureteropelvic junction obstruction: a multi-institutional experience." *Urology*, *79*(2), 351-355. doi: 10.1016/j.urology.2011.10.019.

[30] Autorino, Ricardo., Christopher, Eden., Alaa, El-ghoneimi., Giorgio, Guazzoni., Nicolormaria, Buffi., Craig, A. Peters., Robert, J. Stein. & Matthew, Gettman. (2014). "Robot-assisted and laparoscopic repair of ureteropelvic junction obstruction: a systematic review and meta-analysis." *European Urology*, *65*(2), 430-452. doi: 10.1016/j.eururo.2013.06.053.

[31] Shadpour, Pejman., Reza, Kaffash Nayyeri., Reza, Daneshvar., Hormoz, Salimi. & Hadi, Radfar. (2012). "Prospective clinical trial to compare standard colon-reflecting with transmesocolic laparoscopic pyeloplasty." *BJU International.*, *110*(11), 1814-8. doi: 10.1111/j.1464-410X.2012.11081.x.

[32] Gupta Narmada, P., Satyadip, Mukherjee., Rishi, Nayyar., Ashok, Kumar Hemal. & Rajeev, Kumar. (2009). "Transmesocolic robot-assisted pyeloplasty: single center experience." *Journal of Endourology*, *23*(6), 945-948. doi: 10.1089/end.2008.0430.

[33] Patel Manish, N., Sanjeev, A. Kaul., Rajesh, Laungani., Daniel, Eun., Mahendra, Bhandari., Mani, Menon. & Craig, G Rogers. (2009). "Retroperitoneal robotic renal surgery: technique and early results." *Journal of Robotic Surgery*, *3*(1), 1. doi: 10.1007/s11701-009-0123-0.

[34] Wu, YunJian., Qiang, Dong., Ping, Han., LiangRen, Liu., Li, Wang. & Qiang, Wei. (2012). "Meta-analysis of transperitoneal versus retroperitoneal approaches of laparoscopic pyeloplasty for ureteropelvic junction obstruction." *Journal of Laparoendoscopic & Advanced Surgical Techniques*, *22*(7), 658–662. doi: 10.1089/lap.2011.0508.

[35] Tan, Hung-Jui., Zaojun, Ye., William, W. Roberts. & Stuart, J. Wolf. (2011). "Failure after laparoscopic pyeloplasty: prevention and management." *Journal of Endourolology*, *25*(9), 1457-1462. doi: 10.1089/end.2010.0647.

[36] Ilie, Cristian P., Christopher, J. Luscombe., Ian, Smith., Jane, Boddy., Dan, Mischianu. & Anurag, Golash. (2011). "Routine day-case laparoscopic pyeloplasty: a paradigm shift?" *Journal of Endourology*, *25* (5), 797-801. doi: 10.1089/end.2010.0486.

[37] Hellstrom, J., Giertz, G. & Lindblom, K. (1951). "Pathogenesis and treatment of hydronephrosis." *J Belg Urol*, *20*(1), 1–6.

[38] Menon, Prema., Katragadda, L. N. Rao., Kushaljit, S. Sodhi., Bhattacharya, A., Akshay, K. Saxena. & Bhagwant, R. Mittal. (2015). "Hydronephrosis: comparison of extrinsic vessel versus intrinsic ureteropelvic junction obstruction groups and a plea against the vascular hitch procedure." *Journal of Pediatric Urology*, *11*(2), 80.e1–6. doi: 10.1016/j.jpurol.2014.10.014.

[39] Szydelko, Thomas., Wojciech, Apoznanski., Piotr, Koleda., Leslaw, Rusiecki. & Dariusz, Janczak. (2015). "Laparoscopic pyeloplasty with cephalad translocation of the crossing vessel—a new approach to the Hellström technique." *Wideochir Inne Tech Maloinwazyjne*, *10*(1), 25–29. doi: 10.5114/wiitm.2015.48695.

[40] Villemagne, T., Fourcade, L., Camby, C., Szwarc, C., Lardy, H. & Leclair, M. D. (2015). "Long-term results with the laparoscopic transposition of renal lower pole crossing vessels." *Journal of Pediatric Urology.*, *11*(4), 174.e1–7. doi: 10.1016/j.jpurol.2015.04.023.

[41] Ates, Mutlu., Yasar, Ozgok., Yugit, Akin., Murat, Arslan., Murat, Akand. & Mustafaf, Burak Hoscan. (2015). "Laparoscopic stepwise-cut double initial stay suture pyeloplasty: our novel surgical technique." *Journal of Laparoendoscopic & Advanced Surgical Techniques*, *25*(3), 228–233. doi: 10.1089/lap.2014.0552.

[42] De Cicco, Carlos., Maria, Lorena Ret dávalos., Ben, Van Cleynenbreugel., Jasper, Verguts. & Philippe, Robert Koninckx. "Iatrogenic ureteral lesions and repair: a review for gynecologists." *The Journal of Minimally Invasive Gynecology*, *14*(4), 428-435. doi: 10.1016/j.jmig2007.01.003.

[43] Hemal, Ashok K., Rishi, Nayyar., Narmada, P. Gupta. & Lalgudi, N. Dorairajan. (2010). "Experience with robot assisted laparoscopic surgery for upper and lower benign and malignant ureteral pathologies." *Urology*, *76*(6), 1387-1393. doi: 10.1016/j.urology.2010.01.044.

[44] Lee, Ziho., Elton, Llukani., Christopher, E. Reilly., Jack, H. Mydlo., David, I. Lee. & Daniel, D. Eun. (2013). "Single surgeon experience with robot-assisted ureteroureterostomy for pathologies at the proximal, middle, and distal ureter in adults." *Journal of Endourology*, *27*(8), 994-999. doi: 10.1089/end.2013.0075.

[45] Fifer Gordon, L., Mathew, C. Raynor., Patrick, Selph., Michael, E. Woods., Eric, M. Wallen., Davis, P. Viprakasit., Matthew, E. Nielsen., Angela, M. Smith. & Raj, S. Pruthi. (2014). "Robotic ureteral reconstruction distal to the ureteropelvic junction: a large single institution clinical series with short-term follow up." *Journal of Endourology*, *28*(12), 1424-1428. doi: 10.1089/end.2014.0227.

[46] Witters, S., Cornelissen, M. R. & Vereecken, R. (1986). "Iatrogenic ureteral injury: Aggressive or conservative treatment." *American Journal of Obstetrics & Gynecology*, *155*, 582–584.

[47] Zinman, Leonard M., John, A. Libertino. & Robert, A. Roth. (1978). "Management of operative ureteral injury." *Urology*, *12*, 290–303.

[48] Paick, Jae-Seung., Sung, Kyu Hong., Moon-Soo, Park. & Soo, Woong Kim. (2006). "Management of postoperatively detected iatrogenic lower ureteral injury: Should

ureteroureterostomy really be abandoned?" *Urology*, *67*, 237–241. doi: 10.1016/j.urology.2005.08.041.

[49] Gellhaus, Paul T., Akshay, Bhandari., Francesca Monn, M., Thomas, A. Gardner., Prashanth, Kanagarajah., Christopher, E. Reilly., Elton, Llukani., Ziho, Lee., Daniel, D. Eun., Hani, Rashid., Jean, V. Joseph., Ahmed, E. Ghazi., Guan, Wu., Ronald, S. Boris., et al. (2015). "Robotic management of genitourinary injuries from obstetric and gynaecological operations: a multi-institutional report of outcomes." *BJU International*, *115*(3), 430-436. doi: 10.1111/bju. 12785.

[50] Hansen, Moritz H., Matthew, Hayn. & Patrick, Murray. (2016). "The use of bowel in urologic reconstructive surgery." *Surgical Clinics of North America*, *96*(3), 567–582. doi: 10.1016/j.suc.2016.02.011.

[51] Matlaga, Brian R., Ojas, D. Shah., Lois, J. Hart. & Dean, G. Assimos. (2003). "Ileal ureter substitution: a contemporary series." *Urology.*, *62*, 998–1001.

[52] Bonfig, R., Gerharz, E. W. & Riedmiller, H. (2004). "Ileal ureteric replacement in complex reconstruction of the urinary tract." *BJU International*, *93*, 575–580. doi: 10.1111/j.1464-410X.2003.04672.x.

[53] Chung, Benjamin I., Karim, J. Hamawy., Leanoard, N. Zinman. & John, A. Libertino. (2006). "The use of bowel for ureteral replacement for complex ureteral reconstruction: long term results." *The Journal of Urology*, *175*, 179–184. doi: 10.1016/s0022-5347(05)00061-3.

[54] Armatys, Sandra A., Matthew, J. Mellon., Stephen, D. W. Beck., Michael, O. Koch., Richard, S. Foster. & Richard, Bihrle. (2009). "Use of ileum as ureteral replacement in urological reconstruction." *The Journal of Urology*, *181*, 177–181. doi: 10.1016/j.juro.2008.09.019.

[55] Wolff, Benoit., Emmanuel, Chartier-Kastler., Pierre, Mozer., Alain, Haertiig., Marc-Olivier, Bitker. & Morgan, Roupret. (2011). "Long-term functional outcomes after ileal ureter substitution: a single-center experience." *Urology*, *78*(3), 692–695. doi: 10.1016/j.urology.2011.04.

[56] Foret, Jessica. & Heusghem, C. (1953). "Replacement of both ureters by an ileal graft." *Lancet*, *1*(6772), 1181.

[57] Brandao, Luis Felipe., Riccardo, Autorino., Homayoun, Zargar., Humberto, Laydner., Jayram, Krishnan., Dinesh, Samarasekera., Georges-Pascal, Haber., Jihad, H. Kaouk., Sricharan, Chalikonda. & Robert, J. Stein. (2014). "Robotic ileal ureter: a completely intracorporeal technique." *Urology*, *83*(4), 951-954. doi: 10.1016/j.urology. 2013.11.035.

[58] Chopra, Sameer., Charles, Metcalfe., Raj, Satkunasivam., Shalini, Nagaraj., Carlee, Becker. & Andre, Luis de Castro Abreu. (2016). "Initial Series of Four-Arm Robotic Completely Intracorporeal Ileal Ureter" *Journal of Endourology*, *30*(4), 395-399. doi: 10.1089/end.2015.0674.

[59] Stein, Raimund., Peter, Rubenwolf., Christopher, Ziesel., Mohamed, M. Kamal. & Joachim, W. Thuroff. (2013). "Psoas hitch and Boari flap ureteroneocystostomy" *BJU International.*, *112*, 137–55. doi: 10.1111/bju.12103.

[60] Castillo, Octavia A., Juan, P. Litvak., Marcelo, Kerkebe., Ruben, Olivares. & Ruben, D. Urena. (2005). "Early experience with the laparoscopic boari flap at a single institution" *The Journal of Urology*, *173*(3), 862-865. doi: 10.1097/01.ju 0000152157.25984.ae.

[61] Do, Minh., Panagiotis, Kallidonis., Hasan, Qazi., Evangelos, Liatsikos., Thi, Phuc Ho., Anja, Dietel. & Jens-Uwe, Stolzenberg. (2014). "Robot-assisted technique for boari flap ureteral reimplantation: is robot assistance beneficial?" *The Journal of Endourology*, *228*(6), 679-685. doi: 10.1089/end.2013.0775.

[62] Politano, Victor A. & Wyland, F. Leadbetter. (1958). "An operative technique for the correction of Vesicoureteral reflux." *The Journal of Urology*, *79*(6), 932–941. doi: 10.1016/S0022-5347(17)66369-9.

[63] Stolzenburg, Jens-Uwe., Bhavan, P. Rai., Minh, Do., Anja, Dietel., Evangelos, Liatsikos., Roman, Ganzer., Hasa, Qazi., Aurus, Duarado Meneses. & Panagiotis, Kallidonis. (2016). "Robot-assisted technique for Boari flap ureteric reimplantation: replicating the techniques of open surgery in robotics." *BJU International*, *118*(3), 482-484. doi: 10.1111/bju.13502.

[64] Choi Yong, Sun., Lee, Sung Hyun., Cho, Hyuk Jin., Lee, Dong Hwan. & Kim, Sup Kang. (2017). "Outcomes of ureteroscopic double-J ureteral stenting for distal ureteral injury after gynecologic surgery." *International Urogynecology Journal*, pp. 1-6. doi: 10.1007/s0019.

[65] Boysen, William R., Jonathan, S. Ellison., Christina, Kim., Chester, J. Koh Paul Noh., Benjamin, Whittam., Balke, Palmer., Aseem, Shukla. & Andrew, Kirsch Mohan S. Gundeti. (2017). "Multi-Institutional Review of Outcomes and Complications of Robot-Assisted Laparoscopic Extravesical Ureteral Reimplantation for Treatment of Primary Vesicoureteral Reflux in Children." *The Journal of Urology*, *197*(6), 1555-1561. doi: 10.1016/j.uro.2017.01.062.

[66] Patil Nilesh, N., Alexandre, Mottrie., Bala, Sundaram. & Vipul, R. Patel. (2008). "Robotic-assisted laparoscopic ureteral reimplantation with psoas hitch: a multi-institutional, multinational evaluation" *Urology*, *72*(1), 47-50. doi:10.1016/ j.urology.2007.12.097.

[67] Isac, Wahib., Jihad, Kaouk., Faith, Altunrende., Emad, Rizkala., Riccardo, Autorino., Shahab, P., Hillyerm, Humberto Laydner., Jean, Alexandre Long., Ahmad, Kassab., Ali, Khalifeh., Kamol, Panumatrassame., Remi, Eyraud., Tommaso, Falcone., Georges, Pascal Haber. & Robert, J. Stein. (2013). "Robot-assisted ureteroneocystostomy: technique and comparative outcomes." *Journal of Endourology.*, *27*(3), 318-323. doi: 0.1089/end.2012.0196.

[68] Wason, Shaun E. L., Raymond, S. Lance., Robert, W. Given. & John, B. Malcolm. (2015). "Robotic-Assisted Ureteral Re-implantation: A Case Series." *Journal of Laparoendoscopic & Advanced Surgical*, *25*(6), 503-507. doi: 10.1089/ lap.2014.0051.

[69] Naude, J. H. (1999). "Buccal mucosal grafts in the treatment of ureteric lesions." *BJU International*, *83*, 751–754. doi: 10.1046/j.1464-410x.1999.00019.x.

[70] Kroepfl, Darko., Heinrich, Loewen., Virgilijus, Klevecka. & Michael, Musch. (2009). "Treatment of long ureteric strictures with buccal mucosal grafts." *BJU International*, *105*, 1452–1455. doi: 10.1111/j.1464-410X.2009.08994.x.

[71] Badawy Abdelbasset, A., Ahmad, Abolyosr., Saleem, D. Mohamed. & Abuzeid, M. Abdelmoneim. (2010). "Buccal mucosa graft for ureteral stricture substitution: initial experience." *Urology*, *76*, 971–975. doi: 10.1016/j.urology.2010.03.095.

[72] Zhao Lee, C., Yuka, Yamaguchi., Darren, J. Bryk., Sarah, A. Adelstein. & Michael, D. Stifelman. (2015). "Robot-Assisted Ureteral Reconstruction Using Buccal Mucosa." *Urology*, *86*(3), 634-638. doi: 10.1016/j.urology.2015.06.006.

[73] Lee, Ziho., Benjamin, T. Waldorf., Eric, Y. Cho., Jeffrey, C. Liu., Michael, J. Metro. & Daniel, D. Eun. (2017). "Robotic Ureteroplasty with Buccal Mucosa Graft for the Management of Complex Ureteral Strictures." *The Journal of Urology* 198(6):1430-1435. doi: 10.1016/j.juro.2017.06.097.

[74] Zhao Lee, C., Aaron, C. Weinberg., Ziho, Lee., Mark, J. Ferretti., Harry, P. Koo., Michael, J. Metro., Daniel, D. Eun. & Michael, D. Stifelman. (2018). "Robotic Ureteral Reconstruction Using Buccal Mucosa Grafts: A Multi-institutional Experience." *European Urology*, *73*(3), 419-426. doi: 10.1016/ j.eururo. 2017.11.015.

[75] Filipas, D., Fisch, M., Fichtner, J., Fitzpatrick, J., Berg, K., Storkel, S., Hohenfellner, R. & Thuroff, J. W. (1999). "The histology and immunohistochemistry of free buccal mucosa and full-skin grafts after exposure to urine." *BJU International*, *84*, 108–1011. doi: 10.1046/j.1464-410x.1999. 00079.x.

[76] Chapple, Christopher., Daniela, Andrich., Anthony, Atala., Guido, Barbagli., Andre, Cavalcanti., Sanjay, Kulkarni., Altaf, Mangera. & Yosuke, Nakajima. (2014). "SIU/ICUD consultation on urethral strictures: the management of anterior urethral stricture disease using substitution urethroplasty" *Urology*, *83*(supplement 3a), s31–47. doi: 10.1016/j.urology.2013.09.012.

[77] A. MelnikoffSur le replacement de l'uretere par anse isolee de l'intestine grele *Rev Clin Urol*, *1* (1912), p. 601.

[78] Jang Thomas, L., Merrill Matschke, H., Jonathan, N. Rubenstein., Chris, M. Gonzalez. (2002). "Pyeloureterostomy with interposition of the appendix." *The Journal of Urology*, *168*(5), 2106-2107. doi: 10.1016/S0022-5347(05)64306-6.

[79] Thomas, A., Eng, M. M., Hagan, C., Power, R. E. & Little, D. M. (2004). "Appendiceal substitution of the ureter in retroperitoneal fibrosis." *The Journal of Urology*, *171* (6), 2378. doi: 10.1097/01.ju.0000125333.41865.52.

[80] Duty, Brian D., Jessica, E. Kreshover., Lee, Richstone. & Louis, R. Kavoussi. (2015). "Review of appendiceal onlay flap in the management of complex ureteric strictures in six patients." *BJU International*, *15* (2), 282-287. doi: 10.1111/ bju.12651.

[81] Yarlagadda, Vidhush., Jeffrey, W. Nix., Daniel, G, Benson. & Patrick, Selph J. (2017). "Feasibility of Intracorporeal Robotic-Assisted Laparoscopic Appendiceal Interposition for Ureteral Stricture Disease: A Case Report." *Urology*, *109*, 201-205. doi:10.1016/ j.urology.2017.08.017.

In: Encyclopedia of Surgery (22 Volume Set)
Editors: Andreas Lehrer and Kristin Mueller
ISBN: 978-1-53618-329-0
© 2020 Nova Science Publishers, Inc.

Chapter 254

ROBOTIC SURGERY FOR UROLOGIC MALIGNANCIES

Jay D. Raman, MD
Urology, Penn State Health Milton S. Hershey Medical Center,
Hershey, PA, US

1. INTRODUCTION

Urologic surgery for both benign and malignant etiologies has evolved towards minimally invasive approaches when feasible and safe. Conventional laparoscopic surgery represented the initial minimally invasive breakthrough with demonstrable benefits across various disease processes with respect to perioperative morbidity, convalescence, and return to standard activities of daily living [1]. Laparoscopy, however, is not without challenges including a relatively steep learning curve, need for advanced surgical skill set, as well as dexterity to operate straight, non-articulating tools with two dimensional optical viewing [2].

In that regard, robotic-assisted laparoscopic surgery or robotic surgery represents the next iteration of minimally invasive surgery (MIS) with benefits for urologists both comfortable and not comfortable with conventional laparoscopy. Although initially developed with primary intent for cardiac surgery, robotics was rapidly embraced by urologists for a realm of surgical indications. Specifically, those urologic surgeons familiar with laparoscopy noted improved visualization with the three dimensional resolution coupled with precise movement using articulating instrumentation. Furthermore, urologists with more rudimentary MIS skills found the platform more easily adaptable with a flattened learning curve [3].

When considering applications for urologic malignancies, the robotic approach has been applied to prostate cancer (radical prostatectomy), bladder cancer (radical cystectomy), kidney tumors (partial and radical nephrectomy), upper-tract urothelial carcinoma (radical nephroureterectomy or segmental ureteral resection), as well as other less common malignancies [2].

In the subsequent sections, we briefly discuss the experience with prostate cancer but thereafter the attention is focused on robotic applications and data for two of these urologic cancers which have demonstrated the greatest areas of growth over the past five years. We specifically choose these two index robotic operations both due to growth but also the related

scientific work that has been expended to better define their relative roles in the disease management process. In that regard, we focus on robotic assisted radical cystectomy (RARC) and robotic assisted partial nephrectomy (RAPN).

2. ROBOTIC-ASSISTED RADICAL PROSATECTOMY

When historically considering urologic oncologic robotic procedures, prostate cancer surgery demonstrates the most extensive experience with the longest existing track record [4]. Radical prostatectomy (RP) can be performed by an open or laparoscopic approach (with our without robotic assistance). Contemporary studies have highlighted an incredible diffusion of robotic-assisted radical prostatectomy (RARP) increasing from 0.3% of all cases in 2001 to over 85% of cases after 2010 [5]. Population-based reports as well as meta-analyses all demonstrate that RARP compares favorably with the open approach with equivalent oncologic and potentially superior quality of life and functional outcomes following surgery [6].

As surgical experience for RARP has evolved, the indications are identical as open radical prostatectomy particularly with consideration of high risk patients with locally advanced (T3-T4) tumors without obvious clinical metastasis. The critical elements of RARP entail achieving a negative surgical margin, maintenance of the external genitourinary sphincter (for urine continence), and preservation of the neurovascular bundles (when possible and appropriate) to aid in recovery of sexual function [7]. Of the 3 outcomes described above, cancer control is paramount with biochemical recurrence patterns and survival rates being key indicators although requiring a relatively long duration of follow-up to reach such endpoints. Therefore, positive surgical margin rate (PSM) remains a relatively easily measured oncologic outcome that reflects the quality of the cancer surgery. In RARP series originating from centers of excellence, the overall PSM rates ranges between 9-15% for pT2 disease and 25-35% for pT3 disease [8]. Pre-operative imaging with a 3-Tesla pelvic MRI obtained 4-6 weeks after prostate biopsy provides an excellent adjunctive imaging study to better delineate surgical anatomy at time of prostatectomy [9].

The apical prostatic dissection is one of the most challenging steps at RARP owing to several factors [7]. Firstly, the apex of the prostate is surrounding by a number of structures including the pubic bone, dorsal venous complex, neurovascular bundles, and rectourethralis muscle all of which require preservation thereby greatly limiting the physical working space. Secondly, the apex of the prostate often lacks a true capsule thereby blurring some of the anatomic planes of dissection. Finally, individual patient anatomy is most variable in this location with the potential for an apical notch (distal beak of prostatic tissue protruding above or below the urethra) that can contribute to a positive margin [10]. Critical steps to maintain functional urethral length includes cold or athermal division of the dorsal venous complex with hemostasis prior to dividing the urethra. Such a maneuver keeps a relatively bloodless plane critical for maximizing urethral length without yielding a positive surgical margin [11].

Finally, nerve preservation is a critical element to maintain erectile function following RARP. The neurovascular bundles carry both vascular elements as well as nerve tissue that emanate from the pudendal artery and course within the periprostatic fascia. Experienced RARP surgeons have suggested using the periprostatic venous plexus as an anatomic

landmark to establish dissection within various fascial compartments enveloping the prostate [12]. Thus, depending upon the clinical and tumor characteristics of individual cases, dissection may be carried out in one of three planes including the intrafascial plane (complete nerve sparing), the interfascial plane (partial nerve sparing) or extrafascial plane (non-nerve sparing). Furthermore, the use of hydrodissection techniques may further develop these planes whilst hypothermic cooling can reduce any potential thermal injury to these key anatomic structures [13]. Details on these technical refinements have been summarized well in several contemporary reviews of the literature [14].

In summary, RARP now represents the surgical standard of care for prostate cancer with clearly defined surgical technique and measurable oncological and functional outcomes. The precision and magnification afforded by the robotic platform have contributed to improved surgical margin status, continence, and potency outcomes.

3. ROBOTIC-ASSISTED RADICAL CYSTECTOMY (RARC)

Bladder cancer represents 4.7% of all new cancer cases in the United States [15]. In 2017, there were estimated to be 79,030 new cases of bladder cancer with 16,870 cancer-related deaths thereby making it the second most common urologic cancer following prostatic malignancy [15]. Radical cystectomy with extended pelvic lymph node dissection and urinary diversion represents the standard of care for patients with muscle-invasive bladder cancer (MIBC) as well as high risk non-muscle invasive bladder cancer (NMIBC) who are at risk for disease recurrence or progression [16]. Oncologic outcomes particularly when used in combination with appropriate perioperative systemic chemotherapy remain superior to other modalities when considering local control, recurrence-free, and disease-specific survival [17].

Radical cystectomy (RC) is a complex operation in a relatively comorbid patient population. Complication rates even from regionalized centers of excellence are greater than 50% despite streamlined pathways that govern post-operative care for these patients [18]. As a consequence, the potential role of MIS approaches for RC have been broaches in recent years with early case reports highlighting feasibility as well as the potential for less blood loss, decreased post-operative rates of ileus, and a potential shorter hospitalization [19, 20].

3.1. Indications for RARC

The indications for RARC are similar to that for open radical cystectomy and are clearly delineated in the AUA/ASCO/SUO/ASTRO and EAU treatment of non-metastatic muscle invasive bladder cancer guidelines [21]. In summary, RC is an appropriate therapy for organ-confined (cT2) or locally advanced (cT3/cT4) N0M0 bladder cancer. Additionally RC can be an appropriate initial treatment option for some patients with: 1) high-grade, NMIBC (Ta/T1/Tis) that recurs following treatment with intravesical Bacillus Calmette-Guerin (BCG); as well as 2) intermediate-risk papillary urothelial carcinoma disease not readily controlled by transurethral resection and adjuvant intravesical therapies.

It must be acknowledged that patients who are candidates for RARC represent a highly selected population when compared to open RC counterparts. Specifically, the presence of

locally advanced disease (cT4), morbid obesity with a body mass index (BMI) > 35, and bulky lymphadenopathy all represent relative contraindications for the robotic approach. Furthermore, patients with uncorrected coagulopathy and significant prior abdominal surgery and/or radiotherapy present as higher risk cases with potential for prolonged operative times, wound healing issues, or perioperative complications [22]. Such cases typically should be reserved for higher volume surgeons with extensive experience.

3.2. Basic Operative Steps

Although differences may exist amongst surgeons, some of the basic operative steps are shared in common. Access into the abdominal cavity can often be performed by the Veress needle technique with a long 12mm trocar placed at the umbilicus. On the patient's left side, two 8 mm trocars are typically inserted. The first is located approximately 10 cm from the midline port on a line between the umbilicus and the anterior superior iliac spine. The second is located approximately 3 fingerbreadths above the left iliac crest. On the patient's right side, 3 trocars are typically inserted. An 8 mm robotic trocar is inserted approximately 10 cm from the midline port on a line between the umbilicus and the anterior superior iliac spine. A 15 mm trocar is inserted several fingerbreadths above the right iliac crest and a 12 mm trocar is inserted in the right upper quadrant, roughly at the location of where the urostomy is going to be sited to be used both for this case and then for creation of the urostomy. The robotic surgical system is docked after placing the patient in the steep Trendelenburg position.

The sigmoid colon is mobilized out of the deep pelvis and posterior peritoneum is opened yielding dissection of both vasa and seminal vesicles. After dividing the vascular supply of these structures, the posterior perirectal fat plane is dissected. Thereafter, ureters are identified as they course over the iliac vessels. Dissection is performed leaving a judicious amount of adipose and areolar tissue for vascularity. This ureteral dissection is carried to the level of the superior vesicle artery at which point the ureter is doubly clipped and divided with distal tip sent for frozen section.

Thereafter, the lateral aspects of the space or Retzius are exposed with the lateral pedicles of the bladder divided using clips or mechanical stapler devices. At this juncture the bladder dissection is complete to the level of the prostate and the anterior aspect of the space of Retzius is exposed. A 0-Vicryl suture is used across the dorsal venous complex with dissection all the way down well beyond the apex of the gland and to the urethra. The urethra transected with a clip the bladder side to avoid any spillage prior to doing that. Meticulous extended pelvic lymph node dissection is then performed with appropriate urinary diversion performed thereafter.

3.3. Early RARC Series

Early experience with RARC had several common themes. Many were single center series that were performed by high volume robotic surgeons as a “proof of concept.” Namely, these groups sought to demonstrate that RARC was a safe procedure although direct comparisons to an open RC cohort typically were not performed. Additionally, many of these

reports entailed an extracorporeal urinary diversion (ECUD) as opposed to an intracorporeal urinary diversion (ICUD).

One early such series emanated from the University of North Carolina as reported by Pruthi and colleagues [23]. In this series of 100 consecutive RARC operations, the authors focused on pathologic and perioperative outcomes. The majority of the patients had cT1 or cT2 tumors and over 60% had an ileal conduit urinary diversion. This group highlighted favorable perioperative outcomes with a mean EBL of 271cc, OR duration of 4.6 hours, and length of stay of 4.9 days. Notably, 85% of patients in this group were discharged by day 4 or 5 after the operation. Furthermore, complications occurred in 41% of their cohort (8% major complications) with no mortalities within 90 days of surgery.

Other groups have further delved into the perioperative outcomes of RARC and have concluded comparable outcomes to ORC. Specifically, a study comparing postoperative complications in 83 RARC versus 104 ORCs suggested lower rates of major complications (17% vs. 31%) in the MIS cohort. Furthermore, on logistics regression analysis RARC was associated with lower 30 and 90 day post-operative complications [24]. Similar observations were noted in a more recent prospective cohort comparison of 158 radical cystectomy patients undergoing ORC (n = 52), laparoscopic RC (n = 58), or RARC (n = 48). This study noted that RARC had the lowest transfusion and complication rate with the shortest length of stay, albeit with longer OR duration [25].

Juxtaposing this perioperative data highlighting safety were early reports of oncologic outcomes. Specifically, in 2013, Xylinas et al. reported on early to intermediate oncologic outcomes in 175 patients at a median follow-up of 3 years [26]. Recurrence-free and cancer-specific survival at 2-, 3-, and 5-years were 67%, 63%, and 63% (for RFS) and 73%, 68%, and 66% (for CSS), respectively. Appropriately, these authors concluded that RARC with ECUD was a safe and efficient approach with acceptable mid-term oncologic control. Similar work by Dasgupta et al. further emphasized that intermediate oncologic outcomes with RARC are encouraging with an overall and recurrence-free survival of 95% and 90%, respectively, at a maximum of 3.5 years post-surgery [27]. These numbers appear particularly favorable although may be a function of relatively short duration of follow-up interval.

3.4. Data from the International Bladder Cancer Robotic Consortium

With these promising initial data, the logical extension was multicenter collaborations formally referred to as the International Robotic Cystectomy Consortium (IRCC). This consortium consisted of 22 high volume surgeons from 15 international community and academic practices who pooled their retrospective RARC data to report on key metrics and index measures. In 2013, this group critically appraised complications following RARC and noted 30- and 90-day complication rates of 41% and 48%, respectively [28]. The majority of these complications were minor (Clavien I and II). Finally, the 30- and 90-day post-RARC mortality rate was 1.3% and 4.2%, respectively.

Surgical margin status is a known risk factor for urothelial cancer recurrence. The IRCC reported an overall positive soft tissue margin rate of 6.8% which increased with pathologic stage [29]. Specifically, the positive margin rate was 1.5% of pT2 disease, 8.8% for pT3 cancer, and 39% for pT4 cancers. These data warrant particular attention as a positive soft

tissue margin for urothelial carcinoma likely portends a high likelihood of disease recurrence and potential progression.

Lymphadenectomy for urothelial carcinoma can be both diagnostic as well as therapeutic. However, the feasibility, technical nuances, and lymph node (LN) yield of an extended pelvic lymph node dissection have surfaced as concerns with the robotic approach. Fortunately, with improved surgical experience (likely gaining improved confidence in operating around the vascular structures) as well as refinements in the surgical systems, concerns with RARC LN dissection have largely been placated. Specifically, both a non-randomized comparative study and a randomized prospective trial have suggested equivalent LN yield between the open and robotic cohorts [30, 31]. Additionally, the IRCC concluded that the rates of lymphadenectomy at RARC for advanced BC are similar to those of ORC series [32]. In this collaborative series, 83% of patients underwent a LND with a median of 17.8 LN removed. Interestingly (but likely not surprisingly), they hypothesized that learning curve may play a role in RARC LND with a volume relationship noted with surgical experience.

Finally, it is essential to highlight that the above metrics all lead back to the adequacy of oncologic control of RARC. In that regard, in 2015 the IRCC published long-term oncologic outcomes on a cohort of 743 bladder cancer patients with a median follow-up of 67 months [33]. Here, the authors noted a recurrence-free, cancer-specific, and overall survival of 67%, 75%, and 50%, respectively. Collectively, these data from a large collaborative (albeit retrospective) further supported that RARC was not compromising outcomes for bladder cancer patients.

3.5. Prospective, Randomized RARC vs. ORC Studies

While the above-mentioned studies (both single and multicenter) are promising, the optimal comparative studies are prospective, randomized trials.

In 2010, Nix and colleagues from the University of North Carolina published on prospective RARC vs. ORC trial with the primary endpoint being LN yield and secondary endpoints being perioperative and other pathologic outcomes [30]. When considering the primary study endpoint of LN yield there was equivalece (19 vs. 18 LN harvested), although many of the secondary endpoints favored the RARC approach. Specifically, RARC cases had lower EBL ($p < 0.0001$), shorter time to flatus ($p = 0.0013$), time to BM ($p = 0.0008$), and lower use of in-house analgesia in morphine equivalents ($p = 0.0044$).

In 2013, a similar size study designed as a non-inferiority prospective study was published by Parekh et al. [34] In this study, the primary endpoints included margin status, LN yield, and perioperative outcomes while the secondary endpoints included quality of life (QOL) and functional recovery. The RARC group was noted to have lower EBL (400 vs. 800cc, $p = 0.003$) and a greater number of patients had a shorter length of stay ($p = 0.03$). These observations were similar to that noted by the previously mentioned Nix study. This group, however, also carefully annotated patient QOL and well-being every 3 months from the time of surgery to 1-year after using the Functional Assessment of Cancer Therapy: Vanderbilt Index [35]. Interestingly, they noted no differences in any of the well-being domains (personal, functional, social, emotional) at any of the time points between the two groups. These suggested equivalence in modalities although was surprising in the absence of quality of life benefit from the minimally invasive approach.

More recently, the Memorial Sloan Kettering (MSKCC) group published their clinical trial of 60 RARC vs. 58 ORC with the primary endpoint being 90-day Clavien Grade II –V complications [36]. As with the prior studies, secondary endpoints were also incorporated and included high grade complications, OR duration, patient QOL, and cost. In contrast to the prior randomized studies, the experience from MSKCC yielded an exclusively negative study noting no differences in complications (62% RARC vs. 60% ORC), lower EBL but longer OR duration for RARC, and without pathologic differences. Furthermore, in this study, the mean hospital stay was 8 days in each arm, no differences in QOL scores at 3- and 6-months post-surgery, and the RARC approach was costlier across all types of urinary diversion.

The final single center prospective randomized trial was the CORAL trial which was published in 2016 by Khan and colleagues [37]. This study differed from the prior studies in that it was a three-arm trial comparing 20 RARC vs. 20 ORC vs. 20 LARC. Similar to prior studies, the primary endpoint was 30- and 90-day complications with secondary endpoints being perioperative clinical and pathologic outcomes and QOL. Interestingly, in this study, there were endpoints that favored each of the different approaches with some challenges in how to reconcile such observations. In particular, ORC had a significantly greater 30-day complication rate than LRC (70% vs. 26%), but no significant difference when compared to RARC (70% vs. 55%). Ninety-day complications were not different between any of the cohorts. Finally, the RARC group had the longest OR duration, the ORC had the longest time to oral intake, and LRC had the highest rate of disease recurrence. It is unclear how to reconcile these latter noted differences.

3.6. Future Directions

Thus far, RARC has been proven to be technically feasible with similar perioperative and oncologic outcomes when compared to ORC. Future directions are largely three-fold in nature to better define the role of RARC in the treatment of the MIBC patient.

The first critical element, which has already occurred but not fully reported, is evaluating RARC versus ORC in a larger prospective study. As one can discern from the prior section, the previous studies are small and have variable primary and secondary endpoints which confound the ability to fully synthesize the data. The recently completed RAZOR trial may help address this question [38]. This prospective, randomized multicenter trial evaluated outcomes from 350 patients (175 in each arm) undergoing RARC or ORC with the primary endpoint being oncologic non-inferiority at 2-years and secondary endpoints being perioperative and pathologic outcomes, functional recovery, and QOL. Early data that was recently presented at the 2017 American Urologic Association (AUA) annual meeting suggests that the RARC group had shorter hospital stay (6.5 vs. 7 days, $p = 0.023$), lower EBL (363 vs. 829 mL, $p < 0.0001$), less intraoperative (13.6% vs. 33.6%, $p < 0.001$) and post-operative (25.6% vs. 41.0%, $p < 0.001$) transfusions. Conversely, ORC had a shorter OR duration (361 min vs. 425 min, $p < 0.001$) and a lower positive soft tissue margin rate (4.5% vs. 10.6%, $p = 0.042$). There were no differences in extensiveness of LND, complications, final pathology, or 2-year progression free survival (80.2% RARC vs. 79.1% ORC, HR 0.80, $p = 0.31$). Final data are still pending, and these will define the role to a greater degree.

The second element is teasing out whether the method of urinary diversion may impact the potential benefits of RARC. Specifically, it can be argued that the data to date suggests

equivalence of RARC and ORC although almost all of these series utilized an extracorporeal urinary diversion (ECUD). Perhaps a totally intracorporeal approach (ICUD) may afford the complete benefits of MIS? In 2014, Desai and colleagues published on a series of 132 totally robotic intracorporeal neobladder creations after RC at two high volume centers of excellence (USC, Karolinska) [39]. These authors observed a mean operative time of 7.6 hours, EBL of 430cc, and hospital duration of 11 days highlighting the challenges and advanced skill set needed. Also in 2014, the IRC consortium compared ICUD versus ECUD in a cohort of 935 RARC patients [40]. Specifically, 167 ICUD were compared to 768 ECUD with comparison of perioperative and pathologic outcomes. Interestingly, these authors noted no differences in operative duration. ICUD patients had a longer hospital duration (9 vs. 8 days, $p = 0.086$) but also a lower complication rate (OR 0.68, $p = 0.02$). Clearly, the surgical reconstruction of diversion is a key metric of consideration when looking at RARC going forward. Nonetheless, at centers of excellence, the volume of ICUD procedures continues to grow [41].

Finally, further analysis of cost is needed to define the role of RARC. In 2014, Leow et al. performed a propensity-matched comparison of morbidity and costs of RARC and ORC using the premier prospective database between 2004 and 2010 [42]. In this mismatched cohort of over 34,000 ORC versus 2100 RARC, the authors concluded higher 90 day costs for RARC primarily attributable to OR duration and supplies. In a decision analysis model, however, the group clearly demonstrated that if OR duration and LOS decreased below certain thresholds, the RARC approach had lower associated costs. The size mismatch in cohorts highlights the early RARC experience, and such cost consideration merit further discussion as experience matures [43].

4. Robotic-Assisted Partial Nephrectomy (RAPN)

Kidney cancer represents 3.8% of all new cancer cases in the United States [15]. In 2017, there were estimated to be 63,990 new cases of kidney cancer with 14,400 cancer-related deaths resulting in it being the 3rd most common type of urologic malignancy. The rates of kidney cancer have continued to increase over time from 7.1 cases per 100,000 persons in 1975 to 15.2 cases per 100,000 in 2014 [15]. Despite this increase in incidence of kidney cancer, survival rates have improved with 5-year relative survival rates increasing from approximately 50% in the 1970s to over 75% in the more contemporary era [44].

Although the rise in kidney cancer incidence is multifactorial, a principal contributing factor is the incidental diagnosis of smaller renal masses (SRMs) on axial cross-sectional imaging [45]. These SRMs are generally smaller tumors (as their name implies), more indolent in nature, and readily managed with excellent long-term survival rates. The American Urologic Association (AUA) recently released revised guidelines to better standardize the management of patients with small renal tumors [46]. These guidelines largely focus on the management of localized tumors $\leq$ 4cm (cT1a) or 4-7cm (cT1b) in size. Furthermore, the key elements of the guidelines focus on the use of partial nephrectomy irrespective of surgical approach (open or MIS).

The 2017 AUA Guidelines highlight that urologists should prioritize the use of PN when possible for the cT1a renal mass owing to the superior renal function outcomes (when compared to radical nephrectomy), excellent oncologic control, and comparative oncologic

outcomes to radical nephrectomy (RN) for similar size tumors. Emphasis is placed on using PN in patients with an anatomic or functional solitary kidney, bilateral renal tumors, a history of familial kidney cancer, baseline chronic kidney disease (CKD), or proteinuria. Suggestion is also made for PN in patients at risk for declining kidney function including moderate or severe hypertension, diabetes mellitus, recurrent urinary stone disease, or obesity. Finally, the guidelines underscore that cancer control through negative surgical margins is paramount while effort should be made to maximally preserve renal function by optimizing residual functional renal parenchyma and minimizing the duration of warm ischemia. In summary, PN is indicated for tumors $\leq$ 7cm in size whenever technically feasible even in the presence of a normal contralateral kidney.

4.1. Indications for RAPN

Historically, PN was exclusively performed via the open approach. With the increased familiarity of MIS originating with the original laparoscopic nephrectomy by Clayman and colleagues, experience has continued to grow and expand [47]. Indeed, both pure laparoscopy and a hybrid robot-assisted laparoscopy have increasingly been used for PN. Admittedly, a barrier for laparoscopic partial nephrectomy (LPN) is that it is a challenging procedure requiring both complex oncologic extirpation and reconstruction while working on a highly vascularized organ with the goal of minimizing warm ischemia time (WIT). For example, in a single surgeon experience of 800 LPN performed by an experienced laparoscopist, Gill et al. reported a mean WIT of 32 minutes for the first 500 procedures with a WIT of under 20 minutes in only approximately 15% of cases [48]. Furthermore, the complication rates were almost 25% in the first 275 cases with a reduction to 15% in the subsequent 289 cases.

For these reasons as well as the widespread diffusion of robotic technology, RAPN has increasingly been adopted in the surgical management of SRMs. Indeed, it can be argued that the robotic platform has simplified and accelerated two critical elements of the operation; namely, dissection through the renal parenchyma and renorrhaphy. Additionally, the use of a robot facilitates the dissection and mobilization of the kidney, especially for the approach to the upper pole and posterior tumors, which is often challenging for standard laparoscopy. Collectively, these have contributed to a significant growth of RPN in practice and perhaps even the technique of choice when the technology and expertise is available [49].

4.2. RAPN vs. LPN

Prior to delving into the specific nuances of RAPN, it warrants consideration to first discuss comparisons between the two MIS approaches. Overall, one can summarize the data by emphasizing that high volume expert surgeons note good experience with both modalities although RAPN appears to yield shorter operative duration, longer warm ischemia (WIT), and less blood loss. A few of the most pertinent studies are highlighted below.

An early single institution study by Aron and colleagues involved a matched-pair analysis of 24 cases (12 RAPN and 12 LPN) controlling for several different clinical and tumor-related variables including age, gender, BMI, performance status, as well as tumor size and location [50]. Although a relatively small study, these authors noted comparable perioperative

outcomes including operative duration, blood loss, WIT, as well as hospital duration. In addition, when considering renal function outcomes 3-months after surgery (as measured by eGFR), the results were also comparable. It is important to note that this series emanated from high volume experienced surgeons with expertise in LPN.

A much larger series which was comparative and multicenter in 2009 by Benway et al. noted similar observations albeit with conclusions that mild favored the robotic approach [51]. In particular, in this retrospective study of consecutive LPN (n = 118) and RAPN (n = 129) performed by one of three surgeons, no significant differences were noted between the groups. Subset analysis based on complexity revealed that tumor complexity had no effect on operative time or estimated blood loss for robot assisted partial nephrectomy, although complexity did affect these factors for laparoscopic partial nephrectomy. In addition, for simple and complex tumors robot assisted partial nephrectomy provided significantly shorter warm ischemic time than laparoscopic partial nephrectomy (15.3 vs 25.2 minutes for simple, $p < 0.0001$; 25.9 vs 36.7 minutes for complex, $p = 0.0002$).

More contemporary data continues to favor RAPN when feasible and available. In 2011 Pierorazio and colleagues from John Hopkins evaluated outcomes and the learning curve for 150 patients undergoing RAPN (n = 48) or LPN (n = 102) by a single surgeon [52]. These authors noted that RAPN appeared to have shorter operative duration (150 vs 182, $p < 0.001$), lower WIT (13.3 vs 15.3, $p < 0.001$), and less EBL (118 vs 206, $p = 0.005$) compared with LPN. Furthermore, following a learning curve of approximately 25 cases, the transition from LPN to RAPN was not associated with immediate benefits. Additionally, a subsequent series of approximately 500 minimally invasive PN procedures has further underscored these findings and observations [53]. In particular, Khalifeh et al. reviewed 261 RAPN compared to 231 LPN and noted that the robotic group was significantly more morbid (Charlson comorbidity index 3.75 vs 1.26), included more complex tumors (R.E.N.A.L. score 5.98 vs 7.2), and had lower operative (169.9 vs 191.7 minutes) and warm ischemia (17.9 vs 25.2 minutes) time, intraoperative (2.6% vs 5.6%, each $p < 0.001$) and postoperative (24.53% vs 32.03%, $p = 0.004$) complications, and positive margin rate (2.9% vs 5.6%, $p < 0.001$). Finally, these authors noted a greater percentage of RAPN cases achieved the "trifecta" defined as a combination of warm ischemia time less than 25 minutes, negative surgical margins, and no perioperative complications (58.7% vs 31.6%, $p < 0.001$).

Additionally, recently reported systematic reviews and meta-analysis further compared outcomes of LPN and RAPN. The power of such systematic reviews is pooling data from a larger number of sources although the quality of data that is input into the analysis can drive the results. Specifically, Froghi and colleagues performed a meta-analysis of 6 non-randomized comparative studies collectively including over 250 patients and noted that perioperative outcomes were similar between modalities. [54] Specifically, six studies matched the selection criteria. In all, 256 patients were analyzed (40% RPN and 60% LPN). There was no significant different in EBL ($p = 0.12$, 95% confidence interval [CI] -12.01 to 104.26). Similarly, there was no significant different in WIT between the groups ($p = 0.23$, 95% CI -15.22 to 3.70). Also, LOS ($p = 0.22$, 95% CI -0.38 to 0.09) and overall postoperative complication rates were not significantly different between the groups ($P = 0.84$, 95% CI -0.05 to 0.06). Subsequently, Aboumarzouk et al. performed a similarly designed study including 7 non-randomized observational studies [55]. This analysis included over 300 and 400 cases of RAPN and LPN, respectively, and noted that RAPN was associated with significantly shorter WIT. Specifically, there was no significant difference between the two

groups in any of the demographic parameters except for age. There was no difference between the two groups regarding operative times ($p = 0.58$), estimated blood loss ($p = 0.76$), or conversion rates ($p = 0.84$). The RAPN group had significantly less warm ischemic time than the LPN group ($p = 0.0008$). There was no difference regarding postoperative length of hospital stay ($p = 0.37$), complications ($p = 0.86$), or positive margins ($p = 0.93$).

Taken together, these data underscore that while LPN is technically feasible, the results of RAPN are favorable both in the novice and experienced surgeon. As such, RAPN has increasingly become the modality of choice for minimally invasive partial nephrectomy. In fact, when one evaluates population-based studies such as that originating from the Nationwide Inpatient Sample (NIS), the adoption of LPN has not been widespread, being adopted in only 9% of all the PN cases performed in the US from 2008 to 2010 [56].

4.3. Nuances of RAPN Surgical Technique

One of the inherent challenges in critically evaluating RAPN outcomes is the variations in technical elements of the procedure that are individually reported as outcome measures of the index procedure. These are discussed in further details in the subsequent sections with the hope of addressing each of these in a greater degree of isolation. Prior to delving into these details, basic steps of the operative procedure are outlined. Following induction of anesthesia, patients have a urethral catheter and are placed in the flank up position. Veress needle insertion is performed to insufflate the abdomen and a 12mm trocar is placed approximately 15cm from the costal margin. After confirming the absence of metastatic disease, the following trocars are then inserted: two 8 mm trocars upper quadrant and left lower quadrant as well as one or two 12 mm trocars were inserted in the upper and lower midline.

The colon is mobilized off the medial surface of the kidney with identification of the psoas muscle, ureter, and gonadal vessels. The ureter is dissected off the psoas muscle permitted dissection towards the main renal hilum. The hilar vessels are delineated through confirmation with preoperative imaging. The lesion is then localized with confirmation and depth ascertained by use of intraoperative ultrasonography.

Depending upon lesion complexity, tumors are excised either by clamping the renal artery, vein, both, or neither. Renal repair is performed in two layers with distinct closure of the collecting system. Fat is then tacked over the defect. Hemostatic agents can be used but are often not necessarily while incurring excess cost.

4.3.1. Transperitoneal vs. Retroperitoneal RAPN

The surgical approach (transperitoneal versus retroperitoneal) is the first of these RAPN modifications which merits discussion. In short, each has the potential advantage and likely its own role when considering tumor location, lesion complexity, patient body habitus, and prior surgical history. To date, RAPN is usually performed through the transperitoneal approach due to familiarity with the intraperitoneal anatomy and working space of surgical instrumentation. Of note, however, is the potential advantages of the retroperitoneal approach which avoid bowel and visceral structure manipulation, direct access to the kidney and hilar vasculature, and ease of dissection for posterior tumors. Although comparative studies of surgical approach are limited (and likely flawed), a recent meta-analysis concluded that, in

appropriately selected patients, the retroperitoneal approach can shorten the operation time, reduce the estimated blood loss and shorten the length of hospital stay [57]. These authors concluded that the retroperitoneal approach may be equally safe and be faster compared with transperitoneal partial nephrectomy.

Indeed, as described above, the ideal approach is likely a balance of surgeon comfort and lesion location. An anterior hilar lesion is likely best managed by a transperitoneal approach whilst a posterior upper pole tumor is more easily accessed by staying in the retroperitoneum.

4.3.2. Method of Hilar Control

One of the historical tenets of kidney tumor resection involved clamping of the main renal artery and vein thereby reducing blood loss during incision into the kidney. Such principles seek to create a relatively bloodless field with the vascular clamps removed following repair of the defect. The concept of early unclamping following the closure of the inner medullary defect initially reported by Gill and colleagues (and subsequently other authors) has permitted a reduction in the procedural warm ischemia time [58].

This concept of decreasing the WIT has spawned increasing reports of "zero ischemia" or "off-clamp" RAPN. Initial focus with this off-clamp technique initially focused on tumors with lower lesion complexity (as measured by RENAL, PADUA, or C-index nephrometry scores) and demonstrated both good renal preservation as well as acceptable perioperative outcomes [59]. Versions of this "zero ischemia" approach has even included systemic reductions in blood pressure to induced a relative hypotensive state during the resection process [60]. Obviously, while both feasible and tenable, the latter of these approaches does raise concerns with regards to regional and central operative hypotension.

Perhaps the more readily adopted technique (particularly for more complex tumors) is the selective or super-selective clamping of tertiary or higher-order arterial branches to create an ischemia microenvironment in the tumor and adjacent parenchyma without compromising blood supply to the remainder of the kidney [61]. Such techniques require superior pre-operative axial imaging notably a CT scan or MRI with three-dimensional reconstruction of the kidney vasculature thereby allowing potential dissection of the secondary, tertiary, and subsequent branches tracking towards the tumor which can be clipped or controlled with vascular bulldog clamps [62]. Ancillary real time imaging with near-infrared fluorescence imaging allows for visualization of vascularized versus devascularized sections at time of tumor resection thereby providing immediate feedback regarding the accuracy of the selective clamping [63].

It is important to note that "selective clamping" as well as "off-clamp" RAPN are technically challenging even for the high-volume robotic surgeons. Indeed, when employed successfully, the outcomes data have elements that are favorable. Specifically, there appears to be better short-term renal preservation with superior eGFR measurements at both discharge as well as months after the operation. Additionally, volumetric measurements of the renal parenchyma on axial CT or MRI imaging suggest improved preservation when compared to the use of global renal ischemia. This, however, appears to come at a cost with reports of potentially longer operative duration, operative blood loss, as well as need for transfusion [64]. Thus, although very promising, vascular microdissection and super-selective clamping remain a challenge outside of centers of excellence.

Finally, one interesting surgical iteration or variant of the unclamped partial nephrectomy is a hybrid endovascular and robotic/laparoscopic approach [65]. In this setting, a endovascular radiology approach is used to occlude the tumor vessels after which the LPN or RAPN proceeds with tumor ischemia achieved from the embolization process. The early data are interesting in that the contrast dye load does not appear to negatively impact the renal function of either kidney. The biggest challenge of such an approach is the need for a purpose-built suite capable of both interventional radiology and robotic or laparoscopic surgery.

4.3.3. Additional Technical Aspects of RAPN

Presently, intraoperative ultrasonography is a critical element for margin identification in renal neoplasms which are endophytic or extending deep into the urinary collecting system. Furthermore, robotic ultrasound probes can be used, which are directly controlled by the console surgeon [66]. Intraoperative ultrasonography is a key technical component for all robotic renal surgeons irrespective of lesion complexity.

Renal repair or renorrhaphy can be performed by one of several techniques. Several groups advocate closure of the inner medullary defect without parenchymal closure to avoid ischemia that may devascularize these segments [67]. Other groups advocate a sliding clip technique with either interrupted or horizontal mattress closure of the parenchyma [68]. All of these closure modalities warrant investigation through volumetric analysis on axial imaging to better estimate degree of renal parenchymal preservation [69].

Finally, various fibrinogen coagulation enhancers and tissue sealants can be applied on the defect, along with bolsters. However, their usefulness is debatable and costs may not be insignificant. In 2016, Maurice and colleagues reviewed 544 RAPN procedures of which hemostatic agents (HA) were used in 240 (44.1%) [70]. The mean number of agents per case was 1.4 ± 0.73, including 77 (14.2%), 52 (9.6%), and 39 (7.2%) cases in which cellulose, fibrin, or gelatin-based agents were used alone, respectively, and 72 (13.2%) cases in which multiple agents were used. The mean cost of HA per case was $\$488 \pm 421$. Nearly 90% of cases were performed by surgeons who were beyond their learning curves. Overall, 13 (2.4%) patients were transfused, and the median hemoglobin decline was 2.2 g/dL (IQR, 1.4-3.0 g/dL). On univariate analysis, HA use and type of HA were not significantly associated with blood transfusion ($p = 0.20$ and $p = 0.29$, respectively), but were associated with hemoglobin decline ($p = 0.01$ and $p = 0.02$, respectively). The authors concluded that hemaostatic agent use does not alter postoperative bleeding outcomes after RAPN, suggesting that their routine use in this setting merits reconsideration.

4.4. Outcomes of RAPN

Outcomes analysis of RAPN is challenging to analyze as an amalgam due to inherent variability in surgeon experience, technique, lesion complexity, and patient driven factors. Therefore, one of the optimal methods of analysis is to look at various different types of clinical scenarios and attempt to examine these somewhat distinctly.

4.4.1. Multicenter Studies

Before diving into specific scenarios, multicenter studies do provide some framework and high-level view of RAPN outcomes. Although imperfect, multicenter studies do provide some context for RAPN in the setting of being high volume referral centers of excellence. In 2015, Lista and colleagues investigated the margin, ischemia, and complications (MIC) system achievement rate within a population of patients managed by RAPN [71]. In this multicenter study of 339 patients with cT1 masses, cancer control was defined as the absence of positive surgical margin, ideal threshold of warm ischemia time (WIT) was considered ≤20 minutes, and safety was defined as the absence of major complications. In this study, the overall MIC rate was 67% with a median WIT of 17 minutes (range, 7-51 minutes) and positive surgical margins were found in 22 patients (6.5%). Overall postoperative and major complication rates were 14.5% (n = 49) and 3.8% (n = 13), respectively. Similar complications data was reported by Spana et al. in a multicenter series of 450 RAPN operations [72]. In this dataset, the overall complication rate was 15.8% with the majority of complications being minor Clavien I or II, and under 5% of complications being Clavien III or greater.

4.4.2. Hilar Renal Tumors

Hilar renal tumors present as an anatomically more complex lesion with a greater risk of perioperative bleeding and urine leak given proximity to vascular and urinary drainage tube structures. With respect to hilar tumors, several authors have demonstrated that RAPN can be a relatively safe option in this patient cohort with comparable outcomes to tumors in different locations. Specifically, in 2011, Dulabon and colleagues compared outcomes of 41 patients with hilar tumors versus 405 patients with tumors in non-hilar regions [73]. The authors noted that the hilar tumors required a longer WIT for excision (26.3 min vs. 19.6 min, $p < 0.0001$) albeit without any differences in pathologic or perioperative outcomes. These authors therefore concluded that RAPN is a feasible approach for hilar tumors without adverse sequelae in experienced robotic surgeons. Similar work by Eyraud et al. in a single institution series compared 294 non-hilar tumors with 70 hilar tumors [74]. Analogous to what was noted in the above work, surgeries for hilar tumors were associated with longer operative duration (210 vs. 180 minutes, $p< 0.001$), longer WIT (27 vs. 17 min, $p < 0.001$), and increased blood loss (250 vs. 200 ml, $p = 0.04$). However, these differences did not translate into clinical differences with regards to transfusion rates, length of stay, complications, or positive margin rates. Additionally, the longer warm ischemia time in the hilar cases did not translate to inferior renal function outcomes.

4.4.3. Larger and Complex Tumors

Tumor complexity can broadly be captured by evaluating both larger tumor size as well as those with greater nephrometry score. With regards to tumor size, two multicenter series by Ficarra et al. and Petros et al. demonstrated the feasibility of partial nephrectomy for cT1b tumors with a WIT under 25 minutes and a low rate of intraoperative and post-operative complications [75, 76]. Such findings, however, are not universally applicable across all studies [77]. Notably, tumors of greater complexity beyond size alone can be reasonably managed by robotic surgery. A single institution study of almost 50 cases with renal tumors having a PADUA score ≥10 (high complexity) noted a reasonably short WIT (median, 16 minutes), acceptable complication rate (4.5% intraoperative and 23% post-operative, and

good renal function outcomes (no decline in the serum creatinine level and eGFR 6 months after surgery) [78]. Obviously, much of this must be taken in the context of high volume surgeons performing these more challenging RAPN.

4.4.4. Special Situations

Traditionally, consideration has been made for the use of OPN in certain situations related to baseline CKD, multifocal tumors, solitary renal units, and other similar factors. The thought process has been the ability to potentially work at a faster speed in a hypothermic environment in these more complex situations. Admittedly, although the experience in these situations is less robust, evidence indicates that RAPN is feasible in such cases. For example, Kumar and colleagues reported on a multicenter cohort of 1197 consecutive patients who underwent RAPN of which 172 patients had preexisting CKD (estimated glomerular filtration rate [eGFR] of 15-60 ml/min per 1.73 m^2) [79]. Perioperative results of 121 patients were compared against propensity score-matched controls without CKD (eGFR ≥60 ml/min per 1.73 m^2). The study noted that patients with baseline CKD had a lower percentage eGFR decrease at first follow-up (-5.1 vs -10.9), which remained significant at a mean follow-up of 12.6 mo (-2.8 vs -9.1, $p < 0.05$), and they had less CKD upstaging (11.8% vs 33.1%). CKD patients were also less likely to be discharged in the first two postoperative days (39.7% vs 56.2%, $p = 0.006$) and had a higher rate of surgical complications (21.5% vs 10.7%, $p = 0.007$).

The experience with solitary (anatomic or functional) renal units is limited to expert RAPN surgeons with robust expertise. In 2013, Hillyer and colleagues reviewed outcomes of RAPN in a mult-center cohort but focused on the 26 patients (3%) with a solitary renal unit.(80) Perioperative outcomes included a median warm ischemia time of 17 minutes with two reported 2 intraoperative complications (both vascular injuries) At a median follow-up was 6 month, renal function did not change significantly as measured by estimated glomerular filtration rate (-15.8%; $p = 0.13$) and importantly none of the patients required dialysis. In this unique clinical scenario, RAPN also appears to confer an advantage when compared to other MIPN techniques. Specifically, in 2013, Panumatrassamee et al. compared 52 LPN and 15 robot-assisted RAPN procedures performed in a solitary kidney [81]. These authors noted that the median operative time (225 vs 171 min, $p = 0.02$), warm ischemia time (19 vs 15 min, $p = 0.04$) and hospital stay (4 vs 3 days, $p = 0.03$) were significantly shorter in the robotic group. There were no significant differences were found in terms of EBL, transfusions, complications, pathological results, margin status and post-operative renal function. However, long-term hemodialysis was required for three patients in the laparoscopic group (6%) and none of the patients in the robotic group. One can argue that the superior renal repair afforded by robotics may play a key role in this situation where ischemic interval may be paramount.

MIPN can also potentially be performed in patients with multiple renal masses in the same kidney. Clearly, although both LPN and RAPN have been described, patients must be counseled regarding the higher risk of open conversion. The group at the National Cancer Institute has reported on many of these cases in the setting of inherited kidney cancer syndromes. Specifically, in 2009, Boris and colleagues reported on their experience in resecting 24 tumors in 9 patients using robotic assistance. In this experience, one patient required open conversion whilst three were able to be performed without clamping the renal hilum [82]. Subsequently in 2013, Abreu et al. performed a matched-pair analysis of 66

patients (33 with multiple tumors and a similar number with a single tumor) [83]. Interestingly, EBL and WIT were similar between the groups although the median operative duration and hospital stay were longer for the multiple tumor cohort. Additionally, the complication rate was higher in the multiple tumor group (33% vs. 21%).

The final special situation that warrants mention is the role and feasibility of MIPN in re-operative tumor surgery. These cases have the potential for significant perirenal scarring and tissue planes may be obscured from prior work. One can argue that these cases should only be undertaken by high volume surgeons who are facile with operative salvage especially with risk of bleeding. In that regard, in 2008, Turna and colleagues reported on LPN in 25 cases who had previously had an OPN performed. Not surprisingly, the WIT (36 minutes) and EBL (215mL) were greater than what is observed for *de novo* MIPN. Nonetheless, patients recovered well with no intraoperative complications reported and a 12% postoperative complication rate [84]. More recently, Autorino et al. reported on 12 tumors removed in 9 patients of which one third of patients had a solitary renal unit. The median (range) RENAL nephrometry score for the resected masses was 7 (4-8). The warm ischemia time was 17.5 min and in three of the nine patients an unclamped procedure was performed. No intraoperative complications were registered, whereas only two minor complications occurred postoperatively. There were no renal unit losses and all surgical margins were negative [85].

CONCLUSION

Robotic assisted surgery for urologic malignancies is increasingly becoming the standard of care. Certainly, for some indications such as prostate cancers, robotics accounts for the vast majority of index cases. In other disease processes, experience is growing with promising short-term and intermediate term data. This chapter highlights experience with robotic cystectomy for bladder cancer and partial nephrectomy for kidney tumors. Future work is needed to define the role across a greater number of index procedures.

REFERENCES

[1] Hemal AK, Menon M. Robotics in urology. *Curr Opin Urol*. 2004;14(2):89-93.

[2] Babbar P, Hemal AK. Robot-assisted urologic surgery in 2010 - Advancements and future outlook. *Urol Ann*. 2011;3(1):1-7.

[3] Piechaud P. State of the art: urologic surgery. *J Visc Surg*. 2011;148(5 Suppl): e27-9.

[4] Sukumar S, Rogers CG, Trinh QD, Sammon J, Sood A, Stricker H, et al. Oncological outcomes after robot-assisted radical prostatectomy: long-term follow-up in 4803 patients. *BJU Int.* 2014;114(6):824-31.

[5] Tsui C, Klein R, Garabrant M. Minimally invasive surgery: national trends in adoption and future directions for hospital strategy. *Surg Endosc*. 2013;27(7): 2253-7.

[6] Tewari A, Sooriakumaran P, Bloch DA, Seshadri-Kreaden U, Hebert AE, Wiklund P. Positive surgical margin and perioperative complication rates of primary surgical

treatments for prostate cancer: a systematic review and meta-analysis comparing retropubic, laparoscopic, and robotic prostatectomy. *Eur Urol*. 2012;62(1):1-15.

[7] Sood A, Jeong W, Peabody JO, Hemal AK, Menon M. Robot-assisted radical prostatectomy: inching toward gold standard. *Urol Clin North Am*. 2014;41(4): 473-84.

[8] Badani KK, Kaul S, Menon M. Evolution of robotic radical prostatectomy: assessment after 2766 procedures. *Cancer*. 2007;110(9):1951-8.

[9] Riney JC, Sarwani NE, Siddique S, Raman JD. Prostate magnetic resonance imaging: The truth lies in the eye of the beholder. *Urol Oncol*. 2018.

[10] Yossepowitch O, Briganti A, Eastham JA, Epstein J, Graefen M, Montironi R, et al. Positive surgical margins after radical prostatectomy: a systematic review and contemporary update. *Eur Urol*. 2014;65(2):303-13.

[11] Majoros A, Bach D, Keszthelyi A, Hamvas A, Mayer P, Riesz P, et al. Analysis of risk factors for urinary incontinence after radical prostatectomy. *Urol Int*. 2007;78(3):202-7.

[12] Tewari AK, Patel ND, Leung RA, Yadav R, Vaughan ED, El-Douaihy Y, et al. Visual cues as a surrogate for tactile feedback during robotic-assisted laparoscopic prostatectomy: posterolateral margin rates in 1340 consecutive patients. *BJU Int*. 2010;106(4):528-36.

[13] Wenger H, Razmaria A, Eggener S, Raman JD. Nerve Bundle Hydrodissection and Sexual Function after Robot Prostatectomy. *JSLS*. 2017;21(4).

[14] Tewari A, Takenaka A, Mtui E, Horninger W, Peschel R, Bartsch G, et al. The proximal neurovascular plate and the tri-zonal neural architecture around the prostate gland: importance in the athermal robotic technique of nerve-sparing prostatectomy. *BJU Int*. 2006;98(2):314-23.

[15] Siegel RL, Miller KD, Jemal A. Cancer Statistics, 2017. *CA Cancer J Clin*. 2017;67(1):7-30.

[16] Skinner EC, Stein JP, Skinner DG. Surgical benchmarks for the treatment of invasive bladder cancer. *Urol Oncol*. 2007;25(1):66-71.

[17] Ritch CR, Balise R, Soodana Prakash N, Alonzo D, Almengo K, Alameddine M, et al. Propensity matched comparative analysis of survival following chemoradiation or radical cystectomy for muscle invasive bladder cancer. *BJU Int*. 2017.

[18] Mossanen M, Krasnow RE, Lipsitz SR, Preston MA, Kibel AS, Ha A, et al. Associations of specific postoperative complications with costs after radical cystectomy. *BJU Int*. 2017.

[19] Haber GP, Crouzet S, Gill IS. Laparoscopic and robotic assisted radical cystectomy for bladder cancer: a critical analysis. *Eur Urol*. 2008;54(1):54-62.

[20] Guru KA, Kim HL, Piacente PM, Mohler JL. Robot-assisted radical cystectomy and pelvic lymph node dissection: initial experience at Roswell Park Cancer Institute. *Urology*. 2007;69(3):469-74.

[21] Woldu SL, Bagrodia A, Lotan Y. Guideline of guidelines: non-muscle-invasive bladder cancer. BJU Int. 2017;119(3):371-80.

[22] Yuh BE, Ciccone J, Chandrasekhar R, Butt ZM, Wilding GE, Kim HL, et al. Impact of previous abdominal surgery on robot-assisted radical cystectomy. *JSLS*. 2009;13(3):398-405.

[23] Pruthi RS, Nielsen ME, Nix J, Smith A, Schultz H, Wallen EM. Robotic radical cystectomy for bladder cancer: surgical and pathological outcomes in 100 consecutive cases. *J Urol.* 2010;183(2):510-4.

[24] Ng CK, Kauffman EC, Lee MM, Otto BJ, Portnoff A, Ehrlich JR, et al. A comparison of postoperative complications in open versus robotic cystectomy. *Eur Urol.* 2010;57(2):274-81.

[25] Khan MS, Challacombe B, Elhage O, Rimington P, Coker B, Murphy D, et al. A dual-centre, cohort comparison of open, laparoscopic and robotic-assisted radical cystectomy. *Int J Clin Pract.* 2012;66(7):656-62.

[26] Xylinas E, Green DA, Otto B, Jamzadeh A, Kluth L, Lee RK, et al. Robotic-assisted radical cystectomy with extracorporeal urinary diversion for urothelial carcinoma of the bladder: analysis of complications and oncologic outcomes in 175 patients with a median follow-up of 3 years. *Urology.* 2013;82(6):1323-9.

[27] Dasgupta P, Rimington P, Murphy D, Elhage O, Challacombe B, Khan MS. Robotically assisted radical cystectomy. *BJU Int.* 2008;101(12):1489-90.

[28] Johar RS, Hayn MH, Stegemann AP, Ahmed K, Agarwal P, Balbay MD, et al. Complications after robot-assisted radical cystectomy: results from the International Robotic Cystectomy Consortium. *Eur Urol.* 2013;64(1):52-7.

[29] Hellenthal NJ, Hussain A, Andrews PE, Carpentier P, Castle E, Dasgupta P, et al. Surgical margin status after robot assisted radical cystectomy: results from the International Robotic Cystectomy Consortium. *J Urol.* 2010;184(1):87-91.

[30] Nix J, Smith A, Kurpad R, Nielsen ME, Wallen EM, Pruthi RS. Prospective randomized controlled trial of robotic versus open radical cystectomy for bladder cancer: perioperative and pathologic results. *Eur Urol.* 2010;57(2):196-201.

[31] Richards KA, Hemal AK, Kader AK, Pettus JA. Robot assisted laparoscopic pelvic lymphadenectomy at the time of radical cystectomy rivals that of open surgery: single institution report. *Urology.* 2010;76(6):1400-4.

[32] Hellenthal NJ, Hussain A, Andrews PE, Carpentier P, Castle E, Dasgupta P, et al. Lymphadenectomy at the time of robot-assisted radical cystectomy: results from the International Robotic Cystectomy Consortium. *BJU Int.* 2011;107(4):642-6.

[33] Raza SJ, Wilson T, Peabody JO, Wiklund P, Scherr DS, Al-Daghmin A, et al. Long-term oncologic outcomes following robot-assisted radical cystectomy: results from the International Robotic Cystectomy Consortium. *Eur Urol.* 2015;68(4):721-8.

[34] Parekh DJ, Messer J, Fitzgerald J, Ercole B, Svatek R. Perioperative outcomes and oncologic efficacy from a pilot prospective randomized clinical trial of open versus robotic assisted radical cystectomy. *J Urol.* 2013;189(2):474-9.

[35] Messer J, Parekh DJ. Perioperative outcomes and Oncologic Efficacy from a Pilot Prospective Randomized Clinical Trial of Open Versus Robotic Assisted Radical Cystectomy. *J Urol.* 2013.

[36] Bochner BH, Sjoberg DD, Laudone VP, Memorial Sloan Kettering Cancer Center Bladder Cancer Surgical Trials G. A randomized trial of robot-assisted laparoscopic radical cystectomy. *N Engl J Med.* 2014;371(4):389-90.

[37] Khan MS, Gan C, Ahmed K, Ismail AF, Watkins J, Summers JA, et al. A Single-centre Early Phase Randomised Controlled Three-arm Trial of Open, Robotic, and Laparoscopic Radical Cystectomy (CORAL). *Eur Urol.* 2016;69(4):613-21.

[38] Smith ND, Castle EP, Gonzalgo ML, Svatek RS, Weizer AZ, Montgomery JS, et al. The RAZOR (randomized open vs robotic cystectomy) trial: study design and trial update. *BJU Int*. 2015;115(2):198-205.

[39] Desai MM, de Abreu AL, Goh AC, Fairey A, Berger A, Leslie S, et al. Robotic intracorporeal urinary diversion: technical details to improve time efficiency. *J Endourol.* 2014;28(11):1320-7.

[40] Ahmed K, Khan SA, Hayn MH, Agarwal PK, Badani KK, Balbay MD, et al. Analysis of intracorporeal compared with extracorporeal urinary diversion after robot-assisted radical cystectomy: results from the International Robotic Cystectomy Consortium. *Eur Urol*. 2014;65(2):340-7.

[41] Hussein AA, May PR, Jing Z, Ahmed YE, Wijburg CJ, Canda AE, et al. Outcomes of Intracorporeal Urinary Diversion after Robot-Assisted Radical Cystectomy: Results from the International Robotic Cystectomy Consortium. *J Urol*. 2017.

[42] Leow JJ, Reese SW, Jiang W, Lipsitz SR, Bellmunt J, Trinh QD, et al. Propensity-matched comparison of morbidity and costs of open and robot-assisted radical cystectomies: a contemporary population-based analysis in the United States. *Eur Urol.* 2014;66(3):569-76.

[43] Hu JC, Chughtai B, O'Malley P, Halpern JA, Mao J, Scherr DS, et al. Perioperative Outcomes, Health Care Costs, and Survival After Robotic-assisted Versus Open Radical Cystectomy: A National Comparative Effectiveness Study. *Eur Urol*. 2016;70(1):195-202.

[44] Wong MCS, Goggins WB, Yip BHK, Fung FDH, Leung C, Fang Y, et al. Incidence and mortality of kidney cancer: temporal patterns and global trends in 39 countries. *Sci Rep.* 2017;7(1):15698.

[45] Hollingsworth JM, Miller DC, Daignault S, Hollenbeck BK. Rising incidence of small renal masses: a need to reassess treatment effect. *J Natl Cancer Inst*. 2006;98(18):1331-4.

[46] Campbell S, Uzzo RG, Allaf ME, Bass EB, Cadeddu JA, Chang A, et al. Renal Mass and Localized Renal Cancer: AUA Guideline. *J Urol*. 2017;198(3):520-9.

[47] Clayman RV, Kavoussi LR, Soper NJ, Dierks SM, Meretyk S, Darcy MD, et al. Laparoscopic nephrectomy: initial case report. *J Urol.* 1991;146(2):278-82.

[48] Gill IS, Kamoi K, Aron M, Desai MM. 800 Laparoscopic partial nephrectomies: a single surgeon series. *J Urol.* 2010;183(1):34-41.

[49] Shiroki R, Fukami N, Fukaya K, Kusaka M, Natsume T, Ichihara T, et al. Robot-assisted partial nephrectomy: Superiority over laparoscopic partial nephrectomy. *Int J Urol.* 2016;23(2):122-31.

[50] Aron M, Koenig P, Kaouk JH, Nguyen MM, Desai MM, Gill IS. Robotic and laparoscopic partial nephrectomy: a matched-pair comparison from a high-volume centre. *BJU Int*. 2008;102(1):86-92.

[51] Benway BM, Bhayani SB, Rogers CG, Dulabon LM, Patel MN, Lipkin M, et al. Robot assisted partial nephrectomy versus laparoscopic partial nephrectomy for renal tumors: a multi-institutional analysis of perioperative outcomes. *J Urol.* 2009;182(3):866-72.

[52] Pierorazio PM, Patel HD, Feng T, Yohannan J, Hyams ES, Allaf ME. Robotic-assisted versus traditional laparoscopic partial nephrectomy: comparison of outcomes and evaluation of learning curve. *Urology.* 2011;78(4):813-9.

[53] Khalifeh A, Autorino R, Hillyer SP, Laydner H, Eyraud R, Panumatrassamee K, et al. Comparative outcomes and assessment of trifecta in 500 robotic and laparoscopic partial nephrectomy cases: a single surgeon experience. *J Urol.* 2013;189(4):1236-42.

[54] Froghi S, Ahmed K, Khan MS, Dasgupta P, Challacombe B. Evaluation of robotic and laparoscopic partial nephrectomy for small renal tumours (T1a). *BJU Int.* 2013;112(4):E322-33.

[55] Aboumarzouk OM, Stein RJ, Eyraud R, Haber GP, Chlosta PL, Somani BK, et al. Robotic versus laparoscopic partial nephrectomy: a systematic review and meta-analysis. *Eur Urol.* 2012;62(6):1023-33.

[56] Ghani KR, Sukumar S, Sammon JD, Rogers CG, Trinh QD, Menon M. Practice patterns and outcomes of open and minimally invasive partial nephrectomy since the introduction of robotic partial nephrectomy: results from the nationwide inpatient sample. *J Urol*. 2014;191(4):907-12.

[57] Fan X, Xu K, Lin T, Liu H, Yin Z, Dong W, et al. Comparison of transperitoneal and retroperitoneal laparoscopic nephrectomy for renal cell carcinoma: a systematic review and meta-analysis. *BJU Int.* 2013;111(4):611-21.

[58] Stonier T, Rai BP, Trimboli M, Abroaf A, Patel A, Gowrie-Mohan S, et al. Early vs. standard unclamping technique in minimal access partial nephrectomy: a meta-analysis of observational cohort studies and the Lister cohort. *J Robot Surg.* 2017;11(4):389-98.

[59] Simone G, Papalia R, Guaglianone S, Gallucci M. 'Zero ischaemia', sutureless laparoscopic partial nephrectomy for renal tumours with a low nephrometry score. *BJU Int.* 2012;110(1):124-30.

[60] Gill IS, Patil MB, Abreu AL, Ng C, Cai J, Berger A, et al. Zero ischemia anatomical partial nephrectomy: a novel approach. *J Urol*. 2012;187(3):807-14.

[61] Ng CK, Gill IS, Patil MB, Hung AJ, Berger AK, de Castro Abreu AL, et al. Anatomic renal artery branch microdissection to facilitate zero-ischemia partial nephrectomy. *Eur Urol*. 2012;61(1):67-74.

[62] Dwivedi DK, Chatzinoff Y, Zhang Y, Yuan Q, Fulkerson M, Chopra R, et al. Development of a Patient-specific Tumor Mold Using Magnetic Resonance Imaging and 3-Dimensional Printing Technology for Targeted Tissue Procurement and Radiomics Analysis of Renal Masses. *Urology*. 2017.

[63] Borofsky MS, Gill IS, Hemal AK, Marien TP, Jayaratna I, Krane LS, et al. Near-infrared fluorescence imaging to facilitate super-selective arterial clamping during zero-ischaemia robotic partial nephrectomy. *BJU Int.* 2013;111(4):604-10.

[64] Rosen DC, Paulucci DJ, Abaza R, Eun DD, Bhandari A, Hemal AK, et al. Is Off Clamp Always Beneficial During Robotic Partial Nephrectomy? A Propensity Score-Matched Comparison of Clamp Technique in Patients with Two Kidneys. *J Endourol.* 2017;31(11):1176-82.

[65] Panayotopoulos P, Bouvier A, Besnier L, Rousselet MC, Nedelcu C, Baize N, et al. Laparoscopic partial nephrectomy following tumor embolization in a hybrid room. Feasibility and clinical outcomes. *Surg Oncol*. 2017;26(4):377-81.

[66] Kaczmarek BF, Sukumar S, Petros F, Trinh QD, Mander N, Chen R, et al. Robotic ultrasound probe for tumor identification in robotic partial nephrectomy: Initial series and outcomes. *Int J Urol*. 2013;20(2):172-6.

[67] Bahler CD, Dube HT, Flynn KJ, Garg S, Monn MF, Gutwein LG, et al. Feasibility of omitting cortical renorrhaphy during robot-assisted partial nephrectomy: a matched analysis. *J Endourol*. 2015;29(5):548-55.

[68] Benway BM, Wang AJ, Cabello JM, Bhayani SB. Robotic partial nephrectomy with sliding-clip renorrhaphy: technique and outcomes. *Eur Urol*. 2009;55(3): 592-9.

[69] Bahler CD, Cary KC, Garg S, DeRoo EM, Tabib CH, Kansal JK, et al. Differentiating reconstructive techniques in partial nephrectomy: a propensity score analysis. *Can J Urol*. 2015;22(3):7788-96.

[70] Maurice MJ, Ramirez D, Kara O, Malkoc E, Nelson RJ, Caputo PA, et al. Omission of Hemostatic Agents During Robotic Partial Nephrectomy Does Not Increase Postoperative Bleeding Risk. *J Endourol*. 2016;30(8):877-83.

[71] Lista G, Buffi NM, Lughezzani G, Lazzeri M, Abrate A, Mistretta A, et al. Margin, ischemia, and complications system to report perioperative outcomes of robotic partial nephrectomy: a European Multicenter Observational Study (EMOS project). *Urology*. 2015;85(3):589-95.

[72] Spana G, Haber GP, Dulabon LM, Petros F, Rogers CG, Bhayani SB, et al. Complications after robotic partial nephrectomy at centers of excellence: multi-institutional analysis of 450 cases. *J Urol*. 2011;186(2):417-21.

[73] Dulabon LM, Kaouk JH, Haber GP, Berkman DS, Rogers CG, Petros F, et al. Multi-institutional analysis of robotic partial nephrectomy for hilar versus nonhilar lesions in 446 consecutive cases. *Eur Urol*. 2011;59(3):325-30.

[74] Eyraud R, Long JA, Snow-Lisy D, Autorino R, Hillyer S, Klink J, et al. Robot-assisted partial nephrectomy for hilar tumors: perioperative outcomes. *Urology*. 2013;81(6):1246-51.

[75] Ficarra V, Bhayani S, Porter J, Buffi N, Lee R, Cestari A, et al. Robot-assisted partial nephrectomy for renal tumors larger than 4 cm: results of a multicenter, international series. *World J Urol*. 2012;30(5):665-70.

[76] Petros F, Sukumar S, Haber GP, Dulabon L, Bhayani S, Stifelman M, et al. Multi-institutional analysis of robot-assisted partial nephrectomy for renal tumors >4 cm versus </= 4 cm in 445 consecutive patients. *J Endourol*. 2012;26(6):642-6.

[77] Volpe A, Amparore D, Mottrie A. Treatment outcomes of partial nephrectomy for T1b tumours. *Curr Opin Urol*. 2013;23(5):403-10.

[78] Volpe A, Garrou D, Amparore D, De Naeyer G, Porpiglia F, Ficarra V, et al. Perioperative and renal functional outcomes of elective robot-assisted partial nephrectomy (RAPN) for renal tumours with high surgical complexity. *BJU Int*. 2014;114(6):903-9.

[79] Kumar RK, Sammon JD, Kaczmarek BF, Khalifeh A, Gorin MA, Sivarajan G, et al. Robot-assisted partial nephrectomy in patients with baseline chronic kidney disease: a multi-institutional propensity score-matched analysis. *Eur Urol.* 2014;65(6):1205-10.

[80] Hillyer SP, Bhayani SB, Allaf ME, Rogers CG, Stifelman MD, Tanagho Y, et al. Robotic partial nephrectomy for solitary kidney: a multi-institutional analysis. *Urology*. 2013;81(1):93-7.

[81] Panumatrassamee K, Autorino R, Laydner H, Hillyer S, Khalifeh A, Kassab A, et al. Robotic versus laparoscopic partial nephrectomy for tumor in a solitary kidney: a single institution comparative analysis. *Int J Urol*. 2013;20(5):484-91.

[82] Boris R, Proano M, Linehan WM, Pinto PA, Bratslavsky G. Initial experience with robot assisted partial nephrectomy for multiple renal masses. *J Urol.* 2009;182(4):1280-6.

[83] Abreu AL, Berger AK, Aron M, Ukimura O, Stein RJ, Gill IS, et al. Minimally invasive partial nephrectomy for single versus multiple renal tumors. *J Urol.* 2013;189(2):462-7.

[84] Turna B, Aron M, Frota R, Desai MM, Kaouk J, Gill IS. Feasibility of laparoscopic partial nephrectomy after previous ipsilateral renal procedures. *Urology*. 2008;72(3):584-8.

[85] Autorino R, Khalifeh A, Laydner H, Samarasekera D, Rizkala E, Eyraud R, et al. Repeat robot-assisted partial nephrectomy (RAPN): feasibility and early outcomes. *BJU Int*. 2013;111(5):767-72.

In: Encyclopedia of Surgery (22 Volume Set)
Editors: Andreas Lehrer and Kristin Mueller
ISBN: 978-1-53618-329-0
© 2020 Nova Science Publishers, Inc.

Chapter 255

APPLICATIONS OF ROBOTIC-ASSISTED SURGERY IN UROGYNECOLOGY

Sarah A. Huber[1,*], MD and Patrick J. Culligan[2,†], MD
[1]Department of Urology, Weill Cornell Medicine,
New York, NY, US
[2]The Center for Female Pelvic Health, Department of Urology,
Weill Cornell Medicine, New York, NY, US

INTRODUCTION

The field of urogynecology focuses on the treatment of female pelvic disorders, the most common of which are pelvic organ prolapse and stress urinary incontinence. The etiology of these problems are multifactorial, with multiple genetic and environmental factors, including childbirth, obesity, smoking, and prior hysterectomy [1, 2]. Wu et al. calculated a weighted prevalence of 25% for one or more pelvic floor disorders in US women and predicted a doubling in the prevalence by 2050 due to an aging population [3]. There is an 11-19% lifetime risk of women undergoing at least one operation for urinary incontinence and pelvic organ prolapse with a 29.2% risk for reoperation in this cohort [4, 5]. In 2010, it was estimated that approximately 300,000 surgeries for pelvic organ prolapse were performed in the US, and this is expected to increase as the prevalence rises [6].

Minimally invasive approaches to the treatment of urogynecologic problems have had a growing role in surgical management. Compared to vaginal and open abdominal surgery, laparoscopic urogynecologic procedures have consistently better or at least non-inferior outcomes with lower complication rates, blood loss, postoperative recovery, and incision cosmesis [7, 8]. Since the first laparoscopic Burch colposuspension was performed in 1991, there has been a growing trend toward the utilization of laparoscopy, particularly with

* Corresponding Author's Email: sah2757@med.cornell.edu. Sarah Huber MD, FACOG. Fellow in Female Pelvic Medicine and Reconstructive Surgery, Weill Cornell Medicine.
† Corresponding Author's Email: pjc9007@med.cornell.edu. Patrick Culligan MD, FACOG, FCS. Director of Urogynecology, Weill Cornell Medicine, Professor of Urology and Gynecology, Professor of Urology in Obstetrics and Gynecology, FPMRS Fellowship Director.

robotic-assistance, as the mode of choice for certain urogynecologic procedures [9–12]. In 2005, the FDA approved of the use of robotic applications in gynecologic surgery, and subsequently, the rate of its implementation in all fields of gynecology has increased about 25% per year [13]. Within the field of urogynecology, the addition of robotic instrumentation provides improved visualization of the peritoneal cavity and easier access to the presacral space and space of Retzius, both of which are heavily involved in standard urogynecologic surgical methods. Ob/Gyn resident training has begun to incorporate validated simulated robotic training courses into their didactics, and as a result, young physicians are completing residency with competency in robotic gynecologic surgery [14–17]. These factors, combined with the comparable outcomes and low complication rates, have encouraged urogynecologists to adopt this approach in their routine practice.

The following chapter addresses the standard approach to the more common robotic urogynecologic procedures and also discusses new trends and future innovations in robotic surgery for prolapse. We will also review the standard robotic set-up and perioperative considerations for urogynecologic surgery.

GENERAL CONSIDERATIONS

Preoperative Planning

Patient selection criteria for a robotic urogynecologic surgery versus vaginal, abdominal, or laparoscopic surgery are similar to those in other surgical fields. Factors that affect the decision to proceed with robotic surgery include patient preference, surgeon skill level, as well as the indication for surgery and other planned procedures. Other characteristics that may sway one toward robotic surgery specifically include prior pelvic surgery, concern for pelvic adhesions, and a foreshortened vagina. Although obesity may increase operative time, it does not appear to affect surgical morbidity or blood loss, and shows similar success when compared to normal-weight individuals [18, 19].

All patients should undergo the standard preoperative workup and clearance assessment as supported by ACOG and ACC/AHA [20, 21]. This includes a review of medical co-morbidities with appropriate focused testing as well as a pregnancy test if indicated [22]. If a hysterectomy is planned, patients must have a current pap smear. Routine screening for occult uterine cancer is controversial due to the lower detection rate of non-endometrial histologies; however, endometrial biopsy and/or pelvic ultrasound may prove beneficial for preoperative counseling and surgical planning [23, 24]. Preoperative bowel preparations are no longer recommended for routine urogynecologic surgery, aside from procedure-indicated rectal washout in the operating room [25].

Perioperative Management

As the patient will be in steep Trendelenburg position for an extended period of time, positioning and stabilization at the beginning of the case is critical. Although there are a variety of ways to safely position patients, we have found that the use of a foam pad under the

body with neutrally-positioned arms sitting in foam-cushioned sleds adequately stabilizes and protects the patient throughout surgery. A Foley catheter is placed for continuous bladder drainage unless contraindicated for the procedure.

At our institution, we routinely place a preoperative transverse abdominis plane (TAP) block, as it has been found to significantly reduce postoperative pain [26–28]. Once anesthesia has been completed, the patient is placed in dorsal lithotomy position with the buttocks to the edge of the disassembled table. We advise the use of leg stabilizing movable stirrups (Allen or Yellowfin, Allen Medical®, Acton, MA) which protect the peroneal nerve from injury and allow for maneuvering the patient between low and high lithotomy during various stages of the surgery. In our practice, we routinely use a pneumatic sequential compression device in low-risk patients until ambulatory after surgery to prevent DVT/VTE formation. Other preventative options, including medical anticoagulation regimens and recommendations for high-risk patients, are followed in compliance with the 9th edition guidelines from the ACCP and ACOG [29, 30].

In accordance with ACOG guidelines and based on recommendations from the CDC, perioperative antibiotics are routinely administered for all urogynecology procedures as these are considered to involve clean-contaminated surgical sites [31, 32]. First-line treatments include a single-dose weight-based first-generation cephalosporin (cefazolin), clindamycin plus gentamicin or quinolone, or metronidazole plus gentamicin or quinolone with re-dosing as needed. A skin prep with chlorhexidine or povidone iodine of the abdomen is performed as well as a vaginal prep with either povidone iodine or chlorhexidine with 4% alcohol. In studies comparing vaginal preparation solutions, chlorhexidine is the more effective at reducing bacterial colony counts; however, povidone iodine is currently the more readily available option in most hospitals [32–34].

During surgery, constant communication with the anesthesia team must be maintained as the steep Trendelenburg positioning combined with the CO2 pneumoperitoneum can place stress on the cardiopulmonary system and affect systemic vascular pressures. Older patients, longer operative times, high maximum end-tidal CO2, and a greater number of surgical port incisions place an added risk [35]. Improved operative efficiency with close coordination with anesthesia can effectively reduce these risks, allowing for safe completion of the procedure without complication.

Trocar Placement

As the majority of urogynecologic procedures focus on the same pelvic anatomy with similar requirements for range of motion and space accessibility, the robotic trocar placement stays relatively consistent in non-complex cases. Variations to the standard port placements for each procedure will be discussed separately; however, the anatomical landmarks to guide correct placement should always be identified.

The robotic camera port typically is placed intraumbilically or supraumbilically at the level of L3 to L4 depending on surgeon preference and patient anatomy. We prefer an umbilical entry as it allows for easier specimen extraction, less pain, and better cosmesis. In obese patients, placement superior to the umbilicus may be considered, as their umbilicus tends to be more caudally displaced. Initial entry method can be left to surgeon preference; however, at our institution, we initiate entry with a Veress needle through the umbilicus

followed by CO2 insufflation once a low entry pressure is confirmed. Once appropriate abdominal distention has been obtained, a blunt tipped trocar is placed through the extended umbilical incision through the fascia and into the peritoneal cavity with visual confirmation of correct location. When placing the trocar in thin patients, we insert it at a somewhat acute angle to avoid intestinal or vessel injury as the aortic bifurcation sits at L4 to L5 and the left common iliac vein may be aberrantly located directly below the umbilicus [36]. We typically will place a 10-12mm trocar at the start of the case to aid in specimen removal and suture or mesh insertion.

Lateral instrument port placement differs based on the da Vinci robotic version, currently in the Si or Xi format. In general, Si trocars for urogynecologic procedures are distributed in a "W" layout (Figure 1). A line is marked 16cm cephalad to the superior margin of the pubic symphysis following insufflation. Two ports are placed 9cm lateral to this mark on the right and left. A third port is placed in the left lateral abdomen 4cm superior and 3cm lateral to the umbilical camera port.

Xi port placement is in a more linear pattern with the trocars placed 8cm apart from each other along a transverse plane at the level of the umbilicus (Figure 2).

Both Si and Xi port placement includes a 3-5mm assistant port about 5cm lateral to the camera port in the right upper quadrant of the abdomen.

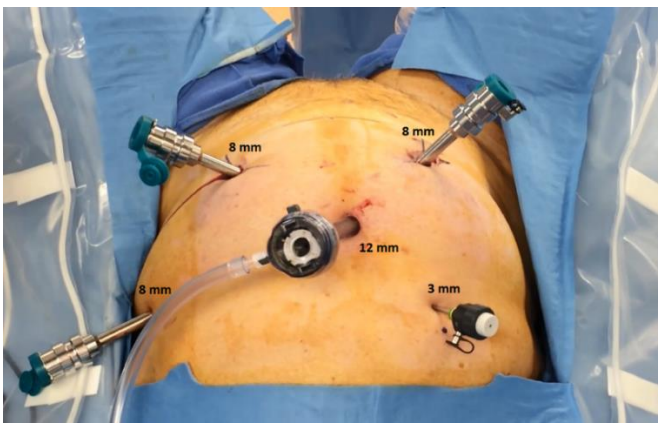

Figure 1. Standard trocar placement using da Vinci Si for urogynecologic procedures.

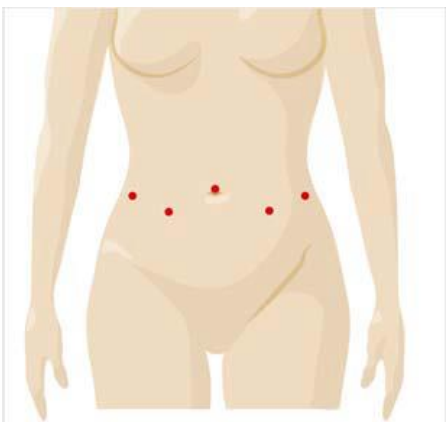

Figure 2. Standard trocar placement using da Vinci Xi for urognyecologic procedures.

When placing the lateral ports, the superficial epigastric vessels and deeper inferior epigastric vessels ideally should be identified prior to insertion. The superficial circumflex iliac artery is at risk for injury with placement of the left far lateral trocar. Another potential area of bleeding with lateral trocar insertion is the median umbilical ligament (obliterated urachus) which can have a vascular remnant.

SURGERIES FOR PELVIC ORGAN PROLAPSE

Oftentimes, patients with a symptomatic prolapse will report symptoms of bothersome vaginal pressure or a bulge that significantly affects their quality of life. In an effort to better classify the degrees of prolapse, a quantification system, known as the POP-Q, has been implemented in patient evaluation and counseling. Typically patients with Stage 2 or greater prolapse, that is prolapse at or past the level of the hymen, will be symptomatic [37]. Prolapse can manifest along the anterior vaginal wall, posterior vagina wall, or vaginal apex or cervix, often occurring together. Options for management include observation with lifestyle modifications and pelvic floor exercises, pessaries, or surgical therapy. Laparoscopic surgery has been increasingly used to address apical prolapse with concomitant anterior or posterior prolapse. Three procedures will be discussed below that have proven effective for apical suspension.

Sacrocolpopexy

Abdominal sacrocolpopexy was initially published in the literature in 1962 by Lane. At the time, he described a technique to affix the vaginal apex to the sacral promontory using a graft. Although the technique has changed over the years, the principles of a permanent attachment of the apex to the anterior longitudinal ligament at the sacrum using an implanted strengthening material has proven to be a highly effective and safe treatment, establishing it as the "gold standard" for apical prolapse repair [38, 39].

The first laparoscopic sacrocolpopexy was performed in 1994 by Nezhat with demonstrable high success rates and lower blood loss and recovery time compared to open abdominal sacrocolpopexy [40]. With the introduction of robotic assistance and the FDA approval for its use in gynecologic surgery in 2005, surgeons began to apply this technology to sacrocolpopexy. They found that robotic surgery reduced some of the technical difficulties associated with straight-stick instrument manipulation and improved visualization, particularly of the deep pelvis and sacral promontory. This enabled a more careful, precise dissection of the planes for mesh attachment which theoretically would optimize the support [41].

Technique with Concomitant Supracervical Hysterectomy

Port placement is similar to other urogynecologic procedures and depends on the da Vinci format as mentioned above. If a supracervical hysterectomy with or without bilateral salpingectomy or salpingo-oophorectomy is indicated, that will be performed first. We

typically start with monopolar scissors, bipolar Maryland forceps, and a single tooth tenaculum in the robotic instrument ports.

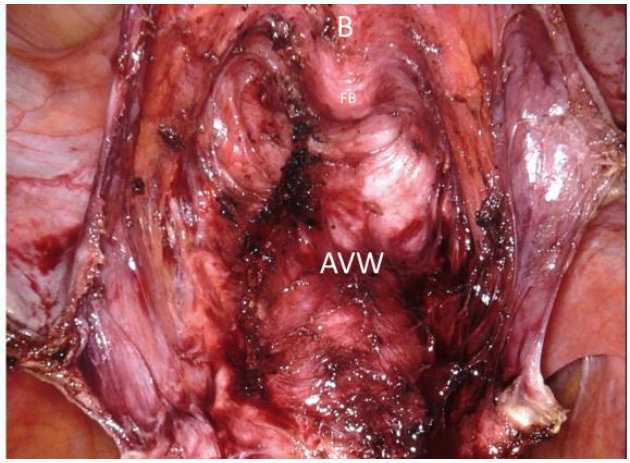

Figure 3. Completion of anterior vaginal wall dissection in robotic-assisted laparoscopic sacrocolpopexy. B: bladder, FB: outline of foley balloon, AVW: anterior vaginal wall.

The robotic single tooth tenaculum grasps the anterior cervix and retracts it anteriorly and cephalad toward the sacral promontory, thus supplanting the use of a vaginal manipulator. Using a mixture of sharp and blunt dissection, the anterior peritoneum is dissected away from the cervix and vaginal wall, thus safely displacing the bladder away from the areas of anterior mesh attachment. An atraumatic grasper is introduced through the assistant port and applied to the cut edge of peritoneum immediately cephalad to the bladder which is then retracted anteriorly and cephalad. This applies adequate counter-traction to allow improved visualization of the vesicovaginal plane. Dissection continues until the vaginal sulci are encountered laterally and the bladder neck is reached caudally, confirmed by Foley balloon identification (Figure 3).

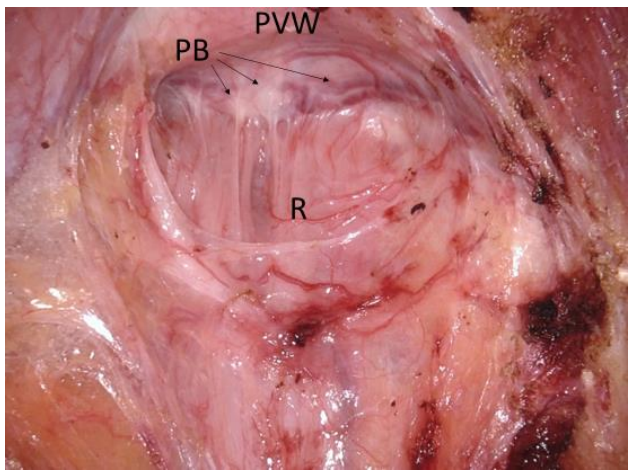

Figure 4. Completion of posterior vaginal wall dissection in robotic-assisted laparoscopic sacrocolpopexy. PB: perineal body, PVW: posterior vaginal wall, R: Rectum.

The tenaculum is then used to grasp the posterior cervix which is pulled anteriorly in the direction of the pubic symphysis. After identification of the rectal reflection and the course of the uterosacral ligaments, an incision in the peritoneum is made at the cervix and carried out laterally to the uterosacral ligaments. The posterior vaginal wall is isolated from the underlying tissue via blunt and sharp dissection through the rectovaginal space. This is carried distally until the perineal body and rectal reflection is encountered (Figure 4). A robotic grasper can be gently applied to the posterior peritoneum and pararectal adventitial tissue to provide counter-traction during dissection.

Dissection of the tissue overlying the anterior longitudinal ligament is accomplished by tenting of the peritoneum, allowing safe entry to the retroperitoneal space. At this point, we allow CO2 to enter the incised space to create tissue separation. Before proceeding further, the common iliac vein, middle sacral, and hypogastric vessels as well as the right ureter should be identified. It is important that hemostasis is optimized at this stage of the procedure; therefore, small vessels should be identified promptly and coagulated prior to transection. With blunt dissection in a mainly cephalad-caudad rather than a transverse direction, about 2cm of anterior longitudinal ligament is exposed around the level of S1-S2 which reduces the risk of sacral bleeding [42]. The superficial peritoneal incision is extended down the right paracolic gutter half-way between the ureter and colon until it communicates with the incised posterior peritoneal edge created during the posterior dissection. The 3rd arm is required to sweep the bowel to the left side and anteriorly to better visualize the space and to provide tissue counter-traction. By sweeping the colon to the left sidewall, the surgeon can effectively overlay the peritoneum against the sacral promontory to facilitate entry into the presacral space (Figure 5).

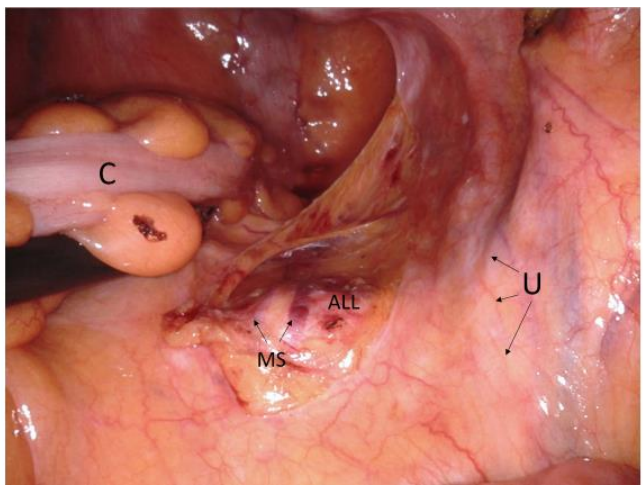

Figure 5. Dissection of anterior longitudinal ligament. ALL: anterior longitudinal ligament, MS: middle sacral vessels, U: right ureter, C: colon swept medially.

A lightweight Y mesh that has previously been cut to a length of 6 to 8 cm anteriorly and 8 to 11 cm posteriorly is passed through the camera port. In cases where there is no cervical stump, the length of the anterior and posterior vaginal arms may be shorter. Prior to passage of the mesh in to the abdomen, we loosely tie the anterior arm to the sacral arm to avoid visual obstruction from the loose mesh (Figure 6). Six CV-4 polytetrafluoroethylene (PTFE,

Origami Surgical, Madison, NJ) sutures on a tapered needle, cut to 8 inches, and one 10-inch 0 poliglecaprone (Monocryl®, Ethicon, Sommerville, NJ) suture on a tapered needle are also passed through the camera port. This can be expedited with the use of a contained laparoscopic suture delivery system which facilitates the introduction of the sutures in one pass through the camera port and allows for the assistant port to be 3-5mm (Figure 7). At this point the scissors and forceps are replaced with a large suturecut needle driver and a second large needle driver.

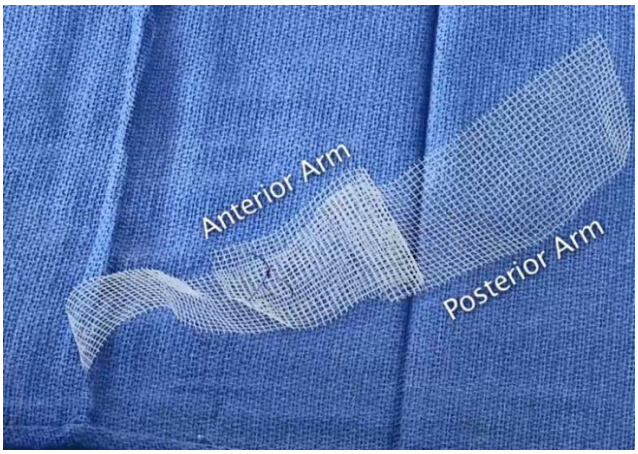

Figure 6. Ultra-lightweight Y-mesh with anterior arm cut to 6 cm and posterior arm to 10 cm. A loose knot is placed through the anterior arm and sacral arm.

The posterior vaginal arm of the mesh is attached to the posterior vaginal wall using permanent PTFE suture in an interrupted fashion while the cervix is under anterior traction using the tenaculum. The mesh knots are most easily placed starting with three distal sutures, taking care to avoid the rectovaginal junction while incorporating some of the fibers of the perineal body if possible. This creates a support frame along the total length of the posterior vaginal wall. Two midline sutures are placed 2cm proximally followed by two additional sutures even more proximal near the lateral borders of the dissection. Additional sutures can be applied to secure the mesh all the way to the cervix or uterosacral ligaments. It is helpful at times to lessen cervical traction when applying the most apical mesh sutures. Approximately 6 to 10 sutures should be placed on the posterior wall.

The loose knot holding the anterior vaginal arm to the sacral arm is cut, and the anterior vaginal arm is laid in the vesicovaginal space and attached to the anterior vaginal wall using permanent sutures. In order to improve visualization and create counter-traction, the tenaculum pulls the anterior cervix cephalad and the surgical assistant retracts the cut anterior peritoneal edge. Similar to the suturing of the posterior arm, three PTFE sutures are initially placed at the most distal end of the dissection around the level of the bladder neck followed by additional midline and lateral sutures at 2cm intervals moving proximally until the cervix is reached. The knots should lie anterior to the mesh and should total about 6 to 10 sutures along the anterior wall.

Once the vaginal walls and apex are secured to the mesh, the peritoneal incisions overlying this area are reapproximated using 0 poliglecaprone in a modified purse-string fashion, starting at the midline of the rectovaginal posterior peritoneal edge and then

proceeding in a clockwise fashion, incorporating the remnants of the round ligaments and anterior cut edge of the anterior peritoneum. Once the right lateral border of the peritoneal incision has been reached, the suture is taken over the mesh and the right and left edges of the rectovaginal/paracolic incised peritoneum are reapproximated. This effectively covers the vaginal arms of the mesh and begins to bury the sacral arm of the mesh inside the paracolic peritoneal tissue.

The sacral arm of the mesh is grasped with a non-crushing forceps, such as the tip-up or double fenestrated grasper and pulled toward the sacrum. The mesh is tensioned based on a vaginal exam performed by the surgical assist or primary surgeon (Figure 8). The vaginal walls should feel supported but not taut. Excess sacral mesh is cut and removed by the assistant. Two permanent sutures are placed perpendicularly through the anterior longitudinal ligament distal to the sacral promontory drop-off and back through the mesh. Care must be taken to place secure sutures through the ligament without too much depth and distal to the intervertebral disc in order to avoid intervertebral disc injury or osteomyelitis [43–46]. The remaining paracolic peritoneal incision is reapproximated using the same purse-string monofilament poliglecaprone, completely burying the mesh (Figure 9). A repeat vaginal exam is performed as a well as a cystoscopy at the end of the procedure.

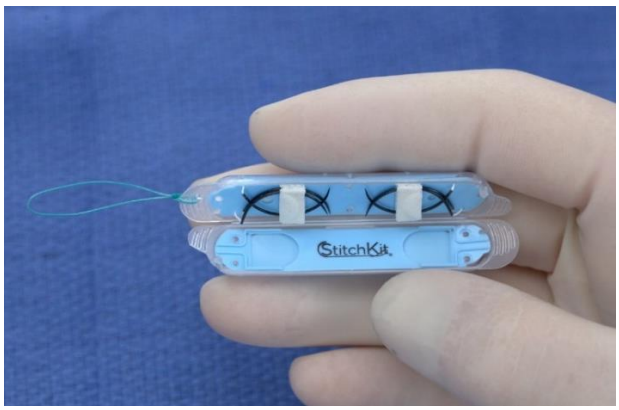

Figure 7. Suture delivery canister (Stitchkit®, Origami Surgical, Madison, NJ) containing six CV-4 PTFE sutures.

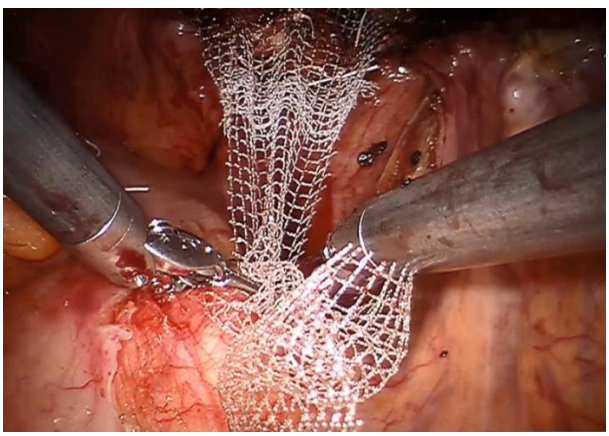

Figure 8. Tensioning of mesh prior to suturing down onto anterior longitudinal ligament.

Technique with Prior Total Hysterectomy

For patients with a prior total hysterectomy, a 13 x 3.5cm Breisky vaginal retractor or coated non-conductive stent (Marina Medical, Sunrise, FL) is placed into the vagina to delineate the anterior and posterior walls at the vaginal apex during dissection. We prefer these non-tapered instruments rather than an EEA sizer which only extends the vaginal apex. The bladder may be backfilled to further identify its location in order to avoid inadvertent cystotomy. Once dissection is complete, the sacrocolpopexy is performed using the same technique as above. We typically will avoid placement of sutures around the area of the previous vaginal cuff incision in order to reduce the risk for mesh exposure.

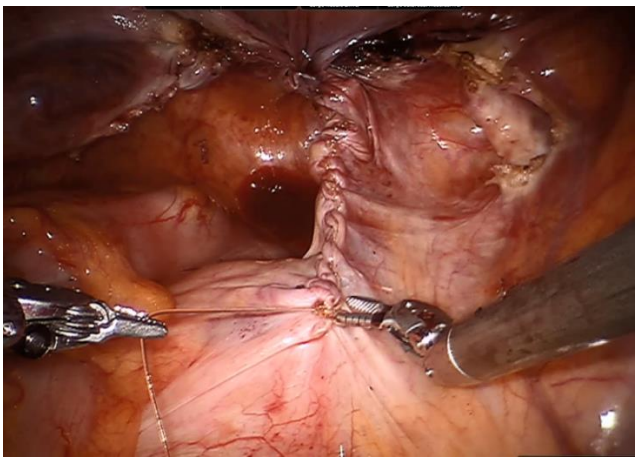

Figure 9. Completed robotic-assisted laparoscopic sacrocolpopexy with peritoneal closure.

Concomitant Procedures

Concomitant procedures can be easily performed in conjunction with sacrocol-popexy. It is now standard practice to screen patients prior to surgery for baseline stress urinary incontinence (SUI) or risk for de novo SUI. In these cases, a suburethral sling or other anti-incontinence procedure can be performed at completion of the sacrocolpopexy.

Complications

In a systematic review of 27 studies evaluating robotic-assisted sacrocolpopexy, the composite intraoperative complication rate was 3% and postoperative complication rate was 11% with only 2% classified as serious [47]. Reported complications of minimally invasive sacrocolpopexy include GI or GU injury, other bowel sequelae such as ileus, obstruction, or herniation, vascular injury, vertebral disc puncture, spondylitis and osteomyelitis, sacral nerve root injury, conversion to open procedure, and mesh erosion.

Erosion of mesh into the vagina has been estimated to occur in about 2% of robotic sacrocolpopexy cases; however, the absolute prevalence is unclear as multiple factors involved in technique and patient selection increase the risk for mesh erosion, creating variations in the published research [47]. Some of these risk factors include mesh material selection (specifically ePTFE mesh), concurrent total hysterectomy, vaginal atrophy and smoking [48, 49]. As a result, recent recommendations have advised uterine preservation or supracervical hysterectomy at the time of sacrocolpopexy when using polypropylene mesh

[50]. In fact, supracervical hysterectomy alone appears to decrease the risk of mesh erosion in laparoscopic sacrocolpopexy by about 4-fold [51]. The true risk for mesh erosion associated with transvaginal vaginal wall dissection and mesh suture is unclear with inconsistent conclusions drawn from the available literature; therefore, out of caution, we perform our entire procedure robotically without any transvaginal dissection [51, 52]. By incorporating the techniques of supracervical hysterectomy, robotic mesh attachment, and careful initial robotic dissection, we have had no mesh exposures in our practice [53].

Outcomes

Compared to other methods of apical prolapse repair, sacrocolpopexy via any approach is superior to vaginal surgery. Patients who underwent vaginal apical repair rather than sacrocolpopexy were more likely to report awareness of their prolapse after surgery (relative risk 2.11), undergo repeat surgery (relative risk 2.28), have objective recurrent prolapse (relative risk 1.89), and were at increased risk of postoperative stress urinary incontinence and dyspareunia [39]. In a single arm prospective study using ultra-lightweight mesh on 120 patients with Stage 2 or greater prolapse, there was an 89% objective success rate and 94% clinical cure rate at one year [54]. In a similar study using lightweight Y mesh, the 1 year clinical cure rate was 95% and objective cure rate was 84% [53]. Mean operative time and estimated blood loss were 148 ± 27.6 min and 51.2 ± 32mL, respectively. A 2014 systematic review and meta-analysis in which 27 articles were included, robotic-assisted laparoscopic sacrocolpopexy (RSC) had a cumulative objective cure rate of 84-100% and subjective cure rate of 92-95% [47].

Implant Selection

Various materials have been used as the fixation media in sacrocolpopexy; however, synthetic Type I macroporous polypropylene mesh remains the most popular option due to is efficacy and availability with a low adverse effect profile. Recently, ultra-lightweight mesh (technology-density 19 g/m^2) has emerged as a promising material that maintains integrity, thus guaranteeing successful outcomes, while reducing the "mesh load" on the attached tissue [53, 54]. Other non-synthetic materials can be used including fascia lata and porcine dermal graft with reasonably good outcomes. In a 12-month follow up RCT comparing porcine dermis to synthetic mesh, the anatomic cure rate was 80% versus 86% using porcine mesh or polypropylene mesh, respectively [55]. However, when a similar study was performed with fascia lata versus polypropylene mesh, the synthetic material was superior in all objective measures at one year, but showed no significant difference at 5 years with using a composite objective and subjective measure [56, 57].

In our practice, we use an ultra-lightweight mesh such as Restorelle® Y mesh (technology-density 19 g/m^2, Coloplast A/S, Humlebæk, Denmark) for our sacrocolpopexy procedures. Biologic materials can be considered for use in patients on a case-by-case basis, specifically for women with an increased risk for mesh exposure or who may undergo radiation treatments in the future.

Sacrohysteropexy

Sacrohysteropexy is a procedure we reserve for patients with symptomatic apical prolapse who desire future pregnancy. Similar to sacrocolpopexy, the vagina, cervix, and uterus are brought cephalad by fixation of an implant material to the anterior longitudinal ligament of the sacrum. While some techniques describe attachment of mesh to the anterior pubocervical fascia and posterior cervix at the proximal portion of the rectovaginal space via openings in the broad ligaments, we opt to attach mesh only to the posterior aspect in order to allow for unrestricted uterine expansion during pregnancy [58, 59].

Technique

The equipment is set up in a similar fashion as described for sacrocolpopexy above. A uterine manipulator is placed within the uterus and Foley catheter in the bladder. The peritoneum is incised over the sacral promontory and carried down to the anterior longitudinal ligament as described above [60]. The peritoneal incision is then extended along the right paracolic gutter toward the right uterosacral ligament for eventual mesh burying. With anterior retraction of the uterus, the rectovaginal space is entered near the level of the cervix and carried down to the perineal body. A single sheet of 5x15cm lightweight mesh is placed along the posterior vaginal wall from the perineum to the base of the internal cervical os, incorporating fibers from the distal end of the uterosacral ligaments, using interrupted PTFE sutures on a tapered needle. After appropriate tensioning via vaginal exam by the surgical assistant, the excess mesh is cut and attached to the anterior longitudinal ligament with two PTFE sutures. A 10-inch 0 poliglecaprone on a tapered needle is used to close the posterior peritoneum over the vaginally attached mesh, creating a “neo-cul-de-sac,” and the remainder of the mesh is buried under the reapproximated paracolic peritoneum.

The anterior wall and uterine body are uninvolved; however, some patients may report some pain during pregnancy that can be resolved with vaginal pessary placement to relieve downward pressure. Although anterior prolapse can be addressed using this method via apical suspension, these patients may need repeat prolapse surgery for anterior descent in the future [61, 62].

Complications

Intraoperative complications are similar to sacrocolpopexy and appear to occur in similar frequencies. An understandably low rate of vaginal mesh exposure occurs due to the uterine preservation, more limited dissection and suturing, and younger patient age. Although limited literature is available, successful pregnancies have been documented following sacrohysteropexy with no effect on mesh integrity following delivery [60, 62].

Outcomes

As sacrohysteropexy is a relatively new procedure, outcomes data is limited; however, promising results are being published. In a 2014 prospective study of 140 women with a follow up time of 1 to 4 years, 89% of patients described their prolapse as “very much” or “much” better with positive improvement in pelvic floor symptomatology and objective measurements [63]. A recent comparative study of laparoscopic sacrohysteropexy and vaginal mesh hysteropexy found similar anatomic (77% vs 80%; adjusted odds ratio, 0.48; P = .20)

and symptomatic (90% vs 95%; adjusted odds ratio, 0.40; P = .22) outcomes at one year [64]. A 5-year study of 37 patients who underwent robotic-assisted laparoscopic sacrohysteropexy showed an 81% success rate in treating uterine prolapse; however, 43% of women demonstrated some degree of anterior wall prolapse and 21.6% of women had posterior prolapse [65]. Subjective quality of life scores remained high even 5 years after surgery.

High Uterosacral Ligament Suspension

Although sacrocolpopexy is the preferred surgery for apical prolapse, other procedures can be performed if a sacrocolpopexy is contraindicated. While there are many different approaches, the only other intraperitoneal approach of any efficacy is the high uterosacral ligament suspension. In our practice, we will typically offer uterosacral ligament suspension to patients who may be undergoing radiation at some point (i.e., patients with concomitant apical prolapse and gynecologic cancer) who are having robotic surgery or for patients who need to undergo a total hysterectomy with removal of the cervix for cervical dysplasia.

Technique

After trocar placement as discussed above, the robotic patient cart is either docked between the legs or parallel to the patient's left side per surgeon preference. A 0° robotic camera is placed through the umbilical port and the remainder of the robotic arms are aligned and connected to their respective trocars. Using antero-cephalad vaginal retraction with a probe in post-hysterectomy patients or a uterine manipulator in patients still with a uterus, tension is placed on the uterosacral ligaments to improve visualization and to allow isolation of the ligaments from surrounding tissue. In patients undergoing a concomitant robotic-assisted total laparoscopic hysterectomy, this is performed prior to colpotomy while the uterus is devitalized but still attached to the connective structures. At this point, the pelvic course of the bilateral ureters is assessed, as they can come within 1 to 2cm lateral to the ligament at this location [66]. Two sutures are placed lateral to medial on the more proximal portions of each uterosacral ligament as it dives posteriorly and cephalad toward the sacrum. Our suture of choice is PTFE, but delayed absorbable suture can also be used. If a hysterectomy is performed at the same time, the colpotomy is completed and uterus and cervix removed through the vagina. The sutures are then passed through the ipsilateral pubocervical and rectovaginal fascia and embedded within the vaginal cuff tissue, avoiding full-thickness penetration through the epithelium. Open cuffs are then closed with polyglactin sutures prior to tying down the uterosacral sutures. A third row of sutures can be placed if the uterosacral ligaments are elongated and additional suspension is required. Plication of the sutures at the midline is not necessary. After tying down the sutures, the apex of the vagina should be suspended above the level of the ischial spines in a midline position. A cystoscopy should be performed prior to removal of the ports to ensure ureteral patency.

Complications

Serious complications from laparoscopic high uterosacral ligament suspension (HUSLS) are rare. The main risk of the procedure is ureteral kinking or injury which occurs in up to 11% of vaginally approached cases [67]. In a recent retrospective study by Barbier and

colleagues, there was a significant difference in rate of ureteral compromise, occurring in 10% of the vaginal procedures and 0% of the laparoscopic procedures [68]. Although the risk for ureteral injury is much lower when performed laparoscopically, likely due to improved visualization and the opportunity to incise the overlying peritoneum to "release" the ureter away from the ligament, intraoperative cystoscopy is crucial to confirm ureteral patency and function. If the ureter appears to be poorly functioning, the offending suture is removed which typically resolves problem. Other reported complications include bowel or bladder injury, hemorrhage, pelvic infection with abscess formation, vaginal exposure of nonabsorbable suture material, and dyspareunia.

Outcomes

Initial studies comparing laparoscopic to vaginal high uterosacral ligament suspension identified better objective outcomes with higher apices, better subjective symptoms, as well as a lower risk for ureteral compromise in the laparoscopic cohorts [69–72]. One study followed 133 laparoscopic patients for 2 to 7 years postoperatively, reporting a 12.8% prolapse recurrence rate, comparable than vaginal HUSLS. Of note, the tensile strength of the sutures placed vaginally or laparoscopically has been found to be equivalent, suggesting that laparoscopic suture and knot tying does not compromise the integrity of the suspension [73]. In summary, laparoscopically approached high uterosacral ligament suspension appears to be as effective as a vaginal approach with a lower complication profile.

Although uterosacral suspension can be performed with the uterus remaining in situ, known as uterosacral hysteropexy, success rates tend to be lower. A study by Bedford et al. reported objective success rates (POP-Q stage <2 in all compartments) for uterosacral hysteropexy 41% for therapeutic procedures, compared to 59% with hysterectomy plus HUSLS after a median follow-up of 2.5 years, although reoperation rates between the two were the same. Apical failures were identified in 27% of the hysteropexy group and 11% of the hysterectomy with colposuspension group [74].

SURGERY FOR RECTAL PROLAPSE

Ventral Rectopexy

Rectal prolapse with defecatory dysfunction is an under-recognized condition that is often concurrent with urogenital prolapse. In fact, 38% of urogenital prolapse patients demonstrate rectal prolapse on defecography [75]. One option for treatment of symptomatic rectal prolapse and obstructed defecation is a ventral mesh rectopexy which can be performed concomitantly with a sacrocolpopexy or other urogynecologic surgery [76].

Technique – Traditional Ventral Mesh Rectopexy

Traditional laparoscopic ventral mesh rectopexy, as described by D'Hoore et al., with robotic Si modification involves the initial placement of an infraumbilical 12-mm robotic camera port, two 8-mm robotic ports placed midclavicularly lateral to the umbilicus with a third robotic instrument port in the right flank [77]. Two assistant ports are suggested at the suprapubic region and left flank. Careful anterior rectal mobilization is performed with care

taken to spare the nerve supply. The rectovaginal septum is dissected distally to the pelvic floor just proximal to the dentate line. Mesh is sutured laterally to the pelvic floor muscles lateral to the rectum without direct rectal wall fixation. The proximal arm of the mesh is attached to the sacral promontory similar to sacrocolpopexy. Nonabsorbale suture is used for fixation.

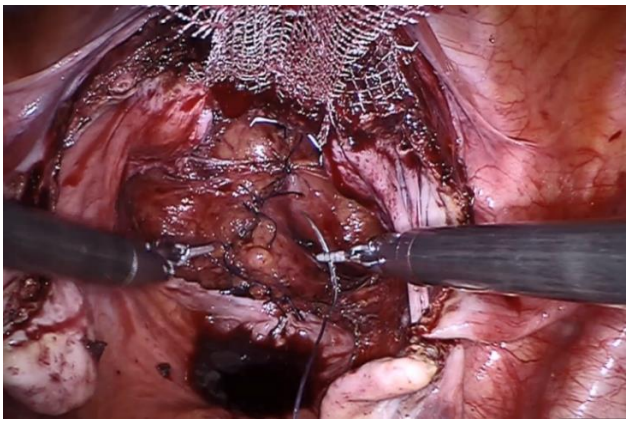

Figure 10. Completed anterior midline plication of pararectal adventitia prior to attachment to posterior vaginal wall mesh arm.

Technique – Modified Ventral Rectopexy for Concomitant Sacrocolpopexy

At our institution, we have developed a novel approach to the surgical treatment of patients with concurrent apical prolapse and rectal or posterior wall prolapse with defecatory dysfunction and distended rectum. The beginning of the case proceeds in the same method as sacrocolpopexy. However, during posterior dissection, the rectum is dissected from the lateral connective tissue down to the perineal body. Multiple interrupted 0 polyglactin sutures on a tapered needle are used to plicate the adventitia lateral to the rectum across the midline, effectively reducing the rectal caliber to a more normal size. These sutures are placed in a stepwise fashion from the perineum to the rectal reflection at the cul-de-sac, taking care to avoid incorporation of the later pelvic floor musculature (Figure 10). The Y-shaped mesh is then attached to the perineal body and posterior vaginal wall with nonabsorbable suture. The previously placed perirectal sutures are used to fasten the posterior aspect of the mesh to the anterior plication over the rectum thus making the vagina and lateral adventitial tissue to the rectum more of a unified system. The apex and anterior vaginal wall mesh is attached in the standard fashion of sacrocolpopexy, and the sacral arm of the mesh is attached at the S1-S2 segment of the anterior longitudinal ligament after appropriate tensioning. The mesh is buried under the peritoneum and other indicated procedures are performed.

Complications

In addition to the risk for conversion to open, as well as the risk for bowel/bladder/ gynecologic injury, mesh erosion into the vagina or rectum as well as pelvic sepsis from mesh infection have been reported. As multiple approaches to rectopexy have been reported with limited prospective research, true complication risks are unknown.

Outcomes

As with other procedures, the adaptation to a minimally invasive approach has improved postoperative pain and shortened length of stay [78]. Additionally, laparoscopic ventral rectopexy has been found to have a shorter return bowel function and lower morbidity. A long-term follow up study identified a 7% recurrence rate at 5 years and 11% rate at 10 years after laparoscopic rectopexy [79]. A comparative study between 44 robotic-assisted ventral mesh rectopexy patients and 74 conventional laparoscopic ventral mesh rectopexy showed a significant difference in postoperative obstructed defecation symptoms in favor of the robotic approach; however, 6-month recurrence rates were similar at 6.8% and 4%, respectively [80]. A recent small randomized controlled trial of robotic or conventional laparoscopic ventral rectopexy showed no difference in anatomical or functional changes with a significant reduction in descent of the anorectum and vaginal apex with straining in both groups [81].

SURGERY FOR STRESS URINARY INCONTINENCE

Burch Colposuspension

Also known as Burch urethropexy, Burch colposuspension serves as an effective anti-incontinence procedure when a midurethral sling is contraindicated for bothersome stress urinary incontinence. Given the excellent outcomes and safety profile of the midurethral sling procedures, we tend to only offer a Burch colposuspension to patients who are likely to undergo pelvic radiation in the future, such as patients with a known gynecological cancer. Although first described by Burch in 1961, the later Tanagho modification emphasizing removal of retropubic fat to allow for fibrosis was an important development that has been widely adopted and will be described here [82, 83]. Although the initial entry into the space of Retzius can be achieved via an extraperitoneal approach robotically, the more commonly used approach for robotic-assisted surgery has been transperitoneally; therefore, we will focus on that technique [84].

Technique

Robotic instruments are inserted and aligned as previously described, and a Foley catheter is placed in the bladder. Other procedures can be performed prior to colposuspension; however, in cases with concomitant sacrocolpopexy, tensioning and fixation to the sacral promontory should be performed after completion of the colposuspension.

The bladder may be backfilled with 300mL sterile water (diluted methylene blue can also be used) in order to identify the superior boundary of the bladder dome, although this is usually not necessary. The obliterated medial umbilical ligaments are identified as the lateral borders of the dissection plane and the space of Retzius is entered using posterior and cephalad retraction of the overlying peritoneum which is incised about 2-4cm cephalad from the bladder dome. A mixture of blunt and sharp dissection with monopolar scissors and bipolar Maryland forceps is used to open the space toward Cooper's ligaments distally, aiming for the posterior-superior aspect of the pubic symphysis. At this point, the backfilled bladder is drained. Hemostasis is important during dissection as pooled blood in the space can severely obstruct visualization of the paraurethral and paravaginal tissue. The dissection

should proceed distally and laterally with no midline cutting in order to avoid urethral injury or injury to the dorsal vein of the clitoris. However, excessive lateral dissection can injure the obturator neurovascular bundle. Dissection is complete when the pubic symphysis, bladder neck, Cooper's ligaments, vagina, and arcus tendinous fasciae pelvis can be seen.

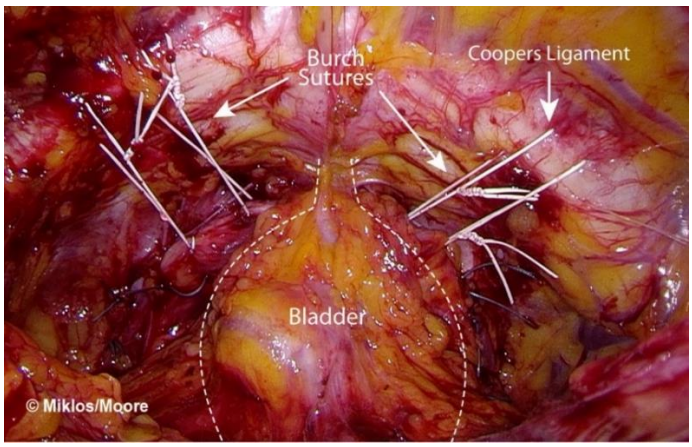

Figure 11. Placement of Burch colposuspension sutures (courtesy Miklos and Moore Urogynecology, Georgia).

The urethrovesical junction can be best visualized with medial retraction of the bladder and anterior-cephalad digital vaginal pressure by the surgical assistant. Nonabsorbable ePTFE double armed sutures (Gore-Tex®, Gore, Flagstaff, AZ) are placed on the vaginal wall at the level of the bladder neck with care taken to avoid penetration into the vaginal epithelium. We recommend taking a double bite of vaginal tissue to ensure good tension distribution along the wall. A second pair of nonabsorbable sutures are placed on either side, cephalad to the previous sutures. All four sutures are placed through their corresponding ipsilateral segments of Cooper's ligaments. Vaginal pressure is released by the surgical assistant and the sutures are tied down with the knots sitting on top of the ligament, leaving about 1.5cm of distance between the paravaginal fascia and Cooper's ligament (Figure 11). If too tight, this can lead to postoperative urethral obstruction. A cystoscopy is performed at the end of the procedure after desufflation to assess for bladder or urethral injury.

A paravaginal repair can be performed at the same time if indicated for anterior wall prolapse. While placing the Burch sutures, three additional stitches can be placed between the vaginal wall and arcus tendinous fasciae pelvis and fibers of the obturator internus muscle at 1 to 2 cm intervals until the posteriorly directed defect is closed.

Complications

Reported perioperative complications of laparoscopic Burch colposuspension have included injury to the urinary tract or bowel, vessel damage requiring transfusion, and infection including an abscess in the space of Retzius. Similar to the open approach, postoperative outcomes can include detrusor overactivity, voiding dysfunction, urethral obstruction, fistula formation, pain, or posterior compartment prolapse. It has been estimated that approximately 2% of laparoscopic cases are complicated by an injury to the lower urinary tract which is predominantly cystotomy to the bladder dome [85]. The overall complication

rate of laparoscopic colposuspension is much lower than via laparotomy. However, it is imperative that cystoscopy be performed intraoperatively in order to promptly identify and address injury, as early detection is associated with decreased morbidity [86].

Outcomes

In a randomized controlled trial from 2004, seventy-two patients underwent either tension-free vaginal tape (TVT) or laparoscopic colposuspension with a mean follow up of 20.6 months [87]. Although the study noted the presence of urodynamic stress incontinence at 12 months post-surgery in 18.8% of the colposuspension group compared to 3.2% in the TVT group, they did report improvement in the number of incontinent episodes per week in both groups. In a long-term follow up study with a median 65 months duration, 58% of colposuspension patients and 48% of TVT patients reported urinary incontinence at 4-8 years after surgery which did not meet significance [88]. However, the true advantage of the midurethral slings lies in the low complication rate with rapid recovery and low cost, causing it to become the gold-standard treatment for stress urinary incontinence.

However, if a Burch colposuspension is indicated, a laparoscopic or robotic-assisted laparoscopic approach is preferred [87–89]. A study by Kitchner et al. showed non-inferiority between laparoscopic and open colposuspension with objective cure rates at 24 months of 70.1 and 79.7% and subjective cure rates of 54.6% and 54.9%, respectively [90]. However, open colposuspension has been noted to have greater blood loss, greater risk of urinary retention, and a longer hospital stay than a laparoscopic approach [91]. A 10-year study of outcomes following laparoscopic versus open colposuspension noted a deterioration in subjective cure rates at 6 months at 10 years of 71% to 52% in the laparoscopic group compared to 67% to 36% in the open group [92]. Although data is limited on robotic outcomes, one can assume that the laparoscopic findings would correlate given the similar approach.

VESICOVAGINAL AND VESICOUTERINE FISTULA REPAIR

Urogenital fistulas are devastating conditions that affect women's health and quality of life significantly. Whereas traumatic vaginal and cesarean deliveries are the most common cause of vesicovaginal and vesicouterine fistulas globally, in the US, unidentified or incompletely repaired bladder injuries at the time of gynecologic surgery are the primary causes. Fistulas can be repaired vaginally, abdominally, or laparoscopically. The intent of the fistula repair is to obliterate the non-anatomic communicating tract between the two organs. Standard practice dictates waiting 3 months after the causative injury to improve tissue quality prior to surgery. Interestingly, about 12% of fistulas naturally resolve within that period and surgery is not indicated [93].

Technique – Vesicovaginal Fistula Repair

At the start of the procedure, we recommend stenting of the fistulous tract via passage of the stent cystoscopically followed by vaginal retrieval of the passed end with uterine packing

forceps. A Foley catheter is not used during the procedure. The robotic portion of the procedure proceeds by placing the trocars in the layout described in the beginning of the chapter with parallel or side-docking recommended. If pneumoperitoneum is compromised by the fistula, then a lubricated laparotomy sponge can be placed in the vagina. The vesicovaginal space is carefully dissected similar to the methods applied in sacrocolpopexy. Dissection is carried down until the stent is visualized and the defect is fully isolated from the proximal and distal tissue (Figure 12). If the vesicovaginal plane is difficult to visualize due to inflammation, then an O'Conor transvesical approach can be performed by bivalving the bladder until the fistula tract is seen [94, 95]. The walls of the fistulous tract are sharply removed from the surrounding healthy tissue to improve the quality of the reapproximated tissue. In general, the use of cautery is limited in order to avoid tissue devascularization or necrosis. If the fistula is located in the midline, then closure is unlikely to cause any ureteral kinking. However, if lateral, ureteral stenting may be considered prophylactically.

The bladder defect is closed with interrupted 2-0 polyglactin sutures in two layers. The first layer is a full-thickness reapproximation with the second layer serving as an imbrication layer. The integrity of the repair is tested by filling the bladder with 400-500mL of sterile water or saline which can be diluted with methylene blue. The vagina is closed with interrupted braided delayed absorbable suture in layers and should be hemostatic at the completion of the defect closure.

The peritoneal incision made at the beginning of the procedure to access the vesicovaginal space is closed with 0 poliglecaprone in order to protect the repair from intrusion of the bowel. Alternatively, an omental flap can be placed between the bladder and vaginal suture lines; however, this is not advised in women who are planning future pregnancy. At the end of the procedure, a cystoscopy is performed and an extended Foley catheter is placed. If the fistula repair is in close proximity to the bladder neck and could be in contact with the Foley catheter, then a suprapubic catheter should be considered as an alternative. If there is concern for bleeding or infection, then a drain may be considered postoperatively.

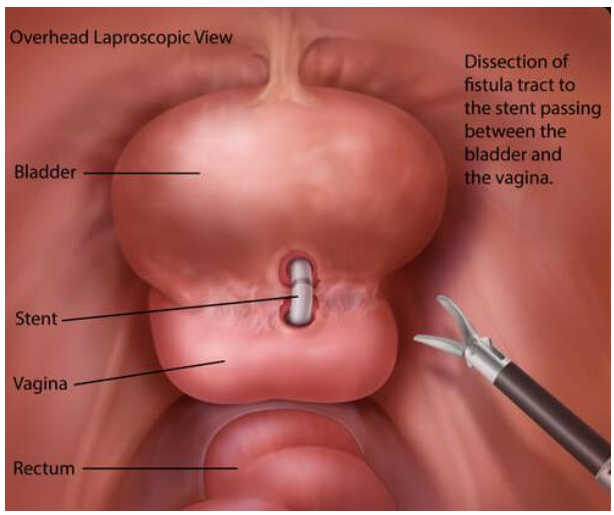

Figure 12. Completion of vesicovaginal space dissection and identification of fistula sutures (courtesy Miklos and Moore Urogynecology, Georgia).

Technique – Vesicouterine Fistula Repair

The overall dissection technique is similar to a laparoscopic intraperitoneal approach for vesicovaginal fistula described above with the option of an O'Conor transvesical dissection as needed. As for vesicovaginal fistulas, we advise sharp excision of the tract and reapproximation of the healthy surrounding tissue in layers using absorbable sutures. An omental flap can also be considered to maintain separation of the bladder and uterine layers and improve the vascular supply. If a hysterectomy is planned, then the fistulous tract is transected between the bladder and uterine layers and excised. After completion of the hysterectomy, the bladder is repaired in two layers of interrupted absorbable suture.

Complications

The typical complications include enterotomy, conversion to open surgery, or recurrence. Rare complications of UTI, vascular injury, and lower extremity compartment syndrome from prolonged lithotomy have also been reported [96]. Postoperatively, patients can develop incontinence and de novo urinary urgency although the true risk of this has not been extensively studied.

Although rare, GU fistulas may develop in areas of tumor necrosis following localized radiation therapy. It is imperative to biopsy the fistula tract prior to repair as these areas are at high risk to have tumor recurrence.

Outcomes

Numerous factors have been associated with better success rates of genitourinary fistula repair. These include surgeon expertise, prior repair, amount of fibrosis (for example, from radiation therapy), fistula size, fistula etiology, and location [97]. Minimally invasive repair for GU fistulas have a success rate of 86-100% inclusive of all simple and complex fistulas [96, 98]. When compared to abdominal GU fistula repair, robotic-assisted repair has been found to have a significantly less blood loss and shorter hospital stay and recovery [99]. As a result, the robotic approach is becoming increasingly popular as the route of choice.

The use of an interposition flap has been debated, specifically for patients at higher risk for failure and known comprised wound healing, such as cancer patients. Multiple flaps have been described in the literature, including omental, peritoneal, urachal, rectus abdominus muscle, perisigmoid fat, porcine graft, and epiploica [100–102]. To date, there have been no prospective comparative studies evaluating the use of flaps. However, surgeons have reported excellent outcomes without flap usage, so its utility is unclear [103–105].

In the case of vesicouterine fistulas, the impact of a concomitant hysterectomy has not been studied extensively; however, this has been found to be a safe and effective procedure which can be offered to patients with no plan for future childbearing [106].

FUTURE INNOVATIONS IN ROBOTIC UROGYNECOLOGIC SURGERY

The role of robotic surgery in urogynecology is constantly expanding, particularly with advancements in the use of robotic surgery for pelvic mesh removal and the use of single-port robotic surgery for urogynecologic procedures.

In situations of pelvic mesh erosion into the bladder and bowel, the use of the robot has provided improved visualization of the affected areas where tissue planes are non-anatomical and often difficult to see (Figure 13). Combined approaches that utilize both robotic as well as a transvaginal, cystoscopic, or endoscopic surgical components allows surgeons to completely resect bothersome mesh with lower morbidity than an open procedure [107]. Although still in the early phases with no prospective large-scale research available given the rarity of these complications, results have proved promising.

Though relatively new to urogynecologic surgery, single-port robotic surgery has been showing encouraging results. Stemming from the success of laparoendoscopic single-site surgery (LESS), robotic single-port surgery minimizes the risk of complications from trocar placement while still providing all the benefits of robotic surgery. Additionally, the single incision site provides better cosmesis than the 5 incisions created using traditional robotic surgery. The da Vinci® Single-Site® surgery configuration involves placement of a 8.5mm camera, two 5mm robotic instruments, and a 5/10mm assistant port through a five-lumen port that can fit through a 1.5cm incision just above the umbilicus [108, 109]. Application of single-site robotic surgery in benign gynecology has shown shorter operative time, less blood loss, and lower cumulative cost compared to multiple port surgery without any difference in surgical outcomes [110]. The feasibility of single-port sacrocolpopexy has been demonstrated through case reports, but larger-scale trials are still pending [108]. The current drawbacks to robotic single-port urogynecologic surgery involve a more limited selection of instruments, particularly the unavailability of a monopolar scissor, and the difficulty with triangulation of instruments over areas of dissection or suturing [111]. As these problems resolve with newer innovations, it is likely that single-port surgery will become increasingly incorporated into urogynecologic surgery, particularly those involving midline surgery.

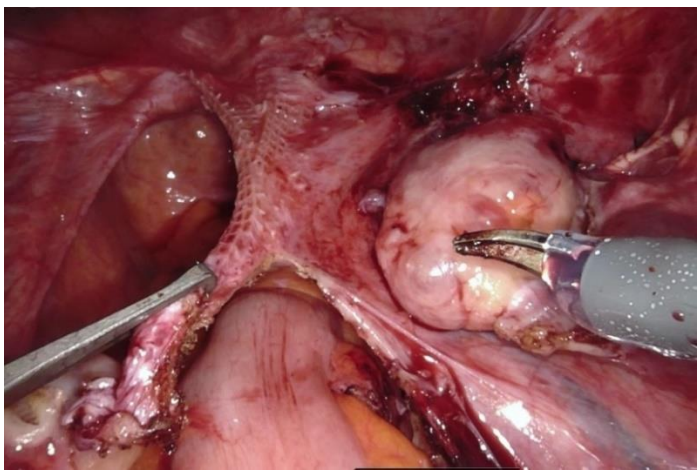

Figure 13. Robotic resection of sacrocolpopexy mesh following spontaneous sacral detachment.

CONCLUSION

Robotic-assisted surgery has had a tremendous impact in urogynecology, improving surgical outcomes and patient satisfaction across all metrics. We anticipate that as newer technologies develop and the urogynecology community becomes increasingly committed to the application of robotics, its utility will become even more widespread and diverse.

REFERENCES

[1] Altman, D., Forsman, M., Falconer, C., and Lichtenstein, P. (2008). Genetic influence on stress urinary incontinence and pelvic organ prolapse. *Eur Urol 54*, 918–922.

[2] Mant, J., Painter, R., and Vessey, M. (1997). Epidemiology of genital prolapse: observations from the Oxford Family Planning Association Study. *Br J Obstet Gynaecol 104*, 579–585.

[3] Wu, J. M., Vaughan, C. P., Goode, P. S., Redden, D. T., Burgio, K. L., Richter, H. E., and Markland, A. D. (2014). Prevalence and trends of symptomatic pelvic floor disorders in U.S. women. *Obstet Gynecol 123*, 141–148.

[4] Olsen, A. L., Smith, V. J., Bergstrom, J. O., Colling, J. C., and Clark, A. L. (1997). Epidemiology of surgically managed pelvic organ prolapse and urinary incontinence. *Obstet Gynecol 89*, 501–506.

[5] Smith, F. J., Holman, C. D. J., Moorin, R. E., and Tsokos, N. (2010). Lifetime risk of undergoing surgery for pelvic organ prolapse. *Obstet Gynecol 116*, 1096–1100.

[6] *Update on the Safety and Effectiveness of Transvaginal Placement for Pelvic Organ Prolapse*.

[7] Betschart, C., Cervigni, M., Contreras Ortiz, O., Doumouchtsis, S. K., Koyama, M., Medina, C., Haddad, J. M., la Torre, F., and Zanni, G. (2017). Management of apical compartment prolapse (uterine and vault prolapse): A FIGO Working Group report. *Neurourol Urodyn 36*, 507–513.

[8] Coolen, A.-L. W. M., van Oudheusden, A. M. J., Mol, B. W. J., van Eijndhoven, H. W. F., Roovers, J.-P. W. R., and Bongers, M. Y. (2017). Laparoscopic sacrocolpopexy compared with open abdominal sacrocolpopexy for vault prolapse repair: a randomised controlled trial. *Int Urogynecol J 28*, 1469–1479.

[9] Elterman, D. S., Chughtai, B. I., Vertosick, E., Maschino, A., Eastham, J. A., and Sandhu, J. S. (2014). Changes in pelvic organ prolapse surgery in the last decade among United States urologists. *J Urol 191*, 1022–1027.

[10] Jonsson Funk, M., Edenfield, A. L., Pate, V., Visco, A. G., Weidner, A. C., and Wu, J. M. (2013). Trends in use of surgical mesh for pelvic organ prolapse. *Am J Obstet Gynecol 208*, 79.e1–7.

[11] Skoczylas, L. C., Turner, L. C., Wang, L., Winger, D. G., and Shepherd, J. P. (2014). Changes in prolapse surgery trends relative to FDA notifications regarding vaginal mesh. *Int Urogynecol J 25*, 471–477.

[12] Vancaillie, T. G., and Schuessler, W. (1991). Laparoscopic bladderneck suspension. *J Laparoendosc Surg 1*, 169–173.

[13] Committee opinion no. 628: robotic surgery in gynecology. (2015). *Obstet Gynecol 125*, 760–767.

[14] Pilka, R., Gágyor, D., Študentová, M., Neubert, D., and Dzvinčuk, P. (2017). Laparoscopic and robotic sacropexy: retrospective review of learning curve experiences and follow-up. *Ceska Gynekol 82*, 261–267.

[15] Lucereau, B., Thaveau, F., Lejay, A., Roussin, M., Georg, Y., Heim, F., Lee, J. T., and Chakfe, N. (2016). Learning Curve of Robotic-Assisted Anastomosis: Shorter than the Laparoscopic Technique? An Educational Study. *Ann Vasc Surg 33*, 39–44.

[16] Passerotti, C. C., Franco, F., Bissoli, J. C. C., Tiseo, B., Oliveira, C. M., Buchalla, C. A. O., Inoue, G. N. C., Sencan, A., Sencan, A., do Pardo, R. R., et al. (2015). Comparison of the learning curves and frustration level in performing laparoscopic and robotic training skills by experts and novices. *Int Urol Nephrol 47*, 1075–1084.

[17] Akl, M. N., Long, J. B., Giles, D. L., Cornella, J. L., Pettit, P. D., Chen, A. H., and Magtibay, P. M. (2009). Robotic-assisted sacrocolpopexy: technique and learning curve. *Surg Endosc 23*, 2390–2394.

[18] Eddib, A., Danakas, A., Hughes, S., Erk, M., Michalik, C., Narayanan, M. S., Krovi, V., and Singhal, P. (2014). Influence of Morbid Obesity on Surgical Outcomes in Robotic-Assisted Gynecologic Surgery. *J Gynecol Surg 30*, 81–86.

[19] Gallo, T., Kashani, S., Patel, D. A., Elsahwi, K., Silasi, D.-A., and Azodi, M. (2012). Robotic-assisted laparoscopic hysterectomy: outcomes in obese and morbidly obese patients. *JSLS 16*, 421–427.

[20] Fleisher, L. A., Fleischmann, K. E., Auerbach, A. D., Barnason, S. A., Beckman, J. A., Bozkurt, B., Davila-Roman, V. G., Gerhard-Herman, M. D., Holly, T. A., Kane, G. C., et al. (2014). 2014 ACC/AHA guideline on perioperative cardiovascular evaluation and management of patients undergoing noncardiac surgery: a report of the American College of Cardiology/American Heart Association Task Force on Practice Guidelines. *Circulation 130*, e278–333.

[21] *Overview of preoperative evaluation and preparation for gynecologic surgery - UpToDate* Available at: https://www.uptodate.com/contents/overview-of-preoperative-evaluation-and-preparation-for-gynecologic-surgery [Accessed December 13, 2017].

[22] Manley, S., de Kelaita, G., Joseph, N. J., Salem, M. R., and Heyman, H. J. (1995). Preoperative pregnancy testing in ambulatory surgery. Incidence and impact of positive results. *Anesthesiology 83*, 690–693.

[23] Vallabh-Patel, V., Saiz, C., Salamon, C., Francis, A., Pagnillo, J., and Culligan, P. (2016). Prevalence of occult malignancy within morcellated specimens removed during laparoscopic sacrocolpopexy. *Female Pelvic Med Reconstr Surg 22*, 190–193.

[24] Ramm, O., Gleason, J. L., Segal, S., Antosh, D. D., and Kenton, K. S. (2012). Utility of preoperative endometrial assessment in asymptomatic women undergoing hysterectomy for pelvic floor dysfunction. *Int Urogynecol J 23*, 913–917.

[25] Fanning, J., and Valea, F. A. (2011). Perioperative bowel management for gynecologic surgery. *Am J Obstet Gynecol 205*, 309–314.

[26] Ra, Y. S., Kim, C. H., Lee, G. Y., and Han, J. I. (2010). The analgesic effect of the ultrasound-guided transverse abdominis plane block after laparoscopic cholecystectomy. *Korean Journal Anesthesiol 58*, 362–368.

[27] Ripollés, J., Mezquita, S. M., Abad, A., and Calvo, J. (2015). Analgesic efficacy of the ultrasound-guided blockade of the transversus abdominis plane - a systematic review. *Braz J Anesthesiol 65*, 255–280.

[28] Saliminia, A., Azimaraghi, O., Babayipour, S., Ardavan, K., and Movafegh, A. (2015). Efficacy of transverse abdominis plane block in reduction of postoperation pain in laparoscopic cholecystectomy. *Acta Anaesthesiol Taiwan 53*, 119–122.

[29] Gould, M. K., Garcia, D. A., Wren, S. M., Karanicolas, P. J., Arcelus, J. I., Heit, J. A., Samama, C. M., and American College of Chest Physicians (2012). Prevention of VTE in nonorthopedic surgical patients: Antithrombotic Therapy and Prevention of Thrombosis, 9th ed: American College of Chest Physicians Evidence-Based Clinical Practice Guidelines. *Chest 141*, e227S–77S.

[30] *Prevention of Deep Vein Thrombosis and Pulmonary Embolism* - ACOG Available at: https://www.acog.org/Resources%20And%20Publications/Practice%20Bulletins/Committee%20on%20Practice%20Bulletins%20Gynecology/Prevention%20of%20Deep%20Vein%20Thrombosis%20and%20Pulmonary%20Embolism.aspx [Accessed December 13, 2017].

[31] ACOG Committee on Practice Bulletins–Gynecology (2009). ACOG practice bulletin No. 104: antibiotic prophylaxis for gynecologic procedures. *Obstet Gynecol 113*, 1180–1189.

[32] Berríos-Torres, S. I., Umscheid, C. A., Bratzler, D. W., Leas, B., Stone, E. C., Kelz, R. R., Reinke, C. E., Morgan, S., Solomkin, J. S., Mazuski, J. E., et al. (2017). Centers for disease control and prevention guideline for the prevention of surgical site infection, 2017. *JAMA Surg 152*, 784–791.

[33] American College of Obstetricians and Gynecologists Women's Health Care Physicians, and Committee on Gynecologic Practice (2013). Committee Opinion No. 571: Solutions for surgical preparation of the vagina. *Obstet Gynecol 122*, 718–720.

[34] Culligan, P. J., Kubik, K., Murphy, M., Blackwell, L., and Snyder, J. (2005). A randomized trial that compared povidone iodine and chlorhexidine as antiseptics for vaginal hysterectomy. *Am J Obstet Gynecol 192*, 422–425.

[35] Murdock, C. M., Wolff, A. J., and Van Geem, T. (2000). Risk factors for hypercarbia, subcutaneous emphysema, pneumothorax, and pneumomediastinum during laparoscopy. *Obstet Gynecol 95*, 704–709.

[36] Nezhat, F., Brill, A. I., Nezhat, C. H., Nezhat, A., Seidman, D. S., and Nezhat, C. (1998). Laparoscopic appraisal of the anatomic relationship of the umbilicus to the aortic bifurcation. *J Am Assoc Gynecol Laparosc 5*, 135–140.

[37] Swift, S. E., Tate, S. B., and Nicholas, J. (2003). Correlation of symptoms with degree of pelvic organ support in a general population of women: what is pelvic organ prolapse? *Am J Obstet Gynecol 189*, 372–7; discussion 377.

[38] Barber, M. D., and Maher, C. (2013). Apical prolapse. *Int Urogynecol J 24*, 1815–1833.

[39] Maher, C., Feiner, B., Baessler, K., Christmann-Schmid, C., Haya, N., and Brown, J. (2016). Surgery for women with apical vaginal prolapse. *Cochrane Database Syst Rev 10*, CD012376.

[40] Nezhat, C. H., Nezhat, F., and Nezhat, C. (1994). Laparoscopic sacral colpopexy for vaginal vault prolapse. *Obstet Gynecol 84*, 885–888.

[41] Rosenblum, N. (2012). Robotic approaches to prolapse surgery. *Curr Opin Urol 22*, 292–296.

[42] Sutton, G. P., Addison, W. A., Livengood, C. H., and Hammond, C. B. (1981). Life-threatening hemorrhage complicating sacral colpopexy. *Am J Obstet Gynecol 140*, 836–837.

[43] Nosseir, S. B., Kim, Y. H., Lind, L. R., and Winkler, H. A. (2010). Sacral osteomyelitis after robotically assisted laparoscopic sacral colpopexy. *Obstet Gynecol 116 Suppl 2*, 513–515.

[44] Muffly, T. M., Diwadkar, G. B., and Paraiso, M. F. R. (2010). Lumbosacral osteomyelitis after robot-assisted total laparoscopic hysterectomy and sacral colpopexy. *Int Urogynecol J 21*, 1569–1571.

[45] Crisp, C. C., Herfel, C. V., Pauls, R. N., Westermann, L. B., and Kleeman, S. D. (2016). Critical anatomy relative to the sacral suture: A postoperative imaging study after robotic sacrocolpopexy. *Female Pelvic Med Reconstr Surg 22*, 33–36.

[46] Good, M. M., Abele, T. A., Balgobin, S., Schaffer, J. I., Slocum, P., McIntire, D., and Corton, M. M. (2013). Preventing L5-S1 discitis associated with sacrocolpopexy. *Obstet Gynecol 121*, 285–290.

[47] Serati, M., Bogani, G., Sorice, P., Braga, A., Torella, M., Salvatore, S., Uccella, S., Cromi, A., and Ghezzi, F. (2014). Robot-assisted sacrocolpopexy for pelvic organ prolapse: a systematic review and meta-analysis of comparative studies. *Eur Urol 66*, 303–318.

[48] Cundiff, G. W., Varner, E., Visco, A. G., Zyczynski, H. M., Nager, C. W., Norton, P. A., Schaffer, J., Brown, M. B., Brubaker, L., and Pelvic Floor Disorders Network (2008). Risk factors for mesh/suture erosion following sacral colpopexy. *Am J Obstet Gynecol 199*, 688.e1–5.

[49] Wu, J. M., Wells, E. C., Hundley, A. F., Connolly, A., Williams, K. S., and Visco, A. G. (2006). Mesh erosion in abdominal sacral colpopexy with and without concomitant hysterectomy. *Am J Obstet Gynecol 194*, 1418–1422.

[50] Costantini, E., Brubaker, L., Cervigni, M., Matthews, C. A., O'Reilly, B. A., Rizk, D., Giannitsas, K., and Maher, C. F. (2016). Sacrocolpopexy for pelvic organ prolapse: evidence-based review and recommendations. *Eur J Obstet Gynecol Reprod Biol 205*, 60–65.

[51] Tan-Kim, J., Menefee, S. A., Luber, K. M., Nager, C. W., and Lukacz, E. S. (2011). Robotic-assisted and laparoscopic sacrocolpopexy: comparing operative times, costs and outcomes. *Female Pelvic Med Reconstr Surg 17*, 44–49.

[52] Higgs, P. J., Chua, H. L., and Smith, A. R. B. (2005). Long term review of laparoscopic sacrocolpopexy. *BJOG 112*, 1134–1138.

[53] Culligan, P. J., Gurshumov, E., Lewis, C., Priestley, J. L., Komar, J., Shah, N., and Salamon, C. G. (2014). Subjective and objective results 1 year after robotic sacrocolpopexy using a lightweight Y-mesh. *Int Urogynecol J 25*, 731–735.

[54] Salamon, C. G., Lewis, C., Priestley, J., Gurshumov, E., and Culligan, P. J. (2013). Prospective study of an ultra-lightweight polypropylene Y mesh for robotic sacrocolpopexy. *Int Urogynecol J 24*, 1371–1375.

[55] Culligan, P. J., Salamon, C., Priestley, J. L., and Shariati, A. (2013). Porcine dermis compared with polypropylene mesh for laparoscopic sacrocolpopexy: a randomized controlled trial. *Obstet Gynecol 121*, 143–151.

[56] Culligan, P. J., Blackwell, L., Goldsmith, L. J., Graham, C. A., Rogers, A., and Heit, M. H. (2005). A randomized controlled trial comparing fascia lata and synthetic mesh for sacral colpopexy. *Obstet Gynecol 106*, 29–37.

[57] Tate, S. B., Blackwell, L., Lorenz, D. J., Steptoe, M. M., and Culligan, P. J. (2011). Randomized trial of fascia lata and polypropylene mesh for abdominal sacrocolpopexy: 5-year follow-up. *Int Urogynecol* J *22*, 137–143.

[58] Mourik, S. L., Martens, J. E., and Aktas, M. (2012). Uterine preservation in pelvic organ prolapse using robot assisted laparoscopic sacrohysteropexy: quality of life and technique. *Eur J Obstet Gynecol Reprod Biol 165*, 122–127.

[59] Paek, J., Lee, M., Kim, B. W., and Kwon, Y. (2016). Robotic or laparoscopic sacrohysteropexy versus open sacrohysteropexy for uterus preservation in pelvic organ prolapse. *Int Urogynecol J 27*, 593–599.

[60] Lewis, C. M., and Culligan, P. (2012). Sacrohysteropexy followed by successful pregnancy and eventual reoperation for prolapse. *Int Urogynecol J 23*, 957–959.

[61] Jefferis, H., Price, N., and Jackson, S. (2017). Laparoscopic hysteropexy: 10 years' experience. *Int Urogynecol* J *28*, 1241–1248.

[62] Jefferis, H., Price, N., and Jackson, S. (2017). Pregnancy following laparoscopic hysteropexy-a case series. *Gynecol Surg 14*, 16.

[63] Rahmanou, P., White, B., Price, N., and Jackson, S. (2014). Laparoscopic hysteropexy: 1- to 4-year follow-up of women postoperatively. *Int Urogynecol J 25*, 131–138.

[64] Gutman, R. E., Rardin, C. R., Sokol, E. R., Matthews, C., Park, A. J., Iglesia, C. B., Geoffrion, R., Sokol, A. I., Karram, M., Cundiff, G. W., et al. (2017). Vaginal and laparoscopic mesh hysteropexy for uterovaginal prolapse: a parallel cohort study. *Am J Obstet Gynecol 216*, 38.e1–38.e11.

[65] Grimminck, K., Mourik, S. L., Tjin-Asjoe, F., Martens, J., and Aktas, M. (2016). Long-term follow-up and quality of life after robot assisted sacrohysteropexy. *Eur J Obstet Gynecol Reprod Biol 206*, 27–31.

[66] Siff, L. N., Jallad, K., Hickman, L. C., and Walters, M. D. (2017). Surgical anatomy of the uterosacral ligament colpopexy. *Female Pelvic Med Reconstr Surg.*

[67] Margulies, R. U., Rogers, M. A. M., and Morgan, D. M. (2010). Outcomes of transvaginal uterosacral ligament suspension: systematic review and metaanalysis. *Am J Obstet Gynecol 202*, 124–134.

[68] Barbier, H. M., Smith, M. Z., Eto, C. U., Welgoss, J. A., Von Pechmann, W., Horbach, N., and Gruber, D. D. (2015). Ureteral compromise in laparoscopic versus vaginal uterosacral ligament suspension: A retrospective cohort. *Female Pelvic Med Reconstr Surg 21*, 363–368.

[69] Rardin, C. R., Erekson, E. A., Sung, V. W., Ward, R. M., and Myers, D. L. (2009). Uterosacral colpopexy at the time of vaginal hysterectomy: comparison of laparoscopic and vaginal approaches. *J Reprod Med 54*, 273–280.

[70] Diwan, A., Rardin, C. R., Strohsnitter, W. C., Weld, A., Rosenblatt, P., and Kohli, N. (2006). Laparoscopic uterosacral ligament uterine suspension compared with vaginal hysterectomy with vaginal vault suspension for uterovaginal prolapse. *Int Urogynecol J Pelvic Floor Dysfunct 17*, 79–83.

[71] Krantz, T. E., McKuen, M. J., and Medina, C. (2015). Uterosacral ligament suspension complications between laparoscopic and transvaginal approaches. *J Minim Invasive Gynecol 22*, S65.

[72] Turner, L. C., Lavelle, E. S., and Shepherd, J. P. (2016). Comparison of complications and prolapse recurrence between laparoscopic and vaginal uterosacral ligament suspension for the treatment of vaginal prolapse. *Int Urogynecol J 27*, 797–803.

[73] Culligan, P. J., Miklos, J. R., Murphy, M., Goldberg, R., Graham, C., Moore, R. D., Hainer, M., and Heit, M. H. (2003). The tensile strength of uterosacral ligament sutures: a comparison of vaginal and laparoscopic techniques. *Obstet Gynecol 101*, 500–503.

[74] Bedford, N. D., Seman, E. I., O'Shea, R. T., and Keirse, M. J. N. C. (2013). Effect of uterine preservation on outcome of laparoscopic uterosacral suspension. *J Minim Invasive Gynecol 20*, 172–177.

[75] Mellgren, A., Johansson, C., Dolk, A., Anzén, B., Bremmer, S., Nilsson, B. Y., and Holmström, B. (1994). Enterocele demonstrated by defaecography is associated with other pelvic floor disorders. *Int J Colorectal Dis 9*, 121–124.

[76] Cullen, J., Rosselli, J. M., and Gurland, B. H. (2012). Ventral rectopexy for rectal prolapse and obstructed defecation. *Clin Colon Rectal Surg 25*, 34–36.

[77] Wong, M. T. C., Meurette, G., Rigaud, J., Regenet, N., and Lehur, P.-A. (2011). Robotic versus laparoscopic rectopexy for complex rectocele: a prospective comparison of short-term outcomes. *Dis Colon Rectum 54*, 342–346.

[78] Solomon, M. J., Young, C. J., Eyers, A. A., and Roberts, R. A. (2002). Randomized clinical trial of laparoscopic versus open abdominal rectopexy for rectal prolapse. *Br J Surg 89*, 35–39.

[79] Byrne, C. M., Smith, S. R., Solomon, M. J., Young, J. M., Eyers, A. A., and Young, C. J. (2008). Long-term functional outcomes after laparoscopic and open rectopexy for the treatment of rectal prolapse. *Dis Colon Rectum 51*, 1597–1604.

[80] Mantoo, S., Podevin, J., Regenet, N., Rigaud, J., Lehur, P. A., and Meurette, G. (2013). Is robotic-assisted ventral mesh rectopexy superior to laparoscopic ventral mesh rectopexy in the management of obstructed defaecation? *Colorectal Dis 15*, e469–75.

[81] Mäkelä-Kaikkonen, J. K., Rautio, T. T., Koivurova, S., Pääkkö, E., Ohtonen, P., Biancari, F., and Mäkelä, J. T. (2016). Anatomical and functional changes to the pelvic floor after robotic versus laparoscopic ventral rectopexy: a randomised study. *Int Urogynecol J 27*, 1837–1845.

[82] Burch, J. C. (1961). Urethrovaginal fixation to Cooper's ligament for correction of stress incontinence, cystocele, and prolapse. *Am J Obstet Gynecol 81*, 281–290.

[83] Tanagho, E. A. (1976). Colpocystourethropexy: the way we do it. *J Urol 116*, 751–753.

[84] Khan, M. S., Challacombe, B., Rose, K., and Dasgupta, P. (2007). Robotic colposuspension: two case reports. *J Endourol 21*, 1077–1079.

[85] Speights, S. E., Moore, R. D., and Miklos, J. R. (2000). Frequency of lower urinary tract injury at laparoscopic burch and paravaginal repair. *J Am Assoc Gynecol Laparosc 7*, 515–518.

[86] Sadik, S., Onoglu, A. S., Mendilcioglu, I., Sehirali, S., Sipahi, C., and Taskin, O. (2000). Urinary tract injuries during advanced gynecologic laparoscopy. *J Am Assoc Gynecol Laparosc 7*, 569–572.

[87] Paraiso, M. F. R., Walters, M. D., Karram, M. M., and Barber, M. D. (2004). Laparoscopic Burch colposuspension versus tension-free vaginal tape: a randomized trial. *Obstet Gynecol 104*, 1249–1258.

[88] Jelovsek, J. E., Barber, M. D., Karram, M. M., Walters, M. D., and Paraiso, M. F. R. (2008). Randomised trial of laparoscopic Burch colposuspension versus tension-free vaginal tape: long-term follow up. *BJOG 115*, 219–25; discussion 225.

[89] Dean, N., Herbison, P., Ellis, G., and Wilson, D. (2006). Laparoscopic colposuspension and tension-free vaginal tape: a systematic review. *BJOG 113*, 1345–1353.

[90] Kitchener, H. C., Dunn, G., Lawton, V., Reid, F., Nelson, L., Smith, A. R. B., and COLPO Study Group (2006). Laparoscopic versus open colposuspension–results of a prospective randomised controlled trial. *BJOG 113*, 1007–1013.

[91] Ankardal, M., Ekerydh, A., Crafoord, K., Milsom, I., Stjerndahl, J.-H., and Engh, M. E. (2004). A randomised trial comparing open Burch colposuspension using sutures with laparoscopic colposuspension using mesh and staples in women with stress urinary incontinence. *BJOG 111*, 974–981.

[92] Barr, S., Reid, F. M., North, C. E., Hosker, G., and Smith, A. R. B. (2009). The long-term outcome of laparoscopic colposuspension: a 10-year cohort study. *Int Urogynecol J Pelvic Floor Dysfunct 20*, 443–445.

[93] Oakley, S. H., Brown, H. W., Greer, J. A., Richardson, M. L., Adelowo, A., Yurteri-Kaplan, L., Lindo, F. M., Greene, K. A., Fok, C. S., Book, N. M., et al. (2014). Management of vesicovaginal fistulae: a multicenter analysis from the Fellows' Pelvic Research Network. *Female Pelvic Med Reconstr Surg 20*, 7–13.

[94] O'Conor, V. J., and Sokol, J. K. (1951). Vesicovaginal fistula from the standpoint of the urologist. *J Urol 66*, 579–585.

[95] Chibber, P. J., Shah, H. N., and Jain, P. (2005). Laparoscopic O'Conor's repair for vesico-vaginal and vesico-uterine fistulae. *BJU Int 96*, 183–186.

[96] Miklos, J. R., Moore, R. D., and Chinthakanan, O. (2015). Laparoscopic and Robotic-assisted Vesicovaginal Fistula Repair: A Systematic Review of the Literature. *J Minim Invasive Gynecol 22*, 727–736.

[97] Sjøveian, S., Vangen, S., Mukwege, D., and Onsrud, M. (2011). Surgical outcome of obstetric fistula: a retrospective analysis of 595 patients. *Acta Obstet Gynecol Scand 90*, 753–760.

[98] Tenggardjaja, C. F., and Goldman, H. B. (2013). Advances in minimally invasive repair of vesicovaginal fistulas. *Curr Urol Rep 14*, 253–261.

[99] Gupta, N. P., Mishra, S., Hemal, A. K., Mishra, A., Seth, A., and Dogra, P. N. (2010). Comparative analysis of outcome between open and robotic surgical repair of recurrent supra-trigonal vesico-vaginal fistula. *J Endourol 24*, 1779–1782.

[100] Dutto, L., and O'Reilly, B. (2013). Robotic repair of vesico-vaginal fistula with perisigmoid fat flap interposition: state of the art for a challenging case? *Int Urogynecol J 24*, 2029–2030.

[101] Perveen, K., Gupta, R., Al-Badr, A., and Hemal, A. K. (2012). Robot-assisted laparoscopic repair of rare post-cesarean section vesicocervical and vesicouterine fistula: a case series of a novel technique. *Urology 80*, 477–482.

[102] Watts, K. L., Ho, R., Ghavamian, R., and Abraham, N. (2017). Robot-assisted extravesical vesicovaginal fistula repair utilizing laparoscopically mobilized omental flap interposition. *Int Urogynecol J 28*, 641–644.

[103] Miklos, J. R., and Moore, R. D. (2015). Laparoscopic extravesical vesicovaginal fistula repair: our technique and 15-year experience. *Int Urogynecol J 26*, 441–446.

[104] Miklos, J. R., and Moore, R. D. (2015). Laparoscopic transperitoneal extravesical approach to vesicovaginal fistula repair without omental flap: a novel technique. *Int Urogynecol J 26*, 447–448.

[105] Kelly, E., Wu, M. Y., and MacMillan, J. B. (2017). Robotic-assisted vesicovaginal fistula repair using an extravesical approach without interposition grafting. *J Robot Surg.*

[106] Hemal, A. K., Sharma, N., and Mukherjee, S. (2009). Robotic repair of complex vesicouterine fistula with and without hysterectomy. *Urol Int 82*, 411–415.

[107] Wilkinson, M. N., O'Sullivan, O. E., and O'Reilly, B. A. (2017). Role of robotics in managing mesh and suture complications of prior pelvic organ prolapse surgery. *J Robot Surg 11*, 91–92.

[108] Matanes, E., Lauterbach, R., Mustafa-Mikhail, S., Amit, A., Wiener, Z., and Lowenstein, L. (2017). Single port robotic assisted sacrocolpopexy: our experience with the first 25 cases. *Female Pelvic Med Reconstr Surg 23*, e14–e18.

[109] Intuitive Surgical - *da Vinci Surgical System Si* Available at: https://www.intuitivesurgical.com/products/davinci_surgical_system/da-vinci-single-site/ [Accessed December 17, 2017].

[110] Bogliolo, S., Ferrero, S., Cassani, C., Musacchi, V., Zanellini, F., Dominoni, M., Spinillo, A., and Gardella, B. (2016). Single-site Versus Multiport Robotic Hysterectomy in Benign Gynecologic Diseases: A Retrospective Evaluation of Surgical Outcomes and Cost Analysis. *J Minim Invasive Gynecol 23*, 603–609.

[111] Giannini, A., Russo, E., Mannella, P., and Simoncini, T. (2017). Single site robotic-assisted apical lateral suspension (SS R-ALS) for advanced pelvic organ prolapse: first case reported. *J Robot Surg 11*, 259–262.

In: Encyclopedia of Surgery (22 Volume Set)
Editors: Andreas Lehrer and Kristin Mueller
ISBN: 978-1-53618-329-0
© 2020 Nova Science Publishers, Inc.

Chapter 256

ROBOTIC SURGERY: CLINICAL PERCEPTIONS, APPROACHES, AND CHALLENGES IN GYNECOLOGIC ONCOLOGY

Tommaso Grassi[1], MD, Valentina Zanfagnin[2], MD, Stephanie R. DeJong[2], MD, Jvan Casarin[3], MD and Andrea Mariani[4,*], MD

[1]Division of Gynecologic Surgery, Mayo Clinic, Rochester, MN, US
Clinic of Obstetrics and Gynecology, University of Milan-Bicocca, San Gerardo Hospital, Monza, Italy
[2]Division of Gynecologic Surgery, Mayo Clinic, Rochester, MN, US
[3]Division of Gynecologic Surgery, Mayo Clinic, Rochester, MN, US
Department of Obstetrics and Gynecology, University of Insubria, Varese, Italy
[4]Obstetrics and Gynecology, Division of Gynecologic Surgery, Department of Obstetrics and Gynecology, Division of Gynecologic Surgery, Mayo Clinic, Rochester, MN, US

ABBREVIATIONS

BMI	Body Mass Index
BSO	bilateral salpingo-oophorectomy
DFS	Disease-Free Survival
EC	Endometrial Cancer
FIGO	International Federation of Obstetrics and Gynecology
ICG	Indocyanine green
IHP	Inferior Hypogastric Plexus
IMA	Inferior mesentery artery
LVSI	Lympho-Vascular Space Invasion

∗ Corresponding Author's Email: mariani.andrea@mayo.edu.

MIS	Minimally Invasive Surgery
NCCN	National Comprehensive Cancer Network
OC	Ovarian Cancer
OR	Operating Room
OS	Overall Survival
QoL	Quality of Life
RCT	Randomized Controlled Trial
RH	Radical Hysterectomy
SLN	Sentinel lymph node
U.S.	United States

INTRODUCTION

The introduction of minimally invasive surgery (MIS) has represented a milestone in the management of patients affected by gynecologic malignancies. Laparoscopic and robotic techniques have reduced the rates of intraoperative and postoperative complications as well as the length of hospitalization, leading to shorter post-operative recovery period and earlier initiation of adjuvant treatments [1-4]. Despite these advantages, the diffusion of laparoscopy in gynecologic oncology has been limited by the steep learning curve, longer operative times, and limitations of the instruments when compared to laparotomy techniques. Conversely, the adoption of robotic surgery has steadily risen in the last decade. The reasons for its success can be linked to the preservation of the benefits of MIS techniques while overcoming some of the limitations of laparoscopy [5-8]. In this chapter, the origin, indications, and challenges of robotic surgery in gynecology are discussed, with a specific focus on gynecologic oncology.

1. HISTORY AND CONTRIBUTION OF ROBOTIC SURGERY IN GYNECOLOGIC ONCOLOGY

1.1. The Origin of Robotic Surgery in Gynecologic Oncology

The first reported gynecologic surgery robotic procedures consisted of a series of laparoscopic tubal re-anastomoses with robotic assistance in 1999 and 2000. Eleven cases were performed at the Cleveland Clinic Foundation with the AESOP and the Zeus robotic surgical systems (Computer Motion Inc., Goleta, CA) [9, 10]. Eight re-anastomoses were performed at the University Hospital Saint-Pierre, Belgium with the da Vinci surgical system (Intuitive Surgical Inc., Sunnyvale, CA) [11]. In 2002, the first robotic hysterectomies with bilateral salpingo-oophorectomy (BSO) were performed at the University of Texas Medical Branch using the da Vinci surgical system [12]. A robotic infracolic omentectomy, with concomitant pelvic and para-aortic lymphadenectomy for an early stage ovarian cancer was described in the same series. Subsequently, in 2003, a case of successful robotic ovarian transposition was performed with the da Vinci at the University of Nebraska Medical Center [13].

Beginning in 2004, three series of robotic-assisted laparoscopy for benign and malignant gynecologic lesions were described at the University of Michigan Medical Center [14-16].The primary intent was to assess the feasibility of robotic surgery in a gynecologic surgical setting. Among the group of patients with malignant disease (two ovarian, one early stage fallopian tube, and four endometrial cancers), six of them successfully underwent pelvic and para-aortic lymphadenectomy, and three underwent an omentectomy with peritoneal staging biopsies. In these cases, the da Vinci robotic surgical system was repositioned from the pelvis to the upper-abdomen, without requiring conversion to laparotomy [15].

The success of this technique led to the United States Food and Drug Administration approval of the da Vinci Surgical System for clinical use in gynecology in 2005 (Figure 1) Following this, a growing number of robotic surgical procedures was reported for gynecologic malignancies, specifically in endometrial cancer, early-stage cervical cancer and ovarian cancer [17-21].

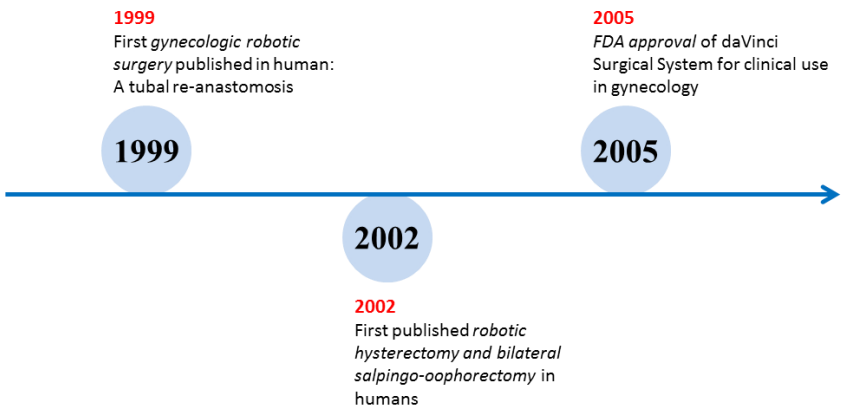

Figure 1. Timeline of the origin of robotic surgery in gynecology.

The primary purpose of the introduction of robotic surgery at Mayo Clinic was to facilitate the use of MIS in the treatment of gynecologic malignancies [22]. One of the first robotic procedures for gynecologic malignancy was performed on April 9, 2003 by Magrina et al. [20] at Mayo Clinic Scottsdale. A robotic radical hysterectomy was performed and subsequently followed by 27 similar cases performed in women affected by cervical and endometrial cancer between April 2003 and September 2006. Although the Zeus robotic system was used initially, the da Vinci Surgical System was eventually adopted in 2004. The implementation of robotic gynecologic surgery at Mayo Clinic Rochester started in 2007 with the acquisition of the da Vinci System in the Division of Gynecology in Rochester, Minnesota [23, 24].

1.2. The Contribution of Robotic Surgery to MIS in Gynecologic Oncology

Before the implementation of robotic surgery, minimally invasive gynecologic surgery had limited use in the United States (U.S.). A cross-sectional analysis of the Nationwide Inpatients Sample database demonstrated a total of 518,828 women underwent hysterectomy

for benign conditions in 2005 [25]. Among them, at that time, only 14% of the hysterectomies were performed laparoscopically, 64% were performed abdominally and 22% performed vaginally. In another study, the rate of open abdominal hysterectomies for any indication decreased from 65% in 1998 to 54.2% in 2010. The percentage of traditional laparoscopic hysterectomies increased to 15.5% in 2006 then declined to 8.6% in 2010. The rate of robotic hysterectomy quickly rose from 0.9% in 2008 to 8.2% in 2010 [26].

In the field of gynecologic oncology, the use of MIS has been rapidly increasing since the introduction of robotic surgery [27-29]. Between 2007 and 2011, 32,560 women underwent hysterectomy for non-metastatic endometrial cancer, according to the Nationwide Inpatient Sample Database [27]. The rate of patients that underwent minimally invasive hysterectomy increased from 22% in 2007 to 50.8% in 2011 due to the widespread adoption of robotic surgery (Figure 2). Similarly, the number of institutions performing MIS in more than 80% of patients with non-metastatic endometrial cancer shifted from 1.5% in 2007 to 18.9% in 2011.

The rate of MIS continues to increase. In a recent study from our group, the percentage of laparotomies performed for surgical staging of non-disseminated endometrial cancer was significantly lower than the MIS (Figure 3) [28]. In the American College of Surgeons' National Surgical Quality Improvement Project database, among the 12,283 patients included from 2008 to 2014, the percentage of laparotomies decreased from 74.3% to 26.4%, while the MIS approach increased from 24.2% to 71.4%.

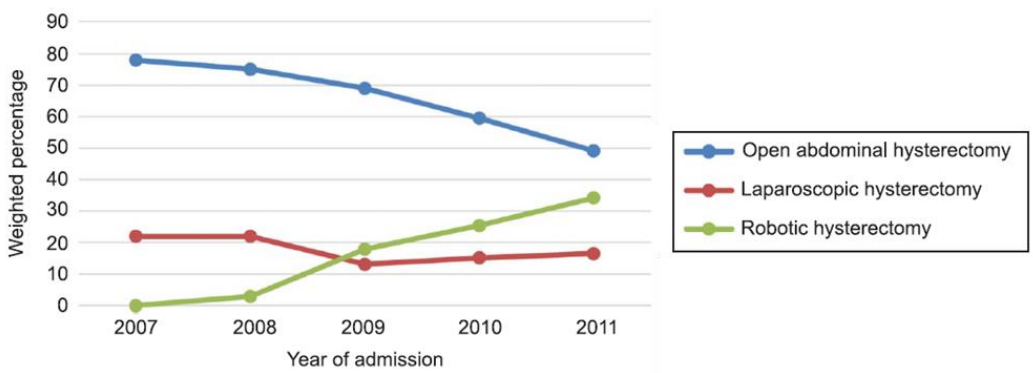

Figure 2. Percentage of patients with non-metastatic endometrial cancer that underwent open, laparoscopic, or robotic hysterectomy per year [27]. Used with permission from Amanda Fader, R. Weise, Abdulrahman Sinno, et al: Utilization of Minimally Invasive Surgery in Endometrial Cancer Care: A Quality and Cost Disparity. *Obstet Gynecol*, 127 (1), 91-100, https://journals.lww.com/greenjournal.

A similar transition from laparotomy to MIS techniques (in particular to robotic surgery) happened at Mayo Clinic. In patients with non-stage IV endometrial cancer, the rate of open surgeries decreased from 79% in 2007 to 34% in 2012, and robotic procedures increased from 4% to 56% in the same period [24].

The same shift in surgical approaches has been seen in the management of early-stage cervical cancer. As described in the Perspective Database, among the 1894 women that underwent radical hysterectomy (RH) for cervical cancer, the rate of open RH decreased from 98% to 67% in the period 2006-2010 [30]. In contrast, laparoscopic RH rates increased from 2% to 23%, and the percentage of robotic RH grew to 10% from the first case in 2007 to 2010.

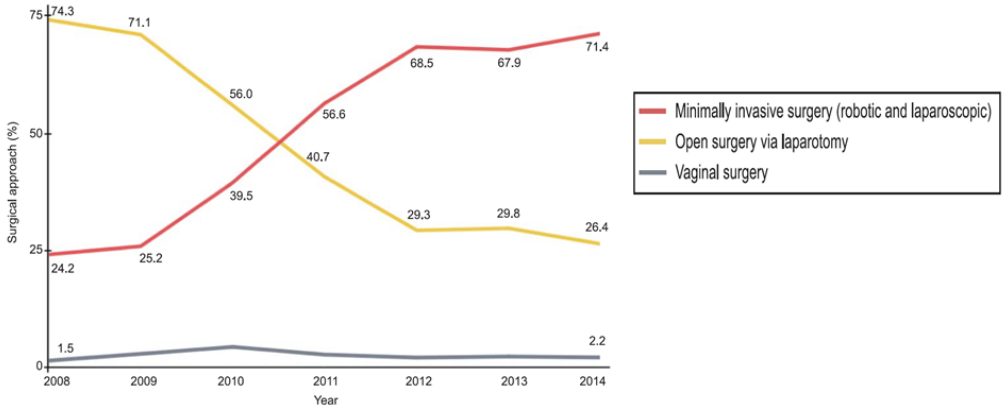

Figure 3. Trends of MIS, laparotomy and vaginal surgery for non-disseminated endometrial cancer per year [28]. Used with permission from Jvan Casarin, Francesco Multinu, Daniel Ubl, et al: Adoption of Minimally Invasive Surgery and Decrease in Surgical Morbidity for Endometrial Cancer Treatment in the United States. *Obstet Gynecol*, 131 (2), 304-311, https://journals.lww.com/greenjournal.

In summary, the implementation of the robotic technique, during the last decade, allowed to make the transition towards a widespread use of MIS at a national level in gynecology in the U.S.

2. Robotic Surgery for Gynecologic Oncology: Evidence and Challenges

The advent of robotic surgery represented a paradigm shift in the surgical approach to gynecologic diseases. Since its introduction, numerous studies have been published focusing not only on the surgical outcomes and survival but also on the costs that the procedure carries. In the next paragraphs, the evidence and challenges accompanying robotic surgery in gynecologic oncology are discussed.

2.1. Robotic Surgery versus Traditional Surgical Approaches

Overall, minimally invasive procedures have shown a decrease in surgical morbidity and length of hospital stay when compared to laparotomy without a detrimental effect on oncologic outcomes [1-4, 31]. However, the clinical benefits are less evident when the two major minimally invasive approaches (laparoscopy and robotic surgery) are compared.

Since its initial development in a dry-laboratory setting, robotic surgery was able to have superior performance in several tests, specifically: surgical time, accuracy, comfort and speed of suturing, economy of motion, and operator learning curve [32-37]. The limitations of conventional laparoscopy were overcome and significant improvements were included (three-dimensional stereoscopic vision, wristed instrumentation, improved ergonomics, and minimization of the effects of hand tremors). However, when the two procedures were compared in a Cochrane review in 2014, neither approach was superior [38]. Longer surgical time but shorter hospital stay were described in patients that underwent a robotic

hysterectomy for benign disease, while a difference in rate of complications was not detected [38-41]. No safety or efficacy data was reported in oncologic patients [38-41]. The limited number of randomized controlled trials (RCTs) available for benign disease as well as lack of data for malignacy left the authors unable to draw clear conclusions.

Since that time, clinical trials have attempted to compare clinical outcomes (such as operative time, perioperative complications, quality of life (QoL), survival) and social benefits (health care system costs, length of hospital stay) of the three surgical approaches (laparotomy, laparoscopy, and robotic) for different surgical indications. Some trials ongoing at the time of this publication are outlined below.

- *LACC trial*. A biphasic RCT in patients with early-stage cervical cancer was initiated in 2008 directed by collaborators at Queensland Centre for Gynaecological Cancer (Australia) and M.D. Anderson Cancer Center (Houston, Texas) [42]. Patients are randomized between laparoscopic (conventional or robotic-assisted) RH and abdominal RH. The primary outcome is disease-free survival (DFS), while the secondary outcomes include patterns of recurrence, pelvic floor function, QoL, overall survival (OS), feasibility of sentinel lymph node biopsy, treatment-related morbidity, and costs.
- *ROBOGYN – NCT01247779.* A French trial initiated in 2010 with a primary focus on perioperative morbidity at six months in patients affected by cervical and uterine cancers who underwent laparoscopic or robotic surgery [43].
- *NCT00671827*. An observational study directed by M.D. Anderson Cancer Center initated in 2008, with an aim to analyze the length of surgical procedures, type of surgical procedures and the perioperative complications of robotic surgery in patients with gynecologic cancers [44].
- *ROBOTHYST – NCT01526655*. A Swedish RCT comparing open abdominal and robotic hysterectomy in patients with a low stage, low grade endometrial cancer [45]. Initiated in 2012, the primary outcome is to assess the perioperative QoL for patients. The secondary aims are six-week post-operative complications, evaluation of tissue damage, effects on the immune system, and the impact on health care system costs.
- *NCT02292914*. A Brazilian randomized clinical trial compares robotic surgery with traditional surgical approaches in patients with different tumors (including uterine cancer) [46]. Initiated in 2014, the primary aim is measurement of postoperative complications with secondary outcomes including ICU and hospital length of stay, operative time, QoL, OS and DFS.

2.2. Costs of Robotic Surgery

Robotic surgery costs and sustainability in the current health care system have been major obstacles since the introduction of the surgical modality. The costs of robotic surgery are impacted by direct costs (purchase of the robotic system, maintenance, disposable instrumentation), and indirect costs (extended operating time, reduction of efficient operating room (OR) utilization). Moreover, an increase in the costs can be seen anytime an indication for modality use is broadened without taking into account the actual benefits for the patients.

As an example, after the introduction of robotic surgery in a subset of patients affected by prostate cancer, a shift from non-surgical to surgical treatment was seen without any measurable benefit to patients in regards to outcomes and QoL [47].

In order to validate the cost-effectiveness of a surgical procedure, a variety of models can be conducted [24, 48-51]. A decision analysis was performed for patients diagnosed with endometrial cancer and costs were compared between open, laparoscopic and robotic surgical procedures. Three models were utilized for this purpose: a societal perspective model, a hospital perspective model with robot costs, and a hospital perspective model without robot costs [48]. The first two models included the costs of purchasing and maintaining a robotic system, while in the third model the hospital has previously purchased the robot and this cost was not included in the analysis. Only the first model included the costs of lost wages for patients and patient's caregivers. In all three models, the lowest costs per patient were associated with laparoscopic procedures ($10,128, $6,581 and $6,581 for first, second, and third models respectively). In contrast, the costs per case for robotic surgery were $11,476, $8,770 and $7,478. In the societal model, robotic surgery would become the most cost effective approach in the presence of either a reduction of the disposable material costs (Figure 4A) or proof of a most prompt return to daily activity for patients could be provided (Figure 4C). Instead, robotic surgery would be the least cost effective if case volume was insufficient (in this specific analysis, less than 13 cases per month, Figure 4B). In both of the other two models, robotic costs would be equal to or less than laparoscopic costs, if the costs of robotic disposable material were decreased.

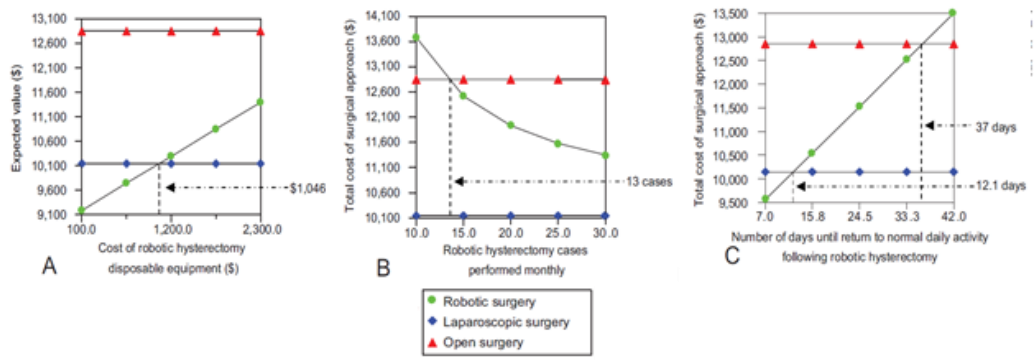

Figure 4. Comparison of different surgical approach costs in the societal perspective model. The total cost of each surgical method is represented on the Y-axis. The variables of the X-axis are below each figure [48]. Used with permission from Jason Barnett, John Judd, Jennifer Wu, et al: Cost comparison among robotic, laparoscopic, and open hysterectomy for endometrial cancer. *Obstet Gynecol*, 116 (3), 685-693, https://journals.lww.com/greenjournal.

An analysis conducted using the Perspective Database focused on the association between hospital and surgeon robotic procedure volume and costs of robotic surgery [52]. A cohort of 10,906 patients who underwent minimally-invasive hysterectomy for endometrial cancer was assessed. When fewer than 5 robotic cases have been performed, the cost of robotic surgery procedures for the hospital is $10,469. When greater than 50 robotic procedures have been performed, the cost to the hospital decreases to $9,256. In the same way, a reduction of costs varied based on surgeon volume: for surgeons whose previous

volume was fewer than 5 cases, average cost was $10,252. For surgeons whose previous case volume was more than 50 cases, average cost was $7,955.

A recent retrospective study from Mayo Clinic compared 251 patients with endometrial cancer who underwent robotic surgical staging to 384 open surgical staging procedures (timeframe: 2007-2012) [24]. Although the anesthesia and OR costs were significantly higher in the robotic group, the costs related to the post-operative period (assessed 30 days postoperative) were significantly lower in the robotic group ($19,128 vs. $20,389 for open surgery). Although open techniques were associated with shorter operating times, when compared to robotic cases, there was an increase in the length of hospital stay, postoperative complications, perioperative transfusions, and readmission rate. Furthermore, as expertise increased over the study period, the operative time and the length of stay significantly decreased for the robotic. These improvements may positively influence the actual costs of the robotic surgery.

Although these results appear encouraging, the final analysis presented some limitations. In the first analysis, complications and readmission rates were not included in the models [48]. In the second analysis, pre-operative characteristics of the patients and tumors were not taken into account [52]. The Mayo Clinic study carries the usual intrinsic biases of non-randomized, single-institution retrospective studies, and did not analyze indirect and amortization costs [24].

It should also be noted that at its introduction, laparoscopy was initially considered more costly than laparotomy for gynecologic procedures. [53]. Similar to arguments against robotic surgery today, laparoscopy was initially scrutinized for increased costs related to disposable instruments (compare to Figure 4A). Hopefully, a change in the costs can be expected in the near future, and ongoing and future trials will likely yield more comprehensive results.

2.3. Technical Issues in Robotic Surgery for Gynecologic Oncology: The Learning Curve

The learning curve starts with development of proficiency in OR set-up, patient positioning, bedside assisting, functional port-placement and robot docking [54]. Current debate revolves around techniques and parameters to assess surgeon proficiency in robotic surgery [55].

In gynecologic oncology, the learning curve for robotic surgery was mainly studied in endometrial cancer cases. The number of surgical procedures needed to achieve proficiency and efficiency was investigated in the first 105 robotic endometrial cancer staging surgeries at the Ohio State University [56, 57]. They defined “proficiency” as the number of procedures after which the operative time curve began to level out. “Efficiency” was described as the number of procedures after which the operative time curve plateaued. The time from patients’ entrance into the OR to incision, skin to skin time, and console time significantly decreases with the increasing number of the robotic procedures. Proficiency was gained on average after 20 cases. The estimated blood loss and the lymph node yield during lymphadenectomy were not significantly different between the first 20 cases and subsequent cases. The rate of conversion to laparotomy was higher in the first 50 cases [56]. In a more detailed analysis of the first 79 robotic surgical staging procedures for endometrial cancer, it was demonstrated

that each part of the surgical procedure required a different number of cases to gain efficiency (Table 1) [57]. However, for the case as a whole and each individual portion, the only significant variation in operative time was between the first twenty cases and the subsequent cases. The lymph node yield, estimated blood loss and length of hospital stay were not different with increased surgical robotic experience.

At the Renown Regional Medical Center in Reno, Nevada, the first 122 robotic procedures and the first 122 laparoscopic procedures were compared in patients who underwent hysterectomy and lymphadenectomy for endometrial cancer [58]. Analysis demonstrated that 49 cases were necessary to gain proficiency in the laparoscopic group, versus 24 cases in the robotic group. The total operative time and blood loss were significantly lower after 24 robotic cases were completed. A varying number of cases were described in order to gain proficiency in the robotic surgery group for each portion of the surgical procedures (Table 1). Furthermore, robotic surgery was associated with a lower rate of conversion to open procedures, smaller volumes of blood loss, fewer major complications, and shorter length of hospital stay. After comparison, the two learning curves for the two minimally invasive approaches favored robotic surgery. Although robotic and laparoscopic surgery have shown a difference in the learning curve in dry-laboratory settings [32, 59], the previous laparoscopic experience of a surgeon may have influenced the learning curve for robotic surgery in the clinical setting [57, 58].

Table 1. Number of procedures required to gain proficiency and efficiency in robotic surgery for endometrial cancer patients. NA, not available; OR, operating room

Procedures	Proficiency [58] (Number of procedures)	Efficiency [57] (Number of procedures)
Hysterectomy	8	78 (including cuff closure)
Patient OR entry to incision	NA	22
Incision to robot docking	NA	45
Port placement	10	NA
Robot docking	10	NA
Para-aortic lymphadenectomy	17	70
Vaginal cuff closure	21	77
Console time	NA	69
Patient OR entry to exit	24	70
Pelvic lymphadenectomy	55	55
Skin to skin time	NA	64

The learning curve for robotic surgery in the setting of cervical cancer has been less frequently reported [60, 61]. In a retrospective series, a single surgeon with previous laparoscopic experience performed 65 robotic RHs and pelvic lymphadenectomies [60]. A significant reduction of median skin to skin time, docking time, console time, and blood loss were observed after 28 cases without a significant difference in pelvic lymph nodes yield or length of hospital stay. In another small retrospective series of 37 cervical cancer patients, a single surgeon with previous laparoscopy experience demonstrated significantly decreased operative time and blood loss after performing a robotic hysterectomy and pelvic lymphadenectomy in 12 patients [61].

Surgeon proficiency and efficiency significantly depend on the robotic surgical team: anesthesiologists, surgical technicians, circulating nurses, and bedside assistants [62, 63]. A single institution study from 2010 compared the differences in surgical outcomes between a team containing formally trained surgical assistants and those with a team with less structured training. [63]. The robot docking time and instrument exchange time were significantly reduced in the group that received formal training and the average degree of work satisfaction was significantly higher.

2.4. Technical Issues in Robotic Surgery for Gynecologic Oncology: Patient Positioning and Preparation

Patient positioning represents an essential step in robotic surgery [54]. Once the surgical procedure is underway, undocking is required before proceeding to any change in patient's position. Interestingly, an OR table that allows moving the patient's position during surgery without undocking the robot is now available. This system permits the surgeon to move the table and the robot simultaneously to facilitate ideal exposure of the surgical field. The patient is required to be placed in the dorsal lithotomy position with the buttock at the edge of the table. Shoulder braces, chest straps, and underbody foam mattress may be used to achieve safe positioning while avoiding nerve injuries. The arms are padded and placed to the sides of the patient in the anatomically neutral position with the thumb pointing up.

Stirrups are used to facilitate leg repositioning allowing for adequate visualization of the cervix for injection of indocyanine green (ICG) in patients who require sentinel lymph nodal dissection. Allen Yellofins stirrups (Allen Medical, Acton MA) are frequently used which allow for flexion, external rotation and abduction of the hips throughout the procedure without the need for repositioning (see *Lymph node assessment*). After proper positioning, the stomach should be deflated with an orogastric tube, which is left in place during the entire operation.

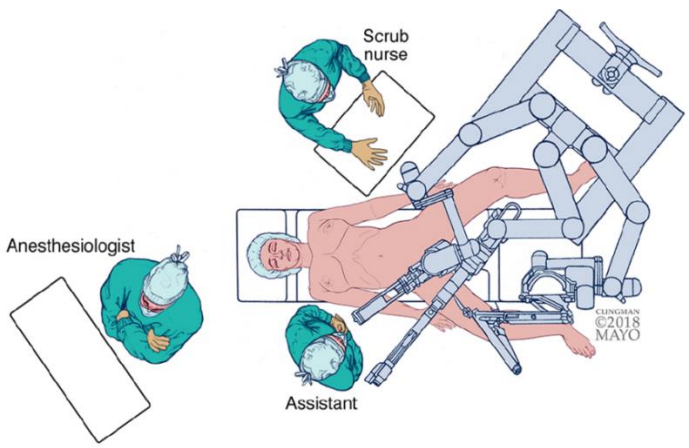

Figure 5. OR configuration: position of da Vinci Si, surgical assistant, and scrub nurse. Used with permission of Mayo Foundation for Medical Education and Research. All rights reserved.

In gynecologic cancer cases, different configurations may be utilized in the OR to perform robotic procedures. In our institution, use of the da Vinci Xi requires positioning on the patient's left side while the da Vinci Si requires positioning at the left lower corner or between the patient's feet (Figure 5). The operative console is positioned outside the surgical field. The first assistant stands to the right of the patient while the scrub nurse/surgical scrub technician stands on the left (Figure 5).

In robotic surgery, as previously described, it is critical to have a dedicated and trained surgical team who is skilled in manipulating the robot at the bedside. The team is crucial to avoid delays and difficulties during the surgical procedure. In fact, the primary surgeon is not scrubbed in, and for this reason the rest of the surgical team must be reasonably independent in managing minor surgical issues (i.e., bedside assisting, docking and undocking, exchanging instruments, cleaning the camera, and adjustment of the pneumoperitoneum).

3. Robotic Surgery for Gynecologic Oncology: Clinical Indications

3.1. Endometrial Cancer

3.1.1. Introduction

In the U.S., the most common female genital tract malignancy is the adenocarcinoma of the endometrium, with an estimated incidence of 61,380 women and 10,920 deaths in 2017 [64]. At the time of diagnosis, 67% of women have disease confined to the uterus, and only 8% of women have a distant metastatic disease [64]. Despite these characteristics, uterine corpus cancer was the cause of 4% of estimated cancer deaths among women in 2017 and an increase of 2% in mortality rate was described from 2010 to 2014 [64]. Thus, risk stratifying patients is important for prognosis and tailoring a particular patient's therapy. Currently, the stratification of patients with endometrial cancer is based on the International Federation of Obstetrics and Gynecology (FIGO) stage and characteristics of the pathological specimen (tumor histology, differentiation grade, myometrial invasion, lymphovascular space invasion (LVSI), tumor size) [65, 66]. If the disease is resectable and without distant visceral metastases, the recommended treatment is total simple extra-fascial hysterectomy (Type A according to Querleu-Morrow classification [67] or type I according to Piver-Rutlege classification [68] - Table 6), bilateral salpingo-oophorectomy (BSO), and surgical staging [69]. In a patient with pre-operative early stage disease, a minimally invasive surgical approach is considered the standard when technically feasible [69]. Lymph node assessment is dependent on the pre- and intra-operative findings, but typically is part of required surgical staging [70]. Recently the National Comprehensive Cancer Network (NCCN) accepted sentinel lymph node (SLN) sampling as an alternative to evaluate the lymph node status without proceeding to pelvic and para-aortic lymphadenectomy [69].

3.1.2. Do Different Surgical Approaches Correspond to Different Surgical Outcomes?

Abdominal laparotomy was the traditional surgical approach for hysterectomy in cases of endometrial cancer. Many retrospective studies supported the fact that laparotomy is

associated with a decreased operative time when compared to MIS but carries higher risk of postoperative complications, higher rate of major blood loss, increase in mean hospital stay and higher costs of care [27, 71-73]. Two RCTs (LAP-2, LACE trial) and a Cochrane Database Systematic review confirmed that for patients with presumed early stage endometrial cancer, laparoscopic hysterectomy reduced operative morbidity (including lower rate of surgical site infection, transfusion, and venous thromboembolism) and length of hospital stay compared to laparotomy without jeopardizing OS and DFS [1-4, 74]. Thus, MIS is considered the standard approach whenever technically feasible [69].

3.1.2.1. Robotic Surgery versus Laparotomy

Surgical staging via robotic technique has been reported to have significantly longer operative time, but on the other hand also produced fewer complications, shorter length of hospital stay, lower estimated blood loss and transfusions, and a similar number of total lymph nodes obtained (Table 2) [49, 75-88]. As reported in Table 2, data on longer operative time in robotic surgery are discordant. In one retrospective study, 155 robotic surgical staging procedures for endometrial cancer were compared with 150 open surgical staging cases [82]. Although the rate of full pelvic and para-aortic lymphadenectomy was similar in the two groups, the skin to skin operative time was significantly lower in the robotic group. Furthermore, in the robotic group total blood loss was less, mean hospital stay was shorter, and the rate of postoperative complications (such as ileus, postoperative infections, cardiopulmonary complications, anemia, and transfusion) and readmission was significantly lower. The time from OR entry to exit was similar between the two groups. Authors of this study postulated this may be influenced by the extensive laparoscopic and robotic experience and confidence of the surgeon and of the surgical team [62, 82, 89]. In another retrospective study, optimization of port placement allowed for single docking of the robotic system throughout the entire procedure, although comprehensive para-aortic lymphadenectomy was performed [75]. The result was a reduction of the total operative time.

The Mayo Clinic experience is described in Table 2 (*Bogani, 2016* [24]). Improvement in perioperative transfusions (4.4% versus 23.2%) and readmission rate within 30 days (3.6% versus 12.8%) were observed after implementation of robotic surgery with a similar intraoperative complication rate compared to laparotomy. The rate of moderate or worse post-operative complications was 7.6% for robotic procedure and 30% for laparotomy, while the rate of severe or worse complications was 3.2% and 9.6%, respectively. The rate of conversion from robotic surgery to laparotomy was 10%. Interestingly, during the study period, the operative time and the length of stay significantly decreased for the robotic group, probably due to the increasing expertise of the surgical team.

A Swedish randomized single-institution trial (RASHEC study) was designed to explore the oncologic and surgical safety of robotic staging for presumed FIGO stage I-II high-risk endometrial cancer compared to open abdominal surgery [90]. The surgical staging consisted of hysterectomy, BSO, pelvic and para-aortic lymphadenectomy. The primary outcome was the number of dissected para-aortic lymph nodes (infra-renal para-aortic lymphadenectomy), and secondary outcomes included the number of dissected pelvic lymph nodes, the rate of perioperative complications and 30-day readmission as well as health care costs. The final protocol analysis included 96 women with similar characteristics in the two groups. The mean number of para-aortic lymph nodes was 20.9 for the robotic group, and was not inferior to the mean number lymph nodes obtained from the open abdominal surgery group (22 lymph

nodes). The mean number of pelvic nodes was lower for robotic surgery (22 lymph nodes) compared to laparotomy (28 lymph nodes), but the amount obtained with robotic approach is still considered adequate to stage [91].Comparisons in operative time, hospital stay and perioperative complications are reported in Table 2. The robotic group demonstrated smaller volumes of blood loss, while 30-day readmission rate was similar between the two groups. The health care costs (including costs of ward care, OR, post-operative care, complication costs and amortization costs of robotic surgery) were lower for the robotic surgery cohort.

Table 2. Robotic surgery versus laparotomy in endometrial cancer patients. *Intraoperative time: skin to skin time. †Intra- and post-operative complications evaluated according to different methods in each study. IQR, interquartile range; Post-op: post-operative

	Number of patients		Mean operative time* (min)		Intra- and post-operative complications† (%)		Mean length of hospital stay (days)	
	Open	Robotic	Open	Robotic	Open	Robotic	Open	Robotic
Bell, 2008 [49]	40	40	108 ±41	184 ±41	27.5	7.5	4 ±1.5	2.3 ±1.3
Boggess, 2008 [75]	138	103	146 ±48	191 ±36	29.7	5.8	4.4 ±2	1 ± 0.2
DeNardis, 2008 [76]	106	56	79 ±17	177 ±55	20.8	3.6	3.2 ±1.2	1 ± 0.5
Jung, 2010 [78]	56	28	187 ±76	193 ±60	25	7	median 10.8 (8–58) (range)	median 7.9 (4–17) (range)
Lim, 2010 [79]	36	56	137 ±32	162 ±53	19.4	14.3	4.9 ±1.9	1.6 ±0.7
Subramaniam, 2011 [80]	104	73	138 ±53	246 ±75	50	13.7	5 ±2.5	2.7 ±1.8
Coronado, 2012 [81]	192	71	157 ±33	189 ±35	34.9	21.1	8.1 ±4.8	3.5 ±3.4
ElSahwi, 2012 [82]	150	155	141 ±28	123 ±40	only post-op 27	only post-op 10	4 ±3	1.5 ±2
Nicole, 2012 [83]	79	102	132 (51-258) (min-max)	203 (84-396) (min-max)	21.5	6.9	3.8 (1-15) (min-max)	1.4 (1-9) (min-max)
Chiou, 2015 [85]	129	86	195 ±67	156 ±46	2.3	2.3	5.8 ±5.5	3.1 ±1.1
Eklind, 2015 [86]	48	40	179 (97-306) (range)	127 (68-195) (range)	/	/	4.8 (2-11) (range)	1.8 (1-5) (range)
Bogani, 2016 [24]	384	251	median 168 (138-216) (IQR)	median 270 (216-324) (IQR)	31.3	8	median 4 (3-5) (IQR)	median 1 (1-2) (IQR)
Herling, 2017 [88]	158	202	102 ±34	120 ±46	26	13	6 ±3.5	3 ±1.8
Salehi, 2017 [90] - RASHEC	48	48	median 187 (109-300) (range)	Median 233 (166-320) (range)	41.7	25	median 5 (4-9) (range)	median 2 (1-5) (range)

Despite a paucity of data, oncologic outcomes showed no differences between the two surgical approaches, both in DFS and OS (Table 3) [81, 85, 92, 93]. A retrospective survival analysis of 370 surgically staged non-stage IV endometrial cancers compared laparoscopy, laparotomy and robotic approaches [85]. The baseline characteristics of the patients and the number of pelvic lymph nodes obtained were similar in the three groups. The rates of DFS and OS at 18 months are reported in Table 3. No significant difference was described between the three groups.

Table 3. Survival analysis in patients with endometrial cancer that underwent surgery. DFS, disease-free survival; EC, endometrial cancer; NA, not available; OS, overall survival; n, number

Author	FIGO Stage	Follow-up time (years)	Surgical technique (n of patients)		DFS (%)	OS (%)
Coronado, 2012 [81]	All stages EC	3	Robotic (n=71)		92	95
			LPS (n= 58)		83.1	100
			LPT (n= 38)		38.7	93.6
Brudie, 2013 [93]	All stages EC	3 years - DFS 5 years - OS	Robotic (n= 86)		89.3	89.1
Kilgore, 2013 [92]	IA	5	Robotic	n= 360	85.2	94.2
	IB			n= 56	80.2	85.9
	II			n= 16	69.8	77.4
	III			n= 59	69	68.6
	IV			n= 9	NA	44.4
Chiou, 2015 [85]	Non-stage IV EC	1.5	Robotic (n= 86)		98.8	98.8
			LPS (n= 150)		91.3	98.0
			LPT (n= 129)		88.4	94.6

In summary, robotic surgery represents a safer approach when compared to open abdominal procedures, despite the longer operative time.

3.1.2.2. Robotic Surgery versus Traditional Laparoscopy

Several retrospective studies compared surgical outcomes of these two minimally invasive approaches (Table 4) [75, 78, 79, 81, 83, 85, 94-98]. Some studies have reported robotic surgery resulting in decreased estimated blood loss, rate of transfusions and rate of conversion compared to laparoscopy. Other studies have shown an advantage of laparoscopy with a lower percentage of complications and shorter operative time compared to robotic surgery.

In a retrospective series, 103 patients with endometrial cancer that underwent robotic surgical staging were compared to two historical cohorts of 138 staging laparotomies and 81 staging laparoscopies [75]. The clinical characteristics of the patients were similar, except for a lower average BMI in the laparoscopic group compared to the other two groups. Some surgical parameters are reported in Tables 2 and 4. Robotic surgery presented a significantly higher number of harvested lymph nodes (both in pelvic and para-aortic areas), and the lowest quantity of estimated blood loss. Although a similar rate of conversion to laparotomy was reported, one of the more frequent reasons for conversion in the laparoscopic group was poor visualization. This problem was reduced in the robotic surgery cohort.

A single-center RCT was conducted in Finland from December 2010 to October 2013 aiming to compare surgical outcomes in robotic laparoscopy and traditional laparoscopy for patients with endometrial cancer [99]. Ninety-nine patients with pre-operative assessment of grade 1 and 2 endometrial cancer were randomized to one of the MIS approaches and underwent hysterectomy, BSO, and pelvic lymphadenectomy. The patients' characteristics and median number of dissected pelvic lymph nodes were similar in the two groups (23 versus 25 for laparoscopy and robotic respectively). The skin to skin operating time and the overall complication rate are reported in Table 4. The median total time spent in the OR was significantly higher for the laparoscopic group (228 versus 197 minutes). The robotic group ad a higher rate of overall complications, due to the higher rate of major postoperative

complications (22% vs. 10% in the laparoscopic group). The percentage of intraoperative complication was higher for laparoscopy (8% versus 0%). These differences were not statistically significant.

Table 4. Robotic surgery versus laparoscopy in endometrial cancer patients. *Intraoperative time: skin to skin time. †Intra- and post-operative complications evaluated according to different methods in each study. LPS, laparoscopy; NA, not available; RCT, randomized controlled trial

	Number of patients		Mean operative time* (min)		Intra- and post-operative complications † (%)		Mean length of hospital stay (days)		Conversion rate (%)	
	LPS	Robotic	LPS	Robotic	LPS	Robotic	LPS	Robotic	LPS	Robotic
Bell, 2008 [49]	30	40	171 ±36	184 ±41	20	7.5	2 ±1.2	2.3 ±1.3	NA	NA
Boggess, 2008 [75]	81	103	213 ±35	191 ±36	13.6	5.8	1.2 ±0.5	1 ±0.2	4.9	2.9
Jung, 2010 [78]	25	28	165 ±43	193 ±60	8	7.1	median 7.7 (5-21) (range)	median 7.9 (4-17) (range)	0	0
Lim, 2010 [79]	56	56	192 ±56	163 ±53	26.8	14.3	2.6 ±0.9	1.6 ±0.7	7.1	1.7
Coronado, 2012 [81]	84	71	218 ±54	189 ±35	28.5	21.1	4.6 ±4	3.5 ±3.4	8.3	2.4
Leitao, 2012 [94]	302	347	median 184 (80–445) (range)	median 213 (96–533) (range)	14	10	median 2 (1-15) (range)	median 1 (0–5) (range)	13	11
Nicole, 2012 [83]	115	102	133 (48-306) (min-max)	203 (84-396) (min-max)	2.6	6.9	1.4 (1-9) (min-max)	1.4 (1-9) (min-max)	7	8
Cardenas-Goicoechea, 2013 [96]	244	187	161 ±59	218 ±59	27.8	21.4	1.9 ±2	2.5 ±2.1	4.1	0.5
Seror, 2014 [97]	106	40	201 ±24	248 ±27	32.1	25	7.2 ±1.1	6.9 ±0.7	9.4	0
Chiou, 2015 [85]	150	86	179 ±59	156 ±46	1.3	2.3	3.7 ±2.2	3.1 ±1.1	NA	NA
Mäenpää, 2016 [99] - RCT	49	50	median 170 (126-259) (range)	median 139 (86-197) (range)	24	36	2 (1-2)	1 (1-2)	10.2	0

From the few survival analyses available in the literature, the two MIS approaches seem to be comparable (Table 5) [81, 85, 92, 93, 100]. From 2003 to 2010, in a retrospective series of patients with endometrial cancer, 183 women underwent robotic surgery, and 232 underwent laparoscopy [100]. The population characteristics were similar between two groups, and the median follow-up was 38 months for the robotic group and 58 months for the laparoscopic group. During the follow-up, 14.8% of patients in the robotic group had a recurrence, while 12.1% in the laparoscopic group experienced recurrence. The patterns of recurrence were similar. The 3-year DFS and OS for robotic and laparoscopic group are

reported in Table 5. In multivariate analysis, advanced stage, non-endometrioid histology, and tumor grade affected DFS significantly, while histology and tumor grade were significant for OS. The surgical approach was not identified as an independent factor affecting recurrence and survival, in both the univariate and multivariate analysis.

Table 5. Survival analysis comparison between robotic and laparoscopic groups for endometrial cancer. *EC, endometrial cancer; LPS, laparoscopy; Robot, robotic*

	EC inclusion criteria	Number of patients		Estimated Survival analysis at	DFS		OS	
		Robot	*LPS*		*Robot*	*LPS*	*Robot*	*LPS*
Coronado, 2012 [81]	Primary endometrial adenocarcinoma	71	84	3 years	92%	83.1%	95%	100%
Cardenas-Goicoechea, 2014 [100]	Surgically staged EC	183	232	3 years	83.3%	88.4%	93.3%	93.6%
Chiou, 2015 [85]	Surgically staged EC – FIGO stage IA to IIIC	86	150	1.5 years	98.8%	91.3%	98.8%	98%

As previously reported, MIS is now considered the standard of care for the surgical staging of endometrial cancer [69]. The choice between laparoscopy and robotic surgery may be related to different factors. Although surgical outcomes of the two approaches are comparable, the advantages of robotic-surgery include motion, ergonomics, dexterity of instruments, the three-dimensional tremorless image of the operating field, higher visibility and precision, and a faster learning curve. Moreover, robotic surgery is feasible in obese women, broadening the number of patients that can undergo a minimally invasive approach for endometrial cancer [94].

3.2. Cervical Cancer

3.2.1. Introduction

Despite high incidence and mortality for cervical cancers diagnosed in less developed countries, the estimated number of new cervical cancer diagnoses in the United States in 2017 was 12,820 with 4,210 estimated deaths [64]. The striking event in the reduction of cervical cancer incidence and mortality rate was the introduction of cervical cancer screening with the Papanicolaou (Pap) test and, more recently, the HPV test [101]. Despite the widespread screeening in the US, about 40% of cervical cancers are diagnosed during the reproductive age years [102]. In fact, in 2012 the second cause of cancer death among women from 20 to 39 years old was cervical cancer [103].

According to NCCN guidelines, a surgical approach is indicated in early-stage cervical cancer [104]. When a conservative or fertility-sparing procedure is not indicated, the traditional surgical approach is hysterectomy and bilateral pelvic lymph node dissection (with the possibility of considering SLN mapping) (Table 6) [104]. The type of hysterectomy depends on the FIGO stage of cervical cancer (Table 6) [105, 106]. Currently, hysterectomy is classified into four types according to the Querleu & Morrow classification system (A - D) [67, 107] or historically, into five classes (I - V) according to the Piver-Rutlege classification

[68]. The difference among the hysterectomy classes is related to the escalating radical nature of the approach (Table 6).

Table 6. Types of hysterectomy. Modified from NCCN guidelines [104].
LVSI, lymphovascular space invasion

	Hysterectomy Types		
	Simple/ Extrafascial hysterectomy (Type A)	Modified Radical hysterectomy (Type B)	Radical hysterectomy (Type C)
Indication (non-fertility sparing setting)	Stage IA1	Stage IA1 with LVSI and Stage IA2	Local disease without apparent metastasis: Stage IB1 and IB2; selected stage IIA
Vaginal margin	None	1-2 cm margin	Upper $^1/_4$ to $^1/_3$ of the vagina
Ureters	Not mobilized	Tunneled through broad ligament	Tunneled through broad ligament
Parametrium	Resected at uterine and cervical border	Divided where ureter transits the broad ligament	Divided at pelvic sidewall
Uterosacral ligaments	Divided at cervical border	Partially resected	Divided near sacral region
Bladder	Mobilized to base of cervix	Mobilized to upper vagina	Mobilized below middle vagina
Rectum	Not mobilized	Mobilized below the cervix	Mobilized below middle vagina

3.2.2. Minimally Invasive Approaches

As previously described, MIS provides a less morbid approach to gynecologic oncology surgery without endangering the oncologic outcomes. Several retrospective studies [108-116] and few randomized clinical trials [117, 118] compared laparoscopic and open RH for women with early-stage cervical cancer. In a prospective randomized phase II trial conducted in England, 15 women with FIGO stage IB1 cervical cancer with size less than 2 cm were randomized to RH via laparoscopic versus open abdominal surgery [117]. Longer operative time was described for laparoscopic surgery, but a lower median duration of bladder catheterization, median blood loss and median opiate requirement in the first 36 hours after surgery were discovered. Furthermore, laparoscopy was described as less radical compared to laparotomy, due to the lower mean resected vaginal cuff length, mean resected cardinal ligament length and mean resected uterosacral ligament length.

Until the advent of robotic surgery, the radical surgical treatment of cervical cancer was rarely performed with a minimally invasive approach in the U.S. [55, 119, 120]. In 2015, a survey was sent to the members of the Society of Gynecologic Oncology on the use of MIS in gynecologic oncology procedures [119]. Seventy five percent of the respondents indicated they utilize the robot for RH and pelvic lymphadenectomy, and indicated they have not performed these with traditional laparoscopy. The impact of MIS (both robotic and laparoscopic) in cervical cancer patients was investigated in many studies. In a retrospective study of 1894 patients with cervical cancer registered in the National Perspective Database between 2006 and 2010, 1610 underwent an open RH, 217 a laparoscopic and 67 a robotic one [30]. Throughout the study period, the rate of laparotomy decreased from 98% in 2006 to

67% in 2010. Overall, the perioperative complications were less common in the MIS group (9.2% in the laparoscopy group, 13.4% in the robotic group and 15.8% in the laparotomy group). Furthermore, the rate of transfusions (5.1% in the laparoscopy group, 4.5% in the robotic group and 15% in the laparotomy group) and the median length of stay (two days for laparoscopy, one day for robotic and three days for laparotomy) were lower in the MIS group. Unfortunately, median costs were significantly higher in the minimally invasive approaches: $9618 for open RH, $10,176 for the robotic and $11,774 for the laparoscopic approach.

3.2.2.1. Robotic Surgery versus Laparotomy and Traditional Laparoscopy

Many retrospective studies compared the robotic approach with laparoscopy and laparotomy in attempt to identify the best surgical procedure for early cervical cancer management (Table 7 - 8) [30, 31, 121-145].

A retrospective multi-center study compared 491 women with early-stage cervical cancer who underwent open or robotic type II and III (comparable to type B and C) RH between 2005 and 2011 [140]. As described in Table 7, the mean operative time was longer for robotic surgery. The lymph node yield was similar between the two groups. The rate of estimated blood loss ≥ 150 ml was significantly lower for robotic surgery (20% vs. 96%), as well as transfusions rate (3% vs. 7%) and the rate of patients with a hospitalization time > 3 days (40% vs. 85%). The overall complication rate was similar between the two groups, although the percentage of moderate or worse postoperative complications was higher in the robotic group (22% vs. 18%). The intraoperative complications were higher in the laparotomy group (4% vs. 10%). The survival analysis showed similar recurrence-free survival and overall survival with a mean follow-up of 34.6 months for the robotic group and 45.2 months for the laparotomy group. The rate of recurrence was 9% for both the groups and the mortality rate was 3% for robotic surgery and 4% for open surgery.

Many other retrospective studies showed the feasibility of robotic surgery for a RH in early-stage cervical cancer in comparison laparotomy (Table 7). In one of these studies, the skin to skin operative time for type III (type C) RH was significantly shorter for robotic surgery compared to a historical cohort of open abdominal surgery and the average number of lymph nodes resected was higher in the robotic group (33.8 vs. 23.3) [121].

Studies comparing robotic and laparoscopic approaches for RH are shown in Table 8. A meta-analysis compared 1161 patients that underwent an MIS for cervical cancer with particular attention to safety and efficacy of robotic surgery in these cases [143]. No RCTs were available for the analysis. 468 patients underwent a robotic RH, and 693 underwent a laparoscopic RH. There was no difference in skin to skin operative time, the conversion rate, rate of intraoperative complications, or lymph nodes yield between the two groups. The estimated blood loss was significantly less and hospital stay was significantly shorter in the robotic group. The rate of postoperative complications, recurrence rate, and DFS were similar between the two groups. The data on resected vaginal cuff length and resected parametrial size were insufficient to perform the meta-analysis, but the two retrospective studies that described these outcomes showed similar results between the two groups [132, 133]. Two other meta-analyses reported similar results [31, 120].

Table 7. Comparison of laparotomy versus robotic surgery for RH. *Intraoperative time: skin to skin time. †Intra- and post-operative complications evaluated according to different methods in each study. ¥ Types of RH according to Querleu & Morrow classification system or Piver-Rutlege classification (see Table 6). NA, not available; OR, operating room; RH, radical hysterectomy

	Type of RH[¥]	Number of patients		Mean operative time[*] (min)		Intra- and post-operative complications [†] (%)		Mean length of hospital stay (days)	
		Open	Robotic	Open	Robotic	Open	Robotic	Open	Robotic
Boggess, 2008 [121]	III (C)	49	51	248 ±49	211 ±46	Only post-op 16.3	Only post-op 7.8	3.2	1
Ko, 2008 [122]	III (C)	32	16	Median (range) 200 (92-305)	Median (range) 268 (191-362)	25	18.8	Median (range) 4 (3-8)	Median (range) 1.5 (1-4)
Magrina, 2008 [123]	II (B)	19	15	145 ±17	161 ±30	22.9	25.9	3.2 ±1	1.8 ±1
	III (C)	16	12	192.3 ±29	226 ±27			4.1 ±1.3	1.6 ±0.7
Estape, 2009 [125]	NA	14	32	114 ±36	144 ±48	28.6	21.9	4 ±1.7	2.6 ±2.1
Maggioni, 2009 [126]	B1	23	24	200 ±66	272 ±42	Similar % NA		5 ±2.4	3.7 ±1.2
	C1	17	16						
Cantrell, 2010 [127]	III (C)	64	63	Median (range) 240 (181-420)	Median (range) 213 (75-290)	6.3	4.8	Median (range) 4 (3-8)	Median (range) 1 (1–3)
Geisler, 2010 [128]	III (C)	30	30	166	154	NA	NA	NA	NA
Halliday, 2010 [129]	II (B)	5	1	283 ±63	351 ±51	70.8	19	7.2 ±5.3	1.9 ±0.9
	III (C)	19	15						
Nam, 2010 [130]	II – III (B - C)	32	32	210 ±88	219 ±78	Similar % NA		16.9 ±7.2	11.6 ±4.2
Schreuder, 2010 [131]	III (C)	14	14	Total OR time Median (range) 225 (170-330)	Total OR time Median (range) 434 (264–610)	21.4	7.1	Median (range) 9 (7-16)	Median (range) 4 (3-14)
Sert, 2011 [132]	II – III (B - C)	26	35	163 ±27	264 ±70	46.2	20	9.2 ±2	3.8 ±0.9

Table 7. (Continued)

	Type of RH[¥]	Number of patients		Mean operative time[*] (min)		Intra- and post-operative complications [†] (%)		Mean length of hospital stay (days)	
		Open	Robotic	Open	Robotic	Open	Robotic	Open	Robotic
Soliman, 2011 [133]	NA	30	34	Total OR time 265 (139-438) (range)	Total OR time 328 (241-528) (range)	50	20.6	4	1
Gortchev, 2012 [135]	III (C)	175	73	168 ±31	152 ±27	5.1	4.1	9.6 ±1	4.1 ±0.7
Chen, 2014 [137]	NA	44	24	303 ±76	192 ±51	9.1	4.2	11.2 ±3.3	4.6 ±2.6
Mendivil, 2016 [139]	C1	39	58	143 ±52	173 ±47	15.4	5.2	5.04 ±3.02	2.50 ±4.54
Sert, 2016 [140]	II – III (B - C)	232	259	156 ±57	220 ±53	36.2	32.4	NA	NA
Zanagnolo, 2016 [142]	B1	49	101	208 ±52.0	283 ±45	Less post-op complication for robotic. % NA		5.23 ±2	3.9 ±1.9
	C1	53	102						
Shah, 2017 [145]	NA	202	109	NA	257 (129-352) (range)	23	9	median in hour (range) 112.6 (32-2,336.2)	median in hour (range) 42.7 (9-177.7)

Table 8. Comparison Laparoscopy versus Robotic surgery for RH. *Intraoperative time: skin to skin time. †Intra- and post-operative complications evaluated according to different methods in each study. ¥ Types of RH according to Querleu & Morrow classification system or Piver-Rutlege classification (see Table 6). NA, not available; OR, operating room; RH, radical hysterectomy

	Type of RH[¥]	Number of patients		Mean operative time[*] (min)		Intra- and post-operative complications [†] (%)		Mean length of hospital stay (days)		Conversion rate (%)	
		LPS	Robotic	LPS	Robotic	LPS	Robotic	LPS	Robotic	LPS	Robotic
Magrina, 2008 [123]	II (B)	17	15	192 ±19	161 ±30	19.4	25.9	2.7 ±1.9	1.8 ±1	0	0
	III (C)	14	12	255 ±22	226 ±27			2.1 ±0.7	1.6 ±0.7	0	0
Estape, 2009 [125]	NA	17	32	132 ±42	144 ±48	35.3	21.9	2.3 ±1.4	2.6 ±2.1	NA	NA
Nezhat, 2008 [124]	NA	30	13	323 (232-453) (range)	318 (200-464) (range)	26.7	46.2	3.8 (2-11)	2.7 (1-6)	0	0

	Type of RH[¥]	Number of patients		Mean operative time[*] (min)		Intra- and post-operative complications [†] (%)		Mean length of hospital stay (days)		Conversion rate (%)	
		LPS	Robotic	LPS	Robotic	LPS	Robotic	LPS	Robotic	LPS	Robotic
Sert, 2011 [132]	II – III (B - C)	7	35	364 ±57	264 ±70	85.7	20	8.4 ±2.8	3.8 ±0.9	NA	NA
Soliman, 2011 [133]	NA	31	34	338 (191–442) (range)	328 (241–528) (range)	41.9	20.6	2	1	16	3
Tinelli, 2011 [134]	II (B)	17	4	255 ±25	323 ±30	23.7	26.1	4 ± 2	3 ± 1	0	0
	III (C)	59	19								
Gortchev, 2012 [135]	III (C)	46	73	232 ±62	152 ±27	2.2	4.1	4.8 ±0.5	4.1 ±0.7		
Chong, 2013 [136]	C1	50	50	211 ±47	230 ±36	26	14	8.7 ±3.1	9.6 ±5.6	0	0
Chen, 2014 [137]	NA	32	24	293 ±65	192 ±51	9.4	4.2	9.0 ±2.7	4.6 ±2.6	3	0
Kim, 2014 [138]	II (B)	4	1	Median (range) 236 (162-397)	Median (range) 317 (194-704)	8.7	21.7	Median (range) 9 (6-18)	Median (range) 9 (6-30)	NA	NA
	III (C)	65	22								
Mendivil, 2016 [139]	C1	49	58	107 ±29	173 ±47	8.2	5.2	3 ±2.3	2.5 ±4.5	0	0
Vizielli, 2016 [141]	NA	42	21	Median (range) 260 (120–670)	Median (range) 246 (180–300)	40.5	23.8	Median (range) 4 (2–5)	Median (range) 6 (4–15)	0	0

In these retrospective series no difference in DFS and OS was observed between the three surgical approaches [127, 138-140, 142, 143, 145]. The results of a biphasic RCT (LACC trial) to compare MIS (laparoscopic and robotic surgery) and open abdominal RH for early-stage cervical cancer patients are expected in 2018 and DFS is the primary outcome [42, 117]. Patterns of recurrence, pelvic floor function, QoL, OS, feasibility of SLN biopsy, treatment-related morbidity and costs are the secondary outcomes.

4. NEW FRONTIERS IN GYNECOLOGIC ONCOLOGY ROBOTIC SURGERY

4.1. Obese Patients

Obesity is one of the leading risk factors for the development of endometrial cancer [146, 147]. Traditionally, obesity was considered a relative contraindication to conventional laparoscopy due to the poor exposure of the operative field (pelvis and retroperitoneum). Recently, many studies are showing that MIS reduces the risk of postoperative complications in this subgroup of patients [148, 149].

A phase III RCT comparing laparoscopy versus laparotomy modalities for surgical staging for early-stage uterine cancer (LAP-2 study) has been completed [2, 150]. The use of laparoscopy showed a reduction of successful surgical staging and an increase of conversion to laparotomy with increasing BMI (conversion rate of 25.8% in the overall population of the study, while 57.1% in BMI ≥40 kg/m^2). The primary clinical reason for conversion to laparotomy was poor exposure and visibility.

In retrospective series of patients with endometrial cancer, robotic surgical staging produced similar outcomes to laparotomy with fewer conversions compared to laparoscopy, even despite a higher BMI noted in those patients [75, 151]. Several studies confirmed that particularly in obese women, robotic surgery overcomes the traditional limitations of inadequate exposure of the operative field encountered in laparoscopy. It simultaneously produces similar surgical outcomes as laparotomy while reducing perioperative complications (Table 9) [80, 152-154].

A retrospective cohort of 73 patient with endometrial cancer and BMI ≥30 kg/m^2 underwent surgical management via robotic surgery or laparotomy [80]. Mean BMI was 41.9 kg/m^2 in the laparotomy group and 39.8 kg/m^2 in the robotic group. No difference was observed in the rate of lymphadenectomy performed and in the number of total lymph nodes obtained, although the median operative time was higher in the robotic cohort. The previously described benefits of robotic surgery (decreased blood loss, fewer transfusions and shorter length of hospital stay) were confirmed in this subgroup of patients. The rate of complications and the conversion rate are described in Table 9. Particularly notable was the significant difference in wound complications (4.1% in the robotic cohort versus 20.2% in the laparotomy cohort).

In another retrospective cohort study of patients with endometrial cancer and BMI ≥30 kg/m^2, 129 underwent surgical staging via robotic approach and 110 via laparotomy [152]. The rate of lymphadenectomy performed and the number of total lymph nodes obtained was similar between the two groups. In the robotic group, significantly fewer wound

complications was diagnosed (Table 9), but more vaginal cuff complications were described (4.7% versus 0%). The total amount of other complications (transfusions, renal failure, 30-day hospital readmission, ICU admission, ileus and small bowel obstruction) was significantly lower in the robotic group.

With the increasing prevalence of obesity in the population [155], two other subgroups of patients have significant clinical relevance in endometrial cancer: the morbidly obese women (BMI ≥40 kg/m^2) and the super morbidly obese women (BMI ≥50 kg/m^2) [153, 156-161].

A retrospective cohort of 426 women with endometrial cancer and BMI ≥40 kg/m^2 underwent primary surgery at Memorial Sloan Kettering Cancer Center, New York. Two hundred and ninety nine cases were performed via laparotomy, 125 via MIS (robotic or laparoscopy) and two via a vaginal approach [156]. This study demonstrated that in this group of patients, the rate of MIS grew from the 6% in the "laparoscopy era" (1993-2007) to the 57% during the "robotic era" (2008-2012), finally plateauing around 78% by 2012. MIS, compared to laparotomy, had a significantly lower median estimated blood loss (125 mL versus 250 ml), lower rate of perioperative blood transfusions (0% versus 11%), shorter median length of hospital stay (one day versus five days). The total complication rate was significantly lower in the minimally invasive group (15% versus 36%), with notable decrease in wound complications (6% versus 27%). Robotic approaches, when compared to laparoscopy, had a less median estimated blood loss (50 ml versus 100 ml) and a lower median length of hospital stay (one day versus two days). The rate of conversion was higher in the laparoscopic group than the robotic one (12% versus 3%). The operative time and the rate of complications were similar between the two groups (robotic versus laparoscopy: 193 min versus 190 min; Table 9). A cost analysis found that laparotomy had the highest costs in the immediate perioperative period, up to 30 days postoperative, and up to 6 months postoperative. Of note, the operative time was longer in the MIS group when compared to laparotomy (191 minutes versus 170 minutes).

A retrospective study was conducted on 56 super morbidly obese women with endometrial cancer (BMI ≥50 kg/m^2) [158]. The goal was to study the feasibility, adequacy, and safety of robotic surgical staging in this subgroup of patients. A comparison between this subgroup and lower-weight patients found no differences in the yield of removed pelvic and para-aortic nodes. Blood loss, complication rate, recurrence, and survival were similar, but in patients with BMI ≥50 kg/m^2, there was a higher conversion rate (19.6% versus 8%).

These studies have shown the possible advantages of robotic surgery over laparoscopy in the subgroup of obese patients with endometrial cancer. It is important to note that all these studies were retrospective. Furthermore, obesity is a clinical situation that requires specialized and multidisciplinary approaches and a surgical plan that considers all aspects of the patient's health.

4.2. Elderly and Very Elderly Patients

More than 40% of patients with endometrial cancer are 65 years of age or older at the time of diagnosis, and among them more than 15% are older than 75 [162]. In this group of patients, the behavior of endometrial cancer has been described as more aggressive [163], and characterized by the presence of aggressive histological types, high histological grade and advanced stage [163]. However, these patients are more likely to have incomplete surgical

staging procedures or non-standard adjuvant treatments [164-167]. When compared to laparotomy, robotic surgery has shown a higher rate of comprehensive surgical staging, less blood loss, and a lower rate of perioperative complications both in the elderly (65 - 80 years old) and in the very elderly (≥ 80 years old) subgroups [167-172]. Despite these advantages, it must be acknowledged that elderly and very elderly patients have an intrinsic higher risk of surgical morbidity compared to younger patients [169, 173]. The balance of risks and benefits in this population remains undefined but robotic surgery is yielding promising results for a population that continues to rapidly increase.

4.3. Sentinel Lymph Node (SLN)

A significant current debate in the literature is the role of lymphadenectomy in endometrial cancer. Lymph node assessment is an important component of surgical staging in endometrial cancer for its diagnostic and prognostic functions and can help direct adjuvant therapies [70]. The debate is ongoing, due to the absence of proven survival benefit with lymphadenectomy for patients with early-stage endometrial cancer, with a significant increase in morbidity and costs [174-176].

SLN evaluation in endometrial cancer has a high rate of metastatic detection (86%) high sensitivity to detect node-positive disease (97% - 95% CI 85-100) and high negative predictive value (99.6% - 95% CI 97.9–100), as reported by the recent FIRES trial [177-181]. The NCCN has accepted SLN as an alternative to evaluate lymph node status and thus, many institutions (including Mayo Clinic) adopted SLN without proceeding to lymphadenectomy in patients for whom the SLN procedure is successful [69, 182-185].

In this evolving process, MIS play an essential role. MIS and SLN are a promising method to reduce morbidity, without compromising survival outcomes. The increasing expansion of each of these two procedures is lending a hand to the extension of the other [186, 187].

4.4. Other Gynecologic Cancers: Ovarian and Vulvar Cancer

Ovarian cancer (OC) is a relatively rare disease [188], but it represents the 5th leading cause of cancer death among women in the U.S. [64]. More than 60% of OC are diagnosed at an advanced stage [188], typically with diffuse intraperitoneal abdominal disease. An optimal debulking (no evidence of macroscopic disease at the conclusion of the surgery) is one of the leading prognostic factors [189, 190]. Due to ability to thoroughly explore the entire abdominal cavity, laparotomy is preferred to MIS in many institutions. Descriptions of robotic surgical approaches in OC are limited to case series [191-196], and the technique has been described as feasible in selected patients, such as those with early stage of disease or in selected cases of interval debulking surgery following neoadjuvant chemotherapy [191, 196]. Different robotic approaches have been described depending on disease location [191, 195, 197]. In this context, the higher maneuverability of da Vinci Xi may lead to future application of robotic surgery in OC.

Table 9. Complications and conversion rate comparison between robotic surgery and other surgical approaches in obese women. LPS, laparoscopy; LPT, laparotomy; MIS, minimally invasive surgery; n, number; NA, not available; Overall: wound + not wound-related complications

		Robotic surgery			Non-robotic surgical approach			
		Complications		Conversion to LPT		Complications		Conversion to LPT
Author, year Number of patients (n)	BMI kg/m^2	*Wound related*	*Non-wound related*		Surgical approach	*Wound related*	*Non-wound related*	
Gehrig, 2008 [154] (n = 49)	≥30	*Overall* 12%		0%	LPS (n = 32)	*Overall* 15%		6%
Seamon, 2009 [153] (n = 109)	≥30	2%	11%	15.6%	LPT (n = 191)	17%	27%	/
Subramanian, 2011 [80] (n = 73)	≥30	4.1%	9.6%	11%	LPT (n = 104)	20.2%	29.8%	/
Tang, 2012 [152] (n = 129)	≥30	13.9%	27.9%	10.9%	LPT (n = 110)	32.7%	50%	/
Bernardini, 2015 [157] (n = 45)	≥35	4.4%	20%	8.9%	LPT (n = 41)	19.5%	29%	/
Chan, 2015 [160] (n = 422)	≥40	*Overall* 8%		NA	LPT (n = 567)	*Overall* 13%		/
					LPS (n = 98)	*Overall* 23%		NA
Corrado, 2016 [161] (n= 70)	≥40	*Overall* 8.6%		0%	/	/	/	/
Leitao, 2016 [156] (n = 87)	≥40	6% (MIS)	*Overall* 16% (Robotic)	3% (Robotic)	LPT (n = 299)	27%	*Overall* 36%	/
					LPS (n = 38)	6% (MIS)	*Overall* 13%	12%
Mendivil, 2015 [159] (n = 13)	≥40	0%	15.4%	7.7%	LPS (n = 16)	6.3%	0%	6.3%
					LPT (n = 24)	0%	16.7%	/
Stephan, 2015 [158] (n = 56)	≥50	12.4%	19.6%	19.6%	/	/	/	/

Vulvar cancers are rare tumors [198]. In these cases, a feasible robotic approach has been described for video-assisted inguinal lymphadenectomy [199], but is not yet accepted as a standard of practice.

4.5. Recurrent Gynecologic Cancers and Pelvic Exenteration

In patients with recurrent gynecologic neoplasms, the objective of any surgical procedures is to reach as complete a cytoreduction as possible while balancing perioperative morbidities. MIS, and specifically robotic surgery, may have a beneficial impact in this setting.

Robotic surgery has been described as a feasible approach for patients with localized recurrent OC without carcinomatosis [197, 200-202]. Its use has also been described in radical procedures such as pelvic exenteration for cervical and endometrial cancer recurrences [203-208]. In this aggressive procedure, the pelvic organs are completely resected with high rates of perioperative morbidity and mortality [209, 210]. Although case reports and case series have suggested a robotic approach is a feasible option in terms of perioperative and pathologic outcomes [203-208], a comparison of surgical and oncologic outcomes among different surgical techniques is still lacking.

5. DESCRIPTION OF SURGICAL TECHNIQUES

5.1. Total Hysterectomy

A total hysterectomy with bilateral salpingo-oophorectomy is indicated as part of surgical staging for patients with a diagnosis of endometrial cancer. The surgical technique performed at the Mayo Clinic for these cases is described below. At Mayo Clinic, endometrial cancer is the primary gynecologic oncology indication for robotic surgery.

After positioning the patient in a lithotomy position, the stomach is deflated with an orogastric tube, which is left in place throughout the entire operation. Our preferred technique for the creation of the pneumoperitoneum is open laparoscopy (dissection through the umbilicus and peritoneal entry under direct vision). An alternative approach is the insertion of a Verres needle through an umbilical incision. Pneumoperitoneum to 15 mm Hg is then created.

After insertion of the first trocar and the camera port (at the level of the umbilicus, or three to five centimeters above it depending on patient habitus and uterine pathology), a total number of three 8-mm ancillary robotic trocars are inserted under direct visualization (Figure 6). One ancillary trocar is usually added to allow the surgical assistant to access to the pelvis with laparoscopic instruments (vessel sealer devices, graspers, bowel retractor, suction irrigator), and to pass sutures to the surgeon (Figure 6).

After trocars are safely inserted, a meticulous inspection of the abdominal cavity is accomplished and every suspicious lesion is biopsied.

In a low lithotomy position with legs padded in Yellofin stirrups, the patient is gently tilted into full Trendelenburg. It should be remembered that maintaining a patient in steep

Trendelenburg for more than three hours may predispose to brachial plexus injury, corneal abrasions, posterior ischemic optic neuropathy, laryngeal edema and cerebral edema [211]. However, these complications are possible but rare.

Appropriate instrumentation is crucial to completing a successful robotic procedure. A bipolar grasper is usually placed in the non-dominant robotic hand, in order to facility grasping, coagulating and sealing vessels throughout the procedure. In the dominant hand port, a unipolar spatula, monopolar shears (scissors), are typically placed to facilitate dissection. ProGrasp forceps (atraumatic graspers) are typically inserted into the additional port to facilitate dissection.

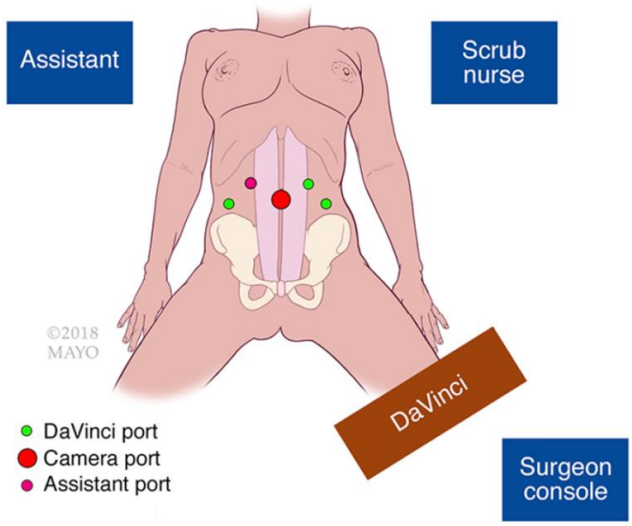

Figure 6. Trocar position with da Vinci Si located caudal to the abdomen and to the patient's left side. It should be noted that, with the da Vinci Xi, it is possible to position all the robotic trocars on a horizontal line at the level of the umbilicus, while the robot is positioned on the left side of the patient, at our institution. Used with permission of Mayo Foundation for Medical Education and Research. All rights reserved.

Different surgeons tend to prefer different instruments. The disadvantage of a unipolar spatula is that it does not allow spreading of tips and tissue separation for plane identification. In our opinion, monopolar scissors are better instruments to achieve these surgical movements. In difficult cases (elevated BMI or challenging anatomy), the Ligasure (Medtronic, Minneapolis, MN) is utilized for sealing and transecting large vessels. The Ligasure is an instrument which combines both pressure and energy to create vessel fusion and has been associated with decreased blood loss and operative time [212, 213].

With the aid of a uterine manipulator or the ProGrasp da Vinci retractor, the uterus is elevated off the pelvic floor, and the surgeon begins on one side of the pelvis. At Mayo Clinic, the uterine manipulator is not used routinely. Instead, a blunt probe (apple probe (Apple Medical, Marlborough, MA) or vaginal dilator) is used to elevated the uterus and demarcate the vaginal fornices. This probe proves useful especially at the time of development of the vesicovaginal space and for the anterior and posterior colpotomy.

The hysterectomy is started by grasping the uterine cornua with the ProGrasp, elevating and laterally displacing it to put the tissues on tension. The round ligament is cauterized and

cut, the posterior leaf of the broad ligament is opened with a monopolar instrument, and the retroperitoneum is exposed. Carbon dioxide from the pneumoperitoneum enters the retroperitoneum and assists in facilitating dissection. The incision on the posterior leaf of the broad ligament is extended to the pelvic brim to facilitate identification of the ureter and the iliac vessels.

The ureter can be identified transperitoneally (usually near the pelvic brim, just medial of the infundibulopelvic ligament), or retro-peritoneally. Our recommendation is to identify the ureter retro-peritoneally during this initial dissection. This step typically requires minimal time and allows adequate lateral mobilization of the ureter. It aids in procedural safety by allowing easier identification of pelvic anatomy.

After the identification of the ureter, the external iliac vessels and infundibulopelvic ligament may be identified. A peritoneal window below the ovarian ligament is created, and the ovarian vessels are divided using bipolar current either from a robotic instrument or a vessel sealer.

The third robotic arm (typically the ProGrasp) then moves to grasp the bladder peritoneum and the uterus is allowed to relax posteriorly. The anterior leaf of the broad ligament is incised toward the direction of the bladder. The peritoneum is incised superficially; avascular areolar tissue is exposed and dissected. This continues as the bladder is identified and mobilized anteriorly with the uterus positioned posteriorly. The apple probe proves useful to place the anterior vagina on tension and identify the vesico-vaginal plane. When this plane is obscured (such as in patients who have had Cesarean deliveries), it may be useful to fill the bladder with saline or other sterile solution to assist in identification.

At this point, the uterine vessels can be identified and skeletonized. The medial leaf of the posterior peritoneum is incised at the level of the uterosacral ligament to allow the ureter to displace slightly posterior and lateral. This also thins the tissue at the level of anticipated colpotomy. The third robotic arm may be used to provide counter-traction on the uterus to expose the cardinal ligament. In selected cases, coagulation of the uterine artery with the Ligasure may increase efficiency of this step. The vascular stump is then gently mobilized laterally. During this mobilization, medial coagulation with the bipolar instrument is usually required. The same procedure is then performed on the contralateral side.

The development of the vesicouterine or vesicovaginal reflection can now be continued. The previously incised bladder peritoneum is grasped by the third robotic arm to provide counter-traction while dissecting the bladder away from the para-cervical fascia. During this step, an assistant positioned between the patient's legs must apply pressure to the apple probe against the cervix to displace it away from the bladder.

Colpotomy is performed using monopolar cauterization. The ascending vaginal branches are cauterized bilaterally to ensure hemostasis at the vaginal corners and the vagina in circumferentially incised. The vagina is placed on tension by the apple probe. The incision is usually started in the anterior midline until a full thickness vaginal incision is made and the apple probe visualized. The colpotomy is continued laterally along vagina (as a "frown shaped" incision). Then the cervix is grasped and the posterior colpotomy is completed. It is essential to use all robotic and assistant arms to optimize visualization during this circumferential incision to avoid that incidental or unplanned injury occurs to the adjacent structures.

In obese patients, the posterior colpotomy is better performed separately. The posterior vagina is placed on tension with the apple probe and the colpotomy is performed starting at

the posterior midline, then continuing laterally (with a "smiling shape"). The uterus is delivered through the vagina after being grasped with a ring forceps by the assistant located between the patient's legs. Once the uterus is extracted, the vaginal cuff closure is performed robotically. Our preference is to start at the right lateral corner. A running submucosal closure is performed and allows appropriate approximation and eversion of the vaginal mucosal edges. This is believed to minimize the risk of vaginal cuff dehiscence. The second layer of vaginal cuff closure is performed as a running suture with the goal to imbricate the edges of the first layer. The use of the third arm can be useful to maintain counter-traction and elevate the vaginal cuff to facilitate the closure. Before completing the operation, hemostasis is accurately checked.

5.2. Radical Hysterectomy

Radical hysterectomy (type C according to Querleu & Morrow classification system [67, 107] – Table 6) is the most frequent type of surgical procedure for cervical cancer. The majority of these procedures are now being completed through a minimally invasive modality, attributable to the adoption of robotic surgery [119, 214].

Historically, RH is related to a high prevalence of bladder and rectal dysfunctions [215]. A nerve-sparing RH [216] has been described to decrease these dysfunctions [214, 216-218], without jeopardizing oncologic outcomes [219] and can be performed robotically.

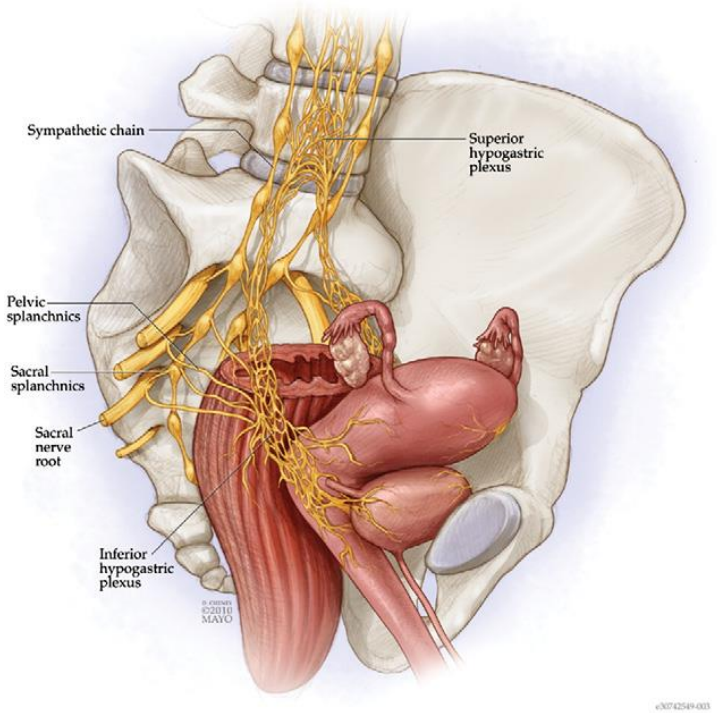

Figure 7. Splanchnic nerves, superior and inferior hypogastric plexus [220]. Used with permission of Mayo Foundation for Medical Education and Research. All rights reserved.

Nerve-sparing RH is defined by preservation of the hypogastric plexus (superior and inferior) and splanchnic nerves (including sympathetic and parasympathetic fibers as well as visceral afferent sensory fibers (Figure 7 and 8). The procedure has been very well described by Dr. Magrina from Mayo Clinic Scottsdale [220]. We learned from him and we follow his technique in our group at Mayo Clinic Rochester. We will describe it here accordingly.

The 3D vision, amplification and tremor control provided by the robot allows visualization and precision during radical dissection.

When completing a RH, the para-vesical and para-rectal spaces are thoroughly dissected and prepared. The intersection of the uterine artery and the ureter, the uterine vein, and the deep uterine vein are identified. The parametrium and the parametrial vessels (including the superior vesical and uterine arteries) are transected with the Ligasure at their origin from the hypogastric artery and vein to the level of the deep uterine vein. In the posterior pararectal space below the deep uterine vein, the "neural portion" of the parametrium can be identified containing the pelvic splanchnic nerves (Figure 8) [221]. In the type C1 (nerve sparing) RH this portion is preserved, while in a type C2 (non-nerve sparing) RH this part is not preserved [107].

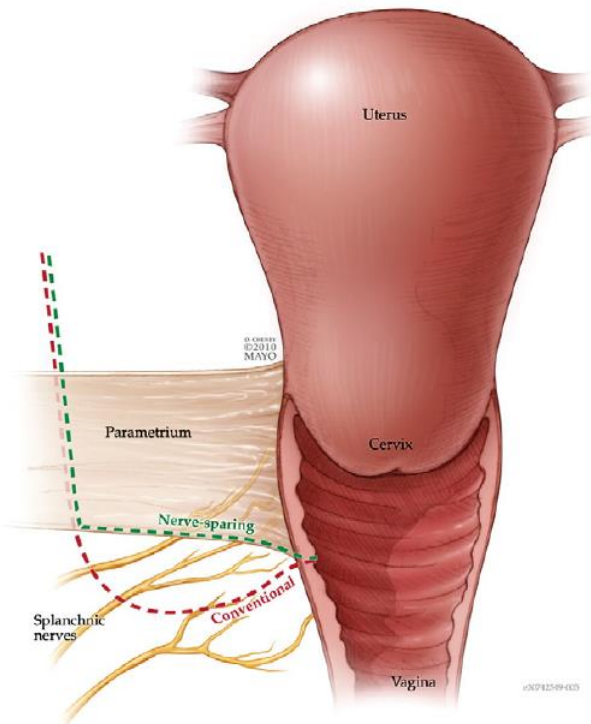

Figure 8. Preservation of the splanchnic nerves during the parametrial resection of a nerve-sparing RH (type C1) versus a conventional RH (type C2) [220]. Used with permission of Mayo Foundation for Medical Education and Research. All rights reserved.

The inferior hypogastric plexus (IHP - union of the superior hypogastric plexus with the pelvic splanchnic nerves) may be identified by mobilizing the caudal edge of the transected parametrium cranially [107, 222]. A monopolar spatula is used to horizontally incise the

peritoneum of the cul-de-sac in order to open the rectovaginal space. Blunt dissection of this space is then performed. Both the uterosacral ligaments must be identified. The ventral mobilization of the uterus with the ProGrasp can assist in this process. The IHP is located in the lateral portion of the uterosacral ligaments. It may be helpful to consider the uterosacral ligaments as being composed of a lateral "neural" portion and a medial "ligamentous" portion [220, 223]. A monopolar spatula is used to divide these two portions of the uterosacral ligaments selectively, mobilizing and preserving the IHP. After this dissection, the medial uterosacral ligaments are transected at the level of the anterior rectal wall. Preservation of the hypogastric plexus is the key to the type C1 RH, while in type C2 this plexus is transected.

Attention is then turned to the anterior compartments. The ureter must be identified at its entrance into the parametrial tunnel. The tunnel must be widened until a surgical instrument can be inserted and the ureter unroofed. After opening the ventral portion of the vesico-uterine ligament, the ureter must be retracted laterally and the anterior vesico-uterine ligament dissected. The IHP is identified below the dorsal border of the parametrium. The IHP must be mobilized dorsally and laterally. Now, the posterior vesico-uterine ligament must be identified and isolated, using the avascular space below the ureter entry into the bladder (Figure 9). During the transection of the posterior vesico-uterine ligament, the dorsal portion of this ligament (near to the inferior vesical artery) must be preserved. In this portion, the IHP fibers, entering the bladder and the vagina, can be identified [220, 224]. The transection of the posterior vesico-uterine ligament at this point must be performed in close proximity to the ureter. The dissection of the paravaginal tissues with the monopolar spatula is then performed. The IHP fibers are located near the lateral side of the vaginal wall. To prevent the transection of these fibers during the vaginal transection, the IHP can be mobilized, along the lateral portion of the vagina, below the level of transection.

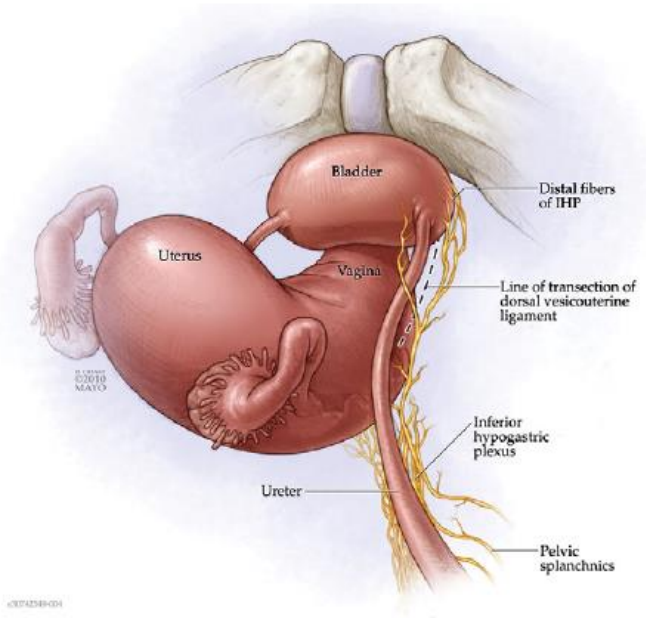

Figure 9. Fibers of the IHP run along the dorsal vesico-uterine ligament [220]. Used with permission of Mayo Foundation for Medical Education and Research. All rights reserved.

5.3. Lymph Node Assessment

The boundaries for a systematic pelvic lymphadenectomy are: superiorly the common iliac artery; inferiorly the circumflex iliac vein; laterally the pelvic sidewall and the mid psoas muscle; medially the hypogastric artery and the obliterated umbilical artery (its terminal branch) and dorsally the obturator nerve and obturator fossa.

The boundaries for the para-aortic lymphadenectomy are the following (from right to left side): the right psoas muscle, the right ureter (medial to the psoas muscle and lateral to the inferior vena cava, crossing the bifurcation of the common iliac artery), the vena cava (lateral to the aorta), the aorta and the common iliac arteries, the superior hypogastric plexus (superficially, below the bifurcation), the left common iliac vein, the right and left renal arteries and the left renal vein, the left ureter, the sigmoid colon, the lumbar vessels (artery and vein) and the left psoas muscle.

During the lymph node dissection, particular attention must be paid to possible anatomic variants (vascular, neurologic, and urologic). Sympathetic and parasympathetic nerves (sympathetic chain, post-ganglionic sympathetic fibers, and hypogastric plexus) can be preserved to avoid organs dysfunctions related to the procedure (i.e., nerve-sparing procedure) [225] (Figure 10).

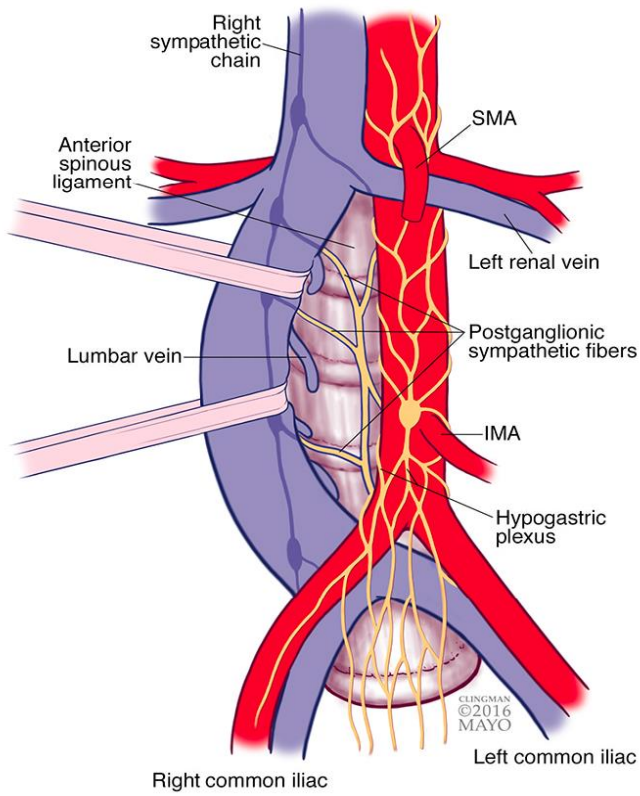

Figure 10. Superior hypogastric plexus and its branching in front of the sacral promontory (Open abdominal view). Used with permission of Mayo Foundation for Medical Education and Research. All rights reserved.

5.3.1. Sentinel Lymph Node Biopsy

As previously described, our group does not recommend full lymphadenectomy for patients in which SLN sampling procedure is successful.

Different tracers, injection techniques and sites of injection into the cervix have been described [226, 227]. At Mayo Clinic, the patient is positioned into low lithotomy and stirrups are used for leg repositioning to facilitate an adequate visualization of the cervix for the injection of the tracer. Four milliliters of Indocyanine Green (ICG) are injected into the cervix at 3 and 9 o'clock. In each site, a superficial injection (1-3 mm) is performed. The purpose is to deliver the dye in the layer of the cervix from which most of lymphatic channels originate. Typically, a lymphatic channel draining from the cervix crosses the obliterated umbilical artery to the most common sentinel nodes localizations: the external iliac artery or the superior part of the obturator fossa. A less frequent localization includes the iliac pre-sacral region, at the level of the iliac bifurcation (Figure 11).

A near-infrared camera is required to localize the sentinel node when ICG is selected as the tracer. For a correct identification of the primary drainage node of the uterine body, it is crucial to open the avascular surgical spaces appropriately. The para-vesical space must always be opened to identify a possible sentinel node in the obturator fossa. Also, constant knowledge of the ureter's location is critical to avoid injury.

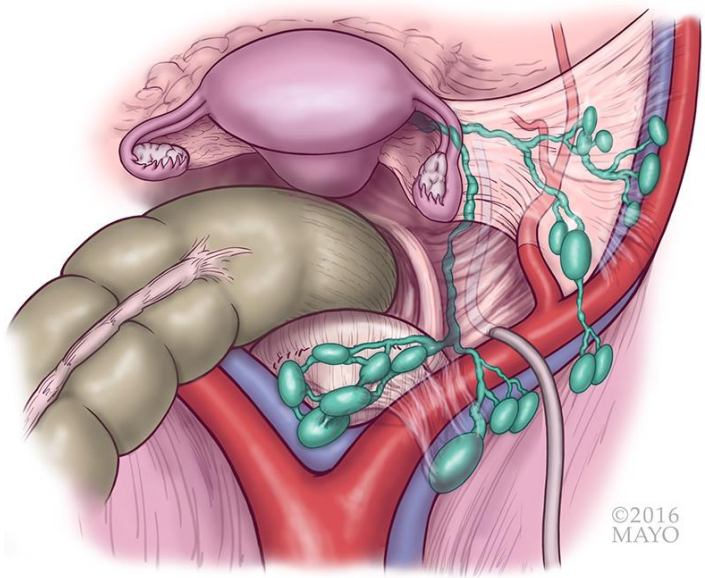

Figure 11. Lymphatic drainage of the uterine body. Two main lymphatic paths: one that drains mainly into the medial external iliac artery or in the superior part of the obturator fossa; the second one drains into the iliac pre-sacral region, following the mesoureter. Used with permission of Mayo Foundation for Medical Education and Research. All rights reserved.

5.3.2. Pelvic Lymphadenectomy

The identification of anatomic landmarks (such as the umbilical artery, ureter and external iliac vessels) is of paramount importance in robotic pelvic lymphadenectomy.

The peritoneum is opened at the level of the round ligament. For this description, we will assume that the retroperitoneum has been already opened and the ureter identified, as described in the hysterectomy portion of this chapter. Before starting the lymphadenectomy, the para-vesical space must be opened. It is lateral to the obliterated umbilical artery and medial to the external iliac vessels. In the very obese patients, in whom the external iliac vessels are not easily identified, it is important to start the dissection laterally, above the iliopsoas muscle, and gradually move medially, until the external iliac vessels are identified.

5.3.2.1. External Iliac and Common Lymph Nodes

The dissection starts caudally, on the anterior surface of the external iliac vessels with the most anterior landmark being the circumflex iliac vein [228]. The genito-femoral nerve on the ventral aspect of the psoas muscle is followed along its course and is detached from the surrounding lymph nodes. The cranial end of the lymphatic tissue is divided using bipolar electrocautery at the level of the common iliac vessels. Reaching the common iliac vessels may require appropriate retraction of the bowel and the ureter in obese patients. The lymph nodes are then grasped and retracted in a medial direction to allow gentle blunt and sharp dissection of the underlying vein.

5.3.2.2. Obturator Lymph Nodes

At this point, the external iliac vessels are gently mobilized medially, separating them from the lateral muscular tissue. Remaining lateral to the vessels, the deep obturator lymphatic tissue is mobilized medially from the pelvic sidewall. This step facilitates subsequent complete dissection of the deep pelvic lymph nodes. The dissection then continues medially at the level of the obturator and internal iliac arteries. During this step, the obturator nerve is visualized and bluntly freed from the surrounding lymphatic tissue thus allowing entry into the obturator fossa. Particular attention must be paid not to injure the accessory obturator vein, which may bleed if damaged. If appropriate, to facilitate this part of the dissection, this vein may be clipped and cut. The dissection then continues cephalad, until the deep nodes are encountered at the level of the iliac bifurcation. The lumbosacral trunk should be visualized deep posterior and laterally in order to safely perform a full dissection.

5.3.2.3. Internal Iliac Lymph Nodes

The lymph node bundle is retracted medially, and the internal iliac vessels are denuded from the lymphatic tissue. The lymph node bundle is usually removed en-bloc. To obtain an adequate staging, the external and internal iliac arteries, the bifurcation of the common iliac artery, and the obturator nerve should be all visible at the end of the procedure.

5.3.3. Para-Aortic Lymphadenectomy

The feasibility of a complete robotic para-aortic staging up to the level of the left renal vein may be challenging, especially in severely obese women [229].

Before starting the dissection, the peritoneum is first opened at the mid-portion of the right common iliac artery, and then the incision is extended up to the aortic bifurcation to open the retroperitoneum and to expose the surgical field. The peritoneal edges are kept on tension by the third robotic arm, by the assistant, or by straight needles creating a “peritoneal tent.” It is prudent to mobilize the bowel far from the operative field. A laparoscopic fan retractor can serve this purpose well. Similarly, the omentum or 1-2 sponges can be used to

manipulate the bowel and help keep the operative field visible. In obese patients, the epiploic tags of the sigmoid may be sutured against the left abdominal wall to hold the bowel outside of the operative field. The visualization and dissection of para-aortic lymph nodes above the inferior mesentery artery (IMA) (especially on the left side) may be limited in obese patients. An advantage of the da Vinci Xi robot allows visualization and assessment of the upper para-aortic area without repositioning the robot (which is sometimes necessary with the da Vinci Si) [230]. The positioning of the camera trocar above the umbilicus (more cranial than the other ports) at the beginning of the procedure may facilitate the visualization of the upper para-aortic area. The positioning of the third arm on the right side of the patient will help facilitate tissue retraction and exposure. The right ureter, the common iliac vessels, the aorta and vena cava must be clearly identified before starting the dissection.

5.3.3.1. Right Para-Aortic Lymph Nodes

The first lymph nodes to be dissected are on the right side of the right common iliac artery and then on the right and anterior portion of the aorta. In fact, the large arteries are less likely to bleed than the veins, and the vessels in this area only rarely present significant anatomical variation. The dissection continues with the removal of the inter-aortic nodes, followed by the lymph nodes anterior and lateral to the vena cava. The dissection is extended cranially until the entrance of the renal vein into the vena cava.

5.3.3.2. Left Para-Aortic Lymph Nodes

A supplementary extension of the peritoneal incision is performed to obtain optimal exposure of the left aortic lymph nodes. The left ureter is identified as well. After gentle retraction of the sigmoid mesentery by the assistant, the infra-mesenteric nodes can be removed from the bifurcation of the aorta to the level of the IMA with meticulous blunt and sharp dissection. The third robotic arm or a fan retractor is usually helpful in exposing the lower left para-aortic area.

Exposure of the infra-renal left lymph node packet can be obtained by either preserving or dividing the IMA at its origin from the aorta with a vessel-sealing device. The division of the IMA is usually safe in patients who are not elderly and/or with major vascular disease [169]. The lymph nodes can be removed from the IMA to the left renal vein and medial to the left ovarian vein. During the entire procedure, particular attention should be paid to avoid injury to the lumbar vessels, the left common iliac vein, and the left ureter.

CONCLUSION

- The utilization of minimally invasive surgery in the field of gynecologic oncology has increased during the last decade, mainly due to the advent and implementation of robotic surgery.
- Advantages of robotic surgery include: a fast learning curve to gaining surgical proficiency and efficiency, feasibility and safety in the obese and morbidly obese populations, and facilitation of novel procedures such as sentinel lymph node mapping and biopsy.

- The primary disadvantage is the cost of the modality itself. However, it has been demonstrated that an increase in the volume of the procedures performed on one robotic system can balance the initial purchasing expenses.
- Current indications for robotic surgery in gynecologic oncology are endometrial and cervical cancer staging. The utilization of the technique in ovarian and vulvar cancer is under investigation.

REFERENCES

[1] Galaal, K., et al., Laparoscopy versus laparotomy for the management of early stage endometrial cancer. *Cochrane Database of Systematic Reviews*, 2012(9).

[2] Walker, J. L., et al., Laparoscopy Compared With Laparotomy for Comprehensive Surgical Staging of Uterine Cancer: Gynecologic Oncology Group Study LAP2. *Journal of Clinical Oncology*, 2009. 27(32): p. 5331-5336.

[3] Walker, J. L., et al., Recurrence and Survival after Random Assignment to Laparoscopy versus Laparotomy for Comprehensive Surgical Staging of Uterine Cancer: Gynecologic Oncology Group LAP2 Study. *Journal of Clinical Oncology*, 2012. 30(7): p. 695-700.

[4] Obermair, A., et al., Improved surgical safety after laparoscopic compared to open surgery for apparent early stage endometrial cancer: Results from a randomised controlled trial. *European Journal of Cancer*, 2012. 48(8): p. 1147-1153.

[5] Boggess, J. F., Robotic surgery in gynecologic oncology: evolution of a new surgical paradigm. *Journal of Robotic Surgery*, 2007. 1(1): p. 31-37.

[6] Nezhat, F., Minimally invasive surgery in gynecologic oncology: Laparoscopy versus robotics. *Gynecologic Oncology*, 2008. 111(2, Supplement): p. S29-S32.

[7] Mettler, L., et al., Robotic assistance in gynecological oncology. *Current Opinion in Oncology*, 2008. 20(5): p. 581-589.

[8] Mendivil, A., Holloway, R. W. and Boggess, J. F. Emergence of robotic assisted surgery in gynecologic oncology: American perspective. *Gynecol Oncol*, 2009. 114(2 Suppl): p. S24-31.

[9] Falcone, T., et al., Full Robotic Assistance for Laparoscopic Tubal Anastomosis: A Case Report. *Journal of Laparoendoscopic & Advanced Surgical Techniques*, 1999. 9(1): p. 107-113.

[10] Falcone, T., et al., Robotic-assisted laparoscopic microsurgical tubal anastomosis: a human pilot study. *Fertility and Sterility*, 2000. 73(5): p. 1040-1042.

[11] Degueldre, M., et al., Robotically assisted laparoscopic microsurgical tubal reanastomosis: a feasibility study. *Fertility and Sterility*, 2000. 74(5): p. 1020-1023.

[12] Diaz-Arrastia, C., et al., Laparoscopic hysterectomy using a computer-enhanced surgical robot. *Surgical Endoscopy and Other Interventional Techniques*, 2002. 16(9): p. 1271-1273.

[13] Molpus, K. L., Wedergren, J. S. and Carlson, M. A. Robotically Assisted Endoscopic Ovarian Transposition. JSLS: *Journal of the Society of Laparoendoscopic Surgeons*, 2003. 7(1): p. 59-62.

[14] Advincula, A. P., et al., Preliminary experience with robot-assisted laparoscopic myomectomy. *J Am Assoc Gynecol Laparosc,* 2004. 11(4): p. 511-8.
[15] Reynolds, R. K., Burke, W. M. and Advincula, A. P. Preliminary Experience with Robot-Assisted Laparoscopic Staging of Gynecologic Malignancies. *JSLS: Journal of the Society of Laparoendoscopic Surgeons,* 2005. 9(2): p. 149-158.
[16] Reynolds, R. K. and Advincula, A. P. Robot-assisted laparoscopic hysterectomy: technique and initial experience. *The American Journal of Surgery,* 2006. 191(4): p. 555-560.
[17] Marchal, F., et al., Telerobotic-assisted laparoscopic hysterectomy for benign and oncologic pathologies: initial clinical experience with 30 patients. *Surgical Endoscopy and Other Interventional Techniques,* 2005. 19(6): p. 826-831.
[18] Field, J. B., et al., Computer-enhanced robotic surgery in gynecologic oncology. *Surgical Endoscopy,* 2007. 21(2): p. 244-246.
[19] Sert, B. and Abeler, V. Robotic radical hysterectomy in early-stage cervical carcinoma patients, comparing results with total laparoscopic radical hysterectomy cases. The future is now? *The International Journal of Medical Robotics and Computer Assisted Surgery,* 2007. 3(3): p. 224-228.
[20] Magrina, J. F., et al., Robotic radical hysterectomy: Comparison with laparoscopy and laparotomy. *Gynecologic Oncology,* 2008. 109(1): p. 86-91.
[21] Fanning, J., Fenton, B. and Purohit, M. Robotic radical hysterectomy. *American Journal of Obstetrics and Gynecology,* 2008. 198(6): p. 649.e1-649.e4.
[22] Magrina, J. F. and Zanagnolo, V. L. Robotic surgery for cervical cancer. *Yonsei Med J,* 2008. 49(6): p. 879-85.
[23] Woelk, J. L., et al., Cost Differences among Robotic, Vaginal, and Abdominal Hysterectomy. *Obstetrics & Gynecology,* 2014. 123(2): p. 255-262.
[24] Bogani, G., et al., Incorporating robotic-assisted surgery for endometrial cancer staging: Analysis of morbidity and costs. *Gynecologic Oncology,* 2016. 141(2): p. 218-224.
[25] Jacoby, V. L., et al., Nationwide Use of Laparoscopic Hysterectomy Compared with Abdominal and Vaginal Approaches. *Obstetrics & Gynecology,* 2009. 114(5): p. 1041-1048.
[26] Wright, J. D., et al., Nationwide Trends in the Performance of Inpatient Hysterectomy in the United States. *Obstetrics & Gynecology,* 2013. 122(2): p. 233-241.
[27] Fader, A. N., et al., Utilization of Minimally Invasive Surgery in Endometrial Cancer Care: A Quality and Cost Disparity. *Obstetrics & Gynecology,* 2016. 127(1): p. 91-100.
[28] Casarin, J., et al., Adoption of Minimally Invasive Surgery and Decrease in Surgical Morbidity for Endometrial Cancer Treatment in the United States. *Obstet Gynecol,* 2018.
[29] Wright, J. D., et al., Comparative Effectiveness of Minimally Invasive Hysterectomy for Endometrial Cancer. *J Clin Oncol,* 2016. 34(10): p. 1087-96.
[30] Wright, J. D., et al., Comparative effectiveness of minimally invasive and abdominal radical hysterectomy for cervical cancer. *Gynecologic Oncology,* 2012. 127(1): p. 11-17.

[31] Liu, Z., et al., Superiority of robotic surgery for cervical cancer in comparison with traditional approaches: A systematic review and meta-analysis. *Int J Surg*, 2017. 40: p. 145-154.

[32] Yohannes, P., et al., Comparison of robotic versus laparoscopic skills: is there a difference in the learning curve? *Urology*, 2002. 60(1): p. 39-45.

[33] Hernandez, J. D., et al., Qualitative and quantitative analysis of the learning curve of a simulated surgical task on the da Vinci system. *Surgical Endoscopy and Other Interventional Techniques*, 2004. 18(3): p. 372-378.

[34] Moorthy, K., et al., Dexterity enhancement with robotic surgery. *Surgical Endoscopy and Other Interventional Techniques*, 2004. 18(5): p. 790-795.

[35] Prasad, S. M., et al., Surgical robotics: Impact of motion scaling on task performance. *Journal of the American College of Surgeons*, 2004. 199(6): p. 863-868.

[36] Sarle, R., et al., Surgical Robotics and Laparoscopic Training Drills. *Journal of Endourology*, 2004. 18(1): p. 63-67.

[37] Chandra, V., et al., A comparison of laparoscopic and robotic assisted suturing performance by experts and novices. *Surgery*, 2010. 147(6): p. 830-839.

[38] Liu, H., et al., Robot-assisted surgery in gynaecology. *Cochrane Database of Systematic Reviews*, 2014(12).

[39] Paraiso, M. F. R., et al., A randomized trial comparing conventional and robotically assisted total laparoscopic hysterectomy. *American Journal of Obstetrics and Gynecology*, 2013. 208(5): p. 368.e1-368.e7.

[40] Sarlos, D., et al., Robotic Compared With Conventional Laparoscopic Hysterectomy: A Randomized Controlled Trial. *Obstetrics & Gynecology*, 2012. 120(3): p. 604-611.

[41] Reza, M., et al., Meta-analysis of observational studies on the safety and effectiveness of robotic gynaecological surgery. *British Journal of Surgery*, 2010. 97(12): p. 1772-1783.

[42] Obermair, A., et al., A Phase III Randomized Clinical Trial Comparing Laparoscopic or Robotic Radical Hysterectomy with Abdominal Radical Hysterectomy in Patients with Early Stage Cervical Cancer. *Journal of Minimally Invasive Gynecology*, 2008. 15(5): p. 584-588.

[43] Narducci, F. and Lambaudie, E. *Perioperative Morbidity in Gyneco-oncology According to the Procedure: Coelioscopy Versus Robot-assisted Coelioscopy*, in NCT01247779. 2016: https://ClinicalTrials.gov/show/NCT01247779.

[44] Soliman, P., *Evaluation of Robot-Assisted Surgery in Gynecologic Oncology*, in NCT00671827. https://ClinicalTrials.gov/show/NCT00671827.

[45] Lundin, E. and Kjölhede, P. K. *Robot Assisted Laparoscopic Hysterectomy vs. Abdominal Hysterectomy in Endometrial Cancer*, in NCT01526655 2016: https://ClinicalTrials.gov/show/NCT01526655.

[46] Cecconello, I. and Ribeiro-Junior, U. *Prospective Analysis of Robot-Assisted Surgery*, in NCT02292914. 2016: https://ClinicalTrials.gov/show/NCT02292914.

[47] Barbash, G. I. and Glied S. A. New Technology and Health Care Costs — The Case of Robot-Assisted Surgery. *New England Journal of Medicine*, 2010. 363(8): p. 701-704.

[48] Barnett, J. C., et al., Cost Comparison Among Robotic, Laparoscopic, and Open Hysterectomy for Endometrial Cancer. *Obstetrics & Gynecology*, 2010. 116(3): p. 685-693.

[49] Bell, M. C., et al., Comparison of outcomes and cost for endometrial cancer staging via traditional laparotomy, standard laparoscopy and robotic techniques. *Gynecologic Oncology,* 2008. 111(3): p. 407-411.

[50] Leitao, M. M., et al., Cost-Effectiveness Analysis of Robotically Assisted Laparoscopy for Newly Diagnosed Uterine Cancers. *Obstetrics & Gynecology,* 2014. 123(5): p. 1031-1037.

[51] Lau, S., et al., Outcomes and Cost Comparisons After Introducing a Robotics Program for Endometrial Cancer Surgery. *Obstetrics & Gynecology,* 2012. 119(4): p. 717-724.

[52] Wright, J. D., et al., An Economic Analysis of Robotically Assisted Hysterectomy. *Obstetrics & Gynecology,* 2014. 123(5): p. 1038-1048.

[53] Hidlebaugh, D. A., Cost and quality-of-life issues associated with different surgical therapies for the treatment of abnormal uterine bleeding. *Obstet Gynecol Clin North Am,* 2000. 27(2): p. 451-65.

[54] Lim, P. C. and Kang, E. How to prepare the patient for robotic surgery: before and during the operation. *Best Practice & Research Clinical Obstetrics & Gynaecology,* 2017. 45(Supplement C): p. 32-47.

[55] Ramirez, P. T., et al., Robotic-assisted surgery in gynecologic oncology: A Society of Gynecologic Oncology consensus statement: Developed by the Society of Gynecologic Oncology's Clinical Practice Robotics Task Force. *Gynecologic Oncology,* 2012. 124(2): p. 180-184.

[56] Seamon, L. G., et al., Robotic hysterectomy and pelvic-aortic lymphadenectomy for endometrial cancer. *Obstet Gynecol,* 2008. 112(6): p. 1207-13.

[57] Seamon, L. G., et al., A detailed analysis of the learning curve: Robotic hysterectomy and pelvic-aortic lymphadenectomy for endometrial cancer. *Gynecologic Oncology,* 2009. 114(2): p. 162-167.

[58] Lim, P. C., Kang, E. and Park, D. H. A comparative detail analysis of the learning curve and surgical outcome for robotic hysterectomy with lymphadenectomy versus laparoscopic hysterectomy with lymphadenectomy in treatment of endometrial cancer: A case-matched controlled study of the first one hundred twenty two patients. *Gynecologic Oncology,* 2011. 120(3): p. 413-418.

[59] Moore, L. J., et al., Robotic technology results in faster and more robust surgical skill acquisition than traditional laparoscopy. *Journal of Robotic Surgery,* 2015. 9(1): p. 67-73.

[60] Yim, G. W., et al., Learning curve analysis of robot-assisted radical hysterectomy for cervical cancer: initial experience at a single institution. *J Gynecol Oncol,* 2013. 24(4): p. 303-312.

[61] Li, X. L., Du, D. F. and Jiang, H. The learning curves of robotic and three-dimensional laparoscopic surgery in cervical cancer. *J Cancer,* 2016. 7(15): p. 2304-2308.

[62] Mäenpää, M., et al., Implementing robotic surgery to gynecologic oncology: the first 300 operations performed at a tertiary hospital. *Acta Obstetricia et Gynecologica Scandinavica,* 2015. 94(5): p. 482-488.

[63] Sgarbura, O. and Vasilescu, C. The decisive role of the patient-side surgeon in robotic surgery. *Surgical Endoscopy,* 2010. 24(12): p. 3149-3155.

[64] Siegel, R. L., Miller, K. D. and Jemal, A. Cancer statistics, 2017. *CA: A Cancer Journal for Clinicians,* 2017. 67(1): p. 7-30.

[65] Creasman, W. T., et al., Surgical pathologic spread patterns of endometrial cancer: A gynecologic oncology group study. *Cancer,* 1987. 60(S8): p. 2035-2041.
[66] Keys, H. M., et al., A phase III trial of surgery with or without adjunctive external pelvic radiation therapy in intermediate risk endometrial adenocarcinoma: a Gynecologic Oncology Group study. *Gynecologic Oncology,* 2004. 92(3): p. 744-751.
[67] Querleu, D. and Morrow, C. P. Classification of radical hysterectomy. *Lancet Oncol,* 2008. 9(3): p. 297-303.
[68] Piver, M. S., Rutledge, F. and Smith, J. P. Five classes of extended hysterectomy for women with cervical cancer. *Obstet Gynecol,* 1974. 44(2): p. 265-72.
[69] National Comprehensive Cancer Network. *Uterine Neoplasm* (version 1.2018). 2018 February 9, 2018]; Available from: https://www.nccn.org/professionals/physician_gls/pdf/uterine.pdf.
[70] Mariani, A., et al., Prospective assessment of lymphatic dissemination in endometrial cancer: a paradigm shift in surgical staging. *Gynecol Oncol,* 2008. 109(1): p. 11-8.
[71] Scalici, J., et al., The trend towards minimally invasive surgery (MIS) for endometrial cancer: An ACS–NSQIP evaluation of surgical outcomes. *Gynecologic Oncology,* 2015. 136(3): p. 512-515.
[72] Mannschreck, D., et al., Disparities in Surgical Care Among Women With Endometrial Cancer. *Obstetrics & Gynecology,* 2016. 128(3): p. 526-534.
[73] Kornblith, A. B., et al., Quality of Life of Patients With Endometrial Cancer Undergoing Laparoscopic International Federation of Gynecology and Obstetrics Staging Compared With Laparotomy: A Gynecologic Oncology Group Study. *Journal of Clinical Oncology,* 2009. 27(32): p. 5337-5342.
[74] Janda, M., et al., Effect of Total Laparoscopic Hysterectomy vs Total Abdominal Hysterectomy on Disease-Free Survival Among Women with Stage I Endometrial Cancer: A Randomized Clinical Trial. *JAMA,* 2017. 317(12): p. 1224-1233.
[75] Boggess, J. F., et al., A comparative study of 3 surgical methods for hysterectomy with staging for endometrial cancer: robotic assistance, laparoscopy, laparotomy. *American Journal of Obstetrics and Gynecology,* 2008. 199(4): p. 360.e1-360.e9.
[76] DeNardis, S. A., et al., Robotically assisted laparoscopic hysterectomy versus total abdominal hysterectomy and lymphadenectomy for endometrial cancer. *Gynecologic Oncology,* 2008. 111(3): p. 412-417.
[77] Gaia, G., et al., Robotic-Assisted Hysterectomy for Endometrial Cancer Compared With Traditional Laparoscopic and Laparotomy Approaches: A Systematic Review. *Obstetrics & Gynecology,* 2010. 116(6): p. 1422-1431.
[78] Jung, Y. W., et al., Robot-assisted staging using three robotic arms for endometrial cancer: comparison to laparoscopy and laparotomy at a single institution. *J Surg Oncol,* 2010. 101(2): p. 116-21.
[79] Lim, P. C., Kang, E. and Park, D. H. Learning curve and surgical outcome for robotic-assisted hysterectomy with lymphadenectomy: case-matched controlled comparison with laparoscopy and laparotomy for treatment of endometrial cancer. *J Minim Invasive Gynecol,* 2010. 17(6): p. 739-48.
[80] Subramaniam, A., et al., A cohort study evaluating robotic versus laparotomy surgical outcomes of obese women with endometrial carcinoma. *Gynecologic Oncology,* 2011. 122(3): p. 604-607.

[81] Coronado, P. J., et al., Comparison of perioperative outcomes and cost of robotic-assisted laparoscopy, laparoscopy and laparotomy for endometrial cancer. *European Journal of Obstetrics & Gynecology and Reproductive Biology*, 2012. 165(2): p. 289-294.

[82] ElSahwi, K. S., et al., Comparison between 155 cases of robotic vs. 150 cases of open surgical staging for endometrial cancer. *Gynecologic Oncology*, 2012. 124(2): p. 260-264.

[83] Nicole, N., et al., Robotic Assisted, Total Laparoscopic, and Total Abdominal Hysterectomy for Management of Uterine Cancer. *Journal of cancer therapy*, 2012. 3(2): p. 162-166.

[84] Ran, L., et al., Comparison of Robotic Surgery with Laparoscopy and Laparotomy for Treatment of Endometrial Cancer: A Meta-Analysis. *PLOS ONE*, 2014. 9(9): p. e108361.

[85] Chiou, H. Y., et al., Comparing robotic surgery with laparoscopy and laparotomy for endometrial cancer management: A cohort study. *International Journal of Surgery*, 2015. 13(Supplement C): p. 17-22.

[86] Eklind, S., et al., A Prospective, Comparative Study on Robotic Versus Open-Surgery Hysterectomy and Pelvic Lymphadenectomy for Endometrial Carcinoma. *International Journal of Gynecological Cancer*, 2015. 25(2): p. 250-256.

[87] Herling, S. F., et al., Health-related quality of life after robotic-assisted laparoscopic hysterectomy for women with endometrial cancer — A prospective cohort study. *Gynecologic Oncology*, 2016. 140(1): p. 107-113.

[88] Herling, S. F., et al., Robotic-assisted laparoscopic hysterectomy for women with endometrial cancer. *Dan Med J*, 2017. 64(3).

[89] Paley, P. J., et al., Surgical outcomes in gynecologic oncology in the era of robotics: analysis of first 1000 cases. *American Journal of Obstetrics and Gynecology*, 2011. 204(6): p. 551.e1-551.e9.

[90] Salehi, S., et al., Robot-assisted laparoscopy versus laparotomy for infrarenal paraaortic lymphadenectomy in women with high-risk endometrial cancer: A randomised controlled trial. *European Journal of Cancer*, 2017. 79(Supplement C): p. 81-89.

[91] Bakkum-Gamez, J. N., et al., The impact of surgical guidelines and periodic quality assessment on the staging of endometrial cancer. *Gynecologic Oncology*, 2011. 123(1): p. 58-64.

[92] Kilgore, J. E., et al., Recurrence-free and 5-year survival following robotic-assisted surgical staging for endometrial carcinoma. *Gynecologic Oncology*, 2013. 129(1): p. 49-53.

[93] Brudie, L. A., et al., Analysis of disease recurrence and survival for women with uterine malignancies undergoing robotic surgery. *Gynecologic Oncology*, 2013. 128(2): p. 309-315.

[94] Leitao, M. M., Jr., et al., Introduction of a computer-based surgical platform in the surgical care of patients with newly diagnosed uterine cancer: outcomes and impact on approach. *Gynecol Oncol*, 2012. 125(2): p. 394-9.

[95] Wright, J. D., et al., Comparative Effectiveness of Robotic Versus Laparoscopic Hysterectomy for Endometrial Cancer. *Journal of Clinical Oncology*, 2012. 30(8): p. 783-791.

[96] Cardenas-Goicoechea, J., et al., Integration of robotics into two established programs of minimally invasive surgery for endometrial cancer appears to decrease surgical complications. *J Gynecol Oncol,* 2013. 24(1): p. 21-8.

[97] Seror, J., et al., Laparoscopy vs Robotics in Surgical Management of Endometrial Cancer: Comparison of Intraoperative and Postoperative Complications. *Journal of Minimally Invasive Gynecology,* 2014. 21(1): p. 120-125.

[98] Zakhari, A., et al., Laparoscopic and robot-assisted hysterectomy for uterine cancer: a comparison of costs and complications. *Am J Obstet Gynecol,* 2015. 213(5): p. 665.e1-7.

[99] Mäenpää, M. M., et al., Robotic-assisted vs traditional laparoscopic surgery for endometrial cancer: a randomized controlled trial. *American Journal of Obstetrics and Gynecology*, 2016. 215(5): p. 588.e1-588.e7.

[100] Cardenas-Goicoechea, J., et al., Survival analysis of robotic versus traditional laparoscopic surgical staging for endometrial cancer. *Am J Obstet Gynecol,* 2014. 210(2): p. 160 e1-160 e11.

[101] Ronco, G., et al., Efficacy of HPV-based screening for prevention of invasive cervical cancer: follow-up of four European randomised controlled trials. *Lancet,* 2014. 383(9916): p. 524-32.

[102] Cannistra, S. A. and Niloff, J. M. Cancer of the uterine cervix. *N Engl J Med,* 1996. 334(16): p. 1030-8.

[103] Siegel, R. L., K. D. Miller, and A. Jemal, Cancer statistics, 2016. *CA Cancer J Clin,* 2016. 66(1): p. 7-30.

[104] National Comprehensive Cancer Network. *Cervical cancer* (Version 1.2018). 2018 February 13, 2018]; Available from: https://www.nccn.org/professionals/physician_gls/pdf/cervical.pdf.

[105] Pecorelli, S., Zigliani, L. and Odicino, F. Revised FIGO staging for carcinoma of the cervix. *Int J Gynaecol Obstet,* 2009. 105(2): p. 107-8.

[106] FIGO staging for carcinoma of the vulva, cervix, and corpus uteri. *Int J Gynaecol Obstet,* 2014. 125(2): p. 97-8.

[107] Cibula, D., et al., New classification system of radical hysterectomy: emphasis on a three-dimensional anatomic template for parametrial resection. *Gynecol Oncol,* 2011. 122(2): p. 264-8.

[108] Hong, J. H., et al., Can laparoscopic radical hysterectomy be a standard surgical modality in stage IA2-IIA cervical cancer? *Gynecol Oncol,* 2012. 127(1): p. 102-6.

[109] Park, J. Y., et al., Laparoscopic compared with open radical hysterectomy in obese women with early-stage cervical cancer. *Obstet Gynecol,* 2012. 119(6): p. 1201-9.

[110] van de Lande, J., et al., Open versus laparoscopic pelvic lymph node dissection in early stage cervical cancer: no difference in surgical or disease outcome. *Int J Gynecol Cancer,* 2012. 22(1): p. 107-14.

[111] Taylor, S. E., et al., Radical hysterectomy for early stage cervical cancer: laparoscopy versus laparotomy. *JSLS,* 2011. 15(2): p. 213-7.

[112] Li, G., et al., A comparison of laparoscopic radical hysterectomy and pelvic lymphadenectomy and laparotomy in the treatment of Ib-IIa cervical cancer. *Gynecol Oncol,* 2007. 105(1): p. 176-80.

[113] Frumovitz, M., et al., Comparison of total laparoscopic and abdominal radical hysterectomy for patients with early-stage cervical cancer. *Obstet Gynecol,* 2007. 110(1): p. 96-102.

[114] Steed, H., et al., A comparison of laparascopic-assisted radical vaginal hysterectomy and radical abdominal hysterectomy in the treatment of cervical cancer. *Gynecol Oncol,* 2004. 93(3): p. 588-93.

[115] Jackson, K. S., et al., Laparoscopically assisted radical vaginal hysterectomy vs. radical abdominal hysterectomy for cervical cancer: a match controlled study. *Gynecol Oncol,* 2004. 95(3): p. 655-61.

[116] Abu-Rustum, N. R., et al., Total laparoscopic radical hysterectomy with pelvic lymphadenectomy using the argon-beam coagulator: pilot data and comparison to laparotomy. *Gynecol Oncol,* 2003. 91(2): p. 402-9.

[117] Naik, R., et al., Laparoscopic assisted radical vaginal hysterectomy versus radical abdominal hysterectomy--a randomised phase II trial: perioperative outcomes and surgicopathological measurements. *BJOG,* 2010. 117(6): p. 746-51.

[118] Campos, L. S., et al., Postoperative pain and perioperative outcomes after laparoscopic radical hysterectomy and abdominal radical hysterectomy in patients with early cervical cancer: a randomised controlled trial. *Trials,* 2013. 14: p. 293.

[119] Conrad, L. B., et al., Role of Minimally Invasive Surgery in Gynecologic Oncology: An Updated Survey of Members of the Society of Gynecologic Oncology. *Int J Gynecol Cancer,* 2015. 25(6): p. 1121-7.

[120] Shazly, S. A., et al., Robotic radical hysterectomy in early stage cervical cancer: A systematic review and meta-analysis. *Gynecol Oncol,* 2015. 138(2): p. 457-71.

[121] Boggess, J. F., et al., A case-control study of robot-assisted type III radical hysterectomy with pelvic lymph node dissection compared with open radical hysterectomy. *Am J Obstet Gynecol,* 2008. 199(4): p. 357.e1-7.

[122] Ko, E. M., et al., Robotic versus open radical hysterectomy: a comparative study at a single institution. *Gynecol Oncol,* 2008. 111(3): p. 425-30.

[123] Magrina, J. F., et al., Robotic radical hysterectomy: comparison with laparoscopy and laparotomy. *Gynecol Oncol,* 2008. 109(1): p. 86-91.

[124] Nezhat, F. R., et al., Robotic radical hysterectomy versus total laparoscopic radical hysterectomy with pelvic lymphadenectomy for treatment of early cervical cancer. *JSLS,* 2008. 12(3): p. 227-37.

[125] Estape, R., et al., A case matched analysis of robotic radical hysterectomy with lymphadenectomy compared with laparoscopy and laparotomy. *Gynecol Oncol,* 2009. 113(3): p. 357-61.

[126] Maggioni, A., et al., Robotic approach for cervical cancer: comparison with laparotomy: a case control study. *Gynecol Oncol,* 2009. 115(1): p. 60-4.

[127] Cantrell, L. A., et al., Survival outcomes for women undergoing type III robotic radical hysterectomy for cervical cancer: a 3-year experience. *Gynecol Oncol,* 2010. 117(2): p. 260-5.

[128] Geisler, J. P., et al., Robotically assisted laparoscopic radical hysterectomy compared with open radical hysterectomy. *Int J Gynecol Cancer,* 2010. 20(3): p. 438-42.

[129] Halliday, D., et al., Robotic radical hysterectomy: comparison of outcomes and cost. *J Robot Surg,* 2010. 4(4): p. 211-6.

[130] Nam, E. J., et al., A case-control study of robotic radical hysterectomy and pelvic lymphadenectomy using 3 robotic arms compared with abdominal radical hysterectomy in cervical cancer. *Int J Gynecol Cancer*, 2010. 20(7): p. 1284-9.

[131] Schreuder, H. W., et al., From open radical hysterectomy to robot-assisted laparoscopic radical hysterectomy for early stage cervical cancer: aspects of a single institution learning curve. *Gynecol Surg*, 2010. 7(3): p. 253-258.

[132] Sert, M. B. and V. Abeler, Robot-assisted laparoscopic radical hysterectomy: comparison with total laparoscopic hysterectomy and abdominal radical hysterectomy; one surgeon's experience at the Norwegian Radium Hospital. *Gynecol Oncol*, 2011. 121(3): p. 600-4.

[133] Soliman, P. T., et al., Radical hysterectomy: a comparison of surgical approaches after adoption of robotic surgery in gynecologic oncology. *Gynecol Onco*l, 2011. 123(2): p. 333-6.

[134] Tinelli, R., et al., Robotics versus laparoscopic radical hysterectomy with lymphadenectomy in patients with early cervical cancer: a multicenter study. *Ann Surg Oncol*, 2011. 18(9): p. 2622-8.

[135] Gortchev, G., et al., Robot-assisted radical hysterectomy—perioperative and survival outcomes in patients with cervical cancer compared to laparoscopic and open radical surgery. *Gynecological Surgery*, 2012. 9(1): p. 81-88.

[136] Chong, G. O., et al., Robot versus laparoscopic nerve-sparing radical hysterectomy for cervical cancer: a comparison of the intraoperative and perioperative results of a single surgeon's initial experience. *Int J Gynecol Cancer*, 2013. 23(6): p. 1145-9.

[137] Chen, C. H., et al., Comparing robotic surgery with conventional laparoscopy and laparotomy for cervical cancer management. *Int J Gynecol Cancer*, 2014. 24(6): p. 1105-11.

[138] Kim, T. H., et al., Robotic versus laparoscopic radical hysterectomy in cervical cancer patients: a matched-case comparative study. *Int J Gynecol Cancer*, 2014. 24(8): p. 1466-73.

[139] Mendivil, A. A., et al., Survival rate comparisons amongst cervical cancer patients treated with an open, robotic-assisted or laparoscopic radical hysterectomy: A five year experience. *Surg Oncol*, 2016. 25(1): p. 66-71.

[140] Sert, B. M., et al., Robot-assisted versus open radical hysterectomy: A multi-institutional experience for early-stage cervical cancer. *Eur J Surg Oncol*, 2016. 42(4): p. 513-22.

[141] Vizzielli, G., et al., Robotic Total Mesometrial Resection versus Laparoscopic Total Mesometrial Resection in Early Cervical Cancer: A Case-Control Study. *J Minim Invasive Gynecol*, 2016. 23(5): p. 804-9.

[142] Zanagnolo, V., et al., Clinical and Oncologic Outcomes of Robotic Versus Abdominal Radical Hysterectomy for Women with Cervical Cancer: Experience at a Referral Cancer Center. *Int J Gynecol Cancer*, 2016. 26(3): p. 568-74.

[143] Zhou, J., et al., Robotic vs laparoscopic radical hysterectomy for cervical cancer: a meta-analysis. *Int J Med Robot*, 2016. 12(1): p. 145-54.

[144] Park, D. A., et al., Surgical and clinical safety and effectiveness of robot-assisted laparoscopic hysterectomy compared to conventional laparoscopy and laparotomy for cervical cancer: A systematic review and meta-analysis. *Eur J Surg Oncol*, 2017. 43(6): p. 994-1002.

[145] Shah, C. A., et al., Surgical and oncologic outcomes after robotic radical hysterectomy as compared to open radical hysterectomy in the treatment of early cervical cancer. *J Gynecol Oncol*, 2017. 28(6): p. e82.

[146] Calle, E. E. and Kaaks, R. Overweight, obesity and cancer: epidemiological evidence and proposed mechanisms. *Nat Rev Cancer*, 2004. 4(8): p. 579-591.

[147] Renehan, A. G., et al., Body-mass index and incidence of cancer: a systematic review and meta-analysis of prospective observational studies. *The Lancet*, 2008. 371(9612): p. 569-578.

[148] Bouwman, F., et al., The impact of BMI on surgical complications and outcomes in endometrial cancer surgery—An institutional study and systematic review of the literature. *Gynecologic Oncology*, 2015. 139(2): p. 369-376.

[149] Iavazzo, C. and I. D. Gkegkes, Robotic assisted hysterectomy in obese patients: a systematic review. *Arch Gynecol Obstet*, 2016. 293(6): p. 1169-83.

[150] Gunderson, C. C., et al., The impact of obesity on surgical staging, complications, and survival with uterine cancer: A Gynecologic Oncology Group LAP2 ancillary data study. *Gynecologic Oncology*, 2014. 133(1): p. 23-27.

[151] Seamon, L. G., et al., Minimally invasive comprehensive surgical staging for endometrial cancer: Robotics or laparoscopy? *Gynecologic Oncology*, 2009. 113(1): p. 36-41.

[152] Tang, K. Y., et al., Robotic surgical staging for obese patients with endometrial cancer. *American Journal of Obstetrics and Gynecology*, 2012. 206(6): p. 513.e1-513.e6.

[153] Seamon, L. G., et al., Comprehensive Surgical Staging for Endometrial Cancer in Obese Patients: Comparing Robotics and Laparotomy. *Obstetrics & Gynecology*, 2009. 114(1): p. 16-21.

[154] Gehrig, P. A., et al., What is the optimal minimally invasive surgical procedure for endometrial cancer staging in the obese and morbidly obese woman? *Gynecologic Oncology*, 2008. 111(1): p. 41-45.

[155] Ogden, C. L., et al., Prevalence of childhood and adult obesity in the united states, 2011-2012. *JAMA*, 2014. 311(8): p. 806-814.

[156] Leitao, M. M., et al., Impact of Robotic Platforms on Surgical Approach and Costs in the Management of Morbidly Obese Patients with Newly Diagnosed Uterine Cancer. *Annals of Surgical Oncology*, 2016. 23(7): p. 2192-2198.

[157] Bernardini, M. Q., et al., Surgical outcome of robotic surgery in morbidly obese patient with endometrial cancer compared to laparotomy. *Int J Gynecol Cancer*, 2012. 22(1): p. 76-81.

[158] Stephan, J. M., et al., Robotic surgery in supermorbidly obese patients with endometrial cancer. *American Journal of Obstetrics and Gynecology*, 2015. 213(1): p. 49.e1-49.e8.

[159] Mendivil, A. A., et al., A Comparison of Open Surgery, Robotic-Assisted Surgery and Conventional Laparoscopic Surgery in the Treatment of Morbidly Obese Endometrial Cancer Patients. *JSLS: Journal of the Society of Laparoendoscopic Surgeons*, 2015. 19(1): p. e2014.00001.

[160] Chan, J. K., et al., Robotic versus laparoscopic versus open surgery in morbidly obese endometrial cancer patients — A comparative analysis of total charges and complication rates. *Gynecologic Oncology*, 2015. 139(2): p. 300-305.

[161] Corrado, G., et al., Robotic Hysterectomy in Severely Obese Patients with Endometrial Cancer: A Multicenter Study. *J Minim Invasive Gynecol,* 2016. 23(1): p. 94-100.
[162] National Cancer Institute. *SEER Cancer Stat Facts: Uterine Cancer*. February 23, 2018]; Available from: http://seer.cancer.gov/statfacts/html/corp.html.
[163] Bourgin, C., et al., Endometrial cancer in elderly women: Which disease, which surgical management? A systematic review of the literature. *Eur J Surg Oncol,* 2016. 42(2): p. 166-75.
[164] Eggemann, H., et al., Management of elderly women with endometrial cancer. *Gynecol Oncol,* 2017. 146(3): p. 519-524.
[165] Torgeson, A., et al., Disparities in care for elderly women with endometrial cancer adversely effects survival. *Gynecol Oncol,* 2017. 147(2): p. 320-328.
[166] Poupon, C., et al., Management and Survival of Elderly and Very Elderly Patients with Endometrial Cancer: An Age-Stratified Study of 1228 Women from the FRANCOGYN Group. *Ann Surg Oncol,* 2017. 24(6): p. 1667-1676.
[167] Bourgin, C., et al., Impact of age on surgical staging and approaches (laparotomy, laparoscopy and robotic surgery) in endometrial cancer management. *Eur J Surg Oncol,* 2017. 43(4): p. 703-709.
[168] Lavoue, V., et al., Impact of robotics on the outcome of elderly patients with endometrial cancer. *Gynecol Oncol,* 2014. 133(3): p. 556-62.
[169] Zeng, X. Z., et al., Outcome of robotic surgery for endometrial cancer as a function of patient age. *Int J Gynecol Cancer,* 2015. 25(4): p. 637-44.
[170] Guy, M. S., et al., Comparative outcomes in older and younger women undergoing laparotomy or robotic surgical staging for endometrial cancer. *Am J Obstet Gynecol,* 2016. 214(3): p. 350.e1-350.e10.
[171] Backes, F. J., et al., Perioperative Outcomes for Laparotomy Compared to Robotic Surgical Staging of Endometrial Cancer in the Elderly: A Retrospective Cohort. *Int J Gynecol Cancer,* 2016. 26(9): p. 1717-1721.
[172] Zakhari, A., et al., Hysterectomy for Uterine Cancer in the Elderly: A Comparison Between Laparoscopic and Robot-Assisted Techniques. *Int J Gynecol Cancer,* 2016. 26(7): p. 1222-7.
[173] Wright, J. D., et al., Morbidity and mortality of surgery for endometrial cancer in the oldest old. *Am J Obstet Gynecol,* 2011. 205(1): p. 66.e1-8.
[174] Benedetti Panici, P., et al., Systematic pelvic lymphadenectomy vs. no lymphadenectomy in early-stage endometrial carcinoma: randomized clinical trial. *J Natl Cancer Inst,* 2008. 100(23): p. 1707-16.
[175] Kitchener, H., et al., Efficacy of systematic pelvic lymphadenectomy in endometrial cancer (MRC ASTEC trial): a randomised study. *Lancet,* 2009. 373(9658): p. 125-36.
[176] Dowdy, S. C., et al., Prospective assessment of survival, morbidity, and cost associated with lymphadenectomy in low-risk endometrial cancer. *Gynecol Oncol,* 2012. 127(1): p. 5-10.
[177] Rossi, E. C., et al., A comparison of sentinel lymph node biopsy to lymphadenectomy for endometrial cancer staging (FIRES trial): a multicentre, prospective, cohort study. *Lancet Oncol,* 2017. 18(3): p. 384-392.
[178] Holloway, R. W., et al., Sentinel lymph node mapping and staging in endometrial cancer: A Society of Gynecologic Oncology literature review with consensus recommendations. *Gynecol Oncol,* 2017. 146(2): p. 405-415.

[179] How, J., et al., Comparing indocyanine green, technetium, and blue dye for sentinel lymph node mapping in endometrial cancer. *Gynecol Oncol,* 2015. 137(3): p. 436-42.
[180] Ballester, M., et al., Detection rate and diagnostic accuracy of sentinel-node biopsy in early stage endometrial cancer: a prospective multicentre study (SENTI-ENDO). *Lancet Oncol,* 2011. 12(5): p. 469-76.
[181] Cormier, B., et al., Sentinel lymph node procedure in endometrial cancer: A systematic review and proposal for standardization of future research. *Gynecol Oncol,* 2015. 138(2): p. 478-85.
[182] Barlin, J. N., et al., The importance of applying a sentinel lymph node mapping algorithm in endometrial cancer staging: beyond removal of blue nodes. *Gynecol Oncol,* 2012. 125(3): p. 531-5.
[183] Zahl Eriksson, A. G., et al., Comparison of a sentinel lymph node and a selective lymphadenectomy algorithm in patients with endometrioid endometrial carcinoma and limited myometrial invasion. *Gynecol Oncol,* 2016. 140(3): p. 394-9.
[184] Ducie, J. A., et al., Comparison of a sentinel lymph node mapping algorithm and comprehensive lymphadenectomy in the detection of stage IIIC endometrial carcinoma at higher risk for nodal disease. *Gynecol Oncol,* 2017. 147(3): p. 541-548.
[185] Soliman, P. T., et al., A prospective validation study of sentinel lymph node mapping for high-risk endometrial cancer. *Gynecol Oncol,* 2017. 146(2): p. 234-239.
[186] Paley, P. J., et al., A prospective investigation of fluorescence imaging to detect sentinel lymph nodes at robotic-assisted endometrial cancer staging. A*m J Obstet Gynecol,* 2016. 215(1): p. 117.e1-7.
[187] Hagen, B., et al., Indocyanine green fluorescence imaging of lymph nodes during robotic-assisted laparoscopic operation for endometrial cancer. A prospective validation study using a sentinel lymph node surgical algorithm. *Gynecol Oncol,* 2016. 143(3): p. 479-483.
[188] National Cancer Institute. *SEER Cancer Stat Facts: Ovarian Cancer*. February 23, 2018]; Available from: https://seer.cancer.gov/statfacts/html/ovary.html.
[189] Chang, S. J. and R. E. Bristow, Evolution of surgical treatment paradigms for advanced-stage ovarian cancer: redefining 'optimal' residual disease. *Gynecol Oncol,* 2012. 125(2): p. 483-92.
[190] Winter, W. E., 3rd, et al., Prognostic factors for stage III epithelial ovarian cancer: a Gynecologic Oncology Group Study. *J Clin Oncol,* 2007. 25(24): p. 3621-7.
[191] Magrina, J. F., et al., Robotic approach for ovarian cancer: perioperative and survival results and comparison with laparoscopy and laparotomy. *Gynecol Oncol,* 2011. 121(1): p. 100-5.
[192] Feuer, G. A., et al., Perioperative and clinical outcomes in the management of epithelial ovarian cancer using a robotic or abdominal approach. *Gynecol Oncol,* 2013. 131(3): p. 520-4.
[193] Nezhat, F. R., et al., Comparison of perioperative outcomes and complication rates between conventional versus robotic-assisted laparoscopy in the evaluation and management of early, advanced, and recurrent stage ovarian, fallopian tube, and primary peritoneal cancer. *Int J Gynecol Cancer,* 2014. 24(3): p. 600-7.
[194] Chen, C. H., et al., Comparison of robotic approach, laparoscopic approach and laparotomy in treating epithelial ovarian cancer. *Int J Med Robot,* 2016. 12(2): p. 268-75.

[195] Minig, L., et al., Robotic Surgery in Women with Ovarian Cancer: Surgical Technique and Evidence of Clinical Outcomes. *J Minim Invasive Gynecol,* 2016. 23(3): p. 309-16.
[196] Ackroyd, S. A., et al., Interval robotic cytoreduction following neoadjuvant chemotherapy in advanced ovarian cancer. *J Robot Surg, 2*017.
[197] Holloway, R. W., et al., Robotic-assisted resection of liver and diaphragm recurrent ovarian carcinoma: description of technique. *Gynecol Oncol,* 2011. 120(3): p. 419-22.
[198] National Cancer Institute. *SEER Cancer Stat Facts: Vulvar Cancer.* February 23, 2018]; Available from: https://seer.cancer.gov/statfacts/html/vulva.html.
[199] Jain, V., et al., Robotic-Assisted Video Endoscopic Inguinal Lymphadenectomy in Carcinoma Vulva: Our Experiences and Intermediate Results. *Int J Gynecol Cancer,* 2017. 27(1): p. 159-165.
[200] Magrina, J. F., et al., Analysis of secondary cytoreduction for recurrent ovarian cancer by robotics, laparoscopy and laparotomy. *Gynecol Oncol,* 2013. 129(2): p. 336-40.
[201] Escobar, P. F., et al., Feasibility and perioperative outcomes of robotic-assisted surgery in the management of recurrent ovarian cancer: a multi-institutional study. *Gynecol Oncol,* 2014. 134(2): p. 253-6.
[202] Eriksson, A. G. Z., et al., Minimal access surgery compared to laparotomy for secondary surgical cytoreduction in patients with recurrent ovarian carcinoma: Perioperative and oncologic outcomes. *Gynecol Oncol,* 2017. 146(2): p. 263-267.
[203] Lim, P. C., Robotic assisted total pelvic exenteration: a case report. *Gynecol Oncol,* 2009. 115(2): p. 310-1.
[204] Lambaudie, E., et al., Robotically-assisted laparoscopic anterior pelvic exenteration for recurrent cervical cancer: report of three first cases. *Gynecol Oncol,* 2010. 116(3): p. 582-3.
[205] Davis, M. A., et al., Robotic-assisted laparoscopic exenteration in recurrent cervical cancer Robotics improved the surgical experience for 2 women with recurrent cervical cancer. *Am J Obstet Gynecol,* 2010. 202(6): p. 663.e1.
[206] Vasilescu, C., et al., Entirely robotic total pelvic exenteration. *Surg Laparosc Endosc Percutan Tech,* 2011. 21(4): p. e200-2.
[207] Lawande, A., et al., Robotic total pelvic exenteration. *J Robot Surg,* 2014. 8(1): p. 93-6.
[208] Puntambekar, S., et al., Initial experience of robotic anterior pelvic exenteration at a single institute. *Int J Gynaecol Obstet,* 2014. 126(1): p. 41-4.
[209] Chatterjee, S., et al., National trends in total pelvic exenteration for gynecologic malignancies. *Am J Obstet Gynecol,* 2016. 215(3): p. 395-6.
[210] Hockel, M. and N. Dornhofer, Pelvic exenteration for gynaecological tumours: achievements and unanswered questions. *Lancet Oncol,* 2006. 7(10): p. 837-47.
[211] Gainsburg, D. M., Anesthetic concerns for robotic-assisted laparoscopic radical prostatectomy. *Minerva Anestesiol,* 2012. 78(5): p. 596-604.
[212] Tamussino, K., et al., Electrosurgical bipolar vessel sealing for radical abdominal hysterectomy. *Gynecol Oncol,* 2005. 96(2): p. 320-2.
[213] Levy, B. and Emery, L. Randomized trial of suture versus electrosurgical bipolar vessel sealing in vaginal hysterectomy. *Obstet Gynecol,* 2003. 102(1): p. 147-51.
[214] Cibula, D., et al., Late morbidity following nerve-sparing radical hysterectomy. *Gynecol Oncol,* 2010. 116(3): p. 506-11.

[215] Butler-Manuel, S. A., et al., Self-assessment of morbidity following radical hysterectomy for cervical cancer. *J Obstet Gynaecol*, 1999. 19(2): p. 180-3.
[216] Fujii, S., et al., Anatomic identification and functional outcomes of the nerve sparing Okabayashi radical hysterectomy. *Gynecol Oncol*, 2007. 107(1): p. 4-13.
[217] Long, Y., et al., Clinical efficacy and safety of nerve-sparing radical hysterectomy for cervical cancer: a systematic review and meta-analysis. *PLoS One*, 2014. 9(4): p. e94116.
[218] Sakuragi, N., et al., A systematic nerve-sparing radical hysterectomy technique in invasive cervical cancer for preserving postsurgical bladder function. *Int J Gynecol Cancer*, 2005. 15(2): p. 389-97.
[219] Basaran, D., et al., Oncological outcomes of nerve-sparing radical hysterectomy for cervical cancer: a systematic review. *Ann Surg Oncol*, 2015. 22(9): p. 3033-40.
[220] Magrina, J. F., et al., Robotic nerve-sparing radical hysterectomy: feasibility and technique. *Gynecol Oncol*, 2011. 121(3): p. 605-9.
[221] Kato, T., Murakami, G. and Yabuki, Y. Does the cardinal ligament of the uterus contain a nerve that should be preserved in radical hysterectomy? *Anat Sci Int*, 2002. 77(3): p. 161-8.
[222] Baader, B. and Herrmann, M. Topography of the pelvic autonomic nervous system and its potential impact on surgical intervention in the pelvis. *Clin Anat*, 2003. 16(2): p. 119-30.
[223] Butler-Manuel, S. A., et al., Pelvic nerve plexus trauma at radical hysterectomy and simple hysterectomy: the nerve content of the uterine supporting ligaments. *Cancer*, 2000. 89(4): p. 834-41.
[224] Kuwabara, Y., et al., New method to prevent bladder dysfunction after radical hysterectomy for uterine cervical cancer. *J Obstet Gynaecol Res*, 2000. 26(1): p. 1-8.
[225] Ceccaroni, M., et al., Neuro-anatomy of the posterior parametrium and surgical considerations for a nerve-sparing approach in radical pelvic surgery. *Surg Endosc*, 2013. 27(11): p. 4386-94.
[226] Abu-Rustum, N. R., Sentinel lymph node mapping for endometrial cancer: a modern approach to surgical staging. *J Natl Compr Canc Netw*, 2014. 12(2): p. 288-97.
[227] Niikura, H., et al., Tracer injection sites and combinations for sentinel lymph node detection in patients with endometrial cancer. *Gynecol Oncol*, 2013. 131(2): p. 299-303.
[228] Todo, Y., et al., Survival effect of para-aortic lymphadenectomy in endometrial cancer (SEPAL study): a retrospective cohort analysis. *Lancet*, 2010. 375(9721): p. 1165-72.
[229] Geppert, B. and Persson, J. Robotic infrarenal paraaortic and pelvic nodal staging for endometrial cancer: feasibility and lymphatic complications. *Acta Obstet Gynecol Scand*, 2015. 94(10): p. 1074-81.
[230] Magrina, J. F., et al., Robotic transperitoneal infrarenal aortic lymphadenectomy: technique and results. *Int J Gynecol Cancer*, 2010. 20(1): p. 184-7.

In: Encyclopedia of Surgery (22 Volume Set)
Editors: Andreas Lehrer and Kristin Mueller
ISBN: 978-1-53618-329-0
© 2020 Nova Science Publishers, Inc.

Chapter 257

TRANSORAL ROBOTIC SURGERY: TREATMENT OF HEAD AND NECK DISEASE

Changxing Liu[1], MD, Mark Swanson[2], MD and Niels Kokot[2], MD

[1]USC Caruso Department of Otolaryngology - Head and Neck Surgery, Keck School of Medicine of USC, Los Angeles, CA, US
[2]USC Caruso Department of Otolaryngology - Head and Neck Surgery, Keck School of Medicine of USC Head and Neck and Microvascular Reconstructive Surgery, Los Angeles, CA, US

INTRODUCTION

Since the da Vinci Surgical System (Intuitive Surgical, Sunnyvale, CA) was approved by the Food and Drug Administration in December 2009 for the management of T1 to T2 head and neck cancers, transoral robotic surgery (TORS) has rapidly spread throughout the United States, with a sudden shift from primary chemoradiation therapy (CRT) for early oropharyngeal cancers toward first-line TORS. Currently, TORS is used mostly for the resection of oropharyngeal as well as select hypopharyngeal and supraglottic tumors.

There are three main reasons for this quick shift from CRT to first-line TORS for early oropharyngeal cancers [1]:

First, and most importantly, the widespread use of CRT resulted in significant acute and chronic morbidity, and the skepticism has been mounting as to the net benefit of first-line CRT in terms of overall survival (OS) and quality of life (QOL) in comparison to first-line definitive surgery for early stage oropharyngeal squamous cell carcinoma (SCC). The introduction of a surgical modality with lower morbidity than traditional open approaches has provided the impetus toward reconsidering treatment paradigms [2]. Also, the demographics of oropharyngeal cancer have been changing, from older patients with chronic tobacco and alcohol abuse and multiple comorbidities, to younger, otherwise healthy, patients with human papillomavirus (HPV)-associated oropharyngeal SCC [3-6]. This has made the concerns surrounding the benefits of first-line CRT use more prominent since the long term morbidity

of radiation therapy can be more significant in younger patients [7]. The long-term effects of primary CRT versus first-line surgery on QOL and OS must be carefully considered in this new patient demographic [8, 9].

Second, the increasingly dominant use of first-line CRT over the past several decades led to new generation of head and neck surgeons with less experience in performing open procedures for early stage oropharyngeal SCC, so they were open for a new surgical modality that may reduce the treatment-related morbidity for the younger, healthier HPV-positive patient population.

Third, the safety and oncologic data resulting from other minimally invasive surgical modality, such as transoral laser microsurgery (TLM), provided a solid ground on which a novel minimally invasive technique could take hold [2]. Not surprising that the increasingly younger patient demographic with HPV-positive oropharyngeal SCC, combined with the novel minimally invasive approach offered by TORS is tipping the scale back toward definitive surgery.

Beside the aforementioned reasons for the wide use of TORS in the United States, the TORS approach features several important advantages over traditional and other minimally invasive surgical approaches. TORS has been shown to be an effective surgical alternative for open surgeries as it can achieve negative margins while avoiding some of the morbidity and disfigurement from external approaches [10]. In general, benefits of TORS include three dimensional magnified, and 'around the corner' views, the 'wristed' instruments allowing for translation of intuitive hand movements into small, finely controlled movements of the instruments and negation of tremor. Specific to the head and neck, TORS allows the surgeon to view and dissect technically difficult anatomical areas, without the need for external incisions and without compromising local control or survival [11, 12]. For patients, the TORS procedure has been shown to improve functional outcomes in speech and swallowing while maintaining good oncologic outcomes compared to open procedures [13]. The TORS approach also has a short learning curve [14], which makes it appealing to new surgeons. After an initial learning phase, the operating time including robot setup time was comparable to traditional endoscopic surgery.

INDICATIONS AND PATIENT SELECTION

McLeod and Melder performed the first application of the da Vinci surgical robot for endolaryngeal surgery in 2002 to resect a vallecular cyst [15]. The case was a proof of concept, opening up the use of the robot in the field of head and neck surgery. Subsequently, extensive research on application of the da Vinci surgical robot in performing endoscopic surgery in the oropharynx, larynx, and hypopharynx was performed by the University of Pennsylvania group. The study started on an airway mannequin [16], progressing to cadaveric dissections [17-19], and later to a canine model [20, 21]. After the success in the preclinical phase of the study, the group embarked on Phase I clinical trials in 2006 with case series on resection of base of tongue cancers [17], tonsillar cancers [22], and supraglottic cancers [23]. The FDA approved the use of the da Vinci surgical robot for endoscopic resection of early T-stage (T1–T2) head and neck cancers in 2009. The operation was subsequently named "transoral robotic surgery" (TORS). Other centers expanded TORS for resection of early

cancers in the hypopharynx, larynx, and nasopharynx [24]. After adoption of its use in early upper aerodigestive tract cancers, several centers subsequently confirmed the technical feasibility, safety, oncologic outcomes, and functional improvements that TORS resection is capable of [22, 25-27]. As of 2014, TORS is approved by the FDA for the resection of benign and cancerous tumors of the oropharynx classified as T1 and T2 and for benign tongue base resection procedures. It also has increasing use in resecting cancers in the larynx and hypopharynx, and tumors in the skull base, as showed in table 1. TORS for benign conditions, especially tongue base resection for obstructive sleep apnea, has been increasingly investigated.

Given the properties of TORS, the ideal TORS candidates will include the following characteristics [1]:

1. No general contraindications to surgery
2. Primary tumor is functionally well resectable, without significant long-term impairment
3. No radiologic sign of extracapsular extension (ECE) of the draining lymph nodes
4. Clear surgical margins likely to be achieved for the primary tumor,(ideally 5 mm)
5. Surgery is likely to result in the reduction or elimination of adjuvant CRT.

Hans et al. identified contraindications of TORS [28], including patients with contraindications to general anesthesia, unresectable tumors (related to size or location of the tumor), invasion of tumor into the mandible, advanced tongue base tumors requiring >50% resection of the tongue, advanced pharyngeal tumors requiring >50% resection of the posterior wall, and vertebral involvement. The current technology limits transoral access to the larynx and hypopharynx in patients with poor neck extension or anterior larynx exposures. In addition, patients with anatomic restrictions such as trismus can make adequate exposure impossible. As technology improves with smaller instruments and single port docking, surgical access to patients with unfavorable anatomy will broaden indications for the transoral approach.

Table 1. List of transoral robotic procedures currently performed or investigated, excluding cadaveric experiments

Robotic radical tonsillectomy
Robotic tongue base resection
Robotic supraglottic laryngectomy
Robotic partial laryngectomy
Robotic hypopharyngectomy
Robotic total laryngectomy
Robotic-assisted transoral laser excision (oropharynx, larynx, and hypopharynx)
Robotic-assisted insetting of flaps
Robotic microvascular anastomosis for free flaps
Robotic lingual tonsillectomy for sleep apnea
Robotic resection of parapharyngeal tumors
Robotic nasopharyngectomy

DISADVANTAGES OF TORS

The da Vinci surgical robot was not originally designed to be deployed in the head and neck region, which can result in arm collisions in small working space. It is still too bulky to use in places like the anterior skull base. A new surgical robot (model: da Vinci Xi) with a smaller footprint and less chance of arms collision has already been launched in the market, but, unfortunately, it has not been specifically designed for transoral use and FDA approval for TORS has not been sought. Competing robotic systems and single port platforms are being designed and investigated [29, 30].

Lack of tactile feedback is another criticism of robotic surgery and this is also true for TORS. Robotic surgeons currently substitute the tactile sensation mainly with visual cues to a certain extent, but visual cues could not entirely replace tactile sensation. VerroTouch (U. of Pennsylvania Haptics Group, Philadelphia USA) is an early attempt to produce an external add-on to the da Vinci surgical robot to provide haptic feedback to the operating surgeon [31, 32]. A small-scale survey of the advantage of the VerroTouch system has been completed by eleven robotic surgeons and the majority welcomed the addition of the haptic feedback, but none found it essential.

Currently, TORS mainly uses monopolar and bipolar cautery for hemostasis. They tend to work inefficiently in deep dissection due to difficult visualization and too much debris from the cautery. An ultrasonic dissector would be a better instrument for dissection around areas prone to bleeding like venous plexus in the pterygoid plexus and parapharyngeal space, but the current robotic ultrasonic dissector is too bulky and lacks articulation. So, the development of alternative energy-source instruments for hemostasis and dissection and their integration with robotic instruments will be a welcomed innovation.

The other disadvantage of robotic procedures is the high cost. The cost of the robot, disposable and nondisposable robotic instruments, dedicated and delicate micro-instrumentation, and robot-specific supplies all are expensive [33, 34]. This is however been an area of study which has demonstrated a comparable cost effectiveness to chemoradiation with possible reduced overall treatment-related costs owing to reduced late gastrostomy and tracheostomy tube dependence.

Also, the surgical procedure is technically challenging and necessitates the training of all levels of surgical personnel. Due to its special configuration and different room setting, to prevent injury while operating the robot during the TORS procedure, the surgical team must remain aware of the patient risks. Potential patient injuries include lip and dental injury, mucosal injury, facial lacerations, mandible fracture caused by rotation of robotic instrument, cervical spine injury caused by robotic instrument torque, ocular injury, and post-operative airway edema [33, 34].

PRACTICAL SET UP AND SAFETY CONSIDERATIONS OF TORS SURGERY

When it comes to the practical set up of TORS surgery, it should be emphasized here that, while many operating rooms have personnel trained in the use of the da Vinci® Robotic

System for other specialties, appropriate TORS specific training is necessary for all members of the team who will participate in the planning and execution of TORS procedures.

The size of the operating room used for TORS procedures should be large enough to accommodate the considerable amount of equipment required. The night before surgery the team assigned to the case should review the TORS procedure manual and the physician's preference card.

Primary equipment required for TORS:

1. da Vinci® Robot (which consists of patient-side cart, surgeon consoles, and vision cart)
2. Laryngoscopy and airway carts
3. Secondary video tower
4. Procedural case cart (contains all the needed instrumentation)
5. Surgical high-magnification camera head (0 and 30 degree angled view)
6. High-definition 3D imaging system
7. Robotic instruments (selected by surgeon in advance)
    a. Maryland dissecting forceps
    b. spatula tip monopolar cautery
8. Cautery unit with Bovie pedal and bipolar pedal (for assistant at bedside), two Bovie pads, and reusable bipolar cord.
9. Oral retractors such and Crow-Davis or FK retractors

Other equipment and instrumentation required for TORS include patient's surgical bed with gel pads and mattress and warming blanket, three sterile surgical tables, two Mayo stands, sequential compression device, chairs with height adjustment capability - two at bedside (for the nurse and the bedside surgical assistant), one for the teaching console (if applicable), and one at surgeon console, and three rectangular OR instrument carts and one small square OR instrument cart. Other routine surgical instruments, in addition to the da Vinci® Robotic System and its components, are used by the surgical assistant at the bedside should include surgical headlight, lip and tongue retractors, needle holders, debakey forceps, metzenbaum or tonsil scissors, hemostats, suction cautery, Yankauer suction, small and medium vascular clips.

The universal protocol is performed and general endotracheal anesthesia is induced after the patient enters the room. A single lumen reinforced tube should be used, and can be an oral or nasal intubation depending on surgeon preference. In either case, the endotracheal tube in placed in the side contralateral to the tumor. The bed is turned 180° with the patient's feet towards anesthesia. An extended breathing circuit is used to reach the endotracheal tube (Figure 1). Both of the patient's arms are wrapped in gel arm wraps and tucked. The patient's head is placed on a low profile "gel donut." The assistant to the surgeon positioned at the patient's head attends to the surgical site with handheld instruments. The assistant observes the surgical site directly and on one of the video monitors and performs tasks such as suctioning, cautery, applying vascular clips, and ensuring that robotic arms do not cause injury to patient.

Afterwards, the patient-side cart is moved to the edge of the patient bed and aligned at a 30° angle from the long axis of the patient surgical bed. A mouth gag and retractor, depending on the type of procedure and patient anatomy, are placed for TORS procedure with

good oropharynx and the lesion exposure. The surgeon should place the desired mouth gag before final positioning of the patient-side cart. Once the mouth gag is placed, it should be suspended using a low profile suspension device to avoid interference from the robotic arms. The suspension device should be fixed to the patient surgical bed on the side opposite the patient-side cart. After the mouth gag is in place, the robotic arms are moved and positioned over the patient's chest. The trocars are then placed in the trocar holders, and camera-endoscope arm is positioned with trocar in the center of the patient's mouth. The right and left instrument arms are placed just inside the corners of the mouth taking care not to put pressure on the lips or teeth (Figure 2).

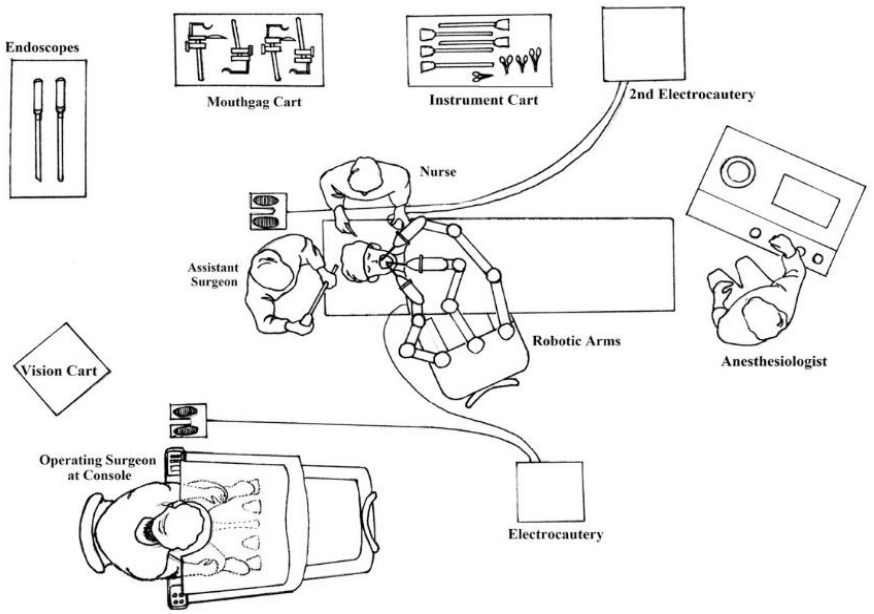

Figure 1. Operating room set up for da Vinci TORS.

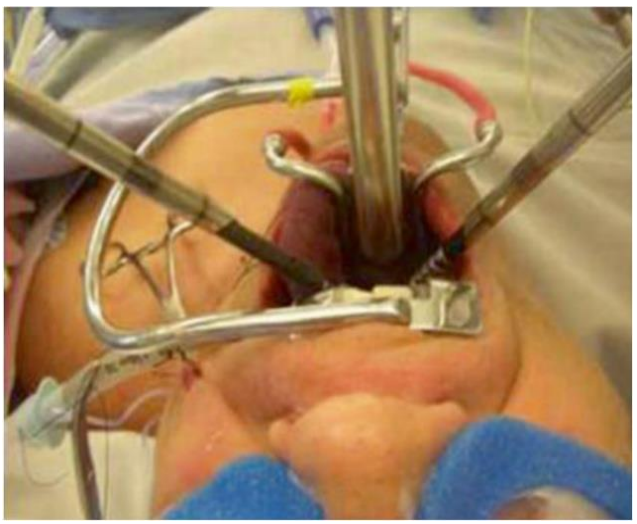

Figure 2. Position of the cannula, camera and instrument arms relative to the mouth gag and oral cavity.

Special considerations:

1. Airway fire:

The risk of fire is present when a laser is to be used during TORS or even when use the cautery arm of the da Vinci® Robot. The first steps when a fire is noted are to turn off the oxygen and remove the endotracheal tube. The mouth gag or retractor may need to be released first before the endotracheal tube can be removed completely. There should be 1 L of saline in an open container available to be poured in the mouth. If the fire is extinguished, ventilation should be reestablished. The endotracheal tube should be inspected for missing parts that may be still be in the airway. A bronchoscopy can be performed to evaluate the airway for remaining foreign bodies and retrieve them if present [35].

2. Eye protection:

"Optigard eye protection" (Dupaco Inc, USA) or a similar rigid eye protection should be used for all TORS procedures. They are adhesive backed, foam goggles with hard plastic lenses that are placed over the patient's eyes to protect them from any possible pressure from any of the robotic or surgical instruments (Figure 2).

3. Lip/mouth injury:

A white latex free silicone tooth guard is placed over the teeth to provide a level of protection. A clear plastic "lip retractor" should be used to protect the lips from injury by the instrument arms of the robot. This can be placed before or after placement of the mouth gag.

POSTOPERATIVE CARE

The recovery course will depend on the extent of the surgery and how good the patient's general health condition. In our practice, if patients have extensive TORS oropharyngeal resection, they are often kept intubated overnight for potential postoperative hemorrhage and airway obstruction. For this reason, IV corticosteroids are routinely given perioperatively for 24 hours. Otherwise, most patients with limited resections can extubated and transferred to an ICU or step-down unit. Depending on the extent of the surgery, a nasogastric feeding tube may be needed, and can be removed once the patients starts oral liquids. Typically, oral feeding is started on the first postoperative day in conjunction with a speech pathologist. Pain management should be adequate for quick recovery of dysphagia.

As with any procedure, there are risks we should be aware of. The exact risk will vary depending on the extent and type of TORS, and including surgical site bleeding, dysarthria, dysphagia, and even salivary fistula. With staged neck dissection and TORS, the chances of this decrease. When patients have dysartheria or dysphagia, speech therapy should be consulted, and pain control should be adequate.

STEPS OF TORS RADICAL TONSILLECTOMY

Differently from plain tonsillectomy in which dissection is carried through the peritonsillar space to excise the contents of the tonsillar fossa (i.e., the tonsil), radical tonsillectomy includes the resection of the walls of the tonsillar fossa. Dissection is done laterally to the constrictor muscle, into the parapharyngeal space, which provides the surgical margin required for oncologic safety. Weinstein et al. described TORS radical tonsillectomy [36] based on a previous transoral nonrobotic radical tonsillectomy (lateral oropharyngectomy) technique [37]. TORS provides an unparalleled vision and dexterity offered by the robotic instrumentation that allows the procedure to be highly effective and reproducible [38].

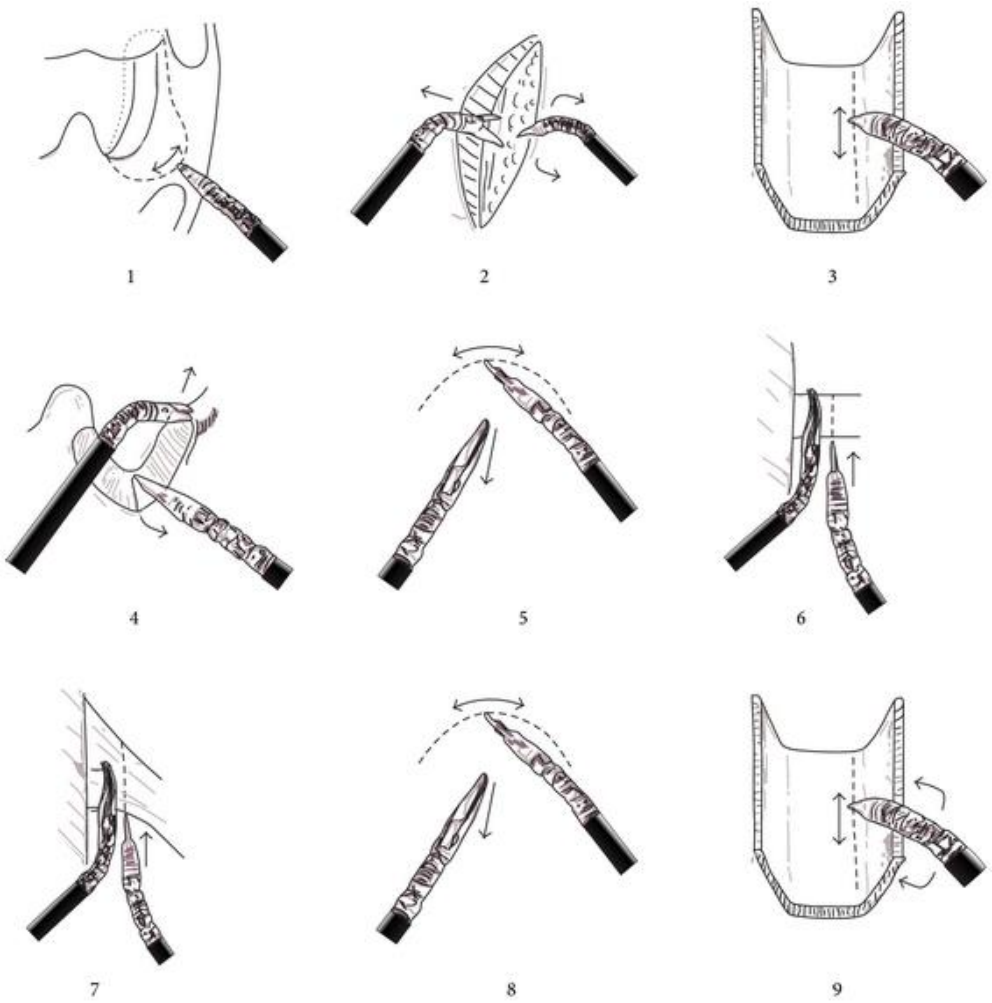

Figure 3. Steps in radical tonsillectomy.

Step 1. Initial incision to mark the superior and lateral superficial limits (dashed line). The incision is made with the monopolar cautery in a question-mark fashion to extend into

the pterygomandibular raphe. The dotted line shows the inferior and medial superficial limits that will be marked later.

Step 2. Deep dissection starts after transecting the superior constrictor muscle. The parapharyngeal fat pad is reached and bluntly dissected laterally.

Step 3. An index cut in the posterior pharyngeal mucosa marks the superficial medial limit.

Step 4. The superior limit is completed with full width transection of the tonsillar pillars.

Step 5. Inferior superficial limit in the tongue base.

Steps 6 and 7. Completion of the lateral limit by transection of the styloglossus (step 6) and stylopharyngeus muscles and the rest of connective tissue attachments (step 7).

Step 8. Completion of the inferior limit (deep tongue base).

Step 9. Completion of the deep medial limit (superior constrictor muscle) approaching either medially, laterally, superiorly, or inferiorly depending on the exposure.

Specimen is then completely free and can be taken out of the surgical field by the assistant. A couple of sutures can be done from the remaining posterior pharyngeal wall to the soft palate, to help nasopharyngeal closure when swallowing. The rest of the wound is left open; a hemostatic agent can be applied topically. No reconstruction is required. Intraoperative margins should be free of disease by frozen sections.

TORS IN UNKNOWN PRIMARY CANCERS

A common presentation for HPV related oropharynx cancer is a patient with a neck mass from metastatic squamous cell carcinoma with an unknown location of the primary tumor. Positive HPV testing on a fine-needle aspiration of the neck mass correlates with an oropharyngeal primary tumor location, especially in the context of a young non-smoker patient. The primary lesion is often small or hidden from view in the depths of the lymphoid tissue crypts, making identification difficult even with a thorough exam and endoscopy. Patients present with an unknown primary head and neck malignancy in 2-5% of cases, and traditional localization methods of PET-CT and direct laryngoscopy with tonsillectomy and biopsies fails to localize the tumor in 50-70% of patients [39]. This can be due to small primary tumors which are difficult to visualize or palpate due to their location in the crypts of the tonsil and tongue base lymphoid tissue.

Without identification of the primary tumor, a wide treatment field of high dose radiation to incorporate both palatine and lingual tonsils is undertaken to cover likely locations of the unfound primary tumor. This treatment leads to increased morbidity compared to the limited surgical resection or targeted Intensity-Modulated Radiotherapy that can be applied when the tumor location is identified. In addition to reduced treatment toxicity, localization of the primary tumor increases survival rates and local control.

The improved magnified visualization and oropharyngeal access of TORS and transoral laser microsurgery has allowed for a new approach to localizing head and neck cancers of unknown primary. After failure to identify the primary tumor with rigid endoscopy, one commonly adopted protocol is to perform an ipsilateral palatine tonsillectomy and lingual tonsillectomy to be evaluated for frozen section. If the site is still not found, the contralateral lingual tonsillectomy is performed. When the primary site is located, immediate oncologic

resection with frozen section evaluation of margins is performed using the TORS technique [40, 41]. This approach led to identification and resection of the primary tumor in 80-89% of unknown primary tumors, which lead to reduced treatment toxicities and improved quality of life [41-43].

The TORS approach to lingual tonsillectomy has been a useful tool in many centers for localizing unknown primary cancers. Localization has allowed for reduced treatment morbidity by reducing the size of the required radiation fields and allowing for de-intensification of the treatment dose if negative margins are obtained. The ultimate goal of these treatment protocols are improved swallowing and speech outcomes with excellent local oncologic control.

TORS IN RECURRENT OROPHARYNGEAL CANCERS

Transoral surgery has been adopted by many cancer centers with a growing number of series published with good oncologic and functional outcomes. The use of TORS for salvage of oropharyngeal cancers after radiation failure is not as well reported, but has important clinical implications. In the recurrent setting, there are many factors that can lead to increased difficulty with a transoral surgery. First, exposure of the tumor can be more difficult owing to radiation fibrosis and trismus which limits access of the robotic instrumentation. Additionally, mucosal edema and skip lesions may obscure the tumor boundaries, necessitating wider margins. Another consideration is that dissection in the proximity of the internal carotid artery can be riskier owing to obliteration of dissection planes from radiation. There is also the consideration that the radiated tissue will not heal as well, which increases the risk for oropharyngeal hemorrhage and delayed wound healing by secondary intention.

Although the data have been limited, there is increasing expansion of indications in carefully selected salvage cases. One case series of 64 patients who had TORS for salvage surgery compared to 64 patients with traditional open salvage approaches, showed an improved rate of tracheostomy use, feeding tube dependence, hospital stay, blood loss, and positive margin rate. The TORS group also had a better 2-year recurrence free survival rate (74% vs 43%) [44]. Although this study was not randomized and is subject to selection bias, it demonstrates the feasibility and oncologic success of TORS for recurrent cancers. This has been validated by other studies with positive margin rates around 7% with acceptable functional outcomes in swallowing, trach dependence, and safety [45, 46].

Studies have shown a low rate (1.4-7.5%) of minor or major oropharyngeal bleeding after transoral surgery [47, 48]. Although the bleeding rate was not statistically significant between salvage surgeries and primary surgeries [47, 48], there was a 1% rate fatal oropharyngeal hemorrhages in the salvage setting, which was the highest risk for advanced stage and pyriform sinus tumors [49]. Data is currently being collected as to whether prophylactically ligating the facial and lingual artery will decrease this risk.

Careful patient selection must be used when determining candidacy for transoral surgery in the salvage setting, but oncologic and functional results compare favorably to traditional open approaches. Particular attention must be made for hemostasis and prophylactic artery ligation to prevent life-threatening post-operative hemorrhage. It is now recommended to prophylactically ligate the ipsilateral facial and lingual artery at the time of neck dissection to

reduce the risk of severe oropharyngeal hemorrhage. In addition, visualized vessels in the tongue base and tonsillar defect require mechanical clips. Caution should be used in selecting patients for transoral robotic surgery if they have pre-existing coagulopathy, anticoagulation medications, uremia, or cirrhosis due to the risk of life-threatening bleeding.

FUTURE DIRECTIONS AND ONGOING RESEARCH

HPV related oropharynx cancer is more responsive to surgery and radiation than smoking related cancers, which has led to improved prognosis for these patients. With the biology of these tumors being different, the goals of care have shifted to achieving the same oncologic outcomes but reducing treatment morbidity by de-escalating therapy. A large randomized control trial ECOG 3311 utilizing transoral surgery for HPV related oropharynx squamous cell carcinoma is underway. The primary objective is to evaluate the 2-year progression free survival, swallowing, and quality of life in patients treated with adjuvant low-dose (50Gy) radiotherapy versus standard dose (60Gy) in intermediate risk patients. In this study, patients with T1 and T2, N1-N2b disease undergo transoral resection and neck dissection. If they have low risk tumors (N0-N1, negative margins, no extracapsular extension), they are observed with no adjuvant therapy. Patients with high risk tumors (>1mm extracapsular extension, 5 or more metastatic lymph nodes, or positive margins), undergo concurrent chemoradation with 66Gy. Those patients who fall into an intermediate risk category are randomized to adjuvant radiotherapy of 50 or 60Gy and followed for 2 years. This study provides an exciting opportunity to de-escalate therapy for patients' whose treatments are currently based on historical data for smoking related cancers. The molecular biology of HPV related and smoking related cancers differs, resulting in different tumor behavior and treatment response, so separating these clinical entities and tailoring treatment may result in persistence of good oncologic outcomes with reduced treatment related morbidity.

Another avenue of ongoing development is in the re-design of the robot being used. The most commonly used DaVinci Si system requires 3 arms to enter the mouth, which results in a tight working space and instrument collisions. In addition, patients with poor neck extension, large tongues, trismus, or anterior larynx can be difficult to expose with the current instrumentation. Ongoing efforts to develop a single-port system that will deploy 3 arms and a camera are underway, which will likely result in a shorter set-up time and more efficient use of the limited workspace for tumor extirpation.

The evolving technology has potential to utilize the transoral approach for greater proportion of patients and with tumors deeper in the aerodigestive tract. This could include improved access to the nasopharynx, hypopharynx, and larynx, which are difficulty to access with current instrumentation. While progressing in the transoral surgery realm, it will be important to continue to collect safety, oncologic, and functional outcome data to provide the best treatment options for our patients.

REFERENCES

[1] Lörincz, B. B., Jowett, N., Knecht, R. Decision management in transoral robotic surgery: Indications, individual patient selection, and role in the multidisciplinary treatment for head and neck cancer from a European perspective. *Head Neck* 2016; 38:E2190–E2196.

[2] Adelstein, D. J., Ridge, J. A., Brizel, D. M. et al. Transoral resection of pharyngeal cancer: summary of a National Cancer Institute Head and Neck Cancer Steering Committee Clinical Trials Planning Meeting. *Head Neck* 2012;34:1681–1703.

[3] Hashibe, M., Sturgis. E. M. Epidemiology of oral-cavity and oropharyngeal carcinomas: controlling a tobacco epidemic while a human papillomavirus epidemic emerges. *Otolaryngol Clin North Am* 2013;46:507–520.

[4] Nichols, A. C., Palma, D. A., Dhaliwal, S. S., et al. The epidemic of human papillomavirus and oropharyngeal cancer in a Canadian population. *Curr Oncol* 2013;20:212–219.

[5] Ramqvist, T., Dalianis, T. Oropharyngeal cancer epidemic and human papillomavirus. *Emerg Infect Dis* 2010;16:1671–1677.

[6] Ramqvist, T., Dalianis, T. An epidemic of oropharyngeal squamous cell carcinoma (OSCC) due to human papillomavirus (HPV) infection and aspects of treatment and prevention. *Anticancer Res* 2011;31:1515–1519.

[7] Bentzen, S. M., Rosenthal, D. I., Weymuller, E. A., Trotti, A. Increasing toxicity in nonoperative head and neck cancer treatment: investigations and interventions. *Int J Radiat Oncol Biol Phys* 2007;69(2 Suppl):S79–S82.

[8] Maxwell, J. H., Mehta, V., Wang, H. et al. Quality of life in head and neck cancer patients: impact of HPV and primary treatment modality. *Laryngoscope* 2014;124:1592–1597.

[9] Broglie, M. A., Soltermann, A., Haile, S. R. et al. Quality of life of oropharyngeal cancer patients with respect to treatment strategy and p16-positivity. *Laryngoscope* 2013;123:164–170.

[10] White, H., Ford, S., Bush, B. et al. Salvage surgery for recurrent cancers of the oropharynx: comparing TORS with standard open surgical approaches. *JAMA Otolaryngol. Head Neck Surg*. 2013; 139: 773–8.

[11] Sansoni, E. R., Gross, N. D. The role of transoral robotic surgery in the management of oropharyngeal squamous cell carcinoma: a current review. *Curr. Oncol. Rep*. 2015; 17: 432.

[12] Choby, G. W., Kim, J., Ling, D. C., et al. Transoral robotic surgery alone for oropharyngeal cancer: quality-of-life outcomes. JAMA Otolaryngol. *Head Neck Surg*. 2015; 141: 499–504.

[13] Shah, S., Goldenberg. D. Robotic surgery for oropharyngeal cancer. *Rambam Maimonides Med J*. 2014;5(2): e0014.

[14] Weinstein, G. S., O'Malley Jr, B. W., Snyder, W., Sherman, E., Quon, H. Transoral robotic surgery: radical tonsillectomy. *Arch. Otolaryngol. Head Neck Surg*. 2007; 133: 1220–6.

[15] McLeod, I. K., Melder, P. C. Da Vinci robot-assisted excision of a vallecular cyst: a case report. *Ear Nose Throat J*. 2005;84(3):170–172.

[16] Hockstein, N. G., Nolan, J. P., O'malley Jr, B. W., Woo, Y. J. Robotic microlaryngeal surgery: a technical feasibility study using the da Vinci surgical robot and an airway mannequin. *Laryngoscope*. 2005;115(5):780–785.

[17] O'Malley Jr, B. W., Weinstein, G. S., Snyder, W., Hockstein, N. G. Transoral robotic surgery (TORS) for base of tongue neoplasms. *Laryngoscope*. 2006;116(8):1465–1472.

[18] Hockstein, N. G., O'Malley Jr, B. W., Weinstein, G. S. Assessment of intraoperative safety in transoral robotic surgery. *Laryngoscope*. 2006;116(2):165–168.

[19] Hockstein, N. G., Nolan, J. P., O'Malley Jr, B. W., Woo, Y. J. Robot-assisted pharyngeal and laryngeal microsurgery: results of robotic cadaver dissections. *Laryngoscope*. 2005;115(6):1003–1008.

[20] O'Malley Jr, B. W., Weinstein, G. S., Hockstein, N. G. Transoral robotic surgery (TORS): glottic microsurgery in a canine model. *J Voice*. 2006;20(2):263–268.

[21] Weinstein, G. S., O'malley Jr, B. W., Hockstein, N. G. Transoral robotic surgery: supraglottic laryngectomy in a canine model. *Laryngoscope*. 2005;115(7):1315–1319.

[22] Weinstein, G. S., O'malley Jr, B. W., Snyder, W., Sherman, E., Quon, H. Transoral robotic surgery: radical tonsillectomy. *Arch Otolaryngol Head Neck Surg*. 2007;133(12):1220–1226.

[23] Weinstein, G. S., O'malley Jr, B. W., Snyder, W., Hockstein, N. G. Transoral robotic surgery: supraglottic partial laryngectomy. *Ann Otol Rhinol Laryngol*. 2007; 116(1):19–23.

[24] Park, Y. M., Lee, W. J., Lee, J. G. et al. Transoral robotic surgery (TORS) in laryngeal and hypopharyngeal cancer. *J Laparoendosc Adv Surg Tech A*. 2009; 19(3):361–368.

[25] Genden, E. M., Desai, S., Sung, C. K. Transoral robotic surgery for the management of head and neck cancer: a preliminary experience. *Head Neck*. 2009;31(3):283–289.

[26] Vergez, S., Lallemant, B., Ceruse, P. et al. Initial multi-institutional experience with transoral robotic surgery. *Otolaryngol Head Neck Surg*. 2012;147(3):475–481.

[27] Weinstein, G. S., O'Malley Jr, B. W., Magnuson, J. S., et al. Transoral robotic surgery: a multicenter study to assess feasibility, safety, and surgical margins. *Laryngoscope*. 2012;122(8):1701–1707.

[28] Hans, S., Delas, B., Gorphe, P., Menard, M., Brasnu, D. Transoral robotic surgery in head and neck cancer. *Eur Ann Otorhinolaryngol Head Neck Dis*. 2012;129 (1):32-37.

[29] Ozer, E., Waltonen, J. Transoral robotic nasopharyngectomy: a novel approach for nasopharyngeal lesions. *Laryngoscope*. 2008;118(9): 1613–1616.

[30] Roppenecker, D. B., Meining, A., Horst, G., Ulbrich, H., Lueth, T. C. Interdisciplinary development of a single-port robot. Robotics and Biomimetics (ROBIO). *IEEE International Conference on*. 2012:612–617.

[31] Dallan, I., Castelnuovo, P., Montevecchi, F., et al. Combined transoral transnasal robotic-assisted nasopharyngectomy: a cadaveric feasibility study. *Eur Arch Otorhinolaryngol*. 2012;269(1):235–239.

[32] Kuchenbecker, K. J., Gewirtz, J., McMahan, W., et al. VerroTouch: HighFrequency Acceleration Feedback for Telerobotic Surgery. In: *Haptics, Generating and Perceiving Tangible Sensations*. Vol 6191. Lecture Notes in Computer Science. Berlin, Heidelberg: Springer Berlin Heidelberg; 2010:189–196.

[33] Weinstein, G. S., O'Malley Jr. B. W. *Transoral Robotic Surgery* (TORS). San Diego, CA: Plural Publishing; 2011.

[34] Selber, J. C., Sarhane, K. A., Ibrahim, A. E., Holsinger, F. C. Transoral robotic reconstructive surgery. *Semin Plast Surg*. 2014;28(1):35-38.

[35] Hockstein, N. G., O'Malley Jr, B. W., Weinstein, G. S. Assessment of intraoperative safety in transoral robotic surgery. *Laryngoscope*. 2006;116(2):165-168.

[36] Weinstein, G. S., O'Malley Jr., B. W., Snyder, W., Sherman, E. and Quon, H. Transoral robotic surgery: radical tonsillectomy. *Archives of Otolaryngology—Head and Neck Surgery*. 2007;133 (12):1220–1226.

[37] Holsinger, F. C., McWhorter, A. J., Ménard, M., Garcia, D. and Laccourreye, O. Transoral lateral oropharyngectomy for squamous cell carcinoma of the tonsillar region: I. Technique, complications, and functional results. *Archives of Otolaryngology—Head and Neck Surgery*. 2005;131(7): 583–591.

[38] Weinstein, G. S., Quon, H., Newman, H. J., et al. Transoral robotic surgery alone for oropharyngeal cancer: an analysis of local control. *Archives of Otolaryngology—Head and Neck Surgery*. 2012; 138 (7): 628–634.

[39] Fu, T. S., Foreman, A., Goldstein, D. P., de Almeida, J. R. The role of transoral robotic surgery, transoral laser microsurgery, and lingual tonsillectomy in the identification of head and neck squamous cell carcinoma of unknown primary origin: a systematic review. *Journal of otolaryngology - head & neck surgery = Le Journal d'oto-rhino-laryngologie et de chirurgie cervico-faciale*. 2016;45(1):28.

[40] Byrd, J. K., Smith, K. J., de Almeida, J. R., Albergotti, W. G., Davis, K. S., Kim, S. W., et al. Transoral Robotic Surgery and the Unknown Primary: A Cost-Effectiveness Analysis. *Otolaryngology--head and neck surgery: official journal of American Academy of Otolaryngology-Head and Neck Surgery*. 2014;150(6):976-82.

[41] Hatten K. M., O'Malley Jr., B. W., Bur, A. M., Patel, M. R., Rassekh, C. H., Newman, J. G., et al. Transoral robotic surgery-assisted endoscopy with primary site detection and treatment in occult mucosal primaries. *JAMA otolaryngology-- head & neck surgery*. 2017. 143(3):267-273.

[42] Durmus, K., Patwa, H. S., Gokozan, H. N., Kucur, C., Teknos, T. N., Agrawal, A., et al. Functional and quality-of-life outcomes of transoral robotic surgery for carcinoma of unknown primary. *The Laryngoscope*. 2014;124(9):2089-95.

[43] Graboyes, E. M., Sinha, P., Thorstad, W. L., Rich, J. T., Haughey, B. H. Management of human papillomavirus-related unknown primaries of the head and neck with a transoral surgical approach. *Head & neck*. 2015;37(11):1603-11.

[44] White, H., Ford, S., Bush, B., Holsinger, F. C., Moore, E., Ghanem, T., et al. Salvage surgery for recurrent cancers of the oropharynx: comparing TORS with standard open surgical approaches. *JAMA otolaryngology-- head & neck surgery*. 2013;139(8):773-8.

[45] Dabas, S., Dewan, A., Ranjan, R., Dewan, A. K., Shukla, H., Sinha, R. Salvage transoral robotic surgery for recurrent or residual head and neck squamous cell carcinoma: A single institution experience. *Asian Pacific journal of cancer prevention: APJCP*. 2015;16(17):7627-32.

[46] Dean, N. R., Rosenthal, E. L., Carroll, W. R., Kostrzewa, J. P., Jones, V. L., Desmond, R. A. et al. Robotic-assisted surgery for primary or recurrent oropharyngeal carcinoma. *Arch Otolaryngol Head Neck Surg*. 2010;136(4):380-4.

[47] Asher, S. A., White, H. N., Kejner, A. E., Rosenthal, E. L., Carroll, W. R., Magnuson, J. S. Hemorrhage after transoral robotic-assisted surgery. *Otolaryngology--head and*

neck surgery: official journal of American Academy of Otolaryngology-Head and Neck Surgery. 2013;149(1):112-7.

[48] Salassa, J. R., Hinni, M. L., Grant, D. G., Hayden, R. E. Postoperative bleeding in transoral laser microsurgery for upper aerodigestive tract tumors. *Otolaryngology--head and neck surgery: official journal of American Academy of Otolaryngology-Head and Neck Surgery*. 2008;139(3):453-9.

In: Encyclopedia of Surgery (22 Volume Set)
Editors: Andreas Lehrer and Kristin Mueller
ISBN: 978-1-53618-329-0
© 2020 Nova Science Publishers, Inc.

Chapter 258

ROBOTIC SURGERY: EVOLUTION, CHALLENGES AND THE FUTURE

Richard S. Lazzaro[1], MD, Byron Patton[2], MD, Landon Guntman[3], MD and Faiz Bhora[4], MD

[1]Division of Thoracic Surgery, Lenox Hill Hospital,
Robotic Thoracic Surgery Northwell Health, Cardiothoracic Surgery,
Donald and Barbara Zucker School of Medicine
at Hofstra/Northwell, New York, NY, US
[2]Lenox Hill Hospital, Cardiothoracic Surgery,
Donald and Barbara Zucker School of Medicine
at Hofstra/Northwell, New York, NY, US
[3]Department of Thoracic Surgery,
Mount Sinai St. Luke's and Mount Sinai West Hospital's,
New York, NY, US
[4]Thoracic Surgery, Mount Sinai St. Luke's and Mount Sinai West Hospital's,
Thoracic Surgery, Icahn School of Medicine, New York, NY, US

ABSTRACT

With any new or emerging technology, especially ones that may be paradigm shifting, come the rightfully asked questions, "Is this really going to be an improvement?", or "Are the benefits worth the trouble/cost?", and "What are the relevant applications?" Every aspect of robotic surgery has been under investigation since it stepped on the scene. The greatest challenge for early adopters of robotics, and even for the current generation of robotic surgeons, is how to fully incorporate this still burgeoning technology into our surgical culture's future from an academic, clinical, financial, and administrative perspective. It is the aim of this chapter to realize our robotic evolution while openly addressing its challenges now and in the future.

EVOLUTION

The history of surgical innovation was assessed and discussed by Riskin et al in 2006 [1]. The concepts of *enabling technology* and *disruptive technology* were presented; as was the impact upon adoption rates and market share. *Enabling technology* not only allows one to improve one's current performance, but also helps develop new abilities. In the field of surgery, enabling technology can be utilized to perform more complex procedures minimally invasively and to improve outcomes. Minimally invasive surgery (MIS) pulmonary sleeve resections, neo bladders, Whipple procedures, and redo surgery are now possible to a greater number of surgeons. *Disruptive technology* has the potential to topple industry leaders and change market shares. Focusing on emerging markets, these new innovations start slowly, and eventually pass their competitors [1].

Disruptive technology such as the introduction of laparoscopic instrumentation and laparoscopic surgery, was often met with skepticism, meticulous oversight (thoroughly necessary), and appropriate critique. After all, before any new skill is ever acquired comes unfamiliarity, frustration, practice, and finally competence. Early utilization of laparoscopic technique for cholecystectomy was associated with increased rates of common bile duct injuries, when compared to open surgery. With experience, and progression along the learning curve, the incidence of bile duct injuries did decrease [2]. The majority of bile duct injuries are the results of visual misinterpretation, which can be mitigated with cognitive map timeouts where the critical anatomy is reassessed prior to proceeding with the procedure [3, 4]. The appropriate spotlight on these outcomes led to improvement in training. With experience, the rates of common bile duct injuries associated with laparoscopic surgery decreased, becoming similar to that of an open approach [5]. The learning curve has been studied for virtually every surgical procedure where robotics is used and, does not take as long to overcome as one might assume.

For robotics to even stand a chance at being accepted by conservative surgeons, it had to achieve results equal to, or greater, than that of both open and current minimally invasive surgery or it would be disregarded—nothing more than an exorbitant gadget.

Studying a group of surgeons with varying degrees of laparoscopic expertise, Chang *et al.* observed similar times and scores in robotic vs. laparoscopic knot-tying tasks, after only 4-6 hours of robotic training. Furthermore, after an additional 2-4 hours of robotic training their times and scores significantly improved, surpassing their previous laparoscopic skills, suggesting robotics may be easier to learn than laparoscopy [6].

Melfi and Mussi highlight the importance of standardizing procedures and establishing operative schemes to ensure safety and surety in robotic surgery. They propose that it takes approximately 20 days, or 20 procedures, for both the surgeon and his team to complete adequate training. This learning curve is not only for the surgical procedure itself, but includes robotic setup, optics setup, trocar placement, patient positioning, and robot cart positioning [7]. Though their study was based on lung lobectomy, the principles established are universal and the learning curve identified was found to be similar in other cases including thyroidectomy, colorectal resection, and gynecologic procedures [8-10].

Management of complications is initially impacted through identification of anatomy and avoidance of the injury. Intraoperative recognition of the injury can lead to repair and, hopefully, mitigation of the impact of the injury. Although uncommon, bleeding remains the

most dreaded minimally invasive complication. With experience, management of bleeding can be performed robotically [11]. Cerfolio described the 4 P's: poise, pressure, preparedness, and proximal control to manage intraoperative thoracic vascular injury successfully. These principles are applicable to other specialties.

Fortunately, there are ways to practice robotic skills without fear of making a mistake and harming a patient. Open access simulations provide the ability to progress along the learning curve at will. While wet and dry labs allow the practice of basic skills with the actual clinical robot, virtual reality provides the opportunity to practice entire surgical procedures with a simulated robot in a simulated patient. Both have merit along with their disadvantages, thus a multifaceted approach to training is likely to yield optimum results [12].

A learning technique used in every professional sport to critique and guide practice is video review and feedback (i.e. game film). Carter *et al.* applied this "game film" concept to robotic surgery training and demonstrated that peer reviewed videos accelerated residents' progression along the learning curve [13]. Unfortunately, because robotic surgery is not fully adopted as part of all residencies, there is no universally accepted curriculum [14]. Though, as interest in robotic surgery continues to grow along with the development of new technologies, it is only a matter of time before formal training in robotics is commonplace in residency. In fact, some programs have already composed robotic curricula and avouch that safe implementation, even in the small community hospital setting, is entirely feasible [15-18].

Finally, as technology advances, along with surgical instrumentation and image guidance systems, surgical procedures and outcomes may become more consistent with decreased operator variability. Surgical simulators are used not only to train surgeons on the correct utilization of the instrument but can also facilitate procedural development. 3-D and 4-D reconstructed CT scans can be utilized for preoperative planning but may one day be seamlessly integrated into the video image to guide surgical procedures beyond the capabilities of current platforms, creating a virtual roadmap of surgery beyond what is visible to the naked eye.

CHALLENGES

Adopting and *incorporating* new technology into the operating room can be extremely polarizing. Resistance to change must be challenged by enthusiastic supporters of a new disruptive technology. The successful adoption of robotic assisted surgery requires intensive team management as well as risk assessment and mitigation strategies. Inevitably, obstacles will arise and must be overcome through a team-based approach.

As opposed to risk avoidance, another risk management strategy can be described as mitigation of risk. This approach revolves around learning as much as you can about the new surgical technology by following the training pathway, which routinely employs online learning, laboratory training with robotic technology, case observations, and proctored surgical procedures.

Current digital media as well as the Internet provides a great venue to view surgical videos. Surgical societies and journals provide peer-reviewed videos which can be extremely valuable to review and learn procedures. Finally, for the surgeon who is embarking on a robotic assisted pathway, it is extremely important that those surgeons consider incorporating

the robot assisted platform into procedures which they are already performing routinely and competently, so the stress associated with this new technology is not compounded by the concomitant need to learn and perform a new surgical procedure.

Early experience with robotic assisted surgery requires following the path of an "all in" strategy. A crucial step in the safe adoption of robotic assisted surgery is aligning the shared vision and common purpose of the nursing team, anesthesia team, as well as the bedside assistant surgeon. Each team member is encouraged to speak up during the procedure with any questions or concerns. They must also learn a new room set up, including new instruments, while adapting to the surgeon sitting at the console a short distance from the field. By aligning the core team members, the growing pains experienced by the OR team can be overcome as they progress through the learning curve together.

Eventually, the setup and docking of the robot become fluid and effortless, anesthesia learns the subtle nuances that distinguish a robotic assisted case from a non-robotic case, and the bedside assistant becomes comfortable with changes associated with the surgeon not being directly across from them. Having a dedicated and consistent bedside assistant is important to maximize efficiency and minimize operative times. Surgical residents should first be trained as bedside assistants, but ultimately sit at a dual console system and train as robotic surgeons. Learning curves may be helpful to gauge the ability of a surgeon to proficiently perform a specific procedure. However, many experienced robotic surgeons continue to improve over time without a plateau in the curve.

The added costs of a robotic assisted platform including acquisition, maintenance, instrumentation, and potential additional operating room time must be considered in light of the effectiveness of the procedure [19]. Once purchased, the cost of robotic assisted platforms, such as da Vinci (Intuitive Surgical, Sunnyvale, CA), are offset by enhanced utilization.

Early adopters become obligate team leaders and experts in room setup, operating room efficiency, minimization of instrument usage as well as members of robotic surgical committees. Through participation in robotic steering committees, the surgeon leader interfaces with anesthesia colleagues, nursing leadership, as well as administrative leaders including financial officers. Robotic steering committees provide the framework in a multidisciplinary fashion to help maximize outcomes, standardize care, and minimize cost. It is through this group where credentialing and re-credentialing protocols are developed, OR efficiency is measured, and outcomes and cost are addressed. Through these relationships, meaningful progress can be made in regard to preservation of excellence in outcomes and minimization of cost.

The da Vinci robot is the leader in the field with the greatest market share, but as competing robotic platforms are introduced, the cost of robotic assisted surgery to healthcare systems will likely decrease. As cost becomes less of a concern and outcomes are improved, the surgeon is left to view robotic assisted surgery as enabling technology. Once competent and efficient in routine procedures, the surgeon can expand the scope of minimally invasive surgery and realize new goals.

THE FUTURE

The goal of individual surgeons is to become better, more efficient, and less invasive. Standardizing surgical procedures such that there is less variance would allow for the development of consistent hyper-performers: best surgeons with best outcomes. More than the development of smaller instruments, the emphasis should and is becoming directed towards the further development of preoperative imaging (3D and 4D CT scans) to guide the surgeon in preoperative planning and intra-operative decision making. Enhanced communication with the OR team as part of the time out further engages OR team as valued members, which provides the potential benefit of enhanced team building, job satisfaction and outcomes.

Working collaboratively with industry, managing conflicts of interest as well as potential bias, preoperative imaging should, and one day will, be merged with the surgeon's visual field; utilizing real time fusion of the preoperative imaging, as opposed to picture in picture, will potentially not only provide a roadmap of critical structures, but could be used to deliver a guided path to the performances often necessary to attain best outcomes.

Incorporation of technology such as Doppler ultrasound to the top of instruments would further assist the surgeon by identifying soon to be divided structures as vascular or safe to divide. As Matisse once said, "I don't paint things, I only paint the difference between things." Great surgeons do not dissect structures directly, they dissect or more precisely dissect and divide the tissue between critical anatomical structures.

The incorporation of artificial technology and augmented reality should facilitate the adoption of minimally invasive approaches to all procedures. Developing augmented reality could be utilized to game-ify surgery such that the surgeon could perform multiple simulated surgeries tailored to the specific patient's imaging; the ultimate in personalized surgery.

Developing new controllers to guide the instruments may further change the way we perform surgery and may provide a mechanism, whereby, if we can align the doctor patient relationship, ethics, insurance and the law, perhaps, instead of advising so many of our colleagues, who call for intra-operative advice, we may be able to assist our colleague with real time proctoring and/or assistance in the OR to optimize patient outcomes.

CONCLUSION

Surgical robotics is becoming less invasive, deliberately intelligent, and strikingly visceral. Features such as image-on-lay, global positioning system (GPS) map of operative field, data integration, artificial intelligence, automated surgery, tumor margin assessment will be standard features of the future operating platform. With robotic technology evolving so precipitously, it is impossible to tell where we will be in 10 years, let alone 50 years. Regarding the laparoscopic revolution only 30 years ago, Dr. Jacques Perissat insightfully urged us all, "…for the first time, surgery no longer involves any physical contact between the surgeon's hand and his patient. Let us hope that this will not lead to total absence of a human relationship in the surgical operation" [20].

REFERENCES

[1] Riskin, D. J., Longaker, M. T., Gertner, M., et al. Innovation in Surgery: A Historical Perspective. *Ann. Surg.*, 2006; 244:686 - 93. doi:10.1097/ 01.sla.0000242706.91771.ce.

[2] Moore, M. J., Bennett, C. L. The learning curve for laparoscopic cholecystectomy. The Southern Surgeons Club. *Am. J. Surg.*, 1995; 170:55 - 9.

[3] Way, L. W., Stewart, L., Gantert, W., et al. Causes and prevention of laparoscopic bile duct injuries: analysis of 252 cases from a human factors and cognitive psychology perspective. *Ann. Surg.*, 2003; 237:460 - 9. doi:10.1097/ 01.SLA.0000060680. 92690.E9.

[4] Sutherland, F., Dixon, E. The importance of cognitive map placement in bile duct injuries. *Can. J. Surg.*, 2017; 60:424 - 5. doi:10.1503/cjs.008816.

[5] Halbert, C., Pagkratis, S., Yang, J., et al. Beyond the learning curve: incidence of bile duct injuries following laparoscopic cholecystectomy normalize to open in the modern era. *Surg. Endosc.*, 2016; 30:2239 - 43. doi:10.1007/s00464-015-4485-2.

[6] Chang, L., Satava, R. M., Pellegrini, C. A., et al. Robotic surgery: identifying the learning curve through objective measurement of skill. *Surg. Endosc.*, 2003; 17:1744 - 8. doi:10.1007/s00464-003-8813-6.

[7] Melfi, F. M. A., Mussi, A. Robotically Assisted Lobectomy: Learning Curve and Complications. *Thorac. Surg. Clin.*, 2008; 18:289 - 95. doi:10.1016/ J.THORSURG. 2008.06.001.

[8] Gharagozloo, F., Margolis, M., Tempesta, B., et al. Robot-Assisted Lobectomy for Early-Stage Lung Cancer: Report of 100 Consecutive Cases. *Ann. Thorac. Surg.*, 2009; 88:380 - 4. doi:10.1016/J.ATHORACSUR.2009.04.039.

[9] Barrie, J., Jayne, D. G., Wright, J., et al. Attaining Surgical Competency and Its Implications in Surgical Clinical Trial Design: A Systematic Review of the Learning Curve in Laparoscopic and Robot-Assisted Laparoscopic Colorectal Cancer Surgery. *Ann. Surg. Oncol.*, 2014; 21:829 - 40. doi:10.1245/s10434-013-3348-0.

[10] Yaribakht, S., Guillemin, F., Harter, V., et al. New approach of learning curve for robotic-assisted gynecologic oncology surgery. *Gynécologie Obs. Fertil.*, 2015; 43: 348 - 55. doi:10.1016/J.GYOBFE.2015.02.004.

[11] Cerfolio, R. J., Bess, K. M., Wei, B., et al. Incidence, Results, and Our Current Intraoperative Technique to Control Major Vascular Injuries During Minimally Invasive Robotic Thoracic Surgery. *Ann. Thorac. Surg.*, 2016; 102:394 - 9. doi:10.1016/j.athoracsur.2016.02.004.

[12] Liss, M. A., Abdelshehid, C., Quach, S., et al. Validation, Correlation, and Comparison of the da Vinci Trainer ™ and the da Vinci Surgical Skills Simulator ™ Using the Mimic ™ Software for Urologic Robotic Surgical Education. *J. Endourol.*, 2012; 26:1629 - 34. doi:10.1089/end.2012.0328.

[13] Carter, S. C., Chiang, A., Shah, G., et al. Video-based Peer Feedback Through Social Networking for Robotic Surgery Simulation. *Ann. Surg.*, 2015; 261:870 - 5. doi:10.1097/SLA.0000000000000756.

[14] Bhora, F. Y., Al-ayoubi, A. M., Rehmani, S. S., et al. Robotically Assisted Thoracic Surgery: Proposed Guidelines for Privileging and Credentialing. *Innov. Technol. Tech. Cardiothorac. Vasc. Surg.*, 2016; 11:386 - 9. doi:10.1097/ imi.0000000000000320.

[15] Oviedo, R. J., Hospital. JSLS *J. Soc. Laparoendosc. Surg*., 2016; 20:e2016.00056. doi:10.4293/JSLS.2016.00056.

[16] Winder, J., Robertson, J. C., Alrajhi, S. First 101 Robotic General Surgery Cases in a Community. S., Juza, R. M., Sasaki, J., et al. Implementing a robotics curriculum at an academic general surgery training program: our initial experience. *J. Robot. Surg.*, 2016; 10:209 - 13. doi:10.1007/s11701-016-0569-9.

[17] Ayloo, S., Roh, Y., Choudhury, N. Robotic cholecystectomy: training of residents in use of the robotic platform. *Int. J. Med. Robot. Comput. Assist. Surg.*, 2014; 10:88 - 92. doi:10.1002/rcs.1525.

[18] Schreuder, H., Wolswijk, R., Zweemer, R., et al. Training and learning robotic surgery, time for a more structured approach: a systematic review. *BJOG An Int. J. Obstet. Gynaecol.*, 2012;119:137 - 49. doi:10.1111/j.1471-0528.2011.03139.x.

[19] Gkegkes, I., Mamais, I., Iavazzo, C. Robotics in general surgery: A systematic cost assessment. *J. Minim. Access Surg.*, 2017; 13:243. doi:10.4103/0972-9941.195565.

[20] Périssat, J. Laparoscopic Surgery: A Pioneer's Point of View. *World J. Surg.*, 1999; 23:863 - 8. doi:10.1007/s002689900590.

In: Encyclopedia of Surgery (22 Volume Set)
Editors: Andreas Lehrer and Kristin Mueller
ISBN: 978-1-53618-329-0
© 2020 Nova Science Publishers, Inc.

Chapter 259

ROBOTIC SURGERY IN BENIGN GYNECOLOGY

Yonghee K. Cho[1], MD and Gerald Harkins[2], MD
[1]Division of Minimally Invasive Gynecologic Surgery,
Pennsylvania State College of Medicine, Hershey, PA, US
[2]Obstetrics and Gynecology, Minimally Invasive Gynecologic Surgery,
Pennsylvania State College of Medicine, Hershey, PA, US

INTRODUCTION

In 2000, the da Vinci Surgical System became the first, and only, approved robotic system by the US Food and Drug Administration (FDA) for general laparoscopy. Five years later, the FDA extended its approval to include gynecologic surgery. Since then, over three million robotic cases have been performed worldwide [1]. In the U.S. alone, it is estimated that more than 2,025 hospitals offer robotic assisted surgery [2]. With gynecologic surgery making up over 50% of robotic cases in the U.S., its application in the field of gynecology has grown exponentially [1].

The advantages of robotic surgery have allowed more gynecologic surgeons to feel at ease with laparoscopic surgery. Robotic surgical techniques have been described for a wide range of gynecologic surgical conditions from abnormal uterine bleeding, fibroids, endometriosis/adenomyosis, ovarian cysts, infertility, pelvic organ prolapse and malignancy. This has resulted in an increase in minimally invasive surgery and a decrease in open abdominal surgery.

Despite its growing popularity, the use of robotic assisted laparoscopy has been controversial. When a vaginal route is not feasible or safe, the American Congress of Obstetricians and Gynecologists (ACOG) advocates for laparoscopic surgery over open abdominal surgery; however, its stance on the role of robotic assisted laparoscopy remains mixed [2, 3].

From a technology stand point there are many advantages to the robotic system over conventional laparoscopy. The three-dimensional view improves the surgeon's visual spatial orientation and overcomes the depth limitations of traditional two-dimensional laparoscopy. The Endo-wrist technology with 7 degrees of freedom allows for superior freedom and

dexterity, allowing for more facile complex dissection. The robotic arms eliminate operator tremors, while reducing surgeon fatigue. For those in practice with limited assistance, the robotic system also allows the primary surgeon to control the camera and up to 3 instruments at a time. These benefits are particularly useful in the obese patient [1, 4]. The dual console system also facilitates the practical education of a new learner.

When looking at patient and operative outcomes in benign gynecologic surgery, robotic assisted laparoscopy and conventional laparoscopy appear to be comparable, with some studies suggesting superior outcomes in robotic assisted procedures. Both surgeries afford minimal estimated blood loss, safe same-day discharge, early patient mobilization, decreased post-operative complications, improved quality of life, similar rate of conversion to open surgery and overall deceased patient morbidity [5–8]. Studies also show decreased post-operative pain in those undergoing robotic assisted surgery, resulting in decreased need for analgesics and shorter hospitalizations [1, 8]. This is thought to be due to decreased irritation and increased tissue protection afforded by the remote center.

While the advantages of the robotic system are vast, there are disadvantages. When the robotic system was first on the market, many found the docking process to be time consuming and cumbersome. The system is viewed as bulky, as it requires a patient side cart, surgical console as well as trained specialty support staff. The lack of tactile feedback can also pose challenges to the operator. However, as the surgical community gained more experience and the technology advanced from the Si to the Xi system, many of these difficulties were overcome. A randomized control trial by Deimling et al. found that when performed by an experienced surgeon, there was no statistically significant difference in operating time between robotic-assisted laparoscopic hysterectomy and standard laparoscopic hysterectomy [9].

In the gynecology literature, the cost of robotic surgery is the most commonly cited deterrent for use. The system is associated with high equipment costs, maintenance fees and utilizes disposable parts [6]. Multiple cost analysis studies have been conducted, with varying conclusions. While utilizing the robot may increase equipment costs, many argue that shorter operative times, decreased hospital stay and complication rates may make up the cost difference. A study by Moawad et al. found that robotic hysterectomies for uteri weighing greater than 750 grams was found to have an improved cost profile [10]. This suggests that in the appropriate context, robotic surgery may be more financially sound. Therefore, utilization of robotic surgery in gynecology should be based on the individual patient, surgeon skill, support staff, and equipment availability.

While the debate between robotic assisted laparoscopy vs. conventional laparoscopy still remains, the utilization of robotic assisted surgery continues to grow, forever changing the practice of minimally invasive gynecologic surgery.

GYNECOLOGIC SURGICAL ANATOMY

Upon entry into the abdomen, a survey of the abdomen and pelvis should be performed. To best view the pelvic anatomy, the patient should be placed in appropriate Trendelenburg and the bowel swept out of the pelvis.

If present, the uterus sits between the bladder and the rectum. It is made up of the fundus, corpus and cervix. It is supported by a series of ligaments (Figure 1). The round ligament of

the uterus sits just anterior of the fallopian tube and exits the pelvis through the deep inguinal ring. This ligament helps to maintain the anteversion of the uterus. Connecting the uterus to the lateral pelvic sidewalls on either side of the uterus and cervix are the broad ligament and cardinal ligament. The uterosacral ligaments run posterior run from the posterior cervix to the anterior sacrum. Together, the uterosacral and cardinal ligaments help provide pelvic floor support to the uterus and prevent prolapse.

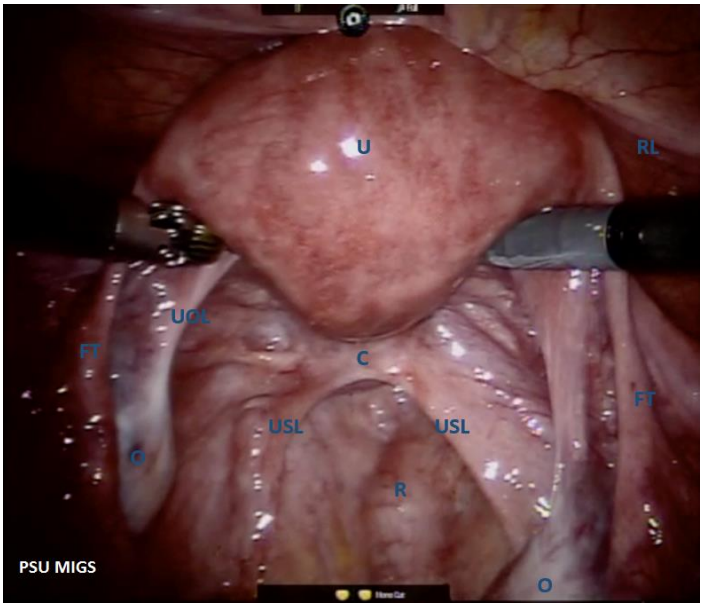

Figure 1. Laparoscopic view of normal pelvic anatomy. U = Uterus; RL = Round Ligament; UOL = Utero-Ovarian Ligament; FT = Fallopian Tube; C = Cervix; O = Ovary; USL = Uterosacral Ligament; R= Rectum.[1]

The adnexa are comprised of the fallopian tubes, ovaries and their supporting structures. The fallopian tube is ~10cm in length and is separated into the isthmus, ampulla, infundibulum and fimbria (Figure 2). They are connected by the mesosalpinx and insert into the uterus at the cornua. The ovaries attach to the uterus via the utero-ovarian ligament. The infundibulopelvic (IP) ligament, also known as the suspensory ligament, contains the ovarian vessels and connects the ovary to the pelvic sidewall.

The distal half of the ureter runs through the pelvis. It crosses the pelvic brim and enters the pelvis anterior to the bifurcation of the common iliac artery. The IP ligament sits superior and lateral to the ureter. As the ureter courses lateral to medial, it travels along the pelvic sidewall in the infraovarian fossa. At the level of the cervico-uterine junction, the ureter crosses just below the uterine artery. It then travels along the cardinal ligament before entering the bladder trigone.

1 All images in this chapter are courtesy of the Department of Minimally Invasive Gynecologic Surgery at the Penn State Hershey Medical Center.

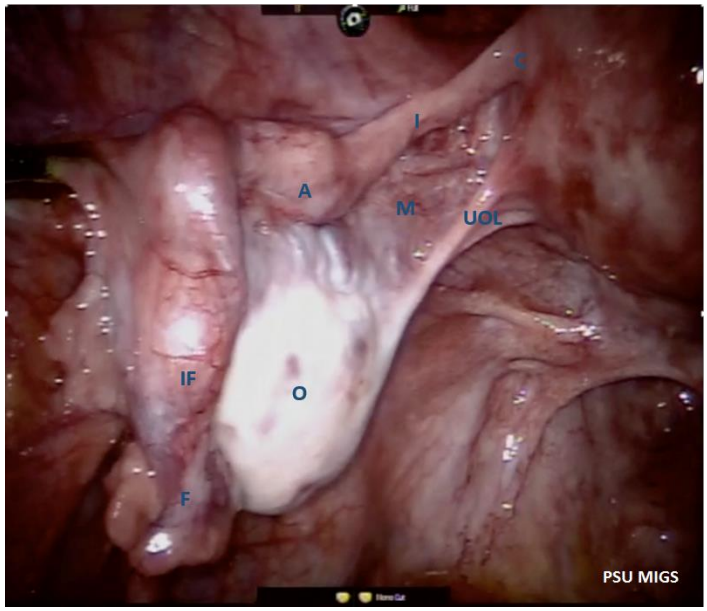

Figure 2. Laparoscopic view of normal adnexal anatomy. F = Fimbria; IF = Infundibulum; A = Ampulla; I = Isthmus; C = Cornua; O = Ovary; M = Mesosalpinx; UOL = Utero-Ovarian Ligament.

The rectosigmoid colon is attached via physiologic adhesions to the left pelvic brim. It descends posterior to the uterus and below the uterosacral ligaments. The bladder sits anterior to the uterus. An avascular space known as the vesico-uterine space sits between the two. This space is used to dissect the bladder off of the uterus and cervix at the time of hysterectomy.

TECHNIQUES AND CONSIDERATIONS FOR GYNECOLOGIC SURGERY

Positioning

All surgery begins with proper positioning of the patient. Poor patient positioning can result in long-term nerve damage, facial trauma and unnecessarily difficult surgery. When utilizing the robotic platform, access to the surgical field must also be considered for the robotic arms and camera.

In gynecologic surgery, the dorsal lithotomy position is favored. Most gynecologic surgeries require uterine manipulation or delineation of the bladder. The dorsal lithotomy position allows for ease of access to the vagina and bladder.

When positioning the legs, Allen Yellofin stirrups (Allen Medical Systems Inc, Acton, MA, USA) are used. For larger patients, Allen Ultrafin stirrups (Allen Medical Systems Inc, Acton, MA, USA) may be used. Care should be taken to align the patient's ankle, knee and contralateral shoulder. The patient's ankles rest at a 90-degree angle in the stirrup. The knees are bent between 70-90 degrees. In high lithotomy, the maximum hip flexion should be 90 degrees. When the patient is in low lithotomy, the hip should not extend greater than 120 degrees. The distance between the legs at the perineum should be 90 degrees. Points of

pressure should be avoided, regardless of the position of the legs. Hyperextension, hyperflexion and excessive pressure of the lower extremities can result in permanent nerve damage to the femoral, lateral femoral cutaneous and common peroneal nerves.

The patient's buttocks should be resting at or slightly over the table's edge. Care should be taken to assess adequate lumbar and sacral support. This allows for placement and adequate usage of a uterine manipulator. Access to the perineum and vagina also allows for ease of specimen removal through this orifice when indicated.

In order to achieve optimal access to the patient, the arms should be tucked. The patient's arms should rest straight with the thumbs aiming upward. The wrists should also be placed in an anatomically neutral position. This can be achieved with a sheet, foam padding or padded arm sleds. Once the arms are padded and tucked, the patient's IV and blood pressure cuff should be checked to ensure that they are optimally functioning.

As the patient will be placed in Trendelenburg, care should be taken to prevent the patient from sliding on the operating table. There are a variety of ways this can be achieved ranging from egg crate foam, the Bean Bag Positioner (AliMed Inc, Dedham, MA, USA), to the Pink Pad (Xodus Medical, New Kensington, PA, USA) memory foam system. Regardless of which system is used, it is recommended a tilt test be performed. This ensures that the patient is secure on the table and is able to tolerate Trendelenburg prior to starting the procedure.

Special consideration to the patient's face, in particular the eyes, need to be taken in robotic assisted surgery. The surgeon is removed from the bedside and is less aware of the extracorporeal movements of the robotic arms and camera. Therefore, the patient's face should be adequately protected. A foam mask or placement of a Mayo stand above the patient's head can be utilized [11]. Tam et al. describe a modification of the Head Butler (Tri-Medical Corporation, Portland, OR, US) that allows for protection of the patient's face and chest, while providing a platform for placement of instrumentation [12].

Abdominal Entry and Trocar Placement

Prior to the start of the procedure, it is recommended that a pelvic examination be performed under anesthesia. This allows the surgeon to assess the shape and mobility of the uterus, adnexa and any other palpable pelvic pathology and better plan for appropriate port placement [13]. An orogastric tube should be placed prior to abdominal entry to decompress the stomach [14]. Once the patient is prepped and draped, the bladder should be drained with a Foley catheter. An indwelling catheter should be considered for longer cases or if back filling of the bladder is anticipated. If indicated, a uterine manipulator can then be placed at this time.

Trocar insertion is often viewed as the most hazardous part of laparoscopy as it accounts for up to 40% of laparoscopic complications [15]. The literature does not support the superiority of Veress needle, open laparoscopy or direct trocar entry over the other [14]. Therefore, initially entry into the abdomen should be undertaken based on surgeon experience and patient history. In patients with a complex surgical history, Palmer's point is often favored as the safer initial point of entry over the umbilicus [15]. Once access has been safely achieved, all subsequent trocars should be placed under direct visualization to avoid any unnecessary injuries to the surrounding structures and organs.

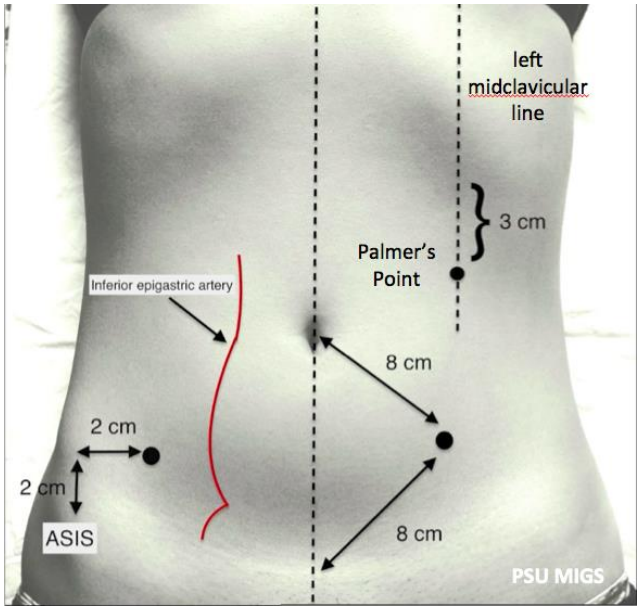

Figure 3. Port Placement.

For the vast majority of gynecologic surgery, the lower uterine segment and cervix serve as the focal point [13]. Therefore, the camera is most commonly placed at the umbilicus. Large pathology may warrant placement of a supraumbilical port in order to achieve adequate visualization. Once the endoscopic port is placed, two 8-mm ports are placed in the right and left lower quadrants under direct visualization. These ports should be placed approximately two finger breaths medial and superior to the anterior-superior iliac spines, while maintaining a minimal distance of 8-10cm between the endoscope and focal point [11, 13]. The assistant port should be placed in the left upper quadrant, taking care to triangulate between the endoscopic and left lower quadrant port. If the fourth robotic arm is needed, the port should mirror the assistant port on the contralateral side [13]. When determining trocar placement, the anterior abdominal wall anatomy should always be assessed to minimize the risk of a vascular or nerve injury (Figure 3).

Docking

Once the ports are placed, the patient should be placed in appropriate Trendelenburg position. Atraumatic laparoscopic instruments can be utilized to sweep the bowel out of the surgical field and into the upper abdomen. The patient's bed should be positioned to allow adequate space for the robotic system to be docked.

While the robotic system can be either center or side docked, side docking is preferable in gynecology. This allows for assistant access to the pelvis for uterine manipulation and specimen removal. The cart can be docked on either side of the patient, based upon surgeon preference and handedness.

ROBOTIC ASSISTED TOTAL LAPAROSCOPIC HYSTERECTOMY

With over 600,000 cases per year, the hysterectomy is one of the most commonly performed surgical procedures in the United States. This accounts for more than $5 billion health care dollars [16]. The fast learning curve and advantages of the robotic system is thought to have made the minimally invasive hysterectomy more attainable to those less apt at conventional laparoscopy [17]. In 2015, 263,000 hysterectomies were performed robotically [13]. Thus, the robotic platform plays a significant role in the minimally invasive hysterectomy.

Indications

Indications for a benign hysterectomy range from recurrent cervical dysplasia, endometriosis, chronic pelvic pain, pelvic organ prolapse and abnormal uterine bleeding. Symptomatic uterine leiomyomas are the most common reason for a hysterectomy [3, 18]. Regardless of the indication, multiple studies have been performed confirming the benefits of a minimally invasive hysterectomy.

When undergoing a minimally invasive route, patients can have a same-day discharge, decreased post-operative pain, minimal blood loss and improved patient satisfaction compared to an open abdominal approach. When looking at standard laparoscopic hysterectomy versus robotic-assisted laparoscopic hysterectomy, the studies suggest that the two are comparable [6, 13, 17]. A multicenter analysis performed by Lim et al. found that with high-volume experience, robotic-assisted benign hysterectomies may provided improved outcomes when compared to vaginal, abdominal and conventional laparoscopy [7].

While the robotic system can be utilized for straightforward hysterectomies, its advantages are maximized in the more complex cases. Patients with a history of multiple abdominal or pelvic surgeries, advanced endometriosis or pelvic inflammatory disease/tubal ovarian abscess are at a higher likelihood of having severe adhesive disease. This agility and fine dissection capabilities of the robotic system can help facilitate safe lysis of extensive adhesions caused by an adverse medical or surgical history.

For enlarged uteri, it was previously thought that the upper limit for a minimally invasive approach was greater than 15 weeks gestation or weighing >500 grams [19]. With the advancement in laparoscopic skills and technology, these boundaries have been pushed to uteri well beyond 1,000 grams. Utilization of the robotic fourth arm can aid in the manipulation of heavy pathology and helps decrease assistant and surgeon fatigue. However, if the fundus approaches the costal regions, safe port placement cannot be achieved and an open approach should be undertaken. A robotic approach is also unlikely to be successful if the width of the uterus limits mobility and access to the pelvic sidewalls.

Surgical Techniques

The steps for a robotic assisted total laparoscopic hysterectomy mirror that of a conventional laparoscopic and abdominal hysterectomy.

Upon entry into the peritoneum, a global assessment of the abdomen and pelvis should be performed. Care should be taken to identify the ureters prior to beginning the hysterectomy. As the robotic platform is often favored for complex patients with suspected adhesive disease, retroperitoneal dissection with ureterolysis may need to be performed. Should the pelvic anatomy be significantly distorted, it is recommended that the anatomy be normalized prior to proceeding.

Once the anatomy has been normalized, the round ligament is grasped and transected. For those patients undergoing a salpingo-oophorectomy, the infundibulopelvic (IP) ligament is then isolated, taking care to dissect it away from the ureter. Upon isolation, the IP ligament is carefully transected using the surgeon energy source of choice. For those retaining their ovaries, it is recommended that a prophylactic salpingectomy be offered to decrease the risk of ovarian cancer [20]. This is accomplished by identifying the fimbria and serially transecting the mesosalpinx. Once the fallopian tube has been detached close to the cornua, the utero-ovarian ligament can then be desiccated and transected.

Once the adnexa and the round ligament are detached, the leaves of the broad ligament begin to fall open. The anterior and posterior leaves of the broad ligament are then opened and transected to expose the lateral uterine anatomy. The vesicouterine peritoneal fold is then identified and transected to create a bladder flap. The vesicouterine space is then developed and the bladder dissected off the uterus and cervix.

The uterine vessels are then skeletonized prior to their ligation. Care is taken to ligate the uterine vessels as proximal to the uterine corpus as feasible. At the level of the cervicouterine junction, the ureters run 1.5-2cm below the uterine artery and are at high risk for injury during transection of the uterine vessels. The cardinal ligament is then cut down to the level of the uterosacral ligament. Each successive bite is taken medial to the previous, resulting in lateralization and protection of the ureter.

Once both sides of the uterus and cervix have been taken down and the bladder flap completed, the colpotomy can then be made. Upward tension is crucial at this stage, whether provided from a uterine manipulator with a colpotomy cup or a sponge stick. This tension allows for lateralization of the ureters and defining anatomical landmarks, in particular the cervicovaginal junction. After completion of the colpotomy, the specimen can then be passed through the vaginal opening to be assessed by pathology. Larger specimens can be removed via a mini-laparotomy or contained, manual morcellation. Please refer to the leiomyoma section of this chapter for further details.

The vaginal cuff can be closed in a variety of ways. Techniques include, a running stitch, serial figure-of-eight stitches and closure in one vs. two layers. If available, barbed suture should be utilized as studies have shown it to decrease operative time, blood loss and vaginal dehiscence rates [21–23]. To reduce the risk of post-hysterectomy apical prolapse, it is recommended that uterosacral ligament suspension be considered at time of vaginal cuff closure [24].

At the conclusion of the hysterectomy, a cystoscopy should be performed to assess ureteral and bladder integrity. The ureter's close proximity to the pelvic organs places it at risk for damage. Ureteral injuries are classically described as occurring at one out of four times during a hysterectomy—transection of the infundibulopelvic ligament, ligation of the uterine artery, at the level of the uterosacral ligaments, and at the time of vaginal cuff closure. While cystoscopy will not rule out a delayed thermal or ischemic injury, it will aid in the

diagnosis of a transection or suture ligation injury. Indigo carmine, Methylene blue or Phenazopyridine can be used to dye the urine and better visualize ureteral jets.

ADNEXAL MASSES

Adnexal masses are commonly encountered. It is estimated that 289,000 women undergo evaluation for an adnexal mass annually [25]. In the United States, it is estimated that up to 10% of women will undergo surgery for an adnexal mass [25].

Clinical Assessment of Adnexal Masses

Due to concerns for underlying malignancy, adnexal masses often provide diagnostic and management quandaries. When working up an adnexal mass, the goal is to determine the likelihood the mass is malignant or benign. Patients with ovarian cancer have improved overall survival rates when managed with or by a gynecologic oncologist [26]. Therefore, those patients who are suspected to have an underlying malignancy should be referred to a gynecologic oncologist.

The most important independent risk factor for ovarian cancer is age, as the incidence sharply increases after menopause [25, 26]. The most important personal risk factor is a strong family history of breast or ovarian cancer. 9-24% of epithelial ovarian cancers are due to BRCA 1 or 2 germline mutations [27]. Therefore, a thorough personal and family history is crucial.

The differential diagnosis for a benign adnexal mass is broad and includes, functional cysts, hemorrhagic cysts, endometriomas, mature teratomas/dermoid cysts, serous cystadenomas, mucinous cystadenomas, hydrosalpinx, paratubal cysts, ovarian remnant, tubo-ovarian abscess, ovarian torsion and ectopic pregnancy. Therefore, the clinical presentation is often varied and reflective of the diagnosis. Patients report symptoms ranging from acute to chronic pain, pressure (due to mass effect) and dyspareunia. If due to an infections process, some may experience general malaise with nausea and vomiting. All women of reproductive age should undergo a pregnancy test to assess for an ectopic pregnancy. Symptoms of bloating, abdominal or pelvic pain, difficulties with the bowels and bladder, early satiety and weight loss may be concerning for an ovarian malignancy, particularly in the post-menopausal patient.

While a thorough pelvic exam is recommended for all patients, the exam is often limited by the patient's body habitus, especially in patients with a BMI >30 [26]. If the adnexa are palpable, findings of irregular borders, limited mobility, solid consistency, nodularity, bilaterality and ascites are concerning for malignancy. However, these findings can also be found in benign pathology such as endometriomas, infectious processes, hemorrhagic corpus luteum and leiomyomas [26]. Therefore imaging plays a critical role in the work-up of an adnexal mass.

If the overall clinical picture is suspicious for an underlying malignancy, tumor markers can be obtained. CA 125 is most commonly associated with epithelial cancers of the ovary. It is more specific and has a higher positive predictive value in the post-menopausal patient

[26]. If the clinical picture is more suggestive of a malignant germ cell tumor, a beta-hcg, alpha-fetoprotein and L-lactate dehydrogenase can be considered. Abnormal or postmenopausal bleeding, signs of hyperestrogenism and a solid pelvic mass are consistent with a granulosa cell tumor. In this instance, an inhibin level should be obtained.

Imaging of Adnexal Masses

Ultrasound is the imaging modality of choice in gynecology. When assessing the adnexa, a transvaginal approach is favored. Ultrasound allows for the evaluation of size, composition and vascular characteristics of the adnexal mass in question.

Ultrasound findings concerning for malignancy are size >10cm, papillary or solid components, thick septations, ascites and high color Doppler flow [26]. However, some benign conditions will present with these findings. For example, mature teratomas will often have a solid component. Findings consistent with a benign etiology are thin, smooth walls, absence of solid components, absent of septations and lack of internal blood flow [26]. Endometriomas on ultrasound are hypoechoic with a uniform, 'ground-glass' appearance. Hemorrhagic cysts will have a fishnet or lacey, reticular pattern (Figure 4).

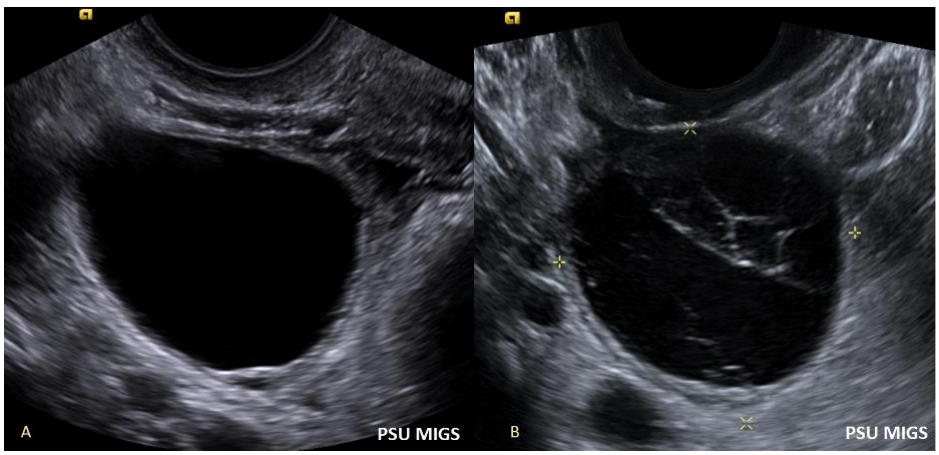

Figure 4. A: Simple ovarian cyst with anechoic fluid surrounded by a thin rim of ovarian tissue.
B: Lacy reticular pattern of a hemorrhagic ovarian cyst.

While MRI and CT scans are not recommended to routinely assess adnexal masses, they do have a role in specific cases. If there is difficulty ascertaining the origin of the pelvic mass, an MRI is often superior to ultrasound at delineating the origin of the mass. When malignancy is suspected, CT imaging can evaluate for the presence of metastasis.

Management of Adnexal Masses

Currently, ACOG recommends the following patients with an adnexal mass be referred to gynecologic oncologist:

- Postmenopausal with elevated CA 125 level, ultrasound findings suggestive of malignancy, ascites, a nodular or fixed pelvic mass, or evidence of abdominal or distant metastasis.
- Premenopausal women with very elevated CA 125 level, ultrasound findings suggestive of malignancy, ascites, a nodular or fixed pelvic mass, or evidence of abdominal or distant metastasis.
- Premenopausal or postmenopausal with an elevated score on a formal risk assessment test such as the multivariate index assay, risk of malignancy index, or the Risk of Ovarian Malignancy Algorithm or one of the ultrasound-based scoring systems from the International Ovarian Tumor Analysis group [26].

Observation of an adnexal mass is indicated in the following situations:

- If the mass is benign appearing on imaging and examination and the patient is asymptomatic.
- Simple cysts measuring <10cm in size in both the pre- and post-menopausal patient.
- Patients deemed to be poor surgical candidates, secondary to multiple comorbidities suspected to result in significantly high morbidity and mortality if surgery were to be undertaken [26].

These patients can be monitored with repeat imaging. Currently, no standard interval or duration for follow-up ultrasounds have been defined [26]. If the patient is undergoing expectant management, they should be counseled on signs and symptoms of an ovarian torsion. Patients with adnexal masses measuring between 6 cm and 10 cm are at an increased risk for an ovarian torsion [28].

Surgical management should be considered in the symptomatic patient, especially if there is low likelihood of the mass spontaneously resolving. If feasible, a laparoscopic approach should be used when surgically managing these patients.

Surgical Approach to the Adnexal Mass

Surgical management of an adnexal mass can range from cystectomy, salpingectomy to oophorectomy depending on the etiology. In the adolescent patient and the patient desiring fertility, ovarian conservation should be prioritized.

Aspiration of a cyst should be avoided if there is any concern for malignancy. Indications for aspiration would be a tubo-ovarian abscess and diagnosis of suspected advanced ovarian cancer in patients who will undergo neoadjuvant therapy [26]. Drainage of benign simple cysts is not definitively therapeutic and is therefore recommended against.

Cystectomy

The vast majority of ovarian cysts are encapsulated with a layer of epithelium (Figure 5). An avascular space sits between this epithelium and cyst. The development of this space is critical when performing a cystectomy to avoid rupturing the cyst.

After careful assessment of the patient's anatomy, an incision is made along the antimesentaric surface of the ovary, taking care to minimize involvement of the extensive vascularity of the ovarian base [28]. This can be accomplished using monopolar scissors or an ultrasonic scalpel. The incision is carried through the ovarian stroma down to the level of the cyst wall and can be extended as needed to successfully enucleate the cyst.

Once the level of the cyst wall is reached, the cut epithelial edge is then grasped using a grasper, such as the fenestrated bipolar, Maryland or Prograsp. A combination of blunt and sharp dissection is then utilized to develop the avascular plane between the epithelium and cyst wall. Cautery can be used as points of bleeding are encountered. However, a cystectomy should have minimal blood loss if the correct plane is entered. The fourth robotic arm or surgical assistant can aid in stabilizing the adnexa and provide additional traction and counter traction for the dissection.

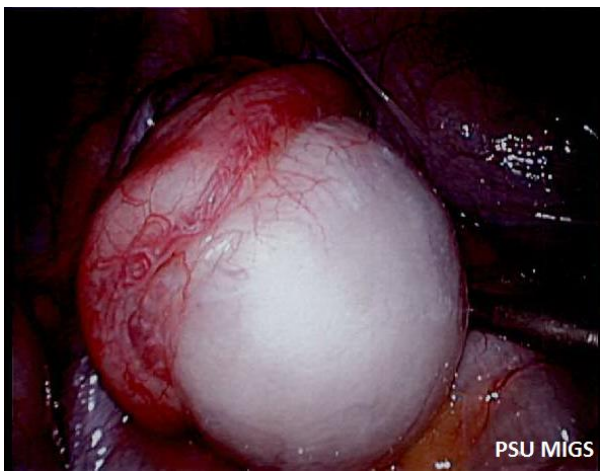

Figure 5. Left ovarian cyst.

Upon removal of the cyst, the surgical bed should be assessed for hemostasis. Once hemostasis has been adequately achieved, no further intervention is necessary. Despite its distended and splayed appearance, the ovary will return to normal proportions without surgical reapproximation [25].

Extreme caution should be used to avoid rupturing the cyst. Should this occur, the cyst wall should still be removed. By grasping the cyst wall and capsule near the plane of dissection, traction and counter traction can be applied to separate the cyst wall. If a mature teratoma ruptures at the time of removal, copious irrigation should be used to decrease the risk of developing a chemical peritonitis [28, 29].

Once the procedure has been completed, the specimen should be placed in an endoscopic specimen retrieval bag prior to removal. If the contained specimen is too large to be removed from the endoscopic port site, the incision can be enlarged, the cyst can be ruptured and

drained inside of the bag or contained hand morcellation can be performed if the cyst is solid [25]. Care should be taken not to damage the bag in this process.

Salpingo-Oophorectomy

Prior to beginning an oophorectomy, the course of the pelvic ureter and its relation to the infundibulopelvic (IP) ligament must be identified. The ureter runs close to the IP ligament and is at high risk for injury at time of oophorectomy. If indicated, the surgeon should be prepared to perform a retroperitoneal dissection to appropriately identify the ureter and create adequate space between the ureter and desired surgical site.

Once the ureter is safely away from the intended surgical site, the ovarian vessels are ligated within the IP ligament. The ligament is then transected. The posterior leaf of the broad ligament is then incised down toward the utero-ovarian ligament. Posterior to the round ligament, the utero-ovarian ligament and fallopian tube are then identified, grasped, cauterized and transected.

The ovary and fallopian tube can then be placed into an endoscopic bag and removed through an endoscopic port site.

Ovarian Remnant Syndrome

Ovarian remnant syndrome (ORS) is a rare condition in which women who have previously undergone an oophorectomy develop residual ovarian tissue. This often results in pelvic pain and an adnexal mass [30]. The mechanism of this disease is not well understood, but is thought to be due to incomplete removal of ovarian tissue on a microscopic level.

Patients with a history of endometriosis, pelvic adhesive disease, pelvic inflammatory disease or multiple pelvic surgeries are at higher risk for ORS [30, 31]. In a case series done by Benton et al. all patients with a pathologically confirmed ovarian remnant had a prior history endometriosis [32]. It is thought that anatomic distortion caused by these pathologies make it difficult to completely excise the ovary. This results in an increased risk for developing ORS [31]. Additionally, despite ligation of the ovarian blood supply, adherent ovarian tissue to the pelvic peritoneum or adjacent viscera can become neovascularized and responsive to gonadotropins [30].

If ORS is suspected, evaluation with a pelvic ultrasound, CT or MRI is warranted. A FSH and LH can be obtained; however, cases of ORS have been documented in patients with postmenopausal levels of FSH and LH [30, 31]. Ultimately, confirmation of an ovarian remnant requires pathologic diagnosis.

Patients with ORS most commonly present with pelvic pain and an adnexal mass. As a result, most opt to undergo surgical management. Laparoscopy provides optimal visualization, as remnants can be as small as a single centimeter. Due to the complex nature of ovarian remnant syndrome, robotic assisted operative laparoscopy is often preferred over conventional laparoscopy.

As patients with ORS often have a complex gynecologic and surgical history, adhesions are frequently encountered. The ureter is also at high risk of injury, as ovarian remnants are often found in the retroperitoneal space. Therefore, surgeons performing an excision of an ovarian remnant must be skilled at extensive retroperitoneal dissection and ureterolysis. If there is difficulty locating the remnant, pre-operative imaging can aid in locating the mass.

Once the remnant is found, care is taken to dissect it away from the pelvic sidewall and any vital structures, down to its blood supply (Figure 6). To decrease the risk of leaving behind remnants of the ovarian cortex, blunt dissection should be minimized [30]. After the blood supply is isolated, it is then ligated and transected. The remnant should then be placed in an endoscopic bag for removal.

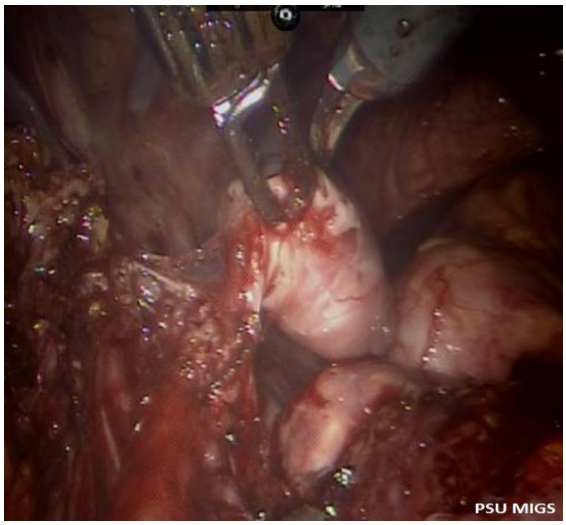

Figure 6. Ovarian remnant dissected off the left lateral pelvic sidewall, down to its blood supply.

LEIOMYOMAS

Leiomyomas, also known as fibroids, are the most common benign tumors of the female genital tract. They are the leading indication for hysterectomy in the United States [33]. It is estimated that by the age of 50, 70% of Caucasian women and >80% of African American women will have leiomyomas [34]. This results in $4.1 to $9.4 billion dollars spent annually on the management of leiomyomas in the U.S. [33].

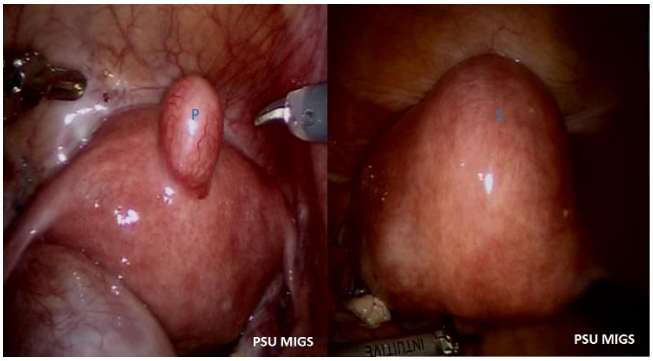

Figure 7. To the left is an image of a pedunculated uterine leiomyoma (P). To the left is an image of a subserosal leiomyoma.

Leiomyomas are the result of monoclonal proliferation of smooth muscle cells. They can be subserosal, submucosal, intramural and pedunculated in location (Figure 7). Leiomyomas are sensitive to ovarian steroid hormones, as they contain both estrogen and progesterone receptors. Risk factors for the development of fibroids include age, early menarche delayed pregnancy, decreased parity, caffeine and alcohol use, obesity and hypertension [33].

Clinical Assessment of Leiomyomas

While the majority of leiomyomas are asymptomatic, the two most commonly reported symptoms are abnormal uterine bleeding and pelvic pressure [34]. Patients often note heavy or prolonged bleeding that can result in significant iron deficiency anemia. The mass effect of leiomyomas can result in significant pelvic pressure, urinary frequency and obstruction, constipation and dyspareunia [34]. The size and location of the leiomyoma can also result in subfertility.

As most women will present with abnormal uterine bleeding, it is recommended an endometrial biopsy be obtained in all women over the age of 45 or those with risk factors for an underlying uterine malignancy such as obesity, polycystic ovarian syndrome or history of unopposed estrogen. Other causes of abnormal uterine bleeding should be ruled out as well. If the bleeding is significant or the patient is symptomatic, a CBC to assess for anemia is warranted. For patients reporting urinary symptoms or flank pain, assessment of the renal system is recommended to check for ureteral obstruction and hydronephrosis.

Figure 8. MRI of a grossly enlarged uterus due to multiple leiomyomas (L). ES denotes the endometrial stripe.

When leiomyomas are palpated on pelvic examination, the uterus typically correlates with a 12 weeks gravid uterus, at minimum [33]. The uterus will feel enlarged with irregular boarders.

If leiomyomas are suspected, it is recommended that patients undergo a pelvic ultrasound. A saline infused hysterogram can be utilized to delineate submucosal fibroids. While CT scans have limited value in the evaluation of leiomyomas, MRIs can provide additional valuable information. MRI cannot only provide the size, number and vascularization of the fibroid, but it can provide a map of their location relative to the endometrium, myometrium and serosa (Figure 8) [18, 33]. This is particularly useful when planning a laparoscopic myomectomy.

Management of Leiomyomas

For women desiring fertility or declining hysterectomy, a variety of options exist for the management of leiomyomas. However, hysterectomy is the only option for definitive treatment and prevention of recurrence [34]. Given the adverse cost, long-term results and safety profile of most non-surgical options, most patients ultimately undergo some form of surgery.

In patients wishing to avoid surgery, medical therapy is geared towards the patient's symptoms. Contraceptive steroids can be utilized to control uterine bleeding. For those wishing to avoid hormones, tranexamic acid and non-steroidal anti-inflammatory drugs (NSAIDs) can be considered [33]. These methods have not been shown to decrease leiomyoma or uterine volume and often only provide short-term relief [34].

Gonadotropin-releasing hormone agonists (GnRHa) have been shown to reduce leiomyoma size and excessive menstrual bleeding. Within three months of treatment, a 35-65% reduction in volume can be seen [34]. These effects are temporary, with resumption of previous leiomyoma size upon cessation of treatment. In addition to its poorly tolerated hypoestrogenic side effects of hot flashes and vaginal dryness, long-term use of GnRHa can result in significant bone loss. For patients on GnRHa for greater than 6 months, add back therapy must be provided.

The optimal use of GnRHa is in the pre-operative period. For patients with significant anemia, this can provide patients time to improve their anemia and rebuild their iron stores prior to surgery. The ability to shrink fibroids and overall uterine size could also mean the difference between an abdominal vs. minimally invasive route of surgery. However, by distorting the planes of dissection, GnRHa can increase the difficulty of a myomectomy and the operating time [33, 35].

Uterine artery embolization (UAE) is another option for management of leiomyomas. Under fluoroscopic guidance, interventional radiologists utilize a transcutaneous femoral approach to access the uterine arteries. The uterine arteries are then embolized using polyvinyl alcohol particles of trisacryl gelatin microspheres, with or without supplemental metal coils [34]. This results in the devascularization and involution of leiomyomas. The most common complication from UAE is postembolization syndrome [18]. While successful pregnancies have been documented after UAE, this procedure has been associated with impaired ovarian reserve and increased pregnancy complications, in particular, abnormal placentation [34]. Limited data is available regarding pregnancy after UAE, and is generally recommended against or with caution [33, 34].

For patients desiring fertility or who wish to retain their uterus, myomectomy should be considered. Myomectomy has also been shown to improved pregnancy rates. The route of

myomectomy is dictated based upon the size and location. Submucosal fibroids that occupy the endometrial cavity can be managed via operative hysteroscopy. For intramural, subserosal and pedunculated leiomyomas, a laparoscopic approach should be taken if feasible. It is important to counsel patients that after myomectomy, the five year risk of recurrence ranges from 20-40% [18].

Robotic Assisted Laparoscopic Myomectomy

Despite its increased cost, some believe robotic assisted laparoscopic myomectomy to be superior to conventional laparoscopy [6]. The conversion rate to an open procedure is 0-5% for robotic assisted laparoscopic myomectomy vs. 11.3% for conventional lapaoscopy [33, 34]. Robotic assisted laparoscopic myomectomy has been shown to have lower intraoperative blood loss and shorter length of hospital stay, while affording patients all the same benefits of the conventional route.

The benefits of the robotic platform are particularly pronounced during myomectomy. Suturing with conventional laparoscopy is often perceived as difficult and cumbersome. Robotic assisted suturing is more facile, resulting in improved quality of sutures [6]. As the closure of the myometrial defect at time of myomectomy often requires closure in multiple layers, this can make a significant difference. The improved surgical accessibility of the robotic system also helps to overcome difficulties such as posterior fibroids and obesity [2].

Myomectomy

Upon docking, the patient's anatomy should be adequately assessed. Preoperative imaging can be helpful in mapping the anticipated location of the leiomyomas. A variety of interventions exist to help decrease intraoperative bleeding including intrauterine injection of vasopressin, tranexamic acid, misoprostol and a tourniquet [33]. Each method carries its own unique risks and benefits and should be utilized per the surgeon's discretion.

Once located, an incision is made into the serosa and myometrium down to the level of the leiomyoma. While unipolar cautery can be used to accomplish this, studies have shown the Harmonic Scalpel to provide a cleaner dissection with less blood loss [33, 35]. When feasible, a transverse incision is recommended to facilitate suturing and knot tying [33].

After the hysterotomy is created, the myometrium will begin to retract. A laparoscopic tenaculum can be placed on the myoma for manipulation and creation of counter-traction if needed. The edge of the hysterotomy is then grasped and the plane of dissection is carefully developed using a combination of blunt and sharp dissection (Figure 9). If fertility is desired, care should be taken to circumvent the endometrial cavity if at all possible.

When multiple myomectomies are being performed, it is recommended that the minimum number of incisions needed be placed. It is advised that no more than three to four incisions be placed in the uterus [18]. Therefore, multiple leiomyomas should be removed from a single incision if feasible. As the leiomyomas are removed, a strict count should be kept to ensure all specimens are removed at the conclusion of the case. Some surgeons may opt to string the leiomyomas together with suture.

Once the leiomyoma has been enucleated, the hysterotomy is then closed in multiple layers. If the endometrium is breached, the defect should be closed with 3-0 or 4-0 suture. Care should be taken to avoid penetration of the cavity to avoid intracavitary adhesion

formation [33]. Depending on the depth, the myometrium can be closed in one or two layers. The serosa is then closed. A running stitch of barbed suture can be used for the myometrial and serosal layer [18, 33].

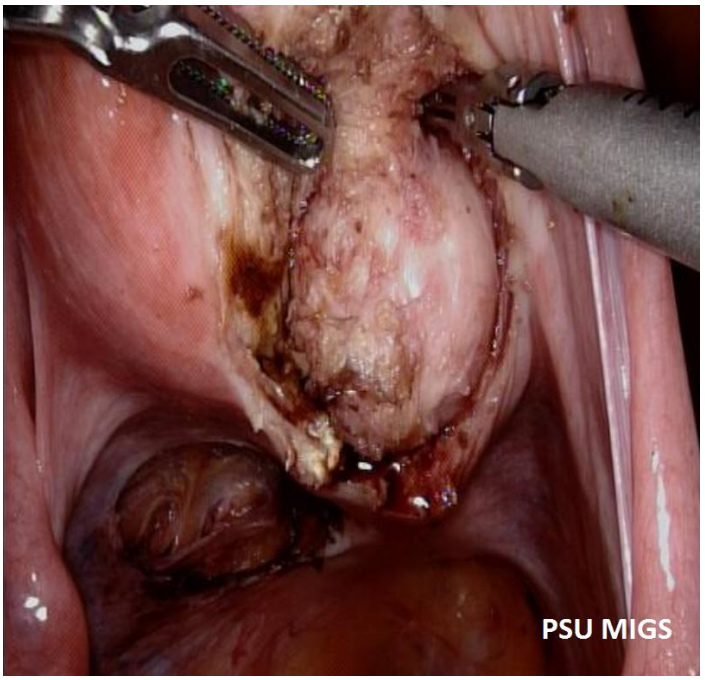

Figure 9. Robotic assisted enucleation of a uterine leiomyoma.

Due to concerns for uterine rupture, delivery via cesarean section is recommended for patients who subsequently achieve a viable pregnancy.

Specimen Removal

While leiomyosarcomas are extremely rare, approximately 2-3/1,000 hysterectomies performed for leiomyomas will find an underlying sarcoma [34]. After a highly publicized case involving an undiagnosed leiomyosarcoma that was removed via uncontained, power morcellation, the FDA discouraged the use of the laparoscopic power morecellator during the time of hysterectomy and myomectomy in 2014 [33]. The power morcellators were subsequently taken off the market. This resulted in a transition to contained, hand morcellation of large specimens.

For specimen removal, the GelPOINT access platform (Applied Medical, Rancho Santa Margarita, CA, US) may be placed through a 2-3 cm mini-laparotomy at the umbilicus. The umbilicus is recommended for improved cosmetics. All leiomyomas should be placed inside an FDA-approved endoscopic specimen bag. While smaller leiomyoms may fit through the mini-laparotomy, larger specimens may require contained, hand morcellation. This technique can also be applied for the removal of enlarged uteri.

To perform contained morcellation, it is recommended that the Extracorporeal C-Incision Tissue Extraction (ExCITE) technique be used. The specimen bag is brought up through the incision and opened. A self-retaining wound retractor is then placed inside of the bag. The

specimen is then grasped and a reverse c-shaped incision is made on the specimen with an 11-blade scalpel. Serial c-incisions are made to create a long strip of tissue. Constant upward traction is applied to facilitate rolling of the specimen.

During contained morcellation, pneumoperitoneum should be maintained to keep a safe distance from the underlying bowel. The scalpel should also be kept at an angle to avoid damaging the specimen bag and therefore, placing the patient at risk for seeding.

ENDOMETRIOSIS AND CHRONIC PELVIC PAIN

Endometriosis is defined as the ectopic growth of endometrial glands and stroma. It is most commonly found in the pelvic peritoneum but can be found in the ovaries, rectovaginal septum, ureter, bladder, bowel, pericardium, pleura and previous scar tissue.

Approximately 6-10% of reproductive aged women are affected by endometriosis [36]. In women with infertility and chronic pelvic pain, the prevalence of endometriosis is 38% and 71-87% respectively [36]. Risk factors for endometriosis are early menarche, short menstrual cycles, heavy prolonged cycles and family history of endometriosis [36]. Patients with a decreased risk are those with a higher parity, increased duration of lactation and participation in regular exercise [36].

Pathogenesis of Endometriosis

There are multiple theories on the pathogenesis of endometriosis including Sampson's theory, lymphatic or vascular spread, coelomic metaplasia and induction theory. Retrograde menstruation, also known as Sampson's Theory, is the most commonly accepted theory. However, the presence of endometriosis in ovarian tissue stroma, vulva, pleura and umbilicus (Villars nodule) suggests other mechanisms. Therefore, the pathophysiology of endometriosis is likely multifactorial.

Sampson's theory, also known as the theory of retrograde menstruation, describes dissemination of endometrial tissue into the peritoneal cavity via retrograde menstruation through the fallopian tubes at the time of menses [28]. Baboon models for endometriosis, largely performed by T. M. D'Hooghe et al. have widely supported this theory [37, 38]. However, while the vast majority of women will experience retrograde menstruation as a normal phenomenon of menses, only 6-10% of women have endometriosis.

The theory of lymphatic or vascular spread suggests that endometrial tissue is spread by aberrant lymphatics or vasculature. This is supported by the presence of extra pelvic endometriosis, exclusive retroperitoneal endometriosis and the lymphatic spread of endometrial adenocarcinoma; however, limited data exists on this theory [28].

The theory of coelomic metaplasia hinges on the pluripotential tissue of the parietal peritoneum. It is thought that this tissue undergoes metaplastic transformation into tissue histologically identical to that of normal endometrium. The is supported by the presence of endometriosis in the ovary and in the absence of menstruation— for example, premenarche and postmenopausal women and men treated with estrogen following orchiectomy for prostate cancer [28].

Induction theory suggests that hormonal and biological factors induce differentiation of undifferentiated cells into endometrial tissue. These factors can be either exogenous or directly released from the endometrium. In vitro studies have supported this theory [28].

Clinical Presentation and Work-Up of Endometriosis

While the classic clinical presentation of endometriosis is described as painful menses, the presentation is often more varied and complex. Aside from dysmenorrhea, patients often report chronic pelvic pain, dyspareunia, menorrhagia, infertility and sacral back pain. Endometriosis can also affect the bowels and bladder. As a result, patients may describe perimenstrual tenesmusm, diarrhea, constipation, cramping, dyschezia, hematochezia, dysuria, hematuria and dysuria.

In patients with endometriosis, a pelvic exam may reveal tenderness, uterosacral ligament nodularity or an adnexal mass, if an endometrioma is present. Vaginal endometriosis can be found by performing a careful speculum exam (Figure 10). For patients with abdominal wall endometriosis, a nodule is often palpated near the site of a previous surgical incision.

The role of imaging in endometriosis is limited. The vast majority of the lesions are small and will not be present on ultrasound, MRI or CT scan. Therefore, the utility of imaging is in the detection of endometriomas, adenomyosis and nodular extra-pelvic endometriosis. If bladder or colon involvement is suspected, a cystoscopy and colonoscopy should also be performed.

For the definitive diagnosis of endometriosis, the gold standard is histologic confirmation of lesions removed at the time of surgery. Histologic findings consistent with endometriosis are endometrial glands and stroma, with varying amounts of inflammation and fibrosis [36]. Given the small size of most lesions, a laparoscopic approach should be taken.

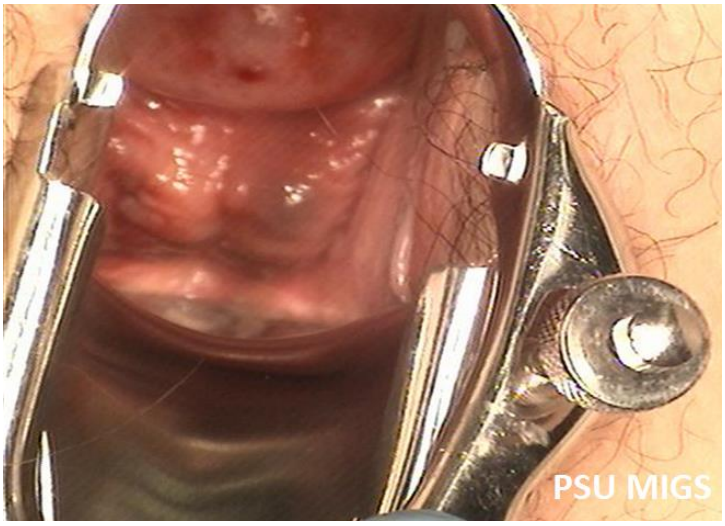

Figure 10. Nodule of vaginal endometriosis.

Medical Management of Endometriosis

Endometriosis lesions cause an increase in cyclooxygenase-2 activity, resulting in an increase in prostaglandins. They create chronic inflammation via increased active macrophages and inflammatory cytokines [36]. An increased density of nerve fibers can also be seen in these lesions, as nerve growth factor is highly expressed. This accounts for much of the chronic pain symptoms associated with endometriosis. Therefore, NSAIDs are recommended for management of pain. For patients with evidence of long-term nerve damage from the disease, neuromodulators such as gabapentin, pregabalin and amitriptyline can also be utilized.

One of the key components of the development of endometriosis is the overproduction of local estrogen by increased aromatase activity and progesterone resistance [36]. Patients frequently report significant pain with menses as well. Hence, most hormonal options for the management of endometriosis are focused on achieving amenorrhea and decreasing estrogenic effects. Combined oral contraceptive pills, progesterone only options—such as Depo-Provera, Norethindrone and the levonorgestrel-releasing intrauterine device, and gonadotropin releasing hormone agonists can be used to achieve this.

Robotic Assisted Surgical Approach and Management of Endometriosis

Surgery for the management of endometriosis should be used judiciously. As with medical management of endometriosis, surgery is also associated with a significant recurrence rate of pain. A retrospective study by Shakiba et al. showed the reoperation rate for women who underwent an operative laparoscopy for endometriosis at 2-, 5- and 7- years to be 20.6%, 46.7% and 55.4% respectively [39]. Therefore, prior to undergoing any surgery for endometriosis, patients should be well counseled on realistic goals and outcomes.

While biopsy of endometriotic appearing lesions is not required, it is recommended for pathological confirmation of the disease [36]. Discrepancies between the intra-operative appearance of lesions and histology are not uncommon. Endometriosis is classically described as a blue-black, powder-burn lesion; however, the physical appearance of endometriosis can be quite varied. Lesions can appear red, white or vesicular. If the disease has been long standing, there can be evidence of chronic inflammation and scaring. Patients can also develop a frozen pelvis (Figure 11).

Staging for endometriosis is based upon the intra-operative findings. The stage is described as a number I-IV, correlating with minimal, mild, moderate or severe disease [40]. This is determined based on the type, size and location of the lesions of endometriosis, extent of adhesions and presence of posterior cul-de-sac obliteration found at the time of surgery, per the American Society for Reproductive Medicine's guidelines for the classification of endometriosis [36]. However, it is important to keep in mind that the severity of symptoms does not always correlate with the extent of disease found at the time of laparoscopy. Therefore, the intra-operative findings should not sway the post-operative management of endometriosis.

In order to optimize patient outcome, the goal of endometriosis surgery is to completely remove all visible areas of endometriosis, lyse all adhesions, and restore normal pelvic anatomy [41]. If endometriosis of the bowel or bladder is suspected, the respective surgical

subspecialties should be readily available for intra-operative consultation at the time of surgery. The da Vinci Xi system's ability to access any anatomic landmark from virtually every position makes it an optimal surgical platform when anticipating a multi-disciplinary approach to surgery.

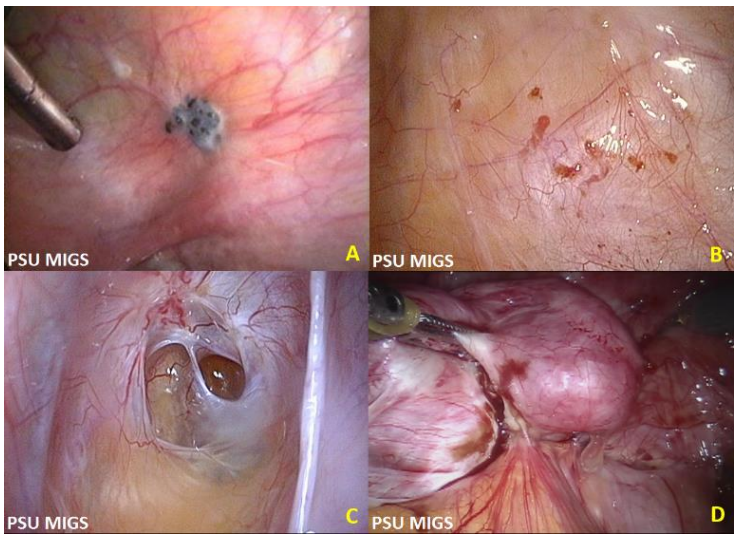

Figure 11. A: Classic black powder burn-lesion of endometriosis. B: Red lesions of endometriosis. C: Peritoneal damage due to endometriosis. D: Frozen pelvis of Stage IV endometriosis.

Surgical Approach

Once the abdomen is entered and trocars are placed, care must be taken to systematically evaluate the abdomen and pelvis. All pelvic surfaces and organs should be thoroughly assessed, including the ureteric ridge and infraovarian fossa. It is recommended that the diaphragm, bladder, colon and appendix be assessed for endometriosis as well.

Superficial endometriosis lesions are generally seen on the peritoneal, serosal and ovarian surfaces [40]. The depth perception of the robotic platform is advantageous for identifying superficial lesions as it allows for enhanced visualization of cobblestoning and terrain changes [41]. A study performed by Mosbrucker et al. showed the 3D/HD robotic scope was associated with a 2.36 times likelihood of detecting a confirmed lesion of endometriosis compared to conventional 2D laparoscopy [41]. The use of Firefly fluorescence or narrow band imaging technology can also enhance the visualization of lesions (Figure 12). Once these superficial lesions are found, they can be either excised or ablated.

Deeply infiltrating endometriosis is defined as a nodule of endometriosis measuring >5mm in depth. These lesions are often found along the uterosacral ligaments, posterior cul-de-sac, vagina, bowel, bladder and ureter [40]. These lesions should be completely excised, as complete excision has been shown to decrease pain and the rate of symptomatic recurrence [40, 42]. In addition to being hypervascular, these lesions can be densely adherent, and often near vital organs and structures. The enhanced dexterity of the robotic system allows for more facile and precise dissection of these nodules.

Particularly in stage III and IV endometriosis, dense adhesions of the pelvic organs are frequently encountered. A key component in fertility-sparing, surgical management of

endometriosis is restoration of normal pelvic anatomy. Therefore, adhesiolysis should be undertaken. Surgeons should also be prepared to perform ureterolysis and dissect in the pararectal and paravesicular spaces.

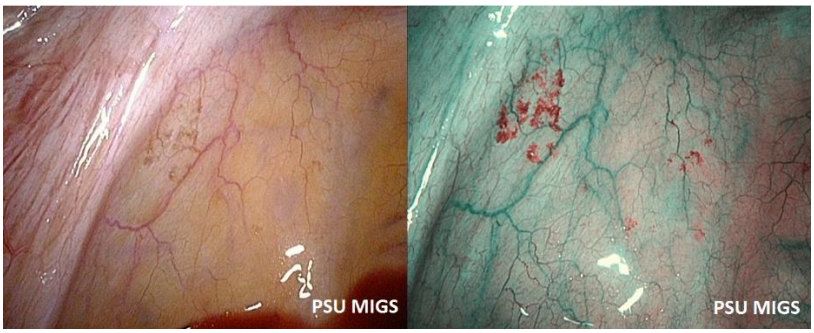

Figure 12. Side by side view of vesicular endometriosis comparing with and without narrow band imaging.

In patients who no longer desire fertility, hysterectomy is a viable option for management, with or without ovarian conservation. The retrospective study performed by Shakiba et al. showed that 23% of patients with ovarian conservation and 8.3% of patients who did not undergo conservation underwent a subsequent surgery for endometriosis by 7-years post-op [39]. The surgery free time between those with and without ovarian conservation was not statistically different for patients between 30-39 years of age [39]. Therefore patients should be counseled extensively regarding the risks and benefits of an oophorectomy.

To delay symptomatic recurrence, it is recommended that some form of hormonal suppression therapy be started in the post-operative period in patients not seeking immediate fertility [40].

Endometrioma

Endometriomas result from the proliferation of endometriotic lesions in the ovary. Due to the collection of blood over time, when ruptured, these cysts release a chocolate brown fluid. Recommendation for removal is varied, with some suggesting removal if the size is >3cm [36]. If surgery on the ovary is undertaken, care should be taken to preserve as much ovarian tissue as possible.

Recurrence rates for endometriomas are quite high, particularly if they are only drained at the time of surgery. It is recommended that the cyst wall be completely excised. If this is not feasible, coagulation of the wall should be attempted; however, this is associated with a higher rate of recurrence of pain compared to excision [36].

Please refer to the section “Surgical Approach to the Adnexal Mass” for details on completing a cystectomy.

Adenomyosis

Adenomyosis is the presence of ectopic endometrial glands and stroma within the myometrium. As a result, myometrial contractility is impaired. Patients can experience abnormal uterine bleeding as well as pelvic pain. Hysterectomy is the standard treatment for

adenomyosis [42]. Symptomatic management for those who desire to retain fertility can be challenging. The levonorgestrel IUD can be utilized in those patients looking to avoid surgery.

If an adenomyoma is found, an adenomyomectomy can be considered. Unlike leiomyomas, adenomyomas do not have a capsule and is often not well demarcated from normal myometrium. The enhanced 3-D visuals of the robotic platform can help to differentiate between normal myometrium and the adenomyoma. The surgical approach and principles for adenomyomectomy mirror that of a myomectomy for leiomyomas.

Please refer to the section on "Robotic Assisted Laparoscopic Myomectomy" for further details.

Endometriosis of the Bowel

5.3-12% of women with endometriosis will have deeply infiltrating endometriosis involving the bowel [43, 44]. Lesions of the rectum and rectosigmoid junction account for 70-93% of intestinal endometriosis (Figure 13) [45]. In addition to the traditional symptoms of endometriosis, patients frequently report deep dyspareunia, non-cyclic pelvic pain, dyschezia and hematochezia. Many patients will also carry the diagnosis of irritable bowel syndrome. If endometriosis of the bowel is found, management with a colorectal surgeon is advised.

Due to scaring and fibrosis, these lesions respond poorly to hormonal management and ultimately will require surgery [45]. Options for management range from surgical excision of the nodule to segmental resection. To aid in this decision, patients should undergo a colonoscopy as well imaging such as an MRI or transvaginal or transrectal ultrasound. Size, depth, extent of the lesion and presence of stenosis are utilized to determine the need for a segmental resection. A nodule >3cm, involvement of the muscularis or >40% involvement of the bowel circumference often favors segmental resection [43–45]. In these instances, excision alone will place the bowel at risk for stenosis.

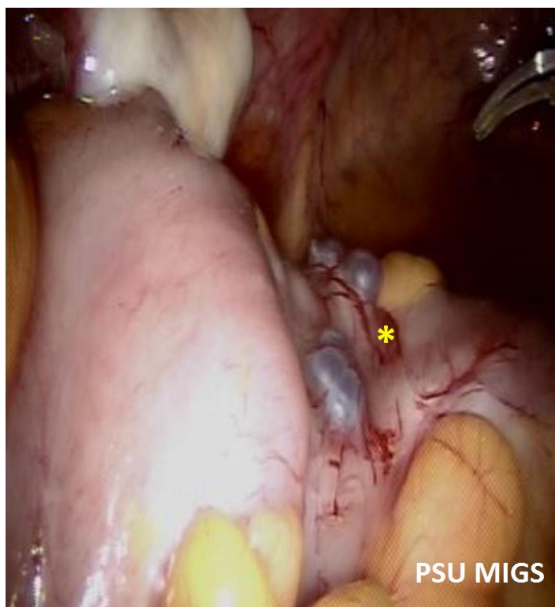

Figure 13. Endometriosis nodules of the sigmoid colon.

Complications range from anastomotic leakage, fistula formation and obstruction [43]. Surgical management of low rectal lesions is associated with a higher rate of leaks and transient neurogenic bladder dysfunction [44].

REFERENCES

[1] Alkatout I, Mettler L, Maass N, Ackermann J. Robotic surgery in gynecology. *J Turkish Ger Gynecol Assoc*. 2016;17(4):224-232. doi:10.5152/jtgga.2016.16187.

[2] Csorba R. [Robotic surgery in gynecology]. *Orv Hetil*. 2012;153(25):967-972. doi:10.1556/OH.2012.29373.

[3] Nicolaides KH. C ommittee opinion. *Obstet*. 2016;128(654):1-4. doi:10.1016/ S0140-6736(16)31898-0.

[4] Advincula AP, Wang K. Evolving Role and Current State of Robotics in Minimally Invasive Gynecologic Surgery. *J Minim Invasive Gynecol*. 2009;16(3):291-301. doi:10.1016/j.jmig.2009.03.003.

[5] Korsholm M, Mogensen O, Jeppesen MM, Lysdal VK, Traen K, Jensen PT. Systematic review of same-day discharge after minimally invasive hysterectomy. *Int J Gynecol Obstet*. 2017;136(2):128-137. doi:10.1002/ijgo.12023.

[6] Lauterbach R, Matanes E, Lowenstein L. Review of Robotic Surgery in Gynecology—The Future Is Here. *Rambam Maimonides Med J*. 2017;8(2):e0019. doi:10.5041/ RMMJ.10296.

[7] Lim PC, Crane JT, English EJ, et al. Multicenter analysis comparing robotic, open, laparoscopic, and vaginal hysterectomies performed by high-volume surgeons for benign indications. *Int J Gynecol Obstet*. 2016;133(3):359-364. doi:10.1016/ j.ijgo.2015.11.010.

[8] Gala RB, Margulies R, Steinberg A, et al. Systematic Review of Robotic Surgery in Gynecology: Robotic Techniques Compared With Laparoscopy and Laparotomy. *J Minim Invasive Gynecol*. 2014;21(3):353-361. doi:10.1016/j.jmig.2013.11.010.

[9] Deimling TA, Eldridge JL, Riley KA, Kunselman AR, Harkins GJ. Randomized controlled trial comparing operative times between standard and robot-assisted laparoscopic hysterectomy. *Int J Gynaecol Obstet*. 2017;136(1):64-69. doi:10. 1002/ijgo.12001.

[10] Moawad GN, Abi Khalil ED, Tyan P, et al. Comparison of cost and operative outcomes of robotic hysterectomy compared to laparoscopic hysterectomy across different uterine weights. *J Robot Surg*. 2017. doi:10.1007/s11701-017-0674-4.

[11] Lim PC, Kang E. How to prepare the patient for robotic surgery: before and during the operation. *Best Pract Res Clin Obstet Gynaecol*. 2017:1-16. doi:10.1016/ j.bpobgyn. 2017.04.008.

[12] Tam T, Harkins G, Estes S. The head butler with design modification: A useful mountable shelf for the operating table in robotic surgery. *J Robot Surg*. 2014;8(1):73-76. doi:10.1007/s11701-013-0409-0.

[13] Simpson KM, Advincula AP. The Essential Elements of a Robotic-Assisted Laparoscopic Hysterectomy. *Obstet Gynecol Clin North Am*. 2016;43(3):479-493. doi:10.1016/j.ogc.2016.04.008.

[14] Makai G, Isaacson K. Complications of gynecologic laparoscopy. *Clin Obstet Gynecol*. 2009;52(3):401-411. doi:10.1097/GRF.0b013e3181b0c080.

[15] Shirk GJ, Johns A, Redwine DB. Complications of laparoscopic surgery: How to avoid them and how to repair them. *J Minim Invasive Gynecol*. 2006;13(4):351. doi:10.1016/j.jmig.2006.06.002.

[16] Advancing Minimally Invasive Gynecology Worldwide A. AAGL Position Statement: Robotic-Assisted Laparoscopic Surgery in Benign Gynecology AAGL Advancing Minimally Invasive Gynecology Worldwide. *J Minim Invasive Gynecol*. 2013;20(1):2-9. doi:10.1016/j.jmig.2012.12.007.

[17] Ridgeway BM, Buechel M, Nutter B, Falcone T. Minimally Invasive Hysterectomy: An Analysis of Different Techniques. *Clin Obstet Gynecol*. 2015;58(4):732-739. doi:10.1097/GRF.0000000000000149.

[18] Kim S, Luu TH, Llarena N, Falcone T. Role of robotic surgery in treating fibroids and benign uterine mass. *Best Pract Res Clin Obstet Gynaecol*. 2017:1-12. doi:10.1016/j.bpobgyn.2017.04.004.

[19] Ito TE, Vargas M V., Moawad GN, et al. Minimally Invasive Hysterectomy for Uteri Greater Than One Kilogram. *JSLS J Soc Laparoendosc Surg*. 2017; 21(1):e2016.00098. doi:10.4293/JSLS.2016.00098.

[20] Prevention OC. *CO 620 Salpingectomy for Ovarian Cancer Prevention*. 2017;(February 2016):1-4.

[21] Nawfal AK, Eisenstein D, Theoharis E, Dahlman M, Wegienka G. Vaginal Cuff Closure during Robotic-Assisted Total Laparoscopic Hysterectomy: Comparing Vicryl to Barbed Sutures. *JSLS J Soc Laparoendosc Surg*. 2012;16(4):525-529. doi:10.4293/108680812X13462882736772.

[22] Rettenmaier MA, Abaid LN, Brown J V., Mendivil AA, Lopez KL, Goldstein BH. Dramatically reduced incidence of vaginal cuff dehiscence in gynecologic patients undergoing endoscopic closure with barbed sutures: A retrospective cohort study. *Int J Surg*. 2015;19:27-30. doi:10.1016/j.ijsu.2015.05.007.

[23] Siedhoff MT, Yunker AC, Steege JF. Decreased Incidence of Vaginal Cuff Dehiscence after Laparoscopic Closure with Bidirectional Barbed Suture. *J Minim Invasive Gynecol*. 2011;18(2):218-223. doi:10.1016/j.jmig.2011.01.002.

[24] Abbott JA, Bajzak KI, Green IC, et al. AAGL Practice Report: Practice Guidelines on the Prevention of Apical Prolapse at the Time of Benign Hysterectomy. *J Minim Invasive Gynecol*. 2014;21(5):715-722. doi:10.1016/j.jmig.2014.04.001.

[25] Sisodia RMC, Del MG. *CMI en masa anexial*. 2015;58(1):66-75.

[26] ACOG Committee on Practice Bulletins--Gynecology. 174_Evaluation and Management of Adnexal Masses. *Obstet Gynecol*. 2016;128(5):e210-e226. doi:10.1097/AOG.0000000000001768.

[27] American College of Obstetricians and Gynecologists Bulletin. Clinical management guidelines for obstetrician gynecologists. *Am J Obs Gynecol*. 2009; 95(103):1-9.

[28] Hoffman BL, Schorge JO, Schaffer JI, Halvorson LM, Bradshaw KD, Cunningham FG. *Williams Gynecology*. Second. Dallas, TX: McGraw-Hill Medical; 2012.

[29] Hessami SH, Kohanim B, Grazi R V. Laparoscopic excision of benign dermoid cysts with controlled intraoperative spillage. *Am Assoc Gynecol Laparosc*. 1995;2(4):479-481. doi:10.1016/S1074-3804(05)80075-1.

[30] Magtibay PM, Nyholm JL, Hernandez JL, Podratz KC. Ovarian remnant syndrome. *Am J Obstet Gynecol*. 2005;193(6):2062-2066. doi:10.1016/j.ajog.2005.07.067.

[31] Arden D, Lee T. Laparoscopic Excision of Ovarian Remnants: Retrospective Cohort Study with Long-term Follow-up. *J Minim Invasive Gynecol*. 2011; 18(2):194-199. doi:10.1016/j.jmig.2010.12.002.

[32] Benton A, Deimling TA, Pacis M, Harkins GJ. Ovarian remnant syndrome: a retrospective evaluation of surgical management. *Gynecol Surg*. 2016;13:353-357.

[33] Flyckt R, Coyne K, Falcone T. Minimally Invasive Myomectomy. *Clin Obstet Gynecol*. 2017;60(2):252-272. doi:10.1097/GRF.0000000000000275.

[34] ACOG Committee on Practice Bulletins--Gynecology. Alternatives to hysterectomy in the management of leiomyomas. ACOG Practice Bulletin No. 96. *Obstet Gynecol*. 2008;112:201-207.

[35] Morita M. Laparoscopic myomectomy for symptomatic uterine myomas. *J Med Soc Toho Univ*. 2008;55(3):218-222. doi:10.1016/j.fertnstert.2004.09.011.

[36] ACOG Committee on Practice Bulletins--Gynecology. Management of endometriosis. Practice Bulletin No.114. *Obstet Gynecol*. 2010;116:223-236.

[37] D'Hooghe TM, Bambra C, Raeymaekers B, Koninckx PR. Increased incidence and recurrence of retrograde menstruation in baboons with spontaneous endometriosis. *Hum Reprod*. 1996;11:2022-2025.

[38] D'Hooghe TM. Clinical relevance of the baboon as a model for the study of endometriosis. *Fertil Steril*. 1997;68(4):613-625. doi:10.1016/S0015-0282(97) 00277-X.

[39] Shakiba K, Bena J, McGill K, Minger J, Falcone T. Surgical treatment of endometriosis: a 7-year follow-up on the requirement for further surgery. *Obstet Gynecol*. 2008;111:1285-1292.

[40] Luu TH, Uy-Kroh MJ. New Developments in Surgery for Endometriosis and Pelvic Pain. *Clin Obstet Gynecol*. 2017;60(2):245-251. doi:10.1097/GRF.00000000000 00282.

[41] Mosbrucker C, Somani A, Dulemba J. Visualization of endometriosis: comparative study of 3-dimensional robotic and 2-dimensional laparoscopic endoscopes. *J Robot Surg*. 2017:1-8. doi:10.1007/s11701-017-0686-0.

[42] Chung YJ, Kang SY, Choi MR, Cho HH, Kim JH, Kim MR. Robot-assisted laparoscopic adenomyomectomy for patients who want to preserve fertility. *Yonsei Med J*. 2016;57(6):1531-1534. doi:10.3349/ymj.2016.57.6.1531.

[43] De Cicco C, Corona R, Schonman R, Mailova K, Ussia A, Koninckx PR. Bowel resection for deep endometriosis: A systematic review. *BJOG An Int J Obstet Gynaecol*. 2011;118(3):285-291. doi:10.1111/j.1471-0528.2010.02744.x.

[44] Abrão MS, Petraglia F, Falcone T, Keckstein J, Osuga Y, Chapron C. Deep endometriosis infiltrating the recto-sigmoid: Critical factors to consider before management. *Hum Reprod Update*. 2015;21(3):329-339. doi:10.1093/humupd/ dmv003.

[45] Ercoli A, Bassi E, Ferrari S, et al. Robotic-assisted conservative excision of retrocervical-rectal deep infiltrating endometriosis: a case series. *J Minim Invasive Gynecol*. 2017;(Md). doi:10.1016/j.jmig.2017.03.011.

In: Encyclopedia of Surgery (22 Volume Set)
Editors: Andreas Lehrer and Kristin Mueller
ISBN: 978-1-53618-329-0
© 2020 Nova Science Publishers, Inc.

Chapter 260

ANTIBIOTIC PROPHYLAXIS IN BARIATRIC SURGERY

Andrés García-Marín[1,*] and Mercedes Pérez-López[2]
[1]Department of Pathology and Surgery, University Miguel Hernández, Elche, Spain
[2]Department of Nursery, University Hospital San Juan de Alicante, Alicante, Spain

ABSTRACT

Obesity is a significant risk factor for surgical site infection. Antibiotic prophylaxis in bariatric procedures has not been adequately evaluated.

The chapter summarizes the recent evidence about microbiology, recommended antibiotics, dosages and other routes of administration in obese and morbidly obese patients undergoing bariatric procedures.

Keywords: antibiotic prophylaxis, surgical site infection

INTRODUCTION

Surgical site infection (SSI) is defined as infection ocurring within 30 days after surgery (or within 1 year if an implant is left in place), which may be incisional (superficial or deep) or organ/space [1].

Obesity is considered a risk factor for SSI independently of other comorbidities and, specifically in clean and clean-contaminated abdominal procedures, so antibiotic prophylaxis is always needed in laparoscopic and open bariatric procedures [2-4].

The goal of antimicrobial prophylaxis is to control bacterial burden maintaining antibiotic levels above the minimum inhibitory concentration of the bacteria throughout the procedure. General principles are:

* Corresponding Author's Email: andres.garciam@goumh.umh.es.

A) Intravenous administration.
B) Antibiotic: narrower-spectrum agents to cover the typical microorganisms, bactericidal activity, extended half life, good tissue distribution and low adverse effects.
C) Posology: maximum dose, 30-60 minutes before the start of the procedurewith special attention to intraoperative redosing [1, 3].

BARIATRIC SURGERY

Microbiology

The main involved microorganisms in bariatric procedures are grampositive cocci (*Staphylococcus spp.*, *Streptococcus spp.*and, less frequently, *Enterococcus spp.*) and, in the case of gastrointestinal anastomosis, gramnegative bacilli (*Escherichia coli, Proteus spp.*, *Klebsiella spp.*) and anaerobes (*Bacteroides spp.*) are included [3, 5].

ANTIBIOTICS

The recommended antibiotic depends on the bariatric procedure. For surgeries above the duodenum, cefazolin and, in patients with β-lactam allergies, vancomycin and gentamicin, clindamycin and gentamicin or levofloxacin are preferred. For surgeries below the duodenum, amoxicillin-clavulanic and, in patients with β-lactam allergies, moxifloxacin, levofloxacin and metronidazole or gentamicin and metronidazole are preferred [1, 3, 6].

DOSAGES

The alteration in body composition in obese patients involves a higher risk of erroneous dosing and, therefore, a possibletherapeutic failure or toxicity.

There is a little pharmacokinetic and pharmacodynamic evidence related to the optimal dose in bariatric procedures [3, 7].

The main parameters for doses calculation are:

a) Body mass index (BMI): weight (kg)/height (meters)^2.
b) Ideal weight:
   Men: 50 + 0.9 x [height (centimeters) – 152].
   Women: 45.5 + 0.9 x [height (centimeters) – 152].
c) Adjusted weight: corrective factor x (total weight – ideal weight) + ideal weight. Corrective factor represents the percentage of excess of weight in which antibiotic is estimated to be distributed and varies between 0.25 – 0.4 [3].

Suggested initial dose and time to redosing for recommended antibiotics would be:

a) Cefazolin and amoxicillin-clavulanic: 2 gr., with dose repetition if the surgery lasts more than 3-4 hours. There are different studies related to the assessment of the adequate antibiotic prophylaxis. Anlicoara et al. described a higher concentration of cefazolin in adipose tissue with 2 gr preoperative followed by continuous infusion of 1 gr diluted in 250 ml of saline solution, above the minimum inhibitory concentration of the main causal agents of the SSI [8], whereas Chen et al. have reported cefazolin protective levels in serum and adipose tissue with a 2 gr., and they concluded that neither high dose of cefazolin (3-4 gr.) nor intraoperative redosing are necessary [9].
b) Gentamicin: 5-7 mg/kg of adjusted weight with a corrective factor of 0.47. Dose repetition is not required [3].
c) Vancomycin: 15 mg/kg of total weight (maximum dose 2 gr.). Dose repetition is not required [3, 10].
d) Clindamycin: 900-1200 (BMI ≥ 50) mg., with dose repetition if the surgery lasts more than 6 hours [1, 2].
e) Quinolones: maximum doses, levofloxacin 500-750 (BMI ≥ 50) mg. and moxifloxacin 800 mg [1, 3].
f) Metronidazole: 15 mg/kg of total weight. Dose repetition is not required.
g) Cefoxitin. Brunetti et al. evaluated plasma and adipose tissue concentrations of cefoxitin after preoperative standard dose (2 gr.) in 6 patients undergoing sleeve gastrectomy and they described subtherapeutic concentrations in subcutaneous tissue at the time of closure so they recommend more studies to define the appropriate dosage [11]. Moine et al. described that weight-based dosing regimen (40 mg/kg of total weight) was better than fixed dose, although the desired pharmacodynamic targets were suboptimal in serum and subcutaneous tissue, so more studies are needed [12].
h) Ertapenem. Borracci et al. evaluated the standard dose of 1 gr of ertapenem in 10 female patients undergoing bariatric surgery and they concluded that it may not provide optimal clinical levels to prevent SSI [13].

OTHER ROUTES OF ADMINISTRATION

The application of topical, subcutaneous and intraperitoneal antibiotics has also been studied.

Peritoneal lavage with antibiotic solution has been used by many surgeons in abdominal surgery to reduce the bacterial load and possibly minimize the risk of SSI [14]. Ruiz-Tovar et al. performed a randomized clinical trial comparing peritoneal lavage with antibiotic solution (gentamicin 240 mg. – clindamycin 600 mg. dissolved in 500 ml. of physiologic saline) versus physiologic saline after laparoscopic sleeve gastrectomy and they described a significant reduction in peritoneal contamination, inflammatory markers, post-operative pain and a shorter length of hospital stay in the group of antibiotic solution. More studies with a higher sample size are needed to obtain significant conclusions about SSI with peritoneal lavage with antibiotic solution [15].

Alexander et al. evaluated the infusion of kanamycin solution 0.1% into the subcutaneous at the time of closure in 837 patients undergoing open bariatric procedures in addition to standard intravenous prophylaxis. SSI developed in subcutaneous tissues of 0.72% of patients and they concluded that prolonged contact with kanamycin solution reduced SSI in the deep subcutaneous space. However, no control group was included in the study, so more studies are needed to evaluate the use of topical solutions and the SSI [16].

REFERENCES

[1] Chopra, T., Zhao, J., Alangaden, G., Wood, M., Kaye, K. Preventing surgical site infections after bariatric surgery: value of perioperative antibiotics regimens. *Expert Rev. Pharmacoecon Outcomes Res.*, 2010; 10:317-28.

[2] Winfield, R. D., Reese, S., Bochicchio, K., Mazuski, J. E., Bochicchio, G. V. Obesity and the risk for surgical site infection in abdominal surgery. *Am. Surg*., 2016; 82:331-6.

[3] Badía Pérez, J. M., Arroyo García, N., Guirao Garriga, X. Profilaxis antibiótica en cirugía. En: Badía Pérez, J. M., Guirao Garriga, X. *Infecciones quirúrgicas*. 2ª ed. Madrid: Arán Ediciones SL; 2016. p. 179-205.

[4] Sauerland, S., Angrisani, L., Belachew, M., Chevallier, J. M., Favretti, F., Finner, N., et al. Obesity surgery: evidence-based guidelines of the European Association for Endoscopic Surgery (EAES). *Surg. Endosc*., 2005; 19:200-21.

[5] Martín García-Almenta, E., Ruiz-Tovar Polo, J., Sánchez Santos, R. *Vía clínica en cirugía bariátrica*. Albacete: Asociación Española de Cirujanos; 2017.

[6] Fischer, M. I., Dias, C., Stein, A., Meinhardt, N. G., Heineck, I. Antibiotic prophylaxis in obese patients submitted to bariatric surgery. A systematic review. *Acta Cir. Bras*., 2014; 29:209-17.

[7] Freeman, J. T., Anderson, D. J., Hartwig, M. G., Sexton, D. J. Surgical site infections following bariatric surgery in community hospitals: a weighty concern? *Obes. Surg*., 2011; 21:836-40.

[8] Anlicoara, R., Ferraz, A. A., da P. Coelho, K., de Lima Filho, J. L., Siqueira, L. T., de Araujo, J. G., et al. Antibiotic prophylaxis in bariatric surgery with continuous infusion of cefazolin: determination of concentration in adipose tissue. *Obes. Surg*., 2014; 24:1487-91.

[9] Chen, X., Brathwaite, C. E., Barkan, A., Hall, K., Chu, G., Cherasard, P., et al. Optimal cefazolin prophylactic dosing for bariatric surgery: no need for higher doses or intraoperative redosing. *Obes. Surg*., 2017; 27:626-9.

[10] Rybak, M. J., Lomaestro, B. M., Rotschafer, J. C., Moellering, R. C., Craig, W. A., Billeter, M., et al. Vancomycin therapeutic guidelines: a summary of consensus recommendations from the infectious diseases Society of America, the American Society of Health-System Pharmacists and the Society of Infectious Diseases Pharmacists. *Clinc. Infect. Dis*., 2009; 49:325-7.

[11] Brunetti, L., Kagan, L., Forrester, G., Aleksunes, L. M., Lin, H., Buyske, S., Nahass, R. G. Cefoxitin plasma and subcutaneous adipose tissue concentration in patients undergoing sleeve gastrectomy. *Clin. Ther*., 2016; 38:204-10.

[12] Moine, P., Mueller, S. W., Schoen, J. A., Rothchild, K. B., Fish, D. N. Pharmacokinectic and pharmacodynamic evaluation of a weight-based dosing regimen of cefoxitin for perioperative surgical prophylaxis in obese and morbidly obese patients. *Antimicrob. Agents Chemother.*, 2016; 60:5885-93.

[13] Borracci, T., Adembri, C., Accetta, G., Berti, J., Cappellini, I., Lucchese, M., et al. Use of the parenteral antibiotic ertapenem as short term prophylaxis in bariatric surgery: a pharmaco-kinetic-pharmacodynamic study in class III obese female patients. *Minerva Anestesiol.*, 2014; 80:1005-11.

[14] Williams, M. D., Champion, J. K. Experience with routine intraabdominal cultures during laparoscopic gastric bypass with implications for antibiotic prophylaxis. *Surg. Endosc.*, 2004; 18:755-6.

[15] Ruiz-Tovar, J., Llavero, C., Muñoz, J. L., Zubiaga, L., Díez, M., Obelche Group. Effect of peritoneal lavage with clindamycin-gentamicin solution on postoperative pain and analytic acute-phase reactants after laparoscopic sleeve gastrectomy. *Surg. Infect. (Larchmt),* 2016; 17:357-62.

[16] Alexander, J. W., Rahn, R., Goodman, H. R. Prevention of surgical site infections by an infusion of topical antibiotics in morbidly obese patients. *Surg. Infect. (Larchmt),* 2009; 10:53-7.

In: Encyclopedia of Surgery (22 Volume Set)
Editors: Andreas Lehrer and Kristin Mueller
ISBN: 978-1-53618-329-0
© 2020 Nova Science Publishers, Inc.

Chapter 261

THROMBOEMBOLIC PROPHYLAXIS

Jaime Ruiz-Tovar[1,*] and Carolina Llavero[2]
[1]Department of Surgery, Universidad Autónoma de Madrid, Spain
[2]Department of Surgical Nursery, Sureste Hospital, Madrid, Spain

ABSTRACT

Obesity is associated with an increased risk of thromboembolic events. Venous thromboembolisms are the most common postoperative medical complications after bariatric surgery. Moreover, most bariatric procedures actually are performed by laparoscopic approach, implying an increased intraabdominal pressure during the surgical procedure that may favor the development of thrombus. The incidence of deep vein thrombosis (DVT) after laparoscopic bariatric surgery is about 3%. The prolonged anti-Trendelenburg position is considered the most important risk factor for venous thromboembolisms.

DVT is probably the most easily detected complication associated with venous thromboembolism, as it tends to appear with unilateral pain in the lower limb, associated with gastrocnemic edema and tenderness. DVT alone is not a life-threatening condition, but its main risk is migration of the thrombus and the development of PE.

Therefore, bariatric surgery is considered a high-risk procedure for thromboembolic events. Actual recommendations are to include low molecular weight heparins (LMWH) and compression stockings in the primary prophylaxis of thromboembolic events.

Keywords: bariatric surgery, thromboembolic prophylaxis

INTRODUCTION

According to the World Health Organization (WHO), there are 1.6 billion overweight and 400 million obese people worldwide. Bariatric surgery has demonstrated to be the most effective and sustainable method for the regulation of morbid obesity, superior to both pharmaceutical interventions and combinations of diet and lifestyle regimens. Therefore, the

* Corresponding Author's Email: jruiztovar@gmail.com.

number of bariatric procedures performed, mainly in developed countries, is increasing every year [1, 2].

Obesity itself is associated with an increased risk of thromboembolic events. Moreover, most bariatric procedures are actually performed by a laparoscopic approach, implying an increased intraabdominal pressure during the surgical procedure that may favor the development of thrombus. Therefore, bariatric surgery is considered a high risk procedure for thromboembolic events [3, 4].

MORBID OBESITY AS RISK FACTOR

It has been determined that obesity is associated with a hypercoagulability status. Morbidly obese patients present increased fibrinogen levels that may reach twofold the normal value. It has been proved that venous circulation flow is slower in the infradiaphragmatic territory and especially in the lower limbs. Both facts, associated with disorders in several coagulation factors, favor the appearance of venous thrombosis, thrombophlebitis, and thromboembolic events, mainly pulmonary thromboembolisms (PE), which are the first cause of mortality in obese patients.

Venous stasis and hypercoagulability improve with weight loss, mostly after bariatric surgery. This improvement is achieved several months after the surgical procedure, when an important weight reduction has been obtained. More than 90% of patients undergoing any bariatric procedure present a relevant reduction of their hypercoagulability.

PE is also the most frequent cause of mortality in the immediate postoperative course of any kind of surgery in obese patients. Thus, they are considered as high-risk subjects, requiring intense prophylactic measures (mechanical and pharmacological) [5-7].

Laparoscopic Bariatric Surgery

Venous thromboembolism is the most common postoperative medical complication after bariatric surgery. The incidence of deep vein thrombosis (DVT) after laparoscopic bariatric surgery is about 3% and that of pulmonary embolism (PE) is less than 1%. However, mortality associated with PE is estimated to be between 50% and 75% [8-10].

In laparoscopic abdominal surgery, the increase of intraabdominal pressure by the pneumoperitoneum, the prolonged operation time, and the anti-Trendelenburg position are considered risk factors for venous thromboembolisms. Moreover, hypercapnia induces vasoconstriction. It has been also demonstrated that surgical dissection induces the release of procoagulant cytokines. Other causes of venous thromboembolism after bariatric surgery is dehydration, especially after restrictive procedures, when patients hardly drink [11].

CLINICAL MANIFESTATIONS AND DIAGNOSIS

Venous thromboembolisms are often a challenging issue for the medical staff. DVT is probably the most easily detected complication associated with venous thromboembolism, as

it tends to appear with unilateral pain in the lower limb, associated with gastrocnemic edema and tenderness.

DVT alone is not a life-threatening condition, but its main risk is migration of the thrombus and the development of PE. The gold standard method for the diagnosis of DVT is Doppler ultrasonography (US).

PE usually appears with sudden unexplained dyspnea without any relevant features at the physical examination and on X-ray plain films. Laboratory data may show increased levels of D dimers, which present high sensitivity but low specificity for the suspicion of PE. The gold standard test for the diagnosis is a contrast-enhanced thoracic computed tomography (CT) scan showing a filling defect in the pulmonary arteries or their branches [11].

Antithromboembolic Prophylaxis (Primary Prophylaxis)

Venous thromboembolisms are life-threatening conditions. Several measures, including prophylactic low molecular weight heparins (LMWH) and compressive stockings, are adopted to reduce their incidence. Up to the present there is no consensus about the optimal dosage of LMWH in the antithromboembolic prophylaxis for patients undergoing bariatric surgery. The dosage must be adjusted according to the weight of the patient, implying the need of administration of high preoperative doses.

Intra- and postoperative bleeding is one of the main complications of bariatric surgery. Many surgeons fear these complications and administer lower doses of LMWH than that recommended by most groups (Enoxaparin 0.5 mg/kg/day or Bemiparin 5000 UI/day or Dalteparin 50 UI/kg/day or Nadroparin 4100 UI/day) [12-15]. However, other authors report that this dose is insufficient because these patients are at high risk of developing thrombotic events [16-18].

The postoperative prolongation of prophylaxis is also a debated issue as some authors defend that a prolongation of 5–7 days is enough, whereas others report the need for maintaining it during 1 month, considering laparoscopic bariatric surgery as a high-risk procedure performed in high-risk patients [19-21]. In our opinion, a preoperative dose of 0.5 mg/ kg/day administered 12 h before surgery and maintained postoperatively for 1 month is an adequate scheme for pharmacological antithromboembolic prophylaxis. We also fear intraoperative bleeding, but at these doses, it is not especially relevant in our experience. However, a postoperative thromboembolic event is a life-threatening condition for us that, once established, could be very difficult to manage.

Compression stockings must be maintained during the surgical event and postoperatively until the patient is able to make a proper ambulation [22, 23].

Screening for Asymptomatic Venous Thromboembolism (Secondary Prophylaxis)

As has already been mentioned, venous thromboembolisms are asymptomatic in many cases. In DVT it is especially important to achieve an early diagnosis to avoid the development of life-threatening conditions, such as PE. With this aim, our group performed a prospective observational study of 100 consecutive patients undergoing laparoscopic sleeve

gastrectomy as a bariatric procedure. DVT and porto-spleno-mesenteric vein thrombosis (PSMVT) were investigated 3 months after surgery with Doppler US and contrast-enhanced abdominal CT scan. The results of this study revealed that 2% presented unnoticed DVT and 1% unnoticed PSMVT. All these patients were asymptomatic. According to these results, we concluded that a routine postoperative screening with Doppler US or contrast-enhanced CT seems to be unnecessary [24].

REFERENCES

[1] Colquitt JL, Picot J, Loveman E, et al. Surgery for obesity. *Cochrane Database Syst Rev* 2009; 2, CD003641.

[2] Martın Duce A, Dıez del Val I. Surgery for morbid obesity. *Clinical Guidelines of the Spanish Surgical Association.* Aran, 2007, Madrid.

[3] Avenell A, Brown TJ, McGee MA, et al. What are the long-term benefits of weight reducing diets in adults? A systematic review of randomized controlled trials. *J Hum Nutr Diet* 2004; 17:317–335.

[4] Rewers M, Zaccaro D, D'Agostino R, et al. Insulin Resistance Atherosclerosis Study investigators. Insulin sensitivity, insulinemia, and coronary artery disease: the Insulin Resistance Atherosclerosis Study. *Diabetes Care* 2004; 27:781–787.

[5] Solomon H, Liu GY, Alami R, et al. Benefits to patients choosing preoperative weight loss in gastric bypass surgery: new results of a randomized trial. *J Am Coll Surg* 2009; 208:241–245.

[6] Mhuircheartaigh J, Abedin S, Bennett AE, et al. Imaging features of bariatric surgery and its complications. *Semin Ultrasound CT MR* 2013;34:311–324.

[7] Switzer NJ, Mangat HS, Karmali S. Current trends in obesity: body composition assessment, weight regulation, and emerging techniques in managing severe obesity. *J Interv Gastroenterol* 2013;3:34–36.

[8] Stroh C, Birk D, Flade R, et al. Evidence of thromboembolism prophylaxis in bariatric surgery: results of a quality assurance trial in bariatric surgery in Germany from 2005 to 2007 and review of literature. *Obes Surg* 2009; 19:928–936.

[9] Melinek J, Livingston E, Cortina G, et al. Autopsy findings following gastric bypass surgery for morbid obesity. *Arch Pathol Lab Med* 2002;126:1091–1095.

[10] Chan MM, Hamza N, Ammori BJ. Duration of surgery independently influences risk of venous thromboembolism after laparoscopic bariatric surgery. *Surg Obes Relat Dis* 2013; 9:88–93.

[11] Cottam DR, Mattar SG, Barinas-Mitchell E, et al. The chronic inflammatory hypothesis for the morbidity associated with morbid obesity: implications and effects of weight loss. *Obes Surg* 2004;14:589–600.

[12] Brotman DJ, Shihab HM, Prakasa KR, et al. Pharmacologic and mechanical strategies for preventing venous thromboembolism after bariatric surgery: a systematic review and meta-analysis. *JAMA Surg* 2012; 148:675–686.

[13] Ikesaka R, Delluc A, Le Gal G, et al. Efficacy and safety of weight-adjusted heparin prophylaxis for the prevention of acute venous thromboembolism among obese patients

undergoing bariatric surgery: a systematic review and meta-analysis. *Thromb Res* 2014; 133:682–687.

[14] Becattini C, Agnelli G, Manina G, et al. Venous thromboembolism after laparoscopic bariatric surgery for morbid obesity: clinical burden and prevention. *Surg Obes Relat Dis* 2012; 8:108–115.

[15] Erviti J. Low molecular weight heparins. In: *Navarra pharmacotherapeutic informative bulletin.* http://www.cfnavarra. es/WebGN/SOU/publicac/BJ/textos/ v6n5.htm.

[16] Gomez-Ambrosi J, Salvador J, Rotellar F, et al. Increased serum amyloid A concentrations in morbid obesity decrease after gastric by-pass. *Obes Surg* 2006;16:262–269.

[17] O'Brien KD, Brehm BJ, Seeley RJ, et al. Diet induced weight loss is associated with decreases in plasma serum amyloid A and C-reactive protein independent of dietary macronutrient composition in obese subjects. *J Clin Endocrinol Metab* 2005;90:2244–2249.

[18] Ruiz-Tovar J, Oller I, Tomas A, et al. Midterm impact of sleeve gastrectomy, calibrated with a 50-Fr bougie, on weight loss, glucose hemostasis, lipid profiles and comorbidities in morbidly obese patients. *Am Surg* 2012; 78:969–974.

[19] Chivot C, Robert B, Lafaye N, et al. Laparoscopic sleeve gastrectomy: imaging of normal anatomic features and postoperative gastrointestinal complications. *Diagn Interv Imaging* 2013;94:823–834.

[20] Langer FB, Reza Hoda MA, Bohdjalian A, et al. Sleeve gastrectomy and gastric banding: effects on plasma ghrelin levels. *Obes Surg* 2005;15:1024–1029.

[21] Rosenberg JM, Tedesco M, Yao DC, et al. Portal vein thrombosis following laparoscopic sleeve gastrectomy for morbid obesity. *JSLS* 2012; 16:639–643.

[22] Singh P, Sharma M, Ghandhi K, et al. Acute mesenteric vein thrombosis after laparoscopic gastric sleeve. *Surg Obes Relat Dis* 2010;6:107–108.

[23] Huerta S, Li Z, Livingston EH. Outcome of portal injuries following bariatric operations. *Obes Surg* 2006; 16:105–109.

[24] Alsina E, Ruiz-Tovar J, Alpera MR, et al. Incidence of deep vein thrombosis and thrombosis of the portal-mesenteric axis after laparoscopic sleeve gastrectomy. *J Laparoendosc Adv Surg Tech* A 2014; 24:601–605.

In: Encyclopedia of Surgery (22 Volume Set)
Editors: Andreas Lehrer and Kristin Mueller
ISBN: 978-1-53618-329-0
© 2020 Nova Science Publishers, Inc.

Chapter 262

ANTIEMETIC PROPHYLAXIS

Esther García Villabona[1,*], Carmen Vallejo Lantero[1] and Graciela García Villabona[2]

[1]Anesthesiology Department, Hospital Universitario de La Princesa, Madrid, Spain
[2]Anesthesiology Department, Hospital Universitario Marqués de Valdecilla, Santander, Spain

ABSTRACT

Postoperative nausea and vomiting (PONV) are still frequent, despite the continuing investigation and development of new drugs and techniques. These condition contribute to increase hospital costs, delay discharge from the hospital, demand unexpected hospitalizations, and decrease patient satisfaction. Postoperative nausea and vomiting usually develop in the first 24 postoperative hours and can lead to significant morbidity. In abdominal surgeries, the increase in intraabdominal pressure jeopardizes the stitches, increases central venous pressure, and increases the risk of aspiration of gastric contents. Electrolyte imbalances and an increase in intracranial pressure can also be observed. The effort during vomiting increases postoperative pain and autonomous responses.

Laparoscopic gastroplasties are associated with a high incidence of postoperative nausea and vomiting and the number of those procedures has been increasing progressively, hence the need to identify methods to prevent those undesirable events in this patient population.

Multimodal antiemetic prophylaxis has been recommended for patients who have multiple risk factors. Unfortunately, provider compliance with recommended antiemetic prophylaxis protocols is low historically. In bariatric patients, it was observed that those undesirable effects can have an incidence of almost 80% when prophylaxis is not used. Given these results, it would be logical to attempt to further lower the PONV rates. [9]

Keywords: postoperative nausea and vomiting (PONV), risk score, antiemetics

* Corresponding Author's Email: esthergarciavillabona@gmail.com.

INTRODUCTION

Among the millions of patients undergoing surgery with general anesthesia each year, many suffer from postoperative nausea, vomiting, or both (PONV). Severe nausea can be so draining and debilitating that patients have rated it as more serious than postoperative pain. In obese patients undergoing bariatric surgery, vomiting increases the risk of pulmonary aspiration of gastric contents and suture dehiscence. It may even lead to esophageal rupture, subcutaneous emphysema, and bilateral pneumothoraces. In addition, PONV can delay patient discharge from the postanesthesia care unit (PACU), and it is a leading cause of unexpected hospital admission after surgery. [3]

This chapter has the next goals:

A. Identify wich patients are at risk for PONV: RISK SCORE.
B. Establish factors that reduce the baseline risks for PONV.
C. Determine the most effective antiemetic drugs.
D. Create an algorithm to identify patients at increased risk for PONV and suggest effective prophylactic strategies.
E. Describe PONV treatment with or without prophylaxis.

PATIENTS AT RISK FOR PONV

In bariatric patients, the most common event for prolonged postanesthesia recovery is PONV. Patients having bariatric surgery have several known risk factors related to PONV, but some of these factors may be only simple associations. [9]. For objective risk assessment, it is recommended to focus on those conditions that independently predict PONV after accounting for other confounding factors. Independent risk factors have been identified.

- *The most likely causes of PONV are anesthesia related: volatile anesthetics, nitrous oxide, and postoperative opioids.*

The effect of volatile anesthetics on PONV is dose-dependent and particularly prominent in the first 2 to 6 hours after surgery. In a study of more than 1100 patients, volatile anesthetics were the single greatest factor affecting the incidence of emesis in the first 2 h after operation, and volatile anesthetic use increased PONV in a dose-dependent manner, irrespective of the choice of the agent. Nitrous oxide may contribute to PONV in several ways. It may act upon the dopamine and opioid receptors in the brain, produce changes in middle ear pressure, and cause bowel distension as it diffuses into closed cavities. [26]

Irrespective of the specific drug given, postoperative opioids also increase the risk for PONV in a dose-dependent manner, and this effect appears to last for as long as opioids are used for pain control in the postoperative period. Opioid analgesia primarily involves central μ, κ, and δ receptors in the rostral anterior cingulate cortex and the brainstem. However, opioid activity at peripheral receptors in the gut inhibits the release of acetylcholine from the mesenteric plexus and stimulates μ receptors, which reduces muscle tone and peristaltic

activity. Consequent delayed gastric emptying and gastric distension activate visceral mechanoreceptors and chemoreceptors, which trigger nausea and vomiting via a serotonergic signalling pathway.

This explains why the incidence of PONV is lower with opioid-free regional anesthesia and anesthesia regimens with reduced opioid consumption through the use of non-opioid analgesics, perioperative alpha-2 agonists, and beta-blockers.

- Despite the triggers mentioned above, many patients do not experience PONV, most likely because the development of PONV also depends on the individual patient's susceptibility. *Patient-specific risk factors for PONV in adults include female sex, a history of PONV and/or motion sickness, nonsmoking status, and young age.*

Female gender is the strongest overall predictor of PONV. An estimated 40% of female surgical patients who receive postoperative opioid analgesics have PONV. The mechanism relating female gender to increased incidence of PONV is yet unknown. The incidence of PONV varies with the phase of the menstrual cycle, but menstrual hormonal fluctuations are unlikely to be responsible for PONV.

A history of PONV, motion sickness, or both indicates an underlying susceptibility to PONV. A genome-wide association study to identify potential genetic markers for susceptibility to PONV found that patients with a history of severe, intractable PONV were more likely to have first-degree relatives with a history of PONV than those with no history of PONV.

The mechanism for the reduced incidence of PONV in smokers compared with non-smokers is also not well understood. One theory suggests that chronic exposure to polycyclic aromatic hydrocarbons in cigarette smoke might induce the cytochrome P450 isoenzymes (CYP2E1) responsible for phase 1 (first pass) metabolism of volatile anesthetics. However, given that only a small percentage of volatile anesthetics gets metabolized (e.g., 0.02% of desflurane), it appears unlikely that liver enzyme induction could account for such wide variation in the incidence of PONV between smokers and non-smokers. Thus, it has been proposed as an explanation that the protective effect of smoking may be due to functional changes in neuroreceptors from chronic exposure to nicotine, and thus nicotine withdrawal rather than nicotine exposure reduces smokers' susceptibility to PONV.

The incidence of PONV generally decreases with age. An underlying mechanism may be the reduced autonomic reflexes with increasing age. However, it should be noted that this is true for adults only, as the incidence of PONV increases with age in children, with a relatively low reported incidence below the age of 3. [8]

Type of surgery is strongly believed to be a risk factor for PONV, yet it is difficult to prove that it is an independent risk factor. Certain types of surgery may be associated with a frequent incidence of PONV (e.g., abdominal surgeries), not because of a specific emetogenic pathway, but could be as a result of a long exposure to general anesthesia and higher doses of opioids.

There is not enough evidence for other commonly believed risk factors as anxiety, menstrual cycle, perioperative fasting, nasogastric tube or supplemental oxygen. [1]

Risk Score

Historically, there have been several problems with the prevention of PONV. First, the efficacy of prophylactic antiemetic interventions in the daily surgical setting is often disappointing. Second, there is no evidence that prophylaxis decreases the likelihood of unanticipated admission. Third, it remained unclear whether prophylaxis of PONV is less cost-effective than treatment of established symptoms. And finally, with prevention strategies, patients who actually do not need any prophylaxis are unnecessarily exposed to a drug, and are thus put at risk of suffering from unnecessary adverse drug reactions.

Antiemetics, like all drugs, carry some risk for adverse effects. These effects range in severity from mild headache to possibly more meaningful QTc prolongations that may rarely be associated with cardiac arrest.

Therefore, a patient's baseline risk for PONV should be objectively assessed using a validated risk score that is based on independent predictors, so the number and choice of prophylactic antiemetics can be titrated against the patient's risk. Even though there is strong evidence for a couple of truly independent risk factors for PONV, none of those risk factors taken alone as a single predictor is clinically sufficient for a risk assessment or to make clinical decisions about the need for prophylactic antiemetics. Therefore, a patient's baseline risk for PONV should be objectively assessed using a validated risk score that is based on these independent predictors. Indeed, use of PONV risk scores has been demonstrated to significantly reduce the institutional rate of PONV. The 2 most commonly used risk scores for inpatients undergoing balanced anesthesia are the Apfel score and the Koivuranta score. [4, 1, 3]

The Apfel simplified risk score is a predictive model, wich was developed in european patients undergoing balanced anesthesia. It is based on 4 predictors: female gender, history of PONV and/or motion sickness, nonsmoking status, and use of postoperative opioids. According to this score, the risk factors are each assigned a value of 1. The incidence of PONV with the presence of 0, 1, 2, 3, and 4 risk factors is about 10%, 21%, 39%, 61%, and 79%, respectively. It could be considered patients with 0–1, 2 or 3, and more risk factor as "low," "medium," and "high" risk categories, respectively.

Given that several antiemetics are now generic and inexpensive, some experts suggest it may be appropriate to give 1 or 2 antiemetics to all patients. However, this strategy puts the low-risk patients at unnecessary risk for rare but well-described side effects. Although risk scores are an objective approach to assessing the patient's risk for PONV, they are not completely predictive, with sensitivity and specificity of between 65% and 70%. In addition, other clinically relevant aspects should also be taken into consideration by the anesthesia care provider, such as whether vomiting after bariatric surgery would pose a significant medical risk. [3, 4]

REDUCE BASELINE RISKS

Reducing baseline risk factors can significantly decrease the incidence of PONV. Strategies recommended to reduce baseline risk include:

1) *Avoidance of general anesthesia by the preferential use of regional anesthesia.*
2) *Preferential use of propofol infusions.*
3) *Avoidance of nitrous oxide.*
4) *Avoidance of volatile anesthetics.*
5) *Minimization of perioperative opioids.*
6) *Adequate hydration.*

The IMPACT study evaluated 6 strategies to reduce PONV in more than 5000 high-risk patients. They found that a combination of propofol and air/oxygen (total IV anesthesia [TIVA]) had additive effects, reducing PONV risk by approximately 25%. Use of propofol for induction and maintenance of anesthesia decrease the incidence of early PONV (occurring within the first 6 hours).

These findings are supported by 2 meta-analyses demonstrating that avoiding nitrous oxide reduced PONV risk, but only if the baseline risk of vomiting is high. Omitting N2O does not affect nausea or complete control of emesis. There is evidence showing that volatile anesthetics were the primary cause of early PONV (0–2 hours after surgery), but that they did not have an impact on delayed PONV (2–24 hours after surgery). [5]

Baseline risk for PONV can also be reduced by minimizing postoperative opioids. To achieve satisfactory analgesia without opioids, alternate modalities of pain management may be used. RCTs and meta-analyses showed that multimodal analgesic regimens which decreased the opiod consumption also decreased the incidence of opioid-related nausea and vomiting. These morphine sparing effect could be arised by the use of regional techniques, antiinflamatory drugs, cyclooxygenase-2 inhibitors and low doses of intraoperative ketamine. [7]

Adequate IV fluid hydration is an effective strategy for reducing the baseline risk for PONV. However, there was no difference in efficacy between crystalloids and colloids when similar volumes were used in surgeries associated with minimal fluid shifts.

ANTIEMETIC DRUGS

The etiology of nausea and vomiting is multifactorial and it is related with four types of neurotransmitters: serotonin, dopamine, acetylcholine, and histamine. They modulate the chemoreceptor trigger zone located in the area postrema. Antiemetics are classified according to their action on these receptors and normally affect one of them. Therefore, the use of a single drug might not be adequate and the association of two or more drugs might be necessary to obtain better results. [9]

The recommended pharmacologic antiemetics for PONV prophylaxis in adults include:

a. *5-Hydroxytryptamine (5-HT3) Receptor Antagonists* (ondansetron, dolasetron, granisetron, tropisetron, ramosetron, and palonosetron),
b. *Neurokinin-1 (NK-1) Receptor Antagonists* (aprepitant, casopitant, and rolapitant),
c. *Corticosteroids* (dexamethasone and methylprednisolone),
d. *Butyrophenones* (droperidol and haloperidol),
e. *Antihistamines* (dimenhydrinate and meclizine),
f. *Anticholinergics* (transdermal scopolamine [TDS]).

Recommendations given are evidence based, and not all the drugs have a Food and Drug Administration (FDA) indication for PONV.

Other proposed strategies were found to be not effective for PONV prophylaxis like music therapy, isopropyl alcohol inhalation, intraoperative gastric decompression, the proton pump inhibitor esomeprazole, ginger root, nicotine patch to nonsmokers, cannabinoids and intraoperative supplemental oxygen. Morindal citrofolin linn (noni fruit) showed effectiveness in reducing early postoperative nausea.

a) 5-HT3 Receptor Antagonists

Ondansetron is a highly effective antiemetic that has been used successfully for both the prophylaxis and treatment of postoperative nausea and vomiting (PONV) in high-risk surgical patients. [4, 12]

Most of the available research on the 5-HT3 receptor antagonists involves ondansetron, which has greater antivomiting than antinausea effects. Ondansetron is the "gold standard" compared with other antiemetics. It exerts its actions by inhibiting the release of serotonin by enterochromaffin cells in the stomach; those receptors are found in the termination of afferent fibers that travel in the vagus nerve to the postrema region of the solitary tract nucleus, responsible for emesis. [9]

It has a recommended dose of 4 mg. The effect of the ondansetron 8 mg oral disintegrating table is equivalent to the 4 mg IV dose. Ondansetron is as effective as other 5-HT3s including ramosetron 0.3 mg. It is also as effective as dexamethasone and haloperidol 1 mg IV, with no difference in effect on the QTc interval. However, it is less effective than aprepitant for reducing emesis and palonosetron for the incidence of PONV.

Timing of Administration

Ondansetron, dolasetron, granisetron, and tropisetron are most effective in the prophylaxis of PONV when given at the end of surgery, although some data on dolasetron suggest timing may have little effect on efficacy. Palonosetron is typically given at the start of surgery.

Adverse Effects

The 5-HT3 receptor antagonists have a favorable side effect profile, and while generally considered equally safe, all except palonosetron affect the QTc interval. In June 2012, the U.S. FDA recommended the dose of ondansetron for chemotherapy-induced nausea and vomiting should not exceed 16 mg in a single dose because of risks of QT prolongation. In December 2012, the FDA notified that the 32 mg single IV dose will no longer be marketed. However, there was no change in the recommended dose of ondansetron 4 mg to prevent PONV. Other adverse effects of Ondansetron are: headache, elevated liver enzymes, and constipation.

b) NK-1 Receptor Antagonists

Aprepitant is an NK-1 receptor antagonist with a 40-hour half-life. In 2 large RCTs, aprepitant (40 and 80 mg per os) was similar to ondansetron in achieving complete response (no vomiting and no use of rescue antiemetic) for 24 hours after surgery. The clinical

experience with the use of aprepitant is still limited, and its role in routine prophylaxis is not established.

Other NK-1 receptor antagonists have not been approved for use.

c) Corticosteroids

The corticosteroid dexamethasone effectively prevents nausea and vomiting in postoperative patients. A prophylactic dose of 4 to 5 mg IV for patients at increased risk for PONV is recommended after anesthesia induction rather than at the end of surgery. Dexamethasone has an effective antiemetic effect throughout the first 24 hours of the postoperative period. On the contrary, if administered at the end of anesthesia, dexamethasone did not provide an effective antiemetic effect during the immediate postoperative period of 0–2 hours. [10, 1]

For PONV prophylaxis, the efficacy of dexamethasone 4 mg IV is similar to ondansetron 4 mg IV and droperidol 1.25 mg IV and each independently reduced PONV risk by approximately 25%.

More recent studies increasingly use the higher dose of dexamethasone 8 mg IV rather than the minimum effective dose of 4 to 5 mg. Preoperative dexamethasone 8 mg enhances the postdischarge quality of recovery in addition to reducing nausea, pain, and fatigue. Dexamethasone also has dose-dependent effects on quality of recovery. At 24 hours, patients receiving dexamethasone 0.1 vs 0.05 mg/kg required less opioid and reported less nausea, sore throat, muscle pain, and difficulty falling asleep.

Adverse Effects

Data on safety of perioperative dexamethasone are inconclusive. In most studies, a single dose of perioperative dexamethasone does not appear to increase the risk of wound infection. However, it has been reported that intraoperative dexamethasone 4 to 8 mg may confer an increased risk of postoperative infection. In addition, some studies showed significant increases in blood glucose that occur 6 to 12 hours postoperatively in normal subjects, those with impaired glucose tolerance, and type 2 diabetic and obese surgical patients who receive dexamethasone 8 mg. In view of this evidence, use of dexamethasone in labile diabetic patients is relatively contraindicated.

Methylprednisolone 40 mg IV is effective for the prevention of late PONV. There is no evidence to suggest that the adverse effect of methylprednisolone is any different from dexamethasone.

d) Butyrophenones

Butyrophenones produce central nervous system (CNS) depression, and they are potent antiemetics. Droperidol produces its action centrally at sites where dopamine, norepinephrine, and serotonin act. As a principal mechanism it has been suggested that droperidol may occupy GABA receptors at the postsynaptic membrane; this may reduce synaptic transmission and result in a buildup of dopamine in the intersynaptic cleft. A subsequent imbalance in dopamine and acetylcholine is thought to occur, which results in an alteration of normal transmission of signals in the CNS, as, for instance, in the emetic centre in the chemoreceptor trigger zone.

Droperidol has been used as an antiemetic in perioperative medicine for almost 40 yr. Extensive clinical experience with a drug is no guarantor for that drug to be clinically really useful. There was some evidence that the timing of administration of prophylactic droperidol may have an impact on its early antiemetic efficacy, but not there after. From a pharmacokinetic point of view it seems to be reasonable to administer a prophylactic antiemetic intervention shortly before the patient awakes and possibly needs the antiemetic protection. Droperidol is most effective when administered at the end of surgery. The antinausea effect is not dose-dependent, is more pronounced than the anti-vomiting effect, and is short-lived. Sedation and drowsiness are dose-dependent, extrapyramidal symptoms are rare, and there is a protective effect against headache. [11]

Prophylactic doses of droperidol 0.625 to 1.25 mg IV are effective for the prevention of PONV.

Adverse Effects

Droperidol and other, older antiemetic drugs have been repeatedly discredited because of their apparent increased risk of potentially major adverse effects. The situation with droperidol is different, because this drug is clearly antiemetic in the doses used in clinical practice. Its antinausea effect, for instance, is likely to be the best currently available. Thus, it may be worthwhile to balance the estimates of the antiemetic efficacy of droperidol against its estimates for harm. Extrapyramidal symptoms is a major adverse reaction of drugs acting at the dopamine receptor. There was a lack of data to test dose-responsiveness; it can only be speculated that lower doses of droperidol would decrease the risk of extrapyramidal reactions. Visual disturbances, urinary retention, and occulogyric crisis have been described. The clinical relevance of these events and their relation to droperidol, however, is unclear.

It has been known for a long time that droperidol, as a CNS depressant, produces a drowsy and placid subject who tends to fall into a sleep from which he can be readily aroused. Indeed, droperidol increased the likelihood of sedation and drowsiness; an obvious dose response could be described.

There was strong evidence for a protective effect of droperidol against postoperative headache. This puts into question general statements on the increased risk of toxicity with droperidol. We do not know if there is a relationship between an increased risk of sedation and the anti-headache effect. The favourable effect on headache is yet another reason why droperidol should be combined with a 5-HT3receptor antagonist, since 5-HT3 receptor antagonists increase the risk of headache.

Many physicians stopped using droperidol in 2001 due to the FDA “black box” restrictions on its use. However, the droperidol doses used for the management of PONV are extremely low, and it is believed that at these dosing levels, droperidol is unlikely to be associated with significant cardiovascular events. Several studies have documented the equal QTc effects of droperidol versus ondansetron. Due to this warning, droperidol is not the first choice for PONV prophylaxis in many countries.

Haloperidol has antiemetic properties when used in low doses and has been investigated as an alternative to droperidol. At doses much lower than those used to treat psychiatric disorders (0.5 to 2 mg IM or IV), haloperidol effectively reduced PONV risk. At these doses, sedation does not occur, and cardiac arrhythmias are not reported.

Haloperidol carries a risk of QTc prolongation in its label and is not recommended as first-line therapy. Haloperidol 1 mg IM or IV may be regarded as an alternative to droperidol.

Of potential interest, haloperidol may be given IM or orally. Its efficacy can be increased when combined with other antiemetics (dexamethasone or ondansetron). It should be noted that the use of haloperidol as an antiemetic or the IV route of administration is not an FDA-approved indication.

e) Antihistamines

Dimenhydrinate is an antihistamine with antiemetic effects. The recommended dose is 1 mg/kg IV. Data from placebo-controlled trials suggest that its antiemetic efficacy may be similar to the 5-HT3 receptor antagonists, dexamethasone, and droperidol. There is not enough data available to establish the optimal timing and dose response for dimenhydrinate administration or its side effect profile. Direct comparisons with other antiemetic drugs are lacking.

f) Anticholinergics

A systematic review of TDS showed that it is useful as an adjunct to other antiemetic therapies. The patch effectively prevented nausea and vomiting postoperatively up to 24 hours. It can be applied the evening before surgery or 2 to 4 hours before the start of anesthesia due to its 2- to 4-hour onset of effect.

Adverse effects associated with TDS are generally mild, the most common being visual disturbances, dry mouth, and dizziness. Dry mouth occurs mostly on the first day of use. A higher prevalence of visual disturbances can be observed at 24 to 48 hours. TDS is useful for control of nausea in the setting of PCA.

g) Other Antiemetics

Phenothiazines

Perphenazine is a phenothiazine derivative that has been used for the prevention of PONV at doses between 2.5 mg to 5 mg IV or IM. A systematic review from 6 RCTs demonstrated a relative risk reduction for PONV with a recommended dose of 5 mg IV, with no increase in sedation and drowsiness when compared with placebo.

Metoclopramide

Metoclopramide is a weak antiemetic and at a dose of 10 mg is not effective in reducing the incidence of nausea and vomiting. Despite having been used extensively in anesthetic practice, is not antiemetic in the recommended doses in the perioperative period. [11]

Metoclopramide's dose-response curve was evaluated in relation to other antiemetics. Metoclopramide high doses (25-50 mgr) are neccesaty to obtain an effect similar to ondansetron 4 mg. Dyskinesia or extrapyramidal symptoms can increase with increasing metoclopramide doses.

Propofol

Propofol is a sedative-hypnotic widely used for induction and maintenance of general anesthesia and monitored anesthesia care sedation with local or regional anesthesia. Numerous studies have demonstrated propofol has antiemetic properties. The median plasma propofol concentration associated with an antiemetic response was much lower (343 ng/ mL) than the concentration ranges associated with general anesthesia (3–6 mcg/mL) or sedation

(1–3 mcg/mL), allowing propofol to have antiemetic properties in the subhypnotic dose range.

Propofol used as part of TIVA is recommended to reduce baseline risk for PONV. The benefit of a small dose propofol infusion (bolus of 1 mg/kg followed by an infusion at 20 mcg/kg/min), either by itself or in combination with other antiemetics, has been shown to reduce PONV. Propofol, in small doses (20 mg as needed), can be used for rescue therapy for patients in the direct care environment, for example, PACU, and has been found as effective as ondansetron. However, the antiemetic effect with low doses of propofol is likely brief.

- *Alpha2-Agonists:* In a meta-analysis, perioperative systemic alpha2-adrenoceptor agonists (clonidine and dexmedetomidine) showed a significant albeit weak and short-lived antinausea effect. This effect may be explained by direct antiemetic properties of alpha2-agonists or its opioid-sparing effect, although the biological basis remains obscure.
- *Mirtazapine* is a noradrenergic and specific serotonergic antidepressant. Prophylactic mirtazapine delays the onset of PONV. Mirtazapine plus dexamethasone reduces the incidence of late PONV by >50% compared with dexamethasone alone. Less rescue medication is needed with the combination of antiemetics.
- *Gabapentin* doses of 600 mg per os given 2 hours before surgery effectively decreases PONV. Given 1 hour before surgery, gabapentin 800 mg per os is as effective as dexamethasone 8 mg IV, and the combination is better than either drug alone.
- *Midazolam* decreases nausea and vomiting compared with placebo. Midazolam 2 mg when administered 30 minutes before the end of surgery was as effective as ondansetron 4 mg. Midazolam 1 mg/h was as effective as a subhypnotic dose of propofol 1 mg/kg/h when given at the end of surgery. Midazolam 2 mg given 30 minutes before end of surgery decreased PONV more effectively than midazolam for premedication.

ANTIEMETIC PROPHYLAXIS ALGORITHM

There are at least four major receptor systems involved in the etiology of postoperative nausea and vomiting (PONV). The concept of combination antiemetic therapy was first introduced in 1988 by Parikh in chemotherapy induced vomiting. Its success prompted similar research in the field of PONV. There are enough evidence published comparing the relative efficacy of combination *vs* single agent antiemetic prophylaxis. [13] All these studies support the combination therapy for PONV. Apfel et al. demonstrated that the effects of antiemetics acting on different receptors are additive.

The efficacy of an intervention thus depends critically on patients' baseline risk. Interestingly, there were no significant interactions among the antiemetic interventions, among the anesthetic interventions, or among the antiemetics and the anesthetics. The resulting relative risk of nausea and vomiting associated with a combination of interventions can thus be directly calculated as the product of the individual relative risks. As a consequence, the absolute risk reduction provided by a second or third intervention is less

than that provided by the initial intervention (irrespective of which combination is chosen). Multiple interventions should thus generally be reserved for patients at high risk for postoperative nausea and vomiting or those in whom nausea and vomiting would be especially dangerous.

Because each tested antiemetic agent and the use of total intravenous anesthesia reduced the relative risk of nausea and vomiting to a similar extent, the logical sequence is to use the least expensive or safest intervention first. Additional interventions that cost more or that are associated with a greater chance of adverse effects will further reduce the absolute risk, but to a lesser extent than will the initial intervention. Combining prophylactic interventions therefore markedly increases costs and the likelihood of adverse effects while providing progressively less additional absolute benefit.

Management techniques such as total intravenous anesthesia cannot be used once postoperative nausea and vomiting have begun. Dexamethasone, similarly, prevents postoperative nausea and vomiting only when given near the beginning of surgery, probably by reducing surgery-induced inflammation. Moreover, "rescue" treatments are ineffective when the same drug has already been used prophylactically. [4, 11]

Adults at moderate risk for PONV should receive combination therapy with drugs from different classes as the efficacy is optimized when a combination of drugs with different mechanisms of action are administered.

The 5-HT3 antagonists have better antiemetic than antinausea efficacy but are associated with headache. These drugs can be used in combination with droperidol, which has greater antinausea efficacy and is associated with lower risk of headache. The 5-HT3 antagonists can also be effectively combined with dexamethasone. Combination therapy regimens using ondansetron with either droperidol or dexamethasone are most widely studied.

To know about dose-responsiveness is important for two reasons. First, when larger doses are not much more efficacious than smaller doses, the smaller doses are likely to be more cost-effective. Second, smaller doses may be less harmful. [14] It has been suggested that when used as combination therapy, dexamethasone doses should not exceed 10 mg IV, droperidol doses should not exceed 1 mg IV, and ondansetron doses in adults should not exceed 4 mg and can be much lower. Multiple studies confirm the effectiveness of combination therapy with dexamethasone.

Patient-Controlled Analgesia

Approximately one-third of patients who are treated with opioids for postoperative pain will have nausea and vomiting. Droperidol effectively reduced the risk of nausea and vomiting, when given concomitantly with morphine in a PCA device. Other studies evaluating the effects of various other antiemetics on PCA-related PONV showed a benefit (Ramosetron, Ondansetron, TDS).

Nonpharmacologic Prophylaxis

A meta-analysis of 40 articles including more than 4500 subjects concluded that P6 stimulation with different acupuncture modalities reduces nausea, vomiting, and the need for

rescue antiemetics compared with sham stimulation. The efficacy of P6 stimulation is similar to that of prophylactic antiemetics such as ondansetron, droperidol, metoclopramide, cyclizine, and prochlorperazine. In subgroup analysis, there was no difference in effectiveness in adults compared with children or invasive versus noninvasive modalities for P6 stimulation. The timing of transcutaneous acupoint electrical stimulation does not impact PONV, with similar reductions being achieved with stimulation initiated before or after induction of anesthesia. Neuromuscular stimulation over the median nerve also reduces the incidence of PONV in the early postoperative period, particularly when tetanic stimulation is used.

Other Methods and Alternative Therapies

Low-dose naloxone (0.25 mcg/kg/h), reduced nausea and vomiting and decreased the need for rescue medication compared with placebo. Lower infusion rates were also effective in reducing the incidence of nausea and sedation induced by tramadol infusion.

PONV TREATMENT

When nausea and vomiting occur postoperatively, treatment should be administered with an antiemetic from a pharmacologic class that is different from the prophylactic drug initially given. If no prophylaxis was given, the recommended treatment is a low-dose 5-HT3 antagonist. The 5-HT3 antagonists are the only drugs that have been adequately studied for the treatment of existing PONV. The doses of 5-HT3 antagonists used for treatment are smaller than those used for prophylaxis: ondansetron 1.0 mg; granisetron 0.1 mg; and tropisetron 0.5 mg. All the 5-HT3 antagonists, except palonosetron (that has not been studied for PONV treatment), are equally antiemetic for the treatment of established PONV.

Alternative treatments for established PONV include dexamethasone (2 to 4 mg IV), droperidol, (0.625 mg IV), or promethazine (6.25 to 12.5 mg IV). Propofol, 20 mg as needed, can be considered for rescue therapy in patients still in the PACU and is as effective as ondansetron. However, the antiemetic effect with low doses of propofol is probably brief.

Repeating the medication given for PONV prophylaxis within the first 6 hours after the initial dose conferred no additional benefit. During the first 4 postoperative hours, patients who failed PONV prophylaxis with ondansetron 4 mg did not respond either to a second administration of ondansetron 4 mg or to crossover with granisetron 0.1 or 1 mg.

If more than 6 hours has elapsed, it may be possible to achieve some effect with a second dose of a 5-HT3 antagonist or butyrophenone (droperidol or haloperidol), but this has not been demonstrated in clinical trials and should only be attempted if triple therapy has been used for prophylaxis and if no alternatives are available for rescue that have not been used for prophylaxis. Readministration of longer-acting drugs, for example, dexamethasone, TDS, aprepitant, and palonosetron is not recommended. The attempt at rescue should be initiated when the patient complains of PONV and, at the same time, an evaluation should be performed to exclude an inciting medication or mechanical factor for nausea and/or vomiting.

Contributing factors might include an opioid PCA, blood draining down the throat, or an abdominal obstruction. [1]

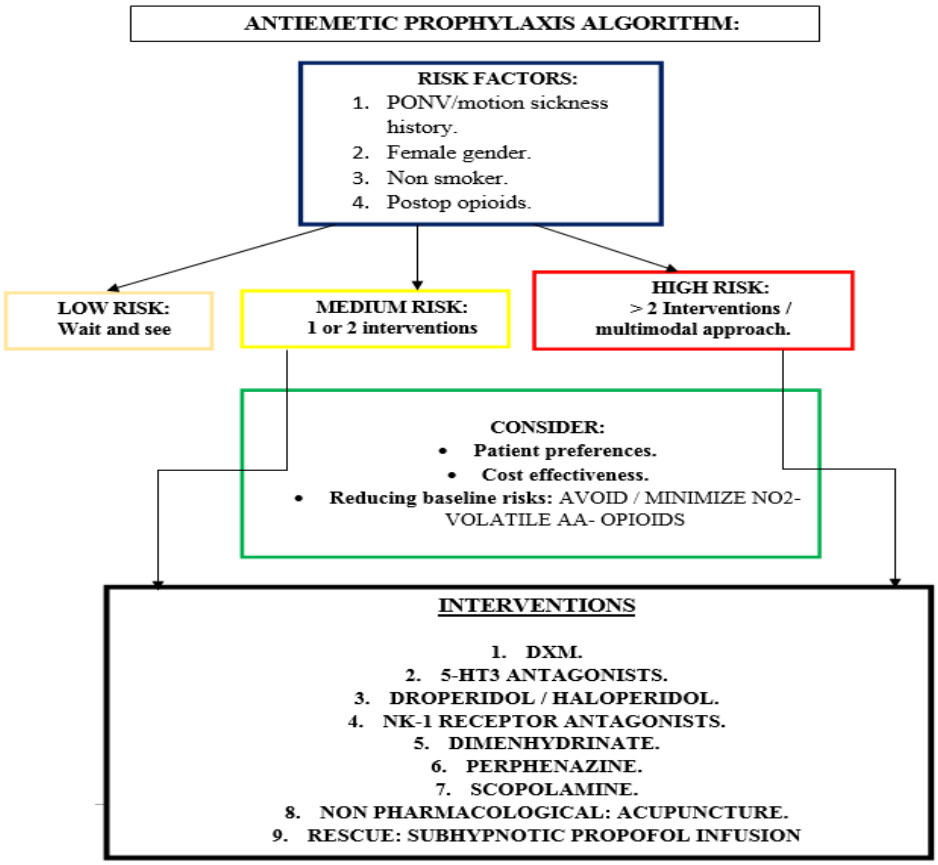

Figure 1. PONV prophylaxis.

KEY POINTS

1. Postoperative nausea and vomiting (PONV) are among the most common adverse events after bariatric surgery. Compared with other postoperative complications, PONV is of minor medical importance; it almost never kills, and it never becomes chronic. However, PONV may be very distressing for patients and workload for nursing staff is increased. Intractable PONV creates considerable extra costs for health care systems.
2. A patient´s baseline risk for PONV should be objectively assessed using a validated risk score (Apfel Score) that is based on independent predictors: female gender, history of PONV and/or motion sickness, nonsmoking status, and use of postoperative opioids.
3. PONV prophylaxis should be considered for patients at moderate to high risk for PONV. Among the interventions considered, a reduction in baseline risk factors and

use of nonpharmacologic therapy are least likely to cause adverse events. Depending on the level of risk, prophylaxis should be initiated with monotherapy or combination therapy using multiple interventions.

4. Antiemetic combinations are recommended for patients at moderate and high risk for PONV. Combining interventions has an additive effect in risk reduction.
5. The safety of antiemetics is well established considering the huge amount of clinical data available and their summary in valid meta-analyses. Limited adverse effects have been associated with the use of minimum effective doses of most recommended antiemetics.
6. When rescue therapy is required, the antiemetic should be chosen from a different therapeutic class than the drugs used for prophylaxis, and potentially one with a different mode of administration. If PONV occurs within 6 hours postoperatively, patients should not receive a repeat dose of the prophylactic antiemetic. An emetic episode more than 6 hours postoperatively can be treated with any of the drugs used for prophylaxis (except dexamethasone, TDS, aprepitant, and palonosetron).

REFERENCES

[1] Gan TJ, Diemunsch P, Habib AS, Kovac A, Kranke P, Meyer TA, Watcha M, Chung F, Angus S, Apfel CC, Bergese SD, Candiotti KA, Chan MT, Davis PJ, Hooper VD, Lagoo-Deenadayalan S, Myles P, Nezat G, Philip BK, Tramèr MR; Consensus guidelines for the management of postoperative nausea and vomiting. Society for Ambulatory Anesthesia. *Anesthesia & Analgesia:* January 2014 - Volume 118 - Issue 1 - p 85–113.

[2] Apfel CC, Heidrich FM, Jukar-Rao S, et al. Evidence-based analysis of risk factors for postoperative nausea and vomiting. *Br J Anaesth* 2012;109:742-53.

[3] Apfel CC, Philip BK, Cakmakkaya OS, Shilling A, Shi YY, Leslie JB, Allard M, Turan A, Windle P, OdomForren J, Hooper VD, Radke OC, Ruiz J, Kovac A. Who is at risk for postdischarge nausea and vomiting after ambulatory surgery? *Anesthesiology* 2012;117:475-86.

[4] Apfel CC, Korttila K, Abdalla M, Kerger H, Turan A, Vedder I, Zernak C, Danner K, Jokela R, Pocock SJ, Trenkler S, Kredel M, Biedler A, Sessler DI, Roewer N; IMPACT Investigators. A factorial trial of six interventions for the prevention of postoperative nausea and vomiting. *N Engl J Med* 2004;350:2441-51.

[5] Tramèr M, Moore A, McQuay H. Omitting nitrous oxide in general anesthesia: metaanalysis of intraoperative awareness and postoperative emesis in randomized controlled trials. *Br J Anaesth*. 1996;76:186-93.

[6] Apfel CC, Kranke P, Katz MH, Goepfert C, Papenfuss T, Rauch S, Heineck R, Greim CA, Roewer N. Volatile anesthetics may be the main cause of early but not delayed postoperative vomiting: a randomized controlled trial of factorial design. *Br J Anaesth* 2002;88:659-68.

[7] Guay J, Nishimori M, Kopp S. Epidural local anesthetics versus opioid-based analgesic regimens for postoperative gastrointestinal paralysis, vomiting and pain after abdominal surgery. *Cochrane Database Syst Rev.* 2016 Jul 16;7:CD001893.

[8] Weingarten TN, Hawkins NM, Beam WB, Brandt HA, Koepp DJ, Kellogg TA, Sprung Factors associated with prolonged anesthesia recovery following laparoscopic bariatric surgery: a retrospective analysis. *J. Obes Surg.* 2015 Jun;25(6):1024-30.

[9] Mendes MN, Monteiro Rde S, Martins FA. Prophylaxis of postoperative nausea and vomiting in morbidly obese patients undergoing laparoscopic gastroplasties: a comparative study among three methods. *Rev Bras Anestesiol.* 2009 Sep-Oct;59(5):570-6. Portuguese.

[10] Wang JJ, Ho ST, Tzeng JI, Tang CS. The effect of timing of dexamethasone administration on its efficacy as a prophylactic antiemetic for postoperative nausea and vomiting. *Anesth Analg* 2000; 91:136-9.

[11] Henzi I, Sonderegger J, Tramèr MR. Efficacy, dose-response, and adverse effects of droperidol for prevention of postoperative nausea and vomiting. *Can J Anaesth* 2000; 47:537-51.

[12] Sun R, Klein KW, White PF. The effect of timing of ondansetron administration in outpatients undergoing otolaryngologic surgery. *Anesth Analg* 1997; 84:331-6.

[13] Habib AS, El-Moalem HE, Gan TJ. The efficacy of the 5-HT3 receptor antagonists combined with droperidol for PONV prophylaxis is similar to their combination with dexamethasone. A meta-analysis of randomized controlled trials. *Can J Anaesth* 2004; 51:311–9.

[14] Kazemi-Kjellberg F, Henzi I, Tramèr MR. Treatment of established postoperative nausea and vomiting: a quantitative systematic review. *BMC Anesthesiol* 2001; 1:2-12.

[15] Liu FL, Cherng YG, Chen SY, Su YH, Huang SY, Lo PH, Lee YY, Tam KW. Postoperative recovery after anesthesia in morbidly obese patients: a systematic review and meta-analysis of randomized controlled trials. *Can J Anaesth.* 2015 Aug; 62(8):907-17.

In: Encyclopedia of Surgery (22 Volume Set)
Editors: Andreas Lehrer and Kristin Mueller
ISBN: 978-1-53618-329-0
© 2020 Nova Science Publishers, Inc.

Chapter 263

NUTRITIONAL PROPHYLAXIS: WEIGHT LOSS FOR THE REDUCTION OF SURGICAL RISK

Irene Portero Larragueta
Rey Juan Carlos Hospital, Móstoles, Madrid

ABSTRACT

Surgical risk depends directly on comorbidities, age, and body mass index. Obesity is not only associated with a wide range of comorbidities, is has important implications for them as well.

In fact, some of these comorbidities could be easily controlled or even cured just by loosing weight.

In this scenario, it seems logic that weight loss before bariatric surgery would reduce surgical risk in morbidity obese patients. This logic thinking has been demonstrated by many scientific studies and reviews.

Many techniques and diets have been tested over the last decade to achieve this goal.

Nowadays low calorie diets months before surgery, along with very low calorie diets 4 to 8 weeks prior to surgery seem to be the most effective approach.

Keywords: risk, comorbidities, preoperative

INTRODUCTION

Every surgical procedure has possible complications. The risk of having these complications in the perioperative period is what we call surgical risk. Many scores have been developed to predict postoperative outcomes, and have proven their efficacy over the past decade. One thing they have all in common is the importance of comorbidities to define surgical risk.

Obesity has implications for, and is associated with an important number of comorbidities, such as type-2 diabetes, cardiovascular and respiratory diseases and, even, some types of cancer.

Due to the unsatisfactory results with medical interventions, the number of bariatric surgeries has increased dramatically since 2000. In this time, surgical procedures have been improved with minimally invasive laparoscopic surgery and very short recovery times. This, along with the good results achieved (in terms of maintenance of weight loss, and improvement or resolution of associated diseases), have led to an increasing number of high-risk and older candidates to bariatric surgery.

SURGICAL RISK IN MORBID OBESE PATIENTS

There is little evidence to suggest that being moderate overweight would increase surgical risk in young adults, but morbidity and mortality increases dramatically if BMI > 30. The risk of premature death doubles in individuals with BMI > 35. Sudden unexplained death is 13 times more likely in morbidity obese women compared with non-obese.

Overweight men participating in the Framingham study had a mortality rate 3.9 times greater than the normal weight group. Morbidity obese patients are at a much greater risk of mortality from diabetes, cardiorespiratory and cerebrovascular disorders, as well as some types of cancer.

As has been said before, surgical risk depends directly on coexisting diseases. These are the most common comorbidities associated with morbid obesity, and the ones responsible for mayor postoperative complications at the same time:

1. Respiratory Comorbidities

Respiratory physiopathology of morbid obesity patients: lung compliance and functional residual capacity decline exponentially with increasing BMI, witch impairs the capacity to tolerate periods of apnea. Total respiratory resistance is increased, leading to an increase of work of breathing. Oxygen consumption and carbon dioxide production are increased due to a higher metabolic activity of the excess fat and the increased workload on supportive tissues. In exercise, oxygen consumption rises more sharply than in non-obese individuals, which implies respiratory muscle inefficiency. Defects in gas exchange are usually only modest, but this deteriorates dramatically on induction of anesthesia.

Obstructive sleep apnea: 5-10% of morbidity obese patients have OSA, and obesity is the principal risk factor of it. Recurrent and untreated apnea leads to hypoxemia and hypercapnia, which leads to polycythemia and increased risk of heart and cerebrovascular disease; and in extreme cases, right ventricular failure.

Obesity hypoventilation syndrome: it is a long term consequence of untreated OSA, in which the acid-base disorder remains present during the day.

Anesthetic Implications

Induction of anesthesia can be complicated in a patient with an increased risk of difficult or failed intubation. Mask ventilation is likely to be difficult because of upper airway obstruction and reduced pulmonary compliance. In this case, periods of hypoxemia and hypercapnia may increase pulmonary resistance and precipitate right heart failure.

Pulmonary complications are more common in the obese patient, and they are more sensitive to the effects of sedative drugs, which can increase their respiratory impairment in the postoperative period.

The hazards of OSA may be at their worst some days after surgery; with the obvious implications for the duration of postoperative oximetry and oxygen therapy.

2. Cardiovascular Comorbidities

Cardiovascular pathophysiology: total blood volume is increased with most of this extra volume distributed to the fat organ. There is a linear relationship between cardiac weight and body weight, as a consequence of dilation and eccentric hypertrophy of the left ventricle that results in reduced compliance and left ventricle diastolic function. Morbidity obese tolerate badly exercise with an increase in cardiac output being achieved by increasing heart rate without an increase in stroke volume or ejection fraction.

Hypertension: up to 60% of the obese patients suffer mild to moderate hypertension, and up to 10%, severe hypertension. The exact mechanism for hypertension in the obese is not known. Weight loss has been shown to reduce hypertension.

Ischemic heart disease: obesity is an independent risk factor for ischemic heart disease.

Cardiac arrhythmias: may be precipitated by: hypoxia, hypercapnia, coronary artery disease, OSA.

Anesthetic Implications

In order to avoid perioperative complications, the patient should have a detailed cardiovascular examination. Morbidity obese patients often have very limited activity and would appear to be asymptomatic even when they have significant cardiovascular disease. Hypertension and signs of heart failure must be investigated and, if found, correctly treated.

3. Diabetes Mellitus

Obesity is an important independent risk factor for type 2 diabetes. All obese patients undergoing bariatric surgery should be investigated for the presence of high blood glucose levels, and if needed, correctly treated. Uncontrolled high blood glucose levels increases wound infection and myocardial infarction risks.

4. Thromboembolic Disease

The risk of deep-vein thrombosis and pulmonary embolism of obese patients undergoing abdominal surgery (non-malignant) is twice the risk of non-obese patients in similar circumstances. It is the commonest complication after bariatric surgery, and pulmonary embolism remains the first mortality cause.

Many factors contribute to the increased risk: prolonged immobilization, polycythemia, increased abdominal pressure, cardiac failure and decrease of fibrinolytic activity.

Measures to prevent venous thromboembolism are mandatory.

Surgical Implications

Morbid obesity is an anesthetic challenge, but it is also associated with some surgical difficulties. Creation of and maintenance of pneumoperitoneum is particularly difficult, due to wall thickness; which leads to a poor visualization of the surgical field.

Other factors, such as hepatomegaly and intraabdominal fat tissue, could compromise surgical technique.

All of these challenges, could mean a longer surgery and, in some cases, the need of open field surgery.

WEIGHT LOSS REDUCES SURGICAL RISKS

The growing number of high-risk patients referred for bariatric surgery has stimulated investigators to expand preoperative assessment programs to attempt to identify surgical risk factors and to prepare patients better for surgery.

Studies have shown that high risk patients face much higher surgical risks than the morbidity and mortality rates described in recent literature. Optimal preparation for high-risk individuals with significant comorbid medical problems remains controversial. Various modalities that possibly decrease risk, including preoperative weight loss, intragastric balloon placement, and staging procedures, have been described.

It appears only logic that physiologic improvements associated with preoperative weight loss would reduce the rate of postoperative complications, which affect length of stay. Numerous reports have confirmed the beneficial effects of even limited weight loss on comorbid medical conditions, such as hypertension, diabetes mellitus, degree of visceral fat, liver size, thromboembolism predisposition, and severity of sleep apnea.

In fact, short-term modest weight loss has been shown to improve cardiometabolic parameters, thereby positively affecting the multiple medical problems.

For example, deep vein thrombosis complicated with pulmonary embolism, is the first cause of mortality in patients undergoing bariatric surgery; thus, improvements in blood coagulopathy and fibrinolysis and an increase in antithrombin III may be an important factor in reducing hospital lengths of stay. Morbidity obese patients with hepatomegaly from fat and glycogen infiltration can undergo increased operating room time and morbidity owing to the inability to retract the liver adequately and increased vascularity. Modest weight loss of just 5% to 10% has been shown to significantly reduce apneic episodes and improve gas exchange.

There is conflicting data in literature as to the true effect of a preoperative weight loss regimen on postoperative complications after bariatric surgery. In 2011, a systematic review concluded that “little evidence is available to support or refute the routine use of preoperative weight reduction in bariatric surgery”. This was also true regarding its effects on perioperative morbidity and postoperative complications. One main reason for the conflicting results might be the heterogeneity of study protocols and the relatively small number of included patients in most studies.

Given the low rates of mayor complications and mortality after bariatric surgery nowadays (3 and < 0'3% respectively), it is very difficult to find statistically significant differences in the studies. But what we do know is that this morbid-mortality is associated with three factors: male gender, older patients, and higher BMI; being this last one the only factor we can change.

Recent studies and reviews over the past five years give us now enough evidence to strongly recommend preoperative weight loss in all patients undergoing bariatric surgery.

In fact, although some of the complications are reduced in patients with low and medium-high BMI, there is a decrease in the relative risk of all complications in relation to the degree of preoperative weight loss in patients within the highest BMI range.

Reduced technical complexity after preoperative weight loss might be one possible explanation for the effect on postoperative complications. Numerous studies have demonstrated that a two weeks' low or very low calorie diets regimen reduce liver and visceral fat volume with improved visibility and access to the hiatal region.

Early complications such as infections and anastomotic leakage are also reduced. The most plausible explanation for the effects might be related to the fact that patients exposed to pre- operative VLCD could be expected to have a better glucose control in the postoperative period. It is amply demonstrated that a period of hypocaloric nutrition in obese, insulin-resistant subjects will improve insulin sensitivity, mainly due to depletion of glycogen stores and in- creased glucose uptake. Therefore, patients with improved insulin sensitivity before operation are likely to have better glucose control postoperatively, which has been convincingly demonstrated to be associated with improved outcome after surgery. This is in particular regarding infectious complications.

It seems that approximately 10% of total weight loss is to be recommended to achieve a more pronounced effect compared with a modest preoperative weight loss in the range of 5%. Moreover, patients in the higher range of BMI could be expected to benefit more from preoperative weight loss compared with patients with a less pronounced degree of obesity.

PREOPERATIVE NUTRITIONAL MANAGEMENT

The dramatic change to the bariatric surgery patient's digestive system after surgery warrants education and training prior to surgery. The first step in this process is the preoperative evaluation.

Medical history, laboratory tests and potentially psychiatric assessment and treatment are the major components of the assessment.

The patient's eating behaviour and weight history is an important part of the evaluation. Obtaining an overall view of the patient's nutrition history is important in determining potential barriers to a successful surgical outcome. Identifying these barriers may allow for planning and treatment protocols that increase the likelihood that those patients will achieve clinically significant weight loss post-surgery.

Surgical candidates should be seen by a registered dietitian or other nutrition expert, who will assess the patient's current diet and nutrition knowledge, and also provide education for the postoperative period.

The baseline lab levels can help to differentiate between complications, deficiencies due to the surgery, noncompliance with supplement regimen or pre-existing deficiencies.

In addition to the standard laboratory assessments, other social and demographic factors that could impact the patient's ability to comply with the guidelines should be assessed. As has been shown with many health behaviours, living in an environment that is supportive of positive changes is predictive of success in making changes.

Some of these factors may include ability to afford supplements, high-protein foods, access to food recommended, etc. Assessment of the impact of the patient's socioeconomic status on their surgical outcome is also an important factor to consider in the preoperative phase, especially because socioeconomic problems are prevalent in the bariatric surgery population.

Preoperative Diet

We should divide the preoperative period in two phases:

1. Early Phase

It begins at the very first time the patient is decided to enter a bariatric surgery protocol; and it would be extended throughout all preoperative assessments, tests, visits and preparations.

Morbidity obese patients have tried a very large number and different types of diets, supervised or not by physicians. And have lost and gain weight several times, making very hard for them to really compromise with any nutritional treatment.

At this early stage, a not very restrictive low calorie diet must be initiated (1200-1500kcal/day). Patient should be talk into all the beneficial effects of weight loss before surgery. It must be explained that the ultimate purpose of this diet is a slow weight loss in order to reduce surgical risks and complications. We are looking for an 8% reduction in body weight in 4-6 months.

Besides the primary goal of reducing surgical risks, adherence to nutritional treatment can help the surgeon choose the optimal surgical technique.

There are four types of diet attending to their composition:

Low energy diet: 800-1500kcal/day, balanced (10-15% protein, 50-65% carbohydrates and 25-35% fat). A rapid weight loss can be achieved, but it is usually rapidly regain due to lack of treatment adherence.

Low carbohydrate diet: < 30% carbohydrates, and > 40% fat. Weight loss is fast because of both fat intake and own fat tissue lipolysis. This diet improves insulin resistance, but is associated with and increased LDL-cholesterol levels. They show an important weight loss in 6 months, but it is regained in less than 12 months.

Low fat diet: fat restriction should be the first approach, due to its energetic value. A Cochrane review shows that the sole fat restriction does not lead to a higher weight loss than any other type of diet, concluding that what matters is the energy restriction.

High protein diet: protein is the most satiating nutrient, making the energy intake in this diet very low. On the other hand, cholesterol and uric acid increases because of the increase of animal fats.

Actual scientific evidence recommends a balanced low energy diet, not very restrictive in order to maintain treatment adherence.

It is also important a correct meal planning, dividing daily intake in 5 to 6 meals, reducing fasting periods.

2. Immediate Preoperative Period

Between 2 to 8 weeks prior to surgery, with the aim to obtain a 5-10% of weight loss to reduce surgical risks and facilitate surgical technique as has been exposed.

The very low calorie diet at this phase can be achieved only by a very restrictive diet, by substituting meals with specially designed very low-calorie formulas or by a combination of the two of those approaches, each of them with advantages and disadvantages:

Diet: very low calorie diet means a 450-800kcal/day intake. They are cheap, but difficult to assume. Morbid obese patients are used to large energy intakes, and they are ussually not able to stick to them.

Formulas: the very low calorie diet (600kcal/day) is achieved from commercially available specialities in different forms (sachets for smoothies or soup 200kcal each). They have a very tight composition, high protein (50g of high biological value protein), with 13.5 grams of fat and 67.5 grams of carbohydrates, plus vitamins and trace elements. Daily intake of two litres of water is recommended, because its main side effect is constipation. Treatment duration longer than 8 to 10 weeks of is not recommended unless the supervision of an endocrinologist, to monitor both liver and kidney function.

Some studies have shown higher rates in weight loss leading to a mayor risk reduction.

The principal challenge of this diet is the treatment adherence, which can be difficult to some patients, due to the lack of variety in flavours or textures.

This is why some groups support the combination of the two approaches.

Other strategies: The use of an intragastric balloon before surgery has been studied especially in super obese patients (Body mass index above 50 and even 60kg/m2). For its placement it is required an upper gastrointestinal endoscopy under sedation or general anaesthesia, which has to be repeated for its withdrawal, six months after its placement. There are some contraindications to its use as the presence of ulcerative disease or previous gastric surgery. Complications occurred in 10% (desuflation, migration, vomiting) requiring sometimes the early withdrawal before reaching its target. Nowadays it is not recommended.

REFERENCES

Adrianzén Vargas, M., Cassinello Fernández, N., Ortega Serrano, J. Preoperative weight loss in patients with indication of bariatric surgery:which is the best method? *Nutr. Hosp*., 2011; 26:1227-1230.

Alami, R. S., Morton, J. M., Schuster, R., et al. Is there a benefit to preoperative weight loss in gastric bypass patients? A prospective randomized trial. *Surg. Obes. Relat. Dis.*, 2007; 3:141–145; discussion 145–146.

Alvarado, R., Alami, R., Hsu, G. et al. The impact of preoperative weight loss in patients undergoing laparoscopic Roux-en-Y gastric bypass. *Obes. Surg*., 2005; 15: 1282- 1286.

Benotti, P. N., Still, C. D., Wood, G. C., et al. Preoperative Weight Loss Before Bariatric Surgery. *Arch. Surg*., 2009; 144: 1150–1155.

Busetto, L., Segato, G., De Luca, M. et al. Preoperative weight loss by Intragastric Balloon in super-obese patients treated with laparoscopic gastric banding: A case-control study. *Obes. Surg*., 2004; 14, 671-676.

Carbajo, M. A., Castro, M. J., Kleinfinger, S., et al. Effects of a balanced energy and high protein formula diet (Vegestart complet®) vs. low-calorie regular diet in morbid obese patients prior to bariatric surgery (laparoscopic single anastomosis gastric bypass): a prospective, double-blind randomized study. *Nutr. Hosp*., 2010; 25:939-948.

Cassie, S., Menezes, C., Birch, D. W., et al. Effect of preoperative weight loss in bariatric surgical patients: a systematic review. *Surg. Obes. Relat. Dis.*, 2011; 7:760–767; discussion 767.

Christopher, D. Still, Peter Benotti, G. Craig Wood, Glenn, S. Gerhard, Anthony Petrick, Mary Reed, William Strodel. Outcomes of Preoperative Weight Loss in High-Risk Patients Undergoing Gastric Bypass Surgery. *Arch. Surg*., 2007; 142(10):994-998.

Claes Anderin, Ulf. O. Gustafsson, Niklas Heijbel, Anders Thorell. Weight Loss Before Bariatric Surgery and Postoperative Complications. Data From the Scandinavian Obesity Registry (SOReg). *Ann. Surg*., 2015; 261:909–913.

Colles, S. L., Dixon, J. B., Marks, P., et al. Preoperative weight loss with a very – low - energy diet: quantitation of changes in liver and abdominal fat by serial imaging. *Am. J. Clin. Nutr*., 2006; 84:304–311.

DeMaria, E. J., Murr, M., Byrne, T., et al. Validation of the obesity surgery mortality risk score in a multicenter study proves it stratifies mortality risk in patients undergoing gastric bypass for morbidobesity. *Ann. Surg*., 2007; 246:578–584.

Edholm, D., Kullberg, J., Haenni, A., et al. Preoperative 4-week low-calorie diet reduces liver volume and intrahepatic fat, and facilitates laparoscopic gastric bypass in morbidly obese. *Obes. Surg.*, 2011; 21: 345–350.

Fernández Meré, L. Obesidad, anestesia y cirugía bariátrica. *Rev. Esp. Anestesiol. Reanim*., 2004; 51: 80-94.

Livhits, M., Mercado, C., Yermilov, I., et al. Does weight loss immediately before bariatric surgery improve outcomes: a systematic review. *Surg. Obes. Relat. Dis.*, 2009; 5:713–721.

Liu, R. C., Sabnis, A., Forsyth, C. C., et al. The effects of acute preoperative weight loss on laparoscopic Roux-en-Y gastric bypass. *Obes. Surg.,* 2005; 15: 1396-1402.

Mrad, B. A., Stoklossa, C. J., Birch, D. W. Does preoperative weight loss predict success following surgery for morbid obesity? *Am. J. Surg.,* 2008; 195:570-573.

Peter, N. Benotti, Christopher D. Still, G. Craig Wood, Yasir Akmal, Heather King, Hazem El Arousy, Horatiu Dancea, Glenn S. Gerhard, Anthony Petrick, William Strodel. Preoperative Weight Loss Before Bariatric Surgery. *Arch. Surg.*, 2009 December; 144(12): 1150–1155.

Pournaras, D. J., Osborne, A., Hawkins, S. C., et al. Remission of type 2 diabetes after gastric bypass and banding: mechanisms and 2 year outcomes. *Ann. Surg*., 2010; 252:966–971.

Riess, K. P., Baker, M. T., Lambert, P. J., et al. Effect of preoperative weight loss on laparoscopic gastric bypass outcomes. *Surg. Obes. Relat. Dis*., 2008; 4:704-708.

Ruiz-Tovar, J., Oller, I., Llavero, C., et al. Pre-Operative and Early Post-Operative Factors Associated with Surgical Site Infection after Laparoscopic Sleeve Gastrectomy. *Surg. Infect*., 2013; 14:369-373.

Still, C. D., Peter Benotti, P., Craig Wood, C. et al. Outcomes of preoperative weight loss in high-risk patients undergoing gastric bypass surgery. *Arch. Surg.*, 2007; 42;10: 994-998.

Van Nieuwenhove, Y., Dambrauskas, Z., Campillo-Soto, A., et al. Preoperative very low-calorie diet and operative outcome after laparoscopic gastric bypass: a randomized multicenter study. *Arch. Surg.*, 2011; 146:1300–1305.

In: Encyclopedia of Surgery (22 Volume Set)
Editors: Andreas Lehrer and Kristin Mueller
ISBN: 978-1-53618-329-0
© 2020 Nova Science Publishers, Inc.

Chapter 264

PROPHYLAXIS OF POSTOPERATIVE CHOLELITHIASIS

Dennis Cesar Levano-Linares[1,*], MD, Patricia Sanchez-Salcedo[2,†], Gustavo Díaz García[1], MD, David Alías Jimenez[1], MD, PhD, Manuel Durán Poveda[1], MD, PhD and Jaime Ruíz-Tovar[1], MD, PhD

[1]Department of Surgery, University Hospital Rey Juan Carlos, Mostoles, Madrid, Spain
[2]Department of Surgical Nursery, Fundacion Jimenez Diaz, Madrid, Spain

ABSTRACT

In recent years, the prevalence of morbid obesity treated with bariatric surgery has increased rapidly. Surgery has been demostrated to be the most effective method to achieve long-term sustained weight loss in the morbidly obese with resolution of most co-morbilities. Some studies indicated a high prevalence of gallstone disease of 10–20% in the general population in industrialized nations. However, only 1–5% of the patients will progress to a symptomatic disease necessitating a cholecystectomy. The prevalence of cholelithiasis, symptomatic or not, is directly correlated to the body mass index (BMI).

In patients after bariatric surgery, the incidence of gallstones or sludge is clearly higher compared to the overall population, ranging from 28 to 71%. These can cause serious problems such as acute cholecystitis, choledocholithiasis and pancreatitis.

Rapid weight loss and altered gallbladder function increase the risk of biliary stone formation. Therefore, the surgical technique chosen in each patient may play an important role in the formation of postoperative cholelithiasis in the medium or long term.

Keywords: bariatric surgery, cholelithiasis

∗ Corresponding Author's Email: cesdenlinares@gmail.com.
† Patricia Sanchez-Salcedo, RN.

INTRODUCTION

In recent years, the prevalence of morbid obesity treated with bariatric surgery has increased rapidly [1]. Cholelithiasis is not uncommon after weight-reduction surgery. This phenomenon was observed and reported in the early 1990s among patients with rapid weight loss [2, 3].

The incidence of cholelithiasis that has been detected with the ultrasound (US) was reported at 45% in the obese population. Moreover, the prevalence of gallbladder disease is nearly 2-fold higher than that which had been detected within the US when evaluated by gross and histologic examination after cholecystectomy [4]. Obese individuals have a higher prevalence of not only cholelithiasis but also complications like cholecystitis, obstructive jaundice, and pancreatitis when compared with the nonobese population [5]. Despite such high incidence, to perform a cholecystectomy for asymptomatic gallbladder disease in obese patients is not routinely recommended because it can lead to higher morbidity [6].

While the risk of gallstone formation increases 8-fold in patients with BMI >40kg/m2 [7], it also increases 5-fold in patients who underwent bariatric surgery compared with normal population [8].

Bariatric surgery causes rapid weight loss and cholelithiasis is common after surgery, with a high incidence within the first 12 months following the procedure. There are many factors associated with the development of gallstones, but the most important are female sex, age >40 years old, and a fast weight loss (losing more than 1.5 kg weekly) [9, 10]. Also, hyper saturation of bile with cholesterol, decreased gallbladder contractility for division of hepatic branch of the vagus nerve, increased levels of mucin that promote the precipitation of crystals contribute to gallstone formation [4, 11].

There is not a clear consensus for the management of gallbladder pathology associated with bariatric surgery patients, especially in asymptomatic cases. There is a wide variety of treatments, such as ¨preventive¨ preoperative, prophylactic concomitant or postoperative cholecystectomy. Other options include medical (ursodeoxycholic acid) and conservative (observational) management.

SURGICAL TECHNIQUE AND CHOLELITHIASIS

The question: "What bariatric procedure increases the risk of cholelithiasis and/or choledocholithiasis?" has promoted several studies and it was concluded that the main component that leads to the formation of gallstones was the rapid loss of weight, mainly in the first 6 months, regardless of the technique chosen [12].

In malabsorptive procedures, such as laparoscopic Roux-en-Y gastric bypass (LRYGB), cholelithiasis develops due to changes in the composition of bile, with increases in the calcium and mucin contents leading to the formation of supersaturated or lithogenic bile that crystalizes, deposits, and eventually forms cholesterol gallstones [13]. However, since laparoscopic sleeve gastrectomy (LSG) is a purely restrictive procedure with an intact bowel transit and entero-endocrine system, the details of the mechanism of cholelithiasis development after LSG remain unclear. It was assumed that the division of the lesser omentum during bariatric procedures may cause inadvertent injury to the haptic branch of the

left vagus nerve, which controls the gallbladder motility [14, 15]; motility dysfunction can thus supervene, resulting in stasis of bile and subsequently cholelithiasis.

Cholelithiasis expected to be less common after LSG or laparoscopic gastric banding (LGB) than LRYGB, because the nutrients continue to follow the normal gastrointestinal tractus [16, 17]. Nevertheless, it was reported no difference in gallstone formation between LSG and LRYGB [16]. Likewise, the highest frequency of cholelithiasis was reported as 71% in patients who underwent LRYGB [18]. Controversially, only 3-16% of these patients turn into symptomatic cases [19-21]. In another retrospective analyze of 1397 bariatric surgery patients (32-month mean follow-up), the incidence of post-bariatric surgery development of cholelithiasis was 10.53% (8.42% for LSG, 13.4% for LRYGB, and 12.7% for mini gastric bypass) and the highest incidence of symptomatic cholelithiasis requiring surgery was detected in LRYGB group (4.54%) [20].

PROPHYLACTIC CONCOMITANT CHOLECYSTECTOMY

Concomitant cholecystectomy (CC) during open bariatric surgery was a common practice at the beginning. The rate of CC has decreased with the development of laparoscopic surgery and most surgeons abstained from CC [22, 23].

Today, there is no consensus on the management of the gallbladder at the time of bariatric surgery. Some authors CC due to probability of postoperative complications and long hospitalization [7]. Controversially, some also reported decreasing rate of postoperative complications and hospitalization time after CC in patients with bypass surgery.

Studies about gallbladder pathologies with the comparison of bariatric procedures give conflicting results. Tsirline et al. reported a 3-fold increase in cholecystectomy incidence after LRYGB when compared to LSG (10.6 vs. 3.5%) [24]. On the other hand, it was reported that the frequency of symptomatic gallstones after LRYGB and LSG was not significantly different (6.1 vs. 5.7%) [25].

As a result, management of asymptomatic gallbladder stones for LSG and LRYGB should be different.

LRYGB

LRYGB is currently the standard bariatric procedure. The gallbladder management during LRYGB is controversial. Three different approaches have been proposed: first, prophylactic CC in all obese patients undergoing LRYGB [26-28]; second, a selective approach, based on which cholecystectomy is only performed in the presence of gall stones [10, 29, 30] or biliary symptoms [31-33]; third, a wait and see approach, based on which no CC is performed and patients receive prophylactic medication against biliary disease like ursodeoxycholic acid [34, 35].

The latest Bariatric Surgery Guidelines suggest that patients undergoing LGBP also undergo prophylactic cholecystectomy (with a positive US) to prevent gallbladder complications (grade B).

In a meta-analysis based on 13 studies including 6,048 patients provides profound evidence that a prophylactic CC during LRYGB should be avoided in patients without cholelithiasis and exclusively be performed in patients with symptomatic biliary disease. Only 6.8% of the patients without CC during LRYGB progress to symptomatic disease requiring a cholecystectomy. One of the reasons to routinely perform a CC with LRYGB is the concern of later severem biliary complications such as choledocholithiasis or biliary pancreatitis, particularly since endoscopic retrograde cholangiopancreatography (ERCP) is difficult if not impossible to perform after LRYGB. However, the existing data for the general population in industrialized nations indicate that the majority of patients rarely develop complications without first having at least one previous episode of biliary colic [36-39]. Therefore, choledocholithiasis and biliary pancreatitis does certainly not justify a CC as a routine procedure during LRYGB for obese patients. More importantly, however, the CC increased the overall perioperative complication rate by 1.1% (6.2% with CC versus 5.1% without CC).

One mea-analysis provides compelling evidence that prophylactic cholecystectomy in the absence of biliary disease at the time of LRYGB should be avoided. The risk to develop choledocholithiasis or biliary pancreatitis is very low in patients without undergoing a CC during LRYGB.

LSG

There is a paucity of data regarding preoperative evidence of gallstones, incidence of cholelithiasis with concomitant complications, and gallstone formation after LSG. There are only a few studies comparing bariatric procedures concerning gallbladder disease, but the majority of the patients had been performed LRYGB in these studies [4, 12, 17]. Although the incidence of symptomatic gallstones requiring cholecystectomy after LSG was reported as 0.9–7.5%, in two different studies [40, 41], there is insufficient evidence about patient selection for CC, and prophylactic cholecystectomy has never been recommended during LSG.

LSG does not include any bypassed intestinal segment and therefore does not affect the entero-hepatic circulation so endoscopic treatment of bile duct stones would be easier when needed.

Despite CC being reported as safe during LSG, the largest study, with 180 patients, includes intraoperative bile duct injuries with a ratio of 1.1% [42]. Although this ratio can be considered as acceptable, management of bile duct injuries will be more complicated in an obese patient especially in the early postoperative period of bariatric surgery, and evenmortality can occur. Additionally, CC prolongs the operative time and may need additional trocars for optimal access.

Today, it is suggested only observation for asymptomatic gallbladder stones for several reasons. First, cholecystectomy in obese patients may be technically challenging due to body habitus and high intra-abdominal pressure [43]. Second, conventional trocar placement of bariatric surgery and cholecystectomy are different, and this may cause visual and procedural difficulties. Third, the anatomy after LSG allows endoscopic management of bile duct stones when needed. Finally, obesity is reported as a risk factor for conversion to open surgery and bile duct injuries [44, 45].

PROPHYLACTIC URSODEOXYCHOLIC ACID THERAPY

Ursodeoxycholic acid (UDCA) is generally used to dissolve gallstones in patients who do not want surgery as the first treatment option and is also indicated in patients with a high risk of cholecystectomy. UDCA is a bile acid and normally it is produced by the body that is stored in the gallbladder. UDCA acts by inhibiting cholesterol secretion in bile, thereby preventing the supersaturation of bile and cholesterol stone formation.

In literature, UDCA use has been supported after bariatric surgery, especially within the first 6 months after surgery for preventing gallstone formation.

Analysis of different dosages has suggested that 300–600mg/day significantly reduces gallstone formation and can be used in patients after bariatric surgery without associated cholecystectomy (grade A). A recent meta-analysis of 5 randomized controlled trials involving 521 patients found that the rate of gallbladder disease/ gallstone formation was significantly lower in patients receiving postoperative ursodiol (8.8 vs. 27.7%; $p = 0.01$). Most of the benefits of such management have been observed within the first 6 months; longer follow-up found no difference in the incidence of de novo gallbladder disease [46]. Because of the heterogeneity of available studies, it has not been clearly established whether this treatment affected the rates of symptomatic disease and emergency cholecystectomy [47].

Another concern is related to the side effects of ursodeoxycholic acid, including diarrhea, skin rash, and decompensation of previous liver diseases [48], which can result in lower patient compliance [10].

REFERENCES

[1] Kohn, G. P., Galanko, J. A., Overby, D. W., Farrell, T. M. Recent trends in bariatric surgery case volume in the United States. *Surgery*, 2009; 146(2):375-80.

[2] Bennion, L. J., Grundy, S. M. Risk factors for the development of cholelithiasis in man (second of two parts). *N Engl. J. Med.*, 1978; 299(22):1221-7.

[3] Diehl, A. K. Epidemiology and natural history of gallstone disease. *Gastroenterol. Clin. North Am.*, 1991; 20(1):1-19.

[4] Shiffman, M. L., Sugerman, H. J., Kellum, J. M., Brewer, W. H., Moore, E. W. Gallstone formation after rapid weight loss: a prospective study in patients undergoing gastric bypass surgery for treatment of morbid obesity. *Am. J. Gastroenterol*., 1991; 86(8): 1000-5.

[5] Torgerson, J. S., Lindroos, A. K., Näslund, I., Peltonen, M. Gallstones, gallbladder disease, and pancreatitis: cross-sectional and 2-year data from the Swedish Obese Subjects (SOS) and SOS reference studies. *Am. J. Gastroenterol*., 2003; 98(5):1032-41.

[6] Worni, M., Guller, U., Shah, A., Gandhi, M., Shah, J., Rajgor, D., et al. Cholecystectomy concomitant with laparoscopic gastric bypass: a trend analysis of the nationwide inpatient sample from 2001 to 2008. *Obes. Surg*., 2012; 22(2):220-9.

[7] Grover, B. T., Kothari, S. N. Biliary issues in the bariatric population. *Surg. Clin. North Am*., 2014; 94(2):413-25.

[8] Jonas, E., Marsk, R., Rasmussen, F., Freedman, J. Incidence of postoperative gallstone disease after antiobesity surgery: population-based study from Sweden. *Surg. Obes. Relat. Dis*., 2010; 6(1):54-8.

[9] Iglézias Brandão de Oliveira, C., Adami Chaim, E., da Silva, B. B. Impact of rapid weight reduction on risk of cholelithiasis after bariatric surgery. *Obes. Surg*., 2003; 13(4):625-8.

[10] Villegas, L., Schneider, B., Provost, D., Chang, C., Scott, D., Sims, T., et al. Is routine cholecystectomy required during laparoscopic gastric bypass? *Obes. Surg*., 2004; 14(2):206-11.

[11] Shiffman, M. L., Shamburek, R. D., Schwartz, C. C., Sugerman, H. J., Kellum, J. M., Moore, E. W. Gallbladder mucin, arachidonic acid, and bile lipids in patients who develop gallstones during weight reduction. *Gastroenterology*, 1993; 105(4):1200-8.

[12] Coupaye, M., Castel, B., Sami, O., Tuyeras, G., Msika, S., Ledoux, S. Comparison of the incidence of cholelithiasis after sleeve gastrectomy and Roux-en-Y gastric bypass in obese patients: a prospective study. *Surg. Obes. Relat. Dis*., 2015; 11(4):779-84.

[13] Manatsathit, W., Leelasincharoen, P., Al-Hamid, H., Szpunar, S., Hawasli, A. The incidence of cholelithiasis after sleeve gastrectomy and its association with weight loss: A two-centre retrospective cohort study. *Int. J. Surg*., 2016; 30:13-8.

[14] Shaffer, E. A. Review article: control of gall-bladder motor function. *Aliment Pharmacol. Ther.*, 2000; 14 Suppl. 2:2-8.

[15] Muramatsu, S., Sonobe, K., Tohara, K., Tanaka, T., Mizumoto, A., Ibuki, R., et al. Effect of truncal vagotomy on gallbladder bile kinetics in conscious dogs. *Neurogastroenterol. Motil.*, 1999; 11(5): 357-64.

[16] Li, V. K., Pulido, N., Martinez-Suartez, P., Fajnwaks, P., Jin, H. Y., Szomstein, S., et al. Symptomatic gallstones after sleeve gastrectomy. *Surg. Endosc*., 2009; 23(11):2488-92.

[17] Li, V. K., Pulido, N., Fajnwaks, P., Szomstein, S., Rosenthal, R., Martinez-Duartez, P. Predictors of gallstone formation after bariatric surgery: a multivariate analysis of risk factors comparing gastric bypass, gastric banding, and sleeve gastrectomy. *Surg. Endosc.*, 2009; 23(7):1640-4.

[18] Wudel, L. J., Wright, J. K., Debelak, J. P., Allos, T. M., Shyr, Y., Chapman, W. C. Prevention of gallstone formation in morbidly obese patients undergoing rapid weight loss: results of a randomized controlled pilot study. *J. Surg. Res*., 2002; 102(1):50-6.

[19] Taylor, J., Leitman, I. M., Horowitz, M. Is routine cholecystectomy necessary at the time of Roux-en-Y gastric bypass? *Obes. Surg.*, 2006; 16(6):759-61.

[20] Mishra, T., Lakshmi, K. K., Peddi, K. K. Prevalence of Cholelithiasis and Choledocholithiasis in Morbidly Obese South Indian Patients and the Further Development of Biliary Calculus Disease After Sleeve Gastrectomy, Gastric Bypass and Mini Gastric Bypass. *Obes. Surg.*, 2016; 26(10):2411-7.

[21] Lalor, P. F., Tucker, O. N., Szomstein, S., Rosenthal, R. J. Complications after laparoscopic sleeve gastrectomy. *Surg. Obes. Relat. Dis*., 2008; 4(1):33-8.

[22] Liem, R. K., Niloff, P. H. Prophylactic cholecystectomy with open gastric bypass operation. *Obes. Surg*., 2004; 14(6):763-5.

[23] Weiss, A. C., Inui, T., Parina, R., Coker, A. M., Jacobsen, G., Horgan, S., et al. Concomitant cholecystectomy should be routinely performed with laparoscopic Roux-en-Y gastric bypass. *Surg. Endosc.*, 2015; 29(11):3106-11.

[24] Tsirline, V. B., Keilani, Z. M., El Djouzi, S., Phillips, R. C., Kuwada, T. S., Gersin, K., et al. How frequently and when do patients undergo cholecystectomy after bariatric surgery? *Surg. Obes. Relat. Dis*., 2014; 10(2):313-21.

[25] Moon, R. C., Teixeira, A. F., DuCoin, C., Varnadore, S., Jawad, M. A. Comparison of cholecystectomy cases after Roux-en-Y gastric bypass, sleeve gastrectomy, and gastric banding. *Surg. Obes. Relat. Dis.*, 2014; 10(1):64-8.

[26] Ahmed, A. R., O'Malley, W., Johnson, J., Boss, T. Cholecystectomy during laparoscopic gastric bypass has no effect on duration of hospital stay. *Obes. Surg*., 2007; 17(8):1075-9.

[27] Kim, J. J., Schirmer, B. Safety and efficacy of simultaneous cholecystectomy at Roux-en-Y gastric bypass. *Surg. Obes. Relat. Dis.*, 2009; 5(1):48-53.

[28] Nougou, A., Suter, M. Almost routine prophylactic cholecystectomy during laparoscopic gastric bypass is safe. *Obes. Surg.*, 2008; 18(5): 535-9.

[29] Hamad, G. G., Ikramuddin, S., Gourash, W. F., Schauer, P. R. Elective cholecystectomy during laparoscopic Roux-en-Y gastric bypass: is it worth the wait? *Obes. Surg*., 2003; 13(1):76-81.

[30] Tucker, O. N., Fajnwaks, P., Szomstein, S., Rosenthal, R. J. Is concomitant cholecystectomy necessary in obese patients undergoing laparoscopic gastric bypass surgery? *Surg. Endosc.*, 2008; 22(11): 2450-4.

[31] D'Hondt, M., Sergeant, G., Deylgat, B., Devriendt, D., Van Rooy, F., Vansteenkiste, F. Prophylactic cholecystectomy, a mandatory step in morbidly obese patients undergoing laparoscopic Roux-en-Y gastric bypass? *J. Gastrointest. Surg*., 2011; 15(9):1532-6.

[32] Patel, J. A., Patel, N. A., Piper, G. L., Smith, D. E., Malhotra, G., Colella, J. J. Perioperative management of cholelithiasis in patients presenting for laparoscopic Roux-en-Y gastric bypass: have we reached a consensus? *Am. Surg*., 2009; 75(6):470-6; discussion 6.

[33] Swartz, D. E., Felix, E. L. Elective cholecystectomy after Roux-en-Y gastric bypass: why should asymptomatic gallstones be treated differently in morbidly obese patients? *Surg. Obes. Relat. Dis.*, 2005; 1(6):555-60.

[34] Scott, D. J., Villegas, L., Sims, T. L., Hamilton, E. C., Provost, D. A., Jones, D. B. Intraoperative ultrasound and prophylactic ursodiol for gallstone prevention following laparoscopic gastric bypass. *Surg. Endosc*., 2003; 17(11):1796-802.

[35] Tucker, O., Soriano, I., Szomstein, S., Rosenthal, R. Management of choledocholithiasis after laparoscopic Roux-en-Y gastric bypass. *Surg. Obes. Relat. Dis*., 2008; 4(5):674-8.

[36] Sakorafas, G. H., Milingos, D., Peros, G. Asymptomatic cholelithiasis: is cholecystectomy really needed? A critical reappraisal 15 years after the introduction of laparoscopic cholecystectomy. *Dig. Dis. Sci*., 2007; 52(5):1313-25.

[37] Attili, A. F., Capocaccia, R., Carulli, N., Festi, D., Roda, E., Barbara, L., et al. Factors associated with gallstone disease in the MICOL experience. Multicenter Italian Study on Epidemiology of Cholelithiasis. *Hepatology*, 1997; 26(4):809-18.

[38] Muhrbeck, O., Ahlberg, J. Prevalence of gallstone disease in a Swedish population. *Scand. J. Gastroenterol*., 1995; 30(11):1125-8.

[39] Beckingham, I. J. ABC of diseases of liver, pancreas, and biliary system. Gallstone disease. *BMJ*, 2001; 322(7278):91-4.

[40] Dakour Aridi, H., Sultanem, S., Abtar, H., Safadi, B. Y., Fawal, H., Alami, R. S. Management of gallbladder disease after sleeve gastrectomy in a selected Lebanese population. *Surg. Obes. Relat. Dis.*, 2016; 12(7):1300-4.

[41] Hasan, M. Y., Lomanto, D., Loh, L. L., So, J. B. Y., Shabbir, A. Gallstone Disease After Laparoscopic Sleeve Gastrectomy in an Asian Population-What Proportion of Gallstones Actually Becomes Symptomatic? *Obes. Surg.*, 2017; 27(9):2419-23.

[42] Raziel, A., Sakran, N., Szold, A., Goitein, D. Concomitant cholecystectomy during laparoscopic sleeve gastrectomy. *Surg. Endosc.*, 2015; 29(9):2789-93.

[43] Lambert, D. M., Marceau, S., Forse, R. A. Intra-abdominal pressure in the morbidly obese. *Obes. Surg.*, 2005; 15(9):1225-32.

[44] Pavlidis, T. E., Marakis, G. N., Ballas, K., Symeonidis, N., Psarras, K., Rafailidis, S., et al. Risk factors influencing conversion of laparoscopic to open cholecystectomy. *J. Laparoendosc. Adv. Surg. Tech. A.*, 2007; 17(4):414-8.

[45] Aziz, H., Pandit, V., Joseph, B., Jie, T., Ong, E. Age and Obesity are Independent Predictors of Bile Duct Injuries in Patients Undergoing Laparoscopic Cholecystectomy. *World J. Surg.*, 2015; 39(7):1804-8.

[46] Adams, L. B., Chang, C., Pope, J., Kim, Y., Liu, P., Yates, A. Randomized, Prospective Comparison of Ursodeoxycholic Acid for the Prevention of Gallstones after Sleeve Gastrectomy. *Obes. Surg.*, 2016; 26(5):990-4.

[47] Uy, M. C., Talingdan-Te, M. C., Espinosa, W. Z., Daez, M. L., Ong, J. P. Ursodeoxycholic acid in the prevention of gallstone formation after bariatric surgery: a meta-analysis. *Obes. Surg.*, 2008; 18(12): 1532-8.

[48] Hempfling, W., Dilger, K., Beuers, U. Systematic review: ursodeoxycholic acid--adverse effects and drug interactions. *Aliment Pharmacol. Ther.*, 2003; 18(10):963-72.

In: Encyclopedia of Surgery (22 Volume Set)
Editors: Andreas Lehrer and Kristin Mueller
ISBN: 978-1-53618-329-0
© 2020 Nova Science Publishers, Inc.

Chapter 265

PROPHYLACTIC MEASURES TO REDUCE STAPLE LINE LEAKS AND BLEEDING

Irene Ortega-Vázquez*
Infanta Sofía University Hospital, European University of Madrid
San Sebastian de los Reyes, Madrid, Spain

ABSTRACT

Background: Laparoscopic gastric sleeve (LGS) is a safe bariatric procedure, growing in popularity due to its technical simplicity and good weight loss outcomes. Bleeds and staple line leak are the most common complications. The postoperative staple line leak does not adversely impact the weight loss and resolution of comorbidities. However, this complication can result in prolonged hospitalization, increased morbidity, sepsis, multi-organ failure and even death. We perform a systematic review to identify patient-factors and surgical strategies that may decrease leak and bleeds after LSG.

Results: Causes of leak are classified as mechanical, technical and ischemic causes. Identified patient-related risk factors are high BMI, ASA, hypertension and degenerative joint disease**.** The possible contribution of NSAIDs requires further investigation.

Essential surgical technique recommendations include: use a bougie size ≥ 40 Fr; use appropriate cartridge colors from antrum to fundus; follow a proper staple line, with a wide berth around bougie at the incisura angularis; stay away from the angle of His at least 1 cm; check the bleeding from the staple line and avoid 1-stage revisional sleeve concomitant with band removal in high risk patients**.**

Controversy exits regarding efficacy of staple line reinforcement, surgeons should selectively use those tools until this matter is clarified.

Routine intraoperative methylene blue test is not effective in preventing or predicting postoperative staple line leak.

Conclusions: Laparoscopic gastric sleeve can be performed with low postoperative morbidity and mortality. Standardization of the technique can contribute to decrease postoperative leak rate.

Keywords: sleeve gastrectomy, leak, bleeding, buttressing, oversewing

* Corresponding Author's Email: Email:irova13@gmail.com.

INTRODUCTION

The laparoscopic gastric sleeve (LSG) was first described by Hess and coworkers [1] in 1998. It was initially conceived as a restrictive component of the biliopancreatic diversion with duodenal switch (BPD-DS) for high-risk patients. After observing marked weight loss with LSG the procedure was eventually adopted as a step approach in the laparoscopic era. As such, it was adopted as the first step for super morbidly obese patients followed by laparoscopic BPD-DS or a laparoscopic Roux-en-Y gastric bypass (LRYGB) [2, 3, 4].

Subsequently, LSG was studied as a definitive operation, recognized as a safe and effective primary metabolic/bariatric surgical operation by the American Society for Metabolic and Bariatric Surgery and the American College of Surgeons [5, 6, 7]. Currently, LSG represents the most common metabolic and bariatric procedure in the USA, accounting for 42% of these operations [8]. LSG has been associated with 57.6% mean excess weight loss (EWL) at 1 year and 70.1% (EWL) at 3 years, superior to restrictive procedures and comparable to malabsortive-restrictive and primarily malabsortive procedures over the intermediate term [4].

One of the most attractive aspects of LSG is its relatively procedural "simplicity" [3]. The current procedure involves a stapled mostly vertical transection of the stomach and removal of the left gastric fundus body and proximal left antrum to create a tubular alimentary channel along the stomach´s lesser curvature [4]. Food restriction, early satiety, decrease production on GLP-1 and PYY-36 have been associated changes after LSG [9, 10].

It offers an immediate restriction without need for postoperative adjustments, and no foreign body implanted. It has the advantages of preserving gastrointestinal continuity and the absence of an enteric anastomosis, minimizing nutritional and mineral deficiencies and avoiding dumping syndrome, internal hernias and related complications [3, 4, 7, 11].

In short- and mid- term follow-up, LSG has the lowest procedure-related morbidity compared with RYGB and LAGB [4]. Staple line leaks, bleeding, and strictures are the commonly reported complications following LSG. Bleeding from the staple line can occur in 1-2% patients after LSG, although it is usually less serious than a staple line leak, which implies a long hospital stay, delayed recovery and is the leading cause of death after LSG [12]. Nevertheless, the development of a leakage does not adversely impact the weight loss and resolution of comorbidities in the mid-term [13].

Based on the data of 12799 LSG, the International Sleeve Gastrectomy Expert Panel Consensus Statement 2011, established a leak rate of 1.06%, but the leak rate can vary between 1% and 3% for primary procedure and more than 10% in revision procedures [7].

PATHOGENESIS

Staple line leakage is the most dreadful complication after LSG. This complication is often highly clinically significant and can result in prolonged hospitalization, increased morbidity, sepsis, multiorgan failure, and even death.

Causes of leak are classified as mechanical, technical and ischemic factors [13].

Tobacco use, steroid and medical inmunosupression, supermorbid obesity, NSAID use, diabetes, malnutrition, Crohn´s disease have been associated with increased rates of gastric leak. We should encourage the patient to modify risk factors.

Leaks are more common among cases requiring blood transfusion (26.2% versus 1.08%, P = .0031), higher BMI, higher ASA-stage, longer operating times, when cases were converted to open surgery and revisional surgery [13].

Stapler-related problems or tissue ischemia may lead to impaired tissue healing and dehiscence of the staple line if higher intraluminal pressures are reached. Leaks do to ischemia usually occur around postoperative days 5 to 7, when the healing is between the inflammatory and fibrotic phases, whereas more leaks occur in the first 48 hours, which suggests and additional mechanical cause [14].

Although the technique has wide-spreaded among bariatric surgeons; there is significant intraoperative variation in technique that makes comparison of results difficult. This heterogeneity may be a significant factor in complication rate, as well as surgical team experience [7, 14, 15].

Outcomes for bariatric surgery have dramatically improved in the past decade and the leak rate after LSG has been decreasing as experience with the technique has increased. The leak rate in Germany significantly decreased over time and since 2010, the leak rate is constantly < 2% [13]. It has been recently published that surgeons who performed 43 or more cases per year had a leak rate < 1%.

We will perform a literature review and discuss several prophylactic measures and pitfalls to avoid in order to minimize staple line bleeding and leakage.

PROPHYLACTIC MEASURES

1. Bougie Size

There is an increasing trend to use narrower bougies or to begin the division of the stomach closer to the pylorus to presumably reduce the risk of long-term weight regain. Debate exists whether the creation of a tighter sleeve (i.e., smaller) has a higher leak and stenosis rate at the expense of more weight loss16. This is presumably related to an increase in intraluminal pressure.

However, although weight loss is less rapid for those with bougie size > 40 Fr, the weight loss continued, resulting in similar weight loss in three years. Utilizing bougie ≥ 40 Fr. may decrease leak without impacting % EWL up to 3 years [16, 17].

2. Distance from the Pylorus

The evaluation of Spanish registry data found that beginning the gastrectomy close to the pylorus resulted in better weight loss [18]. Other authors prefer to begin the resection more than 4 cm away from the pylorus, with the aim of preserving the gastric antrum, decreasing intraluminal pressure and improving gastric emptying (and potentially decrease leak) [19, 20].

The meta-analysis published by Parikh suggests that distance to the pylorus does not affect leak rate or weight loss. The report from the Metabolic and Bariatric Surgery Accreditation and Quality Improvement Program found that distance from the pylorus had no impact on leaks or bleeds, but showed an increase in weight loss with larger distances [8].

3. Stapling

Gastric wall thickness has been reported to vary, it is thick in the antrum (3.1mm), moderate in the body (2.4mm) and thin in the fundus (1.7mm) [14, 21]. It is not appropriate to use staples with closed height less than 1.5mm on any part of the sleeve (blue) [7].

There has been a movement toward using appropriate staple height for the different components of the sleeve gastrectomy, that is, moving towards a higher staple height for the antrum and thicker stomach, in revisions and when buttress material is used (not less than green, this would be a 2.0mm staple height). The height of the buttress decreases the actual height of the staple and a longer staple height should be considered for safe and proper closure [2, 7, 17, 19].

Stapling at the incisura angularis and the angle of Hiss are crucial steps which should be attempted carefully.

Narrowing the sleeve too much at the incisura angularis may contribute to create leaks at the gastroesophageal junction after LSG. It is advisable to maintain a wide berth around bougie at the curve of incisura [17, 20, 22].

Most leaks (89%) are located proximal [14]. Special care should be applied to limit the posterior dissection at the proximal stomach, preserving the posterior attachments and blood supply in the cardia region. While firing the proximal linear stapler, it is essential to angle the stapler to the left, more than 15mm away from the true gastroesophageal junction [7, 22].

4. Reinforcement of the Staple Line

Reinforcement has been proposed as a method for preventing leaks and bleeding after LSG [7, 16, 19, 23].

Several tools have been proposed to reinforce the staple line and prevent or decrease the staple line leak: oversewing, absorbable synthetic buttress material, bovine pericardium, thrombix matrix and fibrin glue (Tissel, Baxter Corp.) [13, 19, 23].

There has been an increasing trend to use buttressing material along the staple line, although this remains controversial. Earlier studies have reported decreased bleeding with the use of buttressing material such as Bioabsorbable Seamguard and a decreased postoperative morbidity. However several studies have shown no clear benefit of staple line reinforcement.

In the analysis of 241 leaks from 15,576 LSG at the German Bariatric Surgery Registry, oversewing the staple line was associated with the lowest risk of death [13] and was superior to staple line buttressing and no reinforcement.

The use of both, oversewing and buttressing, resulted in the highest leak rate. This finding was also reported in the publication from the Metabolic and Bariatric Surgery Accreditation and Quality Improvement Program including 189,477 sleeve gastrectomies [8].

In contrast, Choi [24] reviewed 1335 obese subjects that had undergone LSG and found that reinforcement decreased the risk of a leak without difference between oversewing and buttressing techniques. Interestingly, oversewing seemed to increase the risk of a staple line hemorrhage.

In 2015, Shikora [25] issued a meta-analysis comparing four different reinforcement methods (no reinforcement, oversewing, biocompatible glycolide copolymer and bovine pericardium). Reinforcement was associated with significantly less bleeding and leak rate. The better outcomes were achieved with bovine pericardial buttress.

On the other hand, Gagner [4] published another systematic review comparing the same four reinforcement methods and reported that the leak rate was lower using the absorbable buttressing material.

Despite the fact that literature about staple line reinforcement has contradictory results on leak rates, it definitely minimizes staple line hemorrhage [7, 26]. While the effect of reinforcement on staple line leak remains unclear, it should be used selectively according to surgeon preferences and patient risk.

Independently of the method of reinforcement, another simple gesture suggested by other authors is the apposition of omentum to rest in proximity to the completed staple line [22].

5. Check for Intraoperative Bleeding

Bleeding from staple line can also occur after LSG, in 1 to 2% of patients [12].

Staple line bleeding is considered a direct predisposing factor for leakage after LSG. Hematoma over the suture line affects its vascularity and vitality. It is generally agreed to check carefully staple line for intraoperative bleeding [17].

Recently an observation was made that routine elevation of systolic blood pressure (SBP) to 140 mmHg at the end of stomach resection and oversewing the staple line minimized hemorrhagic complications. Elevation of SBP allowed better identification of intraoperative bleeding [27].

6. Blood Pressure and NSAIDs

A recently published study has found that obese patients with preexisting hypertension and degenerative joint disease have a significant higher risk of postoperative staple line leak [13].

The authors indicate that there is a mayor use of non-steroidal anti-inflammatory drugs (NSAIDs) in these patients. They speculated that NAIDS gastrointestinal toxicity could interfere with staple line healing and suggest discontinuation of NSAIDs prior to surgery or high dose proton pump inhibitor therapy postoperatively [13].

Staple line bleeding is considered a direct predisposing factor for leakage after LSG. Hematoma, over the suture line affects its vascularity and integrity. The regular use of NSAIDs may increase the risk of postoperative bleeding [13]. Nevertheless, further investigation is required to determine the role of NSAIDs in staple line leakage before any recommendation can be made.

Hypertension, especially when not adequately controlled with medication, is a known marker for cardiovascular disease which may deteriorate local blood supply and thus, may increase the risk of staple line disruption [13]. Other authors suggest that hypertension is a surrogate marker for central obesity, which makes the procedure technically more difficult, therefore increasing the postoperative complication rate.

The question about blood pressure and a risk of bleeding in postoperative period should be raised. One study [28] did not show the association between hemorrhagic complications after LSG and high blood pressure levels in postoperative period.

Hypertensive disease should be evaluated and treated pre-operatively in bariatric patients, and close monitorization of blood pressure during the postoperative course should be ensured [13, 22].

7. Intraoperative Leak Testing

Although it is commonly performed, several studies have concluded that intraoperative methylene blue test has no correlation with leak due to laparoscopic sleeve gastrectomy and is not predictive of the later development of staple line leak [29, 30, 31].

Leak tests require the use of nasogastric or orogastric tubes to deliver high pressure dye and there are reported instances of these tubes causing perforations. In fact, Stroh [30] and Bingham [31] postulated that leak testing may increase the risk of postoperative leak.

Other studies have suggested that intra-operative leak test can be negative even when there is a proven leak on CT in patients taken back to theatre, questioning the sensitivity of this test in the first instance [32].

Methylene blue testing has no role in predicting post-operative anastomotic or staple line leak and negative leak test should not be taken as false reassurance of staple line or anastomotic integrity in patients whose post-operative course deviates from the norm [33].

In addition, whilst methylene blue has a reasonable safety profile and is used widely in a host of surgical techniques, it is known to have caused anaphylaxis.

We can conclude that there is no role for its routine use in primary bariatric surgery. Discontinuation of this practice would reduce risk of anaphylaxis, cost, and intra-operative time [33].

8. Revisional Surgery

Conversion of adjustable gastric band to laparoscopic sleeve gastrectomy is feasible with low morbidity and mortality, but multiple reports have indicated higher morbidity and staple line leaks when this is performed as a single-stage procedure [11, 12].

It seems reasonable to consider stage revisional procedure in high risk patients.

CONCLUSION

Pathogenesis of leakage after LSG can be attributed to mechanical, technical or ischemic causes. Many factors can predispose to leakage after LSG which are either technically related

or patient related. Awareness of these predisposing factors and technical tips may decrease the incidence of postoperative leakage.

Within this review, we analyze factors promoting leak and provide technical recommendations to avoid leak after LSG based on the available evidence and expert consensus which encompasses: to use a bougie size ≥ 40 Fr; to use appropriate cartridge colors from antrum to fundus; to follow a proper staple line, with a wide berth around bougie at the incisura angularis; to stay away from the angle of His at least 1 cm; to check the bleeding from the staple line and to avoid 1-stage revisional sleeves concomitant with band removal in high risk patients.

Distance from the pylorus has no impact on leaks or bleeds but increasing distance can impact adversely on weight loss.

Controversy exists regarding efficacy of staple line reinforcement; surgeons should selectively use those tools until this matter is clarified.

Further investigation is required to establish the contribution of high blood pressure and NSAIDs to both bleeding and staple line leak complications.

Routine intraoperative methylene blue test has not proved to be effective in preventing or predicting postoperative staple line leak and should be abandoned.

REFERENCES

[1] Hess, D. S., Hess, D. W. Biliopancreatic diversión with a duodenal switch. *Obes. Surg*. 1998; 8:267-282.

[2] Gagner, M., Hutchinson, C., Rosenthal, R. Fifth International Consensus Conference: current status of sleeve gastrectomy. *Surg. Obes. Relat. Dis.* 2016 May;12(4):750-756.

[3] Fridman, A., Moon, R., Cozacov, Y., Ampudia, C., Lo Menzo, E., Szomstein, S., Rosenthal, R. J. Procedure related morbidity in bariatric surgery: a retrospective short- and mid-term follow-up of a single institution of the American College of Surgeons Bariatric Surgery Centers of Excellence. *J. Am. Coll. Surg.* 2013 Oct;217(4):614-20.

[4] Gagner, M., Buchwald, J. N. Comparison of laparoscopic sleeve gastrectomy leak rates in four staple-line reinforcement options: a systematic review. *Surgery for Obesity and Related Diseases* 10 (2014) 713–724.

[5] ASMBS Clinical Issues Committee. Updated position statement on sleeve gastrectomy as a bariatric procedure. Surg. *Obes. Relat. Dis.* 2012 May-Jun;8(3):e21-6.

[6] Hutter, M. M., Schirmer, B. D., Jones, D. B., Ko, C. Y., Cohen, M. E., Merkow, R. P. et al. First report from the American College of Surgeons Bariatric Surgery Center Network: laparoscopic sleeve gastrectomy has morbidity and effectiveness positioned between the band and the bypass. *Ann. Surg*. 2011;254: 410–20, discussion 420–2.

[7] Rosenthal, R. J.; International Sleeve Gastrectomy Expert Panel, Diaz AA, Arvidsson D, Baker RS, Basso N, et al. International sleeve gastrectomy expert panel consensus statement: best practice guidelines based on experience of >12.000 cases. *Surg. Obes. Relat. Dis.* 2012 Jan-Feb;8(1):8-19.

[8] Berger, E. R., Clements, R. H., Morton, J. M., Huffman, K. M., Wolfe, B. M., Nguyen, N. T. et al. The impact of different surgical techniques on outcomes in laparoscopic sleeve gastrectomies: the first report from the Metabolic and Bariatric Surgery

Accreditation and Quality Improvement Program (MBSAQIP). *Ann. Surg.* 2016 Sep;264(3):464-73.

[9] Marceau, P., Cabanac, M., Frankham, P. C., Hould, F. S., Lebel, S., Marceau, S., et al. Accelerated satiation after duodenal switch. *Surg. Obes. Relat. Dis*. 2005;1:408–12.

[10] Serra, C., Pérez, N., Bou, R., et al. Laparoscopic sleeve gastrectomy. A bariatric procedure with multiple indications. *Cir. Esp.* 2006;79: 289–92.

[11] Ramly, E. P., Alami, R. S., Tamim, H., Kantar, R., Elias, E., Safadi, B. Y. Concomitant removal of gastric band and sleeve gastrectomy: analysis of outcomes and complications from the ACS-NSQIP database. *Surg. Obes. Relat. Dis*. 2016 Jun;12(5):984-8.

[12] Durmush, E. K., Ermerak, G., Durmush, D. Short-term outcomes of sleeve gastrectomy for morbid obesity: does staple line reinforcement matter? *Obes. Surg*. 2014 Jul;24(7):1109-16.

[13] Benedix, F., Poranzke, O., Adolf, D., Wolff, S., Lippert, H., Arend, J., et al; Obesity Surgery Working Group Competence Network Obesity. Staple Line Leak After Primary Sleeve Gastrectomy-Risk Factors and Mid-term Results: Do Patients Still Benefit from the Weight Loss Procedure? *Obes. Surg.* 2017 Jul;27(7):1780-1788.

[14] Timucin, Aydin M., Aras, O., Karip, B., Memisoglu, K. Staple Line Reinforcement Methods in Laparoscopic Sleeve Gastrectomy: *Comparison of Burst Pressures and Leaks*. JSLS. 2015 Jul-Sep; 19(3).

[15] Ghosh, S. K., Roy, S., Chekan, E., Fegelman, E. J. A narrative of intraoperative staple line leaks and bleeds during bariatric surgery. *Obes. Surg.* 2016 Jul;26(7):1601-6.

[16] Parikh, M., Issa, R., McCrillis, A., Saunders, J. K., Ude-Welcome, A., Gagner, M. Surgical strategies that may decrease leak after laparoscopic sleeve gastrectomy: a systematic review and meta-analysis of 9991 cases. *Ann. Surg.* 2013;257:231–7.

[17] Iossa, A., Abdelgawad, M., Watkins, B. M., Silecchia, G. Leaks after laparoscopic sleeve gastrectomy: overview of pathogenesis and risk factors. *Langenbecks arch. surg.* 2016 sep;401(6):757-66.

[18] Sánchez-Santos, R., Masdevall, C., Baltasar, A., Martínez-Blázquez, C., García Ruiz de Gordejuela, A., Ponsi, E., et al. Short- and midterm outcomes of sleeve gastrectomy for morbid obesity: the experience of the Spanish National Registry. *Obes. Surg.* 2009;19:1203–10.

[19] Ferrer-Márquez, M., Belda-Lozano, R., Ferrer-Ayza, M. Technical controversies in laparoscopic sleeve gastrectomy. *Obes. Surg.* 2012;22:182–7.

[20] Bellanger, D. E., Greenway, F. L. Laparoscopic sleeve gastrectomy, 529. Cases without a leak: short-term results and technical considerations. *Obes. Surg.* 2011;21:146–50.

[21] Baker, R. S., Foote, J., Kemmeter, P., Brady, R., Vroegop, T., Serveld, M. The science of stapling and leaks. *Obes. Surg.* 2004 Nov-Dec;14(10):1290-8.

[22] Warner, D. L., Sasse, K. C. Technical details of laparoscopic sleeve gastrectomy leading to lowered leak rate: Discussion of 1070 Consecutive Cases. *Minim. Invasive Surg*. 2017; 2017: 4367059.

[23] Consten, E. C., Gagner, M., Pomp, A., Inabnet, W. B. Decreased bleeding after laparoscopic sleeve gastrectomy with or without duodenal switch for morbid obesity using a stapled buttressed absorbable polymer membrane. *Obes. Surg.* 2004 Nov-Dec;14(10):1360-6.

[24] Choi, Y. Y., Bae, J., Hur, K. Y., Choi, D., Kim, Y. J. Reinforcing the staple line during laparoscopic sleeve gastrectomy: does it have advantages? A meta-analysis. *Obes. Surg.* 2012 Aug;22(8):1206-13.

[25] Shikora, S. A., Mahoney, C. B. Clinical Benefit of Gastric Staple Line Reinforcement (SLR) in Gastrointestinal Surgery: a Meta-analysis. *Obes. Surg*. 2015 Jul; 25(7):1133-41.

[26] Abou, R. A., Basile, M., El Masri, H. Gastric leaks post sleeve gastrectomy: review of its prevention and management *World J. Gastroenterol*. 2014 Oct 14;20(38):13904-10.

[27] De Angelis, F., Abdelgawad, M., Rizzello, M., Mattia, C., Silecchia, G. Perioperative hemorrhagic complications after laparoscopic sleeve gastrectomy: four-year experience of a bariatric centre of excellence. *Surg. Endosc.* 2016 Dec 23.

[28] Janik, M. R., Rogula, T., Kowalewski, P., Walędziak, M., Matłok, M., Brągoszewski, J., et al. Case-control study of postoperative blood pressure in patients with hemorrhagic complications after laparoscopic sleeve gastrectomy and matched controls. *Obes. Surg.* 2017 Jul; 27(7):1849-1853.

[29] Sethi, M., Zagzag, J., Patel, K., Magrath, M., Somoza, E., Parikh, M. S. et al. Intraoperative leak testing has no correlation with leak after laparoscopic sleeve gastrectomy. *Surg. Endosc.* 2016 Mar;30(3):883-91.

[30] Stroh, C., Köckerling, F., Volker, L., Frank, B., Stefanie, W., Christian, K. et al. Results of more than 11,800 sleeve gastrectomies. *Ann. Surg.* 263 (5) (2016) 949–955.

[31] Bingham, J., Lallemand, M., Barron, M., Kuckelman, J., Carter, P., Blair, K. et al. Routine intraoperative leak testing for sleeve gastrectomy: is the leak test full of hot air? *Am. J. Surg.* 211 (5) (2016)943–947.

[32] Mizrahi, I., Tabak, A., Grinbaum, R., Beglaibter, N., Eid, A., Simanovsky, N. et al. The utility of routine postoperative upper gastrointestinal swallow studies following laparoscopic sleeve gastrectomy. *Obes.Surg.* 24 (9) (2014) 1415–1419.

[33] Kirby, G. C., Macano, C. A. W., Nyasavajjala, S. M., Sahloul, M., Nijjar, R., Daskalakis, M. et al. The Birmingham experience of high-pressure methylene blue dye test during primary and revisional bariatric surgery: a retrospective cohort study. *Ann. Med. Surg.* (Lond) 2017 Nov; 23: 32–34.

In: Encyclopedia of Surgery (22 Volume Set)
Editors: Andreas Lehrer and Kristin Mueller
ISBN: 978-1-53618-329-0
© 2020 Nova Science Publishers, Inc.

Chapter 266

POSTOPERATIVE ILEUS PROPHYLAXIS: ENHANCED RECOVERY AFTER SURGERY (ERAS)

Pablo Royo-Dachary [*] ***and Helen Almeida-Ponce***
Department of Surgery, University of Zaragoza, Zaragoza, Spain

ABSTRACT

Postoperative ileus is a common complication following abdominal surgery. Although ileus per se does not endanger the patient's life, it does lengthen the hospital stay, produces a considerable increase in resources and greatly worsens the patient's well-being. It is one of the pillars on which the ERAS (enhanced recovery after surgery) protocols are centred, together with pain control and correct preoperative optimization. Its etiological mechanism is multifactorial, so to achieve a correct prevention we must know which is the pathophysiology that leads to postoperative ileus and act at different levels to minimize its incidence. Many postoperative measures have been proposed to prevent the appearance of postoperative ileus, some of them without a clear demonstrated benefit. Throughout the next chapter we will review the current evidence regarding these measures.

Keywords: postoperative ileus, prophylaxis, ERAS

INTRODUCTION

A correct working of the digestive system requires a good intestinal propulsive function. The gut has a basic structural organization that includes distinct muscle layers. Intestinal movements are divided into propulsives and mixing ones, and are regulated by multiple nervous and hormonal feedback mechanisms.

Although the manipulation produced during abdominal surgery has traditionally been associated with a decrease in these movements during the postoperative period, not all

[*] Corresponding Author's Email: proyo@unizar.es.

segments in the gastrointestinal tract are equally affected. Although ileus classically refers to dysmotility of the small bowel, postoperative ileus can selectively affect the stomach, small intestine or the colon, each with a different mechanism and clinical presentation, and each managed differently.

Gastroparesis refers to abnormal gastric motility, which results in delaying of gastric emptying. It is usually associated with medical conditions, as diabetes, but can also occur after abdominal surgery. The stomach recovers a normal activity 24-48 hours after surgery.

Colonic ileus is often seen in elderly patients and usually is related to bedridden patients. It can take up to 3-5 days for the colon to recover a normal function after surgery.

In the case of the small intestine, the movements of mixing and propulsion are simultaneous, although is the abolishment of the propulsion movements that will cause the situation of intestinal ileus. Usually it recovers a normal activity several hours after surgery.

Enhanced recovery after surgery (ERAS) protocols have an evidence based approach to this condition focusing on its prevention by selecting the most adequate techniques for surgery, anaesthesia and other perioperative measures for each patient.

BOWEL PHYSIOLOGY

Propulsion movements can be initiated at any point of the intestine, and cause peristaltic waves that propel the chemo in an anal direction with a velocity of 0.5 to 2 cm/sec (the velocity is higher in the proximal than in the distal intestine). These waves usually cease at 3-5 cm, and rarely span more than 10 cm. All these factors make the speed of the chyme in the intestine about 1cm/minute, so in physiological situations, it takes 3 to 5 hours for the chyme to reach from the pylorus to the ileocecal valve.

When it reaches the ileocecal valve, the intestinal contents can be blocked by it for hours, until a new meal triggers the *gastroileal reflex*, which forces the passage of the chyme into the caecum.

Bowel Innervation

The enteric nervous system is the most complex subdivision of the peripheral nervous system. Two different nerve plexus will form a complex neural network that functions independently of the central nervous system and extends from the esophagus to the internal anal sphincter. Two main components are the myenteric plexus of Auerbach (located between the longitudinal and circular muscle layers) and the Meissner plexus (of submucosal location). The myenteric plexus regulates the contraction and relaxation of the muscle fibers that cause peristaltic movements, while the submucosal plexus is responsible for providing the intestinal lumen sensors, regulating gastrointestinal blood flow and controlling cellular function and secretion of epithelial cells.

In addition to neurons, this enteric nervous system also has enteric glial cells and interstitial Cajal cells. Glial cells form a barrier around the capillaries similar to the blood-brain barrier, while interstitial Cajal cells, that share characteristics of nerve and muscle cells,

act as intestinal pacemakers. They generate and transmit electrical activity that controls smooth muscle function, generating peristaltic movements.

With aging, this enteric nervous system suffers a decrease in neuronal cells, resulting in a dysmotility that clinically manifests itself as constipation, incontinence or defecation alterations. Some pathological conditions associated with obesity, such as diabetes or vascular diseases, can accelerate or simulate this aging process, causing a basal situation of intestinal dysmotility.

The extrinsic nervous system is responsible for modulating the function of the enteric nervous system, and comprises the parasympathetic fibers of the vagus and sacral nerves, which produce excitatory response of smooth muscle fibers and sphincter relaxation, and the sympathetic fibers of the thoracolumbar nervous system, which produces the opposite effect. Sympathetic innervation comes from the solar plexus, a ganglionic ensemble comprising the celiac node, the upper mesenteric nodes, and the aorticorenal nodes, located around the origin of the celiac trunk. These lymph nodes receive nerve afferences from the major (T6-T9), minor (T10-T12), and the inconstant lower (T12) splanchnic thoracic nerves. The efferent branches innervate the digestive tract through the celiac plexus (coronary-stomachic, hepatic and splenic), upper mesenteric plexus and lower mesenteric plexus. The parasympathetic innervation of the vagus nerve regulates up to the splenic angle of the colon, while the innervation of the descending colon, sigma and rectum will come from the sacral parasympathetic.

Nervous and Hormonal Signs

Peristalsis of the small intestine increases after meals due to the *gastroenteric reflex*, triggered by the distension of the stomach and led by the myenteric plexus from the stomach to the rest of the small intestine.

There are also hormonal factors, such as gastrin, cholecystokinin, insulin and serotonin, which stimulate intestinal motility and are secreted at different stages of food digestion. Secretin and glucagon inhibit bowel motility.

The role of ghrelin, whose main function is to regulate appetite, is being widely studied in the bariatric patient. One of its functions is promoting gastric emptying and intestinal motility. This is secreted mainly in gastric fundus and liver cells, so the removal of the gastric fundus, within the different techniques of bariatric surgery, results in a decrease of circulating ghrelin and an abolition of this stimulus. A drastic decrease in this hormone has been found after a vertical gastrectomy, while after gastric bypass and biliopancreatic bypass, a less marked decrease has been found.

Fasting Peristalsis

When eating, the stimulating effect of food controls intestinal movements, but during fasting periods, a special pattern of activity called *motor-migratory complex* occurs. It has three different patterns of motility: neuromuscular rest (phase 1), irregular contractions that vary in amplitude and intensity (phase 2), and uninterrupted contractions of propagation

(phase 3). This motor pattern is under the control of the enteric nervous system and is independent of extrinsic control.

POSTOPERATIVE ILEUS

Ileus is defined clinically as: mechanical, dynamic or adynamic obstruction of the bowel due to failure of the smooth muscle to contract, in absence of mechanical obstruction, occurring during the first postoperative days. It was classically considered to be a physiological and almost mandatory response after abdominal surgery. This alteration of motility was considered to last between 0 and 24 hours for the small intestine, 24 to 48 hours for the stomach, and from 48 to 72 hours for the large intestine, therefore it was only considered pathological when appearing beyond third postoperative day. Today this physiological dysmotility is being discussed, as it seems to be much shorter than previously thought. Prolonged postoperative ileus diagnosis is actually considered when two or more of the following signs or symptoms are present: nausea or vomiting, inability to tolerate oral diet over 24 h, absence of flatus over 24 h, distension, radiologic confirmation occurring on or after day 4 postoperatively without prior resolution of physiological postoperative ileus.

Disparity of criteria for its definition has been the main difficulty for the study of postoperative ileus. While some authors have used solid diet tolerance as an endpoint for their studies, others have considered the elapsed time to first deposition or first flatus, making the different studies carried out incomparable.

It is sometimes difficult to separate postoperative ileus from postoperative nausea and vomiting, a multifactorial postoperative complication that shares many of the characteristics and physiopathology of postoperative ileus. Nausea and vomiting usually occur in the first 24 hours after surgery and are closely related to the anesthesia performed. They require a correct preoperative risk assessment and prophylaxis with antiemetics accordingly with it. Apfel's assessment scale is currently the most widely used, due to its simplicity and usefulness, for the assessment of preoperative risk, and the routine use of its prophylaxis has been validated in multiple studies.

POSTOPERATIVE ILEUM PHYSIOPATHOLOGY

After surgery, mechanisms that affect the normal functioning of the intestinal movement will be put in motion, causing gastrointestinal dysmotility. Some of these mechanisms are as follows:

Inflammation

Intestinal manipulation and surgical aggression trigger an inflammatory response in the intestine. This inflammatory response is not limited to the manipulated segment, but spreads throughout the entire intestine, and not manipulated areas of intestine may be affected.

Studies in animals have shown that manipulation degree is related to leucocyte infiltration of the muscular intestinal layer, and to intestinal dysmotility degree.

Intestinal manipulation will cause macrophages activation, which will release nitric oxide (NO) and proinflammatory prostaglandins through induced nitric oxide synthase (NOS) and cyclooxygenase-2 (COX-2), resulting in a muscular dysfunction of the intestine. The inactivation of these macrophages with Semapimod, an anti-cytokine molecule, has managed to prevent postoperative ileus in rodents. Low doses of celecoxib (COX-2 inhibitor) have shown to reduce paralytic ileus development after major abdominal surgery in animals, although they have failed to accelerate the recovery of intestinal peristalsis after surgery in humans.

Laparoscopic surgery, which is increasingly spreading in all fields of surgery, especially bariatric surgery, reduces intestinal manipulation and aggression, minimizing the inflammatory bowel response to surgery. Correct surgical technique and careful manipulation of tissues are necessary to prevent the appearance of postoperative ileus.

Inhibitor Nerve Reflexes

There are inhibitory nerve reflexes that act locally through afferent signals from the spinal cord. These reflexes activate the sympathetic system, causing inhibition of intestinal motility. Blocking these reflexes by placing an epidural catheter may also improve postoperative ileus.

Neurohormonal Peptides

Some substances such as nitric oxide, vasoactive intestinal peptide or P substance may also decrease intestinal motility. These substances have also been linked to the appearance of postoperative ileus.

Other substances, such as motilin and ghrelin, are related with improvement of intestinal movements.

Opioids

The inhibitory effect that opioids have on intestinal motility is widely known. They increase muscle resting tone and decrease mobility, causing intestinal spasms in the small intestine and decreasing colonic propulsive movements.

Diagnosis of Ileus

Postoperative ileus diagnosis combines a clinical suspicion and imaging tests. Regardless of the segment of bowel involved, it is imperative to exclude obstructive cause first. The diagnosis of ileus is presumed once obstruction has been excluded.

Gastroparesis

It should be suspected by its symptoms, such as early satiety, nausea, vomiting, eructation, and gastroesophageal reflux. Due to the restrictive component of most bariatric techniques, most of this symptoms can be present in common postoperative course, making it difficult to recognize gastroparesis from an obstruction due to inflammation or stenosis. A gastric emptying x-ray with gastrographin can be used to exclude obstructive causes.

Small-Bowel Ileus

In this entity, abdominal distension is added to the symptoms of gastroparesis previously described. Plain radiographs reveal air-fluid levels and dilated bowel loops. Gastrographin can be used to exclude an obstructive cause, and when in doubt, a CT scan can be used to exclude obstruction (rotation or stricture of the foot of the Roux-n-Y, errors when assembling the circuits, abscess compression, etc.).

Colonic Ileus

Colonic ileus is also characterized by abdominal distension, sometimes marked. Although it is the colon that is primarily involved, up-stream small-bowel dilatation can also be seen if the ileocecal valve is incompetent. CT, contrast enema studies, and endoscopy may help in ruling out mechanical obstruction due to volvulus or a mass lesion.

RISK FACTORS

Risk of developing postoperative ileus may be influenced by different factors. General anesthesia itself has been related to ileus, although this has not been proven. The general risk factors known to date are:

Prolonged Abdominal or Pelvic Surgery

Prolonged abdominal surgery, and pelvic surgery in particular, have been shown as risk factors for developing postoperative ileus in randomized controlled trials.

Open Surgery

Open surgery results in an increased intestinal manipulation, which leads to increased risk of postoperative ileus. Type of incision has not been identified as risk factor for postoperative ileus.

Late Feeding

The outdated use of routinely nasogastric tubes and delayed initiation of oral feeding has been linked to a delay in the onset of intestinal motility. On the other hand, early oral feeding has been associated with earlier onset of intestinal motility.

Intraabdominal Inflammation

Peritonitis itself can cause a situation of intestinal ileus due to bowel inflammation.

Postoperative Complications

Complications such as pneumonia or intestinal abscesses increase the risk of postoperative ileus.

Intra or Postoperative Bleeding

Although estimated blood loss has been associated with postoperative ileus, no differences have been shown for intra- or extra-abdominal bleeding.

Use of Opioids or Other Medications

As mentioned before, opioids are strongly related to postoperative ileus. Other medications may also decrease contractile forces, change patterns of contractions, and/or delay transit throughout the gut: Calcium channel blockers, nitrates, antineoplastic agents, antidiarrheal, oral iron preparations, anticholinergic substances, several antidepressants, anti-emetics, etc.

In addition to previously mentioned risk factors for abdominal surgery, there are others conditions, especially prevalent in the obese patient, that can cause intestinal dysfunction, such as:

Diabetes

Diabetes, a co-morbidity with high prevalence in the morbidly obese patient, produces a variety of important metabolic alterations that may impact digestive system. High glucose levels cause neuronal depolarization and increased intracellular calcium (enteric neuron glucotoxicity), causing alterations in the function of the intestinal pacemaker. There may also be a loss of enteric neurons (with decreased Cajal cells and impaired pacemaker function) or neuronal dysfunction. These manifestations are related to neural degeneration typically found in long-term patients.

Many studies have found that patients affected by diabetes mellitus have more gastrointestinal symptoms than control individuals. The most prevalent symptoms are diarrhea, constipation, gastric fullness, heartburn and faecal incontinence, most of which are exacerbated by episodes of stress. With regard to glycemic control, studies are contradictory when establishing a relation between glycemic control and symptom intensity.

Gastroparesis is the main motor complication of diabetes mellitus in the gastrointestinal tract. It is more common in females and no relation to body mass index has been statistically demonstrated. In different studies, gastric emptying dysfunction for solids and liquids has been observed in approximately 50% of diabetic patients. Alterations in gastric motility are mainly: Abnormal relaxation of the gastric fundus altering the gastric accommodation, changes in the motility itself and antral hypomotility after duodenal contraction, secondary to the absence of phase 3 of the migratory motor complex. Pylorus spasm is often observed, which may contribute to deterioration of gastric emptying. Most frequent symptoms are: early gastric plenitude and meteorism rather than nausea or vomiting and are generally correlated with severe alterations in gastric emptying.

Constipation is the main problem related to the large intestine in diabetic patients. It has been documented that colonic transit may be delayed due to autonomic neuropathy. However hyperglycemia itself is capable of inhibiting gastrocolic response, colonic peristaltic waves and rectal perception.

BMI

Some studies have suggested a correlation between body mass index (BMI) and postoperative ileus, although it has not been confirmed in multivariate analysis.

ENHANCED RECOVERY PROTOCOLS: MEASURES TO PREVENT POSTOPERATIVE ILEUS

Many measures have been tested to prevent the appearance of postoperative ileus, although the effectiveness of these measures is unequal. Some of these have not been proven by scientific studies, and even proven harmful to the patient in some cases. The following is a summary of the different measures according to their usefulness and scientific evidence:

EFFECTIVE AND POTENTIALLY EFFECTIVE INTERVENTIONS

Midthoracic Epidural

The epidural use of local anesthetics blocks the afferent nociceptive sensory pathways, achieving correct analgesia and decreasing the need for opioids or other oral analgesics. In addition to this analgesic effect, it also causes a blockage of the efferent sympathetic nerve pathways (T6-L1), which results in a stimulation of intestinal motility and an increase in gastrointestinal blood flow, providing a potential benefit in those patients undergoing major

abdominal surgery. To achieve this effect, the catheter should preferably be placed at the mid-thoracic level (T2-T9), which achieves better analgesic quality, fewer complications and less lower extremity blockages. The use of local analgesics and opioids by epidural route improves pain control without the negative effects that opioids have when administered by other routes.

Epidural catheterization in major laparoscopic abdominal surgery presents better analgesic results than intravenous opioids, however, there are no overall significant differences in postoperative complications. Epidural catheterization does not decrease the average post-surgical hospital stay, but on the other hand it does not increase patient discomfort or anxiety as a result of the technique. There is controversy over whether a return to normal bowel function would be improved, with articles supporting and opposing the latter but with little consistency on both sides of the argument.

Patients undergoing laparoscopic surgery who have had epidural catheterization have a better intraoperative respiratory profile, better oxygenation levels, improved visceral blood flow and lower serum lactate levels, which makes it a good option for patients with restrictive pathology or low vital capacity, as occurs in a large number of obese patients.

Given the above, the risk-benefit of epidural catheterization should be assessed individually, especially in those patients with a worse pulmonary profile predicted, and other types of analgesic strategies, such as blocking the transverse plane, the application of spinal analgesia or opioid analgesia controlled by the patient, should be considered for non eligible patients, in an attempt to avoid the use of opioids with long half-life.

Minimally Invasive Surgery

Laparoscopy is a minimally invasive surgical technique that reduces postoperative pain and, at the same time, preserves intestinal peristalsis, reduces postoperative complications and shortens the length of hospital stay without increasing mortality in patients undergoing major abdominal surgery.

Minimally invasive surgery reduces surgical aggression and bowel manipulation, reducing postoperative ileus. A direct relation between the length of the incision in a laparotomy and the risk of postoperative ileus has been demonstrated.

Mu-Opioid Receptor Antagonists

Methylnaltrexone and Alvimopan are better than placebo for reversing constipation and increased time of opioid-induced gastrointestinal transit, and Alvimopan appears to be safe and effective in treating postoperative ileus. On the other hand, there is insufficient evidence to confirm the safety or efficacy of Naloxone or Nalbufin in the treatment of opioid-induced bowel dysfunction.

Limit the Use of Opioids

As we have already seen, opioids can cause intestinal ileus, so we must avoid them if possible. Nonsteroidal anti-inflammatory drugs, such as ketorolac, are attractive alternatives to opiate analgesics, both for their anti-inflammatory effect and for their opiate-sparing properties. However, they can cause bleeding, renal insufficiency, and gastritis, drawbacks that limit their applicability and duration of use.

Surgical Technique

A meticulous surgical technique, avoiding excessive manipulation, reduces the inflammatory reaction, reducing the risk of postoperative ileus.

Goal-Directed Fluid Therapy

Both deficient and excessive fluid repositioning are associated with postoperative complications. Taking into account that traditionally the insensible losses have been overestimated, which has resulted in an excess in the amount of fluid therapy administered, there is a tendency to use "restrictive regimens," meaning the replacement of losses during surgery avoiding overload, with the aim of achieving a fluid balance close to zero, without variations in the patient's body weight.

Goal-directed fluid therapy allows the amount of fluids administered to be individually adjusted. It consists of the infusion of fluids boluses, following a protocol, in order to reach a specific hemodynamic or tissue perfusion goal.

Perioperative fluid therapy has a direct effect on surgical results, the prescription of fluids must be adapted to the individual needs of each patient. The objective of fluid therapy in surgical patients is to maintain an adequate circulatory volume, avoiding as far as possible the overload, trying to achieve a zero balance in the perioperative, avoiding weight gain.

The use of goal-guided fluid therapy may reduce postoperative complications and hospital stay in high- and low-risk patients, but associated mortality reduction has not yet been demonstrated.

INEFFECTIVE OR UNPROVEN INTERVENTIONS

Laxatives

Fast-track programs in elective colon surgery have reported that laxatives, together with thoracic epidural analgesia, early oral feeding, and early mobilization, achieve normalization of gastrointestinal function within 48 hours in most patients. A randomized trial showed significantly shorter time to first postoperative bowel movement in the laxative group (a median of 45 versus 69 hours), but there was no effect on postoperative pain or postoperative nausea and vomiting.

Early Enteral Nutrition

Traditionally, food and fluids were avoided postoperatively for a period of time, based upon the assumption that gastrointestinal motility returned slowly; therefore, feeding soon after surgery was expected to result in vomiting and worsened postoperative ileus. Systematic reviews have shown that early enteral nutrition is not harmful and does not result in increased duration of postoperative ileus; rather, it reduces the length of postoperative ileus and hospital stay. However, some patients may not tolerate early postoperative feeding and will experience nausea or vomiting, therefore the benefit remains unproven.

Other Dietary Measures

Chewing Gum

The effect of chewing gum on postoperative bowel recovery has been studied in several randomized trials. Feeding with gum has shown some efficacy in improving bowel function return. Chewing sugarless gum following elective intestinal resection has been associated with a reduction in time to flatus, decreased time to bowel movement, and a reduction in length of hospital stay. Although the analysis is limited by methodologic deficiencies and some heterogeneity, there are no apparent downsides of chewing gum. No differences in postoperative complications, readmissions, or reoperations were demonstrated. Thus, chewing gum to accelerate postoperative gastrointestinal recovery can be suggested.

Bran

Two small observational studies investigating the use of 8 to 10 days of preoperative bran supplementation reported that patients on supplemented diets were more likely to pass flatus within 24 hours of surgery (78 versus 5 percent). Still more evidence is required to reach a recommendation level.

Coffee

The effects of coffee intake on bowel motility appear to be related to alterations in colonic motor activity, but whether this is related to caffeine or other components in the coffee is unknown. Coffee consumption significantly decreased the time to the first bowel movement, time to tolerance of solid food, and time to first flatus. Although promising, use of coffee for this purpose is yet to be established.

Pharmacologic Treatment

With the exception of peripherally acting mu-opioid receptor antagonists (e.g., alvimopan) discussed above, no other pharmacologic treatments (including metoclopramide, erythromycin, or neostigmine) have shown benefits in accelerating postoperative gastrointestinal recovery. A variety of other agents targeting the known pathophysiologic pathways are under investigation.

Early Mobilization

Bed rest increases insulin resistance, loss of muscle mass and strength, and alters lung function. Early mobilization after surgery has been proposed as a possible way to counteract insulin resistance due to immobilization and reduce respiratory complications.

No studies have been found in the scientific literature aimed specifically at evaluating the influence of early mobilization, on the day of surgery, as a preventive measure of postoperative ileus.

The only study evaluating the effect of early postoperative mobilizations on the resolution of postoperative dysmotility did not find a benefit. However, early ambulation is recommended for its other benefits, most notably reduction in thromboembolic complications.

Gastrografin

Gastrografin is a water soluble, hyperosmolar oral contrast agent commonly used for computed tomography (CT) imaging. Although Gastrografin has been used therapeutically to treat adhesive small bowel obstruction [93], its efficacy in treating prolonged postoperative ileus remains unproven. Based upon available evidence, we do not recommend using Gastrografin in the treatment of prolonged postoperative ileus beyond diagnostic purposes.

Gastrografin has been studied in two small randomized trials of patients who had prolonged ileus after surgery. In one trial, orally administered Gastrografin accelerated time to flatus or stool (18.9 versus 32.7 hours) and time to resolution of abdominal distension (52.8 versus 77.7 hours), but did not affect time to resolution of nausea and vomiting (64.5 versus 74.3 hours) or time of tolerance of oral diet (75.8 versus 90.0 hours) [94]. The other trial reported no significant differences in mean time to resolution of postoperative ileus between the Gastrografin and control groups (9.1 versus 10.3 days), but length of stay, time needing a nasogastric tube, and time until tolerance of oral intake all tended to improve with Gastrografin.

POTENTIALLY HARMFUL INTERVENTIONS

Routine Use of SNG

The use of a nasogastric tube as gastrointestinal decompression method is not recommended for it has proven to: delay oral tolerance, delay hospital discharge, not to improve intestinal function and to not prevent anastomotic failure, fascia dehiscence or incisional hernia. It is also useless in avoiding pulmonary complications (atelectasis, aspiration, pneumonia, fever and pharyngolaryngitis) nor abdominal discomfort (abdominal distension, nausea and vomiting). Patients recover intestinal mobility earlier without NGS, achieving oral tolerance in 80-90% of patients in the first 24 hours and associated shorter hospital stays, lower risk of infections and improvement of hyperglycemic control.

COX-2 Inhibitors

Intestinal manipulation appears to increase cyclooxygenase-2 (COX-2) expression and rise prostaglandin levels, which, in turn, decreases jejunal contractility. COX-2 inhibition may improve gastrointestinal motility. One randomized trial reported that patients treated with a COX-2-specific inhibitor had a significantly shorter recovery time (time to return of bowel sounds, first bowel movement, tolerance of solid diet, and discharge) and less opioid use when compared with patients on a standard postoperative patient-controlled analgesia (PCA) morphine-only regimen after colorectal resection. However, these agents are associated with a variety of adverse effects, particularly disturbances in intestinal healing leading to potential risk of anastomotic dehiscence.

REFERENCES

[1] Hansen CT, Sørensen M, Møller C, et al. Effect of laxatives on gastrointestinal functional recovery in fast-track hysterectomy: a double-blind, placebo-controlled randomized study. *Am J Obstet Gynecol* 2007; 196:311.e1.

[2] Li S, Liu Y, Peng Q, et al. Chewing gum reduces postoperative ileus following abdominal surgery: a meta-analysis of 17 randomized controlled trials. *J Gastroenterol Hepatol* 2013; 28:1122.

[3] Corcoran T, Rhodes JE, Clarke S, et al. Perioperative fluid management strategies in major surgery: a stratified meta-analysis. *Anesth Analg* 2012; 114:640.

[4] Artinyan A, Nunoo-Mensah JW, Balasubramaniam S, et al. Prolonged postoperative ileus-definition, risk factors, and predictors after surgery. *World J Surg* 2008; 32:1495.

[5] Grupo de trabajo Vía Clínica de Recuperación Intensificada en Cirugía Abdominal (RICA). Vía clínica de recuperación intensificada en cirugía abdominal (RICA). Ministerio de Sanidad, Servicios Sociales e Igualdad. Instituto *Aragonés de Ciencias de la Salud*; 2015.

[6] Grupo de trabajo de la Guía de Práctica Clínica sobre Cuidados Perioperatorios en Cirugía Mayor Abdominal. Guía de Práctica Clínica sobre Cuidados Perioperatorios en Cirugía Mayor Abdominal. Ministerio de Sanidad, Servicios Sociales e Igualdad. Instituto Aragonés de Ciencias de la Salud (IACS); 2016 *Guías de Práctica Clínica en el SNS*.

[7] Lewis SJ, Egger M, Sylvester PA, Thomas S. Early enteral feeding versus "nil by mouth" after gastrointestinal surgery: systematic review and meta-analysis of controlled trials. *BMJ* 2001; 323:773.

[8] Mangesi L, Hofmeyr GJ. Early compared with delayed oral fluids and food after caesarean section. *Cochrane Database Syst Rev* 2002; CD003516.

[9] Sculati O, Bardi M, et al. A simple method for resolving postoperative ileus in an early stage in obstetric and gynecological surgery. *Curr Ther Res* 1981; 29:997.

[10] Sculati O, Giampiccoli G, Gozzi B, et al. Bran diet for an earlier resolution of post-operative ileus. *J Int Med Res* 1982; 10:194.

[11] Müller SA, Rahbari NN, Schneider F, et al. Randomized clinical trial on the effect of coffee on postoperative ileus following elective colectomy. *Br J Surg* 2012; 99:1530.

[12] Rushfeldt CF, Sveinbjørnsson B, Søreide K, Vonen B. Risk of anastomotic leakage with use of NSAIDs after gastrointestinal surgery. *Int J Colorectal Dis* 2011; 26:1501.

[13] Klein M, Krarup PM, Burcharth J, et al. Effect of diclofenac on cyclooxygenase-2 levels and early breaking strength of experimental colonic anastomoses and skin incisions. *Eur Surg Res* 2011; 46:26.

[14] Marulanda Sierra VA. Manifestaciones gastrointestinales de la diabetes mellitas. *Rev Col Gastroenterol* 2006; 21 (1); 39-56.

[15] Biondo S, Miquel J, Espin-Basany E, Sanchez JL, Golda T, Ferrer-Artola AM, Codina-Cazador A, Frago R, Kreisler E.A Double-Blinded Randomized Clinical Study on the Therapeutic Effect of Gastrografin in Prolonged Postoperative Ileus After Elective Colorectal Surgery. *World J Surg*. 2016 Jan;40(1):206-14.

[16] Vather R, Josephson R, Jaung R, Kahokehr A, Sammour T, Bissett I. Gastrografin in Prolonged Postoperative Ileus: A Double-blinded Randomized Controlled Trial. *Ann Surg.* 2015 Jul;262(1):23-30.

[17] Vather R, Trivedi S, Bissett I. Defining postoperative ileus: results of a systematic review and global survey. *J Gastrointest Surg*. 2013 May;17(5):962-72.

[18] Vather R, Josephson R, Jaung R, et al. Development of a risk stratification system for the occurrence of prolonged postoperative ileus after colorectal surgery: a prospective risk factor analysis. *Surgery* 2015; 157:764.

In: Encyclopedia of Surgery (22 Volume Set)
Editors: Andreas Lehrer and Kristin Mueller
ISBN: 978-1-53618-329-0
© 2020 Nova Science Publishers, Inc.

Chapter 267

PROPHYLAXIS OF STRESS ULCERS, ANASTOMOTIC ULCERS AND GASTROESOPHAGEAL REFLUX DISEASE

Pablo Priego*
Department of General Surgery, Division of Esophagogastric and Bariatric Surgery, Ramón y Cajal University Hospital, Madrid, Spain

ABSTRACT

Although stress ulcers are not a specific complication after bariatric surgery, its incidence and mortality among all patients in intensive care unit is not insignificant. Anastomotic or marginal ulcers (mainly after Roux-en-Y gastric bypass) and gastroesophageal reflux disease (GERD) are two situations more related to bariatric surgery. Association between GERD and obesity is extremely important, not only because several studies have shown that weight loss and lifestyle modifications are important in reducing the symptoms of GERD, but also because different surgeries have different impacts on the GERD symptomatology and that careful assessment may be needed before performing bariatric surgery in patients with GERD. Recommendations about prophylaxis, treatment and how to avoid these problems are described in this chapter.

Keywords: stress ulcers, anastomotic ulcers, marginal ulcers, gastroesophageal reflux disease, bariatric surgery, prophylaxis, treatment

INTRODUCTION

Stress-related gastric mucosal damage or stress ulceration (SU) has been documented to occur after many major physiologic insults, including trauma, major operative procedures, burn injury and during critical illness [1]. SU were once a major cause of morbidity and

* Corresponding Author's Email: papriego@hotmail.com.

mortality in critically ill patients. However, with the advent of ulcer prophylaxis and improved critical care, surgical intervention is only necessary for a small number of patients with life-threatening hemorrhage or perforation [2]. Different aspects of epidemiology, pathophysiology, risk factors, prognosis and prophylaxis of SU in the intensive care unit (ICU) are discussed in this chapter [3].

Obesity is an epidemic on the rise all over the world. The Roux-en-Y gastric bypass (RYGB) is the most used bariatric surgical procedure worldwide. Marginal ulceration (MU) remains a morbid complication of RYGB, occurring in 1% to 16% of patients [4]. Although the mechanisms underlying the development of MU have not been completely elucidated, ulcers may be caused by the peptic action of the acid juice from the gastric pouch acting on the small bowel not alcalinized by biliopancreatic juice. Prevention and management of MU after RYGB is still a matter of debate. Different aspects regarding risk factors, prophylaxis, recommendations and treatments are analyzed [5, 6].

To end up, there is an interesting relationship between gastroesophageal reflux disease (GERD) and bariatric surgery [7, 8]. The prevalence of GERD has been described in >50% of obese patients. Increases in the prevalence of obesity and GERD have paralleled one another over the past decade. Several studies have shown that weight loss and lifestyle modifications are important in reducing the symptoms of GERD [9]. Association between obesity and GERD is extremely important, because a critical review of the literature suggests that different surgeries have different impacts on the symptomatology of GERD and that careful assessment may be needed before performing bariatric surgery in patients with GERD. Different aspects of GERD pathophysiology regarding different bariatric procedures, outcomes and recommendations will be discussed.

STRESS ULCERS PROPHYLAXIS

Stress ulcers usually occur in the fundus and body of the stomach, but sometimes develop in the antrum, duodenum, or distal esophagus. Normally, SU tend to be limited to superficial capillary; however, deeper lesions may also occur and cause massive bleeding or perforation. Incidence of gastrointestinal (GI) bleeding range from 1.5 to 8.5 percent among all ICU patients, but may be as high as 15 percent among patients who do not receive stress ulcer prophylaxis [10]. Furthermore, GI bleeding due to SU is associated with increased mortality. In the prospective cohort study of Cook et al. [10], mortality was higher among ICU patients with clinically important GI bleeding than among those without bleeding (49% vs. 9%).

Pathogenesis

The exact mechanism by which gastric SU develops remains controversial. Classically, it has been as a result from an imbalance between mucosal protection and gastric acid production.

a) *Impaired mucosal protection:* The stomach is normally protected by a glycoprotein mucous layer that forms a physical barrier to hydrogenion diffusion and traps

bicarbonate. This barrier may be denuded by increased concentrations of refluxed bile salts or uremic toxins, which are common in critically ill patients [11, 12]. In addition, its synthesis may be decreased when there is poor gut perfusion caused by shock, sepsis, or trauma [13, 14].

b) *Hypersecretion of acid:* Hypersecretion of acid due to excessive gastrin stimulation of parietal cells has been detected in patients with head trauma. However, excessive gastric acid production is probably not the principle factor leading to its development, as a pH greater than 3.5–4.0 is evident in only 20–60% of critically ill patients [15-17].

Finally, *Helicobacter pylori* infection may also contribute to SU, but the evidence is of limited quality [18, 19].

Risk Factors

Based on the current literature review, the most universally accepted risk factors for SU are prolonged mechanical ventilation (more than 48 h) and coagulopathy [20]. The incidence of clinically important GI bleeding among patients with one or both of these risk factors was 3.7 percent, compared to 0.1 percent among patients with neither risk factor.

Other identified risk factors for SU include shock, sepsis, multiple injuries, spinal cord injury, hepatic failure, acute renal failure, and requirement of high-dose steroids [20, 21].

Glucocorticoid therapy alone has not been conclusively shown to be a risk factor for stress ulceration [20], however, it is commonly cited as an indication for stress ulcer prophylaxis [22].

Prophylaxis

Based on guideline recommendations, SU prophylaxis should be administered to all critically ill patients who are at high risk for GI bleeding [23-25]. That includes:

- Coagulopathy, defined as a platelet count <50,000 per m^3, an International Normalized Ratio (INR) >1.5, or a partial thromboplastin time (PTT) >2 times the control value
- Mechanical ventilation for >48 hours
- History of GI ulceration or bleeding within the past year
- Traumatic brain injury, traumatic spinal cord injury, or burn injury
- Two or more of the following minor criteria: sepsis, an intensive care unit (ICU) stay more than one week, occult GI bleeding for six or more days, or glucocorticoid therapy (more than 250 mg hydrocortisone or the equivalent)

In addition, many physicians also provide SU prophylaxis to patients with traumatic brain injury, traumatic spinal cord injury, or thermal injury (>35 percent of the body surface area) [26].

Another important question is whether a patient who is receiving enteral nutrition also requires pharmacological SU prophylaxis. Based on different observational and randomized trials, it is known that enteral nutrition alone may reduce the risk of GI bleeding due to SU and that SU prophylaxis may be ineffective or harmful among these patients [27-30].

Recommendations

Regarding last update revision of Weinhouse et al. [3] about stress ulcers prophylaxis in the intensive care unit, final recommendations are the following:

- In critically ill patients, histamine-2 receptor antagonists (H2 blockers), proton pump inhibitors (PPIs), and antacids reduce GI bleeding when compared to placebo or no prophylaxis.
- For critically ill patients who have risk factors for SU, it is recommended prophylaxis with agents that suppress gastric acid (eg, PPI, H2 blockers, antacid) rather than no prophylaxis (*Grade 1B*).
- For critically ill patients without risk factors, SU prophylaxis should be considered on a case-by-case basis. Considerations include whether the patient is receiving enteral nutrition, how long the patient is expected to be without enteral nutrition, the severity of the patient's illness, and the patient's comorbidities.
- For critically ill patients who are able to receive enteral medications and in whom SU prophylaxis is indicated, it is suggested an oral PPI rather than an alternative prophylactic agent (*Grade 2B*).
- For critically ill patients who cannot receive enteral medications and in whom SU prophylaxis is indicated, it is suggested an intravenous H2 blocker or an intravenous proton pump inhibitor (*Grade 2B*).

BARIATRIC SURGERY AND MARGINAL ULCERATION

Marginal ulceration remains a morbid complication of RYGB, occurring in 1% to 16% of patients [4]. According to the literature, 60% of marginal ulceration develops within 6 months after RYGB. However, they can occur up to 5 years postoperatively [5].

Clinical appearance of MU ranges from asymptomatic, severe abdominal pain, lack of appetite, abnormal weight loss, or nausea and vomiting. Furthermore, MU may cause anemia due to chronic occult bleeding (10.2% of patients after RYGB), stomal stenosis or perforation [5]. The diagnosis of a marginal ulcer is established by upper endoscopy.

Although the mechanisms underlying the development of marginal ulceration have not been completely elucidated, the etiology of this complication is likely to be multifactorial [6]. Traditionally, numerous mechanisms underlying the development of MU have been currently discussed in the literature. These can be divided into surgical and nonsurgical risk factors [5]. Concerning *surgical risk factors,* small-vessel ischemia and anastomotic tension are suggested as the most important causes [31]; but persistent acidity in a large gastric pouch [32] and foreign body reaction has also been involved [33, 34]. On the other hand, concerning

nonsurgical risk factors can be included, exogenous substances (smoking, NSAID), and H. pylori infection [35-37].

In order to identify independent risk factors for MU and with a follow-up of 64 months and 3% of marginal ulcer rate, Bhayani et al. [38] have reported that on univariate analysis, hypertension, gastroesophageal reflux disease, hyperlipidemia, and sleep apnea were significantly correlated with margin ulceration. However, on multivariate analysis, the odds of marginal ulcer formation were 7.84 among hypertensive patients with a 95% confidence interval of 1.75-35.06 (P = 0.007). In this study, preoperative hypertension was the only significant predictor of marginal ulcer disease.

Gastric Acid

Classically, the role of gastric acid has been considered essential for development of marginal ulceration [6]. However, recently studies have found a virtual absence of acid secretion within the gastric pouch after gastric bypass in patients with marginal ulcers [32, 39].

Theoretically, the secretion of gastric acid from parietal cells of gastric pouch will led to a peptic digestion of the unprotected jejunal mucosa, causing the marginal ulceration [32]. Furthermore, the gastrojejunostomy is not reached by the alkaline fluid secreted by glands of the duodenum. Therefore, the gastrojejunal anastomosis may be exposed to the undiluted acidic juice produced by the gastric pouch, subsequently leading to margin ulceration development. For this reason, large pouch size (>50 ml) was thought to predispose patients to marginal ulceration. Indeed, reducing the size of the gastric pouch has shown to decrease the incidence of marginal ulcers [40].

Another question regarding the gastric pouch is the orientation. It is known that the lesser curvature has a high concentration of parietal cells, so if we create a pouch limited to the cardia as Sapala et al. [41] proposed; the rate of marginal ulceration would decrease.

Stapled line leakage with a resultant gastrogastric fistula is another factor that could increase the rate of marginal ulceration. If the gastric remnant is connected with the pouch, the greater volume of low-ph fluid will digest the jejunal mucosa, and the incidence of marginal ulceration will be higher [6].

Anyway, and to summarize gastric acid seems to predispose patients to the development of marginal ulcers, supported by evidence that acid suppression alone is effective in healing marginal ulcers.

Foreign Body

The foreign body (staples or suture material) used to build the anastomoses between the gastric pouch and the jejunum has been suggested to cause an inflammatory reaction and lead to ulcer formation. Furthermore, several studies have reported that the marginal ulceration rate was significantly higher when the gastrojejunal anastomoses were created with stapler or permanent suture rather than absorbable suture [34, 42]. In contrast, the technique used to fashion the gastrojejunostomy (hand sewn vs. linear vs. circular) was not found to have an impact on marginal ulceration development in other studies [43].

Exogenous Substances

In the same way as in the general population, non-steroidal anti-inflammatory drugs (NSAID) are believed to predispose to marginal ulceration after RYGB [44]. Furthermore, smoking is also related with the development of marginal ulceration [45]. Regarding smoking, some bariatric surgeons consider leaving smoking a condition prior to perform any bariatric procedure.

Helicobacter Pylori

Classically, *helicobacter pylori* has been implicated as a possible etiology agent in the development of margin ulcers after RYGB [46]. Theoretically, patients preoperatively screened and treated for *H. pylori* had fewer incidences of margin ulcers than those not screened or eradicated [47]. On the other hand, Rasmussen et al. [6] have demonstrated that preoperative *H. pylori* infection, although adequately treated was higher among patients who had a marginal ulceration (32%) as among those who did not (12 %) [48].

Prevention and Management

Prevention and management of marginal ulceration after RYGB is still controversial. Proton pump inhibitors (PPIs) are an efficient option for the prevention and treatment of peptic ulcers [49]. However, despite the preventative use of treatment-dose PPIs, marginal ulceration may still occur in up to 16% of post-RYGB patients [5].

Nevertheless, the management of marginal ulceration after RYGB can be treated conservatively or surgically. Conservative treatment includes the eliminating known risk factors of peptic ulcers (Smoking, alcohol, NSAIDs, stress, hypertension), and treatment with antacids (PPI). Initial medical treatment consists of gastric acid suppression with a six-week course of PPI, with or without the addition of sucralfate, followed by a repeat endoscopy to ensure healing. An upper gastrointestinal series or a computed tomography (CT) scan with oral contrast should be performed to rule out a gastrogastric fistula, because this complication is associated to 72% of marginal ulceration [31].

The success rate of this conservative management ranges between 68 to 88% [31, 50, 51]. Hereby, most of bariatric surgeons employ PPI as the first-line and single treatment. However, it is important to notice that there is no consensus regarding the duration of therapy and whether therapy should be continued after marginal ulceration resolution. Furthermore, the correct dosage and the need for combination of different acid reducing agents remain unclear [5].

Despite the best conservative therapy, 30% of patients will need surgical revision for therapy refractory or recurring marginal ulceration [5, 39]. Surgical options are various and include redoing the gastrojejunostomy combined with pouch resizing. In a classical study this technique was successful in up to 87% of cases [5]. Other surgical options are reduction of acid production by truncal vagotomy [52] or gastric remnant resection, pouch resection with subsequent esophagojejunostomy, and RYGB reversal. However, although feasible, RYGB reversal has not been shown to be an effective marginal ulceration treatment [53, 54].

In unstable patients, due to a perforated peptic ulcer, a Graham patch can be used to seal any perforation, the local area washed out, and a feeding tube placed.

Unfortunately, there is no consensus for the prevention and management of primary or refractory anastomotic ulcer, and no recommendations can be drawn from the available literature. So it is advised to create more multicenter and prospective studies in order to define strategies of prevention and treatment of this painful and unresolved condition after RYGB.

BARIATRIC SURGERY AND GASTROESOPHAGEAL REFLUX DISEASE (GERD)

The prevalence of gastroesophageal reflux disease (GERD) has been described in >50% of obese patients compared to 10-20% in the general population. Increases in the prevalence of obesity and GERD have paralleled one another over the past decade [8, 55]. Moreover, and because the prevalence of GERD is markedly higher in overweight and obese individuals as compared to those with normal BMI, GERD itself is now recognized as a obesity-related comorbidity [56, 57].

The etiology is not completely understood, but basically, the development of GERD is due to a failure of the anti-reflux barrier that comprises the lower esophageal sphincter (LES) and the crural portion of the hiatus. Normally, this is associated to an increased pressure from the stomach secondary to a hiatus hernia or increased intra-abdominal pressure [8].

This failure of the anti-reflux barrier can lead to either short-term symptoms including heartburn, regurgitation, dysphagia and chest pain or long-term ones like esophagitis, strictures, Barrett esophagus or esophageal adenocarcinoma [7].

Association between obesity and GERD is extremely important, because a critical review of the literature suggests that different surgeries have different impacts on the symptomatology of GERD and that careful assessment may be needed before performing bariatric surgery in patients with GERD. Indeed, when surgical treatment of GERD is indicated in a severely obese patient, bariatric surgery rather than fundoplication should be strongly considered. However, diagnosis of GERD in obese patients is not always easy to do. Many patients with subjective claims of GERD have serious difficulties to correlate objectively with esophageal functional studies, making studies based on subjective claims difficult to analyze.

Several studies have shown that weight loss and lifestyle modifications are important in reducing the symptoms of GERD. However, with regards to bariatric surgery and its effect on GERD, studies have shown inconsistencies with different types of bariatric surgery. Pallati et al. [58] presented a prospective study with the Bariatric Outcomes Longitudinal Database (American Society of Metabolic and Bariatric Surgery Center of Excellence program) in order to compare the efficacy of various bariatric procedures in the improvement of GERD. Of a total of 116.136 patients, 36.938 patients had evidence of GERD preoperatively. After excluding patients undergoing concomitant hiatal hernia repair or fundoplication, there were 22.870 patients with 6-month follow-up. All common bariatric procedures improve GERD; however, GERD score improvement was best in RYGB patients (56.5%; 7955 of 14.078) followed by Adjustable Gastric Banding (46%; 3773 of 8207) and Sleeve Gastrectomy patients (41%; 240 of 585).

Gastric Banding

The effects of Laparoscopic Adjustable Gastric Banding (LAGB) on GERD are controversial [7]. While for several studies, LAGB appears to provide short-term improvement of reflux symptoms, esophagitis and normalized pH monitoring results [59]. There is, however, a group of patients who experience a new reflux symptoms and esophagitis in the long term, although it is difficult to be sure whether these are a result of pathologic GERD or complications from gastric banding [60-62]. The mechanism by which LAGB may improve GERD is not well characterized, but is thought to include weight loss, increase in LES pressure, and reconstitution of the angle of His. On the other hand, it has been supposed that the poorer GERD outcomes following LAGB might be attributable to an unrecognized hiatal hernia at the time of initial band placement, which has led most bariatric surgeons to suggest that the presence of hiatal hernia is a contraindication to LAGB [63].

Sleeve Gastrectomy

Sleeve gastrectomy (SG) has reached wide popularity during the last decades, due to the lower morbid-mortality rates in compare to RYGB, and the excellent results regarding weight loss and resolution of comorbidities. Moreover, SG has rapidly become popular as a standard alone bariatric operation. At the same time, there are some concerns regarding its long-term results and postoperative GERD. As with LAGB, early data regarding the impact of SG on GERD are controversial too, and very little long-term or comparative data regarding SG and GERD are available [7].

Classically, sleeve gastrectomy has been associated with an increase rate of postoperative reflux. However, the interpretation of the results are not standardized, because most studies investigate the presence of GERD by assessing symptoms and the use of PPI reducing medications only [9]. In 2011, Chiu et al. [64] performed a systematic review on 15 studies in order to evaluate the effect of SG on GERD. Four of these studies found an increased prevalence of GERD after SG, and seven showed reduced prevalence of GERD after SG, so results were inconclusive.

To date, only a few studies objectively analyzed patients by esophageal manometry and 24 ph-metry [65-73]. Regarding manometric changes, published data were controversial [65-71]. Some small studies [65] have found a significant decrease in LES, proposing the partial section of the sling fibers of the cardia as cause of this finding. On the other hand, Petersen et al. [66] reported an increase in LES pressure regardless of the weight loss, proposing that this manometric change was related to the position of the stapler regarding to the angle of His. The closer the staple line to the gastroesophageal junction, the higher the LES pressure is.

Indeed, only 4 studies [68, 70-72] have objectively study the presence of pathologic reflux by 24-h Multichannel Intraluminal Impedance ph-metry (MII ph-metry) monitoring or 24 ph-metry with same controversial results. Meanwhile, Del Genio et al. [68], Gorodner et al. [70] and Georgia et al. [71] showed a significant increase of the median DeMeester's score (almost 2.5 times higher than the preoperative one) and "de novo" GERD after SG (already 30%), Rebecchi et al. [72] showed a significantly decreased DMS and total %ph, with only a 5.4% of "de novo GERD."

Meanwhile, data regarding LES function are controversial, it is suggested that there is an important role of the surgical technique on the incidence of postoperative GERD [9]. Main surgical technical issues are: a relative narrowing of the mid portion of the sleeve, a redundant upper part of the sleeve and the presence of a concomitant hiatal hernia [73].

a) The shape of the gastric sleeve plays a major role in leading to GERD. The remnant gastric pouch, being much more restrictive, may increase gastric pressure by reducing gastric compliance and emptying, and decreasing volume and dispensability [7]. Keidar et al. [75] found that most part of patients when a barium swallow was performed had a combination of dilated upper portion of the sleeve and relative narrowing of the mid-stomach. These two anatomical situations were due to a too narrow construction of the sleeve in association with retention of part of the gastric fundus by stapling far away from the left pillar of the crura, in order to decrease the rate of leakage.

Avoiding any anatomical obstruction at incisura angularis level, we can reduce the pressure in the proximal gastric sleeve and reduce leak rates in the short term and fundus dilatation and/or GERD in the long term. Another important factor appears to be distance of the final staple line from angle of His. It is true that going too close to esophagus, the leaks rate increases and going too far risks leaving behind a bigger fundus and may predispose to reflux. Stapling 1 cm away from the angle of His would appear to be a reasonable compromise in most patients.

On the other hand, SG may also contribute to reducing of GERD by accelerating gastric emptying and increasing weight loss, it is associated with a decrease of abdominal pressure. It was also suggested that long-term resolution of GERD could be explained by increase in compliance and restoration at the angle of His, which occurs about 3 years postoperatively [7].

b) The impact of the size of the bougie on the prevention of GERD after SG is unclear [76]. While it is known that smaller bougies are associated with leaks secondary to gastric strictures at incisura angularis, the use of larger bougies might also favour the development of GERD due to a reduce of weight loss, dilation of upper part of stomach and in consequence an increased number of residual parietal cells [9].
c) Finally, the presence of a hiatal hernia is not considered by many surgeons a contraindication to SG [76]. However, results remain controversial because all studies based their results on symptom evaluation instead of assessing postoperative GERD with 24-phmetry. Recently, a study of Mahawar et al. [77] has tried to investigate the results and technical aspects of simultaneous SG and hiatal hernia repair, but although most studies reported a decrease on GERD symptoms when hiatal hernia was repaired, these results were opposite to other ones found by other authors [78, 79].

Different authors have proposed several associated techniques in order to treat GERD simultaneously to the performing of SG. Recently, Nocca et al. [80] presented their preliminary pilot study of patients operated with a Nissen anti-reflux valve added to a standard SG (N-Sleeve). Authors report that this technique provides an adequate reflux

control with no clear interference on the expected bariatric results of a standard SG with a 1 year follow-up.

Other technical option has been described by Da Silva et al. [81]. They have proposed an alternative technique of sleeve gastroplasty combined with Nissen fundoplication for morbidly obese patients who present significant GERD called Laparoscopic Sleeve-Collis-Nissen gastroplasty (LSCNG). With a population of 122 patients, one-year follow-up showed a significant decrease in the prevalence of esophagitis (100 vs. 13.6%) and the use of PPIs (92 vs. 13.6%). The percentages of excess weight loss 1 and 3 years after the surgery were 64.4 ± 7.2 and $60.4 \pm 8.1\%$, respectively. However, an although LSCNG is a novel, technically feasible surgery with a low incidence of procedure-related complications, prospective studies are required to assess the real impact of this procedure on the improvement of GERD symptoms.

Finally, Galvez-Valdovinos et al. [82] has recently published and old technique for treatment of GERD, but specially adapted to treatment of GERD in patients in which a SG is going to be performed. In this study, 15 patients with SG who presented with hiatal hernia and GERD, a ligamentum teres cardiopexy was performed. In this procedure, the ligamentum teres is released from its umbilical connection and the hernia reduced by manual traction, freeing the last 3–5 cm of esophagus in the abdomen. The distal ligamentum teres is fixed with one stitch to the apex of the angle of His, one at the gastroesophageal junction, and one joining the gastric fundus to the esophagus. The remainder of the ligamentum teres is fixed over itself with four to six stitches, forming a necktie cardiopexy. The procedure concludes with diaphragmatic crura closure. After 6 months, 13 patients (86.6%) achieved successful results, defined as resolution of GERD, no PPI use, and manometry measurement over 12 mmHg after surgery. However, two patients (13.3%) required continued PPI.

On the other hand, and once GERD has occurred after SG, medical therapy with PPIs represents the initial treatment of choice [83, 84]. However, in case of failure of PPI therapy, conversion to RYGB is suggested [85, 86]. Very recently, new approaches like the LYNX® Reflux Management System and the Stretta® procedure has been proposed in patients with GERD and hypotensive LES [87, 88].

To summarize, prospective and randomized studies with long follow-up and objective evaluation of GERD are needed before drawing a conclusion. As such, SG in the setting of significant GERD should be recommended with caution. However, whether a SG has to be carried out in presence of hiatus hernia (severe adhesions, Crohn's disease, patient preference, etc.), attention should be paid to several technical factors in order to reduce incidence and prevalence of GERD postoperatively.

Roux-En-Y Gastric Bypass

RYGB accounts for over half of the currently performed bariatric operation in the United States, and seems to be the most effective bariatric procedure in the alleviation of GERD [89, 90]. Nowadays, it is considered as the gold standard bariatric procedure for obese patients with symptoms of GERD and/or presenting hiatal hernia.

It is also important to note that some studies have assessed the use of RYGB as revision surgeries to laparoscopic Nissen fundoplication procedures that have failed to alleviate GERD symptoms or as I have mentioned before in patients with previous SG in which uncontrolled

GERD has developed. Moreover, several studies have reported it is also very effective in treating symptoms related to GERD in a similar way that with Nissen fundoplication [91-93].

Its efficacy in treating GERD is thought to be related to the relatively low acid production of the small-volume (15-30 ml) gastric pouch. As I have mentioned before in the pathophysiology of marginal ulceration, the cardiac region of the stomach where the pouch is created has been shown to lack parietal cells, so it should not produce acid. Smith et al. [94] have shown basal and stimulated gastric acid secretion to be virtually absent from the gastric pouch after RYGB. Moreover, bile reflux is also eliminated using an alimentary limb measuring at least 100 cm in length. Furthermore, the small pouch minimizes any reservoir capacity to promote regurgitation [89]. Finally, RYGB improves GERD because of the additional benefit of significant weight loss.

Basically, maybe one of the most important factors that contributes to GERD improvement is the size of gastric pouch. Indeed, if we compare GERD remission in super-obese patients (BMI $\geq$ 50 kg/m^2) who underwent RYGB with duodenal switch (DS), the first ones had a higher rate of GERD resolution than those who underwent DS, despite the greater weight loss seen in the latter group [94].

Some studies that included patients with morbid obesity and RYGB have reported complete improvement of symptoms in 80% of the cases and discontinuation of anti-secretory therapy in 97% of them [90, 94, 96].

Mejía-Rivas et al. [96], observed that the mean weight loss 6 months after RYGB was 42.5 ± 9.7 kg, representing 71% of the decrease in the weight excess. Moreover, 6 months after surgery, reflux symptoms disappeared in 90% of the patients. Indeed, the abnormal exposure to acid in the esophagus was normalized in 95% of the cases and the percentage of time with pH < 4 decreased from 10.7 ± 6 to 1.6 ± 1.2 after RYGB. There also was a significant reduction in the number of reflux episodes, number of long refluxes, DMS and symptom index. Symptoms after RYGB were heartburn in 10% and regurgitation in 5% of the patients. None of the patients had dysphagia.

These results were very similar to those obtained by Patterson [97] and Ortega [98] in that they observed that weight reduction after a RYGB favors improvement in reflux symptoms and decrease in the esophageal exposure to acid measured by an ambulatory 24-h pH-metry.

To sum up, nowadays RYGB is considered treatment of choice of patients with obesity and GERD symptoms; however, as I have mentioned before and following the results published in literature regarding SG, could be performed in selected cases.

REFERENCES

[1] Nathens AB, Maier RV. Prophylaxis and management of stress ulceration. *Surgical Treatment: Evidence-Based and Problem-Oriented*. Ed. Holzheimer RG, Mannick JA. Munich: Zuckschwerdt 2001. ISBN-10: 3-88603-714-2.

[2] Mercer DW, Goede MR. Management of stress ulcers. *UpToDate* (Accessed on April 17, 2017).

[3] Weinhouse GL. Stress ulcer prophylaxis in the intensive care unit. *UpToDate* (Accessed on June 28, 2017).

[4] Garrido Jr AB, Rossi M, Lima Jr SE, et al. Early marginal ulcer following Roux-en-Y gastric bypass under proton pump inhibitor treatment: prospective multicentric study. *Arq Gastroenterol*. 2010; 47(2):130–4.
[5] Steinemann DC, Bueter M, Schiesser M, Amygdalos I, Clavien PR, Nocito A. Management of Anastomotic Ulcers After Roux-en-Y Gastric Bypass: Results of an International Survey. *Obes Surg* 2014; 24:741-746.
[6] Rasmussen JJ, Fuller W, Ali MR. Marginal ulceration after laparoscopic gastric bypass: an analysis of predisposing factors in 260 patients. *Surg Endosc*. 2007; 21(7):1090–4.
[7] El-Hadi M, Birch DW, Gill RS, Karmali S. The effect of bariatric surgery on gastroesophageal reflux disease. *Can J Surg* 2014; 57 (2):139-144.
[8] Patti MG. Gastroesophageal reflux disease and severe obesity: Fundoplication or bariatric surgery? *World J Gastroenterol* 2010; 16 (30):3757-3761.
[9] Rebecchi F, Allaix ME, Patti MG, Schlottmann F, Morino M. Gastroesophageal reflux disease and morbid obesity: to sleeve or not to sleeve? *World J Gastroenterol* 2017; 23(13): 2269-2275.
[10] Cook DJ, Fuller HD, Guyatt GH, et al. Risk factors for gastrointestinal bleeding in critically ill patients. Canadian Critical Care Trials Group. *N Engl J Med* 1994; 330:377.
[11] Ritchie WP Jr. Role of bile acid reflux in acute hemorrhagic gastritis. *World J Surg* 1981; 5:189.
[12] Schindlbeck NE, Lippert M, Heinrich C, Müller-Lissner SA. Intragastric bile acid concentrations in critically ill artificially ventilated patients. *Am J Gastroenterol* 1989; 84: 624.
[13] Navab F, Steingrub J. Stress ulcer: is routine prophylaxis necessary? *Am J Gastroenterol* 1995; 90: 708.
[14] Geus WP, Lamers CB. Prevention of stress ulcer bleeding: a review. *Scand J Gastroenterol* Suppl 1990; 178:32.
[15] Bowen JC, Fleming WH, Thompson JC. Increased gastrin release following penetrating central nervous system injury. *Surgery* 1974; 75:720.
[16] Stremple JF, Molot MD, McNamara JJ, et al. Posttraumatic gastric bleeding: prospective gastric secretion composition. *Arch Surg* 1972; 105:177.
[17] Watts CC, Clark K. Gastric acidity in the comatose patient. *J Neurosurg* 1969; 30:107.
[18] Maury E, Tankovic J, Ebel A, et al. An observational study of upper gastrointestinal bleeding in intensive care units: is Helicobacter pylori the culprit? *Crit Care Med* 2005; 33:1513.
[19] Robertson MS, Cade JF, Clancy RL. Helicobacter pylori infection in intensive care: increased prevalence and a new nosocomial infection. *Crit Care Med* 1999; 27:1276.
[20] Cook DJ. Stress ulcer prophylaxis: gastrointestinal bleeding and nosocomial pneumonia. Best evidence synthesis. *Scand J Gastroenterol* Suppl 1995; 210:48.
[21] Martin LF, Booth FV, Reines HD, et al. Stress ulcers and organ failure in intubated patients in surgical intensive care units. *Ann Surg* 1992; 215:332.
[22] Daley RJ, Rebuck JA, Welage LS, Rogers FB. Prevention of stress ulceration: current trends in critical care. *Crit Care Med* 2004; 32:2008.
[23] ASHP Therapeutic Guidelines on Stress Ulcer Prophylaxis. ASHP Commission on Therapeutics and approved by the ASHP Board of Directors on November 14, 1998. *Am J Health Syst Pharm* 1999; 56:347.

[24] Spirt MJ, Stanley S. Update on stress ulcer prophylaxis in critically ill patients. *Crit Care Nurse* 2006; 26:18.

[25] Barletta JF, Bruno JJ, Buckley MS, Cook DJ. Stress Ulcer Prophylaxis. *Crit Care Med* 2016; 44:1395.

[26] Guillamondegui OD, Gunter Jr OL, Bonadies JA, Coates JE, Kurek SJ, De Moya MA, Sing RF, Sori AJ. Practice management guidelines for stress ulcer prophylaxis. *EAST Practice Management Guidelines Committee Chicago* 2008. p. 24.

[27] Pingleton SK, Hadzima SK. Enteral alimentation and gastrointestinal bleeding in mechanically ventilated patients. *Crit Care Med* 1983; 11:13.

[28] Raff T, Germann G, Hartmann B. The value of early enteral nutrition in the prophylaxis of stress ulceration in the severely burned patient. *Burns* 1997; 23:313.

[29] Cook D, Heyland D, Griffith L, Cook R, Marshall J, Pagliarello J. Risk factors for clinically important upper gastrointestinal bleeding in patients requiring mechanical ventilation. Canadian Critical Care Trials Group. *Crit Care Med* 1999; 27:2812.

[30] Marik PE, Vasu T, Hirani A, Pachinburavan M. Stress ulcer prophylaxis in the new millennium: a systematic review and meta-analysis. *Crit Care Med* 2010; 38:2222.

[31] Patel RA, Brolin RE, Gandhi A. Revisional operations for marginal ulcer after Roux-en-Y gastric bypass. *Surg Obes Relat Dis*.2009; 5(3):317–22.

[32] Mason EE, Munns JR, Kealey GP, et al. Effect of gastric bypass on gastric secretion. *Am J Surg*. 1976; 131(2):162–8.

[33] Vasquez JC, Wayne Overby D, Farrell TM. Fewer gastrojejunostomy strictures and marginal ulcers with absorbable suture. *Surg Endosc*.2009; 23(9):2011–5.

[34] Sacks BC, Mattar SG, Qureshi FG, et al. Incidence of marginal ulcers and the use of absorbable anastomotic sutures in laparoscopic Rouxen-Y gastric bypass. *Surg Obes Relat Dis*. 2006; 2(1):11–6.

[35] Azagury DE, Abu Dayyeh BK, Greenwalt IT, et al. Marginal ulceration after Roux-en-Y gastric bypass surgery: characteristics, risk factors, treatment, and outcomes. *Endoscopy*. 2011; 43(11):950–4.

[36] Wilson JA, Romagnuolo J, Byrne TK, et al. Predictors of endoscopic findings after Roux-en-Y gastric bypass. *Am J Gastroenterol*.2006; 101(10):2194–9.

[37] Scheffel O, Daskalakis M, Weiner RA. Two important criteria for reducing the risk of postoperative ulcers at the gastrojejunostomy site after gastric bypass: patient compliance and type of gastric bypass. *Obes Facts.* 2011; 4 Suppl 1:39–41.

[38] Bhayani NH, Oyetunji TA, Chang DC, Cornwell EE 3rd, Ortega G, Fullum TM. Predictors of marginal ulcers after laparoscopic Roux-en-Y gastric bypass. *J Surg Res*. 2012; 177(2):224-7.

[39] MacLean LD, Rhode BM, Nohr C, et al. Stomal ulcer after gastric bypass. *J Am Coll Surg*. 1997; 185(1):1–7.

[40] Printen KJ, Scott D, Mason EE. Stomal ulcers after gastric bypass. *Arch Surg* 1980; 115: 525–527.

[41] Sapala JA, Wood MH, Sapala MA, Flake TM Jr. Marginal ulcer after gastric bypass: a prospective 3-year study of 173 patients. *Obes Surg* 1998; 8: 505–516.

[42] Capella JF, Capella RF. An assessment of vertical banded gastroplasty–Roux-en-Y gastric bypass for the treatment of morbid obesity. *Am J Surg* 2002; 183: 117–123.

[43] Bendewald FP, Choi JN, Blythe LS, et al. Comparison of hand-sewn, linear-stapled, and circular-stapled gastrojejunostomy in laparoscopic Roux-en-Y gastric bypass. *Obes Surg*. 2011; 21(11):1671–5.

[44] Higa KD, Boone KB, Ho T. Complications of the laparoscopic Roux-en-Y gastric bypass: 1,040 patients: what have we learned? *Obes Surg* 2000; 6: 509–513.

[45] Ben-Meir A, Sonpal I, Patterson L, Schreiber H, Salomone M, Sharma K, Kumar A, Marshall JB. Cigarette smoking, but not NSAID or alcohol use or comorbidities, is associated with anastomotic ulcers in Roux-en-Y gastric bypass (RYGB) patients. *Surg Obes Relat Dis* 2005; 1: 263.

[46] Cleator IGM. Ulcerogenesis following gastric procedures for obesity. *Obes Surg* 1996; 6: 260–261.

[47] Schirmer B, Erenoglu C, Miller A. Flexible endoscopy in the management of patients undergoing Roux-en-Y gastric bypass. *Obes Surg* 2002; 12: 634–638.

[48] Kelly J, Perugini RA, Wang QL, Czerniach DR, Flahive J, Cohen PA. The presence of Helicobacter pylori is not associated with longterm anastomotic complications in gastric bypass patients. *Surg Endosc* 2015 29:2885–2890.

[49] Coblijn UK, Lagarde SM, de Castro SM, Kuiken SD, van Tets WF, van Wagensveld BA. The influence of prophylactic proton pump inhibitor treatment on the development of symptomatic marginal ulceration in Roux-en-Y gastric bypass patients: a historic cohort study. *Surg Obes Relat Dis*. 2016; 12(2):246-52.

[50] Carrodeguas L, Szomstein S, Soto F, et al. Management of gastrogastric fistulas after divided Roux-en-Y gastric bypass surgery for morbid obesity: analysis of 1,292 consecutive patients and review of literature. *Surg Obes Relat Dis.* 2005; 1(5):467–74.

[51] Sanyal AJ, Sugerman HJ, Kellum JM, Engel KM, Wolfe L. Stomal complications of gastric bypass: incidence and outcome of therapy. *Am J Gastroenterol*. 1992; 87(9):1165–9.

[52] Hunter J, Stahl RD, Kakade M, Breitman I, Grams J, Clements RH. Effectiveness of thoracoscopic truncal vagotomy in the treatment of marginal ulcers after laparoscopic Roux-en-Y gastric bypass. *Am Surg*. 2012; 78(6):663-8.

[53] Simper SC, Erzinger JM, McKinlay RD, Smith SC. Laparoscopic reversal of gastric bypass with sleeve gastrectomy for treatment of recurrent retrograde intussusception and Roux stasis syndrome. *Surg Obes Relat Dis*. 2010; 6(6):684–8.

[54] Himpens J, Dapri G, Cadiere GB. Laparoscopic conversion of the gastric bypass into a normal anatomy. *Obes Surg*. 2006; 16(7):908–12.

[55] Tutuian, R. Obesity and GERD: pathophysiology and effect of bariatric surgery. *Curr Gastroenterol Rep*. 2011; 13:205–212.

[56] El-Serag HB, Ergun GA, Pandolfino J, Fitzgerald S, Tran T, Kramer JR. Obesity increases oesophageal acid exposure. *Gut* 2007; 56: 749-755.

[57] Hampel H, Abraham NS, El-Serag HB. Meta-analysis: obesity and the risk for gastroesophageal reflux disease and its complications. *Ann Intern Med* 2005; 143: 199-211.

[58] Pallati, PK, Shaligram, A., Shostrom, VK, Oleynikov, D., McBride, CL, Goede, M. R. Improvement in gastroesophageal reflux symptoms after various bariatric procedures: review of Bariatric Outcomes Longitudinal Database. *Surg Obes Relat Dis*. 2014; 10:502–507.

[59] Iovino P, Angrisani L, Tremolaterra F, Nirchio E, Ciannella M, Borrelli V, Sabbatini F, Mazzacca G, Ciacci C. Abnormal esophageal acid exposure is common in morbidly obese patients and improves after a successful Lap-band system implantation. *Surg Endosc* 2002; 16: 1631-1635.

[60] Suter M, Dorta G, Giusti V, Calmes JM. Gastric banding interferes with esophageal motility and gastroesophageal reflux. *Arch Surg* 2005; 140: 639-643.

[61] Klaus A, Gruber I, Wetscher G, Nehoda H, Aigner F, Peer R, Margreiter R, Weiss H. Prevalent esophageal body motility disorders underlie aggravation of GERD symptoms in morbidly obese patients following adjustable gastric banding. *Arch Surg* 2006; 141: 247-251

[62] Gutschow CA, Collet P, Prenzel K, Hölscher AH, Schneider PM. Long-term results and gastroesophageal reflux in a series of laparoscopic adjustable gastric banding. *J Gastrointest Surg* 2005; 9: 941-948.

[63] Greenstein RJ, Nissan A, Jaffin B. Esophageal anatomy and function in laparoscopic gastric restrictive bariatric surgery: implications for patient selection. *Obes Surg* 1998; 8: 199-206.

[64] Chiu S, Birch DW, Shi X, Sharma AM, Karmali S. Effect of sleeve gastrectomy on gastroesophageal reflux disease: a systematic review. *Surg Obes Relat Dis*. 2011; 7:510–515.

[65] Braghetto I, Lanzarini E, Korn O, Valladares H, Molina JC, Henriquez A. Manometric changes of the lower esophageal sphincter after sleeve gastrectomy in obese patients. *Obes Surg* 2010; 20: 357-362.

[66] Petersen WV, Meile T, Kuper MA, Zdichavsky M, Konigsrainer A, Schneider JH. Functional importance of laparoscopic sleeve gastrectomy for the lower esophageal sphincter in patients with morbid obesity. *Obes Surg* 2012; 22:360-366.

[67] Kleidi E, Theodorou D, Albanopoulos K, Menenakos E, Karvelis MA, Papailiou J, Stamou K, Zografos G, Katsaragakis S, Leandros E. The effect of laparoscopic sleeve gastrectomy on the antirreflux mechanism: can it be minimized? *Surg Endosc* 2013; 27: 4625-4630.

[68] Del Genio G, Tolone S, Limongelli P, Brusciano L, D'Alessandro A, Docimo G, Rossetti G, Silecchia G, Iannelli A, Del Genio A, Del Genio F, Docimo L. Sleeve gastrectomy and development of "de novo" gastroesophageal reflux. *Obes Surg* 2014; 24: 1436-1441.

[69] Burgerhart JS, Schotborgh CA, Schoon EJ, Smulders JF, Van de Meeberg PC, Siersema PD, Smout AJ. Effect of sleeve gastrectomy on gastroesophageal reflux. *Obes Surg* 2014; 24: 1436-1441.

[70] Rebecchi F, Allaix ME, Giaccone C, Ugliono E, Scozzari G, Morino M. Gastroesophageal reflux disease and laparoscopic sleeve gastrectomy: a physiopathologic evaluation. *Ann Surg* 2014; 260: 909-914.

[71] Gorodner V, Buxhoeveden R, Clemente G, Solé L, Caro L, Grigaites A. Does laparoscopic sleeve gastrectomy have any influence on gastroesophageal reflux disease? Preliminary results. *Surg Endosc* 2015; 29: 1760-1768.

[72] Georgia D, Stamatina T, Maria N, Konstantinos A, Konstantinos F, Emmanouil L, Georgios Z, Dimitros T. 24-h Multichannel Intraluminal Impedance PH-metry 1 Year After Laparoscopic Sleeve Gastrectomy: an Objective Assessment of Gastroesophageal Reflux Disease. *Obes Surg* 2017; 27: 749-753.

[73] Thereaux J, Barsamian C, Bretault M, Dusaussoy H, Lamarque D, Bouillot JL, Czernichow S, Carette C. ph monitoring of gastro-oesophageal reflux before and after laparoscopic sleeve gastrectomy. *Br J Surg* 2016; 103: 399-406.

[74] Daes J, Jiménez ME, Said N, Daza JC, Dennis R. Laparoscopic sleeve gastrectomy: symptoms of gastroesophageal reflux can be reduced by changes in surgical technique. *Obes Surg* 2012; 22: 1874-1879.

[75] Keidar A, Appelbaum L, Schweiger C, Elazary R, Baltasar A. Dilated upper sleeve can be associated with severe Postoperative gastroesophageal dysmotility and reflux. *Obes Surg* 2010; 20:140-147.

[76] Gagner M, Hutchinson C, Rosenthal R. Fith International Consensus Conference: current status of sleeve gastrectomy. *Surg Obes Relat Dis* 2016; 12: 750-756.

[77] Mahawar K, Carr WRJ, Jennings N, Balupuri S, Small PK. Simultaneous sleeve gastrectomy and hiatus hernia repair: a systematic review. *Obes Surg*. 2015; 25:159–166.

[78] Santonicola A, Angrisani L Cutolo P, Formisano G, Iovino P. The effect of laparoscopic sleeve gastrectomy with or withoug hiatal hernia repair on gastroesophageal reflux disease in obese patients. *Surg Obes Relat Dis* 2014; 10: 250-255.

[79] Samakar K, Mckenzie T, Tavakkoli A, Vernon AH, Robinson MK, Shikora SA. The effect of laparoscopic sleeve gastrectomy with concomitant hiatal hernia repair on gastroesophageal reflux disease in the morbidly obese. *Obes Surg*. 2016; 26:61–66.

[80] Nocca D, Skalli EM, Boulay E, Nedelcu M, Fabre JM, Loureiro M. Nissen Sleeve (N-Sleeve) operation: preliminary results of a pilot study. *Surg Obes Relat Dis* 2016; 12(10): 1832-1837.

[81] Da Silva LE, Alves MM, El-Ajouz TK, Ribeiro PC, Cruz RJ Jr. Laparoscopic Sleeve-Collis-Nissen gastroplasty: a safe alternative for morbidly obese patients with gastroesophageal reflux disease. *Obes Surg*. 2015; 25:1217–1222.

[82] Gálvez-Valdovino R, Cruz Vigo JL, Marín Santillán E, Funes-Rodríguez JF, López-Ambriz G, Domínguez-Carrillo LG. Cardiopexy with ligamentum teres in patients with hiatal hernia and previous sleeve gastrectomy: an alternative treatment for gastroesophageal reflux disease. *Obes Surg*. 2015; 25:1539–1543.

[83] Hendricks L, Alvarenga E, Dhanabalsamy N, Lo Menzo E, Szomstein S, Rosenthal R. Impact of sleeve gastrectomy on gastroesophageal reflux disease in a morbidly obese population undergoing bariatric surgery. *Surg Obes Relat Dis* 2016; 12: 511-517.

[84] Sheppard CE, Sadowski DC, De Gara CJ, Karmali S, Birch DW. Rates of reflux before and after laparoscopic sleeve gastrectomy for severe obesity. *Obes Surg* 2015; 25: 763-768.

[85] Iannelli A, Debs T, Martini F, Benichou B, Ben Amor I, Gugenheim J. Laparoscopic conversion of sleeve gastrectomy to Roux-en-Y gastric bypass: indications and preliminary results. *Surg Obes Relat Dis* 2016; 12: 1533-1538.

[86] Casillas RA, Um SS, Zelada Getty JL, Sachs S, Kim BB. Revision of primary sleeve gastrectomy to Roux-en-Y gastric bypass: indications and outcomes from a high-volume center. *Surg Obes Relat Dis* 2016; 12: 1817-1825.

[87] Desart K, Rossidis G, Michel M, Lux T, Ben-David K. Gastroesophageal reflux management with the LINX® System for gastroesophageal reflux disease following laparoscopic sleeve gastrectomy. *J Gastrointest Surg* 2015; 19: 1782-1786.

[88] Auyang ED, Carter P, Rauth T, Fanelli RD. SAGES clinical spotlight review: endoluminal treatments for gastroesophageal reflux disease (GERD). *Surg Endosc* 2013; 27: 2658-2672.

[89] Frezza EE, Ikramuddin S, Gourash W, Rakitt T, Kingston A, Luketich J, Schauer P. Symptomatic improvement in gastroesophageal reflux disease (GERD) following laparoscopic Roux-en-Y gastric bypass. *Surg Endosc* 2002; 16:1027-31.

[90] Perry Y, Courcoulas AP, Fernando HC, et al. Laparoscopic Roux-en- Y gastric bypass for recalcitrant gastroesophageal reflux disease in morbidly obese patients. *JSLS* 2004; 8:19-23.

[91] Patterson EJ, Davis DG, Khajanchee Y, Swanstrom LL. Comparison of objective outcomes following laparoscopic Nissen fundoplication versus laparoscopic gastric bypass in the morbidly obese with heartburn. *Surg Endosc* 2003; 17:1561-5.

[92] Raftopoulos I, Awais O, Courcoulas AP, Luketich JD. Laparoscopic gastric bypass after antireflux surgery for the treatment of gastroesophageal reflux in morbidly obese patients: initial experience. *Obes Surg* 2004; 14:1373-80.

[93] Zainabadi K, Courcoulas AP, Awais O, Raftopoulos I. Laparoscopic revision of Nissen fundoplication to Roux-en-Y gastric bypass in morbidly obese patients. *Surg Endosc* 2008; 22:2737-40.

[94] Smith SC, Edwards CB, Goodman GN. Symptomatic anc clinical improvement in morbidly obese patients with gastroesophageal reflux disease following Roux-en-Y gastric bypass. *Obes Surg* 1997; 7: 479-484.

[95] Prachand VN, Ward M, Alverdy JC. Duodenal switch provides superior resolution of metabolic comorbidities independent of weight loss in the super-obese (BMI > or = 50 kg/m2) compared with gastric bypass. *J Gastrointest Surg* 2010; 14: 211-220.

[96] Mejía-Rivas MA, Herrera-López A, Hernández-Calleros J, Herrera MF, Valdovinos MA. Gastroesophageal Reflux Disease in Morbid Obesity: The Effect of Roux-en-Y Gastric Bypass. *Obes Surg* 2008; 18:1217–1224.

[97] Patterson EJ, Khajanchee YS, Swanstrom LL, et al. Objective assessment of the effect of laparoscopic gastric bypass on esophageal pH and motility in morbidly obese patients with GERD. *Obes Surg* 2001; 11:408 (abst 102).

[98] Ortega J, Escudero MD, Mora F, Sala C, Flor B, Martinez-Valls J, Sanchiz V, Martinez-Alzamora N, Benages A, Lledo S. Outcome of esophageal function and 24-hour esophageal pH monitoring after vertical banded gastroplasty and Roux-en-Y gastric bypass. *Obes Surg* 2004; 14:1086–94.

In: Encyclopedia of Surgery (22 Volume Set)
Editors: Andreas Lehrer and Kristin Mueller
ISBN: 978-1-53618-329-0
© 2020 Nova Science Publishers, Inc.

Chapter 268

POSTOPERATIVE PAIN PROPHYLAXIS AND MANAGEMENT

Carmen Vallejo Lantero*, MD and Esther García Villabona, MD
Anesthesiology Department of Hospital Universitario de La Princesa, Madrid, Spain

ABSTRACT

Increasing numbers of patients with morbid obesity are presenting for surgery and their acute pain management requires an evidence-based clinical update. Due to the strong association between obesity and certain medical conditions, bariatric surgery patients are at increased risk for a variety of medical complications after surgery. Obstructive sleep apnea is extremely common in obese bariatric surgical candidates. Though overall evidence is limited, multimodal analgesia with a step-wise, severity-based, opioid-sparing approach appears to improve acute pain management in morbid obesity. The perioperative use of non-opioid adjuvants appears to offer further improvements in patient's safety and outcomes.

Keywords: pain management, bariatric surgery, obesity, postoperative pain, opioid-sparing

INTRODUCTION

Morbid obese population is increasing every year worldwide, and laparoscopic bariatric surgery has a central role in their treatment. The pathophysiology of obesity, typical comorbilities and the high prevalence of obstructive sleep apnea (OSA) amongst patients make safe analgesic management difficult. Studies have indicated that the incidence of OSA may be as high as 77% in those seeking surgery [1]. Narcotic pain medications can decrease upper airway tone and unmask or exacerbate sleep apnea [2]. Apneic episodes precipitating heart block perioperatively in bariatric surgery patients have also been documented [3]. For these reasons, the American Society of Anesthesiologists task force on perioperative

* Corresponding Author's Email: c.vallejo_26@hotmail.com.

management of patients with OSA recommends minimizing or avoiding perioperative narcotic administration to these patients [4].

Therefore, acute pain management in overweight patients poses two main problems: choice of the most suitable and safest analgesic techniques specific to this patients group and an appropriate location to provide these techniques, the monitoring, required to assure their safety [5].

The goal of postoperative pain management is the provision of comfort, early mobilization and improving respiratory function without causing inadequate sedation and respiratory compromise. Though overall evidence is limited, multimodal analgesia with a step-wise, severity- based, opioid-sparing approach appears to improve acute pain management in morbid obesity. The perioperative use of non-opioid adjuvants appears to offer further improvements in patient's safety and outcomes [6].

RISK FACTORS FOR POSTOPERATIVE PAIN IN MORBID OBESITY

Obstructive Sleep Apnea in Obesity

In morbid obesity, conventional opioid-based acute pain during intraoperative and postoperative pain management is associated with the risk of sedation, airway obstruction and respiratory depression. This is particulary common in patients with various types of sleep disordered breathing, including OSA. Opioid adminstration is associated with central apnea, and has been reported to enhance obstructive apnea in predisposed patients. Because of the high incidence of OSA in obese patients and other studies showing that morbidly obese patients have increased perioperative obstruction and desaturation even without OSA, the focus with regard pain management has to be on opioid sparing multimodal approaches [7]. Efforts to limit complicatios from postoperative pain management have led to expert opinion based guidelines for postoperative care of patients with OSA. Prominent amongst these are the recommendations to avoid background or continuous infusions with Patients Controlled Analgesia (PCA) systems, appropiate level and duration of postoperative monitoring. The guidelines prefer exclusion of opioids from neuroaxial techniques in favors of local anesthetics and the use of non-steroidal anti-inflammatory drugs (NSAIDs) to reduce adverse events of opioids by opioid-sparing effects. They recommend supplemental oxygen postoperatively and continuous positive airway pressure (CPAP) or non-invasive positive pressure ventilation (NIPPV) in the postoperative setting for patients using these modalities preoperatively [4]. Regarding monitoring, the guidelines favor continuous pulse oximetry with observation (in ICU or step-down unit, by telemetry or observer), but not intermittent bedside monitoring. Intense monitoring should be continued until saturation remains above 90% during sleep without supplemental oxygen.

Drug Dosing

The physiological changes associated with morbid obesity impact upon the phamacokinetics of anesthetic and analgesic drugs. Drug dosing is generally based on the

volume of distribution for the loading dose and on the clearance for maintenance. In the obese patient, the volume of distribution is increased if the drug is distributed both in lean and fat tissues whereas the anesthetic drug clearance is usually normal or increase. When calculating dosing based on weight, it is important to consider that using the patient's total body weigt can result in overdosing medications [6]. Obesity increases both fat and lean masses; however, the percentage of fat tissue increases more than does the lean mass, affecting the apparent volume of distribution of anesthetic drugs according to their lipid solubility [8]. With the exception of neuromuscular antagonists, lean body weight (LBW) is the optimal dosing scalar for most drugs used in anaesthesia including opioids and anaesthetic induction agents , especially as cardiac output is significantly correlated to LBW, except in individuals with obesity cardiomyopathy [9]. As we see the different possibilities in the treatment and prevention of pain in the obese patient, we will indicate the most appropiate doses for each one of them.

PAIN MANAGEMENT IN OBESE PATIENT

The role of multimodal analgesia and non-opioid adjuvant therapy has been shown to be beneficial in a variety of procedure-specific postoperative pain management protocols. In the general surgical population, Enhanced Recovery after Surgery (ERAS) protocols have shown that effective postoperative pain management is an essential component of recovery outcomes, as it promotes early feeding, ambulation and discharge with reduced complications. In patients with morbid obesity, these specific outcomes would also not be desirable, they are probably essential [6]. Recent data on the efficacy and safety of multimodal pain management strategies for weight loss surgery are consistent with this accepted approach of opioid-sparing postoperative analgesia in the general surgical patient population [10]. It is widely accepted adjuvants such as ketamine, lidocaine and pregabalin, directed to the management of acute hyperalgesia, play a mayor role in the treatment of acute pain in morbidly obesity.

Acetaminophen and NSAIDs

Non opioid analgesics should be considered wherever possible.

- *Acetaminophen* has been repeatedly shown to decrease opiod requirements in the perioperative setting and even contribute to shorter length of stay. Obese patients have increased rates of hepatic phase 2 conjugation and clear acetaminophen rapidly, but whether dosing intervarls should be reduced and daily doses increased is highly contentious. A small subset of morbidly obese patients go on to develop hepatic steatosis and ultimately cirrhosis, so increased dosing as a routine is not without risks, and caution is advised. *Acetaminophen is an important foundational (World Health Organization WHO Step I) analgesic for optimal pain control with decreased opioid consumption (Grade B)* [6].

- *Ketorolac*. Non-steroidal anti-inflammatory drugs are the most widely used component of multimodal anesthesia. The perioperative use of ketorolac alone or in combination with local anesthesia leads to significant improvement of postoperative pain control[5]. Similarly, an intraoperative infusion of ketorolac reduced pain scores and decreasing the incidence of postoperative nausea and vomiting (PONV). One study identifies the potential risk of bleeding during bariatric surgery, though there was no difference in terms of transfusion. So, *Ketorolac administered perioperatively has a role as a part of the foundational (WHO Step I) analgesic, but further studies of dose, safety and side effects specific to morbid obesity are needed (Grade C)* [6].

Intermediate Analgesics: Tramadol and Tapentadol

Tramadol and Tapentadol are both intermediate-potency (WHO Step II) analgesics that may benefit surgical patients due to their multimodal mechanisms of action. Tramadol may be particularly useful when combined with acetaminophen. The use of tapentadol has not been yet reported specifically in this patient population. The current recommendation consider that *Tramadol may be appropiate intermediate or Step II analgesic for postopertaive pain in patients with morbid obesity (Grade B)* [6].

Opioids Analgesics

To achieve satisfactory pain control in obese patients after surgery, use of opioids is often inevitable. Through the review of the literature base on the evidence available for the management of acute pain on morbid obesity, the current recommendations conclude that the use of opioid PCA should be limited to patients with moderate to severe postoperative pain, probably when oral opioid therapy is not possible. Basal or continuous opioid infusions in patients with morbid obesity and particularly those with undiagnosed or untreated OSA should be avoided. Patients with suspected sleep disordered breathing must be observed with overnight monitoring of respiratory adequacy, during the entire time PCA is used *(Grade C)* [6].

Adjuvants Analgesics

- *Pregabalin/Gabapentin*: Both of them plays an increasing role as a component of multimodal analgesia in non obese patients. In morbidly obese patients, single preoperative adminstration of 150 mg pregabalin resulted in improved analgesia, was opioid-sparing and reduced adverse effects such as nausea and vomiting [5]. Similarly, preoperative administration of 100 mg of gabapentin also produced significantly lower pain scores in recovery with less nausea-vomiting compared with placebo. However, pregabalin and gabapentin may be associated with increased sedation and postoperative respiratory depression. Current recommendations consider that *pregabalin and gabapentin may be useful adjuvants to opioids in*

postoperative pain control (Grade C) [6]. There is no consensus for dose, frecuency or duration treatment. Their use in the perioperative period requires careful assessment of the risk-benefit in patients with morbily obese and/or OSA.

- *Ketamine* (NMDA antagonist) is increasingly used as an analgesic adjunct in the postoperative settings. Low doses of ketamine used in morbidly obese lead to a significant reduced opioid consumption and reduced need for rescue analgesia importantly. Limiting factors for ketamine are co-existing severe arterial hypertension and cardiac failure, although the induction of hypertension by low-dose ketamine is unlikely. For this reasons, *low dose (0,1-0,5 mg/kg) ketamine as a single bolus or infusion has a potential role as a safe adjuvant analgesic (Grade C)* [6].
- *Dexmedetomidine* is an α 2 receptor agonist with sedative and analgesic sparing properties. Various studies in morbidly obese population have shown that dexmedetomidine infusion perioperatively is safe and may help to minimize narcotic requeriments, length of stay after laparoscopic bariatric procedures and decrease antiemetic use and the risk of developing PONV [11, 12]. When clonidine is used as a premedication, it has found to be more sedating and associated with bradycardia and hypotension. *Dexmedetomidine infusion can be used to reduce opioid consumption and decreases PONV (Grade B)* [6].
- *Lidocaine.* Intraoperative intravenous lidocaine has previosly been shown to have a significant effect on improving postoperative pain control, especially in abdominal surgery. Very little information is available in patients with morbid obesity indicating a significant decrease in opioid consumption in PACU and at 24 hours post analgesia regimen. According to the previous considerations, *systemic lidocaine may reduce analgesic consumption and improve postoperative pain (Grade B)*, but few studies are available and optimal dosing schedule in patients with morbid obesty is yet to be determined.
- *Sugammadex.* It has been shown that sugammadex allows a faster neuromuscular recovery after rocuronium muscle relaxation and prevents postoperative residual curarization. In a recent study comparing sugammadex with the adminstration with neostigmina, sugammadex is associated with less pain felt in the PACU. This "opioid-sparing" effect, combined with less PONV allows a faster discharge from the PACU. There is not enough evidence to make a recommendation about it, needing to carry out more studies for this purpose [13].

Regional Techniques

TAP blocks: Transvesus abdominis plane (TAP) block has been studied as a potential technique to aid with pain management in bariatric surgery. It has been shown to reduce morphine use and PONV in abdominal surgery. Other studies have found limited or no statistically significant difference in outcomes with this block. One potential explanation may be that, there is no significant added benefit of TAP block if local anesthetic is also infiltrated at trocar insertion sites. Like all regional techniques, the efficacy of TAP block is also operator dependent, and in patients with morbidly obesity the performance of TAP blocks may be more difficult. Current recommendations consider that, *TAP blocks may be of some*

benefit in patients with morbid obesity undergoing certain types of abdominal surgery, especially laparoscopic procedures (Grade C) [6].

Intraperitoneal and wound modalities: Continuous administration of local anesthetic has been reported at wound and/or intraperitoneal infusions.

Some studies that examines the use of continuos bupivacaine wound infusion in laparoscopic weight loss surgery (WLS) lasting up to 96 hours. There was a statistically significant decrease in opioid consumption, but this benefit was not sustained beyond the infusion and there was no improvement in patient pain scores.

On the other hand, intraperitoneal bupivacaine infusions have found a statistically improvement in pain scores and total opioid consumption. Likewise, the use of a one-time spray of bupivacaine applied at the esophagueal hiatus once the pneumoperitoneum is establish, resulted in statistically significant decreased in analgesic consumption, incluiding shoulder tip pain. For this reasons, *these loco-regional analgesic modalities contribute to optimizing pain in open abdominal and laparoscopic surgical procedures (Grade C)*. Further investigations, standarization and technique refinement are required [6].

Neuroaxial techniques. Neuroaxial techniques for pain management have been shown in numerous studies to be highly efficient in reducing opioid-related complications. Continuation of regional anesthesia techniques into the postoperative period to provide analgesia is regarded particular useful in obese patients undergoing open bariatric surgery. Neuroaxial techniques in morbid obesity have been primarily studied in the context of obstetric anesthesia; only a few studies are available in non-obstetric patients with morbid obesity. Epidural analgesia in patients submit to open bariatric surgery resulted in better pain scores, patient satisfaction, early recovery and ambulation. Then, *epidural analgesia improves pain and control and promotes earlier ambulation in patients with morbid obesity undergoing non-obstetrical non-laparoscopic abdominal procedures (Grade B)* [6].

Multimodal Analgesia

In addition to the techniques that have been highlighted above, there are studies which have examined multimodal analgesia by combining several of these modalities to optimize pain control, whether in combination or without the use of opioids. The classic multimodal approach includes the use of foundational analgesics and preincision wound infiltration with or without opioid PCA. This resulted in statistically significant lower postoperative opioid use, less sedation and higher patient satisfaction in PACU. *A multimodal pain management strategy for post-surgical acute pain optimizes pain control and reduces opioid consumption (Grade B)* [6].

CONCLUSION

Despite the increasing incidence of obesity in our society and the resulting demand for bariatric surgery, there is little evidence to guide the management of postoperative pain in these patients. Although intuitively, obesity seems to be a major risk factor for respiratory complications after surgery, the evidence does not support this notion as long as it is not

accompained by OSA. The overall consensus subscribes the concept of multimodal analgesia by the use of opioid-sparing analgesic strategies, including local anesthetics, nonsteroideal antiinflamatory medications and possibly adjuvants to reduce the risk of opioid-induced respiratory complications.

REFERENCES

[1] O'Keeefe, T., Patterson, E. J. Evidence supporting routine polysomnography before bariatric surgery. *Obes. Surg.* 2004;14:23-26.

[2] Hillman, D. R., Platt, P. R., Eastwood, P. R. The upper airway during anesthesia. *Br. J. Anaesth.* 2003;91:31-39.

[3] Block, M., Jacobson, L. B., Rabkin, R. A. Heart block in patients after bariatric surgery accompanying sleep apnea. *Obes. Surg*. 2001;11:627-630.

[4] American Society of Anesthesiologists. Practice guidelines for the perioperative management of patients with obstructive sleep apnea. *Anesthesiology* 2006;104:1081-1093.

[5] Schung, S. A., Rayman, A. Posoperative pain management of the obese patient. *Best Pract. Res. Clin. Anaesthesiol.* 2011;25:73-81.

[6] Budiansky, A. S., Margarson, M. P. Acute pain management in morbid obesity- an evidence based clinical update. *Surg. Obes. Relat. Dis.* 2017;13:523-532.

[7] Cullen, D. J. Obstructive sleep apnea and postoperative analgesia – a potencially dangerous combination. *J. Clin. Anesth.* 2001;13:83-85.

[8] Casati, A., Putzu, M. Anesthesia in the obesa patient: Pharmacokinetic considerations. *J. Clin. Anesth.* 2001;17:134-145.

[9] Ingrande, J., Lemmens, H. J. M. Dose adjustment of anaesthetics in the morbidly obese. *Br. J. Anaesth.* 2010;105:16-23.

[10] Schumann, R., Jones, S. B., Cooper, B. et al. Update on best practce recommendations for anesthesic perioperative care and pain management in weight loss surgery, 2004-2007. *Obesity* 2009;17:889-894.

[11] Dholakia, C., Garren, M., Boncyk, J. The impact of perioperative dexmedetomidine infusion on postoperative narcotic use and duration of stay after laparoscopic bariatric surgery. *J. Gastrointest. Surg.* 2007;11:1556-59.

[12] Tufanogullari, B., White, P. F., Peixoto, M. P. et al. Dexmedetomidine infusion during laparoscopic bariatric surgery: the effect on recovery outcomes variables. *Anesth. Analg.* 2008; 106:1741-48.

[13] Castro, D. S., Leão, P., Borges, S. et al. Sugammadex reduces postoperative pain after laparoscopic bariatric surgery: A randomized trial. *Surg. Laparosc. Endosc. Percutan. Tech.* 2014;24:420-23.

In: Encyclopedia of Surgery (22 Volume Set)
Editors: Andreas Lehrer and Kristin Mueller
ISBN: 978-1-53618-329-0
© 2020 Nova Science Publishers, Inc.

Chapter 269

THE USE OF PROPHYLACTIC MESH IN OPEN AND LAPAROSCOPIC BARIATRIC SURGERY

Montiel Jiménez-Fuertes*
General and Digestive Surgery, Rey Juan Carlos University Hospital, Madrid, Spain

ABSTRACT

Incisional hernia is one of the most common late complications in bariatric surgery. Prophylactic mesh placement is associated with a lower rate of postoperative incisional hernia compared to standard primary closure after open bariatric surgery, without a significant increase in the risk of mesh infection. There are no studies to support the use of prophylactic mesh in laparoscopic bariatric surgery.

Keywords: prophylactic mesh, incisional hernia, bariatric surgery

INTRODUCTION

Incisional hernia is one of the most common complications of abdominal surgery, and bariatric surgery is not an exception. The European Hernia Society (EHS) has developed guidelines on the technique and materials considered more suitable for closing the incisions of the abdominal wall [1]. One of the recommendations is to avoid the use of the middle line incisions. However, the most of the operations are still carried out through these incisions. For the closure of these incisions a continuous suture with slow absorption material is recommended. A large prospective randomized study [2] has confirmed the findings previously published by a Swedish group [3], where it was recommended the use of the technique of small points (small bites) for the closure of laparotomies. Despite this, after 12 months of follow up, 13% of the patients in the study presented an incisional hernia. In patients with risk factors and studies with a more prolonged follow-up, the reported incidence

* Corresponding Author's Email: montiel.jimenez@hospitalreyjuancarlos.es.

of incisional hernia is even higher [4, 5]. These risk factors include obesity, wound infection, aortic aneurysm and oncological surgery.

Surgery for the treatment of incisional hernias presents a high recurrence rate [6], and it is burdened with high social cost and health resources [7]. For all this, the prevention of incisional hernias should be considered a top priority.

To avoid high rates of incisional hernia despite the correct closure of the incision, and especially in high–risk patients, reinforcement of the closure of abdominal wall with a prosthesis has been described [1]. The main factor for the resistance to the adoption of this preventive measure is the infection or other complications related to the use of prosthesis [8]. Basta et al. [9] reported a risk stratification model for incisional hernia (IH) development in bariatric surgery. This was associated with additional readmissions and complications and greater cost and resource utilization. This risk stratification tool identifies candidates for prophylactic mesh, which may optimize outcomes while mitigating the cost. Predictors for IH included open surgical approach (hazard ratio [HR] = 10.3), malnutrition (HR = 3.10), prior abdominal surgery (HR = 2.89), and body mass index >60kg/m2 (HR = 2.60). Based on these risk factors, patients were stratified into low-, moderate-, and high-risk categories for IH development. Of the high-risk patients, 15.2% developed IH compared with 0.6% of low-risk patients (C-statistic = 0.85).

PROPHYLACTIC MESH IN OPEN BARIATRIC SURGERY

High Body Mass Index (BMI) is a well-known risk factor for the development of postoperative incisional hernia [10], and this problem often needs another operation for its repair, resulting in increased health cost, potential comorbidities and patient dissatisfaction [11]. In high-risk patients undergoing laparotomy, prophylactic mesh has been shown to be more cost-effective than primary closure, with decreased odds of postoperative hernia development in a subanalysis of open bariatric surgery studies [12, 13].

There are only eight studies aimed at the prevention of the development of incisional hernia in open bariatric surgery (Table 1) [8, 14-20]. Surgical Site Infection (SSI) and seroma formation are the most common complications after mesh placement.

A recent systematic review and meta-analysis [21] has shown that the use of prophylactic mesh placement during abdominal wall closure in open bariatric surgery is associated with significantly lower odds of postoperative incisional hernia development compared to standard primary closure.

The standard recommendation for fascial closure is a small bites technique with 4:1 suture length to wound length ratio, but this technique is not the one used in the studies of abdominal wall closure in open bariatric surgery [1]. In this analysis, there were not higher odds of developing SSI or seroma formation with prophylactic mesh, compared to the closure in bariatric surgery without prosthesis [14]. The use of meshes in clean-contaminated surgery raises concerns about an increased risk of infection.

Table 1. Use of prophylactic mesh in open bariatric surgery

Author	Study	N	n with mesh	Mesh position	Mesh	Follow Up (months)	SSI without mesh	SSI with mesh	Incisional Hernia without mesh	Incisional Hernia with mesh	Conclusion
Pans 1998	RCT	288	144	Intraperitoneal	polyglactin	30	5/144	4/144	41/144	33/144	Mesh Not effective
Strzelczyk 2002	CC	60	12	Supraaponeurotic	polypropylene	13	-	-	9/48	0/12	effective
Strzelczyk 2006	RCT	74	36	Retromuscular	polypropylene	28	11%	14%	8/38	0/36	Effective
Herbert 2009	C	16	16	Intraperitoneal	3 different composite mesheses	6	-	3/16	-	1/16	Not safe because high rate of infection
Llaguna 2011	CC	134	59	Intraperitoneal	AlloDerm®	17	2%	9%	11/62	1/44	Effective
Curro 2012	CC	95	45	Retromuscular	polypropylene	12-24	3/50	1/45	15/50	2/45	Safe and effective
Abo-Ryia 2013	RCT	64	32	Preperitoneal	polypropylene	48	5/32	5/32	9/32	1/32	Safe and effective
Sarr 2014	RCT	380	185	Intraperitoneal	Surgisis®	24	4%	12%	38/141	32/139	Not effective Increase complications

RCT: Randomized controlled trial; CC: control cases; C: Cohorts.

Two of the published studies evaluated biologic meshes, with the idea that wound or mesh infections would be decreased with the use of biologic rather than synthetic mesh [17, 20]. Sarr et al. reported a wound infection rate of 11.9% with the placement of a bioprosthesis compared to 3.6% in the primary closure group ($p > 0.003$) [19]. In contrast, Llaguna et al. found no difference in wound infection rates between the bioprosthesis group compared to the primary closure group (9.09% versus 1.61%, $p = 0.07$) [20]. The comparative efficacy of biologic versus synthetic mesh for prophylaxis against hernia formation in bariatric surgery has not been studied yet, but the results of the meta-analysis [21] suggest that prosthetic mesh, such as polypropylene or polyglactin do not significantly increase the risk for SSI, compared to biologic mesh.

While mesh appears beneficial in preventing incisional hernias, there is no differences in surgical site infection, seroma or wound leakage, but there are only a few studies supporting its routine use, and more quality studies are needed to recommend the use of prophylactic mesh in open bariatric surgery.

PROPHYLACTIC MESH IN LAPAROSCOPIC BARIATRIC SURGERY

Laparoscopic approach has been a revolution in surgery, and bariatric procedures are not an exception. An increasing number of bariatric surgeries are performed laparoscopically. Laparoscopic surgery reduces, but not eliminates, the rate of incisional hernia. One of the problems of this approach is the development of hernias in port-site incisions, and the real incidence is unknown (Table 2). The accepted rate for port-site site hernias is about 3%. Patients undergoing bariatric surgery are more susceptible to suffer from this complication, because the obesity is an increased risk factor and because the bariatric surgery looks for a programmed undernutrition, which has no beneficial effects on the healing of surgical wounds [22].

Table 2. Incidence of trocar site hernia in laparoscopic bariatric surgery

Author	n	Follow up (months)	% IH	Trocar size	Trocar position
Shauer 2000	275	114	0,36	-	-
Johnson 2006	747	20	1,3	10	umbilical
Tuooli 2008	1000	97	0,1	-	-
Hussain 2009	63	43	0	5, 10	

The only classification of port-site hernias is Tonouchi's one (Table 3) [23]. It is accepted that large port-site orifices should be sutures, to prevent herniation, but in morbidly obese patients, the closure of the anterior fascia is very difficult and does not prevent from preperitoneal herniation. Both, the diameter of the port and the mechanism of introduction may have a direct influence on the development of a hernia. Orifices greater than 10 mm have a greater possibility of developing port-site hernias. Most of the authors agree than Hasson

port orifices and those greater than 10 mm should always be closed, but the closure of the fascial defect is very difficult in morbidly obese patients. Different devices and methods have been developed to solve this problem, from the simple utilization of a Reverdin needle to complex instruments designed for advanced laparoscopic surgery.

Table 3. Tonouchi classification for trocar site hernia

	Early-onset tpe	Late-onset type	Special type
Caracteristics	Dehiscence of peritoneum, anterior and posterior fascia	Dehiscence of anterior and posterior fascial plane	Dehiscence of all abdominal wall
Interval	A few days	Several months	A few days to 10 d
Main manifestation	Small bowel obstruction	Hernia without small bowel obstruction	Protusion of intestine and or omentum
Scheme	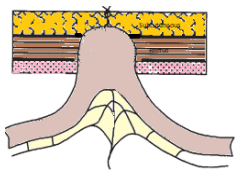	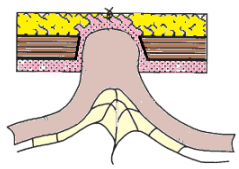	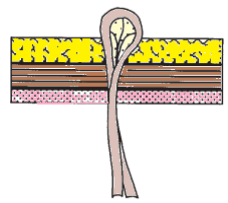

There is no consensus regarding the type of port and when to close the port holes. According to Latyf et al. [24], the use of blade trocars should be avoided, and the expansion ones are recommended, closing the holes over 8 mm, because these ports make less abdominal wall trauma, allowing the reapproximation of the muscles when they are removed. Fascial closure in morbidly obese patients is a hard difficult task, and it does not prevent completely hernia development [25].

Only a total wall closure system the complete cover of the defect is assured, though herniation may happen even after a correct closure. Pilone et al. [26] reported an incidence of assure hernia of 1.6% in patients with laparoscopic bariatric surgery without closure of the ports, with 54 months of follow up. Oblique placement of 12 mm ports allow to consider not closing the holes, minimizing in this way the appearance of hernias at this level. In certain procedures, as in vertical gastrectomy, sometimes it is necessary to expand one of the 12 mm or 15 mm trocars to extract the stomach and it is advisable to close this enlarged trocar to avoid a hernia in this place. In reference to the closure of these 15 mm trocars or 12 mm extended during vertical gastrectomy, some authors have proposed the use of intra-abdominal meshes, with a double objective: on one hand, they reduce the possibility of hernias at this level taking account the difficulties of closing the holes through an anterior approach in the obese, given the great thickness of the adipose tissue they present; and on the other, because by avoiding the closure with transfascial needle under direct vision, the possibilities of existence of pain is decreased, which facilitates the recovery of the patient.

Since the direct closure of the trocar orifices is technically complex and its results are variables, reinforcement has been proposed as a solution with a prosthetic material. These meshes are in most cases of polypropylene with a permanent or absorbable cover, that allows its contact with intra-abdominal viscera. The main problem of these meshes is the fact of leaving an intr-abdominal material, in addition to a potential increase of seromas and infections, and the extra-cost of the procedure. On the other hand, the use of these meshes

also has advantages, such as the reduction of postoperative pain since it prevents closing the holes with tension sutures, especially when this closure is performed with a transmural needle.

There are no randomized control trials, prospective observational studies or retrospective cohort studies using the prophylactic mesh insertion during laparoscopic bariatric surgery. Sánchez Pernaute et al. described the technique of prophylactic insertion of polytetrafluoroethylene (PTFE) mesh at the time of laparoscopic bariatric surgery in 216 patients, reporting a reduction of port site hernia from 3% to 1.3%, and recommended its use in larger diameter orifices in bariatric patients [27]. The mesh easily covers the whole peritoneal defect, preventing also preperitoneal Richter's hernia, and fills the trocar path all through the subcutaneous, fascial and muscular planes with a polypropylene band, which generates an inflammatory local response that should help to prevent future herniations after weight loss. There are no studies evaluating outcomes after prophylactic mesh insertion during laparoscopic bariatric surgery. Randomized control trial studies on mesh prophylaxis for port site incisional hernia are needed.

In addition to the need for more studies on prophylactic mesh in open and laparoscopic bariatric surgery, analysis of the cost-effectiveness of mesh use will also be critical in determining the benefit of changing routine practice to include prophylactic mesh for the closure. Previous cost-analysis on prophylactic mesh use in high-risk abdominal laparotomy patients, not restricted, but including bariatric surgery, found that mesh is more effective, less costly, and overall more cost-effective than standard primary suture closure [28].

REFERENCES

[1] Muysoms, F., Antoniou, S., Bury, K., Campanelli, G., Conze, J., Cuccurullo, D., et al. European Hernia Society guidelines on the closure of abdominal wall incisions. *Hernia*, 2015; 19:1-24.

[2] Deerenberg, E. B., Harlaar, J. J., Steyenberg, E. W., Lont, H. E., van Doorn, H. C., Heisterkamp, J., et al. Small bites versus large bites for closure of abdominal midline incisions (STITCH): a double-blind, multicentre, randomised controlled trial. *Lancet*, 2015; 386:1254-60.

[3] Millbourn, D., Cengiz, Y., Israelsson, L. A. Effect of stitch length on wound complications after closure of midline incisions: a randomized controlled trial. *Arch. Surg.*, 2009; 144:1056-9.

[4] Den Hartog, D., Dur, A., Kamphuis, A., Tuinebreijer, W. E., Kreis, R. W. Comparison of ultrasonography with computed tomography in the diagnosis of incisional hernias. *Hernia*, 2009; 13:45-8.

[5] Fink, C., Baumann, P., Wente, M., Knebel, P., Bruckner, T., Ulrich, A., et al. Incisional hernia rate 3 years after midline laparotomy. *Br. J. Surg.*, 2014; 101:51-4.

[6] Helgstrand, F., Rosenberg, J., Kehlet, H., Strandfelt, P., Bisgaard, T. Reoperation Versus Clinical Recurrence Rate After Ventral Hernia Repair. *Ann. Surg.*, 2012; 256:955-8.

[7] Gillion, J.-F., Sanders, D., Miserez, M., Muysoms, F. The economic burden of incisional ventral hernia repair: a multicentric cost analysis. *Hernia*, 2016; 20:819-30.

[8] Herbert, G. S., Tausch, T. J., Carter, P. L. Prophylactic mesh to prevent incisional hernia: A note of caution. *Am. J. Surg.*, 2009; 197: 595-8.

[9] Basta, M. N., Mirzabeigi, M. N., Shubinets, V., Kelz, R. R., Williams, N. N., Fischer, J. P. Predicting incisional hernia after bariatric surgery: a risk stratification model based upon 2161 operations. *Surg. Obes. Relat. Dis*., 2016; 12:1466-1473.

[10] Capella, R. F., Iannace, V. A., Capella, J. F. Reducing the incidence of incisional hernias following open gastric bypass surgery. *Obes. Surg.*, 2007; 17:438-44.

[11] Gecim, I. E., Kocak, S., Ersoz, S., Buin, C., Aribal, D. Recurrence after incisional hernia repair: results and risk factors. *Surg. Today*, 1996. 26:607-9.

[12] Bhangu, A., Fitzgerald, J. E., Singh, P., Battersby, N., Marriot, P., Pinkney, T. Systematic review and meta-analysis of prophylactic mesh placement for prevention of incisional hernia following midline laparotomy. *Hernia*, 2013; 17:445-455.

[13] Fischer, J. P., Basta, M. N., Wink, J. D., Krishnan, N. M., Kovach, S. J. Cost-utility analysis of the use of prophylactic mesh augmentation compared with primary fascial suture repair in patients at high risk for incisional hernia. *Surgery,* 2015. 158:700-11.

[14] Pans, A., Elen, P., Dewe, W., Desaive, C. Long-term results of polyglactin mesh for the prevention of incisional hernias in obese patients. *World J. Surg*., 1998. 22:479-482.

[15] Strzelczyk, J., Czupryniak, L., Loba, J., Wasiak, J. The use of polypropylene mesh in midline incision closure following gastric by-pass surgery reduces the risk of postoperative hernia. *Langenbecks Arch. Surg*., 2002; 387:294-7.

[16] Strzelczyk, J. M., Szymański, D., Nowicki, M. E., Wilczyński, W., Gaszynski, T., Czupryniak, L. Randomized clinical trial of postoperative hernia prophylaxis in open bariatric surgery. *Br. J. Surg.*, 2006; 93:1347-50.

[17] Llaguna, O. H., Avgerinos, D. V., Nagda, P., Elfant, D., Leitman, M., Goodman, E. Does prophylactic biologic mesh placement protect against the development of incisional hernia in high-risk patients? *World J. Surg*., 2011; 35:1651-1655.

[18] Curro, G., Centorrino, T., Low, V., Sarra, G., Navarra, G. Long-term outcome with the prophylactic use of polypropylene mesh in morbidly obese patients undergoing biliopancreatic diversion. *Obes. Surg*., 2012; 22:279-82.

[19] Abo-Ryia, M. H., El-Khadrawy, O. H., Abd-Allah, H. S. Prophylactic preperitoneal mesh placement in open bariatric surgery: a guard against incisional hernia development. *Obes. Surg.*, 2013; 23:1571-4.

[20] Sarr, M. G., Hutcher, N. E., Snyder, S., Hodde, J., Carmody, B. A prospective, randomized, multicenter trial of Surgisis Gold, a biologic prosthetic, as a sublay reinforcement of the fascial closure after open bariatric surgery. *Surgery,* 2014; 156:902-8.

[21] Dasari, M., Wessel, C. B., Hamad, G. G. Prophylactic mesh placement for prevention of incisional hernia after open bariatric surgery: a systematic review and meta-analysis. *Am. J. Surg.*, 2016; 212:615-622.

[22] Sugerman, H. J., Kellum, J. M. Jr., Reines, H. D., DeMaria, E. J., Newsome, H. H., Lowry, J. W. Greater risk of incisional hernia with morbidly obese than steroid-dependent patients and low recurrence with prefascial polypropylene mesh. *Am. J. Surg*., 1996; 171:80-4.

[23] Tonouchi, H., Ohmori, Y., Kobayashi, M., Kusunoki, M. Trocar site hernia. *Arch. Surg*., 2004 Nov.; 139(11):1248-56.

[24] Latyf, R., Slater, R., Garner, J. P. The vermiform appendix presenting in a laparoscopic port site hernia. *J. Minim. Access Surg.*, 2011; 7:181-3.

[25] Cottam, D. R., Gorecki, P. J., Curvelo, M., Weltman, D., Angus, L. D., Shaftan, G. Preperitoneal herniation into a laparoscopic port site without a fascial defect. *Obes. Surg.*, 2002; 12:121-3.

[26] Pilone, V., Di Micco, R., Hasani, A., Celentano, G., Monda, A., Vitiello, A., et al. Trocar site hernia after bariatric surgery: Our experience without fascial closure. *Int. J. Surg.*, 2014; 12(Suppl. 1):S83-6.

[27] Sánchez-Pernaute, A., Perez-Aguirre, E., Garcia Botella, A., Rodriguez, L. et al. Prophylactic closure of trocar orifices with an intraperitoneal mesh (ventralex) in laparoscopic bariatric surgery. *Obes. Surg*., 2008; 18:1489-91.

[28] Fischer, J. P., Basta, M. N., Wink, J. D., Krishnan, N. M., Kovach, S. J. Cost-utility analysis of the use of prophylactic mesh augmentation compared with primary fascial suture repair in patients at high risk for incisional hernia. *Surgery*, 2015. 158:700-11.

In: Encyclopedia of Surgery (22 Volume Set)
Editors: Andreas Lehrer and Kristin Mueller
ISBN: 978-1-53618-329-0
© 2020 Nova Science Publishers, Inc.

Chapter 270

PROPHYLAXIS OF INTERNAL HERNIAS

Manuel Ferrer-Márquez*, MD and Maria José Solvas-Salmerón
Department of Bariatric Surgery, Torrecárdenas Hospital, Almería, Spain

ABSTRACT

Understanding the complications of bariatric surgery is essential for their prevention and reduction of their incidence. Bowel obstruction is the most frequent late complication after gastric bypass, and its consequences can be devastating. The following chapter discusses possible prophylactic measures aimed at preventing the occurrence of this complication.

Keywords: internal hernia, closure of mesenteric defects, non-absorbable suture, small bowel obstruction

1. INTRODUCTION

Complications associated with derivative bariatric techniques may become frequent. Therefore, they should be performed by surgeons experienced in obesity surgery and advanced laparoscopic techniques [1-4]. Among these complications, internal hernias are the most frequent cause of bowel obstruction after bariatric surgery. Knowledge and prevention are essential in order to reduce their occurrence and, consequently, the morbimortality associated with the surgical technique as much as possible.

2. INTERNAL HERNIA AFTER BARIATRIC SURGERY

Internal hernia may be defined as “a defect of unusual size within a body cavity, into which intestines may intrude and become incarcerated or strangulated” [5].

It is currently the most frequent (0.5-12%) late complication after derivative bariatric techniques, and can be life-threatening to patients. Therefore, our knowledge is essential for prevention, early diagnosis and effective treatment [6-8].

It is difficult to know the real incidence of internal hernias since many patients are lost in follow-up, and each group studying this pathology presents different follow-up intervals.

Three anatomical spaces have been described as the possible sites for the internal hernias caused by this surgery [9].

1) The mesocolic space, in the entrance orifice for the alimentary limb when it is passed through the mesocolon.
2) The Petersen space, between the mesenteric of the alimentary limb and the mesocolon.
3) The intermesenteric space behind the jejunojejunal anastomosis.

It is important to note that these spaces do not exist in the patient naturally, but rather are created by the surgeon when performing these surgical techniques.

Although any mixed technique can cause this type of complication, gastric bypass is the most studied bariatric technique.

The most common site for internal hernias after a retrocolic gastric bypass is the mesocolic tunnel (transmesocolic hernia), whereas in the case of an antecolic gastric bypass it is the Petersen space [10].

Despite all the advantages of laparoscopic surgery, the rate of internal hernias has increased with the use of these techniques [11]. This seems to be due, on the one hand, to the small amount of adhesions formed by the minimally invasive techniques and, on the other hand, to the fact that many surgeons do not systematically close the defects created after surgey with a non-absorbable running suture.

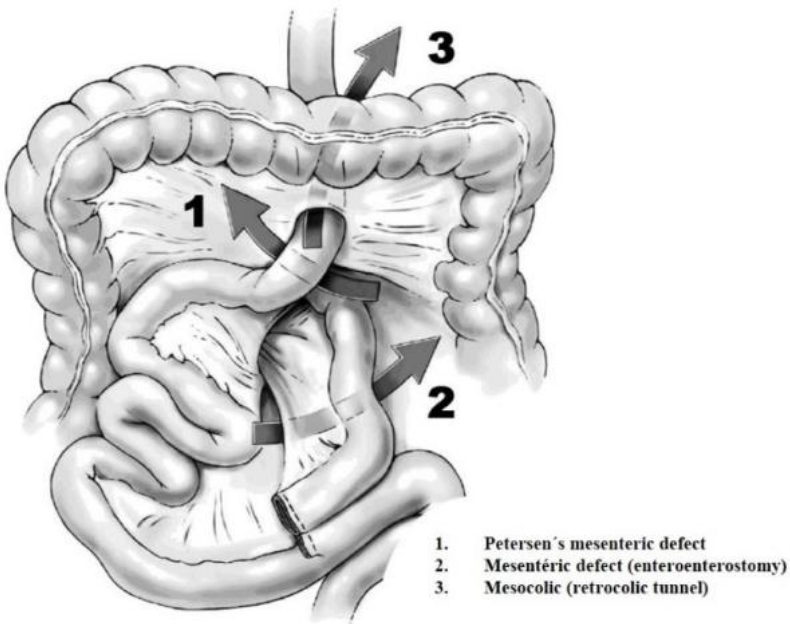

Figure 1. Spaces created in the retrocolic gastric bypass.

Internal hernias usually appear two years after surgery [12], after the patient has lost weight. This fact appears to be a factor for opening potential spaces in which hernias may occur because of the elongation of the mesentery and the laxity of the mesenteric defect. Occurrence can be acute or chronic. When acute clinical signs are presented, the indication for urgent revisional surgery should not be delayed, as a delay in diagnosis could have fatal consequences for the patient. In the event of chronic clinical condition, the patient usually presents vague symptomatology such as intermittent periumbilical or epigastric abdominal pain, with or without vomiting, probably related to episodes of incarceration and spontaneous resolution of the bowel loops.

A simple abdominal X-ray rarely helps diagnosis; Computed Tomography (CT) with intravenous and enteral contrast appears to be the most useful test for the diagnosis of internal hernias. However, it may occasionally show inconclusive or falsely negative results. Typical signs of internal hernia include mesenteric torsion, dilatation of bowel loops, presence of collections or pneumoperitoneum in advanced cases, and even ischemia. In any case, exploratory laparoscopy is the diagnostic-therapeutic procedure that confirms the findings [13].

Figure 2. Abdominal CT: Dilated jejunal loops with caliber change in relation to possible internal hernia are observed.

3. METHODS OF PROPHYLAXIS IN THE LITERATURE

Understanding the complications of laparoscopic gastric bypass is essential in preventing their occurrence. Over the last few years, different mechanisms aimed at reducing the rate of internal hernias after bariatric surgery have been proposed. To date, however, questions about which technique would lead to better outcomes still remain. Among the issues to consider are the following:

- Antecolic or retrocolic gastrojejunal anastomosis.
- Systematically closed or untreated defects when creating the anastomosis.
- Closure by running suture or loose stitches.
- Use of absorbable or non-absorbable suture.
- Closure by sutures or other suitable means.

In this section, we will try to show what the literature suggests about these issues.

For several years, there has been controversy about how to ascend the Roux-en-Y loop to the stomach **(***antecolic or retrocolic*). Proponents of the first approach argue that it is simpler, has less surgical risk, and eliminates the risk of herniation through the mesocolic space. Nevertheless, support for the second variant is based on different features: Given the fact that the route is shorter, the loop has less tension to perform the anastomosis, there is a lower risk of ischemia and bleeding, since the omentum division is not necessary as in the antecolic variant, and it facilitates the revision of the surgery in the future if needed. Several authors have reported a decrease in the internal hernia rate when ascending the loop in an antecolic fashion. Thus, Comeau et al., [14] reported in their series a tendency to reduce the incidence of internal hernias from 6%, using the retrocolic approach, to 3.3% with the antecolic technique ($p < 0.01$). Ahmed et al., [15] concluded, in a series of 2572 patients, that the antecolic variant was associated with a significant reduction in the incidence of internal hernias. A study by Escalona et al also showed a significantly higher internal hernia rate with the retrocolic vs. antecolic technique (9.3% vs 1.8% respectively; $p < 0.0001$), and the retrocolic positioning was identified in the multivariate analysis as a factor for internal hernias ($p < 0.001$) [16]. Other groups reported similar results by modifying the ascending loop from retrocolic to antecolic positioning [17, 18].

The *closure of the defect* has been agreed by many authors as the best way to reduce the incidence of hernias [19-22]. However, it is still at present a subject for debate. It can be a technically difficult process that is not exempt from risks, which increases the overall risk of the surgery. Several authors mention risks such as mesenteric tearing, with consequent hematoma formation or mesenteric vessel damage; the tension of the gastrojejunal or jejunojejunal anastomoses, caused by the sutures; and adhesions, which may cause small bowel obstruction [23].

Some researchers suggest that partial closure of the defect may be even more dangerous than leaving it open, stating that the existence of a small orifice can increase the risk of incarceration. Others, however, argue that, in order not to underestimate the size of the defect, an adequate surgical field exposure (with the bowel and mesentery in a properly aligned fashion) is essential. The closure, therefore, should be performed from the base of the mesentery to the intestinal border, or vice versa.

Champion and Williams [24] were the first to compare closure versus nonclosure of the defect in a long series of patients who underwent gastric bypass with the retrocolic approach, without showing differences in the incidence of internal hernias between both groups (4.1% in the closure group vs 4.7% in the nonclosure group).

In contrast, Carmody et al., [25] reported a significant reduction of internal hernias after retrocolic gastric bypass when using systematic closure (0.6%) compared with nonclosure (7.5%) of the mesenteric defect.

While Rosas et al., [26] failed to show statistically significant differences between two randomized groups (closure vs nonclosure of the defect), the number of patients included in the study was insufficient to enable drawing solid conclusions (n = 50 in the closure group vs n = 55 in the nonclosure group).

In a recent meta-analysis, which included 45 articles and 31320 patients, the lowest incidence of internal hernias was shown in the group with antecolic variant and closure of all defects (1%; p <0.001), followed by the nonclosure antecolic group and the retrocolic group with closure of the mesenteric and mesocolic defects (both 2%; p <0.001). The authors concluded that an antecolic approach and the closure of both mesenteric and Petersen defects reported the lowest incidence of hernias after gastric bypass [27].

Two clinical trials have been implemented in order to clarify the benefits of the mesenteric closure. The first multicenter clinical trial was conducted in Sweden [28], in which two branches were compared: closure (n = 1259) or nonclosure (n = 1248) of the mesenteric defect. At 3-year follow-up, the incidence of reintervention due to bowel obstruction was significantly lower in the closure group (p = 0.0002). The results show that the closure of mesenteric defects with non-absorbable running suture during laparoscopic gastric bypass significantly reduces the need for reintervention because of bowel obstruction during the three years after surgery. In any case, the closure of the defect was associated in the study with a longer operative time and increased complications in the early postoperative period (mainly by jejunostomy torsion).

The second study of interest is a Danish study (NCT01595230) that is currently enrolling patients. Five hundred patients will be randomized between closure of the intermesenteric defects with staples and leaving the defects open. The primary outcome is internal hernia development after 5 years of follow-up [29].

Regarding the type of closure to be performed, most authors suggest the use of a non-absorbable running suture, arguing that the risk of internal hernia increases over time, and that non-absorbable sutures facilitate the formation of adhesions, which are needed for the closure of the orifices. The use of intermittent stitches presents a higher failure rate, which could be caused by the significant weight loss suffered by these patients and the progressive mesenteric thinning, which may cause the occurrence of small gaps, which over time increase in size and enable the entry of bowel loops [9].

In recent years, barbed sutures have been used more frequently to try to reduce the surgical complications that intracorporeal sutures present, as well as surgical time [30]. In any case, there are no studies regarding the closure of mesenteries that compare this type of suture with conventional ones.

The use of sutures compared to other techniques such as glue or clips is a subject for discussion. While sutures have a higher tensile strength, clips have been tested with promising results. Thus, Aghajani et al support the closure of mesenteries in order to reduce the risk of internal hernias, and propose a simplified method for their closure by using clips [31].

Other factors have been proposed in order to decrease the occurrence of internal hernias: Quebbemann and Dallal suggest that a leftward orientation of the Roux limb in LRYGB will result in a significantly lower rate of internal hernia [32]; Nandipati et al report that the anticlockwise rotation of the Roux limb allowed the jejunojejunostomy to be located on the left side of the abdomen, allowing the jejunojejunostomy to lie in its more natural position on the left side of the mesenteric axis (counterclockwise 0.7% vs clockwise 6.9%; p = 0.0018)

[12]. There are other surgical techniques such as nondivision of the jejunal mesentery [33], placement of an antiobstruction stitch, and left or right Roux limb configuration.

Understanding the factors that may cause small bowel obstruction after mixed bariatric surgery and performing a precise surgery considering the aforementioned issues will minimize the incidence of this complication, the results of which can be catastrophic.

REFERENCES

[1] Dayer-Jankechova, A., Fournier, P., Allemann, P., Suter, M. Complications After Laparoscopic Roux-en-Y Gastric Bypass in 1573 Consecutive Patients: Are There Predictors? *Obes. Surg.* 2016 Jan;26(1):12-20.

[2] Schauer, P., Ikramuddin, S., Hamad, G., Gourash, W. The learning curve for laparoscopic Roux-en-Y gastric bypass is 100 cases. *Surg. Endosc.* 2003 Feb;17(2):212-5.

[3] Ferrer-Márquez, M., Solvas-Salmerón, M. J., Moreno-Marín, P., Belda-Lozano, R., Ferrer-Ayza, M., Rosado-Cobián, R. Utilidad de un aula laparoscópica en la implantación de un programa de cirugía de la obesidad. *BMI* 4.1.8 (155-157) www.bmilatina.com.

[4] Sánchez-Santos R, Ruiz de Adana JC. Las sociedades científicas y la impericia: programa de formación en cirugía bariátrica. *Cir. Esp.* 2013;91(4):209-210.

[5] Stern, L. E., Warner, B. W. (2002). Congenital internal abdominal hernias: incidence and management. In: Fitzgibbons, R. J., Greenburg, A. G. (eds). *Nyhus & Condon's hernia*. Lippincott Williams & Wilkins, Philadelphia, pp. x–x.

[6] Higa, K., Ho, T., Tercero, F. et al. Laparoscopic Roux-en-Y gastric bypass: 10- year follow-up. *Surg. Obesity Rel. Dis.* 2011;7:516-25.

[7] Aghajani, E., Jacobsen, H. J., Nergaard, B. J. et al. Internal hernia after gastric bypass: a new and simplified technique for laparoscopic primary closure of the mesenteric defects. *J. Gastrointest. Surg.* 2012;16:641-5.

[8] O'Rourke, R. W. Management strategies for internal hernia after gastric bypass. *J. Gastrointest. Surg*. 2011;15:1049-54.

[9] Higa, K., Boone, K., Arteaga González, I., López-Tomassetti Fernández, E. Mesenteric closure in laparoscopic gastric bypass: surgical technique and literature review. *Cir. Esp.* 2007 Aug;82(2):77-88.

[10] Merkle, E., Hallowell, P., Crouse, C., Nakamoto, D. A., Stellato, T. A. Roux-en-Y gastric bypass for clinically severe obesity: normal appearance and spectrum of complications at imaging. *Radiology* 2005; 234:674-83.

[11] Nimeri, A. A., Maasher, A., A Shaban, T., Salim, E., Gamaleldin, M. M. Internal Hernia Following Laparoscopic Roux-en-Y Gastric Bypass: Prevention and Tips for Intra-operative Management. *Obes. Surg.* 2016 Sep;26(9):2255-2256.

[12] Nandipati, K. C., Lin, E., Husain, F., Srinivasan, J., Sweeney, J. F., Davis, S. S. Counterclockwise rotation of Roux-en-Y limb significantly reduces internal herniation in laparoscopic Roux-en-Y gastric bypass (LRYGB). *J. Gastrointest. Surg*. 2012 Apr;16(4):675-81.

[13] Kristensen, S. D. 1., Naver, L., Jess, P., Floyd, A. K. Effect of closure of the mesenteric defect during laparoscopic gastric bypass and prevention of internal hernia. *Dan. Med. J.* 2014 Jun;61(6):A4854.

[14] Comeau, E., Gagner, M., Inabnet, W. B., Herron, D. M., Quinn, T. M., Pomp, A. Symptomatic internal hernias after laparoscopic bariatric surgery. *Surg. Endosc.* 2005 Jan;19(1):34-9.

[15] Ahmed, A. R., Rickards, G., Husain, S., Johnson, J., Boss, T., O'Malley, W. Trends in internal hernia incidence after laparoscopic Roux-en-Y gastric bypass. *Obes. Surg.* 2007 Dec;17(12):1563-6.

[16] Escalona, A., Devaud, N., Pérez, G., Crovari, F., Boza, C., Viviani, P., et al. Antecolic versus retrocolic alimentary limb in laparoscopic Roux-en-Y gastric bypass: a comparative study. *Surg. Obes. Relat.* Dis. 2007;3:423–7.

[17] Champion, J. K. (2002) Small bowel obstruction after laparoscopi Roux-en-Y gastric bypass. *Obes. Surg.* 12: 197–198.

[18] Felix, E. L., Brown, J. E. (2002) Preventing small bowel obstruction after laparoscopic Roux-en-Y gastric bypass. *Obes. Surg.* 12: 197.

[19] Schauer, P. R., Ikramuddin, S., Gourash, W., Ramanathan, R., Luketich, J. (2000) Outcomes after laparoscopic Roux-en-Y gastric bypass for morbid obesity. *Ann. Surg*. 4: 515–529.

[20] See, C., Carter, P. L., Elliot, D., Mullenix, P., Eggebroten, W., Porter, C., Watts, D. (2002) An institutional experience with laparoscopic gastric bypass complications seen in the first year compared with open gastric bypass complications during the same period. *Am. J. Surg.* 183: 533–538.

[21] Serra, C., Baltasar, A., Bou, R., Miro, J., Cipagauta, L. A. (1999) Internal hernias and gastric perforation after a laparoscopic gastric. *Obes. Surg.* 9: 546–549.

[22] de la Cruz-Muñoz, N., Cabrera, J. C., Cuesta, M., Hartnett, S., Rojas, R. Closure of mesenteric defect can lead to decrease in internal hernias after Roux-en-Y gastric bypass. *Surg. Obes. Relat Dis.* 2011 Mar-Apr;7(2):176-80.

[23] Madan, A. K., Lo Menzo, E., Dhawan, N., Tichansky, D. S. Internal Hernias and Nonclosure of Mesenteric Defects During Laparoscopic Roux-en-Y Gastric Bypass. *Obes. Surg.* 2009 May;19(5):549-52.

[24] Champion, J. K., Williams, M. Small bowel obstruction and internal hernias after laparoscopic Roux-en-Y gastric bypass. *Obes. Surg.* 2003 Aug;13(4):596-600.

[25] Carmody, B. 1., DeMaria, E. J., Jamal, M., Johnson, J., Carbonell, A., Kellum, J., et al. Internal hernia after laparoscopic Roux-en-Y gastric bypass. *Surg. Obes. Relat. Dis.* 2005 Nov-Dec;1(6):543-8.

[26] Rosas, U., Ahmed, S., Leva, N., Garg, T., Rivas, H., Lau, J., Russo, M., Morton, J. M. Mesenteric defect closure in laparoscopic Roux-en-Y gastric bypass: a randomized controlled trial. *Surg. Endosc.* 2015 Sep;29(9):2486-90

[27] Geubbels, N., Lijftogt, N., Fiocco, M., van Leersum, N. J., Wouters, M. W., de Brauw, L. M. Meta-analysis of internal herniation after gastric bypass surgery. *Br. J. Surg.* 2015 Apr;102(5):451-60.

[28] Stenberg, E., Szabo, E., Ågren, G., Ottosson, J., Marsk, R., Lönroth, H., et al. Closure of mesenteric defects in laparoscopic gastric bypass: a multicentre, randomised, parallel, open-label trial. *Lancet.* 2016 Apr 2;387(10026):1397-1404.

[29] Kristensen, S. D. 1., Naver, L., Jess, P., Floyd, A. K. Effect of closure of the mesenteric defect during laparoscopic gastric bypass and prevention of internal hernia. *Dan. Med. J.* 2014 Jun;61(6):A4854.

[30] Ferrer-Márquez, M., Belda-Lozano, R. Barbed sutures in general and digestive surgery. Review. *Cir. Esp*. 2016 Feb;94(2):65-9.

[31] Aghajani, E., Jacobsen, H. J., Nergaard, B. J., Hedenbro, J. L., Leifson, B. G., Gislason, H. Internal hernia after gastric bypass: a new and simplified technique for laparoscopic primary closure of the mesenteric defects. *J. Gastrointest. Surg*. 2012 Mar;16(3):641-5.

[32] Quebbemann, B. B., Dallal, R. M. The orientation of the antecolic Roux limb markedly affects the incidence of internal hernias after laparoscopic gastric bypass. *Obes. Surg.* 2005 Jun-Jul;15(6):766-70.

[33] Cho, M., Pinto, D., Carrodeguas, L., Lascano, C., Soto, F., Whipple, O., et al. Frequency and management of internal hernias after laparoscopic antecolic antegastric Roux-en-Y gastric bypass without division of the small bowel mesentery or closure of mesenteric defects: review of 1400 consecutive cases. *Surg. Obes. Relat. Dis.* 2006 Mar-Apr;2(2):87-91.

In: Encyclopedia of Surgery (22 Volume Set)
Editors: Andreas Lehrer and Kristin Mueller
ISBN: 978-1-53618-329-0
© 2020 Nova Science Publishers, Inc.

Chapter 271

EPIDEMIOLOGY OF SURGICAL SITE INFECTION

Pablo Priego*, MD, PhD
Department of General Surgery, Division of Esophagogastric and Bariatric Surgery,
Ramón y Cajal University Hospital, Madrid, Spain

ABSTRACT

Surgical site infection (SSI) refers to an infection that occurs within 30 days after surgery in the part of the body where the surgery took place. These infections may be superficial (involving the skin only) or deep incisional infections or infections involving organs, implanted materials or body spaces. True epidemiology of SSI is difficult to identify due to the heterogeneous nature of these infections. In fact, incidence can change between procedures, hospitals, surgeons and patients. SSIs are the first most frequently reported nosocomial infections, accounting for 30% of such infections among hospitalised patients. Moreover, SSI is implicated in one-third of postoperative deaths and accounts for 8% of all deaths caused by a nosocomial infection. Furthermore, SSI incurs considerable increases in healthcare costs. In most SSIs, the responsible pathogens originate from the patient's endogenous flora. The most commonly isolated organisms in clean surgery are *Staphylococcus aureus*, coagulase negative staphylococci, meanwhile in clean-contaminated or contaminated surgery; the most frequent organisms are *Enterococcus* spp. and Escherichia *coli*.

This review aims at exploring epidemiology, bacteriology and risk factors associated with SSI.

Keywords: epidemiology, surgical site infection, microbiology, risk factors, pathogens

HISTORY

The introduction of anesthetics encouraged more surgery, which inadvertently caused more dangerous patient post-operative infections. The concept of infection was unknown until relatively modern times.

* Corresponding Author's Email: papriego@hotmail.com.

The modern concept of asepsis evolved in the 19th century, when Ignaz Semmelweis showed that hand washing prior to delivery reduced puerperal fever [1]. However, until the pioneering work of Joseph Lister in the 1860s, most physicians believed that chemical damage from exposures to bad air (miasma) was responsible for infections in wounds, and facilities for washing hands or a patient's wounds were not available.

Lister became aware of the work of chemist Louis Pasteur, who showed that rotting and fermentation could occur under anaerobic conditions if micro-organisms were present. Lister experienced spraying carbolic acid on his instruments as an antiseptic, and found that this remarkably reduced the incidence of gangrene and surgical site infections (SSIs). His work was groundbreaking and laid the foundations for a rapid advance in infection control that saw modern antiseptic operating theatres widely used within 50 years [1].

Nowadays, strategies for the prevention of SSIs are based both on reducing the risk of bacterial contamination and on improving the patient's defences against infection. This requires a 'bundle' approach, with attention to multiple patient-related and procedure-related risk factors. Evidence-based guidelines for the prevention of SSIs have been published by the Centers for Disease Control (CDC) [2] and World Health Organitation [3]. However, the development of such guidelines is complicated by the heterogeneous nature of SSIs, which makes it difficult to generalise findings from a study in a specific patient population to a wider setting, and by the fact that the impact of many routine practices (e.g. wearing surgical gloves) cannot be evaluated for ethical or logistic reasons.

DEFINITION

The expression 'surgical site infection' (SSI) was introduced in 1992 in order to replace the previous concept of 'surgical wound infection' [4]. SSI refers to an infection that occurs after surgery in the part of the body where the surgery took place. These infections may be superficial (involving the skin only) or deep incisional infections, or infections involving organs, implanted materials or body spaces (Figure 1).

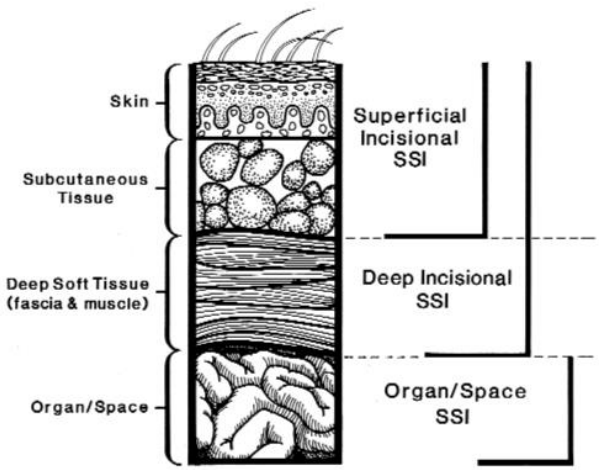

Figure 1. Classification of SSIs according to the Centers for Disease Control National Nosocomial Infections Surveillance (CDC NNIS) System. Reproduced with permission from Mangram et al. [5].

Criterion	CDC 1988	CDC 1992	SISG	NPS	PHLS
Purulent discharge in or exuding from the wound or observed on direct examination	I		✓	✓	✓
Painful spreading erythema indicative of cellulitis			✓	✓	
Purulent drainage	D	SI/D			
Purulent drainage from a drain placed beneath the fascial layer	D				
Purulent drainage from a drain placed through a stab wound into the organ/space		OS			
Organisms isolated from fluid or tissue from the wound	I	SI			
Organisms isolated from fluid or tissue in the organ/space		OS			
Surgeon/physician diagnosis	I/D	SI/DI/OS			
Surgeon deliberately opens wound, unless wound is culture-negative	I/D	SI/DI			
Wound spontaneously dehisces	D	SI/DI			
Pain	D	SI/DI			
Tenderness	D	DI	✓	✓	
Fever › 38°C	D	DI	✓	✓	
Localized swelling (oedema)		SI	✓	✓	
Redness or extending margin or erythema		SI	✓	✓	
Patient still receiving active treatment for a wound with discharged pus				or ✓	
Heat		SI			
Abscess or other evidence of infection found on direct examination	D	DI/OS			

*Reproduced from reference 4.

CDC: Centers for Disease Control and Prevention; SISG: Surgical Infection Study Group; NPS: National Prevalence Survey; PHLS; Public Health Laboratory Service.

CDC 1988 definitions: I, incisional surgical wound infection; D, deep surgical wound infection. CDC 1992 definitions: SI, superficial incisional; DI, deep incisional; OS, organ/space. The SISG and NPS allow fever (›38°C), tenderness, oedema, an extending margin of erythema or if the patient is still receiving treatment for the wound.

Figure 2. Definitions of SSI (Reproduced with permission from Global guidelines for the prevention of surgical site infection. World Health Organization (2016) [3].

SSI is also defined as an infection that occurs within 30 days after the operation and involves the skin and subcutaneous tissue of the incision (superficial incisional) and/or the deep soft tissue (for example, fascia, muscle) of the incision (deep incisional) and/or any part of the anatomy (for example, organs and spaces) other than the incision that was opened or manipulated during an operation (organ/space) [3].

There are many definitions of SSI and a systematic review identified as many as 41 different definitions. However, only five were described as being standardized definitions created by multidisciplinary groups (Figure 2).

The period of surveillance during the first 30 postoperative days or 1 year in case of receiving implants has been modified in the last years by CDC. Currently, it has been stablished two different kind of classifications regarding procedures and these period of surveillance change from 30 to 90 days in them (Table 1) [6].

Table 1. Period of surveillance for deep or organ/space surgical infection recommended by CDC (2015)

Period of surveillance for deep or organ/space surgical infection recommended by CDC (2015)	
Surveillance of 30 days	Surveillance of 90 days
Aortic aneurysm Amputation of extremity Appendectomy Hepatobiliopancreatic surgery Cholecystectomy Colorectal surgery Gastric surgery Small bowell surgery Neck, thyroid an parathyroid surgery Splenectomy Explorer laparoscopy Ovarian surgery Abdominal or vaginal hysterectomy Caesarean surgery Kidney, liver and cardiac transplantation Thoracic surgery	Breast surgery Herniorraphy Implanting a pacemaker Peripheral vascular surgery Hip and knee prosthesis Spinal surgery Craneothomy Open bone fracture
Superficial SSIs are only controlled for 30 days with independence of type of surgery	

Surgical Wound [3]

Surgical wound refers to a wound created when an incision is made with a scalpel or other sharp cutting device and then closed in the operating room by suture, staple, adhesive tape, or glue and resulting in close approximation to the skin edges.

Surgical wounds are classified according to level of contamination into four classes. This classification allow a better prediction of risk of infections and wound healing outcomes, thus allowing most favorable treatment for each type of surgical wound.

Clean: refers to an uninfected operative wound in which no inflammation is encountered and the respiratory, alimentary, genital or uninfected urinary tracts are not entered. In addition, clean wounds are primarily closed and, if necessary, drained with closed drainage. Operative incisional wounds that follow non-penetrating (blunt) trauma should be included in this category if they meet the criteria.

Clean-contaminated: refers to operative wounds in which the respiratory, alimentary, genital or urinary tracts are entered under controlled conditions and without unusual contamination. Specifically, operations involving the biliary tract, appendix, vagina and oropharynx are included in this category, provided no evidence of infection or major break in technique is encountered.

Contaminated: refers to open, fresh, accidental wounds. In addition, operations with major breaks in sterile technique (for example, open cardiac massage) or gross spillage from the gastrointestinal tract, and incisions in which acute, non-purulent inflammation is encountered, including necrotic tissue without evidence of purulent drainage (for example, dry gangrene), are included in this category.

Dirty or infected: includes old traumatic wounds with retained devitalized tissue and those that involve existing clinical infection or perforated viscera. This definition suggests that the organisms causing postoperative infection were present in the operative field before the operation.

EPIDEMIOLOGY

SSIs are a common cause of healthcare-associated infection (HAI). True epidemiology of SSI is difficult to identify due to the heterogeneous nature of these infections. In fact, incidence can change between procedures, hospitals, surgeons and patients [7]. Data from the United States and Spain show that SSIs are the first most frequently reported nosocomial infections, accounting for 30% of such infections among hospitalised patients. Furthermore, SSI is a serious complication of surgical procedures that occurs after approximately 2-7% of surgeries. However, its incidence depends on the surgical procedure, the surveillance criteria used, and the quality of data collection.

Moreover, SSI is the most common complication following major gastrointestinal surgery, affecting between 25% and 40% of patients after midline laparotomy (especially in transplantation and surgical oncology) [8]. Fortunately, the increasing use of minimally invasive surgery approach has resulted in a decrease in the incidence of SSIs.

Actually, SSI occurs 17 days after surgery with a range of 6-41 days. In colorectal surgery, 70% of SSI develops after discharge home [9].

Impact of SSIs on Healthcare Resources

SSI is implicated in one-third of postoperative deaths and accounts for 8% of all deaths caused by a nosocomial infection. Furthermore, SSIs cause pain and discomfort, increase hospital stay, require readmission to hospital or intensive care unit (ICU) treatment, and deffinitively put patients at greater risk of secondary infectious complications [5].

Kirkland et al. [10], reported that the relative risk for death associated with SSIs was 2.2, and those for readmission and ICU treatment were 5.5 and 1.6, respectively. Moreover, patients with SSIs required longer hospitalization (11 vs. 6 days) when compared with uninfected patients, and the median extra duration attributable to SSIs was between 5 to 10 days [11].

As a result, SSIs incur considerable increases in healthcare costs. The hospital-related cost of a single SSI has been estimated at $12,000–$35,000 and estimates of annual nationwide hospital costs of SSI have ranged from $3 billion to $10 billion [12].

MICROBIOLOGY

In most SSIs, the responsible pathogens originate from the patient's endogenous flora. Type of organisms isolated depends on type of surgery. The most commonly isolated organisms in clean surgery are *Staphylococcus aureus*, coagulase negative staphylococci,

meanwhile in clean-contaminated or contaminated surgery, the most frequent organisms are *Enterococcus* spp. and *Escherichia coli* [13, 14].

Results form EPINE study of Spain in 2013 [15], shows that in gastrointestinal surgery, SSI is secondary to gram-negative germens in 60% and gram-positive cocos in 32%. Most frequent isolated organisms are *Escherichia coli* (28%), *Enterococcus spp.* (15%), *Streptococcus spp.* (8%), *Pseudomonas aeruginosa* (7%), coagulase negative staphylococci (5%), *Staphylococcus aureus* (5%, methicilin-resistant 2%), *Candida spp.* (4%), *Klebsiella spp.* (4%), *Enterobacter spp.* (4%), *Proteus mirabilis* (3%) and *Bacteroides fragilis* (3%) [6].

Nowadays, there are an increase proportion of infections caused by pathogens antimicrobial resistance, like methicilin-resistant *Staphylococcus aureus* (MRSA) or *Candida*. This could be indicative to the increasing number of immunocompromised surgical patients or even severely ill, as well as to the widespread overuse of broad-spectrum antibiotics. This MRSA infection not only is associated with long and expensive hospitalizations but also with high mortality rates.

Less frequent are infections caused by *Serratia marcescens, Moxarella osloensis, Rhizopus oryzae, Clostridium perfringens, Rhodococcus bronchialis, Nocardia farcinica, Legionella pneumophila, Legionella dumoffii* and *Pseudomonas multivorans.* However, when these infections are detected, a meticulous epidemiologic investigation must be taking.

Pathogens of concern that cause SSIs may be introduced to the site of wound or surgery via several routes like the patient's endogenous flora or preoperative infection sites remote from the operative, particularly in patients undergoing insertion of a prosthesis or other implant. In addition to the patient's endogenous flora, SSI pathogens may originate from exogenous sources such as members of the surgical team, the operating theatre environment, and instruments and materials brought within the sterile field during the procedure.

The risk of an SSI developing after microbial contamination of the surgical site will depend on the dose and virulence of the pathogen and the patient's level of resistance, according to the relationship

$$\text{Risk of SSI} = \frac{\text{Dose of bacterial contamination} \times \text{virulence}}{\text{Resistance of patient}}$$

The risk of SSI is considered to be significant when organisms in the tissue exceed 105 organisms per gram of tissue, although lower doses may be required if foreign material such as sutures is present. The virulence of the organism relates to its ability to produce toxins or other factors that increase its ability to invade or damage tissue. When the balance between the patient's defense system and the number of pathogenic organisms is disrupted SSIs occur. Mortality rates in patients infected with highly virulent pathogens such as MRSA may be as high as 74% [7].

RISKS FACTORS FOR SSIS

A number of patient-related and procedure-related factors have been shown to influence the risk of SSIs (Table 2). These include patient-related (endogenous factors) and procedure-related (exogenous factors). Some variables are obviously not modifiable, such as age and gender. However, other potential factors can be improved to increase the likelihood of a

positive surgical outcome, such as nutritional status, tobacco use, correct use of antibiotics and the intraoperative technique [7].

The risk of SSI in an individual patient can be estimated using various scoring systems. Culver et al. in 1991 [16], reported the National Nosocomial Infections Surveillance (NNIS) SSI Risk Index. This is the most frequent index in order to calculate the probability of SSI. This index has a range of 0-3, and is calculated by assigning one point for each of three variables (Table 3):

a) Duration of surgery longer than the approximate 75th percentile of the duration of the specific operation being performed (1 point)
b) Type of surgery: The presence of a contaminated, dirty or infected, wound (1 point)
c) Classification of the American Society of Anesthesiologists score: A score of > 3 (i.e., mild systemic disease) is assigned with 1 point.

Table 2. Patient-related and procedure-related factors that may influence the risk of surgical site infections (adapted from Mangram et al.) [5]

Patient-related	Procedure-related
Age	Duration of surgical scrub
Nutritional status	Skin antisepsis
Diabetes	Preoperative shaving
Smoking	Preoperative skin preparation
Obesity	Duration of operation
Coexistent infection at a remote body site	Antimicrobial prophylaxis
Colonisation with micro-organisms	Operating room ventilation
(particularly *Staphylococcus aureus*)	Inadequate sterilisation of surgical instruments
Altered immune response	Foreign material in the surgical site
Length of preoperative hospital stay	Surgical drains
	Surgical technique
	-poor haemostasis
	-failure to obliterate dead space
	-tissue trauma

Korol et al. [17] performe a systematic review of 57 studies and identify an increased risk of SSI with the following factors: a high body mass index, a severe score according to the US National Nosocomial Infections Surveillance (NNIS) risk Index, severe wound class, diabetes and a prolongation of surgery duration. Furthermore, a metaanalysis of Zhang et al. [18], suggested that diabetes mellitus is significantly associated with an increased risk of SSI. Indeed, in European studies [19], it has also been identified a longer duration of surgery, an American Society of Anesthesiologists score of at least 3 and a pre-surgery hospital stay of at least 2 days as factors associated with an increased risk of SSI, while videoscopic procedures reduced SSI rates.

Recently, a systematic review conducted by WHO [20-33], tried to describe the relationship between surgical volume and the risk of SSI. A moderate quality of evidence showed that surgical procedures performed in high-/medium volume hospitals have lower SSI rates compared to low-volume hospitals (OR: 0.69; 95% CI: 0.55-0.87 and OR: 0.80; 95% CI: 0.69-0.94, respectively). In addition, there was a moderate quality of evidence that surgical procedures performed by high- or medium-volume surgeons have lower SSI rates

(OR: 0.67; 95% CI: 0.55-0.81 and OR: 0.73; 95% CI: 0.63-0.85, respectively) compared to low volume hospitals. However, there was controversial evidence when high- and medium-volume hospitals were compared and it remains unclear whether there is a linear relationship between procedure/surgeon volume and the SSI rate.

Table 3. Estimation of preoperative SSI risk based on the National Nosocomial Infections Surveillance System (NNISS)

Estimation of preoperative SSI risk based on the National Nosocomial Infections Surveillance System (NNISS)			
NNISS			
1- Duration of surgery longer than the approximate 75th percentile of the duration of the specific operation being performed (1 point) 2-Type of surgery: The presence of a contaminated, dirty or infected, wound (1 point) 3- ASA score of >3 is assigned with 1 point.			
KEYS			
	ASA I	A normal healthy patient	
	ASA II	A patient with mild systemic disease	
	ASA III	A patient with severe systemic disease	
	ASA IV	A patient with severe systemic disease that is a constant threat to life	
	ASA V	A moribund patient who is not expected to survive without the operation	
	ASA VI	A declared brain-dead patient whose organs are being removed for donor purposes	
T: Cross point for surgery Appendectomy 1 hour Pancreas, liver and biliar tract surgery 4 hours Cholecystectomy 2 hours Colon surgery 3 hours Gastric surgery 3 hours Smallo bowel surgery 3 hours Laparotomy 2 hours Another procedures in the digestive tract 3 hours			
RISK OF INFECTION			
0 points: 1.5% 1 point: 2.9% 2 points: 6.8% 3 points: 13%			

CLASSIFICATION OF THE SEVERITY OF THE SSI: THE ASEPSIS SCORE

Having a valid, reliable and sensitive scoring system to assess the signs and symptoms of SSI can allow prompt treatment as well as evaluation of its management. The ASEPSIS scoring system, derived from cardiac surgery, was the only established referenced scoring system to assess for SSI. The acronym of ASEPSIS is *Additional treatment, Serous discharge, Erythema, Purulent exudates, Separation of deep tissues, Isolation of bacteria and Stay as inpatient prolonged over fourteen days* [34].

ASEPSIS score evaluates the severity of SSI during the first postoperative week assigning points to several factors (antibiotics, drainage of pus, debridement, evisceration, microbiology). This score classifies postoperative infection in five categories (from satisfactory healing to severe infection) and may evaluate daily the score [6] (Table 4).

Table 4. ASEPSIS score

	Proportion of wound affected (%)					
Wound	**0**	**< 20**	**20-39**	**40-50**	**60-79**	**>80**
characteristics						
Serous exudates	0	1	2	3	4	5
Erythema	0	1	2	3	4	5
Purulent exudates	0	2	4	6	8	10
Separation of Deep tissues	0	2	4	6	8	10

Criteria	**Points**
Additional treatment	
-Antibiotics	10
-Drainage of pus under local anesthesia	5
-Debridement of wound general anesthesia	10
Serous discharge	Daily 0-5
Erythema	Daily 0-5
Purulent exudates	Daily 0-10
Separation of deep tissues	Daily 0-10
Isolation of bacteria	10
Stay as inpatient prolonged over 14 days	5

Total score	**Category of infection**
0-10	Satisfactory healing
11-20	Disturbance of healing
21-30	Minor wound infection
31-40	Moderate wound infection
>40	Severe wound infection

REFERENCES

[1] Thorwald J (2005). *Das Jahrhundert der Chirurgen*. [*The Century of Surgeons*.] Edition Destino, S.A. Pag 1-662.

[2] Berríos-Torres SI, Umscheid CA, Bratzler DW, Leas B, Stone EC, Kelz RR, Reinke CE, Morgan S, Solomkin JS, Mazuski JE, Dellinger EP, Itani KMF, Berbari EF, Segreti J, Parvizi J, Blanchard J, Allen G, Kluytmans JAJW, Donlan R, Schecter WP for the Healthcare Infection Control Practices Advisory Committee (2017). Centers for Disease Control and Prevention Guideline for the Prevention of Surgical Site Infection, 2017. *JAMA Surg* ;152(8):784-791.

[3] *Global guidelines for the prevention of surgical site infection*. World Health Organization (2016). Pag. 1-186.

[4] Horan TC, Gaynes RP, Martone WJ, Jarvis WR, Emori TG (1992). CDC definitions of noscomial surgical site infections, 1992: a modification of CDC definitions of surgical wound infections. *Infect Control Hosp Epidemiol*; 13: 606-608.

[5] Mangram AJ, Horan TC, Pearson ML, Silver LC, Jarvis WR (1999). Hospital Infection Control Practice Advisory Committee. Guideline for prevention of surgical site infection, 1999. *Infect Control Hosp Epidemiol*; 20: 247-278.

[6] Badía JM (2016). Surgical site infection: definition, classification and risk factors. *Clinical guidelines of Spanish Association of Surgeons. Surgical Infections.* Aran SL. 2ª edición. Pag. 97-116.

[7] Owens CD, Stoessel K (2008). Surgical site infections: epidemiology, microbiology and prevention. *Journal of Hospital Infection*; 70(S2) 3–10.

[8] Collaborative GS (2017). Determining the worldwide epidemiology of surgical site infections after gastrointestinal resection surgery: protocol for a multicentre, international, prospective cohort study (GlobalSurg 2). *BMJ Open*;7:e012150. doi:10.1136/ bmjopen-2016-012150.

[9] Limón E, Shaw E, Badia JM, Piriz M, Escofet R, Gudiol F, Pujol M (2014). Post-discharge surgical site infections after uncomplicated elective colorectal surgery: impact and risk factors. The experience of the VINCat Program. *J Hosp Infection*; 86:127-132.

[10] Kirkland KB, Briggs JP, Trivette SL, Wilkinson WE, Sexton DJ (1999). The impact of surgical-site infections in the 1990s: attributable mortality, excess length of hospitalization, and extra costs. *Infect Control Hosp Epidemiol*; 20:725-730.

[11] DiPiro JT, Martindale RG, Bakst A, Vacani PF, Watson P, Miller MT (1998). Infection in surgical patients: effects on mortality, hospitalization, and postdischarge care. *Am J Health Syst Pharm*; 55:777-781.

[12] Baker AW, Dicks KV, Durkin MJ, Weber DJ, Lewis SS, Moehring RW, Chen LF, Sexton DJ, Anderson DJ (2016). Epidemiology of Surgical Site Infection in a Community Hospital Network. *Infect Control Hosp Epidemiol*; 37(5): 519–526.

[13] Múñez E, Ramos A, Álvarez de Espejo T, Vaque J, Sánchez-Payá J, Pastor V, Asensio A (2011).Microbiology of surgical site infections in abdominal tract surgery patients. *Cir Esp*; 89:606-612.

[14] Magill, SS, et al. (2012) Prevalence of healthcare-associated infections in acute care hospitals in Jacksonville, Florida. *Infection Control Hospital Epidemiology*; 33(3):283-291.

[15] Estudio EPINE-EPPS 2013. *Study of prevalence of nosocomial infections in Spain.*

[16] Culver DH, Horan TC, Gaynes RP, Martone WJ, Jarvis WR, Emori TG, Banerjee SN, Edwards JR, Tolson JS, Henderson TS, Hughes JM, and the National Nosocomial Infections Surveillance System (1991). Surgical wound infection rates by wound class, operative procedure, and patient risk index. *Am J Med*; 91:152S-157S.

[17] Korol E, Johnston K, Waser N, Sifakis F, Jafri HS, Lo M, et al. (2013). A systematic review of risk factors associated with surgical site infections among surgical patients. *PLoS One*; 8(12):e83743.

[18] Zhang Y, Zheng QJ, Wang S, Zeng SX, Zhang YP, Bai XJ, et al. (2015). Diabetes mellitus is associated with increased risk of surgical site infections: A meta-analysis of prospective cohort studies. *Am J Infect Control;*43(8):810-815.

[19] Marchi M, Pan A, Gagliotti C, Morsillo F, Parenti M, Resi D, et al. (2014). The Italian national surgical site infection surveillance programme and its positive impact, 2009 to 2011. *Euro Surveill*;19(21): pii: 20815.

[20] Anderson DJ, Hartwig MG, Pappas T, Sexton DJ, Kanafani ZA, Auten G, et al. (2008). Surgical volume and the risk of surgical site infection in community hospitals: size matters. *Ann Surg*; 247(2):343-349.

[21] Hervey SL, Purves HR, Guller U, Toth AP, Vail TP, Pietrobon R (2003). Provider volume of total knee arthroplasties and patient outcomes in the HCUP nationwide inpatient sample. *J Bone Joint Surg (Am)*;85-a(9):1775-1783.

[22] Jalisi S, Bearelly S, Abdillahi A, Truong MT (2013). Outcomes in head and neck oncologic surgery at academic medical centers in the United States. *Laryngoscope*; 123(3):689-698.

[23] Meyer E, Weitzel-Kage D, Sohr D, Gastmeier P (2011). Impact of department volume on surgical site infections following arthroscopy, knee replacement or hip replacement. *BMJ Qual Saf*; 20(12):1069-1074.

[24] Muilwijk J, van den Hof S, Wille JC (2007). Associations between surgical site infection risk and hospital operation volume and surgeon operation volume among hospitals in the Dutch nosocomial infection surveillance network. *Infect Control Hosp Epidemiol*; 28(5):557-563.

[25] Namba RS, Inacio MC, Paxton EW (2012). Risk factors associated with surgical site infection in 30,491 primary total hip replacements. *J Bone Joint Surg (Br)*; 94(10):1330-1338.

[26] Patel HJ, Herbert MA, Drake DH, Hanson EC, Theurer PF, Bell GF, et al. (2013). Aortic valve replacement: using a statewide cardiac surgical database identifies a procedural volume hinge point. *Ann Thorac Surg*; 96(5):1560-1565; discussion 5-6.

[27] Wu SC, Chen CC, Ng YY, Chu HF (2006). The relationship between surgical site infection and volume of coronary artery bypass graft surgeries: Taiwan experience. *Infect Control Hosp Epidemiol*; 27(3):308-311.

[28] Geubbels EL, Wille JC, Nagelkerke NJ, Vandenbroucke-Grauls CM, Grobbee DE, de Boer AS (2005). Hospital-related determinants for surgical site infection following hip arthroplasty. *Infect Control Hosp Epidemio*l; 26(5):435-441.

[29] Katz JN, Losina E, Barrett J, Phillips CB, Mahomed NN, Lew RA, et al. (2001). Association between hospital and surgeon procedure volume and outcomes of total hip replacement in the United States medicare population. *J Bone Joint Surg (Am);* 83-a(11):1622-1629.

[30] Katz JN, Barrett J, Mahomed NN, Baron JA, Wright RJ, Losina E (2004). Association between hospital and surgeon procedure volume and the outcomes of total knee replacement. *J Bone Joint Surg (Am)*; 86-a(9):1909-1916.

[31] Kreder HJ, Deyo RA, Koepsell T, Swiontkowski MF, Kreuter W (1997). Relationship between the volume of total hip replacements performed by providers and the rates of postoperative complications in the state of Washington. *J Bone Joint Surg (Am)*; 79(4):485-494.

[32] Nguyen NT, Paya M, Stevens CM, Mavandadi S, Zainabadi K, Wilson SE (2004). The relationship between hospital volume and outcome in bariatric surgery at academic medical centers. *Ann Surg*; 240(4):586-593.

[33] Shah SN, Wainess RM, Karunakar MA (2005). Hemiarthroplasty for femoral neck fracture in the elderly surgeon and hospital volumerelated outcomes. *J Arthroplasty*; 20(4):503-508.

[34] Leaper DJ (2010). Risk factors for and Epidemiology of Surgical Site Infections. *Surg Infect;* 11(3): 283-287.

In: Encyclopedia of Surgery (22 Volume Set)
Editors: Andreas Lehrer and Kristin Mueller
ISBN: 978-1-53618-329-0
© 2020 Nova Science Publishers, Inc.

Chapter 272

ADEQUATE NUTRITIONAL SUPPORT FOR THE PROPHYLAXIS OF SURGICAL SITE INFECTION

Andrei Sarmiento[1,*], MD, Grace Amesquita[2], MD and Ramiro Carbajal[3], MD

[1]Metabolic and Bariatric Surgeon, Hospital Santa Rosa, Lima, Perú
[2]Intensive care unit (ICU), Hospital Santa Rosa, Lima, Perú
[3]Metabolic and Bariatric Surgeon, Hospital Edgardo Rebagliati, Lima, Perú

ABSTRACT

Surgical site infections (SSI) are one of the most commonly reported healthcare-associated infections worldwide and have adverse effects on patient health and hospital resources. There are several risk factors to develop SSI and include malnutrition. A large part of all patients in the hospital are at nutritional risk, the prevalence of malnutrition is up to 50-55%. Due to this high prevalence current recommendations to avoid the hospital burden to SSIs include identify the presence of malnutrition adopting specific nutritional goals to preoperative and postoperative period.

Keywords: surgical site infections, malnutrition, nutritional support

INTRODUCTION

According to the World Health Organization (WHO) healthcare-associated infections are avoidable infections that affect hundreds of millions of people each year worldwide, and surgical site infection (SSI) is the most frequent healthcare-associated infection in low-income countries, affecting up to a third of patients who had surgery. The incidence of SSI is much lower in high-income countries, while urinary tract infection is the most frequent. SSI is still the second most common in Europe and the USA. In low and middle-income countries the incidence rates ranging from 1.2 to 23.6 per 100 surgical procedures and a pooled

* Corresponding Author's Email: andreisarmiento@hotmail.com.

incidence of 11.8%. By contrast, SSI rates vary between 1.2% and 5.2% in developed countries [1, 2].

Surgical site infection (SSI) is defined by the United States Centers for Disease Control and Prevention as infection related to an operative procedure that occurs at or near the surgical incision within 30 days of the procedure or within 90 days if prosthetic material is implanted at surgery [3].

Several risk factors predispose SSI and are known in the literature. Patient and operation characteristics that may influence the risk of surgical site infection development according to the Centers for Disease Control and Prevention guideline. Patient factors include (age, nutritional status, diabetes, smoking, obesity, coexistent infections at a remote body site, colonization with microorganisms, altered immune response length of preoperative stay). Procedure factors include the duration of surgical scrub, skin antisepsis, preoperative shaving, preoperative skin preparation, duration of operation, antimicrobial prophylaxis, operating room ventilation, inadequate sterilization of instruments, foreign material in the surgical site, surgical techniques, surgical drains) [3, 4]. There are other factors influencing patient to develop SSI for example, Hypoalbuminemia [5].

Nowadays, the relationship between nutritional status and the immune system is well known. Malnutrition impairs immune response may make patients highly susceptible to postoperative infections. Hence, patients with malnutrition may suffer a range of poor outcomes including increased risk of death, sepsis and poor wound healing [6, 7]. This chapter summarizes the recent evidence about the identification and intervention of the malnutrition in the surgical patient to avoid surgical site infections.

MALNUTRITION AS A RISK FACTOR

About 20%–50% of all patients in hospitals are found at risk of under-nutrition, depending on the definition, clinical setting, and screening tools. A large part of these patients at nutritional risk when admitted to the hospital, and in most of the patient's malnutrition develops negatively during the hospital stay [6]. The elderly patients and patients suffering from chronic diseases are more exposed to nutritional risk than other patients [7, 8]. Despite three decades of collective development of knowledge, contemporary malnutrition rates do not appear to have reduced significantly [9]. This can be prevented if special attention is paid to the nutritional care of patients.

Malnutrition is characterized by the presence of two or more of the following characteristics: Insufficient energy intake, weight loss, loss of muscle mass, loss of subcutaneous fat, localized or generalized fluid accumulation or decreased functional status [10].

In general, contributors to adult malnutrition have been described in a number of recent studies. Factors identified include inadequate intake, inadequate access to food, increased nutrient requirements associated with complications of the presenting disease or condition, complications that develop during the course of a hospital stay, and/or complications that occur as a result of treatment, declines in mental, sensory, and/or physical function, changes in metabolism and body composition associated with the aging process itself, and any combination of these factors. In addition to personal contributors to undernutrition, a number

of institutional barriers also contribute to undernutrition's incidence and prevalence. These include factors such as a lack of routinely implemented nutrition screening/assessment protocols, failure to recognize undernutrition, failure to provide nutrition intervention to undernourished patients in a timely/coordinated manner, confusion regarding "ownership" of the nutrition screening, assessment, and intervention process, failure to measure or monitor body weight and/or food and nutrient intake, lack of feeding assistance, and low priority given to nutrition status in institutional settings [11, 12].

Clearly, there may be marked variability in the impact of nutrition among patients with different stages of disease, or even different treatments (e.g., chemotherapy, radiotherapy, advanced disease, serious comorbidities, and emergency surgery). However, patients who are malnourished have compromised immunity and are at significantly higher risk for developing SSI. The provision of nutrition support to patients before surgery has been shown to be effective in reducing SSI among surgical colorectal cancer patients [13, 14, 15].

Malnutrition is a major contributor to increased morbidity and mortality, decreased function and quality of life, increased frequency and length of hospital stay, and higher health care costs [16].

NUTRITIONAL SCREENING

Nutrition screening is only the initial step in the identification of patients who are malnourished or at risk to develop. Effective nutritional screening tools should be easy to use, valid and reliable. The screening process should be performed by trained personnel (medical or other health personnel). The Joint Commission on Accreditation of Healthcare Organizations (JCAHO) now mandates that all hospitals conduct nutrition screening within 24 hours of hospital admission [17, 18].

Nutrition assessments may lead to recommendations for improving nutrition status (e.g., some intervention such as change in diet, enteral or parenteral nutrition, or further medical assessment) or a recommendation for re-screening. Unfortunately, nutritional screening and his interventions are inadequate and infrequent. This is reflected in the fact that only 1 in 5 hospitals have formal nutrition screening, also only 1 out of 5 patients receives any preoperative nutrition intervention, therefore is urgently necessary training personnel and implement multidisciplinary teams [19, 20].

In the clinical and research practice BMI (Body mass index) is the most commonly used marker of nutritional status. However, BMI and weight do not alone provide enough information in terms of assessment of nutritional deficit and sarcopenia [21].

There are several tools to nutrition screening with established reliability and validity, each with specific anthropometric and/or diet related criteria measurements, and are appropriate for use in the acute care or medical-surgical adult patient population:

- Nutrition Risk Screening 2002 (NRS-2002)
- Malnutrition Screening Tool (MST)
- Malnutrition Universal Screening Tool (MUST)
- Nutrition Screening Tool (NST)
- PONS (perioperative nutrition screen) score [20]

There is not universal consensus that what tool is the best. however, the European guidelines recommend the Malnutrition Universal Screening Tool (MUST) for the nutritional evaluation of adults in the community; Nutritional Risk Screening 2002 (NRS-2002) for the detection of undernutrition and the risk of its development in hospital settings and Mini-Nutritional Assessment (MNA) for elderly patients in home-care programs, nursing homes and hospitals. No one of before mentioned test except PONS has been specifically designed for use in the perioperative period [22, 23].

The NRS-2002 and Nutrition Risk in Critically ill (NUTRIC) tools are recommended for use in critically ill adult patients due to their ability to account for nutrition status in relation to disease severity [24].

Recently, American Society for Enhanced Recovery (ASER) and Perioperative Quality Initiative (POQI) conducted an extensive literature review and developed and proposed a novel perioperative nutrition screen—the PONS score (perioperative nutrition screen (PONS)). The PONS is a modified version of the Malnutrition Universal Screening Tool (MUST) that has been modified for perioperative use. The PONS determines the presence of nutrition risk based on a patient's BMI, recent changes in weight, reported recent decrease in dietary intake, and preoperative albumin level. In addition, the PONS includes evaluation of preoperative albumin level, as this is a predictor of postoperative complications, including morbidity/mortality [20].

NUTRITIONAL PREOPERATIVE INTERVENTIONS

Nutrition support intervention in patients identified by screening and assessment as at risk for malnutrition or malnourished may improve clinical outcomes. Nutrition intervention in malnourished patients was associated with improved nutrition status, nutrient intake, physical function, and quality of life. In addition, hospital readmissions were reduced. Considering the high prevalence of malnutrition and its repercussions in patient morbidity-mortality and healthcare cost, nutritional screening measures must be included in an integrated nutritional care plan for patients while in the hospital. PONS score has been specifically designed for use in perioperative period is the reason that we recommend to implement this screening tool in surgical patients [6, 19, 20].

- PONS questions for clinic-based perioperative nutrition screening
- Does the patient have a low BMI <18.5 kg/m2 (<20 in >65 y of age)?
- Has the patient experienced a weight loss >10% in past 6 months?
- Has the patient had a reduced oral intake by >50% in the past week? (and/or)
- Does the patient have a preoperative serum albumin <3.0 g/dL?

According to the PONS score subdivide patient in two categories:

- Nutrition Pathway in Low Nutrition Risk Perioperative Patients
  (i.e., PONS < 1 and Albumin [ALB] > 3.0).
  Patients should be encouraged to take in healthy high-protein (with high-quality protein sources, such as eggs, fish, and lean meats/dairy) complex carbohydrate-rich

diets preoperatively. However, many patients will not be able to meet optimal suggested perioperative energy goals of 25 kcal/kg/d and 1.5–2 g/kg/d of protein (~1 g/pound of ideal/adjusted body weight) from routine food intake. Thus, we encourage patients to take high-protein ONSs (oral nutritional supplements) or IMN (immunonutrition) during the perioperative period unrelated to nutritional status [20, 25, 26].

- Nutrition Pathway in Patients Found to Be at Nutrition Risk
  (i.e., PONS > 1 or ALB < 3.0).
  In patients found to be at nutrition risk, we recommend high-protein ONS or IMN be given before surgery. This should have a goal of delivering at least 1.2 g/kg/d total of protein. It is the consensus of the group that high-protein ONS should contain >18 g/protein/serving in a balanced formula. A reasonable goal for most patients is 3 high-protein ONS servings per day. Previous data use preoperative ONS demonstrated benefits on the reduction of surgical-site infections in selected weight-losing patients. Again, because many patients do not meet their energy needs from normal food, especially malnourished patients, it is the consensus of this consensus group to encourage the use of high-protein ONS or IMN. As patient compliance with ONS intake (2–3× a day) is essential for benefit, it is vital to emphasize the key role of ONS in preoperative therapy. Further, cost-effectiveness of ONS in hospitalized patients has been shown in a recent large systematic review [27, 28, 29].

In this context, there are some meta-analyses showed that a multiple nutrient-enhanced nutritional formula (arginine, glutamine, omega 3, fatty acids, nucleotides) was associated with significantly reduced SSI incidence compared with a standard formula, both in the RCTs, however the quality of the evidence was rated very low. Regarding the use of nutritional supplements enhanced with a single nutrient (either arginine, glycine, or branched chain amino acids) with standard nutrition, meta-analyses showed no difference in the risk of SSI although the quality of evidence was low. Notwithstanding, WHO recommends that multiple nutrient enhanced formulas can be used to prevent SSIs in adult patients undergoing major surgery, nevertheless some factors could be considered such as resources and product availability should be carefully assessed, particularly in settings with limited resources [30].

In addition, there are some recommendations that could be adopted according to the Perioperative Quality Initiative (POQI) [20, 30].

Is recommended that patients who are screened as being at nutritional risk before major surgery receive preoperative ONSs for a period of at least sevent days. This may be achieved with either of the following:

- IMN formulas (containing arginine and fish oil)
- High-protein ONS (2–3× a day, minimum of 18g protein/dose)

Is recommended that for patients who are screened as being at nutritional risk before major surgery, where oral nutrition supplementation via ONS is not possible, that a dietician be consulted and an enteral feeding tube be placed and home EN (enteral nutrition) initiated for a period of at least sevent days. If neither oral nutrition supplementation via ONS nor EN

is possible, or when protein/kcal requirement (>50% of recommended intake) cannot be adequately met by ONS/EN, we recommend preoperative PN (parenteral nutrition) to improve outcomes. Is recommend preoperative fasting from midnight be abandoned. Patients undergoing surgery who are considered to have minimal specific risk of aspiration, we encourage unrestricted access to solids for up to 8h before anesthesia and clear fluids for oral intake up to two hours before the induction of anesthesia.

Is recommend a preoperative carbohydrate drink containing at least 45g of carbohydrate to improve insulin sensitivity (except in type I diabetics due to their insulin deficiency state). We suggest that complex carbohydrate (e.g., maltodextrin) be used when available [31].

NUTRITIONAL POSTOPERATIVE INTERVENTIONS

Postoperative nutritional support is vital in maintaining nutritional status during the catabolic postoperative period and underscored by evidence for early and sustained feeding after surgery as part of ERPs (enhanced recovery pathways) protocols [32].

There are some recommendations that could be adopted according to the Perioperative Quality Initiative (POQI) [20].

Is recommend that a high-protein diet (via diet or high-protein ONS) be initiated on the day of surgery in most cases, with exception of patients without bowel in continuity, with bowel ischemia, or persistent bowel obstruction. Traditional “clear liquid” and “full liquid” diets should not be routinely used.

Is recommend reaching an overall protein intake goal is more important than total calorie intake in the postoperative period.

It is recommended standardized protocols for postoperative nutrition support be instituted.

IMN should be considered in all postoperative major abdominal surgical patients for at least 7 days.

In patients who meet criteria for malnutrition, who are not anticipated to meet nutritional goals (>50% of protein/kcal) through oral intake, we recommend early EN or tube feeding within 24 h. Where goals are not met through EN, we recommend early PN, in combination with EN if possible.

Is recommend when using gastric residual volume’s as a marker of feeding tolerance, a cutoff of >500 mL should be used before the tube feeds being suspended or tube feed/EN rate reduced.

In patients started on EN and/or PN, we recommend continuation of EN or PN support for patients who are not able to take in at least 60% of their protein/kcal requirements via the oral route.

Is recommend posthospital high-protein ONS in all patients after major surgery to meet both calorie and protein needs, especially in the previously malnourished, elderly and sarcopenic patient.

NUTRITION IN ILL CRITICAL PATIENTS

Nutritional support during critical illness attenuates the metabolic response to stress, prevents oxidative cellular injury, and modulates the immune system. The stress response to critical illness causes wide fluctuation in metabolic rate.

The hyper-catabolic phase can last for 7–10 days and is manifested by an increase in oxygen demands, cardiac output, and carbon dioxide production. Caloric needs may be increased by up to 100% during this phase. The goal is to provide ongoing monitoring and support with high-protein feedings while avoiding overfeeding and underfeeding. Nutritional modulation of the stress response includes early EN (enteral nutrition), appropriate macro-nutrient and micro-nutrient delivery, and glycemic control [33].

Primary goals of nutritional support and care are to: Preserve and maintain lean muscle mass, provide continuous assessment, reassessment, and modification to optimize outcome, monitor the patient for tolerance and complications such as refeeding syndrome, prevent protein energy malnutrition by giving higher protein content while providing adequate total calories; monitor nutrition goals and target achievement rate of >50% within the first week, and prevent accumulation of a caloric deficit. Indirect calorimetry should be used when available or when predictive equations are known to be inaccurate [33].

The Society of Critical Care Medicine and the American Society of Parenteral and Enteral Nutrition (SCCM/ASPEN), the European Society for Clinical Nutrition and Metabolism (ESPEN), the Academy of Nutrition and Dietetics (AND), and the Canadian Clinical Practice Guidelines for Nutritional Support (CCPG) have developed best practice recommendations:

Nutritional support should be initiated early within the first 24–48 hours in critically ill patients. Current EN practice recommendations are: Preferentially feed via the enteral route, initiate EN within 24–48 hours, reduce interruptions of EN for nursing care and bedside procedures to prevent underfeeding, maintain head of bed (HOB) elevation to reduce aspiration risk, accept GRV (Gastric Residual Volume) up to 500 mL before reducing or stopping EN in the absence of clear signs of intolerance, use motility agents to improve tolerance and reduce GRV, and promote post-pyloric feeding tube placement when feasible. Current PN (Parenteral Nutrition) practice recommendations are to: Only use PN when enteral route is not feasible, use PN based on the patient's nutritional risk classification for malnutrition, delay PN up to seven days if the patient is in Nutritional Risk Class I or II, initiate PN early if the patient is in Nutritional Risk Class III or IV, convert to EN as soon as tolerated to reduce the risks associated with PN. Use of trophic or "trickle feeding" and permissive underfeeding may be beneficial [33, 35].

Use of pharmaconutrients and immunonutrition: Omega-3 fatty acids (fish oils) may be beneficial in acute respiratory distress syndrome (ARDS) patients, use high omega-3 fatty acid to omega-6 fatty acid ratios. The use of arginine, glutamine, nucleotides, antioxidants, and probiotics may be beneficial in specific patients. The use of arginine should be avoided in patients with severe sepsis [36].

REFERENCES

[1] Allegranzi B, Bagheri Nejad S, Combescure C, et al. Burden of endemic health-care-associated infection in developing countries: systematic review and meta-analysis. *Lancet* 2011.

[2] WHO. *Report on the burden of endemic health care-associated infection worldwide*. Geneva: World Health Organization, 2011.

[3] Horan TC, Gaynes RP, Martone WJ, et al. CDC definitions of nosocomial surgical site infections, 1992: a modification of CDC definitions of surgical wound infections. *Am J Infect Control* 1992; 20:271.

[4] Nolan MB, Martin DP, Thompson R, et al. Association Between Smoking Status, Preoperative Exhaled Carbon Monoxide Levels, and Postoperative Surgical Site Infection in Patients Undergoing Elective Surgery. *JAMA Surg* 2017; 152:476.

[5] Hennessey DB, Burke JP, Ni-Dhonochu T, et al. Preoperative hypoalbuminemia is an independent risk factor for the development of surgical site infection following gastrointestinal surgery: a multi-institutional study. *Ann Surg 2010*; 252:325.

[6] Culebras JM. Malnutrition in the twenty-first century: an epidemic affecting surgical outcome. *Surg Infect (Larchmt)* 2013, 14: 237–43.

[7] Bernabeu-Wittel M, Jadad A, Moreno-Gavino L, et al. Peeking through the cracks: an assessment of the prevalence, clinical characteristics and health-related quality of life (HRQoL) of people with polypathology in a hospital setting. *Arch Gerontol Geriatr* 2009.

[8] Edington J, Boorman J, Durrant ER, et al. The Malnutrition Prevalence Group. Prevalence of malnutrition on admission to four hospitals in England. *Clin Nutr* 2000; 19(3):191–195.

[9] Rasmussen HH, Kondrup J, Staun M, Ladefoged K, Kristensen H, Wengler A. Prevalence of patients at nutritional risk in Danish hospitals. *Clin Nutr 2004*; 23(5):1009–1015.

[10] Malone A, Hamilton C. The Academy of Nutrition and Dietetics/The American Society for Parenteral and Enteral Nutrition [ASPEN] consensus malnutrition characteristics: Application in practice. *Nutrition clinical practice. 2013*; 28(6), 639-650.

[11] White J, Stotts N, Jones S, Granieri, E. Managing post acute malnutrition (undernutrition) risk. *Journal of parenteral and enteral nutrition* 2013; 37(6), 816-823.

[12] Barker LA, Gout BS, Crowe TC. Hospital malnutrition: prevalence, identification and impact on patients and the healthcare system. *Int J Environ Res Public Health*. 2011;8(2):514-527.

[13] Brigid MG, Evelyn K, Shelley R, Reducing the risk of surgical site infection using a multidisciplinary approach: an integrative review. *J Multidisciplinary Healthcare* 2015; 8: 473–487.

[14] Schneider SM, Veyres P, Pivot X, et al. Malnutrition is an independent factor associated with nosocomial infections. *Br J Nutr* 2004;92(1):105–111.

[15] Horie H, Okada M, Kojima M, Nagai H. Favorable effects of preoperative enteral immunonutrition on a surgical site infection in patients with colorectal cancer without malnutrition. *Surg Today* 2006;36(12):1063–1068.

[16] National Alliance for Infusion Therapy and the American Society for Parenteral and Enteral Nutrition Public Policy Committee and Board of Directors. Disease-related malnutrition and enteral nutrition therapy: a significant problem with a cost-effective solution. *Nutr Clin Pract* 2010; 25:548-554.

[17] Skipper A, Ferguson M, Thompson K, Castellanos V. Nutrition Screening Tools an Analysis of the Evidence. *Journal of Parenteral and Enteral Nutrition* 2012; 36(3), 292-298.

[18] Joint Commission on Accreditation of Healthcare Organizations. *Comprehensive Accreditation Manual for Hospitals*. Oakbrook Terrace, IL: *JCAHO*; 2005.

[19] Charles M, Charlene C, et al. A. S. P. E. N. Clinical Guidelines Nutrition Screening, Assessment, and Intervention in Adults. *Journal of Parenteral and Enteral Nutrition* 2011; 35(1):16-24.

[20] Paul EW, Franco C, David C, et al. American society for enhanced recovery and perioperative quality initiative joint consensus statement on nutrition screening and therapy within a surgical enhanced recovery pathway. *Anesth Analg 2018*; 126(6):1883-1895.

[21] Kuźnar-Kamińska B, Batura-Gabryel H, Brajer B, Kamiński J. Analysis of nutritional status disorders in patients with chronic obstructive pulmonary disease. *Pneumonol Alergol Pol* 2008; 76(5):327-33.

[22] van Bokhorst-de van der Schueren MA, Guaitoli PR, Jansma EP. Nutrition screening tools: does one size fit all? A systematic review of screening tools for the hospital setting. *Clin Nutr* 2014; 33(1):39-58.

[23] Sorensen J, Kondrup J, Prokopowicz J, Schiesser M, Krahenbuh L, Meier R et al. EuroOOPS study group. EuroOOPS: an international, multicenter study to implement nutritional risk screening and evaluate clinical outcome. *Clin Nutr* 2008; 27: 340–349.

[24] McClave SA, Taylor BE, MartindaleRG, et al. Guidelines for the Provision and Assessment of Nutrition Support Therapy in the Adult Critically Ill Patient Society of Critical Care Medicine (SCCM) and American Society for Parenteral and Enteral Nutrition (ASPEN). *Journal of Parenteral and Enteral Nutrition* 2016; 40(2), 159-211.

[25] Miller KR, Wischmeyer PE, Taylor B, McClave SA. An evidence- based approach to perioperative nutrition support in the elective surgery patient. *J Parenter Enteral* Nutr 2013; 37:39S–50S.

[26] Braga M, Ljungqvist O, Soeters P, Fearon K, Weimann A, Bozzetti F. ESPEN guidelines on parenteral nutrition: surgery. *Clin Nutr* 2009; 28:378–386.

[27] Grass F, Bertrand PC, Schäfer M, et al. Compliance with preoperative oral nutritional supplements in patients at nutritional risk—only a question of will? *Eur J Clin Nutr* 2015; 69:525–529.

[28] Elia M, Normand C, Norman K, Laviano A. A systematic review of the cost and cost effectiveness of using standard oral nutritional supplements in the hospital setting. *Clin Nutr* 2016; 35:370–380.

[29] Fukuda Y, Yamamoto K, Hirao M, et al. Prevalence of malnutrition among gastric cancer patients undergoing gastrectomy andoptimal preoperative nutritional support for preventing surgical site infections. *Ann Surg Oncol* 2015;22(suppl 3): S778–S785.

[30] WHO. *Gobal guidelines for the prevention of surgical site infections*. World Health Organization, Geneva, 2016.

[31] Harbis A, Perdreau S, Vincent-Baudry S, et al. Glycemic and insulinemic meal responses modulate postprandial hepatic and intestinal lipoprotein accumulation in obese, insulin-resistant subjects. *Am J Clin Nutr 2004*; 80:896–902.

[32] Osland E, Yunus RM, Khan S, Memon MA. Early versus traditional postoperative feeding in patients undergoing resectional gastrointestinal surgery: a meta-analysis. *JPEN J Parenter Enteral Nutr* 2011; 35:473–487.

[33] Mark S. Siobal, Jami E. Baltz. A Guide to the Nutritional Assessment and Treatment of the Critically Ill Patient. *American association for respiraty care* 2013, 007-029.

[34] Rice TW, Wheeler AP, Thompson BT, et al. Initial trophic vs full enteral feeding in patients with acute lung injury: the EDEN randomized trial. *JAMA* 2012; 307(8):795-803.

[35] Poulard F, Dimet J, Martin-Lefevre L, et al. Impact of not measuring residual gastric volume in mechanically ventilated patients receiving early enteral feeding: a prospective before-after study. *J Parenter Enteral Nutr* 2010; 34(2):125-130.

[36] Marik PE, Zaloga GP. Immunonutrition in high-risk surgical patients: a systematic review and analysis of the literature. *J Parenter Enteral Nutr* 2010; 34(4):378-386.

In: Encyclopedia of Surgery (22 Volume Set)
Editors: Andreas Lehrer and Kristin Mueller
ISBN: 978-1-53618-329-0
© 2020 Nova Science Publishers, Inc.

Chapter 273

PREOPERATIVE BATH AND SHAVE

Cristina Bernabeu Herraiz*, MD
and Lorena Rodríguez Cazalla, MD
Department of General and Digestive Surgery, University Hospital San Juan, Alicante, Spain

ABSTRACT

Surgical site infection is one of the most common complication in surgery, that increases length of hospital stay and health cost. This chapter is focused on preoperative bath and hair removal. There is neither clear evidence about the benefits to reduce surgical site infection for preoperative showering or bathing with chlorhexidine nor routine hair removal, which should be performed if it is necessary with clippers instead of razors.

Keywords: Surgical site infection, preoperative bath and shower, skin antiseptics, preoperative hair removal

INTRODUCTION

Surgical site infection (SSI) is a major problem for patients undergoing surgery because it increases not only the cost of health care related to a need of antibiotic therapy and a higher length of hospital stay, but also affects patient recovery [1, 2]. Surgeons and health care authorities pay attention to prevent SSI, since up to 60% of them are avoidable applying adequate prevention programs [1-3].

This chapter is focused on preoperative showering or bathing and hair removal.

* Corresponding Author's Email: cristina.bernabeu.h@gmail.com.

PREOPERATIVE BATH

Whole body bathing or showering with soap or skin antiseptics is a widespread practice before surgery to reduce skin resident and transient bacteria. However the most important question is whether preoperative bathing or showering with antiseptics reduce the incidence of SSI in comparison with their potential for harm such as changes in patterns of bacteria resistance, skin hipersensitivity, etc.

Webster and Osborne reviewed randomized clinical trials comparing antiseptic preparation (4% chlorhexidine gluconate) for preoperative bathing or showering with non-antiseptic preparations or no washing over a 26-year period between 1983 and 2009 (seven trials with 10.157 participants). Three trials involving 7.791 patients compared chlorhexidine with placebo did not result in a significant reduction in SSI with a relative risk of 0.91 (0.80 - 1.04). Three trials involving 1.443 patients compared bar soap with chlorhexidine and there was no significant differences with a relative risk of 1.02 (0.57 - 1.84) and three trials of 1.192 patients compared bathing with chlorhexidine with no washing and only one found a significant difference in favour of bathing with chlorhexidine (relative risk 0.36 [0.17 - 0.79]. Authors concluded that this review does not provide clear evidence of benefit for preoperative showering or bathing with chlorhexidine over other wash products to reduce SSI [4]. Smaller studies have not found differences between patients who washed with chlorhexidine and those who did not wash preoperatively [5-7].

Chlebicki et al. performed a meta-analysis of sixteen trials involving 17.932 patients, 7.952 received a chlorhexidine bath and 9.980 with others. Chlorhexidine bathing did not significantly reduce overal incidence of SSI when compared with soap, placebo or no shower or bath (relative risk 0.90 [0.77 - 1.05]) [8].

PREOPERATIVE SHAVE

Preparation the patient for surgery has traditionally included the routine hair removal from the incision site because its presence can interfere with the exposure, the suturing and the application of adhesive drapes. However some studies claim that preoperative hair removal is harmful, increase SSI and should be avoided [9, 10].

Hair can be removed by several different ways which include shaving, clipping the hair and using a chemical creams. Shaving is the commonest and cheapest method, it uses a sharp blade, which is drawn over the patient's skin to cut hair close to the surface of the skin. Clippers use fine teeth to cut hair close to the patient's skin, leaving around one millimetre of hair in length. Depilatory creams are chemicals which dissolve the hair itself, but is a slower process, because the cream has to remain in contact with the hair for between five and 20 minutes, that's why there is a risk of irritant or allergic reactions to the cream. During the process of shaving, the skin may experience microscopic cuts and abrasions. It is believed that microorganisms are able to colonize these cuts, thus contaminating the surgical incision site and causing wound infections. That's why clippers they are thought to reduce the risk of cuts and abrasions because do not come into contact with the patient's skin. This hair removal practice can be done everywhere (home, wards, theaters...) but research has suggested, that

hair removal should not take place in the operating theatre as loose hair may contaminate the sterile surgical field [11].

Tanner et al. performed a meta-analysis of fourteen trials; six trials compared hair removal (shaving, clipping or depilatory cream) with no hair removal and found no statistically significant difference in SSI rates. Three trials that compared shaving with clipping showed significantly more SSI associated with shaving (relative risk 2.09 [1.15 - 3.80]. Seven trials found no significant difference in SSI rate when hair removal by shaving was compared with depilatory cream (relative risk 1.53 [0.73 - 3.21]. One trial compared two groups that shaved or clipped hair on the day of surgery compared with the day before surgery and there was no statistically significant difference in SSI rate. Authors concluded that there was no significantly differences between hair removal and not hair removal; however, when it is necessary to remove hair, the evidence suggests that clippers are associated with fewer SSI than razors [9].

Lefebvre et al. performed a meta-analysis of nineteen randomized controlled trials and they described no significant differences between the absence of hair removal and chemical depilation (relative risk 1.05 [0.55 - 2.00]) or clipping (relative risk 0.97 [0.51 - 1.82]) as well as a higher significantly risk of SSI when shaving is used for hair removal in comparison with clipping (relative risk 0.55 [0.38 - 0.79], chemical depilation (relative risk 0.60 [0.36 - 0.97] or no depilation (relative risk 0.56 [0.34 - 0.96]) [12].

Kowalski et al. conducted a single-center randomized clinical trial, 834 patients to clipped group and 844 to not-clipped group. The overall rate of SSI in the per-protocol analysis was 6.12% in clipped group and 6.32% in not-clipped group (absolute risk difference -0.20 [-2.61 to 2.21%]). Authors concluded that SSI rate was similar between hair removal by clipping or not in patients undergoing general surgical procedures [13].

REFERENCES

[1] World Health Organization. *Global Guidelines for the Prevention of Surgical Site Infection*. Geneva: WHO; 2016.

[2] Gómez-Romero, F. J., Fernández-Prada, M., Navarro-Gracia, J. F. Prevention of Surgical Site Infection; analysis and narrative. Review of Clinical Practice Guidelines. *Cir. Esp.*, 2017; 95(9):490 - 502.

[3] EPINE Wordkgroup. EPINE-EPPS 2017 Study. *Spanish Society of Preventive Medicine, Public Health and Hygiene* [Internet]. Available at: http://hws.vhebron.net/epine/Global/EPINE-EPPS%202017%20Informe%20Global%20de%20España%20Resumen.pdf.

[4] Webster, J., Osborne, S. Preoperative bathing or showering with skin antiseptics to prevent surgical site infection. *Cochrane Database of Systematic Reviews*, 2015, Issue 2. Art. No.: CD004985. DOI: 10.1002/14651858.CD004985.pub5.

[5] Kamel, C., McGahan, L., Polisina, J., Miezwinski-Urban, M., Embil, J. M. Preoperative skin antiseptic preparations for preventing surgical site infections: a systematic review. *Infect. Control Hosp. Epidemiol.*, 2012; 33(6):608 - 617.

[6] Thomas, L., Maillard, J. Y., Lambert, R. J., Russell, A. D. Development of resistance to chlorhexidine diacetate in Pseudomonas aeruginosa and the effect of a "residual" concentration. *J. Hosp. Infect.*, 2000; 46(4):297 - 304.

[7] Chlebicki, M. P., Safdar, N., O'Horo, J. C., Maki, D. G. Preoperative chlorhexidine shower of bath for prevention of surgical site infection: a meta-analysis. *Am. J. Infect. Control.*, 2013; 41(2):167 - 173.

[8] Chlebicki, M. P., Safdar, N., O'Horo, J. C., Maki, D. G. Preoperative chlorhexidine shower of bath for prevention of surgical site infection: a meta-analysis. *Am. J. Infect. Control.*, 2013; 41(2):167 - 173.

[9] Tanner, J., Norrie, P., Melen, K. Preoperative hair removal to reduce surgical site infection. *Cochrane Database of Systematic Reviews*, 2011, Issue 11. Art. No.: CD004122. DOI: 10.1002/ 14651858.CD004122.pub4.

[10] Ruiz-Tovar, J., Badia, J. M. Prevention of surgical site infection in abdominal surgery. A critical review of the evidence. *Cir. Esp.*, 2014; 92(4):223 - 231.

[11] Phippen, M., Papanier, M. *Patient care during operative and invasive procedures*. Philadelphia: WB Saunders Co, 2000.

[12] Lefebvre, A., Saliou, P., Lucet, J. C., Mimoz, O., Keita-Perse, O., Grandbastien, B., et al. Preoperative hair removal and surgical site infections: network meta-analysis of randomized controlled trials. *J. Hosp. Infect.*, 2015; 91(2):100 - 108.

[13] Kowalski, T. J., Kothari, S. N., Mathiason, M. A., Borgert, A. J. Impact of hair removal on surgical site infection rates: a prospective randomized noninferiority trial. *J. Am. Coll. Surg.*, 2016; 223(5):704 - 711.

In: Encyclopedia of Surgery (22 Volume Set)
Editors: Andreas Lehrer and Kristin Mueller
ISBN: 978-1-53618-329-0
© 2020 Nova Science Publishers, Inc.

Chapter 274

MECHANICAL BOWEL PREPARATION

Andrés García Marín[1] and Mercedes Pérez López[2]
[1]Department of General and Digestive Surgery, Hospital Hellín, Albacete, Spain
[2]Department of Nursery, Alicante, Spain

ABSTRACT

The chapter summarizes the recent evidence about the role of mechanical bowel preparation in combination with oral antibiotic prophylaxis in comparison with No Preparation or mechanical bowel preparation alone in the prevention of postoperative morbidity, surgical site infection, anastomotic leakage and ileus, mortality rate and *Clostridium difficile* infection.

Keywords: mechanical bowel preparation, oral antibiotic prophylaxis, surgical site infection, anastomotic leakage, ileus, colorectal surgery, mortality

INTRODUCTION

Surgical site infection (SSI) is a major problem for patients undergoing colorectal surgery (CRS) because it increases not only the cost of health care related to a need of antibiotic therapy and a higher length of hospital stay, but also affects patient recovery and survival [1-3].

Mechanical bowel preparation (MBP) and oral antibiotic prophylaxis (OAP) are specific strategies to prevent SSI in CRS.

MBP defined as oral preparations prior to surgery to clear out solid stool has been studied in randomized controlled trials (RCT). Rollins et al. concluded in a recent meta-analysis of 36 RCT that MBP does not impact in postoperative morbidity and mortality, as well as it produces fluid and electrolyte disturbances and patient dissatisfaction [2, 4].

In fact, Enhanced Recovery After Surgery Society and the American Society for Enhanced Recovery do not recommend the use of MBP without OAP before elective CRS [5, 6].

OAP with nonabsorbable luminal antibiotics, mainly the combination of an aminoglycoside (neomycin or kanamycin) with erythromycin or metronidazole, was firstly proposed in 1971 by Rosenberg and Nichols [7, 8].

Table 1. Comparison between MBP + OAP and MBP alone, No Preparation and OAP [2]

	Studies	RR (95% CI)
30-day mortality		
MBP + OAP vs MBP	17 (14 RCT and 3 CS)	0.58 (0.44-0.76)
MBP + OAP vs No Preparation	2 CS	0.36 (0.17-0.76)
MBP + OAP vs OAP	3 (2 RCT and 1 CS)	0.58 (0.34-0.97)

CS: Cohort Studies. MBP: Mechanical Bowel Preparation. OAP: Oral Antibiotic Prophylaxis. RCT: Randomized Clinical Trial. RR (95% CI): relative risk (95% confidence interval).

RECENT EVIDENCE

Overall, the combination of MBP + OAP is associated with a significant reduction in global morbidity, SSI, anastomotic leakage, postoperative ileus and 30-day mortality in comparison with MBP alone, No Preparation and OAP alone [1, 2, 9-14].

A summary of the evidence related to 30-day mortality is presented in table 1, and related to SSI (table 2), anastomotic leakage (AL) and postoperative ileus in table 3.

The value of different regimens of oral antibiotics is being evaluated. McSorley et al. conducted a meta-analysis and they concluded that there was a similarly significant effect on SSI with the use of a combination of aminoglycoside and erythromycin (OR 0.40 [0.25 - 0.64]) or aminoglycoside and metronidazole (OR 0.51 [0.39 - 0.68]) [1].

Evidence about *Clostridium difficile* infection was enough for the comparison between MBP + OAP versus MBP in 14 studies (10 RCT and 4 cohort studies), without significant differences (RR 0.94 [0.55 - 1.61]) [2].

Table 2. Comparison between MBP + OAP and MBP alone, NP and OAP [2]

	Studies	RR (95% CI)
SSI		
MBP + OAP vs MBP	35 (26 RCT and 9 CS)	0.51 (0.46-0.56)
MBP + OAP vs NP	4 CS	0.54 (0.43-0.68)
MBP + OAP vs OAP	4 (2 RCT and 2 CS)	0.98 (0.64-1.50)
MBP + OAP vs MBP in laparoscopic vs open approach	Open: 19 RCT. Laparoscopic: 2 RCT	Open: 0.55 (0.44-0.69) Laparoscopic: 0.74 (0.43-1.29)

CS: Cohort Studies. MBP: Mechanical Bowel Preparation. NP: No Preparation. OAP: Oral Antibiotic Prophylaxis. RCT: Randomized Clinical Trial. RR (95% CI): relative risk (95% confidence interval). SSI: Surgical Site Infection.

Table 3. Comparison between MBP + OAP and MBP alone, NP and OAP [2]

AL		
MBP + OAP vs MBP	22 (17 RCT and 5 CS)	0.62 (0.55-0.70)
MBP + OAP vs NP	2 CS	0.52 (0.45-0.59)
MBP + OAP vs OAP	3 (2 RCT and 1 CS)	0.79 (0.59-1.05)
MBP + OAP vs MBP in laparoscopic vs open approach	Open: 9 RCT. Laparoscopic: 2 RCT	Open: 0.69 (0.30-1.60) Laparoscopic: 0.68 (0.28-1.65)
Ileus		
MBP + OAP vs MBP	5 (2 RCT and 3 CS)	0.72 (0.52-0.98)
MBP + OAP vs NP	2 CS	0.72 (0.68-0.77)
MBP + OAP vs OAP	3 (2 RCT + 1 CS)	0.83 (0.73-0.95)
Overall morbidity		
MBP + OAP vs MBP	6 (4 RCT + 2 CS)	0.67 (0.63-0.71)

AL: Anastomotic Leakage. CS: Cohort Studies. MBP: Mechanical Bowel Preparation. NP: No Preparation. OAP: Oral Antibiotic Prophylaxis. RCT: Randomized Clinical Trial. RR (95% CI): relative risk (95% confidence interval).

CONCLUSION

The combination of MBP and OAP was associated with a significant reduction in overall morbidity, SSI, AL, ileus and 30-day mortality in comparison with MBP alone and No Preparation and only in ileus and 30-day mortality in comparison with OAP alone. However, there was not significant differences in *Clostridium difficile* infection.

REFERENCES

[1] McSorley, S. T., Steele, C. W., McMahon, A. J. Meta-analysis of oral antibiotics, in combination with preoperative intravenous antibiotics and mechanical bowel preparation the day before surgery, compared with intravenous antibiotics and mechanical bowel preparation alone to reduce surgical-site infections in elective colorectal surgery. *BJS Open*, 2018; 2:185 - 194.

[2] Rollins, K. E., Javanmard-Emamghissi, H., Acheson, A. G., Lobo, D. N. The role of oral antibiotic preparation in elective colorectal surgery: a meta-analysis. *Ann. Surg.*, 2018 Dec. 3 [Epub ahead of print].

[3] Badia, J. M., Arroyo-García, N. Mechanical bowel preparation and oral antibiotic prophylaxis in colorectal surgery: analysis of evidence and narrative review. *Cir. Esp.*, 2018; 96(6):317 - 325.

[4] Rollins, K. E., Javanmard-Emamghissi, H., Lobo, D. N. Impact of mechanical bowel preparation in elective colorectal surgery: a meta-analysis. *World J. Gastroenterol.*, 2018; 24(4):519 - 536.

[5] Gustafsson, U. O., Scott, M. J., Schwenk, W., Demartines, N., Roulin, D., Francis, N., et al. Guidelines for perioperative care in elective colonic surgery: Enhanced Recovery After Surgery (ERAS®) Society recommendations. *Clin. Nutr.*, 2012; 31(6):783 - 800.

[6] Holubar, S. D., Hedrick, T., Gupta, R., Kellum, J., Hamilton, M., Gan, T. J., et al. American Society for Enhanced Recovery (ASER) and Perioperative Quality Initiative (POQI) joint consensus statement on prevention of postoperative infection within an enhanced recovery pathway for elective colorectal surgery. *Perioper. Med.,* (Lond) [Internet] 2017; 4. Available at: https://www.ncbi.nlm.nih.gov/pmc/ articles/ PMC5335800/pdf/13741_2017_Article_59.pdf.

[7] Rosenberg, I. L., Graham, N. G., De Dombal, F. T., Goligher, J. C. Preparation of the intestine in patients undergoing major large-bowel surgery, mainly for neoplasms of the colon and rectum. *Br. J. Surg.,* 1971; 58(4):266 - 269.

[8] Nichols, R. L., Condon, R. E. *Preoperative preparation of the colon Surg. Gynecol. Obstet.,* 1971; 132 (2):323 - 337.

[9] Yost, M. T., Jolissaint, J. S., Fields, A. C., Whang, E. E. Mechanical and oral antibiotic bowel preparation in the era of minimally invasive surgery and enhanced recovery. *J. Laparoendosc. Adv. Surg. Tech. A.*, 2018; 28(5):491 - 495.

[10] Toh, J. W. T., Phan, K., Ctercteko, G., Pathma-Nathan, N., El-Khoury, T., Richardson, A., et al. The role of mechanical bowel preparation and oral antibiotics for left-sided laparoscopic and open elective restorative colorectal surgery with and without faecal diversion. *Int. J. Colorectal. Dis.,* 2018; 33(12):1781 - 1791.

[11] Ohman, K. A., Wan, L., Guthrie, T., Johnston, B., Leinicke, J. A., Glasgow, S. C., et al. Combination of oral antibiotics and mechanical bowel preparation reduces surgical site infection in colorectal surgery. *J. Am. Coll. Surg.,* 2017; 225(4):465 - 471.

[12] Chen, M., Song, X., Chen, L. Z., Lin, Z. D., Zhang, X. L. Comparing mechanical bowel preparation with both oral and systemic antibiotics versus mechanical bowel preparation and systemic antibiotics alone for the prevention of surgical site infection after elective colorectal surgery: a meta-analysis of randomized controlled clinical trials. *Dis. Colon Rectum*, 2016; 59(1):70 - 78.

[13] Ambe, P. C., Zarras, K., Stodolski, M., Wirjawan, I., Zirngibl, H. Routine preoperative mechanical bowel preparation with additive oral antibiotics is associated with a reduced risk of anastomotic leakage in patients undergoing elective oncologic resection for colorectal cancer. *World J. Surg. Oncol.,* [Internet] 2019; 17. Available at: https://www.ncbi.nlm.nih.gov/pmc/articles/ PMC6335695/pdf/12957_2019_Article_1563.pdf.

[14] Battersby, C. L. F., Battersby, N. J., Slade, D. A. J., Soop, M., Walsh, C. J. Preoperative mechanical and oral antibiotic bowel preparation to reduce infectious complications of colorectal surgery – the need for updated guidelines. *J. Hosp. Infect.,* 2019; 101(3):295 - 299.

In: Encyclopedia of Surgery (22 Volume Set)
Editors: Andreas Lehrer and Kristin Mueller
ISBN: 978-1-53618-329-0
© 2020 Nova Science Publishers, Inc.

Chapter 275

ANTIBIOTIC PROPHYLAXIS

Noel Rojas-Bonet[1,*] and Maria del Mar García-Navarro[2]
[1]Department of General and Digestive Surgery, University Hospital San Juan, Alicante, Spain
[2]Department of Internal Medicine, University General Hospital of Alicante, Alicante, Spain

ABSTRACT

The chapter summarizes the recent evidence about microbiology, indications, recommended antibiotics, timing and dosages in patients undergoing general and digestive procedures.

Keywords: antibiotic prophylaxis, surgical site infection

INTRODUCTION

Surgical site infections (SSI) is defined as infection related to a surgical procedure that occurs within 30 days of the procedure or withing 90 days if prosthetic material is implanted at surgery, which may be incisional (superficial or deep) or organ/space [1].

The goal of antimicrobial prophylaxis is to control bacterial burden, mantaining antibiotic levels above the minimum inhibitory concentration throughout the surgical procedure in order to reduce the risk of infection [1].

EPIDEMIOLOGY

The estimated incidence of SSI ranges from 1% in minimally invasive surgery to 5% in invasive surgery. However, this percentage is probably underestimated, as up to 50% of post-surgical infections occur after discharge [2, 3].

* Corresponding Author's Email: noel.rojas@goumh.umh.es.

The severity of surgical site infections depends on many factors: type of surgery, surgical technique, bacterial inoculum, responsible organism (as well as mono or polymicrobial) and patient characteristics and comorbidities.

Patient risk factors (modifiable and non-modifiable) can contribute to the development of infections and complications [3].

Risk factors whose presence have been directly related to torpid evolution and higher infection rates of the surgical site are those conferring greater difficulty in healing and therefore will increase the period of vulnerability for the appearance of superinfections: age, smoking, the nutritional status, the immunosuppression both intrinsic (primary immunodeficiency, HIV, cancer...) and extrinsic (corticoids, chemotherapy) that hinders the adequate inflammatory response and the defense against the potential risk of infections, diabetes, obesity, peripheral edema and immobilization [4].

Thus, a relationship is found between the comorbidities of the patients and the prevalence of SSI after invasive surgery (ASA I 1.7%, ASA II 4.1%, ASA III 7.3%, ASA IV 7.9%, ASA V 14.3%) [3, 4].

MICROBIOLOGY

The main involved microorganisms in SSI are those found in the skin, mainly grampositive cocci (*Staphylococcus spp.*, *Streptococcus spp.* and, less frequently, *Enterococcus spp.*) and those found in abdominal cavity, mainly gram-negative bacilli (*Escherichia coli, Proteus spp., Klebsiella spp.*) and anaerobes (*Bacteroides spp.*) [1].

GENERAL PRINCIPLES OF ANTIBIOTIC PROPHYLAXIS

General principles are intravenous administration and selection of adequate antibiotic with correct posology.

The antibiotic should present a narrow spectrum to cover the typical microorganisms, bactericidal actitiy, extended half life, good tissue distribution and low adverse effects including a low rate of *Clostridium difficile* infection. According to this, the recommended antibiotic for surgeries above the duodenum in abdominal cavity, neck and breast surgeries would be cefazolin and, in patients with β-lactam allergies, vancomycin and gentamicin, clindamycin and gentamicin or levofloxacin whereas for surgeries below the duodenum, amoxicillin-clavulanic and, in patients with β-lactam allergies, moxifloxacin, levofloxacin and metronidazole or gentamicin and metronidazole are preferred.

The administration should be performed 30-60 minutes before the start of the procedure; if it is administered more than 120 minutes before, the risk of infection is double that if it is administered in the 120 minutes prior to surgery. If the administration is delayed until after the surgical initiation, the risk of infection is multiplied by 5 [1, 3, 5-9].

Intraoperative redosing is recommended when bleeding greather than 1500 mililiters occurs or surgical procedure lasts more than two half-life of the antibiotic, only for amoxicillin-clavulanic acid at 2-3 hours, cefazolin at 4 hours and clindamycin at 6 hours. Intraoperative redosing is not required for gentamicin / tobramycin, metronidazole and

vancomycin [3, 5-9]. Classical administration with redosing is controversial. In fact, Kirby et al. conducted a colorectal study comparing standard bolus-dosed antibiotic with continuous administration throughout surgery monitoring serum antibiotic concentrations and they showed that the rates of SSI were lower with continuous administration [10].

Postoperative redosing in clean and clean-contaminated surgeries is not recommended with high level of evidence once the surgical incision has been closed, even if drainage is required [3, 6, 8].

Dosing adjustment should be performed according to the patient comorbidities and weight, since the alteration in body composition in obese patients involves a higher risk of erroneous dosing and, therefore, a possible therapeutic failure or toxicity [1, 11, 12]:

- Cefazolin and amoxicillin-clavulanic acid (80 - 160kg): 2gr. Patients lower than 80kg. 1gr., whereas the dosage in patients higher than 160kg is controversial (same or high dose of 3 - 4gr).
- Cefuroxime (> 80kg): 3gr. Patients lower than 80kg. 1.5g.
- Gentamicin: 5 - 7mg/kg.
- Vancomycin: 15mg/kg, with maximum dose of 2gr.
- Clindamycin: 600 – 900. In patient with body mass index higher than 50 kg/m2, a high dose of 900 – 1200 is recommended.
- Metronidazole: 15mg/kg.

INDICATIONS

Indications for antibiotic prophylaxis are controversial, depending on the type of surgery. Antibiotic prophylaxis is not always needed for clean surgery since the rate of SSI is very low; it should only be administered in some patients such as oncological and plastic breast surgery, intravascular devices placement, splenectomy in immunosuppression situations and mesh surgery in high risk patients [13-15]. Antibiotic prophylaxis is always needed in clean-contaminated and contaminated procedures; however, it is still unclear in elective laparoscopic cholecystectomy in low-risk patients, considering high risk patients immunosuppressive therapy or disease, ASA ≥ III, acute or chronic cholecystitis 6 weeks before surgery, open conversion surgery or intraoperative rupture of the gallbladder [17-19].

REFERENCES

[1] Garcia-Marin, A., Perez-Lopez, M. Antibiotic Prophylaxis. In: Ruiz-Tovar, J. Prophylaxis in Bariatric Surgery. New York: *Nova Biomedical*, 2018, p. 1 - 7.

[2] Sociedad Española de Medicina Preventiva, Salud Pública e Higiene [Spanish Society of Preventive Medicine, Public Health and Hygiene] (2017). *ESTUDIO EPINE-EPPS* 2017. [Internet] Available at: http://hws.vhebron.net/epine/Global/EPINE-EPPS%202017%20Informe%20Global%20de%20Espa%C3%B1a%20Resumen.pdf.

[3] Berríos-Torres, S. I., Umscheid, C. A., Bratzler, D. W., Leas, B., Stone, E. C., Kelz, R. R., et al. Centers for Disease Control and Prevention Guideline for the Prevention of Surgical Site Infection, 2017. *JAMA Surg.*, 2017; 152(8):784 - 791.

[4] Sørensen, L. T. Wound healing and infection in surgery. The clinical impact of smoking and smoking cessation: a systematic review and meta-analysis. *Arch. Surg.*, 2012; 147(4):373 - 83.

[5] Bowater, R. J., Stirling, S. A., Lilford, R. J. Is antibiotic prophylaxis in surgery a generally effective intervention? Testing a generic hypothesis over a set of meta-analyses. *Ann. Surg.*, 2009; 249(4):551 - 556.

[6] Alexander, J. W., Solomkin, J. S., Edwards, M. J., Updated recommendations for control of surgical site infections. *Ann. Surg.*, 2011; 253(6):1082 - 1093.

[7] Liu, Z., Dumville, J. C., Norman, G., Westby, M. J., Blazeby, J., McFarlane, E., et al. Intraoperative interventions for preventing surgical site infection: an overview of Cochrane Reviews. *Cochrane Database of Systematic Reviews*, 2018, Issue 2. Art. No.: CD012653. DOI: 10.1002/14651858.CD012653.pub2.

[8] Ruiz Tovar, J., Badia, J. M. Prevention of surgical site infection in abdominal surgery. A critical review of the evidence. *Cir. Esp.*, 2014; 92(4):223 - 231.

[9] de Jonge, S. W., Gans, S. L., Atema, J. J., Solomkin, J. S., Dellinger, P. E., Boermeester, M. A. Timing of preoperative antibiotic prophylaxis in 54,552 patients and the risk of surgical site infection: A systematic review and meta-analysis. *Medicine*, (Baltimore) [Internet] 2017; 96. Available at: https://www.ncbi.nlm.nih.gov/pmc/articles/PMC5521876/pdf/medi-96-e6903.pdf.

[10] Kirby, A., Asín-Prieto, E., Burns, F. A., Ewin, D., Fatania, K., Kailavasan, M., et al. Colo-Pro: a pilot randomised controlled trial to compare standard bolus-dosed cefuroxime prophylaxis to bolus-continuous infusion-dosed cefuroxime prophylaxis for the prevention of infections after colorectal surgery. *Eur. J. Clin. Microbiol. Infect. Dis.*, 2019; 38(2):357 - 363.

[11] Peppard, W. J., Eberle, D. G., Kugler, N. W., Mabrey, D. M., Weigelt, J. A., Association between Pre-Operative Cefazolin Dose and Surgical Site Infection in Obese Patients. *Surg. Infect.*, (Larchmt). 2017; 18(4):485 – 490.

[12] Hussain, Z., Curtain, C., Mirkazemi, C., Gadd, K., Peterson, G. M., Zaidi, S. T. R., Prophylactic Cefazolin Dosing and Surgical Site Infections: Does the Dose Matter in Obese Patients. *Obes. Surg.*, 2019; 29(1):159 - 165.

[13] Zapata-Copete, J., Aguilera-Mosquera, S., García-Perdomo, H. A. Antibiotic prophylaxis in breast reduction surgery: a systematic review and meta-analysis. *J. Plast. Reconstr. Aesthet. Surg.*, 2017; 70(12):1689 - 1695.

[14] Simons, M. P., Smietanski, M., Bonjer, H. J., Bittner, R., Miserez, M., Aufenacker, T. J., et.al. International guidelines for groin hernia management. *Hernia*, 2018; 22(1):1 - 165.

[15] Vamvakidis, K., Rellos, K., Tsourma, M., Christoforides, C., Anastasiou, E., Zorbas, K. A. et al. Antibiotic prophylaxis for clean neck surgery. *Ann. R Coll. Surg. Engl.*, 2017; 99(5):410 - 412.

[16] Sarkut, P., Kilicturgay, S., Aktas, H., Ozen, Y., Kaya, E. Routine Use of Prophylactic Antibiotics during Laparoscopic Cholecystectomy Does Not Reduce the Risk of Surgical Site Infections. *Surg. Infect.*, (Larchmt). 2017; 18(5):603 – 609.

[17] Matsui, Y., Satoi, S., Kaibori, M., Toyokawa, H., Yanagimoto, H., Matsui, K., et al. Antibiotic prophylaxis in laparoscopic cholecystectomy: a randomized controlled trial. *PloS One*, [Internet] 2014; 9. Available at: https://www.ncbi.nlm.nih.gov/pmc/articles/PMC4156368/pdf/pone.0106702.pdf.

[18] Matsui, Y., Satoi, S., Hirooka, S., Kosaka, H., Kawaura, T., Kitawaki, T., Reappraisal of previously reported meta-analyses on antibiotic prophylaxis for low-risk laparoscopic cholecystectomy: an overview of systematic reviews. *BMJ Open*, [Internet] 2018; 8. Available at: https://www.ncbi.nlm.nih.gov/pmc/articles/PMC5857705/pdf/bmjopen-2017-016666.pdf.

[19] Ruangsin, S., Laohawiriyakamol, S., Sunpaweravong, S., Mahattanobon, S. The efficacy of cefazolin in reducing surgical site infection in laparoscopic cholecystectomy: a prospective randomized double-blind controlled trial. *Surg. Endosc.*, 2015; 29(4):874 - 881.

In: Encyclopedia of Surgery (22 Volume Set)
Editors: Andreas Lehrer and Kristin Mueller
ISBN: 978-1-53618-329-0
© 2020 Nova Science Publishers, Inc.

Chapter 276

HANDS AND SKIN PREPARATION

Lorena Rodríguez Cazalla* *and Cristina Bernabeu Herraiz*
Department of General and Digestive Surgery, University Hospital San Juan, Alicante, Spain

ABSTRACT

Surgical site infection is one of the most frequent complications in abdominal surgery. Hands hygiene and surgical site skin preparation are measures to prevent it. The common techniques are hand scrubbing and hand rubbing, but there is no firm evidence that one type is better than another. Skin preparation is a standard of care that must always be carried out before any invasive procedure and should include an alcohol-based antiseptic agent.

Keywords: surgical site infection, prevention, surgical hand antisepsis, hand hygiene, surgical skin preparation, antiseptic

INTRODUCTION

Surgical site infection (SSI) is one of the most frequent complications in abdominal surgery. It represents one of the most important clinical and economic problems for healthcare systems. This complication is associated with longer hospital stay, the decrease in patient's quality of life and the increase in morbidity, mortality and health costs. Currently, SSI represents in the United States of America around 22% of nosocomial infections [1, 2].

There are many different points in the care pathway where prevention of SSI can take place. This includes antiseptic cleansing of the hands for those who are operating on the patient and also the preparation of the patient's skin. This chapter focuses on these two procedures.

* Corresponding Author's Email: lorena.rc2605@gmail.com.

SURGICAL HAND PREPARATION

Historically, hands hygiene has been considered a measure of personal care. However, the relationship between hand washing and the spread of the disease was established in the 19th century thanks to the studies of *Semmelweis* in Vienna and *Holmes* in Boston, who established that hospital-acquired infections are transmitted through the hands of health personnel [3]. Currently, hands hygiene is considered one of the most important measures to prevent the spread of pathogens in healthcare settings [4].

The objective of the surgical hand preparation is to decrease the release of skin bacteria from the hands of the surgical team and to avoid contamination of the surgical field, especially in the case of unnoticed rupture of the sterile glove during the procedure, since the surgical glove is the most important barrier for the migration of microorganisms between the hands of the surgical team and the patient [5, 6]. However, 18% (range: 5-82%) of sterile gloves present perforations after surgery, and over 80% of the cases these perforations are unnoticed by the surgeon. After two hours of surgery, 35% of sterile gloves showed puncture [7].

Surgical hand antisepsis is perhaps the oldest preventative measure used to decrease the incidence of SSI and whose technique has changed most in recent years; for example, during the 19th and 20th century the friction of the skin with a brush was very important but nowadays this practice is totally discouraged due to the skin damages that produces (it is recommended that the friction will be done with the palm of the hand or with a soapy sponge for a single use) [8].

Leclair in 1990 defined antiseptic as "a chemical agent that reduces the microbial population on the skin" [9]. The ideal antiseptic is one that significantly decreases the number of microorganisms in contact with the skin, has broad spectrum, acts quickly with lasting effect, does not produce skin irritation or toxicity and its repeated use is safe [10]. At present, there are several available antiseptic agents, such as:

- Alcohols (60-95%): broad spectrum, fast speed of action, no persistent activity, flammable.
- Chlorhexidine (0.5-4%): broad spectrum, intermediate speed of action, persistent activity, good tolerability, may damage inner ear, eyes and nerve tissue.
- Iodophors (0.5-10%): broad spectrum, intermediate speed of action, decreased effectiveness on contact with organic material, skin irritant, contraindicated in pregnant women, babies and during lactation.
- Phenol derivates (0.5-4%): slow speed of action, no persistent activity, activity neutralized by non-ionic surfactants.
- Triclosan (0.1-2%): no action against viruses and fungi, intermediate speed of action, persistent activity.

Surgical Hand Scrubbing

Surgical hand scrubbing is defined by antisepsis with water and aqueous solution. The most common solutions used for surgical hand scrubbing are chlorhexidine gluconate and povidone iodine.

The application technique, according to World Health Association (WHO), consists of: 1. Scrub each side of each finger, between the fingers, and the back and front of the hand for 2 minutes; 2. Scrub the arms, keeping the hand higher than the arm for all time, wash each side of the arm from the wrist to the elbow for 1 minute; 3. Repeat the process on the other hand and arm; 4. Rinse hands and arms by passing them through the water from fingertips to elbow; 5. Dry hands and arms with sterile towel [12].

Surgical Hand Rubbing

Surgical hand rubbing is defined by antisepsis with alcohol-based solutions, also called waterless scrub.

The application technique, according to the WHO, has a duration of 2 minutes and consists of: 1. Apply 5 ml of solution in the palm of the left hand; 2. Introduce the fingers of the right hand into the solution; 3. Extend the rest of the solution by the right hand upwards reaching the elbow; 4. Apply 5 ml of solution on the right palm and repeat steps 2, 3 and 4 with the left hand and arm; 5. Apply 5 ml more on the left palm by rubbing the solution between the fingers of both hands until the wrists [12].

Recommendations

The Association for Perioperative Practice (AfPP 2011) recommends a prewash with soap and water prior to the first antisepsis of the day to remove dirt (organic material). Most guidelines forbid the use of jewelry, watches or artificial nails in the surgical team's hands [13].

In 2016, Tanner et al. performed a review of four studies about the effect of hand antisepsis in the prevention of SSI and they concluded that there is no strong evidence about the best hand antisepsis. It seems that chlorhexidine reduces the bacterial load on hands more than povidone iodine, but less than the compounds combined with alcohol [9].

Benedetta et al., reviewed six studies (three randomized clinical trials and three observational studies) that compared hand rubbing with hand scrubbing without significant differences related to the incidence of SSI [14].

The WHO recommends that surgical hand preparation be done either by scrubbing with a suitable antimicrobial soap and water or using an alcohol-based hand rub before donning sterile gloves (*strong recommendation, moderate quality of evidence*) [14].

SURGICAL SKIN PREPARATION

The goal of surgical site skin preparation with antiseptics is to reduce the microbial load of the skin before incision and, therefore, decreasing the incidence of SSI [14]. Decontamination of the skin is a standard of care that must always be carried out before any invasive procedure [15, 16].

The three agents mostly used in the surgical site skin preparation are chlorhexidine gluconate, povidone iodine and alcohols, although there are many more available options [4, 15].

The alcoholic compounds are the most microbiologically active agents, but its anti-microbial effect disappears after a few minutes, are inflammable and contraindicated on mucose membranes. Its use for surgical preparation has therefore been practically discontinued. Antisep-tics such as chlorhexidine gluconate and povidone iodine are less active than alcohol, but have a greater residual effect. Both can be found in aqueous or alcoholic solutions, the latter being more effective [17].

There are several randomized clinical trials that have compared chlorhexidine-based antiseptics with iodine-based antiseptics in the preoperative preparation of the skin. Most of them have been underpowered to detect differences in SSI rates [18]. Benedetta et al. performed a meta-analysis of twelve randomized clinical trials and they concluded that alcohol-based antiseptics solutions were more effective than aqueous solutions in reducing the risk of SSI (combined OR 0.60 [0.45-0.78]). More specifically, a decrease in SSI risk was observed when comparing the use of alcoholic chlorhexidine with aqueous povidone iodine (combined OR 0.65 [0.47-0.90]) [14]. However, it is important to bear in mind that these studies are comparing two antiseptics combined (chlorhexidine and alcohol) against just one (povidone iodine), attributing the disinfecting power to chlorhexidine and forgetting the role of alcohol [19]. A recent clinical trial showed that the use of alcoholic chlorhexidine for preoperative skin antisepsis at cesarean delivery was associated with a significantly lower risk of SSI than was the use of iodine–alcohol [20].

The recommendations of the main scientific societies are:

- *NICE (2013):* prepare the skin at the surgical site immediately before incision using an antiseptic (aqueous or alcohol-based) preparation, povidone-iodine or chlorhexidine are most suitable [21].
- *Cochrane (2015):* preoperative skin preparation with 0.5% chlorhexidine in methylated spirits was associated with lower rates of SSIs following clean surgery than alcohol-based povidone iodine [10].
- *WHO (2016):* the panel recommends alcohol-based antiseptic solutions that are based on chlorhexidine gluconate for surgical site skin preparation (*strong recommendation; low to moderate quality of evidence*) [14].
- *CDC (2017):* perform skin preparation with an alcohol-based antiseptic agent unless contraindicated (*strong recommendation; high-quality evidence*) [22].

The antiseptic agent must be applied with a specific applicator or sterile capsule, clamp and gauze, brushing the skin with forward and backward movements. The application must be carried out for about 30 seconds, allowing the product to dry for at least 2 minutes [23].

REFERENCES

[1] Anthony T, Long T, Hynan LS, Sarosi GAJ, Nwariaku F, Huth J, et al. Surgical complications exert a lasting effect on disease-specific health-related quality of life for patients with colorectal cancer. *Surgery.* 2003;134(2):119-125.

[2] Magill S, Edwards J, Bamberg W, Beldavs Z, Dumyati G, Kainer M, et al. Multitaste point-prevalence survey of health care-associated infections. *N Engl J Med.* 2014;370 (13):1198-1208.

[3] Best M, Neuhauser D. Ignaz Semmelweis and the birth of infection control. *Qual Saf Health Care.* 2004;13(3):233-234.

[4] Boyce JM, Pittet D, Healthcare Infection Control Practices Advisory Committe, HICPAC/SHEA/APICIDSA Hand Hygiene Task Force. Guideline for Hand Hygiene in Health-Care Settings. Recommendations of the Healthcare Infection Control Disease Practices Advisory Committee and the HICPAC/SHEA/APIC/IDSA Hand Hygiene Task Force. Society for Healthcare Epidemiology of America/Association for Professionals in Infection Control/Infectious Diseases Society of America. *MMWR Recomm Rep.* 2002;51(RR-16):1-45.

[5] Kampf G, Goroncy-Bermes P, Fraise A, Rotter M. Terminology in surgical hand desinfection- a new Tower of Babel in infection control. *J Hosp Infect.* 2005;59(3):269-271.

[6] Hübner NO, Goerdt AM, Stanislawski N, Assadian O, Heidecke CD, Kramer A, et al. Bacterial migration through punctured surgical gloves under real surgical conditions. *BMC Infect Dis [Internet]* 2010;10. Available at: https://www.ncbi.nlm.nih.gov/pmc/articles/PMC2909237/pdf/1471-2334-10-192.pdf.

[7] Widmer A. Surgical hand hygiene: scrub or rub?. *J Hosp Infect.* 2013;83 (Suppl 1):S35-S39.

[8] Widmer A, Rotter M, Voss A, Nthumba P, Allegranzi B, Boyce J, et al. Surgical hand preparation: state-of-the-art. *J Hosp Infect.* 2010;74(2):112-122.

[9] Tanner J, Dumville J, Norman G, Fortnam M. Surgical hand antisepsis to reduce surgical site infection. *Cochrane Database of Systematic Reviews 2016,* Issue 1. Art. No.: CD004288. DOI: 10.1002/14651858.CD004288.pub3.

[10] Dumville JC, McFarlane E, Edwards P, Lipp A, Holmes A, Liu Z. Preoperative skin antiseptics for preventing surgical wound infections after clean surgery. *Cochrane Database of Systematic Reviews* 2015, Issue 4. Art. No.: CD003949. DOI: 10.1002/14651858.CD003949.pub4.

[11] Machet L, Fourtillan E, Vaillant L. Antisépticos. *EMC Tratado de Medicina.* Elsevier; 2016.

[12] World Health Organization. Surgical hand preparation: state-of-the-art. In *WHO Guidelines on Hand Hygiene in Health Care: First Global Patient Safety Challenge Clean Care is Safer Care.* Geneva; World Health Organization; 2009. p. 54-60.

[13] *The Association for Perioperative Practice* [Internet]. United Kingdom; 2011. Available at: http://afpp.org.uk/books-journal/books/book-123.

[14] Allegranzi B, Bischoff P, De Jonge S, Kubilay NZ, Zayed B, Gomes SM, et al. New WHO recommendations on preoperative measures for surgical site infection

prevention: an evidence-based global perspective. *Lancet Infect Dis.* 2016;16(12):e276-e287.

[15] Sidhwa F, Itani K. Skin preparation before surgery: Options and Evidence. *Surg Infect (Larchmt).* 2015;16(1):14-23.

[16] Anderson DJ, Podgorny K, Berríos-Torres SI, Bratzler DW, Dellinger EP, Greene L, et al. Strategies to prevent surgical site infections in acute care hospitals: 2014 update. *Infect Control Hosp Epidemiol.* 2014;35(6):605-627.

[17] Ruíz-Tovar J, Badia JM. Prevention of surgical site infection in abdominal surgery. A critical review of the evidence. *Cir Esp.* 2014;92(4):223-231.

[18] Ban KA, Minei JP, Laronga C, Harbrecht BG, Jensen EH, Fry DE, et al. American College of Surgeons and Surgical Infection Society: Surgical Site Infection Guidlines, 2016 Update. *J Am Coll Surg.* 2017;224(1):59-74.

[19] Maiwald M, Chan E. The forgotten role of alcohol: a systematic review and meta-analysis of the clinical efficacy and perceived role of chlorhexidine in skin antisepsis. *PLoS One* [Internet] 2007;7. Available at: https://www.ncbi.nlm.nih.gov/pmc/articles/PMC3434203/pdf/pone.0044277.pdf.

[20] Tuuli MG, Liu J, Stout MJ, Martin S, Cahill AG, Odibo AO, et al. A Randomized Trial Comparing Skin Antiseptic Agents at Cesarean Delivery. *N Engl J Med.* 2016;374 (7):647-655.

[21] *National Institute for Health and Care Excellence* [Internet]. Available at: http://www.nice.org.uk/guidance/qs49.

[22] Berríos-Torres SI, Umscheid CA, Bratzler DW, Leas B, Stone EC, Kelz RR, et al. Centers for Disease Control and Prevention Guideline for the Prevention of Surgical Site Infection. *JAMA Surg.* 2017;152(8):784-791.

[23] Spanish Society of Preventive Medicine, Public Health and Hygiene. "*Zero Surgical Site Infection*" Project [Internet]; 2017. Available at: http://infeccionquirurgicazero.es/images/stories/recursos/protocolo/2017/3-1-17-documento-Protocolo-IQZ.pdf.

In: Encyclopedia of Surgery (22 Volume Set)
Editors: Andreas Lehrer and Kristin Mueller
ISBN: 978-1-53618-329-0
© 2020 Nova Science Publishers, Inc.

Chapter 277

HYPEROXYGENATION, HYPOTHERMIA PREVENTION, NORMOGLYCEMIA AND NORMOVOLEMIA

Esther García Villabona*, MD and Carmen Vallejo Lantero, MD
Anesthesiology Department, Hospital Universitario de La Princesa,
Madrid, Spain

ABSTRACT

Surgical site infections (SSIs) are defined as infections anatomically associated with a surgical procedure performed in an operating room and not present prior to the operation. They have been shown to account for up to 16% of healthcare-associated infections. The rate of surgical site infection varies depending on the type of procedure, with rates of less than 1% for orthopaedic procedures and rates of over 10% for large bowel surgery. They can often be prevented with appropriate care before, during and after surgery. [1]

Keywords: surgical site infection, oxygenation, temperature, normovolemia, hiperglycemia.

INTRODUCTION

Surgical site infection (SSI) is a type of healthcare-associated infection in which a surgical incision site becomes infected after a surgical procedure. These infections represent an important problem for patients and a significant financial burden for the health care system. [2]

Many factors in the patient's journey through surgery have been identified as contributing to the risk of SSI. Therefore, the prevention of these infections is complex and requires the integration of a range of preventive measures before, during and after surgery.

There is evidence that optimizing blood flow to the surgical incision, we can decrease surgical site infection rates through the avoidance of hypothermia, hypoxia and decreased

* Corresponding Author's Email: esthergarciavillabona@gmail.com.

perfusion. If an infection does develop, appropriate treatment will minimise morbidity resulting from the infection.

Ideally, perioperative fluid therapy prevents tissue hypoxia by maximizing the cardiac output and thus improving arterial oxygenation. Nevertheless, an adequate assessment of normovolemia remains complicated.

On the other hand, several observational studies showed that hyperglycaemia is associated with an increased risk of SSI in both diabetic and non-diabetic patients. Conflicting results have been reported about the optimal target levels of blood glucose and the ideal timing for glucose control (intra- and/or postoperative).

METHODS

Hyperoxygenation

It has been claimed that patients undergoing surgery with general anesthesia could benefit from a higher than normal inspired oxygen fraction (FiO2). Some authors have suggested that a high FiO2 is a simple, inexpensive, and low risk intervention, and that the broader use of this technique should be encouraged in patients undergoing major abdominal procedures. [3]

Several trials have been published on the use of high fractions of inspired oxygen concentration (FiO2) during the perioperative period and the potential association with lower rates of SSI. This intervention consists of providing patients with 80% oxygen compared to the usual administration of 30% oxygen. Patients are routinely given 100% oxygen for 30 seconds to 2 minutes prior to intubation and then maintained on either "normoxia," defined as oxygen at FiO2 30% or 35%, or "hyperoxia," defined as oxygen at FiO2 80%.

The arguments for providing oxygen levels beyond the standard 30% are largely based on two notions. The first is that the surgical incision may not be adequately perfused and might receive substantially higher oxygen if there is a higher partial pressure of oxygen in the blood. The other concept is that host defense systems might be further improved by higher oxygen partial pressures, particularly by enhancing neutrophil oxidative killing. This argument devolves down to the affinity of the nicotinamide adenine dinucleotide phosphate (NADPH) oxidase for oxygen. The Michaelis constant for the enzyme for oxygen is 5-20 μM Hg O2. It has been shown that oxygen tension at infected sites is greatly reduced compared with most uninfected tissues (P02 approximating 25 mM of oxygen ≈3% oxygen). [1]

Overall, it has been shown (with a moderate quality of evidence) that increased perioperative FiO2 (80%) is beneficial in reducing SSI when compared to standard perioperative FiO2 (30-35%) in patients undergoing surgical procedures under general anaesthesia with endotracheal intubation. The benefit of hyperoxygenation tended to be greater in open colorectal surgery than in other types of abdominal surgery. Many authors have considered that subgroup as the most likely to profit from a high FiO2. The question then is, whether this benefit is of clinical relevance. Although the degree of antiinfective efficacy of high FiO2 seems weak and perhaps disappointing, it seems to be similar to conventional antibiotic prophylaxis in many surgical settings. As most patients in these trials had received prophylactic antibiotics, we may conclude on the efficacy of high FiO2 as a supplemental antiinfection strategy only. It would be difficult to test the efficacy of high FiO2

alone from an ethical perspective because the administration of prophylactic antibiotics is widely considered as a standard of care. [3]

Potential Harms

Some authors are cautious about the use of increased FiO2. Skepticism has been partly related to the fact that high FiO2 may have deleterious effects on the airways. One hundred percent oxygen at induction or at the end of general anesthesia has been suggested to promote atelectasis over a few minutes, and to cause alteration in gas exchange.

However, this increase in atelectasis has been described after the administration of 100% FiO2 compared to 80% FiO2 and showed a meaningful difference between the two concentrations. Moreover, none of the clinical trials investigating the administration of 80% FiO2 that reported adverse events showed a significant difference in pulmonary complications or other adverse events.

Patients with chronic obstructive pulmonary disease should be evaluated preoperatively and their perioperative anesthesia needs to be designed to minimize complications as the risks of high inspiratory concentrations of oxygen may outweigh the benefits for these patients. [3]

Hypothermia Prevention

Hypothermia is defined as a core temperature below 36°C and is common during and after major surgical procedures lasting more than 2 hours. The human body has a central compartment comprising the major organs where temperature is tightly regulated, and a peripheral compartment where temperature varies widely. Heat loss is compensated by reducing blood flow through the skin and increasing heat production, mainly by inducing muscular activity (shivering) and increasing the basal metabolic rate. Typically, the periphery compartment may be 2ºC to 4ºC cooler than the core compartment. [4]

Causes of Hypothermia

The most common events leading to hypothermia are the exposure to a cold operating room environment and the anaesthetic-induced impairment of thermoregulatory control.

- Skin surface exposure during the perioperative period can increase heat loss. In addition, cool intravenous and irrigation fluids directly cool patients.
- Sedatives and anaesthetic agents inhibit the normal response to cold, resulting in an improved blood flow to the periphery and increased heat loss.

During the early period of anaesthesia, these effects are seen as a rapid decrease in core temperature caused by redistribution of heat from the central to the peripheral compartment. This early decrease is followed by a more gradual decline, reflecting ongoing heat loss. With epidural or spinal analgesia, the peripheral blockade of vasoconstriction below the level of the nerve block results in vasodilatation and greater ongoing heat loss.

Complications of Hypothermia

Inadvertent non-therapeutic hypothermia is considered to be an adverse effect of general and regional anaesthesia and can cause different complications.

a) Cardiac complications are the principal cause of morbidity during the postoperative phase because of the release of noradrenaline causing peripheral vasoconstriction and hypertension.
b) Prolonged recovery from anaesthesia and a longer length of hospital stay.
c) Even moderate hypothermia (35ºC) can alter physiological coagulation mechanisms by affecting platelet function and modifying enzymatic reactions. Decreased platelet activity results in increased bleeding and a greater need for transfusion.
d) Moderate hypothermia can also reduce the metabolic rate, manifesting as a prolonged effect of certain drugs used during anaesthesia and some uncertainty about their effects. This is particularly significant for elderly patients.
e) The maintenance of normothermia might reduce the incidence of surgical site infection, but all available studies in this field measure core and not peripheral temperature. The reported lower core temperatures result in a reduced cutaneous temperature at the operative site. Recent health care bundles and guidelines for SSI prevention recommend that body temperature should be maintained above 35.5-36°C during the perioperative period. [1]

Recommended Measures to Prevent Hypothermia

1. Perioperative care:

- Patients, relatives and carers should be informed that staying warm before surgery will lower the risk of postoperative complications.
- When using any temperature recording or warming device, healthcare professionals should be trained in their use.
- Measure the patient's temperature using a site that produces either: a direct measurement of core temperature, or a direct estimate of core temperature that has been shown in research studies to be accurate to within 0.5ºC of direct measurement. These sites are: pulmonary artery catheter, distal oesophagus, urinary bladder, zero heat-flux (deep forehead), sublingual, axilla, rectum.

2. Preoperative phase:

The preoperative phase is defined as the hour before induction of anaesthesia, during which the patient is prepared for surgery.

- Each patient should be assessed for their risk of inadvertent perioperative hypothermia and potential adverse consequences before transfer to the theatre suite.
- Patients should be managed as higher risk if any 2 of the following apply:
  a) American Society of Anesthesiologists (ASA) grade II to V (the higher the grade, the greater the risk)

b) Preoperative temperature below 36.0°C (and preoperative warming is not possible because of clinical urgency)
c) Undergoing combined general and regional anaesthesia
d) Undergoing major or intermediate surgery
e) At risk of cardiovascular complications

- The patient's temperature should be measured and documented in the hour before the surgery.
- If the patient's temperature is below 36.0°C, start active warming preoperatively unless there is a need to expedite surgery because of clinical urgency.
- If the patient's temperature is 36.0°C or above, start active warming at least 30 minutes before induction of anaesthesia, unless this will delay emergency surgery.
- Forced air warming seems to have beneficial effect in terms of a lower rate of surgical site infection and complications, at least in those undergoing abdominal surgery, compared to not applying any active warming systems.
- Maintain active warming throughout the intraoperative phase.
- On transfer to the theatre suite:
  - active warming should be continued (or re-started as soon as possible)
  - the patient should be encouraged to walk to theatre where appropriate.

3. Intraoperative phase

The intraoperative phase is defined as total anaesthesia time, from the first anaesthetic intervention through to patient transfer to the recovery area of the theatre suite.

- The patient's temperature should be measured and documented before induction of anaesthesia and then every 30 minutes until the end of surgery.
- Induction of anaesthesia should not begin unless the patient's temperature is 36.0°C or above (unless there is a need to expedite surgery because of clinical urgency, for example bleeding or critical limb ischaemia).
- In the theatre suite the ambient temperature should be at least 21°C while the patient is exposed. The ambient temperature may be reduced once active warming is established to allow better working conditions using equipment to cool the surgical team.
- The patient should be adequately covered throughout the intraoperative phase to conserve heat, and exposed only during surgical preparation.
- Intravenous fluids (500 ml or more) and blood products should be warmed to 37°C using a fluid warming device.
- Warm patients intraoperatively from induction of anaesthesia, using a forced-air warming device, if they are:
  a) having anaesthesia for more than 30 minutes or
  b) having anaesthesia for less than 30 minutes and are at higher risk of inadvertent perioperative hypothermia.

Consider a resistive heating mattress or resistive heating blanket if a forced-air warming device is unsuitable.

- The temperature setting on forced-air warming devices should be set at maximum and then adjusted to maintain a patient temperature of at least 36.5°C.
- All irrigation fluids used intraoperatively should be warmed in a thermostatically controlled cabinet to a temperature of 38°C to 40°C.

4. Postoperative phase

The postoperative phase is defined as the 24 hours after the patient has entered the recovery area of the theatre suite.

- The patient's temperature should be measured and documented on admission to the recovery room and then every 15 minutes.
- If the patient's temperature is below 36.0°C, they should be actively warmed using forced-air warming until they are discharged from the recovery room or until they are comfortably warm.
- Patients should be kept comfortably warm when back on the ward.
- If the patient's temperature falls below 36.0°C while on the ward: they should be warmed using forced-air warming until they are comfortably warm. Their temperature should be measured and documented at least every 30 minutes during warming [4, 5].

Hyperglycemia Prevention

Blood glucose levels rise during and after surgery due to surgical stress. Surgery causes a stress response that results in a release of catabolic hormones and the inhibition of insulin. Moreover, surgical stress influences pancreatic beta-cell function, which results in lower plasma insulin levels. Taken together, this relative hypoinsulinaemia, insulin resistance and excessive catabolism from the action of counter-regulatory hormones make surgical patients at high risk for hyperglycaemia, even non-diabetic patients. [6]

Several observational studies showed that hyperglycaemia is associated with an increased risk of SSI and therefore an increased risk of morbidity, mortality and higher health care costs in both diabetic and non-diabetic patients and in different types of surgery .

A recent systematic review and cohort meta-analysis including 16 studies [7] concluded that use of an evidence- based, surgical care bundle for patients undergoing colorectal surgery significantly reduced the risk of SSI. Although none of the studies in this analysis used the identical SSI care bundles, all included elements from a core group of interventions, including appropriate antibiotic prophylaxis, normothermia, appropriate hair removal, and glycemic control for hyperglycemic patients.

Hyperglycemia is a known risk factor for infection because it impedes the normal physiologic responses to infection. In vivo studies show that hyperglycemia is associated with accelerated nonenzymatic glycosylation of proteins or the nonenzymatic addition of sugar molecules to the exposed lysine residues on extracellular proteins. Short-term glycosylation of immunoglobulins inactivates them. Furthermore, hyperglycemia impairs leukocyte function, including abnormalities in granulocyte adherence, impaired phagocytosis, delayed

chemotaxis, and depressed bactericidal activity. The degree of hyperglycemia that has been shown to impair phagocytic function, both in vivo and in vitro, is approximately 200 mg/dL. More important, the degree of phagocytic impairment can be reversed with control of glucose level. [8]

Conflicting results have been reported regarding the different treatment options to control hyperglycaemia in diabetic and non- diabetic patients, the optimal target levels of blood glucose and the ideal timing for glucose control (intra- and/or postoperative). The general consensus remains that glucose levels greater than 200 mg/dL is detrimental, but the lower limit and the tightness of control is debatable. Moreover, some studies targeting relatively low perioperative glucose levels have highlighted the risk of adverse effects associated with intensive protocols as they may cause hypoglycaemia. [9]

Overall low-quality evidence shows that a protocol with more strict blood glucose target levels has a significant benefit in reducing SSI rates when compared to a conventional protocol. There was evidence that the effect was smaller in studies that used intensive blood glucose controls intraoperatively only compared to studies that used an intensive protocol postoperatively or both intra- and postoperatively.

Meta-regression analysis showed that the benefit of an intensive protocol over a conventional protocol was consistent in both patients with and those without diabetes, and whether commenced during or after surgery. Among the intensive protocols, the effect was similar in studies with a target blood glucose level of ≤110 mg/dL and an upper limit target level of 110-150 mg/dL. [10]

Five studies reported significantly more hypoglycaemic measurements in the intensive group compared with the control group. Although these events were asymptomatic, with none of the studies reporting clinical consequences, it remains unknown to what extent these hypoglycaemic episodes harm patients in the long term and whether this potential harm outweighs the reduced risk of SSI. [10]

Targeting stricter and lower blood glucose levels with an intensive protocol of perioperative glucose control reduces SSI without increasing the risk of death or stroke. Although the optimal target level cannot be derived from published data, the summary data of present systematic review and meta-analysis indicate that target glucose levels of less than 150 mg/dl in the perioperative period can be achieved safely with minimal risk of asymptomatic hypoglycaemic events and with no significant increase in serious adverse events. [10]

Due to the risk of hypoglycaemia, targeting lower levels should be avoided. While most recommendations focus on the diabetic patient only, those issuedby SHEA/IDSA and the American College of Physicians apply to all surgical patients. They recommend either target levels between 140-200 mg/dL or upper limits of 180 mg/dL or 198 mg/dL. [6]

Thus, the Global Guidelines for the prevention of surgical site infection endorsed by WHO, unanimously agreed that the recommendation to use protocols for intensive perioperative blood glucose control should apply to both diabetics and non-diabetics. However, the available evidence did not allow the definition of an optimal target level of blood glucose. [6]

Normovolemia

Wound infections are serious complications of surgery. Oxidative killing by neutrophils is the most important defense against pathogens causing surgical infections. Because oxygen is the substrate for oxidative killing, the rate of bacterial killing depends on sufcient tissue oxygenation. Wound healing and resistance to infection are dependent on tissue oxygen tension. Sufficient tissue oxygenation is essential for collagen synthesis and wound repair and is improved by adequate arterial oxygenation. [11]Ideally, perioperative fluid therapy prevents tissue hypoxia by maximizing the cardiac output and thus improving arterial oxygenation.

Fluid overload leads to a decrease in muscular oxygen tension. Due to surgical trauma, a systemic inflammatory response arises, which leads to a fluid shift to the extravascular space. Following a large fluid shift, generalized oedema may occur, which decreases tissue oxygenation and impedes tissue healing. By contrast, hypovolemia leads to arterial and tissue hypoxia due to a decrease in cardiac output. The optimal fluid (colloid or crystalloid) or strategy of fluid management (goal-directed, liberal or restricted) remains a subjet of controversy. [1]

Perioperative goal-directed therapy (GDT) aims to match the increased oxygen demand incurred during major surgery, by flow-based haemodynamic monitoring and therapeutic interventions to achieve a predetermined haemodynamic endpoint. [12] Several metaanalyses of RCTs have shown that goal-directed fluid therapy (GDT) reduces postoperative morbidity and length of hospital stay, especially in high-risk patients undergoing major surgery.

Few organizations have issued recommendations regarding the maintenance of normovolemia. The UK-based NICE recommends maintaining adequate perfusion during surgery. Based on an evidence update in 2013, it is stated that haemodynamic GDT appears to reduce SSI rates. [6]

Overall low quality evidence shows that intraoperative GDT has significant benefit in reducing the SSI rate compared to standard fluid management. This effect is shown also for GDT in the postoperative period. Considering the low quality evidence above-mentioned, the WHO in the second edition of the Global Guidelines for the prevention of surgical site infection agreed to suggest the use of GDT intraoperatively and decided that the strength of this recommendation should be conditional. [6] The guidelines developers group highlighted that a widely-accepted definition for normovolemia is needed. Future studies including large well-designed RCTs with clear definitions should aim at identifying the most accurate and least invasive method of measuring normovolemia and assess its influence with regard to tissue oxygenation and normothermia.

Peri-operative goal-directed therapy, using fluids and/or inotropes, typically involves the use of haemodynamic targets to optimize oxygen delivery. A systematic literature search identified three haemodynamic management goals: stroke volume optimization by fluid therapy; maintenance of a target mean arterial pressure by vasopressor therapy; maintenance of a target cardiac index $\geq$2.5 l/min per m^2 by inotropic therapy. [13] The use of an algorithm is helpful, while considering that local resources and expertise may vary and limit possibilities for the optimal strategy. Indeed, the variety of effective algorithms on a multitude of outcomes indicates that having an algorithm for a specific goal is the most important factor, more than any particular algorithm associated with the effect of GDT.

CONCLUSION

During surgery patients are kept in a stable condition by the operating team. All tissues heal most effectively in optimal conditions of oxygenation, perfusion and body temperature.

Intraoperative high FiO2 may be regarded as a supplemental strategy to further decrease the risk of surgical site infection in patients receiving prophylactic antibiotics without increasing the risk of postoperative atelectasis.

Inadvertent perioperative hypothermia is a common but preventable complication of perioperative procedures that is associated with an increased risk of surgical site infection and other postoperative complications. Surgical patients are at risk of developing hypothermia before, during or after surgery. Maintaining normothermia throughout this period (except if cooling is required for medical reasons) will therefore reduce the risk of infection at the surgical site and ensure that patients feel comfortably warm at all times.

Hyperglycemia is a known risk factor for infection. Overall low-quality evidence shows that a protocol of control for blood glucose levels has a significant benefit in reducing SSI rates. The effect was similar in studies with a more intensive target blood glucose level and an upper limit target. Available evidence did not allow the definition of an optimal target level of blood glucose. Due to the risk of hypoglycaemia, targeting lower levels should be avoided.

At present, there is no universal definition of normovolemia or a standardized method for its assessment. Low quality evidence shows that intraoperative GDT has significant benefit in reducing the SSI rate. Considering that both fluid overload and hypovolemia are likely to affect other clinical outcomes, actual recommendations suggest the use of GDT intraoperatively, but the strength of this recommendation should be conditional.

REFERENCES

[1] World Health Organization. *Global guidelines for the prevention of surgical site infection*. WHO, Geneva; 2016.

[2] National Institute for Health and Care Excellence. Surgical site infection: prevention and treatment of surgical site infection. *Clinical guideline 74*. NICE, London 2008. Last updated: February 2017.

[3] Hovaguimian F, Lysakowski C, Elia N, Tramèr MR; Effect of intraoperative high inspired oxygen fraction on surgical site infection, postoperative nausea and vomiting, and pulmonary function: systematic review and meta-analysis of randomized controlled trials. *Anesthesiology.* 2013 Aug:119(2):303-16. doi: 10.1097/ALN.0b013e31829aaff4.

[4] National Institute for Health and Care Excellence. Hypothermia: prevention and management in adults having surgery. *Clinical guideline 65*. NICE, London 2008. Last updated: December 2016.

[5] Madrid E, Urrútia G, Roqué I Figuls M, Pardo-Hernández H, Campos JM, Paniagua P, Maestre L, Alonso-Coello P. Active body surface warming systems for preventing complications caused by inadvertent perrioperative hypothermia in adults. *Cochrane Database Syst Rev.* 2016 Apr 21; 4:CD009016. doi: 10.1002/14651858.

[6] *Global guidelines for the prevention of surgical site infection*, second edition ISBN 978-92-4-155047-5. World Health Organization 2018.

[7] Carmichael JC, Keller DS, Baldini G, et al. Clinical Practice Guidelines for Enhanced Recovery After Colon and Rectal Surgery from the American Society of Colon and Rectal Surgeons and Society of American Gastrointestinal and Endoscopic Surgeons. *Dis Colon Rectum* 2017; 60: 761–784.

[8] Ng R, Oo A, Liu W, et al. Changing glucose control target and risk of surgical site infection in a Southeast Asian population. *J Thorac Cardiovasc Surg*. 2015;149(1):323-8.

[9] Griesdale DE, de Souza RJ, van Dam RM, Heyland DK, Cook DJ, Malhotra A, et al. Intensive insulin therapy and mortality among critically ill patients: a meta-analysis including NICE-SUGAR study data. *CMAJ*. 2009;180(8):821-827.

[10] De Vries FEE, Gans SL, Solomkin JS, et al. Meta-analysis of lower perioperative blood glucose target levels for reduction of surgical-site infection. *BJS* 2017; 104: e95–e105.

[11] Kabon B, Akca O, Taguchi A, Nagele A, Jebadurai R, Arkilic CF, et al. Supplemental intravenous crystalloid administration does not reduce the risk of surgical wound infection. *Anesth Analg.* 2005;101:1546-53.

[12] Cecconi M, Corredor C, Arulkumaran N, Abuella G, et al. Clinical review: Goal-directed therapy. What is the evidence in surgical patients? The effect on different risk groups. *Crit Care* 2013;17:209.

[13] Feldheiser A, Conroy P, Bonomo T, et al. Development and feasibility study of an algorithm for intraoperative goal directed haemodynamic management in noncardiac surgery. *J Int Med Res* 2012;40: 1227-1241.

In: Encyclopedia of Surgery (22 Volume Set)
Editors: Andreas Lehrer and Kristin Mueller
ISBN: 978-1-53618-329-0
© 2020 Nova Science Publishers, Inc.

Chapter 278

ADHESIVES AND WOUND PROTECTORS

Dennis César Lévano-Linares[1,*], MD
and Patricia Sanchez-Salcedo[2,†]
[1]Department of Surgery, University Hospital Rey Juan Carlos, Mostoles, Madrid, Spain
[2]Department of Surgical Nursery, Fundacion Jimenez Diaz, Madrid, Spain

ABSTRACT

Surgical site infections (SSI) are the most frequent complications in surgery procedures. Despite the use of standard surgical techniques (antiseptic skin preparation, sterile draping, and antibiotics) that could prevent perioperative wound infections, wound infection following clean-contaminated procedures occurs in more than 10%. SSI contribute substantially to postoperative morbidity and mortality and have been shown to significantly increase the mean length of hospital stays and treatment costs. Thus, devices to reduce SSI incidence are of great medical and economic importance. Adhesive draps and plastic wound protectors were originally designed to be a simple, easy-to-use, and cost-effective device that reduces the contact between bacteria and incisions,

and provides a relatively disease-free environment for the operator, which could reduce the SSI substantially.

Keywords: surgical site infections, plastic wound protectors, wound infection

INTRODUCTION

Surgical site infection (SSI) is one of the most common hospital acquired infections in the field of surgery. SSI leads to increased overall health care cost and is associated with a prolonged hospital stay, more complex wound care needs, more frequent visits to outpatient clinics, and higher rates of hospital readmission and morbidities [1]. Thus, SSI rates have been used to evaluate outcome measures of surgical quality worldwide. Risk factors affecting

* Corresponding Author's Email: cesdenlinares@gmail.com.
† Patricia Sanchez-Salcedo, RN.

the SSI rate can be categorized into 2 main groups: patient related and procedure related [2]. Patient-related factors include generally nonmodifiable factors such as patient age, body mass index, malnutrition, comorbidities (such as uncontrolled diabetes mellitus or anemia), and American Society of Anesthesiologists (ASA) score. Meanwhile, procedure-related factors can be controlled to a degree and therefore may be modified in an effort to reduce the risk of SSI; these include the method of skin preparation, meticulous dissection and reduced operating time, use of minimally invasive surgery compared with conventional open surgery, and use of prophylactic antibiotics. Physical wound protection can reduce the rate of SSI in patients undergoing abdominal surgery. Most abdominal surgeries are performed with a clean-contaminated or contaminated-incisional wound because these often require manipulation or resection of the bowel or biliary tract. In particular, emergency abdominal surgeries are more likely to consist of contaminated and dirty wounds. Therefore, in these cases, it is especially important to physically protect the incisional wound from sources of infection such as bowel content spillage to reduce the SSI rate. Adhesive drapes, antimicrobial skin sealants and impervious plastic wound protectors (IPWP)—so-called wound edge protectors, circular wound edge protectors or plastic ring wound protectors—have been used to protect the incisional wound and reduce SSI rates [3]. However, the effectiveness of these wound protectors on reducing the SSI rate remains unclear. For example, despite the expected clinical benefit of IPWP to reduce the rate of SSIs and the favorable results reported by several studies [4], some prospective series and randomized clinical trials (RCT) have reported disappointing results of the effect of IPWPs on reducing SSI rates in patients undergoing abdominal surgery [5]. In this chapter, we will analyze the effectiveness of each of the devices used in the protection of the skin and the surgical wound in patients undergoing abdominal surgery and the updated recommendations on their use.

WOUND PROTECTORS

The use of adhesive membrane barriers over the skin of the surgical site emerged 50 years ago as a possible solution to minimise endogenous cross-contamination during surgery [6]. The initial idea relied on the principle of reducing exposure of the surgical site to bacteria inherent in the surrounding skin or to airborne bacteria in the operating room. Major applicability was expected in clean surgeries, where the skin is considered the main source of bacteria. Unfortunately, however, no evidence in support of plastic adhesive drapes was found in a recently updated systematic review RCT including five studies and 3082 participants(2). In fact, a 23% increase in the risk of SSI was found in the group that received adhesive drapes. In the 1960s, other devices were described and then developed based on the concept of combining a non-traumatic surgical wound retractor with a protective membrane covering of the incisional margin in abdominal surgeries. Such protective covers or ‘wound protectors’ were hypothesised to be an improvement over adhesive membrane barriers as they were believed to reduce intraoperative contamination while concomitantly preserving the temperature and humidity of the surgical wound. In support of this hypothesis, early studies demonstrated reduced exposure of the surgical wound to enteric bacteria at the end of gastrointestinal operations [7, 8]. These results were further supported by several RCT, which demonstrated that wound protectors were efficacious in reducing the incidence of incisional

SSI as compared to usual care in patients undergoing gastrointestinal surgeries [4, 9, 10]. There are different impervious circular wound edge protectors (CWEP), but they all fall into two main categories: a.) devices with a single semirigid plastic ring placed into the abdominal cavity after laparotomy with an impervious drape attached, which comes out of the abdomen to protect the incisional edges (single-ring device) and b.) devices with two semi-rigid plastic rings connected by an impervious drape (Figure 1).

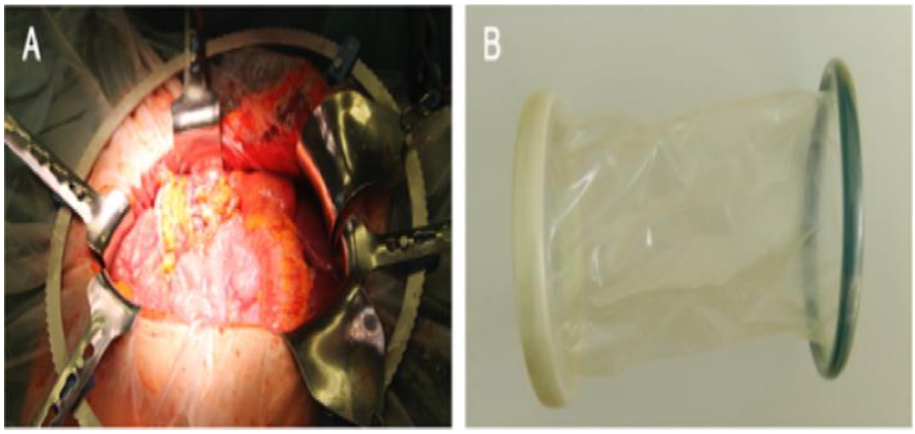

Figure 1. Circular wound edge protectors (CWEP). A single-ring device. B double-ring device [11].

Table 1. Recommendations on the use of WP devices according to available guidelines [14]

Guidelines (year issued)	Recommendations on the use of WP devices
SHEA/IDSA practice recommendation (2014)	Use impervious plastic WPs for gastrointestinal and biliary tract surgery.
NICE (2013 update)	Wound edge protection devices may reduce the SSI rate after open abdominal surgery, but the current lack of high-quality studies implies that more research is needed.

These new surgical devices comprise a non-adhesive plastic sheath attached to a single or double rubber ring that firmly secures the sheath to the wound edges. The device is intended to facilitate the retraction of the incision during surgery without the need for additional mechanical retractors and cloths. Theoretically, commercially-available CWEP are intended to reduce wound edge contamination to a minimum during abdominal surgical procedures, including contamination from outside (clean surgery) and inside the peritoneal cavity (clean-contaminated, contaminated and dirty surgery). Although these surgical devices are already on the market, their real usefulness and cost-effectiveness warrants additional evidence-based analysis. Few organizations have issued recommendations regarding the use of CWEP devices. The UK-based NICE states that wound edge protection devices may reduce SSI rates after open abdominal surgery, but no recommendation is given due to the lack of further high-quality evidence [12]. However, SHEA/IDSA guidelines recommend the use of impervious plastic CWEP for gastrointestinal and biliary tract surgery [13].

While CWEP effectively protect wound edges from bacterial invasion their clinical effectiveness has been disputed and their widespread use has been hampered by conflicting trial results with some authors reporting beneficial effects [10] while others found no benefit [15].

Two previous smaller reviews based on limited patient numbers and low-quality evidence reported a beneficial effect of CWEP, but called for adequately powered, high-quality trials [16] which have been conducted since then. A recently meta-analysis of RCT, evaluated whether diverse types of wound protectors may reduce the risk of SSI among patients undergoing gastrointestinal or biliary surgery [17]. Among six trials, which enrolled 1008 patients, it was found that the pooled estimated risk of SSI among patients fitted with wound protectors during surgery was 0.55 (95% CI 0.31 to 0.98) times the pooled estimated risk of SSI in control groups. Moreover, among patients treated with dual-ring versus single-ring wound protectors, the pooled estimated risk of SSI was 0.31 (95% CI 0.14 to 0.67) times the pooled estimated risk in the control groups. As blinding status of outcome assessors was identified as a significant source of between study heterogeneity, the design of the wound protector as well as the method of outcome classification may be important considerations for the design of future wound protector trials.

According to the actual evidence, it is recommended the use of CWEP devices in clean-contaminated, contaminated and dirty abdominal surgical procedures for the purpose of reducing the rate of SSI.

ADHESIVE DRAPES AND GOWNS

Drapes and gowns are available for single-use or multiple-use, with varying compositions. Adhesive plastic incise drapes are used on a patient's skin after surgical site preparation, with or without antimicrobial impregnation, and the surgeon performs the incision of the drape and the skin simultaneously. In available guidelines, there are conflicting recommendations on the use of plastic adhesive drapes, mainly discouraging their use. There are no recommendations on the use of single-use or reusable drapes and gowns for the purpose of SSI prevention. We did a systematic review to investigate the use of sterile disposable or reusable drapes and surgical gowns, and separately the use of plastic adhesive incises drapes, for the purpose of SSI prevention. Results from non-randomised studies have produced conflicting results about the efficacy of this approach, but no systematic review has been conducted to date to guide clinical practice. A recent meta-analysis [2] of the impact of adhesive drapes on SSI included 5 studies with a total 3082 patients comparing adhesive drapes versus no drape, and 2 with a total 1113 patients comparing iodine-impregnated adhesive drapes versus no drape. SSI rates were higher in the adhesive drape groups; iodine impregnation was not associated with any significant difference in SSI. The WHO also performed a meta-analysis assessing adhesive drapes with and without antiseptic impregnation [14] and found no benefit in terms of SSI between using or not using adhesive drapes. Some allergic reactions occurred with impregnated drapes.

Considering the evidence, including potential issues of availability and costs in low-resource settings and the ecological effect, the expert panel suggested that either sterile disposable non-woven or sterile reusable woven drapes and gowns can be used. However,

adhesive incise drapes (with or without antimicrobial properties) should not be used for the purpose of preventing SSI.

ANTIMICROBIAL SKIN SEALANTS

Antimicrobial skin sealants, usually composed of cyanoacrylate, are sterile liquids applied to the skin after skin preparation, ahead of incision; on drying, they form a film that is meant to prevent migration towards the surgical site for several days. The WHO experts performed a meta-analysis of the contribution of antimicrobial skin sealants to prevention of SSI, based on 8 randomized trials and 1 observational study, with a total 1974 patients [14], and found no significant impact compared to standard skin preparation. Cyanoacrylate is a generic term referring to a class of compounds that readily polymerize to create sealants. The first cyanoacrylates were discovered in 1942 when searching for a compound that would form a solid adhesive for weapon development. Noted as a wondrous compound that stuck to everything it came into contact with, it quickly fell out of favor. With time, however, uses for these compounds were reexplored. Perhaps the most well-known, household cyanoacrylate, ethyl-2-cyanoacrylate, is more commonly known as SuperGlue. In 1998, the Food and Drug Administration (FDA) approved another cyanoacrylate, 2-octyl-cyanoacrylate, for use as a surgical incision sealant.

More commonly known by trade names such as Dermabond (Ethicon, Somerville, NJ), this compound readily polymerizes when exposed to skin, blood, or moisture creating a barrier to the migration of bacteria into surgical incisions. Additionally, cytotoxic compounds released by this polymerization reaction exhibit bactericidal properties [18].

A number of studies have tried to ascertain if cyanoacrylates can effectively reduce the rate of SSI. Again, results have been mixed and study subject numbers small making it difficult to make a recommendation supporting the widespread use of this compound for the purpose of reducing SSI, particularly in light of its expense. In 2010, Chambers et al. performed a best evidence review evaluating the use of cyanoacrylate glue on sternal surgical incision infections. In this review, a substantial benefit reducing both superficial and deep surgical incision infections in cardiac surgery was observed when cyanoacrylate was applied post-operatively (4.9% versus 2.1%) or even preoperatively (10.8% versus 2.7% or 7.8% versus 1.1% depending on the study) [19]. Enthusiasm for applying these antimicrobial sealants immediately prior to incision has been particularly observed in the cardiothoracic literature. In 2011, Iyer et al. published a study evaluating patients undergoing cardiac bypass in which saphenous vein harvesting was performed bilaterally. In each patient, one leg was pre-treated with sealant whereas the contralateral leg was not pre-treated. Treated legs developed a 2% incidence of infection, whereas untreated legs became infected in 25% of patients. The study was terminated after 47 patients were enrolled [20]. A larger, randomized trial by von Eckardstein et al. comparing patients who underwent cardiac surgery, allocated 146 patients to pretreatment with cyanoacrylate sealant to sternal and graft harvest sites and 147 patients to no treatment. In this study, there was a 35% relative risk reduction in the rate of SSI in pretreated patients. Furthermore, in subgroup analysis, this study showed an 83% relative risk reduction in obese patients who received pre-treatment [21].

In 2010, Lipp et al. performed a systematic review submitted to the Cochran Database including all randomized trials evaluating the use of cyanoacrylate sealants as a pretreatment of skin incisions. Sufficient evidence supporting the use of such sealants was not found and studies noted to be lacking in rigor and quality [22]. In 2014, Vierhout et al. randomized 47 patients undergoing lower extremity revascularization surgery to closure with cyanoacrylate. Although there was a trend to less SSI (4% vs 9%), this study failed to reach statistical significance [23].

Therefore—also to avoid unnecessary costs—antimicrobial sealants should not be used after surgical site skin preparation for the purpose of reducing SSI.

IMPREGNATED DRESSINGS

The 1999 Guideline for Prevention of Surgical Site Infection is clear in its recommendations for management of post-operative surgical incision dressings stating that surgical incisions should be protected with a sterile occlusive dressing for 24 to 48 h post-operatively [24]. Furthermore, when a dressing must be changed, sterile technique should be employed. Beyond simple sterile dressings, there has been question raised as to the benefit of enhancing dressings with antibacterial agents. In particular, a number of studies have attempted to show improved surgical incision healing and decreased SSI in surgical incisions treated with silver impregnated surgical incision dressings. It has long been believed that silver containing compounds have antibacterial properties. In 2011, the Cochrane Database released a review of sixteen randomized trials employing silver impregnated dressings. Unfortunately, it was noted that these trials were too small and of poor quality. It was concluded that there is no evidence that one type of dressing is better than another. In addition, one study even showed slowed surgical incision healing in patients treated with impregnated dressings. In 2012, Biffi et al. again evaluated the use of silver impregnated dressings in patients undergoing surgery for colorectal cancer. Fifty-eight patients' surgical incisions were covered with silver-impregnated dressings and 54 patients' surgical incisions were covered with standard dry sterile dressings. After a follow-up of 30 days, a trend to fewer surgical site infections were noted in the silver dressing group (15.5% vs 20.4%), but this was not statistically significant [25].

REFERENCES

[1] Hollenbeak CS, Murphy D, Dunagan WC, Fraser VJ. Nonrandom selection and the attributable cost of surgical-site infections. *Infect Control Hosp Epidemiol*. 2002;23(4):177-82.

[2] Webster J, Alghamdi A. Use of plastic adhesive drapes during surgery for preventing surgical site infection. *Cochrane Database Syst Rev.* 2015(4):CD006353.

[3] Williams JA, Oates GD, Brown PP, Burden DW, McCall J, Hutchison AG, et al. Abdominal wound infections and plastic wound guards. *Br J Surg.* 1972;59(2):142-6.

[4] Cheng KP, Roslani AC, Sehha N, Kueh JH, Law CW, Chong HY, et al. ALEXIS O-Ring wound retractor vs conventional wound protection for the prevention of surgical site infections in colorectal resections (1). *Colorectal Dis.* 2012;14(6):e346-51.

[5] Pinkney TD, Calvert M, Bartlett DC, Gheorghe A, Redman V, Dowswell G, et al. Impact of wound edge protection devices on surgical site infection after laparotomy: multicentre randomised controlled trial (ROSSINI Trial). *BMJ.* 2013;347:f4305.

[6] PAYNE JT. An adhesive surgical drape. *Am J Surg*. 1956;91(1):110-2.

[7] Mohan HM, McDermott S, Fenelon L, Fearon NM, O'Connell PR, Oon SF, et al. Plastic wound retractors as bacteriological barriers in gastrointestinal surgery: a prospective multi-institutional trial. *J Hosp Infect.* 2012;81(2):109-13.

[8] Horiuchi T, Tanishima H, Tamagawa K, Sakaguchi S, Shono Y, Tsubakihara H, et al. A wound protector shields incision sites from bacterial invasion. *Surg Infect (*Larchmt). 2010;11(6):501-3.

[9] Horiuchi T, Tanishima H, Tamagawa K, Matsuura I, Nakai H, Shouno Y, et al. Randomized, controlled investigation of the anti-infective properties of the Alexis retractor/protector of incision sites. *J Trauma.* 2007;62(1):212-5.

[10] Reid K, Pockney P, Draganic B, Smith SR. Barrier wound protection decreases surgical site infection in open elective colorectal surgery: a randomized clinical trial. *Dis Colon Rectum.* 2010;53(10):1374-80.

[11] Mihaljevic AL, Müller TC, Kehl V, Friess H, Kleeff J. Wound edge protectors in open abdominal surgery to reduce surgical site infections: a systematic review and meta-analysis. *PLoS One.* 2015;10(3):e0121187.

[12] Leaper D, Burman-Roy S, Palanca A, Cullen K, Worster D, Gautam-Aitken E, et al. Prevention and treatment of surgical site infection: summary of NICE guidance. *BMJ*. 2008;337:a1924.

[13] Anderson DJ, Podgorny K, Berríos-Torres SI, Bratzler DW, Dellinger EP, Greene L, et al. Strategies to prevent surgical site infections in acute care hospitals: 2014 update. *Infect Control Hosp Epidemiol.* 2014;35 Suppl 2:S66-88.

[14] Leaper DJ, Edmiston CE. World Health Organization: global guidelines for the prevention of surgical site infection. *J Hosp Infect.* 2017;95(2):135-6.

[15] Psaila JV, Wheeler MH, Crosby DL. The role of plastic wound drapes in the prevention of wound infection following abdominal surgery. *Br J Surg.* 1977;64(10):729-32.

[16] Gheorghe A, Calvert M, Pinkney TD, Fletcher BR, Bartlett DC, Hawkins WJ, et al. Systematic review of the clinical effectiveness of wound-edge protection devices in reducing surgical site infection in patients undergoing open abdominal surgery. *Ann Surg.* 2012;255(6):1017-29.

[17] Edwards JP, Ho AL, Tee MC, Dixon E, Ball CG. Wound protectors reduce surgical site infection: a meta-analysis of randomized controlled trials. *Ann Surg.* 2012;256(1):53-9.

[18] de Almeida Manzano RP, Naufal SC, Hida RY, Guarnieri LO, Nishiwaki-Dantas MC. Antibacterial analysis in vitro of ethyl-cyanoacrylate against ocular pathogens. *Cornea.* 2006;25(3):350-1.

[19] Chambers A, Scarci M. Is skin closure with cyanoacrylate glue effective for the prevention of sternal wound infections? *Interact Cardiovasc Thorac Surg.* 2010;10(5):793-6.

[20] Iyer A, Gilfillan I, Thakur S, Sharma S. Reduction of surgical site infection using a microbial sealant: a randomized trial. *J Thorac Cardiovasc Surg. 2*011;142(2):438-42.

[21] von Eckardstein AS, Lim CH, Dohmen PM, Pêgo-Fernandes PM, Cooper WA, Oslund SG, et al. A randomized trial of a skin sealant to reduce the risk of incision contamination in cardiac surgery. *Ann Thorac Surg*. 2011;92(2):632-7.

[22] Lipp A, Phillips C, Harris P, Dowie I. Cyanoacrylate microbial sealants for skin preparation prior to surgery. *Cochrane Database Syst Rev.* 2013(8):CD008062.

[23] Vierhout BP, Ott A, Reijnen MM, Oskam J, van den Dungen JJ, Zeebregts CJ. Cyanoacrylate skin microsealant for preventing surgical site infection after vascular surgery: a discontinued randomized clinical trial. *Surg Infect* (Larchmt). 2014;15(4): 425-30.

[24] Mangram AJ, Horan TC, Pearson ML, Silver LC, Jarvis WR. Guideline for Prevention of Surgical Site Infection, 1999. Centers for Disease Control and Prevention (CDC) Hospital Infection Control Practices Advisory Committee. *Am J Infect Control*. 1999;27 (2):97-132; quiz 3-4; discussion 96.

[25] Biffi R, Fattori L, Bertani E, Radice D, Rotmensz N, Misitano P, et al. Surgical site infections following colorectal cancer surgery: a randomized prospective trial comparing common and advanced antimicrobial dressing containing ionic silver. *World J Surg Oncol.* 2012;10:94.

In: Encyclopedia of Surgery (22 Volume Set)
Editors: Andreas Lehrer and Kristin Mueller
ISBN: 978-1-53618-329-0
© 2020 Nova Science Publishers, Inc.

Chapter 279

WOUND IRRIGATION

Gilberto González Ramírez*
Universidad de Guadalajara Jalisco, México
Department of Surgery and Bariatric Surgery,
Centro Medico Puerta de Hierro, Guadalajara Jalisco, México

ABSTRACT

There are different challenges in the course of a surgery treatment. These go from the type of surgical procedure until the adequate close of the incision. In this scenario, the wound needs an environment that gives the best or almost the best conditions for normal healing. In such conditions, to avoid surgical site infection (SSI) at the time of the surgery or later and to keep clean the wound is one of the main factors to achieve a good environment with the sequence of hormonal activation and inflammatory response, stimulating the regeneration of the tissue with a properly closure. In this chapter, we will talk about the wound irrigation, the different type of solutions to do it, which one is more effective and why in our opinion, and which is the actual consensus about this practice. There are several opinions and different experiences around the world, sometimes more supported by evidence and other not so much.

Keywords: wound irrigation, wound management, surgical site infection, incision, solutions, healing, clousure

INTRODUCTION

Despite extensive scrutiny, multiple collaborative efforts, and significant advances in infection prevention practices, approximately 500,000 surgical site infections (SSIs), with an associated cost estimated at $10 billion, occur annually in the United States alone [1, 2].

At the 2013 annual Association for Professionals in Infection Control and Epidemiology conference, a focus group of key thought leaders in infection prevention and epidemiology,

* Corresponding Author's Email: gilpchmd@yahoo.com.mx.

including epidemiologists, surgeons, and infection prevention directors for major health care systems, convened to address the implications of different surgical irrigation practices. The group agreed that, in an era where health care-associated infections rank as the fifth leading cause of death [3] and carry an attributable per patient cost ranging from $80,000 to $110,000 [4, 5], closer investigation of surgical irrigation practices, as an integral part of the infection prevention process, is warranted [1].

A complete wound history along with anatomic and specific medical considerations for each patient provides the basis of decision making for wound management. It is essential to apply an evidence-based approach and consider each wound individually in order to create the optimal conditions for wound healing [6].

Without proper cleansing and wound care, these acute wounds can lead to complications, such as poor healing and infection. Optimizing wound healing through proper acute wound management involves removal of harmful debris/necrotic tissue, exploration for underlying injuries, control of bacterial burden and appropriate closure [6].

BACKGROUND

Surgical Site Infection

Postoperative surgical site infection (SSI) represents as one of the most frequent complications following abdominal surgery. In the USA, an estimated 300,000 to 500,000 cases of SSI occur annually [8, 24]. Similar figures are reported from Germany [7, 9], the UK [10], and France [11]. The incidence of SSI varies substantially, depending on the type and site of surgery [8]. According to recent high-level randomized controlled trials (RCTs) with standardized SSI definitions, rates range from around 15 % (BaFo trial [12]; PROUD trial [13] up to 25 % (ROSSINI trial) [14] following laparotomy for visceral surgery. SSIs contribute substantially to postoperative morbidity and mortality and have been shown to significantly increase the mean length of hospital stay and treatment costs [11, 15, 24]. Therefore, measures to prevent SSI are urgently needed [16].

Surgical site infections are recognized as a common surgical complication, occurring in about 3% of all surgical procedures and in up to 20% of patients undergoing emergency intra-abdominal procedures [17, 18].

Surgical site infections (SSIs) are an adverse outcome of surgery accounting for the majority of healthcare- associated infections around the world [20, 21]. In developing countries, more than one in ten of all surgical procedures is complicated by an SSI [22]. Although the overall risk of SSIs is much lower in developed countries, they remain a serious threat to patient safet [20, 21]. Such infections increase morbidity and mortality rates and prolong hospital stays [19, 20, 23, 24].

Many factors have been associated with the risk of SSI, and consequently, a range of preventive measures has been proposed. One of these is prophylactic intra-operative wound irrigation (pIOWI), a seemingly simple intervention defined by the flow of a solution across the surface of an open wound to achieve tissue hydration. It removes and dilutes body fluids, bacteria, and cellular debris and additionally may have a bactericidal effect when additives, such as antibiotics or antiseptic agents are used (see Table 1 for an overview of the definitions

used). As many as 97% of surgeons commonly practice IOWI [25, 26]. Nonetheless, it is not part of general practice in every country or hospital. Moreover, methods differ depending on the patient population, surface of application, technique, and solutions used. Similar variations in methods and results can be observed in studies investigating the effect of IOWI [18, 27, 28].

Among the available guidelines on SSI prevention, few have addressed the topic of IOWI and give contradictory recommendations. The guidelines from the United Kingdom National Institute for Health and Care Excellence (NICE), issued in 2008 and updated in 2013, advised against IOWI and intra-peritoneal lavage [29]. In contrast, the 2014 guidelines of the Society for Healthcare Epidemiology of America (SHEA) and the Infectious Diseases Society of America (IDSA) recommend using antiseptic incision lavage [28]. Many of the solutions commonly used for irrigation are not licensed for open incisions by the U.S. Food and Drug Administration [18, 28, 30].

Infection may occur within the surgical site at any depth, starting from the skin itself and extending to the deepest cavity that remains after resection of an organ. Superficial SSI involves tissues down to the fascia (Figure 1), whereas deep SSI extends beneath the fascia but not intracavitary. Organ/space infections are subfascial or intracavitary, but if related directly to an operation, are considered to be SSIs [18].

Table 1. Systematic Review and Meta-Analysis of Randomized Controlled Trials Evaluating Prophylactic Intra-Operative Wound Irrigation for the Prevention of Surgical Site Infections Stijn W. de Jonge,[1,*] SURGICAL INFECTIONS Volume 18, Number 4, 2017 a Mary Ann Liebert, Inc. DOI: 10.1089/sur.2016.272 [19]

Prophylactic intra-operative wound irrigation (pIOWI)	The flow of a solution across the surface of an open wound to achieve wound hydration. It physically removes and dilutes body fluids, bacteria, and cellular debris and has a bactericidal effect when additives such as antibiotics or antiseptic agents are used
Intra-operative wound irrigation as therapeutic intervention	CDC wound class IV was considered a pre-existent infection; irrigation field was considered to be therapeutic, not prophylactic
Intra-operative wound irrigation as prophylactic intervention	CDC wound class I–III was considered potentially contaminated; irrigation was considered to be prophylactic Irrigation of the newly made incision was always considered prophylactic, regardless of the wound classification, as the incision did not exist prior to the procedure and established infection was impossible.
Syringe pressure irrigation	Solution delivered with a syringe with an intravenous catheter applying force by hand.
Pulse pressure irrigation	Irrigation with a mechanical device that delivers pulsatile saline irrigation.
US Centers for Disease Control and Prevention (CDC) surgical wound classification	**Class I/Clean:** An uninfected operative wound in which no inflammation is encountered and the respiratory, alimentary, genital, or uninfected urinary tract is not entered. In addition, clean sites are closed primarily and, if necessary, drained with closed drainage. Operative incisions that follow non-penetrating (blunt) trauma should be included in this category if they meet the criteria. **Class II/Clean–Contaminated:** An operative wound in which the respiratory, alimentary, genital, or urinary tracts are entered under controlled conditions and without unusual contamination. Specifically, operations involving the biliary tract, appendix, vagina, and oropharynx are included in this category, provided no evidence of infection or major break in technique is encountered. **Class III/Contaminated:** Open, fresh, accidental wounds. In addition, operations with major breaks in sterile technique (e.g., open cardiac massage) or gross spillage from the gastrointestinal tract, and incisions in which acute, nonpurulent inflammation is encountered, are included in this category. **Class IV/Dirty–Infected:** Old traumatic wounds with retained devitalized tissue and those that involve existing clinical infection or perforated viscera. This definition suggests that the organisms causing postoperative infection were present in the operative field before the operation.

Cellulitis is infection-related erythema of skin (although other tissues may be affected) without drainage or fluctuance. Abscess refers to localized collections of purulent material within tissue. Necrotizing soft tissue infections (NSTIs) invade tissue widely and rapidly, causing widespread tissue necrosis. When fascia is involved, the infection is referred to correctly as necrotizing fasciitis [18].

Bacteria's Biofilm

The importance of biofilm formation as an element of wound infection has recently been stressed [31]. When bacteria proliferate in wounds, they form microcolonies, which attach to the wound bed and secrete a glycocalyx, or any kind of extracellular matrix, and take up an inter- dependent surface-attached existence. These microbial communities, called 'biofilms,' protect the organisms against antibiotics, antiseptics and host immune defences [32]. Almost all bacterial species form biofilm in vivo [33], thus representing a therapeutic challenge in many, if not most, bacterial diseases. Biofilm formation has also been linked to the emergence of a variety of opportunistic pathogens, such as *Staphylococcus epidermidis* and *Pseudomonas aeruginosa*, which contribute to persistent infections by changing environmental parameters [34, 84].

Definitions

Primary closure, also known as healing by first intention, represents closure of a wound at the time of initial presentation. Wound edges are approximated with suture, adhesives, staples, or strips after appropriate wound management techniques are applied.

Delayed primary closure represents a delay in wound closure for approximately 3–5 days. This is ideal for delayed presentations or for wound infection concerns. If there are no signs of infection and the wound margins appear healthy, removal of devitalized tissue and subsequent primary closure is appropriate.

Healing by secondary intention represents those wounds that are allowed to heal through contraction—a natural, unaided physiologic property. While appropriate wound management practices are involved, no attempt is made to aid wound closure [6].

Clean surgical procedures are those where the operation has affected only integumentary and musculoskeletal soft tissues. Clean- contaminated procedures are those where a hollow viscus (e.g., alimentary, biliary, genitourinary, respiratory tract) has been opened under controlled circumstances (e.g., elective colon surgery). Contaminated procedures are those where bacteria has been introduced extensively into a normally sterile body cavity, but for a period of time too brief to allow infection to become established during surgery (e.g., penetrating abdominal trauma, enterotomy during adhesiolysis for mechanical bowel obstruction). Dirty procedures are those where the surgery is performed to control established infection (e.g., colon resection for complicated diverticulitis) [18].

Normal acute wounds usually progress through an orderly sequential trajectory of hemostasis, proliferation, maturation, and remodeling [35]. After initial injury to the dermal tissue, hemostasis is established by platelet aggregation, fibrin clot formation, and the subsequent coagulation pathways. Local migration of neutrophils and macrophages initiates

an acute inflammatory response to help prevent microbial overgrowth as well as initiate wound healing. During the proliferative phase, deficiencies in soft tissue are replaced with healthy new granulation tissue and matrix material. As healing progresses, the majority of type III collagen formed by fibroblasts is converted to type I collagen to enhance soft tissue strength and integrity [6, 36].

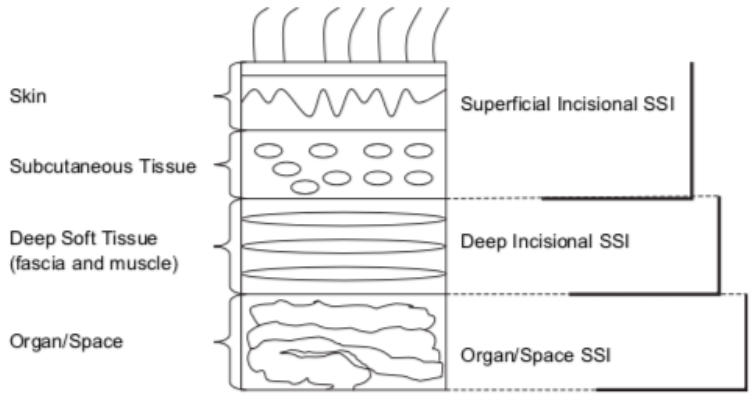

Figure 1. Surgical site infections. (Adapted from Mangram AJ, Horan TC, Pearson ML, et al. The Hospital Infection Control Practices Advisory Committee. Guideline for the prevention of surgical site infection, 1999. *Infect Control Hosp Epidemiol* 1999; 20:247-80).

To ensure the normal physiology of healing, wounds must have sufficient blood supply. Inflammation, infection, or residual debris may delay or prevent adequate healing. As healing occurs, wound tensile strength will approach 20% at 3 weeks and 60% by 4 months [6, 35].

The primary goals for wound care are to attain a functional closure, decrease potential risk for infection, and minimize scar formation [6, 37].

Proper wound preparation improves healing and outcomes. While evidence-based recommendations for wound care exist, many practitioners continue to treat wounds based on personal preference—some employing unnecessary or possibly detrimental techniques [6, 38].

Pressure Irrigation

Wound irrigation is arguably the most important step for optimizing wound healing as long as there is sufficient pressure and volume. Irrigation pressure recommendations that are often cited in the literature come mostly from studies in chronic wounds (such as pressure ulcers). Many studies either failed to describe how pressure was measured or identify the actual realized pressure on the tissues. Within the realm of acute wound management, the term ‘high pressure’ irrigation is frequently used to describe the best practice for wound irrigation. However, it is important to understand that this term reflects a wide range of pressures and a paucity of well-supported literature as to the deliverable irrigant pressure [6].

Classically, equipment used for irrigation has included bulb syringes, syringes with an attached needle or catheter, intravenous or irrigation fluid in plastic containers with a pour cap or nozzle, and pressure canisters. Puncturing containers of irrigation fluid and manually

squeezing are inadequate for pressure irrigation [39]. Studies have shown that when using a syringe with an attached 19-gauge needle, pressures range from 11 to 31 psi—however, only 8 psi may reach the wound [39, 40]. Current medical devices have been designed to provide a more consistent and measurable application of wound irrigation pressure. Clinicians currently believe that these advances may provide a better approach to wound cleansing [6, 41].

There is some evidence that very high pressure irrigation may actually increase infection rates due to further tissue damage. This is particularly evident in highly vascularized wounds, such as the face and scalp [6, 42].

A study by Chisholm found no difference in infection rates of lacerations that required closures when irrigation was done using a pressure canister compared to a syringe/needle irrigation (5.0% vs. 3.6%; P = 0.05) [43]. Longmire found that high pressures of 13 psi, generated by using a needle and syringe, were effective in reducing inflammation and infection when compared to irrigation using a bulb syringe associated with lower pressures [40]. Pressures of 8–12 psi in the wound are believed to overcome the adhesive forces of the introduced bacterium [40, 43]. However, both of these studies were limited by the inability to measure consistent pressures across the tissue beds being irrigated [6].

Irrigation Volume

Irrigation volumes of 50 to 100 ml per cm of laceration length have been reported [44, 43]. The volume of irrigation should be adjusted to the wound characteristics and degree of contamination. All wound surfaces should be irrigated and may require pulling open the wound edges and flaps for exposure [44]. Repeat irrigation has been recommended after any re-examination of the wound [6, 45].

Irrigation Solution

Decontamination, including brushing off any dry chemicals prior to copious irrigation, is an essential part of the initial wound management. It is important to consider toxicological exposure as it relates to wound irrigation. Antiseptic solutions, such as povidone-iodine, chlorhexidine, and hydrogen peroxide, are toxic to tissues and may impede acute wound healing [41]. The current literature supports no difference in ED wound infection rates when using potable tap water versus saline in adult and pediatric populations [46]. Further, studies comparing saline irrigation with diluted 1% povidone-iodine have shown no difference in infection rates [43, 47, 48]. A study of chemical burns (N = 24) recommended copious amounts of potable tap water or saline for irrigation and decontamination [6, 49].

There are 3 critical variables in the surgical irrigation process: delivery, volume, and solution additives. In the absence of formal guidelines, anecdotal evidence suggests that a wide variety of practices are used with regard to each of these three variables [1].

Delivery

Surgical irrigation delivery includes choosing delivery method, pressure (the American College of Surgeons [ACS] defines high pressure as 15 to 35 psi and low pressure as 1 to 15 psi [50], and continuous or pulsatile flow. Neither the ACS nor the Association of periOperative Registered Nurses (AORN) has published practice recommendations on surgical irrigation delivery [1].

A number of studies have been performed to evaluate optimal pressures for wound irrigation. The majority of these have shown high-pressure irrigation to be most effective in bacteria and foreign material removal; however, high-pressure irrigation has also been associated with impairment of the local immune response, tissue damage, and propagation of bacteria deeper into tissue or bone [51]. These negative effects suggest that high-pressure lavage should be limited to conditions where contamination is severe and the anticipated difficulty in bacterial removal outweighs the potential of propagation of bacteria [51]. Whereas no official guidelines exist for optimal pressures, recommendations have suggested utilizing pressures of 8 to 12 psi in traumatic wounds in an effort to overcome the adhesive forces of bacteria [1, 52].

Volume

Similar to the lack of data on delivery of surgical irrigation, there are no official recommendations on irrigant fluid volumes [51]. Additionally, there are no published human studies. Animal studies have indicated that increasing volume improves bacteria and foreign material removal to a point, but excessive volume also reduces the concentration of beneficial cytokines involved in the correct healing procedure. Thus, optimal volumes remain undefined [1, 51, 53].

Additives

Over the years, however, a variety of different additives, commonly grouped into the categories of antibiotics, surfactants, and antiseptics, have been combined with irrigation fluids in an attempt to optimize infection prevention. Unfortunately, there are few well-designed clinical trials looking at these practices and, hence, no established clinical guideline [1, 54].

Intraoperative Wound Irrigation (IOWI)

Intraoperative wound irrigation is the flow of a solution across the surface of an open wound to achieve wound hydration and it is widely practised to help prevent SSI [55, 56]. It is intended to act as a physical cleaner by removing cellular debris, surface bacteria and body fluids, to have a diluting effect on possible contamination, and to function as a local

antibacterial agent when an antiseptic or antibiotic agent is used. Up to 97% of surgeons state that they use intraoperative irrigation [55, 57].

However, practices vary depending on the patient population, the surface of application and solutions used. Similar variations in methodology and results can be observed in studies investigating the effect of wound irrigation [57, 58].

Results Forty-one RCTs reporting primary data of over 9000 patients were analyzed. Meta-analysis on the effect of IOWI with any solution compared to no irrigation revealed a significant benefit in the reduction of SSI rates (OR = 0.54, 95% confidence Interval (CI) [0.42; 0.69], $p < 0.0001$) [16].

Meta-analysis showed a significant benefit of IOWI with any solution in comparison to no irrigation [16].

Further, sub- group analysis showed that the estimated effect in reduction of postoperative SSI was significant only for IOWI with topical antibiotics or PVP-I but not for saline [16].

IOWI with Saline

Plain saline is a widely used irrigation solution, as it is isotonic and does not interfere with wound healing [59]. Furthermore, it is generally used to clean wounds from blood clots and necrotic tissue. However, evidence for IOWI with saline to prevent SSI is scarce. Only three RCTs comparing saline with no irrigation were identified [60, 61, 62], and meta-analysis showed no statistically significant effect on the rate of SSIs (Figure 4c, OR = 0.64, 95% CI [0.28; 1.46], $p = 0.29$) [16].

IOWI with PVP-I

Much debate has also surfaced over the use of PVP-I, and the use of this solution has been removed from many wound management regimes because of a putative negative effect on tissue regeneration. PVP-I demonstrates dose-dependent levels of tissue toxicity but is still better tolerated than preparations containing chlorhexidine or octenidine [63]. However, when studied in a clinical context, a recent evidence-based review of the effects of PVP-I solutions on wound healing failed to show a negative effect [64]. Consequently, the majority of high-quality trials analyzed in that review supported the use of PVP-I for IOWI. The NICE guidelines do not recommend the use of IOWI or intra-operative skin redisinfection with PVP-I products [10, 16, 65]. Nevertheless, the recently published recommendations for SSI prophylaxis by the World Health Organization (WHO) recommend its use at at a 10% concentration, diluted in plain saline [83].

IOWI with Topical Antibiotics

In clinical practice, IOWI with solutions containing antibiotics used to be widespread in the 1980s, especially in dirty-contaminated abdominal or trauma/orthopedic surgery [66].

Currently, guidelines do not support the use of antibiotic IOWI anymore, due to the lack of evidence for their benefit and the potential enhancement of microbial resistance [10, 16].

Especially in obese patients, who are predisposed to develop SSI, infusion of topical antibiotics to the wound allowed to achieve higher local concentrations in the poorly perfused subcutaneous adipose tissue than by intravenous application [67]. In line with this data, a significant reduction of SSIs in this subgroup analysis of 19 trials comparing IOWI with antibiotic solutions vs. no irrigation (Figure 4a; OR = 0.39, 95% CI [0.27; 0.55], $p < 0.0001$). However, different antibiotics, concentrations, and applications were used meaning that heterogeneity was high and no regime can currently be recommended unequivocally [16].

HOWEVER IN ONE META-ANALYSIS THE AUTHORS CONSIDERED...

Evidence of low quality shows that prophylactic incisional irrigation with aqueous PVP-I solution has a significant benefit on the SSI rate, particularly in clean and clean- contaminated wounds. No dose–response effect was detected. Referring to incisional irrigation with saline, evidence of moderate to very low quality shows a significant effect on SSI rate when applied with force or using pulse pressure, but not with regular irrigation. There is no significant benefit to the use of antibiotic solutions for prophylactic incisional wound irrigation or for the use of pIOWI in the abdomen or mediastinum [19].

The most commonly used irrigation solution is saline followed by aqueous PVP-I or antibiotic solutions [68, 69, 70]. The efficacy and clinical safety of irrigation with these solutions has been the subject of debate [19, 71, 72].

Wound irrigation using aqueous chlorhexidine (CHX) may be an alternative when extrapolating the favourable results from alcohol-based CHX used for pre-operative skin preparation, but clinical data are lacking. The results of aqueous 0.05% chlorhexidine gluconate as a wound irrigation fluid in the laboratory and animal studies are promising [19, 73, 74].

Charles E. Edmiston Et al. they considered the CHG (clorhexidine glouconato), as other alternative to wound irrigation, and they consider ... A new focus for the use of CHG in surgical patients involves irrigation of the wound prior to closure with 0.05% CHG followed by saline rinse. Recent laboratory studies suggest that, following a 1-minute exposure, 0.05% CHG produces a >5-log reduction against selective health care-associated pathogens and reduces microbial adherence to the surface of implantable biomedical devices [75].

STATEMENTS OF DIFFERENT SCIENTIFIC SOCIETIES ABOUT WOUND IRRIGATION

World Health Organization

- The panel considers that there is insufficient evidence to recommend for or against saline irrigation of incisional wounds before closure for the purpose of preventing SSI [57]

- The panel suggests considering the use of irrigation of the incisional wound with an aqueous PVP-I solution before closure for the purpose of preventing SSI, particularly in clean and clean- contaminated wounds [57]
- The panel suggests that antibiotic incisional wound irrigation before closure should not be used for the purpose of preventing SSI. *(Conditional recommendations/low quality of evidence)* [57]

Centers for Disease Control and Prevention. Guideline for the Prevention of Surgical Site Infection, 2017

- 9A. Consider intraoperative irrigation of deep or subcutaneous tissues with aqueous iodophor solution for the prevention of SSI. Intraperitoneal lavage with aqueous iodophor solution in contaminated or dirty abdominal procedures is not necessary. (Category II–weak recommendation; moderate-quality evidence suggesting a trade-off between clinical benefits and harms.) [76]
- 10. Randomized controlled trial evidence was insufficient to evaluate the tradeoffs between the benefits and harms of repeat application of antiseptic agents to the patient's skin immediately before closing the surgical incision for the prevention of SSI. (No recommendation/unresolved issue) [76].

World Health Organization. Global Guidelines for the Prevention of Surgical Site Infection

Saline wound irrigation: There is insufficient evidence to recommend for or against saline irrigation of incisional wounds for the purpose of preventing SSI [77].

Povidone iodine irrigation: Consider the use of irrigation of the incisional wound with an aqueous povidone iodine solution before closure for the purpose of preventing SSI, particularly in clean and clean-contaminated wounds [77].

Antibiotic irrigation: Antibiotic incisional wound irrigation before closure should not be used for the purpose of preventing SSI [77].

There are a homogeneous consensus, however still a lack of randomized trials in the actual literature.

GENERAL CONCLUSION

High-quality evidence from future RCTs using standardized outcome parameters is awaited urgently to clearly establish the role of IOWI in abdominal surgery on an evidence-based level in order to encounter the substantial problem of this huge health care burden worldwide [16].

Wound irrigation remains controversial as a means of reducing the risk of SSI. There is little information to suggest that routine low-pressure washing of an incision with saline reduces the risk of SSI [78], but high pressure (i.e., pulse-irrigation) may be beneficial [79].

An increasing body of knowledge suggests that topical antibiotics placed into the incision during surgery can minimize the risk of SSI [80, 81], but it might be desirable to accomplish the same result with topical antiseptics rather than antibiotics to minimize the possibility of the development of resistance [18].

Josie Chundamala et al. In their conclusions they said:

> In conclusion, the evidence suggests that povidone-iodine irrigation may be effective in preventing surgical site infection. However, more studies, especially double-blind RCTs, should be conducted to determine the "ideal" solution of povidone-iodine irrigation as well as specific risks associated with its use [82].

CONCLUSION

In our experience, we consider that the irrigation of the wound with saline solution plays a role for intraoperative cleaning the wound of detritus, residual material, fibrine, clots or even intraluminal gastric or intestinal content. However, there is insufficient evidence to support its isolated use for prevention of SSI. The wound irrigation with a pvp-i solution has demonstrated more evidence as preventive measure, mainly in clean or clean-contaminated procedures. In more contaminated areas, there is not enough evidence to establish a strong recommendation, but it makes sense to apply this measure also in contaminated or dirty surgeries, as it may only represent a benefit. There is no evidence of adverse effects or development of bacterial resistance associated with its use.

On the other hand, we do not recommended the addition of antibiotic in the solution for irrigation. Actual evidence has demonstrated that antibiotics do not imply a further reduction in SSI rate than that of pvp-i solutions, and represent a risk for development of bacterial resistances. There is some evidence that topical antibiotic may be beneficial in obese patients, but further studies must be conducted to clarify this item.

In conclusion, volume, pressure and addition of drugs are items that still remain controversial. More randomized trials in these issues are necessary to get more evidence-based experience.

REFERENCES

[1] Surgical wound irrigation: A call for evidence-based standardization of practice Sue Barnes RN, BSN, CIC , Maureen Spencer RN, MEd, CIC, Denise Graham , Helen Boehm Johnson MD, *American Journal of Infection Control* 42 (2014) 525-9.

[2] Anderson DJ, Kaye KS, Classen D, Arias KM, Podgorny K, Burstin H, et al. Strategies to prevent surgical site infections in acute care hospitals. *Infect Control Hosp Epidemiol* 2008;29:551-61.

[3] Stone PW. Economic burden of healthcare-associated infections: an American perspective. Expert Rev Pharmacoeconomics *Outcomes Res* 2009;9:417-22.

[4] Tubaki VR, Rajasekaran S, Shetty AP. Effects of using intravenous antibiotic only versus local intrawound vancomycin antibiotic powder application in addition to intravenous antibiotics on postoperative infection in spine surgery in 907 patients. *Spine* 2013;38:2149-55.

[5] Greco G, Shi W, Michler R, Blackstone E, Kron I, Moquete E, et al. *The economic impact of healthcare associated infections in cardiac surgery*. 2013. Accessed December 30, 2013.

[6] Acute wound management: revisiting the approach to assessment, irrigation, and closure considerations Bret A. Nicks & Elizabeth A. Ayello & Kevin Woo & Diane Nitzki-George & R. Gary Sibbald Received: 26 April 2010 / Accepted: 30 June 2010 / Published online: 27 August 2010 # Springer-Verlag London Ltd 2010 *Int J Emerg Med* (2010) 3:399–407 DOI 10.1007/s12245-010-0217-5.

[7] Gastmeier P, Brandt C, Sohr D, Babikir R, Mlageni D, Daschner F et al. (2004) Postoperative Wundinfektionen nach stationären und ambulanten Operationen. *Bundesgesundheitsbl Gesundheitsforsch Gesundheitsschutz* 47(4):339–344. doi:10. 1007/s00103-004-0805-8.

[8] de Lissovoy G, Fraeman K, Hutchins V, Murphy D, Song D, Vaughn BB (2009) Surgical site infection: incidence and impact on hospital utilization and treatment costs. *Am J Infect Control* 37(5):387–397. doi:10.1016/j.ajic.2008.12.010.

[9] Geffers C (2011) *Postoperative Wundinfektionen*. Institut für Hygiene und Umweltmedizin der Charité, Berlin.

[10] National Institute for Health and Clinical Excellence (NICE) (2008) Surgical site infection—prevention and treatment of surgical site in- fection. *NICE Clinical Guideline* 74. RCGO, London.

[11] Lamarsalle L, Hunt B, Schauf M, Szwarcensztein K, Valentine WJ (2013) Evaluating the clinical and economic burden of healthcare- associated infections during hospitalization for surgery in France. *Epidemiol Infect* 141(12):2473–2482. doi:10.1017/ s0950268813000253.

[12] Mihaljevic AL, Schirren R, Ozer M, Ottl S, Grun S, Michalski CW et al. (2014) Multicenter double-blinded randomized controlled trial of standard abdominal wound edge protection with surgical dressings versus coverage with a sterile circular polyethylene drape for preven- tion of surgical site infections: a CHIR-Net Trial (BaFO; NCT01181206). *Ann Surg* 260(5):730–739. doi:10.1097/SLA. 0000000000000 954.

[13] Diener MK, Knebel P, Kieser M, Schuler P, Schiergens TS, Atanassov V et al. (2014) Effectiveness of triclosan-coated PDS Plus versus uncoated PDS II sutures for prevention of surgical site infection after abdominal wall closure: the randomised controlled PROUD trial. *Lancet* 384(9938):142–152. doi:10.1016/S0140- 6736 (14)60238-5.

[14] Pinkney TD, Calvert M, Bartlett DC, Gheorghe A, Redman V, Dowswell G et al. (2013) Impact of wound edge protection devices on surgical site infection after laparotomy: multicentre randomised controlled trial (ROSSINI Trial). *BMJ* 347:f4305. doi:10.1136/bmj. f4305.

[15] Merle V, Germain JM, Chamouni P, Daubert H, Froment L, Michot F et al. (2000) Assessment of prolonged hospital stay attributable to surgical site infections using appropriateness evaluation protocol. *Am J Infect Control* 28(2):109–115.

[16] Intra-operative wound irrigation to reduce surgical site infections after abdominal surgery: a systematic review and meta-analysis Tara C. Mueller & Martin Loos & Bernhard Haller & André L. Mihaljevic & Ulrich Nitsche & Dirk Wilhelm & Helmut Friess & Jörg Kleeff & Franz G. Bader Received: 22 September 2014 / Accepted: 1

February 2015 / Published online: 14 February 2015 # Springer-Verlag Berlin Heidelberg 2015 Langenbecks *Arch Surg* (2015) 400:167–181 DOI 10.1007/s00423-015-1279-x.

[17] Barie PS. Surgical site infections: Epidemiology and prevention. *Surg Infect* (Larchmt)2002; 3(Suppl 1):S9–21.

[18] Surgical Site Infections Philip S. Barie, MD, MBA*, Soumitra R. Eachempati, MD. Division of Critical Care and Trauma, Department of Surgery P713A, Weill Medical College of Cornell University, 525 East 68 Street, New York, NY 10021, USA. *Surg Clin N Am* 85 (2005) 1115–1135.

[19] Systematic Review and Meta-Analysis of Randomized Controlled Trials Evaluating Prophylactic Intra-Operative Wound Irrigation for the Prevention of Surgical Site Infections Stijn W. de Jonge,[1,]* *Surgical Infections* Volume 18, Number 4, 2017 a Mary Ann Liebert, Inc. DOI: 10.1089/sur.2016.272.

[20] Magill SS, Edwards JR, Bamberg W, et al. Multistate point-prevalence survey of health care-associated infec- tions. *N Engl J Med* 2014;370:1198–1208.

[21] Grisˇkevicˇiene_ J. *European Centre for Disease Prevention and Control. Surveillance of Surgical Site Infections in Europe 2010–2011*. Stockholm. ECDC. 2013.

[22] Allegranzi B, Bagheri Nejad S, Combescure C, et al. Burden of endemic health-care-associated infection in de- veloping countries: Systematic review and meta-analysis. *Lancet* 2011;377:228–241.

[23] De Lissovoy G, Fraeman K, Hutchins V, et al. Surgical site infection: Incidence and impact on hospital utilization and treatment costs. *Am J Infect Control* 2009;37:387–397.

[24] Kirkland KB, Briggs JP, Trivette SL, Wilkinson WE, Sexton DJ (1999) The impact of surgical-site infections in the 1990s: attribut- able mortality, excess length of hospitalization, and extra costs. *Infect Control Hosp Epidemiol* 20(11):725–730. doi:10.1086/501572.

[25] Whiteside OJ, Tytherleigh MG, Thrush S, et al. Intra- operative peritoneal lavage: Who does it and why? *Ann R Coll Surg Engl* 2005;87:255–258.

[26] Pivot D, Tiv M, Luu M, et al. Survey of intraoperative povidone–iodine application to prevent surgical site infec- tion in a French region. *J Hosp Infect* 2011;77:363–364.

[27] Raymond DP, Pelletier SJ, Crabtree TD, et al. Surgicalinfection and the age in population. *Am Surg* 2001;67:827–32.

[28] Pomposelli JJ, Baxter JK III, Babineau TJ, et al. Early postoperative glucose control predicts nosocomial infection rate in diabetic patients. *JPEN J Parenter Enteral Nutr* 1998;22:77–81.

[29] Latham R, Lancaster AD, Covington JF, et al. The association of diabetes and glucose control with surgical-site infections among cardiothoracic surgery patients. *Infect Control Hosp Epidemiol* 2001; 22:607–12.

[30] Delgado-Rodriguez M, Medina-Cuadros M, Martinez-Gallego G, et al. Total cholesterol, HDL cholesterol, and risk of nosocomial infection: a prospective study in surgical patients. *Infect Control Hosp Epidemiol* 1997;18:9–18.

[31] James GA, Swogger E, Wolcott R, Pulcini ED, Secor P, Sestrich J, Costerton JW, Stew- art PS: Biofilms in chronic wounds. *Wound Repair Regen* 2008;16:37–44.

[32] Lewis K: Riddle of biofilm resistance. *Anti- microb Agents Chemother* 2001;45:999–1007.

[33] Jefferson KK: What drives bacteria to pro- duce a biofilm? *FEMS Microbiol Lett* 2004; 236:163–173.

[34] Evaluation of the Efficacy and Tolerability of a Solution Containing Propyl Betaine and Polihexanide for Wound Irrigation M. Romanelli V. Dini S. Barbanera M. S. Bertone Wound Healing Research Unit, Department of Dermatology, University of Pisa, Pisa, Italy *Skin Pharmacol Physiol* 2010;23(suppl 1):41–44 DOI: 10.1159/000318266.

[35] Barbul A (2005) Wound healing. In: Brunicardi FC, Andersen DK, Billiar TR et al. (eds) *Schwartz's principles of surgery, Eighthth edn*. The McGraw-Hill Companies, Inc, Columbus, pp 165–182.

[36] Woo K, Ayello EA, Sibbald RG (2007) The edge effect: current therapeutic options to advance the wound edge. *Adv Skin Wound Care* 20(2):99–11.

[37] Percival NJ (2002) Classification of wounds and their management. *Surgery* 20(5):114–117.

[38] Howell JM, Chisholm CD (1992) Outpatient wound preparation and care: a national survey. *Ann Emerg Med* 21(8):976–981.

[39] Singer AJ, Hollander JE, Subramanian S, Malhotra AK, Villez PA (1994) Pressure dynamics of various irrigation techniques com- monly used in the emergency department. *Ann Emerg Med* 24 (1):36–40.

[40] Longmire AW, Broom LA, Burch J (1987) Wound infection following high-pressure syringe and needle irrigation. *Am J Emerg Med* 5(2):179–81.

[41] Rodeheaver GT, Ratliff (2008) Wound cleansing, wound irrigation, wound disinfection. In: Krasner D, Rodeheaver G, Sibbald RG (eds) Chronic wound care, Chapter 34. *HMP Communications*, Malvern.

[42] Hollander JE, Singer AJ, Valentine SM, Shofer FS (2001) Risk factors for infection in patients with traumatic lacerations. *Acad Emerg Med* 8(7):716–720.

[43] Chisholm CD, Cordell WH, Rogers K, Woods JR (1992) Comparison of a new pressurized saline canister versus syringe irrigation for laceration cleansing in the emergency department. *Ann Emerg Med* 21(11):1364–1367.

[44] Lammers RL, Hudson DL, Seaman ME (2003) Prediction of traumatic wound infection with a neural network-derived decision model. *Am J Emerg Med* 21(1):1–7.

[45] Grotz MR, Allami MK, Harwood P, Pape HC, Krettek C, Giannoudis PV (2005) Open pelvic fractures: epidemiology, current concepts of management and outcome. *Injury* 36(1):1–13.

[46] Fernandez R, Griffiths R (2008) Water for wound cleansing. *Cochrane Database Syst Rev* 23(1):CD003861.

[47] Khan MN, Naqvi AH (2006) Antiseptics, iodine, povidone iodine and traumatic wound cleansing. *J Tissue Viability* 16(4):6–10.

[48] Watt BE, Proudfoot AT, Vale JA (2004) Hydrogen peroxide poisoning. *Toxicol Rev* 23(1):51–57.

[49] Cartotto RC, Peters WJ, Neligan PC, Douglas LG, Beeston J (1996) Chemical burns. *Can J Surg* 39(3):205–211.

[50] Prucz RB, Sullivan SR, Klein MB. *Acute wound care. ACS surgery: principles and practice.* Ontario, Canada: Decker Intellectual Properties; 2012.

[51] Anglen JO. Wound irrigation in musculoskeletal injury. *J Am Acad Orthop Surg* 2001;9:219-26.

[52] Hays EP. Wound care: from door to discharge. *Proceedings of the Boston Scientific Assembly*; October 6, 2009; Boston, MA.

[53] Gabriel A, Schraga E, Windle ML. *Wound irrigation*. 2011. Available from: www.emedicine.medscape.com/article/1895071. Accessed July 20, 2013.

[54] Edmiston CE, Bruden B, Rucinski MC, Henen C, Graham MB, Lewis BL. Reducing the risk of surgical site infections: doeschlorhexidine gluconate provide a risk reduction benefit? *Am J Infect Control* 2013;41:549-55.

[55] Suzuki T, Sadahiro S, Maeda Y, Tanaka A, Okada K, Kamijo A. Optimal duration of prophylactic antibiotic administration for elective colon cancer surgery: A randomized, clinical trial. *Surgery*. 2011;149(2):171-8.

[56] Baas-Vrancken Peeters MJ, Kluit AB, Merkus JW, Breslau PJ. Short versus long-term postoperative drainage of the axilla after axillary lymph node dissection. A prospective randomized study. *Breast Cancer Res Treat.* 2005;93(3):271-5.

[57] *Global Guidelines for the Prevention of Surgical Site Infection. I*. World Health Organization. ISBN 978 92 4 154988 2 Subject headings are available from WHO institutional repository © World Health Organization 2016.

[58] Clegg-Lamptey JN, Dakubo JC, Hodasi WM. Comparison of four-day and ten-day post- mastectomy passive drainage in Accra, Ghana. *East Afr Med J*. 2007;84(12):561-5.

[59] Fernandez R, Griffiths R, Ussia C (2002) Water for wound cleansing. *Cochrane Database Syst Rev* 4, CD003861. doi:10.1002/14651858. cd003861.

[60] Cervantes-Sanchez CR, Gutierrez-Vega R, Vazquez-Carpizo JA, Clark P, Athie-Gutierrez C (2000) Syringe pressure irrigation of subdermic tissue after appendectomy to decrease the incidence of postoperative wound infection. *World J Surg* 24(1):38–41, discussion -2.

[61] Al-Ramahi M, Bata M, Sumreen I, Amr M (2006) Saline irrigation and wound infection in abdominal gynecologic surgery. *Int J Gynaecol Obstet* 94(1):33–36. doi:10.1016/ j.ijgo.2006.03.030.

[62] Gungorduk K, Asicioglu O, Celikkol O, Ark C, Tekirdag AI (2010) Does saline irrigation reduce the wound infection in caesarean deliv- ery? *J Obstet Gynaecol* 30(7):662–666. doi:10.3109/01443615.2010. 494206.

[63] Harrop JS, Styliaras JC, Ooi YC, Radcliff KE, Vaccaro AR, Wu C (2012) Contributing factors to surgical site infections. *J Am Acad Orthop Surg* 20(2):94–101. doi:10.5435/jaaos-20-02-094.

[64] Banwell H (2006) What is the evidence for tissue regeneration im- pairment when using a formulation of PVP-I antiseptic on open wounds? *Dermatology* 212(Suppl 1):66–76. doi:10.1159/000089202.

[65] Alexander JW, Solomkin JS, Edwards MJ (2011) Updated recom- mendations for control of surgical site infections. *Ann Surg* 253(6): 1082–1093. doi:10.1097/SLA. 0b013e31821175f8.

[66] Tejwani NC, Immerman I (2008) Myths and legends in orthopaedic practice: are we all guilty? *Clin Orthop Relat Res* 466(11):2861– 2872. doi:10.1007/s11999-008-0458-2.

[67] Alexander JW, Rahn R, Goodman HR (2009) Prevention of surgical site infections by an infusion of topical antibiotics in morbidly obese patients. *Surg Infect* 10(1):53–57. doi:10.1089/sur.2008.038.

[68] Whiteside OJ, Tytherleigh MG, Thrush S, et al. Intra- operative peritoneal lavage: Who does it and why? *Ann R Coll Surg Engl* 2005;87:255–258.

[69] BusinessWire. *Survey Conducted at AORN Congress Re- veals Need for New and Better Surgical Site Infection Prevention Strategies*. 2013 [Available at: www. businesswire.com/news/home/20130311005412/en/Survey-Conducted-AORNCongress -Reveals-Surgical-Site.

[70] Galland RB, Saunders JH, Mosley JG, et al. Prevention of wound infection in abdominal operations by peroperative antibiotics or povidone–iodine: A controlled trial. *Lancet* 1977;2:1043–1045.

[71] Barnes S, Spencer M, Graham D, et al. Surgical wound irrigation: A call for evidence-based standardization of practice. *Am J Infect Control* 2014;42:525–529.

[72] Edmiston CE Jr, Bruden B, Rucinski MC, et al. Reducing the risk of surgical site infections: Does chlorhexidine gluconate provide a risk reduction benefit? *Am J Infect Control* 2013;41(5 Suppl):S49–S55.

[73] Edmiston CE Jr, Bruden B, Rucinski MC, et al. Reducing the risk of surgical site infections: Does chlorhexidine gluconate provide a risk reduction benefit? *Am J Infect Control* 2013;41:S49–S55.

[74] Platt J, Bucknall RA. An experimental evaluation of anti- septic wound irrigation. *J Hosp Infect* 1984;5:181–188.

[75] Reducing the risk of surgical site infections: Does chlorhexidine gluconate provide a risk reduction benefit? Charles E. Edmiston, Jr. PhD, *American Journal of Infection Control* 41 (2013) S49-S55.

[76] Centers for Disease Control and Prevention Guideline for the Prevention of Surgical Site Infection, 2017 Sandra I. Berríos-Torres, MD *JAMA Surg*. 2017;152(8):784-791. doi:10.1001/jamasurg.2017.0904 Published online May 3, 2017. Corrected on June 21, 2017.

[77] WHO. *Global guidelines for the prevention of surgical site infection*.

[78] Platell C, Papadimitriou JM, Hall JC. The influence of lavage on peritonitis. *J Am Coll Surg* 2000;191:672–80.

[79] Cervantes-Sanchez CR, Gutierrez-Vega R, Vasquez-Carpizio JA, et al. Syringe pressure ir- ritation of subdermic tissue after appendectomy to decrease the incidence of postoperative wound infection. *World J Surg* 2000;24:38–41.

[80] Andersen B, Bendtsen A, Holbraad L, et al. Wound infections after appendectomy. I. Acontrolled trial on the prophylactic efficacy of topical ampicillin in non-perforated appendicitis. *Acta Chir Scand* 1972;138:531–6.

[81] O'Connor LT Jr, Goldstein M. Topical perioperative antibiotic prophylaxis for minor clean inguinal surgery. *J Am Coll Surg* 2002; 194:407–10.

[82] The efficacy and risks of using povidone- iodine irrigation to prevent surgical site infection: an evidence-based review Josie Chundamala, MA; James G. Wright, MD, *MPH Can J Surg*, Vol. 50, No. 6, December 2007 473.

[83] Allegranzi B, ZayedB, Bischoff P, et al. New WHO recommendations in intraoperative and postoperative measures for surgical site infection prevention: an evidence-based global perspective. *Lancet Infect Dis* 2016;16:e288-e303.

[84] Costerton, JW, Stewart PS, Greenberg, EP: Bacterial biofilm: a common cause of persis- tent infections. *Science* 1999;284:1318–1322.

In: Encyclopedia of Surgery (22 Volume Set)
Editors: Andreas Lehrer and Kristin Mueller
ISBN: 978-1-53618-329-0
© 2020 Nova Science Publishers, Inc.

Chapter 280

TOPICAL INTRAPERITONEAL IRRIGATION

Jaime Ruiz-Tovar[1,*], MD, PhD and Carolina Llavero[2,†]
[1]Center of Excellence for the Study and Treatment of Obesity and Diabetes, Valladolid, Spain
[2]Department of Surgical Nursery, Sureste Hospital, Madrid, Spain

ABSTRACT

Peritoneal irrigation achieves a reduction in bacterial contamination. The addition of antibiotics has shown some benefits in experimental studies, but human ones have obtained controversial results. The evidence about the use of antiseptics is limited.

In this chapter we will review the available evidence.

Keywords: peritoneal irrigation, antibiotic, surgical-site infection

INTRODUCTION

Peritoneal lavage has been adopted by many surgeons for use in abdominal operations. This lavage usually consists of peritoneal irrigation with a variable volume of 0.9% sodium chloride (normal saline). The effects of lavage have been widely studied for management of patients with bacterial peritonitis, although the appropriate volume and carrier remain unclear, as does the benefit of including antibiotics or antiseptics. To reduce the morbidity and mortality of intraabdominal infections, surgeons aim to isolate and control the source of contamination. Lavage has been proposed to remove bacterial contamination and other materials that may promote bacterial proliferation (e.g., blood) and proinflammatory cytokines that may enhance local inflammation. Therefore, flushing the peritoneal cavity may reduce the bacterial load, inhibit bacterial proliferation, and possibly minimize peritoneal adhesions. Antibiotics may be combined with the lavage to further reduce bacterial survival. Antibiotics used have included metronidazole, gentamicin sulfate, cephalothin, lincomycin,

[*] Corresponding Author's Email: jruiztovar@gmail.com.
[†] Carolina Llavero, RN.

kanamycin, doxycycline, and ampicillin. Nearly all of the previously reported studies were conducted in peritonitis situations, and most of them were under experimental conditions and stated that antibiotic lavage was safe. However, the efficacy of the lavage was not always demonstrated, especially when comparisons were made with historic controls.

Clearly, the efficacy of peritoneal irrigations in peritonitis is unclear. The concept of lavaging a contaminated or infected peritoneal cavity makes good sense intuitively. However, because microbes adhere to mesothelial cells, it is very difficult to wash them off the peritoneal surface. During fecal contamination of the peritoneal cavity, it has been demonstrated that bacteria that adhered to the mesothelium were resistant to intraperitoneal lavage, resulting in only transitory reductions of bacterial populations. Peritoneal irrigation with normal saline is not sufficient to eliminate all fecal contamination produced during the surgical act. The results obtained after antibiotic lavage defend the hypothesis that the topical effect of the antibiotics could completely inhibit the growth of bacteria in the peritoneum, even when microorganisms have adhered to the mesotelial cells. Diverse antimicrobial drugs have been used in different studies, most of which were peritonitis cases.

The results obtained are contradictory. Some authors have presented similar mortality and intra-abdominal infection rates compared with normal saline irrigation; others have shown antibiotic lavage to protect against intra-abdominal infection and reduce the mortality rate by up to 65%. A meta-analysis clearly shows the superior value of antibiotics in lavage during experimental peritonitis compared with saline lavage. Although including antibiotics in lavage solutions optimizes survival in peritonitis, the use of simple saline irrigation is still better than no lavage, rejecting the classical affirmation that irrigation contributes to contamination spread throughout the peritoneal cavity.

Peritoneal lavage with a single antibiotic drug is probably sufficient to impair the growth of some, but not all, bacterial colonies. Previous studies have not specified which microorganisms survived after antibiotic lavage. Logically, bacterial growth cannot be impaired by antibiotics to which the microorganisms are resistant.

Tolhurst Cleaver and colleagues reported that intraperitoneal antibiotic lavage accelerated wound healing and reduced the infection rate. Diverse factors contribute to the occurrence of wound infection, but infections arising from a contaminated peritoneal cavity are particularly common, indicating that wound infection rates are higher after a contaminated operation than after a clean one.

Qadan et al., noted that extrapolating results from animal models of peritonitis and antibiotic lavage to human disease is often disappointing, because in experimental peritonitis, the interval between the onset of peritonitis and the start of the lavage treatment is usually only 1 or 2 hours, which is not representative of the clinical situation (characterized by a longer time interval). A long interval between the onset of peritonitis and treatment leads to exponential growth of the microorganisms. In this situation, an antibiotic lavage would not be sufficient to control such concentrations of microorganisms but may be sufficient for lower concentrations of bacteria. Thus, peritoneal irrigation with antibiotic solutions has more sense as a prophylactic measure in elective surgery, rather than as treatment in peritoneal cases.

PROPHYLAXIS OF SSI WITH ANTIBIOTIC PERITONEAL IRRIGATION

In 2012, our group conducted a prospective randomized clinical trial, analyzing the peritoneal irrigation with normal saline (Group 1) vs the irrigation with a clincamycin-gentamicin solution (Group 2), on SSI after elective colorectal surgery. Inclusion criteria were a diagnosis of colorectal neoplasms and plans to undergo an elective operation with curative aims. An open surgical approach was used in all the patients included. Exclusion criteria were a preoperative diagnosis of chronic renal failure (because of the risk of nephrotoxicity associated with intraperitoneal gentamicin absorption) or an anastomotic leak in the postoperative course, which would represent a bias in the diagnosis of intra-abdominal infection. A CT scan with a rectal contrast enema was performed either on the fifth day after surgery or earlier if there was a strong clinical suspicion of an anastomotic leak. This procedure identified anastomotic leaks presenting as intra-abdominal abscesses rather than peritonitis.

Perioperative systemic antibiotics (ciprofloxacin 400 mg and metronidazol 1,500 mg; single dose preoperatively, within 30 minutes of incision, and redosed after 4 hours when the surgery is prolonged over that time) were used in both groups. No mechanical bowel preparation took place in any patient.

A total of 108 patients were included in the study. Five patients were excluded because they presented an anastomotic leak. In total, 51 patients were analyzed in Group 1 and 52 in Group 2. The patient sample consisted of 62% men and 38% women, with a mean age of 69.9 years. The preoperative diagnosis was adenocarcinoma in all patients. There were no differences in comorbidities and tumor stages between groups. Tumors were located in the right colon (17%), the transverse colon (3%), the left colon (50%), and the rectum (27%). In 3 patients, 2 synchronic neoplasms were detected in different locations of the colon. There were no significant differences in the surgical techniques between groups. Anastomosis was performed in 70% of the patients, leaving a terminal stoma in 30%. There were no significant differences in the distribution of patients with stomas between groups.

Anastomotic leaks appeared in 5 patients (5%), including 3 patients in Group 1 and 2 patients in Group 2 (nonsignificant, NS). Mortality was 3%, affecting 2 patients in Group 1 and 1 patient in Group 2 (NS). Causes of mortality were an anastomotic leak and sepsis in 2 patients and nosocomial pneumonia in 1 patient. Median hospital stays were 6 days (range 5 to 32 days) in Group 1 and 6.5 days (range 5 to 14 days) in Group 2 (NS).

The wound infection rates were 14% in Group 1 and 4% in Group 2 ($p = 0.009$; [odds ratio]OR4.94;95%CI 1.27 to 19.19). There was no significant association between any of the comorbidities and wound infection. Intraabdominal abscess rates were 6% in Group 1 and 0% in Group 2 ($p = 0.014$; OR 2.14; 95% CI 1.13 to 3.57). All abscesses were smaller than 4 cm and therefore were conservatively managed without requiring percutaneous drainage, so we could not obtain a sample of them for culture.

Microbiologic samples were obtained only from patients assigned to Group 2. The culture of sample 1 (before any lavage) was positive in 68% of the cases. Detected microorganisms were *Escherichia coli (E coli)* (94% of the samples),

Streptococcus spp (27%), *Enterococcus faecalis* (9%), *Pseudomonas aeruginosa* (6%), and *Klebsiella spp* (3%). The culture of sample 2 (after lavage with normal saline) was positive in 59% of the cases, and the same microorganisms identified in the culture of sample

1 were found in the culture of sample 2. The culture of sample 3 (after lavage with the antibiotic solution) was positive in 2 patients (4%). Detected microorganisms were *Klebsiella spp* and *Streptococcus salivarius*. The antibiogram of these microorganisms revealed that they were both resistant to gentamicin and clindamycin. There was no significant difference between the infection rates of samples 1 and 2 ($p = 0.162$). However, when comparing samples 1 and 3 and samples 2 and 3, a significant difference in the infection rate was observed ($p = 0.001$ in both cases).

The prophylactic effect of lavage in elective clean contaminated surgery is understood even less than in peritonitis because few such studies have been conducted, apart from our one. In our study, we showed that an antibiotic lavage is very effective. We demonstrated that an antibiotic lavage impairs microbiologic growth and reduced the positive culture. These data have clinical correlations because the intra-abdominal infection rate was reduced from 6% in Group 1 (only saline lavage) to 0% in Group 2 (saline lavage followed by antibiotic irrigation). Our study presents 2 main differences with the reported literature. First, our sample included patients undergoing elective colorectal surgery (contaminated surgery), but who did not present with peritonitis, as described in most reported studies. A limited number of outdated studies have analyzed the effect of prophylactic peritoneal lavage on postoperative infection. Such studies have shown a reduction in the number of aerobic and anaerobic bacteria in the peritoneal fluid after an intervention that included irrigation with a tetracycline solution, but they have not correlated these data with clinical variables. The second main difference in our study is the combination of antibiotic drugs (gentamicin and clindamycin). These 2 drugs present a synergistic effect and provide wide-spectrum protection against Gram-negative and anaerobic microorganisms, which represent the main flora of the colon.

In our study, we also observed a significant reduction in wound infections in the group undergoing an antibiotic lavage, compared with the group undergoing saline irrigation. These data show that when the peritoneal cavity remains sterile, there is a lower risk of bacteria migrating from the abdominal cavity through the fascia to the subcutaneous tissue. As in the 2 patients with positive cultures after antibiotic lavage, the same bacteria found in the culture were also responsible for the wound infection.

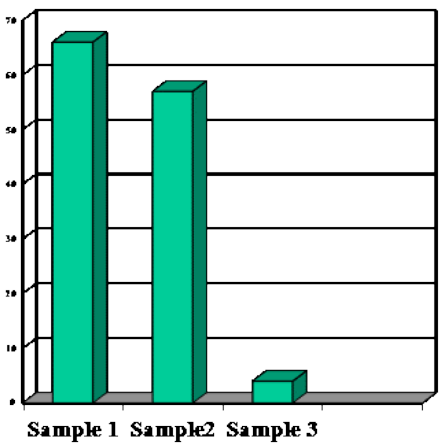

Figure 1. Peritoneal contamination before any lavage (Sample 1), after irrigation with normal saline (Sample 2) and after irrigation with antibiotic solution (Sample 3).

The conclusion of this study was that antibiotic lavage of the peritoneum before abdominal wall closure is associated with a lower incidence of intraabdominal abscesses and wound infection. Microbiologic cultures of the peritoneal surface at the end of an elective colorectal operation were positive in 68% of the cases. A normal saline lavage did not significantly reduce the number of positive cultures, in contrast to an antibiotic one (gentamicin-clindamycin), which resulted in negative cultures for all sensitive microorganisms. This study would support the use of antibiotical perritoneal irrigation as prophylactic measure against SSI. Moreover, the main criticism of the use of topical antibiotics is the development of eventual resistant microorganisms against the drugs used. In our opinion, the antibiotics used should be those ones not usually employed for treatment aims. In our study we used clindamycin, which is not a drug currently used for the treatment of intra-abdominal infections, and despite gentamicin is frequently used for the treatment of gramnegative infections, it is true that there are other more powerful aminoglucosides for treatment uses, and even gentamicin is included in many systemic prophylaxis protocols. Further studies must be conducted to confirm these hypotheses.

Topical Peritoneal Irrigation with Antiseptic Agents

Antiseptic agents, such as Polyvinylpirrolidone (Iodine Povidone) or Chlorhexidine have demonstrated an antibacterial effect and are currently used for topical antisepsia of skin or mucosae. However, the peritoneal surface has the characteristic of absorption and this limits the applicability of several drugs to this surface.

Experimental studies with peritoneal Povidone irrigation have demonstrated a significant reduction of SSI. Povidone irrigation reduces the permeability of the mesotelium to bacteria and, consequently might reduce the systemic spread of the microrganisms.

Studies on human have been conducted on patients with peritoneal carcinomatosis, aiming to reduce the tumoral load. However, this topical administration has shown a certain peritoneal absorption and may lead to systemic toxicity. Moreover, several patients developed sclering peritonitis. Thus, peritoneal Povidone administration is actually not recommended.

Periotneal irrigation with Chlorehexidine has also demonstrated in experimental studies a significant reduction of bacterial contamination. However, an important chemical irritation was also observed, leading to extense inflammatory response. Long-term follow-up of these patients has shown the development of peritoneal adhesion and bowel obstruction. However, the latter has not been confirmed in recent animal studies. Thus, the role of topical Chlorhexidine in peritoneal irrigations must be further elucidated.

CONCLUSION

Peritoneal irrigation achieves a reduction in bacterial contamination. The addition of antibiotics has shown some benefits as prophylactic measure against SSI. However, there is still no enough evidence to be a recommended measure by scientific societies. Povidone and Chlorhexidine solutions seems to be associated with greater adverse events than benefits and are actually not recommended for peritoneal irrigation.

REFERENCES

Adam U, Ledwon D, Hopt UT. Programmed lavage as a basic principle in therapy of diffuse peritonitis. *Langenbecks Arch Surg* 1997;382:18–21.

Araujo ID, Grossi GC, Diniz SO, et al. Effects of the povidone-iodine (PVPI) in treatment of bacterial peritonitis induced in rats. *Acta Cir Bras* 2010; 25:322-327.

Edmiston CE Jr, GoheenMP, Kornhall S, et al. Fecal peritonitis: microbial adherence to serosal mesothelium and resistance to peritoneal lavage. *World J Surg* 1990;14:176–183.

Grant SW, Hopkins J, Wilson SE. Operative site bacteriology as an indicator of postoperative infectious complications in elective colorectal surgery. *Am Surg* 1995;61:856–861.

Hall JC,Heel KA, Papadimitriou J, Platell C. The pathobiology of peritonitis. *Gastroenterology* 1998;114:185–196.

Horiuchi T, Tanishima H, Tamagawa K, et al. A wound protector shields incision sites from bacterial invasion. *Surg Infect (Larchmt)* 2010;11:501–503.

Parc Y, Frileux P, Schmitt G, et al. Management of postoperative peritonitis after anterior resection: experience from a referral intensive care unit. *Dis Colon Rectum* 2000;43:579–587.

Platell C, Papadimitriou JM,Hall JC. The influence of lavage on peritonitis. *J Am Coll Surg* 2000;191:672–680.

Qadan M, Dajani D, Dickinson A, Polk HC. Meta-analysis of the effect of peritoneal lavage on survival in experimental peritonitis. *Br J Surg* 2010;97:151–159.

Ruiz-Tovar J, Santos J, Arroyo A, et al. Effect of Peritoneal Lavage with Clindamycin-Gentamicin Solution on Infections after Elective Colorectal Cancer Surgery. *J Am Coll Surg* 2012;214:202-207.

Saha SK. Efficacy of metronidazole lavage in treatment of intraperitoneal sepsis. A prospective study. *Dig Dis Sci* 1996;41: 1313–1318.

Shams WE, Hanley GA, Orvik A, et al. Peritoneal lavage using chlorhexidine gluconate at the end of colon surgery reduces postoperative intra-abdominal infection in mice. *J Surg Res* 2015; 195:121-127.

Silverman SH, Ambrose NS, Youngs DJ, et al. The effect of peritoneal lavage with tetracycline solution on postoperative infection. A prospective, randomized, clinical trial. *Dis Colon Rectum* 1986;29:165–169.

Sortini D, Feo CV,Maravegias K, et al. Role of peritoneal lavage in adhesion formation an survival rate in rats: an experimental study. *J Invest Surg* 2006;19:291–297.

Thoroughman J, Alker l, Collins J. Spreading organisms by peritoneal lavage. *Am J Surg* 1968;115:339–340.

Tolhurst Cleaver CL, Hopkins AD, Kee Kwong KC, Raftery AT. The effect of postoperative peritoneal lavage on survival, wound healing and adhesion formation following fecal peritonitis: an experimental study in the rat. *Br J Surg* 1974;61: 601–604.

In: Encyclopedia of Surgery (22 Volume Set)
Editors: Andreas Lehrer and Kristin Mueller
ISBN: 978-1-53618-329-0
© 2020 Nova Science Publishers, Inc.

Chapter 281

PROPHYLACTIC VACUUM THERAPY

Montiel Jiménez-Fuertes*
General and Digestive Surgery, Rey Juan Carlos University Hospital,
Madrid, Spain

ABSTRACT

Surgical site infections are an important complication after surgery, affecting the quality of life and the economic cost. It is important to note that infections are multifactorial, involving both surgical and patient factors. To decrease the occurrence of infections, surgeons frequently use several tools to reduce the incidence of them. Strategies that prevent surgical site infection (SSI) are increasingly important and current literature suggests that incisional Negative Pressure Wound Therapy (iNWPT) is a promising intervention.

Keywords: negative pressure wound therapy, prophylaxis, incision management, surgical-site infection

INTRODUCTION

Surgical site infections (SSI) are the most common cause of nosocomial infection, because they are the 38% of all hospital-acquired infections. Though the overall incidence of SSI is low, the highest rates occur after abdominal surgery [1].

Surgical site infections (SSI) are categorized as superficial incisional, deep incisional, and organ/space based on the depth of the infection, they can increase healthcare costs by approximately $20,000 per admission, and add an average of 10 days of length-of-stay [2]. Given this effect on patient outcomes and costs, much work has been done to develop interventions that can decrease the rate of SSI. The most data have been produced in the fields of colorectal, gynecology, and urology which involve manipulation of the gastrointestinal or genitourinary systems; or in fields in which placement of prostheses require all effort to

* Corresponding Author's Email: montiel.jimenez@hospitalreyjuancarlos.es.

reduce SSI, such as orthopedics, neurosurgery and cardiothoracic. There have been many skin closure adjuncts employed to reduce SSI, pre-closure, wound irrigation, and some are post-closure such as topical antibiotic agents and incisional negative pressure wound treatment (iNPWT) applied to a closed incision. All, however, remain debatable as to their efficacy despite having been studied in many surgical settings.

Incisional Negative Pressure Wound Treatment

Incisional negative pressure wound treatment (iNPWT) has emerged as a useful tool to reduce surgical site infections (SSIs) [3]. INPWT technology has been developed like Prevena™ (KCI USA, Inc., San Antonio, TX) and Pico (Smith & Nephew Inc, Andover, MA) systems. Both have been created to develop prophylactic measures to prevent complications via application immediately after surgery in high-risk closed surgical incisions. NPWT involves the controlled application of continuous sub-atmospheric pressure to the wound. While NPWT technology is an established and accepted treatment for non-healing wounds and open surgical incisions following infection, a small but growing number of clinical studies have been published based on the hypothesis that negative pressure dressings improve healing of closed wounds.

Figure 1. Prevena™ Incision Management system: 1: closed wound; 2-11: customizable prevena placemet step by step; 12: final view with de dressing working.

Prevena™ Incision Management system consists of a vacuum therapy suction unit that is connected to a dressing tube by a canister for fluid collection, and a precut peel-and-place reticulated open-cell foam dressing specifically designed for use over closed surgical incisions that are at high risk for post-surgical complications (*Figures 1 and 2*). The dressing has a plated non-adherent layer surrounding the foam and a semi-permeable adhesive drape.

Pico systems is canister-free, the pump generates a negative pressure of – 80 mmHg (for 7 days of therapy) and is connected to a dressing that manages the fluid away from the wound or closed incision through a unique combination of absorbency and evaporation.

An increased understanding of the science behind incisional NPWT and its effects on wound and periwound tissue is essential to expand the use of incisional NPWT. Well-described mechanisms of action of incisional NPWT include protection of the incision site from external infectious sources and help in holding incision edges together [4]. Incisional NPWT also removes fluids and infectious materials from the surgical site, which is especially important in critical anatomical locations. Other mechanisms of action, particularly at the cellular and molecular level, are less understood and the subject of ongoing research [5].

Figure 2. Prevena™ Incision Management system. A: Abdominal closed wound; B: Prevena™ in place and working.

EFFECTS OF INCISIONAL NEGATIVE WOUND PRESSURE DRESSING IN WOUNDS

Surgical incisions disrupt the cutaneous layer that normally doesn't let bacteria entering the body. In healthy people it takes three to six days for reepithelialization to restore the barrier function of the skin. Risk factors such as diabetes or contaminated surgical fields such as related to abdominal surgical procedures with intestinal anastomoses result in prolonged time to healing [6]. Post-operative colonization of surgical sites is associated with increased risk of SSI [7].

NPWT's ways to prevent SSIs includes completely eliminating dead space, removing fluid and blood, improving blood flow and preventing the formation of subcutaneous seromas/hematomas that become secondarily infected. In addition, INPWT is thought to decrease local inflammatory response and cell death by increasing the oxygen gradient across a wound.

The NPWT dressing is applied to the surgical site under sterile conditions, after which a continuous amount of sub-atmospheric pressure is applied for several post-operative days. Most studies report use of - 80 or -125mm Hg of sub-atmospheric pressure, for a length of five to seven days after operation.

Jansen et al. [5] demostrated a correlation between external negative pressure applied by the iNPWT system and the pressure within the wound. Even low external negative pressure (about 50 mmHg) led to relevant negative pressure within the wound.

Barrier Function of NPWT

Because of its non-occlusive nature, gauze and other dressings are permeable to bacteria [8]. Lawrence et al. [9] have demonstrated that bacteria can pass through up to 64 layers of dry gauze in a *in vitro* study. In contrast, iNPWT uses a foil that is impermeable to pathogens. INPWT devices have the ability of the dressing to serve as a barrier against external contamination, and this was verified through a Phi-X 174 bacteriophage challenge. This test indicated that there was no pathogenpenetration through the foil [10]. Moreover, the subatmospheric pressure results in close approximation of the foil to several centimeters of skin, while also approximating both incisional edges. Anything that passes through the incision is also directed away from the surgical site as a result of the direction of suction, and in this way it acts as a barrier against external bacteria. This is in line with the clinical results of Grauhan et al. [11], who have found that iNPWT resulted in a significant reduction of SSI from (grampositive) skin flora after cardiac surgical procedures in obese individuals (1/75 vs. 10/75, $p = 0.009$). Moreover, because an iNPWT dressing commonly is left in place for 7 days, less dressing changes [12] and bedside examinations take place, and by decreasing the exposure of the surgical site to potential colonization from the nurses.

Seroma, Hematoma and Edema Reduction

Seroma development is one of the most commonly reported complication, and both are associated with an increased risk of SSI [13]. Hematomas and seromas result from the accumulation of blood and serum, respectively, in internal spaces. Even with an excellent surgical technique, bleeding, inflammation and serum extravasation may occur, resulting in increased probability of infection, slower healing, additional clinic visits and surgical re-interventions.

In vivo studies have provided evidence of improved fluid flow with four days of continuous INPWT (Prevena™ Incision Dressing) under −125 mmHg over clean, closed incisions, showing that its application, when compared with semi-permeable film dressing (Tegaderm™ Dressing, St. Paul, MN, USA), significantly decreased the amount of porcine subcutaneous dead spaces beneath superficial closed incisions indicating reduced

haematoma/seroma [14]. In humans, there are several randomized controlled trials, of which several reported decreased seroma and hematoma formation, but there are others that didn't see this effect [15-19].

Edema has a detrimental effect in wound healing because of the increased diffusion distance for oxygen, and the oxygen is important for bacterial clearance [20]. It has been suggested that iNPWT is effective at reducing edema, which increases tissue oxygenation and thereby bacterial clearance [21].

Effect of iNPWT on Perfusion and Necrosis

A good perfusion and oxygenation are essential for a good surgical site healing. In the first animal study on NPWT, Morykwas et al. [22] have shown that the cutaneous application of NPWT onto ischemic skin flaps made a significant reduction of cutaneous necrosis in their porcine model. Correspondingly, cutaneous application of NPWT results in a perfusion increase when applied to intact skin of healthy volunteers [23], and in significantly increased perfusion at post-operative days four, seven, and 21, as measured with laser Doppler perfusion imaging [24-25].

Wound Dehiscence

The biomechanic effects of iNWPT on closed wounds have been evaluated with computer models and they showed that iNPWT reduces the lateral distraction force in wounds [26], and this is important because a wound dehiscence increases the risk or SSI due to bacteria contamination.

SSI

INPWT seems to be effective in the prevention of SSI acting as a barrier which avoids bacteria contamination of the wound before healing, improving the lymphatic and bood flow, reducing seroma, hematoma, edema and wound dehiscence. This suggests that iNPWT is a favorable prevention strategy to consider. This is substantiated in part by the clinical data available, as assessed in meta-analyses that show that iNPWT reduces SSI [1]. This suggests that iNPWT is effective in reducing the risk of SSI in all types of surgical procedures, and likely even in the types of operations where no clinical data exist yet. Because of these results, the World Health Organization recommends to consider iNPWT for all highrisk surgical sites [27].

CONCLUSION

INPWT is an effective intervention as the result of its barrier function and optimization of the wound microenvironment. Incorporation of iNPWT in SSI prevention bundles is recommended supported by the data available in this moment.

REFERENCES

[1] Zwanenburg, PR; Tol, BT; de Vries, FEE; Boermeester, MA. Incisional Negative Pressure Wound Therapy for Surgical Site Infection Prophylaxis in the Post-Antibiotic Era. *Surg Infect (Larchmt)*., 2018, Sep 29 [Epub ahead of print].

[2] Lawrence, SA; McIntyre, CA; Pulvirenti, A; Seier, K; Chou, Y; Gonen, M; et al. Perioperative Bundle to Reduce Surgical Site Infection after Pancreaticoduodenectomy: A Prospective Cohort Study. *J Am Coll Surg*., 2019, Jan 7.

[3] Scalise, A; Calamita, R; Tartaglione, C; Pierangeli, M; Bolletta, E; Gioacchini, M; et al. Improving wound healing and preventing surgical site complications of closed surgical incisions: a possible role of Incisional Negative Pressure Wound Therapy. A systematic reviewof the literature. *International Wound Journal*, 2016, 1260–1281.

[4] Wilkes, RP; Kilpad, DV; Zhao, Y; Kazala, R; McNulty, A. Closed incision management with negative pressure wound therapy (CIM): biomechanics. *Surg Innov*., 2012, 19, 67-75.

[5] Jansen-Winkeln, B; Niebisch, S; Scheuermann, U; Gockel, I; Mehdorn, M. Biomechanical Effects of Incisional Negative Wound Pressure Dressing: An *Ex Vivo* Model Using Human and Porcine Abdominal Walls. *Biomed Res Int.*, 2018, 7058461.

[6] Streubel, PN; Stinner, DJ; Obremskey, WT. Use of negative-pressure wound therapy in orthopaedic trauma. *J Am Acad OrthopSurg*, 2012, 20(9), 564-574.

[7] Turtiainen, J; Hakala, T; Hakkarainen, T; Karhukorpi, J. The impact of surgical wound bacterial colonization on the incidence of surgical site infection after lower limb vascular surgery: A prospective observational study. *Eur J Vasc Endovasc Surg*, 2014, 47, 411–417.

[8] Sood, A; Granick, MS; Tomaselli, NL. Wound dressings and comparative effectiveness data. *Adv Wound Care (New Rochelle)*, 2014, 3, 511–529.

[9] Lawrence, JC. Dressings and wound infection. *Am J Surg*, 1994, 167, 21S–24S.

[10] FDA. PREVENA_ Incision Management System 510(k) *Premarket Notification*., 2010. www.accessdata.fda.gov/ cdrh_docs/pdf10/ K100821.pdf.

[11] Grauhan, O; Navasardyan, A; Hofmann, M; Müller, P; Stein, J; Hetzer, R. Prevention of poststernotomy wound infections in obese patients by negative pressure wound therapy. *J Thorac Cardiovasc Surg*, 2013, 145, 1387–1392.

[12] Nherera, LM; Trueman, P; Karlakki, SL. Cost-effectiveness analysis of single-use negative pressure wound therapy dressings (sNPWT) to reduce surgical site complications (SSC) in routine primary hip and knee replacements. *Wound Repair Regen*, 2017, 25, 474–482.

[13] Vieira, BL; Qin, CD; Jordan, SW; Gutowski, KA; Kim, J. Assessing the association between seroma and surgical site infection in immediate breast reconstruction. *Plast Reconstr Surg Glob Open*, 2016, 4, (Suppl 9), p. 170.

[14] Kilpadi, DV; Cunningham, MR. Evaluation of closed incision management with negative pressure wound therapy (CIM): hematoma/seroma and involvement of the lymphatic system. *Wound Repair Regen*, 2011, 19, 588–96.

[15] Hyldig, N; Birke-Sorensen, H; Kruse, M; Vinter, C; Joergensen, JS; Sorensen, JA; et al. Metaanalysis of negative-pressure wound therapy for closed surgical incisions. *Br J Surg*, 2016, 103, 477–486.

[16] Angspatt, A; Laopiyasakul, T; Pungrasmi, P; Suwajo, P. The role of negative-pressure wound therapy in latissimus dorsi flap donor site seroma prevention: A cohort study. *Arch Plast Surg*, 2017, 44, 308–312.

[17] de Vries, FE; Atema, JJ; Lapid, O; Obdeijn, MC; Boermeester, MA. Closed incision prophylactic negative pressure wound therapy in patients undergoing major complex abdominal wall repair. *Hernia*, 2017, 2, 583–589.

[18] Redfern, RE; Cameron-Ruetz, C; O'Drobinak, SK; Chen, JT; Beer, KJ. Closed incision negative pressure therapy effects on postoperative infection and surgical site complication after total hip and knee arthroplasty. *J Arthroplasty*, 2017, 32, 3333–3339.

[19] Nickl, S; Steindl, J; Langthaler, D; et al. First experiences with incisional negative pressure wound therapy in a highrisk poststernotomy patient population treated with pectoralis major muscle flap for deep sternal wound infection. *J Reconstr Microsurg*, 2018, 34, 1–7.

[20] Knighton, DR; Fiegel, VD; Halverson, T; Schneider, S; Brown, T; Wells, CL. Oxygen as an antibiotic. The effect of inspired oxygen on bacterial clearance. *Arch Surg*, 1990, 125, 97–100.

[21] Perry, KL; Rutherford, L; Sajik, DM; Bruce, M. A preliminary study of the effect of closed incision management with negative pressure wound therapy over high-risk incisions. *BMC Vet Res*, 2015, 11, 279.

[22] Morykwas, MJ; Argenta, LC; Shelton-Brown, EI; McGuirt, W. Vacuum-assisted closure: A new method for wound control and treatment: Animal studies and basic foundation. *Ann Plast Surg*, 1997, 38, 553–562.

[23] Timmers, MS; Le Cessie, S; Banwell, P; Jukema, GN. The effects of varying degrees of pressure delivered by negative-pressure wound therapy on skin perfusion. *Ann Plast Surg*, 2005, 55, 665–671.

[24] Atkins, BZ; Tetterton, JK; Petersen, RP; Hurley, K; Wolfe, WG. Laser Doppler flowmetry assessment of peristernal perfusion after cardiac surgery: Beneficial effect of negative pressure therapy. *Int Wound J*, 2011, 8, 56–62.

[25] Peter Suh, HS; Hong, JP. Effects of incisional negativepressure wound therapy on primary closed defects after superficial circumflex iliac artery perforator flap harvest: Randomized controlled study. *Plast Reconstr Surg*, 2016, 138, 1333–1340.

[26] Loveluck, J; Copeland, T; Hill, J; Hunt, A; Martin, R. Biomechanical modeling of the forces applied to closed incisions during single-use negative pressure wound therapy. *Eplasty*, 2016, 16, e20.

[27] Allegranzi, B; Zayed, B; Bischoff, P; Kubilay, NZ; Zayed, B; Gomes, SM; et al. New WHO recommendations on intraoperative and postoperative measures for surgical site infection prevention: An evidence-based global perspective. *Lancet Infect Dis*, 2016, 16, e288–e303.

In: Encyclopedia of Surgery (22 Volume Set)
Editors: Andreas Lehrer and Kristin Mueller
ISBN: 978-1-53618-329-0
© 2020 Nova Science Publishers, Inc.

Chapter 282

ANTIMICROBIAL SUTURES

Jaime Ruiz-Tovar[1], MD, PhD and Carolina Llavero[2,*]
[1]Center of Excellence for the Study and Treatment of Obesity
and Diabetes, Valladolid, Spain
[2]Department of Surgical Nursery, Sureste Hospital, Madrid, Spain

ABSTRACT

The suture used for the aponeurotical closure might influence in the incidence of surgical-site infection (SSI). Microrganisms adhere to the suture material, specially in multifilament ones, and can show a relevant proliferation far away from the action of prophylactic systemic antibiotics. The use of sutures embebbed with antiseptic agents has demonstrated to reduce the incidence of incisional SSI.

The aim of this chapter is to review the actual evidence about this issue and to show the most relevant recommendations of several scientific societies.

Keywords: antimicrobial sutures, triclosan-coated sutures, surgical site infection

INTRODUCTION

Surgical-site infection (SSI) is one of the most frequent complications of abdominal surgery. It is associated with prolonged hospital stay, reduction of quality of life and increases of morbidity, mortality and sanitary costs. The reported incidence of SSI depends, among other factors, on the definition of SSI. The Centers for Disease Control (CDC) define SSI as the infection appearing in the surgical incision or close to it, during the first 30 days after surgery, or up to 3 months postoperatively, when a prosthesis has been placed. SSI occurs when the bacterial inoculum overcomes the ability of the immune system to control it. The bacterial contamination in abdominal surgery comes from the skin and the target organs during the surgical intervention.

* Carolina Llavero, RN.

The determinants of infection are the surgeon, the pathogen and the patient. The surgeon is the main modulator of surgical infection. Its experience and ability might reduce the inoculum to small dimensions, amenable to be controlled by the host defenses. A correct surgical act comprises a careful management of the tissues, a correct hemostasis, to avoid unnecessary prolongations of the surgical act and to minimize the exit of intraluminal content. Factors depending on the patient include comorbidities, obesity, tobacco habit and elderly. During the last decades, the pattern of microrganisms causing the infection has not changed, but the rate of resistant microrganisms.

The surgeon has pharmacological and non-pharmacological measures to reduce bacterial contamination from the surgical field and consequently the incidence of SSI. During the las decade, the use of bundles has become popular, as groups of systematic measures used for the prevention of postoperative complications. These bundles have been especially popular in colorectal surgery, which are considered high-risk procedures for infectious complications. In 2004, the CDC began the *Surgical Infection Prevention Project* (SIP), to assure the follow-up of several basic evidence-based measures for SSI prevention (adequate use of antibiotic prophylaxis, its administration 1h before skin incision and stop before 24h after surgery, appropriate hair removal and maintenance of normotermia). When applying these measures, Hendrick et al. reported in 2007 a better implementation of the prophylaxis protocol and a SSI reduction from 25.6% to 15.9% in colorectal surgery. However, a similar study did not confirm these findings, despite an improvement in all the aspects of the prophylaxis process. In 2011, a randomized study of 211 colorectal surgeries compared the implementation of a classic bundle with a bundle including, avoidance of mechanical colon preparation and oral antibiotic administration. Despite improvements in the implementations were observed, an increase in SSI rate from 24% to 45% was detected. In Spain, a multicentric observational study, analyzing the incidence of SSI in colorectal surgery, with implementation of a bundle similar to that from the SIP project, obtained a SSI rate of 23.1% in 611 colorectal interventions.

In conclusion, the adoption of bundles of evidence-based preventive measures against SSI lead to an improvement in the surgical process. The adhesion to the bundles by means of a check-list has shown to reduce SSI rates. However, there are still unknown factors implied in the development of SSI, that must be further investigated.

SUTURES EMBEBBED WITH ANTISEPTIC AGENTS

The use of sutures coated or embebbed with antiseptics are preventive measures against SSI, that can be implemented by the surgeon. Several studies has demonstrated that the suture used for the aponeurotical closure is a relevant factor that might influence the incidence of SSI. Bacteria adhere to the filaments of the suture, especially in multifilament ones. Thus, monofilament sutures are widely recommended for fascial closures, as with these sutures there is a lower place for bacterial accommodation.

In abdominal surgery, bacterial contamination comes from the digestive tract (*Enterobacteriacea* and anaerobic microrganisms) and from the saprophytic flora of the skin (grampositive). Sutures coated with antiseptic agents were designed to form a barrier against the bacterial transit from the intraperitoneal cavity to the subcutaneous tissue, that might lead

to the development of incisional SSI. Moreover, their bactericide effect would prevent from bacterial adhesion to the suture filaments.

The most employed antiseptic agent used to coat the sutures is Triclosan (2,4,4-trichloro-2-hydroxi-diphenileter). In preclinical studies, Triclosan has demonstrated to reduce the bacterial load in the wound and to slow bacterial growth, inhibiting the synthesis of bacterial fatty acids.

Triclosan-coated sutures have been analyzed in different surgical procedures in humans, though most of them were conducted in clean and clean-contaminated ones. Among them, colorectal surgery has been the most widely procedure investigated, as the high incisional SSI rates that present, make these approaches as the most amenable to perform investigations on them. However, Triclosan-coated sutures have also demonstrated their efficacy in dirty surgery. A previous study of our group evaluated the efficacy of Triclosan-coated sutures in fecal peritonitis, revealing that the use of these sutures might reduce the incidence of incisional SSI in up to 80%.

Evidence

Up to date, 10 meta-analyses have been published, evaluating the efficacy of Triclosan-coates sutures, demonstrating all of the a reduction in SSI rates, ranging from 24% to 84%.

Wang et al. were the first who published a systematic review and meta-analysis on Triclosan-coated sutures in 2013. They included 17 clinical trials and 3720 patients were enrolled. Triclosan-coated sutures showed a 30% reduction of SSI. Subgroup analyses revealed homogeneous results in adults, abdominal procedures, and clean and clean-contaminated procedures.

The same year, Sajid et al. conducted a systematic review of clinical trials evaluating the effect of antibacterial sutures on skin closure. Seven studies with 1631 patients were included. They concluded that Triclosan-coated sutures reduced the SSI rate, but a significant reduction of hospital stay could not be observed.

Edmiston et al. performed a systematic review of 13 clinical trials with 3668 patients, showing that the use of antibacterial sutures was associated with a 31% global reduction of SSI, but it can reach up to 47% in selected populations.

The same authors published the next year a new systematic revision, including more rigorous methodology and updated the results with 2 additional clinical trials (totally 15 clinical trials and 4800 patients). They concluded that the use of Triclosan-coated sutures reduced the SSI risk in 33%. Depending on the degree of contamination, they observed that the risk reduction was applicable to clean, clean-contaminated and contaminated procedures, with evidence grade 1A.

In 2015, Apisarnthanarak et al. published a systematic review, including 22 clinical trials and 7 non-randomized studies. A 26% reduction of SSI risk was observed among clinical trials and a 47% reduction among non-randomized studies. In abdominal surgeries a 44% reduction was determined.

Guo et al. published in 2013 a meta-analysis of 13 clinical trials with 5256 participants. They performed a subgroup analysis based on the type of suture (Polyglactine 910 or Polydioxanone), coated or not with Triclosan. Globally, coated sutures were associated with a 24% lower risk of SSI. Depending on the type of surgery, the SSI risk was reduced a 30% in

abdominal surgery within the patients undergoing Triclosan-coated sutures, but significant differences were not established in cardiac, mammary or other extra-abdominal procedures. The beneficial effect was determined both with the use of Triclosan-coated Polyglactine or Polydioxanone sutures, when compared with their corresponding Triclosan-free sutures. SSI reduction was associated with reduction of hospital stay and sanitary costs.

In 2017, Wu et al. performed a meta-regression analysis to determine if the effect of Triclosan varies depending on the type of suture or procedure. They included 13 clinical trials and 5 observational studies. Triclosan-coated sutures presented a 28% lower SSI rate among clinical trials and 42% lower risk among observational studies. The effect of the Triclosan coat was similar in the different types of sutures and procedures. The quality of evidence was moderate.

De Jonge published a 39% reduction of SSI risk with the use of Triclosan-coated sutures, after analyzing 21 clinical trials and 6462 patients.

Leaper et al. analyzed the clinical and economic impact of the use of these sutures. They analyzed 34 studies. Despite the incisional SSI rate was lower with the use of Triclosan coated sutures, the reduction was more pronounced in contaminated and dirty procedures. A 39% SSI reduction was estimated implying a mean sanitary cost reduction of 105€ per procedures among all types of surgeries, with 65€ reduction in clean surgeries and 285€ in contaminated or dirty ones.

In contrast, the meta-analysis of Konstantelias et al., including 30 studies, 19 of the clinical trials, and more than 15000 patients, observed that the use of Triclosan-coated sutures was associated with lower SSI risk in clean, clean-contaminated and contaminated procedures, but not in dirty ones. Specifically in colorectal surgery, they determined a reduction of 42% in the risk of SSI development. Moreover, a lower risk of wound dehiscence was also observed.

RECOMMENDATIONS OF SCIENTIFIC SOCIETIES

Based on all this scientific evidence, diverse organizations and societies have published recommendations, supporting the use of Triclosan-coated sutures.

World Health Organization (WHO)

In the paragraph 4.22 of the WHO recommendations for SSI prevention, the panel of experts recommend the use of Triclosan-coated sutures to reduce SSI, independently of the type of surgery. Evidence was cataloged as moderate. The effect seems to be independent from the type of suture (monofilament or multifilament), surgical procedure and wound contamination.

To establish this recommendation, 13 clinical trials and 5 observational studies were analyzed, including more than 7400 patients, comparing Triclosan-coated vs conventional sutures. The recommendation established by the WHO is considered conditional, as coated sutures are more expensive and their availability is limited in many countries. However, the uses of Triclosan-coated sutures might reduce mean hospital stay and, consequently, sanitary

costs. They mentioned the possibility of development of resistances as a worrisome issue, but the daily absorption of Triclosan in many products, such as hand soap, is superior to that associated to a Triclosan-coated suture.

Centers for Disease Control and Prevention (CDC)

In the paragraph 2C, within the non-parenteral antimicrobial prophylactic measures, the use of Triclosan-coated sutures is included (Category II, low recommendation grade, moderate evidence). The evidence suggests that benefits compense prejudices. No benefit was observed for the prevention of organ/space SSI.

This recommendation was based on the analysis of 14 randomized controlled studies, including 5388 patients.

There is no evidence of antimicrobial resistances, adverse events or wound dehiscence.

American College of Surgeons and Surgical Site Infection Society

Historically, Triclosan-coated sutures were not recommended for SSI prevention, but actually there is enough evidence to support their use. Diverse studies have demonstrated a lower risk of SSI development with their use, when compared with standard sutures, including multiple clinical trials. Additionally, systematic reviews and meta-analysis have confirmed this effect.

Thus, these societies recommend the use of antibacterial sutures, but with 2 conditions:

- They must be used exclusively for the suture of aponeurotic layers, subcutaneous tissue and skin in abdominal surgeries, but their use is not justified for visceral sutures.
- The contamination grade must be clean or clean-contaminated. There is no enough evidence to justify their use in contaminated or dirty procedures.

REFERENCES

Allegranzi, B; Zayed, B; Bischoff, P; et al. New WHO recommendations on intraoperative and postoperative measures for surgical site infection prevention: an evidence-based global perspective. *Lancet Infect Dis*., 2016, 16, e288-e303.

Anthony, T; Long, J; Hynan, LS; Sarosi, Jr. GA; Nwariaku, F; Huth, J; et al. Surgical complications exert a lasting effect on disease-specific health-related quality of life for patients with colorectal cancer. *Surgery*., 2003, 134, 119–25.

Anthony, T; Murray, BW; Sum-Ping, JT; Lenkovsky, F; Vornik, VD; Parker, BJ; et al. Evaluating an evidence-based bundle for preventing surgical site infection. A randomized trial. *Arch Surg*., 2011, 146, 263–9.

Apisarnthanarak, A; Singh, N; Bandong, AN; et al. Triclosan-coated sutures reduce the risk of surgical site infections: a systematic review and meta-analysis. *Infect Control Hosp Epidemiol*, 2015, 36, 169-179.

Blumetti, J; Luu, M; Sarosi, G; Hartless, K; McFarlin, J; Parker, B; et al. Surgical site infections after colorectal surgery: Do risk factors vary depending on the type of infection considered? *Surgery*., 2007, 142, 704–11.

Daoud, FC; Edmiston, CE; Jr. Leaper, D. Meta-analysis of prevention of surgical site infections following incision closure with triclosan-coated sutures: robustness to new evidence. *Surg Infect*, 2014, 15, 165-181.

De Jonge, SW; Atema, JJ; Solomkin, JS; et al. Meta-analysis and trial sequential analysis of triclosan-coated sutures for the prevention of surgical-site infection. *Br J Surg*, 2017, 104, 118-133.

Dimick, JB; Chen, SL; Taheri, PA; Henderson, WG; Khuri, SF; Campbell, Jr. DA. Hospital costs associated with surgical complications: A report from the private sector National Surgery Quality Improvement Program. *J Am Coll Surg*., 2004, 199, 531–7.

Edmiston, CE; Jr. Daoud, FC; Leaper, D. Is there an evidence-based argument for embracing an antimicrobial (triclosan)-coated suture technology to reduce the risk for surgical-site infections? A meta-analysis. *Surgery*, 2013, 154, 89-100.

Guo, J; Pan, L; li, Y; et al. Efficacy of triclosan-coated sutures for reducing risk of surgical site infection in adults: a meta-analysis of randomized clinical trials. *J Surg Res*, 2016, 201, 105-117.

Horan, TC; Andrus, M; Dudeck, MA. CDC/NHSN surveillance definition of health care-associated infection and criteria for specific types of infections in the acute care setting. *Am J Infect Control*., 2008, 36, 309–32.

Hedrick, TL; Heckman, JA; Smith, RL; Sawyer, RG; Friel, CM; Foley, EF. Efficacy of protocol implementation on incidence of wound infection in colorectal operations. *J Am Coll Surg.*, 2007, 205, 432–8.

Itani, KM; Wilson, SE; Awad, SS; Jensen, EH; Finn, TS; Abramson, MA. Ertapenem versus cefotetan prophylaxis in elective colorectal surgery. *N Engl J Med.*, 2006, 355, 2640–51.

Konstantelias, AA; Andriakopoulou, CS; Mourgela, S. Triclosan-coated sutures for the prevention of surgical-site infections: a meta-analysis. *Acta Chir Belg*, 2017, 117, 137-148.

Leaper, D; Edmiston, CE; Jr. Holy, CE. Meta-analysis of the potential economic impact following introduction of absorbable antimicrobial sutures. *Br J Surg*, 2017, 104, 134-144.

Masini, BD; Stinner, DJ; Waterman, SM; et al. Bacterial adherence to suture materials. *J Surg Educ*, 2011, 68, 101-104.

McMurry, LM; Oethinger, M; Levy, SB. Triclosan targets lipid synthesis. *Nature*, 1998, 394, 531-532.

Murray, BW; Huerta, S; Dineen, S; Anthony, T. Surgical site infection in colorectal surgery: A review of nonpharmacologic tools of prevention. *J AM Coll Surg.*, 2010, 211, 812–22.

Nve Obiang, E; Badia Perez, JM. Surgical site infection: Definition, classification and risk factors. In: Guirao Garriga X, Arias Diaz J. Clinical guidelines of the Spanish Surgical Society. *Surgical infections. Madrid: Aran*, 2006, p. 99–120.

Pastor, C; Artinyan, A; Varma, MG; Kim, E; Gibbs, L; Garcia- Aguilar, J. An increase in compliance with the surgical care improvement project measures does not prevent surgical site infection in colorectal surgery. *Dis Colon Rectum.*, 2010, 53, 24–30.

Ruiz-Tovar, J; Alonso, N; Morales, V; et al. Association between Triclosan-Coated Sutures for Abdominal Wall Closure and Incisional Surgical Site Infection after Open Surgery in Patients Presenting with Fecal Peritonitis: A Randomized Clinical Trial. *Surg Infect*, 2015, 16, 588-594.

Sajid, MS; Craciunas, L; Sains, P; et al. Use of antibacterial sutures for skin closure in controlling surgical site infections: a systematic review of published randomized, controlled trials. *Gastroenterol Rep*, 2013, 1, 42-50.

Serra-Aracil, X; García-Domingo, MI; Parés, D; Espin-Basany, E; Biondo, S; Guirao, X; Orrego, CA; et al. Surgical site infection in elective operations for colorectal cancer after the application of preventive measures. *Arch Surg.*, 2011, 146, 606–12.

Tang, R; Chen, HH; Wang, YL; Changchien, CR; Chen, JS; Hsu, KC; et al. Risk factors for surgical site infection after elective resection of the colon and rectum: A single-center prospective study of 2809 consecutive patients. *Ann Surg.*, 2001, 234, 181–9.

Wang, ZX; Jiang, CP; Cao, Y; et al. Systematic review and meta-analysis of triclosan-coated sutures for the prevention of surgical-site infection. *Br J Surg*, 2013, 100, 465-473.

Wu, X; Kubilay, NZ; Ren, J; et al. Antimicrobial-coated sutures to decrease surgical site infections: a systematic review and meta-analysis. *Eur J Clin Microbiol Infect Dis*, 2017, 36, 19-32.

In: Encyclopedia of Surgery (22 Volume Set)
Editors: Andreas Lehrer and Kristin Mueller
ISBN: 978-1-53618-329-0
© 2020 Nova Science Publishers, Inc.

Chapter 283

WOUND COVER: TOPICAL ANTIBIOTICS OR ANTISEPTICS

Helen Almeida Ponce* *and Pablo Royo Dachary*
Department of Surgery, University of Zaragoza,
Zaragoza, Spain

ABSTRACT

Wound coverage is thought to play a role on the prevention of surgical site infection (SSI). Dressings and antiseptics after surgical procedures are widely used and topical antibiotics have been studied by many authors although not included in clinical guidelines. Furthermore, combinations of these three elements are broadly available in clinical practice as an attempt to improve SSI prevention or to potentiate dressings actions on chronic or infected wounds.

Keywords: dressings, topical antibiotics, antiseptics, wounds

INTRODUCTION

In general surgery, the acceptable rate of infection following clean surgery is less than 5%, nevertheless, even within cohorts with a low overall risk of infection, some procedures may be at higher risk, and infection rates may be greater than 5% in these high-risk groups.

Wound coverage is a typical conduct throughout the world and common to all surgical and medical disciplines that involve a wound. It could be meant to protect the wound from external aggressive or contaminant agents, to add compression and avoid further bleeding, to manage exudates, to enhance the healing process or to avoid patient's traumatic reaction to the sight of their injuries. The role of wound coverage in the prevention of the surgical site infection (SSI) appears to be obvious, as it implies a physical barrier to external elements, but SSI rates remain the same, indicating that external sources are not the only element behind them and leaving an open door to other preventive actions.

* Corresponding Author's Email: helen.almeida.p@outlook.es.

Many initiatives have been suggested and tested in order to prevent or reduce surgical site infection in patients operated on for non-septic processes. In this context, antibiotic infusion is one of multiple measures used to achieve this goal, and its intravenous administration is clearly demonstrated and globalized, same as standard aseptic and antiseptic solutions to reduce the microbial contaminant exposure prior to the surgical procedure. On the other hand, wound coverage following surgical procedures, with elements such as topical antibiotics, antiseptics and dressings is still controversial, and actual guidelines do not include their systematic use after general surgery.

In this chapter we review the existing evidence on the role of wound cover in the prevention of surgical site infection.

WOUND DRESSINGS

Several attributes of an ideal wound dressing have been described according to the British National Formulary, these include: the ability of the dressing to absorb and contain exudate without leakage or strike-through, lack of particulate contaminants left in the wound by the dressing, thermal insulation, impermeability to water and bacteria, suitability of the dressing for use with different skin closure methods, avoidance of wound trauma on dressing removal, frequency with which the dressing needs to be changed, provision of pain relief, cosmesis and comfort, effect on formation of scar tissue, and transparency to aid visualisation of the wound.

Table 1 resumes the wide variety of dressings existing nowadays, as a result of their evolution towards achieving the attributes of an ideal dressing for different types of wounds, potentially improving their capacity to prevent infections, favour the healing process or bettering patients experience.

Table 1. Simplified classification of wound dressings

Wound dressing	Potential Benefits	Potential risks	Use	Considerations
Wound exposure	Allow follow-up without manipulation	Exposition to environmental contamination	Clean wounds	Some patients may not feel comfortable
Basic dressing				
Absorbent	Simple and inexpensive. Easy to change	Risk of maceration in high exudative wounds	Common wounds	Early (<48h) versus delayed (>48h) change has demonstrated no benefit
Low-adherence	Avoid adhesion to wound tissues	Low absorption capacity	Exposed tissues with risk of adhesion.	They are either non-medicated (e.g., paraffin gauze dressing), or medicated (antibiotics, antiseptics. etc.).

Advanced dressings				
Transparent film dressings	Provide a moist healing ambient	Dressing changes are less frequent	Clean wounds	Won't adhere to a moist surface
Foams	Crates a humid ambient to improve wound healing. Avoid adherence to wound	Dressing changes are less frequent	Moderate exudative wounds	Not recommended in wounds with dead spaces. Certain antiseptics may damage the foam product
Hydrocolloids 	Exudate management	Dressing changes are less frequent (every 3-7 days)	High exudative wounds	May cause peri wound maceration
Vacuum assisted	Accelerate wound healing improving vascularization	More expensive	Complex wounds with lack of tissue	Pay attention to bowel exposure
Antimicrobial	Active SSI prophylaxis. Skin decontamination		Potentially infected wounds	Could include antibiotics (e.g., neomycin) or antiseptics (e.g., silver)
Skin adhesives	Act as a barrier	There is no scientific evidence of their benefits	Closure of minor skin wounds and for additional suture support	Contain enbucrilate or octyl 2-cyanoacrylate

Basic Dressings

The most frequently used dressing for clean surgical wounds. Basic dressings perfectly fulfil the mission of isolation from external elements. They are simple and inexpensive and allow daily replacements easily. They have an absorbent surface to manage small exudates.

Drawbacks are: 1. their inability to handle highly exudative wounds, which can cause maceration and hinder wound closure; and, 2. allergic reactions or blisters on the skin due to high adherence.

Low adherence basic dressings may contain agents to prevent tissue adhesion, such as vaseline. This is very useful in wounds with exposed tissues, but also greatly diminishes the ability to absorb exudates.

There is no evidence of benefits of early (once every less than 48 hours) versus delayed (once every 48 hours or more) change of basic dressings in terms of wound infection.

Advanced Dressings

They emerge as a result of the extensive research on the different characteristics and requirements of wounds, not only those produced by surgical procedures (clean, contaminated or urgent) but also chronic wounds in diabetic, malnourished, immobilized patients, etc.

The groups most commonly found on general practice and their main characteristics are described in the following section.

Transparent film dressings	
They provide a moist healing environment, protect the wound from mechanical trauma and bacterial invasion, act as a blister roof or "second skin" and they are waterproof. Because of their flexibility, they can be used in awkward locations such as joints or skin folds. Transparency makes it easy to visualize the wound bed. Although these dressings can't absorb fluid, they're permeable to moisture allowing one-way passage of carbon dioxide and excess moisture vapor away from the wound. They reduce manipulation as it is not necessary to replace the dressing while the wound shows no signs of infection. Some patients may not feel comfortable with wound visibility. They need healthy skin around the wound because its adhesive properties are deactivated by moisture.	
Indications	Contraindications
Partial-thickness wounds with no or minimal drainage When protection is needed for intact skin, for example, protection of bony prominences such as elbows and heels from friction To promote debridement of eschar To protect and secure I.V. catheters To secure another dressing.	Contraindicated in patients with moderate to heavy exudate, third-degree burns, suspected or active infection, fungal infection, or active herpetic lesions. These dressings can cause peri wound maceration. Not recommended for patients with fragile or thin skin, especially elderly patients, or patients receiving steroids, to avoid epidermal stripping or skin tears.
Foams	
A porous structure that can absorb fluids into air-filled spaces by capillary action. The most commonly used foam is polyurethane. Silicone foam is less frequently used as the primary absorbent in wound dressing, but it is often applied as an adhesive wound contact layer. These dressings may have variable thickness and can be adhesive or non-adhesive. They are commonly supplied with a film-backing, which has the purpose of providing a water and microbial resistant barrier to the environment. They can be used as primary dressing or secondary dressing in combination with amorphous gels applied to the wound bed to provide moisture. The hydrogels are not absorbed into the foam due to their high viscosity.	
Indications	Contraindications
Acute and chronic wounds of both partial and full thickness Medium to heavy exudate.	Certain antiseptics may damage the foam product (e.g., iodine, chlorhexidine, hypochlorite, ether, hydrogen peroxide, oxygenated water, and sodium hypochlorite)

<table>
<tr><td colspan="2">Hydrocolloids:</td></tr>
<tr><td colspan="2">They contain gel-forming agents (a gelatine or sodium carboxymethylcellulose) held within an adhesive compound, which is laminated in place on a foam or film, generally made of polyurethane. The end product is an advanced wound dressing that resembles an absorbent, flexible wafer, typically both waterproof and self-adhering. Hydrocolloid dressings are occlusive, providing a moist healing environment, autolytic debridement and insulation. Changes should be done every 3 to 7 days depending on wound conditions and type of hydrocolloid.</td></tr>
<tr><td>Indications</td><td>Contraindications</td></tr>
<tr><td>Non-infected wounds with scant to moderate drainage
Necrotic or granular wound
Dry wound
Partial- or full-thickness wound
Protection of intact skin or a newly healed wound.</td><td>Not recommended for wounds with heavy exudate, sinus tracts, or when infection is present
Assessment can be difficult if the hydrocolloid dressing is opaque
May become dislodged if the wound produces heavy exudate
May curl or roll at the edges
Upon removal, dressing residue may adhere to the wound bed and there may be an odour
May cause peri wound maceration
May cause trauma/injury to fragile skin upon removal
May cause hypergranulation</td></tr>
<tr><td colspan="2">Impregnated dressings</td></tr>
<tr><td colspan="2">Gauze, bandage, etc. treated with a special chemical agent that promotes increased wound healing and a generally more sterile environment. These compounds must be paired with a secondary dressing, as they are generally non-adherent to most wound beds. There are several preferred impregnating mixtures, and each one has its own use and benefits.
1. Silver impregnated dressings: silver is utilized to help reduce the spread of bacteria and other harmful contaminants. Most often, physicians will pair silver with alginate or foam dressings, which improve its bacteria-fighting capabilities. They can be used on almost any wound, including heel abrasions and various ulcers.
2. Honey impregnated dressings: Like silver, honey has broad-spectrum applications. The acid found in honey causes an uptick in oxygenation, which makes the wound bed all but inhospitable for most forms of bacteria. It’s worth noting, though, that there are several different kinds of honey – like fireweed, sage and orange blossom – and each variety is uniquely potent as an antimicrobial agent.
3. Iodine impregnated dressings: This chemical is used extensively as a powerful disinfectant. Among a number of trials, iodine worked best in healing chronic ulcers and low-level burns, as the chemical was adept at destroying bacteria in these unique wound beds.
4. Methylene blue dressings: methyl blue is proven against several bacteria, including vancomycin-resistant enterococcus. This wound agent is normally paired with gentian violet which is best at combating a variety of fungal strains. Hydrofera Blue is one of the most popular dressings featuring this methyl-gentian combination. This dressing is used to treat everything, from **diabetic ulcers,** to wounds that come as a result of acute respiratory distress syndrome. Hydrofera Blue is noted for being more absorbent than other dressings, especially silver and foam, and doesn’t hinder growth factor activity.
5. Antibiotic dressings: they are non-toxic and can work effectively on the target sites without damaging hosts tissues. Some of the most commonly used are quinolones such as ciprofloxacin, ofloxacin, levofloxacin, etc; gentamycin, doxycycline, nitrofurantoin, etc.</td></tr>
<tr><td colspan="2">Vacuum-assisted closure (VAC):</td></tr>
<tr><td colspan="2">This device decreases air pressure on the wound. This can help the wound heal faster by gently removing fluid from the wound over time, reducing swelling, favouring wound´s cleansing and removing bacteria. A wound VAC also helps pull the edges of the wound together. And it may stimulate the growth of new tissue that helps the wound close.
A wound vacuum system has several parts. A foam or gauze dressing is put directly on the wound. An adhesive film covers and seals the dressing and wound. A drainage tube leads from under the adhesive film and connects to a portable vacuum pump. This pump removes air pressure over the wound either constantly, or in cycles. The dressing is changed every 24 to 72 hours.</td></tr>
</table>

Indications	Contraindications and risks
Highly exudative wounds that require frequent changes of other types of dressings. Wounds healing by first or second intention provided that they have no bleeding or exposed bowels	Negative pressure should not be used in wounds with active or known risk of: Bleeding Enteric fistula
Skin adhesives	
Cyanoacrylate tissue adhesives combine cyanoacetate and formaldehyde in a heat vacuum along with a base to form a liquid monomer. When the monomer comes in contact with moisture on the skin's surface, it chemically changes into a polymer that binds to the top epithelial layer. This polymer forms a cyanoacrylate bridge, binding the two wound edges together and allowing normal healing to occur below. The conversion from monomer to polymer occurs rapidly, preventing seepage of the adhesive below the wound margins, as long as the edges are well apposed. Heat is often generated during the change from monomer to polymer, and this heat may be felt on occasion by patients during application to the skin. Cyanoacrylates have also been shown to have antimicrobial properties. The adhesive acts as its own water-resistant bandage, and no added coverings are needed. Patients may shower normally and pat the area dry. The adhesive will spontaneously peel off in five to 10 days.	
Indications	Contraindications
Wounds healing on first intention Non-exudative wounds with clean edges	High risk of wound exudate or wound infection Topical antibiotics should not be applied to the closed wound for this would break down the adhesive and cause early peeling.

Studies to assess the effectiveness of dressings in the prevention of SSI have compared wound exposure to basic and advanced dressings, and basic contact dressings to advanced, antimicrobial and adhesive dressings. No recommendation based on evidence has emerged from the existing data.

Wound Cover versus Wound Exposure

It is uncertain whether there is a difference in SSI risk between basic wound dressing and wound exposure. Two trials were carried (Law in 1987 and Phan in 1993), comparing both clean and potentially contaminated surgery, with a combined total of 409 patients. No differences were found in SSI in the comparison groups. Both trials have a very low certainty evidence and a high risk of bias and their findings are summarized in Table 2.

Table 2. Wound exposure vs basic wound dressing

Author, year	Type of surgery	No.	SSI in covered vs exposed wounds	RR
Law, 1987	Clean	112	3/59 (5%) vs 1/53 (2%)	0.37 95% CI 0,4-3,46
Phan, 1993	Potentially contaminated	297	21/102 (21%) vs 29/105 (28%)	1.34 95% CI 0,82 – 2,19

In 2011, Siah et al. compared a silver dressing with wound exposure in 166 participants undergoing various types of elective colorectal surgery classified as clean/contaminated. No significant differences were found, as 8/83 (10%) in the exposed wound group developed SSI, compared with 1/83 (1%) in the silver-dressed wound group (RR: 8.00, 95% 1.02 to 62.55) with evidence of very low certainty, downgraded once for risk of bias and twice for imprecision by the Cochrane research team.

Dressings Compared with Other Type of Dressings

Many studies have been conducted comparing multiple kinds of dressings, in order to determine effectiveness in the prevention of SSI, and other characteristics such as ease of removal, effect on pain, costs, etc., but, as with other broad fields, heterogenicity in measurement scales and reported results, makes it difficult to draw conclusions.

Basic Wound Contact Dressings versus Film Dressings

Eight trials including 1089 patients (pooling all trials), compared a basic wound contact dressing with a film dressing. Five of these trials evaluated wounds resulting from 'clean' surgical procedures (Cosker 2005; De Win 1998; Law 1987; Moshakis 1984; Wynne 2004). According to the Cochrane revision on the subject, for clean surgery "*There is uncertain evidence on the risk of SSI between basic wound contact-dressed wounds and film-dressed wounds (RR 1.34; 95% CI 0.70 to 2.55); very low certainty evidence downgraded once for risk of bias and twice for imprecision*."

Two studies evaluated wounds resulting from surgical procedures with mixed, or unclear, contamination classifications. The trials included a variety of basic wound contact dressings including gauze and surgical absorbents. Similarly, whilst the comparators were all film dressings of different brands. Table 3 summarizes de results of these two trials.

Table 3. Basic wound contact dressing *versus* film dressing

Author, year	Type of surgery	No.	SSI in contact vs film dressings	RR
Gardezi, 1983	Clean/contaminated	100	6/50 (12 %) vs 3/50 (6%)	0.50 95% CI 0.13- 1.89
Rohde, 1979	Unclear	90	24/46 (52 %) vs 14/44 (32%)	0.61; 95% CI 0.36 to 1.02. In favour of the film dressing.

Basic Contact Wound Dressings Compared with Hydrocolloid Dressings

Six trials with a pooled total of 792 participants investigated the effect of a basic wound contact dressing compared with a hydrocolloid dressing (Holm 1998; Michie 1994; Persson 1995; Shinohara 2008; Wikblad 1995; Wynne 2004). The basic wound contact dressings were predominantly gauze.

Michie, Wikblad y Wynne described results on SSI after clean surgery, but each author on different terms, hence, no pooled data analysis was possible and there is no joint conclusion available; Wynne found no differences between hydrocolloid-dressed 6/267; (2%) and basic wound contact-dressed wounds 6/243; (3%) (RR 0.91; 95% CI 0.30 to 2.78).

The pooled data from the three trials that presented SSI data on contaminated surgery (Holm 1998; Persson 1995; Shinohara 2008) showed no differences between groups with a RR 0.57; 95% CI 0.22 to 1.51.

Basic Wound Contact Dressings Compared with Silver Dressings

Eight trials with a pooled total of 1959 patients, examined differences between these two types of dressings. Two authors included participants undergoing clean surgery (Dickinson Jennings 2015; Politano 2011). Six studies compared the use of a basic wound dressing with a silver-containing dressing in surgery at risk of contamination. Four studies involved

colorectal surgery (Biffi 2012; Kriegar 2011; Prather 2011; Ruiz-Tovar 2015). Bennett randomized 524 participants who had undergone a caesarean section and Ozaki randomized 500 people undergoing a non-emergency surgical procedure for peripheral vascular disease.

After analysing data of the two groups (clean surgery = 2 studies and potentially contaminated surgery = 6 studies) the Cochrane revision on the subject concludes that it is uncertain whether silver dressings increase or reduce SSI for either group with a RR 1.11; 0.47 to 2.62 for clean surgery and RR 0.83; 95% CI 0.51 to 1.37 for the potentially contaminated group.

Basic Wound Contact Dressing Compared with Non-Silver Antimicrobial Dressings

Martin-Trapero randomized 197 participants undergoing elective laparoscopic cholecystectomy to a basic wound contact or a Phenilmetil biguanide (PHMB) impregnated antimicrobial dressing. SSI in the wound contact dressing group was 5% (5/101); while the PHMB dressing-treated group had 1% (1/96). As the 95% CIs are wide and include benefits (in terms of reduced SSI risk) and harms (in terms of increased SSI risks) differences between the two groups remain unclear (RR 0.21, 95% CI 0.03 to 1.77).

Conclusion

Authors of the Cochrane revision conclude that there is insufficient evidence to determine whether covering surgical wounds healing by primary intention, with wound dressings, reduces the risk of surgical site infections (SSIs), or if any particular type of wound dressing reduces the risk of infections more than another. The review also failed to demonstrate any clear advantage of one dressing type over another (or wound exposure) for improved scarring, pain control, patient acceptability or ease of removal.

TOPICAL ANTIBIOTICS

The role of topical antibiotics has not been consistently supported by evidence and, therefore, they are not included in current guidelines for the prevention of SSI. There are thought to be benefits in using antibiotics topically rather than orally, or intravenously, as topical antibiotics act only on the area of the body where they are applied, there is less likelihood of unwanted effects that affect the whole body, such as nausea and diarrhea. Topical antibiotics are also thought to reduce the chances of bacterial resistance.

The most common method of application of topical antibiotics is in the form of an ointment. Other possible delivery methods include cream, lotion, solution, gel, tincture, foam, paste, powder, and impregnated dressings. An ointment base classically contains 80% oil and 20% water, and therefore is more occlusive and will drive the medication into the skin more rapidly than a solution or cream base; thus, ointments are an optimal delivery method for topical antibiotics.

In 2016 the Cochrane Database of Systematic Reviews selected 10 randomized controlled trials, including 6466 patients, assessing the effectiveness of topical antibiotics on preventing

SSI, to determine whether the application of topical antibiotics to surgical wounds that are healing by primary intention reduces the incidence of SSI and the incidence of adverse outcomes (allergic contact dermatitis, infections with patterns of antibiotic resistance and anaphylaxis). All forms of topical antibiotics were included (creams, impregnated dressings, ointments, etc) provided that their application followed wound closure by primary intention. Silver and antiseptic impregnated dressings were excluded given that these substances did not match the definition of antibiotic.

The results of this systematic review are summarized in the following sections as they gather the most recent evidence on the subject.

Topical Antibiotic versus No Topical Antibiotic

The results of eight trials were pooled (5427 participants) using a random-effects model. The -no topical antibiotic- group included: inert ointment (Dire 1995; Dixon 2006; Heal 2009; Smack 1996) and no treatment (Caro 1967; Dixon 2006; Gilmore 1973a; Kamath 2005; Khalighi 2014). There were *fewer SSIs with topical antibiotics than without* (RR 0.61; 95% CI 0.42 to 0.87). There was an absolute risk difference of 20 fewer SSIs per 1000 patients (95% CI 7 fewer to 31 fewer) and a *number needed to treat to benefit* (NNTB) with topical antibiotics to avoid one additional SSI (NNT) of 50. There was moderate inter study heterogeneity (I^2 = 44%). The quality of evidence for this outcome was graded as moderate, downgraded once for the proportion of the information from studies at high risk of selection bias, as this was sufficient to affect the interpretation of the results, a sensitivity analysis was performed to examine the effect of removing the studies at high risk of bias on I^2 and RR (Caro 1967; Dixon 2006; Gilmore 1973). The effect estimate was robust to removal of high risk of bias studies (RR 0.49, 95% CI 0.35 to 0.67; 3026 participants; 5 studies; I2 = 0%).

No clear difference between groups for risk of allergic contact dermatitis was found (RR 3.94, 95% CI 0.46 to 34.00).

Topical Antibiotic versus Topical Antibiotic

One study (99 participants) was a head-to-head comparison of mupirocin and neomycin (Hood 2004). There was no clear evidence of a difference between mupirocin and neomycin in risk of SSI (RR 0.20; 95% CI 0.01 to 4.14; P = 0.3). The quality of evidence for this outcome was rated as very low. Another study was a four-arm trial; two arms of which were antibiotic arms combination ointment (neomycin sulphate, bacitracin zinc, and polymyxin B sulphate) versus bacitracin zinc (Dire 1995). Comparison of the results for these two arms showed no clear evidence of a difference in risk of SSI (RR 0.83; 95% CI 0.26 to 2.63; 219 participants, P = 0.75).

These two trials did not compare similar topical antibiotics and so were not pooled. The quality of evidence of this outcome was rated as very low and was downgraded twice for risk of bias and once for imprecision.

There was no information available for the outcomes of allergic contact dermatitis or anaphylaxis for either study.

Topical Antibiotics versus Antiseptic

Five trials that compared topical antibiotics with antiseptics were pooled (1299 participants) to examine effects on risk of SSI. There were fewer SSIs in those treated with topical antibiotics than with antiseptics (RR 0.49, 95% CI 0.30 to 0.80). This difference reflected an absolute difference in risk of 43 fewer cases of SSI per 1000 people treated with topical antibiotics instead of antiseptics (95% CI 17 fewer to 59 fewer per 1000; NNTB of 24). There was minor inter study heterogeneity (I^2 = 12%). The quality of evidence for this outcome was rated as moderate and was downgraded. A sensitivity analysis was performed to examine the effect of removing the studies at high risk of bias on I^2 and RR (Gilmore 1973a; Iselin 1990). The overall effect was robust to removal of the high risk of bias studies (RR 0.39, 95% CI 0.20 to 0.76) and heterogeneity was reduced (I^2 = 0%).

Two trials (541 participants) compared the effects of topical antibiotics and antiseptics on the rates of allergic contact dermatitis. Pooled analysis indicated no clear evidence of a difference (RR 0.97, 95% CI 0.52 to 1.82; I2 = 0%, P = 0.92). One of the two studies was at high risk of bias and the other was at unclear risk of bias. The overall quality of the evidence was rated as very low

Conclusion

Topical antibiotics probably prevent surgical site infection (SSI) whether compared with antiseptic or to no topical antibiotic (moderate quality evidence). The Cochrane review only identified studies involving clean (class1), clean contaminated (class 2), and contaminated (class 3) surgery, and no conclusions regarding dirty-contaminated (class 4) surgery can be drawn.

In clean surgery, where the baseline infection rate is already low, and the absolute risk reduction in SSI is smaller, the use of topical antibiotics is probably not justified. In classes 2 and 3, the actual reduction in the rate of infection was 4.3% on average when the use of topical antibiotic was compared with antiseptic, and 2% when compared to no treatment, this means it would require 24 patients, on average, to be treated with topical antibiotics instead of antiseptics, and 50 patients to be treated with topical antibiotics, compared to no treatment, in order to prevent one wound infection.

The Cochrane Database review was unable to draw conclusions regarding the effects of topical antibiotics on adverse outcomes, such as allergic contact dermatitis, due to lack of statistical power. It was also unable to draw conclusions regarding the impact of increasing topical antibiotic use on antibiotic resistance.

ANTISEPTICS

The application of antiseptics such as povidone or chlorhexidine at the end of a surgical procedure, after wound closure and prior to the application of any kind of dressing, is widely extended, though it is very hard to find any scientific base to this practice. Regardless of the

background of this conduct, after tissue manipulation, bleeding, etc. it seems only logical to repeat antiseptic procedures if not to reduce SSI, at least to improve wounds appearance.

Antiseptics are chemical agents that reduce the microbial population on the skin. They should gather certain attributes to be consider ideal, such as: kill all bacteria, fungi, viruses, protozoa, tubercle bacilli and spores; be non-toxic; be hypoallergenic; be safe to use in all body regions; not to be absorbed; have residual activity; be safe for repetitive use.

Several antiseptic agents are available for preoperative preparation of skin at the incision site. Most commonly used include iodine as iodine, povidone iodine, cadexomer iodine or povidone; chlorhexidine as polyhexamethylene biguanide or chlorhexidine. Some authors also include silver as an antiseptic or antimicrobial since it does not meet the criteria that defines antibiotics, but it is not used for skin preparation.

Studies that asses the effectivity of antiseptics versus topical antibiotics or dressings impregnated with these substances compared with other types of dressings are detailed in the sections above.

REFERENCES

Atiyeh, Bishara S., Saad A. Dibo, y Shady N. Hayek. 2009. “Wound Cleansing, Topical Antiseptics and Wound Healing.” *International Wound Journal* 6 (6): 420-30. https://doi.org/10.1111/j.1742-481X.2009.00639.x.

Berger, R. S., A. S. Pappert, P. S. Van Zile, y W. E. Cetnarowski. 2000. “A Newly Formulated Topical Triple-Antibiotic Ointment Minimizes Scarring.” *Cutis* 65 (6): 401-4.

Dumville, Jo C, Trish A Gray, Catherine J Walter, Catherine A Sharp, Tamara Page, Rhiannon Macefield, Natalie Blencowe, Thomas KG Milne, Barnaby C Reeves, y Jane Blazeby. 2016. “Dressings for the Prevention of Surgical Site Infection.” Cochrane Wounds Group. *Cochrane Database of Systematic Reviews*. https://doi.org/10.1002/14651858.CD003091.pub4.

Dumville, Jo C, Emma McFarlane, Peggy Edwards, Allyson Lipp, Alexandra Holmes, y Zhenmi Liu. 2015. “Preoperative Skin Antiseptics for Preventing Surgical Wound Infections after Clean Surgery.” Cochrane Wounds Group. *Cochrane Database of Systematic Reviews*. https://doi.org/10.1002/14651858.CD003949.pub4.

Heal, Clare F, Jennifer L Banks, Phoebe D Lepper, Evangelos Kontopantelis, y Mieke L van Driel. 2016. “Topical Antibiotics for Preventing Surgical Site Infection in Wounds Healing by Primary Intention.” Cochrane Wounds Group. *Cochrane Database of Systematic Reviews*. https://doi.org/10.1002/14651858.CD011426.pub2.

Hirsch, Tobias, Hans-Martin Seipp, Frank Jacobsen, Ole Goertz, Hans-Ulrich Steinau, y Lars Steinstraesser. 2010. “Antiseptics in Surgery.” *Eplasty* 10 (may): e39.

Kowalczuk, J. 2006. “British National Formulary for Children 2005.” *Quality and Safety in Health Care* 15 (1): 76-76. https://doi.org/10.1136/qshc.2005.016881.

Kramer, Axel, Joachim Dissemond, Simon Kim, Christian Willy, Dieter Mayer, Roald Papke, Felix Tuchmann, y Ojan Assadian. 2018. “Consensus on Wound Antisepsis: Update 2018.” *Skin Pharmacology and Physiology* 31 (1): 28-58. https://doi.org/10.1159/000481545.

Law, N. W., y H. Ellis. 1987. "Exposure of the Wound--a Safe Economy in the NHS." *Postgraduate Medical Journal* 63 (735): 27-28.

Lee, Ingi, Rajender K. Agarwal, Bruce Y. Lee, Neil O. Fishman, y Craig A. Umscheid. 2010. "Systematic Review and Cost Analysis Comparing Use of Chlorhexidine with Use of Iodine for Preoperative Skin Antisepsis to Prevent Surgical Site Infection." *Infection Control & Hospital Epidemiology* 31 (12): 1219-29. https://doi.org/10.1086/657134.

Phan, M., P. Van der Auwera, G. Andry, M. Aoun, G. Chantrain, R. Deraemaecker, P. Dor, D. Daneau, P. Ewalenko, y F. Meunier. 1993. "Wound Dressing in Major Head and Neck Cancer Surgery: A Prospective Randomized Study of Gauze Dressing vs Sterile Vaseline Ointment." *European Journal of Surgical Oncology: The Journal of the European Society of Surgical Oncology and the British Association of Surgical Oncology* 19 (1): 10-16.

Ruiz Tovar, Jaime, y Josep M. Badia. 2014. "Prevention of surgical site infection in abdominal surgery. A critical review of the evidence." *Cirugía Española* 92 (4): 223-31. https://doi.org/10.1016/j.ciresp.2013.08.003.

Ruiz-Tovar, Jaime, Carolina Llavero, Vicente Morales, y Carlos Gamallo. 2015. "Total Occlusive Ionic Silver-Containing Dressing vs Mupirocin Ointment Application vs Conventional Dressing in Elective Colorectal Surgery: Effect on Incisional Surgical Site Infection." *Journal of the American College of Surgeons* 221 (2): 424-29. https://doi.org/10.1016/j.jamcollsurg.2015.04.019.

Toon, Clare D, Charnelle Lusuku, Rajarajan Ramamoorthy, Brian R Davidson, y Kurinchi Selvan Gurusamy. 2015. "Early versus Delayed Dressing Removal after Primary Closure of Clean and Clean-Contaminated Surgical Wounds." Cochrane Wounds Group. *Cochrane Database of Systematic Reviews*. https://doi.org/10.1002/14651858.CD010259.pub3.

In: Encyclopedia of Surgery (22 Volume Set)
Editors: Andreas Lehrer and Kristin Mueller
ISBN: 978-1-53618-329-0
© 2020 Nova Science Publishers, Inc.

Chapter 284

CLINICAL EXAMINATION, IMAGING AND BASIC SURGICAL TECHNIQUES

Peter Stefanic*[*]*, MD, PhD
Department of Vascular Surgery, East Slovak Institute of Cardiovascular Diseases,
Medical Faculty of Safarik University, Kosice, Slovakia

ABSTRACT

Vascular diseases comprise disorders of the arteries, veins and lymphatic system. This chapter provides a comprehensive overview of basic physical examinations in patients with arterial and venous system disorders. As in other parts of the surgery, and in vascular surgery, history and clinical examination play a very important role. Clinical examination in vascular surgery requires an appreciation of the whole patient with a focus on specific findings typical for patients with vascular disease. Adequate analysis of signs and symptoms often requires the multidisciplinary representation of several experts in vascular surgery, angiology, and radiology. A standard examination of a patient with a vascular disease consists of a standard clinical examination, laboratory procedures and imaging. The main imaging studies for vascular surgery are duplex ultrasonography (DUS), CT-angiography, MR-angiography, and digital subtraction angiography (DSA). This chapter also provides a comprehensive overview of basic vascular surgery techniques. Although the first successful arterial reconstructions appeared at the beginning of the 20th century, the active management of arterial diseases had developed since 1950 when new techniques of vascular surgery had been established. Based on this fact, we can claim that vascular surgery is a young surgical field department. The development of imaging in vascular surgery, particularly DSA, has also significantly contributed to the development of new, modern endovascular treatments. Nowadays, well-designed clinical trials have become the "gold standard" for the assessment of new diagnostic methods and treatments.

Keywords: clinical examination, arterial reconstructions, endarterectomy, CT-angiography, MR –angiography, digital subtraction angiography, vascular graft

[*] Corresponding Author's Email: pstefanic@vusch.sk.

ABBREVIATIONS

AAA	Abdominal Aortic Aneurysm
CT	Computed Tomography
CVD	Cardiovascular Disease
DSA	Digital Subtraction Angiography
DUS	Duplex Ultrasonography
DVT	Deep Venous Thrombosis
GSV	Great Saphenous Vein
MRI	Magnetic Resonance Imaging
PAD	Peripheral Arterial Disease
PTFE	Polytetrafluoroethylene
PET/CT	Positron Emission Tomography
SPECT/CT	Single Photon Emission Computed Tomography/Computed Tomography
SSV	Small Saphenous Vein

INTRODUCTION

Vascular diseases comprise disorders of the arteries, veins and lymphatic system [1]. Atherosclerotic-related cardiovascular disease (CVD) is the leading cause of death in all regions of developed countries [2]. An estimated 17.9 million people died from CVDs in 2016, representing 31% of all global deaths. Of these deaths, 85% are due to heart attack and stroke. Over three-quarters of CVD deaths take place in low- and middle-income countries. Out of the 17 million premature deaths (under the age of 70) due to noncommunicable diseases in 2015, 82% are in low- and middle-income countries, and CVDs caused 37% [3]. Peripheral artery disease (PAD) is no exception, so greater focus is required on prevention of the disease in low- and middle-income countries. PAD impairs quality of life and is associated with a significantly increased risk of major cardiovascular events and death; PAD is the essential cause of amputation worldwide [4].

However, during the last twenty years, CVD age-specific death rates fell by greater than 40% in high-income countries, which is also probably related to modern diagnostic methods [5]. As in other parts of surgery, including vascular surgery, patient history, and clinical examination play a very important role. Adequate analysis of signs and symptoms often requires the multidisciplinary representation of several experts in vascular surgery, angiology, and radiology [1]. First, when a patient comes to the hospital, the patient's main complaints should be determined and the physical examination should be correlated with the history and should also provide a bridge to the pathophysiology of the disease process [6]. When the patient's history is known and physical examination is completed, imaging diagnostic studies can be ordered, if necessary, to localize the vascular disease or quantify the extent of the vascular pathological process. The main imaging studies for vascular surgery are DUS, CT-angiography, MR-angiography, DSA and also in some specific situation, single photon emission computed tomography/computed tomography (SPECT/CT) and positron emission tomography (PET)/CT. Determining the correct diagnosis always begins by identifying the signs and symptoms of the patient. It is important to get a chronological description of the

development and progression of the patient's main complaint from the first symptom to the present [7]. After proper diagnosis, another very important thing is an indication of surgical, endovascular, or conservative treatment [8]. Although surgical techniques in vascular surgery have undergone modification for several years, standard surgical techniques are used for the treatment of both arterial and venous diseases. Although the first successful arterial reconstructions appeared at the beginning of the 20th century, the active management of arterial diseases has developed since the 1950s when new techniques of vascular surgery have been established. It should be mentioned here that *Alexis Carrel* was awarded the Nobel Prize in Medicine in 1912 for inventing the modern vascular suture that is still used today.

In 1947, Dos Santos performed the first femoral endarterectomy. Dubost did the first resection of a ruptured aneurysm of abdominal aorta and replacement by allograft in 1952. The first resection of carotid bifurcation for prevention of recurrent cerebral ischemia was carried out by Eastcott in London in 1954. The great development of vascular surgery brought the introduction of prosthetic grafts by Vorhees in 1952. That enabled De Backey to resect abdominal aortic aneurysm and replace it with a synthetic graft in 1955. Seldinger performed the first angiography with a catheter in 1952, and more than twenty years later Gruntzig, in 1974, was the first who did percutaneous transluminal angioplasty and started the modern era of endovascular treatment [9].

CLINICAL EVALUATION

In surgery, including vascular surgery, history and physical examination play a crucial role. It is possible to make a diagnosis and predict the underlying anatomic pathology based on patient history and basic physical examination alone. The anatomy of the vascular disease often correlates with the location of symptoms. The physical examination should progress from inspection to palpation and auscultation. During the inspection, it is necessary to monitor skin changes such as atrophy, edema, cyanosis or mottling, pallor and rubor, tissue loss, and ulceration. All skin changes should be identified, quantified, and fully described. Motor limbs function should also be documented and quantified. During palpation, differences in temperature and sensation should be noted and compared with the contralateral side. All pulses should be evaluated and classified in typical places (carotid artery, brachial artery, radial and ulnar artery, femoral, and popliteal artery, anterior, and posterior tibial artery) [10]. The initial onset of clinical symptoms that may indicate acute or chronic vascular disease, and the location of all symptoms is also essential. Also important are factors which aggravate or relieve symptoms, for example, activity, leg position, temperature, or pressure [7, 8].

History, Signs, and Symptoms in a Patient with Artery Disease

When arterial occlusive disease affects peripheral arteries of the lower extremities, we speak about PAD (peripheral arterial disease). Peripheral artery disease can be acute – acute artery occlusion or chronic – chronic peripheral artery disease with typical symptoms of chronic artery insufficiency. Patients with the PAD most commonly have long-standing

symptoms [11, 12]. Peripheral arterial insufficiency is predominantly a disease of the lower extremities. Pain is syndrome typical for ischemia, which can appear after walking in the form of claudication or it can also be present without physical exercising in the form of rest pain. Both claudication and rest pain are typical symptoms of chronic peripheral artery disease [11]. PAD symptoms can be described as cramping, aching, fatigue, or numbness. Symptoms for PAD are secondary, as a result of decreased circulation, and the relief occurs promptly after the cessation of activity. Claudication is distinguished from other types of pain in the extremities (because of lactic acid accumulation in the muscles) in that it does not occur at rest. Depending on the location of the arterial stenosis or occlusion, the patient may have claudication pain in any of the three major muscle groups of the lower extremity: the buttock - aortoiliac occlusion, thigh femoropopliteal, and tibial occlusion, or calf - tibial occlusion. The triad of intermittent claudication of thigh and buttock muscles, impotence, and diminished or absent femoral pulses are associated with aortoiliac occlusion and is often referred to as Leriche syndrome. PAD symptoms are aggravated if the patient lies down and elevates the extremity. Ischemic pain awakens patients at night [7, 11]. For progressive atherosclerotic obstructive disease, ischemic pain at rest and developing non-healing ulcers or wounds (Figure 1) are typical. Defects are usually very painful. Chronic ischemia produces gradual soft tissue and muscle atrophy. Patients with progressive critical limb ischemiamay very often sleep with their foot continually hanging over the edge of the bed. Small atheroembolic debris arising from atherosclerotic plaque or emboli can occlude small peripheral arteries. Those patients will have a painful bluish discoloration of digits, resulting in “blue toe syndrome.” Involved fingers are felt by patients as cold and numb to touch, and the toes are blue. PAD most commonly occurs in older patients (20% of people older than 65 years) [13]. In younger patients, symptoms like PAD can be associated with popliteal artery obstruction from muscular or tendinous entrapment and aneurysm or mucinous degeneration of the artery [7, 14].

Figure 1. Critical limb ischemia – wet gangrene.

The discomfort of the upper extremity associated with activity can be associated with stenosis or occlusion of the axillary or subclavian arteries. Symptoms are induced by physical activity and relieved by rest [15].

Specific is Thoracic Outlet Syndrome where the subclavian artery (figure 2), vein, or brachial plexus and its trunks are compressed within the scalene triangle. Compression can occur due to muscle abnormality or more often bone abnormalities, such as a cervical rib or anomalous first rib. Chronic compression can develop into thromboembolism, occlusive disease, or an aneurysm. Arterial symptoms are less common and often the result of peripheral emboli. The most common is neural TOS. Patients will complain of arm fatigue, finger numbness, pain, and discomfort when they are working with the arms elevated above the head, or when performing abduction of the arm [16].

Figure 2. DSA, thoracic outlet syndrome, subclavian artery compression with anomalous rib and brachial artery occlusion.

Acute artery occlusion is associated with very intense pain, which occurs very suddenly. Specific clinical symptoms for acute artery occlusion are “6 Ps” pallor, pain, paresthesia, paralysis, pulselessness, and poikilothermia. The other typical clinical manifestation of ischemia is coolness. Loss of sensitivity and further loss of motoric function of muscles and paralysis are the main signs of acute ischemia [17]. In acute artery occlusion, the patient will first notice a change in the skin color, a decrease in sensation, and coolness to the touch [7]. After these signs, motoric dysfunction of extremities starts. Motoric dysfunction is consistent with severe limb-threatening ischemia. Those patients do not have good collateral circulation; therefore, ischemia is sudden and severe. Arterial injuries have similar acute symptoms. Embolism is typical for patients with atrial fibrillation [7, 9, 17].

Symptoms of extracranial carotid artery disease are most often caused by embolization of the internal carotid artery by atrial fibrillation or thrombosis of the artery at the atherosclerotic plaque. Arterial emboli account for approximately one-quarter of ischemic strokes in Europe and North America. 80% of these originate from extracranial carotid atherosclerotic lesions

(Figure 3) [18, 19]. The most common lesion is at the bifurcation of the common carotid artery.

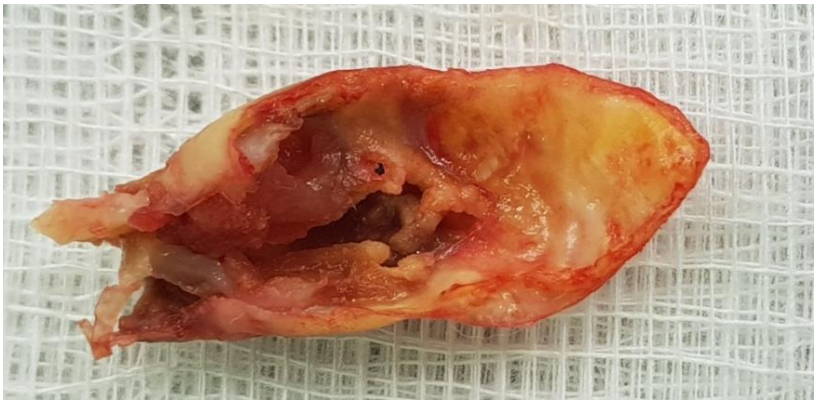

Figure 3. Atherosclerotic plaque from the internal carotid artery.

The neurologic dysfunction associated with microemboli may appear as sudden transient ischemic attacks (TIA), or if the symptoms persist, it is an ischemic stroke – the patient had an ischemic lesion in the brain. An embolus to the ophthalmic artery, the first branch of the internal carotid artery, produces a temporary monocular loss of vision called amaurosis fugax [9, 19]. Acute occlusion of a common or internal carotid artery leads to the sudden onset of neurological symptoms as expressive aphasia, hemiparesis, or hemiplegia contralateral to the occlusion site. Neurological symptoms also depend on collateral brain arteries' function. In the worst case, the occlusion of the internal carotid artery may also lead to coma and death [20].

Pain in the back can be the main symptom of a rupture of abdominal aorta aneurysm (AAA). Patients with AAA are usually asymptomatic until they expand or rupture. Patients may feel back, flank, abdominal, or groin pain for some time before rupture. At times, AAA may cause symptoms from local compression, including early satiety, nausea, vomiting, compression urinary symptoms, or venous thrombosis from venous compression. Other symptoms include abdominal pain, groin pain, embolic phenomena affecting the toes [9, 21, 22]. Very often, patients may describe a pulse in the abdomen and may feel a big pulsatile mass. Quick expanding AAA commonly causes sudden, severe, and constant low back, flank, abdominal, or groin pain. The most typical manifestation of rupture is abdominal or back pain with a pulsatile abdominal mass. The pain usually irradiates into the back and occasionally into the inguinal region. Transient hypotension should prompt consideration of rupture because this finding can progress to frank shock. Unfortunately, the classic triad of pain, a pulsatile abdominal mass, and hypotension are not always present [9, 22].

Peripheral artery aneurysms (Figure 4) are usually asymptomatic but sometimes may manifest themselves with symptoms when there is local compression of other structures such as nerves or veins, with ischemia, or rarely with rupture. Symptoms from recurrent peripheral embolization to the leg are often transient. Thrombosis of the peripheral aneurysm and consequent thrombosis of peripheral arteries is another severe complication of the peripheral aneurysm. Thrombosis of aneurysm leads to acute limb ischemia, and the clinical manifestation is the same as acute ischemia [23].

Figure 4. Peripheral artery aneurysms – brachial artery.

Chronic mesenteric ischemia is also characterized by abdominal pain, which characteristically appears 15-30 minutes after the beginning of a meal and lasts for an hour or longer. Other clinical signs are weight loss, fear of eating, postprandial abdominal discomfort, and epigastric bruit. The early hallmark of acute mesenteric ischemia is severe pain but minimal physical findings. The abdomen remains soft, with little or no tenderness. Later, as bowel necrosis develops, signs of peritonitis appear with marked abdominal tenderness, guarding, rigidity, and no bowel sounds. If bowel ischemia progresses, the stool may be heme-positive. The usual signs of shock develop and are frequently followed by death [24, 25].

Physical Examination in Patients with Arterial Disease

A complete physical examination for patients with suspected arterial disease consists of several steps. Physical examination begins with observation and inspection.

Inspection

The peripheral arterial disease is very often associated with atrophy of the calf muscles, atrophy of the skin – shin appearance, loss of hair over the lower part of the leg. In the initial stages of PAD, pallor is present in the lower extremities. In advanced stages of ischemia, dependentrubor is observed, and the distal part of the leg and the digits may appear reddish. In patients with critical limb ischemia, the foot may appear edematous, and the skin is tense because the patient hangs the foot over the bed (to relieve the pain). Formation of ischemic ulcerscan is observed in a patient with critical ischemia. Ischemic ulcers are usually situated on the peripheral parts of extremities, toes, heels, fingertips, and these ulcers are often small and circinate with pale grayish granulation tissue in the base. Ischemic ulcers can progress to tissue gangrene, which can be dry eschar or wet due to purulent (microbial infection) or serous drainage [7, 11, 12].

On the other hand, in patients with acute occlusion of the artery, the extremities appear pale or cyanotic, and the part of extremities under the occlusion are too cold and cool to

touch. Loss of sensitivity and further loss of motoric function of muscles are the main signs of acute ischemia [7, 17].

The signs and symptoms of extracranial carotid artery disease are very diverse. Characteristic of the symptomatic patient with internal carotid artery stenosis is some neurological deficit. The most common can be ipsilateral facial numbness, sensory loss, transient monocular blindness, dysarthria, aphasia, monoparesis, hemiparesis, hemisenzoric deficit or vertigo and dizziness [20].

Some aneurysms, e.g., in the popliteal region, may be visible as large pulsating masses [23].

Pulse Examination

Physical examination of the arteries' function begins with the pulse examination – pulse palpation. If possible, the examiner should use the fingertips of the hand and avoid the thumb. Palpation should start lightly and increase in pressure gradually. Pulses can be palpated in the neck, arms, legs, and trunk and always should be palpated and compared bilaterally. We can document that a pulse is absent, decreased, or normal [1, 26].

The carotid pulse may be palpated in the mid-neck region, anterior to the sternocleidomastoid muscles. Especially on the neck, pulse contour can impart information concerning heart function, valvular heart disease, or proximal stenosis [7].

Pulses on upper extremities are examined on brachial, radial and ulnar arteries. The brachial pulse is superficial, and it may be palpated along the inferior border of the biceps muscle. The radial and ulnar pulse are palpated in the wrist. The radial artery is more superficial than ulnar, so the pulsations in the radial artery are usually easy to palpate [1, 10].

On the legs, pulses may be examined at four levels of arteries. The common femoral artery pulse can be palpated in the inguinal area around the inguinal ligament (one-third of the distance from the pubis to the anterior superior iliac spine). The popliteal artery pulse is more difficult to palpate because the muscle obscures the popliteal artery. It may be difficult to palpate in obese or very muscular patients. The patient's leg should be partially flexed and relaxed. The examiner should use both hands to palpate pulse in the popliteal fossa. The examiner's hands encircle and support the knee from each side. On the foot, the posterior tibial pulse can be examined below the medial malleolus. The dorsal pedal artery is localized on the dorsum of the foot between the second and third metatarsal bones. The artery usually lies lateral to the extensor hallucis tendon. In this area, the dorsal pedal artery pulse can be examined [1, 27].

Remember that in patients with PAD, the examiners may have confusion with their own pulse.

During pulse palpation, the size of the artery should be assessed too. Typically, an aneurysm is a pulsatile mass of the palpated artery. Typical localization for aneurysms is the abdominal aorta, popliteal artery, common femoral artery, and subclavian artery. Popliteal aneurysms are commonly bilateral and more frequently associated with AAA. Most aneurysms can be palpated as pulsatile masses, for example, abdominal aorta aneurysm; many patients also feel a big pulsatile mass in the abdomen. Aneurysm of the abdominal aorta can be palpated in thin patients by having them relax their abdominal muscle and then palpating deeply. Pulsatile expansion detected below the umbilicus indicates extension into the iliac

arteries. Most symptomatic iliac aneurysms can be palpated as pulsatile masses on abdominal or rectal examinations. The femoral aneurysm may compress the vein, which causes unilateral edema of the leg [1].

Auscultation

On auscultation of the healthy vessel, nothing is heard. The presence of a bruit is caused by turbulence of blood flow and suggests significant vascular pathology (arterial stenosis, local arterial compression, aneurysmal dilation, or arteriovenous fistula) [27]. If stenosis progresses, the pitch of thrill increases. If stenosis progresses to near occlusion, the intensity of the thrill may decrease. The span of the bruit is also very important because if the bruit continuation into diastole, it points to severe stenosis. Continuous bruits during the systole and diastole are significant for arterio-venous connections [1].

History, Signs, and Symptoms in a Patient with Venous Disease

Clinical signs and symptoms of venous disease are more passive and demonstrate fewer signs than arterial disease. Several acute and chronic diseases of the venous system are manifested by swelling or edema. The etiology of edema may be venous (superficial or deep veins of the lower extremity disease), or nonvenous (disease of the lymphatic system or other systemic illnesses). The disease of the venous system may by acute or chronic and can involve one or both extremities. The clinical history is particularly very important in the evaluation of a patient with the venous disease [1, 28].

The acute venous disease may be presented as superficial vein thrombosis or deep vein thrombosis of the lower extremities and also by thrombophlebitis or varicophlebitis.

Superficial venous thrombosis is associated with inflammation around the vein, erythematous areas overlying a superficial vein. The patient complains of pain along the vein; the affected area is warm, erythematous, and indurated (palpable mass). The symptoms of superficial venous thrombosis are a result of the local inflammation associated with the venous thrombosis. The superficial vein may be distended proximal to the thrombosis [29]. Thrombophlebitis of upper extremities most often involve the cephalic and basilic veins or their branches and is frequently associated with intravenous catheters [30].

Superficial vein thrombosis of the lower extremities is frequently associated with venous varicosities. In the lower extremity, thrombophlebitis typically involves the great saphenous vein and its branches on the medial parts of the leg, but sometimes also small saphenous vein [29, 30].

Deep vein thrombosis (DVT) is the formation of blood clots in the deep veins, predominantly affecting the deep veins of lower extremities (the calf veins, femoral vein, popliteal vein, or exceptionally affecting the deep veins of the pelvis [31]. Deep venous thrombosis is most often associated with a recent patient history of trauma, surgery, travel, using anticonception pills or prolonged immobility [32]. Typical symptoms are swelling, pain, discomfort, pressure, warmth, or fullness in the extremity. Elevation of the affected leg ameliorates the pain, discomfort, and fullness. Deep thrombosis of the distalpopliteal or crural veins is associated with edema of the calf. The left leg is the most frequent site for venous

thrombosis in pregnancy. If the occlusion is in the iliac or proximal femoral part of the vein, the symptoms are presented as edema and cyanosis of the entire extremity. The symptoms are more frequently unilateral, but sometimes if the occlusion is localized in both the iliac vein and also in the inferior cava vein, the swelling is bilateral [31].

The specific type of DVT is phlegmasia. This type of deep vein thrombosis is associated with the vast extent of thrombosis (inferior cava vein, iliac vein, femoral vein). It is very dangerous because the whole leg is edematic, and increased compartment pressure leads to reduced blood flow in the leg. Phlegmasia alba dolens is characterized by swollen, painful, and blanching without cyanosis, while phlegmasia cerulea dolens is characterized by these features in addition to cyanosis, which characteristically progresses from distal to proximal areas and bulla formation [31, 32].

Patients with repeated DVT or thrombophlebitis may have a diagnosis of cancer, and the deep vein thrombosis is a secondary sign of other serious diseases. This is extremely important in the differential diagnosis. Repeated deep vein thrombosis may damage the valves of the vein, and these patients have a chronic problem with swelling of extremities [31].

Chronic venous insufficiency (CVI) typically refers to lower extremity edema, skin trophic changes, and discomfort secondary to venous hypertension. Chronic venous insufficiency can occur after 5 or more years after the first episode of deep venous thrombosis: patients complain about the discomfort, fatigue, itching, cramping, and swelling of the extremity. Long-standing venous hypertension and edema can result in the development of venous stasis ulcers which are usually localized at the medial malleolus. The ulcer is always localized in the skin, changed by hyperpigmentation, lipodermatosclerosis, fibrosis, hyperkeratosis, cellulitis, and atrophy, which are typical changes of chronic venous insufficiency [33].

The most common disease of the lower extremities of the superficial vein is varicose veins. Varicose veins are tortuous and dilated parts of superficial veins caused by hypertension in the vein system together with venous valves insufficiency. Patients complain of leg pain, discomfort, burning, or fullness. Symptoms are reduced by leg elevation. Long-term untreated varicose veins may lead to venous stasis ulcers, skin changes, and rupture with hemorrhage [33, 34].

Deep venous thrombosis on the upper extremities is not as frequent as thrombosis of deep leg veins. Occlusion of subclavian or axillary veins is associated with swelling of the entire arm, localized neck or shoulder pain. Signs of venous congestion such as swelling or edema, pain, cyanosis, and dilation of the superficial veins are among the typical, but not specific symptoms [35]. Thoracic outlet syndrome can be presented as unilateral arm swelling or as deep subclavian vein thrombosis. These symptoms are associated with upper extremity exercise and activity [16]. Subclavian and jugular vein thrombosis is more often associated with hemodialysis vein catheters or central venous catheters [36]. Superficial vein thrombosis and thrombophlebitis of upper extremities are the most commonly associated with indwelling venous catheters [30].

Physical Examination in Patients with Venous Disease

After a detailed history, a thorough physical examination should follow. In the physical assessment of patients with suspected venous system disease, it is, of course, also essential to examine the arterial system. The doctor should begin with inspection, palpation, and then perform noninvasive imaging, ultrasonography, which has a dominant position in examining the venous system. The presence of any swelling, edema, ulcers, skin changes which may be related to venous disease should be noted and described in detail.

Patients with superficial thrombophlebitis have a localized area of erythema and induration. The affected area is painful and warm to the touch, and the involved vein can be felt as a subcutaneous cord. Inflammation most often spreads along the affected vein. Superficial thrombophlebitis may or may not be associated with swelling of the extremity [29].

Diagnosis of deep vein thrombosis is more difficult than superficial thrombophlebitis because clinical findings for superficial thrombophlebitis are sufficient to make the diagnosis. On inspection, the most common clinical findings of deep vein thrombosis usually include unilateral leg swelling under the occlusion of the vein. Patients complain about tenderness, fullness, and pain over the involved vein. On palpation, in thin patients, the cords may be palpated in the inguinal area (common femoral vein) under the inguinal ligament. The affected extremity is more often warmer, and superficial veins are more prominent and visually better (Figure 5). Patients with phlegmasia cerulean dolens have their entire leg massively swollen, full, warm to touch and cyanotic. If compartment pressure increases, the arterial blood flow in the affected limb is reduced when the leg is cold, palid and sensorimotoricdeficit can be presented [31, 32, 37].

The main sign for deep vein thrombosis is Homan's sign of calf pain with passive foot dorsiflexion. This examination maneuver should always be performed upon suspicion of deep vein thrombosis. To confirm the correct diagnosis, ultrasonography imaging needs to be performed [31, 37].

Figure 5. Common femoral vein thrombosis – the left leg.

Patients with varicose veins usually complain of leg discomfort, which is described as burning, and the patient may have a feeling of heavy legs. Swelling of the foot and calf may be present and increase during the day [38]. Patients with varicose veins should be examined

in the standing position because the veins are full of blood. On inspection, the varicose veins are presented as dilated, tortuous, superficial veins (Figure 6) [34].

Figure 6. Varicose veins.

Sometimes, inflammation of the varicose vein may be presented (Figure 7). The area affected by inflammation is painful to touch, warm, and erythematous [30, 38].

Figure 7. Varicophlebitis.

Varicosities along the medial side of the leg are generally related to the great saphenous vein or its perforating branches. On the other hand, varicosities along the posterior side and lateral side of the calf are usually associated with the small saphenous vein. The main cause of varicosities formation is incompetence at the saphenofemoral junction or saphenopopliteal

junction, and also may be related to incompetent deep and perforating veins. If the incompetence at the junction is present, the blood flow is reversed and long term high venous blood pressure had dilatated the veins [38]. By palpation, when the patient is in standing position, we detect the range of varicosities which can be a small dilatated tortuous vein, but in some patients, varicosities may be like a cluster of grapes. The great saphenous vein communicates with the deep vein by Hunter, Dodd, Boyd, Cockett, Sherman, and many other vein perforators. The Dodd perforator is located on distal third on the medial side of the thigh. Boyd perforators are located on the proximal third on the medial side of calf under the knee, and the Cockett and Sherman perforators are located at the distal part of the calf and the ankle [39]. Sometimes if perforator insufficiency is present, on palpation, we may find the fascial defects. On palpation, pressure on the insufficient perforator may be painful for the patient. Above the place of an insufficient perforator, we monitor skin changes or bulging. Long-standing superficial venous insufficiency can result in chronic venous stasis changes, (atrophy, hyperpigmentation, fibrosis, and induration) and progression stage can result in venous stasis ulcers (Figure 8) around distal part of the leg and ankle. The venous stasis ulcers are large with irregular borders, moist and erythematous and the skin around may be shiny. The base of the ulcer is usually composed of granulation tissue [33, 34, 38, 39].

Figure 8. Venous ulcer.

Physical examination of patients with varicose veins consists of many tests, for example, Brodie-Trendelenburg test, Perthes test, the cough test, and many others [40].

Distinguishing superficial from deep perforator venous incompetence is possible by using the Brodie-Trendelenburg test. The patient is in the supine position; the leg under investigation is elevated to drain the varicosities. A tourniquet is applied just below the saphenofemoral junction then the patient is asked to stand up. If the tourniquet prevented the filling of the varicosities, the site of reflux is deemed to be the saphenofemoral junction. If a venous refill is less than 30 seconds, it is the evidence of an incompetent deep and perforator system. The Perthes test can help evaluate the cause of deep vein incompetence [40].

The Perthes test is performed in standing position. A tourniquet is applied below the knee, and the patient is asked to do ten heel raises on the spot or walk around. If the varicosities are emptied, the site of reflux is determined to be above the tourniquet. If the varicosities become visible or distended, perforator incompetence and deep vein insufficiency are the cause of the problem. Pain associated with heel raising suggests the possibility of DVT [40, 41].

Saphenofemoral, saphenopopliteal insufficiency, and perforator insufficiency are nowadays usually diagnosed by ultrasonography.

IMAGING

In most cases, the diagnosis of arterial or venous disease can be made based on history and physical examination. Physical examination and testing add a degree of objectivity which can confirm or bring into question the vascular disease. Noninvasive imaging examinations are preferred to diagnostic, monitoring the progression of the disease, or monitoring the results of revascularization procedures.

The main imaging examinations in vascular surgery are duplex ultrasonography (Figure 9), computed tomography (Figure 10), magnetic resonance imaging (Figure 11), and digital subtraction angiography (Figure 12).

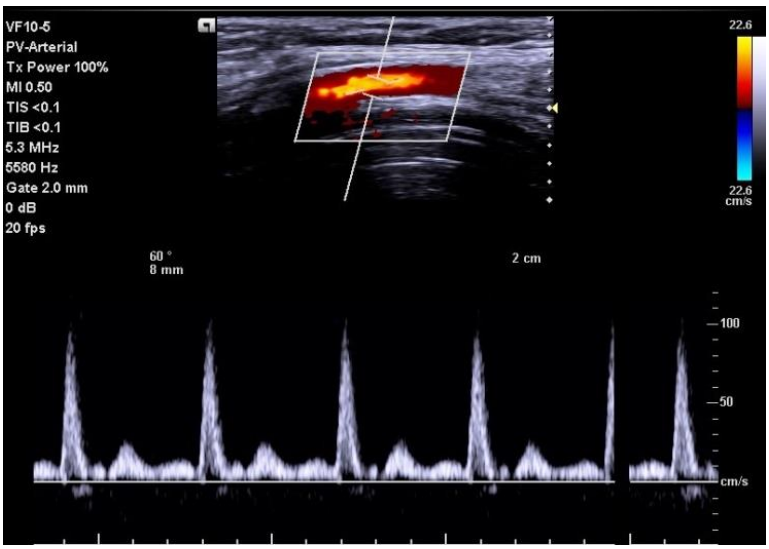

Figure 9. Duplex ultrasonography – brachial artery.

Figure 10. CT-angiography.

Figure 11. MR-angiography.

Figure 12. Digital subtraction angiography.

Duplex Ultrasonography

During the last 20 years, progress in DUS has led to its current central role in the diagnostics of vessel disease. DUS is the best diagnostic; perioperative and postoperative screening imagine examination for the evaluation of arterial and venous disease. It is a non-invasive imaging method and for its full availability is considered to be the first line one. The advantage of the DUS examination is its high specificity, sensitivity, non-invasiveness, high availability, low cost, the possibility of endless repetition in monitoring the dynamics of the atherosclerotic process and also the absence of radiation [42, 43].

DUS in-vessel system is performed by a linear multi-frequency probe with a frequency range of 5-10 MHz. The probe generates and then also receives the reflected ultrasound wave, thereby generating an echo that is the source of information in the DUS examination. The instrument analyzes the intensity and frequency shift of the reflected wave from the interface of two physically different media. Essentially, it is a mechanical wave with a frequency of 2 to 15 MHz, which spreads in tissue at different speeds depending on the type of medium – tissue [43]. It is better to use a convex probe in some special situations, for example, to evaluate abdominal vessel or iliac arteries and veins.

DUS combines the evaluation of blood flow (pulsed Doppler spectral analysis) and anatomic information (B-mode and color Doppler imaging). We can get a morphological image of arteries and veins in B mode, and it is a simple evaluation of aneurysm or pseudoaneurysm. Also, in B mode, it is possible to evaluate the morphology of the atherosclerotic plaque in the cross-section. In cross-section, we can measure the width, assess the echogenicity, homogeneity, and surface of the atherosclerotic plaque [43, 44]. Based on echogenicity, this examination makes it possible to distinguish an acute embolic arterial closure from a chronic arterial closure. Using the Doppler effect, we can obtain information about arterial and venous blood flow.

Velocities are detected as frequency shifts in reflected ultrasound from the flowing red blood cells. The arterial narrowing causes an increase in speed at the site of the stenosis and dampening of the velocity waveform beyond [9, 45]. Based on this principle, we can use the Doppler spectral curve to show the blood flow in individual vessels, determine the flow rate, the flow pattern (laminar flow, turbulent flow), which in practice means that we can assess the presence of artery stenosis and determine its size. Doppler can distinguish between a normal, reduced, or abnormal flow [43]. Typical Doppler waveform in peripheral arteries has a triphasic quality. The presence of a triphasic signal nearly always rules out clinically significant stenosis or obstruction. Critical stenosis in blood flow causes dampening of the waveform, which becomes blunted –monophasic. Monophasic Doppler signals that result from the arterial occlusive disease may be difficult to distinguish from venous signals [45]. DUS is a sensitive and specific tool for the assessment of most venous disorders. Ultrasonography is usually used to detect acute deep venous thrombosis and venous reflux and also to evaluate chronic venous obstruction. The linear array transducer 4- to 7-MHz is best for assessing most veins, which are normally 1 to 3 cm below the skin [43, 45].

Deep veins, in the abdomen or pelvis, are better assessed by using lower frequency curvilinear transducers for deeper penetration. Low blood flow settings are most often used. During the vein ultrasonography, four components should be examined: visualization, compressibility, flow, and augmentation [46]. In real time imaging, we can control vein valves. Valsalva's maneuver closes the vein valves, the blood flow stops, and the subfascial

veins expand. If the vein valves are insufficient, the blood flow is reversed. Healthy veins have a thin wall and a different shape. The probe easily compresses healthy veins. In thrombosis, the vein flow stops, and the lumen of the vein is incompressible. Fresh thrombus is hypoechogenic, and the venous lumen is extensively broadened [43]. Part of the ultrasound examination in varicose is the assessment of the saphenofemoral and saphenopopliteal sufficiency. The reflux time in saphenofemoral and saphenopopliteal is assessed in the Valsalva maneuver, eventually proximal compression. The pathological is considered to be above 1 second. In addition to the assessment of the saphenofemoral or saphenopopliteal junction, we also investigate the width of the GSV and SSV. We try to identify the proximal and distal reflux point according to the extent and location of the varicose veins. Duplex sonography is also the method of choice in assessing the size and sufficiency of perforators. Perforator with the confirmed directional flow with reflux time above 0.5 seconds is considered insufficient with dilatation above 4 mm [47].

Computed Tomography

Conventional arteriography, nowadays, is no longer considered the standard imaging modality for vascular disease, because arteriography is an invasive imaging method. At present, CT angiography is the most widely used to diagnose vascular conditions since it is a minimally invasive examination [48].

CT angiography uses a narrow beam of X-rays, intravenous contrast and high-powered computers to generate images of bones, soft-tissues, and vessels in the body. Because there is no need to thread a catheter through the body, a CT-angiography is usually faster and causes less discomfort than traditional angiography. Optimal visualization of the vessels by CT-angiography was not possible until the availability of helical CT. The main advantage of this CT type is the ability of imaging a larger part of the body in a shorter time. This rapid scanning enables visualization of the vessels during the short period when a bolus of contrast medium passes the imaged volume. In this examination, 50-130ml of intravenous contrast is applied for the best visualization of the vessels. The timing of the initiation of image acquisition relative to the injection of the contrast medium is very important for maximizing visualization of vessels in the scanned volume [48, 49].

CT- angiography is not very precise in the quantification of strongly calcified lesions. CT- angiography is a crucial imaging method for the diagnosis of aneurysms and planning of their treatment and is also often used for diagnosis of mesenteric artery stenosis and aneurysms. CT is an excellent modality to evaluate venous pathologies, for example, mesenteric venous thrombosis. The advantage of CT- angiography over other imaging methods is its excellent availability, quick performance, prize, and minimum invasivity [9, 48].

CT angiograms are usually performed for the following reasons [48, 50]:

- To detect aneurysms
- To determine whether any blood vessels are torn
- To examine the atherosclerotic plaque composition
- To assess the degree of artery stenosis

- To investigate vascular problems in the brain, such as stroke or cerebral bleeding
- To examine any malformations of the blood vessels
- To control the effectiveness of an earlier endovascular treatment
- To evaluate the results of a bypass surgery
- Angiograms are usually used by surgeons to plan open or endovascular surgery.

The main disadvantage of CT-angiography is the radiation for the patient and the nephrotoxicity of the contrast. Side effects of radiation play an essential role in the clinical decision of whether to order a CT scan, particularly in children. Another disadvantage is the use of nephrotoxic contrast in patients with kidney disease. Large doses of contrast agent used in CT angiography increased the incidence of contrast nephropathy, which is the third most common cause of iatrogenic acute renal failure [49].

Magnetic Resonance Imaging

MRI uses a powerful magnetic field, radio frequency pulses, and a computer to produce detailed pictures of organs, soft tissues, vessels, bone, and virtually all other internal body structures. MRI demonstrates a superior ability to investigate the anatomic and perfusion characteristic of various tissues and organs without radiation injury (not use ionizing radiation) or invasiveness, MRI is usually performed in the detection, diagnosis, staging, grading, and treatment of various diseases [51].

MR-angiography is similar to CT-angiography and uses paramagnetic contrast medium that is applied intravenously. The contrast material most commonly used for an MRI exam contains a metal called gadolinium. Contrast medium is not based on iodine and can be used in case of iodine allergies and in patients with renal insufficiency, which is a significant advantage compared with CT-angiography. The advantage of MRI and MR-angiography over CT/CT-angiography is better soft tissue visualization and better quantification of calcified lesions. High-resolution “bright blood” and “black blood” sequential MRI analysis is capable of the accurate analysis of the ingredients in atherosclerotic plaques and the evaluation of the severity of carotid artery stenosis [51, 52].

MR-angiography is used to [52]:

- identify abnormalities, such as aneurysms, arteriovenous malformation, congenital abnormalities
- detect atherosclerotic plaque and their composition
- detect renovascular disease or visualize blood flow to help prepare for a kidney transplant
- detect injury to arteries
- evaluate arteries feeding a tumor before surgery
- identify dissection of arteries
- detect pulmonary embolism
- evaluate the obstructions of vessels.

Disadvantages of MRI/ MR-angiography are worse availability and higher price compared to CT/CT-angiography. Moreover, CT/CT-angiography is a quicker imaging examination than MRI/MR-angiography. Noteworthy is also the fact that MRI/MR-angiography cannot be used by patients with pacemakers, metallic implants (vessel clips, coils). The procedure time may be shorter than a traditional angiography and requires no recovery period [9].

Digital Subtraction Angiography

The quality of DUS, MR-angiography, and CT-angiography has improved during the past ten years, and in many clinical cases, DUS, MR-angiography or CT-angiography became the preferred choice for the planning of either endovascular or surgical procedures. Angiography is used if we intend to treat patient endovascular or if the information obtained by ultrasound, CT-angiography eventually from MR-angiography is not sufficient for the planning of surgical treatment. Angiographic imaging works on the principle of visualization of vessels filled with contrast medium at the time of radiographic exposure [8, 9, 53]. Contrast medium is applied directly to the arterial system, usually via a catheter (4 – 5 F/1.2-1.5mm) in the right common femoral artery or brachial/radial artery. Patients with stenosis or occlusions in the aortoiliac region have angiography performed through the radial or brachial artery. Contrast medium is usually composed of molecules containing iodine. Contrast medium can be applied to the artery by power injector or manually [8]. The advantage of angiography is that it most precisely identifies the anatomy of arterial occlusive disease and also that endovascular treatment is immediately possible during the diagnostic process. Angiography was very often crucial for planning of infrainguinal arterial reconstructions and also for imaging of arteries of upper extremities and imaging of vessels of hemodialysis access. The disadvantage is using of iodine contrast medium, which can lead to an allergic reaction or can worsen renal functions. Rarely, impaired kidney function or kidney failure can occur following a DSA, especially if you already suffer from kidney disease. Also rarely, severe allergic reactions can occur, especially among people who have had previous allergic reactions to the contrast dye. The other disadvantage is arterial invasivity, which can lead to bleeding. Acute pain, numbness or coolness in arm or leg may signify blockage of the artery. That´s why angiography is not used as a first line imaging method nowadays [8, 53].

BASIC SURGICAL METHODS

Surgical treatment of vascular diseases generally consists of basic vascular surgical procedures used to treat arterial as well as venous lesions.

Arterial Incision

Whenever we open the vessel, the vessel should be secured with clamps. We open the vessel with a knife which should cut the vessel directly perpendicular to the lumen of the

vessel so that the incision in the vessel is straight. When we open the vessel with a knife, the microscissors can be used to enlarge the incision. We make oblique or perpendicular incisions on the vessel if we only plan to perform an embolectomy with a Fogarty catheter and not a big reconstruction. Oblique or perpendicular incision prevents stenosis at the site of vascular opening [54].

Closure of the Arterial Incision

We are currently using monofilament polypropylene non-absorbable atraumatic fiber for the suture. It is a very thin fiber and therefore needs to be tied at least six times. The suture is always placed from within outward at each end of the arteriotomy and then tied. One arm of the suture is then run to the center of the vessel incision. The suture at the other end of the arteriotomy is also run to the center, where it is tied to the first suture. This is a simple running stitch (Figure 13) [8, 54, 55].

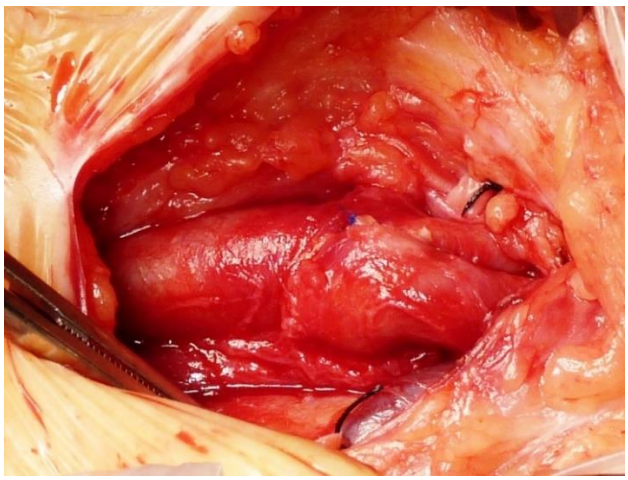

Figure 13. Simple running stitch – an end to side anastomosis.

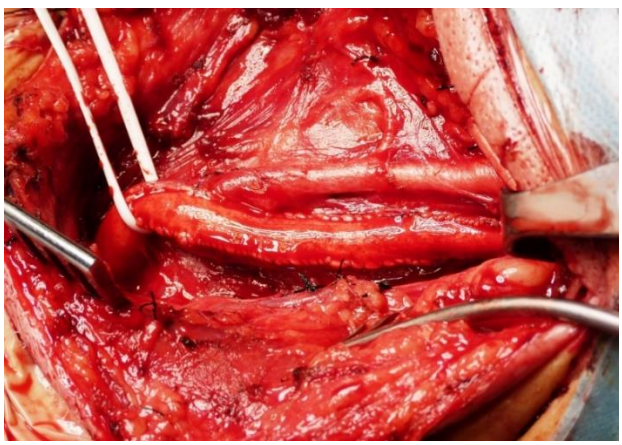

Figure 14. Arteriotomy closed by synthetic patch.

If the vessel is narrow and there is a risk of stenosis, it is necessary to close the vessel with the patch, which can be synthetic (prosthetic) or autologous (great saphenous vein). The synthetic or autologous patch is usually used if the artery is less than 5 mm in diameter, in case of presence of significant atherosclerotic plaque at an arteriotomy site, a jagged arteriotomy, or a very tortuous artery. The closure of the vessel by the patch is referred to as a surgery angioplasty. The patch is sutured to the edges of the arteriotomy by one or two running stitches (Figure 14). Surgery angioplasty should not widen the vessel because it would lead to aneurysmal dilatation. However, it should prevent stenosis from exiting the direct vessel suture. In children; it is appropriate to use individual simple stitches concerning the growth of the organism [8, 54, 55].

Embolectomy

Embolectomy is considered to be one of the most common vascular operations, although the number of endovascularly treated patients with acute arterial occlusion has recently increased.

This procedure consists of a transverse or oblique incision on the artery that is closest to it. Subsequently, through the incision, we introduce the Fogarty catheter into the artery centrally to the point above the occlusion, inflate the balloon with water and slowly withdraw the catheter to feel light resistance, suggesting that the balloon touches the artery wall. When the catheter is withdrawn from the artery, the embolus is pushed out through the incision (Figure 15). If we have done the embolectomy properly, there is a quality pulsing inflow. Subsequently, we place the clamp centrally on the artery and through the incision by Fogarty catheter pass into the periphery, inflate the balloon and then pull out the embolus, then rinse the artery with a heparin solution. If we have been successful enough, there is a good backflow from the artery. Angiographic control of artery patency can be performed immediately through the incision. We close the arteriotomy with a tight continuing or single stitch [8, 55].

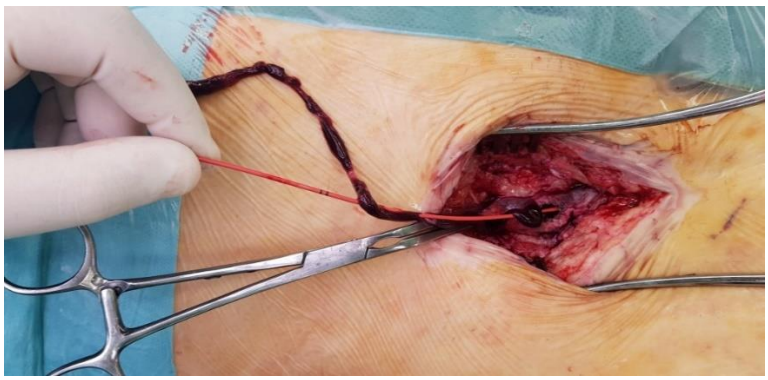

Figure 15. Embolectomy by Fogarty catheter.

Endarterectomy

Endarterectomy is also one of the most frequent operations of vascular surgery. If the artery diameter is more than half a centimeter, and the atherosclerotic disease process is localized, an endarterectomy is very attractive.

This procedure involves the removal of atherosclerotic plaques that compromise the blood flow (Figure 16). The tunica intima and half part of tunica media of vessel wall are removed, leaving behind the outer part of the media and the adventitia. It can be performed as the sole therapeutic procedure (carotid endarterectomy) or in combination with bypass or endovascular intervention. It should not be performed in an aneurysmal artery because the remaining adventitial layer is too weak and degenerated to withhold arterial pressure. The artery is opened longitudinally, and the plaque is separated from the artery wall in the direction of the arteriotomy and removed. The arteriotomy can be closed primarily or with a synthetic or venous patch. The proximal ending of endarterectomy sharply with scissors without leaving a significant protruding edge. The distal endpoint of the endarterectomy should be flat with a smooth transition from the endarterectomized to the nonendarterectomized part of the surface. Sometimes the atherosclerotic plaque may extend further distally, with no visible end in the open part of the artery, then transaction of the atherosclerotic plaque is necessary, which results in a shelf between the endarterectomized and nonendarterectomized part. In such a situation, suture of the intima and plaque to the adventitia is needed to avoid plaque lifting or dissection by blood flow upon reperfusion. One end of the suture is placed in the atherosclerotic plaque near distal endpoint, and the other suture is placed at the junction of the endarterectomy. The surface area should always be without debris. If the artery is wide enough, close the arteriotomy with a tight continuing stitch, but if the artery is narrow and there is a risk of stenosis, it is necessary to close with the patch [55].

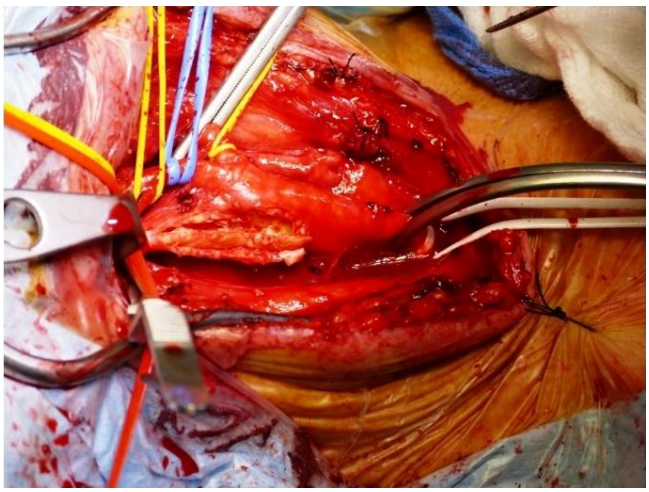

Figure 16. Carotid endarterectomy.

Bypass

This vascular procedure is standard to manage the occlusive disease or to replace dilatated or injured vessels. The bypass is usually the most frequent operation of vascular surgery. Sometimes a combination of endarterectomy and bypass is needed to treat, for example, PAD. With the help of a natural (GSV) (Figure 17) or synthetic graft (Dacron, PTFE - polytetrafluorethylene), a surgical bypass routes blood flow around the area of blockage. When a good GSV or sufficient length is not available for bypass, surgeons may choose to use other veins from the arm or leg or to use an artificial synthetic graft. However, there is a fall-off in results for these alternatives. Synthetic grafts are usually used to bypass larger arteries or extra anatomical bypass, but below the groin, the smaller femoral and popliteal vessels are often best bypasses using the patient's own GSV. The surgery does not cure the disease or remove the blockage [8, 55].

Figure 17. Great saphenous vein for bypass.

Usually, the bypass is situated in the anatomical pathways of the affected artery. The graft will sometimes lie deep within the leg, and sometimes just beneath the skin. The precise name given to the procedure depends on where the bypass starts and where it finishes (aorto-femoral, iliofemoral, femoropopliteal, femorotibial, and popliteal-pedal bypass). The most common type of bypass is femoropopliteal (Figure 18), which is used to treat superficial femoral artery occlusion. It possibly uses a natural (GSV) or synthetic graft to create the detour around the blockage beginning at your groin/thigh crease and ending at the inner knee (proximal femoropopliteal bypass), or sometimes the calf (distal femoropopliteal bypass). The graft is sewn to the artery at both ends with fine stitches. For an aortic bypass, a synthetic graft made of fabric (Dacron) or plastic (PTFE, Gortex) is used.

Sometimes extra-anatomical bypass grafting is needed, which is a recognized method of re-vascularisation [8, 54, 55].

The term extra-anatomic bypass applies to any bypass graft that is placed in a site different from that of the native arterial segment being bypassed [56, 57]. The most common examples of the extra-anatomic bypass in the past and also today are axillofemoral and femorofemoral crossover bypass and their combination [58]. Less common and more complex bypasses include obturator, thoracofemoral, and supraceliac-to-iliofemoral bypasses.

Extra-anatomical bypasses offer a treatment strategy for patients in whom the risks of conventional anatomic bypasses make their use prohibitive. Nowadays, they are usually used in situations where there is an active graft infection (including mycotic aortic aneurysms, infected aortic prostheses, aortoenteric fistulae, infected femoral artery aneurysm, prosthetic graft groin infection), multiple abdominal operations that result in adhesions, history of radiation, or to avoid performing surgery in previously operated anatomical planes [59, 60].

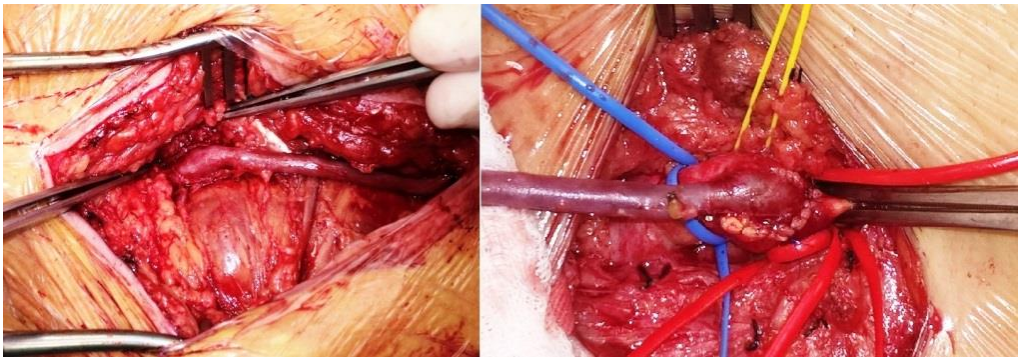

(A) (B)

Figure 18. Femoropopliteal venous bypass – (A) distal anastomosis and (B) proximal anastomosis.

Bypass surgery carries significant risks, including cardiovascular complications, blood clots, infections, and even death. The most serious complication is the infection of synthetic graft that is very difficult to treat. Overall, bypass surgery is immediately successful in 90 to 95% of cases. The lifespan of a surgical bypass depends on the health of the arteries, the type of graft used (GSV grafts last longer than synthetic), other comorbidities, such as diabetes, kidney failure and also lifestyle (smoking). The short and long-term success of the procedure is most closely linked to two main factors. The first is the material employed for the bypass graft itself, and the second is the quality of arteries in the lower leg to which the graft is attached [8, 61].

Careful assessment of the risks and benefits before surgery, as well as a diligent medical, anesthetic, and surgical care, ensure the best outcomes following bypass operations.

TYPE OF GRAFTS

Surgical bypass is very often used in the treatment of arterial and venous disorders (occlusions, aneurysms, arterial, and vein injuries). The success of surgical bypass is directly dependent on the conduit used, which can be biologic or synthetic. The ideal vascular graft should be durable, resistant to thrombosis and infection, readily available, and cheap. It is best for the graft to have similar properties to the vessel part to be replaced. In vascular surgery, we use two main types of vascular grafts (biological and synthetic grafts). Although the perfect vascular graft does not exist, the autogenous vascular graft is closest to the ideal graft [62].

1. Biological Grafts

A) Autologous - Venous autologous graft
- Arterial autologous graft

B) Allogenous

C) Xenografts

Autologous vascular grafts are taken from the patient. As an autologous material in vascular surgery, an artery or a vein can be used. The most common used venous autologous graft is GSV. Other veins, as the SSV or cephalic vein from the arm, are rarely used. The great saphenous vein is the preferred conduit for bypass because long lengths of vein can be harvested, removal is inconsequential, and the vein removal procedure is effortless. Advantages of the autologous vein are excellent patency, venous graft needs flow only 50ml/min not to thrombose, and superior resistance to infection. The disadvantages of the venous grafts are that they are of small diameter and may be used only for peripheral artery bypasses and not for aortic and iliac artery replacement. The other problem of autologous venous grafts is the limited amount of appropriate autologous grafts in one individual. The great saphenous vein is commonly used for the bypass of the lower and upper extremity artery and also for carotid, coronary, and visceral artery. On the other hand, GSV has also been preferentially used in the reconstruction of arteriovenous fistulae needed for hemodialysis [8, 62, 63].

Autologous arterial grafts are used less frequently than venous grafts in vascular surgery. Arterial grafts (internal mammary artery) are standardly used in cardiac surgery for aortocoronary bypass. The desobliterated segment of occluded superficial femoral artery can be used as an arterial graft, in a situation when appropriate GSV or SSV graft is not available, especially in patients with prosthetic graft infection [62, 63].

Allogenous grafts (allografts) are arteries or veins that are transplanted from one individual to another within the same species. Allografts in vascular surgery have been used mostly in three distinct clinical settings: bypass in the absence of suitable autogenous graft, arteriovenous access reconstruction, and replacement of infected prosthetic grafts. When the autogenous GSV is not available, alternative allogenous GSV conduit can be used for lower extremity revascularization. Also, for arteriovenous access reconstruction, a donor vein can be used, if the autogenous conduit is not suitable. One of the treatment options for infected aortic prostheses is reconstruction with aortic allograft. The allogenous grafts tend to form aneurysms and rupture or produce stenoses. This is due to the degeneration of the allogenous grafts by immunological mechanisms. The patency of bypasses with allogenous grafts are worse compared to the patency of autologous or prosthetic grafts [8, 62, 64].

A special type of vascular grafts is xenograft. Xenografts are vessels transplanted from an individual of non-human species to an individual of human species. The most often use of xenograft are those from the bovine pericardium. The main indication for the usage of xenografts is the treatment of prosthetic infections. They are better used as allogenous grafts and have comparable patency [64].

2. Prosthetic Grafts

Although the functions of autogenous vascular grafts (arterial and vein) are many, there exist multiple clinical situations in which these grafts are inadequate. These unmet demands led to the development of prosthetic grafts. Various materials have been tried for the manufacture of the vascular graft. Standard materials used for the production of prosthetic vascular grafts are polyethylene terephthalate (Dacron) and polytetrafluoroethylene (PTFE). These grafts are used with excellent success for the bypass of large vessels, an aortoiliac region mainly (Dacron), and also for infrainguinal revascularization (PTFE, Dacron). Armored vascular grafts are commonly used for extra-anatomic bypasses. Synthetic grafts offer almost endless availability and a wide variety of sizes. In general, synthetic grafts cannot be used in infected areas, because the risk of infection, structural deformation, and also occlussion is very high. The disadvantage of synthetic grafts is that they are prone to thrombose more often, compared to the autologous grafts because prosthetic grafts need a higher flow of 150 ml/min not to thrombose. Prosthetic grafts patency rates are acceptable for aorto-iliac reconstruction because of high flow in aortic and iliac circulation and low outflow resistance. On the other hand, infrainguinal reconstruction is associated with low graft patency because of high outflow resistance. In the pediatric population, the inability of synthetic prostheses to match the growth of the child is an additional limitation for use [8, 65].

CONCLUSION

Clinical examination in vascular surgery requires an assessment of the whole patient with a focus on specific findings typical for patients with vascular disease. Adequate analysis of signs and symptoms often requires the multidisciplinary representation of several experts in vascular surgery, angiology, and radiology.

The main imaging studies for vascular surgery are duplex ultrasonography, CT-angiography, MR-angiography, and digital subtraction angiography. Knowledge of basic imaging is essential for proper diagnosis and a subsequent indication of either surgical or endovascular treatment of vascular diseases.

The chapter also provided a comprehensive overview of basic vascular surgery techniques which represent necessary knowledge of every vascular surgeon. Despite the massive development of endovascular treatment, knowledge of vascular surgical treatments is essential, very often finding that surgical treatment is the only possible healing method for rescuing not just extremity but also life. Nowadays, well-designed clinical trials have become the “gold standard” for the assessment of new diagnostic methods and treatments.

REFERENCES

[1] Backman, J.A. and Creager, M.A. (2004). Clinical examination of the vascular system. In: *Vascular Surgery Principles and Practice, Third Edition, Revised and Expanded,*

edited by Hobson II R.W, Wilson, S.E. and Veith, F.J. New York, Marcel Dekker, Inc., ISBN: 0-8247-0819-9.

[2] Bonow, R.O., Smaha, L.A., Smith, S.C. et al. (2002). World Heart Day 2002: the international burden of cardiovascular disease: responding to the emerging global epidemic. *Circulation,* 106(13):1602-1605.

[3] https://www.who.int/news-room/fact-sheets/detail/cardiovascular-diseases-(cvds).

[4] Fowkes, F.G., Aboyans, V., Fowkes, F.J. et al. (2017). Peripheral artery disease: epidemiology and global perspectives. *Nat Rev Cardiol*, 3:156-170. doi: 10.1038/ nrcardio.2016.179.

[5] Ford, E.S., Ajani, U.A., Croft, J.B. et al. (2007). Explaining the decrease in U.S. deaths from coronary disease, 1980-2000. *N Engl J Med,* 356(23): 2388-2398. doi: 10.1056/NEJMsa053935.

[6] Katzel, L.I., Sorkin, J., Bradham, D. et al. Comorbidities and the entry of patients with the peripheral arterial disease into an exercise rehabilitation program. (2000). *J Cardiopulm Rehabil*, 20:165–171.

[7] Goodney, P.P. (2014). Patient Clinical Evaluation. In: *Rutherford´s Vascular Surgery,* 8th edition, edited by Cronenwett, J.L. and Johnston, K.W. Philadelphia, Elsevier Saunders, ISBN: 978-1-4557-5304-8.

[8] Krajicek, M., Peregrin, J.H., Rocek, M. et al. (2007). *Surgical and interventional treatment of vascular diseases.* Praha, Grada Publishing a.s., 2007. 436 p. ISBN: 978-80-247-0607-8. (Book in Czech).

[9] Sihotsky, V. (2014). Arterial Surgery. In: *Surgery for Medical Students*, edited by Frankovicova, M., Katuchova, J. et al. Kosice, UPJS, ISBN:978-80-8152-581-0.

[10] Chrobak, L. et al. (2007). *Propedeutics of Internal Medicine.* Praha, Grada Publisihin, a.s., 244p. ISBN 978-80-247-1309-0. (Book in Czech).

[11] Olin, J.W. and Sealove, B.A. Peripheral Artery Disease: Current Insight into the Disease and Its Diagnosis and Management. *Mayo Clin Proc,* 85(7): 678–692. doi: 10.4065/mcp.2010.0133.

[12] Hirsch, A.T., Haskal, Z.J., Hertzer, N.R. et al. (2005). ACC/AHA 2005 Practice guidelines for the management of patients with peripheral arterial disease (lower extremity, renal, mesenteric, and abdominal aortic): a collaborative report from the American Association for Vascular Surgery/Society for Vascular Surgery, Society for Cardiovascular Angiography and Interventions, Society for Vascular Medicine and Biology, Society of Interventional Radiology, and the ACC/AHA Task Force on Practice Guidelines (Writing Committee to Develop Guidelines for the Management of Patients with Peripheral Arterial Disease): endorsed by the American Association of Cardiovascular and Pulmonary Rehabilitation; National Heart, Lung, and Blood Institute; Society for Vascular Nursing; TransAtlantic Inter-Society Consensus; and Vascular Disease Foundation. *Circulation,* 113:e463–e654. doi: 10.1161/ CIRCULATIONAHA.106.174526.

[13] Sharma, A.M., Norton, P.T. and Zhu, D. (2014). Conditions Presenting with Symptoms of Peripheral Arterial Disease. *Semin Intervent Radiol,* 31(4): 281–291. doi: 10.1055/s-0034-1393963.

[14] Aufderheide, T.P. (2014). Peripheral Arteriovascular Disease. In: *Rosen´s Emergency Medicine Concepts and Clinical Practice 8th Edition,* edited by Marx J., Hockberger R. and Walls R, Philadelphia, Elsevier Saunders, eBook ISBN: 9781455749874.

[15] Mubarik, A. and Iqbal, A.M. (2019). Subclavian Artery Thrombosis. In: *StatPearls.* Treasure Island (FL): StatPearls Publishing. https://www.ncbi.nlm.nih.gov/books/NBK537275/.

[16] Hussain, M.A., Aljabri, B. and Al-Omran, M. (2016). Vascular Thoracic Outlet Syndrome. *Semin Thorac Cardiovasc Surg,* 28(1):151-157. doi: https://doi.org/10.1053/j.semtcvs.2015.10.008.

[17] Acar, R.D., Sahin, M. and Kirma, C. (2013). One of the most urgent vascular circumstances: Acute limb ischemia. *SAGE Open Med,* 1: doi: 10.1177/2050312113516110.

[18] Rockman, C.B. and Maldonado T.S. (2014). Cerebrovascular Disease: General Considerations. In: *Rutherford´s Vascular Surgery,* 8th edition, edited by Cronenwett, J.L. and Johnston K.W. Philadelphia, Elsevier Saunders, ISBN: 978-1-4557-5304-8.

[19] Naylor, A.R., Ricco, J.B., DeBorst, G.J., et al. (2018). Management of Atherosclerotic Carotid and Vertebral Artery Disease: 2017 Clinical Practice Guidelines of the European Society for Vascular Surgery, (ESVS). *Eur J Vasc Endovasc Surg,* 55:3-81. doi:10.1016/j.ejvs.2017.06.021.

[20] Szilasiova, J. (2011). Selected chapters from special neurology for students of dentistry. Kosice, *UPJS*, 234p. ISBN: 9788070978696. (Book in Slovak).

[21] Holt P.J.E. and Thompson M.M. (2014). Abdominal Aortic Aneurysms: Evaluation and Decision Making. In: *Rutherford´s Vascular Surgery,* 8th edition, edited by Cronenwett, J.L. and Johnston K.W. Philadelphia, Elsevier Saunders, ISBN: 978-1-4557-5304-8.

[22] Moxon, J.V., Parr1, A., Emeto, T.I. et al. (2010). Diagnosis and monitoring of abdominal aortic aneurysm: Current status and future prospects. *Curr Probl Cardiol,* 35(10): 512–548. doi: 10.1016/j.cpcardiol.2010.08.004.

[23] Hall, H.A., Minc, S., Babrowski, T. (2013). Peripheral artery aneurysm. *Surg Clin North Am,* 93(4):911-923, doi: 10.1016/j.suc.2013.04.008.

[24] Björck, M., Koelemay, M., Acosta, S. et al. (2017). Editor's Choice – Management of the Diseases of Mesenteric Arteries and Veins. Clinical Practice Guidelines of the European Society of Vascular Surgery (ESVS). *Eur J Vasc Endovasc Surg,* 53: 460e510e. doi: https://doi.org/10.1016/j.ejvs.2017.01.010.

[25] Hohenwalter, E.J. (2009). Chronic Mesenteric Ischemia: Diagnosis and Treatment. *Semin Intervent Radiol,* 26(4): 345–351. doi: 10.1055/s-0029-1242198.

[26] Moran, J.F. (1990). Pulse. In: *Clinical Methods: The History, Physical, and Laboratory Examinations.* 3rd edition, edited by Walker, H.K., Hall, W.D. and Hurst, J.W. Boston, Butterworths. Available from: https://www.ncbi.nlm.nih.gov/books/NBK278/.

[27] Hill, R.D. and Smith, R.B. III. (1990). Examination of the Extremities: Pulses, Bruits, and Phlebitis. In: *Clinical Methods: The History, Physical, and Laboratory Examinations.* 3rd edition, edited by Walker, H.K., Hall, W.D. and Hurst, J.W. Boston, Butterworths. Available from: https://www.ncbi.nlm.nih.gov/books/NBK350/.

[28] Gorman, W.P., Davis, K.R. and Donnelly, R. (2000). Swollen lower limb: General assessment and deep vein thrombosis. *BMJ,* 27: 1453–1456. doi: https://doi.org/10.1136/bmj.320.7247.1453.

[29] Litzendorf, M.E. and Satiani, B. (2011). Superficial venous thrombosis: disease progression and evolving treatment approaches. *Vasc Health Risk Manag,* 7: 569–575. doi: 10.2147/VHRM.S15562.

[30] Stvrtinova, V., Dukat, A., Dzupina, A. et al. (2011). Superficial thrombophlebitis – diagnostics and treatment. *Vask Med*, 3(S1): 4–14.

[31] Kesieme, E., Kesieme, Ch., Jebbin, N. et al. (2011). Deep vein thrombosis: a clinical review. *J Blood Med*, 2: 59–69. doi: 10.2147/JBM.S19009.

[32] Madaric, J. and Vulev, I. (2012). Deep iliofemoral venous thrombosis – the most important cause of pulmonary thromboembolism: treatment. *Vask med*, 4(3-4): 50–55.

[33] Patel, S.K. and Surowiec, S.M. (2019). Venous Insufficiency. In: *StatPearls Treasure Island* (FL): StatPearls Publishing. https://www.ncbi.nlm.nih.gov/books/NBK430975/.

[34] Mazuch, J. et al. (2006). *Surgical aspects of chronic venous insufficiency of lower extremities.* Martin, KD Osveta, 188 p. ISBN: 80-8063-212-XA. (Book in Slovak).

[35] Heil, J., Miesbach, W., Vogl, T. et al. (2017). Deep Vein Thrombosis of the Upper Extremity. *Dtsch Arztebl Int*, 114(14): 244–249. doi: 10.3238/arztebl.2017.0244.

[36] Wall, C., Moore, J. and Thachil, J. (2016). Catheter-related thrombosis: A practical approach. *J Intensive Care Soc*, 17(2): 160–167. doi: 10.1177/1751143715618683.

[37] Lurie, F. and Paolini, D. (2014). Acute Deep Venous Thrombosis: Clinical and Diagnostic Evaluation. In: *Rutherford´s Vascular Surgery*, 8th edition, edited by Cronenwett, J.L. and Johnston, K.W. Philadelphia, Elsevier Saunders, ISBN: 978-1-4557-5304-8.

[38] Campbell, B. (2006). Varicose veins and their management. *BMJ*, 333: 287–292. doi: 10.1136/bmj.333.7562.287.

[39] Lurie, F. and Puggioni, A. (2014). Chronic Venous Insufficiency: Treatment of Perforator Vein Incompetence. In: *Rutherford´s Vascular Surgery*, 8th edition, edited by Cronenwett, J.L. and Johnston, K.W. Philadelphia, Elsevier Saunders, ISBN: 978-1-4557-5304-8.

[40] Kim, J., Richards, S. and Kent, P.J. (2000). Clinical examination of varicose veins – a validation study. *Ann R Coll Surg Engl*, 82: 171-175.

[41] Krishnan, S. and Nicholls, S.C. (2005). Chronic Venous Insufficiency: Clinical Assessment and Patient Selection. *Semin Intervent Radiol*, 22(3): 169–177. doi: 10.1055/s-2005-921961.

[42] Dufek, M. (2003). Atherosclerosis in neurology. *Interni Med*, 5(5): 16 – 21.

[43] Cholt, M. (2013). *Vascular sonography repetitorium, ultrasound vascular diagnostics and atlas of findings on DVD.* Praha, Grada Publishing a.s., 327 p. ISBN: 978-80-247-3974-8.

[44] Koelemay, M.J.V., Hartog, D., Prins, M.H. et al. (1996). Diagnosis of arterial disease of the lower extremities with duplex ultrasonography. *BJS*, 83(3):404 – 409. https://doi.org/10.1002/bjs.1800830336.

[45] Kohler, T.R and Sumner, D.S. (2014). Vascular Laboratory: Arterial Physiologic Assessment. In: *Rutherford´s Vascular Surgery*, 8th edition, edited by Cronenwett, J.L. and Johnston, K.W. Philadelphia, Elsevier Saunders, ISBN: 978-1-4557-5304-8.

[46] Leon, L.R. Jr. and Labropoulos, N. (2014). Vascular Laboratory: VenousDuplex Scanning**.** In: *Rutherford´s Vascular Surgery*, 8th edition, edited by Cronenwett, J.L. and Johnston, K.W. Philadelphia, Elsevier Saunders, ISBN: 978-1-4557-5304-8.

[47] Bojdova, E. (2011). Chronic venous disease – clinical diagnosis and examination. *Vask. Med*, 3(4): 144–147.

[48] Kumamaru, K.K., Hoppel, B.E., Mather, R.T. et al. (2010). CT Angiography: Current Technology and Clinical Use. *Radiol Clin North Am*, 48(2): 213–235. doi:10.1016/j.rcl.2010.02.006.

[49] Blankensteijn, J.D. and Schultze Kool, L.J. (2014). Computed Tomography. In: *Rutherford´s Vascular Surgery*, 8th edition, edited by Cronenwett, J.L. and Johnston, K.W. Philadelphia, Elsevier Saunders, ISBN: 978-1-4557-5304-8.

[50] Rubin, G.D., Leipsic, J., Schoepf, U.J. et al. CT Angiography after 20 Years: A Transformation in Cardiovascular Disease Characterization Continues to Advance. *Radiology*, 271(3): 633–652. doi:10.1148/radiol.14132232.

[51] Xian, J.F., Chen, M. and Jin, ZY. (2015). Magnetic Resonance Imaging in Clinical Medicine: Current Status and Potential Future Developments in China. *Chin Med J*, 128(5): 569–570. doi: 10.4103/0366-6999.151637.

[52] Litt, H. and Carpenter, J.P. (2014). Magnetic Resonance Imaging. In: *Rutherford´s Vascular Surgery*, 8th edition, edited by Cronenwett, J.L. and Johnston, K.W. Philadelphia, Elsevier Saunders, ISBN: 978-1-4557-5304-8.

[53] Mclafferty, R.B. (2014). Arteriography. In *Rutherford´s Vascular Surgery*, 8th edition, edited by Cronenwett, J.L. and Johnston, K.W. Philadelphia, Elsevier Saunders, ISBN: 978-1-4557-5304-8.

[54] Veith, F.J. (2004). Vascular Surgical Techniques. In: *Vascular Surgery Principles and Practice, Third Edition, Revised and Expanded*, edited by Hobson II R.W., Wilson, S.E. and Veith, F.J. New York, Marcel Dekker, Inc., ISBN: 0-8247-0819-9.

[55] Sidawy, A.N. and Neville, R.F. (2014). Technique: Open Surgical. In: *Rutherford´s Vascular Surgery*, 8th edition, edited by Cronenwett, J.L. and Johnston, K.W. Philadelphia, Elsevier Saunders, ISBN: 978-1-4557-5304-8.

[56] Aboian, E. and Rao, A.S. (2014). Extra-Anatomic Bypass. In: *PanVascular Medicine*, edited by Lanzer P. Berlin, Springer, Heidelberg. Online ISBN: 978-3-642-37393-0.

[57] Appleton, N.D., Bosanquet, D., Morris-Stiff, G. et al. (2010). Extra-anatomical bypass grafting – a single surgeon's experience. *Ann R Coll Surg Engl*, 92(6): 499–502. doi: 10.1308/003588410X12664192076890.

[58] Rutherford, R.B., Patt, A. and Pearce, W.H. (1987). Extra-anatomic bypass: A closer view. *J Vasc Surg*, 6:437-446.

[59] Shakhnovich, I. (2014). Extra – anatomic bypass grafts. In: *Color Atlas and Synopsis of Vascular Diseases*, edited by Dean, S.M. and Satiani, B. New York, McGraw-Hill Education., ISBN: 978-0-07-174951-0.

[60] Ascher, E., Veith, F.J. and Gopal, K. (2012). Extra-anatomic Bypasses In: *Haimovici's Vascular Surgery*, 6th Edition, edited by Ascher E. New Jersey, Blackwell Publishing Ltd., Online ISBN: 9781118481370. doi: 10.1002/9781118481370.

[61] Collins, T.C., Nelson, D. and Ahluwalia, J.S. (2010). Mortality following operations for lower extremity peripheral arterial disease. *Vasc Health Risk Manag*, 6: 287–296.

[62] Kalish, J., Farber, A. (2014). Biological Grafts. In: *Rutherford´s Vascular Surgery*, 8th edition, edited by Cronenwett, J.L. and Johnston, K.W. Philadelphia, Elsevier Saunders, ISBN: 978-1-4557-5304-8.

[63] Barceli, S.A. (2014). Autogenous Grafts. In: *Rutherford´s Vascular Surgery*, 8th edition, edited by Cronenwett, J.L. and Johnston, K.W. Philadelphia, Elsevier Saunders, ISBN: 978-1-4557-5304-8.

[64] Kieffer, E., Gomes, D., Chiche, L. et al. (2004). Allograft replacement for infrarenal aortic graft infection: Early and late results in 179 patients. *J Vasc Surg*, 39(5):1009-1017. doi:10.1016/j.jvs.2003.12.040.

[65] Qu, Z., Chaikof, E.L. (2004). Prosthetic Grafts. In: *Rutherford´s Vascular Surgery*, 8th edition, edited by Cronenwett, J.L. and Johnston, K.W. Philadelphia, Elsevier Saunders, ISBN: 978-1-4557-5304-8.

In: Encyclopedia of Surgery (22 Volume Set)
Editors: Andreas Lehrer and Kristin Mueller
ISBN: 978-1-53618-329-0
© 2020 Nova Science Publishers, Inc.

Chapter 285

AORTIC ARCH AND SUPRAAORTIC BRANCHES

***František Saboľ**, MD, PhD**
Department of Heart Surgery of East Slovak Institute of Cardiovascular Diseases,
Pavol Jozef Safarik University, Kosice, Slovakia

ABSTRACT

The introduction of the chapter focuses on embryology and anatomy of the aortic arch, which directly follows the text focused on congenital developmental aortic defects, their manifestation and surgery. Furthermore, attention is drawn to the most feared diagnoses of aneurysm and aortic arc dissection. The description of surgical interventions in this anatomical site includes both the standard purely surgical procedures and the currently preferred hybrid approaches. The chapter also includes summarizing of forms of brain protection during surgical intervention. The author thus tried to give a comprehensive surgical view of the discussed issue.

Keywords: aortic arch, cerebral protection strategies, aortic arch aneurysm, aortic dissection

EMBRYOLOGY, ANATOMY AND PHYSIOLOGY OF THE AORTIC ARCH

The development of the aorta begins in the third week of fetal development. It is a complex and complicated process that can lead to a number of physiological variations and also pathological malformations. The primitive aorta consists of two anterior and two posterior branches. The anterior branches then form the aortic sac and the posterior branches the tissue for the descending aorta. There are six arches between the anterior and the posterior aortic structures. The definitive anatomy of the aorta and its basic branches is due to the regression of some parts of these primitive structures, while others form definitive structures. In principle, the first arch creates the arteria maxillaris, the second arch the arteria stapedia and the arteria hyoidea. The third arches then form the arteria carotis communis. The fourth left arch creates the final arch of the aorta. A part of the primitive anterior right aorta further creates the truncus brachiocephalicus [1]. The fifth arches regress rapidly and often are not

* Corresponding Author's Email: fsabol@vusch.sk

even present and finally the sixth arches form the pulmonary arteries [2]. On the dorsal aorta then starts the seventh intersegmental artery as a prerequisite for the formation of an arteria subclavia bilaterally (Figure 1) [1].

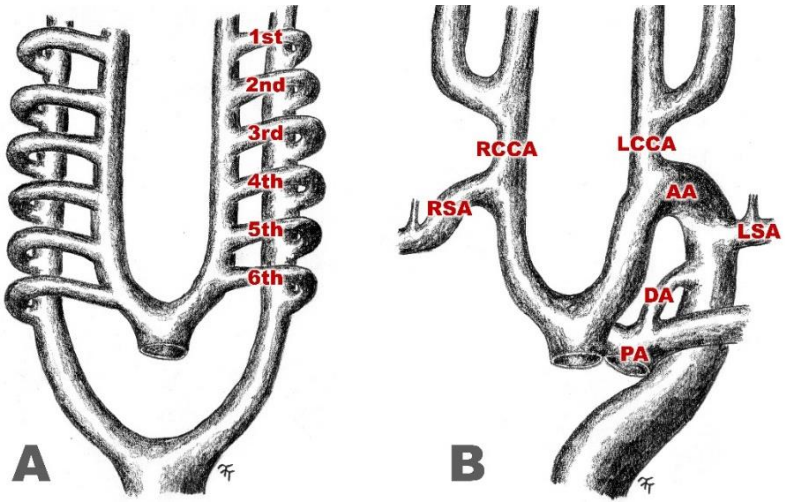

Figure 1. Aortic development (1st – 6th - 1st – 6th pharyngeal branch; AA – aortic arch; DA – ductus arteriosus; LCCA – left common carotid artery; LSA – left subclavian artery; PA – pulmonary artery; RCCA – right common carotid artery; RSA – right subclavian artery).

Thus, the normal left-sided aortic arch originates from the fourth left-sided primitive aortic arch. Truncus brachiocephalicus originates from right-sided anterior primitive aorta. Thus, by regression of the posterior right primitive aorta distal to the seventh intersegmental artery, a part of the definitive right artery subclavia is formed. It finally embryologically consists in the proximal-distal direction of the fourth right aortic arch, part of the right dorsal aorta, and the right seventh intersegmental artery. The fifth arch bilaterally and the sixth aortic arch on the right physiologically disappear. From the left-sided fourth arch as the base for the aortic arch remains a separate of both the aorta carotis communis and the left subclavian artery. This branching is present in 70% to 80% of the healthy population. The most frequent variation is the common separation of the left-sided arteria carotis communis with the right-sided arteria carotis communis. This type of the arch can be also found in cats. Further the common division of arteria carotis communis sinistra from arteria brachiocephalica dextra is present at 9 to 13% of population. In 5 to 6% of patients, we find a separate division of the arteria vertebralis sinistra arteria from the aorta, proximal to the left-sided arteria subclavia [1].

Arcus aortae is a continuation of the ascending aorta. It begins slightly to the right of the medial plane behind the second sternocostal joint. The arch runs first to the left diagonally back to the left side of the front wall of the trachea. Subsequently, it crosses the trachea from the left and continues caudally to the body of the fourth thoracic vertebra where it passes into the descending thoracic aorta. There is a slight narrowing, aortic isthmus, at the interface of the aortic arch and its descending part behind the sinister subclavian artery. It is located in the prenatal ductus arteriosus site. Thus, the entire arch of the aorta lies in the mediastinum superius, surrounds the left bronchus and reaches the height of the centre of the manubrium sterni which means about 2.5 cm below the jugular fossa. The aortic arch shadow is also

visible in the anterior-posterior image of the chest. At the beginning it reaches a width of 28mm, at the end 20mm. To the left of the aortic arch lies the left pleural cavity. On the left edge the aortic arch crosses the phrenicus nerve and the vagus nerve that produces the laryngeus recurrens nerve. That surrounds the ligamentum arteriosum and returns cranially on the right side of the aortic arch. The trachea, the plexus cardiacus profundus, the nervus laryngeus recurrens dexter, the oesophagus, the ductus thoracicus, and the vertebral bodies [3, 4] are then on the right and behind the aortic arch.

From the arch separate the truncus brachiocephalicus, arteria carotis communis sinistra and arteria subclavia sinistra, which are crossed from the front by vena brachiocephalica sinistra. The separation of the first of the branches varies from the beginning of the arch to the highest point of the arch. More rarely, the left-sided branches may separate together as the left-sided truncus brachiocephalicus. However, we can also find an individual separation of arteria carotis interna and arteria carotis externa directly from the aortic arch. The right arteria subclavia normally separates from the truncus brachiocephalicus beyond the upper edge of the sternoclavicular articulation. Initially, it heads slightly cranially behind the clavicle, subsequently behind the musculus scalenus anterior, over the right rib into the axilla where it turns into the arteria axillaris. The left arteria subclavia separates from aortic arch mostly individually, then it also extends beyond the musculus scalenus anterior [3, 4].

Compared to the ascending or the descending aorta, the pressure load of the aortic arch is loaded with increased pulse tension as well as increased blood flow [5]. Pulsatile stress loads the aortic arch in both the longitudinal and the circumferential directions. Due to the elongation of the aortic arch described in the older population, we can assume a higher pulsatile stress in the longitudinal direction of the aortic arch. In supraaortic branches, the pulsatile stress is considerably limited. This stress affects both the development of aortic arch diseases and the long-term stability of implanted stentgrafts [5].

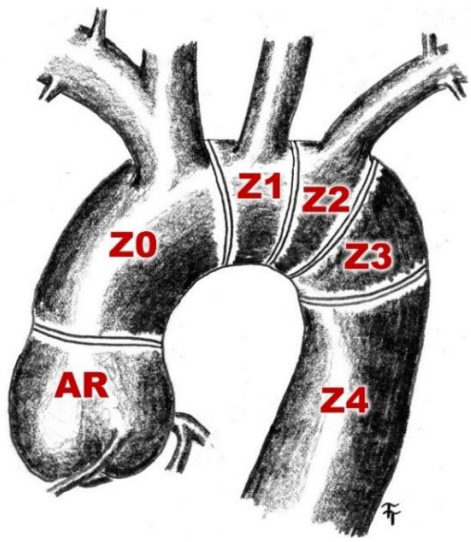

Figure 2. Ishimaru classification of the aortic arch landing zones (AR – aortic root; Z0 – ascending aorta up to the truncus brachiocephalicus; Z1 – part of the aortic arch between truncus brachiocephalicus and arteria carotis communis l.sin; Z2 – part of the aortic arch between arteria carotis communis l.sin and arteria subclavia l.sin; Z3 – proximal descending thoracic aorta distal to the arteria subclavia l.sin; Z4 – midportion of the thoracic descending aorta) – free according to [5].

In terms of interventional endovascular medicine, we divide the thoracic aorta according to Ishimaru classification into landing zones. Landing zones represent parts of the aorta unequivocally characterized by the possibility of stentgraft anchoring at the site. The portion of the aorta from the sinotubular junction to the distal edge of the truncus brachiocephalicus is Z0. The Z1 zone is linked to Z0 and ends at the distal edge of separation of the left arteria carotis communis. The continuation is zone Z2 ending at the distal edge of the left arteria subclavia. Another zone is zone Z3, which represents the proximal part of the thoracic descending aorta (Figure 2). Another part of the thoracic aorta is called zone Z4, which is further subdivided into subdivisions marked with letter T and a number correlating to the number of the thoracic vertebra at that height. The most proximal part of the Z4 zone due to the proximity of the fourth thoracic vertebra in this topographic location is represented by the T4 segment [5].

CONGENITAL MALFORMATIONS

The incidence of congenital anomalies in the aortic arch in the literature varies from 0.5% to 3% [6]. These variations are due to a defect in embryogenesis and are closely related also to the development of the descending aorta. The diagnoses as anomalous separation of the right arteria subclavia, the presence of Kommerel diverticulum and the coarctation of the aorta, despite the close association with the aortic arch, will be discussed in the chapter on the descending aorta. In the following text we will deal with malformations directly affecting the aortic arch, namely the double aortic arch, the right aortic arch, the persistent fifth aortic arch and the interrupted aortic arch [1].

Double Aortic Arch

The double aortic arch is formed by the persistence of both the right and the left fourth primitive aortic arches, while each side produces ipsilaterally both the arteria carotis communis and the arteria subclavia. This anomaly is most often manifested as a vascular ring when the surrounding of the trachea and the esophagus causes their suppression and consequently dyspnea and/or dysphagia. It is already manifested in early childhood, usually as dyspnea, wheezing and stridor accentuated with the baby's cry. The right-hand side is usually more developed with a larger diameter, in some cases the left-hand side is also atrophied, occurring only as a fibrotic band, where we can also define the condition as a right-sided aortic arch. The preserved fibrotic band, in contrast to the isolated right-hand arch, leads to the above-mentioned manifestation caused by the vascular ring already in early childhood [1]. In vascular ring symptomatology, whether in complete double arch or right-hand arch and fibrotic left side, ligation and transection of one side is indicated depending upon side dominance (Figure 3) [1].

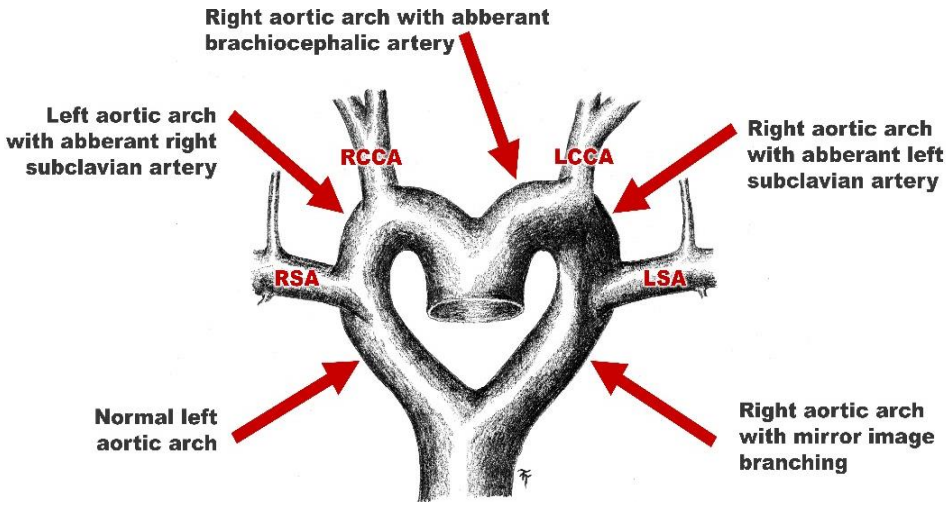

Figure 3. Embryogenesis of the aortic arch and congenital anomalies (pointers show localization of the aortic arch regression and attributed congenital anomalies; LCCA – left common carotid artery; LSA – left subclavian artery; RCCA – right common carotid artery; RSA – right subclavian artery).

Right Aortic ARCH

The right aortic arch is created by preserving the right-hand fourth primitive aortic arch and more, or less, by the atresia of the left-sided fourth arch. There are several anatomical variants of this diagnosis depending on the site of involution of the left-sided part (Figure 3).

The right aortic arch with the aberrant left arteria subclavia and retroesophageal diverticulum is the most common modality of this diagnosis [7]. The pathology is due to the regression of the left fourth primitive aortic arch at a level between the separation of the arteria carotis communis and the arteria subclavia. A portion of the left dorsal aorta often persists, thus forming a retro-esophageal diverticulum, from which subsequently separates the left arteria subclavia. This nozological unit, after double aortic arch, is the second most common malformation causing a vascular ring with symptomatology of esophageal and respiratory depression in early childhood. Further, it can be supplemented by persistent left-sided ductus arteriosus or ligamentum arteriosum located between pulmonary artery and retro-esophageal recess [1, 8].

The second modality of the right-sided aortic arch is the presence of an aberrant left arteria subclavia without retroesophageal diverticulum. It arises from the involution of the left fourth and sixth primitive aortic arch, whereby the left posterior aorta does not participate in the definitive descending aorta. An important fact is the absence of the left-sided ductus arteriosus, thus severely disrupting the vascular ring. Thus, possible coarctation of the aorta may occur on the right arch in the usual height correlating with the leftward variant. The diagnosis may itself be asymptomatic but is often associated with other cardiac anomalies such as Fallot's tetralogy, less often coarctation of the aorta [1, 9].

In the right-sided aortic arch can be preserved also the left-sided truncus brachiocephalicus and the atresia of the left-sided arch occurs already above the separation of the left-sided arteria carotis communis. Right-sided arteria carotis communis, right-sided arteria subclavia and left-sided truncus brachiocephalicus with retro-esophageal course are

gradually withdrawing from the right-sided arch. At that time, the ductus arteriosus also leaves the left-sided truncus brachiocephalicus to form the vascular ring.

The right-side aortic arch with mirror separation of branches is the second most common variant of the right-sided arch. At that time, the left-sided arch disappears below the separation of the seventh intersegmental artery. This diagnosis is associated with up to 98% of congenital heart defects such as Fallot's tetralogy, truncus arteriosus, tricuspid atresia, and large vessel transposition with pulmonary valve stenosis [1]. By default, the diagnosis does not produce a vascular ring. The anomaly is usually associated with the left-sided ductus arteriosus, which connects the left-sided pulmonary artery and the left-sided subclavian artery but does not form a vascular ring. The right-sided ductus arteriosus is more rare. Even less frequently is described the ductus arteriosus connecting the left-sided arteria pulmonaris and the descending aorta as the remainder of the sixth left-sided arterial arch. This rare combination is already manifesting itself as a vascular ring [1, 10].

Isolation of aortic branches is a rare diagnosis based on two pathological atresia of aortic arch, separating one branch that remains connected only to the pulmonary blood circulation via the persistent ductus arteriosus [1, 11, 12]. Isolated left arteria subclavia is the most common form of aortic branch isolation and is associated in about half of the cases with other congenital heart defects. It arises from the regression of the fourth left aortic arch above and below the separation of arteria subclavia. The right aortic arch then gradually produces the left-sided arteria carotis communis, the right-sided arteria carotis communis, and the right-sided arteria subclavia. The anomaly may lead to congenital subclavian steal syndrome with vertebrate basilar insufficiency [1, 12].

Persistent Fifth Aortic Arch

The double lumen aorta is one of the rare birth defects of the aortic arch with an incidence of 1: 330 of all developmental heart defects [2, 13]. For the first time, this anomaly was described by Van Pragh in 1969, who suggested the persistence of embryonic fifth aortic arch as the caudal component of the double cavity in adulthood [14]. The persistent fifth aortic arch has two forms: systemic-systemic junction and systemic-pulmonary junction. The double lumen begins on the arch near the separation of the truncus brachiocephalicus. The systemic-systemic form of the fifth arch persistence is represented by a subsequent junction with the fourth arch at the level of the descending aorta, producing a double lumen aorta. The systemic-pulmonary form means the distal junction of the fifth arch to the sixth arch, which represents the pulmonary artery (Figure 4) [2]. Akhfash et al present three subtypes of the retained fifth aortic arch: the two-lumen aortic arch, with the two cavities permeable, the interruption of the cranial arch that arises from the fourth aortic arch, with the preserved flow through the fifth caudal aortic arch and the systemic-pulmonary fifth aortic arch [15]. A common coincidence of the preserved fifth aortic arch is coarctation of the aorta, open ductus arteriosus, bicuspid aortic valve, atrioventricular septal defect, interrupted aortic arch, pulmonary atresia, Fallot tetralogy, atresia of tricuspid valve and ventricular septal defect, although we can find in literature also isolated occurrence of this diagnosis [13, 15-17]. In the presence of a double lumen aorta as a form of persistence of the fifth aortic arch, we find two aortic lumens separated by aortic wall duplication, with no larger structures passing between them in contrast to the true double aortic arch, and no arterial branches leaving the caudal

lumen [15]. As a possible etiology of persistence of the fifth aortic arch, whether in systemic-systemic or systemic- pulmonary form, the microdeletion of chromosome 22q11.2 [1, 2] has been reported in the literature.

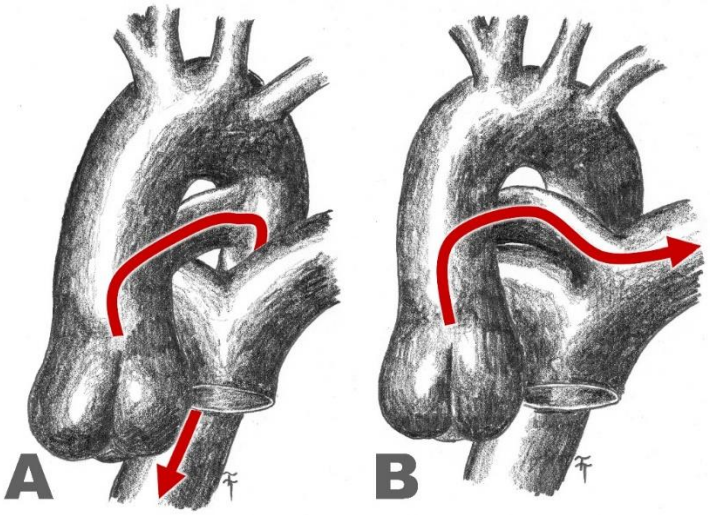

Figure 4. Persistent fifth aortic arch (A – systemic-to-systemic form; B – systemic-to-pulmonary form).

Not all authors acknowledge the theory that the etiologically of persistent fifth aortic arch is behind the formation of the double lumen aorta [18]. Gupta et al. presented a case report analysis denying this fact. Other authors also point out that the fifth aortic arch is present only in about half of the embryos on the eleventh day of development, and its degeneration proceeds extremely rapidly towards the primitive posterior aorta [15, 18]. According to these papers, a separation proximal to truncus brachiocephalicus and a fusion with the fourth aortic arch beyond the separation of the left arteria subclavia [18] is required to establish the diagnosis of persistent fifth aortic arch. Thus, according to these and other authors, the double lumen aorta is most often caused by collateral channels around the fourth aortic arch [18-21]. Although the etiological origin of the double-lumen aorta is controversial, this diagnosis remains unconditionally a possible congenital malformation of the aortic arch without the need for intervention in its asymptomatic condition, however a possible complication in some surgical but mainly endovascular interventions.

Interrupted Aortic Arch

The interrupted aortic arch is a rare malformation with an incidence of two per 100,000 live births. It is defined by the complete disruption of continuity between the ascending and the descending aorta. The blood flow is secured by an unclosed ductus arteriosus. Symptomatology is similar to aortic coarctation symptomatology occurring during the first two weeks of life and requiring surgical intervention. Based on the location of the aortic arch interruption, we recognize three kinds of its interruption [1, 22].

In Type A of interrupted aortic arch, the arch is interrupted distally to the left arteria subclavia. Regression occurs at a later embryonic stage where the arteria subclavia is already proximal. It represents about 30-40% of all interrupted aortic arches [1].

Type B is characterized by an arch interruption between the left arteria carotis communis and the left arteria subclavia. It is formed by the atresia of the fourth aortic arch in the early embryonic phase. It is the most common form of disrupted aortic arch and is often associated with the deletion of chromosome 22q11.2 [1, 22]. It is associated with the presence of other anomalies, including the bicuspid aortic valve, subaortic stenosis, ventricular septal defect and subclavian artery anomalies [1]. Pathophysiology and manifestation are often associated with minimal left ventricular expenditure, left ventricular outflow tract obstruction and ventricular septal defect, but with preserved cerebral perfusion [22-24].

In type C, the aortic arch atresia is most proximal, that is, between the truncus brachiocephalicus and the left arteria carotis communis. It is manifested in the development defect of the most proximal part of the fourth and the third aortic arch [1]. It is extremely rare and represents only 5% of all aortic arch interruptions [1, 22].

AORTIC ARCH ANEURYSM

In December 1948, Rudolph Nissen at the Brooklyn Jewish Hospital in New York operated Albert Einstein for the thoracic aortic aneurysm. Due to the extent of the finding and the possibility of the then thoracic aortic medicine, the surgeon just covered the ventral two thirds of the aneurysm with yellow cellophane. Albert Einstein then lived for 6 years until an aortic wall rupture occurred [25]. Today's medicine offers for this diagnosis a number of progressive solutions with relatively optimistic post-operative results.

Indications for urgent aortic aneurysm surgery include its rupture, pseudoaneurysm, and aortic dissection, which will be discussed below. Indications for elective aneurysm surgery are an enlargement of the aortic diameter by more than 1cm per year, a diameter above 6cm and a diameter above 5cm in patients who are indicated for surgery for an ascending or descending aortic aneurysm, or in patients with Marfan syndrome or a positive family history of rupture or dissection [3].

Medical history should be taken into account when examining the patient. The family history of this disease is relatively frequent and may confirm to the surgeon an indication of surgery in borderline situations [26]. Computerized tomography and magnetic resonance imaging are recommended as imaging methods, both with appropriate contrast media. Coronary angiography and ultrasound examination of the heart are also indicated in view of the incidence of disease in the elderly in order to consider concomitant cardiac surgery on the heart [3]. In a patient indicated for elective surgery, a thorough examination of the supraaortic branches of the aorta is required to identify patency of both arteriae carotis communis and arteriae carotis interna as well as arteria vertebralis. In the case of a positive personal history of stroke, computerized tomography of the brain is further indicated to determine the extent of damage and the possibility of post-operative comparative examination at the clinical manifestation of neurological complications [3].

Anesthesia in aortic arch surgery is similar to anesthesia in cardiac surgery. Standard monitoring should include invasive measurement of pressure on arteria radialis and arteria

femoralis, Swan-Ganz catheter and central venous catheter. Perioperative transesophageal echocardiography is recommended to monitor the ejection fraction and satisfactory flow in the aortic arch. Some workplaces also use perioperative encephalography. Our workplace uses cerebral oximetry in correlation with other works to monitor the correct selective cerebral antegrade perfusion. This allows for consideration of the conversion of unilateral selective cerebral antegrade perfusion to bilateral due to insufficient anatomical conditions as well as early detection of possible complications, including catheter blockage or its migration [27]. Another option, which is also not used in our workplace, is the transcranial Doppler examination, which brings with it increased dependence on the expertise of the investigating physician. Cohn et al. recommend an initial dose of 1g of methyl prednisone when initiating extracorporeal circulation, assuming a duration of hypothermia of more than ½ hour followed by a repeated dose of 125mg four times within the first 24 hours and then every 12 hours on the second postoperative day [3, 28].

For perfusion, the protocol used in cardiac surgery can be used. After cannulation of the right-sided arteria axillaris, an extracorporeal circulation is triggered. Echocardiographic monitoring is recommended, especially in field of dissection. In surgical procedures involving also the descending aorta, a concomitant cannulation of the arteria femoralis for perfusion of the lower half of the body and shortening the necessary length of the arrest is a useful method. The non-pulsatile flow during extracorporeal circulation increases cerebral vascular resistance, leading during the operation to an increase in the pressure required for sufficient perfusion of brain tissues and maintenance of satisfactory cerebral oxygenation. Furthermore, in correlation with other workplaces, in our workplace we use local cooling of head by applying ice [3]. Other specificities of cerebral protection during surgery will be discussed below.

Medial sternotomy, as a gold standard for cardiac surgery approaches, provides sufficient visualization of the ascending aorta, the aortic arch, and the proximal portion of the descending aorta about 5 cm behind the separation of the left-sided arteria subclavia. In case of need, the incision may be further extended along the edge of the left sternocleidomastoid muscle. Further, the visualization is limited by the course of the vena brachiocephalica sinistra, which can be interrupted if necessary and reconstructed at the end of the operation. If aortic involvement requires resection of a larger part of the aorta, thoracosternotomy or bilateral anterior thoracotomy is useful as a surgical approach, however it carries higher risks of postoperative respiratory insufficiency and phrenicus nerve damage [3, 29].

In spite of the rapidly developing endovascular technique also in the field of the aortic arch, the open surgical approach remains a still used strategy. Hui et al. report very optimistic results of open aortic surgery with a 30-day mortality of 5% to 9.7% and an incidence of stroke from 2.8% to 6.2% [5]. Thus, the carrier theme remains cerebral perfusion during surgery.

Cerebral Protection Strategies in Aortic Arch Surgery

One of the most important components of aortic arc surgery is to maintain circulation in the supra-aortic branches to prevent perioperative hypoperfusion of the brain. The patient undergoing this surgery is at risk of developing neurological complications and the management of the entire operation must be tailored to minimize this risk. However, there is

not known any universally and unambiguously most optimal solution, and several modifications of individual steps for patient protection are therefore discussed. Early attempts at both aortic and descending aortic surgery were accompanied by frequent hypoxic peripheral organ damage and neurological deficits. Systemic hypothermia was one of the first methods of neurological protection during circulatory arrest. The first study involving aortic arch reconstruction using deep hypothermia with circulatory arrest dates from 1975 [30]. Subsequently, methods of selective antegrade and selective retrograde brain perfusion using less deep hypothermia were introduced.

Circulatory arrest in the head and the brain was an unconditional part of aortic arch replacement in the past. Circulation interruption time is called “circulatory arrest” and provides bloodless vessel manipulation and the possibility of sewing its anastomosis. We divide two types of neurological complications of these operations, permanent neurological damage and temporary neurological damage. Permanent neurological damage, also referred to as perioperative stroke, is due to the embolism of a solid particle, most commonly a piece of atherosclerotic plaque, or bubble to vessels supplying brain tissue, resulting in ischemic sudden stroke in its basin. On the other hand, temporary neurological involvement does not have an anatomical correlate and is due to insufficient brain tissue perfusion at the time of surgery. Computer tomography or magnetic resonance imaging is most often negative in this case and clinical manifestation is only due to global cerebral ischemia [31]. Thus, to ensure the protection of both organs and the brain, the temperature of the organism and tissues is reduced during circulation to reduce the metabolic demands of the individual organs. Brain tissue has significantly higher metabolic requirements than other tissues. Today we know that when the body temperature drops to 15 degrees Celsius, the metabolic demands of the brain are reduced to only 84% [32]. Griepp et al. in their time declared that lowering body temperature is a sufficient protective method of protecting neurological tissue with excellent results [30]. Currently there are used several techniques of the most frequently combined application of hypothermia and selective perfusion of neurological tissues [31].

Deeply hypothermic circulatory arrest without or with selective perfusion of some tissues is the simplest form of cerebral protection. In principle, it does not need monitoring of brain perfusion and is a popular access strategy for surgeons and workplaces where aortic arc surgery is not a frequent surgical procedure. After connecting the patient to extracorporeal circulation, the patient's cooling phase is provided by cooling the blood with a heat exchanger. It is important to keep the heat gradient between venous blood aspirated from the patient's body and arterial blood from the extracorporeal circulation less than 10 degrees Celsius, which prevents air bubble formation. The overall duration of patient cooling and preparation for surgery itself is thus dependent on multiple parameters including extracorporeal circulation blood flow, temperature gradient, but also the patient´s weight and tissue specificities. Although the method is not dependent on special investigative techniques, monitoring parameters such as time, temperature, venous oxygenation, and electro-encephographic activity increases the patient safety. The temperature is monitored both at the inlet and the outlet of the blood from the extracorporeal circulation as well as in the individual tissues, most often in the esophagus, bladder and rectum. Using hypothermia without another method of brain perfusion, arrest may be initiated on the basis of esophageal or nasopharyngeal temperature, due to the correlation of temperatures in this site with brain tissue temperature. In general, it is recommended to reach a temperature between 14.1 and 20 degrees Celsius. When the temperature limit is reached, the extracorporeal circulation is

stopped, allowing to operate in a bloodless environment. After the completion of the necessary phase of reconstruction, the extracorporeal circulation and circulation are restored after careful removal of the vascular gas from vascular basin [31]. Initial works targeted at aortic arch reconstruction used this protection in isolation [30]. Nowadays, in order to provide sufficient neurological protection in isolated use of deep hypothermal arrest, the recommended duration of the arrest is 40 minutes [31, 33, 34]. Svensson et al. report mortality of 6.3%, incidence of sudden stroke of 4.8%, need of dialysis of 2.3% in isolated use of arrest in deep hypothermia, with mean duration of arrest in group of 31 minutes [33]. The authors further point to a sudden upward trend in the risk of developing a sudden stroke in excess of 40 minutes of arrest [33]. Thus, complex performance has led to the introduction of a combined cerebral protection strategy [31].

The history of using retrograde cerebral perfusion is not associated with aortic arc surgery but with the treatment of iatrogenic massive air embolism [35]. Retrograde perfusion is performed by applying cold oxygenated blood to the upper vena cava, what leads to the perfusion of the upper half of the body, including the brain, in the retrograde direction. Universally, blood is applied at a flow rate of 200 to 400 mL/min, giving a pressure of 15 to 25 mmHg [31]. Correct application can be verified by draining dark deoxygenated blood from the arterial system of the upper half of the body. The method has several positives. First of all, it is the ability to wash out mechanical embolisms from the arterial circulation of the brain, then maintenance of controlled hypothermia of the brain, and, last but not least, promotion of brain metabolism by the continuous application of oxygenated blood. The combined use of deep hypothermia and retrograde cerebral perfusion thus provides better results and a lower risk of neurological complications following surgical performance on the aortic arch. Coselli and Lemaire compared the effectiveness of isolated deep hypothermia and combined hypothermia with retrograde perfusion in 479 patients. The authors report that the combination with retrograde cerebral perfusion significantly reduces mortality and the risk of sudden stroke [36]. Other authors document that supplementing hypothermia with retrograde cerebral perfusion has a significant protective potential for sudden stroke and mortality [37]. Despite these positive results, the incidence of insufficient cerebral protection is still present and the mortality rate, even when using the combined approach, is 3.4% [36].

Another method of reducing the risk of neurological complications during aortic arc surgery is selective antegrade cerebral perfusion, first described by De Bakey et al. [38]. It is generally accepted that antegrade blood flow will provide more effective oxygenation of brain tissues compared to retrograde flow when oxygenated blood is applied via the upper hollow vein. Technically, this method is feasible by several modifications. Bilateral application is universally performed by the application of oxygenated blood to the left arteria carotis communis and truncus brachiocephalicus after the opening of the aortic arch. The risk lies in the air embolism as well as in the embolism by the solid particles released from the atherosclerotic plaques during cannulation. In addition, the cannulae increase opacity in the operating field. Several authors, including our workplace, prefer selective antegrade brain perfusion by applying oxygenated blood to the right arteria axillaris [39-41]. The operation begins with sutura of 8mm end to side vascular prosthesis on the right-sided arteria axillaris, into which is inserted the arterial extracorporeal circulation line (Figure 5). The venous line is introduced either via the vena femoralis pathway or through the right atrial ear as standard. During the arrest, the truncus brachiocephalicus and the left-side arteria carotis communis are clamped and the extracorporeal circulation is reduced to approximately 10mL/kg/min. The

flow is further adapted to the depth of hypothermia. The pressure can be monitored by cannula introduced into the right-sided arteria radialis. Left hemisphere perfusion is ensured by collateral circulation (Figure 7). At its insufficiency perfusion of this part of the brain is at risk and selective perfusion must be supplemented with another arterial cannula applied directly to the left-sided arteria carotis communis. However, the papers show that right side cannulation of the arteria carotis communis is not necessary for intact Willis circuit [42-44]. Moreover, manipulation of the right-sided arteria carotis communis may increase the incidence of perioperative sudden stroke [45].

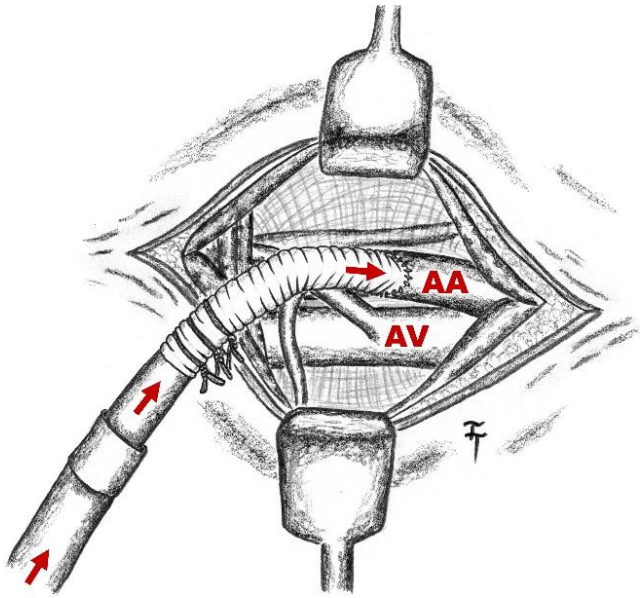

Figure 5. Axilary artery cannulation by using of 8mm vascular protheses (AA – axillary artery; AV – axillary vein).

The use of selective cerebral perfusion makes it possible to replace deep hypothermia with a milder form. Total arrest is converted to lower body arrest using selective brain perfusion and low temperature is designed to protect other organs, peripheral tissues, and spinal cord. The lower metabolic demands of these organs impose lower demands on hypothermia and metabolism compared to the brain. The combination of appropriate hypothermia and selective anterograde brain perfusion is currently a popular standard used worldwide, even in our center [31, 41]. For half-arch replacement, hypothermia at 28 to 29 degrees Celsius is recommended, with studies presenting a mortality of 4.3% for elective procedures and 7.7% for emergent procedures, a transient neurological deficit of 1.9% for elective procedures, and 4.6% for emergent procedures, an incidence of sudden stroke 3.8% for elective surgery and 6.2% for emergent surgery and incidence of renal failure 2.4% for elective and 9.2% for emergent surgery [40]. At full arch replacement, the studies recommend a temperature of 25 to 26 degrees Celsius and demonstrate a mortality of 9.7%, an incidence of transient neurological disorders of 2.8%, a sudden stroke of 5.6%, and a renal failure with a need for dialysis of 2.8% [46-49].

Due to the habits of different workplaces, there are currently no universal rules for using cerebral protection. The parameters and differences of the selected protection include several

basic parameters, to which belong the site of the arterial line cannulation of the extracorporeal circulation, the target temperature of the selected hypothermia, the use of anterograde or retrograde selective cerebral perfusion, and the use or non-use of bilateral anterograde perfusion. Although some studies compare two methods to some extent, a complete randomized study has not been performed to definitively compare the benefits and limitations of all methods and the choice remains more focused on workplace habits than objective results. When using several methods at one workplace, we most often encounter the use of deep hypothermia with retrograde cerebral perfusion and moderate hypothermia combined with anterograde selective cerebral perfusion [31]. Chen et al. conclude this subject with two arguments. First and foremost, the combination of hypothermia with selective cerebral perfusion is a method superior to the use of isolated hypothermia that produces better results. Further, on the one hand, the choice of anterograde or retrograde selective perfusion does not affect the incidence of sudden stroke, but on the other hand, the use of anterograde choice decreases the incidence of transient neurological postoperative complications [31, 50-52]. Our experience prefers standard right-sided axillary artery cannulation and continuous monitoring of cerebral saturations. At insufficient cerebral saturation, we then recommend the addition of bilateral selective cerebral perfusion. If it is not possible to use this technique, which represents anatomical malformations such as aberrant right subclavian artery, damage to the proximal part of the right subclavian artery by dissection or stenosis, then it is necessary to look for an alternative in the spectrum of the above-mentioned procedures.

Safi et al. present in a group of 117 patients undergoing the first period of operation by elephant trunk procedure presents 5.1% 30-day mortality [53]. Interestingly, according to the study, 37% of patients did not undergo the second part of surgical performance on the descending aorta [53]. Other authors present 8% mortality after identical surgery [54]. Coselli et al. in the group of 227 patients present 6% early and 9% late mortality with only a 3% incidence of sudden stroke and a relatively low incidence of other neurological consequences [55]. Other minor studies also show relatively low perioperative and moderate long-term mortality [3, 56, 57]. Cohn et al. present a group of 206 patients undergoing electively aortic arch surgery, giving an average arrest time of 30 minutes and subsequent hypothermia of 69 minutes. As the most common etiology, they report chronic dissection and atherosclerosis. To risk factors Cohn et al. assign chronic obstructive pulmonary disease, insulin-dependent diabetes mellitus, hemodialysis and reoperation [3]. The authors report 6.8% of hospital mortality with a risk of sudden stroke at the level of 3.3%. The most common postoperative complications included long-term intubation, transient neurological deficiency, reoperation for bleeding and temporary or permanent renal failure. The stay in the intensive care unit was on average 3 days and the hospitalization time after the surgery was 11 days [3].

AORTIC ARCH DISSECTION

Aortic dissection is a condition in which a tear in the lamina intima of the aortic wall leads to the redirection of the blood stream into the aortic wall. Thus, a false lumen for blood flow is formed between the intima and the medium. The acute forms of each dissection type carry high lethality. In the Stanford classification we distinguish type A dissection, where the intimal tear occurs in the ascending aortic site and type B when the tear is located in the

descending aorta (Figure 6) [3]. In this chapter, we will only deal with the acute form of type A dissection.

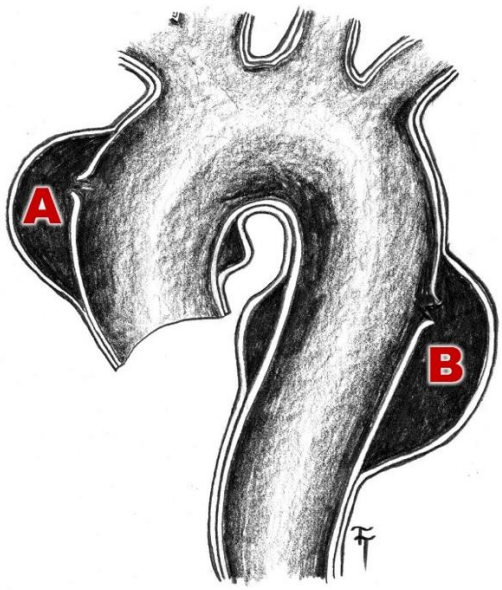

Figure 6. Type A, and type B of Stanford aortic dissection classification according to the position of the dissection originate.

Acute dissection type A is a disease with high mortality. Half of the patients die within 2 days from the onset of disease [58]. Some studies suggest that mortality increases by 1% every hour when not diagnosed. The high mortality rate of delayed diagnosis confirms that this disease should be considered in every suspected symptomatology. In hemody-namically unstable patients suspected of having a pericardial tamponade or hemorrhagic shock, transport to the operating room is indicated. Investigations and operations such as transesophageal echocardiography or the introduction of a central venous catheter are only indicated in the operating room, possibly under general anesthesia, for the risk of hypertension in painful exercise. In the first step it is necessary to fulfill the conditions for the possibility of immediate pericardiotomy and the connection of the patient to extracorporeal circulation [3].

In hemodynamically stable patients, it is important to measure the pressure on both upper limbs and stabilize it to a higher measured value. Stabilization of arterial pressure is necessary to reduce transmural stress in the aorta wall and reduce the risk of rupture, as well as to prevent further propagation of dissection by reducing the pressure in the false lumen. Thus, stabilization of systolic pressure between 90 and 110 mmHg at a heart rate of up to 60 beats per minute is necessary [59]. Equally important is pain therapy to reduce catecholamine leaching. Thus, conservative therapy in stable patients includes opioids, beta-blockers, vasodilators, particularly nitrates. In the contraindication of beta-blockers, the drug of choice are calcium channel blockers [3].

The aim of an urgent operation is to prevent the emergence of a state incompatible with life by redirecting blood flow to the right lumen. Complications of dissection resulting in patient death include rupture of the aortic wall into the pericardial or pleural cavity,

dissection, or closure of coronary arteries and acute aortic valve regurgitation of the severe grade. The contraindication of acute surgery is not the age or the current neurological status of the patient, due to the possibility of his improvement after the blood flow redirection and the stabilization of hemodynamic parameters. Also, the time lag from the first symptoms or the symptoms of false lumen thrombotization do not guarantee the non-development of further complications of the condition and thus do not cause the operation to be unindicated. Some works in these situations prefer elective performance without undue delay instead of emergent performance [3, 60]. The aim of the surgery is to replace the aorta in the extent of its disability, to rehabilitate the complications and to thoroughly control the blood flow redirection to the right lumen.

SURGICAL PROCEDURES

For both the aneurysm and dissection of the thoracic aorta, we choose a similar surgical strategy to try to replace the entire affected aorta. An alternative is to prepare the distal portion of the affected tissue for the next endovascular procedure, or surgery on the thoracoabdominal aorta. In this chapter, we will discuss the most commonly used surgical procedures on the aortic arch, often combined with intervention on the ascending aorta and aortic root. The next chapter then focuses on procedures uncondi-tionally followed by endovascular performance directly on the aortic arch.

Bentall Procedure with Hemiarch Replacement

Bentall half-arch surgery is a surgical procedure indicated for aortic valve involvement with an aneurismal enlargement of the ascending aorta intervening the first half of the aortic arch. As a surgical approach, we choose medial sternotomy and cannulate predilectionally the right- sided arteria axillaris and the right atrium via right atrial ear. During the preparation of hypothermia, we have the possibility of preparation of the surgical field with the determination of the extent of surgery. In this phase, the whole-body perfusion is ensured by the arteria axilaris. On the transverse clamp of the ascending aorta, we most often use anterograde cardioplegia applied selectively to the coronary orifice intermittently. If necessary, retrograde cardioplegia can also be applied via the sinus coronarius. Myocardial protection is supplemented by local ice cooling. Further, the aortic root and the coronary artery orifice with the target are prepared. Most often we use a mechanical valve conduit with a tubular prosthesis, the size being chosen according to anatomical conditions. As an alternative, a combination of biological prosthesis with tubular prosthesis is offered in elderly patients. The conduit is fixed to the aortic position by the intraanular method of individual stitches on the pads, the choice of conduit of 1 to 2 mm narrower than the measured aortic ring size is important. In the case of unsatisfactory anatomical conditions, a supraanular fixation is possible when the conduit should correlate with the measured aortic ring size. Subsequently, we perform the coronary artery suture into the conduit.

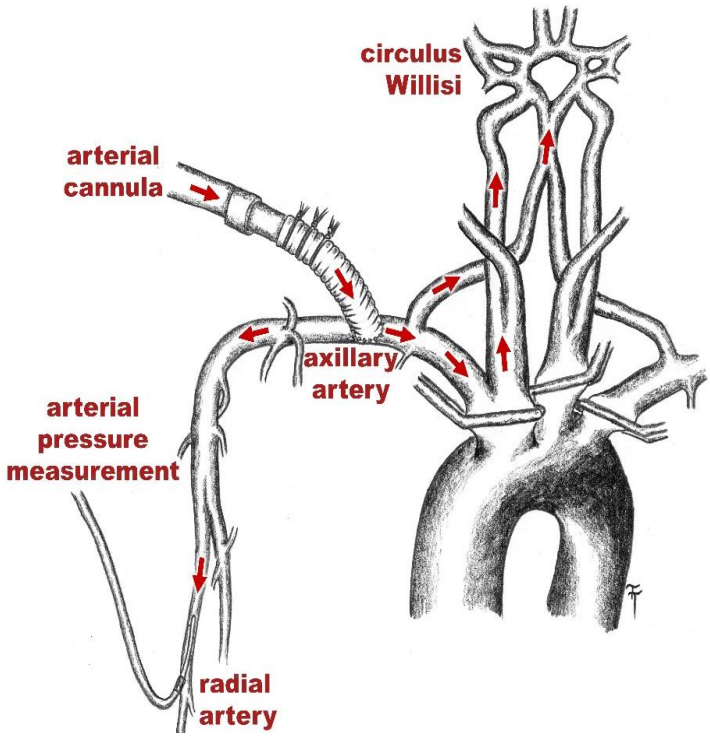

Figure 7. Blood flow after axillary artery cannulation and supraaortic branches clamping.

Once the appropriate degree of hypothermia has been reached, the performance can be extended to intervene on the aortic arch. Cohn et al. recommend arrest only after reaching the esophageal temperature of 18 degrees Celsius and oxygenation in vena jugularis 95% [3]. Then is placed a clamp on the truncus brachiocephalicus, the left arteria carotis communis and the left arteria subclavia. The aortic clamp can be removed, and the aortal arch revision is possible. The upward aorta and proximal part of the aortic arch are excised. On convexity, the incision is proximal to the separation of the truncus brachiocephalicus, then on the concavity of the arch intimately proximal to the separation of the ligamentum arteriosum while maintaining the nerve laryngeus reccurens. The technique of distal anastomosis between the tubular prosthesis and the aortic arch is chosen according to the quality of the aortic wall. A sandwich technique is recommended where the graft is invaginated inside the aorta, which is also covered by a Teflon pad outside [61]. Another option is to use an implantable felt, which also meets hemostatic demands. After completion of anastomosis and venting of the aortic arch, the implanted prosthesis is then clamped and the whole-body perfusion is restored. After re-circulation, isothermia can be gradually restored. The last suture is the suture of both prostheses with subsequent venting of the heart cavities and reperfusion. Disconnection from the extracorporeal circulation is possible after reaching the isotherm. When the aortic root is not affected, the performance can be limited to the supracoronary replacement of the ascending aorta with aortic half-arch replacement (Figure 8).

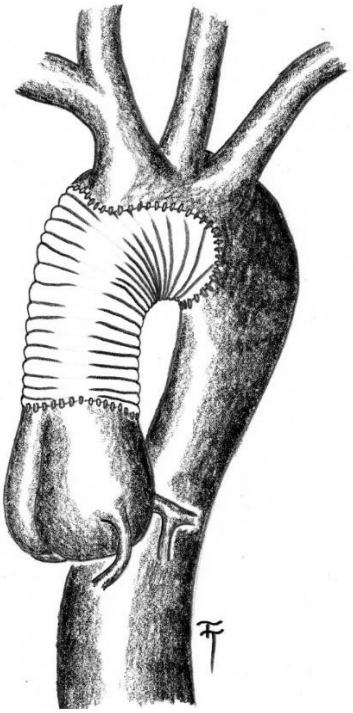

Figure 8. Supracoronary replacement with hemiarch replacement.

Elephant Trunk Procedure

Primarily, the elephant trunk procedure was designed as a surgical solution to the aortic arch aneurysm followed by surgical treatment of the thoracic descending or toracoabdominal aorta from the left-sided thoracotomy approach [25]. Despite the preferred endovascular approaches, the descending aortic aneurysm of larger dimensions remains the primary diagnosis for surgical open intervention.

As such, the technique offers both the possibility of a concomitant operation and the approach in two separate steps, with the second step selecting a surgical or endovascular approach. However, the independent sternotomy makes the current visualization of both the ascending and the descending aorta very complicated. However, two-stage surgery carries the risk of bleeding in field surgery after primary surgery [54, 62]. The main advantage of this technique is that, after the primary operation, a prosthesis is left in the descending aorta that extends significantly below the site of the primary surgery suture (Figure 9). Thus, the anastomosis itself is performed in the second step in a safe healthy tissue of the descending aorta. The second unavoidable advantage in the second step is the possibility of clamping the graft itself, which minimizes perioperative bleeding and the possibility of a perioperative rupture of the aortic wall [62, 63].

The indication is the extent of thoracic aortic involvement requiring intervention on the aorta of two surgical approaches, assuming that the replacement of the aorta and the arch made from sternotomy will be complemented by surgery on the descending aorta from the lateral thoracotomy approach [25]. The indication may be more frequently an aneurysm but

less often a thoracic aortic dissection. Thus, in more than 90% this procedure is indicated electively [54, 63, 64].

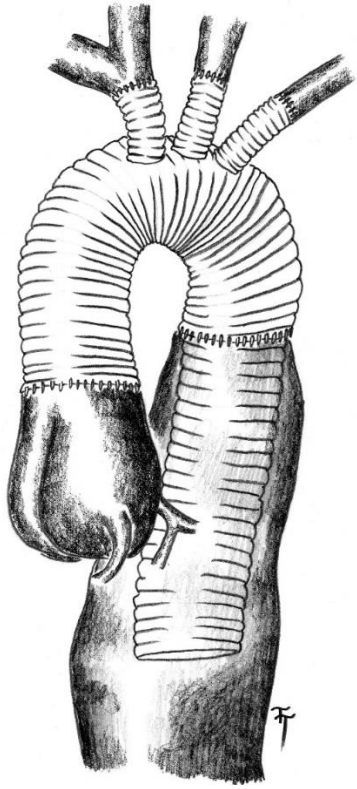

Figure 9. Elephant trunk procedure.

The introduction of the operation copies the procedure for half arch replacements. The extracorporeal circulation is introduced via the left arteria axillaris and the right atrial ear. Vena femoralis remains the choice. Immediately after initiating the extracorporeal circulation, we start with hypothermia of the patient. The procedure on the ascending aorta and the root of the aorta is chosen according to the extent of the affection of this anatomical site. Both Bentall and David or Yacoub surgery, as well as supracoronary replacement of the ascending aorta without intervention on the aortic root [41, 65], are considered. Upon achieving appropriate hypothermia, we switch to selective upper body perfusion. If the aortic wall is not affected in the locality of separation of supra-aortic branches, we can leave these on one target, where a linear prosthesis can be used for the elephant trunk technique with sewing the supra-aortic branches as an only target. With the need for tissue exclusion between the supra-aortic branches, more often with aortic dissection, we prepare each of the three supra-aortic branches selectively and select the graft with prefabricated separations for the suture of these arteries. The distal suture is performed at the boundary of the passage of the aortic arch and the descending aorta, while maintaining the nervus laryngeus reccurens. Distal anastomosis is performed on an invaginated prosthesis inserted into the descending aorta. After the suture is completed, the inner part of the prosthesis is exvaginated. The outer part remains definitively retracted in the descending aorta ready for performance from the lateral thoracotomy

approach. Subsequently, we perform a suture of the supraaortic branches according to the chosen preference and prosthesis. Further, it is possible to put the clamp on the prosthesis, trigger the perfusion of the whole body of the patient and heating of the patient. Thus, the final steps are the proximal suture according to the desired extent of resection and disconnection of the patient from the extracorporeal circulation.

The distance between surgical intervention of sternotomy and thoracotomy varies considerably, mainly according to the extent of aortic involvement and fragility of the descending aorta structures, which correlates with the risk of its rupture or dissection by postponing the second step of the procedure. In the literature, we find time intervals of one hour to 60 months from primary surgery [25, 62, 64]. The specific operating procedure will be described in the chapter dedicated to the descending aorta.

A variant of this operation is the reverse elephant trunk, where the primary operation is performed on the descending aorta, leaving the invaginated prosthesis. In the performance of the aortic arch, after the visualization and the incision of the aortic arch, we find an invaginated graft in the descending aorta, which we exvaginate and the operation proceeds as standard. Reverse elephant trunk technique is indicated especially in congenital developmental defects of the descending aorta, where this part of the aorta is more risky for possible rupture than the aortic arch.

Johnson et al. report the following possible complications of this procedure: graft closure, graft kinking, neurological complications, mediastinitis, need for tracheostomy, renal insufficiency, thoracotomy requiring hemorrhage, death, clot formation around distal anastomosis, peripheral thromboembolism, paralysis of nervus laryngeus reccurens and complete paralysis of vocal cords [25].

Frozen Elephant Trunk Procedure

If the indication for elephant trunk is more often aneurysm in thoracic aorta, then in frozen elephant trunk it is mainly the dissection in this site. Frozen elephant trunk differs from the soft variant so that a portion of the prosthesis distal to the distal anastomosis with the aorta is not formed by the vascular prosthesis but by the stentgraft. The dissection progressing to the descending aorta and any other tears in the intimal layer at this site are so occluded by the stentgraft. In addition, this anatomical modification, while still more distal to the dissection progression, permits direct establishment of endovascular therapy on this prosthesis. Currently used prostheses allow the suture of supra-aortic branches both on one target when this portion of the aorta is not affected and also separately on the prefabricated separations of the prosthesis which additionally has a fourth vascular prosthesis for application of cardiopulmonary bypass.

ENDOVASCULAR A HYBRID PROCEDURE ON AORTIC ARCH AND DEBRANCHING TECHNIQUE

Despite the simultaneous progression of techniques increasingly favoring separate endovascular procedures also on the aortic arch, hybrid performance is still preferred in this

site. Hybrid performance is a fusion of benefits of both the open surgery and the endovascular procedures, offering the patient an optimal result. Hybrid performances on the aortic arch can in principle be divided into several types explained in the following subchapters. The Ishimaru classification introduced in the chapter devoted to anatomy is used as an anatomical guide.

Table 1. Selected series of hybrid arch repairs [5]

Years of study/study	N	30 days or in hospital mortality	Stroke	Retrograde dissection	Reintervention	Survival/follow up
2003-2011[66]	66	9%	5%	3%	14%	72%/5years
2005-2012[67]	47	8%	8%	2.7%	2.7%	48%/5years
1997-2009 [68]	47	19%	6.3%	6.3%	27.6%	59%/3years
2005-2011 [69]	29	6.9%	10.3%	0%	6.9%	79%/1.5year
2005-2008 [70]	28	0%	0%	0%	7%	70%/3years.
2005-2010 [71]	27	11.1%	0%	0%	0%	78%/1.5year
2005-2009 [72]	27	11%	11%	-	0%	-

Mortality of hybrid performance in aortic arch is 6% to 11%. Studies containing a higher percentage of emergent procedures present higher mortality [5, 68]. However, the input sets of the individual files vary considerably in parameters such as the stentgraft loading direction and the left subclavian artery revascularization. Multicenter studies present comparable results of open surgical methods and landingzone-0 targeted hybridization methods [73]. Further studies present also comparable results of both techniques with slightly better results of the open surgical solution in parameter of 30day mortality [74] Importantly, in postoperative follow-up, statistically significantly benefit patients treated with open surgery with a lower risk of developing a new aortic episode [5]. In conclusion it can be stated that groups in either study or multivariate analysis are not fully comparative, and each group contains also patients completely unsuitable for another type of performance. An endovascular approach is associated with a lower risk of post-bleeding, an open surgical approach with a lower incidence of spinal cord injury. Thus, the surgeon or angiologist should modify the procedure both on the basis of the particular patient and on the practice and experience of the particular workplace [75].

Hybrid Arch Type I Repair

In the field where the aneurysm is limited only to the aortic arch, at the intact ascending aorta and the Z3/4 zone of the Ishimaru classification, we can ensure the passage of the supraaortic branches by their debranching into a healthy ascending aorta (Figure 10). One branched prosthesis is most often used for this purpose. In the case of a specific situation and the inability to revascularize the supra-aortic branches by this most frequent way, other options discussed below come into consideration [5].

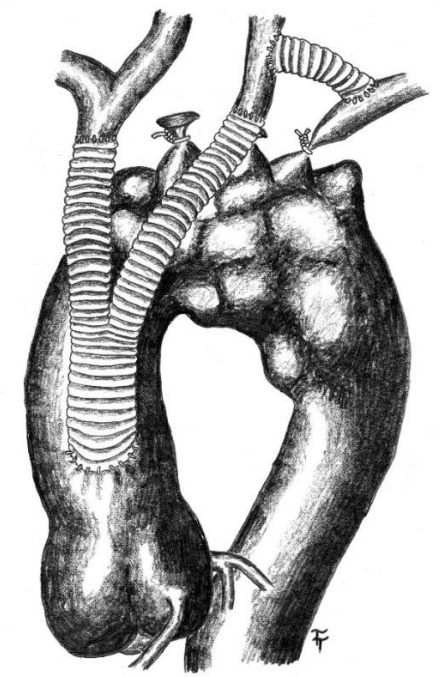

Figure 10. Debranching of the truncus brachiocephalicus and left arteria carotis communis with extraanatomical bypass to left subclavian artery and ligation of its proximal part in the field of unaffected landing zone Z0.

The risk of developing endoleak and retrograde dissection is due to considerations of stentgraft implantation to use the 0-Ishimuru zone as the basic landing zone. Surgical revascularization of supraaortic arteries remains a condition, either by transposition or bypass. The need for this revascularization is also encountered in the need to overlap the separation of the truncus brachyocephalicus, or when the diameter of this branch is not sufficient to revascularize the entire upper half of the body [5]. With good condition of the ascending aorta, it is possible to perform complete debranching without the use of extracorporeal circulation through medial sternotomy using the partial clamp of the ascending aorta. There is a number of variations in this revascularization. It is necessary to consider the status of the ascending aorta, the risk of stenosis of the supra-aortic branches as well as the postoperative complications of the sternotomy itself [5, 76]. After revascularization of the supraaortic branches, ligation or coiling of the original separations is recommended as a prevention of later endoleak [5].

Hybrid Arch Type II Repair

In the field, when the aneurysm reaches also the ascending aorta, namely the Z0 zone of Ishimaru classification, simple stentgraft implantation is not possible, even after the debranching of the supraaortic branches, especially due to the high risk of retrograde dissection of the ascending aorta. Thus, the ascending aorta must be by cardiosurgical

intervention using extracorporeal circulation replaced by a prosthesis with implanted separations of supraaortic branches of the aorta [5].

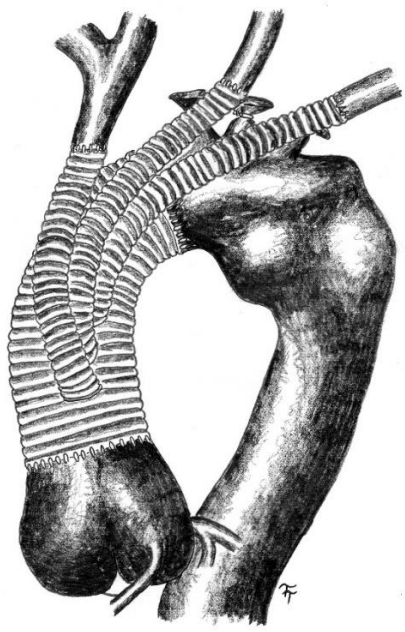

Figure 11. Supracoronary replacement of ascending aorta with debranching of all supraaortic branches.

In the field of affection of the ascending aorta provided that the patient tolerates extracorporeal circulation, is indicated a supracoronary replacement of the ascending aorta, possibly Bentall surgery with the debranching of the supraaortic branches into the vascular prosthesis. Thus, the supra-aortic branches withdraw from the prosthesis or several consecutive vascular prostheses (Figure 11). The procedure greatly eliminates the risk of retrograde endoleak [5].

Hybrid Arch Type III Repair

This type represents the aneurysmal distribution of the ascending aorta, the aortic arch and the descending thoracic aorta. It is therefore necessary to solve the whole course of the thoracic aorta. Surgical open substitution of the ascending aorta and the aortic arch with elephant trunk implantation or frozen elephant trunk followed by endovascular intervention of the descending thoracic aorta with direct stentgraft attachment to elephant trunk prosthesis or stentgraft frozen elephant trunk are recommended [5].

Management of Supraaortic Branches and Left Subclavian Artery Dilemma

Extraanatomical bypasses at this site are usually a solution if the aneurysm reaches the proximal edge of the truncus brachiocephalicus or the left arteria carotis communis. The

management of the left arteria subclavia and the left arteria carotis communis can generally be solved without the need for sternotomy by the incision on the neck. The carotid-subclaval bypass allows the Z2 anchoring zone to be used in the second step. Expansion of extraanatomical bypass between both arteria carotis communis allows the intervention angiologists to use also the Z1 zone [5]. Sequence transposition via hemisternotomy is also used. The debated issue is the necessity of maintaining the revascularization of the left arteria subclavia. Recent recommendations by Society for Vascular Surgery recommend continuing to revascularize the left arteria subclavia in planned procedures but leave the surgeon to decide on the perioperative findings in emergencies [5, 77, 78]. In planned interventions of this type it is necessary to perform pre-operatively the arteriography of cerebral arteries including the Willis circuit. It is important to exclude whether the left arteria thoracica interna is used for myocardial revascularization, the absence of the right arteria vertebralis, the carotid stenosis, and the incomplete Willis circuit. The potential for use of the left arteria subclavia in type I endoleak therapy is a fact against the revascularization of this artery during primary surgery. On the other hand, the risk of ischemia with the need for secondary revascularization, type II endoleak and the onset of sudden stroke in hypoperfusion of the left arteria vertebralis [5, 79], is increased in the case of non-vascularization. Hui et al. conclude this by stating that the incidence of sudden stroke is the same in physiological intracerebral circulation, as in the revascularized and occluded left arteria subclavia (4.6% vs 3.6%) [5].

Total Endovascular Approaches and Future Directions

Significant development of endovascular techniques in the abdominal aortic site has also led to the development of methods aimed at the thoracic aorta and the aortic arch. Phenestrated stentgrafts, stentgrafts with branches for supra-aortic branches of the aortic arch are put into practice at the time of this publication. The development of these methods opens the possibility of independent endovascular therapy of aortic arch diseases. However, recent studies still offer only small groups of patients, rather reminiscent of case studies with only short-term follow-up [5, 80, 81]. Further studies will show if this modality offers a new pathway in the treatment of aortic arch diseases.

REFERENCES

[1] Hanneman, K., Newman, B., Chan, F. (2017). Congenital Variants and Anomalies of the Aortic Arch. *Radiographics*, 37: 32-51.

[2] Kligerman, S., Blum, A., Abbara, S. (2009). Persistent fifth aortic arch in a patient with a history of intrauterine thalidomide exposure. *J Cardiovasc Comput Tomogr*, 3: 412-4.

[3] Cohn, L., Adams, D. H. (2017). *Cardiac Surgery in the Adult*. New York City: McGraw-Hill, 1456.

[4] Čihák, R. (2016). *Anatomie* 3. Praha: Grada, 832.

[5] Hui, D. S., Fleischman, F. (2017). Diagnostic and Treatment Dilemmas of the Aortic Arch. *Cardiol Clin*, 35: 347-355.

[6] Kanne, J. P., Godwin, J. D. (2010). Right aortic arch and its variants. *J Cardiovasc Comput Tomogr*, 4: 293-300.
[7] Turkvatan, A., Buyukbayraktar, F. G., Olcer, T., et al. (2009). Congenital anomalies of the aortic arch: evaluation with the use of multidetector computed tomography. *Korean J Radiol*, 10: 176-84.
[8] Yuan, H., Li, Y., He, L., et al. (2019). Right-sided aortic arch and Kommerell diverticulum with aberrant left subclavian artery: Preliminarily diagnosed by echocardiography. *Echocardiography*, 36: 618-20.
[9] Ojha, V., Vadher, A., Chandrashekhara, S. H., et al. (2019). Isolation of left subclavian artery in Tetralogy of Fallot with right aortic arch: A rare association diagnosed on dual source CT. *J Cardiovasc Comput Tomogr*, [Epub ahead of print].
[10] Nair, K. K. M., Ganapathi, S., Inamdar, S., et al. (2018). Incidentally detected right aortic arch with mirror image branching in a patient with rheumatic calcific mitral valve disease. *Natl Med J India*, 31: 22-23.
[11] Olejnik, P., Kunovsky, P., Venczelova, Z., et al. (2018). Right aortic arch with isolated left subclavian artery: a rare association with coarctation of the left pulmonary artery. *Kardiol Pol*, 76: 1113.
[12] Catton, K. G., Setty, S. P. (2018). Anomalous left subclavian artery from the pulmonary artery in a neonate. *Asian Cardiovasc Thorac Ann*, 26: 476-478.
[13] Warrier, D., Shah, S., John, C., et al. (2012). A rare association with patent ductus arteriosus. *Ann Pediatr Cardiol*, 5: 191-3.
[14] Van Praagh, R., Van Praagh, S. (1969). Persistent fifth arterial arch in man. Congenital double-lumen aortic arch. *Am J Cardiol*, 24: 279-82.
[15] Al Akhfash, A. A., Al Mutairi, M. B., Al Habshan, F. M. (2009). Persistent fifth aortic arch diagnosed by echocardiography and confirmed by angiography: Case report and literature review. *J Saudi Heart Assoc*, 21: 245-8.
[16] Tehrai, M., Saidi, B., Goudarzi, M. (2012). Multi-detector computed tomography demonstration of double-lumen aortic arch--persistent fifth arch--as an isolated anomaly in an adult. *Cardiol Young*, 22: 353-5.
[17] Naimo, P. S., Vazquez-Alvarez Mdel, C., d'Udekem, Y., et al. (2016). Double-Lumen Aortic Arch: Persistence of the Fifth Aortic Arch. *Ann Thorac Surg*, 101: e155-6.
[18] Gupta, S. K., Bamforth, S. D., Anderson, R. H. (2015). How frequent is the fifth arch artery? *Cardiol Young*, 25: 628-46.
[19] Gupta, K., Bhuvana, V., Bansal, V., et al. (2018). Absent right superior vena cava and persistent left superior vena cava in a patient with bicuspid aortic valve with aortic stenosis. *Ann Card Anaesth*, 21: 212-214.
[20] Lorandeau, C. G., Hakkinen, L. A., Moore, C. S. (2011). Cardiovascular development and survival during gestation in the Ts65Dn mouse model for Down syndrome. *Anat Rec (Hoboken)*, 294: 93-101.
[21] Geyer, S. H., Weninger, W. J. (2012). Some mice feature 5th pharyngeal arch arteries and double-lumen aortic arch malformations. *Cells Tissues Organs*, 196: 90-8.
[22] Ramirez Alcantara, J., Mendez, M. D. Aortic, Interrupted Arch. *StatPearls*. *Treasure Island* (FL), 2018.
[23] Hayashi, K., Kimura, N., Ohno, M., et al. (2018). Thoracic Endovascular Aortic Repair for Pseudoaneurysm after Interrupted Aortic Arch Repair. *Ann Vasc Dis*, 11: 549-552.

[24] Malec, E., Kleinerueschkamp, F., Januszewska, K. (2019). Aortic atresia with the interrupted aortic arch and an pulmonary-coronary fistula: the unique constellation for survival. *Interact Cardiovasc Thorac Surg*, [Epub ahead of print].

[25] Johnson, P. T., Corl, F. M., Black, J. H., et al. (2011). The elephant trunk procedure for aortic aneurysm repair: an illustrated guide to surgical technique with CT correlation. *AJR Am J Roentgenol*, 197: W1052-9.

[26] Elefteriades, J. A. (2002). Natural history of thoracic aortic aneurysms: indications for surgery, and surgical versus nonsurgical risks. *Ann Thorac Surg*, 74: S1877-80; discussion S1892-8.

[27] Orihashi, K., Sueda, T., Okada, K., et al. (2005). Malposition of selective cerebral perfusion catheter is not a rare event. *Eur J Cardiothorac Surg*, 27: 644-8.

[28] Griepp, E. B., Griepp, R. B. (1992). Cerebral consequences of hypothermic circulatory arrest in adults. *J Card Surg*, 7: 134-55.

[29] Kouchoukos, N. T., Masetti, P., Mauney, M. C., et al. (2008). One-stage repair of extensive chronic aortic dissection using the arch-first technique and bilateral anterior thoracotomy. *Ann Thorac Surg*, 86: 1502-9.

[30] Griepp, R. B., Stinson, E. B., Hollingsworth, J. F., et al. (1975). Prosthetic replacement of the aortic arch. *J Thorac Cardiovasc Surg*, 70: 1051-63.

[31] Chen, E. P., Leshnower, B. G. (2016). Temperature Management for Aortic Arch Surgery. *Semin Cardiothorac Vasc Anesth*, 20: 283-288.

[32] McCullough, J. N., Zhang, N., Reich, D. L., et al. (1999). Cerebral metabolic suppression during hypothermic circulatory arrest in humans. *Ann Thorac Surg*, 67: 1895-9; discussion 1919-21.

[33] Svensson, L. G., Crawford, E. S., Hess, K. R., et al. (1993). Deep hypothermia with circulatory arrest. Determinants of stroke and early mortality in 656 patients. *J Thorac Cardiovasc Surg*, 106: 19-28; discussion 28-31.

[34] Gega, A., Rizzo, J. A., Johnson, M. H., et al. (2007). Straight deep hypothermic arrest: experience in 394 patients supports its effectiveness as a sole means of brain preservation. *Ann Thorac Surg*, 84: 759-66; discussion 766-7.

[35] Mills, N. L., Ochsner, J. L. (1980). Massive air embolism during cardiopulmonary bypass. Causes, prevention, and management. *J Thorac Cardiovasc Surg*, 80: 708-17.

[36] Coselli, J. S., LeMaire, S. A. (1997). Experience with retrograde cerebral perfusion during proximal aortic surgery in 290 patients. *J Card Surg*, 12: 322-5.

[37] Estrera, A. L., Miller, C. C., 3rd, Lee, T. Y., et al. (2008). Ascending and transverse aortic arch repair: the impact of retrograde cerebral perfusion. *Circulation*, 118: S160-6.

[38] De Bakey, M. E., Crawford, E. S., Cooley, D. A., et al. (1957). Successful resection of fusiform aneurysm of aortic arch with replacement by homograft. *Surg Gynecol Obstet*, 105: 657-64.

[39] Halkos, M. E., Kerendi, F., Myung, R., et al. (2009). Selective antegrade cerebral perfusion via right axillary artery cannulation reduces morbidity and mortality after proximal aortic surgery. *J Thorac Cardiovasc Surg*, 138: 1081-9.

[40] Leshnower, B. G., Myung, R. J., Thourani, V. H., et al. (2012). Hemiarch replacement at 28 degrees C: an analysis of mild and moderate hypothermia in 500 patients. *Ann Thorac Surg*, 93: 1910-5; discussion 1915-6.

[41] [41.]Kolesar, A., Bily, B., Spak, L., et al. (2015). "V" aortoplasty of the proximal descending aorta in the elephant trunk procedure. *J Cardiothorac Surg*, 10: 13.

[42] Ye, J., Dai, G., Ryner, L. N., et al. (1999). Unilateral antegrade cerebral perfusion through the right axillary artery provides uniform flow distribution to both hemispheres of the brain: A magnetic resonance and histopathological study in pigs. *Circulation*, 100: II309-15.

[43] Urbanski, P. P., Lenos, A., Blume, J. C., et al. (2008). Does anatomical completeness of the circle of Willis correlate with sufficient cross-perfusion during unilateral cerebral perfusion*? Eur J Cardiothorac Surg*, 33: 402-8.

[44] Rosinski, B. F., Idrees, J. J., Roselli, E. E., et al. (2018). Cannulation strategies in acute type A dissection repair: A systematic axillary artery approach. *J Thorac Cardiovasc Surg*, [Epub ahead of print].

[45] Zierer, A., Risteski, P., El-Sayed Ahmad, A., et al. (2014). The impact of unilateral versus bilateral antegrade cerebral perfusion on surgical outcomes after aortic arch replacement: a propensity-matched analysis. *J Thorac Cardiovasc Surg*, 147: 1212-7; discussion 1217-8.

[46] Leshnower, B. G., Kilgo, P. D., Chen, E. P. (2014). Total arch replacement using moderate hypothermic circulatory arrest and unilateral selective antegrade cerebral perfusion. *J Thorac Cardiovasc Surg*, 147: 1488-92.

[47] Zierer, A., El-Sayed Ahmad, A., Papadopoulos, N., et al. (2012). Selective antegrade cerebral perfusion and mild (28 degrees C-30 degrees C) systemic hypothermic circulatory arrest for aortic arch replacement: results from 1002 patients. *J Thorac Cardiovasc Surg*, 144: 1042-49.

[48] Khaladj, N., Shrestha, M., Meck, S., et al. (2008). Hypothermic circulatory arrest with selective antegrade cerebral perfusion in ascending aortic and aortic arch surgery: a risk factor analysis for adverse outcome in 501 patients. *J Thorac Cardiovasc Surg*, 135: 908-14.

[49] Tsai, J. Y., Pan, W., Lemaire, S. A., et al. (2013). Moderate hypothermia during aortic arch surgery is associated with reduced risk of early mortality. *J Thorac Cardiovasc Surg*, 146: 662-7.

[50] Misfeld, M., Leontyev, S., Borger, M. A., et al. (2012). What is the best strategy for brain protection in patients undergoing aortic arch surgery? A single center experience of 636 patients. *Ann Thorac Surg*, 93: 1502-8.

[51] Usui, A., Miyata, H., Ueda, Y., et al. (2012). Risk-adjusted and case-matched comparative study between antegrade and retrograde cerebral perfusion during aortic arch surgery: based on the Japan Adult Cardiovascular Surgery Database : the Japan Cardiovascular Surgery Database Organization. *Gen Thorac Cardiovasc Surg*, 60: 132-9.

[52] Barnard, J., Dunning, J., Grossebner, M., et al. (2004). In aortic arch surgery is there any benefit in using antegrade cerebral perfusion or retrograde cerebral perfusion as an adjunct to hypothermic circulatory arrest? *Interact Cardiovasc Thorac Su*rg, 3: 621-30.

[53] Safi, H. J., Miller, C. C., 3rd, Estrera, A. L., et al. (2001). Staged repair of extensive aortic aneurysms: morbidity and mortality in the elephant trunk technique. *Circulation*, 104: 2938-42.

[54] Schepens, M. A., Dossche, K. M., Morshuis, W. J., et al. (2002). The elephant trunk technique: operative results in 100 consecutive patients. *Eur J Cardiothorac Surg*, 21: 276-81.

[55] Coselli, J. S., Buket, S., Djukanovic, B. (1995). Aortic arch operation: current treatment and results. *Ann Thorac Surg*, 59: 19-26; discussion 26-7.

[56] LeMaire, S. A., Price, M. D., Parenti, J. L., et al. (2011). Early outcomes after aortic arch replacement by using the Y-graft technique. *Ann Thorac Surg*, 91: 700-7; discussion 707-8.

[57] Kazui, T., Washiyama, N., Muhammad, B. A., et al. (2001). Improved results of atherosclerotic arch aneurysm operations with a refined technique. *J Thorac Cardiovasc Surg*, 121: 491-9.

[58] Anagnostopoulos, C. E., Prabhakar, M. J., Kittle, C. F. (1972). Aortic dissections and dissecting aneurysms. *Am J Cardiol*, 30: 263-73.

[59] Wheat, M. W., Jr., Palmer, R. F., Bartley, T. D., et al. (1965). Treatment of Dissecting Aneurysms of the Aorta without Surgery. *J Thorac Cardiovasc Surg*, 50: 364-73.

[60] Scholl, F. G., Coady, M. A., Davies, R., et al. (1999). Interval or permanent nonoperative management of acute type A aortic dissection. *Arch Surg*, 134: 402-5; discussion 405-6.

[61] Strauch, J. T., Spielvogel, D., Lansman, S. L., et al. (2005). Long-term integrity of teflon felt-supported suture lines in aortic surgery. *Ann Thorac Surg*, 79: 796-800.

[62] Heinemann, M. K., Buehner, B., Jurmann, M. J., et al. (1995). Use of the "elephant trunk technique" in aortic surgery. *Ann Thorac Surg*, 60: 2-6; discussion 7.

[63] Safi, H. J., Miller, C. C., 3rd, Estrera, A. L., et al. (2004). Staged repair of extensive aortic aneurysms: long-term experience with the elephant trunk technique. *Ann Surg*, 240: 677-84; discussion 684-5.

[64] LeMaire, S. A., Carter, S. A., Coselli, J. S. (2006). The elephant trunk technique for staged repair of complex aneurysms of the entire thoracic aorta. *Ann Thorac Surg*, 81: 1561-9; discussion 1569.

[65] Kolesar, A., Toporcer, T., Bajmoczi, M., et al. (2018). Aortic Valve Repair of a Stenotic Unicuspid Aortic Valve in Young Patients. *Ann Thorac Surg*, 105: 1351-1356.

[66] Czerny, M., Weigang, E., Sodeck, G., et al. (2012). Targeting landing zone 0 by total arch rerouting and TEVAR: midterm results of a transcontinental registry. *Ann Thorac Surg*, 94: 84-9.

[67] Vallabhajosyula, P., Szeto, W., Desai, N., et al. (2013). Type I and Type II hybrid aortic arch replacement: postoperative and mid-term outcome analysis. *Ann Cardiothorac Surg*, 2: 280-7.

[68] Geisbusch, P., Kotelis, D., Muller-Eschner, M., et al. (2011). Complications after aortic arch hybrid repair. *J Vasc Surg*, 53: 935-41.

[69] Preventza, O., Aftab, M., Coselli, J. S. (2013). Hybrid techniques for complex aortic arch surgery. *Tex Heart Inst J*, 40: 568-71.

[70] Hughes, G. C., Daneshmand, M. A., Balsara, K. R., et al. (2009). "Hybrid" repair of aneurysms of the transverse aortic arch: midterm results. *Ann Thorac Surg*, 88: 1882-7; discussion 1887-8.

[71] Ferrero, E., Ferri, M., Viazzo, A., et al. (2012). Is total debranching a safe procedure for extensive aortic-arch disease? A single experience of 27 cases. *Eur J Cardiothorac Surg*, 41: 177-82.

[72] Bavaria, J., Milewski, R. K., Baker, J., et al. (2010). Classic hybrid evolving approach to distal arch aneurysms: toward the zone zero solution. *J Thorac Cardiovasc Surg*, 140: S77-80; discussion S86-91.

[73] Preventza, O., Garcia, A., Cooley, D. A., et al. (2015). Total aortic arch replacement: A comparative study of zone 0 hybrid arch exclusion versus traditional open repair. *J Thorac Cardiovasc Surg*, 150: 1591-8; discussion 1598-600.

[74] Tokuda, Y., Oshima, H., Narita, Y., et al. (2016). Hybrid versus open repair of aortic arch aneurysms: comparison of postoperative and mid-term outcomes with a propensity score-matching analysis. *Eur J Cardiothorac Surg*, 49: 149-56.

[75] Chakos, A., Jbara, D., Yan, T. D., et al. (2018). Long-term survival and related outcomes for hybrid versus traditional arch repair-a meta-analysis. *Ann Cardiothorac Surg*, 7: 319-327.

[76] Simek, M., Hajek, R., Kalab, M., et al. (2018). Strategies preventing deep sternal wound infection in cardiac surgery review. *Rozhl Chir*, 97: 414-418.

[77] Hajibandeh, S., Hajibandeh, S., Antoniou, S. A., et al. (2016). Meta-analysis of Left Subclavian Artery Coverage With and Without Revascularization in Thoracic Endovascular Aortic Repair. *J Endovasc Ther*, 23: 634-41.

[78] Matsumura, J. S., Lee, W. A., Mitchell, R. S., et al. (2009). The Society for Vascular Surgery Practice Guidelines: management of the left subclavian artery with thoracic endovascular aortic repair. *J Vasc Surg*, 50: 1155-8.

[79] Peterson, M. D., Wheatley, G. H., 3rd, Kpodonu, J., et al. (2008). Treatment of type II endoleaks associated with left subclavian artery coverage during thoracic aortic stent grafting. *J Thorac Cardiovasc Surg*, 136: 1193-9.

[80] Yap, H. Y., Chong, T. T., Tay, H. L., et al. (2019). Fenestrated Endovascular Repair of Zones 1 and 2 Aortic Arch Pathologies. *Ann Vasc Surg*, 54: 145 e1-145 e9.

[81] Soliman, H., El-Ganainy, M. N., Darweesh, R. M., et al. (2018). Short term outcome of thoracic endovascular aortic repair in patients with thoracic aortic diseases. *Egypt Heart J*, 70: 89-94.

In: Encyclopedia of Surgery (22 Volume Set)
Editors: Andreas Lehrer and Kristin Mueller
ISBN: 978-1-53618-329-0
© 2020 Nova Science Publishers, Inc.

Chapter 286

DESCENDING AND THORACOABDOMINAL AORTA

Tomáš Toporcer*[*]*, MD, PhD
Department of Heart Surgery of East Slovak Institute of Cardiovascular Diseases,
Pavol Jozef Safarik University, Kosice, Slovakia

ABSTRACT

After the anatomical summarizing, the first part of the chapter deals mainly with congenital developmental defects of the descending aorta, including mainly various forms of right-sided aortic arch, but also patent ductus arteriosus and aortic coarctation. The next part of the text summarizes the current knowledge of aneurysm and dissection of the descending aorta. The third part is then focused on surgical procedures in this part of the aorta, including various forms of lower half of body perfusion during surgery. In the end, attention is drawn to the traumatic lesions of the descending aorta.

Keywords: descending aorta, aortic aneurysm, aortic dissection, descending aorta injury

ANATOMY OF THE DESCENDING AORTA

The descending thoracic aorta begins distal to the left arteria subclavia spacing at the level of the third to fourth thoracic vertebra and ends at the level of the twelfth rib where it passes through the hiatus aorticus diaphragm [1]. In the cranial course, it touches the chest vertebrae from the front left. More caudally, it gets to the medial plane. In front of the aorta is the esophagus and the heart. To the left of the aorta is the vena hemiazygos, to the right the vena azygos. The ductus thoracicus protrudes between the aorta and the esophagus and the parietal pleura touches it bilaterally from the lateral side. Branches of this part of the aorta include arteriae intercostales posteriores and arteria phrenica superior, as parietal branches. Further are rami bronchiales, rami oesophagei, rami pericardiaci and rami mediastinales, as visceral branches [2]. The Adamkiewicz artery (ramus spinalis aortae) is another clinically

[*] Corresponding Author's Email: topyto@gmail.com.

important branch of the descending thoracic aorta and it is the main branch for spinal perfusion in this locality. There is significant variability at it, either from intercostal arteries at the level of the 9th to the 11th intercostal space, or directly from the aorta [1].

The descending abdominal aorta is a continuation of the thoracic part, beginning with the passage of the aorta through the diaphragm and ending at the level of the fourth lumbar vertebra by bifurcation on the arteriae iliacae communes. The entire abdominal aorta lies retroperitoneally. On the right of the aorta is the vena cava inferior and, on both sides, we find lumbar lymph nodes. In this course, the aorta gives off the arteria phrenica inferior and arterie lumbales as parietal branches. As the visceral branches are then paired the arterial suprarenales mediae, arteriae renales and arteriae testiculares or ovaricae and unpaired the truncus coeliacus, arteria mesenterica superior and arteria mesenterica inferior [2].

CONGENITAL MALFORMATIONS

The most common congenital malformations and descending aortic developmental disorders include the anomalous separation of the right arteria subclavia - with or without diverticulum of Kommerell, bilateral ductus arteriosus, coarctation and pseudocoarctation of the descending aorta. All these malformations are related to embryogenic disorders [3].

Left Aortic Arch with Aberrant Right Subclavian Artery

The left aortic arch with aberrant right subclavian artery is the most common congenital developmental disorder of the thoracic aorta with an incidence of 0.5% - 2% [3, 4]. The anomaly arises from the regression of the right-sided arch between the right arteria carotis communis and the right subclavian artery. Thus, the right posterior aorta forms the definitive retro-esophageal portion of the right subclavian artery. The aberrant right subclavian artery is thus the most distal large branch of the thoracic aorta with typical retroesophageal course to the right cranially. The anomaly is typically isolated, less frequently it can be associated with aortic coarctation, patent ductus arteriosus, ventricular septal defect, or vertebral artery anomalies. In Down syndrome patients it is present in up to one-third of patients. Typically, the malformation is asymptomatic, without necessity of intervention, only about in 10% it can cause esophageal suppression with a typical symptom of dysphagia lusoria [3, 4].

Left Aortic Arch with Diverticulum of Kommerell

The diverticulum of Kommerell is the descending aortic aneurysm at the site of separation of aberrant subclavian artery (Figure 1). It is the remnant of the right-sided posterior primitive aorta. This rare diagnosis was first described by Kommerell in 1936, in a case report of a patient with left-sided aortic arch and diverticulum in the proximal course of the descending aorta [5]. Despite the specific first description, the name Kommerell diverticulum is now used for the descending aortic aneurysm, from which separates the aberrant subclavian artery, either at the left or at the right aortic arch. At the incidence of

aberrant subclavian artery in 0.8% to 2% of the population and the fact that the diverticulum of Kommerell is present in 20% to 60% of these separations, a total incidence in more than 0.5% of the population can be expected [6-10].

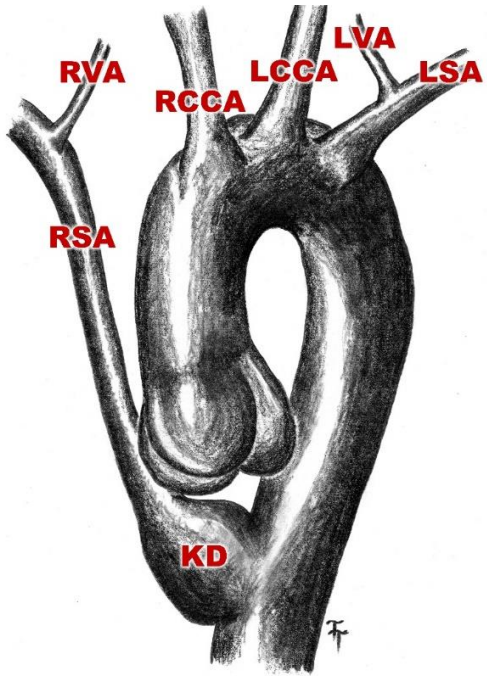

Figure 1. Kommerell diverticulum with aberrant right subclavian artery (LCCA – left common carotid artery; LSA – left subclavian artery; LVA – left vertebral artery; KD – diverticulum of Kommerell; RCCA – right common carotid artery; RSA – right subclavian artery; RVA – right vertebral artery).

The fact remains that only 5% of patients with diverticulum of Kommerell report symptomatology caused by the suppression of surrounding anatomical structures. This symptomatology represents a wide range of symptoms that can be manifested in different age groups. Very early childhood symptomatology is caused by the esophageal and tracheal suppression, which is due to the vascular ring rather than the diverticulum itself. In late childhood or adult symptomatology, symptoms are most commonly caused by diverticulum dilatation. On the other hand, diverticulum wall dissection or spontaneous rupture occurs in 19% to 44% of cases. The papers suggest that the degeneration of diverticulum wall media leads to its dilatation and surgical intervention should be indicated at its growth [5, 11]. Ikeno et al. recommend surgical intervention in asymptomatic patients already at diverticulum of 50mm [5]. On the other hand, there are currently no clear indication criteria and recommended procedures for the therapy of this nozological unit [5].

Several options are currently described when indicating an operation. In childhood, many authors use the possibility of diverticulum exclusion without reconstructing the subclavian artery, which is very well tolerated in childhood. On the other hand, such performance in adult patients must be considered as suboptimal and not recommended [5]. In adult patients, some authors prefer to replace a portion of the descending aorta by sewing the aberrant subclavian artery at this site [5]. Other authors prefer to replace the descending aorta and to bridge the subclavian artery with bypass [12]. Thus, revascularization can be performed in

situ, or by connecting the arteria subclavia with the ipsilateral arteria carotis communis [10, 12]. In situ restoration brings two advantages - a complex one-step solution and avoidance of bypass surgery on the neck with the risk of sudden vascular accident and laryngeus reccurens nerve and phrenicus nerve injury. Further, we cannot omit to mention the risk of later bypass thrombosis. The disadvantage of in situ reconstruction is then the length of the formed subclavian artery [13]. Nevertheless, it is favored by most authors [5]. Other authors prefer as indicated performance the replacement of the entire aortic arch and part of the descending aorta [14]. The development of endovascular medicine has also been successful in the treatment of this anatomical modality [15]. In view of the many alternatives and confusion in the recommendations for the treatment of diverticulum of Kommerell, we can conclude that there is no ideal therapeutic approach, and each operating variant carries specific risks.

The results of the operation are relatively satisfactory, both after in-situ reconstruction of the subclavian artery and after the extraanatomical solution. Tanaka et al. reported an early mortality rate of only 11% for an almost 95% acute performances [10]. In endovascular intervention, the 1-year mortality rate is 2.6% [10]. Although some authors condemn this method because of the absence of aneurysm volume reduction and endoleak risk, which does not ensure the withdrawal of symptomatology, which is mainly due to the suppression of surrounding structures, long-term results are not available at the time of this publication.

Patent Ductus Arteriosus

The patent ductus arteriosus is the persistence of the open link between the aorta and the pulmonary truncus. Ductus is required for intrauterine fetal circulation and should be spontaneously closed on days 2 to 3 after birth. Its persistence leads to overload of pulmonary circulation on the one hand and systemic hypoperfusion on the other. The major risk factors for this congenital malformation are delivery before gestational week 28, excessive infusion therapy, respiratory insufficiency, sepsis, phototherapy, and application of furosemide [16, 17]. On the other hand, the open ductus arteriosus leads to bronchopulmonary dysplasia, necrotizing enterocolitis, renal insufficiency, diastolic heart failure, lagging neurological development and retinopathy in the neonate. It may also be a direct cause of neonatal mortality [16, 18]. In the field of severe pulmonary hypertension, or other complex congenital heart defects, the persistent ductus arteriosus allows the maintenance of systemic circulation by a short circuit from the truncus pulmonalis to the aorta. On the other hand, in its isolated occurrence, the short circuit is the opposite thus overloading the pulmonary circulation [16]. Prior to the echocardiography era, diagnosis of the patent ductus arteriosus was based on the presence of cardiomegaly in the x-ray image, edema of the lung and murmur. The first surgical therapy for this defect was made in 1938. In 1972, Elliot and Starling first pointed out the role of prostaglandin in the development of this defect. Since 1976, chloroquine has been used as a prostaglandin antagonist and since 1977 indomethacin [16].

Whether a child is born in time or prematurely, closure of the ductus arteriosus may be delayed or fail completely. However, the risk at premature births increases significantly. The persistent ductus arteriosus can be defined as pathological after the third day after delivery [16, 17]. The persistence of the open ductus arteriosus immediately after delivery in the absence of other congenital developmental disorders will cause reversion of the flow from the aorta to the pulmonary truncus. Thus, the pulmonary circulation is temporarily volume

overloaded and the systemic circulation is hypovolemic, which is called "ductal steal". During intrauterine development, the ductus arteriosus remains open due to prostaglandin receptors. On the one hand, the expression of receptors for these substances is higher at this stage of development, and their systemic circulation is higher [19, 20]. Oxygen acts on the ductus arteriosus as a constrictor. Hemodynamically, the ductus arteriosus is also variable. The shorter length of the ductus arteriosus leads to its higher flow. This is also increased by the higher systemic vascular resistance and, on the other hand, by the decrease in pulmonary resistance. Further, the flow is increased by prostaglandins and lower blood viscosity [16].

Late diagnosis of persistent ductus arteriosus has significant clinical consequences and therefore the significance of this shortening must be properly diagnosed. The most common symptomatology includes cardiovascular, renal, respiratory and gastrointestinal consequences of this congenital malformation. The most characteristic cardiovascular symptoms include wide pulse wave, hypertension, and audible murmur. The turbulent flow of blood in the ductus arteriosus produces a typical murmur for this diagnosis. In addition, the volume overload of the pulmonary artery also overloads the left compartments of the heart. The decrease in systemic perfusion is particularly marked during diastole, which significantly affects the myocardium, due to its dependence on circulation during this phase of heart rhythm [21]. Further, circulatory changes by hypoperfusion manifest themselves on the kidneys by fluid retention, metabolic acidosis, and oliguria. Laboratory parameters suggest hyponatremia and elevated creatinine concentrations. Ultrasound examination can confirm the zero and even reverse flow of the renal arteries in diastole [16]. Hypoperfusion activates the renin-angiotensin-aldosterone pathway with subsequent reuptake of sodium and water. Supranormal pulmonary circulation with volume overload results in pulmonary edema, the need for assisted ventilation, pulmonary bleeding, and bronchopulmonary dysplasia [16, 17]. Volume overload reduces pulmonary resistance, which in turn increases the volume of blood flowing through the ductus arteriosus. Surfactant deficiency in premature infants only increases the risk of pulmonary edema [16]. Systemic hypotension and reverse flow during diastole also cause gastrointestinal hypoperfusion.

Suspicion of patent ductus arteriosus can be assumed in the accumulation of several symptoms, including clinical status, laboratory parameters and specific X-ray findings. However, echocardiography is necessary to unequivocally confirm or disprove the diagnosis itself. The newborn is characterized by the presence of dyspnea, a wide pulse, hypertension, malnutrition and rejection of food intake and, last but not least, a holosystolic murmur. Laboratory examination points to acidosis and elevation of inflammatory markers, especially C-reactive protein [19]. Subsequently, there is an elevation of the B-type natriuretic peptide and troponin T. The X-ray of the chest documents cardiomegaly and pulmonary congestion. However, a similar set of traits may also be present in neonates with other congenital developmental defects. Echocardio-graphy is the gold standard in screening methods for both anatomy and pathophysiology of persistent ductus arteriosus. Thus, we have available parameters such as diameter of ductus arteriosus and its hemodynamics, as well as hemodynamic parameters of the left atrium and ventricle, as well as peripheral circulation, especially in the renal artery. The diameter of ductus arteriosus greater than 1.5 mm measured at the first 31 hours after delivery in neonates born before 29th week is the best early predictor of the patent ductus arteriosus with a sensitivity of 83% and a specificity of 90% [22]. Other evaluated parameters are the flow through the ductus arteriosus, the size of the left atrium, filling left atrial pressures, and the presence of reverse flow in the middle cerebral or

upper mesenteric artery [23]. An important marker is the pulsatile flow through the ductus arteriosus, which demonstrates the high quantity of short circuit and balancing the pressures in aorta and pulmonary truncus at the end of the diastole. The high filling pressures of the left atrium also confirm the volume overload of both the pulmonary circulation and the left heart components. The absence of end-diastolic flow or the presence of reverse flow in the middle cerebral or upper mesenteric artery already document a negative effect on peripheral circulation [16, 23].

Therapy of patent ductus arteriosus leads to its closure or minimization of effects on circulation. The therapy is divided into conservative, pharmacological, surgical and endovascular. Conservative therapy involves reducing left ventricular preload and improving gas exchange in the overloaded pulmonary bed. Furosemide, on the one hand, optimizes circulation, on the other hand, negatively affects the physiological closure of the duct, while its application leads to elevation of prostaglandin concentrations with an additional adverse effect. An invasive or non-invasive respiratory regimen with a positive end-expiratory pressure of 5 cm water column is suitable. Respiration optimization also has a protective effect on the left ventricle of the heart. Another point is an increase in hematocrit over 35% to 40% in order to increase blood viscosity and reduce flow through the ductus arteriosus [24]. Pharmacotherapy has been a key point in the therapy of its patency since the discovery of the role of prostaglandin in maintaining the ductus arteriosus. Prostaglandin inhibitors lead to natural ductus arteriosus constriction. Mainly non-selective inhibitors including indomethacin, ibuprofen and acetaminophen are used. Important is the management of other drugs and their interactions, in particular the association with gentamicin due to nephrotoxicity and glucocorticoids due to the risk of perforation of gastrointestinal tract [16, 25]. Failure of pharmacotherapy is an indication of surgical or endovascular intervention [16]. The oldest therapy for the patent ductus arteriosus is surgical ligation. The surgery is performed via the left-sided thoracotomy with the application of a vascular clip. A change in hemodynamic ratios leads to immediate changes in circulation hemodynamics, yet it is burdened by a wide range of complications including bronchopulmonary dysplasia, chylothorax and cardiopulmonary failure [16, 17, 19]. Intervention literature does not indicate any contraindications. The method of transvenous occlusion of the ductus arteriosus is currently being introduced [26]. A paper presenting percutaneous intervention in neonates weighing less than 2 kilograms is published. The paper presents earlier pulmonary rehabilitation after percutaneous intervention compared to a surgical open approach [27]. Dislocation of the device to the pulmonary bed is reported as a possible complication.

The last question remains the correct timing of therapy and possible intervention in these patients. In general, treatment should be initiated within 12 hours of delivery or at the first signs of hemodynamic instability. Prophylactic therapy with indomethacin should be indicated within 12 hours of delivery at preterm labor or very low birth weight. Studies show that timely application of indomethacin reduces the risk of intracerebral bleeding and the need for surgical intervention for patent ductus arteriosus [16, 17, 19]. On the other hand, indomethacin does not reduce the incidence of chronic pulmonary disease or neurological outcomes [28]. Conrad et al. in their review work state, that the prophylactic application of indomethacin is not indicated [16]. However, early screening of the patent ductus arteriosus is recommended so that a possible targeted therapy can be initiated even before the first clinical manifestation of the hemodynamic consequences of the short circuit. Early therapy leads to both a reduction in the incidence of complications and a generally higher success rate of

pharmacological treatment itself and a reduction in the need for surgical intervention [29]. Recent studies have documented a decrease in the frequency of indications for both pharmacological and interventional therapies, leading to a gradual tightening of their indication criteria [30, 31].

Aortic Coarctation

Aortic coarctation represents 5 to 8% of all congenital heart defects and affects about 0.4% of live births (Figure 2) [32]. It may occur on its own but is often associated with other congenital heart developmental disorders. In half of the cases it is associated with developmental aortic valve defects, most commonly with bicuspid aortic valve. Other common comorbidities include aortic arch hypoplasia, subaortic stenosis, mitral valve abnormalities, patent ductus arteriosus, and inter-chamber and inter-atrial septal defects [33-35]. Coarctation is defined as the sequential narrowing of the aortic lumen, caused by the thickening of the medial layer of the aortic wall [33, 36]. Its occurrence is also associated with aortic arteriopathy, especially near coarctation itself. It is localized most often on the opposite side of the aorta to the ductus arteriosus entry site but it may be located also above or below this level [33, 35]. Etiopathogenesis has not been definitively elucidated, and there are currently three theories of the origin of this congenital developmental defect pointing to three different time windows of its origin. Some authors point to abnormal embryonic development. Another group of authors presents a reduced intrauterine flow through this area of the aorta followed by regression. Finally, it is the excess tissue of the ductus arteriosus found in the wall of the descending aorta, which causes its narrowing early in the postnatal period [37]. Further multiple genetic mutations and syndromes are associated with aortic coarctation. First, it is Turner syndrome, then DiGeorg syndrome and Noonan's syndrome [33].

Figure 2. Aortic coarctation with most commonly localization and ductus arteriosus.

Prenatal diagnostics reduces early postnatal morbidity and mortality and reduces the costly and risky transfer of newborns to cardio centers with the possibility of preparing a pregnant woman. Prenatal ultrasound screening is the underlying diagnostic method for these diseases. Prenatal heart diagnosis should include four ultrasound sections of the heart, a three-chamber, four-chamber view, and an examination of left and right ventricular outflow tract [38]. However, we must say that despite the rapid progress in this diagnostic method, prenatal diagnosis of aortic coarctation is complicated. Therefore, many scoring systems are being used to at least partially objectify this diagnosis. Here we include the z-score of the aortic arch, isthmus/ductal score and score of pulmonary artery/aorta [33].

Despite prenatal diagnostics, the number of patients diagnosed is also early postnatal. Upon closure of the ductus arteriosus, aortic obstruction occurs with hypoperfusion of the lower body, including the kidneys. Abdominal hypoperfusion leads to metabolic disruption. In addition, congestion of the left heart can lead to its failure. Non-closure of the ductus arteriosus may partially supplement blood flow to the lower half of the body and ease symptomatology [33, 36]. Classical aortic coarctation symptomatology includes delayed, attenuated, or completely absent pulsation to the femoral artery, differential pressure in the upper and lower extremities greater than 20mmHg, and systolic murmur [33]. Comorbidity in the sense of aberrant subclavian artery or aortic arch hypoplasia may cause uneven pressures on the right and the left upper extremities and disturb the diagnosis of coarctation when comparing pressures on the specific upper and lower extremities. Aberrant subclavian artery is present in about 3 to 4% of aortic coarctation patients [39]. Newborns with symptomatic coarctation are indicated for the administration of prostaglandin E1 in order not to close the ductus arteriosus and to reduce symptomatology to the time of surgery. In the case of subclinical symptomatology, only patient monitoring is indicated. Surgery or intervention should be indicated early in order to prevent left ventricular hypertrophy due to increased afterload and subsequent heart failure [40, 41]. In late diagnosis, hypertension, intracranial aneurysms with risk of bleeding, left ventricular hypertrophy with congestive heart failure and suprastenotic dilatation of the aorta occur [35, 37].

Although X-ray is not the first-choice diagnostic method, the visible shadow of the pre-stenosis or post-stenosis aortic dilatation and the fourth-rib shadowing caused by the dilatation of the intercostal artery as collateral circulation may lead to considering the diagnosis of coarctation [35]. Ultrasonography has a much greater value in diagnosis with the possibility of a more accurate representation of the stenotic part of the aorta as well as the quantification of pressure gradients [33, 35]. Due to the location, transesophageal examination is even more accurate. Ultrasonography may also indicate possible comorbidities and left ventricular status [33]. Computed tomography provides advantageous morphological assessment of both the stenosis itself and the surrounding structures. However, the radiation burden largely limits repeated monitoring, especially of pediatric patients. Other negatives are the nephrotoxic effect of the contrast agent, as well as the inability to dynamically evaluate the pressure ratios. The elimination of radiation exposure thus prefers the use of magnetic resonance, especially when it comes to repeating the examination in patient monitoring. The use of gadolinium further enhances both the aortic and the collateral circulation imaging [42]. Contrast medium flow analysis may further evaluate stenosis pressure gradients and collateral circulation [42, 43]. Newer magnetic resonance methods also allow quantification of aortic wall stress and recalculation of collateral circulation capacity [44]. However, the examination needs to eliminate patient movement, which is very limited in children. On the other hand,

modern examinations include invasive catheter angiography, as the gold standard for aortic coarctation, allowing accurate representation of both the stenosis itself and the collateral circulation [35].

The non-treatment of hemodynamically significant coarctation leads to significant shortening of life by complications such as: congestive heart failure, endocarditis, aortic rupture, or stroke [33, 35]. In particular, the severity of stenosis and the presence of other congenital co-morbidities affect survival itself. Even in the absence of pressure differences between the upper and the lower half of the body caused by the developed collateral circulation, hemodynamically significant coarctation is indicated for surgical correction [33]. The aim of the correction is to reduce the aortic gradient and reduce hypertension. Proper timing of intervention is critical. Early intervention carries the risk of restenosis with the necessary reintervention, while later surgery the risk of developing hypertension and developing aneurysms [33, 36].

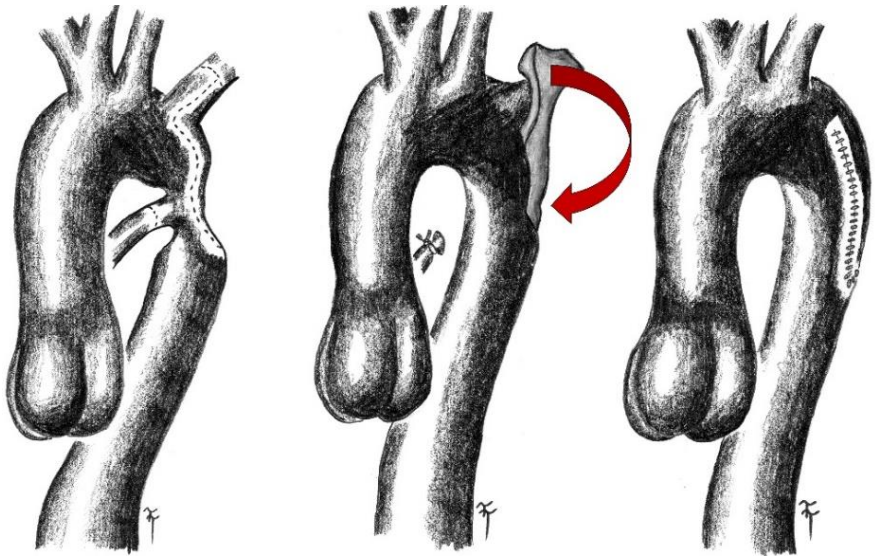

Figure 3. Subclavian- flap aortoplasty of artic coarctation.

In neonates and young children, surgical intervention is the method of choice. Child age and anatomical conditions lead to the choice of one of several applicable surgical procedures. For mild stenosis, the preferred option is end-to-end anastomosis resection with approach from left thoracotomy [45]. In older children with prolonged stenosis, the most popular method is aortoplasty with a patch from the subclavian artery, but it brings with itself a higher risk of restenosis (Figure 3) [37]. In adults, when it is not necessary to think about the further growth of an individual, the first-choice method is resection with implantation of interposition [37]. Extraanatomic bypass is the method of choice in adults with a large network of collateral circulation. In the perioperative period, the patient is particularly at risk of paradoxical hypertension, complications of laryngeus recurrens nerve injury and subclaval steal phenomenon. Rare, but described, is a spinal cord injury with paraplegia [33, 37, 46].

Balloon angioplasty, as another therapy option, can be done in three to six-month old toddlers. Earlier intervention is not possible for the still active ductus arteriosus tissue. In general, it is a palliative technique in high-risk patients which is able to delay the definitive

solution after stabilizing the condition and improving the patient's fitness [33]. Dilation causes multiple ruptures of the intimal aortic layer followed by wall rearrangement, which on the one hand delays the risk of restenosis, but on the other hand increases the risk of wall dissection and rupture [39]. The risk of restenosis after this performance increases with decreasing age at the time of intervention. Stent implantation after dilatation increases the long-term stability of this therapy, reduces the risk of restenosis as well as aneurysm formation. The method is preferred in adults. Its application in children brings about the necessity of redilatation at the aortic growth as well as more frequent restenosis in intima hypertrophy. The future offers growing and biodegradable stents, but they do not yet have long-term results [33].

Therapy results are controversial. A quarter of patients undergo cardiovascular intervention [47]. Recoarctation is found in 4-14% of patients. The higher incidence is in patients less than one year old [33]. Further, reinterventions are needed more frequently after balloon angioplasty with or without stent implantation compared to surgical intervention. Due to the high coincidence of coarctation and bicuspid aortic valve, aortic regurgitation or stenosis in hemodynamic borderline recoarctation is a frequent indication for surgery [33, 34]. Further, the aortic wall prior to coarctation exhibits reduced levels of smooth muscle cells and increased collagen levels, which affects local hemodynamics and increases the incidence of prestenotic dilatation. The incidence of aneurysm is 13% in patients after correction of coarctation, with a higher proportion of patients with plasty by help of patch [47]. Hypertension as an additional complication has an incidence of 35-68%, with a higher proportion of patients who have undergone coarctation correction at a later age. The exact etiology of hypertension formation after correction of coarctation is unclear and the hypotheses point to abnormal baroreceptor function, specific aortic arch geometry, persistent subclinical stenosis at the coarctation site, and renin-angiotensin-aldosterone system disorder [33]. Left ventricular hypertrophy at the time of coarctation may lead to late myocardial fibrosis with subsequent heart failure. In particular, the subendocardial fibrosis present demonstrates insufficient flow through the coronary artery with insufficient diastolic perfusion. The risk of ventricular failure with later coarctation intervention increases [33, 36].

Pseudocoarctation

Pseudocarcation is a much more rare diagnosis than coarctation. It is characterized by a kind of cranking of the descending aorta at the site of the ductus arteriosus. Unlike coarctation, neither the pressure gradient nor the collateral circulation is present. The embryological nature is the pathological fusion of the dorsal aorta and the fourth primitive aortic arch. The result is a pathological extension of the descending aorta. The unit is mostly asymptomatic without the need for correction performance. An indication for surgery is then rare symptomatology or aortic aneurysm formation in this site. The etiology of aneurysm formation in this diagnosis is the turbulent blood flow in the elongated aorta [4, 33].

Aneurysm of Descending Aorta

Aneurysm of the descending aorta represents aortic affection distal to the left subclavian artery. If the disease is limited cranially from the diaphragm, we call it the descending

thoracic aortic aneurysm (DTAA). If the disease crosses the diaphragm and affects also the abdominal aorta, we call it thoracoabdominal aortic aneurysm (TAAA). The view of the etiological agent of this diagnosis has changed. In the early twentieth century, the disease was most often the result of tertiary syphilis. Later and up to now, the etiology of aneurysm development has been due to aortic wall media degeneration, discussed in a later chapter, atherosclerosis, connective tissue disease, aortitis, coarctation, infection and trauma [48].

At the time of diagnosis, the majority of patients are asymptomatic, and the diagnosis is determined as a random imaging finding. Up to almost 50% of patients with this diagnosis may be asymptomatic, with symptomatology triggered by a process of aortic wall rupture or dissection [49]. Of the 57% of symptomatic patients, rupture is symptomatic in up to 9%. The most typical symptom is back pain between the shoulder blades. In the case of dilatation of the part of the aorta crossing the diaphragm, the disease may appear as an abdominal pain in the epigastrium. Less typical symptomatology resulting from the suppression of surrounding structures is hoarseness, cough, hemoptysis, dysphagia, and gastrointestinal obstruction or bleeding [48]. The more severe symptomatology then comes from the suppression of the vagus nerve and the laryngeus reccurens nerve. The mycotic form is often associated with erosion of adjacent vertebrae. Computerized tomography and magnetic resonance imaging are recommended as the first-choice imaging method for suspected diagnosis. The addition of contrast medium to examination may also reveal the presence of intraluminal thrombus, dissection, intramural hematoma, retroperitoneal hematoma, rupture and periaortal fibrosis, indicating inflammatory etiology of the disease [48]. Today, rarely used aortography is used as a method of choice.

In asymptomatic patients, the anatomical dimensions of the aorta are indicative of therapy. An aortic diameter of more than 5 to 6 cm, or an increase in diameter of more than 1 cm per year, presents a risk of rupture with indication of elective surgery [48]. In patients with connective tissue disease, such as Marfan syndrome, the aneurysm is indicated for surgery at earlier stages, i.e., with a smaller anatomical diameter. If the anatomical condition of the indication of surgery is not met, strict conservative therapy of hypertension and control at least once a year is indicated. In the case of symptomatic patients, it is not essential to fulfill the anatomical indication. As therapy, both endovascular percutaneous intervention and open surgery are contemplated.

In selecting endovascular or surgical therapy, it is the most important to evaluate the anatomical characteristics of aneurysm and physiological reserve of the patient [50]. The open surgical method shows good results and benefits in the long run, but it is more burdensome for the patient. Endovascular therapy is an alternative, especially for patients with cardiac and renal comorbidities, as well as patients after surgery at this site, or at very old age. The endovascular method compared to surgery is characterized by lower periprocedural morbidity and mortality [51-53]. On the other hand, a narrow landing zone, excessive aneurysm angulation, significant intraluminal thrombus, or significant calcification of the aneurysm wall significantly disadvantage and endanger the successful outcome of endovascular intervention. As a method of choice in at-risk patients with a narrow landing zone, hybrid performance is appropriate, when debranching of the aortic arch creates enough room for subsequent endovascular intervention [54]. Other methods such as elephant trunk are listed in the chapter on aortic arch. In case of caudal progression of the disease, the possibility of debranching the abdominal visceral branches of the aorta is also possible [55-57].

Current View of Etiology of Thoracic Aortic Aneurysm

Hypertension is the most important risk factor for thoracic aortic disease [58-60]. All factors that increase the pulsatile tension of the aortic wall then also act as risk factors for these diseases. Genetic predisposition is the second most important risk factor. In 20% of patients diagnosed with thoracic aortic aneurysm, a genetic mutation related to this disease has been proved [60, 61]. Renard et al. identify more than 15 genes whose mutation can affect the risk of aneurysmal aortic wall changes [62]. A bicuspid aortic valve is the most associated with these diseases from congenital heart abnormalities. Further, an association with a higher age and a higher incidence in men are known [60]. On the other hand, some studies document diabetes mellitus as a protective risk factor [63-65]. Further, a large proportion of patients with a positive family history and proven disease has no established etiological genetic predisposition [61]. In contrast, Marfan syndrome is one of the consistently studied etiological conditions of the disease based on the Fas Binding Factor 1 (FBF1) mutation leading to the disbalance of fibrillin-1 followed by aneurysm, or directly by aortic dissection [66, 67]. Aneurysmal changes in the aorta are caused by changes in the medial layer of its wall, which contains more than fifty interrelated microstructures of elastic fibers and smooth muscle [60]. Association of aneurysm formation with impaired smooth muscle function and reduction of total number of smooth muscle cells is expected, resulting in insufficient resistance to pressure loading. Further, a change in the extracellular matrix is described in terms of reducing the proportion of elastic fibers with accumulation of proteoglycans and collagen [60, 68, 69]. Similar changes, but to a lesser extent, can also be observed in healthy individuals depending on age.

We currently know two mouse experimental models of aortic disease in Marfan syndrome. The first is Fbn1 mgR/mgR, which grows to the dissection stage within 8 months and Fbn1 C1039/+ where the aneurysm develops without progression to the dissection stage [70, 71]. Initial works have suggested an increased level of transformation growth factor-β (TGF-β) in these experimental models, leading to the application of losartan as an angiotensin II antagonist - type I receptor (At1r) to disrupt this pathological pathway in patients with Marfan syndrome. However, clinical studies have not confirmed the benefits of losartan, which would replace the use of β-blockers [72, 73]. However, the role of TGF- β remains important, as evidenced by genetic mutations directly affecting its transcription and also affecting the formation of aortic aneurysms [74].

The TGF-β family is involved in pathophysiological pathways affecting a wide range of mechanisms, including the modulation of smooth muscle cells, as well as the production and remodeling of the extracellular matrix [75-77]. Factors trigger their responses through receptors and Smad 2/3 binding: Smad4, as well as through non-Smad pathway supported by mitrogen-activated protein kinases (MAPKs), which can also transfer angiotensin II stimuli [60]. Experimental works directly demonstrate that the administration of losartan causes At1r blockade and leads to the prevention of aneurysm in experimental animals. Thus, the authors suggested that the overproduction of TGF-β due to At1r stimulation was responsible for aneurysm in patients with Marfan syndrome [70]. Increased TGF-β activity has also been reported for mutations that do not directly affect its transcription, including fibulin-4, α-actin specific for smooth muscle and myosin heavy chain [78-80]. The heterozygous forms of mutation of intermediates involved in this pathophysiological pathway also affect change of TGF-β production [60]. Thus, TGF-β is involved in multiple points and multiple mechanisms

in the pathogenesis of aortic aneurysm, which makes it not easy to use as a therapeutic point of action. Thus, new studies using genetically modified mice have denied the original works that put TGF-β at the center of the pathomechanism between Marfan syndrome and aneurysm formation. Blocking TGF-β at an early postnatal period in Fbn1 mgR/mgR mice accelerated rather than prevented aortic dissection [81]. Further studies have confirmed the negative effect of genetic inhibition of TGF- β by the Tgfbr2 gene on the development of dissection in this experimental model [82-84]. Further, elevated levels of Smad2 and Erk1/2 in the aneurismatically altered aortic wall of Fbn1 C1039/+ mice [85] have not been confirmed. The development of aneurysmatic aortic dilatation in blocking Tgfbr2 in healthy mice reintroduces the pathophysiological pathway of TGF- β into the etiopathogenesis of aortic aneurysm formation [82, 83]. Further, inactivation of Tghbr2 will cause smooth muscle cell disruption, decreased insulin-like growth factor 1 (IGF1) production, and impaired mechanical strength of binding of media and adventitia in the aortic wall [83]. Reflecting the protective influence of affecting the pathophysiological pathway of TGF- β on the development of aneurysm in patients with Marfan syndrome and genetically non-knockout mice, the application of drugs targeted at this pathomechanism, especially in childhood, could prevent or at least slow down the development of aortic aneurysm in children with Marfan syndrome [86]. The controversial effect of the disruption of the TGF- β pathway by its genetic blockade and medical affecting at Fbn1 C1039/+ mice remains a fact [83]. Further, due to the fact that neutralization of TGF-β leads to the progression of aneurysm formation and the application of losartan has a protective effect in Fbn1 mgR/mgR mice, the theory that TGF-β is an unequivocal mediator of At1r hyperactivity in accelerating the formation of aneurysm is refuted [81]. The role of TGF-β in the later formation of aneurysm in Fbn1 mgR/mgR mice was confirmed by prolonged survival and its later development when TGF-β neutralizing agents were applied early after termination of vascular embryogenesis [81]. Thus, by the summary of the results of controversial studies we find a parallel in the effect of TGF-β as a suppressor of early tumor growth and, on the other hand, a promoter of metastatic dissemination at its later stage [60].

Despite the controversies discussed above, it is now generally accepted that the angiotensin II pathway is significantly involved in the progression of both thoracic and abdominal aneurysms of the aorta [87, 88]. The angiotensin II pathway is upregulated by differential mechanisms in different experimental models of aortic aneurysm. The fact that genetic inactivation of At1ar in Fbn1 C1039/+ mice does not prevent the formation of aneurysm, has led to the theory that the protective effect of losartan rests on another than primary target receptor of this substance [89]. Given the inactivation of the effect of losartan by inhibiting NO synthase and the protective effect of endothelial NO synthase on the formation of aneurysm in Fbn1 C1039/+ mice, it has been hypothesized that the released endothelial NO can promote the effect of losartan [89, 90]. This includes endothelial cell dysfunction in the pathomechanisms of aneurysm formation as such. Despite the significant progress in the detection of aortic aneurysm pathomechanisms, we have only a limited possibility of slowing down its development in risk individuals. Surgical and/or interventional therapies continue to be therapies without a full-fledged alternative.

DISSECTION OF DESCENDING AORTA

Aortic dissection means a rupture of the intimal layer, with blood passing between the intima and the medium and forming a false lumen. Although the first mention of this diagnosis is very historic, the first anatomical description comes from the seventeenth and eighteenth centuries. From the same period comes also the Maunoir's term-dissection. The first therapeutic intervention then comes from the beginning of the twentieth century, when fenestration was created for hypoperfusion therapy [48]. In the mid-twentieth century, Abbott and Paulin developed a method of coating aorta with cellophane to prevent rupture. Albert Einstein was treated with a similar technique [48]. Surgical techniques for the treatment of this nosological unit have also improved with the development of extracorporeal circulation [91].

Aortic dissection classification is based on the site of its onset and localization of progression. The subtype is then subclassified on the basis of its origin. For an acute dissection is considered a dissection with onset less than 2 weeks ago. The term chronic is reserved for dissection of the aorta with time of onset more than 2 months ago. Subacute dissection refers to an intermediate stage with an onset time of more than 2 weeks and less than 2 months [48]. Two classifications are most commonly used today for anatomical definition. DeBakey classification divides aortic dissections based on disease localization and progression (Figure 4). This classification more precisely defines anatomical disability and is more suitable for comparison of individual therapeutic procedures in vascular surgery [48, 92]. Stanford classification is strictly functional based on the localization of the intimal rupture site.

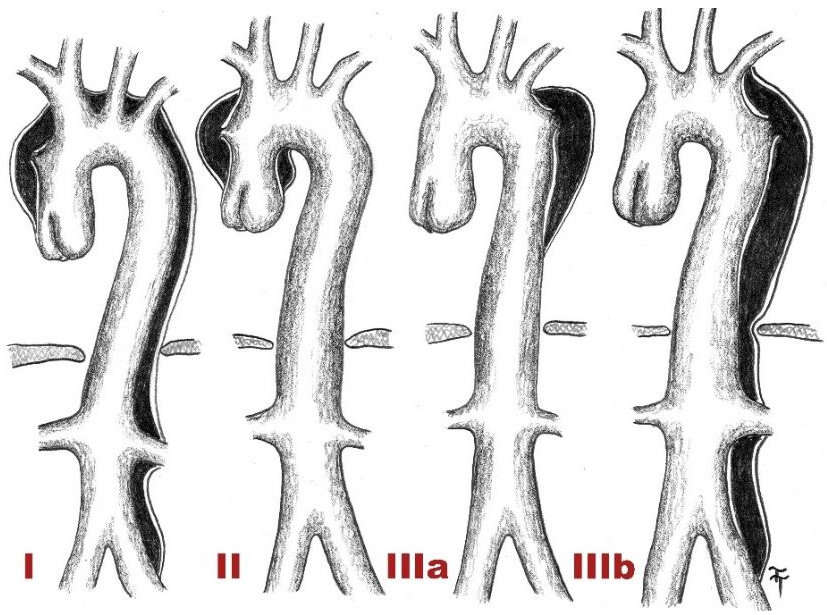

Figure 4. DeBakey aortic dissection classification.

Aortic dissection is the most common lethal diagnosis affecting the aorta. The works document a three-fold higher incidence compared to abdominal aortic rupture [93]. The

worldwide incidence of this disease varies between 5 and 30 cases per million inhabitants per year. Lethal cases that fail to be diagnosed should be added to this incidence. Cohn et al. present a significantly more frequent occurrence of type A dissection compared to type B [48]. There are several hypotheses on the etiological cause of tear in the intimal layer, several of which are based on biochemical abnormalities in the medial layer of the aortic wall. However, the direct relationship between intimal rupture and media necrosis has not been explained. In addition, media degeneration is described only in a minority of patients with dissection, particularly in children [94]. Another theory describes hemorrhage in the aorta wall from vasa vasorum that weakens the intima and conditions its rupture. However, intramural hematoma is found only in less than a quarter of patients with dissection [95]. Another group of authors points to the penetration of atherosclerotic ulcer with subsequent spread to the environment, justifying the same indication criteria for the therapy of penetrated atherosclerotic ulcer as aortic dissection [96]. Despite the ambiguity of the etiopathological origin of the dissection, several risk factors have been identified, including arterial hypertension, Ehler-Danlos syndrome, Marfan syndrome, Turner syndrome, Sheehan syndrome, Cushing syndrome, cystic aortic disease, aortitis, iatrogenic aortic wall damage, bicuspid aortic valve, trauma, aortic coarctation, congenital aortic stenosis, polycystic kidney, pheochromocytoma and others [48]. In general, these are factors that increase the mechanical load on the aortic wall or reduce its mechanical strength. Hypertension is found in two thirds of patients with dissection [97]. Next, we will only deal with type B dissection, which falls into this chapter.

Type B aortic dissection represents about 40% of all aortic dissections and its course is less destructive compared to type A [48, 97]. More than half of the patients are able to heal a defect in conservative therapy, and only about 20-30% of patients undergo emergency surgery or intervention. Conditions requiring intervention include aortic rupture, aortic expansion, hemodynamic instability, persistent pain, hypertension unresponsive to treatment, and in particular peripheral tissue hypoperfusion [48, 97, 98]. The most common cause of death in this nozological unit is rupture of the aorta and hypoperfusion of the visceral organs [48]. In the case of sufficiency of conservative progression-free therapy, only 10% mortality during hospitalization can be expected [98]. During the first year, the survival rate drops to 85%, and in a 5-year follow-up, 29% overall mortality can be expected [99]. On the other hand, in patients indicated for surgical performance, the 30-day mortality rate is 30% [97]. These values have led to intensive introduction of endovascular methods that show mortality in the same group of patients at 5% [100]. In view of the results of invasive and conservative therapy, the indication of interventional or surgical therapy in aortic dissection type B is the sole risk of life-threatening complications [101, 102]. Thus, indications include persistent uncontrollable pain, medically untreatable hypertension, fast-growing aortic diameter, progression of the extent of dissection despite utilized conservative therapy, signs of development of rupture, or hypoperfusion in the catchment area of the affected aorta [48].

The goal of endovascular intervention, which is now the first choice in the treatment of type B aortic dissection, is to redirect the blood flow to the right lumen and to ensure tissue perfusion from the branch lines in the intervened site. Obliteration of the false lumen is desired, but not unconditional, however its thrombosis will, in the long run, provide stabilization of the aortic wall and limit the increase in aneurysm size. The stentgraft should cover and obture the primary intimal rupture, leading to thrombotization of the false lumen and reperfusion of the outgoing branches. If the reperfusion of the outgoing branches is

unsuccessful, the possibility of the intima festering at the site of separation is then possible, thereby transferring blood from the false to the right lumen of the aortic branch. Subsequently, the site may be covered with a stent [103]. If necessary, another stent can be implemented directly into the outgoing branch. With high intimal tear localization, stentgraft implantation can also cover the separation of subclavian artery of l.sin, except when the left arteria thoracica interna is used for myocardial revascularization, Willis circuit incompleteness, left vertebral artery domination, or vertebral artery occlusion. In these cases, performance is only feasible after its revascularization [104]. The need for higher stengraft implantation requires debranching of the aortic arch, which is discussed in another chapter.

Open surgical intervention for dissecting a descending aorta is performed under general anesthesia with selective pulmonary ventilation. Monitoring of pressure via radial artery and femoral artery is necessary. A dreaded complication is the spinal cord injury leading to paraplegia occurring in one third of patients [48, 105, 106]. In order to protect the spinal cord, several protective measures are introduced, including cerebrospinal fluid drainage, perioperative bypass between left atrium and femoral artery and reimplantation of arteria intercostalis [107]. As the surgical approach, the left posterolateral thoracotomy is selected at the patient's right flank position. In the case of intervention in the abdominal aorta, we extend the incision and use a transperitoneal or retroperitoneal approach. In emergent operation, the strategy of the various workplaces is controversial. One group of authors recommends minimizing the surgical procedure to the part of the aorta most affected by dissection, rarely exceeding one-third of the thoracic descending aorta. Other workplaces, on the other hand, are expanding the performance on the whole aneurysmatically dilated aorta [48].

SURGERY PROCEDURES

One of the most important parts of the open surgical solution of the descending aortic aneurysm is the protection of peripheral tissues and organs, which we will deal with later. Schepens et al. describe the surgical procedure as follows [108]. The patient's position is on the right side with a 60-degree pelvic flexion and selective intubation to visualize the left pleura. The authors recommend continuous monitoring of ECG, arterial pressure, central venous pressure and pressure in the truncus pulmonalis. It is necessary to implant four venous catheters of sufficient diameter to allow rapid transfusion therapy. The authors recommend two cell-saver devices and continuous monitoring of patient diuresis. Further, continuous measurement of intrathecal pressure by a catheter implanted between the third and fourth lumbar vertebrae is also recommended, while the pressure should not exceed 10 mmHg. If all procedures are observed epidural cooling is not required according to the authors. If targeted hypothermia is not used, the patient is let spontaneously slowly cooled down to 32 degrees Celsius. When the aneurysm interferes with the aortic arch, the authors choose deep hypothermia. As an operative approach, the lateral thoracotomy in the sixth intercostal extended by diafragmatomy is selected. The abdominal aorta is visualized by retroperitoneal approach. Left atrial cannulation is performed via the upper or lower pulmonary vein, rarely via the left atrial ear. If the proximal part of the aorta is not affected, the authors do not rule out this cannulation site either. Blood is applied through the arterial line to the femoral artery (Figure 6). When the left ventricular bypass is triggered, we clamp the descending aorta

gradually in the cranio-caudal direction with the gradual sewing of all anastomoses. Further, the application of 300mL of cold crystalloid solution every 20 minutes to renal arteries is recommended. Schepens et al. do not recommend the selective application of blood from the left ventricular bypass to the visceral branches of the aorta. Patient warming may be either active or spontaneously slow during the stay in intensive care unit [108].

Organ Ischemic Injury Protection

The first option to protect peripheral tissues and organs is hypothermia [109]. The patient is linked to full extracorporeal circulation, most often via the peripheral cannulation of the arteria and vena femoralis. After the extracorporeal circulation is triggered, we start cooling the patient with an arterial temperature of 15 degrees Celsius. We use left-sided thoracotomy as the surgical approach. When ventricular fibrillation develops, a decompression suction catheter is placed through the tip into the left ventricle. When the temperature reaches 20 degrees Celsius, we stop the extracorporeal circulation, we clamp the descending aorta distally from the proximal suture site. The lower body is perfused 1 - 1.5 L/min while maintaining hypothermia. Subsequently, we perform a suture of proximal anastomosis. At anatomical availability other perfusion lines can be implanted into the left arteria carotis communis and truncus brachiocephalicus with a flow rate of 10mL/kg/min. After the end of proximal anastomosis, we start also the circulation of the upper half of the body by flowing 1 - 1.5 L/min. We perform suture of individual branches of the aorta in cranio-caudal direction with possible selective perfusion especially of visceral branches (0.2 - 0.3 L/min). Upon completion of the visceral branch suture, we can begin to warm the patient [109].

The Gott shunt represents the link between the aortic arch and the descending aorta below the surgical intervention site (Figure 5). Verdant uses a 9mm heparin coated prosthesis. To prevent undetected malfunctions of this method, the authors recommend applying a flow meter to the shunt. In the study was reported one case of failure resulting in spinal cord injury due to ischemia. The mean systolic pressure in the lower half of the body was 61 mmHg with optimal functionality of the method [110].

Left ventricular bypass represents a newer methodology compared to Gott shunt. Cannulated is the pulmonary vein and the blood is applied to the arterial system of the lower half of the body without a reservoir by a centrifugal pump (Figure 6). It is recommended to administer a partial dose of heparin with an activated clotting time (ACT) of 150 seconds. The authors recommend monitoring of radial and femoral pressure, cardiac output, venous saturation, central venous pressure and pressure in the truncus pulmonalis [110]. Verdant presents a 9mm Gott shunt 3L per minute in the treatment of the descending aortic traumatic injury, and a 4L per minute at use of controlled left ventricular bypass. Thus, the incidence of spinal cord injury during performance was eliminated from 3/40 patients at Gott shunt to 4/98 at left ventricular bypass [110].

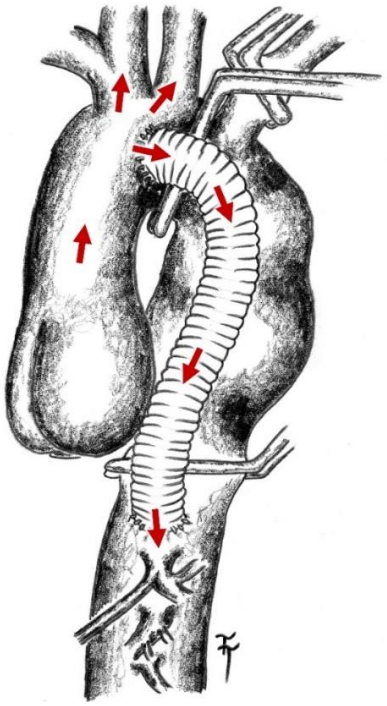

Figure 5. Gott shunt.

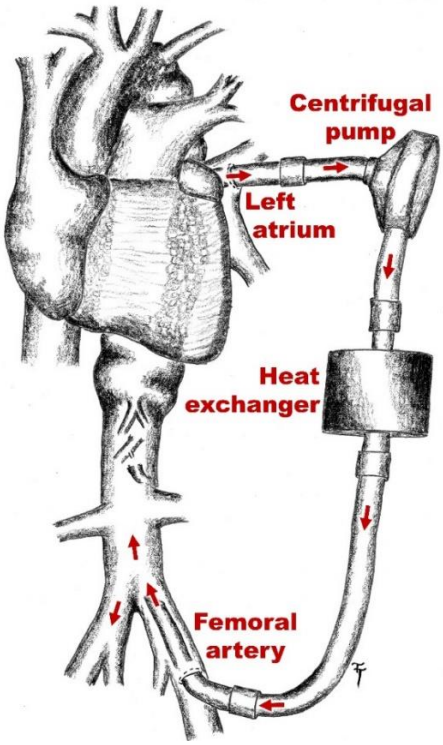

Figure 6. Left heart bypass.

The use of partial cardiopulmonary bypass is another controlled form of lower body perfusion in the operation of the descending thoracic aorta (Figure 7). Its use is associated with a low incidence of ischemic damage to peripheral tissues, particularly spinal cord [111]. The venous line is most commonly introduced via the peripheral cannulation into the right atrium of the heart, from where the blood is drawn into the extracorporeal circulation. There it is subsequently oxygenated and applied to the arterial system of the lower half of the body, most commonly via the peripheral cannulation of the femoral artery. This ensures a fully controlled double circulation. Respiration and oxygenation of the upper half of the body is mostly ensured by selective intubation. The perfusionist by modification of the flow through the venous line modulates the preload of the heart and the cardiac output under invasive pressure monitoring, most commonly the radial artery or the brachial artery. The flow through the arterial cannula of the extracorporeal circulation itself then again ensures the perfusion of the lower half of the body. The method is also applicable at aberrant separation of the subclavian artery. Nakamura et al. present the use of this method in three patients with aortic coarctation with optimal outcome [112]. The method is a very suitable alternative for workplaces with experience in using cardiopulmonary bypass with peripheral cannulation. The disadvantage remains the need for full heparinization of the patient due to the use of the oxygenator.

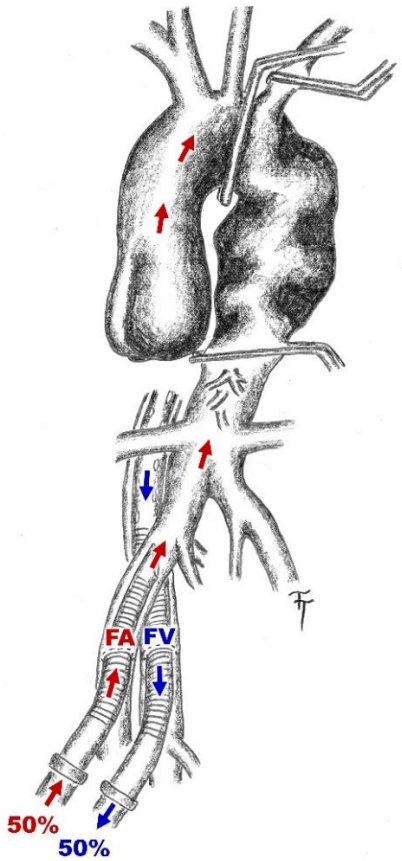

Figure 7. Partial cardiopulmonary bypass (FA – femoral artery; FV – femoral vein).

Results and Benefits of Open and Endovascular Descending Aorta Therapy

Harky et al. in 2019 published a review and meta-analysis comparing endovascular and surgical treatment of aortic diseases [113]. A population of more than 14,000 patients points to a preference for open surgical approach in young patients, where the group of patients undergoing surgery was nearly 5 years younger. The group of patients undergoing endovascular therapy showed a higher coincidence of coronary heart disease, hypertension, and chronic renal failure. Despite the lack of definite indications and contraindications, endovascular therapy was mostly chosen in patients where an open surgical approach would be a high risk [113, 114]. Most patients in meta-analysis represented patients with degenerative aneurysms limited to descending aorta. Given the high proportion of this diagnosis in meta-analysis (99% in open surgery and 96% in endovascular treatment), most interventions were also conducted in an elective regimen (83% in open surgery and 81% in endovascular treatment) [113].

Cheng et al. in their meta-analysis involving more than 5.5 thousand patients, present higher mortality after open surgery compared to endovascular intervention over 30 days (OR = 2.27), one year (OR = 1.36) and 3 years (OR = 1.09). However, with a longer follow-up time, the difference was no longer significant [115]. Harky et al. present significantly higher mortality during hospitalization when using endovascular intervention, which may be partly due to higher age and more frequent comorbidities in this patient group. However, survival assessments after one and five years did not show a statistically significant difference. The authors conclude that the unambiguous conclusion of the evaluation of the benefits of better survival after one of these methods cannot be stated but given the more frequent co-morbidities and similar survival of the patients, they assume a slightly better endovascular outcome compared to open surgery [113, 116]. More can be expected from studies with longer postoperative patient follow-up. Further works also focus on the risk of neurological complications after a single type of procedure, while Gopaldas et al. in a study involving more than 11.5 thousand patients, find a comparable risk of neurological complications after each approach [114]. Harky et al. find higher incidence of postoperative paraplegia (OR = 2.07, p = 0.007) in open surgical intervention [113]. However, various studies included in this meta-analysis used different methods of spinal protection. Better results of surgical open approach are found in the assessment of vascular postoperative or post-intervention complications [114, 115]. Other benefits of the endovascular approach are lower risk of cardiac and renal complications and shorter hospitalization (p = 0.0004). In view of the risk of complications and reintervention, the authors prefer an open surgical approach [113]. Further studies with longer-term follow-up will bring the most important differences.

TRAUMA OF DESCENDING AORTA

The most common reason for traumatic thoracic aortic involvement is road accidents. Currently, we have seen a long-term increase in the incidence of this disease. This was due to the increasing incidence of injuries themselves in the 20th century, followed by the increasing quality of emergent medicine in the 21st century [117]. Even today, there is still a high mortality rate for these patients, which in the past was 80% [117]. Today, about 38% of

patients survive primary trauma and 4% die on the way to hospital. Survival of 24 hours after injury remains at 20% [118, 119]. Chest injury is the second most common cause of death following head trauma in road accidents and accounts for about 15% of all injuries treated in emergency department worldwide [120].

The most common location of traumatic aortic injury is, due to anatomic fixation, isthmus. The mechanism of injury is deceleration associated with chest compression, resulting in torsion and retraction of the aortic wall tissue. Mokrade et al. explain the significantly lower incidence of ascending aortic trauma not by the absolute lower number of injuries but by the severity of the wall destruction in this site, which mostly leads to immediate death [117]. In addition to traffic accidents, thoracic aortic injuries arise during crushing, fall from height and deceleration injuries in sports activities [117-119].

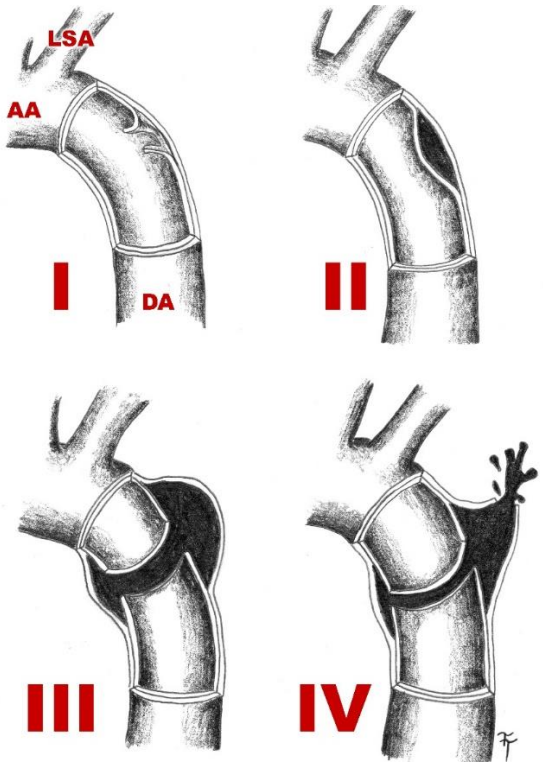

Figure 8. Classification of traumatic injuries of the thoracic aorta (AA – aortic arch; DA – descending aorta; LSA – left subclavian artery).

The initial management of a patient with suspected thoracic aortic trauma depends both on the overall condition of the patient and the associated injuries. Although transesophageal echocardiography is the primary choice for the diagnosis of thoracic aortic injury, the first imaging examination is usually computerized tomography, which should be performed as soon as possible considering the patient's condition [120, 121]. Computer tomography allows both accurate diagnosis of aortic injury itself and the diagnosis of associated injuries to other organs. Magnetic resonance imaging (MRI) also offers an alternative, but the examination is not normally available in continuous operation, moreover the length of the examination may

cause unwanted delay in therapy. Further, angiography is not unconditional for diagnosis, but it precedes the endovascular intervention itself as standard [117].

Computer tomography examination is also aimed at determining the aortic injury class, which is an unconditional step in determining treatment strategy. Starnes et al. published a classification that divides injuries into two basic groups. The first group is findings without abnormality on the outer contour of the aorta, which includes grade I and II. The second group consists of findings with an abnormality of the outer contour of the aorta. This group includes grade III and IV [122]. This allows for a simple and rapid determination of the severity of the injury as well as its therapy strategy. The severity of the finding is further confirmed and enhanced by the presence of mediastinal hematoma, left-sided hemothorax, and the presence of pseudocoarctation [123]. Attention should be paid to the presence or absence of changes in the external contour of the aorta, since it significantly affects the choice of the next therapeutic procedure. To identify grade I and II, the authors recommend multiplanar reconstruction, which may be more complicated in axial sections. Accurate localization of damage is directly a prerequisite for successful possible endovascular intervention [124]. The therapeutic plan is then still influenced by coincidence of injury of brain, spinal cord, abdominal cavity, pelvis as well as other traumatic changes. However, the examination is burdened with false positivity especially for the presence of movement artifacts. Computerized tomography with ECG synchronization or transesophageal ultrasonography is indicated when diagnosis is ambiguous [117]. On the other hand, the trauma image can falsely imitate the diverticulum of the aortic wall at the site of the ductus arteriosus, the hematoma mediastinal caused by the injury of the venous system, or other extra aortic anatomical structure [117].

The presence of a traumatic change in the aortic wall is not necessarily an indication for surgical revision or percutaneous intervention, and some injuries can also be managed conservatively [123]. Grade I and II injuries can also be managed by conservative therapy with consistent patient monitoring. Conservative therapy is sufficient for more than half of these injuries, and only 5% show progression of the finding with necessary change in treatment strategy [125]. Grade III injuries require intervention, while a more optimal endovascular intervention with stentgraft implantation is often sufficient. Therapy should be indicated within 24 hours of injury. However, excessive delay in intervention increases the risk of rupture with possible fatal consequences for the patient. Grade III with signs of marked damage and grade IV should be treated emergently, immediately endovascularly, or surgically. Harris et al. define a lactate level > 4mmol/L, mediastinal hematoma > 10mm and at least a 4-fold increase in aortic diameter at the trauma site compared to the undamaged portion as a rupture prognostic factor [125].

Even in the treatment of traumatic aortic injuries, the progression of interventional endovascular percutaneous techniques has been observed over the past two decades. Some studies present a 30-day mortality and a survival rate of two-year follow-up at 93.7% in a successful 2.1% procedure [126, 127]. Other works report a 4% mortality rate during the procedure. Total periprocedural mortality is also affected by associated injuries and reaches 16%. The risk of spinal cord injury with a neurological deficit is less than 1% in this intervention [128, 129].

Surgical treatment remains the method of choice as another possible alternative at contraindication or unavailability of intervention therapy. Verdant published a study involving 138 patients undergoing open surgery for traumatic thoracic aortic injury [110].

The authors present a hospitalization mortality rate of 5%, while during the evaluation the mortality was reduced from 7.5% using the Gott shunt to 4% when the left ventricular bypass method was introduced. In the last 68 patients, the authors present a mortality rate of 1.4% after the adoption of the methodology. The authors report a newly created paraplegia only in one case because of the unrecognized malfunction of Gott shunt. Four patients were paraplegic already before surgery. The length of the aortic clamp was 29.3 ± 13 minutes in the study [110]. The aim of the surgical intervention in the traumatic damage of the descending aorta is periprocedural sufficient tissue perfusion with prevention of spinal cord damage.

REFERENCES

[1] Townsend, C. M., Beauchamp, R. D., Evers, B. M., et al. (2016). *Sabiston Text Book of Surgery*. Philadelphia: Saunders Elsevier, 2176.

[2] Čihák, R. (2016). *Anatomie* 3. Praha: Grada, 832.

[3] Hanneman, K., Newman, B., Chan, F. (2017). Congenital Variants and Anomalies of the Aortic Arch. *Radiographics*, 37: 32-51.

[4] Landeras, L. A., Chung, J. H. (2019). Congenital Thoracic Aortic Disease. *Radiol Clin North Am*, 57: 113-125.

[5] Ikeno, Y., Koda, Y., Yokawa, K., et al. (2018). Graft Replacement of Kommerell Diverticulum and In Situ Aberrant Subclavian Artery Reconstruction. *Ann Thorac Surg*, 107: 770-9.

[6] Jakanani, G. C., Adair, W. (2010). Frequency of variations in aortic arch anatomy depicted on multidetector CT. *Clin Radiol*, 65: 481-7.

[7] Muller, M., Schmitz, B. L., Pauls, S., et al. (2011). Variations of the aortic arch - a study on the most common branching patterns. *Acta Radiol*, 52: 738-42.

[8] Celikyay, Z. R., Koner, A. E., Celikyay, F., et al. (2013). Frequency and imaging findings of variations in human aortic arch anatomy based on multidetector computed tomography data. *Clin Imaging*, 37: 1011-9.

[9] Ergun, E., Simsek, B., Kosar, P. N., et al. (2013). Anatomical variations in branching pattern of arcus aorta: 64-slice CTA appearance. *Surg Radiol Anat*, 35: 503-9.

[10] Tanaka, A., Milner, R., Ota, T. (2015). Kommerell's diverticulum in the current era: a comprehensive review. *Gen Thorac Cardiovasc Surg*, 63: 245-59.

[11] Cina, C. S., Althani, H., Pasenau, J., et al. (2004). Kommerell's diverticulum and right-sided aortic arch: a cohort study and review of the literature. *J Vasc Surg*, 39: 131-9.

[12] Kim, K. M., Cambria, R. P., Isselbacher, E. M., et al. (2014). Contemporary surgical approaches and outcomes in adults with Kommerell diverticulum. *Ann Thorac Surg*, 98: 1347-54.

[13] Kouchoukos, N. T., Masetti, P. (2007). Aberrant subclavian artery and Kommerell aneurysm: surgical treatment with a standard approach. *J Thorac Cardiovasc Surg*, 133: 888-92.

[14] Tsukui, H., Aomi, S., Yamazaki, K. (2014). Surgical strategy for Kommerell's diverticulum: total arch replacement. *J Thorac Cardiovasc Surg*, 148: 1423-7.

[15] Idrees, J., Keshavamurthy, S., Subramanian, S., et al. (2014). Hybrid repair of Kommerell diverticulum. *J Thorac Cardiovasc Surg*, 147: 973-6.
[16] Conrad, C., Newberry, D. (2019). Understanding the Pathophysiology, Implications, and Treatment Options of Patent Ductus Arteriosus in the Neonatal Population. *Adv Neonatal Care*, 19: 179-87.
[17] Benitz, W. E., Committee on, F., Newborn, A. A. o. P. (2016). Patent Ductus Arteriosus in Preterm Infants. *Pediatrics*, 137: e20153730.
[18] Elsayed, Y. N., Fraser, D. (2017). Patent Ductus Arteriosus in Preterm Infants, Part 1: Understanding the Pathophysiologic Link Between the Patent Ductus Arteriosus and Clinical Complications. *Neonatal Netw*, 36: 265-272.
[19] Bardanzellu, F., Neroni, P., Dessi, A., et al. (2017). Paracetamol in Patent Ductus Arteriosus Treatment: Efficacious and Safe? *Biomed Res Int*, 2017: 1438038.
[20] El-Mashad, A. E., El-Mahdy, H., El Amrousy, D., et al. (2017). Comparative study of the efficacy and safety of paracetamol, ibuprofen, and indomethacin in closure of patent ductus arteriosus in preterm neonates. *Eur J Pediatr*, 176: 233-240.
[21] Sehgal, A., McNamara, P. J. (2012). Coronary artery perfusion and myocardial performance after patent ductus arteriosus ligation. *J Thorac Cardiovasc Surg*, 143: 1271-8.
[22] Wyllie, J. (2015). Neonatal echocardiography. *Semin Fetal Neonatal Med*, 20: 173-80.
[23] Schena, F., Francescato, G., Cappelleri, A., et al. (2015). Association between Hemodynamically Significant Patent Ductus Arteriosus and Bronchopulmonary Dysplasia. *J Pediatr*, 166: 1488-92.
[24] Letshwiti, J. B., Semberova, J., Pichova, K., et al. (2017). A conservative treatment of patent ductus arteriosus in very low birth weight infants. *Early Hum Dev*, 104: 45-49.
[25] Constance, J. E., Reith, D., Ward, R. M., et al. (2017). Risk of nonsteroidal anti-inflammatory drug-associated renal dysfunction among neonates diagnosed with patent ductus arteriosus and treated with gentamicin. *J Perinatol*, 37: 1093-1102.
[26] Rodriguez Ogando, A., Planelles Asensio, I., de la Blanca, A. R. S., et al. (2018). Surgical Ligation Versus Percutaneous Closure of Patent Ductus Arteriosus in Very Low-Weight Preterm Infants: Which are the Real Benefits of the Percutaneous Approach? *Pediatr Cardiol*, 39: 398-410.
[27] Ramirez Alcantara, J., Mendez, M. D. Aortic, Interrupted Arch. *StatPearls. Treasure Island (FL)*, 2018. Feb 10.
[28] El-Khuffash, A., James, A. T., Corcoran, J. D., et al. (2015). A Patent Ductus Arteriosus Severity Score Predicts Chronic Lung Disease or Death before Discharge. *J Pediatr*, 167: 1354-1361 e2.
[29] Evans, N. (2015). Preterm patent ductus arteriosus: A continuing conundrum for the neonatologist? *Semin Fetal Neonatal Med*, 20: 272-7.
[30] Bixler, G. M., Powers, G. C., Clark, R. H., et al. (2017). Changes in the Diagnosis and Management of Patent Ductus Arteriosus from 2006 to 2015 in United States Neonatal Intensive Care Units. *J Pediatr*, 189: 105-112.
[31] Olsson, K. W., Jonzon, A., Sindelar, R. (2019). Early haemodynamically significant patent ductus arteriosus does not predict future persistence in extremely preterm infants. *Acta Paediatr*, Epub ahead of print.
[32] Singh, S., Hakim, F. A., Sharma, A., et al. (2015). Hypoplasia, pseudocoarctation and coarctation of the aorta - a systematic review. *Heart Lung Circ*, 24: 110-8.

[33] Dijkema, E. J., Leiner, T., Grotenhuis, H. B. (2017). Diagnosis, imaging and clinical management of aortic coarctation. *Heart*, 103: 1148-1155.

[34] Jashari, H., Rydberg, A., Ibrahimi, P., et al. (2015). Left ventricular response to pressure afterload in children: aortic stenosis and coarctation: a systematic review of the current evidence. *Int J Cardiol*, 178: 203-9.

[35] Karaosmanoglu, A. D., Khawaja, R. D., Onur, M. R., et al. (2015). CT and MRI of aortic coarctation: pre- and postsurgical findings. *AJR Am J Roentgenol*, 204: W224-33.

[36] O'Brien, P., Marshall, A. C. (2015). Coarctation of the aorta. *Circulation*, 131: e363-5.

[37] Cardoso, G., Abecasis, M., Anjos, R., et al. (2014). Aortic coarctation repair in the adult. *J Card Surg*, 29: 512-8.

[38] Evans, W., Castillo, W., Rollins, R., et al. (2015). Moving towards universal prenatal detection of critical congenital heart disease in southern Nevada: a community-wide program. *Pediatr Cardiol*, 36: 281-8.

[39] Gewillig, M., Budts, W., Boshoff, D., et al. (2012). Percutaneous interventions of the aorta. *Future Cardiol*, 8: 251-69.

[40] Nigro, G., Russo, V., Rago, A., et al. (2012). Heterogeneity of ventricular repolarization in newborns with severe aortic coarctation. *Pediatr Cardiol*, 33: 302-6.

[41] Soslow, J. H., Kavanaugh-McHugh, A., Wang, L., et al. (2013). A clinical prediction model to estimate the risk for coarctation of the aorta in the presence of a patent ductus arteriosus. *J Am Soc Echocardiogr*, 26: 1379-87.

[42] Shepherd, B., Abbas, A., McParland, P., et al. (2015). MRI in adult patients with aortic coarctation: diagnosis and follow-up. *Clin Radiol*, 70: 433-45.

[43] Holloway, B. J., Rosewarne, D., Jones, R. G. (2011). Imaging of thoracic aortic disease. *Br J Radiol*, 84 Spec No 3: S338-54.

[44] Riesenkampff, E., Fernandes, J. F., Meier, S., et al. (2014). Pressure fields by flow-sensitive, 4D, velocity-encoded CMR in patients with aortic coarctation. *JACC Cardiovasc Imaging*, 7: 920-6.

[45] Brown, M. L., Burkhart, H. M., Connolly, H. M., et al. (2013). Coarctation of the aorta: lifelong surveillance is mandatory following surgical repair. *J Am Coll Cardiol*, 62: 1020-5.

[46] Selioutski, O., Bhatt, A., Kelly, A. G. (2017). Acute paraplegia in a patient with repaired coarctation of aorta. *Neurol Clin Pract*, 7: e16-e18.

[47] Chen, S. S., Dimopoulos, K., Alonso-Gonzalez, R., et al. (2014). Prevalence and prognostic implication of restenosis or dilatation at the aortic coarctation repair site assessed by cardiovascular MRI in adult patients late after coarctation repair. *Int J Cardiol*, 173: 209-15.

[48] Cohn, L., Adams, D. H. (2017). *Cardiac Surgery in the Adult.* New York City: McGraw-Hill, 1456.

[49] Panneton, J. M., Hollier, L. H. (1995). Nondissecting thoracoabdo-minal aortic aneurysms: Part I. *Ann Vasc Surg*, 9: 503-14.

[50] Greenberg, R. K., Clair, D., Srivastava, S., et al. (2003). Should patients with challenging anatomy be offered endovascular aneurysm repair? *J Vasc Surg*, 38: 990-6.

[51] Leurs, L. J., Bell, R., Degrieck, Y., et al. (2004). Endovascular treatment of thoracic aortic diseases: combined experience from the EUROSTAR and United Kingdom Thoracic Endograft registries. *J Vasc Surg*, 40: 670-9; discussion 679-80.

[52] Makaroun, M. S., Dillavou, E. D., Kee, S. T., et al. (2005). Endovascular treatment of thoracic aortic aneurysms: results of the phase II multicenter trial of the GORE TAG thoracic endoprosthesis. *J Vasc Surg*, 41: 1-9.

[53] Rachel, E. S., Bergamini, T. M., Kinney, E. V., et al. (2002). Endovascular repair of thoracic aortic aneurysms: a paradigm shift in standard of care. *Vasc Endovascular Surg*, 36: 105-13.

[54] Gottardi, R., Lammer, J., Grimm, M., et al. (2006). Entire rerouting of the supraaortic branches for endovascular stent-graft placement of an aortic arch aneurysm. *Eur J Cardiothorac Surg*, 29: 258-60.

[55] Flye, M. W., Choi, E. T., Sanchez, L. A., et al. (2004). Retrograde visceral vessel revascularization followed by endovascular aneurysm exclusion as an alternative to open surgical repair of thoracoabdominal aortic aneurysm. *J Vasc Surg*, 39: 454-8.

[56] Fulton, J. J., Farber, M. A., Marston, W. A., et al. (2005). Endovascular stent-graft repair of pararenal and type IV thora-coabdominal aortic aneurysms with adjunctive visceral reconstruction. *J Vasc Surg*, 41: 191-8.

[57] Svensson, L. G., Kim, K. H., Blackstone, E. H., et al. (2004). Elephant trunk procedure: newer indications and uses. *Ann Thorac Surg*, 78: 109-16; discussion 109-16.

[58] LeMaire, S. A., Russell, L. (2011). Epidemiology of thoracic aortic dissection. *Nat Rev Cardiol*, 8: 103-13.

[59] LeMaire, S. A., McDonald, M. L., Guo, D. C., et al. (2011). Genome-wide association study identifies a susceptibility locus for thoracic aortic aneurysms and aortic dissections spanning FBN1 at 15q21.1. *Nat Genet*, 43: 996-1000.

[60] Milewicz, D. M., Ramirez, F. (2019). Therapies for Thoracic Aortic Aneurysms and Acute Aortic Dissections. *Arterioscler Thromb Vasc Biol*, 39: 126-136.

[61] Coady, M. A., Davies, R. R., Roberts, M., et al. (1999). Familial patterns of thoracic aortic aneurysms. *Arch Surg*, 134: 361-7.

[62] Renard, M., Francis, C., Ghosh, R., et al. (2018). Clinical Validity of Genes for Heritable Thoracic Aortic Aneurysm and Dissection. *J Am Coll Cardiol*, 72: 605-615.

[63] Prakash, S. K., Pedroza, C., Khalil, Y. A., et al. (2012). Diabetes and reduced risk for thoracic aortic aneurysms and dissections: a nationwide case-control study. *J Am Heart Assoc*, 1: jah3-e000323.

[64] Takagi, H., Umemoto, T., Group, A. (2017). Negative Association of Diabetes with Thoracic Aortic Dissection and Aneurysm. *Angiology*, 68: 216-224.

[65] Tsai, C. L., Lin, C. L., Wu, Y. Y., et al. (2015). Advanced complicated diabetes mellitus is associated with a reduced risk of thoracic and abdominal aortic aneurysm rupture: a population-based cohort study. *Diabetes Metab Res Rev*, 31: 190-7.

[66] Ramirez, F., Dietz, H. C. (2007). Marfan syndrome: from molecular pathogenesis to clinical treatment. *Curr Opin Genet Dev*, 17: 252-8.

[67] Glebova, N. O., Cameron, D. E., Black, J. H., 3rd (2018). Treatment of thoracoabdominal aortic disease in patients with connective tissue disorders. *J Vasc Surg*, 68: 1257-1267.

[68] Ladich, E., Yahagi, K., Romero, M. E., et al. (2016). Vascular diseases: aortitis, aortic aneurysms, and vascular calcification. *Cardiovasc Pathol*, 25: 432-41.

[69] Cikach, F. S., Koch, C. D., Mead, T. J., et al. (2018). Massive aggrecan and versican accumulation in thoracic aortic aneurysm and dissection. *JCI Insight*, 3: pii: 9716.

[70] Habashi, J. P., Judge, D. P., Holm, T. M., et al. (2006). Losartan, an AT1 antagonist, prevents aortic aneurysm in a mouse model of Marfan syndrome. *Science*, 312: 117-21.

[71] Pereira, L., Lee, S. Y., Gayraud, B., et al. (1999). Pathogenetic sequence for aneurysm revealed in mice underexpressing fibrillin-1. *Proc Natl Acad Sci U S A*, 96: 3819-23.

[72] Milleron, O., Arnoult, F., Ropers, J., et al. (2015). Marfan Sartan: a randomized, double-blind, placebo-controlled trial. *Eur Heart J*, 36: 2160-6.

[73] Forteza, A., Evangelista, A., Sanchez, V., et al. (2016). Efficacy of losartan vs. atenolol for the prevention of aortic dilation in Marfan syndrome: a randomized clinical trial. *Eur Heart J*, 37: 978-85.

[74] Boileau, C., Guo, D. C., Hanna, N., et al. (2012). TGFB2 mutations cause familial thoracic aortic aneurysms and dissections associated with mild systemic features of Marfan syndrome. *Nat Genet*, 44: 916-21.

[75] Gal, P., Toporcer, T., Vidinsky, B., et al. (2009). Simple interrupted percutaneous suture versus intradermal running suture for wound tensile strength measurement in rats: a technical note. *Eur Surg Res*, 43: 61-5.

[76] Gal, P., Toporcer, T., Vidinsky, B., et al. (2006). Early changes in the tensile strength and morphology of primary sutured skin wounds in rats. *Folia Biol (Praha)*, 52: 109-15.

[77] Gal, P., Vidinsky, B., Toporcer, T., et al. (2006). Histological assessment of the effect of laser irradiation on skin wound healing in rats. *Photomed Laser Surg*, 24: 480-8.

[78] Renard, M., Callewaert, B., Baetens, M., et al. (2013). Novel MYH11 and ACTA2 mutations reveal a role for enhanced TGFbeta signaling in FTAAD. *Int J Cardiol*, 165: 314-21.

[79] Renard, M., Holm, T., Veith, R., et al. (2010). Altered TGFbeta signaling and cardiovascular manifestations in patients with autosomal recessive cutis laxa type I caused by fibulin-4 deficiency. *Eur J Hum Genet*, 18: 895-901.

[80] Guo, D. C., Pannu, H., Tran-Fadulu, V., et al. (2007). Mutations in smooth muscle alpha-actin (ACTA2) lead to thoracic aortic aneurysms and dissections. *Nat Genet*, 39: 1488-93.

[81] Cook, J. R., Clayton, N. P., Carta, L., et al. (2015). Dimorphic effects of transforming growth factor-beta signaling during aortic aneurysm progression in mice suggest a combinatorial therapy for Marfan syndrome. *Arterioscler Thromb Vasc Biol*, 35: 911-7.

[82] Hu, J. H., Wei, H., Jaffe, M., et al. (2015). Postnatal Deletion of the Type II Transforming Growth Factor-beta Receptor in Smooth Muscle Cells Causes Severe Aortopathy in Mice. *Arterioscler Thromb Vasc Biol*, 35: 2647-56.

[83] Li, W., Li, Q., Jiao, Y., et al. (2014). Tgfbr2 disruption in postnatal smooth muscle impairs aortic wall homeostasis. *J Clin Invest*, 124: 755-67.

[84] Wei, H., Hu, J. H., Angelov, S. N., et al. (2017). Aortopathy in a Mouse Model of Marfan Syndrome Is Not Mediated by Altered Transforming Growth Factor beta Signaling. *J Am Heart Assoc*, 6: pii: e004968.

[85] Lindsay, M. E., Schepers, D., Bolar, N. A., et al. (2012). Loss-of-function mutations in TGFB2 cause a syndromic presentation of thoracic aortic aneurysm. *Nat Genet*, 44: 922-7.

[86] Cannaerts, E., van de Beek, G., Verstraeten, A., et al. (2015). TGF-beta signalopathies as a paradigm for translational medicine. *Eur J Med Genet*, 58: 695-703.

[87] Yu, C., Jeremy, R. W. (2018). Angiotensin, transforming growth factor beta and aortic dilatation in Marfan syndrome: Of mice and humans. Int *J Cardiol Heart Vasc*, 18: 71-80.

[88] Kuang, S. Q., Geng, L., Prakash, S. K., et al. (2013). Aortic remodeling after transverse aortic constriction in mice is attenuated with AT1 receptor blockade. *Arterioscler Thromb Vasc Biol*, 33: 2172-9.

[89] Sellers, S. L., Milad, N., Chan, R., et al. (2018). Inhibition of Marfan Syndrome Aortic Root Dilation by Losartan: Role of Angiotensin II Receptor Type 1-Independent Activation of Endothelial Function. *Am J Pathol*, 188: 574-585.

[90] Oller, J., Mendez-Barbero, N., Ruiz, E. J., et al. (2017). Nitric oxide mediates aortic disease in mice deficient in the metalloprotease Adamts1 and in a mouse model of Marfan syndrome. *Nat Med*, 23: 200-212.

[91] De Bakey, M. E., Cooley, D. A., Creech, O., Jr. (1955). Surgical considerations of dissecting aneurysm of the aorta. *Ann Surg*, 142: 586-610; discussion, 611-2.

[92] Beall, A. C., Jr., Lewis, J. M., Weibel, J., et al. (1966). Angiographic evaluation of the vascular surgery patient. *Surg Clin North Am*, 46: 843-62.

[93] Coady, M. A., Rizzo, J. A., Goldstein, L. J., et al. (1999). Natural history, pathogenesis, and etiology of thoracic aortic aneurysms and dissections. *Cardiol Clin*, 17: 615-35; vii.

[94] Larson, E. W., Edwards, W. D. (1984). Risk factors for aortic dissection: a necropsy study of 161 cases. *Am J Cardiol*, 53: 849-55.

[95] Coady, M. A., Rizzo, J. A., Elefteriades, J. A. (1999). Pathologic variants of thoracic aortic dissections. Penetrating atherosclerotic ulcers and intramural hematomas. *Cardiol Clin*, 17: 637-57.

[96] Sundt, T. M. (2007). Intramural hematoma and penetrating atherosclerotic ulcer of the aorta. *Ann Thorac Surg*, 83: S835-41; discussion S846-50.

[97] Hagan, P. G., Nienaber, C. A., Isselbacher, E. M., et al. (2000). The International Registry of Acute Aortic Dissection (IRAD): new insights into an old disease. *JAMA*, 283: 897-903.

[98] Fattori, R., Tsai, T. T., Myrmel, T., et al. (2008). Complicated acute type B dissection: is surgery still the best option?: a report from the International Registry of Acute Aortic Dissection. *JACC Cardiovasc Interv*, 1: 395-402.

[99] Umana, J. P., Lai, D. T., Mitchell, R. S., et al. (2002). Is medical therapy still the optimal treatment strategy for patients with acute type B aortic dissections? *J Thorac Cardiovasc Surg*, 124: 896-910.

[100] Eggebrecht, H., Nienaber, C. A., Neuhauser, M., et al. (2006). Endovascular stent-graft placement in aortic dissection: a meta-analysis. *Eur Heart J*, 27: 489-98.

[101] Erbel, R., Alfonso, F., Boileau, C., et al. (2001). Diagnosis and management of aortic dissection. *Eur Heart J*, 22: 1642-81.

[102] Tsai, T. T., Nienaber, C. A., Eagle, K. A. (2005). Acute aortic syndromes. *Circulation*, 112: 3802-13.

[103] Patel, H. J., Williams, D. M., Meerkov, M., et al. (2009). Long-term results of percutaneous management of malperfusion in acute type B aortic dissection: implications for thoracic aortic endovascular repair. *J Thorac Cardiovasc Surg*, 138: 300-8.

[104] Adams, J. D., Garcia, L. M., Kern, J. A. (2009). Endovascular repair of the thoracic aorta. *Surg Clin North Am*, 89: 895-912, ix.

[105] Coselli, J. S., LeMaire, S. A., de Figueiredo, L. P., et al. (1997). Paraplegia after thoracoabdominal aortic aneurysm repair: is dissection a risk factor? *Ann Thorac Surg*, 63: 28-35; discussion 35-6.

[106] Cunningham, J. N., Jr., Laschinger, J. C., Spencer, F. C. (1987). Monitoring of somatosensory evoked potentials during surgical procedures on the thoracoabdominal aorta. IV. Clinical observations and results. *J Thorac Cardiovasc Surg*, 94: 275-85.

[107] Safi, H. J., Hess, K. R., Randel, M., et al. (1996). Cerebrospinal fluid drainage and distal aortic perfusion: reducing neurologic complications in repair of thoracoabdominal aortic aneurysm types I and II. *J Vasc Surg*, 23: 223-8; discussion 229.

[108] Schepens, M. A., Heijmen, R. H., Ranschaert, W., et al. (2009). Thoracoabdominal aortic aneurysm repair: results of conventional open surgery. *Eur J Vasc Endovasc Surg*, 37: 640-5.

[109] Corvera, J., Copeland, H., Blitzer, D., et al. (2017). Open repair of chronic thoracic and thoracoabdominal aortic dissection using deep hypothermia and circulatory arrest. *J Thorac Cardiovasc Surg*, 154: 389-395.

[110] Verdant, A. (2010). Contemporary results of standard open repair of acute traumatic rupture of the thoracic aorta. *J Vasc Surg*, 51: 294-8.

[111] Sandrio, S., Karck, M., Gorenflo, M., et al. (2014). Results of using cardiopulmonary bypass for spinal cord protection during surgical repair of complex aortic coarctation. *Cardiol Young*, 24: 113-9.

[112] Nakamura, E., Nakamura, K., Furukawa, K., et al. (2018). Selection of a Surgical Treatment Approach for Aortic Coarctation in Adolescents and Adults. *Ann Thorac Cardiovasc Surg*, 24: 97-102.

[113] Harky, A., Kai Chan, J. S., Ming Wong, C. H., et al. (2019). Open versus Endovascular Repair of Descending Thoracic Aortic Aneurysm Disease: A Systematic Review and Meta-analysis. *Ann Vasc Surg*, 54: 304-315 e5.

[114] Gopaldas, R. R., Huh, J., Dao, T. K., et al. (2010). Superior nationwide outcomes of endovascular versus open repair for isolated descending thoracic aortic aneurysm in 11,669 patients. *J Thorac Cardiovasc Surg*, 140: 1001-10.

[115] Cheng, D., Martin, J., Shennib, H., et al. (2010). Endovascular aortic repair versus open surgical repair for descending thoracic aortic disease a systematic review and meta-analysis of comparative studies. *J Am Coll Cardiol*, 55: 986-1001.

[116] Orandi, B. J., Dimick, J. B., Deeb, G. M., et al. (2009). A population-based analysis of endovascular versus open thoracic aortic aneurysm repair. *J Vasc Surg*, 49: 1112-6.

[117] Mokrane, F. Z., Revel-Mouroz, P., Saint Lebes, B., et al. (2015). Traumatic injuries of the thoracic aorta: The role of imaging in diagnosis and treatment. *Diagn Interv Imaging*, 96: 693-706.

[118] Lee, W. A., Matsumura, J. S., Mitchell, R. S., et al. (2011). Endovascular repair of traumatic thoracic aortic injury: clinical practice guidelines of the Society for Vascular Surgery. *J Vasc Surg*, 53: 187-92.

[119] Arthurs, Z. M., Starnes, B. W., Sohn, V. Y., et al. (2009). Functional and survival outcomes in traumatic blunt thoracic aortic injuries: An analysis of the National Trauma Databank. *J Vasc Surg*, 49: 988-94.

[120] Eghbalzadeh, K., Sabashnikov, A., Zeriouh, M., et al. (2018). Blunt chest trauma: a clinical chameleon. *Heart*, 104: 719-724.

[121] Patterson, B. O., Holt, P. J., Cleanthis, M., et al. (2012). Imaging vascular trauma. *Br J Surg*, 99: 494-505.

[122] Starnes, B. W., Lundgren, R. S., Gunn, M., et al. (2012). A new classification scheme for treating blunt aortic injury. *J Vasc Surg*, 55: 47-54.

[123] Rabin, J., DuBose, J., Sliker, C. W., et al. (2014). Parameters for successful nonoperative management of traumatic aortic injury. *J Thorac Cardiovasc Surg*, 147: 143-9.

[124] Voitle, E., Hofmann, W., Cejna, M. (2015). Aortic emergencies-diagnosis and treatment: A pictorial review. *Insights Imaging*, 6: 17-32.

[125] Harris, D. G., Rabin, J., Kufera, J. A., et al. (2015). A new aortic injury score predicts early rupture more accurately than clinical assessment. *J Vasc Surg*, 61: 332-8.

[126] Oberhuber, A., Erhard, L., Orend, K. H., et al. (2010). Ten years of endovascular treatment of traumatic aortic transection – a single centre experience. *Thorac Cardiovasc Surg*, 58: 143-7.

[127] Zipfel, B., Chiesa, R., Kahlberg, A., et al. (2014). Endovascular repair of traumatic thoracic aortic injury: final results from the relay endovascular registry for thoracic disease. *Ann Thorac Surg*, 97: 774-80.

[128] Tang, G. L., Tehrani, H. Y., Usman, A., et al. (2008). Reduced mortality, paraplegia, and stroke with stent graft repair of blunt aortic transections: a modern meta-analysis. *J Vasc Surg*, 47: 671-5.

[129] Xenos, E. S., Abedi, N. N., Davenport, D. L., et al. (2008). Meta-analysis of endovascular vs open repair for traumatic descending thoracic aortic rupture. *J Vasc Surg*, 48: 1343-51.

In: Encyclopedia of Surgery (22 Volume Set)
Editors: Andreas Lehrer and Kristin Mueller
ISBN: 978-1-53618-329-0
© 2020 Nova Science Publishers, Inc.

Chapter 287

ABDOMINAL AORTA, ILIAC, AND SPLANCHNIC ARTERIES

Vladimir Sihotsky*[*]*, MD, PhD
Department of Vascular Surgery,
East Slovak Institute of Cardiovascular Diseases,
Medical Faculty of Safarik University, Kosice, Slovakia

ABSTRACT

Surgery of the abdominal aorta, iliac, and splanchnic arteries is mainly performed due to occlusive disease or aneurysms. Aortoiliac atherosclerosis, the most common reason for the occlusive process, clinically presents as intermittent claudication or more advanced critical limb ischemia (CLI). The diagnosis is based on computed tomographic angiography (CTA) or conventional arteriography of the abdominal aorta and its branches. The treatment is indicated in clinical cases of limited claudication or CLI. The therapy may be endovascular or surgical. The gold standard of surgical reconstructions in the aortoiliac atherosclerosis is aortobifemoral bypass.

Atherosclerosis of splanchnic arteries leads to mesenteric ischemia. The treatment can be either interventional, which is the method of first choice, or surgical. Open surgical reconstructions for the mesenteric ischemia are targeted mainly at the superior mesenteric artery and may be an antegrade bypass, from the suprarenal aorta, or the retrograde bypass, mostly from the common iliac arteries.

An abdominal aortic aneurysm (AAA) is dangerous due to the risk of rupture, which has total mortality rate of 75%. The diagnosis of ruptured abdominal aortic aneurysm is based on a quick ultrasound or CTA. The treatment may be either endovascular or surgical. Both methods are possible and have comparable outcomes. Prevention of rupture is the treatment of AAA in the asymptomatic stage. For therapy in the asymptomatic stage are indicated aneurysms over 5.5 cm in transverse diameter. The crucial imaging study for the diagnosis of AAA is CTA. The treatments may be similarl to the ruptured aneurysms surgical or endovascular treatments. Endovascular aneurysmatic repair (EVAR) of AAA is less invasive but has worse long term durability compared to the open surgery. Thus, EVAR is indicated in patients with suitable aortic

[*] Corresponding Author's Email: vsihotsky@vusch.sk.

anatomy and the elderly. Open surgery may be considered as a method of first choice in younger patients with longer life expectancy. Aneurysms of splanchnic arteries may lead to severe bleeding. This treatment is indicated for symptomatic aneurysms and those aneurysms which are over 2 cm in transverse diameter.

Keywords: aortoiliac atherosclerosis, abdominal aortic aneurysm, mesenteric ischemia, splanchnic artery aneurysms

ABBREVIATIONS

AAA	Abdominal aortic aneurysm
ABI	Ankle-brachial index
ACE	Anevrysme de l'aorte abdominale
ARDS	Acute respiratory distress syndrome
CA	Celiac axis
CAD	Coronary artery disease
CFA	Common femoral artery
CIA	Common iliac artery
CLI	Critical limb ischemia
CT	Computed Tomography
CTA	Computed Tomographic Angiography
CVD	Cerebrovascular disease
DREAM	Dutch Randomized Endovascular Aneurysm Management
EIA	External iliac artery
EVAR	Endovascular aneurysm repair
ICA	Internal carotid artery
IMA	Inferior mesenteric artery
LDL	Low-density lipoprotein
MOF	Multiorgan failure
MRA	Magnetic resonance angiography
MRI	Magnetic Resonance Imaging
OVER	Open versus Endovascular Repair
PAD	Peripheral arterial disease
PET-CT	Positron Emission Tomography-Computed Tomography
PTFE	Polytetrafluoroethylene
RA	Renal arteries
SFA	Superficial femoral artery
SMA	Superior mesenteric artery
TACS	Trans-Atlantic Inter-Society Consensus
UKSAT	United Kingdom Small Aneurysm Trial
VAC	Vacuum-assisted closure

INTRODUCTION

Arterial reconstructions of the abdominal aorta, iliac, and splanchnic arteries are performed mainly due to aortoiliac atherosclerosis, as the obliterative disease and aortoiliac aneurysms. The first aortoiliac reconstruction was performed by Wylie in the U.S.A. In 1951, he made thrombendarterectomy of aortic bifurcation because of atherosclerotic obliteration [1]. The first reconstruction because of aortic aneurysm was done by Dubost in Paris in 1951 [2]. He reestablished the continuity after resection of a ruptured aortic aneurysm by a preserved human aortic graft. In 1954, De Backey and Cooley referred about six cases of ruptured aortic aneurysms to be also replaced by human aortic allografts [3].

However, further development of aortoiliac reconstruction was not possible because of the lack of human aortic allografts, which represented the only possibility of the restoration of the aortic flow. The situation was changed the invention of prosthetic grafts, constructed from Vinyon N by Vorhees in 1952 [4]. These grafts started to be widely used in the bridging of arterial defects and arterial reconstructions. The golden era of aortoiliac arterial reconstructions began with the invention of prosthetic grafts, and the aortobifemoral bypass started to become the "gold standard" of the surgical treatment of aortoiliac atherosclerosis [5]. The introduction of endovascular treatment of aortic pathologies was the second important factor that changed treatment possibilities. Gruntzig in 1974 was the first to do percutaneous transluminal angioplasty and started the modern era of endovascular treatment. At the beginning of the new millennium, the extensive development of interventional procedures changed approaches in the treatment of aortoiliac pathologies. Surgery is reserved only for patients with the most advanced disease. Aortoiliac reconstructions are performed as the surgical treatment of aortoiliac atherosclerosis that cannot be treated endovascularly, mainly TACS D patients, according to the TASC classification [6].

The surgical treatment of AAA is indicated for patients with an asymptomatic AAA with more than 5.5 cm in the transverse diameter or patients with ruptured aneurysms [7]. Endovascular treatment of asymptomatic or ruptured AAA should be indicated for patients with appropriate anatomy of AAA, but results of trials are conflicting and do not prefer a stentgraft placement [8, 9]. Arterial reconstructions at visceral branches of the abdominal aorta are not commonly performed. The primary indication of them is chronic visceral ischemia and visceral aneurysms.

AORTOILIAC OCCLUSIVE DISEASE: GENERAL CONSIDERATIONS

Etiology

The common reason of walking disability is chronic lower extremity ischemia. Typical symptoms include claudication and critical limb ischemia. These symptoms are caused by peripheral arterial disease (PAD), the disease which is characteristic for older patients. The United States National Health and Nutrition Examination Survey reported a 4.3% prevalence of PAD in the overall population, and 14.5% in patients more than 69 years old [10]. PAD is defined when an ankle-brachial index (ABI) is less than 0.9 even if the symptoms are not present [11]. The most common reason for PAD is aortoiliac and peripheral artery

atherosclerosis. The other causes are thromboangiitis obliterans, fibromuscular dysplasia, popliteal aneurysms, and entrapment syndrome are much less common [6].

The risk factors for peripheral artery atherosclerosis are male gender, smoking, diabetes, dyslipidemia, old age, hypertension, hyperhomocysteinemia, and renal insufficiency and are similar to the general atherosclerotic risk factors [12, 13, 14]. Thus, patients with PAD have cerebrovascular disease (CVD) and coronary artery disease (CAD) more often than the rest population [15].

Pathology

The main reason for aortoiliac occlusive disease is atherosclerosis and is often combined with infrainguinal atherosclerosis. The aortoiliac disease typically begins at the distal aorta and the common iliac artery origins and slowly progresses proximally and distally. Some theories are trying to explain why namely the distal aorta is confined by aortoiliac atherosclerosis. The explanation may be the fact that laminar blood flow changes to turbulent flow on the aortic bifurcation and continues distally along the common iliac arteries. The turbulent flow may increase share stress at the endothelium and result in small ruptures that lead to the development of atherosclerosis. The disease slowly progresses and may lead to total aortic occlusion. Collateral circulation has time for development. The primary compensatory networks develop from the lumbar and hypogastric vessels and connect to circumflex iliac, hypogastric, femoral, and deep femoral arteries. In more advanced obstructions, collaterals include the internal mammary artery–to–inferior epigastric arteries and the superior mesenteric artery–to–inferior mesenteric artery and hemorrhoidal artery pathway. The latter collateral comprises the arc of Riolan and the inferior mesenteric artery. It is necessary to recognize the presence of such significant collaterals because it should be preserved during operation [16].

Brewster divides aortoiliac atherosclerosis into three types (Figure1) [16]:

Type I, the localized disease, is confined to the distal abdominal aorta and common iliac arteries.

Type II, the more widespread intra-abdominal disease, is present.

Type III, the pattern denotes multilevel disease with associated infrainguinal occlusive lesions.

The incidence of type I is about 10%. This type has developed a good collateral system; the distal arterial system is not involved by atherosclerosis and thus lead rarely to critical limb ischemia. This type is typical for younger individuals with less underlying disease and smokers. Type II occurs in about 25% and type III in about 65% of patients. These types are more typical for men. Patients with type II and type III are typically older and are much more likely to have underlying diseases such as hypertension, diabetes, and associated atherosclerotic disease of cerebral, coronary, and splanchnic arteries. Progression of the arterial occlusive process is also more likely in such patients than in patients with the more localized aortoiliac disease. For these reasons, most patients with type III have symptoms of more advanced ischemia, such as ischemic rest pain or ischemic tissue necrosis [16, 17].

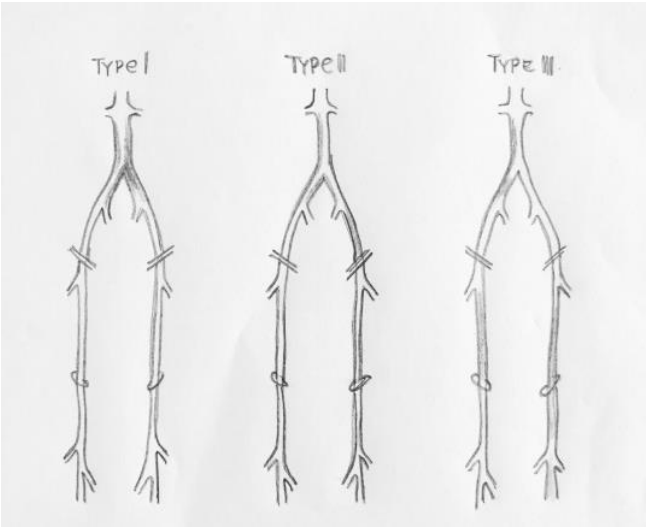

Figure 1. Three types of Brewster's classification.

Clinical Manifestation

Patients with aortoiliac atherosclerosis and hemodynamic impairment may present with typical claudication of the calf alone or also with the involvement of the thigh, hip, or buttock. About 5% of patients with limb claudication proceed yearly to critical limb ischemia.

Critical limb ischemia (CLI) is a more advanced stage of aortoiliac atherosclerosis and is typical for more advanced atherosclerosis, also involving infrainguinal arteries (type II and type III of aortoiliac atherosclerosis). The CLI manifests as rest pain and ischemic ulceration or gangrene of the forefoot or toes, representing a reduction in distal tissue perfusion below resting metabolic requirements (Figure 2). The clinical diagnosis is objectively confirmed by hemodynamic measurements such as systolic ankle pressure less than 50 mm Hg and toe pressure less than 30 mm Hg [18].

There are two main widely used classification of arterial occlusive disease symptoms. The Fountaine classification is more used in Europe, while the Rutherford classification more used in the United States.

The Fontaine classification describes four stages of the arterial occlusive disease [19]:

Stage I – Asymptomatic

Stage I includes patients who are asymptomatic for most of the time, but in whom a thorough history may reveal non-specific, subtle symptoms, such as paresthesia. Physical examination may reveal cold extremities, reduced peripheral pulse, or murmurs in the peripheral arteries.

Stage II – Intermittent claudication. Patients often have a constant distance at which the pain appears:

Stage IIa – Intermittent claudication after more than 200 m of walking.

Stage IIb – Intermittent claudication after less than 200 m of walking.

Stage III – Rest pain. Rest pain appears mainly in the night when the legs are raised on to the bed, which decreases the gravitational effect present by day. Also during the night, the lack of sensory stimuli allows patients to concentrate on their legs.

Stage IV – Ischaemic ulcers or gangrene (which may be dry or wet).

The Rutherford classification describes seven stages of peripheral artery disease [20, 21]:

Stage 0 – Asymptomatic.

Stage 1 – Mild claudication.

Stage 2 – Moderate claudication – the distance that delineates mild, moderate, and severe claudication are not specified in the Rutherford classification, as it is in the Fontaine classification.

Stage 3 – Severe claudication.

Stage 4 – Rest pain.

Stage 5 – Ischemic ulceration not exceeding ulcers of the digits of the foot.

Stage 6 – Severe ischaemic ulcers or frank gangrene.

About 30% of male patients may have problems achieving an erection due to inadequate pelvic perfusion. Symptoms associated with terminal aortic occlusion are thigh, hip, or buttock claudication, atrophy of the leg muscles, impotence, and reduced femoral pulses are described as Leriche's syndrome.

Figure 2. Critical limb ischemia. CLI of the right lower limb, wet gangrene at the third and the fourth finger, stage IVb of Fontaine classification.

Diagnosis

The diagnosis of aortoiliac atherosclerosis can be made based on a history of claudication and absence of femoral pulses.

The ankle-brachial index (ABI) is determined by dividing the systolic pressure obtained by Doppler insonation at the ankle by the brachial arterial pressure. Usually, the ABI is 1.0, or a value below 0.90 which indicates occlusive disease. Any patient who has an ankle-brachial index (ABI) of less than 0.90 has significant PAD, even if the symptoms are absent.

Imaging Studies

Color duplex ultrasound can supply sufficient information to permit intervention in selected cases. Duplex ultrasound is considered the first line examination before more invasive methods like CT-angiography or conventional angiography.

CTA is useful for imaging the arterial tree (Figure 3). CTA has improved and is the dominant preoperative imaging modality for aortic aneurysm disease today, but infrainguinally, the caliber of the arteries and the presence of calcification in vessels, especially in diabetic patients, may limit the ability of computed tomographic angiography.

Magnetic resonance angiography (MRA) is continually improving and can be used to obtain images similar in quality to angiography in most cases. MRA does not show calcifications and gives a better visualization of crural vessels than CTA.

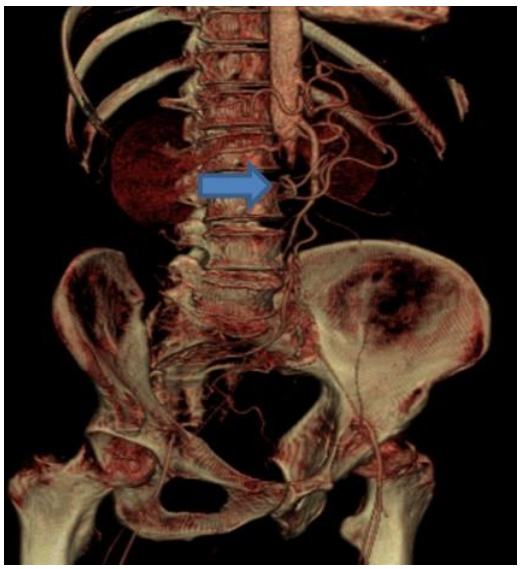

Figure 3. CT angiography, 3D reconstruction, of subrenal occlusion of the abdominal aorta due to aortoiliac atherosclerotic disease. The occlusion is marked by an arrow.

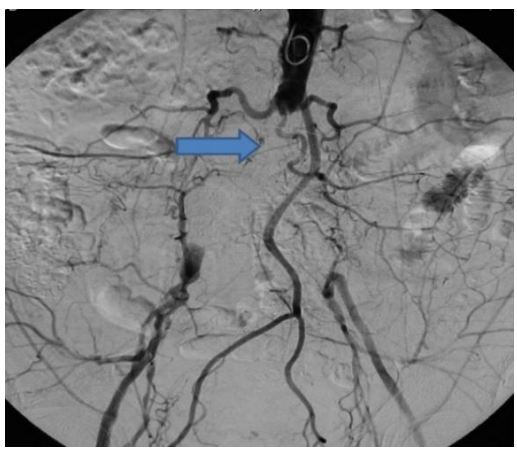

Figure 4. Arteriography (angiography), chronic occlusion of the distal abdominal aorta (marked by an arrow).

Conventional arteriography (angiography) provides detailed anatomic information about the aortoiliac and peripheral arterial disease, more precise compared to CTA or MRA. Aortoiliac surgery can be planned based on good-quality CTA or MRA, but conventional arteriography remains the "gold standard " of preoperative imaging before aortoiliac arterial reconstruction, especially for the patients with CLI and infrainguinal disease (Figure 4). The definitive distinction about the imaging study should be left on the operating surgeon [22].

Treatment

Nonoperative Treatment

Patients with claudication seek treatment for the relief of limiting pain. These patients exhibit a more benign form of atherosclerosis concerning limb viability, with amputation rates of 1% to 7% at five years. The natural history of untreated CLI is more dangerous and leads to limb loss more frequently than does claudication. Patients with CLI have a limb loss rate of about 25% in one year [6].

Nonoperative treatment is based on:

1. Reduction of cardiovascular risk factors – all patients should stop smoking. Reduction of elevated lipid levels. Statins are extremely useful in reducing LDL cholesterol
2. Exercise rehabilitation for claudicants – exercise ranging from unsupervised walking to regular supervised training on a treadmill significantly improves walking ability During every session, the patient should be asked to walk until the limit of lower limb pain is reached, followed by a short period of rest till pain relief is achieved, then a return to exercise.
3. Pharmacotherapy – for aortoiliac occlusive disease represents the antiplatelet agents, aspirin, clopidogrel. Only pentoxifylline and cilostazol have achieved importance in the treatment of intermittent claudication. Pentoxifylline produces a modest improvement in walking distance, but some patients experience substantial long-term symptom relief with pentoxifylline, while others do not [5]. Cilostazol is a phosphodiesterase III inhibitor with a vasodilator, antiplatelet, and antilipid activity. Cilostazol also inhibits smooth muscle cell proliferation and platelet aggregation [5]. Cilostazol has shown increased maximal walking distances up to 50% and also significant improvements in health-related quality of life [5]. Despite the improving results of pharmacotherapy, remain endovascular and surgical revascularization, essential treatment modalities for patients with symptomatic aortoiliac atherosclerosis.

Indication for Invasive Treatment

Indication for arterial reconstructions in patients with the aortoiliac occlusive disease is disabling claudication or CLI. Disabling claudication is a relative indication and means the claudication that limits patients in everyday life. The annual rate of limb loss in patients with claudication is about 1% [22]. The indication for arterial reconstruction should take into account patients age, overall status, and underlying diseases. For example, for a 50-year-old

patient who is active, claudications after 200 m may be disabling, while for an older individual claudications after 50 meters may not represent limitations in everyday activities. The decision for endovascular or surgical treatment should be carefully and individually considered.

Endovascular Treatment

Approximately 70-80% of PAD patients indicated to invasive treatment are managed endovascularly, the rest of 20-30% patients are treated surgically. The decision of surgical or endovascular treatment is made according to TACS (Trans-Atlantic Inter-Society Consensus) criteria [6]. The TASC working group has classified anatomic patterns of disease involvement (types A through D) for the aortoiliac (Figure 5-8) segments, based on recommended treatment (endovascular versus open surgery). The TASC working group advocated endovascular treatment for TASC type A lesions and surgical treatment for TASC type D lesions. For TASC type B and C lesions, the authors concluded that there was insufficient evidence to recommend one modality over the other definitively [6].

TYPE A LESIONS (Figure 5) [6]

- Unilateral or bilateral stenoses of the common iliac artery
- Unilateral or bilateral single short (3 cm) stenosis of the external iliac artery (EIA)

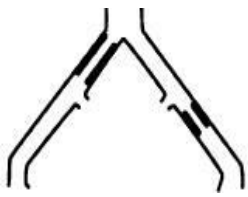

Figure 5. Type A lesion of TASC Classification.

TYPE B LESIONS (Figure 6) [6]

- Short (3 cm) stenosis of the infrarenal aorta
- Unilateral common iliac artery (CIA) occlusion
- Single or multiple stenoses totaling 3−10 cm involving the EIA not extending into the common femoral artery (CFA)
- Unilateral EIA occlusion not involving the origins of internal iliac or CFA

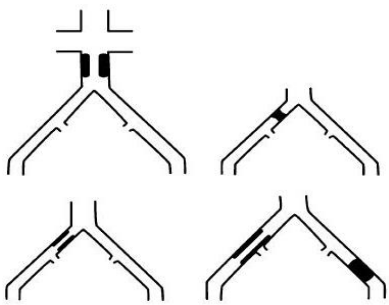

Figure 6. Type B lesions of TASC Classification.

TYPE C LESIONS (Figure 7) [6]

- Bilateral CIA occlusions
- Bilateral EIA stenoses 3–10 cm long not extending into the CFA
- Unilateral EIA stenosis extending into the CFA
- Unilateral EIA occlusion that involves the origins of internal iliac and/or CFA
- Heavily calcified unilateral EIA occlusion with or without the involvement of origins of internal iliac and/or CFA

Figure 7. Type C lesions of TASC Classification.

TYPE D LESIONS (Figure 8) [6]

- Infrarenal aortoiliac occlusion
- Diffuse atherosclerotic disease involving the aorta and both iliac arteries requiring treatment
- Diffuse multiple atherosclerotic stenoses involving the unilateral CIA, EIA, and CFA
- Unilateral occlusions of both CIA and EIA
- Bilateral occlusions of EIA
- Iliac stenoses in patients with AAA requiring treatment and not amenable to endograft placement or other lesions requiring open aortic or iliac surgery

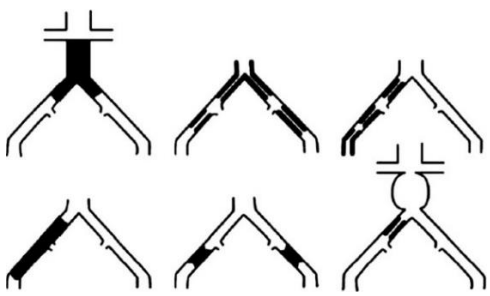

Figure 8. Type D lesions of TASC Classification.

Endovascular therapy consists of image-guided techniques to treat diseased arterial segments from within the lumen of the vessel. Access to the arterial system is established by the insertion of valved sheaths, usually percutaneously, often through the common femoral artery. Once the target lesion is accessed, therapeutic maneuvers, such as angioplasty, or devices, such as stents, can be delivered. In many arterial beds, endovascular therapy is more commonly utilized than open surgical treatment because of its minimally invasive nature and reduction of short-term morbidity and mortality. Percutaneous transluminal angioplasty, with or without placement of an intravascular stent, is often the treatment of choice when the

stenoses or even occlusions are relatively short and localized. Stents and stentgrafts are commonly used from the aortic bifurcation to the distal popliteal artery. For short stenotic segments in larger, more proximal vessels, the results of endovascular therapies are good with 1- year success rates of 85% in common iliac disease and 70% in external iliac disease. The success of endovascular treatment for lower extremity occlusive disease is inversely related to the complexity of the lesion.

Finally, the selection of the best method of revascularization for a patient with claudication is based on a balance between the risks of the specific intervention and the durability of improvement that can be expected from the intervention. Thus, the natural history of claudication is relatively benign; that balance usually does not favor open surgery. In contrast, its relatively low morbidity and mortality make endovascular therapy particularly attractive, and when it is anatomically feasible, endovascular treatment is generally preferred to open surgery for most cases of claudication. Usually, short stenoses and occlusions are treated endovascularly. However, the longer and multiple occlusions and lesions that cannot be treated interventionally are indicated for surgery.

AORTOILIAC OCCLUSIVE DISEASE: SURGICAL TREATMENT

Preoperative Management

Careful evaluation of the factors that influence operative risk and postoperative complications is an essential component of the surgical management of the aortoiliac occlusive disease. Patient selection for surgery should be based on an assessment of the patient's underlying conditions, functional limitations, and life expectancy. Particular attention should be given to those patients with the identified risk factors of cardiac, renal, or pulmonary disease. Almost half of the patients undergoing surgery for the aortoiliac occlusive disease have coronary artery disease [23]. Comorbidities such as cerebrovascular, hepatic, and hematologic, should also be evaluated [22].

Aortic or Bilateral Iliac Artery Occlusion

Aortoiliac Endarterectomy

Aortoiliac endarterectomy, the first arterial reconstruction performed in this region, was introduced by Wyllie in 1951 [1]. During the next decade, endarterectomy became the standard surgical treatment therapy for severe aortoiliac occlusive disease. The further introduction of prosthetic grafts led to the development of aortic bypass grafting techniques. The indisputable advantage of endarterectomy is the absence of a prosthetic graft, eliminating the risk of infectious complications associated with use of prosthetic grafts. Aortoiliac endarterectomy is technically more demanding than bypass surgery but can be an alternative for younger patients with longer life expectancy (Figure 9).

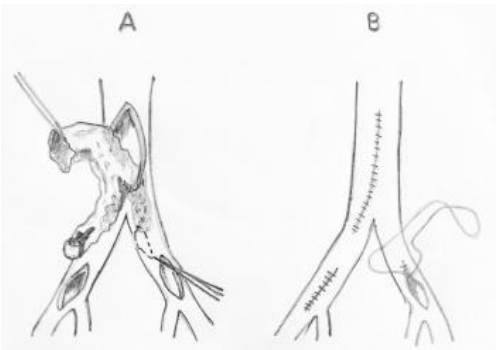

Figure 9. An aortoiliac endarterectomy.

Aortobifemoral Bypass

The "gold standard" of aortoiliac reconstructions is aortobifemoral bypass. The goal of this operation is the restoration of blood flow from the subrenal aorta to both common and deep femoral arteries.

Figure 10. Aortobifemoral bypass: an end-to-side anastomosis.

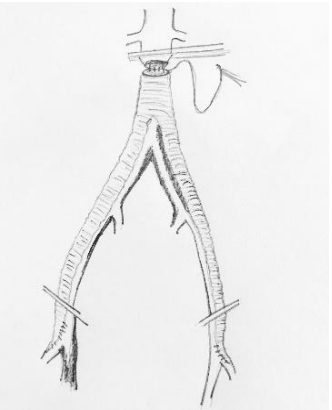

Figure 11. Aortobifemoral bypass: an end-to-end anastomosis.

The operation is performed under general anesthesia, mainly from the transperitoneal approach. For the purpose reverse, bifurcated prosthetic grafts are used. Dacron grafts are favored to the PTFE grafts. The proximal anastomosis is placed on the subrenal aorta, and the distal anastomoses are targeted at the femoral arteries. The proximal anastomosis is usually constructed in an "end-to-side" manner that enables restoration of the blood flow distally to the inferior mesenteric artery and also to the internal iliac arteries (Figure 10). The anastomosis is performed in an "end-to-end" manner in cases of concomitants aneurysmatic dilatation of the aorta (Figure 11). The disadvantage of the "end-to-end" anastomosis is the decrease of the blood flow to the inferior mesenteric and pelvic arteries that may lead to mesenterial or pelvic ischemia. The distal anastomoses are targeted to the common femoral artery. It is crucial to perform adjunctive profundoplasty to place the tip of the distal anastomosis at the deep femoral artery (Figure 12). This type of the distal anastomosis preserves the long term patency of bypasses, especially in the individuals with the occluded superficial femoral artery (SFA) [22].

The long term results of the aortobifemoral bypasses are excellent. The five-year patency is 85%-90% and the ten-year patency is 75-85% [22]. Perioperative mortality is low, about 1-2% [22].

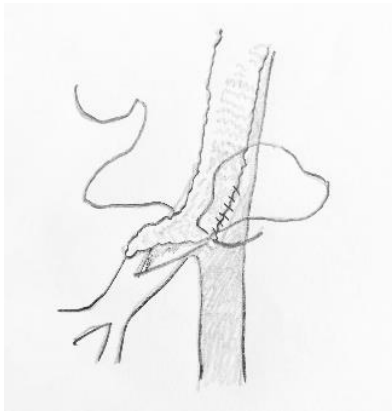

Figure 12. Adjunctive profundoplasty.

Multilevel Occlusive Disease

In patients with synchronous aortoiliac occlusive and superficial femoral artery (SFA) disease, we prefer to perform the first step aortobifemoral bypass with adjunctive profundoplasty. Almost 80% of patients with multilevel occlusive disease manifest symptomatic improvement after aortobifemoral bypass grafting alone, and they do not require further revascularisation of SFA [24].

Retroperitoneal Approach

The retroperitoneal approach to the infrarenal aorta is a well-accepted alternative to the transperitoneal technique. This option may be advantageous in patients with a history of previous abdominal operations, or severe cardiopulmonary disease. The literature has not consistently supported reported benefits of reduced pulmonary morbidity and lower rates of postoperative bowel obstruction. The main disadvantage of the retroperitoneal approach

represents the difficulty in accessing the right renal and iliac arteries and the right groin, particularly in obese patients [25].

Unilateral iliac Artery Occlusion

Unilateral iliac artery occlusion can be treated endovascularly. When the lesion is classified as TASC C or D stage (Figure 13), surgery is the preferred option. Options of surgical therapy are:

1. Direct iliac endarterectomy
2. Iliofemoral bypass
3. Extra-anatomic cross over femorofemoral bypass.

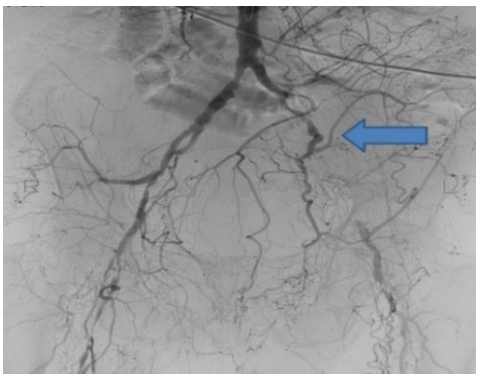

Figure 13. Arteriography (angiography), aortoiliac occlusive disease. Multiple severe stenoses of iliac arteries. Occlusion of the left external iliac artery (marked by an arrow) and severe stenoses of the right common and external iliac artery.

1. The direct iliac endarterectomy can be considered in younger patients, similarly to aortoiliac endarterectomy. We can solve long occlusions of CIA and AIE. Direct iliac endarterectomy is performed from a retroperitoneal approach. Endarterectomy of the CIA is done from a longitudinal incision at the artery. Endarterectomy of the EIA can be done either from the groin by Volmar loop endarterectomy or from the longitudinal incision at the EIA. Vessels are sutured directly after the endarterectomy. Groin incisions are often necessary for both situations to fix the intimal flap at the CFA distally. The advantage of the procedure is the absence of any prosthetic material and reduced risk of infectious complications. After direct iliac endarterectomy, there is the remaining possibility to perform the aortobifemoral bypass. The disadvantages of the procedure are the facts that the operation is demanding from a technical point of view and necessity of the retroperitoneal approach. We chose this possibility in the case of the unilateral iliac lesion, which cannot be treated endovascularly, and the patients are fit for a retroperitoneal approach. This operation may be bringing therapy to the definitive aortobifemoral bypass.

2. The unilateral iliofemoral bypass is performed more rarely than the aortobifemoral bypass. Hence, it does not solve the apparent atherosclerotic stenosis at the aortic division and also has the disadvantages of using prosthetic material and demanding retroperitoneal approach. This procedure can resolve the situation when the direct iliac endarterectomy from the retroperitoneal incision is not technically feasible. This reconstruction is performed usually using dacron graft.
3. The femorofemoral cross over bypass is the most commonly used extra-anatomic bypass. The main advantage of the bypass is that it can be constructed from the inguinal incision. The reconstruction does not require a peritoneal or retroperitoneal incision and thus is less invasive. This bypass is an excellent solution for patients who are not fit for aortic surgery. The operation is started by inguinal incision at the site of the patent iliac and femoral artery. When the quality of the pulse is sufficient, we can perform contralateral inguinal incision and find the appropriate segment of the common femoral or the deep femoral artery with good outflow. The bypass is performed mainly with armored Dacron grafts and maybe in "U," "inverted C" (Figure 14) or "S" configuration. We prefer the "S" configuration of bypasses when the anastomosis at the donor femoral artery is placed proximally to the distal anastomosis. In this situation the angle of the proximal anastomosis is more appropriate. The bypass may also be constructed with the great saphenous vein. We chose the great saphenous vein as the graft when there is a high risk of infection or when the inflow and outflow parameters for the reconstruction are not optimal (Figure 15). The venous cross over bypass is a better solution for patients with not optimal donor iliac artery and also with SFA occlusion at the donor or recipient site.

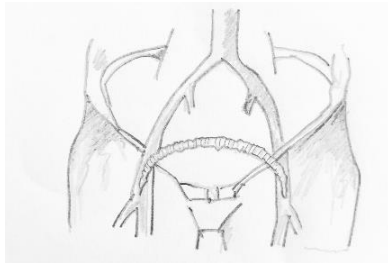

Figure 14. "Inverted C" configuration of a femorofemoral cross over bypass.

Figure 15. Arteriography (angiography): "U" configuration of a venous femorofemoral cross over bypass.

The perioperative mortality of femorofemoral cross over the bypass is dependent on patient selection but should be under 5% in elective operations. The primary and secondary patency of femorofemoral cross over bypass at five years is about 60% and 70%, respectively [22].

Complications after Aortoiliac Reconstructions

Early Complications

Morbidity after aortic surgery for the occlusive disease is reported at 17% to 32% [22]. Cardiac complications are the most common reason for mortality, followed by pulmonary complications [26]. Cardiac complications result from the hemodynamic stress associated with the operation and the obligatory fluid shifts in the early postoperative period. Myocardial infarction occurs up to 5%, and prevention is the use of the antiplatelet drug.

Pulmonary complications occur in elderly patients and those with chronic obstructive pulmonary disease, a history of smoking, or poor preoperative nutrition [27]. The incidence is up to 7%, and postoperative rehabilitation and exercises are essential in the prevention.

Renal failure can occur due to perioperative blood loss and hypotension after aortic declamping. This complication occurs in 1-8% and can lead to hemodialysis [22].

Bleeding is a severe complication after aortic surgery, occurs up to 2%, and can lead to hemorrhagic shock with fatal consequences when not treated [28]. The most dangerous is anastomotic bleeding that requires immediate surgery with additional hemostatic stitches at the anastomotic site. Aortic surgery can be associated with hypocoagulation status, especially when the heparin reversal is not complete. This situation can be treated conservatively with fresh frozen plasma. Bleeding, which continues after conservative treatment, requires surgery.

Acute limb ischemia occurs up to 3% after aortoiliac reconstructions and can be due to graft occlusion or distal embolization. The treatment is surgical thrombectomy of the graft.

Lesion of the ureter is another major complication after aortic surgery, which occurs only in 1% of cases and is caused by direct injury during the operation [22]. The treatment is the reconstruction of the ureter.

Left colon ischemia is another dangerous complication and can lead to left colon necrosis with fatal consequences. The incidence of complication is up to 2% [29]. It is crucial to preserve the patency of at least one or both the internal iliac arteries or inferior mesenteric artery.

Paraplegia after aortic surgery can occur in 0.25% of cases and is due to diminished blood flow in lumbar and internal iliac arteries during aortic clamping

Late Complications

Graft occlusion is the most common late complication. It can be seen in as many as 30% of patients after ten years [22]. Occlusion of the whole graft, in the case of the aortobifemoral bypass, is rare. Much more common is occlusion of only one limb. The reason is neointimal hyperplasia or the development of atherosclerosis at the distal anastomosis. The graft occlusion presents clinically as acute limb ischemia. The treatment is graft thrombectomy, and the stenosis of the distal anastomosis which usually requires an interposed graft at the next patent segment of the deep femoral artery.

Anastomotic false aneurysms are rare in the modern era compared with the early experience of aortic surgery, but they can be seen as a late complication in 1% to 5% of cases [30]. They appear secondary to a weakening in the suture line as a result of structural fatigue or fabric degeneration. However, they may be a first sign of the graft infection.

Graft infection is one of the most dangerous complications of aortic surgery and is associated with high morbidity and mortality. Incidence of graft infections is reported in up to 1.5% of cases [31]. The reasons for graft infections can be perioperative contamination of the graft with microbes. For example, perioperative contact with patient's skin can lead to graft infection. Gastrointestinal procedures concomitant to vascular surgery can also lead to perioperative contamination of the graft. Direct contact of the small intestine and the graft may lead to communication and graft-enteric fistula with the consequence of the graft infection. Also, repeated groin incisions may lead to graft infection. Graft infection leads to chronical sepsis, and the most dangerous complications are the graft-enteric fistula with severe bleeding into the gastrointestinal tract. The diagnosis is based on CT or PET-CT imaging. The graft infection is complicated to treat and is associated with mortality of up to 20% [31].

Only isolated groin infections can be treated with antibiotics, and vacuum-assisted closure device (VAC) Removal of the whole graft is often necessary. The continuity of the aortic flow and the blood supply to the lower limbs must be restored. The blood flow to the lower extremities can be ensured by an extra-anatomic axillobifemoral bypass or in situ bypasses with the graft constructed from the deep femoral vein. Another possibility of in situ reconstructions is to use human aortic allografts or xenografts, mainly bovine xenopericardial grafts. Intravenous antibiotic treatment is mandatory at least at six weeks. In the cases of graft-enteric fistula, the defect at the small intestine or duodenum must be sutured or resected [32].

ABDOMINAL AORTIC ANEURYSM: GENERAL CONSIDERATIONS

An enlargement of an artery to at least 1.5 times its standard diameter is defined as an aneurysm [33]. The expanding vessel elongates as well as dilates. A true aneurysm involves intima, media, and adventitia. A false aneurysm, also called pseudoaneurysm, is characterized by a disruption of the arterial wall, which does not include all layers of the wall, and a possible pulsatile hematoma not contained by the artery wall but by a fibrous capsule. A false aneurysm caused by infection is called a mycotic aneurysm. Aneurysm of the abdominal aorta (AAA) is dilatation of the abdominal aorta to over 3 cm in transverse diameter.

Epidemiology

Abdominal aortic aneurysms are found in 2% of the elderly male population. The incidence is higher of patients with coronary artery disease (5%). In the U.S., ruptured AAA is the 13th leading cause of death overall and the third leading cause of death in men's population older than 65 years [34]. As many as 50% of patients with femoral or popliteal aneurysms have aortic aneurysms. About 60% percent of patients with the AAA have an aneurysm in other localization, mainly iliac aneurysms, but also popliteal or thoracic. Ninety-

five percent of aneurysms of the abdominal aorta begins distally to the renal arteries. They are called infrarenal aneurysms of the abdominal aorta [33].

Etiology

Majority of AAAs are of atherosclerotic (degenerative) origin. The relationship of atherosclerosis to aneurysm creation is complicated, but both aneurysms and obliterative manifestations can be found in the same patient. Activation of metalloproteinases in the media can lead to proteolysis and degradation of the aortic wall [35].

Aneurysms of the abdominal aorta can also be of inflammatory origin and are associated with an inflammatory component, which often starts a fibrotic reaction around the aneurysm and can lead to ureteral obstruction as the process. The precise etiology of inflammatory aneurysms is not clear [36].

Infectious AAA may result from a primary infection of the aortic wall and also can be caused by blood-borne seeding of an infectious process. Infectious aortic aneurysms are caused mainly by the Salmonella species [33].

Also, injuries can lead to the formation of posttraumatic false aneurysms. A particular type of AAA are aneurysms caused by abnormalities of connective tissue as Marfan's syndrome and Ehlers-Danlos syndrome [33].

Risk Factors

Plenty of mechanisms have been proposed as the cause of abdominal aortic aneurysms. In terms of risk factors, cigarette smoking has a powerful influence on developing an aortic aneurysm, with an 8:1 preponderance of AAAs in smokers compared with nonsmokers. So-called "hard" risk factors for the development of AAAs are smoking, male gender, and hypertension [33]. Patients with AAA are elderly, and thus have more underlying diseases such as coronary artery disease, hypertension, and pulmonary disease.

Aneurysm Rupture Risk

Risk of rupture increases with the transverse diameter of AAA. Data derived from The United Kingdom Small Aneurysm Trial (UKSAT) have shown the most complex estimates of aneurysm rupture risk in patients randomized to nonoperative management. The UKSAT was the first randomized trial that compared early open repair with surveillance for AAAs. The study showed a low risk of rupture in aneurysms below 5cm in transverse diameter and relatively high risk of rupture in aneurysms in transverse diameter over 6.0cm (Table 1). The operative mortality of patients undergoing surgery was 5.8% in this trial [37] The UKSAT, and also further studies showed that there is no benefit for surgery in asymptomatic aneurysms in diameter below 5.5 cm [37, 38]. This data led to current recommendations for surgical treatment in aneurysms over 5.5 cm in transverse diameter for men and over 5.0 cm in transverse diameter for women, or enlargement over 1.0 cm during one year [39].

Table 1. Range of rupture rates for a given diameter of AAA [33]

AAA diameter (cm)	Annual rupture risk (%)
3.0-3.9	0.3
4.0-4.9	0.5-1.5
5.0-5.9	1.0-11
6.0-6.9	11-22
over 7.0	over 30

ABDOMINAL AORTIC ANEURYSM: NON-RUPTURED

Clinical Presentation

The vast majority of non-ruptured AAA are asymptomatic. The finding of an AAA is during abdominal imaging for an unrelated condition. Sometimes patients may feel a pulsatile mass in the abdomen.

Symptomatic aneurysms are intact aneurysms which cause back pain due to pressure on nerves or erosion into vertebral bodies. The pain may irradiate to the abdomen, groin, or lower limbs. Severe pain in the absence of rupture may be present in cases of the rare inflammatory aneurysms that are surrounded by a perianeurysmal retroperitoneal inflammatory reaction. Eighty percent of aneurysms over 5 cm in transverse diameter are palpable as a pulsatile mass. AAA may present with peripheral microembolization to toes causing a "blue toe syndrome."

Imaging Studies

Ultrasound is a first line method for initial confirmation of AAA and is also the least expensive. Repeated ultrasound examinations are cost-effective for observing small aneurysms.

Computed tomographic angiography is an essential imaging study for the diagnosis of AAA (Figure 16, 17). It provides a much more accurate measurement compared to ultrasound. CTA should be performed from the aortic root to iliac arteries because about 60% of AAAs have synchronous aneurysms, especially in the thoracic aorta or iliac arteries. CTA is crucial for the decision for the type of treatment and also for the follow-up. The disadvantage of CTA is the fact that CTA is more expensive than ultrasound and involves exposure to radiation and intravenous contrast material.

Magnetic Resonance Imaging (MRI) represents an alternative to CTA. The advantage is the absence of exposure to ionizing radiation. The disadvantages of MRI are high cost and limited availability. MRI is a perfect solution for patients with a heavy allergy to iodine.

Indications for operation [39]:

1. Asymptomatic AAA is indicated to surgery
   a) When an expansion of asymptomatic AAA is more than 1 cm in 12 months is present.
   b) When the diameter of asymptomatic AAA is more than 5.5 cm in men

c) When the diameter of asymptomatic AAA is more than 5.0 cm in women

2. Symptomatic AAA

Symptomatic AAA of any diameter without proven rupture should be operated on within 48 hours.

3. Ruptured AAA

Ruptured AAA of any diameter should be operated on immediately.

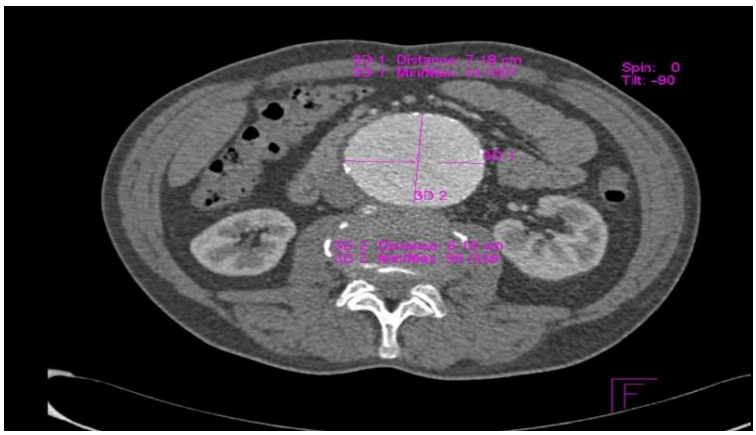

Figure 16. CTA, aneurysm of the abdominal aorta in a transverse scan.

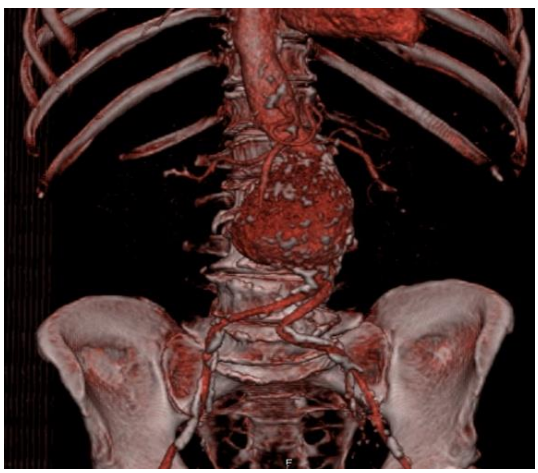

Figure 17. CTA, 3-dimensional reconstruction of aneurysm of the abdominal aorta.

Preoperative Management

Elective open repair is associated with high mortality rate of up to 5% [7]. Thus, patients for elective repair should be carefully prepared. Evaluation of cardiac, pulmonary, renal, and

metabolic status should be performed. Hypertension and metabolic diseases should be compensated for. In patients with AAA and concomitant stenosis of the internal carotid artery (ICA) of over 70%, a carotid endarterectomy of ICA before aneurysm repair should be performed. Older patients not fit for open surgery should be considered for endovascular treatment [39].

Operation

Operation because of AAA is performed under general anesthesia and starts with laparotomy. The use of cell-savers is recommended, then this device may decrease the postoperative mortality and also the rate of complications, especially in patients with ruptured AAA [39]. After mobilization of the duodenum, we reach the aortic neck. Then we prepare both iliac arteries. When iliac arteries are not dilatated over 2.5 cm in transverse diameter, it is not necessary to replace the iliac artery. After administration of heparin, we can clamp aorta subrenally and common iliac arteries below the aneurysm. After the opening of the aneurysmatic sac, lumbar arteries must be sutured to stop the backflow bleeding. Afterward, we can reconstruct the aorta with a tube Dacron graft from the subrenal part to the aortic division (Figure 18, 20).

When also iliac arteries are dilatated over 2.5cm, an aortobiiliacal reconstruction with a bifurcated (reverse Y-shaped) Dacron graft should be performed (Figure 19, 21). The distal anastomoses are placed at the division of the common iliac artery. When the aneurysmatic dilatation proceeds at the internal iliac arteries, they must also be ligated. It is crucial to preserve the patency of at least one or both internal iliac arteries or inferior mesenteric artery, otherwise left colon ischemia may occur.



Figure 18. Surgical repair of AAA with a tube graft.

In cases of the short subrenal neck, we must place an aortic clamp above one or above both renal arteries to safely construct proximal anastomosis. In the case of suprarenal clamping, the proximal anastomosis and restoration of the blood flow to renal arteries should be completed within 30 minutes. Afterward, we cover the graft with aneurysmatic tissue to

avoid the direct contact between the graft and small bowel to prevent secondary graft-enteric fistula.

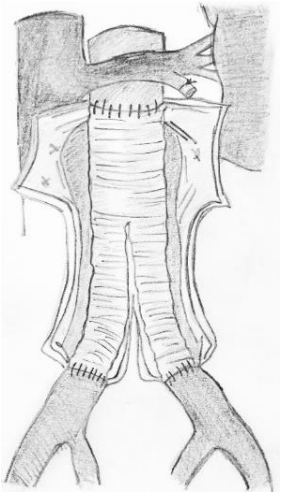

Figure 19. Surgical repair of AAA with a bifurcated graft.

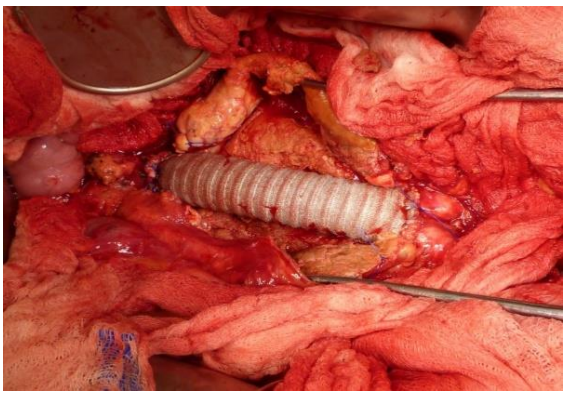

Figure 20. Operation: surgical repair of AAA, using a tube Dacron graft.

Figure 21. Operation: surgical repair of AAA, using a bifurcated Dacron graft.

Complications

Mortality and Early Complications

Historically, open surgical repair of AAA was associated with one of the highest mortality rates among all elective surgical operations; mortality rates were reported up to 7.5% in the 1990's [42]. However, with improving anesthesiologic methods and surgical technique mortality rates after elective open surgical repair have decreased and now range from 3.0% -5.0 % [33].

Early, and late complications after open surgical repair of AAA are very similar to early complications after aortic reconstructions due to aortoiliac occlusive disease. Postoperative severe complications occur by up to 28% [43].

Cardiac, pulmonary, and renal complications are the most common complications after open surgical repair of AAA. They are associated with prolonged anesthesia, aortic clamping, blood loss, and hypotension after aortic de-clamping.

Bleeding after open surgical repair of AAA occurs in up to 1.2% of cases [43] and can be from anastomoses, lumbal, iliac arteries or veins or retroperitoneal tissue. The bleeding is often massive and requires a prompt surgical revision. All anastomoses and the retroperitoneal surface should be checked before closing the retroperitoneum and abdomen. Heparin reversal is also essential in the prevention of the postoperative bleeding.

Ischemia of the left colon is also severe The incidence is up to 6% and occurs especially when also the internal iliac arteries are involved in the aneurysmatic process. It is crucial to ensure the blood supply to at least one internal iliac artery or to perform reinsertion of the inferior mesenteric artery (IMA) to the graft during reconstruction. Otherwise, we risk fatal necrosis of the left colon [43].

Acute limb ischemia, lesion of ureter, and paraplegia may also occur after open surgery of AAA similarly as after aortoiliac reconstructions due to aortoiliac atherosclerosis [43].

Late Complications

The graft occlusion is not so typical after the open surgical repair of AAA as in arterial reconstructions due to aortoiliac atherosclerosis. The main reason is that the patients with AAA have mainly good out-low compared to the patients with occlusive aortic disease.

Severe complications are graft infections that occur in up to 1.5% of cases [32]. The graft infection is mainly due to the secondary graft-enteric fistula, when there was a contact between the small intestine and the prosthetic graft left during the primary operation. The connection between the small intestine and the graft leads to the graft-enteric erosion and graft-enteric fistula with prosthetic graft infection afterward. The graft infection is a life-threatening condition, as it can lead to severe bleeding from anastomosis. It often requires the entire graft removal and in situ reconstructions mainly with deep femoral veins or the extra-anatomic bypass. The mortality of graft infections is high, reported up to 20% [43].

Isolated Iliac Artery Aneurysms

Iliac artery aneurysms generally occur in conjunction with AAA in about 40-50% of cases. Isolated iliac aneurysms are unusual. The physical examination can suggest the

diagnosis of large (>4cm) iliac artery aneurysms. Most symptomatic iliac aneurysms can be palpated as pulsatile masses on abdominal or rectal assessment. Iliac aneurysms are usually found incidentally on ultrasound or CT. Isolated aneurysm of the common iliac artery is indicated for a repair when the transverse diameter is more than 3.5cm [33]. The main risk of this aneurysm is, similarly to AAA, a rupture with massive bleeding and the mortality up to 40 % [33].

An isolated iliac aneurysm can be treated with a tubular Dacron graft, mainly from the retroperitoneal approach. More common is aneurysm of iliac artery associated with dilatation of the abdominal aorta or the aneurysm of the abdominal aorta and in such situations, reconstruction with a bifurcated Dacron graft is necessary[40]. When the aneurysm is anatomically convenient, endovascular treatment can also be considered.

ABDOMINAL AORTIC ANEURYSM: RUPTURED

Epidemiology

Mortality of ruptured AAA is high, up to 75%. Approximately one-half of patients with a rupture of AAA do not survive transport to the hospital, and only one half of those who survived transport will survive the perioperative period [40].

Clinical Presentation

Patients that present with sudden, severe abdominal pain that usually irradiates into the back and occasionally into the inguinal region. Shock can be profound, manifested by peripheral vasoconstriction, hypotension, and anuria. Unfortunately, the classic triad of pain, a pulsatile abdominal mass, and hypotension are not always present. Rupture is a first presentation of AAA in about 80% of cases. A rare form of rupture is perforation of AAA into the vena cava inferior, causing sudden onset of heart failure [33].

Imaging Studies

A first line imaging study for confirmation of a ruptured AAA is ultrasound. Finding of aneurysmatic dilatation and perianeurysmatic hematoma is typical for the rupture. In hemodynamically stable patients, we can consider CTA for better evaluations of relationship to renal arteries or the diameter of iliac arteries (Figure 22). However, hemodynamically unstable patients can further CTA lead to a fatal delay, so in such an unstable patient, we indicate an urgent operation based only on ultrasound examination.

Figure 22. CTA of a ruptured AAA, hematoma in retroperitoneum is marked by an arrow.

Preoperative Management

Thus, the crucial fact in preoperative management in patients with a ruptured AAA is to avoid any delay. Patient with a ruptured AAA should undergo surgery as soon as possible. That is why we prefer to operate on patients with a ruptured AAA based only on ultrasound because the CTA may represent further delay. A delay of 1 minute represents an approximately 1% increase in mortality. It is very important not to raise the systolic blood pressure over 100 mm Hg since this may increase bleeding. Aggressive volume resuscitation in preoperative management of ruptured AAAs before proximal aortic control leads to increased postoperative mortality [41]. Recommended is hypotensive volume resuscitation with keeping blood pressure at about 80-90 mm Hg [39].

Operation

The operation for a ruptured AAA is similar to the elective cases. Cell savers are mandatory [39]. Proximal aortic clamping should be performed as soon as possible. In cases when we cannot obtain proximal aortic control subrenally, there is a possibility of supraceliac aortic clamping beneath the diaphragm. The supraceliac clamping can stop bleeding, but it should be as brief as possible, then this may lead to visceral ischemia. Systemic heparinization is generally avoided during repair of ruptured AAA, although heparinized saline solutions can be administered directly into the common iliac arteries to reduce distal thrombosis [40]. The reconstruction may be performed with a tube Dacron graft when iliac arteries are not involved (Figure 18). In the case when iliac arteries are dilatated over 2.5cm, reconstruction with a bifurcated Dacron graft should be done (Figure 19).

Mortality and Complications

Despite advances in anesthesiology, critical care, and surgical techniques, the mortality of ruptured AAA still remains at approximately 50%. Usage of cell savers and the concentration

of operations to the high volume centers are factors that may improve post operational outcomes [39, 40].

Hypotension and extensive blood loss during rupture of AAA can lead to cardiac complications. Myocardial infarction, arrhythmias, congestive heart failure, and cardiac arrest are life-threatening situations that can increase the mortality after aortic rupture. Preexisting coronary artery disease can increase the risk of cardiac complications [40].

Acute respiratory distress syndrome (ARDS) develops in up to 47% of cases. Preexisting chronic obstructive pulmonary disease is a risk factor for ARDS. ARDS is associated with a mortality rate of up to 64% [44].

Rupture of AAA can lead to renal dysfunction, and renal failure, and approximately 10-40% of patients require dialysis (11%-40%). Renal dysfunction is increased in those with suprarenal cross-clamping, longer duration of aortic cross-clamping, preexisting renal insufficiency, shock, and increased age [40]. Liver failure can also occur in the postoperative course. Multiorgan failure (MOF) may occur up to 35% with very high mortality. The incidence of death in patients with postoperative MOF is reported to range from 64% to 93% [40].

One of the most severe complications is postoperative bleeding. It may be due to prolonged hypothermia and coagulopathy after blood loss associated with rupture. The incidence of postoperative bleeding after the open surgical repair of ruptured AAA is up to 14%. Quick operation, correction of hypothermia, supplementation of blood loss, coagulation factors, and correction of acidity as soon as possible is the primary prevention of postoperative coagulopathy. Usage of heparin during operations because of ruptured AAA should be avoided. Spinal cord and left colon ischemia can also occur. The incidences are higher compared with the elective open surgical repair due to hypotension and blood loss associated with the aortic rupture.

The rate of the highest grade colonic ischemia is 10% and is associated with a mortality rate of 50% [45]. The overall risk of spinal cord ischemic complications is reported to be 2.3% [45].

Abdominal compartment syndrome can also occur after the open surgical repair of ruptured AAA. The incidence is up to 10% [40] and is associated with retroperitoneal hematoma and edema. In the case of abdominal compartment syndrome, delayed abdominal closure should be planned [40].

ABDOMINAL AORTIC ANEURYSM: ENDOVASCULAR THERAPY

General Considerations

Endovascular aneurysm repair (EVAR**)** means that the stent graft is inserted into an aneurysm and is sealed above and below the aneurysm, in so-called sealing zones. Juan Parodi, in 1991, was the first who used stentgraft for the treatment of an aortic aneurysm [46]. From there the field of vascular surgery has been changed and the era of endovascular aneurysm repair (EVAR) was born. Today in the U.S, about 60% of all elective cases of aneurysm of abdominal aorta are treated by EVAR.

Endovascular repair requires that the aorta proximal to the aneurysm have a cylindrical configuration for at least 1.5 cm to allow adequate sealing of stentgraft and iliac arteries that are of sufficient size and limited tortuosity so that the device can be introduced from the femoral arteries (Figure 23). Only 40-60% of aneurysms are anatomically suitable for endovascular treatment. The assessment of anatomical suitably of an AAA is based on CTA.

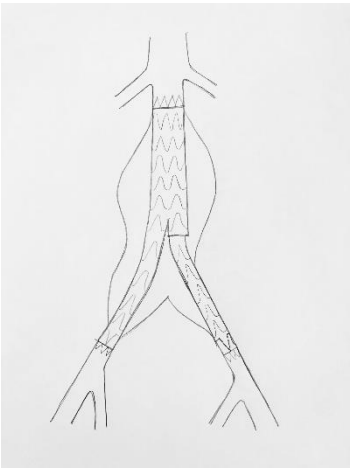

Figure 23. A stent graft in AAA.

Endoleak

The essential intermediate or long-term adverse outcome is persistent perfusion of the aneurysm (endoleak). These are divided into five types of denoting clinical importance.

A type I endoleak means ineffective proximal or distal sealing. Endoleak I is the most serious since it can lead to aneurysmatic sac enlargement and sac rupture even with an implanted stentgraft. Type I endoleak can be divided into two subtypes. Type IA endoleak means the leak through the proximal sealing zone, and type IB endoleak is the leak through the distal (iliac) sealing zone.

A type II endoleak means that the aneurysm is filled by backflow from patent lumbar arteries or the inferior mesenteric artery. Because of backflow, they have relatively low pressures and do not lead to aneurysm enlargement.

Leaking through the components of the stentgraft is a type III endoleak. This can o lead to expansion of the aneurysm and requires urgent repair, similarl to endoleak type I.

Type IV is caused by graft fabric porosity, which may result in a generalized mild blush of contrast medium within the aneurysm sac. This type of endoleak occur less frequently with current-generation stent grafts and is observed within 30 days of graft implantation.

Type V endoleak, (endotension) is defined as elevated sac aneurysm pressure without a visible endoleak. It is believed that the etiology is an undetected endoleak or transmission of systemic pressure through the thrombus.

Complications of EVAR

One of the most severe complications is the migration of the graft, with the incidence up to 8.4%, and that refers to the caudal movement of the stent graft, which may lead to loss of proximal fixation and result in type IA endoleak with further growth of the aneurysm and increased risk of rupture. It requires the proximal stent graft extension or surgical explantation of the graft.

Occlusion of the stent graft limb occurs after 3% to 7% of EVAR procedures over a nine-month to the four year period [46]. It is more frequent in patients with the aortoiliac occlusive disease and stenotic or tortuous iliac arteries. This type of complication can be treated endovascularly or surgically by performing a femorofemoral cross over bypass.

Neck dilatation, the juxtarenal part of the aorta dilates not as common as the infrarenal aorta, but can also dilatate following EVAR, that results in migration and type I endoleak and risk of rupture [46]. Neck dilatation is treated similarly as the graft migration with the proximal extension or with the open surgical graft explantation.

Pelvic ischemia can manifest as buttock claudication, buttock necrosis, spinal cord ischemia, left colon, and erectile dysfunction. It occurs as a consequence of occlusion of one or both internal iliac arteries in the presence of an aneurysm of the common or internal iliac artery [46].

Occlusion of the renal artery occurs either from inadvertent stent graft coverage of the renal artery or from its embolization. Stent graft coverage most commonly occurs peri-procedurally. Occlusion of both renal arteries may lead to renal failure with hemodialysis. The treatment can be endovascular or renal stenting to preserve renal artery flow. If this is not possible, open hepatorenal bypass should be performed [46].

Infection of the stent-graft is rare, with a small incidence of 0.2% to 0.7%. Treatment can be conservative, or when the conservative treatment is not successful, sepsis can lead to the necessity of graft removal [46].

Results

Four randomized trials were performed to compare open surgery with EVAR for treatment of AAA: the EVAR I (Endovascular aneurysm repair) trial, DREAM (Dutch Randomized Endovascular Aneurysm Management) trial, OVER (Open Versus Endovascular Repair) trial, and French ACE (Anevrysme de l'aorte abdominale, Chirurgie versus Endoprothese) trial [39]. The results of those randomized trial were similar. EVAR was associated with a lower 30 day postoperative mortality (0.5-1.7%) compared with the mortality of open surgical repair (1.3-4.7%) in all four of those trials. The early survival benefit was lost after three years in all the studies. The latest outcomes of the EVAR I study showed significantly higher mortality in the EVAR group after eight years, mainly associated with the aneurysm sac rupture [8]. The EVAR, DREAM, and the ACE trial showed significantly higher re-intervention rate in the EVAR group [39].

Thus, EVAR should be considered in all patients. It is reasonable to suggest an open surgery first strategy in younger, fit patients with a life expectancy over ten years [39].

SPLANCHNIC ARTERIES

Splanchnic arteries represent the celiac axis (CA), superior mesenteric artery (SMA), inferior mesenteric artery, and renal arteries (RA).

The celiac axis divides shortly after its origin into the three main arteries: the common hepatic artery, splenic artery, and left gastric artery. The celiac axis ensures blood supply to the organs of the upper abdomen such as the liver, stomach, duodenum, spleen, and pancreas.

The superior mesenteric artery is a crucial vessel for blood supply to abdominal organs like the small intestine, right, and transverse colon. The pancreaticoduodenal arteries represent collateral between the CA and SMA.

The inferior mesenteric artery supplies the left colic flexure, left colon, and rectum with blood — Arcus Riolani represents collaterals between the SMA and IMA (Figure 24). In case of the patent the superior mesenteric artery and internal iliac arteries, the IMA may be ligated.

The renal arteries ensure the blood supply to both kidneys.

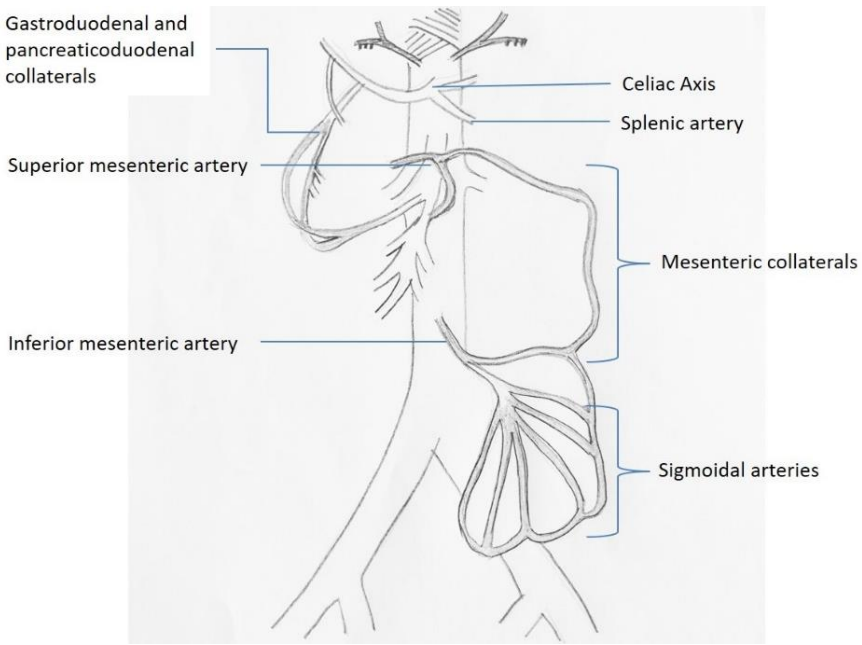

Figure 24. Splanchnic blood supply.

Occlusion of Splanchnic Arteries

Acute Mesenteric Ischemia

Sudden occlusion of the SMA presents as acute mesenteric ischemia. The main reason for acute occlusion is atrial fibrillation in 50%, thrombosis the atherosclerotic plaques in about 30% of cases, and the rest can be caused by functional spasms or aortic dissection type Stanford B [47]. Acute occlusion of the other splanchnic arteries is rarely noted.

Acute mesenteric ischemia is a highly morbid disorder. Patients present classically with excruciating diffuse abdominal pain, out of proportion to physical finding. Acute mesenteric

ischemia leads to bowel paralysis, and later to ischemia of the bowel that proceeds to the bowel necrosis with bowel perforation and peritonitis. The diagnosis can be difficult and is based on ultrasound or CTA. Also, arteriography can confirm the diagnosis of acute occlusion of the SMA.

Treatment

When the reason for acute mesenteric occlusion is embolism, an embolectomy of the SMA is the treatment option. When the embolectomy is performed within 6 hours, intestinal ischemia is reversible and intestinal resection is not necessary. When the embolectomy of the SMA is done 4-6 hours after the acute occlusion, then the bowel ischemia is mostly irreversible, and the gut resection is not necessary. After the embolectomy, the second look laparotomy should be performed within 48 hours to evaluate the vitality of the intestine. If inevitable, the bowel resection can be done during the second look operation. Thrombosis of the SMA cannot be treated by simple embolectomy. Thrombosis of the superior mesenteric artery at atherosclerotic plaques may be rarely revascularized, and a massive bowel resection is necessary in the majority of cases. In the rare case when the small intestine is still vital, a bypass can be considered. The bypass can be anterograde from the suprarenal aorta to the SMA beneath the occlusion. Alternatively, the other possibility is a retrograde bypass, mainly from the right common iliac artery to the SMA. In cases when the bowel resection might follow bypass surgery, we prefer a venous bypass with the graft from the great saphenous vein, hence the consecutive bowel resection might be a risk factor for the infection of the prosthetic graft.

The mortality rate of acute mesenteric ischemia remains high. Patients who require massive bowel resection survive rarely or, if they survive, can develop the incapacitating short-gut syndrome [48].

Chronic Mesenteric Ischemia

Atherosclerosis is the cause of obstructive lesions in the visceral arteries in the vast majority of cases. Vasculitis (e.g., lupus erythematosus, Takayasu disease) is much less frequent [49]. The superior mesenteric artery is crucial for the blood supply to abdominal organs. Chronic stenosis or occlusion of the SMA can lead to chronic mesenteric syndrome. Stenosis or occlusions of the celiac axis can be asymptomatic.

The disease clinically presents with pain, which characteristically appears 15-30 minutes after the beginning of a meal and lasts for an hour or longer. Pain is occasionally so severe and prolonged that opiates are required for relief. The pain leads to the fear of eating, and weight loss is characteristic for the diagnosis. The disease is sometimes called abdominal angina.

The diagnosis is based on CTA or arteriography. Arteriography in the anteroposterior and especially the lateral projections demonstrate both the arterial lesion and the patterns of collateral blood flow (Figure 25). CTA or MRA can also confirm the diagnosis. Many gastrointestinal diseases can have similar symptoms as chronic pancreatitis or chronic gastritis, so before setting of the diagnosis of chronic mesenteric ischemia other conditions with the same clinical presentation should be excluded.

Figure 25. Arteriography (angiography): stenosis of the celiac axis (lateral projection).

Treatment

Treatment options are targeted to the SMA as the main splanchnic artery. The attempts of revascularization of the CA should be considered only after revascularization of the SMA.

Percutaneous transluminal angioplasty and stenting of the SMA or the CA have gained acceptance as the first line of therapy for mesenteric ischemia.

Surgical revascularization of the superior mesenteric and coeliac axis is performed when interventional treatment is not possible or was completed and failed. Either endarterectomy or bypass surgery can be done to obtain surgical revascularization of the SMA. Endarterectomy is reserved for short stenoses or occlusions in the origin of the SMA. When more extended occlusions are present, bypass surgery is indicated. The bypass can be anterograde, targeted from the suprarenal aorta retropancreatically at the celiac axis (Figure 26) or the SMA. The other possibility is a retrograde bypass from the distal aorta or the common iliac artery at the SMA below the occlusion (Figure 27). The anterograde bypass has better inflow from the suprarenal aorta but is more technically demanding. Suprarenal origin grafts are not ideal for patients with compromised pulmonary or cardiac functions or those with extensive atherosclerosis or calcification of the supraceliac aorta. The retrograde bypass has worse inflow from the common iliac artery or the distal aorta but is technically easier to perform and is better for higher risk patients. The long term results are similar, so both techniques are possible [50].

The surgery of the CA should be performed only in patients with the patent SMA and persistent mesenteric symptoms. Firstly, an attempt for interventional treatment should be performed. When this is not possible, open surgery should be considered. Revascularization of the CA can be done by transaortic endarterectomy and anterograde or retrograde bypass. When the concomitant SMA atherosclerosis is present, the bypass can be targeted at both arteries, the SMA and CA. The operation should be avoided in patients with acute vasculitis as the underlying cause of mesenteric ischemia, high-dose steroids, and immunosuppressive agents are indicated instead [49].

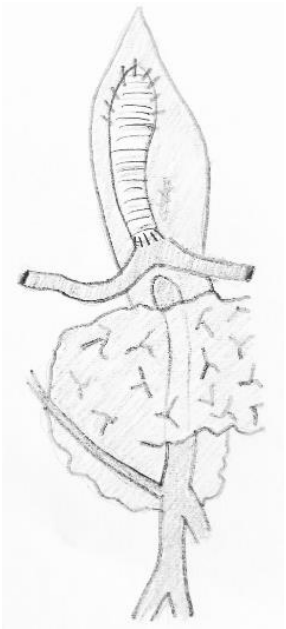

Figure 26. An antegrade aortoceliac bypass.

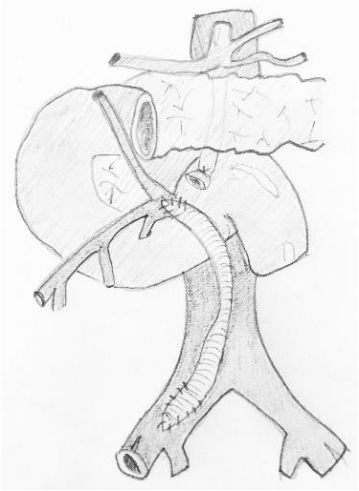

Figure 27. A retrograde aorto-superior mesenteric artery bypass.

Renovascular Disorders

Atherosclerosis characteristically produces stenosis at the orifice of the main renal artery. The lesion usually consists of aortic atheroma. Renal artery stenosis is more common in males over age 45 and is bilateral in about 95% of cases. Fibromuscular dysplasia usually involves the middle and distal thirds of the main renal artery and may extend into the distal thirds of the main renal artery and may extend into the branches [47]. Fibromuscular dysplasia is typical for fertile women.

Clinical Findings

Most patients are clinically asymptomatic, but irritability and emotional depression are seen in a few. Persistent elevation of the diastolic pressure is often the only abnormal physical finding. Renal atherosclerosis can lead to declining renal function and chronic renal failure. Noninvasive or minimally invasive imaging of the renal arteries is justified when the patient has a precipitous drop in blood pressure or decreased renal function with an ACE inhibitor. Renal arteriography is the most accepted method for delineating the obstructive lesion [51].

Treatment

Patients with renovascular hypertension require aggressive medical treatment and management of modifiable risk factors. Percutaneous transluminal angioplasty and stenting of renal arteries is the preferred procedure for most patients. In the very young, surgery is still the primary mode of treatment due to concern regarding the long-term durability of angioplasty and stenting. Surgery is indicated in patients with renovascular hypertension, which is refractory to medical or endovascular treatment or as an attempt for salvage of renal functions. Surgical repair also is required for failed angioplasty and stenting. Surgery represents either transaortic endarterectomy of the origin of the renal artery or bypass surgery (aorto-renal bypass) [47].

Splanchnic Artery Aneurysms

Aneurysms of splanchnic arteries are a rare condition, but they require clinical attention because of their lethal nature. The incidence of splanchnic arteries aneurysm in the general adult population is estimated to range from 0.1% to 2% [53].

Splenic Artery Aneurysms

Splenic artery aneurysms are the most common, and they account for more than 60% of splanchnic artery aneurysms. Women are affected four times more than men. The diagnosis is based mainly on CTA (Figure 28). Aneurysms of splenic artery manifest with rupture, which leads to massive intraperitoneal bleeding with sudden hemorrhagic shock. Bleeding from a ruptured aneurysm of the splenic artery can be fatal. Rupture during pregnancy tends to occur in the third trimester and is associated with a 75% maternal death rate and 90% fetal death rate [52].

The diagnosis is based on CTA or ultrasound examination. Intervention is indicated for patients with aneurysms more than 2 cm in transverse diameter or for patients with symptomatic aneurysms. Endovascular repair with covered stent grafts is ideal with the use of microcatheters. Laparoscopic ligation of the artery is also feasible. When endovascular treatment is not possible, surgical resection of aneurysm and replacement with a venous or prosthetic graft is the treatment of choice [52].

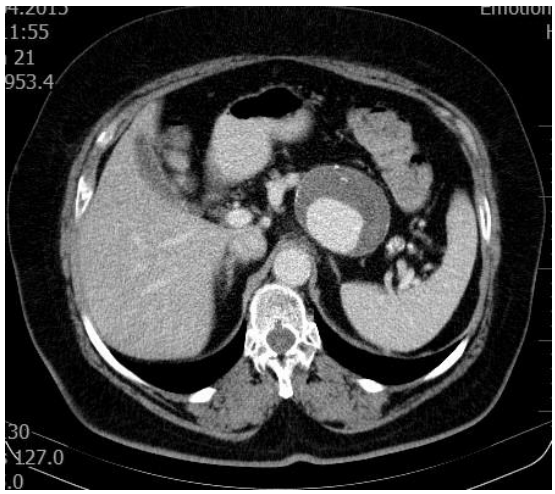

Figure 28. CT angiography of aneurysm of the splenic artery.

Aneurysms of Other Splanchnic Arteries

Hepatic artery aneurysms account for 20% of splanchnic artery aneurysms. There is a 2:1 male-to-female ratio.

Aneurysms of superior mesenteric artery account for 5% of all splanchnic artery aneurysms. Indication for the treatment is a size of more than 2 cm in transverse diameter. Operative therapy for mycotic superior mesenteric artery aneurysms includes ligation if there are adequate collaterals or replacement with a segment of the autogenous vessel.

Renal Artery Aneurysms

This uncommon aneurysm occurs in less than 0.1% of the population and is often associated with hypertension.

Aneurysms of splanchnic arteries and aneurysms of renal arteries are generally indicated for the treatment when they are above 2cm in transverse diameter or when they are symptomatic. The main complication of them is fatal bleeding. Diagnosis is based mainly on CTA. Treatment method of choice is an endovascular intervention. When endovascular treatment is not possible, open surgical treatment is necessary.

REFERENCES

[1] Wylie, E. J., Kerr, E., and Davies, O. (1951). Experimental and clinical experiences with the use of fascia lata applied as a graft about major arteries after thrombo-endarteriectomy and aneurysmorrhaphy. *Surg Gynecology Obstet,* 93: 257-72.

[2] Dubost, C., Allary, M., and Oeconomos, N. (1952). Resection of an aneurysm of the abdominal aorta: reestablishment of the continuity by a preserved human arterial graft, with result after five months. *A. M. A. archives of surgery*. 64:405-8.

[3] Cooley, D. A. and DeBakey, M. E. (1954): Ruptured aneurysms of the abdominal aorta: excision and homograft replacement. *Postgrad Med,* 16:334–342,

[4] Voorhees, A. B. Jr., Jaretzki, A. 3rd., and Blakemore, A. H. (1952): The use of tubes constructed from vinyon "N" cloth in bridging arterial defects. *Ann Surg*, 135:332-6.

[5] Simons, J. and Schanzer, A. (2014). Lower Extremity Arterial Disease: Decision Making an Medical Treatment. In *Rutherford's Vascular Surgery, 8th edition*, edited by Cronenwett, J. L. and Johnston, K. W. 1675-1699. Philadelphia, Elsevier Saunders, ISBN: 978-1-4557-5304-8.

[6] Norgren, L., Hiatt, W. R., Dormandy, J. A. et al. (2007): TASC II Working Group. Inter- society consensus for management of peripherial arterial disease *Int Angiol*, 26:81-157.

[7] Moll, F. L., Powell, J. T., Fraedrich, G., et al. (2011). Management of abdominal aortic aneurysms clinical practice guidelines of the European society for vascular surgery. *Eur J Vasc Endovasc Surg*, 41:S1-S58. doi:10.1016/j.ejvs.2010.09.011.

[8] Patel, R., Sweeting, M. J., Powell, J. T., et al. (2016). EVAR trial investigators. Endovascular versus open repair of abdominal aortic aneurysm in 15-years' follow-up of the UK endovascular aneurysm repair trial 1 (EVAR trial 1): a randomised controlled trial. *Lancet*. 388:2366-2374. doi: 10.1016/S0140-6736(16)31135-7.

[9] Becquemin, J. P., Pillet, J. C., Lescalie, F., et al. (2011). A randomized controlled trial of endovascular aneurysm repair versus open surgery for abdominal aortic aneurysms in low- to moderate-risk patients. *J Vasc Surg*, 53:1167-1173.e1. doi: 10.1016/j.jvs.2010. 10.124.

[10] Selvin, E., and Elvinger, T. P. (2004). Prevalence of and risk factors for peripheral arterial disease in the United States: results from the National Health and Nutrition Examination Survey, 1999-2000. *Circulation*, 110:738–743.

[11] Hiatt, W. R. (2001). Medical treatment of peripheral arterial disease and claudication. *N Engl J Med*, 344:1608–1621.

[12] Sumner, A. D., Khalil, Y. K., and Reed, J. F. 3rd.(2012). The relationship of peripheral arterial disease andmetabolic syndrome prevalence in asymptomatic US adults 40 years and older: results from the National Health and Nutrition Examination Survey (1999-2004). *J Clin Hypertens (Greenwich)*, 14:144–148.

[13] Conen D, Everett, B. M., Kurth, T., et al (2011). Smoking, smoking cessation, [corrected] and isk for symptomatic peripheral artery disease in women: a cohort study. *Ann Intern Med*, 154:719–726.

[14] Huxley, R. R., and Woodward, M. (2011). Cigarette smoking as a risk factor for coronary heart disease in women compared with men: a systematic review and metaanalysis of prospective cohort studies. *Lancet*, 378:1297–1305.

[15] Hirsch, A. T., Criqui, M. H., Regensteiner, J. G., et al(2001). Peripheral arterial disease detection, awareness, and treatment in primary care. *JAMA* 286:1317–1324.

[16] Brewster, D. C. (2005). Direct Reconstruction for Aortoiliac Occlusive Disease. In *Vascular Surgery, 6th edition*, edited by Rutherford, R. B. 1106-1135. Philadelphia, Elsevier Saunders, ISBN 0-7216-0299-1.

[17] Brewster, D. C. (1997). Current controversies in the management of aortoiliac occlusive disease. *J Vasc Surg*, 25:365.

[18] Hirsch, A. T., Haskal, Z. J., Hertzer, N. R., et al (2006). ACC/AHA Guidelines for the Management of Patients with Peripheral Arterial Disease (Lower Extremity, Renal, Mesenteric, and Abdominal Aortic): A Collaborative Report from the American Associations for Vascular Surgery/Society for Vascular Surgery, Society for

Cardiovascular Angiography and Interventions, Society for Vascular Medicine and Biology, Society of Interventional Radiology, and the American College of Cardiology/American Heart Association Task Force on Practice Guidelines (Writing Committee to Develop Guidelines for the Management of Patients with Peripheral Arterial Disease)—Summary of Recommendations. *J Vasc Interv Radiol,* 17:1383–1397.

[19] Andreozzi, G. M., Arosio, E., Martini, R., et al. (2008). Consensus document on intermittent claudication from the Central European Vascular Forum 1st edition - Abano Terme (Italy) - May 2005 2nd revision - Portroz (Slovenia) September 2007. *Int Angiol*, 27:93-113.

[20] Aboyans, V., Ricco, J. B., Bartelink, M. E. L., et al. (2018). 2017 ESC Guidelines on the Diagnosis and Treatment of Peripheral Arterial Diseases, in collaboration with the European Society for Vascular Surgery (ESVS): Document covering atherosclerotic disease of extracranial carotid and vertebral, mesenteric, renal, upper and lower extremity arteriesEndorsed by: the European Stroke Organization (ESO)The Task Force for the Diagnosis and Treatment of Peripheral Arterial Diseases of the European Society of Cardiology (ESC) and of the European Society for Vascular Surgery (ESVS). *Eur Heart J*. 39:763-816. doi: 10.1093/eurheartj/ehx095.

[21] Leriche, R., and Morel, A. (1948). The Syndrome of Thrombotic Obliteration of the Aortic Bifurcation. *Ann Surg,* 127:193-206.

[22] Menard, M. T. and Belkin, M. (2014). Aortoiliac Disease: Direct Aortoiliac Reconstruction. In *Rutherford's Vascular Surgery, 8th edition*, edited by Cronenwett, J. L. and Johnston, K. W. 1701-1721. Philadelphia, Elsevier Saunders, ISBN: 978-1-4557-5304-8.

[23] Gerhard-Herman, M. D., Gornik, H. L., Barrett, C. et al. (2017). 2016 AHA/ACC Guideline on the Management of Patients with Lower Extremity Peripheral Artery Disease:Executive Summary. *Vasc Med*, 22:NP1-NP43. doi:10.1177/1358863X 17701592.

[24] Faries, P. L., LoGerfo, F. W., Hook, S. C., et al. (2001). The impact of diabetes on arterial reconstructions for multilevel arterial occlusive disease. *Am J Surg*, 181:251-5.

[25] Ma, B., Wang, Y. N., Chen, K. Y., et al. (2016). Transperitoneal versus retroperitoneal approach for elective open abdominal aortic aneurysm repair. *Cochrane Database Syst Rev*, 5;2:CD010373. doi: 10.1002/14651858.CD010373.pub2.

[26] Huded, C. P., Goodney, P. P., Powell, R. J., et al. (2012). The impact of adjunctive iliac stenting on femoral-femoral bypass in contemporary practice. *J Vasc Surg*, 55:739-45. doi:10.1016/j.jvs. 2011.10.036.

[27] Hertzer, N. R., Bena, J. F., and Karafa, M. T. (2007). A personal experience with direct reconstruction and extra-anatomic bypass for aortoiliofemoral occlusive disease. *J Vasc Surg*, 45:527-535.

[28] Back, M. R., Johnson, B. L., Shames, M. L. et al. (2003). Evolving complexity of open aortofemoral reconstruction done for occlusive disease in the endovascular era. *Ann Vasc Surg*, 17:596-603.

[29] Steele, S. R. (2007). Ischemic colitis complicating major vascular surgery. *Surg Clin North Am*, 87:1099-114.

[30] Li, H. L., Chan, Y. C., and Cheng, S. W. (2018). Current Evidence on Management of Aortic Stent-graft Infection: A Systematic Review and Meta-Analysis. *Ann Vasc Surg*, 51:306-313. doi: 10.1016/j. avsg.2018.02.038.

[31] Armstrong, P. A., Back, M. R., Wilson, J. S., et al. (2005). Improved outcomes in the recent management of secondary aortoenteric fistula. *J Vasc Surg*, 42:660-6.

[32] Sihotsky, V., Berek, P., Mathews, A. J., Kopolovets, I. et al. (2018). Infected thoracic stentgraft and prosthetic graft with replacement by human aortic allograft. *Cor et vasa*, doi:10.1016/j.crvasa.2018.06.002.

[33] Holt, P. J. E. and Thompson, M. M. (2014). Abdominal Aortic Aneurysms: Evaluation and Decision Making. In *Rutherford's Vascular Surgery, 8th edition*, edited by Cronenwett, J. L. and Johnston, K. W. 1999-2023. Philadelphia, Elsevier Saunders, ISBN: 978-1-4557-5304-8.

[34] Anjum, A., and Powell, J. T. (2012). Is the incidence of abdominal aortic aneurysm declining in the 21st century? Mortality and hospital admissions for England & Wales and Scotland. *Eur J Vasc Endovasc Surg*, 43:161-6. doi:10.1016/j.ejvs.2011.11.014.

[35] Johnson, J. L. (2017). Metalloproteinases in atherosclerosis. *Eur J Pharmacol*, 816:93-106. doi: 10.1016/j.ejphar.2017.09.007.

[36] Eagleton, M. J. (2018). Inflammation in abdominal aortic aneurysms: cellular infiltrate and cytokine profiles. *Vascular*, 20:278-83. doi:10.1258/vasc.2011.201207.

[37] Horton, R. (1998). Mortality results for randomised controlled trial of early elective surgery or ultrasonographic surveillance for small abdominal aortic aneurysms. The UK Small Aneurysm Trial Participants. *Lancet*, 352:1649–1655.

[38] Lederle, F. A., Wilson, S. E., Johnson, G. R. et al. (2002). Immediate repair compared with surveillance of small abdominal aortic aneurysms. *N Engl J Med*, 346:1437-44.

[39] Wanhainen, A., Verzini, F., Van Herzeele, I. et al. (2019) Editor's Choice - European Society for Vascular Surgery (ESVS) 2019 Clinical Practice Guidelines on the Management of Abdominal Aorto-iliac Artery Aneurysms. *Eur J Vasc Endovasc Surg*, 57:8-93. doi: 10.1016/j.ejvs.2018.09.020.

[40] Mentha, M. and Byrne J. (2014). Abdominal Aortic Aneurysms: Ruptured. In *Rutherford's Vascular Surgery, 8th edition*, edited by Cronenwett, J. L. and Johnston, K. W. 2062-2082. Philadelphia, Elsevier Saunders, ISBN: 978-1-4557-5304-8.

[41] Dick, F., Erdoes, G., Opfermann, P., et al (2013). Delayed volume resuscitation during initial management of ruptured abdominal aortic aneurysm. *J Vasc Surg*, 57:943-50. doi: 10.1016/j.jvs.2012.09.072.

[42] Bradbury, A. W., Adam, D. J., Makhdoomi, K. R., et al. (1998). A 21-year experience of abdominal aortic aneurysm operations in Edinburgh. *Br J Surg*, 85:645-7.

[43] Woo, E. Y. and Damraurer, S. M. (2014). Abdominal Aortic Aneurysms: Open surgical repair. In *Rutherford's Vascular Surgery, 8th edition*, edited by Cronenwett, J. L. and Johnston, K. W. 2062-2082. Philadelphia, Elsevier Saunders, ISBN: 978-1-4557-5304-8.

[44] Johnston, K. W. (1994). Ruptured abdominal aortic aneurysm: six-year follow-up results of a multicenter prospective study. Canadian Society for Vascular Surgery Aneurysm Study Group. *J Vasc Surg*, 19:888-900.

[45] Megalopoulos, A., Vasiliadis, K., Tsalis, K. et al. (2007). Reliability of selective surveillance colonoscopy in the early diagnosis of colonic ischemia after successful

ruptured abdominal aortic aneurysm repair. *Vasc Endovascular Surg*. 41:509-15. doi: 10.1177/1538574407306797.

[46] Fairman, R. M. and Wang G. J. (2014). Abdominal Aortic Aneurysms: Endovascular Treatment. In *Rutherford's Vascular Surgery, 8th edition*, edited by Cronenwett, J. L. and Johnston, K. W. 2043-2061. Philadelphia, Elsevier Saunders, ISBN: 978-1-4557-5304-8.

[47] Krajicek, M. (2007). Visceralni tepny. In *Chirurgicka a intervencni lečba cevnich onemocneni*. Edited by Krajicek, M. 273-284. Praha, Grada Publishing, ISBN 978-80-247-0607-8. (book in Czech).

[48] Martin, M. and Wyers, M. C. (2014). Mesenteric Vascular Disease: Acute Ischemia. In *Rutherford's Vascular Surgery, 8th edition*, edited by Cronenwett, J. L. and Johnston, K. W. 2398-2412. Philadelphia, Elsevier Saunders, ISBN: 978-1-4557-5304-8.

[49] Oderich, G. S. (2014). Mesenteric Vascular Disease: Chronic Ischemia. In *Rutherford's Vascular Surgery, 8th edition*, edited by Cronenwett, J. L. and Johnston, K. W. 2373-2396. Philadelphia, Elsevier Saunders, ISBN: 978-1-4557-5304-8.

[50] Kruger, A. J., Walker, P. J., Foster, W.J., et al. (2007). Open surgery for atherosclerotic chronic mesenteric ischemia. *J Vasc Surg*, 46:941-5.

[51] Islam, A. and Geary, R. L. (2014). Renovascular Disease: general Consideration. In *Rutherford's Vascular Surgery, 8th edition*, edited by Cronenwett, J. L. and Johnston, K. W. 2270-2284. Philadelphia, Elsevier Saunders, ISBN: 978-1-4557-5304-8.

[52] Lakin, R. O. and Kashyap, V. S. (2014). Splanchnic Artery Aneurysms. In *Rutherford's Vascular Surgery, 8th edition*, edited by Cronenwet, J. L. and Johnston, K. W. 2220-2235. Philadelphia, Elsevier Saunders, ISBN: 978-1-4557-5304-8.

[53] Pulli R, Dorigo W, Troisi N et al. Surgical treatment of visceral artery aneurysms: A 25-year experience. *J Vasc Surg*. 2008 Aug;48(2):334-42. doi: 10.1016/j.jvs.2008.03.043.

In: Encyclopedia of Surgery (22 Volume Set)
Editors: Andreas Lehrer and Kristin Mueller
ISBN: 978-1-53618-329-0
© 2020 Nova Science Publishers, Inc.

Chapter 288

CAROTID AND VERTEBRAL ARTERIES

Vladimir Katuch*[*]*, MD, PhD
Department of Neurosurgery, Medical Faculty of Safarik University
and University Hospital, Košice, Slovakia

ABSTRACT

Stroke is the second most frequent reason for death in the world and the most frequent reason for disability of the older population in developed countries. There are more than 150,000 new strokes in the UK each year [1, 2]. Of these, one in eight is fatal within 30 days, while one in four is fatal within a year [2]. Approximately 15% of ischaemic strokes are preceded by a transient ischaemic attack (TIA). Thromboembolism from an ipsilateral carotid artery stenosis is responsible for about 20% of all strokes [3, 4]. Two landmark randomised trials: the North American Symptomatic Carotid Endarterectomy Trial (NASCET) and the European Carotid Surgery Trial (ECST), demonstrated the benefit of performing carotid endarterectomy in symptomatic patients [5, 6].

Keywords: carotid artery surgery, carotid occlusive disease, carotid endarterectomy, surgical treatment, postoperative complication

INTRODUCTION

Stroke is the second largest cause of death in the world, causing 6,700,000 deaths each year, [1, 2] and is the fourth most significant cause of death in the UK [1-3]. There are more than 150,000 new strokes in the UK each year. Of these, one in eight is fatal within 30 days, while one in four is fatal within a year [2]. Approximately 15% of ischaemic strokes are preceded by a transient ischaemic attack (TIA). With the aging of the general population and the availability of noninvasive imaging studies, carotid artery stenosis is a disease commonly

[*] Corresponding Author's Email: vladimir.katuch@upjs.sk.

seen in general medical practice. Thromboembolism from an ipsilateral carotid artery stenosis is responsible for about 20% of all strokes [3, 4].

Treatment alternatives are primarily between medical management, carotid endarterectomy, and endovascular techniques as combined angioplasty and stenting. Carotid endarterectomy (CEA) is the "gold standard" for treatment of patients with symptomatic severe or moderate stenosis since the results of the North American Symptomatic Carotid Endarterectomy Trial (NASCET) and the European Carotid Surgery.

Trial (ECST) was published nearly two decades ago [5, 6]. Perioperative stroke, defined as any stroke that occurs within 30 days after carotid endarterectomy, remains a known complication of carotid endarterectomy in patients with symptomatic and asymptomatic carotid stenosis. Numerous clinical trials have established rates of perioperative stroke, showing a range of 3.5%–5.5% for symptomatic patients [7, 8] and 1.4%–2.5% for asymptomatic patients [9-11]. Based on these findings, international guidelines increasingly recommend that carotid endarterectomy be performed within two weeks of an ischaemic cerebrovascular event (TIA or minor stroke) in symptomatic patients with ipsilateral high- (70-99%) or moderate-degree (50-69%) carotid artery stenoses [11-15].

PATHOPHYSIOLOGY OF CAROTID ARTERY STENOSIS

Atherosclerotic plaques begin to form in the carotid artery at 20 years of age. In the extracranial circulation, plaques typically start on the back wall of the common carotid artery (CCA). As they enlarge, they encroach on the lumen of the internal carotid artery (ICA). The risk of stroke correlates with the degree of stenosis and with certain types of plaque morphology and is also increased in hypercoagulable states and with increased blood viscosity. Vulnerable plaques are atherosclerotic plaques likely to cause thrombotic complications or those that tend to progress rapidly (Figure 1). Criteria for vulnerable plaques include intimal thickening, plaque fissure, lipid/necrotic core with thin fibrous cap, calcification, thrombus, intraplaque hemorrhage, and outward remodeling. Some of these features can be identified with high-resolution MRI [16-18].

The human body has adequate innate protection against stroke and brain injury from vascular ischemia. The circle of Willis ensures that there is significant collateral circulation, which protects the brain from infarction due to proximal vessel occlusion. With more distal blockage, however, infarction is the rule rather than the exception. The size of infarction depends directly on the availability and size of pial–pial collaterals. Collateral flow is essential, as many patients with symptomatic stroke have evidence of previous infarction that remained small and asymptomatic due to the presence of collateral flow. The ischemic injury occurs under many different circumstances, most commonly thromboembolism or atherosclerotic disease. There are many other causes, including trauma, vascular inflammatory diseases, hemorrhage, hypercoagulable states, and venous thrombosis [16-19].

In contrast to other tissues, the brain is subject to several properties, such as its strict reliance on glucose and oxygen as an energy substrate, autoregulation of blood flow, and presence of the blood-brain barrier, that makes ischemia a very complex and multifactorial process [18-20].

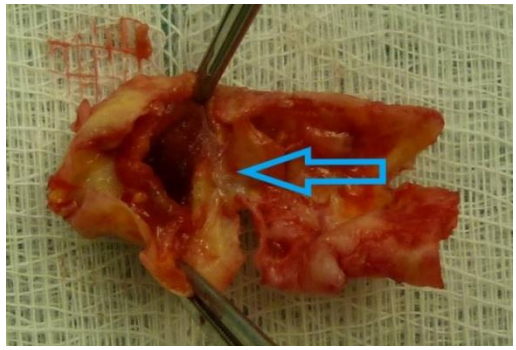

Figure 1. Vulnerable carotid plaque after endarterectomy, ulceration in the plaque is marked by an arrow.

The terms stroke and cerebrovascular accidents are generally synonymous; they entail an acute neurologic deficit of a vascular etiology caused by ischemia or hemorrhage. The brain meets its metabolic demands solely by utilizing glucose and oxygen. These must be continuously delivered as the brain has virtually no energy reserve. Ischemia occurs when the delivery of either glucose or oxygen fails to meet the metabolic demand of the tissue. Hypoxia refers to decreases in the partial pressure of oxygen, whereas anoxia suggests the complete absence of oxygen in blood flow delivered to the tissue. Cerebral infarction occurs after the death of neuronal or glial cells in the affected region [21, 22].

Ischemia can be classified as either complete or incomplete, and global or focal. Global ischemia, such as that caused by cardiac arrest, affects blood flow to all areas of the brain similarly. There is little opportunity for collateral supply and regional variations in susceptibility to ischemia cause variability in the volume of infarction. The duration of global ischemia that is compatible with life is generally quite brief, and the deficits sustained during anoxic brain injury after cardiac arrest are often severe [23-25].

Focal ischemia is most often thromboembolic but also results from subarachnoid hemorrhage, intracerebral hemorrhage, and trauma. In general, focal ischemia produces less severe and more focal deficits than global ischemia. The volume of the infarct is defined not only by the vulnerability of specific populations of cells but also the variability and competence of collateral blood flow to the affected area (Figure 2) [16-19].

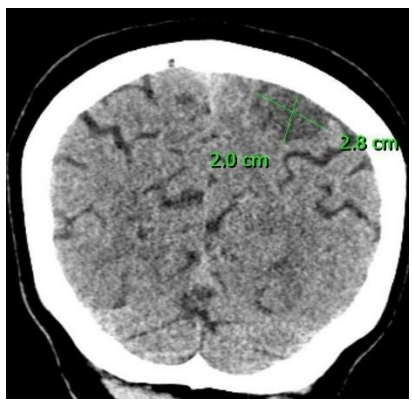

Figure 2. CT: ischemic brain lesion, 2.0 x 2.8 cm in diameter.

Collateral Circulation for ICA Stenosis/Occlusion

The effects of ICA stenosis/occlusion may be improved by collateral blood flow Potential alternate routes for blood to reach brain tissue include [16]:

1) Flow through the circle of Willis
    a) From contralateral ICA through the anterior communicating artery
    b) From forwarding flowthrough the ipsilateral posterior communicating artery
2) Retrograde flow through ophthalmic artery parasitizing blood from both external carotid arteries (ECA) via:
    a) facial artery – angular artery – dorsal nasal artery – and medial palpebral artery
    b) maxillary artery
    c) transverse facial artery – lateral palpebral artery
    d) superficial temporal artery – supraorbital artery
3) proximal maxillary artery – anterior tympanic artery – a caroticotympanic branch of ICA
4) cortical-cortical anastomoses
5) dural – leptomeningeal anastomoses

Collateral Circulation for Vertebrobasilar Stenosis/Occlusion

Available collaterals depend on the site of occlusion. In basilar artery occlusion, collateral flow is via posterior communicating arteries or anastomoses between the superior cerebellar artery and the posterior inferior cerebellar artery. In proximal vertebral artery occlusion, the collateral flow is via a) ECA – occipital artery – muscular branches of the vertebral artery, or b) Thyrocervical trunk – ascending cervical artery – direct connection or spinal radicular arteries – vertebral artery, or c) contralateral vertebral artery and ascending cervical artery via spinal radicular branches and anterior spinal artery [16].

Stroke in Young Adults

Only 3% of ischemic strokes occur in patients under 40 years of age. Over 10% of ischemic strokes occur in patients under 55 years [16, 26]. Incidence is 10 per 100,000 persons age 35-44 years, and 73 per 100,000 persons for age under 55 years. In etiology, trauma is the most common cause of strokes (22%) in patients under 45 years [27]. Most of the rest are covered by the small number of etiologies listed below [16, 26-28]:

1) Atherosclerosis: 20%, but less common than in the older population
2) Embolism with recognized source: 20%
    a) Cardiac origin is the most common
    b) Fat embolism syndrome
    c) Paradoxical embolism
    d) Amniotic fluid embolism

3) Vasculopathy: 10%
    a) Inflammatory – Takayasu's, infective like tubeculosis or syphilis, or ophthalmic zoster, amphetamine abuse, mucormycosis or associated with systematic disease
    b) Non-inflammatory – fibromuscular dysplasia, carotid or vertebral artery dissections, moyamoya disease, homocystinuria
4) Coagulopathy: 10%
5) Peripartum 5%
6) Miscellaneous cases: 35%
    a) Uncertain etiology
    b) Oral contraceptives
    c) Venous thrombosis
    d) Migraine
    e) Cocaine abuse

SYMPTOMS OF ATHEROSCLEROTIC CAROTID ARTERY STENOSIS

Carotid artery lesions are considered symptomatic if there are one or more lateralizing ischemic episodes appropriate to the distribution of the lesion. A lesion is considered to be asymptomatic if the patient only has non-specific visual complaints, dizziness, or syncope not associated with TIA or stroke. The majority (80%) of atherothrombotic strokes occur without warning symptoms. Asymptomatic carotid stenosis is usually discovered as a carotid bruit. Accuracy of a bruit in predicting ICA is 50-83% and sensitivity is as low as 24% [29, 30]. The symptomatic carotid disease may present as a TIA reversible ischaemic neurologic deficit (RIND) or stroke with any of the following findings:

1) Retinal insufficiency or infarction (central retinal artery is a branch of the ophthalmic artery

Ipsilateral Monocular Blindness

a) Maybe temporary: amaurosis fugax, also known as transient monocular blindness, four types:

Type I – embolic, described "like a black curtain coming down" in one eye, complete loss of vision lasts 1-2 minutes

Type II - flow related. Retinal hypoperfusion – desaturation of color, usually described as a graying of vision

Type III – vasospastic. May occur with migraines.

Type IV – miscellaneous. May occur with anticardiolipin antibodies

b) Blindness may be permanent

2) Middle cerebral artery symptoms:

   a) Contralateral motor or sensory TIA (arm and face worse than leg)
   b) Language deficits if the dominant hemisphere involved [16, 29, 30].

INVESTIGATION OF THE EXTENT OF CAROTID ARTERY DISEASE

Despite a great deal of research on the subject, there are no data to support a particular testing algorithm. Doppler, CTA, and MRA are acceptable initial screening tests. In patients with an abnormal screening test, a common strategy is to obtain a second confirmatory noninvasive test to evaluate the carotid bifurcation before the intervention. The combination of carotid ultrasound and MRA has proved cost effective with excellent reliability. If two noninvasive tests are discordant, catheter angiography should be considered before intervention [16, 30, 31].

Duplex Doppler Ultrasound

B-mode image evaluates the artery in a cross-sectional plane, and spectrum analysis shows blood flow. Doppler ultrasound performs poorly with a “string sign” and cannot scan above the angle of the mandible. Lower frequencies give a greater depth of penetration, but the signal definition is sacrificed. Sensitivity is 88%, and specificity is 76% [18, 33, 34].

Magnetic Resonance Angiography (MRA)

MRA may obviate the need for angiography in some cases of carotid stenosis, specifically in symptomatic patients with a focal “gap” of signal intensity loss with the distal reappearance of the signal. MRA sometimes overestimates the degree of stenosis. The sensitivity of MRA is 91%, and specificity is 88% for extracranial carotid disease. 2D TOF-MRA is adequate, contrast MRA shows more but is not necessary for surgical lesions.

MRA can be performed at the time as MRI with stroke protocol in TIA/stroke patients, and also detects thrombus or dissection. As with Doppler, he has difficulties distinguishing very severe stenosis from occlusion. MRA is more expensive and time-consuming as Doppler and is more challenging to perform if the patient is critically ill, unable to lie supine, or has claustrophobia, a pacemaker or ferromagnetic implants. High-resolution MRI may also detect vulnerable plaques [18, 35-38].

Computed Tomography Angiography (CTA)

CTA involves ionizing radiation (x-rays) and IV iodinated contrast, limiting its use in patients with dye allergies and renal dysfunction. Results are comparable to MRA and Doppler. CTA can be performed within a few seconds and yields high-resolution images of

all vessels from the aortic arch through the intracranial/extracranial vessels as well as the surrounding soft tissues (Figure 3 and Figure 4). In a meta-analysis, sensitivity and specificity for detection were 85% and 93% respectively. Another potential advantage of CTA is the ability to obtain CT perfusion studies at the same time [18, 39, 40].

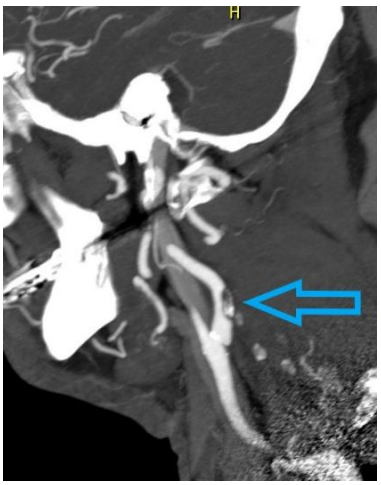

Figure 3. CTA: Stenosis of the ICA in the sagital scan, marked by an arrow.

Figure 4. CTA: Occlusion of the ICA in the sagital scan, marked by an arrow.

Angiography

The “gold standard” test is a catheter arteriogram (Figure 5). It cannot be justified as a screening test because it is invasive, and too costly and risky (recent data show under 1% risk of the transient or permanent deficit, and risk is 2-3 times higher in symptomatic patients than in asymptomatic). Also, unlike duplex Doppler and MRA, it does not provide any

information about the thickness of the plaque. Angiography also allows performing the opportunity to perform endovascular intervention if indicated [16, 18].

Figure 5. Angiography: Severe stenosis of the left ICA, marked by an arrow.

TREATMENT OF CARIOTID ARTERY STENOSIS

Treatment alternatives are primarily between the following:

1) Medical management
2) Carotid endarterectomy
3) Endovascular techniques: combined angioplasty and stenting

Medical Management

What constitutes "best medical management" has not been precisely determined, and recommendations are always changing. Some of the following are utilized:

1) Antiplatelet therapy
   a) Aspirin (ASA)
   b) Clopidogrel, either alone or in combination with ASA
   c) Combination of extended-release dipyridamole and ASA (no benefit from dipyridamole alone)
2) Antihypertensive therapy as appropriate
3) Proper control of diabetes if present

4) Patients with asymptomatic atrial fibrilation should be treated with anticoagulation
5) Antilipid therapy if needed – statins
6) Intervention to help patients to quit smoking [18, 41-43].

Carotid Endarterectomy

The literature supports significant variability in the technique of CEA. Controversy exists between a transverse or longitudinal incision, performing surgery under general or local anesthesia, intraoperative monitoring via 16-channel EEG, compressed spectral EEG, ICA stump backpressure, xenon-enhanced cerebral blood flow monitoring, transcranial Doppler, or no monitoring at all, the use of shunting during the period of occlusion, a standard longitudinal arteriotomy or the use of an eversion technique, and finally a primary arteriotomy closure or the use of autologous or prosthetic (Dacron or polytetrafluorethylene) patch closure [44, 45].

Despite the variation, no technique has been shown to have overwhelming superiority with any degree of statistical significance. It is recommended that the individual surgeon should continue with the technique with which he or she is comfortable and has established a pattern of success. Adequate morbidity and mortality data must be closely monitored; this means a 30-day overall rate of stroke and death under 3% for asymptomatic patients and 6% for symptomatic cases.

Anesthesia

Carotid endarterectomy can be performed safely under general, local, or regional anesthesia, and the General Anesthesia versus Local Anesthesia for Carotid Surgery (GALA) trial was unable to show a significant difference in outcomes between local or general anesthesia [46]. A recent review of 42,265 cases through the National Surgical Quality Improvement Program database found a significantly decreased risk of 30-day postoperative myocardial infarction in CEA performed under local or regional anesthesia when compared to CEA under general anesthesia. Although this study highlights the disproportionate number of surgeons who perform the procedure under general anesthesia (88,7%), local anesthesia has a loyal following of surgeons who argue that patient evaluation is superior to EEG monitoring during the time of cross-clamping. Harbaugh has shown excellent results in his great series of CEA patients with local or regional anesthesia. This serves as a suitable alternative in high-risk patients because it has been shown to reduce the risk of perioperative cardiopulmonary complications significantly. Furthermore, another study comparing local and general anesthesia by Wellman found a significant difference in EEG changes potentially requiring shunt placement in patients undergoing surgery while under local (6,3%) versus general (15,7%) anesthesia, although there was no difference in outcome or complications. The authors hypothesized an increased sensitivity of EEG in patients under general anesthesia as a possible etiology [14].

Surgical Procedures

Carotid endarterectomy is well established as a stroke-preventing treatment. Two distinct operative approaches are in widespread use: eversion carotid endarterectomy and

conventional carotid endarterectomy. In the 1950s, De Bakey first described the eversion carotid endarterectomy technique, a transection of the CCA just below the bifurcation with eversion of the ICA and ECA, with subsequent end-to-end reanastomosis of the CCA [47].

Conventional Carotid Endarterectomy

Carotid endarterectomy is performed by using longitudinal or oblique cervical incision, then exposure of the carotid bifurcation is obtained by division of the facial vein. Careful dissection is mandatory to avoid iatrogenic lesions of the hypoglossal, vagal and recurrent laryngeal nerve, causing dysphonia and hoarseness. Gently manipulation of the arteries (if it is necessary) should be done to prevent cerebral embolization. Usually, 2500-5000 unit of Heparin is routinely administered before clamping, and a longitudinal arteriotomy is performed from the distal CCA to the ICA as far as the end of the plaque (Figure 6). Insertion of a shunt to preserve flow depends upon the appearance of appropriate neurological symptoms when the operation is performed with the patient awake or based upon indirect evidence of insufficient collateral flow assessed by the carotid stump pressure lower than 50 mmHg (Figure 7). A 50% reduction in flow velocity detected in the middle cerebral artery by transcranial doppler if the operation is performed under general anesthesia [48].

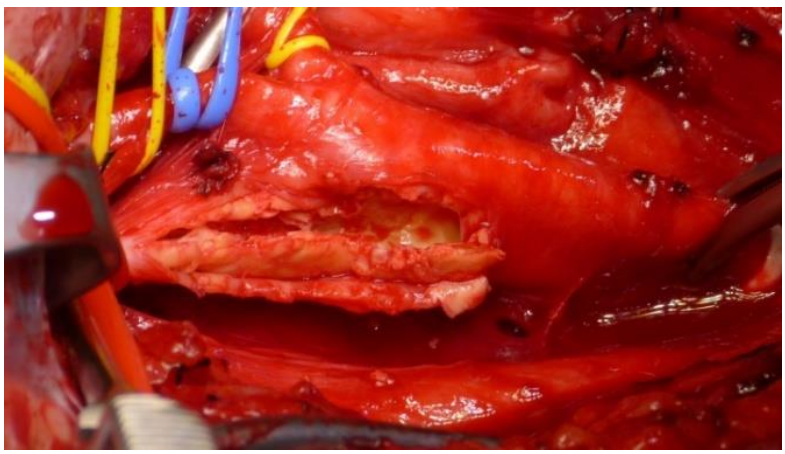

Figure 6. Convetional endarterectomy: Arteriotomy at the CCA and ICA. Atherosclerotic plaque is visible in the inner layer of the arterial wall, without a shunt.

To remove the plaque, dissection is initiated in a subadventitial plane using the gentle dissector, and it is carried out meticulously, separating the lesion from the arterial wall. Complete removal of the lesion should always be attempted, in case that the dissection is in the correct plane the plaque goes out distally. Usually, tacking sutures of the distal intima are not necessary. Clearing of the external carotid artery ostium and its initial segment is performed routinely, and proximally, in the common carotid, the lesion is cut with scissors to avoid fragmentation and irregularities. Extreme care is taken to remove all remaining fragments of plaque and intimal flaps, which may be a source of secondary embolization or lead to secondary thrombosis [14, 48, 49].

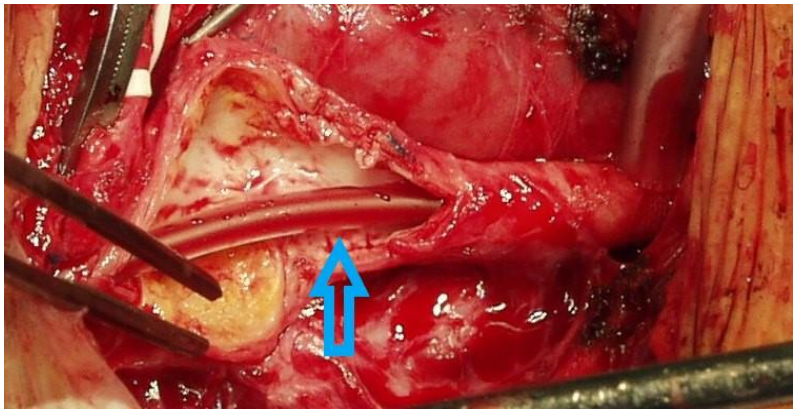

Figure 7. Conventional endarterectomy: A shunt inserteted into the CCA (left side) and ICA (right side). The shunt is marked by an arrow.

The arteriotomy is routinely closed with a Dacron patch, aiming to enlarge the artery and to prevent early recurrent restenosis secondary to proliferative fibrosis [14, 50], to correct kinking of the artery immediately distal to the endarterectomized segment and to reduce postoperative neurological morbidity (Figure 8) [51]. Clamps are released sequentially to allow an initial flush through the ECA and to prevent cerebral embolization. The vein can also be used, but there is no convincing evidence of its additional advantage over the Dacron patch [48].

Perioperative completion assessment is routinely performed with a color flow duplex scan to identify technical defects such as thrombus, floating flaps more than 2 mm or residual stenosis, which, if present, require prompt correction [52].

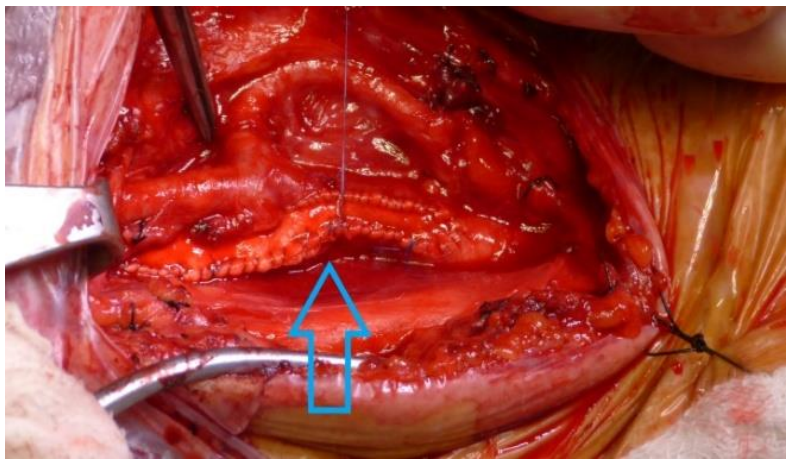

Figure 8. Convetional endarterectomy: Completed Dacron patch plasty of the CCA and ICA. The patch is marked by an arrow.

Monitoring with transcranial doppler is continued in the recovery room to detect brain embolization, and if there is evidence of repeated high-intensity transient signals, this could correspond to thrombus formation at the end of endarterectomized part of the artery. Administration of 250 ml Dextran 40 is performed intravenously, and usually, this is

sufficient to ensure its disappearance. However, if there is a persistence of high-intensity transient signals despite the Dextran administration, immediate cervical re-exploration is carried out, the arteriotomy opened, and thrombectomy of the carotid artery performed to prevent a significant stroke [48].

Drainage is always required, and routine closure of subcutaneous tissues and skin performed after careful inspection and perfect hemostasis.

Eversion Carotid Endarterectomy

Eversion carotid endarterectomy technique is performed under general anesthesia. The patient is placed on the operating table in the supine position with the head hyperextended and turned away from the operative side. The skin incision is made parallel to the anterior border of the sternocleidomastoid muscle. Exposure and clamping of the CCA, external carotid artery ECA and ICA are made in the usual way. Systemic heparinization is used. A right-angled bulldog clamp should control the ICA well beyond the distal end of the atheromatous plaque. The CCA is entered with a scalpel, and immediately than using scissors gently, the arteriotomy is extended in the distal direction toward the fork of the carotid bifurcation. The incision should be made precisely parallel to the axis of the ECA. Gentle scissors are then used for complete transection of the ICA (Figure 9). Transection permits complete mobilization of the artery and additional traction downward offers extra length of exposure. Endarterectomy is started at the stump of the ICA, and the plane is developed between the outermost layers of the media and the adventitia [52, 53].

The atheroma is circumferentially separated and detached while the outer layer of the vessel is everted. Fine atraumatic vascular forceps are required for these manipulations. The eversion is progressively continued to the distal part of the artery, and the atheroma is detached like a cast. Gentle traction results in complete removal of the atheromatous core, providing a slight fading and tapering endpoint (Figure 10) [52, 53].

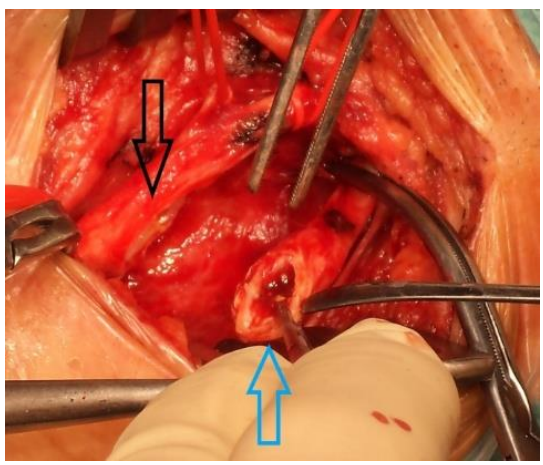

Figure 9. Eversion endarterectomy: Transsected stumpf of the ICA, marked by a blue arrow. A black arrow marks the CCA.

As the atheroma is removed, the luminal surface and the transition between the endarterectomized and nonendarterectomized segment of the ICA are assessed carefully. Heparinized saline is used to flood the field to remove intimal or medial debris. Flaps or

residuals are gently removed only by circumferential traction since cephalic traction can cause inadvertent intimal dissection of the ICA endpoint [52-54].

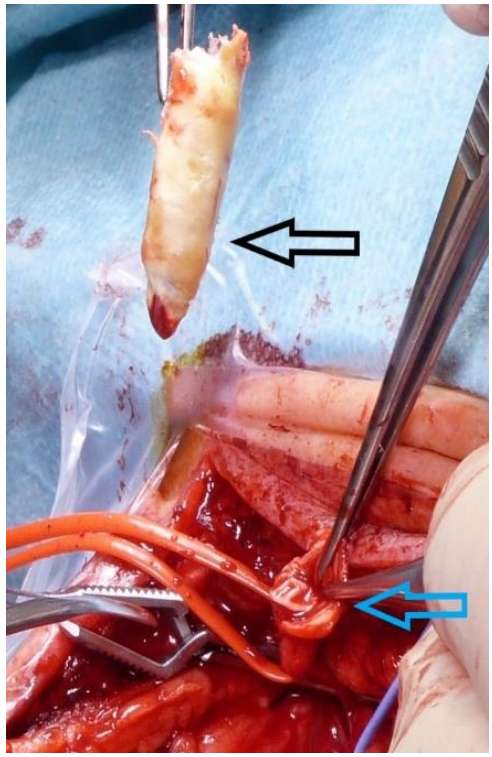

Figure 10. Eversion endarterectomy: plaque removal. The stumpf of the ICA after endarterectomy is marked by a blue arrow, while a black arrow marks the completely removed atherosclerotic plaque.

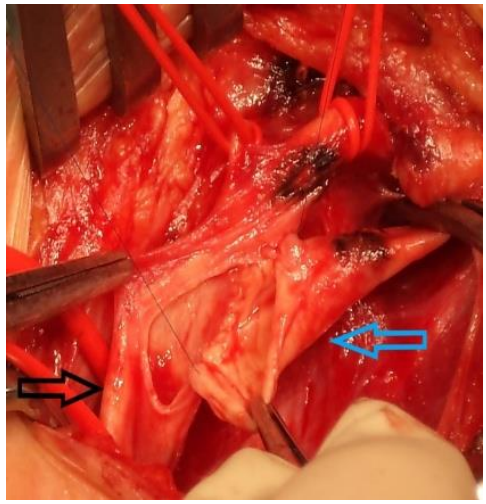

Figure 11. Eversion endarterectomy: The posterior wall of the anastomosis between the CCA (a black arrow) and ICA (a blue arrow) is completed.

The next step is the attempted endarterectomy of the ECA and CCA. Circumferential mobilization of the plaque is achieved by utilizing the closed jaws of a dissector. After the proximal division of the plaque, the endarterectomy is carried out into the ECA orifice as distal as possible. The arterial wall of the ICA is drawn proximal, and the reimplantation of the artery to its normal position is performed. The anastomosis begins at the bifurcation fork using a simple running 6-0 synthetic monofilament suture. The posterior wall is reconstructed first with tiny bites (Figure 11). Before the completion of the anterior wall of the anastomosis, all clamps are removed sequentially to allow back bleeding and to wash out any thrombogenic debris [52, 53].

Kiskinis recommended at this stage of the procedure dilators of appropriate size, up to 4.5 mm in diameter, may be used to dilate the extracranial segment of the ICA. Angioscopy may also be used to verify the anatomic result. Angioscopy yields an excellent visualization of the whole endarterectomized luminal surface and the endpoint of the ICA (Figure 12). After completion of the anastomosis, the blood flow is restored first to the ECA and then to the ICA. In cases with distal flaps or plaque detachment, intraoperative stent deployment may secure the distal endpoint [52].

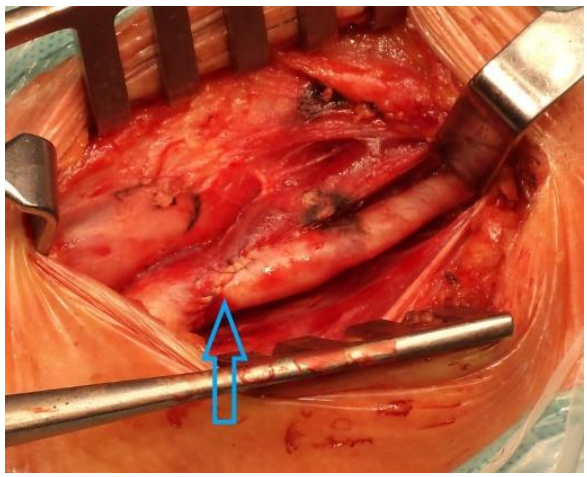

Figure 12. Eversion anastomosis: Completed reinsertion of the ICA into the CCA. The anastomsosis is marked by a blue arrow.

Many authors agreed with the advantages of the modified carotid endarterectomy technique over the open endarterectomy, especially that the longitudinal arteriotomy of the ICA is avoided and subsequently the suture line does not interfere with the lumen of the vessel. Furthermore, the use of a patch in patients with small arteries, such as women and children, is not necessary. This method is appropriate for the correction of coiling, kinking, or tortuosity of the ICA in the presence of arteriosclerotic lesions. After completion of the endarterectomy, an ICA segment of appropriate length is resected and the vessels reimplanted. On the other hand, there are some disadvantages. Among the disadvantages of eversion carotid endarterectomy is the limitation of an internal shunt placement when it is required. During the procedure of eversion endarterectomy of the ICA, only a CCA to ECA shunt can be easily used for cerebral protection. In some complex cases, when the transition endpoint of the ICA is not smooth and/, or the plaque is extended distally, the replacement of

the ICA by a graft may be necessary [50, 52]. In such cases, the interposition of synthetic or saphenous vein grafts may be used [55].

Many studies have compared standard and eversion techniques for endarterectomy. The EVEREST trial compared the two methods in a randomized, prospective study published in 2000 [56]. Over a 2.5-year period, 1,353 patients were randomized to undergo eversion (n = 678) or standard (n = 675) CEA. The incidence of ipsilateral stroke was 3.3% in the eversion group and 2.2% in the standard group. There were no statistically significant differences in the rate of stroke or death between the two groups. At four years of follow-up, the cumulative restenosis risk was significantly lower in the eversion group when compared with the standard group. The most common complication after carotid endarterectomy is blood pressure instability requiring medical treatment. A recently published meta-analysis reviewed the role of surgical technique in postoperative blood pressure. The study reviewed six published reports and found that patients who underwent eversion carotid endarterectomy were more likely to develop postoperative hypertension than those in the standard carotid endarterectomy group ($P < 0.0001$), and those who underwent standard carotid endarterectomy were more likely to develop postoperative hypotension. There was no difference in the rates of myocardial infarction, stroke, death, or hematoma [57]. It may be that the increased dissection of the carotid bulb and ICA required for the eversion technique is responsible for this phenomenon. Regardless, close blood pressure monitoring in the immediate postoperative period is required, regardless of technique [52, 53].

Endovascular Techniques: Carotid Artery Angioplasty and Stenting

In recent years, endovascular treatment of carotid stenosis has been developed as an alternative to carotid endarterectomy with several potential advantages. Endovascular treatment avoids an incision in the neck with the risk of cranial or cutaneous nerve damage and potentially reduces general surgical complications, such as myocardial infarction. Surgically inaccessible lesions distant to the carotid bifurcation can be treated, and hospital stay is usually shorter than for surgery. On the other hand, endovascular treatment does not remove the atherosclerotic plaque and may dislodge thrombus or plaque material during the procedure, causing an embolic stroke. Another concern has been that residual stenosis after incomplete dilation or recurrence of carotid stenosis might limit the long-term effectiveness of endovascular treatment in preventing strokes [57].

Endovascular treatment involves the insertion of a catheter in the femoral artery at the groin under local anesthesia, which is then advanced to the site of the stenosis in the internal carotid artery. In the early years of endovascular treatment, the stenosis was dilated by inflating a balloon mounted to the catheter tip (balloon angioplasty), without routine insertion of stents. The first insertion of stents, carotid artery stenting, has since replaced balloon angioplasty as the endovascular technique of choice. Primary stenting has several advantages over balloon angioplasty: the risk of periprocedural carotid dissection is reduced, and if dissection occurs, adverse consequences such as carotid occlusion or thrombo-embolism might be minimized, because the stent maintains laminar flow across the stenosis and seals the site of dissection [57, 59, 60]. Superior dilation achieved by stenting is also likely to lower the rate of residual or recurrent stenosis compared with balloon angioplasty[58-61].

The investigators concluded that there is equipoise between carotid endarterectomy and carotid artery stenting and provided data regarding the value of anatomic features and

comorbid conditions on treatment outcomes. At the 4-year follow-up, the rates of the primary endpoint (any periprocedural stroke, myocardial infarction, or death or postprocedural ipsilateral stroke) were similar in both the carotid endarterectomy and carotid artery stenting recipients (6.8% and 7.2%, respectively; p = 0.51). However, during the periprocedural period (within 30 days after the procedure), a statistically significant higher rate of stroke was observed among patients undergoing carotid artery stenting than among those undergoing carotid endarterectomy (4.1% versus 2.3%; p =0.01), whereas patients undergoing carotid endarterectomy had a significantly higher rate of myocardial infarction than did those undergoing carotid artery stenting (2.3% versus 1.1; p = 0.03). However, the overall rates of stroke, myocardial infarction, or death within the periprocedural period were similar to the two approaches (5.2% with carotid endarterectomy and carotid artery stenting 4.5% with carotid artery stenting; P = 0.38) [12, 13, 60-62].

Detailed analysis of periprocedural stroke events in CREST showed that when strokes occurred, they were typically ipsilateral to the treated artery and of minor clinical effect (median National Institutes of Health Stroke Scale score of 2 within 1 month) [13, 61, 63, 64]. The median time of the development of stroke was 0 days after the procedure, which suggests that these events were directly related to the procedure. In addition, the development of periprocedural stroke in association with carotid artery stenting was related to high-risk plaque characteristics, such as the presence of plaque ulcerations. Rates of restenosis, defined as in-stent stenosis of 70% or more or complete occlusion, were similar 2 years after stent placement (6.0% and 6.3%, p = 0.58) [12, 13, 61]. Female sex, history of diabetes, hyperlipidemia, and smoking were associated with increased risk of restenosis [61, 62].

CONCLUSION

Stroke is the second most frequent reason for death in the world and the most common reason for disability of the older population in developed countries. Symptoms of the extracranial carotid disease are most often not the result of hypoperfusion but are caused by emboli. In Europe and North America, arterial embolisms account for about a quarter of the causes of stroke, originating from atherosclerotic lesions of the carotid artery. The most common injury is a bifurcation of the carotid artery, and the microemboli result from TIA. If symptoms persist, it is a stroke or cerebrovascular accident. Embolism into the ophthalmic artery causes a temporary monocular loss of vision called amaurosis fugax or permanent blindness because the ophthalmic artery is the first branch of the ICA.

Indications for surgical or endovascular treatment are indicated: for asymptomatic patients with stenosis of internal carotid artery more than 70% or symptomatic patients with stenosis of internal carotid artery more than 50%. Symptomatic patients are those that had a stroke or TIA within 180 days. Asymptomatic patients are those that had stroke or TIA before more than 180 days or those that did not have any stroke or TIA.

Contraindications of treatment are occlusion of the internal carotid artery. Surgically it is possible to do revascularization of carotid occlusion. However, there is a high risk of fatal bleeding in the ischemic area of the brain after such revascularization. Hence revascularization of occlusion of the internal carotid artery is contraindicated. The only exception is the interval within the first 6 hours after occlusion. Only within this interval,

acute occlusion of the carotid artery can be operated. Another contraindication is unstable neurological finding, stroke in evolution. Revascularization of a neurologically unstable patient could also lead to intracerebral bleeding. Patients with expected live survival less than two years and patients in generally bad status are contraindicated for treatment too.

Carotid angioplasty and stenting are an alternative method of carotid revascularization. Carotid stenting has a higher risk of embolization and stroke compared to carotid endarterectomy. Therefore, carotid stenting is indicated only in patients with a high risk of the operation. High-risk patients are those with severe cardiac or pulmonary disease, who are after neck radiotherapy or who have had carotid endarterectomy previously. Early studies of carotid angioplasty and stenting have shown promise with similar morbidity and mortality rates to carotid endarterectomy, but later studies showed a higher risk of stroke by carotid stenting and higher risk of myocardial infarct by carotid endarterectomy. Carotid stenting has already become the primary treatment option for occlusive lesions of the origins of the arch and recurrent stenosis after treatment.

REFERENCES

[1] Bamford, J., Sandercock, P., Dennid, M. et al. (1988). A prospective study of acute cerebro-vascular disease in the community. The Oxfordshire Community Stroke Project 1981-1986. (I) Methodology, demography and incident cases of first ever stroke. *J Neurol Neurosurg Psychiatry*, 51:1373-1380.

[2] Dunbabin, D., Sandercock, P. (1991). Investigation of acute stroke: what is the most effective strategy? *Postgrad Med J*, 67:259-270.

[3] Malmgren, R., Bamford, J., Warlow, C. P. et al. (1989). Projecting the number of patients with first ever strokes and patients newly handicapped by stroke in Englans and Wales. *Br Med J*, 298:656-660.

[4] Dennis, M. S., Bamford, J. M., Sandercock, P. A. et al. (1989). Incidence of transients ischemic attacks in Oxfordshire, England. *Stroke*, 20:333-339.

[5] Barnett, H. J., Taylor, D. W., Eliasziw, M. et al. (1998). Benefit of carotid endarterectomy in patients with symptomatic, moderate or severe stenosis. North American symptomatic carotid endarterectomy trial collaborators. *N Eng J Med*, 339:1415–1425.

[6] Donnan, G. A., Davis, S. M., Chambers, B. R. et al. (1998). Randomised trial of endarterectomy for recently symptomatic carotid stenosis:final results of the MRC European Carotid Surgery Trial (ECST). *Lancet*, 351:1379–1387.

[7] Eckstein, H. H., Ringleb, P., Allenberg, J. R. et al. (2008). Results of the Stent-Protected Angioplasty versus Carotid Endarterectomy (SPACE) study to treat symptomatic stenoses at 2 years: a multinational, prospective, randomised trial. *Lancet Neurol*, 7:893–902.

[8] Ederle, J., Bobson, J., Fearherstone, R. L. et al. (2010). Carotid artery stenting compared withendarterectomy in patients with symptomatic carotid stenosis (InternationalCarotid Stenting Study): an interim analysis of a randomised controlled trial. *Lancet*, 375:985–997.

[9] Rothwell, P. M., Goldstein, L. B. (2004). Carotid endarterectomy for asymptomatic carotidstenosis: asymptomatic carotid surgery trial. *Stroke*, 35:2425–2427.

[10] Halliday, A., Harrison, M., Hayter, E. et al. (2010). 10-year stroke prevention after successful carotid endarterectomy for asymptomatic stenosis (ACST-1): a multicentre rando- mised trial. *Lancet*, 376:1074–1084.

[11] Reddy, R. P., Karnati, T., Massa, R.E. et al. (2019). Association between perioperative stroke and 30-day mortality in carotid endarterectomy: A meta-analysis. *Clin Neurol Neurosurg*, 181:44-51.

[12] Brott, G., Hobson, R. W., Howard, G. et al. (2010). Stenting versus endarterectomy for treatment of carotid-artery stenosis. *N Engl J Med*, 363:11–23.

[13] Hill, M. D., Brooks, W., Mackey, A. et al. (2012). Stroke after carotid stenting and endarterectomy in the carotid revascularization endarterectomy versus stenting trial (CREST). *Circulation*, 126:3054–3061.

[14] Marcus, J., Knopman, J., Stieg, P. E. (2017). Carotid Endarterectomy. In *Youmans & Winn Neurological Surgery, 7th edition*, edited by Winn H. R. 3096-3106. Philadelphia, Elsevier Saunders, ISBN: 978-0-323-28782-1.

[15] Loftus, I. M., Paraskevas, K. I., Johal, A. et al. (2016). Delays to Surgery and Procedural Risks Following Carotid Endarterectomy in the UK National Vascular Registry. *Eur J Vasc Endovasc Surg*, 52:438-443.

[16] Andakuz, N., Park, M. S., Greenberg, M. S. (2016) General Information and Stroke Physiology. In *Handbook of Neurosurgery*, *8th edition*, edited by Greenberg, M. S. 1264-1279. New York, Thieme, ISBN: 978-1-6262-3241-9.

[17] Bauer, A. M., Dempsey, R. J. (2015) The Pathophysiology of Cerebral Ischemia. In *Neurovascular Surgery, 2 nd edition*, edited by Spetzler, R. F., Kalani, M. S., Nakaji, P. 203-215. New York. Thieme, ISBN: 978-1-60406-759-0.

[18] Andakuz, N., Park, M. S., Greenberg, M. S. (2016) Evaluation and Treatment for Stroke. In *Handbook of Neurosurgery*, *8th edition*, edited by Greenberg, M. S. 1280-1300. New York, Thieme, ISBN: 978-1-6262-3241-9.

[19] Goldstein, L. B., Adams, R., Alberts, M. J. et al. (2006). Primary prevention of ischemic stroke. *Stroke*, 37:1583–1633.

[20] Fine-Edelstein, J. S., Wolf, P. A., O'Leary, D.H. et al. (1994). Precursors of extracranial carotid atherosclerosis in the Framingham Study. *Neurology*, 44:1046–1050.

[21] Hillen, T., Nieczaj, R., Munzberg, H. et al. (2000). Carotid atherosclerosis, vascular risk profile and mortality in a population-based sample of functionally healthy elderly subjects: the Berlin ageing study. *J Intern Med*, 247:679–688.

[22] Autret, A., Pourcelot, L., Saudeau, D. et al. (1986). Stroke risk in patients with carotid stenosis. *Lancet*, 1:888–890.

[23] Abbott, A. L., Merican, J., Pearce, D. C. et al. (2019). Asymptomatic Carotid Stenosis Is Associated With Circadian and Other Variability in Embolus Detection. *Front Neurol*, 10:322.

[24] Soenens, G., Moreels, N., Vermassen, F. et al. (2019). Evolution of surgical treatment of carotid artery stenosis: a single center observational study. *Acta Chir Belg*, 17:1-9.

[25] Mazzaccaro, D., Stegher, S., Occhiuto, M. T. et al. (2015). Treatment of significant carotid artery stenosis in 1824 patients. *J Cardiovasc Surg (Torino)*, 56:107-118.

[26] You, R. X., McNeil, J. J., O'Malley, H. M. et al. (1997). Risk factors for stroke due to cerebral infarction in young adults. *Stroke*,28:1913-1918

[27] Adams, H. P., Butler, M. J., Biller, J. et al. (1986). Nonhemorrhagic Cerebral Infarction in Young Adults. *Arch Neurol*, 43:793-796.

[28] Hilton-Jones, D., Warlow, C. P. (1985). The causes of stroke in the young. *J Neurol*, 232:137-143.

[29] Moneta, G. L., Taylor, D. C., Nicholls, S. C. et al. (1987). Operative versus Nonoperative Management of Asymptomatic High-Grade Internal Carotid Artery Stenosis. *Stroke*, 18:1005–1010.

[30] Kistler, J. P., Furie, K. L. (2000). Carotid Endarterectomy Revisited. *N Engl J Med*, 342:1743–1745.

[31] Johansson, E. P., Wester, P. (2008). Carotid bruits as predictor for carotid stenoses detected by ultrasonography: an observational study. *BMC Neurol*, 8:23.

[32] Koelemay, M. J., Nederkoorn, P. J., Reitsma, J. B. et al. (2004). Systematic review of computed tomographic angiography for assessment of carotid artery disease. *Stroke*, 35:2306–2312.

[33] Saxena, A., Ng, E. Y. K., Lim, S. T. (2019). Imaging modalities to diagnose carotid artery stenosis: progress and prospect. *Biomed Eng Online*, 18:66.

[34] Buskens, E., Nederkoorn, P. J., Buijs-Van Der Woude, T. et al. (2004). Imaging of carotid arteries in symptomatic patients: costefectiveness of diagnostic strategies. *Radiology*, 233:101–112.

[35] Debrey, S. M., Yu, H., Lynch, J. K. et al. (2008). Diagnostic accuracy of magnetic resonance angiography for internal carotid artery disease: a systematic review and meta-analysis. *Stroke*, 39:2237–2248.

[36] Cai, J. M., Hatsukami, T. S., Ferguson, M. S. et al. (2002). Classification of human carotid atherosclerotic lesions with in vivo multicontrast magnetic resonance imaging. *Circulation*, 106:1368–1373.

[37] Saam, T., Cai, J., Ma, L. et al. (2006). Comparison of symptomatic and asymptomatic atherosclerotic carotid plaque features with in vivo MR imaging. *Radiology*, 240:464–472.

[38] Saam, T., Hatsukami, T. S., Takaya, N. Et al. (2007). The vulnerable or high-risk, atherosclerotic plaque: noninvasive MR imaging for characterization and assessment. *Radiology*, 244:64–77.

[39] Fitzpatrick, L. A., Berkovitz, N., Dos Santos, M. P. et al (2017). Vulnerable carotid plaque imaging and histopathology without a dedicated MRI receiver coil. *Neuroradiol J*, 30:120-128.

[40] Yuan, J., Makris, G., Patterson, A. et al. (2018). Relationship between carotid plaque surface morphology and perfusion: a 3D DCE-MRI study. *MAGMA*, 31:191-199.

[41] Halkes, P. H., van Gijn, J., Kappelle, L. J. et al. (2006). Aspirin plus dipyridamole versus aspirin alone after cerebral ischaemia of arterial origin (ESPRIT): randomised controlled trial. *Lancet*, 367:1665–1673.

[42] Sacco, R. L., Diener, H. C., Yusuf, S. et al. (2008). Aspirin and extended-release dipyridamole versus clopi- dogrel for recurrent stroke. *N Engl J Med*, 359:1238-1251.

[43] Diener, H. C., Bogousslavsky, J., Brass, L. M. et al. (2004). Aspirin and clopidogrel compared with clopidogrel alone after recent ischaemic stroke or transient ischaemic

attack in high-risk patients (MATCH): randomised, double-blind, placebo-controlled trial. *Lancet*, 364:331–337.

[44] Chalouhi, N., Chitale, R., Jabbour, P. M. et al. (2015). Carotid Diseases. In *Neurovascular Surgery, 2 nd edition*, edited by Spetzler, R. F., Kalani, M. S., Nakaji, P. 243-251. New York. Thieme, ISBN: 978-1-60406-759-0.

[45] Bookland, M., Loftus, C. M. (2015). Carotid Endarterectomy. In *Neurovascular Surgery, 2 nd edition*, edited by Spetzler, R. F., Kalani, M. S., Nakaji, P. 252-261. New York. Thieme, ISBN: 978-1-60406-759-0.

[46] Gough MJ. The GALA Trial collaborators. (2008). The GALA trials – a summary of the findings. *Eur J Vasc Endovasc Surg*, 36:505-506.

[47] De Bakey, M. E., Crawford, E. S., Cooley, D. A. et al. (1959). Surgical considerations of occlusive disease of innominate, carotid, subclavian, and vertebral arteries. *Ann Surg*, 149:690-710.

[48] Fernandes, J. F., Pedro, L. M. (2007). Extracranial carotid endarterectomy technique. In *Vascular Surgery, 1st edition*, edited by Liapis, C. D., Balzer, K., Benedetti, F., Fernandes e Fernandes, J. 137-153. Berlin-Heidelberg-New York. Springer, ISBN: 10 3-540-30955-1

[49] Yadav, J. S., Wholey, M. H., Kuntz, R. E. et al. (2004). Protected carotid-artery stenting versus endarterectomy in high-risk patients. *N Engl J Med*, 351:1493-1501.

[50] Eikelboom, B. C., Ackerstaff, R. G., Hoeneveld, H. et al. (1998). Benefits of carotid patching: a randomized study. *J Vasc Surg*, 7:240-247.

[51] Hayes, P. D., Lloyd, A. J., Lennard, N. et al. (2000). Transcranial Doppler-directed Dextran-40 therapy is a cost-effective method of preventing carotid thrombosis after carotid endarterectomy. *Eur J Vasc Endovasc Surg*, 19:56–61.

[52] Kiskinis, D. A., Saratzis, N. A., Saratzis, A. (2007). Eversion Carotid Endarterectomy Technique. In *Vascular Surgery, 1st edition*, edited by Liapis, C. D., Balzer, K., Benedetti, F., Fernandes e Fernandes, J. 155-161. Berlin-Heidelberg-New York. Springer, ISBN: 10 3-540-30955-1.

[53] Sullivan, T. M. (2019). Carotid Endarterectomy: The Eversion Technique. A look at the eversion approach to CEA, including technical tips, available data, and how to decide when this might be the best option. *Endovascular Today*, 18:70-74.

[54] Maguire, S. C., Elnagarl, M., Nazar, A. et al. (2019). A comparison of outcomes of eversion versus conventional carotid endarterectomy: one centre experience. *Ir J Med Sci*, online. https://doi.org/10.1007/s11845-019-02026-3.

[55] Lee, J. H., Suh, B. Y. (2014). Comparative results of conventional and eversion carotid endarterectomy. *Ann Surg Treat Res*, 87:192-196.

[56] Paraskevas, K. I., Robertson, V., Saratzis, A. N. et al. (2018). An Updated Systematic Review and Meta-analysis of Outcomes Following Eversion vs. Conventional Carotid Endarterectomy in Randomised Controlled Trials and Observational Studies. *Eur J Vasc Endovasc Surg*, 55:465-473.

[57] Leo, H. B., Engelter, S. T., Lyrer, P. A. (2012). Carotid artery stenting. *Swiss Med Wkly*, 142:w136.

[58] Diethrich, E. B., Ndiaye, M, Reid, D. B. (1996). Stenting in the carotid artery: initial experience in 110 patients. *J Endovasc Surg*, 3:42–62.

[59] Roubin, G. S., New, G., Iyer, S. S. et al. (2001). Immediate and late clinical outcomes of carotid artery stenting in patients with symptomatic and asymptomatic carotid artery stenosis: a 5-year prospective analysis. *Circulatio*n, 103:532–537.

[60] Zhang, X., Ma, H., Li, L. et al. (2019). A meta-analysis of transfemoral endovascular treatment of common carotid artery lesions. *World Neurosurg*, 123:89-94.

[61] Munich, S. A., Mokin, M., Krishna, C. et al. (2017). Carotid Artery Angioplasty and Stenting. In *Youmans & Winn Neurological Surgery, 7th edition*, edited by Winn H. R. 3107-3123. Philadelphia, Elsevier Saunders, ISBN: 978-0-323-28782-1.

[62] Lal, B. K., Beach, K. W., Roubin, G. S. et al. (2012). Restenosis after carotid artery stenting and endarterectomy: a secondary analysis of CREST, a randomised controlled trial. *Lancet Neurol*, 11:755-763.

In: Encyclopedia of Surgery (22 Volume Set)
Editors: Andreas Lehrer and Kristin Mueller
ISBN: 978-1-53618-329-0
© 2020 Nova Science Publishers, Inc.

Chapter 289

PERIPHERAL ARTERIAL DISEASE: UPPER EXTREMITY ARTERY DISEASE, LOWER EXTREMITY ARTERY DISEASE, ACUTE LIMB ISCHEMIA

Mária Kubíková**, MD, PhD
Department of Vascular Surgery, East Slovak Institute of Cardiovascular Diseases,
Pavol Jozef Safarik University, Kosice, Slovakia

ABSTRACT

Lower limb ischemia is a serious problem that affects the health and quality of life of 2-5% of the population in industrialized countries. Lower limb ischemic disease is one of the most severe diseases that vascular specialists encounter.

With the growing age of the population in industrialized countries, it also poses a significant health problem (it is the most common vascular disease in the population).

Patients with PAD are in high-risk of cerebrovascular and cardiovascular complications. Proper management and assessment of the overall condition with determining the most appropriate treatment are important for disease prognosis. In the healthcare centers, it is recommended to set up a multidisciplinary Vascular team to make decisions for the management of patients with PADs [40].

Access to these patients involves early detection of risk factors, elimination of known existing risk factors (smoking cessation, healthy diet, and physical activity) and the proper treatment of diseases such as diabetes and hypertension. Long-term antiplatelet therapy is also essential. In most patients, conservative treatment is sufficient. Interventions are only indicated in case of severe limiting claudication or critical ischemia when a limb is at risk. The first interventional trial in patients with a suitable lesion is endovascular treatment - PTA and additional methods for their low complications and less invasiveness. Interventional therapy may be endovascular or classical open surgery or a combination of both. Bypass surgery when using autologous VSM remains the gold standard. Primary amputation has a diminishing role in the treatment of CLI with an expansion of endovascular techniques [50].

* Corresponding Author's Email: mkubikova@vusch.sk

Optimal management of acute lower limb ischemia is based on the severity of the ischemia at presentation.

Upper extremity vascular disorders are less common compared to lower-extremity vascular disease and are rare in comparison to those involving the lower extremities. Upper extremity arterial disease evaluation, diagnosis, and treatment represent a much different spectrum than those of lower extremities. The management is difficult and requires an assessment of vascular structure and function. Upper extremity vascular disease due to atherosclerosis is mostly situated at the level of the brachiocephalic trunk and the subclavian and axillary arteries. In most asymptomatic patients, medical treatment is the option of choice. When revascularization is considered, both endovascular and open surgical options can be proposed, according to lesion characteristics and the patient's risk [40].

Keywords: upper extremity, lower extremity, artery, disease, acute, chronic, ischemia, atherosclerosis, diagnosis, treatment, revascularisation, amputation

ABBREVIATIONS AND ACRONYMS

ABPI	ankle-brachial pressure index
ACD	absolute claudication distance
ADP	arteria dorsalis pedis
AF	atrial fibrillation
ALI	acute limb ischemia
AP	arteria poplitea
AS	atherosclerosis
ATP	arteria tibialis posterior
BASIL	bypass versus angioplasty in severe ischemia of the leg
BMT	best medical therapy
CABG	coronary artery bypass grafting
CAD	coronary artery disease
CFA	common femoral artery
CKD	chronic kidney disease
CLI	chronic limb ischemia
CLTI	chronic limb-threatening ischemia
CRP	C-reactive protein
CTA	computed tomography angiography
CVS	cardiovascular
CWD	continual-wave Doppler
DCB	drug coated balloon
DES	drug eluting stent
DSA	digital subtraction angiography
DUS	duplex ultrasound
ECG	electrocardiogram
ESC	European Society of Cardiology
ESVS	European Society of Vascular Surgery
HDL	high – density lipoprotein

GSV	great saphenous vein
IC	intermittent claudication
IVUS	intravascular ultrasound
LDL	low-density lipoprotein
LEAD	lower extremity arterial disease
MI	myocardial infarction
MRA	magnetic resonance angiography
MRI	magnetic resonance imaging
MWD	maximal walking distance
PAD	peripheral arterial disease
PFA	profunda femoral artery
PPCI	profunda-popliteal collateral index
PTA	percutaneous transluminal angioplasty
SBP	systolic blood pressure
SFA	superficial femoral artery
TASC	The Transatlantic Consensus
TBI	toe-brachial index
USG	ultrasound
VSM	vena saphena magna
WD	walking distance
Wifi	wound, ischemia and foot infection

INTRODUCTION

Lower limb ischemia is a serious problem that affects the health and quality of life of 2-5% of the population in industrialized countries. Lower limb ischemic disease is one of the most severe diseases that vascular specialists encounter.

The title “peripheral arterial (occlusive) disease” (PAD) for diseases of peripheral arteries is used in the world literature [1] and means especially lower extremities.

With the growing age of the population in industrialized countries, it also poses a significant health problem (it is the most common vascular disease in the population).

Not only is the lower limb disease itself dangerous, but the atherosclerosis (AS) of the lower extremities is also a marker of systemic AS disease, especially cardiovascular and cerebrovascular disease.

The prognosis of these diseases is the same, with the mortality rate about 30% within five years, while in patients with critical limb ischemia, the five-year mortality is 50% [2].

The most severe consequence of PAD is severe limb ischemia, which is characterized by intolerable claudication, resting distal pain, skin ulcerations and trophic defects up to gangrene, which leads to amputation without adequate treatment.

Amputation is a serious handicap for the majority of people because it limits their daily activities, and in most cases, the sick person is dependent on the permanent care of another person.

DEFINITION

The most commonly used definition for PAD is a resting index (ABPI-"ankle-brachial" index) of less than 0.9 [3, 4]. Patients may be clinically asymptomatic, may have intermittent claudication (IC) - is a symptom of muscular lower limb pain brought by exertion and relieved by rest or may have chronic critical limb ischemia (CLI) with night pain, rest pain, tissue loss.

EPIDEMIOLOGY OF PAD

The incidence (the rate of new cases of the disease) and prevalence (the actual number of cases alive with the disease) of PAD increases with age. For 60 and more years, it is estimated at 10-30%. The incidence of lower limb ischemia in diabetic patients is four times higher than in the general population and increases with increasing age [5].

The actual incidence of CLI is difficult to estimate, but based on the number of amputations, the prevalence of 500-1000 per million inhabitants [6] is estimated, although this is probably underestimated. In a group of 20,000 patients aged 40-69 years, the reported CLI of 0.24%, similar in both sexes, which increased with age and the presence of risk factors [7]

Disease progression: 20% of PAD patients look for a doctor, while another 20% have difficulties but do not pay attention to them. In 75% of men, claudication never causes a serious problem. Intermittent claudications progress to rest pain or gangrene in 15-20% of patients [8].

NATURAL HISTORY OF PAD

It is different in asymptomatic patients and patients with claudication and those with CLI. Patients with asymptomatic PAD and IC have the same increased risk of developing myocardial infarction (MI) and stroke [3]. The mortality for s IC is about 30-42% /40-65% in 5/10 years, with the risk of amputation being less than 5%.

CLI mortality is up to 25% per year and 50% after five years [2, 9] mainly due to cardiovascular 55% and 10% in cerebrovascular diseases. The risk of amputation per year is up to 35% [10]. The risk of limb loss increases if the patient continues to smoke.

HISTORY

The first vascular reconstruction was carried out by the English surgeon Hallowell in 1759 when he treated brachial artery injury with a wall suture.

Ambroise Paré is considered the founder of modern amputation surgery. At the beginning of l6th century, he used a ligature to stop bleeding in amputated limbs after injury for the first time.

Alexis Carrel is considered the father of vascular and transplant surgery. Carrel also developed today's basic vascular surgery procedures. He was awarded the Nobel Prize for Medicine for his extensive work in 1912.

New advances in anesthesia, blood transfusion, the discovery of new antibiotics, heparin in clinical practice, the introduction of angiography and special sewing materials (all this after World War II) contributed to the rapid development of vascular surgery. While at this time, the main drawback of growth was the lack of a suitable vascular replacement, there are now many ways to replace, eventually, reconstruct damaged or obliterated vessels. The first femoral endarterectomy was performed in 1947 by Dos Santos. Dubost did the first resection of ruptured aneurysm of abdominal aorta and replacement by allograft in Paris in 1952. The first resection of carotid bifurcation for prevention of recurrent cerebral ischemia was carried out by Eastcott in London in 1954.

The fast development of vascular surgery brought the introduction of prosthetic grafts by Vorhees in 1952. That enabled De Backey to resect abdominal aortic aneurysm and replace it with synthetic graft in 1955. Seldinger performed the first angiography with a catheter in 1952. Dotter and Judkins first described percutaneous transluminal angioplasty (PTA) in 1964 that used a coaxial catheter. Gruntzig in 1974 was the first who did PTA and started the modern era of endovascular treatment [11].

Over the past 30 years, the care for patients with vascular diseases has changed significantly. Vascular medicine, which uses invasive diagnostics and therapeutic methods, has now gone into a period of less invasive diagnosis and treatment, represented by ultrasound (USG) methods, endoscopy, and invasive radiology. Revolutionary changes are appearing in vascular surgery all the time. Duplex ultrasonography (DUS) and less invasive radiology - computed tomography angiography (CTA), magnetic resonance angiography (MRA), three-dimensional ultrasound visualization and three-dimensional MRAs allow a more detailed view of the arterial bed, refine diagnosis and contribute to less discomfort and morbidity [12].

The consequence of the rapid development and improvement of endovascular techniques is that open surgical interventions are progressively replaced by technologies that use catheters, balloons, balloons, and stents coated with drugs and stent grafts. The methods are used alone or in combination with one or more surgical procedures.

An essential part of the rapid development is the improvement of MRA with the refinement of hardware and software and non-nephrotoxic contrast-media. Smart communication technology makes medical education and communication much faster and more accessible.

ETIOLOGY

The most common cause of PAD is atherosclerosis (AS) in 90%. AS is a generalized disease that affects the arterial system, especially the lower extremities.

Complex genetic and environmental interactions lead to structural and functional abnormalities and reduction of blood flow.

Nonatherosclerotic disorders causing lower limb ischemia are: primary and secondary vasculitis (Takayashu Morbus, Kawasaki Morbus, Buerger’s Morbus, postirradiation arteritis,

vasculitis in rheumatoid arthritis). Vasoneuroses and fibromuscular dysplasia are less common. More often, we encounter the consequences of metabolic disorders in diabetes mellitus [9].

The peripheral arterial disease can exceptionally be caused by persistent sciatic artery, cystic degeneration, popliteal artery entrapment syndrome, tumors, and others.

RISK FACTORS FOR PAD

PAD is one of the most severe clinical manifestations of atherosclerosis. There are several risk factors associated with disease progression.

a) non-modifiable: age, gender, and ethnicity
b) modifiable: cigarette smoking (risk increased four fold), diabetes mellitus (two-fold), hypertension (2,5-4 fold), hypercholesterolemia, chronic renal failure, high fibrinogen level, CRP(C-reactive protein), (patients with elevated CRP are at higher risk of postoperative cardiovascular events) [13]).

ETHIOPATOGENESIS

Atherosclerosis is a capital global problem with high cardiovascular mortality. The clinical picture depends on the organ involvement, the intensity, the duration of action of atherosclerosis, and the associated diseases. A combination of risk factors increases the risk of atherosclerosis 16 times as much as one risk factor. According to Rose's theory, inflammation and endothelial dysfunction with lipid accumulation play a significant role in atherosclerosis. Inflammation is either a defensive or damaging reaction. Atherosclerosis is now considered a chronic inflammation [14]. Inflammation plays a critical role in atherosclerosis and the development of a vulnerable plaque [15]. AS is manifested either by dilation or stenosis with arterial occlusion.

Artery narrowing and occlusion: The arteries of the human body are dimensioned to have the ability to increase the flow rate several times with a corresponding decrease in peripheral resistance. Reducing the area of the lumen must reach about 75% (corresponding to a 50% reduction in diameter). So that the constriction becomes apparent in rest conditions. Tissues and organs whose flow rate increases significantly as a result of a decrease in peripheral resistance are sensitive to smaller restrictions in such a situation. At the constriction site, the laminar flow changes to turbulent, resulting in blood particle deposition and fibrin apposition, endothelial deterioration, and breakdown. Thus, the progression of the constriction is further promoted to ultimately the complete closure of the remaining lumen by thrombus

Compensation mechanisms: the metabolic compensation is created thanks to the decrease of resistance in muscles, developing of collaterals, and increasing the oxygen extraction. The clinical picture emerges depending on the location of the narrowing and the rate of closure. The principal compensation mechanism for significant stenosis is collateral circulation. The slower the progression of the obliterating process, and the less the disease process is affecting the river that serves the collateral circulation, the better the development of the collateral

circulation. Under certain favorable circumstances, it can entirely or largely compensate the arterial closure. Collateral develops more in the proximal sections while parallel arteries also dilate. Atherosclerosis preferentially involves the distances of the arteries and their branching. That's why we talk about its segmental character.

Aneurysms: The aneurysm is when a specific section of an artery is significantly expanded from that adjacent to an otherwise normally large artery. Aneurysms are divided by shape and etiology. We divide them into the right (all the layers of the vascular wall form the aneurysm wall), and the false ones (the wall consists of only one layer of the vascular wall, or just surrounding scar tissue). The arterial aneurysm is always a progressive disease and threatens the patient with rupture, with subsequent bleeding, compression of surrounding structures, peripheral embolism but also thrombosis.

Critical limb ischemia (CLI): develops when arterial lesions reduce blood flow to such an extent that it is unable to supply the nutritional requirements of tissues. This situation is most common in multisegmental artery disease. In some cases, the hemodynamic parameters of arterial lesions are multiplied by chronic venous insufficiency or by a decrease in cardiac output. Patients with severe peripheral arterial occlusion of lower extremities have impaired microcirculation resulting from decreased perfusion pressure, which may lead to continuous ischemic pain and or tissue loss [16]. In addition to the reduction of total blood flow, the CLI also has a maldistribution of cutaneous microcirculation [3, 6]. Saving the cutaneous microcirculation is essential for a good prognosis. Thus, after successful revascularization, the determinant factor is not only the recovery of the macrocirculation but also microcirculation, which is essential for skin nutrition and must be taken into account. After restoring the blood circulation, another clinical condition arises - reperfusion with consequences both local and systemic. These two conditions are closely related therefore the term ischemic-reperfusion syndrome is appropriate [17].

Definition of Critical Limb Ischemia

The term critical limb ischemia describes the condition, where the function and vitality of extremities are compromised due to decreased perfusion. During arduous and risky treatment, not only the limb itself, but also the patient's life is endangered. If the extremity is not saved and the patient survives, the quality of his life is significantly affected.

Based on the time factor in the emergence of limb threat, we distinguish two types of critical limb ischemia: acute and chronic.

ACUTE LIMB ISCHEMIA

It is the result of occlusion of a native artery or vascular/endovascular prosthesis. Emerges suddenly from acute occlusion of the artery in connection with significant tissue congestion. The sudden closure of the previously unchanged artery is due to embolism when 80% of the emboli is of cardiac origin [18, 19]. In situ thrombosis in a native artery is now the commonest cause of acute limb ischemia (ALI). It may be the result of rupture of an atherosclerotic plaque or critical flow arrest at the site of an atherosclerotic stenosis), others

causes are: aortic dissection or embolization, surgery, heart failure, thrombotic tendency, popliteal aneurysm, bypass grafts, endovascular treatment, iatrogenic, traumatic, phlegmasia coerulea dolens, ergotism [20].

The revised (2007) Transatlantic Inter-Society Consensus [3] defines acute leg ischemia (ALI) as any sudden decrease in limb perfusion, causing a potential threat to limb viability.

As collateral circulation is not developed, there is a risk of irreversible damage to the limb in a very short time. The treatment of these diseases is always urgent and immediate [17. Treatment consists of restoring blood flow and tissue perfusion as quickly as possible. An essential therapeutic effort in acute lower limb ischemia is the rapid removal of the occlusion or the solution by intervention or surgical treatment. The main symptoms of acute occlusion of the limb arteries are intense pain, pale, waxy appearance, cold, loss of sensitivity, no pulse distal to occlusion, sudden limb weakness, positive Ratschow positional test [21].

MANAGEMENT OF ACUTE LOWER LIMB ISCHEMIA

Classification of acute limb ischemia is based on the severity of arterial ischemia, which helps determine the urgency of intervention and has implications for the outcome. The categories are based on clinical findings and Doppler measurements. Patients are grouped into the following categories [20]:

I Viable
IIa Threatened (salvageable if promptly treated)
IIb Threatened (salvageable if immediately treated)
III Irreversible

Table 1. Clinical categories of acute limb ischemia [24]

Grade	Category	Sensory loss	Motor deficit	Prognosis
I	Viable	None	None	No immediate threat
IIA	Marginally threatened	None or minimal (toes)	None	Salvageable if promptly treated
IIB	Immediately threatened	More than toes	Mild/ moderate	Salvageable if promptly revascularized
III	Irreversible	Profound, anaesthetic	Profound, paralysis (rigor)	Major tissue loss, permanent nerve damage inevitable

Clinical presentation: the symptoms depend on the size of artery occluded and whether collaterals have developed beforehand. Complete occlusion of a proximal artery in the absence of performed collateral vessels results in the classical clinical presentation of pain, pallor, pulselessness, paresthesia, paralysis, and cold leg. If the flow is not restored rapidly, irreversible ischemia develops after 6-12 hours.

When an arterial occlusion occurs as part of a chronic process in the presence of well-established collaterals, the leg is less severely ischemic.

Initial management: the anatomical location of the arterial occlusion can be diagnosed. Patients presenting with ALI are often in poor general health. Dehydration with catheter monitoring of urine output, hypoxia, cardiac failure, and pain all are managed, venous blood should be taken for full blood count, glucose, urea and electrolytes, electrocardiogram (ECG) and cardiologic assessment. An initial bolus of intravenous calcium heparin 5000U is appropriate for most patients, and analgesics should be given as soon as possible.

Class I ischemia: (viable) intervention may be risky, and there is an argument for conservative treatment. In class II ischemia, requires intervention, in IIa (marginally threatened), there is time for investigation and semielective intervention. IIb (immediately threatened with pain at rest, sensory loss and muscle weakness) - the acute leg with sensorimotor deficit requires urgent intervention. Any delay in treating risks limb loss. In class III or irreversible ischemia, there is no indication to revascularization.

Upper limb ischemia: Arm ischemia is seldom limb threatening, and most arm ischemia is due to embolism. An only small number of patients present with class II b critical ischemia and should undergo urgent surgical intervention [22].

Medical therapy: anticoagulation, hydration, analgesia, improving oxygenation.

Endovascular treatment: catheter-directed thrombolysis - thrombolytic agents dissolve the occluding arterial thrombus, the percutaneous mechanical thrombectomy-the procedure is performed in the angiography suite and can remove thrombus from the arteries. They may be classified according to their mode of action (hydrodynamic, aspiration, fragmentation, rotation and aspiration).

Surgical treatment: balloon catheter embolectomy introduced by Fogarty, completion angiogram should always be performed in evaluating the completeness of thrombus removal. After failed open balloon thrombectomy bypass procedures are available. Endarterectomy is most commonly performed for in situ occlusion of the common femoral artery.

In lower extremity to prevent a post-reperfusion compartment syndrome extremity, four-compartment fasciotomies should be performed in patients with long-lasting ischemia.

Complications: Multiple organ dysfunction, acute renal failure due to myoglobinuria, compartment syndrome – a patient should be monitored for any signs of compartment syndrome.

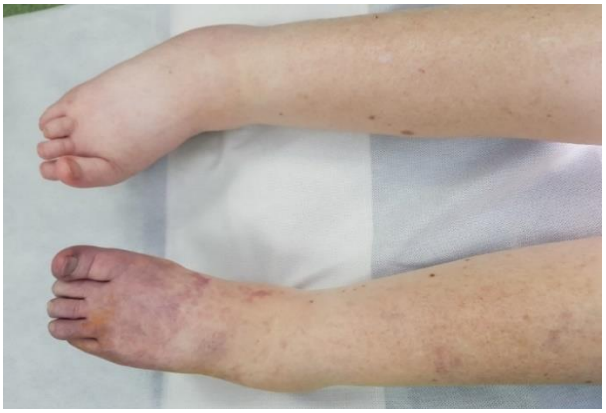

Figure 1. Embolisation of left lower extremity- popliteal artery (category II b).

Figure 2a. The left lower extremity after embolectomy.

Figure 2b. The left lower extremity after embolectomy.

CHRONIC LIMB ISCHEMIA

The chronic form of critical lower limb ischemia develops gradually (months and years), and the potential for the development of collateral circulation plays an important role in its development. This form is characterized by multisegmental involvement of the arterial bed, practically always with the involvement of significant damage to the leg and leg arteries.

Severity of PAD is commonly reported by two classification systems.

The most common is the original classification of leg limb ischemia according to Fontaine and Rutherford [23], both of which are equally valid. The simplest is the original Fontaine classification, it is based on clinical symptoms and consists of a four stages: 1st stage - latent stage: it is free of subjective manifestations, but the basic and functional angiological examinations detect objective signs of AS. 2nd stage - claudication stage (IC) manifested by spasmodic pain developing on walking in the muscle groups distal to the arterial obstruction and the symptoms relief within 5-10 minutes of cessation of exercise. The second stage may be further subdivided into stages II.A and II.B and II.C, for which the characteristic absolute claudication distance (ACD) is greater than 200 m (A); or less than 200 m (B); and less than 50 m (C). (Table 1). Stage III is defined as the presence of rest pain:

III.A - rest pain in a horizontal position that recedes when the limb hangs and III.B – constant pain in feet. Stage IV represents ischemic lesions such as ulceration or gangrene. In practice stage III. And IV. according to Fontaine corresponds to the WHO definition of CLI. Like the definition, Fontain's classification is not reliable in diabetics.

The Rutherford classification [24] of the severity of PAD can be considered a more modern version of the Fontaine scheme: it was formulated 43 years later and is based on new knowledge of epidemiology and pathophysiology, the possibility of revascularization as well as clinical outcomes. Rutherford's classification divides lower limb artery disease PAD into 3 degrees and six categories (Table 2).

Table 2. Classification of peripheral arterial disease. Stages according to Fontaine, and categories according to Rutherford (TASC II, 2007)

Fontaine		Ruhterford		
Stage	Clinic	Degree	Category	Clinic
I	Asymptomatic	0	0	Asymptomatic
IIa	Mild claudications	I	1	Mild claudications
IIb	Moderate to severe claudications	I	2	Moderate to severe Claudications
		I	3	Severe claudications
III	Ischaemic rest pain	II	4	ischaemic rest pain
IV	Ulcerations or gangrene	III	5	small loss of tissue
		III	6	Extensive tissue loss

The European Consensus defines (chronic) critical limb ischemia as rest pain for more than two weeks, and/or ulceration/gangrene, and an ankle pressure of < 50 mm Hg or a toe pressure of < 30 mm Hg (9) [6].

According to the recommendations of the TASC II Working Group [3], the clinical definition of critical limb ischemia is as follows:

> (Recommendation 16) - The term critical limb ischemia should be used for all patients with chronic ischemic rest pain, ulcers or gangrene, attributable to objectively proven arterial occlusive disease. CLI is chronic and must be distinguished from acute limb ischemia.

CLI patients are at high risk. The risk of developing myocardial infarction (MI), stroke, and vascular death is three times higher in patients with CLI than in patients with intermittent claudication [25]. 40% of patients have symptoms from coronary artery stenosis, 10-15% have symptoms related to carotid artery stenosis, and 30-40% are treated for hypertension. About 50% of patients die within five years of the onset of vascular symptoms [3], due to MI and stroke [26]. Atherosclerosis is a systemic disease that simultaneously affects several vascular regions. Therefore, it is essential to examine the patient with CLI comprehensively.

DIAGNOSIS

Correct diagnosis and assessment of the results of individual examinations co-determine the efficacy of therapy [27]. The diagnostic and therapeutic assessment aims to save the limb, improve the quality of life of the patient, and reduce the morbidity and the mortality.

History taking and physical examination of the arterial system plays a very important role.

History taking: claudication pain - typical pain (ache, cramp, tightening) developing on walking that forces the patient to slow down or stop, with a relief of symptoms within a few minutes, feeling cold in the limb, tingling, permanent rest pain. The patient must be asked about the history of ischemic heart disease and cerebrovascular disease.

Physical Examination

a) Inspection: color variations of skin, specifically cyanosis and pallor, hair growth, condition of the toenails, atrophic skin and muscles, skin ulcerations (their base, their borders).
b) Palpation: is used to detect peripheral arterial pulsations, evaluation for edema, vibrations, and extremity surface temperature.
c) Auscultation: assessments of peripheral arterial bruits and pathologic venous hums.

Exercise challenge: examination the extremity following an exercise challenge (Prusik, Ratschow, Allen‘s test)

ABPI (ankle-brachial pressure index) measurement: is measured by using a tourniquet and insonating the pedal arteries with Doppler ultrasound. The systolic blood pressure is taken from the brachial artery and from the pedal arteries. ABPI is calculated as the ratio of the ankle to the systolic brachial pressures. The characteristic cut-off point for the peripheral arterial disease is less than 0.9 in rest (normal 1,0-1,2) [1].

Blood pressure taken from the pedal and digital arteries is an important tool of estimating treatment outcomes. ABPI should be a routine part of vascular examination [3].

Risk factors: all patient should be invesigated for risk factors for AS-all require a full blood count, erythrocyte sedimentation rate, urea, electrolytes, blood glucose, and lipid levels.

Vascular laboratory: the aim is focusing on and revealing the etiology of the disease. The special investigation methods should include both macro and microcirculation examinations. In patients with diabetic foot, a thorough neurological examination (pain, temperature, skin touch and vibration sensitivity, reflexes) is also required.

Nonvasive and Invasive Investigations

1. The use of Doppler waveforms originally implemented using hand-held continuous-wave Doppler devices - ABPI ratio must be correlated with analysis of the Doppler arterial wave-forms used to obtained pressures. Normal arterials waveforms demonstrate a tri-or bi-phasic pattern.

2. Duplex ultrasound (Figure 3a,b) is a non-invasive imaging study, and for its wide availability is considered to be the first line examination method. This technology combines the evaluation of blood flow (pulsed Doppler spectral analysis) and anatomic (B-mode and color Doppler imaging) information. We can collect the morphological image of arteries and veins by ultrasound. Ultrasound is able to recognize aneurysms and false aneurysm. Using the Doppler effect, we can obtain information about the arterial and venous flow. Doppler can

distinguish between normal, reduced, or abnormal flow. The reliability of arterial duplex testing depends on factors that include the expertise of the examiner and the knowledge and experience of the interpreting physician. Testing performed in an accredited vascular laboratory has sufficient diagnostic accuracy for clinicians and often avoid performing more invasive, expensive diagnostic testing, such as computed tomography, magnetic resonance imaging or angiography [11, 28].

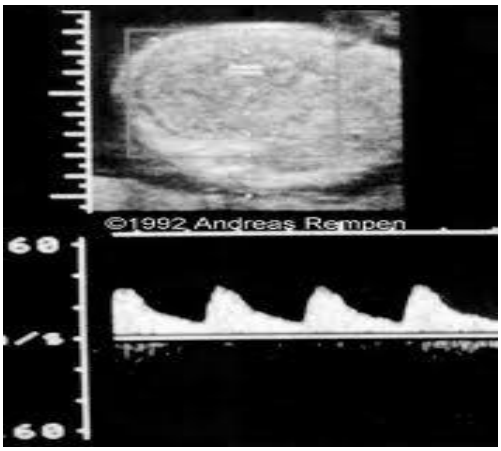

Figure 3a Duplex ultrasound [11].

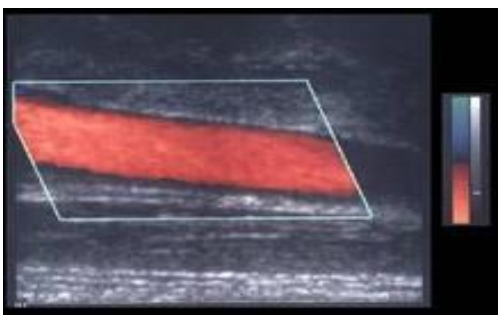

Figure 3b. Duplex ultrasound [11].

- Radiological investigations (if an invasive or operative solution is assumed).

3. Magnetic resonance angiography (MRA): is performed by applying an external magnetic field, gradients, and an oscillating magnetic field, the radiofrequency field. The combination of these three types of large magnetic fields enables to produce a visualization of the human´s body, known as MR images. It is based on MRI with using paramagnetic contrast medium that is applied intravenously. Its advantage compared to CT-angiography is that contrast medium used by MRA is not based on iodine and can be used by iodine allergies and in renal insufficiency. The other advantage of MRA over CT-angiography is better quantification of calcified lesions. Disadvantages of MRA are worse availability and higher price compared to CT-angiography. Moreover, CT-angiography is quicker than MRA. Important is also the fact that patients cannot use MRA with pacemakers and metallic implants.

4. Computed tomography (CT): is also a minimally invasive imaging study. Visualization of vessels on CT is limited by the similar densities of blood and soft tissue. Administration of intravenous contrast medium can solve this problem-computed tomographic angiography (CTA), 50-130ml of intravenous contrast is applied. Rapid scanning enables visualization of the vessels during the short period that a bolus of contrast medium passes the imaged volume. Thus faster times and increased numbers of detectors allow a larger part of the body to be imaged as the bolus of contrast medium passes (Figure 4). Data obtained by computed tomography angiography make possible 3-dimensional reconstruction of the arterial system, so-called Volume Rendering Technique (VRT). 2D reconstructions MPR (Multi Planar Reconstruction) enable to make scan in any section of the examined tissue. This is important for planning of operation of aneurysms and false aneurysms. Timing of the initiation of image acquisition relative to the injection of the contrast medium is very important for maximizing visualization of vessels in the scanned volume. CTA is used for planning of vascular reconstruction in thoracic, aortoiliac, femoral and supraaortal region. CTA has its limitations, especially in imagining of popliteal, crural arteries and also arteries of upper extremities. CTA is not very precise in the quantification of strongly calcified lesions. Advantage of CTA over other imaging methods is its very good availability [11].

The UK National Clinical Guideline Lower Limb Peripheral Artery disease: diagnosis and management, recommends CT angiography to people with a peripheral arterial disease who need further imaging prior to revascularisation (after duplex ultrasound), if CE-MRA is contraindicated or no-tolerated [29].

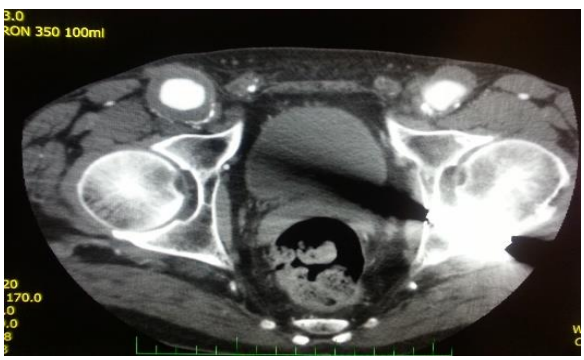

Figure 4. Computed tomography with contrast medium.

5. Angiography: Digital subtraction angiography (DSA) is often referred to as the gold standard in the investigation of PAD. Contrast angiography is one of the most important imaging studies in vascular surgery. Contrast medium is applied directly to the arterial system, usually via a catheter in the right common femoral artery. Patients with stenoses or occlusions in the aortoiliac region have angiography performed through the radial or brachial artery. Advantage of this method is that DSA most precisely identifies the anatomy of arterial occlusive disease (Figure 5, 6). Angiography is crucial for planning of infrainguinal arterial reconstructions and also for imaging of arteries of upper extremities. A disadvantage of the method is using of iodine contrast medium, which can lead to an allergic reaction or can worsen renal functions. The other disadvantage of angiography is its invasivity. Severe bleeding from the femoral artery that requires surgical intervention is about 1%. Thus DSA is

now reserved for situations, where here is an intention to proceed to endovascular intervention and is not used as a first line imagine method nowadays.

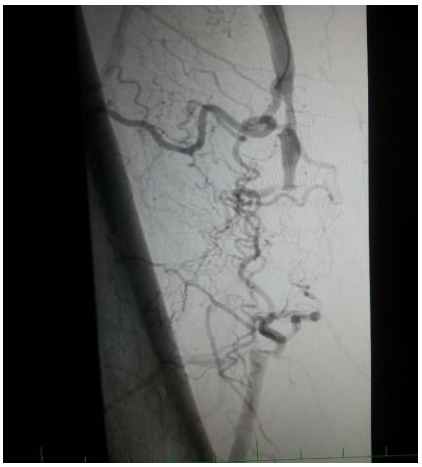

Figure 5. Angiogram - an occlusion of superficial femoral artery with the development of collateral circulation.

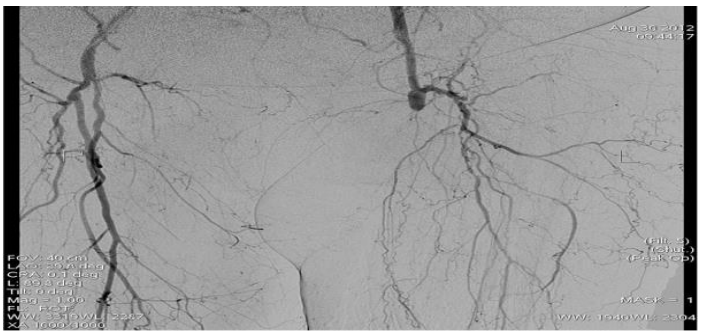

Figure 6. Angiogram - an occlusion of both superficial femoral arteries.

6. Carbon dioxide (CO_2) angiography: The use of CO_2 is not associated with nephrotoxicity ad allergic reactions. However, caution needs to be exercised in the use of CO_2 in situations where there is a risk of gas trapping and ischemia (mesenteric, carotid angiography) [30].

7. Intravascular ultrasound (IVUS) Intravascular ultrasonography is an invasive examination that mediates a detailed intraarterial image. It can alert to wall dissection, and no contrast and radiation are needed.

8. Angioscopy allows visualizing the interior of the vessel accurately. The usage is mainly in some therapeutic procedures (valvulotomy, embolectomy, thrombectomy, endarterectomy).

9. Other investigation methods: Determination of the claudication interval (distance walked by the patient without claudication). Treadmill exercise testing is used to provide objective evidence of the patient's walking capacity. Oscillography, plethysmography, Doppler ultrasound wave analysis, segmental pressure analysis [31]. Microcirculation

investigation: the investigation of the nutritional status of the skin. It is a videocapillaroscopy, measuring tissue oxygen partial pressure by transcutaneous oximetry ($TcpO_2$). Laser Doppler flowmetry studies skin perfusion to a depth of 1 mm and measures both nutritional and thermoregulatory blood flow. Fluorescent videomicroscopy is also possible.

MANAGEMENT OF CHRONIC CRITICAL LOVER LIMB ISCHEMIA

Routine examinations: Doppler examinations of supraaortic branches, USG of the abdominal aorta, ECG and chest X-ray, if needed. Examination of blood count, platelet count, urea, electrolytes, glucose, CRP, haemocoagullation status [32], cholesterol, triglycerides, respiratory and renal function are important. Based on these findings, an exact internal examination is needed.

Complementary examinations are: exercise ECG, ventilometry, echocardiography, radionuclide ventriculography, Holter monitoring, cardiac catheterization, and coronary angiography are also indicated if necessary. Patients with a history of venous thrombosis or recurrent arterial occlusion should be screened to exclude thrombophilic status (C, S, AT III, lupus anticoagulant, anticardiolipin). The X-ray of the bones is obligatory in the case of a defect or ulceration to exclude osteomyelitis or diabetic neuroarthropathies. For defects in the lower extremities, microbiological examination and targeted antibiotic therapy of infected defects is required. Inflammatory biomarker levels correlate with the severity of PAO and the clinical presentation of the disease in patients with infrainguinal bypasses. Patients with elevated CRP are at higher risk of postoperative cardiovascular events [13].

Macrocirculation examination: continuous Doppler (CWD) is available for the flow examination, duplex ultrasonography currently under certain conditions may also be an alternative to angiographic examination and may decide on the indication for revascularization in the case of CLI [28]. In CLI, duplex ultrasonography allows for the examination of arteries that are not shown in angiography, also allows for VSM examination and mapping of its quality and progression, whether it is suitable for autogenous bypass. Furthermore, it is oscillography which in diabetic patients only has a 10% utility for mediocalcinosis. The basic diagnostic examination method for PAD is the measurement of systolic pressure in the ankle area by Doppler ultrasound meter. We consider not only the absolute pressure values on both lower extremities but also the ankle-brachial pressure index (ABPI), which is the ratio between the systolic pressure measured on the ankle and the shoulder [1]. The ankle pressure is measured using a Doppler probe which is attached to ADP or ATP. The manometer cuff is loaded on the tibia. We then compare the systolic pressure on the shoulder and the ankle and determine the ABPI. Measurements are taken over the patient's 20 minutes rest period. Normal values are 0.9-1.2; more than 1.2 indicates mediocalcinosis; 0.9-0.5 is mostly in claudication, an index of less than 0.5 indicates critical limb ischemia.

In the rigidity of the artery wall, especially in diabetics, it is recommended to measure peripheral pressure on toes. Here, the measured pressure of less than 30 mmHg is in severe ischemia. We continue to determine profundapopliteal collateral index-PPCI [33], in diabetic patients with incompressible vessels, a “pole test” where the hydrostatic pressure is measured when the limb is elevated [34, 35]. If we choose arterial intervention (reconstruction or percutaneous transluminal angioplasty (PTA), digital subtraction angiography of the

abdominal aorta with renal vessels and limb angiography is also needed to visualize the run-off vessels. DSA angiography remains the gold standard, especially if revascularization is planned and simultaneous endovascular performance is preferred [36]. With the development of technology and refinement of less invasive but accurate imaging methods in post-ultrasonography diagnostics, MRA, and CTA (high-quality instrumentation and staffing, ambulatory examinations) are preferred [29]. MR angiography can avoid the use of contrast media but has its drawbacks and interpretation depends on software and the subjective factor of the evaluator. In addition to severe renal insufficiency, the administration of gadolinium is relatively contraindicated due to the possibility of nephrogenic systemic fibrosis. Intravascular ultrasonography is an invasive examination that mediates a detailed intraarterial image. Angioscopy allows accurately to visualize the interior of the vessel. It is mainly used in some therapeutic procedures (valvulotomy, embolectomy, thrombectomy, endarterectomy).

TREATMENT FOR SYMPTOMATIC PAD

Medical Treatment for Symptomatic PAD

PAD is a common disease, and patients with PAD have limited mobility and quality of life. In addition, PAD is a significant marker of cardiovascular (CVS) risk. PAD patients are six times more at risk of cardiac death, and asymptomatic patients are at risk too. Especially in asymptomatic patients and IC patients, appropriate treatment is underestimated. The main goal of PAD treatment is to reduce CVS risk and improve symptoms of the disease. Risk factors need to be treated and corrected. Smoking cessation, increased physical activity, as well as anti-aggregation treatment, reduction of obesity leads to a significant reduction in CVS morbidity and mortality. Unfortunately, a large proportion of patients are not adequately treated [4, 32]. Statins and antiplatelet therapy reduce IM, stroke by 23% in PAD [3, 37, 38].

The treatment strategy for PAD is described in the International Guidelines [38, 39, 40]. Exercise therapy is most effective in terms of the long-term improvement of the claudication interval, as well as the cost of treatment [41]. It also reduces cardiovascular mortality. Few vascular patients have access to these programs. Mazari et al. [42], found that the combination of endovascular revascularization with interval walk reduced the number of re-interventions as well as the cost of treatment.

Pharmacologic therapy: vasoactive drugs are the choice: Cilostazol is indicated for PAD without pain at rest, without defects. It has antithrombotic activity, inhibits platelet activation and aggregation, has vasodilator properties, affects triacylglycerol and HDL cholesterol concentrations. There is evidence, that it prolongs the claudication distance to twice the placebo and the effect of pentoxifylline. Naftidrofuryl oxalate also prolongs the claudication interval. Pentoxyphylin extends the claudication interval by 12%, according to AHA recommendations [38], 3x400mg is recommended as an alternative therapy to Cilostazol, to prolong the claudication interval in patients with IC (level of evidence A). Sulodexide is effective in the treatment and/or prevention of PAD. It protects the endothelium, has an antithrombotic and antiproliferative effect, has a rheological effect as confirmed by the SUAVIS (arterial arm) study, extending significantly painless and maximum claudication

distance [43]. At the same time, the incidence of serious cardiovascular adverse events was more than 2-fold lower in the Sulodexide group compared to placebo.

Antiplatelet and antithrombotic medications: antiplatelet drugs reduce the risk of vascular death, IM, and stroke by approximately 25% in PAD patients. Single antiplatelet therapy is recommended in symptomatic patients [40].

The effect of L-Arginine, carnitine, Ginko Biloba, E vitamin, and chelates in IC is questionable. Prostaglandin E1 and prostacyclin are indicated in CLI. They reduce pain and improve defect healing but are limited to a small percentage of patients, thromboembolism prophylaxis [44], systemic antibiotic therapy, thrombolytic therapy (urokinase, streptokinase, rTPA), hemodilution (if hematocrit is increased even with good patient hydration), pain treatment.

Therapeutic angiogenesis and cell therapy are possible - only small patient populations are available.

Risk Factor Identification and Modification (Total and Local)

Smoking is the most serious risk factor in the development of PAD, and the association between smoking and CLI is well known [2, 45].

Diabetic patients have two to four times the rate of PAD compared to nondiabetic patients and are more likely to have infrapopliteal PAD than nondiabetic subjects [46]. As with non-diabetics, PAD progression is also more rapid in diabetics. Diabetes is an independent risk factor for postoperative complications and amputations [47]. Chronic management should lower the level of glycated hemoglobin to less than 7.0%.

Dyslipidemia: The treatment of dyslipidaemia with statins reduces the risk of cardiovascular event in patients with atherosclerosis The 2013 American College of Cardiology (American Heart Association (ACC/AHA) guidelines recommend consideration of statin therapy for primary prevention in all patients with a 10-year risk of atherosclerotic vascular disease of >7.4% and no longer recommends to a particular lipid level target [38].

Hypertension: Numerous studies show that arterial hypertension is 2-3 times more common in PAD patients than in the normal population. Current European recommendations for antihypertensive therapy in high-risk patients recommend achieving a target pressure of less than 140/90mmHg in non-diabetics and less than 130/80mmHg in diabetics and chronic renal failure patients. The use of ACE inhibitors in PAD patients reduces vascular death, IM and stroke, regardless of their ABI. In addition, the use of ACE inhibitors is associated with lower mortality after infrainguinal reconstruction operations [48].

Hyperhomocysteinemia: shows an independent factor in the development of PAO

Treatment: coronary heart disease, lung disease, and renal failure

Local risk factors that contribute to the development of skin necrosis must also be intensively treated. Edema, infection (antibiotics by culture, local wound treatment, necrectomy, incision, drainage of abscesses)

Education of patients: The patient must cooperate: requires regular medication, a lifestyle change with a healthy diet is needed, the patient must give up smoking, increase physical activity, change eating habits and reduce excess body weight[49]. In particular, the diabetic foot is a serious medical problem. Training exercises under supervision are part of the treatment.

General measures: bed rest, limb positioning, prevention of pressure sores, treatment of pain, epidural anesthesia, treatment of the swelling.

Epidural and spinal cord stimulation

Lumbar sympathectomy:

Intermittent pneumatic compression

Retrograde intravenous perfusion

Alternative medicine: Mainly in connection with IV. Stage of PAD, several options are confirmed. There are no control studies confirming their validity. Alternative medicine includes hyperbaric oxygen therapy, external application of growth factors, enzyme therapy.

Amputation: this remains the last option to avoid or halt general complications of irreversible limb ischemia. For bedridden patients, femoral amputation may be the best option

Revascularisation - Intervention and Surgical Treatment for Chronic Lower Limb Ischemia

Lower extremity revascularization may be endovascular, open or a combination of both. In high-income countries, there has been an increase in the proportion of patients undergoing endovascular revascularization procedures, with decreasing open-surgical revascularisation procedures, in-hospital mortality and major amputation [50]. Changed new recommendation in PAD guidelines for infra-popliteal lesions is: endovascular first (IIa level), bypass using GSV (I level), and endovascular therapy (IIa level) [40].

The aim of the treatment: in the claudicants is the prolongation of the claudication interval, and in the CLI it is the removal of pain and healing of the defects as well as the salvage of the functional limb.

The choice of appropriate treatment is individual and depends on a number factors, including clinical presentation (Rutherford classification-functional stage of the disease), TASC classification of lesions, and the general condition of the patient [51]. The choice of method depends on the extent of the disease, co-morbidity, technical possibilities, and evidence base of results. In new concept: ESC guidelines (Concept for Lower extremity artery disease) [40]- Chronic limb-threatening ischemia (CLTI) defines the most severe form of PAD in lower extremities. Beyond ischemia, wound and infection should be evaluated to stratify the amputation risk (new Wifi classification) [52]. TASC classification excluded from the guidelines.

Investigations prior to revascularization: risk factors, previous interventions, and cerebrovascular events. It is important to thoroughly evaluate the patient's overall condition and risk. The extent and location of the disease are confirmed by DUS, CTA, MRA, or by angiography. It is also important to examine the venous system [38].

Indications for revascularization of lower extremities are: limiting claudication, rest pain and non-healing arterial defects when we can improve the patient's quality of life and we can expect to survive for several months [51].

Contraindications for revascularization of lower extremities are: in patients with resting ischemic pain, extensive non-healing wounds, and gangrene, overwhelming sepsis arising from the foot, late presentation of acute limb ischemia. Then primary amputation is often the best treatment alternative [45].

Figure 7. Irreversible ischemia of lower extremities.

Figure 8. Failed revascularization and demarcation of ischemic area.

The Transatlantic Consensus (TASC) was established in 2000 under prof. J. Dormandy and R.B Rutherford. It concerns epidemiology, diagnosis, and treatment of PAD [45]. Sixteen European and North American professional companies participated in its processing. After completion in r. 2007 was the TASC II document established [3].

TASC [45] classified PAD based on anatomical localization and disease severity (ABCD). In general, endovascular treatment is recommended for A/B type lesions and surgical treatment for C/D type lesions. Both modalities of intervention for B/C lesions are accepted. The choice depends on the patient´s risk and the surgeon's experience [53], estimated duration of intervention, presence of a suitable vascular graft [54] and the patient's preference should also be taken into account. The determinant of success in endovascular therapy is the anatomical and morphological characteristics of the lesion. In open revascularization it is the quality of bypass [3, 24, 51]. For both types of revascularization the quality of "run off" arteries is important. Recent works suggest that direct revascularization of the ischemic site with a direct revascularization procedure to the source artery (angiosome-distinct block of tissue fed by source arteries, the area with tissue loss) has better results than indirect revascularization in interventions [55].

Table 3a. TASC classification of femoropopliteal lesions TASC II 2007 – summary recommendations

Segment/ recommendations	Mostly PTA Type A	PTA preferred Type B	Surgical treatment preferred Type C	Mostly surgical treatment Type D
Femoral	Stenosis AFS below 10 cm or occlusion below 5 cm	Stenosis AFS or occlusion below 15 cm	Stenosis AFS or occlusion more than 15 cm	Complete AFS or popliteal occlusion
Popliteal	Occlusion below 5 cm	Popliteal stenosis	Recurrent disease	
Crural	Here, there are not categories A and B		Stenosis below 4 cm or occlusions below 2 cm	Diffuse disease or occlusions above 2 cm
Results	There are excellent results in both groups A and B		PTA/stent has a temporary effect and is indicated if surgery is contraindicated for technical causes, or for the patient	Endovascular approach is not recommended, it is possible only in case of critical ischaemia, and impossibility of surgical treatment

Table 3b. TASC classification of femoropopliteal lesions TASC II 2007 – summary recommendations

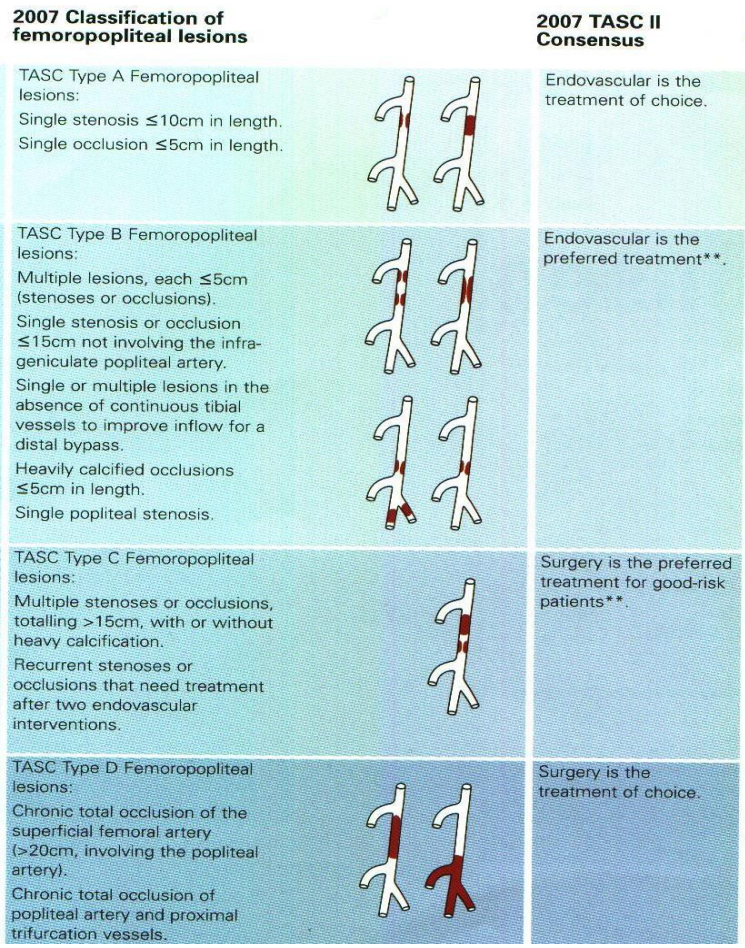

First and foremost, good patency of the aortoiliac bed must be ensured before infrainguinal vascular reconstruction can be performed [56]. However, complex reconstruction requires adequate operational risk, appropriate graft, and sufficient outflow [57].

In general, if there is a choice between endovascular and surgical treatment, the first option is preferred. The choice depends on the extent and degree of arterial disease. The risks and prospects of success for each case need to be considered.

Endovascular Treatment for PAD

While the frequency of surgical interventions is decreasing, the number of endovascular interventions has increased several times. Thanks to the continuous improvement of techniques and technologies, it is more effective and long-term results demonstrate safety and durability. PTA and stenting are most commonly used for the revascularization of short and medium length lesions, the development of new techniques and technologies such as subintimal angioplasty, stentgrafts, mechanical and laser atherectomy allow for longer stretches of recanalization and many vascular specialists promote endovascular treatment first.

Technically, the methods can be combined. The development of drug-eluting stents (DES) and drug-coated balloons with the antiproliferative drug paclitaxel (DCB) offers the possibility of reducing the number of restenosis after endovascular treatment. The Tack Endovascular System spot treats dissections with a short 6mm long self-expanding stent - reduces the amount of metal, thereby reducing the inflammatory response. Endovascular treatment is less invasive and also suitable for high-risk polymorbid patients with reintervention if needed. For a low incidence of complications, it is recommended as the first choice method. For the patient, it is preferred that after diagnostic angiography (which remains the gold standard in the investigation of PAD) if the planned revascularization is followed immediately by the endovascular intervention [58].

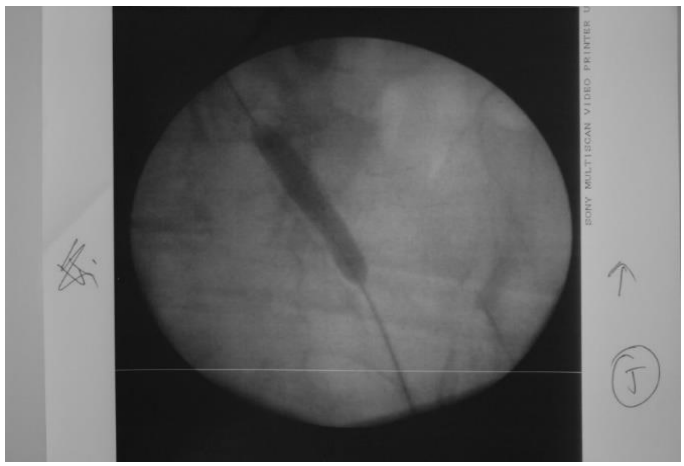

Figure 9. Balloon angioplasty (left iliac artery).

Figure 10. Stent in left superfitial femoral artery.

An immediate technical success rate of infrapopliteal interventions is reported in the range of 82-98%, 1-year primary patency 78-85%, and more than 86-97% success in limb salvage. Drug-eluting stents have been proven to be the most durable therapy for short-to moderate-length lesions below the knee [50].

Complications of Endovascular Treatment

About 10% of patients after endovascular interventions have complications that may result in open surgery, amputation or death (hematoma, thrombosis, dissection, pseudoaneurysm, a-v fistula, bleeding, peripheral embolism, infection, foreign body, endoleak, implant dislocation) Overall complications: renal failure, IM, stroke in 1% [59].

However, endovascular interventions have shorter duration than surgical bypass, and more frequent reinterventions are needed, especially in cases of diffuse or long occlusions [24].

Surgical Treatment for PAD

Surgical treatment is an option. Bypass, with a venous conduit of high-quality vena saphena magna (VSM), represents the gold standard for revascularization, especially in CLI [57, 59, 60] and are confirmed by many studies [53]. Despite the promising results of intervention therapy, surgical treatment-bypasses-are still needed in a specific group of CLI patients. Femoropopliteal bypasses have excellent long-term results, even where endovascular treatment was not possible [61]. Surgical treatment is still the gold standard (the basis of chronic ischemic limb management) and is still widely used mainly for the aortoiliac area where long-term patency is high (about 90% in 1 year).

An extensive BASIL study [59,62] found no significant difference in one-year survival with a preserved limb (71% in surgery and 68% in endovascular treatment), patients after surgery who survived more than 2 years after the intervention had significantly lower risk of amputation and death.

Recommendations referring to BASIL trial: revascularization for CLI: survival presumption less than 2-years - recommended as first balloon angioplasty, especially if no autologous vein is available. Presumption of survival for more than 2-years - bypass surgery is usually recommended as first-line treatment, especially if a suitable autologous vein is available.

Neville et al. [63] noted that open surgery compared to endovascular procedures resulted in significantly faster and more frequent complete healing of the wounds.

In CLI, lesions are most commonly localized in the femoral and crural arteries, especially in patients with diabetes mellitus where the lesions are diffuse and multi-stage [64]. Proximal lesions are less common, and infrainguinally there is an assumption of multi-stage changes. In these conditions, femoropopliteal and femorocrural bypasses, possibly popliteocrural, femoro or popliteopedal bypasses are needed for reconstruction. Patients undergoing revascularization for CLI had 88% l-year limb salvage [24]. Perfect detailed angiography with visualization of pedal vessels is essential for these procedures.

Profundoplasty or iliofemoral interposition has the highest importance as an inflow procedure [50].

Figure 11. Venous femorotibilalis posterior bypass placed subcutaneously.

Infrainguinal Reconstructions

Several procedures according to the type of occlusion are available for reconstructive surgery for peripheral arterial vascular occlusions [24, 45].

- Semi-closed femoropopliteal endarterectomy: It cannot be considered a standard operation as it has low patency [65, 66].
- Endarterectomy with or without patch - common femoral artery disease is treated almost exclusively by an open surgery.
- Surgical bypass conduit should preferably be a single graft, but splicing of venous segments is sometimes required. If a tibial anastomosis is performed with synthetic material a vein cuff is generally recommended to improve patency.

- Above-knee femoropopliteal bypass in CLI which can provide at least one in-line blood vessel to the foot
- Below-knee femoropopliteal bypass: Conduit can be placed subcutaneously on the medial side of the knee joint or subfascially in the popliteal area.
- Bypasses to crural vessels - All can be led subcutaneously or along the course of the vessels [18].
- Femoropedal bypass

Figure 12. Bypass femoropoplitealis proximalis.

Figure 13. Bypass femoropoplitealis distalis.

Proximal anastomosis at the site with adequate inflow should be undertaken. It would be the common femoral artery, but maybe SFA or PA, even profunda femoris artery (PFA) [9, 16]. Location of distal anastomosis: a place where run-off is appropriate [67].

Figure 14. Bypass popliteo-tibialis posterior.

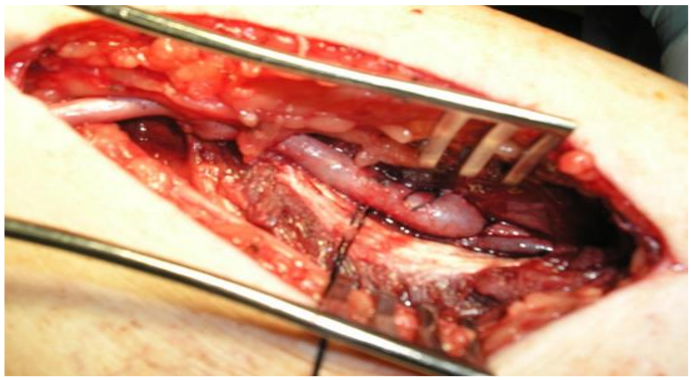

Figure 15. Venous femorocrural bypass cum VSM - anastomosis end to side to ATP.

Figure 16. Femorocrural bypass with successful complet revasculrisation of crural vessels (angiography).

Profundoplasty - isolated endarterectomy and patch repair of the profound femoral artery. It has value in improving direct perfusion to the thigh and indirect to the calf. It may reduce the severity of claudication and ischemic rest pain in patients in III. and IV. stage of the disease usually leads to the disappearance of resting pain, but the healing of larger trophic defects is inadequate [68].

Another method of limb salvage in critical ischemia with extensive defects is the combined pedal bypass method and free muscle lobe. It is a technically very demanding operation that requires the cooperation of a vascular surgeon and a plastic surgeon who has skills in microsurgery [27]. By combining pedal bypass and free muscle lobe, good results can be achieved in patients with non-healing diabetic ulcers.

In CLIs where arteries are not reconstructable, venous arterialization is still possible. This method may be the last option for limb salvage. The average one-year limb salvage is in the range of 64-77%, and the annual secondary bypass patency is 39-53% [69].

Table 4. Recommendations on revascularisation of femoropopliteal occlusive lesions (for patients with intermittent claudication and severe chronic limb ischemia)

Recommendations on revascularization of femoro-popliteal occlusive lesions[c]

Recommendations	Class[a]	Level[b]
An endovascular-first strategy is recommended in short (i.e. <25 cm) lesions.[302,303]	I	C
Primary stent implantation should be considered in short (i.e. <25 cm) lesions.[304,305]	IIa	A
Drug-eluting balloons may be considered in short (i.e. <25 cm) lesions.[77,306–310]	IIb	A
Drug-eluting stents may be considered for short (i.e. <25 cm) lesions.[302,309,311]	IIb	B
Drug-eluting balloons may be considered for the treatment of in-stent restenosis.[312,313]	IIb	B
In patients who are not at high risk for surgery, bypass surgery is indicated for long (i.e. ≥25 cm) superficial femoral artery lesions when an autologous vein is available and life expectancy is >2 years.[314]	I	B
The autologous saphenous vein is the conduit of choice for femoro-popliteal bypass.[264,315]	I	A
When above-the-knee bypass is indicated, the use of a prosthetic conduit should be considered in the absence of any autologous saphenous vein.[264]	IIa	A
In patients unfit for surgery, endovascular therapy may be considered in long (i.e. >25 cm) femoro-popliteal lesions.[312]	IIb	C

[a] Class of recommendation.

[b] Level of evidence.

[c] These recommendations apply for patients with intermittent claudication and severe chronic limb ischaemia.

Combined and Hybrid procedures: Hybrid surgical procedures in vascular surgery represent the use of a combination of endovascular techniques and conventional angiosurgical procedures in one session.

Endovascular and conventional angiosurgical techniques can be combined over a period of time - combined procedures: conventional angiosurgery - endovascular performance, or endovascular performance - conventional angiosurgery. Hybrid and combined operative and endovascular treatments offer less-invasive but effective treatment in patients with multiple artery disease.

Complications after Surgical Revascularizations on the Arterial System

Causes of complications: Errors in surgical treatment as an underestimation of the patient's overall condition, poor evaluation of angiography, underestimation of perioperative findings and technical errors are the most common source of complications [18].

Postoperative complications: are general and typical local for vascular reconstructions:

- Reconstruction closure: a) Early (less than 30 days) - is indicated for revision. The cause may be a poor indication, technical error during the operation, and high peripheral resistance. The solution is a revision, thrombectomy, correction of technical error, graft exchange. Most errors can be avoided using peroperative angiography. b) intermediate: (1-12) months and c) late: (over 12 months). The cause of the last two is thrombosis, fibrosis of the venous valves, intimal hyperplasia, a progression of the disease, scarred scars. The treatment in this case is the correction of left proximal and distal stenoses, in the correction of distal anastomosis, when there was a technical error, further by the new bypass, thrombectomy, thrombolysis, eventually PTA
- Peroperative and postoperative bleeding. The causes are local (cut stitches, ligature slip, suture canal, side structures) and overall (hemostasis disorder and hemocoagulation).
- Pseudoaneurysm in anastomosis: the causes may be on the part of the patient (severe AS changes), material (poor quality) but also the surgeon. Pseudoaneurysms tend to grow with the risk of rupture or thrombosis. The indication for correction is absolute [33].
- Peripheral embolism
- Wound healing disorders in an inguinal area, including lymphatic fistula, cutaneous necrosis of the wound, injury n. saphenous
- Sepsis after peripheral reconstruction in gangrene
- Infection of vascular graft: the most severe threat to the patients´ life or vitality of the limb and vascular surgeon confronts a challenging task [70]. The incidence is reported to be between 0.8-6%. Mortality of prosthetic sepsis is 20-75%.

    - Aneurysm during implanted autogenous veins
    - Formation of compartment syndrome
    - Peripheral edema
    - Psychic decompensation: Bohner (2000) in [71] reports a 38.9% incidence of postoperative delirium in patients undergoing reconstructive vascular surgery. Severe postoperative complications are more frequent in these patients (38.1% versus 18.2%).

Figure 17. Femoropopliteal proximal bypass distal anastomosis abscess.

Figure 18. Wound healing after successful vascular reconstruction.

Treatment after Interventions

Table 5. Recommendations for the management of patients with intermittent claudication [40]

Recommendations for the management of patients with intermittent claudication

Recommendations	Class[a]	Level[b]
On top of general prevention, statins are indicated to improve walking distance.[30,178]	I	A
In patients with intermittent claudication:		
• supervised exercise training is recommended[273,287–289]	I	A
• unsupervised exercise training is recommended when supervised exercise training is not feasible or available.	I	C
When daily life activities are compromised despite exercise therapy, revascularization should be considered.	IIa	C
When daily life activities are is severely compromised, revascularization should be considered in association with exercise therapy.[288,290]	IIa	B

[a] Class of recommendation.
[b] Level of evidence.

Table 6. Recommendations on the management of chronic limb-threatening ischemia [40]

Recommendations on the management of chronic limb-threatening ischaemia

Recommendations	Class[a]	Level[b]
Early recognition of tissue loss and/or infection and referral to the vascular team is mandatory to improve limb salvage.[317]	I	C
In patients with CLTI, assessment of the risk of amputation is indicated.[317]	I	C
In patients with CLTI and diabetes, optimal glycaemic control is recommended.[318,319]	I	C
For limb salvage, revascularization is indicated whenever feasible.[314]	I	B
In CLTI patients with below-the-knee lesions, angiography including foot runoff should be considered prior to revascularization.	IIa	C
In patients with CLTI, stem cell/gene therapy is not indicated.[328]	III	B

CLTI = chronic limb-threatening ischaemia.
[a] Class of recommendation.
[b] Level of evidence.

Aggressive drug treatment reduces cardiovascular mortality while improving bypass patency [24]. In particular, the effects of risk factors should be eliminated [49]. Important are statins and antiplatelet therapies, and anticoagulant therapy [1, 38], if necessary. Single Antiplatelet therapy is recommended in symptomatic PAD (Aspirin 75-100 mg daily, or Clopidogrel 75 mg daily). After a percutaneous intervention, dual antiplatelet therapy (Aspirin and Clopidogrel) is recommended for 1-month, then monotherapy. After open surgery single antiplatelet therapy or oral anticoagulation is recommended [40].

CONCLUSION

Patients with PAD are in high-risk of cerebrovascular and cardiovascular complications. Proper management and assessment of the overall condition with determining the most appropriate treatment are important for disease prognosis. In the healthcare centers, it is recommended to set up a multidisciplinary vascular team to make decisions for the management of patients with PADs [40].

Access to these patients involves early detection of risk factors, elimination of known existing risk factors (smoking cessation, healthy diet, and physical activity) and the proper treatment of diseases such as diabetes and hypertension. Long-term antiplatelet therapy is also essential. In most patients, conservative treatment is sufficient. Interventions are only indicated in case of severe limiting claudication or critical ischemia when a limb is at risk. The first interventional trial in patients with a suitable lesion is endovascular treatment - PTA and additional methods for their low complications and less invasiveness. However, long lesions continue to demonstrate poor patency.

Interventional therapy may be endovascular or classical open surgery or a combination of both. Bypass surgery when using autologous VSM remains the gold standard. Primary amputation has a diminishing role in the treatment of CLI with expansion of endovascular techniques [50].

UPPER EXTREMITY VASCULAR DISORDERS

Upper extremity vascular disorders are less common compared to lower-extremity vascular disease. They affect about 10% of people. Most patients with upper extremity peripheral arterial disease are asymptomatic. Thanks to a good network of collaterals [72] patient´s difficulties are considerably smaller. On the other side, the disorders can cause problems such as ischemic pain, blue finger syndrome, open wounds, gangrene, or even loss of body parts.

Causes of Upper Extremity Vascular Disease

The most common causes of upper extremity vascular disease are:

Atherosclerosis: Upper-extremity artery disease due to atherosclerosis is less common compared to lower-extremity artery disease, and the closed sections are usually only short. Mostly is the stenosis or obliteration localized at the level of the brachiocephalic trunk, and the subclavian and axillary arteries and can present as a subclavian steal syndrome (dizziness, syncope, upper arm claudication), or arm ischemia.

Thoracic outlet syndrome: Costoclavicular narrowing can cause functional or fixed stenosis of the subclavian artery in the strait or just behind it and can also involve the vein or brachial plexus. The embolization to the peripheral vessels may occur; most frequent are symptoms due to pressure on the brachial plexus.

Embolic: Arterial limb embolism results in a sudden finger, hand, forearm, and sometimes shoulder pain. Acral parts are pale and cool. According to the degree of ischemia, sometimes we can find partial or complete sensory loss and muscle paralysis (motor or sensory impairment). Embolism is mostly associated with atrial fibrillation or follows a myocardial infarction.

Figure 19. Hand necrosis as a result of late diagnosis of embolism the a. axillaris.

Aneurysms are uncommon but may cause serious problems (ischemia, peripheral embolization). Possible causes can be atherosclerosis, thoracic outlet compression syndrome, congenital abnormality of the origin and the course of the right subclavian artery, repetitive trauma to hands.

Other systemic diseases and anatomic abnormalities that can cause upper extremity vascular disease:

Vasculitis, Giant cell arteritis, Takayasu arteritis, Radiation artery fibrosis, Buerger's disease, Raynaud´s disease, Fibromuscular dysplasia, Ergotism, Cytotoxic drugs, Arterial drug injection, Diabetes mellitus, Myeloproliferative disorders, hypercoagulative status, cryoglobulins, repetitive trauma, injury, iatrogenic lesions. Connective tissue disease and several arterititides are infrequent causes of upper-extremity occlusive disease [73].

Figure 20. Upper limb ischemia in systemic disease.

Symptoms of Upper Extremity Vascular Disease

Figure 21. Hand ischemia in steel syndrome.

Figure 22. Hand ischemia in steel syndrome.

Symptoms of upper extremity occlusive vascular disease include discomfort, muscle fatigue or ischemic rest pain, claudications, tightness, heaviness, cramping, or weakness in one or both of arms. Digital necrosis or athero-embolisation is less common. Stenotic lesion of a brachiocephalic and left subclavian artery may present with upper extremity ischemia or vertebrobasilar insufficiency.

Diagnosis

Clinical history: personal and family history, risk factors and comorbidities, lifestyle habits, previous occupations, pertinent medical history, risk factors for atherosclerosis. Establishing whether symptoms are the result of vasospasm or a fixed arterial obstruction [73]. The former is characterized by intermittent symptoms. The manifestations of obstruction are generally unremitting.

Clinical examination: pulse palpation including axillary, brachials, radial, and ulnar pulses, palpation, and auscultation of the supraclavicular region, blood pressure should be measured in both arms (asymmetric). When thoracic outlet syndrome is suspected, the Adson maneuver, in which the head is rotated away from the involved side, is performed, Allen´s test [74]

Laboratory testing: When clinically suspected, it can be assessed by

Duplex ultrasound (DUS)

Computed tomography angiography (CTA) or

Magnetic resonance angiography (MRA),

Digital subtraction angiography (DSA),

Positron emission tomography is useful for the diagnosis of arteritis (Takayasu disease, giant cell arteritis) [40].

Treatment for Upper Extremity Vascular Disease

Treatment varies from pharmacological therapy for vasospastic and vasculitis syndromes to endovascular and operative approaches for stenoses and occlusions.

In most asymptomatic patients, medical treatment is the option of choice. However, the goal is also to treat the underlying causes (risk factor control). Trombolytic agents have been used to recanalize medium and small vessel occlusions with variable success [75].

When revascularization is considered, both endovascular and open surgical options can be proposed, according to lesion characteristics and the patient's risk.

Revascularization can be proposed in cases of severe/disabling symptoms, bilateral stenosis, stenosis with ipsilateral arteriovenous fistula for dialysis, patients planned for coronary artery bypass graft surgery or those already operated on with ipsilateral internal mammary artery grafted to coronary arteries with evidence of myocardial ischemia [40]. Open surgical approach and endovascular treatment can both be proposed according to lesion characteristics and the patient´s risk including angioplasty and stenting, transpositions (subclavian-carotid), bypasses (carotid-subclavian, axilloaxillary, carotidaxillary, carotidcarotid bypass, and thoracic outlet surgery).

Table 7. Recommendations on the management of subclavian artery stenosis [40]

Recommendations	Class[a]	Level[b]
In symptomatic patients with subclavian artery stenosis/occlusion revascularization should be considered	IIa	C
In symptomatic patients with a stenotic/occluded subclavian artery, both revascularization options (stenting or surgery) should be considered and discussed case by case according to the lesion characteristics and patient's risk	IIa	C
In asymptomatic subclavian artery stenosis, revascularization: ♦ should be considered in the case of proximal stenosis in patients undergoing CABG using the ipsilateral internal mammary artery	IIa	C
♦ should be considered in the case of proximal stenosis in patients who already have the ipsilateral internal mammary artery grafted to coronary arteries with evidence of myocardial ischaemia	IIa	C
♦ should be considered in the case of subclavian artery stenosis and ipsilateral arteriovenous fistula for dialysis	IIa	C
♦ may be considered in the case of bilateral stenosis, in order to be able to monitor blood pressure accurately	IIb	C

CABG= coronary artery bypass graft surgery.
[a] Class of recommendation.. [b] Level of evidence.

Thoracic Outlet Syndrome

Thoracic outlet syndrome (TOS) describes a variety of symptoms caused by compression of the brachial plexus or subclavian vessels at the thoracic outlet (costoclavicular narrowing). In more than 90% of all thoracic outlet syndrome [76] symptoms are neurological. There is controversy concerning the diagnosis and treatment of N-TOCS (neurogenic thoracic outlet compression syndrome). Arterial complications are often associated with bone abnormalities. The initital arterial laesion is fibrotic thickening with intimal damage and post-stenotic dilatation, leading to aneuryzmal degeneration with mural thrombus and the risk of

embolization [73]. Arterial reconstruction and first rib or cervical rib resection are indicated in all patients with arterial complications of TOS.

Upper limb embolism: presents with symptoms that include pulselessness, pallor, pain, and paresthesias. Emboli of cardiac origin are most common, particularly in patients with atrial fibrillation [19] or following myocardial infarction. The brachial bifurcation is the most frequently involved site for an embolus to lodge. Most emboli can be retrieved through a distal brachial transverse arteriotomy [73].

CONCLUSION

Vascular diseases of the upper extremity are rare in comparison to those involving the lower extremities. Upper extremity arterial disease evaluation, diagnosis, and treatment represent a much different spectrum than those of lower extremities. The management is difficult and requires an assessment of vascular structure and function.

Upper extremity vascular disease due to atherosclerosis is mostly situated at the level of the brachiocephalic trunk and the subclavian and axillary arteries.

When clinically suspected, it can be assessed by DUS, CTA, or MRA.

In most asymptomatic patients, medical treatment is the option of choice. Revascularization can be proposed in cases of severe disabling symptoms, bilateral stenosis, stenosis with ipsilateral arteriovenous fistula for dialysis, patients planned for coronary artery bypass graft surgery or those already operated on with ipsilateral internal mammary artery grafted to coronary arteries with evidence of myocardial ischemia.

When revascularization is considered, both endovascular and open surgical options can be proposed, according to lesion characteristics and the patient's risk [40].

REFERENCES

[1] Štvrtinová, V., Šefránek, V., Murín, J. et al. (2006). SAS, SCCH, SKS, SIS, SRS: Guidelines for diagnosis for diagnosis and treatmet of peripheral arterial limb disease. *Cardiol,* 15(6): 317 -323.

[2] Dormandy, J., Mahir, M., Ascady, G. et al. (1989). Fate of the patient with chronic leg ischaemia. *Cardiovasc Surg,* 38: 50-7.

[3] Norgren, L., Hiatt, W. R., Dormandy, J. A et al. (2007). Inter-Society Consensus for the Management of Periferal Arterial Disease (TASC II). *Eur J Vasc Endovasc Surg,* 33, suppl. 1: S1-S75.

[4] Rieger, H. (1999). Epidemiology of periferal arterial occlusive disease (POAD). *International Angiol,* 18, suppl.1: 11-12.

[5] Reiber, G. E., Lipsky, B., A., Gibbons, G. W. (1998). The Burden of Diabetic Foot Ulcers. *Am J Surg,* l76, Suppl 2A: 5S-10S.

[6] European Working Group on Critical Leg Ischaemia. (1991). Second European Consensus Document on Chronic Critical leg Ischaemia. *Circulation,* 84, suppl. 5: 1-26.

[7] Jensen, S. A., Vatten, L. J., Myhre H. O. (2006). The prevalence of chronic critical lower limb ischaemia in a population of 20,000 subjects 40-69 years of age. *Eur J Vasc Endovasc Surg*, 32: 60-65.

[8] Jelnes, R., Gaardsting, O., Jensen, K. H. et al. (1986). Fate in intermittent claudication: outcome and risk factors. *BMJ*, 293: 1137-40.

[9] Kubíková, M. (2008). The importance of peripheral vascular reconstruction in rescue of the lower extremity threatened by ischemic disease. Doctor´s thesis. *Medical faculty, University P.J Šafarik, Košice, Slovakia*: 1-104. (book in Slovak).

[10] Marston, W. A., Davies, S. W., Armstrong, B., et al. (2006). Natural history of limbs with arterial insufficiency and chronic ulceration treated without revascularisation. *J Vasc Surg*. 44: 108-14.

[11] Sihotský, V. (2017). Arterial Surgery. In *Surgery for Medical Students. 2-nd revised edition*. Frankovičová , M., Kaťuchová, J. et al. Edited by Faculty of Medicine, Pavol Jozef Šafarik University in Košice Equilibria s.r.o., Košice: 379-400. ISBN 978-80-8152-202-4.

[12] Lee E. S., Dawson, D. L., Pevec W. C. (2007). Vascular Surgery: An Update**.** *Am Fam Physician*, 75: 85-90.

[13] Owens, C. D., Ridker, P. M., Belkin, M. et al. (2007). Elevated C-reactive protein levels are associated with postoperative events in patiens undergoing lower extremity vein bypass surgery. Selected Abstracts from the January Issue of the Journal of vascular Surgery. *Eur J Vasc Endovasc Surg*. 33: 128-30**.**

[14] Kaperonis, E. A., Liapis, C. D., Kakisis J. D. et al. (2006). Inflammation and Atherosclerosis. *Eur J Vasc Endovasc Surg*, 31: 386-393.

[15] Hanson, G. K. (2005). Inflammation, atherosclerosis and coronary artery disease. *N Engl J Med*, 352: 1685-1695.

[16] TransAtlantic Inter-Society Consensus (TASC) Working Group. (2000). Management of Periferal Arterial Disease (PAD). *International Angiol*, 19, suppl.1 to N.1: S1-S310. Vajó, J. (1996).

[17] *Sudden angio-surgical episodes and acute ischemic-reperfusion syndrome in clinical practice*. Košice, Mauro press. Approved by the Dean of the Faculty of Medicine of Pavol Jozef Safarik Univerisy as a publication for postgraduate education of doctors and supplementary literature in the field of surgery for medical students: 1-148. ISBN 80-967477-3-8 (book in Slovak).

[18] Firt, P., Hejnal, J., Vaněk I. (1991). *Vascular surgery.* Prague, Avicenum, medical press: 127-l46. ISBN 80-201- 0047-4. (book in Czech).

[19] Kubíková, L., Valočík, G., Kurečko, M. et al. (2018). Left atrial appendage strain rate is predictive of thromboembolism in patients with nonvalvular atrial fibrillation. *Eur Heart Journal*, 39, suppl 1: https://doi.org/10.1093/eurheartj/ehy566.P5354.

[20] Frank, L., Hinchliffe, R. J. (2019). Management of acute lower limb ischaemia. In Loftus I., Hinchliffe, R. J.´s *Vascular and Endovascular surgery,* Sixth edition, edited by Elsevier, Printed in Great Britalin: 102-119: ISBN: 978-0-7020-7253-6.

[21] Gavorník, P. (1998). Angiology. *Komenius University press, Bratislava*, 1´st edition: 1-145. ISBN 978-80-8140-083-4.

[22] Earnshaw, J. J. (2010). Acute ischemia: Evaluation and Decision Making. In *Rutherford's Vascular Surgery, 7-th edition*. Edited by SAUNDERS/Elsevier, Philadelphia: 2389-2398. ISBN 978-1-4160-5223-4.

[23] Brunkwall, J., Bottomley, J. (2009). Assessement of chronic lower limb ischaemia. In *Beard, J. D. and Gaines, P. A. Vascular and Endovascular Surgery, 4-th edition*, edited by Saunders Elsevier : 392, 24. ISBN 9780702030116.

[24] Rutherford, R. B., Baker, J. D., Ernst, C. et al. (1997). Recommended standards for reports dealing with lower extremity ischemia: revised version. *J Vasc Surg*, 26: 517-38.

[25] Novo, S., Coppola, G. and Milio, G. (2004). Critical limb ischaemia: definition and natural history. *Curr Drug Targets Cardiovasc Haematol Disord*, 4: 219-225.

[26] Veith, F. J., Gupta, S. K., Wengerter, K.R. et al. (1990). Changing Arteriosclerotic Disease patterns and Management Strategies in Lower –limb-Threatening Ischemia. *Ann Surg*, 212: 402- 412. Staffa R. (2005). Rescue of critically ischemic limb. Pedal bypass. Prague, edited by Grada Publishing a.s. : 1-110.

[27] Ascher, E., Mazzariol, F., Hingorani, A. et al. (1999). The Use of Duplex Ultrasound Arterial Mapping as an Alternative to Conventional Arteriography for Primary and Secondary Infrapopliteal Bypasses. *Am J Surg*, 178: 162-165.

[28] NICE Lower limb peripheral arterial disease: diagnosis and management. (2012) *National Institute for Health and Clinical Excellence*: Clinical guideline[CG147]. August 2012, https://www.nice.org.uk/guidance/cg147/chapter/1-guidance.

[29] Mylankai, K. J., Fitridge, R. (2019). Assessement of chronic lower limb ischaemia. In Loftus I., Hinchliffe, R. J.´s *Vascular and Endovascular surgery.* Sixth edition, edited by Elsevier, Printed in Great Britalin: 13-35. ISBN: 978-0-7020-7253-6.

[30] Abela, G. S. (2004). *Peripheral vascular disease*. Lippincott Williams & Wilkins, Philadeplphia, PA 19106 USA: 51. ISBN 0-7817-4383-4.

[31] Kubíková, M. (2014). Critical lower limb icheamia – disease management. *Atherosclerosis.* 18: 594-600.

[32] Šefránek, V. (2001). Diseases of limb arteries and their surgical treatment. *Bratislava,* Slovak Academic Press, s.r.o.: 1-240.

[33] Pahlsson, H.,I., Wahlberg, E., Olofsson, P. and Swedenborg, J. (1999). The Toe Pole Test for evaluation of Arterial Insufficiency in Diabetic Patients. *Eur J Vasc Endovasc Surg*, l8: l33-137.

[34] Paraskevas, N., Ayari, R., Malikov, S.et al. (2006). „Pole Test" Measurements in Critical leg Ischaemia. *Eur J Vasc Endovasc Surg*, 31: 253-257.

[35] Roztočil, K., Slíva, J. (2014). Cilostazol in treatment of lower limbs ischeamic disease. *Pharmacotehrapy*, 10: 4.

[36] Rana, N. R., Mc Lafferty R. B., (2010). Arteriography. In*: Rutherford´s Vascular Surgery 7-th edition,* Cronenwett and Johnston, Edited by Saunders/Elsevier, Philadelphia: 285-303. ISBN 978-1-4160-5223-4.

[37] Anderson, J. L., Halperin, J. L., Albert, N. et al. (2013). Management of Patients With Periferal Artery Disease (Compilation of 2005 and 2011 ACCF/AHA Guideline Recommendations). A report of the American College of Cardiology Foundation/ American Heart Association Task Force on Practice Guidelines. *J Am Coll Cardiol*, 61(14): 15551570.doi:10.1016/j.jacc 2013.01.004.

[38] Conte, M.S., Pomposelli, F.B, Clair, D. G., Geraghty PJ, McKinsey JF, Mills JL et al. (2015). Society for Vascular Surgery practice guidelines for atherosclerotic occlusive disease of the lower extremities: managemment of asymptomatic disease and claudication. *J Vasc Surg* , 61 (3 Suppl.): 25-41.

[39] Authors/Task Force Members a, Aboyans V, Ricco JB, Bartelink MLEL, Bjorck M, Brodman M, Cohnert T, Collet JP, Czerny M, De Carlo M, Debus S, Espinola-Klein CH, Kahan T, Kownator S, Mazzolai L, Naylor AR, Roffi M, Rôther J, Sprynger M, Tendera M, Teppe G, Venermo M, Vlachopoulos Ch, Desormais I.(2018). 2017 ESC Guidelines on the Diagnosis and Treatment of Peripheral Arterial Diseases, in collaboration with the European Society for Vasular Surgery (ESVS). *Eur J Vasc Endovasc Surg*, 55: 305-368.

[40] Hageman, D, Fokkenrood, H. J. P., Essers, P. P. M. et al. (2017). Improved Adherence to a Stepped-care Model Reduces Costs of Intermittent Claudication Treatment in The Netherlands. *Eur J Vasc Endovasc Surg*, 54: 51-57.

[41] Mazari, F.A., Khan, J. A., Carradice D. et al. (2012). Randomized clinical trial of percutaneous transluminal angioplasty, supervised exercise and combined treatment for intermittent claudication due to femoropopliteal arterial disease. *Br J Surg*, 99(1): 39-48.

[42] Coccheri and an Italian Collaborative group. (2002). Study SUAVIS. *Eur Heart J*, 23:1057-1065.

[43] Rusin, V. I., Rumjancev, K. Ye., Kopolovets, I. (2014). Prevention of the Thromboembolism in the surgical practice. *Scientific Bulletin of Uzhhorod University, Series Medicine*, 2(50):125-128.

[44] TransAtlantic Inter-Society Consensus (TASC) Working Group. (2000). Management of Periferal Arterial Disease (PAD). *International Angiololy*, 19, suppl.1 to N.1: S1-S310.

[45] Jude, E. B., Ozibo, S. O., Chalmers, N. et al. (2001). Peripheral arterial disease in diabetic and nondiabetic patients. *Diabetes Care*, 24: 1433-1437.

[46] Virkunnen, J., Heikkinen, M., Lepäntalo, M. et al: Finnvasc Study Group. (2004). Diabetes as an independent risk factor for early postoperative complications in critical limb ischemia. *J Vasc Surg*, 40 (4): 761-767.

[47] Gottsätter, A. (2006). Managing Risk Factors for Atherosclerosis in Critical Limb Ischaemia. *Eur J Vasc Endovasc Surg*, 32: 478-483.

[48] Khan, S., Cleanthis, M., Smout J. et al. (2005). Life-style Modification in Peripheral Arterial Disease. *Eur J Vasc Endovasc Surg*, 29: 2-9.

[49] Varcoe, R.L. (2019). Intervention for chronic lower limb ischaemia. In Loftus I., Hinchliffe, R. J.´s *Vascular and Endovascular surgery*, Sixth edition, edited by Elsevier, Printed in Great Britalin: 44-61: ISBN: 978-0-7020-7253-6.

[50] Pennywell, D. J., Tan, T. W., Zhang, W. W. (2014). Optimal management of infrainguinal arterial occlusive disease. *Vasc Health Risk Management*, 10: 599-608.

[51] Mills, Sr. J. L., Conte, M. S., Armstrong, D. G., Pomposelli, F.B., Schanzer, A., Sidawy, A. N. et al. (2014). The Society for Vascular Surgery Lower Extremity Threatened Limb Classification System: risk stratification based on wound, ischemia, and foot infection (Wifi). *J Vasc Surg*, 59: 220-234.e2.

[52] Conte, M.S. (2013). Critical appraisal of surgical revascularisation for critical limb ischemia. *J Vasc Surg*, 57, (Suppl 2): 8S-13S.

[53] Frankovičová, M. (1994). Vascular graft in reconstructive surgery. *Folia fac.Med Univ. Šafarikiannae Cassoviensis.* LI: 171-177.

[54] Bosanquet, D. C., Glasbey, J. C. D., Williams, I. M. et al. (2014). Systematic Review and Meta-Analysis of Direct Versus Indirect Angiosomal Revascularisation of Infrapopliteal Arteries. *Eur J Vasc Endovasc Surg,* 48: 88-97.

[55] Šefránek, V., Tomka, J., Molčan, T., Dulka, T. (1998). Our concept of complex vascular reconstruction of chronic lower limb ischemia. *Practic phlebology,* 2: 66-68.

[56] Rutherford, R. B., Darell, N. J., Bergentz, S. E. et al. (1998). Factors affecting the patency of infrainguinal by pass. *J Vasc Surg,* 8: 236-246.

[57] Brownrigg, J. R. W., Apelqvist, J., Bakker, K. et al. (2013). Evidence - based Management of PAD and the Diabetic Foot. *Eur J Vasc Endovasc Surg,* 45: 673-81.

[58] Bradbury, A. W., Adam, D. J., Bell, J. et al. (2010). Bypass versus agioplasty in severe ischaemia of the leg (BASIL) trial: analysis of amputation free and overall survival by treatment received. *J Vasc Surg,* 51: 18S-31S.

[59] Kodama, A., Sugimoto, M., Kuma, S. et al. (2014). Clinical Outcomes After Infrainguinal Bypass Grafting for Critical Limb Ischaemia in Patients With Dialysis-dependent End-stage Renal Failure. *Eur J Vasc Endovasc Surg,* 48: 695-702.

[60] Uhl, C., Grosch, C., Hock, C., Topel I., Steinbauer M. (2017). Comparison of Long-term Outcomes of Heparin Bonded Polytetrafuoroethylene and Autologus vein Below Knee Femoropopliteal Bypasses in patients with Critical Limb ischaemia. *Eur J Vasc Endovasc Surg,* 54(2): 203-211.

[61] Bradbury A.W., Ruckley C.V. , Fowkes F.G.R., Forbes J.F., Gillespie I., Adam D.J., Beard J.D., Cleveland T., Bell J., Raab G., Storkey H. (2005). Bypass versus agioplasty in severe ischaemia of the leg (BASIL): Multicentre, randomised controlled trial. *Lancet*, 366: 1925-1934.

[62] Neville, R. F., Attinger, C. E., Bulan, E. J. et al. (2009). Revascularization of a specific angiosome for limb salvage: does the target artery matter?. *Ann Vasc Surg,* 23: 367-73.

[63] Mazuch, J., Mištun a, D., Mazuchová, J. (2016). Angiosurgical aspects of diabetic foot. *Case studies in angiology,* 5: 39-44.

[64] Heider, P., Hofmann, M., Maurer, P. C., Sommoggy , S. (1999). Semi-closed Femoropopliteal Tromboendarterectomy: a Prospective Study. *Eur.J.Vasc. Endovasc. Surg,* l8: 43-47.

[65] Devalia, K., Magee, T. R. and Galland R.B. (2006). Remote Superfitial Femoral Endarterectomy: Long-term Results. *Eur J Vasc Endovasc Surg,* 31: 262-265.

[66] Luther, M., Lepäntalo, M. (1997). Arterial Reconstruction to the Foot Arteries – A Viable Option?. *Eur J Surg*, 163: 659-665.

[67] Diehm, N., Savolainen, H., Mahler F., et al. (2004). Does deep femoral arterial revascularisation as an isolated procedure play role in chronic critical limb ischemia?. *J Endovasc Ther,* 11: 119 -124.

[68] Lu, X.W., Idu, M.M., Ubbink, D. T. and Legemate, D. A. (2006). Meta-analysis of the Clinical Effectiveness of Venous Arterialisation for Salvage of Critically Ischaemic Limbs. *Eur J Vasc Endovasc Surg,* 31: 493-499.

[69] Bartoš, J. (1994). *Complications and reoperations after reconstruction vascular surgery*, Edited by Grada Publishing and Avicenum, Praha:1- 164 s. (book in Czech).

[70] Gopalan, P. D., Burrows, R. C. (2003). Critical care of the vascular surgery patient. *Critical Care Clinics*, 19: 109-125.

[71] Levin, P. M., Rich, N. M., Hutton, J. E. Jr. (1971). Collaternal circulation in arterial injuries. *Arch Surg*, 102: 392.

[72] Ricco, J. B., Belmonte, R. (2019). Vascular disorders of the upper limb. In Loftus I., Hinchliffe, R. J.´s *Vascular and Endovascular surgery*, Sixth edition, edited by Elsevier, Printed in Great Britalin: 168-184: ISBN: 978-0-7020-7253-6.

[73] Kestlerova M. (1991). Vascular access for hemodialysis. In Firt, P., Hejnal, J., Vaněk I. *Cévní chirurgie*. Praha, Avicenum, health publishing house: 364-377. ISBN 80-201-0047-4. (book in Czech).

[74] Yakubov, S. J., Nappid, F., Candela, R. J., George, B. S. (1993). Successful prolonged infusion of urokinase for the hypothenar hammer syndrome. *Catheter cardiovasc Diagn*, 29: 301-303.

[75] Sanders, R. J., Hammond, S. L., Rao, N. M. (2007). Diagnosis of thoracic outlet syndrome. *J Vasc Surg*, 46: 601-4.

In: Encyclopedia of Surgery (22 Volume Set)
Editors: Andreas Lehrer and Kristin Mueller
ISBN: 978-1-53618-329-0
© 2020 Nova Science Publishers, Inc.

Chapter 290

VASCULAR TRAUMA

Ivan Kopolovets*, MD, PhD
Department of Vascular Surgery, East Slovak Institute of Cardiovascular Diseases, Kosice, Slovakia
Uzhhorod National University, Medical Faculty, Department of Surgical Diseases, Uzhhorod, Ukraine

ABSTRACT

Clinical manifestations of vascular trauma are diverse. The severity of the patient's condition depends on the nature of the vascular trauma, the extent of blood loss, co-existent soft tissue, vein, nerve, and bone injuries, and ischemia duration. Adequate assessment of the patient's condition allows choosing appropriate treatment tactics and improving treatment results. Reconstructive surgeries provide successful treatment of vascular injuries.

Keywords: vascular trauma, bleeding, osteo-vascular injuries, traumatic aneurysm, traumatic arteriovenous fistula, iatrogenic vascular injuries, postischemic syndrome

ABBREVIATIONS

AAST-OIS	the American Association for the Surgery of Trauma Organ Injury Scaling
CT	computed tomography
NCTH	noncompressible truncal hemorrhage

* Corresponding Author's Email: i.kopolovets@gmail.com.

INTRODUCTION

Among different trauma types, great vessel traumas account for 2% of the cases [1]. Clinical manifestations of vascular trauma are diverse and are determined to a large extent by the nature of vascular wall injury, the caliber of the damaged artery, the anatomical and topographic peculiarities of the damaged area, the presence of co-existent vein, bone, or nerve injury, the extent of the affected soft tissues, the severity of the patient's general condition, the extent of blood loss, the degree of ischemia, etc. [2, 3].

There are various classifications of vascular traumas; however, the most commonly used classifications are those involving trauma mechanism and localization, the nature of clinical manifestations, and the effects of vascular trauma [1].

Classification of Vascular Traumas [4]

Open Injury

1. By trauma mechanism:
   - vulnus punctum;
   - vulnus incisum;
   - vulnus caesum;
   - vulnus conguassatum;
   - vulnus sclopetarium.
2. By the nature of vascular damage:
   - tangential wound that does not extend into the lumen;
   - lateral wound;
   - penetrating wound;
   - circular rupture of the vessel with the loss of its portion along its length;
   - circular rupture of the vessel without the loss of its portion along its length.
3. By clinical manifestations:
   - recent traumas:
     a) external bleeding;
     b) anemia;
     c) shock;
     d) ischemia;
     e) limb gangrene.
   - traumas complicated by:
     a) pulsatile hematoma;
     b) secondary bleeding;
     c) infected hematoma.
4. By the degree of damage to the surrounding tissues:
   - isolated artery or vein injury:
     a) single;
     b) multiple;
   - combined artery and vein injury.

Closed Injury

1. By trauma mechanism:
   - blow;
   - compression;
   - sprain.
2. By the nature of vascular damage:
   - bruise without intramural hematoma;
   - bruise with intramural hematoma;
   - rupture of single layers of the blood vessel;
   - blood vessel rupture:
     a) intraparietal;
     b) circular.
   - crush of all the layers of the blood vessel;
   - compression of the vessel by a bone fragment or a sprained limb segment;
   - puncture of the vessel wall with a bone fragment;
   - disconnection of the lateral branch from the vascular trunk.
3. By clinical manifestations:
   - recent traumas
     a) shock;
     b) arterial spasm;
     c) intermuscular hematoma;
     d) ischemia;
     e) limb gangrene.
   - traumas complicated by:
     a) pulsatile hematoma;
     b) joint contracture in the affected limb;
     c) venous or arterial insufficiency.
4. By the degree of damage to the surrounding tissues:
   - isolated injury;
   - combined injury to the great vessels and the surrounding tissues or the internal organs;
   - The effect of the injuries to the great vessels:
   - traumatic arterial aneurysm;
   - traumatic arteriovenous fistula;
   - disease of the ligated vessel;
   - ischemic contracture

Recent traumas are those diagnosed within the first 3 days after occurrence. Complicated traumas include those diagnosed since the 3rd day after occurrence within the next 6 weeks [5].

The classification is acording to a three-level system, which is based on the wound localization and the possibility to stop bleeding. [6].

Level 1: Peripheral injuries are localized distally from the axillary artery or vein (the upper limb) or the common femoral artery or vein (the lower limb) and are responsible for the

smallest percentage (14%) of bleeding-related fatalities. This was mainly due to wide distribution of the emergency military tourniquets or compression bandages which were used in 56% of the cases.

Level 2: Proximal axillary vessel injuries or axillary vessel injuries. Bleeding is difficult to stop with a compression bandage or a tourniquet.

Level 3: Intracavitary injuries to the chest or the abdomen and pelvis. To treat this category of patients is a very difficult task due to noncompressible truncal hemorrhage (NCTH) which is the main cause of death in approximately 67% of the cases.

This categorization scheme is most useful for penetration or battlefield trauma. However, it can be used for any vascular trauma related to bleeding. Today the AAST-OIS (the American Association for the Surgery of Trauma Organ Injury Scaling) classification for traumatic vascular injuries including the cervical, thoracic, abdominal and peripheral regions is available [7]. This classification system focuses primarily on the precise identification of the blood vessel and does not involve the severity of vascular trauma or the degree of hemorrhage or ischemia. Thus, it provides little additional information on the results or treatment. The clinical picture of vascular injuries includes general and local signs.

Clinical signs depend on the nature of the injury, the damaged vessel size, the presence of bone or nerve injury, the extent of soft tissue injury, the patient's general condition that depends on the severity of blood loss, the presence of shock, and the degree of limb ischemia. In open vascular injuries, the first clinical signs are bleeding and manifestations of anemia in the form of pale skin, low blood pressure, and tachycardia [8, 9].

Local signs of open arterial injury include its localization in the projection of the blood vessels, external arterial bleeding, hematoma, and the phenomena of limb ischemia [10]. In a partial rupture of the artery, bleeding usually lasts longer than in complete rupture of the artery when it can stop due to arterial contraction, an inward twisting of the intima followed by thrombosis of the lumen which is caused by the development of hypotonia The absence of bleeding does not exclude arterial injury. In arterial injury, a pulsating mass is often formed. Tense pulsatile hematoma is usually limited, being located along the blood vessel. An important sign of arterial damage is a weak or absent pulse within the vessels located distal to the damaged area [11]. In 80% of the cases, the signs of inadequate blood supply to the limb in the form of ischemic pain and impaired sensitivity. Ultrasound scans should be an integral part of the algorithm for examining the patients with injuries to the great vessels [3]. In arterial injuries, the primary goal of treatment is to save the patient's life and then to preserve limb viability and restore normal limb functions. Therefore, the main task is to stop bleeding.

Bleeding can be stopped in the following ways [12, 13]:

- to press down on the artery proximally to or at the site of damage with a finger;
- to apply a sterile pressure dressing;
- to apply tamponade in combination with a compression bandage;
- to apply a tourniquet;
- to ligate the artery;
- to apply the hemostatic forceps.

Tamponade

The effectiveness of tamponade depends on its proper application. The closer a tampon is to the site of vascular injury in the wound is inserted and the tighter it is, the faster the desired effect is achieved, especially in the cases when the injury is on the lateral wall of the vessel.

Hemostatic Forceps

A safer method to clamp off blood vessels is to apply the hemostatic forceps. However, this procedure may be accompanied by damage to the surrounding nerve trunk and crushing of the arterial wall along its length. These factors should limit the use of forceps, which are not intended to stop bleeding. In such cases, atraumatic vascular clamps with a ridge surface are advisable. To clamp off small blood vessels, it is better to use the bulldog clamps.

Tourniquet Application

The tourniquet should be applied as close as possible to the site of vascular damage while protecting the underlying tissues with a soft pad. The tourniquet should be removed or loosened every hour while applying finger compression over the artery to stop bleeding. The tourniquet should be applied as tightly as necessary until the bleeding stops. In venous injuries, if the tourniquet is not tight enough, it increases bleeding. It is recommended to avoid tourniquet application if possible, as it results in critical limb ischemia. In addition, the tourniquet is a strong shock-producing factor which increases the risk of infectious complications.

Temporary Prosthesis

The use of temporary prosthesis allows the stopage of bleeding, the restoration of regional hemodynamics, and the prevention of irreversible changes in the affected limb; it also creates favorable conditions for limb-sparing surgery.

Artery Ligation

Artery ligation should be performed only if there are strict indications. They include the cases when reconstructive surgery is impossible, since the patient's condition is critical, when secondary arrosive bleeding occurs from the blood vessels in the infected wound, when vascular damage is complicated by limb gangrene, and when there is damage to the blood vessels that have no functional importance for circulation. In vascular injury, the blood vessel should be ligated as close as possible to the site of vascular damage to preserve more collaterals, which ensure limb viability.

Medical Care at the Prehospital Stage

Medical care for all the patients with vascular trauma at the prehospital stage consists of [9, 14]:

- performing hemostasis (tamponade, compression bandages, temporary shunting, applying hemostatic forceps, etc.)
- ensuring airway patency;

- anti-shock measures, prevention of air embolisms (in venous injuries); prevention of infection (antibiotics, tetanus toxoid); hospitalization of the patient for providing specialized care.

Diagnostics

Diagnostics depends on the patient's condition, the nature of the injury , and clinical manifestations. Optimal diagnostic methods include computed tomography (CT) angiography (Figure 1), diagnostic angiography (Figure 2), and ultrasound scan of the blood vessels [15, 16].

If there is an injury in the projection of the vascular bundle with the symptoms of active bleeding, surgery is performed without any additional examination methods. The indications for arterial reconstructions depend on limb viability, which is not always determined by the time that elapsed since the injury. The localization and nature of the injury, the possibility of collateral circulation, and the state of hemodynamics and microcirculation are important as well [17, 18].

Figure 1. CT angiography: occlusion of popliteal artery after blunt injury.

Figure 2. Angiography: Traumatic lesions of popliteal artery.

Surgical Treatment

Cervical Vessel Injuries

The exposure of the carotid arteries and jugular veins on the neck is performed through the incision along the anterior edge of the sternocleidomastoid muscle. The injury to the first portion of the common carotid artery requires the cervical sternal approach [19, 20]. The nature of vascular damage determines the extent of reconstructive surgery. All devitalized tissues are removed. In case of injuries to the external carotid arteries and their branchesand the external jugular veins, no reconstructive surgery is needed, and they may be limited to the ligation of the affected vessels. In linear injuries or partial transection of the common and internal carotid arteries, vascular suture is used. In case of complete transection of the artery after resection of the crushed edges, diastasis can be prevented by mobilizing the ends of the blood vessels and creating the circular anastomosis. Vascular trauma that is accompanied by a significant defect in the vessel wall requires autovenous patch plasty or autovenous prosthetic repair (by means of the great saphenous vein) [21, 22, 23] (Figure 3).

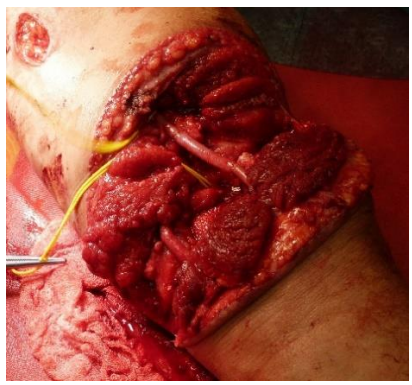

Figure 3. Autovenous prosthetic repair of a. brachialis (using the great saphenous vein).

ABDOMINAL VASCULAR INJURIES

The most common causes of abdominal vascular injuries are penetrating traumas caused by sharp, pointed objects and gunshot traumas, which account for 90% of all abdominal vascular injuries. Blunt abdominal trauma which is accompanied by vascular damage (up to 9%) usually results from motor vehicle collisions. The inferior vena cava is the most commonly injured abdominal vessel (41%); the abdominal aorta is relatively rarely injured in blunt traumas (17%). Isolated abdominal aortic injuries account for 2% of the cases. If the abdominal aorta and its branches are damaged and internal bleeding occurs, injured people often die at the scene of the accident [24, 25].

In vascular trauma, the abdomen is conventionally divided into three anatomical areas [24]:

- Zone 1 includes the midline retroperitoneum extending from the aortic hiatus to the sacral promontory. This zone is subdivided into the supramesocolic and

inframesocolic areas. The supramesocolic area contains the suprarenal aorta and its major branches (the celiac axis, the superior mesenteric artery, and the renal arteries), the supramesocolic inferior vena cava with its major branches, and the superior mesenteric vein. The inframesocolic area contains the infrarenal aorta and the inferior vena cava.

- Zone 2 (left and right) includes the kidneys, the paracolic gutter, and the renal vessels.
- Zone 3 includes the pelvic retroperitoneum and contains the iliac vessels.

Some authors add Zone 4 in the perihepatic area that contains the hepatic artery, the portal vein, the retrohepatic inferior vena cava, and the hepatic veins [26].

Clinical manifestations of abdominal vascular injury include signs of internal bleeding and damage to the abdominal organs. If after vascular trauma retroperitoneal bleeding occurs, a large abdominal hematoma is formed that can reduce the blood loss. It may be difficult to diagnose blunt abdominal trauma with co-existent vascular injuries in a relatively stable patient's condition. During examination, diagnostic ultrasound should be used first to detect retroperitoneal hematoma or free fluid (blood) in the abdominal cavity. In isolated abdominal aortic injury, intimal rupture followed by aortic thrombosis is rare. Such mechanism of vascular injury is typical for elderly patients with significant atherosclerotic changes when the plaque is detached. In such cases, the determinative symptoms include ischemia of the lower extremities and visceral organs. Retroperitoneal hematoma may not be formed. During the ultrasound scan, the degree of abdominal aortic injury may be determined. Intimal rupture may result in aortic dissection extending distally into the iliac arteries. The presence of the wound penetrating to the abdominal cavity, or the retroperitoneal space on the patient's body always serves as an indication for surgery. Midline laparotomy is considered as an optimal approach in abdominal vascular injuries. When restoring the integrity of the aortic wall and branches, sutures are used, whereas in more serious injuries, autovein plasty or prosthetic repair are applied. In patients with gastrointestinal injuries and co-existent abdominal aortic injuries, when the use of synthetic prosthesis is dangerous due to peritonitis, the extra-anatomic bypass is performed.

Isolated injuries to the visceral branches of the abdominal aorta are rare; they are commonly caused by vascular trauma during surgery. During ultrasound scans, blunt renal trauma looks mostly like perirenal hematoma and is accompanied by impaired urine passage on excretory urograms. The most common signs of blunt renal artery trauma that manifests itself as thrombosis are hypertonia, headache, proteinuria, microhematuria, and kidney pain. Angiography allows detecting renal artery occlusion that is confirmed by retrograde blood flow through the renal vein. In unilateral injury to the renal artery, injury to the celiac artery and the mouth of the superior mesenteric artery, thoraco-phreno-lumbotomy should be performed. In bilateral injury, midline or transverse laparotomy is performed. Reconstructive surgery includes suturing and angioplasty using the allograft or autovein. If there are severe injuries and it is impossible to perform reconstructive surgery, nephrectomy is used [27, 28, 29].

The development of endovascular technique allowed using prosthetic grafts in traumas that has some advantages for a patient, namely less blood loss; neither laparotomy nor long-term anaesthesia is needed. These advantages are successfully used when treating arteriovenous fistulae and posttraumatic pseudoaneurysm [30, 31].

SURGICAL TACTICS FOR MAJOR VEIN INJURIES

The frequency and structure of complications arising in large vein injuries is largely determined by the nature, extent, and localization of trauma and time that elapsed since the injury.

Classification of Venous Injuries

- closed injuries;
- open injuries;
- isolated injuries.

Venous injuries with co-existent damage to:

- corresponding artery.
- limb bones;
- soft tissues;
- large nerve;
- multiple damage.

By the nature of damage:

- complete vein rupture;
- partial vein rupture;
- crushed vein, vein defect;
- lateral, penetrating injuries;
- bruise, vein distortion.

By clinical manifestations:

- uncomplicated;
- complicated by:
  - bleeding;
  - blood loss, shock;
  - venous hematoma;
  - phlebothrombosis;
  - venous insufficiency;
  - limb ischemia;
  - traumatic asphyxia;
  - air embolism.

By venous injury localization:

- neck;
- chest;
- abdomen, pelvis;
- upper extremities;
- lower extremities.

Surgical treatment of venous injuries is characterized by a range of specific peculiarities caused by low blood pressure, slow blood flow, thinness of venous wall, and higher tendency to form blood clots [32, 33].

In venous injuries, bleeding of varying intensity is almost inevitable. However, in some cases, venous bleeding that occurred at the time the vein was damaged or immediately after it stops its own. This characteristic feature of venous bleeding should be always considered, as it may lead to diagnostic and tactical errors at the hospital stage of treatment. The main methods to stop bleeding in the hospital are to apply tamponade or hemostatic forceps, to ligate the damaged veins, or to perform temporary prosthetic repair [34].

Wound tamponade as a method of preliminary or permanent hemostasis may be effective in case of its proper application in combination with a compression bandage. In most cases of venous bleeding, correctly applied compression bandage provides good hemostasis. However, in more than half of the cases, venous injuries are accompanied by damage to the corresponding artery. Therefore, the application of tamponades may be ineffective, as it does not exclude the possibility of re-bleeding.

The application of the hemostatic forceps may be accompanied by damage to the surrounding nerve trunk and crushing of the great vessels that further reduces the possibility of reconstructive surgery. Thus, in venous trunk injuries, atraumatic vascular clamps should be used to arrest bleeding. The ligation of the major veins may be carried out to achieve preliminary or permanent hemostasis. The number of indications for vein ligation is currently decreasing. During vein ligation, venous circulation disorders that result in limb amputation and death are rather rare, while chronic venous insufficiency often causes severe disability [35, 36]. The indications to the ligation of the venous trunks that are extremely critical include the patient's condition, large infectious wounds, injuries to the paired or saphenous veins in the preservation of venous blood flow through the deep veins, and the impossibility of replacing the damaged vessel due to the limited possibilities of autovein plasty [9, 37].

Surgery for Vein Injuries

After surgical revision of the great vessels, vascular clamps or stay sutures are applied to the peripheral end of the injured vein and the proximal branches. Thrombi are removed from the peripheral or central portion of the vein by aspiration, stripping, or by means of balloon catheters. The venous bed is flushed with saline sodium chloride and heparin (100:1). The ends of the injuries vein are treated. The anastomosis should be made in the oblique plane rather than perpendicular to the axis of the vessels that prevents anastomotic stricture and reduces the risk of vein stenosis. When restoring blood flow, the vascular clamp is removed from the peripheral end of the vein [38].

The success of reconstructive surgery largely depends on complete thrombus removal. In case of incomplete blood clot removal, thrombi in the lumen of the venous trunk lead to ascending thrombosis of the venous bed after surgery.

If there is a large vein defect or a minimal tension along the axis, or it is impossible to approximate the ends of the blood vessels after their treatment, autovein plasty is indicated. If the patient's condition is extremely critical and there is an infectious wound, autovein plasty is contraindicated.

In groin injuries and during surgery (phlebectomy of varicose veins, herniotomy, Ducuing surgery, or vein catheterization), the proximal portion of the femoral vein is commonly injured [39].

In most cases of femoral artery injury, heavy bleeding below the inguinal ligament is observed. When stopping such bleeding, the vein is often additionally injured during the application of the hemostatic forceps and closure of the surrounding tissues with sutures. As a result, a wall defect in the femoral vein occurs which requires patch plasty [40].

VASCULAR SURGERY IN OSTEO-VASCULAR INJURIES

In patients with osteo-vascular injuries, bone integrity should be restored first, and then, surgery can be performed to repair damaged blood vessels and nerves. In osteo-vascular injuries, blood flow, especially collateral circulation, is significantly disturbed due to compression by bone fragments, hematoma, swollen tissues, and obstruction by thrombi [41, 42]. In fractures and dislocations, the femoral-popliteal segment is uniquely susceptible to injury. This fact should be considered when providing medical care to patients with knee joint fractures.

Surgical tactics are determined by the severity of ischemic disorders. If it is necessary to transport the patient, temporary prosthetic repair of the blood vessels is performed [43]. The choice of method for vascular reconstruction depends on the degree of damage which can be seen during the revision of the damaged area. Prior to reconstructive surgery, all the thrombi are removed from the peripheral vascular bed using a Fogarty catheter. The rupture and crush of the blood vessels serve as indications for autovein or patch plasty. Considering the importance of adequate venous blood flow, the damaged veins should also be repaired. In irreversible limb ischemia, primary amputation is performed [44, 45].

SURGICAL TREATMENT OF NERVE INJURIES

In some cases of osteo-vascular injuries, nerve damage is observed. In open injuries when nerve damage is obvious, surgery is the only method to restore lost function of the limb. Primary nerve suture results in better results than secondary one if the following principle of surgical treatment is followed: nerve repair must be tension free. If primary nerve repair cannot be performed without any tension, neuroplasty is considered. Nerve suture and neuroplasty should be applied to the limb placed in the physiological position [46, 47].

The following three types of nerve suture are mainly used:

- epineural suture;
- bundle suture;
- funicular suture.

SURGICAL TACTICS FOR TRAUMATIC ANEURYSM

Great vessel injuries can result in traumatic aneurysms. Long and narrow wound channel and parietal vascular injury occurring during trauma contribute to the development of aneurysms as well. The incidence rate of traumatic aneurysm is 6-18%. The diverse nature of great vessel injuries determines multiple variations of arterial and arteriovenous aneurysms. It takes a certain period of time (during which a fibrous capsule is formed around the pulsatile hematoma) for traumatic aneurysm to develop. The period of traumatic aneurysm formation can vary from person to person. Some patients develop aneurysms within 4-8 weeks after injury, while in other patients, it is observed within the first 4 weeks after injury. Thus, it may be difficult to differentiate pulsatile hematoma from traumatic aneurysm [48].

The most common traumatic aneurysms are found in the femoral artery; the popliteal, brachial and common carotid arteries are not a common site for traumatic aneurysms.

In most cases, it is not difficult to diagnose traumatic aneurysms. The most characteristic clinical sign is the presence of a pulsatile bulge over which a systolic murmur is heard. In combined arterial and venous injuries, arteriovenous fistula may develop [49].

TRAUMATIC ARTERIOVENOUS FISTULA

Arteriovenous fistula is an abnormal direct connection between an artery and a vein which occurs in cases of the impairment of vessel wall integrity due to trauma, namely ballistic trauma, knife injury, blunt trauma, etc. [50]. Arteriovenous fistulae usually occur in the areas where the artery is found close to the vein, namely in the neck, the thigh, or the axilla. In arteriovenous fistulae, blood flows directly from an artery into a vein due to the pressure difference between the arteries and veins. The volume of blood flowing through the fistula depends on its diameter. In large-diameter fistula, blood circulates within the venous system. Due to this, central hemodynamics undergoes some changes, namely circulating blood volume increases, cardiac output increases, total peripheral resistance reduces, size of the heart increases, and heart failure develops. The compensation of disorders occurs due to an increase in heart rate, cardiac cavity dilatation, and reduction in peripheral resistance. In addition to the aforementioned changes, there are some other changes associated with increased venous pressure in the area of the fistula which result in vein dilatation, venous valve lesions, and trophic changes. Subjective sensations the patients with traumatic arteriovenous fistulae experience are very diverse. They can include both the phenomena associated with impaired arterial circulation (pain, weakness, limb numbness, etc.) and those associated with impaired venous outflow (limb edema, superficial venous dilatation, trophic changes, etc.). General symptoms associated with impaired cardiac activity (fatigue, shortness of breath, palpitation, pain in the heart area, etc.) are often observed. The diagnosis is made based on the anamnestic data, the patient's complaints, and the results of physical

examination and instrumental methods (Doppler sonography, angiography and CT angiography) which allow accurate determination of the localization of the fistula, its size and shape, the nature and extent of damage to the blood vessels, as well as peculiarities of the collateral circulation. Surgical approach is the leading therapeutic option when treating arteriovenous fistulae. The timing of surgery depends on the degree of regional circulation impairment and hemodynamic impairment. The fistulae resulted in heart failure must be treated surgically as soon as possible. During surgery, after the exposure of the blood vessels and aneurysm sac, the volume of surgery is determined depending on the degree of changes in the wall of the blood vessels that form arteriovenous fistula. If there is only a single channel connecting the artery and the vein, the simplest intervention is used. In this case, arteriovenous fistula may be ligated. The case is considered more serious if there is a direct contact between the wall of an artery and the vein, especially in case of long-standing fistulae which are characterized by the development of significant aneurysmal dilatations. In simpler cases, after the mobilization of the artery and the vein, lateral vascular sutures are used. To prevent recurrence, the muscles or fascia are often placed between the artery and the vein. In cases of extended fistulae and the presence of aneurysm, different modified methods of patch reconstruction and reconstruction by means of prosthetic interposition grafts are used [51].

SURGICAL TACTICS FOR IATROGENIC VASCULAR INJURIES

Arterial injury resulting in hematoma or pseudoaneurysm complicates approximately 1-1.8% of diagnostic studies of the aorta and the great vessels. The major veins can be injured during their catheterization as well. After superior and inferior vena cava cannulation, bleeding from the subclavian vein into the pleural cavity, hemomediastinum, subclavian and iliac vein thrombosis, and large paravasal hematoma in the absence of arterial injury may be observed.

In some cases, venous bleeding as a complication of surgery creates much more difficulties for achieving hemostasis than arterial bleeding. If there is bleeding from the injured vessel, the hemostatic forceps should not be applied without visual control. It is necessary to press down on the vessel with a finger and apply a limb bandage. Quality compression may serve as an effective method to stop bleeding in post-puncture iatrogenic femoral, iliac, and jugular vascular injuries. The attempt to stop bleeding through the closure of vessel bleeding area with sutures, which involves a large amount of surrounding tissue, is considered dangerous as it may result in the involvement of other important structures. Surgeons often try to visualize the blood vessels by widening the wound channel. In this case, bleeding complicates the manipulations within the wound. The hemostatic forceps are applied to the site of suspected injury without visual control that results in additional damage to the blood vessels and nerve trunks. Surgical revision of the major artery and vein should always be carried out in the projection of the neurovascular bundle. After bleeding has stopped, the access to the injured vessel should be carefully widened, and the central and peripheral ends of the artery or the vein should be mobilized. In arterial and venous injuries, reconstructive surgery is typically required. Minor vascular injuries can be repaired by transverse closure or plasty, while major vascular injuries are repaired using shunt or reconstructive surgery by means of auto- or heterogenous material [52, 53].

Postoperative Period of the Patients with Vascular Trauma

The peculiarities of the postoperative period of the patients with vascular trauma are determined by the severity of the general condition, the extent of blood loss, the nature of vascular damage and ischemia degree, the type of surgery, time that elapsed since the injury, and other factors. In addition to general principles of treating tissue injuries, there are some peculiarities of managing the patients after vascular reconstructive surgeries. After surgery, the patients are transferred to the intensive care unit to provide intensive care, control vital body functions, and continue anti-shock therapy [54].

The prevention of wound infection from the very beginning of treatment is of extreme importance. Therefore, the process of surgical wound debridement is strictly regulated. If the area of tissue injury is large, surgical debridement should be carried out as follows. First, contaminated and crushed tissues are excised, and, then, after vascular repair, devitalized tissue is repeatedly removed. Antibiotic therapy with broad-spectrum antibiotics and their combinations should start intraoperatively and be continued for 5-7 days after surgery [34].

The prevention of repaired vessel thrombosis in the patients with vascular injuries in the postoperative period is of great importance as well. For this purpose, indirect coagulants are used. In the postoperative period, anticoagulant therapy should be continued until complete mobilization. In arterial reconstruction, from the very beginning of treatment, antiplatelet agents should be used in addition to anticoagulant therapy [11].

TREATMENT OF POSTISCHEMIC SYNDROME

One of the most serious complications of acute limb ischemia is the body's response to the revascularization of the ischemic limb. The development of homeostatic disorders in response to ischemic limb revascularization is associated with toxic substances developing in tissues in case of circulatory hypoxia that are released from an ischemic organ and enter the bloodstream. In the postoperative period, in order to eliminate intoxication and hemodynamic disorders after blood flow reconstruction, intensive care should be provided for patients with acute limb ischemia. The prevention of limb edema is of great importance. If there are any signs of compartment syndrome, fasciotomy is required (Figure 4) [12, 55].

Figure 4. Fasciotomy in patient with compartment syndrome.

GUNSHOT INJURIES AND EXTREMITY VASCULAR INJURIES

During World War II, bleeding was the leading cause of death on the battlefield (35%), apart from death due to shock and blood loss. At the stage of medical evacuation, extremity vascular injuries accounted for 96% of all vascular traumas. Isolated artery injury was detected in 47.1% of the cases, combined artery and vein injuries were observed in 49.2% of the cases, and isolated vein injury was seen in 3.7% of the cases. The incidence of injuries to the large arteries was as follows: head and neck injuries were diagnosed in 1.21% of the cases; chest injuries were found in 0.54% of the cases; abdominal and pelvic injuries were seen in 1.13% of the cases; upper extremity injuries were detected in 38.5% of the cases; lower extremity injuries were diagnosed in 56.47% of the cases [56].

If acute blood loss is not massive, the body starts to compensate for blood loss. The main compensatory mechanisms are:

- contraction of the small arteries and veins and mobilization of blood from blood pools, which, in combination with tachycardia and accelerated blood flow, helps replenish the blood supply;
- release of the fluid from tissues to the bloodstream;
- reduction in circulatory hypoxia due to the increase in pulmonary ventilation and oxygen uptake by hemoglobin in the lungs in case of rapid breathing.

However, acute blood loss is a factor which significantly contributes to a complicated clinical course of injury due to severe microcirculatory disorders, tissue hypoxia, and decreased immunobiological mechanisms of body's defense. In addition, posthemorrhagic anemia contributes to the development of complications such as pyogenic and anaerobic infections.

Classification of Wartime Extremity Vascular Injuries (Todd E. Rasmussen/Charles J. Fox) BO 160-1

Triage Categories and Management Guidelines for Wartime Extremity Vascular Injuries

Category I: isolated vascular injury

- One surgical team required;
- Vascular injury, restoration of flow, reconstruction, and limb salvage take priority;
- Extremity tourniquet may be removed in the operating room in coordination with the anesthesia team;
- Venous injury should be repaired;
- Complex or lengthy reconstructions acceptable.

Category II: vascular injury in conjunction with other non–life-threatening injuries

- Two-team approach preferable to treat vascular and other injury;

- Vascular injury, restoration of flow, reconstruction, and limb salvage take priority;
- Extremity tourniquet may be removed in the operating room in coordination with the anesthesia team;
- Venous injury should be repaired;
- Complex or lengthy reconstructions acceptable.

Category III: multiple vascular injuries

- Two-team approach preferable to treat multiple vascular injuries;
- Vascular injury, restoration of flow, reconstruction, and limb salvage take priority;
- Extremity tourniquet may be removed in the operating room in coordination with the anesthesia team;
- Diminished role for venous injury repair;
- Diminished role for complex or lengthy reconstructions.

Category IV: vascular injury in conjunction with life-threatening injuries

- Two-team approach optional after life-threatening injury is stabilized;
- Life-threatening torso, neck, or head injury takes priority;
- Extremity tourniquets should remain in place until the life-threatening injury is stabilized;
- Diminished role for venous injury repair;
- Diminished role for complex or lengthy reconstructions.

Clinical Picture of Vascular Injuries

Bleeding is the main sign of vascular injury, being a pathognomonic sign of this injury type. The nature of bleeding allows making diagnosis and determining the extent of emergency care. Bleeding that occurs in gunshot injuries are classified according to time of its occurrence, the nature and caliber of the vessel, and the site of bleeding [45].

Types of bleeding include arterial bleeding, venous bleeding, arteriovenous (mixed) bleeding, capillary bleeding, and parenchymatous bleeding [36].

Depending on bleeding direction, there are external bleeding, interstitial bleeding, and intracavitary bleeding.

Depending on bleeding time, there are primary bleeding, secondary bleeding, initial bleeding, delayed bleeding, and recurrent bleeding or rebleeding.

Diagnostics of vascular injuries are based on the general signs of blood loss and local symptoms of vascular damage:

- history of heavy bleeding after injury;
- general signs of significant blood loss including thirst, heart palpitation, seeing black spots, or floaters, pale skin and mucous membranes, rapid, weak pulse rate, shortness of breath, and sometimes loss of consciousness;
- location of wound channel in the large vessel area;
- skin discoloration and cold limb;

- hematoma that extends along the large vessels;
- absent or weak peripheral pulse distal to the wound on the injured side;
- pulsation and pathologic vascular murmurs during auscultation of the large vessels;
- ischemic pain in the injured limb;
- ischemic contracture.

Principles of Providing Medical Care and Treatment of Patients with Great Vessel Injuries at the Stages of Medical Evacuation

Treatment of gunshot vascular injuries is a difficult task at all the stages of medical evacuation. Serious complications such as bleeding, embolism, ischemic gangrene, acute anemia, paralysis, etc. developing on the battlefield necessitate the proper organization of emergency care.

Treatment of vascular injuries includes the following steps [32, 34]:

- temporary (preliminary) stopage of bleeding followed by immediate transport of the patient to the surgical department;
- surgery for vascular injury (permanent hemostasis);
- treatment of acute blood loss and prevention of its consequences;
- prevention of ischemic limb gangrene, wound infection and other postoperative complications;
- functional treatment of concomitant soft tissue, bone and nerve injuries.

The main methods of achieving permanent hemostasis in great vessel injury are:

- restoration of vessel integrity (vascular suture, prosthetic repair);
- ligation of the blood vessel in the wound;
- ligation of the blood vessel along its length.

Specifics of gunshot injuries:

1. Each gunshot injury is primary infected.
2. The artery can be closed with sutures in recent injuries by following aseptic techniques; the possibility of postoperative period should be considered.
3. In traumatic aneurysms, surgery should be performed 1.5-2 months after injury.

The need for blood flow restoration is determined by the degree of tissue ischemia:

- compensated ischemia – active movements and sensation distal to injury site are preserved; no vascular surgery is needed;
- uncompensated ischemia – no active movements; dramatically reduced tactile and pain sensations in the limb; blood flow is needed to be restored within the first hours after injury;
- irreversible ischemia – local or total muscle contracture; vascular surgery is not indicated.

SECONDARY BLEEDING

In vascular injuries, in addition to primary bleeding which was stopped by a health care professional or stopped its own, delayed bleeding may occur. Such bleeding is always dangerous as, firstly, it always occurs unexpectedly and is usually massive, and, secondly, it occurs in an anemic, weakened patient [54].

Early secondary bleeding may occur due to pulling the blood clot out from the injured vessel after the patient recovered from traumatic shock and normal blood pressure was restored. Imperfect immobilization and inappropriate transportation play a significant role in the development of secondary bleeding as they contribute to traumatization, displacement of bone fragments and foreign bodies, and obstruction of the injured vessel. Such bleeding occurs within the 1st-5th days after injury [37].

Late secondary bleeding occurs due to infection of the wound, which may result in thrombus melting or necrosis (arrosion) of the vessel walls. In addition, secondary bleeding can be caused by the pressure sores of the injured vessel wall due to the pressure exerted by adjacent metal or bone fragments and other foreign bodies. Sometimes pressure sores may be caused by drainage tubes or tampons which were close to the blood vessel for a long period of time [38].

Secondary bleeding due to the rupture of pulsatile hematoma or traumatic aneurysm is considered a complication. The clinical picture of secondary bleeding includes its unexpectedness.

Warning signs of bleeding include:

- sudden increase in body temperature without any signs of wound infection;
- pulsation at the sites where only murmurs were heard;
- murmurs and pulse disorders;
- presence of blood spots or small blood clots in the wound.

To stop secondary bleeding, the ligation of the blood vessel in the wound is used; however, it is not always possible. In most cases, the blood vessels are ligated along their length. In some cases of secondary bleeding, it is necessary to amputate the limb, since it is the only way to save the patient's life.

The results of treatment can be improved by:

- rapid evacuation of the wounded from the battlefield;
- improved resuscitation methods (blood transfusion before hospitalization);
- reconstructive vascular surgeries.

CONCLUSION

Clinical manifestations of vascular trauma are diverse. The severity of the patient's condition depends on the nature of vascular trauma, the extent of blood loss, co-existent soft tissue, vein, nerve, and bone injuries, ischemia duration. Adequate assessment of the patient's

condition allows choosing an appropriate treatment tactics and improving treatment results. Reconstructive surgeries provide successful treatment of vascular injuries.

REFERENCES

[1] Martin, M. J. and Long, W. B. (2014). Vasc trauma history. In *Rutherford's Vascular Surgery*, 8th edition, edited by Cronenwett, J. L. and Johnston, K. W. 2422 -2437. Philadelphia, Elsevier, ISBN 978-1-4557-5304-8.

[2] Perkins, Z. B., De'Ath, H. D., Aylwin, C., (2012). Epidemiology and outcome of vascular trauma at a British Major Trauma Centre. *Eur J Vasc Endovasc Surg.*, 44(2):203-9. doi: 10.1016/j.ejvs.2012.05.013. Epub 2012 Jun 2.

[3] Rozycki, G. S., Tremblay, L. N., Feliciano, D. V., (2003). Blunt vascular trauma in the extremity: diagnosis, management, and outcome. *J Trauma.*, 55(5):814-24. DOI:10.1097/01.TA. 000008 7807.44105.AE\.

[4] Rich, N. M. (2011). Vascular trauma historical notes. Perspect *Vasc Surg Endovasc Ther*., 23(1):7-12. doi: 10.1177/1531003511403496.

[5] White, J. M., Stannard, A., Burkhardt, G. E., et al. (2011). The epidemiology of vascular injury in the wars in Iraq and Afghanistan. *Ann Surg.*, 253(6):1184-9. doi: 10.1097/SLA.0b013e31820752e3.

[6] Alarhayem, A. Q., Cohn, S. M, Cantu-Nunez, O., et al. (2006). Impact of time to repair on outcomes in patients with lower extremity arterial injuries. *J Vasc Surg*., 69(5):1519-1523. doi: 10.1016/j.jvs. 2018.07.075.

[7] Quan, R. W., Adams, E. D., Cox, M. W., et al. (2006). The management of trauma venous injury: civilian and wartime experiences. *Perspect Vasc Surg Endovasc Ther*., 18(2):149-56. doi:10.1177/1531003506293452.

[8] MacLeod, J. B., Cohn, S. M., Johnson, E.W, et al. (2007). Trauma deaths in the first hour: are they all unsalvageable injuries? *Am J Surg.*, 193(2):195-9. doi:10.1016/ j.amjsurg.2006.09.010.

[9] Kauvar, D. S. and Kraiss, L. W. (2014). Vasc trauma extrem. In *Rutherford's Vascular Surgery*, 8th edition, edited by Cronenwett, J. L. and Johnston, K. W. 2485 -2501. Philadelphia, Elsevier, ISBN 978-1-4557-5304-8.

[10] Bilgen, S., Türkmen, N., Eren, B. and Fedakar, R. (2009). Peripheral vascular injury-related deaths. *Ulus Travma Acil Cerrahi Derg.*, 15(4):357-61. PMID:19669965.

[11] Clouse, W. D., Rasmussen, T. E., Peck, M. A., et al. (2007). In theater management of vascular injury: 2 years of the Balad Vascular Registry. *J Am Coll Surg.*, 204(4):625-32.

[12] Kauvar, D. S., Sarfati, M. R, Kraiss, L. W., et al. (2011). National trauma databank analysis of mortality and limb loss in isolated lower extremity vascular trauma. *J Vasc Surg.*, 53(6):1598-603. doi: 10. 1016/j.jvs.2011.01.056.

[13] Kragh, J. F., Walters, T. J., Baer, D. G., et al. (2009). Survival with emergency tourniquet use to stop bleeding in major limb trauma. *Ann Surg.*, 249(1):1-7. doi: 10.1097/SLA.0b013e31818842ba.

[14] Ball, C. G. and Feliciano, D. V. (2010). Damage control techniques for common and external iliac artery injuries: have temporary intravascular shunts replaced the need for ligation? *J Trauma,* 68(5):1117-20. doi: 10.1097/TA.0b013e3181d865c0.

[15] Franz, R. W., Shah, K. J., Halaharvi, D., et al. (2011). A 5-year review of management of lower extremity arterial injuries at an urban level I traumacenter. *J Vasc Surg.*, 53(6):1604-10. doi: 10.1016/j.jvs. 2011.01.052.

[16] Seamon, M. J., Smoger, D., Torres, D. M., et al. (2009). A prospective validation of a current practice: the detection of extremity vascular injury with CTangiography. *J Trauma,* 67(2):238-43; discussion 243-4. doi: 10.1097/TA.0b013e3181a51bf9.

[17] Loh, S. A., Rockman, CB., Chung, C., Existing trauma and critical care scoring systems underestimate mortality among vascular trauma patients. *J Vasc Surg.*, 53(2):359-66. doi: 10.1016/j.jvs.2010.08.074.

[18] Lopera, J. E., Suri, R., Cura, M., et al. (2008). Crural artery traumatic injuries: treatment with embolization. *Cardiovasc Intervent Radiol.*, 31(3):550-7. doi: 10.1007/ s00270-008-9309-5.

[19] Starnes, B. W. and Arthurs, Z. M. (2014). Vasc trauma head. In *Rutherford's Vascular Surgery*, 8th edition, edited by Cronenwett, J. L. and Johnston, K. W. 2438-50. Philadelphia, Elsevier, ISBN 978-1-4557-5304-8.

[20] Mutze, S., Rademacher, G., Matthes, G., et al. (2005). Blunt cerebrovascular injury in patients with blunt multiple trauma: diagnostic accuracy of duplex Doppler US and early CT angiography. *Radiology*, 237(3):884-92. Epub 2005 Oct 26. doi: 10.1148/radiol.2373042189.

[21] Ellis, PK., Kennedy, PT. and Barros, D'Sa AA. (2001). Successful exclusion of a high internal carotid pseudoaneurysm using the Wallgraft endoprosthesis. *Cardiovasc Intervent Radiol.*, 25(1):68-9. doi:10.1007/s00270-001-0058-y.

[22] Biffl, W. L., Egglin, T., Benedetto, B., et al. (2006). Sixteen-slice computed tomographic angiography is a reliable noninvasive screening test for clinically significant blunt cerebrovascular injuries. *J Trauma,* 60(4):745-51; discussion 751-2. doi: 10.1097/01.ta.00 00204034.94034.c4.

[23] Kumar, V. (2004). Endovascular treatment of penetrating injury of axillary vein with Viabahn endoprosthesis. *J Vasc Surg.*, 40(6):1243-4. doi:10.1016/j.jvs.2004.09.022.

[24] Demetriades, D. and Inaba, K. (2014). Vasc trauma abdomen. In *Rutherford's Vascular Surgery*, 8th edition, edited by Cronenwett, J. L. and Johnston, K. W.2466-2484. Philadelphia, Elsevier, ISBN 978-1-4557-5304-8.

[25] Asensio, J. A., Chahwan, S., Hanpeter, D., et al. (2000). Operative management and outcome of 302 abdominal vascular injuries. *Am J Surg.*, 180(6):528-33; discussion 533-34. PMID: 11182412.

[26] Kirkpatrick, A. W., Roberts, D. J., De Waele, J. (2013). Intra-abdominal hypertension and the abdominal compartment syndrome: updated consensus definitions and clinical practice guidelines from the World Society of the Abdominal Compartment Syndrome. *Intensive Care Med.*, 39(7):1190-206. doi: 10.1007/s00134-013-2906-z. Epub 2013 May 15.

[27] Kao, C. C., Huang, T. H., Chen, C. W., et al. (2019). Blunt abdominal aortic injury may accompany bowel transection. *Interact Cardiovasc Thorac Surg.*, 1;28(4):657-658. doi: 10.1093/icvts/ivy 286.

[28] Tomic, I., Dragas, M., Vasin, D., et al. (2018). Seat-Belt Abdominal Aortic Injury-Treatment Modalities. *Ann Vasc Surg.*, 53:270.e13-270.e16. doi: 10.1016/j.avsg. 2018.05.047.

[29] Miura, F., Takada, T., Ochiai, T., et al. (2006). Aortic occlusion balloon catheter technique is useful for uncontrollable massive intraabdominal bleeding after hepato-pancreato-biliary surgery. *J Gastrointest Surg*., 10(4):519-22. doi: 10.1016/j.gassur. 2005.09.019.

[30] White, J. M. Cannon, J. W., Stannard, A., et al. (2001). Endovascular balloon occlusion of the aorta is superior to resuscitative thoracotomy with aortic clamping in a porcine model of hemorrhagic shock. *Surgery*, 150(3):400-9. doi: 10.1016/j.surg.2011.06.010.

[31] Mayer, D., Pfammatter, T., Rancic, Z., et al. (2009). 10 years of emergency endovascular aneurysm repair for ruptured abdominal aortoiliac aneurysms: lessons learned. *Ann Surg.* 249(3):510-5. doi: 10.1097/SLA.0b013e31819a8b65.

[32] Quan, R. W., Gillespie, D. L., Stuart, R.P., et al. (2008). The effect of vein repair on the risk of venous thromboembolic events:a review of more than 100 traumatic military venous injuries. *J Vasc Surg.*, 47(3):571-7. doi: 10.1016/j.jvs.2007.10.056.

[33] Subramanian, A., Vercruysse, G., Dente, C., et al. (2008). A decade's experience with temporary intravascular shunts at a civilian level I trauma center. *J Trauma*, 65(2):316-24; discussion 324-26. doi: 10.1097/TA.0b013e31817e5132.

[34] Vertrees, A., Fox, C. J., Quan, R. W., et al. (2009). The use of prosthetic grafts in complex military vascular trauma:a limb salvage strategy for patients with severely limited autologous conduit. *J Trauma*, 66(4):980-3. doi: 10.1097/TA.0b013e 31819c59ac.

[35] Morrison, J. J. and Rasmussen, T. E., (2012). Noncompressible torso hemorrhage: a review with contemporary definitions and management strategies. *Surg Clin North Am.*, 92(4):843-58. doi: 10.1016/j.suc.2012.05.002.

[36] Stannard, A., Brown, K., Benson, C., (2011). Outcome after vascular trauma in a deployed military trauma system. *Br J Surg.*, 98(2):228-34. doi: 10.1002/bjs.7359.

[37] Kragh, J. F., Walters, T. J., Baer, D. G., et al. (2008). Practical use of emergency tourniquets to stop bleeding in major limb trauma. *J Trauma*, 64 (2 Suppl):38-49; discussion S49-50. doi: 10.1097/ TA. 0b013e31816086b1.

[38] Martin, M., Izenberg, S., Cole, F., et al., (2012). A decade of experience with a selective policy for direct to operating room trauma resuscitations. *Am J Surg.*, 204(2):187-92. doi: 10.1016/j.amjsurg. 2012.06.001.

[39] Giannakopoulos, T. G. and Avgerinos, E. D. (2017). Management of Peripheral and Truncal Venous Injuries. *Front Surg*., 24;4:46. eCollection. doi: 10.3389/fsurg.2017. 00046.

[40] Nguyen, T., Kalish, J. and Woodson, J. (2010). Management of civilian and military vascular trauma: lessons learned. *Semin Vasc Surg*. 2010 Dec;23(4):235-42. doi: 10.1053/j.semvascsurg.2010.11. 004.

[41] Moniz, M. P., Ombrellaro, M. P., Stevens, S. L., et al. (1997). Concomitant orthopedic and vascular injuries as predictors for limb loss in blunt lower extremity trauma. *Am Surg.*, 63(1):24-8. PMID: 8985067.

[42] Konstantiniuk, P., Fritz, G., Ott, T., et al. (2011). Long-term follow up of vascular reconstructions after supracondylar humerus fracture with vascular lesion in childhood. *Eur J Vasc Endovasc Surg.*, 42(5):684-8. doi: 10.1016/j.ejvs.2011.06.028.

[43] Rasmussen, T. E., Clouse, W. D., Jenkins, D. H., et al. (2006). The use of temporary vascular shunts as a damage control adjunct in the management of wartime vascular injury. *J Trauma,* 61(1):8-12; discussion 12-5. doi: 10.1097/01.ta.0000220668.84405. 17.

[44] Dua, A., Patel, B., Kragh, J. F., et al. (2012). Long-term follow-up and amputation-free survival in 497 casualties with combat-related vascular injuries and damage-control resuscitation. *J Trauma Acute Care Surg.,* 73(6):1517-24. doi: 10.1097/TA.0b013e 31827826b7.

[45] Gwinn, D. E., Tintle, S. M., Kumar, A. R., et al. (2011). Blast-induced lower extremity fractures with arterial injury: prevalence and risk factors for amputation after initial limb-preserving treatment. *J Orthop Trauma,* 25(9):543-48. doi: 10.1097/BOT.0b013e 3181fc6 062.

[46] Topuz, A. K., Eroğlu, A., Atabey, C. and Cetinkal, A. (2013). Surgical treatment outcomes ın peripheral nerve lesions due to gunshot injuries: assessment of 28 cases. *Ulus Travma Acil Cerrahi Derg*., 19(3):235-40. doi: 10.5505/tjtes.2013.02073.

[47] Zarkadas, P. C., Throckmorton, T. W. and Steinmann, S. P. (2008). Neurovascular injuries in shoulder trauma. *Orthop Clin North Am.,* 39(4):483-90. doi: 10.1016/j.ocl. 2008.06.005.

[48] Mansour, M. A. and Gorsuch, J. M. (2007). Diagnosis and management of pseudoaneurysms. *Perspect Vasc Surg Endovasc Ther*., 19(1):58-64. doi: 10.1177/ 1531003506298074.

[49] Corriere, M. A. and Guzman, R. J. (2005).True and false aneurysms of the femoral artery. *Semin Vasc Surg*., 18(4):216-23. doi: 10.1053/ j.semvascsurg.2005.09.008.

[50] Stolt, M., Braun-Dullaeus, R., Herold, J., at al. (2018). Do not underestimate the femoral pseudoaneurysm. *Vasa*, 47(3):177-185. doi: 10.1024/0301-1526/a000691.

[51] Kaźmierski, P., Wąsiewicz, M., Chrząstek, J., et al. (2018). Endovascular treatment of iatrogenic arteriovenous fistula of the iliac vessel. *Adv Clin Exp Med*., 27(10):1371-1375. doi: 10.17219/acem/ 69859.

[52] Hans, S. S., Vang, S. and Sachwani-Daswani, G. (2018). Iatrogenic Major Venous Injury Is Associated with Increased Morbidity of Aortic Reconstruction. *Ann Vasc Surg*., 47:200-204. doi: 10.1016/j. avsg.2017.08.004.

[53] Reuben, B. C., Whitten, M. G., Sarfati, M., et al. (2007). Increasing use of endovascular therapy in acute arterial injuries: analysis of the National Trauma Data Bank. *J Vasc Surg.*, 46(6):1222-26. doi:10. 1016/j.jvs.2007.08.023

[54] Greer, L. T., Patel, B., Via, K. C., et al. (2012). Management of secondary hemorrheage from early graft failure in military extremity wounds. *J Trauma Acute Care Surg*., 73(4):818-24. doi: 10.1097/TA. 0b013e3182587f32.

[55] Farber, A., Tan, T. W., Hamburg, N. M., et al. (2012). Early fasciotomy in patients with extremity vascular injury is associated with decreasd risk of adverse limb outcomes: a review of the National Trauma Data Bank. *Injury,* 43(9):1486-91. doi: 10.1016/j. injury.2011.06.006.

[56] Eastridge, B. J., Mabry, R. L., Seguin, P., (2012). Death on the battlefield (2001-2011): implications for the future of combat casualty care. *J Trauma Acute Care Surg.,* 73(6 Suppl 5):431-37. doi: 10.1097/TA.0b013e3182755dcc.

In: Encyclopedia of Surgery (22 Volume Set)
Editors: Andreas Lehrer and Kristin Mueller
ISBN: 978-1-53618-329-0
© 2020 Nova Science Publishers, Inc.

Chapter 291

VASCULAR ACCESS FOR HEMODIALYSIS, VENOUS INSUFFICIENCY, AND ITS TREATMENT

Norbert Torma*, MD, PhD
Angiosurgical Department of Medical Faculty of Safarik University,
Košice, Slovakia

ABSTRACT

Chronic kidney disease is characterized by a gradual loss of kidney function. The most common causes of kidney malfunction are diabetes mellitus, high blood pressure, and glomerulonephritis. Chronic renal disease may not be apparent until a kidney function is significantly decreased. Treatment is focused on the treatment of underlying causes to slow the progression of kidney dysfunction. Once kidney functions are significantly impaired and progress to end-stage kidney failure, the patient may need dialysis. There are different types of dialysis, between them hemodialysis with three primary methods to gain access to the blood for hemodialysis. This chapter deals with the creation, maturation of native access, and graft possibilities.

Chronic venous insufficiency is a medical condition in which blood pools in the veins, straining the walls of the vein. Venous insufficiency syndromes are most frequently caused by valvular incompetence in the superficial venous system- the most widely great saphenous vein, but may also be caused by valvular incompetence in the high-pressure deep venous system or may result from the congenital absence of venous valves. Chronic venous insufficiency represents a spectrum of conditions ranging from simple telangiectases or reticular veins to more advanced stages. The most devastating is such as skin fibrosis, bleeding, and venous ulceration. The initial management of insufficiency involves conservative measures to reduce symptoms and prevent the development of secondary complications and the progression of the disease. They include compressive leg garments and pharmacologic therapy. Traditional surgical techniques and newer interventional methods are reserved for an unsatisfactory response to conservative measures and patients with progression of a disease.

* Corresponding Author's Email: norko@post.sk.

Keywords: AV access, AV fistula, AV graft, central venous catheter, chronic venous insufficiency, stripping, radiofrequency of varicose veins, endovenous laser therapy, mechanicochemical vein ablation, adhesive vein ablation

ABBREVIATIONS

AV	arteriovenous
AVF	arteriovenous fistula
AVG	arteriovenous graft
CO	cardiac output
CPR	cardiopulmonary recirculation
CVI	chronic venous insufficiency
DM	diabetes mellitus
DVT	deep vein trombosis
E-S	end to side
GSV	great saphenous vein
KDOQI	Kidney Disease Outcomes Quality Initiative
LA	local anesthesia
LMWH	low molecular weight heparin
NKF-KDOQI	national kidney foundation-Kidney Disease Outcomes Quality
PAO, PAD	peripheral arterial disease
PTA	percutaneous transluminal angioplasty
PTFE	polytetrafluoroetylen
SSV	short saphenous vein
US	ultrasound

INTRODUCTION

Three primary methods are used to obtain access to the blood for hemodialysis: an arteriovenous fistula and a synthetic graft either arteriovenous graft or venous catheter. The type of access is influenced by some factors such as the course of a patient's renal failure and the condition of the vasculature of the upper extremity. Patients can have multiple access procedures, usually because an AV fistula or graft is maturing, and a catheter is still being used.

Chronic Venous Insufficiency typically begins with mild symptoms but left untreated it can progress permanent skin changes with darkened discoloration and more serious medical condition involving bleeding, complicated wounds, and skin infections. Early intervention and prevention of complications as wounds, bleeding, or infections are the goals of treatment. The treatment plan is aimed at decreasing the blood pressure in the veins to reduce swelling and symptoms and increasing the return blood flow back to the heart. The goal of surgical and endovenous procedures in the treatment of chronic venous disease is to remove or obliterate incompetent veins or to isolate the reflux source from the rest of the vascular system.

VASCULAR ACCESS FOR HEMODIALYSIS

Arteriovenous Fistula

Two types of arteriovenous fistula are available- native arteriovenous fistula (AVF) and arteriovenous fistula with a graft (AVG). AVF is the first option for hemodialysis with best primary patency rate and the lowest complication frequency and with lowest mortality and morbidity [1]. AVF is preferred over AVG and central venous catheters. Only in patients with nonoptimal vessel status is AVG preferred over AVF.

The main principles for creating AVF are:

- Handedness- first AVF on a nondominant limb (left in a right-handed person)
- Starting with most distal localization
- The end-to-side technique of anastomosis
- Direct AVF are preferable over transposition

In a forearm, AVF should be localized on the volar surface, an upper arm on the lateral or anterior surface.

AVF must be able to be repeatedly cannulated, part of a vein minimally 10cm long for repetitive cannulations, localized just belove a skin, with sufficient blood flow for sufficient hemodialysis.

Creation of AVF minimally six weeks before the first cannulation- time for maturation. AVG ideally two weeks prior cannulation.

AVF maturation is vascular remodeling as a result of increased blood flow in a feeding artery and draining vein [2]. After the creation of AVF blood flow must increase to a level that provides adequate delivery for dialysis machine and vessel must dilatate for safe and effective cannulation. Increased blood flow, decreased peripheral resistance, shear, and hoop stress are important factors for dilatation of a vein and thickening of their wall. The thicker wall is important factors allowing repeated cannulation of a vein. AVF is ready for hemodialysis if fulfills rule 6 which say that six weeks after creation, the vein has diameter 6mm, blood flow through AVF is over 600ml/min and vein is no more than 0,6cm belove a skin.

Before the creation of AVF is important vascular mapping to prevent problems with AVF maturation. After vascular mapping, with suitable conditions, we can create one of the following AVF: simple direct, transposition, translocation, or percutaneously [3, 4, 5, 6, 7].

Simple direct AVF is made of artery and vein in their normal positions. The vein is transected and than end-to-side (E-S) anastomosed with adjacent feeding artery.

Radio-Cephalic AVF in Fossa Tabatiere (Foveola Radial)

Fossa tabatiere – space between tendon musculus extensor pollicis brevis and musculus abductor pollicis longus on the medial side and laterally tendon of musculus extensor pollicis longus. In this space is localized, up to the fascia vena cephalica and under the fascia branch of arteria radialis. Vena cephalica is anastomosed with a dorsal branch of arteria radialis to create AVF. In local anesthesia (LA), after preparation of artery and vein is performed 5mm long anastomosis E-S [8].

Distal Radio-Cephalic AVF (on the Wrist)

Anastomosis between a.radialis and v.cephalica. The incision in LA is oblique with distant end over a vein. This is typical Cimino- Brescia AVF, but originally with side-to-side anastomosis.

Distal Basilico-Ulnar AVF (on the Wrist)

Distal basilicoulnar shunt between a.ulnaris, and v.basilica. A diameter of artery and vein should be sufficient for the creation of AVF and Allen test must be negative. Under suitable vascular conditions can be created as a second shunt after failed radiocephalic shunt.

Proximal Radio-Cephalic AVF (Forearm)

Similar shunt like distal radiocephalic AVF between a. radialis, and v. cephalica. The incision is again oblique, but anastomosis is localized deeper.

Arteriovenous AV Shunt in Fossa Cubitalis

After exhaustion of all forearm, approaches can be AVF created in the cubital region. This area is sometimes the first option in patients with DM or with obesity, in patients with a hypoplastic vascular bed in the forearm and in patients with postthrombotic changes of a vein in the forearm. AVF in the forearm, mainly in patients with DM and mediocalcinosis, have a higher rate of failure. AVF localized in the cubital region, have in comparison with forearm localization higher rate of steal syndrome. In the cubital region can be as a venous conduit used v. cephalica, v. basilica, v. mediana cubiti or v. perforans (Gracz operation). In this, the last type of AVF, there is the lowest rate of steal syndrome, and through v. mediana cubiti are dilatated both of veins- v. cephalica and v. basilica. Feeding artery in this cubital region is a. brachialis.

Brachiobasilic AVF with Transposition of a Vein

This type of AVF is one of the latest access possibilities in the upper extremity. The reason for transposition is a fact, that basilic vein lays in the subfascial area and for successful puncture and sufficient cannulation should be transposed. Preparation of a vein can be done through one long incision or more shorter ones. After hydrodilatation of a vein anastomosis E-S, long 5mm is sufficient. The procedure can be performed as a one stage operation or two steps of operation (first anastomosis, second transposition). In obese patients is sometimes a better option transposition of a vein over simple anastomosis. Different types of vein transposition shunts are possible, like a simple direct AVF. The proximal part of a vein is left intact, and in the distal portion, tributaries are dissected, and the vein is transposed into a tunnel or pocket that serves as a bed for vein. This procedure can also be performed at a lower extremity and can be performed as a two-stage operation [9, 10].

AV translocation fistula is a technique where a vein is removed from its normal position. The procedure is similar to AV graft techniques. The translocated vein is anastomosed with the feeding artery and outflow vein. This requires venovenous and venoarterial anastomosis. The most frequently used veins for translocation are great and short saphenous veins and femoral vein. The femoral vein is used very rarely because of potentially perioperative severe complications.

AVF in Lower Extremity

In cases when from different reason, it is impossible to perform AVshunt in the upper extremity, it is possible to perform it on the lower extremity. The rate of complication is higher, and cannulation is also more problematic and less comfortable for the patient and personal. The great saphenous vein can be anastomosed with a. tibialis posterior, behind the inner ankle, or with a. popliteal. Another possibility is to perform the loop technique with great saphenous vein and with anastomosis to a. femoralis communis.

AV Graft Techniques

AV graft (AVG) is the second option in patients where it is impossible to perform native AVF. The benefit of this type of access is a shorter time of maturation (healing) in comparison to a native AVF, better cannulation, and longer area of cannulation.

Failure of the Mature Hemodialysis AVF

Primary AVF is defined as an AVF that never been used for hemodialysis or failure of AVF within period three months of use. The risk factor of primary failure is obesity, older age, female gender, cardiovascular disease, thrombophilia, diabetes, and surgeon skills. The incidence of primary failure increases because of the older age of the patient, more frequent comorbidities- as diabetes, PAO, heart disease, and range till 60%. Also, type and its localization influence maturation and patency of AVF [11, 12].

Before creating of AVF is important vascular mapping. Patients with insuitable vessels are not a good candidate for AVF. In these patients, with sufficient and appropriate feeding artery may be the best option AVG [11]. AVG will be a place for hemodialysis and stepwisely higher circulation will dilate veins for secondary access. When planning the first option is nondominant hand. Planning of AV fistula creation is ideally four months before the first cannulation and minimally six weeks before first use. After the creation of AVF, there is an increase in blood flow in the feeding artery, outflow veins, decreasing venous resistance, and starts vascular remodeling called maturation. Due to increased blood flow, increase shear and hoop stress, production and secretion of mediators by endothelium. All these changes lead to dilatation of a vein and thickening of its wall, thanks to the hemodynamic principle, that a perturbed system attempts to return to its baseline stress state. The clinical definition of maturity requires that AVF is used, can be repetitively cannulated and provides adequate blood flow for hemodialysis. The rule of 6 sets by Kidney Disease Outcomes Quality Initiative (KDOQI) guidelines describes parameters associated with the maturity of AVF. The AVF will be usable for hemodialysis if six weeks after creation is the external diameter of vein 6mm, blood flow 600ml/min, and AVF is no more deep as 0,6 cm from the skin. The diameter of maturated AVF is important not only for repetitive cannulation but also for providing adequate blood flow. Thickening of a wall decrease hoop stress and decrease the risk of extravasation after cannulation [13, 14].

Process of AVF development goes through three stages:

1) Creation of AVF
2) Physiologically mature AVF- AVF that has the potential to be a vascular access
3) Clinically functional AVF

The most common lesion associated with non-maturation of AVF is juxta-anastomotic stenosis. This stenosis occurs within 4cm from anastomosis, that decreases blood flow, interrupts maturation and can be a cause of early thrombosis of AVF. If blood flow after the creation of AVF is insufficient for maturation, or during maturation significantly decrease, it should be treated by the endovascular intervention (PTA) or by surgical reconstruction. Surgical reconstruction includes the creation of new anastomosis or correction of primary anastomosis, implantation of vein interpositum, vein patching or graft interposition early before thrombus formation.

Arterials stenoses are much less common cause of nomaturation AVF and AVF failure as venous stenosis. Feeding artery is responsible only for 5% stenosis lesion responsible for nomaturation of AVF. A peripheral draining vein in 10% and almost 80% is a stenotic problem directly in AVF (juxta-anastomotic, body of AVF).

Monitoring and Surveillance of AV Access

Not all stenotic lesion needs to be treated. A stenotic lesion is significant if narrowing of a vascular lumen is equal or more as 50% together with clinical symptoms, abnormal finding, and abnormal blood flow. NKF-KDOQI 2004 and Society for Vascular Surgery 2008 guidelines recommend a routine physical examination of AV access every week [14, 15].

Clinical monitoring includes an examination of the AV access, monitoring of problems with hemodialysis, and decrease of Kt/V [16]. Abnormalities during the physical examination as a swelling, pulse, thrill, bruit alterations, problems with hemodialysis or decreased Kt/V may signal problems with AV access. Kt/V is a method for measuring a hemodialysis dose. Kt/V is defined as the dialyzer clearance of urea (**K**) multiplied by the duration of the dialysis treatment **(t**, minutes) divided by the volume of distribution of urea in the body (**V**, ml). An unexplained decrease of Kt/V (> 0.2) during normally prescribe hemodialysis signalize some problem with AV access. Problems with and during hemodialysis such as prolonged bleeding from puncture sites, problems with cannulation, insufficient blood flow in consideration of target blood flow may also signal a problem with AV access. Surveillance includes blood flow intra – access monitoring, ultrasound (US) examination, and measurement of static hemodialysis venous pressure.

For measurement of intra access flow exists several methods. Ultrasound dilution is the most commonly used. Special flow/dilution probes can measure flow by injection of saline solution through the venous line when dialysis lines are reversed. Dilution information as a result of mixing of blood with the saline is collected by the sensor at the arterial line. The flow procedure should be repeated at least three times, and any fluctuation in the flow rate is an indicator of a potential access problem.

Online measurement of dialysate is measured by placing the conductivity probes on the dialyzer inlet and outlet lines from the access and provides a measure of ion flux during dialysis. By changing the dialysate/water proportion, a significant electrolyte gradient is established between the blood and the dialysate, which results in a conductivity change from

the inlet to the outlet port. This is a function of sodium dialysance and reflects the movement of electrolytes into the patient. Access blood flow (Q_A) from dialysate can be calculated with bloodlines in either their normal position (D) or reverse position (D_{rev}).

In variable flow, Doppler measurement is the flow rate calculated from the change in Doppler signal in the access using variable pump rates. This method uses two needles introduced into the access for collecting the blood from the arterial side (QA), to feed into the dialysis pump circuit (QB), and back to the venous stream from the other needle. The dialysis blood pump circuits form a parallel circuit with access. The Doppler signal is measured in the access between the two needles (QR) as a function of the pump rate, which is calculated as QR = QA – QB. Using various values of pump speed, a function S = F (QB) is modeled and the intercept at which $_QR = 0$ is calculated.

Glucose pump test uses a constant glucose bolus into the arterial line and withdrawal of blood from the venous line before and after the infusion. By knowing the concentration of the infused glucose concentration (C_i), and measurement of glucose levels before (C_{a1}) and during infusion (C_{a2}) by using bedside glucometer, the access blood flow (Q_a) can be calculated.

Transcutaneous access flow monitor uses an optical sensor that is placed on the skin immediately above the access. An indicator fluid is injected into the venous line that mixes with blood, and effectively reduces changing the hematocrit concentration, recorded over time by the hematocrit sensor. The difference in hematocrit concentration is used to calculate the intra-access blood flow. The method measures the hematocrit concentration in the blood by the properties of reflection of light by red cells.

The thermodilution technique uses the change in dialysate temperature when mixed with blood to calculate the intra-access blood flow rate. With temperature-sensitive thermistors, which detect changes in temperature downstream over a period of time when cold injectate of known volume and heat is introduced in the access.

US measurement of peak velocity flow ratio across a stenotic lesion. A rate> 2 is suspect from severe stenosis.

During static venous dialysis, the pressure is intra-graft pressure measured by dialysis needles connected to a manometer before starting hemodialysis. Ratio > 0,6 is suspect from severe stenosis.

Angiography should be reserved for patients with any physical findings of abnormality or by evidence of abnormality by other methods. Noninvasive monitoring methods have high predictive value in detecting hemodynamically significant stenosis. Indications for angiography:

1) The suggestion of stenotic lesion by physical examination – pain and arm swelling, prolonged bleeding time from cannulation points, recurring thrombotisation of blood, problematic cannulation of a shunt, highlighted venous collaterals
2) Unexplained, persistent, decreased Kt/V> 0.2
3) Directly measured low flow rate > 400ml/min
4) Increasing of a venous pressure > 150mmHg during three subsequent hemodialyses at flow 200-250ml/min.
5) Recirculation of a Urea > 10%

For endovascular therapy are indicated stenotic lesion > 50% in combination with clinical findings of AV shunt abnormalities, abnormal physical findings, and abnormal blood flow measurement. Endovascular treatment of stenotic lesion by angioplasty become a method of choice for AV access stenosis. The techniques of angioplasty are similar to other angioplasty procedure, with different types of balloons and procedure can be completed with implantation of a stent or stentgraft. Anatomic criteria of successful angioplasty by NKF-K/DOQ is no more than 30% residual stenosis remaining following angioplasty. Patency of angioplasty varies, depending on lots of factors as a type of AV shunt (graft, fistula) or maturity of the shunt (maturated, nomaturated). The expected six months patency of AV access following angioplasty for access dysfunction should be > 50%. If the AV shunt doesnˇt meet this goal, options include surgical revision or implantation of stents/stentgrafts. Implantation of stents/stentgrafts is accepted in cases where its use extend AV shunt life and salvage of failed shunt. Definite indications for stent/stent graft implantation are:

1) Acute angioplasty failure- residual stenosis after angioplasty > 30%, before placement of stent/stentgraft is recommended repeat angioplasty with more extent balloon
2) Rapid recurrence- two clinically significant recurrences in a period of three months. If a patient is a good candidate for surgical intervention, should be considered for surgical revision.
3) Vein rupture- when the damage of a vein is profuse with extravasation, it must be treated with implantation of stentgraft. In stage III is indicated prolonged balloon tamponade, if problems continue should consider implantation of a stent, if prolonged inflation of a balloon doesn´t tend to stabilize the situation. In the stage, IV is indicated placement of a stentgraft over disruption (Table 1).

Table 1. Classification system of vein damage during angioplasty based upon clinical significance

Stage	Clinical significance
I	The blush of radiocontrast adjacent to the vein
II	Extravasation stable- not affecting blood flow
III	Extravasation stable-affecting blood flow
IV	Disruption of vein- unstable extravasation

Complications of an AV Shunts

Bleeding after the operation, creation of AVF can be the result of heparin therapy, due to dysfunction of thrombocytes or imbalance of hemostasis [17, 18].

Surgical bleeding is managed by suture or ligation or repair. Nonsurgical minor bleeding is treated by hemostatic product.

Other cause of bleeding can be venous hypertension due to stenotic venous lesions. Prolonged bleeding from cannulation point is a result of venous hypertension, stenosis in a venous segment or hyperfunction of AVF (long anastomosis). Bleeding combined with compartment syndrome is an indication for urgent surgical therapy [19].

Stenosis of AVF is the most frequent complication and can lead to nomaturation of an AVF. Primary failure of a shunt is defined as a shunt that has never been used for hemodialysis, or that fails within three months of use [20, 21, 22].

Stenotic vascular lesions can develop anywhere. In maturated AVFa most common type of stenosis is Juxta anastomotic stenosis occurring within first 5 cm of AVF, adjacent to the arterial anastomosis. Stenosis can be directly in anastomosis- anastomotic stenosis, in venous juxta-anastomotic stenosis, or combination of both. Sometimes, mainly in transposed AVF, in the juxta-anastomotic area can be swing point stenosis too [23, 24].

Otherwise is swing point stenosis localized more distally from anastomosis in the angle of transposition or cephalic arch. For this type of stenosis is the typical extreme angle of vein involved in AVF or its drainage vein. Cephalic arch stenosis is most frequently in patients with brachiocephalic AVF. Cephalic arch drains blood from a cephalic vein, and arch stenosis can be seen with either type of shunt with cephalic anastomosis.

Central vein stenosis can occur anywhere within a central vein. A patient who had previously implanted central venous catheters, cardiac devices, or other endoluminal devices. Another possibility is compression of a subclavian vein due to costoclavicular compression. Compression veins in patients with thoracic outlet syndrome. Thoracic central venous obstruction encompasses a spectrum of central venous disease and is classified in Table 2. Predominant mechanisms are vein injury by endoluminal device, endoluminal obstruction related to a thrombus, extrinsic compression, and hemodynamic abnormalities causing intimal hyperplasia.

Table 2. Types of thoracic central venous obstruction

Type	Obliterated veins
I	One internal jugular vein, or subclavian vein
II	Brachiocephalic vein unilateral or Ipsilateral obstruction of the internal jugular vein and subclavian vein
III	Both brachiocephalic veins
IV	Superior vena cava with any constellation of others veins

Arterial stenosis is less frequently cause of AVF failure compared with venous stenosis. They can develop at any part of the arterial segment, but stenosis of the anastomosis is a most frequent in association with juxta-anastomotic stenosis. Higher rate of inflow stenosis is in forearm compared with upper arm AVF. Arterial stenosis leads to decreased blood flow and inadequate dialysis and finally to thrombosis of access.

Thrombosis

Almost all thrombosed AVF have associated pathological anatomy. The rate of thrombosis of AVF is one-sixth of the AV graft. Arterial lesions result in a decrease in blood inflow, and venous lesions increase resistance to blood flow, and both can lead to thrombosis. Sometimes stenosis can so diminish blood flow, that it is not detectable. Amount of thrombus varies considerably, in aneurysmal AVF contains a large volume of thrombus. A large volume of thrombus is typical for thrombosed AVF associated with central venous stenosis, or obliteration. In 20% of patients with thrombosed AVF is etiology different from stenosis. Thrombosis of AVF in these cases is due to hypotension, heart failure, dehydration, infection, hemocoagulation disorders [17, 25].

From the point of time, occlusion of AV access can be divided into an early and late.
The causes of an early occlusion of AV access are:

1) Technical errors- dissection of a vessel, narrowing of a vessel, anastomosis, sensitization of a vein during preparation and ligation of collateral.
2) Tactical errors- thin, inappropriate vascular system, postinflammatory changes, central vein obliteration, the disproportion between artery and vein.
3) Systemic causes-thrombophilia, low blood pressure, low heart output.

Late occlusion of an AV access is in 90% caused by intimal hyperplasia, then the progression of atherosclerotic changes and post-cannulation changes of the venous system.

Many techniques have been used to treat thrombosed AVF. The main condition of successful treatment is treatment no only thrombosed part of AVF but also the treatment of a cause- most frequently stenosis. Surgical thrombectomy is complicated by the presence of old, organized, and adherent part of thrombus. In cases with juxta-anastomotic stenosis is possible either correction of stenosis by surgical method or neo anastomosis proximally. Endovascular treatment is a better option, mainly in a patient with stenotic lesions far from the anastomosis. The patient with aneurysmatic AVF is indicated for resection and new anastomosis.

Aneurysm and False Aneurysm

Maturation and dilatation of the venous segment is normal finding after creation AVF. In approximately 15%, AVF is dilatation more progressive with increasing risk of complications. A cause of extreme dilatation can be stenotic lesion (before and after anastomosis), extremely high blood flow or repetitive cannulation in the same venous point. False aneurysm (Pseudoaneurysm) is frequently result of puncture damage of posterior wall of vein or infection. An aneurysm can result in thrombotic or bleeding complications. In aneurysmatic and thrombotic AVF is inevitable resect dilatated segment of AVF with inherent thrombus with new anastomosis more proximal. Anerysmoraphia is the possible modality of treatment in a patient with the long dilatated venous part, without thrombotic masses. Pseudoaneurysm is more frequent in AVG, often with infection and in this causes should be all AVG removed. In causes without infection is possible option resection and implantation of new graft. The indication for a repair and treatment of aneurysm include symptomatic aneurysm, evidence of infection, and aneurysm with thromboembolic complications or insufficient blood flow due to thrombotic changes.

Venous Hypertension

The most frequent cause of venous hypertension in a dialyzed patient is stenosis or occlusion of central thoracic veins. The most frequent cause of stenosis or obliteration of central veins is the previous implantation of the catheter. Risk factors are prolonged implantation of tunneled and no tunnel catheters, repetitive cannulations of central veins and infection. Treatment of stenotic lesion may be surgical or endovascular. In cases of central venous stenosis is preferred endovascular therapy with or without stent implantation. Surgical treatment was frequently used previously, dominantly with extra-anatomic procedures.

Infection

Infection is the second most frequent cause of access loss. Infection of AVF is very rare. Early (till 30 days after the operation) infection is always localized in the anastomosis. Without treatment progress infection to the formation of the pseudoaneurysm with bleeding, or progress to rupture of the anastomosis with profuse bleeding. The most frequent cause of late (more than 30 days from an operation) infection is cannulation and infection of a hematoma. This late infection consists of 94% of all infection AVF complications. Leading etiologic agent is Gram-positive cocci, less frequently Gram-negative cocci [26].

Ischemic monomyelitic neuropathy is a rare complication, typically with the profound sensory and motoric deficit, predominantly in a patient with brachial artery inflow. Incidence is less than 1%, with immediate onset after the creation of vascular access and treatment is immediate ligation of access to prevent permanent neurologic damage.

Coronary steal syndrome can be present in a patient with a coronary bypass with internal mammary artery where AV shunt can activate retrograde blood flow in the mammary artery and cardiac ischemic symptoms.

Neuropathy as a result ischemic injury from vascular steal, mechanic compression or trauma, or due to local amyloid deposition leading to carpal tunnel syndrome can be seen rarely.

Hemodynamic Complications – Hyperfunctional AV Shunt

More than 50% of hemodialysed patients have cardiac problems. Creation of AVG or AVF causes an acute decrease in systemic vascular resistance and a secondary increase in cardiac output [27]. In a patient with heart failure and ejection fraction < 20% are bad candidates for an arteriovenous shunt, they have the highest risk of clinical aggravation and fatal outcome after AVF creation. In this group of the patient, the first option for hemodialysis is the insertion of a central venous catheter [28]. Before creation AV shunt each patient should be classified using the New York Heart Association functional classification (NYHA classes I to IV) and the American College of Cardiology Foundation/American Heart Association stages of heart failure (ACC/AHA stages A to D) [29]. Patient with stage C ACC/AHA and NYHA I-II are candidates for distal radiocephalic shunt, patients with stage C ACC/AHA and NYHA III-IV, or ACC/AHA stage D are candidates for the venous catheter. Normal flow through AV shunt, sufficient for hemodialysis is over 500ml/min. With time, the vein is more dilatated and flow through AV shunt increase and can lead to heart failure. By Vascular access society guidelines, high flow AV shunt (AVF, AVG) is defined as a flow-through shunt > 1,5l/min, and cardiopulmonary recirculation > 20% Cardiopulmonary recirculation (CPR) is a relation between shunt flow (Qa) and cardiac output(CO). Than CPR = Qa/CO.

Patients with AV shunt related heart failure management begins with medicament therapy of arterial hypertension, heart failure, diuretics, and by adjustment of hemodialysis for better volume control [30, 31, 32, 33]. If despite this precautions hearth failure progress, we should reduce blood flow of AV shunt and close all unused AV shunts. If this step is insufficient, we should close the AV shunt and insert a catheter for hemodialysis.

Indications to reduce blood flow on the AV access:

1) Heart failure + Qa>1600ml/min and/or Qa/CO> 0,3
2) Steal syndrome + Qa in patient with AVF > 800ml/min, +Qa in patients with AVG >1200ml/min
3) Prevention of heart failure when Qa > 2000ml/min and/or Qa/CO > 0,3

To correct blood flow of hyperfunctional AV shunt or correct ischemia, we have several techniques: PRAL, TRA, RUDI, DRILL, MILLER, BANDING, PAI options (see also vascular steal)

PRAL – proximal radial artery ligation. The technique to decrease blood flow in distal radiocephalic AVF. By ligation of the radial artery, just proximal from anastomosis, in patients with patent ulnar artery decrease blood flow by 1/3.

TRA- transposition of the radial artery. Complicating procedure with the preparation of whole radial artery involving transposition from the forearm to the elbow level to replace the brachial artery by the distal radial artery inflow.

Hemodynamic Complications – Vascular Steal

In approximately 20% of patients with AV shunt is reduced perfusion of a more distal extremity as a result of shunting. For severe ischemic symptoms are typical loss of sensation or weakness are occurring in 4% of patients, and they require intervention. The cause of severe ischemia can be a stenotic arterial lesion, absence of collateral flow, and creation of high- flow AV shunt in a patient with DM or PAD. Intervention prevents serious sequela of ischemia, and revascularization is impossible, AV shunt has to be ligated. PTA is effective only in patients with inflow arterial stenosis or PAD. Other options are corrective operations to decrease blood flow through AV shunt or procedures to the reduction of steal phenomena and to increase more peripheral blood supply [35, 36, 37, 38].

A most studied procedure is DRILL- Distal revascularisation-Interval ligation procedure. This procedure comprises ligature of brachial artery just belove arteriovenous anastomosis and creation of brachio-brachial bypass operation, where proximal anastomosis must be minimally 10cm proximally from a. brachialis ligature for successful revascularization. The procedure can be performed as a single stage operation or staged procedure. This type of revascularisation is usable in both AVF and AVG procedures, primarily performed on the brachial artery.

Another technique to correct steal syndrome of AV shunt with primary anastomosis on the brachial artery is RUDI-Revision using distal flow procedure. The principle of this method is ligation of a venous segment of AVF and creation of a new anastomosis, with the new venous segment, transposed or translocated (distal part of v. cephalic) Distal anastomosis is on the radial artery and proximal on v.cephalica. In the absence of native veins, a graft can be used for the bypass procedure. By using the feeding artery with smaller diameter, we decrease blood flow -and we lengthen the cannulation segment of a shunt.

PAI- proximalisation of arterial inflow, this procedure converts the arterial supply of the arteriovenous access to a more proximal artery with higher capacity by using a small-caliber polytetrafluoroethylene graft as a feeder.

BANDING- a simple method to reduce blood flow of AV shunt by increasing venous resistance. 1-2cm distally from AV anastomosis is vein stitches with a cuff to reduce blood flow.

MILLER - Minimally Invasive Limited Ligation Endoluminal-assisted Revision is a modification to the traditional banding procedure, which markedly improves banding outcomes. A modified banding procedure requires a small (1-2 cm) skin incision to the place of a ligature and utilizes a 4 or 5 mm diameter endoluminal balloon to achieve the desired reduction of inflow size [39, 40, 41].

Less severe symptoms, sense of coolness and paresthesia are frequently present, and they improve in a period of weeks with a development a collateral blood flow.

Steal syndrome has four stages:

- Stage 1 – without steal
- Stage 1 – moderate steal (no therapy required, sense of coolness)
- Stage 2 – moderate steal (therapy individually indicated, intermittent ischemia, claudication)
- Stage 3 – severe steal (surgical treatment indicated, rest pain, defect)

AV Graft

In contrast to native AV fistulas, AV graft (AVG) don´t need time to maturation and can be accessed for hemodialysis in short time after implantation. For hemodialysis is graft usable within 24 hours after AVG creation, but better is wait approximately two weeks to the first cannulation [42]. This period is enough for tissue ingrowth and resolution of surgical inflammation and edema. Because of a higher rate of infectious complication and a higher rate of failure in comparison to native AVF, implantation of prothesis is indicated only in patients with no possibility to perform native AVF and in patients when it is certain, that in short time hemodialysis will be starting [43]. According to the National Kidney Foundation Kidney Disease Outcomes Quality Initiative (NKF-KDQOI) Clinical Practice Guidelines, the preferred AVG site types are the antecubital forearm loop graft and the upper-arm curved graft. Left-right -localization depends on handedness. First AVG should be performed on the nondominant upper extremity; the lower extremity is considered when all possible sites on upper extremity are exhausted or are present stenosis or obliteration of central thoracic veins. In patients with patent and the nonstenotic central thoracic vein is one of the last options, chest wall graft [44]. In patients with type I and II of thoracic central venous obstruction are possible to perform cross – over graft implantation, to connect better arterial feeding artery (a. subclavian, a. axillaris) with the nobliterated draining venous system [45, 46].

There are many types of graft that can be used for the creation of AVG. The most frequently used graft prosthesis for AVF is polytetrafluoroethylene (PTFE) prosthesis. This prosthesis- graft is available either as a normal thickness or as a thin- wall graft. Another possibility is heparin- bounded graft or externally supported grafts. External support in this type of prosthesis provides resistance to kinking and mechanic compression. For patients that need the first hemodialysis shortly after AVG creation (in 24 hours), can be used multilayer-graft, with auto seal property. Tapered grafts with one end with a smaller diameter for arterial anastomosis, to prevent high flow related complications. To prevent venous stenosis, there are commercially available PTFE nitinol reinforced grafts with stent reinforced end inserted into outflow vein or double parts HeRO grafts with nitinol-reinforced silicone single-lumen

outflow catheter. From other grafts, we can use an allograft, xenograft, or tissue-engineered grafts. Cryopreserved allografts can be used to replace infected AVG and can be prepared from a great and short saphenous vein or brachial and cephalic veins. This cryogenics can be placed in the setting of systemic or local infection in patients with a history of repeated PTFE infections and exhaustion of vascular access sites. This cryogenics may be placed at a new site or old graft site. Advocates of the same site implantation argue by salvaging of angioaccess. From xenografts can be used bovine carotid artery, mesenteric vein or ureter as a conduit. Tissue engineering products are not commercially available.

Complications of AVG

A complication of AVG is similar to that AVF, but more frequently in AVG are an infectious complication and thrombotic complication [47, 48, 49]. Stenosis is localized in this type of AV access in the venous anastomosis, almost in 2/3 of cases. Other sites of stenosis are intragraft stenosis due to intimal hyperplasia, peripheral vein (other as veno-prothetic anastomosis) due to blood flow turbulence and central vein stenosis as a result of the previous cannulation [50, 51, 52]. Infectious complications continues to be among the leading causes of morbidity and mortality in patient with AVG and central venous access [26]. Infection account for more than 12% of all death among hemodialysed patients. Vascular access is responsible for 48–73% of all bacteremias in the hemodialysis population. Majority of this bacteremias are caused by staphylococci and is associated with a high rate of mortality and metastatic complications (septic endocarditis, arthritis, osteomyelitis...). The incidence of infection is highest in central venous catheters and higher in AVG in comparison to AVF. Postoperative wound infection or poor aseptic technique may cause infection of AVG. Actually, the majority of AVG are of PTFE material and repetitive cannulation, perigraft hematoma formation, prolonged postdialysis bleeding from graft, and poor hygienic standard of personal increase the likelihood of AVG infection. 30 day (early infection) AVG infection rate is 6%. Treatment strategy depends on signs and clinical status. Minor infection – local infection can be treated by antibiotic therapy and local measures. Abscess formation in the proximity of a graft or infection of a prosthesis should be treated more aggressively. This encompasses excision of an infected segment of PTFE, but the better option is total graft excision, because of the high rate of recurrent infection with necessity nevertheless total graft excision finally. Silent graft infection with bacteriemia and without clinical signs may be undetected.

Central Venous Access

Insertion of a central venous catheter is one of possible modality to perform hemodialysis in a patient with end-stage kidney disease. A central venous access device is defined as a catheter whose tip is located in the superior vena cava, in the right atrium, or the inferior vena cava. Access is obtained by a percutaneous puncture to cannulate the vein.

Central venous catheters are classified based on a duration of catheter use, place, and type of insertion and number of lumens. Nontunneled centrally inserted central catheters are placed percutaneously with the catheter exiting the skin in the vicinity of the venous cannulation site (jugular, subclavian, femoral). They are most commonly used for temporary

access. Tunneled central venous catheters traverse a subcutaneous tunnel between the catheterized vein and the skin exit site. They can be with or without a cuff to anchor it in place and limit bacterial entry. Cuffed, tunneled catheters are most frequently used for chronic hemodialysis procedure. Factors influencing catheter selection are the duration of venous access, number of lumens needed, and patients consideration. A common indication for the placement of a central venous catheter is no or inadequate peripheral venous access. Nontunneled central venous catheters are in place for a few days to no more than one to two weeks and are usually placed into peripheral veins of the upper extremity. Nontunneled catheters avoiding the subclavian site are used for short-term access when acute hemodialysis is indicated and are not recommended as short-term access in patients with low glomerular filtration rates (<45 ml minute, IIIb stage). Femoral catheters are used to a single dialysis session. They are composed of materials such as polyurethane, polyethylene, polyvinyl chloride, and medical-grade silicone. They are different from the point of outer diameter ranges from 8 to 13.5 French (Fr), configuration (straight, curved) and of different lengths. They are rigid with the risk of vessel trauma, with a conically pointed tip and for insertion from the left side should be used longer one. After insertion, immediate X-ray chest control should be done, exclude complications, and verify the tip catheter position.

Tunneled catheters are used for acute and also for chronic dialysis. They are a good option for a patient with bad vascular access to patients with a suitable vascular bed for arteriovenous anastomosis. Even for a patient with acute renal failure are tunneled catheters better with a lower rate of infection complications in comparison with notunneled catheters. With tunneled cuffed catheter patient can leave hospital and tissue ingrowth into the cuff and prevent malposition of a catheter. Cuff is localized in a subcutaneous tissue between skin and vein entrance points. Quality of dialysis is also better with cuffed tunneled catheters, that allows higher blood flow in comparison to non-tunneled catheters. A typical tunneled catheter is curved, double lumen and with cuff.

Central Venous Catheter-Related Complications

Infection is more frequently present in notunneled catheters compared to tunneled catheters. Tissue ingrowth and cuff in tunneled catheters reduce the risk of infectious complications. Femoral catheters are more susceptible to infection than thoracic catheters. Infection may originate from the skin of patients with migration along with the catheter, poor personal hygiene, hematogenous spread from other sites. In tunneled catheters, infection external to the cuff is classified as exit site infection, whereas infection that extends in the tunnel proximal to the cuff are labeled as tunnel infections. Tunnel infection is frequently associated with bacteriemia. Poor hygiene and DM are a risk factor for exit site infection. Treatment relates to the antibiotic therapy and removal of a catheter and replaces by a new one at the new venotomy place [53, 54, 55, 56, 57].

Vein stenosis/Thrombosis. After cannulation of a vein, in the site of vein trauma starts healing, which leads to the fibrillization and sterilization of a vein. Repeated cannulation at the same point leads to the reinjures. Another place of a vein trauma and possible point of stenosis is a part of vein repetitively chafed by a tip catheter and also turbulent blood flow beyond the tip of a catheter which stimulates endothelial proliferation. Vein thrombosis and stenosis are frequently present in subclavian rather than jugular catheters. Most central venous stenosis is asymptomatic and starts to be symptomatic after the creation of a

peripheral, ipsilateral AV access. Symptoms of central stenosis/thrombosis depend on the extension of stenosis or thrombosis and collateral circulation. Central vein thrombosis responds to anticoagulation and thrombolytic therapy with consecutive angioplasty, eventually implantation of stents/stent grafts [58, 59].

Catheter malfunction when blood/saline cannot be drawn from a catheter or saline cannot be infused into catheter, causes are mechanical (kinking, the tip of a catheter pushed against the wall), thrombotic (external or internal thrombosis) (Table 3).

Table 3. Types of a catheter-related thrombus

Intrinsic thrombus	Extrinsic thrombus
Intraluminal thrombus- thrombus inside of a catheter	Central vein thrombus- catheter with complete thrombosis of a vein
Tip thrombus- thrombus in the tip of a catheter	Mural thrombus- thrombus on the wall of a vein in a place of its contact with a tip of a catheter
Sheat thrombus- thrombus as a part of a sleeve around a catheter	Atrial thrombus- thrombus in a right atrium

Malfunction of a catheter, from the point of timing, is early or late. Malfunction immediately after implantation means, that catheter never functioned adequately. This is a technical problem and after retracting should be placed in a correct position. The most frequent cause of late dysfunction, previously working adequately, are thrombotic complications (Table 3). When symptomatic thrombosis is present, the catheter should be removed and a new one inserted. In patients with extrinsic thrombosis, the catheter should be extracted, starting anticoagulation therapy and in the presence of big atrial thrombus surgically removed.

CHRONIC VENOUS INSUFFICIENCY AND VENOUS SURGERY

Duplex ultrasonography is the most frequently used modality to evaluate lower extremity chronic venous disorders encompass a large spectrum of morphologic and functional abnormalities of the venous system. They can present in childhood as congenital lesions or acquired disorders that by adulthood are quite common.

Veins of the lower extremity consist of superficial and deep systems joined by venous perforators. The saphenofemoral junction is marked by branches of the greater saphenous vein, circumflex iliac vein, the external pudendal vein, the superficial epigastric vein, ad the medial and lateral accessory saphenous veins. Deep veins of the leg lie in the courses of the arteries. Two or three venue concomitants accompany each tibial artery. Knowledge of lower extremity venous anatomy is inevitable in understanding the physiology of venous flow.

Anatomy, Physiology, and Pathophysiology of the Venous System

The anatomy of the veins of the lower limbs is hugely variable, but there is order in the variability. The veins of the lower extremities are divided into three systems: the superficial, the deep, and the perforating (vv.perforantes) venous systems.

Superficial veins drain the area between the skin and muscles fascia, carrying blood to the deep venous system. The saphenofemoral junction is an essential part of the function of the venous system during deep venous thrombosis and in the treatment of varicosities. The main trunks of the superficial venous system are greater and lesser saphenous veins.

Deep veins are located close to the arteries. Perforating veins perforate the muscular fascia to connect superficially with deep venous systems. The important perforating vein is the Cockett´s (medial ankle), Boyd´s (proximal medial calf) and Dodd´s (medial upper leg). In the standard limb, the perforating veins permit the unidirectional flow of blood from the superficial to the deep venous systems through a set of one- way valves. Perforating veins are either direct- permitting the superficial venous system to communicate directly with main deep veins or indirect- such that they connect with the deep veins by way of muscular veins.

Communicating veins (collateral veins, tributary veins) are veins that interconnect with veins of the same system.

The lower limb veins below ligament contain valves in their lumen and along their entire length that allow blood flow only from the periphery to the heart against the force of gravity. The tone of the veins, arteriovenous coupling (transfer of a pulse from artery to a neighboring vein) accompanied by the suction effect of the heart and thoracoabdominal pump function of breathing helps in this process. This, in combination with competent venous valves, guarantees blood flow to the heart by muscle contraction.

Disruption of the venous blood flow plays a key role in venous disease progression. This can be caused by incompetence of venous valves (primary – inherited, secondary- acquired) acute or chronic occlusion of a vein, increase of resistance to blood flow (e.g., stenosis), or any combination of these abnormalities. This abnormalities stepwisely progress to the state of continuous venous hypertension of the lower limb with a wide variety of symptoms and signs.

The state of continuous venous hypertension of the lower limb is described as a Chronic venous insufficiency (CVI). Signs of CVI may be present in the form of heavy leg, pain, hyper or depigmentation of the skin, eczematoid dermatitis, and other skin changes. The typical changes of the skin are divided into 1- corona phlebectatica: dilatation of venules of the foot and edema, 2- stasis eczema: hyper or depigmentation of the skin, 3- florid and healed cutaneous ulceration.

Leg pain is the commonest complaint in venous disease, and its chronic nature means that it impacts significantly on patient´s quality of life. Venous pain is frequently associated with other unpleasant sensations like a feeling of heaviness, cramps, the tension in the legs, pruritus. The intensity of the pain is not correlated with the severity of the venous disease, and many patients with venous pain have no objective clinical or paraclinical abnormalities. The likely trigger for this pain is hypoxia caused by venous stasis, with local inflammatory reaction and activation of nociceptors in the vein wall.

Swelling- edema is an early symptom of venous disease. Usually, edema is mild and limited to the area just above the shoe line around malleolar and resolves with bed rest and after the limb has been elevated. With more advanced varicose, veins the edema progress up to the mid-calf region and normally pitting edema progress to chronic edema with subcutaneous fibrosis and than edema fail to pit.

A VEIN-TERM consensus of an American Venous Forum (AVF), the European Venous Forum (EVF), the International Union of Phlebology (IUP), the American College of Phlebology (ACP), and the International Union of Angiology (IUA) standardize venous nomenclature:

Chronic venous disorder- the full spectrum of morphological and functional abnormalities of a venous system.

Chronic venous disease- when morphological and functional abnormalities of long duration are manifested by signs and symptoms indicating the need for treatment and further investigation.

Chronic venous insufficiency- describe patients with the chronic venous disease who display more advanced clinical signs, such as significant edema, skin changes, or ulceration.

Diagnostic Steps of Investigation

The physical examination may play an important role in guiding therapy. The patient´s limb is inspected in a standing position. The presence of the ankle venous flare underneath the medial malleolus is one of the first signs of CVI. Telangiectasias are defined as dilatated intradermal venules less than 1 mm in size; reticular veins are dilatated, subdermal, non-palpable veins 3mm or less in size and varicose veins are dilatated, palpable, subcutaneous veins larger than 3 mm. Edema indicates more advanced venous disease. The presence of skin changes or venous ulcer should be described with its size and depth.

Classification of truncal varicosity of greater saphenous vein, as described by Hach, is divided into four groups: I- saphenofemoral incompetence, II- varicosity between the groin and upper calf, III- varicosity from saphenofemoral junction to proximal lower extremity and IV – varicosity of the entire great saphenous vein.

In all patients with varicose veins, the extent of damage to superficial and deep veins should be described by clinical examination and by Duplex Ultrasonography. The traditional functional tests (Perthes, Trendelenburg, Tourniquet) are seldom used, and phlebography is reserved only for more complex cases (e.g., valve vein surgery).

Venous system for the management of CVI. The duplex ultrasound examination should demonstrate the anatomic patterns of veins and abnormalities of venous blood flow in the limbs. By ultrasound should be determined incompetent greater and lesser saphenous vein, the extent of reflux, other relevant veins that show reflux or the source of filling of all superficial varicous veins and the state of the deep venous system.

Venous reflux is defined as retrograde flow in the reverse direction to physiological flow lasting for more than 0,5 s.

Because of its reliability, the use of Duplex scanning in combination with a functional hemodynamic measurement technique is accepted as the preoperative standard diagnostic procedure.

Varicose Veins

- Dilated, tortuous superficially passed veins in the lower extremities, usually bilateral
- Asymptomatic or as a symptomatic may be associated with localized pain, nocturnal cramps
- Pigmentation, ulceration, and edema suggest concomitant venous stasis disease
- Increased frequency after pregnancy

Varicose veins are very common, afflicting 10-20% of the world´s population and are more than 3 mm thick. They involve great and small saphenous vein, saphenous tributaries, or nosaphenous superficial tributaries. Mainly they are accompanied by reflux in the venous system, but they can also be as isolated varicosities. Abnormally dilated veins occur in different locations in the body. Varicosities of the legs were firstly described in 1550 BC. They are primary or secondary. Many varicose veins are asymptomatic and are an only aesthetic problem. If symptomatic may be associated with localized pain, burning sensation, a diffuse ache or heaviness in the calf or phlebitis. The varicosities are dilated, tortuous, elongated veins predominantly on the medial aspect of the lower extremity. A complication of varicose veins includes thrombosis and bleeding with the need for conservative and invasive therapy.

Classification

CEAP classification is used for chronic venous insufficiency (CVI). C means clinical presentation, E means etiology, A means anatomy, and P means pathophysiology. In clinical praxis is the most used C like Clinical presentation. E, A, P are used not so often.

C-Clinical Presentation

No visible or palpable signs of venous disease (C0) - patient with or without difficulties.

Telangiectasias/reticular veins (C1) are small skin and sub-skin vessels in diameter < 1 mm (teleangíectasia or spider veins) or < 3-4 mm. They are normally visible, mainly in persons with thin, transparent skin.

Varicose veins (C2) are subcutaneous vein with a diameter over 3-4mm and are frequently tortuous. The can involve main venous trunks (great and short saphenous vein), their tributaries, or collateral superficial leg veins.

Edema (C3) is due to the increased volume of fluid in sub-skin tissue and skin.

Pigmentation or eczema (C4a) Pigmentation is caused by hemosiderin deposits in the skin as a result of extravasation of red cells. They are localized below the knee, with maximal localization in the ankle region. Eczema is caused by venous disease, but not always accompanied by varies.

Lipodermatosclerosis (4b) trophic changes of skin and sub-skin tissue due to venous hypertension. Diffuse chronic inflammation, followed by fibrosis and scaring any color changes of the skin. Atrophia Blanche is localized white change surrounded by dilated capillaries and by hyperpigmentation.

Healed venous ulcer (C5) typically localized in the medial part of a calf with other clinical symptoms of CVI around.

Active venous ulcer (C6) defect of skin in an ankle or calf. The depth and area is very varied, and the healing process is complicated, mainly in ulcers with a long history.

E-Etiology

Congenital (Ec) congenital vascular abnormalities from birth or developed later during life.

Primary (Ep) from different causes, mainly from reflux in truncal veins.

Secondary (Es) secondary venous disorders, most frequently from trauma and thrombosis.

A-Anatomy

Superficial venous system (As) contains veín between fascia and skin. The major veins are great short saphenous veins and their accessory veins.

Perforating veins (Ap) connect the deep and superficial venous system. They can be divided into direct and indirect veins. Direct communicating veins, frequently located medially in the thigh and calf and they could be the cause of primary and recurrent varicose veins.

Deep venous system (Ad) veins bounded by muscle fascia. They are intramuscular and intermuscular. The intermuscular are more important in the development of chronic venous disease. The intermuscular veins include the popliteal vein, crural veins, femoral common, deep veins.

Anatomy not specified (An) if an anatomic location is not identified.

P-Pathophysiology

Venous reflux (Pr) is abnormal, retrograde blood flow through the venous segment. The valves are damaged by trauma or thrombosis, or by congenital valvular abnormalities. Reflux can be localized in superficial, deep or perforating veins, local or in the entire venous trunk. Reflux in a deep venous systém is associated with more ulcers defect in comparison to reflux in the superficial venous system, but ulceration is also possible as a result of superficial venous reflux.

Venous obstruction (Po) that impedes blood flow. Over time thrombus remains as a scar or is spontaneously resorbed (partially or totally), and the venous segment is without functional valves, that results in reflux.

Venous reflux and obstruction (Pr,o) when both entities are present.

Reflux not specified (Pn) when neither reflux nor obstruction is identified.

Corona phlebectatica as a no part of CEAP classification, are small intradermal veins, localized in medial or lateral ankle. More frequently present in patients with reflux.

Klippel- Trenaunay syndrome is congenital disorder and is characterized by the presence of varicosities (venous malformation), capillary malformations, limb overgrowth, and possible lymphatic anomalies.

Clinical Severity

There are several measurement tools that help to objectively follow patient response to clinical management. Venous clinical severity score (VCSS) from ten clinical parameters that are graded from zero to three depending upon severity classify severity disease, like CEAP classification.

Table 4. VCSS score (every parameter has a maximum of three points)

Pain or discomfort of presumed venous origin
Varicose veins >=3mm in standing
Venous edema
Pigmentation
Inflammation: Erythema related to cellulitis, dermatitis or venous eczema
Induration
Number of active ulcers
Duration of active ulcers
Size of active ulcers
Compression therapy

Venous disability score (VDC) quantifies physical problems due to CVI (Table 5.)

Table 5. Venous disability score

score	symptoms
0	asymptomatic
1	asymptomatic: usual daily activities without compression therapy
2	symptomatic: usual daily activities with compression therapy or elevated legs
3	symptomatic: unable to carry out daily activities even with compression or elevated legs

Venous segmental disease score (VSDS) grades major venous segments according to the presence of reflux and obstruction. Each anatomic segment is weighted with points to maximum 10points for reflux and 10 points for obstruction (Tables 6,7).

Table 6. Points of VDSD for reflux (to total point count either a posterior tibial vein or more than 2 of calf veins)

points	venous segment		points
	tight	calf	
0,5	small saphenous vein	posterior tibial vein	1
1	great saphenous vein	more than 2 of calf veins	2
0,5	perforator, tight	perforator, calf	1
2	popliteal vein		
1	femoral vein		
1	deep femoral vein		
1	The common femoral vein or above		

Table 7. Points of VDSD for obstruction

points	venous segment
1	great saphenous vein
1	calf veins multiple
2	popliteal vein
1	femoral vein
1	deep femoral vein
2	common femoral vein
1	iliac vein
1	inferior vena cava

Table 8. Villalta score (points: 5-9 Mild, 10-14 moderate, 15–48 severe, points less than four not present

symptoms	clinical signs
pain	pretibial edema
cramps	skin induration
heaviness	hyperpigmentation
paresthesia	redness
pruritus	venous ectasia
	pain on calf compression
	+ venous ulcer: present 15 pts, absent 0 pts

Villalta scale for patients with the postthrombotic syndrome. Helps identify and treat patients in the early stages of the disease. Symptoms and clinical signs are calculated depending on their severity (none:0, mild:1, moderate:2, severe:3). Total points count over 15 indicates a patient with severe postthrombotic difficulties (Table 8).

Aberdeen Varicose Vein Questionnaire (AVVQ) as a tool is acceptable to patients and could be used as a guide for referral for specialist varicose vein assessment. The questionnaire consists of 13 questions (7 questions for both lower extremities), from this one diagram (question 1) where patient draw the location of their varicose veins. Total score results are from zero to 100, with zero representing the best score, and 100 the worst one. The modification and conversion of the AVVQ into an electronic version should ease the adoption of this tool at home and possibly the reduced expense and inconvenience of unnecessary appointments when they were not eligible for Health systems funded treatment.

Charing Cross venous ulcer questionnaire (CCVUQ) was developed to provide a valid quality-of-life measure for patients with venous ulcers.

Treatment

Treatment for varicose veins can be divided into two categories: conservative therapy: medical and compression therapy and interventional therapy: surgical procedure, sclerotherapy, and endovenous ablation.

Nonsurgical Therapy

Compression therapy of the lower leg is an effective intervention and cornerstone in the prevention and treatment of venous and lymphatic diseases. Compression therapy prevents edema and accelerate of the venous blood flow and is especially essential when ulcus cruris is present. Medical compression therapy includes static and dynamic mechanical compression provided by garments and different devices [60].

Static compression includes hosiery and bandages, in dynamic compression, we use a different form of pumps and sleeves. Static compression therapy is characterized by a constant pressure gradient of a sleeve or bandage against extremity. This pressure gradient increases deep vein flow velocity and venous return, improve microcirculation, improve lymphatic drainage, and decrease venous pressure. This compression also reduces the extent

of edema, lipodermatosclerosis, pain, skin changes, and helps in an ulcer healing [61]. Many studies showed a benefit action of compression therapy for ulcer healing and showed more than 97% healing rate in patient compliant for therapy, where this therapy decrease inflammation and expression and activation of metalloproteases and increase the healing rate and reduction of ulcer.

Compression hosiery for treating symptoms of CVI are available in four compression grades. To prevent exudation of fluids from vessels, to inhibit symptoms of severe CVI, the pressure gradient in an ankle region should be more than 35-40 mmHg. For more severe grades of CVI are indicated high-grade pressure stockings. Extra firm stocking, with compression pressure over 40mmHg, is reserved for patients with lymphedema (Table 9).

Table 9. Types of stockings in CVI

Class	Pressure (mmHg)	Indication
I	15 – 20	minor varicosities, tired aching legs, swelling of ankle and foot
II	20 - 30	moderate varicosities and swelling, phlebitis, after ablation
III	30 - 40	severe varicosities and swelling, post-DVT, active ulcer
IV	>40	lymphedema

Length of stocking varies from knee-high, tight-high to pantyhose stocking. Type of stocking, from the point of length view, depends on the proximal point of reflux. Stocking should compress this region too. In the absence of reflux, the length of a prescribed stocking depends on patient preference [62]. The spike of stocking can be open or closed. There are also some custom products; the most favorable are zippered stockings, used mainly by patients who don´t have strength or mobility to pull on stocking. In this, pulling on, the maneuver can be helpful, donner (wireframe or tube-like sleeve), butter or silk hose under the high-grade pressure stocking.

Dynamic compression or intermittent compression and is usable in patients who don´t tolerate static compression. The device consists of a single chamber or multi chambers, which inflate sequentially from foot to the knee and thigh.

Contraindication of compression therapy is PAO, heart failure, and acute cellulitis, infection, skin necrosis.

Medical therapy with the vasoactive drug has been shown to increase venous tone and improve venous and lymphatic drainage. Venoactive drugs are prescribed mainly to improve edema and symptoms, and the most commonly used are flavonoids, more particularly, micronized flavonoids. They increase venous tone by inhibiting noradrenalin breakdown by catechol-O-methyltransferase to prolong noradrenergic activity. They protect microvascular permeability by inhibiting adhesion and migration of leukocytes, production of inflammatory, leukocyte and endothelial mediators (L-selectin, ICAM-1, VCAM-1) [63]. They increase lymphatic drainage and peristalsis of lymphatic veins and decrease capillary permeability. Another positive effect is reduced aggregation of leukocytes, local inflammatory process, and their migration into the vein wall. By limiting red cell aggregation, they decrease blood viscosity and increase blood velocity. Moreover, finally, they facilitate fibrinolysis.

Pharmacologic therapy can be categorized as venoactive drugs and rheologic drugs. Venoactive drugs are of a plant origin and synthetic origins (Table 10).

Table 10. Types of venoactive drugs

Origin	Drugs
Plant	Gamabenzopyrones – Flavonoids (Diosmin, Hesperidin) Rutosides (rutin, troxerutin) Alfabenzopyrones - coumarins Saponins – horse chestnut seed extract, Ruscus aculeus extract (Aescin) Other: anthocyanins, proanthocyanidins- grape seed extract, red wine leaf extract, gingko balboa extract, Centella asiatica extract
Synthetic	Calcium dobesilat, Naftazone, Tribenozid, Benzarone

The alpha-benzopyrone coumarin has been used either alone or in combination with other drugs for the treatment of lymphedema, and several studies have reported favorable results, but its hepatotoxicity has dramatically limited the use of coumarin. Flavonoids inhibit leukocyte activation, adhesion, and migration and modify leukocyte-endothelial interactions, inhibiting the expression of intercellular adhesion molecules (ICAM-1) and vascular adhesion molecules, and prevent endothelial damage. Rutosides are indicated as an antiedematous agent in venous disorders by increasing venous tone by blocking inactivation of noradrenaline, reduce the symptoms of venous disease, particularly swelling, and improve hemodynamic venous function. After the admission of a Naftazone venoconstrictor effect and lowering of serum beta-glucuronidase levels was seen and it acts on vessel wall permeability and on abnormalities of endothelial cells. Tribenoside decreases capillary permeability and has anti-inflammatory and analgesic actions [64]. Calcium dobesilate decreases capillary permeability and blood viscosity and improves lymphatic drainage. Benzarone has fibrinolytic properties and inhibits platelet aggregation.

Rheologic drugs affect the flow properties of blood. Aspirin and Pentoxifylline accelerate healing of venous ulcers. Stanozolol- oral steroid- stimulates blood fibrinolysis and helps with improvement in the area of lipodermatosclerosis, reduced skin thickness, and possibly faster ulcer healing. Prostacyclin is a potent vasodilator inhibits platelet aggregation, and adhesion increases red blood cell deformability, alters neutrophil function (including free radical production) and capillary permeability, and may help repair damaged endothelium. Sulodexide has antithrombotic and profibrinolytic activity related to its affinity for antithrombin III and heparin cofactor II and effects on leukocyte-platelet activation and has antithrombotic, profibrinolytic, and fibrinogen-lowering properties too.

Surgical Treatment

Surgical removal of varicose veins is often for cosmetic reasons. Noncosmetic indications include symptomatic varicosities, or the treatment of venous hypertension with skin or subcutaneous tissue changes, such as lipodermatosclerosis, atrophy blanche, ulceration, or hyperpigmentation have developed.

The indication for surgery is largely based on patient preference. Choice of treatment is the also affected by symptoms, cost, available medical resources, insurance reimbursement and physical training as well as the presence or absence of deep venous insufficiency, the characteristics of the affected vein and potential for iatrogenic complications.

In primary varicosity (genetic) is surgical therapy indicated for saphenous, perforating, and branch vein varicosities [65]. In secondary varicosities (e.g., postthrombotic) the decision on surgical therapy has to be made carefully, and sufficient blood flow has to be ensured from lower extremity to the heart after surgery.

The treatment aims are to ablate reflux from deep system to superficial. This is in 70% of cases reflux from femoral vein to greater saphenous vein, so-called saphenofemoral reflux. In 20% we can see reflux from popliteal vein to lesser saphenous vein, so-called popliteoparval reflux. In 10% of cases, it is reflux from the deep system to the superficial system through perforators. Indications for surgical treatment include pain, that can be persistent or disabling, erosion of the overlying skin with bleeding, recurrent superficial thrombophlebitis, and manifestations of chronic venous insufficiency (particularly ulceration). In patients with an incompetent valve at the saphenofemoral junction, high ligation and stripping of the saphenous system are performed [66]. Today, the saphenous vein can also be ablated by either radiofrequency ablation (RFA) or endovenous laser treatment (EVLT).

Standard Varicose Vein Surgery

Standard varicose vein surgery remains the gold standard of therapy and involves ligation and disconnection of the great and small saphenous at their junction with the deep venous system. Ligation of the great saphenous vein involves tying off the vessel at the saphenofemoral junction accompanied by stripping of the great saphenous vein. Ligation alone, without stripping of the vein is associated with a high varicose vein recurrence. After ligation of great saphenous vein and tributary veins, the saphenous vein is tied to the tip of a stripper, and the vein with a stripper is pulled down through small incision. Stripping first of all requires that a stripper be passed into the saphenous vein [67]. The site of a small distal incision depends on a type of truncal varicosity as described by Hach (see above) if the stripper is inserted upwards. When the saphenous vein is insufficient along its whole length, a small distal incision is located at the ankle – total stripping of a vein. Stripping to the knee (partial stripping) reduces the risk of saphenous nerve injury.

Figure 1. Classical stripping of an SSV- stripper inside an SSV.

Another possibility of stripping is when the stripper is inserted downwards (from the groin into a saphenous vein), but there is a risk of the head of the stripper entering saphenous collateral.

For short saphenous vein is recommended limited stripping of the vein to the mid-calf, because of possible injury to the sural nerve. (Picture.1) The proximal, small transverse incision in the knee crease is located about 3 to 5 cm distal to the saphenopopliteal junction and with stripping using the same techniques as described for the great saphenous vein.

A complication of a surgical procedure includes hematoma, postoperative bleeding, infection, nerve injury, thrombosis, lymph leak [68]. The risk of recanalization with open surgery is zero, enlargement of other veins in the extremity can occur over time. Recurrence rates of surgical technique are associated with varicose vein between 20 and 28 percent.

Phlebectomy

Phlebectomy involves removing abnormal veins, not including saphenous veins. Under local anesthetic – outpatient procedure- small incision are made in the skin, and large varicose veins are removed using phlebotomy hook. This procedure is well tolerated, and complications are rare, but recurrence is high if the source of the reflux is not treated. If present, reflux should be abolished by some method (standard surgery – see above, endovenous procedures – see below) and phlebectomy is adjuvant to saphenous vein surgery [68].

Transilluminated powered phlebectomy (TIPP) is an alternative to traditional phlebectomy. During the procedure, an endoscopic transilluminator is inserted beneath the skin to illuminate the vein cluster that needs to be resected. A suction device with guarded blades (resector) is then introduced via another incision at the other end of the varicose vein, and the veins are cut and removed by suction [69]. This techniques has the proposed advantages of decreasing the number of incisions and reducing operative time.

Endovenous Procedures

In the last decade, endovenous ablation procedures have become a frequently used therapy for saphenous varicose veins. The endovenous thermal ablation techniques currently available are: endovenous laser ablation, radiofrequency ablation, and endovenous steam ablation. All endovenous techniques act by destroying the inner lining of the vein allowing the vein to seal off and turn into fibrous tissue, which is gradually removed by the body [71]. Endovenous procedures are recommended for great saphenous vein, short saphenous vein, accessory saphenous veins, Giacomini vein and cranial extension of a short saphenous vein, other superficial veins situated in the subcutaneous tissue, insufficient perforating veins, residual intrafascial veins after treatment and some of the venous malformations. Specific requirements for the segmental radiofrequency method is at least 10cm vein segment or 5 cm segment of a vein if a shorter heating element is used. For incompetent perforating veins, we need special radiofrequency stylet device, or for endovenous laser, there are no such restrictions. In veins that contain synechiae/membrane webs/postthrombotic changes the use of a special guide-wires, manual maneuvers or multiple entry sites are necessary. Absolute contraindications of endovenous procedures are acute deep vein thrombosis, acute superficial phlebitis, acute infections at the puncture sites, and deep venous obstruction if the vein to be treated is functional collateral. Relative contraindications are: immobile or hardly ambulating

patient, significant peripheral arterial disease with ankle-brachial index >0,5, pregnancy, elevated thromboembolic risk- thromboprophylaxis should be considered, significant uncompensated leg edema which cannot be adequately monitored by ultrasound for thrombosis and allergy to local anesthetics- tumescence without local agent or another agent should be used. Relative contraindications from a local point of view are tortuous vein difficult to catheterize, the diameter of a vein at the accessing segment < 3mm, partly occluded venous segment and vein segment to be treated shorter than necessary for catheter placement [73].

Endovenous Laser Ablation

Endovenous laser treatment (ELVES, EVLA) treats varicose veins using an optical fiber that is inserted into the vein. Then laser light, normally in the infrared portion of the spectrum, shines into the interior of the vein (Figure 2). This causes shrinking of a vein, and the optical fiber is slowly withdrawn. Minor complications can occur, as thrombophlebitis, pain, hematoma, edema, and infection [74].

During the procedure, a catheter bearing a laser fiber is inserted under US guidance into the great or short saphenous vein, small saphenous vein through a small puncture by puncturing with a 16F or 18F needle. Then guidewire is passed through the needle into the vein up to the level of the junction with the deep venous system, the needle is removed, and through a small cutaneous incision of 3 mm, an introducer sheath is placed over the guide wire and is positioned a few centimeters below the junction. Subsequently, the laser introduced after removing the guide wire. The catheter is then placed, also under ultrasound guidance, to the level of the groin in GSV insufficiency, or knee position in SSV insufficiency. A local anesthetic is injected around the vein (tumescence) using the US to give the local anesthetic solution around the vein, in full length of the treated vein. The laser is activated while the catheter or laser fiber is slowly withdrawn, resulting in obliteration of the saphenous vein along its entire length. The leg is bandaged after the procedure. Immediately after procedures can patient leave an ambulance [75, 81].

Figure 2. ELVES 1470 nm catheter just before completion of a procedure (lights indicated a tip of a catheter, sheat already pulled out).

Many medical laser systems for vein ablation use a 980 nm wavelength, but the top is a system uses a 1470 nm wavelength, which has greater absorption by water, blood and soft tissue in the vein wall. With radial fiber that reflects the laser beam using a prism and the laser energy is emitted in 360- degree manner, thus allowing homogenous irradiation of the vein wall and making it possible to prevent perforation [76, 82].

Endovenous Radiofrequency Procedure

Several systems for radiofrequency ablation exist VNUS Closure Fast (segmental RFA) and radiofrequency-induced thermotherapy (RFITT). Segmental RFA is currently more popular method (Figure 3).

Segmental RFA has a 7 cm therapeutic distal segment that heats to 120°C. Similar to endovenous laser therapy, perivenous tumescent anesthesia is applied to optimize surface contact and to decrease pain and risk of dysesthesia. External compression enhances contact of the catheter with the vein wall. During the procedure, a small incision is made, like in laser ablation for catheter insertion. The catheter delivers energy to the wall of the vein and cause of a vein to seal it, and blood can no longer travel through it. The vein can be absorbed into the bloodstream. After the damaged veins have been sealed, blood is naturally re-routed through healthier veins in the body. Compressive bandages or medical elastic stockings are indicated for one week after treatment [77, 83].

Endovenous radiofrequency is a minimally invasive treatment modality. It's alternative to stripping in the treatment of varicose veins and offers patients effective results with less pain, bleeding, and shorter recovery times than traditional procedures. This procedure can be performed for cosmetic or medical purposes, depending on each patient's condition and goals for treatment.

Figure 3. Just prior Radiofrequency catheter insertion. (sheat inserted inside of GSV).

Endovenous Steam Procedure

Endovenous steam ablation is another method of thermal vein ablation. It works with steam to a maximum temperature of 120°C. Under the US control vein is punctured with a 16-gauge needle. After puncturing the vein, the steam catheter is passed through the hollow

needle into the vein, and positioned 3 cm from the junction, under ultrasound guidance. Tumescent anesthesia is administered into the perivenous space to reduce pain, cool the perivenous tissue, and to decrease venous diameter. After activation, the catheter releases small "puffs" of steam and is pulled back in a stepwise fashion. At the first activation, 3 cm below the saphenofemoral or saphenopopliteal junction, four puffs of steam should be administered, while exerting gentle manual pressure on the junction. Further along the vein, two or three puffs of steam can be applied at 1 cm intervals depending on vein diameter. After the procedure, patients wear medical elastic compression and to mobilize immediately after the treatment.

All of these three above mentioned procedures are tumescent procedures. They are performed under local tumescent anesthesia, without the need for general or spinal anesthesia. Tumescent anesthesia reduces pain, cools perivenous tissue, and decreases the venous diameter. During tumescent anesthesia is a large volume of very dilute lidocaine (or another anesthetic) infiltrated around a vein, with the inserted catheter by the thin needle. The tumescent solution makes a shrinking of a vein around a catheter and sets apart nerves [78, 87].

One of the possible complications after thermal ablation techniques is an endovenous heat-induced thrombosis (EHIT) (Table 11).

Table 11. Types of EHIT

Type	Localization
I	Thrombus below superficial epigastric vein
II	Thrombus up to the origin of superficial epigastric vein
III	Thrombus up to, but not into the common femoral vein
IV	Thrombus bulging into the common femoral vein, but no adherent
V	Thrombus extending into common femoral vein and adherent to the wall
VI	Trombotic occlusion of a common femoral vein

EHIT I or II is identified, serial duplex imaging weekly with observation should be performed until thrombus regression into a superficial vein is noted. Antiplatelet therapy may be initiated in case of EHIT II. If EHIT III or IV is identified on duplex scan, low molecular weight heparin is initiated and continued, along with weekly duplex imaging and evaluation, until thrombus regression. Other possible complications include nerve injuries, bruising/hematoma, skin burns, superficial and deep venous thrombosis.

Other possibilities of vein destroying are mechanicochemical and chemical methodsThese methods are notumescent and nothermal, and they are performed without tumescent anesthesia (except local anesthesia – puncture site of the vein – insertion of a catheter).

MOCA: Mechanochemical Ablation

The catheter (Clarivein) consists of two components - a wire rotating at high speed that damages the inner lining combined with injection of liquid sclerosant to complete venous occlusion. This mechanical-chemical ablation technique is unique. This venous ablation technique employs a hybrid (dual-injury) technique built into one catheter-based delivery

system. Endomechanical abrasion of the vessel is produced by the tip of the catheter's rotating wire (mechanical component), and endovenous chemical ablation is induced simultaneously by the injection of a sclerosant drug sprayed from the tip of the catheter as it is pulled back [80, 86]. The combination is a very efficient and painless way to seal the vein. Catheter generates no heat. There is absolutely no risk of thermal injury and no need for the use of tumescent anesthetic.

Figure 4. Clarivein in GSV.

Chemical Methods

The VenaSeal closure system is the non-tumescent, non-thermal, non-sclerosant procedure that uses a proprietary medical adhesive delivered endovenously to close the vein. After the vein is accessed, the catheter is inserted into the vein, and the tip of a catheter under ultrasound guidance 5 cm away from the sapheno-venous junction positioned. A clinician conducts a series of trigger pulls to deliver the medical adhesive. Through the catheter, the adhesive – cyanoacrylate - is given to the diseased vein that needs treatment. Just as with other vein treatment, blood is then rerouted to other healthy veins. The obliterated vein will undergo a process of hardening, sclerosis, and will be gradually absorbed by the body. Unlike other vein treatments, you will not be required to wear compression stockings after treatment.

After all endovenous techniques, very rarely, but the potential complication is an anatomic failure of a procedure. Clinical failure, in contrast to an anatomic failure, means recurrent clinical symptoms and/or varicose veins. Anatomic failure means persisting or recurrence of reflux after the procedure (Table 12).

Table 12. Types of failure after endovenous procedures

Type	Definition
I – non-occlusion	veins that failed to occlude initially and never occlude during follow-up
II - recanalization	veins that were initially confirmed to be occluded but later recanalized, either partially or completely
III - groin reflux	situation in which the vein trunk was occluded but reflux persisted in the groin region. This type of failure often involves an ASV.

Varicose vein recurrence is reported with long-term follow-up at rates that are in extensive retrospective studies between 7 to 14 percent of patients. Other complications of ablative methods include hematomas/bruising, phlebitis reaction, deep and superficial venous thrombosis, thermal damage of skin and surrounding tissue and nerves in thermal methods.

Sclerotherapy

Telangiectasia, reticular veins, and varicose veins are visible signs of venous disease and can also occur in the absence of another symptom of a venous disorder [84]. Sclerotherapy is indicated in patients, to treat symptoms and signs of venous disorders, or for esthetic reasons. By these techniques is possible also treat truncal veins with reflux and perforators. Sclerotherapy can be performed in all stages of CVI, and the patient may be either symptomatic or asymptomatic from symptoms of CVI or because of cosmetic reasons. Also, patients with bleeding complications and with stigmata of recent bleeding may benefit from sclerotherapy. Absolute contraindication to the procedure is acute thrombosis or phlebitis and allergy to liquid. It should also be avoided in pregnant women/breastfeeding. A relative contraindication is patients with PAO and DM due to micro- macroangiopathy. Increased risk of postprocedural thrombotic complications is in patients with thrombophilia and inability to mobilize. A history of migraine headache and patent foramen ovale carry a higher risk due to microembolisation.

Sclerosant can be divided into three groups: osmotic agents, detergents, and corrosive/irritant.

Osmotic agents destroy the vessel by dehydration and disruption of the cell wall. The agent is rapidly diluted, and the effect is typically localized, and systemic toxicity is minimal. However, they cause pain during injection and local damage if they are extravasated. The most commonly used are hypertonic saline (23,4%) and a combination of dextrose with hypertonic saline.

Detergents act by disrupting cell membranes. Disrupting of a membrane is caused by the mechanism of protein theft denaturation. Detergents should be used at a concentration appropriate for the formation of micelles, and this micelle starts endothelial damage. Damage of a vein occurs within minutes of the administration of these agents. Typically detergent sclerosants include polidocanol, sodium tetradecyl sulfate, sodium morrhuate, and ethanolamine oleate used mainly for endoscopic control of bleeding.

Irritant/corrosive agents act by a different mechanism and vary greatly in chemical nature and properties, and some are quite dangerous.

These agents are ethanol and phenol, polyiodinated iodine (which can cause full-thickness vessel destruction in seconds), chromated glycerine, and glycerine/lidocaine/.

Liquid sclerotherapy is usually applied to telangiectasias, spider veins, and small varicosities that persist after vein stripping. Complications, including allergic reactions, thrombophlebitis, and skin necrosis or hyperpigmentation, are rare. When a vessel is treated sequentially form bigger to smaller, from deeper to superficial, over 90% of vessel can be treated. Sclerotherapy can be realized as an additional procedure to previous surgical or endovenous therapy, or as a separate therapy for smaller vessel liquid sclerotherapy and for bigger vessels as foam sclerotherapy.

Foam sclerotherapy is the application of foam into the vessels. Under US guidance, also known as ultrasound-guided sclerotherapy, is a technique for eliminating varicose veins, particularly larger ones. It's performed by injecting the veins with a foam that causes the veins

to scar inside, so that they eventually harden, close up, and disappear. Foam sclerotherapy mixes a chemical (EU – aethoxysklerol) and a gas (air), yielding a thicker, creamy consistency. The foam sclerosant drug is more efficacious than the liquid one in causing sclerosis, for it does not mix with the blood in the vessel and in fact displaces it, thus avoiding dilution of the sclerosant to cause maximal sclerosant action and is useful for longer and larger veins. The foam is produced manually, actually the most popular method is Tessary method (Figure 5). Foam is produced by two syringes, filled by liquid of different concentration, connected by medical three-way tap and then, moved the plungers of both syringes back and forth for 20 times to produce sclerosing foam. With higher concentrated foam (3%) is possible occlude even GSV and SSV, but recurrence of reflux is higher in relation to endovenous ablative methods.

Figure 5. Foam sclerotherapy of atypically localized transfascial insufficient perforating vein.

Saphenous Sparing Operations − ASVAL, CHIVA

Traditional surgery gives a radical solution in the treatment of CVI and varicose veins by phlebectomy of varicose collateral veins and high ligation and stripping of the saphenous vein. The theory is based on the principle that the varicose veins spread from top to bottom, and then a smaller collateral veins of the leg, which are the real varicose veins, superficial and therefore visible [72].

However, it does not explain the numerous cases of varicose veins with saphenous veins not affected by the disease.

ASVAL – ambulatory selective vein ablation under local anesthesia involves ambulatory phlebectomy of all varicose tributaries, with preservation of the great saphenous vein and small saphenous vein, irrespective of their competence. The saphenous vein is preserved. Even if GSV is affected by the varicose disease, simply because of removing the dilatated collateral veins. By this step is possible to fully recover its function. The ASVAL method is based on the ascending theory of varicose vein evolution, on the premise that reflux usually ascends from the tributaries toward the saphenous trunk. The main argument in favor of preserving the great saphenous vein is the essential physiologic role that the saphenous vein

could play in superficial drainage and, to a lesser extent, its availability as revascularization material. ASVAL approach may be performed using endovenous techniques. There are good technical success rates and clinical results disease in patients with segmental GSV reflux and a competent terminal valve.

CHIVA- conservative ambulatory hemodynamic management of varicose veins is a method to decrease the superficial venous pressure. The goal of CHIVA is to decrease the hydrostatic pressure by ligations placed in specific areas in the superficial venous system and to maintain the drainage function of the superficial veins, usually via a reversed flow. The CHIVA method is performed in an outpatient setting and under local anesthetic.

When varicose veins form in the venous system, the blood flows in the wrong direction in some places. Affected regions are tied off (ligated) according to a predetermined plan to restore correct blood flow through the remaining veins.

Surgery of a Deep Venous System

Deep venous reflux in the lower limbs is defined as reflux affecting the deep venous system. The reflux can be segmental or axial. Axial reflux means uninterrupted reflux from the groin to calf and segmental is limited reflux to a segment (e.g., femoral, popliteal...). Deep venous reflux mostly arises from three aetiologies: secondary - CEAP classification: Es (post-thrombotic syndrome), primary- CEAP classification: Ep (primary deep valve incompetence) and congenital – CEAP classification: Ec (congenital valve malformation).

Es (see above CEAP classification) is the most common etiology (60–85% of cases), and valve lesion is a consequence of thrombosis or inflammation of the vein wall, followed by a recanalization. Valve has been completely or partially damaged and retracted and adherent to the vein wall. Ascending and descending phlebography is crucial examination method before the operation.

Correction of a Deep Venous System

Valvuloplasty aims are to restore the competence of the valve by correcting the anatomical defect.

Operations in Valvular Insufficiency of a Deep Venous System

Internal Valvuloplasty

First proposed by Kistner, variations in the technique have been proposed by Raju, Sottiurai, and Tripathi to improve the valve exposure and to perform the surgical correction. The main goal is reducing the risk of tearing the free edges during the phlebotomy. This technique involves venotomy and correction of the valve leaflet defects under direct visualization.

External Valvuloplasty

Valvuloplasty is performable without phlebotomy by narrowing the lumen with some stitches at the cusp insertion angle: Transmural valvuloplasty. Transcommisural valvuloplasty

has the same purpose but unlike the former requires stitching of the cusp insertion. External valvuloplasty can be made with or without endoscopic supervision.

External Valve Banding

The principle of external valve banding is to reduce the caliber of the vein without opening of a vein to restore valve competence. Different materials for banding the vein have been used: Dacron cuff, Venocuff, Venocuff, polytetrafluoroethylene (PTFE) and bovine pericardium.

Vein Transplant

Vein transplant principle consists in inserting a segment of a competent valvulated vein. The best and most usable are brachial and axillary veins. The brachial vein transplant was described by Taheri and the axillary vein transplant by Raju. This segment is implanted in the incompetent deep venous network. The best-matched size for femoral level is the axillary vein; form popliteal vein is the best option the brachial vein.

Neovalve

The principle is to construct an autologous valve by using the patient's venous tissue. The neovalve can be created with the GSV termination, opportunely sectioned, shaped and invaginated into the femoral vein to function as a valve or by dissecting the vein wall to obtain a flap, which will work as a valve after adequate fixation [85]. The technique for constructing a neovalve is not always the same and it depends on the anatomical condition of the wall.

Operations for Obstruction of the Deep Venous System

Unilateral occlusions of the pelvic veins may be corrected by a Palma operation. In the classic Palma operation, the contralateral long saphenous vein is suprapubicly led to the opposite side and is anastomosed end-to-end or end-to-side with the common femoral vein of the occluded side for venous drainage. Also spirally wall reinforced PTFE grafts showed favorable results.

Circumscribed occlusions of the superficial femoral vein can be interposed by the May-Husni operation. Thereby the ipsilateral long saphenous vein is implanted end-to-side into the popliteal vein. This second operation is recommended to perform under the protection of a temporary av-fistula, which increase flowthrough venous bypass and decrease the probability of bypass thrombosis. The May–Husni procedure is rarely used because of the small number of patients with post-thrombotic segmental femoral vein obstruction alone.

Deep Vein Thrombosis

- Pain in the thigh or calf sometimes accompanied by edema. Half of the patients are asymptomatic
- History of recent surgery, trauma, cancer, prolonged immobilization, or oral contraceptive use
- The clinical impression is accurate in 50% of cases
- Venous duplex ultrasound is the diagnostic modality of choice

The Virchow is the cornerstone for assessment of risk factors for DVT.

The cause, in most cases, is multifactorial. The diagnosis of DVT cannot be made solely based on presenting symptoms and signs; up to half of the patients with acute thromboses have no abnormality detectable in the involved extremity. Duplex ultrasound has now become the test of choice. It is a noninvasive examination, with specificity and sensitivity of greater than 95%. Magnetic resonance venography shows promise as a new diagnostic study for this disorder. Measurement of D-dimer levels is too nonspecific.

Treatment

Treatment is concentrated to reduce the incidence of complications associated with DVT. Short-term complications include recurrent DVT or pulmonary thromboembolism, while long-term complications include the development of varicose veins and chronic venous insufficiency. The primary treatment of DVT is systemic anticoagulation. Warfarin is administered after therapeutic heparinization. LMWH in the treatment of DVT is safe and effective as standard unfractionated heparin in the treatment of DVT.

Superficial Vein Thrombosis

- Erythema, induration, and tenderness along the superficial vein
- Usually spontaneous but can follow venous cannulation

Superficial thrombophlebitis may appear spontaneously in patients with varicose veins, in pregnant or postpartum women, or patients with thromboangiitis obliterans or Behcet disease. The patient is presents complaining of localized extremity pain and redness. Areas of induration, erythema, and tenderness correspond to dilated and often thrombosed superficial veins. Superficial thrombophlebitis must be distinguished from other entities as ascending lymphangitis, cellulitis, erythema nodusum, erythema induratum, and panniculitis.

Treatment

The treatment of superficial thrombophlebitis starts with the administration of nonsteroidal anti-inflammatory drugs, local heat, elevation, and support stockings or elastic wraps. Septic thrombophlebitis requires treatment with broad-spectrum intravenous antibiotics. Chronic venous insufficiency can result from congenital venous valvular insufficiency or can result from previous venous thrombosis.

REFERENCES

[1] O'Hare, A. M., Allon, M., Kaufman, J. S. (2010). Whether and when to refer patients for predialysis AV fistula creation: complex decision making in the face of uncertainty. *Seminars in dialysis* 23:452-5.

[2] DeSilva, R. N., Patibandla, B. K., Vin, Y., et al. (2013). Fistula first is not always the best strategy for the elderly. *J American Soc Nephrol*, 24:1297-304.

[3] Mallios, A., Jennings, W. C., Boura, B., et al. (2018). Early results of percutaneous arteriovenous fistula creation with the Ellipsys Vascular Access System. *J Vasc Surg*, 68:1150-56.

[4] Radosa, C. G., Radosa J. C., Weiss, N., et al. (2017). Endovascular Creation of an Arteriovenous Fistula (endoAVF) for Hemodialysis Access: First Results.*Cardio Interven Radiol* 40:1545-51.

[5] Lok, C. E., Rajan, D. K., Clement, J., et al. (2017). Endovascular Proximal Forearm Arteriovenous Fistula for Hemodialysis Access: Results of the Prospective, Multicenter Novel Endovascular Access Trial (NEAT). *AJKD*, 70:486-97.

[6] Hull, J. E., Jennings, W. C., Cooper, R. I., et al. (2018). The Pivotal Multicenter Trial of Ultrasound-Guided Percutaneous Arteriovenous Fistula Creation for Hemodialysis Access. *J Vasc Endovasc Surg* 2018; 29:149-58.

[7] Georgiadis, G. S., Georgakarakos, E. I., Antoniou, G. A., et al. (2014). Correlation of pre-existing radial artery macrocalcifications with late patency of primary radiocephalic fistulas in diabetic hemodialysis patients. *J Vasc Surg* 60:462-70.

[8] Cerneviciute, R., Sahebally, S. M., Ahmed, K., et al. (2017) Regional Versus Local Anaesthesia for Haemodialysis Arteriovenous Fistula Formation: A Systematic Review and Meta-Analysis. *Eur J Vasc Endovasc Surg*, 53:734-42.

[9] Cooper, J., Power, A. H., DeRose, G., et al. (2015). Similar failure and patency rates when comparing one- and two-stage basilic vein transposition. *J Vasc Surg*. 61:809-16.

[10] Agarwal, A., Mantell, M., Cohen, R., et al. (2014). Outcomes of single-stage compared to two-stage basilic vein transposition fistulae. *Sem Dial*, 27:298-302.

[11] Chitalia, N., Ross, L., Krishnamoorthy, M., et al. (2015). Neointimal hyperplasia and calcification in medium-sized arteries in adult patients with chronic kidney disease. *Sem Dial* 28: E35-40.

[12] Lee, T., Thamer, M., Zhang, Y., et al. (2015). Outcomes of Elderly Patients after Predialysis Vascular Access Creation. *J Am Dial* 26:3133-40.

[13] Georgiadis, G. S., Georgakarakos, E. I., Antoniou, G. A., et al. (2014). Correlation of pre-existing radial artery macrocalcifications with late patency of primary radiocephalic fistulas in diabetic hemodialysis patients. *J Vasc Surg* 60:462-70.

[14] Vascular Access 2006 Work Group. (2006) Clinical practice guidelines for vascular access. *Am J Dis* 48 Suppl 1: S176-247.

[15] Gameiro, J., Fonseca, J. A., Lopes, J. A. (2018). Management of end-stage vascular access failure patients: a retrospective analysis, *Portugal J Nephrol Hyper*, 32, 357-63.

[16] Chytilová Eva, a kol. (2015). Cévní přístupy pro hemodialýzu, *Mlada fronta*, 105-137.

[17] D'Ayala, M, Smith, R. M., Martone, C. et al. (2008). The effect of systemic anticoagulation in patients undergoing angioaccess surgery. *Ann Vasc Surg*, 22:11-15.

[18] Irish, A. B., Viecelli, A. K., Hawley, C. M., et al. (2017). Effect of Fish Oil Supplementation and Aspirin Use on Arteriovenous Fistula Failure in Patients Requiring Hemodialysis: A Randomized Clinical Trial. *JAMA Internal Medicine*, 177:184-93.

[19] Macrae, J. M., Ahmed, S. B., Hemmelgarn, B. R., Alberta Kidney Disease Network. (2014). Arteriovenous fistula survival and needling technique: long-term results from a randomized buttonhole trial. *A J Kidn Dis*, 63:636-42.

[20] Jennings, W. C., Galt, S. W., Shenoy, S., et al. (2014). The Venous Window Needle Guide, a hemodialysis cannulation device for salvage of uncannulatable arteriovenous fistulas. *J Vasc Surg* 60:1024 -32.

[21] Long, B., Brichart, N., Lermusiaux P., et al. (2011). Management of perianastomotic stenosis of direct wrist autogenous radial-cephalic arteriovenous accesses for dialysis. *J Vasc Surg*, 53:108-14.

[22] Wong, B., Muneer, M., Wiebe, N., et al. (2014). Buttonhole versus rope-ladder cannulation of arteriovenous fistulas for hemodialysis: a systematic review. *Am J Kid Dis*, 64:918-36.

[23] Di Nicolò, P., Cornacchiari, M., Mereghetti, M., Mudoni, A. (2017). Buttonhole Cannulation of the AV Fistula: A Critical Analysis of the Technique. *Sem Dial*, 30:32-8.

[24] Swinnen, J., Lean Tan, K., Allen, R., et al. (2015). Juxta-anastomotic stenting with aggressive angioplasty will salvage the native radiocephalic fistula for dialysis. *J Vasc Surg*, 61:436-42.

[25] Kitrou, P. M., Spiliopoulos, S., Katsanos, K., et al. (2015) Paclitaxel-coated versus plain balloon angioplasty for dysfunctional arteriovenous fistulae: one-year results of a prospective randomized controlled trial. *J Vasc Int Rad*, 26:348-53.

[26] D Amato-Palumbo. S., Kaplan A. A., Feinn R.S et al. (2013). A retrospective study of microorganisms associated with vascular Access in hemodialysis patients. *Oral Surg Oral Med Oral Pathol Oral Radio.* 115:56 – 61.

[27] Cerneviciute, R., Sahebally, S. M., Ahmed, K., et al. (2017) Regional Versus Local Anaesthesia for Haemodialysis Arteriovenous Fistula Formation: A Systematic Review and Meta-Analysis. *Eur J Vasc Endovasc Surg*, 53:734-42.

[28] Feldman, L., Tkacheva, I., Efrati, S., et al. (2014). Effect of arteriovenous hemodialysis shunt location on cardiac events in patients having coronary artery bypass graft using an internal thoracic artery. *Ter Aph Dial*, 18:450-4.

[29] Cuthbert, G. A., Kirmani, B. H., Muir, A. D. (2014). Should dialysis-dependent patients with upper limb arterio-venous fistulae undergoing coronary artery bypass grafting avoid having ipsilateral in situ mammary artery grafts? *Interact Cardiovasc Thorac Surg.*, 18:655-60.

[30] O'Hare, A. M., Bertenthal, D., Walter, L. C., et al. (2007). When to refer patients with chronic kidney disease for vascular access surgery: should age be a consideration? *Kidney Int* 71:555-61.

[31] Beaulieu, M. C., Dumaine, C. S., Romann, A., Kiaii, M .(2017). Advanced age is not a barrier to creating a functional arteriovenous fistula: a retrospective study. *J Vasc Access* 18:307-9.

[32] Alkhouli, M., Sandhu, P., Boobes, K., et al. (2015). Cardiac complications of arteriovenous fistulas in patients with end-stage renal disease. *Nephrology*, 35:234-45.

[33] Reque, J., Garcia-Prieto, A., Linares, T., et al. (2017). Pulmonary Hypertension Is Associated with Mortality and Cardiovascular Events in Chronic Kidney Disease Patients. *Am J Nephrol*, 45:107-14.

[34] Wheaton, A. G., Cunningham, T. J., Ford, E. S., et al. (2015). Employment and activity limitations among adults with the chronic obstructive pulmonary disease-United States, 2013. *Morbidity and Mortality weekly report*, 64:289-95.

[35] Miller, G. A., Goel, N., Friedman, A., et al. (2010). The MILLER banding procedure is an effective method for treating dialysis-associated steal syndrome. *Kidney Int*, 77:359-66.

[36] Misskey, J., Yang, C., MacDonald, S., et al. (2016). A comparison of revision using distal inflow and distal revascularization-interval ligation for the management of severe access-related hand ischemia. *Journal of Vascular and endovascular surgery*, 63:1574-81.

[37] Scali, S. T., Chang, C. K., Raghinaru, D., et al.: (2013). Prediction of graft patency and mortality after distal revascularization and interval ligation for hemodialysis access-related hand ischemia. *J Vasc Surg*, 57:451-58.

[38] Aimaq, R., Katz, S. G. (2013). Using distal revascularization with interval ligation as the primary treatment of hand ischemia after dialysis access creation. *J Vasc Surg*, 57:1073-8.

[39] Napoli, M., Prudenzano, R., Russo, F., et al. (2010). Juxta-anastomotic stenosis of native arteriovenous fistulas: surgical treatment versus percutaneous transluminal angioplasty. *The J Vasc Access*, 11:346-49.

[40] Ene-Iordache, B., Remuzzi, A. (2012). Disturbed flow in radial-cephalic arteriovenous fistulae for hemodialysis: low and oscillating shear stress locates the sites of stenosis. *Nephrology, dial, Transplant,* 27:358-68.

[41] Atkar, R. K., MacRae, J. M. (2013). The buttonhole technique for fistula cannulation: pros and cons. *Curr Opin Nephrol Hypertens*, 22, 629-36.

[42] Morselli, C., Chiari, P., Aliberti, T., et al. (2015). Sharp versus blunt dialysis needle use with buttonhole method: Open randomized trial. *Journal of renal care,* 41:213-21.

[43] Dixon, B. S. (2012). Fish oil and hemodialysis graft patency: does time matter? *JAMA.* 307:1859-60.

[44] Russell, T. E., Kasper, G. C., Seiwert, A. J., et al. (2017). Cilostazol May Improve Maturation Rates and Durability of Vascular Access for Hemodialysis. *Vasc Endovasc Surg*, 51:120-24.

[45] Vaux, E., King, J., Lloyd, S., et al. (2013). Effect of buttonhole cannulation with a polycarbonate PEG on in-center hemodialysis fistula outcomes: a randomized controlled trial. *Am J kidney dis*, 62:81-8.

[46] Kundu, S. (2010). Review of central venous disease in hemodialysis patients. *J Vasc Intervent Radiol*, 21:963-8.

[47] Quaretti, P., Galli, F., Moramarco, L. P., et al. (2016). Stent Grafts Provided Superior Primary Patency for Central Venous Stenosis Treatment in Comparison with Angioplasty and Bare Metal Stent: A Retrospective Single Center Study on 70 Hemodialysis Patients. *Vasc Endovasc Surg*, 50:221-30.

[48] Leontiev, O., Shlansky-Goldberg, R. D., Stavropoulos, S. W., et al. (2014) Should all inflow stenoses be treated in failing autogenous hemodialysis fistulae? *J Vasc Intervent Radiol*, 25:542-47.

[49] Fu, N., Joachim, E., Yevzlin, A. S., et al. (2015). A Meta-analysis of Stent Placement vs. Angioplasty for Dialysis Vascular Access Stenosis. *Seminars in Dial* 28:311-7.

[50] Ulloa, J. G., Kirkpatrick, V. E., Wilson, S. E., Williams, R. A. (2014). Stent salvage of arteriovenous fistulas and grafts. *Vasc Endovasc Surg*, 48:234-8.

[51] Dolmatch, B. L., Duch, J. M., Winder, R., et al. (2012). Salvage of angioplasty failures and complications in hemodialysis arteriovenous access using the FLUENCY Plus

Stent Graft: technical and 180-day patency results. *J Vasc Intervent Radiology*, 23:479-87.

[52] Kakisis, J. D., Avgerinos, E., Giannakopoulos, T., et al. (2012). Balloon angioplasty vs. nitinol stent placement in the treatment of venous anastomotic stenoses of hemodialysis grafts after surgical thrombectomy. *J Vasc Surg*, 55:472-8.

[53] Vesely, T. M., Ravenscroft, A. (2016). Hemodialysis catheter tip design: observation on fluid flow and recirculation. *J Vasc Access*, 17: 29- 39.

[54] Ash, S. R. (2008). Advances in tunneled central venous catheters for dialysis: design and performance. *Seminars in dial*, 21, 504-15.

[55] Hockenhull, J. C., Dwan, K. M., Smith G. W., et al. (2009). The clinical effectiveness of central venous catheters treated with anti-infective agents in preventing catheter-related bloodstream infections: a systematic review. *Critic care Medicine*, 37, 702-12.

[56] Chatzinikolau, I., Finkel, K., Hanna, H. et al. (2003). Antibiotic-associated catheters for the prevention of vascular catheter-related infections. A prospective, randomized study. *Am J Med*, 115, 352-7.

[57] Nassar, B. M., Ayus, J. C. (2001). Infectious complications of the hemodialysis access. *Kidney internat*, 60,1-13.

[58] Haskal, Z. J., Saad, T. F., Hoggard, J. G., et al. (2016). Prospective, Randomized, Concurrently-Controlled Study of a Stent Graft versus Balloon Angioplasty for Treatment of Arteriovenous Access Graft Stenosis: 2-Year Results of the RENOVA Study. *J Vasc Intervent radiol*, 27:1105-14.

[59] Falk, A., Maya, I. D., Yevzlin, A. S. (2016). RESCUE Investigators. A Prospective, Randomized Study of an Expanded Polytetrafluoroethylene Stent Graft versus Balloon Angioplasty for In-Stent Restenosis in Arteriovenous Grafts and Fistulae: Two-Year Results of the RESCUE Study. *J Vasc Intervent Radiol* 27:1465-76.

[60] Allegra C., Antignati P. L., Carlizza A. (2007). Recurrent varicose veins following surgical treatment: Our experience with five years follow-up. *Eur J Vasc Endovasc Surg*, 33:751 – 756.

[61] Creton D. (1999). 125 reintervention for recurrent popliteal varicose veins after excision of the short saphenous vein. Anatomical and physiological hypotheses of the mechanism of recurrence. *J Mal Vasc*, 24: 30 – 37.

[62] Greiner M., Gilling-Smith G. L. (2007). Let varices originating from the pelvis: Diagnosis and treatment, *Vascular*, 2: 70 -78.

[63] Hua R. W., Yi M. Q., et al. (2014) Causes of recurrent lower limb varicose veins after surgical interventions in 141 limbs- Five-year retrospective analysis of two centers. *Vascular*, 22: 267 – 273.

[64] Lepage P. A., Villavicencio J. L., Gomez E. R. (1999) The valvular anatomy of the iliac venous system and its clinical implication. *J Vasc. Surg*. 14: 678 – 683.

[65] Parés J. O., Juan j., Tellez R et al. (2010) Stripping versus the CHIVA method: a randomized controlled trial. *Ann Surg.* 251: 624 – 631.

[66] Perrin M. (2014) Presence of varices after operative treatment: a review. *Phlebolymphology*, 3: 158 – 168.

[67] Perrin M. (2015) Presence of varices after operative treatment: a review. *Phlebolymphology*. 22: 5 – 11.

[68] Pieri A., Vannuzzi A., Nicolucci A. (1990) Anatomy of the gonadal veins. A reappraisal. *Surgery*. 109: 735 – 739.

[69] Pittaluga P., Chastanet S., Guex J. J. (2008) Great saphenous vein stripping with preservation of sapheno-femoral confluence: Hemodynamic and clinical results. *J Vasc Surg*. 47:1300 – 1305.

[70] Theivacumar N. S., Darwood R., Gough M. J. (2009) Neovascularisation and recurrence 2 years after varicose vein treatment for sapheno- femoral and great saphenous vein reflux: a comparison of surgery and endovenous laser ablation. *Eur J Vasc Endovasc Surg*. 38: 203 – 207.

[71] Van der Velden S. K., Lawaetz M., et al. (2016) Predictors of Recanalization of the Great Saphenous Vein in Randomized Controlled Trials 1 Year After Endovenous Thermal Ablation. *Eur J Vasc Endovasc Surg*. 52: 234 – 241.

[72] Wang h., Chen Q., Fei Z., et al. (2016) Hemodynamic classification and CHIVA treatment of varicose veins in lower extremities (VVLE). *Int J Clin Exp Med*. 2: 2465 – 2471.

[73] Bishawi M., Bernstein R., Boter M., et al. (2014) Mechanochemical ablation in patients with chronic venous disease: A prospective multicenter report. *Phlebology*. 29: 397-400.

[74] Boersma D., Kornmann V. N., van Eekeren R. R., et al. (2016) Treatment modalities for small saphenous vein insufficiency: systematic review and meta-analysis. *J Endovasc Ther*. 23: 199-211.

[75] Flessenkämper I., Hartmann M., Hartmann K. et al. (2016) Endovenous laser ablation with and without high ligation compared to high ligation and stripping for treatment of great saphenous varicose veins: Results of a multicentre randomized controlled trial with up to 6 years follow-up. *Phlebology*. 31: 23-33.

[76] Gauw S. A., Lawson J. A., van Vlijmen-van Keulen C. J. et al. (2016) Five-year follow-up of a randomized, controlled trial comparing saphenofemoral ligation and stripping of the great saphenous vein with endovenous laser ablation (980 nm) using local tumescent anesthesia. *J Vasc Surg*. 63: 420-428.

[77] Gloviczki P., Merrell S. W., Bower T.C. (1991) Femoral vein valve repair under direct vision without venotomy: A modified technique with the use of angioscopy. *J Vasc Surg*. 14: 645 – 648.

[78] Go S. J., Cho B. S., Mun Y. S., et al. (2016) Study on the long-term results of endovenous laser ablation for treating varicose veins. *Int J Angiol*. 25: 117-120.

[79] Helmy E. K., ElKashef O., Elbaz W.: (2011) Great saphenous vein radiofrequency ablation versus standard stripping in the management of the primary varicose veins-a randomized clinical trial. *Angiology*. 62:49-54.

[80] Merchant R. F. Pichot O., Myers K. A. (2005) Four-year follow-up on endovascular radiofrequency obliteration of great saphenous reflux. *Dermatol Surg*. 31: 129-134.

[81] Morrison N. (2005) Saphenous ablation: what are the choices, laser or RF energy. *Semin Vasc Surg*. 18: 15-18.

[82] Nael R., Rathbun S. (2009) Treatment of varicose veins. *Curr Treat Options Cardiovasc Med*. 11: 91-103.

[83] Nicolini P. (2005) Treatment of primary varicose veins by endovenous obliteration with the VNUS closure system: results of a prospective multicentre study. *Eur J Vasc Endovasc Surg*. 29: 433-439.

[84] Nijsten T., van den Bos R. R., Goldman M. P., et al. (2009) Minimally invasive techniques in the treatment of saphenous varicose veins. *J Am Acad Dermatol.* 60: 110-119.

[85] O'Donnell T. F., Balk E. M., Dermody M., et al. (2016). Recurrence of varicose veins after endovenous ablation of the great saphenous vein in randomized trials. *J Vasc Surg Venous Lymphat Disord.* 4: 97-105.

[86] Quarto G., Amato B., Giani U., et al. (2016) Comparison of traditional surgery and laser treatment of incontinent great saphenous vein. Results of a meta-analysis. *Ann Ital Chir*. 87: 61-67.

[87] Rass K., Frings N., Glowacki P., et al. (2015) Same site recurrence is more frequent after endovenous laser ablation compared with high ligation and stripping of the great saphenous vein: 5-year results of a randomized clinical trial (RELACS study). *Eur J Vasc Endovasc Surg*. 50: 648-656.

[88] Sadick N. S. (2005) Advances in the treatment of varicose veins: ambulatory phlebectomy, foam sclerotherapy, endovascular laser, and radiofrequency closure. *Dermatol Clin*. 23: 443-455.

In: Encyclopedia of Surgery (22 Volume Set)
Editors: Andreas Lehrer and Kristin Mueller
ISBN: 978-1-53618-329-0
© 2020 Nova Science Publishers, Inc.

Chapter 292

COMPLICATIONS AND RECOVERY IN VASCULAR SURGERY

Peter Berek*, MD, PhD
Department of Vascular Surgery, East Slovak Institute of Cardiovascular Diseases,
Pavol Jozef Safarik University, Kosice, Slovakia

ABSTRACT

The problem of postoperative complications in vascular surgery continues to be relevant. The development of postoperative complications is influenced by many factors, mainly the polymorbidity of patients, eyelids, and the multiplicity of atherosclerosis. It is accepted to allocate the general and local, early and late postoperative complications. General complications include syndrome of acute circulatory failure, cardiac decompensation, respiratory decompensation, renal decompensation, neurologic decompensation, hemocoagulative decompensation, mental decompensation. Of the local complications, the main place is occupied by bleeding and infection. Causes of early and late postoperative hemodynamic complications (thrombosis, false aneurysm of the anastomoses) are divided into major and concomitant. The main reasons include surgical errors (technical errors in the implementation of the anastomoses, excess or tension of the shunt, its torsion) and the failure of the distal bed. To the accompanying - violations of the blood coagulation system and general hemodynamic disorders. For the prevention of postoperative complications plays an important role preoperative preparation, risk stratification, and optimal drug therapy are necessary, intraoperative and postoperative prevention of infection. During surgery, it is important to choose an optimal and adequate volume of surgery considering the patient's age and polymorbidity. In the postoperative period, intensive postoperative monitoring and early rehabilitation of the patient are of great importance.

Keywords: vascular postoperative complications, bleeding, false aneurysm, infection, thrombosis, ischemia, compartment syndrome, amputation

* Corresponding Author's Email: berekp67@gmail.com

ABBREVIATIONS

AAA – abdominal aortic aneurysm
ARDS – acute respiratory distress syndrome
ARF – acute respiratory failure
CRP – C-reactive protein
CTA – computed tomography angiography
MODS – multiple organ dysfunction syndrome
PDGF – platelet-derived growth factor
PET – positron emission tomography
PMI – perioperative myocardial infarction
SIRS – systemic inflammatory response syndrome
TIA – transient ischemic attack
Tcp02 – transcutaneous oxygen tension

INTRODUCTION

The number of vascular bed surgeries increases with the increase in the prevalence of vascular diseases and the epidemic of diabetes mellitus. Most patients with peripheral arterial diseases are polymorbid being at high risk of developing postoperative complications [1, 2]. Also, postoperative complications may result from diagnostic or technical errors, namely inadequate or incomplete interpretation of the objective methods of examination (angiography, computed tomography angiography (CTA)) and surgical errors (inadequate assessment of intraoperative findings, technical errors, etc.) [3]. In vascular surgery, there are general and local complications. In terms of the period of occurrence, they are divided into early and late complications [4, 5].

GENERAL COMPLICATIONS

The development of general complications is affected by patients' polymorbidity. According to statistics, among vascular patients, coronary lesions and cerebral atherosclerosis are diagnosed in 40-60% of the cases, atherosclerosis of the renal arteries is found in 23-42% of the cases, diabetes mellitus and its complications are detected in 15-20% of the patients [2]. General complications include syndrome of acute circulatory failure, cardiac decompensation, respiratory decompensation, renal decompensation, neurologic decompensation, hemocoagulative decompensation, mental decompensation (Table 1).

Syndrome of acute circulatory failure is the leading cause of complications and mortality among the patients who underwent cardiac or vascular surgery. The most serious manifestation of acute circulatory failure is a circulatory shock, which is a clinical syndrome characterized by inadequate tissue oxygenation leading to decreased oxygen intake, anaerobic metabolism and lactic acidosis [6, 7].

Table 1. General complications

Syndrome of acute circulatory failure	
Decompensation	Cardiac
	Respiratory
	Renal
	Neurologic
	Hemocoagulative
	Mental
Multiple organ dysfunction syndrome	

Depending on the etiological factor in the operated patients, there are the following types of shock:

Cardiogenic shock (acute heart failure):

- initially low myocardial functional reserves;
- perioperative myocardial infarction;
- myocardial contractile dysfunction;
- cardiac rhythm disturbances and cardiac conduction defect;
- pericardial tamponade.

Hypovolemic shock (a decrease in total blood volume):

- bleeding;
- dehydration.

Distributive shock (excessive vasodilation):

- anaphylactic shock;
- septic shock;
- neurogenic shock.

Obstructive shock (physical obstruction of the great vessels):

- pulmonary embolism;
- superior vena cava syndrome.

Traditionally, clinical signs of shock are impaired consciousness, low temperature of the extremities, pale and mottled skin, a weak rapid pulse, low blood pressure and a decrease in urine output (oliguria/anuria) [8].

In addition to severe hemodynamic abnormalities, the severity of acute circulatory failure depends on several factors which may lead to the inadequate supply of organs and tissues with oxygen on the background of relatively normal central hemodynamics:

- low oxygen-carrying capacity of the blood (anemia and/or arterial hypoxemia);
- humoral imbalance;
- electrolyte imbalance;
- peripheral arteriovenous shunting;
- increased blood flow rate on the background of a decrease in the metabolic rate;
- capillary stasis due to inadequate perfusion and disseminated intravascular coagulation (DIC) syndrome;
- increased metabolic activity in the absence of cardiac efficiency reserves;
- impaired oxygen diffusion through the capillary wall due to increasing tissue swelling.

In the early postoperative period, the metabolic rate increases due to surgical aggression, activation of the sympathoadrenal system, high body temperature, energy expenditure for rewarming due to parenteral administration of cold solutions. Thus, the increase in cardiac output after surgery is considered as an adequate response of the circulatory system to surgical trauma [9].

Cardiac complications can manifest themselves as angina pectoris, heart failure, arrhythmia, myocardial infarction, death [10]. Acute myocardial infarction observed during surgery or in the early postoperative period is a complication of surgical treatment and is known as perioperative myocardial infarction (PMI). Most patients develop myocardial infarction during surgery or within the first postoperative day [11]. Pathogenetically important risk factors for developing PMI are the poor state of the distal bed of the coronary arteries, preoperative unstable angina, lesions of the left main coronary artery [12].

The diagnosis of PMI is based on the analysis of the clinical picture, electrocardiography data, the study of serum enzymes and echocardio-graphy [13]. The generally accepted clinical criteria for myocardial infarction have no informative value during and after surgery. The first signs of myocardial infarction in such patients are, as a rule, acute circulatory failure, persistent rhythm disturbances, sudden circulatory arrest. The gold standard of ECG diagnostics of macro-focal PMI is the presence of a new Q wave in one or more leads with a duration of not less than 0.04 sec which is seen on the ECG within 28-48 hours if there are no conduction abnormalities [11, 14].

Treatment of Complications

- maintenance of adequate circulation and respiration;
- prevention and treatment of life-threatening arrhythmias;
- attempts to restore coronary blood flow at the site of occlusion (angioplasty, coronary artery stenting; emergency surgery - coronary artery bypass graft surgery) which should be performed not later than 6 hours after the development of PMI;
- measures aimed at limiting the infarct zone (intra-aortic balloon pump counterpulsation, beta blockers, calcium antagonists, preparations affecting metabolism);
- anticoagulant and antiplatelet therapy;
- prevention and treatment of comorbid complications.

The mortality rate in PMI ranges between 20 and 24%; however, if PMI co-exists with cardiogenic shock, the mortality rate reaches 60-90%. Therefore, the selection of the patients and pharmacological optimization of cardiovascular risk factors before surgery are extremely important [11, 15].

Respiratory Complications

Acute respiratory failure, atelectasis, bronchospasm, analgesic-induced hypoventilation or hypoventilation resulting from residual neuromuscular blockade, infection, pulmonary edema, acute respiratory distress syndrome (ARDS), pulmonary failure [16].

Acute Respiratory Failure

There are two types of acute respiratory failure (ARF) – hypoxemic and hypercapnic. ARF may result from the disorders at the following levels:

- central neural respiratory control;
- regulation at the level of the peripheral nervous system and neuromuscular transmission;
- the capability of the respiratory muscles and chest framework;
- air way patency.

In the early postoperative period, ARF may occur as a result of the combination of the factors above [17]. When arterial hypoxemia develops, the following compensatory factors are involved: hyperventilation, pulmonary blood flow redistribution due to increased pulmonary artery pressure, increased cardiac efficiency, elevated hemoglobin levels due to reserves stored in the body depot. In acute cases, the efficiency of compensatory mechanisms is limited; as a result, organ and tissue hypoxia may develop [7].

Table 2. Etiological factors involved in the development of acute renal failure

Prerenal	Parenchymal	Postrenal
Decreased cardiac output, cardiogenic shock	Nephrotoxic factors Radiological contrast media	Ureteral obstruction
Pronounced hemolysis during the transfusion of incompatible blood	Myoglobinuria	A blood clot in the urinary bladder
Septic shock	Acute tubular necrosis	Urethral obstruction
Hypovolemia	Renal artery embolism and thrombosis	

Renal Complications

Acute renal failure. Prerenal failure is caused by hypovolemia or dysfunction due to decreased cardiac output. Renal parenchymal failure results from acute tubular necrosis. Postrenal failure is less common and is caused by ureteral or urethral obstruction [18]. To prevent renal failure, it is important to provide renal protection during vascular surgeries, especially in patients with the predictors of chronic renal failure [19].

Multiple Organ Dysfunction Syndrome

Multiple organ dysfunction syndrome (MODS), also known as multiple organ failure (MOF), is one of the most serious complications occurring in the postoperative period. The trigger mechanism of the development of multiple organ failure of any genesis is systemic inflammatory response syndrome (SIRS). The process of its formation in non-specific and does not depend on the etiology of the critical condition [20, 21].

Preoperative risk factors for the development of MODS include:

- the patient's a critical condition;
- patient's age over 60 years;
- cardiovascular failure;
- diabetes mellitus;
- renal failure;
- respiratory failure with obstructive disorders and a decrease in pulmonary function and oxygenation.

MODS may develop due to the occurrence of the following complications during surgery and in the early postoperative period:

- massive blood loss and hemotransfusion;
- the shock of various etiology;
- anaphylactic reactions;
- acute lung injury and respiratory distress syndrome;
- prolonged artificial blood circulation

In the late postoperative period, a person develops sepsis which results from a systemic response to microbial invasion.

- Neurological complications: acute cerebrovascular disease and transient ischemic attack (TIA).
- Coagulation complications: hypercoagulable and hypercoagulable states, the inefficiency of anticoagulant therapy.
- Mental decompensation: The development of postoperative delirium in 38.9% of the patients who underwent vascular surgeries. In this group of the patients, severe postoperative complications were more common (38.1% versus 18.2%) [22, 23].

LOCAL COMPLICATIONS

Local complications develop in the surgical field and are local. Considering the specificity of arterial reconstructions, local complications are often dramatic [5]. In terms of the period of occurrence, they are divided into early complications which develop within the first postoperative hours and days and late complications which occur several months or years after surgery [23, 24].

Table 3. Vascular Complications

Local vascular complications
Reconstruction thrombosis
Thromboembolic complications
Reconstruction infection
Bleeding
Anastomotic pseudoaneurysm
Deep vein thrombosis
Local nonvascular complications
Lymphatic fistulae (most often in the subinguinal region)
Postoperative extremity swelling
Compartment syndrome
Local peripheral nerve injury and ischemic neuropathy
Operative wound infection
Sexual dysfunction
Ureteral obstruction. Intraoperative injury during aortic reconstruction
Remote vascular complications
Visceral ischemia (more often colon ischemia)
Spinal cord ischemia
Atherothrombotic complications -peripheral microemboli

EARLY VASCULAR COMPLICATIONS

Early vascular complications include those occurring directly in the postoperative period and during hospitalization. They include bleeding, early reconstruction occlusion, early infection, lymphorrhea, nerve, and spinal cord injuries [25, 26].

Bleeding

Bleeding occurs most often within the first postoperative hours. It is caused by a technical error or hypocoagulable state which is associated with heparinization or antiaggregant therapy [27, 28].

There are the following types of bleeding:

a) bleeding from the anastomosis site or suture line due to suture abrasion or too wide suture spacings.At the site of suture abrasion, moderate bleeding occurs. This type of

bleeding is stopped by compression of the anastomosis site and heparin neutralization. Bleeding may be caused by injury from arterial clamps (in case of pronounced atherosclerotic changes) or traction sutures used in the dissection of blood vessels as well.

b) bleeding from a surgical wound due to the slipping off of the ligature from the vessel, inadequate coagulation of small blood vessels. Vascular injury may occur while suturing the surgical wound (injury with a needle). In this case, bleeding is usually stopped by tightening the suture.

c) bleeding from the great saphenous vein when it is used as a conduit for a bypass. In this case, bleeding may be caused by the slipping off of the ligature or clip from the dissected collateral branch. This type of bleeding occurs most commonly in poor blood outflow that increases the pressure exerted on the wall of the great saphenous vein.

Blood Loss Criteria

If surgical bleeding is accompanied by secondary disorders of hemostasis, within the first hours, if there are signs of bleeding, conservative hemostatic therapy is performed – the normalization of coagulation parameters – plasma, erythrocyte concentrate, hemostatic therapy. If heparin is active, it is neutralized with protamine sulfate. It is often a very difficult task to differentiate between the surgical cause of bleeding and hemostatic disorders. In such cases, it is very important to prevent massive blood loss. Massive blood loss and hemotransfusion result in DIC syndrome, SIRS and MODS [10]. If bleeding continues after conservative measures, emergency surgery is performed.

Tactics of treating bleeding patients depend on their clinical condition and the volume of wound secretion in the Redon drain canisters. If in the early postoperative period, the volume of blood secreted is 200-300 ml or there is an active blood secretion to the Redon drain canisters within several hours after two transfusions and hemostatic therapy, it is indicated to perform re-surgery to stop bleeding. On general examination, the patient presents with pallor, low blood pressure and hemoglobin levels. At the site of the surgical wound, resistance phenomena associated with hematoma progression may be observed. After carotid endarterectomy, in addition to the resistance on the neck, bleeding patients may develop signs associated with compression by hematoma which manifest themselves as a tracheal deviation, breathing and swallowing difficulties and sometimes there is the need for intubation [28].

During abdominal or retroperitoneal surgery, a hematoma may be not visualized when examining the patient. The lack of the secretion to the drain or minimal secretion does not mean that there are no signs of bleeding since the Redon drainage system may be impassable due to the presence of the blood clots. Diagnostic criteria include the patient's clinical condition, hemoglobin concentration and the objective methods of examination. The latter involves an ultrasound scan, CT (Figure 1).

Blood loss is considered to be significant if within 2-4 hours in the absence of pronounced coagulation disorders or the presence of hypercoagulation signs, there is the loss of 70 ml/m^2 of hemorrhagic fluid with the hematocrit close in value to blood hematocrit through the drain. This is the indication for re-surgery to achieve hemostasis.

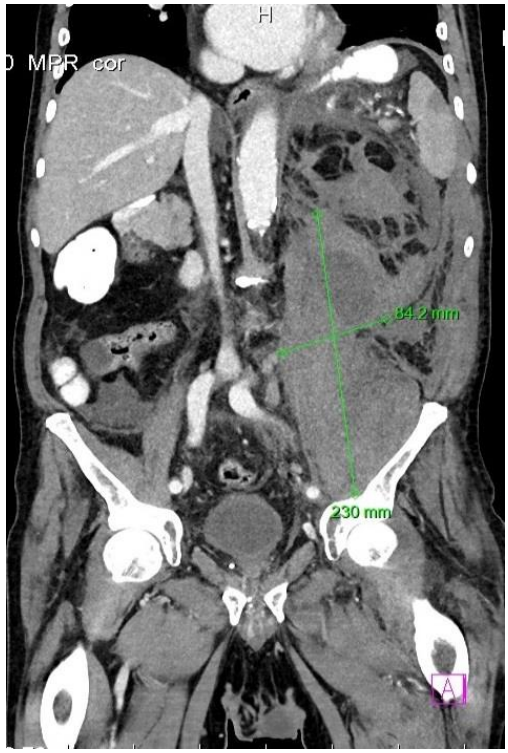

Figure 1. CT angiography of retroperitoneal hematoma.

During emergency surgery, the revision of the surgical wound is performed. During vascular surgery, the revision of arterial reconstruction zone is required. If the blood leaks out at the anastomosis site, the hemostatic suture is applied. If the suture is abraded, the method of choice is the mattress suture which reduces the possibility of suture abrasion. If there is bleeding from the collateral vessels, the ligature is placed, or the sutures are applied over the bleeding site. If there is bleeding from small collateral vessels, coagulation is used. In the case of diffuse bleeding, in addition to coagulation, local hemostatic agents can be used.

Reconstruction Occlusion

There is early and late occlusion of the reconstruction. Early occlusion is that occurring within 30 days after surgery. Late occlusion is that occurring 30 days after primary surgery [29].

Early occlusion is observed in approximately 5% of the cases; in 25% of these cases, it is caused by a technical error during surgery [30].

There are the following causes of early occlusion:

a) incorrect indication for surgery:
   - the bypass is performed in case of: a) weak blood inflow; b) poor blood outflow (peripheral injury).

- use of prosthetic material in patients with weak blood inflow and peripheral injury that increases the risk of thrombosis.

b) incorrect surgical technique:
   - error in the proximal anastomosis;
   - rotation or refraction of the prosthesis or the vein;
   - error in the distal anastomosis.

In lower extremity arterial reconstructions, bypass occlusion manifests itself as ischemia, namely lower extremity pain, the absence of pulse below the distal anastomosis, cold extremity, sensory and motor deficit [5, 30].

The diagnosis is clarified by an ultrasound scan or angiography in addition to the clinical picture [31].

In carotid artery reconstructions, acute occlusion manifests itself as acute cerebrovascular disease. CTA is the best method of carotid artery occlusion verification.

In visceral artery reconstructions, acute occlusion manifests itself as visceral ischemia; however, the clinical course is not so dramatic as that in acute carotid artery occlusion or lower extremity bypass occlusion.

A. mesenteric superior or inferior occlusion may manifest itself as gastric ischemia with the progression to gangrene, perforation, and peritonitis [32].

Visceral reconstruction occlusion is verified by CTA. Renal artery reconstruction occlusion may manifest itself as oliguria or anuria.

Indications for Surgical Revision in Acute Occlusion after Arterial Reconstruction

Lower Extremity Bypass Occlusion

Bypass thrombectomy with a Fogarty catheter is performed in the region of the distal anastomosis; it is necessary to pass through the proximal anastomosis and restore blood flow to the bypass. Then, the revision of the distal vascular bed through the distal anastomosis is performed. If in the region of the distal anastomosis, it is difficult to pass through the proximal anastomosis, it is better to open the wound in the region of the proximal anastomosis and to perform the revision of the blood flow and the anastomosis itself through small access in the proximal anastomosis region.

One of the most common problems is intima dissection which creates favorable conditions for occlusion. In such a case, it is better to disconnect the anastomosis, to perform intima fixation and to create the anastomosis again [33].

In case of prosthesis rotation, it is necessary to disconnect the distal anastomosis, to align the graft along the axis and to create the distal anastomosis again.

If there is no technical error, occlusion may be caused by incomplete removal of the blood clots when restoring the circulation, air embolism or an insufficient dose of heparin during the primary reconstruction. In this case, the only thrombectomy is performed. If bypass occlusion occurs several times, it is necessary to exclude the hypercoagulable state.

Infection

In vascular surgery, infection is an important problem [34]. It is necessary to differentiate between wound infection occurring in approximately 5% of the cases and prosthetic infection that develops in 0.2-1% of the cases [35]. The risk of developing infection is higher in urgent patients as compared to those undergoing elective surgeries [36]. Infections are classified according to the Szilagyi classification [37].

I. Phlegmon of the surgical wound
II. Infection of the subcutaneous tissue
III. Infection of the vascular prosthesis

The patients with infection Grade, I and II according to the Szilagyi classification, are at higher risk of developing prosthetic infection [38].

Infections are classified as early, if they occur within three months after surgery, or late, if they occur three months after surgery [39].

The prosthesis may be infected in the following ways:

a) intraoperative contamination through the surgical wound;
b) spread of infection by bacteremia;
c) mechanical erosion into the gastrointestinal or genitourinary tracts;
d) spread of infection per continuities.

Risk factors for the development of infection [40]:

a) poor adherence to the principles of intraoperative aseptic techniques;
b) emergency surgery;
c) hematoma or seroma in the postoperative period;
d) long-term surgery or hospitalization;
e) postoperative wound infection.

Re-surgery is an additional risk factor for remote prosthetic infection. In addition to local risk factors, general risk factors such as diabetes mellitus, chronic renal failure, immunosuppression, hormonal therapy increase the risk of infection as well [41].

The most common causative pathogen of prosthetic infection is *Staphylococcus aureus* [42]. Over recent years, in patients with aortoenteric fistulae, infections caused by *Staphylococcus epidermidis* or gram-negative bacteria have been observed more often [43]. Mycotic infections are rare, but if they are present, they occur due to *Candida albicans* and are typical for the immunocompromised patients.

Treatment of infection in vascular surgery is problematic and is often followed by limb loss [44, 45]. Clinical manifestations of prosthetic infection occur over time. Infection in the early postoperative period is caused by wound contamination due to the reconstruction in a potentially infected field, for example in trauma. Wound contamination may be caused by contact with the gastrojejunal tract when placing the aortobifemoral prosthesis [40, 46].

The inguinal wounds are associated with the highest risk of wound infection due to their proximity to the anogenital region. Infections caused by *Staphylococcus epidermidis* or gram-negative bacteria are more virulent. Clinical signs of inflammation include swelling, redness,

pain, fever. If the prosthesis is infected, bleeding or prosthetic occlusion may occur at the anastomosis site [47]. Bleeding may be massive and fatal. Infections caused by *Staphylococcus epidermidis* are less virulent. Most commonly, they manifest themselves several months or even years after surgery [38].

Typical clinical manifestation is anastomotic pseudoaneurysm or fluid collection around the prosthesis (Figure 2).

Figure 2. CT angiography - Perigraft fluid collection.

Systemic signs of infection are rare. The diagnosis is made based on clinical manifestations. The cultivation of the wound and fluid accumulated around the prosthesis is of great importance. The blood test indicates leukocytosis, elevated pro-inflammatory parameters (C-reactive protein (CRP), procalcitonin). Positive blood culture is observed in 5% of the cases only [43].

An ultrasound scan may detect hematoma, seroma or abscess in the subcutaneous tissue or around the prosthesis [48]. If CT 3 months after surgery illustrates the presence of fluid and air around the prosthesis, it indicates prosthetic infection (Figure 3). CTA may show pseudoaneurysm which is also typical for prosthetic infection.

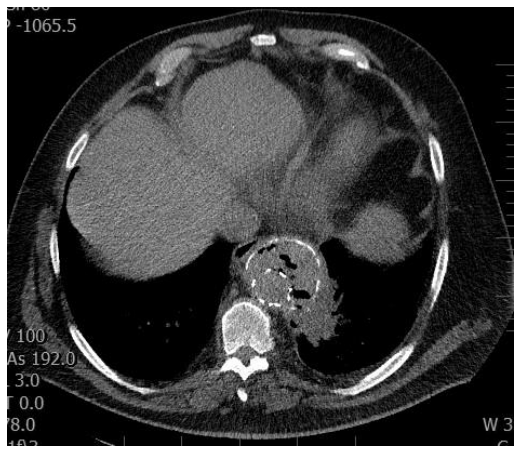

Figure 3. CT angiography - air around the prosthesis.

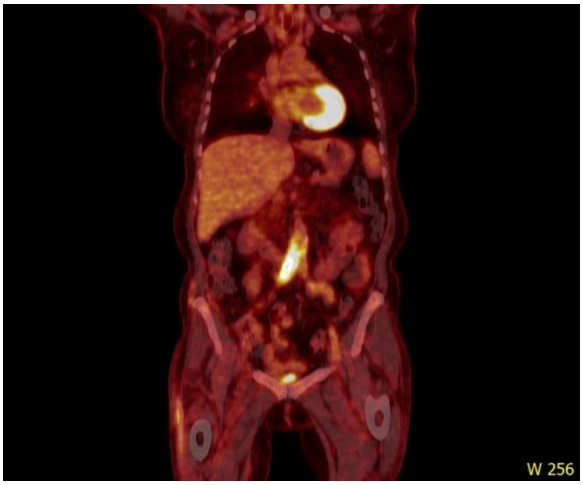

Figure 4. PET-CT infected prosthesis of aortobifemoral graft.

The next objective method of diagnosing prosthetic infection is leukocyte scintigraphy. The accuracy of this examination in detecting infection is 80-90%. Over recent years, positron emission tomography (PET) scan or PET in combination with CT (PET-CT) have been used for diagnosing prosthetic infection more frequently (Figure 4).

If aortoduodenal fistula is suspected, endoscopic examination of the distal portion of the duodenum is recommended [49].

Treatment

If the infection is localized in the subcutaneous tissue above the bypass, this means that infection Grade I and II according to the Szilagyi classification is present [37]. Treatment includes wound revision and debridement. The wound should be left open for daily dressings. In addition to necrotomy, antibiotic therapy based on the results of antibiotic susceptibility testing should be prescribed [50]. If the infection spreads to deeper layers, there is a need to open all the infected areas and perform necrotomy. The bypass can be preserved in patients with less virulent infection, and those with the signs of infection occurred up to 3 months after primary surgery, or if the infectious process spreads only to the part of the bypass [42]. Treatment of venous bypass infection may be successful for the preservation. The principle of treating infection is standard, namely intravenous antibiotic therapy, local necrotomy and vacuum therapy [50]. Even though some publications reported the efficacy of conservative treatment in 84% of the cases, in general, prosthetic infection was successfully cured using conservative treatment in 15% of the bypasses only [38]. In other cases, the entire bypass or it's infected part needed to be removed. If primary surgery was performed in the patient with intermediate claudication, it is possible not to create a new bypass but to perform venous plasty in the areas where anastomoses were created. However, in most cases, there is a need for limb revascularization. The possibilities of revascularization are as follows [51]:

a. extra-anatomic bypass;
b. in situ bypass.

The extra-anatomic bypass is a traditional method of choice for treating the prosthetic infection which includes the removal of the prosthesis, necrotomy of the infected area and extra-anatomic reconstruction [45, 52]. In the aortoiliac region, extra-anatomic reconstruction means as follows: the removal of the aortobifemoral bypass, suturing of the distal aorta (blind suture) and lower extremity revascularization using the axillofemoral bypass (Figure 5).

Figure 5. CT angiography of the axillofemoral bypass.

In case of only one aortobifemoral bypass graft infection, it is possible to extract the infected graft of the aortobifemoral bypass with further reconstruction using the prosthetic material, bypassing the infection in the inguinal wounds via foramen obturatum [46, 51]. On the medial side of the thigh, the distal anastomosis is placed on the superficial femoral artery. In extra-anatomic reconstructions, limb loss up to one year ranges between 10 and 25%; the perioperative mortality rate is 15-22%; 60-80% of the patients live more than one year. Axillofemoral bypass infection occurs in 3-25% of the cases [52].

The results above of extra-anatomic reconstructions have led to the search for new opportunities to perform in situ anatomic reconstructions [53, 54]. The patients with less virulent infection are more suitable for in situ arterial reconstructions. In such a case, to replace an infected prosthesis, there are the following options [55, 56]:

a) the great saphenous vein;
b) the femoral vein;
c) antibiotic-loaded prosthesis;
d) cryopreserved arterial allograft.

The great saphenous vein has a smaller diameter; therefore, it cannot be used for the aortoiliac region. However, it is the method of choice for the femorofemoral crossover bypass or the reconstruction in case of infection in the infrainguinal area [54].

In the 90's of the last century, some research works where the femoral vein was used for in situ reconstructions appeared [46]. The superficial femoral vein was dissected on the thigh immediately below the bifurcation of the common femoral vein (Figure 6).

Figure 6. Vein interpositum from common femoral artery to deep femoral artery (Superficial femoral vein).

After such a procedure, approximately 15% of the patients developed deep vein insufficiency. It is possible to perform in situ reconstructions of the aortobifemoral prosthesis using two femoral veins [51]. After such procedure, Clagett noted perioperative mortality in 10% of the cases, bypass patency six years after surgery in 80% of cases and extremity preservation six years after surgery in 90% of cases. Fifty-two percent of the patients lived more than five years [54].

The next possibility is in situ reconstruction using a cryopreserved arterial allograft from the donor aortoiliac region (Figure 7).

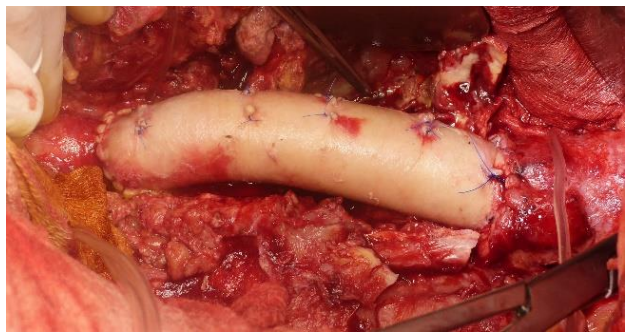

Figure 7. Aortal allograft (intraoperation photography).

The results were similar to those when performing reconstruction using the femoral vein. The disadvantage was a higher possibility of aneurysmal graft expansion, stenosis and the risk of degeneration which occurred in 5-20% of the cases [53]. In some case, the antibiotic-loaded prosthesis can be used for in situ reconstructions. The most frequently used antibiotic is rifampicin. This type of surgery is indicated for patients with slightly virulent infection without general inflammatory signs. The antibiotic-loaded prosthesis can replace only one

part of the aortobifemoral bypass prosthesis [56]. If this in situ reconstruction is performed in the abdominal cavity, the prosthesis should be covered by the omentum. In surgery in the groin, the prosthesis should be covered by the muscle. After surgery, the patients should undergo intravenous antibiotic therapy for six weeks. After using an antibiotic-loaded prosthesis, reinfection is observed in 5-10% of the cases. A 2-6-week course of intravenous antibiotic therapy is required after both extra-anatomic reconstruction and in situ replacement of the prosthesis [53].

Considering the fact that infection is one of the most serious complications in vascular surgery with a high percentage of limb loss and mortality, its prevention is of great importance [57]. The requirement for the prevention of prosthetic infection includes strict adherence to the principles of aseptic and antiseptic techniques and the limitation of direct contact of the prosthesis with the skin [58]. An important stage is maintaining hemostasis during surgery and adequate drainage of potential hematomas or seromas [44]. To prevent prosthetic infection, it is important to avoid single-stage interventions in the gastrointestinal or genitourinary tracts with arterial reconstruction. Also, antibiotic prophylaxis is required [59].

Lymphatic Secretion

The main arteries are located along lymphatic vessels. During dissection, lymphatic collectors may be damaged. Each arterial reconstruction has the risk of lymphatic secretion in the postoperative period [60]. Anastomotic drainage removes lymphatic secretion, if it is present. A non-drained seroma may serve as the risk factor for infection development.

In most cases, lymphatic secretion stops after several days. If the signs of lymphorrhea persist over a week, surgical revision is required. Methylene blue is applied distally to the dorsal surface of the operated extremity, and after several minutes, the affected lymphatic collector who needs to be sutured is visualized in the groin [61]. Complications such as chylous ascites or chylothorax are less common [62].

Nerve and Spinal Cord Injuries

Nerve injuries after arterial reconstructions are rare. They can be caused by direct nerve damage during surgery, ischemic nerve damage or insufficient revascularization in spinal cord injury [63, 64]. Among arterial reconstructions, nerve injury occurs most often during carotid endartere-ctomy accounting for 5-7% of the cases. Most commonly, n. hypoglossus, n. facialis, and n. laryngeus recurrens are damaged [65].

In most cases, these iatrogenic injuries are transitory in nature. Damage to the femoral nerve and the upper extremity nerves is rare. During venous surgery, when stripping the great saphenous vein, n. safenus is most often injured accounting for 27-35% of the cases [66].

The prevention of nerve injuries is a careful dissection of the anatomical structures with the knowledge of topographical anatomy and functioning of the nerves. The prevention of n. safenus injury also involves limited stripping during which only the great saphenous vein above the knee is removed [66].

Spinal cord ischemic injury occurs during surgical repair of the thoracic aorta and accounts for 2-10% of the cases. During aortoiliac reconstructions, the risk of spinal cord ischemia is 0.25% [66]. The artery which most frequently branches off from one of the paired intercostal arteries at the level of Th8-Th12 is important for the spinal cord blood supply. At

the same time, the origin of the artery of Adamkiewicz is variable, and it can branch off from the lumbar arteries. The internal pelvic arteries are also involved in the spinal cord blood supply. Paraplegia can be caused by the circulatory arrest in the lumbar arteries during aortic clamping or the removal of the internal pelvic arteries from the circulation. Due to the variability in the spinal cord blood supply, it is difficult to predict the development of its ischemia during vascular surgeries. To prevent possible spinal cord ischemia, it is recommended to preserve the circulation by maintaining flow through at least one of the internal iliac arteries [26, 65].

LATE COMPLICATIONS

Late infection is that occurring 30 days after primary surgery.

Late Occlusion of Arterial Reconstruction

Late occlusion of arterial reconstruction occurs 30 days after primary surgery [24].
Factors involved in the development of late occlusions of arterial reconstructions:

a) bypass localization;
b) replacement material for reconstruction;
c) rate of disease development;
d) long-term anticoagulant and antiplatelet therapy.

Localization

The determination of whether the bypass is passable is made during the observation period, for example for a year, three or five years [24]. Primary patency is defined as an uninterrupted patency with no bypass surgery. Secondary patency is defined as patency after bypass surgery to avoid its occlusion or after thrombolysis or thrombectomy after bypass occlusion.

Neointimal Hyperplasia

Neointimal hyperplasia is a common cause of remote bypass occlusion. Neointimal hyperplasia refers to the proliferation of all the intimal structures, especially smooth muscle cells which results in a significant increase in the volume of the extracellular fluid [67, 68]. The trigger mechanism is vascular wall injury which occurs during each reconstruction. The main role is played by platelets which release a platelet-derived growth factor (PDGF) when breaking down on the affected surface. This factor serves as a mitogen for smooth muscle cells and leads to their rapid multiplication. The process of developing neointimal hyperplasia lasts as long as several weeks due to type I and III collagen production which results from the metabolic activity of smooth muscle cells [63]. Neointimal hyperplasia is typical for distal anastomoses occurring within six months after primary surgery. An objective criterion for

neointimal hyperplasia is an anastomotic stricture. In the case of hemodynamically significant stenosis, percutaneous transluminal angioplasty is the method of choice for prevention of bypass occlusion.

In terms of the period of occurrence, vascular reconstruction occlusion has three stages.

Stage I – up to 3 months. In 25% of the cases, early occlusion is caused by a technical error during surgery [27].

Stage II – 9 months after primary reconstruction. The most common cause is neointimal hyperplasia.

Stage III – 20 months after surgery. The cause is the progression of atherosclerosis.

Diagnosis

Clinical manifestation of bypass occlusion includes limb ischemia. In a venous bypass, there is a tendency toward a gradual occlusion of the bypass which is accompanied by minimal clinical manifestations, while prosthetic bypass occlusion is accompanied by limb ischemia. The current reference standard for the diagnosis is duplex ultrasound, CTA or diagnostic angiography.

Treatment

If there are any indications for endovascular intervention or surgery, the potential success of bypass revascularization and the risk of re-surgery should be assessed [69]. If bypass occlusion is not accompanied by acute limb ischemia, conservative treatment may be used. If interventional therapy is preferable, the method of choice is thrombolytic therapy. If the results are positive, angioplasty or stenting of stenosis that resulted in bypass occlusion is performed (Figures 8-12).

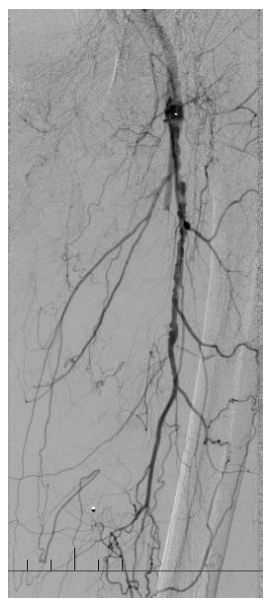

Figure 8. Occlusion of femoro – popliteal prosthetic proximal bypass.

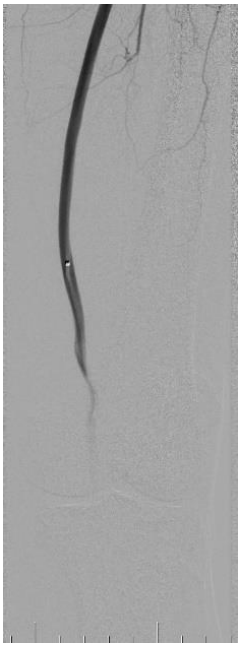

Figure 9. Thrombolytic therapy of femoro – popliteal prosthetic proximal bypass.

Figure 10. Result of successful thrombolytic therapy of femoro – popliteal prosthetic proximal bypass.

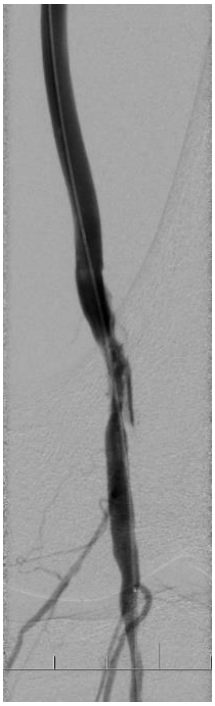

Figure 11. Stenosis of distal anastomosis of femoro – popliteal prosthetic proximal bypass.

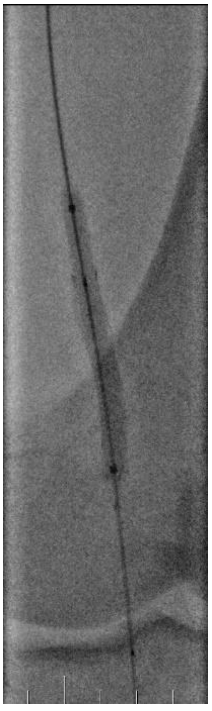

Figure 12. Percutan transluminal angioplasty and stenting of stenosis of distal anastomosis of femoro – popliteal prosthetic proximal bypass.

The next possibility is surgical treatment. Bypass revision and thrombectomy are performed. During revision, the cause of bypass occlusion should be determined. Stenosis at the distal or proximal anastomosis is the most common [24, 70].

Three alternative methods can be used for treatment:

- plasty at the anastomosis site;
- anastomosis resection with the creation of an interposition graft;
- creation of a new bypass.

False aneurysm

Anastomotic false aneurysm occurs in 1 to 5% of the cases [42]. The most common site of a false oaneurysm is the femoral artery.

The possible causes of false aneurysm are:

- disruption in the arterial wall when creating the anastomosis;
- anastomotic tension (short prothesis);
- infection.

In most cases, a false aneurysm is caused by a technical error or infection [28]. Clinical manifestation of bypass occlusion is pulsating resistance. The objective methods of diagnosing anastomotic false aneurysm are ultrasound scan and CTA.

Figure 13. CT angiography – False aneurysm of distal anastomosis of left branch of Aortobifemoral bypass.

A false aneurysm can result in bleeding, bypass occlusion or distal embolization of a thrombus. False aneurysm is treated surgically. It is necessary to perform the revision of the affected anastomosis and to restore the reconstruction by creating an interposition graft. If there is distal anastomotic false aneurysm of the aortobifemoral bypass, the interposition graft should be inserted in the deep femoral artery. If the patency of the superficial femoral artery is preserved, the interposition graft is inserted in its proximal end. During surgery, there is a need to collect the material samples for cultivation to exclude the infection. It is more difficult to treat proximal anastomotic false aneurysm of the aortobifemoral bypass [36]. The method of choice for its treating may be the placement of the stent graft into the proximal anastomosis. These treatment tactics is recommended to be used in patients whose false aneurysm was not caused by the infection [49].

ABDOMINAL AORTA AND ILIAC ARTERIES

The 5-year patency of the aortobifemoral bypass is 90%. The patients over 60 years of age demonstrate better patency of the aortobifemoral bypass as compared to patients under 60 years of age [44]. This may be because atherosclerosis is known to be more aggressive at a young age [26]. In general, the patency of the aortobifemoral bypass is limited by the distal anastomosis; therefore, it is recommended to perform profundoplasty when performing the aortobifemoral bypass [71]. In vascular surgery, infrainguinal reconstructions are reconstructions which most frequently involve bypasses. In the infrainguinal bypass, the blood flow is lower as compared to the aortobifemoral one that may result in worse results. Another cause of poor results may be peripheral injury. The 5-year patency of the femoropopliteal bypass is presented in table 4.

Table 4. The 5-year patency of the femoropopliteal bypass

	The proximal femoropopliteal bypass	The distal femoropopliteal bypass
Venous bypass	75%	50%
Dacron bypass	45%	25%
Polytetrafluoroethylene (PTFE) bypass	35-39%	16%

Extra-anatomic reconstructions demonstrate 5-year patency in 50% of the cases only. This is because the anastomosis geometry is not perfect, the reinforced protheses with worse elasticity are used more often; as a result, the transfer of the pulsating wave is worse.

Complications in Aortic Reconstructions

a) distal embolization – emergency embolectomy is indicated;
b) in an abdominal aortic aneurysm (AAA), intestinal ischemia is observed in 2% of elected surgeries and as much as 60% of emergency surgeries;
c) acute pancreatitis (pain when restoring nutrition, intestinal paresis);

d) acute acalculous cholecystitis;
e) aortoenteric fistula (1%);
f) ureteral injury or obstruction;
g) sexual dysfunction.

Left-Side Colon Ischemia after Aortic Reconstructions

Left-side colon ischemia occurs in 1.5-2% of the cases and is associated with extremely high mortality rates – up to 90% [32]. The restoration or preservation of the blood flow through the inferior mesenteric artery is one of the most effective methods of preventing the development of left-side colon ischemia. In 20% of the cases, the middle colic artery is absent; in such patients, the right colic artery (the branch of the superior mesenteric artery) plays an important role in the blood supply to the left colon, especially when the inferior mesenteric artery is ligated during surgery [72]. The internal iliac arteries are responsible for retrograde collateral revascularization of the left colon directly due to anastomoses of the superior rectal artery and the branches of the inferior mesenteric artery [73]. In the patients with occlusion or subtotal stenosis of the celiac artery and the superior mesenteric artery when the blood supply to the intestine is through the inferior mesenteric artery, an additional collateral blood supply to the left colon via the internal iliac artery is of great importance. The development of acute disorders of the visceral circulation and, accordingly, intestinal ischemia after aortic reconstructions is associated with many factors [32]:

1) unreasonable or improper ligation of the inferior mesenteric artery;
2) the extent of the damage to the visceral branches and the significance of these arteries for the visceral circulation;
3) state and functioning of the direct intercostal anastomosis.

Depending on the severity of the visceral circulation disorders occurring after aortic reconstructions, clinical manifestations of colonic ischemia range from subclinical forms to the development of gangrene and colonic perforation with the development of severe peritonitis.

There are three stages of the pathological process:

1) stage of ischemia;
2) stage of infarction;
3) stage of peritonitis.

After aortic reconstructions, clinical symptoms may occur within 14 days; however, in 75% of the cases, they develop in the first 24-48 hours after surgery. The prevention of left-side colon ischemia in aortoiliac reconstructions consists of the restoration or preservation of the blood supply via the inferior mesenteric artery, if it is possible (Figure 14).

In case of the inferior mesenteric artery ligation, it should be performed as close as possible to the aorta in order not to affect the collateral relation between the left colic artery and the sigmoid arteries [74].

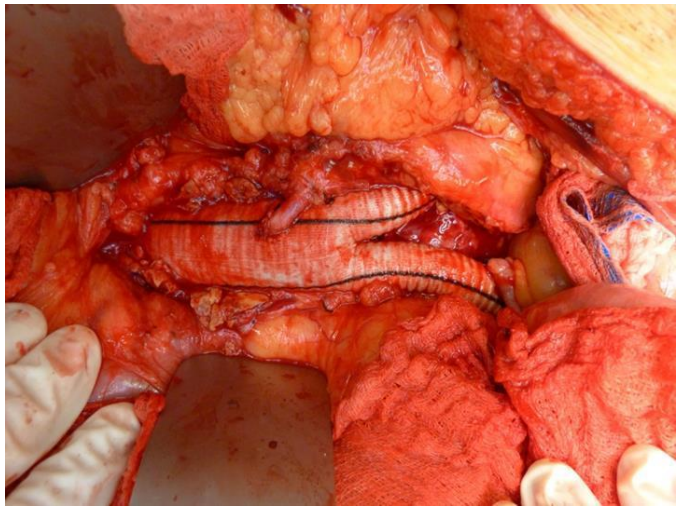

Figure 14. Reconstruction of inferior mesenteric artery.

In the opening of the aneurysm sac, possible embolization of the inferior mesenteric artery should be considered; therefore, it is better to apply a bulldog clamp to the inferior mesenteric artery before opening the aneurysm sac. If to restore the blood supply through the inferior mesenteric artery is impossible, it is important to preserve the blood supply through the internal iliac artery to prevent possible left-side colon ischemia [72].

Aortoenteric Fistula

An aortoenteric fistula is a connection between the aorta and the digestive tract. Primary aortoenteric fistula is a connection between the native aorta and the digestive tract. It occurs most often as a connection between an AAA and the duodenum [49].

Secondary aortoenteric fistula is a connection between the aortic reconstruction and the digestive tract and is one of the most serious complications in vascular surgery. It is observed in 1.6% of the cases [56]. A secondary aortoenteric fistula develops more often after the aortobifemoral bypass as compared to AAA resection. It is more common when performing end-to-side anastomosis as compared to end-to-end anastomosis [39]. The prosthesis communicates most commonly with the duodenum, rarely with the small intestine. The fistula results from direct contact between the prosthesis or pseudoaneurysm of the proximal anastomosis and the duodenum or the small intestine. The impaired integrity of the duodenal wall or the small intestine leads to the leakage of the intestinal contents and direct contact between the prosthesis and the digestive tract [56].

Aortoenteric fistula manifests itself as gastrointestinal bleeding. Bleeding may initially be episodic and minor; massive bleeding may occur later. If the patient develops the signs of gastrointestinal bleeding, possible aortoenteric fistula should be taken into account. It is not easy to make the diagnosis of aortoenteric fistula, since, in duodenoscopy, the source of bleeding may be not visualized [49]. The current reference standard for the diagnosis is CT which can visualize pathological formations in the area of the proximal anastomosis and the prosthesis. PET-CT may serve as an additional diagnostic method as it can visualize fistula localization. The patient may present with the symptoms of chronic sepsis, elevated levels of CRP and procalcitonin. Blood cultures are not always positive. Treatment is difficult. The

principle of treatment is the same as in treating prosthetic infection, namely intravenous antibiotic therapy, prosthesis extraction; resection of the affected area of the digestive tract [35].

There are two methods to exteriorize the prosthetic material:

1) to remove the prosthetic material, to suture the terminal aorta using blind suture, to provide the blood supply to the lower extremities by creating the extra-anatomic bypass, most often the axillofemoral bypass;
2) in situ reconstructions using the femoral vein or the arterial allograft.

However, because it is a case of highly virulent infection caused by gram-negative bacteria, the extra-anatomic bypass is safer. The use of in situ reconstructions alongside with antibiotic-loaded prosthesis is controversial. The mortality rate in the aortoenteric fistula is >50% [41]. To prevent aortoenteric fistula, it is necessary to carefully close the retroperitoneal space with sutures without leaving any direct contact between the prosthesis and the duodenum or the other part of the digestive tract [56].

Sexual Dysfunction

Sexual dysfunction may result from the impairment of the paraaortic hypogastric plexus during aortoiliac reconstructions. Symptoms of sexual dysfunction are present in 25% of men who underwent surgery [21]. The impairment of the paraaortic plexus manifests itself as retrograde ejaculation. Sexual dysfunction may also result in impaired blood supply to the internal iliac arteries that lead to erectile dysfunction.

COMPLICATIONS IN CAROTID ARTERY RECONSTRUCTIONS

Complications in carotid artery reconstructions may be:

A) During carotid endarterectomy, stroke or TIA may occur at the stage of artery identification, artery clamping, intraoperative shunt placement, poor-quality or inadequate endarterectomy [75]. In all these cases, neurological impairment is embolic, and only anti-stroke therapy is required, which, in most cases, leads to complete or nearly complete relief of focal symptoms [28].

In thrombosis of the reconstructed area, emergency reintervention is required.

Thrombosis of the internal carotid artery (ICA) after carotid endarterectomy may be associated with the following factors:

- technical errors during the surgical intervention (narrowing of the vessel with a suture, suturing of the opposite wall, leaving off the unremoved portion of the plaque in the common carotid artery or the ICA, buckling of the intima in the distal ICA);
- cerebral hypoperfusion due to MI, heart arrhythmia, hypotension in blood loss or drug-induced hypotension;
- inadequate postoperative management (inadequate antiplatelet therapy, arterial hypertension).

In the case of re-surgery for thrombosis, it is crucial to follow the following recommendations:

- re-administration of heparin before artery clamping;
- a thorough revision of a distal ICA suture line;
- careful removal of the blood clot in the ICA by aspiration and extraction or using a Fogarty catheter.

B) Intracerebral hemorrhage is a very rare but very formidable complication. In most cases, it is fatal. Hemorrhagic stroke most commonly occurs a few days after surgery; in such complication, medical aid is limited to observations and some conservative recommendations, namely dehydration, maintenance of blood pressure within slightly below normal range, discontinuation of disaggregate or anticoagulant therapy [76].

Postoperative hemorrhage may be caused by:

- ischemic focus that developed after stroke;
- hyperfusion;
- severe arterial hypertension.

C) Local nerve injury (n. laryngeus recurens 6.5%, n. hypoglossus, n. mandibularis, n. laryngeus superior, n. facialis). In 80% of cases, nerve injury during carotid artery surgeries is transitory in nature with functional recovery up to 3-5 months [26].

D) Headache which may result from hyperfusion.

E) Ductus thoracic injury.

F) Central hyperthermia and uncorrected hyperglycemia that are signs of cerebral edema and malacia. This type of complications is mainly fatal [30].

VASCULAR ACCESS COMPLICATIONS IN PATIENTS WITH CHRONIC RENAL FAILURE

Thrombosis is the most common complication. Early thrombosis (from 1 to 7 days) is most commonly caused by technical errors when forming vascular access (narrowing of the anastomosis lumen or its inadequate diameter, vascular torsion, creation of the anastomosis close to the venous valve that impair the blood flow at the anastomosis site; inadequate mobilization of blood vessels, namely the deformation of excessively mobilized blood vessels, trauma to blood vessels during vascular mobilization, hematomas at the anastomosis site and within arteriovenous fistula). Persistent hypotonia and hypercoagulation in the postoperative period lead to arteriovenous fistula thrombosis as well. Up to 25% of arteriovenous fistulae become occluded in the early postoperative period. Late postoperative thrombosis accounts for 12-15% of the cases, and its incidence is determined by fistula dysfunction [77, 78].

Bleeding

The main causes of bleeding are inadequate hemostasis, high blood pressure, purulent and infectious complications, excessive heparin dosage, hypocoagualtion.

Aneurysm

Arteriovenous aneurysm (Figure 15) usually develops due to a large diameter of the anastomosis, frequent vasopuncture in a certain area, proximal venous stenosis. This complication requires surgical correction of vascular access, namely anastomosis reconstruction, resection of the extended fistula segment.

Figure 15. Arteriovenous aneurysm.

Infection

Surgery is associated with a high risk of infection, since the terminal stage of chronic renal failure is characterized by significantly reduced patient's immunity. Purulent and inflammatory complications may account for 5% of the cases involving primary vascular access. The task of an angiosurgeon consists of early detection of this complication that will allow reducing the risk of arrosive bleeding. If bleeding occurred, the vessels should be ligated in the intact zone. To prevent infection, broad-spectrum antibiotics should be prescribed in the postoperative period [79].

Vascular Access to Steal Syndrome

This complication results from steal syndrome and distal limb ischemia due to low perfusion pressure. Vascular access to steal syndrome develops most often when performing

the end-to-end anastomosis. In case of minor severity, there is no need for special treatment. In case of significant circulatory disorders in the distal limb, fistula elimination or the reconstruction of the anastomosis (end-to-end anastomosis) which allows eliminating steal syndrome are needed [80].

Complications Associated with Using Central Venous Catheters

Infectious Complications

The catheter itself or the space surrounding it may be the source of infection. To avoid infectious complications, it is necessary to follow all the rules of central venous catheter placement and maintenance [79].

Thromboembolic Complications

At the end of the catheter, large blood clots or thin fibrin layers can be formed. Large blood clots usually lead to change in the pressure curve and the difficulties when trying to get blood from the catheter or flushing it. The patients often develop limb swelling, and if the catheter was inserted through the internal jugular vein, neck pain or jugular vein distension might appear. In the case of venous catheter thrombosis, it must be removed or replaced.

AMPUTATION IN VASCULAR SURGERY

Despite the great achievements in modern angiology and angiosurgery, in 28-47% of the patients with critical ischemia, above-knee amputation of the lower extremity is the only surgery that relieves severe pain [81]. Vascular reconstructions not always result in quality limb revascularization. In 6-15% of the cases, the attempts to jugulate the phenomena of critical ischemia are unsuccessful, and surgeons have to perform limb amputation according to secondary indications [82]. The frequency of performing lower limb amputation in patients with vascular diseases is as follows: above-knee amputation – 39.1%, below-knee amputation – 23.6%, foot amputation – 6.4%, transmetatarsal amputation – 30.9% [81, 83].

Severe complications such as tissue necrosis and postoperative wound infection after below-knee amputation result in re-amputation at the above-knee level in approximately 50% of the patients [84].

Above-knee amputation causes patient's functional disability. Only 30.3% of the patients who underwent such surgery use the prosthesis successfully. After below-knee amputation, this number reaches 69.4% [85].

To determine treatment tactics for the patients with the ischemic ulceronecrotic lesions of the lower extremity, attention should be paid to the following factors [86]:

I. whether there is a possibility to perform vascular reconstructions in the affected limb. The severity of the patient's general condition, the presence of comorbidities, the degree of the damage to the arterial limb bed are assessed;

II. whether there is a possibility to perform organ-preserving surgery in the foot, including minor amputations (the spread of ulceronecrotic tissue lesions of the foot; nature and extent of purulent complications);
III. the strategy and tactics of limb amputation are determined.

Classification of Amputations

Limb amputation is the traumatic or surgical removal of the peripheral part of the limb at the bone level.

Disarticulation (exarticulation) is the surgical removal of the peripheral part of the limb at the articulation level.

Foot resection is the surgical removal of the foot segment with one or more toes in the longitudinal direction.

Classification of Limb Amputations [87]

- according to indications – primary amputation, secondary amputation, re-amputation;
- according to terms of performing – emergency amputation, urgent amputation, and elective amputation;
- according to surgical tactics – one-stage surgery, two-stage surgery;
- according to the extent: minor amputation, major amputation;
- according to the method of tissue dissection: guillotine amputation, circular amputation, flap amputation, exarticulation of any limb segment;
- according to the method of stump formation – fascioplastic amputation, tendoplastic amputation, myoplastic amputation, osteoplastic amputation.

The indications for primary limb amputation in acute and chronic occlusive vascular diseases is dry and wet gangrene of the peripheral segment (or segments) of the limb [88]. Secondary amputations are carried out according to secondary indications that include ineffective conservative long-term therapy if it is impossible to perform vascular reconstructions; failed surgical reconstruction of the great vessels in patients with severe pain [89].

Re-amputation is limb amputation at a higher level as compared to previously performed amputation [90]. The indications for re-amputations are purulent and necrotic complications in the postoperative period and severe pain with trophic changes in the stump. Minor amputations include amputations of the foot or hand at different levels. In patients with critical ischemia, minor amputations are possible only in the case of compensating distal blood flow [91].

Large amputations include amputations at any level of the shin, forearm or upper arm.

An absolute contraindication for limb amputation is the patient's agonal state [90].

Selection of Amputation Level

Amputation/exarticulation of a single toe, resection and distal amputation of the foot are performed in case of [87, 89]:

- preserved or restored blood supply to the lower third of the tibia;
- tibiofemoral index of > 0.6;
- the transcutaneous oxygen tension (Tcp02) value at the amputation level of > 30 mm Hg.

Below-knee amputation is performed in case of:

- the spread of ischemic and purulent foci to the lower end of the tibia as it is impossible to form the stump of the foot at the lowest level possible;
- preserved or restored blood flow through the deep femoral artery with a good filling in the area of the knee joint;
- the value of the gradient between the lower and the upper thirds of the tibia of <30 mm Hg;
- the Tcp02 value at the amputation level (a border between the lower and the upper thirds) of >30 mm Hg.

Above-knee amputation is performed in case of:

- it is impossible to preserve the tibia;
- preserved or restored blood flow through the common and deep femoral arteries;
- the value of the gradient between systemic (the upper arm) and segmental (the upper third of the thigh) blood pressure of <30 mm Hg;
- the Tcp02 value at the amputation level of >30 mm Hg.

Thigh disarticulation is performed in case of:

- it is impossible to perform above-knee amputation due to the presence of devitalized tissues on the posterior and outer surface of the upper third of the thigh;
- lack of main blood flow in all the arteries of the thigh;
- reduction in the Tcp02 value to <30 mm Hg at the level of the upper third of the thigh.

Finger amputation or disarticulation is performed in case of:

- the value of the gradient between the upper third of the contralateral (unaffected) upper arm and the lower third of the forearm of <30 mm Hg when measuring systemic blood pressure;
- preserved or restored blood supply to the lower third of the forearm;
- the Tcp02 value at the amputation level of >30 mm Hg.

Forearm amputation is performed in case of:

- the spread of ischemic and purulent foci to the forearm as it is impossible to form the stump of the hand;
- the value of the gradient between the lower third of the upper arm and the upper third of the forearm of <30 mm Hg when measuring segmental blood pressure;
- preserved or restored blood flow through the deep brachial artery with good perfusion in the elbow joint;
- the Tcp02 value at the amputation level of >30 mm Hg.

Upper arm amputation is performed in case of:

- it is impossible to preserve the forearm;
- the value of the gradient between the affected and unaffected upper arm of <30 mm Hg when measuring systemic blood pressure;
- preserved or restored blood flow through the axillary artery;
- the Tcp02 value at the upper arm amputation level of > 30 mm Hg.

Toe Amputation

Depending on the extent of the necrotic lesion, the following amputations are performed:

- toe amputation at the middle phalanx level;
- toe amputation at the proximal phalanx level;
- toe disarticulation;
- toe amputation according to Garengeot (removal of all the toes at the level of the metatarsophalangeal joints).

Foot Amputation and Resection

- surgical resection of the foot;
- Transmetatarsal amputation;
- Lisfranc (tarsometatarsal) amputation.

Marginal resection of the foot is surgical removal of the foot segment with one or more toes along the outer or inner edge.

Sectoral resection of the foot is surgical removal of the foot segment with one or more inner toes (II-IV)

Transverse foot resection is foot amputation.

Upper Limb Amputation

The indications for upper limb amputation include gangrene due to obliterative atherosclerosis (extremely rare), diffuse arteriovenous angiodysplasia accompanied by impaired macro- and microcirculation, trophic disorders, severe pain, impossible surgical correction of the blood flow, untreated forms of thromboangiitis obliterans [92]. In the ischemic ulceronecrotic lesions, upper limb amputations are performed with an attempt to preserve as much of the residual limb length as possible [93].

CONCLUSION

The patients with peripheral arterial disease are considered as high-risk patients. The severity of this category of patients is due to their polymorbidity, namely hypertension, cardiac pathology, diabetes mellitus, renal failure. An additional high-risk factor is smoking. Surgery may provoke the decompensation of chronic disease; therefore, it is important to minimize risk factors. In the preoperative period, preoperative preparation, risk stratification, and optimal drug therapy are necessary. During surgery, it is important to choose an optimal and adequate volume of surgery considering the patient's age and polymorbidity. In the postoperative period, intensive postoperative monitoring and early rehabilitation of the patient are of great importance. In the case of early postoperative complications, an adequate assessment of the patient's condition and emergency surgery, if necessary, are important. It is timely re-surgery that significantly reduces postoperative mortality rates in case of early postoperative complications. Centralization of vascular patients results in the reduction in postoperative complications.

REFERENCES

[1] Young, E.L., Karthikesalingam, A., Huddart, S., et al. (2012). A systematic review of the role of cardiopulmonary exercise testing in vascular surgery. *Eur J Vasc Endovasc Surg.*, 44(1):64-71. doi: 10.1016/j.ejvs.2012.03.022.

[2] Moran, J., Wilson, F., Guinan, E., et al. (2016). Role of cardiopulmonary exercise testing as a risk-assessment method in patients undergoing intra-abdominal surgery: a systematic review. *Br J Anaesth.*, 116(2):177-91. doi: 10.1093/bja/aev454.

[3] Schanzer, A., Hevelone, N., Owens, C.D., et al. (2007). Technical factors affecting autogenous vein graft failure: observations from a large multicenter trial. *J Vasc Surg.*, 46(6):1180-90; discussion 1190. doi: 10.1016/j.jvs.2007.08.033.

[4] Back, M. (2014). Local Complications: Graft Infection. In *Rutherford´s Vascular Surgery*, 8th edition, edited by Cronenwett, J.L. and Johnston, K.W. 657-72. *Philadelphia, Elsevier*, ISBN 978-1-4557-5304-8.

[5] Khuri, S.F., Henderson, W.G., DePalma, R.G., et al. (2005). Determinants of long-term survival after major surgery and the adverse effect of postoperative complications. *Ann Surg.*, 242(3):326-41. PMID:16135919.

[6] Boiron, L., Hopper, K. and Borchers, A. (2019). Risk factors, characteristics, and outcomes of acute respiratory distress syndrome in dogs and cats: 54 cases. *J Vet Emerg Crit Care*, 29(2):173-79. doi: 10.1111/vec.12819.

[7] Bagan, P., Bouayad, M., Benabdesselam, A., et al. (2011). Prevention of pulmonary complications after aortic surgery: evaluation of prophylactic noninvasive perioperative ventilation. *Ann Vasc Surg*, 25(7): 920-22. doi: 10.1016/j.avsg.2010.10.020.

[8] Beattie, W.S., Wijeysundera, D.N., Karkouti, K. et al. (2010). Acute surgical anemia influences the cardioprotective effects of beta-blockade: a single-center, propensity-matched cohort study. *Anesthesiology*, 112(1):25-33. doi: 10.1097/ALN.0b013e3181c5dd81.

[9] Ford, M.K., Beattie, W.S., Wijeysundera, D.N., et al. (2010). Systematic review: prediction of perioperative cardiac complications and mortality by the revised cardiac risk index. *Ann Intern Med.*, 5;152(1):26-35. doi: 10.7326/0003-4819-152-1-201001050-00007.

[10] Golubovic, M., Stanojevic, D., Lazarevic, M. A., et al. (2018). Risk Stratification Model for Cardiovascular Complications during the 3-Month Period after Major Elective Vascular Surgery. *Biomed Res Int.*, 9;2018:4381527. doi: 10.1155/2018/4381527. eCollection 2018.

[11] Wilkins, C.E., Herrera, T.L., Nagahiro, M.K., et al. (2019). Outcomes of Hemodynamic Support with Impella for Acute Myocardial Infarction Complicated by Cardiogenic Shock at a Rural Community Hospital without on-Site Surgical Back-up. *J Invasive Cardiol.*, 31(2):23-29. PMID: 30700627.

[12] du Fay de Lavallaz J., Puelacher, C., Lurati Buse G., et al. (2018). Daytime variation of perioperative myocardial injury in non-cardiac surgery and effect on outcome. *Heart.* 12. pii: heartjnl-2018-313876. doi: 10.1136/heartjnl-2018-313876.

[13] Nagele, P., Brown, F., Gage, B.F., et al. (2013). High-sensitivity cardiac troponin T in prediction and diagnosis of myocardial infarction and long-term mortality after noncardiac surgery. *Am Heart J.*, 166(2):325-32.e1. doi: 10.1016/j.ahj.2013.04.018.

[14] Bjurman, C., Larsson, M., Johanson, P., et al. (2013). Small changes in troponin T levels are common in patients with non-ST-segment elevation myocardial infarction and are linked to higher mortality. *J Am Coll Cardiol.*, 1;62(14):1231-38. doi: 10.1016/j.jacc.2013.06.050.

[15] Poloński, L., Gasior, M., Wasilewski, J., et al. (2003). Outcomes of primary coronary angioplasty and angioplasty after initial thrombolysis in the treatment of 374 consecutive patients with acute myocardial infarction. *Am Heart J.*, 145(5):855-61.

[16] Villar, J., Ambrós, A., Mosteiro, F., et al. (2019). A Prognostic Enrichment Strategy for Selection of Patients with Acute Respiratory Distress Syndrome in Clinical Trials. *Crit Care Med.*, 47(3):377-85. doi: 10.1097/CCM.0000000000003624.

[17] Jaber, S., Michelet, P. and Chanques, G. (2010). Role of non-invasive ventilation (NIV) in the perioperative period. *Best Pract Res Clin Anaesthesiol.*, 24(2):253-65.

[18] Gurakar, M., Locham, S., Alshaikh, H.N., et al. (2019). Risk factors and outcomes for bowel ischemia after open and endovascular abdominal aortic aneurysm repair. *J Vasc Surg.*, 5. pii: S0741-5214(19)30132-6. doi: 10.1016/j.jvs.2018.11.047.

[19] Black, J.H. (2013). Renal protection in juxtarenal and suprarenal aortic aneurysm surgery. *Semin Vasc Surg.*, 26(4):193-98. doi: 10.1053/j.semvascsurg.2014.06.005.

[20] Schraag, S. (2016). Postoperative management. *Best Pract Res Clin Anaesthesiol.*, 30(3):381-93. doi: 10.1016/j.bpa.2016.06.001.

[21] Muehling, B.M., Ortlieb, L., Oberhuber, A., et al. (2011). Fast track management reduces the systemic inflammatory response and organ failure following elective infrarenal aortic aneurysm repair. *Interact Cardiovasc Thorac Surg.*, 12(5):784-88. doi: 10.1510/icvts.2010.262337.

[22] Fadayomi, A.B., Ibala, R., Bilotta, F., et al. (2018). A Systematic Review and Meta-Analysis Examining the Impact of Sleep Disturbance on Postoperative Delirium. *Crit Care Med.*, 46(12):e1204-e1212. doi: 10.1097/CCM.0000000000003400.

[23] Styra, R., Larsen, E., Dimas, M.A., et al. (2019). The effect of preoperative cognitive impairment and type of vascular surgery procedure on postoperative delirium with associated cost implications. *J Vasc Surg.*, 69(1):201-209. doi: 10.1016/j.jvs.2018.05.001.

[24] Stone, H.D. and Walsh, D.B. (2014). Local Complications: Graft Thrombosis. In In *Rutherford´s Vascular Surgery*, 8th edition, edited by Cronenwett, J.L. and Johnston, K.W. 693-703. Philadelphia, Elsevier, ISBN 978-1-4557-5304-8.

[25] Menard, MT. and Belkin, M. (2014). Aortoiliac Disease: Direct Aortoiliac Reconstruction. In *Rutherford´s Vascular Surgery*, 8th edition, edited by Cronenwett, J.L. and Johnston, K.W. 2039-2062. Philadelphia, Elsevier, ISBN 978-1-4557-5304-8.

[26] Antip, R. (2014). Local Complications: Nerve Injury. In *Rutherford´s Vascular Surgery*, 8th edition, edited by Cronenwett, J.L. and Johnston, K.W. 732-41. *Philadelphia, Elsevier*, ISBN 978-1-4557-5304-8.

[27] Prechel, M. and Walenga, J.M. (2008). The laboratory diagnosis and clinical management of patients with heparin-induced thrombocy-topenia: an update. *Semin Thromb Hemost.*, 34(1):86-96. doi: 10.1055/s-2008-1066027.

[28] Naylor, AR. (2017). Medical treatment strategies to reduce perioperative morbidity and mortality after carotid surgery. *Semin Vasc Surg.*, 30(1):17-24. doi: 10.1053/j.semvascsurg.2017.04.006. Epub 2017 Apr 29.

[29] Mazzaccaro, D., De Febis, E., Settembrini, A.M., et al. (2014). Long-term results of PTFE trilaminate graft versus venous graft and composite graft for below-the-knee revascularization. *J Cardiovasc Surg (Torino)*, 55(5):685-91. Epub 2014 Jul 10.

[30] Berceli, S.A., Hevelone, N.D., Lipsitz, S.R., et al. (2007). Surgical and endovascular revision of infrainguinal vein bypass grafts: analysis of midterm outcomes from the PREVENT III trial. *J Vasc Surg.*, 46(6):1173-79. Epub 2007 Oct 22.

[31] Awopetu, A.I., Moxey, P., Hinchliffe, R.J., et al. (2010). Systematic review and meta-analysis of the relationship between hospital volume and outcome for lower limb arterial surgery. *Br J Surg.*, 97(6):797-803. doi: 10.1002/bjs.7089.

[32] Ryer, E.J., Kalra, M., Oderich, G.S., et al. (2012). Revascularization for acute mesenteric ischemia. *J Vasc Surg.*, 55(6):1682-9. doi: 10.1016/j.jvs.2011.12.017.

[33] Goodney, P.P., Beck, A.W., Nagle, J., et al. (2009). National trends in lower extremity bypass surgery, endovascular interventions, and major amputations. *J Vasc Surg.*, 50(1):54-60. doi: 10.1016/j.jvs.2009.01.035.

[34] Weis-Müller, B.T., Rascanu, C., Sagban, A., et al. (2011). Single-center experience with open surgical treatment of 36 infected aneurysms of the thoracic, thoracoabdominal, and abdominal aorta. *Ann Vasc Surg.*, 25(8):1020-25. doi: 10.1016/j.avsg.2011.03.009.

[35] Brossier, J., Lesprit, P., Marzelle, J., et al. (2010). New bacteriological patterns in primary infected aortoiliac aneurysms: a single-centre experience. *Eur J Vasc Endovasc Surg.*, 40(5):582-88. doi: 10.1016/j.ejvs.2010.07.020.

[36] Beck, A. and Velazquez-Ramirez, G. (2014). Infected Aneurysms. In *Rutherford´s Vascular Surgery*, 8th edition, edited by Cronenwett, J.L. and Johnston, K.W. 2236-48. Philadelphia, Elsevier, ISBN 978-1-4557-5304-8.

[37] Szilagyi, D.E., Smith, R.F., Elliott, J.P., et al. (1972). Infection in arterial reconstruction with synthetic grafts. *Ann Surg.*, 176(3):321-33. PMCID: PMC1355400.

[38] Elens, M., Dusoruth, M., Astarci, P., et al. (2018). Management and Outcome of Prosthetic Vascular Graft Infections: A Single Center Experience. *Vasc Endovascular Surg.*, 52(3):181-87. doi: 10.1177/1538574418754453.

[39] Laser, A., Baker, N., Rectenwald, J., et al. (2011). Graft infection after endovascular abdominal aortic aneurysm repair. *J Vasc Surg.*, 54(1):58-63. doi: 10.1016/j.jvs. 2010.11.111.

[40] Shukuzawa, K., Ohki, T., Maeda, K., et al. (2018). Risk factors and treatment outcomes for stent graft infection after endovascular aortic aneurysmrepair. *J Vasc Surg.*, 21. pii: S0741-5214(18)32482-0. doi: 10.1016/j.jvs.2018.10.062.

[41] Sharif, M.A., Lee, B., Lau, L.L., et al. (2007). Prosthetic stent graft infection after endovascular abdominal aortic aneurysm repair. *J Vasc Surg.*, 46(3):442-48.

[42] Ylönen, K., Biancari, F., Leo, E., et al. (2004). Predictors of development of anastomotic femoral pseudoaneurysms after aortobifemoral reconstruction for abdominal aortic aneurysm. *Am J Surg* 187:83–87.

[43] Cartery, C., Astudillo, L., Deelchand, A., et al. (2011). Abdominal infectious aortitis caused by streptococcus pneumoniae: a case report and literature review. *Ann Vasc Surg.*, 25(2):266.e9 - 16. doi: 10.1016/j.avsg.2010.07.014. Epub 2010 Oct 6.

[44] Hsu, R.B., Tsay, Y.G., Wang, S.S., et al. (2017). Surgical treatment for primary infected aneurysm of the descending thoracic aorta, abdominal aorta, and iliac arteries. *J Vasc Surg.*, 36(4):746-50.

[45] Li, H.L., Chan, Y.C. and Cheng, S.W. (2018). Current Evidence on Management of Aortic Stent-graft Infection: A Systematic Review and Meta-Analysis. *Ann Vasc Surg.*, 51:306-313. doi: 10.1016/j.avsg.2018.02.038.

[46] Nordanstig, J., Törngren, K., Smidfelt, K., et al. (2019). Deep Femoral Vein Reconstruction of the Abdominal Aorta and Adaptation of the Neo-Aortoiliac System Bypass Technique in an Endovascular Era. *Vasc Endovascular Surg.*, 53(1):28-34. doi: 10.1177/1538574418801100.

[47] Bianchi, P., Nano, G., Cusmai, F., et al. (2009). Uninfected para-anastomotic aneurysms after infrarenal aortic grafting. *Yonsei Med J.*, 50(2):227-38. doi: 10.3349/ ymj.2009.50.2.227.

[48] Vogt, P.R. (2011). Arterial allografts in treating aortic graft infections: something old, something new. *Semin Vasc Surg.*, 24(4):227-33. doi:10.1053/j.semvascsurg.2011. 10.008.

[49] Raman, S.P., Kamaya, A., Federle, M., et al. (2013). Aortoenteric fistulas: spectrum of CT findings. *Abdom Imaging.*, 38(2):367-75. doi: 10.1007/s00261-012-9873-7.

[50] Mayer, D., Hasse, B., Koelliker, J. et al. (2011). Long-term results of vascular graft and artery preserving treatment with negative pressure wound therapy in Szilagyi grade III

infections justify a paradigm shift. *Ann Surg*., 254(5):754-59; discussion 760. doi: 10.1097/SLA.0b013e3182365864.

[51] McBride, O.M. and Chalmers, R.T. (2017). Follow-up and surveillance of vein grafts: when and how to intervene to prevent complications. *J Cardiovasc Surg (Torino)*, 58(2):284-92. doi: 10.23736/S0021-9509.16.09839-6. Epub 2016 Dec 19.

[52] Smeds, M.R., Duncan, A.A. And Harlander-Locke, M.P. (2016). Treatment and outcomes of aortic endograft infection. *J Vasc Surg*., 63(2):332-40. doi: 10.1016/j.jvs.2015.08.113.

[53] Harmouche, M., Loreille, F., Le Bars, F. et al. (2018). Aortic treatment of native infection by reconstruction with the Omniflow II biologic prosthesis. *J Vasc Surg Cases Innov Tech.*, 4(4):296-300. doi: 10.1016/j.jvscit.2018.08.003. eCollection 2018 Dec.

[54] Ali, A.T., Modrall, J.G., Hocking, J., et al. (2009). Long-term results of the treatment of aortic graft infection by in situ replacement with femoral popliteal vein grafts. *J Vasc Surg.*, 50(1):30-39. doi: 10.1016/j.jvs.2009.01.008.

[55] Bisdas, T., Bredt, M., Pichlmaier, M., et al. (2010). Eight-year experience with cryopreserved arterial homografts for the in situ reconstruction of abdominal aortic infections. *J Vasc Surg.*, 52(2):323-30. doi: 10.1016/j.jvs.2010.02.277.

[56] Oderich, G.S., Bower, T.C., Hofer, J., et al. (2011). In situ rifampin-soaked grafts with omental coverage and antibiotic suppression are durable with low reinfection rates in patients with aortic graft enteric erosion or fistula. *J Vasc Surg.*, 53(1):99-106, 107.e1-7; discussion 106-7. doi: 10.1016/j.jvs.2010.08.018.

[57] Kieffer, E., Gomes, D., Chiche, L., et al. (2004). Allograft replacement for infrarenal aortic graft infection: early and late results in 179 patients. *J Vasc Surg.*, 39(5):1009-17.

[58] Khaladj, N., Pichlmaier, U., Stachmann, A., et al. (2013). Cryopreserved human allografts/homografts for the management of graft infections in the ascending aortic position extending to the arch. *Eur J Cardiothorac Surg.*, 43(6):1170-5. doi: 10.1093/ejcts/ezs572.

[59] Cernohorsky, P, Reijnen, M.M, Tielliu, I.F., et al. (2011). The relevance of aortic endograft prosthetic infection. *J Vasc Surg.*, 54(2):327-33. doi: 10.1016/j.jvs.2010.12.067.

[60] Diener, H., Larena-Avellaneda, A. and Debus, ES. (2009). Postope-rative complications in vascular surgery. *Chirurg.*, 80(9):814-26. doi: 10.1007/s00104-009-1692-1.

[61] Miller, T.A. and Turk, A.E. (2004). The Lymphatic System. In *Vascular Surgery Principles and Practice Third Edition, Revised and Expanded*, edited by Hobson, R.W., Wilson, S.E. and Veith, F.J. 1037-49. *New York, Marcel Dekker, Inc.*, ISBN 0-8247-0819-9.

[62] Hirata, N., Ueno, T., Amemiya, A., et al. (2003). Advantage of earlier thoracoscopic clipping of thoracic duct for post-operation chylothorax following thoracic aneurysm surgery. *Jpn J Thorac Cardiovasc Surg*. 2003 Aug;51(8):378-80. doi: 10.1007/BF02719471

[63] Banga, P.V., Oderich, G.S. and Reis de Souza, L. (2016). Neuromonitoring, Cerebrospinal Fluid Drainage, and Selective Use of Iliofemoral Conduits to Minimize Risk of Spinal Cord Injury During Complex Endovascular Aortic Repair. *J Endovasc Ther.*, 23(1):139-49. doi: 10.1177/1526602815620898.

[64] Tanaka, A., Safi, H.J. and Estrera, A.L. (2018). Current strategies of spinal cord protection during thoracoabdominal aortic surgery. *Gen Thorac Cardiovasc Surg.*, 66(6):307-14. doi: 10.1007/s11748-018-0906-1.

[65] Fokkema, M., de Borst, G.J., Nolan, B.W., et al. (2014). Clinical relevance of cranial nerve injury following carotid endarterectomy. *Eur J Vasc Endovasc Surg.*, 47(1):2-7. doi: 10.1016/j.ejvs.2013.09.022.

[66] Shimizu, H. and Yozu, R. (2011). Current strategies for spinal cord protection during thoracic and thoracoabdominal aorticaneurysm repair. *Gen Thorac Cardiovasc Surg.*, 59(3):155-63. doi: 10.1007/s11748-010-0705-9.

[67] Haruguchi, H., and Teraoka, S. (2003). Intimal hyperplasia and hemodynamic factors in arterial bypass and arteriovenous grafts: a review. *J Artif Organs.*, 6(4):227-35. DOI: 10.1007/s10047-003-0232-x.

[68] Handa, M., Li, W. and Morioka, K. (2008). Adventitial delivery of platelet-derived endothelial cell growth factor gene prevented intimal hyperplasia of vein graft. *J Vasc Surg.*, 48(6):1566-74. doi: 10.1016/j.jvs.2008.07.029.

[69] Halter, G., Orend, K.H. and Sunder-Plassmann, L. (2003). Clinical pathways - intervention or surgery for acute ischemia of the extremities. *Chirurg.*, 74(12):1118-27.

[70] de Donato, G., Setacci, F., Sirignano, P., et al. (2014).The combination of surgical embolectomy and endovascular techniques may improve outcomes of patients with acute lower limb ischemia. *J Vasc Surg.*, 59(3):729-36. doi: 10.1016/j.jvs.2013.09.016.

[71] Chiesa, R., Marone, E.M., Tshomba, Y., et al. (2009). Aortobife-moral bypass grafting using expanded polytetrafluoro-ethylene stretch grafts in patients with occlusive atherosclerotic disease. *Ann Vasc Surg.*, 23(6):764-69. doi: 10.1016/j.avsg.2009.01.004.

[72] Senekowitsch, C., Assadian, A., Assadian, O., et al. (2006). Replanting the inferior mesentery artery during infrarenal aortic aneurysm repair: influence on postoperative colon ischemia. *J Vasc Surg.*, 43(4):689-94. DOI: 10.1016/j.jvs.2005.12.016.

[73] Sakamoto, I., Mori, M., Nishida, A., et al. (2003). Coil embolization of iliac artery aneurysms developing after abdominal aortic aneurysm repair with a conventional bifurcated graft. *J Endovasc Ther.*, 10(6):1075-81. DOI: 10.1177/152660280301000608.

[74] Inuzuka, K., Unno, N. and Yamamoto, N. (2010). Assessment of pelvic hemodynamics during an open repair of an infrarenal abdominal aortic aneurysm. *Surg Today.*, 40(8):738-44. doi: 10.1007/s00595-009-4126-2.

[75] Schermerhorn, M.L., Fokkema, M., Goodney, P., et al. (2013). The impact of Centers for Medicare and Medicaid Services high-risk criteria on outcome aftercarotid endarterectomy and carotid artery stenting in the SVS Vascular Registry. *J Vasc Surg.*, 57(5):1318-24. doi: 10.1016/j.jvs.2012.10.107.

[76] Abreu, P., Nogueira, J., Rodrigues, F.B., et al. (2017). Intracerebral hemorrhage as a manifestation of cerebral hyperperfusion syndrome after carotidrevascularization: systematic review and meta-analysis. *Acta Neurochir (Wien).*, 159(11):2089-97. doi: 10.1007/s00701-017-3328-4.

[77] Marcelin, C., D'Souza, S., Le Bras, Y. (2018). Mechanical Thrombectomy in Acute Thrombosis of Dialysis Arteriovenous Fistulae and Grafts Using a Vacuum-Assisted Thrombectomy Catheter: A Multicenter Study. *J Vasc Interv Radiol.* 29(7):993-997. doi: 10.1016/j.jvir.2018.02.030. Epub 2018 May 30.

[78] Yang, C.C., Yang, C.W., Wen, S.C., et al. (2012). Comparisons of clinical outcomes for thrombectomy devices with different mechanisms in hemodialysis arteriovenous fistulas. *Catheter Cardiovasc Interv.*, 15;80(6):1035-41. doi: 10.1002/ccd.24408.

[79] Böhlke, M., Uliano, G., Barcellos, F.C. (2015). Hemodialysis catheter-related infection: prophylaxis, diagnosis and treatment. *J Vasc Access.* (5):347-55. doi: 10.5301/jva. 5000368.

[80] Jennings, W.C., Brown, R.E. and Ruiz, C. (2011). Primary arteriovenous fistula inflow proximalization for patients at high risk for dialysis access-associated ischemic steal syndrome. *J Vasc Surg.*, 54(2):554-58. doi: 10.1016/j.jvs.2011.01.031.

[81] Singh, N. and Clouse, D. (2014). Upper Extremity Arterial Disease: Amputation: In *Rutherford´s Vascular Surgery*, 8th edition, edited by Cronenwett, J.L. and Johnston, K.W. 1885-900. Philadelphia, Elsevier, ISBN 978-1-4557-5304-8.

[82] Krueger, C.A., Wenke, J.C., Ficke, J.R., et al. (2012). Ten years at war: comprehensive analysis of amputation trends. *J Trauma Acute Care Surg.*, 73(6 Suppl 5): S 438-44. doi: 10.1097/TA.0b013e318275469c.

[83] Tintle, S.M., Baechler, M.F., Nanos, G.P., et al. (2012). Reopera-tions following combat-related upper extremity amputations. *J Bone Joint Surg Am.*, 15;94(16):e1191-96.

[84] Bianchi, C. and Abou-Zamzam, A.M. (2014). Lower Extremity Amputation: General Considerations. In *Rutherford´s Vascular Surgery*, 8th edition, edited by Cronenwett, J.L. and Johnston, K.W. 1836-47. Philadelphia, Elsevier, ISBN 978-1-4557-5304-8.

[85] Sauter, C.N., Pezzin, L.E., Dillingham, T.R., et al. (2013). Functional outcomes of persons who underwent dysvascular lower extremity amputations: effects of postacute rehabilitation setting. *Am J Phys Med Rehabil.*, 92(4):287-96. doi: 10.1097/PHM. 0b013e31827d620d.

[86] Taylor, S.M., Kalbaugh, C.A., Blackhurst, D.W., et al. (2005). Preoperative clinical factors predict postoperative functional outcomes after major lower limb amputation: an analysis of 553 consecutive patients. *J Vasc Surg.*, 42:227-34.

[87] Eidt, J.F. and Kalapatapu, V.R. (2014). Lower Extremity Amputation: Techniques and Results. In *Rutherford´s Vascular Surgery*, 8th edition, edited by Cronenwett, J.L. and Johnston, K.W. 1847-66. Philadelphia, Elsevier, ISBN 978-1-4557-5304-8.

[88] Wu, J.T., Wong, M., Lo, Z.J. et al. (2017). A Series of 210 Peripheral Arterial Disease Below-Knee Amputations and Predictors for Subsequent Above-Knee Amputations. *Ann Vasc Dis.*, 10(3). pii: oa.17-00046. doi: 10.3400/avd.oa.17-00046.

[89] Henry, A.J., Hevelone, N.D., Hawkins, A.T., et al. (2013). Factors predicting resource utilization and survival after major amputation. *J Vasc Surg.*, 57(3):784-90. doi: 10.1016/j.jvs.2012.09.035.

[90] van Netten, J.J., Fortington, L.V., Hinchliffe, R.J. (2016). Early Post-operative Mortality After Major Lower Limb Amputation: A Systematic Review of Population and Regional Based Studies. *Eur J Vasc Endovasc Surg.*, 51(2):248-57. doi: 10.1016/j.ejvs.2015.10.001.

[91] Hanley, M.A., Jensen, M.P., Smith, D.G., et al. (2007). Preamputa-tion pain and acute pain predict chronic pain after lower extremity amputation. *J Pain.*, 8(2):102-9.

[92] Raichle, K.A., Osborne, T.L., Jensen, M.P., et al. (2015). Preoperative state anxiety, acute postoperative pain, and analgesic use in persons undergoing lower limb amputation. *Clin J Pain.*, 31(8):699-706. doi: 10.1097/AJP.0000000000000150.

[93] Dillingham, T.R., Yacub, J.N., Pezzin, L.E., et al. (2011). *Determinants of postacute care discharge destination after dysvascular lower limb amputation*, 3(4):336-44. doi: 10.1016/j.pmrj.2010.12.019.

In: Encyclopedia of Surgery (22 Volume Set)
Editors: Andreas Lehrer and Kristin Mueller
ISBN: 978-1-53618-329-0
© 2020 Nova Science Publishers, Inc

Chapter 293

LAPAROSCOPIC SLEEVE GASTRECTOMY

Pablo Priego*, MD, PhD
Department of General Surgery, Division of Esophagogastric
and Bariatric Surgery, Ramón y Cajal University Hospital,
Madrid, Spain

ABSTRACT

Nowadays, laparoscopic sleeve gastrectomy is the most frequent bariatric procedure worldwide. However, and although this technique seems to be very simple, some important surgical details are essential in order to prevent potential severe complications after surgery. The aim of the chapter is to describe and show our standardized technique based on different surgical pictures.

Keywords: laparoscopic sleeve gastrectomy, surgical technique

INTRODUCTION

Nowadays, laparoscopic sleeve gastrectomy (LSG) has evolved since its beginnings, experiencing increasing popularity worldwide in comparison with other bariatric procedures like the Roux-en-Y gastric bypass and adjustable gastric banding [1].

The main reason of this popularity is not only because LSG is a less complex surgical technique, but also because it has demonstrated durable long-term weight loss and metabolic improvements in obese patients [2].

LSG was first conceived as a first step (restrictive component) of a two staged procedure that included a duodenal switch for high-risk patients [3].

Over time, as minimally invasive techniques advanced and surgical experience increased, the procedure was adopted as a first line treatment option for morbid obesity [4].

* Corresponding Author's Email: papriego@hotmail.com.

INDICATION

1. Primary weight loss procedure.
2. Initial stage of two-staged approach in superobese patients.
3. Component of laparoscopic biliopancreatic diversion with duodenal switch (BPD-DS) or Single anastomosis duodenoileal with sleeve gastrectomy (SADI-s).

PREOPERATIVE PREPARATION

The preoperative work-up for bariatric surgery is performed by a multidisciplinary team, including surgeons, endocrinologists, dieticians, gastroenterologists, anesthesiologists and psychiatrists, who combine a medical, nutritional, and endocrinology workup to evaluate potential surgical candidates.

Preoperative assessment included abdominal ultrasound, barium swallow, upper gastrointestinal endoscopy, analytic evaluation of the nutritional status and in selected cases a polysomnography, fibroscan, 24ph-metry and manometry.

ANESTHESIA

An enhanced recovery after surgery (ERAS) programme is followed with an opioid-free anesthesia. Central vein and bladder catheters were not used.

SURGICAL TECHNIQUE

Instrumentation

1. Three 12mm and one 5mm ports
2. Nathanson liver retractor
3. 30º scope
4. Harmonic scalpel
   (Harmonic ACE; Johnson & Johnson)
5. Veress needle
6. Three atraumatic graspers
   (one of the long size)
7. Suction irrigator
8. Echelon 60mm (gold and blue cartridges)
   (Johnson & Johnson)
9. Peristrip-dry
10. Gauzes
11. Clip applicator (optional)

PATIENT, PORT AND SURGEON POSITIONS

a) Patient Position

Patients are placed on an operating table in supine position with legs and arms opened.

Intermittent pneumatic compression devices are used to help prevent blood clots in the deep veins of the legs. The legs and hips are secured with safety straps to prevent bowing or buckling of the knees or ankles.

No urinary catheter is needed. Patient is placed in anti-Trendelemburg position allowing the transverse colon and small intestine to fall in a caudal direction. An orogastric tube of 32Fr is placed into the stomach in order to calibrate the sleeve during stapling and transection (Figure 1).

Figure 1. Patient position.

b) Port Position

Pneumoperitoneum to a pressure of 12-14mm Hg is achieved through Veress needle technique at Palmer point in the left upper quadrant. A primary, 12-mm port is inserted at the junction of the upper two third and lower one third of the line joining the xiphoides to the umbilicus. This is the camera port. Two 12-mm working port are inserted in the left and right quadrant area in the midclavicular line. A 5-mm port is inserted in the epigastrium. A Nathanson liver retractor is used to retract the left lobe of the liver. Another 5-mm port is placed on the left in anterior axillary line at the level of the umbilicus. This is used by the second assistant on the left side. This is used mainly to retract the stomach or to lift it up (Figure 2).

c) Surgeon Position

The operating surgeon stands in the space between the legs of the patient.

The camera assistant is on the left of the operating surgeon. The first assistant surgeon stands on the right side of the operating surgeon.

Monitor is placed on the upper part of the patient for assistant and surgeon view (Figure 3).

Figure 2. Port position.

Figure 3. Surgeon position.

PROCEDURE

a) Identification of Angle of His

The dissection begins identifying the angle of His, taking down the fat pad which covers the upper part of the fundus. An important trick is to visualize the left crura of the diaphragm.

Once the crura is identified, gauze is placed between the fundus and the spleen.

Mobilizing this fat pad provides us with an adequate exposure of this area for optimal stapling and transection of the stomach.

If left crura of diaphragm is not easily visualized because of splenomegaly or an excess of fatty tissue of the patient, do not care and place the gauze in that space. Any hiatal hernias should be addressed at this time and repaired in a posterior fashion (Figure 4-10).

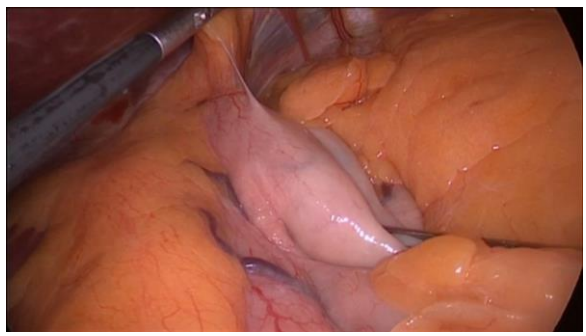

Figure 4. Identification of the angle of His.

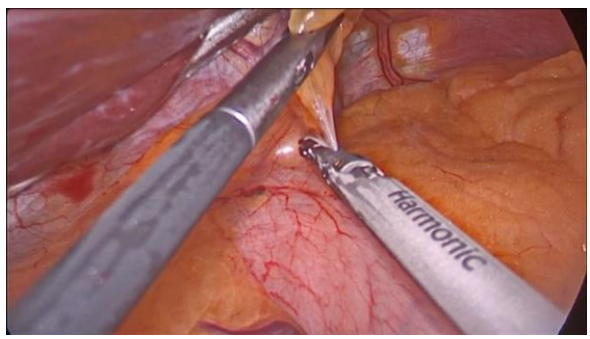

Figure 5. Section of the fat pad.

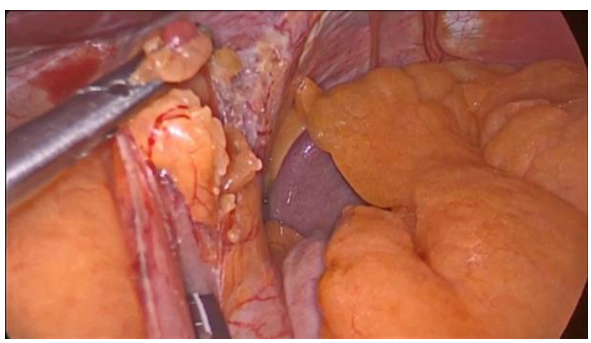

Figure 6. Section of the fat pad until visualization of the left crura.

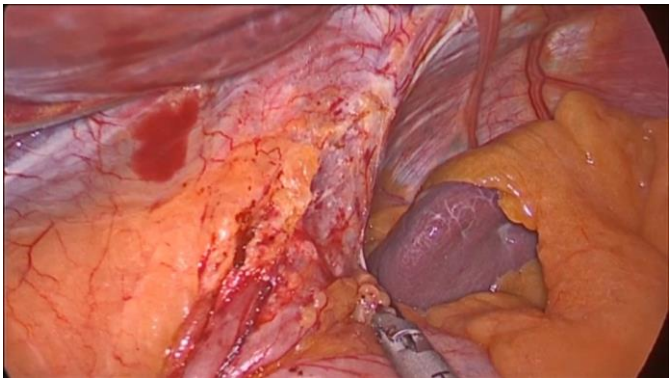

Figure 7. Visualization of the left crura.

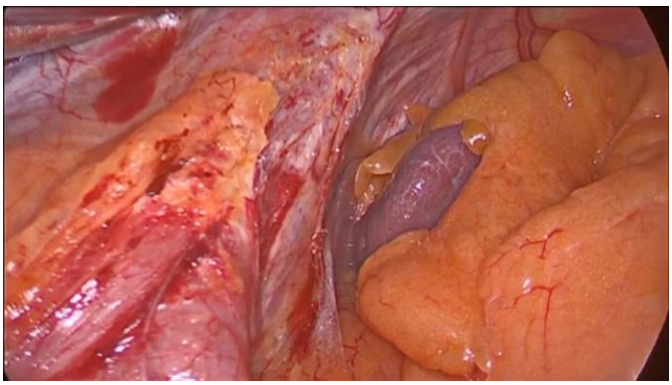

Figure 8. Visualization of the left crura (continued).

b) Mobilization of Greater Curvature

Using the harmonic device, a window is made into the omental bursa approximately at the level of the incisura angularis because this place is easier to enter into the omental transcavity.

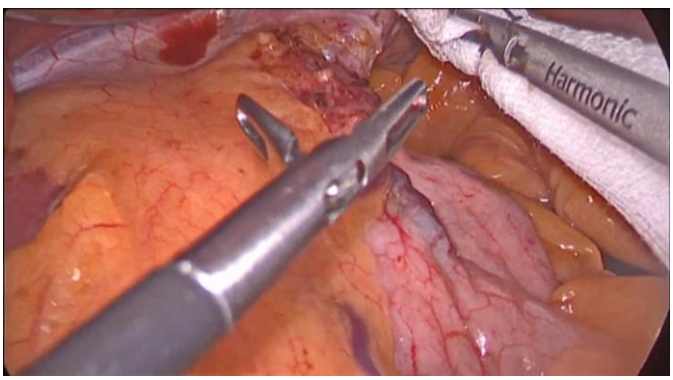

Figure 9. Placement of a gauze in the space between left crura and the spleen.

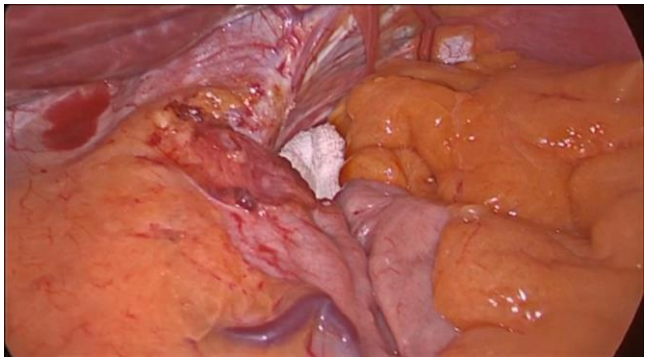

Figure 10. Placement of a gauze in the space between left crura and the spleen (continued).

Proceed superiorly sealing and dividing the short gastric vessels directly on the serosa of the stomach until the left crura and the gauze are visualized. Great care must be taken when dissecting and sealing the short gastric vessels because they are at high risk for intraoperative and postoperative bleeding. First assistant has to retract very carefully the greater omentum of patient to the left size of the abdomen and the left hand of the surgeon has to retract the stomach to the right size. Sometimes, and when there are several adhesions and the left crura cannot be visualized, the first assistant can take the posterior part of the fundus towards the patient's right side and thus inferiorly the surgeon has a better exposure of the cardias, spleen and left crura (Figure 11-26).

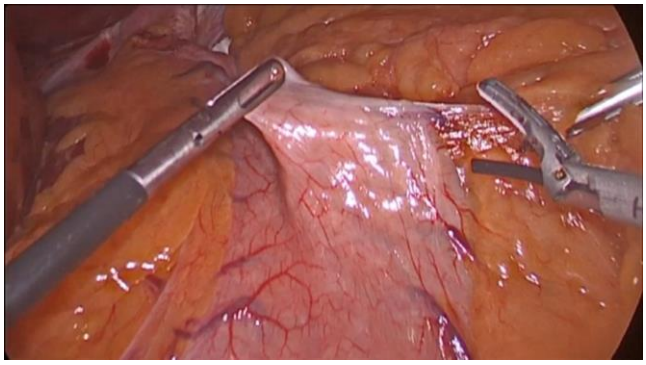

Figure 11. Division of the short gastric vessels.

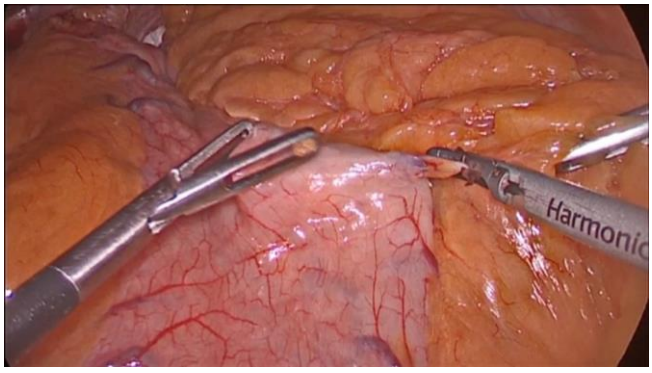

Figure 12. Division of the short gastric vessels (continued).

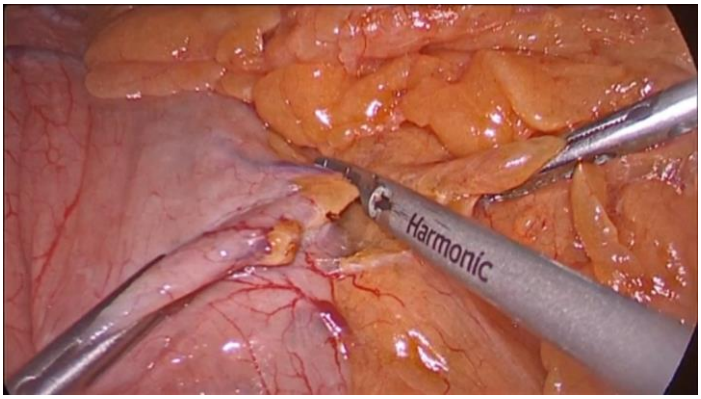

Figure 13. Division of the short gastric vessels (continued).

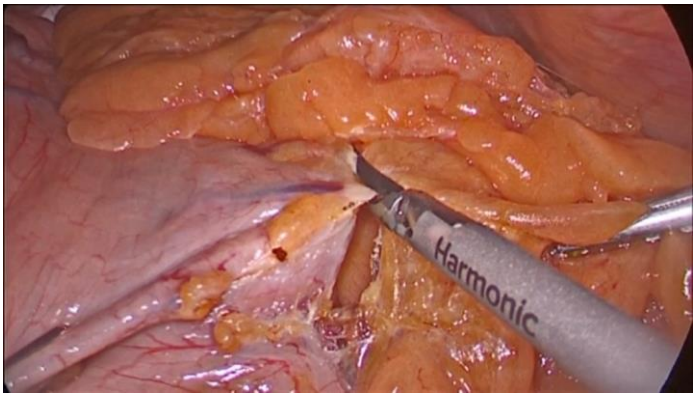

Figure 14. Division of the short gastric vessels (continued).

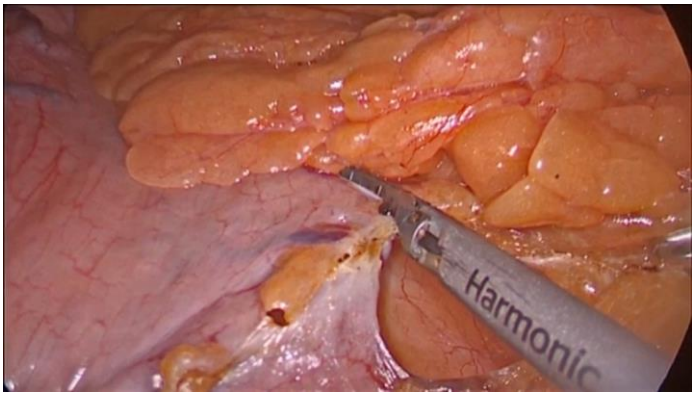

Figure 15. Division of the short gastric vessels (continued).

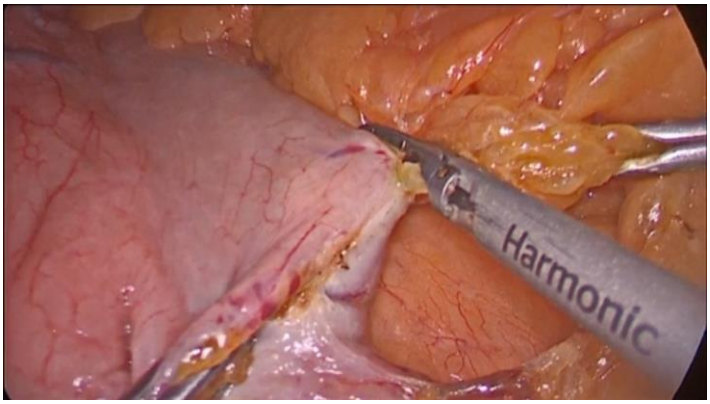

Figure 16. Division of the short gastric vessels. The division continues crainially.

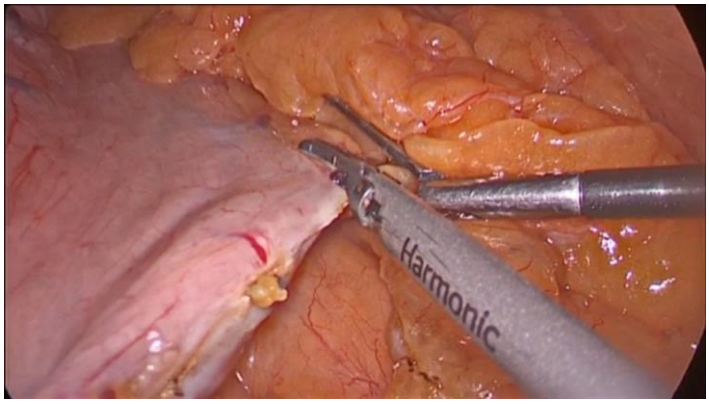

Figure 17. Division of the short gastric vessels (continued).

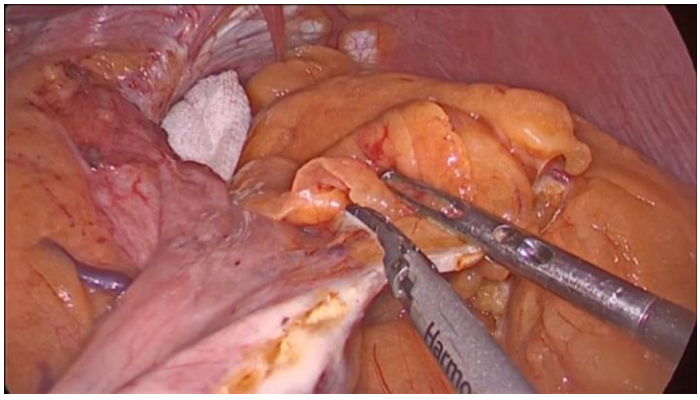

Figure 18. Division of the short gastric vessels (continued).

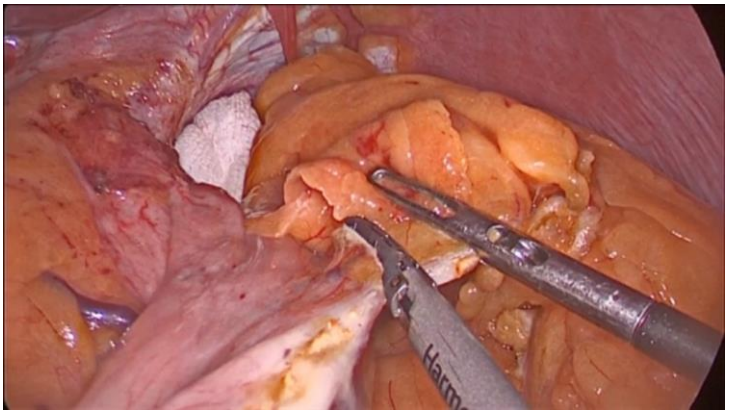

Figure 19. Division of the short gastric vessels (continued).

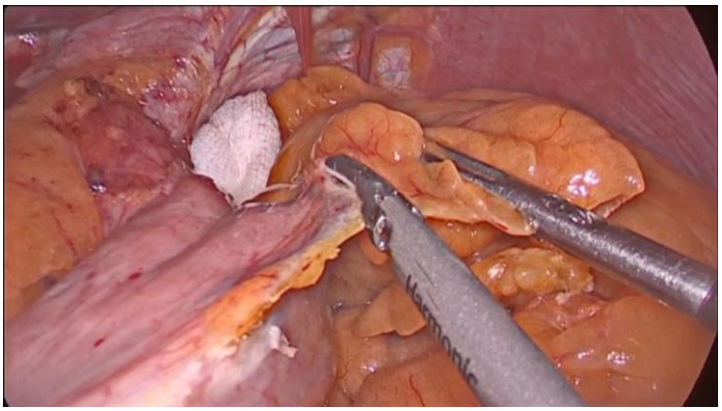

Figure 20. Division of the short gastric vessels (continued).

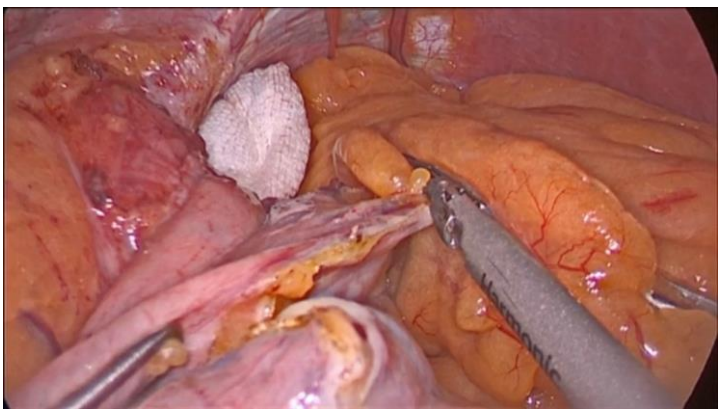

Figure 21. Division of the short gastric vessels (continued).

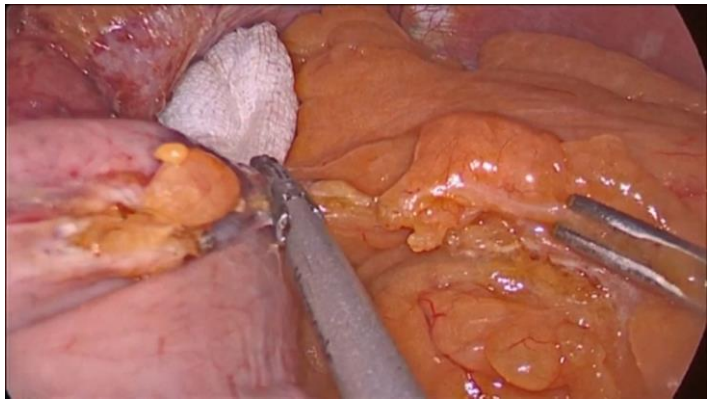

Figure 22. Division of the short gastric vessels (continued).

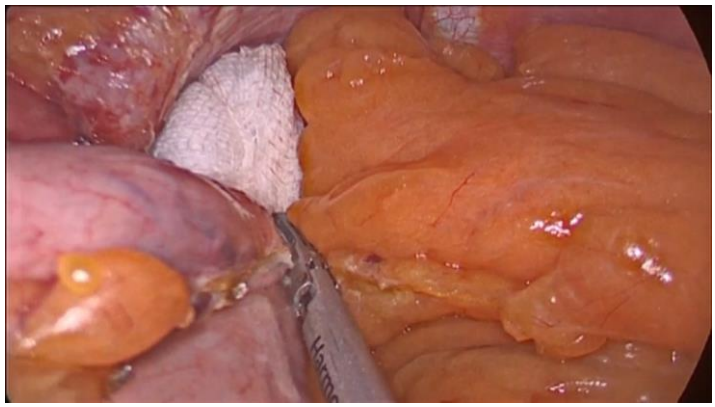

Figure 23. Division of the short gastric vessels. The section continues cranially until reaching the left crura (marked by the gauze placement).

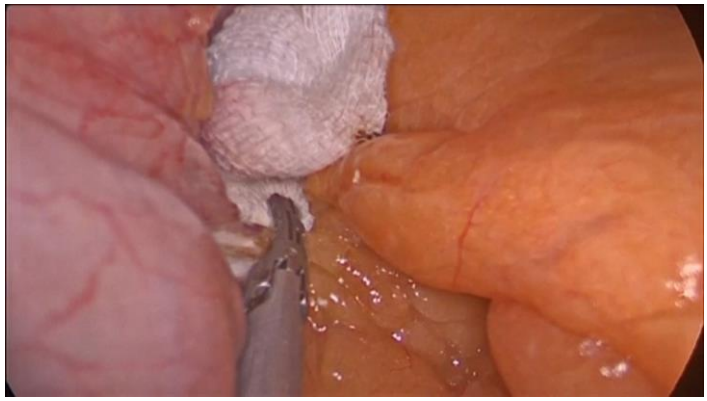

Figure 24. Division of the short gastric vessels. The section continues cranially until reaching the left crura (marked by the gauze placement).

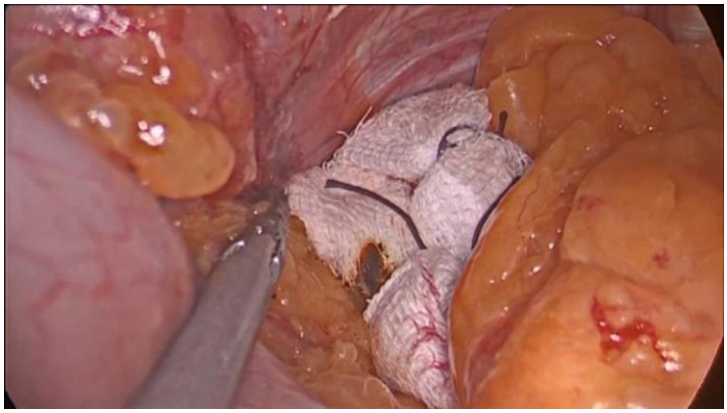

Figure 25. Division of the short gastric vessels. The section continues cranially until reaching the left crura (marked by the gauze placement).

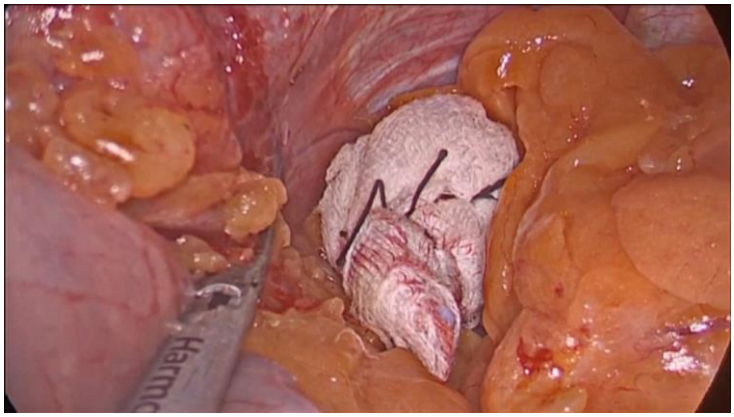

Figure 26. Division of the short gastric vessels. The section continues cranially until reaching the left crura (marked by the gauze placement).

c) Mobilization of the Antrum

Once the left crura is identified, proceed with the division of greater omentum inferiorly towards the pylorus (4 - 6cm proximally to it) avoiding to injury the right gastroepiploic vessels and gastroduodenal artery (Figure 27-34).

d) Mobilization of the Posterior Part of Stomach

Mobilization of stomach finalized by taking down any associated adhesions between the stomach and the anterior-superior part of the pancreas until the left crura (Figure 35-36).

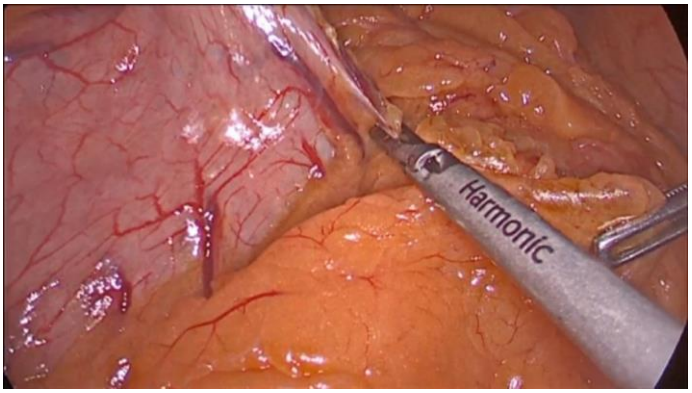

Figure 27. Division of greater omentum inferiorly towards the pylorus.

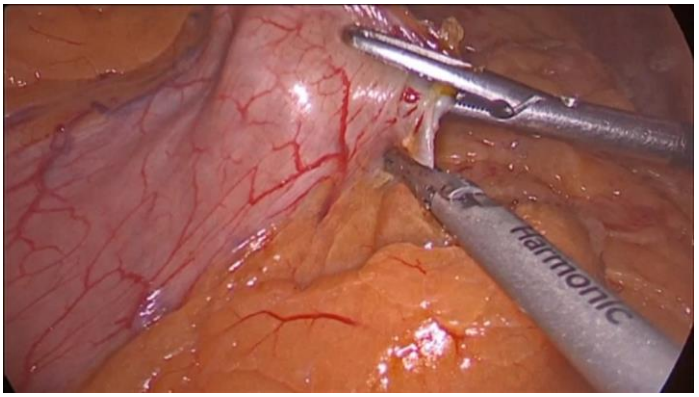

Figure 28. Division of greater omentum inferiorly towards the pylorus (continued).

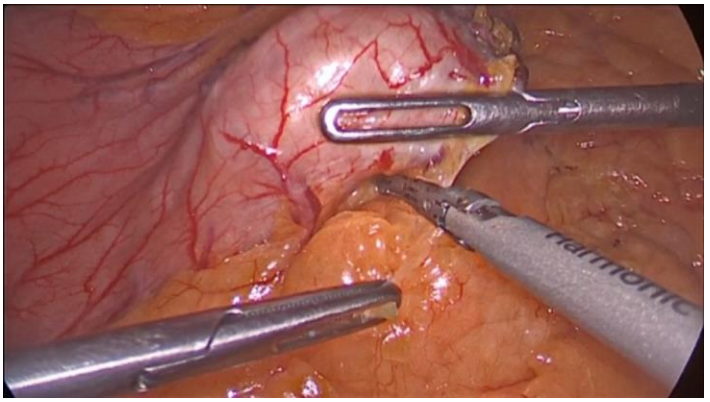

Figure 29. Division of greater omentum inferiorly towards the pylorus (continued).

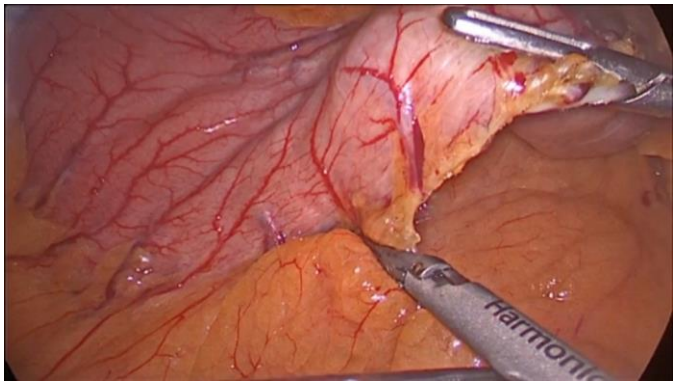

Figure 30. Division of greater omentum inferiorly towards the pylorus (continued).

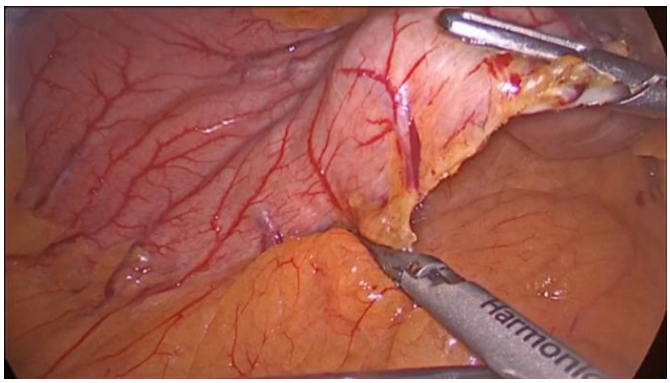

Figure 31. Division of greater omentum inferiorly towards the pylorus (continued).

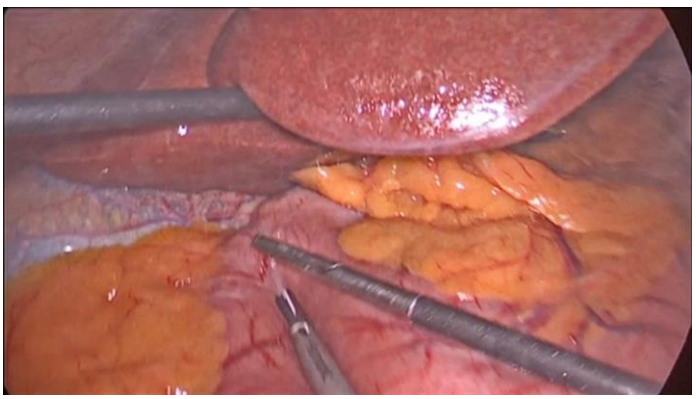

Figure 32. Identification of the pylorus and measurement of 4-6 cm cranial to the pylorus to mark the limit of section of the greater omentum.

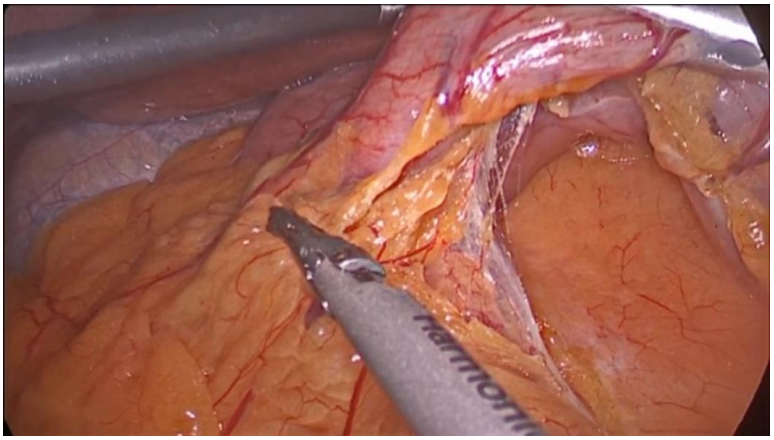

Figure 33. Division of greater omentum inferiorly towards the marked point 4-6cm cranial to the pylorus.

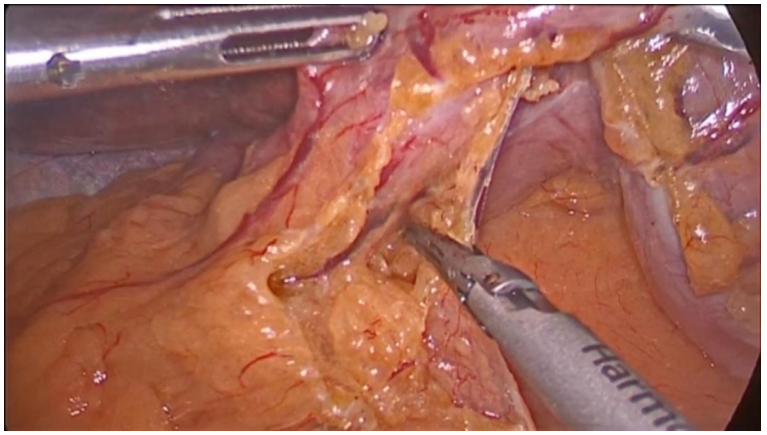

Figure 34. Division of greater omentum inferiorly towards the marked point 4-6cm cranial to the pylorus (continued).

e) Gastrectomy

Once the dissection is completed, a 32-French blunt-tipped bougie tube is slowly advanced under direct visualization to the level of the pylorus (Figure 37-40).

A 60mm gold cartridge is used to staple 4-6cm proximal to the pylorus (from 12mm trocar of right hypocondrium). We always reinforced all the cartridges with peristrip-dry. Before firing the stapler, the bougie tube must be visualized passing distal to the stapler along the lesser curvature.

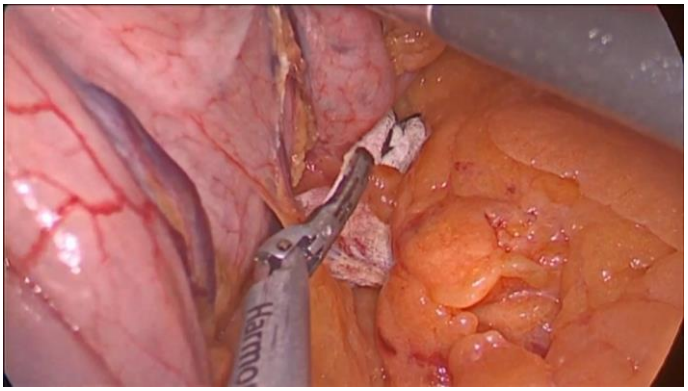

Figure 35. Division of posterior adhesions to ease the pass of the bougie.

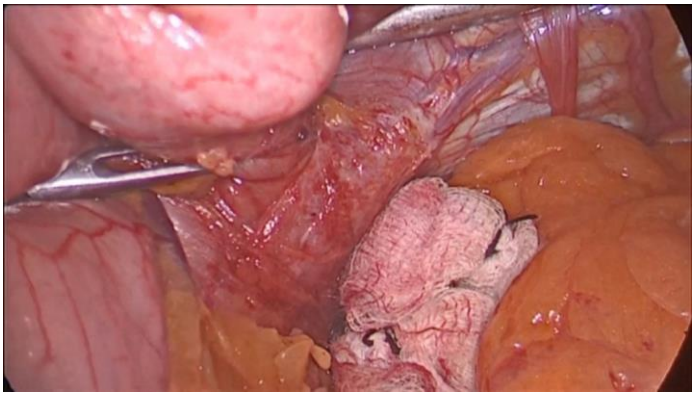

Figure 36. Insertion of the calibration bougie.

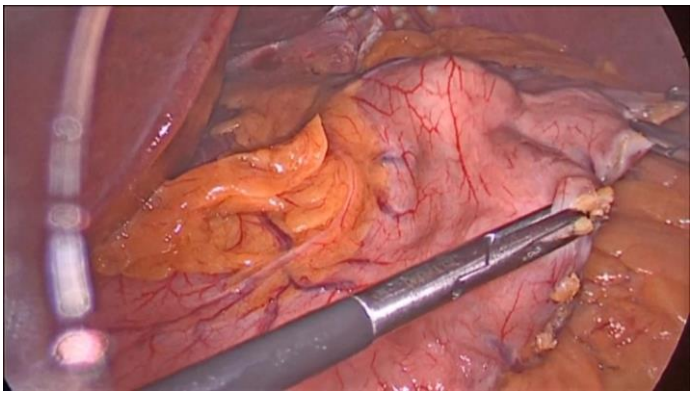

Figure 37. With the grasper in the left hand of the surgeon the bougie is directed towards the antrum, adjacent to the lesser curvature.

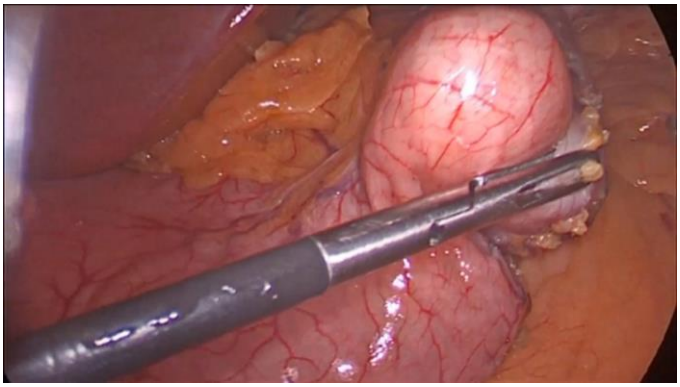

Figure 38. With the grasper in the left hand of the surgeon the bougie is directed towards the antrum, adjacent to the lesser curvature (continued).

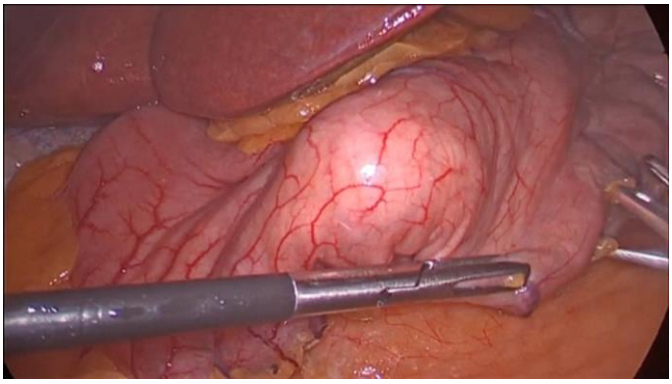

Figure 39. With the grasper in the left hand of the surgeon the bougie is directed towards the antrum, adjacent to the lesser curvature (continued).

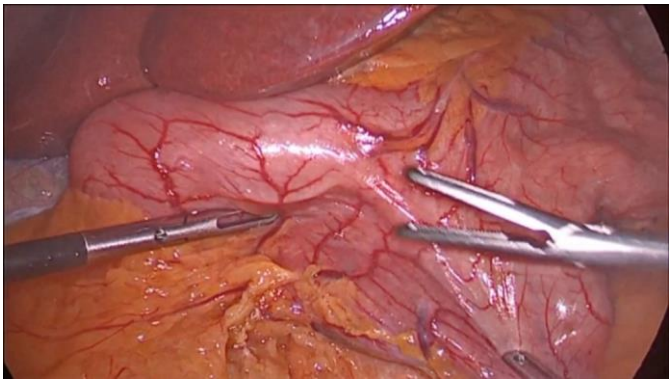

Figure 40. With the grasper in the left hand of the surgeon the bougie is directed towards the antrum, adjacent to the lesser curvature (continued).

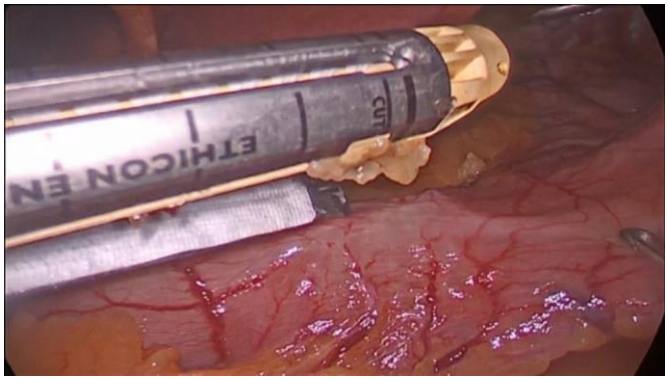

Figure 41. Before firing the stapler, the bougie tube must be visualized passing distal to the stapler along the lesser curvature.

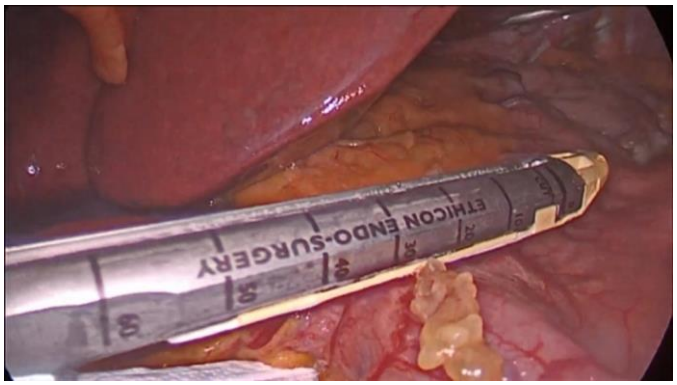

Figure 42. Before firing the stapler, the bougie tube must be visualized passing distal to the stapler along the lesser curvature (continued).

The second cartridge (60mm gold) is in proximity to the incisura angularis and care must be taken in order to avoid stenosis at this level.

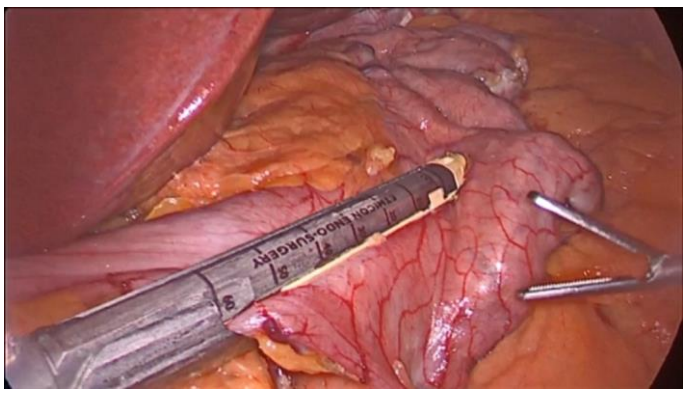

Figure 43. Before firing the stapler, the bougie tube must be visualized passing distal to the stapler along the lesser curvature (continued).

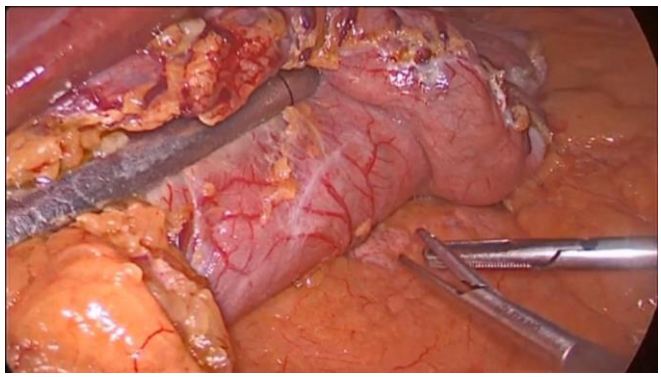

Figure 44. Before firing the stapler, the bougie tube must be visualized passing distal to the stapler along the lesser curvature (continued).

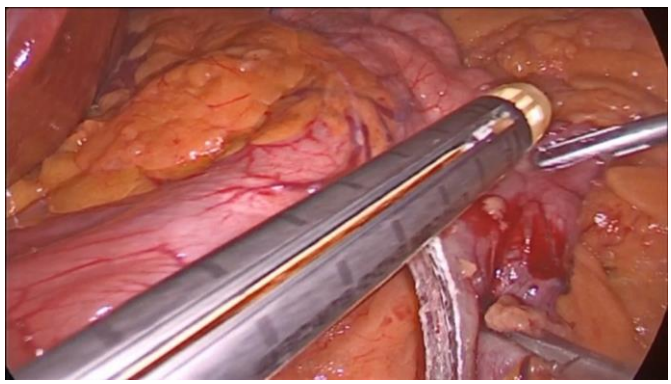

Figure 45. The cartridge is reinforced with peristrips dry.

This second cartridge is also introduced through the 12mm trocar in right hypocondrium (Figure 41-46).

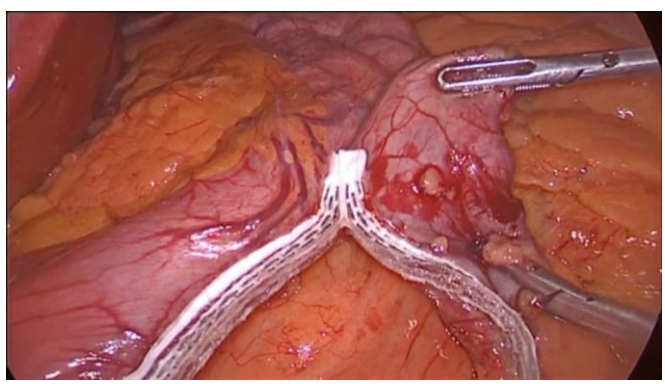

Figure 46. The cartridge is reinforced with peristrips dry (continued).

Following cartridges (60mm blue) are introduced through the 12mm trocar on left hypocondrium towards the upper part of the stomach. At this point it is critical to properly expose the anterior and the posterior aspect of the stomach using lateral traction (first assistant). This prevents a corkscrewing effect of the sleeve as well as avoiding leaving a large posterior fundus.

It is important to avoid stapling too close to the gastroesophageal junction because it is a vascular watershed area and damage could lead to ischemia and a higher leak rate (Figure 47-66).

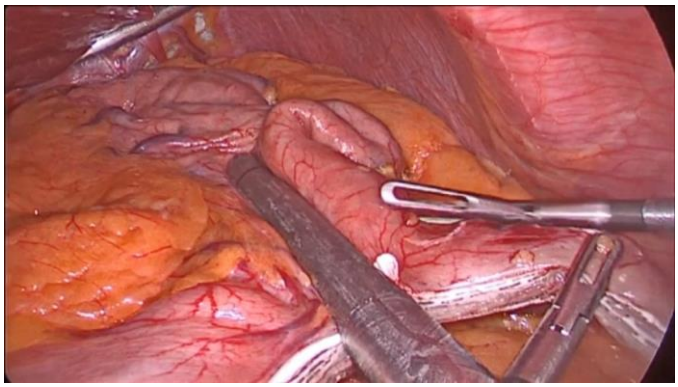

Figure 47. the first 2 cartridges are introduced through the port on right hypochondrium. Following cartridges are introduced through the trocar on the left hypocondrium.

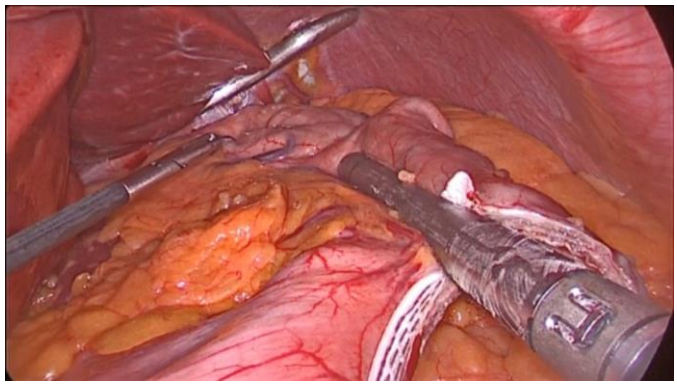

Figure 48. Following cartridges are introduced through the 12mm trocar on left hypocondrium towards the upper part of the stomach.

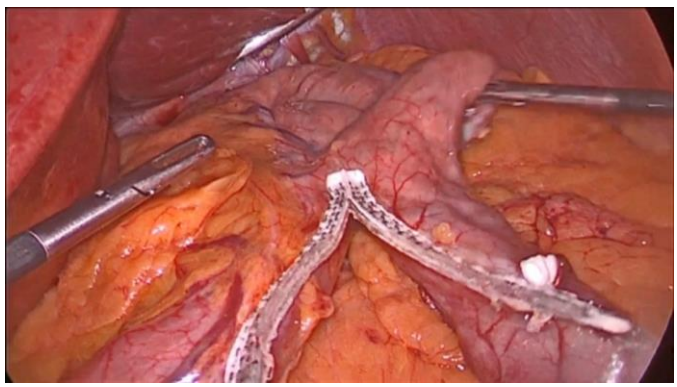

Figure 49. Following cartridges are introduced through the 12mm trocar on left hypocondrium towards the upper part of the stomach (continued).

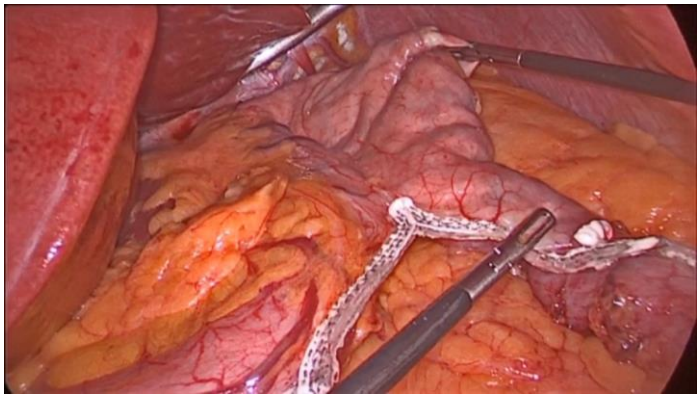

Figure 50. Following cartridges are introduced through the 12mm trocar on left hypocondrium towards the upper part of the stomach (continued).

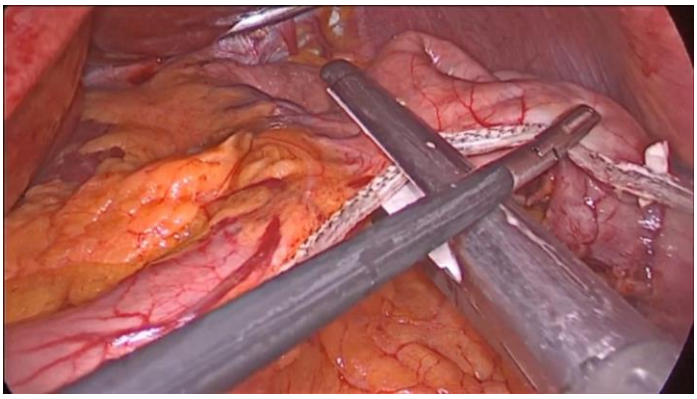

Figure 51. Following cartridges are introduced through the 12mm trocar on left hypocondrium towards the upper part of the stomach (continued).

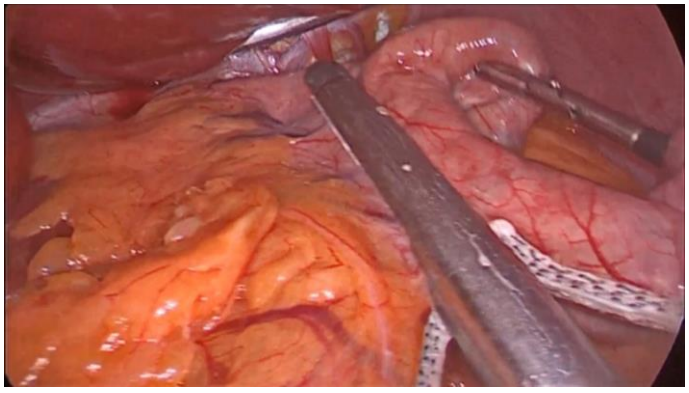

Figure 52. Following cartridges are introduced through the 12mm trocar on left hypocondrium towards the upper part of the stomach (continued).

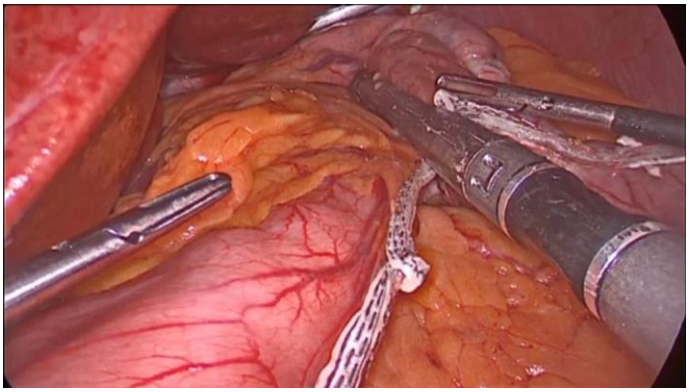

Figure 53. Following cartridges are introduced through the 12mm trocar on left hypocondrium towards the upper part of the stomach (continued).

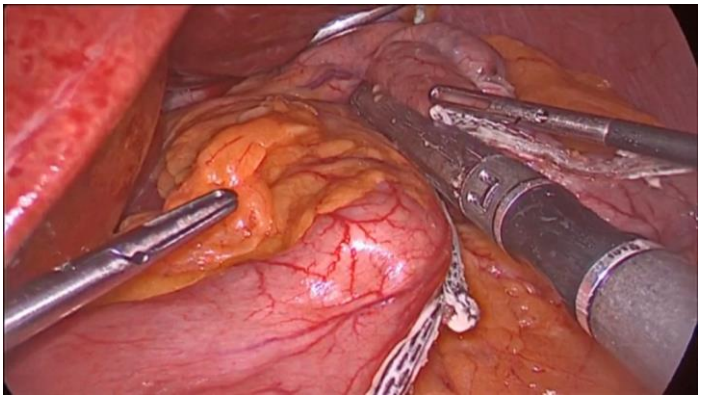

Figure 54. Following cartridges are introduced through the 12mm trocar on left hypocondrium towards the upper part of the stomach (continued).

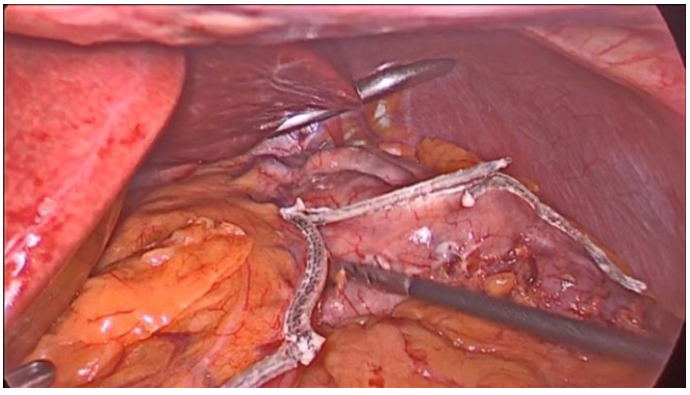

Figure 55. The first assistant performs a lateral traction to prevent from leaving a large posterior fundus.

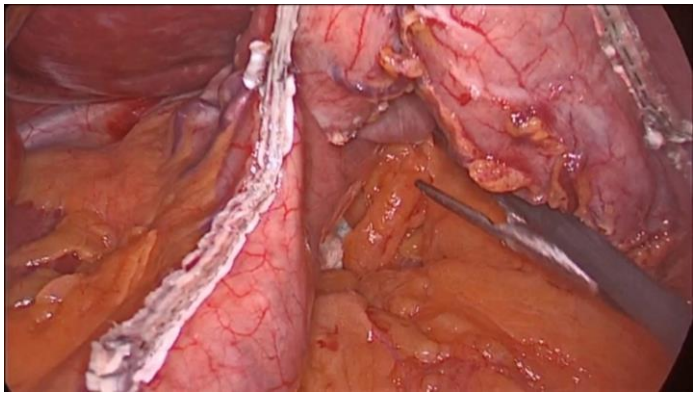

Figure 56. The first assistant performs a lateral traction to prevent from leaving a large posterior fundus (continued).

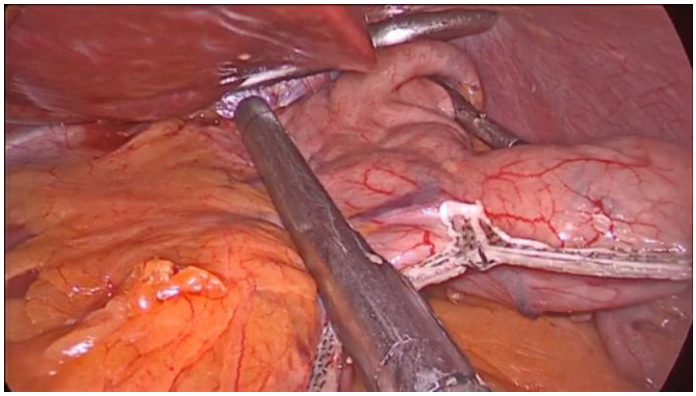

Figure 57. The first assistant performs a lateral traction to prevent from leaving a large posterior fundus (continued).

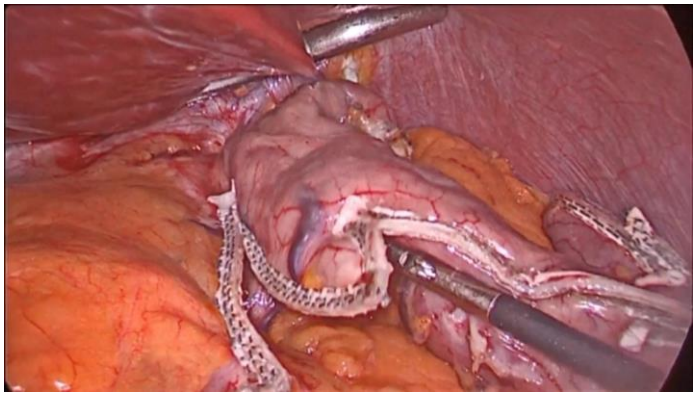

Figure 58. The first assistant performs a lateral traction to prevent from leaving a large posterior fundus (continued).

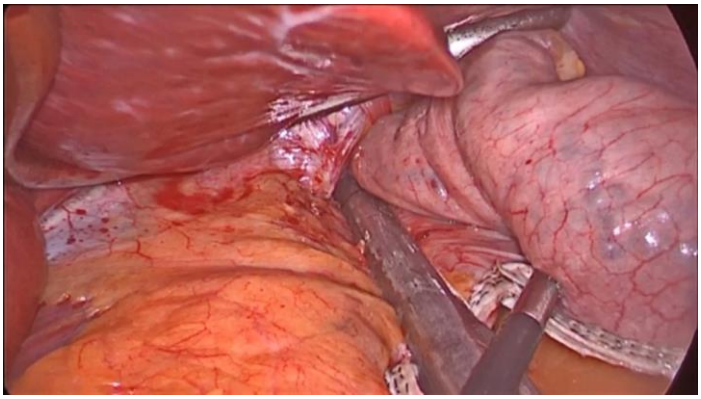

Figure 59. The first assistant performs a lateral traction to prevent from leaving a large posterior fundus (continued).

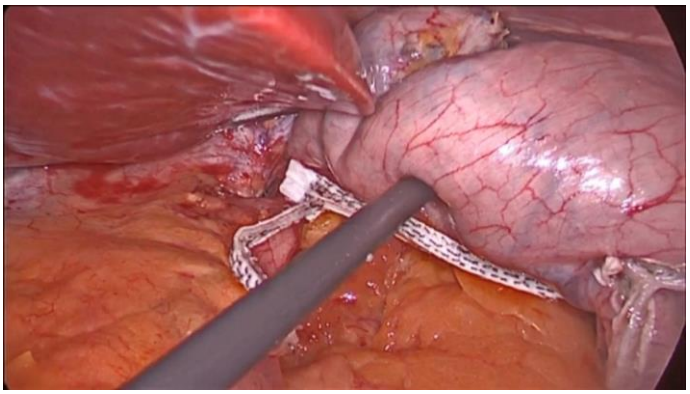

Figure 60. The first assistant performs a lateral traction to prevent from leaving a large posterior fundus (continued).

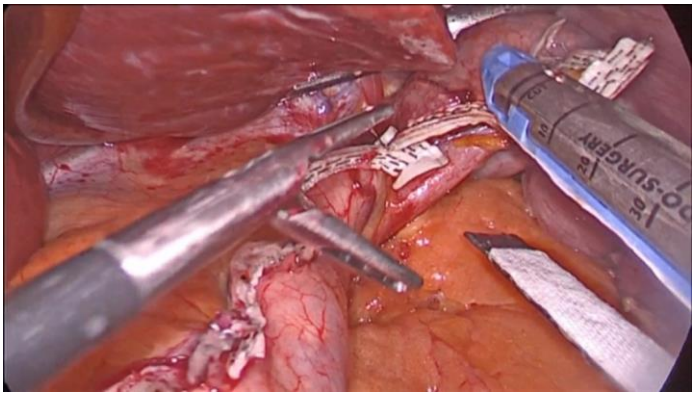

Figure 61. The first assistant performs a lateral traction to prevent from leaving a large posterior fundus (continued).

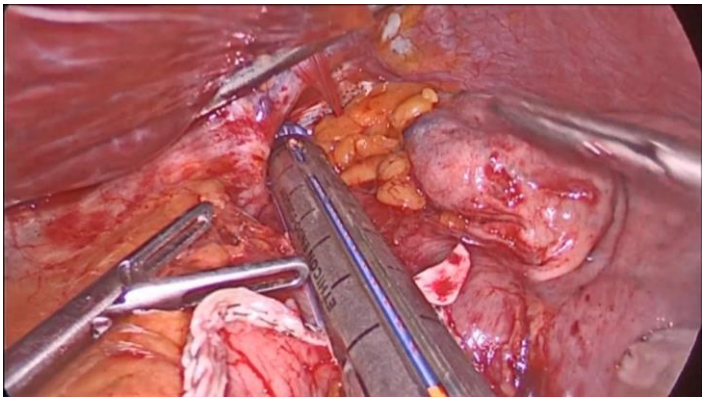

Figure 62. The first assistant performs a lateral traction to prevent from leaving a large posterior fundus (continued).

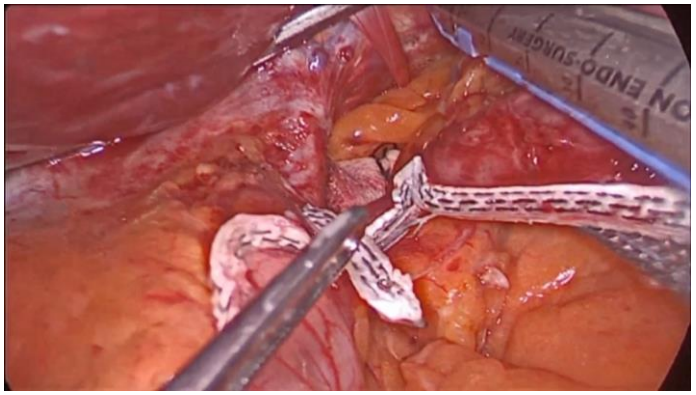

Figure 63. The first assistant performs a lateral traction to prevent from leaving a large posterior fundus (continued).

Figure 64. The first assistant performs a lateral traction to prevent from leaving a large posterior fundus (continued).

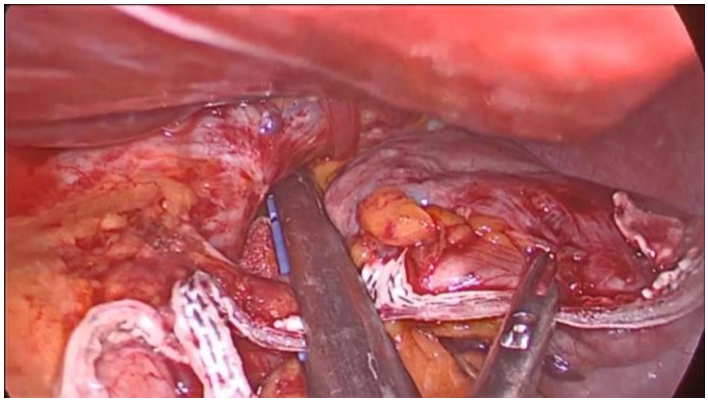

Figure 65. The first assistant performs a lateral traction to prevent from leaving a large posterior fundus (continued).

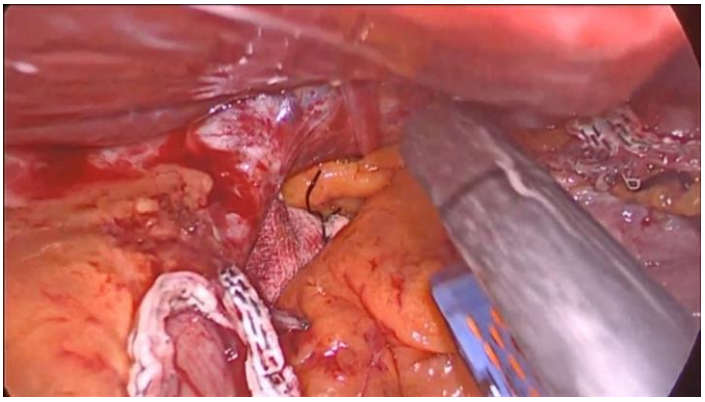

Figure 66. The first assistant performs a lateral traction to prevent from leaving a large posterior fundus (continued).

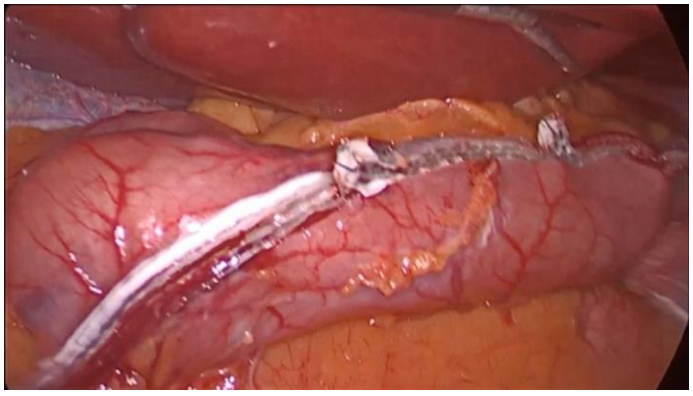

Figure 67. The first assistant performs a lateral traction to prevent from leaving a large posterior fundus (continued).

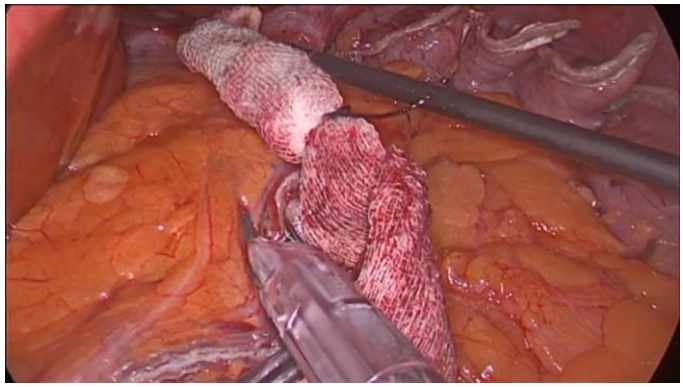

Figure 68. The presence of staple line bleeding is checked.

f) Checking the Staple Line

Once the sleeve is created, we have to check the absence of bleeding in the staple line (Figure 67- 69).

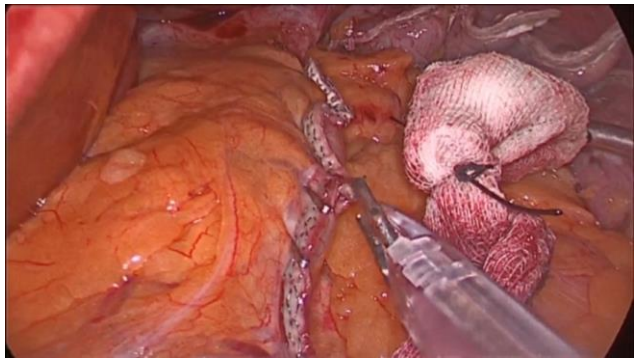

Figure 69. The presence of staple line bleeding is checked (continued).

If bleeding is observed, haemostasia with clips is performed. Finally, a methylene blue test is performed, excluding any spillage of blue contents into the peritoneal cavity. The orogastric tube is removed after the tightness test (Figure 70-72).

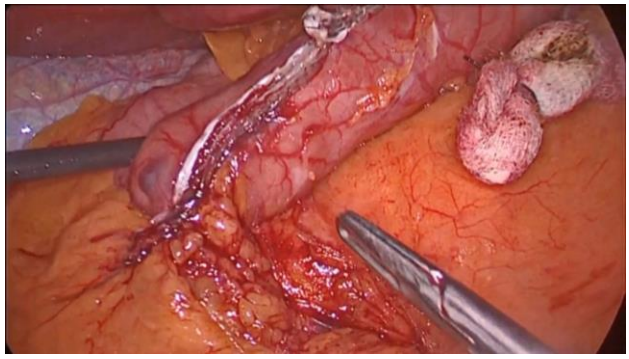

Figure 70. The presence of staple line bleeding is checked (continued).

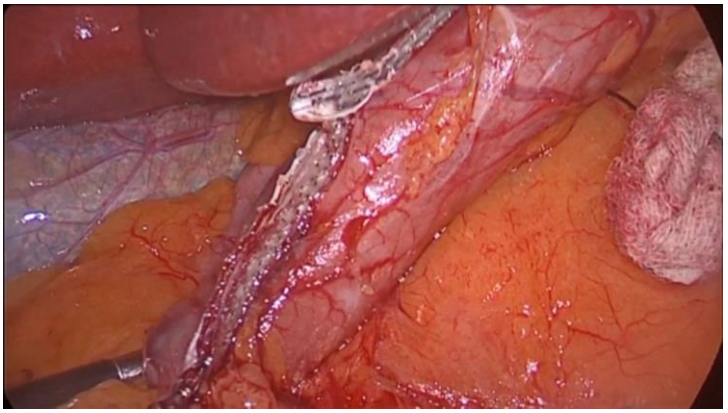

Figure 71. The presence of staple line bleeding is checked (continued).

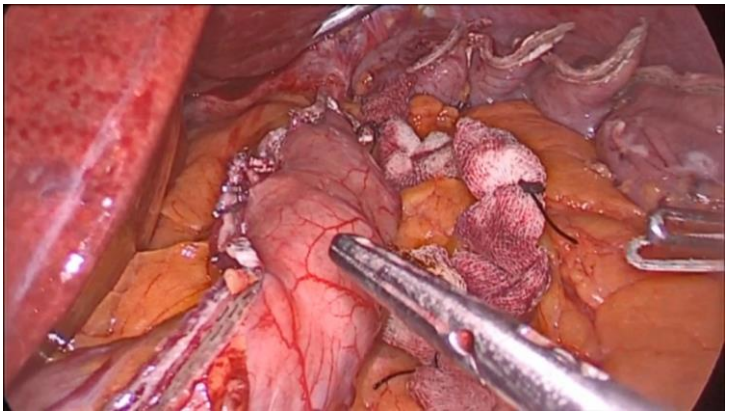

Figure 72. The presence of staple line bleeding is checked (continued).

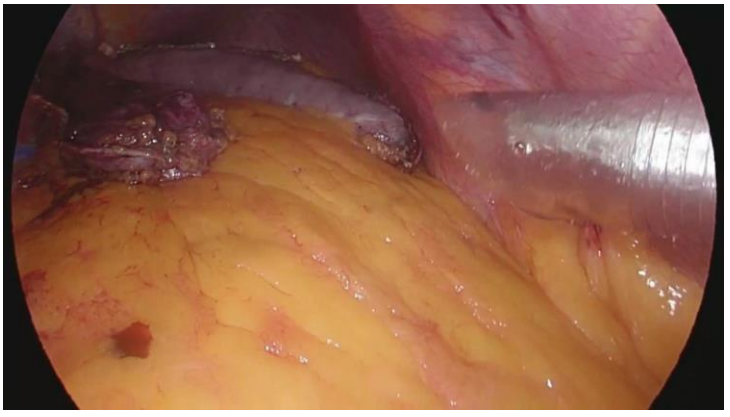

Figure 73. Methylene blue test is performed, excluding any spillage.

Figure 74. Methylene blue test is performed, excluding any spillage (continued).

Figure 75. The excluded stomach is then removed through the 12-mm port site (left hypocondrium) under direct visualization without bag.

Figure 76. Resected specimen.

Surgical drains are not necessary unless there is high concern for bleeding or leak postoperatively. The excluded stomach is then removed through the 12-mm port site (left hypocondrium) under direct visualization without bag (Figure 73-76).

REFERENCES

[1] Hayes Kellen, Eid George (2016). Laparoscopic Sleeve Gastrectomy. Surgical Technique and Perioperative Care. *Surg. Clin. N Am.*, 96:763 - 771.

[2] Emile, S. H., Elfeki, H., Elalfy, K., Abdallah, E. (2017). Laparoscopic Sleeve Gastrectomy Then and Now: An Updated Systematic Review of the Progress and Short-term Outcomes over the Last 5 Years. *Surg. Laparosc. Endosc. Percutan. Tech*., 27(5):307 - 317.

[3] Chu, C., Gagner, M., Quinn, T., Voellinger, D. C., Feng, J. J., Inabnet, W. B., Herron, D., Pomp, A. (2002). Two-stage laparoscopic BPD/DS. An Alternative Approach to Super-Super Morbid Obesity. *Surg. Endosc*., S187.

[4] Gagner, M., Hutchinson, C., Rosenthal, R. (2016). Fifth International Consensus Conference: current status of sleeve gastrectomy. *Surg. Obes. Relat. Dis.*, 12(4):750 - 756.

In: Encyclopedia of Surgery (22 Volume Set)
Editors: Andreas Lehrer and Kristin Mueller
ISBN: 978-1-53618-329-0
© 2020 Nova Science Publishers, Inc

Chapter 294

LAPAROSCOPIC ADJUSTABLE GASTRIC BANDING

Marta Cuadrado Ayuso, MD, Rocio Franco Herrera, MD, PhD and Jesús Lago Oliver*, MD, PhD
Department of General Surgery, Division of Esophagogastric and Bariatric Surgery, Ramón y Cajal University Hospital, Madrid, Spain
Department of General Surgery, Rey Juan Carlos University Hospital, Madrid, Spain
General Surgery, Bariatric Surgery, Instituto de Obestidad Jesús Lago, Madrid, Spain

ABSTRACT

Laparoscopic Adjustable Gastric Banding (LAGB) is still a popular bariatric procedure that is minimally invasive and without irreversible anatomical changes, and although the indications have decreased in the last years it still has some indications. The aim of this chapter is to describe the surgical technique of LAGB.

Keywords: laparoscopic adjustable gastric banding, surgical technique

INTRODUCTION

Adjustable gastric banding was introduced as a bariatric procedure and rapidly spread for its simplicity and low morbidity [1]. Considered as a "pure restrictive" procedure, placing a band tightly around the stomach, this could not explain the weight loss and the action of the band. Activation of a peripheral satiety mechanism without physically restricting meal size has been proposed as a mechanism of action [2]. In the last years, there has been an important decrease in LAGB procedures, mainly attributed to doubts regarding is effectiveness in long-term results, but still is indicated in specific populations [3].

* Corresponding Author's Email: marta.cuadrado@salud. madrid.org.

INDICATION

Indication for Laparoscopic Adjustable Gastric Band (LAGB) are the same as any bariatric procedures.

A body mass index of at least 40 or 35 in association with any comorbidities.

A careful selection of patients should be made and a multidisciplinary approach is recommended.

Patients at lower BMI, at the extremes of age or with more significant co-morbidities, are potential candidates.

Long-term follow up is required after LAGB.

PREOPERATIVE PREPARATION

All patients should receive prophylaxis with cephalosporin intravenous before induction of anesthesia.

Anesthesia

General Anesthesia is required to perform the surgical procedure. Local Anesthesia is injected around laparoscopic ports at the end of the procedure.

SURGICAL TECHNIQUE

Instrumentation

1. One 15 mm trocar and three 5 mm ports
2. Liver retractor
3. 5mm 30º scope
4. Veress needle
5. Two atraumatic graspers
6. Finger
7. Lap-band

PATIENT, PORT AND SURGEON POSITIONS

a) Patient Position

The patient is placed in supine position. Fixation around the knees is needed to prevent sliding as the procedure requires a forced anti-Trendelemburg position.

Figure 1. Patient position.

b) Port Position

Pneumoperitoneum in made by inserting a Veress needle above the umbilicus until a pressure of 12-14 mm Hg is reached.

Then a 5mm port is inserted at the same place for the camera.

A 15mm port is placed in the right hypochondrium under direct vision to allow the band insertion.

Two 5mm ports are placed, one under the xiphoid for the liver retractor and the other in the left upper quadrant. (Figure 2).

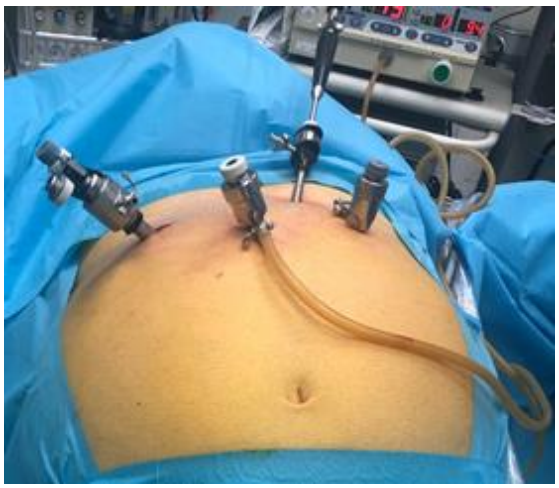

Figure 2. Port position.

c) Surgeon Position

The surgeon stands in the right side of the patient, and the assistant stands on the left holding the camera and the liver retractor.

PROCEDURE

a) Band Preparation and Insertion

The band is prepared according the manufacturer's specifications.

Figure 3. Band preparation.

The band is inserted through the 15mm port.

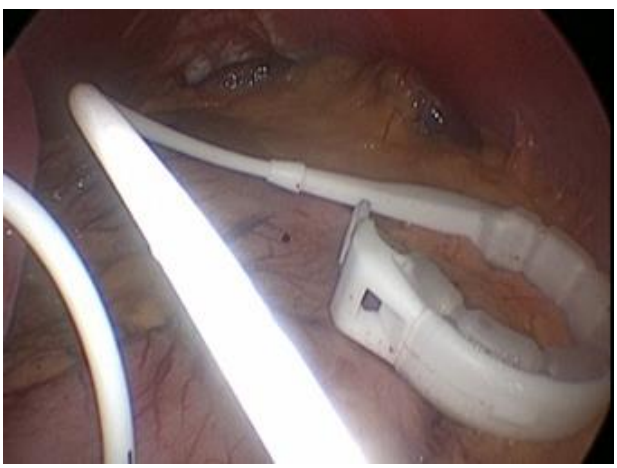

Figure 4. Band insertion.

b) Pars Flaccida Opening

The procedure begins with the opening of the pars flaccida. Then the lesser curvature is retracted to the patient´s left to expose the right crus of the diaphragm.

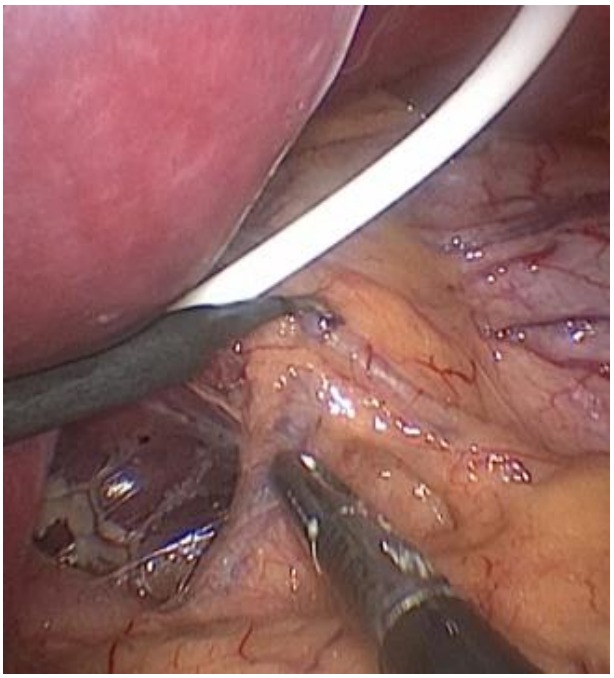

Figure 5. Opening of the pars flaccida.

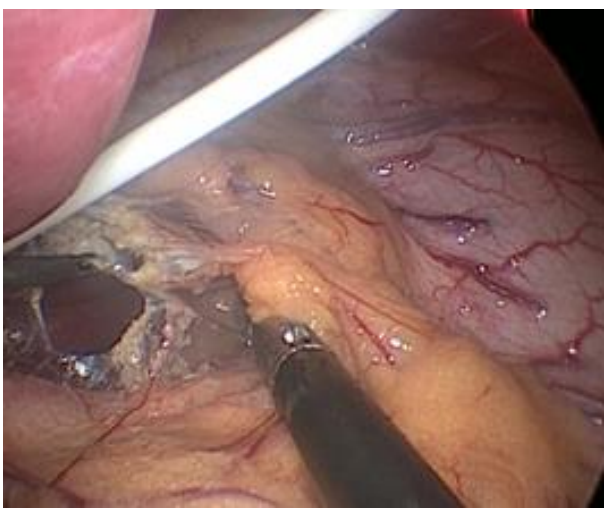

Figure 6. Opening of the pars flaccida (continued).

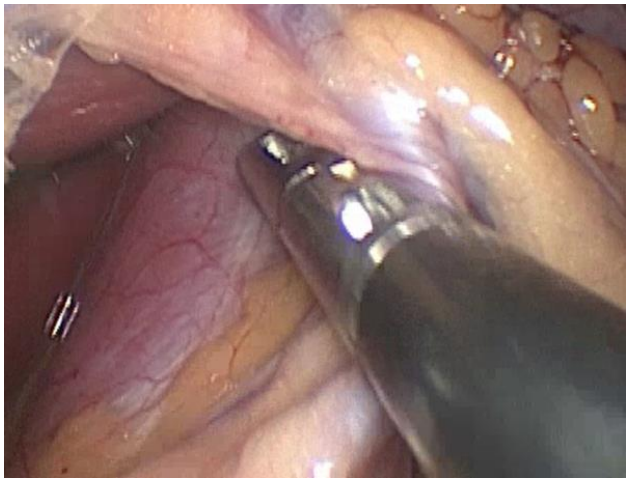

Figure 7. The lesser curvature is retracted to the patient´s left to expose the right crus of the diaphragm.

c) Tunnel Creation

Once the right crus has been identified, a minimal incision is made in the peritoneum in the lower aspect of the crus, to allow the passage of the finger.

Bluntly, a tunnel behind the stomach is created with the finger towards the His angle.

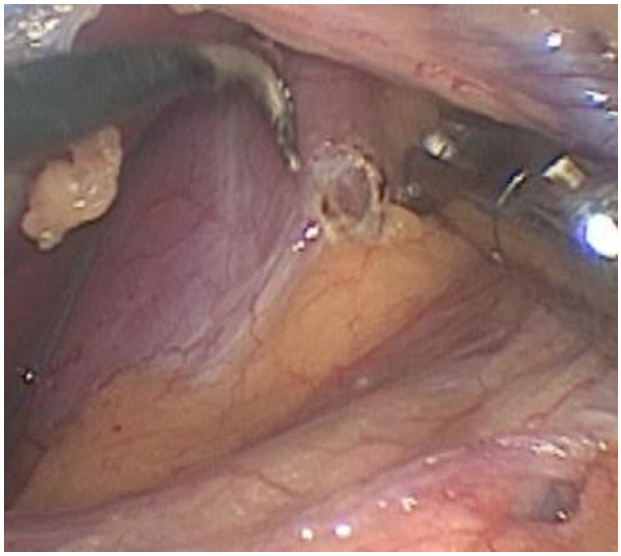

Figure 8. A minimal incision is made in the peritoneum in the lower aspect of the crus, to allow the passage of the finger.

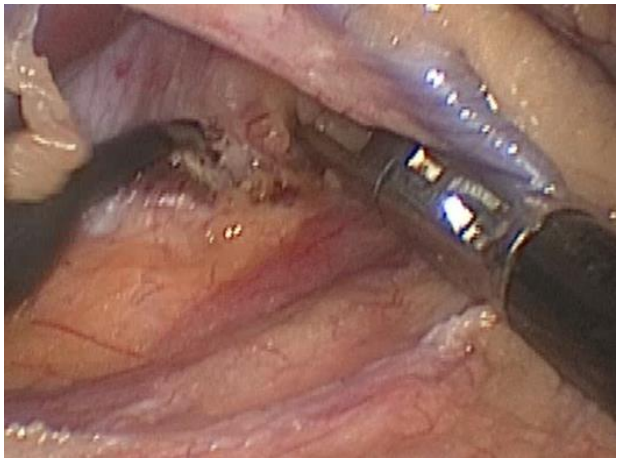

Figure 9. A tunnel behind the stomach is created with the finger towards the His angle.

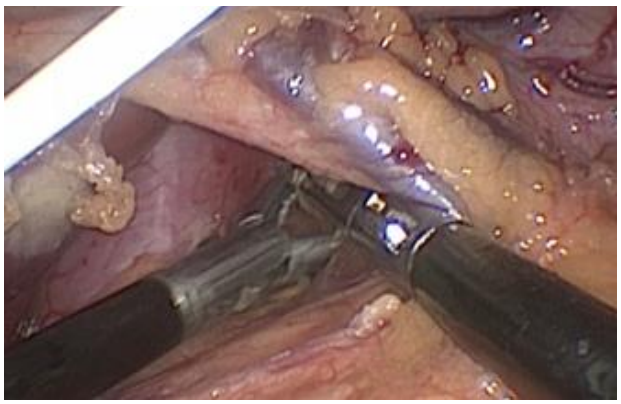

Figure 10. A tunnel behind the stomach is created with the finger towards the His angle (continued).

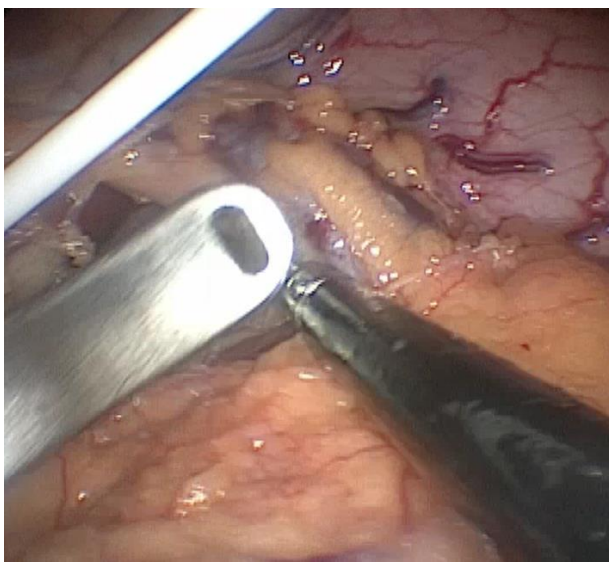

Figure 11. A tunnel behind the stomach is created with the finger towards the His angle (continued).

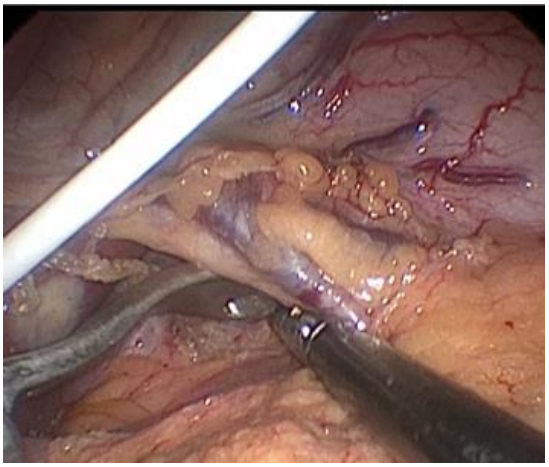

Figure 12. A tunnel behind the stomach is created with the finger towards the His angle (continued).

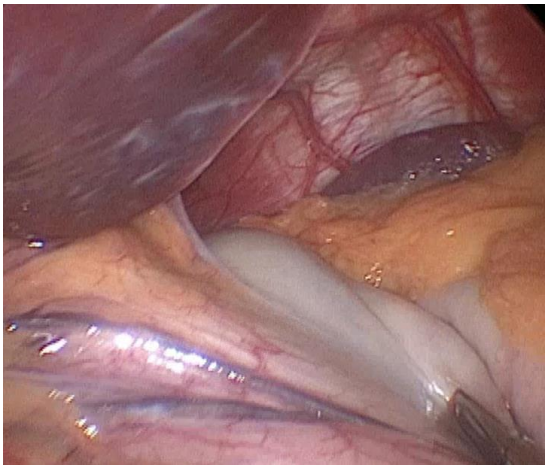

Figure 13. A tunnel behind the stomach is created with the finger towards the His angle (continued).

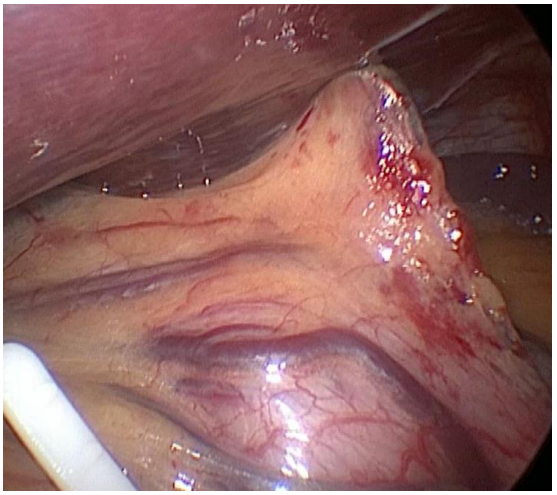

Figure 14. A tunnel behind the stomach is created with the finger towards the His angle (continued).

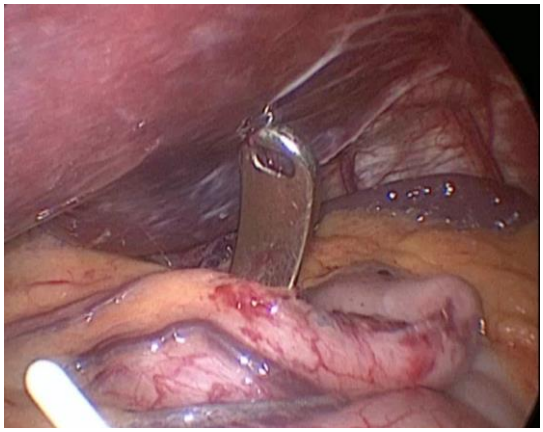

Figure 15. A tunnel behind the stomach is created with the finger towards the His angle (continued).

d) Band Placement

Carefully, the edge of the band is placed in the finger´s eye, and with a minimal traction, the band is left behind the stomach.

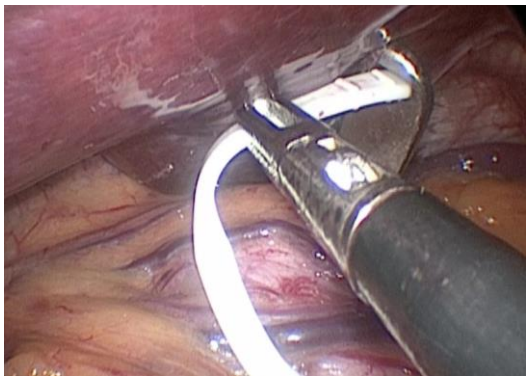

Figure 16. The edge of the band is placed in the finger´s eye, and with a minimal traction, the band is left behind the stomach.

Figure 17. The edge of the band is placed in the finger´s eye, and with a minimal traction, the band is left behind the stomach (continued).

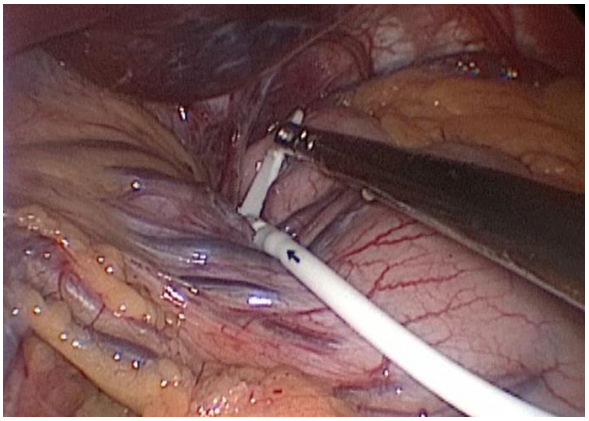

Figure 18. The edge of the band is placed in the finger´s eye, and with a minimal traction, the band is left behind the stomach (continued).

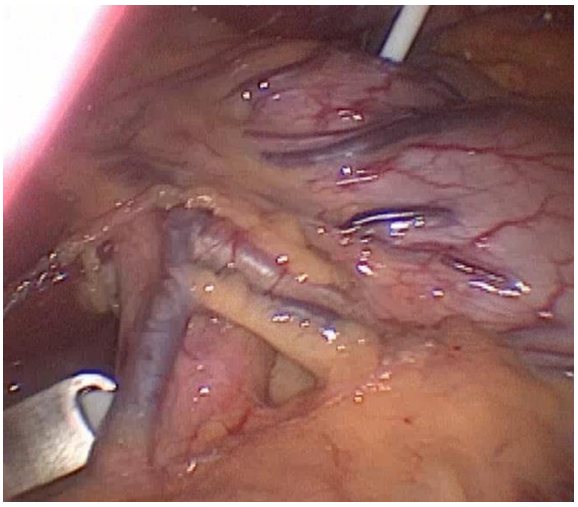

Figure 19. The edge of the band is placed in the finger´s eye, and with a minimal traction, the band is left behind the stomach (continued).

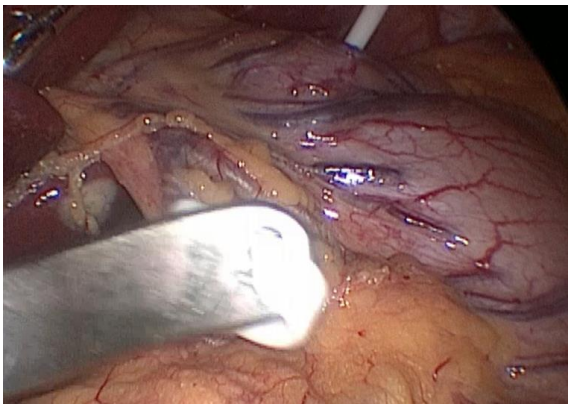

Figure 20. The edge of the band is placed in the finger´s eye, and with a minimal traction, the band is left behind the stomach (continued).

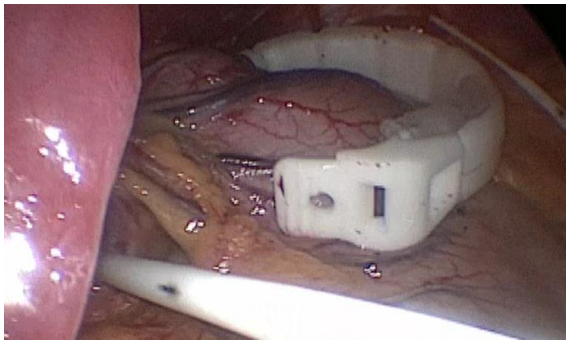

Figure 21. The edge of the band is placed in the finger´s eye, and with a minimal traction, the band is left behind the stomach (continued).

e) Band Closure

When the band is in place, the tube is passed through the band buckle and close tight until it is secured.

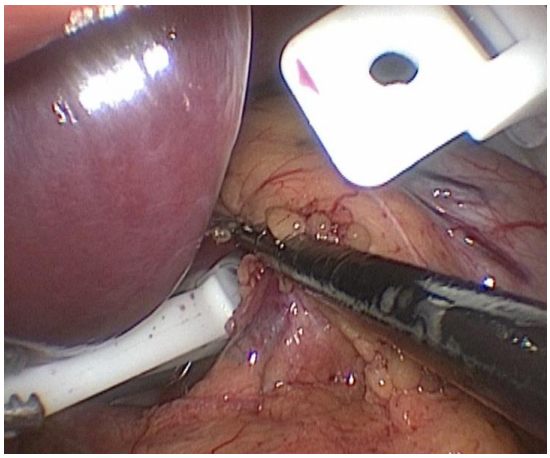

Figure 22. The tube is passed through the band buckle and close tight until it is secured.

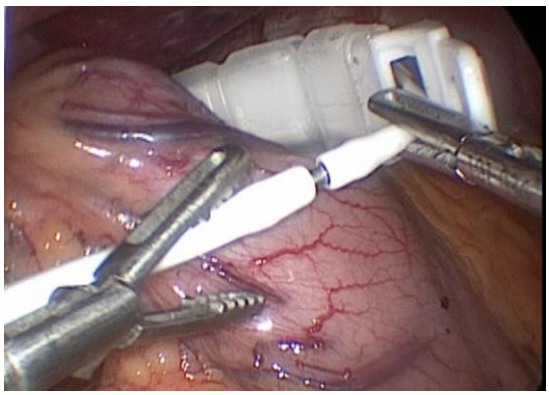

Figure 23. The tube is passed through the band buckle and close tight until it is secured (continued).

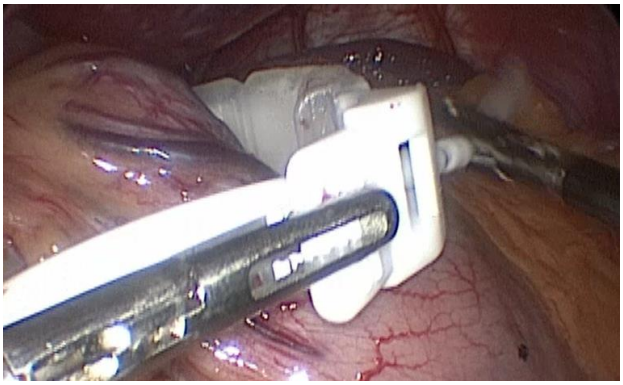

Figure 24. The tube is passed through the band buckle and close tight until it is secured (continued).

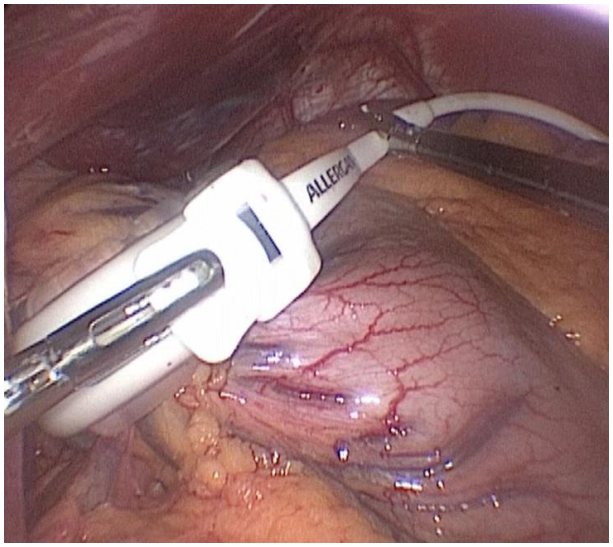

Figure 25. The tube is passed through the band buckle and close tight until it is secured (continued).

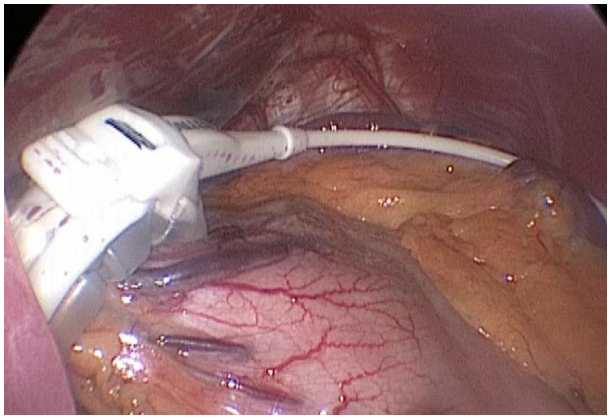

Figure 26. The tube is passed through the band buckle and close tight until it is secured (continued).

f) Band Fixation

The fundus is wrapped over the band and secured to the stomach pouch above by interrupted sutures.

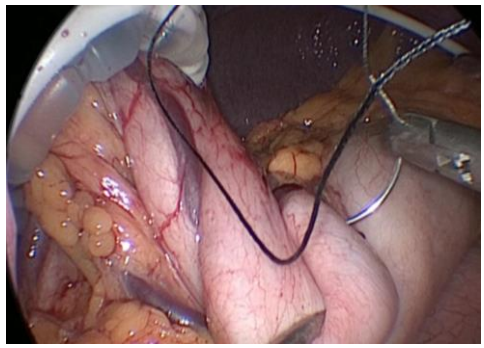

Figure 27. The fundus is wrapped over the band and secured to the stomach pouch above by interrupted sutures.

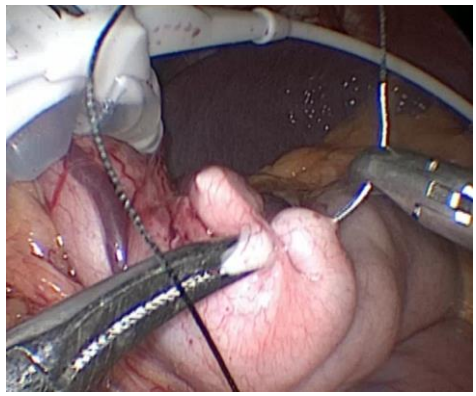

Figure 28. The fundus is wrapped over the band and secured to the stomach pouch above by interrupted sutures (continued).

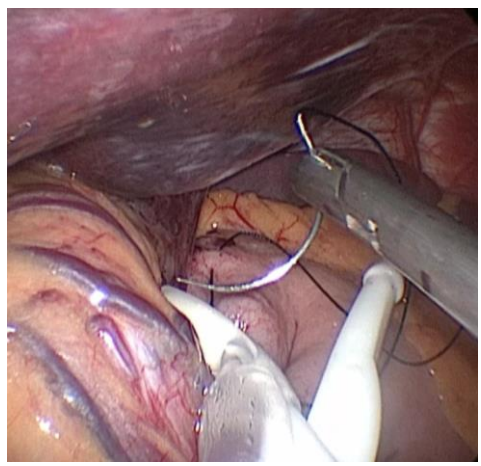

Figure 29. The fundus is wrapped over the band and secured to the stomach pouch above by interrupted sutures (continued).

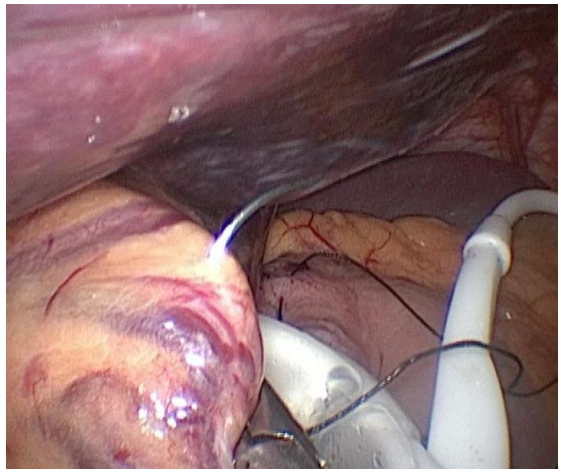

Figure 30. The fundus is wrapped over the band and secured to the stomach pouch above by interrupted sutures (continued).

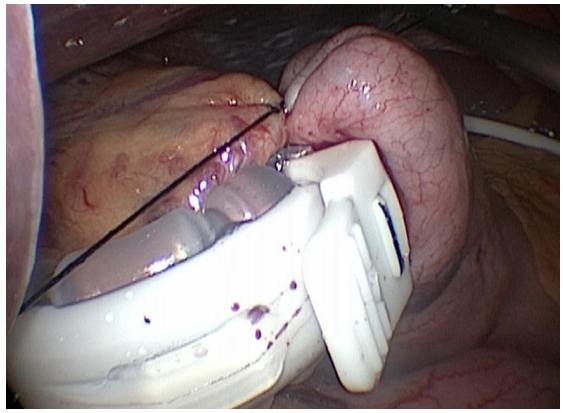

Figure 31. The fundus is wrapped over the band and secured to the stomach pouch above by interrupted sutures (continued).

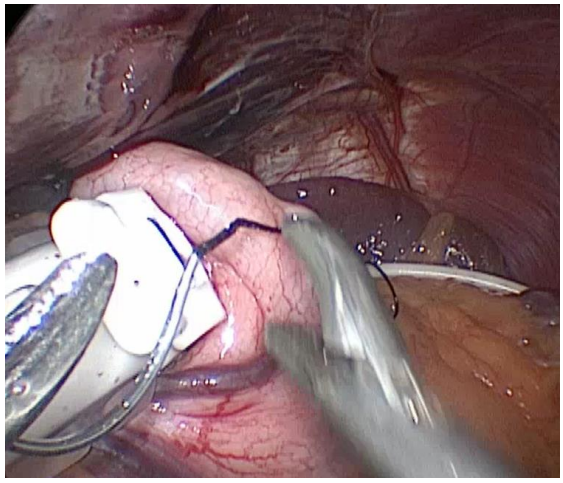

Figure 32. The fundus is wrapped over the band and secured to the stomach pouch above by interrupted sutures (continued).

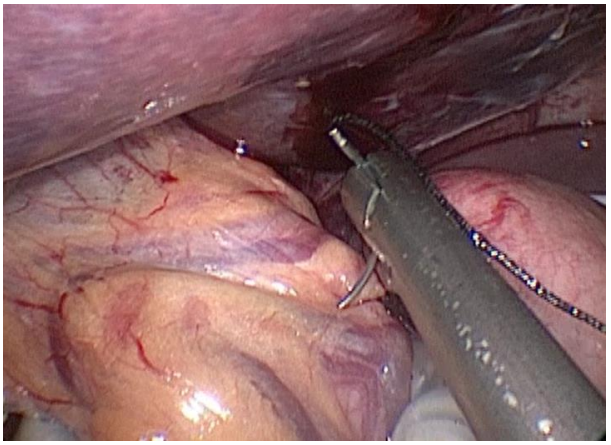

Figure 33. The fundus is wrapped over the band and secured to the stomach pouch above by interrupted sutures (continued).

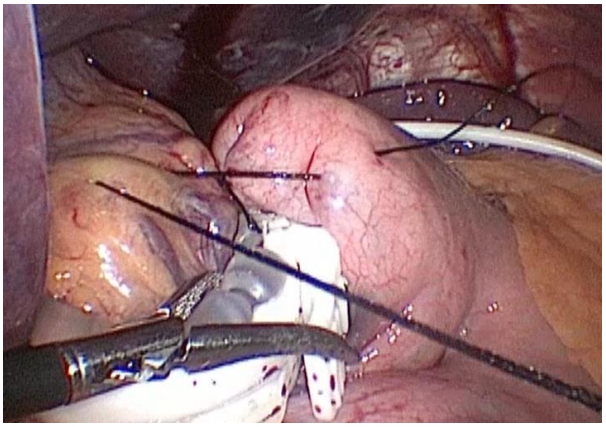

Figure 34. The fundus is wrapped over the band and secured to the stomach pouch above by interrupted sutures (continued).

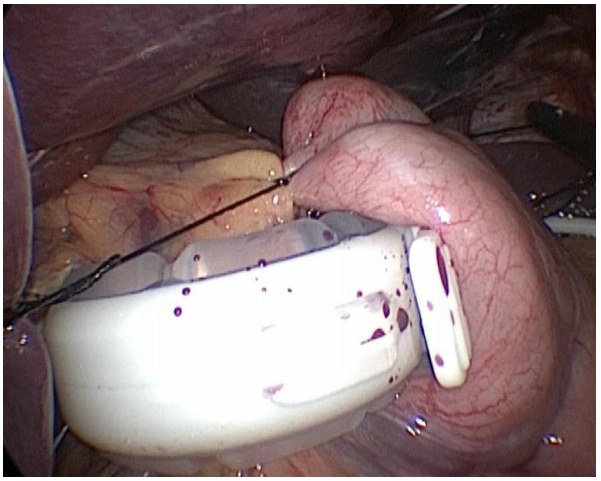

Figure 35. The fundus is wrapped over the band and secured to the stomach pouch above by interrupted sutures (continued).

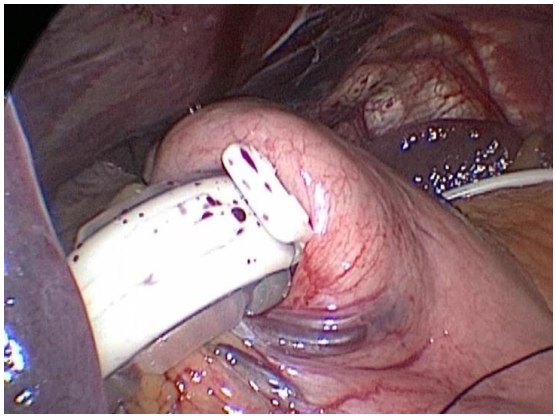

Figure 36. The fundus is wrapped over the band and secured to the stomach pouch above by interrupted sutures (continued).

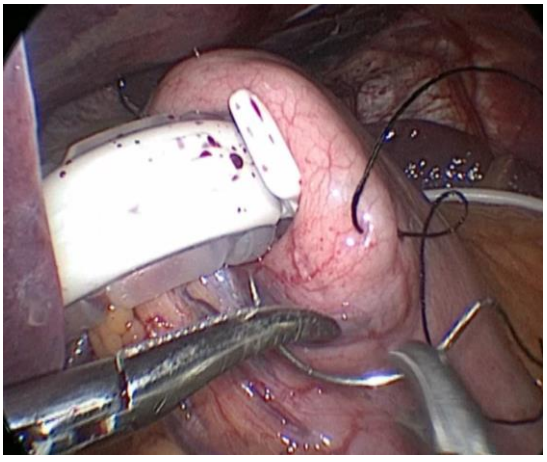

Figure 37. The fundus is wrapped over the band and secured to the stomach pouch above by interrupted sutures (continued).

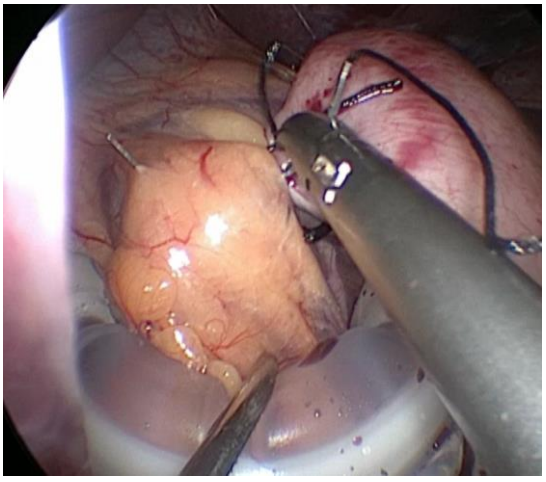

Figure 38. The fundus is wrapped over the band and secured to the stomach pouch above by interrupted sutures (continued).

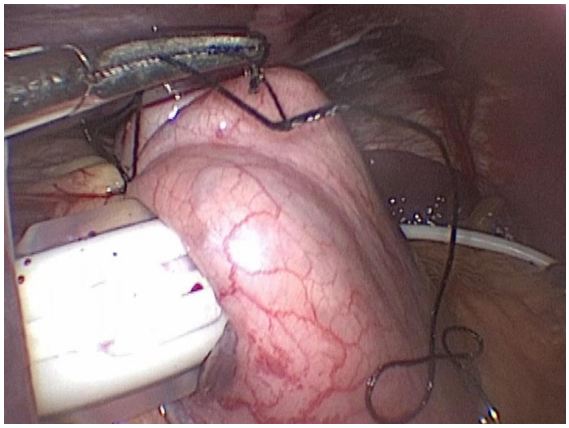

Figure 39. The fundus is wrapped over the band and secured to the stomach pouch above by interrupted sutures (continued).

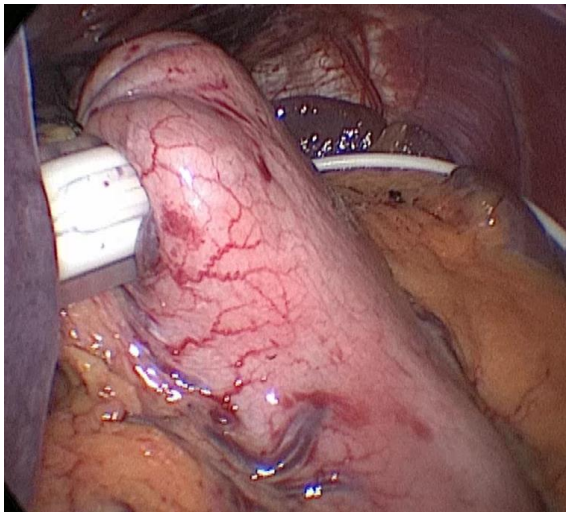

Figure 40. The fundus is wrapped over the band and secured to the stomach pouch above by interrupted sutures (continued).

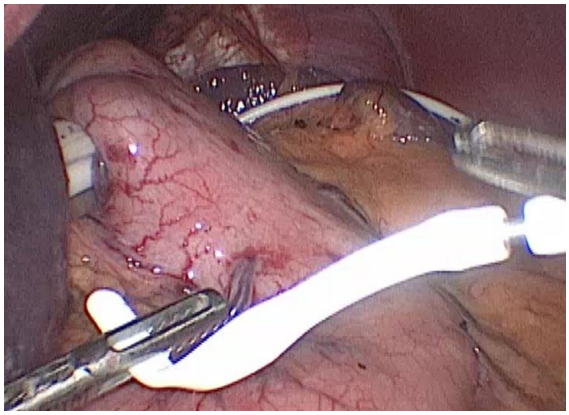

Figure 41. The fundus is wrapped over the band and secured to the stomach pouch above by interrupted sutures (continued).

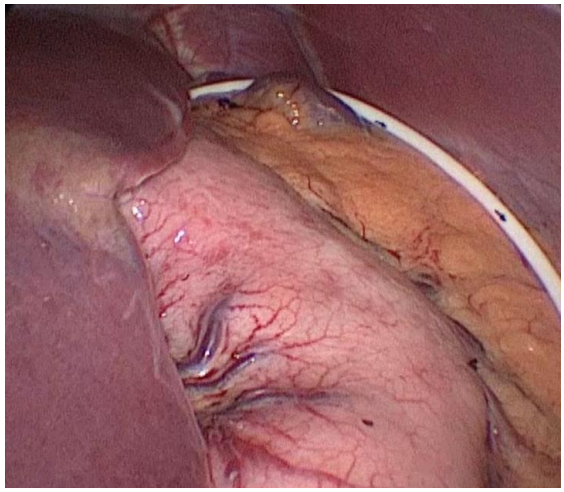

Figure 42. The fundus is wrapped over the band and secured to the stomach pouch above by interrupted sutures (continued).

g) Port Placement

The tip of the band is grasped and pulled out through the 15mm trocar.

The liver retractor is then removed as so are the ports under direct vision to detect any bleeding. Local anesthesia is placed under vision. The pneumoperitoneum is released.

The band is connected to the port, and a pocket just above or under the port incision is created until the fascia is exposed. Three non-absorbable sutures are placed for the port fixation.

h) Closure

5 mm ports are closed with non absorbable 5/0 suture.

15mm port is closed with absorbable intradermic suture.

REFERENCES

[1] Cadiere GB, Bruyns J, Himpens J, et al. Laparoscopic gastroplasty for morbid obesity. *Br J Surg*. 1994; 81: 1524.

[2] Burton PR, Brown WA. The mechanism of weight loss with laparoscopic adjustable gastric banding: induction of satiety not restriction. *Int J Obes*. 2011; 35: S26-S30.

[3] Angrisani L, Santonicola A, Iovino P, et al. Bariatric surgery world-wide 2013. *Obes Surg*. 2015; 25: 1822-32.

In: Encyclopedia of Surgery (22 Volume Set)
Editors: Andreas Lehrer and Kristin Mueller
ISBN: 978-1-53618-329-0
© 2020 Nova Science Publishers, Inc

Chapter 295

LAPAROSCOPIC NISSEN-SLEEVE GASTRECTOMY

Alejandro Garcia Muñoz-Najar, MD,
Camilo Castellon Pavon, MD, PhD, Manuel Duran, MD, PhD
and Jaime Ruiz-Tovar, MD, PhD
Bariatric Surgery Unit, Rey Juan Carlos University Hospital,
Madrid, Spain

ABSTRACT

Gastroesophageal reflux (GERD) is considered a disease related to morbid obesity whose incidence in obese population varies between 30 - 50%. Obese patients with GERD are not good candidates for anti-reflux procedures because of a high incidence of failure.

Despite the advantages of laparoscopic sleeve gastrectomy (LSG), it is associated with a postoperative GERD rate of 10 to 20%, regardless of preoperative diagnosis. For this reason, in obese patients with GERD, the Roux-en-Y gastric bypass (RYGB) is considered the gold standard, although several studies suggest that the association of hiatoplasty and/or fundoplication with LSG can guarantee a reduction of the postoperative ERGE, which varies from 20 to 34%.

Keywords: nissen - sleeve gastrectomy, fundoplication, gastroesophageal reflux, surgical technique

INTRODUCTION

Gastroesophageal reflux disease (GERD) is a common clinical problem of the digestive tract, with an incidence of 30 - 50% in obese patients. Because obesity is a risk factor for the development of GERD, the increasing prevalence of obesity worldwide has coincided with the increased prevalence of GERD. Laparoscopic Nissen fundoplication is an effective treatment for patients with severe GERD and has a sustained long-term benefit [1-7].

Several authors believe that Nissen laparoscopic fundoplication may be an obstacle to the application of bariatric surgery in the treatment for morbidly obese patients with GERD [8]. However, there is a growing group of bariatric surgeons who believe that a fundoplication associated with LSG is an excellent technique for the control of GERD with good weight loss control. It is a technique that must also be taken into account in cases where there is duodenal or intestinal pathology, in which gastric bypass is not indicated.

INDICATION

1. Primary weight loss procedure.
2. Obese patients with esofagitis, GERD or Barrett´s esophagus
3. Obese patients with GERD with any intestinal disease or structural lesions of the gastric or duodenal mucosa in which a RYGB would not be advisable.

PREOPERATIVE PREPARATION

In the case of this technique, in addition to the preoperative assessment of a multidisciplinary team, made up of various medical specialties involved in the treatment of morbid obesity (endocrinology, pulmonology, psychiatry, nutritionist, surgery), it is important to conduct a functional study of the esophagus and endoscopic and radiological study of the esophagogastroduodenal tract (upper gastrointestinal endoscopy, barium swallow GI transit, 24-hours ph-metry and manometry)

Anesthesia

An enhanced recovery after surgery (ERAS) programme can be followed with an opioid-free anesthesia. Central vein and bladder catheters are not necessary.

SURGICAL TECHNIQUE

Instrumentation

At our institution we used the following surgical matherial for this technique:

1. Two 12mm, one 11mm and one 5mm ports
2. Liver retractor
3. 30º scope
4. Harmonic scalpel (Harmonic ACE; Johnson & Johnson)
5. Veress needle
6. Two traumatic clinch
7. Suction-irrigator

8. Non-absorbable sutures of Ethibond® 2.0 (Johnson-Johnson Inc. US)
9. Echelon 60mm (golden cartridges) (Johnson & Johnson, USA)
10. Staple-line reinforcement material
11. Gauzes
12. Clip applicator (optional)

PATIENT, PORT AND SURGEON POSITIONS

a) Patient Position

Patients are placed on an operating table in supine position with legs opened and the right arm opened.

Figure 1. Patient position.

Intermittent pneumatic compression devices are used to prevent thromboembolic events. The legs and hips are secured with safety straps. Once all the ports are inserted, the patient is placed in anti-Trendelemburg position. An orogastric tube of 38 - 40 Fr is placed into the stomach in order to calibrate the sleeve and the fundoplication during stapling and transection (Figure 1).

b) Port Position

Pneumoperitoneum to a pressure of 12 - 14mmHg is achieved through Veress needle technique or using the optical trocar. A primary, 11-mm port is inserted at the junction of the upper two thirds and lower one third of the line joining the xiphoides to the umbilicus. This is the camera port.

Two 12-mm working ports are inserted in the left and right quadrant areas at the level of the midclavicular line.

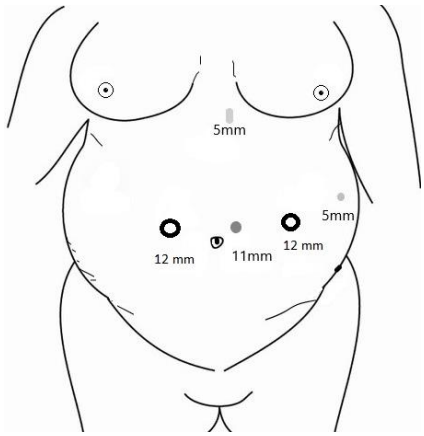

Figure 2. Port position.

A 5-mm port is inserted in the epigastrium. A liver retractor is used to retract the left lobe of the liver.

Another 5-mm port is placed on the left side in anterior axillary line at the level of the umbilicus. This is used by the first assistant on the left side to retract the stomach or to lift it up (Figure 2).

c) Surgeon Position

The operating surgeon stands in the space between the legs of the patient. The camera or 1st assistant is on the right of the operating surgeon. The scrub nurse stands on the right side of the 1st assistant.

Monitor is placed on the upper part of the patient for assistant and surgeon view (Figure 3).

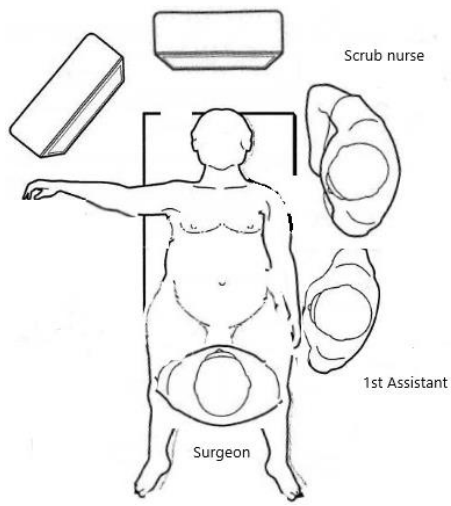

Figure 3. Surgeon position.

PROCEDURE

a) Identification of the Angle of His

The dissection begins identifying the angle of His. A trick is to visualize the left crura of the diaphragma.

If there is a large fat patch, a careful resection is recommended (Figure 4-6).

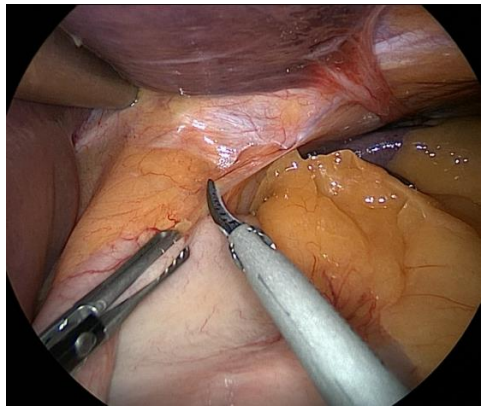

Figure 4. The dissection begins identifying the angle of His.

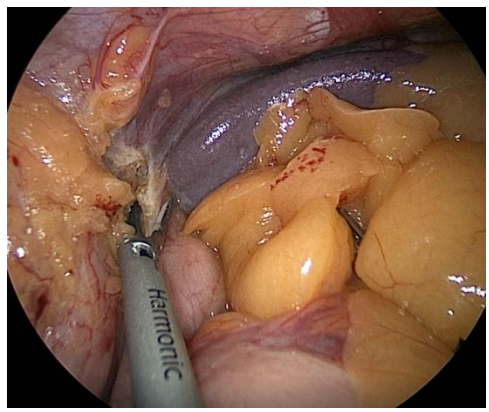

Figure 5. The dissection begins identifying the angle of His (continued).

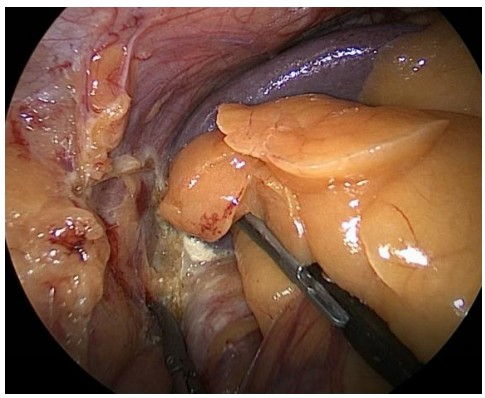

Figure 6. The dissection begins identifying the angle of His (continued).

b) Revision of the Hiatus

In this technique, it is crucial to check the esophageal hiatus to dissect and reduce a hiatal hernia when present. Therefore, the hiatus should be approached by the left crura, already dissected at the beginning of the surgery, and by the right crura, dividing the pars flacida of the lesser omentum. The right crura must be clearly identified and the hernia sac dissected (Figure 7-12).

An aid can be the passage under the esophagus of a tape or a silicone handle, which the first assistant must displace caudally, to be able to finish the dissection of the hiatus; the abdominal esophagus must be distally descended at least 5cm below the crus and all the anterior and the posterior esophageal hiatal space must be correctly dissected (Figure 13-16).

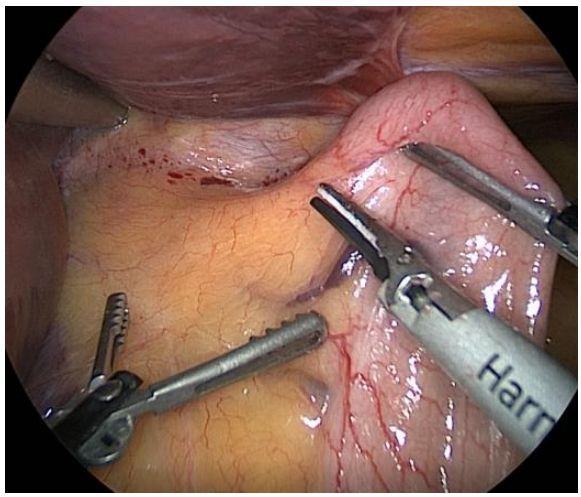

Figure 7. The hiatus should be approached by the left crura.

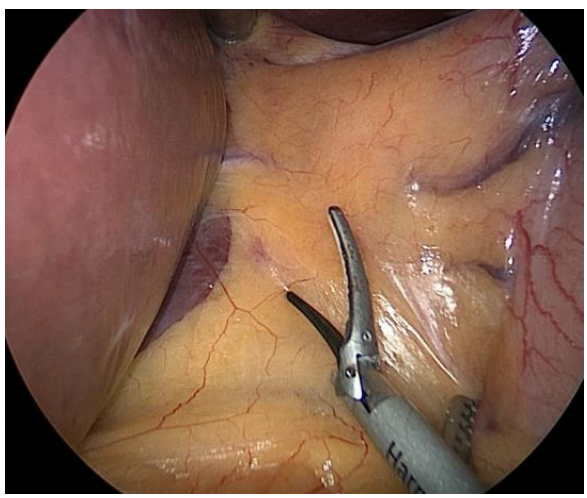

Figure 8. Division of the pars flacida of the lesser omentum.

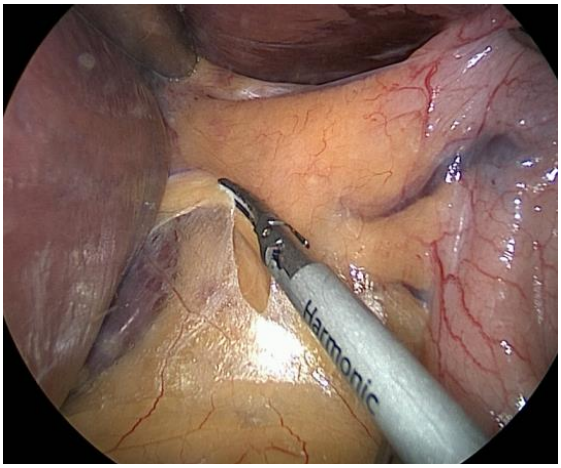

Figure 9. Division of the pars flacida of the lesser omentum (continued).

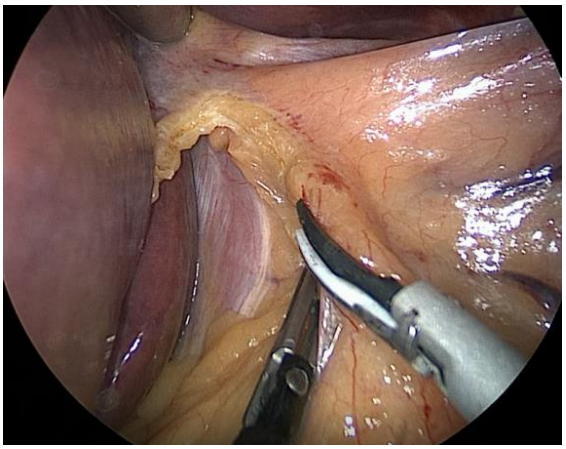

Figure 10. Division of the pars flacida of the lesser omentum. Identification of the right crura.

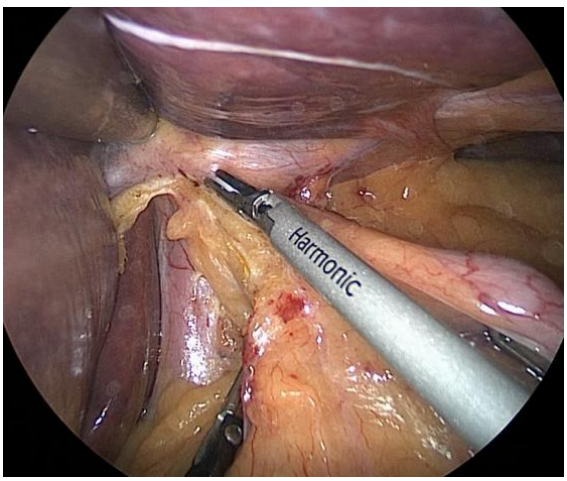

Figure 11. Division of the pars flacida of the lesser omentum. Identification of the right crura (continued).

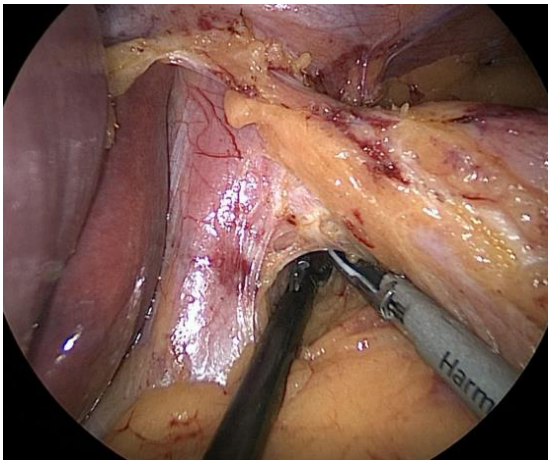

Figure 12. Dissection of the posterior part of the hiatus and performance of a retroesophageal tunnel.

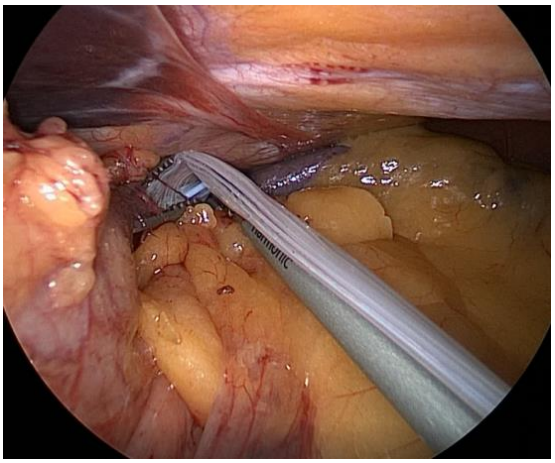

Figure 13. A silicon handle is passed through the retroesophageal tunnel.

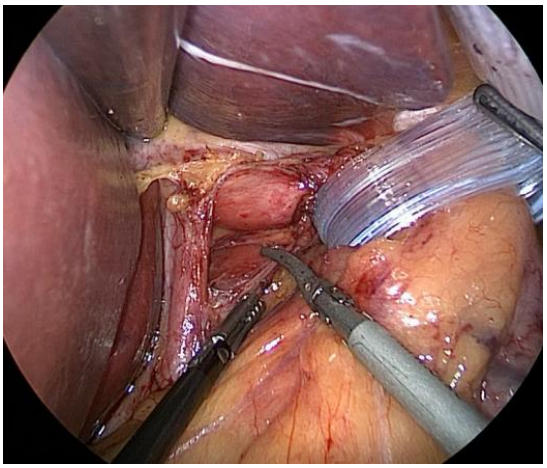

Figure 14. Left lateral traction is done for correct disection of the posterior part of the hiatus and left crura.

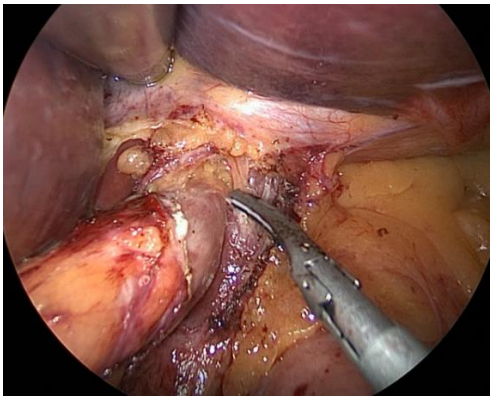

Figure 15. Anterio dissection of the left crura.

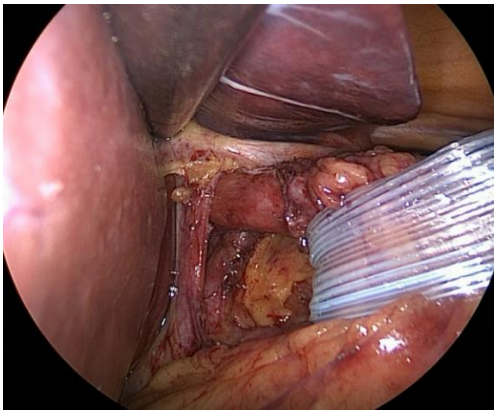

Figure 16. Complete dissection of the hiatus.

It is advisable to close the esophageal hiatus before calibrating it with a 38 - 40 Fr orogastric tube, in order to avoid narrowness that may cause dysphagia (Figure 17). The hiatal orifice must be closed by 1 or 2 non-absorbable simple stitches of Ethibond® 2.0 suture (Figure 18-19).

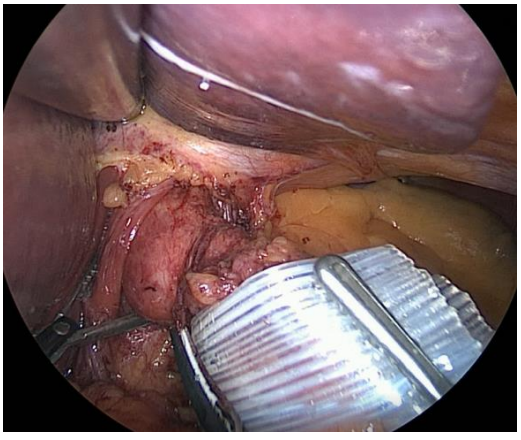

Figure 17. Closure of the hiatus with 1-2 simple stitches.

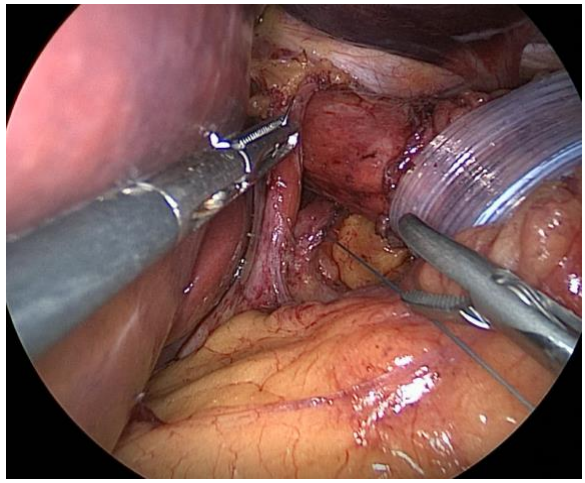

Figure 18. Closure of the hiatus with 1-2 simple stitches (continued).

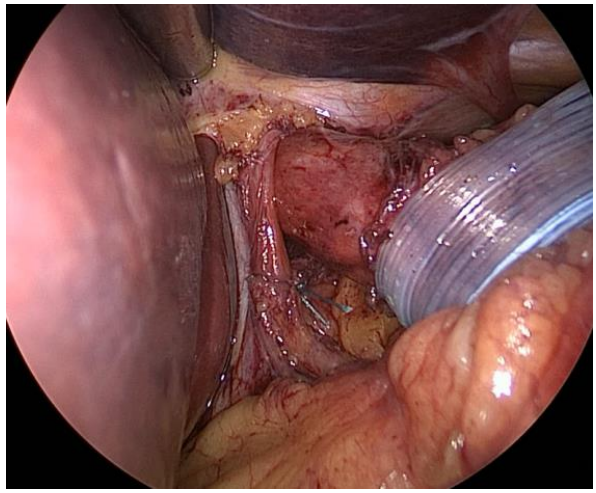

Figure 19. Closure of the hiatus with 1-2 simple stitches (continued).

c) Mobilization of Greater Curvature

The initial point of beginning the gastrolysis is about 5-6 cm from the pylorus at the level of the incisura angularis.

Using the harmonic scalpel, a window is opened into the omental bursa approximately at this level to enter into the omental transcavity (Figure 20-22).

The dissection continues cranially, dividing the short gastric vessels directly on the serosa of the stomach until reaching the left crura (Figure 23-26).

The first assistant has to retract very carefully the greater omentum to the left size of the abdomen and the left hand of the surgeon must retract the stomach to the right side, in order to ease the division of the short gastric vessels close to the left crura (Figure 27-29).

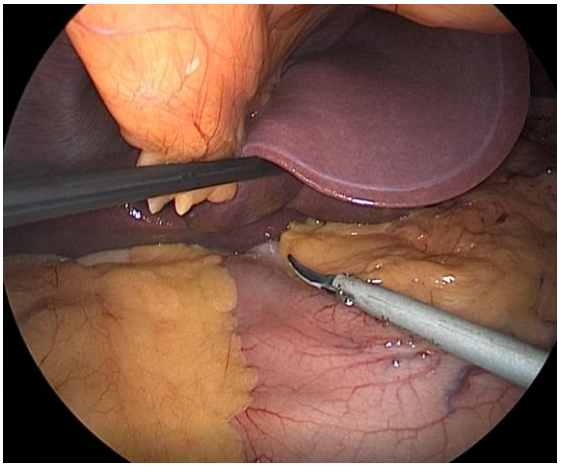

Figure 20. Gastrolysis begins about 5-6 cm from the pylorus at the level of the incisura angularis.

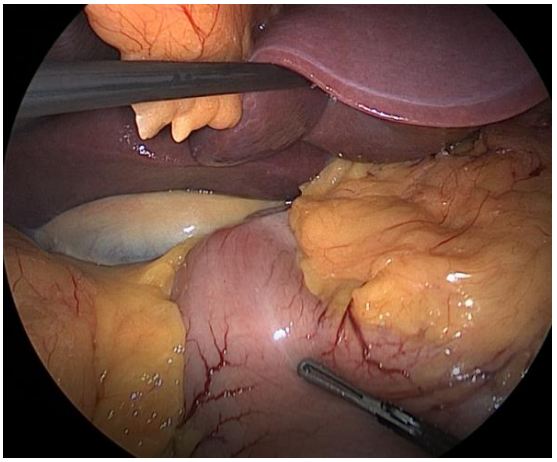

Figure 21. Gastrolysis begins about 5-6 cm from the pylorus at the level of the incisura angularis (continued).

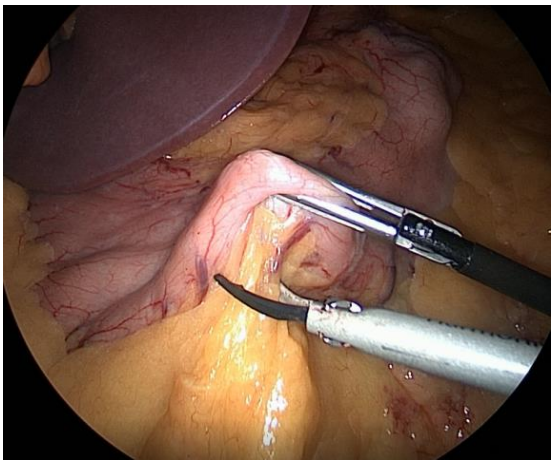

Figure 22. A window is opened into the omental bursa.

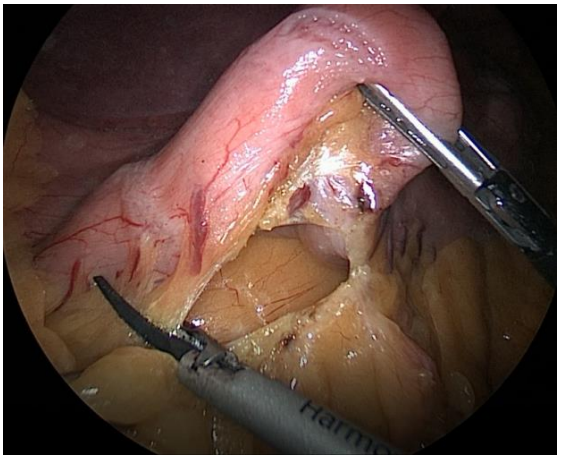

Figure 23. Entrance into the omental transcavity.

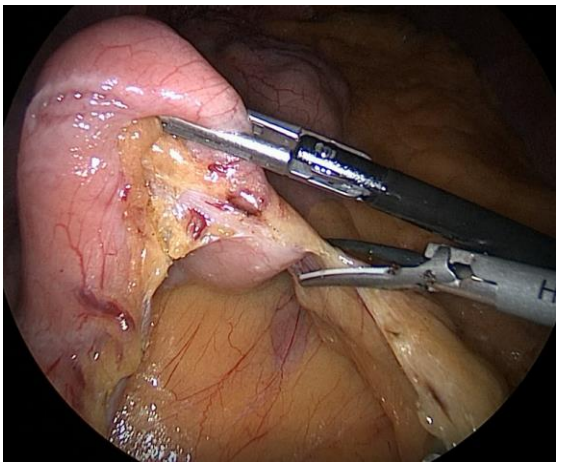

Figure 24. Division of the short gastric vessels cranially.

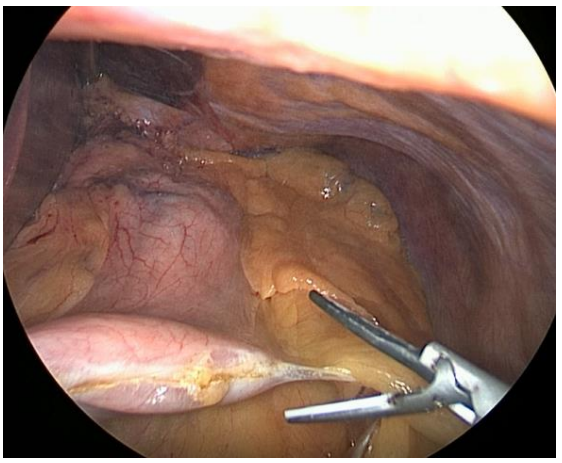

Figure 25. Division of the short gastric vessels cranially (continued).

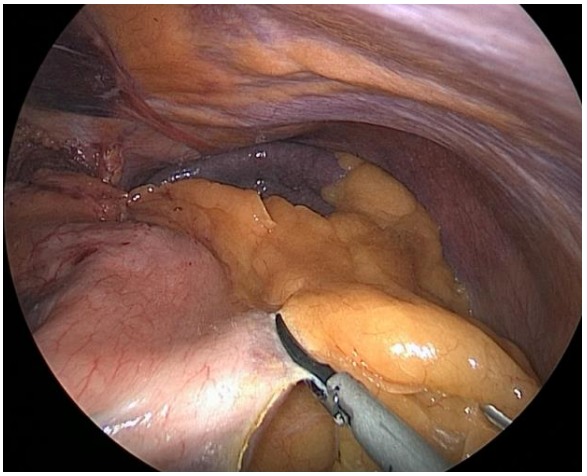

Figure 26. Division of the short gastric vessels cranially (continued).

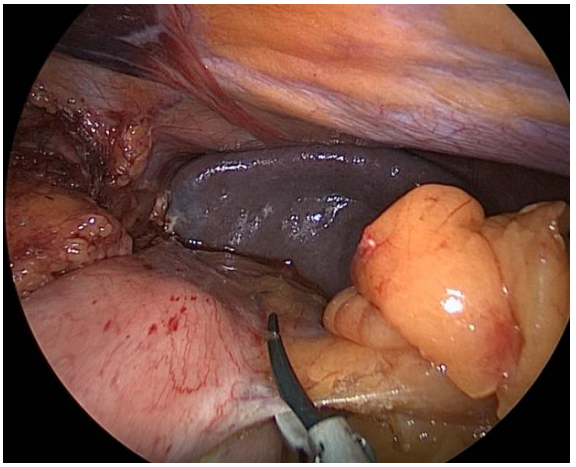

Figure 27. Division of the short gastric vessels cranially (continued).

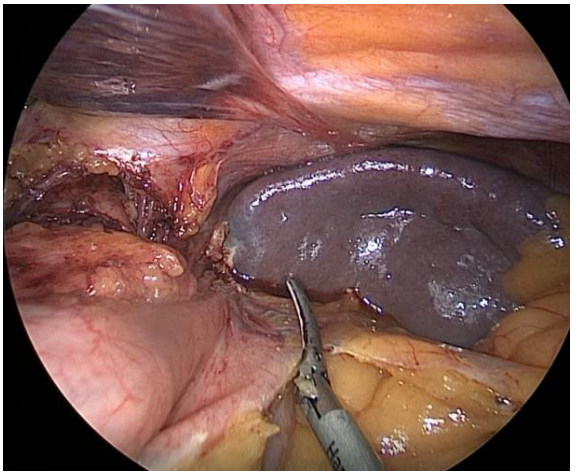

Figure 28. Division of the short gastric vessels cranially (continued).

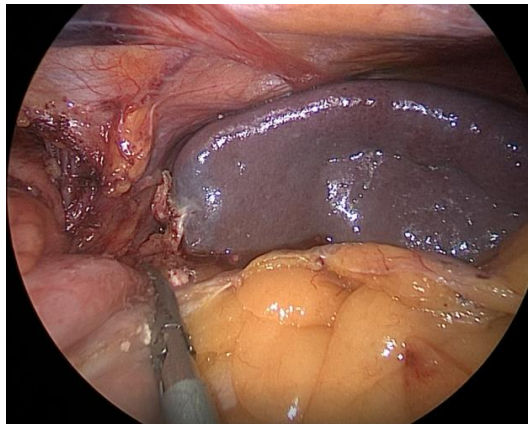

Figure 29. Division of the short gastric vessels cranially (continued).

It is necessary to dissect thoroughly the gastric fundus from the left crura in order to avoid leaving a large posterior fundus. The splenic artery is close to this area and careful dissection must be performed to prevent from its damage (Figure 30).

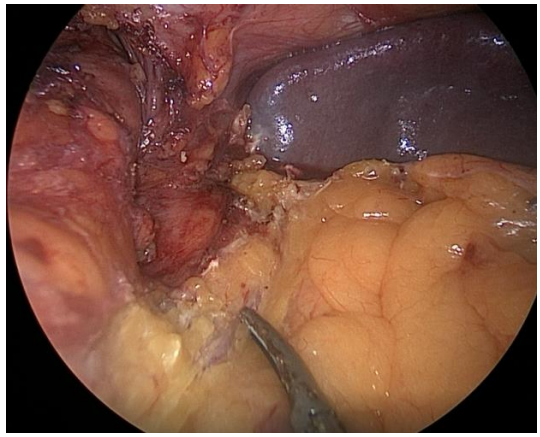

Figure 30. Dissection of the gastric fundus from the left crura to avoid leaving a large posterior fundus.

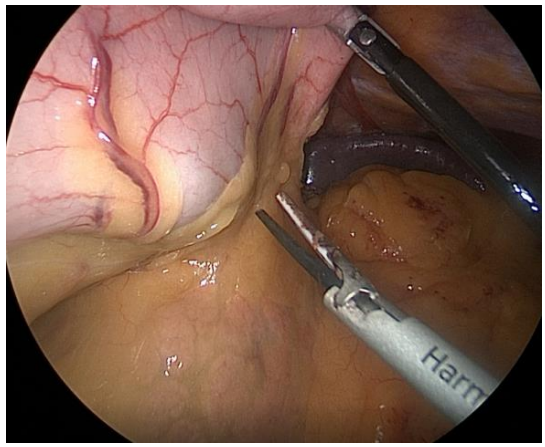

Figure 31. The orogastric tube is progressed completely until its end is positioned in the antrum.

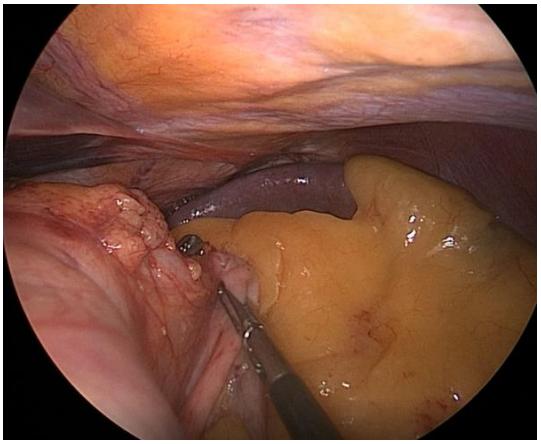

Figure 32. The orogastric tube is progressed completely until its end is positioned in the antrum.

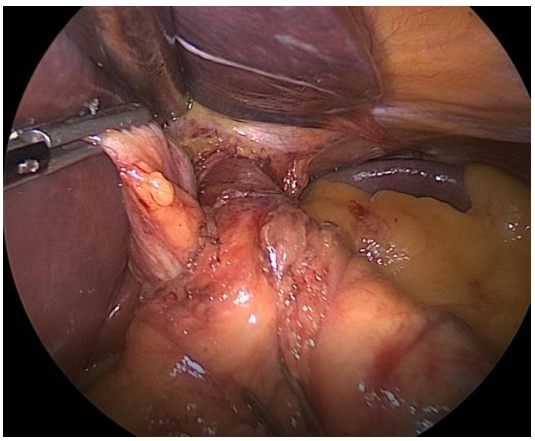

Figure 33. A short Nissen valve is performed.

Once dissected and released the stomach from its adhesions, even on its posterior surface, the orogastric tube is progressed completely until its end is positioned in the antrum. This bougie is useful to calibrate the sleeve and the fundoplication (Figure 31).

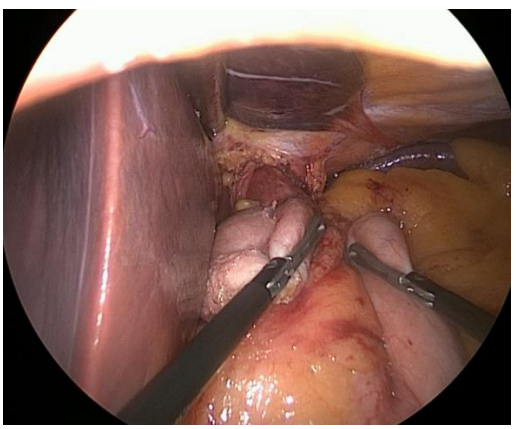

Figure 34. A short Nissen valve is performed (continued).

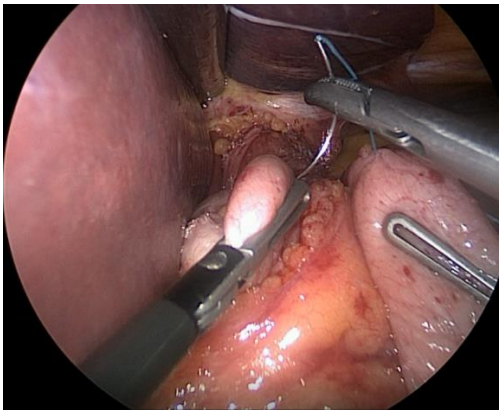

Figure 35. The Nissen valve is fixed with simple stitches.

d) Fundoplication

A short Nissen valve of approximately 3cm is created using 3 Ethibond®3.0 sutures; the cranial stitch is fixed to the superficial muscular layer of the esophagus (Figure 32-40).

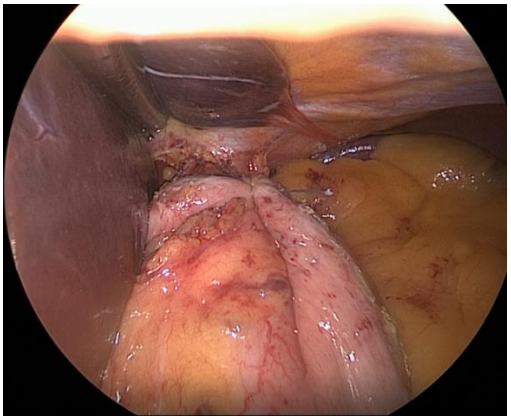

Figure 36. The Nissen valve is fixed with simple stitches (continued).

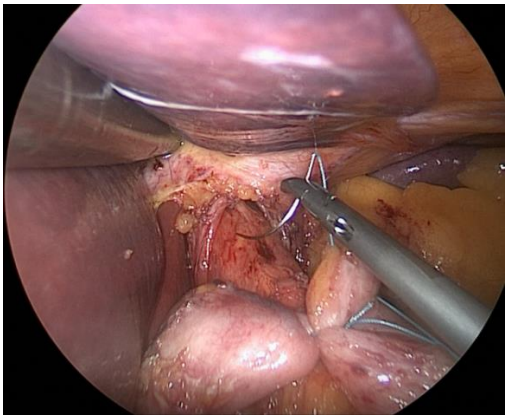

Figure 37. The cranial stitch is fixed to the superficial muscular layer of the esophagus.

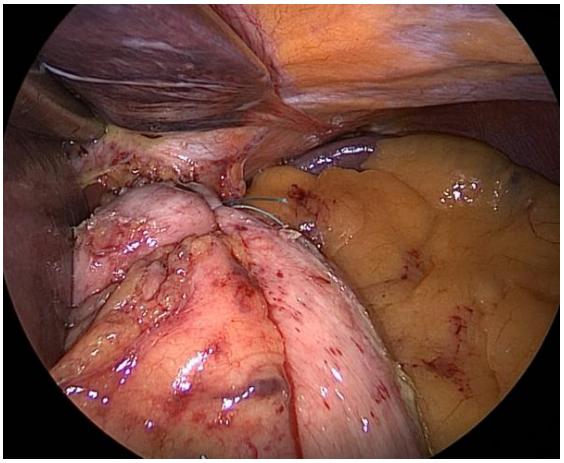

Figure 38. The Nissen valve is fixed with simple stitches (continued).

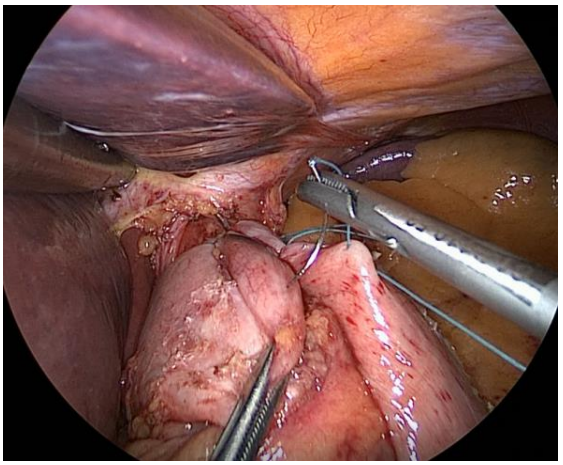

Figure 39. The Nissen valve is fixed with simple stitches (continued).

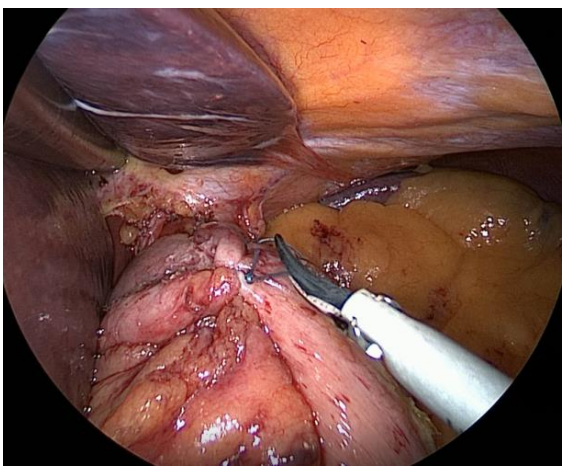

Figure 40. The Nissen valve is fixed with simple stitches (continued).

e) Gastrectomy

Once the fundoplication is completed, a 60mm gold reinforced cartridge is used to staple 4-6cm proximal to the pylorus (from the 12mm trocar on right hypocondrium).

There are some authors who prefer not to use staple line reinforcement. Before firing the stapler, the bougie tube must be visualized passing distal to the stapler along the lesser curvature (Figure 41-43).

The second cartridge (60mm gold reinforced) is in proximity to the incisura angularis and care must be taken in order to avoid stenosis at this level.

This second cartridge also enters through the 12mm trocar on right hypocondrium (Figure 44-46).

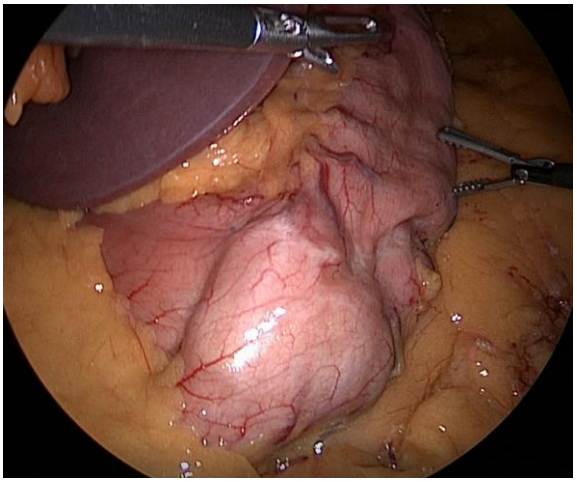

Figure 41. The gastrectomy begins at the level of incisura angularis.

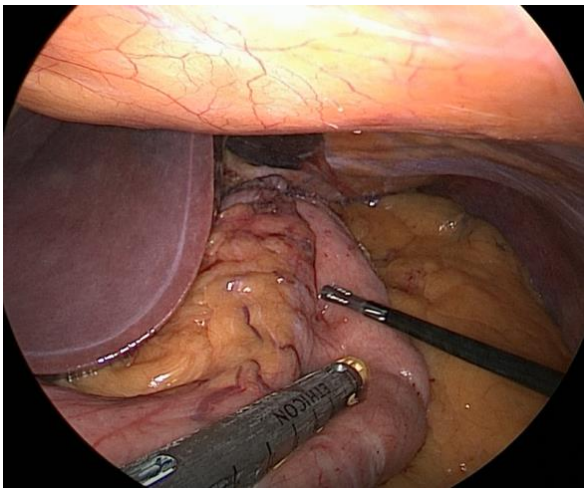

Figure 42. The first cartridge is inserted through the port placed in right hypocondrium.

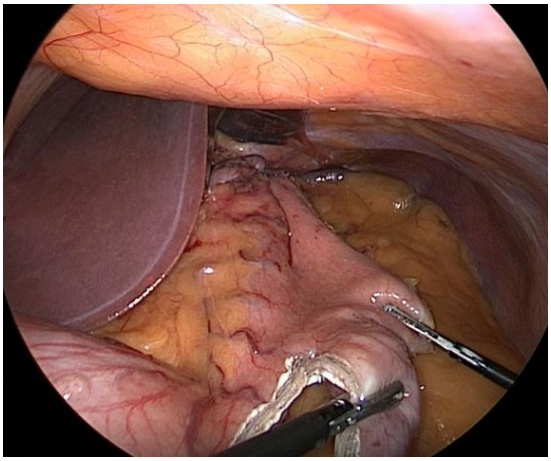

Figure 43. The second cartridge is in proximity to the incisura angularis and care must be taken in order to avoid stenosis at this level.

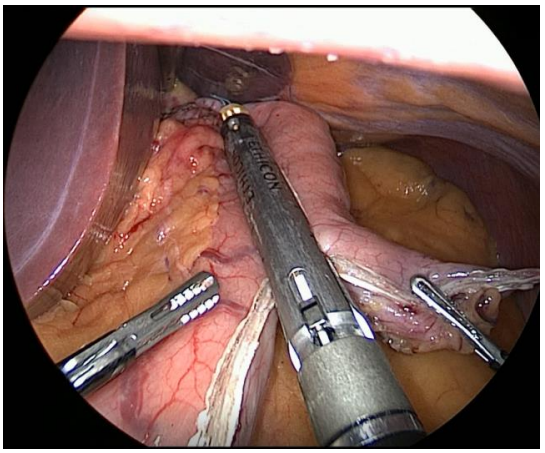

Figure 44. The stapling continues cranially until reaching the fundoplication.

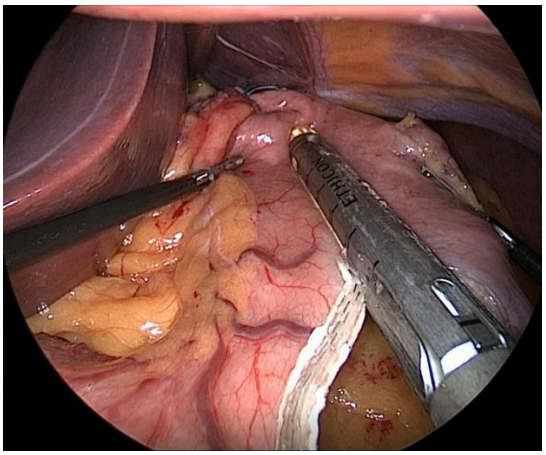

Figure 45. The stapling continues cranially until reaching the fundoplication (continued).

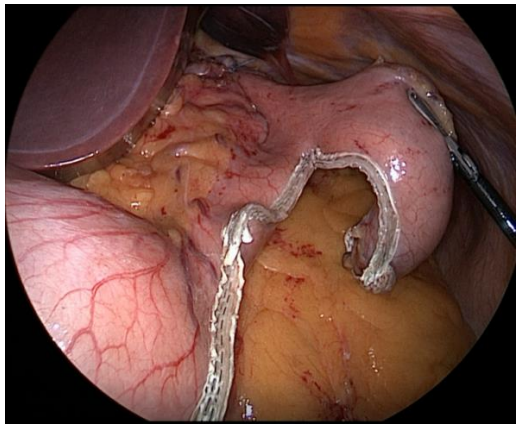

Figure 46. The stapling continues cranially until reaching the fundoplication (continued).

The division of the stomach must reach a balance between not stenosing the valve and not leaving excessive fundus.

Therefore, a stapling with reinforced golden load 60mm is made (Figure 47-49).

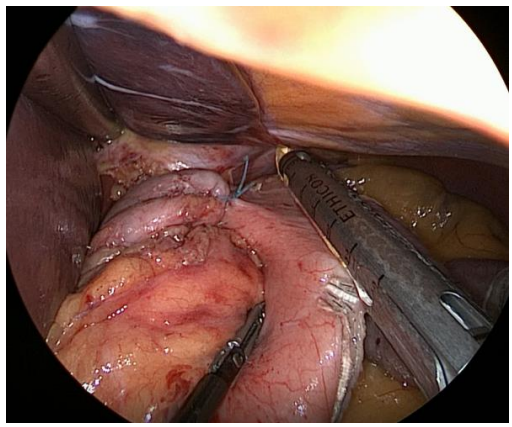

Figure 47. The stapling continues cranially until reaching the fundoplication (continued).

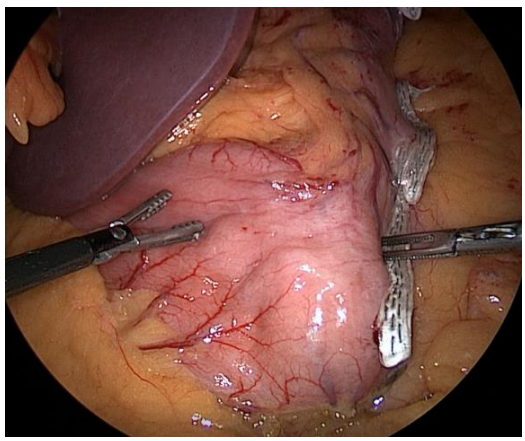

Figure 48. Staple line check.

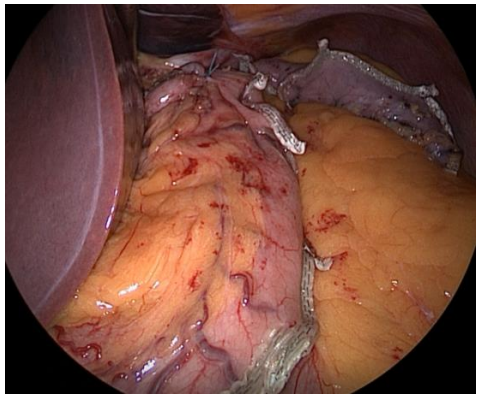

Figure 49. Staple line check (continued).

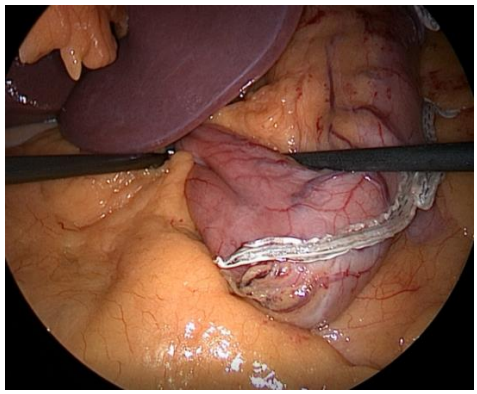

Figure 50. Tightness test.

f) Checking the Staple Line

Once the sleeve is created, we have to check the absence of bleeding in the staple line. If bleeding is observed, haemostasia with clips is carried out. Finally, a methylene blue dye test is performed, excluding any spillage of blue contents into the peritoneal cavity. The orogastric tube is removed after methylene blue test (Figure 50-52).

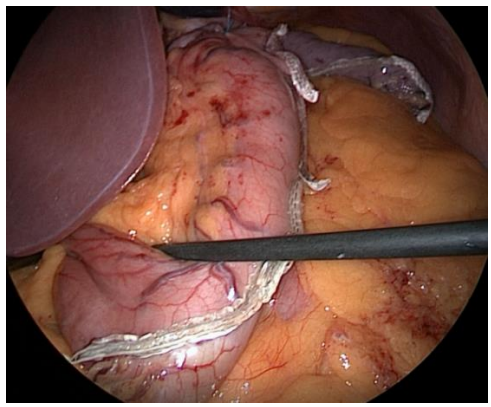

Figure 51. Tightness test (continued).

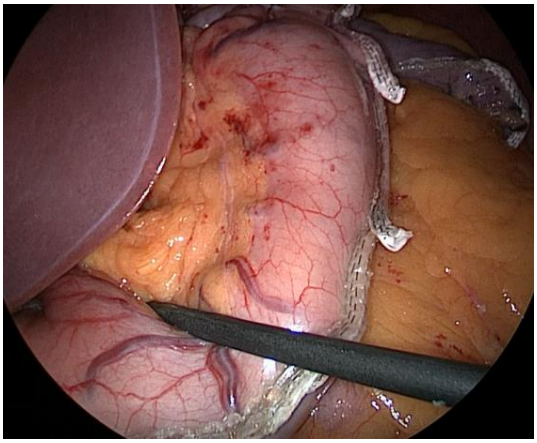

Figure 52. Tightness test (continued).

Surgical drains are not necessary unless there is high concern for bleeding or leak.

The excluded stomach is then removed through the 12-mm port site (left hypocondrium) under direct visualization without bag.

REFERENCES

[1] Prachand, V. N., Alverdy, J. C. Gastroesophageal reflux disease and severe obesity: fundoplication or bariatric surgery? *World J. Gastroenterol.*, 2010; 16(30):3757 - 61.

[2] Varella, J. E., Hinojosa, M. W., Nguyen, N. T. Laparoscopic fundoplication compared with laparoscopic gastric bypass in morbidly obese patients with gastroesophageal reflux disease. *Surg. Obes. Relat. Dis.*, 2009; 5(2):139 - 43.

[3] Chiu, S., Birch, D. W., Shi, X., Sharma, A. M., Karmali, S. Effect of sleeve gastrectomy on gastroesophageal reflux disease: a systematic review. *Surg. Obes. Relat. Dis.*, 2011; 7(4):510 - 5.

[4] Moon, R. C., Teixeira, A. F., Jawad, M. A. Safety and effectiveness of anterior fundoplication sleeve gastrectomy in patients with severe reflux. *Surg. Obes. Relat. Dis.*, 2017; 13(4): 547 - 552.

[5] Nocca, D., Skalli, E. M., Boulay, E., Nedelcu, M., Michel Fabre, J., Loureiro, M. Nissen Sleeve (N-Sleeve) operation: preliminary results of a pilot study. *Surg. Obes. Relat. Dis.*, 2016 Feb. 22. doi: 10.1016/j.soard.2016.02.010 [Epub ahead of print].

[6] Hampel, H., Abraham, N. S., El-Serag, H. B. Meta-analysis: obesity and the risk for gastroesophageal reflux disease and its complications. *Ann. Intern. Med.*, 2005; 143:199 - 211.

[7] Dallemagne, B., Perretta, S. Twenty years of laparoscopic fundoplicaion for GERD. *World J. Surg.*, 2011; 35:1428 - 35.

[8] Stefanidis, D., Navarro, F., Augenstein, V. A. et al. Laparoscopic fundoplication takedown with conversion to Rou-en-Y Gastric bypass leads to excellent reflux control and quality of life after fundoplication failure. *Surg. Endosc.*, 2012; 26:3521 - 7.

In: Encyclopedia of Surgery (22 Volume Set)
Editors: Andreas Lehrer and Kristin Mueller
ISBN: 978-1-53618-329-0
© 2020 Nova Science Publishers, Inc

Chapter 296

LAPAROSCOPIC ROUX-EN Y GASTRIC BYPASS WITH LINEAR STAPLED ANASTOMOSES

Camilo J. Castellón Pavón, MD, PhD,
Alejandro García Muñoz-Najar, MD, PhD,
Jaime Ruiz-Tovar, MD, PhD
and Manuel Durán Poveda, MD, PhD
Bariatric Surgery Unit. Rey Juan Carlos University Hospital,
Madrid, Spain

ABSTRACT

Laparoscopic Roux-en-Y gastric bypass (LRYGB) is the gold standard bariatric procedure. There are many different techniques described. Regardless of the technique used, the LRYGB has excellent outcomes. The aim is to describe our standardized technique with a linear stapled gastrojejunal anatomosis, antecolic Roux limb, and stapled jejunojejunostomy with closure of the intestinal openings with hand sewn knotless unidirectional barbed suture.

Keywords: morbid obesity, bariatric surgery, laparoscopic Roux-en-Y gastric bypass, surgical technique, stapled anastomosis, barbed suture

INTRODUCTION

First laparoscopic Roux-en-Y gastric bypass (LRYGB) was described by Wittgrove et al., in 1994 [1]. Nowadays, LRYGB is the second most common bariatric procedure performed worldwide (30.1%) after sleeve gastrectomy [2]. It is a mixed technique with restrictive and malabsorptive components. In addition, several hormonal mechanisms are involved in weight loss. LRYGB remains the gold standard against which other bariatric techniques are measured because of the very low morbidity and mortality associated good long-term results

(maintained weight loss and obesity-related comorbidities resolved) and excellent quality of life.

Over time, the technique has evolved with several variations with regard the formation of the pouch and the reconstruction of gastrointestinal continuity.

INDICATIONS

1. Body mass index (BMI) ≥ 40 kg/m^2.
2. BMI 35-39,9 kg/m^2 with obesity-related comorbidities or gastroesophageal reflux disease.
3. Metabolic surgery. Patients with BMI 30-34,9 kg/m^2 and uncontrolled type 2 diabetes mellitus or metabolic syndrome.
4. Sweet eaters. In these patients restrictive operations should be avoided. After the LRYGB there is an initial refusal of sweets and a reduce intake in the long term, especially if dumping syndrome exists.
5. Failure of a previous restrictive bariatric operation. When a restrictive technique fails, should not be substituted by other restrictive operation. In this case, LRYGB is the most indicated option.

PREOPERATIVE PREPARATION

Potential candidates should undergo a multidisciplinary evaluation. Preoperative work-up includes abdominal ultrasound, upper gastrointestinal endoscopy, *Helicobacter pylori* testing, psychiatric assessment, laboratory with hormonal study, densitometry and polysomnography in patients with obstructive sleep apnea. All patients are referred to preoperative respiratory rehabilitation. Preoperative weight loss and smoking cessation are highly recommended. Pregnancy avoidance for 12 to 18 months postoperatively is counselled.

Anaesthesiologist analyzes related risk factors (comorbidities, medication). An enhanced recovery after surgery (ERAS) programme is followed in our hospital, as well as an opioid-free anaesthesia. Central venous line and urinary catheter are not used. Our patients routinely receive antibiotic prophylaxis and preoperative thromboembolic prophylaxis with low-molecular-weight heparin the night before the surgery.

The abdomen is prepped and draped in standard sterile fashion.

SURGICAL TECHNIQUE

Equipment

1. Two 12 mm optic trocars, one 11 mm trocar and one 5 mm trocar.
2. Nathanson liver retractor.
3. Camera and a 10 mm, 30-degree angled laparoscope.
4. Two monitors.

5. Harmonic scalpel (Harmonic ACE; Johnson & Johnson).
6. Two graspers and two atraumatic graspers.
7. Suction irrigator.
8. Endostapler: Echelon 60 mm (white and blue cartridges) (Johnson & Johnson).
9. Clip applier.
10. 36 French bougie tube.

PATIENT, PORTS AND SURGEON POSITIONS

a) Patient Position

Patient is positioned supine on the operating table with the legs and the right arm abducted (Figure 1). Appropriated sized intermittent pneumatic compression devices are used on both lower extremities. The legs and hips are secured with safety straps to prevent sliding, bowing or buckling of the knees or ankles. No Foley catheter is needed. A 15-20º reverse Trendelemburg position facilitates the exposition of the angle of His and displaces the transverse colon and small intestine inferiorly in a caudal direction.

Figure 1. Patient position.

b) Team Position

The operating surgeon stands in the space between the patient´s legs. Surgeon´s position should be ergonomic with shoulders relaxed and the forearms at a ≥ 90º angle from the arms. The assistant surgeon is on the patient´s left side. The nurse stands on the left side of the operating surgeon (Figure 2). Two monitors are placed at the level of the head and on the right side of the patient respectively.

Figure 2. Team position.

c) Pneumoperitoneum and Port Placement

Pneumoperitoneum can be achieved with Veress needle, open Hasson trocar or with an optical view trocar. Firstly, we use a 12 mm bladeless optical view trocar (Figure 3) inserted in the left upper quadrant at Palmer´s point (3 cm below the left costal margin on the midclavicular line) (Figure 4). The remaining trocars are inserted under direct visualization. An 11 mm port (camera port) is inserted at the junction of the upper two thirds and lower one third of the xyphoumbilical line (the placement varies depending on the patient´s shape). After this port is placed, the peritoneal cavity is inspected to exclude adhesions and any injury caused by the optical trocar. Another 12 mm working port is inserted in the right upper quadrant at the midclavicular line. In the epigastrium, a Nathanson retractor is used to retract the left lobe of the liver. Finally, a 5 mm port is placed at the left anterior axillary line (Figure 5). This port is used by the assistant, mainly to retract the stomach. Pneumoperitoneum pressure is established at 12-14 mm Hg.

Figure 3. Optical view trocar.

Figure 4. Optical trocar insertion at Palmer´s point.

Figure 5. Ports position.

PROCEDURE (SURGICAL STEPS)

a) Identification of the Angle of His

Dissection is begun with Harmonic scalpel. Cardia´s attachments to the diaphragm are divided and the fat pad at the upper part of the fundus is taken down. In this way, the angle of His and the left diaphragmatic crura is identified and a gauze is left between the fundus and spleen (Figure 6). If a hiatal hernia is addressed, it should be repaired closing diaphragmatic pillars with interrupted stitches.

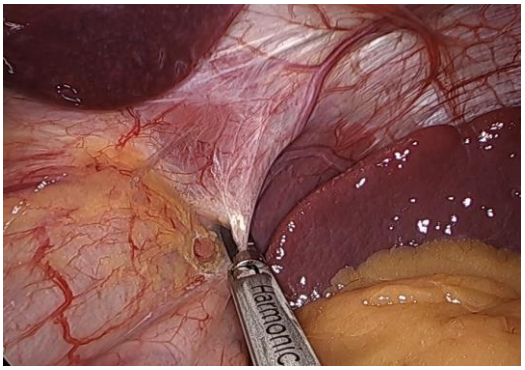

Figure 6. Angle of His dissected with Harmonic scalpel.

b) Creation of the Gastric Pouch

In RYGB a gastric pouch (30 cm^3) from the proximal stomach has to be created. The stomach is pulled laterally by the assistant. Access to the retrogastric space is achieved through a window performed with the harmonic scalpel at the lesser curvature, 6 cm measured from the cardia (Figures 7 and 8).

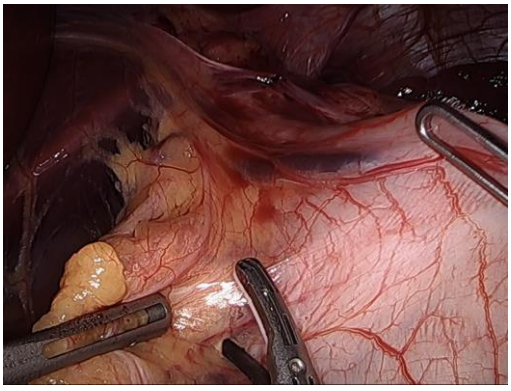

Figure 7. Window performed with the harmonic scalpel close to the gastric wall.

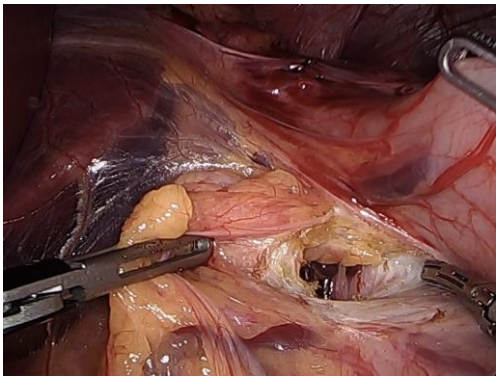

Figure 8. Access to the lesser sac.

Blood supply to the gastric pouch from the left gastric vessels has to be preserved. The stomach is transected horizontally from the lesser curvature using a 45 mm blue load linear endostapler (Figures 9 and 10). Before firing the nasogastric tube has to be removed by the anaesthesiologist.

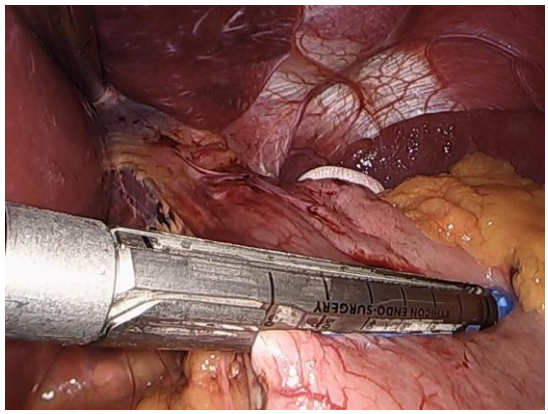

Figure 9. Horizontal gastric transection with blue cartridge stapler.

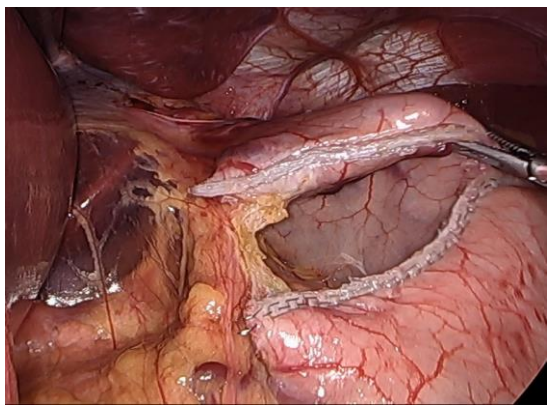

Figure 10. Retrogastric space.

Retrogastric dissection is completed dividing any attachments to ensure that the gastric pouch is not created too large (Figure 11).

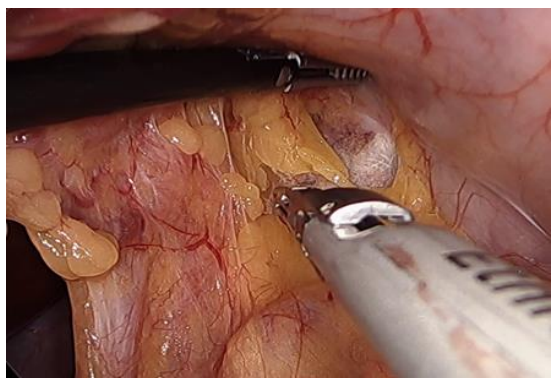

Figure 11. Retrogastric attachment division until reaching the left crus and gauze.

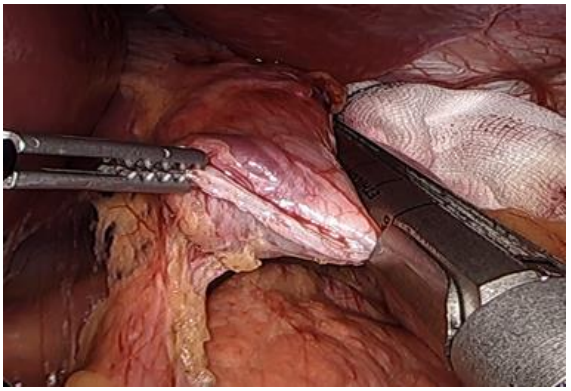

Figure 12. First vertical blue stapler.

The gastric pouch is calibrated with a 36 F bougie. The assistant retracts the stomach laterally to avoid redundancy, and a vertical linear stapling is performed (60 mm blue cartridges) (Figures 12, 13 and 14). Care must be taken to avoid firing too close to the esophageal junction.

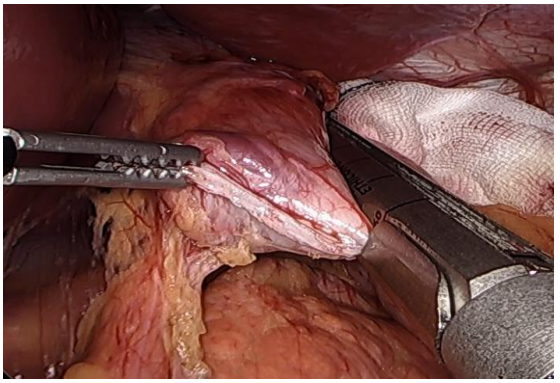

Figure 13. First vertical blue stapler.

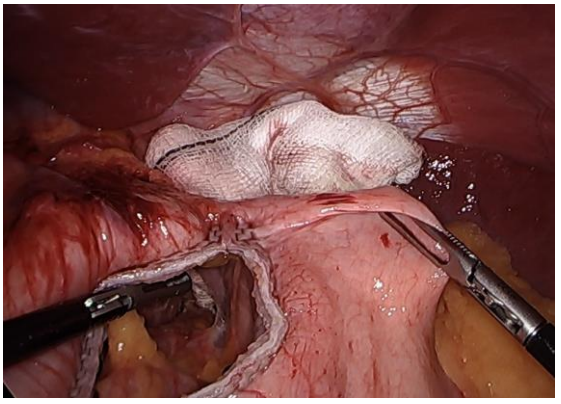

Figure 14. Usually a second staple is needed.

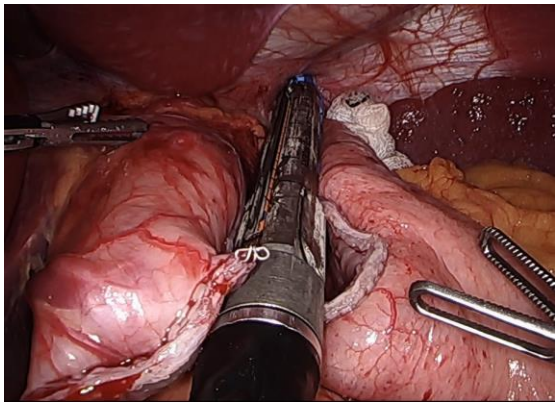

Figure 15. Second vertical staple firing toward the angle of His along the 36 F bougie.

c) Gastrojejunal Anastomosis

The greater omentum is divided (Figures 16 and 17) and the ligament of Treitz is exposed elevating the transverse colon (Figure 18).

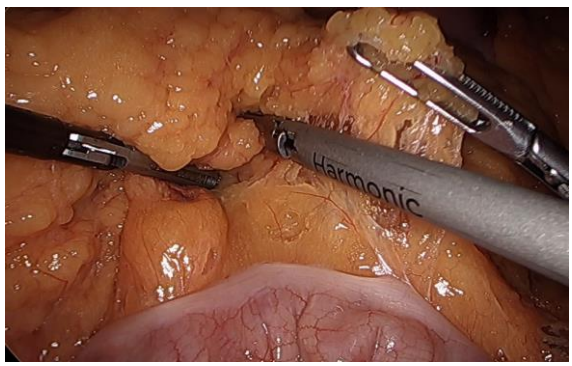

Figure 16. Division of greater omentum with harmonic scalpel, starting close to transverse colon.

Figure 17. Splited omentum.

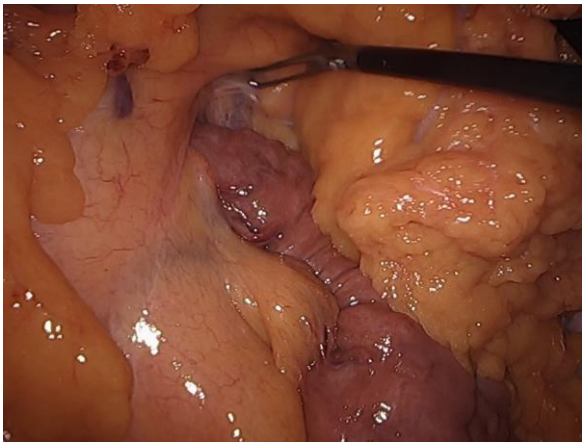

Figure 18. Ligament of Treitz.

From the ligament of Treitz, 60 cm of jejunum are measured distally and the jejunal loop is brought up toward the gastric pouch ascending in an antegastric and antecolic fashion (Figure 19). Managing intestinal loops, atraumatic graspers are recommended.

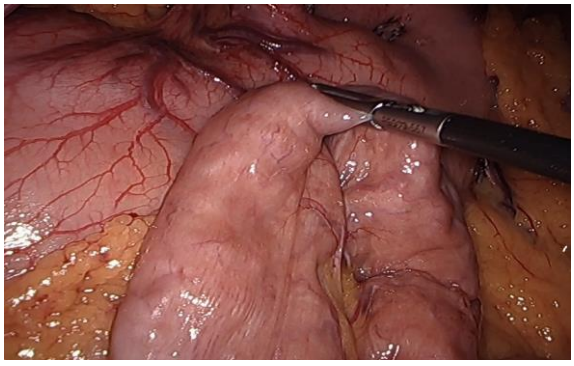

Figure 19. Jejunal loop ascent, anterior to the transverse colon and the remaining stomach.

In selected cases, is helpful a tension-free stitch between the jejunum and the vertical stapled line in the gastric pouch (Figure 20).

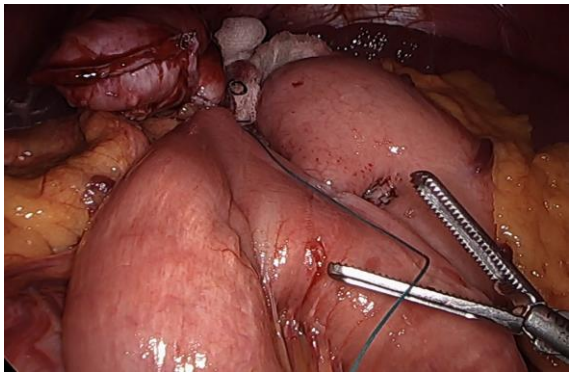

Figure 20. Extracorporeal stitch (Ethibond 2/0) joining the gastric pouch and jejunum.

While the assistant holds the jejunal loop, enterotomies with the harmonic scalpel are performed in the gastric pouch and jejunum (Figures 21 and 22).

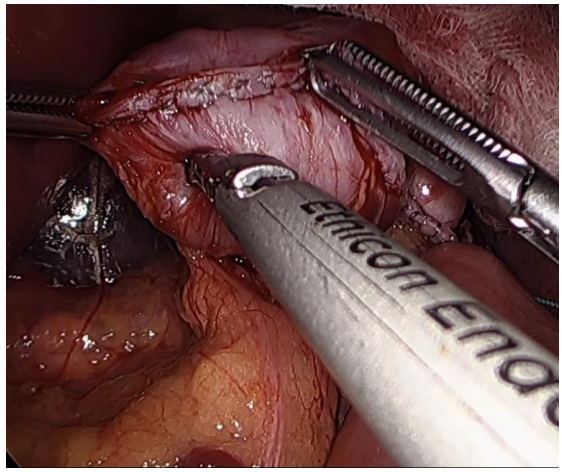

Figure 21. Enterotomy in the posterior wall of the gastric pouch, close to the horizontal stapled line.

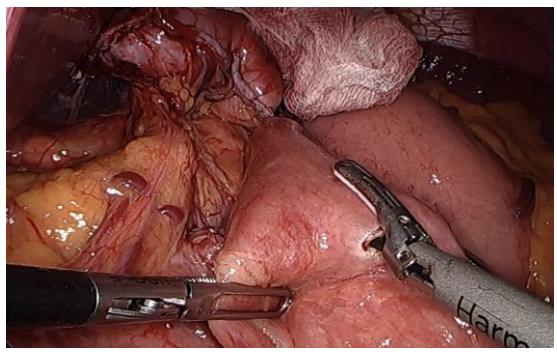

Figure 22. Enterotomy in the antimesenteric border of the jejunum.

White load 60 mm linear endostapler is inserted through the 12 mm port located in the right upper quadrant. Jaws are inserted in both enterotomies to create a gastrojejunal anastomosis 3 cm in length (Figure 23).

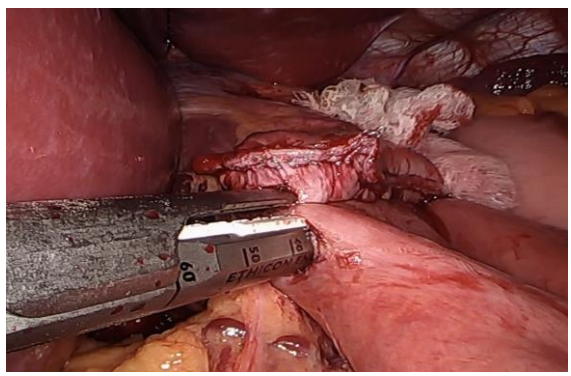

Figure 23. Side to side gastrojejunal anastomosis with white cartridge, inserting only 3 cm before firing.

We close the intestinal opening with hand-sewn knotless unidirectional barbed suture starting at the left corner (Figures 24, 25 and 26).

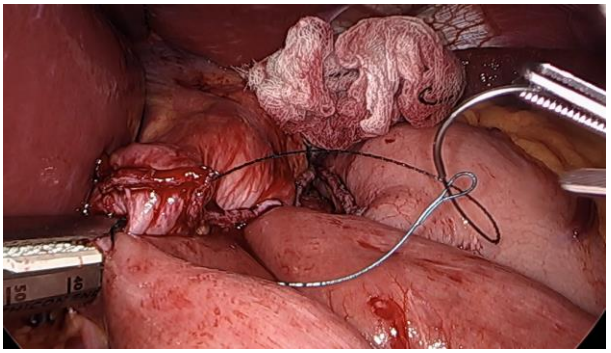

Figure 24. Closure of the intestinal opening with knotless absorbable 2/0 barbed suture. Loop at the beginning of the suture avoids knot tying.

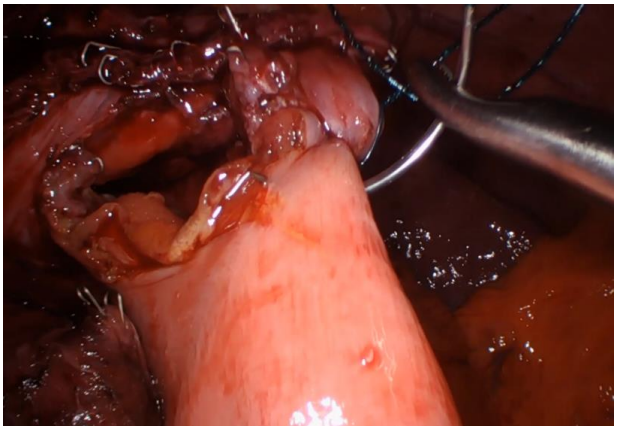

Figure 25. Unidirectional running suture from left to right.

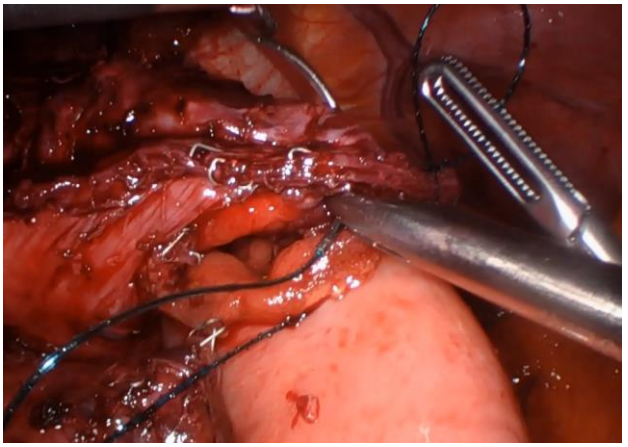

Figure 26. Single-layer full-thickness suture (from down to up).

Continuous suture is finished by taking two additional bites in an opposite direction beyond the end of the enterotomy incision (Figure 27).

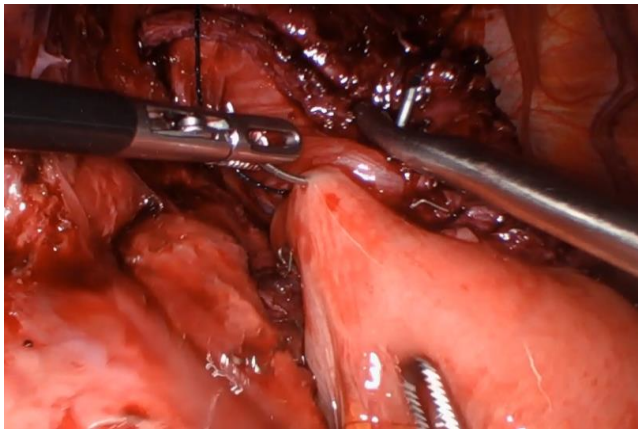

Figure 27. Last stitch in the opposite direction.

When gastrojejunal anastomosis is finished and to prevent the pouch from twisting, a stitch from jejunum (few centimeters distal to the gastrojejunostomy) to the remaining stomach is optional (Figure 28).

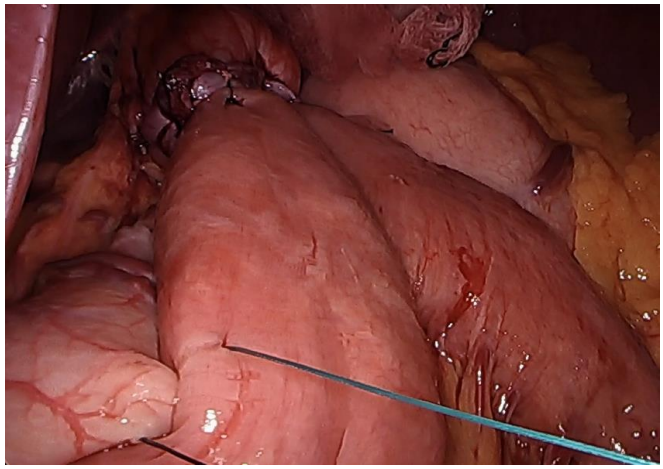

Figure 28. Stitch from the jejunum to the gastric remnant to prevent from anastomotic twisting.

d) Jejunojejunal Anastomosis

150 cm of small intestine are measured from the gastrojejunostomy to be used as the Roux limb (alimentary limb). In patients with BMI greater than 50 kg/m^2 alimentary limb could be longer than 150 cm. Two antimesenteric holes are performed with harmonic scalpel: one in the alimentary limb (Figure 29) and another in the biliopancreatic limb, few centimeters away from the gastrojejunostomy (Figure 30).

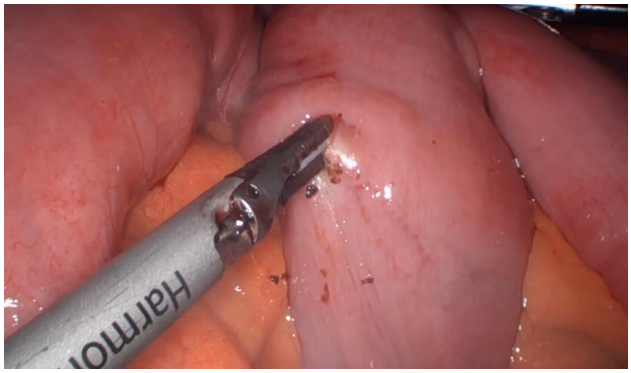

Figure 29. Enterotomy in the antimesenteric border of the small intestine (alimentary limb).

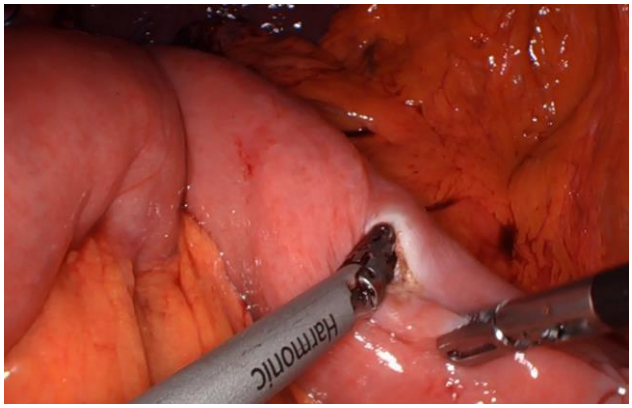

Figure 30. Antimesenteric enterotomy in the biliopancreatic limb.

A white load 60 mm linear stapler is inserted through both enterotomies (Figure 31) and then, a side to side jejunojejunostomy is performed (Figure 32).

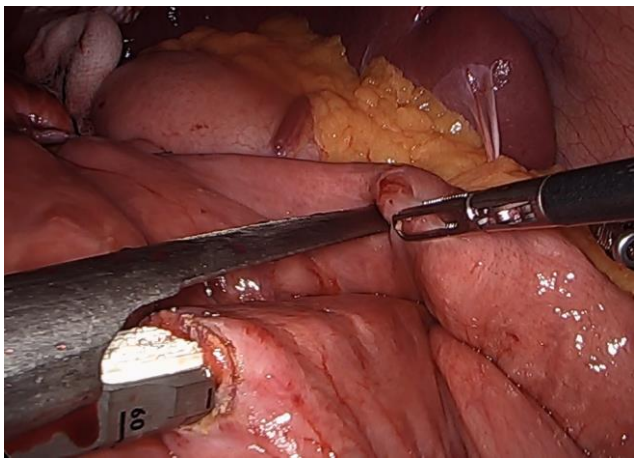

Figure 31. Cartridge introduction through both enterotomies.

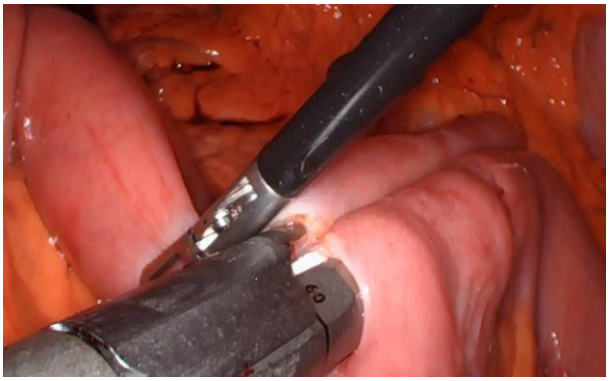

Figure 32. Mechanical side to side jejunojejunostomy.

Intestinal opening is closed with hand-sewn knotless unidirectional barbed suture in the same way as described in the gastrojejunostomy (Figure 33). Suture is extended to close the mesenteric gap.

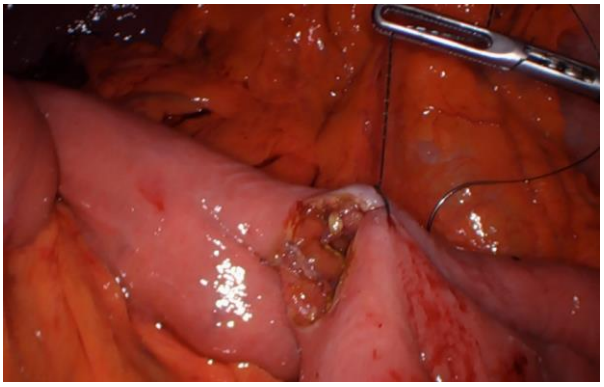

Figure 33. Closure of the intestinal opening in jejunojenunostomy with knotless unidirectional barbed suture.

Finally, a white linear stapler is fired in the jejunum between gastrojejunostomy and the jejunojejunostomy to disconnect both anastomoses (Figure 34).

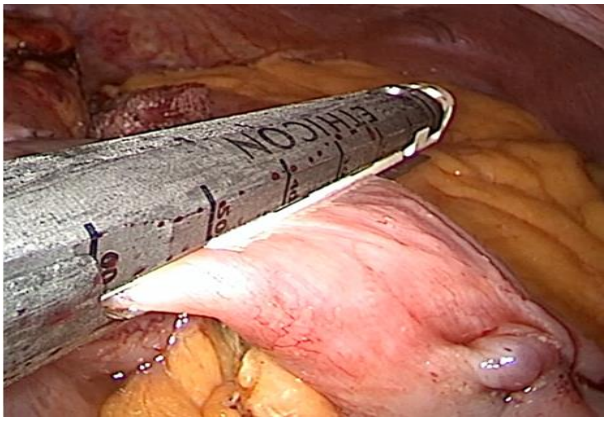

Figure 34. Jejunal section.

e) Checking the Anastomoses and Stapled Lines

Once the bypass is created, the gauze is removed. We have to rule out any bleeding in the stapled lines. If bleeding is observed, haemostasia with clips should be performed. Finally, a methylene blue test is performed, excluding any leakage of blue contents into the peritoneal cavity. Routinely surgical drain is not necessary unless there is high a concern for bleeding or anastomotic leak.

REFERENCES

[1] Wittgrove AC, Clark GW, Tremblay LJ. Laparoscopic gastric bypass, Roux-en-Y: preliminary report of five cases. *Obes. Surg.* 1994; 4: 353-357.

[2] Angrisani L, Santonicola A, Iovino P et al. IFSO worldwide survey 2016: primary, endoluminal and revisional procedures. *Obes. Surg.* 2018; 28 (2): 3783-3794.

In: Encyclopedia of Surgery (22 Volume Set)
Editors: Andreas Lehrer and Kristin Mueller
ISBN: 978-1-53618-329-0
© 2020 Nova Science Publishers, Inc

Chapter 297

LAPAROSCOPIC ROUX-EN-Y GASTRIC BYPASS: CIRCULAR ANASTOMOSIS

Maria Posada*, MD, Gabriel Salcedo, MD,
Jose Ramon Torres, MD and Peter Vorwald, MD, PhD
Department of General Surgery, Division of Esophagogastric and Bariatric Surgery,
Fundación Jimenez Diaz University Hospital, Madrid, Spain

ABSTRACT

Roux-en-Y gastric bypass is considered the gold standard of surgical bariatric procedures and one of the most commonly performed worldwide.

The aim of the chapter is to describe our standardized technique illustrated by surgical pictures.

Keywords: laparoscopic Roux-en-Y gastric bypass; circular anastomosis; surgical technique

INDICATIONS

1. Primary weight loss procedure.
2. As a bariatric procedure in cases of contraindication for sleeve gastrectomy (esophageal reflux disease, Barrett´s esophagus, paraesophageal hernia, severe gastric metaplasia...).

* Corresponding Author's Email: posada.maria@googlemail.com.

PREOPERATIVE WORK-UP

A multidisciplinary team, including surgeons, endocrinologists, dieticians, psychiatrists, psychologists, pulmonologists, gastroenterologists and anesthesiologists, performs preoperative work-up.

Abdominal ultrasound, upper gastrointestinal endoscopy and lab analysis including nutritional status, polysomnography and echocardiogram are routinely performed.

Monthly, a bariatric committee discusses challenging cases.

Only when the multidisciplinary bariatric committee considers that patient is suitable for surgery, the procedure is planned.

Anesthesia

An enhanced recovery after surgery (ERAS) protocol is followed. Arterial catheter to monitor blood pressure and one large peripheral line are inserted. Opioid-free anesthesia is usually performed. Central venous line, nasogastric tube and bladder catheters are not routinely used.

SURGICAL TECHNIQUE

Instrumentation

1. Three 12 mm and two 5 mm ports
2. 30° Scope
3. Veress needle
4. Vessel sealing device (Ligasure™ Maryland, Medtronic™)
5. Suction irrigator
6. Hook
7. 3 laparoscopic dissectors (two 31 cm and one 45 cm long)
8. 3 laparoscopic forceps (two 31 cm and one 45 cm long)
9. 3 atraumatic graspers (one 31 cm and one 45 cm long)
10. 2 Babcock forceps (one 31 cm and one 45 cm long)
11. Adler laparoscopic liver retractor
12. Ligaclip
13. Linear stapling device (Endo GIA™ Ultra 12 mm Universal Stapler, Covidien™). White, blue and golden cartridges (45 and 60 mm, Covidien™)
14. Circular stapling device (EEA™ DST XL 25mm, 3.5 mm, Covidien™)
15. Orogastric Circular Anvil (EEA™Orvil 25mm, Covidien™)
16. Gauzes
17. 2/0 braided non-absorbable suture (Ethibond™)
18. Surgical skin marker´s tip
19. Laparoscopic knot tying device

PATIENT, PORT AND OPERATING STAFF POSITION

a) Patient Position

The patient is placed on the operating Table in the gynecological position.

The left arm is opened, while the right one should be closed if possible to avoid contact with the liver retractor´s holder. The legs are placed on flexible boot stirrups (Figure 1)

A strap fastens on the waist below the umbilicus, to avoid the slipping of the patient while on Trendelenburg´s position. Intermittent pneumatic compression devices are needed in order to decrease the risk of deep vein thrombosis. A urinary catheter is not necessary. The laparoscopy tower is placed near the patient´s right shoulder.

Figure 1. Patient's position.

b) Port Placement

- 5mm port, in the upper right abdomen (liver retraction)
- 5mm port, in the upper left abdomen (1st assistant)
- 12mm port, 10-15 cm below the xiphoid (camera)
- 5mm port, in the right middle abdomen (left-hand surgeon)
- 12mm port, in the left middle abdomen (right-hand surgeon)

Access to the peritoneal cavity is obtained with a Veress needle. The puncture site is located in the upper left abdomen, near the costal margin. An intraperitoneal pressure of 15 mm Hg is achieved.

Usually a 10 mm 30º video laparoscope is used; when a 5 mm 30º video laparoscope is used, the camera port is replaced by a 5 mm port. (Figures 2-5)

Figure 2. Access to the peritoneal cavity is obtained with a Veress needle.

First, a 12-mm port is inserted, in the left upper abdomen, in the midclavicular line below the Veress needle insertion point; this is the surgeons, right-hand working port (Figure 3).

Figure 3. A 12-mm port is inserted, in the left upper abdomen.

All the other ports are placed in a line (at the same level, 10-15 cm distal to the xiphoid) (Figures 4, 5).

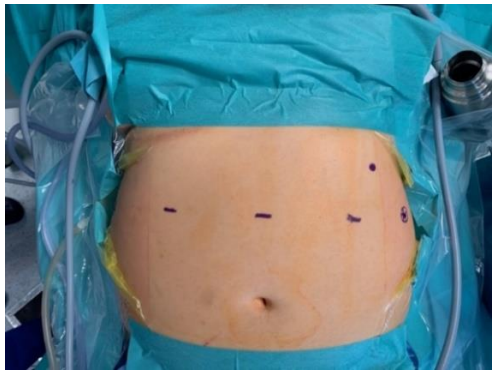

Figure 4. Placement of the ports.

Figure 5. Placement of the ports.

c) Staff Position in the Operating Room

- Gynecological position
- Surgeon between the patient's legs
- 1st assistant on the patient's left side
- 2nd assistant on the patient's right side
- Monitors are placed above the head and one in each side of the patient if available (Figure 6)

Figure 6. Staff position in the operating room.

PROCEDURE

a) Jejuno-Jejunostomy

Greater omentum and transverse colon are retracted cephalad until the Treitz's ligament is exposed. Gentle traction is applied on the first jejunal limb to clearly identify it, using an atraumatic grasper (Figure 7)

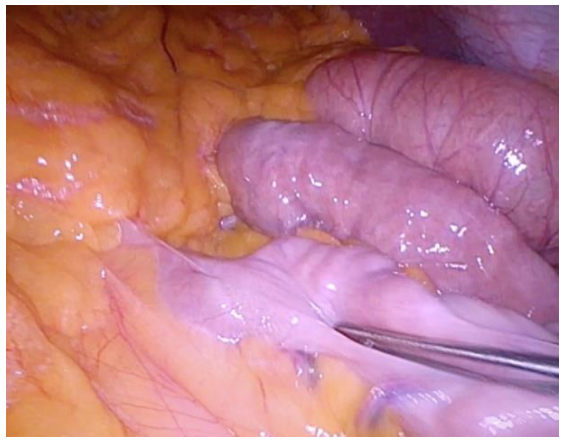

Figure 7. Identification of the angle of Treitz.

Next, we usually use a 70 cm biliary limb. To avoid any kind of technical errors, a stitch is placed between the greater curvature of the stomach and the antimesenteric border of the jejunum, 70 cm distal to the angle of Treitz (Figure 8).

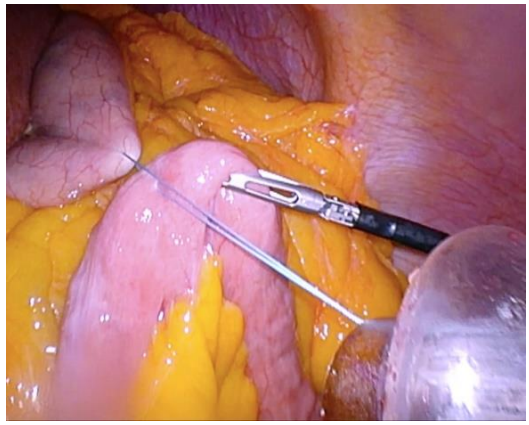

Figure 8. A stitch is placed between the greater curvature of the stomach and the antimesenteric border of the jejunum, 70 cm distal to the angle of Treitz.

Using a skin marker´s tip hold to a dissector, the biliary limb is marked (Figure 9).

Figure 9. The biliary limb is marked.

150 cm of alimentary limb are measured, and a second stitch is placed between the alimentary limb and the biliary limb (Figure 10).

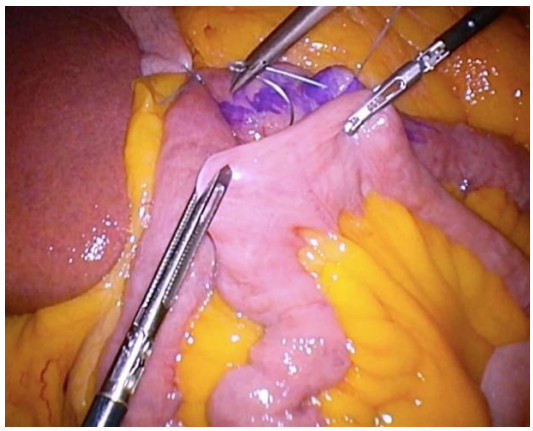

Figure 10. A second stitch is placed between the alimentary limb and the biliary limb.

A side-to-side jejuno-jejunostomy is performed between the alimentary and biliary limbs, using a white 60 mm cartridge of the Endo GIA™ linear stapling device (Figure 11).

The remaining ostium is closed with interrupted 2/0 Ethibond ™ stitches, which are knotted extracorporally (Figure 12).

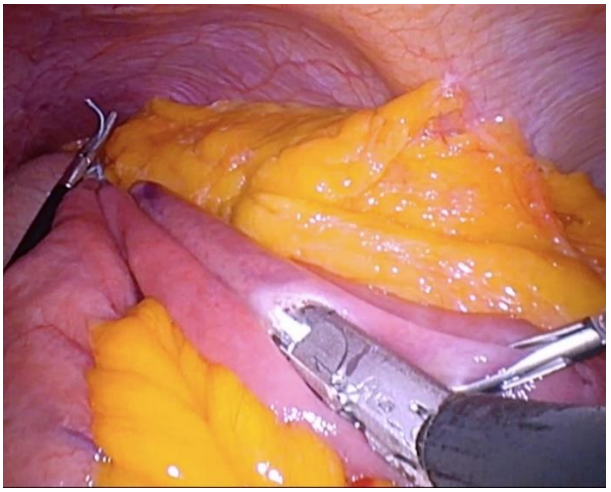

Figure 11. A side-to-side jejuno-jejunostomy is performed between the alimentary and biliary limbs.

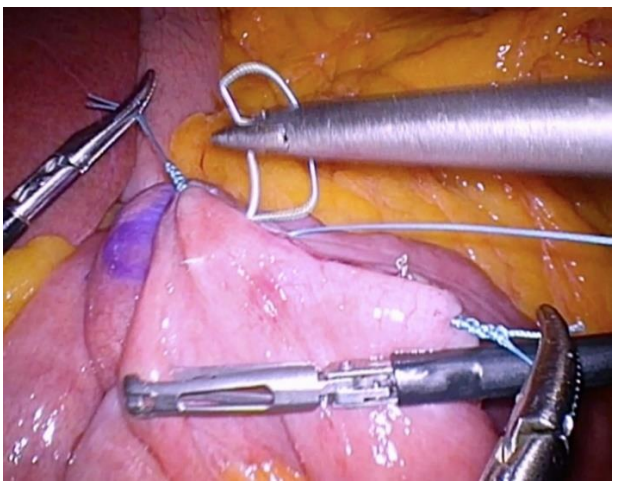

Figure 12. The remaining ostium is closed with interrupted stitches.

b) Gastric Pouch

The patient is placed on a deep anti-Trendelenburg position. Adler retractor is placed through the port in the upper right abdomen, under the posterior surface of the left lobe of the liver, to properly expose the hiatus and the gastroesophageal junction (Figure 13)

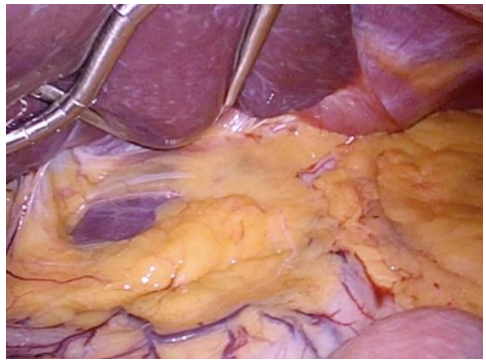

Figure 13. Placement of the Adler retractor.

By pulling the fat pad on the gastroesophageal junction and widely pulling down the fundus, the left crus is exposed and dissected using blunt dissection. Once its base is reached, a gauze is placed there so it can be seen while performing the vertical division of the stomach (Figure 14)

Figure 14. A gauze is placed on the gastroesophageal junction.

The creation of the gastric pouch starts by using the hook to divide the visceral peritoneum. The vessel-sealing device is then used to dissect the hepatogastric ligament right on the lesser curvature of the stomach until the posterior surface of the stomach is reached. (Figures 15-18)

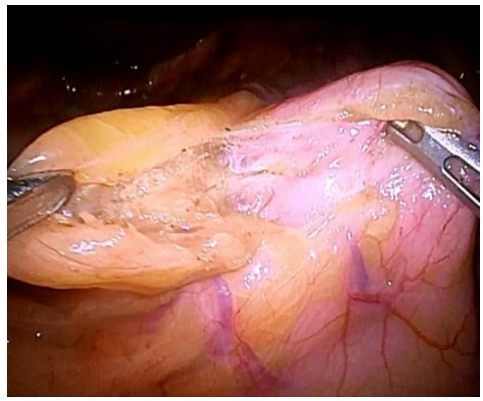

Figure 15. Dissection of the lesser curvature.

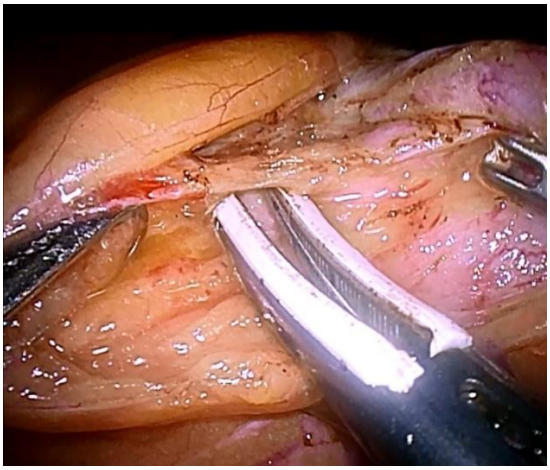

Figure 16. Dissection of the lesser curvature (continued).

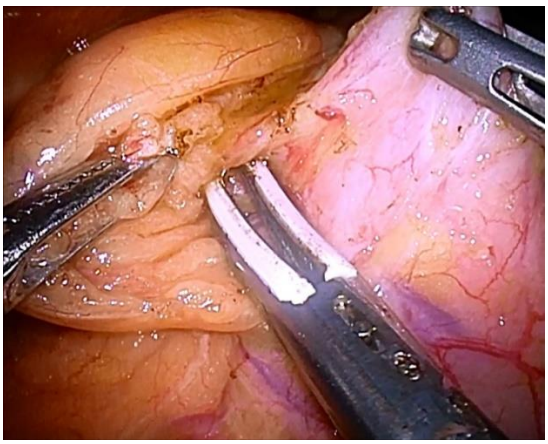

Figure 17. Dissection of the lesser curvature (continued).

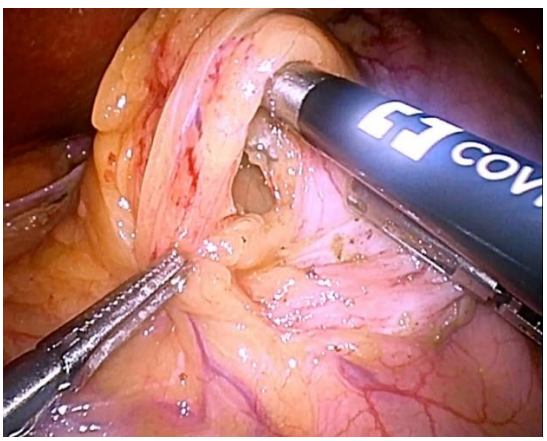

Figure 18. Dissection of the lesser curvature (continued).

The horizontal division of the stomach is done with a 45 mm blue cartridge of the linear stapling device (EndoGIA™). (Figure 19)

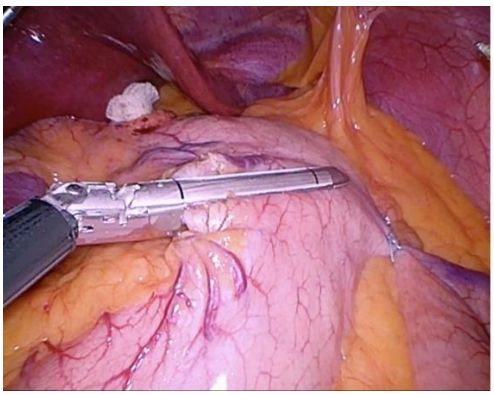

Figure 19. Horizontal division of the stomach.

The vertical division of the stomach is performed with one or two 45 mm golden cartridges of the linear stapling device (EndoGIA ™), once it is checked that the lesser sac is free of adhesions (Figures 20, 21)

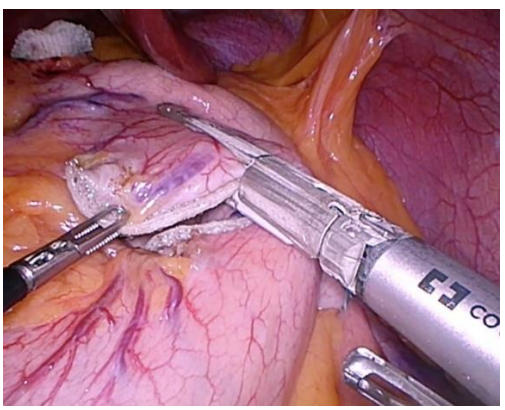

Figure 20. Vertical division of the stomach.

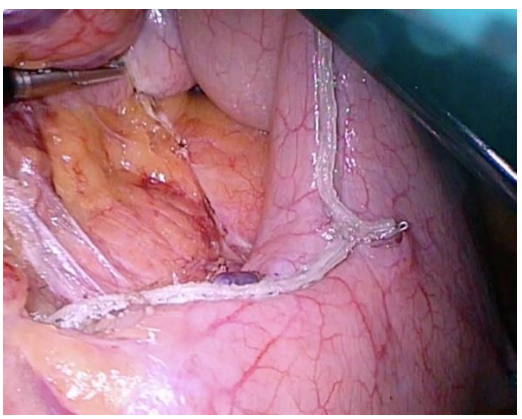

Figure 21. Vertical division of the stomach (continued).

At this point, the goal of the dissection is to find the gauze's tip, placed on the base of the left crura (Figures 22-24).

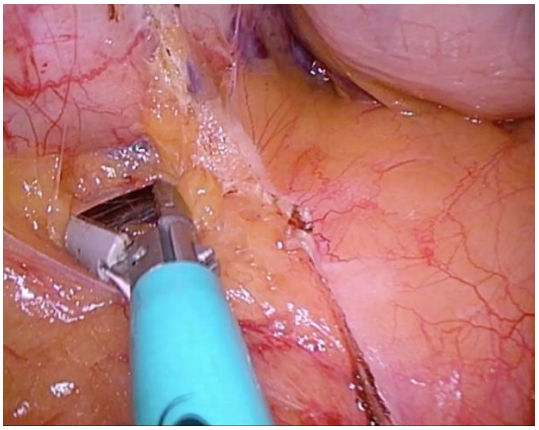

Figure 22. Dissection of the posterior face of the stomach.

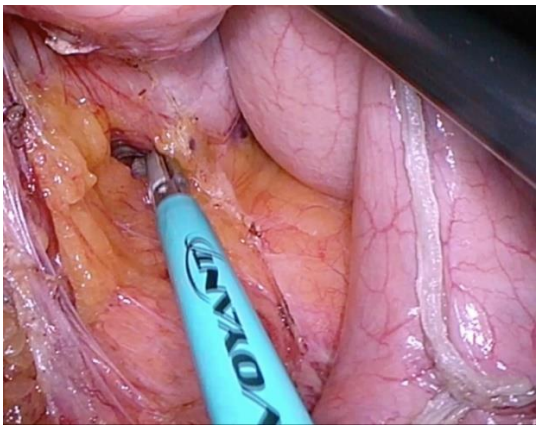

Figure 23. Dissection of the posterior face of the stomach (continued).

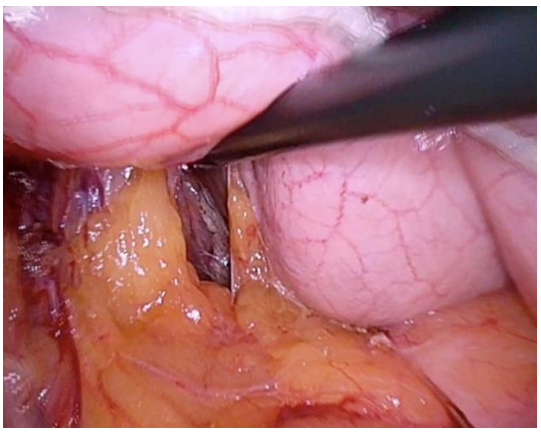

Figure 24. Dissection of the posterior face of the stomach (continued).

The stomach is finally divided using a curved-tip 60 mm golden cartridge of the linear stapling device. Eventually another 45 mm golden cartridge is necessary (Figures 25, 26).

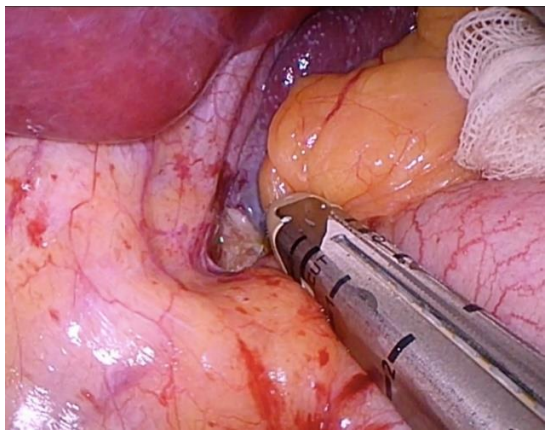

Figure 25. The stomach is finally divided.

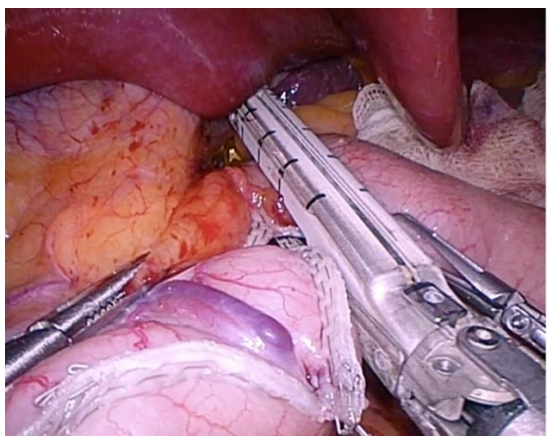

Figure 26. The stomach is finally divided (continued).

Once the pouch is divided, this part of the procedure is completed. (Figure 27)

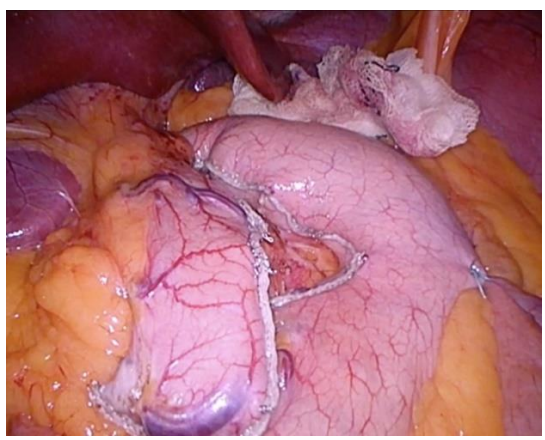

Figure 27. Division of the pouch from the gastric remnant.

c) Positioning the Orvil Device

We usually perform a circular stapled gastrojejunal anastomosis using the DST Series™ EEA™ XL 25mm EEA™ 3.5 stapling device (Figure 28).

Figure 28. Orvil device.

Once the gastric pouch is completed the anesthesiologist passes the orogastric tube (OrVil™ 25mm device) through the esophagus until the tip protrudes on the gastric pouch. (Figures 29-32)

Figure 29. The anesthesiologist passes the OrVil™ device through the esophagus.

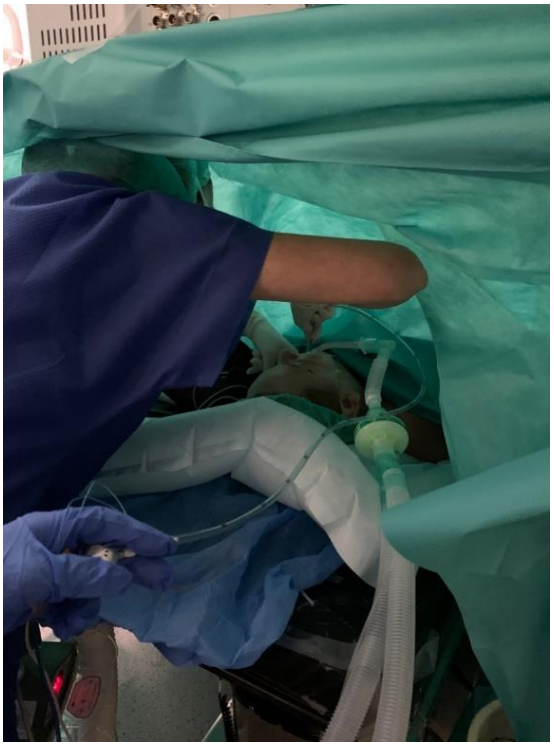

Figure 30. The anesthesiologist passes the OrVil™ device through the esophagus (continued).

Figure 31. The anesthesiologist passes the OrVil™ device through the esophagus (continued).

Figure 32. The anesthesiologist passes the OrVil™ device through the esophagus (continued).

The tip of the orogastric tube (Orvil™ 25mm device) attached to the anvil of the circular stapling device protrudes on the gastric pouch. (Figures 33, 34)

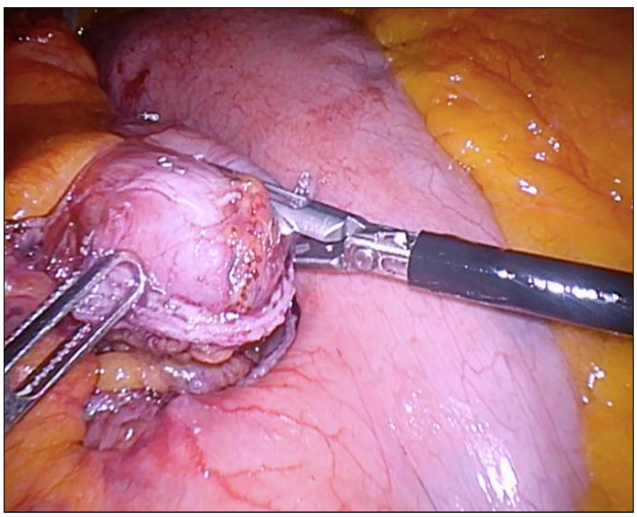

Figure 33. The tip of the Orvil™ protrudes on the gastric pouch.

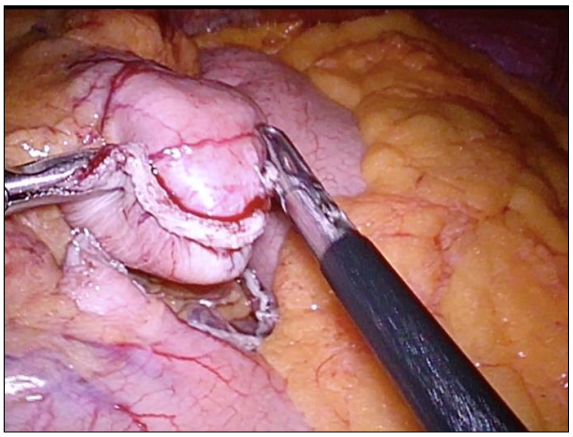

Figure 34. The tip of the Orvil™ protrudes on the gastric pouch (continued).

The gastric pouch is opened with the hook. (Figure 35-37)

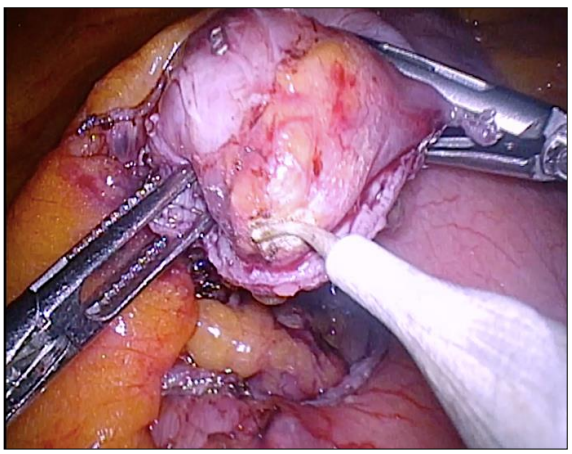

Figure 35. The gastric pouch is opened (continued).

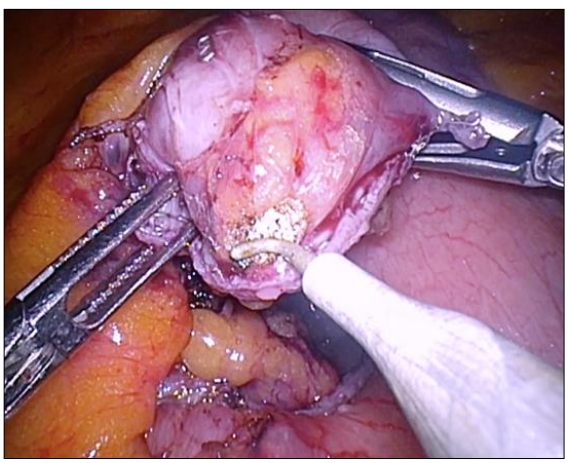

Figure 36. The gastric pouch is opened (continued).

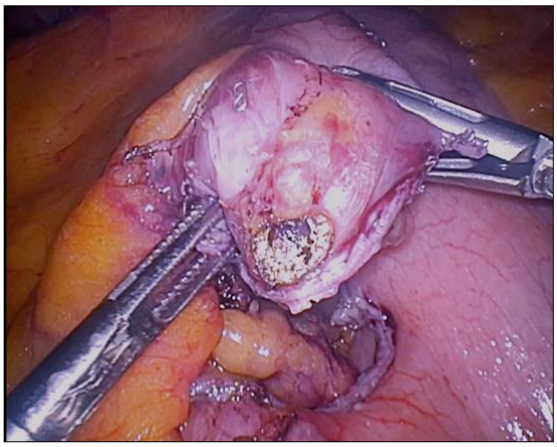

Figure 37. The gastric pouch is opened (continued).

The orogastric tube is grasped and passed through the gastrotomy. (Figures 38-42)

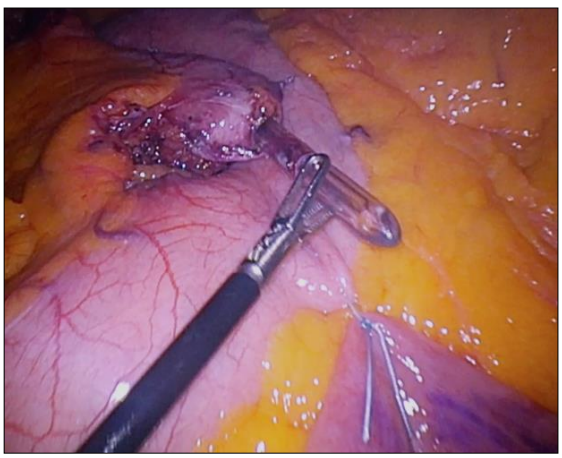

Figure 38. The orogastric tube is passed through the gastrotomy.

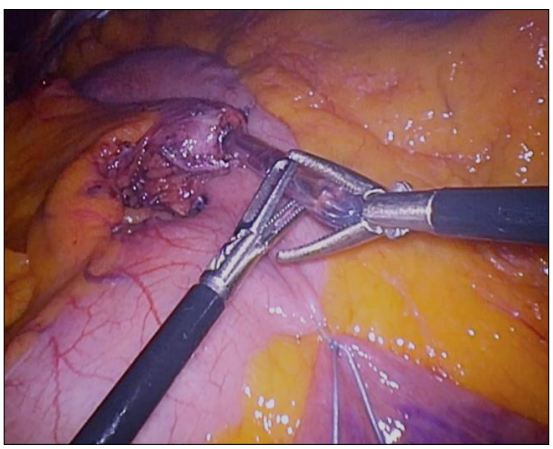

Figure 39. The orogastric tube is passed through the gastrotomy (continued).

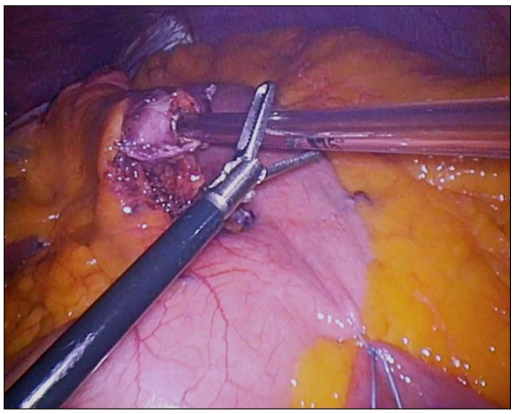

Figure 40. The orogastric tube is passed through the gastrotomy (continued).

Figure 41. Exit of the OrVil device through the port in the left upper quadrant.

The orogastric tube is passed through the port in the left upper abdomen.

Figure 42. Exit of the OrVil device through the port in the left upper quadrant (continued).

The anesthesiologist places upwards the white piece of the anvil head towards the palate and pushes it through the oral cavity while the surgeon pulls the nasogastric tube. (Figures 43-44)

Figure 43. The anesthesiologist places upwards the white piece of the anvil head.

Figure 44. The anesthesiologist places upwards the white piece of the anvil head (continued).

With a Maryland dissector we fix the anvil. (Figures 45, 46)

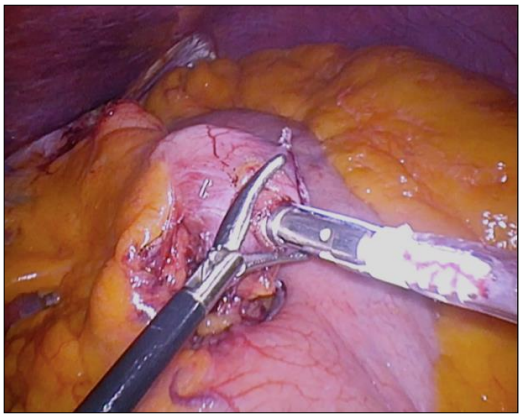

Figure 45. The anvil is fixed.

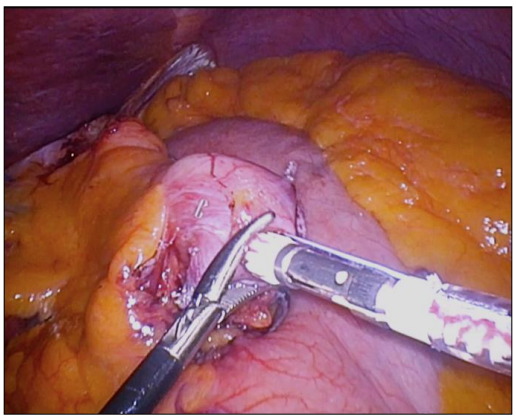

Figure 46. The anvil is fixed (continued).

One leg of the anvil-retaining suture is cut in order to disconnect the anvil from the orogastric tube. (Figures 47-50)

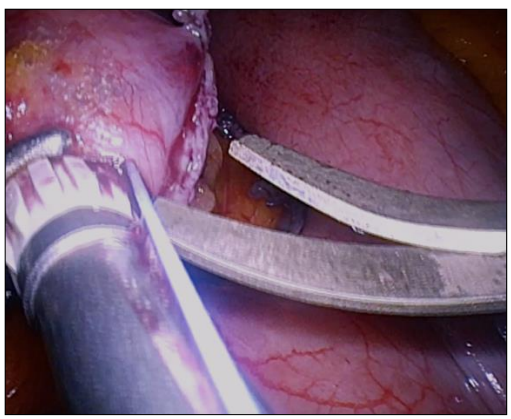

Figure 47. The anvil-retaining suture is cut.

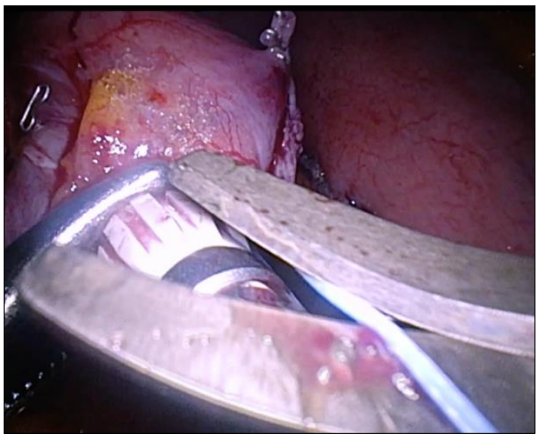

Figure 48. The anvil-retaining suture is cut (continued).

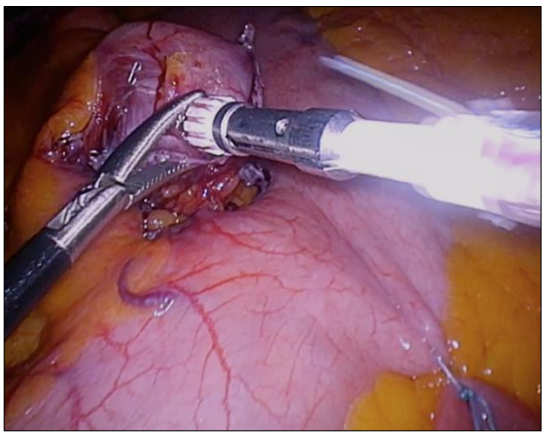

Figure 49. The anvil-retaining suture is cut (continued).

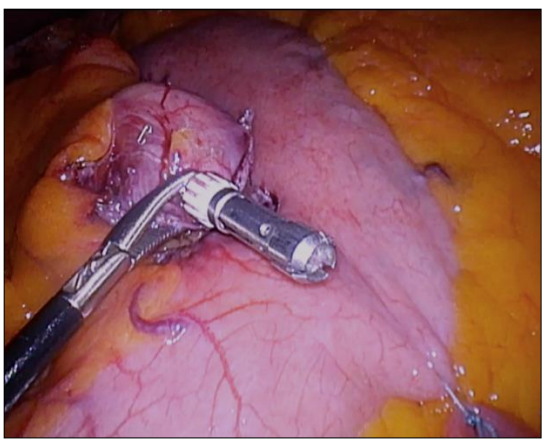

Figure 50. The anvil-retaining suture is cut (continued).

We usually secure the anvil with a suture in order to prevent any slippage into the gastric pouch.

The suture is held in place with a Crile forceps outside the trocar located in the right upper abdomen. (Figures 51-53)

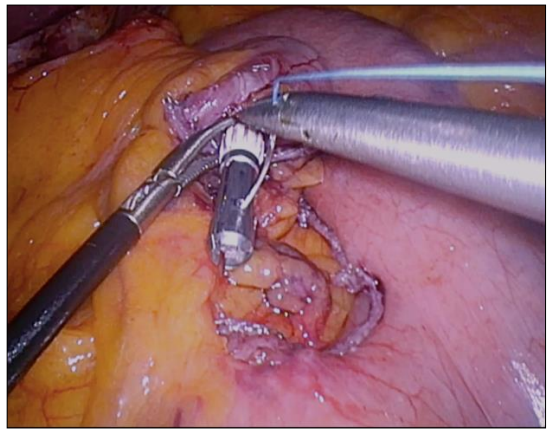

Figure 51. The anvil is secured with a suture to prevent slippage into the gastric pouch.

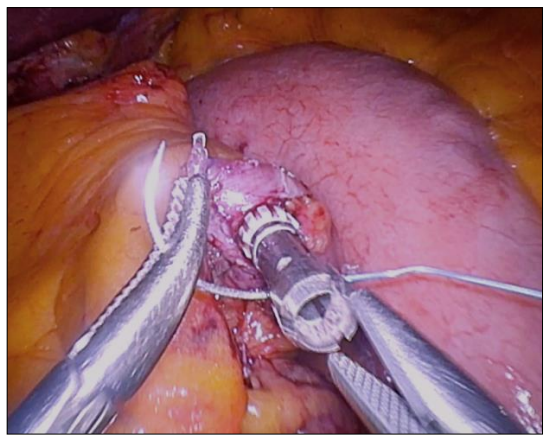

Figure 52. The anvil is secured with a suture to prevent slippage into the gastric pouch (continued).

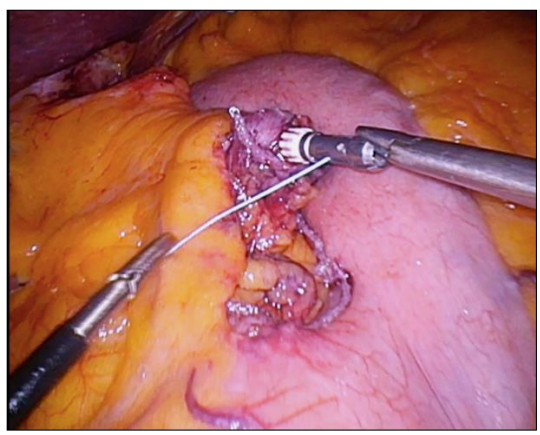

Figure 53. The anvil is secured with a suture to prevent slippage into the gastric pouch (continued).

d) Preparation of the Alimentary Limb

Once the anvil is properly placed, the reverse Trendelenburg position will be changed to a neutral position and the alimentary limb is located. (Figure 54)

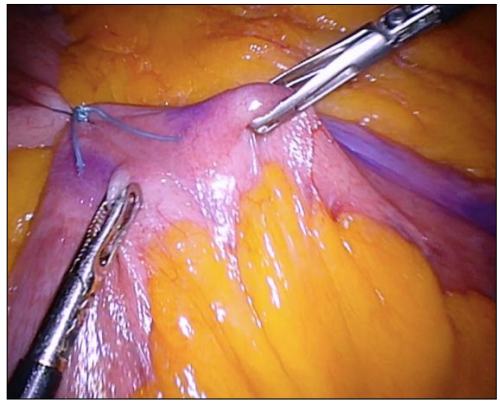

Figure 54. The alimentary limb is located.

The mesentery of the alimentary limb, is dissected with the vessel sealing device close to the stitch which attaches the greater gastric curvature to the small bowel. (Figure 55-57)

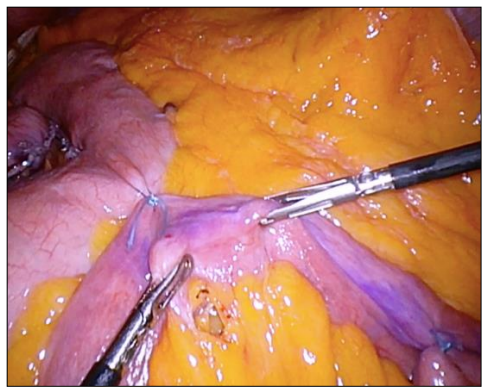

Figure 55. The mesentery of the alimentary limb is dissected.

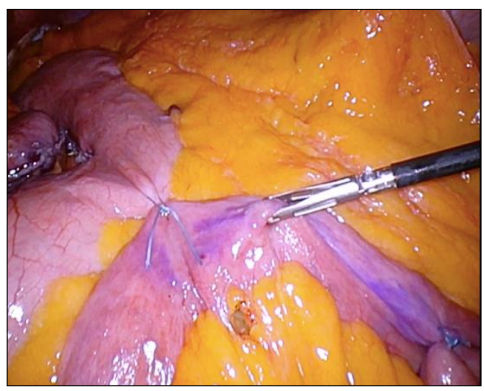

Figure 56. The mesentery of the alimentary limb is dissected (continued).

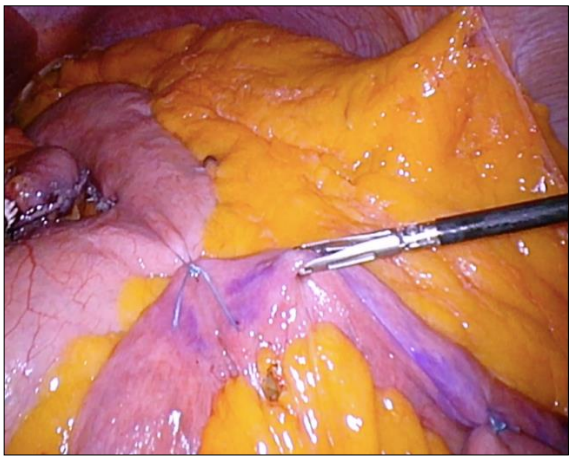

Figure 57. The mesentery of the alimentary limb is dissected (continued).

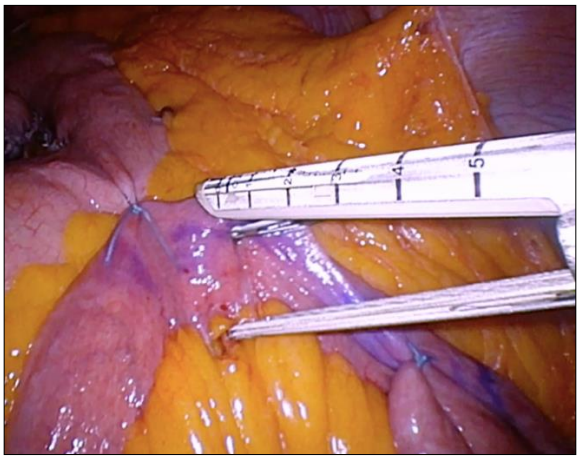

Figure 58. Transection of the jejunum with linear stapling device.

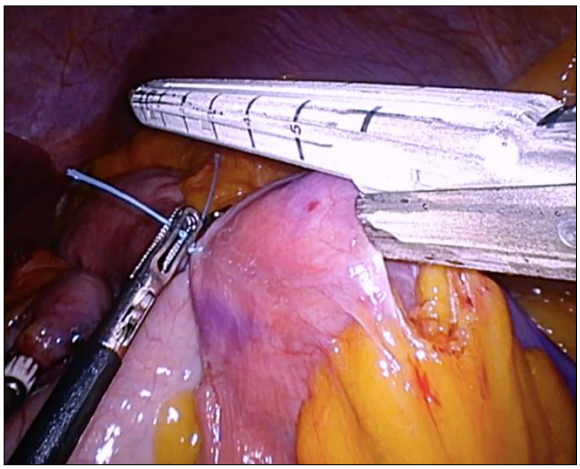

Figure 59. Transection of the jejunum with linear stapling device (continued).

The jejunum is transected with a 60 mm gold cartridge of the linear stapling device, we usually flex the stapler, counterclockwise to obtain a slight oblique transection line, which further on will enable the introduction of the shaft of the circular stapling device. (Figures 58-61)

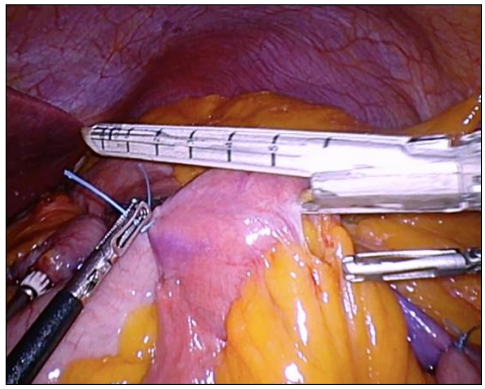

Figure 60. Transection of the jejunum with linear stapling device (continued).

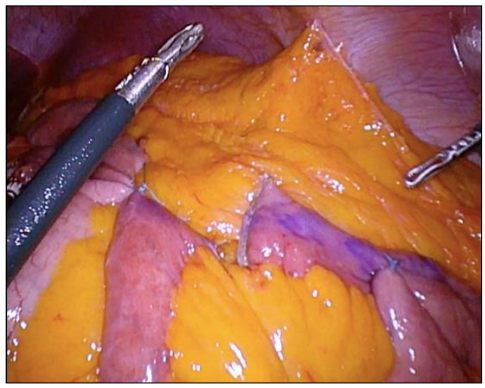

Figure 61. Transection of the jejunum with linear stapling device (continued).

The blind side of the alimentary limb is opened, with the hook, near to the staple line. (Figures 62-64)

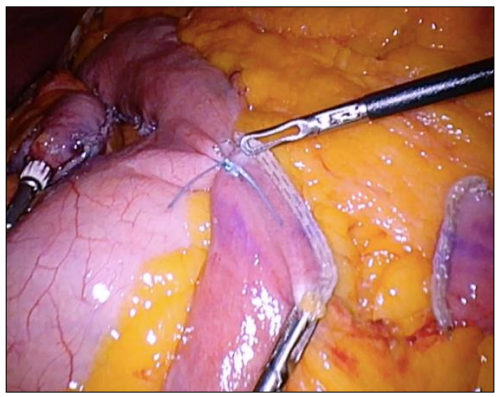

Figure 62. The blind side of the alimentary limb is opened.

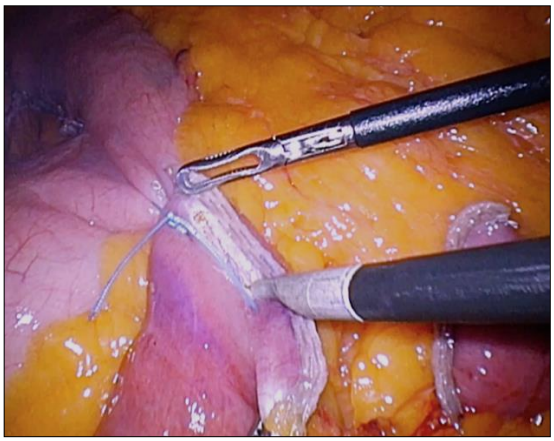

Figure 63. The blind side of the alimentary limb is opened (continued).

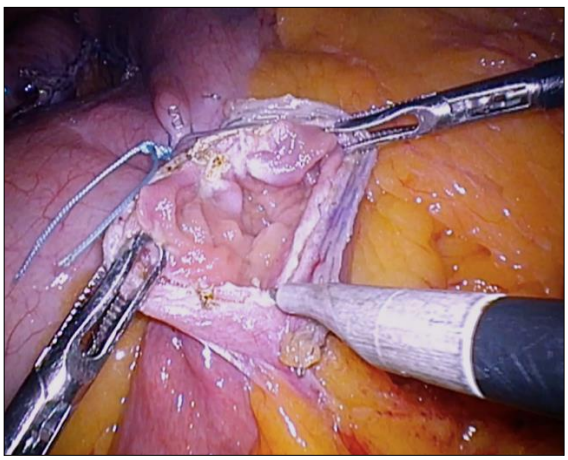

Figure 64. The blind side of the alimentary limb is opened (continued).

The stitch to the greater curvature is cut. (Figure 65)

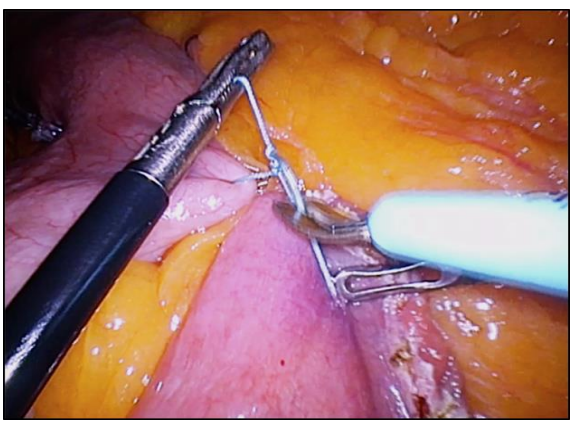

Figure 65. The stitch to the greater curvature is cut.

The mesentery of the jejunum is divided with the vessel sealing device, taking care not to injure the vascular supply of the alimentary or biliary limb. (Figures 66-70)

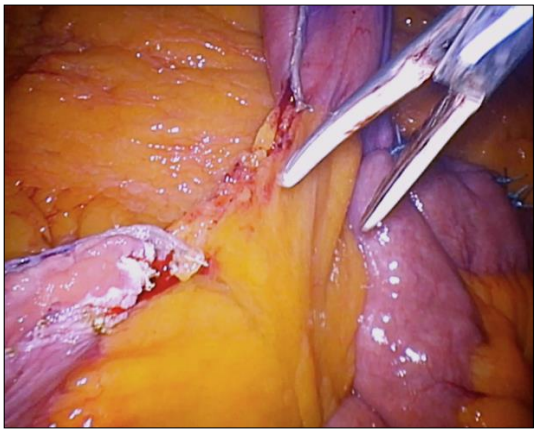

Figure 66. The mesentery of the jejunum is divided.

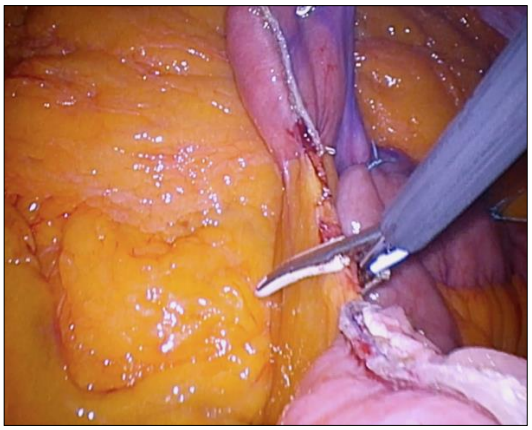

Figure 67. The mesentery of the jejunum is divided (continued).

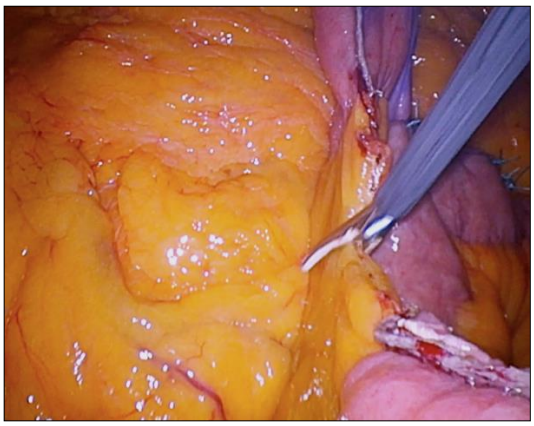

Figure 68. The mesentery of the jejunum is divided (continued).

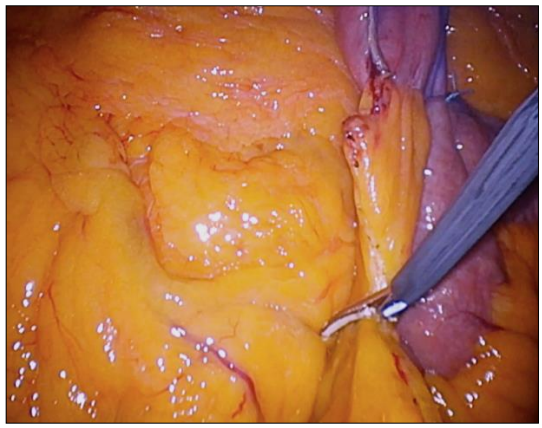

Figure 69. The mesentery of the jejunum is divided (continued).

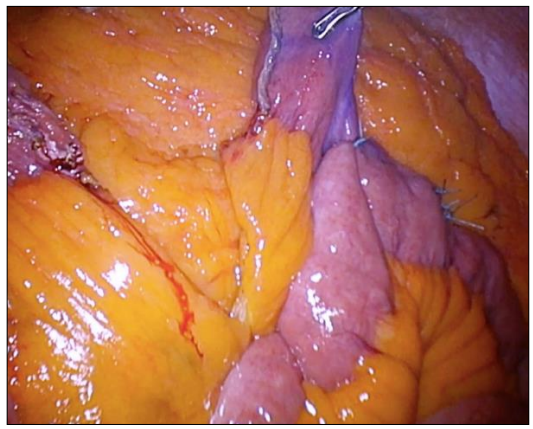

Figure 70. The mesentery of the jejunum is divided (continued).

Before the circular anastomosis is performed we check that the alimentary limb reaches the gastric pouch without tension. (Figure 71)

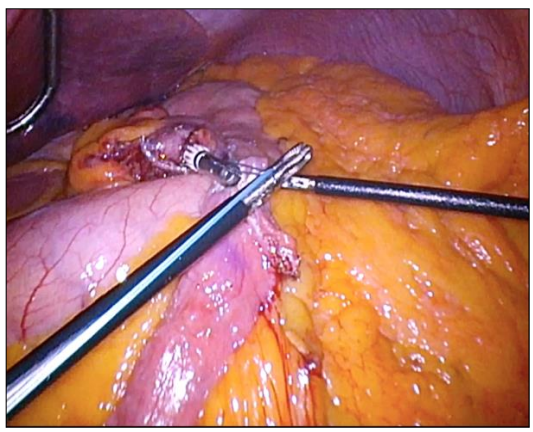

Figure 71. We check that the alimentary limb reaches the gastric pouch without tension.

e) Gastrojejunal Anastomosis

Finally we create an end-to-side gastrojejunal circular anastomosis.

First of all, we enlarge the incision of the 12-mm port site in the left upper abdomen in order to introduce a plastic wound protector (Alexis®) that both protects and retracts the muscular wall facilitating the introduction of the circular stapling device EEA™ DST 25 XL 3,5. To introduce the stapler device through the muscular wall it is very useful to use the TAID®, a cone-shaped plastic device, that we remove once we have introduced the stapler in the abdominal cavity. (Figures 72-80)

Figure 72. Enlargement of the incision of the 12-mm port site in the left upper abdomen.

Figure 73. Enlargement of the incision of the 12-mm port site in the left upper abdomen (continued).

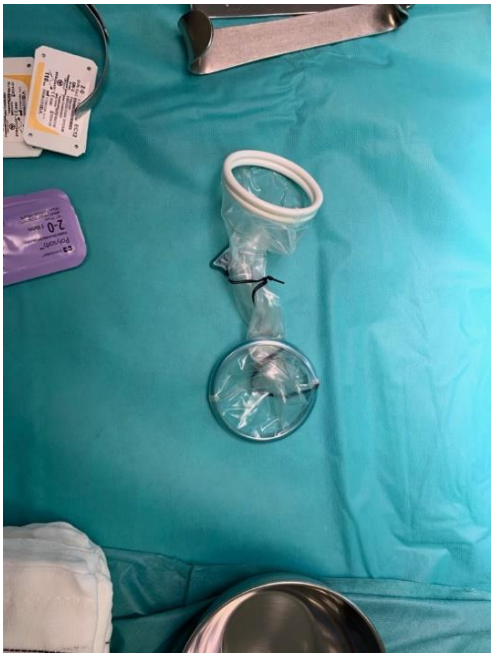

Figure 74. Plastic wound protector (Alexis®).

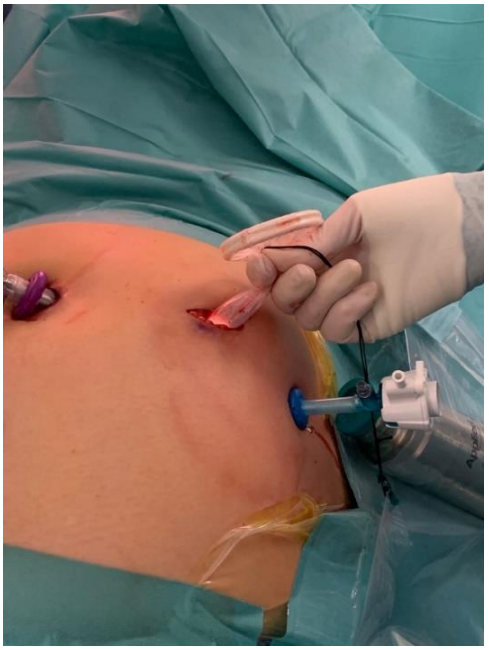

Figure 75. Introduction of the plastic wound protector (Alexis®).

Figure 76. Introduction of the circular stapler with the TAID®, a cone-shaped plastic device.

Figure 77. Introduction of the circular stapler with the TAID®, a cone-shaped plastic device (continued).

Figure 78. Introduction of the circular stapler with the TAID®, a cone-shaped plastic device (continued).

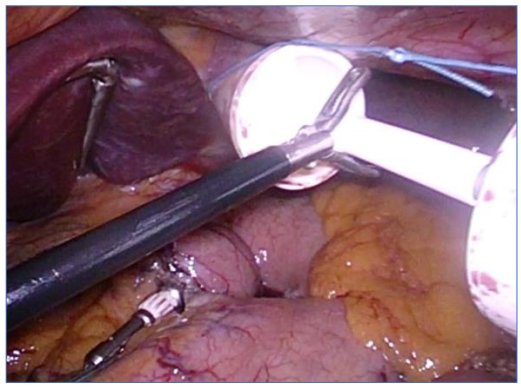

Figure 79. The TAID is removed once the stapler is introduced in the abdomen.

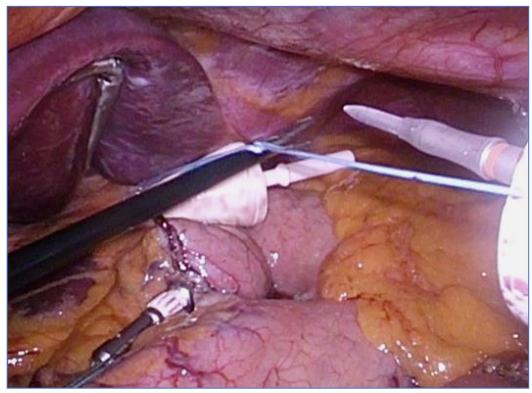

Figure 80. The TAID is removed once the stapler is introduced in the abdomen (continued).

The alimentary limb is anastomosed with the gastric pouch in an end-to-side fashion with the circular stapling device, as no tension is present. We normally secure the anvil with a suture to avoid any slipping into the gastric pouch. This suture is removed before firing the circular stapling device. (Figures 81-90)

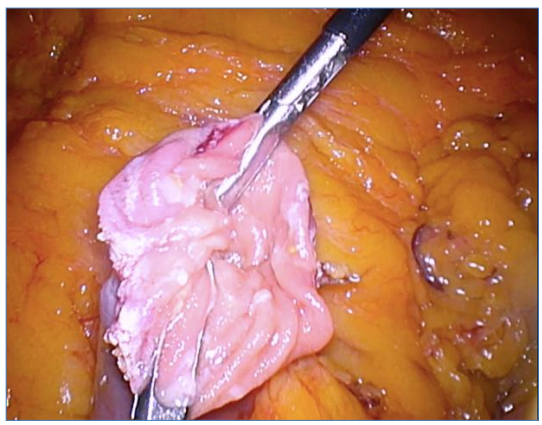

Figure 81. The alimentary limb is anastomosed with the gastric pouch in an end-to-side fashion with the circular stapling device.

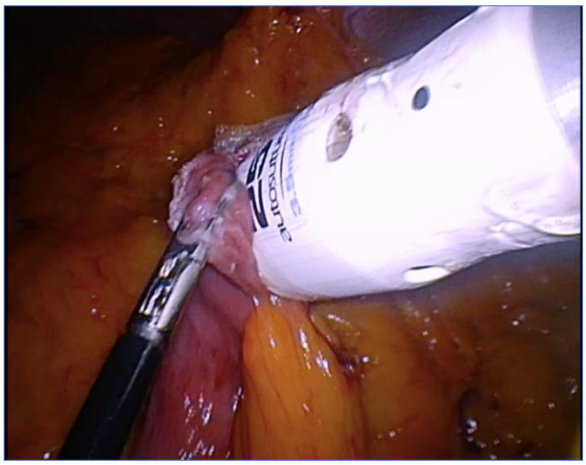

Figure 82. Introduction of the circular stapler through the open jejunum.

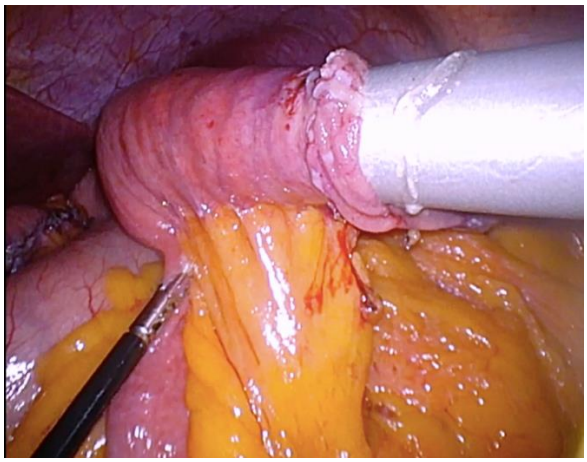

Figure 83. Introduction of the circular stapler through the open jejunum (continued).

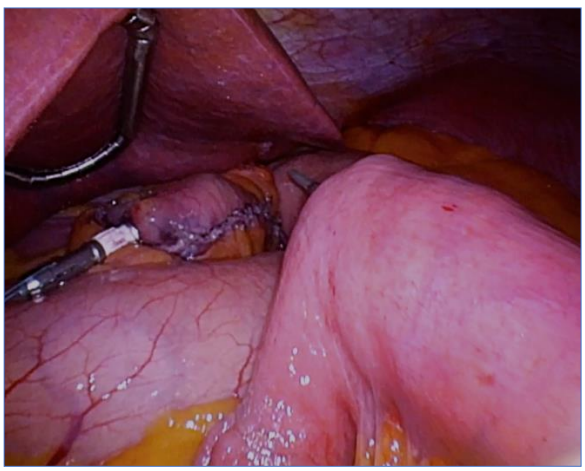

Figure 84. Exit of the tip of the stapler through the jejunal wall to perform and end-to-side anastomosis.

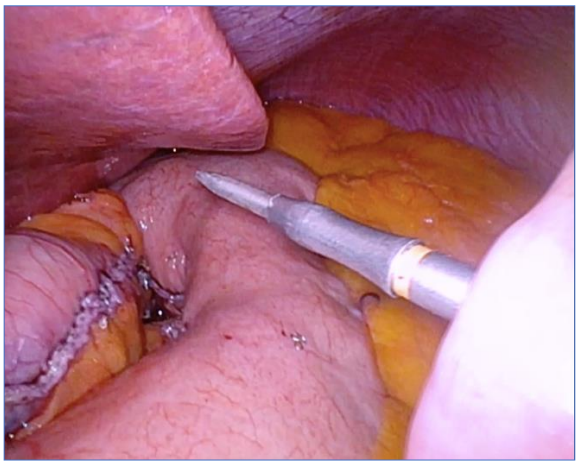

Figure 85. Exit of the tip of the stapler through the jejunal wall to perform and end-to-side anastomosis (continued).

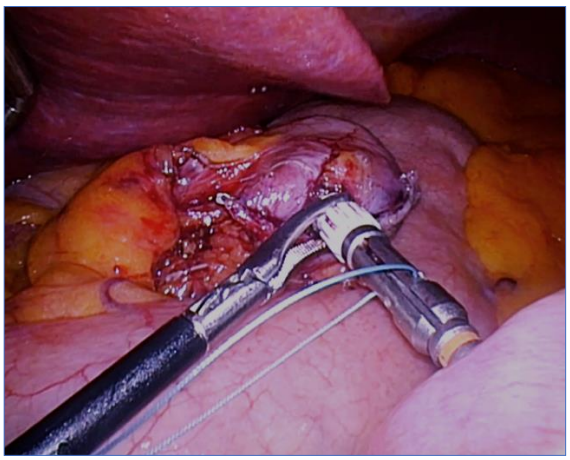

Figure 86. Connection of the tip to the anvil.

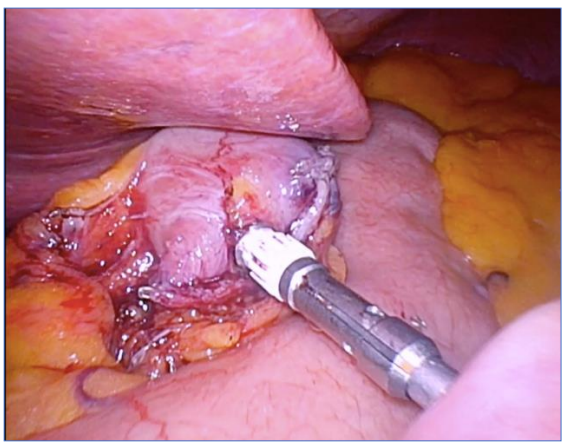

Figure 87. Connection of the tip to the anvil (continued).

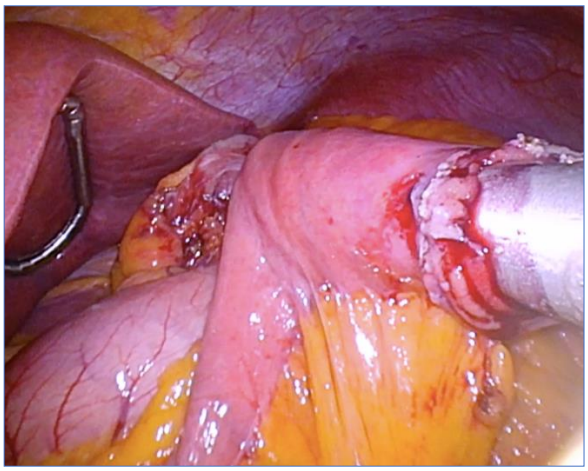

Figure 88. End-to-side anastomosis.

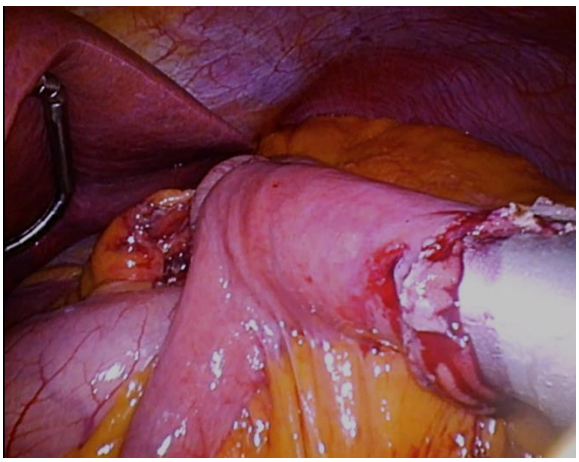

Figure 89. End-to-side anastomosis (continued).

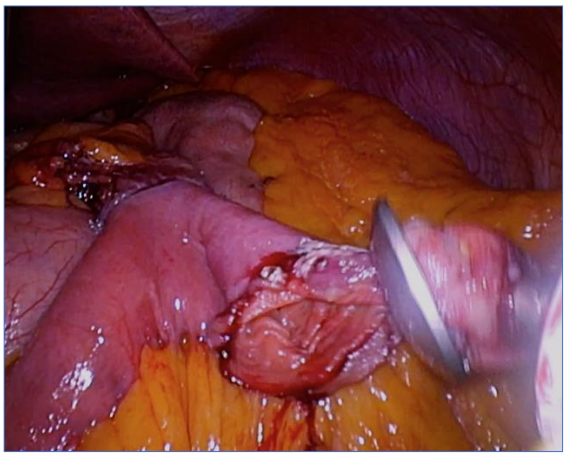

Figure 90. Extraction of the stapler with the anvil adhered.

Once the circular anastomosis is completed, we introduce a 12-mm port through the Alexis. (Figure 91)

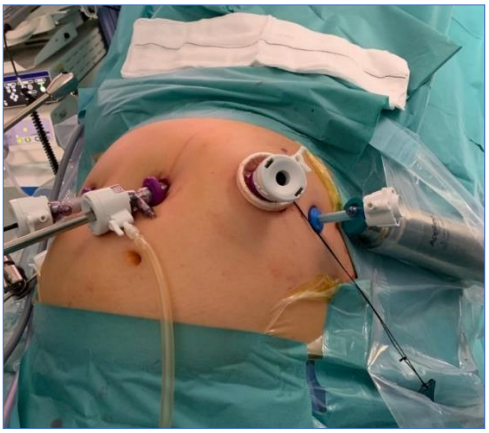

Figure 91. Once the anastomosis is finished, a 12-mm port is introduced through the Alexis.

Finally, the blind and open loop is resected with a 60mm cartridge of the Endo GIA™ linear stapler and extracted with an Endobag (Inzii universal specimen retrieval system, Applied Medical). (Figures 92-94)

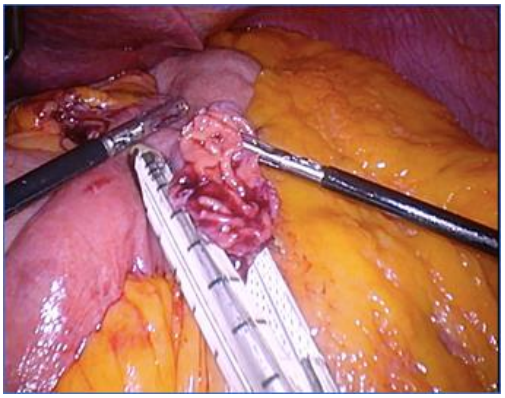

Figure 92. The blind and open loop is resected.

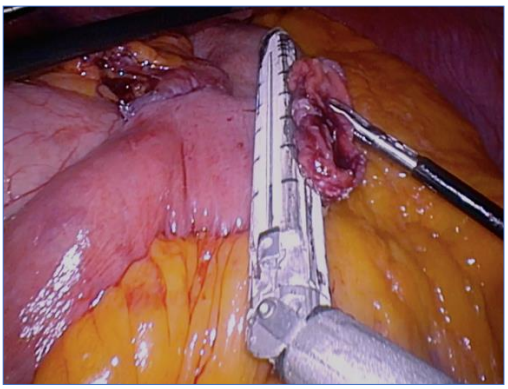

Figure 93. The blind and open loop is resected (continued).

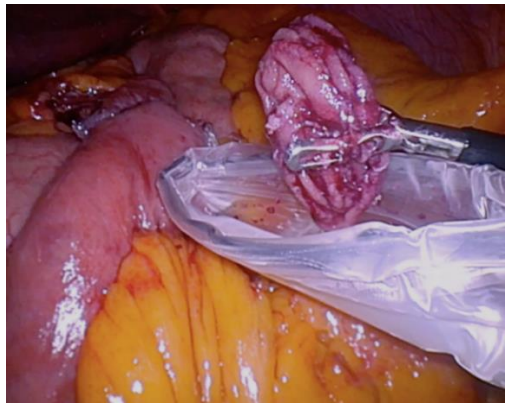

Figure 94. The resected specimen is removed inside a bag.

f) Testing the Anastomosis

Finally we check the integrity of the anastomosis performing an air leak test.

Patient is positioned in steep Trendelenburg position. The abdominal cavity is flashed with saline and the anesthesiologist introduces air in the gastric pouch through a nasogastric tube. (Figures 95-97). Surgical drains are not placed.

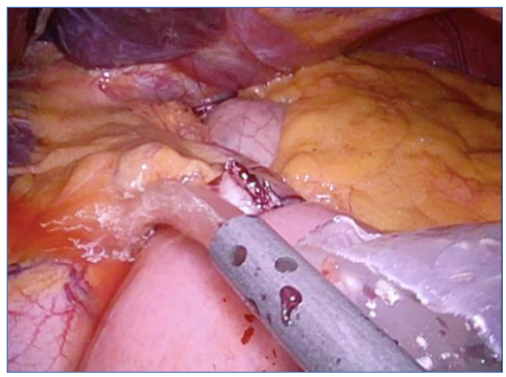

Figure 95. Air leak test.

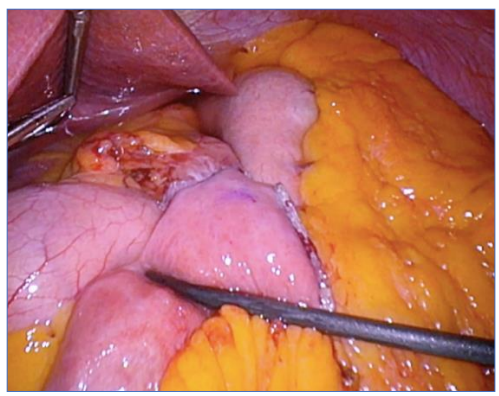

Figure 96. Air leak test (continued).

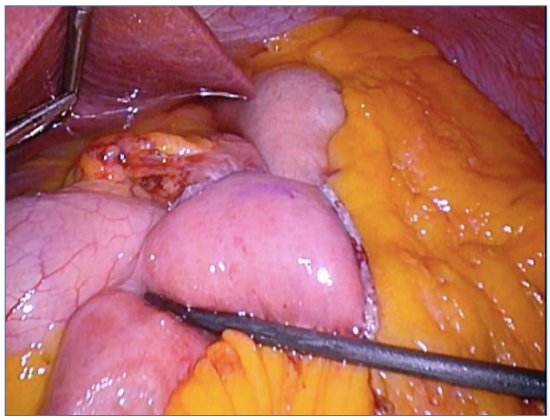

Figure 97. Air leak test (continued).

To finish the surgery we remove the hepatic retractor and all the ports under direct vision.

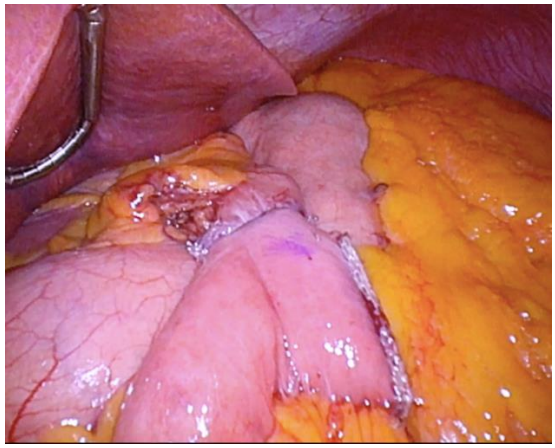

Figure 98. The hepatic retractor and all the ports are removed under direct vision.

In: Encyclopedia of Surgery (22 Volume Set)
Editors: Andreas Lehrer and Kristin Mueller
ISBN: 978-1-53618-329-0
© 2020 Nova Science Publishers, Inc

Chapter 298

LAPAROSCOPIC ROUX-EN-Y GASTRIC BYPASS WITH HAND-SEWN GASTROJEJUNAL ANASTOMOSIS

Alejandro Garcia Muñoz-Najar[1], MD,
Manuel Medina Garcia[2], MD,
Leire Zarain Obrador[1], MD
and Manuel Duran Poveda[1], MD, PhD
[1]Bariatric Surgery Unit, Rey Juan Carlos University Hospital, Madrid, Spain
[2]Bariatric Surgery Unit, Hospital de Fuenlabrada, Madrid, Spain

ABSTRACT

Laparoscopic Roux-en-Y Gastric Bypass (RYGB) is considered the gold standard for the treatment of morbid obesity. However, there is no agreement on the technique that should be used for the gastrojejunal anastomosis (GJA; hand-sewn, linear mechanical, or circular mechanical). The choice of this type of technique may be influenced by the surgeon's preference and experience. It will also depend on the economic state of the institution where the bariatric surgeon works. Many studies have shown that there are no differences between techniques in terms of complications (anastomotic dehiscence, marginal ulcer, bleeding, stricture) or weight loss, whereas other studies observed significant differences between techniques. The aim of this chapter is to present the standard technique of the gastrojejunal hand-sewn anastomosis in RYGB.

Keywords: laparoscopic Roux-en-Y gastric bypass, hand-sewn anastomosis, surgical technique

INTRODUCTION

Bariatric surgery is considered the most effective treatment for morbid obesity, resulting in significant weight loss, as well as improvement of associated comorbidities [1]. Considering surgical techniques, Roux-en-Y gastric bypass (RYGB) is the gold standard

procedure for many surgeons. Actually, it is the second most-frequently performed technique, but in several countries, such as Spain, it is the most common bariatric procedure.

The technique used to perform the gastrojejunal anastomosis (GJA) varies among surgeons. This anastomosis is of vital importance, because the morbidity and the most severe complications of this surgery are associated with its correct performance, such as postoperative leakage (0-6.6%), marginal ulceration (0-8%) and stenosis (0-33%).

GJA can be performed using circular (CS) or linear mechanical staplers (LS), or completely hand-sewn (HS). Surgeons who propose each technique cite several specific advantages: a more consistent size of GJA with CS [2], an anastomosis less prone to stenosis with LS [3], while the HS technique reduces operative costs [4] but is considered more technically demanding [5].

INDICATIONS FOR RYGB

Indications for RYGB can be considered the following ones :

1. Primary weight loss procedure.
2. Ideal technique for metabolic syndrome patients.
3. Patients with esophageal reflux or Barret's disease.

PREOPERATIVE PREPARATION

The completion of the preoperative protocol prior to bariatric surgery requires the participation of several specialties, such as surgeons, endocrinologists, dietitians, gastroenterologists, anesthesiologists, pulmonologists and psychiatrists, who combine a medical, nutritional and endocrinological work-up to evaluate possible surgical candidates. The preoperative assessment included abdominal ultrasound, barium swallowing, upper gastrointestinal endoscopy, analytical determination of nutritional parameters and polysomnography.

SURGICAL TECHNIQUE

Instrumentation

At our institution we used the following surgical matherial for this technique:

1. Two 12 mm, one 11 mm and one 5 mm ports
2. Liver retractor
3. 30° scope
4. Harmonic scalpel (Harmonic ACE; Johnson & Johnson)
5. Veress needle
6. Three atraumatic graspers (one of the long size)

7. Suction-irrigator
8. Absorbable suture 3/0 monofilament
9. Echelon 45 mm (blue and white cartridges) (Johnson & Johnson, USA)
10. Gauzes
11. Clip applicator (optional)

PATIENT, PORT AND SURGEON POSITIONS

a) Patient Position

Patients are placed on an operating table in supine position with closed legs and only the left arm opened. Intermittent pneumatic compression devices are used to help to prevent venous thromboembolisms. The legs and hips are secured with safety straps to the operating table. An orogastric tube of 36 Fr is placed into the stomach in order to calibrate the gastric pouch during stapling and transection (Figure 1).

b) Port Position

Pneumoperitoneum to a pressure of 12-14 mmHg is achieved through Veress needle technique at Palmer point in the left upper quadrant. A first 11-mm port is inserted at the junction of the upper two thirds and lower one third of the line joining the xiphoides to the umbilicus, slightly bleached to the left of the patient. This is the camera port.

Figure 1. Patient position.

Two 12-mm working ports are inserted in the left and right hypochondrium areas in the midclavicular line, the port for left hand slightly more cranially than the port for right hand. A 5-mm port is inserted in the epigastrium. A liver retractor is used to retract the left lobe of the liver.

Another 5-mm port is placed on the left side in anterior axillary line at the level of the umbilicus. This is used by the first assistant, located on the left side of the patient. This is used mainly to retract the stomach or to help in the small bowel mobilization (Figure 2).

c) Surgeon Position

The operating surgeon stands on the right of the patient. The first assistant surgeon stands on the left side of the patient. The camera (second assistant) is on the right side of the operating surgeon. The scrub nurse is beside the first assistant.

Monitor is placed on the upper part of the patient for assistant and surgeon view (Figure 3).

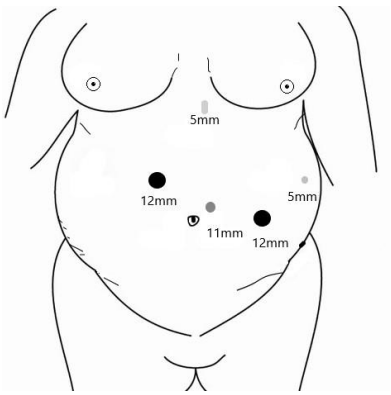

Figure 2. Ports position.

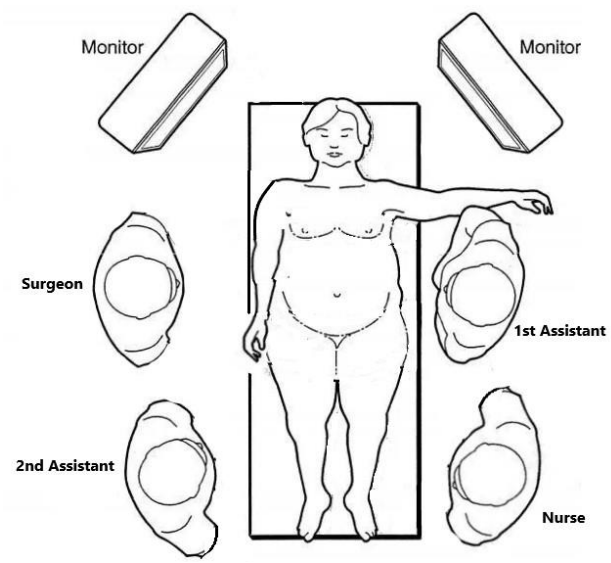

Figure 3. Surgeon position.

Figure 4. Identification of the angle of Treitz.

PROCEDURE

a) Identification of Angle of Treitz

The procedure begins identifying the angle of Treitz, in the mesenterium of the transverse colon (Figure 4). Once the initial part of the jejunum is identified in the angle of Treitz, 60 cm are counted distally. At that point the intestinal section is performed with a white cartridge on the mechanical stapler (Figures 5, 6). The mesenterium of the small intestine is also sectioned at this level, allowing the distal stump to reach the gastric pouch without tension (Figures 7, 8).

b) Alimentary Limb Count

From the distal stump of the sectioned jejunum, 150 cm of jejunum is counted distally. It is at that point where the jejuno-jejunal anastomosis will be performed (Figure 9).

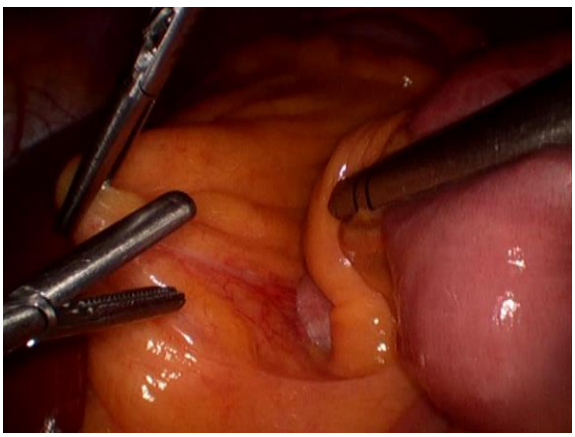

Figure 5. 60 cm of jejunum are measured distally.

Figure 6. 60 cm distal from the angle of Treitz the bowel is sectioned.

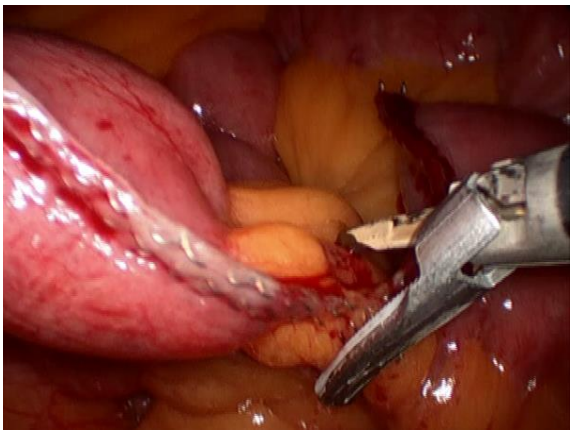

Figure 7. The mesenterium of the small intestine is also sectioned at this level.

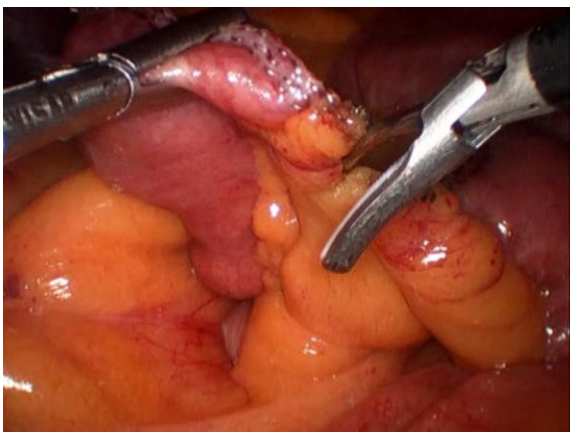

Figure 8. The mesenterium of the small intestine is also sectioned at this level (continued).

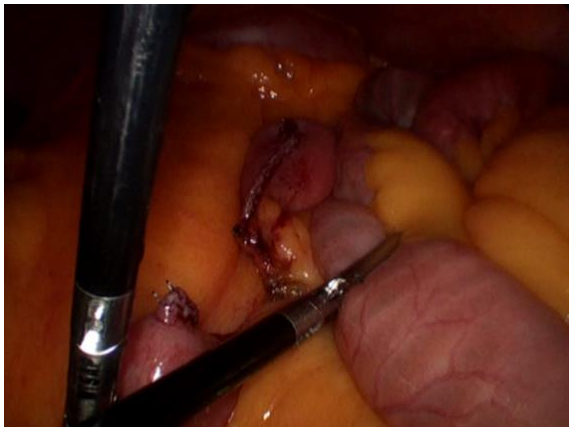

Figure 9. From the distal stump of the sectioned jejunum, 150 cm of jejunum is measured distally.

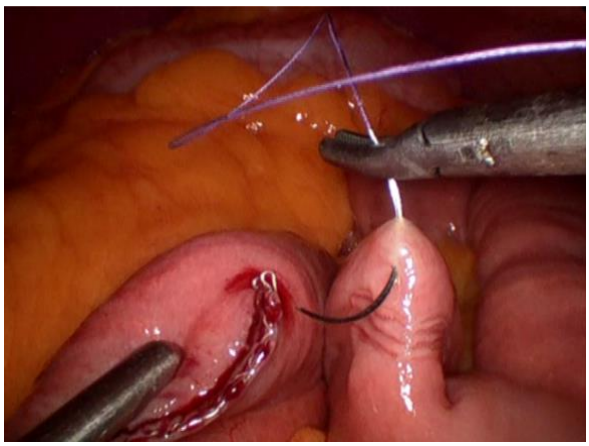

Figure 10. A fixation suture is performed between the biliary limb and the alimentary limb.

c) Jeyuno-Jejunal Anastomosis (JJA)

Once the length of the alimentary limb is counted, a fixation suture is performed between the biliary limb and the alimentary limb (Figures 10, 11). Then an orifice is opened with the harmonic scalpel very close to the suture, until reaching the lumen of both limbs (Figures 12, 13). A jaw of the stapler is inserted into each hole (Figure 14). It is important to check the posterior face of the future jejunum and anastomosis so that it is well aligned, to avoid stapling the mesentery (Figure 15). Carefully the stapler is removed of the JJA. Close attention must be paid to confirm that the stapling line is correctly performed and without signs of bleeding (Figure 16).

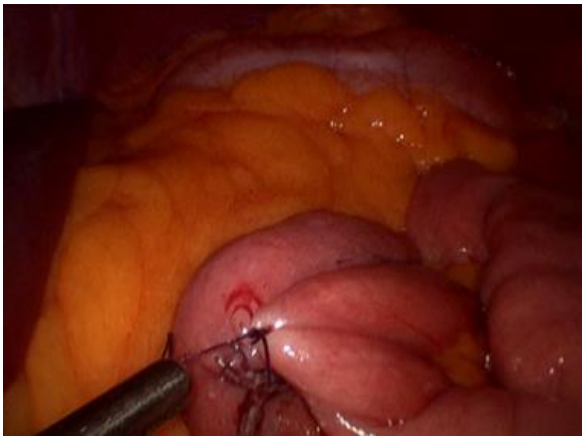

Figure 11. A fixation suture is performed between the biliary limb and the alimentary limb (continued).

Figure 12. Enterotomies in both bowel limbs.

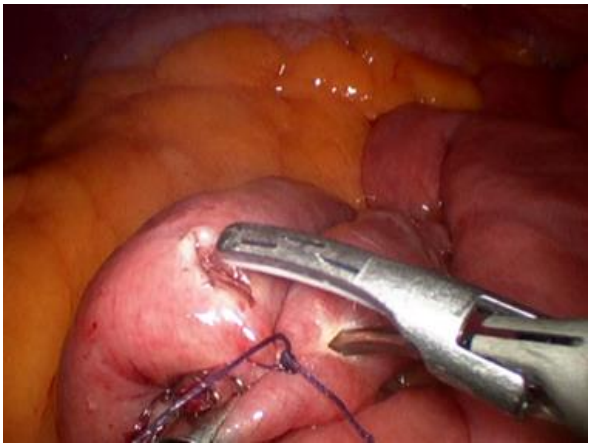

Figure 13. Enterotomies in both bowel limbs (continued).

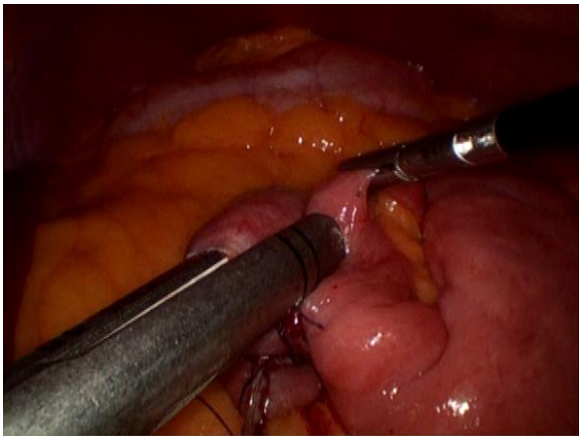

Figure 14. A jaw of the stapler is inserted into each hole.

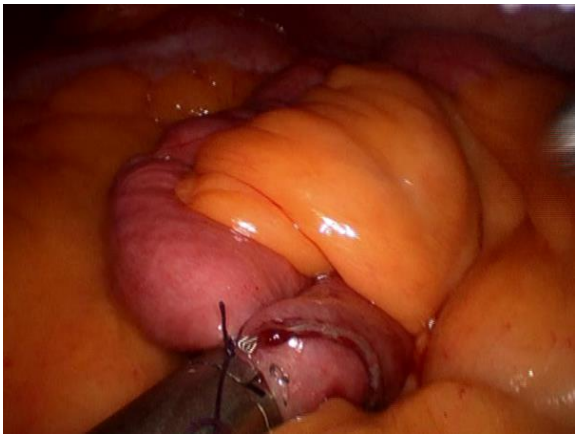

Figure 15. Mechanical anastomosis with linear stapler.

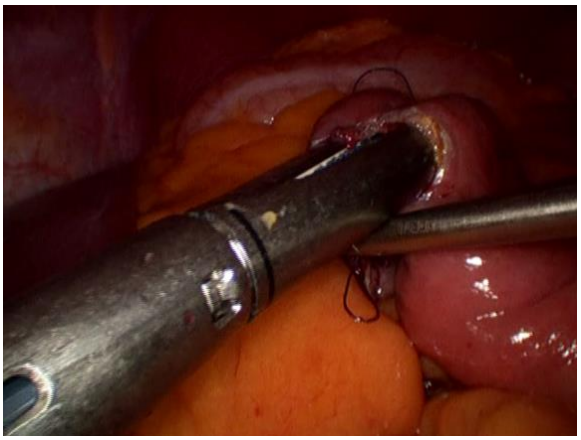

Figure 16. Inspection of anastomosis after removal of the stapler.

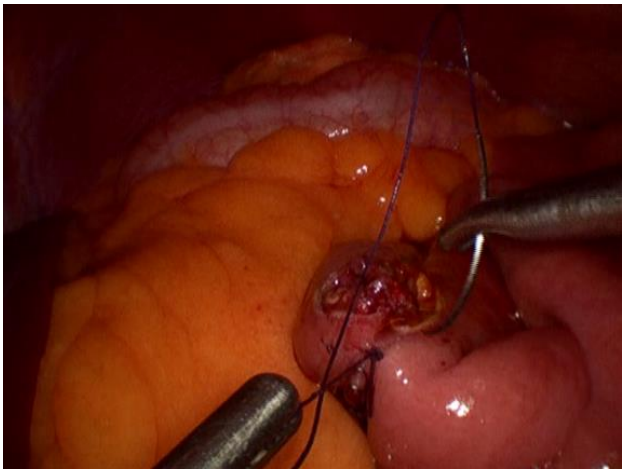

Figure 17. Running suture to close the enterotomies after the jejuno-jejunal anastomosis

Then a running suture is performed to close de orifice, finishing the jejuno-jejunal anastomosis (Figure 17- 19). The closure of the mesenteric defect is optional, and it can be made with a non-reabsorbable suture (Figure 20).

d) Bipartition of the Omentum

To reduce the tension when lifting the alimentary limb for the anastomosis with the gastric pouch, it is convenient to split the omentum in half with the harmonic scalpel (Figure 21).

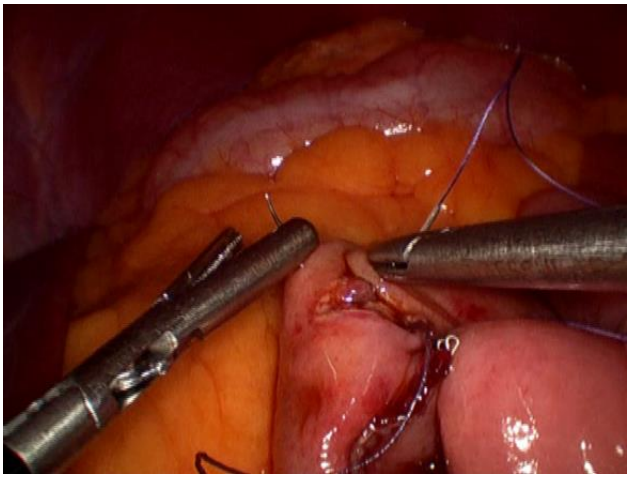

Figure 18. Running suture to close the enterotomies after the jejuno-jejunal anastomosis

Figure 19. Running suture to close the enterotomies after the jejuno-jejunal anastomosis (continued).

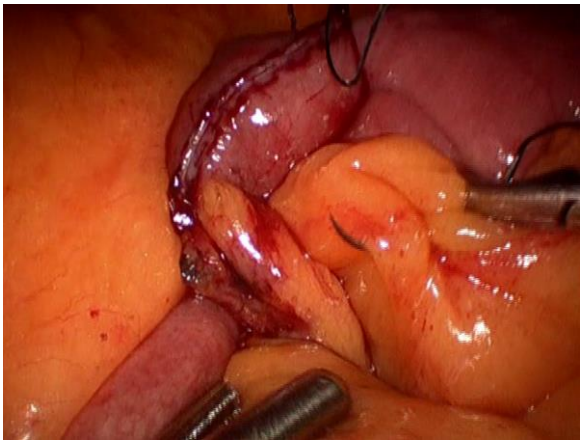

Figure 20. Optional closure of the mesenteric defect.

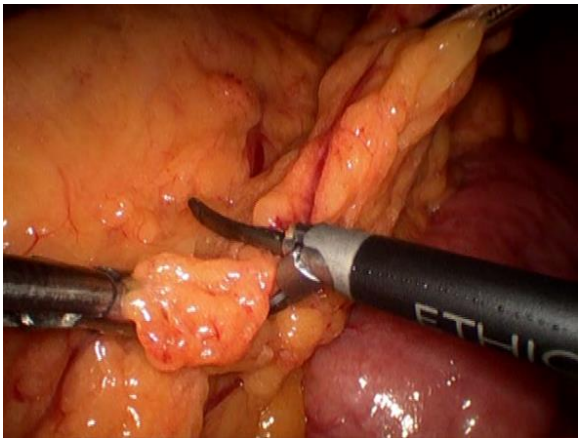

Figure 21. Split of the omentum.

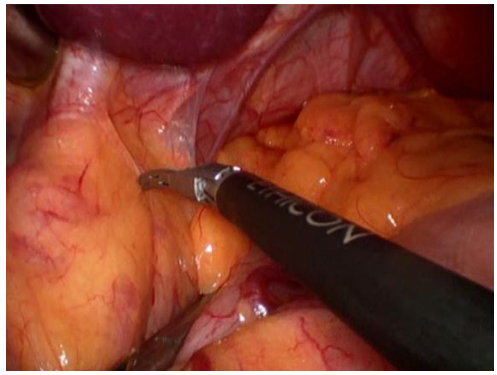

Figure 22. Identification of the angle of His.

e) Identification of Angle of His

The dissection begins identifying the angle of His, taking down the fat patch at the upper part of the fundus. An important trick is to visualize the left crura of the diaphragm. Once the crura is identified, a gauze is placed between the fundus and spleen. The mobilization of the fat patch provides an adequate exposure of this area for optimal stapling and transecting of the stomach. Any hiatal hernias should be addressed at this time and repaired in a posterior fashion (Figures 22, 23).

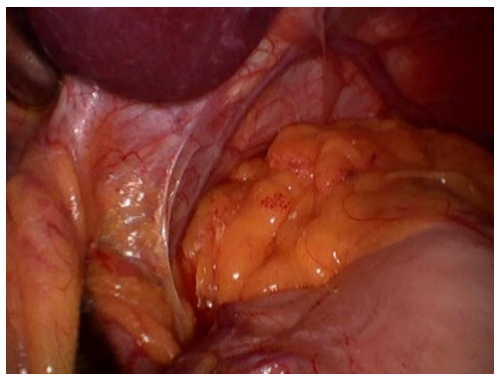

Figure 23. Identification of the left crura.

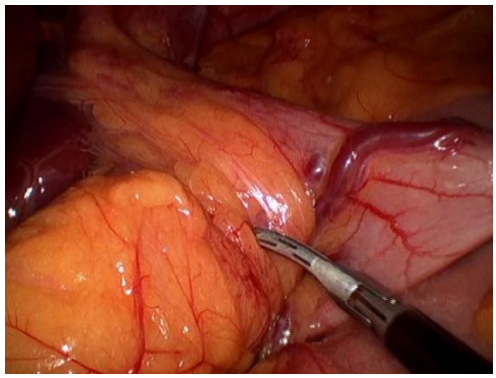

Figure 24. Opening of a window in the lesser curvature.

f) Creation of the Gastric Pouch

Using the harmonic device, a window must be opened in the lesser curvature of the stomach 5-6 cm distal to the esofagogastric junction (Figures 24, 25). Retrogastric adhesions must be freed in order to get into the epiploic transcavity (Figure 26). Once getting into the transcavity a horizontally stapling is performed (Figures 27, 28). Then the rest of the retrogastric adhesion must be divided (Figure 29), in order to remove adhesions or fat from the area where the GJA is going to be performed.

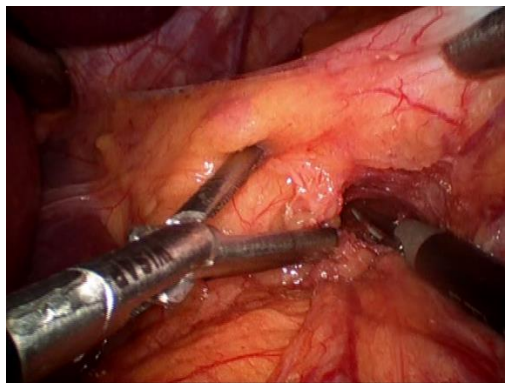

Figure 25. Opening of a window in the lesser curvature (continued).

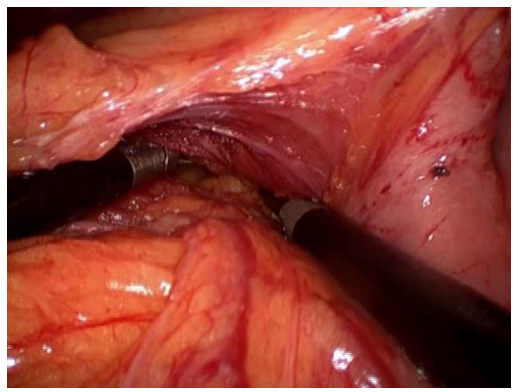

Figure 26. Attempt to enter into the omental transcavity.

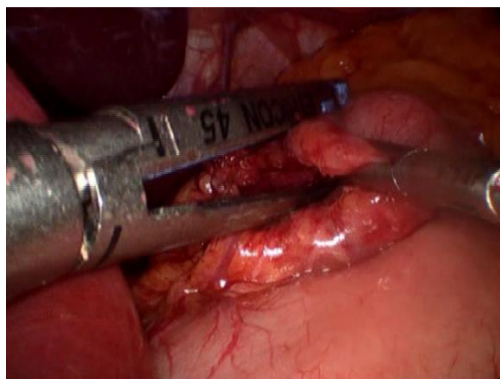

Figure 27. Once entered the transcavity, a horizontal stapling is performed.

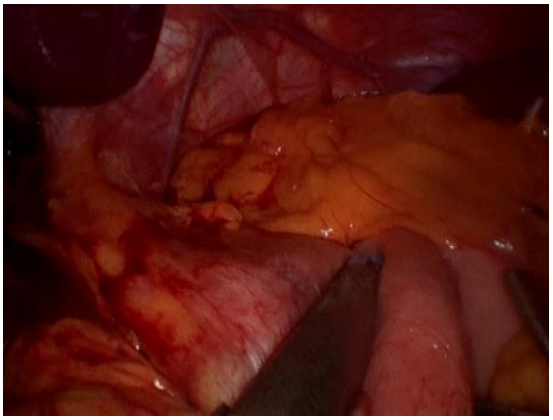

Figure 28. Once entered the transcavity, a horizontal stapling is performed (continued).

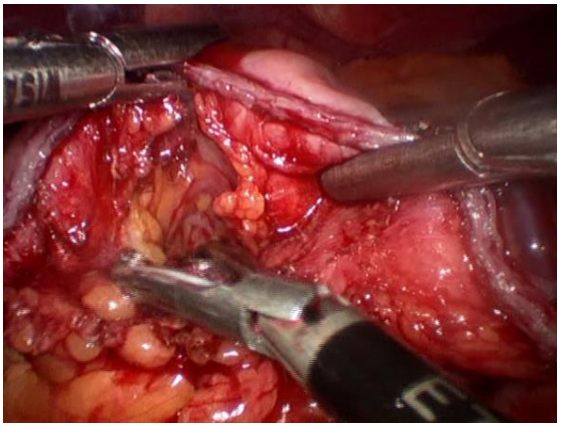

Figure 29. Division of retrogastric adhesions.

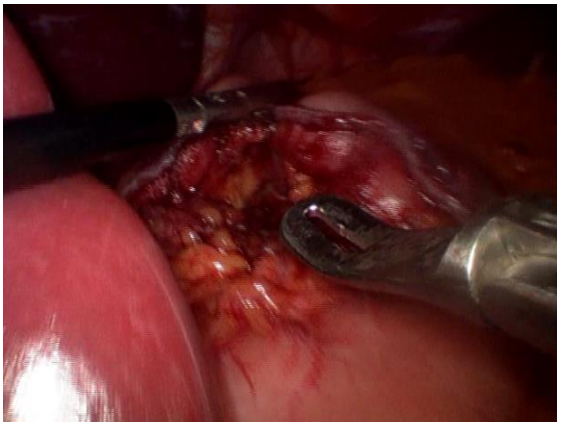

Figure 30. Goldfinger is a helpful tool that can dissect easily the posterior adhesions of the stomach.

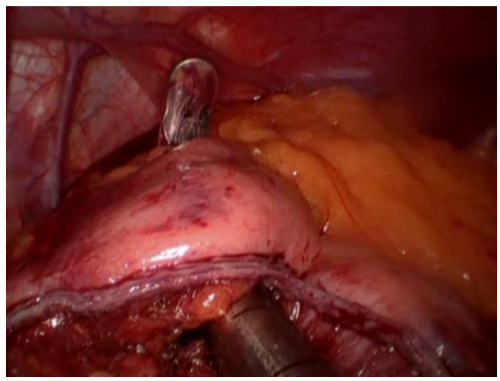

Figure 31. Goldfinger is a helpful tool that can dissect easily the posterior adhesions of the stomach (continued).

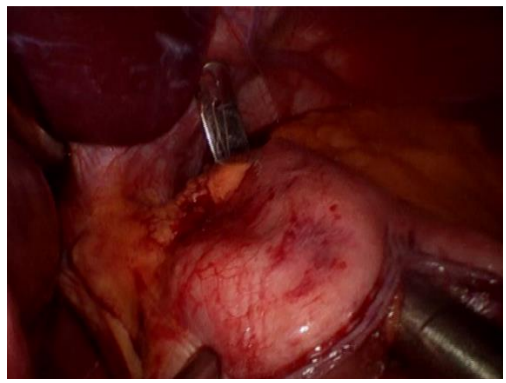

Figure 32. Insertion of the calibration bougie.

The Goldfinger is a helpful tool that can dissect easily the posterior adhesions of the stomach. The second assistant is the one who has to manipulate the instrument and must be extremely aware because of a probable lesion of the spleen (Figures 30, 31).

Once the dissection is completed, a 36-French blunt-tipped bougie tube is slowly advanced under direct visualization (Figure 32). The pouch is confected with 2-3 blue cartridges cranially directed to the angle of His (Figure 33). The Goldfinger is retracted to the left of the patient before firing the stapler in order to avoid leaving too much posterior wall of the gastric pouch (Figure 34).

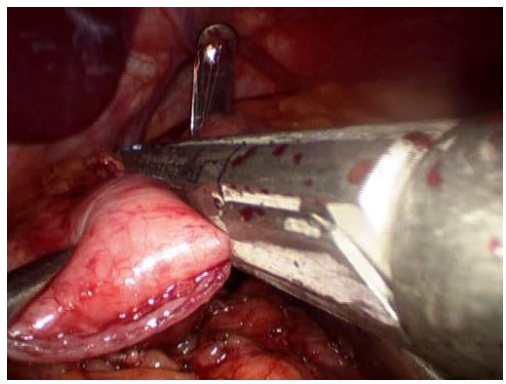

Figure 33. Confection of the pouch with linear stapler.

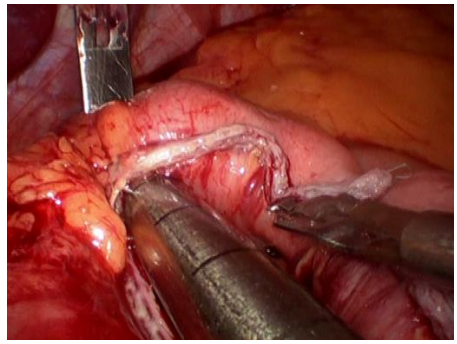

Figure 34. The movement of the Goldfinger to the left prevents from leaving excessive posterior wall of the pouch.

Once finishing the procedure of the gastric pouch, the alimentary limb must be lifted cranially, avoiding a twist of the bowel (Figure 35).

g) Performing the Gastro-Jejunal Anastomosis

A running absorbable monofilament suture 3/0 is made approaching the posterior wall of the alimentary limb and the horizontal staple line of the gastric pouch (Figures 36, 37). After performing the posterior layer of suture, 2 orifices are made in the gastric pouch and the alimentary limb, trying to be conservative with the size of the orifices and that these holes are symmetrically facing in order to avoid twists in the anastomosis (Figures 38-41).

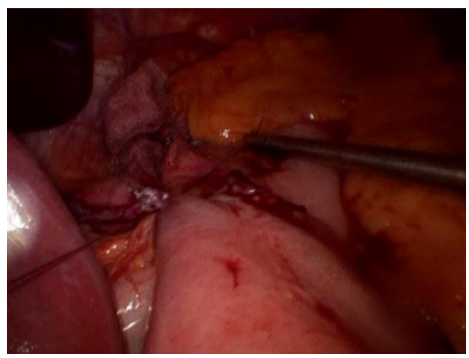

Figure 35. The alimentary limb is lifted cranially.

Figure 36. A running suture is made approaching the posterior wall of the alimentary limb and the horizontal staple line of the gastric pouch.

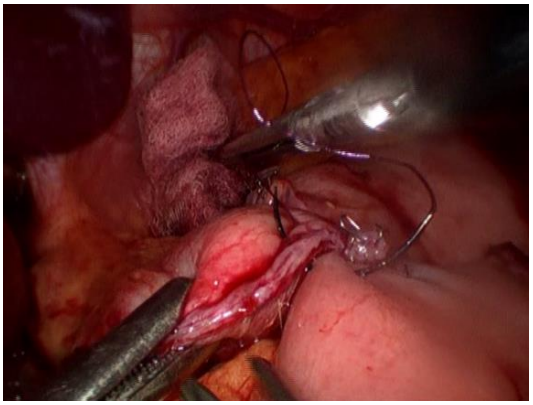

Figure 37. A running suture is made approaching the posterior wall of the alimentary limb and the horizontal staple line of the gastric pouch (continued).

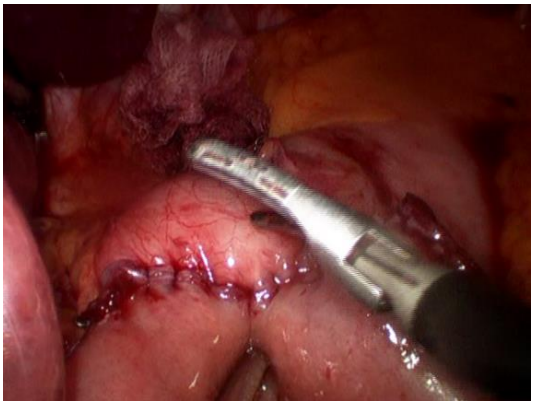

Figure 38. Orifice in the gastric pouch.

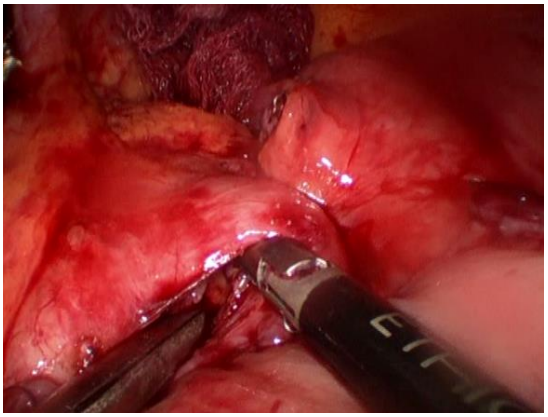

Figure 39. Orifice in the gastric pouch (continued).

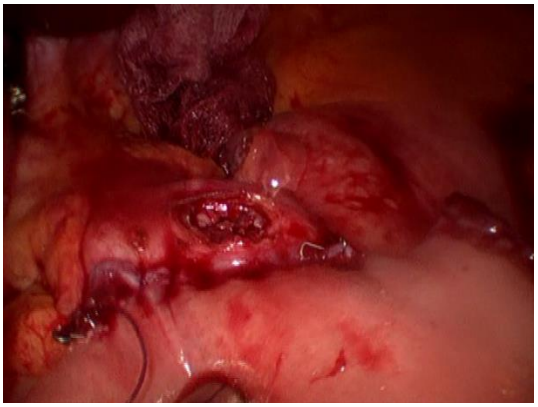

Figure 40. Orifice in the gastric pouch (continued).

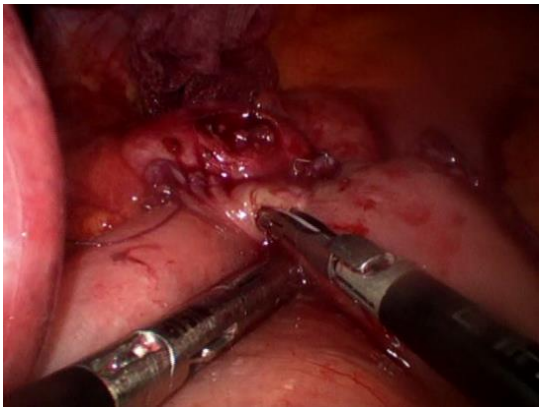

Figure 41. Orifice in the alimentary limb.

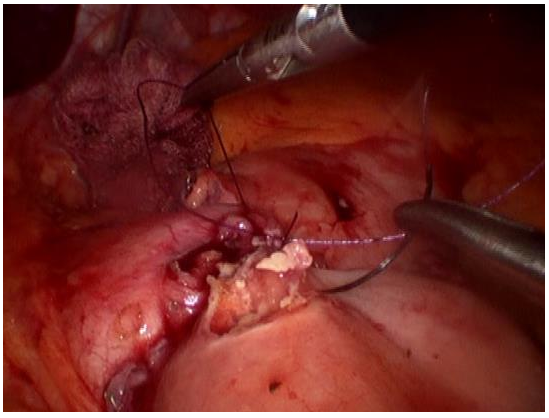

Figure 42. Suture of the second posterior layer of the anastomosis.

The suture of the second posterior layer of the anastomosis begins with a 3/0 re-absorbable suture from lateral to medial direction, avoiding unsutured areas, especially in the vertices. This second posterior suture must include all the layers (serosa, muscular, submucosa and mucosa) (Figures 42-44).

The orogastric tube is then progressed through the future anastomosis through both orifices inside the alimentary limb lumen, to calibrate the final diameter (Figure 45). Subsequently, the suture of the first anterior layer of the anastomosis begins, also in latero-medial direction with 3/0 reabsorbable monofilament material (Figures 46, 47). Finally, it is optional to make a second suture layer on the anterior face with the same suture material (Figure 48).

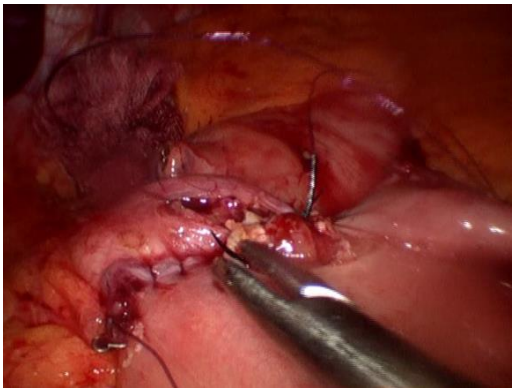

Figure 43. Suture of the second posterior layer of the anastomosis. Transmural and in medial to lateral direction.

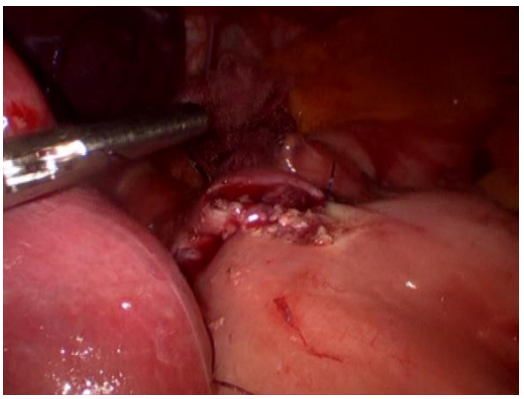

Figure 44. Suture of the second posterior layer of the anastomosis. Transmural and in medial to lateral direction (continued).

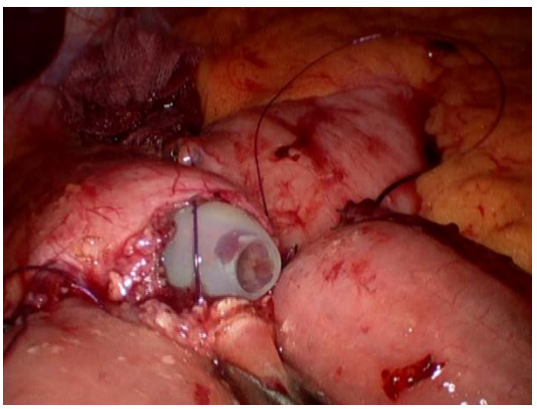

Figure 45. The bougie is progressed through the anastomosis.

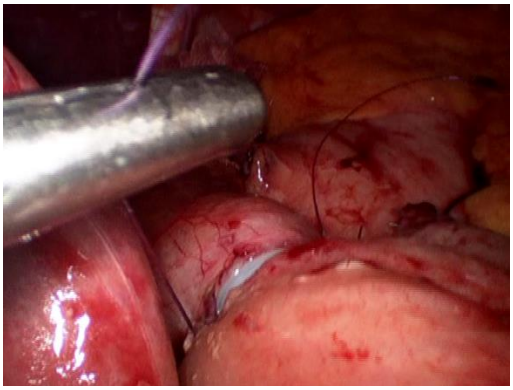

Figure 46. Suture of the first anterior layer of the anastomosis over the bougie.

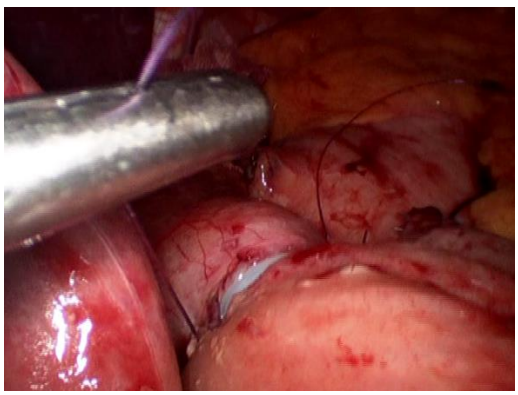

Figure 47. Suture from lateral to medial direction.

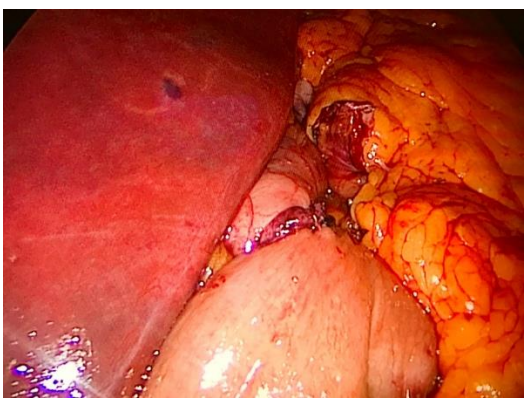

Figure 48. Second anterior layer suture is optional.

h) Checking the Staple Line and Anastomosis Integrity

Once all the procedure is created, intraluminal bleeding in the staple line must be discarded. If bleeding is observed, haemostasia with clips should be performed.

Finally, a methylene blue dye test is performed, excluding any spillage of blue contents into the peritoneal cavity. The orogastric tube is removed after having performed the tightness test.

Surgical drains are not necessary unless there is high concern for bleeding or leak postoperatively.

REFERENCES

[1] Kanerva N, Larsson I, Peltonen M, Lindroos AK, Carlsson LM. Sociodemographic and lifestyle factors as determinants of energy intake and macronutrient composition: a 10-year follow-up after bariatric surgery. *Surg. Obes. Relat. Dis*. 2017; 13(9):1572-1583.

[2] Finks JF, Carlin A, Share D, O'Reilly A, Fan Z, Birkmeyer J, Birkmeyer N. Effect of surgical techniques on clinical outcomes after laparoscopic gastric bypass-results from the Michigan Bariatric Surgery Collaborative. *Surg. Obes. Relat. Dis.* 2011; 7:284-289

[3] Giordano S, Salminen P, Biancari F, Victorzon M. Linear stapler technique may be safer than circular in gastrojejunal anastomosis for laparoscopic Roux-en-Y gastric bypass: a metaanalysis of comparative studies. *Obes. Surg*. 2011; 21:1958-1964.

[4] Jarry J, Wagner T, de Pommerol M, Sa Cunha A, Collet D. Laparoscopic Roux-en-Y gastric bypass: comparison between hand-sewn and mechanical gastrojejunostomy. *Updates Surg*. 2012; 64:25-30.

[5] Kravetz AJ, Reddy S, Murtaza G, Yenumula P. A comparative study of handsewn versus stapled gastrojejunal anastomosis in laparoscopic Roux-en-Y gastric bypass. *Surg. Endosc* 2011; 25:1287-1292.

In: Encyclopedia of Surgery (22 Volume Set)
Editors: Andreas Lehrer and Kristin Mueller
ISBN: 978-1-53618-329-0
© 2020 Nova Science Publishers, Inc

Chapter 299

LAPAROSCOPIC MINI-GASTRIC BYPASS

Dennis Cesar Levano-Linares[1], MD,
Patricia Sanchez Salcedo[2,*], Irene Grao[1], MD,
Manuel Duran Poveda[1], MD, PhD, David Alías Jiménez[1], MD, PhD
and Jaime Ruiz-Tovar[1], MD, PhD
[1]Department of Surgery, Rey Juan Carlos University Hospital, Madrid, Spain
[2]Department of Surgical Nursery, Fundacion Jimenez Diaz, Madrid, Spain

ABSTRACT

Nowadays, laparoscopic Mini-Gastric Bypass (MGB) has become a popular bariatric surgery procedure. MGB is becoming more and more popular as shown by the numerous articles published over the past 15 years, supporting the operation as a short and simple procedure with excellent outcomes and low complication rates. Although this technique seems to be very simple, there is still confusion amongst surgeons. Therefore some important surgical details are essential in order to prevent potential severe complications after surgery. The aim of the chapter is to describe and show our standardize technique basing on different surgical pictures.

Keywords: mini-gastric bypass, surgical procedure

INTRODUCTION

The Laparoscopic Mini-Gastric Bypass (MGB) has become a popular bariatric surgery procedure. Its frequency of performance has increased considerably in the current decade and now is being done as a routine procedure in most countries around the world [1, 2]. MGB was designed to overcome the limitations of RYGB and improve its outcomes. MGB constructs a lesser curvature gastric conduit to or below the "crow's foot" and an anastomosis to an anti-colic loop of jejunum 150-200 cm distal to the Trietz ligament (Figure 1). The MGB was first

* Patricia Sanchez Salcedo, RN.

performed by Rutledge in 1997 [3] in the era of open bariatric surgery and at the dawn of the era of Minimally Invasive Surgery (MIS). The operation is based on sound general surgical principles combining a "non-obstructive" Collis Gastroplasty, which is an esophageal lengthening procedure with a Billroth II ante-colic Loop gastro-jejunostomy. As the medically accurate name (Collis Gastroplasty with Antecolic Billroth II Loop gastro-jejunostomy) was a bit much; and as it was the dawn of the era of MIS, the simple application of these two routine general surgical procedures was named "Mini" Gastric Bypass.

MGB has important technical details like the pouch size, gastro-jejunostomy size and bypass length. When these individual components of the operation are used in different ways, these give different results. There are reports of bypass being used from 150 cm to up to more than 300 cm. MGB gives different results as per the length of the bypass. In addition to this, different surgeons are performing gastrojejunostomy in different ways with different staples varying from 30 mm to 60 mm staple sizes and hand sewn instead of total stapled anastomosis.

Various reports have been published from different parts of the world to document this procedure giving sustained and long-term weight loss comparable to or even better than the classical Roux-en-Y gastric bypass [4]. MGB has only one anastomosis which makes it easy to perform, revise or reverse [5]. There is a growing number of publications supporting this operation to be a short and straightforward procedure with low complication rates and excellent outcomes [6, 7].

MGB addresses many perceived limitations of other procedures and offers many features of an ideal bariatric surgery. It has now been shown in many short- and long-term studies, as well as in many controlled prospective randomized trials, to result in excellent weight loss, good resolution of associated medical illness and very high levels of patient satisfaction [8].

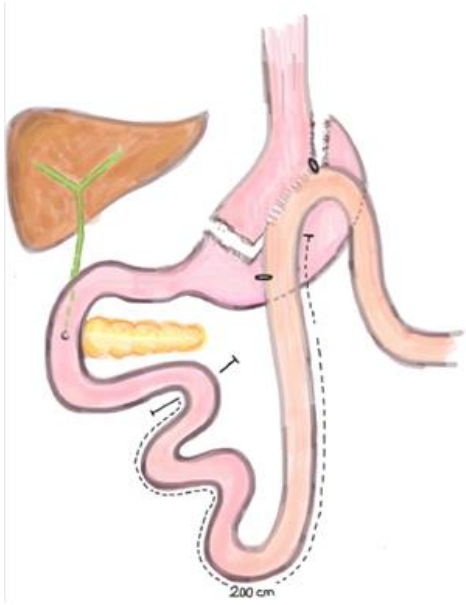

Figure 1. MGB. A vertical channel starting below the crow's foot is stapler-divided proximally going to the left of the angle of His; the long gastric pouch is anastomosed by a wide antecolic gastro-jejunostomy ~200 cm distal to Treitz ligament.

The mechanism of action and the power of MGB is complex and cannot be completely covered here in this technique focused monograph. Suffice to say that a patient survey on over 3,000 of Dr. Rutledge's MGB patients demonstrated a unique non-obstructive restrictive component and a minimal malabsorptive component along with significant fatty food intolerance. Additionally, MGB produces hormonal changes and also affects patient's bile acid pool [9]. Numerous general surgery and bariatric studies show that operations which includes both a gastric and an intestinal component outperforms purely gastric restrictive procedures, like the Gastric Band and Sleeve Gastrectomy [10, 11].

After Rutledge's work, in 2002 Carbajo et al. in Spain (after having performed the RYGB for > 10 years) initiated the OAGB variant of the MGB (the BAGUA—*Bypass Gastrico de Una Anastomosis*) to prevent potential gastroesophageal (GE) reflux [12]. However, after the MGB with its low pressure tube [13], GE reflux has occurred in < 1% and cancer is almost unknown. The MGB and OAGB are followed by superior resolution of co-morbidities, good quality of life, and usual lasting weight loss.

SPECIFIC CONTRAINDICATIONS FOR MGB

1. primary short gut (total small intestine length < 350 cm) or secondary short bowel syndrome (after intestinal resections)
2. Crohn's disease

PREOPERATIVE PREPARATION

The preoperative work-up for bariatric surgery is performed by a multidisciplinary team, including surgeons, endocrinologists, dieticians, gastroenterologists, anesthesiologists and psychiatrists, who combine a medical, nutritional, and endocrinology workup to evaluate potential surgical candidates. The patient follows a strict pre-operative very low-calorie diet (VLCD) as prescribed by our registered nutritionist, preferably for 15 days. The patient follows incentive spirometry exercises and, if need be, pre-operative chest physiotherapy and CPAP/BIPAP non-invasive ventilation.

Anesthesia

An enhanced recovery after surgery (ERAS) programme is followed with an opioid-free anesthesia. Central vein and bladder catheters were not used.

SURGICAL TECHNIQUE

Instrumentation

1. Three 12 mm and one 5 mm ports

2. Nathanson liver retractor
3. 30º scope
4. Harmonic scalpel (Harmonic ACE; Johnson & Johnson)
5. Veress needle
6. Three atraumatic graspers (one of the long size)
7. Suction irrigator
8. Echelon 60 mm (gold and blue cartridges) (Johnson & Johnson)
9. Peristrip-dry
10. Gauzes
11. Clip applicator (optional)

PATIENT, PORT AND SURGEON POSITIONS

a) Positioning of the Patient

The operation is performed with the patient in the supine position with legs open and with 45 degrees inclined position. The attachment of the patient to the surgical table is made by placing two belts (on the abdominal area and below the level of the thighs, respectively). The prevention of thrombotic events is made with use of graduated compression stockings and intermittent pneumatic boots. Urinary bladder catheterization is not used (Figure 2).

Figure 2. Patient initial position.

b) Surgeons Position

The surgeon stands between the legs, with the 1st assistant, who handles the camera and the auxiliary clamp, and the scrub on the right. Monitor is placed on the upper part of the patient for assistant and surgeon view (Figure 3).

Figure 3. Surgeon position.

c) Pneumoperitonium and Placement of the Ports

The pneumoperitoneum is performed by means of a direct puncture with a Veress needle in the left upper quadrant, near the costal margin at the level of the midclavicular line (Palmer's point). The initial pressure is set at 15 mmHg and maintained till the expected pressure (about 15 mmHg) is reached.

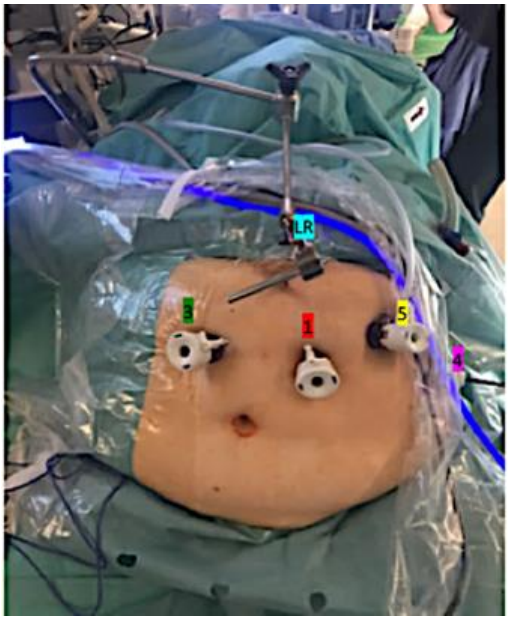

Figure 4. Usual location of ports for the MGB.

The surgery initiates by the placement of the 12 mm permanent trocars for introduction of 30 degrees optics/camera placed at the mesogastrium between 12-15 cm below the xiphoid process and 3 cm to the left of the midline, considered as number 1 trocar. The trocar number 2 of 12 mm is inserted in the epigastrium and then is replaced by a Nathanson liver retractor (LR) that is used to retract the left lobe of the liver. The number 3, disposable of 12 mm, is used by the surgeon's left hand, placed on the right side of the patient in an intermediate position between the previous two, 3-5 cm lateral to the midline. The number 4, also permanent of 5 mm, is placed along the left costal margin in the anterior axillary line to the 1st assistant. The last trocar, number 5, disposable of 12 mm, is placed adjacent to the left costal margin in the hemi-clavicular line to surgeon's right-hand manipulation. The pneumoperitoneum is maintained by trocar number 5 (Figure 4).

PROCEDURE

The operation begins with the dissection of the esophagogastric angle and the opening of the left gastrophrenic ligament with a harmonic scalpel, so as to expose the lateral aspect of the left diaphragmatic crus. Then, the resection of the fat pad of the esophagogastric junction (Belsey's fat) is performed. Then, the surgeon proceeds to open the lesser omentum between the crow's foot (junction of body and antrum of the stomach) and pylorus, next to the insertion of the Latarjet nerve, using a harmonic scalpel until the exposure of the posterior gastric wall (Figures 5-13).

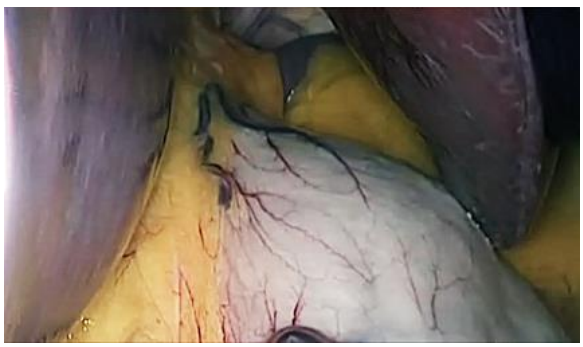

Figure 5. Identification of the angle of His.

Figure 6. Dissection of the fat pad to identify the left crura.

Figure 7. Dissection of the left crura.

Figure 8. Division of phrenoesophageal adhesions.

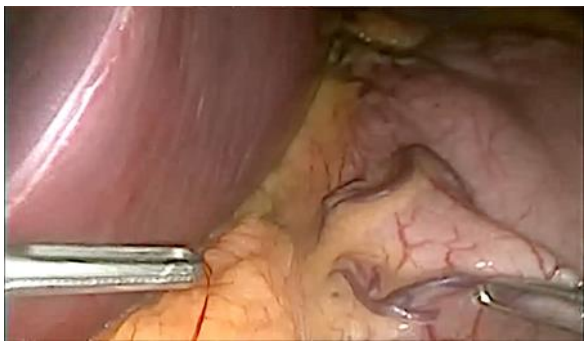

Figure 9. Opening a hole in the lesser curvature to enter the omental transcavity.

Figure 10. Opening a hole in the lesser curvature to enter the omental transcavity (continued).

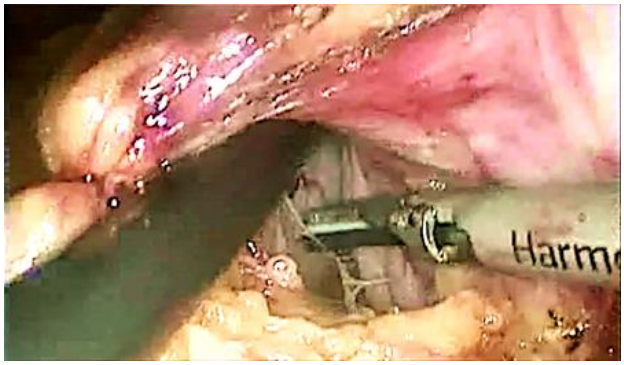

Figure 11. Dissection of retrogastric adhesions.

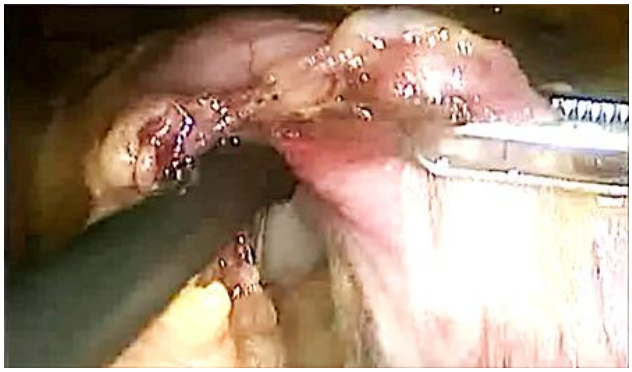

Figure 12. Entrance to the omental transcavity.

Figure 13. Division of retrogastric adhesions.

The gastric pouch must be lengthy and narrow, measuring around 15-18 cm, with a 50-150 ml reservoir capacity. The pouch is created using 01 unit of 60 mm blue cartridges to perform the horizontal section. A gastric calibration tube should be engaged along the lesser curvature of the stomach to guide the vertical section, which will be carry on thanks to 02 to 03 stapler units (Figures 14-21).

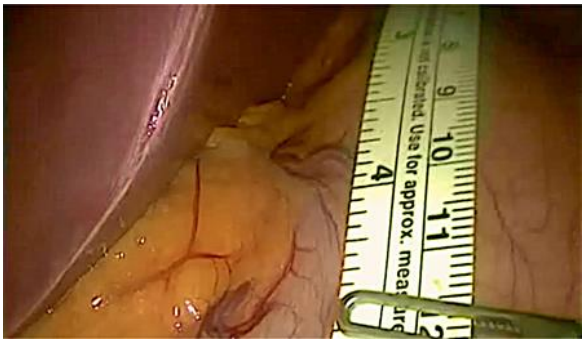

Figure 14. The gastric pouch is measured.

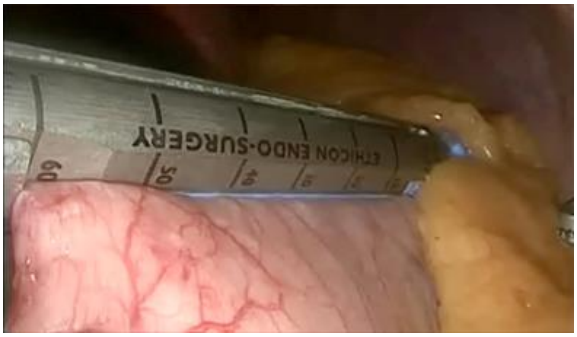

Figure 15. 15cm distally to the hiatus, a horizontal stapling is performed.

Figure 16. Retrogastric adhesions are divided.

Figure 17. A 36-Fr calibration bougie is inserted prior to performing the vertical stapling of the pouch.

Figure 18. Confection of the pouch with vertical staplings.

Figure 19. Confection of the pouch with vertical staplings (continued).

Figure 20. Confection of the pouch with vertical staplings (continued).

Figure 21. Complete separation of the pouch from the gastric remnant.

The Treitz ligament is then identified and the small bowel is counted until 200 cm from the Treitz angle, determining the exclusion of part of the stomach, duodenum, and proximal jejunum from the food pathway. This segment is then attached to the pouch previous section of greater omentum. A vertical or slightly oblique omega-loop, isoperistaltic, antecolic, and side-to-side 25mm-gastrojejunostomy is performed using a 45mm white cartridge; the orifice for the cartridge insertion is closed by means of a continuous suture with 3-0 polydioxanone (Figures 22-33).

Figure 22. Identification of the angle of Treitz.

Figure 23. Measurement of the biliopancreatic limb (200cm).

Figure 24. Division of the greater omentum.

Figure 25. Division of the greater omentum (continued).

Figure 26. Fixation of the biliopancreatic limb to the gastric pouch with a simple stitch, to reduce the tension of the anastomosis.

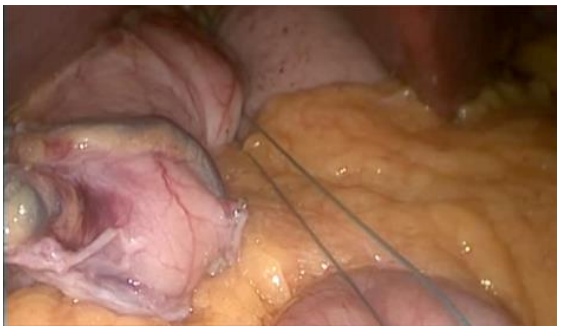

Figure 27. Fixation of the biliopancreatic limb to the gastric pouch with a simple stitch, to reduce the tension of the anastomosis (continued).

Figure 28. Opening of a hole in the pouch.

Figure 29. Enterotomy.

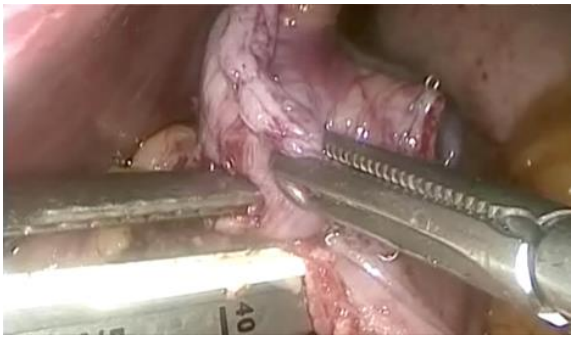

Figure 30. Mechanical linear. Gastroenteral anastomosis.

Figure 31. Closure of the remaining holes with running suture (lateral to medial).

Figure 32. Closure of the remaining holes with running suture.

Figure 33. Finished gastroenteral anastomosis.

Finally, in order to avoid the excess of tension, a stitch between the gastric remnant and the proximal jejunum is performed. Surgical drains are not necessary unless there is high concern for bleeding or leak postoperatively (Figures 34-36).

Figure 34. Stitch between the gastric remnant and the proximal jejunum is performed to reduce tension in anastomosis and prevent from twisting.

Figure 35. Stitch between the gastric remnant and the proximal jejunum is performed to reduce tension in anastomosis and prevent from twisting (continued).

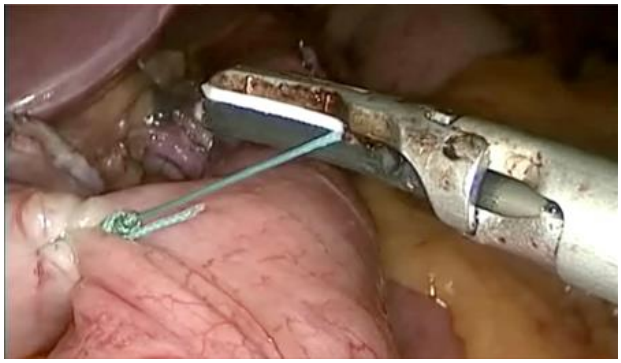

Figure 36. Stitch between the gastric remnant and the proximal jejunum is performed to reduce tension in anastomosis and prevent from twisting (continued).

PRECAUTIONS TO BE TAKEN

1. The gastric pouch should be long and wide.
2. The Initial point of antral division on the lesser curvature of the stomach should be distal to crow's foot, so as to maintain the vascularity of the tip of the gastric pouch, preserving the blood supply arising from the lesser curvature of the stomach, as well as avoiding GE reflux.
   a Adequate channel of the bypassed stomach has to be maintained for the drainage of secreted fluid.
   b Care must be taken to avoid twist in the gastric pouch
   c Perfect hemostasis has to be attained. Energy sources should never be used to achieve hemostasis on the staple-line area.
   d Gastro-jejunostomy should never be less than 25 mm in diameter, maintaining proper alignment of the anastomosis and avoiding twist in the same.

REFERENCES

[1] Kular KS, Manchanda N, Rutledge R. A 6-year experience with 1,054 mini-gastric bypasses-first study from Indian subcontinent. *Obes. Surg.* 2014;24(9):1430-5.

[2] Lee WJ, Ser KH, Lee YC, Tsou JJ, Chen SC, Chen JC. Laparoscopic Roux-en-Y vs. mini-gastric bypass for the treatment of morbid obesity: a 10-year experience. *Obes. Surg.* 2012;22(12):1827-34.

[3] Rutledge R. The mini-gastric bypass: experience with the first 1,274 cases. *Obes. Surg.* 2001;11(3):276-80.

[4] Lee WJ, Yu PJ, Wang W, Chen TC, Wei PL, Huang MT. Laparoscopic Roux-en-Y versus mini-gastric bypass for the treatment of morbid obesity: a prospective randomized controlled clinical trial. *Ann. Surg.* 2005;242(1):20-8.

[5] Almalki OM, Lee WJ, Chen JC, Ser KH, Lee YC, Chen SC. Revisional Gastric Bypass for Failed Restrictive Procedures: Comparison of Single-Anastomosis (Mini-) and Roux-en-Y Gastric Bypass. *Obes. Surg.* 2018;28(4):970-5.

[6] Rutledge R, Walsh TR. Continued excellent results with the mini-gastric bypass: six-year study in 2,410 patients. *Obes. Surg.* 2005;15(9):1304-8.
[7] Noun R, Skaff J, Riachi E, Daher R, Antoun NA, Nasr M. One thousand consecutive mini-gastric bypass: short- and long-term outcome. *Obes. Surg.* 2012;22(5):697-703.
[8] Abdel-Rahim MM, Magdy MM, Mohamad AA. Comparative study between effect of sleeve gastrectomy and mini-gastric bypass on type 2 diabetes mellitus. *Diabetes Metab. Syndr.* 2018;12(6):949-54.
[9] Mika A, Kaska L, Proczko-Stepaniak M, Chomiczewska A, Swierczynski J, Smolenski RT, et al. Evidence That the Length of Bile Loop Determines Serum Bile Acid Concentration and Glycemic Control After Bariatric Surgery. *Obes. Surg.* 2018;28(11):3405-14.
[10] Lee WJ, Almulaifi AM, Tsou JJ, Ser KH, Lee YC, Chen SC. Duodenal-jejunal bypass with sleeve gastrectomy versus the sleeve gastrectomy procedure alone: the role of duodenal exclusion. *Surg. Obes. Relat. Dis.* 2015;11(4):765-70.
[11] Lee WJ, Chong K, Lin YH, Wei JH, Chen SC. Laparoscopic sleeve gastrectomy versus single anastomosis (mini-) gastric bypass for the treatment of type 2 diabetes mellitus: 5-year results of a randomized trial and study of incretin effect. *Obes. Surg.* 2014;24(9):1552-62.
[12] Carbajo MA, Luque-de-León E, Jiménez JM, Ortiz-de-Solórzano J, Pérez-Miranda M, Castro-Alija MJ. Laparoscopic One-Anastomosis Gastric Bypass: Technique, Results, and Long-Term Follow-Up in 1200 Patients. *Obes. Surg.* 2017;27(5):1153-67.
[13] Tolone S, Cristiano S, Savarino E, Lucido FS, Fico DI, Docimo L. Effects of omega-loop bypass on esophagogastric junction function. *Surg. Obes. Relat. Dis.* 2016;12(1):62-9.

In: Encyclopedia of Surgery (22 Volume Set)
Editors: Andreas Lehrer and Kristin Mueller
ISBN: 978-1-53618-329-0
© 2020 Nova Science Publishers, Inc

Chapter 300

LAPAROSCOPIC ONE-ANASTOMOSIS GASTRIC BYPASS (OAGB-BAGUA)

Jaime Ruiz-Tovar[1,*], MD, PhD, Alejandro Garcia[1], MD, Camilo Castellon[1], MD, PhD, Manuel Duran[1], MD, PhD and Carolina Llavero[2,†]

[1]Department of Surgery, Rey Juan Carlos University Hospital, Madrid, Spain
[2]Department of Surgical Nursery, Hospital del Sureste, Madrid, Spain

ABSTRACT

Laparoscopic One-Anastomosis Gastric Bypass (OAGB) is actually the third most-frequent bariatric approach. It has shown an exponential growth during the last decade, based on its easy technique and excellent mid- and long-term results. OAGB-BAGUA appeared as a modification of the Mini-gastric bypass (MGB), aiming to reduce the biliary reflux and measuring the total bowel length, to reduce the risk of malnutrition secondary to an unknown short bowel.

Actually, the IFSO position statement about OAGB established that all the procedures with a single gastro-entero anastomosis must be named as OAGB. Thus, under this acronym are now included MGB, Single-anastomosis gastric bypass, Omega-loop gastric bypass and OAGB-BAGUA. However, the OAGB-BAGUA has a significant difference to the others; it is the only one in which the total bowel length is measured, whereas in the others only the biliopancreatic or the common limb lengths are determined.

Keywords: laparoscopic one-anastomosis bypass, OAGB, BAGUA, surgical technique

[*] Corresponding Author's Email: jruiztovar@gmail.com.
[†] Carolina Llavero, RN.

INTRODUCTION

One-Anastomosis gastric bypass (OAGB-BAGUA) appeared as a modification of the original Mini-Gastric Bypass (MGB). Carbajo developed in 2002 the OAGB-BAGUA aiming to reduce the most frequent complications of MGB (biliary reflux and malnutrition), but preserving the advantages of a single-anastomosis gastroenterostomy. The most important differences between OAGB-BAGUA and MGB are a longer gastric pouch, a calibrated gastroenteroanastomosis at 2.5 cm of diameter (in comparison with 5 cm-wide anastomosis in OAGB), a latero-lateral running suture between the gastric pouch and the biliopancreatic limb (BPL) and the measurement of the total bowel length.

The length of the gastric pouch in OAGB-BAGUA is between 18-20 cm, whereas in the MGB it is around 15cm. The longer the pouch, the lower the risk of biliary reflux reaching the esophagus. The calibration of the anastomosis aims to reduce the biliary reflux from the bowel to the gastric pouch. Moreover, it also reduced the risk of developing Dumping syndrome as it slows the pass of the alimentary bolus to the bowel and consequently reduces the appearance of hormonal peaks. The latero-lateral running suture aims to position the BPL laterally to the gastric pouch, facilitating the pass of its content to the postanastomotic common limb (CL) rather than entering into the gastric pouch. Moreover, it may also reduce the tension on the anastomosis [1-3].

Finally, the measurement of the total bowel length (TBL) is considered by us as a safety issue. The TBL is not a constant among different subjects, ranging between 300 and 800 cm [4]. If we try to establish a technique with constant BPL (like the MGB) or constant CL (like the SAGI), the outcomes will be completely different between patients. If we establish a standard 150-200 cm of BPL like in the MGB and the patient has a TBL of 800 cm, the technique will be unuseful as bariatric approach with a minimal effect on weight loss and probably also on remission of comorbidities. On the other hand, if the patient presents a TBL of 350 cm, he will probably develop a severe malnutrition. Thus, we advocate for measuring the total bowel length and establishing the BPL and CL according to a percentage of TBL. A very aggressive approach, leaving a BPL of 60% of the TBP and a CL of 40% of TBL, with a minimal CL of 200 cm, was initially supported. With this approach mean BMI of 25.1 Kg/m^2 and remission rates of type 2 diabetes (T2D), hypertension and dyslipidemia over 90% after 5 years were obtained. Despite the prevalence of protein malnutrition being very low (0.33%) and there was no need for revisional surgery for this reason, the prevalence of diverse vitamin and mineral deficiencies (iron, vitamin D, vitamin B12,…) was high. Most of these carencies can be satisfactorily managed with oral supplementation. Notwithstanding, we actually may recommend a more conservative approach with a BPL/CL ratio of 50%:50%, leaving at least 250 cm. Our results support that with this ratio, mean BMI was 25.8 Kg/m^2 and remission of comorbidities was very similar to the more aggressive technique, but the supplementation needs were significantly lower [5, 6].

Actually, the IFSO position statement about OAGB [7] established that all the procedures with a single gastro-entero anastomosis must be named as OAGB. Thus, under this acronym are now included MGB, Single-anastomosis gastric bypass, Omega-loop gastric bypass and OAGB-BAGUA. However, these techniques present significant differences between them. Some of them measure the BPL, others the CL [8]. The length of the gastric pouch and the size of the anastomosis are also different. OAGB-BAGUA is the only technique in which the total bowel length is measured.

INDICATIONS FOR OAGB

Indications for OAGB-BAGUA can be considered the following ones:

1. Primary weight loss procedure.
2. Ideal technique for metabolic syndrome patients.
3. Revisional surgery after failure of restrictive procedures

CONTRAINDICATIONS FOR OAGB

1. Total bowel length <350 cm
2. Patients without possibility of follow-up: As in all malabsorptive procedures, a close follow-up is mandatory to rule out nutritional deficiencies and to supplement it accordingly.
3. Inflammatory bowel disease

Relative contraindications can be considered as follows:

1. Active tobacco habit: Increases the risk of anastomotic ulcers
2. Chronic medication intake: The absorption of this drugs cannot be predicted or it can be anarchic
3. Presence of gastroesophageal reflux disease (GERD): Despite several authors defend that OAGB is an excellent therapeutic option for obese patients with GERD, we are a little bit more sceptical with this affirmation. GERD is caused by an incompetent inferior esophagical sphincter, allowing the pass of gastric acid to the esophagus. Despite in OAGB with hiatal hernia the diaphragmatic crus are closed, the sphincter probably still remains incompetent. Thus, it may allow the pass of biliary reflux to the esophagus. In patients with GERD we would rather prefer to perform a Roux-en-Y gastric bypass.

PREOPERATIVE PREPARATION

A multidisciplinary team performed a combined medical, nutritional, and endocrinological work-up to evaluate potential surgical candidates. Preoperative assessment included an analytical evaluation of their metabolic and nutritional status as well as abdominal ultrasound and upper gastrointestinal series. Psychologists undertook additional interviews to evaluate patient's commitment in following guidelines and a strict diet in the postoperative course. A weight loss of at least 10% of the patient's weight was considered an indispensable preoperative condition to undergo the bariatric approach. Therefore, a dietician established a low-calorie diet according to individual needs of each patient and nutritional hypocaloric hyperproteic formulas as their sole nutrition during 2 weeks before surgery. Patients received clear information about potential perioperative complications, as well as precise postoperative guidelines, required nutritional supplementation, and inherent consequences of not following them.

SURGICAL TECHNIQUE

Instrumentation

The following surgical material is necessary to perform this technique:

1. Two 12 mm, one 11 mm and three 5 mm ports
2. Liver retractor
3. 30° scope
4. Harmonic scalpel
5. Veress needle
6. Three atraumatic graspers
7. Suction-irrigator
8. Needle-gripper
9. Absorbable suture 2/0 monofilament (barbed sutures if available)
10. Endostapler (5-6 cartridges)
11. Gauzes
12. Rubber band
13. Clip applicator (optional)

PATIENT, PORT AND SURGEON POSITIONS

a) Patient Position

Patients are placed on an operating table in supine position with open legs and both arms adhered to the trunk. The legs and hips are secured with safety straps to the operating table. Monitor is placed on the upper part of the patient for assistants and surgeon view (Figure 1).

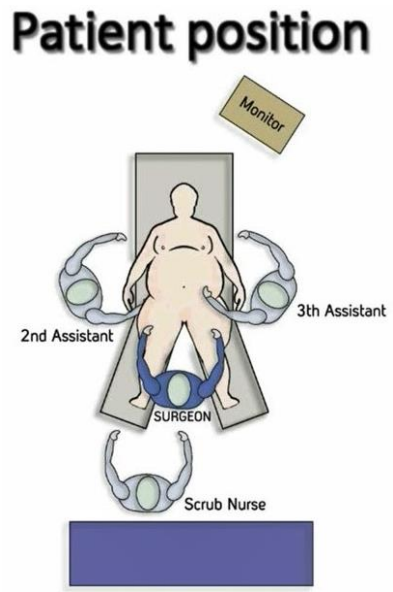

Figure 1. Patient position.

b) Port Position

Pneumoperitoneum to a pressure of 12-14 mmHg is achieved through Veress needle technique at Palmer point. A first 12-mm optical port is inserted at the left flank in the midclavicular line under direct vision. A 10-mm supraumbilical port is placed 15 cm caudal to the xiphoid apophisis slightly bleached to the left of the patient, avoiding inserting it in the line alba. A second 12-mm port is inserted at the right flank in the right midclavicular line. Two 5-mm ports are placed at right and left hypochondria in the anterior axillary lines. Finally, a third 5-mm port is inserted in right iliac fossa (Figures 2 and 3).

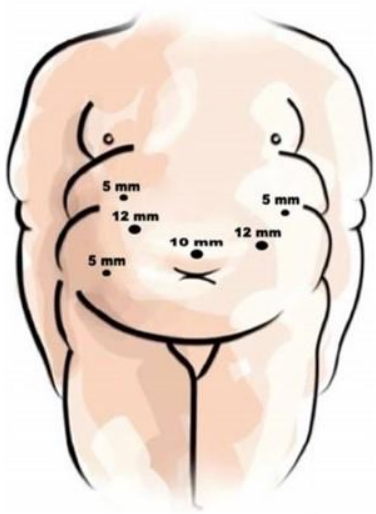

Figure 2. Ports position scheme.

Figure 3. Ports position.

c) Surgeon Position

We initiate our procedure with small bowel measurement from angle of Treitz to ileocecal valve and record TBL. The operating surgeon stands on the right of the patient. The

first assistant surgeon stands between the legs and the camera (second assistant) is on the left side of the operating surgeon (Figure 4).

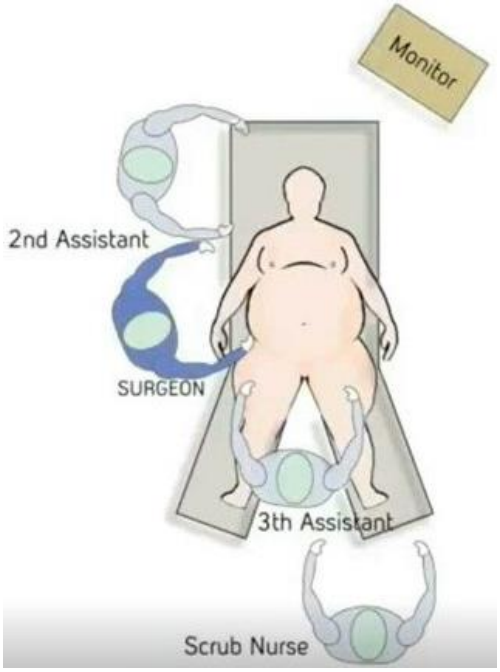

Figure 4. Surgeon position.

Figure 5. Lifting of the greater omentum.

PROCEDURE

a) Bowel Length Measurement

The procedure begins lifting the greater omentum (Figure 5) and identifying the angle of Treitz, in the mesenterium of the transverse colon (Figure 6). The TBL is determined measuring distally from the angle of Treitz angle to the ileocecal valve (Figure 7).

Figure 6. Identification of the angle of Treitz.

Figure 7. Small bowel measurement.

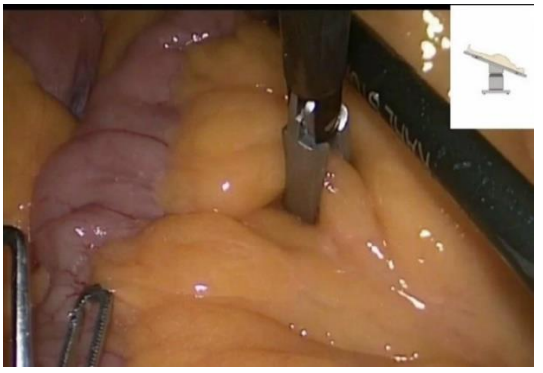

Figure 8. Temporary landmark in the mesenterium at 250 cm of the angle of Treitz.

Figure 9. Measurement of the total bowel length up to the ileocecal valve.

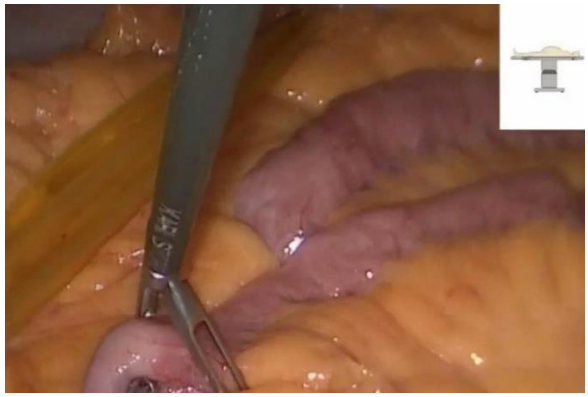

Figure 10. Silicon handle is introduced.

Given that the mean TBL in our patients is around 500 cm, a landmark is temporarily placed at 250 cm from the angle of Treitz, gripping the mesenterium with a grasper (Figure 8).

To continue with further counting of the small bowel up to the ileocecal valve, the patients are moved to Trendelemburg's position (Figure 9).

After having determined the TBL, the site for the anastomosis is decided at a rate of BPL/CL of 50%/50%. A silicon handle is introduced into the abdomen and placed in the decided site for anastomosis (Figure 10). A hole is performed in the mesenterium to introduce the handle, gripping it with a grasper for future elevation of the bowel at the time of performing the anastomosis (Figures 11 and 12).

The correct and tension-free approximation of the selected bowel limb to the incisura angularis of the stomach is corroborated, lifting from the handle cranially (Figure 13).

In case of several tension, the greater omentum is divided to reduce the distance between bowel limb and stomach (Figure 14).

Figure 11. A hole is performed in the mesenterium to introduce the handle.

Figure 12. The silicon handle is introduced through the hole in the mesenterium.

Figure 13. Approximation of the selected bowel limb to the incisura angularis.

Figure 14. Division of the greater omentum.

b) Dissection of Angle of Hiss

After having finished the TBL measurement, the surgeon moves between the legs, the camera assistant reminds on the right side of the patient and the first assistant moves to the left side of the patient. The operating table is now moved to anti-Trendelemburg position (Figure 15). The left lobe of the liver must be retracted using a liver retractor inserted through the 5 mm port placed in right hypochondrium.

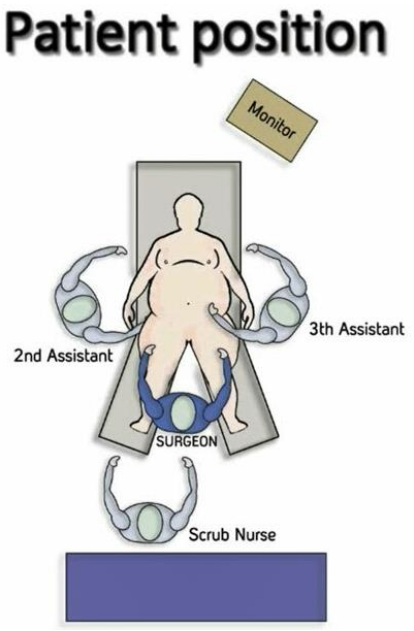

Figure 15. Position of the surgical team for the confection of the gastric pouch and anastomosis.

For the dissection of the angle of Hiss, the first assistant grips the fundus of the stomach with a grasper and pulls it to the left of the patient and downwards (Figure 16). The dissection begins identifying the angle of Hiss, dividing the phreonoesophageal and phrenogastric membranes until obtaining a visualization of the left crura (Figures 17 and 18).

c) Division of the Lesser Omentum

The hepato-gastric ligament is divided from the incisura angularis cranially until visualizing the right diaphragmatic crura (Figure 19). It is important to preserve the hepatic branch of the vagus traversing the lesser omentum, as this nerve has important metabolic effects (Figure 20).

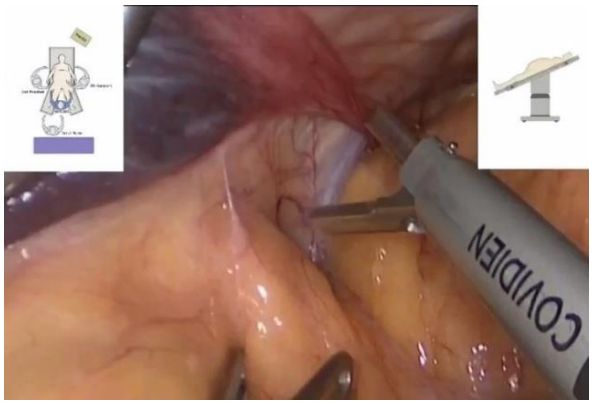

Figure 16. Exposure of the angle of Hiss.

Figure 17. Division of the phreonoesophageal and phrenogastric membranes.

Figure 18. Identification of the left crura.

Figure 19. The hepato-gastric ligament is divided from the incisura angularis cranially.

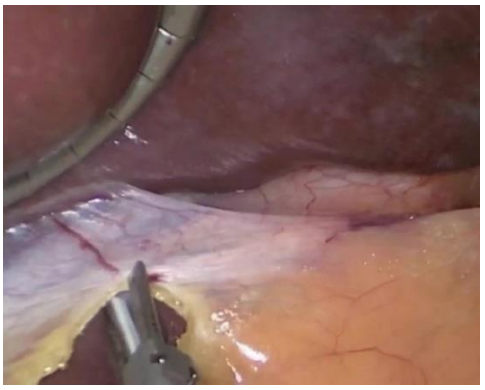

Figure 20. Preservation of the hepatic branch of the vagus.

Once finished the division of the lesser omentum, the anterior part of the phrenoesophageal membrane is divided, in order to allow a better descense of the gastric pouch at the time of performing the anastomosis (Figure 21).

d) Retrogastric Window and Pouch Conformation

The retrogastric window is opened at the level of the inferior branch of the crow's foot (Figure 22). The first assistant pulls from the antrum downwards and the surgeon divides the fat in the lesser curvature until opening a window in the retroperitoneal cavity (Figures 23 and 24).

The stapler is introduced through this retrogastric window and a first cartridge is used to perform the horizontal division of the stomach. The surgeon introduces the stapler with his left hand through the 12-mm port on the right side of the patient. The right hand of the surgeon lifts the stomach upwards in order to descend 1-2 cm the place of division, consequently obtaining a longer pouch (Figure 25).

Figure 21. Division of the anterior part of the phrenoesophageal membrane.

Figure 22. The retrogastric window is opened at the level of the inferior branch of the crow's foot.

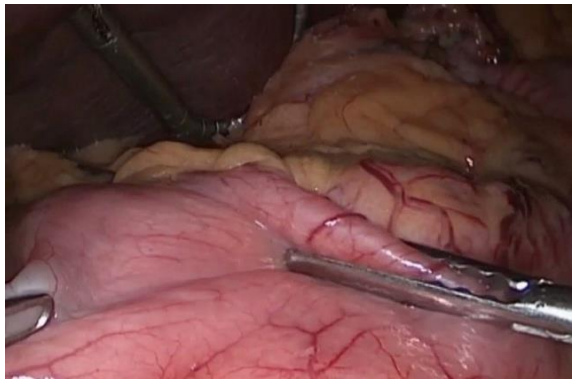

Figure 23. The first assistant pulls from the antrum downwards.

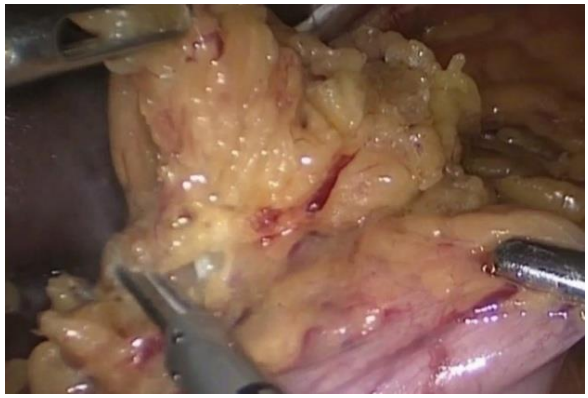

Figure 24. The fat in the lesser curvature is divided until opening a window in the retroperitoneal cavity.

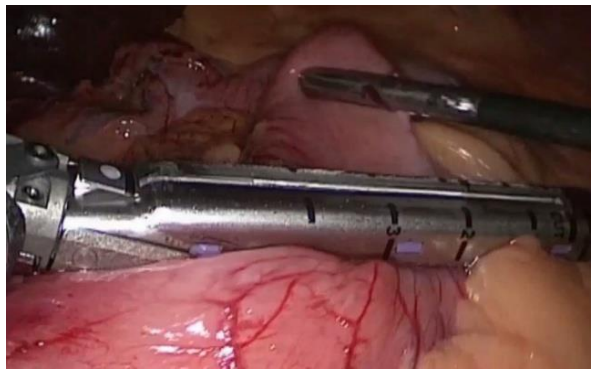

Figure 25. The stapler is introduced through the retrogastric window in the lesser curvature and a first cartridge is used to perform the horizontal division of the stomach.

Then, the surgeon introduces the stapler with his right hand through the 12-mm port on the left side of the patient. The stapler is closed without firing and serves as helpful tool for the correct position of the calibration bougie (Figures 26 and 27). The confection of the pouch is performed with vertical division of the stomach cranially, adjusted to the calibration bougie.

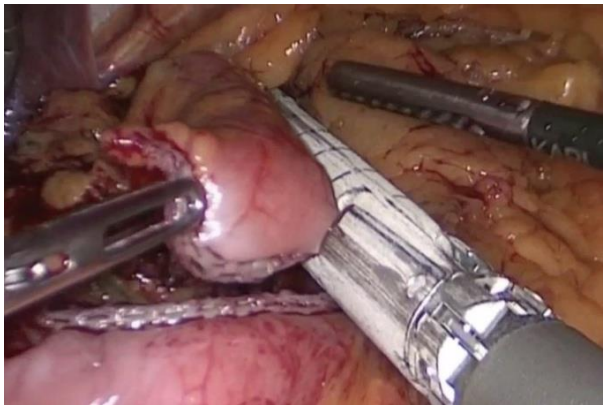

Figure 26. Vertical positioning of the stapler, helping the introduction of the calibration bougie.

Figure 27. Introduction of the calibration bougie.

Three or four cartridges are necessary for the complete transection of the stomach (Figure 28). After the first vertical stapling, the retrograstric fat is divided cranially until reaching an opening window in the angle of Hiss (Figure 29 and 30). The last stapling is performed through the window opened in the angle of Hiss and thereby the section of the stomach is completed (Figures 31 and 32).

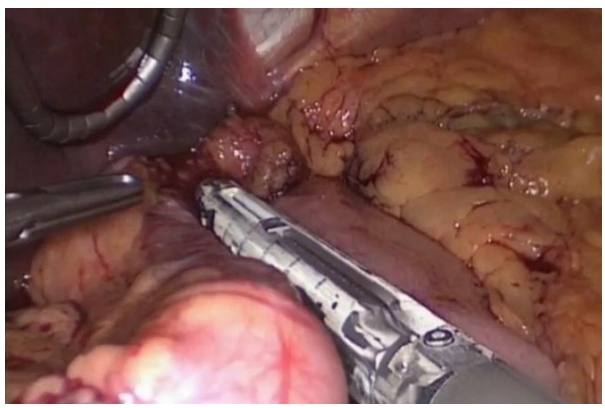

Figure 28. Vertical stapling to construct the gastric pouch.

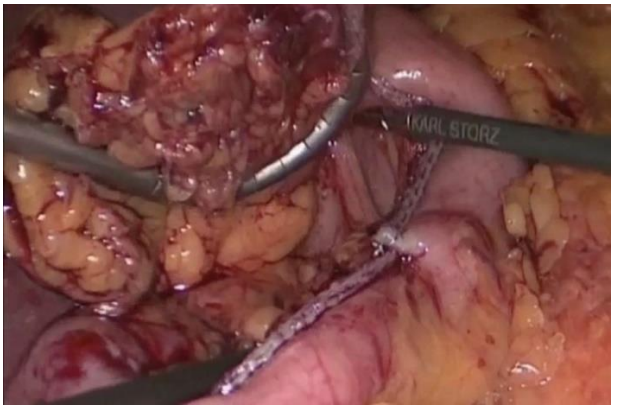

Figure 29. Division of the retrogastric fat.

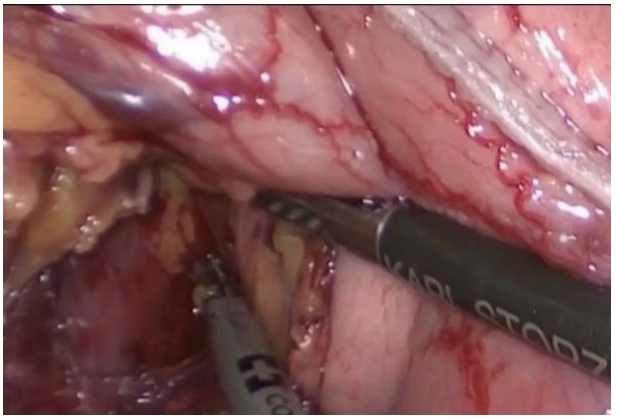

Figure 30. Window in the angle of Hiss, adjacent to the left diaphragmatic crura.

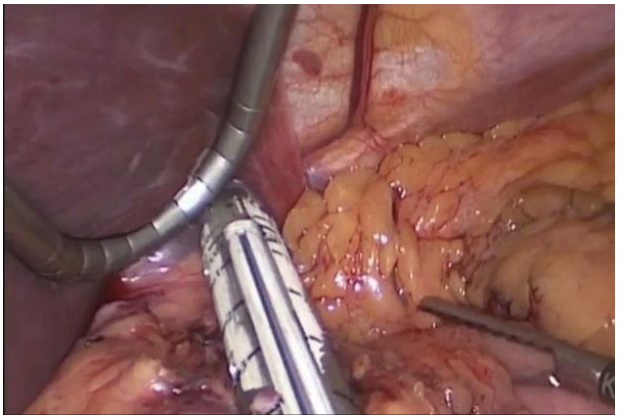

Figure 31. The last stapling is performed through the window opened in the angle of Hiss.

Figure 32. The section of the stomach is completed.

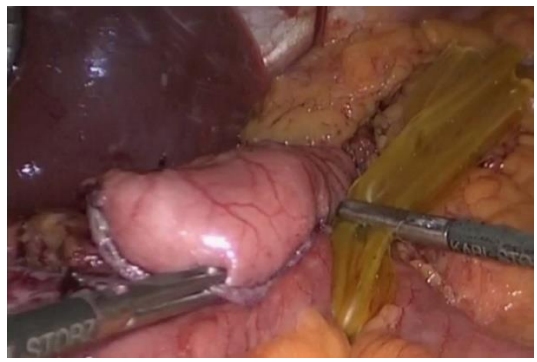

Figure 33. The BP limp is pulled up cranially through the silicon handle.

Figure 34. The running suture begins 8-10 cm cranially from the horizontal staple line (in the middle of the 2nd vertical stapling).

e) Latero-Lateral Gastroenteral Running Suture

Once the confection of the gastric pouch is finished, the next step is the performance of the latero-lateral running suture to attach the BP limb to the lateral face of the gastric pouch. The BP limp is pulled up cranially through the silicon handle (Figure 33). The running suture begins 8-10 cm cranially from the horizontal staple line (Figures 34-36) and continues until to the horizontal staple line (Figures 37-40).

Figure 35. The running suture begins 8-10 cm cranially from the horizontal staple line (in the middle of the 2nd vertical stapling) (continued).

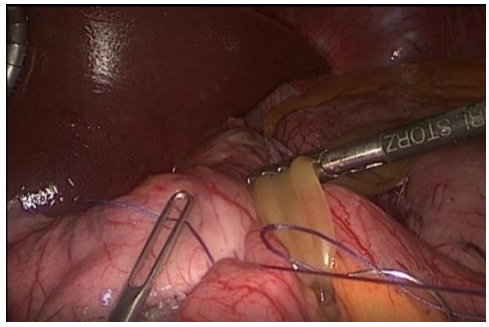

Figure 36. The running suture begins 8-10 cm cranially from the horizontal staple line (in the middle of the 2nd vertical stapling) (continued).

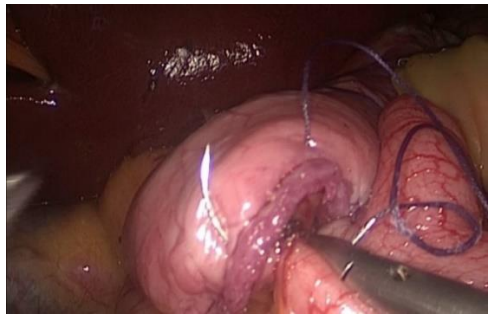

Figure 37. The running suture and continues until to the horizontal staple line.

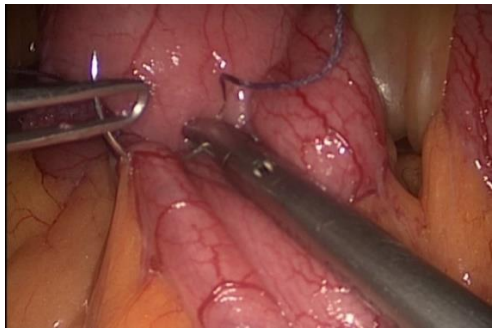

Figure 38. The running suture and continues until to the horizontal staple line.

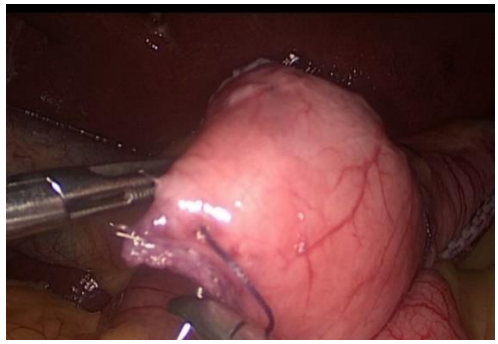

Figure 39. The last stitch in the pouch includes the horizontal staple line.

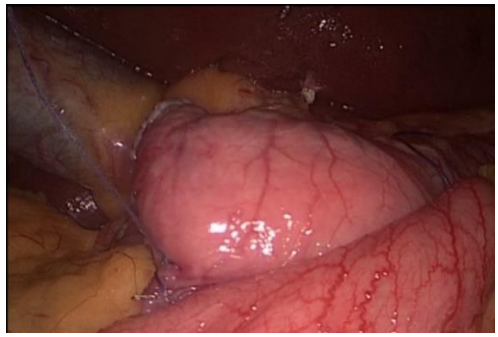

Figure 40. The last stitch in the pouch includes the horizontal staple line (continued).

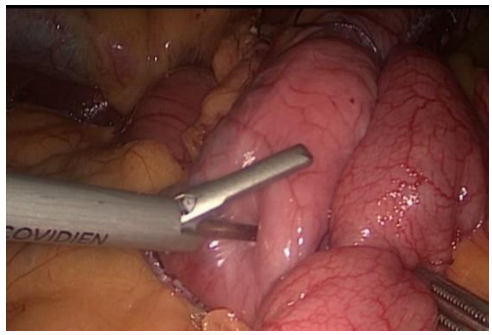

Figure 41. A hole is opened in the anterior face of the gastric pouch with harmonic scalpel.

Figure 42. A hole is opened in the anterior face of the gastric pouch with harmonic scalpel (continued).

f) Anastomosis

Using the harmonic scalpel, a hole is opened in the anterior face of the gastric pouch (Figures 41 and 42) and in the small bowel (Figures 43 and 44).

The stapler is inserted through the holes in the pouch and the bowel. The anastomosis is performed stapling at 25 mm (Figures 45 and 46).

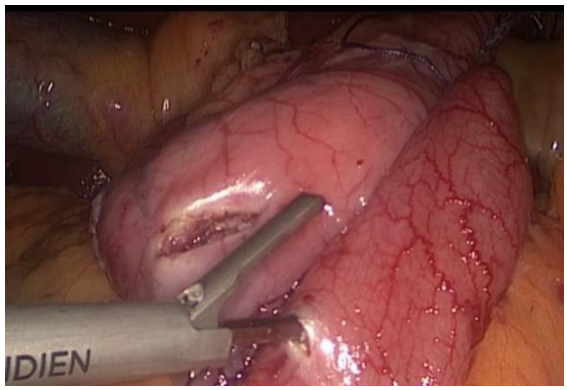

Figure 43. A hole is opened in the small bowel with harmonic scalpel.

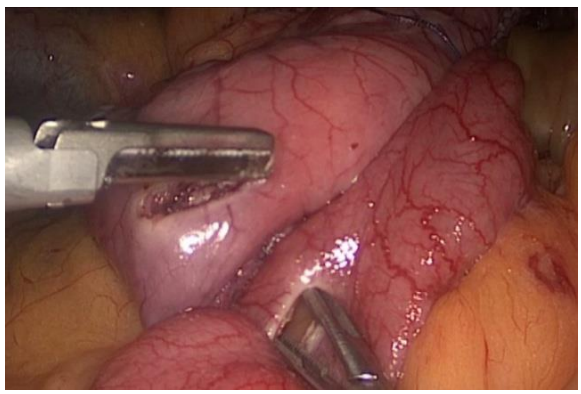

Figure 44. A hole is opened in the small bowel with harmonic scalpel (continued).

Figure 45. The stapler is inserted through the holes in the pouch and the bowel.

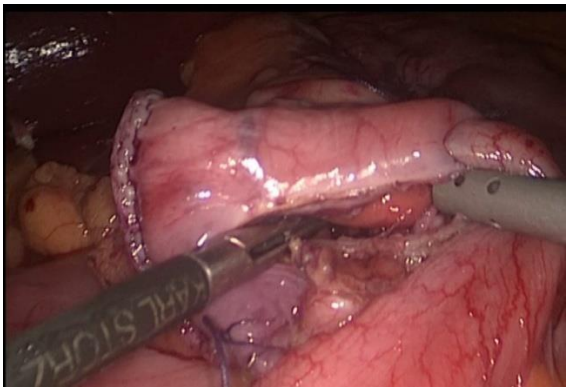

Figure 46. The anastomosis is performed stapling at 25 mm.

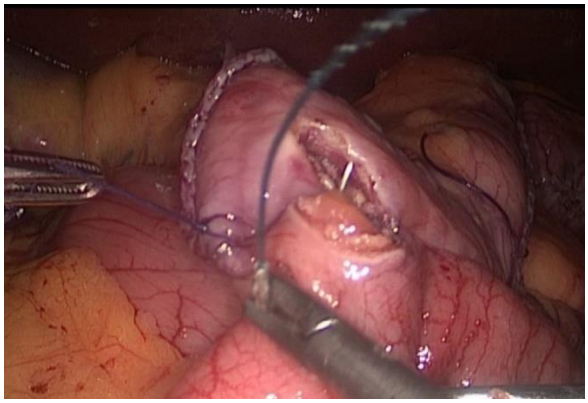

Figure 47. Closure of the anastomotic hole with barbed suture.

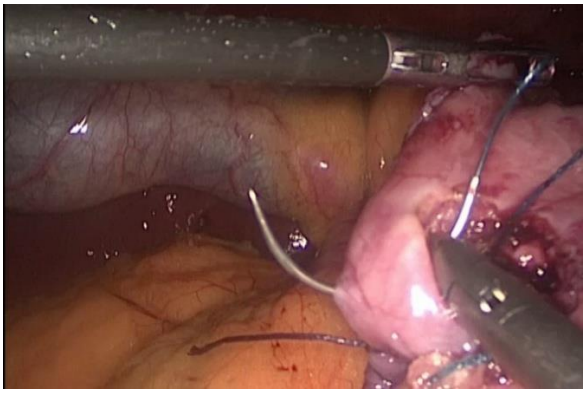

Figure 48. Closure of the anastomotic hole with barbed suture (continued).

The remaining anastomotic hole (entrance of the stapler) is closed with a running suture from distal to proximal (Figures 47-54).

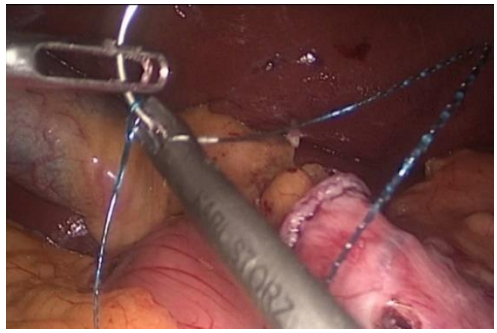

Figure 49. The barbed suture has a loop at the end (knotless suture).

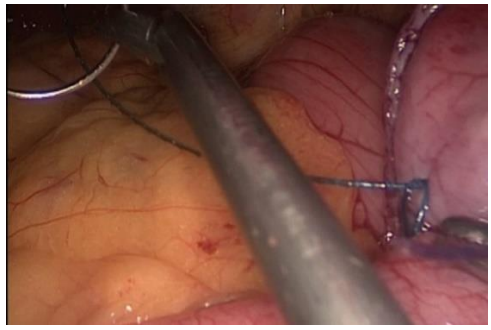

Figure 50. The barbed suture has a loop at the end (knotless suture) (continued).

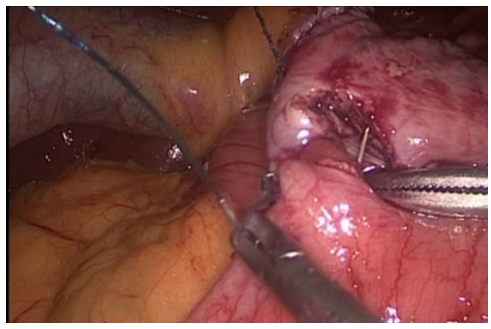

Figure 51. The suture is performed from distal to proximal (left to right), performing the first stitch on the bowel and the second on the pouch.

Figure 52. The suture is performed from distal to proximal, performing the first stitch on the bowel and the second on the pouch (continued).

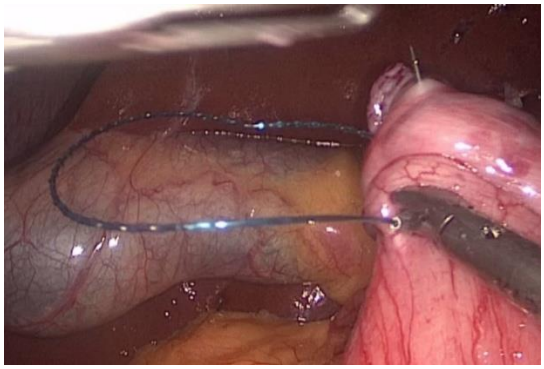

Figure 53. The suture is performed from distal to proximal, performing the first stitch on the bowel and the second on the pouch (continued).

Figure 54. The barbed suture does not require a knot at the end of the suture.

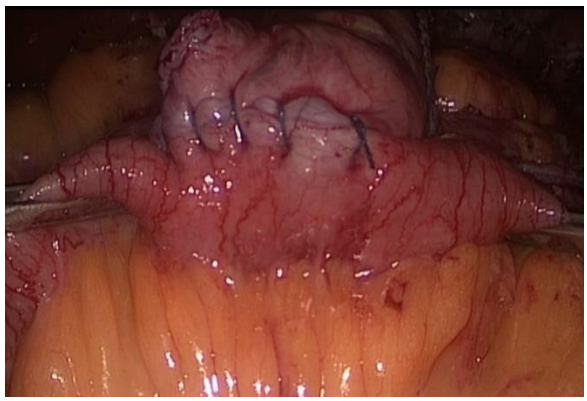

Figure 55. The bowel is clamped proximally and distally to the anastomosis and methylene blue dye is applied through the calibration bougie, in order to rule out anastomotic leaks.

The bowel is clamped proximally and distally to the anastomosis and methylene blue dye is applied through the calibration bougie, in order to rule out anastomotic leaks (Figure 55). The orogastric tube is removed after having performed the tightness test.

Surgical drains are not necessary unless there is high concern for bleeding or leak postoperatively.

REFERENCES

[1] Carbajo MA, Luque-de-Leon E, Jimenez JM, et al. Laparoscopic One-anastomosis gastric bypass: Technique, results and long-term follow-up in 1200 patients. *Obes. Surg*. 2017;27:1153-1167.

[2] Carbajo MA, Castro MJ, Kleinfinger S, et al. Effects of a balanced energy and high protein formula diet (Vegestart complet®) vs. low-calorie regular diet in morbid obese patients prior to bariatric surgery (laparoscopic single anastomosis gastric bypass): a prospective, double-blind randomized study. *Nutr. Hosp*. 2010; 25:939-948.

[3] Luque-de-Leon E, Carbajo MA. Conversion of One-anastomosis gastric bypass (OAGB) is rarely needed if standard operative techniques are performed. *Obes. Surg*. 2016;26:1588-1591.

[4] Tacchino RM. Bowel length: measurement, predictors and impact on bariatric and metabolic surgery. *Surg. Obes. Relat. Dis*. 2015;11:328-334.

[5] Ruiz-Tovar J, Carbajo MA, Jimenez JM, et al. Long-term follow-up after sleeve gastrectomy versus Roux-en-Y gastric bypass versus one-anastomosis gastric bypass: a prospective randomized comparative study of weight loss and remission of comorbidities. *Surg. Endosc*. 2019; 33: 401-10.

[6] Ruiz-Tovar J, Carbajo MA; Jimenez JM, et al. Are there ideal small bowel limb lengths for One-Anastomosis Gastric Bypass (OAGB) to obtain optimal weight loss and remission of comorbitities, with minimal nutritional deficiencies? *World J. Surg.* 2019; in press.

[7] De Luca M, Himpens J, Angrisani L, et al. A New Concept in Bariatric Surgery. Single Anastomosis Gastro-Ileal bypass (SAGI): Technical Details and Preliminary Results. *Obes. Surg*. 2017;27:143-147.

[8] De Luca M, Tie T, Ooi G, et al. Mini gastric bypass-One anastomosis gastric bypass (MGB-OAGB)-IFSO Position Statement. *Obes. Surg*. 2018;28:1188-1206.

In: Encyclopedia of Surgery (22 Volume Set)
Editors: Andreas Lehrer and Kristin Mueller
ISBN: 978-1-53618-329-0
© 2020 Nova Science Publishers, Inc

Chapter 301

LAPAROSCOPIC DUODENAL SWITCH

Nieves Perez-Climent, MD, Carlos Serra, MD, PhD, Miriam Ortin, MD, Rafael Bou, MD and Aniceto Baltasar, MD, PhD
Hospital de Alcoy, Alicante, Spain

ABSTRACT

The duodenal switch procedure was described by DeMeester and colleagues in 1987 as a surgical solution for primary bile reflux gastritis or to decrease the postgastrectomy symptoms seen in patients after distal gastrectomy and gastroduodenostomy. Despite quite favorable outcomes reported in the literature, BPD-DS procedure has not been spread world-wide. One of the reasons for this is that the procedure is difficult to perform laparoscopically.

In this chapter we aim to describe the laparoscopic technique for duodenal switch.

Keywords: Duodenal switch; Laparoscopic technique

INTRODUCTION

The duodenal switch procedure was described by DeMeester and colleagues in 1987 as a surgical solution for primary bile reflux gastritis or to decrease the postgastrectomy symptoms seen in patients after distal gastrectomy and gastroduodenostomy [1]. In 1988, Hess and Marceau [2] adapted this procedure to the treatment of morbid obesity by adding a 75% longitudinal gastrectomy to reduce gastric capacity and acid production and extending the Roux limb to a length similar to that recommended by Scopinaro to induce fat malabsorption.

Michel Gagner [3] was the first to perform the DS by laparoscopy in September 1999 and Aniceto Baltasar [4] did so in May 2000.

The biliopancreatic diversion with duodenal switch (BPD-DS) combines a sleeve gastrectomy with a duodeno-ileal switch. This results in a restricted caloric intake and diversion of bile and pancreatic secretions to induce fat malabsorption.

Despite quite favorable outcomes reported in the literature, BPD-DS procedure has not been spread world-wide. There are 3 reasons for this. First, there is a perception that its malabsorptive component may be associated with metabolic complications, protein caloric malnutrition, or other nutritional deficiencies. Second, the procedure is longer and technically more demanding than other bariatric operations. Third, the procedure is difficult to perform laparoscopically.

INDICATION

1. As a primary weight loss procedure in patients with BMI >50 and metabolic syndrome.
2. As a second step in super obese (BMI > 50) and super super obese (BMI > 60) patients when maximum weight loss has reached the plateau, one year or one year and a half after the sleeve gastrectomy (SG).
3. In case of weight regain after SG.

PREOPERATIVE PREPARATION

Preoperative management of bariatric patients is performed by a multidisciplinary team that includes surgeons, endocrinologists, dieticians, anesthetists, physiotherapists, and psychiatrists, who combine medical, nutritional, and endocrine workup to evaluate potential surgical candidates.

Preoperative assessment includes abdominal ultrasound, biochemical evaluation of the nutritional status, respiratory physiotherapy and in selected cases polysomnography, upper GI contrast study and esophago-gastro-duodenoscopy.

All bariatric patients follow routine preoperative preparation including antibiotic and acid bronchoaspiration prophylaxis, and are admitted to hospital the afternoon before the surgery.

Anesthesia

Laparoscopic BPD-DS is performed under general anesthesia and endotracheal intubation. The patient is placed in French position with sequential compression stockings, and a special operating table fixation is used routinely.

SURGICAL TECHNIQUE

Instrumentation

1. One 12 mm (endopath), one 10 mm (camera trocar), and four 5 mm trocars
2. Nathanson liver retractor
3. 0º and 30º scope
4. Harmonic scalpel (Harmonic ACE; Johnson & Johnson)
5. Four atraumatic graspers
6. Laparoscopic needle holder
7. Suction irrigator device
8. Echelon 60 mm (gold and blue cartridges) (Johnson & Johnson)
9. Gauzes
10. Clip applicator (optional)
11. Sutures; 2/0 Polypropilene, 3/0 maxon, 2/0 silk

TROCARS AND SURGEONS POSITION

Six supraumbilical ports are routinely inserted. Long trocars are sometimes needed in patients who have a very thick abdominal wall. Usually a 12mm right subcostal trocar is inserted under direct vision four fingertips below the ribs, a 10mm supraumbilical trocar (camera) and four 5mm trocars on the left pararectal, right and left anterior axillary line and subxiphoid position (Figure 1).

Figure 1. Trocar position.

Figure 2. Surgeons' position.

Position of surgeons should vary depending on the step of the procedure. In the first part of the surgery (sleeve gastrectomy) the patient is placed in anti-Trendelemburg position and the surgeon stands between the patient's legs and the assistants stand latererally on the right and left side of the patient. Monitors are placed on the upper part at the head of the patient (Figure 2). Pneumoperitoneum is set to maximum pressure of 15 mmHg.

PROCEDURE

a) Sleeve Gastrectomy Step

We start with a 0 silk percutaneous traction of the round ligament to lift the liver. A Nathanson liver retractor is introduced through a 5mm subxiphoid port to retract the left lobe of the liver and to expose the anterior aspect of the stomach Figures 3-6.

Figure 3. Percutaneous traction of the round ligament to lift the liver.

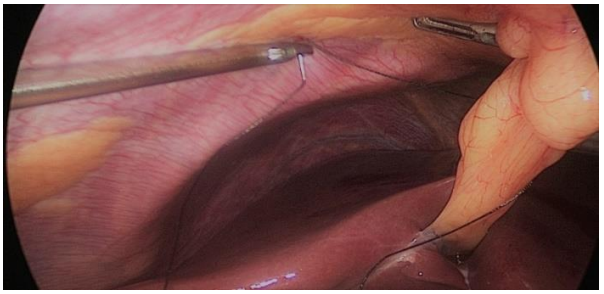

Figure 4. Percutaneous traction of the round ligament to lift the liver (continued).

Figure 5. Percutaneous traction of the round ligament to lift the liver (continued).

Figure 6. Percutaneous traction of the round ligament to lift the liver (continued).

Figure 7. Assistants maintain a gentle traction between the greater curvature and the omentum.

Gastric resection begins by sealing the greater curvature vessels starting at the level of incisura angularis where it is easier to enter into the lesser sac. Once we get into the lesser sac we progress upwards with an ultrasonic dissector (Harmonic-ACE, Ethicon, US). In order to have the best view, assistants maintain a gentle traction between the greater curvature and the omentum.

It is very important to cut all adhesions between the pancreas and the posterior aspect of the stomach.

We continue the fundus liberation until the left crus and the fad pad are both released (Figures 7-14).

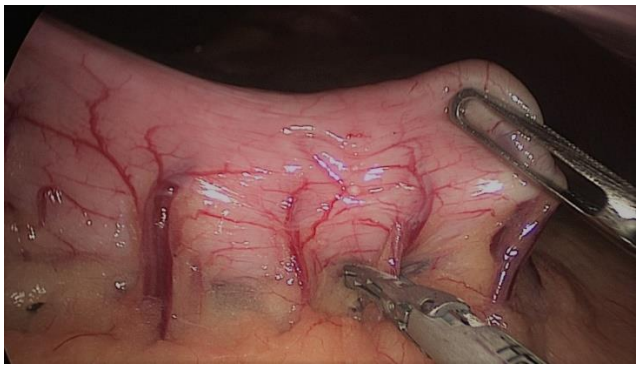

Figure 8. Division of short gastric vessels in the greater curvature.

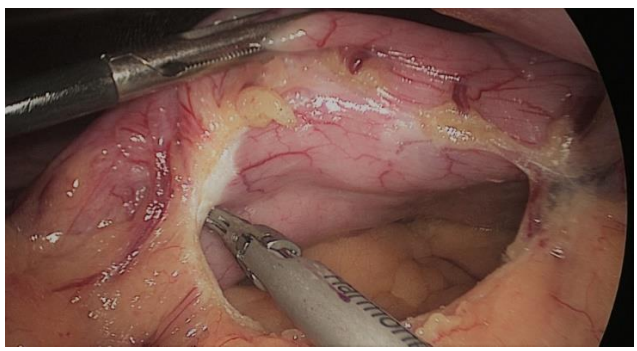

Figure 9. Entrance into the lesser sac.

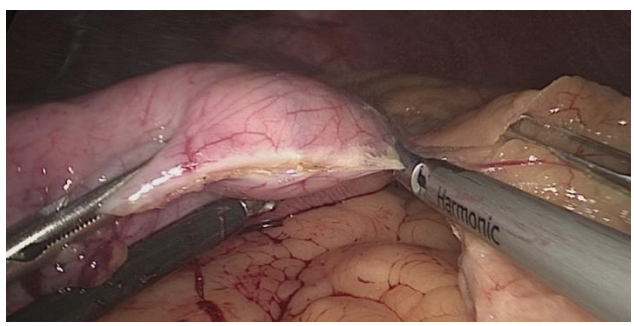

Figure 10. Division of the short gastric vessels cranially.

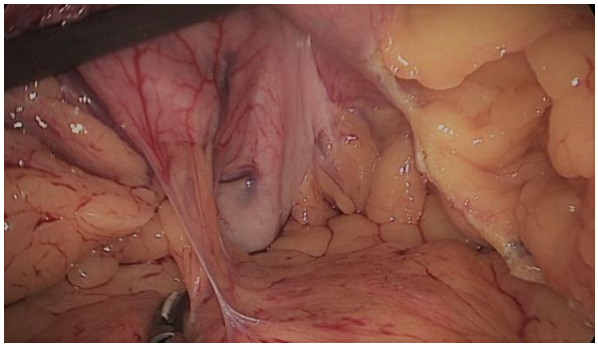

Figure 11. Adhesions between the pancreas and the posterior face of the stomach.

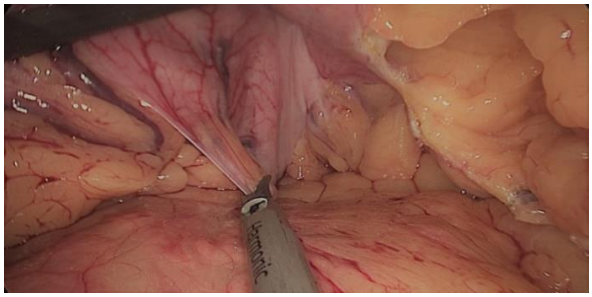

Figure 12. Division of retrogastric adhesions.

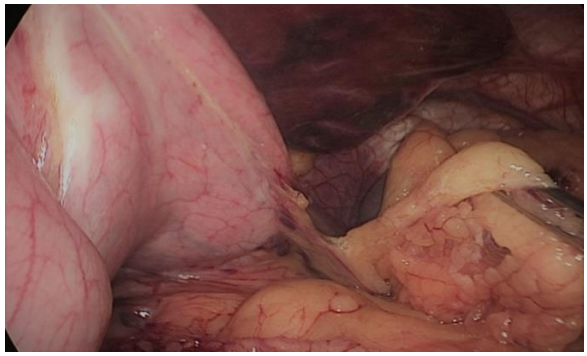

Figure 13. Division of cranial short gastric vessels.

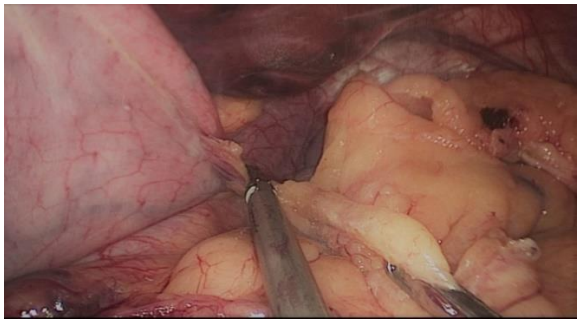

Figure 14. Division of cranial short gastric vessels (continued).

Now is time to pass a 32 french bougie (12mm size) Figure 15.

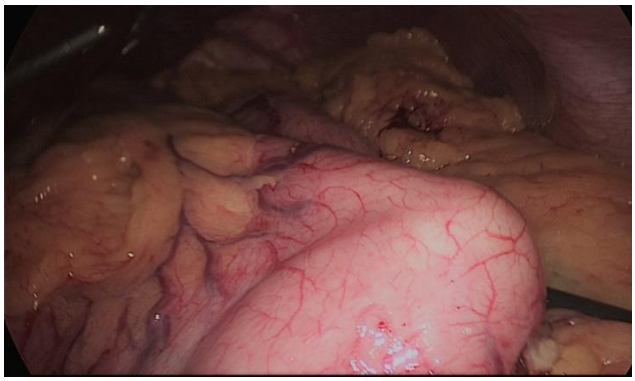

Figure 15. Introduction of calibration bougie.

The assistant on the left side continues downwards from the incisura to the duodenum 2 or 3 cm far from the pylorus. At this point, a retro-duodenal tunnel is created by gentle dissection maneuvers starting from the inferior duodenal margin. The dissection is continued very close to the posterior wall of the duodenum, in a plane superior to the gastroduodenal artery. During this maneuver surgeon and assistants lift the stomach and a little window is created in the superior margin of the duodenum (gastrohepatic ligament) (Figures 16-23)

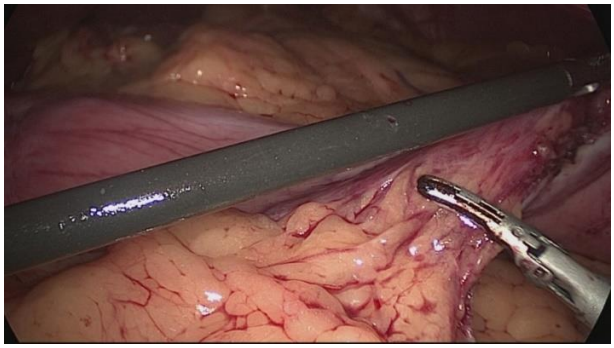

Figure 16. Division of the vessels from the incisura angularis downwards to the duodenum.

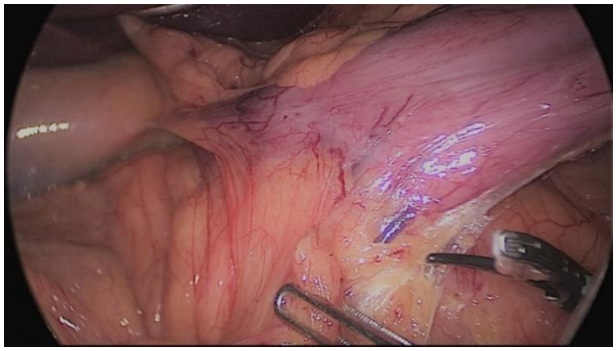

Figure 17. Division of the vessels from the incisura angularis downwards to the duodenum (continued).

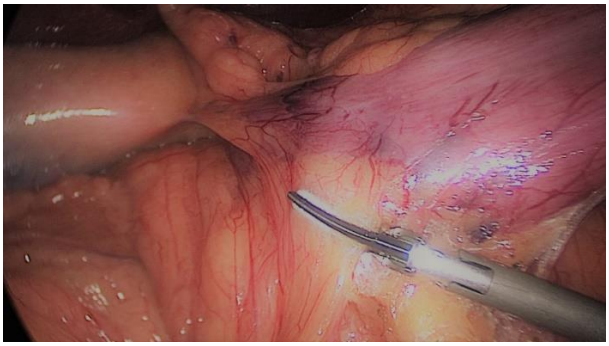

Figure 18. Division of the vessels from the incisura angularis downwards to the duodenum (continued).

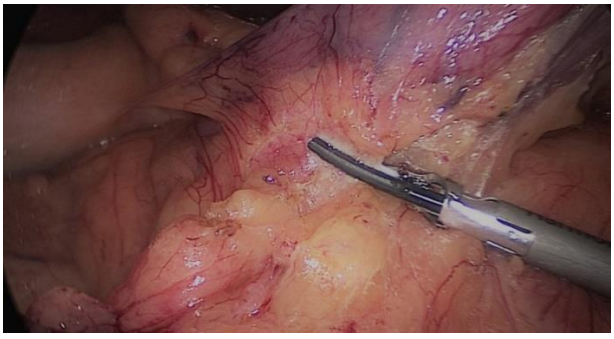

Figure 19. Division of the vessels from the incisura angularis downwards to the duodenum (continued).

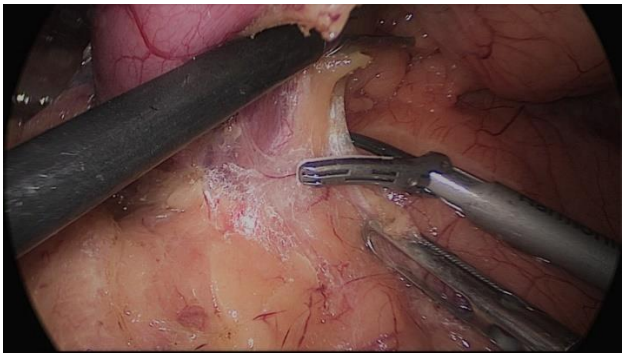

Figure 20. Division of the vessels from the incisura angularis downwards to the duodenum (continued).

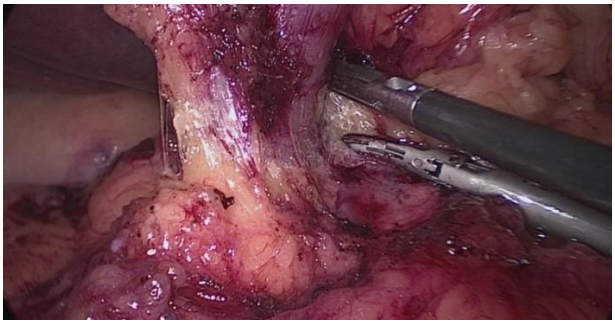

Figure 21. Dissection of the posterior wall of the duodenum.

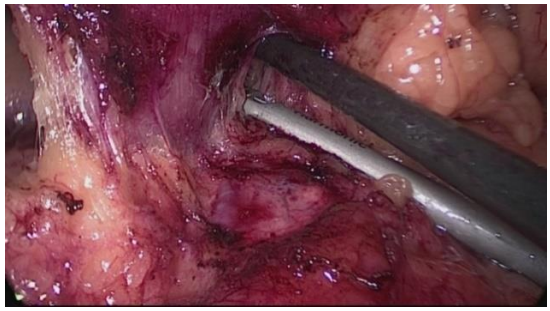

Figure 22. Window is created in the superior margin of the duodenum.

Figure 23. Window is created in the superior margin of the duodenum (continued).

Once we have done the retro-duodenal tunnel, a 60mm endostapler is introduced by the surgeon on the right through the 12mm trocar and pass very gently along the tunnel and the duodenum is divided. The duodenum stapler line is reinforced with a 3/0 Monomax suture[1] (Figures 24-27).

[1] First, we create a sliding self-locking loop at the end of a 3/0 Monomax thread. The needle holder is passed by this loop, and grasps the suture close to the needle before entering the abdominal cavity. We introduce the needle holder by a 12 mm port and start the stitch taking first the omentum and then a sero-serosal stitch high up at the angle of His.

We hold again the suture close to the needle and pass the thread through the sliding loop. Then, the sliding loop and also the knot slide over the suture and this first stitch becomes self-locked with the principles of the Aberdeen knot: the more you pull, the more the knot is locked.

The rest of the suture is a sero-serosal running suture taking the omentum in every stitch and finally an Aberdeen knot ends the suture. We were concerned about the role of the two staples at the end of the thread of our running suture in the development of gastric leaks after LSG. These foreign bodies could be the origin of a hole at the angle of His and, potentially, the cause of the development of a leak at this level. The sliding self-locking first stitch is an easy maneuver that avoids the existence of foreign bodies in a delicate part of the stomach. The aim of this running suture is to stabilize the gastric tube on the one hand and to make hemostasis.

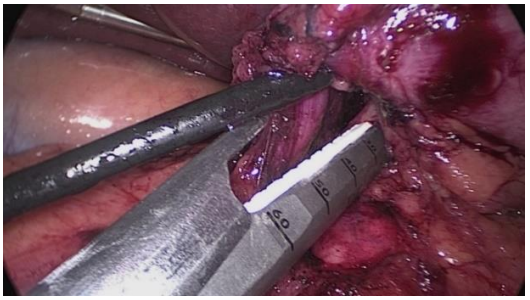

Figure 24. Section of the duodenum with linear stapler.

Figure 25. Section of the duodenum with linear stapler (continued).

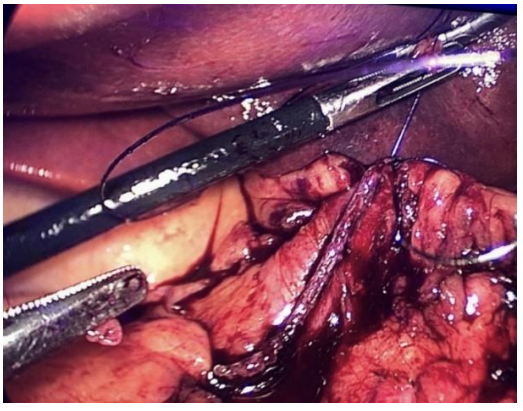

Figure 26. The duodenal staple line is reinforced with a running suture.

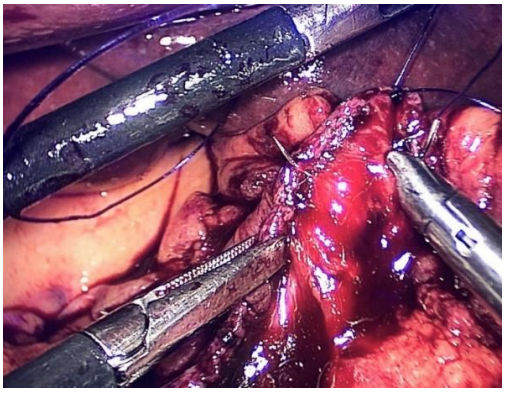

Figure 27. The duodenal staple line is reinforced with a running suture (continued).

The 32-Fr bougie previously inserted is passed through the pylorous into the duodenum. Division of the stomach is started 2 cm above the pylorous, applying a 60mm violet or gold linear stapler inserted through the right side 12 mm port. Before every firing of the stapler the movility of the bougie is mandatory checked. Care must be taken in order to avoid stenosis at the level of the incisura.

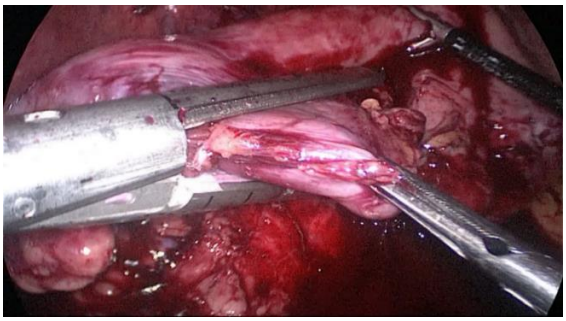

Figure 28. Section of the stomach begins 2cm above the pylorus.

Gastric division progresses all along using 60 mm blue cartridges. At this point it is critical to expose properly the anterior and the posterior aspect of the stomach using lateral traction by the assistant on the left. This prevents a corkscrew shape of the sleeve as well as avoids leaving a large posterior fundus and the risk of postoperative gastroesophageal reflux. A methilene blue dye test is always done to check leaks at the esophagogastric junction and all along the staple line (Figures 28-34).

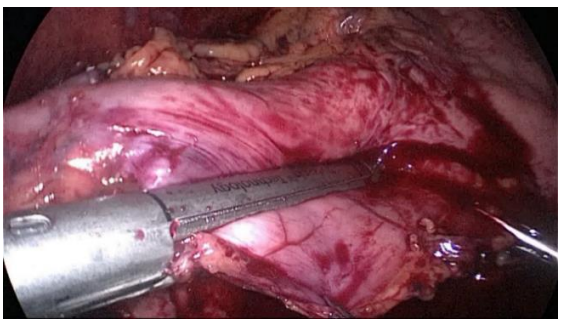

Figure 29. Gastric division progresses along the stomach.

Figure 30. Gastric division progresses along the stomach (continued).

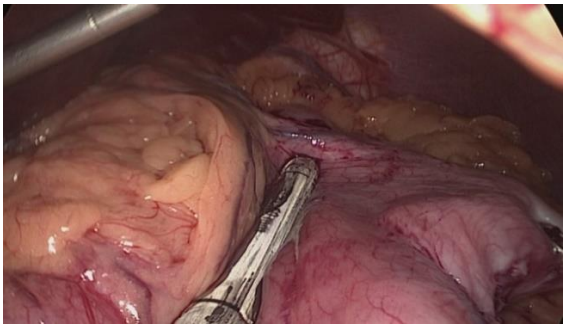

Figure 31. Gastric division progresses along the stomach (continued).

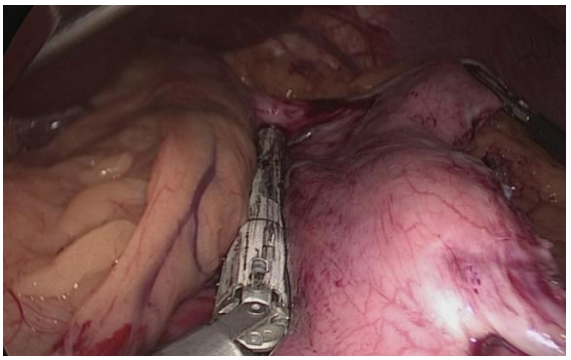

Figure 32. Gastric division progresses along the stomach (continued).

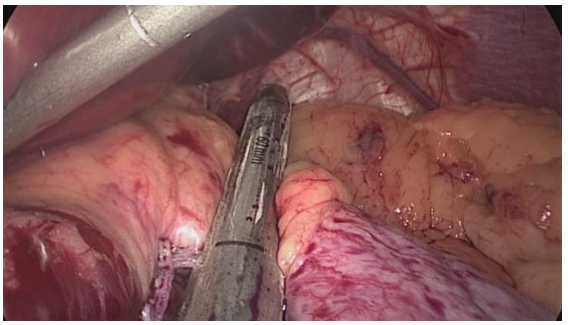

Figure 33. Gastric division progresses along the stomach (continued).

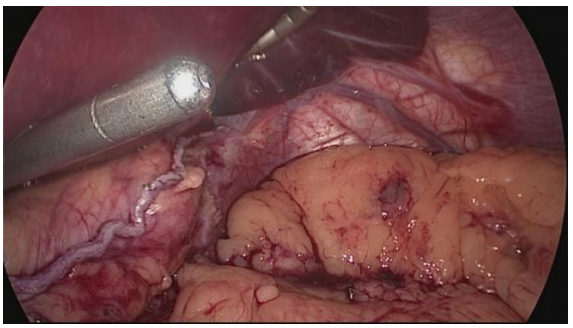

Figure 34. Complete section of the stomach.

The surgeon between the legs reinforces the long gastric stapler line with two 3/0 Monomax running sutures (Figures 35-38).

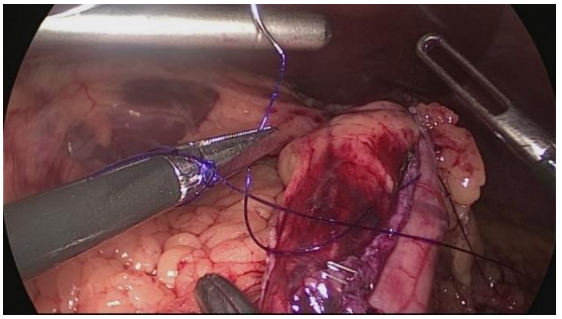

Figure 35. Staple line reinforcement.

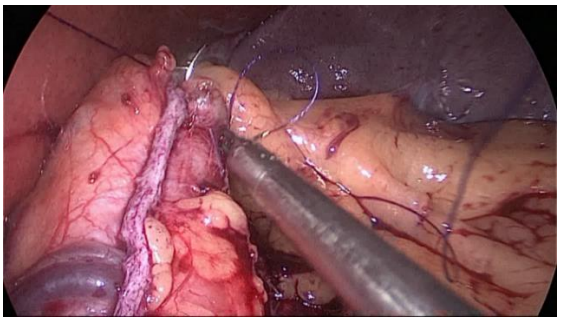

Figure 36. Staple line reinforcement (continued).

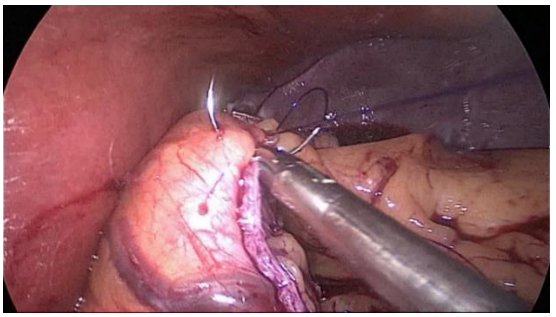

Figure 37. Staple line reinforcement (continued).

Figure 38. Staple line reinforcement (continued).

We finish this part dividing the omentum for an easier and tension-free lifting of the jejunal loop. (Figure 39)

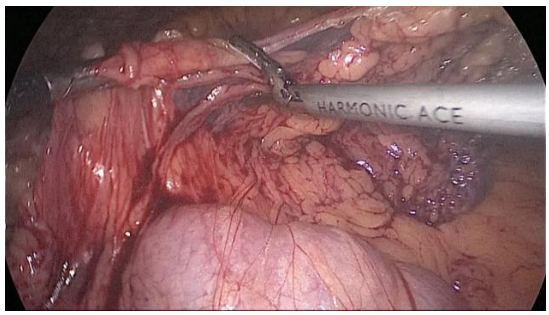

Figure 39. Division of the greater omentum.

b) Biliopancreatic Diversion Step

Patient is changed to Trendelemburg position and the surgeon and the assistants all move to the head of the patient.

Small bowel is measured using atraumatic marked forceps, starting from the ileocecal valve. A 100 cm common channel (CC) is identified and marked using one distal and two proximals clips. Further 250 cm are measured from this level, and a mesenteric window is created with the harmonic scalpel. Small bowel is then transected with a 60mm stapler. The bowel end located on the right (distal ileal end) is moved up supramesocolically becoming the alimentary limb (AL) (Figures 40-47)

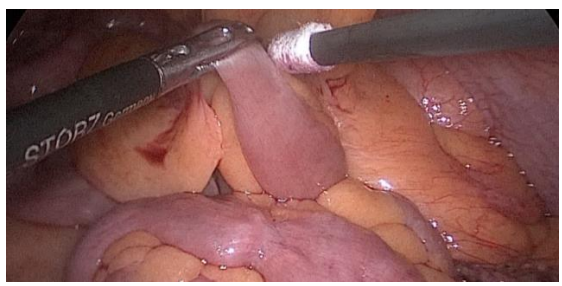

Figure 40. Small bowel is measured using atraumatic marked forceps, starting from the ileocecal valve.

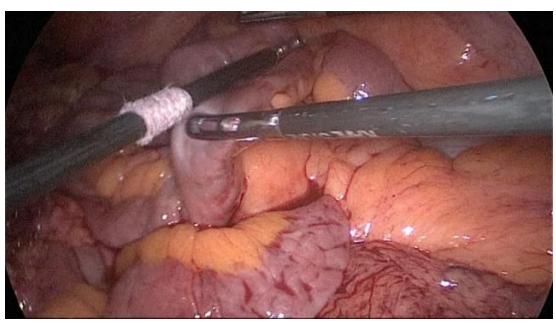

Figure 41. Small bowel is measured using atraumatic marked forceps, starting from the ileocecal valve (continued).

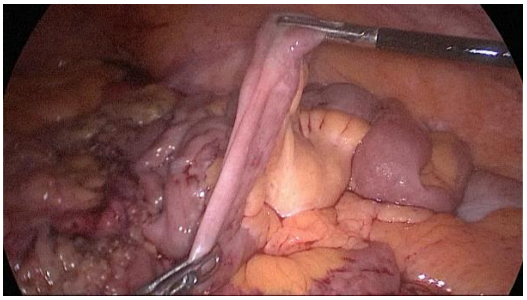

Figure 42. Small bowel is measured using atraumatic marked forceps, starting from the ileocecal valve (continued).

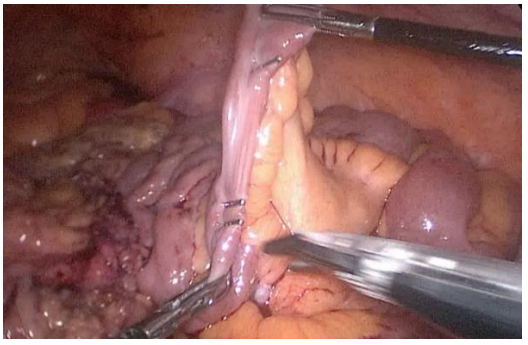

Figure 43. A 100 cm common channel (CC) is identified and marked using one distal and two proximals clips.

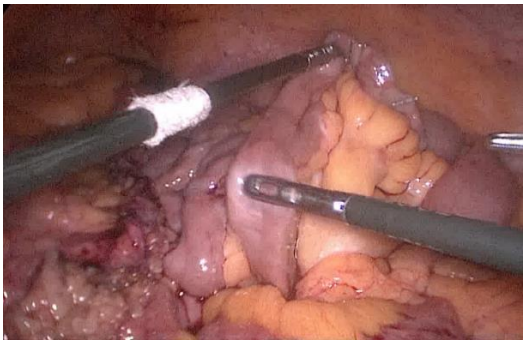

Figure 44. Further 250 cm are measured from this level.

Figure 45. A mesenteric window is created with the harmonic scalpel.

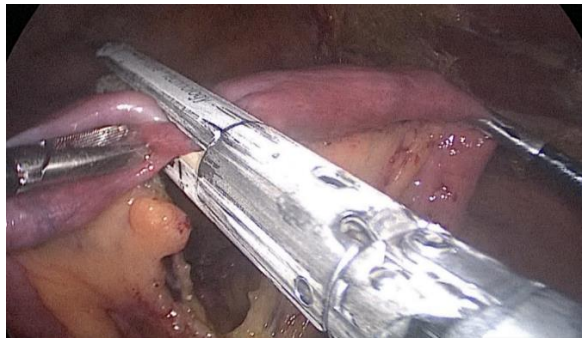

Figure 46. Small bowel is then transected with a 60mm stapler.

Figure 47. The bowel end located on the right (distal ileal end) is moved up supramesocolically becoming the alimentary limb (AL)

The bowel end located on the left (proximal ileal end) will be therefore the biliopancreatic limb (BPL). Next maneuver should be opening the BPL near the stappler line using the harmonic scalpel. Then, the surgeon follows the alimentary limb distally until the previous clips are identified.

A hand sewn termino-lateral anatomosis is done using two threads: one 15 cm. and another 13 cm. long 3/0 Monomax sutures. The long one is used for the posterior layer and the short one for the anterior. The suture is finished by tying both threads.

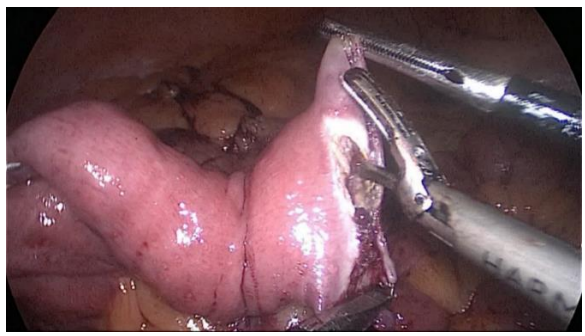

Figure 48. Opening of the BPL near the stapler line using the harmonic scalpel.

Figure 49. The surgeon follows the alimentary limb distally until the previous clips are identified.

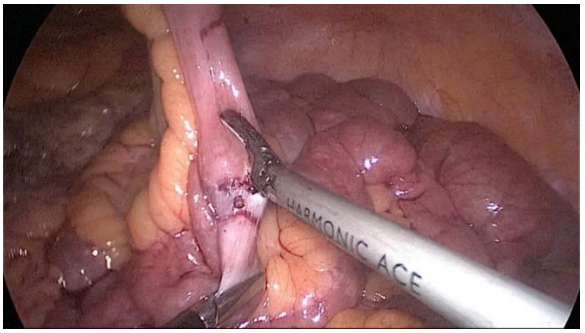

Figure 50. Removal of the clips and performance of enterotomy.

Figure 51. A hand sewn termino-lateral anatomosis is done.

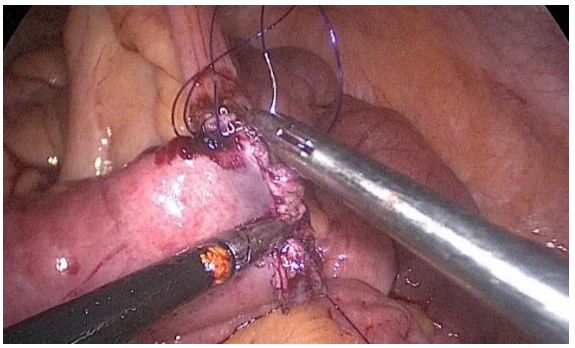

Figure 52. A hand sewn termino-lateral anatomosis is done.

Finally, the mesenteric defect is closed with a running 2/0 polypropilene suture (Figures 53-54),

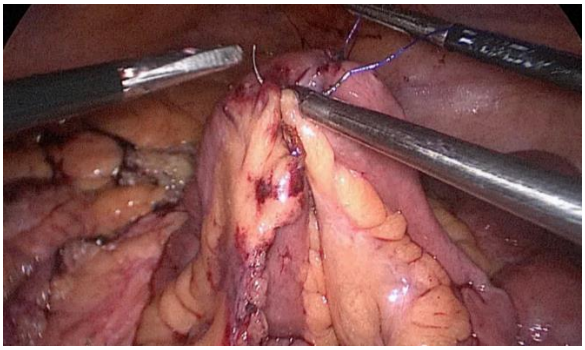

Figure 53. Closure of the mesenteric defect.

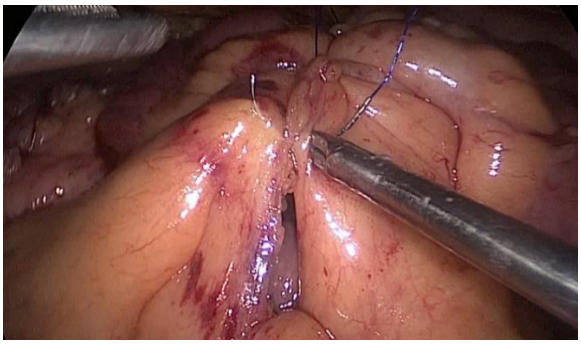

Figure 54. Closure of the mesenteric defect (continued).

c) Duodenoileal Anastomosis Step

Again patient changes to anti-Trendelemburg position and the surgeon moves between the legs.

As we told before the AL had been moved up in an antecolic position.

We recommend using a 2/0 silk stich to approximate the duodenum and the ileum, and then the assistant on the left side holds it and keeps the anastomosis stable (Figure 55).

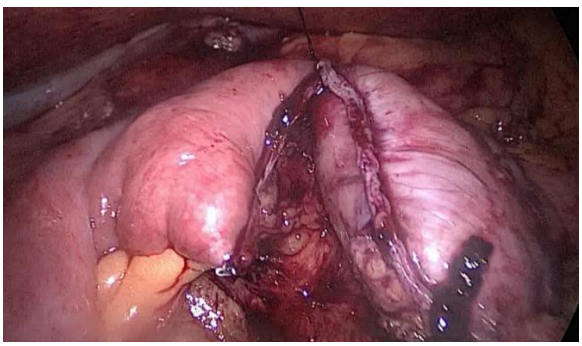

Figure 55. Stich to approximate the duodenum and the ileum.

There are several ways to perform the anastomosis but we prefer a two layers hand sewn terminoterminal anastomosis.

The posterior layer is first done with a 3/0 monomax running suture, without incorporating the staple lines and ensuring the apposition of the two anastomotic stumps. We begin from the superior angle and progress till the end of both staple lines. We finish again with an Aberdeen Knot. The assistant on the left holds the end of this suture (Figures 56-57)

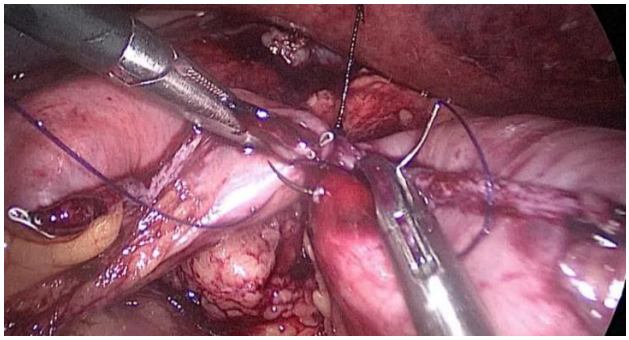

Figure 56. The posterior layer is first done with a running suture.

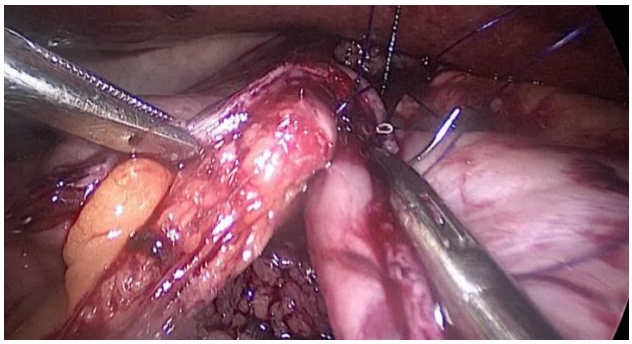

Figure 57. The posterior layer is first done with a running suture (continued).

Then, we open the duodenum and the ileum 1cm far from the staple line using the harmonic scalpel.

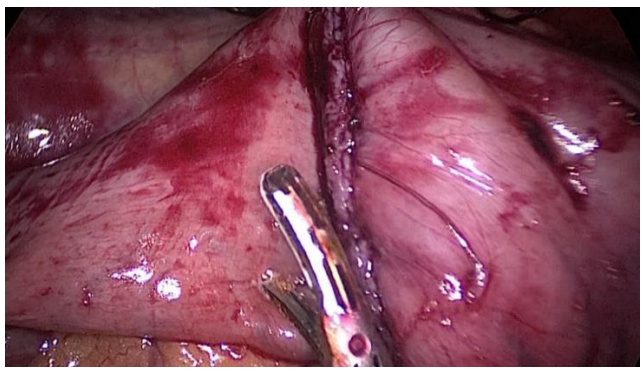

Figure 58. Opening of the duodenum and ileum.

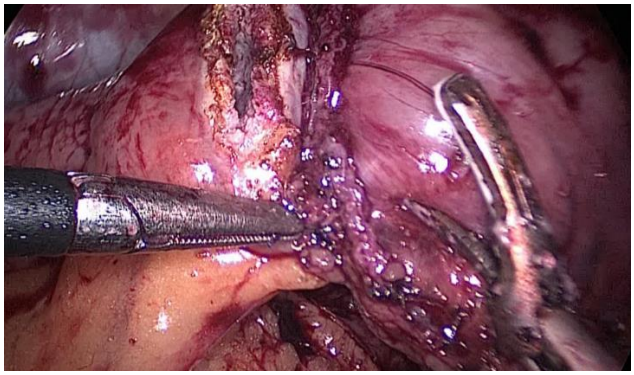

Figure 59. Opening of the duodenum and ileum (continued).

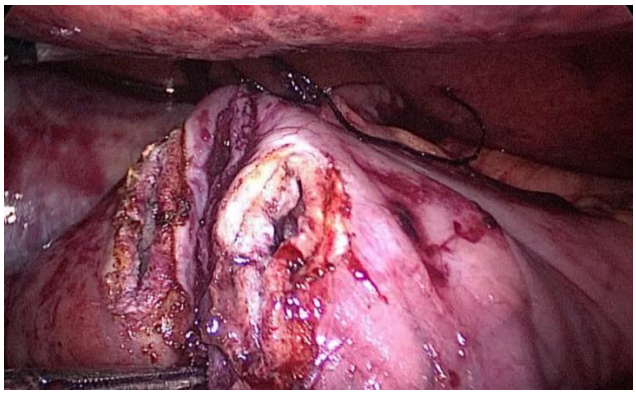

Figure 60. Opening of the duodenum and ileum (continued).

For the inner layer we use two tied threads; one 21 cm and the other one 16 cm long. We use the long one for the posterior layer because we need to take big bites. On the other hand, the anterior inner layer is only seromuscular. The suture is finished by tying both threads and then the anastomosis is finally closed. The last layer (optional) is a 3/0 monomax running seroserosal suture.

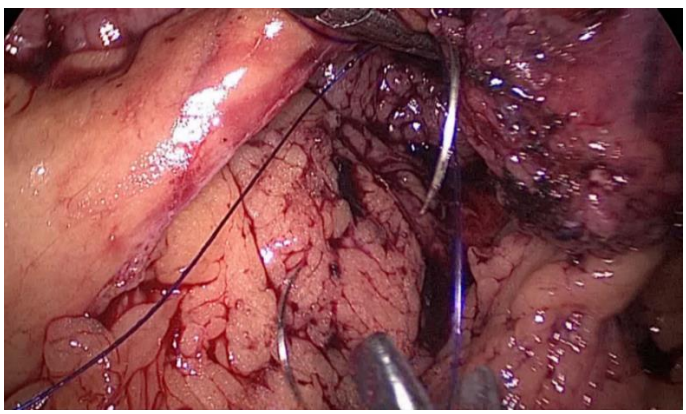

Figure 61. Hand-sewn anastomosis (posterior inner layer).

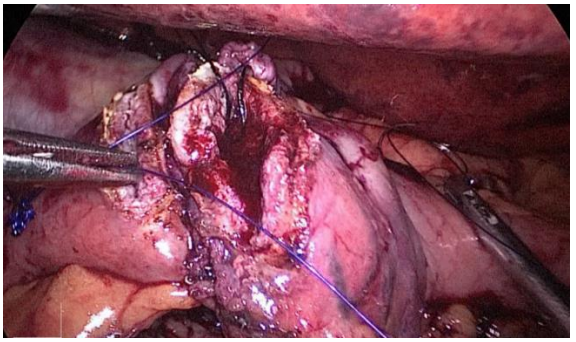

Figure 62. Hand-sewn anastomosis (posterior inner layer).

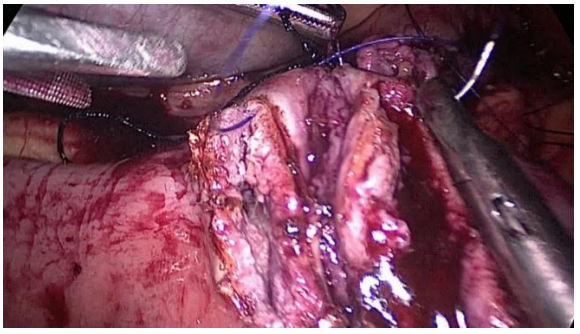

Figure 63. Hand-sewn anastomosis (inner layer).

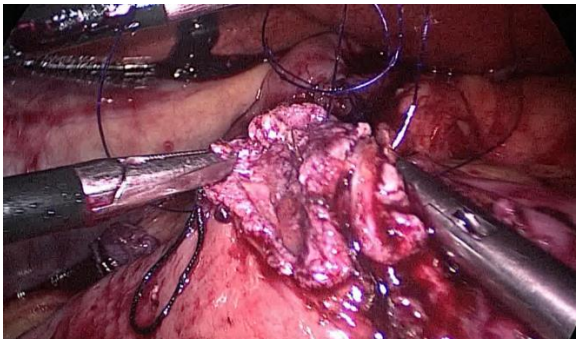

Figure 64. Hand-sewn anastomosis (posterior inner layer).

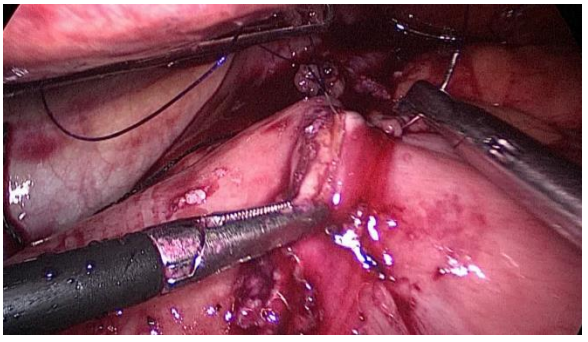

Figure 65. Hand-sewn anastomosis (anterior inner layer).

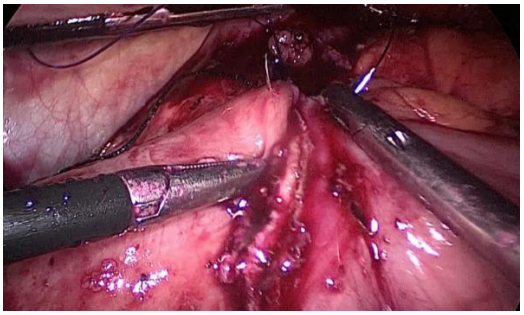

Figure 66. Hand-sewn anastomosis (anterior inner layer).

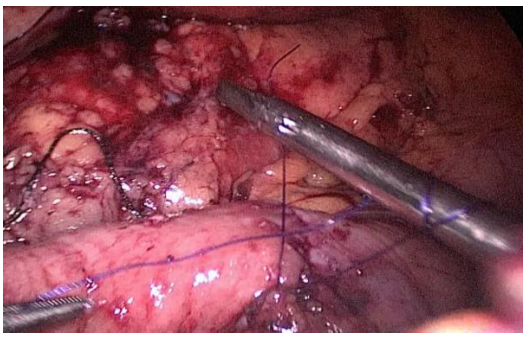

Figure 67. The suture is finished by tying both threads and then the anastomosis is finally closed.

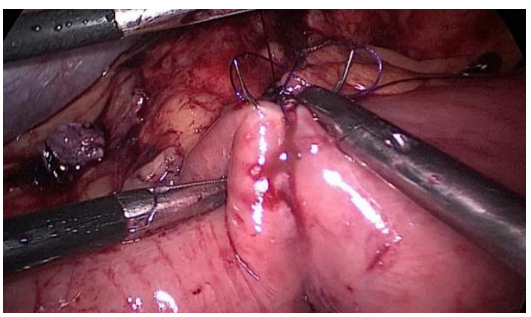

Figure 68. The second anterior layer is optional.

We routinely place a naso-gastric tube and a methylene blue test is performed to check the anastomosis. (Figures 69-70)

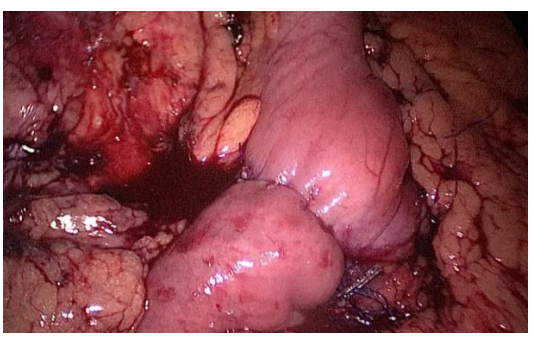

Figure 69. Tightness test.

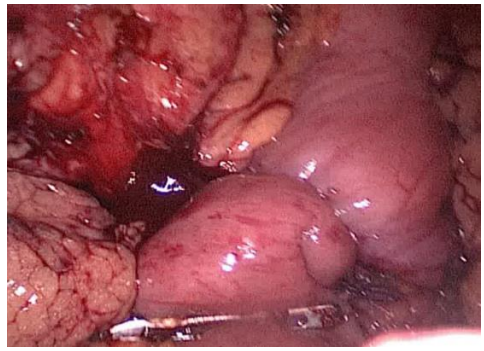

Figure 70. Tightness test (continued).

The excluded stomach is removed from the 12mm port on the right, and a Blake drain is left subhepatic, near the esophago-gastric junction.

We shut the 12mm access under direct vision using a 0 polipropilene Stitch (Figures 71-73).

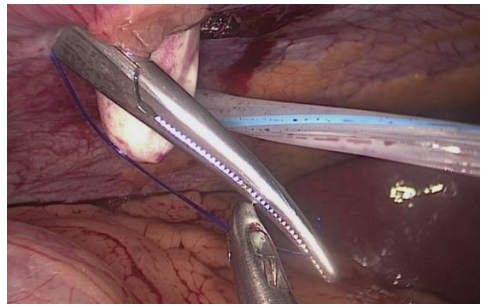

Figure 71. Closure of the ports under direct vision.

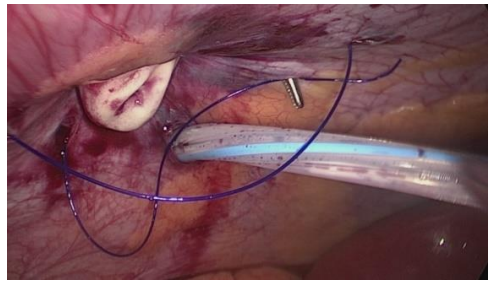

Figure 72. Closure of the ports under direct vision (continued).

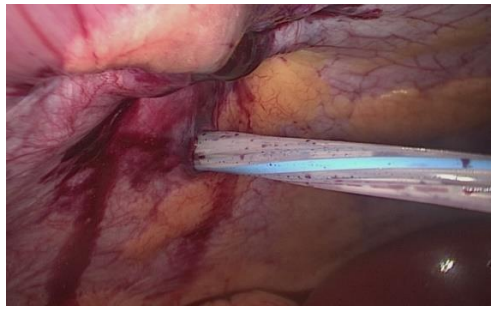

Figure 73. Closure of the ports under direct vision (continued).

REFERENCES

[1] Welch NT, Yasui A, Kim CB, et al. Effect of duodenal switch procedure on gastric acid production, intragastric pH, gastric emptying, and gastrointestinal hormones. *Am. J. Surg.* 1992;163:37-44.

[2] Hess DS, Hess DW. Biliopancreatic diversion with a duodenal switch. *Obes. Surg.* 1988; 8:267-82.

[3] Ren CJ, Patterson E, Gagner M. Early results of laparoscopic biliopancreatic diversion with a duodenal switch: a case series of 40 consecutive patients. *Obes. Surg.* 2000; 10:514-23.

[4] Baltasar A, Bou R, Miró J, et al.: Advances in surgical technique. Laparoscopic duodenal crossing in the treatment of morbid obesity: technique and preliminary study. *Cir. Esp.* 2001; 70:102-4.

[5] Baltasar A, Pérez N, Bou R et al. A switch to the Duodenal Switch. *Glob. J. Obes. Diabetes Metab. Syndr.* 2019, 6: 001-009.

In: Encyclopedia of Surgery (22 Volume Set)
Editors: Andreas Lehrer and Kristin Mueller
ISBN: 978-1-53618-329-0
© 2020 Nova Science Publishers, Inc

Chapter 302

LAPAROSCOPIC BILIOPANCREATIC DIVERSION

Alberto Pagan*, MD, PhD
Division of Esophagogastric and Bariatric Surgery,
Hospital Universitario Son Espases, Palma de Mallorca, Spain

ABSTRACT

Biliopancreatic shunt was originally described by Nicola Scopinaro in 1979 as an alternative to jejunileal bypass for patients with severe obesity. The procedure consists of: 1) partial distal gastrectomy in which the duodenal stump is closed (or bypass of the distal part of the stomach), 2) transection of the small intestine approximately midway between the Treitz ligament and the ileocecal valve, 3) Roux-en-Y gastroenterostomy from the gastric pouch to the distal intestine creating a food limb, and 4) anastomosis of biliopancreatic limb with the alimentary limb 50 cm proximal to the ileocecal valve forms a common limb.

INTRODUCTION

Restrictive techniques such as sleeve gastrectomy are being imposed as those of choice in obesity surgery.

Malabsortive surgery, and specifically biliopancreatic diversion, has an increasingly limited use, related to the metabolic complications derived from its use and what happens in the mid-long term. However, we believe that these complications are related to the systematic breach of dietary recommendations and supplementation of micronutrients of the patient and the lack of periodic clinical and analytical control.

* Corresponding Author's Email: alberto.pagan@ssib.es.

INDICATION

The indications of this procedure are contemplated in the patient who associates the following clinical features:

- Superobese patients with binge eating disorders
- Superobesoe patients with major metabolic comorbidities (Type 2 diabetes mellitus, dyslipidemia)
- Superobese patient with severe gastroesophageal reflux diseases (GERD) documented with pH-metry

PREOPERATIVE PREPARATION

The preoperative work-up for bariatric surgery is performed by a multidisciplinary team, including surgeons, endocrinologists, dieticians, gastroenterologists, anesthesiologists and psychiatrists, who combine a medical, nutritional, and endocrinology workup to evaluate potential surgical candidates. Preoperative assessment included abdominal ultrasound, barium swallow, upper gastrointestinal endoscopy, analytic evaluation of the nutritional status and in selected cases a polysomnography, fibroscan, 24 ph-metry and manometry.

Anesthesia

An enhanced recovery after surgery (ERAS) programme is followed with an opioid-free anesthesia. Central vein and bladder catheters were not used.

SURGICAL TECHNIQUE

Instrumentation

1. Four 12 mm and one 5 mm ports
2. Nathanson liver retractor
3. 30° scope
4. Harmonic scalpel (Harmonic ACE; Johnson & Johnson)
5. Veress needle
6. Three atraumatic graspers
7. Suction-irrigator
8. Signia™ endo-stapler with Tri-Staple™ cartridges (Medtronic)
9. Clip applicator (optional)

PATIENT, PORT AND SURGEON POSITIONS

a) Patient Position

The patient is placed on the surgical table in a modified lithotomy position, requires leg loops and his left arm in complete abduction. The patient's fixation to the surgical table should be considered when Trendelemburg or accentuated Trendelemburg positions are required. Prior to the start of the procedure, mechanical compression devices are placed in the lower extremities.

b) Port Position

Pneumoperitoneum is performed by an umbilical puncture with a Veress needle in most cases and an intra-abdominal pressure of 14-16 mmHg is established.

The position of the trocars is identified by imaginary lines at the midclavicular and left anterior axillary levels (Figure 2 and 3). The usual number of ports is 4, although if there is difficulty in exposing the lesser gastric curvature in the presence of hepatomegaly, an additional subxiphoid trocar should be placed. We prefer the placement of 12-mm trocars to facilitate the eventual introduction of a linear endostapler by any of them.

Figure 1. Patient position.

Figure 2. Port position.

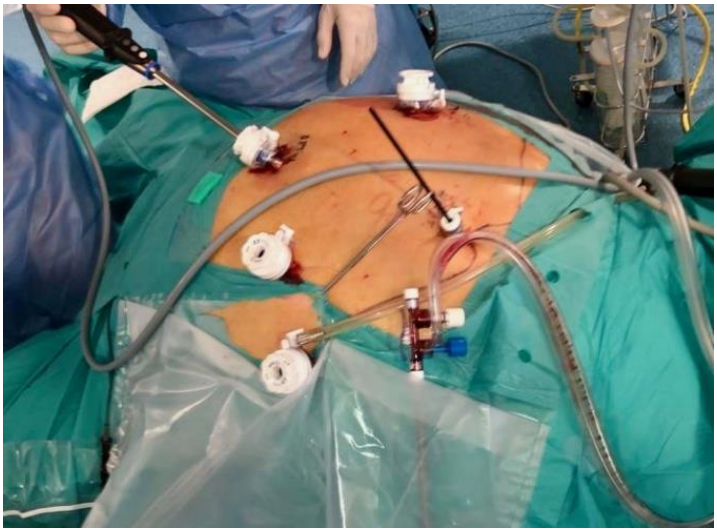

Figure 3. Port position.

c) Surgeon Position

In the inframesocolic time, the operating surgeon is placed on the left side of the patient. The assistants stand on the left side of the surgeon. In the supramesocolic time, the surgeon is placed between the patient's legs and the assistants on each side of the patient.

In the inframesocolic time the video monitor is in front of the surgeon. In supramesocolic time it is located in the patient's bedside. It is useful to have two video monitors (Figure 4, 5).

Figure 4. Surgeon position. Inframesocolic time.

Figure 5. Surgeon position. Supramesocolic time.

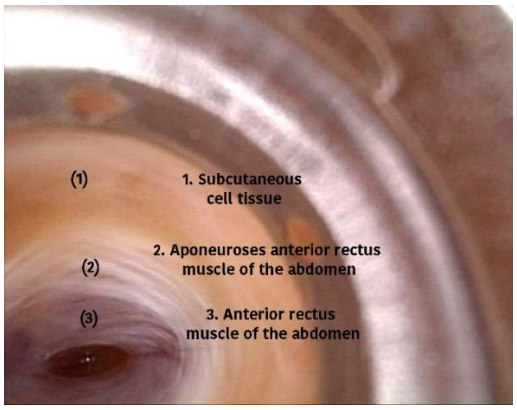

Figure 6. Optical trocar. Mixed access to the abdominal cavity.

PROCEDURE

a) Creation of the Pneumoperitoneum

Pneumoperitoneum is performed by an umbilical puncture with a Veress needle in most cases and an intra-abdominal pressure of 14-16 mmHg is established.

The first trocar to access the abdominal cavity is an optical port, allowing the visualization of the different layers of the abdominal wall.

There is the option of directly accessing the abdominal cavity without the optical trocar, although we consider it a less safe option.

b) Inframesocolic time

The biliopancreatic diversion procedure begins with the inframesocolic time.

The inframesocolic time begins with the measurement of the intestinal segments. To perform it, 2 pre-marked tweezers are used at 5 or 10 cm introduced by the trocars placed in both midclavicular lines.

It may be necessary to mobilize the patient with left lateral decubitus to contribute to the location of structures.

This measurement identifies and creates a common limb 60-70 cm proximal to the ileocecal valve that is marked with metal clips.

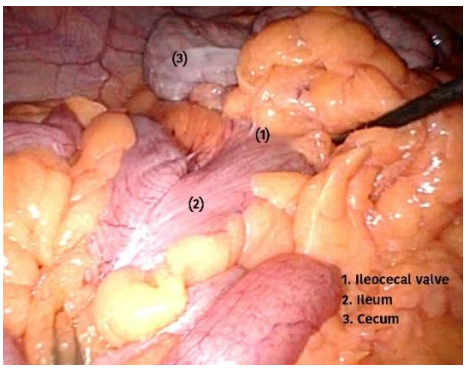

Figure 7. Intestinal measurement starts in ileocecal valve.

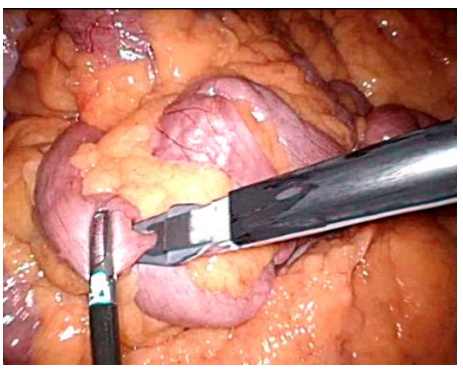

Figure 8. Marking with metal clips common intestinal loop segment.

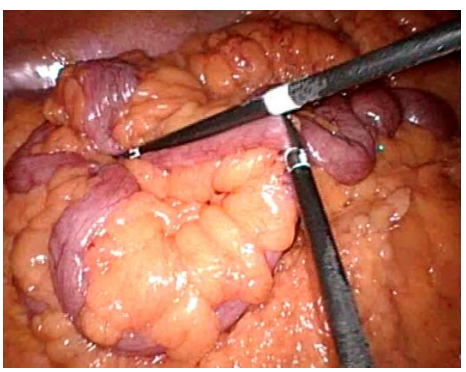

Figure 9. Intestinal segment measurement. Alimentary limb preparation.

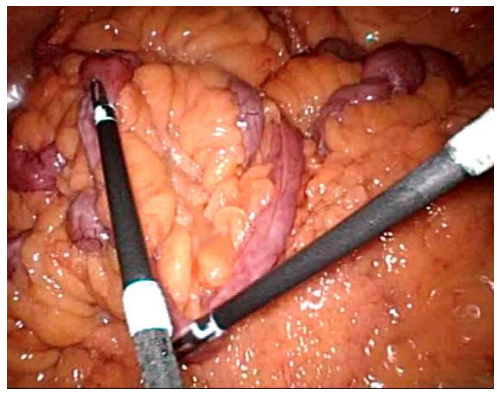

Figure 10. Intestinal segment measurement. Alimentary limb preparation.

Once predefined the future common limb, the measurement of the alimentary limb continues. This measurement is up to 300 cm, obtaining a total bowel segment of 360-370 cm from the ileocecal valve.

The bowel section is performed using a 45 or 60 mm mechanical linear cartridge at the surgeon's discretion using a mechanical endostapler (Signia™ with Tri-Staple™ 2.0 cartridges), obtaining the intestinal segment of the future alimentary limb and the intestinal segment of the biliopancreatic limb.

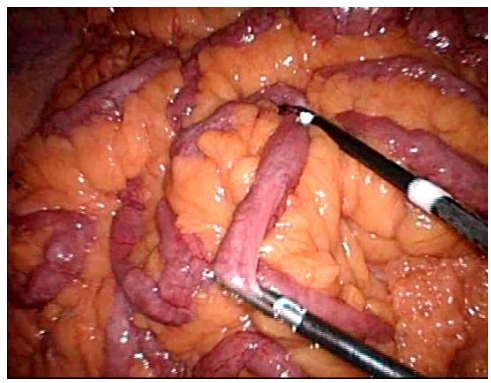

Figure 11. Intestinal segment measurement. Food intestinal loop preparation.

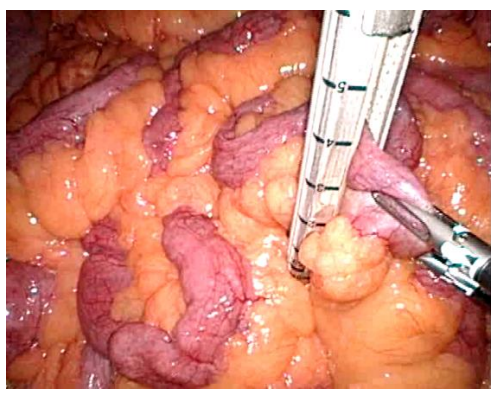

Figure 12. Signia™ with Tri-Staple™ 2.0 cartridges. Intestinal loop section.

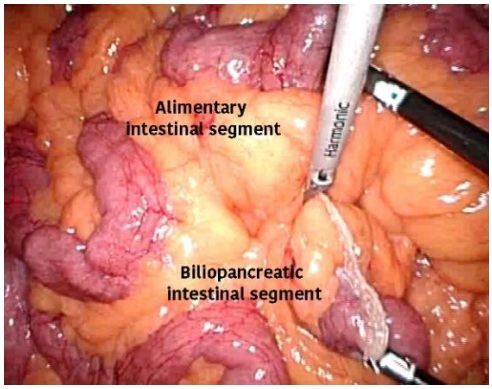

Figure 13. Intestinal segments after section (distal, alimentary limb) (proximal, biliopancreatic limb).

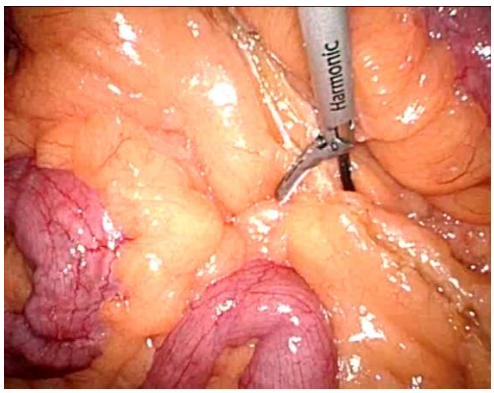

Figure 14. Intestinal mesentery section.

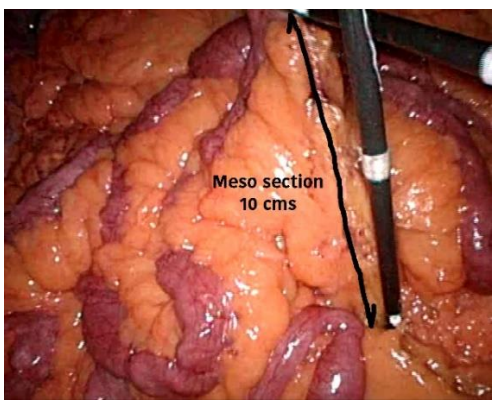

Figure 15. Intestinal mesentery section.

The division of the mesenteric leaf must have a minimum length of 10 cm to favor the mobilization without tension of the intestinal loops.

The descent of the biliopancreatic segment is carried out by moving it over the mesentery of the future alimentary limb to the reference marked with hemoclips at the level of the ileum.

The performance of the jejunoileal anastomosis is facilitated with the confrontation of both intestinal segments by means of a stitch of reabsorbable material. The jejunoileal

anastomosis is performed with a 60 mm mechanical linear stapler, with the subsequent closure of the resulting intestinal orifices with a 2/0 reabsorbable running suture.

The inframesocolic time ends with the closure of the mesenteric leaves from their point of division, to avoid mesenteric gaps and future internal hernias. We use irreabsorbable material for its closure (Figure 21).

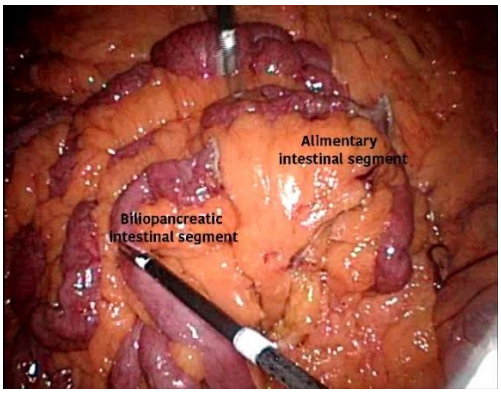

Figure 16. Distal displacement of the biliopancreatic segment.

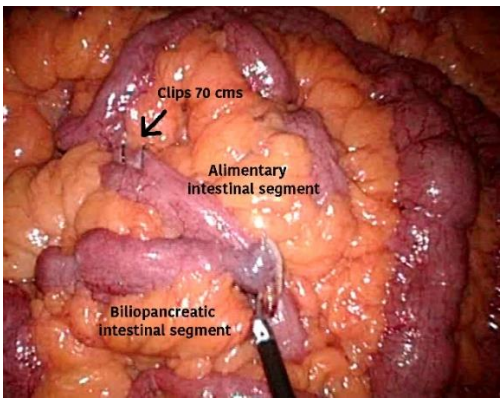

Figure 17. Distal displacement of the biliopancreatic segment. Marks on the distal intestinal segment are identified.

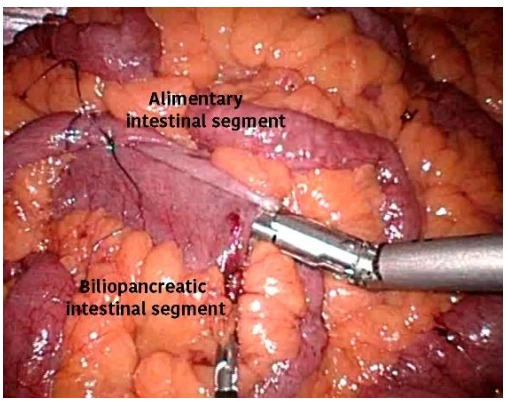

Figure 18. Jejuno-ileal mechanic latero-lateral anastomosis.

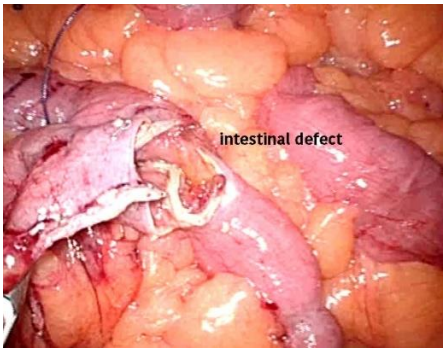

Figure 19. Intestinal enterotomy.

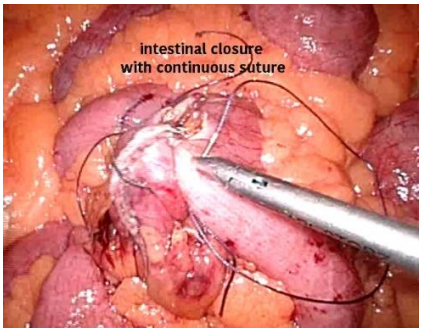

Figure 20. Closure of enterotomy with running suture.

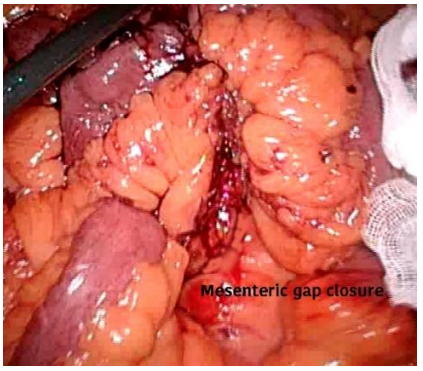

Figure 21. Closure of the mesenteric gap.

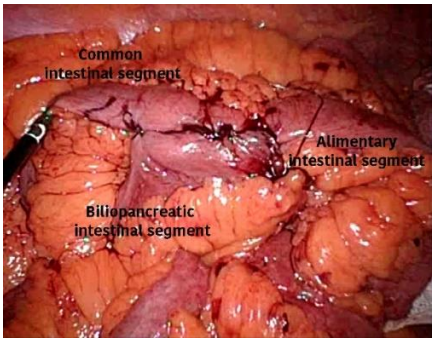

Figure 22. Final anatomical disposition of the jejuno-ileal anastomosis, common limb and alimentary limb.

c) In the Supramesocolic Time

It starts with the patient in an anti-Trendelemburg position. At this time the placement of a fifth trocar close to the xiphoid appendix to separate the left hepatic lobe is assessed.

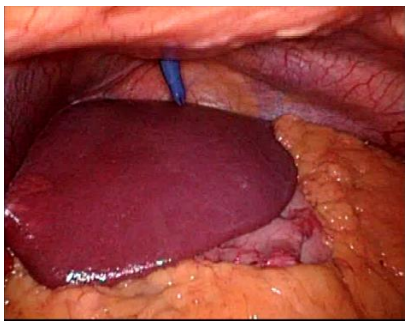

Figure 23. Fifth subxiphoid trocar (optional).

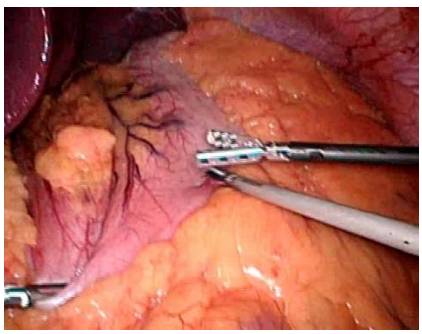

Figure 24. Supramesocolic time. Gastric exposure.

Although the placement of the fifth trocar to separate the hepatic lobe is optional, we prefer its systematic placement to facilitate the performance of the gastrotomy with correct visualization and in a suitable location.

After gastric aspiration, the nasogastric tube should be removed to avoid being trapped with the mechanical suture.

We proceed first with the incision on the gastric lesser curvature until the omental transcavity is reached. To facilitate this dissection, the first assistant's grip should be located in the margin of the gastric serosa near the mesegastrium.

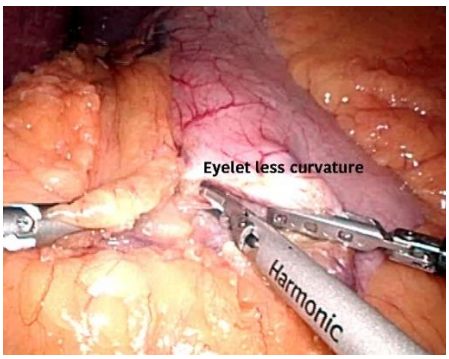

Figure 25. Gastrolysis of the lesser gastric curvature.

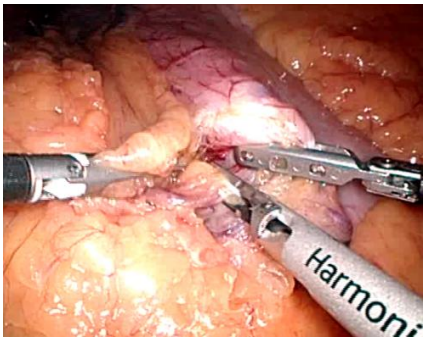

Figure 26. Gastrolysis of the lesser gastric curvature.

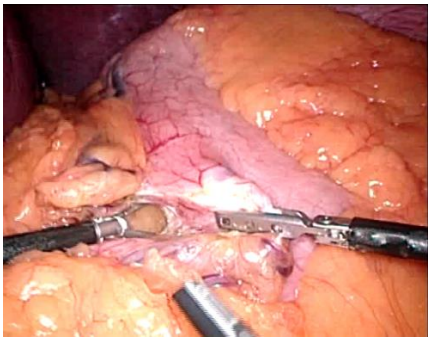

Figure 27. Gastrolysis of the lesser gastric curvature. Access to the transcavity from the gastric lesser curvature.

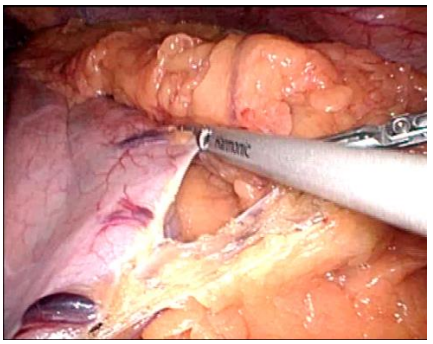

Figure 28. Gastrolysis of the greater curvature.

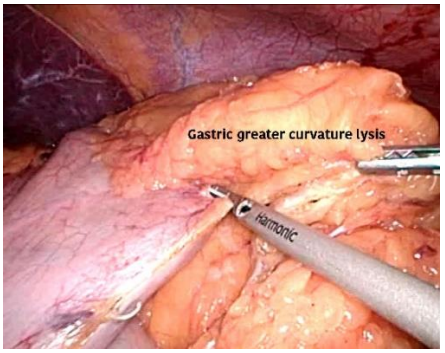

Figure 29. Gastrolysis of the greater curvature.

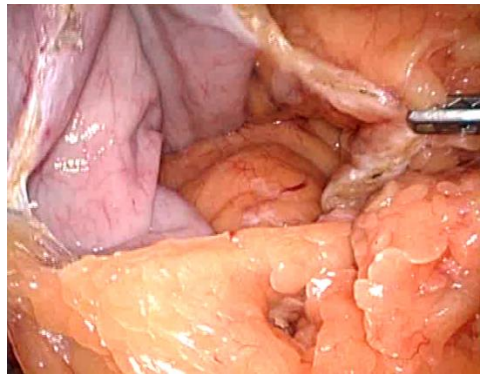

Figure 30. Posterior gastric surface and transcavity view of the omentums.

The level of dissection is defined by the second vessel bifurcation of the left gastric artery.

Next, a wide gastrolysis of the greater gastric curvature is performed to facilitate the mobility of the proximal gastric portion. Once it is finished, the stomach can be easily mobilized to visualize the posterior surface, completing the dissection of the mesogastrium of the gastric minor curvature in its posterior part, when necessary.

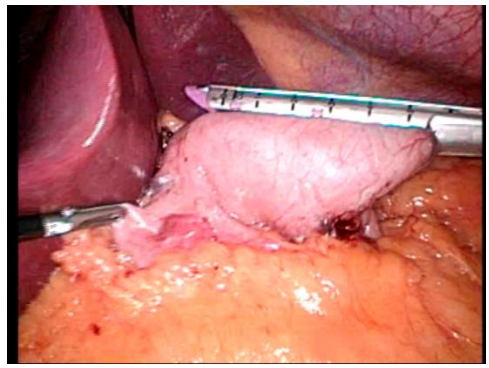

Figure 31. Start of gastrotomy with distal gastric preservation.

Figure 32. Gastrotomy with the first linear cartridge.

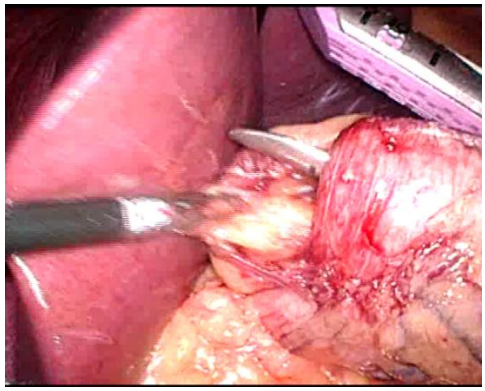

Figure 32. Complete gastric transection.

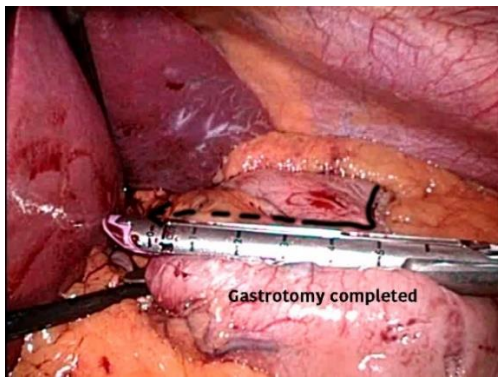

Figure 33. Gastrotomy completed (two cartridges).

The gastric section is made by means of two mechanical linear staplings, that are introduced through the trocar on the anterior axillary line at the level of the avascular part of the greater curvature in the direction of the gap made in the lesser curvature, preserving the distal stomach to eliminate the risk of the duodenal stump leak. Typically, two 60 mm endostapler cartridges are necessary.

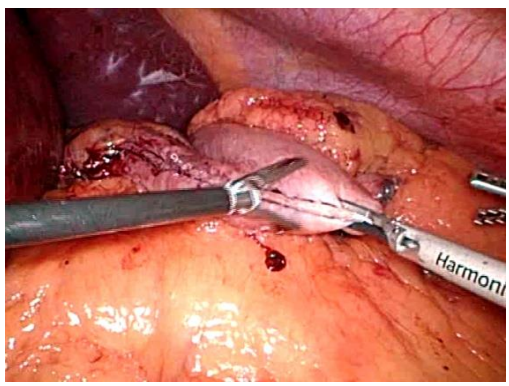

Figure 34. Gastrostomy at the staple line level.

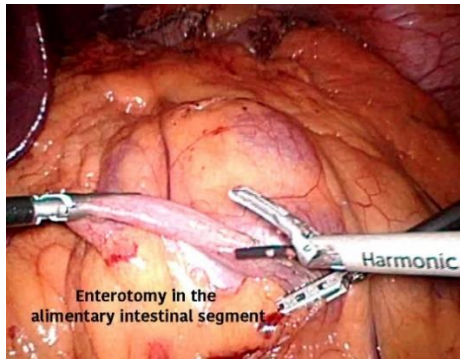

Figure 35. Enterotomy of the alimentary limb.

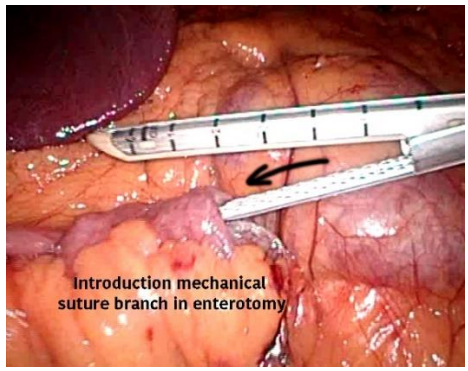

Figure 36. Ascent of the alimentary limb.

A complete section of the stomach should be performed, not a simple stapling of the organ, with an evident separation of the proximal and distal gastric portions to avoid repermeabilization of the staple lines.

An enterotomy of the alimentary limb is performed and one of the parts of the endostapler is introduced in it. This helps to ascend the bowel limb to the proximity of the gastric pouch. A gastrotomy is performed in the posterior face of the pouch at the end of the staple line, close to the greater curvature. The other part of the endostapler is introduced through this gastrotomny and the device is closed to perform the anastomosis.

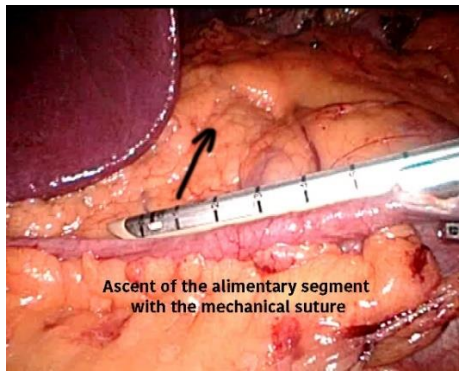

Figure 37. Ascent of the alimentary limb.

Figure 38. Approximation of the alimentary limb to the gastric pouch.

Gastrojejunal anastomosis is made using two cartridges, to obtain a wide anastomosis and prevent future stenosis or inadequate gastric emptying.

After the gastrojejunostomy, we routinely check the presence of bleeding in the staple line.

The gastroenteric gaps can be closed by means of a 60 mm mechanical linear stapling (Figure 42) or with a running suture of 2/0 reabsorbable material.

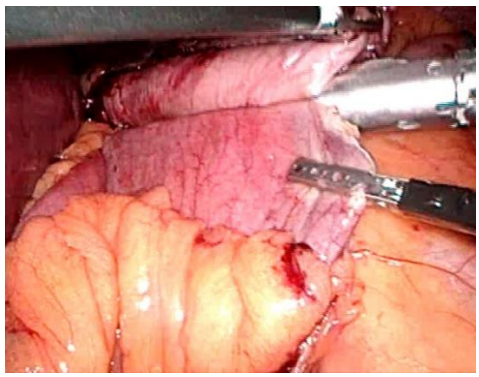

Figure 39. Gastrojejunal anastomosis.

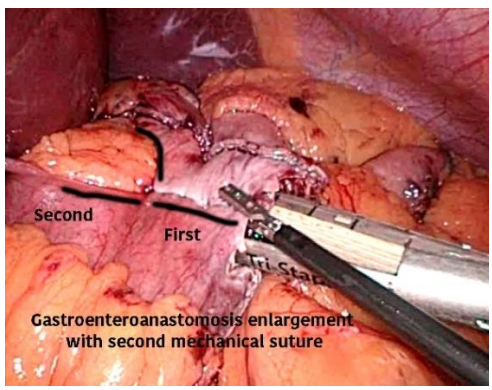

Figure 40. Enlargement of the gastrojejunal anastomosis with a second cartridge.

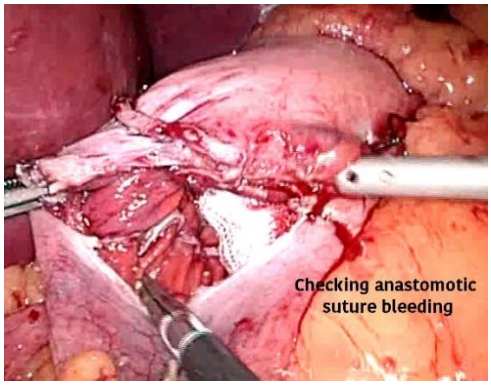

Figure 41. Gastrojejunal anastomosis check. Visulation of the staple line.

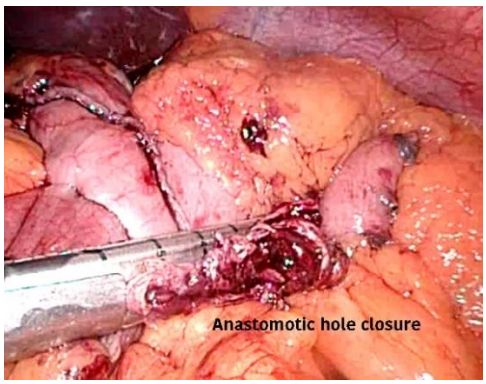

Figure 42. Gastrojejunal enterotomy closure with linear stapling.

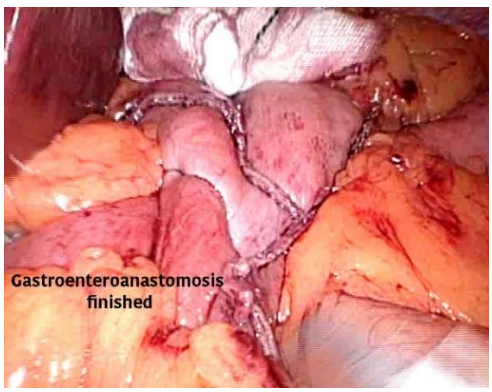

Figure 43. Checking the tightness of the gastrojejunal anastomosis.

After performing the anastomosis, it is optional to insufflate the stomach through the nasogastric tube, introducing methylene blue or air to check the tightness of the suture. After checking the tightness, the nasogastric tube is removed.

Finally, the tension of the mesentery in its antecolic ascent and the absence of bleeding at that level is checked.

Abdominal drains are not routinely placed and are indicated at the surgeon’s discretion.

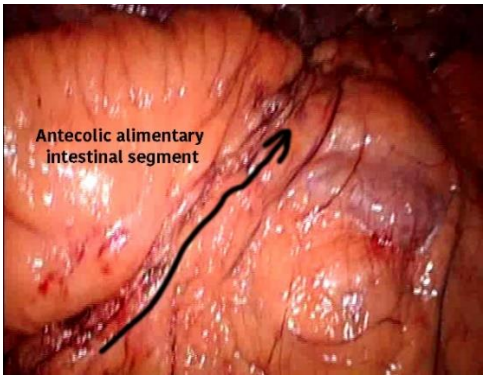

Figure 44. Checking the mesentery of the alimentary limb (antecolic disposition).

Figure 45. Distribution of surgical wounds.

REFERENCES

[1] Buchwald H. A Bariatric Surgery Algorithm. *Obes. Surg.* 2002; 12(6): 733-7.

[2] Dominguez-Díez A, Olmedo-Mendicoague F, Ingelmo-Setién A, et al. Bypass biliopancreático. *Cir. Esp*. 2004;75: 251-258.

[3] Resa JJ, Solano J, Fatás JA, et al. Laparoscopic biliopancreatic diversion: technical aspects and results of our protocol. *Obes. Surg.* 2004;14: 329-333.

[4] Robrecht HGG. Biliopancreatic Diversion in the Surgical Treatment of Morbid Obesity. *World J. Surg*. 2004; 28 (5): 435–444.

[5] Scopinaro N. Biliopancreatic Diversion. *World J. Surg*. 1998; 22 (9): 936–946.

[6] Topart P, Becouarn G, Ritz P. Weight Loss Is More Sustained after Biliopancreatic Diversion with Duodenal Switch than Roux-En-Y Gastric Bypass in Superobese Patients. *Surg. Obes. Relat. Dis.* 2013; 9 (4): 526–530.

In: Encyclopedia of Surgery (22 Volume Set)
Editors: Andreas Lehrer and Kristin Mueller
ISBN: 978-1-53618-329-0
© 2020 Nova Science Publishers, Inc

Chapter 303

INTRODUCTION TO NAFLD AND NASH : ETIOPATHOGENESIS

Soledad García-Gómez-Heras, MD, PhD,
Julio Paredes-González and Raquel Franco-Rodríguez
Human Histology and Pathology, Health Science Department,
Rey Juan Carlos University, Madrid, Spain

ABSTRACT

The liver, a principal metabolic organ, is the target of metabolic disorders which may lead to the development of non-alcoholic fatty liver disease (NAFLD) and non-alcoholic steatohepatitis (NASH). NAFLD and NASH represent different stages of the same disease, and appear to be multifactorial. Etiopathogenesis is complex and currently the underlying mechanisms are not completely understood; there have been different hypotheses describing the pathogenesis; the main three are: the "two hits," "three hits," and "multiple hits" hypotheses. Here, we explain all the factors that seem to influence the development and the outcome of this disease.

Keywords: liver-histology, NASH/NADFL etiopathogenesis, two-hits hypotheses, three- hits hypotheses, multiple-hits hypotheses

INTRODUCTION

The liver, a principal metabolic organ, is frequently the target of various metabolic disorders, which may lead to the development of non-alcoholic fatty liver disease (NAFLD) and non-alcoholic steatohepatitis (NASH). These conditions are associated with obesity and insulin resistance, and they are considered a hepatic manifestation of the Metabolic Syndrome (MS).

Also, liver disease can lead to systemic metabolic abnormalities. NAFLD/NASH is an emerging risk factor for obesity, dyslipidemia, type 2 diabetes, cardiovascular disease, and chronic kidney disease.

The term NAFLD includes a spectrum of fatty liver diseases ranging from simple steatosis to NASH and cirrhosis.

NAFLD is defined as an accumulation of fat in the hepatocytes when excessive drinking of alcohol or any other secondary cause is not present.

NAFLD is considered benign and reversible. Patients who suffer only hepatic steatosis may have a good prognosis in the long term, 10–20% develop NASH, defined as steatosis with hepatic inflammation, hepatocyte injury with or without fibrosis. NASH can progress to more severe stages such as cirrhosis and hepatocellular carcinoma (HCC).

Currently, NAFLD/NASH is one of the most prevalent chronic liver diseases, and is emerging as a global public health threat

THE LIVER

The liver is both an exocrine and endocrine gland, located at the "crossroad" of the digestive tract and the rest of the organism. Some of the main functions of an adult liver include:

- bile production, as the main exocrine function,
- conservation of metabolic balance,
- glycogen storage,
- drug degradation,
- toxin degradation,
- plasma protein synthesis,
- vitamins (A, D and K) processing, and storage,
- iron storage, metabolism, and homeostasis,
- immunoglobulin A secretion,
- secretion of growth actors.

Therefore, the scope of liver disease consequences is large, due to the dependence of other organs on the liver's metabolic functions.

In the embryo, in the 4th week of gestation, the liver starts developing from the hepatic diverticulum, which is an endodermal evagination of the anterior primitive intestine.

Adult liver cells proceed from different embryonic origins:

- the liver bud arises from the anterior intestine, giving place to hepatocytes and the choledocus epithelial lining.
- umbilical and vitelline veins are the origin of vascular sinusoids.
- from the septum transversum: stroma and hepatic capsule, hematopoietic cells, Kupffer cells, smooth muscle, and connective tissue of bile ducts.

During the fetal period, the liver has a double role: bile synthesis (from the 12th week) and hematopoiesis. From the first gestational weeks, groups of hematopoietic cells appear between hepatocytes and the blood vessel walls. The liver assumes its role as hematopoietic organ from the third month to the seventh month of gestation, when such function begins to decrease and the bone marrow becomes the main hematopoietic organ, thus causing liver volume to decrease from 10% of body volume in a 10-gestational week embryo to less than 5% of total body volume in a full-term fetus.

Anatomically, in an adult, the liver is coated with Glisson's capsule, a fibrous connective tissue capsule, and the visceral peritoneum, a serous cover.

Macroscopically, it is divided into four lobes: right, left, quadrate, and caudate lobe or Spiegel's lobe. Such division is only important topographically. The division in functional or surgical segments, based on blood supply and biliary drainage, is more important.

In order to understand the liver's functions and pathology, its vascularization should be described.

Liver Vascularization

This organ presents double irrigation: the portal vein and the hepatic artery (branch of the celiac trunk). They both access through the hepatic hilum. The liver receives blood that has previously irrigated the intestine, the spleen and the pancreas, and thus contains:

- nutritional and toxic substances proceeding from the intestine
- erythrocyte and erythrocyte degradation products from the spleen
- endocrine secretions from the pancreas
- enteroendocrine cell secretions from the digestive tract

The liver is interposed in the course of the blood vessels transporting the substances absorbed in the digestive tract. It is the first organ receiving metabolic substrates and nutritional substances. But it is also exposed to toxic components that may have been absorbed.

Around 75% of irrigation proceeds from the portal vein that carries venous blood that has poor oxygen concentration. Since the blood from the two sources is mixed just before perfusing the hepatocytes, they are never fully exposed to oxygenated blood.

Inside the liver, distribution branches of the portal vein and the hepatic artery deliver blood to sinusoid capillaries which will irrigate the hepatocytes. Branches of the portal vein, arteries, and biliary drainage (which disgorge in a common hepatic duct) flow jointly and create the "portal triad."

Sinusoid capillaries flow in close contact with hepatocytes, disgorge into a central or centrolobular vein, which in turn drains into supralobular veins. The blood leaves the liver through suprahepatic veins, which disgorge in the inferior vena cava.

HISTOLOGICAL ORGANIZATION OF THE LIVER

The liver is formed by the parenchyma, which consists of trabeculae or chords of hepatocytes that are organized in only one cell of thickness in adults. These chords are separated by sinusoid blood capillaries with a lumen of around a 15 micron diameter. The wall is formed by a single layer of endothelial cells with a large number of fenestrations and surrounded by a discontinuous basal membrane. Such organization allows for direct contact among the substances circulating in the blood and the cells forming and surrounding capillaries.

The stroma is a connective tissue connected with the fibrous capsule of Glisson. Blood vessels, lymph vessels, nervous branches, and bile ducts can be found in it. In the connective tissue of the narrow space between hepatocytes and sinusoid capillaries, reticular fibers (or type III fibers) are predominant, whereas collagen I is predominant in portal spaces (Figure 1).

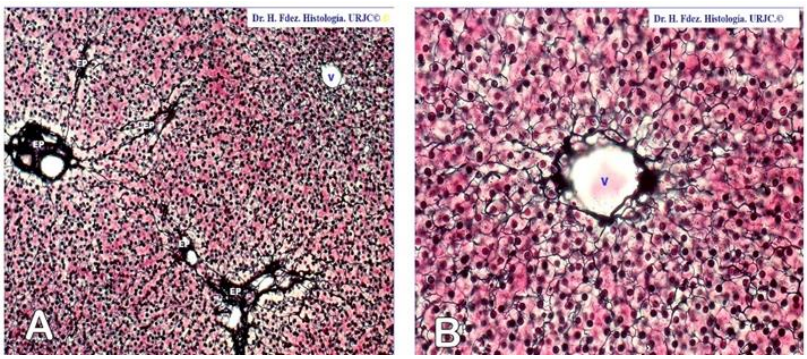

Figure 1. Human Liver. The stroma of liver is constituted by a reticular connective tissue with collagen III, impregnated in black with silver carbonate. As seen in the image A, these fibers increase their proportion in the portal spaces(ES). V: centrilobular vein. Del Rio Ortega Silver Carbonate Technique. 50x. In image B, we can observe in more detail the reinforcement of collagen III around the centrilobular vein. Ortega Silver Carbonate Technique. 200x.

Liver Lobules

There are three possible histological models to describe the structure of the liver: classic lobule, portal lobule, and liver acinus (Figure 2).

Classic Lobule

This is the classical and easiest-to-see mode to consider hepatic organization. It is based on the distribution of the portal vein and the hepatic artery branches inside the organ, and the route followed by the blood coming from these vessels when it perfuses the hepatocytes.

In a hepatic classic lobule, cuts present a more or less hexagonal tissue mass. Each lobule measures 0.2 x 0.7 mm. It is composed of one-cell-thick plates of anastomosed hepatic trabeculae, separated by liver sinusoids. There is a vein at the center, the post-sinusoidal hepatic venule, referred to as the central vein or centrilobular vein, in which sinusoids discharge.

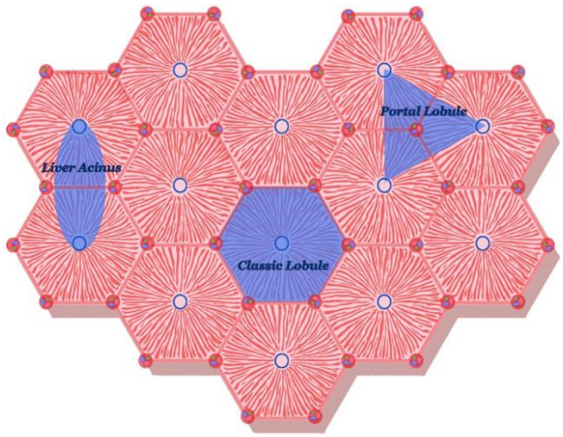

Figure 2. Scheme with the three types of liver lobules.

Hepatocyte plates and the corresponding sinusoids have a radial disposition from the centrilobular vein towards the periphery of the lobule. In the hexagon angles, there are the portal spaces with triads surrounded by loose connective tissue, which is continuous with the Glisson fibrous capsule.

Portal Lobule

Exocrine liver functions stand out, particularly in bile secretion. Therefore, the morphological axis is the interlobular bile duct of the portal triad of the classic lobule.

The external edges are the imaginary lines mapped out connecting the three centrilobular veins that lay closest to that portal triad. These lines define a tissular region similar to a triangle, which includes those portions of the three classic lobules that secrete bile. Bile is drained in the axial bile duct (Figure 3).

Liver Acinus

This is the structural unit that best groups and coordinates blood perfusion, metabolic activity, and hepatic pathology. This structure allows for a description of the liver's exocrine function.

The acinus has a rhomboid shape. The minor axis is defined by the terminal branches of the portal triad, which coincide with the limits of two classic lobules, and the main axis is a perpendicular line drawn between the two centrilobular veins closer to the minor axis. Therefore, in a two-dimensional view, the liver acinus occupies part of two contiguous classic lobules.

Based on this organization, hepatocytes in each acinus are described as lying in three concentric elliptical zones that surround the short axis:

- zone 1: closest to the short axis and the irrigation coming from the portal vein and the hepatic artery branches. This zone corresponds to the periphery of classic lobules.
- zone 3: the most distant to the short axis and the closest to the centrilobular vein. This zone corresponds to the center of the classic lobule, whose hepatocytes surround the centrilobular vein.
- zone 2: between zone 1 and 3, but with no clear limits.

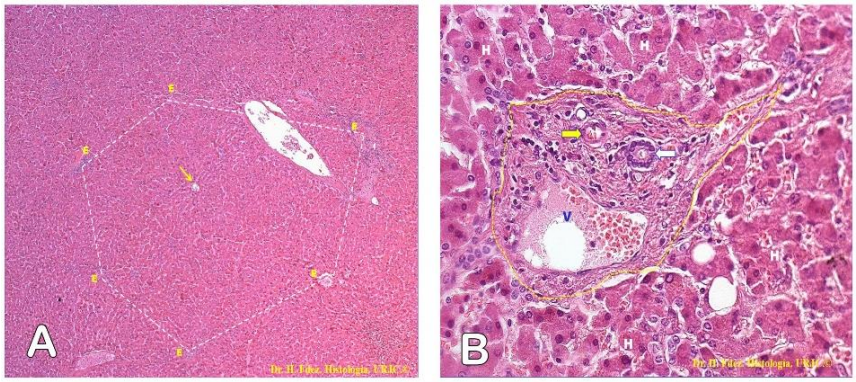

Figure 3. A. Histological image of a human liver, being complicated the delimitation of the lobules (dashed line). We can appreciate the presence of a centrilobular vein (arrow) and portal space around it (E). Hematoxylin-Eosin, 100x. B. Here we can observe a portal space of a human liver. Within the dashed line, portal space and its structures: vein(V), artery (yellow arrow) and bile duct (white arrow). H: liver parenchyma. Hematoxylin-Eosin. 250X.

The division of hepatic parenchyma in zones is indispensable for the description and interpretation of the hepatic lesion distribution due to ischemia, or to exposition to toxic substances, in order to assess the level of tissue degeneration and cell regeneration in every clinical situation.

Due to the sinusoidal blood flow, the oxygen gradient, metabolic activity of hepatocytes and hepatic enzyme distribution vary in the three zones.

Zone 1 cells are the first to receive oxygen, nutrients and toxins from the sinusoidal blood. Thus, they are the first to exhibit morphological alterations after a bile duct obstruction. These cells are also the last to die if there are circulation disorders, and the first to regenerate.

Zone 2 cells have morphological and functional characteristics, as well as responses, that are intermediate between cells in Zones 1 and 3.

Zone 3 cells are the first to suffer ischemic necrosis (centrilobular necrosis) in situations where perfusion is altered, and the first to accumulate lipids. They are the last to respond to toxic substances and biliary stasis.

In Zones 1 and 3, normal variations of enzymatic activity, the amount and dimensions of cytoplasmic organelles, and the size of glycogen cell deposits can be confirmed.

Liver Cells

Hepatocytes

They represent 80% of the parenchyma (Figure 4). They are big polyhedral cells, measuring around 20 x 30 microns. Their big nuclei are located in the cell center, and several are binucleated. The mean life of these cells is relatively long, around 5 months, and they have a huge capacity to regenerate.

200 to 300 *peroxisomes* can be found in the cytoplasm of each cell. Their function is similar to that of mitochondria, and they are a site of important oxygen consumption. A large number of oxidases (which generate hydrogen peroxide), catalases (enzymes degradating

hydrogen peroxide to oxygen and water), D-amino acid oxidase, and alcohol dehydrogenase can be found in them. Peroxisomes intervene in the degradation of fatty acids (through beta-oxidation), in glycogenesis, and in purine metabolism. They also participate in the detox processes that take place in the liver, such as alcohol detox.

The *Smooth Endoplasmic Reticulum* (SER) of hepatocytes can be very extensive, but it will depend on the functional moment. It contains enzymes that participate in the degradation and conjugation of toxins and drugs, cholesterol synthesis enzymes, and enzymes of lipoproteins lipid component. In overburdened liver conditions, due to drugs or hormones, the synthesis of new SER membranes and their associated enzymes is induced. Hypertrophy is also experienced after the administration of alcohol, drugs (phenobarbital, anabolic steroids and progesterone) and certain chemotherapy agents.

Likewise, the *Golgi apparatus* in these cells is very developed with up to 50 dictyosomes, each composed of 3-5 piled cisterns.

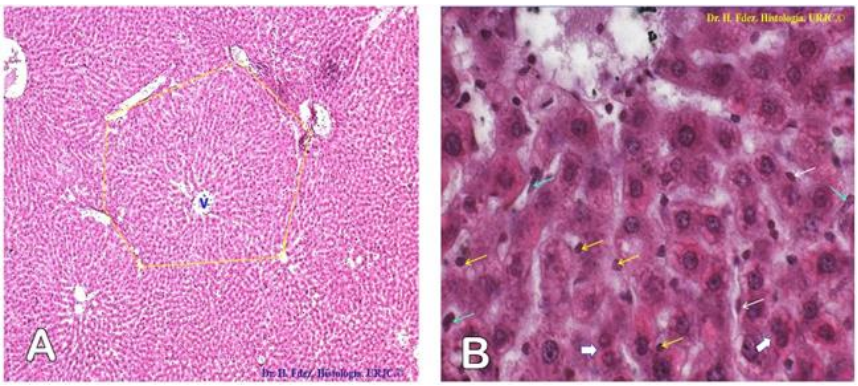

Figure 4. A. Human liver lobule (dashed line). With this histological technique, the stored glycogen in the hepatocytes is highlighted, colored in clear carmine. Carmín de Best Technique. 50 X. B. High-magnification image of the previous preparation. The sinusoids, the hepatocyte cords, as well as the nuclei of the sinusoidal cells (thin white arrows), the Ito cells (yellow arrows) and the Kupffer cells (green arrows) are observed. Carmín de Best Technique. 400 X.

Lysosomes in hepatocytes concentrate close to the bile canaliculus. They can also be a site for normal storing of ferritin, and a ferric accumulation site in certain diseases, due to an excessive deposition.

Macrophages Present in the Liver

Macrophages belong to the phagocytic mononuclear system. Hepatic macrophages consist of resident macrophages called Kupffer cells (KCs) and macrophages that arise from bone marrow-derived monocytes after a stimulus.

KCs lean on the endothelium, and their extensions cross the whole sinusoidal lumen. These are common cells in the endothelial lining of sinusoids, where they create a barrier. They present abundant lysosomes, phagocyte particles and microorganisms that arrive in the hepatic lobules through the blood.

They participate in the final degradation of certain aged or damaged erythrocytes. Erythrocyte and iron fragments, in the form of ferritin, can be observed in their cytoplasm.

They represent a cell of innate immunity. KCs are the body's primary line of defense against microorganisms. Their location is optimal for carrying out their functions inside the

liver. During liver injury, KCs initiate the immunological response by rapidly secreting cytokines and chemokines, which induce the recruitment of other immune cells, including monocytes, into the liver. Both populations of macrophages produce proinflammatory and anti-inflammatory cytokines, contributing to chronic inflammation such as that seen in alcoholic liver disease, NAFLD, NASH and other pathological conditions affecting the liver.

Perisinusoidal Space or Space of Disse

This is a zone for intercellular exchange of substances between the blood and hepatocytes. It is defined as the space between the basal surfaces of hepatocytes and the basal surfaces of endothelial cells and Kupffer cells that line the sinusoids. Because of the large gaps in the endothelial layer and the absence of the continuous basal lamina, no significant barrier exists between the blood plasma in the sinusoid and the hepatocyte plasma membrane.

Because of the broad fenestrations between endothelial cells and the discontinuity in the basal membrane, there is no physical barrier between sinusoid blood and the plasma membranes of hepatocytes. Proteins and lipoproteins synthesized by hepatocytes are directly transferred into the blood through this space. This pathway is for liver secretions other than bile.

Ito Cells (or Stellate Cells)

They can also be found in these spaces. Their origin is mesenchymal, and they are the primary storage site for hepatic vitamin A. In certain liver diseases, chronic inflammation, or cirrhosis, Ito cells lose their ability to store lipids and vitamin A, and they differentiate into cells with characteristics of myofibroblasts, with capacity to synthesize collagen. These cells seem to play an important role in hepatic fibrogenesis. They synthesize and deposit collagen I and II in the portal space, as well as in the connective zone surrounding the centrilobular vein.

An increase in perisinusoidal fibrous stroma is an early sign of liver response to toxic substances.

The cytoplasm of cells contains elements of the contractile apparatus, such as α-actin filaments or desmin intermediate filaments. In situations where contraction of these cells is stimulated, the vascular resistance will be empowered within the sinusoids due to their lumen reduction, leading to portal hypertension. Furthermore, Ito cells participate in extracellular matrix remodeling during recovery from liver injury.

In the fetal liver, islands of hematopoietic cells appear in this space. In cases of chronic anemia in the adult, hematopoietic cells may reappear.

Beyond all that has been explained in this section, the fact that the liver depends on a huge functional reserve remains to be highlighted, and in almost all diseases, except for those causing death, regeneration takes place. After resection of 75% of the liver, there is a small hepatic deterioration, and regeneration restores the liver mass in few weeks. When a massive hepatocellular necrosis occurs, but the connective tissue weft remains intact and the patient survives the metabolic aggression of liver failure, tissue restoration may be almost perfect.

ETIOPATHOGENESIS

Etiopathogenesis is complex and currently the underlying mechanisms are not completely understood; NAFLD and NASH represent different stages of the same disease, and appear to be multifactorial. They occur in response to a chronic inflammatory liver state accompanying obesity, insulin resistance, hepatic steatosis, and oxidative stress. The most progressive forms of NAFLD have been related to metabolic syndrome (ME) and obesity. Both liver parenchymal and nonparenchymal cells are affected.

There have been different hypotheses describing the pathogenesis of NAFLD/NASH. The main three are: the "two hits," "three hits," and "multiple hits" hypotheses.

The classical pathogenetic pathway, originally proposed in 1998, was described as the "two hits hypothesis." This theory stated that damage to the liver tissue begins through aberrant triglyceride accumulation, *the first hit*, which induces *the second hit*, the activation of inflammatory mediators, lipotoxic metabolite-induced mitochondrial dysfunction and oxidative stress. These aggressions lead to steatohepatitis and fibrosis.

The "three hits" theory involves inadequate hepatocyte proliferation after cell death triggered by aberrant lipid accumulation and excessive oxidative stress.

Finally, the "multiple hits" hypothesis involves organ-organ interactions in NASH; inflammatory mediators released from adipose tissue and the liver/gut axis are implicated in NASH pathogenesis. In this model, environmental, metabolic and genetic factors contribute to the development and progression of NASH by affecting diverse organs such as the liver, intestines, and adipose tissue. More specifically, excess caloric or inappropriate intake (environmental factor) increases toxic free fatty acid (FFA) and lipid metabolites (lysophosphatidylcholine (LPC), cholesterol and ceramide) in hepatocytes, leading to hepatic steatosis and hepatocyte sublethal/lethal injuries. Subsequently, hepatocyte-derived cytokines/chemokines and damage-associated molecular patterns (DAMPs) stimulate Kupffer cells (KC) (which promote inflammatory response) and hepatic stellate cells (HSC) (stimulate fibrotic response); this leads to the development of inflammation and fibrosis in the liver. Free fatty acid (FFA) and lipid metabolites derived from diets or synthesized *de novo* also activate KC and HSC. In addition, insulin resistance and obesity (metabolic factor) influence organ crosstalk between the intestine/adipose tissue and the liver, contributing to the development and progression of NASH.

Various studies suggest that variations in several genes related to hepatic lipid metabolism are associated with increased hepatic steatosis in human NAFLD subjects (PNPLA3 (patatin-like phospholipase domain-containing protein 3), TM6SP2 (transmembrane 6 superfamily member 2), and FADS (fatty acid desaturase)). Factors influencing NAFLD and NASH, and collaborating in their development are discussed next.

Lipid Accumulation in the Hepatocytes

In NAFLD, cell lipid accumulation and the subsequent steatosis may result from several mechanisms: excess fat ingestion, increased fat synthesis, decreased fat export and decreased fat oxidation.

Sedentary lifestyle, too caloric diets or inappropriate intake as diets with high glucose, high fructose, high fat or high cholesterol are environmental factors associated with hepatic steatosis and NAFLD/NASH.

In the case of excess dietary glucose or fructose, they enter the liver through the bloodstream after uptake in the small intestine and are subsequently utilized for the production of hepatic triacylglycerol (TG) via de novo fatty acid synthesis, and become a source of hepatic glycogen storage. When there is excessive free fatty acid (FFA) accumulation within hepatocytes generate toxic lipid metabolites and cause hepatocyte injury, consequently, initiation of NASH.

Lipid metabolites such as palmitic acid, lysophosphatidylcholine (LPC), ceramide, and free cholesterol are considered mediators of hepatocellular lipotoxicity and they contribute to the development and progression of NASH. High concentrations are found in the livers of human subjects with NASH.

Palmitic acid has been reported to trigger oxidative stress, endoplasmic reticulum and mitochondrial stresses, causing lipotoxicity and cell death.

LPC generated from palmitic acid triggers mitochondria-dependent apoptotic machinery.

Ceramide synthesized from palmitic acid also causes mitochondrial impairment of the mitochondrial respiratory chain and increases mitochondrial membrane permeability leading to hepatocyte cell death.

Free cholesterol can induce hepatocyte necrosis/apoptosis by depleting mitochondrial glutathione, and can induce hepatocyte necrosis by generating cholesterol crystals within lipid droplets.

Endoplasmic Reticulum (ER) Stress

Endoplasmic reticulum (ER) Stress is associated with the development of NAFL and progression to NASH through direct cell injury and indirect changes in cell signaling pathways.

In situations of hyperinsulinemia and hiperlipidemia, ER stress causes inflammation, apoptosis, and mitochondrial dysfunction.

Increased dietary intake of FFA, *de novo* lipogenesis and adipose lipolysis, together with impaired FFA oxidation, causes an increase in the flux of FFAs within hepatocytes.

Excessive lipid accumulation causes hepatocellular lipotoxicity via cellular and organelle oxidative stresses including endoplasmic reticulum (ER) stress and mitochondrial dysfunction, leading to hepatocyte cell death.

Furthermore, *chronic* ER stress increases the production of reactive oxygen species (ROS). ROS induces activation of nuclear factor Iκκ-β/NF-κB, a master regulator in the production of proinflammatory cytokines (IL-1-β, TNF-α and IL-6).

In addition, chronic ER stress results in hepatic lipid accumulation via activation of de novo fatty acid synthesis in a manner dependent on ER stress-sensing pathways suggesting that a vicious cycle between ER stress and hepatic steatosis may promote the development and progression of NAFLD/NASH.

Activation of Inflammatory Mediators

Steatosis is strongly associated with chronic hepatic inflammation. Different immunological mechanisms are implicated in the NAFLD progression: innate immunity, adaptive immunity, NLRP3 inflammasome activation. As evidence, portal inflammatory infiltrates in human NASH livers are characterized by broad inflammatory cell markers: CD68, CD3, CD8, CD4, CD20, neutrophil elastase, matrix metalloproteinase 9 and interleukins.

Innate Immunity in NAFLD/NASH: Kupffer Cells (KC) and Hepatic Stellate Cells (HCS) in NAFLD/NASH

In NAFLD and its evolution to NASH, the innate immune system is activated by different factors and through different pathways. This creates a vicious cycle difficult to break. Hereunder, some of these factors are discussed.

1. In response to excessive lipids, hepatocytes produce chemokines and pro-inflammatory cytokines (TNF-α, IL-6 and IL-1b); they act on non-parenchymal cells such as KCs and HSCs, which contribute to the progression of NASH.
2. Lipotoxic fatty acids such as palmitic acid and ceramide can activate Kupffer cells and subsequently promote the production of pro-inflammatory cytokines such as CCL2 which recruit more peripheral macrophages, CXCL16 to recruit natural killer T cells, and CXCL1/2/8 to recruit neutrophils (TNFa and IL-6)

In this way, Kupffer cells and recruited innate immune cells coordinately aggravate inflammation in the liver.

Moreover, Kupffer cells and infiltrating macrophages produce several cytokines such as TGFβ, Galectin- 3, platelet-derived growth factor, TNF-α and IL-1β that are able to activate quiescent HSCs and increase their proliferation. More specifically, palmitic acid-induced TNF-α and IL-1β in infiltrating macrophages can cause lipid accumulation and insulin resistance in hepatocytes. Macrophages activated by the palmitic acid, by secreting TNF-α and IL-beta, generate lipid accumulation and insulin resistance in hepatocytes.

3. Apoptotic or necrotic hepatic cells trigger signals for NASH promotion. They release inflammatory cytokines, damage-associated molecular patterns (DAMPs), ATP, uric acid or mitochondrial DNA. DAMPs can cause hepatic inflammation and fibrosis by activating KCs and HSCs via paracrine or endocrine actions.
4. Elevated hepatic expression of inflammatory cytokines such as TNF-α, interleukin-6 (IL-6) and interleukin 1-beta (IL-1β), and activated Kupffer cells, start up the Iκκ-β/NF-κB signaling pathway. Both inflammation and Iκκ-β/NF-κB activation promote carcinogenesis and may also play a key role in hepatocellular carcinoma (HCC) development.
5. Finally, activated Kupffer cells, infiltrating macrophages and hepatocytes secrete NLRP3 inflammasome-dependent IL-1β, which plays a crucial role in the progression of NAFLD/NASH.

The Involvement of Adaptive Immunity: Role of Lymphocytes in NASH

The mechanism involved in the initiation of inflammation in NASH pathogenesis is very similar to other organs. In the initial phase, the resident macrophages secrete chemokines, which recruit CD4+/CD8+ T lymphocytes and NKT cells to the tissue, which enhance macrophage activation and proinflammatory mediator release. Both macrophages and lymphocytes represent the most frequent inflammatory infiltrates of NASH livers. It should be stressed that, in human NASH liver biopsy sections, the portal tract infiltrates are dominated by CD8 (+) lymphocytes.

The B cells also play a critical role in NASH pathogenesis. Lipid peroxidation products from phospholipid oxidation interact with B lymphocytes and are one of the sources of antigens able to promote an adaptive immune response in NASH. As evidence, 40%–60% of patients with NASH have circulating antibodies against lipid peroxidation-derived antigens and the high titers of these antibodies are in parallel with increased risk to develop advanced liver fibrosis.

Insulin Resistance (IR) in NAFLD/NASH Development

Metabolic factors such as obesity, dyslipidemia, and IR come together with NAFLD. In individuals with IR who present excess visceral fat, the influx of FFAs to the liver is increased, thus leading to both triglyceride accumulation and direct lipotoxicity.

Hyperinsulinemia or hyperglycemia, a key feature of insulin resistance, increases hepatic de novo fatty acid synthesis.

So, because of IR, there is greater influx of FFAs to the liver: these undergo β-oxidation or esterification with glycerol to form triglycerides. Additionally, FFAs are able to cause toxicity through directly increasing oxidative stress and activating inflammatory pathways.

On the other hand, insulin resistance in adipose tissue impairs the ability of insulin to suppress lipolysis; consequently, FFAs released from adipose tissue are transported into the liver (FFAs from adipose tissue contribute to 60% of hepatic lipid accumulation).

NAFLD also contributes towards a worsening of IR and the cumulative effect generates a vicious cycle of IR and NAFLD worsening each other. *S*everal abnormalities intrinsic to NAFLD impair insulin receptor signaling, especially: FFAs, tumor necrosis factor-alpha (TNF-α), nuclear factor kappa B (NF-κB), ceramide, Jun N-terminal kinase 1 (JNK1), suppressors of cytokine signaling (SOCS) and cytochrome CYP2E1.

Altered Hepatocyte Proliferation and NAFLD/NASH

Dead hepatocytes are normally replaced by replication of mature hepatocytes so normal liver function is maintained.

In NAFLD, high levels of oxidative stress causes disruption to the regenerative process; mature hepatocytes present impairment of their replication process, and when cell death occurs, the hepatic progenitor cells (HPC) proliferate. These cells have the capacity to differentiate into either hepatocytes or cholangiocytes and may be involved in carcinogenesis

relating both to hepatocellular carcinoma and to cholangiocarcinoma, which are the final and most severe consequences of this clinical picture.

It is observed that there is a strong association between expansion of HPCs and a ductular reaction in liver biopsy specimens in NASH cases. The extent of ductular reactions strongly correlates with the degree of fibrosis, suggesting that HPC expansion/ductular reaction do play an important role in stimulating progressive periportal fibrosis.

Inter-Organ Crosstalk in NAFLD/NASH

Adipose tissue and the intestines have a very important role in NAFLD and NASH pathogenesis.

Adipose Tissue-Liver Axis and NASH

Obesity and the associated insulin resistance contribute to the hepatic steatosis, NAFLD and NASH. As we previously mentioned, impaired suppression of insulin-mediated lipolysis in adipose tissue leads to hepatic steatosis through increased fatty acid uptake of hepatocytes. In addition, inflammation in adipose tissue affects hepatic inflammation.

Intestine-Liver Axis and NASH

As discussed below, the impairment of this axis is an important causal factor in the pathogenesis of obesity related steatosis, NAFLD/NASH, liver cancer and diverse liver diseases.

Intestinal permeability and increased gut microbial translocation contribute to the inflammatory pathway involved in nonalcoholic steatohepatitis (NASH) development.

Numerous studies have investigated the association between increased intestinal permeability and NASH.

A meta-analysis was performed by Luther J et al. In 2015, in order to confirm that, they compared the rates of increased intestinal permeability in patients with NASH with healthy controls. NASH patients are more likely to have increased intestinal permeability compared with healthy controls.

In mice, an experimental high fat diet, like NAFLD/NASH diets, induces a decrease in Paneth cell area and a lower production of antimicrobial peptides by these cells, reduced Goblet cell number and their mucin secretion, while intestinal permeability is increased. HFD-fed mice are more susceptible to experimental colitis, severe colonic inflammation, accompanied by the expansion of selected pathobionts such as *Atopobium* sp.

Consequently, bacteria or bacterial products are able to reach the liver through the portal vein. In the liver, conserved motifs of bacteria and bacterial products are recognized by receptors of Kupffer cells, infiltrating macrophages, and HSCs. Lipopolysaccharides and bacterial DNA stimulate multiple signaling cascades via interactions with TLR receptors leading to hepatic steatosis, inflammation, and fibrosis in the liver.

Evidence suggests that lipid intermediates derived from the intestine trigger the development of NAFLD/NASH.

One of the pathways is via intestinal hypoxia-inducible factor HIF-2α, which regulates ceramide metabolism by positive expression of *Neu3*, the gene encoding neuraminidase 3.

Human-intestine biopsies from individuals with and without obesity revealed that intestinal HIF-2α signaling was positively correlated with body-mass index and hepatic toxicity. This correlation was verified in mice with an intestine-specific disruption of HIF-2α, in which high-fat-diet-induced hepatic steatosis and obesity were substantially lower as compared to control mice. Intestine HIF-2α inhibition with specific inhibitor markedly reduced intestine and serum ceramide levels.

Gut Bacterial Overgrowth in the Pathogenesis of NASH

Gut microbiota analysis revealed that individuals with NAFLD have a lower percentage of Bacteroides with higher levels of Prevotella and Porphyromonas species compared to healthy controls.

Another study found that the inflammasome-mediated dysbiosis of gut microbiota exacerbates hepatic steatosis and inflammation through enhancing liver TNF-α production.

A murine model of high-fat diet–induced (HFD-induced) NAFLD was used. This study demonstrated that gut microbiota influences NAFLD pathogenesis by regulating the bile acid/intestinal FXR (intestinal farnesoid X receptor) axis that alters the ceramide pathway in the liver and, combined with reduced bacterial fermentation in the gut, results in decreased hepatic lipids. Furthermore, this work reveals an essential role for intestinal FXR in controlling liver lipid metabolism and provides a potential therapeutic strategy for the prevention of disease progression in patients with NAFLD.

Hepatic macrophages play a critical role in maintaining immune homeostasis of the liver.

The liver is constantly exposed to antigens and low levels of endotoxins from the gut since 75% of the liver's blood is supplied from the portal vein.

In normal conditions, small amounts of endotoxins from gut bacteria enter the liver and most of them are eliminated by KCs.

However, the altered composition of microbiota, gut permeability increases and hyper-responsibility of KCs to the gut-derived endotoxin can interrupt this tolerance.

M1 macrophages are abundant and play a critical role in driving inflammation and hepatocyte injury. Macrophage M2 activation is initiated by cytokines IL-10 and IL-4 releasing from prolonged ER stressed hepatocytes.

Macrophage in NASH is associated with toll-like receptor TLR4 activation. During liver injury, macrophages release proinflammatory cytokines such as IL-1β, TNF-α, and IL-6 through the activation of TLR4.

When prolonged, this contributes to T cell activation and results in hepatocyte death and subsequent activation of HSCs.

During NASH, liver macrophages engulf an excessive amount of oxidized low-density lipoprotein and form "foam cells." These macrophage-derived foam cells predominantly contain enlarged lysosomes filled with cholesterol and cholesterol crystals. Increased cholesterol storage inside lysosomes of KCs is associated with hepatic inflammation.

REFERENCES

Albano E., Mottaran E., Vidali M. et al. "Immune response towards lipid peroxidation products as a predictor of progression of non-alcoholic fatty liver disease to advanced fibrosis." *Gut.* 2005. Vol. 54, 7:.987–993.

Arora A. S., Jones B. J., Patel T. C., Bronk S. F., Gores G. J. "Ceramide induces hepatocyte cell death through disruption of mitochondrial function in the rat." *Hepatology*. 1997. Vol. 25:958-63.

Baiceanu A, Mesdom P, Lagouge M, Foufelle F. "Endoplasmic reticulum proteostasis in hepatic steatosis." *Nat Rev Endocrinol*. 2016. Vol 12:710–22.

Bieghs V., Verheyen F., van Gorp P. J. et al. "Internalization of modified lipids by CD36 and SR-A leads to hepatic inflammation and lysosomal cholesterol storage in Kupffer cells," *PLoS ONE*. 2012. Vol. 7, 3, ArticleI De 34378.

Bieghs V., van Gorp P. J., Walenbergh S. M. A. et al. "Specific immunization strategies against oxidized low-density lipoprotein:a novel way to reduce non alcoholic steatohepatitis in mice,." *Hepatology*. 2012. Vol. 56, 3:894–903.

Bijnen M., Josefs T., Cuijpers I., Maalsen C. J., van de Gaar J., Vroomen M., et al. "Adipose tissue macrophages induce hepatic neutrophil recruitment and macrophage accumulation in mice." *Gut.* 2018. Vol. 67:1317-27.

Broz P., Dixit V. M. "Inflammasomes: mechanism of assembly, regulation and signalling." *Nat Rev Immunol*. 2016. Vol. 16:407–20.

Cazzo E., Pareja J. C., Chaim E. A. "Nonalcoholic fatty liver disease and bariatric surgery: a comprehensive review." *Sao Paulo Med J*. 2017. 135 (3):277-295.

Chiappini F., Coilly A., Kadar H., Gual P., Tran A., Desterke C., et al. "Metabolism dysregulation induces a specific lipid signature of nonalcoholic steatohepatitis in patients." *Sci Rep*. 2017. Vol7:46658.

Day C. P and James O. F. W. "Hepatic steatosis: innocent bystanderorguiltyparty?" *Hepatology*, 1998, vol. 27, 6:1463– 1466.

Day C. P. and James O. F. W., "Steatohepatitis: a tale of two 'Hits'?." *Gastroenterology*, 1998. vol. 114, 4I:842–845. (Bis).

Del Campo J. A., Gallego P., Grande L. "Role of inflammatory response in liver diseases: Therapeutic strategies." *World J Hepatol*. 2018. Vol. 10:1–7.

Donnelly K. L., Smith C. I., Schwarzenberg S. J., Jessurun J., Boldt M. D., Parks EJ. "Sources of fatty acids stored in liver and secreted via lipoproteins in patients with nonalcoholic fatty liver disease." *J Clin Invest*. 2005. Vol. 115:1343–51.

Eguchi A., Wree A. and Feldstein A. E. "Biomarkers of liver cell death," *Journal of Hepatology*. 2014. Vol.60, 5:1063–1074.

Eslam M, Valenti L, Romeo S. "Genetics and epigenetics of NAFLD and NASH: clinical impact." *J Hepatol*. 2018. Vol 68:268–79.

Fang D. L., Wan Y., Shen W., Cao J., Sun Z. X., Yu H. H., Zhang Q., Cheng W. H., Chen J., Ning B. "Endoplasmic reticulum stress leads to lipid accumulation through upregulation of SREBP-1c in normal hepatic and hepatoma cells." *Mol Cell Biochem*. 2013. Vol. 381:127–137.

Feldstein A. E., Werneburg N. W., Canbay A., Guicciardi M. E., Bronk S. F., Rydzewski R., et al. "Free fatty acids promote hepatic lipotoxicity by stimulating TNF-alpha expression via a lysosomal pathway." *Hepatology*. 2004. Vol. 40:185-94.

Friedman S. L., "Liverfibrosis in 2013: convergent pathways that cause hepatic fibrosis in NASH." *Nature Reviews Gastroenterology & Hepatology*. 2013. Vol.10, .2: 71–72.

Gadd V. L., Skoien R., Powell E. E. et al. "The portal inflammatory infiltrate and ductular reaction in human non alcoholic fatty liver disease," *Hepatology*, 2014. Vol. 59, 4: 1393–1405.

Han MS, Park SY, Shinzawa K, Kim S, Chung KW, Lee JH, et al. "Lysophosphatidylcholine as a death effector in the lipoapoptosis of hepatocytes." *J Lipid Res*. 2008. Vol. 49:84–97.

Henderson NC, Mackinnon AC, Farnworth SL, Poirier F, Russo FP, Iredale J. P., et al. "Galectin-3 regulates myofibroblast activation and hepatic fibrosis." *Proc Natl Acad Sci USA*. 2006. Vol 103:5060–5.

Henao-Mejia J., Elinav E., Jin C. et al. "Inflammasomemediated dysbiosis regulates progression of NAFLD and obesity." *Nature,* 2012. Vol.482: 179–185.

Hirsova P., Gores G. J. "Death receptor-mediated cell death and proinflammatory signaling in nonalcoholic steatohepatitis." *Cell Mol Gastroenterol Hepatol*. 2015. Vol. 1:17–27.

Hirsova P, Ibrahim SH, Gores GJ, Malhi H. "Lipotoxic lethal and sublethal stress signaling in hepatocytes: relevance to NASH pathogenesis." *J Lipid Res*. 2016. Vol 57:1758–70.

Ibrahim S. H., Hirsova P., Gores G. J. "Non-alcoholic steatohepatitis pathogenesis: sublethal hepatocyte injury as a driver of liver inflammation." *Gut.* 2018. Vol. 67:963–72.

Ioannou G. N., Subramanian S., Chait A., Haigh W. G., Yeh M. M., Farrell G. C., et al. "Cholesterol crystallization within hepatocyte lipid droplets and its role in murine NASH." *J Lipid Res*. 2017. Vol. 58:1067–79.

Jiang C., Xie C., Li F., Zhang L., Nichols R. G., Krausz K. W., et al. "Intestinal farnesoid X receptor signaling promotes nonalcoholic fatty liver disease." *J Clin Invest*. 2015. 125:386–402.

Kim K. H. and Lee M. S." Pathogenesis of Nonalcoholic Steatohepatitis and Hormone-Based Therapeutic Approaches. Pathogenesis and Hormone-Based Therapy of NASH." *Frontiers in Endocrinology*. 2018; 9: 485.

Kolios G., Valatas V. and Kouroumalis E. "Role of Kupffer cells in the pathogenesis of liver disease," *World Journal of Gastroenterology. 2006.* Vol. 12, 46:7413–7420.

Lee J. C., Lee H. Y., Kim T. K., Kim M. S., Park Y. M., Kim J., et al. "Obesogenic diet-induced gut barrier dysfunction and pathobiont expansion aggravate experimental colitis." *PLoS ONE*. 2017.12:e0187515.

Li Z., Berk M., McIntyre T. M., Gores G. J., Feldstein A. E. "The lysosomalmitochondrial axis in free fatty acid-induced hepatic lipotoxicity." *Hepatology*. 2008. Vol. 47:1495-503.

Luther J., Garber J. J., Khalili H., Dave M., Bale S. S., Jindal R., et al. "Hepatic injury in nonalcoholic steatohepatitis contributes to altered intestinal permeability." *Cell Mol Gastroenterol Hepatol*. 2015. Vol. 1:222–32.

Luyckx F. H., Lefebvre P. J., Scheen A. J. Non-alcoholic steatohepatitis: Association with obesity and insulin resistance, and influence of weight loss. *Diabetes Metab*. (2000) 26:98–106.

Magee N., Zou A., and Zhang Yuxia. "Pathogenesis of Nonalcoholic Steatohepatitis: Interactions between Liver Parenchymal and Nonparenchymal Cells." *BioMed Research International.* 2016:5170 402.

Mari M, Caballero F., Colell A., Morales A., Caballeria J., Fernandez A., et al. "Mitochondrial free cholesterol loading sensitizes to TNF- and Fas-mediated steatohepatitis." *Cell Metab*. 2006. Vol. 4:185–98.

Marra F, Svegliati-Baroni G. "Lipotoxicity and the gut-liver axis in NASH pathogenesis." *J Hepatol*. 2018. Vol 68:280–95.

Mota M, Banini BA, Cazanave SC, Sanyal AJ. "Molecular mechanisms of lipotoxicity and glucotoxicity in nonalcoholic fatty liver disease." *Hepatology*. 2016; 65:1049-61.

Mouzaki M., Comelli E. M., Arendt B. M. et al. "Intestinal microbiota in patients with nonalcoholic fatty liver disease," *Hepatology*. 2013. Vol. 58, 1: 120–127.

Nobili V., Parola M., Alisietal A. "Oxidativestressparameters in paediatric non-alcoholic fatty liver disease." *International Journal of Molecular Medicine*. 2010. Vol. 26, .4:471–476.

Peverill W., Powell L. W. and R. Skoien. "Evolving concepts in hepathogenesis of NASH: beyond steatosis and inflammation," 2014. *International Journal of Molecular Sciences*. 2014. Vol. 15, 5:8591–8638).

Pradere J. P., Kluwe J., De Minicis S., Jiao J. J., Gwak G. Y., Dapito D. H., et al. "Hepatic macrophages but not dendritic cells contribute to liver fibrosis by promoting the survival of activated hepatic stellate cells in mice." *Hepatology*. 2013. Vol. 58:1461–73.

Richardson M. M., Jonsson J. R., Powell E. E., et al. "Progressive fibrosis in nonalcoholic steatohepatitis: association with altered regeneration and a ductular reaction" *Gastroenterology*. 2007; 133(1):80-90.

Romeo S, Kozlitina J., Xing C., Pertsemlidis A., Cox D., Pennacchio L. A., et al. "Genetic variation in PNPLA3 confers susceptibility to nonalcoholic fatty liver disease." *Nat Genet*. 2008, 40:1461–5.

Sell H., Habich C. and Eckel J. "Adaptive immunity in obesity and insulin resistance." *Nature Reviews Endocrinology*. 2012. Vol. 8, 12: 709–716).

Song E., Ouyang N., Horbelt M., Antus B., Wang M., Exton M. S. "Influence of alternatively and classically activated macrophages on fibrogenic activities of human fibroblasts." *Cell Immunol*. 2000. Vol. 204:19–28.

Sookoian S, Castano GO, Scian R, et al. "Genetic variation in transmembrane 6 superfamily member 2 and the risk of nonalcoholic fatty liver disease and histological disease severity." *Hepatology*. 2015. Vol 61:515–25.

Steneberg P, Sykaras A. G., Backlund F., Straseviciene J., Soderstrom I., Edlund H. "Hyperinsulinemia enhances hepatic expression of the fatty acid transporter Cd36 and provokes hepatosteatosis and hepatic insulin resistance." *J Biol Chem*. 2015. Vol. 290:19034–43.

Svegliati-Baroni G., De Minicis S., Marzioni M. "Hepatic fibrogenesis in response to chronic liver injury: novel insights on the role of cell-to-cell interaction and transition." *Liver Int*. 2008; 28(8):1052-64.

Sutti S., Jindal A., Locatellietal I., "Adaptive immune responses triggered by oxidative stress contribute to hepatic inflammation in NASH." *Hepatology*. 2014 vol. 59, 3:886–897.

Tang T, Sui Y., Lian M, Li Z., Hua J. "Pro-inflammatory activated Kupffer cells by lipids induce hepatic NKT cells deficiency through activation-induced cell death. *PLoS ONE*. 2013. Vol. 8:e81949.

Tilg H. and Moschen A. R. "Evolution of inflammation in nonalcoholic fatty liver disease: the multiple parallel hits hypothesis." *Hepatology*. 2010, vol. 52, 5:1836–1846.

Tsai E., Lee T. P.”Diagnosis and Evaluation of Nonalcoholic Fatty Liver Disease/ Nonalcoholic Steatohepatitis, Including Noninvasive Biomarkers and Transient Elastography.” *Clin Liver Dis*. 2018; 22, 73-92.

Vargas V, Allende H, Lecube A, et al. “Surgically induced weight loss by gastric bypass improves non-alcoholic fatty liver disease in morbid patients with obesity.” *World J Hepatol*. 2012; 4(12):382-8.

Vonghia L., Michielsen P. and. Francque S. “Immunological mechanisms in the pathophysiology of non-alcoholic steatohepatitis.” *International Journal of Molecular Sciences*. 2013. Vol. 14 (10): 19867–19890.

Walenbergh S. M. A., Koek G. H., Bieghs V., and ShiriSverdlov R. “Non-alcoholic steatohepatitis: the role of oxidized low-density lipoproteins,” *Journal of Hepatology*, 2013. Vol. 58, 4: 801–810.

Wan J., Benkdane M., Teixeira-Clercetal F. “M2 Kupffer cells promote M1 Kupffer cell apoptosis: a protective mechanism against alcoholic and non-alcoholic fatty liver disease” *Hepatology*. 2014. Vol. 59, 1:130–142.

Wan X., Xu C., Yu C. and Li Y. “Role of NLRP3 inflammasome in the progression of NAFLD to NASH.” *Canadian Journal of Gastroenterology and Hepatology*. 2016. Vol.2016.

Wang L., Athinarayanan S., Jiang G., et al. “Fatty acid desaturase 1 gene polymorphisms control human hepatic lipid composition.” *Hepatology*. 2015. Vol 61:119-28.

Wei Y., Wang D., Gentile C. L. Pagliassotti M J. “Reducedendoplasmicreticulum luminal calcium links saturated fatty acid-mediated endoplasmic reticulum stress and cell death in liver cells.” *Mol Cell Biochem*. 2009. Vol. 331:31–40.

Wenfeng Z., Yakun W., Di M., Jianping G, Chuanxin W., and H. Chun, “Kupffer cells: increasingly significant role in nonalcoholic fatty liver disease,” *Annals of Hepatology*. 2014. Vol. 13, 5: 489–495.

Winer D. A., Winer S., Chng M. H. Y., Shen L., and E. G. Engleman. “B Lymphocytes in obesity-related adipose tissue inflammation and insulin resistance,” *Cellular and Molecular Life Sciences*. 2014. Vol. 71, 6:1033–1043.

Xie C, Yagai T, Luo Y, Liang X, Chen T, Wang Q, et al. « Activation of intestinal hypoxia-inducible factor 2alpha during obesity contributes to hepatic steatosis.” *Nat Med*. 2017. Vol. 23:1298–308.

Zhan Y. T. and An W., “Roles of liver innate immune cells in nonalcoholicfattyliverdisease,” *World Journal of Gastroenterology*. 2010, vol. 16, 37, 4652–4660.

Zhang Xue-Qun, Cheng-Fu Xu, Chao-Hui Yu, Wei-Xing Chen, and You-Ming Li. “Role of endoplasmic reticulum stress in the pathogenesis of nonalcoholic fatty liver disease.” *World J Gastroenterol*. 2014. Vol. 20(7): 1768–1776.

In: Encyclopedia of Surgery (22 Volume Set)
Editors: Andreas Lehrer and Kristin Mueller
ISBN: 978-1-53618-329-0
© 2020 Nova Science Publishers, Inc

Chapter 304

EPIDEMIOLOGY AND RELEVANCE OF NASH IN PATIENTS WITH MORBID OBESITY

Leire Zarain-Obrador[1], MD
and Manuel Duran-Poveda[1,2,*], MD, PhD
[1]Department of Endocrine and Bariatric Surgery,
King Juan Carlos University Hospital, Madrid, Spain
[2]Department of Surgery, Faculty of Health Sciences,
King Juan Carlos University, Madrid, Spain

ABSTRACT

Obesity, besides being a common risk factor for a wide range of diseases, such as diabetes, cardiovascular disease or cancer, it is associated with an increased risk of developing non-alcoholic fatty liver disease (NAFLD). It also contributes to the progression of different types of liver diseases, including non-alcoholic steatohepatitis (NASH) and even cirrhosis.

The prevalence of NAFLD has risen in the last decades together with obesity and type 2 diabetes mellitus, becoming the most common chronic liver disease worldwide.

The treatment of NAFLD is based on weight loss, which can be achieved by lifestyle modifications, pharmacologic therapy or bariatric surgery.

Keywords: non-alcoholic fatty liver disease, non-alcoholic steatohepatitis, morbid obesity

INTRODUCTION

Obesity is a disease that usually begins in childhood and it is becoming more frequent each day. It occurs as a result of an imbalance between calorie intake and energy expenditure. Obesity is defined by a body mass index (BMI) $\geq$ 30kg/m2 and morbid obesity as a BMI $\geq$ 40kg/m2. There are many factors involved in the development of obesity, including genetic

* Corresponding Author's Email: manuel.duran@hospitalreyjuancarlos.es.

and environmental factors. These factors can lead to the excessive accumulation of body fat and thereby to the onset of metabolic syndrome. Obesity reflects also a generalized proinflammatory state.

Recent research has shown that obesity, besides being a common risk factor for a wide range of diseases, including diabetes, cardiovascular disease and cancer, is associated with an increased risk of non-alcoholic fatty liver disease (NAFLD). Scientific evidence also demonstrates that obesity contributes to the progression of different types of liver diseases. Actually, it represents a risk factor for developing hepatocellular carcinoma (HCC) together with insulin resistance (IR). NAFLD is 6 times more frequent in obese patients than in normal population. Up to 75% of patients with obesity have some degree of fatty deposits in the liver, which can reach 100% when these patients present morbid obesity.

The prevalence of NAFLD has risen in the last decades, similarly to obesity and type 2 diabetes mellitus (T2D), becoming the most common chronic liver disease worldwide. NAFLD has a reported prevalence of 10 to 46% in Europe and in the United States, while the median prevalence reported worldwide is around 20%. The treatment of NAFLD is based on weight loss through lifestyle modifications, pharmacologic therapy and bariatric surgery. Bariatric surgery does not only contribute to weight loss, but it also improves the co-morbidities associated to obesity, such as T2D and pathological liver histological changes like hepatic inflammation and fibrosis.

DEFINITION OF NAFLD AND NASH

NAFLD is defined as an excessive fatty deposit in the hepatocytes in the absence of alcohol intake and of other known causes of fatty liver. NAFLD ranges from simple steatosis to non-alcoholic steatohepatitis (NASH) and even cirrhosis.

NAFL (non-alcoholic fatty liver) hepatic steatosis is present without evidence of significant inflammation, with > 5% of hepatocytes infiltrated with fat. This deposit of fat in the hepatic parenchyma is pathological when it exceeds 5% of the weight of the liver and other viral or metabolic liver diseases and the consumption of alcohol have been ruled out.

In *NASH* (non-alcoholic steatohepatitis) hepatic steatosis is associated with hepatic inflammation that may be histologically indistinguishable from alcoholic steatohepatitis. This condition will be determinant for the development of liver fibrosis and cancer.

Approximately 10 - 25% of patients with NAFLD will develop NASH, and 5 - 8% of those will develop liver cirrhosis within 5 years. After alcoholism and viral infections, NAFLD is the third main cause of liver cirrhosis.

ETIOLOGY

Hepatic steatosis is caused by the excessive accumulation of toxic lipids in the liver, including triglycerides, free fatty acids (FFA), ceramides and free cholesterol. This accumulation can result from the excessive importation of FFA from adipose tissue, from diminished hepatic export of FFA or from impaired beta-oxidation of FFA.

Although NAFLD has been considered the hepatic manifestation of the metabolic syndrome, new researches have shown that the association between NAFLD and metabolic syndrome is bidirectional. Insulin resistance (IR) and chronic inflammation are primarily responsible for these two entities.

The most important mechanisms in hepatic steatosis involve increased visceral adipose tissue, secretion of proinflammatory cytokines and adipokines and release of FFA into the portal system and systemic circulation, causing dyslipidemia and systemic IR. Therefore, IR, dyslipidemia and T2D could play a role in the etiopathogenesis of this entity. Given the importance of visceral adipose tissue, surveillance for patients with NAFLD should take into account an indicator of visceral obesity, and not only rely on BMI. Increases in visceral adipose tissue and intrahepatic fat correlate with increased gluconeogenesis, increased FFA levels and IR. Visceral fat is also associated with liver inflammation and fibrosis in patients with NASH, irrespective of IR, possibly through the mediation of interleukin-6 (a proinflammatory cytokine).

The main pathogenic factor related to steatosis is the increased flow and hepatic uptake of non-esterified fatty acids from excessive peripheral lipolysis, as a consequence of peripheral IR. Research has proved that adipose tissue (especially visceral adipose tissue) is subject to a state of chronic inflammation, with the ability to secrete adipokines. This fact has allowed to relate hepatic inflammation and the metabolic disorders that lead to the accumulation of triglycerides. NAFLD may also be present together with some endocrine diseases, such as polycystic ovary syndrome, hypothyroidism, growth hormone deficiency or hypercortisolism.

CLINICAL FEATURES

NAFLD usually occurs between the fourth and sixth decade of life. Most patients are clinically asymptomatic, although some of them may complain of fatigue, dyspepsia, and vague right upper abdominal discomfort. Regarding physical findings, some patients may have hepatomegaly due to fatty infiltration of the liver, but this is not a common finding and it might be related to patients with more advanced disease. We could also find stigmata of chronic liver disease in patients who have developed cirrhosis.

DIAGNOSIS

The diagnosis of NAFLD requires to rule out any history of alcohol abuse (< 30g/day in men and < 20g/day in women) and other causes of hepatic steatosis, such as hepatitis C virus infection, autoimmune hepatitis, Wilson's disease, medication use, starvation, parenteral nutrition, etc.

Methods for diagnosing NAFLD can be divided into non-invasive and invasive. Among the non-invasive we find laboratory tests and radiographic examinations. As for invasive methods, we refer mainly to liver biopsy, which is the gold standard for the diagnosis of NAFLD. Furthermore liver biopsy is the only method available to differentiate NAFL from NASH.

Most patients with NAFL or mild NASH are asymptomatic and NAFLD is detected accidentally in a routine analysis. Actually elevated liver enzymes are detected in approximately 20% of NAFLD patients.

Regarding *laboratory tests*, aspartate aminotransferase (AST) and alanine aminotransferase (ALT) levels can be normal or moderately elevated. Also an AST: ALT ratio < 1 supports the diagnosis of NASH. Besides liver enzymes, the following tests should also be obtained: anti-hepatitis C virus antibody, hepatitis A IgG, hepatitis B surface antigen, surface antibody and core antibody. We should also obtain iron levels, ferritin, and total iron binding capacity. Finally there is a series of parameters related to autoimmune hepatitis that should be assessed, such as serum gammaglobulin level or antinuclear body. However laboratory tests might be normal, and when they show any abnormality, they are not sufficient for making the diagnosis. In terms of *radiographic examinations*, ultrasound is the most available method and it represents the first-line diagnostic tool for detecting liver steatosis. It is a useful tool for diagnosing moderate to severe degree hepatic steatosis, but its accuracy is limited regarding mild steatosis. There are other methods that are also used, such as computed tomography (CT), magnetic resonance (MRI) and proton magnetic resonance spectroscopy (MRS). CT has limitations such as the fact that there is a potential risk related to its radiation and it has also a limited accuracy in detecting mild steatosis. MRI and MRS provide a highly accurate and reproducible diagnosis for evaluating NAFLD.

We must also take into account FibroScan, which is used to assess liver fibrosis by measuring liver stiffness.

Nevertheless, as non-invasive methods cannot make a distinction between simple steatosis and NASH, liver biopsy remains necessary, especially when radiographic examinations are not consistent with fatty infiltration, when other causes for steatosis have not been excluded or when the patient has signs or symptoms of cirrhosis.

As for *liver biopsy*, it remains the gold standard for the diagnosis of NAFLD and it represents the only method to confirm the diagnosis of NASH as well as for establishing the different stages of fibrosis. However it is only performed when the diagnosis remains unclear after obtaining laboratory tests and hepatic imaging, or if the information provided by the biopsy might condition the patient's treatment. The reason why this technique is so restrictively indicated is that it constitutes an invasive method with possible serious complications. In addition, histological alterations of the liver are not distributed homogeneously and the biopsy may be unrepresentative.

TREATMENT

Although the optimal treatment has yet to be elucidated, the treatment of NAFLD is focused on weight loss. For achieving this goal we count on three therapeutic weapons that can be complementary: lifestyle modifications, pharmacologic therapy and bariatric surgery. The main goal of these therapies is to slow down or stop the disease progression, whether it is in its earliest stages or in the stage of fibrosis or cirrhosis.

For the inflammatory parameters of the liver to improve, patients must lose at least 5% of their total weight. If weight loss exceeds 7%, NASH may be resolved. However, to reduce the degree of liver fibrosis, patients must lose at least 10% of their total weight.

The improvement of NAFLD is directly proportional to the weight loss, regardless of whether it has been achieved through lifestyle changes or bariatric surgery.

Lifestyle Modification

First line therapy for NAFLD includes lifestyle changes aimed at weight loss through low-calorie diets and physical exercise. Weight loss leads to a reduction in both visceral adipose tissue and IR. There are different publications that show a significant reduction of hepatic steatosis after the implantation of lifestyle changes, as well as an improvement in IR and BMI.

It is not clear what kind of exercise is the most beneficial, but it has been shown that adding physical exercise to a low-calorie diet can enhance the benefits in the management of NAFLD and IR, regardless of weight loss.

Pharmacologic Therapy

Nowadays there is not any drug specifically accepted for the treatment of NAFLD, with weight loss being the only treatment that has proved to be effective.

Metformin has beneficial effects in preventing diabetes onset and leads to mild weight loss. These two effects are also beneficial for NAFLD patients, although metformin has not proved to have a direct effect on liver histology.

Another pharmacologic option would be pioglitazone, which also helps in improving IR and histological hepatic disease activity. However, due to its side effects, its general application is not recommended.

Bariatric Surgery

In Europe and North America, the prevalence of NAFLD among patients whose BMI overcomes 40Kg/m2 ranges between 75% an 100%. However, NAFLD alone does not constitute an indication for bariatric surgery at the moment.

Weight loss, regardless the way it is achieved, is the most important factor related to the improvement in the histological characteristics of patients with NAFLD. In fact, this improvement is directly proportional to the weight lost. In this regard, bariatric surgery allows the patient to achieve a greater and sustained weight loss over time. In addition, the main etiologic factors involved in the development of NAFLD are obesity and IR, and there is scientific evidence that bariatric surgery is effective both for weight loss and for the resolution of diabetes mellitus type 2.

As for the most recommended bariatric surgery technique, sleeve gastrectomy and gastrointestinal bypass techniques have proved to be superior to gastric banding in terms of weight loss.

It is important to take into account the stage of liver disease in obese patients with NAFLD undergoing bariatric surgery, since liver cirrhosis is associated with increased postoperative morbidity and mortality. Furthermore it is also important to bear in mind that

the mortality of these patients decreases as the experience of both the medical and surgical team increases.

In the case of obese patients with NAFLD presenting Child-Pugh class A liver cirrhosis without portal hypertension or decompensation, both sleeve gastrectomy and gastrointestinal bypass are recommended. However, it should be borne in mind that some publications describe that gastrointestinal bypass techniques can lead to the massive destruction of adipocytes and an important increase in the levels of free fatty acids that are taken up by the liver, which results in worsening of steatosis, steatohepatitis, or even cirrhosis.

Fortunately this complication was rather related to more aggressive techniques that are no longer performed as the jejunoileal bypass procedure, and it is exceptional to find it after the completion of a Roux-en-Y gastric bypass (RYGB), which is the most common derivative technique today. Nevertheless, since sleeve gastrectomy (SG) does not have a derivative component, it is considered to be more physiological and has less risk of hepatic decompensation both during the immediate postoperative period and during the weight loss that takes place after surgery.

It also allows endoscopic access to the gastric sleeve and duodenum, which may be important depending on the evolution of the hepatopathy of these patients.

Therefore, in obese patients who have developed cirrhosis, surgical treatment will be conditioned by the stage of liver disease presented by the patient, which will be measured using the Child-Pugh scale or the MELD-Score. We must bear in mind that patients with decompensated cirrhosis should not undergo bariatric surgery given the high risk of potentially serious and even fatal complications.

Bariatric surgery using mixed procedures (restrictive and malabsorptive) as a Roux-en-Y gastric bypass, improves liver abnormalities associated with non alcoholic fatty liver disease in morbidly obese patients.

Kalinowski et al. studied the evolution of NAFLD and NASH using intraoperative liver biopsies in patients who underwent bariatric surgery (SG vs RYGB). Patients who underwent SG showed significant improvements in AST, ALT, and gamma-glutamyltransferase at 12 months which revealed a greater improvement in liver abnormalities and inflammation for SG.

Praveen Raj and coworkers showed a greater improvement of steatosis, lobular inflammation, ballooning degeneration and fibrosis among patients with NAFLD who underwent a sleeve gastrectomy in comparison to a Roux-en-Y gastric bypass.

CONCLUSION

We can conclude that it is important to analyze through further studies the benefit of bariatric surgery in patients with NAFLD and high risk of developing cirrhosis, given the existing evidence that these techniques improve both liver steatosis and fibrosis, besides contributing to weight loss and the improvement of insulin resistance.

REFERENCES

Aller, R. Consensus document. Management of Non-alcoholic fatty liver disease: Clinical guidelines. *Gastroenterol. Hepatol.,* 2018;41(5):328 - 349.

Brunner, K. T., Henneberg, C. J., Wilechansky, R. M. et al. Nonalcoholic Fatty Liver Disease and Obesity Treatment. *Curr. Obes. Rep.,* 2019 Apr. 3. doi: 10.1007/s13679-019-00345-1.

Brunt, E. M., Tiniakos, D. G. Alcoholic and non-alcoholic fatty liver disease. In: *Surgical pathology of the GI tract, liver, biliary tract and pancreas*, 2nd ed. Odze, R. D., Goldblum, J. R. (Eds), Elsevier, Philadelphia 2009. P. 1007.

Buqué, X., Aspichueta, P., Ochoa, B. Molecular basis of obesity-related liver steatosis. *Rev. Esp. Enferm. Dig.,* 2008; 100: 565 - 578.

Caldwell, S. H., Oelsner, D. H., Iezzoni, J. C. et al. Cryptogenic cirrhosis: clinical characterization and risk factors for underlying disease. *Hepatology*, 1999; 29:664.

Chalasani, N., Younossi, Z., Lavine, J. E. et al. The diagnosis and management of nonalcoholic fatty liver disease: Practice guidance from the American Association for the Study of Liver diseases. *Hepatology*, 2018; 67:328.

Dietrich, P., Hellerbrand, C. Non-alcoholic fatty liver disease, obesity and the metabolic syndrome. *Best Practice and Research Clinical Gastroenterology*, 2014; 28:637 - 653.

Donnelly, K. L., Smith, C. I., Schwarzenberg, S. J. et al. Sources of fatty acids stored in iver and secreted via lipoproteins in patients with non-alcoholic fatty liver disease. *J. Clin. Invest.,* 2005; 115:1343.

European Association for the Study of the Liver (EASL), European Association for the Study of Diabetes (EASD), European Association for the Study of Obesity (EASO). EASL-EASD-EASO Clinical Practice Guidelines for the management of non-alcoholic fatty liver disease. *J. Hepatol.,* 2016; 64:1388.

Graffy, P. M., Pickhardt, P. J. Quantification of hepatic and visceral fat by CT and MR imaging: relevance to the obesity epidemic, metabolic syndrome and NAFLD. *Br. J. Radiol.,* 2016; 89: 20151024.

Hannah, W. N., Jr., Harrison, S. A. Effect of Weight Loss, Diet, Exercise, and Bariatric Surgery on Nonalcoholic Fatty Liver Disease. *Clinics in liver disease,* 2016;20(2):339 - 350.

Ipsen, D. H., Lykkesfeldt, J., Tveden-Nyborg, P. Molecular mechanisms of hepatic lipid accumulation in non-alcoholic fatty liver disease. *Cellular and Molecular Life Sciences*, 2018; 75: 3313 - 3327.

Jan, A., Narwaria, M., Mahawar, K. K. A Systematic Review of Bariatric Surgery in Patients with Liver Cirrhosis. *Obes. Surg.,* 2015; 25(8): 1518 - 1526.

Kalinowski, P., Paluszkiewicz, R., Wróblewski, T. et al. Ghrelin, leptin, and glycemic control after sleeve gastrectomy versus Roux-en-Y gastric bypass—results of a randomized clinical trial. *Surg. Obes. Relat. Dis.,* 2017; 13:181 - 188.

Kneeman, J. M., Misdraji, J., Corey, K. E. Secondary causes of nonalcoholic fatty liver disease. *Therap. Adv. Gastroenterol.,* 2012; 5(3):199 - 207.

Lee, H. W., Kim, K. J., Jung, K. S. et al. The relationship between visceral obesity and hepatic steatosis measured by controlled attenuation parameter. *PloS ONE*, 2017; 12 (10): e0187066.

Lee, D. H. Imaging evaluation of non-alcoholic fatty liver disease: focused on quantification. *Clin. Mol. Hepatol.,* 2017; 23: 290 - 301.

Ludwig, J., Viggiano, T. R., McGill, D. B. et al. Nonalcoholic steatohepatitis: Mayo Clinic experiences with a hitherto unnamed disease. *Mayo Clin. Proc.,* 1980; 55:434.

Marino, L., Jornayvaz, F. R. Endocrine causes of nonalcoholic fatty liver disease. *World J. Gastroenterol.,* 2015; 21(39):11053 - 11076.

Matteoni, C. A., Younossi, Z. M., Gramlich, T. et al. Nonalcoholic fatty liver disease: a spectrum of clinical and pathological severity. *Gastroenterology,* 1999; 116:1413.

Milic, S., Lulic, D., Stimac, D. Non-alcoholic fatty liver disease and obesity: Biochemical, metabolic and clinical presentations. *World J. Gastroenterol.,* 2014; 20 (28): 9330 - 9337.

Miquilena Colina, M. E., García Monzón, C. Obesity and fatty liver. *Gastroenterol. Hepatol.,* 2011;10:5.

Miquilena Colina, M. E., García Monzón, C. Obesity and liver disease. *Gastroenterol. Hepatol.,* 2010:33:591 - 604.

Nassir, F., Rector, R. S., Hammoud, G. M. et al. Pathogenesis and Prevention of Hepatic Steatosis. *Gastroenterology and Hepatology,* 2015; 11: 167 - 175.

Neuschwander Tetri, B. A., Caldwell, S. H. Nonalcoholic steatohepatitis: summary of an AASLD Single Topic Conference. *Hepatology,* 2003; 37:1202.

Praveen, Raj P., Gomes, R. M., Kumar, S. et al. The effect of surgically induced weight loss on nonalcoholic fatty liver disease in morbidly obese Indians: "NASHOST" prospective observational trial. *Surg. Obes. Relat. Dis.,* 2015; 11(6): 1315 - 22.

Promrat, K., Kleiner, D. E., Niemeier, H. M. et al. Randomized Controlled Trial Testing the Effects of Weight Loss on Nonalcoholic Steatohepatitis (NASH). *Hepatology,* (Baltimore, Md). 2010; 51(1):121 - 129.

Sanders, F. W. B., Acharjee, A., Walker, C., et al. Hepatic steatosis risk is partly driven by increased de novo lipogenesis following carbohydrate consumption. *Genome Biology,* (2018) 19:79.

Sheth, S. G., Gordon, F. D., Chopra, S. Nonalcoholic steatohepatitis. *Ann. Intern. Med.,* 1997; 126:137.

Van der Poorten, D., Milner, K. L., Hui, J. et al. Visceral fat: a key mediator of steatohepatitis in metabolic liver disease. *Hepatology,* 2008; 48:449.

Vargas, V., Allende, H., Lecube, A. et al. Surgically induced weight loss by gastric bypass improves non alcoholic fatty liver disease in morbid obese patients. *World J. Hepatol.,* 2012; 4(12):382 -8.

Vilar-Gomez, E., Martinez-Perez, Y., Calzadilla-Bertot, L. et al. Weight Loss Through Lifestyle Modification Significantly Reduces Features of Nonalcoholic Steatohepatitis. *Gastroenterology,* 2015; 149(2):367 - 378.

In: Encyclopedia of Surgery (22 Volume Set)
Editors: Andreas Lehrer and Kristin Mueller
ISBN: 978-1-53618-329-0
© 2020 Nova Science Publishers, Inc

Chapter 305

FATTY LIVER DEVELOPMENT: IMBALANCE BETWEEN ACQUISITION AND REMOVAL OF LIPIDS

Lorea Zubiaga*, MD, PhD
Lille University, Inserm-U1190, EGID, CHU Lille, Lille, France

ABSTRACT

Fatty liver, hepatic steatosis and Nonalcoholic fatty liver disease (NAFLD) is an umbrella of terms used to describe a range of related disorders characterized by the deposition of triglycerides as droplets in the cytoplasm of hepatocytes. The fatty liver is now considered a multifaceted complex systemic condition. Moreover, recent evidence suggests that this steatosis may progress to an advanced liver fibrosis challenging the previous dogma that "*steatosis is a benign condition*". High levels of insulin and insulin resistance are often associated with hepatic steatosis and although it is necessary, is not sufficient for the disease debut and progress. NAFLD, obesity, Type 2 Diabetes and Metabolic syndrome are linked by a vicious circle which induce several difficulties in the metabolic control and where bariatric and metabolic surgery has changed many paradigms.

Keywords: fatty liver, western diet, *de novo* lipogenesis, fatty acids, very low density lipoprotein, insulin resistance

INTRODUCTION

Fatty liver is the most frequent chronic hepatic disease in developed countries and its prevalence runs in parallels the rise in obesity, type 2 diabetes (T2D) and metabolic syndrome (MetS). This disease is associated to the modern life and its most common interpretation is related to over-nutrition and consumption of well-known western diet [1]. However, the fatty

* Corresponding Author's Email: loreazubiaga@gmail.com.

liver can also be induced by endocrine disorders, viral infections or side effects of pharmacological therapies. In most cases it is an ailment that causes no symptoms and it moves silently generating tissue damage to liver parenchyma, which can lead to fibrosis as NASH, them cirrhosis and finally the liver failure [2].

Fatty liver begins with the aberrant accumulation of triglycerides (TG) in the liver. The pathogenesis of this disease remains poorly understood and its evolution of the liver steatosis is directly interconnected to classic components of the metabolic syndrome as: hyperglycemia, hyper-insulinemia, insulin resistance and hypertriglyceridemia [3]. However, most of the patients with fatty liver display all of these conditions independent of body weight [4]. In fact, the "lean NAFLD" phenotype has a renewed interest among researchers. This fact is due to that this condition developments selectively increase in visceral adiposity without changes in the body mass index and, sometimes, even with normal waist circumference [5]. This "lean NAFLD" patient develops metabolic problems and cardiovascular disease similarly to obese patients and this is a worrisome problem, because these patients are difficult to diagnose and even more difficult to treat [6]. However, the "lean NAFLD" allow us to study the genetic component of this disease. A recent publication confirms that the fatty liver development and progression derive from a complex interplay between genetic and environmental factor [7], and we should probably distinguish a strong genetic component of the disease from the metabolic origin as such as in the diabetes (type 1 diabetes/MODY/T2D) [8]. However, in this assessment we will focus on the physiopathology hypotheses of this disease that are closer to obesity, concentrating the concepts on the damage associated with environmental rather than genetic causes and without entering the complex world of inflammatory and immunological signals that also accompany this disease.

ASSUMPTIONS AND DATA

Fatty Acids as a Regular Fuel for Energy

As a central regulator of lipid homeostasis, the liver is responsible for directing the synthesis of new fatty acids, their export and subsequent redistribution to other tissues, as well as their utilization as energy substrates [9]. Nearly all forms of fatty acids have an even number of carbon atoms and they can be presented as individual fatty acids or free fatty acids (FFA) and also as non-esterified fatty acids (NEFA) [10]. Fatty acids are the foremost metabolic fuel in the body and they play a central role providing energy to the majority of tissues (except brain, which use glucose) particularly during fasting. Circulating FFA are reabsorbed in various organs where, if not oxidized, they accumulate as intra-cytoplasmic droplets of TG or like some lipid intermediates, such as the diacyl-glycerols (DAG), molecules which, sometimes can promote cell lipotoxicity [11]. In the liver, the major storage form of FFA is in triglycerides (TG) shape. The selection of TG as energy resource in the body comes from two physicochemical properties: TG provides greater caloric density (9 kcal/g) than other substrates (4 kcal/g from carbohydrates or proteins) and they can accumulate to high levels in the cell with no adverse osmotic or colloidal effects. However, the lipids accumulation on the liver is defined as the deposition of TG as droplets in the cytoplasm of hepatocytes in more that 5% of these cells [12].

Buildup of Lipids in the Liver Is a Normal Response to Fasting

Hepatic lipid accumulation occurs transiently as a metabolic adaptation to continuous food deprivation (fasting or starvation). In humans, this period normally corresponds to 12–24 h without food intake [13]. In the first phase of fasting, the hepatic glucose output is derived both from gluconeogenesis and glycogenolysis. Both process entail a reduction of glycogen stores in the liver. However, if an extra demand of energy occurs during this period, hormonal signals stimulate adipose tissue to release NEFA into circulation to address to the liver where they will be used as energy substrates. Within a prolonged period of fasting the reduction of hepatic glycogen stores further stimulates adipose tissue lipolysis. This feedback is essential to maintain a constant supply of energy to the body [9]. During this process the liver upregulates expression of the hepatic fatty acid transporter. Fatty acids in the liver act as main substrate for the oxidative process and to generate ketones. In this way, the liver maintains two mechanisms that prevent the oxidation of amino acids in the hepatic parenchyma. Avoiding oxidation of amino acids is essential for normal functions in the cells. During a period of starvation (fasting periods prolonged for more than 60 hours) the accumulation of hepatic lipids is higher but also begins the second phase of the liver as an energy provider through the transformation of those lipids into molecules that can travel to other organs and make up for the energy deficit (as ketone bodies and lipoproteins) [14]. In this sense, the lipid stockpiling in the liver and the transformation of them in energy seems to be a protective mechanism to all body when food intake is compromised [13].

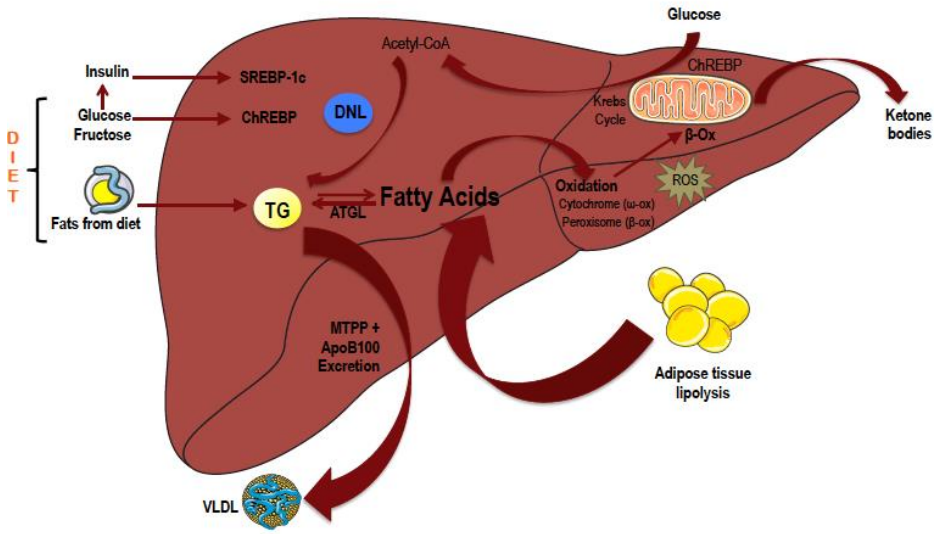

Figure 1. Lipid metabolism in the liver.. Processes that increase the entry of fatty acids and triglycerides or reduce their exit can cause hepatic steatosis. The main sources of FFA are: diet, endogenous synthesis and lipolysis in peripheral tissues. Carbohydrate intake increases glucose and insulin levels, which activate two transcription factors (ChREBP and SREBP-1c) in the liver that promote de novo lipogenesis (DNL). FFAs have several possible destinations within the hepatic parenchyma: 1) Esterified by adipose triglyceride lipase (ATGL) and stored as triglycerides (TG) in lipid droplets. 2) Metabolized by oxidation processes (B-ox or W-ox) forming substrates for a new synthesis (Acetyl-CoA) and also as reactive oxygen species (ROS). They can also form ketone bodies that are expelled into the circulation. 3) Packed with apoB100 by means of Microsomal triglyceride transfer protein (MTTP) and segregated in the blood as low-density lipoproteins (VLDL).

The mechanisms that promote the liver fat piling up are not fully elucidated but it has been hypothesized that when the fatty acids acquisitions exceeds the capacity for removal them, these fatty acids are over-stored. The fatty acids used for hepatic TG formation are derived from three sources: (1) diet, (2) De Novo synthesis, and from (3) the adipose tissue. In the other side, fatty acids that arrives to the liver parenchyma have three major destinations: (a) They can be oxidized to produce energy and ketone bodies, (b) re-esterified to TG and stored in droplets, or (c) coupled to apolipoproteins and secreted as very-low-density lipoproteins (VLDL) [15]. An overview of each of these processes is described in Figure 1 and will be described below.

Fatty Liver and Diet

The increasing prevalence of fatty liver the increased in the general population over the past 40 years is due to changes in the quantity and composition of food. Specifically, has been attributed to the widespread availability of the so-called western diet that is rich in saturated fats and refined sugars [16]. The western diet (WD) is mainly described as a high-fat/high-sugar diet or specifically as high-cholesterol/sucrose (fructose) diet. Regardless of the combination of the elements that define the WD, what is relevant in this nutritional form is the fact that this diet promotes hepatic steatosis in conjunction with altered liver transcriptomic and metabolomic profiles. These altered profiles completely modify the signals that control liver functions, inducing phenomena that can be paradoxical. For example, giving the order to increase the internal storages when in reality there is already an excess of fats [1].

Analyzing in detail the effect of the WD it has described the influence of hypercaloric diets on fatty liver. Indeed, when talking about high-calorie diets, it is easy to understand diets rich in saturated fatty acids (SFA). However, the studies analyzing the hypercaloric point of view usually have been undertaken using different degrees of energy excess and the macronutrient of interest are the carbohydrates [2]. In fact, some of these studies have demonstrated that an acute consumption of a high-fructose diet leads to a significant increase in liver fat content [17]. The most plausible hypothesis for this phenomenon is that fructose consumption routes dietary carbons directly to the liver in a promptly manner to enter biosynthetic pathways, including De Novo lipogenesis (DNL) [18]. The way in which this process predisposes to fat accumulation will be described later in the reading. Nonetheless, when comparing hypercaloric diets enriched in either fructose or glucose it would appear that both influence liver fat accumulation in a similar manner [19]. The majority of carbohydrates in the WD coming from added extrinsic sugars (Ex. sucrose and corn syrup). The added sugars universally present in modern food are added to enhance the taste in some beverages and processed food and they are consumed unnoticed manner. Both sucrose and corn syrup are composed of approximately 50/50 proportion of fructose/glucose and these two sugars consumed in combination are more deleterious and more inclined to stimulates DNL than when they are taken isolated [20].

On the other hand, faced with the same amount of calories, the predominant effect is the composition of macronutrients in the diet. Thus, a diet composed mainly of SFA will be more harmful even if it has a lower calorie intake [2]. Diets rich in SFA cause an increase in the accumulation of hepatic TG, while diets rich in monounsaturated fatty acids (MUFA) or

polyunsaturated fatty acids (PUFA) tend to decrease the TG in the liver. The mechanism by which the SFA lead to an accumulation of TG is not yet clarified, although it has been suggested that the lipotoxity of this kind of fat alters per se the oxidative stress of the cell (at the endoplasmic reticulum level and/or mitochondrial) [21]. There are also hypotheses that point to a disordered metabolism of phospholipids [22] or to alterations in the regulation of lipogenic genes, which promote the production and accumulation of TG. In general, all of these ideas pose a disturbance of liver to handle a high flow of lipids from the diets. As these lipids cannot enter the oxidation or lipoprotein production pathways, they accumulate in the parenchyma [11]. Supporting this idea, Koopman et al. reported that the accumulation of fat in the liver was noticeably greater when the same amount of calories were consumed in a greater number of intakes during the day; i.e., isocaloric high fat diets taken 5 times a day (meals + snacks) were more harmful than taken 3 times (meals) a day [23]. Therefore, in the development of fatty liver not only the number of calories is important, but also how they are distributed in relation to the composition of macronutrients, as well as the frequency with which these calories are ingested during the day.

Adipose Tissue Lipolysis and Hepatic Lipid Uptake

When energy demand exceeds metabolic energy from diet, NEFAs are mobilized from white adipose tissue (WAT) by the lipolysis. Lipolysis process is stimulated by the catecholamines while the insulin is the key signal to inhibit it. During fasting and intense exercise, insulin levels are low, allowing norepinephrine, cortisol and growth hormone to synergistically stimulate lipolysis from the WAT, allowing an increase of circulating fatty acid availability [24]. Hormonally regulated lipolysis depends on the activity of the lipolytic enzyme, hormone-sensitive lipase (HSL). Insulin and catecholamines from sympathetic nervous system (SNS) modulate HSL activity by decreasing and increasing respectively the energetic signals coming from the adipocytes. SNS activity also stimulates cortisol release. The metabolic response of WAT to corticoids also depends on the duration of exposure, where chronic stimulation induces the lipolysis by transcriptionally regulation of HSL [25]. Excessive lipolysis and adipose tissue fatty acid release into circulation results in ectopic accumulation of lipids as liver and the vascular system.

In obesity, as in fasting periods, there is a rise in sympathetic activity and adipose tissue lipolysis [26]. This increased lipolytic response is associated to the excess of the adiposity, characterized by a decreased lipolytic capacity in subcutaneous adipose tissue and an increased lipolysis from VAT [27]. In subcutaneous adipose tissue, obesity decreases HSL expression, limiting sensitivity to adrenergic stimulation. However, in obesity there is an increase of sensitivity to catecholamine-induced lipolysis in the visceral fat so, catecholamine-stimulated lipolysis depends on the regional adipose tissue depot. The reduction of the lipolytic hormone expression along with increased adipose tissue mass results in more adipose-tissue-derived fatty acids entering circulation in obese than in normal- weight individuals [28]. Moreover, in obesity the clearance by skeletal muscle is decreased. This phenomenon allows the increased lipolysis in the adipose tissue results in hyperlipidemia and an increased hepatic lipid uptake, which, is critical for the development of hepatic TG accumulation [29].

De novo Lipogenesis

Hepatic *De novo* lipogenesis (DNL) is the biochemical process of fatty acids synthesis from acetyl-CoA subunits coming from different pathways, most commonly from glycolysis and carbohydrate catabolism [30]. The DNL is driven by two transcription factors that are widely expressed in the liver and in the adipose tissue: the Sterol Response Element Binding Protein 1c (SREBP1c) and the Carbohydrate Response Element Binding Protein (ChREBP). Both factors regulate expression of key lipogenic genes to produce the fatty-acid synthase and the acetyl-CoA carboxylase, the two key enzymes of DNL. These enzymes use the acetyl-CoA and the malonyl-CoA derived from glucose catabolism (or other carbon precursors) to generate palmitate [31]. Usually, the palmitate has detrimental effects in the body; however, the palmitate synthesized by DNL, can be modified by endogenous enzymes to produce multiple lipid species that are easily to storage [32].

Under normal physiological conditions, an increase of circulating glucose is followed by a rise in lipogenic enzyme expression, which stimulates hepatic glucose clearance and storage of the carbons as fatty acids and TG. Carbohydrates en general and specially glucose regulate directly the ChREBP activity. In the same sense, postprandial hyperglycemia leads to increase circulating insulin and this hormone stimulates SREBP1c in the liver. Thus, the hyperglycemic and hyperinsulinemic conditions are closely linked to DLN. In addition, SREBP1c indirectly contributes to the development of hepatic insulin resistance, since enhanced lipogenesis and subsequent accumulation of harmful lipid species, such as DAG, which in turn may interfere with insulin signaling [11].

While glucose is the main substrate for DNL, fructose is a highly lipogenic substrate which can provides an extended number of carbons. The importance of fructose as a lipogenic substrate comes from the main function of the liver in fructose clearance. In the first pass of portal circulation after meal ingestion, the liver sequesters 71% of dietary fructose, while only takes 13% of glucose [33]. Moreover, fructose is phosphorylated at carbon 1 rather than carbon 6, so it cannot be used to synthesize glycogen but instead is quantitatively converted to glyceraldehyde-3-phosphate, providing the main substrate for DLN. Similarly, fructose may bypass the critical regulatory step catalyzed by phosphofructokinase-1 in glycolysis [34] so it can enter directly to biosynthesis reactions. Even more, fructose also potentiates glucose-stimulated insulin secretion and also increases the activation of ChREBP. In this way, a diet rich in fructose increases ChREBP binding to DNA nearly four fold [35]. This has implications that mean fructose may reinforce some of the pathogenic mechanisms leading to fatty liver via DLN.

Another pathway associated with DLN is mediated by excess in glucocorticoids. The 11β-hydroxysteroid dehydrogenase type 1 (11β-HSD1) is a key enzyme that catalyzes the intracellular conversion of cortisone to physiologically active cortisol and it is an NADPH-dependent enzyme highly expressed in key metabolic tissues as the liver and the adipose tissue. The expression of this enzyme is up-regulated in obesity leading to an excess of glucocorticoid production cortisol overproduction from adipose tissue is an important stimulus for the liver's lipogenic pathways, however local liver cortisol production is much more active to stimulate the fatty acids production. In fat, corticoids contribute to driving hepatic steatosis by decreasing lipid oxidation and increasing DNL and TG esterification [13].

Fatty Acids Oxidation and Ketogenesis

Oxidation of fatty acids occurs principally in the mitochondria, providing a source of energy to generate ATP especially when circulating glucose levels are low. During this process, fatty acid chains are broken apart into acetic acid fragments and generates acetyl-CoA molecules that are further oxidized by the citric acid cycle (TCA/Krebs cycle) to produce carbon dioxide and water and release energy. This process is traditionally called Beta-oxidation (β-ox). β-ox is primarily facilitated by the hepatocytes mitochondria due the action of the mitochondrial tri-functional protein (MTP), an enzyme that catalyzes the last 3 steps of this process [36]. Hepatic β-ox in response to lipid accumulation prevents lipotoxicity and providing extra energy when in periods of starvation, the gluconeogenesis is insufficient. In this sense, limiting β-ox process is usually associated to a severe exacerbation of hepatic lipid accumulation [37].

However, the oxidation also can be developed in the cytoplasm by the peroxisomes (β-ox) or cytochromes (ω-ox). These two last settings usually are activated due to mitochondria lack the ability to oxidize very long chain fatty acids or when exists environments with lipid overload. However, these two processes generate considerable amounts of reactive oxygen species (ROS), oxidative stress, and toxic dicarboxylic acids, potentially promoting inflammation and hepatic damage [15]. Indeed, lipid oxidation by these pathways can produce a damage into mitochondrial DNA further diminish mitochondrial function, establishing a self-perpetuating vicious cycle to exacerbate mitochondrial dysfunction and oxidative stress [38].

DNL is usually responsible for the steatosis resulting from high-frutose diets. However, fructose can also promotes the inhibition of β-ox via carnitine palmitoyltransferase I (CPT1) activity inhibition. This enzyme regulates the formation of acyl-carnitines by catalyzing the transfer of the acyl group of a long-chain fatty acyl-CoA from coenzyme A to l-carnitine. The resulting product is often Palmitoylcarnitine the first committed intermediate produced during fatty acid synthesis. But, inhibition of CPT1 resulting increases malonyl-CoA synthesis and chronically downregulates the expression of beta-oxidative genes [13]. One again, the hepatic lipid accumulation resulting from dietary fructose also affects another process, which is key in the lipids distribution.

β-ox is upregulated in the post-absorptive state and reduced in the postprandial state, a response mediated by systemic substrate and hormone concentrations. For example, the glucagon stimulates β-ox by upregulation of peroxisome proliferator-activated receptor α (PPARα) activity, while insulin and glucose downregulates β-ox by suppressing adipose tissue TG lipolysis, reducing the delivery of fatty acids to the liver and increasing hepatic DNL [11]. Thus, obesity can causes a decrease in beta-oxidation, which contributes to lipid accumulation [38].

Ketogenesis is the catabolic process for ketone bodies production through breakdown of fatty acids. This process supplies energy under circumstances such as fasting or caloric restriction to certain organs, particularly the brain, heart and skeletal muscle. This event is notably important when the gluconeogenesis process is insufficient and can cause hypoglycemia. As energy requirements are urgent the liver oxidizes fats and manufactures ketone bodies [39]. Ketogenesis occurs constantly in a compensatory amount in healthy individuals but it can also take place when there is insufficient insulin (Ex. in type 1 diabetes), particularly during periods of “ketogenic stress”. In these cases, pushing the body to

chronically supply itself with energy from ketone bodies can create a lethal condition called ketoacidosis. Fatty acids are enzymatically broken down in β-ox to form acetyl-CoA. However, if the amounts of acetyl-CoA generated in this process overwhelm the capacity of the TCA cycle, acetyl-CoA is then used instead in biosynthesis of ketone bodies. Hepatic ketogenesis could potentially contribute to control and avoid fatty liver pathogenesis, because it is activated in states of FFA circulation and diminished carbohydrate availability concentrations are very low. But, in obesity the raised FFA levels exceed the ketogenic machinery as various substrates and enzymes from this process cannot be recycled at the same rate as they are consumed. On the other hand, hyperglycemia acts as inhibitor of ketogenesis. In both pathways, the decrease of ketone bodies production rate allows the lipids accumulation in the liver [37].

Liver Lipoprotein Management

A central metabolic role of the liver is to maintain plasma glucose within narrow physiological limits regardless of the nutritional state of the animal. In energy excess, glucose is converted to fatty acids, which are further used to synthesize TG. Hepatic TG derives from: 1) uptake of circulating fatty acids; 2) uptake of circulating remnants of VLDL and chylomicron (lipase action); and 3) through the hepatic DNL TG can be stored or incorporated into very-low-density lipoproteins (VLDL) and secreted into the blood. VLDL synthesis by the liver involves complex processes such as synthesis and the coordinated assembly of protein components (apolipoproteins) and of hydrophilic (phospholipids, free cholesterol) and hydrophobic (triacylglycerols (TAG), cholesteryl esters) lipid components. VLDL particles are formed in the endoplasmic reticulum, where apolipoprotein B100 (apoB100) is lipidated in a process catalyzed by the enzyme microsomal triglyceride transfer protein (MTTP) [40]. Consequently, apoB100 and MTTP are key elements in hepatic VLDL secretion and in maintaining hepatic lipid homeostasis and some genetic defect in one of these 2 elements is associated with the presence of fatty liver. The production and transport of the VLDL is an efficient source of energy either for storage in adipose tissue or for its utilization by muscles [41].

The precise mechanisms responsible for the close relationship between fatty liver and obesity are still unknown, but is evident to think that if exist a blockade of hepatic VLDL production and secretion, this situation results in an accumulation of TG in the liver favoring the development of fatty liver. However, other hypotheses have been proposed with the insulin in the target. Postprandial insulin can suppress hepatic VLDL production by a number of mechanisms, including the down-regulation of the MTTP gene expression, increasing degradation of apoB within hepatocytes and inhibiting the maturation of VLDL. However, the suppressive effect of insulin on VLDL production is reversed in chronic hyperinsulinemia conditions. In addition, it has been reported that high levels of insulin plus insulin-resistence do not decrease the production of the VLDL, but instead they stimulated it [42] as in obesity, T2D and MetS. In this sense, the IR of adipose tissue leads to higher circulating NEFA concentrations, and an increased FFA flux to the liver stimulating hepatic TG synthesis so, lipids storages increase in a first stage of fatty liver. The excess of lipids in the liver parenchyma also impairs hepatic extraction of insulin. Hepatic insulin resistance is also linked to an increasing TG synthesis and VLDL production and secretion as VLDL-TG.

Despite higher VLDL-TG secretion in patients with fatty liver, regular VLDL-apoB100 secretion did not change, suggesting that hepatic steatosis patients do not secrete additional, but instead larger and more TG-rich, VLDL particles. Nevertheless, enormous VLDL particles cannot be secreted when they have a diameter that exceeds that of the sinusoidal endothelial pores [11]. This situation can be another cause for lipids accumulation in the liver parenchyma.

Glucoregulatory Hormones

Insulin

Most patients with fatty liver have hyperinsulinemia and IR at the same time, leaving to glimpse that insulin seems to be associated in several disturbances in the called metabolic diseases [43]. In fact, postprandial hyperinsulinemia is present in 100% of NAFLD individuals and usually is independent of diabetes status [44]. Insulin promotes the DLN and glycerol-neogenesis, both pathways are raised in steatosis, even in non-diabetic patients, contributing to the synthesis of hepatic TG and the promotion of fatty liver. In NAFLD patients the IR promotes the activation of hepatic stellate cells, which are the trigger that initiates the fibrogenesis process that characterize NASH [45]. In the same manner, hepatic synthesis of palmitate (via DNL stimulated by insulin) can cause increases the risk of lipotoxicity and cell damage. Moreover, hyperinsulinemia and IR are considered better predictors of hepatic injury than visceral adiposity [46]. Therefore, insulin high levels and IR conditions are linked with abnormal concentration of lipoproteins, elevated VLDL production, high levels of plasmatic cholesterol, TG and LDL that allows to cardiovascular diseases.

Glucagon

Glucagon function is opposite that of insulin since glucagon stimulates glucose production via activation of hepatic glycogenolysis and gluconeogenesis by glycolysis inhibition. It also regulates fatty acid metabolism via stimulation of peripheral lipolysis, reduction of malonyl-CoA and stimulation of fatty acid oxidation. Elevated plasma concentrations of glucagon have been reported in patients with cirrhosis, chronic hepatitis and fatty liver disease. In this last group, fasting high levels of glucagon were reported whether or not the patients were diabetic [47]. This evidence has suggested that hyperglucagonemia may have originated from a liver-steatosis rather than a pancreatic compensatory signals in the T2D evolution. As in the case of insulin, know if exists a previous hormone-resistance in the tissues, or if the resistance is due to hormonal overstimulation is still the dilemma. However, it was proposed that the level of liver TG may be involved in the mechanism of HF diet-induced glucagon resistance in the liver. This suggestion is supported the TG levels correlated inversely proportional to the glucagon-stimulated hepatic glucose production. Impairment in the expression of glucagon receptors it has been also linked to the liver fat content [48].

CONCLUSION

A balance between lipid acquisition and disposal establishes intrahepatic fat levels. In general, it has been reported that liver acquires lipids through the uptake of circulating fatty acids (from the diet or adipose tissue lipolysis) and via DNL. Conversely, lipids may be consumed through beta-oxidation ketogenesis and through export VDLD particles. Regarding this, it is possible guess why bariatric surgery is useful in the manage of the fatty liver, since the vast majority of techniques reduces hepatic fat acquisition pathways and regulates IR, common factor in this metabolic disorders.

REFERENCES

[1] Sarr O, Mathers KE, Zhao L, Dunlop K, Chiu J, Guglielmo CG, et al. Western diet consumption through early life induces microvesicular hepatic steatosis in association with an altered metabolome in low birth weight Guinea pigs. *J Nutr Biochem.* 2019;67:219-33. Epub 2019/04/15. doi: 10.1016/j.jnutbio.2019.02.009. PubMed PMID: 30981986.

[2] Parry SA, Hodson L. Influence of dietary macronutrients on liver fat accumulation and metabolism. *J Investig Med.* 2017;65(8):1102-15. Epub 2017/09/28. doi: 10.1136/jim-2017-000524. PubMed PMID: 28947639; PubMed Central PMCID: PMCPMC 5749316.

[3] Saponaro C, Gaggini M, Gastaldelli A. Nonalcoholic fatty liver disease and type 2 diabetes: common pathophysiologic mechanisms. *Curr Diab Rep.* 2015;15(6):607. Epub 2015/04/22. doi: 10.1007/s11892-015-0607-4. PubMed PMID: 25894944.

[4] Chitturi S, Abeygunasekera S, Farrell GC, Holmes-Walker J, Hui JM, Fung C, et al. NASH and insulin resistance: Insulin hypersecretion and specific association with the insulin resistance syndrome. *Hepatology.* 2002;35(2):373-9. Epub 2002/02/05. doi: 10.1053/jhep.2002.30692. PubMed PMID: 11826411.

[5] Lonardo A, Targher G. NAFLD: Is There Anything New under the Sun? *Int J Mol Sci.* 2017;18(9). Epub 2017/09/13. doi: 10.3390/ijms18091955. PubMed PMID: 28895919; PubMed Central PMCID: PMCPMC5618604.

[6] Wattacheril J, Sanyal AJ. Lean NAFLD: An Underrecognized Outlier. *Curr Hepatol Rep.* 2016;15(2):134-9. Epub 2016/09/27. doi: 10.1007/s11901-016-0302-1. PubMed PMID: 27668144; PubMed Central PMCID: PMCPMC5030075.

[7] Stender S, Kozlitina J, Nordestgaard BG, Tybjaerg-Hansen A, Hobbs HH, Cohen JC. Adiposity amplifies the genetic risk of fatty liver disease conferred by multiple loci. *Nat Genet.* 2017;49(6):842-7. Epub 2017/04/25. doi: 10.1038/ng.3855. PubMed PMID: 28436986; PubMed Central PMCID: PMCPMC5562020.

[8] Gastaldelli A. Insulin resistance and reduced metabolic flexibility: cause or consequence of NAFLD? *Clin Sci (Lond).* 2017;131(22):2701-4. Epub 2017/11/08. doi: 10.1042/CS20170987. PubMed PMID: 29109303.

[9] Nguyen P, Leray V, Diez M, Serisier S, Le Bloc'h J, Siliart B, et al. Liver lipid metabolism. *J Anim Physiol Anim Nutr (Berl).* 2008; 92(3):272-83. Epub 2008/05/15. doi: 10.1111/j.1439-0396.2007.00752.x. PubMed PMID: 18477307.

[10] Ratnayake WM, Galli C. Fat and fatty acid terminology, methods of analysis and fat digestion and metabolism: a background review paper. *Ann Nutr Metab.* 2009;55(1-3):8-43. Epub 2009/09/16. doi: 10.1159/000228994. PubMed PMID: 19752534.

[11] Ipsen DH, Lykkesfeldt J, Tveden-Nyborg P. Molecular mechanisms of hepatic lipid accumulation in non-alcoholic fatty liver disease. *Cell Mol Life Sci.* 2018;75(18):3313-27. Epub 2018/06/25. doi: 10.1007/s00018-018-2860-6. PubMed PMID: 29936596; PubMed Central PMCID: PMCPMC6105174.

[12] Szczepaniak LS, Nurenberg P, Leonard D, Browning JD, Reingold JS, Grundy S, et al. Magnetic resonance spectroscopy to measure hepatic triglyceride content: prevalence of hepatic steatosis in the general population. *Am J Physiol Endocrinol Metab.* 2005;288(2):E462-8. Epub 2004/09/02. doi: 10.1152/ajpendo.00064.2004. PubMed PMID: 15339742.

[13] Geisler CE, Renquist BJ. Hepatic lipid accumulation: cause and consequence of dysregulated glucoregulatory hormones. *J Endocrinol.* 2017;234(1):R1-R21. Epub 2017/04/22. doi: 10.1530/JOE-16-0513. PubMed PMID: 28428362.

[14] Anton SD, Moehl K, Donahoo WT, Marosi K, Lee SA, Mainous AG, 3rd, et al. Flipping the Metabolic Switch: Understanding and Applying the Health Benefits of Fasting. *Obesity* (Silver Spring). 2018;26(2):254-68. Epub 2017/11/01. doi: 10.1002/oby.22065. PubMed PMID: 29086496; PubMed Central PMCID: PMCPMC5783752.

[15] Cohen JC, Horton JD, Hobbs HH. Human fatty liver disease: old questions and new insights. *Science.* 2011;332(6037):1519-23. Epub 2011/06/28. doi: 10.1126/science.1204265. PubMed PMID: 21700865; PubMed Central PMCID: PMCPMC3229276.

[16] Hodson L, Rosqvist F, Parry SA. The influence of dietary fatty acids on liver fat content and metabolism. *Proc Nutr Soc*. 2019:1-12. Epub 2019/04/04. doi: 10.1017/S0029665119000569. PubMed PMID: 30942685.

[17] Ngo Sock ET, Le KA, Ith M, Kreis R, Boesch C, Tappy L. Effects of a short-term overfeeding with fructose or glucose in healthy young males. *Br J Nutr.* 2010;103(7):939-43. Epub 2009/11/26. doi: 10.1017/S0007114509992819. PubMed PMID: 19930762.

[18] Tappy L, Le KA, Tran C, Paquot N. Fructose and metabolic diseases: new findings, new questions. *Nutrition.* 2010;26(11-12):1044-9. Epub 2010/05/18. doi: 10.1016/j.nut.2010.02.014. PubMed PMID: 20471804.

[19] Johnston RD, Stephenson MC, Crossland H, Cordon SM, Palcidi E, Cox EF, et al. No difference between high-fructose and high-glucose diets on liver triacylglycerol or biochemistry in healthy overweight men. *Gastroenterology.* 2013;145(5):1016-25 e2. Epub 2013/07/23. doi: 10.1053/j.gastro.2013.07.012. PubMed PMID: 23872500.

[20] Silbernagel G, Lutjohann D, Machann J, Meichsner S, Kantartzis K, Schick F, et al. Cholesterol synthesis is associated with hepatic lipid content and dependent on fructose/glucose intake in healthy humans. *Exp Diabetes Res.* 2012;2012:361863. Epub 2011/12/29. doi: 10.1155/2012/361863. PubMed PMID: 22203835; PubMed Central PMCID: PMCPMC3235776.

[21] Puri P, Baillie RA, Wiest MM, Mirshahi F, Choudhury J, Cheung O, et al. A lipidomic analysis of nonalcoholic fatty liver disease. *Hepatology.* 2007;46(4):1081-90. Epub 2007/07/27. doi: 10.1002/hep.21763. PubMed PMID: 17654743.

[22] Leamy AK, Egnatchik RA, Young JD. Molecular mechanisms and the role of saturated fatty acids in the progression of non-alcoholic fatty liver disease. *Prog Lipid Res.* 2013;52(1):165-74. Epub 2012/11/28. doi: 10.1016/j.plipres.2012.10.004. PubMed PMID: 23178552; PubMed Central PMCID: PMCPMC3868987.

[23] Koopman KE, Caan MW, Nederveen AJ, Pels A, Ackermans MT, Fliers E, et al. Hypercaloric diets with increased meal frequency, but not meal size, increase intrahepatic triglycerides: a randomized controlled trial. *Hepatology.* 2014;60(2):545-53. Epub 2014/03/29. doi: 10.1002/hep.27149. PubMed PMID: 24668862; PubMed Central PMCID: PMCPMC4265261.

[24] Djurhuus CB, Gravholt CH, Nielsen S, Pedersen SB, Moller N, Schmitz O. Additive effects of cortisol and growth hormone on regional and systemic lipolysis in humans. *Am J Physiol Endocrinol Metab.* 2004;286(3):E488-94. Epub 2003/11/06. doi: 10.1152/ajpendo.00199.2003. PubMed PMID: 14600073.

[25] Watt MJ, Holmes AG, Pinnamaneni SK, Garnham AP, Steinberg GR, Kemp BE, et al. Regulation of HSL serine phosphorylation in skeletal muscle and adipose tissue. *Am J Physiol Endocrinol Metab.* 2006; 290(3):E500-8. Epub 2005/09/29. doi: 10.1152/ajpendo.00361.2005. PubMed PMID: 16188906.

[26] Thorp AA, Schlaich MP. Relevance of Sympathetic Nervous System Activation in Obesity and Metabolic Syndrome. *J Diabetes Res.* 2015;2015:341583. Epub 2015/06/13. doi: 10.1155/2015/341583. PubMed PMID: 26064978; PubMed Central PMCID: PMCPMC4430650.

[27] Wang S, Huang Y, Xu H, Zhu Q, Lu H, Zhang M, et al. Oxidized tea polyphenols prevent lipid accumulation in liver and visceral white adipose tissue in rats. *Eur J Nutr.* 2017;56(6):2037-48. Epub 2016/06/09. doi: 10.1007/s00394-016-1241-x. PubMed PMID: 27271251.

[28] Howe HR, 3rd, Heidal K, Choi MD, Kraus RM, Boyle K, Hickner RC. Increased adipose tissue lipolysis after a 2-week high-fat diet in sedentary overweight/obese men. *Metabolism. 2*011;60(7):976-81. Epub 2010/11/03. doi: 10.1016/j.metabol.2010.09.007. PubMed PMID: 21040937; PubMed Central PMCID: PMCPMC3868457.

[29] Wilson CG, Tran JL, Erion DM, Vera NB, Febbraio M, Weiss EJ. Hepatocyte-Specific Disruption of CD36 Attenuates Fatty Liver and Improves Insulin Sensitivity in HFD-Fed Mice. *Endocrinology.* 2016;157(2):570-85. Epub 2015/12/10. doi: 10.1210/en.2015-1866. PubMed PMID: 26650570; PubMed Central PMCID: PMCPMC4733118.

[30] Hellerstein MK. De novo lipogenesis in humans: metabolic and regulatory aspects. *Eur J Clin Nutr.* 1999;53 Suppl 1:S53-65. Epub 1999/06/12. PubMed PMID: 10365981.

[31] Sanders FW, Griffin JL. De novo lipogenesis in the liver in health and disease: more than just a shunting yard for glucose. *Biol Rev Camb Philos Soc.* 2016;91(2):452-68. Epub 2015/03/06. doi: 10.1111/brv.12178. PubMed PMID: 25740151; PubMed Central PMCID: PMCPMC4832395.

[32] Ameer F, Scandiuzzi L, Hasnain S, Kalbacher H, Zaidi N. De novo lipogenesis in health and disease. *Metabolism.* 2014;63(7):895-902. Epub 2014/05/13. doi: 10.1016/j.metabol.2014.04.003. PubMed PMID: 24814684.

[33] Muratoglu M, Kuyumjian J, Kalant N. First-pass hepatic uptake and utilization of glucose in the rat. *Biochem J.* 1986;233(1):245-8. Epub 1986/01/01. doi: 10.1042/bj2330245. PubMed PMID: 3954727; PubMed Central PMCID: PMCPMC1153010.

[34] Basaranoglu M, Basaranoglu G, Sabuncu T, Senturk H. Fructose as a key player in the development of fatty liver disease. *World J Gastroenterol.* 2013;19(8):1166-72. Epub 2013/03/14. doi: 10.3748/wjg.v19.i8.1166. PubMed PMID: 23482247; PubMed Central PMCID: PMCPMC3587472.

[35] Koo HY, Miyashita M, Cho BH, Nakamura MT. Replacing dietary glucose with fructose increases ChREBP activity and SREBP-1 protein in rat liver nucleus. *Biochem Biophys Res Commun.* 2009;390(2):285-9. Epub 2009/10/06. doi: 10.1016/j.bbrc.2009.09.109. PubMed PMID: 19799862.

[36] Amako Y, Munakata T, Kohara M, Siddiqui A, Peers C, Harris M. Hepatitis C virus attenuates mitochondrial lipid beta-oxidation by downregulating mitochondrial trifunctional-protein expression. *J Virol.* 2015;89(8):4092-101. Epub 2015/02/13. doi: 10.1128/JVI.01653-14. PubMed PMID: 25673715; PubMed Central PMCID: PMCPMC4442397.

[37] Mannisto VT, Simonen M, Hyysalo J, Soininen P, Kangas AJ, Kamin-ska D, et al. Ketone body production is differentially altered in steatosis and non-alcoholic steatohepatitis in obese humans. *Liver Int.* 2015;35(7):1853-61. Epub 2014/12/24. doi: 10.1111/liv.12769. PubMed PMID: 25533197.

[38] Nassir F, Ibdah JA. Role of mitochondria in nonalcoholic fatty liver disease. *Int J Mol Sci.* 2014;15(5):8713-42. Epub 2014/05/20. doi: 10.3390/ijms15058713. PubMed PMID: 24837835; PubMed Central PMCID: PMCPMC4057755.

[39] Geisler CE, Ghimire S, Bogan RL, Renquist BJ. Role of ketone signaling in the hepatic response to fasting. *Am J Physiol Gastrointest Liver Physiol.* 2019;316(5):G623-G31. Epub 2019/02/16. doi: 10.1152/ajpgi.00415.2017. PubMed PMID: 30767679.

[40] Minehira K, Young SG, Villanueva CJ, Yetukuri L, Oresic M, Hellerstein MK, et al. Blocking VLDL secretion causes hepatic steatosis but does not affect peripheral lipid stores or insulin sensitivity in mice. *J Lipid Res.* 2008;49(9):2038-44. Epub 2008/06/03. doi: 10.1194/jlr.M800248-JLR200. PubMed PMID: 18515909; PubMed Central PMCID: PMCPMC3837456.

[41] Lonardo A, Lombardini S, Scaglioni F, Carulli L, Ricchi M, Ganazzi D, et al. Hepatic steatosis and insulin resistance: does etiology make a difference? *J Hepatol.* 2006;44(1):190-6. Epub 2005/09/20. doi: 10.1016/j.jhep.2005.06.018. PubMed PMID: 16168516.

[42] Duvillard L, Florentin E, Pont F, Petit JM, Baillot-Rudoni S, Penfornis A, et al. Endogenous chronic hyperinsulinemia does not increase the production rate of VLDL apolipoprotein B: proof from a kinetic study in patients with insulinoma. *J Clin Endocrinol Metab.* 2011;96(7):2163-70. Epub 2011/03/25. doi: 10.1210/jc.2010-2946. PubMed PMID: 21430026.

[43] Bugianesi E, McCullough AJ, Marchesini G. Insulin resistance: a metabolic pathway to chronic liver disease. *Hepatology*. 2005;42(5):987-1000. Epub 2005/10/27. doi: 10.1002/hep.20920. PubMed PMID: 16250043.

[44] Manchanayake J, Chitturi S, Nolan C, Farrell GC. Postprandial hyperinsulinemia is universal in non-diabetic patients with nonalcoholic fatty liver disease. *J Gastroenterol Hepatol.* 2011; 26(3):510-6. Epub 2010/12/16. doi: 10.1111/j.1440-1746.2010.06528.x. PubMed PMID: 21155882.

[45] Gaggini M, Morelli M, Buzzigoli E, DeFronzo RA, Bugianesi E, Gastaldelli A. Non-alcoholic fatty liver disease (NAFLD) and its connection with insulin resistance,

dyslipidemia, atherosclerosis and coronary heart disease. *Nutrients.* 2013;5(5):1544-60. Epub 2013/05/ 15. doi: 10.3390/nu5051544. PubMed PMID: 23666091; PubMed Central PMCID: PMCPMC3708335.

[46] Perseghin G. Lipids in the wrong place: visceral fat and nonalcoholic steatohepatitis. *Diabetes Care.* 2011;34 Suppl 2:S367-70. Epub 2011/05/06. doi: 10.2337/dc11-s249. PubMed PMID: 21525484; PubMed Central PMCID: PMCPMC3632209.

[47] Junker AE, Gluud LL, van Hall G, Holst JJ, Knop FK, Vilsboll T. Effects of glucagon-like peptide-1 on glucagon secretion in patients with non-alcoholic fatty liver disease. *J Hepatol.* 2016;64(4):908-15. Epub 2015/12/03. doi: 10.1016/j.jhep.2015.11.014. PubMed PMID: 26626496.

[48] Charbonneau A, Unson CG, Lavoie JM. High-fat diet-induced hepatic steatosis reduces glucagon receptor content in rat hepatocytes: potential interaction with acute exercise. *J Physiol.* 2007;579(Pt 1):255-67. Epub 2006/10/21. doi: 10.1113/jphysiol.2006.121954. PubMed PMID: 17053032; PubMed Central PMCID: PMCPMC2075374.

In: Encyclopedia of Surgery (22 Volume Set)
Editors: Andreas Lehrer and Kristin Mueller
ISBN: 978-1-53618-329-0
© 2020 Nova Science Publishers, Inc

Chapter 306

HISTOPATHOLOGY OF NAFLD AND NASH

Soledad García-Gómez-Heras*
Human Histology and Pathology, Health Science Department,
Rey Juan Carlos University, Madrid, Spain

ABSTRACT

The histopathological features of adult NAFLD/NASH are: hepatocellular steatosis, hepatocellular ballooning, inflammatory infiltrate, fibrosis, glycogenated nuclei, apoptotic hepatocytes, Mallory-Denk Bodies (MDBs), iron deposition, megamitochondria and ductular reaction. The necessary components for the diagnosis of NASH are: steatosis (accentuated in zone 3), lobular inflammation (mixed, mild) and hepatocellular ballooning (most apparent near steatotic liver cells, typically in zone 3). Fibrosis is not necessary for the diagnosis of NASH, although it is usually present.

There are different histopathological scoring systems and all have both pros and cons. The methods currently used to semi-quantitatively evaluate the histological lesions of NAFLD are: the NAFLD Activity Score (NAS) and Fibrosis Score by the NASH Clinical Research Network (NASH-CRN) and the 'Fatty Liver Inhibition of Progression (FLIP)' Algorithm and Steatosis, Activity, and Fibrosis (SAF) Score. These ideas will be, discussed in this chapter.

Keywords: histopathology, NASH, hepatocellular-Steatosis, Mallory-Den bodies, steatohepatitic hepatocellular carcinoma, liver fibrosis

HISTOPHATOLOGICAL LESIONS IN THE LIVER

From a morphological point of view, the liver is an organ with a limited repertoire of responses against aggression. Regardless of the cause, five types of response can be observed.

* Corresponding Author's Email: soledad.garcia@urjc.es.

1. Inflammation

The hepatocyte lesion associated with the arrival of acute or chronic inflammatory cells to the liver is called hepatitis. The attack to liver cells expressing viable antigens by sensitized T lymphocytes is a frequent cause for the hepatic lesion. Inflammation may be limited to the lymphocytes' point of entry (portal spaces) or spread to the rest of parenchyma.

Although hepatocyte necrosis can precede inflammation, it can also be the other way around. When hepatocytes experience necrosis or apoptosis, the macrophages in charge of withdrawing the remainders quickly phagocytize the dead cells and generate groups of inflammatory cells in an otherwise normal parenchyma. Foreign bodies, microorganisms, and different drugs can trigger these granulomatous-type reactions.

2. Degeneration

Alterations that are secondary to toxic or immune aggressions can make hepatocytes adopt a swollen and edematous aspect, ballooning degeneration), with irregular blots in the cytoplasm and huge empty spaces.

Another possibility is when the biliar material retained confers a swollen and diffuse spongy appearance to hepatocytes, vacuolar degeneration.

In viable hepatocytes, different types of substances (like iron, copper, fat or retained biliar material) can accumulate. The concentration of fat droplets inside hepatocytes is called steatosis. When they are multiple tiny droplets that do not displace the nucleus, this is called microvacuolar steatosis, typical of acute alcoholic liver disease, Reye syndrome, and acute hepatic steatosis of pregnancy.

In livers of obese or diabetic patients, a single huge vacuole can be found. It is able to displace the nucleus. This lesion constitutes macrovacuolar steatosis.

3. Cell Death

Any important aggression to the liver can cause hepatocyte destruction.

When cell death is caused by immune or toxic mechanisms, it takes place through apoptosis, in which isolated hepatocytes retract, show pyknosis, and acquire an intensely eosinophilic aspect. Other hepatocytes may swell osmotically and break, in the so-called hydropic degeneration or lithic necrosis.

In the case of necrosis, liver cells appear a bit stained and mummified with a greater frequency due to ischemia (coagulative necrosis).

In the context of ischemia and various pharmacologic and toxic reactions, hepatocellular necrosis is distributed throughout the regions surrounding central veins (centrolobulillar necrosis). Mediozonal or pure periportal necrosis are rare.

In the most severe toxic or inflammatory lesions, apoptosis or necrosis of contiguous hepatocytes may comprehend adjacent lobules following a porto-portal pattern, porto-central pattern, or centro-central pattern (bridging necrosis).

Necroses in whole lobules (submassive necrosis) or in most part of liver parenchyma (massive necrosis) normally cause liver failure.

4. Fibrosis

Tissue generates fibrous tissue as a response to inflammation or to a direct toxic aggression.

This collagen deposit has everlasting consequences for hepatocyte irrigation and perfusion patterns. In the first stages, fibrosis arises in the interior or around porta spaces or central veins, or deposits directly in sinusoids. Over time, fibrous bands end up joining liver regions (porto-portal, porto-central or centro-central). This process is called bridging fibrosis.

Unlike other lesions that are reversible, fibrosis normally is an irreversible consequence of liver lesions. However, under certain circumstances, fibrosis has shown to decrease when the liver lesion has stopped. The best known cases of fibrosis regression are hepatic schistosomiasis infection and hereditary hemochromatosis.

5. Cirrhosis

When fibrosis and parenchymal lesions are maintained, the liver will end up subdivided into nodules of hepatocytes in regeneration, surrounded by scar tissue, and this is called cirrhosis.

It is one of the main causes of death in the Western world. Regardless of etiology, end-stage cirrhosis is characterized by:

- fibrous walls, in the form of delicate bands or wide scars replacing several adjacent lobules.
- parenchymal nodules, caused by the regeneration of hepatocytes that were isolated, of a size ranging from small (less than 3 mm diameter or micronodules) and large (up to several cm diameter or macronodules).
- alteration of the whole liver architecture.

Cirrhosis pathogenesis. The three main anatomopathological mechanisms that combine to produce cirrhosis are hepatocellular death, regeneration, and progressive fibrosis.

Regarding fibrosis, an element to consider is that the normal liver contains types I, III, and IV interstitial collagen. It concentrates in porta spaces and around centrolobulillar veins, with occasional bands in the parenchyma. A delicate reticular grid of IV collagen is arranged in the space between endothelial cells in the sinusoids and hepatocytes (space of Disse). In cirrhosis, type I and III collagen, as well as other components of extracellular matrix, deposit in all portions of lobules, thus causing endothelial cells of the sinusoids to lose their fenestrations. Furthermore, bypasses generate between the porta vein and the liver vein, as well as between the liver artery and the portal vein. All these processes finally transform the sinusoids of fenestrated endothelial channels, where interexchange of solutes between plasma and hepatocytes is free, into vascular channels of a greater pressure and slow flow, in which such solute interexchange does not take place. The impairment is especially marked in the movement of proteins between hepatocytes and plasma.

The greatest part of collagen excess present in cirrhosis seems to come from perisinusoidal Ito cells orstellate cells that store fat and are located in the space of Disse. Although, in normal conditions, their main function is to store vitamin A and lipids, during

cirrhosis development they activate and lose their retinol ester deposits and transform into myofibroblastic cells. The stimuli for collagen synthesis and deposit can come from several sources:

- chronic inflammation with synthesis of inflammatory cytokines, TNF, IL-1.
- cytosine production by stimulated endogenous cells (Kupffer cells, endothelial cells, hepatocytes, and epithelial cells in biliary ducts).
- alteration of extracellular matrix.
- direct stimulation of stellate cells by toxins.

TYPICAL NAFLD AND NASH LIVER LESIONS

Histopathologically, non-alcoholic fatty liver disease (NAFLD) is classified into two categories: only hepatocellular steatosis, and nonalcoholic steatohepatitis (NASH), where necroinflammatory damage appears associated with steatosis.

Simple steatosis generally has a benign clinical course, but one third of NAFLD cases progress and advance to NASH, liver cirrhosis and hepatocellular carcinoma (HCC).

The histopathological characteristics of NASH have been established since 2002. The necessary components for the diagnosis of NASH are: steatosis (accentuated in zone 3), lobular inflammation (mixed, mild) and hepatocellular ballooning (most apparent near steatotic liver cells, typically in zone 3). Fibrosis is not necessary for the diagnosis of NASH, although it is usually present.

Most hepatopathologists diagnose NASH according to these criteria, although a complete consensus has not been reached, as we will later explain.

Below are explained the histopathological features of adult NASH. (Figure 1.)

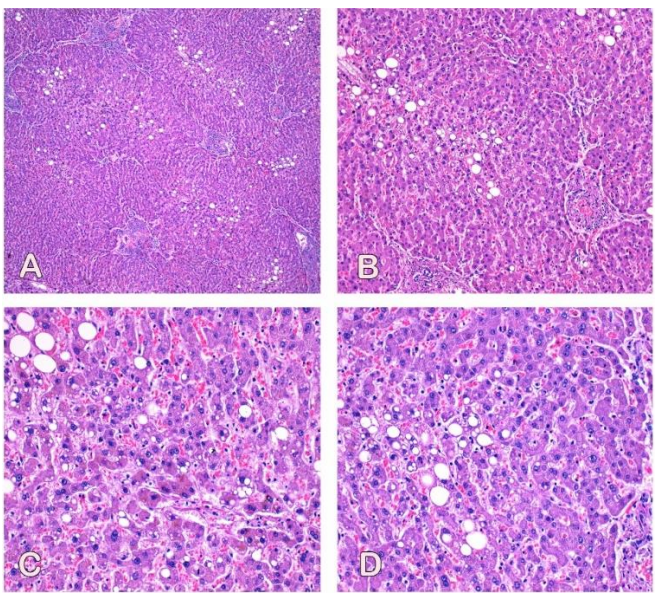

Figure 1. Histopathological lesions in NASH liver. A. hematoxiline-eosin, 100x. B. Portal inflammatory infiltrate. 200x. C and D. Hepatocellular steatosis. 400x.

1. Hepatocellular Steatosis

More than 5% of hepatocytes with steatosis is the hallmark of NAFLD.

It is usually macrovesicular, as a single large fat droplet nearly fills or occupies the cytoplasm of hepatocytes, pushing the nucleus to the periphery.

In few cases it can be observed where the cytoplasm of hepatocytes is filled with tiny lipid droplets and the nucleus is located centrally in the cell.

It usually begins in zone 3, and as the diseases progresses, liver affectation extends and becomes severe steatosis. This latter may end up being panacinar steatosis. As the severity of steatosis increases, other accompanying lesions appear as lobular inflammation and zone 3 fibrosis.

In cases of panacinar steatosis, it appears associated with ballooning, Mallory-Denk bodies (MDBs) and advanced fibrosis

2. Hepatocellular Ballooning

Ballooning hepatocellular injury is the other key diagnostic feature of steatohepatitis.

This lesion reflects hepatocellular injury. It is characterized as having swollen or "balloon-shaped" hepatocytes that loose the sharp angles and exhibit a clear and non-vacuolar cytoplasm.

These hepatocytes may or may not be larger than non-pathological hepatocytes, fat droplets and/or Mallory-Denk Bodies (MDBs) may be observed in their cytoplasm.

Studies using electron microscopy and immunostaining have evaluated the nature of ballooned hepatocytes. It results from alteration of cytokeratins 8 and 18, the cytoskeleton intermediate filament; they are disrupted and dispersed to the periphery.

In slides stained with hematoxylin and eosin, the recognition of ballooned hepatocytes may be difficult; the loss of cytokeratin 8/18 immunostaining can serve as an objective marker of ballooned hepatocytes.

3. Inflammatory Infiltrate

This can be lobular and portal inflammation.

The lobular inflammation in NASH is usually mild and, when abundant, suggests another or associated causes such as alcohol or drug toxicity.

It consists of a mixed inflammatory cell infiltrate: lymphocytes, neutrophils, eosinophils and Kupffer cells (KC).

It is possible to find an infiltrate predominantly lymphocytary.

Aggregates of neutrophils are rare in NASH and only become prominent around very damaged hepatocytes, and then we can observe ballooned hepatocytes with MDB in the cytoplasm surrounded by neutrophils. This lesion is referred to as "satellitosis". Satellitosis can be occasionally seen in NASH, but is more common in alcoholic hepatitis.

KCs aggregates near sinusoidal capillaries are often found in Nash. They form sparce lobular microgranulomes.

Likewise, lipogranulomas, fat droplets mixed with inflammatory cells and collagen also appear.

Portal inflammation in NAFLD/NASH is usually absent or mild, and consists mainly of lymphocytes. Greater than mild and chronic portal inflammation is associated with the amount and location of steatosis, ballooning and advanced fibrosis Therefore, it could be considered a marker of advanced disease. Finally, when portal inflammation is disproportionately severe, the possibility of concurrence with other liver diseases as hepatitis C or autoimmune hepatitis should be considered.

4. Fibrosis

Fibrosis is a major feature since the stage of fibrosis influences overall and liver related mortality, regardless of the presence or severity of other histological features.

Fibrosis in NASH is observed and associated with an active necroinflammatory reaction. It has a characteristic pattern: perisinusoidal or pericellular and typically begins in zone 3 as a delicate perisinusoidal deposition.

Usually periportal fibrosis develops, with or without zone 3 pericellular fibrosis. In cases of evolution and worsening of the diseases, bridging fibrosis and end-stage cirrhosis appears. In very advanced cases of fibrosis or cirrhosis, steaotosis and necroinflammatory reactions disappear. This state is known as burn-out NASH or cryptogenic cirrhosis.

Particularly in adult NAFLD patients' post-obese intervention, it is possible to see very fine non-zonal sinusoidal fibrosis or any stage of fibrosis without any features of NASH.

NASH-related cirrhosis is most commonly macronodular or mixed.

5. Glycogenated Nuclei

Glycogenated nuclei are vacuolated nuclei observed usually in periportal hepatocytes, and commonly occur in NASH. The presence of glycogenated nuclei is useful for discriminating between NASH and alcoholic steatohepatitis (ASH), as they are rarely observed in ASH.

6. Apoptotic Hepatocytes (Acidophil Bodies)

Often we can observe apoptotic hepatocytes in NASH. These are found in sinusoids as eosinophilic rounded bodies, with hyperchromatic nuclear fragments.

7. Mallory-Denk Bodies (MDBs)

They are eosinophilic irregular-shaped aggregates found in the cytoplasm of hepatocytes.

These structures are usually observed in ballooned hepatocytes in zone 3, and mainly consist of cytokeratins 8 and 18, ubiquitin, and p62.

The presence of MDBs is not definitively required, but is helpful for the diagnosis of NASH. MDBs are not specific to NASH; they are also observed in other liver diseases including chronic cholestasis, HCC and alcoholic hepatitis, where MDBs are also observed in non-ballooned hepatocytes.

8. Iron Deposition

Iron accumulation in NAFLD/NASH is usually mild, and can occur within hepatocytes, the sinusoidal lining cells of the reticuloendothelial system, or both.

The signification of iron deposition in NASH remains unclear. Alenti et al., in 2010, reported that iron accumulation was predominant in hepatocytes and was associated with advanced fibrosis in NASH. However, Nelson et al., in 2011, indicated that NASH patients with iron accumulation in the reticuloendothelial system were more likely to have advanced fibrosis compared to patients with iron accumulation in hepatocytes.

9. Megamitochondria

They are crystal-shaped eosinophilic structures in the cytoplasm of hepatocytes. They may be the result of injury from lipid peroxidation, or could represent an adaptive change.

They are observed most commonly in hepatocytes with microvesicular steatosis. Megamitochondria in NASH are distributed equally in all zones, and are abundant similarly in low- and high-stage groups.

10. Ductular Reaction

This refers to ductular proliferation at the portal tract interface. It arises from progenitor cells in the periportal area, and is accompanied by neutrophils and stromal changes. In NASH, the extent of ductular reaction is associated with fibrosis.

11. Steatohepatitic Hepatocellular Carcinoma (SH-HCC)

NASH can progress to liver cirrhosis and HCC.

However, the pathological features of HCC derived from NASH have not been elucidated.

In 2009, the 5-year incidence of HCC for cirrhotic NASH was reported to be 11.3%.

In 2010, Salomao et al., described a distinctive histological variant of HCC that they termed SH-HCC. SH-HCC shows features that resemble non-neoplastic steatohepatitis, including large droplet steatosis, ballooning of malignant hepatocytes, MDBs, inflammation, and pericellular fibrosis.

In a 2012 study, the same group reported that the prevalence of SH-HCC in all HCC cases was 13.5%. Almost all cases of SH-HCC occurred in patients with underlying

steatohepatitis. It was diagnosed in 35.7% of HCC patients with either NASH or alcoholic liver disease, compared with only 1.3% of HCC patients with other chronic liver diseases.

Subsequently, Jain et al. in 2012, reported that SH-HCC was much more common in cirrhotic NASH patients compared with those with alcoholic cirrhosis.

ASSESSMENT SCALES

There are different histopathological scoring systems. All share the assessment of four histological lesions: extent of steatosis, grade of inflammation, hepatocyte ballooning, and staging of fibrosis. All have both pros and cons which will be discussed here.

The methods currently used to semi-quantitatively evaluate the histological lesions of NAFLD and to cover the spectrum of the disease are:

- the NAFLD Activity Score (NAS) and Fibrosis Score by the NASH Clinical Research Network (NASH-CRN).
- the 'Fatty Liver Inhibition of Progression (FLIP)' Algorithm and Steatosis, Activity, and Fibrosis (SAF) Score.

The first scale proposed by Brunt et al. in 1999 was purely histological.

In 1999, there were no systems for grading necroinflammatory activity or fibrosis as did exist for various other forms of chronic liver disease. Brunt EM et al., wanted to develop such a grading system. After the revision of liver biopsies from patients with nonalcoholic steatohepatitis from Saint Louis University Health Sciences Center, they concluded that histological lesions considered to be significant were: steatosis, ballooning, and intra-acinar and portal inflammation. They developed a staging score where they classified the necroinflammatory grades of NASH as grade 1 (mild), grade 2 (moderate), and grade 3 (severe) based on the degree of hepatocellular steatosis, ballooning and inflammation (intralobular and portal). (Table 1). The range is from 0 to 8.

Steatosis grade ranges 0 to 3, where normal liver (grade 0) contains fat in < 5% of hepatocytes, and grade 1, grade 2, and grade 3 steatosis refer to at least 5%, 33%, or 66% of steatotic hepatocytes, respectively.

Lobular inflammation is graded 0 to 3 based on the number of inflammatory foci in a given area.

Grading of ballooning ranges 0 to 2 and is mainly based on the number of ballooned hepatocytes.

For staging and quantifying liver fibrosis based on the location and extent of fibrosis, the scoring system is: stage 1, zone 3 perisinusoidal fibrosis; stage 2, portal fibrosis with the abovementioned stage 1; stage 3, bridging fibrosis in addition to stage 2; and stage 4, cirrhosis.

In 2005, The NASH Clinical Research Network (NASH CRN) designed and validated the histological NAFLD Activity Score (NAS) scoring system that addresses the full spectrum of NAFLD/NASH lesions. (Table 2).

Table 1. NAFLD/NASH Scale proposed by Brunt et al. in 1999

GRADING	Grade 1 (MILD)	Steatosis up to 66%
		Ballooning: occasional in zone 3
		Intralobular inflammation: scattered polymorphs ± lymphocytes
		Portal inflammation: no or mild
	Grade 2 (MODERATE)	Steatosis: any degree
		Ballooning: obvious, predominantly zone 3
		Intralobular inflammation: polymorphs and chronic inflammation noted
		Portal inflammation: mild to moderate
	Grade 3 (SEVERE)	Steatosis: panacinar
		Ballooning: ballooning and disarray obvious, predominantly in zone 3
		Intralobular inflammation: scattered polymorphs ± mild chronic inflammation
		Portal inflammation: mild or moderate.
STAGING	Stage 1	Zone 3 perisinusoidal/pericellular fibrosis, focal or extensive
	Stage 2	Zone 3 perisinusoidal/pericellular fibrosis + focal or extensive periportal fibrosis
	Stage 3	Zone 3 perisinusoidal/pericellular fibrosis + portal fibrosis + bridging fibrosis
	Stage 4	Cirrhosis

It is based on the notion in liver disease that the necroinflammatory lesions and the stage of fibrosis should be separately evaluated because the former are potentially more reversible than the latter.

Table 2. NAFLD/NASH Scale propsed in 2005 by The NASH Clinical Research Network (NASH CRN)

NAFLD ACTIVITY SCORE(NAS) and FIBROSIS SCORE By the CLINICAL RESEARCH NETWORK (NASH-CNR)			**POINTS**
	Steatosis(S)	< 5%	0
		5 - 33%	1
		34 - 66%	2
		> 66%	3
	Lobular Inflammation(Ll)	0	0
		< 2/20x	1
		2 - 4/20x	2
		> 4/20x	3
	Ballooning (B)	None	0
		Few	1
		Many	2
	Fibrosis Stage(F)	None	0
		Zone 3 perisinusoidal, delicate	1a
		Zone 3 perisinusoidal, dense	1b
		Portal only	1c
		1[a] or 1b + portal	2
		bridging	3
		Cirrhosis	4
SCORES	**NAS: S + Ll + B = 0 - 8**		

Based on Brunt, they classified the necroinflammatory grades of NASH as grade 1 (mild), grade 2 (moderate), and grade 3 (severe) according to the degree of hepatocellular steatosis, ballooning and inflammation (intralobular and portal).

NASH CRN subclassified Bunt stage 1 into 3 categories: stage 1A, mild perisinusoidal fibrosis in zone 3; stage 1B, moderate perisinusoidal fibrosis in zone 3; and stage 1C, only portal/periportal fibrosis. Stage 1C fibrosis is observed occasionally in children or severely obese patients.

Currently, the NAS is one of the most widely used histological classifications for NAFLD/NASH and its use is recommended for defining and quantifying disease activity in observational and interventional trials of NAFLD/NASH.

But, accumulating evidence indicates that the NAS is poorly correlated with metabolic risk factors and is unable to predict both the risk of fibrosis progression [and (liver-related and overall) mortality in NAFLD.

In 2012, Bedossa et al., wanted to build an algorithm along with a scoring system for histopathologic classification of liver lesions that covered the entire spectrum of lesions in morbidly obese patients.

They suggest that the SAF score evaluates the grade of steatosis (S), the grade of activity (A), and the stage of fibrosis (F). The A grade (A0 to A4) is computed by adding grades of ballooning to lobular inflammation.

They built an algorithm for the histopathological lesions segregating lesions into normal liver, NAFLD, or nonalcoholic steatohepatitis (NASH) based on semiquantitative evaluation of steatosis, hepatocellular ballooning, and lobular inflammation. For each case, the SAF score was created including the semiquantitative scoring of steatosis (S), activity (A), and fibrosis (F).

Compared to the NAS score, the SAF scores the grading of hepatocellular ballooning based chiefly on both size and shape of ballooned hepatocytes.

At variance with the NAS, the SAF score does not include steatosis in the activity score. The philosophy behind this is that, compared to hepatocellular ballooning and lobular inflammation, steatosis *per se* is an arguable prognostic marker of disease progression. Moreover, the fibrosis stage, although an acknowledged outcome modifier in chronic liver disease owing to various etiologies, is not part of NAS.

The SAF score allows for the definition of categories of NAFLD severity (mild disease when $A < 2$ and $F < 2$ vs. significant disease when $A \geq 2$ and/or $F \geq 2$), defined by hepatocellular ballooning, lobular inflammation, and fibrosis, that is, those parameters of recognized prognostic significance in NAFLD.

In 2014, the European FLIP (Fatty Liver Inhibition of Progression Consortium) designed the FLIP algorithm based on the SAF score to decrease interobserver variations among pathologists and to be implemented in pathology practice. The aim of this study was to determine whether the use of the SAF score and FLIP algorithm can decrease interobserver variations among pathologists. The FLIP algorithm based on the SAF score should decrease interobserver variations among pathologists and is likely to be implemented in pathology practice.

The FLIP algorithm (Table 3) is based on semi-quantitation of the three elementary liver histological features. Steatosis is graded 0 to 3, ballooning 0 to 2, and lobular inflammation 0 to 2.

Table 3. NAFLD/NASH Scale proposed by European FLIP (Fatty Liver Inhibition of Progression Consortium) in 2014

SAF/FLIP ALGORITHM			**POINTS**
	Steatosis(S)	< 5%	0
		5 - 33%	1
		34 - 66%	2
		> 66%	3
	Lobular Inflammation(Ll)	0	0
		< 2/20x	1
		2 - 4/20x	2
		-	-
	Ballooning (B)	None	0
		Clusters, reticulated cytoplasm	1
		Enlarged hepatocytes	2
	Fibrosis Stage(F)	None	0
		Zone 3 perisinusoidal, (all), or portal only	1
		Zona 3 + periportal	2
		-	-
		-	-
		bridging	3
		Cirrhosis	4
SCORES	**SAF: S + ACTIVITY(A: Ll + B) + FIBROSIS = S0 - 3 A0 - 4 F0 - 4**		

The FLIP algorithm aims at enabling a binary classification: NASH as opposed to "steatosis without NASH". NASH is diagnosed based on the combination of all three elementary histological features provided that each of these three features has a grade ≥ 1.

DIFFERENTIAL DIAGNOSIS BETWEEN NASH AND OTHER DISEASES AFFECTING THE LIVER

After a complete and detailed medical history, obviously taking into account clinical information regarding alcohol intake, a differential diagnosis with the following diseases should be made:

- alcoholic liver disease (ASH).
- drug-induced liver injury.
- Wilson's disease.
- α1-antitrypsin deficiency.
- viral hepatitis.

From a histological point of view, the differential diagnosis between NASH and ASH is the most frequent. The main differences with ASH are:

1. Features that are more common in NASH than ASH include severe steatosis, glycogenated nuclei, and lipogranulomas. Fibrosis in NASH shows a lattice pattern.
2. Histological features more common in ASH than NASH include:

- Canalicular cholestasis.
- MDBs in ASH are numerous and well formed.
- A prominent ductular reaction.
- Acute inflammation and fibrosis in the portal tract.
- Fibrosis in alcoholic liver disease shows a solid pattern on reticulin-stained slides.
- Necroinflammatory activity in ASH is more severe than in NASH.
- Sclerosing hyaline necrosis and veno-occlusive lesions are observed occasionally in alcoholic liver disease, but these lesions have not been reported in NAFLD.

REFERENCES

Alenti, L; Fracanzani, AL; Bugianesi, E; Dongiovanni, P; Galmozzi, E; Vanni, E; Canavesi, E; Lattuada, E; Roviaro, G; Marchesini, G; Fargion, S. "HFE genotype, parenchymal iron accumulation, and liver fibrosis in patients with nonalcoholic fatty liver disease". *Gastroenterology*., 2010, 138, 905-912.

Angulo, P; Kleiner, DE; Dam-Larsen, S; et al. "Liver fibrosis, but no other histologic features; is associated with long-term outcomes of patients with nonalcoholic fatty liver disease". *Gastroenterology*., 2015, 149, 389–97.

Ballestri, S; Nascimbeni, F; Romagnoli, D; et al. "The independent predictors of non-alcoholic steatohepatitis and its individual histological features: insulin resistance, serum uric acid, metabolic syndrome, alanine aminotransferase and serum total cholesterol are a clue to pathogenesis and candidate targets for treatment". *Hepatol Res*., 2016, 46, 1074–1087.

Bedossa, P; Poitou, C; Veyrie, N; et al. "Histopathological algorithm and scoring system for evaluation of liver lesions in morbidly obese patients". *Hepatology*., 2012, 56, 1751–1759.

Bedossa, P; Consortium, FP. "Utility and appropriateness of the fatty liver inhibition of progression (FLIP) algorithm and steatosis, activity, and fibrosis (SAF) score in the evaluation of biopsies of nonalcoholic fatty liver disease". *Hepatology*., 2014, 60, 565–575.

Bedossa, P. "Pathology of non-alcoholic fatty liver disease". *Liver International*, 2017, 37, (Suppl. 1), 85–89.

Brunt, EM; Janney, CG; Di Bisceglie, AM; NeuschwanderTetri, BA; Bacon, BR. "Nonalcoholic steatohepatitis: a proposal for grading and staging the histological lesions". *Am J Gastroenterol*, 1999, 94, 2467-2474.

Brunt, EM; Tiniakos, DG. "Alcoholic and non-alcoholic fatty liver disease". In: Odze RD, Goldblum JR, Crawford JM. *Pathology of the GI tract, liver, biliary tract and pancreas*. Philadelphia. Ed Saunders, 2009, 1087-1114.

Brunt, EM; Tiniakos, DG. "Histopathology of nonalcoholic fatty liver disease". *World J Gastroenterol*, 2010, 16, 5286-5296.

Brunt, EM. "Non-alcoholic fatty liver disease: what's new under the microscope?" *Gut*, 2011, 60, 1152-1158.

Brunt, E; Kleiner, D; Wilson, L; Belt, P; Neuschwander, B." The NAS and The Histopathologic Diagnosis in NAFLD: Distinct Clinicopathologic Meanings". *Hepatology*., 2011, 53(3), 810–820.

Brunt, EM; Kleiner, DE; Wilson, LA; et al. "Nonalcoholic fatty liver disease (NAFLD) activity score and the histopathologic diagnosis in NAFLD: distinct clinicopathologic meanings". *Hepatology*., 2011, 53, 810–820.

Cohen, JC; Horton, JD; Hobbs, HH. "Human fatty liver disease: old questions and new insights". *Science*, 2011, 332, 1519-1523.

Ekstedt, M; Franzen, LE; Mathiesen, UL; et al. "Low clinical relevance of the nonalcoholic fatty liver disease activity score (NAS) in predicting fibrosis progression" *Scand J Gastroenterol*., 2012, 47, 108–115.

Ekstedt, M; Hagstrom, H; Nasr, P; et al. "Fibrosis stage is the strongest predictor for disease-specific mortality in NAFLD after up to 33 years of follow-up". *Hepatology*., 2015, 61, 1547–1554.

Feldstein, AE; Gores, GJ. Apoptosis in alcoholic and nonalcoholic steatohepatitis. *Front Biosci*., 2005, 10, 3093-3099.

Jain, D; Nayak, NC; Saigal, S. "Hepatocellular carcinoma in nonalcoholic fatty liver cirrhosis and alcoholic cirrhosis: risk factor analysis in liver transplant recipients". *Eur J Gastroenterol Hepatol*, 2012, 24, 840-848.

Kleiner, DE; Brunt, EM; Van Natta, M; et al. "Design and validation of a histological scoring system for nonalcoholic fatty liver disease". *Hepatology*., 2005, 41, 1313–1321, 21.

Le, TH; Caldwell, SH; Redick, JA; Sheppard, BL; Davis, CA; Arseneau, KO; Iezzoni, JC; Hespenheide, EE; Al-Osaimi, A; Peterson, TC. "The zonal distribution of megamitochondria with crystalline inclusions in nonalcoholic steatohepatitis." *Hepatology*., 2004, 39, 1423-1429.

Nakano, M; Fukusato, T. "Histological study on comparison between NASH and ALD". *Hepatol Res*., 2005, 33, 110-115.

Nelson, JE; Wilson, L; Brunt, EM; Yeh, MM; Kleiner, DE; Unalp-Arida, A; Kowdley, KV. "Relationship between the pattern of hepatic iron deposition and histological severity in nonalcoholic fatty liver disease." *Hepatology*, 2011, 53, 448-457.

Neuschwander-Tetri, BA; Caldwell, SH. "Nonalcoholic steatohepatitis: summary of an AASLD Single Topic Conference". *Hepatology*, 2003, 37, 1202-1219.

Ong, J; Younossi, ZM; Reddy, V; Price, LL; Gramlich, T; Mayes, J; Boparai, N. Cryptogenic cirrhosis and posttransplantation nonalcoholic fatty liver disease. *Liver Transpl*, 2001, 7, 797-801.

Pinto, HC; Baptista, A; Camilo, ME; Valente, A; Saragoça, A; de Moura, MC. "Nonalcoholic steatohepatitis. Clinicopathological comparison with alcoholic hepatitis in ambulatory and hospitalized patients". *Dig Dis Sci*., 1996, 41, 172-179.

Richardson, MM; Jonsson, JR; Powell, EE; Brunt, EM; Neuschwander-Tetri, BA; Bhathal, PS; Dixon, JB; Weltman, MD; Tilg, H; Moschen, AR; Purdie, DM; Demetris, AJ; Clouston, AD. "Progressive fibrosis in nonalcoholic steatohepatitis: association with altered regeneration and a ductular reaction". *Gastroenterology*, 2007, 133, 80-90.

Salomao, M; Yu, WM; Brown, RS; Emond, JC; Lefkowitch, JH. "Steatohepatitic hepatocellular carcinoma (SH-HCC): a distinctive histological variant of HCC in hepatitis C virus related cirrhosis with associated NAFLD/NASH". *Am J Surg Pathol*, 2010, 34, 1630-1636.

Salomao, M; Remotti, H; Vaughan, R; Siegel, AB; Lefkowitch, JH; Moreira, RK. "The steatohepatitic variant of hepatocellular carcinoma and its association with underlying steatohepatitis". *Hum Pathol*., 2012, 43, 737-746.

Skoien, R; Richardson, MM; Jonsson, JR; Powell, EE; Brunt, EM; et al. Heterogeneity of fibrosis patterns in non-alcoholic fatty liver disease supports the presence of multiple fibrogenic pathways". *Liver Int*, 2013, 33, 624-632.

Tiniakos, DG. Nonalcoholic fatty liver disease/nonalcoholic steatohepatitis: histological diagnostic criteria and scoring systems. *Eur J Gastroenterol Hepatol*, 2010, 22, 643-650.

Yatsuji, S; Hashimoto, E; Tobari, M; Taniai, M; Tokushige, K; Shiratori, K. "Clinical features and outcomes of cirrhosis due to non-alcoholic steatohepatitis compared with cirrhosis caused by chronic hepatitis C". *J Gastroenterol Hepatol*, 2009, 24, 248-254.

Younossi, ZM; Reddy, V; Price, LL; Gramlich, T; Mayes, J; Boparai, N. "Cryptogenic cirrhosis and posttransplantation nonalcoholic fatty liver disease". *Liver Transpl*, 2001, 7, 797-801.

Younossi, ZM; Stepanova, M; Rafiq, N; et al. "Pathologic criteria for nonalcoholic steatohepatitis, interprotocol agreement and ability to predict liver-related mortality". *Hepatology*., 2011, 53, 1874–1882.

Yoshihisa, T; Fukusato, T. "Histopathology of nonalcoholic fatty liver disease/nonalcoholic steatohepatitis". *World J Gastroenterol.*, 2014, 20(42), 15539-15548.

Zatloukal, K; French, SW; Stumptner, C; Strnad, P; Harada, M; Toivola, DM; Cadrin, M; Omary, MB. "From Mallory to Mallory-Denk bodies: what, how and why?" *Exp Cell Res*, 2007, 313, 2033-2049.

In: Encyclopedia of Surgery (22 Volume Set)
Editors: Andreas Lehrer and Kristin Mueller
ISBN: 978-1-53618-329-0
© 2020 Nova Science Publishers, Inc

Chapter 307

LIVER BIOPSY AS THE "GOLD STANDARD" IN NASH DIAGNOSIS

Soledad García-Gómez-Heras*, MD, PhD,
Julio Paredes-González and Raquel Franco-Rodríguez
Human Histology and Pathology, Health Science Department,
Rey Juan Carlos University, Madrid, Spain

ABSTRACT

Liver biopsy is the "gold standard" for the diagnosis and evaluation of NAFLD/NASH disease. It is an invasive procedure but we can confirm, characterize the severity of parenchymal changes, and distinguish between NAFLD, steatohepatitis and NASH, associated with the progression of liver injury. Also, it provides a semi-quantitative evaluation of the severity of injuries (Assessment Scales), extremely useful in clinical trials.

The histological and anatomopathological study is a set of procedures fully used both for diagnoses and for investigation. Such procedures require meticulous care in their elaboration due to the sensitivity of these techniques. The different steps in the processing of the tissue are explained in this chapter.

Keywords: liver biopsy, diagnosis, histopathology, NASH, NAFLD, gold-standard

INTRODUCTION

Liver biopsy is the "gold standard" for the diagnosis and evaluation of NAFLD/NASH disease. The histopathological evaluation of liver biopsy samples remains central in a patient with clinical signs of NAFLD to exclude other causes of chronic liver disease, to confirm or to exclude the diagnosis of NAFDL/NASH, to evaluate the severity if it is confirmed and to demonstrate if patients have cirrhosis.

* Corresponding Author's Email: soledad.garcia@urjc.es.

Advantages of Liver Biopsy

Liver biopsy plays a unique role compared to non-invasive assessments; thanks to the biopsy we can confirm and characterize the severity of parenchymal changes, distinguish between NAFL, processes that are considered to be slowly progressive, and steatohepatitis, NASH, associated with the progression of liver injury. Also, it provides a semi-quantitative evaluation of the severity of injuries (Assessment Scales, see below), extremely useful in clinical trials.

None of the non-invasive techniques tests can determine if liver injury and fibrosis is really due to NAFLD or to another coexistent liver disorder. On the one hand, nor ultrasound nor computerized tomography (CT) can determine if patients actually have NASH.

On the other hand, elastography and magnetic resonance imaging (MRI) attempt to diagnose NASH base on the assessment of fibrosis and presume that patients with suspected NAFLD and fibrosis have NASH.

Disadvantages of Liver Biopsy

It is an invasive procedure, which requires hospitalization in nearly 3% of cases and is complicated by a 0.3% mortality.

Liver biopsy does have risk of clinical complications, small but real, including:

- pneumothorax.
- pain.
- significant bleeding, 0.3% of persons with a normal platelet count and normal levels of clotting factors.

Additionally, the histopathological NAFLD liver lesions are not uniformly distributed; the liver is not affected homogenously ans as the size of biopsy sample represents a small fraction of the entire organ, the significance of the sample is a subject that should be taken into account.

Because all the above, liver biopsy cannot be considered as a screening procedure in high-risk patient populations; liver biopsy is also unsuitable in long-term monitoring of patients with NAFLD and assessing their response to therapy. Thus, it should definitely be restricted only to those patients who have a high probability of significant liver fibrosis.

Gunn et al. proposed that a liver biopsy should be performed in the following cases:

- All features of metabolic syndrome and obesity.
- T2DM and elevated liver transaminases.
- Normal BMI with elevated liver transaminases
- Elastography greater than 6 kPa.
- Elevated value with a fibrosis scoring system.
- Reliable elastography value cannot be obtained because of obesity.
- Patients are not motivated to lose weight.

And a deferred Liver biopsy when:

- Two or fewer features of metabolic syndrome.
- Normal liver transaminases and absence of T2DM.
- Elastography less than 6 kPa.
- Low value with a fibrosis scoring system.
- Patients are motivated to lose weight.

PROCESSING OF LIVER SAMPLES OBTAINED BY BIOPSY

The histological and anatomopathological study allows us to observe tissues and their different structures, the cells that make it up, and even their ultra-structure through a set of techniques called histological techniques. This set of procedures is fully used both for diagnoses and for investigation. Such procedures require meticulous care in their elaboration due to the sensitivity of these techniques. Therefore, one needs to be aware that an incorrect procedure in any of these steps will produce an altered image that could lead to incorrect results.

Biopsy Types

Samples for the histological study come from biopsies. The biopsy is a surgical procedure from which a small cell tissue sample is obtained from a lesion, tissue or organ for subsequent processing and study under a microscope. Depending on the amount of extracted material and the method used, biopsies can be classified in several types:

1. Incisional Biopsy

Incisional biopsy is that in which only a piece of tissue, mass, or tumor is surgically obtained. Two additional types can be found inside this category:

- *percutaneous biopsy.* The sample is obtained by introducing a needle into the tissue or lesion. The result is a tissue cylinder whose thickness depends on the needle's gauge. Based on the gauge, they are classified in FNAB (fine-needle aspiration biopsy) or CNB (core-needle biopsy).
- *endoscopic biopsy.* The sample is obtained using an endoscope, which is a thin flexible tube that has a light source and a camera at one end. This camera relays high resolution images of the studied site to a television screen.

2. Excisional Biopsy

Excisional biopsy is that in which a full organ, tumor or lesion is surgically obtained.

In this chapter, we will focus on liver biopsy. The study target and source for the samples in this biopsy is the liver. Sampling takes place through percutaneous biopsy, transvenous and/or laparoscopic biopsy.

Percutaneous liver biopsy is the most used. It involves the introduction of a thin needle through the abdomen to reach the liver in order to draw a sample. The sampling is assisted by imaging methods, such as echography or computed tomography. Two types of needles are used for the liver puncture, thus generating two different hepatic cylinders. In one of them, the cylinder is obtained by means of the cut, as with Trucut or Vin Vilverman needles; in the other by means of suction, as with Menghini, Klatskin or Jamshidi needles. In recent years, a new type of automatic needle for biopsies has been developed. This is Trucut-type needles for trimming, which do not need manual handling.

Transvenous liver biopsy takes place by introducing, through the jugular vein, a specially designed hollow tube that allows for the introduction, inside of it, of a biopsy needle, as well as for the extraction of tissue samples when the liver is reached.

Laparoscopic liver biopsy is guided by a laparoscope, which is a flexible tube that has a light and a camera. It is introduced in the abdominal cavity through small incisions. Air is then inserted into the cavity leaving an observation and working area, in order to monitor the liver state on the surface, and to take samples in areas of interest.

Processing of the Tissue (Figure 1)



Figure 1. The steps in the processing of liver samples obtained through biopsy. A. Fixation. B. Paraffin embedding. C. and D. Block preparation. E. Obtention of tissue cuts with a minot-type microtome. F. Staining the samples.

1. Fixation

Whatever the means of obtaining the tissue sample, the first step after obtaining the sample is the sample fixation process. This is of vital importance, because it will be a determinant for good development of the other procedures. With this process, we intend to preserve the tissue for study in a state as close as possible to what it was when it was in vivo. To do this, we need to prevent cell autolysis and to stop enzymatic processes. We also have to avoid the action of bacteria, which would start putrefaction processes. And, at the same time, we also want to provide the sample with the hardness necessary for handling it easily, and for its posterior sectioning process.

In order to have the sample fixed correctly and efficiently, the following premises should be taken into account:

- The tissue must come into contact with the fixation agent as soon as possible. The best way to do this is to make a perfusion. To do so, liquid fixative is introduced into the circulating system so that it reaches the tissue. Obviously, such process is not possible in a hospital biopsy, and is normally more used in test animals.
- The volume of liquid fixative should be ten to twenty times greater than the volume of the sample, in order to let it work more efficiently. The fixative is recommended to be at a temperature of 4ºC-5ºC. The sample must be free of blood, mucus, or any other product that could hinder the liquid fixative's penetration into the tissue. Therefore, it is recommended to rinse the sample with physiological or buffered saline solution (in order to prevent an osmotic imbalance from damaging the specimen). Likewise, the liquid fixative used should have an osmotic balance with the sample. To be sure, saline solutions can be used as a solvent for the fixation agent.
- Sample size. The type of tissue should also be born in mind. If we are going to work with a compact or lax tissue, the liquid fixation agent will be able to penetrate with more or less ease. If the tissue presents membranes hampering the fixative's introduction, and of course, the thickness of the sample: it is always recommended to have a thin sample with edges being as flat as possible.
- The fixative should not cause any alterations in the tissue, such as retractions or swelling, or any change that could affect its morphology. Any variations introduced in the tissue, should be in order to make the posterior handling of the piece easier, or to improve its tinctorial strength.
- The specimen's fixation time must be optimal. It is not recommended to leave the tissue in the fixation agent too long or, obviously, too little time. The optimal time depends on the type of fixative or the fixative mixture used. Each one has an ideal fixation time, which should be followed.

There are several ways to classify fixatives. One of the main ways is depending on whether they act physically or chemically on the tissue. *Fixation through physical processes* takes place by freezing the tissue. This method presents advantages and disadvantages. The main advantage is speed and wide conservation of antigens, enzymes, and proteins, which makes it a very useful fixation for intraoperative biopsies, and for histochemical and immunohistochemical techniques. Some of its weaknesses are the short durability of the

samples, the need for expensive frozen storage systems, the huge risk of breaking tissue structures during the freezing process despite using buffered solutions to prevent the formation of crystals in the cells, etc. The most widely used substances for freezing are liquid nitrogen and isopentane at -50ºC, which is the most commonly used for cryodesiccation and cryosubstitution.

Tissue *fixation through chemical processes* takes place through chemical substances that are normally used in an aqueous solution. They act on the tissue by stabilizing it and stopping its processes, while they also act as a bactericide to preserve it. They can be classified as simple or compound fixatives, based on the amount of substances that comprise them: just one or several.

They can also be classified according to how they act on the tissue.

Some fixatives act by dehydrating tissue. They generate protein denaturing, leading to a quick outflow of water from the tissue structures. Some examples are methanol, chloroform, ethanol and acetone.

There are also fixatives whose action takes place through *salt formation*. These normally have a great capacity to penetrate the tissue, and these fixatives spread throughout tissues at a rapid pace. But, at the same time, they present the disadvantage that the formation of those salts creates a crust on the sample, thus minimizing penetration. Therefore, they are normally adequate to be used in fixation mixtures, but are rarely used individually. Examples of these fixatives are mercury chloride or "corrosive sublimate", which is very often used for hematopoietic pathologies, potassium dichromate, which is very good for preparing tissues for silver impregnation techniques, or the picric acid, which is useful as it does not dissolve fat or glycogen, and has a slight decalcification action.

Others take action through *protein reticularization*. They generate protein denaturation, in which hydrogen bridges break, and a reticular polypeptide net is generated. Formaldehyde and formol, with all their variations, glutaraldehyde or osmium tetroxide, which are used in electronic microscopy techniques, are some of the fixatives in this group.

Since *formaldehyde and formol* are part of the most used fixatives, their advantages and disadvantages will be discussed a bit deeper. Formol is used so frequently because of its versatility for fixing all tissue structures. Its tissue penetration rate is not as rapid as other fixatives acting through dehydration, but it still is well above fixatives acting by forming salts. It performs very well as a bactericide and causes almost no tissue alteration phenomena, such as retraction or an excessive hardening. It is effective for the fixation of lipid structures, and normally leaves no deposits in the tissue nor does it interfere with posterior staining. It is very affordable, and can be used both as a single fixation agent, and in fixative mixtures. Its main disadvantages include irritating vapors and its current classification by the European Parliament as a carcinogen category 1B and mutagen category 2. Therefore, it must always be used with all protection measures available. It is also unstable when exposed to sunlight and the atmosphere. If the pH of the formol dissolution decreases below 6, crystals called formolic pigments may start depositing in the tissues, thus altering the posterior staining image. In order to solve these stability problems, the pH, and to improve any issues that could arise due to osmotic differences with the sample, formol 4% is normally used in a buffer solution such as a phosphate, which we call buffered formol.

Finally, there are *fixatives that act through changes in the colloidal state*. They decrease the pH of colloidal solutions where there are proteins and make them precipitate. Among them, we find acetic acid, which preserves nucleoproteins and nucleic acids well, and chromic

acid, which is an excellent structural fixative, and acts as mordant of the tissue in stainings where basic coloring will be used.

Regarding *fixative mixtures*, they can be divided into formol-containing or formol-free mixtures. Below, some examples are listed. Among the fixative mixtures with formol, the following can be found:

- *Bouin's solution:* its fixation time goes from 4 to 24 hours, depending on the sample thickness. It requires posterior washes in ethanol at 80% until picric acid remnants are removed. It requires special attention to prevent the piece from hardening too much due to the successive washes in ethanol. It is recommended to include the sample immediately after that. This fixation is efficient in embryonic or testicular samples, and acts as mordent in techniques such as Masson's trichrome staining. However, it is discouraged in kidney samples, due to the alterations generated in the resulting image.
- *Ciaccio's fixative:* its fixation time is 48 hours, and after that, a wash under running water for 24 hours is required. Using this fixative is recommended for lipid tissues or with high fat content.
- *Susa-Heidenhain mixture:* its fixation time goes from 1 to 12 hours. After that time, samples require washes in ethanol 80%. Afterwards, they can be preserved in ethanol 70% for a while. This mixture presents a slight decalcification power.

Among the fixative mixtures that contain no formol, are the following:

- *Carnoy's solution:* This mixture has a maximum fixture time of 2 hours, due to its great capacity for penetrating tissues. Afterwards, samples must be washed with absolute ethanol. Apart from the fixation process, this mixture also acts as sample dehydrating, leaving this step ready for posterior inclusion. It is a much recommended fixation to preserve nucleic acids, Nissl lumps, fibrillary proteins, myofibrilles, and glycogen.
- *Zenker's fixative:* This mixture requires a solution made at the time of use. Its maximum fixation time goes from 2 to 48 hours. Samples fixed in Zenker, once cut and deparaffinized, need to undergo a process called dezenkering. This involves treating the sample with an iodized solution, and then with a sodium thiosulfate solution to remove residues that mercury salts leave on the tissue. This fixation is much used for bone marrow and other hematopoietic tissues, as well as for lymphoid tissue, due to the good preservation of nuclei. It also acts as a mordent in some stainings, such as the phosphotungstic acid-hematoxylin stain.

We would also like to mention the fixation patterns that require histological techniques such as *electron microscopy*. Samples for transmission or scanning electron microscopy need a fixation according to the special needs required for the observation of samples at such magnifications and the particular workings of these microscopes. In these cases, a double or triple fixation is used. The first agent normally is a fixative belonging to the aldehyde family (glutaraldehyde is the most frequently used), although formaldehyde or even other types of fixatives such as potassium permanganate or uranyl acetate can also be used. Based on the

ultra-structures that we want to observe, some fixatives will be more adequate than others. It is of vital importance that the fixative be in a buffer solution favoring a stable pH, with no changes in the sample's osmolarity, and that it have an appropriate ionic constitution so as to prevent the cell components from being extracted or precipitate during the fixation process. One of the most used is 2% glutaraldehyde in phosphate or in cacodylate buffer solution. After this fixation, samples are fixed again in an osmium tetroxide solution at 1% buffered solution. Before this second fixation, and given the slow penetration rate of both fixatives, the samples need to be cut or "carved" creating 1 cubic millimeter in order to promote their correct fixation and to facilitate cutting and handling of the samples, in addition to the posterior observation under the microscope. After the second fixation, the third one should be with uranyl acetate as the fixative agent. The third fixation can be skipped depending on the specific needs of the sample.

2. Embedding

After the fixation of the tissue, and for its posterior observation and study in the microscope, the embedding process must start. The objective of embedding is to provide the sample with a determined consistency or hardness so as to allow for later obtaining sections or cuts of the tissue. This will also prevent fragmentation and will preserve the structure and characteristics of cells with very little interference. As far as possible, such cuts, should be fine, regular and homogeneous.

The consistency and hardness needed for the tissue is obtained by infiltrating liquid substances into the tissue. They will subsequently solidify due to refrigeration or polymerization, and the desired hardness will be obtained. Based on the sample type, and bearing in mind the technique selected for the posterior study, we can choose from among the embedding media types. According to the characteristics of embedding media, they can be classified into:

- *Hydrophilic* embedding media: such as gelatin, polyethylene glycol, and OCT.
- *Hydrophobic* embedding media: such as paraffin, celoidine, and different types of resins (such as acrylic, polyester, or epoxy resins).

Tissue Embedding in Hydrophilic Embedding Media

Bearing in mind that tissues are mainly composed of water, and that hydrophilic embedding media are soluble in water, this type of embedding allows us to work directly with the hydrated tissue. Within this embedding type, we find, among others:

Gelatin

If the tissue has previously been fixed, before starting gelatin embedding, such fixture has to be removed from the tissue through washes in running water. Since gelatin is water soluble, there is no need to dehydrate or rinse the tissue. Another advantage of gelatin is that its melting point is low. Therefore, tissue samples are spared the downsides of working with high temperatures (>40ºC) during the process. Embedding takes place by means of successive baths in gelatin with different increasing concentrations at 37ºC.

OCT (Optimal Cutting Temperature Compound)

The OCT is composed of polyvinyl alcohol, polyethylene glycol, and reserved composition excipients (Ames type) acting as cryoprotectants.

This type of embedding is currently the most widely used for obtaining frozen cuts, because it favors cutting in cryostats at very low temperatures (-20ºC) and, therefore, allows us to work with samples with no need for previous fixation.

Tissue Embedding in Hydrophobic Embedding Media

These embedding media, since they are not water miscible, force us to perform a series of previous steps to the embedding media in order to remove all the water that the tissue contains. If the sample is not correctly embedded in the embedding medium, it will spoil, and performing regular and homogeneous cuts will be very difficult. Among hydrophobic embedding media, paraffin is currently the most often used. We also find celoidine, but less frequently. There are other embedding hydrophobic media, such as different types of resins (acrylic, polyester, epoxy), that are chosen based on the type of technique subsequently used and the type of microscopy used for the visualization. Since paraffin is the most common embedding medium, we will focus on it, and will use paraffin to explain the different steps needed and in common, with certain differences for all embeddings with hydrophobic embedding media.

Paraffin Embedding

Paraffin is formed by mixtures of saturated hydrocarbons. It is solid at room temperature, and depending on its type of hydrocarbon mixture, has a melting point ranging from 40ºC to 70ºC. The most used paraffins normally have a melting point around 60ºC.

Paraffin is not water miscible. And taking into account that most fixatives, and tissues themselves, contain water, we have to take a series of steps to replace that water with an organic solvent to allow the liquid paraffin to correctly embed the tissue. We divide those steps into:

1. *Dehydration.* Dehydration is the process by which water is completely removed from the sample to be embedded. It takes place by means of chemical agents or dehydration reactants, or through physicochemical procedures (cryodesiccation and cryosubstitution). The dehydration process takes place through repeated baths in increasing alcohol content solutions (50º, 70º, 80º, 96º, 100º (absolute alcohol)). It is performed gradually so as to prevent the tissue from retracting. According to the type of tissue and sample size, the optimal time and number of baths in different concentrations is calculated to avoid a too long exposition that could cause an excessive tissue hardening. The main dehydration agents are: ethyl alcohol (the most used), methyl alcohol, acetone, butyl alcohol, dioxane, isopropyl alcohol, etc. The main characteristics of a good dehydration agent are: it must not alter tissue structures and must be miscible with the intermediate solvent or the clearing agent that will be subsequently used.
2. *Clearing or dealcoholisation.* This is the process through which the dehydration agent is substituted by a substance miscible with the embedding medium that will be used. The clearing process takes place by means of successive baths in the chosen clearing agent. The duration and amount of these baths depends on the characteristics

of the clearing liquid and the type and size of the tissue sample. The selection of the clearing agent or the intermediate solvent will be mainly based on its own characteristics, including: speed for the removal of the dehydration agent, lack of hardening or tissue retraction, appropriateness to the dehydration agent and the embedding medium, etc. The main clearing agents or intermediate solvents are: xylene, toluene, chloroform.

3. *Infiltration or Impregnation.* This is the process through which we fully infiltrate or fill the tissue sample with the chosen embedding medium. The objective of this process is to completely occupy with inclusion medium the space that was previously occupied with the water contained in the tissue. This way, we provide the homogeneity and hardness necessary for obtaining fine quality cuts of the study sample. The infiltration or impregnation process takes place through successive baths in liquid paraffin. These baths must be changed frequently, since they get saturated with clearing agent and this could generate changes in paraffin characteristics, thus hampering the posterior trimming. The length and number of baths in liquid paraffin will depend, as always, on the characteristics of the chosen paraffin (and the inclusion medium of use at that moment), as well as the type and size of the tissue sample.

   Currently, there are automatic processors, which have different vases or recipients to perform the baths in the different liquids and thermal vases for paraffins with a mechanic transport system across them that is regulated by a time programmer. This enables performing the embedding process on a high number of samples and optimizes time, since the process can continue over night.

4. *Block Preparation.* This is the process through which we obtain a tissue block embedded in the embedding medium through slow cooling until reaching 10ºC-15ºC. In order to facilitate sample identification, the embedding process and the posterior block preparation, the sample is placed in a kind of capsule or cassette. These cassettes allow for maintaining the sample immersed in a liquid by means of the opening for infiltration they have on their entire surface.

   Apart from cassettes, for block preparation, we need special molds. These molds are normally metallic (favors cooling) and of different sizes than can be adjusted to the sample size. These molds fit perfectly in the cassettes used for embedding. In summary, cassettes facilitate block preparation, their arrangement in the microtome for the obtaining of tissue sections or cuts, and their subsequent archiving.

   In order to create the blocks, certain devices called “embedding stations” will be used. These stations have a liquid paraffin dispenser, a hot plate with light and a magnifier for sample orientation, and a cold plate for solidification of the block.

Tissue Embedding in Other Hydrophobic Embedding Media

Embedding media other than paraffin are normally chosen when the tissue characteristics so require such as when a tissue is too hard (undecalcified bones), when it contains structures that become affected by heat (enzyme study), when the tissue has several parts with different consistencies, or when the study requires very thick or very thin cuts. Among these other hydrophobic embedding media, plastic embedding stands out.

Plastic Embedding

This type of embedding uses acrylic resins (methylmethacrylate, glycol methacrylate, etc.) or epoxi type, and is based on the polymerization of an elemental substance of low molecular weight until transforming it into a solid, clear, and very hard compound. The following stand out:

- *Methylmethacrylate Embedding.* The elemental substance used here as an embedding medium is monomeric methylmethacrylate. This type of embedding is chosen for very hard tissue samples, such as undecalcified bones. One advantage of methacrylates is that their elasticity and hardness can be modified according to the amount of monomers that the final mixture contains. This allows for adapting to the tissue type to be embedded.
- *Embedding for Electron Microscopy.* To observe the cell's ultrastructure, it is indispensable to obtain very thin tissue cuts (nanomers), called ultrathin cuts, and to use a transmission electron microscope. In order to obtain ultrathin cuts, the tissue needs to be hardened. To that end, the most used media to embed tissue are the epoxi-type resins, or, less frequently, acrylic resins (methacrylate). In electron microscopy, the embedding process is very similar to paraffin embedding, since the same steps have to be followed, but with different substances: fixation (glutaraldehyde), post-fixation, dehydration (ethanol and acetone), intermediate solvents (epoxypropane or propylene oxide), embedding and polymerization in the embedding medium (60ºC) (epoxy resins: araldite, Epon resin, Spurr's resin).

3. Obtention of Tissue Cuts

In order to observe the characteristics of the different tissues and their cell structures through various microscopes, very thin cuts need to be performed. Otherwise, problems with light diffusion and penetration appear in optical microscopes, and electron penetration in transmission electron microscopes. The ideal thickness of cuts for their correct observation ranges from a few nanomers to hundreds of microns. The thinner the tissue sample cut has to be, the harder the tissue needs to be. Its hardness will depend on the tissue characteristics, the fixation process, the embedding process, and the selection of the embedding medium. Another way of hardening the tissue is through freezing.

In order to obtain such cuts of tissue samples, some devices called microtomes are used. These devices allow for performing cuts of micrometric thickness, fine enough to be observed with microscopes. There are different types of microtomes, such as: oscillating or rocking microtome, Minot-type or rotary microtome, sliding microtome, freezing microtome, cryostat, cryomicrotome, and ultramicrotome. The selection of the microtome type will depend on the desired thickness of the cuts, the embedding medium where the tissue is immersed, and the tissue hardening process, which can be by freezing or embedding. Microtomes for tissues embedded in paraffin are the most commonly used for optical microscopy, and ultramicrotome for transmission electron microscopy. Cryostat is also frequently used for optical microscopy, since it allows for sectioning unembedded tissue, and even tissue without fixation, resulting in a time saving and an easier process.

4. Staining

Once our sample is cut, the next issue to address is the fact that human and animal tissues normally are colorless. Exceptions include certain parts where melanic pigments can be found in cells, colored erythrocytes, or some type of metallic deposits, or other materials coloring cell cytoplasms. Since sample structures are not apparent without staining, they need to undergo that process. To do so, we exploit the capacity of tissues to incorporate and fix colored substances in their interior.

These substances, which we call dyes, normally derive from benzene, which is an aromatic hydrocarbon with a characteristic ring in its molecular structure. These substances can have a natural origin, either plants or animals, or can derive from aniline, which is artificially obtained from tar or coal.

These dyes are classified according to their *staining affinity* for the various components of tissues. Thus, there are *alkaline dyes*, which are aniline molecules containing one or more positive charges in the molecule's colored portion. They have affinity for the acid structures of the tissue, such as nucleic acids, and nuclear structures, such as hematoxylin. *Acid dyes* are anilines that include negative charge in the molecule's colored portion. They show affinity for basic structures in cells and tissues, such as cell cytoplasm. Eoisin is an example. There are also *neutral dyes* using another type of system, such as physical impregnation, to stain tissues.

Tissue components that react with alkaline dyes are called *Basophilic dyes*, whereas components or structures reacting with acid dyes are called *Acidophilic dyes*.

Also available are other dyes called metachromatic dyes, which show *Metachromasia* when staining. They include toluidine blue and thionine. Metachromasia is the property by which, when dyes get fixed to determined tissue structures, these structures become stained in a different color other than their own. This happens because the staining molecule polymerizes when it comes into contact with certain polyanion-rich tissue parts. The resulting polymer has light absorption properties different from those of the original molecule. These cell or tissue structures that are dyed differently with metachromatic dyes are called chromatropes. For example, if toluidine blue was used as metachromatic dye, the result would be a tissue mostly dyed blue, and certain structures such as mast cell granules, or the fundamental matter of cartilages could be purple dyed.

Dyes have different *means of action* when it comes to fixing into tissues. The means may be *physical* in which the solvent acts as a mode of transport for the dye molecules that are more soluble in the tissue than in the solvent. This is normally the most characteristic course of action in fat staining. Another case is based on great volume dye molecules selectively depositing, forming insoluble molecular aggregates on certain structures, and becoming trapped in the tissue, within the net of fibers and cells. This is the case of silver impregnation.

Chemical methods are based on the appearance of a chemical reaction between the structure which is the object of the staining, and the dye itself, resulting in a new chromogen. These methods are unique to histochemistry.

Physicochemical mechanisms are based on unions between molecules due to their electrostatic charge. Molecules with different charges unite. Stainings where acid structures join alkaline dyes, and alkaline structures join acid dyes are based on this mechanism, as it has previously been discussed for basophilia and acidophilia.

Generally, when we dyed our samples, we found that the vast majority of dyes are water-soluble. The cut obtained from the paraffin block is embedded in this substance, which is not

water miscible. Thus, in order to stain the samples, they need to undergo a process in which all the paraffin is removed from the cuts, and the tissue is then left in an aqueous medium. Such process is called *Deparaffinization*. It is the antagonistic process to the one suffered by the sample when it was embedded in paraffin. It basically includes the same elements but in the opposite order. Therefore, the samples will first be subject to successive baths in xylene, which will remove all paraffin from the tissue. The samples can be introduced for a few minutes in a heater at 60ºC to help in this process, as this will turn the paraffin into a liquid state, and it will be more easily removed. After that, the sample will be bathed several times in absolute ethanol, to take the xylene away completely. Afterwards, the sample will be bathed again several times in ethanol 96% in order to hydrate the sample little by little. Then, the sample will repeatedly be bathed in running water. Some laboratories add more ethanol steps with decreasing concentrations before starting with water. But these two steps cited above are the strictly necessary ones, except in the case of an especially delicate sample.

Once our sample is stained, and before placing it under the microscope, the sample needs to undergo the *mounting process*. This process involves preparing the sample to be as clearly observable as possible under the microscope. And, at the same time, gives us the option to preserve the already stained sample for aftertime and successive observations. The easiest way to do that is by placing a coverslip on the sample. This is used for *in vivo* samples stained with vital dyes. These samples are not expected to last for a long time; they are prepared for a particular observation. Some stainings or techniques need mounting in an aqueous medium, because a different mounting would interfere with the staining, creating artefacts or impeding their observation. This is the case of fluorescence, and sometimes certain immune-histochemical products. In those cases, the sample is covered with a mounting medium such as gelatin or buffered glycerin, and a coverslip is placed on it. It is then sealed with lacquer to increase its durability. Even then, this type of sample has a very limited duration, since it is easily degraded. The *permanent mounting* of samples takes place in a resin medium, which apart from preserving, also improves the light refractive index, thus helping to achieve a better observation under the optical microscope. Nowadays, the most common method is to use artificial resins. But in the past, resins from trees such as Canada balsam or Dammar gum were normally used. These resins are not water miscible. Therefore, again, the sample will have to undergo a process in which water will be replaced with ethanol in an increasing concentration. And that ethanol will be followed by baths in xylene to remove the ethanol from the tissue, and prepare the sample for the resin. These baths in xylene are also called rinse. And once the xylene and ethanol are both totally removed, some drops of resin or mounting medium will be put on the sample, and a coverslip will be placed on it, preventing the formation of bubbles as far as practicable. When the resin is dry, the sample is then ready for observation under the microscope. And its durability is quite long.

Next, we proceed to describe some of the techniques most frequently used for studying liver biopsies.

Hematoxylin-Eoisin Technique

This is one of the most used techniques in laboratory practice, both for clinical diagnosis and research. This technique is very adequate for a general vision of the tissue, which will show distinguishably nuclear staining, and cytoplasm staining. It is very simple, consists of only two steps, and is quick. Nuclear staining takes place through hematoxylin staining, cytoplasm staining, and the background eosin staining. Staining in these two dyes is based on

physicochemical methods. Therefore, to sum up, hematoxylin is basophilic and will stain acid structures in the tissue; eosin is acidophilic and will complement the process by staining alkaline structures in the tissue.

In the particular case of a *liver biopsy*, this technique is useful to assess the grade of preservation of liver structures, to detect Mallory bodies, and to assess cell ballooning.

The first part of the staining is made with hematoxylin, which is a vegetal origin dye extracted from logwood trees (*Haematoxylum Campechianum*) originating from Central America. A substance is extracted in the form of crystals that turn purple when they oxidize. This substance is used as a dye in the textile industry. These crystals have no staining capacities. They need to undergo an oxidation process to obtain a substance called hematein. This oxidation process can take place spontaneously when the crystals are exposed to atmospheric oxygen, or be induced by adding oxidizing chemical agents. Apart from these oxidizing agents, metallic salts are usually added, and they provide a greater staining capacity and a more specific affinity for acid structures, which are stained in the blue range of colors. Depending on the type of metallic salt used, different types of hematoxylin will be obtained: aluminum hematoxylin such as Harris' or Mayer's, iron hematoxylins such as Weigert's or Hedenhaim's, chrome hematoxylin, etc. each with its pros and cons. In our case, we used Carazzi's hematoxylin, since we have been very pleased with the results.

The second part of the staining is performed by Eosin, which is a xanthene dye obtained from the interaction of bromine with fluorescein, which contributes with its characteristic autofluorescence. As a result, there are two types of eosin: yellowish or eosin Y, and bluish or eosin B that differ according to the bromine atoms they contain. Eosin Y has a greater content, and is the one we chose to use. It shows staining affinity for cell and tissue alkaline structures, staining them in colors ranging from orangey to pink or red. It can be used both in water and alcohol solutions. In water solutions, it is necessary to add some type of substance protecting it from contamination, such as thymol or formol drops.

The reagents needed for this technique are:

Carazzi's Hematoxylin:

- 1 gram hematoxylin
- 0.2 grams potassium iodate
- 50 grams potassium alum
- 200 milliliters glycerin
- 800 milliliters distilled water

The reagents are added, in order, to a mortar in which they homogenize before the next reagent is added. In the end, a fine powder is obtained, which will then be slowly mixed with glycerin. Finally, water will be added, and the resulting mixture will be left for oxidation in contact with light and atmospheric oxygen for 15 days before use.

Watery Eosin:

- 5 grams yellowish eosin or eosin Y
- 500 milliliters distilled water

Some thymol will be added to the eosin solution in order to prevent its contamination.

The *technical procedure* is as follows:

- Dewax and hydrate the cuts.
- Introduce the cuts in Carazzi's hematoxylin, from 10 to 15 minutes, depending on its maturation or oxidation state.
- Wash off in running water for 10 minutes, until the purple color of the cuts turns blue.
- Introduce the cuts in eosin for 30 seconds.
- Without washing, dehydrate, clear and mount with resin.

During dehydration of the samples, eosin also differentiates, thus removing its excess.

Results will show nuclei and nucleic acids in a range of blues, cytoplasm in orangey or pinkish, and cell structures such as collagen in pink. This way, staining will be useful for observing the general structure and the cell state of our liver biopsy.

Masson's Technique

Masson's technique is a trichrome stain designed for observing collagen fibers and connective tissue. In trichrome staining, dyes are normally intended for differentially staining various tissue structures. Thus, a nuclear stain, a cytoplasmic stain, and a collagen fiber stain will be used. Differential staining is founded, in part, upon the size of pores in various tissue components when the proteins reticulate as a result of fixation, which is much laxer in collagen structures than in cell cytoplasm structures. And it also partly depends on the treatment with phosphotungstic acid and phosphomolybdic acid underwent by the tissue to improve the affinity of collagen fibers for the dye.

This technique is of special interest in the case of liver biopsy for observing and assessing the degree of distribution of fibrosis.

If the samples have been fixed in formol, treatment with Bouin's fixative solution is appropriate, since it will act as mordant for the next staining.

The *reagents* that used are:

Weigert's Iron Hematoxylin

Solution A

- 1 gr hematoxylin
- 100 mL absolute ethanol

Solution B

- 4 mL ferric chloride at 29%
- 95 mL distilled water
- 1 mL hydrochloric acid

At the time of use, a working solution is generated by mixing solution A and B in equal proportions and well mixed.

Biebrich Scarlet and Acid Fucsin Solution

- 90 mL of Biebrich Scarlet in aqueous solution at 1%
- 10 mL of Acid Fucsin in aqueous solution at 1%
- 1 mL glacial acetic acid

Phosphotungstic Acid and Phosphomolybdic Acid Solution

- 5 gr phosphotungstic acid
- 5 gr phosphomolybdic acid
- 200 mL distilled water

Aniline Blue Solution

- 2.5 gr aniline blue
- 2 mL glacial acetic acid
- 100 mL distilled water

Acetic Acid Solution at 1%

- 1 mL glacial acetic acid
- 99 mL distilled water

The *technical procedure* is as follows:

- Dewax and hydrate the cuts.
- Wash off in distilled water.
- If the fixation has not been carried out with Bouin's fixative, perform a post-fixation with Bouin's solution for 12 hours at room temperature, or for one hour in a heater at 58-60ºC.
- Wash off with abundant running water to remove all fixative remaining. Then wash off in distilled water.
- Dye with Weigert iron hematoxylin for 10 minutes.
- Wash off in running water for 10 minutes.
- Wash off with distilled water.
- Dye with the Biebrich Scarlet and Acid Fucsin solution for 15 minutes**.**
- Wash off with distilled water.
- Differentiate the cuts with the phosphotungstic-phosphomo-lybdic acid solution from 10 to 15 minutes.
- Dye with aniline blue from 5 to 10 minutes.
- Differentiate the cuts with the acetic acid solution at 1% from 2 to 3 minutes.
- Wash off in distilled water.

During the staining, we can control microscopically whether or not the phosphotungstic-phosphomolybdic acid solution has correctly differentiated and that the collagen fibers of the tissue do not appear red. If, after differentiation, the red color persisted, that means that the acid solution needs more time to act.

The *results* will show the nucleus dyed in black, muscle fibers, cytoplams and keratin in red tones, and collagen fibers in deep blue.

Gomori's Reticulin Technique

This is a silver impregnation technique. This type of technique relies on silver salts that react with certain parts of tissues, normally electronegative structures that can attract silver ions. These ions, once fixed onto the structures, are forced to precipitate by means of the action of reducing agents, delivering a metallic silver pigment. Gomori's technique, more

precisely, is a two-stage silver impregnation that uses potassium hydroxide as the source and formol as the reducing agent. It uses potassium permanganate as oxidizing agent, potassium disulphite to whiten the cuts, and ferric alum as mordent.

The optimal result for this method depends in part on the wash that takes place before reduction with formol. Its duration should be determined empirically. It is also important to tone the samples with gold chloride. This gives a bluish grey color to precipitated silver, removes unspecific silver remnants, and gives collagen fibers a purple color.

With this technique in *liver biopsies*, as in previous cases, we observe and assess the distribution degree of fibrosis.

Neutral formol at 10% is recommended as the most adequate fixation. This technique can be used in paraffin, celoidine and freezing cuts. Cuts are recommended to be 6-7 microns thick, so as to allow for following the course of reticular fibers in tissue thickness.

The *reagents* that will be used are:

Potassium Disulphite at 2%

- 4 gr potassium disulphite
- 200 mL distilled water

Ferric Alum at 2%

- 4 gr ferric alum
- 200 mL distilled water

Ammoniacal Silver Solution

- 25 mL silver nitrate at 10%
- 5 mL sodium hydroxide at 10%

These two solutions are mixed, and ammonia is added drop by drop, until the silver precipitate is completely dissolved, and the resulting solution is completely transparent. To the consequential solution volume, an equivalent volume of distilled water is added. It is then filtered and let set for 12 hours in the dark. The excess of ammonia will evaporate. Once evaporated, this solution is preserved in a refrigerator at 4ºC and protected from light.

Neutral Formol at 10%

- 20 mL commercial formalin
- 180 mL distilled water

The solution's pH is measured and then adjusted to pH 7, using a sodium hydroxide solution.

Gold Chloride at 0.2%

- 0.4 gr gold chloride
- 200 mL distilled water

Sodium Thiosulphate at 2.5%

- 5 gr sodium thiosulphate
- 200 mL distilled water

Neutral Red at 1%

- 2 gr neutral red
- 200 mL distilled water

The *technical procedure* is:

- Dewax and hydrate the cuts.
- Wash off with distilled water.
- Cover the cuts with potassium permanganate at 1% for 2 minutes.
- Wash off in distilled water.
- Whiten the cuts with potassium disulphite solution at 2% for 1 minute.
- Wash off thoroughly in distilled water several times.
- Treat the cuts with ferric alum at 2% for 1 minute.
- Wash off twice with distilled water.
- Treat the cuts with previously filtered ammoniacal silver solution for 1 minute.
- Wash off the cuts in distilled water for 5 minutes making several changes.
- Reduce the cuts with neutral formol at 10% for 5 minutes.
- Wash off thoroughly with distilled water.
- Treat the cuts with gold chloride solution at 0.2% from 5 to 10 minutes.
- Wash off in distilled water.
- Add potassium disulphite at 2% for 1 minute.
- Wash off in distilled water.
- Treat the cuts with sodium thiosulphate at 2.5% from 1 to 2 minutes.
- Wash off with distilled water.
- Optionally, stain once with neutral red at 1% as a nuclear stain acting as a contrast.
- Wash off with distilled water.
- Dehydrate, clear and mount in resin.

The *results* will show reticular fibers in black, nucleus in grey, and collagen in a light purple tone. If the sample has been contrasted with neutral red, then cell nucleus will appear black.

PAS Technique

This technique's name is an acronym for Periodic Acid Schiff, which is the main reagent in this histochemical technique. This technique is much used for determining mucopolysaccharides, glycoproteins, glycolipids, simple polysaccharides... Schiff reagent is obtained by modifying basic fucsin treating it with sulphurous acid, thus making it lose its characteristic fuchsia color and turning it colorless. Then, when it reacts with carbonyl groups in the tissues, it retrieves its broken double bond and regains its fuchsia color.

Before using Schiff reagent, the technique requires that the tissue has previously been oxydated using periodic acid. This increases the amount of carbonyl groups present in carbohydrates, to make them more evident.

Nuclear staining is generally used as contrast with hematoxylin. In our case, we will use Carazzi's hematoxylin.

In the particular case of liver biopsy, this technique is useful for observing cell glycogen content, and assessing the degree of metabolic alteration suffered by hepatocytes. Hepatocyte content can also be observed in lipofucsin pigment, which is a brown color pigment that

appears in cell cytoplasm as a consequence of fatty acids degradation, and affects cell functionality.

The *reagents* that will be used are:

Carazzi's Hematoxylin
Periodic Acid at 2.5%

- 5 gr periodic acid
- 200 mL distilled water

Shiff Reagent

- 0.25 gr basic diamond fucsin in crystals
- 6 gr sodium dithionite
- 300 mL distilled water

To elaborate, fucsin is blended in a mortar and 150 mL distilled water is added. Separately, the sodium dithionite is mixed with the other 150 mL of distilled water. These are individually filtered, and then slowly mixed by pouring the sodium dithionite solution into the basic fucsin one. The result will be a clear and opalescent solution that must be preserved in a refrigerator at 4ºC and protected from light.

Sodium Disulphite at 2%

- 4 gr sodium disulphite
- 200 mL distilled water

The *technical procedure* is as follows:

- Dewax and hydrate the cuts.
- Treat the cuts with periodic acid at 2.5% for 10 minutes.
- Wash off in running water for 10 minutes.
- Wash off in distilled water.
- Dye the cuts with Schiff reagent for 15 minutes, preferably protected from light.
- Treat with sodium dishulphite at 2% from 3 to 5 minutes.
- Wash off in running water for 10 minutes.
- Wash off in distilled water.
- Dye the cuts with Carazzi's hematoxylin for 5 minutes.
- Wash off the cuts in running water for 10 minutes.
- Dehydrate, clear and mount with resin.

The *results* will show the nucleus in blue, and the positive PAS material in the range of pink to fuchsia. Glycolypids, gangliosides and cerebrosides, mucoproteins in general, neutral mucopolysaccharides, simple polysaccharides like glycogen or glycoproteins of the basal membrane, are all considered to be PAS positive substances. The lipofuscin pigment is also PAS positive.

Perls' Prussian Blue Technique

This is a technique destined for the detection of free iron ions in the tissue, as well as their deposits, such as hemosiderin. Hemosiderin is the deposits of ferric hydroxide that appear in cell cytoplasm or inside macrophages. They are usually the result of natural or pathological degradation of hemoglobin.

The *reagents* that will be used are:

Potassium Ferrocyanide at 5%

- 10 gr potassium ferrocyanide
- 200 mL distilled water

Hydrochloric acid at 5%

- 10 mL commercial hydrochloric acid
- 190 mL distilled water

Carazzi's Hematoxylin

The *technical procedure* is as follows:

- Dewax and hydrate the cuts.
- Wash off with running water.
- Treat the cuts with a potassium ferrocyanide solution at 5% and hydrochloric acid at 5%, equal proportions, for 20 minutes.
- Wash off thoroughly with running water.
- Dye the cuts with Carazzi's hematoxylin for 5 minutes.
- Wash off in running water for 10 minutes.
- Dehydrate, clear and mount with resin.

The *results* will show iron granules in light blue, the cell nucleus in dark blue, and cytoplasms in yellow.

Specific Techniques for Fats

When working to detect fats, their physicochemical properties must be taken into account, because they will limit the methodologies to be used with them in the laboratory. Lipids are water insoluble, but they are very soluble in certain organic solvents, such as ethanol, acetone, chloroform, toluene or xylene. This feature will prevent them from being embedded in paraffin, since the lipid material would get lost in the process. Therefore, embeddings can only take place in water soluble media, such as gelatin. As an alternative frozen cuts of previously embedded material can be used.

The most appropriate fixative for the lipid material is formol, because of its good results when fixing neutral fats. If calcium chloride is also added to it, results are even more improved. This is because calcium ions will make lipids be more stable, and formol will then be able to fix them more efficiently.

When dying, the technique will highlight the presence of homophasic lipid tissue, which is the one to be found in very specific locations in the cell, such as the cytoplasm, without being mixed with any other element. Heterophasic lipids are dispersed throughout the cell

territory, and they are mixed with other substances. It is very difficult to determine their presence.

The staining mechanism to detect these homophasic lipids is a purely physical mechanism, which has much to do with the solubility characteristics of lipids. It is based on the fact that the dye is better dissolved in the lipid than in the medium that will be used for the technique (it will normally be ethanol or acetone). Consequently, there is a trend for dye molecules to migrate from the solution used into tissue lipids. The longer the sample is exposed to the solution with dye, the more intense the resulting color will be. This is because molecules accumulate gradually in lipid deposits.

As a general rule, the solutions of these dyes specific for fats are not usually very stable. Therefore, when possible, it is recommended to make them at the time of use. When that is not possible, the best option is to store them in an airtight container, because instability could make the dye precipitate and then deliver false positives.

When we made these techniques, we selected the cryostat cut of tissue already fixed. We made cuts of 7 to 10 microns. The next explanations of procedures that follow will be made bearing in mind cuts of these characteristics. It also has to be taken into account that since these preparations are made with aqueous mounting, their life is very limited- no more than 15 days it they are conserved at 4ºC in a refrigerator.

Sudan IV Technique

This dye is specific for neutral fats. Special care will be required, since the dye precipitates very easily. Carazzi's hematoxylin will be used as a nuclear contrast dye, since in the Sudan IV technique there are only the lipids of the tissue, and contrast dye is very convenient to put them in context. This hematoxylin can be replaced by any other hematoxylin or by other nuclear dyes.

The *reagents* that will be used are:

Sudan IV Solution

- 1 gr Sudan IV solution
- 50 mL acetone
- 50 mL ethanol at 70%

The *technical procedure* is:

- Wash off cuts in ethanol at 70%.
- Treat the cuts with the Sudan IV solution for 10 minutes.
- Wash off with ethanol at 70%.
- Wash off in distilled water.
- Dye with Carazzi's hematoxylin for 5 minutes.
- Wash off in running water for 10 minutes.
- Without dehydrating, mount in an aqueous medium and seal with a lacquer.

The *results* will show the nucleus in blue, and lipids in a range from orangey-reddish to intense red.

Sudan Black Technique

This dye, as its name indicates, is black. Therefore, we recommend contrast dye for the nucleus with some dye such as neutral red, in order to help acquire a better general picture.

The *reagents* that will be used are:

Sudan Black Solution

- 1 gr Black Sudan solution
- 50 mL acetone
- 50 mL ethanol at 70%

The *technical procedure* is:

- Wash off cuts in ethanol at 70%.
- Treat the cuts with the Sudan Black solution for 10 minutes.
- Wash off with ethanol at 70%.
- Wash off in distilled water.
- Dye with neutral red for 2 minutes.
- Wash off in running water for 10 minutes.
- Without dehydrating, mount in an aqueous medium and seal with a lacquer.

The *results* will show lipids and myelin in black; and if a contrast dye has been performed with neutral red, the nucleus will appear in red.

Sudan Red or III Technique

This technique can also be used in paraffin cuts, bearing in mind that after the embedding process, the amount of lipids that will appear will be much lower than that of the tissue before the embedding process.

The *reagents* that will be used are:

Carazzi's Hematoxylin

Sudan III Solution

- 2 gr Sudan III solution
- 100 mL ethanol at 70%
- 100 mL acetone
- 2 gr Scarlet red

First, Sudan III solution is dissolved into the ethanol at 70%. Once it has been dissolved, acetone is added. And when it is homogeneous, it is dissolved again in Scarlet red. It is very important to thoroughly filtrate this solution before it is applied to the sample so as to prevent the formation of precipitates that could lead to false positives.

The *technical procedure* is:

- Dewax cuts and rehydrate with ethanol 96º.
- Wash off the cuts with ethanol at 50% for 1 minute.

- Treat the cuts with the Sudan III solution that has been previously filtered for 15 minutes in a heater at 60ºC, or for 1 hour at room temperature.
- Quickly wash off the cuts in ethanol at 50%.
- Quickly wash off in distilled water.
- Dye the cuts with Carazzi's hematoxylin for 5 minutes.
- Wash off in water for 10 minutes.
- Mount it in an aqueous medium and seal with a lacquer.

The *results* will show the nucleus in blue, and lipids dyed in red or orangey red.

Oil Red-O Technique

This technique can also be applied to paraffin cuts, bearing in mind that, as in the last case, most of the fats will get lost in the embedding process.

The *reagents* that will be used are:

Propylene glycol at 85%

- 85 mL commercial propylene glycol
- 15 mL distilled water

Carazzi's Hematoxylin

Oil Red-O Solution at 0.5%

- 0.5 gr Oil Red-O
- 100 mL commercial propylene glycol

To prepare Oil Red-O, it is placed in a mortar and a small amount of propylene glycol is added. Then it must be blended and the sample homogenized by gradually adding the rest of propylene glycol. After that, the solution is heated to 95ºC, while continuously stirred until the rest of stain is dissolved. Once it is hot, it is filtered with filter paper and left to rest all night through. The next morning, it will be filtered again through a glass-fiber filter with the help of a vacuum system. If the resulting solution is cloudy, a new filtration must be performed.

The *technical procedure* is:

- Dewax and hydrate the cuts.
- Wash off with propylene glycol at 100% for 5 minutes.
- Dye with the Oil Red-O solution from 48 to 72 hours.
- Wash off the cuts with propylene glycol at 85% from 1 to 2 minutes.
- Dye the cuts with Carazzi's hematoxylin for 5 minutes.
- Wash off in running water for 10 minutes.
- Wash off several times with distilled water.
- Mount it in an aqueous medium and seal with a lacquer.

The *results* will show lipids in red color, and the nucleus in blue tones.

IMMUNOHISTOCHEMICAL TECHNIQUES

Immunohistochemistry is a process through which a specific antigen can be detected, amplified and visualized both at tissue and cell levels. This is achieved by means of the antigen-antibody reaction, which is very specific and of high affinity. In immunohistochemistry, selected antibodies are used to identify specific antigens. In immunohistochemistry, antigen is any substance or molecule that we want to detect. In order to visualize the site where the antigen-antibody reaction takes place, a tracker or marker is needed. Such marking can be done with fluorochromes (immunofluore-scence techniques), with enzymes (immunoenzymatic techniques), with metallic ions in colloidal form (immuno-oro technique) or with radioactive isotopes. The antigen can be detected both through direct marking of the primary antibody (direct method), or indirectly using a secondary or even a tertiary antibody.

In order to better understand the technique and the antigen-antibody reaction, we will explain some basic concepts:

- *Immune response.* This response lays in the identification of a foreign agent. Such identification takes place through two types of molecules: T-cell receptors and immunoglobulines.
- *Antigen.* The substance or substances capable of producing an immune response, either humoral or cellular, or both at the same time (immunogenicity), capable of combining with antibodies and with cell receptors (antigenicity), and capable of producing an allergic reaction (allergenicity). Each antibody is specific for a determined antigen, and binds to a determined part of it, called epitome or antigenic determinant, thus establishing the antigen-antibody specificity.
- *Antibody.* The molecules with antibody activity are generically designated as immunoglobulins. All immunoglobulin molecules present a common structure composed of four polypeptide chains, two long chains (H or heavy chains) and two short chains (L or light chains). According to the primary structure of their heavy chains, they are divided into five classes, and are termed Ig G, Ig A, Ig M, Ig D, and Ig E.

Immunohistochemical Detection Systems

Direct Method

This is the simplest method, and involves only one step applying the specific antibody against the antigen that one wants to demonstrate. The antibody is conjugated with a marker (either fluorescent or enzymatic) that makes the reaction visible under the microscope.

Indirect Method

The first antibody is specific for the antigen that we want to demonstrate, and it is not conjugated with any marker. A second antibody has to be used (developed in an animal of a different species from the first). This second antibody can be marked or not (the second antibody is specific for the first antibody). If the second antibody is not marked, a third

antibody (developed in the same animal species as the first) is used. This third antibody is marked.

Types of Immunohistochemical Techniques

Based on the marker (fluorochrome, enzymes, etc.) and the detection system used (direct or indirect method), different types of immunohistochemical techniques can be found.

Immunofluorescence Techniques

Fluorescence is a form of luminescence, understood as the emission of light generated by a non-thermal energy source, and under the effect of an excitation. Primary fluorescence (autofluorescence) is that spontaneously presented by certain substances. In tissues that do not have this property, fluorescence can be induced (secondary fluorescence) through immunohistochemical techniques, using fluorescent molecules, named fluorochromes, as markers. Fluorochromes are chemical molecules that absorb light at a certain wavelength and deliver a different one. Their excitation spectrums and emissions vary according to the fluorochrome used. The most used fluorochromes in immunofluorescence techniques are: fluorescein, rhodamine, Alexa Fluor, DyLight Fluor, etc. The disadvantage of this type of technique is that it is not permanent marking, since the light emitted by the fluorescent molecule (fluorochrome) vanishes with time. Therefore, it must be preserved from light. In order to visualize the results of this technique type, a special microscope is necessary: fluorescence microscope.

Immunoperoxidase Techniques

In this technique type, peroxidase is the marker used. Peroxidase is an enzyme obtained from horseradish, and it is the most used enzyme tracker. Peroxidase can be used both bonded to the primary antibody (direct technique, the simplest method, but less sensitive for antigens detection) and in immunocomplexes called PAP (peroxidase+antiperoxidase antibody) that will join a bridging antibody (secondary antibody) in the indirect technique. These PAP complexes will be the tracers for the antigen-antibody reaction. Next, the marker will be developed by oxygenated water (H2O2) added as substrate, together with the chromogen appropriate for that enzyme. The reaction takes place when the enzyme binds to the substrate, releasing oxygen, thus causing the chromogen oxydation and originating an insoluble brown product. Peroxidase can be endogenously found in tissues.

Techniques with Alkaline Phosphatase

When tissues are very rich in endogenous peroxidase, alkaline phosphatase is used as the tracer. Sometimes, there is endogenous phosphatase but in a few number of tissues than in normal conditions. In these cases, its endogenous activity requires no inhibition. If needed, it can be inhibited with levamisole. This enzyme is developed using Naphthol-AS-MX phosphate as a substrate, and Fast Red TR or Fast Blue BB as chromogen.

Avidin-Biotin Technique

This type of technique uses biotinylated antibodies. Biotin is a low molecular weight vitamin presenting a high affinity for avidin. Avidin is a high molecular weight glycoprotein that can be found in egg white and in the *Streptomyces avidini* bacteria (streptavidin). An almost irreversible and very rapid interaction takes place between them. Avidin has four connection points with biotin, and can be conjugated with different markers. Its specificity and affinity are much greater. It can be developed by the DAB, if the marker used is peroxidase.

Immunohistochemistry Universal Kit

Currently, there are several universal kits containing al the reagents required in the immunostaining process. Some of them even allow for indiscriminate use with monoclonal and polyclonal antibodies, and enable their development in different colors, choosing the adequate marker and chromogen. Most of these kits use indirect detection systems based on polymers. An important advantage of this detection system is that it normally is ultrasensitive with the associated primary antibody saving.

Immunohistochemistry Techniques Processes

All immunohistochemistry techniques follow a similar process. The differences that may exist in such processes are normally caused by: the type of study sample, the type of tissue used, the fixation system used, whether the sample is embedded or frozen, the embedding media used, the primary antibody to be used, the detection system, and the selected development system. The following scheme shows a summary of the process to follow, which will be discussed later.

1. Deparaffination and hydration of previously identified samples.
2. Antagonist unmasking if necessary.
3. Washout.
4. Enzymatic activity blockade.
5. Washout.
6. Background staining blockade.
7. Primary antibody incubation.
8. Washout.
9. Detection system.
10. Washout.
11. Development system.
12. Washout.
13. Counterstaining.
14. Washout.
15. Dehydration and mounting.

The entire process has to be carefully performed, avoiding whenever possible, interfering or destroying the tissue and cell structure, and conserving its immunoreactivity. All variables in the process affect the outcomes of the immunohistochemistry technique used. The loss of antigenic epitope integrity depends on them.

Fixation

For this process, sample fixation is one of the most important steps. The ideal fixative in immunohistochemistry preserves the antigens' integrity, preserves tissue and cell morphology, prevents the extraction, diffusion or displacement of antigens during the fixation process, and does not interfere with the antigen-antibody reaction. There is no universal fixative. It has to be chosen from among the antagonist groups that one wants to demonstrate. The most used fixative is formaldehyde or formalin (aqueous solution of formaldehyde). It is prepared at 10% starting with commercial formol (formaldehydes at 40%), which gives the solution a final formol concentration of 4%. This fixative generates reticles, creating bonds or cross-linked bridges, and giving as a result a net in which epitopes are masked and the primary antibody is prevented from binding the antigen.

Deparaffination and hydration of Samples

Once the cuts have been rehydrated, it is very important to prevent them from drying out, because when cuts dry in any of the technique's steps, an unspecific staining may take place. To avoid that, the immunostaining process is performed in trays or metallic containers called moist chambers. This helps the cuts remain hydrated and prevents evaporation. A PAP pen can also be used. This is a special marker that creates a fine hydrophobic layer around the cut, which helps dilutions remain exclusively in the regions of interest and maintains the cuts hydrated. It also helps saving antibody.

Antigen Unmasking (For Tissues Fixed in Formol)

Antagonist recovery is the process through which the antigen's molecular structure is restored, and immunoreactiviy is retrieved, thus providing optimal immunohistochemical results. The methods used to obtain an antagonist recovery are:

Enzyme Unmasking

Proteolytic enzymes are normally used with proteinase K, trypsin, pepsin, pronase, etc. These enzymes facilitate the tissue penetration of antibodies, eliminating the protein net that wraps antagonist determinants through the fixation process. This method will depend on: enzyme type and concentration, time and temperature of digestion, tissue type and fixation type. Therefore, the digestion time should be adjusted to each case.

Heat-Induced Unmasking (Heat-Induced Epitope Retrieval-Hier)

Most antibodies used in tissue that has been fixed with formol and embedded in paraffin, then require this method for antigen retrieval. Variables with a greater influence on HIER effectiveness include: temperature, time, tissue fixation time, nature and pH of the retrieval buffer. HIER is normally performed through incubation in a citrate buffer or EDTA, at a temperature of 97ºC-98ºC for 20 minutes. Domestic microwaves or pressure cookers are frequently used for this. But the best option, when available, is to use a scientific microwave, which, unlike previous options, allows for accurately controlling time and temperature.

Enzyme Activity Blockade

This is a method to achieve enzyme activity inhibition for the enzyme used as a marker that can be endogenously found in the tissue. The method involves the incubation of the cuts before the immunological process, applying an agent that blocks in each specific case. If the blockade is not performed, false positives could be obtained in the immunostaining.

Background Staining Blockade

Background staining can be specific or nonspecific. Specific staining can be due to the presence of the study antigen in locations different from those where it was expected to be detected, the existence of antibodies in the primary antiserum acting against different antigens than those expected to be determined, or the passive trapping of antigens, or antigen diffusion, to places where they are not normally found. The most common nonspecific staining is the non-immunological bond of the antibody with certain tissue components, due to hydrophobic and electrostatic forces. The blockade solution binds to binding sites that are not specific inside the tissue, aiming at preventing the nonspecific bonding of primary and secondary antibodies. Cuts are incubated with a protein solution, such as bovine serum albumin (BSA) or normal serum of the same animal species as the secondary antibody. With the objective of ensuring the technique's specificity, an adequate dilution of the primary antibody needs to be achieved, preventing evaporation during incubation, and making the washes be thorough.

Primary Antibody Incubation

Depending on the chosen primary antibody, the corresponding manufacturing company will provide specific indications on its dilution ranges, time and temperature for incubation, detection method, etc. These vary based on the following: type of antibody used, detection method to be used, and whether the tissue used is embedded in paraffin and fixed in formol.

There are two types of antibodies, monoclonal and polyclonal antibodies.

- *Monoclonal* antibodies can be created in mice or rabbits. They are the product of a single clone of plasma cells. Therefore, antibody molecules are all immune-histologically identical, with only one specificity and only one affinity.
- *Polyclonal* antibodies are the mixture of immunoglobulins synthesized by different plasma cell clones that react with different epitopes on the antigen for which they were created. When the optimal dilution of primary antibody has to be determined, titration is needed. Antibody titration is the higher dilution of an antibody, resulting in the maximal specific coloration with the minimal background. It is performed through serial dilutions of an antibody stock solution (1/25; 1/50; 1/100; etc.). The habitual incubation time is one hour at room temperature, 30-60 minutes at 37ºC, and 12 hours or more in a refrigerator at 4ºC.

Detection Systems

In order to make the antibody-antigen union visible under the microscope, it is necessary to use detection and coloring systems. Several types of detection systems can be found. Some of them have already been discussed here.

Development Systems

These development systems are based on the enzyme-substrate reaction. Detection systems use enzymes to transform colorless chromogens into colorful final products as a result of oxidation. This allows for their visualization under the microscope. The most used enzymes are peroxidase and alkaline phosphatase.

Counterstaining or Contrast Staining

Counterstaining is normally used to facilitate the visualization and detection of immunostained tissue areas, distinguishing them from those areas that are not stained. This contrast staining is usually carried out with hematoxylin.

Dehydration and Mounting

Dehydration is achieved through washes in alcohols of increasing concentrations to take the cuts to xylol. The mounting used can be aqueous or permanent, depending on the chromogen type used, and on whether the resulting color product is soluble or not in alcohol and in other organic solvents.

Washes

Throughout the process, several washes are required between subsequent steps. They are performed in order to remove the excess of primary antibody and of other products used during the process. Washes are normally performed with buffered solutions to which a detergent (Triton X-100, Tween 20, etc.) is added. This detergent acts to permeabilize membranes and helps antibodies penetrate adequately and reach the antigens to be detected. Several washes of short duration (5 minutes) are usually more effective than one single longer wash. Given the large number of washes required, some cuts are frequently peeled off. Therefore, using an adhesive is recommended to fix cuts to the slide, with adhesives such as egg albumin, gelatin or poly-L-lysine. It is important not to add too much adhesive, since non-specific background staining could increase.

Controls

Controls are carried out in order to check whether the immunohisto-chemical technique performed is specific, and verify that there are no false negatives or positives.

Negative Controls

An omission of the primary antibody or its replacement by non-immune serum or buffered solution. The same tissue as for the positive control is used. If the results are positive, this will be due to an unspecific fixation.

Positive Controls

These are performed using a tissue cut including the antigen to demonstrate. If the result is negative, the cause is a fixation defect or an error during the technique procedure.

Automated Immunostainers

Thanks to new technologies, devices that perform automatic immunostaining can be found nowadays. They allow for the introduction of slides with tissue cuts, previously tagged

with barcodes for their identification using a reader, and each sample will be applied with the correct reagent. This process is very laborious due to the precision required on each of the samples, and due to the complex electronic mechanism controlled by a computer, which comprises its own thermal source for the antigenic unmasking. This involves a great progress with a reduction in errors while the technique is performed, since times, temperatures, reagent quantities, etc. are not shortened nor exceeded.

REFERENCES

Casado Martín F., Rodríguez Sanjuán J.C., Val-Bernal F., Blanco García C., Herrero Zapatero A. Anatomopathologic and morphometric study of hepatocarcinoma. *The Spanish Journal of Gastroenterology*. 1993; 84 (5):315-8. PMID: 8305258.

De Dios Soler M., Acosta Haab G. "*Immunohistochemistry Guide for Technicians*". 1st Ed. Nacional Cancer Institute. Buenos Aires (Argentina). 2018.

Garcia de Moral Raimundo. "*Laboratory of Pathological Anatomy*". 1st Ed. Madrid (Spain). Interamericana-McGraw Hill Ed. 1993.

Gil Grande L. Blind liver biopsy in current medicine. *Rev Clin Esp.* 2003; 203(5):219-20. PMID:12765566.

Martin Lacave I., Garcia Caballero T., *Atlas of Immunohistochemistry.* 1st Ed. Madrid (Spain). Diaz de Santos Editors. 2012.

Masson P.J. "Trichrome stainings and their preliminary techniques". *J Tech Met.* 1929.

Mc Manus F.J.A. and Mowry Robert W. *"Histological Techniques".* 1st. Ed Atika. Ed. 1968.

Montuenga L. Esteban -Ruiz F.J., Calvo González A. *Techniques in Histology and Cellular Biology.* 2nd Ed. Madrid (Spain). Masson Editors. 2014.

Urpegui García A.M., Morandeira García M.J., Soria Navarro J., Rivas Rodríguez P., Valencia Julve J., Fernández Larripa S., Vallés Varela H. Immunohistochemical markers of cell proliferation in laryngeal carcinoma. *Acta Otorrinolaringol Esp.* 2000. 51(4):279-87. PMID: 10984949.

In: Encyclopedia of Surgery (22 Volume Set)
Editors: Andreas Lehrer and Kristin Mueller
ISBN: 978-1-53618-329-0
© 2020 Nova Science Publishers, Inc

Chapter 308

CONVENTIONAL IMAGING TESTS FOR THE EVALUATION OF NASH

Luis Tomás Ocaña Wilhelmi, MD, PhD,
Bruno Ramos Molina, PhD
and Enrique Glückmann Maldonado, MD
Surgery Department, University of Málaga, Málaga, Spain

ABSTRACT

In the last two decades, enormous progress has been made in the evaluation of NAFLD by non-invasive images, techniques that receive more and more attention. Among these stand out (in addition to others in research that use biological markers and image): Ultrasound, Computerized Tomography, Magnetic Resonance Imaging (PDFF), Magnetic Resonance Spectroscopy, Magnetic Resonance Elastography, Transient Elastography (VCTE, CAP) and ARFI/SWE (Impulse Acoustic Radiation Force/Share Wave Elastography).

The diagnosis is important since it has proven that bariatric surgery is not only cost effective in cases of advanced fibrosis (f3), but also for obese patients with NASH, independently of the stage of fibrosis. Therefore, we must differentiate from the beginning the usefulness of these tests in the three diagnostic spectra of this disease: those that detect steatosis well, its evolution to NASH and fibrosis.

There are so many tests nowadays that are offered for the determination of steatosis and/or fibrosis of our patients, which will have to be adapted to each Center and to speak with the Hepatologist and the Radiologist when evaluating this disease in the best way possible. Thus, depending on the experience and availability of material they have, we may find variability among Hospitals regarding the imaging methods and biomarkers used in the diagnosis of NAFLD/NASH.

Keywords: Conventional Ultrasound (CUS), Computerized Tomography (CT), Magnetic Resonance Imaging (MRI, PDFF), Magnetic Resonance Spectroscopy (MRS), Magnetic Resonance Elastography (MRE), Transient Elastography (VCTE, CAP) and Impulse Acoustic Radiation Force/Share Wave Elastography (ARFI/SWE)

INTRODUCTION

The NAFLD and its evolution to NASH and later Fibrosis, which is complicated with Cirrhosis, Hepatic Failure and Hepatocarcinoma, that requires a transplant or end in the death of the patient, will shortly become one of the most prevalent diseases and that more resources health will need. Of course, it is the most common form of liver disease today [1, 2] affecting 80-100 million people in the United States [3]. We have arrived at this because of the pandemic that is Obesity, and the diseases that are related to it and that make up the Metabolic Syndrome, which as a pernicious vicious circle do nothing but feed back and take the patient to a point of no metabolic return.

The European Clinical Practice Guideline (EASL, EASD, EASO) for the management of NAFLD precisely defines this disease from the point of view of biopsy and image, which is the objective of this chapter. Thus, NAFLD is a mild condition that is characterized by excessive accumulation of liver fat (presence of steatosis in more than 5% of hepatocytes). This percentage is calculated according to the histological analysis or a fat fraction of proton density (providing an approximate estimate of the volume fraction of fatty material in the liver) greater than 5.6%, evaluated well by magnetic resonance spectroscopy of protons (1H-MRS) or by selective magnetic resonance of fat/quantitative water (MRI) [4].

As the clinic is silent, if we do not think about it we will not be able to make the diagnosis, which is not indicated in the general population, but in obese or diabetic patients and who are at risk of liver disease. To make the diagnosis, we will begin with the imaging tests, where MR is the most accurate to determine the volume of liver fat, but it is expensive and not available to all centers. Ultrasound is cheaper and accessible, but it has its limitations. Regarding the biological markers, we still do not have one that is totally reliable in the diagnosis of NASH, so we have to continue investigating, as well as in the different tests available [5]. Finally, we must continue to perform liver biopsy, an authentic gold-standard for the diagnosis of NASH, in patients at risk, either because they already have advanced disease or because of the more than predictable evolution to it.

The key to diagnosis is, therefore, in the non-invasive evaluation. Non-invasive markers should aim to: in the field of primary care, identify the risk of NAFLD in individuals with a high metabolic risk; in the field of secondary and tertiary care, identify individuals with a worse prognosis, for example, those with a severe NASH; monitor the progression of the disease; and predict the response to therapeutic interventions. If these objectives are achieved, the need for liver biopsies could be reduced [4].

Therefore, when a physician sees a patient with non-alcoholic fatty liver disease (NAFLD) in a clinical setting, three general clinical questions arise, which attempt to respond with imaging techniques: does my patient have NAFLD?; Does my patient have a nonalcoholic steatohepatitis (NASH)?; and Does my patient have advanced fibrosis? [6]. We must also ask ourselves which technique is best for each event, if it is cost efficient and what are its limitations.

The need for screening for NAFLD in the general population is highly questioned due to several factors: the high direct and indirect costs of the tests to be performed, the low predictive value of non-invasive tests, the risks of liver biopsy and the lack of effective treatments [7]. However, the progressive form of NAFLD (NASH), particularly when associated with advanced fibrosis, should be identified in at-risk patients (age> 50 years, type

2 diabetes mellitus or MetS), due to its prognostic implications. Similarly, although a family grouping occurs, it is generally not advisable to detect the family, with the exception of cases with defined hereditary diseases, for example, lysosomal acid lipase deficiency [4].

In the last two decades, enormous progress has been made in the evaluation of NAFLD by non-invasive images, techniques that receive more and more attention [6, 8]. Among these stand out (in addition to others in research that use biological markers and image): Ultrasound, Computerized Tomography, Magnetic Resonance Imaging (PDFF), Magnetic Resonance Spectroscopy, Magnetic Resonance Elastography, Transient Elastography (VCTE, CAP) and ARFI/SWE (Impulse Acoustic Radiation Force/Share Wave Elastography).

The available or developing imaging tests assess different properties of the tissue, including diffusion, texture, amount of fat, the amount of bonds in the fat and the stiffness of the liver [6]. Therefore it is important to know the pathophysiology of this disease to understand the new imaging techniques that are being developed and that associate the use of different biomarkers. These phenomena, together with the increase of cytokines and other substances, the damage of mitochondria, the different capacity of diffusion of gases by fatty particles, etc. have made possible the development of very promising techniques for the diagnosis of NAFDL and differentiate it from its progression to NASH.

The diagnosis is important since it has proven that bariatric surgery is not only cost effective in cases of advanced fibrosis (f3), but also for obese patients with NASH, independently of the stage of fibrosis [9]. Therefore, we must differentiate from the beginning the usefulness of these tests in the three diagnostic spectra of this disease: those that detect steatosis well, its evolution to NASH and fibrosis.

There are so many tests nowadays that are offered for the determination of steatosis and/or fibrosis of our patients, which will have to be adapted to each Center and to speak with the Hepatologist and the Radiologist when evaluating this disease in the best way possible. Thus, depending on the experience and availability of material they have, we may find variability among Hospitals regarding the imaging methods and biomarkers used in the diagnosis of NAFLD/NASH.

ECOGRAPHY

Ultrasound has always been used routinely in the preparation and study of our bariatric patients. And it is common for the radiologist to inform us of the presence of Fatty Liver, either with that term or with Hepatic Steatosis. Until now it was something like the “brand of the house” of every overweight patient. And it is because it is more accessible and cheaper than MRI, which is the benchmark.

Ultrasound has shown a sensitivity of 60 to 94% and a specificity of 84 to 95% in the detection of hepatic steatosis, being a first-line acceptable tool for the detection of steatosis in clinical practice, but cannot distinguish NASH of simple steatosis [8]. In addition, it does not reliably detect steatosis when it is <20% or in individuals with a high body mass index (> 40 kg/m^2). Despite its dependence on the operator, ultrasound reliably diagnoses moderate or severe steatosis and provides additional hepatobiliary information.

In this procedure, radiologists review the conventional brightness in the B-mode ultrasound images of the liver and the surrounding structures and evaluate the

ultrasonographic characteristics known for fat content, such as the echogenicity of the liver in relation to the adjacent right kidney and darkness of Liver structures. From these qualitative characteristics, the presence and degree of hepatic steatosis can be inferred. The degree of steatosis can be reported using subjective terms ("mild, moderate, severe") or more formally using the CUS (Conventional Ultrasound) ordinal score designed to coincide with the ordinal scores used by pathologists to classify hepatic steatosis in histology [6].

The main advantages of the CUS is that it is a device available in any center, very well tolerated and safe, that is not expensive and that can be done with ultrasound from any manufacturer. On the other hand, among the main limitations is that the interpretation of the echographic characteristics of each patient is qualitative. In addition, other factors interfere in the test result, independently of the presence of hepatic steatosis, such as the characteristics of the patient (BMI, other liver diseases) and the test itself (observer, instruments such as ultrasound, transducer, probe) [6, 10].

Recent studies have shown that quantitative ultrasound may be superior to conventional ultrasound in detecting hepatic steatosis [11]. Ultrasound has also been used in different scores and studies to identify fatty liver and NASH, given its hyperechogenic and bright pattern [12]. Due to the limitations of other non-invasive tests, conventional ultrasound continues to be the diagnostic modality most commonly used to diagnose and qualify hepatic steatosis [6].

COMPUTERIZED TOMOGRAPHY (CT)

The CT scan is rarely used to look for NAFLD. In general, it is an incidental finding in an abdominal CT performed for another indication. The density of the liver/spleen ratio is typically used to detect hepatic steatosis on computed tomography. However, these studies are not of first indication for the evaluation of hepatic steatosis, since they expose patients to ionizing radiation [6].

In general, it is similar to Ultrasounds, and as limitations it has hemochromatosis and it does not distinguish Steatosis from NASH, and, as we have said, it also produces radiations [10]. It has been used in some studies, such as one on the improvement that bariatric surgery entailed on fatty liver, in which CT scans were performed before and one year after surgery [13].

MAGNETIC RESONANCE IMAGE (MRI)

MR is considered the "gold standard" of imaging techniques [14] and the most accurate method for determining NAFLD. It is also superior to ultrasound to detect steatosis of lesser amounts. It qualitatively and quantitatively identifies the fatty infiltration of the liver thanks to the fact that water and fat protons produce different frequencies in a magnetic field. The most widely used quantitative method is the so-called phase and out-of-phase image processing, in which the signal of the fat protons is added or subtracted, respectively, from the signal of the protons in the water. This makes it an accurate predictor of liver fat content compared to histological evaluation [15].

The term PDFF (Fraction of Fat of Proton Density) indicates a fundamental property of the liver tissue and represents the function of triglyceride protons visible by MR in the sum of triglycerides and water protons, and manages to estimate the hepatic fat content without using the spectroscopy. And it has the benefit that it can obtain a complete image of the liver, locating the area where we are going to measure the infiltration, since the liver fat is heterogeneous and is not evenly distributed, varying from one segment to another [6].

While it is very good at providing quantitative information on the accumulation of fat in the liver and although many MRI techniques have been developed to improve its performance in the diagnostic spectrum of NAFLD, these methods are limited in their ability to detect the coexistence of inflammation or fibrosis. In addition, MRI is expensive, time consuming and movement artifacts, such as breathing, can affect the quality of the image [10].

MRI can detect the quantitative decrease of fatty infiltration in the liver after bariatric surgery and, therefore, could be a valuable tool to monitor NAFLD/NASH after the operation [16]. MRI-PDFF is also useful for evaluating the response to treatment in early-phase NASH trials [17]. It also avoids confounding factors and is unaffected by the field strength of the scanner, patient factors (age, sex, body mass index and etiology of liver disease) and concomitant liver abnormalities such as iron overload or necroinflammation [18].

As a novelty in the use of MR in the search for NASH, DeMILI Test has emerged, as an online diagnostic service that allows, from a standard abdominal MRI, to obtain a report on the presence of NASH and liver fibrosis in a patient. It is accessed through a web platform and is based on two image biomarkers, FIBROmri and NASHmri. And, although it is a method still under evaluation, it already offers encouraging results with average areas under the curve (AUROC) of 0.83 for NASH and 0.85 for significant fibrosis [19].

MAGNETIC RESONANCE SPECTROSCOPY (MRS)

It is today the technique of choice for the quantification of liver fat. In fact, and as we mentioned in the introduction, it is the one used in the European Guidelines for the definition of hepatic steatosis: fat fraction of proton density (providing an approximate estimate of the volume fraction of fatty material in the liver) greater than 5.6% [4]. With the right equipment and when the fat concentration is equal to or greater than 7.48%, it can be 100% accurate [20].

It consists of a very useful non-invasive technique that adds supplementary metabolic information to the anatomical anomalies that appear in radiological images of different diseases. It allows the evaluation, in vivo, of the molecular composition of the liver, and, although it fails in the detection of NASH, it has a high accuracy in the diagnosis of steatosis [8].

The precision of this quantitative method is achieved by separating the spectrum of the water curve from those of lipids and other metabolites, these curves expressed according to their resonance frequency measured in parts per million (ppm). But it has its limitations, since it requires specialized software, being also slow, complex and expensive. It remains, for all this, confined, at the moment, to research studies [10].

ELASTOGRAPHY OF MAGNETIC RESONANCE (MRE)

The search for a technique capable of differentiating steatosis from steatohepatitis seems to have found a possibility in Magnetic Resonance Elastography, in addition to other advantages. The fact that necroinflammation and fibrosis have similar effects could be the basis for differentiating NASH from NAFLD, but differentiates NASH from Fibrosis?. The limitation would be the excessive accumulation of iron [10]. It also seems that it would be profitable in the classification by stages of fibrosis, but, like other methods based on Magnetic Resonance, its availability is scarce in many centers, in addition to requiring an additional external validation [8].

The MRE, which was invented at the Mayo Clinic, is a non-invasive and effective method, which will require three stages to obtain results. In the first place, low frequency longitudinal waves, which deform the parenchyma, will be transmitted to the liver. These waves are transformed into transverse waves, called "cut or shear," which generate the data that is duly recorded. And finally, the analysis of these data, whose measurement, like the Transient Elastography by US, is quantified in kilopascals and that the equipment presents in the form of images.

This technique has a good correlation with liver biopsy, which has been the reason for different meta-analyzes [21, 22]. Thus, the efficacy of MRE in diagnosing fibrosis gave figures ranging between 0.87 and 0.99 under the AUROC curve, depending on whether it was stage of Fibrosis 1, 2, 3 or Cirrhosis, in both studies. And they concluded that the liver hardness measured by EMR increases with the degree of fibrosis. The higher the hardness, the more fibrosis [23].

On the other hand, it is superior on Transmission Elastography measured by Ultrasound, when it comes to achieving success, 94% in MRE over 84% in the US [24]. In addition, the volume of liver tissue that evaluates is much higher, being able to reach 250 cm3, compared to, at most, 20 cm3 of TE, reducing errors as heterogeneous as fibrosis may be, which makes the study be much more representative. Unlike ultrasound, Resonance Elastography is not affected by the presence of ascites or by the narrowness of the intercostal spaces [23].

But it remains the most important challenge to require this technique if it can differentiate steatosis from NASH [25]. Apparently it could do in the early stages of steatohepatitis, since the inflammation could have hardness similar to fibrosis. Thus, even in the absence of fibrosis, which in many cases can accompany necroinflammation from the beginning, MRE could have its usefulness in the early diagnosis of NASH.

Finally, an additional advantage of this method is the ability to perform a "multiparametric" scanning protocol by associating in the same session not only the study of fibrosis, but also the accumulation of fat or iron, adding other MR sequences. And although other authors find that this technique does not have the limitation of body mass, others believe that excessive obesity, together with the inability to sustain apnea, claustrophobia and biliary obstruction, can make testing difficult.

TRANSIENT ELASTOGRAPHY CONTROLLED BY VIBRATION (VCTE)

Transient Elastography (FibroScan, Echosens, Paris, France) is a good tool for the calculation and non-invasive staging of Liver Stiffness Measurement (LSM). It will use the principles of ultrasound, applying low frequency cutting waves created by a vibratory probe at the level of an intercostal space that covers the liver. The elasticity, expressed in kilopascals, is determined by the elastic modulus calculated from the cutting wave velocity of the ultrasound signals.

The stiffness of the liver is determined with the value resulting from having made the calculations of the median of the 10 determinations made when applying the probe on the skin between the ribs of the patient, in the right part of the liver. Your measurements will place the patient at a certain level or degree of Fibrosis, which will have diagnostic implications, follow-up and, of course, treatment, being the average value for healthy people of 5.5 kPa.

When it is a value lower than 7 kPa it means that the level of progression is low, and it is recommended not to start with the treatment. Values between 7 and 9.4 kPa are evidence of moderate fibrosis or also called "level 2," and the patient should be tested with fibroscan regularly. Values between 9.4 and 12 kPa mean that the fibrosis is progressing and is "level 3," and with this result it is necessary to start treatment. When it exceeds 12 kPa, it means that the patient suffers from severe or "level 4" fibrosis, on the threshold of cirrhosis. This result indicates that the treatment or therapy is of an emergency nature.

Regardless of the cause that causes fibrosis, the mean areas under the curve (AUROC) were 0.84, 0.89 and 0.93 for the diagnosis of significant fibrosis, severe fibrosis and cirrhosis, respectively [26]. When the technique is analyzed in a wide series of cases and its comparison with the liver biopsy, it appears especially successful in the detection of more advanced fibrosis, such as F3 and F4, and with a moderate precision for the initial stages of fibrosis (F2). It is therefore a good method to differentiate advanced stages of hepatic fibrosis, compared to early stages [27].

It seems that obesity would be an adverse factor for the effectiveness of this technique, already with BMI above 28%. Therefore, to the conventional probe that reaches a depth of 25-65 mm (M-probe), a deeper probe (XL-probe) has been added that reaches up to 35-75 mm. Another adverse factor is the area analyzed, less than in other imaging techniques such as CT and any modality of MR, which analyze the entire liver. Likewise, situations such as necroinflammation of hepatocytes, cholestasis, elevated central venous pressure and postprandial conditions, can detract from this technique [10].

The greatest application that this method can contribute to the study of NAFLD would be to avoid performing liver biopsies, which according to the works could range from 45% of patients [26], to 60 or even 90% if fibrosis It is more advanced. At a fixed sensitivity, a cut LSM of 6.5 kPa excluded advanced fibrosis with a negative predictive value of 0.91, and a cut LSM of 12.1 kPa excluded cirrhosis with a negative predictive value of 0.99 [27].

Finally, the Controlled Attenuation Parameter (CAP) is nowadays used as a tool that can be useful in the assessment of liver fat. It is available in the latest devices for measuring the rigidity of the liver controlled by vibration (VCTE). The most current studies show that it can be used to detect hepatic steatosis, although it does not provide a reliable quantitative estimate of the liver fat content [6].

ARFI/SWE

ARFI is the Impulse of Acoustic Radiation Force. It is a form of elastography that calculates the elasticity of the liver from acoustic pulses of short duration of a fixed frequency directed to a region and is expressed in KPa. It is good for patients with very high BMI, even above 40 klgr/m2 [10]. Other authors suggest that the use of VCTE in combination with ARFI is highly specific to predict significant fibrosis and may decrease the need for a liver biopsy.

The SWE (supersonic images of cutting waves) is a new technique of ultrasound elastography that has been used for the assessment of liver fibrosis. It has the advantage that being an evaluation in the form of a fan will value a larger region of the liver. It has also been used in the assessment of different chronic liver diseases, being superimposable to other elastographic techniques, such as VCTE and ARFI, and how they are fast, reliable and simple. But it has not appreciably evaluated steatosis in patients with NAFLD [10].

We can conclude by stating that ARFI is a promising image modality to detect advanced fibrosis in patients with liver disease related to obesity. And there are authors who believe that SWE and ARFI provide a better and more reliable estimate of liver fibrosis than VCTE [6].

MONITORING AND CONTROL

When deciding which is the best follow-up for our patients, we must take into account many aspects. Both the risk that the liver disease may progress to cirrhosis, and the workload of all specialists related to the disease, as well as the cost of imaging procedures, are issues to consider. Perhaps for all this, to date, there is no consensus on what would be the best follow-up protocol for these patients. What is agreed is that the surveillance of these patients should include routine biochemical parameters, noninvasive evaluation of fibrosis (imaging techniques, among others) and study of associated comorbidities.

Thus, patients with NAFLD who do not have worsening of their metabolic risk factors, that is, who are stable, should be monitored every 2 or 3 years. However, the control should be annual in those patients who have NASH or Fibrosis. And every 6 months if the evolution of the disease has reached cirrhosis. In these cases, and on an individual basis, the repeat of the biopsy at 5 years may be indicated.

COMPARISON OF THE DIFFERENT TECHNIQUES

Table 1. Efficacy of the imaging tests in the detection of Steatosis, NASH and Fibrosis

Effectiveness of the evidence of image in NAFLD	Steatosis	Nash	Fibrosis
ECOGRAPHY	+	-	-
CT	+	-	-
RMI	+	-	+

Effectiveness of the evidence of image in NAFLD	Steatosis	Nash	Fibrosis
RMS	+	-	+
RME	+	-	+
VCTE	+	-	+
ARFI	-	-	+

Table 2. Limitations of these techniques

	Radiation	Obesity	Claustrophobia	Cost	Time	Artefactors	Operator Dependent	Hemosiderosis
US	-	++	-	+	-	-	+++	-
CT	+++	-	-	++	-	-	-	-
RMI	-	-	+++	++	++	++	-	++
RMS	-	-	+++	+++	+++	++	-	++
RME	-	-	+++	+++	+++	++	-	++
UCTE	-	+	-	+	+	-	-	-
ARFI	-	-/+	-	+	+	-	-	-

Table 3. Comparison of elastographic techniques

Elastography	Cost	Accuracy	Problems
VCTE	+	++	Obesity Cirrhosis
ARFI/SWE	+	++	Obesity Cirrhosis
RME	+++	+++	Hemosiderosis

REFERENCES

[1] Ooi, GJ, Burton, PR, Bayliss, J, Raajendiran, A, Earnest, A, Laurie, C, Kemp, WW, McLean, CA, Roberts, SK, Watt, MJ, Brown, WA. 2019. "Effect of Body Mass Index, Metabolic Health and Adipose Tissue Inflammation on the Severity of Non-Alcoholic Fatty Liver Disease in Bariatric Surgical Patients: a Prospective Study." *Obesity Surgery* 29 (1): 99-108. doi: 10.1007/s11695-018-3479-2.

[2] Tan, CH, Al-Kalifah, N, Ser, KH, Lee, YC, Chen, JC, Lee, WJ. 2018. "Long-term effect of bariatric surgery on resolution of nonalcoholic steatohepatitis (NASH): An external validation and application of a clinical NASH score." *Surgery of Obesity and Related Disease.* 14 (10): 1600-06. Accessed June 6, 2018. doi: 10.1016/j.soard.2018. 05.024.

[3] Alkhouri, N. and Feldstein, A. E. 2016. "Noninvasive diagnosis of nonalcoholic fatty liver disease: are we there yet?." *Metabolism* 65 (8): 1087-95. Accessed February 2, 2016. doi: 10.1016/j.metabol. 2016.01.013.

[4] Marchesini, G. et al. 2016. "EASL-EASD-EASO Clinical Practice Guidelines for the management of non-alcoholic fatty liver disease." *Journal of Hepatology* 64: 1388-402.

[5] López, IC, Aroca, FG, Bernal, MDF, Mompean, JAL, Bernal, ÁB, Martínez, AMH, Barba, EM, Velasco, JAN, Paricio, PP. 2017. "Utility of the ELF Test for Detecting Steatohepatitis in Morbid Obese Patients with Suspicion of Nonalcoholic Fatty Liver Disease." *Obesity Surgery* 27 (9): 2347-53. doi: 10.1007/s11695-017-2606-9.

[6] Loomba, R. 2018. "Role of imaging-based biomarkers in NAFLD: Recent advances in clinical application and future research directions." *Journal of Hepatology* 68: 1296-304.

[7] Chalasani, N, Younossi, Z, Lavine, JE, Charlton, M, Cusi, K, Rinella, M, Harrison, SA, Brunt, EM, Sanyal, AJ. 2018. "The Diagnosis and Management of Nonalcoholic Fatty Liver Disease: Practice Guidance from the American Association for the Study of Liver Diseases." *Journal of Hepatology* 67 (1): 328-357.

[8] Gallego-Durán, R. et al. 2016. "Imaging biomarkers for steatohepatitis and fibrosis detection in non-alcoholic fatty liver disease." *Scientific Reports 6*, Article Number: 31421.

[9] Klebanoff, MJ, Corey, KE, Chhatwal, J, Kaplan, LM, Chung, RT, Hur, C. 2017. "*Bariatric surgery for nonalcoholic steatohepatitis: A clinical and cost-effectiveness analysis*." 65 (4): 1156-64. Accessed February 21, 2017. doi: 10.1002/hep.28958.

[10] Valle Tovo, C, Zambam de Mattos, A, Coral, G, Schild Branco, F, Suwa, E and Alves de Mattos, A. 2015. "Noninvasive imaging assessment of non-alcoholic fatty liver disease: Focus on liver scintigraphy." *World Journal of Gastroenterology* 21 (15): 4432-39. Accessed April 21, 2015. doi: 10.3748/wjg.v21.i15.4432.

[11] Lin, SC, Heba, E, Wolfson, T et al. 2015. "Noninvasive diagnosis of nonalcoholic fatty liver disease and quantification of liver fat using a new quantitative ultrasound technique." *Clinical Gastroenterology and Hepatoly* 13: 1337-45.

[12] Goossens, N et al. 2016. "Nonalcoholic Steatohepatitis Is Associated with Increased Mortality in Obese Patients Undergoing Bariatric Surgery." *Clinical Gastroenterology and Hepatology*. 14 (11): 1619-28. Accessed October 20, 2015. doi: 10.1016/j.cgh. 2015.10.010.

[13] Uehara, D, Seki, Y, Kakizaki, S, Horiguchi, N, Tojima, H, Yamazaki, Y, Sato, K, Yamada, M, Uraoka, T, Kasama, K. 2019. "Long-term Results of Bariatric Surgery for Non-Alcoholic Fatty Liver Disease/Non-alcoholic Steatohepatitis Treatment in Morbidly Obese Japanese Patients." *Obesity Surgery* 29 (4): 1195-201. doi: 10.1007/s11695-018-03641-2.

[14] Cantero, I et al. 2019. "Ultrasound/Elastography techniques, lipidomic and blood markers compared to Magnetic Resonance Imaging in non-alcoholic fatty liver disease adults." *International Journal of Medical Sciences*. 16 (1): 75-83. doi: 10.7150/ ijms.28044.

[15] Tang A, Tan J, Sun M, Hamilton G, Bydder M, Wolfson T, Gamst AC, Middleton M, Brunt EM, Loomba R, et al. 2013. "Nonalcoholic fatty liver disease: MR imaging of liver proton density fat fraction to assess hepatic steatosis." *Radiology* 267: 422-31.

[16] Hedderich, DM, Hasenberg, T, Haneder, S, Schoenberg, SO, Kücükoglu, Ö, Canbay, A, Otto, M. 2017. "Effects of Bariatric Surgery on Non-alcoholic Fatty Liver Disease: Magnetic Resonance Imaging Is an Effective, Non-invasive Method to Evaluate Changes in the Liver Fat Fraction." *Obesity Surgery* 27 (7): 1755-62. doi: 10.1007/s11695-016-2531-3.

[17] Caussy, C, Reeder, SB, Sirlin, CB and Loomba, R. 2018. "Noninvasive, Quantitative Assessment of Liver Fat by MRI-PDFF as an Endpoint in NASH Trials." *Hepatology*. 68 (2): 763-72. doi: 10.1002/hep.29797.

[18] Younossi, ZM, Loomba, R et al. 2018. "Diagnostic Modalities for Nonalcoholic Fatty Liver Disease, Nonalcoholic Steatohepatitis, and Associated Fibrosis." *Hepatology* 68 (1): 349-60. doi: 10.1002/hep. 29721.

[19] Wong, VW et al. 2018. "Noninvasive biomarkers in NAFLD and NASH - current progress and future promise." *Nat Rev Gastroenterol Hepatol*. 15 (8): 461-78. doi: 10.1038/s41575-018-0014-9.

[20] Roldan Valdez, E, Favila, R, Martinez López, M et al. 2008. "Imaging techniques for assessing hepatic fat content in nonalcoholic fatty liver disease." *Ann Hepatol,* 7: 212-20.

[21] Wang, QB, Zhu, H, Liu, LL et al. 2012. "Performance of magnetic resonance elastography and diffusion-weighted imaging for the staging of hepatic fibrosis: A meta-analysis." *Hepatology,* 56: 237-39.

[22] Su, LN, Guo, SL, Li, BX et al. 2014. "Diagnostic value of magnetic resonance elastography for detecting and staging of hepatic fibrosis: A meta-analysis." *Clin Radiol,* 69: 545-52.

[23] Stoopen-Rometti, M et al. 2017. "Diagnosis and quantification of fibrosis, steatosis and hepatosiderosis by means of multiparametric magnetic resonance." *Journal of Gastroenterology of Mexico*. 82 (1): 32-45. doi.org/10.1016/j.rgmx.2016.06.001.

[24] Huwart, L, Sempoux, C, Vicaut, E et al. 2008. "Magnetic resonance elastography for the noninvasive staging of liver fibrosis." *Gastroenterology,* 135: 32-40.

[25] Ajmera, V, Loomba, R. 2018. "Can Elastography Differentiate Isolated Fatty Liver from Nonalcoholic Steatohepatitis?." *Semin Liver Dis.* 38 (1): 14-20. Accessed February 22, 2018. doi: 10.1055/s-0037-1618587.

[26] Tapper, EB et al. 2016. "The Performance of Vibration Controlled Transient Elastography in a US Cohort of Patients With Nonalcoholic Fatty Liver Disease." *American Journal of Gastroenterology*. 111 (5): 677-84. Accessed March 15, 2016. doi: 10.1038/ajg.2016.49.

[27] Siddiqui, MS et al. 2019. "Vibration-Controlled Transient Elastography to Assess Fibrosis and Steatosis in Patients with Nonalcoholic Fatty Liver Disease." *Clinical Gastroenterology and Hepatology*. 17 (1): 156-63. Accessed April 26, 2018. doi: 10.1016/j.cgh.2018.04.043.

In: Encyclopedia of Surgery (22 Volume Set)
Editors: Andreas Lehrer and Kristin Mueller
ISBN: 978-1-53618-329-0
© 2020 Nova Science Publishers, Inc

Chapter 309

MR SPECTROSCOPY AND QUANTIFICATION OF INTRAHEPATOCITARY LIPID CONTENT

Jaime Ruiz-Tovar*, MD, PhD and Carolina Llavero†
Obesity Unit, Garcilaso Clinic, Madrid, Spain

ABSTRACT

Currently, the standard procedure used to evaluate hepatic steatosis is the liver biopsy. This is an invasive practice that presents inherent risks. Increasing evidence suggests that Magnetic resonance imaging (MRI) and MR spectroscopy (MRS) may represent an accurate method to determine the hepatic lipid content.

In this chapter we will review the actual evidence about the use of MR spectroscopy to evaluate liver steatosis and non-alcoholic fatty liver disease (NAFLD).

Keywords: liver steatosis, magnetic resonance, spectroscopy, percentage of lipid content

INTRODUCTION

Nonalcoholic fatty liver disease (NAFLD) is characterized by lipid deposit in the hepatocytes of the liver parenchyma, exceeding the 5% of the liver weight. NAFLD includes a spectrum of disorders ranging from simple steatosis, a relatively benign condition, to nonalcoholic steatohepatitis (NASH) and pericellular or perisinusoidal fibrosis. In some cases, these entities might lead to a cirrhosis stage, similar to the observed in alcoholic hepatitis. The mechanism of NAFLD is still unknown, but involves the development of insulin resistance, inflammatory cytokines and oxidative stress [1, 2].

NAFLD is strongly associated with obesity, mainly with central one, and has become the most common liver disorder in Western countries [3]. The prevalence of NAFLD, in any degree, is estimated around 70% in obese subjects and up to 95% in morbidly obese patients

* Corresponding Author's Email: jruiztovar@gmail.com.
† Carolina Llavero, RN.

[4]. Among patients undergoing bariatric surgery, liver steatosis is the most common degree of the disease, appearing NASH in about 25% of the cases and cirrhosis in 1-3% [5].

The diagnosis of NAFLD is usually made after an incidental discovery of unexplained elevation of liver enzyme levels or when steatosis is observed on imaging. Currently, the standard procedure used to evaluate hepatic steatosis is the histopathological examination of cross-liver sections and the semi-quantitative estimation of the percentage of hepatocytes containing macrovesicular fat. This is an invasive practice that presents inherent risks [1]. Despite there are several series in literature with an elevated number of patients undergoing a liver biopsy during bariatric surgery, without showing any morbidity related with the biopsy [6], for posterior monitoring of the liver status it is necessary to perform a percutaneous liver biopsy, implying an invasive procedure. Moreover, histological examination of cross-liver sections and the determination of the percentage of hepatocytes containing macrovesicular fat, only provides a two-dimensional estimation of a particular biopsy and is subject to inter-individual visual evaluation depending on the pathologist's training, which usually results in overestimation of the liver fat content [7, 8]. Therefore, it is essential to establish new non-invasive approaches to accurately determine the hepatic fat concentration, allowing the correct diagnosis and monitoring of steatosis.

The liver cell injury and intra-hepatocellular accumulation of lipids can be also evaluated by noninvasive tests. Increasing evidence suggests that Magnetic resonance imaging (MRI) and MR spectroscopy (MRS) may represent an accurate method to determine the hepatic lipid content, comparable to the liver biopsy to measure and follow up the fatty liver disease. Thus, they have been postulated as potential screening tools for patients at risk of liver steatosis, such as morbidly obese patients [8].

MRI represents a potential non-invasive technique for assessing hepatic steatosis in three-dimensions. MRS is a suitable method to quantify hepatic lipid content, as the values obtained by MRS are directly related to the molecular triglyceride content [9, 10]. One of the main advantages of using spectroscopy instead of biopsy is that it can be performed contemporaneously with MR imaging and the sampling volumes are larger than the obtained in liver biopsy avoiding misinterpretations if the fat liver distribution is heterogeneous [11, 12].

LIVER STEATOSIS AND BARIATRIC SURGERY

Bariatric surgery achieves an improvement or even complete resolution of NAFLD in morbidly obese patients. This fact has been demonstrated after Roux-en–Y gastric bypass (RYGBP), adjustable gastric banding and malabsorptive procedures (duodenal switch and biliopancreatic diversion) and sleeve gastrectomy (SG) [5, 13-16].

Liver steatosis regression has been associated with an improvement in the lipid profile, which is more likely to occur after malabsorptive techniques. However, a study of our group demonstrated a significant reduction of triglyceride levels and an increase of HDL-cholesterol 12 months after undergoing a sleeve gastrectomy, achieving both parameters values within the normal range. Therefore, an improvement of liver steatosis was observed, as expected. Our results were similar to those reported after Roux-en-Y gastric bypass (90-95% of resolution of the steatosis) [17, 18].

MR IMAGING AND MR SPECTROSCOPY

The MRI protocol performed at our institution included preoperative evaluation 2 weeks prior to surgery and postoperative evaluation at 6 months Postoperatively.

Axial T1-wi dual gradient-echo (TR/TE, 122 ms/5-2 ms; flip angle, 80°; slice thickness, 6 mm; matrix 256 × 256). In addition axial breath hold three dimensional (3D) T1-weighted high resolution isotropic volume examination (THRIVE) (TR/TE, 4/2 ms; flip angle, 10°; reconstructed slice thickness, 2 mm; matrix, 256 × 256) was acquired for volumetric analysis.

Before spectroscopy, for a better voxel placement, fast T2 single shot TSE sequences (TR/TE, 611/100 ms; flip angle 90°, slice thickness/GAP, 9/0.9 mm) were acquired in coronal, sagital and axial planes. MRS was acquired with the single-voxel technique, two voxels were located in different regions within the left and right hepatic lobes to provide a more generalized distribution of fat within the liver. The average voxel volume was of 30 x 30 x 30 mm and 20 x 20 x 20 mm for the voxels located in the right lobe and left hepatic lobe, respectively. The voxel was located avoiding blood vessels, the gall bladder, and fatty tissue. After volume-selective autoshimming, the spectra were obtained with a point-resolved spectroscopy (PRESS) technique (TR/TE/scans = 2000 ms/35 ms/64) without water suppression. Each spectrum consisted of 1,024 complex data points in the time domain with a spectral width of 2,000 Hz. Chemical shift was placed relative to the water signal intensity.

Spectra were analyzed offline in the time domain using the AMARES algorithm included in the MRUI software package as described previously. The relative lipid content was defined by following the formulae [19]:

$$RLC = S_{lipid}/(S_{lipid} + S_{water})$$

For volumetric analysis, manual volumetric segmentations of the liver were performed by manual tracing of the liver on volumetric sequences in the axial plane avoiding the gall bladder and main hepatic vessels at a dedicated workstation (Advantage Workstation, Version 4.3; GE Healthcare Europe, Buc, France).

Steatosis by MRS was determined as absent when detected percentage of lipid content (PLC) was lower than 5%, mild when lower than 10%, moderate when 10-30% and severe when >30%, as described in literature [20-23].

EVALUATION OF LIVER STEATOSIS AFTER SG, ASSESSED BY MR SPECTROCOPY

Indication for undergoing SG was presenting a body mass index (BMI) $\geq$40 Kg/m^2 or BMI $\geq$35 Kg/m^2 with comorbidities. Patients presenting a daily alcohol intake of more than 20 g per day, chronic hepatitis B or C virus infection, hepatotoxic drugs intake or other known liver diseases, presence of pacemaker or any metallic implant not compatible with MR, and claustrophobia, are not evaluated with MR spectroscopy.

We performed a prospective observational study evaluating liver steatosis, as measured by MR spectroscopy in 23 patients undergoing SG, with a mean age of 47.6 ± 10.6 years and

a mean BMI 47.6 ± 6.7 Kg/m^2. Six months after surgery, MR spectroscopy was repeated. At that time, mean BMI 32.2 ± 5.1 Kg/m^2, with a mean excess weight loss of 68.2 ± 18.6%.

Mean preoperative hepatic volume was 1999.9 ± 436.2 ml and 6 months after surgery the liver volume significantly decreased to 1568 ± 170.3 ml ($p = 0.005$). Mean preoperative percentage of lipid content (PLC) was 14.2 ± 15.4% and 6 months after surgery these values decreased to 4.3 ± 3.2% ($p = 0.007$). A significant reduction of steatosis grade was observed, with disappearance of preoperative steatosis in 54.9% of the patients. Six months after surgery, 91.3% of the patients did not present any grade of steatosis.

In our study, we observed a preoperative steatosis incidence calculated with MRS of 63.6%. This steatosis rate is similar to the one observed by some authors, though other reports have shown higher prevalence that could vary from 65 to 80%. The steatosis grade was probably lower among our patients, as all of them followed a strict preoperative diet and a weight loss of at least a 5% of their overweight was a necessary condition to undergo the sleeve gastrectomy as bariatric procedure. It has been demonstrated that establishing strict dietary treatments with a total caloric intake of less than 1000 kcal / day between 2 and 8 weeks before surgery, in order to maximize weight loss during this period of time, result in a reduction of the surgical risk. This weight loss is associated with a reduction of hepatomegalia secondary to liver steatosis. We have observed a positive correlation between hepatic lipid content assessed by MRS and hepatic volume, suggesting that the hepatic volume loss observed after surgery is related to the decrease in the hepatic lipid content, as it has been previously reported in patients undergoing bariatric surgery.

Alterations of AST and ALT are the most frequent conditions found in NAFLD in morbidly obese patients [2], similar to our results. Notwithstanding, Dixon et al. [24] reported that changes in aminotransferase concentrations seems not to predict changes in steatosis. In the same line, a recent study observed a significant reduction of steatosis after bariatric surgery, documented with liver biopsy, but without correlation with AST or ALT levels. In our series, we observed a correlation between liver enzymes and PLC in the preoperative determinations, but the decrease of liver enzymes or the postoperative values did not show any correlation with PLC decrease or postoperative PLC values. Liver steatosis rate in morbidly obese patients ranges between 65-80%, but steatohepatitis appears in only 25% of the case. Hepatocyte fat infiltration might lead to a certain degree of inflammation and cytolysis, but this is especially relevant in severe steatosis grades. Thus, in the preoperative determinations of our series, with more than 25% of patients presenting severe steatosis, more steatohepatitis would be present and therefore a correlation with liver enzymes is possible. Postoperatively, steatosis remains in few patients and just in mild grade with probably absence of steatohepatitis, preventing a positive correlation between both entities [1].

Evaluation of Liver Steatosis after RYGB, Assessed by MR Spectrocopy

A similar study to the previously reported one on patients undergoing SG, was conducted on patients undergoing Roux-en-Y gastric bypass. Inclusion and exclusion criteria were similar. 21 patients were included, with a mean age of 48 ± 10.6 years and a mean BMI of 47.1 ± 10.5 Kg/m^2. Six months after surgery, mean BMI was 31.7 ± 4.9 Kg/m^2 with a mean

excess weight loss of 69.3 ± 17.7%. Preoperative percentage of lipid content (P^LC) was 13.3 ± 10.4%, with a significant decrease up to 3.5 ± 2.6% after surgery. Preoperatively, 70% of the patients presented liver statosis at any degree, while after surgery a complete remission of steatosis was observed in all the cases, excepting one patient with steatosis grade III, decreasisg to a grade I [25, 26].

Comparing these results with those obtained after SG, these are quite similar, concluding equivalent results at 6 months after surgery.

LIMITATIONS OF MR SPECTROSCOPY

The knowledge of percentage of lipid content is relevant, so long it is part of NAFLD and is associated with the progression to NASH or even cirrhosis. However, the disappearnace of liver steatosis after bariatric surgery does not necessary imply the remission of NASH and even less the regression of cirrhosis. Thus, to evaluate these issues, MR spectroscopy is not probably the most accurate method. Serum biomarkers can be helpful, despite their value is still controversial. Liver biopsy remains the gold standard to assess NASH and its evolution after bariatric surgery.

CONCLUSION

After bariatric surgery, a significant reduction of liver steatosis is observed, as demonstrated by a statistically significant reduction in the percentage of intrahepatocitary lipids and liver volume, determined by MR spectros and MRI. These imaging techniques can be considered as noninvasive, accurate methods for monitoring liver steatosis in morbidly obese patients undergoing bariatric surgery.

REFERENCES

[1] Wilkins T, Tadkod A, Hepburn I, et al. Nonalcoholic fatty liver disease: diagnosis and management. *Am. Fam. Physician*. 2013;88:35-42.

[2] Alves de Carvalho MS, Coelho Cabral P, Kruze Grande de Arruda I, et al. Risk factors associated with hepatic steatosis; a study in patients in the Northeast Brazil. *Nutr. Hosp*. 2012;27:1344-1350.

[3] Clark JM, Brancati FL, Diehl AM. Nonalcoholic fatty liver disease. *Gastroenterology* 2002;122:1649-1657.

[4] Clark JM, Alkhuraishi AR, Solga SF, et al. Roux-en-Y gastric bypass improves liver histology in patients with non-alcoholic fatty liver disease. *Obes. Res*. 2005;13:1180-1186.

[5] Pillai AA, Rinella ME. Non-alcoholic fatty liver disease: is bariatric surgery the answer? *Clin. Liver Dis*. 2009;13:689-710.

[6] Subichin M, Clanton J, Makuszewski M, et al. Liver disease in the morbidly obese: a review of 1000 consecutive patients undergoing weight loss surgery. *Surg. Obes. Relat. Dis*. 2015;11:137-141.

[7] Jimenez-Aguero R, Emparanza JI, Beguiristain A, et al. Novel equation to determine the hepatic triglyceride concentration in humans by MRI: diagnosis and monitoring of NAFLD in obese patients before and after bariatric surgery. *BMC Medicine* 2014;12:137-151.

[8] Younossi ZM, Gramlich T, Liu YC, et al. Nonalcoholic fatty liver disease: assessment of variability in pathologic interpretations. *Mod. Pathol.* 1998;11:560-565.

[9] Reeder SB, Cruite I, Hamilton G, et al. Quantitative assessment of liver fat with magnetic resonance imaging and spectroscopy. *J. Magn. Reson. Imaging* 2011;34:729-749.

[10] Tang A, Tan J, Sun M, et al. Nonalcoholic fatty liver disease: MR imaging of liver proton density fat fraction to assess hepatic steatosis. *Radiology* 2013;267:422-431.

[11] Chan DC, Watts GF, Ng TWK, et al. Measurement of liver fat by magnetic resonance imaging: Relationships with body fat distribution, insulin sensitivity and plasma lipids in healthy men. *Diabetes Obes. Metab*. 2006;8:698-702.

[12] Ishii M, Yoshioka Y, Ishida W, et al. Liver fat content measured by magnetic resonance spectroscopy at 3.0 tesla independently correlates with plasminogen activator inhibitor-1 and body mass index in type 2 diabetic subjects. *Tohoku J. Exp. Med*. 2005;206:23-30.

[13] Weiner RA. Surgical treatment of non-alcoholic steatohepatitis and non-alcoholic fatty liver disease. *Dig. Dis*. 2010;28:274-279.

[14] Johansson HE, Haenni A, Zethelius B. Platelet counts and liver enzymes after bariatric surgery. *J. Obes*. 2013;Article ID 567984.

[15] Tai CM, Huang CK, Hwang JC, et al. Improvement of nonalcoholic fatty liver disease after bariatric surgery in morbidly obese Chinese patients. *Obes. Surg.* 2012;22:1016-1021.

[16] Sakçak M, Avsar MF, Hamamci EO, et al. Comparison of early and late changes in immunoglobulins and acute phase reactants after laparoscopic adjustable gastric banding in patients with morbid obesity. *Obes. Surg*. 2010;20:610-615.

[17] Weiner RA. Surgical treatment of non-alcoholic steatohepatitis and non-alcoholic fatty liver disease. *Dig. Dis*. 2010;28:274-279.

[18] Alsina ME, Ruiz-Tovar J, Bernabeu A. Evolution of Liver Steatosis Quantified by MR Imaging and MR Spectroscopy, in Morbidly Obese Patients Undergoing Sleeve Gastrectomy: Short-Term Outcomes. *Obes. Surg*. 2017; 27:1724-1728.

[19] van Werven JR, Marsman HA, Nederveen AJ, et al. Assessment of hepatic steatosis in patients undergoing liver resection: comparison of US, CT, T1-weighted dual-echo MR imaging, and point-resolved 1H MR spectroscopy. *Radiology* 2010;256:159-168.

[20] Moreno-Pérez O, Portilla J, Escoín C, et al. Impact of vitamin D insufficiency on insulin homeostasis and beta cell function in nondiabetic male HIV-infected patients. *HIV Med*. 2013;14:540-548.

[21] Ma X, Holalkere N-S, Kambadakone R A, et al. Imaging-based quantification of hepatic fat: methods and clinical applications. *Radiographics* 2009; 29:1253-1277.

[22] Machann J, Thamer C, Schnoedt B, et al. Hepatic lipid accumulation in healthy subjects: A comparative study using spectral fat-selective MRI and volume-localized 1H-MR spectroscopy. *Magn. Reson. Med*. 2006; 55:913-917.

[23] Thomas EL, Hamilton G, Patel N, et al. Hepatic triglyceride content and its relation to body adiposity: a magnetic resonance imaging and proton magnetic resonance spectroscopy study. *Gut* 2005;54:122-127.

[24] Dixon JB, Bhathal PS, O'Brien PE. Weight loss and non-alcoholic fatty liver disease: falls in gamma-glutamyl transferase concentrations are associated with histologic improvement. *Obes. Surg.* 2006;10:1278-1286.

[25] Vargas V, Allende H, Lecube A, et al. Surgically induced weight loss by gastric bypass improves non alcoholic fatty liver disease in morbid obese patients. *World J. Hepatol*. 2012;4:382-388.

[26] Pontiroli AE, Benetti A, Folini L, et al. Other aspects of bariatric surgery: liver steatosis, ferritin and cholesterol metabolism. *Nutr. Hosp*. 2013;28:104-108.

In: Encyclopedia of Surgery (22 Volume Set)
Editors: Andreas Lehrer and Kristin Mueller
ISBN: 978-1-53618-329-0
© 2020 Nova Science Publishers, Inc

Chapter 310

BIOCHEMICAL MARKERS

Soledad García-Gómez-Heras*, MD, PhD
Department of Histology, Rey Juan Carlos University, Madrid, Spain

ABSTRACT

Liver biopsy, although "gold standard" for the diagnosis of NAFLD/NASH, has some limitations. Nowadays, biochemical markers are an alternative less invasive or noninvasive tests and have the important characteristics of diagnostic tests. They focus on the specific pathways involved in the progression of disease: hepatocyte death or apoptosis, inflammation, fibrosis and oxidative stress.

Keywords: NASH-disgnosis, NAFLD, biochemical markers, non invasive test

INTRODUCTION

The current "*gold standard*" for the diagnosis and stratification of NAFLD is liver biopsy. It can determine necroinflammatory activity, degree of steatosis, and extent of fibrosis. But liver biopsy has some limitations as we have exposed in the other chapter: sample size, bleeding, pain, etc. so it is a resource that cannot be used routinely.

With the increasing incidence of NAFLD, we need to do regular control for NAFLD progression, evaluation of hepatic steatosis, NASH and advanced fibrosis.

The knowledge of whether a patient has simple steatosis or NASH is very important prognostically. Patients with NASH can progress to cirrhosis and therefore should be more actively managed to try and prevent disease progression.

This situation has led to the search of alternative less invasive or noninvasive tests to assess NAFLD. Nowadays, biochemical markers have the important characteristics of diagnostic tests: good cost-effectiveness, ease, and reproducibility. Their presence and level

* Corresponding Author's Email: soledad.garcia@urjc.es.

are not liver specific but they have been associated with pathophysiologic liver disease processes (Pepe et al. 2001, Ruiz-Tovar et al. 2019, Tsai et al., 2018).

Several biomarkers have been proposed for the evaluation of hepatic steatosis, the prediction and progression of NASH and significant/advanced fibrosis. Next we expose some.

LABORATORY DATA

They included platelet count, alanine aminotranspherase (ALT), aspartate aminotranspherase (AST), insulin and albumin levels, in order to analyze the following formulas:

- Hepatic Steatosis Index (HSI) = 8 x ALT/AST + BMI (+2 if T2D yes, +2 if female)
- Liver Fat Score (LFS) = -2.89 + 1.18 x Metabolic Syndrome (Yes: 1; No:0) + 0.45 x T2D (Yes: 2; No:0) + 0.15 Insulin in uU/l + 0.04 x AST in U/L – 0.94 x AST/ALT
- AST to Platelet Ratio Index (APRI) = (AST/ALT x100) / Platelets (10^9/L)
- Fibrosis-4 (FIB-4) = (Age (years) x AST) / (Platelets x ALT)
- Non-alcoholic fatty liver Disease-Fibrosis Score (NAFLDFS) = -1.675 + 0.037 x age + 0.094 x BMI + 1.13 x Diabetes (Yes: 1; No:0) + 0.99 x AST/ALT – 0.013 x Platelet – 0.66 x Albumin.

BIOMARKERS FOCUS ON THE SPECIFIC PATHWAYS INVOLVED IN THE PROGRESSION OF DISEASE

Biomarkers Focus on Hepatocyte Death or Apoptosis

- Serum Cytokeratin 18 (CK18) levels.

Describe initially by Feldstein et al. in 2009, reporting circulating serum levels of CK-18 to be predictive of NASH in patients with NAFLD. It is by far the one that has been the most widely investigated (Castera et al., 2019).

CK18 fragments are major intermediate filaments of hepatocytes. CK-18 fragments come from apoptosis of hepatocytes accomplished by the enzyme caspase 3 and can be measured in serum by immunoassay.

Serum CK18 levels correlate with histologic changes and reflect severity of NASH. Studies have shown its high specificity for NAFLD and fibrosis (Cusi K, et al., 2104; Tsai et al., 2018).

- Fibroblast growth factor 21 (FGF21), showed greater association with disease progression (Shen J, et al. 2012).
- CK18-M65 (uncleaved CK18), with strong accuracy in predicting NASH (Younossi et al., 2008).

Markers of Inflammation

- Ferritin
- C-reactive protein (CRP)

They are nonspecific markers of inflammation that have been shown to be associated with NASH (Hui et al. 2004; Musso et al., 2011; Targher et al., 2006).

- Adipocytokines. They are associated with presence and severity of disease. Studies have shown that low levels of adiponectin and high levels of tumor necrosis factor-a (TNF-a) are associated with higher levels of liver damage (Jarrar et al., 2008; Hui et al., 2004 b)
- Interleukin-6 and interleukin-8. Some studies have shown that are strongly correlated with NASH (Abiru et al., 2006; Ajmera et al., 2017; Wieckowska et al., 2008).

Biomarkers of Fibrosis

- Serum aminotransferases, they are not useful in diagnosing fibrosis but levels often decrease when fibrosis worsens. An AST/ALT ratio greater than 1 has been shown to be predictive of fibrosis because of impaired AST clearance (Williams et al., 1988).
- Hyaluronic acid (HA) production increases in fibrosis and its clearance decreases in advanced liver disease. Studies have reported good correlation of high HA levels with advanced fibrosis. However, different cutoff values were used, rendering interpretation difficult (Hartley et al., 206; Kaneda et al., 2006; Piperno et al., 1998; Suzuki et al., 2005).

Markers of Oxidative Stress

Measurements of serum markers of oxidative stress are difficult because of their volatile nature but they are of interest because oxidative stress contributes to the pathogenesis of NASH; oxidized low-density lipoprotein, malonaldehyde, and thiobarbituric acid reactive substances have been evaluated in predicting NASH but results have been conflicting (Yesilova et al., 2005; Chalasani et al., 2004).

None of the available biomarkers have high sensitivity and specificity able to differentiate NASH from simple steatosis but they provide important information that require a critical interpretation of the results. For this reason, the use of imaging tests further complements the information available. It is desirable to look for the ideal combination between biomarkers and imaging tests (ultrasonography, computed tomography, elastographic techniques, magnetic resonance) (Ruiz-Tovar et al. 2019).

REFERENCES

Abiru S, Migita K, Maeda Y, et al. “Serum cytokine and soluble cytokine receptor levels in patients with nonalcoholic steatohepatitis.” *Liver Int*. 2006; 26:39-45.

Ajmera V, Perito ER, Bass NM, et al. NASH Clinical Research Network. "Novel plasma biomarkers associated with liver disease severity in adults with nonalcoholic fatty liver disease." *Hepatology* 2017; 65:65-77.

Chalasani N, Deeg MA, Crabb DW. Systemic levels of lipid peroxidation and its metabolic and dietary correlates in patients with nonalcoholic steatohepatitis. *Am. J. Gastroenterol*. 2004; 99:1497-502.

Castera L, Friedrich-Rust M and Loomba R. "Noninvasive Assessment of Liver Disease in Patients with Nonalcoholic Fatty Liver Disease." *Gastroenterology*. 2019; 156(5):1264-1281.

Cusi K, Chang Z, Harrison S, et al. "Limited value of plasma cytokeratin-18 as a biomarker for NASH and fibrosis in patients with nonalcoholic fatty liver disease." *J. Hepatol*. 2014; 60(1):167-74.

Feldstein AE, Wieckowska A, Lopez AR, Liu YC, Zein NN, McCullough AJ. "Cytokeratin-18 fragment levels as noninvasive biomarkers for nonalcoholic steatohepatitis: a multicenter validation study." *Hepatology* 2009; 50(4):1072-8.

Hartley JL, Brown RM, Tybulewicz A, et al. "Hyaluronic acid predicts hepatic fibrosis in children with hepatic disease." *J. Pediatr. Gastroenterol. Nutr*. 2006; 43:217-21.

Hui JM, Farrell GC, Kench JG, et al. "High sensitivity C-reactive protein values do not reliably predict the severity of histological changes in NAFLD." *Hepatology* 2004; 39:1458-9.

Hui JM, Hodge A, Farrell GC, et al. "Beyond insulin resistance in NASH: TNFalpha or adiponectin?" *Hepatology* 2004; 40:46-54.

Jarrar MH, Baranova A, Collantes R, et al. "Adipokines and cytokines in nonalcoholic fatty liver disease." *Aliment. Pharmacol. Ther*. 2008; 27:412-21.

Kaneda H, Hashimoto E, Yatsuji S, et al. "Hyaluronic acid levels can predict severe fibrosis and platelet counts can predict cirrhosis in patients with nonalcoholic fatty liver disease." *J. Gastroenterol. Hepatol*. 2006; 21:1458-65.

Musso G, Gambino R, Cassader M, et al. "Meta-analysis natural history of nonalcoholic fatty liver disease (NAFLD) and diagnostic accuracy of non-invasive tests for liver disease severity." *Ann. Med*. 2011; 43:617-49.

Pepe MS, Etzioni R, Feng Z, et al. "Phases of biomarker development for early detection of cancer." *J. Natl. Cancer Inst*. 2001; 93(14):1054-61.

Piperno A, Sampietro M, Pietrangelo A, et al. "Heterogeneity of hemochromatosis in Italy." *Gastroenterology* 1998; 144:996-1002.

Ruiz-Tovar J, Zubiaga L. Validation of biochemical scores for liver steatosis before and 1 year after sleeve gastrectomy. *Surg. Obes. Relat. Dis.* 2019; in press. Doi: 10.1016/j.soard.2019.05.004.

Shen J, Chan HL, Wong GL, et al. "Non-invasive diagnosis of non-alcoholic steatohepatitis by combined serum biomarkers." *J. Hepatol*. 2012; 56:1224-9.

Suzuki A, Angulo P, Lymp J, et al. "Hyaluronic acid, an accurate serum marker for severe hepatic fibrosis in patients with non-alcoholic fatty liver disease." *Liver Int*. 2005; 25:779-86.

Targher G. "Relationship between high-sensitivity C-reactive protein levels and liver histology in subjects with nonalcoholic fatty liver disease." *J. Hepatol*. 2006; 45:879-81.

Tsai E, Lee TP "Diagnosis and Evaluation of Nonalcoholic Fatty Liver Disease/Nonalcoholic Steatohepatitis, Including Noninvasive Biomarkers and Transient Elastography." *Clin. Liver Dis*. 2018; 22(1):73-92.

Wieckowska A, Papouchado BG, Li Z, et al. "Increased hepatic and circulating interleukin-6 levels in human nonalcoholic steatohepatitis." *Am. J. Gastroenterol*. 2008; 103:1372-9.

Williams AL, Hoofnagle JH. "Ratio of serum aspartate to alanine aminotransferase in chronic hepatitis. Relationship to cirrhosis." *Gastroenterology* 1988; 95:734-9.

Yesilova Z, Yaman H, Oktenli C, et al. Systemic markers of lipid peroxidation and antioxidants in patients with nonalcoholic fatty liver disease. *Am. J. Gastroenterol*. 2005; 100:850-5.

Younossi ZM, Jarrar M, Nugent C, et al." A novel diagnostic biomarker panel for obesity-related nonalcoholic steatohepatitis (NASH)." *Obes. Surg*. 2008; 18:1430-7.

In: Encyclopedia of Surgery (22 Volume Set)
Editors: Andreas Lehrer and Kristin Mueller
ISBN: 978-1-53618-329-0
© 2020 Nova Science Publishers, Inc

Chapter 311

EVOLUTION OF LIVER STEATOSIS AFTER SLEEVE GASTRECTOMY

Ramiro Carbajal Nicho[1,*], MD, Andrei Sarmiento Alarcón[2], MD, Nestor Palacios Bran[1], MD and Jorge Orrego Peche[1], MD
[1]Metabolic and Bariatric, Hospital Edgardo Rebagliati, Lima, Perú
[2]Metabolic and Bariatric, Hospital Santa Rosa, Lima, Perú

ABSTRACT

Obesity is a complex, chronic, progressive, and pandemic disease directly associated with the development of NAFLD (NonAlcoholic Fatty Liver Disease), which is considered the commonest liver disease worldwide. In addition, NAFLD is recognized as a condition that may progress to end-stage liver disease like cirrhosis and/or hepatocellular carcinoma, bariatric surgery provides improvement or even histological resolution of NAFLD and NASH (NonAlcoholic SteatoHepatitis).

To date, sleeve gastrectomy is the most commonly performed bariatric procedure worldwide, it has demonstrated acceptable and durable weight loss as well as improve NAFLD and NASH.

Keywords: NAFLD, sleeve gastrectomy, liver steatosis

INTRODUCTION

Nonalcoholic fatty liver disease (NAFLD) is the most important cause of liver disease worldwide that is recognized as the liver component of metabolic syndrome [1, 2]. In addition, the experts suggested that NASH may soon become the most common indication for liver transplantation [3].

The estimated prevalence of non-alcoholic fatty liver disease worldwide is approximately 25% and is present in roughly 95% of patients who undergo bariatric surgery [4, 1].

* Corresponding Author's Email: ramiro.carbajal@gmail.com.

Moreover, the prevalence of NAFLD patients with type 2 diabetes is elevated with a prevalence rate estimated up to 70% [5]. Furthermore, the prevalence of NAFLD in patients who meet the criteria for metabolic syndrome rate has been estimated to be about 79% [6].

NAFLD includes a broad clinical spectrum ranging from nonalcoholic fatty liver to nonalcoholic steatohepatitis (NASH), advanced fibrosis, cirrhosis, and finally hepatocellular carcinoma (HCC) (table 1). It is important to emphasize that there is a strong association between NAFLD and obesity, insulin resistance or type 2 diabetes mellitus (T2DM) as well as dyslipidemia, suggests that NAFLD is the hepatic manifestation of the metabolic syndrome, also those patients have an increased mortality compared with the general population, with an increased risk of cardiovascular disease, hepatocellular carcinoma, and cirrhosis [7, 8].

Bariatric surgery achieves an improvement or even complete resolution of NAFLD in morbidly obese patients, these patients could be treated with laparoscopic sleeve gastrectomy preventing progression of NAFLD. The purpose of this chapter is to summarize the recent evidence about the effect of sleeve gastrectomy on liver steatosis.

NAFLD (NONALCOHOLIC FATTY LIVER DISEASE)

NAFLD is characterized by histological or radiographic evidence of fat accumulation in the liver (hepatic steatosis), with or without associated inflammation or fibrosis (steatohepatitis) after the exclusion of other causes of hepatic steatosis, including excessive alcohol consumption (< 20g in women and < 30g in men results in a low risk for the development of alcoholic liver injury) [9, 3].

Currently, Liver biopsy is the gold standard procedure utilizing the NAFLD activity score (NAS) for characterizing the severity of NAFLD and for diagnosing NASH (table 1) [10, 11].

Table 1. Spectrum of NAFLD

Disease	Subclassification	Most common concurrent disease
NAFDL*	NAFL	**AFLD-alcoholic fatty liver disease, Drug-induced fatty liver disease, Hepatitis C virus-associated fatty liver (genotype3), others, Haemochromatosis, coeliac disease, wilson´s disease, A/hypo-betalipoproteinemia lipoatrophy, hypopituitarism, hypothyroidism, starvation, parenteral nutrition, inborn errors of metabolism
	Pure steatosis	
	Steatosis and mild lobular inflammation	
	NASH	
	Early NASH: No or mild (F0-F1 fibrosis)	
	Fibrotic NASH: Significant (≥ F2) or advanced (≥ 3 bridging) fibrosis	
	NASH-Cirrhosis (F4)	
	Hepatocelular Carcinoma	

* Primary NAFLD: Associated with metabolic risk factors.

** Secondary NAFLD: May coexist with primary NAFLD.

AFLD: Alcoholic Fatty Liver Disease.

NAFL is characterized by steatosis of the liver, involving greater than 5% of parenchyma, with no evidence of hepatocyte injury [3].

NAFLD "is defined by the presence of steatosis in > 5% of hepatocytes according to histological analysis or by a proton density fat fraction (providing a rough estimation of the volume fraction of fatty material in the liver) > 5.6% assessed by proton magnetic resonance spectroscopy (HMRS) or quantitative fat/water selective magnetic resonance imaging (MRI)" [11].

"NASH is defined histologically by the presence of hepatic steatosis and two additional features: lobular inflammation and hepatocyte injury (ballooning)" [12] (Table 1).

NAFLD AND BARIATRIC SURGERY

Despite the increasing numbers of patients with NAFLD, therapeutic options are still limited. Weight loss is the main goal for patients with NAFLD because can lead to an improvement in liver biochemical tests, liver histology, serum insulin levels, and quality of life [13, 14]. In this context, Musso G et al. [15], reported that the 5% body weight reduction resulted in improvement in hepatic steatosis, whereas > 7% reduction was associated with NAS (NAFLD activity score) improvement.

There are several options to obtain weight loss, for instance, lifestyle modification, exercise, healthy diet. Moreover, weight loss is often problematic for patients to continue the needed lifestyle changes long term [16].

Bariatric surgery is the most effective long-term therapy for obesity and its complications and has shown to induce biochemical and histologic remission of NAFLD, through mechanisms of action that are both weight loss-dependent and weight loss-independent [17].

The exact mechanisms that lead to an improvement in NAFLD following bariatric surgery are not completely understood. Since Roux-en-Y gastric bypass (RYGB) is the second bariatric surgical procedure most performed worldwide, it is also the one from which the effects on NAFLD have been most studied, although there is also consistent evidence regarding the effects from gastric banding, sleeve gastrectomy and biliopancreatic diversions [18].

The association between NAFLD and type 2 diabetes mellitus (T2DM) has been well established, which could be explained by the insulin-resistance [17-20].

It comes as no surprise that mechanisms by which bariatric surgery improved the features of NAFLD would be related to weight loss, improvements in T2DM, reduced insulin resistance, reduced hyperlipidemia, and improved components of metabolic syndrome [21, 22].

Other proposed mechanisms would include the altered route of food delivery, which results in changes to the release of the gut and pancreatic hormones, changes in fat distribution, hepatic insulin and free fatty acid metabolism, and changes in adipocytokines and other cytokines [21]. Alterations in hormone secretion affect carbohydrate and lipid metabolism and interfere with hepatic glucose release [21]. In the last few years, recent studies have shown that changes in some gene expression and gut microbiota may also play a pivotal role [23-25].

Yung Lee et al. [26] performed a systematic review and meta-analysis, found that bariatric surgery leads to complete resolution of NAFLD in obese patients. However, some

patients develop new or worsened features of NAFLD, Perhaps, the primary limitation of this study is the heterogeneity between included studies.

Roux-en-Y gastric bypass (RYGB) is the most studied bariatric procedure for its effects on NAFLD, a 2019 systematic review found RYGB to have the greatest impact on NAFLD histology among all bariatric procedures and even suggests that bariatric surgery should be considered as a treatment of NAFLD [27, 28].

Effects of RYGB is discussed in detail in another chapter, in this chapter we will discuss the role of sleeve gastrectomy on NAFLD. At the time of writing this chapter the optimal bariatric procedure for patients with obesity and concomitant NAFLD remains to be defined.

SLEEVE GASTRETOMY AND LIVER STEATOSIS

Currently, laparoscopic sleeve gastrectomy (LSG) is the most common performed bariatric procedure worldwide. LSG is considered to be safe and effective bariatric surgery with durable weight loss. In a recent study, was found that there were no statistically significant differences between sleeve gastrectomy and gastric bypass for weight loss or even to comorbidities such as of type 2 diabetes remission, dyslipidemia resolution, quality of live improvement, and late morbidity.

On the other hand, compared with sleeve gastrectomy, gastric bypass resulted in better resolution of hypertension, based on antihypertensive medication use [29].

Regarding advantages of LSG are low rate of complications, the short operative time, the absence of foreign material, the lack of gastrointestinal anastomosis and malabsorption, there is no mesenteric defects created eliminating the risk of internal hernia and has feasibility to be converted into multiple other bariatric procedures, but there are some issues to be considered such as weight regain, gastroesophageal reflux disease and Barrett's esophagus [30, 31].

Several publications have shown the improvement of NAFLD after bariatric procedures as RYGB as well as adjustable gastric banding (AGB), biliopancreatic diversion (BPD). However, little is known regarding this topic after LSG.

In a recent study Alsina ME, Ruiz-Tovar J and Bernabeu A [32], found that six months after sleeve gastrectomy, a significant reduction of liver steatosis is observed, as demonstrated by reduction in the percentage of intrahepatocitary lipids and liver volume, determined by MRS (Magnetic Resonance Spectroscopy) and MRI (Magnetic Resonance Imaging). In another study Esquivel et al. [33] it was found that sleeve gastrectomy significantly improves NAFLD after 12 months of follow-up, showing even a total regression in some of the patients without cases of worsening of the disease.

Outcomes on prospective data from 236 Patients, Karcz et al. [34] observed significant improvements in AST, ALT, triglycerides and high-density lipoprotein (HDL) levels one and three years after SG. NASH patients showed significant losses of body weight and amelioration of NASH status.

Algooneh et al. [35] did a retrospective study of 84 patients diagnosed with NAFLD prior to undergoing SG.

The diagnosis of NAFLD was achieved based on ultrasonographic imaging. A total of 47 patients (56%) showed complete resolution of NAFLD postoperatively.

Witigo von Schonfels et al. [36] performed a retrospective comparison of metabolic data before and after bariatric surgery and comparison of sleeve gastrectomy and Roux-Y gastric bypass, found that both surgery methods improved the NAS significantly, there was not differences with regard to histological recovery between gastric bypass and Sleeve Gastrectomy.

As has been noted the weight loss and improvements in obesity-related comorbidities, such as Type 2 Diabetes, insulin resistance, and hypertriglyceridemia, after sleeve gastrectomy plays a significant role in the improvement of NAFLD.

On the other hand, sleeve gastrectomy has been shown to result in increased FGF-19, decreased FGF-21, increased adiponectin, and decreased leptin, amylin, and ghrelin levels; no effect was seen on circulating bile acids, these aspects could improve the metabolic syndrome and thus may help improve NALFD [37].

FINAL CONSIDERATIONS

Until now, there is no established therapy and there are no evidence-based clinical guidelines about the treatment of NAFLD.

Sleeve gastrectomy could be a therapeutic option for appropriate, morbidly obese patients with NALFD and NASH, but more studies are needed to determine the long-term effects. Regarding this point, there have not been any adequate prospective, double-blind, controlled trials to provide the data necessary.

REFERENCES

[1] Younossi, Z. M., Koenig, A. B., Abdelatif, D. et al. Global epidemiology of nonalcoholic fatty liver disease—meta-analytic assessment of prevalence, incidence, and outcomes. *Hepatology*, 2016; 64:73 - 84.

[2] Dassanayake, A. S. Nonalcoholic Fatty Liver Disease: Identifying the Disease Burden in Sri Lanka. *Euroasian J. Hepato-Gastroenterol.*, 2018; 8:69 - 72.

[3] Perumpail, B., Khan, M., Yoo, E., Cholankeril, G., Kim, D., Ahmed, A. Clinical epidemiology and disease burden of nonalcoholic fatty liver disease. *World J. Gastroenterol.*, 2017; 23:8263 - 8276.

[4] Machado, M., Marques-Vidal, P., Cortez-Pinto, H. Hepatic histology in obese patients undergoing bariatric surgery. *J. Hepatol.*, 2006; 45:600 - 606.

[5] Kwok, R., Choi, K. C., Wong, G. L. et al. Screening diabetic patients for non-alcoholic fatty liver disease with controlled attenuation parameter and liver stiffness measurements: A prospective cohort study. *Gut*, 2016; 65:1359 - 68.

[6] Soresi, M., Noto, D., Cefalu, A. B., Martini, S., Vigna, G. B., Fonda, M. et al. Nonalcoholic fatty liver and metabolic syndrome in Italy: results from a multicentric study of the Italian Arteriosclerosis society. *Acta Diabetol.*, 2013; 50:241 - 9.

[7] Puig, J., Blasco, G., Daunis-I-Estadella, J., Loshuertos, E., Codina, J., Cuba, V., Ortiz, R., Xifra, G., Ricart, W., Pedraza, S., Federici, M., Fernández-Real, J. M. Nonalcoholic

fatty liver disease and age are strong indicators for atherosclerosis in morbid obesity. *Clin. Endocrinol.*, (Oxf.) 2015; 83:180 - 186.

[8] Zeb, I., Katz, R., Nasir, K., Ding, J., Rezaeian, P., Budoff, M. J. Relation of nonalcoholic fatty liver disease to the metabolic syndrome: The Multi-Ethnic Study of Atherosclerosis. *J. Cardiovasc.*, 2013; 7:311 - 8.

[9] Chalasani, N., Younossi, Z., Lavine, J. E. et al. The diagnosis and management of nonalcoholic fatty liver disease: practice guidance from the American Association for the Study of Liver Diseases. *Hepatology*, 2017; 67:328 - 357.

[10] Wilkins, T., Tadkod, A., Hepburn, I. et al. Nonalcoholic fatty liver disease:diagnosis and management. *Am. Fam. Physician*, 2013; 88:35 - 42.

[11] Hjelkrem, M., Stauch, C., Shaw, J., Harrison, S. A. Validation of the non-alcoholic fatty liver disease activity score. *Aliment Pharmacol. Ther.*, 2011; 34: 214 - 218.

[12] Farrell, G. C., Wong, V. W. S., Chitturi, S. NAFLD in Asia – as common and important as in the west. *Nat. Rev. Gastroenterol. Hepatol.*, 2013; 10:307 - 18.

[13] Keating, S. E., Hackett, D. A., George, J., Johnson, N. A. Exercise and non-alcoholic fatty liver disease: a systematic review and meta-analysis. *J. Hepatol.*, 2012; 57:157 - 166.

[14] Vilar-Gomez, E., Martinez-Perez, Y., Calzadilla-Bertot, L. et al. Weight Loss Through Lifestyle Modification Significantly Reduces Features of Nonalcoholic Steatohepatitis. *Gastroenterology*, 2015; 149:367 - 378.

[15] Musso, G., Cassader, M., Rosina, F., Gambino, R. Impact of current treatments on liver disease, glucose metabolism and cardiovascular risk in non-alcoholic fatty liver disease (NAFLD): a systematic review and meta-analysis of randomised trials. *Diabetologia*, 2012; 55:885 - 904.

[16] Sanyal, A. J., Friedman, S. L., McCullough, A. J. et al. Challenges and opportunities in drug and biomarker development for nonalcoholic steatohepatitis: findings and recommendations from an American Association for the Study of Liver Diseases-U.S. Food and Drug Administration Joint Workshop. *Hepatology*, 2015; 61:1392 - 1405.

[17] Lassailly, G., Caiazzo, R., Buob, D., Pigeyre, M., Verkindt, H., Labreuche, J. et al. Bariatric surgery reduces features of nonalcoholic steatohepatitis in morbidly obese patients. *Gastroenterology*, 2015; 149:379 - 388.

[18] Cazzo, E., Pareja, J. C., Chaim, E. A. Nonalcoholic fatty liver disease and bariatric surgery: a comprehensive review. *Sao Paulo Med. J.*, 2017; 135: 277 - 295.

[19] Gruben, N.; Shiri-Sverdlov, R.; Koonen, D. P. Y.; Hofker, M. H. Nonalcoholic fatty liver disease: A main driver of insulin resistance or a dangerous liaison? Biochim. *Biophys. Acta*, 2014, 1842, 2329 - 2343.

[20] Orlani, G., Giorda, C., Manti, R. et al. The burden of NAFLD and its characteristics in a nationwide population with type 2 diabetes. *J. Diabetes Res.*, 2016; 2016:2931985.

[21] Bugianesi, E., Moscatiello, S., Ciaravella, M. F., Marchesini, G. Insulin resistance in nonalcoholic fatty liver disease. *Curr. Pharm. Des.*, 2010; 16: 1941 - 1951.

[22] Thaler, J. P., Cummings, D. E. Minireview: hormonal and metabolic mechanisms of diabetes remission after gastrointestinal surgery. *Endocrinology*, 2009; 150:2518 - 2525.

[23] Cummings, D. E., Overduin, J., Shannon, M. H. et al. Hormonal mechanisms of weight loss and diabetes resolution after bariatric surgery. *Surg. Obes. Relat. Dis.*, 2005; 1:358 - 368.

[24] Federico, A., Dallio, M., Godos, J., Loguercio, C., Salomone, F. Targeting gut-liver axis for the treatment of nonalcoholic steatohepatitis: translational and clinical evidence. *Transl. Res.*, 2016; 167: 116 - 124.

[25] Wieser, V., Adolph, T. E., Enrich, B., Moser, P., Moschen, A. R., Tilg, H. Weight loss induced by bariatric surgery restores adipose tissue PNPLA3 expression. *Liver Int.*, 2017; 37: 299 - 306.

[26] Lee, Y., Doumouras, A. G., Yu, J. et al. Complete resolution of nonalcoholic fatty liver disease after bariatric surgery: a systematic review and meta-analysis. *Clin. Gastroenterol. Hepatol.*, 2019; 17: 1040 - 1060.

[27] Nickel, F., Tapking, C., Benner, L., Sollors, J. et al. Bariatric Surgery as an Efficient Treatment for Non-Alcoholic Fatty Liver Disease in a Prospective Study with 1-Year Follow-up: BariScan Study. *Obes. Surg.*, 2018; 28: 1342 - 1350.

[28] Tannous, K. Fakhry, Rahul Mhaskar, Theresa Schwitalla et al. Bariatric surgery improves nonalcoholic fatty liver disease: a contemporary systematic review and meta-analysis, *Surgery for Obesity and Related Diseases*, https://doi.org/10.1016/ j.soard.2018.12.002.

[29] Salminen, P., Helmio, M., Ovaska, J., Juuti, A., Leivonen, M., Peromaa-Haavisto, P. et al. Effect of laparoscopic sleeve gastrectomy vs laparoscopic roux-en-Y gastric bypass on weight loss at 5 years among patients with morbid obesity: the SLEEVEPASS randomized clinical trial. *JAMA*, 2018; 319: 241 - 54.

[30] Weight regain following sleeve gastrectomy—a systematic review. Lauti, M., Kularatna, M., Hill, A. G., MacCormick, A. D. *Obes. Surg.*, 2016; 26:1326 - 1334.

[31] Sebastianelli, L., Benois, M., Vanbiervliet, G. et al. Systematic Endoscopy 5 Years After Sleeve Gastrectomy Results in a High Rate of Barrett's Esophagus: Results of a Multicenter Study. *Obes. Surg.*, 2019; 29: 1462 - 1469.

[32] Alsina, M. E., Ruiz-Tovar, J., Bernabeu, A. Evolution of Liver Steatosis Quantified by MR Imaging and MR Spectroscopy, in Morbidly Obese Patients Undergoing Sleeve Gastrectomy: Short-Term Outcomes. *Obes. Surg.*, 2017; 27: 1724 - 1728.

[33] Esquivel, C. M., Garcia, M., Armando, L. et al. Laparoscopic Sleeve Gastrectomy Resolves NAFLD: Another Formal Indication for Bariatric Surgery? *Obes. Surg.*, 2018; 28: 4022 - 4033.

[34] Karcz, W. K., Krawczykowski, D., Kuesters, S. et al. Influence of Sleeve Gastrectomy on NASH and Type 2 Diabetes Mellitus. *J. Obes.*, 2011; 2011:765473.

[35] Algooneh, A., Almazeedi, S., Al-Sabah, S., Ahmed, M., Othman, F. Nonalcoholic fatty liver disease resolution following sleeve gastrectomy. *Surg. Endosc.*, 2016; 30:1983 - 1987.

[36] Von Schönfels, W., Beckmann, J. H., Ahrens, M., Hendricks, A., Röcken, C., Szymczak, S., Hampe, J., Schafmayer, C. Histologic improvement of NAFLD in patients with obesity after bariatric surgery based on standardized NAS (NAFLD activity score). *Surg. Obes. Relat. Dis.*, 2018; 14:1607 - 1616.

[37] Haluzikova, D., Lacinova, Z., Kavalkova, P., Drapalova, J., Krizova, J., Bartlova, M. et al. Laparoscopic sleeve gastrectomy differentially affects serum concentrations of FGF-19 and FGF-21 in morbidly obese subjects. *Obesity, 2013;* 21, 1335 - 1342.

In: Encyclopedia of Surgery (22 Volume Set)
Editors: Andreas Lehrer and Kristin Mueller
ISBN: 978-1-53618-329-0
© 2020 Nova Science Publishers, Inc

Chapter 312

LIVER STEATOSIS AND ROUX-EN-Y GASTRIC BYPASS (RYGB)

Luciano Deluca[1,2,*], MD, Liliana Parasporo[2], MD, Patricio Cal[1,2], MD and Ezequiel Fernández[1,2], MD

[1]Programa de Cirugía Bariátrica, Hospital Churruca, Buenos Aires, Argentina
[2]Centro de Rehabilitación de Cirugía de la Obesidad, Buenos Aires, Argentina

ABSTRACT

Given the known beneficial consequence of weight loss on NASH and the predictable effect of bariatric surgery on weight loss, several studies have explored the potential role of bariatric surgery on the treatment of NASH. To date, RYGB remains the most extensively studied bariatric surgery as a potential NASH therapy.

In this chapter we will review the actual evidence of the effect of RYGB on liver steatosis, NAFLD and NASH.

Keywords: steatosis, obesity, Roux-en-Y gastric bypass, NASH, fatty liver

INTRODUCTION

Nonalcoholic fatty liver disease (NAFLD) is an important cause of chronic liver failure in individuals without significant alcohol consumption [1]. It is the hepatic component of metabolic syndrome and is associated with the deposition of triglycerides into the hepatocytes. NAFLD includes a spectrum of syndromes ranging from pure steatosis (PS) to nonalcoholic steatohepatitis (NASH) to cirrhosis, which can lead to end-stage liver failure or development of hepatocellular carcinoma. While NASH is a condition with a high potential to progress to cirrhosis, PS appears to follow a more benign course, with little or no progression to further liver damage.

* Corresponding Author's Email: deluca.churruca@gmail.com.

As a result of the increasing prevalence of obesity, diabetes and metabolic syndrome, nonalcoholic fat liver disease (NAFLD) has become one of the most common cause of chronic liver disease worldwide [2]. In 2016, 39% of adults were overweight and 16%, obese [3]. In Argentina 60% of the population is overweight, and 5% is obese [4].

Differentiating patients with fibrosis, moderate fibrosis and severe fibrosis can be trickysome. For NAFLD patients, the Original European Liver Fibrosis test has been proposed. It includes variables such as age, tissue inhibitor of matrix metalloproteinase 1, hyaluronic acid and aminoterminal peptide of pro-collagen II. A similar scoring system, the Enhanced Liver Fibrosis panel, excludes age and is also reliable [8]. The limitation for the routine use of these scores is the cost and availa*bility of the specific markers.* Diagnosis of advanced fibrosis is, indeed, an additional indication for bariatric surgery. However, the surgical procedure must induce a slow and progressive weight loss. More aggressive bariatric surgeries leading to more dramatic weight loss and malnutrition may worsen underlying liver disease [5]. Patients with fibrosis have a higher risk for cirrhosis, portal hypertension, hepatocarcinoma and death [6, 7].

RISK FACTORS

Insulin Resistance

It is considered a fundamental step in the development of the metabolic syndrome (MS), which can eventually end type 2 diabetes mellitus (T2DM). Both NAFLD and NASH are strongly linked to insulin resistance, and the relationship between MS and NAFLD is fully recognized. Insulin resistance facilitates the accumulation of fat in both abdominal subcutaneous adipose tissue and visceral abdominal adipose tissue, as well as in the liver.

Gender

NAFLD is more common in man than in women (ratio 2,1), apparently explained by the protective effect of estrogen, which also facilitate insulin function. As estrogen protects, androgens exert a potential ne*gative role in aggressive NASH.*

Ethnicity

The risk related to ethnicity has been researched in large multiethnic populations. It is considered that the prevalence of nonalcoholic fatty liver is higher in the *population of hispanic origin.*

Feeding

In obese patients with NAFLD, fat accumulates in the liver abnormally in the form of triglycerides, which are derived from lipolysis of adipose tissue by 60%, de novo lipogenesis by 26%, and by diet in the form of chylomicrons in 15%. In this abnormal deposit, the dietary imbalance between omega-6 and omega-3 fatty acids appears to be a determining factor. Fructose, which is increasingly consumed as an additive in commercial beverages, can alter lipidic metabolism. There is evidence that high fructose consumption triggers an increase in de novo lipogenesis, dyslipidemia, insulin resistance and obesity with central fat deposition. This de novo stimulus to lipogenesis contributes to increased deposits of fat in the pathogenesis of NAFLD.

PATHOGENESIS

NASH is a metabolic disease probably caused by multifaceted disturbances of hepatic lipid homeostasis. The hystpatogenesis of NAFLD is not fully understood. The theory of the two hits is the most accepted up to date. The first hit is the accumulation of fat in the liver, which takes to oxidative stress. The second hit is the development of inflammation (steatohepatitis).

As a result of insulin resistance vacuols of triglycerides are accumulated by the hepatocyte, leading to fatty liver.

Not all the fatty acids that are inside the liver have an exogenous origin because there is also a synthesis of fatty acids from the acetate. These fatty acids undergo transformations that will lead to different substances: Triglycerides Cholesterol Phospholipids Ketone bodies (after mitochondrial oxidation of fatty acids). Triglycerides bind to apoproteins and form lipoproteins, which is how they leave the liver to the blood. When they increase the fatty acids they accumulate in the form of triglycerides.

Mitochondria are essential for fat metabolism and can be a major source of oxidative stress under conditions of sepsis or lipotoxicity that is associated w*ith mitochondrial dysfunction.*

The fatty accumulation causes changes in hepatocyte's mitochondria leading to the production free radicals, oxidative stress and finally an inflammatory response with risk of fibrogenesis.

Free fatty acids can induce some microsomal lipogenasas of cytochromes p-450 with the consequent production of free radicals, which are hepatotoxic, and lead to the induction of inflammation. The inflammatory process occurs in zone 3 or perisinusoidal. Chronic inflammation stimulates the activation of the strained or ITO cells and progenitors cells of the liver that lead to a reaction at the level of the bile duct with subsequent fibrosis and progression to cirrhosis. This occurs because the stellate or ITO cells, during chronic inflammatory process, lose their ability to store lipids and differentiate into cells with the characteristics of myofibroblasts, which synthesize type 1 and type 3 collagen in the perisinusoidal space with the consequently liver fibrosis developement.

DIAGNOSIS

Diagnosis can be performed according to clinical and imaging criteria. However liver biopsy is the gold standard to assess steatosis, inflammatory activity and fibrosis; and make a differential diagnosis with other liver diseases. Biopsy is necessary but it has its limitations and is not risk-free. Timing is still controversial. Progressively, new studies have been developed and incorporated to investigate the degree of steatosis, inflammation and fibrosis. However standard guidelines are still lacking.

Most patients with NASH are asymptomatic, although some may suffer from fatigue, malaise, or right upper quadrant discomfort. Often the only clinical sign is hepatomegaly, which may not present in all patients. Few have cutaneous signs of chronic liver disease, but ascites, splenomegaly, spider angiomas, and palmar erythema suggest underlying cirrhosis with portal hypertension. However, some patients with NASH may have normal aminotransferase levels. Less than one half of individuals have a higher than normal alkaline phosphatase level, which is almost always modest, and a few have elevated serum conjugated bilirubin levels. The serum albumin and prothrombin time are typically norm*al in the absence of cirrhosis.*

Regarding the lipid profile, the prevalence of metabolic syndrome and insulin resistance increase as the liver fat increases. The triglycerides values may be high, as well as VLDL and LDL and HDL values may be decreased.

Fibrosis is not required to histologically diagnose esteatosis liver, its usually macrovesicular that refers to hepatocytes with a single large intrachytoplastic fat drop displacing the *nucleus to the periphery cell.*

The extent of steatosis is assessed using percentage involvement by steatotic hepatocytes in liver parenchyma and reported as mild (5 - 33%), moderate (33 - 66%), and severe (> 66%). There are main histological scoring systems to grade and stage NASH. Grade refers to the amount of necro-inflammatory activity, which include the degree of steatosis, ballooning, and lobular inflammation. Stage refers to the categorization of the extent and location of fibrosis. The ra*nge of stages goes from 0 to 4.*

Stage 0: no fibrosis
Stage 1: perisinusoidal/pericellular fibrosis
Stage 2: periportal fibrosis
Stage 3: bridging fibrosis
Stage 4: cirrhosis
Stage 4: cirrhosis

MEDICAL TREATMENT

To date, weight loss achieved via lifestyle intervention remains the mainstream treatment of NASH. A recent meta-analysis of 8 randomized controlled trials (RCTs) – 4 of which included post-treatment histology- involving 373 patients, showed that although ≥ 5% total weight loss (TWL) improved hepatic steatosis, a ≥ 7% TWL was required to improve NASH. [13].

Despite its benefits, in a recent trial by Vilar-Gomes et al. less than one third was able to achieve significant weight loss of ≥ 5% and less than 10% was able to achieve weight loss of ≥ 10% in this trial [14].

Other potential therapies to treat NASH include vitamin E, thiazolidinediones, glucagon-like pep- tide-1 (GLP-1) agonist, and obeticholic acid. Thus far, the best evidence is for vitamin E in nondiabetic adults with biopsy-proven NASH; and thiazolidinediones in patients with and without diabetes with biopsy-proven NASH.

Other therapies are currently undergoing research [15]. A low calorie diet (LCD) is recommended prior to the surgery. The optimal duration has not been determined but a preoperative 2-week LCD treatment seems sufficient for most patients in order to decrease liver volume and fat [16].

ROUX-EN-Y GASTRIC BYPASS AS A TREATMENT OF NASH

Given the known beneficial consequence of weight loss on NASH and the predictable effect of bariatric surgery on weight loss, several studies have explored the potential role of bariatric surgery on the treatment of NASH. To date, RYGB remains the most extensively studied bariatric surgery as a potential NASH therapy [17].

Typically, RYGBP involves the creation of a a 30-50 mL pouch by stapling across the stomach, and then setting a Roux-en-Y gastrojejunostomy with a 15 mm stoma. The Roux limb is usually from 60 to 100 cm in length and *the alimentary limb 100 to 200*cm.

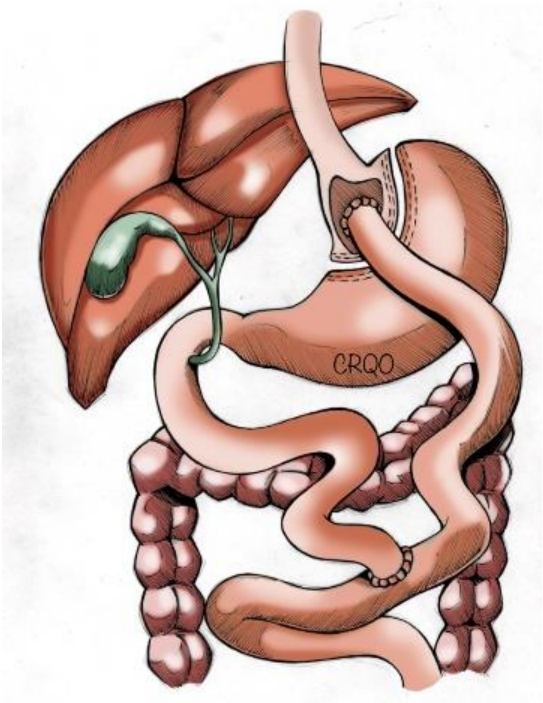

Figure 1. Standard RYGB technique.

Silverman et al. in 1995 evaluated liver histology in 91 patients before and at 2 to 61 months after RYGB. Out of 91 patients, 18 had no steatosis at baseline. Among the 73 remaining patients, 65 experienced reduction in steatosis in follow-up biopsies, 5 with minimal steatosis at baseline showed no change, and 3 had increased steatosis. Thirteen out of 91 patients had perisinusoidal fibrosis (PSF) at baseline—3 with bridging fibrosis, 1 with moderate fibrosis, and 9 with slight fibrosis. Following RYGB, PSF resolved in 10 patients, decreased in 1 patient and remained the same in 2 patients. One patient developed PSF after RYGB [18]. Mathurin et al. conducted a 5-year prospective cohort study on 381 patients with severe obesity. Liver biopsies were performed prior to and at 1 and 5 years after bariatric surgery. Gastric banding, biliopancreatic bypass, and RYGB were performed in 214 (56.2%), 87 (22.8%), and 80 (21%) patients, respectively. Compared to baseline, there was a significant improvement in the prevalence and severity of steatosis (frequency from 82 to 37.7%; extent from 37.4 to 16%) and a significant reduction in NAS (total NAS 1.9 to 1). Inflammation remained unchanged, while levels of fibrosis increased at 5 years (fibrosis stage 0.27 to 0.36). Despite this increase, 96% of patients had fibrosis score ≤ 1 suggesting that there was no clinically significant worsening in fibrosis. [19].

Lassailly et al. in 2015 conducted a 1-year prospective cohort study on 109 patients with biopsy-proven NASH and severe obesity. Liver biopsies were performed prior to and at 1 year after bariatric surgery.

Out of 109 patients, 70 (64.2%), 32 (29.4%), 6 (5.5%), and 1 (0.9%) underwent RYGB, gastric banding, sleeve gastrectomy, and biliopancreatic bypass, respectively. One year after surgery, 85% of patients had NASH remission. Compared to baseline, there was a significant reduction in the prevalence of steatosis from 60 to 10%. In contrast to the data from the previous study, fibrosis improved in 34% of the cohort at 1 year after RYGB [20].

A follow-up meta-analysis in 2015 assessed the effect of bariatric surgery on NAFLD liver histology and/or liver biochemistry. The analysis pooled 29 studies and demonstrated a significant reduction in the incidence of all NAFLD histologic features following bariatric surgery: steatosis (16 studies: reduction in the incidence by 50.2%), ballooning (8 studies: 67.7%), lobular inflammation (7 studies: 50.7%), portal inflammation (4 studies: 13.1%), and fibrosis (12 studies: 11.9%) [21].

Histological changes in liver parenchyma can be seen following weight loss of as little as 3 – 5% improving the steatotic burden. Histologic improvement in NASH can be seen at 7% total body weight loss, and decreased fibrosis is seen with further weight loss.

Weight Loss Surgery's (WLS) benefits go beyond slimming down. They are thought to be due to changes in the entero-insulin axis, helping to realign several dysfunctional processes, including insulin resistance, glucose metabolism, and hyperlipidemia [12]. Following RYGB specifically, there are substantial alterations in incretin signaling as part of this process. Increased concentrations of glucagon-like peptide-1 (GLP-1), elevations of gastric inhibitory peptide (GIP), and changes in substances such as peptide YY and oxyntomodulin after RYGB alter enteric signaling pathways. These incretin effects are unique to RYGB and are not seen with non-surgical weight loss. The immediate metabolic effects of RYGB, evidenced by rapid improvements in postoperative hyperglycemia in patients with T2DM, may play a role in biochemical mechanisms by which NAFLD improves. Conversely, the weight loss from the AGB is uniquely due to restrictive effects, while weight loss through VSG comes about primarily through combined restrictive effects and appetite suppression

through a decrease in ghrelin. Therefore, improvement of weight-related comorbid conditions tends to be higher with RYGB than with these other commonly offered procedures.

A rare and infrequently event associated with Roux-en-Y gastric bypass is aggressive non- alcoholic steatohepatitis. It is associated with rapid weight loss and/or malnutrition. Roux-en-Y gastric bypass is considered a safe procedure if drastic weight loss is avoided in the postoperative course. The mechanism of liver injury in aggressive steatohepatitis is unknown, but rapid fat mobilization in obese patients may potentially cause oxidative stress to the liver. Further study is needed to determine if there is a genetic predisposition to this form of injury and if antioxidants may protect the liver during rapid weight loss or malnutrition [22].

CONCLUSION

Non-alcoholic fatty liver disease is a known metabolic syndrome's comorbidity. It may potentially lead to fibrosis and cirrhosis. Bariatric surgery may lead to improvement and remission. RYGBP is the most evidence-based treatment. However, special care must be taken on patients with f*aster than average weight loss.*

REFERENCES

[1] McCollough, A. J. Update on non-alcoholic fatty liver disease. *J. Clin. Gastroenterol.*, 2002;34:255 - 62.

[2] Nomura, H., Kashiwagi, S., Hayashi, J., Kajiyama, W., Tani, S., Goto, M. Prevalence of fatty liver in a general population of Okinawa, Japan. *Jpn J. Med.*, 1988;27:142 - 9.

[3] World Health Organization (https://www.who.int/en/news-room/fact-sheets/detail/obesity-and-overweight).

[4] http://www.msal.gob.ar/images/stories/bes/graficos/0000001444cnt-2019- //04_4ta-encuesta-nacional-factores-riesgo.pdf.

[5] Pimentel, S. K., Strobel, R., Gonçalves, C. G., Sakamoto, D. G., Ivano, F. H., Coelho, J. C. Evaluation of the nonalcoholic fat liver disease fibrosis score for patients undergoing bariatric surgery. *Arq. Gastroenterol.*, 2010 Apr.-Jun.; 47(2):170 - 3.

[6] Ratziu, V., Giral, P., Charlotte, F., Bruckert, E., Thibault, V., Theodorou, I., Khalil, L., Turpin, G., Opolon, P., Poynard, T. Liver fibrosis in overweight patients. *Gastroenterology*, 2000; 118:1117 - 23.

[7] Teli, M. R., James, O. F., Burt, A. D., Bennett, M. K., Day, C. P. The natural history of nonalcoholic fatty liver: a follow-up study. *Hepatology*, 1995;22:1714 - 9.

[8] Guha, I. N., Parkes, J., Roderick, P., Chattopadhyay, D., Cross, R., Harris, S., Kaye, P., Burt, A. D., Ryder, S. D., Aithal, G. P., Day, C. P., Rosenberg, W. M. Noninvasive markers of fibrosis in nonalcoholic fatty liver disease: validating the European Liver Fibrosis Panel and exploring simple markers. *Hepatology*, 2008; 47: 455 - 60.

[9] Verna, E. C., Berk, P. D. Role of fatty acids in the pathogenesis of obesity and fatty liver: impact of bariatric surgery, *Semin. Liver Dis.*, 2008; 28:407 - 426.

[10] Hannah, Jr. W. N., Harrison, S. A. Effect of weight loss, diet, exercise, and bariatric surgery on nonalcoholic fatty liver disease. *Clin. Liver Dis.*, 2016; 20(2):339 - 50. 15. Mason, E. E., Ito, C. Gastric bypass in obesity. *Surg. Clin. North Am.*

[11] Thomas, S., Schauer, P. Bariatric surgery and the gut hormone response. *Nutrition in clinical practice: official publication of the American Society for Parenteral and Enteral Nutrition*. 2010; 25(2):175 - 82.

[12] Allí, V., Rogers, A. Gastric Bypass and influence on improvement of NAFld. *Curr. Gastroenterol. Rep.*, (2017) 19:25.

[13] Musso, G., Cassader, M., Rosina, F., Gambino, R. Impact of current treatments on liver disease, glucose metabolism and cardiovascular risk in non-alcoholic fatty liver disease (NAFLD): a systematic review and meta-analysis of randomised trials. *Diabetologia*, 2012; 55(4):885 - 904.

[14] Vilar-Gomez, E., Martinez-Perez, Y., Calzadilla-Bertot, L., Torres- Gonzalez, A., Gra-Oramas, B., Gonzalez-Fabian, L., et al. Weight loss through lifestyle modification significantly reduces features of nonalcoholic steatohepatitis. *Gastroenterology*, 2015; 149(2):367 - 78.e5. quiz e14–5.

[15] Chalasani, N., Younossi, Z. The diagnosis and management of non- alcoholic fatty liver disease: *Practice guidance from the American Association for the Study of Liver Diseases*. 2018; 67(1):328 - 57.

[16] Edholm, D., Kullberg, J., Karlson, A., Haenni, A., Ahlstrom, H., Sundbom, M. Changes in liver volume and body composition during 4 weeks of low calorie diet before laparoscopic gastric bypass. *Surgery for Obesity and Related Diseases*, 11 (2015) 602 - 606.

[17] Jirapinyo, P., Thompson, C. Treatment of NASH with gastric bypass. *Current Gastroenterology Reports*, (2018) 20:49.

[18] Silverman, E. M., Sapala, J. A., Appelman, H. D. Regression of hepatic steatosis in morbidly obese persons after gastric bypass. *Am. J. Clin. Pathol.*, 1995; 104(1):23 - 31.

[19] Mathurin, P., Hollebecque, A., Arnalsteen, L., Buob, D., Leteurtre, E., Caiazzo, R., et al. Prospective study of the long-term effects of bar- iatric surgery on liver injury in patients without advanced disease. *Gastroenterology*, 2009; 137(2):532 - 40.

[20] Lassailly, G., Caiazzo, R., Buob, D., Pigeyre, M., Verkindt, H., Labreuche, J., et al. Bariatric surgery reduces features of nonalcoholic steatohepatitis in morbidly obese patients. *Gastroenterology*, 2015; 149(2):379 - 88. quiz e15–6.

[21] Bower, G., Toma, T., Harling, L., Jiao, L. R., Efthimiou, E., Darzi, A., et al. Bariatric surgery and non-alcoholic fatty liver disease: a systematic review of liver biochemistry and histology. *Obes. Surg.*, 2015; 25(12):2280 - 9.

[22] Mahawar, K. K., Parmar, C., Graham, Y., et al. Monitoring of liver function tests after Roux-en-Y gastric bypass: an examination of evidence base. *Obes. Surg*., 2016; 26(10):2516 - 22.

In: Encyclopedia of Surgery (22 Volume Set)
Editors: Andreas Lehrer and Kristin Mueller
ISBN: 978-1-53618-329-0
© 2020 Nova Science Publishers, Inc

Chapter 313

LIVER STEATOSIS REGRESSION AFTER ONE ANASTOMOSIS GASTRIC BYPASS

Luciano Antozzi[1,*], MD, Miguel Angel Carbajo[2], MD, PhD, Priscila Antozzi[1], MD and Carlos Martin Esquivel[3], MD, PhD

[1]Centro de Cirugías Especiales, Bahía Blanca, Argentina
[2]Center of Excellence for the Study and Treatment of Obesity and Diabetes, Valladolid, Spain
[3]Sanatorio Allende, Córdoba, Argentina

ABSTRACT

The association between *Non Alcoholic Fatty Liver Disease* and obesity has been clearly established, with almost all the obese population suffering some degree of it. Nowadays one third of liver transplants secondary to liver failure are due to NAFLD progression and it is estimated that by 2030 it could become the main cause.

Weight loss can significantly improve NAFLD and bariatric surgery is the most effective long term treatment for obesity and metabolic syndrome.

One anastomosis gastric bypass (OAGB) is a powerful technique with results comparable or superior to more established techniques and it should be considered as part of the armamentarium for treating NAFLD.

Keywords: liver steatosis, non alcoholic fatty liver disease, one anastomosis gastric bypass, cirrhosis

INTRODUCTION

Obesity is a pandemia that co-occurs and interacts with undernutrition and climate change, this constitutes a synergy of epidemics that represent the most serious threat to human health and survival [1].

* Corresponding Author's Email: lantozzi@gmail.com.

A large proportion of the obese population suffers metabolic syndrome, type 2 diabetes (T2DM), cardiovascular disease, dyslipidemia and non-alcoholic fatty liver disease (NAFDL). Persistence of this last comorbidity can lead to cirrhosis or hepatocarcinoma.

When liver damage presents with steatosis, steatohepatitis, fibrosis or cirrhosis in patients without alcoholic history, it is considered NAFLD. It affects 10-24% of the general population, but it can rise to 100% when patients are morbidly obese. Besides body fat percentage, central adiposity, hyperinsulinemia and insulin resistance are good predictors of liver dysfunction development [2-8].

Most patients with NAFLD remain asymptomatic or have vague symptoms like fatigue or mild right upper quadrant pain. In stages 3 and 4 of fibrosis, chronic liver disease signs like palmar erythema, telangiectasis or gynecomastia can be found.

During the evaluation of any liver disease, it is important to have initial blood samples of function tests. Most routine biochemical studies have poor correlation with NAFLD. Common blood sample findings are mild to moderate ALT and/or AST elevation. AST/ALT index usually remains under 1 but it rises with fibrosis progression along with gamma-glutamyl transferase. In steatohepatitis, inflammation is present and altered hepatic enzymes are frequently found. Alkaline phosphatase has been found to have statistical association with presence of NAFLD on biopsy [9]. Albumin, prothrombin or bilirubin alteration can indicate liver dysfunction or cirrhosis. In a study with 308 bariatric patients, *highly sensitive C reactive protein* (HSCRP) was found to have utility as an independent predictor of NASH [10].

Ultrasonography has 77% sensitivity and 80% specificity for detecting cirrhosis. For liver steatosis sensitivity rounds 90% with 97% specificity, but it cannot differentiate simple steatosis from steatohepatitis. CT scan and MRI can quantify steatosis and liver volume precisely. Despite imaging studies can detect fatty liver existence, they cannot distinguish hepatic damage severity, this can only be done with liver biopsies, the most precise study for the evaluation of treatment results [11-18].

One third of patients with early stage NASH will progress to fibrosis within 5 to 10 years after the clinical diagnosis has been made when left untreated. Weight loss can produce NAFLD regression, but 90-95% of patients fail to maintain this normal weight with only dietary measures. Bariatric surgery is an important tool to treat obesity comorbidities like NAFLD, being the most commonly performed procedures worldwide Sleeve Gastrectomy (SG) and Roux n Y Gastric Bypass (RYGB). Despite there are concerns about the fast and massive weight loss on liver function, disabsorptive techniques like One Anastomosis Gastric Bypass (OAGB) have demonstrated excellent long-term results. With proper indication and management, this can be a promising treatment for the unstoppable NAFLD rise.

SURGERY AND NAFLD

NAFLD remission or improvement can be related to weight loss, anatomical re-routing, simultaneous remission of comorbidities or by combination of these factors.

There is an established association and coexistence between NAFLD and metabolic comorbidities like insulin resistance (IR), dyslipidemia and T2DM. NAFLD is more severe in diabetic patients and higher rates of fibrosis are found when compared with pre-diabetic or

non-diabetic patients [19]. Metabolic effects like improved glucose homeostasis and lipid metabolism and reduced inflammatory activity that would influence NAFLD are observed after bariatric surgery. These effects are due to glucose and lipids metabolism and cannot be entirely explained by weight loss, since they start almost immediately after surgery. Mechanisms of steatosis and ballooning are linked to IR and the long-term evolution may be predicted by early improvement in IR after surgery [20].

Bile acids (BA) act as metabolic modulators and endogenous mediators of energy expenditure and glycolipid metabolism. Enterohepatic circulation is markedly modified when a bilio-pancreatic limb (BPL) without the presence of food is created. The concentration of primary and secondary BA in the portal vein and liver are found significantly elevated due to early reabsorption of the BP limb rather than accelerated transport to the ileum. The length of BPL is of particular importance and affects BA serum rise and they could be responsible for the glycemic control after surgery [21].

Surgery was found to be cost effective, to increase life expectancy, and quality-adjusted survival in patients with all classes of obesity, regardless of fibrosis stage [22]. Many studies have demonstrated significant improvement in histology and beneficial effects on steatosis but, to date, there are no randomized controlled trials showing histological effects of bariatric surgery in NAFLD patients.

Non-invasive methods to evaluate NAFLD changes after surgery, like serologic measurement of metabolic parameters and radiologic tests, are used to generate scores of steatosis or fibrosis. *Fatty liver liver index, NAFLD liver fat score* (steatosis), *Fibrosis 4 score and NAFLD fibrosis score* (fibrosis) are widely validated. Some publications used this method to analyze results but this cannot diagnose NASH [23, 24]. There is still scant data on the durability of NASH remission after surgery proved with biopsy. This can be a major limitation to indicate or conclude which surgery has best results for each patient.

NASH patients are at the highest risk of liver disease progression and dysfunction. Identification of these patients with biopsy and validated histological scoring is important. Bariatric surgery has been found to reduce hepatic fibrosis and necroinflammatory processes, slowing down the process and development of cirrhosis with further complications or death. This natural history of fibrosis or liver failure progression needs to be considered when a cohort of patients is evaluated, because they are most likely to suffer complications or unfavorable progression after surgery.

If cirrhosis is recognized before surgery, patients should be carefully optimized and informed before proceeding to an operation. Even well compensated Child's A patients can safely have surgery. There is no consensus on which bariatric modality is best suited. Access to biliary system and a simpler scenario if a liver transplant is needed are main advantages [25-28].

RESULTS

Bariatric surgery is more effective than medical treatment to achieve sustained weight loss, control insulin resistance, treat T2DM and reduce cardiovascular events. Regarding NAFLD several cohort studies assess the effect of Biliopancreatic Diversion, OAGB, RYGB, Laparoscopic Adjustable Gastric Band (LAGB) or SG. Resolution or improvement of

steatosis is the usual findings but there are reports of fibrosis worsening or progression. Transient deterioration of the liver condition mainly occur within the initial postoperative period in which nutritional status and transaminases, cholesterol, albumin or transferrin concentrations can be impaired [29]. LAGB and SG are found less detrimental than techniques that involve disabsorption. Initial liver status has to be evaluated to make proper patient and technique selection.

Numerous studies have pointed out an improvement in steatosis after bariatric surgery after 5 years of follow-up. This long-term evolution can be predicted by early improvement in IR following the surgical procedure. Correlation with weight loss is not linear but Glass et al. described regression in fibrosis when at least 10% of body weight is lost [30]. Luo found 83.7% steatosis resolution and a 21.4% decrease in liver volume at 1 month in 49 patients studied, indistinct of SG or RYGB [31].

In the largest study of BS in NAFLD with more than 500 patients, the effects of RYGB and AGB were compared. Improvement and resolution of steatosis, inflammation and fibrosis were observed after one and five years and the authors did not describe any cases of worsening. Best effects on weight loss and liver histology were achieved in the RYGB patients with greater weight loss and better glucose and lipid metabolism [32].

Another study of 160 patients demonstrated resolution or improvement of steatosis and inflammation in most patients, but 3/37 developed de novo steatosis, 3/114 de novo steatohepatitis and 12/56 de novo fibrosis after surgery, however this result could be affected by the short postoperative period between surgery and biopsy [33].

A recent study found histological NASH in 115 out of 1,489 (7.7%) morbid obese patients. After 109 were submitted to RYGB, LAGB or SG, persistent NASH was more frequent in LAGB than gastric bypass patients (30.4% vs. 7.6%; $p = 0.015$). NASH resolution was diagnosed in 85% of RYGB patients [34].

NAFLD activity score (NAS) higher than 4 is highly predictive of NASH and lower than 3 is highly predictive of its absence [35]. Froylich et al. compared RYGB and SG, they found NAS >4 in 15 patients at the time of surgery and postoperative resolution were achieved in 14. Fibrosis also showed a significant improvement, but 12% of patients in the RYGB arm had worsening fibrosis stage postoperatively [36]. Mathurin et al. using NAS score at 1 and 5 years in 381 bariatric patients found improvement in steatosis and ballooning mainly within the first year that persisted up to 5 years. A lack of significant improvement in inflammation and fibrosis stage worsening at 5 years after surgery was also seen. Refractory IR and insufficient weight loss predicted the persistence of steatosis and ballooning [20].

Some degree of clinical or subclinical hepatic injury within the first year of disabsorptive procedures that generate rapid weight loss has been described [37]. Although progression to cirrhosis or liver failure is rare, there are patients that even required liver transplantation after BPD or Scopinaro [38-40].

A transient elevation in transaminases 6 months after BPD was published in a study of 697 patients, these parameters normalized after 12 months [41]. Biopsies found significant reduction of steatosis and NASH grade as well, confirming low detrimental effects of BPD [42].

Baltasar in a study of 470 patients reported that 10 (2.12%) had hepatic dysfunction not related to viral hepatitis or biliary ductal disease after BPD [43]. Ten years later another publication from the same author reported 1.2% liver disfunction and 0.2% liver failure in a series of 929 patients with the same operation [44].

Giannini et al. investigated the safety of BPD in 56 compensated NAFLD patients at 5 years. Of the patients with baseline NAS score 0-2, it remained unchanged after surgery in 76% of the cases and 24% became indeterminate. Of baseline indeterminate NAS patients, 56% remained unchanged, 41% improved and 3% worsened. Among 8 patients with F3-F4 one remained unchanged, 2 improved to F0-F2 and 5 became indeterminate. None of the patients in this series developed liver related complications. They concluded that liver damage does not seem to be a contraindication to BPD [37].

Texeira reported a patient with BMI 69 kg/m2 submitted to single anastomosis duodeno-ileal bypass (SADI). He consulted at the third year after poor follow-up compliance with 83% EWL, hypoalbuminemia, ascites and cirrhosis [45]. He was treated conservatively but later required revision to RYGB (unpublished).

In a large retrospective analysis of 2,241 patients, Scopinaro did not find any liver failure after his procedure was performed [46].

With jejunoileal bypass (JIB) pioneered by Payne and DeWind, an association between disabsorption and liver complications was found. The technique was abandoned because, among other aspects, the possibility of developing hepatic fibrosis was found in 45% of patients and cirrhosis in 8% [47]. In a review of 6,319 patients, mortality after JIB was 2.8%. Twenty one percent of the 179 fatal cases occurred within 1 month after surgery. Only 2.9% of patients showed progression of liver disease. In another review, 10 out of 604 patients (1.7%) died of liver failure [48].

Liver impairment mechanism after disabsorptive procedures remains unclear and some groups suggest to avoid this technique if advanced liver compromise is detected prior to surgery. On the other hand, there is a significant association between metabolic comorbidities remission and NAFLD improvement. Disabsorptive techniques are most efficient in this aspect and it is logical to think that best NAFLD remission would be found after they are performed. Only a few studies evaluated what happens with the metabolic effect of surgery when patients regain weight. With re-emergence of initially controlled T2DM and weight recidivism [49], lessening in the improvement of NAFLD outcomes [50] and liver enzymes rise has been demonstrated [51].

The latest guidelines discussing surgical treatment of NAFLD state that surgery is clearly indicated in patients with NAFLD who also meet the criteria for bariatric surgery, but with no specific statement regarding the choice of the procedure [52-53].

OAGB is among the most efficient bariatric techniques regarding long-term results, not only because of weight loss maintenance but also comorbidities resolution. Despite its relative novelty, this technique will find its place within the therapeutic armamentarium for treating NAFLD.

ONE ANASTOMOSIS GASTRIC BYPASS (OAGB)

In 1997, Dr. Robert Rutledge, during a trauma surgery that required antrectomy and intestinal resection, performed a reconstruction with a single gastro-jejunal anastomosis. This reconstruction led to the mini-gastric bypass (MGB) operation, later applied to treat obesity and related comorbidities being less technically demanding than RYGB. In 2001 Dr. Rutledge made the first presentation of excellent results after 1,274 patients. In 2002, Professor Miguel Carbajo, an experienced bariatric surgeon, performed a modification to avoid potential reflux

entitling the surgery as one-anastomosis gastric bypass (OAGB) or BAGUA in Spanish. [54] Some modifications have been described with time, trying to reach the operations *State-of-the-art.*

In April 2018 the *International Federation for the Surgery of Obesity and Metabolic Disorders* (IFSO) has determined that the standard nomenclature when referring to the mini gastric bypass described by Rutledge and the one anastomosis gastric bypass described by Carbajo should be One anastomosis gastric bypass (OAGB) [55]. Technical aspects are described below.

MGB consists of a long gastric pouch starting 2-3 cm. below the *Crow's foot* that extends to the angle of His. A 4-6 cm. wide termino-lateral gastro-jejunal anastomosis is constructed leaving a BPL of 150-200 cm. without measuring the total bowel length. In the super obese, the recommended distance to *Treitz* ligament is about 250 cm, in the elderly less than 150 cm. and in type II diabetics without major obesity about 150 cm. [56]

OAGB consists of an 18-20 cm. gastric pouch, an anti-reflux valve conformed by suturing the BPL to the gastric pouch and a latero-lateral gastro-intestinal anastomosis. The most significant difference between surgeries is total bowel length measurement. Bowel length has been found to be variable and this can be important enough to predispose a patient to malnutrition or others to weight regain when fix BPL length is used. Dr. Tacchino observed that 3% of women and 2% of men have small bowel shorter than 400 cm, and interestingly in opposition 15% of men and 5% of women have it longer than 800 cm. [57] Drs. Carbajo and Tovar found in a 5 years prospective observational study of 300 patients that the common limb/total bowel length ratio, followed by common limb length are the most accurate parameters to predict 5-year postoperative BMI below 25 Kg/m2. An ideal range between 0.40 and 0.43 was established (unpublished). They found less variability in total bowel length than Tacchino, but again a group of patients with the risk of a common limb too short was detected if TBL is not measured.

This topic is of particular importance if a patient has liver disease, since the procedure can be tailored knowing the existence of this comorbidity. Longer common limb is safer in these cases. A disabsorption too powerful can lead to not only lack of regression of the disease, but progression or liver failure. Rapid weight loss can affect the liver function.

OAGB AND LIVER DISEASE

In a recent systematic meta-analysis, that included studies in English with more than 100 patients as selection criteria, 35 relevant publications about OAGB and 8 registered clinical trials were found. Of this literature review almost every group performed liver function tests and radiologic liver evaluation with US prior to surgical interventions, but results on this topic are barely described.

Eilenberg published a case series of 10 patients with liver dysfunction after RYGB, OAGB and Distal Gastric Bypass. Unfortunately the number of initial surgeries from which this group resulted in is unknown. Three patients had primary OAGB, 2 were converted OAGB after gastric band, 3 had primary RYGB and 2 had RYGB distalization. Clinical presentation was characterized by an increase in liver enzymes, hepato-splenomegaly, thrombocytopenia, impaired coagulation parameters, hypoalbuminemia, and sarcopenia. At

later stages, ascites, pleural effusions, encephalopathy and upper gastrointestinal bleeding. Seven developed steatosis/fibrosis and 3 cirrhosis. Eight patients were successfully treated with nutritional preparation and conversion. One OAGB patient required liver transplantation and one RYGB died of decompensated liver disease prior to conversion [58].

Kruschitz retrospective evaluation of 25 non-diabetic patients who underwent OAGB and 25 RYGB found a transient rise in ALT and AST. De Ritis ratio significantly greater in omega-loop gastric bypass after 12 months and faster reduction of GGT in RYGB were observed. Despite the small sample size and that liver biopsies were not available, this is one of few papers assessing important information on this subject [59].

Spivak published a database analysis of 19,053 patients submitted to SG, 2433 to RYGB and 715 to OAGB. EWL superiority was seen in OAGB. Awareness of liver markers on hepatic condition was raised and authors suggest close follow-up if markers at one year switch from normal to abnormal. The percentage of patients with normal baseline AST/ALT that became abnormal was 10%-11.7% in OAGB patients at the first year after the procedure; ALP levels became abnormal in 15.7%. The percentage of patients who went from abnormal to normal AST, ALT, and GGT was significantly higher and outnumbered that of normal to abnormal patients for all 3 procedures, although the differences were lower in OAGB patients [60].

Carbajo reported a 12 years follow-up retrospective study of a prospective database. Of 1200 consecutive patients T2DM, IR, HT, and sleep apnea either totally resolved or substantially improved within the initial period after OAGB. Remission was also demonstrated in most patients for other metabolic conditions like hyperlipidemia and liver steatosis when the first biochemical tests were ordered at the 3rd postoperative month. At 12 years mean EWL was 70%. Early major complications requiring re-operations occurred in 1.3 % (9 bleedings and 3 leaks). Two percent of the patients reported sporadic clinical reflux that was managed conservatively [61].

A study of 3000 patients submitted to OAGB showed, after 15 years, a slight to moderate decrease in the percentage of full remission in patients with T2DM (from 94% to 90%), hypertension (from 98% to 87%) and hyperlipidemia (from 98 to 86%) but sustained complete remission of fatty liver disease [62].

Drs. Kular and Rutledge reported their results in a retrospective review of prospective data on 1,054 consecutive patients. With a follow-up of 84% at 6 years they found 85% EWL, 93.2% diabetes and 99% fatty liver remission [63].

Garg et al. researched the utility of transient elastography to evaluate the effect of bariatric surgery on hepatic steatosis and fibrosis with liver stiffness measurement (LSM) and controlled attenuation parameter (CAP). Of 124 patients, 32 underwent biopsy at one year. They found no difference in changes of hepatic steatosis, lobular inflammation, ballooning, NASH and fibrosis between LSG, RYGB and OAGB. Biopsy results were comparable to LSM and CAP [64].

In December 2017 a total of 101 experts from 39 countries evaluated 55 topics during a consensus statement meeting. Seventy-six experts agreed that OAGB is an acceptable surgical option in suitable even in patients with Child-Pugh class A cirrhosis without portal hypertension (75.25% consent) [65].

OAGB RESULTS

It is now widely acknowledged that OAGB is an efficacious technique for achieving sustained weight loss [66-67]. Complete remission or improvement of T2DM is among the greatest found in BS [68-71] and comparable with more complex surgeries like BPD [72-74].

Lee evaluated T2DM remission at one year in 249 MGB and 157 RYGB patients. Complete remission was achieved in 55.4% of patients in RYGB group and in 81.9% of patients in MGB group at 1 year. At 5 year follow-up, results were still significantly better in MGB group (70.5% vs. 39.4%) [75]. The same author in a double-blind randomized trial that included 60 patients, showed MGB superiority over SG in patients with BMI 25-35 kg/m2 up to 5 years after surgery. A statistically significant difference in HbA1C was reported (6.1 ± 0.7 vs. 7.1 ± 1.2%, $p < 0.05$) [76]. Another prospective, randomized clinical trial by Lee compared 40 RYGB and 40 MGB at 2 years follow-up. There were no statistically significant differences in WL, quality of life or clinical results. The author concludes that MGB is a simpler technique than RYGB with similar efficacy [77].

Wang et al. in a systematic review and meta-analysis examined the results of OAGB and SG. EWL was greater after OAGB at one ($p = 0.005$) and five years ($p < 0.001$). Remission of diabetes was significantly better in OAGB ($p = 0.002$) [78]. Quan et al. revised 16 studies and showed superiority of MGB regarding EWL and T2DM remission over SG (89.1% vs. 76.3%, $p = 0.004$) and RYGB (93.4% vs. 77.6%, $p = 0.006$) [79].

Magoulitis et al. in a systematic review of 10 studies that included 6761 patients found that EWL, T2DM and dyslipidemia remission were significantly superior in OAGB than SG. Anyway authors mention that regarding this topic only a small number of RCT were found and results should be cautiously interpreted. The same group compared clinical outcomes of OAGB and RYGB one year later and again found superiority in EWL at five years and T2DM remission, but not dyslipidemia [80].

A recent prospective randomized clinical trial by Tovar compared 600 patients submitted to SG, RYGB and OAGB at 1, 2 and 5 years. Excess BMI lost at 1 year was 81.7 ± 6.3 in SG, 81.2 ± 5.9 in RYGB and 100.4 ± 6.7% in OAGB. At 2 years 87 ± 7.1 in SG, 87.2 ± 6.7 in RYGB and 104.3 ± 7% in OAGB. Both measurements showed significantly better result of OAGB, and no statistically significant different between SG and RYGB. Five years after surgery the same results were found. Final results were in SG group BMI 30.8 ± 2.2, in RYGB 29.9 ± 2.3 and OAGB 25.1 ± 1.8 ($p < 0.001$). Five year remission of diabetes was 82% for SG, 86.4% for RYGB and 95.7% in OAGB. ($p = 0.027$). Five year remission of DL was 28.6% for SG, 71% for RYGB and 100% in OAGB. ($p = 0.001$) [81].

Alkhalifah in a retrospective analysis of a prospective database compared 1731 MGB, 805 RYGB and 1107 SG. Maximum weight loss was achieved in all patients at 2 years. MGB showed significant and durable WL at 10 years. At 2 and 5 years MGB group had the highest remission rates of T2DM (95.1%) and dyslipidemia (87.7%). SG had similar efficacy in diabetes remission rate to both bypass procedures, but significantly lower values in the treatment of dyslipidemia [82].

Jammu and Sharma compared SG, RYGB and MGB in 1107 patients with 52% follow up at 7 years. In the long-term excess weight loss was >90% after MGB, 72% after RYGB and 53% after SG. T2DM remission was 56.5% in SG, 75.8% in RYGB and 95.1% in MGB. DLP remission was 52.4% in SG, 74.0% in RYGB and 93.3% in MGB. Hypoalbuminemia was

maximum in MGB. The authors concluded from the results found that MGB was the procedure of choice for patients compliant in taking supplementation [83].

A RCT comparing efficacy of RYGB and OAGB found 60% complete remission of T2DM in OAGB compared with 38% in RYGB [84].

COMPLICATIONS AFTER OAGB

Complications after OAGB are being continuously studied and mostly reported as infrequent. Mortality and early complications rate have been found comparable to SG and RYGB, but with a favorable trend in late complications rate and re-intervention needs. Publications repeatedly mention the possibility of conservative management before the necessity of a surgical intervention. Bile reflux (0.2-2%) and PCM (0.2-1.2%) are main concerns and primary hepatic related complications are not common [85-87].

Revisional surgery is the third most commonly performed bariatric procedure nowadays because of poor primary surgery outcomes. SG can't be reversed, and revision hasn't shown good results, but it is frequently converted. Indications for SG conversion are weight regain, comorbidities persistence and/or GERD. Usually these patients can have a RYGB, BPD or OAGB. After RYGB failure, it is difficult to find a simple and effective solution. Pouch and/or anastomosis reshaping and limb distalization are complex and not very successful. Transformation to OAGB with BPL distalization can achieve comorbidities resolution and weight loss.

OAGB can be revised, converted or reversed with less technical difficulties than RYGB. The main indications are protein calorie malnutrition (PCM), and intractable reflux. These conditions mostly appear within the first 18 months after surgery and should be properly managed clinically before indicating surgery, since most cases respond. Weight regain can also appear in the medium or long-term after MGB.

PCM is associated with poor alimentary habits or to a common limb too short. The incidence is more frequent in vegetarians, diabetic nephropaty, and liver disease patients. Patients can present with lower limbs edema, fatigue and severe hypoalbuminemia.

A systematic review of 12,807 OAGB patients found low postoperative hypoalbuminemia rates (3.4%) and reported occurrence of PCM in 0-3.8% of patients at 2 years [88].

Khalaj et al. in a study of 189 patients submitted to MGB with 200 cm. BPL had the highest published readmission rate secondary to PCM (7/189, 3.7%). Liver function tests were normal in all patients before surgery and 5/7 had different grades of steatosis in US. High serum transaminases was found in only one patient at a mean period of 11.7 +- 4.5 months but rose in 6/7 during follow-up visits. All patients underwent revisional surgery. Of the seven cases, a patient that expired had a history at baseline of DMTII, HT, grade III fatty liver and failed to progress after gastro-gastrostomy. Common limb length in autopsy was 108 cm [89].

Alkhalifah compared SG, RYGB and MGB. Seventy out of 1,731 MGB patients required revision (4%). Malnutrition was the main cause (43 cases) followed by intolerance, and WR. In RYGB revision rate was higher reaching 5.1% with 41.5% secondary to acute internal

herniation, 24.4% for WR and 14.6% for malnutrition. SG revision was highest at 5.2% with 89.6% of the cases secondary to GERD or WR [82].

Jammu and Sharma during their initial experience with a longer BPL >250 cm. had 13.1% of patients with hypoalbuminemia and 3.2% of the cases had to be reversed. This observation changed their approach on limb length supporting a shorter BPL [83].

Motamedi reported a morbidly obese patient who underwent MGB that progressed from a baseline NAS 2/8 to 7/8 nine months after surgery. The case was resolved after gastro-gastrostomy [91].

Finally Robert in a multi-centre, non-inferiority, randomized controlled trial found OAGB to be not inferior to RYGB in terms of weight loss and metabolic outcomes at 2 years. Single adverse events can be interpreted as higher throughout the paper but a detailed reading by Mahawar pointed out that actually there was no significant difference in the proportion of patients with at least one serious adverse event (22% with OAGB vs 19% with RYGB; p = 0.19). Early and late complications combined was the same for both procedures [92]. The incidence of malnutrition at 2 years was also not significantly different between the groups (OAGB 10.8% *vs* RYGB 16.7%; p = 0.34) [84].

CONCLUSION

Bariatric surgery improves NAFLD in patients with obesity. Despite there are reports of increased de novo fibrosis, development of cirrhosis or liver function alterations are infrequent with modern surgical techniques. Natural progression of NAFLD in the common metabolic syndrome - obesity scenario, makes the decision of performing surgery quite easy. Which technique to choose is far more complex and depends on patients condition, possibility of follow-up, dietary habits and medical team experience or preferences.

There are not many publications specifically addressing liver impact of OAGB but this chapter summarizes that weight loss and comorbidities resolution are of importance for NAFLD control. OAGB is becoming a mainstream because it is proving to be superior to other procedures in these aspects.

Groups starting to adopt this technique should be properly trained and compromised with follow-up and monitoring of liver function tests. If a proper technique and supplementation/ diet are utilized, results are optimal and risks minimized.

REFERENCES

[1] "The Global Syndemic of Obesity, Undernutrition, and Climate Change" *The Lancet Commission report.* 2019-02 https://doi.org/10.1016/S0140-6736(18)32822-8.

[2] Kissebah A, Vydelingum N, Murray R. "Relation of body fat distribution to metabolic complications of obesity" *J Clin Endocrinol Metab* 1982 Feb; 54(2): 254-60.

[3] Reaven GM. "Syndrome X: 6 years later" *J Intern Med Suppl* 1994; 736: 13– 22.

[4] Kvist A, Chowdhury B, Grangard U. "Total and visceral adipose tissue volumes derived from measurements with computed tomography in adult men and women: Predictive equations" *Am J Clin Nutr* 1988 Dec; 48(6):1351-61.

[5] Gillum RF. "The association of body fat distribution with hypertension, hypertensive heart disease, coronary heart disease, diabetes and cardiovascular risk factors in men and women aged 18–79 years" *J Chronic Dis* 1987; 40:421–428.

[6] Micciolo R, Bosello O, Ferrari P. " The association of body fat location with hemodynamic and metabolic status in men and women aged 21–60 years" *J Clin Epidemiol* 1991;44:591–608.

[7] Bjorntorp P. "Abdominal obesity and the metabolic syndrome" *Ann Med* 1992 Dec;24(6):465-8.

[8] Johnson D, Prudhomme D, Despres. "Relation of abdominal obesity to hyperinsulinemia and high blood pressure in men." *Int J Obes* 1992 Nov;16(11):881-90.

[9] Cazzo E, Gallo F, Pareja J, Chaim E. "Nonalcoholic Fatty Liver Disease in Morbidly Obese Subjects" Correlation among Histopathologic Findings, Biochemical Features, and Ultrasound Evaluation" *Obes Surg*. 2014 Apr; 24(4): 666–668. doi: 10.1007/s 11695-014-1183-4.

[10] Tan C. H., et al. "HSCRP as surrogate marker in predicting long term effect of bariatric surgery on resolution of non-alcoholic steatohepatitis," *Asian Journal of Surgery* (2018), https://doi.org/10.1016/j.asjsur.2018.04.010).

[11] Palmentieri B, de Sio I, La Mura V. "The role of bright liver echo pattern on ultrasound B-mode examination in the diagnosis of liver steatosis" *Digestive Liver Diseases* 2006 Jul;38(7):485-9.

[12] Joseph A, Saverymuttu S, al-Sam S. "Comparison of liver histology with ultrasonography in assessing diffuse parenchymal liver disease." *Clinical Radiology* 1991 Jan;43(1):26-31.

[13] Karcaaltincaba M, Akhan O. "Imaging of hepatic steatosis and fatty sparing." *European Journal Radiology* 2007 Jan;61(1):33-43.

[14] Joy D, Thava V, Scott B. "Diagnosis of fatty liver disease: is biopsy necessary?" *European Journal Gastroenterology Hepatology* 2003 May;15(5):539-43.

[15] Duman D, Celikel C, Tuney D. "Computed tomography in nonalcoholic fatty liver disease: a useful tool for hepatosteatosis assessment?" *Dig Dis Sci* 2006 Feb;51(2):346-51.

[16] Hussain H, Chenevert T, Londy F. "Hepatic fat fraction: MR imaging for quantitative measurement and display early experience" *Radiology* 2005 Dec; 237(3):1048-55.

[17] Kim S, Lee J, Han J. "Hepatic macrosteatosis: predicting appropriateness of liver donation by using MR imaging- correlation with histopathologic findings" *Radiology* 2006 Jul;240(1):116-29.

[18] Machann J, Thamer C, Schnoedt B. "Hepatic lipid accumulation in healthy subjects: a comparative study using spectral fat-selective MRI and volume-localized 1H-MR spectroscopy" *Magnetic Resonance Medicine* 2006 Apr;55(4):913-7.

[19] Souto, Katia P. et al. "Nonalcoholic fatty liver disease in patients with different baseline glucose status undergoing bariatric surgery: analysis of intra-operative liver biopsies and literature review" *Surgery for Obesity and Related Diseases*, Volume 14, Issue 1, 66 - 73. DOI: https://doi.org/10.1016/j.soard.2017.09.527.

[20] Mathurin P, Pattou F et al. "Prospective Study of the Long-Term Effects of Bariatric Surgery on Liver Injury in Patients Without Advanced Disease" *Gastroenterology* 2009;137:532–540. DOI: https://doi.org/10.1053/j.gastro.2009.04.052.

[21] Ise, I., Tanaka, N., Imoto, H. et al. *Obesity Surgery* (2019) 29: 1901. DOI https://doi.org/10.1007/s11695-019-03790-y.

[22] Klebanoff, MJ, Corey, KE, Chhatwal, J, Kaplan, LM, Chung, RT, Hur, C. "Bariatric surgery for nonalcoholic steatohepatitis: a clinical and cost-effectiveness analysis" *Hepatology.* 2017; 65(4): 1156- 1164.

[23] Perysinakis, I, Pappis, H.C. & Margaris, E. *Obesity Surgery* (2019) 29: 1058. https://doi.org/10.1007/s11695-019-03705-x.

[24] Angulo P et al. "*The NAFLD Fibrosis Score: A Noninvasive System That Identifies Liver Fibrosis in Patients with NAFLD*" DOI 10.1002/hep.21496.

[25] Wu R, Ortiz J, Dallal R. "Is bariatric surgery safe in cirrhotics?" *Hepat Mon* 2013; 13: e8536 DOI: 10.5812/ hepatmon.8536.

[26] Shimizu H, Phuong V, Maia M, Kroh M, Chand B, Schauer PR, Brethauer SA. "Bariatric surgery in patients with liver cirrhosis." *Surg Obes Relat Dis* 2013; 9: 1-6 [PMID: 23201210 DOI: 10.1016/ j.soard.2012.07.021.

[27] Rebibo L, Gerin O, Verhaeghe P, Dhahri A, Cosse C, Regimbeau JM. "Laparoscopic sleeve gastrectomy in patients with NASH- related cirrhosis: a case-matched study" *Surg Obes Relat Dis* 2014; 10: 405-410; quiz 565 DOI: 10.1016/ j.soard.2013.09.015.

[28] Takata MC, Campos GM, Ciovica R, Rabl C, Rogers SJ, Cello JP, Ascher NL, Posselt AM. "Laparoscopic bariatric surgery improves candidacy in morbidly obese patients awaiting transplantation" *Surg Obes Relat Dis* 2008; 4: 159-164; discussion 164-165 DOI: 10.1016/ j.soard.2007.12.009.

[29] Laursen T, Hagemann C, Wei C, Kazankov K, Thomsen K, Knop F, Grønbæk H. "Bariatric surgery in patients with non-alcoholic fatty liver disease - from pathophysiology to clinical effects" *World J Hepatol.* Feb 27, 2019; 11(2): 138-149. DOI: 10.4254/wjh.v11.i2.138.

[30] Glass LM, Dickson RC, Anderson JC, Suriawinata AA, Putra J, Berk BS, et al. "Total body weight loss of >/ = 10% is associated with improved hepatic fibrosis in patients with nonalcoholic steatohepatitis" *Dig Dis Sci* 2015;60(4):1024–30).

[31] Luo, RB, Suzuki, T, Hooker, JC. et al. "How bariatric surgery affects liver volume and fat density in NAFLD patients" *Surg Endosc* (2018) 32: 1675. https://doi.org/10.1007/ s00464-017-5846-9.

[32] Caiazzo R, Lassailly G, Leteurtre E, Baud G, Verkindt H, Raverdy V, Buob D, Pigeyre M, Mathurin P, Pattou F. "Roux-en-Y gastric bypass versus adjustable gastric banding to reduce nonalcoholic fatty liver disease: a 5-year controlled longitudinal study." *Ann Surg* 2014; 260: 893-898; discussion 898-899.

[33] Taitano AA, Markow M, Finan JE, Wheeler DE, Gonzalvo JP, Murr MM. "Bariatric surgery improves histological features of nonalcoholic fatty liver disease and liver fibrosis." *J Gastrointest Surg* 2015; 19: 429-436).

[34] Lassailly G, Caiazzo R, Buob D, Pigeyre M, Verkindt H, Labreuche J, Raverdy V, Leteurtre E, Dharancy S, Louvet A, Romon M, Duhamel A, Pattou F, Mathurin P, "Bariatric Surgery Reduces Features of Non-alcoholic Steatohepatitis in Morbidly Obese Patients." *Gastroenterology* (2015), doi: 10.1053/j.gastro.2015. 04.014.

[35] Kleiner DE, Brunt EM, Van Natta M, et al. "Design and validation of a histological scoring system for nonalcoholic fatty liver disease" *Hepatology* 2005;41(6):1313–21.

[36] Froylich, Dvir et al. "Effect of Roux-en-Y gastric bypass and sleeve gastrectomy on nonalcoholic fatty liver disease: a comparative study" *Surgery for Obesity and Related Diseases*, Volume 12, Issue 1, 127 – 131.

[37] Giannini, EG, Coppo, C, Romana, C. et al. "Long-Term Follow-Up Study of Liver-Related Outcome After Bilio-Pancreatic Diversion in Patients with Initial, Significant Liver Damage" *Dig Dis Sci* (2018) 63: 1946. https://doi.org/10.1007/s10620-018-5052-1.

[38] Auclair M, Martel G, Lapointe R. "Successful orthotopic liver transplantation after bilio-pancreatic diversion with duodenal switch" *Surg Obes Relat Dis*. 2013;9(3):e46-8.

[39] Baltasar A et al. "Liver failure and transplantation after duodenal switch" *Surg Obes Relat Dis*. 2014;10(6):e93-6.

[40] Baltasar A, Serra C, Pérez N, Bou R, Bengochea M. "Clinical hepatic impairment after the duodenal switch" *Obes Surg*. 2004;14(1):77-83.

[41] Keshishian, K. Zahriya, EB. Willes, "Duodenal switch has no detrimental effects on hepatic function and improves hepatic steatohepatitis after 6 months" *Obes. Surg*. 15 (2005) 1418–1423.

[42] Papadia, F, GM. Marinari, G. Camerini, GF. Adami, F. Murelli, F. Carlini, C. Stabilini, N. Scopinaro, "Short-term liver function after biliopancreatic diversion" *Obes. Surg*. 13 (2003) 752–755.

[43] Baltasar, C. Serra, N. Pérez, R. Bou, M. Bengochea, "Clinical hepatic impairment after the duodenal switch," *Obes. Surg*. 14 (2004) 77–83.

[44] Baltasar, "Liver failure and transplantation after duodenal switch" *Surg. Obes. Relat. Dis*. 10 (2014) e93–e96.

[45] Kirkpatrick V, Moon R, Teixeira A, Jawad M. "Cirrhosis following single anastomosis duodeno-ileal switch: A case report" *International Journal of Surgery Case Reports* Volume 45, 2018, Pages 130-132.

[46] Scopinaro N, Adami GF, Marinari GM, et al. "Biliopancreatic diversion." *World J Surg*. 1998;22(9):936-46.

[47] Quaade F. "Jejunoileal bypass for morbid obesity: A bibliographic study and a randomized clinical trial" *Surg Clin North Am* 1979; 59: 1055-69.

[48] Marubbio AT, Rucher RD, Schneider PD et al. "The liver in morbid obesity and following bypass surgery for obesity" *Surg Clin North Am* 1979; 59: 1079-93.

[49] DiGiorgi M, Rosen DJ, Choi JJ, et al. "Re-emergence of diabetes after gastric bypass in patients with mid- to long-term follow-up" *Surg Obes Relat Dis*. 2010;6(3):249–53).

[50] Jimenez, LS, Mendonça Chaim, FH, Mendonça Chaim, FD. et al. "Impact of Weight Regain on the Evolution of Non-alcoholic Fatty Liver Disease After Roux-en-Y Gastric Bypass/ a 3-Year Follow-up" *Obesity Surgery* (2018) 28: 3131. https://doi.org/10.1007/s11695-018-3286-9.

[51] Burza MA, Romeo S, Kotronen A, et al. *"*Long-term effect of bariatric surgery on liver enzymes in the Swedish Obese Subjects (SOS) study" *PLoS One*. 2013;8(3):e60495.

[52] Chalasani N, Younossi Z, Lavine JE, et al. "The diagnosis and management of nonalcoholic fatty liver disease: practice guidance from the American Association for the Study of Liver Diseases" *Hepatology*. 2018;67:328–57.

[53] European Association for the Study of the L, European Association for the Study of D and European Association for the Study of O. "EASL-EASD-EASO clinical practice

guidelines for the management of non-alcoholic fatty liver disease" *J Hepatol*. 2016;64: 1388–402).

[54] Deitel M. "History of the MGB and OAGB Operations" *International Journal of Surgery* https://doi.org/10.1016/j.ijsu.2019.04.018.

[55] Brown W. *"Mini Gastric Bypass-One Anastomosis Gastric Bypass (MGB-OAGB)-IFSO Position Statement Obesity Surgery"* 2018, Volume 28, Number 5, Page 1188.

[56] Rutledge R, Kular K, Manchanda N. "The Mini-Gastric Bypass Original Technique" *International Journal of Surgery*, https://doi.org/10.1016/j.ijsu.2018.10.042.

[57] Tacchino RM. "Bowel length: measurement, predictors and impact on bariatric and metabolic surgery." *Surg Obes Relat Dis* 2015; 11:328-334.

[58] Magdalena Eilenberg, Felix B. Langer, Andrea Beer, Michael Trauner, Gerhard Prager, Katharina Staufer "Significant Liver-Related Morbidity after Bariatric Surgery and Its Reversal—a Case Series" *Obesity Surgery* (2018) 28:812–819.

[59] Kruschitz R et al. "The Effect of Roux-en-Y vs. Omega-Loop Gastric Bypass on Liver, Metabolic Parameters, and Weight Loss" *Obes Surg* (2016) 26:2204–2212 DOI 10.1007/s11695-016-2083-6.

[60] Spivak, Hadar et al. "Omega-loop gastric bypass is more effective for weight loss but negatively impacts liver enzymes: A registry-based comprehensive first-year analysis" *Surgery for Obesity and Related Diseases*, Volume 14, Issue 2, 175 – 180.

[61] Carbajo M, Luque-de-León E, M. Jiménez J, Ortiz-de-Solórzano J, Perez-Miranda M, Castro Alija, M. (2016). "Laparoscopic One-Anastomosis Gastric Bypass: Technique, Results, and Long-Term Follow-Up in 1200 Patients" *Obesity Surgery*. 27. 10.1007/s11695-016-2428-1.

[62] Carbajo MA, Luque-de-León E. "Laparoscopic one-anastomosis gastric bypass (OAGB): Outcomes with 3000 patients during 15 years (Conference)" *17th Mediterranean & Middle Eastern Endoscopic Surgery Association (MMESA) Congress*. Isfahan (Iran) - October 25th– 27th, 2017.

[63] Kular K, Manchanda N, Rutledge R. "A 6-Year Experience with 1,054 Mini-Gastric Bypasses—First Study from Indian Subcontinent" *Obesity Surgery* (2014) 24:1430–1435 DOI 10.1007/s11695-014-1220-3.

[64] Harshit Garg, Sandeep Aggarwal, Shalimar, Rajni Yadav, Siddhartha Dattagupta, Lokesh Agarwal and Samagra Agarwal, "Utility of Transient Elastography (FibroScan) and Impact of Bariatric Surgery on Non- Alcoholic Fatty Liver Disease (NAFLD) in Morbidly Obese Patients" *Surgery for Obesity and Related Diseases*, http://dx.doi.org/10.1016/j.soard.2017.09.005.

[65] Mahawar, Jacques Himpens, Scott A. Shikor, Jean-Marc Chevallier, Mufazzal Lakdawala, Maurizio De Luca, Rudolf Weiner, Ali Khammas, Kuldeepak Singh Kular, Mario Musella, Gerhard Prager, Mohammad Khalid Mirza, Miguel Carbajo, Lilian Kow, Wei-Jei Lee, Peter K. Small. "The First Consensus Statement on One Anastomosis/Mini Gastric Bypass (OAGB/MGB) Using a Modified Delphi Approach" *Obesity Surgery* https://doi.org/10.1007/s11695-017-3070-2.

[66] Musella et al. "The laparoscopic mini-gastric bypass: the Italian experience: outcomes from 974 consecutive cases in a multicenter review and comorbidities resolution" *Surg Endosc* (2014) 28:156–163 DOI 10.1007/s00464-013-3141-y.

[67] Bruzzi, Matthieu et al. "Single anastomosis or mini-gastric bypass: long-term results and quality of life after a 5-year follow-up" *Surgery for Obesity and Related Diseases*, Volume 11, Issue 2, 321 – 326.

[68] Guenzi, M., Arman, G., Rau, C. et al. "Remission of type 2 diabetes after omega loop gastric bypass for morbid obesity" *Surg Endosc (2015)* 29: 2669. https://doi.org/10.1007/s00464-014-3987-7.

[69] Kular K et al. "Seven Years of Mini-Gastric Bypass in Type II Diabetes Patients with a Body Mass Index <35 kg/m2" *Obesity Surgery* (2015) DOI 10.1007/s11695-015-1941-y.

[70] Apers, J., Wijkmans, R., Totte, E. et al. "Implementation of mini gastric bypass in the Netherlands: early and midterm results from a high-volume unit" *Surg Endosc* (2018) 32: 3949. https://doi.org/10.1007/s00464-018-6136-x.

[71] Georgiadou, Despoina et al. "Efficacy and safety of laparoscopic mini gastric bypass. A systematic review" *Surgery for Obesity and Related Diseases*, Volume 10, Issue 5, 984 – 991.

[72] Pontiroli AE, Laneri M, Veronelli A, et al. "Biliary pancreatic diversion and laparoscopic adjustable gastric banding in morbid obesity: their long-term effects on metabolic syndrome and on cardiovascular parameters" *Cardiovascular Diabetology*. 2009;8:3.

[73] Larrad-Jiménez Á, Sánchez-Cabezudo Díaz-Guerra C, de Cuadros Borrajo P, et al. "Short, mid and long-term results of biliopancreatic diversion" *Obes Surg*. 2007;17(2):202–10.

[74] Theodore K. Alexandrides, George Skroubis, Fotis Kalfarentzos "Resolution of diabetes mellitus and metabolic syndrome following Roux-en-Y gastric bypass and a variant of bilio-pancreatic diversion in patients with morbid obesity" *Obes Surg*. 2007;17(2):176–84.

[75] Owaid M. Almalki, Wei-Jei Lee, Keong Chong, Kong-Han Ser, Yi-Chih Lee and Shu-Chun Chen. "Laparoscopic gastric bypass for the treatment of type 2 diabetes: A comparison of roux-en-Y versus single anastomosis gastric bypass" *Surgery for Obesity and Related Diseases*, doi:10.1016/j.soard.2017.12.022.

[76] Wei-Jei Lee & Keong Chong & Yu-Hung Lin & Jih-Hua Wei & Shu-Chun Chen "Laparoscopic Sleeve Gastrectomy Versus Single Anastomosis (Mini) Gastric Bypass for the Treatment of Type 2 Diabetes Mellitus: 5-Year Results of a Randomized Trial and Study of Incretin Effect" *Obesity Surgery* (2014) 24:1552–1562 DOI 10.1007/s11695-014-1344-5.

[77] Wei-Jei Lee, Po-Jui Yu, Weu Wang, Tai-Chi Chen, Po-Li Wei, Ming-Te Huang. "Laparoscopic Roux-en-Y versus Mini-Gastric Bypass for the Treatment of Morbid Obesity A Prospective Randomized Controlled Clinical Trial" *Annals of Surgery* Volume 242, Number 1, July 2005.

[78] Wang FG, Yu ZP, Yan WM et al. "Comparison of safety and effectiveness between laparoscopic mini-gastric bypass and laparoscopic sleeve gastrectomy: a meta-analysis and systematic review" *Medicine* 2017 Baltimore 96:e8924.

[79] Quan Y, Huang A, Ye M et a. (2015) "Efficacy of laparoscopic mini gastric bypass for obesity and type 2 diabetes mellitus: a systematic review and meta-analysis" *Gastroenterol Res Pract* 2015:152852.

[80] Magouliotis D, Tasiopoulou V, Tzovaras G. "One-Anastomosis Gastric Bypass Versus Sleeve Gastrectomy for Morbid Obesity: a Systematic Review and Meta-analysis)" *Clinical Obesity* 8, 159–169, June 2018. doi: 10.1111/cob.12246.

[81] Ruiz-Tovar, J, Carbajo, MA, Jimenez, JM. et al. "Long-term follow-up after sleeve gastrectomy versus Roux-en-Y gastric bypass versus one-anastomosis gastric bypass: a prospective randomized comparative study of weight loss and remission of comorbidities" *Surg Endosc* (2019) 33: 401. https://doi.org/10.1007/s00464-018-6307-9.

[82] Alkhalifah, N, Lee, WJ, Hai, TC. et al. "15-year experience of laparoscopic single anastomosis (mini-)gastric bypass: comparison with other bariatric procedures" *Surg Endosc* (2018) 32: 3024. https://doi.org/10.1007/s00464-017-6011-1.

[83] Gurvinder S. Jammu, Rajni Sharma. "A 7-Year Clinical Audit of 1107 Cases Comparing Sleeve Gastrectomy, Roux-En-Y Gastric Bypass, and Mini-Gastric Bypass" *Obesity Surgery* DOI 10.1007/ s11695-015-1869-2.

[84] Robert, Maud et al. "Efficacy and safety of one anastomosis gastric bypass versus Roux-en-Y gastric bypass for obesity (YOMEGA): a multicentre, randomised, open-label, non-inferiority trial" *The Lancet*, Volume 393, Issue 10178, 1299 – 1309.

[85] Chevallier, JM, Arman, GA, Guenzi, M. et al. "One Thousand Single Anastomosis (Omega Loop) Gastric Bypasses to Treat Morbid Obesity in a 7-Year Period: Outcomes Show Few Complications and Good Efficacy" *Obes Surg* (2015) 25: 951. https://doi.org/10.1007/s11695-014-1552-z.

[86] Noun, R, Skaff, J, Riachi, E. et al. "One Thousand Consecutive Mini-Gastric Bypass: Short- and Long-term Outcome" *Obes Surg* (2012) 22: 697. https://doi.org/ 10.1007/s11695-012-0618-z.

[87] Musella M, Susa A, Manno E, Luca M, Greco F, Raffaelli, M, Stefano E, Milone M, Bianco P, Vilardi A, Damiano I, Segato G, Pedretti L, Giustacchini P, Fico D, Veroux G, Piazza L. (2017). "Complications Following the Mini/One Anastomosis Gastric Bypass (MGB/OAGB): a Multi-institutional Survey on 2678 Patients with a Mid-term (5 Years) Follow-up" *Obesity surgery*. 27. 10.1007/ s11695-017-2726-2.

[88] Parmar, CD & Mahawar, KK. "One Anastomosis (Mini) Gastric Bypass Is Now an Established Bariatric Procedure: a Systematic Review of 12,807 Patients" *Obes Surg* (2018) 28: 2956. https://doi.org/10.1007/s11695-018-3382-x.

[89] Khalaj, A, Kalantar Motamedi, MA, Mousapour, P. et al. "Protein-Calorie Malnutrition Requiring Revisional Surgery after One-Anastomosis-Mini-Gastric Bypass (OAGB-MGB)/ Case Series from the Tehran Obesity Treatment Study" *Obes Surg* (2019) 29: 1714. https://doi.org/10.1007/s11695-019-03741-7.

[90] Johnson, WH. et al. "Surgical revision of loop ("mini") gastric bypass procedure: multicenter review of complications and conversions to Roux-en-Y gastric bypass" *Surgery for Obesity and Related Diseases* 3 (2007) 37–41.

[91] Motamedi et al. "Biopsy-proven progressive fatty liver disease nine months post mini-gastric bypass surgery/ A case study" *International Journal of Surgery Case Reports* 39 (2017) 168–171.

[92] Mahawar, KK. "Findings of YOMEGA Trial Need to Be Interpreted with Caution" *Obes Surg* (2019). https://doi.org/10.1007/s11695-019-03856-x.

In: Encyclopedia of Surgery (22 Volume Set)
Editors: Andreas Lehrer and Kristin Mueller
ISBN: 978-1-53618-329-0
© 2020 Nova Science Publishers, Inc

Chapter 314

SADI-S: CHARACTERISTICS AND RESULTS OF A NOVEL BARIATRIC SURGERY TECHNIQUE. THE ROLE IN NAFLD AND NASH

Esteban Martin-Antona, MD,
Oscar Cano-Valderrama, MD, PhD,
Ester Martin Garcia-Almenta, MD, PhD,
Miguel Josa, MD, PhD and Antonio J. Torres, MD, PhD
Department of Surgery, Hospital Clinico San Carlos, Madrid, Spain

ABSTRACT

SADI-S is a new bariatric procedure that basically consists of a sleeve gastrectomy with a one-anastomosis biliopancreatic diversion. SADI-S has been developed to simplify biliopancreatic diversion without modifying its effectiveness.

Long-term results of SADI-S are lacking but the early and medium-term results are encouraging. Natural history of Non-alcoholic fatty liver disease after SADIS has not been previously studied. However, due to the good results on metabolic comorbidities remission after SADIS, we believe that SADI-S will probably provoque a high percentage of remission in Non-alcoholic fatty liver disease.

Herein, we present a study about the relationship between obesity in bariatric surgery patients and genes that are related to hepatocellular carcinoma. In the future, we will study the change on these genes after SADI-S.

Keywords: bariactric surgery, morbid obesity, non-alcoholic fatty liver disease, non-alcoholic steatohepatitis, Single Anastomosis Duodeno Ileal Bypass with Sleeve Gastrectomy, SADIS

INTRODUCTION

SADI-S is one of the most recent innovations in bariatric surgery. It represents the continuous research and evolution in this field to find more effective and safer solutions when treating the obesity epidemic and metabolic related diseases. As already occurred with the mini-gastric bypass or one anastomosis gastric bypass, single anastomosis duodenoileal bypass with sleeve gastrectomy is basically a one anastomosis biliopancreatic diversión (BPD)-duodenal switch (DS) procedure and represents another alternative in the armamentarium of the bariatric surgeon. As often occurs with novel procedures, the nomenclature is not yet standardized: it is defined according to different authors as single anastomosis ileal bypass, loop duodenal switch, mini-DS, duodenoenteral omega switch, stomach intestinal pylorus-sparing (SIPS) surgery. With some differences in gastric tube size and intestinal bypass length, the principle is the same: it is less demanding and eliminates the Roux limb and can potentially reduce postoperative complications without losing metabolic effectiveness of the BPD-DS [1, 2].

Malabsorptive bariatric techniques were initially derived from the metabolic outcomes of massive intestinal resection (usually following mesenteric infarction). The first bariatric procedures were the jejuno-ileal bypass and jejuno-colic bypass, techniques which gave good weight loss and improvement/remission of the metabolic conditions accompanying obesity.

Unfortunately, these procedures were associated with severe late nutritional complications that caused them to be abandoned [1, 2]. In an attempt to deal with these nutritional complications, Nicola Scopinaro developed the biliopancreatic diversion with the intention of maintaining malabsorption while avoiding major uncontrolled malabsorption, disruption of the enterohepatic cycle, and the presence of a long blind loop. One of the features of Scopinaro's technique was the concept of "the three limbs": the alimentary limb, biliopancreatic limb and the common channel. Over the years, several different groups have demonstrated different results based on the varying length of these limbs. The Scopinaro procedure was modified in 1988 by Hess et al. into the BPD-DS. It offered two advantages over previous operations: a vertical gastrectomy along the greater curvature to preserve the integrity of the antropyloric region, as well as a modification of the length of the common channel to 100 cm [2].

The major obstacles of BPD-DS are its technical complexity, complication rates, and possibility of long-term nutritional issues. Nevertheless, BPD and BPD-DS are considered among the best options for selected morbidly obese patients with associated diseases.

To simplify such an effective procedure and preserve its principles, the single anastomosis duodenoileal bypass with sleeve gastrectomy (SADI-S) was first described in 2007 by Sánchez-Pernaute and Torres [3]. SADI-S compared with DS eliminates the Roux-en-Y gastric bypass by creating an omega loop, and because of pylorus preservation, bile diversion is unnecessary as the natural barrier remains in place. Preservation of the pylorus provides control of solid stool emptying, reducing the chances of dumping syndrome and assisting in the maintenance of a physiologically based rate of gastric emptying. The immediate benefit is the need for only one anastomosis, thus saving operative time and potentially reducing postoperative complications. Moreover, since it does not require a mesenteric opening, there is a reduced risk of internal hernia. SADI-S is a solution to determining a decrease in the postoperative and nutritional effects of BPD-DS while

maintaining weight and metabolic benefits linked to fundus resection, pylorus preservation, duodenal exclusion, ileal brake effect, and fat malabsorption [2].

It also represents a valid option for revisional surgery after failed sleeve gastrectomy (SG). With SADI, the malabsorptive component is added to an essentially restrictive procedure, as the DS is the natural complement to SG for improving weight loss outcomes and sustainability. Furthermore, it is easier for the surgeon to perform a oneloop duodeno-ileal bypass in "virgin territory." Futhermore, when there is evidence of dilation of the sleeve construction, SADI may also be performed with a concomitant resleeve gastrectomy [2].

Moreover, SADI-S is a versatile procedure. According to patient characteristics and surgeon preference, it can be performed with a narrow gastric pouch and a long common channel (300 or 350 cm) or simply remain a malabsorptive procedure with a short common channel (200 or 250 cm) and a wider gastric pouch. Initially, Sanchez-Pernaute technique consisted a wide sleeve gastrectomy (54 French intragastric bougie) and a one-loop duodenal switch with a 200 cm common channel. This was based on analysis of outcomes of BPD variants. The SADI-S with a 200 cm efferent limb, carried an 8% incidence of clinical malnutrition, and 4% of our patients had to be re-operated to lengthen the common channel. Although these lengthening procedures were considered to be secondary to poor dietary compliance, after this experience they chose to perform a safer procedure by enlarging the common channel to 250 cm.

Standardization of nomenclature and technique, together with further studies with long-term outcomes, are needed to confirm the safety and efficacy of SADI-S in the routine surgical management of the obese population.

RESULTS OF SADI-S. WHAT WE KNOW SO FAR

Since SADI-S is a novel technique in bariatric surgery, having been first described by Sanchez-Pernaute et al. in 2007, there is still some lack of long-term results. However, the literature published about this topic reinforces the idea that SADI-S is a safe and effective technique with a similar efficacy to BPD-DS in weight loss and control of comorbidities such as hypertension, sleep apnea and type 2 diabetes mellitus. While some of the induced physiologic mechanisms of both techniques are overlapping, it is thought that others are different and still not well understood.

The prevalence of Non-Alcoholic Fatty Liver Disease (NAFLD) is rising and is estimated to have doubled in the last 20 years, with rates between 2-44% in the European population and 42,6-69,5% in patients with type 2 diabetes mellitus. Reports suggest that 87-94% of bariatric patients demonstrate abnormal non-alcoholic liver pathology [4]. We know that bariatric surgery is associated with a significant reduction in the incidence of a number of histological features of NAFLD as steatosis, fibrosis, hepatocyte ballooning and lobular inflammation. Also, surgery is associated with reduction in liver enzyme levels (ALT, AST, ALP and gamma-GT) [4, 5].

The group of Sanchez-Pernaute pioneered this technique and published some interesting results [6]. For example, for diabetic obese patients they found remission of T2 DM in 84% of operated patients. They have also observed a significative effect of the lypidic profile, with 89% normalizing tryglicerides, 65% HDL, 79% LDL and 96% normal total cholesterol.

Hypertension remitted in 52% and improved in 44%. Also, hypoalbuminemia was detected in 12%, low vitamin A levels in 53% and high PTH levels in 54%. Moreover, this group has observed that in the mid-term SADI-S is at least as effective as other malabsorptive techniques such as BPD/DS and significatively reduces the four main cardiovascular risk factors to a higher extent than RYGB [7].

Zaveri et al. published in 2018 their mid-term outcomes at 4 years [8]. For 437 patients operated, they observed a complication rate of 7,7%. The T2 DM remission rate was 97,6%, and the EWL% was 85,7+/-27,3%.

Shoar et al. published the most complete systematic review about efficacy and safety in 2017 [9]. It comprehended 12 studies including 581 SADI-S patients, being a primary procedure in 87,4% and a conversion procedure in 12,6%. The EWL% average was 85% at 2 years of follow-up. About co-morbidities, a remission rate was observed in 74,1% for T2 DM; 96,3% for HTN; 68,3% for dyslipemia; 63,3% for sleep apnea and 87,5% for GERD. Proteic malnutrition was observed in 34% of patients.

Moreover, some studies have been published in recent years comparing the results of SADI-S with other techniques of bariatric surgery.

Moon et al. published a retrospective study in 2015 comparing the safety and effectiveness of the single versus double anastomosis duodenal switch [10]. They studied 111 SADI-S and 74 DS, obtaining comparable results in terms of weight loss (44,2% vs 48,4% at 24 months). They also recommended a close nutritional follow-up for both techniques, finding hypovitaminosis D in 40% to 60% of the patients studied.

Other groups as Sessa et al., have compared the effects of glucose tolerance testing between SADI-S and other bariatric procedures [11]. They published in 2019 their conclusions. Not surprisingly, BPD and SADI-S seems to be associated to an improvement of insulin sensitivity and glucose homeostasis. Also, a reduced risk of hyperinsulinemia and hypoglycemia was observed, associated with RYGBP and SG.

Also in 2019, Wang et al. published an interesting study using a mildly obese and diabetic rat model to compare diabetes remission and micronutrient deficiency between SADI-S and RYGBP. They divided 30 rats in three equal groups, performing sham operation, SADI-S and RYGB [12]. The two latter groups achieved almost the same efficacy in caloric restriction and fasting plasma glucose control without excessive weight loss. They also showed comparable effects on insulin sensitivity and β cell function. It was remarkable that only RYGB showed changes in gut hormones and vitamin E deficit. These results suggest that diabetes improvement is reached through overlapping and distinct mechanisms in each technique.

About the different mechanisms of action depending on the surgical techniques, Pereira et al. published a study in 2018 where they compared post-prandial hormone profiles between BPD-DS and SADI-S [13]. Two groups of 9 patients each with no past or current diabetes underwent a liquid mixed-meal tolerance test. It was observed that after SADI-s the post-prandial hormone secretion profile presented increased GLP-1, gucagon and insulin secretion when compared to BPD-DS. The authors think that the higher levels of GLP-1 after SADI-S could be attributed to bile acids interactions across a longer intestinal length (300 cm) than in BPD-DS (100 cm). This could also explain in part the higher insulin secretion. About the glucagon secretion, the mechanisms remain unclear, but it could also be triggered by bile acids stimulation. It is apparent that there are some mechanisms that need further investigation to understand these results.

Finally, it is important to note that even when it is reasonable to expect good results in the evolution of NAFLD/NASH after SADI-S, it has also been described by Kirkpatrick et al. at least one case with liver cirrhosis following SADI-S [14]. It is thought that this could be secondary to bacterial overgrowth, protein malnutrition and mobilization of free fatty acids from adipose tissue that could exceed the capacity of the hepatocytes to metabolize and cause steatosis and oxidative damage. All these mechanisms are not unique after SADI-S and it is important to keep in mind this possibility after surgery.

ANALYSIS OF LIVER GENETIC ALTERATIONS IN PATIENTS SUBMITTED TO SADI-S

NAFLD has been related to hepatocellular carcinoma (HCC) [15]. As a first step to understand how NAFLD can promote HCC and how bariatric surgery and SADI-S can avoid HCC provoqued by NAFLD, we have studied the liver genetic alterations in a cohort of patients submitted to SADI-S [16]. In the future, our aim is to analyze if bariatric surgery is able to reverse these genetic alterations.

MATERIAL AND METHODS

Twenty-six patients who underwent surgery in the Department of Surgery of Hospital Clínico San Carlos in Madrid (Spain) were included in the study. Seven patients were control patients not submited to bariatric surgery and 19 patients had morbid obesity and underwent SADI-S as a bariatric surgery procedure. All patients signed an informed consent before being included in the study.

A liver sample was collected during the surgery in all the patients. Patients were classified according to the histologic severity of NAFLD as normal liver, mild/moderate steatosis, severe steatosis and non-alcoholic steatohepatitis (NASH). All the controls had a normal liver sample, mild/moderate steatosis was diagnosed in 14 patients, severe steatosis in 3 patients and NASH in 2. Due to the low number of patients in the severe steatosis and NASH groups, these patients were excluded and control patients were compared to patients with mild/moderate steatosis.

Liver samples were stored at -80°C. RNA was isolated by spraying 25-30 mg of the sample with NucleoSpin RNA/Protein system (Macherey-Nagel, Oensingen, Switzerland). Complementary DNA (cDNA) was synthesized using 1 µg of RNA. First it was mixed during 5 minutes at 65°C with primer poli dT (Roche, Basel, Switzerland) and dNTP (Invitrogen, Carlsbard, California, USA). Then it was mixed during one hour at 50°C with reverse transcriptase Superscript III RNase H Reverse Transcriptase (Invitrogen, Carlsbard, California, USA), DTT and RNA inhibitor RNAsin (Promega, Madrid, Spain). Finally, to get the quantitative PCR (RT-gPCR) the 799HT Perkin-Elmer Applied Biosystems system was used with Fast Start DNA Master SYBR Green I Kit (Roche, Basel, Switzerland).

To decide which genes would be studied, a pool analysis was performed at the beginning of the study. cDNA of different patients in the same histologic group was mixed. These cDNA were analyzed for 70 genes. Sixteen genes were chosen because the genetic expression

was different in the pooled cDNA from controls and patients with NAFLD. Other 32 genes were chosen after reviewing the published information about this issue. Some of the genes that were finally studied were TGF-B, BMP, IGF2, IGF1, IRS, IR receptor, TGF-A, HGF, Met, IL6, TNF, NADPH. NOX2. Alox5, MMP7, MMP9 and alpha-fetoprotein.

Quantitative variables are expressed as mean (QR). Genetic expression in the control and mild/moderate steatosis was compared using Mann-Whitney U test. Results with a $p < 0.05$ were considered statistically significant.

RESULTS

Table 1. Compares the characteristics of patients in the control and mild/moderate steatosis group

	Control	Mild/moderate steatosis	P
Age (years)	44 (32-55)	51 (41-56)	p > 0.05
Gender (% female patients)	71%	53%	p > 0.05
Weight (kg)	122 (92-144)	126 (105-140)	p > 0.05
Body Mass Index (kg/m^2)	42 (35-42)	44 (43-51)	p > 0.05
Glucose (mg/dL)	98 (89-172)	125 (100-147)	p > 0.05
Cholesterol (mg/dL)	209 (165-237)	185 (164-198)	p > 0.05
HDL (mg/dL)	60 (57-63)	48 (41-55)	0.011
LDL (mg/dL)	133 (84-182)	101 (82-126)	p > 0.05
Triglycerides (mg/dL)	93 (73-155)	143 (107-179)	p > 0.05
AST (IU/L)	16 (12-22)	15 (25-42)	p > 0.05
ALT (IU/L)	14 (13-25)	25 (20-30)	0.045
GGT (IU/L)	18 (15-21)	26 (23-50)	p > 0.05
FIB4 Score	0.84 (0.39-1.13)	0.81 (0.66-1.15)	p > 0.05

DISCUSSION

TGF-B2 gene expression was higher in the steatosis group than in the control group. This finding is interesting, as TGF-B genes have been related to fibrotic changes. In fact, TGF-B1 is known to have a central role in the development of liver firosis [17]. Also TGF-B2 is known to be an important fibrotic factor [18]. This increase in TGF-B2 is related to a decrease in its type 1 receptor (TGF-BR1 = ALK5). This finding has also been found in HCC cells [19]. Another change related to TGF-B family is the increase in Inhibin subunit beta A (InhBA). InhBA increase has been found in fibrotic and chirrhotic livers from rats [20].

Follistatin (FST344), which is also related to TGF-B family, is another gene that was found to be increased in patients with mild/moderate steatosis. FST344 has been found to be increased in patients with liver carcinoma and is related to clinical characteristics of bad prognosis and a higher tumoral size in patients with HCC [21-23].

Another interesting finding was the increase of genes that have classically been associated with HCC, such as IGF2 [24] or AFP. Also, genes that have recently been related to HCC, such as AREG and CK18, were increased in patients with mild/moderate esteatosis.

Insulin receptor (IRS2) which has also been related to liver tumors [25] was elevated in the study group. Genes related to metastasis, such as MMP7 and VEGFB were also increased [26].

Table 2. Comparison of genetic expression in control and mild/moderate stestosis group

Genes	p
ADIPOR2	0.028
TNFA	0.05
MMPT	0.046
KRT18	0.045
FST	0.028
TGF-B2	0.03
TGF-BR1	0.038
INHBA	0.044
INSR	0.024
IRS2	0.021
IGF2	0.011
VEGFB	0.029
IRF2	0.039
AFP	0.013
AFM	0.033

Finally, ADIPOR2, the adiponectin receptor gene expression, was also increased. Adiponectin is a cytokine secreted by adipose tissue that regulates glycemic and lipid metabolism. This protein has been related to metabolic disorders of the liver [27].

CONCLUSION

In summary, after studying the liver samples from patients submitted to SADI-S with mild or moderate steatosis we have found an increase in the expression of several genes that could be related to HCC development. In the future, we will study if these changes are reversible. Our aim is to collect liver samples after the surgery to analyze if the genetic alterations disappear with the bariatric surgery.

REFERENCES

[1] Angrisani L. Single Anastomosis Duodenoileal Bypass with Sleeve Gastrectomy. In: Angrisani L. *Updates in Surgery*. Bariatric and Metabolic Surgery. Indications, Complications and Revisional Procedures. Springer-Verlag, 2017: pp 107-115. ISBN 978-88-470-3944-5.

[2] Sánchez-Pernaute A. Single-Anastomosis Duodeno-Ileal Bypass with Sleeve Gastrectomy (SADI-S) Surgery. In: Agrawal S. Obesity, *bariatric and metabolic surgery*. Springer, 2016: pp 463-467. ISBN 978-3-319-04343-2.

[3] Sánchez-Pernaute A, Rubio Herrera MA, Pérez-Aguirre E, et al. Proximal duodenal-ileal end-to-side bypass with sleeve gastrectomy: proposed technique. *Obes. Surg.* 2007; 17:1614-1618.

[4] Bower, G, et al. Bariatric Surgery and Non-Alcoholic Fatty Liver Disease: a Systematic Review of Liver Biochemistry and Histology. *Obes. Surg*. 2015; 25: 2280-2289.

[5] Shouhed, D, et al. The role of bariatric surgery in nonalcoholic fatty liver disease and nonalcoholic steatohepatitis. *Expert Rev. Gastroenterol. Hepatol.* 2017; 11: 797-811.

[6] Sanchez-Pernaute A, et al. Single Anastomosis Duodeno-Ileal Bypass with Sleeve Gastrectomy (SADI-S). One to Three Year Follow-up. *Obes. Surg*. 2010; 20:1720-1726.

[7] Torres A, et al. Cardiovascular risk factors after single anastomosis duodeno-ileal bypass with sleeve gastrectomy (SADI-S): a new effective therapeutic approach? *Curr. Atheroscler. Rep*. 2017; 19:58.

[8] Zaveri H, et al. Mid-term 4-year outcomes with single anastomosis duodenal-ileal bypass with sleeve gastrectomy surgery at a single US center. Zaveri, H, et al. *Obesity Surgery* 2018; 28: 3062-3072.

[9] Shoar S, et al. Single Anastomosis Duodeno-Ileal Switch (SADI-S): a systematic review of efficacy and safety. *Obes. Surg*. 2017; 27: 3110-3117.

[10] Moon RC, et al. Safety and effectiveness of single- versus double-anastomosis duodenal switch at a single institution. *Surg. Obes. Relat. Dis.* 2019; 15: 245-252.

[11] Sessa L, et al. Effect of single anastomosis duodenal-ileal bypass with sleeve gastrectomy on glucose tolerance test: comparison with other bariatric procedures. *Surg. Obes. Relat. Dis.* 2019; in press. doi: 10.1016/j.soard.2019.04.013.

[12] Wang T, et al. Comparison of diabetes remission and micronutrient deficiency in a mildly obese diabetic rat model undergoing SADI-S versus RYGB. *Obes. Surg.* 2019; 29: 1174-84.

[13] Pereira S, et al. Biliopancreatic diversion with duodenal switch (BPD-DS) and single anastomosis duodeno-ileal bypass with sleeve gastrectomy (SADI-S) result in distinct post-prandial hormone profiles. *Int. J. Obes*. 2019; in press. doi: 10.1038/s41366-018-0282-z.

[14] Kirkpatrick V, et al. Cirrhosis following single anastomosis duodeno-ileal switch: a case report. *Int. J. Surg. Case Rep*. 2018; 45: 130-132.

[15] Charrez B, Qiao L, Hebbard B. Hepatocellular carcinoma and non-alcoholic steatohepatitis: the state of the play. *World J. Gastroenterol.* 2016; 28: 2494-2502.

[16] Martinez J, Miguel B, Galocha G, et al. La expresion de los genes relacionados con el carcinoma hepatoeclular en pacientes obesos con enfermedad hepatica grasa no alcohólica. [The expression of the genes related to hepatoeclular carcinoma in obese patients with non-alcoholic fatty liver disease] *Cir. Esp*. 2017; 95: 180.

[17] Dooley S, ten Dijke P. TGF-B in progression of liver disease. *Cell Tissue Res.* 2012. 347: 245-256.

[18] Latasa MU, Gil-Puig C, Fernández-Barrena MG, et al. Oral methylthioadenosine administration attenueates fibrosis and chronic liver disease progression in MDR2-/- mice. *PLoS One*. 2010; 5: e15690.

[19] Mu X, Lin S, Yang J, et al. TGF-G signaling is often attenuated during hepatotumorigenesis, but is retained for the malignancy of hepatocellular carcinoma cells. *PLoS One.* 2013; 8: e63436.

[20] Deli A, Kreidl E, Santifaller, et al. Activins and activin antagonists in hepatocellular carcinoma. *World J. Gastroenterol*. 2008; 14: 1699-1709.

[21] Miyahara K, Nouso K, Morimoto Y, et al. Pro-angiogenic cytokines for prediction of outcomes in patients with advanced hepatocellular carcinoma. *Br. J. Cancer*. 2013; 109: 2072-2078.

[22] Tomoda T, Nouso K, Miyahara K, et al. Prognostic impact of serum follistatin in patients with hepatocellular carcinoma. *J. Gastroenterol. Hepatol*. 2013; 28: 1391-1396.

[23] Hedger MP, Kretser DM. The activins and their binding protein, follistatin. Diagnostic and therapeutic targets in inmlamatory disease and fibrosis. *Cytokine Growth Factor Rev*. 2013; 24: 285-295.

[24] Chun YS, Huang M, Rink L, et al. Expression levels of insulin-like growth factors and receptors in hepatocellular carcinoma: a retrospective study. *World J. Surg. Oncol*. 2014; 12: 231.

[25] Chettouh H, Fartoux L, Aoudjehane L, et al. Mitogenic insulin receptor-A is overexpressed in human hepatocellular carcinoma due to EGFR-mediated dysregulation of RNA splicing factors. *Cancer Res*. 2013; 73: 3974-3986.

[26] Kanda M, Nomoto S, Nishikawa Y, et al. Correlations of the expression of Vascular Endothelial Growth Factor B and its isoforms in hepatocellular carcinoma with clino-pathological parameters. *J. Surg. Oncol*. 2008; 98: 190-196.

[27] Silva TE, Colombo G, Schiavon LL, et al. Adiponectin: A multitasking player in the field of liver diseases. *Diabetes Metabol*. 2014; 40: 95-107.

In: Encyclopedia of Surgery (22 Volume Set)
Editors: Andreas Lehrer and Kristin Mueller
ISBN: 978-1-53618-329-0
© 2020 Nova Science Publishers, Inc

Chapter 315

SIMULTANEOUS LIVER TRANSPLANTATION AND BARIATRIC SURGERY

David Calatayud*[*], *Eva María Montalvá, Javier Maupoey, Andrea Boscá and Rafael López-Andújar
Division of Hepatobiliopancreatic Surgery and Transplants,
Department of Surgery, Hospital Universitari i Politècnic La Fe, Valencia, Spain

ABSTRACT

Combining liver transplant and bariatric surgery at the same time (simultaneous surgery) represents a therapeutical option that can improve, in rapid ways, the basal conditions of NASH and obesity, trying to reduce, in a significant manner, the negative elements attributed to both chronic-inflammatory diseases. Simultaneous surgery can ameliorate some complication intrinsics to transplant surgery, such as rejection, infection, or disease recurrence due to the steatosis. The main disadvantage of simultaneous surgery is the potential to duplicate or potentiate the complications, such as the infections due to leaks in the hepatic or gastric surgical area. Similarly, simultaneous surgery is an aggressive procedure where the patients must adapt to important changes that result from the addition of these two major techniques. In fact, patients undergoing liver transplantation have to modify their diet, especially in the first few months following surgery, and at the same time they must learn to use the new therapeutic arsenal that must be maintained life-long in order to avoid rejection of the new organ. Currently, few quality studies can recommend liver transplantation simultaneously to bariatric surgery. In this sense, it is evident that specialists in hepatology and obesity have to work as a team to develop prospective randomized studies and lay the foundations for this therapeutic option.

Keywords: NAFLD, NASH, liver transplantation, cirrhosis, immunosuppression

[*] Corresponding Author's Email: davidcalatayud1975@gmail.com.

INTRODUCTION

At present, obesity is a worldwide epidemy. It is defined as a Body Mass Index (BMI) over 30 kg/m^2. In 2005, nearly a quarter of the world's adult population was overweighted (BMI $\geq$ 25 kg/m^2), and approximately 10% of the population was obese [1]. By 2030, it is estimated that the projected burden of obesity will reach 2.16 billion overweighted and 1.12 billion obese individuals, representing 38% and 20% of the world's adult population, respectively [1]. Over the last decades the prevalence has been increasing mostly in Occidental countries, despite growing recognition of its harms and social preventive health programs [2, 3]. In 2014, it was estimated that 35% of men and over 40% of women were obese. By 2030, an estimation suggests more than half of the U.S. population will have a BMI $\geq$ 30 kg/m^2 [1, 2, 4].

In 2018 a consensus document from the First Spanish NAFLD meeting in Seville was published, entitled "Management of non-alcoholic fatty liver disease (NAFLD)". The result was a Clinical practice guideline [5], with some interesting data.

Non-alcoholic fatty liver disease (NAFLD) has become the most frequent cause of chronic liver disease in children and adults. NAFLD is associated with the global epidemy of obesity and metabolic syndrome [6-8], and is a growing cause of advanced liver disease [9, 10]. In the next few years, NAFLD and alcoholic liver disease will become the most prevalent causes of chronic liver disease in our countries.

The prevalence of NAFLD increases in parallel to the prevalence of metabolic syndrome and its components, especially obesity and diabetes mellitus (DM) [11-12].

Among patients with DM, the prevalence of NAFLD is estimated at 40 - 70%, and the prevalence of NASH is around 22% [13].

In the United States, cirrhosis due to non-alcoholic steatohepatitis (NASH) has become the second most common indication for the inclusion in the waiting list, and the third indication for liver transplantation (LT) [14-21]. This same trend is observed in the transplantation registries of other countries.

These patients usually have obesity-related comorbidities with an increased the risk of cardiovascular (CV) disease [14-22].

NASH will become the main indication for liver transplantation in the next decade. In patients with obesity and NAFLD who require transplantation, the indication is typically for decompensated liver disease [7]. Weight loss has been shown to decrease the progression of NAFLD [23]. Weight loss can result in improvements in liver fibrosis and hepatic steatosis [24].

Diet and exercise are the medical weight loss options, but the weight reduction obtained is around 10%.

Bariatric surgery (BS) is not usually performed in patients with cirrhosis; but several studies have shown its safety in patients with non-cirrhotic NAFLD and even NASH [25, 26]. In addition, it has been demonstrated that there is a significant improvement in both fibrosis and steatosis, with regression of fibrosis in 75% of patients and resolution of steatosis in 84% of patients two years after BS [27].

There are different techniques of bariatric surgery, although the most frequently performed are Roux-en-Y gastric bypass (RYGB) and sleeve gastrectomy (SG).

RYGB is considered by many authors the gold standard bariatric surgical procedure, but in comparison with other surgical approaches it has a higher risk of complications [28]. This is important when operating on a population of patients that have an inherently higher morbidity surrounding any surgical intervention. In addition, in the context of LT, the malabsorptive component of RYGB surgery may cause alterations in immunosuppression absorption [29], a situation that does not occur when an SG is performed [30].

The indications for bariatric surgery in the general population are: a BMI $\geq$ 35kg/m^2 with obesity-related comorbidities, or a BMI $\geq$ 40kg/m^2 [31]. But in the patient with advanced liver disease or who has already undergone a liver transplant, careful consideration is required.

The timing of surgery continues to be a debate: previous to LT, simultaneous with LT, or delayed after LT.

INTERNATIONAL LIVER TRANSPLANTATION SOCIETY (ILTS) AND OBESITY CONSENSUS

Recently, the International Liver Transplantation Society (ITLS) convened a consensus conference in Venice in 2018, with a global panel of expert hepatologists and transplant surgeons, to develop guidelines on key aspects of NASH in relation to liver transplantation [32].

Some questions were addressed through the critical review of the literature in different working groups to achieve a global consensus through some statements.

Below are the highlights, to focus next on the surgical aspect.

1. *Are the results of liver transplantation different in obese patients?*
   The outcome of LT in patients with NASH-related cirrhosis with or without hepatocellular carcinoma does not differ from that of other liver transplant etiologies as posttransplant survival is similar [14-22, 33-37].
2. *Concerning the natural history of cirrhotic patients on end-stage liver disease, is it different in NASH-related form other etiologies?*
   Patients with NASH-related cirrhosis have increased CV morbidity and mortality compared to patients with cirrhosis of other etiologies. Patients with NASH cirrhosis have lower mortality rates in the compensated state (Child Pugh A) but similar mortality in the decompensated state (Child Pugh B and C) compared to HCV-related cirrhosis [38-43].
3. *Should this increased CV risk be assessed differently in the transplant-listing evaluation?*
   It is described and demonstrated that liver transplant candidates with NASH should be considered at high risk of developing CV events before and after transplantation. The resulting accumulation of CV risk factors should be carefully evaluated by a multidisciplinary team (including a cardiologist and an anesthesiologist at least). The approach to the pre-LT CV assessment will be the same as other etiologies [21-22, 34, 44-53]. There is not enough evidence to recommend a specific CV risk algorithm for NASH patients undergoing LT evaluation. The stress tests should be of interest.

4. *Is it recommended a particular management of comorbidities in the obese candidate for LT?*

A multidisciplinary approach is always recommended to establish a risk minimization plan, with an appropriate screening for hypertension, diabetes, and dyslipidemia. Medical optimization in NASH-patients with indication for LT is strongly recommended [54-61].

5. *What therapeutic strategies are recommended on the NASH patient in the waiting list for LT?*

Cardioselective beta-blockers and statins can be considered in patients with Child A-B NASH-related cirrhosis and CV comorbidities [62-67].

Moderate exercise is recommended with the double objective of losing weight and improving muscle mass. Prehabilitation programs are increasing in different centers, based on the impact on postoperative recovery and morbimortality [68-72].

6. *Can obesity contraindicate LT?*

Class I-III obesity alone is not a contraindication for liver transplantation. However, in the presence of medical comorbidities, particularly concurrent diabetes, rigorous patient selection is strongly recommended [73-84].

Most studies investigating the effect of obesity on posttransplant survival have reported similar posttransplant patient survival across all BMI categories in the absence of concurrent comorbidities.

But most of these studies have limitations regarding DM-specific data, ascites status for corrected BMI, etc. In addition, most studies are retrospective and/or include an unmatched patient population.

Optimal control of comorbidities such as obesity and diabetes before transplantation is difficult with medical treatment. Bariatric surgery should be considered as a good tool to achieve these targets.

7. *Bariatric surgery in obese candidate for LT: What type of BS is the most appropriate? When is the optimal timing for bariatric surgery: before, during or after liver transplantation?*

We will focus this chapter on these questions, with a small review on bariatric surgery.

BARIATRIC SURGERY IN THE SETTING OF LIVER TRANSPLANTATION

Bariatric surgery is a safe and effective treatment for severe obesity. There are many randomized controlled trials and cohort studies that demonstrates this [85-90]. BS has a beneficial long-term impact on the risk of mortality [91-93].

After BS, obesity comorbidities such as diabetes and metabolic syndrome, are often improved or resolved [85, 89].

RYGB (Figure 1A) was traditionally considered the “gold standard” surgical approach because of its short-term weight loss results and its long-term durability. Until 2014, 79.5% of bariatric cases were RYGB [94].

Gastric banding (GB) use is decreasing because of its modest weight loss and poor long-term weight loss durability [95].

The use of SG (Figure 1B) has increased significantly due to lower complication rates with comparable weight loss and resolution of obesity associated conditions [96].

Type of Bariatric Surgery

BS in the context of transplantation has some special considerations.
We only compared SG to RYGB.

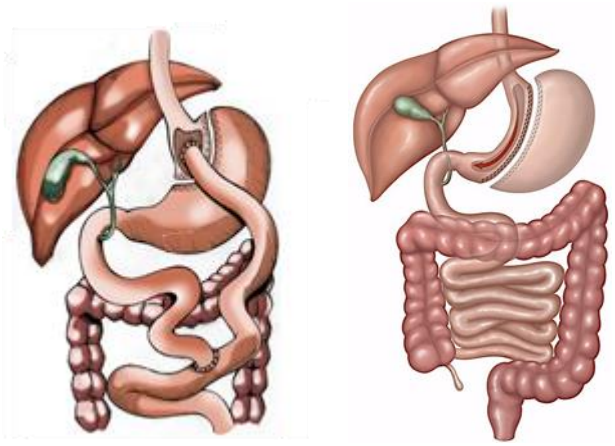

A. Roux-en-Y gastric bypass B. Sleeve gastrectomy

Figure 1. A) Roux-en-Y gastric bypass is a mixed bariatric surgical procedure: restrictive and malabsorptive. B) Sleeve Gastrectomy is a restrictive bariatric surgical procedure, with no malabsorptive component.

Efficacy of GB is limited to case reports. Disadvantages include placement of a foreign body in an immunosuppressed patient with a risk of gastric wall erosion and relative difficulty to endoscopic access if needed.

In many studies, the most common procedure has been SG, up to 100% in some series [97-101]. There are some advantages compared to RYGB:

- technical surgical advantages: minimal additional operative time and no intestinal anastomosis
- postoperative immunosuppression (IS) therapy: it does maintain adequate immunosuppression levels without altering the absorption of medications
- endoscopic procedures: allows endoscopic access to the biliary system for management of posttransplant biliary complications.
- inaccessibility of the gastric remnant if variceal bleeding were to develop when RYGB is performed

Previous reported series have demonstrated steady and gradual EWL% (percentage of excess weight loss) in SG procedure. Takata et al. included both RYGB and SG procedures, SG reported acceptable EWL% (25 - 75%) but lower compared to RYGB [102].

NASH patients constitute a group of increasing LT candidacy. In these patients with metabolic syndrome and other obese-related comorbidities, bariatric prior to transplant or simultaneous LT and BS combined approach might be reasonable in order to have an impact on these risk factors. This should improve both pre and posttransplant outcome.

From Mayo Clinic group in Rochester, one prospective study comparing LT alone to LT-SG demonstrated that the LT + SG group maintained a significantly higher percentage of total body weight loss after 3 years of follow-up. They also had a lower prevalence of hypertension, insulin resistance, and hepatic steatosis and required fewer antihypertensive medications and lipid agents at last follow-up [103].

TIMING OF BARIATRIC SURGERY

Bariatric Surgery before Liver Transplantation

BS in NASH and NAFLD patients has been shown to be effective in both weight loss and improvement in liver pathology [26-27].

In the cirrhotic patients that we find in this group, factors as platelet count, INR, bilirubin, and MELD score can impact on outcomes during BS, with an increased risk and severity of postoperative complications.

Appropriate patient selection may allow pre-LT patients to undergo SG safely. Obesity in LT patients do not increase mortality or worsens graft survival [73]. But, a lower BMI at the time of LT could decrease the risk of wound complications in the short-term and recurrent NASH in the long term [104].

BS before LT seems appropriate for patients with low-MELD score. Particularly with low or no portal hypertension to reduce post-BS morbidity and mortality. This will potentially improve the outcome of LT. Takata and Lin [102, 105] reported significant improvement in metabolic comorbidities, but rates of postoperative complications were significantly higher compared to the general population. But complication rates up to 35% were reported in patients incidentally diagnosed with cirrhosis after BS [106]. This timing could be a good option in low-MELD score patients without portal hypertension.

Simultaneous Liver Transplantation and BS

In 2013, Mayo Clinic published a prospective series of patients who underwent combined LT and SG [107]. In 2018, Mayo Clinic updated their prior experience on long term outcomes [103].

Patients enlisted in the study were all adult patients listed for LT since 2006 with BMI > 35 kg/m^2 (corrected for ascites). These patients were enrolled in an aggressive weight management protocol consisting on dietary education provided by an experienced transplant dietician in subsequent visits until transplantation or achievement of goal weight.

Patients were also evaluated by the same transplant surgeon at the initial and at each subsequent visit to assign a specific weight loss goal (generally BMI < 35 kg/m^2), to further emphasize the long-term benefits of weight loss and to assess progress with weight loss.

Patients were asked to:

1. follow a calorie restricted diet, generally 1200 – 1400 kcal for women and 1400 – 1600 kcal for men,
2. keep an intake record including type, amount and calorie total and bring record to follow-up visits,
3. weigh and record at least once per week and
4. gradually increase activity to 30 – 40 minutes/day, which could be achieved in multiple segments through the day, with walking being the primary recommendation, modified based upon specific patient limitations.

Patients with severe obesity who were unsuccessful with achievement of pretransplant target weight (BMI < 35 kg/m2) who also had a MELD score high enough to allow them to proceed to transplantation underwent a combined liver transplant plus sleeve gastrectomy (LT-SG).

These patients were assessed by the bariatric surgery team and completed the standard bariatric surgery education. All seven LT-SG were performed using deceased donors, with a caval sparing hepatectomy and a duct to duct biliary anastomosis. The SG was performed by an experienced bariatric surgeon following completion of the LT utilizing a 9 mm endoscope placed along the lesser curve of the stomach. A combination of 45-mm 4.8 and 60-mm 3.5 Endo-GIA staple loads were used to resect the antrum and greater curve. Care was taken to leave a small amount of cardia in place in order to avoid injury to the esophagus. The staple line was oversewn using a running 3–0 PDS suture and directly visualized from the lumen of the stomach to ensure hemostasis upon completion, utilizing the previously placed endoscope.

Post-LT management included follow-up visits with the dietician, being counseled on a low-calorie diet plus exercise. Those who underwent combined LT plus SG were seen by the dietician and the bariatric surgery team (surgery, endocrinology and psychology), with the appropriate diet and standard of care in these patients,

In the first report in 2013, obese patients who were unsuccessful with a non-invasive weight loss protocol prior to LT were offered a SG simultaneous with LT (LT-SG) (n = 7). This LT-SG group was compared to a group of obese patients who achieved weight loss via a noninvasive pre-LT weight loss program and underwent LT alone (n = 30). LT-SG group had a MELD of 32 (range 11-40) at time of procedure and 4 out of 7 had NASH as etiology of cirrhosis. Mean operative time was increased by 38 minutes in the LT-SG group and no intraoperative complications were observed. As compared to the non-invasive obesity management, combined LT-SG demonstrated higher resolution of diabetes (100% vs 65,7%) and lower BMI at last follow-up (29 kg/m^2 vs 36 kg/m^2). Two post-operative complications (28.5%) were related to the SG: one staple line leak and one patient with excess weight loss. Heimbach et al. conclude that LT-SG is technically feasible, although not without risk [107].

There are two additional case series/reports of LT-SG from Italy and Israel with similar results: considerable weight loss and no significant perioperative complications [108-109]. But these two articles have two important shortcomings: a short follow-up and a small sample size.

The 2018 publication of the Mayo Clinic provided an update on long-term outcomes for patients who were already enrolled in the 2013 study, plus new recruited patients thereafter [103].

The methodology used with respect to the inclusion criteria was the same as before, but the prevalence of NASH-related cirrhosis is growing over the years. Despite this increasing prevalence, in the US these patients are less likely to be placed on the waitlist, and exhibit higher waitlist mortality, demonstrating that obese patients are disadvantaged on the transplant waiting list [110]. Even that recent reports have noted no difference in patient or graft survival for these patients [73, 75, 111-113]. From the previous Mayo Clinic report in 2013, the aim of this 2018 update was to describe longer-term outcomes, including the dynamics of weight, impact on metabolic outcomes, and quality of life, among these patients after a mean follow-up of 5 ± 2.4 years. They have also provided perioperative and short-term outcomes for the entire cohort of LT + SG patients.

Only patients who were at least 3 years follow-up posttransplantation were included in the long-term outcome analysis. Weight and BMI changes were assessed using the percentage of total body weight loss (%TBWL), frequency of a 10% total body weight loss, and the percentage of excess BMI loss (%EBMIL; where BMI = 25 is the normal value). At last follow-up, Adult Treatment Panel (ATP) III criteria was used to assess for metabolic syndrome [114].

It was also updated the evaluation of diabetes (serum determinations of insulin, Homeostasis model assessment index for insulin resistance (HOMA-IR) [115] was calculated and Hemoglobin A1c (HbA1c) was documented [116].

Hepatic steatosis, defined by ultrasound, computed tomography or biopsy, was also evaluated.

And the questionnaire SF-12 version 2 was used to assess quality of life among patients through a phone interview.

There were 74 patients enrolled with 45 undergoing LT alone and 29 undergoing a combined LT + SG. The mean BMI at the time of transplant for the LT-SG group was 47 kg/m^2 (mean weight at LT of 135 kg) with a reduction in BMI to 31 kg/m^2 at last follow-up.

The complication rates were the same as in the previous study. Complications related to SG included one staple line leak, one excess weight loss (stabilized), and two reflux that stabilized at last follow up.

In order to determine the long-term impact of this protocol, only patients with at least 3 years of posttransplant follow-up are included. At three years follow up, LT-SG patients maintained a significantly higher percentage of total body weight loss (%TBWL) when compared to obese LT patients with no combined procedure (LT 3.9 ± 13.3% vs LT-SG 34.8 ± 17.3%; $p < 0.001$) (Table 1).

Overall, there was no significant difference observed in the LT alone group between the BMI at listing and the BMI at 3 years (40.06 ± 2.99 vs. 38.53 ± 6.53; difference – 1.52 ± 5.46; $P = 0.138$) (Figure 2).

In reference to the metabolic syndrome, as shown in Table 2, patients in the LT-SG group had at long term a lower prevalence of hypertension, insulin resistance and hepatic steatosis, and required fewer lipid agents at last follow-up.

In summary, LT-SG group have more effective and more durable weight loss as well as fewer metabolic complications at last follow up when compared to medical weight loss interventions combined with LT.

Table 1. Bariatric parameters and weight dynamics post-surgery

SEBMI	Listing	Transplant	4 months	1 year	2 years	3 years
Weight						
LT	116.4 ± 15.4	95.4 ± 15.0	91.7 ± 16.3	102.2 ± 21.4	111.4 ± 21.1	109.0 ± 18.7
LT + SG	141.6 ± 23.5	128.5 ± 22.8	98.7 ± 18.4	88.6 ± 13.8	90.9 ± 15.3	94.5 ± 25.6
p value	0.002	< 0.001	0.238	0.014	0.003	0.146
%EBWL						
LT	Baseline	17.7 ± 10.5	20.9 ± 11.7	12.1 ± 14.9	4.0 ± 14.5	3.9 ± 13.3
LT + SG		9.1 ± 7.6	29.6 ± 12.3	36.3 ± 12.0	34.4 ± 12.2	34.8 ± 17.3
p value		0.004	0.038	< 0.001	< 0.001	< 0.001
Total body WL > 10%						
LT	Baseline	83.3%	75%	55.6%	29.4%	26,7%
LT + SG		30.8%	84,6%	100%	100%	100%
p value		0.001	0.703	0.004	< 0.001	< 0.001
BMI						
LT	40.0 ± 2.9	32.7 ± 3.7	31.5 ± 5.0	35.1 ± 6.4	38.3 ± 6.8	38.5 ± 6.5
LT + SG	47.8 ± 4.5	43.4 ± 5.6	33.6 ± 6.6	30.3 ± 6.1	31.5 ± 5.7	30.9 ± 13.2
p value	< 0.001	< 0.001	0.324	0.027	0.005	0.130
%EBIL						
LT	Baseline	46.7 ± 28.0	56.4 ± 31.0	32.2 ± 40.4	11.0 ± 39.0	11.0 ± 35.2
LT + SG		19.4 ± 15.3	63.4 ± 27.2	77.0 ± 25.4	72.2 ± 24.1	82.9 ± 70.0
p value		< 0.001	0.455	< 0.001	< 0.001	0.015

Adapted from: Zamora-Valdes D, Watt KD, Todd AK, et al. Long-Term Outcomes of Patients Undergoing Simultaneous Liver Transplantation and Sleeve Gastrectomy. Hepatology. 2018; 68(2): 485–95.

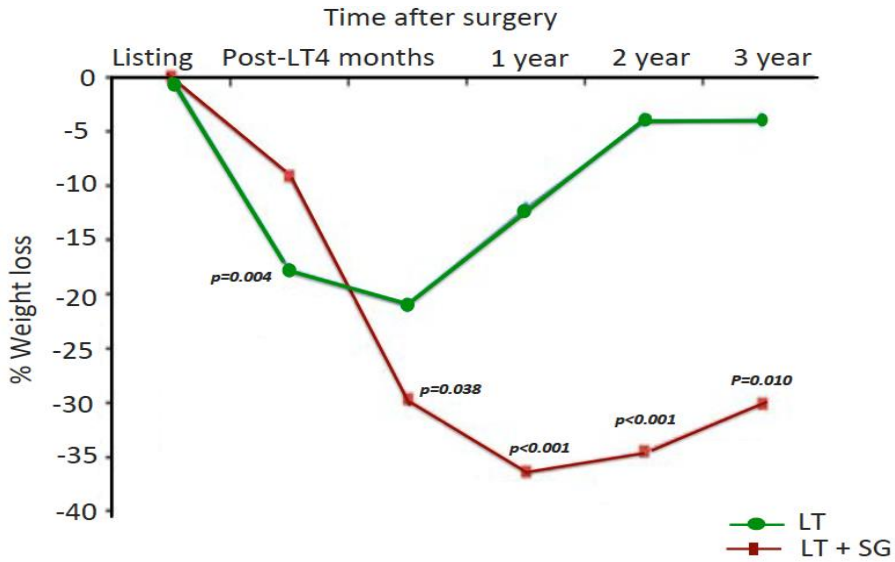

Adapted from: Zamora-Valdes D, Watt KD, Todd AK, et al. Long-Term Outcomes of Patients Undergoing Simultaneous Liver Transplantation and Sleeve Gastrectomy. Hepatology. 2018; 68(2): 485–95.

Figure 2. Percentage of total body weight loss among patients who underwent medical therapy followed by LT and those who underwent LT + SG at listing, transplant, 4 months, 1, 2, and 3 years.

Table 2. Obesity-related Comorbidies at last Follow-up Post-LT

Variable	LT cohort	LT + SG Cohort	p value
Diabetes Mellitus	58.3%	30.8%	0.114
# medication	0.5 ± 0.8	0.3 ± 0.9	0.517
Hypertension	63.9%	23.1%	0.021
# medications	1.0 ± 1.0	0.3 ± 0.7	0.023
Dyslipemia	69.4%	53.8%	0.178
# medications	0.4 ± 0.6	0.1 ± 0.2	0.01
MetS	52.8%	23.1%	0.104
# criteria	2.83 ± 1.0	1.9 ± 0.9	0.008
HS	66.7%	23.1%	0.01

Adapted from: Zamora-Valdes D, Watt KD, Todd AK, et al. Long-Term Outcomes of Patients Undergoing Simultaneous Liver Transplantation and Sleeve Gastrectomy. Hepatology. 2018; 68(2): 485–95.

About the Quality of Life questionnaire, it was a lack of reply, with an overall response rate of 57%. The results of the SF-12 questionnaire showed no significant differences between the two cohorts in any of the categories available.

Bariatric Surgery after Liver Transplantation

This option could be considered since weight loss decreases the risk of recurrent steatosis in the liver graft.

There are few case series with small sample size with a retrospective approach [117-121]. It has been reported a good %EWL and improvement in obesity comorbidities.

Surgeons usually find adhesions and bleeding issues due to reoperation. However, BS after LT is an option for those who develop obesity after transplantation, particularly in patients who were not obese before transplantation.

BS after LT has no impact on comorbidities during the peritransplant period. It has the advantage of a proper selection of patients requiring BS in an elective way, but disadvantages include difficult access to the abdomen and high postoperative morbidity and reoperation rates reported in the literature.

CONCLUSION

NASH is today in 2019 the second major etiology of liver transplantation in the United States, and is expected to become the first in a short time [122]. Obesity comorbidities have a negative impact on graft and patient survival.

Besides, recurrent NAFLD develops in 30 - 60% of patients following LT for NAFLD [123]. This high recurrence rate forces to take preventive measures.

Patients with morbid obesity have more infectious and surgical complications after LT [124-125], and an additional BS may also complicate posttransplantation period.

BS in the peri-transplant period can cause a significant weight loss and a substantial decrease in the incidence of obesity comorbidities, such as diabetes and NASH. This leads to decrease patient morbidity and increase both patient and graft survival.

SG should be considered as a first surgical bariatric option in obese LT patients. SG is a restrictive weight loss procedure that provides durable weight loss results with significant improvement in obesity related comorbidities such as diabetes mellitus, hypertension, and obstructive sleep apnea. In addition, compared to RYGB, there are no changes in IS therapy and the access to the biliary system is maintained.

Bariatric surgery seems to be feasible and effective in morbid obese patients in the setting of liver transplantation, assuming a higher postoperative complication rate.

Bariatric first or concomitant approach might be reasonable for NASH patients who have pre-LT comorbidities including metabolic and CV problems that may complicate the post-transplant period. The optimal type of BS remains unclear, but SG seems to be the preferred approach by most surgeons [97-99, 103].

The optimal time of BS in relation to liver transplantation has not yet been determined.

To date, there are no studies comparing different timing of BS in relation to liver transplantation.

REFERENCES

[1] Kelly, T; Yang, W; Chen, CS; Reynolds, K; He, J. Global burden of obesity in 2005 and projections to 2030. *Int J Obes.*, 2008, 32(9), 1431-1437. doi:10.1038/ijo. 2008.102.

[2] Clinical guidelines on the identification, evaluation, and treatment of overweight and obesity in adults: executive summary. Expert Panel on the Identification, Evaluation, and Treatment of Overweight in Adults. *Am J Clin Nutr*., 1998, 68(4), 899-917. doi:10.1093/ ajcn/68.4.899.

[3] Flegal, KM; Kruszon-Moran, D; Carroll, MD; Fryar, CD; Ogden, CL. Trends in Obesity Among Adults in the United States, 2005 to 2014. *JAMA*., 2016, 315(21), 2284. doi:10.1001/jama.2016.6458.

[4] Wang, Y; Beydoun, MA; Liang, L; Caballero, B; Kumanyika, SK. Will all Americans become overweight or obese? estimating the progression and cost of the US obesity epidemic. *Obesity (Silver Spring).*, 2008, 16(10), 2323-2330. doi:10.1038/oby. 2008.351.

[5] Aller, R; Fernández-Rodríguez, C; lo Iacono, O; et al. Documento de consenso. Manejo de la enfermedad hepática grasa no alcohólica (EHGNA). Guía de práctica clínica. *Gastroenterol Hepatol*., 2018, 41(5), 328-349. doi:10.1016/j.gastrohep. 2017.12.003.

[6] European Association for the Study of the Liver (EASL), European Association for the Study of Diabetes (EASD), European Association for the Study of Obesity (EASO). EASL-EASD-EASO Clinical Practice Guidelines for the management of non-alcoholic fatty liver disease. *J Hepatol.*, 2016, 64(6), 1388-1402. doi:10.1016/ j.jhep.2015. 11.004.

[7] Rinella, ME. Nonalcoholic Fatty Liver Disease. *JAMA*., 2015, 313(22), 2263. doi:10.1001/jama.2015.5370.

[8] Loomba, R; Sanyal, AJ. The global NAFLD epidemic. *Nat Rev Gastroenterol Hepatol.*, 2013, 10(11), 686-690. doi:10.1038/ nrgastro.2013.171.

[9] Zakhari, S; Li, TK. Determinants of alcohol use and abuse: Impact of quantity and frequency patterns on liver disease. *Hepatology*., 2007, 46(6), 2032-2039. doi:10.1002/ hep.22010.

[10] Rehm, J; Mathers, C; Popova, S; Thavorncharoensap, M; Teerawattananon, Y; Patra, J. Global burden of disease and injury and economic cost attributable to alcohol use and alcohol-use disorders. *Lancet* (London, England)., 2009, 373(9682), 2223-2233. doi:10.1016/S0140-6736(09)60746-7.

[11] Williams, CD; Stengel, J; Asike, MI; et al. Prevalence of nonalcoholic fatty liver disease and nonalcoholic steatohepatitis among a largely middle-aged population utilizing ultrasound and liver biopsy: a prospective study. *Gastroenterology*., 2011, 140(1), 124-131. doi:10.1053/j.gastro.2010.09.038.

[12] Lazo, M; Clark, J. The Epidemiology of Nonalcoholic Fatty Liver Disease: A Global Perspective. *Semin Liver Dis.*, 2008, 28(04), 339-350. doi:10.1055/s-0028-1091978.

[13] Machado, M; Marques-Vidal, P; Cortez-Pinto, H. Hepatic histology in obese patients undergoing bariatric surgery. *J Hepatol*., 2006, 45(4), 600-606. doi:10.1016/j.jhep. 2006.06.013.

[14] Wang, X; Li, J; Riaz, DR; Shi, G; Liu, C; Dai, Y. Outcomes of liver transplantation for nonalcoholic steatohepatitis: a systematic review and meta-analysis. *Clin Gastroenterol Hepatol.*, 2014, 12(3), 394-402.e1. doi:10.1016/j.cgh.2013.09.023.

[15] Charlton, MR; Burns, JM; Pedersen, RA; Watt, KD; Heimbach, JK; Dierkhising, RA. Frequency and outcomes of liver transplantation for nonalcoholic steatohepatitis in the

United States. *Gastroenterology*., 2011, 141(4), 1249-1253. doi:10.1053/j.gastro.2011.06.061.

[16] Afzali, A; Berry, K; Ioannou, GN. Excellent posttransplant survival for patients with nonalcoholic steatohepatitis in the United States. *Liver Transplant.*, 2012, 18(1), 29-37. doi:10.1002/lt.22435.

[17] Cholankeril, G; Wong, RJ; Hu, M; et al. Liver Transplantation for Nonalcoholic Steatohepatitis in the US: Temporal Trends and Outcomes. *Dig Dis Sci.*, 2017, 62(10), 2915-2922. doi:10.1007/ s10620-017-4684-x.

[18] Wong, RJ; Chou, C; Bonham, CA; Concepcion, W; Esquivel, CO; Ahmed, A. Improved survival outcomes in patients with non-alcoholic steatohepatitis and alcoholic liver disease following liver transplantation: an analysis of 2002-2012 United Network for Organ Sharing data. *Clin Transplant*., 2014, 28(6), 713-721. doi:10.1111/ctr.12364.

[19] Singal, AK; Hasanin, M; Kaif, M; Wiesner, R; Kuo, YF. Nonalcoholic Steatohepatitis is the Most Rapidly Growing Indication for Simultaneous Liver Kidney Transplantation in the United States. *Transplantation*., 2016, 100(3), 607-612. doi:10.1097/ TP.0000000000000945.

[20] Kemmer, N; Neff, GW; Franco, E; et al. Nonalcoholic Fatty Liver Disease Epidemic and Its Implications for Liver Transplantation. *Transplantation*., October 2013, 1. doi:10.1097/ 01.tp.0000436723.59879.01.

[21] Agopian, VG; Kaldas, FM; Hong, JC; et al. Liver Transplantation for Nonalcoholic Steatohepatitis. *Ann Surg*., 2012, 256(4), 624-633. doi:10.1097/SLA.0b013e31826b4b7e.

[22] Barritt, AS; Dellon, ES; Kozlowski, T; Gerber, DA; Hayashi, PH. The influence of nonalcoholic fatty liver disease and its associated comorbidities on liver transplant outcomes. *J Clin Gastroenterol*., 2011, 45(4), 372-378. doi:10.1097/MCG.0b013e3181eeaff0.

[23] Wadden, TA; Volger, S; Sarwer, DB; et al. A two-year randomized trial of obesity treatment in primary care practice. *N Engl J Med*., 2011, 365(21), 1969-1979. doi:10.1056/NEJMoa1109220.

[24] Romero-Gómez, M; Zelber-Sagi, S; Trenell, M. Treatment of NAFLD with diet, physical activity and exercise. *J Hepatol*., 2017, 67(4), 829-846. doi:10.1016/j.jhep.2017.05.016.

[25] Rabl, C; Campos, GM. The impact of bariatric surgery on nonalcoholic steatohepatitis. *Semin Liver Dis*., 2012, 32(1), 80-91. doi:10.1055/s-0032-1306428.

[26] Weiner, RA. Surgical Treatment of Non-Alcoholic Steatohepatitis and Non-Alcoholic Fatty Liver Disease. *Dig Dis*., 2010, 28(1), 274-279. doi:10.1159/000282102.

[27] Furuya, CK; de Oliveira, CPMS; de Mello, ES; et al. Effects of bariatric surgery on nonalcoholic fatty liver disease: preliminary findings after 2 years. *J Gastroenterol Hepatol.*, 2007, 22(4), 510-514. doi:10.1111/j.1440-1746.2007.04833.x.

[28] Buchwald, H; Williams, SE. Bariatric surgery worldwide 2003. *Obes Surg*., 2004, 14(9), 1157-1164. doi:10.1381/0960892042387057.

[29] Rogers, CC; Alloway, RR; Alexander, JW; Cardi, M; Trofe, J; Vinks, AA. Pharmacokinetics of mycophenolic acid, tacrolimus and sirolimus after gastric bypass surgery in end-stage renal disease and transplant patients: a pilot study. *Clin Transplant.*, 2007, 22(3), 281-291. doi:10.1111/j.1399-0012.2007.00783.x.

[30] Diwan, TS; Lichvar, AB; Leino, AD; et al. Pharmacokinetic and pharmacogenetic analysis of immunosuppressive agents after laparoscopic sleeve gastrectomy. *Clin Transplant*., 2017, 31(6), e12975. doi:10.1111/ctr.12975.

[31] Clinical Guidelines on the Identification, Evaluation, and Treatment of Overweight and Obesity in Adults--The Evidence Report. National Institutes of Health. *Obes Res.*, 1998, 6 Suppl, 2, 51S-209S. http:// www.ncbi.nlm.nih.gov/pubmed/9813653. Accessed June 9, 2019.

[32] Tsochatzis, E; Coilly, A; Nadalin, S; et al. International Liver Transplantation Consensus Statement on End-stage Liver Disease Due to Nonalcoholic Steatohepatitis and Liver Transplantation. *Transplantation*., 2019, 103(1), 45-56. doi:10.1097/ TP.0000000000002433.

[33] Sadler, EM; Mehta, N; Bhat, M; et al. Liver Transplantation for NASH-Related Hepatocellular Carcinoma Versus Non-NASH Etiologies of Hepatocellular Carcinoma. *Transplantation*., 2018, 102(4), 640-647. doi:10.1097/TP.000000000002043.

[34] Vanwagner, LB; Bhave, M; Te, HS; Feinglass, J; Alvarez, L; Rinella, ME. Patients transplanted for nonalcoholic steatohepatitis are at increased risk for postoperative cardiovascular events. *Hepatology*., 2012, 56(5), 1741-1750. doi:10.1002/hep.25855.

[35] Bhagat, V; Mindikoglu, AL; Nudo, CG; Schiff, ER; Tzakis, A; Regev, A. Outcomes of liver transplantation in patients with cirrhosis due to nonalcoholic steatohepatitis versus patients with cirrhosis due to alcoholic liver disease. *Liver Transpl*., 2009, 15(12), 1814-1820. doi:10.1002/lt.21927.

[36] Kennedy, C; Redden, D; Gray, S; et al. Equivalent survival following liver transplantation in patients with non-alcoholic steatohepatitis compared with patients with other liver diseases. *HPB* (Oxford)., 2012, 14(9), 625-634. doi:10.1111/j.1477-2574.2012.00497.x.

[37] Malik, SM; deVera, ME; Fontes, P; Shaikh, O; Ahmad, J. Outcome after liver transplantation for NASH cirrhosis. *Am J Transplant*., 2009, 9(4), 782-793. doi:10. 1111/j.1600-6143.2009.02590.x.

[38] Bosch, J; Harrison, SA; Abdelmalek, MF et al. Hepatic Venous Pressure Gradient Predicts Clinical Disease Progression in Patients With Compensated Cirrhosis Due to Nonalcoholic Steatohepatitis. *Hepatology*., 2017, 66, 244A. http://www.natap.org/ 2017/ AASLD/ AASLD_99.htm.

[39] Hui, JM; Kench, JG; Chitturi, S; et al. Long-term outcomes of cirrhosis in nonalcoholic steatohepatitis compared with hepatitis C. *Hepatology*., 2003, 38(2), 420-427. doi:10.1053/jhep.2003.50320.

[40] Yatsuji, S; Hashimoto, E; Tobari, M; Taniai, M; Tokushige, K; Shiratori, K. Clinical features and outcomes of cirrhosis due to non-alcoholic steatohepatitis compared with cirrhosis caused by chronic hepatitis C. *J Gastroenterol Hepatol*., 2009, 24(2), 248-254. doi:10.1111/j.1440-1746.2008.05640.x.

[41] Sanyal, AJ; Banas, C; Sargeant, C; et al. Similarities and differences in outcomes of cirrhosis due to nonalcoholic steatohepatitis and hepatitis C. *Hepatology*., 2006, 43(4), 682-689. doi:10.1002/ hep.21103.

[42] O'Leary, JG; Landaverde, C; Jennings, L; Goldstein, RM; Davis, GL. Patients with NASH and cryptogenic cirrhosis are less likely than those with hepatitis C to receive

liver transplants. *Clin Gastroenterol Hepatol.*, 2011, 9(8), 700-704.e1. doi:10.1016/ j.cgh.2011.04.007.

[43] Young, K; Aguilar, M; Gish, R; et al. Lower rates of receiving model for end-stage liver disease exception and longer time to transplant among nonalcoholic steatohepatitis hepatocellular carcinoma. *Liver Transpl.*, 2016, 22(10), 1356-1366. doi:10.1002/lt.24507.

[44] Houlihan, DD; Armstrong, MJ; Davidov, Y; et al. Renal function in patients undergoing transplantation for nonalcoholic steatohepatitis cirrhosis: Time to reconsider immunosuppression regimens? *Liver Transplant.*, 2011, 17(11), 1292-1298. doi:10.1002/lt.22382.

[45] Park, CW; Tsai, NT; Wong, LL. Implications of worse renal dysfunction and medical comorbidities in patients with NASH undergoing liver transplant evaluation: impact on MELD and more. *Clin Transplant.*, 2011, 25(6), E606-11. doi:10.1111/j.1399-0012.2011.01497.x.

[46] Lonardo, A; Nascimbeni, F; Mantovani, A; Targher, G. Hypertension, diabetes, atherosclerosis and NASH: Cause or consequence? *J Hepatol.*, 2018, 68(2), 335-352. doi:10.1016/ j.jhep.2017.09.021.

[47] Targher, G; Byrne, CD; Lonardo, A; Zoppini, G; Barbui, C. Non-alcoholic fatty liver disease and risk of incident cardiovascular disease: A meta-analysis. *J Hepatol.*, 2016, 65(3), 589-600. doi:10.1016/j.jhep.2016.05.013.

[48] Manoushagian, S; Meshkov, A. Evaluation of solid organ transplant candidates for coronary artery disease. *Am J Transplant.*, 2014, 14(10), 2228-2234. doi:10.1111/ ajt.12915.

[49] Targher, G; Bertolini, L; Padovani, R; et al. Increased prevalence of cardiovascular disease in Type 2 diabetic patients with non-alcoholic fatty liver disease. *Diabet Med.*, 2006, 23(4), 403-409. doi:10.1111/j.1464-5491.2006.01817.x.

[50] Arslan, U; Türkoğlu, S; Balcioğlu, S; Tavil, Y; Karakan, T; Cengel, A. Association between nonalcoholic fatty liver disease and coronary artery disease. *Coron Artery Dis.*, 2007, 18(6), 433-436. doi:10.1097/MCA.0b013e3282583c0d.

[51] Choi, SY; Kim, D; Kim, HJ; et al. The relation between non-alcoholic fatty liver disease and the risk of coronary heart disease in Koreans. *Am J Gastroenterol.*, 2009, 104(8), 1953-1960. doi:10.1038/ajg.2009.238.

[52] Lu, H; Zeng, L; Liang, B; Shu, X; Xie, D. High prevalence of coronary heart disease in type 2 diabetic patients with non-alcoholic fatty liver disease. *Arch Med Res.*, 2009, 40(7), 571-575. doi:10.1016/j.arcmed.2009.07.009.

[53] Plotkin, JS; Johnson, LB; Rustgi, V; Kuo, PC. Coronary artery disease and liver transplantation: the state of the art. *Liver Transpl.*, 2000, 6(4 Suppl 1), S53-6. doi:[not.

[54] Chalasani, N; Younossi, Z; Lavine, JE; et al. The diagnosis and management of nonalcoholic fatty liver disease: Practice guidance from the American Association for the Study of Liver Diseases. *Hepatology.*, 2018, 67(1), 328-357. doi:10.1002/hep. 29367.

[55] Vargas, JI; Arrese, M; Shah, VH; Arab, JP. Use of Statins in Patients with Chronic Liver Disease and Cirrhosis: Current Views and Prospects. *Curr Gastroenterol Rep.*, 2017, 19(9), 43. doi:10.1007/s11894-017-0584-7.

[56] Dongiovanni, P; Petta, S; Mannisto, V; et al. Statin use and non-alcoholic steatohepatitis in at risk individuals. *J Hepatol*., 2015, 63(3), 705-712. doi:10.1016/ j.jhep.2015.05.006.

[57] Fernández-Miranda, C; Pérez-Carreras, M; Colina, F; López-Alonso, G; Vargas, C; Solís-Herruzo, JA. A pilot trial of fenofibrate for the treatment of non-alcoholic fatty liver disease. *Dig Liver Dis*., 2008, 40(3), 200-205. doi:10.1016/j.dld.2007.10.002.

[58] Goh, GB; Pagadala, MR; Dasarathy, J; et al. Renin-angiotensin system and fibrosis in non-alcoholic fatty liver disease. *Liver Int.*, 2015, 35(3), 979-985. doi:10.1111/liv. 12611.

[59] Musso, G; Gambino, R; Tabibian, JH; et al. Association of non-alcoholic fatty liver disease with chronic kidney disease: a systematic review and meta-analysis. Woodward M, ed. *PLoS Med*., 2014, 11(7), e1001680. doi:10.1371/journal.pmed. 1001680.

[60] Di Maira, T; Rubin, A; Puchades, L; et al. Framingham score, renal dysfunction, and cardiovascular risk in liver transplant patients. *Liver Transpl.*, 2015, 21(6), 812-822. doi:10.1002/lt.24128.

[61] VanWagner, LB; Montag, S; Zhao, L; et al. Cardiovascular Disease Outcomes Related to Early Stage Renal Impairment After Liver Transplantation. *Transplantation*., 2018, 102(7), 1096-1107. doi:10.1097/TP.0000000000002175.

[62] VanWagner, LB; Ning, H; Whitsett, M; et al. A point-based prediction model for cardiovascular risk in orthotopic liver transplantation: The CAR-OLT score. *Hepatology*., 2017, 66(6), 1968-1979. doi:10.1002/hep.29329.

[63] Alvarez-Sotomayor, D; Satorres, C; Rodríguez-Medina, B; et al. Controlling Diabetes After Liver Transplantation: Room for Improvement. *Transplantation*., 2016, 100(10), e66-e73. doi:10.1097/TP.0000000000001399.

[64] Martínez-Saldivar, B; Prieto, J; Berenguer, M; et al. Control of blood pressure in liver transplant recipients. *Transplantation*., 2012, 93(10), 1031-1037. doi:10.1097/TP. 0b013e31824cd5e6.

[65] Dunkelgrun, M; Boersma, E; Schouten, O; et al. Bisoprolol and fluvastatin for the reduction of perioperative cardiac mortality and myocardial infarction in intermediate-risk patients undergoing noncardiovascular surgery: a randomized controlled trial (DECREASE-IV). *Ann Surg.*, 2009, 249(6), 921-926. doi:10.1097/ SLA.0b013 e3181a77d00.

[66] Hindler, K; Shaw, AD; Samuels, J; Fulton, S; Collard, CD; Riedel, B. Improved postoperative outcomes associated with preoperative statin therapy. *Anesthesiology*., 2006, 105(6), 1260-1272, quiz 1289-1290. http://www.ncbi.nlm.nih.gov/pubmed/ 17122590. Accessed June 9; 2019.

[67] Lewis, JH; Mortensen, ME; Zweig, S; et al. Efficacy and safety of high-dose pravastatin in hypercholesterolemic patients with well-compensated chronic liver disease: Results of a prospective, randomized, double-blind, placebo-controlled, multicenter trial. *Hepatology*., 2007, 46(5), 1453-1463. doi:10.1002/hep.21848.

[68] Berzigotti, A; Saran, U; Dufour, JF. Physical activity and liver diseases. *Hepatology*., 2016, 63(3), 1026-1040. doi:10.1002/ hep.28132.

[69] Berzigotti, A; Albillos, A; Villanueva, C; et al. Effects of an intensive lifestyle intervention program on portal hypertension in patients with cirrhosis and obesity: The SportDiet study. *Hepatology*., 2017, 65(4), 1293-1305. doi:10.1002/hep.28992.

[70] Leibovitz, E; Giryes, S; Makhline, R; Zikri Ditch, M; Berlovitz, Y; Boaz, M. Malnutrition risk in newly hospitalized overweight and obese individuals: Mr NOI. *Eur J Clin Nutr*., 2013, 67(6), 620-624. doi:10.1038/ejcn.2013.45.

[71] Debette-Gratien, M; Tabouret, T; Antonini, MT; et al. Personalized adapted physical activity before liver transplantation: acceptability and results. *Transplantation*., 2015, 99(1), 145-150. doi:10.1097/ TP.0000000000000245.

[72] Zenith, L; Meena, N; Ramadi, A; et al. Eight weeks of exercise training increases aerobic capacity and muscle mass and reduces fatigue in patients with cirrhosis. *Clin Gastroenterol Hepatol*., 2014, 12(11), 1920-6.e2. doi:10.1016/j.cgh.2014.04.016.

[73] Leonard, J; Heimbach, JK; Malinchoc, M; Watt, K; Charlton, M. The impact of obesity on long-term outcomes in liver transplant recipients-results of the NIDDK liver transplant database. *Am J Transplant*., 2008, 8(3), 667-672. doi:10.1111/j.1600-6143.2007.02100.x.

[74] Wong, RJ; Cheung, R; Perumpail, RB; Holt, EW; Ahmed, A. Diabetes mellitus, and not obesity, is associated with lower survival following liver transplantation. *Dig Dis Sci.*, 2015, 60(4), 1036-1044. doi:10.1007/s10620-014-3469-8.

[75] Dick, AAS; Spitzer, AL; Seifert, CF; et al. Liver transplantation at the extremes of the body mass index. *Liver Transpl*., 2009, 15(8), 968-977. doi:10.1002/lt.21785.

[76] Kardashian, AA; Dodge, JL; Roberts, J; Brandman, D. Weighing the risks: Morbid obesity and diabetes are associated with increased risk of death on the liver transplant waiting list. *Liver Int*., 2018, 38(3), 553-563. doi:10.1111/liv.13523.

[77] Saab, S; Lalezari, D; Pruthi, P; Alper, T; Tong, MJ. The impact of obesity on patient survival in liver transplant recipients: a meta-analysis. *Liver Int.*, 2015, 35(1), 164-170. doi:10.1111/liv.12431.

[78] Barone, M; Viggiani, MT; Avolio, AW; Iannone, A; Rendina, M; Di Leo, A. Obesity as predictor of postoperative outcomes in liver transplant candidates: Review of the literature and future perspectives. *Dig Liver Dis*., 2017, 49(9), 957-966. doi:10.1016/ j.dld.2017.07.004.

[79] Rustgi, VK; Marino, G; Rustgi, S; et al. Impact of body mass index on graft failure and overall survival following liver transplant. *Clin Transplant*., 2004, 18(6), 634-637. doi:10.1111/j.1399-0012.2004.00141.x.

[80] Conzen, KD; Vachharajani, N; Collins, KM; et al. Morbid obesity in liver transplant recipients adversely affects longterm graft and patient survival in a single-institution analysis. *HPB* (Oxford)., 2015, 17(3), 251-257. doi:10.1111/hpb.12340.

[81] Pelletier, SJ; Maraschio, MA; Schaubel, DE; et al. Survival benefit of kidney and liver transplantation for obese patients on the waiting list. *Clin Transpl.*, 2003, 77-88. http://www.ncbi.nlm.nih.gov/pubmed/ 15387099. Accessed June 9; 2019.

[82] Singhal, A; Wilson, GC; Wima, K; et al. Impact of recipient morbid obesity on outcomes after liver transplantation. *Transpl Int*., 2015, 28(2), 148-155. doi:10.1111/ tri.12483.

[83] Younossi, ZM; Stepanova, M; Saab, S; et al. The impact of type 2 diabetes and obesity on the long-term outcomes of more than 85 000 liver transplant recipients in the US. *Aliment Pharmacol Ther*., 2014, 40(6), 686-694. doi:10.1111/apt.12881.

[84] Dare, AJ; Plank, LD; Phillips, ARJ; et al. Additive effect of pretransplant obesity, diabetes, and cardiovascular risk factors on outcomes after liver transplantation. *Liver Transpl.*, 2014, 20(3), 281-290. doi:10.1002/lt.23818.

[85] Sjöström, L; Lindroos, AK; Peltonen, M; et al. Lifestyle, diabetes, and cardiovascular risk factors 10 years after bariatric surgery. *N Engl J Med.*, 2004, 351(26), 2683-2693. doi:10.1056/ NEJMoa035622.

[86] Maggard, MA; Shugarman, LR; Suttorp, M; et al. Meta-analysis: surgical treatment of obesity. *Ann Intern Med.*, 2005, 142(7), 547-559. http://www.ncbi.nlm.nih.gov/ pubmed/15809466. Accessed June 9, 2019.

[87] McTigue, KM; Harris, R; Hemphill, B; et al. Screening and interventions for obesity in adults: summary of the evidence for the U.S. Preventive Services Task Force. *Ann Intern Med*., 2003, 139(11), 933-949. http://www.ncbi.nlm.nih.gov/pubmed/14644897. Accessed June 9, 2019.

[88] Ma, Y; Pagoto, S; Olendzki, B; et al. Predictors of Weight Status following Laparoscopic Gastric Bypass. *Obes Surg*., 2006, 16(9), 1227-1231. doi:10.1381/ 096089206778392284.

[89] Schauer, PR; Bhatt, DL; Kirwan, JP; et al. Bariatric Surgery versus Intensive Medical Therapy for Diabetes — 3-Year Outcomes. *N Engl J Med*., 2014, 370(21), 2002-2013. doi:10.1056/NEJMoa1401329.

[90] Maciejewski, ML; Arterburn, DE; Van Scoyoc, L; et al. Bariatric Surgery and Long-term Durability of Weight Loss. *JAMA Surg*., 2016, 151(11), 1046-1055. doi:10.1001/ jamasurg.2016.2317.

[91] Murali, SB. Long-term Survival Following Bariatric Surgery in the VA Health System. *JAMA*., 2015, 313(14), 1473. doi:10.1001/ jama.2015.2580.

[92] Adams, TD; Stroup, AM; Gress, RE; et al. Cancer Incidence and Mortality After Gastric Bypass Surgery. *Obesity*., 2009, 17(4), 796-802. doi:10.1038/oby.2008.610.

[93] Sjöström, L; Gummesson, A; Sjöström, CD; et al. Effects of bariatric surgery on cancer incidence in obese patients in Sweden (Swedish Obese Subjects Study): a prospective, controlled intervention trial. *Lancet Oncol.*, 2009, 10(7), 653-662. doi:10.1016/S1470-2045(09)70159-7.

[94] Young, MT; Gebhart, A; Phelan, MJ; Nguyen, NT. Use and Outcomes of Laparoscopic Sleeve Gastrectomy vs Laparoscopic Gastric Bypass: Analysis of the American College of Surgeons NSQIP. *J Am Coll Surg.*, 2015, 220(5), 880-885. doi:10.1016/ j.jamcollsurg.2015.01.059.

[95] Himpens, J; Dapri, G; Cadière, GB. A prospective randomized study between laparoscopic gastric banding and laparoscopic isolated sleeve gastrectomy: results after 1 and 3 years. *Obes Surg*., 2006, 16(11), 1450-1456. doi:10.1381/0960892067788 69933.

[96] Nguyen, NT; Nguyen, B; Gebhart, A; Hohmann, S. Changes in the makeup of bariatric surgery: a national increase in use of laparoscopic sleeve gastrectomy. *J Am Coll Surg.*, 2013, 216(2), 252-257. doi:10.1016/j.jamcollsurg.2012.10.003.

[97] Lazzati, A; Iannelli, A; Schneck, AS; et al. Bariatric surgery and liver transplantation: a systematic review a new frontier for bariatric surgery. *Obes Surg.*, 2015, 25(1), 134-142. doi:10.1007/s11695-014-1430-8.

[98] Lazzati, A; Guy-Lachuer, R; Delaunay, V; Szwarcensztein, K; Azoulay, D. Bariatric surgery trends in France: 2005-2011. *Surg Obes Relat Dis*., 2014, 10(2), 328-334. doi:10.1016/ j.soard.2013.07.015.

[99] Shimizu, H; Phuong, V; Maia, M; et al. Bariatric surgery in patients with liver cirrhosis. *Surg Obes Relat Dis.*, 2013, 9(1), 1-6. doi:10.1016/j.soard.2012.07.021.

[100] Dallal, RM; Mattar, SG; Lord, JL; et al. Results of Laparoscopic Gastric Bypass in Patients with Cirrhosis. *Obes Surg*., 2004, 14(1), 47-53. doi:10.1381/096089204 772787284.

[101] Tariq, N; Moore, LW; Sherman, V. Bariatric Surgery and End-Stage Organ Failure. *Surg Clin North Am.*, 2013, 93(6), 1359-1371. doi:10.1016/j.suc.2013.08.006.

[102] Takata, MC; Campos, GM; Ciovica, R; et al. Laparoscopic bariatric surgery improves candidacy in morbidly obese patients awaiting transplantation. *Surg Obes Relat Dis.*, 2008, 4(2), 159-164, discussion 164-5. doi:10.1016/j.soard.2007.12.009.

[103] Zamora-Valdes, D; Watt, KD; Kellogg, TA; et al. Long-term outcomes of patients undergoing simultaneous liver transplantation and sleeve gastrectomy. *Hepatology*., 2018, 68(2), 485-495. doi:10.1002/hep.29848.

[104] Carson, K; Washington, MK; Treem, WR; Clavien, PA; Hunt, CM. Recurrence of nonalcoholic steatohepatitis in a liver transplant recipient. *Liver Transpl Surg*., 1997, 3(2), 174-176. http:// www.ncbi.nlm.nih.gov/pubmed/9346732. Accessed June 9; 2019.

[105] Lin, MYC; Tavakol, MM; Sarin, A; et al. Laparoscopic sleeve gastrectomy is safe and efficacious for pretransplant candidates. *Surg Obes Relat Dis.*, 2013, 9(5), 653-658. doi:10.1016/ j.soard.2013.02.013.

[106] Braunfeld, MY; Chan, S; Pregler, J; et al. Liver transplantation in the morbidly obese. *J Clin Anesth*., 1996, 8(7), 585-590. http:// www.ncbi.nlm.nih.gov/pubmed/8910182. Accessed June 9, 2019.

[107] Heimbach, JK; Watt, KDS; Poterucha, JJ; et al. Combined liver transplantation and gastric sleeve resection for patients with medically complicated obesity and end-stage liver disease. *Am J Transplant.*, 2013, 13(2), 363-368. doi:10.1111/j.1600-6143. 2012.04318.x.

[108] Tariciotti, L; D'Ugo, S; Manzia, TM; et al. Combined liver transplantation and sleeve gastrectomy for end-stage liver disease in a bariatric patient: First European case-report. *Int J Surg Case Rep.*, 2016, 28, 38-41. doi:10.1016/j.ijscr.2016.09.011.

[109] Nesher, E; Mor, E; Shlomai, A; et al. Simultaneous Liver Transplantation and Sleeve Gastrectomy: Prohibitive Combination or a Necessity? *Obes Surg.*, 2017, 27(5), 1387-1390. doi:10.1007/ s11695-017-2634-5.

[110] Schlansky, B; Naugler, WE; Orloff, SL; Enestvedt, CK. Higher Mortality and Survival Benefit in Obese Patients Awaiting Liver Transplantation. *Transplantation*., 2016, 100(12), 2648-2655. doi:10.1097/TP.0000000000001461.

[111] Bambha, KM; Dodge, JL; Gralla, J; Sprague, D; Biggins, SW. Low, rather than high, body mass index confers increased risk for post-liver transplant death and graft loss: Risk modulated by model for end-stage liver disease. *Liver Transplant.*, 2015, 21(10), 1286-1294. doi:10.1002/lt.24188.

[112] Perez-Protto, SE; Quintini, C; Reynolds, LF; et al. Comparable graft and patient survival in lean and obese liver transplant recipients. *Liver Transplant.*, 2013, 19(8), 907-915. doi:10.1002/lt.23680.

[113] Orci, LA; Majno, PE; Berney, T; Morel, P; Mentha, G; Toso, C. The impact of wait list body mass index changes on the outcome after liver transplantation. *Transpl Int.*, 2013, 26(2), 170-176. doi:10.1111/tri.12017.

[114] Watt, KDS; Charlton, MR. Metabolic syndrome and liver transplantation: a review and guide to management. *J Hepatol.*, 2010, 53(1), 199-206. doi:10.1016/j.jhep. 2010.01.040.

[115] Nolan, JJ; Færch, K. Estimating insulin sensitivity and beta cell function: perspectives from the modern pandemics of obesity and type 2 diabetes. *Diabetologia*., 2012, 55(11), 2863-2867. doi:10.1007/s00125-012-2684-0.

[116] Executive Summary: Standards of Medical Care in Diabetes--2014. *Diabetes Care.*, 2014, 37(Supplement_1), S5-S13. doi:10.2337/dc14-S005.

[117] Tsamalaidze, L; Stauffer, JA; Arasi, LC; et al. Laparoscopic Sleeve Gastrectomy for Morbid Obesity in Patients After Orthotopic Liver Transplant: a Matched Case-Control Study. *Obes Surg.*, 2018, 28(2), 444-450. doi:10.1007/s11695-017-2847-7.

[118] Tichansky, DS; Madan, AK. Laparoscopic Roux-en-Y gastric bypass is safe and feasible after orthotopic liver transplantation. *Obes Surg.*, 2005, 15(10), 1481-1486. doi:10.1381/ 096089205774859164.

[119] Osseis, M; Lazzati, A; Salloum, C; et al. Sleeve Gastrectomy After Liver Transplantation: Feasibility and Outcomes. *Obes Surg*., 2018, 28(1), 242-248. doi:10.1007/s11695-017-2843-y.

[120] Butte, JM; Devaud, N; Jarufe, NP; et al. Sleeve gastrectomy as treatment for severe obesity after orthotopic liver transplantation. *Obes Surg.*, 2007, 17(11), 1517-1519. http://www.ncbi.nlm.nih.gov/ pubmed/18219781. Accessed June 9, 2019.

[121] Elli, EF; Masrur, MA; Giulianotti, PC. Robotic sleeve gastrectomy after liver transplantation. *Surg Obes Relat Dis.*, 2013, 9(1), e20-e22. doi:10.1016/j.soard.2012. 01.010.

[122] Wong, RJ; Aguilar, M; Cheung, R; et al. Nonalcoholic steatohepatitis is the second leading etiology of liver disease among adults awaiting liver transplantation in the United States. *Gastroenterology*., 2015, 148(3), 547-555. doi:10.1053/j.gastro.2014. 11.039.

[123] Yalamanchili, K; Saadeh, S; Klintmalm, GB; Jennings, LW; Davis, GL. Nonalcoholic fatty liver disease after liver transplantation for cryptogenic cirrhosis or nonalcoholic fatty liver disease. *Liver Transpl.*, 2010, 16(4), 431-439. doi:10.1002/lt.22004.

[124] Hakeem, AR; Cockbain, AJ; Raza, SS; et al. Increased morbidity in overweight and obese liver transplant recipients: a single-center experience of 1325 patients from the United Kingdom. *Liver Transpl.*, 2013, 19(5), 551-562. doi:10.1002/lt.23618.

[125] LaMattina, JC; Foley, DP; Fernandez, LA; et al. Complications associated with liver transplantation in the obese recipient. *Clin Transplant.*, 2012, 26(6), 910-918. doi:10.1111/j.1399-0012.2012.01669.x.

In: Encyclopedia of Surgery (22 Volume Set)
Editors: Andreas Lehrer and Kristin Mueller
ISBN: 978-1-53618-329-0
© 2020 Nova Science Publishers, Inc

Chapter 316

NON-SURGICAL TREATMENT OF NASH: THE OTHER OPTIONS

Raúl Bernal-Reyes[1,*], MD and Daniel Bernal-Serrano[2], MD
[1]School of Medicine UNAM, Mexico City, Mexico
Gastroenterologist from National Medical Center IMSS, Mexico City, Mexico
Gastroenterology Consultant at the Spanish Charitable Society, Pachuca, Mexico
[2]Instituto Tecnológico y de Ciencias Superiores de Monterrey, Mexico City, Mexico
London School of Hygiene and Tropical Medicine
and London School of Economics and Political Science, London, UK
Universidad Nacional Autónoma de México, Mexico City, Mexico

ABSTRACT

The best result so far in the non-surgical treatment of NASH has been obtained with diet and physical activity supervised by professionals, this promotes the reduction of body weight and metabolic stabilization. The use of pharmacotherapy is only for patients with NASH in very specific contexts. For example, Pioglitazone and vitamin E can be used, since they have shown acceptable results according to various guides and consensus. Novel medications have shown encouraging results with positive effects in basic science studies or small clinical trials; studies with a larger number of patients and a more rigorous methodology are needed.

Keywords: medical-treatment of NASH, diet, exercise, clinical trials, experimental drugs, pioglitazone, vitamin E

INTRODUCTION

The prevalence of Non-Alcoholic Fatty Liver Disease (NAFLD) has peaked in the last 30 years. This worldwide epidemic has drawn the attention of diverse research groups that, by

* Corresponding Author's Email: raulber@yahoo.com.

delving into the pathophysiology of the disease, have revealed the complex details of the disease. In its original description, the histopathological resemblance to alcoholic steatohepatitis was highlighted [1]; however, the patients with NAFLD have low alcohol consumption: less than 30 grams per day in men, and less than 20 grams per day in women [2]. Ever since Ludwing's article was published in 1980, knowledge about NAFLD has increased. Its physiopathology has been related to diverse factors: high-fat and high-carbohydrate diet, extreme sedentarism, intestinal dysbiosis, insulin resistance, and the activation of macrophages and pro-inflammatory agents, to name the most researched ones.

The notable increase in knowledge about this disease allows us to delve into the physio-pathological steps that represent multiple opportunities for therapeutic action. This recent research interest is one of the reasons why the amount of therapeutic options nowadays is so large. However, many of these options come from preliminary case reports, mostly anecdotal, with poor methodology and rarely reproducible.

This disease's complexity and its multiple comorbidities compel us to consider the treatment of NAFLD in a broader context, since this is not just a liver disease. In fact it is a systemic one, and it is one of the components of the Metabolic Syndrome (MetS). It is estimated that up to 90% of patients with NAFLD have at least one associated component of MetS, usually obesity, followed in frequency by diabetes mellitus type 2 (DM2), dyslipidemia and arterial hypertension. It is recognized that as a patient gathers more components of the MetS, her risk of suffering NAFLD is greater [3]. This explains why commonly these patients require multiple treatments aimed not only at preventing the progression of liver disease, but also at promoting metabolic stability and at limiting the risk of cardiovascular disease, the main cause of death among patients with NASH. Each patient with NAFLD has a clinical profile of its own that makes him different from others, and therefore requires an individualized treatment; what today is known as patient-centered medicine. This is a compelling reason that explains why, today, the possibility of a standardized treatment for patients with NAFLD is remote, and it is an incentive to research into personalized medicine alternatives.

Another factor to have in mind, for therapeutic purposes, is the natural evolution of the disease. Most patients affected by NAFLD have a good prognosis if they remain in the steatosis stage, or Non-Alcoholic Fatty Liver (NAFL). Luckily, these are the majority and an effective change in lifestyle (weigh reduction diet and physical exercise) will suffice to accomplish metabolic stabilization, and even reverse steatosis.

The phenotype of the patients with NASH is different from patients with NAFL stage. These patients have a greater tendency to progression; particularly those in whom fibrosis has started have the worst prognosis for the having liver cirrhosis [4]. Therefore, the efforts to find a useful drug have focused mainly on the control and regression of NASH's characteristic inflammation and fibrosis.

Save for a few exceptions, drug therapy is advised only in patients with biopsy supported NASH diagnosis [5].

The most relevant controlled clinical drug trials have a success rate of less than 50%; therefore, major regulatory agencies have not approved any pharmacological treatment for NASH. Only vitamin E and pioglitazone have shown a limited beneficial effect in very specific contexts; nevertheless, they have the disadvantage of relevant side effects. There is another group of drugs whose reports initially showed good results; however, these were not confirmed when more stringent trials were undertaken. Finally, there is a very promising third

group of drugs that are currently in phase II and phase III studies, they act in different points of the complex pathophysiology of NASH and a lot is expected from them in the years to come.

So far, the best results in the treatment of patients affected with NAFLD have been achieved with significant lifestyle changes. A weight reduction diet combined with physical activity can reduce steatosis, inflammation, and even liver fibrosis. Additionally, lifestyle changes favours metabolic control and stabilization of the comorbidities that frequently accompany NAFLD.

WEIGHT LOSS

Although most patients with NAFLD are overweight or obese, there are also cases of non-obese patients, this variety is known as "*lean NAFLD*". In these patients the presence of other components of MetS is common [6]. This is the reason most of them benefit from weigh reduction, which favours metabolic control and limits hepatic steatosis [7].

The effectiveness of weight reduction has been demonstrated in patients with NAFLD and corroborated with liver biopsies before and after the intervention. A loss of 7% initial body weight achieved a reduction of ≥ 2 points in the NAFLD Activity Score (NAS), with an improvement of fibrosis of up to 50%. When the weight reduction reached ≥ 10%, the improvement or resolution of fibrosis went up to 80% [8]. In general terms, a weight reduction ≥ 3% is enough to significantly reduce steatosis; a weight loss ≥ 7% has an impact on the development of NASH, decreasing the inflammation and hepatocyte ballooning, and a loss ≥ 10% can reduce fibrosis.

Due to the current absence of an approved pharmacological treatment for patients with NASH the fundamental pillars of therapy are lifestyle changes, based on a personalized diet and supervised physical activation. Jointly these promote not only weight reduction, but also metabolic stability and, therefore, a significant reduction in steatosis, inflammation, and hepatic fibrosis. Despite good results, this change in habits is seldom long lasting, and difficulties to treatment attachment remain a problem in the management of these patients.

DIET

The so-called western diet has gradually become omnipresent around the world, replacing traditional diets. This diet is based on the consumption of large portions of fast food; an excess of saturated fats and refined sugars characterizes it. Of the later fructose stands out, which one is used indiscriminately in the food industry and causes hepatocellular damage through different routes [9].

A first goal of a weight loss diet should be to reduce caloric intake. Initially patients with overweight and obesity should be advised to reduced saturated fat and refined sugars, the recommended ratio of nutrients is of approximately 20% protein, 30% fat (predominantly monounsaturated), and 50% carbohydrates. The average fiber intake should be of 25-35 gr. per day. It is very important to let the patients know that they should avoid eating processed foods, particularly sweet drinks because of their high fructose content [10, 11].

The best example of a diet with good results is the Mediterranean diet. It comprises an abundant consumption of fish and poultry as proteins sources, lots of vegetables and fruits, moderate portions of cheese and cereals, olive oil and moderate wine consumption; additionally it implies a significant restriction of red meat, snacks and desserts [12, 13]. The main features of the Mediterranean diet are high-fiber and antioxidant content, as well as properly balanced portions lipid and unrefined sugars. Additionally, the diversity of suggested foods favours greater acceptance and adherence, unlike the irregular compliance that characterizes hypocaloric diets [14].

Ketogenic diet also has been proposed as treatment for NAFLD. It became popular several years ago in morbidly obese patients who were to undertake bariatric surgery, because of its rapid effect of weight loss. It is based on carbohydrate restriction to induce a higher consumption of body fat deposits as main energy source. In other words, it shifts metabolism from a glycolytic state to a lipolytic one as a consequence of carbohydrate shortage, and it uptakes fat as the main source of energy. However, even though this diet has been shown to contribute to body weight loss, it has been questioned for inconveniences such as favouring constipation and a poor attachment of patients due to multiple food restrictions. Recently two relevant facts emerged; the first, that promoting a rapid weight loss could favours an increase in hepatic steatosis, and, the second, that this diet requires vitamin and mineral supplementation [15].

Due to the frequent comorbidities that condition diverse clinical profiles in patients with NAFLD and the metabolic complexity represented by the dietary adjustment, The Mexican Consensus on NAFLD recommends dietary management of these patients to be customized and implemented by a nutritionist, who most consider among other things, the average energy expenditure of each patient [5].

EXERCISE

Physical activity favours the consumption of calories, and a properly executed exercise routine offers benefits in metabolic control and induces weight loss through the mobilization of fat deposits. Biochemical effects of exercise are many fold, among the most notable are reducing insulin resistance, improving lipid metabolism, endothelial function, blood glucose levels, and reducing pro-inflammatory activity, all are common alterations in the patient with NAFLD [16].

A recent systematic review revealed that exercise by itself, even without significant weight loss, can reduce hepatic steatosis in 20% to 30%, regardless of whether being aerobic or resistance exercise [17]. Notwithstanding this, exercise as the sole therapeutic measure is not enough and should be complemented with a proper diet to promote weight loss, the most effective intervention so far [18]. In adults the WHO recommends a moderate aerobic exercise routine of between 150 and 200 minutes per week [19]. As is the case for diet, a professional who advises the patient on the intensity and type of exercise to be performed by each patient should supervise this routine.

PHARMACOTHERAPY

Pharmacological treatment is not for all patients with NAFLD, it is crucial to establish that it is only indicated in patients with NASH and evidence of fibrosis ($F \geq 2$), or in those with a higher risk of progression (DM2, MetS, or persistently elevated ALT) [5]. The ideal treatment should address not only liver damage, but also the associated metabolic alterations: DM2, obesity and dyslipidaemia. Additionally, it should consider cardiovascular risk, since these comorbidities confer an increased risk of disease progression and premature death. Regarding the liver, the ideal drug should reduce hepatic inflammation, hepatocellular damage, correct insulin resistance, and have anti-fibrotic effects [20, 21].

As stated above, to date there is not a single effective and safe pharmacological treatment for all patients with NASH. Therefore, the proposed options are many folds, with very different mechanisms of action and contrasting results.

For the objectives of this review, we will divide the most relevant drugs into three groups:

A. Drugs with some favourable effect.
B. Drugs that are discouraged.
C. Promising drugs in pharmaceutical development

A. Drugs with Some Favourable Effect

Fundamentally two medications, pioglitazone and vitamin E, may be indicated in very specific contexts. The maximum level of histological improvement they have is close to 50%. Both have been evaluated in several studies; the PIVENS study stands out for its good methodology, it included patients with NASH without cirrhosis or diabetes, and obtained acceptable results [22].

Pioglitazone

This drug belongs to the thiazolidinedione family of drugs and is a treatment for DM2. It acts as a *PPAR-* γ receptor agonist with very interesting and diverse pharmacological effects: improvement of insulin sensitivity in adipose tissue, favours the deposit of free fatty acids in adipose tissue instead of in the liver, increases the production of adiponectin, and favours beta-oxidation of fatty acids in the hepatocyte; additionally it might have anti-inflammatory and anti-fibrotic effects [23].

Several adequately controlled trials, with follow-up periods of up to 18 months support its indication in some patients with NASH with or without DM2. They have reported improvement in insulin resistance and aminotransferase levels. Histologically, a significant decrease in steatosis, inflammation and ballooning injury has been shown in hepatocytes. Also, there is an improvement of fibrosis in variable ranges, with a 73% NAS improvement in treated patients vs 24% in those who received placebo; resolution of NASH has been reported in 47% to 51% of treated patients [22, 24-26].

It is important to note that thiazolidinediones also decrease in cardiovascular mortality and cerebrovascular events [27, 28].

This drug is usually well tolerated, although the reported side effects should be considered and discussed with patients. The most common of these is an increase in body weight [22, 26]; others are a putative, and controverted, such as an increased risk for bladder cancer [29, 30] and hip fracture in postmenopausal women due to decreased bone density [31].

Vitamin E

Because of its antioxidant effect, vitamin E has been proposed as an effective option for patients with NASH. Some studies have shown a reduction in steatosis and inflammation, even a reduction in hepatocyte ballooning degeneration [22] the latter was seen in a study of children [32]. However, no effect on fibrosis or resolution of NASH has been reported. Initially it was not recommended for patients with diabetes, however later studies confirmed its utility in them [33].

Like in the case of pioglitazone, this drug also has relevant side effects. The most important is an association between high doses of vitamin E (> 400 UI per day) and mortality [34]. Others adverse effects are an increased risk of prostate cancer and haemorrhagic stroke [35].

Other drugs have early positive results at the laboratory level or in small patient groups. Nevertheless, we lack good quality controlled clinical trials that supports its prescription in patients with NASH. However, some of them could be used to treat some of the frequent comorbidities; this is the case of liraglutide [36-37] and pentoxifylline [38]; this group complements with others like silymarin, silybin-phospatidylcholine, pirfenidone, ademetionine and probiotics. We expect controlled clinical trials to be carried out in the coming years to confirm their effectiveness or to disqualify their use. For now the evidence is insufficient and does not support the prescription to treat patients with NASH [5].

B. Drugs That are Discouraged

In this group are those drugs that initially had good expectations, but whose effectiveness was rejected in subsequent studies, therefore they are not indicated in the treatment of NASH. Among the best known are metformin [39], ursodeoxycholic acid [40, 41], omega-3 fatty acids [42], and fibrates [43, 44].

As previously mentioned, these drugs were launched with quite optimistic reports regarding their therapeutic utility; however, in these cases there is enough clinical evidence from clinical trials and meta-analysis that reject their benefit, or that failed to reproduce the initial results. Therefore, they are not relevant for treating NASH.

Some of these drugs can be used in patients with NAFLD for the management of other comorbidities, such as DM2 or dyslipidemia, but not for fatty liver.

C. Drugs in Development

There is a growing interest of the pharmaceutical industry in developing new medicines with good and definitive results in the treatment of NASH. Currently there are many

molecules in development, some of them in stages as advanced as phase II and phase III, with surprising initial results. They are especially effective in stopping and reversing inflammation and fibrosis. The following is a selection based on their potential benefit and stage of development.

Obeticholic Acid

This is a semisynthetic derivate of chenodeoxycholic acid that works as agonist of farnesoid X receptor (FXR). It reduces the synthesis of bile acids in the liver, as well as lipogenesis and gluconeogenesis, and it stimulates beta-oxidation. In the FLINT study [45], compared obeticholic acid with placebo for 72 weeks; patients in the intervention arm had significant improvement in steatosis, inflammation, hepatocyte ballooning degeneration and fibrosis; a reduction in NAS ≥2 was obtained; higher than that observed in those who received placebo (45% vs. 21% RR 1.9 was achieved; 95% CI 1.3 - 2.8, $p < 0.0002$). A phase III study is currently underway to evaluate its impact on fibrosis. In the same way, similar analogues are in development. The main side effect that has been reported with this drug is pruritus, in up to 23% of those who received it, increased LDL and decreased HDL also have been observed.

Cenicriviroc

It is an antiretroviral that inhibits receptors 2 and 5 of chemokine CC, its use in HIV patients is also investigated; in preliminary studies it has shown good anti-inflammatory and anti-fibrotic effects. In the CENTAUR study [46], an interesting design with a two-year follow-up was implemented. The final results did not reveal significant changes in steatosis or ballooning injury; however, it is noteworthy to say that there was an improvement in fibrosis without NASH worsening and this one was well tolerated.

Elafibranor

It is a *PPAR-αδ* agonist with anti-inflammatory effect. Metabolically its main characteristic is to improve insulin sensitivity and glucose levels as well as to stabilize lipid metabolism. The GOLDEN-505 study showed a better effect in patients with basal NAS ≥ 4 and receiving a higher dose (120mg). In these patients improvement in aminotransferases, serum lipids, glucose and inflammatory markers with significant decrease in fibrosis stage were shown. Elafibranor was well tolerated, improved patient's cardiometabolic risk profile, but induced renal failure in seven patients [47].

Selonsertib

Preliminary reports in a murine model indicate that this inhibitor of the regulatory kinase of signal of apoptosis (ASK1) that promotes liver fibrosis has a good anti-fibrotic effect. This effect was confirmed in a controlled clinical trial that showed the best results among those who received a dose of 18 mg for 24 weeks, resulting in a reduction of ≥ 1 in the stage of fibrosis in 43% of the patients, and in 30% of those who received a lower dose (6mg) [48]. It was also studied in combination with GS-0976 an Acetyl-coA carboxylase (ACC) inhibitor to block the synthesis of fatty acids and reduce steatosis, with good results confirmed by Magnetic Resonance proton density fat fraction (MRI-PDFF) [49]. The phase III trial STELLAR 3 and 4 currently investigates its safety and effectiveness [50].

Emricasan

This drug inhibits caspase and has an anti-apoptotic effect. Preliminary reports found encouraging results with good anti-fibrotic effect in murine models. Currently phase II studies are running in patients with NASH and fibrosis [51].

Aramchol

This drug is a combination of arachidonic and cholic acids, it reduces the synthesis of fatty acids and triglyceride deposits and promotes the intracellular elimination of cholesterol. In a 3-month follow-up study Magnetic Resonance Spectroscopy confirmed that it effectively reduced hepatic steatosis. The drug was well tolerated and no significant side effects were reported [52], a phase IIb study is currently underway [53]. Aramchol has been granted a Fast Track designation status by the FDA for the treatment of NASH.

Combined Treatments

The inherent complexity of the NAFLD's pathophysiology suggests that it is unlikely that a single drug will achieve the best result. Hence, the individualization of treatment through the combination of drugs that allow us to intervene at different metabolic levels is required to stop the progression of the disease and reverse the present damage.

Currently there are few reports of this mixed therapy. An example is the combination of Selonsertib with Sintuzumab, reported by Loomba in a small group of patients; it showed that Sintuzumab achieved an improvement of ≥ 1 in fibrosis stage when combined with Selonsertib (6mg) in up to 40% of patients, compared with only 13% of those who were allocated to Sintuzumab alone [54].

There are other reports for the combination of vitamin E and vitamin C, in theory this dual therapy has the potential to reduce hepatic fibrosis [55]. Also, the combination of sitagliptin and losartan in a murine model was able to inhibit progression of disease [56].

These reports are preliminary and the currently available results for these combinations lack enough evidence to support its clinical use. Controlled design studies with high quality scientific evidence in larger groups of patients are necessary to have solid clinical claims.

CONCLUSION

The alarming increase in the worldwide number of patients with NAFLD demands drugs that offer useful healing alternatives. However, since this is primarily a metabolic disease (associated with other components of the MetS) the variability of its clinical phenotypes is widespread and this limits the use of a universal drug in all patients. On the other hand, the better knowledge of the multiple and complex pathophysiology of this disease has allowed to develop multiple therapeutic proposals with encouraging results. However, until now, none of them has been approved by the main regulatory agencies.

The best result so far has been obtained with diet and physical activity supervised by professionals, this promotes the reduction of body weight and metabolic stabilization. Both interventions are recommended in patients with NAFL and with NASH.

The use of pharmacotherapy is only for patients with NASH in very specific contexts. Pioglitazone and vitamin E can be used, since they have shown acceptable results according

to various guides and consensus. Other medications that have been proposed in preliminary studies, did not confirm their apparent benefits when subjected to more rigorous research methods. Therefore, today they are not recommended for the treatment of NASH; this is the case of metformin, omega-3 fatty acids and ursodeoxycholic acid.

Other novel medications have shown encouraging results with positive effects in basic science studies or small clinical trials; studies with a larger number of patients and a more rigorous methodology are expected to confirm their usefulness. Pirfenidone, liraglutide, silymarin, and probiotics are the most relevant of this group.

Finally, there is a very interesting group of drugs currently undertaking formal studies, with optimistic their initial results. The most relevant are obeticolic acid, cenicriviroc, elafibranor, selonsertib and aramchol. Almost all of them are in phase II and III studies, whose final reports are expected in the coming months.

Given the complexity of this disease, and the diverse clinical scenarios that each patient represents, combined treatment of two, or more drugs is emerging as the most viable therapeutic strategy. For now, in general terms, we hold that diet and exercise have proved useful in most cases and that the future with drug therapy is optimistic. Most likely we will have to combine them depending on each patient comorbidities. That is, we will have to make a suit tailored to each of our patients to achieve metabolic control, stop the progression of the disease, and reverse established liver damage as much as possible.

REFERENCES

[1] Ludwig, J; Viggiano, TR; McGill, DB; Ott, BJ. Nonalcoholic steatohepatitis, Mayo Clinc experience with a hitherto unnamed disease. *Mayo Clin Proc*, 1980, 55, 434-8.

[2] Ratziu, V; Bellentani, S; Cortez-Pinto, H; et al. A position statement on NAFLD/NASH based on the EASL 2009 special conference. *J Hepatol*, 2010, 53, 372-84.

[3] Ong, JP; Younossi, ZM. Epidemiology and Natural History of NAFLD and NASH. *Clin Liv Dis*, 2007, 11, 1-16.

[4] Angulo, P; Kleiner, DE; dam Larsen, S; et al. Liver fibrosis, but no other histologic features, is associated with long-term outcomes of patients with nonalcoholic fatty liver disease. *Gastroenterology*, 2015, 149(2), 389-97.

[5] Bernal-Reyes, R; Castro-Narro, G; Malé-Velázquez, R; et al. The Mexican Consensus on Nonalcoholic Fatty Liver Disease. *Rev Gastroenterol Mex*, 2019, 84(1), 69-99.

[6] Younes, R; Bugianesi, E. NASH in Lean Individuals. *Semin Liver Dis*, 2019, 39, 8695.

[7] Ohkawara, K; Tanaka, S; Miyachi, M; et al. A dose-response relation between aerobic exercise and visceral fat reduction: systematic review of clinical trials. *Int J Obes*, 2007, 31(12), 1786-1797.

[8] Vilar-Gomez, E; Martinez-Perez, Y; Calzadilla-Bertot, L; et al. Weight loss through lifestyle modification significantly reduces features of non-alcoholic steatohepatitis. *Gastroenterology*, 2015, 149, 367-78.

[9] Vos, MB; McClain, CJ. Fructose takes a toll. *Hepatology*, 2009, 50(4), 1004-06

[10] Brea, A; Pintó, X; Ascaso, JF; et al. Non-alcoholic fatty liver disease, association with cardiovascular disease and treatment (II). *Clin Investig Arterioscler*, 2017, 29, 185-200.

[11] Chalasani, N; Younossi, Z; Lavine, JE; et al. The diagnosis and management of non-alcoholic fatty liver disease: Practice guideline by the American Association for the Study of Liver Diseases, American College of Gastroenterology, and the American Gastroenterological Association. *Am J Gastroenterol*, 2012, 107, 811-26.

[12] Grosso, G; Mistretta, A; Frigiola, A; et al. Mediterranean diet and cardiovascular risk factors: a systematic review. *Crit Rev Food Sci Nutr*, 2014, 54, 593-610.

[13] European Association for the Study of the Liver (EASL), European Association for the Study of Diabetes (EASD), European Association for the Study of Obesity (EASO), EASL-EASD-EASO Clinical Practice Guidelines for the management of non-alcoholic fatty liver disease. *J Hepatol*, 2016, 64, 1388-402.

[14] Yki, Järvinen H. Nutritional modulation of non-alcoholic fatty liver disease and insulin resistance. *Nutrients*, 2015, 7(11), 9127-38.

[15] Gupta, L; Khandelwal, D; Kalra, S; et al. Ketogenic diet in endocrine disorders: Current Perspectives. *J Postgrad Med*, 2017, 63(4), 242-51.

[16] Romero-Gómez, M; Zelber-Sagi, S; Trenell, M. Treatment of NAFLD with diet, physical activity and exercise. *J Hepatol*, 2017, 67, 829-46.

[17] Hashida, R; Kawaguchi, T; Bekki, M; et al. Aerobic vs resistance exercise in non-alcoholic fatty liver disease: A systematic review. *J Hepatol*, 2017, 66, 142-152.

[18] Ueno, T; Sugawara, H; Sujaku, K; et al. Therapeutic effects of restricted diet and exercise in obese patients with fatty liver. *J Hepatol*, 1997, 27, 103-107.

[19] World Health Organization. *Global Recommendations on physical activity for health*. Geneva World Health Organization, 2010.

[20] Mazzella, N; Ricciardi, LM; Mazzotti, A; et al. The role of medications for the management of patients with NAFLD. *Clin Liver Dis*., 2014, 18, 73-89,

[21] Ratziu, V; Goodman, Z; Sanyal, A. Current efforts and trends in the treatment of NASH. *J Hepatol*, 2015, 62, S65-75.

[22] Sanyal, AJ; Chalasani, N; Kowdley, KV; et al. Pioglitazone, vitamin E, or placebo for nonalcoholic steatohepatitis. *N Engl J Med*., 2010, 362, 1675-85.

[23] Liss, KH; Flinck, BN. PPARs and non-alcoholic fatty liver disease. *Biochimie*, 2017, 136, 65-74.

[24] Aithal, GP; Thomas, JA; Kaye, PV; et al. Randomized, placebo-controlled trial of pioglitazone in nondiabetic subjects with nonalcoholic steatohepatitis. *Gastroenterology*, 2008, 135, 1176-84.

[25] Belfort, R; Harrison, SA; Brown, K; et al. A placebo controlled trial of pioglitazone in subjects with nonalcoholic steatohepatitis. *N Engl J Med*., 2006, 355, 2297-307.

[26] Cusi, K; Orsak, B; Bril, F; et al. Long-term pioglitazone treatment for patients with non-alcoholic steatohepatitis and prediabetes or type 2 diabetes mellitus: A randomized trial. *Ann Intern Med*, 2016, 165, 305-15.

[27] Lincoff, AM; Wolski, K; Nicholls, SJ; Nissen, SE. Pioglitazone and risk of cardiovascular events in patients with type 2 diabetes mellitus: a meta-analysis of randomized trials. *JAMA*, 2007, 298, 1180-8.

[28] Kernan, WN; Viscoli, CM; Furie, KL; et al. Pioglitazone after ischemic stroke or transient ischemic attack. *N Engl J Med*, 2016, 374(14), 1321-31.

[29] Tuccori, M; Filion, KB; Yin, H; et al., Pioglitazone use and risk of bladder cancer: Population based cohort study. *BMJ*, 2016, 352, i1541.

[30] Lewis, JD; Habel, LA; Quesenberry, CP; et al. Pioglitazone use and risk of bladder cancer and other common cancers in persons with diabetes. *JAMA*, 2015, 314, 265-77.

[31] Pop, LM; Lingvay, I; Yuan, Q; et al. Impact of pioglitazone on bone mineral density and bone marrow fat content. *Osteoporos Int*, 2017, 28, 3261-9.

[32] Lavine, JE; Schwimmer, JB; van Natta, ML; et al. Effect of vitamin E or metformin for treatment of nonalcoholic fatty liver disease in children and adolescents: The TONIC randomized controlled trial. *JAMA*, 2011, 305, 1659-68.

[33] Kowdley, KV; Van Natta, ML; Pai, RK, et al. Abstract 107: Efficacy and safety of vitamin E in nonalcoholic steatohepatitis patients with and without diabetes: Pooled analysis from the PIVENS and FLINT NIDDK NASH CRN Trials, *Hepatology*, 2015, 62(1Suppl), 264A.

[34] Miller, ER; Pastor-Barriuso, R; Dalal, D; et al. Meta-analysis: high-dosage vitamin E supplementation may increase all-cause mortality. *Ann Int Med*, 2005, 142(1), 37-46.

[35] Klein, EA; Thompson, IM; Jr. Tangen, CM; et al. Vitamin E and the risk of prostate cancer: The Selenium and Vitamin E Cancer Prevention Trial (SELECT). *JAMA*, 2011, 306, 1549-56.

[36] Dietrich, M; Jacques, PF; Pencina, MJ; et al. Vitamin E supplement use and the incidence of cardiovascular disease and all-cause mortality in the Framingham Heart Study: Does the underlying health status play a role? *Atherosclerosis*, 2009, 205, 549-53.

[37] Armstrong, MJ; Gaunt, P; Aithal, GP; et al. Liraglutide safety and efficacy in patients with non-alcoholic steatohepatitis (LEAN): A multicentre, double-blind, randomized, placebo-controlled phase 2 study. *Lancet*, 2016, 387, 679-90.

[38] Zeng, T; Zhang, CL; Zhao, XL; et al. Pentoxifylline for the treatment of nonalcoholic fatty liver disease: A meta-analysis of randomized double-blind, placebo-controlled studies. *Eur J Gastroenterol Hepatol*, 2014, 26, 646-53.

[39] Rakoski, MO; Singal, AG; Rogers, MA; et al. Meta-analysis: Insulin sensitizers for the treatment of non-alcoholic steatohepatitis. *Aliment Pharmacol Ther*, 2010, 32, 1211-21.

[40] Leuschner, UF; Lindenthal, B; Herrmann, G; et al. High-dose ursodeoxycholic acid therapy for nonalcoholic steatohepatitis: Adouble-blind, randomized, placebo-controlled trial. *Hepatology*, 2010, 52, 472-9.

[41] Musso, G; Gambino, R; Cassader, M; et al. A meta-analysis of randomized trials for the treatment of nonalcoholic fatty liver disease. *Hepatology*, 2010, 52, 79-104.

[42] Dasarathy, S; Dasarathy, J; Khiyami, A; et al. Double-blind randomized placebo-controlled clinical trial of omega 3 fatty acids for the treatment of diabetic patients with nonalcoholic steatohepatitis. *J Clin Gastroenterol*, 2015, 49, 137-44.

[43] Fernandez-Miranda, C; Perez-Carreras, M; Colina, F; et al. A pilot trial of fenofibrate for the treatment of non-alcoholic fatty liver disease. *Dig Liver Dis*., 2008, 40, 200-5.

[44] Basaranoglu, M; Acbay, O; Sonsuz, A. A controlled trial of gemfibrozil in the treatment of patients with non-alcoholic steatohepatitis. *J Hepatol*, 1999, 31, 384.

[45] Neuschwander-Tetri, BA; Loomba, R; Sanyal, AJ; et al. Farnesoid X nuclear receptor ligand obeticholic acid for non cirrhotic, non-alcoholic steatohepatitis (FLINT). A multicentre, randomized, placebo-controlled trial. *Lancet*, 2015, 385, 956-65.

[46] Friedman, S; Sanyal, A; Goodman, Z; et al. Efficacy and safety study of cenicriviroc for the treatment of non-alcoholic steatohepatitis in adult subjects with liver fibrosis: CENTAUR phase 2b study design. *Contemp Clin Trials*, 2016, 47, 356-65.

[47] Ratziu, V; Harrison, SA; Francque, S; et al. Elafibranor, an agonist of the peroxisome proliferator-activated receptor alpha and delta, induces resolution of nonalcoholic steatohepatitis without fibrosis worsening. *Gastroenterology*, 2016, 150, 1147-59, e5.

[48] Loomba, R; Lawitz, E; Mantry, PS; et al. The ASK1 inhibitor selonsertib in patients with nonalcoholic steatohepatitis: A randomized, phase 2 trial. *Hepatology*., 2017, 67(2), 549-59.

[49] Lawitz, E; et al. Proof of concept study of an apoptosis-signal regulating kinase (ASK1) inhibitor (selonsertib) in combination with an acetyl-CoA carboxylase inhibitor (GS-0976) or a farnesoid X receptor agonist (GS-9674) in NASH. *J Hepathology*, 2018, 68, S57.

[50] Clinical Trials. gov. *Safety and Efficacy of Selonsertib in Adults With Compensated Cirrhosis Due to Nonalcoholic Steatohepatitis (NASH) (STELLAR 4).*

[51] Clinical Trials.gov. *Emricasan, a Caspase inhibitor, for evaluation in subjects with non-alcoholic steatohepatitis (NASH) Fibrosis (ENCORENF),* https://clinicaltrials. gov/ct2/ show/NCT02686762.

[52] Safadi, R; Konikoff, FM; Mahamid, M; et al. The fatty acid-bile acid conjugate Aramchol reduces liver fat content in patients with nonalcoholic fatty liver disease. *Clin Gastroenterol Hepatol*, 2014, 12, 2085-91.

[53] Clinical Trials.gov. *A Clinical Trial to Evaluate the Efficacy and Safety of Two Aramchol Doses Versus Placebo in Patients with NASH*, https://clinicaltrials.gov/ct2/ show/NCT02279524.

[54] Loomba, R; Lawitz, E; Parvez, S; et al. GS-4997, an Inhibitor of Apoptosis Signal-Regulating Kinase (ASK1), Alone or in Combination with Simtu-zumab for the Treatment of Nonalcoholic Steatohepatitis (NASH): A Randomized, Phase 2 Trial. *Hepatology*, 2016, 64(6), Suppl. 119A-120.

[55] Harrison, SA; Torgerson, S; Hayashi, P; et al. Vitamine E and vitamine C treatment improves fibrosis in patients with nonalcoholic steatohepatitis. *Am Gastroenterol*, 2003, 98(11), 2485-90.

[56] Okura, Y; Namisaki, T; Moriya, K; et al. Combined treatment with dipeptidyl peptidase-4 inhibitor (sitagliptin) and angiotensin-II type 1 receptor blocker (losartan) suppresses progression in a non-diabetic rat model of steatohepatitis. *Hepatol Res*, 2017, (47), 12, 1317-28.

In: Encyclopedia of Surgery (22 Volume Set)
Editors: Andreas Lehrer and Kristin Mueller
ISBN: 978-1-53618-329-0
© 2020 Nova Science Publishers, Inc.

Chapter 317

THE USE OF GROIN FLAP FOR UPPER EXTREMITY COVERAGE IN ELECTRICAL BURN PATIENTS: EVIDENCE-BASED CASE REPORTS

Nathania Pudya*[*], *Aditya Warhana and Erythrina Permatasari
Division of Plastic Surgery, Department of Surgery, RSUPN Dr. Cipto Mangunkusumo, Universitas Indonesia, Jakarta, Indonesia

ABSTRACT

Electrical burn injuries commonly occur in the extremities, particularly on the wrists, forearms, and hands. In high-voltage burns, the injury extends deeply and damages the underlying tissue, resulting in tissue ischemia and subsequently, a high probability of extensive tissue necrosis. In electrical burn injuries, nonvital tissue debridement and adequate defect closure determines the outcome of limb salvage. Clarification of the advantages of groin flap use for soft tissue defect closure is required to assist medical practitioners in deciding if groin flap should be considered as an option for upper limb reconstruction due to electrical burns. Two cases of electrical burn injuries to the extremities with two-stage reconstructive surgery using groin flap were reported. We questioned clinically whether a two-stage surgical method affected the morbidity of patients with electrical burns and investigated the correlation between the type of flap harvesting (delayed and non-delayed groin flap) and flap vitality. We also performed a literature search for relevant information regarding the use of groin flap in electrical burns injury using PubMed, ClinicalKey, and Google and initially identified 56 articles. After screening, the application of inclusion and exclusion criteria, and full-text reading, the three remaining articles were appraised in terms of validity, importance, and applicability. According to the literature, the timing of the reconstruction did not appear to affect flap survival and outcome. Moreover, fasciocutaneous flaps are relatively thin, making them ideal for coverage in regions with exposed tendon and bony structure. One study has revealed that the use of fasciocutaneous flaps to cover defects of an acutely burned hand showed a low infection rate comparable with that of muscle flaps, despite the argumentation of a greater susceptibility to infection in comparison to muscle flaps due to a comparatively inferior vascular plexus. No evidence was found from our search

[*] Corresponding Author's Email: nathaniapudya@gmail.com.

of global literature indicating whether the time of flap harvesting affects flap vitality. In conclusion, the use of groin flap as distant pedicle flaps provided an alternative in cases where free flap reconstruction was impossible. The pathophysiology of vascular occlusion causes progressive necrosis of tissue in electrical burn injuries unrelated to the timing of reconstructive surgery. It is critical to debride nonvital soft tissue without jeopardizing the vital structures underlying the burn wound. Although the pliable characteristics that are possessed by groin flap are required to cover small cross-sectional diameter anatomic regions such as the wrist, its bulky appearance requires secondary reconstruction to thin the flap.

Keywords: electrical injury, groin flap, superficial circumflex iliac artery flap, upper extremity, reconstruction

BACKGROUND

Electrical burn injuries are associated with high morbidity and commonly occur in the upper extremities, particularly the wrists, forearms, and hands. The injury extends deeply into the underlying tissue causing tissue damage, thereby resulting in ischemia and subsequently, a high probability of extensive tissue necrosis.

The passage of an electrical current produces heat, leading to tissue damage. Because the current is transmitted along the path of least resistance through the body, it flows along neurovascular bundles. This causes extensive damage that involves the nerves, blood vessels, muscle, skin, tendon, and fat all the way through to the underlying bone. Bones retain the most body heat and possess the highest electrical resistance, particularly in the periosseous tissue such as that between two bones (e.g., tibia–fibula and radius–ulna). This is a contributing factor to delayed vascular occlusion and progressive tissue necrosis [1].

The cross-sectional diameter area of the involved body part affects its resistance and the magnitude of tissue damage. The wrist is an undersized cross-sectional area with tendon and bony structure areas that are highly resistant to heat and more severe damage. The peripheral nerve in minimal cross-sectional areas is located in close proximity to the bone and fibrous tissue. Therefore, an electrical injury is likely to lead to thrombosis of the perineural region, causing compression syndrome of the peripheral nerves. An experimental study conducted by Jia-ke et al., (2009) has shown irreversible vascular damage post burn injury via optical microscopy that was marked by the necrosis of the vascular walls and thrombosis along the areas of arterial endothelium destruction as well as pyknosis of vascular muscle with the presence of fibrinous exudates. Moreover, muscle viability progressively decreased between 30 min to 72 h after the injury, explaining the appearance of degeneration necrosis in certain muscle cells due to coagulation accompanied by myolysis [2].

Reconstructive surgery of electrical burn injuries is divided into primary and secondary stages. Vogt et al., [4] have described primary reconstruction as the surgical procedures performed in the early phases of the burn injury to decrease infection and improve wound healing. These procedures involve the debridement of devitalized tissue and wound closure using stepladder reconstruction (from skin grafting to free flap). In contrast, secondary reconstruction is performed after the burn wounds have healed to enhance the function and aesthetics of the injured area, such as burn scar contracture release [3].

The timing of debridement remains controversial, with several studies both for and against performing treatment during the acute phase. Some literature suggests that primary reconstructive surgery should be performed within the first 3 weeks following an electrical burn injury because the passage of electric current causes vascular changes similar to ischemia–reperfusion injury, which disturbs the capillary blood flow and results in progressive tissue necrosis. Furthermore, several studies have hypothesized that less secondary reconstruction is required if there is an early coverage of exposed functionally important structures during the acute phase [4], [5].

The use of a distant flap, such as groin flap, may be considered as a substitution for free microvascular tissue transfer for the coverage of raw surfaces and important underlying tissue structures in the wrist. The groin flap is an axial fasciocutaneous flap vascularized by the superficial circumflex iliac artery. The artery is located parallel and approximately 2–3 cm distal to the inguinal ligament, able to cover an area of skin between 5 cm inferior and superior to the artery and approximately 5 cm above the anterior superior iliac spine. In cases of extensive coverage, a flap may be raised based upon the adjacent superficial epigastric artery [6]. We present a case series of electrical burn patients with wrist defects that were treated using an axial groin flap and propose this as an alternative method to free flap reconstruction.

CLINICAL QUESTION

According to a case series of electrical burn patients and evidence-based medicine, we posed the following clinical questions: 1) Does the two-stage surgical method affect the morbidity of electrical burn patients? and 2) Does the time of flap harvesting (delayed and non-delayed groin flap) affect flap vitality?

METHODS

Literature Review

We performed a database search of PubMed, ClinicalKey, and Google on May 30, 2019The databases were searched using the Medical Subject Headings (MeSH) terms “Electric Burn Injuries,” “Groin Flap,” “Superficial Circumflex Iliac Flap,” “Upper Extremities,” and “Reconstruction” (Table 1). Inclusion criteria were English literature; adult populations with electrical burn injury in the upper extremities; the provision of preoperative, intraoperative, and follow-up postoperative data; and studies with distant flap intervention. We excluded studies concerning non-burn injury populations, the single intervention of local flap or free microvascular flap surgery, surgical intervention in areas other than the upper extremities, and pediatric populations. Following a full-text reading of the initial screening results, one study of anon-burn injury population was excluded because it was not comparable with the other screened studies (Figure 1).

Table 1. Search strategy used to perform a database search on July 30, 2016

Search Engine	Search Term
PubMed	(“electric injuries”[MeSH Terms] OR (“electric”[All Fields] AND “injuries”[All Fields]) OR “electric injuries”[All Fields] OR (“electrical”[All Fields] AND “injury”[All Fields]) OR “electrical injury”[All Fields]) AND (“groin”[MeSH Terms] OR “groin”[All Fields]) AND (“surgical flaps”[MeSH Terms] OR (“surgical”[All Fields] AND “flaps”[All Fields]) OR “surgical flaps”[All Fields] OR “flap”[All Fields]) AND superficial[All Fields] AND “circumflex”[All Fields] AND (“iliac artery”[MeSH Terms] OR (“iliac”[All
PubMed	Fields] AND “artery”[All Fields]) OR “iliac artery”[All Fields]) AND (“surgical flaps”[MeSH Terms] OR (“surgical”[All Fields] AND “flaps”[All Fields]) OR “surgical flaps”[All Fields] OR “flap”[All Fields]) AND (“upper extremity”[MeSH Terms] OR (“upper”[All Fields] AND “extremity”[All Fields]) OR “upper extremity”[All Fields]) AND (“reconstructive surgical procedures”[MeSH Terms] OR (“reconstructive”[All Fields] AND “surgical”[All Fields] AND “procedures”[All Fields]) OR “reconstructive surgical procedures”[All Fields] OR “reconstruction”[All Fields])
ClinicalKey	electrical injury, groin flap, superficial circumflex iliac artery flap, upper extremity, reconstruction
Google	electrical injury, groin flap, superficial circumflex iliac artery flap, upper extremity, reconstruction

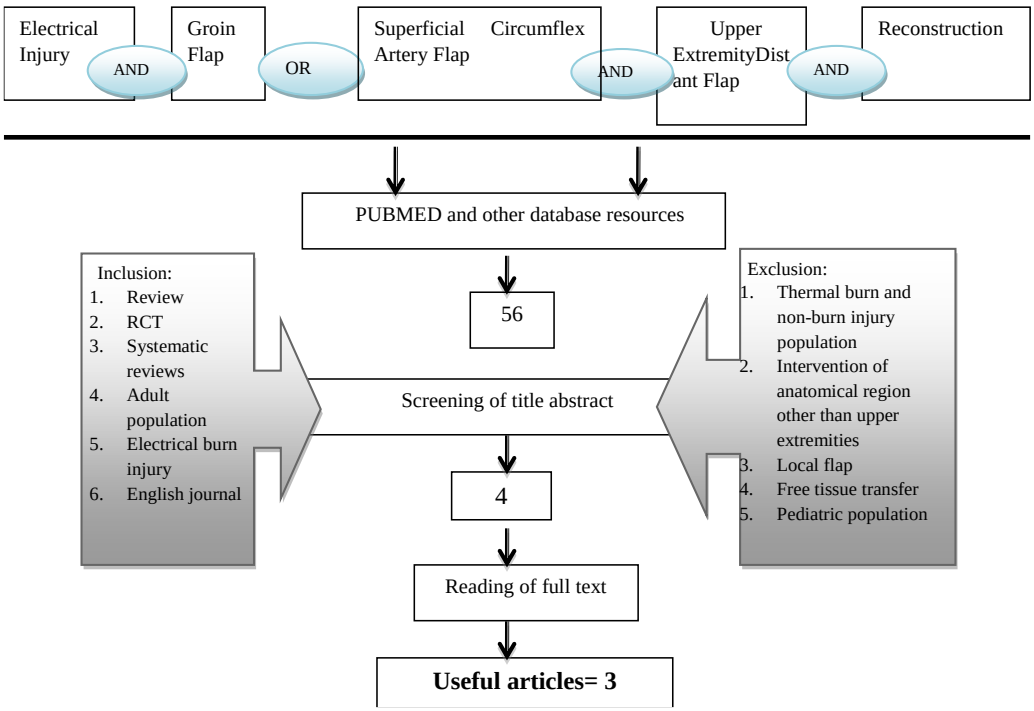

Figure 1. Flow diagram of search strategy of literature performed on July 30, 2016.

Case Studies

We evaluated two case studies of electrical burn injury to the upper extremities with groin flap reconstruction.

RESULTS

Literature Review

The literature search identified three articles meeting our criteria for appraisal. There were one systematic review and two cohort studies, both valued as high-level evidence. Table 1 presents a critical appraisal of the articles. Handschin et al., study [6] included 68 patients with electrical injury, of which 40 suffered from low-voltage electrical burns. Mean burn wound size was 33% ± 22% of the total body surface area, and90% of cases involved the upper extremities. There were three cases wherein the groin flap was used to cover defects in the upper extremities. This study has suggested series debridement for the removal of visible necrotic tissue aggressively followed by immediate reconstruction. Microvascular thrombosis as an indication of flap failure appeared during the first 4 weeks. No information was provided regarding the type of groin flap performed in this study, and there was no history of bleeding reported in the patients undergoing the groin flap re-construction.

Case 1

A 32-year-old male presented at the emergency room with a chief complaint of electrical burn injury in both wrists and lower extremities that had occurred 2 weeks prior. There was no history of trauma, loss of consciousness, or fever. Fasciotomy and excisional debridement had already been performed twice at another hospital.

A raw surface sized 6.5 × 9.5 cm in the left wrist and 3 × 4.5 cm in first web space were noted. The underlying structure was difficult to identify due to eschar and necrotic tissue appearance in the wrist. The raw surface in the first webspace showed a subdermal wound bed with granulation tissue, and the proximal phalanx of the first digit was visible. The range of movement in the hands was limited due to pain and stiffness (Figure 2).

Radiographic findings revealed bilateral soft tissue swelling in the fascia antebrachii. There was subluxation of metacarpophalangeal digit 1 to the radial side and a closed incomplete fracture of the proximal phalanx digit 1 in the left hand. Destruction of the metadiaphysiscortex of the distal right ulnar bone was detected on the anteromedial side with a lytic lesion in the epidiaphysis. There appeared to be periostitis in the metadiaphysis of the distal radius and ulnar joint (Figure 3).

The patient was diagnosed with a deep dermal electrical burn injury of > 9% of the total burn surface area with 2% raw surface. The debridement of nonvital structures, such as tendons (flexor system), muscle, and fat tissues, was performed 20 days after the burn injury (Figure 4). The ulnar artery was identified as compromised owing to thrombosis; however, adequate vascularization was sourced from the radial artery.

Figure 2. First clinical presentation of a 32-year-old male with bilateral electrical burn injury and raw wrist surfaces.

Figure 3. The radiographic findings reveal the appearance of osteomyelitis in the ulnar bone with marked periostitis in the distal region of the right radial bone (left). Subluxation of the left proximal phalange digit 1 to the radial side with an incomplete fracture of the proximal phalange of the left hand (right) is observed.

Figure 4. Post debridement (left) and post bilateral groin flap surgery (right).

Figure 5. Post groin flap surgery, the remaining raw surface was covered with a split-thickness skin graft.

Groin flap coverage of the bilateral raw surface was performed 5 days after debridement surgery (Figure 5). Due to the extensive circumference of the right wrist, the flap inset was delayed until blood flow to the distal portion was adequate. The right groin flap surgery was performed 10 days after the second procedure. The left side groin flap was separated at 21 days and the right-side groin flap at 11 days post debridement surgery. The evaluation of flap vitality was performed intraoperatively, and good vascularization of both flap pedicles was confirmed. A split-thickness skin graft was performed to achieve closure of the raw surface in the digit 1 of the left hand and the remaining raw surface proximal to the left groin flap. Owing to the instability of the distal radius–ulna joint, a transfixion wire was applied by an orthopedic surgeon.

Case 2

A 25-year-old male was diagnosed with a deep dermal electrical burn injury to his left hand that covered 2% of his total body surface area. The injury occurred 10 days prior to hospital admission. There was no history of trauma or loss of consciousness. A raw surface (8 × 4 cm) in the central palm of the hand extending from the proximal palmar crease to distal of the insertion of the flexor digitorum superficial to digits 2–5 in the left hand was present. Another raw surface covered two-thirds of the circumference of the left wrist region. Exposure of underlying soft tissue (tendons and fascia) with granulation tissue was noted in the digits and wrist (Figure 6). The patient underwent debridement of nonvital structures between flexor zone 1 and 3, including flexor tendons, muscle, and fat tissues. Vascularization was found adequate from the radial artery, because of the non-vitality of the ulnar artery.

A left delayed groin flap closure of the raw wrist surface and a full-thickness skin graft was performed at day 13 post burn injury (Figure 7). An intraoperative evaluation of flap vitality showed good vascularization of the flap pedicle. At day 31, the patient underwent separation of the left delayed groin flap. During the postoperative evaluation, the flap showed no wound dehiscence or infection. However, a skin contraction due to healing of the full-thickness skin graft was observed.

Figure 6. First clinical presentation of a 25-year-old male with electrical burn injury covering two-thirds of the circumference of the left wrist and between the central palm of hand to the site of flexor digitorum superficial insertion.

Figure 7. Left delayed groin flap closure at day 13 (left). Post separation of left groin flap (right).

DISCUSSION

Appraised articles are a systematic review and cohort studies, thus it valued as high-level evidences. Figure 2 shows critical appraisal of the articles. Handschin study [5] include 68 patients due to electrical injury and 40 burn patient has low voltage electric burn, with mean size of burn wound 33 +/- 22% of TBSA with commonly involved upper extremities (90%). Total of three groin flap were used to cover defect in upper extremity. This study suggests series debridement for removal visible necrotic tissue aggressively followed by immediate reconstruction. Microvascular thrombosis as failure of flap appeared during the first 4 weeks. No information provided regarding type of groin flap performed in this study, however no history of bleeding reported in the groin flap patient.

Barillo et al., have described six cases of patients with severe hand burns. Three of them underwent primary reconstruction surgery using groin flap to cover the distal regions and fingers. This was followed by liposuction and defatting during the secondary reconstruction procedure at a later stage to decrease the bulkiness of the groin flap. The success rate varied from 50% to 100% flap viability. The Barillo study chose to perform immediate coverage using local, fascial, or fasciocutaneous flaps as well as distant flaps [6].

Jabir et al., have highlighted 12 cases of burn injury that included one patient with electrical burn in whom groin flap reconstruction was performed 4 days post injury. The failure rates were lowest when performed either during the immediate stage (within 5 days of injury) or within the intermediate stage (3 weeks after injury) and were highest when performed during the early stage (15–21 days after injury) [7]. Sabapathy et al., marked secondary reconstruction should be performed in about 6 to 8 weeks after the flap inset consideredema in the flap and induration at the suture line is settled, therefore flap becomes supple and the induration at the suture line reduced [8].

Flap failure was related to inadequate early debridement rather than the timing of reconstruction, and the timing did not appear to affect flap survival and outcome. Fasciocutaneous flaps are relatively thin, making them ideal for coverage in regions with exposed tendon and bony structures. This study revealed that the use of fasciocutaneous flaps to cover acute burn defects of hands demonstrated a low infection rate comparable with that of muscle flaps, despite the argumentation that a greater susceptibility to infection in comparison with muscle flaps would be caused by the comparatively inferior vascular plexus. No global evidence was found in the literature regarding whether the type of flap harvesting affected flap vitality.

Delayed groin flap has disadvantages as multi stage surgery procedure such as immobility of the hand, elbow, and shoulder that will lead to stiffness and edemaformation of the flap and upperextremity as a result of the dependent hand position [9,10]. Graf et al., study highlight decrased mobility of joint in arm, increased with patient'sage [11], furthermore patient aged younger than 50 years hadless likely develop permaent problem with shoulder or elbow mobility. Evaluation post separation flap in mobility of shoulder and elbow joints compared to non injured side in both of patients showed no limitation in movement. Both patient were able to lift hand over 90 degrees and no complained to do daily activities.

Table 2. Evidence-based case report review

	Barillo (2001)	Handschin (2009)	Jabir(2014)
Design	Case series	Case series	Systematic review
Location	America	Zurich	Essex
Population	14-64 years adult population	A 53 yr male, chinese	A 52 yr female, chinese
Anatomical region	Upper extremities injury lower extremities injury	Upper extremitiy	Upper extremity Head and neck Lower extremitiy
Intervention	Groin flap as primary reconstruction	Groin flap as primary reconstruction procedure,	Groin flap with immediate (<5 days), early (5–22 days) and intermediate (23 days–6 weeks) post injury
Outcome	Two stage reconstruction surgery	Multiple stage surgery with serial debridement	Two stage reconstruction , primary reconstruction less than 5 days

CONCLUSION

The use of groin flap as distant pedicle flaps in cases of electrical burn injury provides an alternative when free flap reconstruction cannot be performed. In electrical burn injury, flap compromise is unrelated to the timing of the reconstruction surgery and caused by the pathophysiology of vascular occlusion and progressive tissue necrosis.

The ability to debride nonvital soft tissue without jeopardizing vital structures underlying the burn wound is critical. Pliable characteristics, such as those of groin flap, are required when covering small cross-sectional diameter anatomic regions such as the wrist. However, due to its bulky appearance, secondary reconstruction will be required to thin the groin flap.

REFERENCES

[1] Hunt, J.L., McManus, W.F., Haney, W.P., Pruitt, B.A., Vascular lesions in acute electric injuries. *J. Trauma,* 1974; 14, 461-473.

[2] Jia-ke, C., Li-gen, L., Quan-wen, G., Xiao-peng, S., Hai-jun, Z., Zhi-yong, S., Zhi-qiang, W., Cai, Z. Establishment of soft-tissue-injury model of high-voltage electrical burn and observation of its pathological changes. *Burns,* 2009; 35, 1158-1164.

[3] Arnoldo, B.D., Hunt, J.L., Sterling, J.P., Purdue, G.F. Chapter 38: Electrical Injuries. In: Herndon, D.N.(Ed.), *Total Burn Care.* Saunders; 2012; 433-439.

[4] Vogt, P.M., Niederbichler, A.D., Jokuszies, D. Electrical injury: Reconstructive problems. In: Herndon, D.N. (Ed.), *Total Burn Care.* Saunders; 2012; 441-448.

[5] Handschin, A.E., Vetter, S., Jung, F.J., Guggenheim, M., Künzi, W., Giovanoli, P. A case-matched controlled study on high-voltage electrical injuries vs thermal burns. *J. Burn Care Res.,* 2009; 30, 400-407.

[6] Barillo, D.J., Arabitg, R., Cancio, L.C., Goodwin, C.W. Distant pedicle flaps for soft tissue coverage of severely burned hands : an old idea revisited. *Burns,* 2001;27:613-619.

[7] Jabir, S., Frew, Q., El-Muttardi, N., Dziewulski, P. A systematic review of the applications of free tissue transfer in burns. *Burns,* 2014; 40, 1059-1070.

[8] Strauch, B.,Vasconez, L.O., Hall-Findley, E.J.(Eds.). *Grabb's Encyclopedia of Flaps, Volume II: Upper Extremities.* Boston: Little Brown; 1990.

[9] Arner M, Moller. Morbidity of the pedicled groin flap. A retrospective study of 44 cases. *Scand J Plast Reconstr Surg Hand Surg.*, 1994; 28(2): 143-146.

[10] Goertz, O., Kapalschinski, N., Daigeler, A., et al. The effectiveness of pedicled groinflaps in the treatment of hand defects: Results of 49 patients. *J Hand Surg Am*., 2012;37(10):2088-2094.

[11] Graf, P., Biemer, E. Morbidity of the groin flap transfer: are we gettingsomething for nothing. *Plast Reconstr Surg*., 1992;45:86-88.

In: Encyclopedia of Surgery (22 Volume Set)
Editors: Andreas Lehrer and Kristin Mueller
ISBN: 978-1-53618-329-0
© 2020 Nova Science Publishers, Inc.

Chapter 318

AUTOPSY OF AORTIC DISSECTION AFTER TEVAR INSTALLATION: A CASE REPORT

Yuli Budiningsih and Insil P. Hariyani*
Department of Forensic Medicine and Medicolegal Studies,
Cipto Mangunkusumo National Hospital,
Universitas Indonesia, Jakarta, Indonesia

ABSTRACT

Aortic dissection is a condition in which there is a tear in the aorta's tunica intima layer, leading to separation between the tunica intima and the tunica media, forming a false lumen. The incidence of aortic dissection is reportedly 5–30 cases per 1 million people per year. Thoracic endovascular aortic repair (TEVAR) is a recommended first-line therapy for patients with type B aortic dissection. The reported 30-day mortality rate and major complication rate with TEVAR are 5%–7% and 8%–10%, respectively. We report an autopsy of a 60-year-old German man diagnosed with Stanford type B (DeBakey type III) aortic dissection who underwent a debranching aorto-innominate-carotid graft (Y-graft) and TEVAR surgery. The external examination revealed postsurgical scars on the chest and left inguinal region along with injection marks on both upper extremities. The internal examination revealed blood inside the thorax; heart filled with blood and blood clots; cardiac enlargement; a constricted left coronary artery; an aortic wall laceration; separation of the tunica intima from the tunica media and adventitia throughout the ascending, descending, and abdominal aorta, forming a false lumen containing blood clots; atherosclerosis; and signs of damaged internal organs. There were some vascular Y-graft anastomoses from the ascending aorta to the end of the brachiocephalic artery and just before the branching of the left common carotid and left subclavian arteries. There was also an endovascular graft in the aortic lumen from the aortic arch to the thoracic aorta. Histopathological examination revealed an acute myocardial rupture, atherosclerosis in the left coronary artery, dissection of the aorta accompanied with erythrocyte infiltration in the aortic wall, and signs of internal organ congestion.

* Corresponding Author's Email: insil.pendri@yahoo.com.

Keywords: aortic dissection; acute myocardial infarction; thoracic endovascular aortic repair.

INTRODUCTION

Acute aortic dissection is an age-related cardiovascular disease that has high morbidity and mortality due to complications. Autopsy studies confirm that acute aortic dissection is a life-threatening pathological state [1].

In recent years, 5–30 cases of aortic dissection per 1 million people have been reported annually [2,3]. Population-based studies have confirmed approximately three cases of aortic dissection per 100,000 people per year [1,4]. There are at least 7,000 cases per year in the United States [2].

Thoracic endovascular aortic repair (TEVAR) has recently emerged as the first-line approach for patients with type B aortic dissection. A 30-day mortality rate of 5%–17% and a major complication rate of 8%–10% after installation of TEVAR, have been reported [5].

CASE REPORT

On May 15th, 2017, the Department of Medical Forensic and Medicolegal Studies CMNH received a request from the German Embassy to perform a clinical autopsy on the body of a 60-year-old German man who had died after hospitalized at another hospital.

According to the medical resume, the man was diagnosed with Stanford type B (DeBakey type III) aortic dissection and had been treated for 15 days. His general physical examination revealed that his blood pressure was 190/96 mmHg, his pulse rate was 106 beats/minute, and his respiratory rate was 18 times/minute. The patient had undergone a Y-graft and TEVAR procedures.

The external examination took place on May 15th, 2017, at 16.45 Western Indonesian Time, while the body was still frozen. There were postoperative incision scars on the chest and left inguinal region, along with some needle tracks on both upper extremities.

An internal examination took place on May 15th, 2017, at 18.55 Western Indonesian Time. The examination revealed: 670 and 200 ml of blood inside the right and left thorax, respectively; an opened pericardial sac containing 130 ml of blood and 250 g of blood clots; heart enlargement; constriction of up to 75%–85% of the left coronary artery lumen; two irregular lacerations in the aortic arch (1 cm) and the descending aorta (2 cm), surrounded by infiltrated blood; separation of the tunica intima from the tunica media and adventitia throughout the ascending, descending, and abdominal aorta, forming a false lumen containing blood clots; atherosclerosis along the aortic arch to the abdominal aorta; and some signs of organ damage, such as pulmonary edema and aneurysms in the brain, digestive tract, liver, kidneys, and bladder. There were some vascular Y-graft anastomoses from the ascending aorta to the end of the brachiocephalic artery and just before the branching of the left common

carotid and the left subclavian artery. There was also an endovascular graft in the aortic lumen from the aortic arch to the thoracic aorta.

Histopathological examination revealed an acute myocardial rupture, erythrocyte infiltration, aortic dissection, atherosclerosis in the left coronary artery, and damage to the brain, lungs, liver, and lymph nodes.

DISCUSSION

Aortic dissection is a condition in which the tunica intima and the tunica media of the aorta separate and form a false lumen due to a laceration in the tunica intima. The International Registry of Acute Aortic Dissection reported the incidence of aortic dissection was highest during the sixth and seventh decades and mostly involved 62-year-old men. The incidence was more than twice as high in men than in women (68% vs. 32%). Likely, younger patients were also susceptible; the average age of male and female patients was 60 and 67 years, respectively. Seventy-five percent of patients, including the patient in our study, had a history of hypertension [4,6].

Three main systems are used to classify aortic dissection: DeBakey types I, II, and III; Stanford types A and B; and proximal and distal aortic dissection. The classifications are based on where the laceration in the tunica intima of the aortic wall and the false lumen are located. DeBakey type I is an aortic dissection in which the laceration is located in the ascending aorta and the false lumen is found along the aortic arch. In DeBakey type II, only the ascending aorta is involved. In DeBakey type III, the laceration is in the tunica intima in the descending aorta without involvement of the aortic arch and the ascending aorta. DeBakey type III has two subtypes. In subtype IIIa, the laceration is located only in the thoracic aorta; in subtype IIIb, the laceration also involves the abdominal aorta [1,7].

Stanford type A aortic dissection is located in the ascending aorta (DeBakey types I and II); Stanford type B aortic dissection is located in the descending aorta (DeBakey type III) [1,7].

A recent classification divides aortic dissections into five types, as shown in Figure 1.

The aortic wall is composed of three layers: the innermost tunica intima, the middle tunica media, and the outermost tunica adventitia. Acute aortic dissection occurs from the stress of systemic hypertension, which damages the aortic wall. Generally, this condition begins with a tear in the tunica intima, which then spreads to the tunica media along the aortic wall by pressure from the blood, resulting in a false lumen. The dissection can extend distally, proximally, and, eventually, throughout the aorta. In 90% of cases, a secondary tear in the intimomedia layer forms as the dissection extends, allowing blood to flow back into the true aortic lumen. While the primary laceration is often located in the thoracic aorta, the secondary tear is likely to appear below the descending aorta or in the abdominal aorta [8].

A cohort study by Bailey et al. [9] of 369 autopsies of aortic dissection cases over 16 years (1993–2008) suggested that atherosclerosis was a risk factor in 73% of fatal aortic dissections. The ulcerated atherosclerotic plaque might cause more damage to the tunica intima and lead to aortic dissection [9].

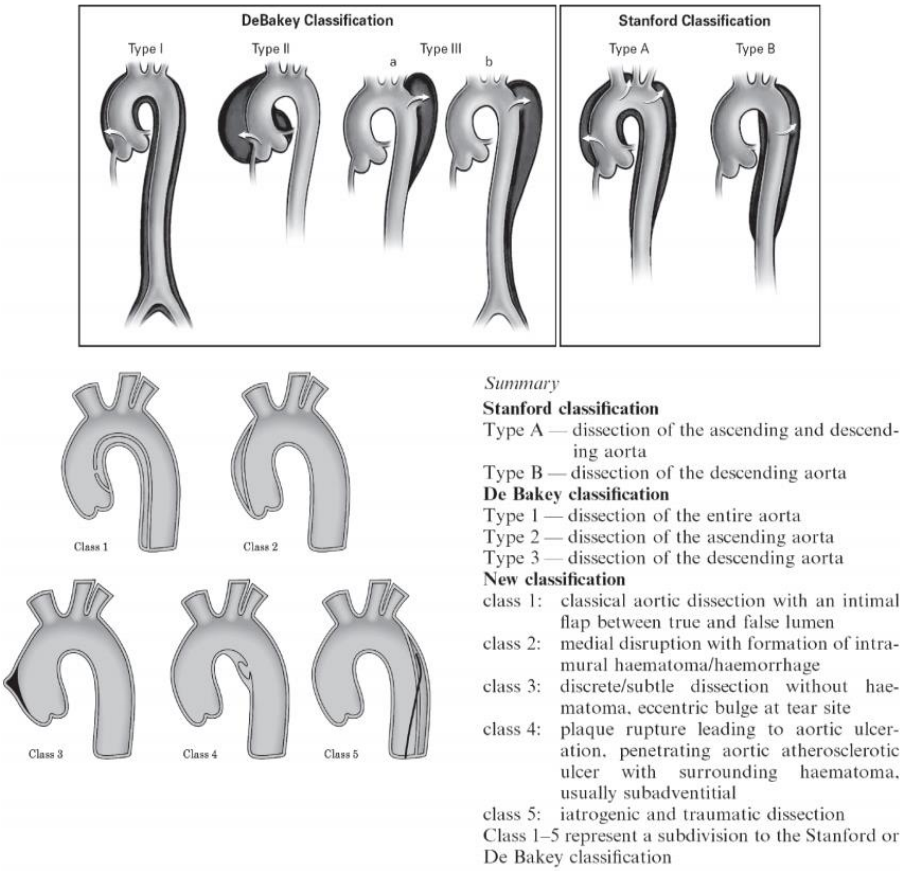

Figure 1. A recent classification of aortic dissections.

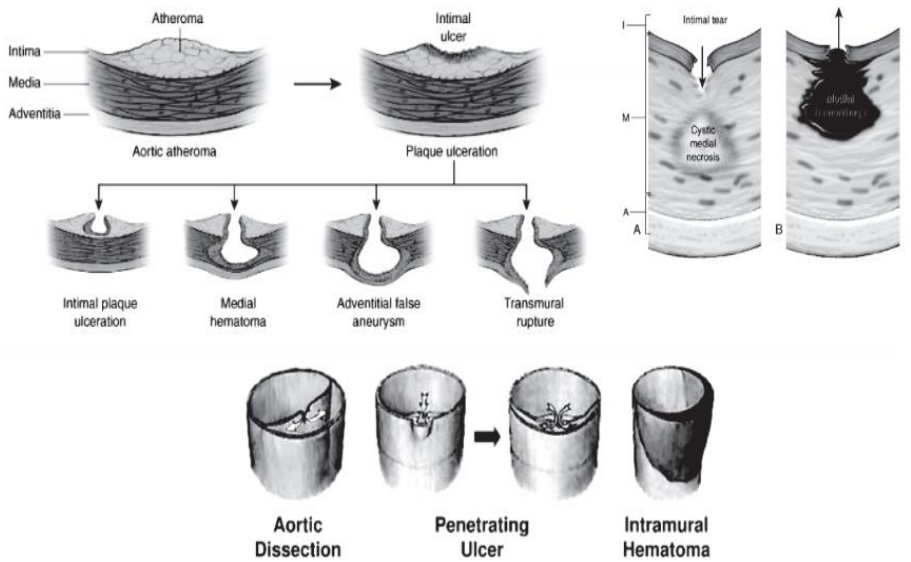

Figure 2. Dissection of the aortic wall.

The recent INSTEAD-XL studies indicated that TEVAR could prolong the lives of aortic dissection patients by five years and delay progression of the Stanford type B aortic dissection, which often occurs as a complication of diseases such as uncontrolled hypertension, ruptured aorta, and end-organ ischemia. However, TEVAR's effectiveness for treating chronic complications of Stanford type B aortic dissection remains controversial [5].

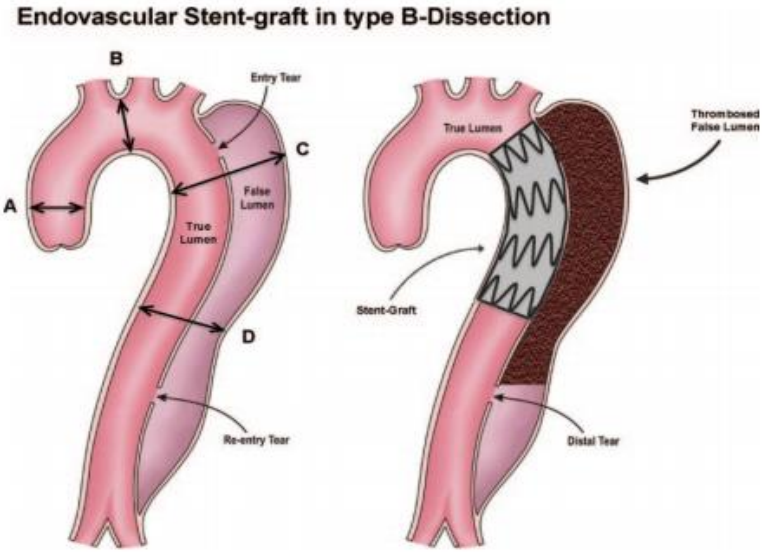

Figure 3. Location of installation of TEVAR for Stanford type B [10] aortic dissection.

Our autopsy results showed that the frailty of the aortic wall due to atherosclerosis led to laceration in the ascending aorta, which resulted in blood flowing out to the cardiac and thorax. Blood inside the cardiac could promote pericardial tamponade and disrupt cardiac movements. We also found a laceration in the tunica intima of the descending aorta and dissection along the descending aorta to the bifurcation of the iliac arteries. We detected a TEVAR graft in the aorta and blood clots inside the false lumen.

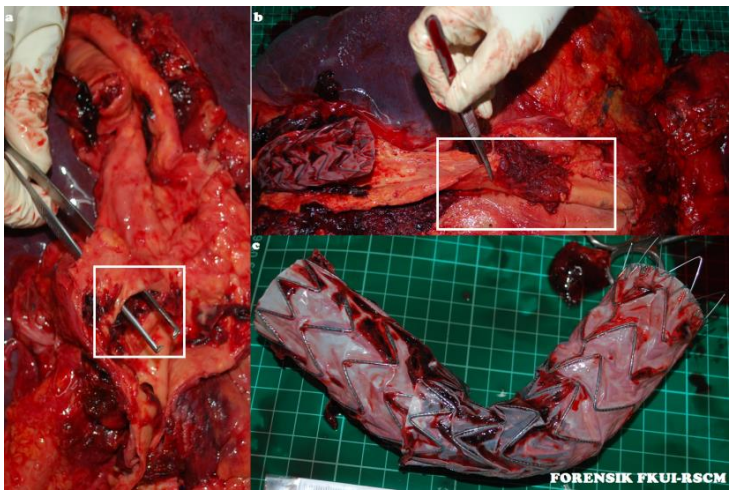

Figure 4. (a) Laceration in the ascending aorta; (b) aortic dissection; (c) TEVAR graft.

Our autopsy also revealed a lumen constriction of up to 75%–85% due to a thickened left coronary artery and an acute myocardial infarction image in the myocardium.

Atherosclerosis of the coronary arteries is a potentially fatal disease. This disease reportedly causes at least 25%–40% of deaths. One interesting finding of our autopsy is that atherosclerotic constriction of the left coronary artery occurred in more than 75% of the lumen. This finding is contrary to most atherosclerotic constriction cases where the constriction occurred in less than 75% of the lumen. Necrotic myocardium may occur if the lumen is constricted by 20% or less, followed by ischemia in the artery distribution area [6, 11].

Figure 5. Blood and blood clots inside the pericardium.

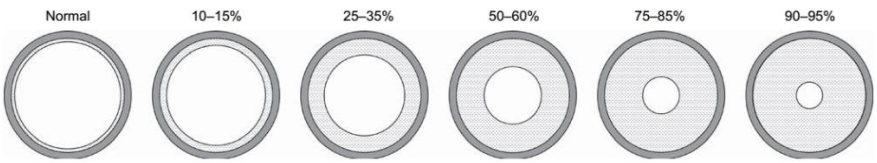

Figure 6. Anatomical cross sections of constriction in atherosclerotic arteries.

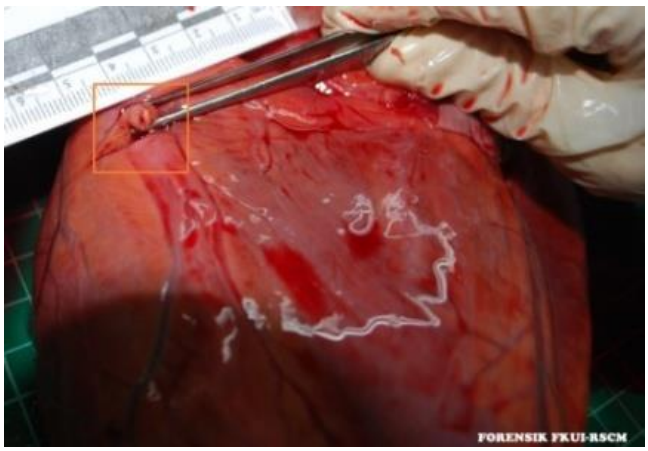

Figure 7. Narrowing of the left coronary artery lumen opening.

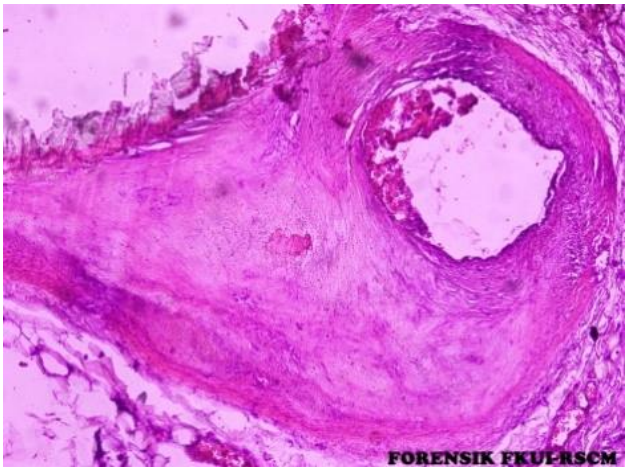

Figure 8. Histopathological image of the left coronary artery.

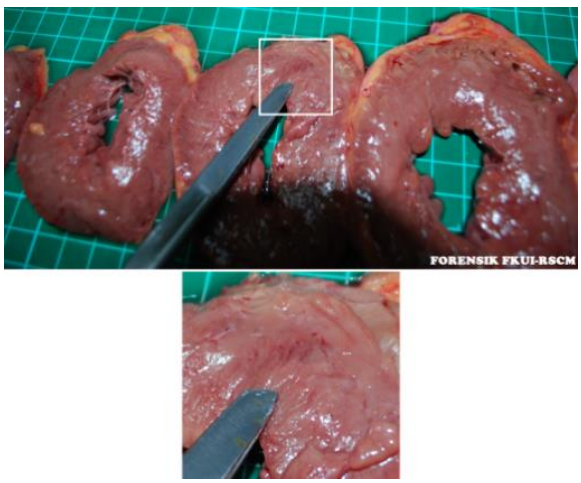

Figure 10. Myocardial infarction.

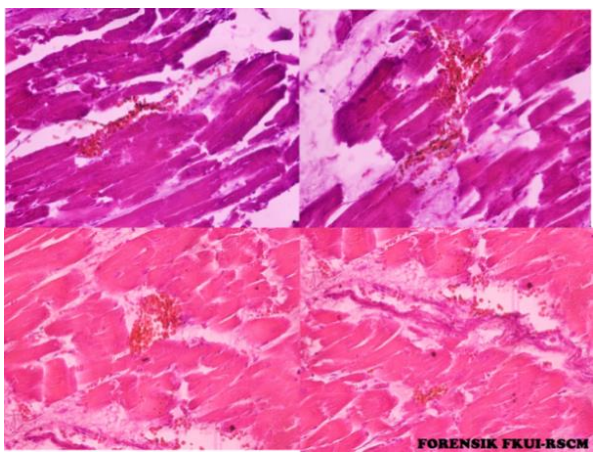

Figure 11. Histopathological image of the myocardium showing myocardial rupture.

This 60-year-old German man appeared to die from natural causes. The external examination revealed several postoperative wounds and signs of damage. The internal examination revealed a TEVAR-corrected Stanford type B (DeBakey type III) aortic dissection. The autopsy also revealed a laceration in the ascending aorta that caused bleeding in the thorax and cardiac. The autopsy confirmed constriction of the left coronary artery lumen by 75%–85% due to atherosclerosis and myocardial infarction. We observed blood and blood clots inside the cardiac that caused cardiac tamponade. The histopathological images confirmed our internal examination findings of myocardial infarction, left coronary artery atherosclerosis, aortic dissection with erythrocyte infiltration, and signs of damage to the brain, lungs, and liver. In this case, cardiac tamponade caused myocardial infarction, which disrupted cardiac movements and led to death.

REFERENCES

[1] Ayala, I., Chen, Y.F. Acute aortic dissection: an update. *Kaohsiung Journal of Medical Sciences*, 2012 28, 299-305.

[2] Isselbacher, E.M. Epidemiology of thoracic aortic aneurysms; aortic dissection; intramural hematoma and penetrating atherosclerotic ulcers. In: Eagle, K.A., Baliga, R.R., Isselbacher, E.M., Nienaber, C.A., editors. *Aortic dissection and related syndromes. Developments in cardiovascular medicine*. Boston: Springer; 2007.

[3] Demengiu, S., Ceausu, M., Hostiuc, S., Curca, G.C., Demengiu, D., Turculet, C. Spontaneous aortic dissection due to cystic medial degeneration report of a sudden death case and literature review. *Romanian Journal of Legal Medicine*, 2009 17, 89-96.

[4] Tai, H.C.H., Chen, W.L. Acute aortic dissection mimicking as ureteral calculus. *Journal of Acute Medicine*, 2016 6, 61-3.

[5] Miyazaki, Y., Furuyama, T., Matsubara, Y., Yoshiya, K., Yoshiga, R., Inoue, K., et al. Thoracic endovascular aortic repair for complicated chronic type B aortic dissection in a patient on hemodialysis with recurrent ischemic colitis. *Surgical Case Reports*, 2016 2, 38.

[6] Saukko, P., Knight, B. Knights *Forensic Pathology*. Fourth Edition. London: CRC Press; 2016.

[7] Tran, T.P., Khoynezhad, A. Current management of type B aortic dissection. *Vascular Health and Risk Management*, 2009 5, 53.

[8] Wahyudi, D., Dakota, I., Kaligis, R.W.M., Sunu, I. *Laporan kasus endovaskular stent graft pada diseksi aorta tipe B*. 2007.

[9] Bailey, K., Duflou, J., Puranik, R. Fatal cases of aortic dissection: an autopsy study. *International Journal of Cardiology*, 2012 158, 148-9.

[10] Nienaber, C.A., Rousseau, H., Eggebrecht, H. Randomized comparison of strategies for type b aortic dissection—the Investigation of Stent Grafts in Aortic Dissection (INSTEAD) Trial. *Journal of Vascular Surgery*, 2010 51, 1321-29.

[11] Dolinak, D., Matshes, EW., Lew, E.O. *Forensic Pathology Principles and Practice*. London: Elsevier Academic Press; 2005.

In: Encyclopedia of Surgery (22 Volume Set)
Editors: Andreas Lehrer and Kristin Mueller
ISBN: 978-1-53618-329-0
© 2020 Nova Science Publishers, Inc.

Chapter 319

RARE OCCURRENCE OF SECONDARY EXTRACRANIAL SINONASAL MENINGIOMA: A CASE REPORT

Renindra Ananda Aman*, MD, PhD,
Adhitya Syahada, MD,
Aryandhito Widhi Nugroho, MD, PhD,
David Tandian, MD, Samsul Ashari, MD,
Syaiful Ichwan, MD and Setyo Widi Nugroho, MD, PhD
Department of Neurosurgery, Faculty of Medicine, RSUPN Dr. Cipto Mangunkusumo, Universitas Indonesia, Jakarta, Indonesia

ABSTRACT

Meningioma is the most common type of benign intracranial tumor. The occurrence of extracranial meningioma is rare, accounting for only 2% of all meningiomas. There are two types of extracranial meningioma: primary and secondary. Primary extracranial meningioma grows extracranially without any connection to intracranial lesions, whereas secondary extracranial meningioma is an intracranial meningioma that extends extracranially. Herein, we report the case of a 45-year-old female patient with secondary extracranial sinonasal meningioma who presented with intermittent headache and unilateral proptosis due to olfactory groove meningioma that expanded to the right ethmoid sinus. Gross tumor resection was achieved in this case.

Keywords: extracranial meningioma, sinonasal meningioma, secondary extracranial meningioma, transitional meningioma

* Corresponding Author's Email: renindra03@yahoo.com.

INTRODUCTION

Meningiomas are originated from meningeal coverings and arachnoid cap cells found in the arachnoid villi at cranial vault and base, as well as in the spinal region [1]. Hitherto, various registries from countries worldwide have shown an increase in meningioma incidence [2-5]. Although studies on meningiomas in general are abound, particular studies on extracranial meningiomas are lacking.

Extracranial, or ectopic, meningioma accounts for approximately 2% of all meningiomas [6-8]. There are two types of extracranial meningioma: primary and secondary. While the former has no connection to intracranial lesions, the latter is a direct extension of intracranial lesions to extracranial sites [6-8]. Due to the rare occurrence of secondary extracranial meningioma, its diagnosis and management requires a thorough and cautious approach. In this report, we present the rare case of a secondary extracranial meningioma in the sinonasal area that originated from the olfactory groove area.

CASE REPORT

A 45-year-old female patient presented with a history of progressive intermittent headache since 3 years, followed by progressive protrusion of the right eye since 2 years ago (see Figure 1). The patient had no complains of blurred vision, visual field deficit, double vision, epistaxis, nasal obstruction, rhinorrhea, and smell disorder. Upon neurologic examination, proptosis was identified with a slight decrease in visual acuity in the right eye (6/8.5 on the Snellen chart), unilateral ophthalmoparesis, unilateral anosmia, and bilateral papilledema. No other abnormalities were found. Contrast-enhanced brain computed tomography (CT) revealed a homogenous hyperdense lesion in the bilateral frontal bone with expansion to the right ethmoidal sinus (see Figure 2). Further imaging with contrast-enhanced

Figure 1. Anterior and lateral view of the patient's face showing obvious protrusion in the right eye.

T1-weighted magnetic resonance imaging (MRI) revealed homogenous hyper-intense enhancement of the lesion (see Figure 3). The patient underwent craniotomy for removal of the tumor, which had areddish-white macroscopic appearance, firm consistency, and could easily bleed (see Figure 4). Histopathologic examinations revealed a grade 1 meningioma

(mixed meningioma, also referred to as transitional meningioma) based on the World Health Organization (WHO) classification (9). The case was uneventful, and the patient was discharged 1 week after surgery. Post-operative CT exhibited gross total tumor removal (see Figure 5).

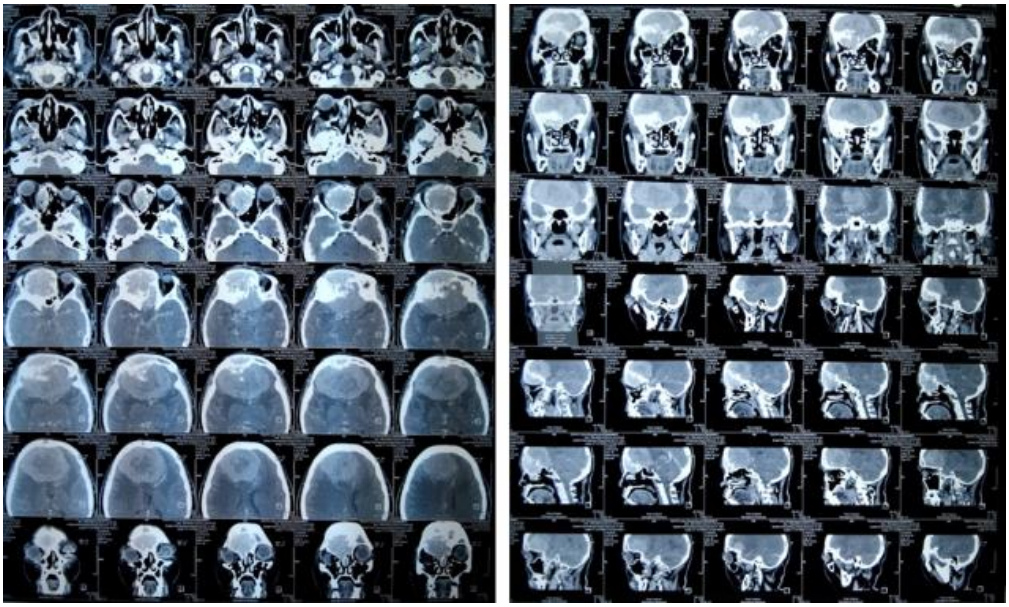

Figure 2. Axial, coronal, and sagittal views of contrast-enhanced computed tomography scan revealed a bilateral frontal mass that expands to the right ethmoidal sinus.

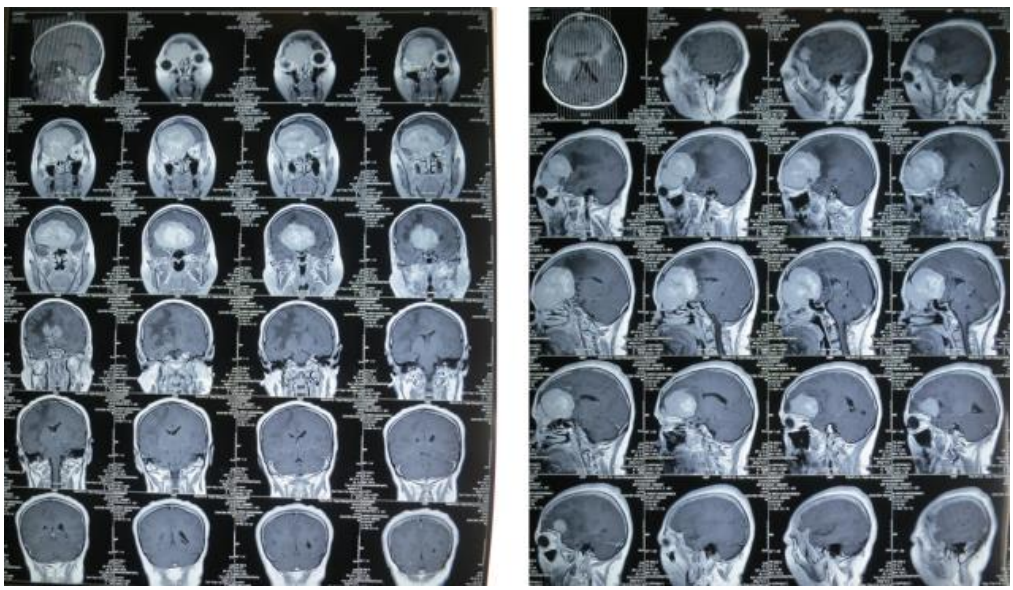

Figure 3. Contrast-enhanced T1-weightedmagnetic resonance imaging revealed a homogenous hyper-intense lesion in the bilateral frontal lobes extending to the right ethmoidal sinus.

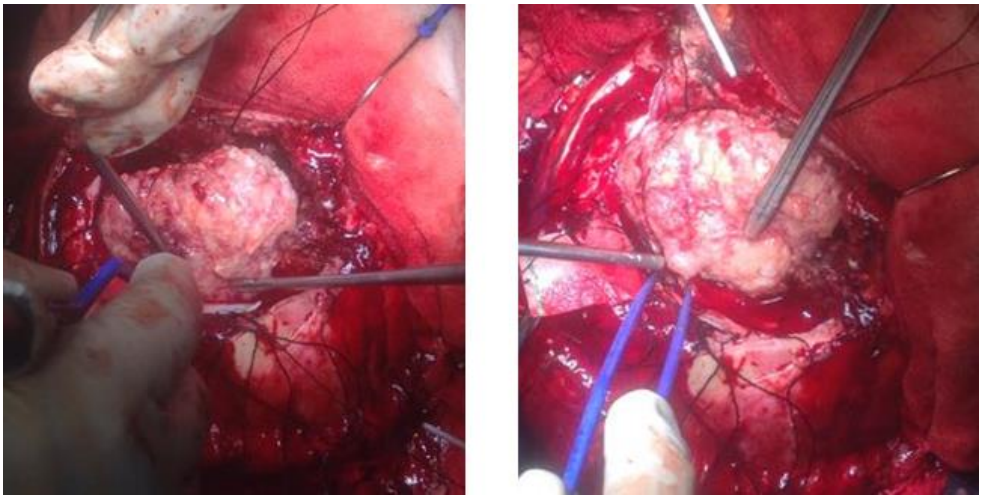

Figure 4. Intraoperative macroscopic view of the lesion: reddish-white appearance, firm, and bleeds easily.

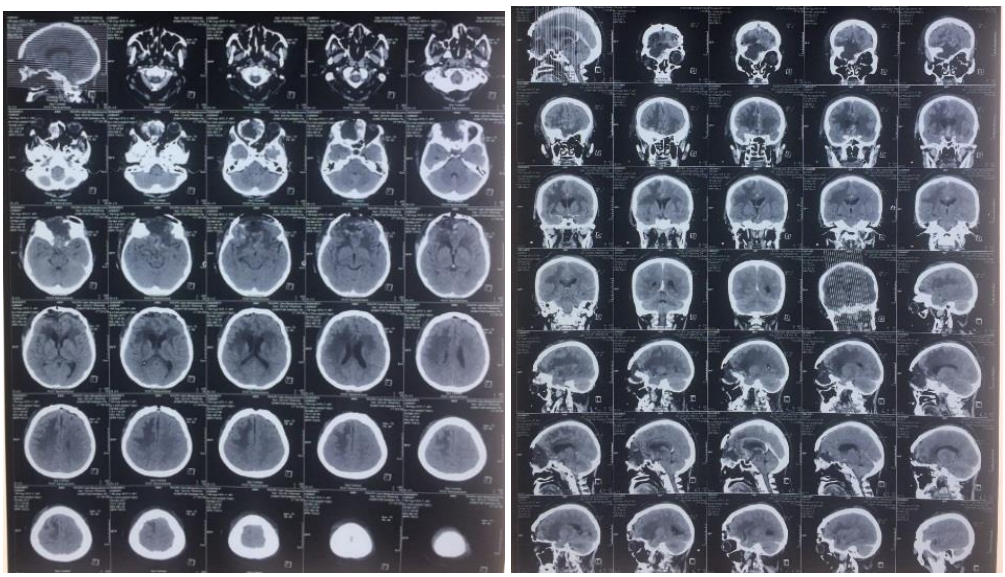

Figure 5. Postoperative axial, coronal, and sagittal computed tomography scan images.

DISCUSSION

Meningioma is the most common benign intracranial tumor, which accounts for 13% – 30% of primary intracranial tumors [6, 7]. Genetic factors, such as neurofibromatosis type-2 and multiple endocrine neoplasia type-1, increase the likelihood of meningiomas [11, 12]. Other risk factors for meningioma are ionized radiation exposure, hormonal exposure, brain trauma, and history of breast cancer. Although there is no evidence that hormonal exposure increases the risk of developing meningioma significantly, its incidence is more prevalent in

women than in men (2:1), particularly for grade I meningioma. Meanwhile, for grade II and III meningiomas, the incidence is higher in men than in women (1.2:1) [10-12].

There are two types of meningioma: intracranial and extracranial. Intracranial meningioma is covered by dura mater, whereas extracranial meningioma is not covered by dura mater. The extracranial subtype accounts for approximately 2% of all meningiomas [6-9]. Extracranial meningioma can be classified into two types: primary and secondary. Meningiomas that arise extracranially without any association with an intracranial mass are referred to as primary extracranial meningiomas. Secondary extracranial meningiomas are extentions from intracranial disease. The tumor may enter the orbit and nasal cavity through preformed bony pathways, surgical defects, or foramina of the skull base [6-8]. Hoye (1960) has developed a classification system of extracranial meningiomas (Table 1) [14]. Another classification system was established by Atherio et al., which divided extracranial meningioma into four groups [15]: (i) primary extracranial meningiomas extending from the skull, (ii) extracranial meningioma arising from the arachnoid cell rests of cranial nerve sheaths, (iii) meningiomas with no obvious connection with the foramina or cranial nerves, and (iv) metastasis of malignant intracranial meningiomas.

Table 1. Hoye classification of extracranial meningiomas [14]

Primary	Secondary
Extracranial extension of a meningioma arising from the neural foramina	Extracranial extension of the meningioma from the intracranial meningioma
Ectopic, without any connection to the neural foramina or intracranial structure	Extracranial extension from metastasis of intracranial meningioma

Several theories regarding the mechanism of primary extracranial meningioma have been proposed, which were as follows: extradural entrapment of arachnoid cells during embryogenesis, ectopic migration of arachnoid cells in the development of peripheral nerves, and metaplasia of mature peripheral nerve sheath or progenitor cells [8]. The most common site for extending intracranial meningioma is the orbit, and other sites include the nasopharyx, scalp, sinuses (frontal sinus, maxillary sinuses, ethmoidale sinus, and sphenoid sinuses), parapharyngeal region, and parotid gland [8]. Although meningiomas have the capability to expand extracranially, they rarely invade the brain [8].

Cautious and systematic anamnesis; physical examinations;and imaging histopathological, and immunohistochemical studies must be conducted to diagnose meningiomasaccurately. Anamnesis and physical examinationscan help identify signs and symptoms with regard to tumor location. In our patient, intermittent progressive headache, unilateral proptosis, and anosmia were identified. Non-contrast-enhanced CT can reveal hyper- or isodense lesion (15% – 20% cases can present with reveal calcification), which enhances homogenously. T1-weighted MRI can reveal iso- to hypo-intense lesions, which are homogenously enhanced with the administration of gadolinium, whereas T2-weighted MRI usually reveal iso- to hyper-intense lesions. Peritumoural edema is observed in 60% of cases [13]. Histopathology studies aim to classify meningiomas according to WHO grading and to determine the most appropriate treatment. Immunohistochemical studies have used vimentin and epithelial membrane antigens for the diagnosis of meningiomas [16]. However, both were not examined in this study.

Gross total resection remains the standard treatment for all meningiomas [13], although this may not be the case for the management of skull base meningiomas. Nevertheless, surgeons should aim to achieve Simpson grade I resection during the first surgery.

CONCLUSION

This study reported a case of secondary extracranial sinonasal meningioma. Physical examinations; cautious and systematic anamnesis; and imaging, histopathological, and immunohistochemical studies must be performed to diagnose this rare type of meningioma accurately. Gross total resection of the tumor, dural attachment, and abnormal bone should be performed to achieve low recurrence, although tumor location may be used as basis for the extent of resection.

REFERENCES

[1] Baldi, I., Engelhardt, J., Bonnet, C., Bauchet, L., Berteaud, E., Grüber, A. & Loiseau, H. (2018). Epidemiology of meningiomas. *Neurochirurgie*, *64*, 5-14.

[2] Ostrom, Q. T., Gittleman, H., Farah, P., Ondracek, A., Chen, Y., Wolinsky, Y., Stroup, N. E., Kruchko, C. & Barnholtz-Sloan, J. S. (2013). CBTRUS Statistical Report: primary brain and central nervous system tumors diagnosed in the United States in 2006–2010. *Neuro-Oncology*, *15*, 1-56.

[3] Radhakrishnan, K., Mokri, B., Parisi, J. E., O'Fallon, M., Sunku, J. & Kurland, L. T (1995). The trends in incidence of primary brain tumors in the population of Rochester, Minnesota. *Annals of Neurology*, *37*, 67–73.

[4] Nakamura, H., Makino, K., Yano, S., Kuratsu, J. & Kumamoto Brain Research Group. (2011). Epidemiological study of primary intracranial tumors: a regional survey in Kumamoto prefecture in southern Japan – 20-year study. *International Journal of Clinical Oncology*, *16*, 314–21.

[5] Surawicz, T. S., McCarthy, B. J., Kupelian, V., Jukich, P. J., Bruner, J. M. & David, F. G. (1999). Descriptive epidemiology of primary brain and CNS tumors: results from the Central Brain Tumor Registry of the United States, 1990–1994. *Neuro-Oncology*, *1*, 14–25.

[6] Counsell, C. E., Collie, D. A. & Grant, R. (1996). Incidence of intracranial tumours in the Lothian region of Scotland, 1989–90. *Journal of Neurology, Neurosurgery, and Psychiatry*, *61*, 143–50

[7] Albu, S., Florian, I. Æ. & Bãciuå, G. (2014). Secondary extracranial meningiomas extending into the paranasal sinuses. *Chirurgia*, *109*, 858-861.

[8] Iaconetta, G., Santella, A., Friscia, M., Abbate, V. & Califano, L. (2012). Extracranial primary and secondary meningiomas. *International Journal of Oral and Maxillofacial Surgery*, *41*, 211-217.

[9] Louis, D. N., Perry, A., Reifenberger, G., von Deimling, A., Figarella-Branger, D., Cavenee, W. K., Ohgaki, K., Wiestler, O. D., Kleihues, P. & Ellison, D. W. (2016). The

2016 World Health Organization Classification of Tumors of the Central Nervous System: a summary. *Acta Neuropathologica, 131*, 803-20

[10] Rogers, L., Barani, I., Chamberlain, M., Kaley, T. J., McDermott, M., Raizer, J., Schiff, D., Weber, D. C., Wen, P. Y. & Vogelbaum, M. A. (2015). Meningiomas: knowledge base, treatment outcomes, and uncertainties. A RANO review. *Journal of Neurosurgery*, *122*, 4-23.

[11] Wiemels, J., Wrensch, M. & Claus, E. B. (2010). Epidemiology and etiology of meningioma. *Journal of Neurooncology*, *99*, 307-314.

[12] Barnholtz-Sloan, J. S. & Kruchko, C. (2007). Meningiomas: causes and risk factors. *Neurosurgical Focus*, *23*, 1-8.

[13] Fogh, S. E., Johnson, D. R., Barker, F. G., Brastianos, P. K., Clarke, J. L., Kaufmann, T. J., Oberndorfer, S., Preusser, M., Raghunathan, A., Santagata, S. & Theodosopoulos, P. V. (2016). Case based review: meningioma. *Neuro-Oncology Practice*, *3*, 120-134.

[14] Sharma, J. K., Pippal, S. K. & Sethi, Y. (2006). A rare case of primary nasoethmoidal meningioma. *Indian Journal of Otolaryngology and Head and Neck Surgery*, *58*, 101-103.

[15] Atherino, C. C. T., Garcia, R. & Lopes, L. J. (1985). Ectopic meningioma of the nose and paranasal sinuses (report of a case). *The Journal of Laryngology & Otology*, *99*, 1161-1166.

[16] Thompson, L. D. & Gyure, K. A. (2000). Extracranial sinonasal tract meningiomas. *The American Journal of Surgical Pathology*, *24*, 640-650.

In: Encyclopedia of Surgery (22 Volume Set)
Editors: Andreas Lehrer and Kristin Mueller
ISBN: 978-1-53618-329-0
© 2020 Nova Science Publishers, Inc.

Chapter 320

THORACIC EPIDURAL ANALGESIA IN A CRITICALLY ILL PATIENT WITH ACUTE PANCREATITIS

Dita Aditianingsih, Raden Besthadi Sukmono*[*], Oryza Eureka, Willy Yant Kartolo and Erika Sasha Adiwongso
Department of Anesthesiology and Intensive Care, Faculty of Medicine,
Universitas Indonesia, Jakarta, Indonesia

ABSTRACT

Currently, there has been an increase in the incidence of acute pancreatitis worldwide. Despite the improvements in access to care, imaging, and interventional techniques, acute pancreatitis continues to be associated with significant morbidity and mortality. Pain control is an important part of supportive management for patients with acute pancreatitis. A 26-year-old woman presented to our emergency department with a distended abdomen and excruciating pain in the upper abdomen. She was diagnosed with acute pancreatitis. She developed acute respiratory distress; thus, she was intubated and admitted to the intensive care unit. Her upper abdominal pain gradually intensified, causing worsening of acute respiratory distress syndrome. Opioids did not considerably relieve her pain; moreover, their side effects worsened acute pancreatitis. Moreover, thoracic epidural analgesia at the T7–T8 interspace was considered for pain management. After the administration of epidural analgesia, pain substantially improved, abdominal distention markedly reduced, amylase and lipase levels gradually returned to normal, and she was eventually weaned off the ventilator. Epidural analgesia is one of the important pain management modalities, and it stops severe acute pancreatitis development by improving splanchnic and pancreatic perfusion, resulting in decreased liver damage and inflammatory responses.

Keywords: thoracic epidural analgesia, acute pancreatitis, ARDS

[*] Corresponding Author's Email: besth25@gmail.com.

INTRODUCTION

The most severe forms of acute pancreatitis (AP) are associated with high morbidity and mortality. AP has an overall mortality rate of approximately 5%, and most patients with severe AP require intubation and mechanical ventilation [1, 2]. Although the pathophysiologic cascade of its development and progress is poorly understood, microcirculatory disturbances are considered important factors [3]. Different therapeutic interventions for improving pancreatic microcirculation have been evaluated in recent years. The current treatment for AP involves supportive medical therapy, which is sometimes associated with endoscopic procedures and/or surgical interventions. Therapeutic efforts are aimed at saving injured tissue from infarction and necrosis by improving microcirculatory perfusion and oxygen supply [2, 3].

Pain control is an important part of supportive management in patients with AP. Therefore, in the absence of any patient-specific contraindications, a multimodal analgesic regimen is recommended, including narcotics, nonsteroidal anti-inflammatory drugs (NSAIDs), and acetaminophen [4, 5]. The optimal recommendation is adherence to the most current acute pain management guidelines in the perioperative setting. However, all patients with AP should receive some form of analgesia in the first 24 hours of hospitalization to avoid compromise of quality of life [6, 7, 8]. Recently, increasing evidence from preclinical and clinical studies has supported the beneficial effects of thoracic epidural analgesia (TEA) in AP, such as improved gut barrier function and splanchnic, pancreatic, and renal perfusion; decreased liver damage and inflammatory responses; and reduced mortality [1]. Here, we present a report on a critically ill patient with AP who was successfully treated with TEA.

CASE REPORT

A 26-year-old woman was referred to our emergency department with excruciating pain in the upper abdomen and a distended abdomen. Her clinical findings supported a diagnosis of AP. She developed acute respiratory distress syndrome (ARDS) and was intubated. She was then admitted to the intensive care unit (ICU) for further management.

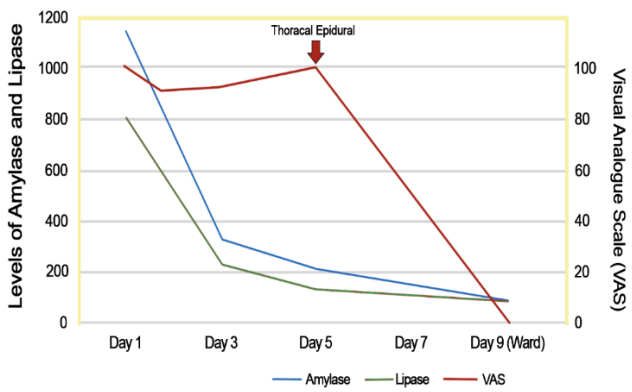

Figure 1. Amylase and lipase levels and pain intensity according to the visual analogue scale during treatment before and after thoracic epidural analgesia in our patient.

Her upper abdominal pain gradually intensified, causing worsening of ARDS and ventilator-patient asynchrony, and therefore, difficulty in ventilator weaning. Several AP laboratory markers, such as amylase and lipase, increased (Figure 1).

Opioids did not significantly relieve her pain; moreover, the side effects worsened her AP. TEA was then considered for pain management, in addition to the prevention of the development of severe AP owing to redistribution of splanchnic blood flow to non-perfused pancreatic regions.

DISCUSSION

The most common and significant complain associated with the diagnosis of AP is pain, and therefore, adequate analgesia represents an important part of the treatment approach [2]. Sensory information from the pancreas is transmitted to the central nervous system via both vagal and spinal pathways. Cell bodies of the spinal afferent pancreatic neurons are located in the T6–L2 dorsal root ganglia, and their axons traverse the splanchnic nerves and celiac plexus before they enter the pancreas [9]. Sensory nerves are responsible for the regulation of pancreatic blood flow, and stimulation of the sensory nerves could produce hyperemia in the pancreatic microcirculation. Previous studies have shown that the protective effects of the sensory nerves on necrotizing pancreatitis are manifested by decreases in plasma amylase and lipase activities, a reduction in the plasma IL-1 level, and an increase in pancreatic DNA synthesis [10, 11].

AP treatment depends mainly on the severity of progression, but almost all cases will require supportive treatments, such as analgesics. Effective treatments of pain in AP range from the administration of simple analgesic drugs, which might be sufficient for patients with mild AP, to the administration of potent opioids, administration of high doses of antibiotics for infected pancreatic necrosis, and even surgical or interventional procedures for cases of severe AP. The World Health Organization analgesic ladder (Figure 2), which includes the use of NSAIDs or their combination with highly potent opioid analgesics in an escalating regime, for the management of abdominal pain mentions the use of interventional strategies depending on the occurrence of AP-related complications [12]. Opioids, such as morphine and its derivatives, are commonly used; however, there is no concrete evidence for their effectiveness and safety. They might hide disease resolution and might increase pain by causing spasms [13]. Besides parenteral pain control, epidural analgesia can be used as an alternative treatment. A previous experimental prospective study assessed the effects of sympathetic block by thoracic epidural anesthesia and found enhanced microcirculatory perfusion and end-organ perfusion and improved survival compared with controls in animal experiments [3]. However, these positive experimental results cannot be automatically transposed to humans since the investigation on regarding the sphlanic perfursion in human have not been cleared [2, 14]. Nevertheless, as the risk of significant morbidity with severe AP is high, it might be reasonable to accept a low rate of TEA complications if a major reduction in mortality is confirmed [14].

TEA can be considered for patients with severe and critical AP who require high doses of opioids for an extended period. Although it has been reported that analgesics could be administered transdermally or rectally, no RCTs have compared the different routes of

administration of the same analgesic in patients with AP [15]. The use of TEA in the acute clinical setting of severe AP and sepsis remains a fascinating area of research. Reliable non-invasive measures of splanchnic perfusion need to be developed for further evaluation of the effects of TEA on basic human physiological parameters and for direct randomized trials in critically ill patients [14].

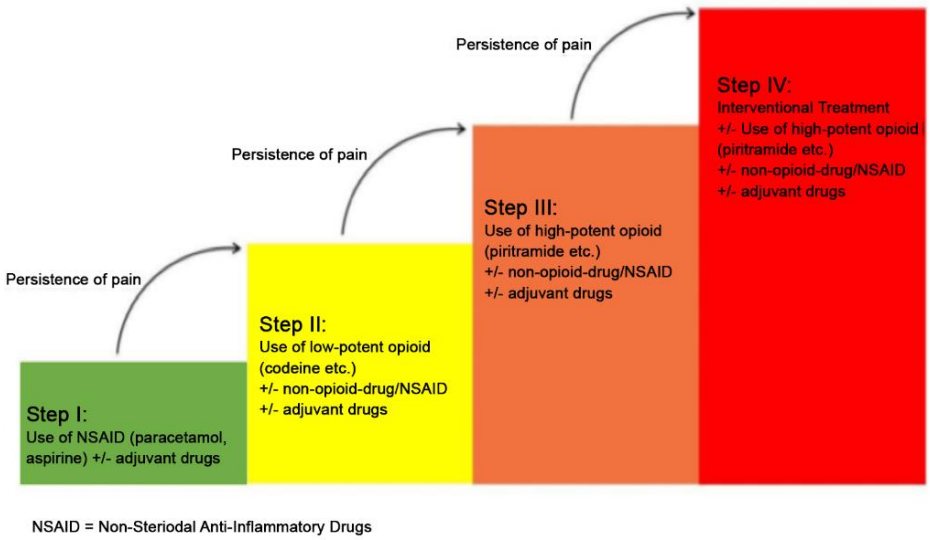

Figure 2. The modified World Health Organization analgesia ladder according to Vargas-Schaffer [12].

In the present case, epidural analgesia had benefits for AP. This approach is safe and titratable and has minimum side effects compared to other modalities in such a patient. TEA installation at level T5 to T10 was proven to be appropriate and cover the affected dermatome, this was shown in significant reduce in VAS, thus the patient became more comfortable, marked by synchronized breathing with ventilator. It also prevented further progression of the disease by improving splanchnic and pancreatic perfusion. Shortly after the epidural regimen, abdominal distention markedly reduced, amylase and lipase levels gradually returned to normal, and the patient was successfully weaned off from the ventilator.

CONCLUSION

Epidural anesthesia has a major role in AP management. It is one of the important pain management modalities, and it stops severe AP development by improving splanchnic and pancreatic perfusion, resulting in decreased liver damage and inflammatory responses.

REFERENCES

[1] Bulyez, S., Pereira, B., Caumon, E., Imhoff, E., Roszyk, L., Bernard, L., Bühler, L., Heidegger, C., Jaber, S., Lefrant, J. Y. & Chabanne, R. (2017). Epidural analgesia in

critically ill patients with acute pancreatitis: the multicentre randomised controlled EPIPAN study protocol. *BMJ Open*, 7: e015280. doi: 10.1136/bmjopen-2016-015280.

[2] Zarnescu, N. O., Barbu, S. T., Zarnescu, E. C., Costea, R. & Neagu, S. (2015). Management of acute pancreatitis in the early stage. *Maedica (Buchar)*, 10: 257-263.

[3] Bachmann, K. A., Trepte, C. J., Tomkötter, L., Hinsch, A., Stork, J., Bergmann, W., Heidelmann, L., Strate, T., Goetz, A. E., Reuter, D. A. & Izbicki, J. R. (2013). Effects of thoracic epidural anesthesia on survival and microcirculation in severe acute pancreatitis: a randomized experimental trial. *Critical Care*, 17: R281. doi: 10.1186/cc13142.

[4] Greenberg, J. A., Hsu, J., Bawazeer, M., Marshall, J., Friedrich, J. O., Nathens, A., Coburn, N., May, G. R., Pearsall, E. & McLeod, R. S. (2016). Clinical practice guideline: management of acute pancreatitis. *Canadian Journal of Surgery*, 59: 128-140. doi: 10.1503/cjs.015015.

[5] Poma, E. M., Santos, C. L., López, B. G., Arbizu, E. A., Olascoaga, F. Z., Petrov, M. S., Morales, F. A., Garralda, M. A., Villarroya, M. C., Riera, J. S. I. & Camps, V. L. (2012). Clinical pathways for acute pancreatitis: Recommendations for early multidisciplinary management. *Medicina Intensiva (English Edition)*, 36: 351-357. doi: 10.1016/j.medine. 2012.02.008.

[6] Pendharkar, S. A. & Petrov, M. S. (2015). Bringing patient-centered care to the fore in diseases of the pancreas. *Gastroenterology Research and Practice*, 2015: 1-6. doi: 10.1155/2015/459214.

[7] Pendharkar, S. A., Plank, L. D., Windsor, J. A. & Petrov, M. S. (2016). Quality of life in a randomized trial of nasogastric tube feeding in acute pancreatitis. *Journal of Parenteral and Enteral Nutrition*, 40: 693-698. doi: 10.1177/0148607115574290.

[8] Pendharkar, S. A., Salt, K., Plank, L. D., Windsor, J. A. & Petrov, M. S. (2014). Quality of life after acute pancreatitis a systematic review and meta-analysis. *Pancreas*, 43: 1194-1200. doi: 10.1097/MPA.0000000 000000189.

[9] Babic, T. & Travagli, R. A. (2016). Neural control of the pancreas. *Pancreapedia Exocrine Pancreas Knowledge Base*. doi: 10.3998/panc.2016.27.

[10] Li, Q. & Peng, J. (2014). Sensory nerves and pancreatitis. *Gland Surgery*, 3: 284-292. doi: 10.3978/j.issn.2227-684X.2013.10.08.

[11] Bockman, D.E. (2007). Nerves in the pancreas: what are they for? *The American Journal of Surgery*, 194: 61-64. doi: 10.1016/j.amjsurg.2007.05.028.

[12] Schorn, S., Ceyhan, G. O., Tieftrunk, E., Friess, H. & Demir, I. E. (2015). Pain management in acute pancreatitis. *American Pancreatic Association*. doi: 10.3998/ panc.2015.15.

[13] Basurto Ona, X., Rigau Comas, D. & Urrutia, G. (2013). Opioids for acute pancreatitis pain. *Cochrane Database of Systematic Reviews*, 7: 79. doi: 10.1002/14651858. CD009179.

[14] Harper, D. & McNaught, C. E. (2014). The role of thoracic epidural anesthesia in severe acute pancreatitis. *Critical Care*, 18: 1-2. doi: 10.1186/cc13718.

[15] Stigliano, S., Sternby, H., de Madaria, E., Capurso, G. & Petrov, M.S. (2017). Early management of acute pancreatitis: A review of the best evidence. *Digestive and Liver Disease*, 9: 585-594. doi: 10.1016/j.dld.2017.01.168.

In: Encyclopedia of Surgery (22 Volume Set)
Editors: Andreas Lehrer and Kristin Mueller
ISBN: 978-1-53618-329-0
© 2020 Nova Science Publishers, Inc.

Chapter 321

PREOPERATIVE THERAPEUTIC PLASMA EXCHANGE WITH HYPOFIBRINOGENEMIA COMPLICATION IN ABO-INCOMPATIBLE LIVING DONOR KIDNEY TRANSPLANTATION

Dita Aditianingsih[1,*], MD, PhD, Rudyanto Soedono[1], MD, Endang Susalit[2], MD, PhD, Willy Yant Kartolo[1], MD and Erika Sasha Adiwongso[1], MD

[1]Department of Anesthesiology and Intensive Care, Faculty of Medicine, Universitas Indonesia, Jakarta, Indonesia
[2]Department of Internal Medicine, Division of Nephrology and Hypertension, Faculty of Medicine, Universitas Indonesia, Jakarta, Indonesia

ABSTRACT

ABO-incompatible kidney transplantation (ABOi-KT) is a strategy to overcome the shortage of organ donors. It is considered a high-risk option because of potential antibody-mediated rejection (AMR); however, it results in improved outcomes because of the use of more potent immunosuppressants in combination with splenectomy and therapeutic plasma exchange (TPE). We reported a case of a 54-year-old male O-blood type recipient who received an A-blood type living donor kidney. The desensitization protocol consisted of a combination of three sessions of TPE with immunosuppressants administered prior to transplantation. The anti-A antibody IgM-IgG titers could be reduced and maintained at a range of 1:32–1:4. Additionally, the fibrinogen level was 245 mg/dl prior to transplantation without any fresh frozen plasma (FFP) replacement. There was massive postoperative bleeding due to the low fibrinogen level. The patient received cryoprecipitates and intravenous tranexamic acid. The bleeding gradually stopped, and the graft function was good. The patient was discharged from the hospital on day-7 post-transplantation. Preoperative TPE was the primary therapy for ABOi-KT in this patient. Only three sessions were performed, but it caused hypofibrinogenemia and

[*] Corresponding Author's Email: ditaaditiaa@gmail.com.

postoperative bleeding. Coagulation factor monitoring and blood component therapy were essential to prevent these complications.

Keywords: ABO-incompatibility, kidney donor, therapeutic plasma exchange, hypofibrinogenemia

INTRODUCTION

Kidney transplantation is the treatment of choice for patients with end-stage renal disease (ESRD); however, there is currently a long waiting list for organ donors. Blood type-incompatible transplantation is one of the alternatives to overcome the shortage of organ donors [1]. ABO-incompatible kidney transplantation (ABOi-KT) is considered a high-risk option because of antibody-mediated rejection (AMR) and declining graft survival. Desensitization protocols for ABOi-KT are designed to improve this outcome. These protocols consist of splenectomy and a combination of immunosuppressants, such as high-dose intravenous immunoglobulin, anti-CD20 monoclonal antibody agents, and therapeutic plasma exchange (TPE) [2]. A splenectomy is performed to remove the major B-cell reservoir and prevent AMR; however, its effect on the immune system is irreversible, and it has a higher risk of infections. In 2004, rituximab, the anti-CD20 monoclonal antibody, was introduced and gradually replaced splenectomy. Rituximab binds to CD20 and produces along-acting B-cell suppression effect by inducing complement cytotoxicity, antibody cytotoxicity, and apoptosis on immature and mature B-cells, except for memory B-cells and plasma cells [3]. Preoperative antibody removal is achieved by plasma exchange or plasmapheresis as a part of desensitization for ABOi-KT. TPE removes high-molecular-weight antibodies from the plasma by using an automated blood cell separator to filter the plasma and separate the immunoglobulins to be discarded. TPE can remove 60%–70% of antibodies per session and is more efficient than classic plasmapheresis, which separates immunoglobulins by centrifugation and removes only 40%–50% of antibodies per session. This method requires a femoral, subclavian, or internal jugular double-lumen catheter insertion to ensure adequate blood flow during the procedure. TPE can be performed prior to or post operation, or both. Most cases require three to seven sessions, depending on the initial or elevated antibody titers post transplantation. Each session removes 1–1.5 times the plasma volume (calculated based on hematocrit and predicted body weight), which is replaced by 5% albumin, fresh frozen plasma (FFP), or both. Albumin is a preferable replacement fluid because it has a lower risk of hypersensitivity and infection transmission compared with FFP. However, TPE has a higher risk of bleeding due to the removal of coagulation factors; therefore, FFP is usually reserved to correct coagulation factor and bleeding complications [4].

CASE REPORT

A 54-year-old male was scheduled to undergo a living donor kidney transplant. His blood type was O rhesus +, and the donor blood type was A rhesus +. The recipient had

hypertension since 2008. He was diagnosed with end-stage chronic kidney disease in 2015 and underwent hemodialysis for four months prior to transplantation. A physical examination revealed a good general appearance, with a body mass index (BMI) of 24.9 kg/m2 and grade I hypertension (BP 140 – 150/70 – 80 mmHg), which was treated with amlodipine 1 × 10 mg, clonidine 4 × 0.15 mg, bisoprolol 1 × 5 mg, and valsartan 1 × 160 mg. The donor-recipient complement-dependent cytotoxicity crossmatching result showed 10% – 20% lysis (negative result). A desensitization protocol was initiated eight days prior to transplantation. The protocol consisted of immunosuppressants (tacrolimus 10 mg/day PO, rituximab 500 mg/m2 IV, mycophenolate mofetil 1,000 mg/day PO, and methylprednisolone 24 mg PO), and TPE was performed with the Prismaflex system (Gambro, Sweden), only three times every other day, five days prior to transplantation. The hemoglobin level of the patient was 6.1 g/dl, and he received a transfusion of leucodepleted packed red cells (PRCs) before the first TPE was conducted. One and a half times the plasma volume was removed, and 5% albumin with anticoagulant heparin was used as the replacement in every session. A timeline of the protocol is explained in Figure 1.

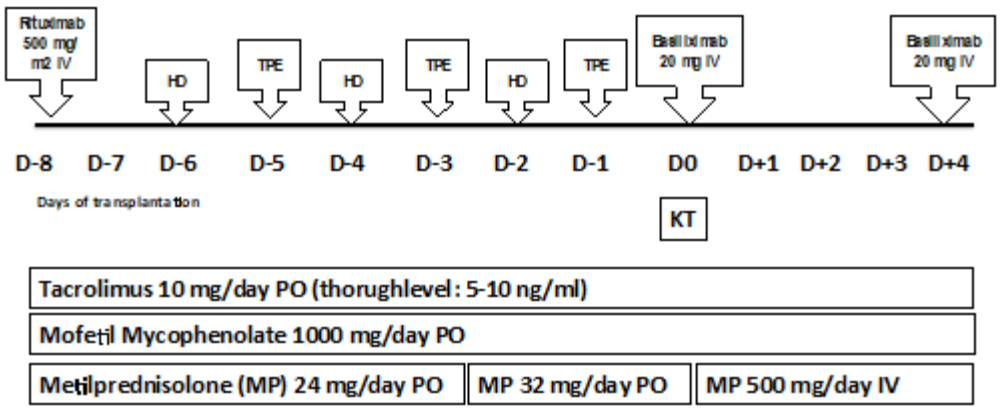

Figure 1. The ABOi-KT desensitization protocol used for this patient. TPE, therapeutic plasma exchange; HD, hemodialysis; KT, kidney transplantation.

INVESTIGATIONS

The initial anti-A antibody IgM-IgG titers were 1:256 – 1:4, which were reduced to 1:64 – 1:4 and 1:32 – 1:4 in response to three sessions of TPE. The prothrombin time (PT), activated prothrombin time (APTT), and fibrinogen levels were within normal limits without any replacement of fresh frozen plasma (FFP) or cryoprecipitate during the TPE sessions prior to surgery. Basiliximab (20 mg) was administered in the morning prior to transplantation. The transplantation procedure took 3 hours and 45 minutes to complete, with a primary warm ischemic time of 2 minutes and 27 seconds, a cold ischemic time of 23 minutes and 12 seconds, and a secondary warm ischemic time of 30 minutes and 24 seconds. The recipient's urine was produced on the 40th minute after reperfusion. During the surgical procedure, the patient received 1,250 cc of IV solution; conversely, the total output was 850 cc, with 250 cc coming from blood loss during the procedure and 600 cc from urine output. The patient had significant bleeding from the wound and 450 cc drainage production of

serous hemorrhage within one hour postoperatively. The hemoglobin level decreased to 6.1 gr/dl, and the fibrinogen level was low (30.2 mg/dl). The graph of antibody titers, creatinine level and fibrinogen level dynamics before, during and after TPE, and after transplantation procedure was explained in Figure 2.

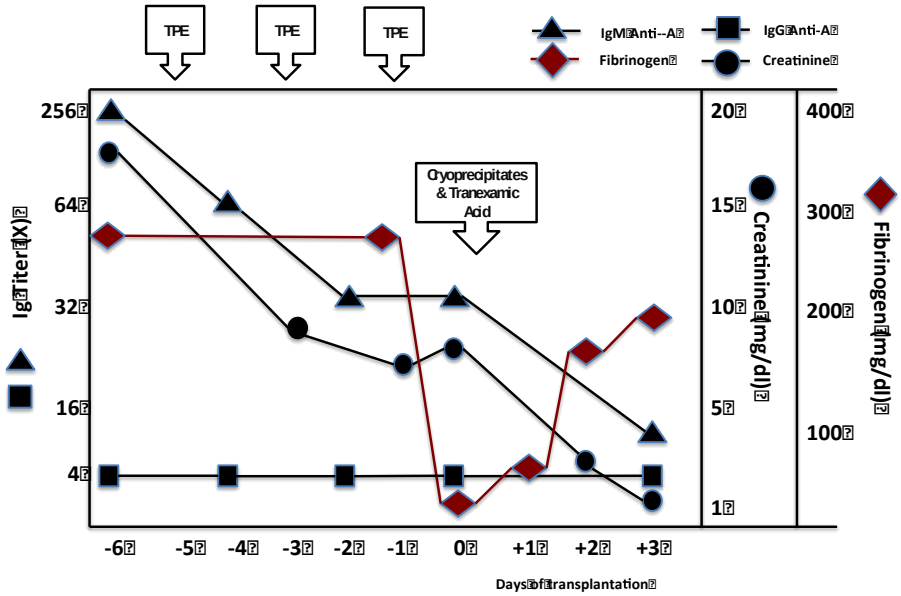

Figure 2. ABO-IgM-IgG antibody titers, creatinine level, and fibrinogen level before and after TPE, during TPE, and after transplantation. TPE, therapeutic plasma exchange; IgM-G, immunoglobulin M-G.

TREATMENT

The patient had significant bleeding from the wound and a drainage production of 450 cc serous hemorrhage within one hour post transplantation. His hemoglobin level decreased to 6.1 gr/dl, and his fibrinogen level was low (30.2 mg/dl). Therefore, 500 ml of leucodepleted PRCs and 10 units of cryoprecipitate were administered along with tranexamic acid, which was given as a1 gram bolus followed by the infusion of 3 grams over 24-hour. The total blood loss after the operation was approximately 840 ml in 17 hours, and drainage production decreased over the next 24 hours. His fibrinogen level increased to 190 mg/dl, and his hemoglobin level was 7.3 gr/dl. The general condition of the patient was stable.

OUTCOME AND FOLLOW-UP

The patient was followed up for seven days post transplantation, and the general condition of the patient was stable. His fibrinogen level increased to 173 mg/dl on postoperation day-1 and to 190 mg/dl on postoperation day-2. His urine output was greater than 1 ml/kgBW/h with serum creatinine level and estimated glomerular rate (eGFR) showed

improvement postoperatively. There was no sign of rejection or transfusion-related complications, and the patient was discharged from the hospital on the 8th day post-transplantation.

DISCUSSION

The principle of the immunosuppressive strategy in ABOi-KT is a desensitization strategy that consists of antibody removal or depletion, induction, and maintenance of immunosuppression agents. Alexandre et al. successfully attenuated the immunologic reaction and prevented hyperacute rejection by initiating a desensitization protocol that involves preoperative splenectomy and plasmapheresis. However, since 2004, splenectomy has rarely been performed because of the elimination effect on the immune system and the increased risk of infection [5]. Rituximab has become an alternative to splenectomy because it reduces B-cell production and attenuates the T-cell response within 1 to 3 days after induction; these responses persist for up to two years [6]. TPE is performed prior to transplantation to maintain the anti-A antibody titer between 1:4 and 1:32 in the beginning of transplantation. Several studies have shown that if the titer is less than 1:32, AMR is unlikely to occur [7]. Two studies also reported that the level of anti-ABO IgG antibodies was a more significant independent risk factor of AMR than IgM [8, 9]. After receiving only three sessions of TPE prior to the operation, this patient reached the following preoperative levels: IgM anti-A 1:32 and IgG anti-A 1:4. Since the prognostic value of the baseline anti-ABO titer is not yet established, it was considered safe to proceed with the transplantation for this patient.

TPE with one plasma volume can remove 40% – 50% of the antibodies per session because of the movement of extravascular constituents to the intravascular compartment and the resynthesizing of antibodies [10]. We performed TPE with 1.5 plasma volumes to increase the efficiency of antibody removal per session, which is calculated by the following formula:

$$(100 - \text{Hematocrit})\% \times (\text{KgBW} \times 70) \times 1.5 \text{ ml}$$

TPE removes anti-ABO antibodies along with plasma proteins, such as albumin, coagulation factors, and important immunoglobulins. It is replaced by 5% albumin solution or ABO group FFP during the sessions. Albumin is preferred to FFP because it has a lower risk of infection, hypersensitivity reaction, and reduced risk of ABO-related rejection. However, TPE increases the risk of bleeding, particularly during and after operation because of depleted coagulation factors other than antibodies. We replaced the 1.5 plasma volumes with only 5% albumin in each TPE session. PT, APTT, and fibrinogen levels were measured after each TPE session. FFP or cryoprecipitate were not used during TPE because the PT and APTT results were normal and the fibrinogen level was always above 100 mg/dl until two days prior to the operation. The patient suffered from bleeding complications after the operation. The fibrinogen level was very low, whereas the PT and APTT levels were still within normal limits. After administering 10 units of cryoprecipitate and tranexamic acid infusions, the bleeding gradually stopped, and the fibrinogen level increased. We closely monitored the

bleeding events for 72 hours since the effects of hypofibrinogenemia may persist for up to three days, although the fibrinogen biosynthesis rate may increase two- to four-fold per day during the acute phase. TPE may reduce fibrinogen levels by 64% – 80% depending on the individual's condition and extensive rate of TPE. Immunoadsorption is another technique that selectively removes immunoglobulins from separated plasma through high-affinity absorbers and only reduces the fibrinogen level by 20% – 35%. However, our center had no experience using this technique. The incidence of bleeding after the TPE was relatively low (0.06% – 2.3%). Hypofibrinogenemia contributes to bleeding complications in patients using anticoagulants who undergo invasive procedures or surgery [11].

Using FFP in addition to 5% albumin as a replacement during TPE can decrease the reduction in fibrinogen levels. However, the prevention of hypofibrinogenemia by FFP administration during TPE is currently not recommended. The FFP replacement is reserved for patients who are already hemostatically compromised or have a high risk of bleeding. This is because of the risk of adverse events, such as hypersensitivity reaction, transfusion-related circulatory overload, and transfusion-related acute lung injury. Cryoprecipitate has similar disadvantages of FFP, but it contains higher concentrations of fibrinogen, factor VIII, and von Willebrand factor with a lower infusion volume. We administered cryoprecipitate combined with a tranexamic acid infusion when the patient presented with significant bleeding and low fibrinogen levels (below 100 mg/dl). Cryoprecipitate and tranexamic acid administration can improve fibrin formation and platelet aggregation. This present combination prevents massive transfusions and is associated with an improved survival rate in trauma-related bleeding [11-13].

CONCLUSION

TPE reduces the fibrinogen level, and FFP or cryoprecipitate may be administered when there is significant bleeding along with low fibrinogen levels or prolonged APTT to reduce the antibody-related risk of transfusion. Pre- and post-TPE fibrinogen levels should be closely monitored in patients who undergo invasive procedures due to the potentially tremendous decrease in fibrinogen levels, which contributes to bleeding complications. In the present patient, the combination of cryoprecipitate transfusion and tranexamic acid administration replenished the fibrinogen level and overcame the bleeding complications with an acceptable amount of blood products.

REFERENCES

[1] Wolfe, R. A., Ashby, V. B., Milford, E. L., Ojo, A. O., Ettenger, R. E., Agodoa, L. Y., Held, P. J. and Port, F. K. (1999). Comparison of mortality in all patients on dialysis, patients on dialysis awaiting transplantation, and recipients of a first cadaveric transplant. *N Engl J Med*, 341: 1725–1730.

[2] Lipshutz, G. S., McGuire, S., Zhu, Q., Zimman, A., Davis, R., Goldfinger, D., Reed, E. F., Wilkinson, A. H., Danovitch, G. M. and Pham, P. T. (2011). ABO-blood type-incompatible kidney transplantation and access to organs. *Arch Surg*, 146: 453–458.

[3] Clatworthy, M. R. (2011). Targeting B-cells and antibody intransplantation. *Am J Transplant*, 11: 1359–1367.

[4] Tobian, A. A., Shirey, R. S., Montgomery, R. A., Tisch, D. J., Ness, P. M. and King, K. E. (2009). Therapeutic plasma exchange reduces ABO titers to permit ABO-incompatible renal transplantation. *Transfusion*, 49: 1248–1254.

[5] Alexandre, G. P., Squifflet, J. P., DeBruyere, M., Latinne, D., Reding, R., Gianello, P., Carlier, M. and Pirson, Y. (1987). Present experiences in a series of 26 ABO-incompatible living donor renal allografts. *Transplant Proc*, 19: 4538–4542.

[6] Clatworthy, M. R. (2011). Targeting B cells and antibody in transplantation. *Am J Transplant*, 11: 1359–1367.

[7] Tobian, A. A., Shirley, R. S., Montgomery, R. A., Cai, W., Haas, M., Ness, P. M. and King, K. E. (2010). ABO antibody titer and risk of antibody-mediated rejection in ABO-incompatible renal transplantation. *Am J Transplant*, 10: 1247–1253.

[8] Gloor, J. M., Lager, D. J., Fidler, M. E., Grande, J. P., Moore, S. B., Winters, J. L., Kremers, W. K. and Stegall, M. D. (2005). A Comparison of splenectomy versus intensive posttransplant antidonor blood group antibody monitoring without splenectomy in ABO-incompatible kidney transplantation. *Transplantation*, 80: 1572–1577.

[9] Toki, D., Ishida, H., Setoguchi, K., Shimizu, T., Omoto, K., Shirakawa, H., Iida, S., Horita, S., Furusawa, M., Ishizuka, T., Yamaguchi, Y. and Tanabe, K. (2009). Acute antibody-mediated rejection in living ABO-incompatible kidney transplantation: Long-term impact and risk factors. *Am J Transplant*, 9: 567–577.

[10] Winters, J. L., Gloor, J. M., Pineda, A. A., Stegall, M. D. and Moore, S. B. (2004). Plasma exchange conditioning for ABO-incompatible renal transplantation. *J Clin Apher*, 19: 79–85.

[11] Zöllner, S., Pablik, E., Druml, W., Derfler, K., Rees, A. and Biesenbach, P. (2014). Fibrinogen reduction and bleeding complications in plasma exchange, immunoadsoprtion and a combination of the two. *Blood Purif*, 38: 160–166.

[12] Morrison, J. J., Dubose, J. J., Rasmussen, T. E. and Midwinterm, M. J. (2012). Military application of tranexamic acid in trauma emergency resuscitation (MATTERS) study. *Arch Surg*, 147: 113–119.

[13] Shakur, H., Roberts, I., Bautista, R., Caballero, J., Coats, T., Dewan, Y., El-Sayed, H., Gogichaishvili, T., Gupta, S., Herrera, J., Hunt, B., Iribhogbe, P., Izurieta, M., Khamis, H., Komolafe, E., Marrero, M. A., Mejia-Mantilla, J., Miranda, J., Morales, C., Olaomi, O., Olldashi, F., Perel, P., Peto, R., Ramana, P. V., Ravi, R. R. and Yutthakasemsunt, S. (2010). Effects of tranexamic acid on death, vascular occlusive events, and blood transfusion in trauma patients with significant haemorrhage (CRASH-2): A randomised, placebo-controlled trial. *Lancet*, 376: 23–32.

In: Encyclopedia of Surgery (22 Volume Set)
Editors: Andreas Lehrer and Kristin Mueller
ISBN: 978-1-53618-329-0
© 2020 Nova Science Publishers, Inc.

Chapter 322

SYMMETRICAL BILATERAL KEYSTONE PERFORATOR ISLAND FLAPS FOR VULVAR RECONSTRUCTION AFTER ONCOLOGICAL RESECTION: A CASE REPORT

Indri Aulia*, Chaula Luthfia Sukasah and Eva Chintia Yessica
External Genitalia Section, Plastic Reconstructive and Aesthetic Surgery Division, Department of Surgery, Universitas Indonesia, Dr. Cipto Mangunkusumo Hospital, Jakarta, Indonesia

ABSTRACT

The vulvoperineal region is key to the urinary and reproductive systems and closely related to the gastrointestinal system. Most vulvar defects are resulted from tumor ablation. Therefore, the reconstruction after oncological resection remains challenging as it aims to restore adequate function with an ideal aesthetic result. We report a case of a 46-year-old female with extramammary Paget's disease of the vulva. She underwent oncological excision for vulvar reconstruction. Keystone perforator island flaps were performed in this patient and it demonstrated a symmetrical bilateral result of vulva subunits. The patient was satisfied with the vulva appearance and no limitations in daily activities was reported. The use of keystone perforator island flaps is a superior option for vulva reconstruction to achieve a symmetrical outcome.

Keywords: Keystone flap, vulvar reconstruction, oncological resection

INTRODUCTION

The vulvoperineal region is key to the urinary, reproductive, and gastrointestinal systems. Most vulvar defects are caused by oncological rescetion [1]. However, the extent of surgery

* Corresponding Author's Email: drindriaulia@gmail.com.

varies from limited resection of pre-cancerous lesions to more extensive, bilateral radical vulvectomy for advanced cancer.

The reconstruction of vulvar defects after oncological resection remains challenging due to the high risk of postoperative infection because the area is easily contaminated and damp [2-4]. Poor wound healing and dehiscence might be also resulted from tension and traction upon movement of the affected region [5, 6]. Therefore, the reconstruction target is to restore adequate function and an ideal aesthetic appearance with minimal postoperative complications.

Various techniques have been developed for the reconstruction of vulvar defects, including the use of pedicled flaps [7-11]. However, this procedure might result in bulky flaps and asymmetrical coverage and could be insufficient for achieving appropriate aesthetic and functional results [12].

CASE

Patients with malignancy, especially vulvar malignancy, are treated with interdisciplinary management. In June 2017, a 46-year-old woman was diagnosed with extramammary Paget's disease of the vulva at the Gynecology Department of Dr. Cipto Mangungkusumo Hospital (Jakarta, Indonesia) and underwent an excision procedure conducted by an oncogynecologist. She was consulted to the Department of Plastic Surgery for further reconstruction of the vulva, which was performed using two keystone perforator island flaps from the lateral sides of the defect.

Figure 1. A: Vulvar defects of the patient with extramammary Paget's disease. B: Design of keystone perforator island flap. C: Immediate postoperative appearance. D–F: appearance of the flap 9 months after reconstruction.

DISCUSSION

Extramammary Paget's disease is an uncommon skin cancer involving genital, anal and perineum area [13]. It initially manifests as rash, scales and crusts that progresses into a wider and more severe lesion. Thus, a reconstructive surgery is necessary following excision of the primary lesion. In this case, we decided to perform keystone perforator island flaps to close the defect.

The keystone perforator island flaps survived in the patient with no complications of wound dehiscence or postoperative infection. In addition, there was no evidence of recurrence during nine months after the surgery. The vulvar region appeared to be symmetrical. Subjectively, the patient was satisfied with the appearance of the reconstructed vulva and had no complaints with urination, sexual activity, or daily activities. However, after the 9-month follow-up, the patient requested a minor revision to flatten the inferior part of the flap, which was slightly bulky. As with the first reconstruction, there were no complications with the revision procedure.

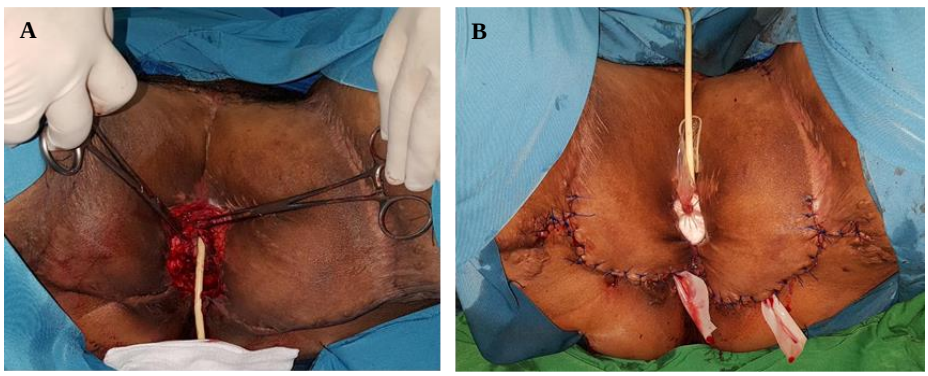

Figure 2. A: Keystone perforator island flap at 9 months after surgery. B: Appearance after revision surgery.

The use of keystone perforator island flaps resulted in symmetrical bilateral outcomes of the vulvar subunits. A 1:1 defect and flap ratio was applied to accurately place the midline. The initial incision and the final sutured lines were placed at the borders of the subunits to create a disguising scar.

CONCLUSION

Based on our experience, we found that keystone perforator island flaps has a lot of advantages for patients with vulvar defects. It has a simple design, symmetrical vulvar subunits results and it is applicable for defects in any part of the vulva. The appearance of the normal vulva is obtained by resurfacing the defect with tissue alike and applying it tightly as a young women's vulva. Minor revision is an additional procedure based on subjective desires in providing the daily needs and self-confidence. In conclusion, we believe that the use of keystone perforator island flaps is a good alternative for achieving functional and ideal aesthetic results of vulvar reconstruction.

REFERENCES

[1] Hockel, M; Dornhofer, N. Vulvovaginalreconstruction for neoplastic disease. *Lancet Oncol.*, 2008, 9, 559-568.

[2] Hashimoto, I; Abe, Y; Nakanishi, H. The internal pudendal artery perforator flap: free-style pedicle perforator flaps for vulva, vagina, and buttock reconstruction. *Plast. Reconstr. Surg.*, 2014, 133, 924-933.

[3] Mericli, AF; Martin, JP; Campbell, CA. An algorithmic anatomical subunit approach to pelvic wound reconstruction. *Plast. Reconstr. Surg.*, 2016, 137, 1004–1017.

[4] McAllister, E; Wells, K; Chaet, M; Norman, J; Cruse, W. Perineal reconstruction after surgical extirpation of pelvic malignancies using the transpelvic transverse rectus abdominal myocutaneous flap. *Ann. Surg. Oncol.*, 1994, 1, 164–168.

[5] Tan, B; Kang, GC; Tay, EH; Por, YC. Subunit principle of vulvar reconstruction: algorithm and outcomes. *Arch. Plast. Surg.*, 2014, 41, 379-386.

[6] Huang, J; Chang, N; Chou, H; Wu, C; Abdelrahman, M; Chen, HY; Cheng, MH. Pedicle perforator flaps for vulvar reconstruction — new generation of less invasive vulvar reconstruction with favorable results. *Gynecol. Oncol.*, 2015, 137, 66-72.

[7] Elken, JA; Aldeek, NF; Hsu, CC; Chang, NJ; Lin, CH. Algorithmic approach to lower abdominal, perineal, and groin reconstruction using anterolateral thigh flaps. *Microsurgery*, 2016, 36, 104-14.

[8] Negosanti, L; Sgarzani, R; Fabbri, E; Palo, S; Oranges, CM; De Iaco, P; et al. Vulvar reconstruction by perforator flaps: algorithm for flap choice based on the topography of the defect. *Int. J. Gynecol. Cancer*, 2015, 25, 1322-7.

[9] Carramaschi, F; Ramos, ML; Nisida, AC; Ferreira, MC; Pinotti, JA.V-Y flap for perineal reconstruction following modified approach to vulvectomy in vulvar cancer. *Int. J. Gynaecol. Obstet.*, 1999, 65, 157-63.

[10] Salgarello, M; Farallo, E; Barone-Adesi, L; Cervelli, D; Scambia, G; Salerno, G; et al. Flap algorithm in vulvar reconstruction after radical, extensive vulvectomy. *Ann. Plast. Surg.*, 2005, 54, 184-90.

[11] John, HE; Jessop, ZM; Di Candia, M; Simcock, J; Durrani, AJ; Malata, CM. An algorithmic approach to perineal reconstruction after cancer resection: experience from two international centers. *Ann. Plast. Surg.*, 2013, 71, 96–102.

[12] Wallace, CG; Kao, HK; Jeng, SF; Wei, FC. Free-style flaps: a further step forward for perforator flap surgery. *Plast. Reconstr. Surg.*, 2009, 124, 19-26.

[13] Parashurama, R; Nama, V; Hutson, R. Paget's disease of the vulva: a review of 20 years experience. *Int. J. Gynecol. Cancer*, 2017, 27, 791-793.

In: Encyclopedia of Surgery (22 Volume Set)
Editors: Andreas Lehrer and Kristin Mueller
ISBN: 978-1-53618-329-0
© 2020 Nova Science Publishers, Inc.

Chapter 323

RECONSTRUCTION OF AURICLE AFTER WIDE EXCISION OF GIANT MULTIPLE CONGENITAL MELANOCYTIC NEVUS OF THE EAR: A RARE CASE REPORT

Dini Widiarni Widodo [*] ***and Ferucha Moulanda***
Department of Otorhinolaryngology Head and Neck, Faculty of Medicine,
Universitas Indonesia - CiptoMangunkusumo General Hospital, Jakarta, Indonesia

ABSTRACT

Congenital melanocytic nevus (CMN) is a benign proliferation of melanocytes that appears at birth or within weeks of life. The condition occurs in 1% – 2% of newborns, with a 2% – 42% and 6% – 14% risk of transforming into malignancy or developing into multiple myeloma. The occurrence of CMN involving the auricular area is uncommon. Although excision of the nevus is the treatment of choice, this procedure is challenging. A wide area of CMN requires extensive excision coupled with a reconstructive procedure. In this article, we present a case of giant CMN in a 6-year-old female with giant pigmented nevi appearing after birth in all parts of her body, particularly the right facial, auricular, post auricular, mastoid, and neck areas. The diagnosis was reached based on the results of a biopsy revealing the presence of melanocytic nevus. Wide excision of the nevus at the right auricular with cartilage exposure was performed and a split-thickness skin graft was used for the reconstruction of the auricle. Postoperative follow-up showed a good outcome.

Keywords: auricular reconstruction, congenital melanocytic nevus, melanocyte, split-thickness skin grafts

[*] Corresponding Author's Email: dini_pancho@yahoo.com.

INTRODUCTION

Congenital melanocytic nevus (CMN) is a benign proliferation of nevus cells (melanocytes) located in the epidermis, dermis, and other tissues. It may cause mutation of genes NRAS Q61 and BRAF V600E, andvaries in severity from mild to life-threatening [1-3, 6]. According to Kopf, giant CMN (GCMN) is defined as nevi that will reach a diameter >20 cm in adult life. In addition, the presence and number of accompanying smaller (satellite) nevi should be recorded and classified into: 1) no lesion; 2) 1–20 lesions; 3) > 20 – 50 lesions; and 4) > 50 lesions. GCMN occurs in 1 per 500,000 births, and is associated with a 2% – 42% and 6% – 14% risk of transforming into a malignancy or developing into multiple myeloma, respectively. The available therapeutic modalities for GCMN include surgery and non-surgical, psychological, and/or clinical intervention with particular attention to discoloration, texture, or the surface of lesions [1, 4, 7-10].

GCMN occurring in the auricular area is considered rare. Moreover, reconstruction following large auricular skin defects frequently poses a surgical challenge. Esthetic concerns include symmetrical projection and maintenance of the shell-like shape. Postoperative complications may include contracture interfering with function, seroma, hematoma, infection, dehiscence, and keloid. Full-thickness skin grafts (FTSGs) and split-thickness skin grafts (STSGs) are alternative options for the coverage of large wounds, offering good functional and cosmetic results. Overall patient satisfaction with regards to the esthetic outcome is high (mean, 9.8). In addition, the rating provided by the surgeons is consistent with patient satisfaction [1, 4, 13].

CASE REPORT

A 6-year-old female was admitted to the CiptoMangunkusumo General Hospital following the appearance of black moles throughout the body especially in the ear, behind the ears, neck and right side of the face from birth. The mole grew larger with the advancing age, and the surface of the mole became thicker, hairy, and blackish in the areas of the face, ears and neck. A biopsy conducted by a dermatologist revealed the presence of melanocyticnevus. Hyperpigmentation appeared in the right auricle, preauricular and post auricula, mastoidarea and neck with size > 40 cm, rough surface, and hypertrichosis without tenderness (Figure 1). There were >50 satellite lesions throughout the body. The ear canal, tympanic membrane, and audiometric examinations were normal.

Figure 1. The patient with GCMN. Appearance of satellite nevi on patient's face and neck (left picture) and appearance of GCMN on right auricle, right side of the face and behind the right ear (right picture).

The patient was diagnosed with GCMN. We performed wide excision of the nevus at the right auricular area until the mastoid area, followed by reconstruction using STSGs from the thigh area placed in the preauricular, auricular, post auricular, and mastoid areas to the right area of the coli (Figure 2). Postoperatively, the patient was hospitalized for 5 dayswith daily skincare and administration of antibiotics, and educated regarding wound care.

Figure 2. Wide ecision and reconstruction with STSGs. Wide excision procedure of right GCMN (right auricular until mastoid area) with preservation of auricle cartilage (Picture A, B and C). Reconstruction of defect with suturing of STSG (Picture D and E).

Figure 3. The patient after surgery.

Follow-up was performed in out patient clinic 10 days postoperatively. The tie-over of the graft was removed, the condition of the graft appeared good, and there was no seepage of blood or active bleeding. The stitches were partially removed on day 14. A wet area was observed at the preauricular and neck areas, and treated with amnion.

Follow-up performed 45 days after surgery showed that the wound was dry and the appearance of the epithelium was good (Figure 3). The stitches in the auricular area were the parts removed last to maintain the shape of the cartilage. The patient was subsequently referred to the Dermatology Department for potential laser treatment.

DISCUSSION

GCMN of the ear is a very rare condition. Surgery is currently the treatment of choice for large-sized lesions. It is paramount to note the following in procedures for children: 1) donor skin, 2) grafting technique, 3) early postoperative care. The nevus must be cautiously excised to fully preserve the underlying perichondrium and avoid the presence of residual nevus. For larger nevi, the treatment plan divides the ear into esthetic units as follows: 1) concha, external auditory meatus, and ear canal; 2) antihelix, crura, and scapha; 3) helical rim; 4) lobule; 5) posterior auricular surface; 6) the region of non-hair-bearing skin above and posterior to the ear adjacent to the scalp; and 7) preauricular area (Figure 4) [1, 2, 12].

The reconstruction of large auricular skin defects frequently poses a surgical challenge. Esthetic concerns include symmetrical projection, maintenance of the shell-like shape of the helix, matching the skin color and textures, size discrepancies, presence and symmetry of the tragus as well as the contour of the antihelix, and the concha bowl. In the auricular region, options for the closure of defects typically include second intention healing, posing a risk of cartilage desiccation and webbing of the contoured surface of the ear [13].

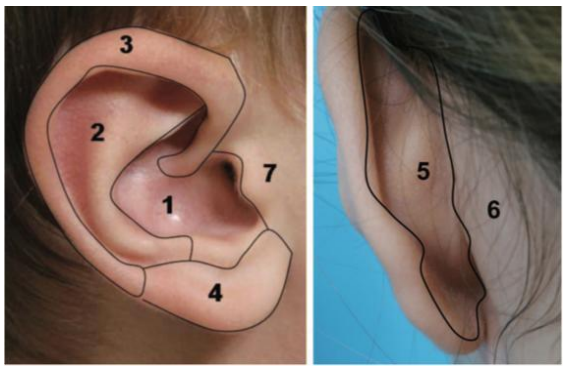

Figure 4. The esthetic units of the ear.

Tailor suturing in the area of auricular is challenging; therefore, it is recommended that the procedure is performed at a sufficiently advanced age (at least at 6 or 7 years of age), for the cartilage to be strong and capable of supporting the graft. The graft can also assist in the evaluation of the risk of recurrence and malignant alterations. FTSGs are an alternative to skin flaps for the auricular region; however, the thickness of FTSGs may be inappropriate for the thin skin of the ear. Failure of FTSGs has been reported in 14% – 30% of reconstruction cases. It has been suggested that STSGs allow rapid coverage of large wounds and offer excellent graft survival. The semitransparent characteristics of STSGs are ideal for covering the wound bed following the excision of an aggressive tumor, as they facilitate the detection of potential recurrence. Notably, thin STSGs match the thin skin of the cartilaginous ear better versus FTSGs, thus offering a distinct advantage [2, 13].

In this case, GCMN of right auricular was treated with wide excision exposing the cartilage, followed by reconstruction of the auricular area using STSGs. Evaluation performed 45 days after surgery showed good outcome.

CONCLUSION

GCMN is a very rare case and require surgical management. Reconstruction of auricle afterwide excision of GCMN is a challenging procedure regarding esthetic, anatomical structure with preservation of auricle cartilage. STSG is the main choice for auricle reconstruction in this case since it allows rapid and match coverage and facilitate detection of potential recurrence [1, 13].

REFERENCES

[1] Viana, A., Gontijo, B. & Bittencourt, F. (2012). Giant congenital melanocytic nevus. *Anais Brasileiros de Dermatologia*, *88*, 863-878.

[2] Adler, N., Margulis, A. & Bauer, B. (2009). Congenital pigmented nevi of the auricle: clinical experience and approach to treatment. *Plastic and Reconstruction Surgery*, *124*, 1932-1939.

[3] Gordon, R. (2013). Skin cancer: an overview of epidemiology and risk factors. *Seminars in Oncology Nursing*, *29*, 160-169.

[4] Salgado, C. M., Basu, D., Nikiforova, M., Bauer, B. S., Johnson, D., Rundell, V., Grunwaldt, L. J. & Reyes-Múgica, M. (2015). BRAF mutations are also associated with neurocutaneousmelanocytosis and large/giant congenital melanocytic nevi. *Pediatric and Developmental Pathology*, *18*, 1-9.

[5] Alikhan, A., Ibrahimi, O. & Eisen, D. (2012). Congenital melanocytic nevi: Where are we now? Part I: Clinical presentation, epidemiology, pathogenesis, histology, malignant transformation and neurocutaneos melanosis. *Journal of the American Academy of Dermatology*, *67*, 1-17.

[6] Scalvenzi, M., Palmisano, F., Cacciapuoti, S., Migliaro, F., Siano, M. & Staibano, S. (2013). Giant congenital melanocytic Naevus with proliferative nodules mimicking congenital malignant melanoma: a case report and review of the literature of congenital melanoma. *Case Reports in Dermatological Medicine*, *1*, 1-6

[7] Nguyen, T., Theos, A., Kelly, D., Busam, K. & Andea, A. (2013). Mitotically active proliferative nodule arising in a giant congenital melanocytic nevus: a diagnostic pitfall. *The American Journal of Dermatopathology*, *35*, 16-21.

[8] Krengeal, S. & Marghoob, A. (2012). Current management approaches for congenital melanocytic nevi. *Dermatologic Clinics*, *30*, 377-387.

[9] Yun, S., Kwon, O., Han, J., Kweon, S., Lee, M., Kim, M., et al. (2012). Clinical characteristic and risk of melanoma development from giant congenital melanocytic nevi in Korea: a nationwide retrospective study. *British Journal of Dermatology*, *166*, 115-123.

[10] Thuile, T., Larcher, L., Gatscher, B., Schwaiger, K., Deluca, J., Fallaha, A., Tappeiner, L., Puviani, M. & Eisendle, K. (2018). Split-thickness skin grafting for reconstruction of auricular skin defects: a statistical analysis. *Deutsche Dermatologische Gesellschaft*, *123*, 1-11.

[11] Depoortere, C., Francois, C., Belkhou, E., Duquennoy-Martinot, V. & Guerreschi, P. (2016). Features of skin graft in pediatric plastic surgery. *Annales de chirurgieplastiqueesthétique*, *7*, 1-10.

In: Encyclopedia of Surgery (22 Volume Set)
Editors: Andreas Lehrer and Kristin Mueller
ISBN: 978-1-53618-329-0
© 2020 Nova Science Publishers, Inc.

Chapter 324

DEVIATED NOSE IN A PATIENT WITH PARRY–ROMBERG SYNDROME: A CASE REPORT

Mirta Hediyati Reksodiputro[1,*], Dewi Puspito Sari[1], Iris Rengganis[2], Endi Novianto[3] and Dini W Widodo[1]

[1]Departement of Otorhinolaringology Head and Neck Surgery, Faculty of Medicine Universitas Indonesia Cipto Mangungkusumo General Hospital, Jakarta, Indonesia
[2]Departement of Internal Medicine, Faculty of Medicine Universitas Indonesia CiptoMangungkusumo General Hospital, Jakarta, Indonesia
[3]Departement of Dermatology and Venereology, Faculty of Medicine Universitas Indonesia CiptoMangungkusumo General Hospital, Jakarta, Indonesia

ABSTRACT

Parry–Romberg syndrome (PRS) is a rare degenerative disease characterized by unilateral, slow, and progressive atrophy of the facial tissue (including muscle, bones, and skin). Patients with this syndrome often develop a deviated nose. Such condition may lead to various aesthetic and functional issues. Septorhinoplasty plays a central role in the successful management of deviated nose. Here, we discuss the management of deviated nose in a patient with PRS along with evaluation of its characteristics, etiology, and pathophysiology. An 18-year/old female with deviated nose and the angle of her mouth toward the right side of the face underwent septorhinoplasty and labioplasty. Post surgery, functional and aesthetic improvements were observed in the deviated nose and facial asymmetry.

Keywords: Parry–Romberg Syndrome, deviated nose, septorhinoplasty surgery

[*] Corresponding Author's Email: citamirta@yahoo.com.

INTRODUCTION

Hemifacial atrophy or Parry–Romberg Syndrome (PRS) is a rare degenerative disease. It is characterized by slow and progressive unilateral atrophy of the facial tissues, including the skin, subcutaneous fat, muscle, cartilage, and bone. This condition was described for the first time by Parry and Romberg in 1846. The onset of disease occurs during the first decade of life. It slowly progresses for 2–10 years, reaching a stable phase between 18 and 21 years of age [1]. The extension of the atrophy is frequently limited to one side of the face. However, it may occasionally spread to the neck and one side of the body. Occasionally, ocular involvement, deviation of mouth and nose to the affected side as well as unilateral exposure of teeth is also noted. Moreover, patients may present with some neurological complications (e.g., trigeminal neuralgia, facial paresthesia, severe headache, and contralateral epilepsy). Identification of antinuclear antibodies in the serum suggests that the PRS is a kind of localized scleroderma.

CASE REPORT

An 18-year-old girl presented to our hospital with complaints of facial asymmetry and deviation of the nose and angle of mouth to the right side of face. After the age of 7 years old, slow shrinking of the right side of the face was noted by her mother. No symptoms of neurological disturbances or systemic problems were identified. Family history was negative for similar complaints. Additionally, no incidences of trauma or infection were observed to coincide with or precede the onset of the deformity. Clinical examination revealed narrowed right nasal cavity, deviated septum, and eutrophy of the inferior concha. Nasal analysis showed deviation of the nasal axis to the right side (< 150°), deviated tip from the basal view, saddle nose below the rhinion axis, and a nasofacial angle of 30° (Figure 1). Rhinomanometry demonstrated higher resistance than normal during inspiration. Additionally, lower air flow in both the right and left nostril at 75 Pa (0.57 Pa/cm3/s and 90.42 Pa/cm3/s, respectively) was noted. The scores of nasal obstruction symptom evaluation and peak nasal inspiratory flowmetry (PNIF) were 35 and 90, respectively. The patient was evaluated by an ophthalmologist and a rheumatologist, and no abnormality was identified. Laboratory examination such as anti-nuclear antibody (ANA) titer in September 2015 was positive, whereas in February 2016, it was negative. Additionally, CRP and ESR were within normal limits. The patient did not receive any medical treatment for immunity disturbance.

In July 2016, the patient underwent septorhinoplasty and labioplasty (Figure 3). Three months after surgery, no nasal congestion was observed, and clinical examination showed a wide right nasal cavity, undeviated septum, and inferior concha eutrophy (Figure 4). An improvement in nasal analysis was observed, with increased angle of nasal axis (174°), no deviated nasal tip, and nasofacial angle post surgery of 40°. Rhinomanometry showed significant changes, with an increased nasal air flow and a lower resistance during inspiration in both the right and left nostrils at 75 Pa (0.41 Pa/cm3/s and 0.37 Pa/cm3/s, respectively) was noted. The scores of nasal obstruction symptom evaluation and PNIF were 10 and 120, respectively.

Figure 1. Pre-operative assessment. Nasal analysis showed a nasal axis deviated to the right from the frontal, lateral, and basal view.

Figure 2. Three-dimensional CT Scan. CT Scan showed no abnormality in the hard tissue, and slight thinning of the soft tissue on the right side of the face, starting from the forehead and buccal cavity.

Figure 3. Intraoperative procedure.

Figure 4. Assessment after three months of surgery.

Nasal analysis showed an improvement in the deviation of the nasal axis from the frontal, lateral, and basal view.

DISCUSSION

In a previous study by Deshingkar et al., it was described that the onset of PRS is insidious. The disease generally manifests itself as an atrophy, with onset during the first decade of life. Prior to becoming quiescent and stabilizing, the syndrome slowly progresses [1]. In this case report, the patient complained of facial asymmetry and deviation of nose and angle of mouth to the right side of face since she was 7 years old. Additionally, 3 years ago, the patient developed nasal congestion. Such findings prove that symptoms slowly develop over the years. In a previous study by Aydin et al., it described that patients with PRS may manifest ophthalmic, and neurological complications. However, the study patient had no symptoms of neurological disturbance and had normal vision [2].

A report by Patel et al. stated that the treatment of PRS should be initiated only after the disease stabilizes [3]. Surgical treatment options depend on the side of atrophy and deformity [3]. The study patient had the deviation of the nose and upper labia to the right side. Consequently, for aesthetic and nasal congestion reasons, the patient underwent plastic reconstruction. Septorhinoplasty and labioplasty were performed after the age of 18 years to ensure that the disease has stabilized and facial growth has slowed down. Of note, performing surgery during facial growth would affect the shape of the nose [2]. Although a deviated nose is one of the greatest challenges in septorhinoplasty, it can be treated with appropriate surgical procedures. Using a precise nasal analysis pre-surgery, the patient was found to have

a C-shape deviation. The anterior rhinoscopy showed a deviated right nasal septum and the rhinomanometry showed resistance during nasal inspiration.

To reduce the congestion caused by deviated nose, the septum had to be reinforced and supported in a midline position. The spreader graft was placed following osteotomies, to secure the cartilage in a midline position. The spreader graft was important to smooth the brow-tip aesthetic line and prevent or correct midvault collapse by stenting open the internal nasal valve. As a consequence, medial displacement of the upper lateral cartilages was prevented. The caudal extension graft was used to enhance nasal tip dynamics by controlling the projection, rotation, and strength of the tip. The alar batten graft was used to reinforce the weakness of the lower lateral cartilage, thereby improving nasal patency in correlation with the nasal valve area. Treatment for the atrophy of the cheeks and forehead will be performed by a dermatologist using hyaluronic filling. Four months after surgery, the patient was in good clinical and aesthetic condition.

CONCLUSION

In conclusion, PRS manifests as an atrophy leading to a variety of either or both aesthetic and functional problems. In the study patient, septorhinoplasty was used to successfully manage the deviated nose caused by PRS. The functional septorhinoplasty provided structural support by means of autologous grafts to preserve and augment the nose without compromising aesthetic and functional results.

REFERENCES

[1] Deshingkar, SA; Barpande, SR; Bhavtangkar, JD; Humble, GJ. Progressive hemifacial atrophy. *Contemp. Clin. Dent.* 2012;3(5), S78-81.

[2] Hasan, A; Zeyne, Y; Husamettin, S; Melike, RM. Parry-Romberg syndrome. *Neurosciences.* 2015 Oct; 20(4), 368-371.

[3] Patel, H; Thakkar, C; Patel, K. Parry Romberg syndrome: A rare entity. J. Maxillofac. *Oral Surg.* 2010 Nov 27;9(3), 247-250.

[4] Nasser, IJG et al. Romberg's syndrome: a series of cases. *Rev. Bras. Cir. Plást.* 2013 Jun; 28(2), 201-4.

[5] Reddy, SS; Devaiah, D; Agarwal, K. Parry Romberg syndrome: Report of two cases with rare dental and skeletal findings. *E-Journal of Dentistry*. 2012 Jul;2(3), 68-71.

[6] Sargunar, B; Ebenezer, V; Balakrishnan, R.; Priya, S. Parry Romberg syndrome-A review of treatment options. *Biomed. Pharmacol. J.* 2014;7(1), 207-211.

[7] Prendergast, PM. Anatomy of the face and neck. In: Shiffman MA, Di Giuseppe A, editor. *Cosmetic Surgery: art and techniques*. Berlin: Springer-Verlag Berlin Heidelberg; 2013; 29-45.

[8] Inanli, S; Binnetogl, A. A combined approach to crooked nose deformity. *Aesth. Plast. Surg*. 2016 Jun;40(3), 360-6.

[9] Ahmad, J; Rohrich, RJ; Lee, MR. The crooked nose. *Clin. Plastic. Surg*. 2016 Jan;43(1), 99-113.

[10] Parilla, C; Artuso, A; Gallus, R; Galli, J; Paludetti, G. The role of septal surgery in cosmetic rhinoplasty. *Acta Otorhinolaryngol. Italica.* 2013 Jun;33(3), 146-153.
[11] Teymoortash, A; Fasunla, JA; Sazgar, AA. The value of spreader graft in rhinoplasty: a critical review. *Eur. Atch. Otorhinolaryngology*. 2012 May;296(5), 1411-16.

In: Encyclopedia of Surgery (22 Volume Set)
Editors: Andreas Lehrer and Kristin Mueller
ISBN: 978-1-53618-329-0
© 2020 Nova Science Publishers, Inc.

Chapter 325

USE OF NASOLABIAL AND NASAL SEPTAL FLAPS FOR UNILATERAL LOWER-THIRD NASAL DEFECTS

Mirta H. Reksodiputro, Satria Dipo Putra Asmoro, Dini W. Widodo and Trimartani Koento*
ORL- HNS Department, University of Indonesia, Jakarta, Indonesia

ABSTRACT

The nose is the most prominent structure in the center of the face and plays an important role in the aesthetics of the face. Nasal defects in the dorsum, ala nasi, nostrils, columella, or septum due to trauma, animal bites, and tumor can lead to loss of function and decrease in aesthetic value. Nasolabial and nasal septal flaps are used for the reconstruction of nasal defects after mass extirpation in the lower third of the nose, particularly in cases of ala nasi defects. Here, we report the case of a patient who underwent reconstruction with a combination of nasolabial and nasal septal flaps for an ala nasi defect due to mass extirpation for basal cell carcinoma. We also conducted an evidence-based literature search tailored to the case.

Keywords: Nasal defect, nasal reconstruction, nasolabial flap, nasal septal flap

INTRODUCTION

Nasal soft tissue can be deformed by accidents, surgical trauma, human or animal bites, tumors, and leishmaniasis. Basal cell carcinoma is rather common, with ~80% of the cases occurring in the head area, of which 40% occur in the skin of the cheeks and nose. Treatment with surgery in these cases often produces nasal defects [1]. External nose surgery is performed to correct the nasal defects, improve the aesthetic appearance of the nose and breathing, and restore the patient's mental health and self-confidence. However, ala nasi reconstruction for deep or broad defects is rather challenging from an aesthetic as well as a

* Corresponding Author's Email: trimartani@yahoo.com.au.

functional perspective. Nasal defects can be reconstructed using many techniques, the best being the use of nasolabial flap, which has a rich blood supply and a suitable texture and color, although it is associated with high donor area morbidity [2]. Nasolabial flap is very useful in ala nasi defect reconstruction [3]. This flap is very well done in elderly patients because it has more flexible skin, and more suitable color evenly. It's difficult to do for patients with hairy skin [4]. Incase with large alae nasi defect, it can be combined with nasal septal flap because it has good blood supply. The septal mucopericondrium can be used for one side in reconstruction [5].

CASE REPORT

A 56-year-old woman underwent wide excision for basal cell carcinoma removal in October 2015 at the Oncology Surgery Division of Dr. Cipto Mangunkusumo Hospital, Jakarta, Indonesia. Reopening of the surgical wound caused a defect on the right side of the lower third of her nose (Figure 1). She did not complain of nasal congestion, recurrent nosebleeds, or pain in the wound. Local examination revealed a 3×1 cm^2 defect in the lateral nasal dorsum toward the right nasal ala nasi, involving the visualizated base of the inferior turbinate mucosa, the right nasal septum, and some of the medial turbinate. The defect edge was hyperemic and dry, with a network of cuffles on the edge of the defect, nasal dorsum, and right nasal collumela. An asymmetrical deflection nasal tip appeared to the right. The trichion, glabella, nasion, rhinion, tip, and subnasal region were not in a straight line. There was no hematoma, edema, laceration, excoriation, or active bleeding.

Reconstruction surgery was perform on November 1, 2016, in the plastic reconstruction division of the otorhinolaryngology outpatient clinic. The island flap surgical technique used a combination of nasolabial and nasal septal flaps. An ear cartilage graft was used as a base support, and the nasal septal mucosa was used to line the nasolabial flap (Figure 2). During follow-up on day 7 postsurgery, the defect was found to be closed, and the nasal septal flap showed growth with no obstruction in the nasal cavity (Figures 3 and 4). During follow-up at 2 months postsurgery, the patient made no complaints of pain, nasal congestion, or runny nose mixed with blood. There was no edema, hematoma, hyperemia, or pus. In addition, there was minimal scar tissue in the surgical wound. Nasoendoscopic examination showed that the surgical wound appeared well; the nasal septal mucosa had formed with good vascularization; the nasal septal flap appeared well; and there was no hematoma, hyperemia, pus, edema, or perforation (Figure 5).

DISCUSSION

The nasolabial flap is very useful in ala nasi defect reconstruction, particularly in the elderly, because of its proximity, suitable color, and ease of use in the nasal recipient area [6]. In addition, the nasolabial flap is rich in blood vessels, including angular arteries (facial artery branches), infraorbital arteries, facial arteries, and infratrochlear arteries, and it is easy to anastomose between the main branches of the blood vessels [9]. Nasolabial flap can combined with nasal septal flaps. Brian, Drisco. defek yang cukup besar pada hidung, dapat

digunakan jabir mukoperikondrium septum pada kaudal septum [7]. Jabir ini di suplai darah dari percabangan arteri labialis superior [8].

Figure 1. Defect of the right lateral lower third of the nose and ala nasi.

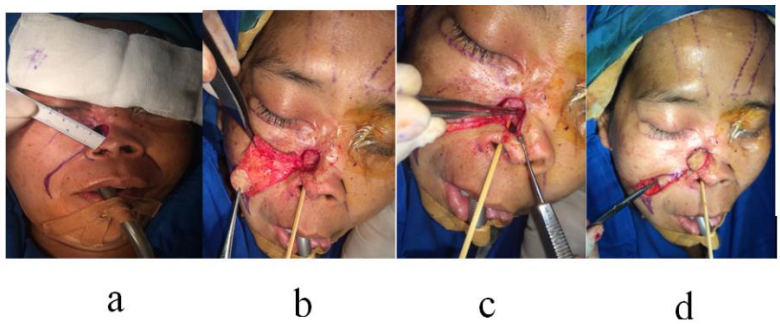

Figure 2. (a) Measuring the nasal defect. (b) Island flap technique combining nasolabial flap with nasal septal flap. (c) Nasal septal flap for lining the nasolabial flap. (d) Closing the flap.

Figure 3. Day 7 postsurgery follow-up.

Figure 4. Nasoendoscopic examination on day 7 postdurgery follow-up. Nasal septal flap growth looks good.

Figure 5. Two-month postsurgery follow-up. The nasal septal flap growth looks good, with no hematoma, hyperemia, pus, edema, or perforation.

In the island flap technique, the nasolabial flap is derived from the cheek area for the reconstruction of nasal defects that are not too large [6]. The nasal septal mocosa is taken as a lining, and an ear cartilage graft is placed above it as support on the contralateral side, making a sandwich [7]. Septal and ear cartilages are used to replace missing parts of the nose and provide good support because of their thin and flexible contours [10].

For a large nasal defect, the mucopericondrium from the nasal septal flap at the caudal septum can be used, which gets blood supply from superior labial artery branches. If needed, most of the one-sided mucopericondrium can be used for reconstruction [2]. The ipsilateral nasal septal flap can be used as a close pedicle, containing superior labial artery branches. This flap is thin and physiological and can be used for defects of the caudal third of the nose [11].

CONCLUSION

This paper had a case female, 56 years old with right alae nasi defect after tumour extirpation. Reconstruction is performed using nasolabial flap combined with nasal septal flap and ear concha cartilage for base. There was good result for aesthetic and function after two month evaluation. Nasolabial and Nasal Septal Flaps are good option for reconstruction of nasal defect with good and favourable results especially in elderly case.

REFERENCES

[1] Javaid, M., & Ahmad, N. (2018). Outcome of Nasolabial flap in Reconstruction of the nasal alar defect. *Turkish Journals of Plastic Sugery*. *Pakistan*, 163-166.

[2] Sand, P. J., & Branham, H. G. (2009). *Skin Grafts and Local Flaps in Facial Plastic Surgery. Nasal Reconstruction.* Chapter 41. New York, NY: Publisher. 660-712.

[3] Werda H. Editor. Coverage of Defects. *Reconstructive Facial Plastic Surgery*. Amsterdam: 2001:12-54.

[4] Rudy J., Triana Jr, Murakami C., Larrabee J. Skin Flap and Local Flaps. In: Papel I., Frodel J., Holt G., Nachlas N., Park S., Toriumi D., et all. Editors. *Facial Plastic Reconstructive Surgery*. 3rd Edition. New York: 2008:41-58.

[5] Brian P., Drisco, Baker S. *Reconstruction of Nasal Alar Defects*. Michigan: 2001:91-100.

[6] Hasan, A. A. (2016). Reconstruction of the nasal defect by nasolabial flaps. *Journal of US-China Medical Science*. *Iraq*, 64-79.

[7] Alam, M., & Goldberg, L. H. (2019). Oblique advancement flap for defects of the lateral nasal supratip. *Arch, Dermatol.*, 1039-1042.

[8] Larrabee W., Makielski K. Editors. Nose. *Surgical Anatomy of the Face*. United State of America: 2000:153-176.

[9] Martini F. editor. *Fundamental Anatomy and Physiology*. *The Respiratory System*. 7th Edition. United State of America. 2006:817-819.

[10] Rahpeyma A, Khajehahmadi S. *The place of nasolabial flap in orofacial reconstruction*. Iran: 2016:80-3.

[11] Soetjipto D., Mangunkusumo E., Wardani R. Hidung. In: Soepardi E., Iskandar N., Bashiruddin J., Restuti R. Editor. *Buku Ajar Ilmu Kesehatan Telinga Hidung dan Tenggorok*. Edisi ketujuh. Indonesia: 2012:96-103.

In: Encyclopedia of Surgery (22 Volume Set)
Editors: Andreas Lehrer and Kristin Mueller
ISBN: 978-1-53618-329-0
© 2020 Nova Science Publishers, Inc.

Chapter 326

SUPERNUMERARY NOSTRIL: A RARE CONGENITAL ANOMALY

Dini Widiarni Widodo [*] ***and Rindy Yunita Pratamisiwi***
Department of Otorhinolaryngology – Head and Neck Surgery,
Faculty of Medicine Universitas Indonesia/Cipto Mangunkusumo General Hospital,
Jakarta, Indonesia

ABSTRACT

Supernumerary nostrils are an extremely rare congenital. The purpose of this study is to prepare a standardized procedure for repairing supernumerary nostrils, and to discuss the probable psychological effect on the patient. Fistulectomy and cartilage graft from the ear were performed to reconstruct the accessory nostril. Surgery was performed at a young age to prevent further disfiguration and to optimize psychological well-being. The result of this study is the wound showed good healing progress over the lateral side of the nose. Although the symmetry between the two nostrils was not ideal, it was acceptable. The repair aims to create a functioning and normal-appearing nose with minimal deformity. The extra nostril can be excised during fistulectomy. The patient can also be offered social skill training to improve their self-esteem and family acceptance and support are important in the rehabilitation of children with facial disfigurations.

Keywords: supernumerary nostril, accessory nostril, psychological effect

INTRODUCTION

A supernumerary nostril is an extremely rare congenital deformity. Also known as triple nostrils or accessory nostril, supernumerary nostril is defined as an abnormal nostril located above the normal nostril. The specific cause and development of supernumerary nostril are not known. The anomaly seems to develop from a localized abnormality of the lateral nasal

[*] Corresponding Author's Email: dini_pancho@yahoo.com.

process at an early embryonic stage. Various types of the anomaly exist, and different surgery techniques to each are required, but there is still no generally accepted method of repair. The goal of repair is to create a functioning and normal-appearing nose with minimal deformity.

CASE PRESENTATION

A 10-year-old male child, who had a supernumerary nostril located beside his left nostril since birth, was referred to our department. He had no history of nasal obstruction. According to his mother, her pregnancy, the child's birth, and his development were uneventful. The patient had no other congenital abnormalities, and there were no reports of this type of deformity in either parent's family history.

On physical examination, the patient had two nostrils on the left side and the normal ipsilateral nostril was a little smaller than that on the other side. The diameter of the accessory nostril was 2 mm, and there was no discharge from any of the nostrils. We found no inferior and middle turbinate in the accessory nostril and no connective structures to the normal nostril. There was also no upper lateral cartilage in the accessory nostril; thus, the nostril felt soft on palpation. There was fibrous tissue without any columellar structure between the left and accessory nostrils. The nasal mucous lining appeared normal, and the patient was classified with type 3-a supernumerary nostril.

The surgery was performed under general anesthesia. The inner nostril was incised following the accessory nasolabial fold, and a left rim incision was then performed. The tissue between the vestibulum and the accessory nostril was widely undermined. No nasal alar and columellar structures were found during the surgery; therefore, alar reconstruction using ear cartilage was planned.

Figure 1. Patient with supernumerary nostril.

The left ear concha was marked and dissected. The cartilage was cut into a 0.5 mm × 0.5 mm piece and then inserted in the undermined vestibulum area to form a normal ala. The remaining subcutaneous and skin tissues were then sutured tightly to prevent hematomas.

The nostril size was adjusted with reference to the size of the normal nostril. The incision was sutured using 5-0 Prolene. The new ala was fixated using aluminum foil paper, and a small piece of nasogastric tube was inserted in the nostril as an internal stent, which was then removed after 3 days.

The wound showed good healing progress over the lateral side of the nose. The symmetry between the two nostrils, although not ideal, was acceptable. No hematoma was observed on the left ear, and the incised area showed no sign of infection. The patient and his parents were satisfied with the result, which boosted his confidence.

Figure 2. Intraoperative procedure.

Figure 3. Postoperative result.

DISCUSSION

Supernumerary nostril is an extremely rare type of congenital nasal anomaly with unclear etiology [1]. The first reported case was published in 1906 by Lindsay, who described a patient with bilateral supernumerary nostrils. Most reported cases of supernumerary nostrils have been unilateral, and were associated with other craniofacial malformations, such as a facial cleft [1-3]. A supernumerary nostril may or may not communicate with the ipsilateral normal nasal cavity, depending on the extent of the anomaly's progression. This condition should not be confused with the double nose deformity, which has two septa, four nostrils, four alae, and four nasal cavities [1-3].

Over the past 5 years, four cases of supernumerary nostril have been documented in English. In 2014, Sah et al. [4] reported a case with an accessory nostril located above the left nostril, which was repaired with an elliptical incision and fistulectomy technique. Trimartani and Widayanti in 2015 [5] and Choi et al. [3] in 2016 reported cases with a left accessory nostril treated by fistulectomy. Further, Asadi et al. [6] reported a case with a supernumerary nostril that was treated using an external rhinoplasty approach.

The preoperative workup for supernumerary nostril cases includes a detailed history with special attention to the prenatal course. A comprehensive physical examination is performed to rule out other craniofacial anomalies [7], and the diagnosis is made based on the clinical appearance, physical examination, and histological features of the accessory nostril [2] Consideration of imaging results such as those of computed tomography scans or magnetic resonance imaging to rule out any intracranial communication or skull base defect is balanced with the risk of anesthesia, which is required for imaging [7].

The scarcity and variation of supernumerary nostrils call for innovation during surgical repair. The goal of repair is to create a functioning and normal-appearing nose with minimal deformity. It is vital to resect the entire fistula tract and to preserve the perviousness of the normal nostril. Additionally, the redundant nasal tract should be eliminated, the nasal width reduced, and the alar base repositioned, all the while maintaining the natural alar skin [7].

Most of the above studies advocated that corrective surgery be performed at a young age to prevent any possible alar deformity or deformation of adjacent structures, thereby minimizing related psychological effects [8].

An imperfect appearance may result in overt teasing, bullying, and unwanted questioning. Social responses may also take the form of more subtle modifications in normal patterns of verbal and non-verbal interactions, such as facial expressions. These unfavorable social responses are the result of stigma, where outsiders subconsciously judge an individual negatively because of their imperfect appearance. Individuals affected by supernumerary nostril who are dissatisfied with or who are unrealistic about their appearance need to be identified. These individuals are "at risk" for developing low self-esteem and could be offered some social skills training to improve their self-confidence and increase their self-esteem [8].

The family environment is an important aspect in the rehabilitation of children with facial deformities. The attitudes, expectations, and degree of support shown by parents are likely to have an enormous influence on a child's perception of their impairment. Surgery for disfigurement usually results in increased self-esteem, self-confidence, and satisfaction with appearance, irrespective of whether an objective improvement is detected by independent observers. Unrealistically high expectations for surgical improvement can result in

dissatisfaction with post-surgical results; therefore, families should be counseled extensively pre-operatively to identify cases where this may be a problem [8].

CONCLUSION

The documented cases of supernumerary nostril until now are still inadequate. To determinate the embryological implications, anatomic presentations and possible additional anomalies with accessory nose, cases need to be further investigated. We aimed to share this rare congenital anomaly within medical field. In this rare deformity, surgery should be performed at an early age to avoid severe impact on the nasal cartilages because of the fistula, deformation of adjacent structures, and the psychologic effects.

REFERENCES

[1] Mishra, LK. Supernumerary nostril: Report of a rare case and a review of the literature. *Plast. Surg. Case Studies*, 2015;1(3):55-56.

[2] Sun, ZY, Li, H, Zhang, MJ, Zhao, H, Xu, W, Xiao, H, Guo YX, Wen, Z, Yin, GQ. Supernumerary Nostril. *Eur. Surg. Res.*, 2009;42:245-248.

[3] Choi, BE, Ko, SO, Shin HK. Supernumerary nostril: a case report. *Maxillofac. Plast. Reconstr. Surg*, 2016;38(1):43. Published 2016 Nov 5.

[4] Sah, BP, Bhandary, S, Pokharel, A, Shilpakar, SL, Chettri, ST, Paudel, D. A supernumerary nostril associated with dermoid cyst: A rare case report and review of literature. *American Journal of Medical Case Reports*. 2014; 2(3):52-54.

[5] Trimartani, Widayant, N. Rinoplasti pada kelainan hidung kongenital. *Oto Rhino Laryngologica Indonesiana*. 2015;45(1):53-60.

[6] Asadi, M, Tabrizi, AG, Jahanshahi, F. Supernumerary nostril in the twin: case report. *JPRI*, 2017;18(1):1-5.

[7] Shaye, DA, Tibesar, RJ. Repair of supernumerary nostril. *J. Craniofac. Surg*. 2014;25(3): 978-979.

[8] Turner, SR, N, Rumsey, JR, Sandy. Psychological aspects of cleft lip and palate. *Eur. J. Orthod.*, 1998;20(4):407-415.

[9] Saiga, A, Mitsukawa, N. Case of supernumerary nostril. *J. Plast. Reconstr. Aesthet. Surg.* 2013 Jan; 66(1): 126-128. DOI: 10.1016/j. bjps.2012.05.014; PMID: 22687717.

[10] Kawamoto, HK Jr. *Rare craniofacial clefts, plastic surgery*. Philadelphia, PA: Saunders; 1990. 4:2922-2973.

[11] Losee, JE, Kirschner, RE, Whitaker, LA, Bartlett, SP. Congenital Nasal Anomalies: A Classification Scheme. *Plast. Reconstr. Surg*. 2004. Feb;113(2):676-89.

In: Encyclopedia of Surgery (22 Volume Set)
Editors: Andreas Lehrer and Kristin Mueller
ISBN: 978-1-53618-329-0
© 2020 Nova Science Publishers, Inc.

Chapter 327

OBJECTIVE MEASURES IN FUNCTIONAL SEPTORHINOPLASTY: TWO CASE REPORTS OF NASAL FORM AND NASAL VALVE RECONSTRUCTION

Trimartani Koento[1], Tiara Melati[2] and Mirta H. Reksodiputro[1,*]
[1]Department of Otorhinolaryngology Head and Neck Surgery,
Plastic Reconstructive Sub Division, Faculty of Medicine, University Indonesia,
Dr. Cipto Mangunkusumo Hospital, Jakarta, Indonesia
[2]Department of Otorhinolaryngology Head and Neck Surgery, Faculty of Medicine,
University Indonesia, Dr. Cipto Mangunkusumo Hospital, Jakarta, Indonesia

ABSTRACT

Nasal valve, which is the narrowest area in the nasal airway passage, is responsible for about half of the total nasal airway resistance. Functional septorhinoplasty is used to achieve an esthetic shape of the nose while preserving adequate nasal and breathing function. Nasal complaints are subjective; thus, objective measurements obtained through active anterior rhinomanometry are needed to correctly identify nasal valve incompetence. We present reports of two cases where changes in nasal airflow and resistance were objectively assessed before and after functional septorhinoplasty using an alar batten graft. Significant changes were observed postoperatively. Improvement was confirmed by assessment of subjective symptoms of nasal obstruction and rhinomanometry data.

Keywords: rhinomanometry, septorhinoplasty, alar batten graft, nasal valve

INTRODUCTION

It is often difficult to objectively quantify the outcomes of functional and esthetic nasal surgery (septoplasty, rhinoplasty, nasal valve surgery, turbinoplasty, and septorhinoplasty)

* Corresponding Author's Email: citamirta@yahoo.com.

[1], as traditional outcome measures rely on quality-of-life and patient satisfaction. The development and validation of objective measures may allow quantification of surgical outcomes. As nasal form and function are closely intertwined, quantitative assessment can better define this relationship and the effects on these parameters following nasal surgery. Rhinomanometry is an objective measure of nasal airflow and resistance that can be applied to outcome-based research to allow improved comparisons of results across studies. Further development of these objective measures can potentially lead to the identification of clinical predictors for surgical success or the development of standard criteria for surgical decision support. This information is useful not only within academia but also within commercial healthcare, given the mounting external pressure for quantifiable outcomes, particularly in the field of facial plastic surgery, which is increasingly being faced with challenges for insurance approvals and justification of procedures. Thus, the need for objective data will only continue to grow.

Several characteristics of objective assessment techniques, such as nasoendoscopic evaluation and rhinomanometry, are important to achieve accurate reproducible results and to ensure cost-effectiveness. Many available objective measures for functional nasal surgery are lacking in one or more of these characteristics, thereby limiting their routine clinical use. However, advances in computed imaging technologies, such as computed tomography scan (CT scan), have facilitated the development of innovative objective assessment tools for nasal surgery. In this article, we have presented an overview of objective measures in both esthetic and functional nasal surgeries and discussed the assessment of objective outcomes of nasal form and function is discussed.

CASE 1

A 24-year-old woman presented with a 5-year history of debilitating nasal obstruction. No other nasal or throat symptoms were noted. On physical examination, there was no nasal deformity or positive sign of Cottle's maneuver (Figure 1). A rigid nasal endoscopic examination showed narrowing of the nasal passages; the internal nasal valves were narrowed, and the inferior turbinates were edematous without septal deviation. The results of anterior active rhinomanometry showed moderate obstruction of right nasal airflow (Figure 2) with a significant reduction in the flow at rest and maximum respiration (Table 1).

Nasal valve incompetence was addressed through septorhinoplasty, multiple outfracturing of the inferior turbinates, and an alar batten graft. The graft donor site was the cartilage from the left auricular conchal cavity; the site was closed and secured with through-and-through sutures. The patient was discharged the following day. One week postoperatively, the patient had no nasal obstruction. A nasal endoscopic examination revealed a broad nasal passage and widened internal nasal valve areas (Figure 3). A second rhinomanometry examination performed at 2 weeks postoperatively revealed a significant improvement in the right nasal airflow at rest and maximum respiration with enhanced nasal resistance (Figure 4, Table 2).

Figure 1. Frontal and basal preoperative views.

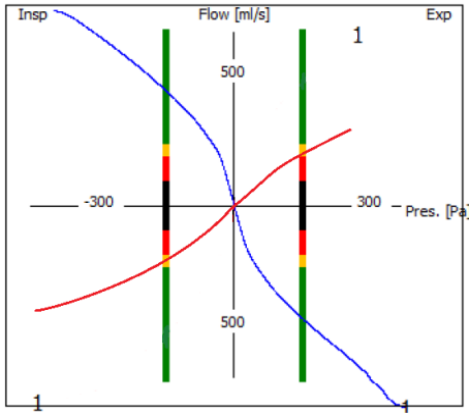

Figure 2. Anterior active rhinomanometry curvature preoperatively.

Table 1. Anterior active rhinomanometry preoperatively data

Pressure	Inspiration			Expiration			Unit
	75 Pa	150 Pa	300 Pa	75 Pa	150 Pa	300 Pa	
Left Airflow	316	456	681	310	452	695	ml/s
Right Airflow	167	257	459	170	235	301	ml/s
Total Airflow	483	716	1140	480	687	996	ml/s
Left Resistance	0.24	0.33	0.44	0.24	0.33	0.43	%
Right Resistance	0.16	0.21	0.26	0.16	0.22	0.3	%

Figure 3. Frontal view before and at 1 week postoperatively.

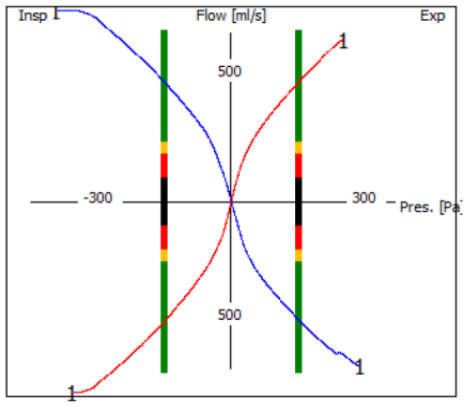

Figure 4. Anterior active rhinomanometry curvature postoperatively.

Table 2. Anterior active rhinomanometry postoperatively data

Pressure	Inspiration			Expiration			Unit
	75 Pa	150 Pa	300 Pa	75 Pa	150 Pa	300 Pa	
Left Airflow	330	493	752	331	485	-	ml/s
Right Airflow	326	496	752	327	489	-	ml/s
Total Airflow	656	989	1540	658	974	-	ml/s
Left Resistance	0.23	0.3	0.4	0.23	0.31	-	%
Right Resistance	0.23	0.3	0.4	0.23	0.31	-	%

CASE 2

A 45-year-old male presented with a chief complaint of nasal obstruction with a history of nasal closed reduction 6 months ago due to an accident (Figure 5). On physical examination, there was no deformity of the nose, with only a scar observed in the right medial canthus. Cottle's maneuver was positive. Nasal endoscopic examination revealed a deviated septum superiorly and collapsed ala nasi during respiration, which reduced the internal nasal valve area. Nasal incompetence in this patient was addressed by septoplasty, and an alar batten graft was placed via the endonasal approach. The patient was discharged the next day, and follow-up examination at 1 week postoperatively was improved, as seen from the nasal endoscopic comparison before and after surgery (Figure 6).

Figure 5. Frontal preoperative view.

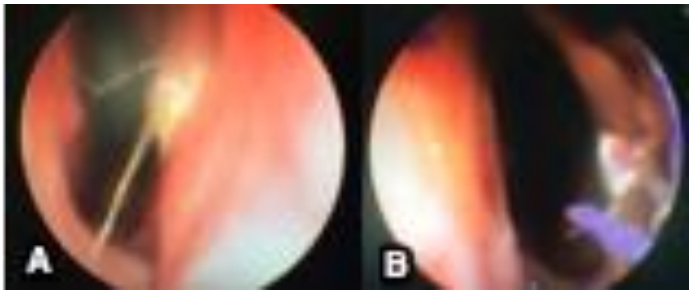

Figure 6. Nasal endoscopic findings: (A) pre- and (B) postoperatively.

DISCUSSION

Objective measurement of nasal obstruction is important to determine a successful surgical outcome. There are many studies that show discrepancy between subjective and objective findings of nasal patency [1]. Therefore objective tools must be reproducible, be able to exclude a mucosal diagnosis, and correctly identify relevant constraints. In the United States, the annual cost of treatment of nasal obstruction exceeds 5 billion USD, with nasal surgery accounting for more than 60 million USD [2]. Rhinomanometry and acoustic rhinometry are expensive, time-consuming, and uncomfortable to the patient [3, 4].

According to Hsu et al. [5], the visual analog scale, the nasal obstruction symptom evaluation questionnaire, and anterior active rhinomanometry are useful tools to assess subjective complaints regarding nasal patency following septoplasty. Rhinomanometry is used to obtain information regarding nasal airflow and resistance. All three of these modalities are helpful in determining the candidacy and success of septoplasty. Bohluli et al. [6] have described the specific equipment and skills required for rhinomanometry, acoustic rhinometry, and computed tomography. The external nasal valve efficacy index by simple photography, which utilizes software to calculate the cross-sectional nostril at rest and respiration, is a relatively simple method that can be routinely performed preoperatively and can be used to document every stage of therapy [6].

Miman et al. [7] identify and classify the shape of the internal nasal valve using nasal endoscopy. In light of the advances in smartphones, Surda et al [8] perform image analysis to measure the angle and cross-section area of the internal nasal valve. Lee et al. [9] and Moche et al. [10] both studies uses standard CT scan to identify and measure the internal nasal valve.

According to Spielmann et al. [11], identification of the specific underlying cause of nasal valve incompetence is necessary to achieve successful reconstruction. Thus, the most appropriate technique may be to strategically address each cause, and the causes vary across cases. While selecting the technique, long-term advantage to the patient must be considered. Furthermore, Spielmann et al. [11] have recommend routine nasal airflow examination both pre- and postoperatively.

A combination of objective tools such as facial photos, Cottle's maneuver, nasoendoscopic findings, and anterior active rhinomanometry is essential for the diagnosis of nasal obstruction due to incompetence of the nasal valve. Such tools allow specific identification of the area of the lesion and are relatively reproducible. Although rhinomanometry may not be available everywhere and access is limited in many facilities,

facial photos, Cottle's maneuver, and nasoendoscopic findings provide integral information, which greatly impacts the selection of the reconstruction technique.

REFERENCES

[1] André, R. F., Vuyk, H. D., Ahmed, A., Graamans, K., Nolst Trenité, G. J., (2009). Correlation between subjective and objective evaluation of the nasal airway. A systematic review of the highest level of evidence. *Clin Otolaryngol.* 34, 518-525.

[2] Chandra, R. K., Patadia, M. O., Raviv, J., (2009). Diagnosis of nasal airway obstruction. *Otolaryngol. Clin. North Am.* 42, 207-225.

[3] Fattahi, T., (2008). Internal nasal valve: significance in nasal air flow. *J. Oral Maxillofac. Surg.* 66, 1921-1926.

[4] Jones, A. S., Viani, L., Phillips, D., Charters, P., (1991). The objective assessment of nasal patency. *Clin. Otolaryngol. Allied Sci*. 16, 206-211.

[5] Hsu, H. C., Tan, C. D., Chang, C. W., Chu, C. W., Chiu, Y. C., Pan, C. J., Huang, H. M., (2017). Evaluation of nasal patency by visual analogue scale/nasal obstruction symptom evaluation questionnaires and anterior active rhinomanometry after septoplasty: retrospective one-year follow-up cohort study. *Clin. Otolaryngol.* 42, 53-59.

[6] Bohluli, B., Varedi, P., Kahali, R., Bagheri, S. C., (2015). External Nasal Valve Efficacy Index: a simple test to evaluate the external nasal valve. *Int. J. Oral Maxillofac. Surg.* 44, 1240-1245.

[7] Miman, M., Deliktas, H., Ozturan, O., Toplu, Y., Akarçay, M., (2006). Internal nasal valve: revisited with objective facts. *Otolaryngol. Head Neck Surg.* 134, 41-47.

[8] Surda, P., Walker, A., Little, S. A., Barnes, M. L., Hassan, D., Toma, A., (2017). Novel outcome measurement tool of the nasal valve surgery image analysis using endoscopic system for smartphones. *Clin. Otolaryngol.* 42, 192-195.

[9] Lee, D. C., Shin, J. H., Kim, S. W., Kim, B. G., Kang, J. M., Cho, J. H., Park, Y. J., (2013). Anatomical analysis of nasal obstruction: nasal cavity of patients complaining of stuffy nose. *Laryngoscope* 123, 1381-1384.

[10] Moche, J. A., Cohen, J. C., Pearlman, S. J., (2013). Axial computed tomography evaluation of the internal nasal vavle correlates with clinical valve narrowing and patient complaint. *Int. Forum Allergy Rhinol.* 3, 592-597.

[11] Spielmann, P. M., White, P. S., Hussai, S. S., (2009). Surgical technique for the treatment of nasal valve collapse: a systematic review. *Laryngoscope* 119, 1281-1290.

In: Encyclopedia of Surgery (22 Volume Set)
Editors: Andreas Lehrer and Kristin Mueller
ISBN: 978-1-53618-329-0
© 2020 Nova Science Publishers, Inc.

Chapter 328

THE ROLE OF VOICE THERAPY IN REDUCING VOICE-RELATED SYMPTOMS IN LARYNGOPHARYNGEAL REFLUX EVALUATED BY REFLUX SYMPTOM INDEX, VOICE HANDICAP INDEX, AND LARYNGOVIDEOSTROBOSCOPY

Elvie Zulka Kautzia Rachmawati*[*], Yonian Gentilis[2], Rahmanofa Yunizaf[1], Susyana Tamin[1], Fauziah Fardizza[1] and Luh Karunia Wahyuni[3]

[1]Department of Otorhinolaryngology Head and Neck Surgery, Faculty of Medicine, Universitas Indonesia, Jakarta, Indonesia
[2]Otorhinolaryngology Head and Neck Surgery Residency Program, Faculty of Medicine, Universitas Indonesia, Jakarta, Indonesia
[3]Department of Physical Medicine and Rehabilitation, Faculty of Medicine, Universitas Indonesia, Jakarta, Indonesia

ABSTRACT

Patients with laryngopharyngeal reflux frequently experience refractory voice-related symptoms that are nonresponsive to antireflux therapy. New options, such as voice therapy, are alternative treatments for laryngopharyngeal reflux. To evaluate the effect of voice therapy in addition to medical antireflux treatment in a patient with laryngopharyngeal reflux with persistent voice-related symptoms with the use of subjective assessment by the Reflux Symptom Index and the Voice Handicap Index and objective evaluation of the vocal cords by laryngovideostroboscopy. A 48-year-old woman with laryngopharyngeal reflux presented with hoarseness and a sensation of lump in her throat for the previous 6 months. The patient had taken a proton-pump inhibitor twice a day and undergone lifestyle modification for 6 months, but there was no significant improvement. Voice therapy along with antireflux therapy and lifestyle

[*] Corresponding Author's Email: zulka.elvie@gmail.com.

modification was then conducted. Evaluation by subjective and objective assessments showed a significant improvement after the comprehensive treatment strategy. After voice therapy and the use of a proton-pump inhibitor, the Reflux Symptom Index decreased from 19 to 10, and the Voice Handicap Index lowered in functional (from 3 to 0) and physical (from 8 to 6) subscales. The stroboscopic findings showed significant improvement in mucosal wave (from 10% to 60%), amplitude (from 20% to 40%), open–closed phase, phase symmetry, and periodicity. Voice therapy should be considered as an adjuvant treatment to antireflux therapy and lifestyle modification in patients with laryngopharyngeal reflux presenting with refractory voice-related symptoms.

Keywords: Antireflux therapy, laryngopharyngeal reflux, laryngovide ostroboscopy, RSI, VHI-10, voice therapy

INTRODUCTION

Laryngopharyngeal reflux (LPR) is defined as the backflow of gastric contents into the larynx and pharynx [1]. LPR may be manifested as laryngeal symptoms such as cough, throat clearing, hoarseness, and globus, as well as signs of laryngeal irritation on laryngoscopy [2]. LPR occurs in 4% to 30% of patients who visit otolaryngology departments [3–5]. Up to 71%–79% of the patients with LPR complain of nonspecific symptoms, including hoarseness [6, 7].

Voice problems in LPR patients are best evaluated by subjective and objective approaches. By assessing the patient early both subjectively, using the Reflux Symptoms Index (RSI) and a 10-item Voice Handicap Index (VHI-10), and objectively, using laryngovideostroboscopy, a more efficient model for evaluation and treatment of the patient may be achieved. Vocal fold pathology in LPR is best diagnosed by laryngovideo-stroboscopy. Among the laryngostroboscopic findings, vocal fold edema has been suggested as the main factor affecting vibration of the vocal folds, leading to hoarseness. In addition, hyperadduction of the true vocal and vestibular folds, the presence of glottal chinks of different lengths, and reduced amplitude and mucosal wave are the main stroboscopic findings [8–11].

Treatment of LPR patients with refractory voice problems is very challenging. Proton-pump inhibitors (PPIs) are still the most effective agents for the treatment of LPR. Belafsky et al., [12] reported that symptom resolution in LPR occurred after 2 months of treatment with PPIs and that the physical findings improved more slowly after at least 6 months of treatment. Refractory voice-related symptoms of LPR that are treated by antireflux therapy have multifactorial causes. The negative loop highlighting the cough and throat clearing secondary to the subsequent accumulation of sticky mucus and globus sensations may be responsible for exacerbation of the tension applied to the mucosa and thus increase vocal microtraumas. Increasing force and subglottal pressure during phonation in the edematous vocal cords may lead to more damage of the mucosal structure. This improper technique of phonation is another factor that prolongs the healing process in injured vocal folds and may cause persistent voice-related symptoms in LPR patients [12–14].

Currently, voice therapy along with medical therapy is the mainstay of treatment for LPR patients with voice problems. The global objective of a program including direct and indirect therapy is the reduction or correction of improper use of the voice. The direct approach aims

to correct posture; reduce tension in the laryngeal and cervical muscles; promote respiratory control, efficient glottal closure, and resonant equilibrium; and improve articulation. The indirect methods include raising awareness of healthy vocal habits and their importance. Voice therapy may also help to reverse mucosal changes secondary to acid reflux, inducing rapid resolution of symptoms and shortening the treatment period. Several studies have shown that voice therapy may improve RSI scores in LPR patients when used either with or without a PPI. Furthermore, behavioral voice therapy may result in alleviation of symptoms and reduction in RSI scores that do not occur with antireflux management only [15, 16].

The current study reports a case of LPR with voice disorder that did not respond to antireflux therapy. Voice therapy was conducted in addition to PPI therapy and resulted in many improvements in subjective and objective laryngeal assessment by RSI, VHI-10, and videostroboscopy. The aim of this study is to describe the importance of comprehensive therapy of PPI together with voice therapy in diminishing refractory voice-related symptoms in LPR.

CASE REPORT

A 48-year-old woman with chief complaints of hoarseness and a sensation of lump in her throat for 6 months came to the otorhinolaryngology outpatient clinic of the Ciptomangunkusumo Hospital. The patient had been previously diagnosed with LPR at a private hospital. She had taken a PPI (lansoprazole, 30 mg twice a day) and undergone lifestyle modification for 6 months; however, the symptoms did not diminish. She was then diagnosed with intractable LPR. The VHI-10 questionnaire, which has been validated for the Indonesian language, was used to subjectively evaluate the severity of the patient's dysphonia. At baseline, her VHI-10 score was 13; her RSI score was 19, with the highest scores for voice problems and globus sensation; and her RFS was 10. Neck palpation revealed increased tension of the extrinsic muscles.

The laryngovideostroboscopic evaluation showed an obvious decrease in the mucosal wave of up to 10%/10% and a decreased vibratory amplitude of up to 20%/20%. Supraglottic activity was 20% in the anteroposterior configuration. The periodicity was irregular, with closed phase dominant. There was phase asymmetry with "snake dance" appearance with posterior chink during the closed phase.

Voice therapy along with LPR medication and lifestyle modification was then advised. Voice therapy was tailored to this patient and constituted a combination of indirect and direct approaches. The indirect approaches included patient education, such as discussion of the impact of muscle tension on function, vocal hygiene, and counseling. The direct approaches included physiologic and symptomatic techniques to manipulate subsystems of voicing (respiration, phonation, and resonance). The voice therapy sessions were approximately 50 to 60 minutes in duration and were conducted weekly. All six sessions were completed in one and a half months.

After this comprehensive treatment, the patient was reassessed by RSI, VHI-10, and laryngovideostroboscopy. The VHI-10 showed good results after treatment, especially in the functional and physical subscales (Table 1). The RSI was successfully decreased into 10 with diminishing of voice problems (from 4 to 2 points) (Table 2). In contrast, the globus sensation

showed only minimal improvement after treatment (from 4 to 3). Laryngovideostroboscopic examination revealed improvement in the edges of the vocal folds and mucosal wave that reached 60%/60% after therapy (Figure 1 and 2). Amplitude, vibratory portion, supraglottic activity, periodicity, lengthening of the closed phase, and phase symmetry also improved after voice therapy and PPI (Table 3). However, the posterior gap during closed phase was still visualized.

Table 1. Voice Handicap Index (VHI-10) scores in a patient with refractory dysphonia due to laryngopharyngeal reflux before and after voice therapy

VHI-10 (Indonesian version)	Baseline	Follow-up
Functional subscale	3	0
Physical subscale	8	6
Emotional subscale	2	2

Table 2. Reflux Symptoms Index (RSI) scores in a patient with refractory dysphonia due to laryngopharyngeal reflux before and after voice therapy

RSI	Baseline	Follow-up
Voice problem	4	2
Clearing throat	2	0
Postnasal drip	3	3
Difficulty swallowing	3	0
Coughing after eating or lying down	0	0
Breathing difficulty	1	0
Annoying cough	0	0
Sensation of lump in the throat	4	3
Heartburn, chest pain	2	2
Total	19	10

Table 3. Evaluation of the vibratory function of the vocal cords in a patient with refractory dysphonia due to laryngopharyngeal reflux by stroboscopy before and after voice therapy

Stroboscopy parameters	Baseline	Follow-up
Mucosal wave (%)	10/10	60/60
Amplitude (%)	20/20	40/40
Glottic closure	Posterior gap	Posterior gap
Vibratory portion (%)	20/20	60/60
Supraglottic activity (%)		
Lateromedial	0	0
Anteroposterior	20	0
Vocal folds edge	Smooth-convex	Normal
Vertical level	On plane	On plane
Periodicity	Irregular	Regular
Open–closed phase	Closed dominant	Normal
Symmetry	Asymmetry	Symmetry

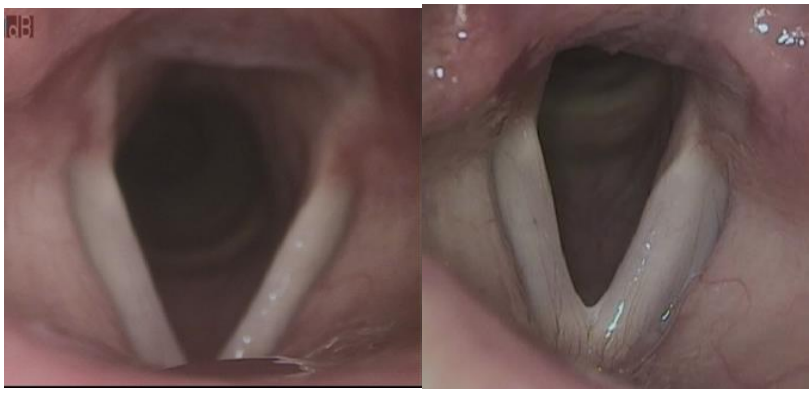

Figure 1. Vocal folds edge improved after voice therapy and proton-pump inhibitor therapy; left, before and right, after therapy.

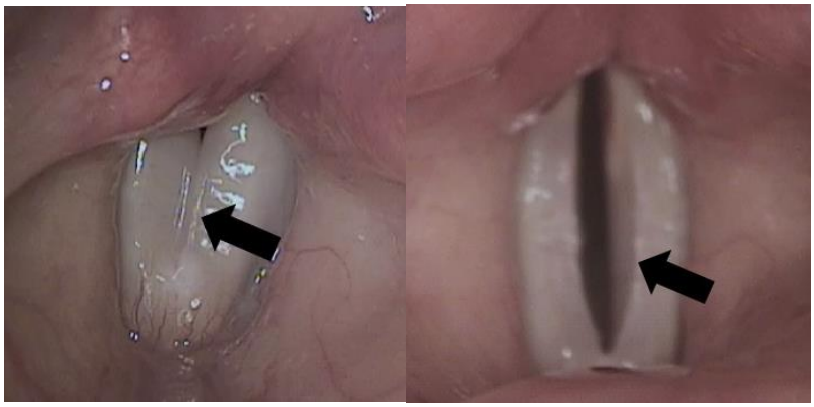

Figure 2. The mucosal wave improved after voice therapy and proton-pump inhibitor therapy; left, before and right, after therapy.

DISCUSSION

According to the Stanford Voice and Swallowing Center Guidelines for LPR Disease, PPIs are the most effective agents for the treatment of LPR [13]. Successful treatment requires high doses for a prolonged period. The PPI should be taken twice daily for at least 6 months, depending on the severity of the LPR changes seen on examination. Improvement of symptoms is expected within 4 to 6 weeks. Usually, the visual signs of improvement according to laryngoscopy lag behind symptomatic relief by several months. Campagnolo et al., [17] recommended that pharmacologic intervention should consist of a minimum of 3 months of treatment with PPIs. Shaw et al., [18] and Pribuisiene et al., [19] analyzed the efficacy of PPIs such as omeprazole and lansoprazole and found a significant response of the laryngeal and voice-related symptoms in 8 weeks. Belafsky et al., [12] reported that symptom resolution occurred after 2 months of therapy with PPIs; however, the physical findings improved more slowly after at least 6 months of treatment. Park et al., [15] reported that 70% of the patients had a good response after 4 months of twice-daily PPI therapy. Thus, twice-daily PPI therapy for at least 4 months is reasonable, and the symptoms should improve by 2

months. However, the patient in this case report was given a PPI for 6 months with no significant subjective improvement.

The persistent voice-related symptoms of LPR treated by antireflux therapy have multifactorial causes. The negative loop highlighting the cough and throat clearing secondary to the subsequent accumulation of sticky mucus and globus sensations may be responsible for exacerbation of the tension applied to the mucosa and thus increase vocal microtraumas [14]. Increasing force and subglottal pressure in edematous vocal cords with abnormalities of vibratory function in reflux laryngitis may lead to more damage to the mucosal structure of the vocal folds. Improper techniques of phonation by LPR patients are another factor that prolongs the healing process in injured vocal folds. The refluxate also causes microtrauma to the lymphoid tissue (lingual tonsils), which may lead to hypertrophy and result in a persistent sensation of lump in the throat. In this condition, the persistent dysphonia caused by ineffective phonation techniques during speaking may induce microtrauma of the vocal folds, which worsens the voice-related symptoms and prolongs the antireflux treatment [14, 20].

Treating persistent vocal problems due to LPR after long-term antireflux therapy is very challenging. Few studies have evaluated the effectiveness of combined medical and voice therapy for this condition. The global objective of voice therapy is the reduction or correction of the improper use of the voice by a program including direct and indirect therapy. The direct approach aims to correct posture; relax the laryngeal and cervical muscles; promote respiratory control, efficient glottal closure, and resonant equilibrium; reduce voice symptoms; improve articulation; and reduce tension in the laryngeal muscles. The indirect methods include raising awareness of healthy vocal habits and their importance. Reposturing of the laryngeal anatomy using laryngeal manipulation, improving the range of motion in the neck and shoulders using manual intervention therapy, and standard physical therapy techniques in conjunction with voice therapy intervention may result in positive changes in outcome measures related to the voice. Lip trills, tongue trills, bilabial fricatives, humming, and phonation into tubes or straws have been used in speech clinics for the treatment of dysphonia. Among these techniques, trill techniques, particularly lip trills, are most commonly used [16].

Voice assessment scales are used to detect the effect of voice therapy in LPR patients. The VHI-10 is a validated voice-related quality of life questionnaire that is used individually to evaluate treatment effectiveness in benign voice disorders. Studies by Rosen et al., [21] and Craig et al., [22] reported that the VHI-10 was applied for the evaluation of treatment efficacy in voice disorders. In this case report, we used the Indonesian version of the VHI-10 that was validated and adapted by Trifani et al., [23]. Voice therapy along with medication resulted in improvement in the functional and physical subscales, but not in the emotional subscale.

Vashani et al., [24] reported that the RSI scores improved in patients who underwent voice therapy. Schneider et al., [16] reported improvements in globus, throat clearing, hoarseness, and postnasal drip after voice therapy in LPR patients, whereas a minority of patients reported improvement in gastroesophageal reflux symptoms (e.g., heartburn). This finding suggests that voice therapy effectively targets voice and laryngeal symptoms in patients with elevated RSI and VHI-10. In this case report, there was improvement in hoarseness and throat clearing, but globus and postnasal drip remained the same. Park et al., [15] showed that the symptom-associated scores (RSI and VHI-10) improved in a clinically significant manner and the time to recovery was shortened by 2 months after voice therapy in LPR patients. The authors also demonstrated that the combination of voice and PPI therapy

provided a significantly greater improvement in the RSI and VHI-10 scores than PPI alone in patients diagnosed with dysphonia due to LPR.

In the stroboscopic findings, the vocal folds in patients with LPR often show mucous dehydration, unlike that in individuals with normal phonation. Woo [20] reported that a "salt and pepper" appearance was often found in the vocal folds of patients with LPR due to mucous dehydration. This was followed by reduction of the amplitude and mucosal wave and lengthening of the closed phase during sustained phonation. This finding suggests that a great driving pressure was necessary during the phonatory gesture. In some circumstances, higher driving pressure leads to increased isometric tension on the vocal folds and presses one or both vocal folds inward and reduces the amplitude of vocal fold vibrations. In this case report, the amplitude of the vocal folds was decreased to 20%/20%. Asymmetric inward compression of the vocal folds results in the abnormal vertical level of the midmembranous portion of the vocal cords. This implies that an increased shear force is being applied to the vocal fold margin. It is thought that this high-acceleration vibration is the primary mechanism of phonotrauma that is responsible for the development of benign mucosal lesions such as polyps and nodules in patients with LPR. The possible muscular hyperfunctional effect may also be secondary to a surface inflammatory reaction in LPR. Other minor pathophysiological mechanisms may be involved in voice changes, such as edema of the supraglottic structures. In this case report, the stroboscopic findings revealed that the mucosal wave was decreased to 10%/10%. Woo [20] reported that the normal mucosal wave was about one-half to two-thirds from the visible oscillating vocal folds. A decreasing mucosal wave is a sign of decreased pliability, elasticity, and viscosity in the cordal cover. Leichen et al., [25] reported that reduced hydration of the SLP in LPR may be associated with a reduction of the thickness of the cordal cover, potentiating the stability and the decrease in the mucosal wave, which is highlighted in some clinical studies. The inflammatory process in SLP modifies the biomolecular composition and biomechanical properties of this layer. Thus, the cordal cover could be less compliant, more viscous, and rigid, thus impacting the quality of the mucosal wave of the vocal folds in LPR patients [20, 25, 26].

The increased viscosity also makes it more difficult to start and maintain movement of the vocal folds, and the increased rigidity makes it more difficult to maintain the stability of the pitch; both of these events lead to irregularities in the vibratory process. In this case report, the periodicity of the vibration of the vocal folds was quite irregular [20, 25, 26].

The smooth-convex edges of the vocal folds in this patient show any fluid extravasation process in SLP and edema in the basal membrane that may lead to a "hot-dog" appearance [20]. There was also a posterior gap during the closed phase in this patient. Woo [20] reported that a posterior glottic chink or midfold contact pattern was often found in the vocal folds of LPR patients. These findings lead to an abnormal vibratory process and may lead to lengthening of the closed phase, phase asymmetry, and irregular periodicity that worsens the quality of a patient's voice. "Snake dance appearance" was revealed in this case report as a sign of the asymmetry of the open and closed phases during vibration [20, 25, 26].

Dehqan et al., [27] showed that voice therapy can cause positive changes in the regularity of vibration and suggested that there can be a decrease in excessive action of the laryngeal muscles and hoarseness. Halawa et al., [28] reported that among patients with dysphonia who had alterations in stroboscopic parameters, improvement in glottal closure, mucosal wave, vocal vibration, and asymmetry was found in 33.9%, 50%, 52.27%, and 68.75% of the cases, respectively, after voice therapy. In this case report, there was improvement of approximately

20% in the mucosal wave, amplitude, and anteroposterior supraglottic activity. There was also significant visual improvement in the periodicity, open–closed phase, and phase asymmetry after voice therapy together with PPI. We believe that these changes in the mucosal structure and vibratory function of the vocal cords led to subjective improvement in the RSI and VHI-10 in this patient.

CONCLUSION

Voice therapy, along with reflux medical treatment and lifestyle changes, is effective in reducing the symptoms in patients with persistent dysphonia due to LPR and should be included in the treatment of patients with LPR that fail to respond to antireflux management. Further research on the effect of voice therapy in LPR patients with dysphonia that do not respond to medical treatment, using subjective assessment tools (VHI-10 and RSI) and objective tools such as stroboscopy and voice acoustic analysis, should be conducted in the future.

REFERENCES

[1] Vakil N, Zanten, Kahrilas S, Dent P, Jones R. The Montreal definition and classification of gastroesophageal reflux disease: a global evidence-based consensus. *Am. J. Gastroenterol.* 2006;101:1900.

[2] VaeziM, Richter J, Stasney C. Treatment of chronic posterior laryngitis with esomeprazole. *Laryngoscope.* 2006;116:254–60.

[3] Sen P, Georgalas C, Bhattacharyya AK. A systematic review of the roleof proton pump inhibitors for symptoms of laryngopharyngeal reflux. *Clin. Otolaryngol.* 2006;31:20–4.

[4] Jin B, Lee YS, Jeong SW, Jeong JH, Lee SH, Tae K. Change of acoustic parameters before andafter treatment in laryngopharyngeal reflux patients. *Laryngoscope* 2008;118:938–41.

[5] Koufman JA, Amin MR, Panetti M. Prevalence of reflux in 113 consecutive patients with laryngeal and voice disorders. Otolaryngol. *Head Neck Surg.* 2000;123:385–88.

[6] Koufman JA. The otolaryngologic manifestations of gastroesophageal refluxdisease (GERD): a clinical investigation of 225 patients using ambulatory 24-hour pH monitoring and an experimental investigation of the role of acid and pepsin in the development of laryngeal injury. *Laryngoscope* 1991;101:1–78.

[7] Sataloff RT, Castell DO, Katz PO. *Reflux Laryngitis and Related Disorders*. 3rd ed. San Diego, CA: Plural Publishing Inc.; 2006.

[8] Ford CN. Evaluation and management of laryngopharyngeal reflux. *JAMA.* 2005;294:1534–40.

[9] Mesallam TA, Stemple JC, Sobeih TM, Elluru RG. Reflux symptom index versus reflux finding score. *Ann. Otol. Rhinol. Laryngol.* 2007;116:436–40.

[10] Woo P. Stroboscopy. *Intepretation of Laryngeal Stroboscopy*. San Diego, CA: Plural Publishing Inc.; 2010. p. 149−166.

[11] Adhami T, Goldblum JR, Richter JE, Vaezi MF. The role of gastric and duodenal agents in laryngeal injury: an experimental canine model. *Am. J. Gastroenterol*. 2004;99:2098–106.
[12] Belafsky PC, Postma GN, Koufman JA. Validity and reliability of the reflux symptom index (RSI). *J. Voice*. 2002;16:274–7.
[13] Sung CK. Laryngopharyngeal reflux protocol. *Stanford Voice and Swallowing Center Guidelines for LPR Disease*. 2016; 1–4.
[14] Van Lierde KM, Claeys S, De Bodt M. Long-term outcome of hyperfunctional voice disorders based on a multiparameter approach. *J. Voice*. 2007;21:179–88.
[15] Park JO, Shim MR, Hwang YS, Cho KJ, Joo YH, Cho JH, et al., Combination of voice therapy and anti-reflux therapy rapidly recovers voice-related symptoms in laryngopharyngeal reflux patients. *Otolaryngol. Head Neck Surg*. 2011;146:92–7.
[16] Schneider SL, Clary M, Fink DS, Wang SX, Chowdury FN, Yadlapati R, et al., Voice therapy associated with a decrease in the reflux symptoms index in patients with voice complaints. *Laryngoscope* 2018;129:1169–73.
[17] Campagnolo AM, Priston J. Laryngopharyngeal reflux: diagnosis, treatment and latest research. *Int. Arch. Otorhinolaryngol.* 2014;18:184–91.
[18] Shaw G, Searl J. Laryngeal manifestations of gastroesophageal reflux before and after treatment with omeprazole. *South. Med. J.* 1997;90: 1115–22.
[19] Pribuisiene R, Uloza V, Kupcinskas L. Perceptual and acoustic characteristics of voice changes in reflux laryngitis patients. *J. Voice*. 2006;20:128–36.
[20] Woo P. Stroboscopy. *Abnormal Vocal Folds Vibration*. San Diego, CA: Plural Publishing Inc.; 2010. p. 89−104.
[21] Rosen CA, Murry T, Zinn A, Zullo T, Sonbolian M. Voice handicap index change following treatment of voice disorders. *J. Voice.* 2000;14:619–23.
[22] Craig J, Tomlinson C, Stevens K, Kotagal K, Fornadley J, Jacobson B, Garrett CG, Francis DO. Combining voice therapy and physical therapy: A novel approach to treating muscle tension dysphonia. *J. Commun. Disord.* 2015;58:169–78.
[23] Trifani S, Hutauruk S. *Uji ValiditasdanReliabilitas Voice Handicap Index-30 Adaptasi Bahasa Indonesia*. Tesis Fakultas Kedokteran Universitas Indonesia. 2018.
[24] Vashani K, Murugesh M, Hattiangadi G. Effectiveness of voice therapy in reflux-related voice disorders. *Dis. Esophagus.* 2009;23:27–32.
[25] Lechien JR, Khalife M, Delvaux V. Pathophysiology, assessment andtreatment of laryngopharyngeal reflux. Rev. Laryngol. *Otol. Rhinol.* 2014;135:163–70.
[26] Reichel O, Mayr D, Durst F, Berghaus A. E-cadherin but not beta-catenin expression is decreased in laryngeal biopsies from patients with laryngopharyngeal reflux. *Eur. Arch. Otorhinolaryngol*. 2008; 265:937–42.
[27] Dehqan A, Scherer RC. Positive effects of manual circumlaryngeal therapy in the treatment of muscle tension dysphonia: long term treatment outcomes. *J. Voice.* 2018;35:1–6.
[28] Halawa WE, Munoz IV, Perez SS. Effectiveness of laryngostroboscopy for monitoring the evolution of functional dysphonia after rehabilitator treatment. *Indian J. Otolaryngol.* 2013;65:322−6.

In: Encyclopedia of Surgery (22 Volume Set)
Editors: Andreas Lehrer and Kristin Mueller
ISBN: 978-1-53618-329-0
© 2020 Nova Science Publishers, Inc.

Chapter 329

MAXILLARY FIBROUS DYSPLASIA RECONSTRUCTION AFTER MAXILLECTOMY

Dini Widiarni Widodo*, PhD and Razki Yorivan, MD
Department of Otorhinolaryngology Head and Neck Surgery, Faculty of Medicine
Universitas Indonesia – Dr. Cipto Mangunkusumo General Hospital, Jakarta, Indonesia

ABSTRACT

Fibrous dysplasia is frequently managed with open maxillectomy, and the technique employed depends on the location of the lesion. Mid-facial reconstruction after maxillectomy is a complicated and difficult process. Clinicians require expertise and must exercise caution when closing the defect, taking into consideration both aesthetics and function. Post-maxillectomy reconstruction using titanium alloplastic material has various advantages. To present a case of maxillary fibrous dysplasia treated with suprastructure maxillectomy followed by reconstruction to close the defect. Reconstruction uses titanium mesh plates and muscle slings, with the facial contour and tissues lost during the suprastructure maxillectomy taken into consideration. Various types of maxillectomy and post-maxillectomy defects have been classified with the aim of facilitating reconstruction and guiding the clinician through the process. The reconstruction of suprastructure maxillectomy using a titanium mesh plate and muscle sling is effective and produces good results in function and aesthetics.

Keywords: fibrous dysplasia, suprastructure maxillectomy, mid-facial reconstruction, titanium mesh plate, muscle sling, aesthetic

INTRODUCTION

Mid-facial defect reconstruction is an intricate and complicated process and represents a major challenge during head and neck tumor surgery. Available management options are pedicle flap, implant, and free flap, which are often combined with transplantation. The main

* Corresponding Author's Email: dini_pancho@yahoo.com.

problem with mid-facial reconstruction is the wide range of defects caused by tumor resection. Corresponding defects not only affect the maxillary bone but also affect the surrounding tissues, facial bone, cranial bone, soft tissue, and orbital bone. An important aspect of maxillary reconstruction is the repair of the maxillary walls. Successful mid-facial reconstruction requires expertise in reconstruction using both implants and a flap to ensure good rehabilitation [1, 2].

Fibrous dysplasia is a fibro-osseous benign lesion with an unknown cause. Fibrous dysplasia lesions in the maxillary area eventually extend to the maxillary sinus, zygomatic bone, sphenoid, and orbital floor. Management of fibrous dysplasia requires taking into consideration the size and location of the lesion. Large lesions require surgical intervention, which may result in significant functional and cosmetic damage to the face and will indirectly affect the quality of life of the patient [3, 4].

This report presents information on a maxillary fibrous dysplasia case treated with suprastructure maxillectomy and subsequently reconstructed with a mesh plate and muscle sling.

FREQUENCY

The frequency of fibrous dysplasia is 1:30,000 individuals, and the disease comprises 2.5% of all bone tumors and 7.5% of all benign bone tumors. The incidence of monostotic fibrous dysplasia is evenly distributed in men and women. This type occurs more often than the polystotic type. The incidence of the polystotic type in men is thrice than that in women. Both types of fibrous dysplasia commonly occur in children and adolescents [5, 6].

Fibrous dysplasia was managed using maxillectomy techniques in 15.2% of 66 cases reported in 2016 in Nigeria. Reports published in 2006 in Malaysia describe the use of maxillectomy for 24 benign maxillary tumor cases, comprising 41% of all cases in the country. The data collected from 2000 to 2009 showed that 26.4% of 65 benign tumor cases were treated with maxillectomy [7–9].

ANATOMY AND PHYSIOLOGY

The mid-facial area includes some of the most prominent structures of the face and separates the oral and orbital cavities. This structure is a polyhedron bounded by skeletal bones. In addition to its structural anatomy, the mid-facial area has functional properties related to breathing, phonation, chewing, swallowing, vision, and smelling. This area has two maxillary bones in the form of polyhedrons separated by the middle part of the face covering the nasal region. The center includes facial features such as the nose, cheeks, and upper lip, whereas the back extends to the anterior skull base. The superoinferior region includes soft tissue and bone from the orbital cavity to the oral cavity, and the middle surface extends towards the temporal bone. This structure includes various tissues surrounded by muscles, skin, and mucosa [10].

An important structure in the mid-facial area is a pair of maxillary bones that join the intermaxilla to form the maxilla. The maxilla contributes to the formation of three cavity

walls, namely, the roof of the mouth, the base and lateral wall of the nose, and the medial orbital wall and base. The maxilla attaches to the lateral side of the zygomatic bone. The attachment consists of the base and lateral wall of the orbit, giving the cheek its distinct shape. The maxillary bone is also associated with the frontal and ethmoid bones, nasal bone, lacrimal bone, inferior nasal turbines, palate, and vomer [1]. The orbit is a structure bordering the mid-facial region. The frontal bone is the superior boundary of the orbit, whereas the inferior boundaries of the orbit are the maxilla, palate, and zygomatic bone. The medial boundaries of the orbit are the frontal, lacrimal, and ethmoid bone. The lateral border is the zygomatic bone. The orbit is located inferior to the anterior fossa of the cranial base and superior to the maxillary sinus and is lateral to the nasal cavity. The anterior border of the orbit is the medial fossa of the cranial base and the temporal fossa (Figure 1) [1].

The mid-facial area has a structure called the support wall. This wall functions to maintain the mid-facial area under normal conditions. This support wall is broadly divided into the vertical and horizontal support walls. The vertical support wall is composed of the nasofrontal, pterygomaxillary, and zygomaticomaxillary borders. The three borders serve as the foundation that maintains the mid-facial area in an upright position, forming the anatomy and function of the maxilla. The zygomaticomaxillary border stretches from the maxillary frontal process along the inferior orbital ridge to the zygomatic process of the frontal bone. The pterygomaxillary border extends from the anterior alveolar ridge to the pterygoid plate of the sphenoid bone. The nasomaxillary border extends from the anterior maxillary alveolus along the piriformis aperture to the nasal process of the maxilla (Figure 2) [2, 10].

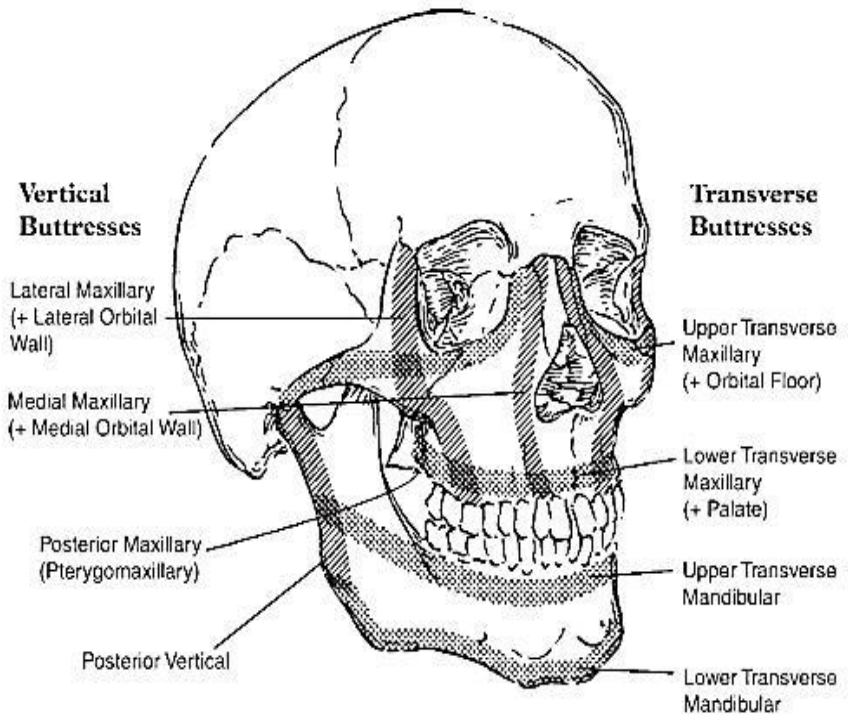

Figure 1. Horizontal and vertical support walls [11].

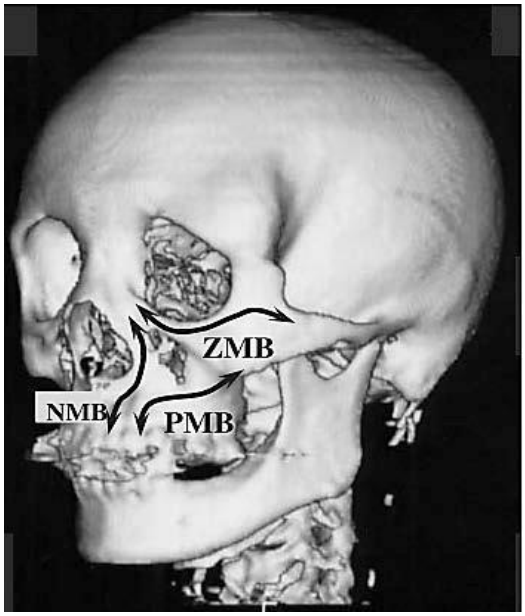

Figure 2. Vertical support wall. Nasomaxillary border (NMB), zygomaticomaxillary border (ZMB), and pterigomaxillary border (PMB) [2].

The muscles that control facial expressions are located in the midline and are covered by facial skin. The outer surface of the face is divided into the cheeks, nose, and lips. All of these units have different characteristics and require special attention during reconstruction. The parotid glands are another important structure on the medial surface and are located in the most lateral region. These glands do not only function as salivary glands but also provide soft tissue for facial contours [10].

The mid-facial blood supply primarily originates from the branch of the external carotid artery. The anastomosis of this artery, such as branching of the infraorbital artery and internal maxillary artery, provides good vascularization to the skin. This pattern of anastomosis branching is very important in the management of mid-facial reconstruction. Mid-facial innervation is provided by cranial nerves, namely, the facial and trigeminal nerves. The facial nerve is responsible for facial movements, and the trigeminal nerve is responsible for the mastication muscle. Sensory innervation of the facial muscles is supplied by the branches of the trigeminal nerve [10].

Facial skin and soft tissue receive arterial supplies from branches of the facial temporal artery, maxilla, and all branches of the external carotid artery. Blood supply to the forehead, eyelids, and upper part of the nose is supplied through the internal carotid system by the ophthalmic artery. Blood supply to the lip region is supplied by inferior and superior labial arteries. The facial artery near the medial canthus next to the nose is the angular artery. The maxillary artery is the terminal branch of the external carotid artery with three main branches: the mental, buccal, and infraorbital arteries. The mental artery is the terminal branch of the inferior alveolar artery that passes through the mental foramen to supply the chin and lower lip. The buccal artery crosses the buccinator muscle to supply the cheek tissue [12].

The infraorbital arteries reach the face through the infraorbital foramen and supply the eyelids, cheeks, and lower nose. The deep temporal artery is the terminal branch of the

external carotid artery and crosses the superficial zygomatic arch in the superficial temporal fascia. The deep temporal artery is divided into anterior and posterior branches at 2 cm above the zygomatic arch. The anterior branch supplies the forehead and forms anastomosis with supraorbital and supratrochlear vessels, whereas the posterior branch supplies the parietal scalp and periosteum. The ophthalmic artery is a branch of the internal carotid system; its branches include the lacrimal, supraorbital, supratrochlear, infratrochlear, and external nasal arteries (Figure 3) [12].

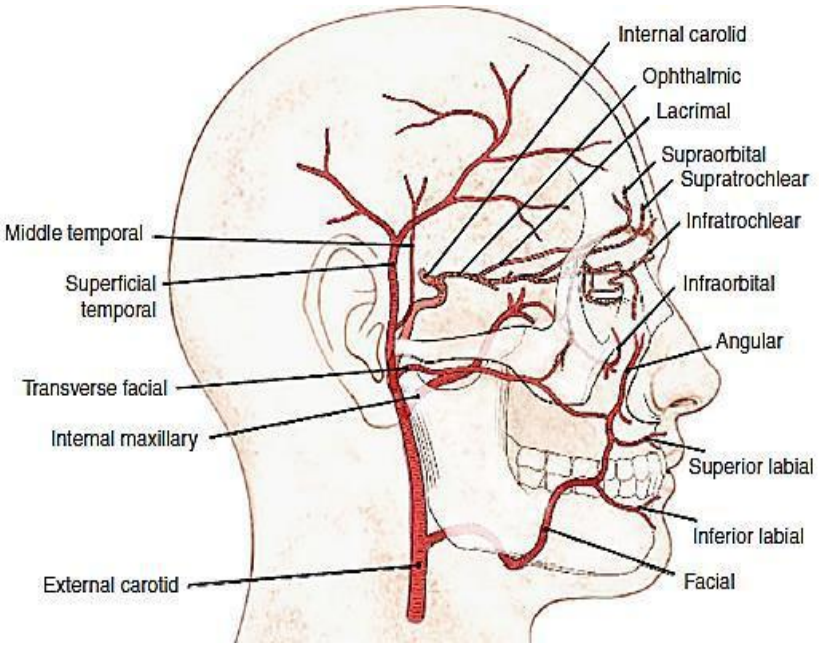

Figure 3. Scheme of facial arteries [12].

FACIAL FAT COMPARTMENTS

Superficial Fat Tissue

The face has several compartments. Each compartment is separated by a network of fine fascia that forms a retaining ligament. The superficial facial fat layer consists of (1) the labial nasal fat compartment; (2) medial, middle, and lateral temporozygomatic fat pads; (3) medial, middle, and lateral temporozygomatic fat pads on the forehead; and (4) superior, inferior, and lateral orbital fat pads [12].

Nasolabial fat is located in the medial cheek adipose compartment and contributes to the nasolabial fold. The orbicularis retaining ligament below the inferior orbital plate borders the superior border of the nasolabial fat compartment and the medial cheek compartment. The middle fat compartment is limited by a group of fascia called the superior zygomatic septum on the superior side. The anterior border of the lateral temporal fat pads is the lateral zygomatic septum, which can be found during a facelift procedure with a dissection medial to the preauricular incision. The superior and inferior orbital fat compartments are located

within the boundary of the orbicularis retaining ligaments located above and below the eye. These periorbital fat pads are separated from each other by the medial and lateral canthus. The lateral orbital fat compartment has two borders: the superior border, which is the inferior temporal septum, and the inferior border, which is the superior zygomatic septum. The main zygomatic muscle is attached to the superficial fat compartment [12].

The anatomy of the superficial subcutaneous fat compartment has an impact on the facial contour. Differences in the volume at each level will cause deviations in the facial contour and loss of facial concavity [12].

Deep Fat Compartment

The suborbicularis oculi fat has two parts: the medial and lateral parts. The medial component is located along the margins of the inferior orbit, from the medial limbus towards the lateral canthus. The lateral component runs from the lateral canthus to the temporal fat pad. The prezygomal space lies between the suborbicularis oculi fat and the zygomatic periosteum. This space has superior borders, which are the orbicularis retaining ligament and the zygomatic retaining ligament. The sublevator fat pad is located medially from the medial suborbicularis fat compartment and is the deepest infraorbital pad. This fat pad is a continuation of the buccal fat pad. The buccal fat pad is an important structure located in the posterolateral part of the superficial maxilla towards the buccinator muscle and extends deep into the anterior part of the masseter muscle. Functionally, the buccal fat pad facilitates the movement of masticatory muscles (Figures 4-7) [12].

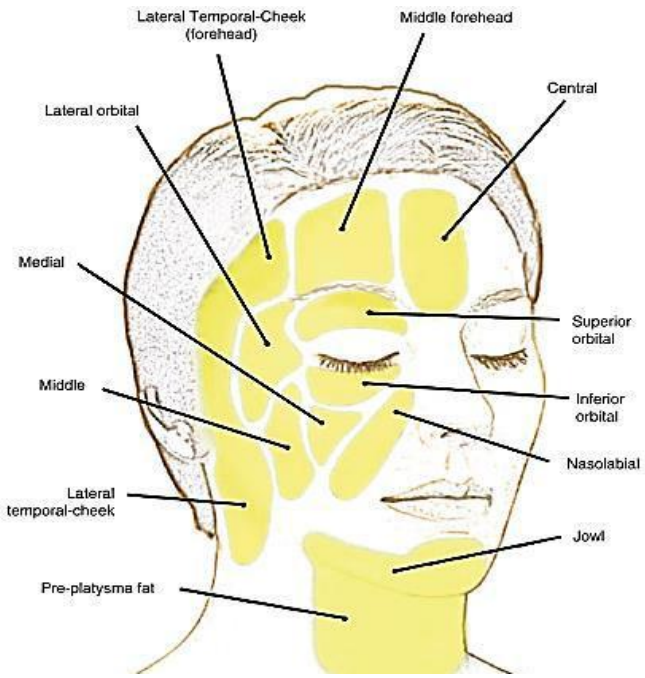

Figure 4. Superficial fat compartment [12].

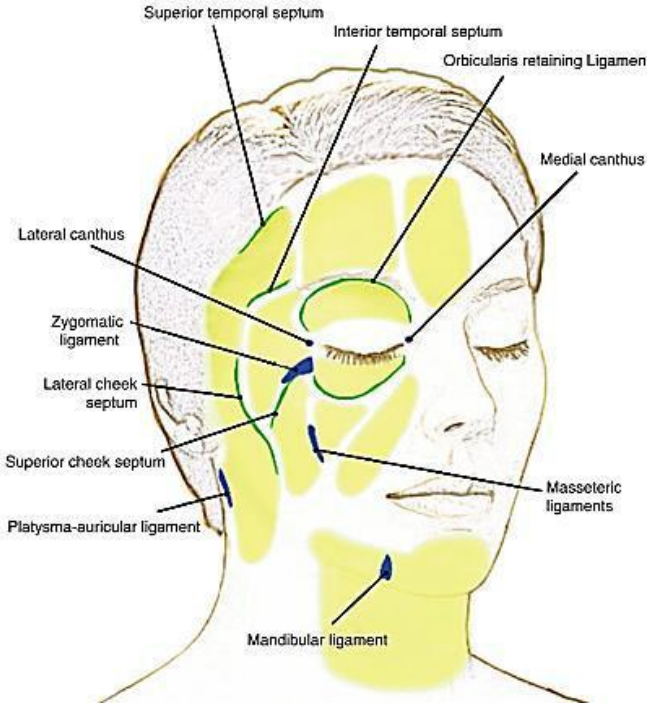

Figure 5. Ligaments between superficial fat compartments [12].

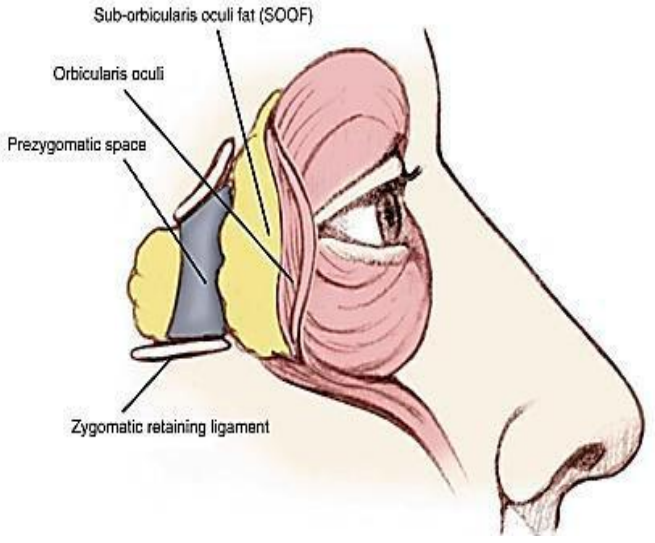

Figure 6. Suborbicularis oculi fat [12].

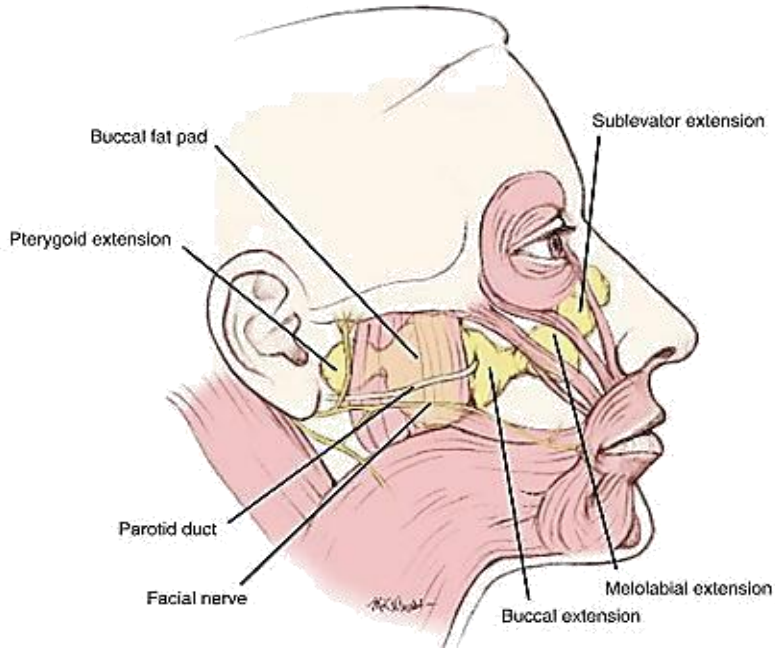

Figure 7. Buccal fat pad [12].

FIBROUS DYSPLASIA

Fibrous dysplasia is an asymptomatic disease. The disease occurs in the maxilla more often than in the mandible. In the maxilla, fibrous dysplasia manifests with edema, no pain, and is sometimes followed by café-au-lait spots. The mass may be large enough to interfere with the chewing function. In the mandible, swelling can involve the labial, buccal, and lingual areas [6, 13].

Extensive maxillary lesions can involve the maxillary sinus, zygomatic bone, sphenoid bone, and orbital base. Unstable swelling that continues to increase for a long time can result in an asymmetrical face shape. Nasal obstruction can occur when the paranasal sinuses are involved. In some cases, exophthalmus and tooth dislocation can occur because of malocclusion. Lesions that extend to the temporal bone can cause hearing loss [13–15].

Fibrous dysplasia lesion is a fibro-osseous lesion. These types of lesions have three variants: monostotic, polystotic, and McCune–Albright syndromes, which are associated with endocrinopathy and hyperpigmentation. Fibrous dysplasia occurs from the mutation of the guanine nucleotide-binding protein alpha-stimulating activity polypeptide 1 (GNAS-1) gene. Proteoblasts are formed because of proliferation and differentiation triggered by c-AMP. The GNAS-1 mutation results in encoding of the α-subunit during transduction of the G-protein signal, which results in the increase of c-AMP production [16, 17].

The severity of the disease depends on when the gene mutation occurred during pregnancy or after birth. If the mutation occurred during the embryonic phase, the osteoblasts, melanocytes, and endocrine cells will carry the gene mutations and express the genes in the form of multiple bone lesions and pigmentation accompanied by endocrine disorders, leading

to the McCune–Albright syndrome. Cells that mutate at the end of the embryonic phase will spread and fuse with bone to form multiple bone lesions, resulting in polystotic type fibrous dysplasia. Gene mutations that occur after birth will result in progenitor cell mutations that attach to one bone, resulting in monostotic type fibrous dysplasia [17,18].

FACIAL INCISION APPROACH

Surgical treatment for maxillectomy requires facial incisions to expose the maxillary bone. The type of incision depends on the tumor location, histology, and the surgeon's experience. Open surgery achieves good exposure of the tumor location, particularly for extensive resection [19].

Open surgery can be performed with various approaches. Five types of incisions can be employed to expose the maxilla: lateral rhinotomy incision, Weber–Ferguson incision, Weber–Ferguson incision with Lynch expansion, Weber–Ferguson incision with lateral expansion, and Weber–Ferguson incision with subciliary expansion [19].



Figure 8. Facial incision scheme. (A) Lateral rhinotomy incision, (B) Weber–Ferguson incision, (C) Weber–Ferguson incision with Lynch expansion, (D) Weber–Ferguson incision with lateral expansion, and (E) Weber–Ferguson incision with subciliary expansion [19].

Lateral rhinotomy is a basic incision that can be performed on the lesion without the involvement of the orbit or palate. The incision starts from the middle of the dorsum nasi to the medial canthus. The incision is performed following the shape of the face along the lateral

edge of the nose to the ala nasi. The Weber–Ferguson incision is performed by continuing the incision in the ala nasi, curving through the nasal vestibule and then continuing with the upper lip edge incision on the philtrum from the nasolabial gap to the vermilion border followed by an incision in the gingivobuccal. After the incision is made and the facial bones are exposed, osteotomy is performed according to the location and size of the tumor. The approach requires calculation of the position of the nasal pyramid as an aesthetic consideration. A tumor that involves the entire nasal cavity and maxillary sinus with posterior sinus wall erosion can be treated using Weber–Ferguson's incision, which enables maximal exposure of the tumor [19, 20].

The Weber–Ferguson incision with Lynch expansion is performed by extending the incision in the middle of the medial canthus towards the lower border of the eyebrows. The aim is to expand the exposure to the ethmoid cells, frontal sinuses, nasolacrimal ducts, and medial canthus ligaments. The Weber–Ferguson incision with lateral expansion is performed by pulling an incision from the middle of the medial canthus to the lateral canthus through the skin folds of the inferior eyelid. The Weber–Ferguson incision with subciliary extension requires an incision just below the inferior eyelid cilia. The Weber–Ferguson incision with lateral and subciliary expansion have a same goals to expanding the exposure of the infraorbital rim and the zygoma (Figure 8) [19].

MAXILLECTOMY

The maxillectomy procedure was first performed in 1820 and was first documented by Liston in 1841 in patients with nasopharyngeal angiofibroma. The aim of this surgical technique is to manage tumors in the nasal cavity, the lateral wall of the nose, and the maxillary sinus by removing the maxillary sinus bone [21, 22].

Several types of maxillectomy have been identified. Based on the writing by Hanna [22], the long-known types of maxillectomy are medial maxillectomy, inferior maxillectomy, superior maxillectomy, subtotal maxillectomy, and total maxillectomy.

Medial maxillectomy involves removing the lateral nasal wall and the medial segment of the maxillary bone, which is bordered by the infraorbital nerve on the lateral side accompanied by a sphenoetmoidectomy. Intracellular maxillectomy is a procedure that involves inferior resection of the maxilla under the infraorbital nerve plane. This technique is most commonly used for tumors in the maxillary alveolar process with minimal extension to the maxillary antrum and hard palate lesions. The combination of sublabial and palatal incisions is used to expose the maxilla followed by osteotomy. Mid-facial degloving can be used for lesions that cross in the midline and bilaterally involve the inferior maxilla [22].

Suprastructure maxillectomy is a procedure performed by maintaining the structure of the hard palate while resecting the floor of the orbit and the upper part of the maxilla. This procedure requires reconstruction of the orbital floor so that the eyeball does not fall towards the maxilla. Subtotal maxillectomy is a variation of maxillary resection in which the resection is carried out depending on the location of the tumor. Total maxillectomy involves resection of the entire maxilla, orbital floor, and palate (Figures 9-11) [22].

Spiro et al. [23] reported another maxillectomy classification based on a study of 403 patients who fulfilled one of the three criteria for maxillectomy. These criteria were related to

the number of maxillary walls resected and can be defined as limited, subtotal, and total maxillectomy.

Limited maxillectomy refers to all types of maxillectomy involving resection of only a maxillary wall in the antrum, usually the medial wall or maxillary base. Subtotal maxillectomy is a procedure in which at least two maxillary walls are resected, including the maxillary antrum floor, but resection does not reach the posterior maxillary wall.

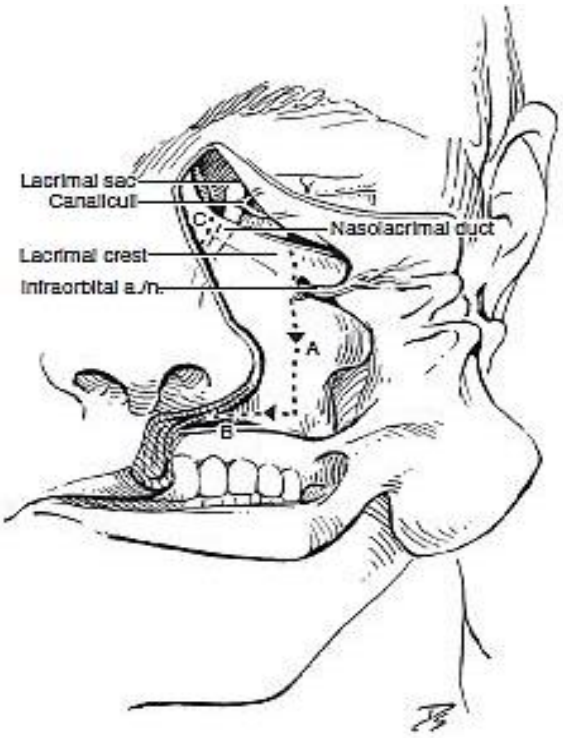

Figure 9. Scheme of medial maxillectomy [22].

Figure 10. Scheme of inferior maxillectomy [22].

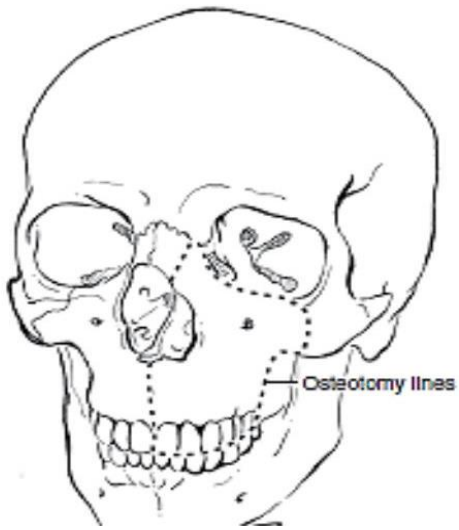

Figure 11. Scheme osteotomy lines of total maxillectomy [22].

This procedure includes resection of the pterygoid plate, soft palate, contralateral maxilla, zygoma, and nasal complex. Total maxillectomy is the removal of the maxilla accompanied by an orbital exenteration [23].

POST-MAXILLECTOMY DEFECT

There are various classifications of post-maxillectomy defects proposed to describe the resulting damage. These classifications were developed to guide reconstruction and rehabilitation [21].

Bidra et al. [24] concluded that the classification of defects must meet surgical and prosthodontic needs, be simple, comprehensive, easy to use, and be able to guide clinicians regarding reconstruction and rehabilitation options. Post-maxillectomy defects are classified into six criteria: dental defects, oronasal or orantral defects, defects of the soft palate and surrounding tissue, defect expansion to the superoinferior area, defect expansion to the anteroposterior area, and defect expansion to the mediolateral area.

Expansion of the superoinferior defect may originate from the oroantral fistule, giving rise to a defect that borders the skull base superiorly and the tongue inferiorly. Therefore, superior and inferior expansion of the defect will extend into the alveolar level, palatal level, paranasal sinuses, orbit, and the anterior base of the skull bone. The size of the defect determines the technique used for reconstruction. The expansion of the anteroposterior defect occurs in the horizontal and sagittal fields with the involvement of the right-left posterior region, and the right-left anterior maxilla. An anterior defect can cause reduced lip movement, scar tissue on the lips, and the collapse of the nose when the nasal bone is removed. Expansion of the mediolateral defect can cause a unilateral defect involving only one maxillary bone, whereas the bilateral defect involves both maxilla. Unilateral defect reconstruction requires less tissue than the reconstruction of bilateral defects. However, this

depends on the tissue conditions, and the reconstruction can be followed by implant placement [24].

Brown et al. [25] classified post-maxillectomy defect into two categories, namely, vertical and horizontal defects. This classification is also reported in the literature review conducted by Bidra et al. [24] Vertical defects are divided into six types: maxillectomy without oronasal fistula, maxillectomy without orbital involvement, maxillectomy with orbital tissue involvement, maxillectomy with orbital enucleation, orbitomaxillary defect, and nasomaxillary defect. Horizontal defects are divided into four types: palate defect without alveolar involvement, unilateral defects less than or equal to half the palate, bilateral defects less than or equal to half the palate, and bilateral defects greater than half the palate (Figures 12, 13).

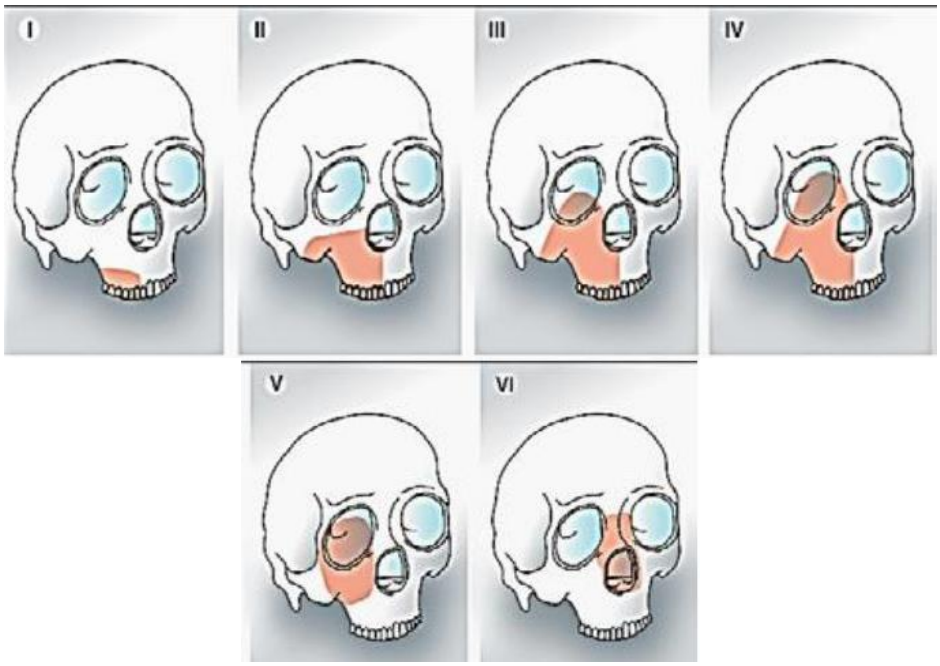

Figure 12. Vertical defect. (I) Maxillectomy without oronasal fistule, (II) maxillectomy without orbital involvement, (III) maxillectomy without orbital tissue involvement, (IV) maxillectomy with orbital enucleation, (V) orbitomaxillary defect, and (VI) nasomaxillary defect [25].

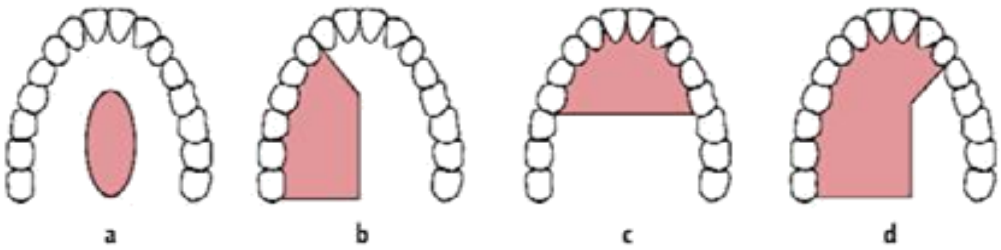

Figure 13. Horizontal defect. (a) Palate defect without alveolar defect, (b) unilateral defects less than or equal to half the palate, (c) bilateral defects less than or equal to half the palate, and (d) bilateral defects greater than half the palate [25].

SUPRASTRUCTURE MAXILLECTOMY RECONSTRUCTION

Maxillofacial reconstruction can be performed with various materials, such as titanium mesh, hydroxyapatite gel, silica gel, bone, and ribs. Use of autologous material for maxillofacial reconstruction will aggravate the condition after maxillectomy due to injuries to the corresponding donor site [26].

The main goal of mid-facial reconstruction is to improve facial contours, eye volume, and position. The irregularity and thinness of the facial and eye anatomy as well as the contours of the face present obstacles to maxillofacial reconstruction. Titanium mesh is the most commonly used material for maxillofacial and orbital reconstruction. The advantages of using titanium mesh for reconstruction include good fabrication quality, stability, tool flexibility, the absence of tissue damage due to donor requirements, and the short duration of surgery. Post maxillectomy and resection, the defect is always extensive from the maxilla towards the zygoma and orbital floor, thus requiring diverse mesh and plates as well as tissue to protect the mesh [26].

The successful reconstruction of orbital floors with titanium mesh depends on two factors. First is the formation recovery of the individual orbital floor, and the second is the precise position of the titanium mesh installation. Important parameters for mid-facial reconstruction with good aesthetic results are contour recovery, maxillary volume, and eyeball position, as well as rehabilitation of the infraorbital area contour. The eyeball position is maintained by a balance between the orbit volume and intraorbital soft tissue. Balance disorders will cause a decrease in orbital content and can cause enophthalmus, which is a post-maxillectomy problem [26].

Alloplastic materials used for reconstruction must be able to integrate with the body. Titanium is a metal material first discovered by William Gregor in 1791 and used commercially in 1950. It was first used for a medical purpose in 1980. This material is anti-corrosive, elastic, unaffected by temperature changes, and has good bio-compatibility. The chemical composition of this material is capable of producing good integration between titanium and bone without causing fibrosis. Titanium will not inhibit tissue growth even with extensive defects in the maxillofacial region because the material interacts well with the soft tissues of the body [27, 28].

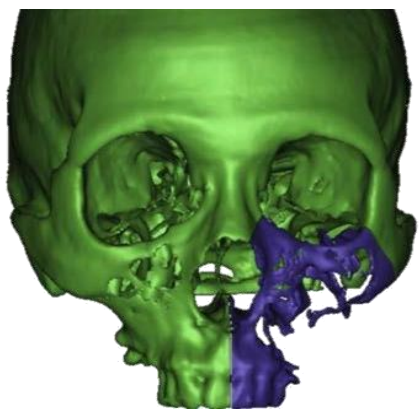

Figure 14. Virtual image of post-maxillectomy defect [26].

Although titanium mesh is an ideal choice for the reconstruction of orbit floors, some risks remain. The main risks are infection and exposure to titanium mesh, especially for tumor patients undergoing radiotherapy. Hypovascular tissue and extensive fibrosis after radiotherapy increase the risk of infection and exposure to titanium mesh (Figures 14, 15) [27].

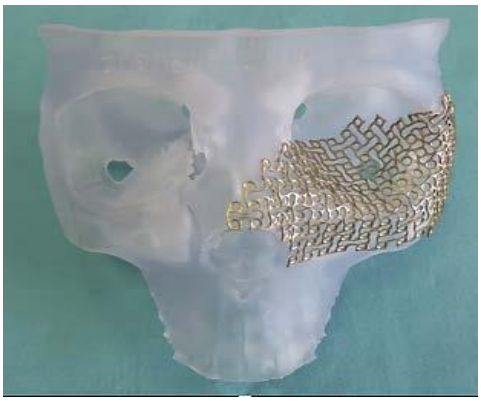

Figure 15. Titanium mesh used in the reconstruction of post-maxillectomy defect [26].

CASE REPORT

This paper presents the case of a patient with fibrous dysplasia treated with suprastructure maxillectomy. Reconstruction was later performed using titanium mesh and muscular buccal muscle slings.

An 11-year-olds girl was referred to the Oncology ENT division for reconstruction after the removal of a left maxillary tumor through suprastructure maxillectomy. The patient had a complaint of swelling in the left cheek accompanied by left eye exophthalmus and decreased vision starting 6 months earlier. She also complained of nasal congestion without nosebleeds and pain starting 4 months before hospital admission.

The patient was examined with computer tomography, which showed the compacting of the maxillary sinus, ethmoid and left sphenoid, with multiple calcification complexes in the ethmoid sinus accompanied by ethmoid, maxillary, and left sphenoid bone destruction extending to the left retrobulbar region, suspected as a sinonasal mass. Examination of magnetic resonance imaging shows a suspected benign solid tumor of the left ethmoid sinus with left orbital thrusting and a left osteomeatal complex that causes left proptosis, left sphenoid, and maxillary sinusitis (Figures 16).

The patient was diagnosed with suspected maxillary fibroma, and suprastructure maxillectomy was planned by Oncology division Department of Otorhino-laryngology Head and Neck Surgery. The tumor tissue was sent to the Anatomy Pathology Department for histopathological examination. Post-maxillectomy, enophthalmus was found in the left eye with a posterior movement when the eyes were tightly closed. The patient was referred to the Plastic Recontruction division Department of Otorhinolaryngology Head and Neck Surgery for post-maxillectomy defect reconstruction.

Figure 16. Asymetrical and protrution eye.

After tumor removal surgery, defects occurred in several locations, including the anterior maxillary wall, medial maxillary wall, inferior wall of the left orbital rhyme, and enophthalmus, with a posterior movement when the eyes were closed firmly. At the beginning of the reconstruction, a sharp dissection was performed to expose the left buccal mucosa and muscle. Afterwards, a sling was created by sewing the end of the muscle to the medial canthus to form eye pads, followed by suturing the left septal mucosa to the medial canthus of the left eye. A titanium plate was sewn onto the buccal muscle sling to match the projection of the nasal lateral wall and form the medial wall of the left maxilla. The titanium mesh was shaped in accordance with the shape of the anterior maxillary wall and then sewn and fixed using screws. The reconstructed defect was closed using subcutaneous sutures following the directions for the Weber–Ferguson incision with Lynch extension to the gingivobuccal.

After the surgery, the patient was given ceftriaxone 2 gr once a day, ranitidine 50 mg twice a day, ketorolac 30 mg three times a day, and tranexamic acid 500 mg three times a day. The patient was fed a liquid diet through the nasogastric tube. An edema of the left orbit appeared and decreased on the second day after surgery, and the left eye appeared parallel to the right. The patient was treated for 5 days in the hospital after the procedure, and the sutures were removed 1 week later. The histological result showed that the fibro-osseous lesion was in accordance with fibrous dysplasia (Figures 17-23).

Figure 17. Buccal muscle sling.

Figure 18. Elevation of the mucosa of the left nasal septum.

Figure 19. The plate was used to reconstruct the medial wall of the left maxilla.

Figure 20. Suturing of Weber–Ferguson incision with Lynch expansion after suprastructure maxillectomy and reconstruction.



Figure 21. Orbital plate and titanium mesh.

Figure 22. Five days after reconstruction.

Figure 23. Three months after reconstruction.

LITERATURE SEARCHING METHOD

A literature search of PubMed, ScienceDirect, and ClinicalKey was performed. The keywords used were “maxillary and orbital floor defect reconstruction” and “titanium mesh,” with clinical questions regarding the effect of titanium mesh use in the surgical management

of suprastructure maxillectomy. The search yielded 310 articles. After screening the results for the latest articles, multiple publications, and compatibility to clinical questions, three relevant articles were obtained (Figure 24).



Figure 24. A literature search of PubMed, ScienceDirect, and ClinicalKey with clinical questions regarding the effect of titanium mesh use in the surgical management of suprastructure maxillectomy.

On the basis of the research by Zhang et al. [26], the use of titanium mesh material is more advantageous than the use of autograph materials. The material provides good results for maxillary and orbital reconstruction due to the complex characteristics of the cheeks and orbit contours. Titanium mesh can follow the contour and is therefore very good at closing defects. Expertise and caution during reconstruction are essential when performing facial reconstruction.

The use of titanium mesh for defect reconstruction after removal of the maxillary tumor leads to good results in repairing the anterior maxillary wall and the orbit base according to the report by Lv et al. [29].

A report by Motiee-Langroudi et al. [28] described the use of titanium mesh for maxillary and orbital base defect reconstruction. The combination of the use of fascia with titanium mesh prevents the fall of orbital fat through the titanium mesh hole.

DISCUSSION

Defect reconstruction post-suprastructure maxillectomy for patients with maxillary fibrous dysplasia is a difficult and complicated procedure. According to the report by Duan et al. [5], the incidence of fibrous dysplasia is equal to 1:30,000 individuals, comprising 7.5% of all benign bone tumors. The percentage of benign tumors managed using the open

maxillectomy technique was 26.4% among the 65 cases recorded from 2000 to 2009 in Malaysia.

The mid-facial area is an important structure on the face due to its anatomical and structural characteristics and functions related to breathing, phonation, chewing, swallowing, vision, and smelling.

The maxillary supporting wall, which is divided into vertical and horizontal supporting walls, is an important component of the facial structure. Vertical walls play a role in maintaining the mid-facial area in an upright position.

The main symptom of fibrous dysplasia is painless swelling of the facial bones, especially the maxilla and mandible. Symptoms of the eyes and nose can occur along with the growth of the lesion. Pushing towards the eyes will result in visual disturbances, whereas pushing towards the nose will result in nasal congestion. These symptoms are in accordance with fibrous dysplasia. Open surgery with maxillectomy is the treatment of choice, and maxillectomy has a variety of classifications. According to the classification proposed by Hanna et al. [22], the appropriate technique for fibrous dysplasia treatment is suprastructure maxillectomy. However, according to the criteria proposed by Spiro et al. [23], the appropriate technique is subtotal maxillectomy. The purpose of open surgery for maxillectomy is to remove the tumor by resecting the maxillary wall involved.

Brown et al. [25] suggested the classification of post-maxillectomy defects with the aim of facilitating reconstruction and guiding the clinician through the process. Bidra et al. [24] conducted a literature review of the classification proposed by Brown et al. The review yielded positive results because the classification divides the types of defects into vertical and horizontal types. The patient in this case report was classified as having a type V vertical defect because she suffered from left-sided facial defects covering the anterior maxillary wall, medial maxillary wall, and inferior orbital rhyme. She also suffered from left eye enophthalmus, which led to the occurrence of orbitomaxillary defects after suprastructure maxillectomy.

The orbitomaxillary defect is caused by attachment of the tumor to the maxilla and tissue around the orbit. The tissues surrounding the nose, maxilla, and orbit are elevated when suprastructure maxillectomy is performed. Suborbicularis fat, orbital retaining ligaments, and part of the orbital base are lifted after maxillectomy, which leads to enophthalmus. Reconstruction is aimed at not only closing the defect but also restoring the function and aesthetics of the face. Therefore, expertise and caution are necessary for good results. The use of mesh plates in post-maxillectomy reconstruction is in accordance with the study by Zhang et al. [26], in which a titanium mesh was used during reconstruction on post-maxillectomy patients with orbital floor defects.

Titanium materials are widely used in reconstruction, not only in the maxillofacial region but also through the body. Titanium is an alloplastic substance that is biocompatible and causes minimal allergic reactions due to the calcium-like chemical composition. The material achieves good integration with bone without causing fibrosis as described by Schubert et al. [27].

The patient described here was treated using a modified titanium mesh plate and muscle sling. Modification of management techniques following reconstruction is sometimes necessary to close the occurring defect. A muscle sling was employed to provide resistance and replace the orbital hanging ligaments, preventing enophthalmus. Reconstruction continued with the installation of titanium mesh as the orbital base while simultaneously

reconstructing the anterior maxillary wall defect to obtain a shape that resembles the wall. The medial maxillary wall defect was reconstructed using a plate to keep the eyeball stable and to form the construction of the lateral nasal wall. The management process for this reconstruction is consistent with the reports by Zhang et al. [26], Lv et al. [29], and Motiee-Langroudi et al. [28] with a little modification to use muscle slings as orbital anchors. The final step involved suturing by observing the aesthetic contours of the face according to the facial fat compartment as described by Prendergast et al. [12].

REFERENCES

[1] Hanasono MM, Skoracki RJ. Mid-facial reconstruction. In: Hanasono MM, Robb GL, Skoracki RJ, Yu, P, editors. *Reconstructive Plastic Surgery of the Head and Neck*. 1st ed. New York: Thieme Medical Publishers Inc; 2016. p. 100–16.

[2] Yamamoto, Y. Mid-facial reconstruction after maxillectomy. *Int J Clin Oncol* 2005, 10, 218–22.

[3] Eachempati, P, Aggarwal, H, Shenoy, V, Baliga, M. Multidisciplinary approach for management of a patient with fibrous dysplasia of maxilla. *Br Med J*. 2015, (6), 1–4.

[4] Tinoco P, Pereira JCO, Filho RCL, Silva FB, Ruela KP. Fibrous Dysplasia of Maxillary Sinus. *Int Arch Otorhinolaryngol*. 2009, 13(4), 214–7.

[5] Duan C, Dai Q, Liu Q, Yu H. Characteristics of sinonasal fibrous dysplasia: experience from a single department. *Acta Otolaryngol*. 2017, (8), 1–6.

[6] MacDonald DS. Maxillofacial fibro-osseous lesions. *Clin Radiol* [Internet]. 2015; 70(1):25–36.

[7] Formete B, Agbara R, Osunde OD, Ogbeifun JO. Maxillectomy and its surgical indications in a tertiary health care centre in north-western Nigeria: Analysis of 66 cases. *J Oral Maxillofac Surgery*; Med Pathol. 2017, 29(3), 198–202.

[8] Mazlina S, Putra SHAP, Shiraz MARM, Hazim MYS, Roszalina R, Abdul ARR. Maxillary sinus tumours - A review of twenty-nine patients treated by maxillectomy approach. *Med J Malaysia*. 2006, 61(8), 284–7.

[9] Peled M, Leiser Y, Wolff A, Abu-El Naaj I. Our experience with maxillectomies - A 10-year retrospective study. *Oral Oncol*. 2011, 47:S146.

[10] Ozkan O, Coskunfirat OK, Ozkan O. Midface Reconstruction. *Semin Plast Surg*. 2010, 1(212), 181–7.

[11] Hopper RA, Salemy S, Sze RW. Diagnosis of Midface Fractures with CT: What the Surgeon Needs to Know. *Radiographics*. 2006, 26(5), 783–94.

[12] Prendergast PM. Cosmetic surgery: Art and techniques. In: Shiffman MA, Di Giuseppe A, editors. *Cosmetic Surgery: Art and Techniques*. 1st ed. Berlin: Springer-Verlag Berlin Heidelberg; 2013. p. 29–45.

[13] El-Mofty SK. Fibro-Osseous Lesions of the Craniofacial Skeleton: An Update. *Head Neck Pathol*. 2014, 8(4), 432–44.

[14] McCarthy EF. Fibro-Osseous Lesions of the Maxillofacial Bones. *Head Neck Pathol*. 2013, 7(1), 5–10.

[15] Suarez-Soto A, de la Hermosa M-CB-R, Minguez-Martínez I, Floría-García LM, Barea-Gámiz J, Delhom-Valero J, et al. Management of fibro-osseous lesions of the

craniofacial area. Presentation of 19 cases and review of the literature. *Med Oral Patol Oral Cir Bucal*. 2013, 18(3), 479–85.

[16] Lee J, FitzGibbon E, Chen Y, Kim H, Lustig L, Akintoye S, et al. Clinical guidelines for the management of craniofacial fibrous dysplasia. *Orphanet J Rare Dis*. 2012, 7(1): S2.

[17] Srichinthu KK, Yoithapprabhunath TR, Chitturi RT, Yamunadevi A, Potsangbam AD, Singh DN. Fibro Osseous Lesions – Classifications; Pathophysiology and Importance of Radiology: A Short Review. *Int Biol Biomed J*. 2016, 2(1), 11–20.

[18] DiCaprio MR, Enneking WF. Fibrous Dysplasia. Pathophysiology; Evaluation; and Treatment. *J Bone Jt Surg*. 2005, 87(8), 1848.

[19] Ho AS, Zanation AM, Ganly I. Malignancies of the Paranasal Sinus. In: Flint PW, Haughey BH, Lund V, Niparko JK, Robbins T, Thomas R, et al., editors. *Cummings Otolaryngology Head and Neck Surgery*. 6th ed. Philadelpia: Elsevier Saunders; 2015. p. 1176– 201.

[20] Tang IP, Shashinder S, Gopala Krishnan G, Narayanan P. Juvenile nasopharyngeal angiofibroma in a tertiary centre: ten-year experience. *Singapore Med J*. 2009, 50(3), 261– 4.

[21] Durrani Z, Hassan SG, Alam SA. A study of classification systems for maxillectomy defects. *J Pak Prosthodont Assoc*. 2013, 1(2), 117– 24.

[22] Hanna E. Maxillectomy. In: I Cohen J, L Clayman G, editors. *Atlas of Head and Neck Surgery*. VII. Philadelpia: Elsevier Saunders; 2016. p. 419–26.

[23] Spiro RH, Strong EW, Shah JP. Maxillectomy and its classification. *Head Neck*. 1997, 19(4), 309–14.

[24] Bidra AS, Jacob RF, Taylor TD. Classification of maxillectomy defects: A systematic review and criteria necessary for a universal description. *J Prosthet Dent*. 2012, 107(4), 261–70.

[25] Brown JS, Shaw RJ. Reconstruction of the maxilla and midface: Introducing a new classification. *Lancet Oncol*. 2010, 11(10), 1001–8.

[26] Zhang W, Mao C, Liu X, Guo C, Yu G-Y, Peng X. Outcomes of orbital floor reconstruction after extensive maxillectomy using the computer-assisted fabricated individual titanium mesh technique. *J Oral Maxillofac Surg*. 2015, 73(10), 1–15.

[27] Schubert W, Gear AJL, Lee C, Hilger P a, Haus E, Migliori MR, et al. Incorporation of titanium mesh in orbital and midface reconstruction. *Plast Reconstr Surg*. 2002, 110(4), 1022–30.

[28] Motiee-Langroudi M, Harirchi I, Amali A, Jafari M. Reconstruction of midface and orbital wall defects after maxillectomy and orbital content preservation with titanium mesh and fascia lata: 3- year follow-up. *J Oral Maxillofac Surg*. 2015, 73(12), 2447.

[29] Lv M, Li J, Shen Y, Wang L, Sun J. The “Drawer-Like” Resection and Reconstruction with Titanium Mesh: A Novel Surgical Technique for Treatment of Giant Ossifying Fibroma in the Maxilla. *J Oral Maxillofac Surg.* 2017, 75(8), 1752–61.

In: Encyclopedia of Surgery (22 Volume Set)
Editors: Andreas Lehrer and Kristin Mueller
ISBN: 978-1-53618-329-0
© 2020 Nova Science Publishers, Inc.

Chapter 330

CLEFT PALATE WITH VELOPHARYNGEAL INSUFFICIENCY: A CASE REPORT

Mirta H. Reksodiputro*[*], *Shally Adhina Putri,
Dini W. Widodo and Trimartani Koento
Department of Otorhinolaryngology Head and Neck Surgery, Faculty of Medicine
Universitas Indonesia –CiptoMangunkusumo General Hospital,
Central Jakarta, Indonesia

ABSTRACT

Cleft palate is a congenital abnormality of the face, in which the palate does not develop normally during pregnancy. It is caused by failure of the fusion of the lateral palatine procesuss, resulting in the persistence of a slit-like opening between the oral and nasal cavities. Velopharyngeal insufficiency is the inability of the velopharyngeal valve to close owing to a deficit in the velopharyngeal structure, and one of the causes is cleft palate. The activities of swallowing and speaking depend on the ability to achieve adequate closure of the velopharyngeal valve. Here we present a 21-year-old man with cleft palate since birth. He had complaints of nasal sounds (rhinolalia) and water/food coming out from the nose every time he swallowed. He underwent surgery to correct this abnormality. Cleft palate closure was performed using the V-Y pushback technique and a posterior pharyngeal flap as this approach can extend the palate and effectively improve speech function. After the surgery, there were no disruptions in eating and drinking, and the patient spoke more clearly and was satisfied. A good understanding of the anatomy, physiology, and pathophysiology of cleft palate is very important for the appropriate management in order to achieve optimal and comprehensive treatment with regard to all aspects of aesthetics, speech, and swallowing ability.

Keywords: Congenital abnormalities, cleft palate, velopharyngeal insufficiency

[*] Corresponding Author's Email: citamirta@yahoo.com.

INTRODUCTION

Cleft palate is a congenital abnormality of the face, in which the palate does not develop normally during pregnancy. It is caused by failure of the fusion of the lateral palatine processes, resulting in the persistence of a slit-like opening between the oral and nasal cavities [1]. Cleft palate is more common in males than females. Additionally, it is more common in Asians (1–2.1/1000 births) than Africans (0.41/1000 births). The etiology of cleft palate is multifactorial. Genetic factors are involved in about 25% of patients with a family history of cleft palate; therefore, the chance is even greater for a future child to be born with a cleft. Environmental factors, such as drug consumption during pregnancy, infection during the first trimester of pregnancy, alcohol consumption, and vitamin deficiency, also contribute to cleft palate [1, 2, 3].

Velopharyngeal insufficiency is the inability of the velopharyngeal valve to close owing to a deficit in the velopharyngeal structure, and one of the causes is cleft palate. The activities of swallowing and speaking depend on the ability to achieve adequate closure of the velopharyngeal valve [4]. Treatment for these abnormalities includes surgery and a complete team approach to help with the multiple complications that can occur in such a case. Here, we present a man with cleft palate who had speech issues. Cleft palate closure was performed using the V-Y pushback technique and a posterior pharyngeal flap. This technique was selected because it can extend the palate and improve speech function [5-6].

CASE REPORT

A 21-year-old man with cleft palate since birth presented with a complaint of nasal sounds (Figure 1A). He also mentioned that water/food came out from the nose every time he swallowed. He had never been treated, as he was not disturbed by the abnormality. However, when he started working, he experienced problems communicating with his coworkers and supervisor. In July 2018, he underwent cleft palate surgery using the V-Y pushback technique. After surgery, he could speak more clearly, although there were still nasal sounds (Figure 1B). After 2 months postoperatively, a small fistula (around 3 mm in diameter) was noted in the surgical area (Figure 1C). Thus, in October 2018, he underwent revision surgery using the V-Y pushback technique and a posterior pharyngeal flap (Figure 2A, B). After the surgery, there were no disruptions in eating and drinking, and he could speak more clearly and was satisfied. In January 2019 (3 months after the revision surgery), he underwent speech assessment, including the mirror test (Figure 3) and kutugajah test to evaluate nasal air emission. He could not correctly pronounce the nasal consonants. There was dew on the mirror; however, he could not correctly pronounce the letters k, i, q, c, j, z, r, d, a, and s. Speech therapy was planned. He was trained several times to pronounce the nasal consonants, and a palatometer was used. Further evaluation is planned 1 month later.

DISCUSSION

In patients with cleft palate, one of the problems is speech function/communication [5]. Our patient with cleft palate underwent surgery using the V-Y pushback technique and a posterior pharyngeal flap, as this approach can extend the palate and improve speech function well [6-9]. In this case, the patient underwent alatoplasty in adulthood, which is usually performed at the age of 10–18 months. Subsequently, the patient received speech therapy to improve nasal air emission and training to pronounce the nasal consonants [10]. In our center, most patients with cleft palate undergo an audiological examination, and if the results are within normal limits, a nasometric examination is performed. Then, palatoplastyis performed, and after 1 month postoperatively, nasometry/ nasopharyn-goscopy is performed to evaluate the velopharyngeal valve and assess the presence of speech disorder.

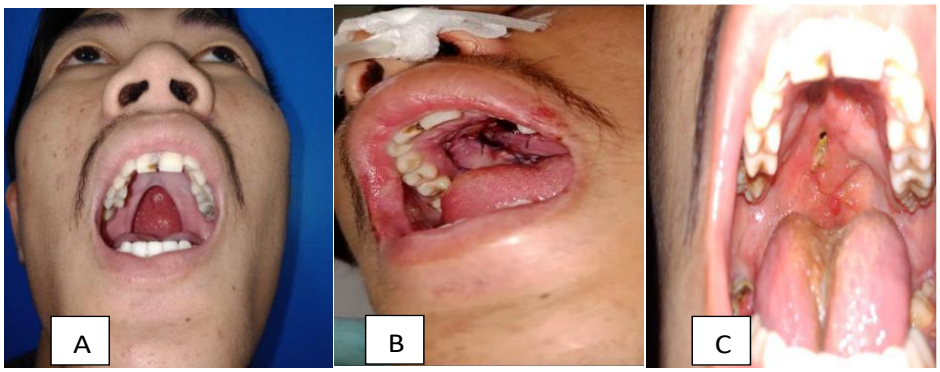

Figure 1. Cleft palate appearance. (A) Before surgery; (B) 3 days after surgery; and (C) 2 months after surgery.

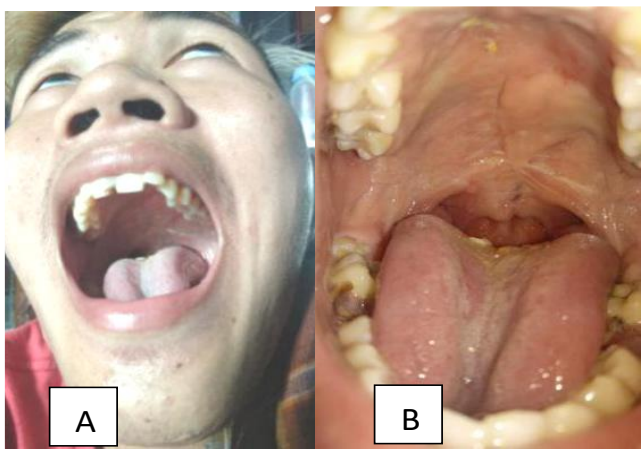

Figure 2. Cleft palate appearance after revision surgery. (A) Fourteen days after revision and (B) 2 months after revision.



Figure 3. Mirror test.

CONCLUSION

In patients with cleft palate, speech function should be examined before and after palatoplasty. Cleft palate is a congenital disorder often found in the social community. A good understanding of the anatomy, physiology, and pathophysiology of cleft palate is very important for appropriate management in order to achieve optimal and comprehensive treatment with regard to all aspects of aesthetics, speech, and swallowing ability.

REFERENCES

[1] Dixon, M. J. & Marazita, M. L. (2011). Cleft lip and palate: synthesizing genetic and environmental influences. *Nature Reviews Genetics*, 12 (3): 168-178.

[2] Khan, M., Ullah, H., Naz, S., Iqbal, T., Ullah, T., Tahir, M. and Ullah, O. (2013). A revised classification of the cleft lip and palate. *The Canadian journal of plastic surgery*, 21 (1): 48-50.

[3] Hagberg, C., Larson, O., Millerad, J. (2008). Incidence of cleft lip, palate and risks of additional malformations. *Cleft Palate Craniofacial Journal*, 35(1): 40–45.

[4] Kummer, A. W. (2014). Resonance and Velopharyngeal dysfunction (VPD). In A. W. Kummer (Ed.), Cleft palate and craniofacial anomalies: *Effects on speech and resonance.* Clifton Park, NY: Cengage Learning. 188-224.

[5] Isik, D., Bora, A., Yuce, S., Davran, R., Kocak, O., Canbaz, Y., Avcu, S. and Atik, B. (2015). Comparison of the effect of the rotation palatoplasty and V-Y pushback palatoplasty techniques on palate elongation with magnetic resonance imaging. *International Journal of Oral and Maxillofacial Surgery*, 44 (6): 738-744.

[6] Sato, F.R, Silva, M. L., Moreira, M. W. (2016). Evaluation of two palatoplasty techniques in patients with cleft palate. *Journal of Otorhinolaryngology Head Neck Surgery*, 1(5): 119-121

[7] Andersson, E. M., Sandvik, L., Semb, G., Abyholm, F. (2018). Palatal fistulas after primary repair of clefts of the secondary palate. *Scandinavian Journal of Plastic and Reconstructive Surgery and Hand Surgery*, 42 (6): 296.

[8] Lu, Y., Shi, B., Zheng, Q., Hu, Q., Wang, Z. (2010). Incidence of palatal fistula after palatoplasty with levatorvelipalatiniretro positioning according to Sommerlad. *British Journal of Oral Maxillofac Surgery*, 48(8):637–40.

[9] Cervenka, B. & Rubistein, B. (2015). Surgical repair of the cleft palate. *Journal of Otolaryngology - Head & Neck Surgery*, 26 (3): 121-126.

[10] Watterson, T., Lewis, K., Brancamp, T. (2015). Comparison of Nasalance scores obtained with the Nasometer 6200 and the Nasometer II 6400. *The Cleft Palate-Craniofacial Journal*, 42 (5): 574-579.

In: Encyclopedia of Surgery (22 Volume Set)
Editors: Andreas Lehrer and Kristin Mueller
ISBN: 978-1-53618-329-0
© 2020 Nova Science Publishers, Inc.

Chapter 331

TONGUE EDEMA AFTER PALATOPLASTY: A CASE REPORT

Rahendra*, Pradini
Department of Anesthesiology and Intensive Care, Faculty of Medicine,
Universitas Indonesia and Cipto Mangunkusumo National Central Hospital,
Jakarta, Indonesia

ABSTRACT

Palatoplasty is a commonly performed procedure in children. A complication of palatoplasty is tongue edema owing to the use of a mouth gag. Tongue edema can compromise the airway and be dangerous for the patient. The objective of this case report was to increase awareness that tongue edema may arise after palatoplasty and to explain how to manage it. We present the case of a 17-month-old female who presented with tongue edema after palatoplasty. Massive tongue swelling developed 2 hours post-surgery. The patient showed signs of upper airway obstruction and was reintubated. The patient was under observation in the intensive care unit for three days until the tongue size returned to the original. A longer observation period in the recovery room after surgery may be required to prevent occurrence of hazardous events after palatoplasty.

Keywords: tongue edema, palatoplasty, airway obstruction

INTRODUCTION

Palatoschisis is a frequently occurring congenital craniofacial disorder. The Centers for Disease Control and Prevention (CDC) has estimated that 2.650 babies are born every year with palatoschisis in the United States [1, 2]. Palatoschisis can cause swallowing, talking, and breathing disorders in sufferers. Palatoplasty needs to be performed to correct this disorder and is typically performed at the age of 9-18 months. Corrections performed in palatoplasty

* Corresponding Author's Email: rahend2k@yahoo.com.

include repair procedures in the hard palate and mole palate. Almost all palatoplasty procedures involve the use of a mouth gag to separate the tongue and cheeks from the surgery area, making it easier for the surgeon to access the operating area [1, 3, 4].

Although the use of a mouth gag in this procedure has been shown to ease surgery, there are many reports of complications arising from suppressing mouth gags to surrounding structures [2, 5, 6]. A complication that arises owing to the suppression of mouth gag is edema of the tongue. Although rare, edema of the tongue can cause upper airway obstruction, which, if not treated properly, has the potential to be life threatening [7-9]. This case report aimed to discuss the management of patients who develop post-palatoplasty tongue edema.

CASE REPORT

A healthy 17-month-old, 10-kg female was scheduled for palatoplasty. The patient had labiopalatoschisis since birth and had undergone surgery for labioschisis at the age of 6 months. Based on the patient's history and examination, there were no complaints or abnormalities other than palatoschisis. She was assessed as ASA 2 with congenital anomaly (palatoschisis). In the operating room, anesthesia was induced by using sevoflurane 8%, which was titrated down to 2.5%. A 24-G infusion line was secured in the patient's left hand. Fentanyl 2.5 mcg/kg (25 mcg) and atracurium 0.5 mg/kg (5 mg) were administered to facilitate intubation. Intubation was performed using direct laryngoscopy, with endotracheal tube size 4 (non-kinking type), fixed at 12 cm. The cuff was not inflated owing to pediatric airway consideration. A throat pack was inserted by the anesthesiologist. The ventilator setting was VC (Volume Control) 80/4/20/40%. No difficulties were faced while performing intubation.

After intubation, the patient's head was placed in a hyperextended position. A mouth gag was inserted by the surgeon. During the surgery, the surgeon changed the mouth gag position several times and increased the pressure because the visualization of the operating field was difficult. However, hemodynamically, the patient was stable with an estimated total blood loss of 50 mL. The surgery lasted for 3.5 hours. Anesthesia was maintained with administration of 2%-2.5% sevoflurane in air with 45% oxygen. At the end of surgery, the throat pack was removed, and the surgeon stitched a palatum pack to block unanticipated bleeding from the surgical site.

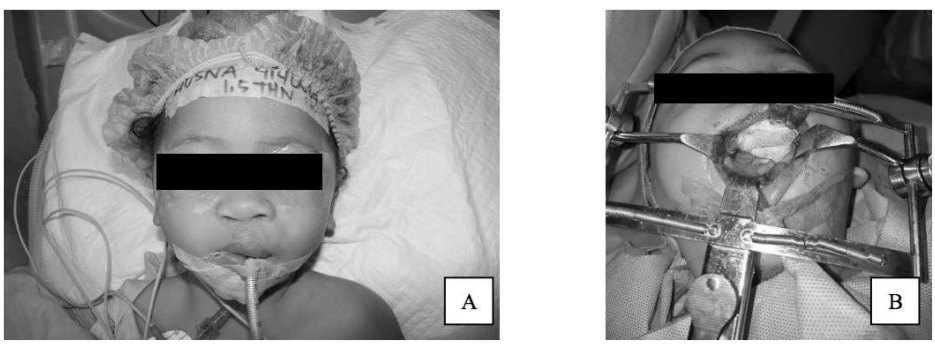

Figure 1. Intraoperative Position. (A) After intubation. (B) After mouth gag insertion.

Figure 2. Tongue swelling. (A) More massive tongue swelling 2 hours post-surgery. (B) Decreased tongue swelling 3 days post-surgery.

At the end of the procedure, the residual neuromuscular block was antagonized, spontaneous ventilation was assessed to be adequate, and extubation was performed. Soon after extubation, the patient showed labored breathing with intercostal retraction. Oxygen saturation decreased to 88%; 100% oxygen was administered via the face mask, but the saturation continued to decrease until 76%. Propofol (25 mg) was injected to sedate the patient, and an LMA was inserted to provide adequate ventilation.

Soon after insertion of LMA, oxygen saturation increased to 100%. The anesthesiologist decided to wait until the effect of propofol subsided. Naloxone 0.01 mg/kg (0.1 mg) was added to reverse any residual opioid. The decision to exert the LMA was made after the patient gained consciousness and spontaneous ventilation was adequate. However, soon after LMA exertion, the patient showed labored breathing with intercostal retraction again, and oxygen saturation decreased to 90%. An oropharyngeal airway sized 0 was inserted, which solved the issue. Oxygen saturation quickly increased to 100%. A quick re-evaluation of the patient's airway was done, and a mild lingual edema was found. The anesthesiologist asked the surgeon to remove the palatum pack, so that air could flow through the oral cavity despite the presence of mild lingual edema. The child could then breathe normally without a period of desaturation. It was decided that the patient would be observed for longer period of time in the recovery room.

Two hours post-surgery, the patient developed a more massive lingual edema and produced a stridor sound, indicative of an impending airway obstruction. The decision to re-intubate the patient was made; reintubation was extremely difficult and was performed within two attempts using C-MAC and bougie. Soon after the intubation, an emergency lingual exploration was performed by the surgeon, which found no bleeding, hematoma, or laceration on the tongue. The patient was transferred to the intensive care unit (ICU) for observation. Dexamethasone was injected daily to reduce tongue swelling. After a 72-h in ICU, the tongue size slowly returned to normal. The patient was then extubated.

DISCUSSION

Airway compromise following palatoplasty may be owing to tongue swelling, laryngeal edema, pharyngeal secretions, blood clots, a retained throat pack, prolonged action of anesthetic agents, or a combination of factors [1, 2, 5, 9]. Tongue swelling is an unusual sequel to cleft palate repair. Ischemia induced by the pressure arising from prolonged use of a mouth gag results in necrosis of the tongue muscle, venous stasis, and lymphedema, resulting in lingual swelling, which indicates tongue ischemia with reperfusion hyperemia and capillary leakage as important mechanisms [3, 4]. Hyperextension of the head may also contribute to an impaired blood flow to the tongue, producing more lingual venous stasis and swelling, necessitating immediate reintubation, which may be extremely difficult [2, 5, 6].

The onset of tongue edema can be insidious over a 2–2.5-h period [3, 8, 9]. This is potentially dangerous because by then, the patient is likely to have been discharged to the general ward. Tongue examination prior to extubation is needed after every palatoplasty surgery. It is important to maintain airway patency until the tongue size returns to normal.

CONCLUSION

Massive tongue swelling can compromise the airway. Periodic release of the mouth gag during palatoplasty prevents prolonged ischemia to the tongue. Once lingual edema develops, it is important to maintain airway patency until the tongue size returns to normal. It is important to keep in mind that reintubation is often difficult. A longer observation may be required especially in an ambulatory setting to prevent a hazardous event.

REFERENCES

[1] Rajesh, M. C., Kuriakose, S., Sukumar, J., Ramdas, E. K., (2013). Massive lingual swelling following cleft palate repair. *J. Anaesthesiol. Clin. Pharmacol.* 29, 262-263.

[2] Dell'oste, C., Savron, F., Pelizzo, G., Sarti, A. C., (2004). Acute airway obstruction in an infant with Pierre Robin syndrome after palatoplasty. *Acta Anaesthesiol. Scand.* 48, 787-789.

[3] Aziz, S. R., Ziccari, V. B., (2009). Severe glossal edema after primary palatoplasty. *J. Oral Maxillofac. Surg.* 67, 1326-1328.

[4] Sherif, R. D., Paymo, S. M., Taub, P. J., (2018) Lingual pressure during dingman-assisted cleft palate repair: an investigatory case series. *Cleft Palate Craniofac. J.* 55, 312-315.

[5] Lees, V. C., Pigott, R. W., (1992). Early postoperative complications in primary cleft lip and palate surgery - how soon may we discharge patients from hospital? *Br. J. Plast. Surg.* 45, 232-234.

[6] Gupta, R., Chhabra, B., Mahajan, R. K., (2001). Macroglossia following palatoplasty causing upper airway obstruction: Case report. *J. Oral Maxillofac. Surg.* 59, 940-941.

[7] Mukozawa, M., Kono, T., Fujiwara, S., Takakura, K., (2011). Late onset tongue edema after palatoplasty. *Acta Anaesthesiol. Taiwan.* 49, 29-31.

[8] Chan, M. T., Chan, M. S., Mu, K. S., Ho, B. P., (1995) Massive lingual swelling following palatoplasty. *Anaesthesia*, 50, 30-34.

[9] Prakash, S., Usha, G., Thakur, P., Mullick, P., (2016) Postoperative supraglottic edema following palatoplasty. *Anaesth. Pain & Intensive Care* 20, 89-91.

In: Encyclopedia of Surgery (22 Volume Set)
Editors: Andreas Lehrer and Kristin Mueller
ISBN: 978-1-53618-329-0
© 2020 Nova Science Publishers, Inc.

Chapter 332

NON-SYNDROMIC UNILATERAL TESSIER NO. 3 FACIAL CLEFT: A RARE CONGENITAL DISEASE

Mirta H. Reksodiputro*[*], Tara C. Mariska, Dini W. Widodo and Trimartani Koento
Department of Otorhinolaryngology, Head and Neck Surgery, Faculty of Medicine, Universitas Indonesia, RSUPN Dr. Cipto Mangunkusumo, Jakarta, Indonesia

ABSTRACT

Facial clefts are extremely rare congenital anomalies. There are various types of clefts, and classifications are required for their description. Nasal anomalies are rare and, currently, there are no standard methods for the management of such defects. The number of operations and types of surgical intervention vary widely according to the pattern and complexity of the deformity. The aim of this case report is to formulate a standardized procedure for there pair of the nasal component of Tessier no. 3 clefts. A nasal dorsum advanced rotational flap was used to close the cleft of ala nasi during the first-stage surgery. Second-stage surgery involved an osteotomy and septoplasty to obtain a better shape for the nasal dorsum. During the third operation, we reconstructed the ala nasi to obtain improved symmetry. The nasal dorsum rotation flap showed good healing over the lateral surface of the nose and in the subciliary region. The closure of the nasal defect was accomplished using a composite downward rotation flap of the ala based on the lateral cleft wall. An advanced rotation-transposition flap was used in the management of a Tessier no 3cleft. We also recommend the use of a superiorly based transposition for extensive lateral nasal wall involvement. In the present case, we performed osteotomy and septoplasty to obtain an improved shape for the nasal dorsum. Although the symmetry between the two nostrils was not ideal, it was acceptable.

Keywords: Tessier no. 3 cleft, advanced rotation-transposition flap

[*] Corresponding Author's Email:citamirta@yahoo.com.

INTRODUCTION

Facial clefts are extremely rare congenital anomalies. There are numerous variations and classifications of clefting. The cleft nasal deformity is mostly associated with cleft lip and palate [1]. The goals of cleft nasal surgery are to re-establish normal nasal tip projection and align the nares and the position of the nasal base. Various techniques have been considered to repair these defects [1, 2].

A facial cleft is an opening or gap in the face, or a malformation of a part of the face. Nasal deformity involves the skin, cartilage, mucosa, and skeletal platform [1, 2]. Fortunately, congenital clefts of the nose, whether isolated or associated with other craniofacial clefts, are rare. The exact incidence remains unknown. The incidence of craniofacial clefts, other than cleft lip and palate, is reported to be 1.4–4.9 cases per 100,000 live births. Even among these cases, a cleft of the nose is rare [3]. Several studies reported that congenital nasal anomalies are rare, with an incidence of one case per 20,000–40,000 livebirths [4]. Nasal anomalies are rarely observed, which may account form is diagnosis and treatment plans that result in a less than satisfactory outcome. Nasal defects are also part of craniofacial clefts and other various well-documented syndromes.

Several theories have been proposed to explain the etiology official clefts. At present, an established theory is the mesodermal penetration theory, which states that clefts occur along potential lines of fusion due to the lack of mesodermal penetration. Without this reinforcement, epithelial breakdown and separation may occur [4].

Facial clefts have been classified according to their pathology, etiology, pathomorphology, topographic anatomy, and time of development. The most commonly used classification for craniofacial clefts is the Tessier classification, proposed by Paul Tessier in 1976 [1]. This classification is based on specific axes (0–14) along the face and the cranium. The orbit divides the cranial clefts (9–14) from facial clefts (0–7), and facial clefts have cranial extensions. Tessier clefts involving the nose are types 0, 1, 2, and 3 with their cranial counterparts. The patterns of nasal clefts are variable, ranging from simple notch or asymmetry of the alar margin to complex complete craniofacial cleft involving the lip, nose, eyelid, brow, forehead, and underlying bones [1, 5, 6].

CASE PRESENTATION

We present an 18-year-old female with a Tessier no. 3 facial cleft. She did not have a history of nasal obstruction or cyanosis at birth. The patient had an isolated unilateral cleft of the left ala nasi, without other congenital abnormalities (Figure 1).

Computed tomography showed only deformities on the mucosa of the ala nasi, without cartilage deformities. Deviation of the nasal septum was observed. However, there were no structural defects of the hard tissue (Figure 2).

Figure 1. A female patient with a left Tessier no. 3 cleft. (A. Anterior view, B. Right lateral view, C. Right oblique view, D. Left lateral view, E. Left oblique view, F. Basal view).

Figure 2. Computed tomography findings showed no abnormality in bone structure.

In this study, we used an advanced rotational local flap for the management of the patient. The incision design was made to obtain an improved symmetry and remove unnecessary structures. We set three reconstructive goals (i.e., reconstruction of the alar rim without a discernible notch, achieving symmetry with the normal side, and closing the secondary defect using local tissues).

The open rhinoplasty approach was performed to locate congenitally deformed anatomical landmarks, especially the cartilaginous framework of the nose. Nasal dorsum advanced rotational flaps were literally based from advanced rotation flaps. This flap design was in the shape of a pattern using ala from the other side. The medial incision was superficial, and a dissection was performed subcutaneously toward the nasomaxillary suture area. A deep dissection was continued lateral to the nasomaxillary suture area to mobilize the flap.

Open rhinoplasty was performed to open the anterior nasal area. This process exposed the alarcartilages. The lateral crura of the affected alarcartilage were dissected away from the nasal mucosa. The lining of the nasal mucosal was stretched and attached anteriorly to close the cleft. The lateral crus of the affected alarcartilage was repositioned laterally to be contiguous with the lateral crus of the lower lateral cartilage. The pedicled skin flap was rotated downward to recreate the alar rim. However, the limitation of this approach was that the flap was unable to rotate too far away to prevent the flap to stretch away and also to make sure the flap got good vascular feeding. (Figure 3). We inserted a nasal tampon to fixate the flap for 3 days.

A follow-up examination performed 1 month after surgery indicated that the flap was in good condition. However, it required additional intervention to obtain an improved ala symmetry. Second-stage surgery (refinement) was performed7 months after the first-stage surgery.

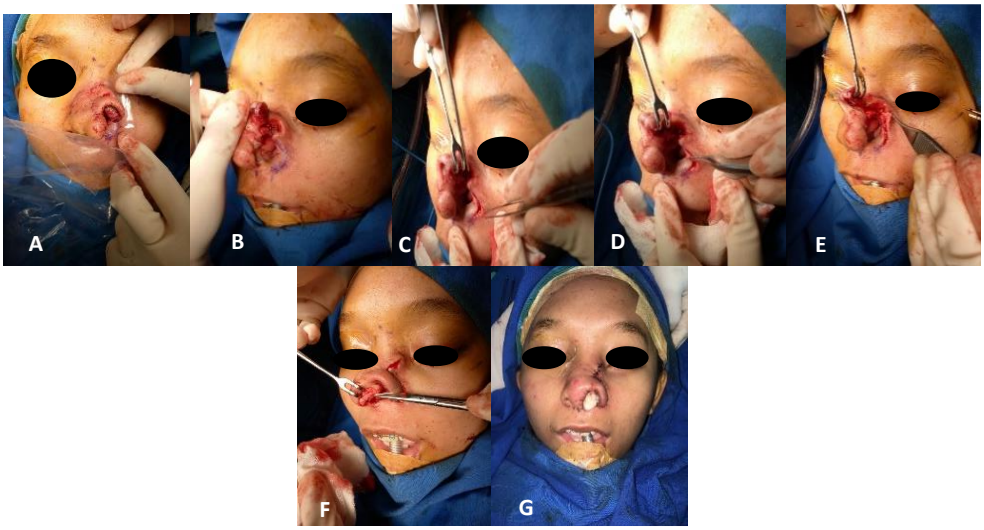

Figure 3. First-stage surgery. (A. Design of incision was to obtain symmetry). (B-E. Superficial and deep dissection and open rhinoplastyof the Nasal dorsum rotational flaps for correction of Tessier no. 3 facial cleft) (F. Removal of unneeded cartilage and mucosa). (G. Closure of the nasal dorsum rotational flaps for correction of Tessier no. 3 facial cleft).

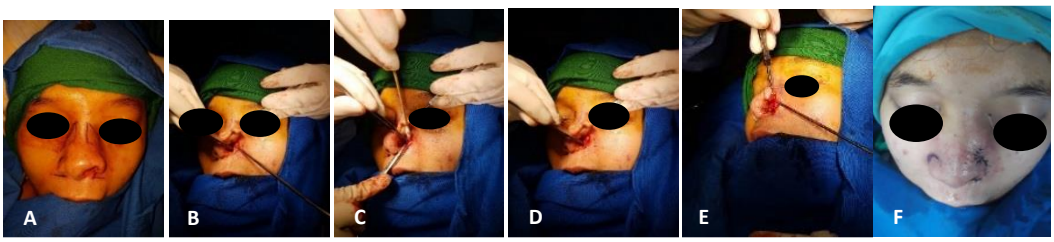

Figure 4. Second-stage surgery. (A. Marking of dorsum and ala nasi incision). (B-E. Undermined ala nasi and removed unneeded structure) (F. Superior view of second stage surgery shows a good shape of dome and ala nasi).

During second-stage surgery, osteotomy was performed to undermine the mucosal segment of the nasal dorsum. We used septoplasty to recreate the ala. In addition, we undermined the ala nasi to reconstruct the dome of ala nasi and obtain an improved shape and good symmetry. Although the symmetry between the two nostrils was not ideal, it was acceptable. Multiple procedures were performed to ensure a good healing process of the graft and closure of the secondary defect (Figure 4).

The results of the nasal dorsum rotation flap showed good healing over the lateral surface of the nose and in the subciliary region. However, scarring over the alarcartilage was suboptimal. The closure of the nasal defect was accomplished using a composite downward rotation flap of the ala based on the lateral cleft wall (Figure 5). The main defects were closures using advanced nasal dorsum rotational flap, while the secondary defect is closed after assessment of tissue availability and the remaining scars. Multiple approaches were performed to obtain an improved shape and symmetry of both nostrils.

Figure 5. Anterior and lateral views prior to surgery (A and D), and 1 month after surgery (B and E) and 2 months (C and F) after second-stage surgery.

DISCUSSION

Paul Tessier studied facial clefts, and his clinical classification has become the current international standard. The cleft crosses the nasal ala between the tail of the alarcartilage and the alarbase, and the tip [1]. The most distinguishing characteristics of the Tessier no. 3 facial clefts are: medial orbital maxillary clefts, characterized by displacement of the medial canthus, superior displacement of the ala nasi cleft lip, alveolus and palate, coloboma of the lower eyelid, nasolacrimal abnormalities, disruption of the medial wall of the antrum, a cleft in the medial wall of the orbit, and teleorbitism.

Considering the rarity and lack of standard guidelines, the management of patients with such facial clefts is challenging. Depending on the degree of malformation, a staged procedure is currently considered the treatment of choice. However, various surgical protocols have been described in the literature, and the selection of approach has not been standardized [3]. The Australian Craniofacial Unit Treatment Protocol, which is one of the most widely accepted protocols for the management official clefts, has suggested early repair of the soft tissue defects and prevention of exposure keratitis. In addition, the protocol states that bone grafting if needed, orthognathic surgery, and rhinoplasty maybe performed after the patient reaches adulthood. Moreover, this protocol propounded the role of tissue expansion in the cheek to accommodate bone grafts. Numerous different types of flaps may be used to repair such lateral defects of the nose, depending on the size, shape, and site of the defects [3].

The main surgical goal in the treatment of patients with Tessier no. 3 clefts is nasal symmetry, which is rarely achieved. Surgeons have proposed different techniques for the repair of Tessier no. 3 facial clefts. Madaree et al. [7] used five local flaps, with two pairs

utilizing the "z" plasty principle to achieve lengthening and the fifth being a turnover flap for additional nasal lining. A full thickness flap of the alar rim was rotated downward, thereby equalizing the external nares. The medially based turnover flap was used to close the gap. Monasterio et al. [8] used a local transposition flap to correct skin shortening between the medial canthus and the eye. A medial flap was rotated to elevate the dystopic canthus, and cheek flaps were advanced to close the gap and lengthen the nose [9, 10].

In the present case, we found that this flap improved alarsymmetry; however, it decreased the nostril area. The main limitation of this technique is the notch in the affected ala that required multiple corrective procedures. Similar results were obtained by Monasterio et al. [8]. These investigators suggested the need for multiple refining procedures and claimed that severe clefts extending along the whole length may be corrected by rotation of longer nasal flaps alone or in combination with forehead flaps.

CONCLUSION

We recommend the use of the advanced rotation-transposition flap for the management of nasal defects associated with Tessier no 3 clefts. We also recommend the use of a superiorly based transposition for cases with extensive lateral nasal wall involvement. In our case, we performed osteotomy and septoplasty to obtain an improved shape for the nasal dorsum. Surgeons may infrequently observe such cases. Consequently, they may not possess the necessary expertise to individualize the corrective procedure. The present technique is simple and can be easily incorporated in the armamentarium of surgeons. A number of studies reported that several surgical procedures are required to obtain an improved shape and nasal symmetry. In the present case, three procedures were performed to achieve acceptable symmetry between the two nostrils.

REFERENCES

[1] Tessier, P. (1976). Anatomical classification facial, cranio-facial and latero-facial clefts. *Journal of Maxillofacial Surgery, 4*, 69-92.

[2] Zhou, Y. Q., Ji, J., Mu, X. Z., Zhang, R. H., Wei, M. & Yu, Z. Y. (2006). Diagnosis and classification of congenital craniofacial cleft deformities. *Journal of Craniofacial Surgery, 17*, 198-201.

[3] Kawamoto, H. K. Jr. (1990). *Rare craniofacial clefts, plastic surgery*. Philadelphia, PA: Saunders.

[4] Losee, J. E., Kirschner, R. E., Whitaker, L. A. & Bartlett, S. P. (2004). Congenital Nasal Anomalies: A Classification Scheme. *Plastic and Reconstructive Surgery, 113*(2), 676-689.

[5] Nishimura, Y. (1993). Embryological study of nasal cavity development in human embryos with reference to congenital nasal atresia. *Acta Anatomica (Basel), 147*, 140.

[6] Arey, L. *Developmental Anatomy: A Textbook and Laboratory Manual of Embryology*. 7th Edition. Philadelphia: Saunders, 1965.

[7] Madaree, A., Morris, W. M. & McGibbon, I. C. (1992). A method of repairing the no 3 facial cleft. *British Journal of Plastic Surgery*, *45*, 44-46.

[8] Ortiz Monasterio, F., Fuente del Campo, A. & Dimopulos, A. (1987). Nasal clefts. *Annals of Plastic Surgery*, *8*, 377.

[9] Ortega, J. & Flor, E. (1969). Incomplete naso-ocular cleft. Case report. *Plastic and Reconstructive Surgery*, *43*, 630-636.

[10] Jinka, J. R., Chekuri, H. & Annavarapu, G. (2012). Isolated cleft of the ala nasi: A report of seven cases. *Indian Journal of Plastic Surgery*, *45*, 512-515.

In: Encyclopedia of Surgery (22 Volume Set)
Editors: Andreas Lehrer and Kristin Mueller
ISBN: 978-1-53618-329-0
© 2020 Nova Science Publishers, Inc.

Chapter 333

OUTCOMES OF RESECTION ARTHRODESIS FOR KNEE MALIGNANCIES

Yogi Prabowo[1], Afif Alhadi[2] and Adisa Yusuf Reksoprodjo[2,*]
[1] Department of Orthopedic and Traumatologic, Faculty of Medicine,
RSUPN Dr. Cipto Mangunkusumo, Universitas Indonesia, Jakarta, Indonesia
[2] Orthopaedic and Traumatology Residency Program, Faculty of Medicine,
Universitas Indonesia, Jakarta, Indonesia

ABSTRACT

Limb salvage surgery with tumor resection and endoprosthesis insertion is currently the preferred treatment for malignancies of the extremity. However, this procedure is not feasible in many cases and requires expensive implants that may not be available or affordable for many patients, such as in developing countries. We present three cases with distinct malignancies of the knee, osteosarcoma, metastatic bone disease due to lung cancer, and spindle cell carcinoma, treated by resection arthrodesis. After wide excision of the tumor, the combination of plates crews and K-nails with bone cement was used for arthrodesis. Functional outcomes were evaluated using the Lower Extremity Functional Scale (LEFS) score. LEFS scores were 24, 30, and 2 6 out of 80, respectively. These low scores reflected substantial loss of limb immobility. Resection arthrodesis is a viable treatment option for limb salvage in cases of knee tumor for which resection and endoprosthesis insertion are not feasible, but functional outcome is limited.

Keywords: limb salvage, resection arthrodesis, functional outcome

INTRODUCTION

Musculoskeletal tumors are relatively rare, accounting for less than 1% of all malignancies [1]. However, the majority of lower extremity tumors affect the knee, a critical

* Corresponding Author's Email: adisayr@gmail.com.

joint for full limb function. Wide resection is reserved for a small subset of patients with biologically more aggressive, recurrent, and extensive tumors. Wide resection and mobile joint reconstruction are preferable for treating tumors around the knee. In certain situations, resection arthrodesis or amputation is suggested. Limb salvage surgery with tumor resection and endoprosthesis insertion is the preferred treatment, but the expensive implants may be unattainable, especially in developing countries. Resection arthrodesis is currently considered a less attractive option due to loss of joint mobility. However, resection arthrodesis does provide a stable limb, and the patient is unlikely to require revision surgery [2, 3]. In this case series, we examined the outcomes of resection arthrodesis for three distinct knee malignancies.

CASE SERIES

The first case (Table 1) was a 15-year-old male who reported pain in his left leg for 18 months before presentation (Figure 1). The patient was diagnosed with osteosarcoma and referred to CiptoMangunkusumo Hospital, where he received four cycles of neoadjuvant chemotherapy before limb salvage surgery with wide excision and ELIAS cancer immune therapy in January 2016 (Figure 2). The wound became infected, however, requiring two corrective surgeries, but neither was successful. In May 2016, the cement was exposed. The patient then underwent knee arthrodesis in December 2016. The postoperative outcome as measured by LEFS score was 24 out of 80, indicating substantial disability (Figure 3).

The second case was a 60-year-old male who reported left leg pain for the past year before presentation. There was no history of trauma or prolonged fever, although he reported a history of weight loss. There was progressive swelling of his left knee (Figure 1). The patient was diagnosed with lung cancer in 2014 and had received curettage and bone cement surgery in December 2015. Pathological examination revealed micro-metastases of adenocarcinoma. Three months later, pain re-emerged in the same region, and X-ray examination confirmed metastatic bone disease of the left distal femur (Figure 2). In October 2016, the patient underwent limb salvage surgery using resection arthrodesis. Postoperative LEFS score was 30 (Figure 3).

The third case was a 16-year-old male who reported pain in his right knee, starting six months before presentation. His knee was swollen and painful, although he could still stand and walk (Figure 1). The patient received three treatments from a bonesetter. Two months later, a nascent lump on the knee had enlarged to the size of a tennis ball. The growth was painful and firm. In April 2016, the patient received a core biopsy, and histopathological examination revealed conventional osteosarcoma (Figure 2). At that time, the lump had grown to the size of a volleyball with no clear margin; was painful, firm, wih solid consistency; and felt warmer than the surrounding tissue. The patient then decided to receive neoadjuvant chemotherapy for three cycles with a regimen of cisplatin, ifosfamide, and adriamycin. After finishing chemotherapy, the lump was still expanding, although no inflammation or ulceration was noted. The patient agreed to limb salvage surgery including wide excision and reconstruction using right knee arthrodesis. Postoperative LEFS score was 26 (Figure 3).

Table 1. Summary of patient information

Patient	Diagnosis	Location of lesion	Time from initial complaint to arthrodesis	Other treatments	Postoperative LEFS score
Male, 15 y	Osteosarcoma	Left leg	16 months (August 2015–December 2016)	4 cycles of neoadjuvant chemotherapy Wide excision and ECI[1] Debridement and implant removal	24
Male, 60 y	Metastatic bone disease from lung carcinoma	Left thigh	2 years (2014−2016)	Chemotherapy for lung carcinoma Curettage and bone cement application	30
Male, 16 y	Osteosarcoma	Right knee	Approximately 1 year (2015−2016)	Neoadjuvant chemotherapy by cisplatin, ifosfamide, and adriamycin	26

y: year, ECI: ELIAS cancer immunotherapy.

Figure 1. Clinical images of the first, second, and third patients (from left to right, respectively).

Figure 2. Preoperative X-ray images of the first, second, and third patients (from left to right).

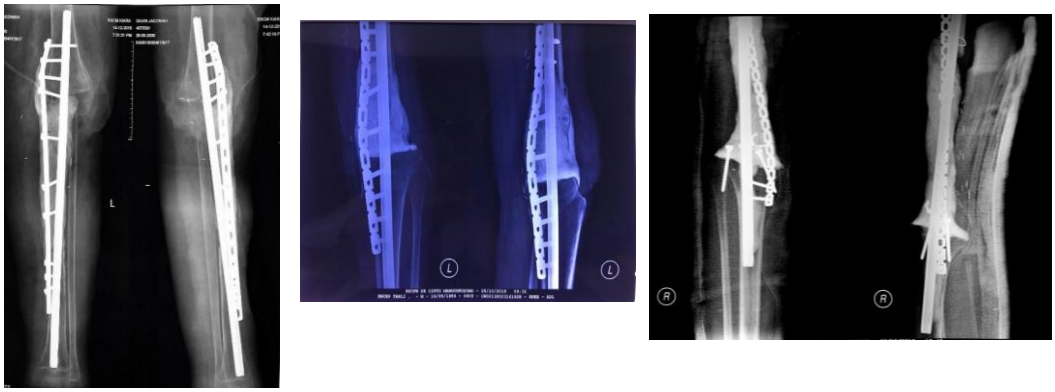

Figure 3. Postoperative X-ray images of the first, second, and third patients (from left to right).

DISCUSSION

The primary goals of knee tumor excision are to prevent recurrence and prolong life, which generally requires wide-margin resection, whereas functional preservation or restoration is secondary [4]. The choice of reconstruction strategy after resection of a tumor around the knee joint is based on many factors. Arthrodesis provides stable, durable, and predictable reconstruction that preserves some leg motion but at the expense of flexion and extension at the knee. Once the decision has been made to perform arthrodesis, the specific technique selected should have demonstrated success with few complications, as this group of patients will probably receive postoperative chemotherapy and some will have limited life expectancy [5].

Enneking and Shirley [6] proposed the following indications for resection arthrodesis: 1) a recurrent benign, potentially malignant, or malignant lesion that involves the distal end of the femur, the knee joint, or the proximal end of the tibia; 2) a tumor location with an adequate plane of uninvolved tissue between the lesion and posterior neurovascular structures for surgical resection according to the degree of aggressiveness of the tumor; and 3) a vigorous patient whose expectations and lifestyle require a stable, painless extremity capable of withstanding demanding function. All three of our cases were deemed suitable for resection arthrodesis based on these criteria [6].

Kwan [7] evaluated the outcomes and complications associated with resection arthrodesis for 22 primary bone tumors (13 giant cell tumors and nine osteosarcomas) around the knee and reported that of 14 patients who returned for final evaluation, 79.8% had satisfactory outcomes according to the Musculoskeletal Tumor Society grading system. A study by Alam [8] evaluating functional outcomes in children with a malignant tumor around the knee joint also supported the efficacy of resection arthrodesis, particularly for pediatric sarcomas around the knee and for cases in which endoprosthesis insertion is not feasible because of young age or lack of resources. In a study by Bassiony et al. [9], all patients receiving resection arthrodesis achieved functional results comparable with endoprosthetic patients. This result was confirmed by Harris et al. [10], who reported that patients functioned similarly and walked with comparable velocities, efficiencies, and oxygen consumption rates whether treated by arthrodesis or arthroplasty.

In our cases, the outcome was measured using the LEFS, which consists of 20 items evaluating the ability to perform everyday tasks, each with a maximum score of 4[11] The LEFS results in our cases indicated substantial functional limitations after arthrodesis. Nonetheless, resection arthrodesis appears preferable to amputation. Shih et al. [12] reported a 5-year survival rate of 39% following arthrodesis for knee osteosarcoma, which was lower than following endoprosthetic insertion (60%) but higher than after amputation (13%).

CONCLUSION

Resection arthrodesis is a viable treatment option for limb salvage in patients with tumors around the knee, although the functional outcome is limited. However, for cases in which prosthesis replacement is unobtainable, arthrodesis with wide excision still salvages a tumorless limb with some functional capacity.

REFERENCES

[1] Siegel R, Miller KD, Jemal A. Cancer Statistic 2016. *CA Cancer J Clin.* 2016; 66(1): 7-30.

[2] Salai M, Neurabay J, Caspi I, Horoszowski H. Resection arthrodesis of the knee in the treatment of tumours – a long-term follow-up. *Int Orthop.* 1997; 21(2): 101-3.

[3] Bassiony AA, Abdelrahman M, Abdelhady A, Assal MK. Resection arthrodesis for the management of aggressive giant cell tumor of the distal femur. *Indian J Orthop.* 2009; 43(1): 67-71.

[4] Chao EY, Sim FH. Functional results following resection arthrodesis about the knee. In *New Developments for Limb Salvage in Musculoskeletal Tumors.* Tokyo: Springer; 1989. p. 567-71.

[5] Kapoor SK, Tiwari A. Resection arthrodesis for giant cell tumors around the knee. *Indian J Orthop.* 2007; 41(2): 124-8.

[6] Enneking WF, Shirley PD. Resection-arthrodesis for malignant and potentially malignant lesions about the knee using an intramedullary rod and local bone grafts. *J Bone Joint Surg Am.* 1977;59(2):223-36.

[7] Kwan MK, Ng ES, Penafort R, Saw A, Sengupta S. Resection arthrodesis for primary bone tumor about the knee. *Med J Malaysia.* 2005;60(C): 66-71.

[8] Alam S. *Functional outcome in children undergoing resection-arthrodesis for malignant tumors around the knee joint.*

[9] Shalaby S, Shalaby H, Bassiony A. Limb salvage for osteosarcoma of the distal tibia with resection arthrodesis, autogenous fibular graft and Ilizarov external fixator. *J Bone Joint Surg.* 2006;88(12):1642-6.

[10] Harris IE, Leff AR, Gitelis S, Simon MA. Function after amputation, arthrodesis or arthroplasty for tumors about the knee. *J Bone Joint Surg Am.* 1990;72(10):1477-85.

[11] Binkley JM, Stratford PW, Lott SA, Riddle DL. The Lower Extremity Functional Scale (LEFS): scale development, measurement properties, and clinical application. *Phys Ther.* 1999;79(4):371-83.

[12] Shih HN, Shih LY. Resection arthrodesis of the knee for osteosarcoma: An alternative when mobile joint reconstruction is not feasible. *Chang Gung Med J*. 2005; 28(6): 411.

In: Encyclopedia of Surgery (22 Volume Set)
Editors: Andreas Lehrer and Kristin Mueller
ISBN: 978-1-53618-329-0
© 2020 Nova Science Publishers, Inc.

Chapter 334

TOTAL SACRECTOMY AND SPINOPELVIC RECONSTRUCTION OF SACROCOCCYGEAL CHORDOMA

Yogi Prabowo[1], Afif Alhadi[2] and Rizky Priambodo Wisnubaroto[2,*]
[1]Department of Orthopedic and Traumatologic, Faculty of Medicine,
RSUPN Dr. Cipto Mangunkusumo, Universitas Indonesia, Jakarta, Indonesia
[2]Orthopaedic and Traumatologic, Faculty of Medicine,
Universitas Indonesia, Jakarta, Indonesia

ABSTRACT

Chordoma is a low-to-intermediate-grade malignant tumor encapsulating the notochord. It is rare, insidious in onset, and frequently diagnosed late. Due to its size, location, and nature, surgical treatment becomes challenging. Here we report a case of sacral chordoma in a 33-year-old woman treated with a combined anterior and posterior approach to remove the tumor enbloc, followed by posterior stabilization using rod–screw system. Total sacrectomy and spinopelvic reconstruction is the treatment of choice for sacral chordoma. We were able to achieve complete resection of the tumor mass with no recurrence after six months of follow-up.

Keywords: sacrum, chordoma, combined posterior and anterior approach, sacrectomy

INTRODUCTION

Chordoma is a low-to-intermediate-grade malignant tumor encapsulating the notochord. It accounts for 1%–4% of all primary malignant bone tumors, is insidious in onset, and frequently has a late presentation. Most chordomas present after the age of 30, with one-third occurring in the sixth decade [1]. This is a slow-growing but locally aggressive tumor and

* Corresponding Author's Email: risky.wisnubaroto@gmail.com.

originates from primitive notochordal elements. This tumor is mainly found along the midline from the base of the skull to the sacrococcygeal region of the pelvis [2].

The treatment goal for sacral chordoma is to achieve en bloc excision with tumor-free margins to maximize local tumor control and survival. However,this is challenging in some cases, as sacral chordomas are difficult to excise entirely because preservation of sacral stability and sacral nerve pathways to the rectum and bladder limits the extent of the surgery [2, 3]. The prognosis for these patients correlated with negative surgical margins, which almost always results in a poor prognosis in patients with intralesional resection [2, 4].

We report a case of sacral chordoma in a 33-year-old woman presenting with radiating pain and bladder obstruction as the primary symptoms. Due to the nature of the tumor involvement, we performed an en bloc sacral resection with the Galveston technique using a combined anterior and posterior approach, achieving stability with pedicle screw and rod fixation.

CASE REPORT

A 33-year-old female patient presented to our office with a chief complaint of ongoing pain in her left hip for four years. The symptoms started with periodic cramps in the hip that radiated to her feet. Though the pain was initially abated with the use of over-the-counter pain killers, some degree of pain remained. Approximately two years ago, the patient started experiencing lower urinary tract symptoms along with worsening hip pain, which had now extended to her left knee. She consulted with an internist and was diagnosed with a urinary tract infection and treated accordingly. However, shortly after that, she was unable to pass urine and was eventually hospitalized. A complete workup was performed, including a CT scan, which revealed an abdominal mass. She was referred to an obstetrician-gynecologist, and a working diagnosis of uterine myoma was made. A follow-up MRI was performed, which showed the bony origin of the tumor. Next, the patient was referred to our outpatient clinic for treatment at CiptoMangunkusumo Hospital.

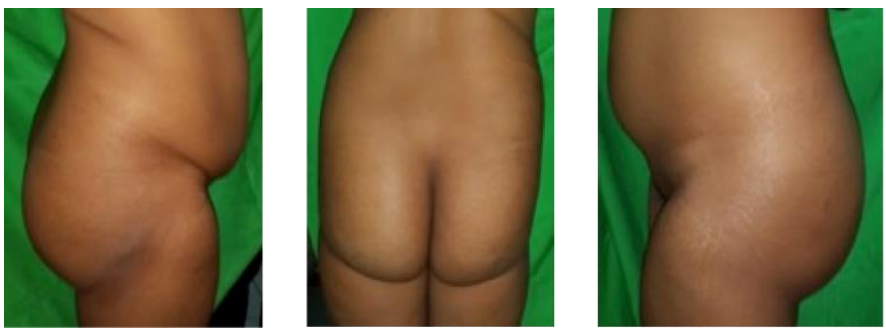

Figure 1. Lateral and anteroposterior view of the sacrum. No remarkable features were noted during the physical examination.

No remarkable features were noted during the physical examination. Examination of the lower back revealed no palpable mass, minimal tenderness of the lower back with palpation, and a visual analog scale score of 2–3. Also, she had a normal range of motion of the hip,

knee, and ankle joints. Neurological examination revealed a sensory deficit in the left lower extremity, particularly the lateral aspect of the foot, along with hypoesthesia in the perianal region. Motor examination of the lower extremity identified slight weakness of the gastrocnemius and peroneus muscles of the left foot (motor score 4/5). In addition, the patient exhibited catheter dependency of the bladder with normal bowel function.

We conducted a pelvic X-ray and an MRI of the whole abdomen and the lumbosacral area. From the plain radiograph of the pelvis, we identified a mass extending to the right sacroiliac joint (S1–S5) that was suggestive of a chordoma.

Figure 2. Anteroposterior and lateral view of the pelvis. The mass extends from S1 to S5, with possible involvement at the right sacroiliac joint.

Next, we obtained an MRI of the lower abdominal and pelvic region, which revealed a dense, lobulated mass with active hemorrhage from S1 to S5, extending to the anterior and posterior, obliterating the anterior visceral organs and spinal cord, respectively, suggestive of chordoma. The mass also appeared to involve the sacrum, the Coccygeus, and part of the left iliac ostium.

A follow-up was done with a CT-guided biopsy of the lesion. The pathology results matched the initial suspicion of the diagnosis, with features characteristic of a chordoma.

From the medical history, physical examination, imaging, pathologic examination, and conferences with a range of specialists, we diagnosed the tumor as sacral chordoma. Surgery is the treatment of choice; thus, the orthopedic and spinal oncology teams performed total sacrectomy and spinopelvic reconstruction, respectively.

We elected to divide the operation into two stages. For the first stage, the tumor was resected, and posterior instrumentation of the cervical spine was performed. For the second stage, pelvic reconstruction with fibular graft was performed in hopes that the patient can sit independently.

In the first stage of the operation using an anterior approach, we made a midline incision along the abdomen to remove the anterior part of the tumor, incising the rectus abdominis and the internal and external oblique muscles. There, we obtained a view of the tumor, which was putting pressure anteriorly on the intraperitoneal organs. Next, we released the anterior mass of the tumor, whereas the vascular team performed ligation of the internal iliac and median sacral arteries. The gastroenterology team preserved the sigmoid colon, created the stoma,

and closed the wound. We prepared the patient in pronation to remove as much of the tumor as possible to ensure a clear margin.

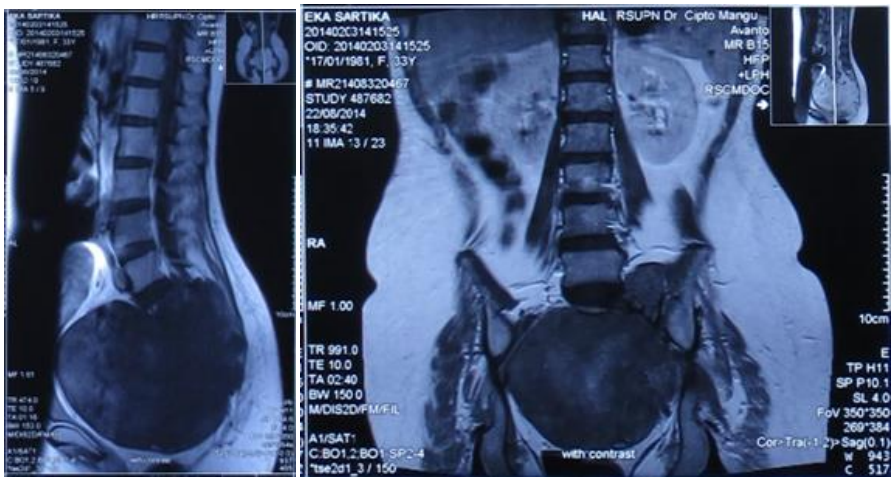

(A) (B)

Figure 3. MRI of the lumbar spine and pelvic region demonstrating the extent of the lesion. (a) Sagittal view showing involvement at L5–S5 and obliteration of the spinal canal. (b) AP view showing the lesion extending to both sacroiliac joints and involving the gluteus minimus and medius muscles.

For the second stage of the operation, we continued the posterior approach to release the posterior portion of the tumor and remove the sacrum and the tumor mass. A longitudinal incision was made through the midline of the sacrum from L2 to the coccyx. The tumor mass extended to the bilateral S1 joints. We removed the tumor and a small amount of the surrounding tissue. The L2–L5 nerve roots were compressed within the tumor mass.

To stabilize the site, we installed pedicle screws at the L2–L4 level, and at the bilateral sacroiliac joint (Galveston technique). We performed laminectomy between L5 and S1 and ligation of the thecal sac, followed by an osteotomy at L5–S1. We removed the tumor and placed the fibular bone allografts. Finally, we closed the wound and installed a closed-suction drain.

Figure 4. Posterior view of the chordoma extending from S1 to S5. Note the presence of nerve roots within the mass.

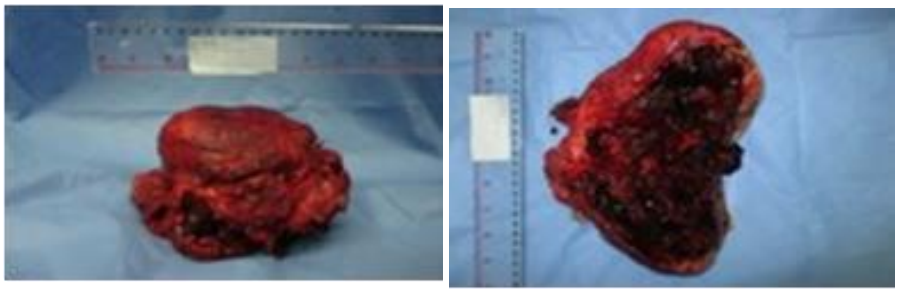

(A) (B)

Figure 5. (a) gross view of the chordoma. (b) The cross-sectional view of the tumor. Note the lobulated mass with fat lobules separated by fibrous bands.

(A) (B) (C)

Figure 6. (a) Direct view of the screws. The allograft used to promote bone healing is not shown. (b) Anteroposterior view of the hip post-operation. (c) Anteroposterior and lateral view of the hip post-operation.

The tumor mass was sent for pathological evaluation. The results were consistent with chordoma, macroscopically, and also microscopically, with the appearance of lobulated cell mass separated by fibrous bands. Besides, the presence of "physaliphorous cells" (pale vacuolated cytoplasm) suggested a chordoma.

DISCUSSION

The clinical features of a chordoma correlate with the location and spread of the neoplasm. As this is a slow-growing tumor, it usually produces-characteristic signs and symptoms, making diagnosis difficult. Pain in the sacrococcygeal region is the most common presenting symptom. The pain is dull and may be felt on the lower back or the tip of the spinal column. Constipation or anuria may be experienced due to the obstruction [1]. The degree of obstruction in the patient made her dependent on the catheter until the time of surgery.

Currently, surgery is still the mainstay of treatment for sacral chordomas. Enbloc excision remains the central tenet in the surgical management of chordoma [5]. Kaiser et al. reported that local recurrence was almost twice as high in patients who underwent en bloc resection with dissection of the tumor capsule at the time of surgery compared with those who had complete en bloc excision without violating the tumor capsule [6]. Today, more aggressive surgery and wider surgical margins have improved the local control of sacral chordomas [7].

Before the operation, we talked to the patient about all of the possible consequences of the operation, including recurrence, reoperations, and diminished functional outcomes [8]. We also acted quickly before the tumor occupied more space in the pelvic area, and before more symptoms occurred and became a further risk to the patient.

For this patient, we used a combined anterior and posterior approach due to the extensive nature of the tumor. This approach is used only for tumors with radiological suspicion of anterior involvement. In most cases, chordomas are extremely difficult to excise completely [9]. A combined anterior and posterior procedure allows for an intralesional/marginal resection of the tumor and the involved vertebra. En bloc resection of primary malignant bone tumors, including chordoma, is shown to increase the survival rate of patients and is a crucial part of the treatment regimen [3].

The extent of sacral resection determines pelvic stability and the need to undergo reconstruction. We performed an osteotomy at L5–S1 and removed the tumor involving the S1 joints. Such a procedure may cause spinopelvic dissociation, resulting in gross instability in the rotational and vertical planes. Therefore, reconstruction and reinforcement are needed to ensure stability [10]. We placed iliac screws and screws at L2–L3–L4 to maintain stability.

Even though our patient received meticulous care, there were some complications. The patient developed a fever with pain at the surgical site. The allografts were identified as the primary cause of infection; thus, we debrided the wound and removed the graft. Also, despite our best efforts at prevention, early signs of decubitus ulcer (bed sore) were noted on the left buttock.

The complication rate after total sacrectomy is quite high, mainly related to wound healing. A second or even third surgery may be required to remove deep wound infection or flap necrosis [11]. Postoperatively, the patient retained her neurological status and experienced less pain. There was no recurrence of the tumor after six months of follow-up.

CONCLUSION

Chordoma is a rare primary bone tumor. Clinicians of different specialties need to recognize these conditions early, as the symptoms are not characteristic and are site-dependent — adequate surgical treatment results in substantial improvement in neurological function and symptoms. Extensive tumor removal using a combined anterior and posterior approach followed by a stable reconstruction may achieve a favorable clinical outcome [3]. Even with strict adherence to protocol, the risk of infection is high,and a second operation may be required [4, 9, 10].

REFERENCES

[1] Mirra, J. M. N. S., Rocca Della, C., Mertens, F. *Pathology and Genetics of Tumours of Soft Tissue and Bone.* (Fletcher CDM, U. K., Mertens F (ed.)). Lyon: IARC Press, 2002.

[2] Rao, B. S. S., Menezes, L. T., Rao, A. D. & John, S. K. (2005). Sacral chordoma–a report of two cases. *Indian journal ofsurgery, 67*.

[3] Jung, Y. Y., &S hin, H. (2009). Combined anterior and posterior en bloc vertebrectomy for lumbar chordoma, *Journal ofkorean neurosurgical society*, *45*, 243-245.

[4] Hulen, C. A., Temple, H. T., Fox, W. P., Sama, A. A., Green, B. A., Eismont, F. J. (2006) Oncologic and functional outcome following sacrectomy for sacral chordoma. *JBJS*, *88*, 1532-1539.

[5] Walcott, B. P., Nahed, B. V., Mohyeldin, A., Coumans, J.-V., Kahle, K. T., Ferreira, Chordoma., M. J. (2012). Current concepts, management, and future directions. *The Lancet oncology*. *13*, e69-e76.

[6] Kaiser, T. E., Pritchard, D. J. & Unni, K. K. (1984). Clinicopathologic study of sacrococcygeal chordoma. *Cancer*, *53*, 2574-2578.

[7] Hsieh, P. C., Xu, R., Sciubba, D. M., McGirt, M. J., Nelson, C., Witham, T. F., Wolinksy, J. P. & Gokaslan, Z. L. (2009). Long-term clinical outcomes following en bloc resections for sacral chordomas and chondrosarcomas: a series of twenty consecutive patients. *Spine*, *34*, 2233-223.

[8] Gallia, G. L., Haque, R., Garonzik, I., Witham, T. F., Khavkin, Y. A., Wolinsky, J. P., Suk, I. & Gokaslan, Z. L. (2005). Spinal pelvic reconstruction after total sacrectomy for en bloc resection of a giant sacral chordoma. *Journal of neurosurgery: Spine*, *3*, 501-506.

[9] Cheng, E. Y., Özerdemoglu, R. A., Transfeldt, E. E. & Thompson Jr, R. C. (1999). Lumbosacral chordoma: prognostic factors and treatment. *Spine*, *24*, 1639.

[10] Okaji, R. Y., Silveira Jr, J. M. D., Nakano, M. K., Kiuti, L. T. & Maiorano, M. C. N. T. (2008). Sacral chordoma en-bloc resection and lumbar-iliac stabilization. *Arquivos de neuro-psiquiatria*, *66*, 400-401.

[11] Varga, P. P. & Lazary, A. (2010). Chordoma of the sacrum: “en bloc” total sacrectomy and lumbopelvic reconstruction. *European Spine Journal*, *19*, 1039-1040.

In: Encyclopedia of Surgery (22 Volume Set)
Editors: Andreas Lehrer and Kristin Mueller
ISBN: 978-1-53618-329-0
© 2020 Nova Science Publishers, Inc.

Chapter 335

LOW BACK AND LEG PAIN INDUCED BY DURAL SCAR FORMATION AFTER LAMINECTOMY FOR LUMBAR CANAL STENOSIS: CASE REPORT AND LITERATURE REVIEW

Ahmad Jabir Rahyussalim[1,2,3,*], Aria Adhitya[1], Tri Kurniawati[2,3] and Khairul Hukmi[1]

[1]Department of Orthopaedic and Traumatology, Faculty of Medicine, Universitas Indonesia-CiptoMangunkusumo General Hospital, Jakarta, Indonesia
[2]Stem Cell and Tissue Engineering Cluster, IMERI Faculty of Medicine, Universitas Indonesia, Jakarta, Indonesia
[3]Stem Cell Medical Technology Integrated Service Unit, CiptoMangunkusumo General Hospital, Jakarta, Indonesia

ABSTRACT

Introduction: Dural scarring may develop after laminectomy, resulting in persistent back and leg pain. Laminectomy for decompression exposes the dura mater, stimulating the growth of scar tissue on the dural surface. Such scarring can impair nerve conduction and induce chronic pain, localized according to the affected spinal levels. *Case Presentation:* A single case of back pain and pain radiating to the lower limbs is reported 12 months following laminectomy at L4−L5. Magnetic resonance images revealed new soft tissue in the posterior region pressing on the dura. *Discussion:* Re-operation was performed for decompression. Intraoperative examination revealed scar tissue around the dural surface at the previous laminectomy site. Decompression and scarectomy were conducted, but the outcome was unsatisfactory because it proved impossible to remove all the scar tissue from the dura without increasing the risk of nerve root damage. As a result, low back pain was mitigated, but the leg pain persisted. *Conclusion:* Laminectomy can result in dural scar formation and chronic pain that is intractable to reparative

* Corresponding Author's Email: rahyussalim71@ui.ac.id.

surgery. Thus, it is critical to institute perioperative procedures that reduce the risk of subsequent dural scar formation.

Keywords: Dura scar, laminectomy, leg pain, fibrosis

INTRODUCTION

Postoperative dural scar formation, involving the paravertebral musculature, thecal sac, and nerve roots, is a frequent cause of recurrent symptoms and pain after lumbar disk surgery [1, 2]. Such dural lesions result from the destruction of epidural fat, intra-spinal hematoma, and advancement of the spinal erector muscles into the spinal canal, [3] and are a major cause of lumbar pain and sciatic irritation after lumbar surgery. The mechanical tethering of nerve roots to the dura by epidural adhesions may contribute to persistent back and leg pain after lumbar laminectomy, termed failed back syndrome [4, 5].

Non-invasive treatments are being developed to reduce neural adhesion to scar tissue. Absorbable, oxidized, regenerated cellulose (Inter-ceed) reduced neural adhesion in a rabbit model following experimental laminectomy [6]. In addition, intraoperative neuromonitoring (IONM) can predict the risks of adverse outcomes, such as paraparesis, paraplegia, and quadriplegia, following spinal surgery [7]. Nonetheless, prevention and treatment of dural scar formation remain substantial challenges for spinal surgeons.

We report a case of dural scar following laminectomy that resulted in progressively worsening low back and radiating leg pain. This case highlights potential complications that should be anticipated before primary surgery and re-operation for scar excision, including preventing a dural tear, as well as the importance of IONM.

CASE ILLUSTRATION

A 36-year-old male with no history of spinal trauma presented with complaints of worsening back pain, radiating to the right and left legs, for the previous two months. It was described as continuous sharp pain with intermittent tingling that was influenced by activity and disappeared in the resting position. He had reported back pain four years earlier, described as dull intermittent pain without spread or tingling, which was treated using pain relievers and physiotherapy. Two years before the current presentation, he reported back pain and was examined by a neurosurgeon, who diagnosed lumbar disc herniation at L4−L5 and performed fenestration and laminectomy. The patient reported being pain free until the previous two months, when he began to experience back pain in the same place. He also suffered weakness during dorsiflexion. An orthopedic spine surgeon recommended reparative surgery after conducting a full examination. The patient provided informed consent to publish anonymized clinical results.

At presentation, lumbosacral MRI showed compression of the right thecal sac and nerve roots caused by right posteroparacentral protrusion of L4 and L5 intervertebral discs (Figure 1). There was also a hyperintensity region on the posterior side of the L3−L5 intervertebral discs from suspected scar tissue. A myelograph revealed mild spinal canal indentation at the

same level as intervertebral discs L4 and L5, which was diagnosed as lumbar canal stenosis due to disk herniation and scar formation (Figure 2).

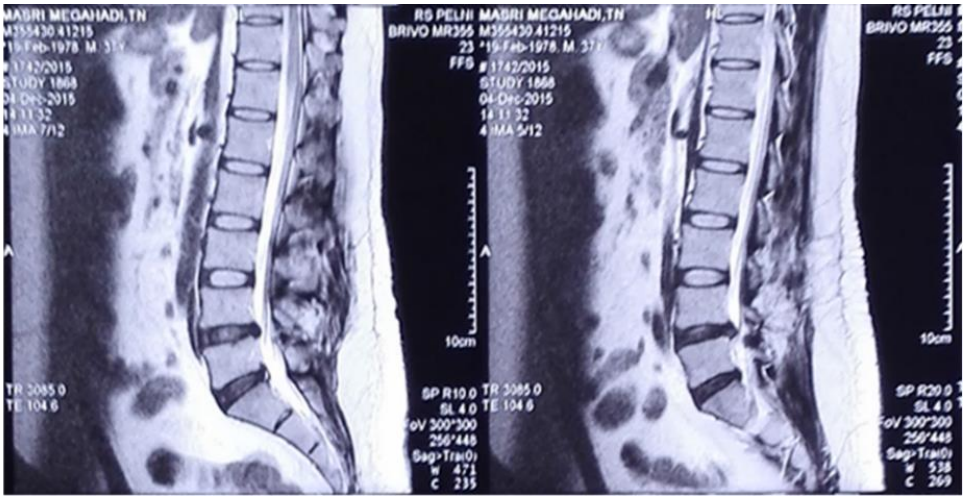

(a)

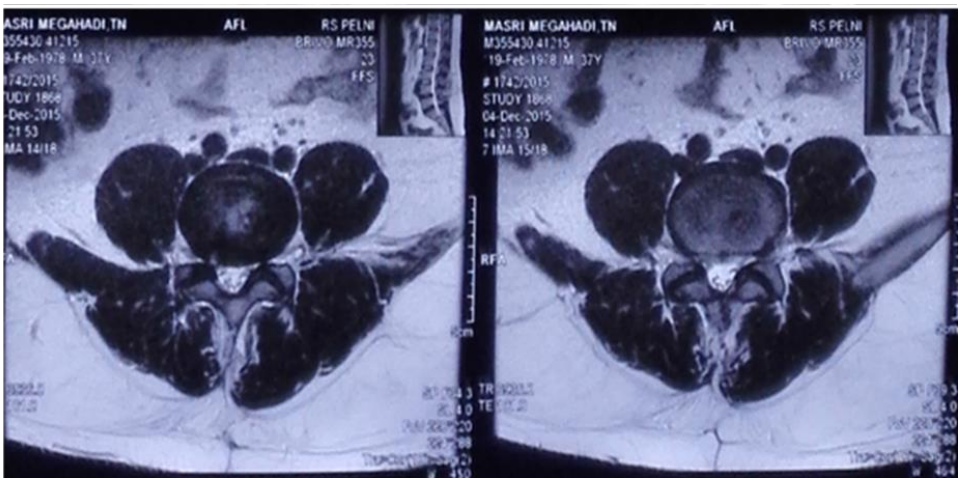

(b)

Figure 1. Preoperative MRI. (a) Sagittal projection showing disk protrusion at the L4−L5 level and a hyperintense defect posterior to L3−L5. (b) Axial projection showing canal stenosis and inflammation of facet joints and flavum ligaments.

Surgery was performed, using the posterior approach, at L4−L5. Scar tissue was attached to the entire dural surface field, measuring about 1.5 cm2 and extending to the edge of the lamina. After pedicle screw fixation (Figure 3), we attempted to free the dural surface of scar tissue. Unfortunately, this proved impossible, so we performed a partial scarectomy and carefully created a floating dura (Figure 4). After surgery, pain symptoms were reduced, sensorimotor functions were normal, and the patient was able to return to his normal activities. However, leg pain persisted during follow-up.

Figure 2. Myelograph showing mild indentation of the spinal canal at the level of intervertebral discs L4 and L5.

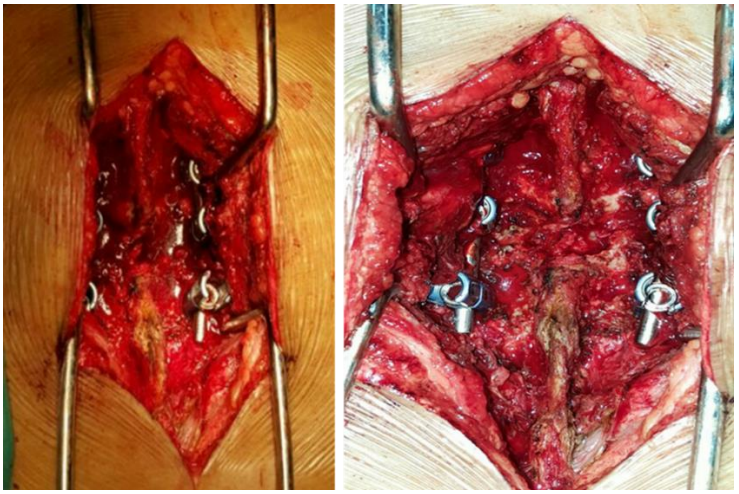

Figure 3. Intraoperative findings. (a) Posterior stabilization with pedicle screw fixation. (b) Exposed dural scar at spinal level L4−L5.

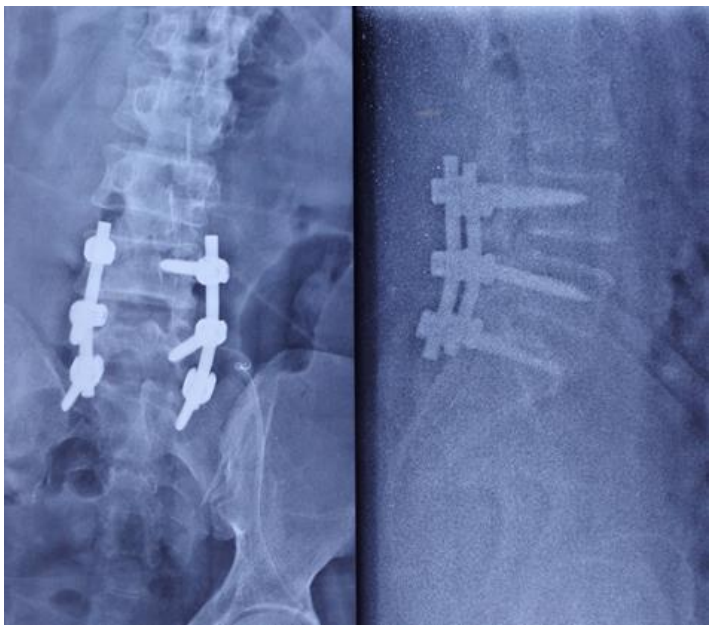

Figure 4. Postoperative X-ray (anteroposterolateral projection). Pedicle screw stabilization at spinal levels L4, L5, and S1.

DISCUSSION

Scar formation around the dura and the nerve root may cause clinically intractable complications following laminectomy. Post-laminectomy scar tissue is formed mainly by invasive fibrous connective tissue from the posterior paraspinal muscles into the postoperative hematoma [6]. Connective tissue from the bony edges of the laminectomy margins may also contribute to a limited extent. Scar tissue invasion into the vertebral canal is suppressed when epidural fatty tissue is present. Even if absent, invasion of scar tissue into the vertebral canal is not very marked. However, the scar tissue may adhere strongly to the dura. Therefore, separating the postoperative hematoma from vertebral canal tissues, including the dura, may inhibit scar tissue from invading the vertebral canal and adhering to the dura [2]. The current case underscores the importance of preventing scar formation in the perioperative period. Intraoperative neuromonitoring is critical for this purpose.

Monitoring during structural spine and spinal cord surgeries may include somatosensory evoked potentials (SSEP), motor evoked potentials (MEP), and electromyography (EMG, free running and stimulated) [8]. MEP directly monitors the motor pathway itself. The persistence of full muscle MEP amplitude usually indicates good central motor function preservation, while substantially reduced MEPs or elevated thresholds can indicate partial, transient, or even permanent central motor deficits. It is currently difficult to explain these different outcomes following MEP reduction. Partial weakness can be difficult to assess in the acute postoperative patient and so may be overlooked, while documented weakness may recover slowly. Thus, long-term evaluation is critical for identifying intraoperative MEP signs of more severe and lasting damage. Note, however, that a partial central motor deficit is possible even without any appreciable intraoperative muscle MEP alteration [8]. Somatosensory

evoked potentials (SSEP) are generated by stimulation of afferent peripheral nerve fibers by electrical, vibrational, or tactile stimuli. Following either mixed nerve or sensory nerve stimulation, SSEPs can be recorded over more proximal portions of the peripheral and central nervous system, including the peripheral nerves, spinal cord, and/or brain [7].

CONCLUSION

A dural scar is a fibrotic lesion that can form after laminectomy and cause recurrence of back pain and (or) radiating leg pain. Scarring is favored by factors such as the fibrous organization of hematomas, keloid reaction, and technical faults in the operation, and may develop into a hypertrophic, enveloping membrane. Pain severity and distribution depends on the dural scar's size and location. Attempts to limit tissue formation involve surgical technique variations, microdiscectomy, anti-inflammatory medications, and several biologic and synthetic materials. However, preventing epidural fibrosis after laminectomy remains a major challenge in spinal surgery.

REFERENCES

[1] Benoist, M; Ficat, C; Baraf P; Cauchoix J. Postoperative lumbar epiduroarachnoiditis. Diagnostic and therapeutic aspects. *Spine*, 1980 5, 432-436.

[2] Lee, CK; Alexander, H. Prevention of post laminectomy scar formation. *Spine*, 1984 9, 545-550.

[3] LaRocca, H; Macnab, I. The laminectomy membrane: Studies in its evolution, characteristics, effects and prophylaxis in dogs. *J. Bone Joint Surg. Br*. 1974 56, 545-50.

[4] Ross, JS; Robertson, JT; Frederickson, RCA. Association between peridural scar and recurrent radicular pain after lumbar discectomy: magnetic resonance evaluation. *Neurosurgery*, 1996 38, 855-861.

[5] Boot, DA; Hughes, SPF. The prevention of adhesions after laminectomy. Adverse results of Zenoderm implantations into laminectomy sites in rabbits. *Clin. Orthop.*, 1987 215, 296-302.

[6] Ikeda, K; Yamauchi, D; Tomita, K. Preliminary study for prevention of neural adhesion using an absorbable oxidized regenerated cellulose sheet. *Hand Surg.*, 2002 7, 11-14.

[7] Takata, Y; Sakai, T; Higashino, K; Matsuura, T; Suzue, N; Hamada, D; Goto, T; Nishisho, T; Tsutsui, T; Goda, Y; Morimoto, M; Abe, M; Mineta, K; Kimura, T; Nitta, A; Hama, S; Higuchi, TC; Jha, S; Takahashi, R; Fukuta, S; Sairyo, K. Review: State of the art: Intraoperative neuromonitoring in spinal deformity surgery. *J. Med. Invest.*, 2015 62, 103-108.

[8] Park, JH; Hyum, SJ. Intraoperative neurophysiological monitoring in spinal surgery. *World J. Clin. Cases*, 2015 3,765-773.

In: Encyclopedia of Surgery (22 Volume Set)
Editors: Andreas Lehrer and Kristin Mueller
ISBN: 978-1-53618-329-0
© 2020 Nova Science Publishers, Inc.

Chapter 336

FUNCTIONAL AND RADIOLOGICAL OUTCOMES IN PATIENTS WITH SPONDYLITIS TUBERCULOSIS AND KYPHOTIC DEFORMITY TREATED USING A TWO-STAGE CORRECTION PROCEDURE: A CASE SERIES

Ifran Saleh and Auliya Akbar*
Orthopedic and Traumatology, Department of Cipto Mangunkusumo General Hospital, Faculty of Medicine, Universitas Indonesia, Jakarta, Indonesia

ABSTRACT

Kyphotic deformity is a devastating complication of spondylitis tuberculosis as it can progress to more severe complications, such as cardiopulmonary dysfunction and nerve compression symptoms. Surgical correction is as important as local infection control itself (through debridement and abscess drainage). There are several approaches for spondylitis tuberculosis with kyphotic deformity, and all are based on the patient's condition and other local considerations, such as hospital and national health policies. This report aims to provide information on the clinical and radiological outcomes after two-stage treatment for kyphotic deformity in patients with spondylitis tuberculosis. We present four cases of kyphotic deformity in patients with spondylitis tuberculosis who underwent two-stage surgery at Cipto Mangunkusumo National Hospital, Jakarta, Indonesia. All patients were female, with a mean age of 37.5 years. The mean follow-up period was 45 months. One patient had a lumbar lesion with loss of lordosis (less than 20° lordosis), and the remaining three had thoracic lesions with a kyphotic angle more than 45°. All patients underwent a two-stage surgery involving initial debridement, kyphotic correction, posterior stabilization, and fusion, followed by anterior fusion with a titanium cage and bone graft. The surgical outcomes were evaluated by comparing the preoperative and postoperative Oswestry Disability Index (ODI) scores and kyphotic angles. After surgery, all patients had good outcomes with reductions in the ODI score and kyphotic angle. The mean ODI score reduced from 20 preoperatively to 5

* Corresponding Author's Email: abay.jabz@gmail.com; First author.

postoperatively. Additionally, the kyphotic angle reduced from 90° preoperatively to 22° postoperatively (after the second stage). Our two-stage procedure for the treatment of spondylitis tuberculosis with kyphotic deformity was associated with good functional and radiological outcomes at long-term follow-up. Thus, we recommend this two-stage procedure as a standard for cases similar to our reported cases.

Keywords: anterior fusion, kyphotic deformity, posterior stabilization, spondylitis tuberculosis

INTRODUCTION

Indonesia has the third highest tuberculosis (TB) endemicity, and spinal TB is quite common, although the exact prevalence of spondylitis tuberculosis (STB) in Indonesia is unclear [1]. The major problems associated with this disease are pain and deformity. Kyphotic deformity has been reported as a disabling complication of spinal infection, as progression causes additional pain, cardiopulmonary symptoms, and possible neurological deficit, in addition to the cosmetic problem itself [2].

Surgical debridement and stabilization are considered in many patients with progressive deformity and abscess formation with or without neurological deficit. Stabilization for deformity correction and maintenance can be achieved either with bone grafts alone or with a combination of grafts and posterior or anterior instrumentation [3].

Implant placement in an infected area remains controversial, partly because it is unclear whether implants interfere with infection control. This has led many authors to treat STB in two stages with initial debridement and bone grafting followed by delayed instrumented fusion. Although approach selection for the surgical treatment of thoracolumbar TB is still being debated, a combined anterior plus posterior approach can help overcome the stability-related drawbacks of the anterior approach alone. However, this approach entails two surgeries (single or staged) with additional morbidity [3].

This report aims to provide information on the clinical and radiological outcomes after two-stage treatment for kyphotic deformity in thoracic and thoracolumbar TB at our center. We present four cases of kyphotic deformity in STB patients who underwent first-stage debridement and decompression followed by second-stage anterior fusion with a titanium mesh cage and graft.

CASE SERIES

Between 2011 and 2016, 15 patients with confirmed STB infection (nine females and six males; mean age, 34.3 years; age range, 13–65 years) were treated surgically with a two-stage procedure involving debridement, kyphotic correction, and stabilization followed by anterior fusion at Cipto Mangunkusumo National Hospital, Jakarta, Indonesia. However, 11 patients were lost to follow-up, and thus, we were able to collect data from only four patients. All four patients were female, and the mean age was 37.5 years. Of these four patients, one had lumbar loss of lordosis and the other three had kyphotic deformity.

In the first stage, we performed debridement, kyphotic correction, and stabilization. All patients were operated under general anesthesia and were placed in the prone position. A posterior midline approach was used in all patients. Debridement was performed by removing necrotic material within the body and disk by using curettes, and any paraspinal abscess was drained. Kyphotic correction was achieved by inserting bilateral pedicle screws at 2–3 cranial and caudal vertebrae. Further correction was achieved after completion of rod insertion by gradual compression between the screws toward the apex of the deformity. Finally, posterolateral fusion was performed by trimming the facets and laminae of the diseased vertebral segments. The bone materials obtained in the trimming process were used as bone grafts.

In the second stage, we performed anterior fusion by the anterior approach. All patients were operated under general anesthesia and were placed in the supine position. Thoracotomy was performed, and then, anterior reconstruction of the vertebral body was performed using a titanium mesh or anterior cage filled with cancellous bone grafts from the iliac spine.

Before surgery and after the first and second stages, we evaluated the kyphotic angle using Subroto Angle Aid (Figure 1 and 2). Subjectively, we determined the disability level using the Oswestry Disability Index (ODI) questionnaire before surgery and at follow-up (more than 6 months) (Figure 3). The ODI questionnaire includes questions that assess a patient's ability to perform activities of daily living.

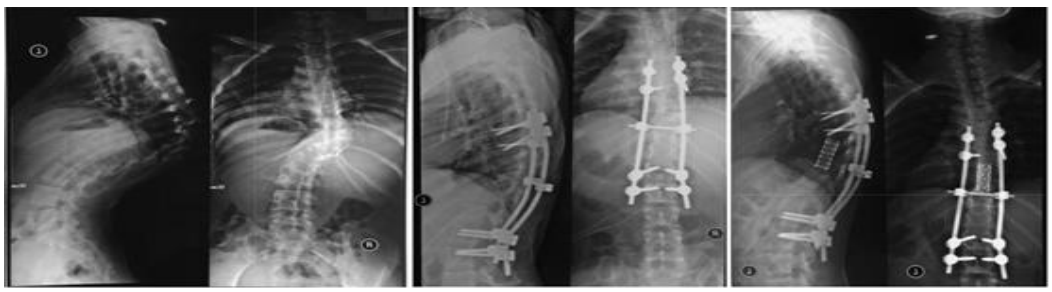

(a) (b) (c)

Figure 1. Radiography in patient 1. (a) Preoperative regional kyphotic angle, 96°; (b) Kyphotic angle after the second stage, 24°; (c) Kyphotic angle at a 4-year follow-up, 28°.

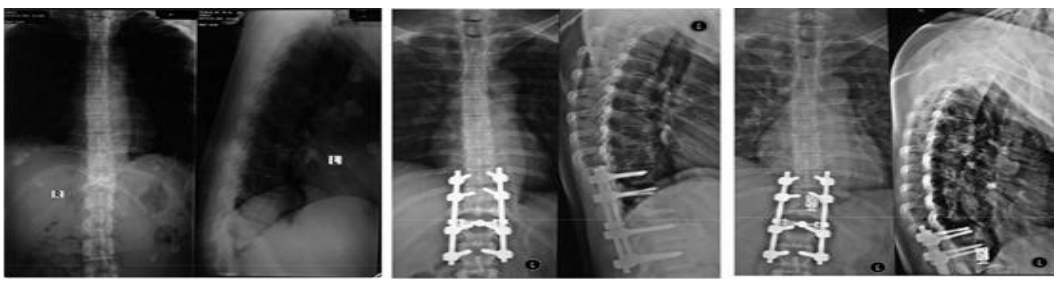

(a) (b) (c)

Figure 2. Radiography in patient 2. (a) Preoperative regional kyphotic angle, 66.74°; (b) Kyphotic angle after the first stage, 27.04°; (c) Kyphotic angle at a 2-year follow-up, 28.05°.

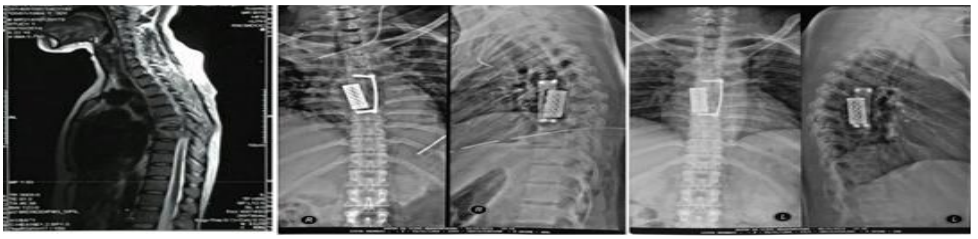

(a) (b) (c)

Figure 3. Radiography in patient 3. (a) Preoperative regional kyphotic angle, 53°; (b) Kyphotic angle after the second stage, 26.5°; (c) Kyphotic angle at a 2-year follow-up, 26.5°.

(a) (b) (c)

Figure 4. Radiography in patient 4. (a) Preoperative lumbar lordotic angle, 13°; (b) Lumbar lordotic angle at a 3-year follow-up, 23.5°; (c) MOHON DILENGKAPI.

Indeks Disabilitas Oswestry (IDO)

Nama: _____

Umur: ___ tahun

Tanggal: _____

Pekerjaan: _____

Bagian 1: Intensitas rasa nyeri
- Saya dapat menahan rasa nyeri tanpa menggunakan obat penghilang rasa nyeri. (Nilai 0)
- Rasa nyerinya agak parah, tetapi saya dapat bertahan tanpa menggunakan obat penghilang nyeri. (Nilai 1)
- Obat penghilang rasa nyeri menghilangkan rasa nyeri secara tuntas. (Nilai 2)
- Obat penghilang rasa nyeri agak menghilangkan rasa nyeri. (Nilai 3)
- Obat penghilang rasa nyeri hanya sedikit meringankan rasa nyeri. (Nilai 4)
- Obat penghilang rasa nyeri sama sekali tidak berpengaruh dan saya tidak menggunakannya. (Nilai 5)

Bagian 2: Perawatan diri
- Saya dapat merawat diri secara normal tanpa menambah rasa nyeri. (Nilai 0)
- Saya dapat merawat diri secara normal tetapi menambah rasa nyeri. (Nilai 1)
- Upaya menambah diri menimbulkan rasa nyeri yang menyebabkan saya melakukakannya dengan perlahan dan hati-hati. (Nilai 2)
- Sayakadang-kadang memerlukan pertolongan tetapi secara umum saya dapat merawat diri. (Nilai 3)
- Saya memerlukan pertolongan setiap hari untuk hampir semua kegiatan merawat diri. (Nilai 4)
- Saya mengalami kesukaran untuk mengganti baju dan membasuh diri dan saya tetap berbaring di tempat tidur. (Nilai 5)

Bagian 3: Mengangkat barang
- Saya mampu mengangkat beban berat tanpa menambah rasa nyeri. (Nilai 0)
- Saya mampu mengangkat beban berat tetapi ini menambah rada nyeri. (Nilai 1)
- Rasa nyeri menghalangi rasa mengangkat beban berat dari lantai tetapi saya dapat melakukannya bila barang tersebut terletak di atas meja atau tempat yang cocok untuk saya. (Nilai 2)
- Rasa nyeri menghalangi rasa mengangkat beban berat tetapi saya dapat mengangkat beban yang ringan sampai agak berat bila terletak di tempat yang cocok untuk saya. (Nilai 3)
- Saya hanya mampu mengangkat beban yang sangat ringan. (Nilai 4)
- Saya tidak mampu mengangkat atau membawa apapun. (Nilai 5)

Bagian 4: Berjalan
- Rasa nyeri tidak menghalangi saya untuk berjalan sejauh apapun. (Nilai 0)
- Rasa nyeri menghalangi saya berjalan lebih dari 1 mil. (Nila 1)
- Rasa nyeri menghalangi saya berjalan lebih dari 0,5 mil. (Nilai 2)
- Rasa nyeri menghalangi saya berjalan lebih dari 0,25 mil. (Nilai 3)
- Saya hanya dapat berjalan dengan bantuan tongkat atau alat penyangga. (Nilai 4)
- Saya hampir selalu berbaring di tempat tidur dan hanya merangkak ke toilet. (Nilai 5)

Bagian 5: Duduk
- Saya dapat duduk di kursi apapun selama yang saya inginkan. (Nilai 0)
- Saya hanya dapat duduk di kursi kesenangan saya untuk waktu yang lama. (Nilai 1)
- Rasa nyeri menghalangi saya duduk lebih dari 1 jam. (Nilai 2)
- Rasa nyeri menghalangi saya duduk lebih dari setengah jam. (Nilai 3)
- Rasa nyeri menghalangi saya duduk lebih dari 10 menit. (Nilai 4)
- Rasa nyeri membuat saya tidak dapat duduk sama sekali. (Nilai 5)

Bagian 6: Berdiri
- Saya dapat berdiri selama yang saya inginkan tanpa menambah rasa nyeri. (Nilai 0)
- Saya dapat berdiri selama yang saya inginkan tetapi menambah rasa nyeri. (Nilai 1)
- Rasa nyeri membuat saya tidak mampu berdiri lebih dari 1 jam. (Nilai 2)
- Rasa nyeri membuat saya tidak mampu berdiri lebih dari 30 menit. (Nilai 3)
- Rasa nyeri membuat saya tidak mampu berdiri lebih dari 10 menit. (Nilai 4)
- Rasa nyeri membuat saya tidak mampu berdiri sama sekali. (Nilai 5)

Bagian 7: Tidur
- Rasa nyeri tidak menghalangi saya tidur dengan nyenyak. (Nilai 0)
- Saya hanya dapat tidur nyenyak dengan meminum obat. (Nilai 1)
- Setelah minum obat, saya tetap tidak dapat tidur lebih dari 6 jam. (Nilai 2)
- Setelah minum obat, saya tetap tidak dapat tidur lebih dari 4 jam. (Nilai 3)
- Setelah minum obat, saya tetap tidak dapat tidur lebih dari 2 jam. (Nilai 4)
- Rasa nyeri membuat saya tidak dapat tidur sama sekali. (Nilai 5)

Bagian 8: Hubungan seks
- Hubungan seks saya berlangsung secara normal dan tidak menambah rasa nyeri. (Nilai 0)
- Hubungan seks saya berlangsung secara normal tetapi agak menambah rasa nyeri. (Nilai 1)
- Hubungan seks saya berlangsung hampir normal tetapi sangat menyakitkan. (Nilai 2)
- Hubungan seks saya sangat terbatas karena rasa nyeri. (Nilai 3)
- Saya jarang sekali berhubungan seks karena rasa nyeri. (Nilai 4)
- Saya tidak pernah berhubungan seks karena rasa nyeri. (Nilai 5)

Bagian 9: Kehidupan sosial
- Kehidupan sosial saya berjalan secara normal dan tidak menambih rasa nyeri. (Nilai 0)
- Kehidupan sosial saya berjalan secara normal tetapi menambah rasa nyeri. (Nilai 1)
- Rasa nyeri tidak banyak berpengaruh pada kehidupan sosial saya selain membatasi kegiatan yang memburuhkan aktivitas fisik seperti berdansa. (Nilai 2)
- Rasa nyeri membatasi aktivitas sosial saya dan saya agak jarang berpergian. (Nilai 3)
- Rasa nyeri membatasi aktivitas sosial saya dan saya agak jarang berpergian. (Nilai 4)
- Saya tidak terlibat dalam kehidupan sosial karena rasa nyeri. (Nilai 5)

Bagian 10: Mengadakan perjalanan
- Saya dapat mengadakan perjalanan ke mana saja tanpa menambah rasa nyeri. (Nilai 0)
- Saya dapat mengadakan perjalanan ke mana saja tetapi hal tersebut menambah rasa nyeri. (Nilai 1)
- Saya dapat mengadakan perjalanan selama lebih dari 2 jam tetapi ini mengakibatkan rasa nyeru cukup parah. (Nilai 2)
- Rasa nyeri menghalangi saya untuk mengadakan perjalanan selama lebih dari 1 jam. (Nilai 3)
- Rasa nyeri menghalangi saya untuk mengadakan perjalanan selama lebih dari 30 menit. (Nilai 4)
- Rasa nyeri menghalangi saya untuk mengadakan perjalanan kecuali untuk pergi ke dokter atau rumah sakit. (Nilai 5)

Skor ODI: jumlah nilai / 50 x 100 = _____ / 50 x 100 = ____%

Interpretasi
- 0% - 20 %Ketidakmampuan minimal
- 21% - 40%Ketidakmampuan moderat
- 41% - 60%Ketidakmampuan berat
- 61% - 80%Lumpuh

81% - 100% Pasien tidak dapat bangun dari tempat tidur

Figure 5. Oswestry Disability Index scale (in Bahasa).

The mean follow-up period was 45 months. All patients reported a better condition postoperatively. The mean preoperative ODI score was 20 (patients 1, 2, 3, and 4: 16, 22, 24, and 18, respectively), and the mean postoperative ODI score was 5 (patients 1, 2, 3, and 4: 2, 8, 4, and 6, respectively). The mean kyphotic angle reduced from 90° preoperatively to 30° after the first stage and 22° after the second stage.

DISCUSSION

Indonesia has the third highest TB incidence worldwide, with an incidence of approximately 1,020,000 (30 per 100,000 population). Although the exact incidence and prevalence of STB in most parts of the world are not known, in countries with a high burden of pulmonary TB, the incidence of STB is expected to be proportionately high [1].

STB is a disease of developing countries and is more likely related to the socio-economic status. Unfortunately, its morbidity involves nerve compromise that eventually results in tetraplegia or severe kyphosis, which can affect cardiopulmonary function. Furthermore, this disease mostly affects young adults in their most productive years, and thus, it reduces productivity and triggers a vicious cycle of poverty. Because of these issues, effective and applicable treatments to prevent further morbidity are urgently required.

The main aims of STB treatment are as follows: (i) TB eradication using anti-TB drugs; (ii) general condition improvement; (iii) deformity prevention or correction using decompression and stabilization; and (iv) prevention or treatment of complications, such as neurological deficit.

Chemotherapy is highly effective for controlling tubercular infection. However, patients treated with chemotherapy alone have an average increase in kyphotic deformity of 15°, and 3%–5% of patients develop kyphosis greater than 60°. Severe kyphosis can lead to immense cosmetic and psychological disturbances in growing children and can cause costopelvic impingement, secondary cardiorespiratory problems, and late-onset paraplegia. Correction of established kyphosis is both difficult and hazardous, with a high rate of complications, even when performed by experienced surgeons. Deformity prevention should be an integral part of any treatment schedule for spinal TB [5].

The role of surgery in STB treatment is still controversial. Surgery is indicated when neurological and spinal deformities are progressive (more than ± 40° of segmental kyphosis, anteroposterior or lateral translation) or when conservative approaches fail to treat the neurological deficit and deformity, severe pain occurs owing to an abscess or spinal instability, and the diagnosis is uncertain (inability to diagnose microbiologically with microscopy, culture, or even polymerase chain reaction for the detection of mycobacterial DNA) [3, 5, 6].

Deformity prevention should be the primary aim in the treatment of spinal TB, as the availability of potent anti-tuberculous drugs has made uncomplicated TB a medical disease. The severity of deformity in spinal TB depends on the extent of vertebral destruction, level of the lesion, and age of the patient, with more severe deformities seen in children and in patients with lesions involving the thoracolumbar spine [7, 8].

Surgery for established deformity is difficult, and it might need to be staged. Additionally, it is hazardous with a significant complication rate. Even with a staged

approach, Yau et al. reported a mortality rate of 10%, and the mean correction amount was only 28%. They advocated that corrective surgery should be performed only in patients with severe deformity, active disease, or imminent paraplegia or death from chest complications [5, 7, 8].

Refinement of surgical techniques, development of new approaches, and availability of rigid spinal instrumentation have made single-stage correction of established deformity relatively safe with good outcomes. Transpedicular decancellation osteotomy, pedicle subtraction osteotomy, and direct internal kyphectomy have been used to treat kyphosis in active as well as healed diseases. Jain et al. reported kyphosis correction through an extra-pleural, anterolateral (costotransversectomy) approach, with a mean kyphosis correction of 27.3° and no persistent neurological deficit. Bezer et al. used transpedicular decancellation osteotomy to correct post-tuberculous deformity, with no neural complications [7, 9, 10].

The two-stage surgery performed in our center was adjusted according to the National Health Insurance coverage policy. The outcomes regarding reductions in the ODI score and kyphotic angle were good and matched our aim for treating the patients. Thus, we recommend this two-stage procedure as a standard for cases similar to our reported cases.

CONCLUSION

Our two-stage procedure for the treatment of spondylitis tuberculosis with kyphotic deformity was associated with good functional and radiological outcomes at long-term follow-up. Thus, we recommend this two-stage procedure as a standard for cases similar to our reported cases.

REFERENCES

[1] Anandita, Y., Basri, C. & Besral, Budiono F. X. (2009). *A brief history of TB control in Indonesia*. World Health Organization, 07. (http://whqlibdoc.who.int/publications/2009/9789241598798_eng.pdf).

[2] Mbata, G. C., Ofondu, E., Ajuonuma, B., Asodike, V. C. & Chukwumam, D. (2012). Tuberculosis of the spine (Pott's disease) presenting as hemiparesis. *African Journal of Respiratory Medicine, 8*(1), 18-20.

[3] Huang, Y., Lin, J., Chen, X., Lin, J., Lin, Y. & Zhang, H. (2017). A posterior versus anterior debridement in combination with bone graft and internal fixation for lumbar and thoracic tuberculosis. *Journal of Orthopaedic Surgery and Research, 12*(150), 1-10.

[4] Issack, P. S. & Boachie-Adjei, O. (2012). Surgical correction of kyphotic deformity in spinal tuberculosis. *International Orthopaedics, 36*, 353-357.

[5] Paudel, S. (2013). Kyphotic deformity in pott's spine. *Journal of Kathmandu Medical College, 2*(4), 201-204.

[6] Jain, A. K. (2010). Tuberculosis of the spine: A fresh look at an old disease. *The Journal of bone and joint surgery, 92*(B), 905-913.

[7] Rajasekaran, S. (2012). Kyphotic deformity in spinal tuberculosis and its management. *International Orthopaedics*, *36*(2), 359.

[8] Tuli, S. M. (1995). Severe kyphotie deformity in tuberculosis of the spine. *International Orthopaedics*, *19*, 327-331.

[9] Fukuta, H., Miyamoto, K., Masuda, T., Hosoe, H., Kodama, H., Nishimoto, H., et al. (2003). Two-stage (posterior and anterior) surgical treatment using posterior spinal instrumentation for pyogenic and tuberculotic spondylitis. *Spine*, *28*, 302-308.

[10] Zhang, H. Q., Li, J. S. & Guo, C. F. (2012). Two-stage surgical management using posterior instrumentation, anterior debridement and allografting for tuberculosis of the lower lumbar spine in children of elementary school age: minimum 3-year follow-up of 14 patients. *Archives of Orthopaedic and Trauma Surgery*, *132*, 1273-1279.

In: Encyclopedia of Surgery (22 Volume Set)
Editors: Andreas Lehrer and Kristin Mueller
ISBN: 978-1-53618-329-0
© 2020 Nova Science Publishers, Inc.

Chapter 337

MANAGEMENT OF NEGLECTED CONUS MEDULLARIS SYNDROME WITH LUMBAR CANAL STENOSIS

Ahmad Jabir Rahyussalim[1,2,3,*], Sammy Saleh Alhuraiby[1], Tri Kurniawati[2,3] and Khairul Hukmi[1]

[1]Department of Orthopaedic and Traumatology, Faculty of Medicine, Universitas Indonesia-Cipto Mangunkusumo General Hospital, Jakarta, Indonesia
[2]Stem Cell and Tissue Engineering Cluster, IMERI Faculty of Medicine, Universitas Indonesia, Jakarta, Indonesia
[3]Stem Cell Medical Technology Integrated Service Unit, Cipto Mangunkusumo General Hospital, Jakarta, Indonesia

ABSTRACT

Conus medullaris syndrome is a complex disease entity that is difficult to define because of its location between the spinal cord and nerve roots. The presenting symptoms are not specific and are often missed by primary doctors, making diagnosis challenging. It is even more difficult because the time since onset plays a major role in the outcome. A 47-year-old female displayed neglected conus medullary syndrome due to a compression fracture of L1 that presented as bladder and defecating dysfunctions and leg pain due to lumbar canal stenosis of L4-L5. A decompression surgical procedure involving total laminectomy at the L1 level, posterior stabilization from T11 to L3, and laminotomy, flavectomy, and discectomy at L4 and L5 were performed in this patient. The patient experienced improved motor function after the operation. Her hypoesthesia also improved. However, her bladder and defecating problem were not resolved. Non-full function restoration likely occurred because of the patient's neglected conus medullaris. However, her function still improved; therefore, surgery was a better option.

Keywords: conus medullaris syndrome, lumbar canal stenosis, spinal cord injury

[*] Corresponding Author's Email: rahyussalim71@ui.ac.id.

INTRODUCTION

The conus medullaris is very susceptible to injury because of its proximity to the commonly injured thoracolumbar junction [1]. Conus medullaris syndrome results in a tremendous burden due to the resultant morbidity, expenses, and resources necessary to treat the disease. This disease affects an estimated 14,000 people in the United States annually [1].

Conus medullaris syndrome is a complex disease entity that is difficult to define because of its location between the spinal cord and nerve roots [2]. This disease manifests itself as back pain, unilateral or bilateral leg pain, weakness or paresthesia, and bladder or bowel incontinence [3]. In thoracolumbar or lumbosacral injuries, conus medullary syndrome should be distinguished from cauda equina syndrome: the latter presents as a spinal cord compression and dysfunction (upper motor neurons) whereas symptoms in the former present as lumbosacral radiculopathies (lower motor neurons) [3]. However, the lesions affecting the transition between the conus medullaris and cauda equina may present symptoms consistent with both upper and lower motor neurons [2, 3]. This research work has been reported in line with the Surgical Case Report criteria [4].

CASE ILLUSTRATION

A 47-year-old female came to the orthopedic clinic with a chief complaint of numbness on both legs and the perianal area that worsened during the month prior to her visit. Five years previously, the patient had fallen from a tree of 2–3 meters in height. She landed in a sitting position. The patient was unable to walk immediately after the fall, and she could not control her urge to urinate or defecate. The patient also felt numbness at the perianal area and the posterior part of both legs. At that time, the patient was still able to move her legs but was reluctant to walk because of back pain. The patient sought treatment at a nearby hospital, and a urinary catheter was inserted, but she was referred for further treatment. The patient continued treatment in the form of massages and was able to walk after 8 months of treatment. After those 8 months, the patient did not continue with the treatment and merely went to a nearby clinic for urinary catheter changes.

After 4 years, the patient went to a nearby hospital for defecation and micturition problems. She was then referred to a larger hospital and was treated by a rehabilitation specialist; however, she was only given analgesics. After 6 months, the patient discontinued treatment. Over the last month, numbness in both calves worsened, accompanied by a tingling sensation.

A physical examination of the spine revealed that there was no wound, deformity, or other evident issues (Figure 1). A neurological examination revealed impairment in sensory and motor function in the S1 region; her motor strength was a 4 (on a scale of 1 to 5), and her sensory function was a 1 (on a scale between 0 and 2). Her patellar (L4) and Achilles (S1) tendon reflexes were normal. Babinsky's reflex and clonus were not present in this patient (Figure 2). Her bulbocavernosus reflex was negative. Additionally, her autonomic nerve function (micturition and defecation control) was disturbed.

Figure 1. Clinical pictures of the patient before treatment.

The laboratory investigation results were unremarkable except for the increased erythrocyte sedimentation rate. A lumbosacral x-ray showed a thoracolumbar kyphotic deformity, osteophyte, loss of height, and sclerotic endplate at the first lumbar vertebrae, and good bone stock, accompanied by narrowed disc space in T12–L1 and L1–L2 (Figure 3). A magnetic resonance imaging (MRI) of the lumbosacral spine showed a compression fracture of the L1 vertebrae with suppression on the conus medullaris and myelopathy at the T12–L1 level. Spondyloarthrosis lumbar with a herniated nucleus pulposus at L2–L3 until L4–5 and nerve root compression at the L3–L4 and L4–L5 levels was also observed (Figure 4).

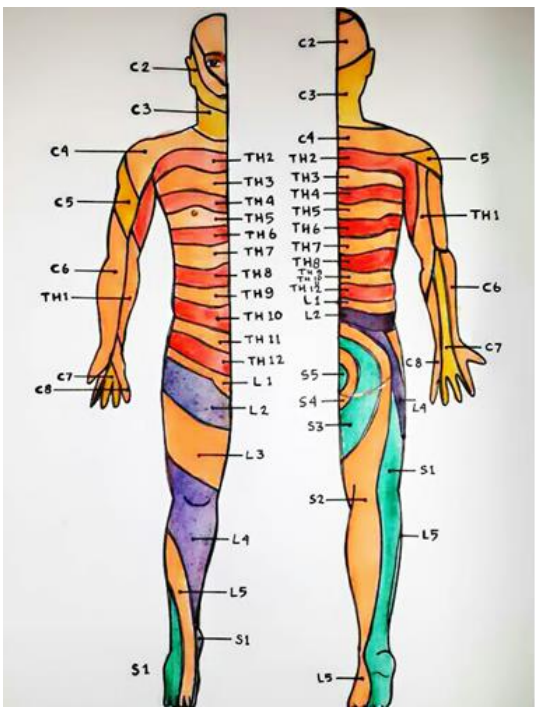

Figure 2. Neurologic examination showing sensory impairment at the S1 level.

(a) (b)

Figure 3. X-ray of the lumbosacral spine: (a) posteroanterior projection and (b) lateral projection.

(a)

(b)

Figure 4. MRI of the lumbar spine. (a) T2-T1 sagittal projection shows a fracture at vertebrae L1. (b) Axial projection shows the fracture line and narrowing of the canal at that level.

Based on her history, physical examination, and laboratory and radiologic investigations, the patient was diagnosed with neglected conus medullary syndrome due to a compression fracture of L1 and leg pain due to lumbar canal stenosis of L4–L5. We had already performed a decompressive surgical procedure consisting of total laminectomy at the L1 vertebrae, posterior stabilization from T11 to L3, and laminotomy, flavectomy, and discectomy at L4 and L5. The surgery lasted three hours. The somatosensory evoked potential and motoric evoked potential were monitored throughout the surgery.

Her postoperative results showed improvement in both sensory and motor functions. In the lower extremities, both sensory function and motor strength at the S1 level increased to 2 and 5, respectively. Her neurological examination showed that the patella and Achilles tendon reflexes were unimpaired. Babinsky's reflex and clonus were still not present. However, the patient still complained of micturition and defecation, similar to the preoperative state.

DISCUSSION

Diagnostics

This patient presented to our clinic with symptoms and signs suggestive of conus medullaris syndrome. The findings from her history and physical examinations were supported by x-ray and MRI examinations that revealed compression at the level of the conus medullaris. However, the patient also presented with leg numbness, which is not consistent with conus medullaris syndrome. The MRI then showed lumbar canal stenosis at the L4 and L5 vertebrae, which is consistent with leg pain. These two clinical entities are seldom found in one patient, which makes this a unique case.

Because the two disorders appeared in one patient, we decided to perform decompression and stabilization for L1 (where the conus medullaris syndrome originated) and only decompression for L4–L5 (where the LCS appeared). Before the surgery, the patient was classified as Frankel D, which improved to Frankel E after the surgery. This is consistent with findings from Rahimi–Moghavar in which all patients classified as Frankel D improved to Frankel E after surgery [5].

Surgical Intervention

We elected to perform a laminectomy using a posterior approach to release the conus medullaris of the L1 from compression. The segment was stabilized using screws and rods (Figure 5). Despite being decompressed, the fourth and fifth lumbar vertebrae were not stabilized because intraoperatively, we determined that the segment was still stable. Neurological deficit and instability were the main indications for surgery, as stated in the literature. Posterior decompression, followed by an instrumentation two levels above and below the injury level are the most common surgical procedures performed [5]. The posterior approach provides excellent visualization and access to the dorsal sac, which is useful for the treatment of the concomitant fracture. The entrapped nerve root compression cannot be accessed through an anterior approach [2].

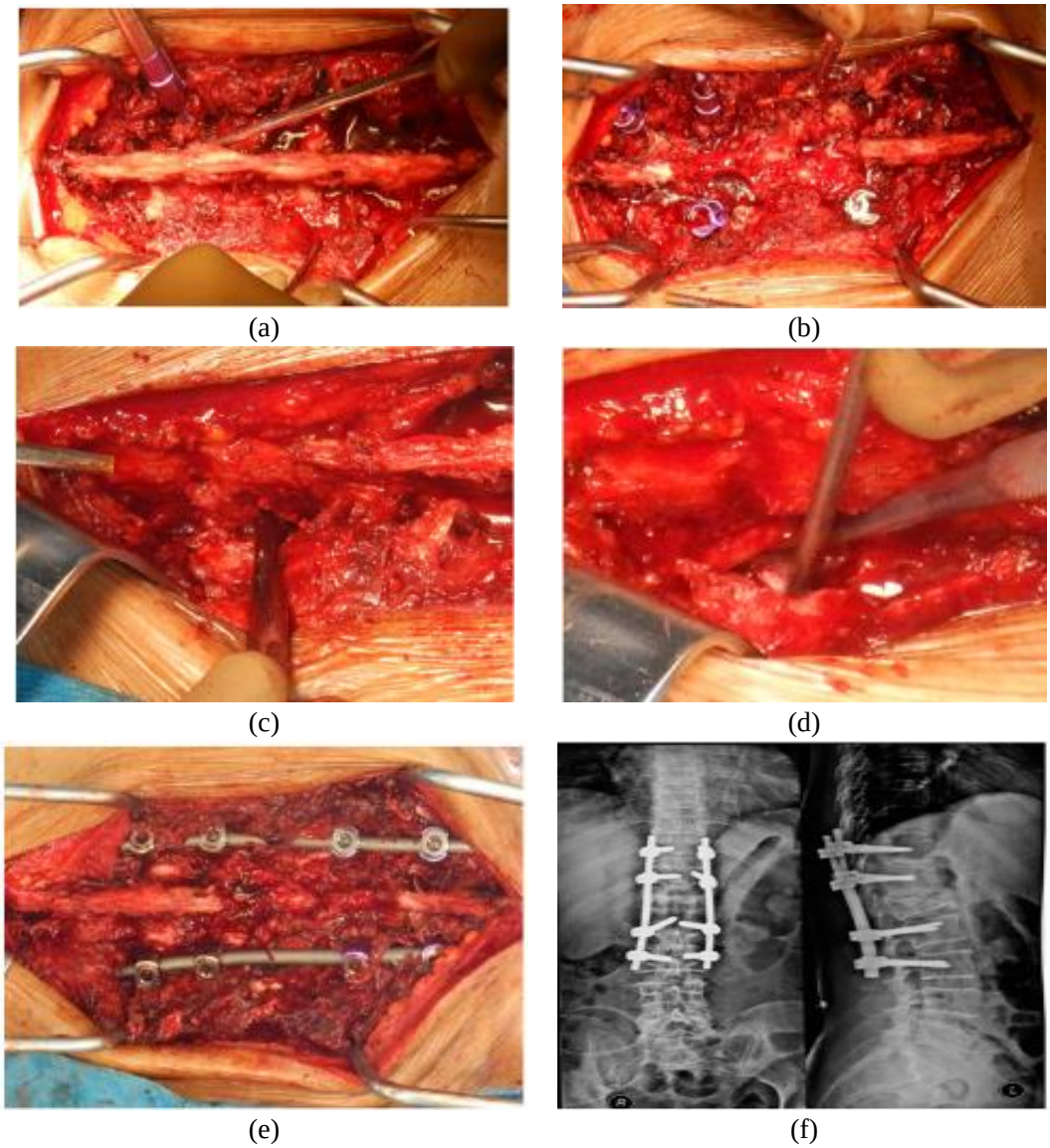

Figure 5. Intraoperative procedure. (a) Exposure; (b) pedicle screw placement and laminectomy of L1; (c) and (d) laminotomy, flavectomy, and discectomy of L4–L5; (e) final instrumentation; (f) X-ray of thoracolumbal post op Ap Lat.

The results of a timely surgical procedure have not been established in patients with conus medullaris syndrome [6-9]. Immediate surgery has been associated with excessive bleeding, which has prompted surgeons to delay treatment for 2 to 3 days; however, this has not yielded significant differences in outcomes. Notably, in conus medullaris syndrome, the decision to perform immediate surgery does not correlate with better results compared with delayed surgery [8-10]. Therefore, the recommendation is to perform surgery within three days of injury to achieve a better prognosis with immediate decompression reserved for those with a progressive neurological deficit with significant thecal sac compression. However, currently, no studies have reported the outcome of surgery performed 5 years after the injury.

This report indicates that even after 5 years, surgery for conus medullaris syndrome still results in improvement in sensory and motor functions [6-8].

Neurologic Impairment

Even after surgery, our patient still complained of poor bladder and bowel function. The results from another study also showed that bladder function displayed the least improvement compared with motor or sensory function. Transfeldt reported that although neurologic improvement occurred in 68% of patients who underwent surgery within 2 years, only 27% of patients reported improvement in bladder function. Although these lesions often have a devastating effect on the quality of life, they do not significantly shorten the lifespan [6-8, 11]. A good outcome was recorded if there was a recovery of one or more motor-root levels in the lower extremities or partial recovery of multiple levels. A fair result was recorded if there was a partial improvement of one or two motor-root levels, and a poor result was shown by no cord or root improvement; however, it would be adequately significant if the case was acute to compare the result, which was difficult to apply to our patient [11, 12]. Further workup and management is necessary to assess the bladder and defecating problems of patients. Several treatment options are available, but rehabilitation therapy is the mainstay of treatment. Currently, stem-cell based regenerative medicine is gaining popularity for spinal cord injuries because it may benefit patients; however, this option has several issues still at stake that must be resolved [13, 14].

CONCLUSION

The management of conus medullaris syndrome includes decompression of the spinal cord level that is injured and providing stability for the structure. Diagnosis is challenging, and management is even more difficult for patients because of its associated complications, particularly when neglected. We presented a case of conus medullaris syndrome due to a neglected compression fracture that coincidentally co-existed with lumbar canal stenosis. Surgery was the elected option, and it improved motoric functions, although the bladder and defecating function results were not satisfactory. Stem-cell-based therapy might benefit the latter problem.

CONFLICT OF INTEREST

The authors declare that there are no conflicts of interest regarding publication of this paper.

INFORMED CONSENT

The authors have obtained consent from the patient.

REFERENCES

[1] Bhandutia AK, Winek NC, Tomycz ND, Altman DT.. Traumatic conus medullaris syndrome: a case report and review of the literature. *JBJS Case Connect.* 2016;6(2):e38.

[2] Radcliff KE, Kepler CK, Delasotta LA, Rihn JA, Harrop JS, Hilibrand AS, Albert TJ, Vaccaro AR. Current management review of thoracolumbar cord syndromes. *Spine J.* 2011;11(9):884-92.

[3] Harrop JS, Hunt GE, Vaccaro AR. Conus medullaris and cauda equina syndrome as a result of traumatic injuries: management principles. *Neurosurg Focus* 2004;16(6):1-23.

[4] Agha RA, Fowler AJ, Saetta A, Barai I, Rajmohan S, Orgill DP and the SCARE Group. The SCARE Statement: Consensus-based surgical case report guidelines. *Int J Surg.* 2016;34:180-6.

[5] Rahimi-Movaghar V, Vaccaro AR, Mohammadi M. Efficacy of surgical decompression in regard to motor recovery in the setting of conus medullaris injury. *J Spinal Cord Med.* 2006;29(1):32-8.

[6] Podnar S. Epidemiology of cauda equina and conus medullaris lesions. *Muscle Nerve* 2007;35(4):529-31.

[7] Podnar S, Oblak C, Vodusek DB. Sexual function in men with cauda equina lesions: a clinical and electromyographic study. *J Neurol Neurosurg Psychiatry* 2002;73(6):715-20.

[8] Demetriades AK, Naik S, Gunasekera L. Conus medullaris syndrome from a transdural disc herniation at the thoracolumbar junction. *Acta neurochirur.* 2010;152(6):1081-2.

[9] Dawodu ST. Cauda equina and conus medullaris syndromes. *Medscape J Med.* 2013;1-14.

[10] Wostrack M, Shiban E, Obermuller T, Gempt J, Meyer B, Ringel F. Conus medullaris and cauda equina tumors: clinical presentation, prognosis, and outcome after surgical treatment. *J Neurosurg Spine.* 2014;20: 335-43.

[11] Fehlings MG, Arvin B. The timing of surgery in patients with central spinal cord injury. *J Neurosurg Spine* 2009;10(1):1-2.

[12] Chou D, Hartl R, Sonntag VK. Conus medullaris syndrome without lower-extremity involvement in L-1 burst fractures: report of four cases. *J Neurosurg Spine* 2006;4(3):265-9.

[13] Tewarie RSN, Hurtado A, Bartels RH, Grotenhuis A, Oudega M. Stem cell-based therapies for spinal cord injury. *J Spinal cord med.* 2009;32(2):105-14.

[14] Rahyussalim AJ, Saleh I, Armin MF, Kurniawati T, Safri AY. Pedicle screw position changing policy for nerve injury problems during screw insertion on thoracolumbar compression fractures. *Int J Surg Case Rep.* 2016;28:155-60.

In: Encyclopedia of Surgery (22 Volume Set)
Editors: Andreas Lehrer and Kristin Mueller
ISBN: 978-1-53618-329-0
© 2020 Nova Science Publishers, Inc.

Chapter 338

ANTERIOR INNOMINATE OSTEOTOMY FOR CLOSURE OF NEGLECTED BLADDER EXSTROPHY: A REPORT OF TWO CASES AND A BRIEF REVIEW OF THE LITERATURE

Aryadi Kurniawan[1,*], MD
and Andi Praja Wira Yudha Luthfi[2], MD
[1]Pediatric Orthopaedics Division, Department of Orthopaedics and Traumatology,
Faculty of Medicine, RSUPN Dr. Cipto Mangunkusumo,
Universitas Indonesia, Jakarta, Indonesia
[2]Department of Orthopaedics and Traumatology, Faculty of Medicine,
University of Indonesia, RSUPN Dr. Cipto Mangunkusumo,
Universitas Indonesia, Jakarta, Indonesia

ABSTRACT

Congenital malformations in bladder and cloacal exstrophy involve the genitourinary tract, musculoskeletal tissue, and occasionally the gastrointestinal tract. Pediatric orthopedists and urological surgeons need to have substantial knowledge in order to properly manage such cases. The foremost goal of orthopedic reconstruction is to reduce pelvic diastasis, which enables closure of the bladder and abdominal wall, while reducing tension. Here, we report two cases of a seven-year-old boy and a 12-year old boy who were referred to our pediatric surgery service with the diagnosis of bladder exstrophy. Preoperatively, the pubic diastasis of the two patients was 6 and 9 cm, respectively. Bilateral anterior innominate osteotomy with external fixator placement was executed by the pediatric urological surgical team following bladder closure. Both patients remained hospitalized for two weeks on bed rest. Skin traction was not applied. External fixators were applied for eight weeks. Immediately after surgery, the diastases were reduced to 4 cm in the 7-year-old patient and 6 cm in the 12-year-old patient. No postoperative complications occurred in either patient and both were able to walk with normal gaits.

[*] Corresponding Author's Email: aryadi.paedortho@gmail.com.

Slight external leg rotation was noted. Urological abnormalities were improved. Despite the technique, it is difficult to achieve perfect closure of the pelvic diastasis in this age group. Pelvic osteotomy remains the most beneficial intervention for corrective exstrophy closure. The bilateral anterior technique is recommended for this procedure and is applicable in neglected cases. Further follow-up is needed to evaluate the effectiveness of this technique.

Keywords: pelvic osteotomy, bladder exstrophy

INTRODUCTION

Classic bladder exstrophy (CBE) is a congenital defect primarily involving the musculoskeletal system and genitourinary tract with an incidence of one case for every 10,000–50,000 live births. The intricacy of congenital malformations, which involves bladder and cloacal exstrophy, involves the genitourinary and musculoskeletal systems, and occasionally the gastrointestinal tract. Correct management of these conditions requires sufficient knowledge of pediatric orthopedists and pediatric urological surgeons. The most significant defect of this congenital malformation is cloacal exstrophy, or CBE with additional intestinal prolapse at the site of bladder exstrophy. In some cases, cloacal exstrophy is accompanied by lipomeningocele or myelomeningocele formation and other congenital malformations, such as anal atresia, colonic hypoplasia, genitalia anomalies, and omphalocele development [1–3].

The mechanism of CBE originates from a defect during embryologic development of the abdominal wall. The genetic and environmental origins of this defect remain unclear, although both are considered contributors. It is now hypothesized that throughout the initial embryonic period, the urogenital part of the cloacal membrane fails to regress caudally consequent to the abnormal caudad position of genital tubercles primordia. The urogenital part of the cloacal membrane fails to ventrally migrate and is displaced anteriorly against the abdominal wall. This position prevents migration of the mesenchyme to the midline of the lower abdominal wall, resulting in a shortage of mesenchyme-derived tissues in this area. Following cloacal membrane rupture to shape the urogenital and anal orifices according to the physiological sequence of embryologic events produces herniation of the viscera of the lower abdomen against the lower abdominal wall, which leads to numerous signs of the epispadias-exstrophy complex, as elaborated earlier [4, 5].

The usage of pelvic osteotomy for the reconstruction of bladder exstrophy deformities has been considerably debated over the past several years. Fundamental descriptive analysis of the bony pelvis and deficiencies and deformities of the muscular pelvic floor in patients with exstrophy have resulted in a better understanding of how reconfiguration of the pelvic ring could provide safe and dependable bladder posterior urethra placement within the pelvis. Over the past 20 years, surgery for bladder exstrophy management has progressed significantly, along with the development of different techniques to acquire good closure and optimal functional outcomes. The ultimate goal of orthopedic reconstruction is to reduce pelvic diastasis, thus allowing for closure of the bladder and abdominal walls, while lessening tension [3, 5, 6].

Here, we report two cases of neglected bladder exstrophy and the outcomes of pelvic osteotomy for exstrophy bladder repair with one-year follow-up. To the best of our knowledge, this is the first case series about the management of pubic diastasis in so-called neglected cases of bladder exstrophy.

CASE 1

Our first patient was a seven-year-old boy who was referred to our Orthopedic Pediatric Surgery Department for repair of anomphalocele and bladder exstrophy (Figure 1a) with a preoperative pubic diastasis size of 6cm (Figure 1b). Bilateral anterior pelvic osteotomy in the supine position was performed in August 2017. Salter osteotomy was performed, during which an oblique inguinal incision was made to the ilium and the innominate bone was bared by separation of the periosteum on each side. The posterior limit of the exposure was the sacroiliac joint and the inferior limit was the pectineal tubercle. The sciatic notch was distinctly recognized and an oblique osteotomy was executed with a saw from the iliac crest to the greater sciatic notch, while evading the sacroiliac joint. The oblique osteotomy resulted in adequate bone for placing external fixator pins into the distal and proximal pelvic segments without invasion of the sacroiliac joint. A number of four parallel 4-mm Shanz screws were subsequently inserted into the distal and proximal pelvic segments. The same procedure was completed on the contralateral side. Repair of the bladder and abdominal soft tissue was later accomplished by the urology team. Next, to complete the repair and reconstruction of the bladder, the fixator pins were connected and compressed using a triangular anterior fragment frame to reduce the diastasis (Figure 1c). An X-ray was obtained intraoperatively to confirm the reduction. No wires were used for fixation of the pubic symphysis.

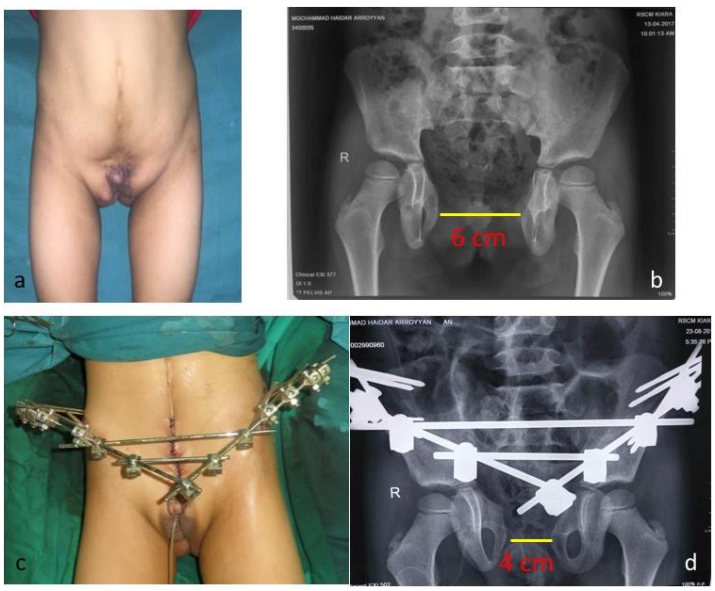

Figure 1. (a) Patient with bladder exstrophy and omphalocele; (b) initially with 6 cm of pubic diastasis; (c) bilateral anterior pelvic osteotomy was performed with external fixation; (d) after surgery, the diastasis was reduced to 4 cm.

Diastasis reduction to 4cm was accomplished immediately in the post-operative period (Figure1d). The patient was bed-rested in the hospital for one week without traction. An external fixator was applied for a total of eight weeks. There were no complications and the patient was able to walk with a normal gait and without any external leg rotation. The urological status of the patient was improved.

CASE 2

Our second patient was a 12-year-old boy who was referred for epispadia correction and pelvic osteotomy. Cloacal exstrophy closure had been completed at another facility (Figure 2a). The patient had a preoperative pubic diastasis of 9cm (Figure 2b). Bilateral anterior pelvic placement with external fixators was performed in October 2017 using a previously described technique, following cloaca closure and repair procedure but parallel to epispadiarepair (Figure 2b). Diastasis reduction to 6 cm was accomplished immediately during the postoperative period (Figure 2d). The patient was hospitalized for two weeks with bed rest but no skin traction. An external fixator was applied for eight weeks. Urological status was improved and no postoperative complications were recorded. Preoperative external rotation of the patient's gait was marginally corrected at postoperative assessment.

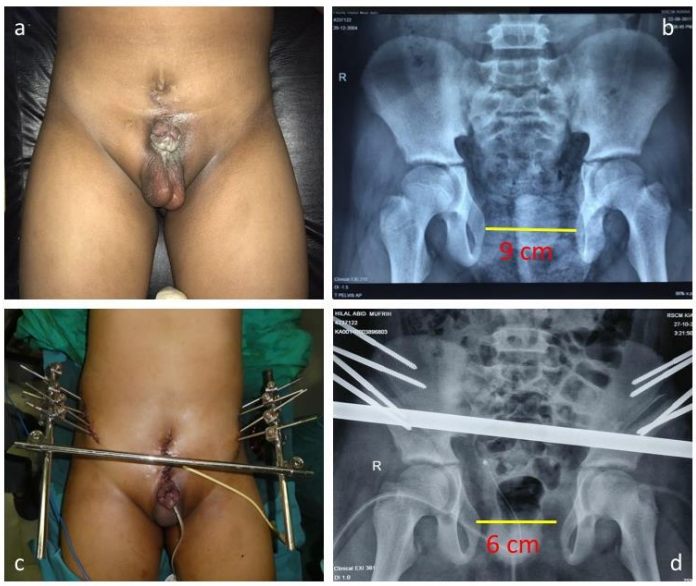

Figure 2. (a) Patient with bladder exstrophy that was performed at another hospital; (b) initial pubic diastasis was 9 cm; (c) bilateral anterior pelvic osteotomy with external fixation; (d) reduced the diastasis to 6 cm after surgery.

DISCUSSION

Despite its rarity, pediatric orthopedists should be familiar with bladder exstrophy so that proper treatment can be performed alongside urological or pediatric surgeons. Our institution

has been conducting follow-up examinations of referred cases such as these. We concluded that pelvic osteotomy parallel to closure of a urological defect is significantly advantageous for gait development and prevention of arthrosis of the hip joints. This technique also supports the performance of urological procedures. In most cases, bladder exstrophy is diagnosed in patients younger than five years. These two cases are exceptional and advanced, due to the older ages of the patients upon presentation. These cases presented challenges to determine the best treatment option for diastasis reduction. Bilateral anterior pelvic osteotomy should be performed as soon as possible, but can be applied in older patients for better deformity correction [2–4, 7-11].

The primary objective of early exstrophy repair is closure of the pubic bones and anterior abdominal wall soft tissue while relieving any tension. Any type of osteotomy can avoid dehiscence of the repaired bladder and abdominal wall. There are numerous techniques for pelvic osteotomy available to fit the surgeon's personal experience and preferences. Anterior pelvic osteotomy for children with bladder exstrophy was first described by Frey and Cohen [12] who reported complications in two patients: partial bladder prolapses in one; and a deep wound infection with total breakdown of the reconstruction in a second. Anterior pelvic osteotomy has several benefits, including versatility for both primary and re-do cases without regard to the patient's age; reasonable surgical duration with no positional changes; and limited anesthetic exposure. Blood loss was also minimal, thus blood transfusion was seldom needed [6, 8–11].

The patient is conditioned in the supine position with elevation of the pelvis using a pad. The bladder is isolated with the use of a sterile drape. A 5cm incision is made 1–2cm distal to the anterior superior iliac spine, similar to the incision for Salter osteotomy. The lateral cutaneous nerve of the thigh was identified and protected. Both sides of the pelvis were subperiosteally exposed by the iliac wings to the extent of the sciatic incision, posteriorly to the extent that the medial ligaments of the sacroiliac joint end and caudally just over the triradiate cartilage (Figure 3) [9].

A small window is opened to the periosteum beside the iliac for control during osteotomy and pin insertion. Subsequent to insertion of a Hohmann spacer into the sciatic incision, oblique osteotomy is completed using an osteotome on the iliac. The lower segment of the pelvis afterward should move medially (Figure 4) [2, 3, 5, 12].

One, or occasionally two, fixator pins are inserted into the lower segment of the ilium and one to two pins into the upper segment of the ilium. The incisions are closed with absorbable intradermal sutures, thus making it possible for the pediatric urological surgeon to completely repair the genitourinary tract. Following the urological procedure, closure of the pubic diastasis can be performed in several ways, as determined by the urologist, using nylon 2-0 sutures, while turning the pelvis internally, thus supporting the sutures. In our cases of older patients or those cases of patients with more extreme diastasis, continuously adjusting the external fixator bar may be necessary for gradual closure of the pelvis. For abdominal wall closure, the bars of the external fixator are placed to retain the pelvis in the correct position [1, 7, 13].

We recommend the use of an external fixator for four to eight weeks. The original technique uses skin traction of both legs during fixation in order to avoid early release of the pins. Nevertheless, skin traction was not applied in the present cases because there is no significant benefit in this age group. Radiographic examination should be performed monthly. The pins are to be removed only upon radiographic evidence of consolidation.

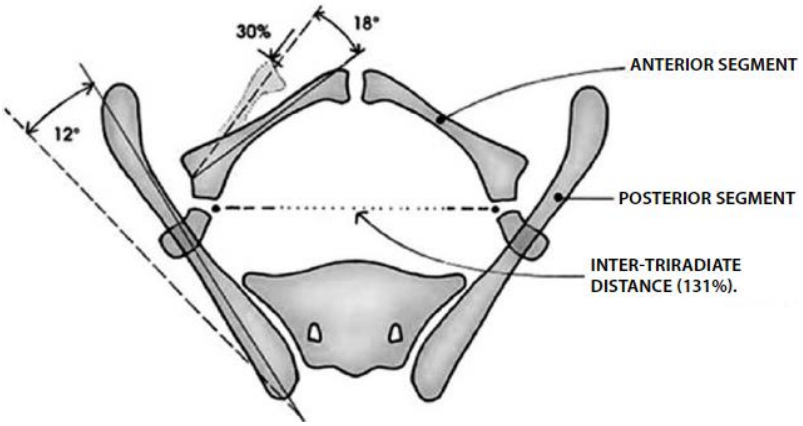

Figure 3. Pelvic anatomy in cases of bladder exstrophy.

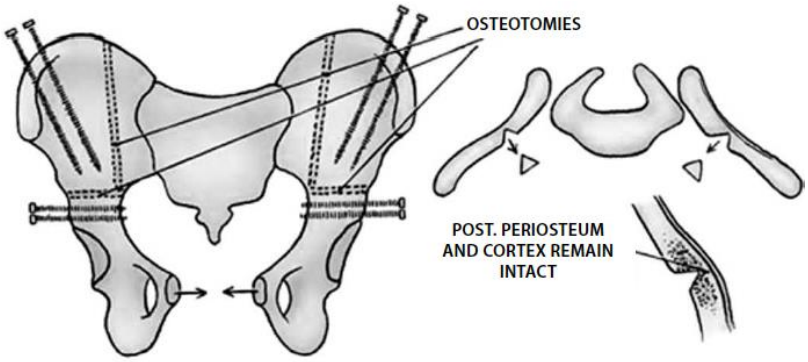

Figure 4. Pelvic anatomy in cases of bladder exstrophy.

The most common complications of this procedure include infection from the pins, transitory paralysis of the lateral cutaneous nerve of the thigh, and postponement of the consolidation process. Cutaneous traction may also cause complications. Less frequent complications include pseudarthrosis, arthrosis, lower-limb dysmetria, and lesions to the sciatic, femoral, and superior gluteal nerves, while deep infection is a relatively rare complication [10, 12–14].

Sponseller et al. [6] in their study described a new perspective on osteotomy for CBE treatment based on anterior innominate osteotomies performed from 1988 to 1996. The procedure was deemed effective with a postoperative continence rate of 76%. Nevertheless, the degree of pubic diastasis reduction was not significantly associated with continence. These findings suggest that while osteotomy could ensure continence by sling restoration of the pelvic floor muscles surrounding the urethra, the position of the pubic rami offers no significant benefit to achieve continence. It was also discovered that more diastasis correction would be retained during the procedure for older children. As the degree of pubic diastasis increases linearly to growth in patients with untreated CBE, younger patients are more likely to achieve lesser correction as a result of more considerable growth than older patients. When the main objective is to improve the widened perineum in CBE, delay of osteotomy until the age of eight years is recommended in order to achieve an optimal degree of correction [4–7].

CONCLUSION

Further techniques for the repair of bladder exstrophy in older children will be explained in the near future. Nonetheless, pelvic osteotomy is still the most beneficial intervention for the success of corrective exstrophy closure in older children. At present, the bilateral anterior technique is the most recommended for this procedure. However, further follow-up of this technique is needed.

REFERENCES

[1] Elsayed, ER, Alam, MN, Sarhan, OM, Elsayed, D, Eliwa, AM, Khalil, S. Closure of bladder exstrophy with a bilateral anterior pubic osteotomy: Revival of an old technique. *Arab J Urol*, 2011, 9, 203-206.

[2] Chiari, G, Avolio, L. Bilateral anterior pubic osteotomy in bladder exstrophy repair: report of increasing success. *Pediatr Surg Int*, 2001, 17, 160-163.

[3] Mattos, CB, Mendes, PH, Boechat, PR, Llerena Júnior, J, Guimarães, LD. Bilateral Anterior Pelvic Osteotomy for closure of bladder exstrophy : description of technique. *Rev Bras Ortop*, 2011, 46, 107-113.

[4] Wild, AT, Sponseller, PD, Stec, AA, Gearhart, JP. The role of osteotomy in surgical repair of bladder exstrophy. *Semin Pediatr Surg*, 2011, 20, 71-78.

[5] Baird, AD, Sponseller, PD, Gearhart, JP. The place of pelvic osteotomy in the modern era of bladder exstrophy reconstruction. *J Pediatr Urol*, 2005, 1, 31-36.

[6] Sponseller, PD, Gearhart, JP, Jeffs, RD. Anterior innominate osteotomies for failure or late closure bladder exstrophy. *J Urol*, 1991, 146, 137-140.

[7] Hassan, MA. Bladder exstrophy closure using anterior pelvic osteotomy of superior pubic rami. *J Fac Med Baghdad*, 2015, 57, 201-204.

[8] Varni, JW, Seid, M, Kurtin, PS. Pediatric health-related quality of life measurement technology: A guide for health care decision makers. *Jcom*, 1999, 6, 33-40.

[9] Stec, AA, Pannu, HK, Tadros, YE, Sponseller, PD, Fishman, EK, Gearhart, JP. Pelvic floor anatomy in classic bladder exstrophy using 3-dimensional computerized tomography: initial insights. *J Urol*, 2001, 4, 1444-1449.

[10] Grady, RW, Mitchell, ME. Complete primary repair of exstrophy. *J Urol*, 1999, 162, 1415-1420.

[11] Baird, AD, Nelson, CP, Gearhart, JP. Modern staged repair of bladder exstrophy: A contemporary series. *J Pediatr Urol*, 2007, 3, 311-315.

[12] Frey, P. Bilateral anterior pubic osteotomy in bladder exstrophy closure. *J Urol*, 1996, 156, 812-815.

[13] Gibbon, AJ, Maffulli, N, Fixsen, JA. Horizontal pelvic osteotomies for bladder exstrophy. *J Bone Jt Surg*, 1991, 73, 896-898.

[14] Riaz, S, Sarwar, S, Umar, M. Fixation of bilateral pelvic osteotomies with external fixator in exstrophy bladder complex. *J Pak Med Assoc*, 2005, 55, 537-539.

In: Encyclopedia of Surgery (22 Volume Set)
Editors: Andreas Lehrer and Kristin Mueller
ISBN: 978-1-53618-329-0
© 2020 Nova Science Publishers, Inc.

Chapter 339

SUCCESSFUL TREATMENT OF FRACTURE AT THE BASE OF THE PROXIMAL PHALANX USING EXTRA-ARTICULAR PERCUTANEOUS K-WIRING WITH THE CONSIDERATION OF SAFE PORTALS: A CASE REPORT

Wahyu Widodo [*] ***and Andi Praja Wira Yudha Luthfi***
Orthopaedic Hand and Microsurgery, Faculty of Medicine,
RSUPN Dr. Cipto Mangunkusumo, Universitas Indonesia, Jakarta, Indonesia

ABSTRACT

Fracture of the phalanges can be caused by trauma under various circumstances. Most phalangeal fractures are unstable. The common treatment for unstable phalangeal fractures is Kirschner wire (K-wire) fixation using the most commonly used technique of extra-articular cross-pinning. Using this technique, a stable fracture can be fixed and early phalanx mobilization can be facilitated. To achieve these goals, the landmarks and safe portals for the insertion of the K-wire to the fracture site of the phalanges must be identified. Here we present the case of a 48-year-old woman with fracture at the base of the proximal phalanx of the left fourth finger. For 3 weeks, she underwent closed reduction and immobilization using the K-wire via the extra-articular cross-pinning technique. After 3 weeks of immobilization using the K-wire, no significant events were observed. After removal of the K-wire, we initiated the rehabilitation program. A desirable range of motion (ROM) was achieved at the metacarpophalangeal joint. The safe portals for the insertion of the K-wire for treating proximal phalanx fractures using the cross-pinning technique must be identified to achieve a desirable ROM. Thus, the extra-articular cross-pinning technique along with the safe portals must be used for treating fractures of the proximal phalanges.

Keywords: fractures, K-wire, phalanges

[*] Corresponding Author's Email: wawidfkui@yahoo.com.

INTRODUCTION

Metacarpals and phalanges are the most common sites of fracture in the upper extremity, and such fractures can result from trauma under various circumstances [1]. Emmet and Breck have reported that 10% of 11,000 fractures were metacarpal or phalange fractures. Moreover, Faraqui et al. [2] have shown that fractures at these sites account for 23% of all below-the-elbow fractures in the United States. Proximal phalanx fractures occur more often than middle and distal phalangeal fractures [3]. Phalangeal fractures usually lead to undesirable outcomes because they are frequently neglected or considered insignificant [4].

The treatment of phalangeal fractures is based on several factors, such as location of intra-articular or extra-articular fracture, deformity, pattern of fractures, open or closed fractures, and correlated injuries adjacent to the fracture site. Age, preference of the surgeon, injury mechanism, and occupational need of the patient must also be considered [1, 5]. Treatment of phalangeal fractures, particularly in the extra-articular middle and proximalphalanx, aims to accomplish satisfactory anatomical reduction, maintenance of stability, and early controlled mobilization. Different treatment methods have been presented, which include buddy strapping, closed reduction internal fixation (CRIF) with Kirschner wires (K-wires), splinting, and open reduction internal fixation with plates and/or screws [3, 6].

Despite the availability of novel materials and techniques, the most commonly used tool for stabilization and fixation in phalangeal fractures is the steel pin, which was first introduced by Martin Kirschner in 1909 [7]. In the CRIF method, the safe portals for percutaneous K-wire insertion must be identified for successful treatment. A safe portal is defined as an area where entry of the K-wire will cause minimal soft tissue damage and will not damage major soft tissues, including those in the extensor tendon, nerve, vascular, and flexor tendon, there by treating pain and promoting active range of motion (ROM).

CASE ILLUSTRATION

A 48-year-old woman was admitted to our emergency department owing to pain and difficulty in moving the metacarpophalangeal (MCP) joint of her left ring finger. Six hours prior to admission, she slipped and fell on the floor, and her body fell on her left hand. She was wearing a ring on her left ring finger at that time. She felt extreme pain on her left ring finger. The patient was right-handed and worked as a nurse. Her general health condition was good, and she did not present with any comorbidities.

Upon examination, swelling and minimal deformity were observed on her left ring finger (Figure 1). Sensation at the distal part was good, and there was no disruption of blood flow to the distal part of the finger. However, she could not move the MCP joint due to extreme pain and swelling.

Based on the radiological findings, an extra-articular fracture was observed at the base of the left proximal phalanx. At the emergency room, we performed closed reduction and immobilized her fingers using ulnar gutter splint and waited for 5 days until swelling in the soft tissue subsided. Treatment with percutaneous K-wiring was recommended, and the risk of joint stiffness and malunion was explained to the patient.

Figure 1. Clinical condition of the left fourth finger.

Figure 2. First radiography image of the left hand showing a fracture with a slight displacement at the base of the fourth finger.

Figure 3. Ulnar gutter splint application was performed in the emergency room.

After 5 days, closed reduction was performed, and we inserted 2 K-wires with extra-articular cross-pinning technique percutaneously under C-arm guidance in the operating room. Regional anesthesia (axillary block) was administered prior to the procedure. First, we flexed the left proximal interphalangeal (PIP) joint of the fourth finger at 90°, and the K-wire was inserted percutaneously, dorsomedially, and dorsolaterally alongside the extensor tendon. Then, C-arm imaging was performed to identify the exact location of the wires. Results showed that the wires were placed properly. The fracture site was stable, and we flexed the MCP joint to ensure that the wire was not placed intra-articularly. The ring and middle fingers were protected with buddy tapping, and the patient was discharged from the hospital after the surgery.

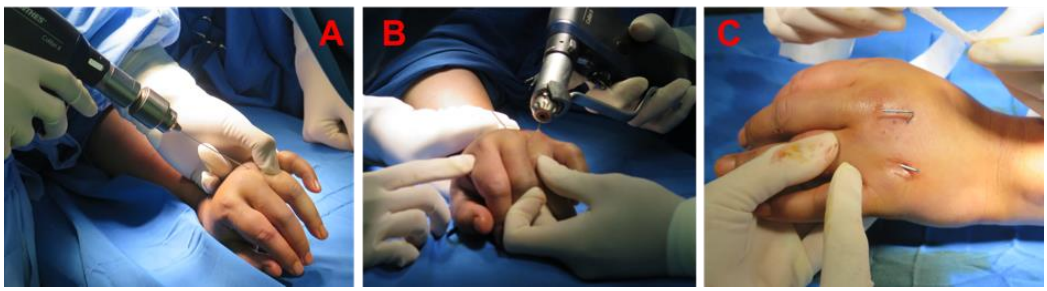

Figure 4. Insertion of the K-wire in the operating room. (a) The metacarpophalangeal joint was flexed; and (b) K-wires were inserted percutaneously; (c) After insertion, the tip of the wire was bended to immobilize the wires.

Figure 5. C-arm imaging confirmed the location of the wires in the operating room.

The patient was followed-up in the clinic after 1 week for wound inspection. The K-wire was removed 3 weeks after surgery, and the patient underwent further intensive physiotherapy with active and passive flexion and extension of the PIP joint. She regained full ROM of the MCP joint after 6 weeks. She was then discharged from the outpatient clinic. During follow-up after 3 months, the flexion and extension of the MCP joint were found to be satisfactory, and deformities were not observed.

Figure 6. Range of motion of the metacarpophalangeal joint was assessed after operation by performing flexion (a) and extension (b) to ensure that the wires were inserted extra-articularly.

Figure 7. Range of motion of the metacarpophalangeal (MCP) joint during follow-up after 3 months. Image shows that flexion and extension of the MCP joint were satisfactory, and no deformities were observed.

DISCUSSION

Metacarpal and phalangeal fractures are more commonly observed in men than in women. The incidence is highest in the younger group due to road accidents, sports injuries, and industrial accidents [4]After reduction of a displaced or unstable proximal phalanx fracture, fixation must be performed with the use of the following implants: K-wires, cerclage wires, screws, plates, tension band wiring, intramedullar devices, external fixator, or staples. The use of the K-wires is the most common fixation method. Such method has several advantages, which include low cost, simple percutaneous application, and minimal disruption of soft tissues, which results in minimal soft tissue damage and preservation of soft tissues and periosteal stability. The removal of pins after fracture healing is not challenging. However, this method also has several disadvantages, which include susceptibility to infections in the pin tract, requirement of additional immobilization over the early healing process, and possible migration of the pin. The K-wires do not offer compression, and they can occasionally distract the fracture site. Although K-wires do not produce rigid fixation, they still provide enough fixation for restricted mobilization. A variety of configurations are commonly used. Each has different degrees of stability. The configurations include crossed-pinning K-wires, parallel K-wires across the fracture site, fixation of intramedullar wire, fixation of transarticular pin or along with wiring to generate a tension band construct, and combination of several types of fixation. The key goal is to achieve stable fixation and early mobilization [8, 9].

Safe corridor can be transcutaneously recognized in the base of the proximal phalanx through the identification of the central tendon at the MCP joint dorsally. It is safe corridor for the insertion of the K-wire on whichever side of the tendon, which has a wide triangular safe cone dorsolaterally and dorsomedially [4]. In our case, after the identification of the extensor tendon, which was located at the middle dorsal part of the MCP joint, the wires were inserted. By flexing the joint, the fracture was reduced. Then, an anterograde pin was placed through the metacarpal head, crossing the MCP joint and the fracture. Fracture immobilization was held for 3 weeks. Next, the pin was removed. Within the first week, the PIP joint motion was initiated. In a previous study, satisfactory results were achieved in 90% of fractures, which were treated within 5 days after injury [1].

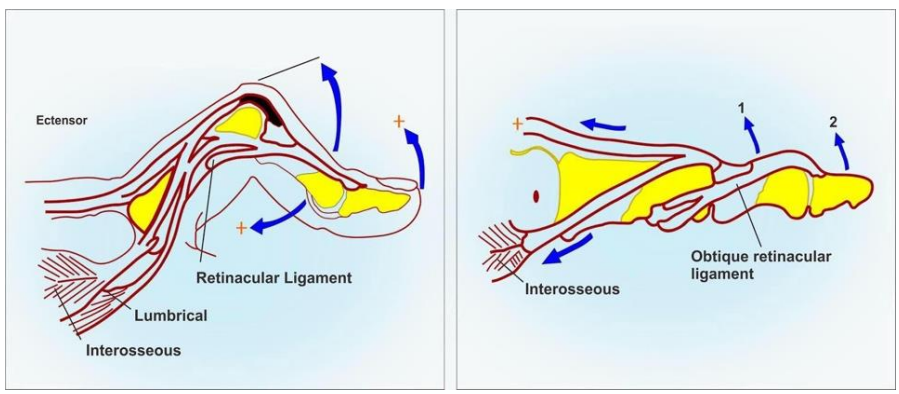

(A) (B)

Figure 8. (a) Safe corridors are distinct in each phalanx in flexed position (yellow). (b) Safe corridors are distinct in the interphalangeal joint in extended position (yellow) [4].

Stiffness is one of the most common issues in phalangeal fractures. Finger immobilization for 3 weeks leads to undesirable clinical results [2]. Therefore, in our case, we pulled out the wires after 3 weeks to prevent joint stiffness or other undesirable results. Passive flexion and extension of the MCP joint were achieved after the entry of the K-wire. Further active and passive MCP joint flexion and extension were continued through physiotherapy after the wire was pulled out.

This systematic review presented conflicting results about CRIF with transarticular or extra-articular K-wire entry [3, 10]. We used the extra-articular percutaneous cross-pinning technique for fixation, attributing to our goal of preserving the ROM of the MCP joint and preventing extensive soft tissue damage, which can result in fibrosis and adhesion adjacent to the extensor mechanism. Joshi [2] hare trospective series of 62 proximal phalanx fractures in 53 patients. The patients were treated with closed reduction and extra-articular percutaneous pinning technique. They had an overall satisfaction rate of 90%. Green and Anderson [2] have retrospectively evaluated 26 fractures in 21 patients and conducted closed reduction and extra-articular percutaneous pinning. An early motion program was initiated, and 18 of 21 patients achieved full ROM. Overall, there are no obvious differences in functional outcomes between percutaneous K-wire fixation and open reduction internal fixation of proximal phalangeal fractures [11].

CONCLUSION

Treatment of fractures at the base of the proximal phalanx using K-wires with the extra-articular percutaneous cross-pinning technique can have desirable clinical outcomes, which include restoration of full ROM. The safe portals for the insertion of the K-wire in treating proximal phalanx fractures with the cross-pinning technique must be identified to prevent soft tissue damage, which could result in unfavorable outcomes, including adhesion and joint stiffness.

CONFLICT OF INTEREST

The authors declare that there is no conflict of interests regarding the publication of this paper.

REFERENCES

[1] Day, C. S., Stern, P. J. (2011). Fractures of the metacarpals and phalanges. In: Wolfe SW, Hotchkiss RN, Pederson WC, Kozin SH (Eds.), *Green's Operative Hand Surgery* (6th edition, pp. 258-282). Philadelphia: Elsevier Inc.

[2] Faruqui, S., Stern, P. J., Kiefhaber, T. R. (2012). Percutaneous pinning of fractures in the proximal third of the proximal phalanx: complications and outcomes. *J. Hand Surg.*37, 1342-1348.

[3] Verver, D., Timmermans, L., Klaassen, C. H., van der Vlies, D. I., Vos, Schep, N. W. L. (2017). Treatment of extra-articular proximal and middle phalangeal fractures of the hand: a systematic review. Strateg. *Trauma Limb Reconstr*.12, 63-76.

[4] Rex, C., Vignesh, R., Javed, M., Balaji, S. C., Premanand, C., Zakki, S. A. (2015). Safe corridors for K-wiring in phalangeal fractures. *Indian J. Orthop.* 49, 388-392.

[5] Carpenter, S., Rohde, R. S. (2013). Treatment of phalangeal fractures phalanx phalangeal fracture treatment hand fracture. *Hand Clin*.29, 519-534.

[6] Haughton, D. N., Jordan, D., Malahias, M., Hindocha, S., Khan, W. (2012). Principles of hand fracture management. *Open Orthop*. J.6, 43.

[7] Edwards, G. S., O'Brien, E. T., Heckman, M. M. (1982). Retrograde cross-pinning of transverse metacarpal and phalangeal fractures. *Brit. Soc. Surg. Hand*.14, 141-148.

[8] Adams, J. E., Miller, T., Rizzo, M. (2013). The biomechanics of fixation techniques for hand fractures. *Hand Clin*.29, 493-500.

[9] Le Nen, D. (2014). Extra-articular fractures of the digital metacarpals and phalanges of the long fingers. *Chir. Main*.33, 1-12.

[10] Al-Qattan, M. M. (2011). Displaced unstable transverse fractures of the shaft of the proximal phalanx of the fingers in industrial workers: reduction and K-wire fixation leaving the metacarpophalangeal and proximal interphalangeal joints free. *J. Hand Surg. Eur*. Vol.36, 577-583.

[11] Gregory S., Lalonde D. H. (2014). Minimally Invasive Finger Fracture Management Wide-awake Closed Reduction, K-wire Fixation, and Early Protected Movement. *Hand Clin* 30. 7-15.

In: Encyclopedia of Surgery (22 Volume Set)
Editors: Andreas Lehrer and Kristin Mueller
ISBN: 978-1-53618-329-0
© 2020 Nova Science Publishers, Inc.

Chapter 340

THE ROLE OF ACUPUNCTURE IN A BREAST CANCER PATIENT WITH CANCER-INDUCED BONE PAIN

Kemas Abdurrohim, MD, Irma Nareswari, MD and Diana Oei*, MD
Department of Medical Acupuncture, RSUPN Dr. Cipto Mangunkusumo, Universitas Indonesia, Jakarta, Indonesia

ABSTRACT

Bone pain is the most common type of cancer-related pain; it often occurs in cases of advanced cancer that have metastasized to bone, particularly prostate cancer, breast cancer, lung cancer, and multiple myeloma. This type of pain is usually severe, persistent, and hard to manage. Current pain-relieving strategies include the use of strong opioids, bisphosphonates, and radiotherapy. However, these approaches may cause unwanted side effects that affect a patient's quality of life. Acupuncture is an adjuvant therapy for pain relief; it has minimal side effects and may improve a patient's quality of life. This paper discusses a 42-year-old female with cancer-induced bone pain who underwent 10 acupuncture treatments at the LI4 Hegu, SP6 Sanyinjiao, SP9 Yinlingquan, ST36 Zusanli, GB34 Yanglingquan, LR3 Taichong, BL23 Shenshu, and GB30 Huantiao acupoints and experienced improvement in pain.

Keywords: acupuncture, bone pain, cancer, non-pharmacological treatment

INTRODUCTION

Cancer pain is common in cancer patients. However, management of this type of pain is often not optimal. About 40–85% of cancer patients suffer from pain. Cancer pain can be seen in all stages of cancer: 25% of newly diagnosed patients, 33% of patients undergoing treatment, and about 75% of patients with advanced cancer [1].

* Corresponding Author's Email: diana.oei@hotmail.com.

Cancer-induced bone pain (CIBP) is often found in patients with prostate cancer, breast cancer, lung cancer, and multiple myeloma [2-4]. Approximately 50% of patients with bone metastases suffer from bone pain. CIBP is often felt in the lower back, pelvic area, long bones, and ribs [5]. The pain generally worsens as the disease progresses and can be divided into ongoing pain and breakthrough pain [2]. Several studies have suggested that CIBP is a unique and complex type of pain since it is caused by the hyperexcitation of cells in the dorsal horn and involves both neuropathic and inflammatory pathways [6-10].

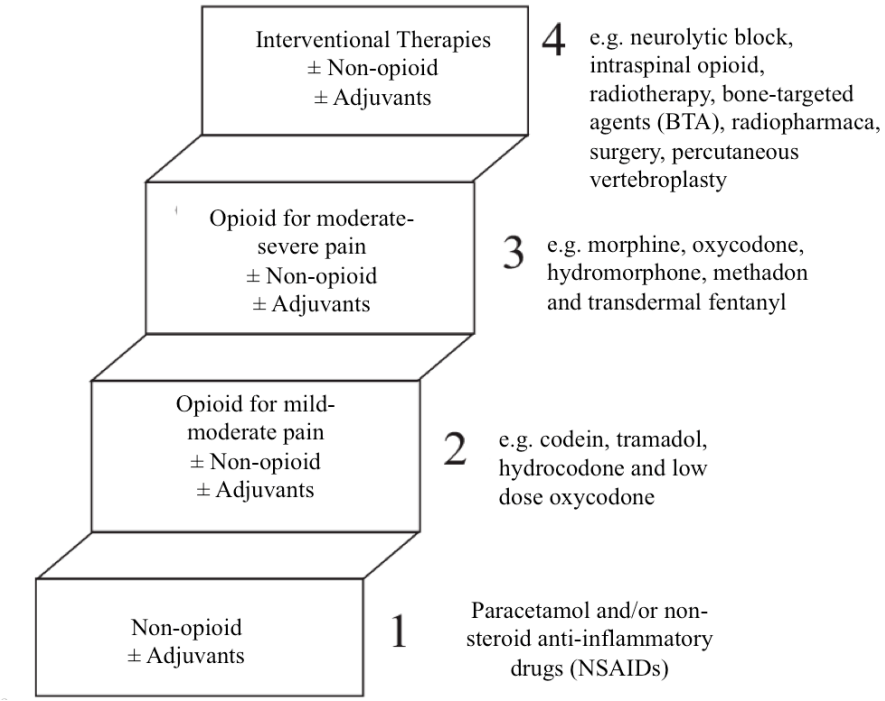

Figure 1. Modified World Health Organization Analgesic Ladder.

The modified World Health Organization analgesic ladder (Figure 1) [13] describes the mainstream therapies for CIBP [11-14]. However, these approaches are often accompanied by adverse effects, including constipation, nausea and vomiting, drowsiness, urinary retention, itch, myoclonus, loss of consciousness, respiratory depression, opioid-induced hyperalgesia, and pain flare, which can decrease the quality of life in such patients [11, 12, 15]. In addition to conventional therapies, acupuncture has been used to manage cancer pain and improve quality of life in cancer patients with minimal side effects [16].

In this report, we present a case of CIBP treated with manual acupuncture as an adjunct treatment to conventional therapies in a patient with breast cancer.

CASE ILLUSTRATION

A 42-year-old female complained of persistent pain (5 months duration) that radiated from the right hip toward the lateral malleolus. The pain was evident upon sitting or lying

down and relieved when walking. At a follow-up 2 months later, she reported worsening of the pain when walking and sleeping. There were no complaints regarding micturition or passing stool.

The patient had a history of breast cancer that had metastasized to the bone 2 years prior. She had undergone six sessions of chemotherapy and was given an aromatase inhibitor (Aromasin) to limit metastases.

The patient went to Cipto Mangunkusumo Hospital for pain management and was suggested to undergo a bone scan. The resulting bone scan showed an increase in bone metastases, which was deemed responsible for the pain. The metastases were seen in the seventh posterior rib (left), seventh thoracic vertebra, second lumbar vertebra, sacrum, right ilium, right ischium, right acetabulum, and right proximal femur.

Pain was measured using the numeric analog scale (NAS). The patient reported a NAS score of 7, even after treatment with pain medication and radiotherapy.

On physical examination, multiple small masses were seen in her right breast; there were scar tissues under her umbilicus and in the inguinal region as the result of ovariectomy, which was part of her cancer treatment. A positive straight leg raise test and Patrick's test were found in this patient indicating the possibility of nerve root involvement in this patient. There was also pain due to pressure around the GB30 Huantiao acupoint.

Manual acupuncture was then administered to this patient twice per week for 5 weeks using a Huanqiu acupuncture needle (0.25×25 mm and 0.25×60 mm). The chosen acupoints were bilateral LI4 Hegu, SP6 Sanyinjiao, SP9 Yinlingquan, ST36 Zusanli, GB34 Yanglingquan, LR3 Taichong, BL23 Shenshu, and right GB30 Huantiao. Manipulation of the needle was performed until a needling sensation (*deqi*) was achieved; the needle was then left in place for 30 min. Thermal stimulation was also applied to the hip using a TDP lamp.

After the first acupuncture treatment, the patients's pain was reduced to a NAS score of 3. She continued taking pain medication between acupuncture treatments. After the third session, the pain NAS score was 0, and the pain was only felt occasionally at night. However, by the fifth session, the pain had returned at a NAS score of 3 but had migrated to her left hip. After the 10th treatment, the NAS score again returned to 0.

DISCUSSION

The pain suffered by this patient is consistent with the results of the bone scan, which revealed metastases in the hip and lower back regions. Although the physiological mechanisms of bone pain are not fully known, several factors may play a role in the mechanism of CIBP, including the release of proinflammatory mediators causing peripheral sensitization, damage to the periosteum from an increase in osteoclastic activity, microfractures, increased pressure within the bone, periosteal stretching, muscle spasms, nerve root infiltration, and nerve compression due to vertebral collapse. CIBP is likely due to a combination of peripheral and central mechanisms involving both neuropathic and inflammatory pathways [12, 16].

In bone metastases, an increase in levels of receptor activator of nuclear factor kappa-B ligand upsets the balance between bone resorption and formation, causing an increase in osteoclastic activity and destruction of the bone. Such bone destruction may lead to pain via

the stimulation of mechanoreceptors in the periosteum; excessive osteoclastic activity may also damage sensory nerve fibers, causing neuropathic-type of pain. Sensory neurons in the periosteum may also be affected by an increase in mechanical stress within the bone that causes pain and increased sensitization [2, 11].

Tumors are known to contain many inflammatory cells. Local inflammatory cells and tumor cells produce various chemical mediators [prostaglandin, endothelin, tumor necrosis factor (TNF)], interleukin-1 (IL-1)] that can stimulate sensory nerve fibers in bones and cause localized acidosis, in turn sensitizing acid-sensing ion channels such as the transient receptor potential vanilloid receptor 1 (TRPV1). Previous studies have shown the importance of TRPV1 in modulating CIBP [2, 11, 12, 15].

CIBP is a unique type of pain in which increases in dynorphin regulation and c-fos expression are seen in the deep dorsal horn. In rat models of CIBP, repeated activation of primary C-fiber afferents by noxious stimulants resulted in a "wind-up" phenomenon, which is characterized by an escalation of nociception by cells in the dorsal horn. This phenomenon causes central sensitization via the stimulation of wide-dynamic range (WDR) cells, which results in the amplification and prolongation of nociception in the central nervous system. This sensitization causes allodynia and hyperalgesia. CIBP also causes central sensitization via the activation of N-methyl-D-aspartate (NMDA)-type glutamate receptors, which is a feature of chronic pain [12].

Changes in the phenotype of dorsal horn neurons, characterized by an increase in WDR neurons, were also seen in CIBP. These changes result in hypersensitivity to mechanical input and movement-related CIBP [16].

Hu et al., (2012) reported that expression of monocyte chemoattractant protein-1 (MCP-1) and CCR2 increases in the spinal cord as the result of neuronal damage in CIBP. MCP-1 is expressed in primary afferent neurons in the spinal cord and is co-expressed with other noxious neuropeptides, such as substance P, calcitonin gene-related peptide, and TRPV1, causing the release of various proinflammatory cytokines and chemokines that can induce central sensitization and worsen CIBP [17, 18].

In traditional Chinese medicine (TCM), the etiology and mechanism of cancer pain can be categorized into stagnation and cachexia, which are characterized by excess and deficiency, respectively. As a general rule, CIBP in the early and middle stages of cancer is considered excess pain, whereas CIBP in advanced cancer is considered deficient or mixed pain. According to TCM, the key to pain relief is to "unblock" the meridian/channel and regulate the qi/blood [19].

The acupuncture points chosen for this patient were gathered from several case reports and studies of CIBP management [6, 20-23]. Local and segmental points, such as GB30 Huantiao, BL23 Shenshu, ST36 Zusanli, and GB34 Yanglingquan, were used to modulate nociception. The activation of type A and type C nerve fibers during acupuncture manipulation stimulates inhibitory mediators and negative feedback mechanisms related to certain autoreceptors, causing the attenuation of afferent signal transmission distal from the acupuncture points [24]. Segmental points also stimulate Aδ fibers in the muscle and skin that synapse with interneurons in the substantia gelatinosa, causing the release of inhibitory neuromodulators, such as enkephalin. This process can decrease the activity of WDR and nociceptive-specific cells, inducing analgesia along the dermatome and its proximal spinal segments [12].

A previous study showed that needling at acupoint GB30 Huantiao decreases the expression of IL-1β [25]. IL-1β is known to facilitate nociception in neuropathic and inflammatory pain via several distinct signal transduction pathways. For example, IL-1β can activate the p38 mitogen-activated protein kinase (MAPK) pathway to cause hyperalgesia; it can also induce the phosphorylation of NR1, a subunit of the NMDA receptor, [25] which plays a role in the transmission of pain in the spinal cord. As previously mentioned, the activation of the NMDA receptor is a feature of chronic pain. Thus, attenuating NMDA receptor activity using acupuncture can help relieve CIBP. A study by Zhang et al., (2008) showed that electroacupuncture at acupoint GB30 Huantiao attenuates the upregulation of preprodynorphin mRNA and dynorphin, resulting in a lessening of hyperalgesia [21].

Several studies have also shown that needling at acupoint ST36 Zusanli along with other acupuncture points can lead to a decrease in the levels of proinflammatory mediators, such as TNF-α, MCP-1, and IL-6, and an attenuation of the expression of Toll-likereceptor 4 (TLR4), myeloid differentiation factor 88, and NF-κB, resulting in CIBP relief [26-28]. A study of adjuvant-induced arthritis showed that needling the ST36 Zusanli, BL23 Shenshu, and GB39 Xuanzhong acupoints increased the expression of vasoactive intestinal peptide, whichis negatively correlated with TLR4 signaling [29]. Both TLR4-p38 MAPK and MCP-1 (with CCR2 in the dorsal horn) play roles in nociception in CIBP [17, 18]. Therefore, attenuating such proinflammatory mediators may improve CIBP. A study conducted in a mouse inflammatory pain model showed that low-frequency electroacupuncture at acupoint ST36 Zusanli attenuated the expression of TRPV1 and TRPV4, which are crucial receptors involved in nerve excitation [30].

Li et al., (2017) showed that acupuncture at the GB34 Yanglingquan acupoint increased progranulin (PGRN) levels. PGRN is a multi-functional growth factor expressed by various cells thatplays a role in wound healing, cancer, and inflammation. An increase in PGRN during acupuncture can attenuate the activation of NF-κB, which is mediated by the competitive binding of TNF-α to TNFR1 and TNFR2 [31]. Chang et al., (2014) showed that needling both SP9 Yinlingquan and ST36 Zusanli acupoints decreased c-Fos expression in laminae II and V in the dorsal horn of the spinal cord. This decrease in c-Fos improves pain caused by inflammation. Acupoint SP6 Sanyinjiao, which decreases proinflammatory macrophages while increasing anti-inflammatory macrophages and IL-10 levels, was chosen for this patient due to its antinociception and anti-inflammatory effects [32]. The combination of the LI4 Hegu, LR3 Taichong, ST36 Zusanli, and SP9 Yinlingquan acupointscan effectively decrease nociceptive pain due to inflammation [33].

As it is known that a decrease in nociception in the dorsal horn via Aδ inputs can be maintained via regular acupuncture sessions [12, 34]. Our patient was advised to undergo acupuncture twice per week for 5 weeks to achieve optimal outcomes.

CONCLUSION

This report describes the benefits of acupuncture as a complementary therapy for CIBP management in a patient who suffers from CIBP despite administration of pain medication and radiotherapy.

REFERENCES

[1] Lu, W; Rosenthal, DS. Acupuncture for cancer pain and related symptoms. *Current Pain and Headache Reports*, 2013, 17, 321.

[2] Luger, NM; Mach, DB; Sevcik, MA; Mantyh, PW. Bone cancer pain: From model to mechanism to therapy. *Journal of Pain and Symptom Management* 2005, 29(*5 Suppl*), S32-S46.

[3] Lipton, A. Pathophysiology of bone metastases: how this knowledge may lead to therapeutic intervention. *Journal of Supportive Oncology*, 2004, 2, 205-213.

[4] Diel, IJ. What do patients with metastatic bone pain need? *European Journal of Cancer Supplements*, 2006, 4, 1-3.

[5] Coleman, RE. Clinical features of metastatic bone disease and risk of skeletal morbidity. *Clinical Cancer Research*, 2006, 12, 6243s–6249s.

[6] Paley, CA; Johnson, MI. Acupuncture for cancer-induced bone pain: a pilot study. *Acupuncture in Medicine*,2011, 29, 71-73.

[7] Urch, CE; Donovan-Rodriguez, T; Dickenson, AH. Alterations in dorsal horn neurones in a rat model of cancer-induced bone pain. *Pain*, 2003, 106, 347-356.

[8] Donovan-Rodriguez, T; Dickenson, AH; Urch, CE. Gabapentin normalizes spinal neuronal responses that correlate with behavior in a rat model of cancer-induced bone pain. *Anesthesiology*, 2005, 102, 132-140.

[9] Urch, CE; Donovan-Rodriguez, T; Gordon-Williams, R; Bee, LA; Dickenson, AH. Efficacy of chronic morphine in a rat model of cancer-induced bone pain: behavior and in dorsal horn pathophysiology. *Journal of Pain*, 2005, 6, 837-845.

[10] Sevcik, MA; Ghilardi, JR; Peters, CM; Lindsay, TH; Halvorson, KG; Jonas, BM; Kubota, K; Kuskowski, MA; Boustany, L; Shelton, DL; Mantyh, PW. Anti-NGF therapy profoundly reduces bone cancer pain and the accompanying increase in markers of peripheral and central sensitization. *Pain*, 2005, 115, 128-141.

[11] Kane, CM; Hoskin, P; Bennett, MI. Cancer induced bone pain. *BMJ*, 2015, 350, h315.

[12] Paley, CA; Bennett, MI, Johnson, MI. Acupuncture for cancer-induced bone pain? *Evidence-Based Complementary and Alternative Medicine*, 2011, 2011, 671043.

[13] Tay, W; Ho, KY. The role of interventional therapies in cancer pain management. *Annals of the Academy of Medicine, Singapore*, 2009, 38, 989-997.

[14] Miguel, R. Interventional treatment of cancer pain: the fourth step in the World Health Organization analgesic ladder? *Cancer Control*, 2000, 7, 149-156.

[15] Costa, L; Ripamonti, CI; Niepel, D; Santini, D Improving quality of life in patients with advanced cancer: Targeting metastatic bone pain. *European Journal of Cancer*, 2017, 71, 80-94.

[16] Paley, CA; Johnson, MI; Bennett, MI. Should physiotherapists use acupuncture for treating patients with cancer-induced bone pain? A discussion paper. *Physiotherapy*, 2011, 97, 256-263.

[17] Hu, JH; Zheng, XY; Yang, JP; Wang, LN; Ji, FH. Involvement of spinal monocyte chemoattractant protein-1 (MCP-1) in cancer-induced bone pain in rats. *Neuroscience Letters*, 2012, 517, 60-63.

[18] Jin, D; Yang, JP; Hu, JH; Wang, LN; Zuo, JL. MCP-1 stimulates spinal microglia via PI3K/Akt pathway in bone cancer pain. *Brain Research*, 2015, 1599, 158-167.

[19] Ling, Y. Traditional Chinese medicine in the treatment of symptoms in patients with advanced cancer. *Annals of Palliative Medicine,* 2013, 2, 141-152.

[20] Zhang, RX; Li, A; Liu, B; Wang, L; Ren, K; Qiao, JT; Berman, BM; Lao, L. Electroacupuncture attenuates bone cancer pain and inhibits spinal interleukin-1 beta expression in a rat model. *Anesthesia and Analgesia*, 2007, 105, 1482-1488.

[21] Zhang, RX; Li, A; Liu, B; Wang, L; Xin, J; Ren, K; Qiao, JT; Berman, BM; Lao, L. Electroacupuncture attenuates bone cancer-induced hyperalgesia and inhibits spinal preprodynorphin expression in a rat model. *European Journal of Pain*, 2008, 12, 870-878.

[22] Su, CF. Home care with acupuncture increased the quality of life in patient with advanced cancer with neuropathic pain induced by bone metastasis: a case report. *Journal of Integrative Medicine*, 2018, 16, 208-210.

[23] Lee, HJ; Lee, JH; Lee, EO; Lee, HJ; Kim, KH; Kim, SH; Lee, KS; Jung, HJ; Kim, SH. Substance P and beta-endorphin mediate electro-acupuncture induced analgesia in mouse cancer pain model. *Journal of Experimental and Clinical Cancer Research*,2009, 28, 102.

[24] Zhang, ZJ; Wang, XM; McAlonan, GM. Neural acupuncture unit: A new concept for interpreting effects and mechanisms of acupuncture. *Evidence-Based Complementary and Alternative Medicine*, 2012, 2012, 429412.

[25] Zhang, RX; Liu, B; Li, A; Wang, L; Ren, K; Qiao, JT; Berman, BM; Lao, L. Interleukin 1β facilitates bone cancer pain in rats by enhancing NMDA receptor NR-1 subunit phosphorylation. *Neuroscience*, 2008, 154, 1533-1538.

[26] Xu, Y; Hong, S; Zhao, X; Wang, S; Xu, Z; Ding, S; Zhang, K; Zhang, Y; Xu, L; Yu, N; Zhao, T; Yan, Y; Yang, F; Liu, Y; Yu, K; Liu, B; Guo, Y; Pang, G. Acupuncture alleviates rheumatoid arthritis by immune-network modulation. *American Journal of Chinese Medicine*, 2018, 46, 997-1019.

[27] Dong, Z-Q; Zhu, J; Lu, D-z; Chen, Q; Xu, Y-l. Effect of electroacupuncture in "Zusanli" and "Kunlun" acupoints on TLR4 signaling pathway of adjuvant arthritis rats. *American Journal of Therapeutics*, 2016, 0, 1-6.

[28] Wen, CK; Lee, TY. Electroacupuncture decreases the leukocyte infiltration to white adipose tissue and attenuates inflammatory response in high fat diet-induced obesity rats. *Evidence-Based Complementary and Alternative Medicine*, 2014, 2014, 473978.

[29] He, TF; Yang, WJ; Zhang, SH; Zhang, CY; Li, LB; Chen, YF. Electroacupuncture inhibits inflammation reaction by upregulating vasoactive intestinal peptide in rats with adjuvant-induced arthritis. *Evidence-Based Complementary and Alternative Medicine*, 2011, 2011.

[30] Chen, WH; Tzen, JTC; Hsieh, CL; Chen, YH; Lin, TJ; Chen, SY; Lin, YW. Attenuation of TRPV1 and TRPV4 expression and function in mouse inflammatory pain models using electroacupuncture. *Evidence-Based Complementary and Alternative Medicine*, 2012, 2012, 636848.

[31] Li, Y; Fan, X; Liu, J; Wu, Y; Zhang, R. Acupuncture at Yanglingquan (GB34) acupoint alleviates lumbar intervertebral disc degeneration in rats. *International Journal of Clinical and Experimental Medicine*, 2017, 10, 2746-2754.

[32] Silva, MDd; Bobinski, F; Sato, KL; Kolker, SJ; Sluka, KA; Santos, ARS. IL-10 cytokine Released from M2 Macrophages is Crucial for analgesic and anti-

inflammatory effects of Acupuncture in a Model of inflammatory Muscle Pain. *Molecular Neurobiology*, 2014, 51, 19-31.

[33] Oh, JH; Bai, SJ; Cho, ZH; Han, HC; Min, SS; Shim, I; Lee, HJ; Lee, H; Lee, BH. Pain-relieving effects of acupuncture and electroacupuncture in an animal model of arthritic pain. *International Journal of Neuroscience*, 2006, 116, 1139-1156.

[34] Filshie, J. Acupuncture for malignant pain. *Acupuncture in Medicine*, 1990, 8, 38-39.

In: Encyclopedia of Surgery (22 Volume Set)
Editors: Andreas Lehrer and Kristin Mueller
ISBN: 978-1-53618-329-0
© 2020 Nova Science Publishers, Inc.

Chapter 341

A RARE CASE OF CD8-NEGATIVE MONOMORPHIC EPITHELIOTROPIC INTESTINAL T-CELL LYMPHOMA

Agnes Stephanie Harahap*, Lydia Kencana, Maria Francisca Ham, Budiana Tanurahardja and Endang S. R. Hardjolukito
Department of Anatomical Pathology, RSUPN Dr. Cipto Mangunkusumo, Universitas Indonesia, Jakarta, Indonesia

ABSTRACT

Monomorphic epitheliotropic intestinal T-cell lymphoma (MEITL) is an uncommon subtype of intestinal lymphoma that is usually found in Asian populations. MEITL causes non-specific gastrointestinal-related symptoms; thus, it is often overlooked and misdiagnosed, resulting in complications and improper therapeutic approaches. A 75-year-old Asian female was admitted to the emergency room with signs and symptoms of ileal obstruction. She had no history of celiac disease. Surgical resection was performed; the tumor consisted of small- to medium-sized tumor cells arranged in a monomorphic and diffuse pattern. The tumor was positive for CD3 and CD56 but negative for CD8. She was diagnosed with MEITL. Although most MEITL tumors are positive for CD3, CD56, and CD8, CD8-negative MEITL has been reported in some studies and is thought to originate from double-negative intraepithelial lymphocytes. We described a rare case of MEITL with an unusual negative CD8 expression.

Keywords: intestinal lymphoma, monomorphic epitheliotropic intestinal T-cell lymphoma (MEITL)

INTRODUCTION

Monomorphic epitheliotropic intestinal T-cell lymphoma (MEITL) is a rare type of intestinal lymphoma that arises from intraepithelial lymphocytes (IELs). MEITL was

* Corresponding Author's Email: agnharahap@gmail.com.

formerly designated as a subtype of enteropathy-associated T-cell lymphoma (EATL) type II. It was recognized as a different entity in the latest WHO classification because of its apparent morphological and immunophenotypic features [1, 2].

Despite its rarity, MEITL occurs worldwide and is the most common type of primary intestinal T-cell lymphoma in Asian populations. MEITL usually manifests with non-specific signs and symptoms, which makes it difficult to diagnose, leading to a higher risk of misdiagnosis and complications as a result of inaccurate therapeutic approaches and procedures. Symptoms range from abdominal pain, weight loss, and diarrhea to intestinal obstruction, which can lead to perforation and bleeding. MEITL is clinically aggressive and generally diagnosed late, with poor prognosis at the time of diagnosis. Therefore, MEITL should always be considered as a differential diagnosis in intestinal tumors, particularly in tumors present in the small intestine [1, 3–5].

MEITL has distinct morphologic and immunophenotypic features. It is composed of monomorphic small- to medium-sized tumor cells that are positive for CD3, CD56, and CD8. However, these expressions vary in some cases, making diagnosis even more difficult. Variations in marker expressions depend on the diverse cellular origin of the tumor.

We present a case of a 75-year-old female with intestinal obstruction due to MEITL with unusual negative CD8 expression.

CASE

A 75-year-old Asian female admitted to the emergency room presented with fever, weakness, nausea and vomiting, abdominal distention, pain, and diarrhea. She had been experiencing abdominal discomfort for approximately 2 months before admission and was assessed as having gastritis. She also had difficulty eating but had no history of celiac disease. A physical examination did not identify any masses or lymphadenopathy at other sites. The laboratory examination showed leukocytosis (14,300/µl) and increased serum Ca125 (185.5 U/mL) levels. Her LDH level was within the normal range (308 U/L). HLA typing was not performed. Chest X-ray showed no mediastinal or lymph node enlargement (Figure 1).

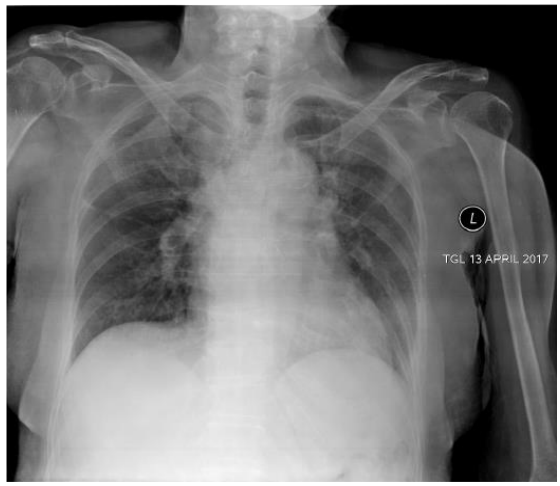

Figure 1. Chest X-ray. No mediastinal orlymph node enlargement was observed.

An abdominal ultrasound showed intestinal inflammation with segmental dilatation and a heterogenous lesion in the lower abdomen compatible with either a fecal mass or tumor. Abdominal computed tomography showed intestinal wall thickening and an ileal mass responsible for obstruction, with dilatation of the proximal segments (Figure 2).

A small intestinal resection was performed. Macroscopically, the tumor measured 4×4×2 cm; it bulged into the serous layer and was whitish and rubbery in consistency. The non-tumorous mucosa showed no marked abnormalities (Figure 3).

Histopathologic examination of the ileal tissue resection showed diffuse transmural proliferation of monotonous medium-sized lymphoid cells with dispersed chromatin, inconspicuous nucleoli, and clear cytoplasm. The tumor lacked inflammatory infiltrates. The adjacent mucosa showed blunting villi and ulcerations. There was also evidence of epitheliotropism characterized by infiltration of lymphocytes in the epithelium. No enteropathy changes (crypt hyperplasia and villous atrophy) or necrosis were found (Figure 4).

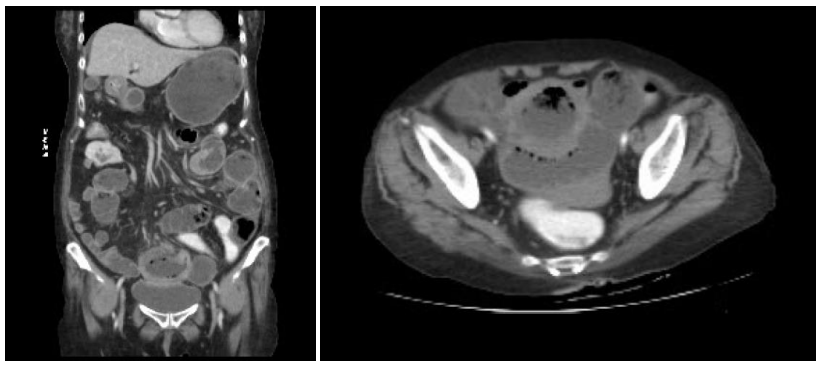

Figure 2. Abdominal CT scan showing intestinal wall thickening and an obstructing mass in the ileum, with proximal intestinal and gastric dilatation.

Figure 3. The tumor appeared as a bulging, whitish, and rubbery mass in the ileal wall (formalin fixed tissue).

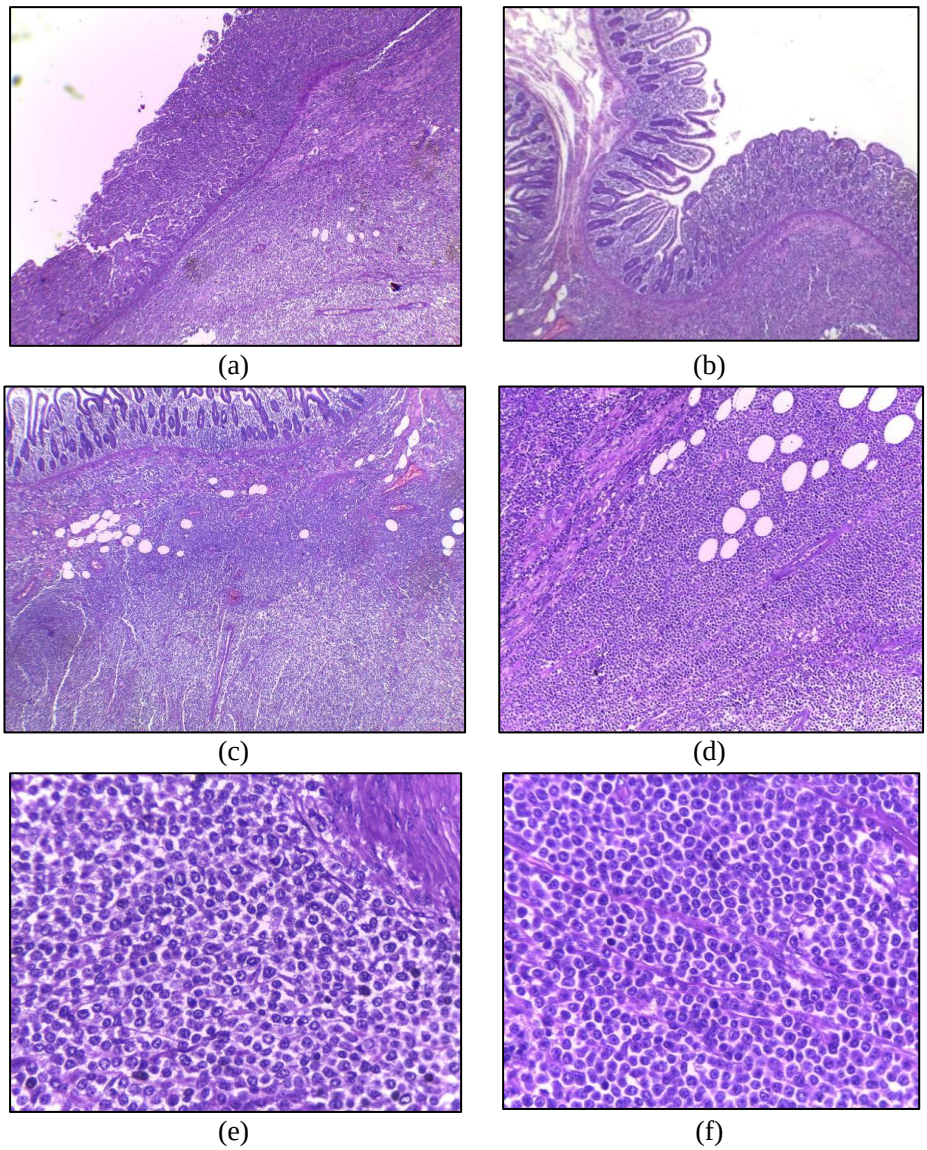

Figure 4. Histopathological features. (a, b) The affected intestinal mucosa showed blunting of the villi and ulceration, H&E 40×. (c) There was a diffuse transmural proliferation of lymphoid cells, H&E 40×. (d) The tumor cells are arranged in a monotonous and diffuse pattern, H&E 100×. (e, f) The tumor consists of medium-sized lymphoid cells with dispersed chromatin, inconspicuous nucleoli, and clear cytoplasm, H&E 400×.

The tumor cells were positive for CD3, CD7, CD56, T-cell intracytoplasmic antigen (TIA)-1, and perforin. The Ki67 proliferation index was 70–80%. Other markers such as CD8, CD4, CD30, CD5, CD20, CD79a, CD10, granzyme B, and Epstein–Barr virus-encoded small RNA (EBER) *in situ* hybridization were all negative. Several important markers (megakaryocyte-associated tyrosine kinase (MATK), CD103, TCRαβ, and TCRγδ) were not available (Figure 5 and 6).

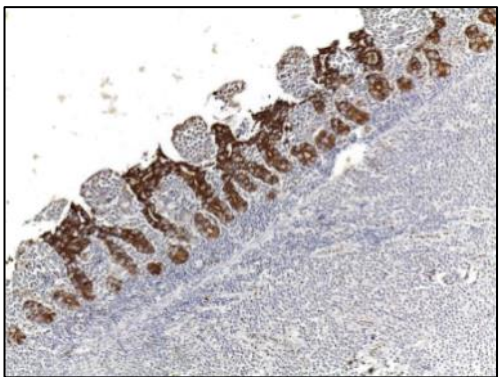

(a)

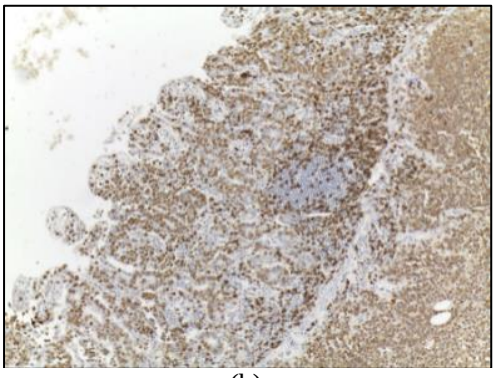

(b)

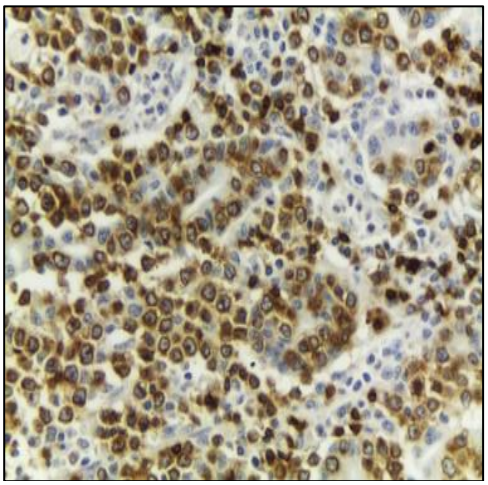

(c)

Figure 5. (Continued).

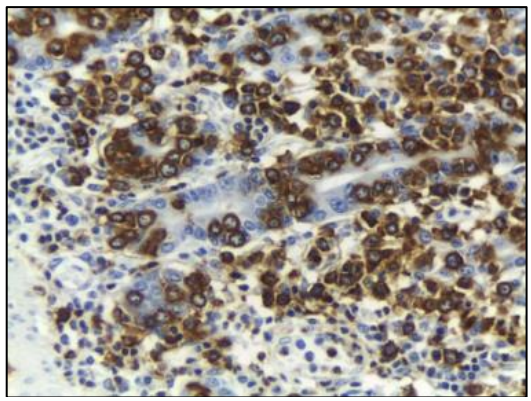

(d)

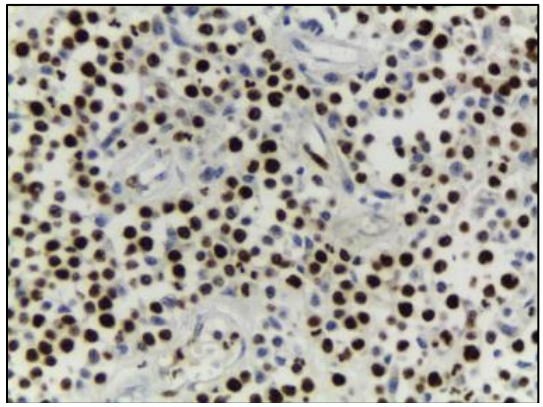

(e)

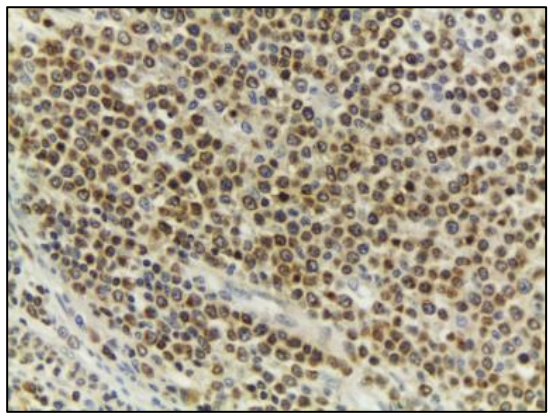

(f)

Figure 5. (Continued).

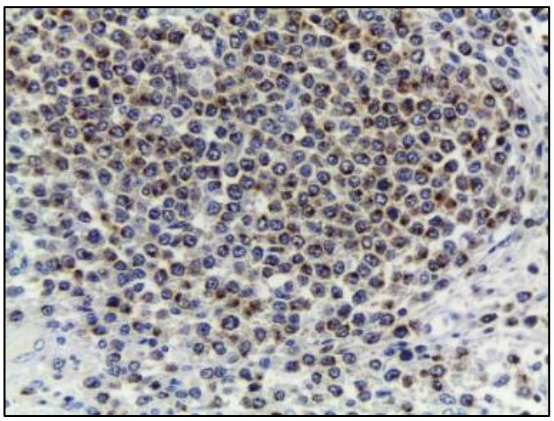

(g)

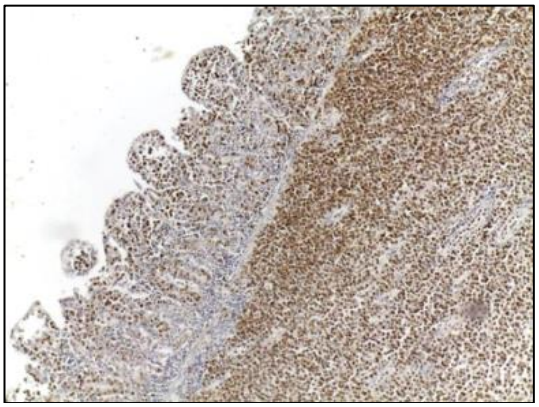

(h)

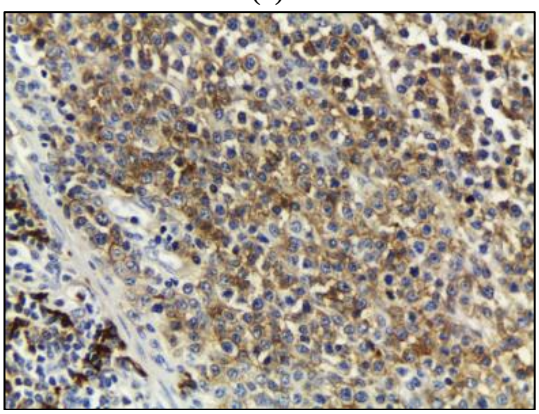

(i)

Figure 5. (Continued).

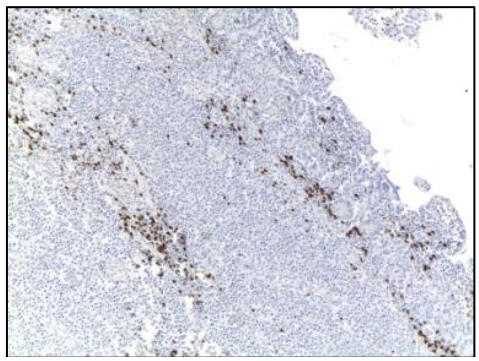

(j)

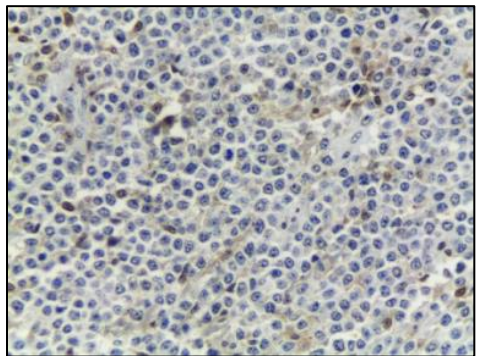

(k)

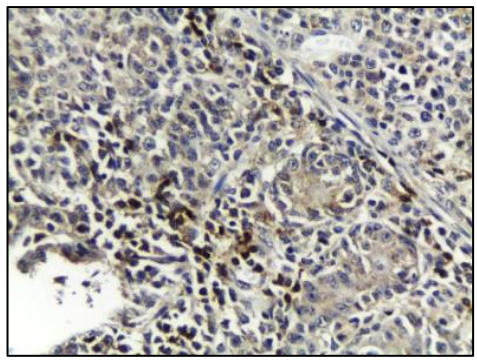

(l)

Figure 5. Immunohistochemistry profile. (a) AE 1/3, negative, 100×; (b, c) CD3, diffusely positive, 100× and 400×; (d) CD7, diffusely positive, 400×; (e) Ki67, positive in 70–80% of tumor cells, 400×; (f) Bcl-2, positive, 400×; (g) TIA1, positive, 400×; (h) perforin, positive, 100×; (i) CD56, positive, 400×; (j) CD20, negative, 100×; (k) CD4, negative, 400×; and (l) CD8, negative, 400×.

The immunohistochemistry features are more identical to those of extranodal NK/T-cell lymphoma, nasal type (ENKTL). However, due to the negative EBER test and no manifestation in nasal, the patient was diagnosed with MEITL. The patient gave up treatment and died within 1 month after surgery.

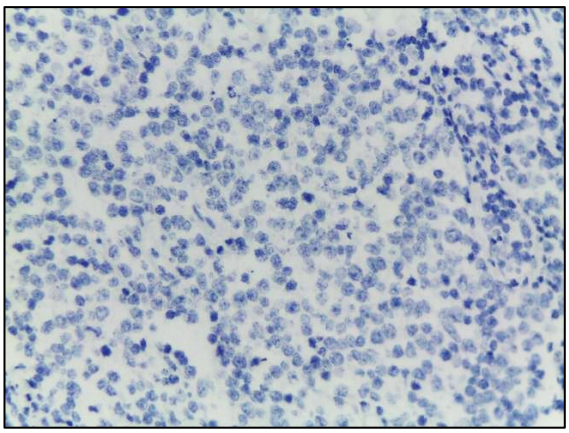

Figure 6. EBER, *in situ* hybridization, 400×.

DISCUSSION

The gastrointestinal tract is the most common extranodal site of lymphoma; 30–40% of all extranodal lymphomas occur here. However, primary lymphoma of the gastrointestinal tract is very rare and constitutes only approximately 1–4% of gastrointestinal malignancies. Most cases of gastrointestinal lymphoma belong to the non-Hodgkin lymphoma (NHL) subtype, such as diffuse large B-cell lymphoma, mucosa-associated lymphoid tissue lymphoma, follicular lymphoma, Burkitt lymphoma, mantle cell lymphoma, peripheral T-cell lymphoma (PTCL), ENKTL, adult T-cell leukemia/lymphoma (ATLL), EATL, and MEITL [6–10].

The current patient presented with gastrointestinal-related signs and symptoms due to intestinal obstruction from an ileal tumor, which can be caused by intestinal lymphoma. According to Dawson [11], intestinal lymphoma is considered primary if it has the following clinical characteristics: (1) no palpable superficial lymphadenopathy, (2) no obvious enlargement of mediastinal lymph nodes due to chest radiographs, (3) normal white blood cell counts (total and differential), (4) predominating bowel lesions in laparotomy, with the affected lymph nodes being in its immediate neighborhood, and (5) no lymphoid tumor involvement in the liver or spleen. The physical, laboratory, and radiologic examination of our patient showed neither lymphadenopathy nor tumor in the liver and spleen. Although the leukocyte count was above normal levels, the signs and symptoms fit four of Dawson's five criteria for primary gastrointestinal lymphoma. The high leukocyte count was likely due to infection because the patient also presented with fever.

The histopathologic features showed medium-sized, monomorphic tumor cells with round nuclei that were arranged in a diffuse pattern, suggesting NHL. Although most primary gastrointestinal lymphomas are of B-cell lineage, the immunophenotype of this patient was CD3-positive and CD20-negative, suggesting that the tumors were of T-cell origin, which occurs in only 9% of primary gastrointestinal lymphomas [8, 11].

The differential diagnosis of T-cell lymphoma in the intestine includes MEITL, EATL, ENKTL, PTCL, ATLL, and gamma delta T-cell lymphoma. The clinical, histopathological, and immunohistochemistry findings of this patient displayed tendencies associated with

primary intestinal T-cell lymphoma. However, considering its rarity, we could not yet exclude the possibility of the tumor representing the extranodal involvement of other T-cell lymphomas [1, 3, 4, 12].

In this case, the immunophenotype of the tumor fit that of MEITL and ENKTL the best. The clinical features, morphology, and immunophenotype of MEITL and ENKTL are described in Table 1.

Our patient was an Asian female in her 70s; therefore, she had a supporting demographic background for both MEITL and ENKTL. The tumor was present as a mass in the ileum and thickening of the intestinal wall with no involvement of other areas was noted; this manifestation is more commonly found in MEITL.

MEITL is composed of monomorphic small- to medium-sized tumor cells, with round and regular nuclei, finely dispersed chromatin, inconspicuous nucleoli, and clear cytoplasm. The tumor cells also show prominent epitheliotropism. MEITL has no known association with celiac disease; thus, the non-neoplastic areas are absent of the features found in celiac disease. The villous architecture is distorted with broad villi as a result of tumor cell expansion in the lamina propria, but no inflammatory background is present. The morphologic features in our case fit those of MEITL [1, 3–5].

The MEITL immunophenotype is quite distinctive: CD3, CD8, and CD56 are positive in most cases, with CD8 and CD56 being highly specific markers. MEITL is negative for CD4 and CD30 and is often negative for CD5 since most MEITL cases express gamma delta T-cell receptor (TCR). The most frequently expressed TCR in MEITL is of the gamma subtype, but some cases express TCR beta, TCR gamma and beta, and CD8 alpha homodimers. Some studies have also reported silent TCR tumor cells. TIA1 is usually positive, whereas the expressions of perforin and granzyme are inconsistent. MATK is expressed in more than 80% of tumor cells in most cases and is a helpful marker to differentiate MEITL from EATL [1, 16, 17].

The tumor cells in our case were positive for CD7, CD56, TIA1, and perforin and negative for CD5, CD4, CD30, and granzyme B, which is in line with the MEITL immunophenotype according to the literature. Intriguingly, CD8 was not expressed. There are, however, some previous reports of CD8-negative MEITL [16, 18–20].

MEITL arises from several subtypes of intestinal IELs that express different types of surface receptors, which is resembled in the immunophenotype. Most IELs express TCR; however, some studies have recently reported TCR-negative IELs. In addition to TCR expression, there are also variations in CD4 and CD8 expressions. During the differentiation process, most lymphocytes undergo positive selection in the thymus before differentiating into single-positive T-cells and migrating into the intestine. By contrast, the remaining lymphocytes are double negative when transferred into the intestine. The latter then differentiate into single-positive T-cells following antigenic stimulation. Both the TCR-positive and TCR-negative and single-positive and double-negative T-cells have the potential to transform into MEITL and affect its immunophenotype. MEITL originating from the double-negative T-cells presents with CD3+ CD8− tumor cells, as in our case. Perforin was positive in this case, which is an uncommon feature in double-negative T-cells and is thus considered aberrant. However, perforin transcription process starts in the stage of double-negative, making it possible to be detected in unusual cases [16, 18, 19].

Table 1. Clinical, morphologic, and immunophenotypic features of MEITL and ENKTL [1,4,13–15]

	MEITL	ENKTL
Clinical features	Abdominal pain, obstruction or perforation, weight loss, diarrhea, gastrointestinal bleeding.	Nasal obstruction-related signs and symptoms in most cases. Intestinal lesions manifest as perforation or gastrointestinal bleeding.
Median age	60 years old	44-54 years old
Male:female ratio	2:1	2:1
Epidemiology	Asia, Hispanic	Asia, Mexico, Central and South America
Frequency	1% of NHL	10% of NHL
Localization	Small intestine, jejunum more often involved than the ileum. It can disseminate to extranodal sites (stomach, large bowel) and regional lymph nodes.	Most commonly involves the nasal cavity. Other sites of involvement include upper aerodigestive tract, skin, soft tissue, gastrointestinal tract, and testes.
Primary/secondary intestinal lesion	Primary	Secondary involvement is more common than primary
Gross appearance	Plaques and nodules	Mass and perforation
Cytological features	Small to medium-sized tumor cells, monomorphic	Broad cytological spectrum. Most tumors consist of medium-sized cells or a mixture of small and large cells.
Necrosis	Uncommon	Common
Inflammatory background	Uncommon	Heavy, can mimic inflammatory process
Mucosa away from tumor	Normal	Normal
CD3	+	+
CD5	−	−
CD56	+	+
CD4	−	−
CD8	+	−
CD7	+	+
CD30	−	±
TIA1	+	+
Granzyme B, perforin	variable	+
HLA-DR	−	+
MATK	+	+
EBV infection	No known association	Very strong association

ENKTL was considered as a differential diagnosis in this case because of the more identical immunophenotype and higher prevalence compared with MEITL. However, when found in the gastrointestinal tract, ENKTL most commonly manifests as an extranodal spread rather than as a primary lesion. According to Dawson's criteria [11], the tumor in our case

was more likely a primary intestinal lymphoma. ENKTL consists of small, medium, large, or anaplastic tumor cells and is usually accompanied by coagulative necrosis admixed apoptotic bodies and inflammatory infiltrate. These morphologic features are not in line with those of our case since there was no inflammatory infiltrate or necrosis. The immunophenotype of ENKTL is CD3+, CD56+, and CD8−, which is identical with the patient's immunophenotype. However, ENKTL is strongly associated with Epstein–Barr virus infection. Although the immunohistochemistry profile might be compatible, the clinical and morphologic features and the negative EBER ruled out ENKTL.

Another possible differential diagnosis of this patient was EATL. EATL is commonly found in Northern Europe, usually occurs in the small intestine, and is associated with celiac disease. The tumor cells are polymorphic and are composed of pleomorphic medium to large cells with prominent nucleoli. EATL is accompanied by an inflammatory background and often necrosis. The features of celiac disease can be found in the adjacent mucosa, particularly in the jejunum. The tumor cells are usually CD3+, CD5−, CD7+, CD4−, CD8−, and CD103+. They also express cytotoxic granule-associated proteins, e.g., TIA1, granzyme B, and perforin. CD30 expression differs according to the cytomorphology, but almost all large-cell EATL are CD30+. In this case, EATL was unlikely because of the demographic background of the patient, no history of celiac disease, and the irrelevant morphologic features. CD103 and MATK immunostaining was necessary to confirm the diagnosis, but these procedures were not available in our country [1, 21].

The patient underwent surgical resection and then stopped treatment and died 1 month later. There is currently no established treatment for MEITL. In most cases, patients undergo surgical resection due to the emergency presentation or the need for a histopathological examination. In our case, the surgery was performed because of the ileal obstruction and to prevent perforation. Surgery followed by chemotherapy tends to have a better outcome than surgery alone. However, the most efficient chemotherapy regimen has yet to be discovered. The most commonly used chemotherapy regimens are CHOP (cyclophosphamide, doxorubicin, vincristine, and prednisone), SMILE (dexamethasone, methotrexate, ifosfamide, L-asparaginase, and etoposide), and IVEMTX (ifosfamide, vincristine, and etoposide/ methotrexate). MEITL is considered aggressive and has a poor prognosis, even when treated using chemotherapy, with a median overall survival of 7 months. Nonetheless, some studies showed that early detection and treatment result in better therapy response and even long-term survival. Some studies also reported the use of hematopoietic stem cells [16, 18, 20].

CONCLUSION

Primary intestinal lymphoma is very rare and often misdiagnosed. Various subtypes of lymphomas can occur in the gastrointestinal tract, with diverse morphology and immunophenotypes. We reported a rare case of primary lymphoma of the gastrointestinal tract, with the immunophenotype suggesting ENKTL. However, because of its clinical and morphologic features and negative EBER test, the patient was diagnosed with CD8-negative MEITL. CD8 and CD56 are the highly specific markers for MEITL, but they might not be expressed in particular cases. The expression of T-cell markers depends on the cellular origin of the tumor. MEITL arises from IELs residing in the intestine, which have diverse

phenotypes and are present in various stages of differentiation. Therefore, it is possible for MEITL to have uncommon and aberrant marker expressions that should not be overlooked.

CONFLICTS OF INTEREST

The authors declare no conflicts of interest.

REFERENCES

[1] Swerdlow SH, Campo E, Harris NL, Jaffe ES, Pileri SA, Stein H, et al. WHO classification of tumors of haemopoietic and lymphoid tissues. Revised 4th edition. *Lyon: International Agency for Research on Cancer*; 2017.

[2] Skinnider BF. Lymphoproliferative disorders of the gastrointestinal tract. *Arch. Pathol. Lab. Med.* 2018;142:44-52.

[3] Weindorf SC, Smith LB, Owens SR. Update on gastrointestinal lymphomas. *Arch. Pathol. Lab. Med.* 2018;142:1347-51.

[4] Medeiros LJ, Miranda RN. *Diagnostic pathology: Lymph nodes and extranodal lymphomas*. 2nd edition. Canada: Elsevier; 2018.

[5] Sun ZH, Zhou HM, Song GX, Zhou ZX, Bai L. Intestinal T-cell lymphomas: A retrospective analysis of 68 cases in China. *World J. Gastroenterol.* 2014; 20:296-302.

[6] Arora N, Manipadam MT, Pulimood A, Ramakrishna BS, Chacko A, Kurian SS, et al. Gastrointestinal lymphomas: pattern of distribution and histological subtypes: 10 years experience in a tertiary centre in South India. *Indian J. Pathol. Microbiol.* 2011;54:712-9.

[7] Freedman AS. Clinical presentation and diagnosis of primary gastrointestinal lymphomas [Internet]; 2019 [cited 2019 Feb 17]. Available from: https://www.uptodate.com/contents/clinical-presentation-and-diagnosis-of-primary-gastrointestinal-lymphomas.

[8] Ghimire P, Wu GY, Zhu L. Primary gastrointestinal lymphoma. *World J. Gastroenterol.* 2011;17:697-707.

[9] Cardona D, Layne A, Lagoo A. Lymphomas of the gastro-intestinal tract - pathophysiology, pathology, and differential diagnosis. *Indian J. Pathol. Microbiol.* 2012;55:1-16.

[10] Wang G, Xu G, Luo G, Shan H, Li Y, Gao X, et al. Primary intestinal non-Hodgkin's lymphoma: a clinicopathologic analysis of 81 patients. *World J. Gastroenterol.* 2011;17:4625-31.

[11] Dawson IM, Cornes JS, Morson BC.Primary malignant lymphoid tumours of the intestinal tract. Report of 37 cases with a study of factors influencing prognosis. *Br. J. Surg.* 1961;49:80-9.

[12] Zing NPC, Fischer T, Zain J, Federico M, Rosen ST. Peripheral T-cell lymphomas: incorporating new developments in diagnostics, prognostication, and treatment into clinical practice-part 2: ENKTL, EATL, indolent T-Cell LDP of the GI tract, ATLL, and hepatosplenic T-Cell lymphoma.*Oncology* 2018;32:e83-9.

[13] Makruasi N, Makruasi S, Trongwongsa T. Enteropathy type II associated T-cell non-Hodgkin lymphoma: a case report. *J. Hematol.* 2015;4:144-7.
[14] Geetha V, Kudva R, Amprayil AJ. Enteropathy associated T cell lymphoma—a case report of an uncommon extranodal T cell lymphoma. *J. Clin. Diagn. Res.* 2014;8:FD10-2.
[15] Haverkos BM, Pan Z, Gru AA, Freud AG, Rabinovitch R, Xu-Welliver M, et al. Extranodal NK/T cell lymphoma, nasal type (ENKTL-NT): an update on epidemiology, clinical presentation, and natural history in North American and European cases. *CurrHematol.vMalig. Rep.* 2016;11:514-27.
[16] Aoyama Y, Tsunemine H, Zushi Y, Maruoka H, Goto Y, Kodaka T, et al. Colonal monomorphic epitheliotropic intestinal T-cell lymphoma with novel phenotype of cytoplasmic CD3 expression. *J. Clin. Exp. Hematop*. 2018;58:102-6.
[17] Tan SY, Chuang SS, Tang T, Tan L, Ko YH, Chuah KL, et al. Type II EATL (epitheliotropic intestinal T-cell lymphoma): a neoplasm of intra-epithelial T-cells with predominant CD8αα phenotype. *Leukemia* 2013;27:1688-96.
[18] Kikuma K, Yamada K, Nakamura S, Ogami A, Nimura S, Hirahashi M, et al. Detailed clinicopathological characteristics and possible lymphomagenesis of type II intestinal enteropathy-associated T-cell lymphoma in Japan. *Hum. Pathol.* 2014;45:1276-84.
[19] Olivares-Villagómez D, Van Kaer L. Intestinal intraepithelial lymphocytes: sentinels of the mucosal barrier. *Trends Immunol.* 2018;39:264-75.
[20] Tse E, Gill H, Loong F, Kim SJ, Ng SB, Tang T, et al.Type II enteropathy-associated T-cell lymphoma: a multicenter analysis from the Asia Lymphoma Study Group. *Am. J. Hematol.* 2012;87:663-8.
[21] Ishibashi H, Nimura S, Kayashima Y, Takamatsu Y, Aoyagi K, Harada N, et al. Multiple lesions of gastrointestinal tract invasion by monomorphic epitheliotropic intestinal T-cell lymphoma, accompanied by duodenal and intestinal enteropathy-like lesions and microscopic lymphocytic proctocolitis: a case series. *Diagn. Pathol.* 2016;11:66.

In: Encyclopedia of Surgery (22 Volume Set)
Editors: Andreas Lehrer and Kristin Mueller
ISBN: 978-1-53618-329-0
© 2020 Nova Science Publishers, Inc.

Chapter 342

A RARE CASE OF CLEAR CELL PAPILLARY RENAL CELL CARCINOMA

Fili Sufangga[1] and Budiana Tanurahardja[2,*]
[1]Anatomical Pathology Residency Program, Faculty of Medicine,
Universitas Indonesia, Jakarta, Indonesia
[2]Department of Anatomical Pathology, Faculty of Medicine,
Universitas Indonesia, Jakarta, Indonesia

ABSTRACT

Clear cell papillary renal cell carcinoma is an indolent neoplasm composed of clear epithelial cells arranged in tubules and a papillary structure, with predominantly linear nuclear alignment away from the basement membrane. In this paper, we report our experience of diagnosing a rare case of clear cell papillary renal cell carcinoma. The patient was a 50-year-old male with a chief complaint of abdominal pain. A computed tomographic abdominal scan revealed a large heterogeneous multicystic mass on the left kidney. On the basis of the macroscopic examination, microscopy, and immunohistochemical staining, we diagnosed the tumor as a clear cell papillary renal cell carcinoma. This tumor is an uncommon variant of a renal cell neoplasm that has distinct histological and immunohistochemical characteristics. Pathologists should be aware of this entity because the biological behavior of this tumor is very different from that of conventional clear cell carcinoma.

Keywords: clear cell papillary renal cell carcinoma, renal cell carcinoma

INTRODUCTION

Renal cell carcinoma (RCC) is the most common malignancy of the kidney, accounting for up to 90% of renal neoplasms in adults. The most common type is clear cell RCC,

* Corresponding Author's Email: budiana.t@gmail.com.

followed by papillary RCC. Clear cell RCC is a malignant tumor composed of cells with clear or eosinophilic cytoplasm. Papillary RCC has a papillary or tubulopapillary structure and is often circumscribed. The papillae are separated by delicate fibrovascular cores with foamy macrophages and hemosiderin. Other subtypesare Xp11.2 translocation-associated RCC and clear cell papillary RCC (CCPRCC) with papillary architectures and a clear cell morphology [1, 2].

CCPRCC is an indolent renal tumor composed of a single layer of cells with clear cytoplasm with tubules and a papillae structure. Tickoo et al. reported a lesion appearing in patients with end-stage kidney disease, but these tumors could be found in otherwise normal kidney. Aydin et al. in a large series reported similar tumors as clear cell tubulopapillary RCC (CCTPRCC) [1, 3-5].

Patients with CCPRCC usually are asymptomatic and sometimes present with abdominal pain. Some tumors are found in the follow-up after dialysis. This tumor accounts for 1%-4% of all resected renal neoplasms. The ages of patients range from 18 to 88 years, with a mean of 70 years. There is no sex predilection [1, 6]. The tumor sizes range from 0.2 to 7.5 cm (mean, 2.0; median, 1.8 cm). The tumor is commonly well defined and well encapsulated with cystic changes, and it sometimes presents as a solitary mass. CCPRCC is characterized by tubular papillary infoldings, and acinar cystic, ribbon-like, and solid patterns are seen in varying proportions. The tumor cells are cuboidal to low columnar, with clear cytoplasm or scant eosinophilic cytoplasm and uniform nuclei with inconspicuous nucleoli arranged linearly away from the basement membrane. Immunohistochemically, these tumors show positivity for cytokeratin 7 (CK7), carbonic anhydrase IX (CA9), and vimentin and negativity for CD10, RCC marker, and alpha-methylacyl-CoA racemase (AMACR). CCPRCC is different from conventional cell RCCsthat are CK7 negative and CD10 positive and from papillary cell carcinomas that are CK7, CD10, and racemase positive [6-9].

Because of its rarity, we report a case of CCPRCC that had overlapping features with those of papillary RCC and clear cell RCC but different genetic and immunohistochemical features and seemed to be indolent, with no detectable metastases.

CASE REPORT

A 50-year-old male patient came to the Islamic Jakarta Hospital on December 20, 2014, with a chief complaint of flank pain and hematuria. He had experienced intermittent flank pain since 1 year prior to hospital admission. During that time, he had gone to a doctor and been told that he had muscle pain. He had a 4-year history of hypertension and was regularly taking captopril 2 × 25 mg. The patient also had experienced hematuria but had ignored it. A history of pain during urination was denied. He had experienced weight loss and felt a mass in his left abdomen 6 months prior to hospital admission. He had a smoking habit of 3-4 cigarettes per day.

On December 20, 2014, he felt severe flank pain and hematuria. He then felt nausea and experienced vomiting. In the Islamic Jakarta hospital, he underwent a computed tomography (CT) abdominal scan without contrast, which revealed a large heterogeneous 9.5 × 11 × 14-cm mass on the left kidney that had already passed through the capsule but not the Gerota fascia. A focus of calcification was also observed.

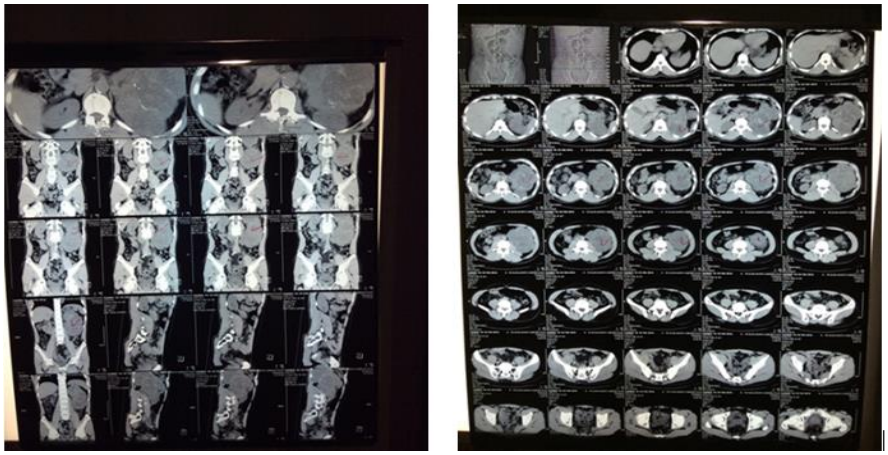

(a) (b)

Figure 1. A Coronal section of the abdomen CT Scan shows a large (9.5 × 11 × 14 cm) heterogeneous mass that has already passed through the capsule but has not yet invaded the Gerotafascia. Calcification is also shown. B. Axial section of the abdomen CT Scan.

Table 1. Patient's laboratory results

Type of examination	Result	Unit
Hemoglobin	13.9	g/dL
Hematocrit	41.6	%
Erythrocyte	4.72	10^6/µL
Leukocytes	7390	µL
Platelets	210.000	µL
Urea	35	mg/dL
Creatinine	1.6	mg/dL
Glomerular filtration rate	50,9	mL/min/1.73m^2
Sodium	143	mEq/L
Potassium	4.94	mEq/L
Chloride	100	mEq/L

The urologist suggested that the patient needed surgery in Dr. Cipto Mangunkusumo Hospital. On February 3, 2015, a nephrectomy was performed. The results of the laboratory testing performed on February 2, 2015, are presented in Table 1.

The specimen was sent to the anatomical pathology laboratory. On macroscopic examination, the size of the left kidney was 18 × 11.5 × 8.5 cm, and the outer surface was smooth, brown in color, and rubbery in consistency. A cut surface showed a multicystic partially solid mass that filled almost all of the kidney parenchyma. The size of the tumor was 17 × 6 × 5 cm. The mass had infiltrated the pelviocalyceal system but had not penetrated the capsule. A microscopic examination showed that the epithelial tumor hadan acinar, multicystic, solid papillary structure. The tumor cells had small, hyperchromatic, vesicular nuclei located on the apical side of the cell. The cytoplasm was mostly clear. The stroma was fibrotic and had been infiltrated by inflammatory cells. The tumor had infiltrated the capsule but had not yet penetrated the perirenal fat. The tumor was diagnosed as a clear cell papillary RCC.

On April 19, 2016, we performed immunohistochemistry staining, including CK7, CD10, AMACR, vimentin, high molecular weight cytokeratin (HMWCK), CK8, CK18, epithelial membrane antigen (EMA), and Ki67 of the tumor to provide supporting results for the diagnosis. The results showed that the tumor was positive for CK8, CK18, EMA, CK7, CD10, HMWCK, and vimentin and negative for AMACR and Ki67 < 1%.

(a) (b)

Figure 2. Gross pathology. (a) The surface of the kidney; (b) Cut surface of the kidney, which shows a multicystic partially solid mass.

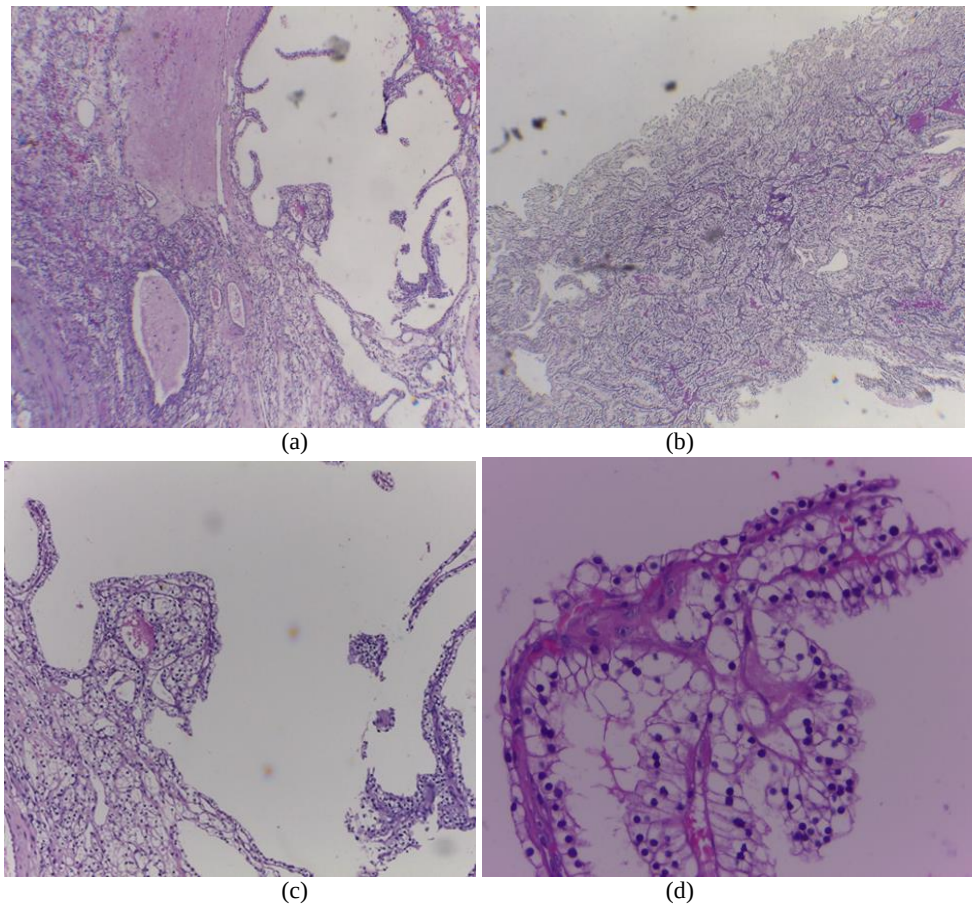

(a) (b)

(c) (d)

Figure 3. Microscopic image showing hematoxylin and eosin staining. A. Cystic and papillary structure (40×). B. Solid structure (40×). C. Papillary structure (100×). D. The nuclei is situated away from the basement membrane (400×).

DISCUSSION

CCPRCC is a low-grade RCC that occurs in both end-stage kidney disease and normal kidneys and is usually located in the renal cortex. More than 95% of tumors are pT1 at presentation and are rarely multilocal or bilateral [6, 7]. Radiographically, CCPRCC is located mid-pole in the kidneys. Some studies have reported that CCPRCC showed frequent heterogeneity suggestive of a mixed solid-cystic nature, and homogeneous solid appearing tumors have also been seen [1, 2, 6].

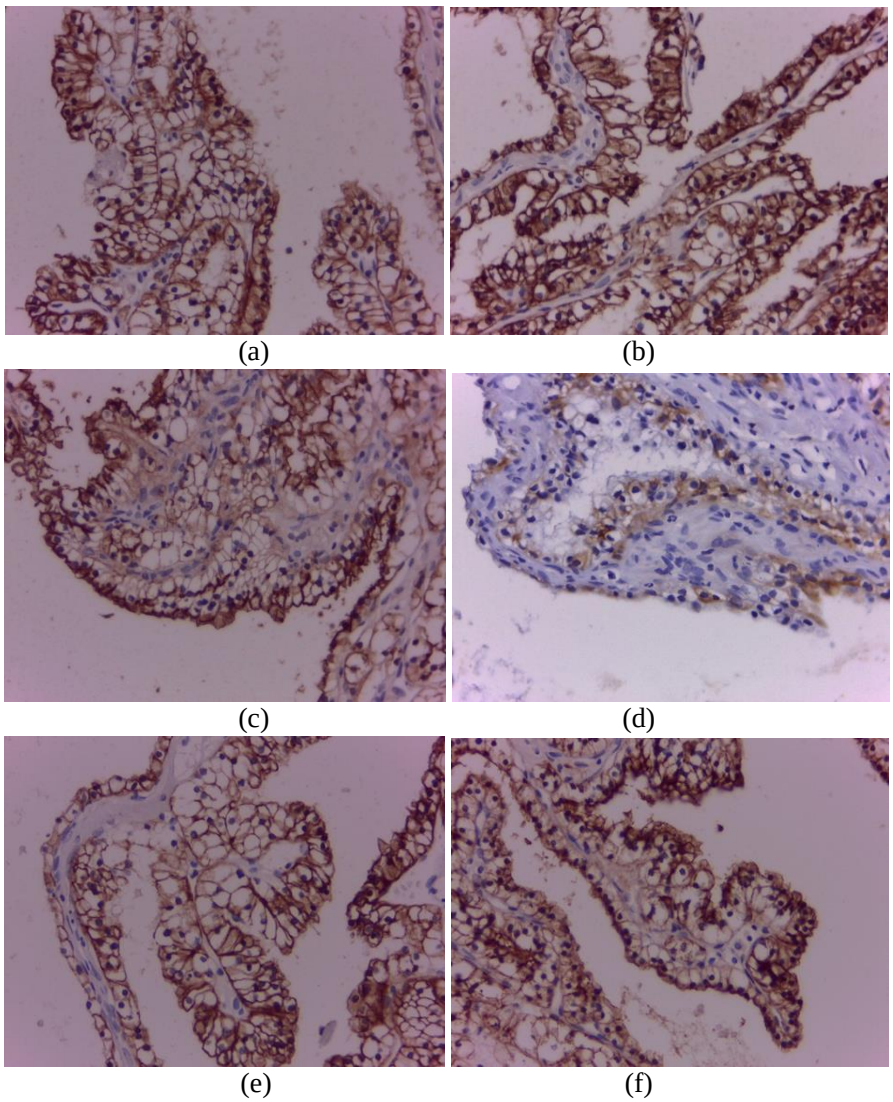

Figure 4. A. Positive staining for CK8 (400×). B. CK18 (400×). C. EMA (400×). D. HMWCK (400×). E. CK7 (400×). F. CD10 (400×).

These tumors are often small, well circumscribed, and well encapsulated. Surface coloration is variable and necrosis is absent. Histopathologically, CCPRCC commonly shows

cystic, tubular, acini, papillary, ribbon-like, and solid patterns in varying proportions. The cells are cuboidal to low columnar, with clear or scant eosinophilic cytoplasm, round uniform nuclei and a low Fuhrman nuclear grade (1 or 2). The cells are arranged linearly away from the basement membrane or toward the apical surface. It is believed that CCPRCC has a better prognosis than those of clear cell RCC and papillary RCC. Smooth muscle and fibrous stroma in varying amounts have been noted. There is no tumor necrosis, perirenal invasion, or lymphovascular invasion in CCPRCC [2, 3, 6].

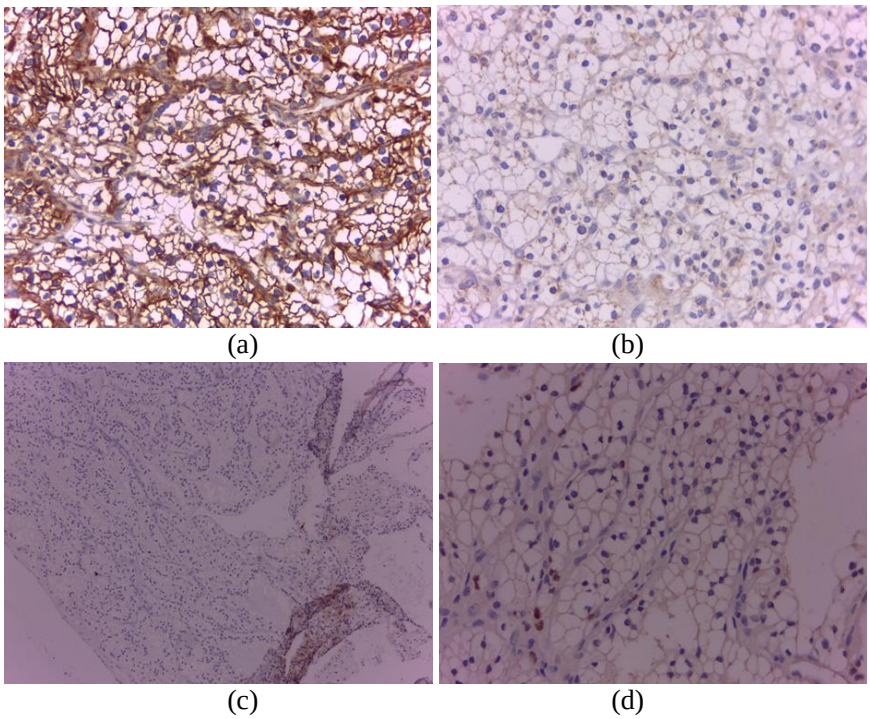

Figure 5. A. Vimentin (+) (400×). B. Negative for AMACR (400×). C and D. Ki67 < 1% (100× and 400×).

Immunohistochemically, tumor cells usually show positive expression for cytokeratin 7, CA9, hypoxia-inducible factor-1, glucose transporter 1, HMWCK, paired box 2 (PAX2), PAX-8, and smooth muscle actin but negative for AMACR, RCC Ma, TFEB, TFE3, parvalbumin, vinculin, and cathepsin K. Most tumors are negative or focally positive for CD10 [1, 9-13]. In renal cell tumors, CK7 is often use to distinguish ccRCC and its differential diagnosis. PRCC and chromophobe RCC are positive for CK7. CCPRCC is diffusely positive in a membranous pattern, which is useful in distinguishing between conventional clear cell carcinoma CCPRCC. CA9 is a hypoxia-induced protein and predominantly positive in clear cell RCC. CA9 is expressed in cup-shaped distribution in CCPRCC. CA9 is useful in differentiating papillary RCC with clear cell changes from clear cell RCC and CCPRCC. CCRCC and CCPRCC are positive for CA9, whereas PRCC is completely negative or may be focally positive. AMACR is usually negative in CCPRCC and shows diffusely strong cytoplasmic staining in PRCC. CD10, a proximal tubule marker, is

positive in conventional clear cell RCC with a membranous pattern [6, 9, 11, 14]. CD10 is variably expressed in most tumors and shows focal staining [15].

This tumor generally lacks genetic abnormalities observed in either conventional clear cell RCC or papillary RCC. CCPRCC does not harbor the chromosome 3p deletions that occur in clear cell RCC or demonstrate trisomies 7 and 17 or loss of Y in papillary RCC. Both mutations and methylation of the VHL gene promoters have not been reported to date [16-18].

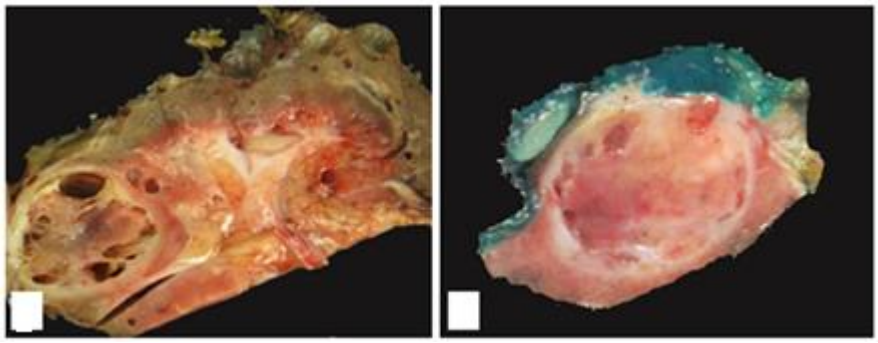

(a) (b)

Figure 6. CCPRCC. A. Macroscopic view of the tumor showing a tan cut surface with a mixed cystic/solid appearance. B. Shown is a pink-tan cut surface with solid architecture and a thin capsule [8].

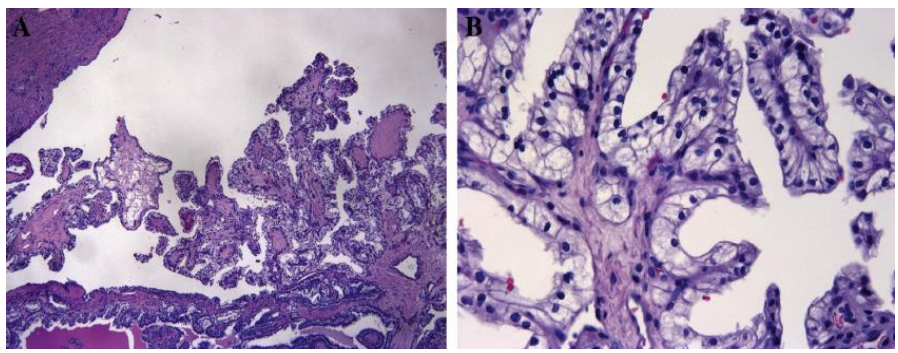

(a) (b)

Figure 7. (a) CCPRCC with papillary architecture (40×); (b) Nuclei situated away from the basement membrane (400×) [9].

The key to distinguishing between CCPRCC and CCRCC includes the pink-tan cut surface and nuclear positioning away from the basement membrane in CCPRCCand golden-yellow cut surface, mitoses, necrosis, vascular invasion, and network of small thin-walled blood vessels in CCRCC. Often, CCRCC is positive for CD10, PAX8, and CA9 and negative for CK7, with variable results for AMACR. Deletion of chromosome 3p and mutation of the VHL gene are seen in CCRCC [1, 15-19]. Macroscopically, papillary RCC is usually well circumscribed and surrounded by a fibrous pseudocapsule. Immunohistochemically, PRCC often shows positivity for CK7, HMWCK, AMACR, RCC marker, and CD10. CK7 expression is more common in type 1 PRCC than in the type 2 tumor [6, 9]. Multilocular

cystic renal cell neoplasms of low malignant potential are indicated byseptated, variably sized, thin-walled cysts separated from the uninvolved renal tissue by a fibrous capsule.

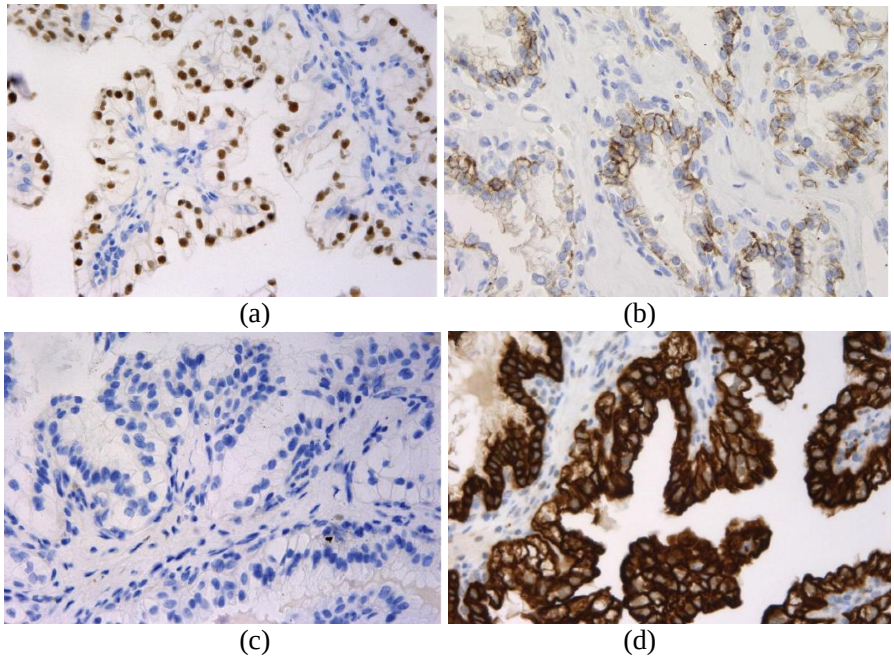

Figure 8. Immunohistochemical staining results. (a) PAX-8, 400x; (b) CA9, 400x; (c) AMACR, 400x; (d) CK7, 400x [9].

These clear cells show low-grade nuclear features lining the cystic spaces within afibrous septa, although solid areas are, by definition, absent. CCPRCC is strongly positive for cytokeratin 34 and betaE12 and negative for AMACR [1, 8, 9]. Multilocular cystic renal cell neoplasms of low malignant potential also show mutations of the VHL gene and deletion of chromosome 3p. Another differential diagnostic is an RCC with Xp11.2 translocations. The most distinctive and common pattern is the presence of a papillary architecture composed of clear cells with high-grade nuclei and some stromal hyaline nodules and psammomatous calcifications. The Xp11.2 translocation type shows the TFE3 protein in nuclear staining [8, 20].

CONCLUSION

In summary, CCPRCC is a relatively common renal cell neoplasm. Pathologists should be aware of the common incidence of this entity and its overlapping features with other RCCs to avoid the misclassification of CCPRCC as a CCRCC and vice versa. In equivocal cases, immunohistochemical stains such as CK7, AMACR, or CD10 are helpful in determining the correct diagnosis.

REFERENCES

[1] Kuroda, N; Ohe, C; Kawakami, F; Mikami, S; Furuya, M; Matsuura, K; et al. (2014). Clear cell papillary renal cell carcinoma: a review. *International Journal of Clinical and Experimental Pathology*, 7: 7312-318.

[2] Gill, S; Kauffman, EC; Kandel, S; George, S; Schwaab, T; Xu B. (2016). Incidence of Clear Cell Papillary Renal Cell Carcinoma in Low-Grade Renal Cell Carcinoma Cases: A 12-Year Retrospective Clinicopathologic Study From a Single Cancer Center. *International Journal of Surgical Pathology*, 24: 207-12.

[3] Bing, Z; Tomaszewski, JE. (2011). Clear cell papillary renal cell carcinoma in the bilateral native kidneys after 2 years of renal transplantation: report of a case and review of the literature. *Case Reports in Transplantation*, 2011: 1-4.

[4] Shi, SS; Shen, Q; Xia, QY; Tu, P; Shi, QL; Zhou, XJ; et al.(2013). Clear cell papillary renal cell carcinoma: a clinicopathology study emphasizing ultrastructural features and cytogenetic heterogeneity. *International Journal of Clinical and Experimental Pathology*, 6: 2936-42.

[5] Liddell, H; Mare, A; Heywood, S; Bennet, G; Chan, HF. (2015). Clear cell papillary renal cell carcinoma: a potential mimic of conventional clear cell renal carcinoma on core biopsy. *Case Reports in Urology*, 1-4.

[6] Srigley, JR; Cheng, L; Grignon, DJ; Tickoo, SK. Clear cell papillary renal cell carcinoma. (2016). In: Moch H, Humphrey PA, Ulbright TM, Reuter VE editors. *World Health Organization Classification of Tumors. Pathology and genetic of tumor of the urinary system and male genital organ.* Lyon: IARC Press; 40-1.

[7] Park, JH; Lee, C; Suh, JH; Moon, KC. (2012). Clear cell papillary renal cell carcinoma: a report of 15 cases including three cases of concurrent other-type renal cell carcinomas. *Korean Journal of Pathology*, 46: 541-47.

[8] Alexiev, BA; Drachenberg, CB. (2014). Clear cell papillary renal cell carcinoma: Incidence, morphological features, immunohistochemical profile, and biologic behavior: A single institution study. *Pathology-Research and Practice*, 210: 234-41.

[9] Pramick, M; Zobier, A; Bing, Z. (2013). Useful immunohistochemical panel for differentiating clear cell papillary renal cell carcinoma from its mimics. *Annals of Diagnostic Pathology*, 17: 437-40.

[10] Zhou, H; Zheng, S; Troung, LD; Ro, JY; Alaya, AG; Shen, SS. (2014). Clear cell papillary renal cell carcinoma is the fourth most common histologic type of renal cell carcinoma in 290 consecutive nephrectomies for renal cell carcinoma. *Human Pathology*, 45: 59-64.

[11] Williamson, SR; Eble, JN; Cheng, L; Grignon, DJ. (2013). Clear cell papillary renal cell carcinoma differential diagnosis and extended immunohistochemical profile. *Modern Pathology*, 26: 697-708.

[12] Alexiev, BA. (2012). Clear cell papillary renal cell carcinoma: A novel category of renal cell neoplasm. *Journal of Cytology and Histology*,3: 1-2.

[13] Yan, WX; Cao, WR; Zhao, J; Zhang, W; Wang, XL; Yuan, Q; et al. (2015). Original Article Clear cell papillary renal cell carcinoma: a clinicopathologic analysis of 6 cases. *Internatinal Journal of Clinical and Experimental Pathology*, 8: 4595-99.

[14] Deml, KF; Schildhaus, HU; Comperat, E; Teichman, AV; Storz, M; Schraml, P; et al. (2015). Clear cell papillary renal cell carcinoma and renal angiomyo adenomatous tumor-two variants of a morphologic, immunohistochemical and genetic distinct entity of renal cell carcinoma. *The American Journal of Surgical Pathology,* 39: 889-901.

[15] Rao, P; Monzon, F; Jonasch, E; Matin, SF; Tamboli, P. (2014). Clear cell papillary renal cell carcinoma in patients with von Hippel-Lindau syndrome—clinicopathological features and comparative genomic analysis of 3 cases. *Human Pathology*, 45: 1966-72.

[16] Rohan, SM; Xiao, Y; Liang, Y; Dudas, ME; Al-Ahmadie, HA; Fine, SW; et al. (2011). Clear-cell papillary renal cell carcinoma: molecular and immunohistochemical analysis with emphasis on the von Hippel–Lindau gene and hypoxia-inducible factor pathway-related proteins. *Modern Pathology*, 24: 1207-20.

[17] Shazad, H; Kehar, SI; Ali, S; Tariq, N. (2014). Expression of Von Hippel-Lindau (VHL) gene mutation in diagnosed cases of renal cell carcinoma. *Pakistan Journal of Medical Sciences*, 30: 880-5.

[18] Petersson, F; Grossmann, P; Hora, M; Sperga, M; Montiel, DP; Martinek, P; et al. (2013). Renal cell carcinoma with areas mimicking renal angiomy oadenomatous tumor/clear cell papillary renal cell carcinoma. *Human Pathology*, 44: 1412-20.

[19] Moch, H; Bonsib, SM; Delahunt, B; Eble, J; Egevad, L; Grignon, DJ; et al. (2016). Clear cell renal cell carcinoma. In: Moch H, Humphrey PA, Ulbright TM, Reuter VE editors. *World Health Organization Classification of Tumors. Pathology and genetic of tumor of the urinary system and male genital organ.* Lyon: IARC Press; 18-21.

[20] Parihar, A; Tickoo, SK; Kumar, S; Arora, VK. (2015). Xp11 translocation renal cell carcinoma morphologically mimicking clear cell-papillary renal cell carcinoma in an Adult Patient: Report of a Case Expanding the morphologic Spectrum of Xp11 Translocation Renal Cell Carcinomas. *International Journal of Surgical Pathology*, 23: 234-7.

In: Encyclopedia of Surgery (22 Volume Set)
Editors: Andreas Lehrer and Kristin Mueller
ISBN: 978-1-53618-329-0
© 2020 Nova Science Publishers, Inc.

Chapter 343

RARE CASE OF MYELOLIPOMATOUS METAPLASIA WITHIN AN ADRENOCORTICAL ADENOMA

Monik Ediana Miranda[1,*], Maria Francisca Ham[2], Agnes Stephani Harahap[2] and Benyamin Makes[2]

[1]Anatomical Pathology Residency Program, Faculty of Medicine, Universitas Indonesia, Jakarta, Indonesia

[2] Department of Anatomical Pathology, Faculty of Medicine, Universitas Indonesia, Jakarta, Indonesia

ABSTRACT

The actual incidence of adrenocortical adenoma (ACA) remains unknown. Data obtained from 2011 to 2015 in Cipto Mangunkusumo Hospital have revealed that only 14 patients presented with adrenal neoplasms; of these patients, 11 were diagnosed with ACA. Myelolipomatous metaplasia is characterized by the presence of foci of hematopoietic cells comprising erythroids, myeloids, and megakaryocytes within a tumor. This metaplasia is an extremely rare finding in adrenal tumors, particularly in ACA. The pathogenesis of myelolipomatous metaplasia remains unclear. Herein, we report the case of a 40-year-old man who presented with a mass in his abdomen. Without any contributory signs and symptoms, the size of the mass increased within 4 months of diagnosis. Computed tomography of the abdomen showed a heterogenous mass in the right suprarenal region with fine demarcated outlines, and the result was indicative of an adrenal carcinoma. The patient underwent adrenalectomy. Based on hematoxylin &eosin (H&E) staining and immunohistochemical analysis, the mass was confirmed to be a non-functional ACA with a myelolipomatous metaplasia. The case was uneventful, and the patient was then discharged with recommendation of an annual follow-up. ACA is a rare type of tumor. Myelolipomatous metaplasia found within an adenoma of the adrenocortex is an even more uncommon finding. The correlation between clinical, radiological, and pathological examination results must be assessed for a more accurate diagnosis. The combination of H&E staining and immunostaining is helpful in facilitating the diagnosis of adrenocortical tumors and metaplasia within the tumor.

[*] Corresponding Author's Email: doktermonik@gmail.com.

Keywords: adenoma; adrenal; myelolipomatous metaplasia

INTRODUCTION

The adrenal gland is a 4-g organ that lies in the suprarenal region. It can be divided into two regions (cortex and medulla). Each zone secretes different hormones and has its own functions. Adrenal neoplasm is defined as a neoplasm arising from the adrenal cells. A tumor arising from the cortical area of the adrenal gland is basically classified as follows: benign adrenocortical adenoma (ACA) and malignant adrenocortical carcinoma (ACC) if invasion is observed [1].

Nodules that are suspected as neoplasms are commonly identified in autopsies. Some are discovered incidentally during annual check-up or imaging screening for other causes. These nodules are referred to as adrenal incidentaloma. Approximately 80% of adrenal incidentaloma is benign and does not secrete hormones (non-functional). Symptoms may be observed depending on tumor location and whether they are functional or not [1, 2].

The actual incidence of ACA is unknown. Data obtained from 2011 to 2015 in Cipto Mangunkusumo Hospital have reported that only 14 patients presented with adrenal neoplasm; of these patients, 11 were diagnosed with ACA, which is typically a unilateral, solitary, and benign neoplasm. With the widespread use of computed tomography (CT) scan of the abdomen, the diagnosis of such condition is increasing. Some studies have reported that the incidence of non-functional adrenal tumors varies between 1.4% and 8.7% based on autopsy studies. The prevalence of adrenal incidentaloma increases with age, and no differences were observed in terms of prevalence based on race and sex [2, 3].

Different types of metaplasia can develop within the adrenal gland. Occasionally, lipomatous foci or bone cell metaplasia can be found. Myelolipomatous metaplasia within an ACA is an extremely rare cause of adrenal incidentaloma. In 2008, only 17 cases of such condition were reported in the English and Japanese literature. The present study aimed to present a rare case of myelolipomatous metaplasia within an ACA and to establish an effective diagnostic approach from the view point of a pathologist if such condition will be encountered in the future [4].

CASE REPORT

A 40-year-old Indonesian male patient was referred by his office physician to the internal medicine department of a hospital in Jakarta in October 2014. The patient was required to undergo an annual check-up resulting in the incidental finding of a large mass in his abdomen. The patient's family and past medical history was not significant. He was free of symptoms, such as palpitation, weight loss, and hypertension. His electrocardiograph and chest radiograph results showed no abnormalities. The general internist performed

ultrasonographic examination and found a mass in the abdomen (Figure 1). A hyperechoic lesion was observed in the right lobus of his liver. The patient was suspected to have a hepatic cellular carcinoma, and the differential diagnosis were hemangioma or a focal fatty infiltration. The internist then recommended whole abdominal contrast-enhanced CT scan and laboratory work up.

The patient had a follow-up consultation a week later with the CT scan and laboratory test results. He was non-reactive for hepatitis C and had normal blood glucose level (fasting glucose level of 85 mg/dL and 2-hour post prandial level of 109 mg/dL), and the following tumor markers were assessed: alpha-fetoprotein (AFP), Ca 19.9, and carcinoembryonic antigen (CEA). The CEA and AFP levels of the patient were within normal limits (CEA: 2.71 [normal value: ≤ 3 ng/mL] and AFP: 2.13 [range: 0–40] ng/mL). The Ca 19.9 level was elevated, which was twice than the normal limit (83.79 U/mL [normal value: < 37 U/mL]). The CT scan result showed a heterogenous mass in the right suprarenal region with fine demarcated outlines, and such result indicated an adrenal carcinoma. The differential diagnosis were changed to adrenal adenoma or adrenal hemorrhage (Figure 2). The patient was then referred to an endocrinologist.

The patient sought consultation from an endocrinologist 4 months after, and the size of the mass increased based on ultrasonographic examination (Figure 1). In February 2015, his body mass index was above the normal limit (26 kg/m^2). His blood pressure was slightly elevated (138/91mmHg). However, the patient's heart rate, respiratory rate, and temperature were normal (99 beats/minute, 17 cycles/minute, and 36.5°C, respectively). The endocrinologist requested for routine blood test, liver function test, uric acid, glucose, bleeding time and electrolyte. All of his laboratory test came back with normal results.

Based on this finding, the endocrinologist referred the patient to a urologist. Three days after, the urologist performed adrenalectomy. The right adrenal gland was resected and was sent to the Department of Anatomycal Pathology at the same hospital. The specimen measured 11.0×10.0×7.0 cm^3, and was a round capsulated mass with fine demarcated outlines, most of which appeared yellow with hemorrhagic areas on the cut surface. Small brown-black lesions that vary in size (0.4–3.0×2.0×2.0 cm^3) were observed (Figure 3).

Histologically, the suprarenal tumor showed a mass that was demarcated with a well-developed fibrous capsule. On the peripheral side, there were ACA and brown-black lesions with fat tissues and widely hemorrhagic areas, hematopoietic cells, fibrotic areas, and brownish pigmentations. No signs of malignancies were observed (Figure 4). Immunohistochemistry staining was conducted at the Ciptomangunkusumo Hospital, and results showed positivity for inhibin, Wilms tumor 1 (WT1), neuron-specific enolase (NSE), vimentin, synaptophysin, Melan-A, calretinin, AE 1/3, and chromogranin as well as low positivity for Ki-67 in the area with suspected ACA. The brown-black lesions tested positive for myeloperoxidase (MPO), cluster of differentiation (CD) 117, CD 3, CD 20, CD 15, multiple myeloma (MUM) 1, CD 68, and CD 138 and negative for CD 34 (Figure 5). Hence, the final diagnosis was ACA with myelolipomatous metaplasia.

(a)

(b)

Figure 1. (a) Result from the first ultrasonography showed a 7×6 cm^2 mass that was suspected to originate from the liver in October 2014. (b) Image from the second ultrasonography in February 2015 showed that the size of the mass increased (9×7 cm^2). After the examination, the tumor was suspected to originate from the suprarenal region.

Figure 2. Result of the computed tomography scan revealed a hypervascular mass in the right adrenal gland with early washout enhancing pattern**.**

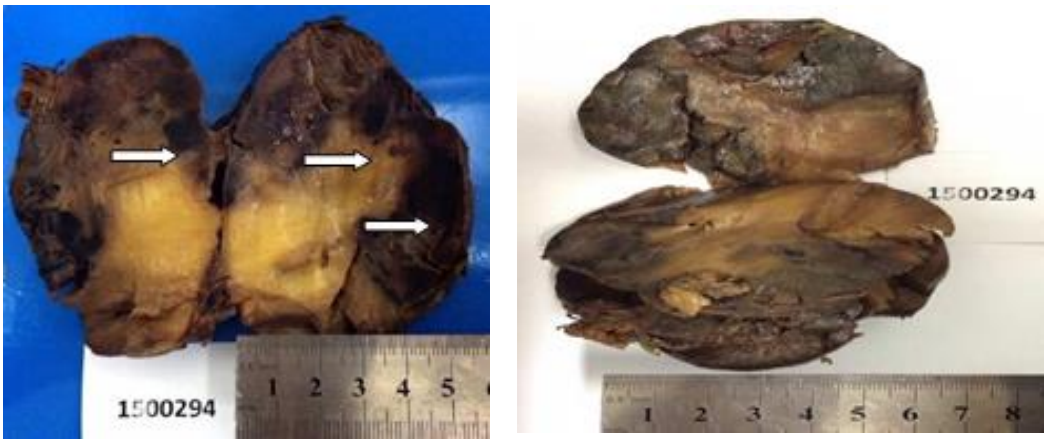

(a) (b)

Figure 3. Macroscopic view of the resected right adrenal gland. (a) View from the longitudinal section showing yellow with brown-black lesions on the cut surface (white arrow showing the brown-black lesion). (b) Posterior view of the image showing yellow-to-brown surface with an intact capsule.

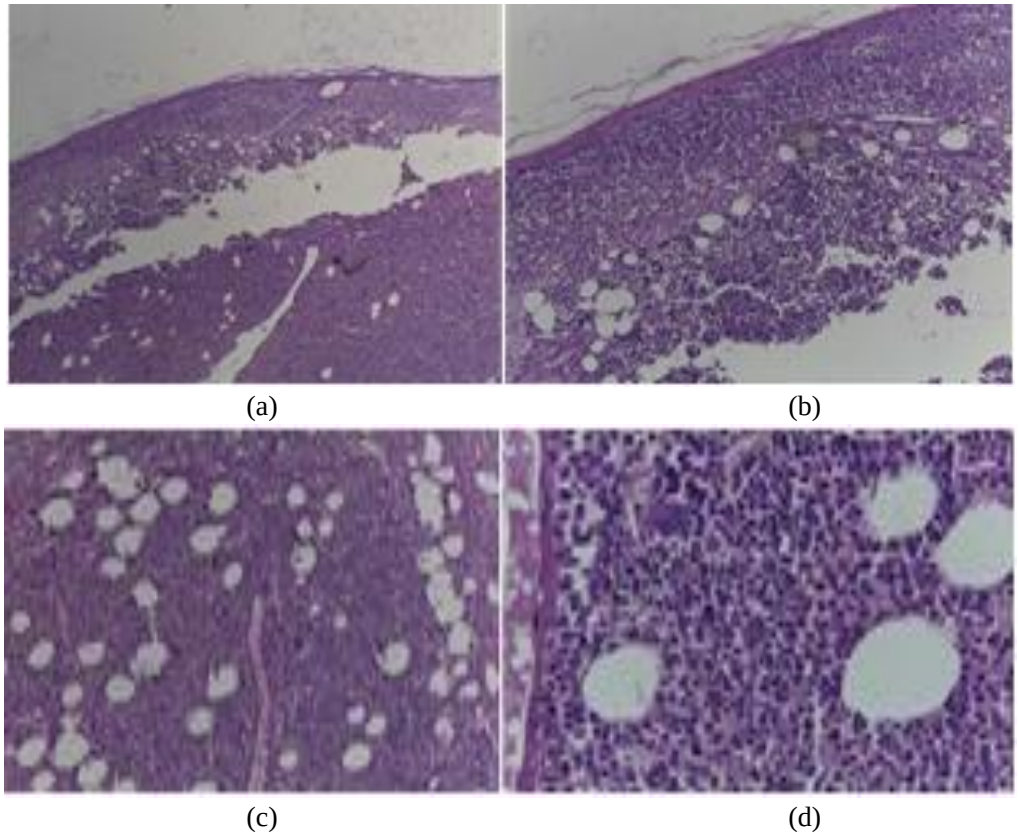

Figure 4. Photomicrograph. (a) Finely demarcated mass with well-developed fibrous capsule indicative of an adrenocortical adenoma (Hematoxylin & Eosin staining, 40x). (b). Higher magnification of the adrenocortical adenoma (Hematoxylin & Eosin staining, 100x). (c) Area from the brown-black lesion showing fat tissues and hematopoietic cells (Hematoxylin & Eosin staining, 100×). (d) Higher magnification of foci of the myelolipoma (Hematoxylin & Eosin staining, 400×).

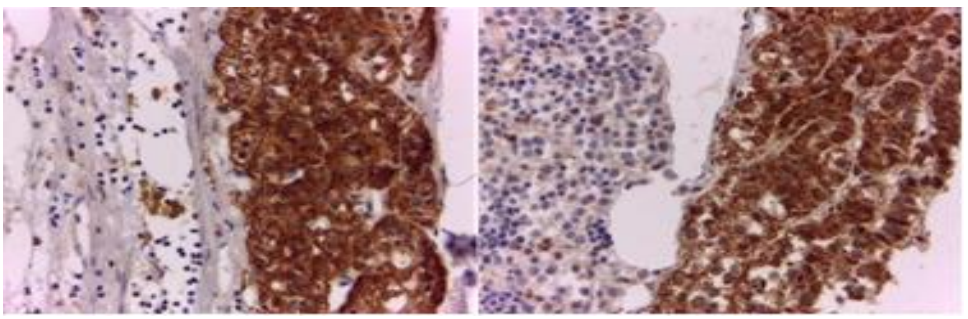

Figure 5. (Continued).

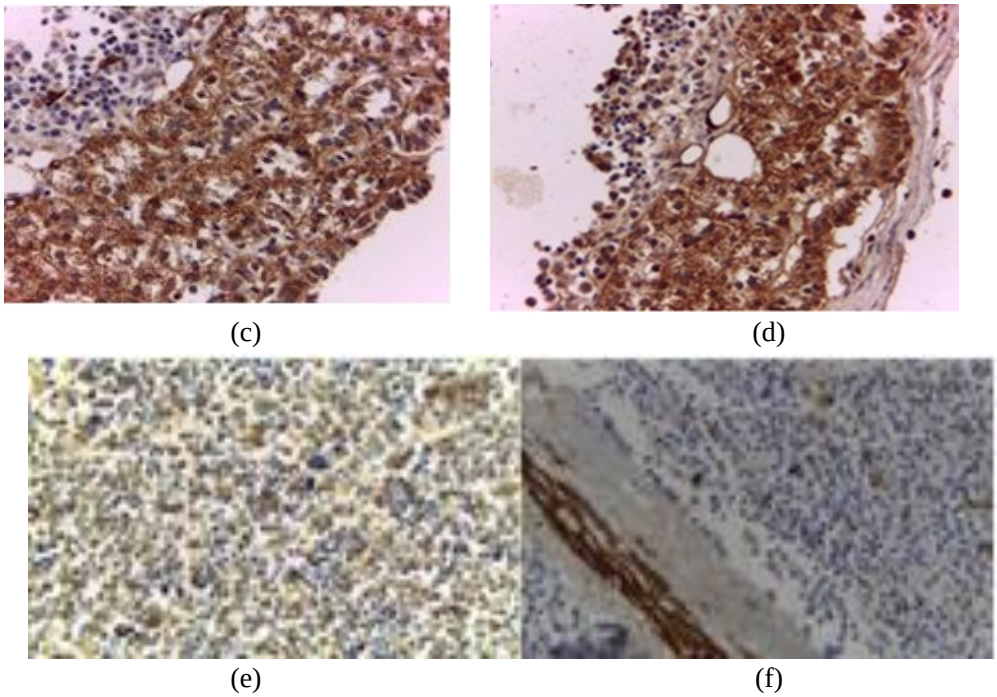

Figure 5. Immunohistochemistry staining results showing cytoplasmic and cell membrane positivity. (a) Inhibin (400×), (b) NSE (400×), (c) WT1 (400×) and (d) S100 (400×). The brown-black lesions showed (e) cytoplasmic positivity for MPO (400×) and (f) negativity for CD 34 (400×).

DISCUSSION

ACA is a rare type of tumor. Myelolipoma within an ACA is even an extremely rare condition. In 2008, only 17 cases of such condition were reported globally. Thirteen of the patients were women with a mean age of 45 years, and the youngest patient was aged 16 years. In general, ACAs have a predilection for woman, and it can occur in any age groups. Moreover, its incidence is equally distributed in both glands. In this case, a 40-year-old male patient presented with right adrenal lesion. No clinical findings, such as hypertension, hypokalemia, or hormonal imbalance, were observed. Hence, it was suspected as benign and non-functional adrenal lesion [4-9].

The widespread use of imaging has resulted in the increasing diagnosis of adrenal incidentaloma, which is an incidental mass. The World Health Organization defined this lesion as an adrenal mass that is identified serendipitously via radiologic examination in the absence of symptoms and clinical findings indicative of adrenal diseases. Imaging procedures can help in the localization of adrenal cortical adenoma. ACAs account for most adrenal masses incidentally found on CT scan in patients with indications other than suspected adrenal pathology and are typically characterized by a well-defined, round homogenous mass. The primary goal of imaging is to distinguish adrenal adenoma, adrenal carcinoma, pheochromocytoma, and metastatic lesions. The lesion in the abdomen of the patient incidentally found. First, the tumor was suspected as a hepatic carcinoma. However, based on

CT scan, which showed a heterogeneous with fine demarcated mass located in the suprarenal region, the physician then suspected the lesion as ACA [1, 5, 6, 10-14].

In the present study, the initial size of the mass was 7x6 cm. After 4 months, the size increased to 9 × 7 cm. The urologist then performed adrenalectomy. According to the American Association of Clinical Endocrinologists and American Association of Endocrine Surgeons (AACE/AAES) medical guidelines for the management of adrenal incidentalomas published in 2009, adrenalectomy after hormonal evaluation is the treatment option for a suspected malignant or indeterminate mass that is ≥ 4 cm on CT scan (Figure 6). Hormonal evaluation was not indicated in this patient due to the lack of obvious clinical signs [13, 15-17].

From the view of a pathologist, a differential diagnosis of a solid adrenal lesion include commonly diagnosed lesions (such as adenoma and pheochromocytoma) and uncommon lesions (including oncocytoma, ganglioneuroma, adrenal/peri-adrenal schwannoma, lipoma, and mature teratoma). We should also accurately differentiate benign lesions from adrenocortical carcinomas due to the fact that the prognosis, follow-up, and therapeutic strategy for ACC are different from those of a benign tumor [2, 14, 18].

The Weiss system is a method widely used to distinguish ACC from benign cortical tumor, including adenoma. The system was established in 1984 and included the following nine-point histopathological criteria: high nuclear grade, more than 5 mitoses per 50 high-power fields, atypical mitotic figures, with < 25% of tumor cells are clear cells, diffuse architecture (more than 33% of tumors), necrosis, venous invasion (smooth muscle in the wall), sinusoidal invasion (no smooth muscle in the wall), and capsular invasion. The presence of three or more criteria highly correlates with subsequent malignant behavior. In this case, only two criteria were observed, and < 25% of tumor cells were clear cells. Moreover, there were 10 mitoses per 50 high-power fields. Thus, based on the Weiss criteria, the adrenal lesion may be a benign lesion [1, 2, 6, 12].

Most ACAs are well-circumscribed intra-adrenal tumors, and some are encapsulated. Hemorrhage and necrosis are rarely observed. They can be tan-to -brown or bright yellow in appearance. Gross specimens obtained from oncocytoma are well-circumscribed adrenocortical lesions with dark tan-to-mahogany brown appearance (which is similar to other oncocytic lesions). They are large in size from 3 to 17 cm. Ganglioneuroma is an encapsulated mass with a solid, homogenous gray-white cut surface. Their size can reach up to 18 cm, and their consistency may range from gelatinous to solid. An adrenal/peri-adrenal schwannoma often appears as a solitary, well-circumscribed tumor enveloped in a fibrous capsule with a solid firm white-tan and homogenous cut surface that may contain cystic changes or hemorrhagic regions. Lipoma appears as a well-circumscribed tumor with a homogenous yellowish cut surface indicative of fat tissues. A mature teratoma showed a neoplasm indicating a mature tissue from the endoderm, mesoderm, and/or ectoderm. Lesions may be malignant if they had a coarsely lobulated appearance, with soft, bulging nodules ranging from yellow- orange to tan in color. A high number of areas with necrosis and hemorrhage are commonly observed. Examination of the gross specimen in this case revealed a rounded capsulated mass with fine demarcated outline, most of which appeared yellow with some of hemorrhagic areas and black-to-brown lesions on the cut surface. However, no necrosis was found. These findings were indicative of benign lesions, most probably an adrenal adenoma [1,6,19].

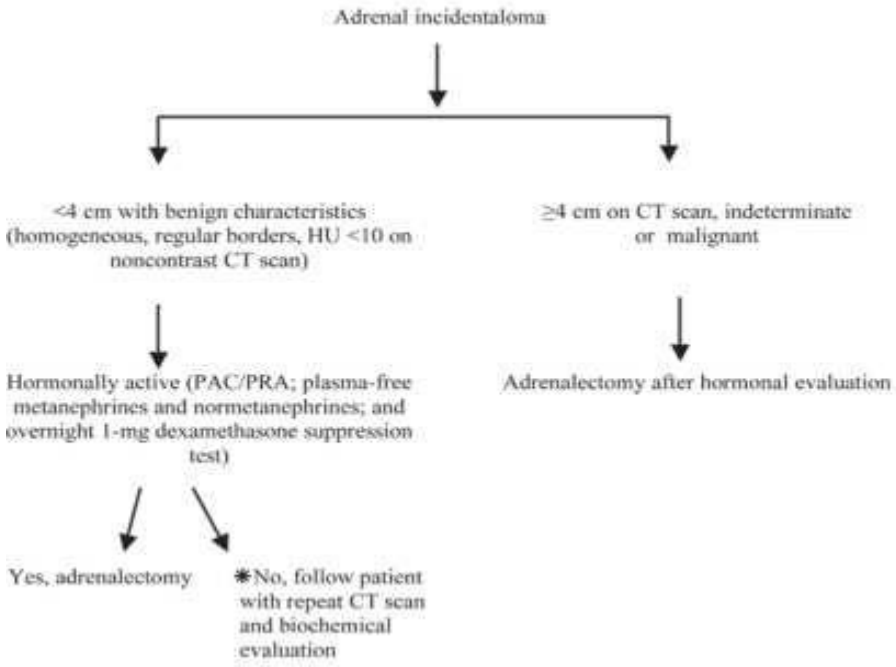

Figure 6. Algorithm for the evaluation and management of an adrenal incidentaloma according to the guidelines of the American Association of Clinical Endocrinologists and American Association of Endocrine Surgeons [13].

The definitive diagnosis of ganglioneuroma and schwannoma can be obtained via microscopic examination. Ganglioneuroma showed an area of Schwann cells with wavy dark nuclei and inconspicuous nucleoli with scant spindled cytoplasm, admixed with mature ganglion cells and eosinophilic cytoplasm, large vesicular nuclei, and prominent nucleoli. Oncocytomas have mitochondriac-rich cells with abundant compact eosinophilic cytoplasm that is finely granular. Adrenal/peri-adrenal schwannomas are microscopically identical to schwannomas found at any other anatomical sites. Spindle cells with alternating areas of compact hypercellularity with irregular streams and elongated spindle cells (Antoni type A) and of loosely-textured hypocellularity with cystic spaces (Antoni type B). In addition, Verocay bodies between the regions of nuclear palisades and thick walled hyalinized blood vessels may be observed. Mature teratomas are also microscopically identical with teratoma found elsewhere. The diagnosis of mature teratoma can be made if there is a minimum of two mature components observed from the endoderm (respiratory or digestive tract), mesoderm (fat tissue), or ectodermal (skin, bones, and chondrous tissue) without any immature component. ACAs consist of clear cells with abundant intracytoplasmic lipid droplets and compact cells with lipid sparse eosinophilic cytoplasm. These cells form cords and/or nests with relatively abundant vasculature or sinusoidal structures. The microscopic findings from this case were a fine demarcated lesion with mixture of clear and compact cells with eosinophilic cytoplasm indicative of adrenal adenoma and focal areas with myeloid and lipid component indicative of a myelolipoma metaplasia [1, 6, 7, 16, 19].

Table 1. Summary of the immunohistochemical staining confirming the adrenal tissues in this case and comparing them with the reference (+: positive, −: negative, n/a: not available) [7, 9-13]

Immunohistochemistry	ACA	Schwannoma	Ganglio-neuroma	ACC	Present case
S-100	+	+	+	+	+
Synaptophysin	+	−	+	+	+
CD-56	+	−	+	+	+
NSE	+	−	+	−	+
Laminin	−	+	−	−	n/a
Collagen IV	−	+	−	−	n/a
Desmin	−	−	−	−	n/a
CD-34	−	−	−	−	−
Keratin	+	−	−	+	+
Actin	+	−	−	+	n/a
Calretinin	+	−	−	+	+
Inhibin	+	−	−	+	+
Bcl-2	+	−	−	−	n/a
Melan-A	+	−	−	+	+

For further confirmation of the diagnosis of solid adrenal lesions, immunohistochemistry examination was conducted. According to Dabbs et al., stainings for markers, such as inhibin A, WT1, and AE 1/3, can be used to confirm of the lesion originated from the adrenal tissues. To distinguish a benign from a malignant lesion, Jia *et al*. have recommended NSE staining as it shows positivity in the cell membrane and cytoplasm. Staining was also performed to confirm that the brown-black lesions observed in the macroscopic examination were myeloid component. The stainings were positive for MPO, focal positive for CD 117, CD 3, CD 20, CD 15, multiple myeloma (MUM) 1, CD 68, and CD 138, and negative for CD 34. The results are depicted in Table 1 [7, 8, 17].

The adrenal gland may present with different metaplasias that can be observed during microscopic examination. Occasionally, we can find lipomatous foci or bone cell metaplasia and even ovarian thecal metaplasia inside the glands. In this case, we found foci of myelolipomatous metaplasia within ACA. The causes of such metaplasia are not fully elucidated. Currently, the most accepted theories were embolization of the bone marrow, embryonic primitive mesenchymal cells, dysregulation of hematopoietic cell apoptosis, and adrenal response to stimuli, such as necrosis, infections, andstress [4, 20, 21].

The overall prognosis of surgically resected ACAs is good. Jia et al., have reported no recurrences and metastases in any of the benign cases. The incidence rate of a benign adenoma developing into an ACC is not well known. However, such phenomenon is extremely rare [2, 11, 13].

CONCLUSION

A 40-year-old male patient presented with an incidental mass in the abdomen. The size of the mass increased within 4 months of diagnosis. The patient was then diagnosed with ACA

with myelolipomatous metaplasia by Hematoxylin & Eosin staining combined with immunohistochemistry staining. ACA is a rare type of tumor. Myelolipomatous metaplasia within an adenoma of the adrenocortex is an extremely rare finding. The correlation between clinical, radiological, and pathological examination results must be assessed to obtain a more accurate diagnosis. The pathogenesis of myelolipomatous metaplasia is still not fully elucidated.

ACKNOWLEDGMENTS

We would like to thank Evelina Kodrat, MD as pathologist who discovered the case and permitted the case to be reported. Nonetheless, thank you for my seniors and beloved fellow residents for the abundant support and encouragement.

REFERENCES

[1] Lack, E.E.(2007). *Tumors of the adrenal glands and extraadrenal paraganglia*. 3rd series. Washington DC: Armed Forces Institute of Pathology. 1-27.

[2] Lloyd, R.V., Tischer, A.S., Kimura, N., McNicol, A.M. & Young Jr, W.F. Tumours of adrenal gland. In: DeLellis RA, Lloyd RV, Heitz PU, Eng C, editors. *Pathology and Genetics of Tumours of Endocrine Organs*. Lyon: IARC Press; 2004; 136-146.

[3] Ridho, F. E., Adam, F. M.&Adam, J. M. (2009). Adrenal incidentaloma. *Acta Med. Indones*., 41 (2): 87-97.

[4] Ong, K., Tan, K.B.&Putti, T.C. (2007). Myelolipoma within a non-functional adrenal cortical adenoma. *Singapore Med. J.*, 48 (7):e200-e202.

[5] Hironobu, S., Yasuhiro, N., Takuya, M., & Takashi, S. Adrenal cortex. In: Lloyd RV, editor. *Endocrine Pathology Differential Diagnosis and Molecular Advances.* Rochester: Springer; 2010; 261-279.

[6] Kanthan, R., Senger, J. L. & Kanthan, S. (2012). Three uncommon adrenal incidentalomas: a 13 year surgical pathology review. *World J. Surg. Oncol.*, 10 (1):1-11.

[7] Wang, C., Sun, Y., Wu, H., Zhao, D., Chen, J. (2014). Distinguishing adrenal cortical carcinomas and adenomas: a study of clinicopathological features and biomarkers. *Histopathology*, 64 (4): 567-576.

[8] Zhang, P. J., Genega, E. M., Tomaszewski, J. E., Pasha, T. L. & LiVolsi, V. A. (2003). The role of calretinin, inhibin, melan-A, BCL-2, and C-kit in differentiating adrenal cortical and medullary tumors: an immunohistochemistry study. *Mod. Pathol*.,16 (6): 591-597.

[9] Delellis, R. A., Shin, S. J. & Treaba, D. O. Immunohistology of endocrine tumors. In: Dabbs DJ. Editor. *Diagnostic Immunohistochemistry Theranostic and Genomic Applications*. 3rd edition. Philadelphia, PA: Saunders-Elsevier; 2011; 291-329.

[10] Lack, E. E. Tumors of the adrenal glands and extraadrenal paraganglia AFIP Atlas of tumor pathology. 4th series. Washington DC: *Amer. Registry of Pathology*: 2007; 91-106.

[11] Jia, A. H., Du, H. Q., Fan, M. H., Li, Y. H., Xu, J. L., Niu, G. F., Niu, G.F., Bai, J., Zhang, G.Z. &Ren, Y.B. (2015).Clinical and pathological analysis of 116 cases of adult adrenal cortical adenoma and literature review. *Onco Targets and Ther*, 8:1251-1257.

[12] Lu, H. S., Gan, M. F., Chen, H. S.,& Huang, S. Q. (2008). Adrenal myelolipoma within myxoid cortical adenoma associated with Conn's syndrome. *J. Zheijang University Sci*. B,9 (6):500-505.

[13] Zeiger, M. A., Thompson, G. B., Duh, Q. Y., Hamrahian, A. H., Angelos, P., Elaraj, D, Fishman, E. & Kharlip, J.(2009).American association of clinical endocrinologists and American association of endocrine surgeons medical guidelines for the management of adrenal incidentalomas. *Endocr. Pract*., 15 (Suppl 1):S1-S20.

[14] Ctvrlik, F., Koranda, P. & Tichy, T. (2014). Adrenal disease: a clinical update and overview of imaging. A review. *Biomed. Pap. Med. Fac. Univ. Palacky Olomouc Czech Repub*., 158 (1):23-34.

[15] Willatt, J., Chong, S., Ruma, J. A. & Kuriakose, J. (2015). Incidental adrenal nodules and masses: the imaging approach. *Int. J. Endocrinol.*, 2015:1-6.

[16] Moreira, S. G. & Pow-sang, J. M. (2002). Evaluation and management of adrenal masses. *Cancer Control*,9 (4):326-334.

[17] Anagnostis, P., Karagiannis, A., Tziomalos, K., Kakafika, A. I., Athyros, V. G. & Mikhailidis, D. P. (2009) Adrenal incidentaloma: a diagnostic challenge. *Hormones*, 8 (3):163-184.

[18] Bialas, M., Okon, K. & Stachura, J. (2008). Primary adrenal tumor- a 16 year experience in a single institution. *Pol. J. Pathol*., 59:101-106.

[19] Lloyd, R. V. (2011). Adrenal cortical tumors, pheochromocytomas and paragangliomas. *Mod. Pathol*., 24 (Suppl 2): S58-S65.

[20] Bishop, E., Eble, J. N., Cheng, L., Wang, M., Chase, D. R., Orazi, A. & O'malley, D. P. (2006). Adrenal myelolipomas show nonrandom X-chromosome inactivation in hematopoietic elements and fat: support for a clonal origin of myelolipomas. *Am. J. Surg. Pathol*., 30 (7):838-843.

[21] Seyle, H. & Stone, H. (1950).Hormonally induced transformation of the adrenal into myeloid tissue. *Am. J. Pathol.*, 23 (2):211-233.

In: Encyclopedia of Surgery (22 Volume Set)
Editors: Andreas Lehrer and Kristin Mueller
ISBN: 978-1-53618-329-0
© 2020 Nova Science Publishers, Inc.

Chapter 344

CHRONIC MYELOID LEUKEMIA IN A BCR-ABL1-POSITIVE PATIENT WITH PANCYTOPENIA AND EXCESSIVE FIBROSIS

***Dian Sari Oethia Vathonati*[1]**
***and Agnes Stephanie Harahap*[2,*]**
[1]Anatomical Pathology Residency Program, Faculty of Medicine,
Universitas Indonesia, Jakarta, Indonesia
[2]Department of Anatomical Pathology, Faculty of Medicine,
Universitas Indonesia, Jakarta, Indonesia

ABSTRACT

Chronic myeloid leukemia (CML) is a myeloproliferative neoplasm of the hematopoietic stem cells, in which granulocytes are the major proliferative component. It is characterized by the chromosomal translocation between chromosomes 9 and 22, resulting in the *BCR-ABL1* fusion gene. *The clinical manifestation*, bone marrow features, and laboratory test results *at the time of diagnosis vary among reported patients and depend on* the phase of CML. Approximately 50% of newly diagnosed cases are asymptomatic and discovered when an abnormal white blood cell count is detected. In some cases, the bone marrow shows variable stages of fibrosis, whereas severe reticulin fibrosis is rarely observed. In this article, we present a patient with uncommon initial features of CML (i.e., pancytopenia, severe bone marrow fibrosis, and the absence of splenomegaly). Histopathological examination of the bone marrow revealed a hypercellular bone marrow with a normal myeloid to erythroid ratio showing myeloid maturation into segmented neutrophils. The number of megakaryocytes with atypical nuclei was increased, forming a cluster. Reticulin staining showed that fibers were increased diffusely and densely with extensive intersections. This increasing number of megakaryocytes and excessive fibrosis resembles primary myelofibrosis. The presence of the *BCR-ABL1* fusion gene confirmed the *diagnosis* of CML. The aim of this report is to share the experience of diagnosing a case of CML with a rare initial clinical course and excessive fibrosis of the bone marrow.

[*] Corresponding Author's Email: agnharahap@gmail.com.

Keywords: *BCR-ABL1*-positive, chronic myeloid leukemia, pancytopenia

INTRODUCTION

Chronic myeloid leukemia (CML) is an acquired myeloproliferative neoplasm, in which granulocytes are the major proliferative component. It arises in hematopoietic stem cells and is associated with chromosomal translocation between the ABL1 gene of chromosome 9 and the BCR gene of chromosome 22. This results in the formation of the Philadelphia (Ph) chromosome [1]. The translocation leads to the production of an abnormal tyrosine kinase enzyme, which causes excessive proliferation and reduced apoptosis in myeloid cells [2, 3]. Notably, the etiology of CML is unknown in most cases. There is an assumption that high-dose ionizing radiation may be linked to an increased incidence of CML. However, most CML cases reported thus far were not exposed to radiation [4].

The incidence of CML varies among countries, ranging from 0.4/100,000 individuals in non-Western countries to 1.75/100,000 individuals in the USA [4]. It can occur in all age groups; however, it is predominantly reported in middle and old age, accounting for 20% of adult leukemia cases [5]. The median age at the time of diagnosis is 57-60 years CML is very rare in children. The male to female ratio is 1.2-1.7:1 [4]. From 2013 to 2016, a total of 41 cases of CML were diagnosed in the Anatomical Pathology Department of the Faculty of Medicine of Cipto Mangunkusumo Hospital, Jakarta, Indonesia. All patients were adults, with most cases reported in fifth decade of life.

CML is characterized by the increased and unregulated proliferation of myeloid cells without loss of their capacity to differentiate [6]. Cells in the myeloid cell line are those arising from myeloid progenitor cells, eventually becoming mature blood cells. These mature blood cells include basophils, neutrophils, eosinophil, monocytes, erythrocytes, and platelets. Although *BCR-ABL1* is found in all myeloid lineages, the initial major finding suggestive of CML is neutrophilic leukocytosis. The BCR-AB1 translocation may also be found in *some lymphoid* and *endothelial cells. Of note,* this *translocation* is *found* in 10% of patients with acute lymphoblastic leukemia [1, 7].

In the USA, CML is diagnosed asymptomatically or incidentally in 40-50% of patients. The condition is often diagnosed following a routine physical examination or blood test. White blood cell counts are increased, and the cells are differentiated and mature [8]. Common signs and symptoms of the chronic phase (CP), usually resulting from anemia and splenomegaly [2], include fatigue, weight loss, malaise, and left upper quadrant fullness or pain [1].

Based on the number of immature white blood cells (blasts cells) observed in the blood or bone marrow as well as other characteristic criteria, CML can be classified into three phases. These phases are important for prognosis and treatment [1]. The phases are CP, the accelerated phase (AP), and the blast phase (BP). The vast majority (90-95%) of patients are diagnosed during the CP, which is the earliest *phase of CML* [2]. The median duration of the CP is 5-6 years and, if left untreated, the disease usually progresses to the AP or BP. The duration of the AP and BP is 6-9 months and 3-6 months, respectively. The BP is the terminal phase of CML [9]. Approximately 30% of patients with CML present with marrow fibrosis, commonly mild or moderate. Notably, advanced bone marrow fibrosis occurs in <5% of

patients [10]. In general, almost all myeloid neoplasms have the potential to induce fiber deposition. Although the highest fibrotic risk is related to an underlying *BCR-ABL1*-negative primary myelofibrosis, it may also be found in *BCR-ABL1*-positive CML [11]. Rarely, CML may present with an unusual profile, rendering the diagnosis challenging [12]. CML may present with excessive bone marrow fibrosis and atypical presence of megakaryocytes, potentially resembling primary myelofibrosis [13, 14].

The aim of this report was to share the experience of diagnosing CML with unusual features, such as pancytopenia and atypical megakaryocytes with excessive fibrosis of the bone marrow. Targeted therapy against CML leads to life-saving remission. Therefore, it is very important to recognize CML at the time of initial diagnosis. In this case, the patient was diagnosed by the presence of the BCR-ABL fusion gene along with results obtained through clinical, laboratory, and histopathological examinations.

CASE REPORT

A 50-year-old male visited Siloam Hospital (Jakarta, Indonesia) in July 2017 with complaints of generalized body weakness, which worsened in the previous 5 days. Dizziness and blurred vision were noted. The patient had a history of two blood transfusions performed in May 2017 in Manado, Indonesia. His vital signs were normal and there was no palpable organomegaly in his abdomen. Laboratory tests, including a complete blood count, were conducted and the results revealed anemia and leukopenia. Therefore, the patient was advised to undergo *bone marrow aspiration and biopsy*.

In August 2017, the patient returned to the same hospital with similar complaints. The laboratory results showed pancytopenia with differential cell count, low blast cell count, and normal segmented neutrophils count (Table 1).

Table 1. Results of the laboratory blood test

Tests	Result, July 2017	Result, August 2017	Unit	Reference interval
Hemoglobin	6.5	3.7	g/dL	13.0-18.0
Hematocrit	18.5	10.4	%	40.0-54.0
Erythrocytes	2.25	1.36	10^6/µL	4.50-6.20
MCV	82.2	76.5	fL	81.00-96.00
MCH	28.9	26.5	pg	27.0-36.0
MCHC	35.1	14.6	g/L	31.0-37.0
White blood cells (WBC)	2.6	1.0	10^3/µL	4.00-10.00
Differential count				
Basophils	0		%	0-1
Eosinophils	0		%	0-4
Band neutrophils	2		%	2-6
Segmented neutrophils	62		%	50-70
Lymphocytes	27		%	20-40
Monocytes	7		%	2-8
Platelets	268	77	10^3/µL	150-400

His pancytopenia was managed mainly through the transfusion of red blood cells and platelets. The level of lactate dehydrogenase in the serum was increased. The liver function test, and the levels of creatinine, bilirubin, and electrolytes were within the normal range. C*hest* radiography showed pneumonic infiltration. Ultrasonography of the abdomen and pelvis revealed a slightly enlarged liver with homogeneous parenchyma. The spleen, bladder, and prostate were normal.

The results of the bone marrow aspiration showed a myeloid to erythroid ratio within the normal range (Table 2). Maturation in the myeloid series presented into segmented neutrophils and the number of blasts was not elevated.

A review of the bone marrow biopsy was also performed at Cipto Mangunkusumo hospital. A histopathological examination revealed a hypercellular bone marrow (Figure 1 a, 1 b) with a normal myeloid to erythroid ratio, showing myeloid maturation into segmented neutrophils (Figure 2 a, 2 b). In addition, the number of megakaryocytes with atypical nuclei was increased, forming a cluster (Figure 3 a, 3 b).

Table 2. Bone marrow aspiration performed in July, 2017

Tests	Result	Unit	Reference interval
Thrombopoiesis			
Megakaryocytes count	-		
Myeloid series			
Myeloblasts	0.0	%	0-1
Promyelocytes	1.0	%	1-5
Myelocytes	*0.0*	%	2-10
Metamyelocytes	*2.0*	%	5-15
Bands	*2.0*	%	10-40
Segmented neutrophils	29.0	%	10-30
Basophil	0.0	%	0-1
Eosinophil	0.0	%	0-3
Myeloid total	34	%	
Erythroid series			
Pro-erythroblasts	0.0	%	0-1
Erythroblasts basophils	*0.0*	%	1-4
Polychromatic erythroblasts	6.0	%	10-20
Orthochromatic erythroblasts	7.0	%	5-10
Erythroid total	13.0	%	
Male to female ratio	2.6:1	%	(2-4):1
Other series			
Lymphocytes	40	%	0-15
Monocytes	7	%	0-2
Plasmocytes	6	%	0-1

Staining with Periodic Acid Schiff (PAS) showed that the number of megakaryocytes was increased. Some megakaryocytes were scattered with small, hypolobated nuclei (Figure 4 a, 4 b). Reticulin staining showed that the fibers were increased diffusely and densely with extensive intersections (Figure 5 a, 5 b). Trichrome staining showed the presence of focal bundles of collagen fibers (Figure 6 a, 6 b). According to the definition established by the World Health Organization, the grade of marrow fibrosis was marrow fibrosis 3. Hence, this

patient was diagnosed with a myeloproliferative neoplasm, suggestive of primary myelofibrosis.

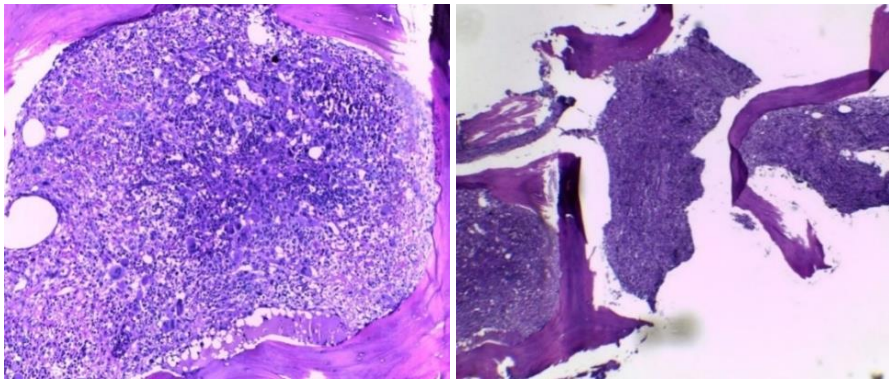

(a) (b)

Figure 1. (a, b) Bone marrow biopsy showed a hypercellular bone marrow (H&E, 40×, 100×).

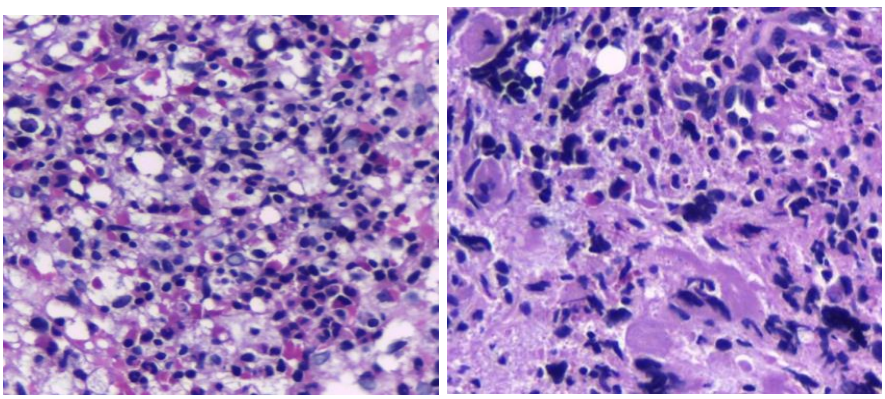

(a) (b)

Figure 2. (a, b) Higher magnification revealed a normal myeloid to erythroid ratio, showing myeloid maturation into segmented neutrophils. The number of blasts was not increased (H&E, 400×).

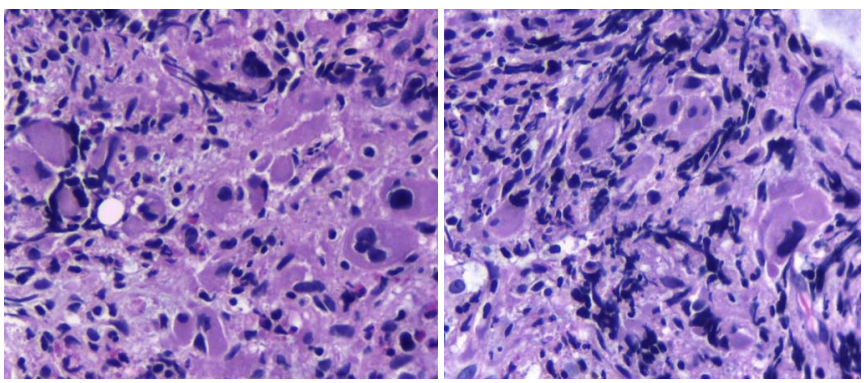

(a) (b)

Figure 3. (a, b) The number of megakaryocytes with atypical nuclei was increased, forming a cluster (H&E 400×).

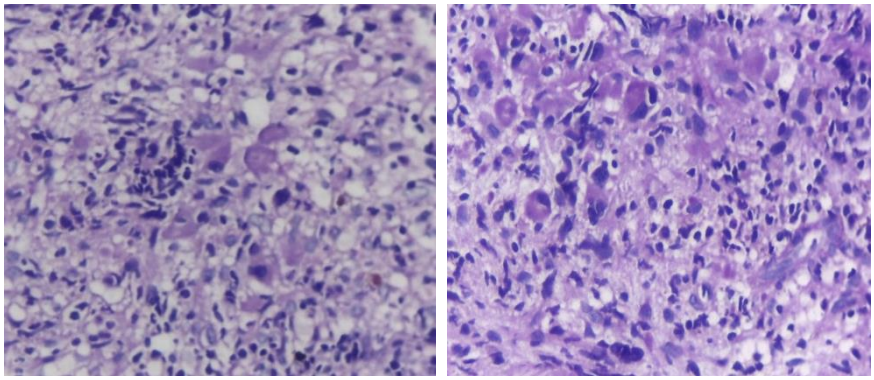

(a) (b)

Figure 4. (a, b) Increased megakaryocytes. Some scattered megakaryocytes were small with hypolobated nuclei (PAS, 40×).

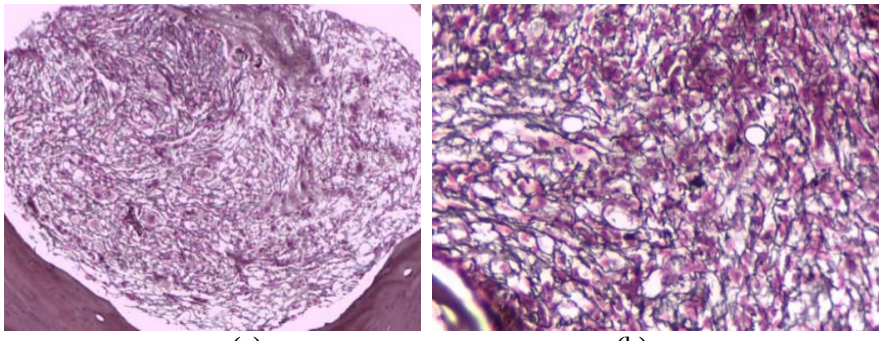

(a) (b)

Figure 5. (a) Reticulin fibers were increased diffusely and densely (Reticulin, 4×). (b) Extensive intersections of reticulin fibers (Reticulin, 40×).

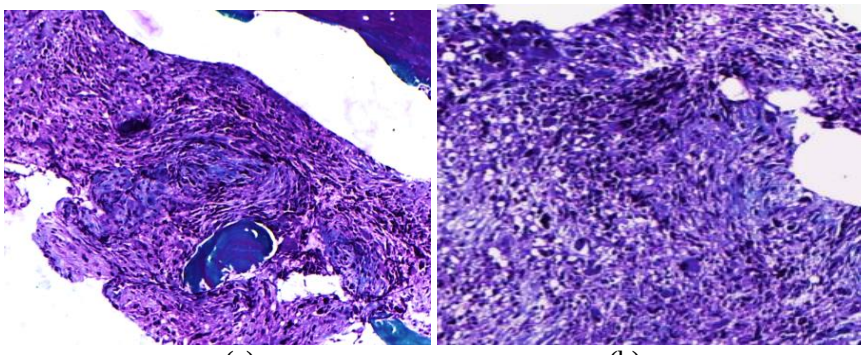

(a) (b)

Figure 6. (A-B) The bone marrow exhibited focal bundles of collagen fibers (Trichrome, 10×).

Subsequently, an evaluation of mutations in the JAK2 gene and the presence of the BCR-ABL1 fusion gene was performed using blood samples to reach a definitive diagnosis.

The presence of the BCR-ABL1 fusion gene was determined through real-time quantitative polymerase chain reaction. The analysis for mutations in the JAK2 gene yielded negative results. The presence of the BCR-ABL1 abnormality confirmed the diagnosis of

CML in this patient. Based on the presence of excessive bone marrow fibrosis and thrombocytopenia (unrelated to therapy), CML at that time was considered to be at the AP.

This patient exhibited uncommon clinical, laboratory, and morphologic bone marrow features to meet the criteria for the diagnosis of CML. In this, case the condition included pancytopenia, absence of splenomegaly, and excessive bone marrow fibrosis, with some megakaryocytes showing atypical nuclei. Owing to the uncommon clinical features, this patient also consulted a pathologist in Germany. He preferred to diagnose this case as CML because of the presence of the *BCR-ABL1* fusion gene. The treating physician had previously encountered a number of similar CML cases with excessive fibrosis and the absence of an increase in size of the spleen. In this case, the majority of megakaryocytes exhibited atypical nuclei. However, a number of megakaryocytes exhibited the "dwarf form," which is typical in CML.

DISCUSSION

The clinical hallmark of CML is leukocytosis, i.e., the uncontrolled production of maturing granulocytes including neutrophils, basophils, and eosinophils in the peripheral blood [15]. Of note, the number of platelets is normal or slightly increased and mild to moderate anemia is usually noted. In our case, the initial peripheral blood findings revealed pancytopenia. The patient had abnormally low levels of red blood cells, white blood cells, and platelets. This condition may be the result of myelofibrosis, which accompanies CML [14]. Myelofibrosis is the presence of reticulin and deposition of collagen, replacing bone marrow hematopoietic cells with fibrous material. The exact pathogenesis of myelofibrosis is not fully understood. However, evidence has demonstrated the role of activating mutation involving CALR, the deregulated expression of pro-inflammatory cytokines, and the impaired bone marrow microenvironment [6].

The bone marrow microenvironment is composed of cells, structural fibrils, and the extracellular matrix. The cellular components include macrophages, fibroblastic cells, adipocytes, and endothelial cells. The most common structural fibrils in the bone marrow are collagen and reticulin. The ground substance includes water, salts, glycosaminoglycans, and glycoproteins. These elements provide a connective tissue structure for the bone marrow and physical support for the hematopoietic progenitor cells. Consequently, the bone marrow microenvironment plays an important role in hematopoiesis [12].

The elevation of pro-inflammatory cytokines is a major biological hallmark of bone marrow fibrosis. This effect is thought to be a consequence of the malignant clone as a modifier of the bone marrow microenvironment. One neoplastic cell type thought to be a major contributor to fibrosis is the megakaryocyte, which exhibits aberrant proliferation [11]. Megakaryocytes produce the transforming growth factor β. This cytokine potently stimulates fibroblasts to produce the extracellular matrix. Moreover, it increases the expression of proteases that inhibit enzymes involved in the degradation of the extracellular matrix [6]. Hence, megakaryocytes are important mediators in the development of bone marrow fibrosis [12].

Table 3. Phases of chronic myeloid leukaemia according to WHO

CML phase	WHO definition
Chronic phase (CP)	- Peripheral blood (PB) shows leukocytosis (12-1000x10^9/L) - Blasts less than 2% of the white blood cells (WBC) - Basophilia is invariably present, eosinophilia is common - Monocytosis may be present, but usually <3% - Platelet ranges from normal to greater than 1000x10^9/L, thrombocytopenia is uncommon. - Bone marrow cellularity is increased - Blasts account < 5% of the marrow cells - Erythroid islands are usually reduced - Megakaryocytes may be normal or slightly decreased in number, 40-50% exhibit moderate to marked proliferation. - Megakaryocytes are smaller than normal and have hyposegmented nuclei (dwarf megakaryocytes) - Moderate to marked reticulin fibrosis correlates with increased numbers of megakaryocytes and associated with an enlarged spleen was found in 30-40% of biopsies
Accelerated phase (AP)	Presence of ≥1 of the following hematological/cytogenetic criteria or provisional criteria concerning the response to therapy with tyrosine kinase inhibitors (TKIs). Hematological/cytogenetic criteria: – Persistent or increasing WBC (>10 × 10^9/L), unresponsive to therapy – Persistent or increasing splenomegaly, unresponsive to therapy – Persistent thrombocytosis (>1,000 × 10^9/L), uncontrolled by therapy – Persistent thrombocytopenia (unrelated to therapy) – Basophil ≥20% in the PB – 10-19% blasts in the PB or bone marrow
Accelerated phase (AP)	– Additional clonal chromosomal abnormalities in the Philadelphia (Ph) chromosome, including major route abnormalities (a second Ph chromosome, trisomy 8, isochromosome 17q, and trisomy 19), a complex karyotype, and abnormalities of 3q26.2 – Any new clonal chromosomal abnormality in Ph+ cells that occurs during therapy – Criteria for the provisional response to TKIs – Hematological resistance (or failure to achieve complete hematological response) to the first TKI – Any hematological, cytogenetic, or molecular indication of resistance to sequential treatment with two TKIs – Occurrence of at least two mutations in the *BCR-ABL1* fusion gene during TKI therapy. Large clusters or sheets of small, abnormal megakaryocytes with marked reticulin or collagen fibrosis
Blast phase	– Blasts ≥20% of the PB WBC, or of the nucleated cells of the bone marrow – Extramedullary blast proliferation

In our case, the predominance of fibrosis and atypical megakaryocytes at presentation confounded the initial diagnosis. This raised the possibility of a differential diagnosis, such as primary myelofibrosis. Mohamed et al. reported a CML case with advanced myelofibrosis

resembling primary myelofibrosis. That case also presented with anemia, thrombocytopenia, and an absence of splenomegaly; however, the white blood count was within the normal range. Therefore, it is recommended that a molecular analysis is performed in patients with myelofibrosis [10].

In patients with CML, various grades of megakaryocytic proliferation can be observed in bone marrow biopsies or cytological smears at the time of diagnosis [15]. CML with marrow fibrosis is more commonly developed in patients with a marked megakaryocytic proliferation [10]. In our case, the histopathological examination of the bone marrow through reticulin staining showed that fibers were increased diffusely and densely with extensive intersections. This finding was consistent with the observed increase in the number of megakaryocytes. This case presented with advanced (grade 3) fibrosis.

CML is classified into three phases that assist in predicting the prognosis. The phases are determined mainly according to the number of immature white blood cells (blasts cells) observed in the blood or bone marrow (Table 3) [1].

The recognition of disease progression, during which the CP develops into the AP and BP, is important for treatment and prognostic purposes. Unfortunately, the clinical and morphological differences between the CP, AP, and BP are not always clear. Large clusters or sheets of small, abnormal megakaryocytes with marked reticulin or collagen fibrosis are suggestive of AP, especially if accompanied by any of the hematological parameters [1]. In our case, the number of megakaryocytes with atypical nuclei was increased, forming a cluster. In addition, thrombocytopenia (unrelated to therapy) was noted. These findings are indicative of the AP.

In the CP, splenomegaly is observed in approximately 70% of CML patients, caused by the infiltration of the red pulp cords by mature and immature granulocytes [1]. In the AP and BP, splenomegaly is due to extra-medullary hematopoiesis. This patient did not exhibit splenomegaly.

The diagnosis of CML is based on the detection of the *BCR-ABL1* fusion gene, which is the underlying abnormality of this disease [12]. This mutation leads to persistently enhanced tyrosine kinase activity. This activity is responsible for maintaining proliferation and inhibiting differentiation and apoptosis. This leads to an excessive number of neoplastic clones in the bone marrow, Furthermore, neoplastic cells replace non-neoplastic hematopoietic and mesenchymal cells (adipocytes) [14]. The real-time quantitative polymerase chain reaction is used to detect the presence of the *BCR-ABL1* mutation. It can detect a single CML cell in 100,000 normal cells isolated from blood or bone marrow samples [16]. The results of this test are reported using the international scale. This analysis was performed in the present patient, showing positivity for *BCR-ABL1*, with 6% on the international scale.

CONCLUSION

CML is an acquired myeloproliferative neoplasm, in which granulocytes are the major proliferative component. It develops in hematopoietic stem cells and is characterized by a chromosomal translocation, resulting in the *BCR-ABL1* fusion gene and the formation of the Ph chromosome. The majority of CML cases are diagnosed on the basis of findings in the

peripheral blood and bone marrow biopsy, combined with the detection of the Ph chromosome. Rarely, a number of CML cases exhibit atypical peripheral blood test results and uncommon histopathological features in the bone marrow biopsy, resembling primary myelofibrosis in the overt fibrotic stage. Therefore, the diagnosis of CML should not be immediately excluded prior to confirming the presence of the Ph chromosome or *BCR/ABL1* rearrangement.

The diagnosis of CML with atypical features (i.e., pancytopenia and excessive fibrosis of the bone marrow) requires the combination of clinical, laboratory, and histopathological examinations, accompanied by the presence of an acquired genetic abnormality, the *BCR/ABL1* fusion gene. An increased awareness of this disease, especially at the CP, may prevent progression to the AP or BP.

REFERENCES

[1] Vardiman, JW; Melo, JV; Baccarani, M; Radich, JP; Kvasnicka, HM. WHO Classification of Tumours of Haematopoietic and Lymphoid Tissues. 5th ed. Lyon*: International Agency for Research on Cancer*; 2017.

[2] Jabbour, EJ. Chronic myeloid leukemia: 2016 update on diagonis, therapy and monitoring. *Am J Hematol*. 2016; 91: 252-65.

[3] Cardama, AQ; Cortes, J. Molecular biology of bcr-abl1 positive chronic myeloid leukemia. *Blood*, 2009; 113: 1619-30.

[4] Hoglund, M; Sandin, F; Simonsson, B. Epidemiology of chronic myeloid leukaemia: An update. *Ann Hematol*. 2015; 94: 241-7.

[5] Frazer, R; Irvine, AE; McMullin, MF. Chronic myeloid leukaemia in the 21st century. *Ulster Med J*. 2007; 76: 8-17.

[6] Zahr, AA; Salama, ME; Carreau, N; Tremblay, D; Verstovek, S; Mesa, R; et al. Bone marrow fibrosis in myelofibrosis: Pathogenesis, prognosis and targeted strategies. *Haematologica*. 2016; 101: 660-71.

[7] Ismail. S; Naffa, R; Yousef, AF. Incidence of BCR-ABL fusion transcripts in healthy individuals. *Mol Med Rep*. 2014; 9:1271-6.

[8] Al-Achkar, W; Wafa, AS; Moassass, F; Klein, E; Liehr, T. Multiple copies of BCR-ABL fusion gene on two isodicentric Philadelphia chromosomes in an imatinib mesylate-resistant chronic myeloid leukemia patient. *Oncol Lett*.2013; 5: 1579-82.

[9] Schiffer, CA; Hehlman, R; Larson, R. Perspective on the treatment of chronic phase and advanced phase CML and Philadelphia chromosome positive ALL. *Leukemia*. 2003; 17: 691-99.

[10] Mohamed, M; Beamish, M; Grabek, J. Chronic myeloid leukemia masquerading as primary myelofibrosis. *J Clin Pathol. Suppl.* 2014; 46: 75-7.

[11] Hussein, K; Stucki-Koch, A; Gohring, G; Kreipe, H; Suttorp, M. Increased megakaryocytic proliferation, pro-platelet deposition and expression of fibrosis-associated factors in children with chronic myeloid leukemia with bone marrow fibrosis. *Leukemia*. 2017; 31: 1540-6.

[12] Kuter, DJ; Bain, B; Mufti, G; Bagg, A; Haserjian, RP. Bone marrow fibrosis: Pathophysiology and clinical significance of increased bone marrow stromal fibres. *Br J Haemtol*. 2007; 139: 351-62.

[13] Dunphy, CH; Hasserjian, RP; George, TI. *Neoplastic Hematopathology: An Atlas and Concise Guide*. New York: Demos Medical; 2013.

[14] Koshy, J; Alperin, J; Jana, B; Markowitz, A; Qian, YW. A case of Philadelphia chromosome positive myeloproliferative neoplasm in a pregnant woman with unusual primary myelofibrosis features. *Case Rep Hematol* 2013;2013: 702831.

[15] Busche, G; Kreipe, HH. *Chronic Blood and Bone Marrow Pathology*. 2nd ed. Churchill Livingstone: Elsevier; 2011.

[16] Bauer, S; Romvari, E. Interpreting molecular monitoring results and international standardization in chronic myeloid leukemia. *J Adv Pract Oncol*. 2012; 3: 151-60.

In: Encyclopedia of Surgery (22 Volume Set)
Editors: Andreas Lehrer and Kristin Mueller
ISBN: 978-1-53618-329-0
© 2020 Nova Science Publishers, Inc.

Chapter 345

CLEAR CELL CHONDROSARCOMA: A CASE REPORT

Ros Nirmawati[1], Evelina Kodrat[1,*] and Errol Untung Hutagalung[2]
[1]Department of Anatomical Pathology, Faculty of Medicine, Universitas Indonesia, Cipto Mangunkusumo Hospital, Jakarta, Indonesia
[2]Department of Orthopaedics and Traumatology, Faculty of Medicine, Universitas Indonesia, Cipto Mangunkusumo Hospital, Jakarta, Indonesia

ABSTRACT

Clear cell chondrosarcoma is a rare variant of low-grade malignant cartilaginous tumor, representing approximately 2% of all chondrosarcomas. In this article, we report a rare case of clear cell chondrosarcoma in a 21-year-old male. Histopathological findings showed abundant clear cytoplasm or a faintly acidophilic cytoplasm with distinct cytoplasmic borders. The nuclei were round, vesicular, and centrally located, with prominent nucleoli. Mitotic figures are uncommon. Follow-up immunohistochemical staining showed positivity for S-100 protein and negativity for other epithelial markers, supporting the diagnosis of clear cell chondrosarcoma. Clear cell chondrosarcoma mostly involves the epiphyseal of long bones, especially in the femur or humerus. Complete surgical excision is the treatment of choice.

Keywords: chondrosarcoma, clear cell chondrosarcoma

INTRODUCTION

Clear cell chondrosarcoma is a rare variant of low-grade malignant cartilaginous tumor, representing approximately 2% of all chondrosarcomas [1]. Unni et al. first described it in 1976, the clear cell chondrosarcoma entity was formerly known as “Clear-cell Variant of Chondrosarcoma” [2,3]. The cytoplasm appears clear due to the abundance of glycogen in tumor cells [1,4]. This condition tends to arise in the epiphyseal area of long bones [1,4-6]. The peak incidence is observed during the third and fourth decades of life [4].

* Corresponding Author’s Email: elina_1610@yahoo.com.

We report this case to avoid the risk of inaccurate diagnosis and recognize the differential diagnosis.

CASE REPORT

A 21-year-old male had a chief complaint of pain ranging from knee up to left hip for almost 2 years and 4 months. The patient then underwent pelvic X-ray and lumbosacral *magnetic resonance imaging* (MRI) examination. The Pelvic X-ray showed an expansile lytic lesion with a wide transition zone on the left proximal femoral. There was no cortical destruction, presence of a soft-tissue mass, or periosteal reaction (Figure 1). MRI results showed lesions that destructed the left femoral head and also appeared a signal with the same intensity as lesions in the surrounding soft tissue and left hip joint (Figure 2.). These findings indicated the presence of an aggressive primary bone tumor.

Figure 1. Pelvic X-ray examination showed the presence of an expansile lytic lesion with a wide transition zone. There was no cortical destruction, presence of a soft-tissue mass, or periosteal reaction (arrow).

Later, the patient underwent an open biopsy of his left femoral head at a hospital. Histological report revealed fragments of lesional tissue, comprising cellular nests of polygonal cells with central nuclei, conspicuous nucleoli, and pale eosinophilic to clear cytoplasm, admixed with small trabeculae of new reactive bone. Scattered multinucleated giant cells were present. In other area of the tumor, small foci resembling conventional chondrosarcoma were present. The tumor cells were immunoreactive for S-100 but negative for MNF116. These results were consistent with clear cell chondrosarcoma.

After one month, the patient underwent a wide excision procedure in another private hospital. The specimen from wide excision was sent to the laboratory of anatomic pathology. By report, the histopathological features showed a solid tumor mass with formation of a malignant osteoid. The tumor cells consisted of chondroblastic and epitheloid cells with pleomorphic and hyperchromatic nucleoli. Mitotic activity was easily observed. Osteoclast-

like giant cell, necrotic area, hemorrhage, and bone marrow were visible in the tumor mass. Based on these findings, this patient was diagnosed as conventional osteosarcoma rather than chondrosarcoma.

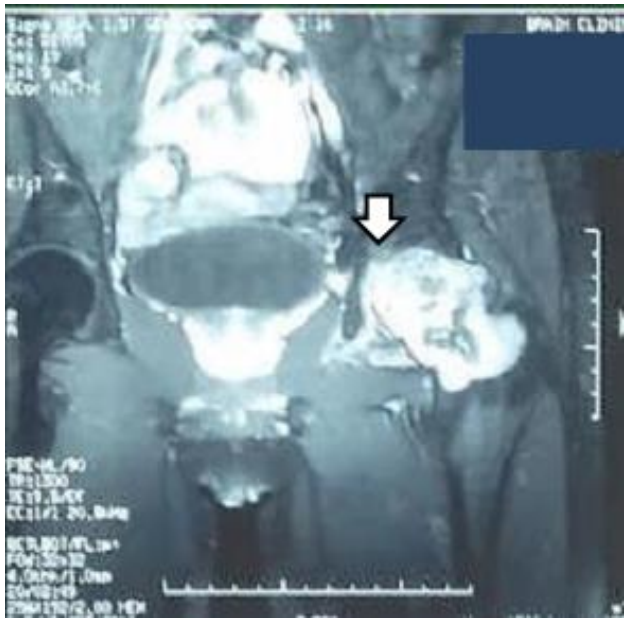

(a)

(b)

Figure 2. Coronal (a) and axial (b) lumbosacral MRI. The MRI results showed lesions that destructed the left femoral head and also appeared a signal with the same intensity as lesions in the surrounding soft tissue and left hip joint. These findings indicated the presence of an aggressive primary bone tumor.

Due to the differences in histological results, this case was discussed at our weekly Clinicopathological Conference (CPC) and suggested to repeat immunohistochemical staining on resection specimen as we were not able to have the slides and paraffin block from the first open biopsy. Based on the slides provided, the histological appearance under low magnification showed that the solid mass consisted of bony trabeculae, with osteoblastic rimming among the tumor cells. The tumor cells were round, with slightly-moderately pleomorphic nuclei; there were large cells with distinct cytoplasmic borders in several areas, prominent nucleoli, and abundant clear or pale eosinophilic cytoplasm. Mitotic activity was infrequent. Multinucleated giant cells and production of cartilage matrix were also visible (Figure 3-6). The repeated immunohistochemical staining results showed that the neoplastic cells were positive for S-100 (Figure 7) and negative for AE1/3, CK8, CK18, CK7, and CK20. These morphological and immunohistochemical staining features were consistent with clear cell chondrosarcoma.

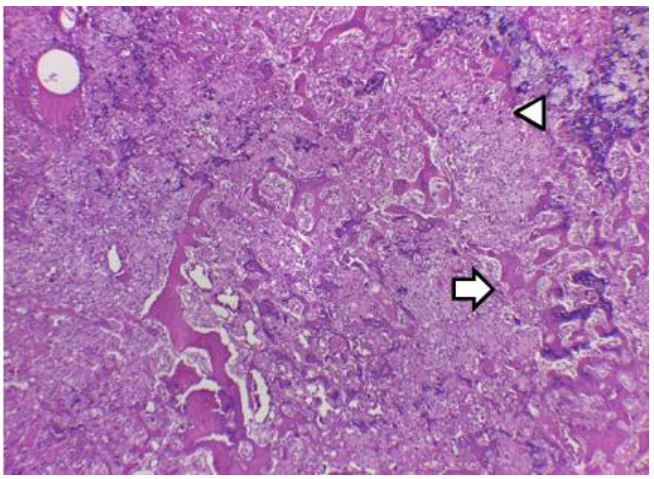

Figure 3. The solid mass consisted of bony trabeculae, with osteoblastic rimming among the tumor cells (arrow). Production of cartilage matrix was also found (arrow head)(H&E, ×40).

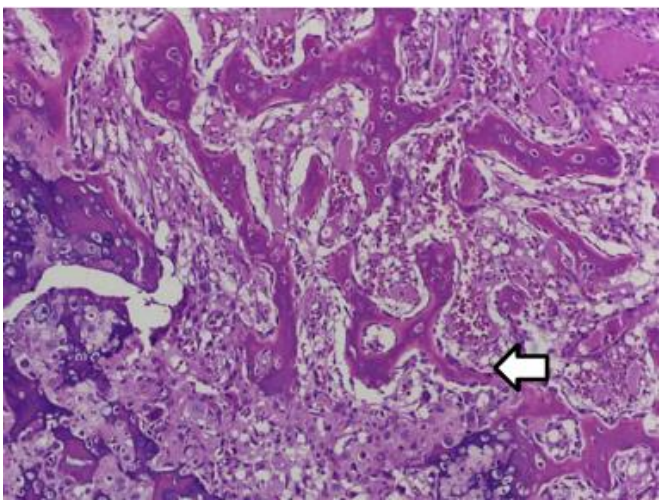

Figure 4. Irregular bony trabeculae with osteoblastic rimming (arrow) (H&E, ×100).

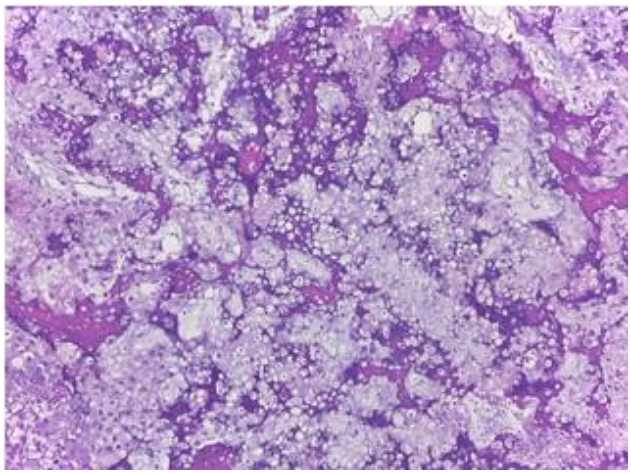

(a)

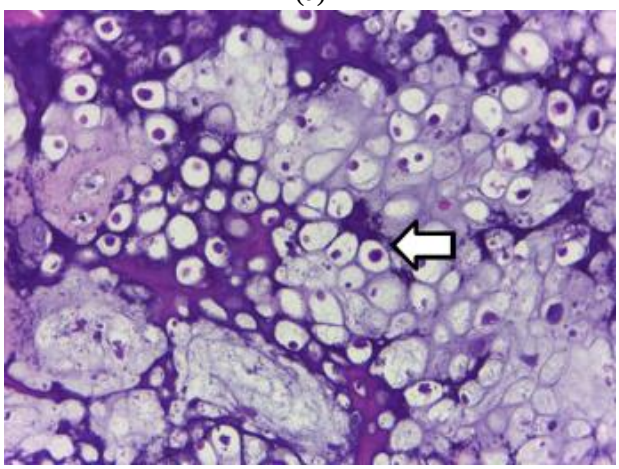

(b)

Figure 5. (a) An area of clear cell chondrosarcoma with production of chondro-osseous matrix (H&E, ×100). (b) The clear cell chondrosarcoma consisted of large round cells with centrally located nuclei, distinct cytoplasmic borders (arrow), and abundant clear and pale eosinophiliccytoplasms (H&E, ×400).

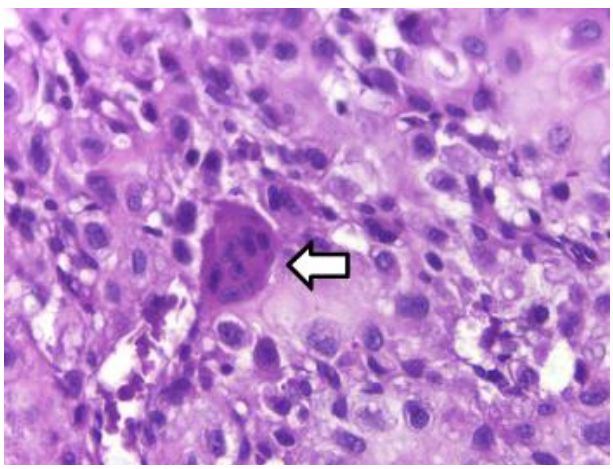

Figure 6. A scattered multinucleated giant cell (arrow) in the tumor (H&E, ×400).

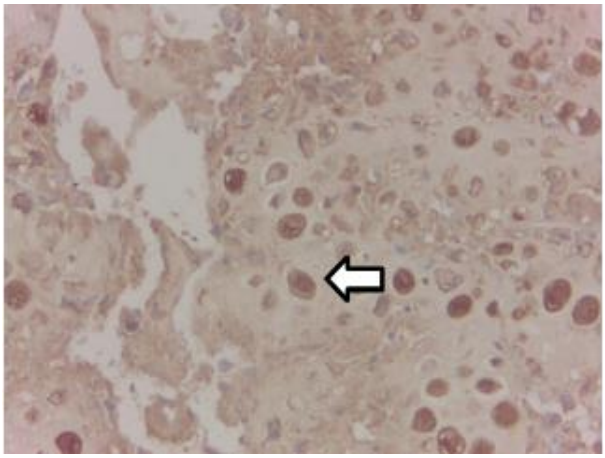

Figure 7. The nuclei of neoplastic cells were positive for the S-100 protein (H&E, ×400).

DISCUSSION

Clear cell chondrosarcoma is a rare variant of chondrosarcoma [1]. It mostly occurs in adults (third to fifth decades of life) with a 2.4:1 male-to-female ratio [1, 4]. The initial symptom is local pain in the affected area, developing in the longterm due to the slow growth of the tumor [1, 2, 4, 6]. Our patient was a 21-year-old male, who had been suffering from pain on his left knee for 2 years prior to his admission to the hospital.

Clear cell chondrosarcoma usually involves the epiphysis of long bones, especially the femur or humerus [1, 4]. Chondroblastoma and GCT of the bone exhibit similar localization with clear cell chondrosarcoma, whereas conventional chondrosarcoma is usually found in the metaphysis or diaphysis of long bones [5].

Clear cell chondrosarcoma is characterized by a distinctive histologic feature i.e., the presence of "clear cells" (abundant clear to faintly acidophilic cytoplasm with distinct borders), whose nuclei are large, vesicular, and centrally located. The nucleoli are usually prominent and mitotic figures are uncommon [1-6]. Histologically, it may resemble chondroblastoma, GCT of the bone, osteoblastoma, or even conventional osteosarcoma [5].

The most common radiological of clear cell chondrosarcoma findings are well-marginated radiolucent areas with distinct reactive borders, an absence of cortical destruction or periosteal reaction, and unusual soft-tissue extension [3,5,7]. The radiological findings of clear cell chondrosarcoma must be differentiated from those of other benign epiphyseal lesions, such as chondroblastoma and GCT of the bone [7-9]. In this report, the pelvic X-ray examination was an expansile lytic lesion with a wide transition zone. There was no cortical destruction, presence of a soft-tissue mass, or periosteal reaction.

Chondroblastoma arises in the epiphysis or epimetaphysis of long bones, more commonly in male and younger patients [10,11]. Radiologically, chondroblastoma is typically a small (3-6 cm), well-demarcated lytic lesion and generally with no bone expansion. Periosteal reaction is frequent and occasionally distant from the primary lesion [10]. Microscopically, the tumor cells are usually surrounded by fine lines of calcification, which are typical in both clear cell chondrosarcomas and chondroblastomas. However, chondroblastoma does not show a clear

cytoplasm, which is typical for clear cell chondrosarcoma. Instead, it shows an oval nucleus with a nuclear groove and a faintly acidophilic cytoplasm [2]. In general, the distinction between chondroblastoma and clear cell osteosarcoma do not necessarily require immunohistochemistry staining. However, in several difficult cases, SOX9 and cytokeratins are useful to distinguish both entities. The expression of SOX9 and cytokeratins is found in chondroblastoma, while it is negative in clear cell chondrosarcoma [10].

Moreover, GCT of the bone affects the same site as clear cell chondrosarcoma [5]. Notably, the radiological and histopathological features are evidently different from those observed for clear cell chondrosarcoma. GCT of the bone is usually found in patients aged 20-40 years, with a slight predominance observed in female patients [12,13]. Plain radiography of GCT showed a large expansile lytic-sclerotic lesion with cortical thinning (the "soap-bubble appearance"). The presence of numerous osteoclast-like giant cells, which contain >20 nuclei, is the hallmark of GCT [4,13,14]. In contrast, scattered multinucleated giant cells in clear cell chondrosarcoma are not associated with the neoplastic process, and they usually contain only 6-8 nuclei [5].

In addition, clear cell chondrosarcoma has a scattered osteoid matrix and a bony trabeculae appearance among the tumor cells resembling conventional osteosarcoma. Osteoid matrix with lace-like appearance and accompanied with an increase level of alkaline phosphatase in the serum prior to surgery should be considered as osteosarcomas, especially in young patients [5,9]. Radiographically, conventional osteosarcoma exhibits a permeative pattern with periosteal reaction, cortical destruction, and the extension of soft-tissue mass [4,15,16]. Meanwhile, clear cell chondrosarcoma exhibits a well-marginated radiolucent area with distinct reactive borders and an absence of cortical destruction [1,3,4]. Conventional osteosarcoma features high-grade nuclei, such as severe nuclear anaplasia and pleomorphism with occasional mineralization [15]. The absence of a clear cell population among the intertrabecular spaces and its location may distinguish osteosarcoma from clear cell chondrosarcoma [4,15].

The presence of an interanastomosing osteoid with osteoblastic rimming may also be considered as osteoblastoma. Osteoblastoma is composed of osteoblasts that are rich in vascularity. The absence of the clear cell feature distinguishes this tumor from clear cell chondrosarcoma [2,4,5,17].

The patient was initially diagnosed with clear cell chondrosarcoma based on histological report from the open biopsy specimen. He underwent wide excision at another private hospital with result showing conventional osteosarcoma. Due to the differences in histological results, the case was presented at CPC and was suggested to repeat the immunohistochemical staining to confirm the diagnosis. The immunohistochemical staining showed positivity for the S-100 protein and negativity for other epithelial markers (i.e., AE1/3, CK8, CK18, CK7, and CK20). The final diagnosis was clear cell chondrosarcoma.

Ancillary staining, such as histochemistry and immunohistochemistry, may assist in confirming the diagnosis of clear cell chondrosarcoma. The content of glycogen in the cytoplasm explains the clear cytoplasm feature and yields positive staining for periodic acid-Schiff [1,4,7]. The nuclei in clear cell chondrosarcomas are strongly positive for the S-100 protein [1,3,4,7,18,19]. Matsuura S et al. investigated the immunohistochemical expression profiles of cytokeratins (i.e., CAM5.2, AE1/AE3, CK7, CK8, CK18, and CK20), epithelial membrane antigen, sex-determining region Y-box 9 (SOX9), type II collagen, runt-related transcription factor 2 (RUNX2), and osteocalcin in clear cell chondrosarcoma. The results

were compared with those observed in chondroblastoma, conventional chondrosarcoma, and osteosarcoma. Both clear cell chondrosarcoma and chondroblastoma showed epithelial and chondrogenic markers. Clear cell chondrosarcomas stain negative for CAM5.2 and the epithelial membrane antigen. The type II collagen immunohistochemistry showed 100 % positivity in clear cell chondrosarcoma while in chondroblastoma showed positivity for about 54%. The cartilagenous component of clear cell chondrosarcoma and chondroblastoma express SOX9 respectively 20% and 54%. Osteocalcin is not detected in the cytoplasm of clear cells; however, it is expressed in osteoblasts and osteocytes within woven bone. RUNX2 up-regulated the promoter activity of osteocalcinin osteosarcoma cell lines, but not in chondrosarcoma or chondrocyte cell lines [19].

The treatment of choice for clear cell chondrosarcoma is a wide and complete surgical excision.Chondrosarcoma has a relatively low proliferation rate, thus, radiotherapy remains ineffective as it aims at actively dividing cells. Systemic treatments, such as chemotherapy, have also been shown to be ineffective [20].

Inappropriate treatment results in recurrence in 16% of patients. En bloc excision is preferable to marginal excision or curettage. Although clear cell chondrosarcoma is commonly considered an indolent tumor; however, lung, brain, and bone metastases have been reported. The average rate of mortality is approximately 10%, while disease-free survival after incomplete removal is 13 years. The overall survival rate in patients with metastasis after initial therapy is approximately 7 years [4].

CONCLUSION

Clear cell chondrosarcoma is a rare variant of low-grade malignant cartilaginous tumor, representing approximately 2% of all chondrosarcomas. Increased awareness regarding this disease may prevent misdiagnosis. Histologically, it may resemble other tumors, such as chondroblastoma, GCT, osteoblastoma, and conventional osteosarcoma. Immunohistochemical features are able to distinguish between the differential diagnoses. Clear cell chondrosarcomas are strongly positive for the S-100 protein. Sufficient clinical data, including location, radiological finding combined with microscopic features, and appropriate ancillary staining are mandatory to avoid misdiagnosis.

CONFLICTS OF INTEREST

None declared.

REFERENCES

[1] McCarthy, E. F., Hogendoorn, P. C. W. (2013). Clear cell chondrosarcoma. In: Fletcher, C. D. M., Bridge, J. A., Hogendoorn, P. C. W., Mertens, F., editors. *WHO classification of tumours of soft tissue and bone* (4th ed. pp.273-274). Lyon: IARC.

[2] Unni, K. K., Dahlin, D. C., Beabout, J. W., Sim, F. H. (1976). Chondrosarcoma: Clear cell variant. A report of sixteen cases. *J. Bone Joint Surg*., 58-A, 676-683.

[3] Ayoub, K. S., Grimer, R. J., Carter, S. R., Mangham, D. C., Davies, A. M., Tillman, R. M. (1999). Clear cell chondrosarcoma of bone. *Sarcoma*., 3, 115-119.

[4] Czerniak, B. (2016). *Dorfman and Czerniak's bone tumor*. (2nd ed). Philadelphia: Elsevier Saunders.

[5] Bjornsson, J., Unni, K. K., Dahlin, D. C., Beabout, J. W., Sim, F. H. Clear cell chondrosarcoma of bone. Observations in 47 cases. *Am. J. Surg. Pathol.*, 8, 223-230.

[6] Itälä, A., Leerapun, T., Inwards, C., Collins, M., Scully, S. P. (2005). An institutional review of clear cell chondrosarcoma. *Clin. Orthop. Relat. Res.*, 440, 209-212.

[7] Present, D., Bacchini, P., Pignatti, G., Picci, P., Bertoni, F., Campanacci, M. (1991). Clear cell chondrosarcoma of bone. A report of 8 cases. *Skeletal Radiol*., 20, 187-191.

[8] Collins, M. R., Koyama, T., Swee, R. G., Inwards, C. Y. (2003). Clear cell chondrosarcoma: radiographic, computed tomographic, and magnetic resonance findings in 34 patients with pathologic correlation. *Skeletal Radiol*., 32, 687-694.

[9] Ishida, T., Yamamoto, M., Goto, H., Yamamoto, A., Machinami, R. (1999). Case Report: Clear cell chondrosarcoma of the pelvis in skeletally immature patient. *Skeletal Radiol*., 28, 290-293.

[10] Kilpatrick, S. E., Romeo, S. (2013). Chondroblastoma. In: Fletcher CDM, Bridge JA, Hogendoorn PCW, Mertens F, editors. *WHO classification of tumours of soft tissue and bone*. (4th ed. pp. 262-263). Lyon: IARC.

[11] Kaim, A. H., Hügli, R., Bonèl, H. M., Jundt, G. (2002). Chondroblastoma and clear cell chondrosarcoma: radiological and MRI characteristics with histopathological correlation. *Skeletal Radiol*., 31, 88-95.

[12] Sobti, A., Agrawal, P., Agarwala, S., and Agarwal, M. (2016). Giant cell tumor of bone-an overview. *Arch. Bone Jt. Surg*., 4, 2-9.

[13] Athanasou, N. A., Bansal, M., Forsyth, R., Reid, R. P., Sapi, Z. (2013). Giant cell tumour of bone. In: Fletcher, C. D. M., Bridge, J. A., Hogendoorn, P. C. W., Mertens, F., editors. *WHO classification of tumours of soft tissue and bone.* (4th ed. pp. 321-324). Lyon: IARC.

[14] Wülling, M., Engels, C., Jesse, N., Werner, M., Delling, G., Kaiser, E. (2001). The nature of giant cell tumor of bone. *J Cancer Res Clin Oncol*., 127, 467-474.

[15] Klein, M. J., Siegal, G. P. (2006). Osteosarcoma, anatomic and histologic variants. *Am J Clin Pathol*., 125, 555-581.

[16] Rosenberg, A. E., Cleton-Jansen, A. M., de Pinieux, G., Deyrup, A. T., Hauben, E., Squire, J. (2013). Conventional osteosarcoma. In: Fletcher, D. M., Bridge, J. A., Hogendoorn, P. C. W., Mertens, F., editors. *WHO classification of tumours of soft tissue and bone*. (4th ed. pp.282-288). Lyon: IARC.

[17] Lucas, D. R. (2010). Osteoblastoma. *Arch. Pathol. Lab. Med*., 134, 1460-1466.

[18] Aigner, T., Dertinger, S., Belke, J., Kirchner, T. (1996). Chondrocytic cell differentiation in clear cell chondrosarcoma. *Hum. Pathol*., 27, 1301-1305.

[19] Matsuura, S., Ishii, T., Endo, M., Takahashi, Y., Setsu, N., Yamamoto, H., et al. (2013). Epithelial and cartilaginous differentiation in clear cell chondrosarcoma. *Hum. Pathol*., 44, 237-243.

[20] Gelderblom, H., Hogendoorn, P. C. W., Dijkstra, S. D., Rijswijk, C. S., Krol, A. D., Taminiau, A. H. M., et al. (2008). The Clinical approach towards chondrosarcoma. *The Oncologist*., 13, 320-329.

In: Encyclopedia of Surgery (22 Volume Set)
Editors: Andreas Lehrer and Kristin Mueller
ISBN: 978-1-53618-329-0
© 2020 Nova Science Publishers, Inc.

Chapter 346

HÜRTHLE CELL CARCINOMA: A RARE CASE WITH UNIQUE MORPHOLOGICAL FEATURES

Familia Bella Rahadiati[1], Agnes Stephanie Harahap[2,*] and Maria Fransiska Ham[2]

[1]Anatomical Pathology Residency Program,
Faculty of Medicine, Universitas Indonesia, Jakarta, Indonesia
[2]Department of Anatomical Pathology, Faculty of Medicine,
Universitas Indonesia, Jakarta, Indonesia

ABSTRACT

Hürthle cell carcinoma (HCC) of the thyroid is an unusual and relatively rare type of thyroid cancer. Small series of HCC patients have been reported in the literature, but because of its relative rarity, its pathological and clinical significance have not been well documented. A 55-year-old woman presented with rapid neck mass enlargement and hoarseness. Thorax X-ray imaging suggested intrathoracic struma. Ultrasonographic examination showed struma nodosa in the right lobe. Fine-needle aspiration biopsy results suggested a follicular neoplasm of Hürthle cell type. Grossly, the right thyroid size was 6 × 5 × 4 cm and was brown, firm, and encapsulated. The cut surfaces were brown and lobulated, with no papillary growth or calcification. A histological examination showed large tumor cells in a trabecular arrangement, rounded nuclei, coarse chromatin, some vesicular with prominent nucleoli, and abundant granular eosinophilic cytoplasm. Another section revealed capsular invasion, and a solid area containing scattered bizarre giant cells with irregular nuclei. The histopatological features and imunohistochemical staining results supported a diagnosis of encapsulated angioinvasive HCC with bizarre nuclei. HCC is a rare type of carcinoma that remains controversial and difficult to diagnose. Careful assessment should be performed to look for bizarre nuclei to prevent overdiagnosis.

Keywords: carcinoma, Hürthle cell, morphology, thyroid, unique

* Corresponding Author's Email: agnharahap@gmail.com.

INTRODUCTION

Thyroid carcinoma is the most common endocrine malignancy. Most these cancers are derived from the follicular epithelial cells of the thyroid gland. The cancers are further divided into sub-groups, depending on the degree of differentiation, and range from well-differentiated thyroid carcinoma (WDTC) to rare undifferentiated (UTC) or anaplastic thyroid carcinoma (ATC) [1, 2].

Hürthle cell tumor (HCT) is a rare thyroid neoplasm of the follicular cell origin, with >75% being composed of cells with oncocytic features. The ability to classify each tumor with oncocytic features as either benign or malignant has remained controversial [3]. HCT has no specific imaging characteristics. Ultrasound alone is unable to distinguish Hürthle cell carcinoma (HCC) from other histological variants. There are preoperative and intraoperative difficulties in discriminating adenoma from carcinoma [4, 5]. Small series of HCC patients have been reported in the literature, but HCC is an understudied cancer with poor prognosis. Because of its relative rarity, its pathological and clinical significance have not been well documented [3, 6].

HCC of the thyroid gland is unusual. It accounts for only approximately 3%-10% of all differentiated thyroid cancers and has the highest incidence of metastasis among the differentiated thyroid cancers [7]. HCC has a more aggressive natural history than that of follicular carcinoma, with a higher rate of locoregional recurrence, distant metastases, and mortality [8]. In the last five years, we have registered nine cases of HCT in Cipto Mangunkusumo Hospital (CMH), which include one case of Hürthle cell adenoma (HCA), four cases of minimally invasive HCC, and four cases of HCC.

HCC is a malignant thyroid neoplasm composed of oncocytes derived from follicular cells crowded with mitochondria, which are also called Hürthle cells, Askanazy cells, or oxyphylic cells [9]. The behavior of Hürthle cell neoplasms is unpredictable [4]. Differentiation of HCA and HCC is performed based on capsular or vascular invasion and the presence of metastases [8]. The prognosis of the malignant types of these tumors remains debatable because some authors have reported that HCA occasionally behaves like HCC [3]. In many HCC, the amount of cytoplasm is less abundant than that in adenoma, which results in an increased nuclear/cytoplasm ratio. A greater percentage of cells are tall, cuboidal or columnar, and scattered bizarre hyperchromatic forms maybe seen only in the adenoma [9].

According to the literature, both benign and malignant thyroid lesions contain so-called “cells of endocrine atypia” or cells with bizarre nuclei. These manifest as single cells or small groups displaying marked cellular and nuclear enlargement, some degree of pleomorphism, marked cellular hyperchromasia, and occasionally macronucleoli randomly dispersed among otherwise differentiated thyroid follicular cells. The presence of these enormous cells can be extremely worrisome and should be carefully assessed to arrive at the correct diagnosis [10]. We describe a rare case of HCC with unique morphological features that were identified in CMH.

CASE REPORT

A 55-year-old woman came to CMH on July 21, 2014, with a chief complaint of neck mass enlargement for the previous 10 months (Figure 1). Her past medical history revealed that the patient had lived with a small nodule the size of a corn kernel in her right neck for the last 12 years but she did not have any nodule-related complaints. However, she noticed that the neck mass began enlarging and had reached the size of a chicken egg over the previous 10 months. She went to the doctor and began taking levothyroxine once a day. She had been taking the drug for one month but then felt exhaustion and experienced palpitation, so she stopped taking the medicine. She also became hoarse but did not feel any pain, experience dyspnea, or notice exophthalmus. She went to a primary health care facility and was then referred to the CMH Internal Medicine department with a diagnosis of toxic struma nodosa and hypertension. She began taking amlodipin 10 mg once a day. She had no history of diabetes mellitus (DM), asthma, or allergy. Her family medical history showed that the patient's father had a history of tumor, the mother had a carcinoma of the cervix, and a sibling had type II DM. The patient was managed in the CMH Internal Medicine department and was scheduled to undergo a fine-needle aspiration biopsy (FNAB) procedure, ultrasound examination, administration of thyroid-stimulating hormone (TSH), and free thyroxine (fT4) laboratory tests.

Figure 1. A lump in the right anterior of the neck that moved upward when swallowing. The lump had a diameter of 6 cm and a firm distinct border. The left lateral border was in the midline, the right lateral border was in the medial sternocleidomastoideus muscle, the inferior border was in the sternal notch, and the superior border was in the hyoid bone.

Chest X-ray showed a soft tissue mass in the right inferior colli that pushed the trachea to the left and suggested intra-thoracic struma (Figure 2). Ultrasound examination of the right lobe showed an isoechoic, rounded heterogeneous lesion that was well demarcated with a regular edge and fully loaded the thyroid's right lobule. The lesion size was 3.7 × 3.34 × 3.3 cm. Intra-lesion calcification was not seen. Doppler technique showed intra-lesion vascularization. The thyroid's left lobe was normal in size and shape, with no focal pathological lesion or calcification. A lesion with a solid and cystic component was seen in

the isthmus. The trachea was located in the midline. Lymph node enlargement was not found. Radiological examination identified a struma nodosa in the right lobe of the thyroid and an isthmus nodule (Figure 3). Laboratory examination showed normal sensitive TSH (sTSH) and fT4. The sTSH level was 1.210 µIU/mL, and the fT4 level was 1.420 ng/dL.

FNAB was performed on August 14, 2014, and the results suggested a follicular neoplasm of Hürthle cell type. Then, the patient was sent to the CMH Surgical Oncology Department. The physical examination revealed a nodule in the right anterior of the neck that moved upward when the patient swallowed. The nodule had a size of approximately 5 × 4 × 3 cm and a firm, mobile, smooth surface. The temperature was the same as that of the surrounding tissue. Jugular, submandible, and submental lymph nodes were not palpable (Figure 1).

On February 6, 2015, the patient underwent isthmolobectomy surgery. Her last laboratory tests showed a normal blood count, except for a differential count, and the routine biochemical blood test results were within normal ranges. Euthyroid state was confirmed by the laboratory result. The preoperative clinical diagnosis was struma nodosa non-toxic suspected as a malignant T3N0M0. Intraoperative pathological consultation using frozen sections supported a diagnosis of WDTC transformed to ATC. According to this result, the surgeon decided to perform a total thyroidectomy in this patient. Tissue samples were sent to the CMH Anatomical Pathology Department.

Figure 2. Chest X-ray image showing a soft tissue mass in the right inferior colli, suggesting an intrathoracic struma. The heart and lung were normal.

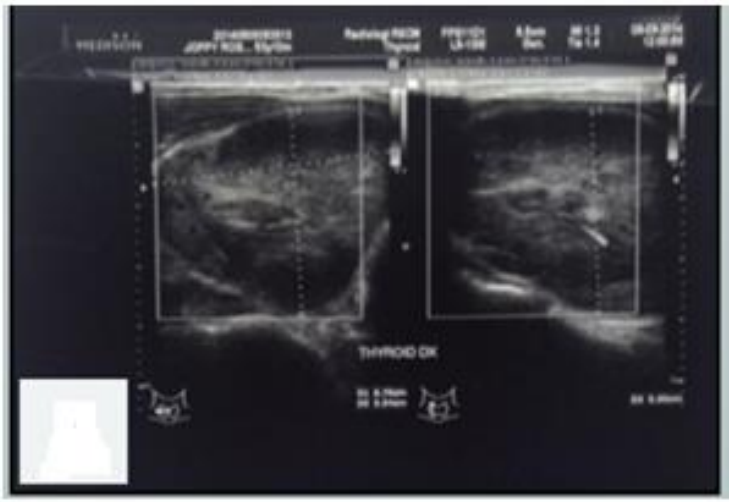

(a)

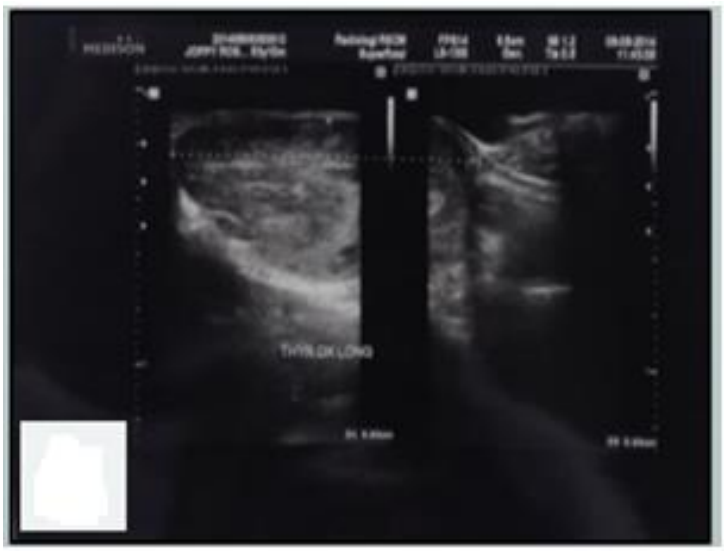

(b)

Figure 3. Ultrasound examination of the right lobe showing a rounded heterogeneous isoechoic lesion with awell-demarcated regular edge and that fully loaded the right lobule of the thyroid. The lesion size is 3.7 x 3.34 x 3.3 cm. Intralesion calcification is not seen.

Cytology Findings

FNAB smears contained diffuse clusters of large cells with abundant granular eosinophylic cytoplasm. These cells had pleomorphic nuclei, coarse chromatin, and some showed prominent nucleoli. There were scattered giant cells and multinucleated giant cells. More than 75% of the aspirate was composed of these oncocyte cells. The FNAB findings suggested a diagnosis of folicular neoplasm of the Hürthle cell type.

Macroscopic and Histologic Presentation

Grossly, the resected right thyroid measured 6 × 5 × 4 cm and was brown to red, firm, and encapsulated. The surface was smooth, and the cut surface was brown and lobulated. Calcification and papillar growth were not seen (Figure 4). The left thyroid lobe measured 3 × 1.5 × 0.5 cm and was brown to black and firm. The sentinel lymph nodes were also sent to the Anatomic Pathology Department.

Figure 4. Gross appearance. The thyroid size is approximately 6 x 5 x 4 cm and is brown to red, firm, and encapsulated. The surface is smooth, and the cut surface is brown tinted and lobulated. Calcification and papillary growth are not seen.

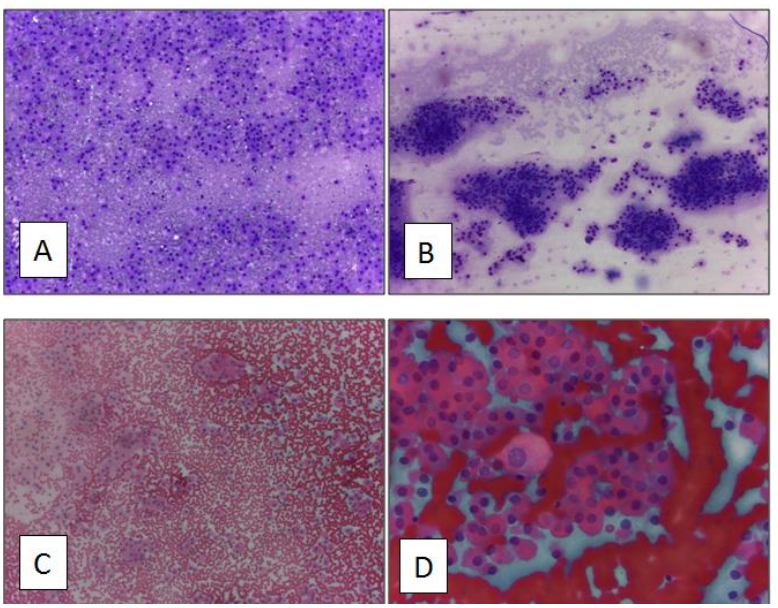

Figure 5. Cytologic features of FNAB. (a, b) Dispersed cluster of epithelial cells with atypical enlarged nuclei and abundant eosinophylic (Giemsastain, 10×). (c, d) The cells have granular eosinophylic cytoplasm (Papanicolaoustain A.100×, B 400×).

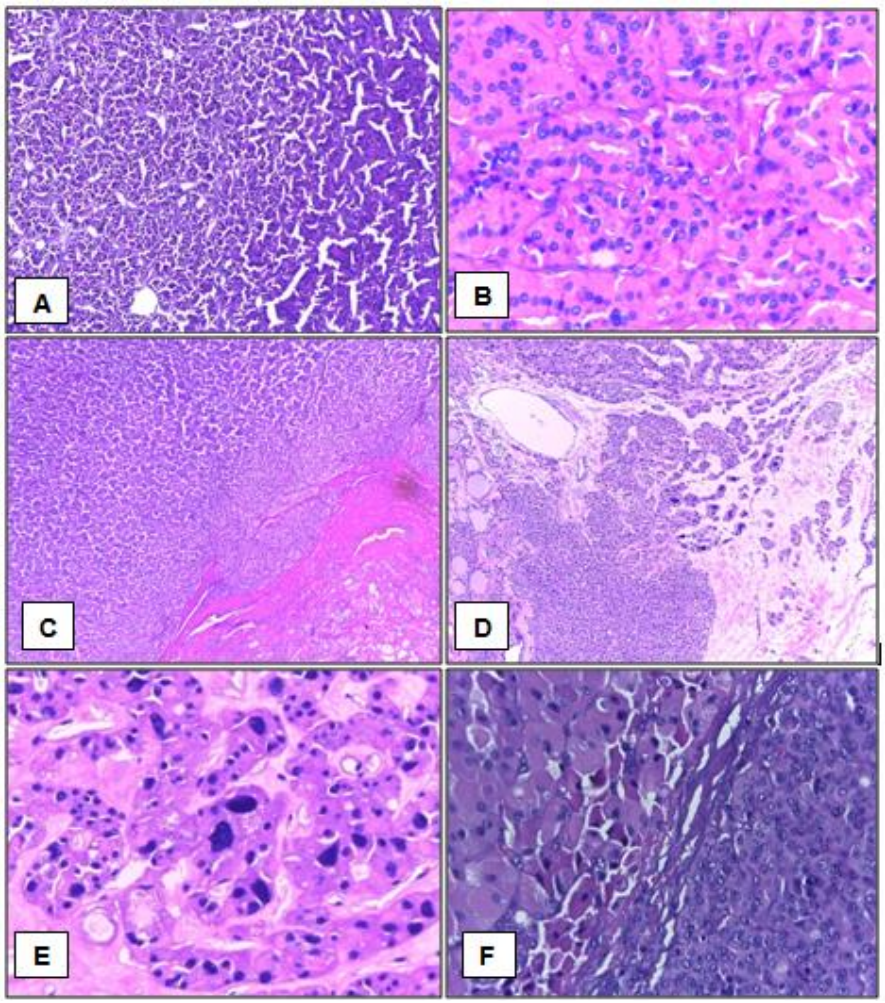

Figure 6. Variable appearance of HCC. (a) The cells are arranged in a trabecular pattern and have columnar to square shapes [hematoxylin and eosin (HE) 10×]. (b) HCC has abundant granular cytoplasm with vesicular nuclei and prominent nucleoli (HE, 4000×). (c) Area of capsular invasion (HE, 40×). (d) Area containing bizarre giant cells with hyperchromatic irregular nuclei (HE, 40×). (e) The tumor shows a follicular pattern with scanty colloid and bizarre cells dispersed among the other cells (HE, 400×). (f) Solid area composed of polygonal large cells with abundant cytoplasm and pleomorphic nuclei (HE, 400×).

Histologic examination showed large tumor cells in a trabecular arrangement, small follicles with scanty colloid, and a solid pattern. The cells were polygonal to square shaped, had distinct cell borders, rounded nuclei, coarse chromatin, some vesicules with prominent nucleoli, and abundant granular eosinophilic cytoplasm (Figure 7). One section shows an area containing bizarre giant cells with irregular hypercromatic nuclei and prominent nucleoli (Figure 8). Another area shows tumor cells with eosinophylic cytoplasm and heights three times their width (Figure 9). The tumor was diagnosed as a mixed tall cell variant of papillary thyroid carcinoma (TCVPTC) and HCC transformed to ATC. Tissue sampling from the left lobe shows adenomatous struma. Non-sentinel nodes were considered to indicate non-specific chronic lymphadenitis. Second opinions and further investigation proved that the correct

diagnosis was HCC with bizarre nuclei. ATC is difficult to manage, its management often need combination of surgery, radiotherapy and chemotherapy [2]. HCC is radio-iodine resistant and the best theraphy approach has emerge controversy between expert. Some expert recommend conservative management while others suggest aggressive treatment [3].

DISCUSSION

FNAB is regarded worldwide as the first approach to thyroid nodule evaluation. It is a simple, safe, and cost-effective method for correctly characterizing the nature of a lesion in >70% cases [11, 12]. In our case, the smears showed dispersed and clustered monotonous proliferation of Hürthle cells and scanty colloid without nuclear features of papillary thyroid carcinoma. The observed features matched the diagnostic criteria for a follicular neoplasm of Hürthle cell type. In general, it is recommended that all patients with cytologically suspicious HCT undergo surgical resection [13-15].

Our patient initially underwent isthmolobectomy. Frozen section examination revealed WDTC transformed to ATC, so the surgeon decided to perform a total thyroidectomy on this patient. The mainstay of treatment for all differentiated thyroid cancers is surgical resection, and HCC is no exception. Once an HCC is histologically confirmed following diagnostic thyroid lobectomy, a complete thyroidectomy should be considered. Histopathological analysis remains the gold standard for diagnosis, although it may be apparent preoperatively if there is evidence of metastasis. Malignant HCT requires aggressive surgery because it is poorly responsive to chemotherapy, does not concentrate iodine, and is generally not radiosensitive.

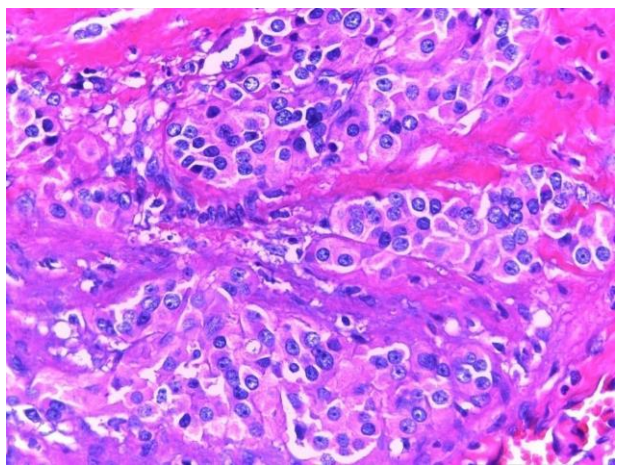

Figure 7. Hürthle cells showing polygonal to square shapes with distinct cell borders, rounded nuclei, coarse chromatin, vesicules with prominent nucleoli, and abundant granular eosinophilic cytoplasm (HE, 400×).

Indeed, because of the relatively reduced avidity of HCC for radioactive iodine, and the resultant compromised efficacy of treatment, complete surgical resection is important [5, 12]. ATC is uncommonly identified as a small incidental finding after surgical resection of a predominantly non-anaplastic tumor. The role for total thyroidectomy when an initial

lobectomy has been performed is based more on the characteristics of non-anaplastic malignancy than on the incidental finding of ATC [16].

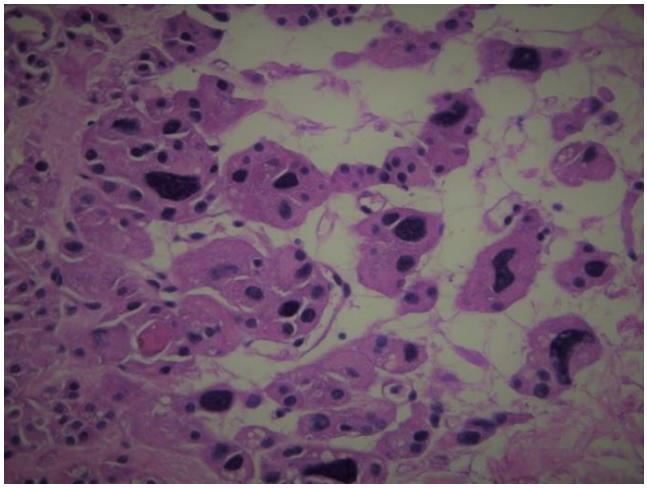

Figure 8. HCT may contain bizarre giant nuclei. This is not an indicator of malignancy, however (HE, 400×).

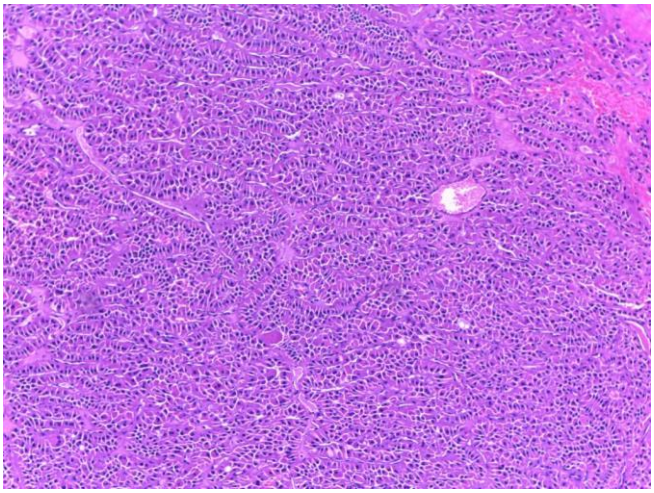

Figure 9. HCT arranged in a trabecular pattern. The cells are tall or columnar. Note the hyperchromatic nuclei. There are no nuclear features of papillary thyroid carcinoma (HE, 100×).

A paraffin block histopathology examination led to a diagnosis of mixed HCC and TCVPTC transformed to ATC. Further examination of the resected thyroid mass showed thyroid tissue containing a malignant tumor mass in a small follicular with scanty colloid trabecular arrangement and some solid areas. The neoplastic cells were mostly polygonal to square in shape, with distinct borders and abundant eosinophilic granular cytoplasm. Some cells were columnar with hyperchromatic nuclei. Nuclear grooves, nuclear clearing, nuclear crowding, and pseudoinclusion were not present. This finding excluded a diagnosis of TCVPTC.

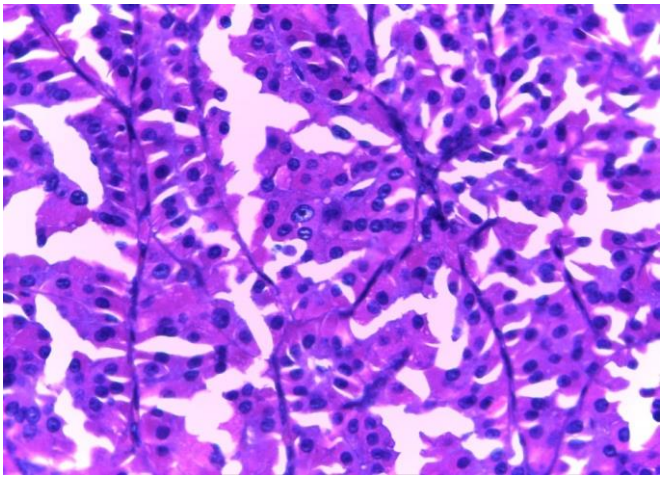

Figure 10. Discohesive growth of neoplastic cells can simulate papillary structure. This is not true papillary growth (HE, 400×).

Hürthle cells are large polygonal cells with distinct borders derived from thyroid follicular epithelium. They contain abundant granular cytoplasm, because of excess mitochondria, and have a large nucleus with a prominent nucleolus. Hürthle cells can be observed in both benign and malignant conditions. The mechanism behind mitochondrial abundance in these conditions is not completely understood, but it is probably a reflection of excessive mitochondrial proliferation and/or decreased mitochondrial degradation [5, 17]. This is a phenomenon of metaplasia that occurs in inflammatory disorders, such as thyroiditis, or other situations that result in cellular stress. Oncocytes proliferation gives rise to hyperplastic and neoplastic nodules [7].

The genetic abnormalities identified in HCT include aneuploidy, H-RAS mutations, allelic alterations, and alterations in mitochondrial DNA [14]. HCT have lower prevalences of RAS gene mutation and PAX8/PPARG rearrangement than those of their counterparts lacking oncocytic change. The TP53 mutation has been identified in 10%-20% of oncocytic follicular carcinomas lacking high-grade or poorly differentiated features, sometimes in association with PTEN mutations [17, 18].

HCC is currently classified as a variant of follicular carcinoma and is also known as oncocytic or oxyphilic carcinoma, which is defined as a thyroid malignancy consisting of ≥75% Hürthle cells. HCC differs from its benign counterpart by the presence of capsular and/or vascular invasion or the presence of metastatic disease [3, 8, 17]. The histologic distinction between HCA and HCC is determined by the presence or absence of capsular and/or vascular invasion [5-19]. HCA can be distinguished from HCC with criteria similar to those for non-Hürthle follicular tumors. HCA is an encapsulated tumor, and no invasion is seen. HCT with capsular invasion is classified as minimally invasive HCC. HCT with limited vascular invasion (<4 vessels) and extensive vascular invasion (>4 vessels) is classified as an encapsulated angioinvasion HCC. Widely invasive HCC shows extensive invasion of the thyroid and extra-thyroidal soft tissue [20]. In our case, we found several foci of capsular invasion and one focal of vascular invasion. Therefore, we categorized our case as an encapsulated, angioinvasive HCC.

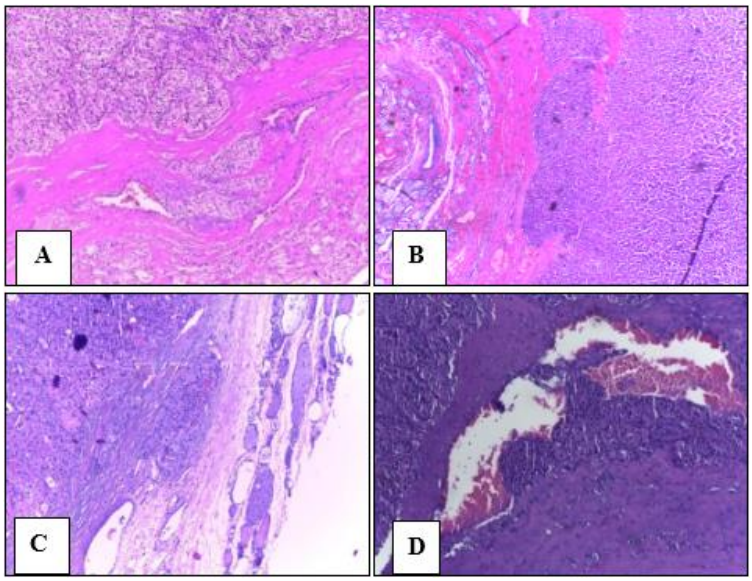

Figure 11. (a-c) Capsular invasion of the tumor. (d) Vascular invasion (a-d, HE, 100×).

HCC prognosis is related to the extent of vascular invasion. The more veins are invaded by tumors, the less favorable the prognosis. Factors other than vascular invasion are associated with overall survival in HCC patients. Goffredo et al. [17] determined that older age, larger tumor size, extrathyroidal tumor extension, and not undergoing surgery were associated with reduced overall survival of HCC. Tumor size is an important feature of biological behavior. A Hürthle cell tumor that is ≥3.5 cm has a 67% risk of malignancy [20].

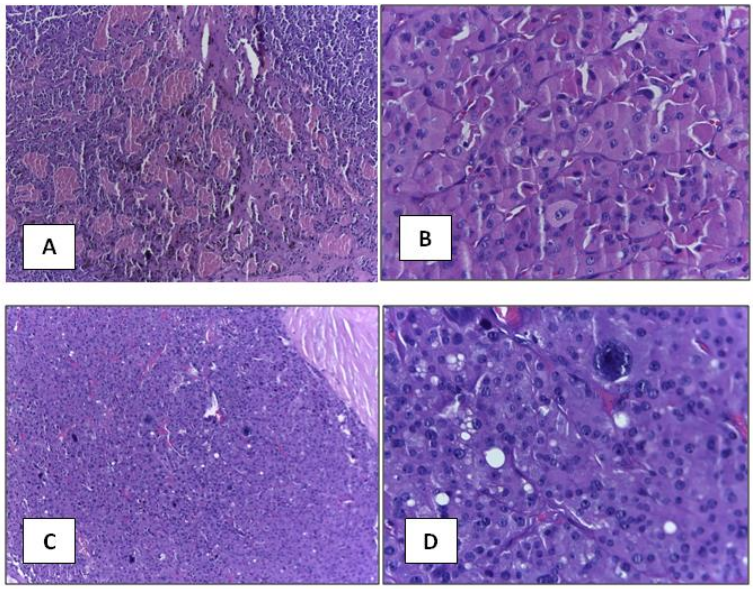

Figure 12. Another feature of HCC. (a) HCC can show hemorrhagic areas. These areas can develop spontaneously or be an effect of previous FNAB (HE, 100×). (b) Solid area with voluminous eosinophilic cytoplasm, vesicular nuclei with prominent nucleoli (HE, 400×). (c, d) Predominantly solid with scattered bizarre nuclei (HE, 10×, HE, 40×).

There are some additional morphological and architectural features that can reliably differentiate benign from malignant HCT. The more accurate parameters for a carcinoma diagnosis include the concept of small-cell dysplasia, large-cell dysplasia, syncytia, crowding, and a dispersive cellular pattern [20]. The presence of mitosis, a solid or trabecular growth pattern, extrathyroidal extension, and presence of lymph node metastases are among the histologic features that predict recurrence [17].

In some neoplasm areas, bizarre giant cells are seen. The cells show large, irregular, bizarre, markedly atypical, hyperchromatic nuclei, and some vesicular with prominent nucleoli. The number of cytoplasms ranged from high to abundant, with eosinophilic and granular characteristics. These findings were previously interpreted as characteristic of the giant cell type of ATC. A second opinion pointed out that giant cells are seen in HCC. According to the literature, both benign and malignant thyroid lesions contain so-called "cells of endocrine atypia" or cells with "bizarre nuclei", these manifest as single cells or small groups displaying marked cellular and nuclear enlargement, some degree of pleomorphism, marked cellular hyperchromasia, and occasionally macronucleoli randomly dispersed among otherwise differentiated thyroid follicular cells. Their occurrence can be extremely worrisome. When these enormous cells are observed in HCT, it is probably better not to definitively diagnose such a case as ATC [10].

We performed some immunohistochemical analyses to support our diagnosis as HCC rather than ATC. HCC will show reactivity to TTF-1 and thyroglobulin, whereas ATC will not react to either marker [10, 21]. In our case, the TTF-1 and thyroglobulin were positive in all areas, including the solid area and the area containing bizarre giant cells.

A small portion of HCC undergoes transformation to ATC [20]. HCC have a greater propensity for malignant transformation to anaplastic carcinomas than do other WDTC [7]. In our case, the immunohistochemical analyses failed to show the ATC transformation since a thyroglobulin marker showed reactivity in all tumor areas. Overdiagnosis of HCC to ATC can cause unnecessary alarm because ATC has short-term survival, with a mortality rate >90% and a mean survival time of six months after diagnosis, whereas HCC has higher survival rates ranging from 85% for minimally invasive lesions to near 10% for widely invasive cases [20].

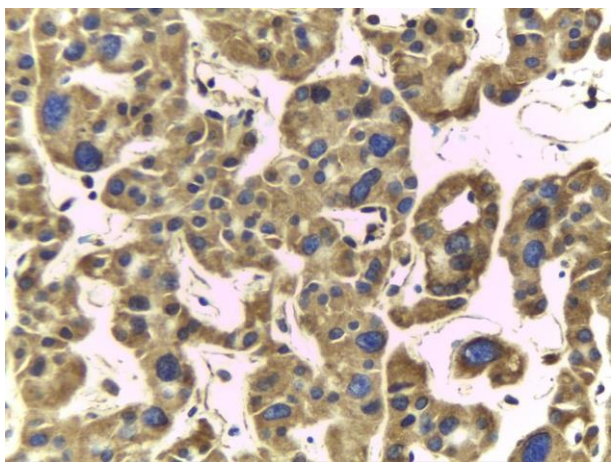

Figure 13. The tumor showed reactivity to thyroglobulin marker (IHC 400×).

CONCLUSION

Hürthle cell proliferation can lead to hyperplastic or neoplastic nodules. HCT is a rare thyroid neoplasm of follicular cell origin, and >75% of these neoplasms are composed of cells with oncocytic features. The diagnoses of HCA and HCC are differentiated based on capsular or vascular invasion and the presence of metastases. HCC's histologic appearance is highly variable. An accurate HCC diagnosis, accompanied by identification of prognostic factors, enables evidence-based management decisions. Bizarre nuclei can occur in benign and malignant HCTs and should be assessed carefully to prevent overdiagnosis.

REFERENCES

[1] Eloy, C; Ferreira, L; Saldago, C; Soares, P; Sobrinho-Simoes M. Poorly differentiated and undifferentiated thyroid carcinomas. *Turk Patoloji Derg* 201531, 48-59.

[2] Li M; Milas M; Nasr C; Brainard JA; Khan MJ; Burkey BB; et al. Anaplastic thyroid cancer in young patient: A contemporary review. *Am. J. Otolaryngol*. 201334, 636-40.

[3] Barnabei, A; Ferretti, E; Baldelli Procaccini, A; Spriano, G; Appetecchia, M. Hürthle cell tumors of the thyroid. Personal experience and review of the literature. *Acta Otorhinolaryngol. Ital*. 200929, 305-11.

[4] Okere, PCN; Olusina, DB; Enyinnah, MO. Hurthe cell tumor of the thyroid gland: Report of a rare case and review of literature. *Niger J. Clin. Pract.* 201417, 375-7.

[5] Ahmadi, S; Stang, M; Jiang, XS; Sosa, JA. Hürthle cell carcinoma: current persepectives. *Onco Targets Ther*. 20169, 6873-84.

[6] Ganly, I; Filho, JR; Eng, S; Ghossein, R; Morris, LGT; Liang, Y; et al. Genomic dissection of Hürthle cell carcinoma reveals a unique class of thyroid malignancy. *J. Clin. Endocrinol. Metab*. 201498, 962-72.

[7] Aytug S. *Hürthle cell carcinoma*. [Internet]. 2015. [cited 2015 April 13] Available from: http://emedicine.medscape.com/article/279462-overview.

[8] Mills, SC; Haq, M; Smellie, WJB; Harmer, C. *Hürthle cell carcinoma of thyroid: Retrospective review of 62 patients treated at Royal Marsden Hospital between 1946 and 2003*. EJSO200935, 230-4.

[9] Rosai, J; De Lellis, RA; Carcangiu Frable, WJ; Tallini, G. Thyroid tumors with oncocytic (Hürthle cell) features. In: Caton MQ; Thomas DS; Silve MC; Black AN; editors. *Atlas of tumor pathology tumors of thyroid and parathyroid glands*. 4th series. Washington; DC. Armed Forces Institute of Pathology. 2014.

[10] Talbot, I; DO; Wakely PE. Undiffentiated (anaplastic) thyroid carcinoma: Practical immunohistochemistry and cytologic look-alikes. *Seminars in Diagnostic Pathology*. 201532, 305-10.

[11] Faquin, WC; Michael, CW; Renshaw, AA; Vielh, P. Folicular neoplasm; Hürthle cell type/suspicious for a follicular neoplasam; Hürthle cell type. In: Ali SZ; Cibas ES; editors. *The Bethesda system for reporting cytopathology*. 2010. London: Springer; 2010. p. 51-73.

[12] Ristevka, N; Satojanoski, S; Gjorceva, DP. Appearance of Hürthle cell carcinoma soon after surgical extirpation of Hürthle cell adenoma and follicular adenoma of the thyroid gland. *Radiol. Oncol*. 201549, 26-31.

[13] Lee, KH; Shin, JH; Ko, ES; Hahn, SY; Kim, JS; Kim, JH; et al. Predictive factors of malignancy with cytologically suspicious for Hürthle cell neoplasm of thyroid nodules. *Int. J. Surg. Res*. 201311, 898-902.

[14] Cannon, J. The significance of Hürthle cells in thyroid disease. *Oncologist* 201116, 1380-7.

[15] Tai, P; Korzeniowski, M; Sadikov, E; Joseph, K; Kirbi, A; Tonita, J; et al. Issues in managing Hürthle cell carcinoma of thyroid: A case report. *Cureus* 20179, 1-6.

[16] Smallridge, RC; Ain, KB; Asa, Sl; Bible, KC; Brierley, JD; Burman, KD; et al. American thyroid association guidelines for management of patients with anaplastic thyroid cancer. *Thyroid* 201222, 1104-37.

[17] Goffredo, P; Roman, SA; Sosa, JA. Hürthle cell carcinoma: A population-level analysis of 3311 patients. *Cancer* 20132, 505-11.

[18] Máximo, V; Lima, J; Prazeres, H; Soares, P; Sobrinho-Simoes, M. The biology and the genetics of Hürthle cell tumors of the thyroid. *Endocr. Relat. Cancer* 201219, 131-47.

[19] Sandoval, MA; Paz-Pacheco, E. Hürthle cell carcinoma of the thyroid. *Case Reports* 20112011, bcr1120103536.

[20] LiVolsi, V; Baloch, ZW; Simoes, SM; Tallini, G. Hürthle (oncocytic) tumors. In: DeLellis, RA; Lloyd, RV; Heinz, PU; Eng, C; editors. *World Health Organization classification of tumors of endocrine organ*. Lyon: IARC; 2017. p. 96-9.

[21] Liu, H; Lin, F. Application of immunohistochemistry in thyroid pathology. *Arch. Pathol. Lab. Med*. 2015139, 71-82.

In: Encyclopedia of Surgery (22 Volume Set)
Editors: Andreas Lehrer and Kristin Mueller
ISBN: 978-1-53618-329-0
© 2020 Nova Science Publishers, Inc.

Chapter 347

INVASIVE BREAST CARCINOMA MIMICKING SECRETORY CARCINOMA: A CASE REPORT

Patricia Fransisca Julianty, Primariadewi Rustamadji [*] ***and Hartono Tjahjadi***
Department of Anatomical Pathology, Faculty of Medicine,
Universitas Indonesia, Jakarta, Indonesia

ABSTRACT

Secretory carcinoma is an exceptionally rare typeof invasive breast cancer in the special subtype classification of World Health Organization 2012. It occurs in <0.15% of all breast cancers and has a distinct histomorphology, which is characterized by the presence of intracellular and extracellular eosinophilic secretory materials. It generally shows triple negativity for estrogen receptor, progesterone receptor, and human epidermal growth factor 2and shows strong reactivity for S-100 protein. We report the case of a 54-year-old woman with invasive breast carcinoma. The histomorphology mimicked that of secretory carcinoma, with unusual immunohistochemical findings typical of secretory carcinoma. However, secretory carcinoma is associated with a characteristic translocation that creates *ETV6–NTRK3* gene fusion, which was not observed in this case. Despite the considerable resemblance with secretory carcinoma, this case was ultimately diagnosed as invasive breast carcinoma of no special type.

Keywords: invasive breast carcinoma, no special type, secretory carcinoma

INTRODUCTION

Invasive breast carcinoma is the most common carcinoma occurring in women and accounts for 23% of all cancers in women globally and 27% in affluent countries. The World Health Organization (WHO) Classification of Tumours of the Breast,Fourth Edition[1],

[*] Corresponding Author's Email: primariadewi@yahoo.com.

categorizesbreast cancers that do not havesufficient characteristics as a specific histological typeknown as "carcinoma of no special type" (NST). Invasive NST carcinoma is the most common type of invasive carcinoma of the breast, accounting for 40%–75% of cases in published series [1].

Secretory carcinoma (SC) is anexceptionally rare type of breast cancer in the special subtype classification of WHO. It occurs in < 0.15% of all breast cancers [2]. Itwas first observedin young children and was therefore initially calledjuvenile breast; later, it was observed to occur in all ages and soTavassoli and Norris recommended the term SC as abetter description of its clinical spectrum and behavior [3]. SCoccurs in both females and malesof ages 9–69 (median, 25) years. Moreover, it can occur in any part of the breast, with the central region being the most frequentlocation[4]. SC has a distinct histomorphology, which is characterized by the presence of intracellular and extracellular eosinophilic secretory materials with papillary, solid, microcystic, and tubular architecture. A consistent findingis thepresence of intracellular and extracellular secretory materials that is positive for periodic acid–Schiff (PAS) staining, resistant to PAS-diastase, and positive for Alcian blue (AB) staining [2, 3]. Moreover, the cells are oflow to moderate nuclear grade and exhibit low mitotic activity [2-4]. SC generally shows triple negativity for estrogen receptor (ER), progesterone receptor (PR), and human epidermal growth factor 2 (HER2), and strong reactivity for S-100 protein [4, 5]. It is associated with a characteristic translocation, t (12;15), whichcreates the *ETV6–NTRK3* gene fusion [2].

Invasive carcinoma NST has prognostic characteristic and management are similar or slightly worse compared to breast cancer as a whole.The prognosisis greatly influenced byclassical variables such as histological grade, tumor size, lymphnode status, vascular invasion, and the predictors of therapeutic response [1]. The prognosis forSC is better thaninvasive carcinoma NST:recurrence and distant metastasis are extremely rare [4], and even lymph node metastasis is associated with excellent prognosis if only a few lymph node are involved [6]. Themanagement of invasive NST carcinoma depends on the prognostic and predictive characteristics [1].There areno consensus guidelines for the treatment of SC because of its rarity, but modified radical mastectomy can be an option for tumors larger than 2 cm in diameterwith poor gross circumscription [6, 7].

Here, we report a case of a 54-year-old woman withinvasive breast carcinoma that mimickedSC; however,it was ultimately found not to have the fusion gene specific to SC. The histomorphology features were deceptive, and little is known about SCand its mimicking; it is therefore useful to report such cases as maximum information can be made available for precise diagnosis.

CASE REPORT

A54-year-old woman presented with a painless lump in her right breast, which she had first noticed two years previously. It had gradually increased in size during the previous year and, 7 months previously, the patient also noticed a mass in the axillary region. There was no history of breast carcinoma in herfamily. She attended our hospital on September 19th 2016. A physical examination revealed a mobile, hard, firm, painless nodule with a well-defined border, located in the upper medial quadrant of her right breast in the areolar region. There

was no skin ulceration or nipple discharge. Ultrasonography showed a heterogenous hypoechoic mass with calcification in the upper inner quadrant of the right breast; it measured 2×2×2.4cm, with an ill-defined margin. In addition, there was enlargement of the right axillary lymph node without a central hilum, measuring 1.5×0.8cm. Abdominal ultrasonography and thoracic X-ray imaging showed no signs of metastatic lesions.

A core needle biopsy was performed on September 29th. The specimen showed epithelial neoplastic cells arranged in a trabecular infiltrative nest with no tubule formation. The nuclei were moderate in size and hyperchromatic, with eosinophilic cytoplasm (Figure 1). The mitotic count was fewer than 5 per 10 high-power fields. No vascular invasion was observed. The tumor was diagnosed as invasive NST carcinoma, grade 2 (tubule score = 3; nuclear score = 2; mitotic score = 1; total score = 6).

A fine needle aspiration biopsy was performed on November 21st as part of a special educational and experimental study. This revealed the tumor cells to be clustered and dispersed, with pleomorphic nuclei, coarse chromatin, and irregular membranes, with eosinophilic cytoplasm and intracytoplasmic vacuolization (Figure 2). The diagnosis was breast carcinoma.

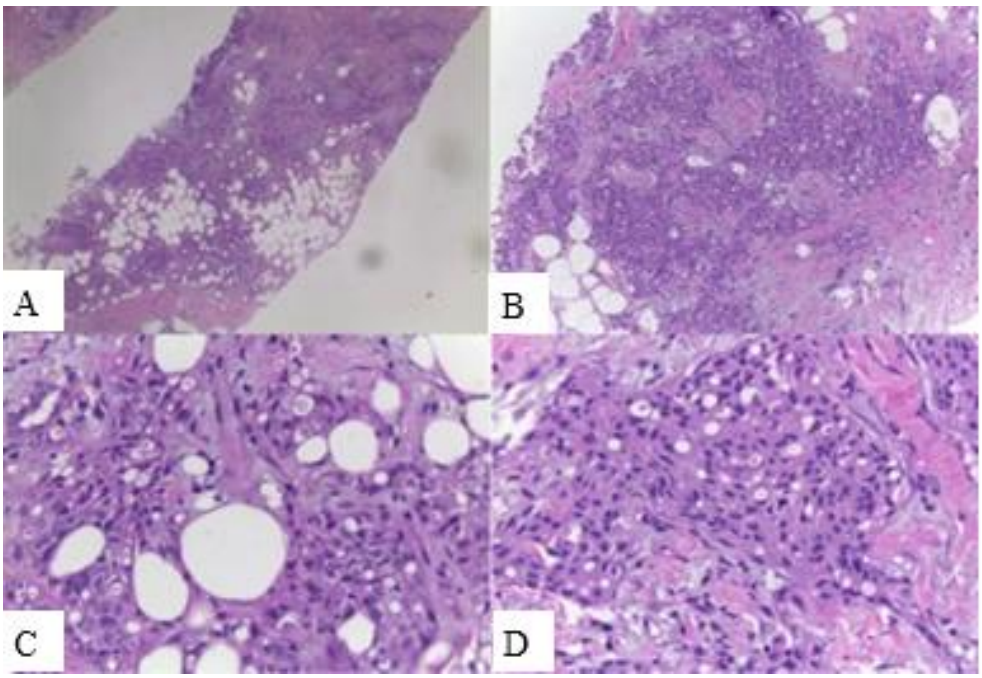

Figure 1. Core biopsy. (a, b) The tumor cells were arranged in a trabecular infiltrative nest. (a) H&E stain,40×. (b) H&E stain,100×. (c, d) The nuclei were moderate in size and hyperchromatic with eosinophilic cytoplasm. Both H&E stain,400×. H&E, hematoxylin and eosin.

A modified radical mastectomy was performed on December 7th and the specimen was sent for pathological examination. On gross examination, the tumor was 3×2.5×2.5cm in size, ill-defined, firm, and white to tan (Figure 3). It was located 2 cm from the areola in the upper inner quadrant.

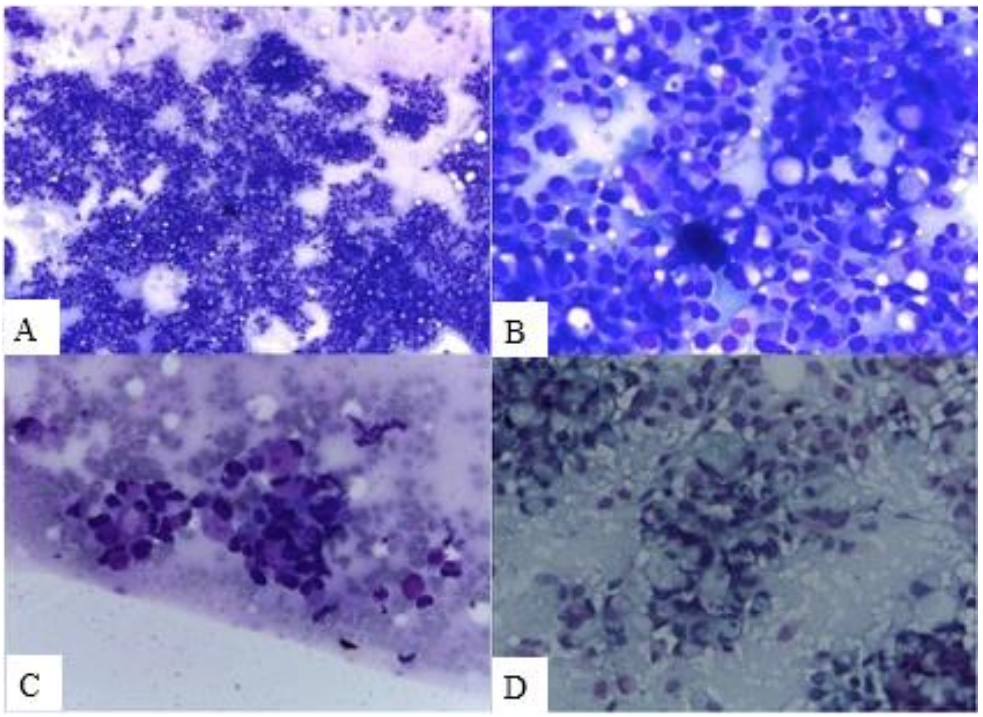

Figure 2. Fine needle aspiration biopsy smears. (a) The tumor cells were clustered. Giemsa stain,100×. (b, c) The tumor cells had pleomorphic nuclei with eosinophilic cytoplasm and intracytoplasmic vacuolization. Giemsa stain, 400×. (d) Clusters of tumor cells. Papanicolaou stain, 400×.

Figure 3. Gross specimen. The tumor was firm and ill-defined.

Microscopic examination showed the tumor mass had a solid pattern with infiltrative nests. Tubule formation was observed in less than 10% of the tumor area. The tumor cells had round or oval nuclei that varied in size from moderate to large. They were vesicular, with scattered nucleoli and eosinophilic to pale cytoplasm. The cytoplasm was vacuolated, with abundant eosinophilic material in the lumina (Figure 4). The mitotic count was 6per10high-power fields. There was no tumor infiltration into the areola, skin, or surgical margins. When

the secretory material was stained with PAS and AB, the PAS staining persisted after diastase digestion (Figure 5). Specimens from dissection of the axillary lymph nodes at levels I and II revealed metastasis in one of the three lymph node. On the basis of these findings, the tumor was diagnosed as SC, grade 2 (tubule score = 3; nuclear score = 3; mitotic score = 1; total score = 7), with a recommendation for immunostaining.

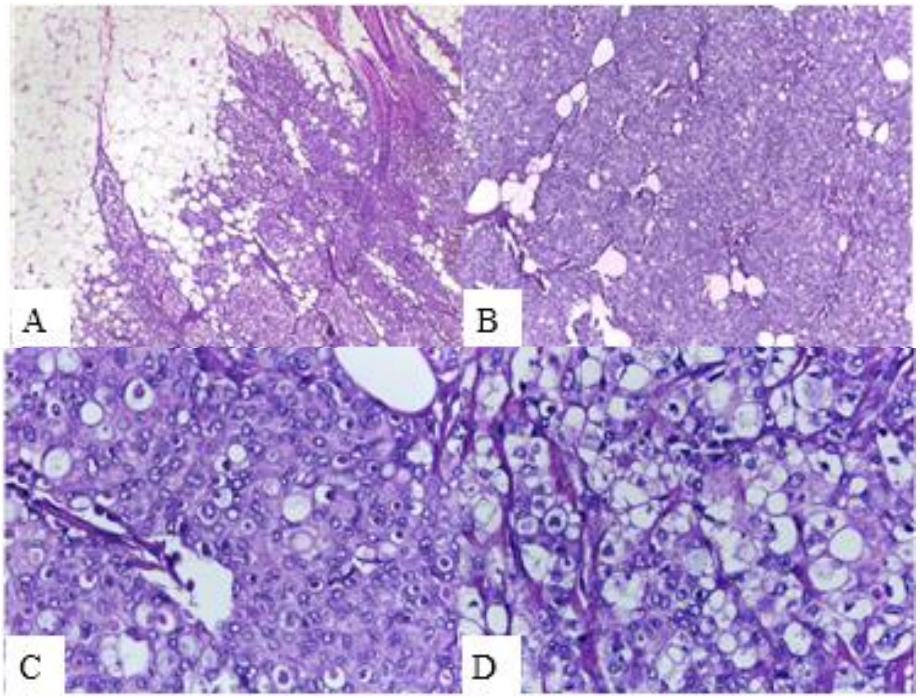

Figure 4. (a, b) Tumor cells showing the solid pattern and infiltrative nest. (a) H&E stain,40×. (b) H&E stain, 100×. (c, d) The tumor cells had round or oval, moderate to large nuclei, which were vesicular, with scattered nucleoli and eosinophilic to pale cytoplasm. The cytoplasm was vacuolated with eosinophilic material. H&E stain, 400×. H&E, hematoxylin and eosin.

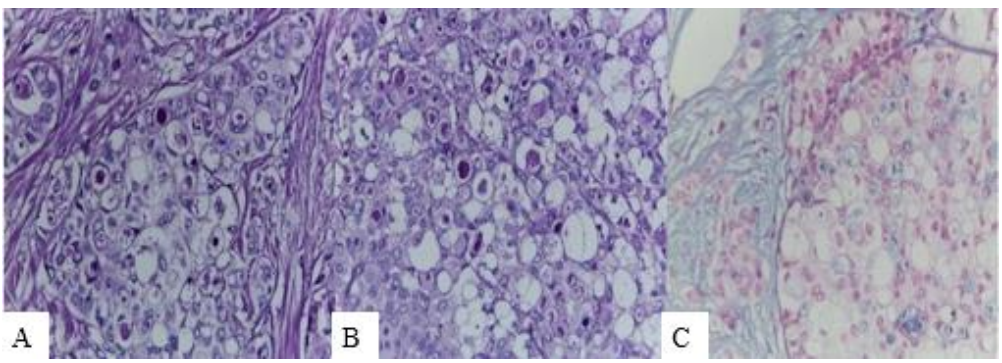

Figure 5. The eosinophilic material. The specimen was (A)positive for periodic acid–Schiff (PAS) staining, (B)resistant to PAS-diastase, (C)and positive for Alcian blue staining. All 400×.

Immunohistochemically, the neoplastic cells were positive for ER (80%), negative for PR, and expressed HER2 with a score of 2+ (weak membranous staining). Subsequent chromogenic in situ hybridization showed no amplification of HER2. In addition, 15% of the tumor cells were positive for Ki67, and the cells were negative for S-100 protein, positive for carcinoembryonic antigen, positive for E-cadherin, and negative for CD117 (Figure 6).

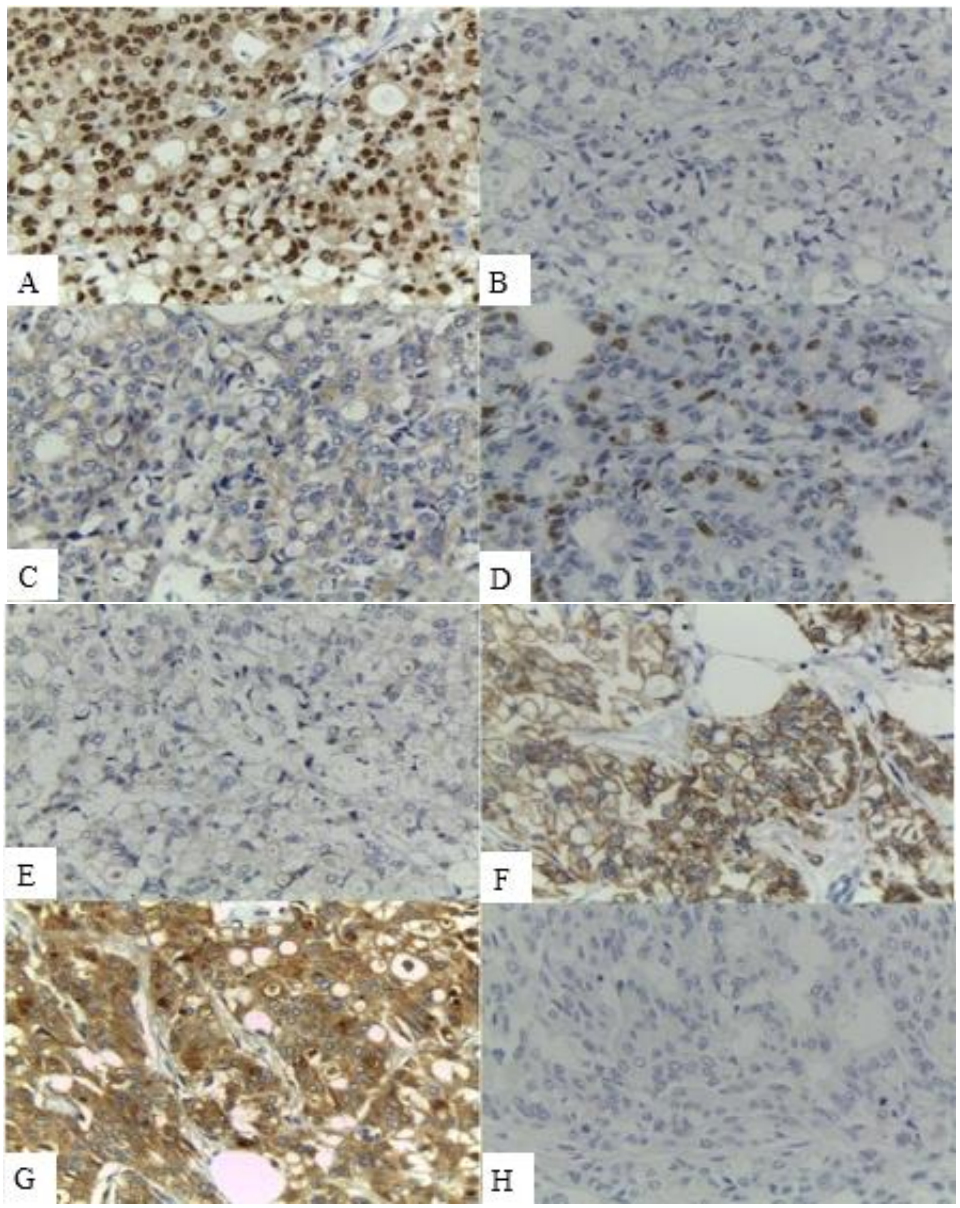

Figure 6. Immunohistochemical staining showed that the cells were (a) estrogen receptor-positive, (b) progesterone receptor-negative, (c) did not overexpress HER2, (d) positive for Ki67 (15%of the cells), (e) negative for S-100 protein, (f) positive for E-cadherin, (g) positive for carcinoembryonic antigen, (h) and negative for CD117. All 400×.

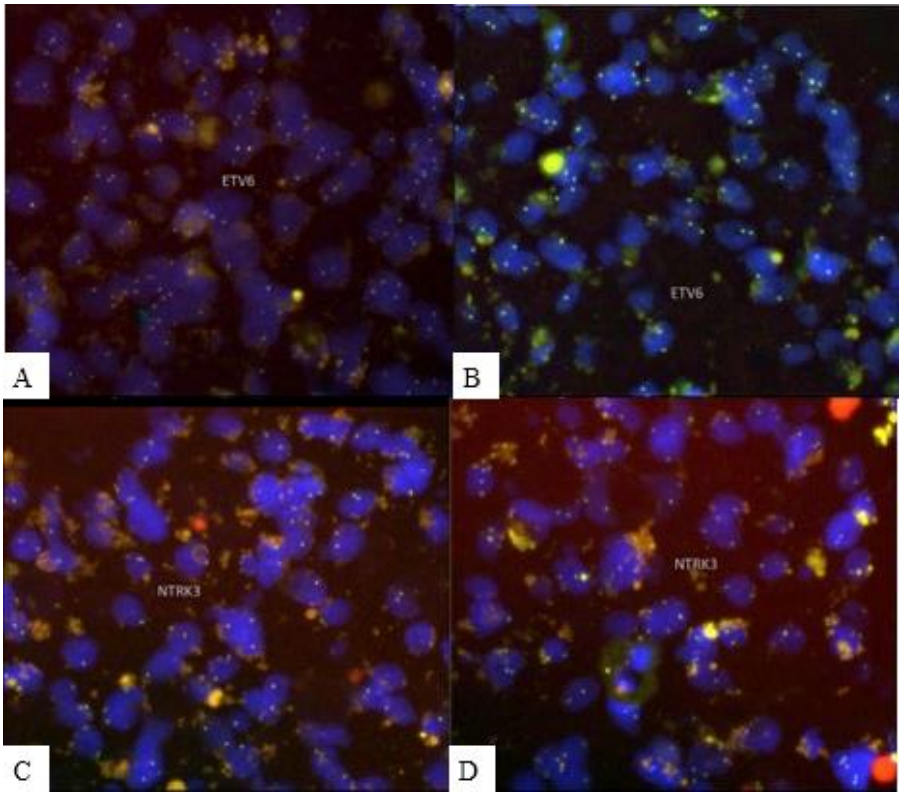

Figure 7. Results of the *ETV6–NTRK3* fusion gene test using a fluorescence in situ hybridization break-apart probe. (a, b) The cells were negative for the *ETV6* translocation. (c, d) The cells were negative for the *NTRK3* translocation.

Aparaffin-embedded cell block was tested for the *ETV6–NTRK3* fusion gene, which characterizes SC, at the Prince of Wales Hospital, Hong Kong, using a fluorescence in situ hybridization break-apart probe kit. This demonstrated the absence of the *ETV6–NTRK3* fusion gene (Figure 7).

The patient was administered aromatase inhibitor hormonal therapy, anastrozole, without chemotherapy or radiotherapy. At 10 months after the surgery, she remains well, without local recurrence or distant metastases.

DISCUSSION

SC is a rare subtype of breast malignancy that accounts for less than 0.15% of all breast cancer [2]. During a six-year period, from January 2011 until December 2016, our hospital experienced only three cases, although none of these were tested for the fusion gene.

The signs and symptoms of our patient initially appeared to be consistent with SC. She was aged 54years; SC has been at ages from 9 to 69 [3], with about one-half of cases older than 20 years, and a substantial number aged between 50 and 69 years [8]. The nodule in her right breast was painless and was first noticed two years two years previously, gradually increasing in size over the previous year. SC is a slow-growing, painless, well-circumscribed,

mobile, palpable mass [2,6]. In our patient, the single mass was 3×2.5×2.5 cm in size, ill-defined, firm, and white to tan in color, and it was located 2 cm from the areola in the upper inner quadrant. SC can occur in any part of the breast, with the central region of the breast the most prevalent location. It usually grows as a single mass and ranges in size from 0.5 to 12 cm (mean, 3 cm) [2, 8]. The cut surface varies from grayish-white or yellow to tan in color [2, 3].

Fine needle aspiration smears of SC are characterized by the presence of a globular structure comprising small, centrally located, mucoid material, usually covered by two or three, or occasionally more, epithelial cells. The presence of grape-like clusters of vacuolated cells can be another helpful cytologic feature. Other findings of SC include prominent intracytoplasmic vacuolization and occasional signet ring cells. Some cells contain granular cytoplasm. The nuclei are crescent-shaped or ovoid, with moderate to low nuclear-to-cytoplasmic ratios. Most of the cells have a bland appearance, although some can appear alignant [8-12]. In our case, the fine needle aspiration smears revealed tumor cells that were clustered and dispersed. It showed a frankly malignant appearance, with pleomorphic nuclei, coarse chromatin, and irregular cell membranes, with eosinophilic cytoplasm and prominent intracytoplasmic vacuolization. Some parts of the smears contained structures that mimicked the globular structures and grape-like clusters that are the most characteristic features of SC [8]. However, although we observed globular structures and prominent intracytoplasmic vacuolization, the tumor cells showed a frankly malignant appearance, which is unusual for SC.

The core biopsy specimen showed the same histological features as the mastectomy specimen. Microscopically, SC is usually circumscribed, although it sometimes exhibits overtly infiltrative growth. It is arranged in papillary, microcystic, ductal, and solid patterns [2, 8]. Our case showed an infiltrative tumor arranged in a solid nest.

SC tumor cells can have secretory or apocrine features. The cytoplasm of the SC cells of a secretory nature is pale to clear, pink or amphophilic, and contains abundant secretions. The nuclei appear to be low-grade and are small to moderate in size, and those with pale chromatin usually contain small uniform nucleoli. The chromatin ranges from dark and finely dispersed to pale and granular. Cells with apocrine features contain granular eosinophilic cytoplasm and the nuclei are characteristic of those of apocrine cells. It is usual to observe both secretory and apocrine types of cell in a carcinoma, although one type can predominate [8]. In our case, the tumor cells had round or oval nuclei that were moderate to large in size, vesicular and with scattered nucleoli. In SC, the tumor cells typically have a blander appearance, with nuclei that are small to moderate in size and less pleomorphic, but SC with intermediate or high nuclear atypia has been reported [13]. SC is usually associated with low mitotic activity [2, 4, 6]. The mitotic activity of our case was as low as that found in SC.

The presence of intracellular and extracellular secretory material that is PAS-positive, PAS-diastase resistant, and AB-positive is a consistent finding in SC [2]. The secretion accumulates within the tumor cells, in glands formed by the tumor cells, and in the microcystic spaces associated with the tumor cells. With hematoxylin and eosin staining, the secretory material appears pale pink or amphophilic, and it often contains lacunar that give the appearance of bubbles [8]. In our case, the vacuolated cytoplasm with abundant eosinophilic material that was PAS-positive, PAS-diastase resistant, and AB-positive led us to diagnose it as a special type of breast carcinoma.

On immunostaining, SC generally shows as triple negative for ER, PR, and HER2, with strong reactivity for S-100 [5]. Our case was ER-positive, but PR-negative and HER2-negative. Although there have been some reported cases of SC that were positive for ER, this is unusual [14-16]. Our case was negative for S-100 protein. We were unable to find any previous reports ofS-100 protein-negative SC, so this finding didnot support the SC diagnosis.

In SC, Ki67 levels vary from less than 1% to 34%, and E-cadherin is positive [8]. In our case, Ki67 was positive in 15% of the nuclear tumor cells and E-cadherin was positive. Positivity or negativity for the carcinoembryonic antigen varies in SC, whereas CD117 is positive in 70% of cases [4, 8]. Our case was positive for the carcinoembryonic antigen and negative for CD117.

The differential diagnosis included acinic cell carcinoma, cystic hypersecretory carcinoma, carcinoma with apocrine differentiation, cribriform carcinoma, glycogen-rich carcinoma, and lipid-rich carcinoma, as well as invasive NST carcinoma [4, 6, 17]. Acinic cell carcinomas, which are even less common than SC, present with cells containing basophilic granules. They can closely resemble SC; as with SC, they are triple negative for ER,PR, and HER2 and usually positive forS-100 protein [4]. Osako *et al.* proposed four markers for distinguishing between SC, acinic cell carcinoma, cystic hypersecretory carcinoma, and common invasive breast carcinoma: *ETV6* rearrangement, amylase, α-lactalbumin, and adipophilin [17]. Cystic hypersecretory carcinomas comprise grossly evident cystic spaces filled with denselyeosinophilic secretory material, with scant cytoplasm [4]. Carcinomas with apocrine differentiation are invasive, with all or nearly all of the tumor cells exhibiting apocrine cytologic features, and no intracellular vacuoles. They are usually negative for ER and PR and positive for androgen receptors [6]. Cribriform carcinomas typically have less cytoplasm and lack the foamy eosinophilic quality. There is often secretion, but this is not darkly eosinophilic, and they are usually positive for ER and PR and negative for HER2 [4]. Glycogen-rich carcinomas show PAS-positivity and are sensitive to diastase digestion, whereas lipid-rich carcinomas show abundant microvacuolated, foamy, or clear cytoplasm due to lipids that are not stained by PAS or AB [6].

Fusion of the *ETV6* and *NTRK3*genes results in a chimeric tyrokinase protein that displays potent transforming activity for fibroblast and mammary ductal epithelial cells. It is characteristic of SC, detected using fluorescence in situ hybridization [2, 8, 18-20]. The absence ofthe*ETV6–NTRK3* fusion gene in our case confirmed that the diagnosis was not SC, despite all its morphological resemblance with SC. Because there were insufficient characteristics to achieve a specific histological type classification, the case was ultimately classified as invasive NST carcinoma.

The prognosis for invasive NST carcinoma is influenced profoundly by the classical variables of histological grade, tumor size, lymphnode status, and vascular invasion and by predictors of the therapeutic response. Invasive NST carcinoma and other invasive breast carcinomas are routinely graded based on an assessment of tubule/gland formation, nuclear pleomorphism, and mitotic count. Grade is a powerful prognostic factor [1]. According to the Elston–Ellis system, our case was grade 2 (moderately differentiated). Invasive carcinomas are divided into four subtypes based on protein expression patterns: luminal A, luminal B, HER2-enriched, and basal [1]. The subtype of our case was luminal A, which has a favorable prognosis.

It is important to differentiate between SC and invasive NST carcinoma because they differ in their prognosis [8, 17]. The prognosis is more favorable for SC: even patients with lymph node metastasis have an excellent prognosis if only a few lymph nodes are involved [6, 21], and recurrence and distant metastases are extremely rare [4].

Invasive NST carcinoma should be managed according to its prognostic and predictive characteristics. Most cases benefit from hormonal treatment, but the benefit of chemotherapy less clear [1]. Because of its rarity, there are no consensus guidelines for the treatment of SC. A recent report describes the successful treatment of a patient with SC with targeted therapy, the tyrokinase inhibitor larotrectinib [22]. In our case, after the modified radical mastectomy and axillary lymph node dissection, the patient was given anastrozole, anaromatase inhibitor, and hormonal therapy.

SUMMARY

SC is a rare breast malignancy, which consistently shows the presence of intracellular and extracellular secretory material that is PAS-positive, PAS-diastase resistant, and AB-positive, and is usually triple negative for ER, PR, and HER2, with strong reactivity for S-100 protein. It is associated with a characteristic translocation that creates *ETV6–NTRK3* gene fusion. The present case showed histomorphology that mimicked SC, with prominent eosinophilic secretory material that stained positive for PAS, PAS-diastase, and AB; however, the nuclear features were more pleomorphic than is typical of SC, and immunostaining showed features unusual for SC (ER-positive and S-100 negative). Cases with histomorphology features of SC but has unusual immunohistochemical findings typical of SC must be tested for the *ETV6–NTRK3* fusion gene prior diagnosed as SC. Despite the resemblance to SC in this case, the absence of the *ETV6–NTRK3* fusion gene excluded SC as a diagnosis and this case was ultimately diagnosed as invasive NST carcinoma.

ACKNOWLEDGMENTS

I would like to thank Gary Tse for helping us with fusion gene examination and his guide, Dr. Diahrini SpPA(K), for support during the process of writing this report. I also would like to thank fellow residents and my beloved friends for theirassistance and support.

REFERENCES

[1] Colditz, G; Chia, KS. Invasive breast carcinoma: introduction and general features. In: Lakhani SR, Ellis IO, Schnitt SJ, Tan PH, Vijver MJ, editors. *WHO classification of tumours of the breast*. 4th ed. Lyon: IARC; 2012. 14-31.

[2] Eusebi, V; Ichihara, S; Salomon, AV; Sneige, N; Sapino, A. Special subtypes. In: Lakhani SR, Ellis IO, Schnitt SJ, Tan PH, Vijver MJ, editors. *WHO classification of tumours of the breast*. 4th ed. Lyon: IARC; 2012. 39-76.

[3] Tavassoli, FA; Norris, HJ; Secretory carcinoma of the breast. *Cancer*, 1979;45:2404-13.

[4] Hicks, DG; Lester, SC. Secretory carcinoma. In: Bennet NI, Cannon TL, Ferrel TW, Gervais LA, Concannon KE, Fassett EC, editors. *Diagnostic pathology breast.* 2nd ed. Philadelphia: Elsevier; 2016. 357-64.

[5] Li, Dali; Xiao, X; Yang, W; Shui, R; Tu, X; Lu, H; et al. Secretory breast carcinoma: a clinicopathological and immunophenotypic study of 15 cases with a review of the literature. *Mod. Pathol*., 2011;25:567-75.

[6] Vasudev, P; Onuma, K. Secretory breast carcinoma, unique, triple-negative carcinoma with a favorable prognosis and characteristic molecular expression. *Arch. Pathol. Lab. Med*., 2011;135:1606-11.

[7] Matos, E. Secretory breast carcinoma-case report and review of the medical literature. *Breast*, 2004;13:353-5.

[8] Koerner FC. Secretory carcinoma. In: Hoda SA, Brogi E, Koerner FC, Rosen PP, editors. *Rosen's breast pathology*. 4th ed. Philadelphia: Wolters Kluwer; 2015. p. 689-701.

[9] Tse, G; Tan, PH; Schmitt, F. *Fine needle aspiration cytology of the breast*. 1sted. Philadelphia: Springer; 2013.

[10] Field, AS. Fine needle aspiration biopsy cytology of breast: a diagnostic approach based on pattern recognition. In: Field AS, Zarka MA, editors. *Practical cytopathology*. Philadelphia: Elsevier; 2017. 147 -231.

[11] Kocjan, G. Diagnostic dilemmas in FNAC cytology-difficult breast lesion. In: *Fine needle aspiration cytology*. Philadelphia: Springer; 2006. 186-211.

[12] Shanthi V, Krishna BA, Rao NM, Sujatha C. Cytodiagnosis of secretory carcinoma of the breast. *J. Cytol.*, 2012;29:63-5.

[13] Han, Y; Zhang, Q; Li, B; Jiang, N; Qiao, Z; Yu, X; et al. Secretory breast carcinoma: a clinicopathological and immunohistochemical study of 7 cases. *Int. J. Clin. Exp. Pathol.* 2016;9:1893-900.

[14] Gabal, S; Talaat, S. Secretory carcinoma of male breast: case report and review of the literature. *Int. J. Breast Cancer*, 2011;2011:1-5.

[15] Yorozuya, K; Takahashi, E; Kousaka, J; Mouri, Y; Yoshida, M; Fujii, K; et al. A case of estrogen receptor positive secretory carcinoma in a 9-year-old girl with ETV6-NTRK3 fusion gene. *Jpn. J. Clin. Oncol*., 2011;42:208-11.

[16] Diallo, R; Schaefer, K; Bankfalvi, A; Decker, T; Ruhnke, M; Wulfing, P; et al. Secretory carcinoma of the breast: a distinct variant of invasive ductal carcinoma assessed by comparative genomic hybridization and immunohistochemistry. *Hum. Pathol.*, 2003; 34:1299-305.

[17] Osako, T; Takeuchi, K; Horii, R; Iwase, T; Akiyama, F. Secretory carcinoma of the breast and its histopathological mimics: value of markers for differential diagnosis. *Histopathology*, 2013;63:509-19.

[18] Euhus, DM; Timmons, CF; Tomlinson, GE. ETV6-NTRK3—Trk-ing the primary event in human secretory breast cancer. *Cancer Cell*, 2002;2:347-8.

[19] Makretsov, N; He, M; Hayes, M; Chia, S; Horsman, DE; Sorensen, PH; et al. A fluorescence in situ hybridization study of ETV6-NTRK3 fusion gene in secretory breast carcinoma. *Gene Chromosome Canc*, 2004;40:152-7.

[20] Tagnon, C;Knezevich, SR; Huntsman, D; Roskelley, CD; Melnyk, N; Mathers, JA; et al. Expression of the ETV6-NTRK3 gene fusion as a primary event in human secretory breast carcinoma. *Cancer Cell*, 2002;2:367-76.

[21] Vieni, S;Cabibi, D;Cipolla, C;Fricano, S;Graceffa, G;Latteri, MA. Secretory breast carcinoma with metastatic sentinel lymph node. *World J Surg Oncol*. 2006;4:88-94.

[22] Shukla, N; Roberts, SS; Baki, MO; Mushtaq, Q; Goss, PE; Park, BH; et al. Successful targeted therapy of refractory pediatric ETV6-NTRK3 fusion-positive secretory breast carcinoma. *JCO Precis Oncol*, 2017;1-8.

In: Encyclopedia of Surgery (22 Volume Set)
Editors: Andreas Lehrer and Kristin Mueller
ISBN: 978-1-53618-329-0
© 2020 Nova Science Publishers, Inc.

Chapter 348

LANGERHANS CELL HISTIOCYTOSIS WITH UNUSUAL NODULAR PATTERN

Imelda Setiana Silitonga[1] and Endang Sri Roostini Hardjolukito[2,*]
[1]Anatomical Pathology Residency Program, Faculty of Medicine,
Universitas Indonesia, Jakarta, Indonesia
[2]Department of Anatomical Pathology, Faculty of Medicine,
Universitas Indonesia, Jakarta, Indonesia

ABSTRACT

Langerhans cell histiocytosis (LCH) is a rare clonal proliferative disorder of Langerhans cells with unknown etiology, which occurs predominantly in male children. Histopathology features show polymorphous cells arranged in diffuse sheets. This case study involved the case of a patient who exhibited a nodular pattern that was unusual for LCH. The aim of this case report is to share experience about the unusual histology of LCH. An eleven-month-old boy presented with enlarged neck and inguinal lymph nodes. Ultrasound showed multiple enlargements of the lymph nodes with hypervascularization and a regular and distinct border. The patient underwent open surgical biopsy and the specimen was sent for histopathology analysis. The histopathology showed a nodular pattern with the characteristics of Langerhans cells that have abundant eosinophilic cytoplasm and the presence of nuclear grooves, nuclear folding, and inflammatory cells. The immunostaining was positive for CD1a, Langerin, S100, and CD68. In most cases of LCH, the morphology features showed polymorphous cells arranged in diffuse sheets. There are to our knowledge no published reports to date that show LCH in the nodular pattern. Whether or not there is different pathogenesis or biological behavior in nodular LCH remains unclear.

Keywords: histopathology, immunostaining, langerhans cell histiocytosis

[*] Corresponding Author's Email: ensrhardjo@gmail.com.

INTRODUCTION

Langerhans cell histiocytosis (LCH) is a rare disease that involves the clonal proliferation of cells with dendritic cell features that can affect many organs. The lesion consists of LCH cells that resemble epidermal antigen-presenting dendritic Langerhans cells [1,2]. LCH was named after the founder Paul Langerhans in 1868, and the Langerhans cell is mononuclear cell, approximately 10 to 15 μm in diameter and contains the Birbeck granules [3].

Patients with LCH can be of any age, but it occurs most commonly in children, with a greater occurrence in males (ratio ranging from 1.2:1 to over 2:1) [3,4,5].

Many names have been used previously to refer to LCH, including histiocytosis X, eosinophilic granuloma, Letterer Siwe disease, and Hand Schüller Christian disease. To date the etiology of LCH is unknown, and there is a lack of understanding regarding the pathogenesis of LCH. The clinical presentation of LCH also varies from isolated single system disease to a life-threatening multisystem condition. Patients may have systemic symptoms like fever, pancytopenia, skin manifestations, widespread bone lesions, lymphadenopathy, and hepatosplenomegaly [1,4-7].

LCH is classified as either a single system or multi system disease whereby the single system disease is when the disease affects only one organ, and the multi system affects two or more organs [7]. Lymph node involvement can be part of a widespread disease that also involves other organ systems. However, LCH can also be localized to one region.

Histology and immunostaining are used to diagnose LCH. Histopathology reveals polymorphous cells arranged in diffuse sheets. There are no reports that show cells arranged in a nodular pattern. The nuclear characteristics are irregular with prominent folds, grooves, fine chromatin, inconspicuous nucleoli, and having moderately abundant eosinophilic cytoplasm. Patients with LCH typically present with a background of inflammatory cells like eosinophils, neutrophils, macrophages, and lymphocytes and the mitotic activity varies in number. LCH is characterized by the expression of CD1a, S100, and Langerin [3,4,8,9]. In 1987, the Histiocyte Society Writing group defined the criteria for the diagnosis of LCH by the presence of Birbeck granules visible via electron microscopy or by positive CD1a immunostaining. Presence of positive CD1a and Birbeck granules in the lesion is the current gold standard for the diagnosis of LCH [5,6,10].

Treatment decisions depend on whether there is a low or high risk of organ involvement and the extent of the disease at the time of diagnosis. Treatment options may include surgery, chemotherapy, radiation, and corticosteroid therapies. Patient prognosis depends on age, the extent of organ involvement, and response to initial treatment [4]. In this research study, we report the clinical and pathologic features of an eleven-month-old boy with LCH and nodular morphologic features.

CASE REPORT

An 11-month-old boy with multiple lumps on his neck for 10–12 days came to a private hospital on 5th December 2014. He underwent a neck ultrasound and chest X-ray on 6th December 2014, and the ultrasound examination showed multiple enlargements of the lymph nodes with hypervascularization and a regular and distinct border. The size of the largest

lymph node was 1.42× 1.35 cm on the right side of the neck and 1.62 × 0.97 cm on the left side of the neck. The thyroid was normal. Lymphadenopathy was concluded from the ultrasound.

The chest X-ray showed the widening of the superior mediastinum with normal heart and hilum, and therefore interstitial pneumonia was concluded.

On the 19th of December 2014, the patient came to the Cipto Mangunkusumo Hospital complaining of a high fever that had persisted for one month. The other complaints were productive cough for one week and multiple lumps on the left and right side of his neck which initially looked like a bean and became bigger within the final two weeks. There was no weight loss, no history of going pale, bleeding, or of abdominal enlargement. There was also no family history of these symptoms. On physical examination, the patient was conscious, had no fever, was 76 cm tall, and weighed 9.1 kg. There were enlarged lymph nodes on the neck and submandible, with the largest size being 1.5 × 2 cm. The nodules were not tender but rather were firm in consistency and fixed to the surrounding tissue. These nodules were also accompanied by an enlarged inguinal lymph node approximately 0.5 cm in diameter.

On pulmonary examination, there were no rales or wheezing. The patient was then diagnosed with bilateral neck lymphadenopathy, and a biopsy was ordered.

On the 20th December 2014, the patient was referred to the pediatric hematology division, and it was suspected that he had a malignancy because there was no response to the antibiotic. Therefore, the next plan for this patient was to wait for the results of the biopsy. The blood test results from the 20th of December 2014 showed a hemoglobin concentration of 9.2 g/dl, 29.7% hematocrit, leukocyte 8920/uL, thrombocyte 614.000/uL, ureum 22 mg/dl, and creatinin 0.20 mg/dl. On the 22nd of December 2014, the laboratory test for LDH was 573 U/L, and on the 24th of December the patient underwent abdominal and neck ultrasound. The result of the abdominal ultrasound was normal while the neck ultrasound showed lymphadenopathy colli with suspected malignancy.

The biopsy was done on the 23rd December 2014, and the histopathology features showed some lymph nodes with the capsule consisting of a tumor mass that had a diffuse pattern and some tumor masses with a nodular pattern that was separated by connective tissue. The tumor cells had round/oval nuclei, some with a nuclear groove, and fine chromatin with abundant eosinophilic cytoplasm.

There were also multinucleated histiocytes. Mitosis was <10/10 HPF. Eosinophils, lymphocytes, and neutrophils were also present. Based on these features we concluded that the patient had Langerhans cell histiocytosis and therefore recommended immunostaining analysis (Figure 1-4).

We also performed immunostaining to support the diagnosis. The immunostaining was positive for CD1a, S100 protein, Langerin (performed by Prof TSY, SGH), and CD68, and negative for LCA, BCL6, CD10 (Figure 5, 6). The immunostaining confirmed the diagnosis of Langerhans cell histiocytosis and the patient received chemotherapy and was given Vinblastin, Etoposide, 6–MP, and Prednisone. At the time of study, the patient was still under control and showing recent signs of improvement.

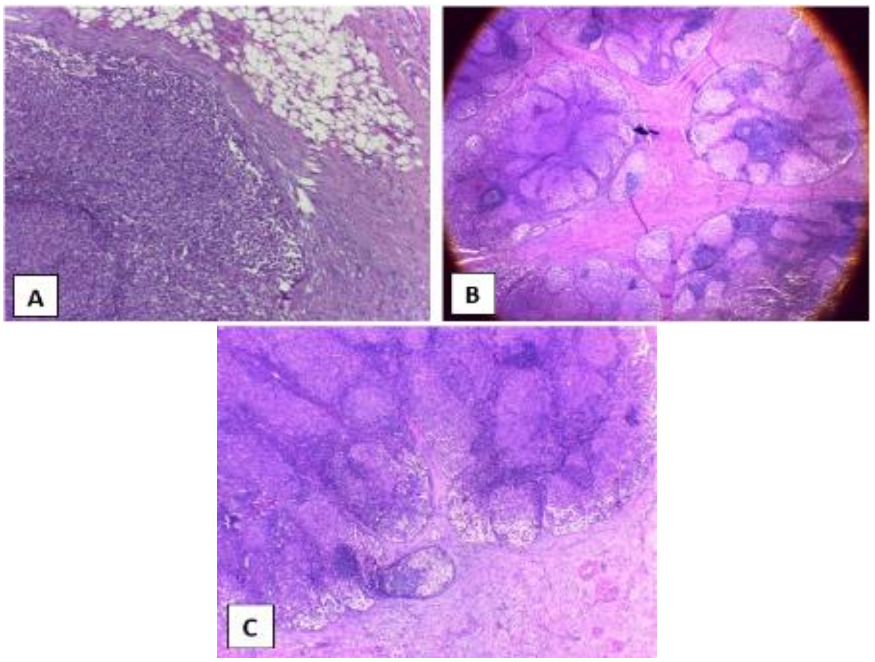

Figure 1. Histopathology features. (a) Diffuse (HE 100x). (b) Nodular (HE 25x). (c) Nodular (HE 40x).

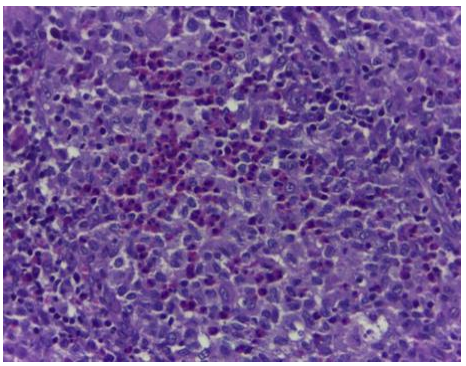

Figure 2. Many eosinophils as background **(**HE 400x).

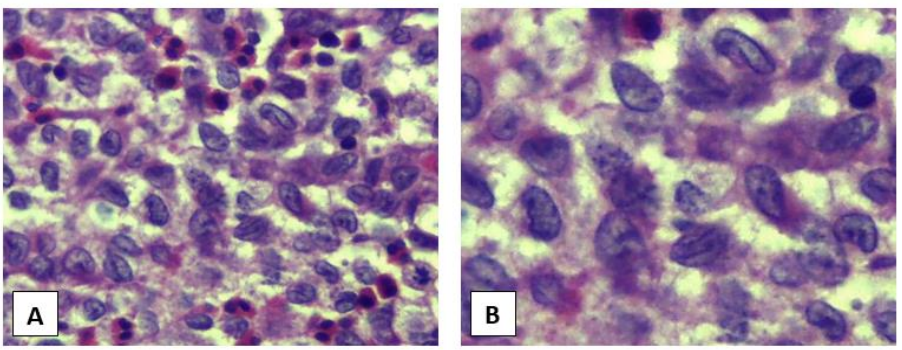

Figure 3. Nuclei characteristics showing nuclear folding and nuclear grooves (a) HE 100x, (b) HE 400x.

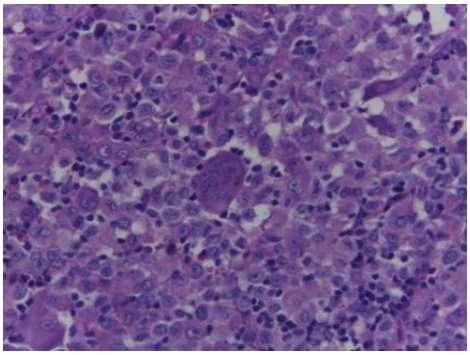

Figure 4. Multinucleated histiocytes (HE 400x).

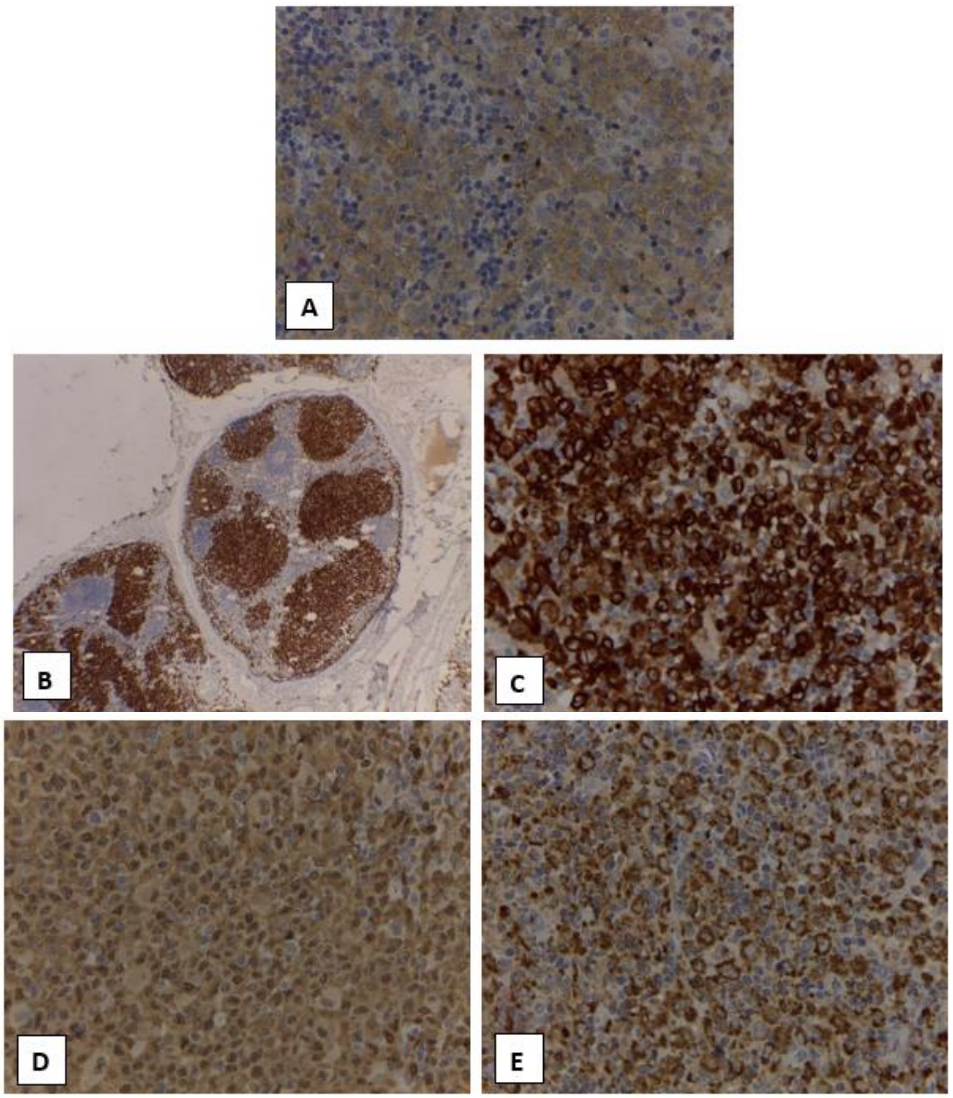

Figure 5. Immunostaining (a) CD1a (IHC 100x), (b) Langerin (IHC 40x), (c) Langerin (IHC 100x), (d) S100 (IHC 100x), and (e) CD68 (IHC 100x).

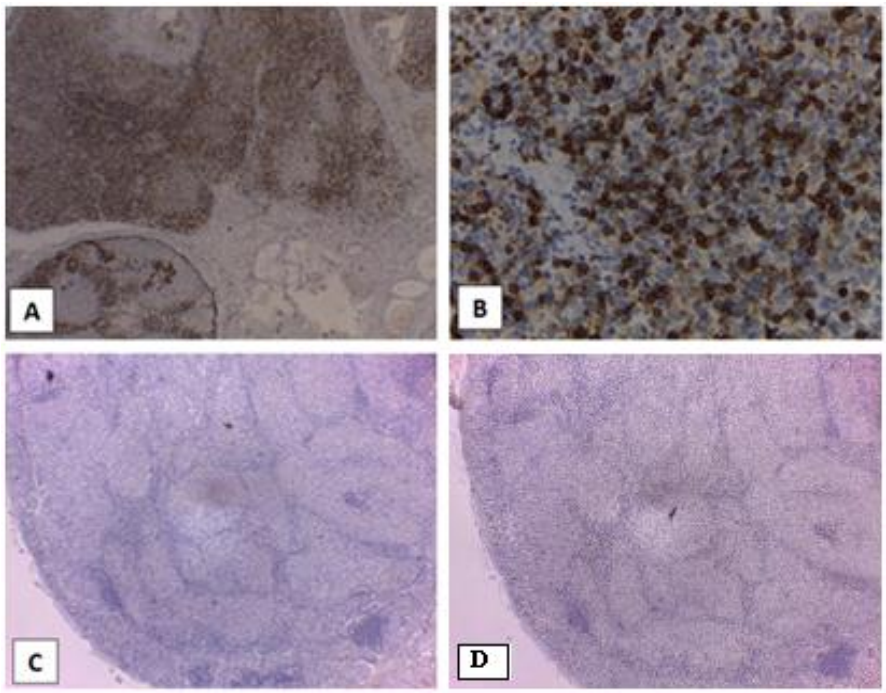

Figure 6. Negative immunostaining (a) LCA (IHC 40x), (b). LCA (IHC 100x), (c) BCL6 (IHC 40x), and (d) CD10 (IHC 40x).

DISCUSSION

LCH is characterized by the proliferation of pathologic cells with the phenotype of Langerhans cells (LCs) [5]. The Langerhans cell is a dendritic cell or antigen that originates from bone marrow and migrates through the blood to regional lymph nodes via the afferent lymphatics. Silberberg-Sinakin et al. in their study demonstrated the migration of Langerhans cell with an attached antigen to the afferent lymphatics and their appearance in the paracortical zone of regional lymph nodes, where they could present antigen to T-lymphocytes. This process is mediated by a local cytokine response. In regional lymph nodes, LCs interact with antigen-specific T-cells that are activated and proliferate to form effector and memory T-cells. LCH cells are derived from mature LCs that have been transformed. Yu et al. in their study demonstrated that LCH cells have little or no alloantigen presenting capacity because of suppressor cytokines that inhibit the function of the LCH cell. LCH cells will produce a wide variety of cytokines. The cytokines include IL-2, IL-3, IL-4, IL-5, IL-7, TNF-α, IL-1α, GM-CSF, IFN-γ and cause decreased apoptosis resulting in the accumulation of LCH cells. Circulating cytokines may be responsible for organ damage and responsible for systemic disease symptoms particularly fever, which may be related to the production of IL-1β and failure to thrive, which may be due to TNF-α production. Little is known about the molecules involved or about the routes taken by homing cells to find their way into the lymph nodes. Chemokines such as CCR1, CCR2, CCR5, CCR6, and CXCR1 are also important for the migration of LCs [5].

The etiology and pathogenesis of LCH are still unclear and whether this is a reactive process or a neoplasm has long been debated. Evidence of clonality in LCH was reported to support LCH as a neoplastic process [1,11]. A mutation of the BRAF proto-oncogene typically occurs in 38%–69% of LCH patients and supports the neoplastic origin. The BRAF mutation activates the RAS-RAF-MEK-ERK pathway that is involved in many neoplastic diseases. Activation of the BRAF gene leads to the production of a BRAF V600E mutant protein and was found in more than half of all LCH cases, suggesting that this is a genuine driver mutation in this disease [12,13].

Patients with LCH can be of any age, but it is most common in children aged one to three years old [7,14]. Males are affected more frequently with the ratio ranging from 1.2:1 to over 2:1. Singh T et al. in their study reported that the incidence of LCH is 0.5–5.4 million/year with children under 15 years old affected more than 50% [13]. There are 40 cases of LCH reported from the Anatomical Pathology Department Faculty of Medicine Cipto Mangunkusumo Hospital from 2005 until 2015. Twenty-one cases were males and 19 cases were females. In our case, the patient was an eleven-month-old boy.

Many organs can be involved in LCH including bone, lung, lymph node, skin, liver, spleen, and bone marrow. The organs have been classified into low and high-risk organs. The low-risk organs include skin, bone, lungs, and lymph nodes. The high-risk organs include liver, spleen, and bone marrow. However, a small subset of LCH patients present with isolated lymphadenopathy and with no other systemic signs or symptoms. Cervical lymph nodes are most frequently affected but supraclavicular, axillary, and inguinal lymph nodes can also be involved [7]. In our case, the patient had a single system and low-risk organ involvement that was neck and inguinal lymph nodes.

The clinical symptoms of LCH are varied and depend on the site of involvement. If affected, the lymph nodes will be enlarged. In our case, the patient had a lump on his neck and inguinal region.

The diagnosis of LCH is based on morphological and immunostaining analysis [10,14]. In our patient, the definitive diagnosis was made based on the morphological and immunostaining analysis of the lymph node biopsy specimens. In most cases of LCH, the morphology shows polymorphous cells arranged in diffuse sheets. There was no report published that showed LCH in nodular patterns. The mechanism by which LCH cells proliferate and accumulate as a nodular aggregate remains unknown. In our case, we found that cells were arranged in nodular features with Langerhans cell characteristics. This is the first case of LCH with nodular features that we have treated at the Cipto Mangunkusumo Hospital. When we first saw this pattern, we thought that it mimics follicular lymphoma. The morphological diagnosis rests on the characteristic morphology of the Langerhans cells. Langerhans cells have moderate to abundant amounts of eosinophilic cytoplasm and the presence of classical nuclear grooves and folds (“twisted towel” nuclei). The background is characteristically rich in eosinophils with varying amounts of macrophages and small lymphocytes, and neutrophils and plasma cells are absent or rare.

Multinucleated histiocytes are more numerous in bone lesions than in skin, lung, or lymph nodes. Immunostaining characteristics for LCH include positivity for CD1a, Langerin, and S100 protein. Additionally, the cells are positive for vimentin, CD68, and HLA-DR. CD45 expression is low. Ki67 is highly variable. We found the features above in the present case. The follicular lymphoma was excluded by immunostaining because it was negative for BCL6 and CD10. Electron microscopy searching for cytoplasmic granules, called Birbeck

granules, wasn't done for this patient. Birbeck granules are specific for Langerhans cell and have a tennis racket-like appearance, are 200–400 nm long and 33 nm wide, and contain the protein Langerin [3,10].

The differential diagnosis of LCH includes Langerhans cell sarcoma, Rosai–Dorfman disease, and Dermatopathic lymphadenopathy [1,9]. Langerhans cell sarcoma can be distinguished from LCH by the presence of high-grade nuclear atypia and high mitotic rate. Rosai–Dorfman disease is sinus histiocytosis with massive lymphadenopathy, and the sinuses are distended by distinctive histiocytes that have round nuclei, central nucleoli, and abundant cytoplasm with well-defined cytoplasmic membranes and common emperipolesis. Langerhans cell sarcoma is most common in children. The immunostainings are positive for the S100 protein and CD68, but negative for CD1a. Dermatopathic lymphadenopathy is composed of interdigitating dendritic cells and Langerhans cells that expand to the paracortical area of the lymph node. Dermatopathic lymphadenopathy has a nodular growth pattern, pigment-laden histiocytes, and absence of necrosis or eosinophil background [9].

Patient prognosis is based at the age of first diagnosis, on whether there is a low or high risk of organ involvement, and on responses to the initial round of therapy. Single system LCH has a good prognosis with more than 80% remaining disease-free after initial therapy. In our case, the patient was 11 months old at first diagnosis, had a single organ LCH that involved the lymph nodes, and responded well to the initial treatment [1,6].

A wide spectrum of treatment modalities has been adopted to deal with LCH, including surgical excision combined with radiotherapy. Other treatment strategies have been suggested and include chemotherapy, isolated radiotherapy, and the use of corticosteroids [15]. In the present case, the patient underwent open surgical biopsy, chemotherapy and was given corticosteroids. He has now completed chemotherapy and is due for follow-up at the clinic once every six months.

CONCLUSION

LCH is a rare disease that can impact any age group but is most commonly seen in young children. In most cases, the morphological features showed polymorphous cells that arrange in diffuse sheets, but the pathologist must be aware that there is another different feature of LCH that was nodular. This pattern mimics follicular lymphoma but was excluded by immunostaining that was negative for BCL6 and CD10. The immunostaining was positive for CD1a, Langerin, S100, and CD68. Whether or not there is different pathogenesis or biological behavior in nodular LCH remains unclear. Treatment options include surgery, radiotherapy, chemotherapy, and corticosteroids. Our patient received Vinblastin, Etoposide, 6-MP, and Prednisone and responded well to the treatments.

REFERENCES

[1] Harmon, C. M., Brown, N. (2015). Langerhans cell histiocytosis: a clinicopathologic review and molecular pathogenetic update. *Archives of Pathology and Laboratory Medicine,* 139: 1211-1214.

[2] Burns, P., Foster, A., Moran, T., Blayne, A. (2010). Multifocal Langerhans cell histiocytosis: a case report. *Irish Journal of Medical Science,* 179: 611-613.

[3] Jaffe, R., Weiss, L. M., Facchetti, F. (2008). Tumours derived from Langerhans cells. In: Swerdlow, S. H., Campo, E., Harris, N. L., editors. *WHO classification of tumours of haematopoietic and lymphoid tissues.* (4th ed.pp.358-360). Lyon: IARC.

[4] Ioachim, H. L., Medeiros, L. J. (2009). Granulocytic, histiocytic, and dendritic cell neoplasms. In: Ioachim, H. L., Medeiros, L. J., editors. *Lymph Node Pathology*. (4th ed.pp. 537-542). Philadelphia: Lippincott Williams & Wilkins.

[5] Abla, O., Egeler, R. M., Weitzman, S. (2010). Langerhans cell histiocytosis: current concepts and treatments. *Cancer Treatment Reviews*, 36: 354-359.

[6] Grana, N. (2014). Langerhans cell histiocytosis. *Cancer Control*, 21: 328-334.

[7] Elia, D., Torre, O., Cassandro, R., Caminati, A.; Harari, S. (2015). Pulmonary Langerhans cell histiocytosis: a comprehensive analysis of 40 patients and literature review. *European Journal of Internal Medicine*, 26: 351-356.

[8] Kumar, V., Abbas, A. K., Aster, J. C. (2015). Diseases of the immune system. In: Kumar, V., Abbas, A. K., Aster, J. C., editors. *Robbins and Cotran pathologic basis of disease.* (9th ed.pp. 192). Philadelphia: Saunders Elsevier.

[9] Weiss, L. (2008). Histiocytic and dendritic cell neoplasms. In: *Lymph Nodes.* (1st ed.pp.237-241). New York: Cambridge University.

[10] Agarwal, P., Kaushal, M. (2014). An unusual presentation of Langerhans cell histiocytosis. *Journal of Cytology*, 31: 227-229.

[11] Rizzo, F. M., Cives, M., Simone, V., Silvestris, F. (2014). New insight into the molecular pathogenesis of Langerhans cell histiocytosis. *The Oncologist*, 19: 151-163.

[12] Morimoto, A., Oh, Y., Shioda, Y., Kudo, K., Immamura, T. (2014). Recent advances in Langerhans cell histioctosis. *Pediatrics International*, 56: 451-461.

[13] Egeler, R. M., Katewa, S., Leenen, P., Beverley, P., Collin, M., Ginhoux, F. et al. (2016). Langerhans cell histiocytosis is a neoplasm and consequently its recurrence is a relapse. *Pediatric Blood and Cancer*, 63: 1704-1712.

[14] Singh, T., Sateesh, C. T., Appaji, L., Aruna, K., Mamatha, H. S., Giri, G. V. et al. (2010). Langerhan's cell histiocytosis: a single institutional experience. *Indian Journal of Medical and Paediatric Oncology*, 31: 51-53.

[15] Allen, C. E., Li, L., Peters, T. L., Leung, H., Yu, A., Man, T. et al. (2010). Cell-specific gene expression in Langerhans cell histiocytosis lesions reveals a distinct profile compared with epidermal Langerhans cells. *Journal of Immunology*, 184: 4557-4567.

In: Encyclopedia of Surgery (22 Volume Set)
Editors: Andreas Lehrer and Kristin Mueller
ISBN: 978-1-53618-329-0
© 2020 Nova Science Publishers, Inc

Chapter 349

PITFALLS IN THE HISTOPATHOLOGICAL DIAGNOSIS OF SCLEROSING RHABDOMYOSARCOMA

Fetisari Kurniawan[1], Nurjati Chairani Siregar[1,*], Ludi Dhyani Rahmartani[2], Marcel Prasetyo[3] and Kshetra Rinaldhy[4]

[1]Department of Anatomical Pathology, Faculty of Medicine, Universitas Indonesia, Cipto Mangunkusumo Hospital, Jakarta, Indonesia
[2]Department of Pediatrics, Faculty of Medicine, Universitas Indonesia, Cipto Mangunkusumo Hospital, Jakarta, Indonesia
[3]Department of Radiology, Faculty of Medicine, Universitas Indonesia, Cipto Mangunkusumo Hospital, Jakarta, Indonesia
[4]Department of Pediatric Surgery, Faculty of Medicine, Universitas Indonesia, Cipto Mangunkusumo Hospital, Jakarta, Indonesia

ABSTRACT

Rhabdomyosarcoma (RMS) is the most common soft tissue malignancy occurring in childhood and adolescence. RMS was previously classified into the following three main subtypes: embryonal, alveolar, and pleomorphic. In the latest classification, a new variant of RMS, spindle/sclerosing RMS, has been included. This variant is rare, occurring in 5%–10% of all cases of RMS. It is characterized by prominent hyaline and sclerosis stroma that mimics an osteoid or chondroid with a pseudovascular, microalveolar, or cord growth pattern. Therefore, it might be easily mistaken during initial evaluation as osteosarcoma, chondrosarcoma, angiosarcoma, infiltrating carcinoma, spindle cell sarcoma, or other RMS types. Awareness of the existence of this entity is important for not only diagnosis but also prognosis and treatment. Here we present the case of a child with sclerosing RMS that was not easily diagnosed. This report aims to discuss the potential diagnostic pitfalls associated with other look-alike sarcomas.

Keywords: rhabdomyosarcoma, sclerosing rhabdomyosarcoma

[*] Corresponding Author's Email: nuryati.chairani@ui.ac.id.

INTRODUCTION

Rhabdomyosarcoma (RMS) is the most common soft tissue malignancy in childhood and adolescence, accounting for 5%–8% of all pediatric malignancies [1, 2]. According to the World Health Organization (WHO) 2013 classification, RMS can be classified into the following four subtypes: embryonal (including botryoides and anaplastic variants), alveolar (including solid and anaplastic variants), pleomorphic, and spindle cell/sclerosing RMS [3].

The latest WHO classification has grouped spindle cell and sclerosing RMSs into a single pathological entity, as both commonly share overlapping histological features. It is considered that spindle cell and sclerosing RMSs are a continuous spectrum [1, 4]. Sclerosing RMS was first reported by Mentzel and Katenkamp in 2000, and since then, additional cases with similar features have been described [5]. This variant is rare and accounts for 5%–10% of all cases of RMS [3, 4, 6]. It occurs over a wide age range (0.3–79 years) and shows male predominance [2, 3, 7, 8]. Its symptoms might vary depending on the location and size. Although spindle cell and sclerosing RMSs are under the same pathological group, their site predilections differ. Spindle cell RMS occurs predominantly in the para-testicular region among pediatric patients and in the head and neck region and at genitourinary sites among adult patients [3, 6]. On the other hand, sclerosing RMS commonly affects the extremities and the head and neck region [2, 6].

Macroscopically, both tumors show a well-demarcated border, with a mean size >5 cm [3, 4, 6]. Additionally, the outer surface appears gray/white. In a cut section, necrosis and hemorrhage might be noted [3]. Histologically, the term spindle cell RMS is used when fascicular or intersecting spindle cell morphology is the prominent feature (>80% of the tumor area), with rare, scattered eosinophilic rhabdomyoblasts [3, 6]. Therefore, it might resemble other spindle cell sarcomas [4]. On the other hand, sclerosing RMS is characterized by abundant production of a hyaline matrix, which imitates a primitive osteoid or chondroid; thus, it might be confused with osteosarcoma or chondrosarcoma at the initial evaluation. The tumor cells are usually arranged in a pseudovascular/microalveolar pattern; thus, the tumor might be mistaken for angiosarcoma or alveolar RMS [3-6]. Most cases show mixed features of spindle and sclerosing patterns. Immunohistochemically, spindle cell RMS shows positivity for desmin (diffuse), myogenin (nuclear expression), smooth muscle actin (SMA), and muscle-specific actin (MSA). On the other hand, sclerosing RMS shows strong positivity for myoD1 [3].

Spindle cell and sclerosing RMSs have distinct genetic abnormalities that differentiate them from other RMS types. They are characterized by the presence of *NCOA2* and *VGLL2*-related fusions in congenital/infantile cases and *MYOD1* mutations co-existing with *PIK3CA* mutations in both pediatric and adult cases [1, 4]. Overall, spindle cell and sclerosing RMSs arising in adult patients have more aggressive behaviors when compared with tumors arising in pediatric patients [4].

Here, we present a child with sclerosing RMS that was not easily diagnosed. This report aims to share the potential diagnostic pitfalls associated with other look-alike sarcomas. Understanding of histopathological features and appropriate use of immunohistochemical analysis are essential to achieve an accurate diagnosis.

CASE REPORT

An 8-year-old girl had an enlarging mass in the left mandibular region since 1 year before admission to our hospital. Initially, she complained about severe toothache at her left jaw. Following tooth extraction, her gum swelled and gradually increased in size, causing difficulty in eating and drinking.

Clinical examination revealed that she was stunted and underweight (both height and weight for age were below −3SD). A large mass measuring 10×5×2.5 cm was noted at the left buccal and mandibular region, and lymphadenopathy measuring 1 cm in diameter was noted at the right colli (Figure 1). Laboratory results indicated hypochromic microcytic anemia (hemoglobin level, 8 g/dL; mean corpuscular volume, 64 fL; mean corpuscular hemoglobin, 19 pg/ml; mean corpuscular hemoglobin concentration, 30 g/dL), leukocytosis (14,500/µL), and thrombocytosis (690,000/µL). She was clinically suspected to have RMS.

Plain radiography and computed tomography showed a multilobulated soft tissue mass extending from the deep maxillary and neck region. Tumoral expansion resulted in bony thinning and deformity of the left zygoma, maxilla, and mandible. The tumor occupied the left oral cavity. There was no significant bone destruction (Figure 2 a-c). Magnetic resonance imaging showed a solid heterogeneous mass with a necrotic component. These findings were consistent with a malignant soft tissue neoplasm (Figure 3 a-d).

Debulking excision surgery was performed, and it resulted in 70% mass reduction. The surgical specimens were sent to the Anatomical Pathology Department. There were 11 resected specimens varying in size from 3×2×0.5 cm to 8×6×3 cm (white to brownish in color), with firm consistency. In a cut section, a yellowish mass was noted without hemorrhage or a necrotic area (Figure 4).

Figure 1. Mass at the left buccal and mandibular region at the initial presentation.

Histopathological examination showed mesenchymal tumor cells arranged in diverse patterns, including solid, microalveolar, and linear patterns (Figure 5 a-c). Some areas showed alternating hypercellular and hypocellular zones (Figure 5 d) with a myxoid stromal

background (Figure 5 e). The tumor cells appeared round/oval and spindle shaped with marked nuclear pleomorphism and bizarre, hyperchromatic, or vesicular nuclei, and some cells showed conspicuous nucleoli and eosinophilic cytoplasm (Figure 5 f). Typical mitosis and atypical mitosis were easily found. A lace-like osteoid matrix mimicking that in osteosarcoma was seen interspersed between tumor cells (Figure 5 g). Additionally, there was prominent hyaline stroma (Figure 5 h). No rhabdomyoblasts were noted. These microscopic findings initially concluded as conventional osteosarcoma.

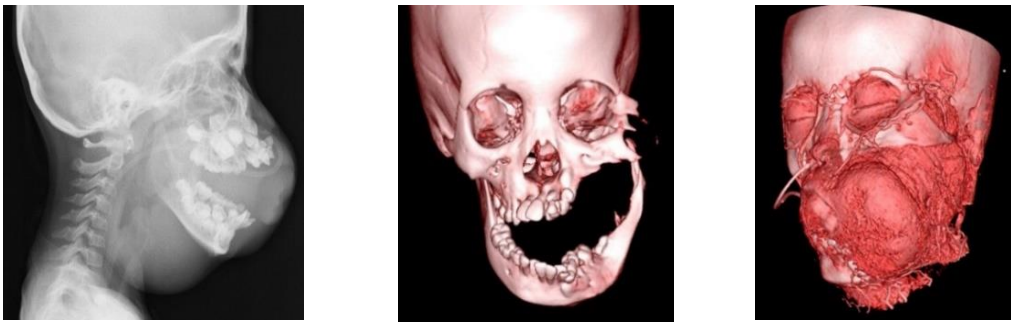

(a) (b) (c)

Figure 2. Radiography and computed tomography. (a) Plain radiography, lateral projection; (b, c) Computed tomography with three-dimensional bone reconstruction.

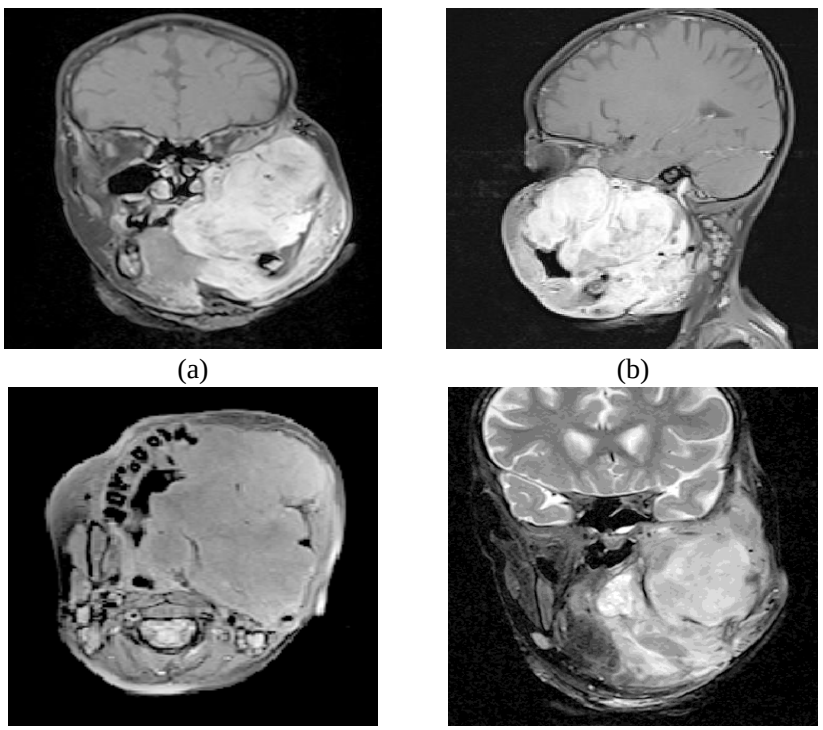

(a) (b)

(c) (d)

Figure 3. Magnetic resonance imaging. (a) T1 contrast, coronal; (b) T1 contrast, sagittal; (c) T1, axial; (d) T2, coronal.

Figure 4. Gross specimens. Firm tumors varying in size (white to brownish in color) without hemorrhage or a necrotic area.

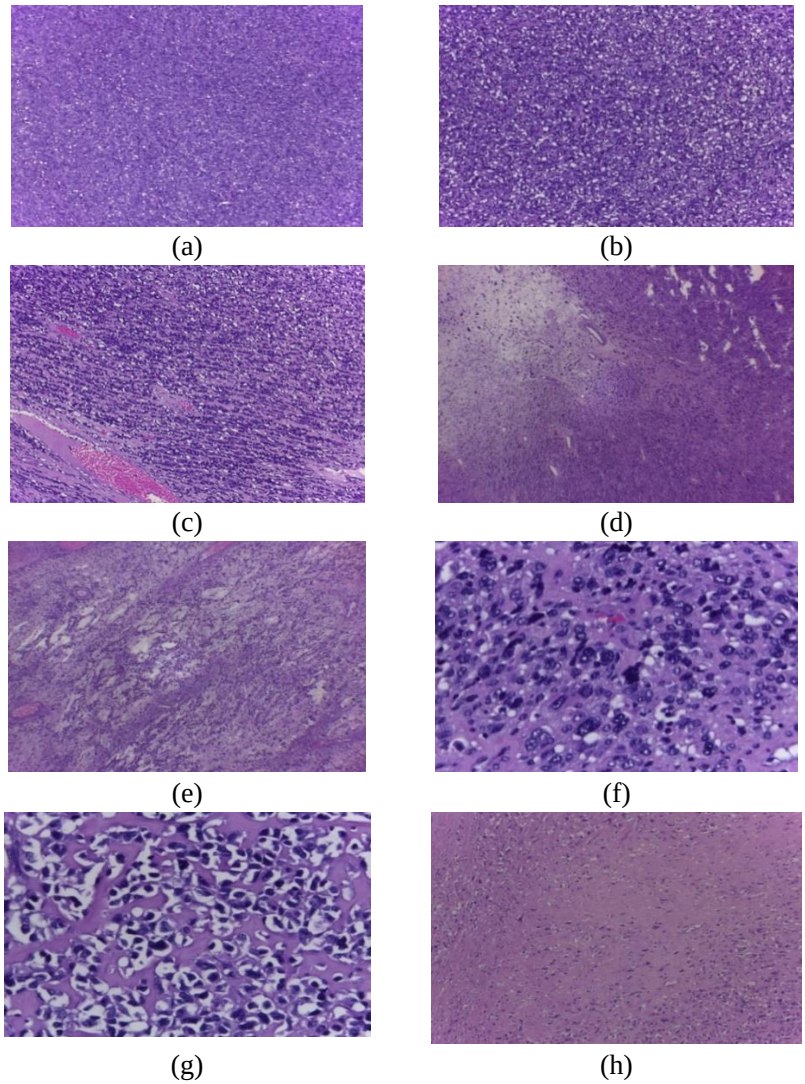

Figure 5. Histological analysis. (a) Solid pattern (hematoxylin and eosin [H&E], magnification 100×); (b) Microalveolar pattern (H&E, 40×); (c) Linear pattern (H&E, 40×); (d) Alternating hypercellular and hypocellular zones (H&E, 40×); (e) Myxoid stromal background (H&E, 40×); (f) Tumor cells and mitosis (H&E, 400×); (g) Osteoid-mimicking matrix (H&E, 400×). (h) Prominent hyaline and sclerosis matrix (H&E, 100×).

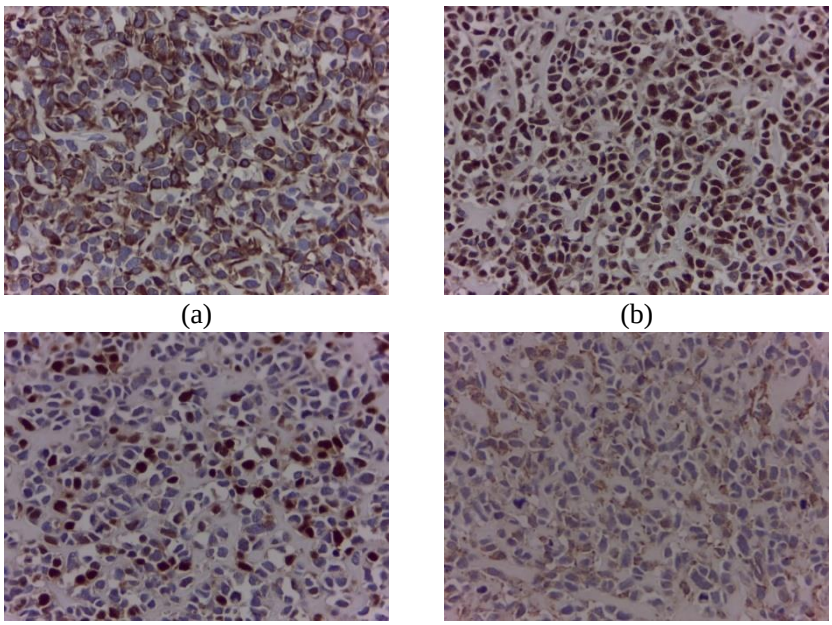

Figure 6. Immunohistochemical analysis. (a) Desmin (cytoplasmic positive, diffuse; magnification 400×); (b) MyoD1 (nuclear strong positive, diffuse; 400×); (c) Myogenin (nuclear positive, focal; 400×); (d) SMA (cytoplasmic positive, focal; 400×).

A tumor board meeting was held owing to the discrepancy between the clinical diagnosis and histopathological results. Immunohistochemical analysis was then performed (Figure 6 a-d). The neoplastic cells were immunopositive for desmin (cytoplasmic positive, diffuse), myoD1 (nuclear strong positive, diffuse), myogenin (nuclear positive, focal), and SMA (cytoplasmic positive, focal). Thus, the diagnosis of sclerosing RMS (WHO grade 3) was confirmed.

DISCUSSION

Sclerosing RMS has been reported to occur over a wide age range, including in pediatric patients, and males are six times more frequently affected than females [2, 3, 7, 8]. The two most common sites of involvement are the extremities and head and neck region [2, 6, 9]. Lesions usually form a large bulky mass with a median size >5 cm [3, 4, 6]. Our present 8-year-old female patient had an enlarging mass measuring 10×5×2.5 cm in her left mandibular region. Our findings are similar to the findings of these previous reports in terms of onset age, predilection site, and tumor size at presentation.

Microscopic examination revealed that the tumor produced abundant hyaline stroma mimicking a primitive osteoid in conventional osteosarcoma. The tumor cells were round/spindle shaped with pleomorphic nuclear and brisk mitotic figures arranged in various patterns. The presence of solid and microalveolar patterns might resemble the appearance of alveolar RMS, alternating cellular zones with myxoid background stroma might resemble the

appearance of embryonal RMS, and a linear pattern might resemble the appearance of metastatic breast carcinoma.

Classically, conventional osteosarcoma has a bimodal age distribution (10–14 years of age and >40 years of age) with long bone predilection sites, especially the femur [3, 10]. It is composed of pleomorphic or anaplastic tumor cells in a permeative pattern with an osteoid lace-like matrix in between cells (Figure 7 a) [3, 10]. It genetically exhibits complex abnormalities [3], and there are no specific immunohistochemical studies to confirm a diagnosis of osteosarcoma [10]. The tumor in our case also showed nuclear pleomorphism with a mimicking osteoid lace-like matrix in between cells (Figure 7 b). It can be very difficult to subjectively distinguish between an osteoid and eosinophilic extracellular matrix [3]. Immunohistochemical analysis confirmed that the origin of the tumor cells was skeletal muscle.

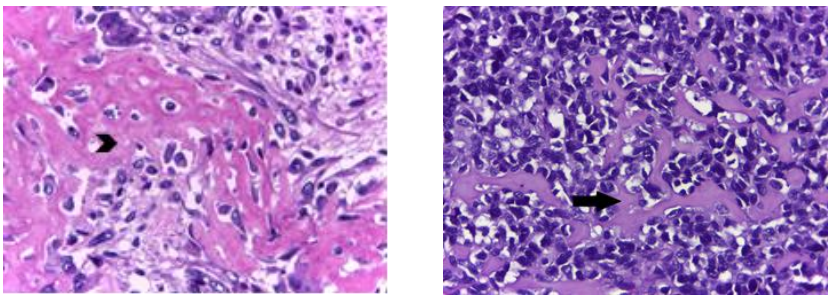

(a) (b)

Figure 7. Comparison between conventional osteosarcoma case and the tumor in the present case. (a) Conventional osteosarcoma with osteoid lace-like matrix (H&E, 400×) (arrow head); (b) Prominent hyaline stroma in sclerosing rhabdomyosarcoma mimicking an osteoid matrix (H&E, 400×) (arrow).

Classically, alveolar RMS arises in adolescents and young adults, with soft tissue extremities as the predilection site [3, 8, 11]. It is composed of nests containing primitive round cell tumors separated by thin fibrous septa creating a pseudoalveolar pattern (Figure 8 a) [3, 11]. The nests usually show central loss of cohesion and are peripherally arranged in a picket fence-like arrangement [3, 12]. Wreath cells with rhabdomyoblastic differentiation might also be noticeable [3]. The solid variant of alveolar RMS lacks fibrous septa and forms a tumor sheet [3]. It genetically exhibits either *PAX3-FOXO1* or *PAX7-FOXO1* fusion genes [3, 13]. Immunohistochemical analysis shows diffusely positive staining for myogenin [3, 12]. On the other hand, in our case, there was a microalveolar pattern formed by hyaline stroma that entrapped a smaller cluster of cells with thicker septa and lack of central loss of cohesion and picket fence-like arrays instead of the classic pseudoalveolar pattern (Figure 8 b) [12]. No rhabdomyoblastic differentiation was seen in our case. In contrast to the alveolar RMS predilection site, the tumor in our case arose in the head and neck region. Moreover, in contrast to the immunohistochemical findings of alveolar RMS, the tumor in our case showed prominent staining for myoD1, with only focal reactivity for myogenin. Unfortunately, molecular testing data were not available to exclude the presence of *PAX-FOXO* fusion genes.

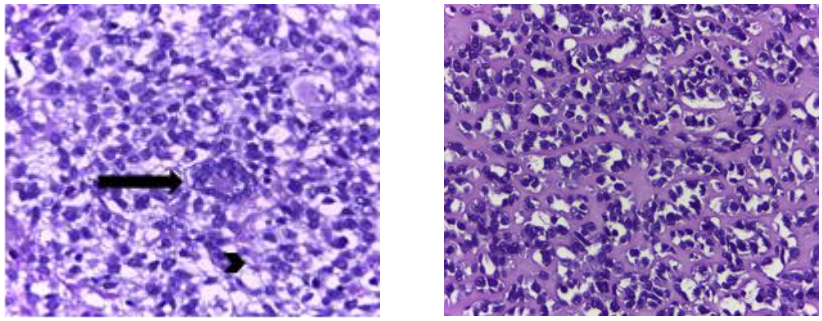

(a) (b)

Figure 8. Comparison between alveolar rhabdomyosarcoma (RMS) case and the tumor in the present case. (a) Alveolar RMS with wreath cell (arrow) and thin fibrovascular septa (arrowhead) (H&E, 400×); (b) Sclerosing RMS with a microalveolar structure (H&E, 400×).

Classically, embryonal RMS affects patients of younger age (typically <5 years) with head and neck region and genitourinary predilections, and only few cases involve the extremities [3]. It involves patternless primitive mesenchymal tumors in various stages of myogenesis with variable cellularity and myxoid stroma (Figure 9 a) [3, 11]. Scattered rhabdomyoblasts are often conspicuous (Figure 9 b) [11, 14]. It genetically exhibits 11p15.5 anomaly [7, 9]. Immunohistochemical analysis shows nuclear positive staining for myoD1 [3]. The tumor in our case also occurred in the head and neck region and showed a prominent profile of myoD1 over myogenin immunohistochemically. Although it histologically exhibited an alternating cellular zone, it lacked rhabdomyoblast differentiation and occurred at an older age compared with typical embryonal RMS (Figure 9 c). Unfortunately, molecular testing data were not available to exclude the presence of 11p15.5 anomaly.

Classically, invasive lobular carcinoma of the breast shows discohesive cells arranged in a single-file linear pattern invading the fibrous stroma (Figure 10 a) [15, 16]. Immunohistochemical analysis shows loss of E-cadherin expression [15]. On the other hand, in our case, the tumor cells lacked discohesiveness (Figure 10 b). Invasive lobular carcinoma of the breast is rarely found in children, and it rarely metastasizes to the head and neck region [3].

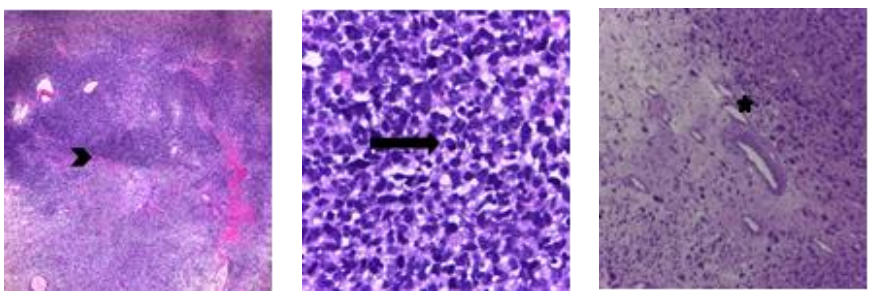

(a) (b) (c)

Figure 9. Comparison between embryonal rhabdomyosarcoma (RMS) case and the tumor in the present case. (a) Embryonal RMS with a marbled appearance (H&E,25×) (arrow head); (b) Rhabdomyoblastic differentiation in embryonal RMS (H&E,400×) (arrow); (c) Sclerosing RMS with alternating cellularity zones (H&E,400×) (star).

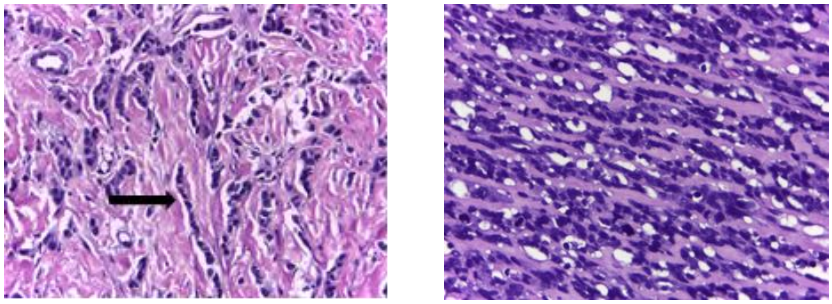

(a) (b)

Figure 10. Comparison between classical invasive lobular carcinoma of the breast case and the tumor in the present case. (a) Classical invasive lobular carcinoma of the breast shows single-file arrangement (H&E, 400×) (arrow); (b) Sclerosing rhabdomyosarcoma shows a linear pattern (H&E, 400×).

CONCLUSION

Spindle cell/sclerosing RMS is a new variant included in the latest WHO classification. Histopathologically, the tumor might show various growth patterns with abundant hyalinized stroma mimicking other look-alike sarcomas. In this report, several differential diagnoses have been presented, including conventional osteosarcoma, alveolar RMS, embryonal RMS, and invasive lobular carcinoma of the breast. The use of immunohistochemical analysis, especially for myoD1 is important in the confirmation of the diagnosis. Recognition and awareness of the existence of this entity and appropriate use of immunohistochemical analysis are essential to achieve an accurate diagnosis.

REFERENCES

[1] Alaggio, R., Zhang, L., Sung, Y. S., Huang, A. C., Chen, C. L., Bisogno, G., Zin, A., Agaram, N. P., LaQuaglia, M. P, Wexler, L. H. & Antonescu, C. R. (2016). A molecular study of pediatric spindle and sclerosing rhabdomyosarcoma identification of novel and recurrent VGLL2-related fusions in infantile cases. *Am. J. Surg. Pathol.*, 40(2), 224-235.

[2] Wang, J., Tu, X. & Sheng, W. (2008). Sclerosing rhabdomyosarcoma: a clinicopathologic and immunohistochemical study of five cases. *Am. J. Clin. Pathol.*, 129, 410-415.

[3] Fletcher, C. D. M., Bridge, J. A., Hogendoorn, P. C. W. & Mertens, F. (2013). *WHO classification of tumours of soft tissue and bone* (4th ed). Lyon: IARC.

[4] Owosho, A. A., Chen, S., Kashikar, S., Zhang, L., Chen, C. L., Wexler, L. H., Estilo, C. L., Huryn, J. M. & Antonescu, C. R. (2016). Clinical and molecular heterogenity of head and neck spindle cell and sclerosing rhabdomyosarcoma. *Oral. Oncol.*, 58, e6-11.

[5] Mentzel, T. & Katenkamp, D. (2000). Sclerosing, pseudovascular rhabdomyosarcoma in adults clinicopathological and immunohistochemical analysis of three cases. *Virchows Arch.*, 436, 305-311.

[6] Yasui, N., Yoshida, A., Kawamoto, H., Yonemori, K., Hosono, A. & Kawai, A. (2015). Clinicopathologic analysis of spindle cell/sclerosing rhabdomyosarcoma. *Pediatr. Blood. Cancer.*, 62, 1011-1016.

[7] Lin, X. Y., Wang, Y., Yu, J. H., Liu, Y., Wang, L., Li, Q. C. & Wang, E. H. (2013). Sclerosing rhabdomyosarcoma presenting in the masseter muscle: a case report. *Diagn. Pathol.*, 8, 18.

[8] Robinson, J. C., Richardson, M. S., Neville, B. W., Day, T. A. & Chi, A. C. (2013). Sclerosing rhabdomyosarcoma: report of a case arising in the head and neck of an adult and review of the literature. *Head Neck Pathol*., 7, 193-202.

[9] Kumar, A., Singh, M., Sharma, M. C., Bakshi, S. & Sharma, B. S. (2014). Review article pediatric sclerosing rhabdomyosarcomas: a review. *ISRN Oncol*., 9.

[10] Nielsen, G. P., Rosenberg, A. E., Deshpande, V., Hornicek, F. J., Kattapuram, S. V. & Rosenthal, D. I. (2017). *Diagnostic pathology bone* (2nd ed). Philadelphia: Elsevier.

[11] Linberg, M. R., Lucas, D., Cassarino, D. S., Gardner, J. M. & Stalling-Archer, K. (2016). *Diagnostic pathology soft tissue tumors* (2nd ed). Philadelphia: Elsevier.

[12] Chiles, M. C., Parham, D. M., Qualman, S. J., Teot, L. A., Bridge, J. A., Ullrich, F., Barr, F. G. & Meyer, W. H. (2004). Sclerosing rhabdomyosarcomas in children and adolescents: a clinicopathologic review of 13 cases from the Intergroup Rhabdomyosarcoma Study Group and Children's Oncology Group. *Pediatr. Dev. Pathol.*, 7, 583-594.

[13] Vadgama, B., Sebire, N. J., Malone, M. & Ramsay, A. D. (2004). Sclerosing rhabdomyosarcoma in childhood: case report and review of the literature. *Pediatr. Dev. Pathol.*, 7, 391-396.

[14] El-Naggar, A., Chan, J. K. C., Grandis, J. R., Takata, T. & Slootweg, P. J. (2017). *WHO classification of head and neck tumours* (4th ed). Lyon: IARC.

[15] Lakhani, S. R., Ellis, I. O., Schnitt, S. J., Tan, P. H. & Vijver, M. J. V. (2012). *WHO classification of tumours of the breast* (4th ed). Lyon: IARC.

[16] Hicks, D. G. & Lester, S. C. (2016). *Diagnostic pathology breast* (2nd ed). Philadelphia: Elsevier.

In: Encyclopedia of Surgery (22 Volume Set)
Editors: Andreas Lehrer and Kristin Mueller
ISBN: 978-1-53618-329-0
© 2020 Nova Science Publishers, Inc

Chapter 350

PRIMARY MALIGNANT GIANT CELL TUMOR OF PROXIMAL RIGHT TIBIA: A RARE CASE REPORT

Mirna Albertina Wijaja[1], Nurjati Chairani Siregar[1,*], Evelina Kodrat[1], Yogi Prabowo[2] and Thariqah Salamah[3]

[1]Department of Anatomical Pathology, Universitas Indonesia, Jakarta, Indonesia
[2]Department of Orthopaedics and Traumatology, Universitas Indonesia, Jakarta, Indonesia
[3]Department of Radiology, Universitas Indonesia, Jakarta, Indonesia

ABSTRACT

Primary malignant giant cell tumor of bone (PMGCTB) refers to a high-grade sarcoma arising from adjacent to benign giant cell tumor located in bone tissue. This type of sarcoma is rare and accounts for approximately 7% of all giant cell tumors. This report shares our experience of diagnosing a rare case. A 53-year-old man presented with a mass on the upper end of his tibia that appeared 6 years before he was admitted to the hospital and had no previous history of radiation therapy or surgery. A radiograph showed an aggressive bone tumor at the metadiaphysis with a suspicious femorotibial joint involvement. Histopathology showed mononuclear cell proliferation, multinucleated giant cells with abundant nuclei, identical with mononuclear cells in the stroma, and a high-grade sarcoma area juxtaposition to the benign giant cell tumor. PMGCTBs arise *de novo* and are extremely rare. From these findings, we concluded this case as PMGCTB. Malignant giant cell tumor of bone (MGCTB) prognosis is poor with a 5-year survival of 50%, and PMGCTB has a better prognosis than secondary MGCTB.

Keywords: primary malignant giant cell tumor, high-grade sarcoma, tibia

[*] Corresponding Author's Email: nuryati.chairani@ui.ac.id.

INTRODUCTION

Jaffe et al., identified giant cell tumor of bone (GCTB) as an entity many years ago and classified it into a primary benign bone tumor that may evolve into a malignant lesion.The etiology of malignant transformation of benign GCTB remains unknown [1-3]. Malignant GCTB (MGCTB) is rare and encompasses 2%–9% of all GCTB. There are only a small number of MGCTB cases published in the literature [4, 5]. In the Cipto Mangunkusumo Hospital, there were two cases reported from 2013 to 2017.

MGCTBs are divided into primary (PMGCTB) and secondary (SMGCTB). PMGCTB is a high-grade sarcoma that presents a *de novo* juxtaposition with conventional giant cell areas. SMGCTB is a high-grade sarcoma that arises at the area previously treated as a conventional GCTB with surgery or radiation. MGCTB diagnosis is challenging because of the variety of malignant tumors containing giant cells. Effective treatment is tough because of the limited existing studies that distinguish PMGCTB, SMGCTB, or post-radiation cancer [4, 5].

The incidence of MGCTB occurs in a wide range of ages, but typically in those 30–55 years of age and more frequently in men with a ratio of 3:1 [6-8]. According to Bertoni F et al., PMGCTB impacts those between 20 and 68 years, whereas SMGCTB impacts those 30–77 years. Both cancers frequently occur in the long bones near the knee joint with 90% of cases located in the meta-epiphyseal segments of the long bones [6, 7].

PMGCTB is extremely unusual and occurs less frequently than SMGCTB. Nascimento et al., reported eight cases, and five cases had been reported by the Mayo Clinic. The most common symptoms of PMGCT are a pain (80%) and swelling (40%) [4, 6]. The radiographic pattern may be identical to conventional GCTB. Most cases are poorly circumscribed. Cortical destruction and soft tissue invasion may occur because of a large area of sarcomatous tissue [9, 10].

Histopathological findings of PMGCTB showed high-grade sarcoma juxtaposed with conventional GCTB areas that are identifiable at the time of the initial presentation. The transition between both components varies considerably. A high-grade sarcoma component includes fibrosarcoma, osteosarcoma, and undifferentiated high-grade pleomorphic sarcoma (UPS) [4-6]. There is a high mitotic activity of both stromal and tumor giant cells, with multiple atypical mitosis present. The prognosis of PMGCTB is still indefinite because of its rareness and short follow-up. Most reports consider the prognosis poor [5, 6].

Here, we report a case of PMGCTB that had a history before the initial presentation and was defined as high-grade sarcomas originating from a giant cell tumor (GCT). The aim of this case report is to define the clinicopathologic and histologic features of malignancy in GCTs.

CASE REPORT

A 53-year-old male presented with a mass on the upper end of his right tibia without a prior history of radiation therapy or surgery. Seven years ago, the patient was in a motorcycle accident that caused a lump on the upper end of his right tibia, but he decided not to go to the hospital. Five years after the accident, the size of the lump remained the same.

One year later, the lump began to grow as large as an egg without pain and made it difficult to walk, but he did not go to the doctor and instead went to a traditional masseur. Five months later, he went to an orthopedic surgeon in Ambon because the lump was getting bigger and was accompanied by pain. He underwent x-ray examination, and the orthopedic surgeon said that there was a benign tumor. He was then referred to the Cipto Mangunkusumo Hospital.

One month later, he went to the Cipto Mangunkusumo Hospital and met the orthopedic surgeon. It was determined that there was a mass on the area below the right knee, which produced serious hemorrhage from the ulcers of the mass, redness, and distal edema. The mass on the right leg was 55 cm in diameter, solid, fixed, and felt warmer than the surrounding tissue (Figure 1). The patient underwent a second x-ray examination and a magnetic resonance image (MRI) while at Cipto Mangunkusumo Hospital (Figures 2 and 3). He also underwent several chest x-rays that showed multiple nodules in both lungs with infiltrates, suggestive of metastasis (Figure 4).

Figure 1. Mass on the upper end of the right tibia.

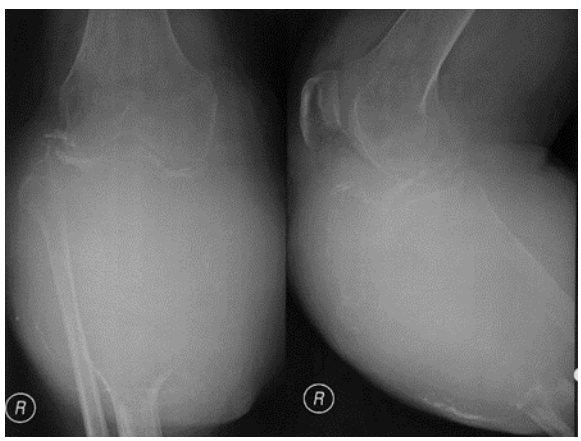

Figure 2. Plain x-ray of the right knee shows an aggressive tumor at metadiaphysis of the upper end of the right tibia. There is a suspicion that the tumor is also present at femorotibial joint (arrow).

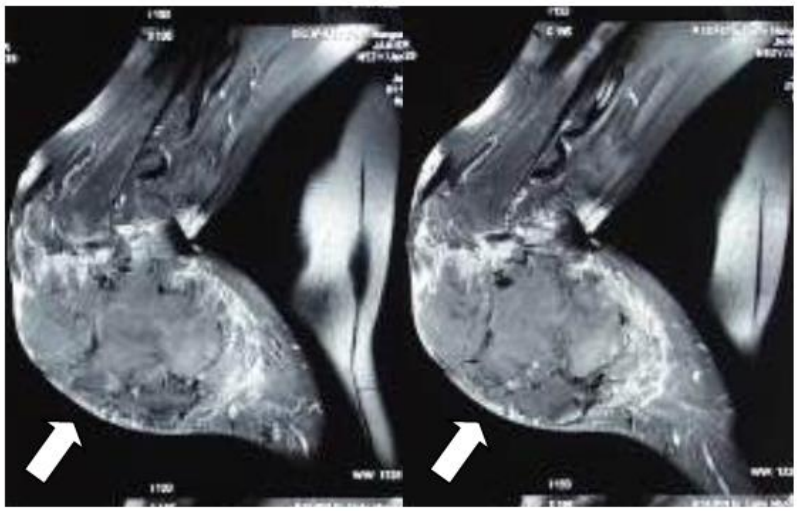

Figure 3. MRI of the right knee shows a mass of solid aggressive tumor, covering epimetadiaphysis of the proximal tibia, femorotibial joint, fibula, and neurovascular anterior tibia (arrow).

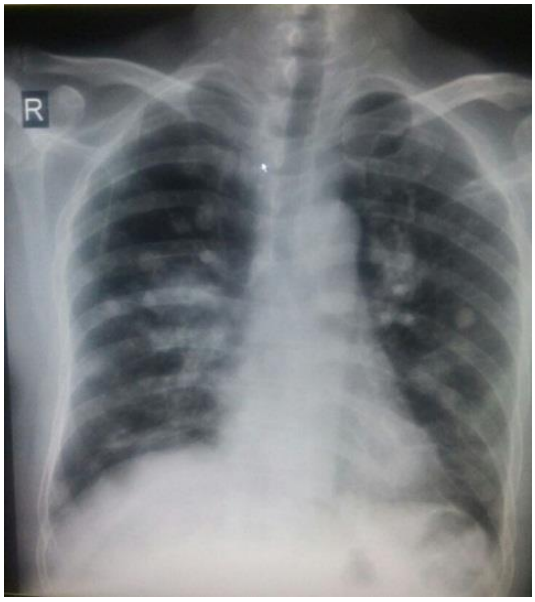

Figure 4. The second chest x-ray showed multiple nodules in both lungs with infiltrates suggestive of metastasis.

Fine-needle aspiration was performed, and cytology showed a predominantly necrotic area with fibrous tissue, a few round or spindle cells occurring in clusters, coarse chromatin, and multiple giant cells. From the cytology, we concluded the mass was a bone lesion containing giant cells that cannot be determined to be either benign or malignant (Figure 5). Nine days later, the patient underwent transfemoral amputation of the lower end of the femur. The specimen was sent to the anatomical pathology laboratory. Dissection revealed a solid mass measuring 17 × 16 × 11 cm, white-brown, and firm. The cut section was yellowish,

uncircumscribed, and contained areas of hemorrhage and necrotic tissue. Representative sections were submitted in 22 blocks (Figure 6).

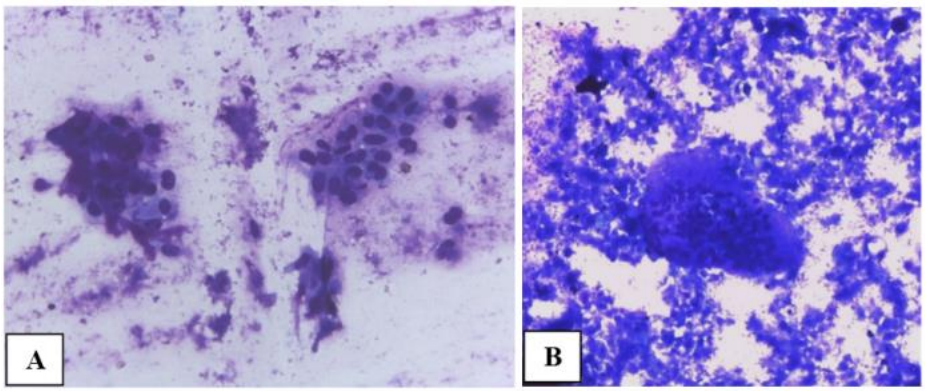

Figure 5. A. Cytology specimen showed round or spindle cells in clusters (Giemsa 100×).
B. Multinucleated giant cell (Giemsa 100×).

Figure 6. Mass from the right leg. Note the uncircumscribed yellowish mass with areas of hemorrhage and necrosis.

The histopathological findings showed an area of benign GCT that consisted of mononuclear cell proliferation, and multinucleated giant cells were sparsely spread in the stromal cells. The stromal cells had round, oval, or some spindle-shaped nuclei, with vesicular chromatin and variably prominent nucleoli. There were abundant nuclei of giant cells, which was identical to the mononuclear cells observed in the stroma. There was also a high-grade sarcoma area juxtaposed to the benign GCT. The sarcomatous area consisted of cells with the spindle, pleomorphic, bizarre nuclear, vesicular chromatin, and prominent nucleoli. The cytoplasms were eosinophilic. Mitotic activity was 9–12/10 HPF, and some had atypical features (Figures 7 and 8). Focal reactive bone formations, intravascular invasion, hemorrhage, and necrotic areas were also found (Figure 9). Histological findings were compatible with PMGCTB.

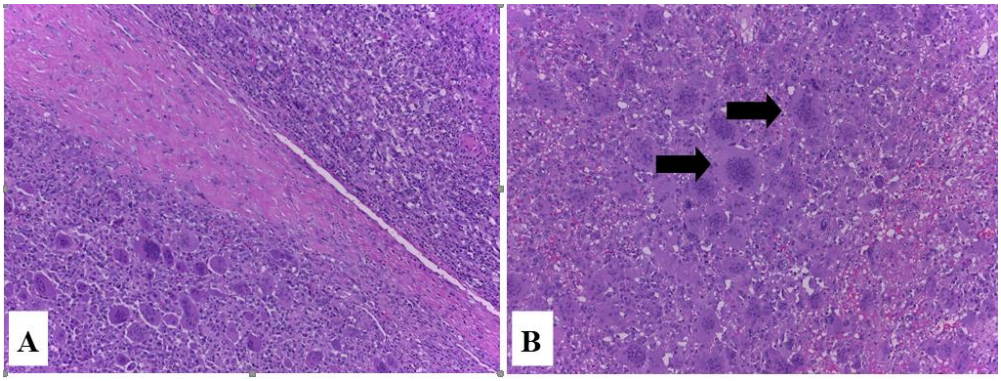

Figure 7. A. The juxtaposition between GCT (on the bottom left) and sarcomatous area (on the upper right, HE 100×). B. Conventional giant cell tumor with scattered multinucleated giant cells (arrow, HE 100×).

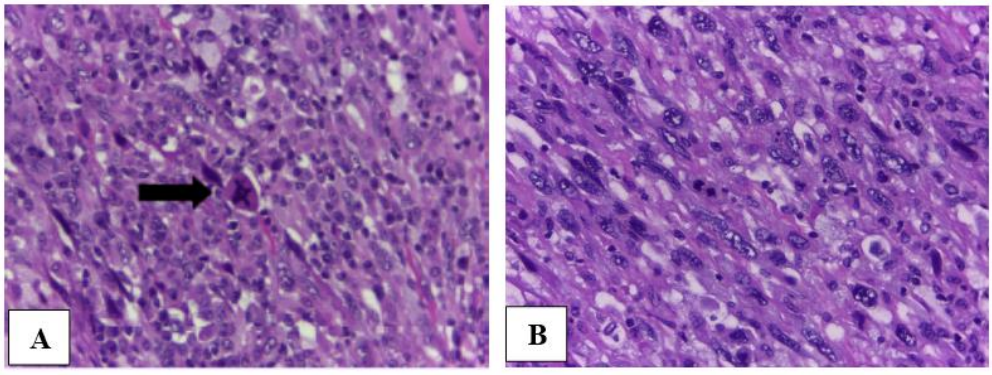

Figure 8. A. Atypical mitotic of high-grade sarcoma (HE 400×). B. High-grade sarcoma (HE 400×).

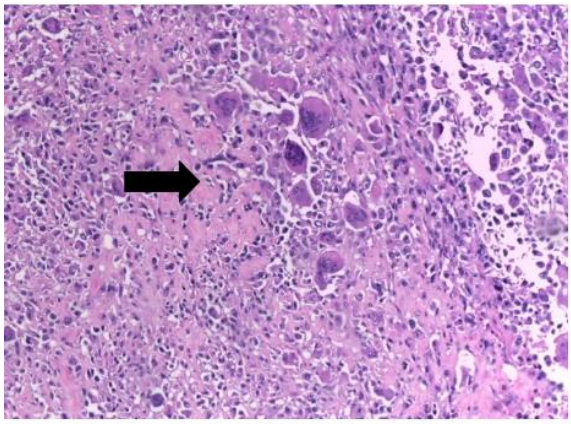

Figure 9. Focal reactive bone formation (arrow) (HE 100×).

After surgery, the patient experienced worsening dyspnea. Cytopathological testing of the sputum was performed and showed a negative result. Three months later, the patient did not receive any chemotherapy due to the long queue, and based on his family, he died because of lung metastasis.

DISCUSSION

In this case, the patient was a 53-year-old male with a mass on the upper end of his right tibia and no history of previous GCT, radiation therapy, or surgery. According to the literature, PMGCTB is a high-grade sarcoma diagnosed during the first treatment for GCTB [4]. PMGCTB typically occurs during the sixth decade of life and more frequently in men [8, 11]. The common sites are at the distal ulna, proximal and distal femur, and proximal tibia (Figure 10) [6], which is consistent with our case.

The x-ray and MRI showed an aggressive bone tumor at the metadiaphysis involving adjacent soft tissue. According to the literature, the radiographic pattern of a PMGCTB may be similar to conventional GCTB. A well-defined lytic lesion involves both the epiphysis and metaphysis. Although well-circumscribed, at least one has a thin cortex and may also be extended or destroyed [9, 11]. Aggressive radiological features such as large soft tissue component or cortical breakthrough may be seen in PMGCTB as well as in SMGCTB and benign recurrences of GCTB. The degree of overlap of the radiological findings in benign and MGCTB makes a histological analysis of tissue critical for diagnosis [8, 12].

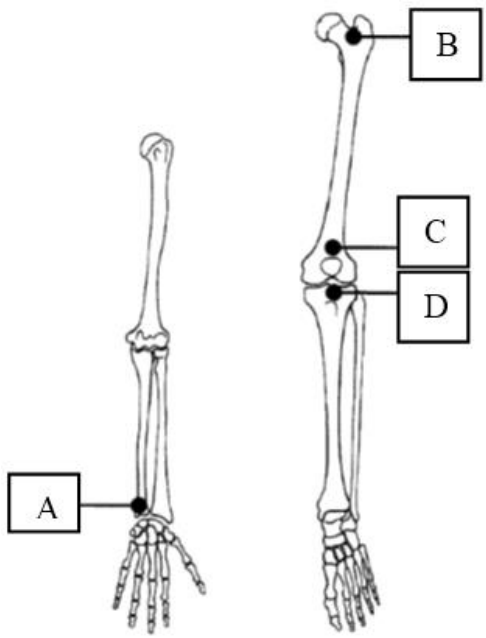

Figure 10. Common sites of PMGCTB. A. Distal ulna. B. Proximal femur. C. Distal femur. D. Proximal tibia [6].

FNAB findings, in this case, showed a predominantly necrotic area and fibrous tissue with a small number of round or spindle cells occurring in clusters, coarse chromatin, and multiple giant cells. From the cytology, we conclude that it was a bone lesion containing giant cells that cannot be determined to be either benign or malignant. Giant cell-rich lesions of bone have overlapping cytological features. Therefore, clinical evaluation and radiological findings can help to distinguish these entities and to aid in an accurate diagnosis [13]. In smears showing giant cells and mononuclear cells, it is wise not to make a definitive

diagnosis of GCTB even if suggested by radiological imaging. With regard to the differential diagnosis of other benign tumors with numerous giant cells, full knowledge of clinical and radiographic data is essential for a correct type-specific diagnosis [14].

Gross evaluation, in this case, showed a solid mass that was white-brown and firm. The cut surface was poorly circumscribed and showed a yellowish mass with areas of hemorrhage and necrotic tissue. Macroscopically, PMGCTB usually does not differ from those of GCTB. However, cut sections of PMGCTB typically appear to be soft, and the tumor tissue was focally gray-white and firm, intermixed with hemorrhagic, brownish-red, or a yellowish area of necrosis [4, 11].

Histopathology, this case showed proliferation of mononuclear cells and multinucleated giant cells with abundant nuclei, which was identical to the mononuclear cells in the stromal and a high-grade sarcoma area adjacent to the benign GCT. There were atypical mitoses, some focal reactive bone formation, and intravascular invasion. In the literature, there were distinct areas of typical GCT juxtaposed with a high-grade sarcoma. The high-grade sarcoma included fibrosarcoma, osteosarcoma, and UPS, whereas in this case, the sarcomatous component was UPS. Mitotic activity is always present, and atypical mitosis is also found [4, 6, 11]. Reactive bone can be present focally and should be appropriately identified as not being an integral part of the lesion [15]. It has been previously hypothesized that permeation of GCTB cells into vessels causes some emboli to escape and be lodged in the pulmonary parenchyma and remain viable [16].

The differential diagnosis of PMGCTB is giant cell-rich osteosarcoma, malignant fibrous histiocytoma (MFH) and SMGCTB. The diagnosis of giant cell-rich osteosarcoma requires a component of malignant bone-forming tumor [15]. In MFH, benign GCT areas are not present, and there are multinucleated giant cells with large and pleomorphic nuclei [11]. In SMGCTB, there is a history of GCTB, the recurrence information and remnants of conventional GCTB are visible microscopically [4].

Low incidence of MGCTB made it difficult to determine an appropriate therapy for this case, and the resulting prognosis was poor. Treatment typically includes surgery combined with chemotherapy and radiotherapy. Unfortunately, chemotherapy results are inconsistent but may increase the 5 year survival rate, yet the benefit disappears when most patients reach 5 years post-surgery [5]. The prognosis is poor and many patients die rapidly [4]. In this case, the patient had surgery and had planned chemotherapy, but he never received the latter. He later died within 3 months of the operation.

The limitations of this case report include the lack of concrete evidence that the patient did die. According to several chest x-rays that showed multiple nodules in both lungs with infiltrates, we anticipate that this information was true due to the suggestive metastasis. There was also no histopathological examination of multiple nodules of both lungs, and the sputum smear was negative.

REFERENCES

[1] Marui, T., Yamamoto, T., Yoshihara, H., Kurosaka, M., Mizuno, K., Akamatsu, T., (2001). De novo malignant transformation of giant cell tumor of bone. *Skeletal Radiol*, 30: 104-108.

[2] Campanacci, M., Baldini, N., Boriani, S., Sudanese, A., (1987). Giant-cell tumor of bone. *JBJS*, 69: 106-114.

[3] Knochentumoren, A., Becker, W.T., Dohle, J., Bernd, L., Braun, A., Cserhati, M., Enderle, A., Hovy, L., Matejovsky, Z., Szendroi, M., Trieb, K., Tunn, PU., (2008). Local recurrence of giant cell tumor of bone after intralesional treatment with and without adjuvant therapy. *J. Bone Joint Surg. Am.* American volume, 90: 1060-1067.

[4] Gong, L., Liu, W., Sun, X., Sajdik, C., Tian, X., Niu, X., Huang, X., (2012). Histological and clinical characteristics of malignant giant cell tumor of bone. *Virchows Archiv*, 460: 327-334.

[5] Domovitov, S.V., Healey, J.H., (2010). Primary malignant giant-cell tumor of bone has high survival rate. *Ann. Surg.* Oncol, 17: 694-701.

[6] Bertoni, F., Bacchini, P., Staals, E.L., (2003). Malignancy in giant cell tumor of bone. *Cancer*, 97: 2520-2529.

[7] Renard, A.J., Veth, R.P., Pruszczynski, M., Wobbes, T., Lemmens, J.A., Van-Horn, J.R., (1994). Giant cell tumor of bone: oncologic and functional results. *J. Surg.* Onco, 57: 243-251.

[8] Heffernan, E.J., O'Sullivan, P.J., Adibeig, M., Louis, L.J., Ryan, A.G., Neilsen, T.O., Munk, P.L., (2007). Primary malignant transformation of giant cell tumor of bone. *Eur. J.* Radiol, 62: 89-93.

[9] Khurana, J.S, McCarthy, E.F. (2010). Giant cell lesions: Giant cell tumor. In: Khurana, J.S., McCarthy, E.F., Zhang, P.J. editors. *Essentials in bone and soft tissue pathology (*pp.134-137). New York: Springer; 2010.

[10] Athanasou, N.A., Bansai, M., Forsyth, R., Reid, R.P., Sapi, Z. (2013). Giant cell tumour of bone. In: Fletcher CDM, Bridge JA, Hogendoorn P, Mertens F, editors. *WHO classification of tumours of soft tissue and bone* (4th ed.pp.321-324). Lyon: IARC.

[11] Nascimento, A.G., Huvos, A.G., Marcove, R.C., (1979). Primary malignant giant cell tumor of bone. A study of eight cases and review of the literature. *Cancer*, 44: 1393-1402.

[12] Bacchini, P., Bertoni, F. (2010). Giant cell tumour of bone. In: Folpe AL, Inwards CY, editors. *Bone and soft tissue pathology: a volume in the series foundations in diagnostic pathology* (1st ed.pp.400-407). Philadelphia: Saunders Elsevier.

[13] Gupta, K., Dey, P., Goldsmith, R., Vasishta, R.K., (2004). Comparison of cytologic features of giant-cell tumor and giant-cell tumor of tendon sheath. *Diagn. Cytopathol*, 30: 14-18.

[14] Jain, M., Aiyer, H.M., Singh, M., Narula, M., (2002). Fine-needle aspiration diagnosis of giant cell tumour of bone presenting at unusual sites. *Diagn. Cytopathol*, 27: 375-378.

[15] Czerniak, B. (2016). Giant cell lesion. In: Czerniak B, editor. *Dorfman and czerniak's bone tumors* (2nd ed. pp. 692-742). Philadelphia: Saunders.

[16] Okubo, T., Saito, T., Mitomi, H., Takagi, T., Torigoe, T., Suehara, Y., Kaneko, K., Yao, T., (2013). p53 mutations may be involved in malignant transformation of giant cell tumor of bone through interaction with GPX1. *Virchows Archiv*, 463: 67-77.

In: Encyclopedia of Surgery (22 Volume Set)
Editors: Andreas Lehrer and Kristin Mueller
ISBN: 978-1-53618-329-0
© 2020 Nova Science Publishers, Inc

Chapter 351

SECONDARY MALIGNANT GIANT CELL TUMOR OF THE BONE: A CASE REPORT AND RARE EXPERIENCE

Fadhlina Muharmi Harahap[1], Nurjati Chairani Siregar[1,*], Yogi Prabowo[2] and Thariqah Salamah[3]

[1]Department of Anatomical Pathology, Faculty of Medicine, Universitas Indonesia, Cipto Mangunkusumo Hospital, Jakarta, Indonesia
[2]Department of Orthopaedic and Traumatology, Faculty of Medicine, Universitas Indonesia, Cipto Mangunkusumo Hospital, Jakarta, Indonesia
[3]Department of Radiology, Faculty of Medicine, Universitas Indonesia, Cipto Mangunkusumo Hospital, Jakarta, Indonesia

ABSTRACT

Giant cell tumor of bone (GCTB) is a primary bone neoplasm composed of mononuclear cells proliferating among scattered macrophages and large, osteoclast-like giant cells. Secondary malignant GCTB is a sarcoma arising at a site where a GCTB has been previously documented. This case report is about a 32- year-old female who presented with right knee pain of one year duration. The patient had a history of bone tumor, at the same site, six years ago. Radiographs showed a mass in the epimetaphy seal, extending into the tibiofemoral and patellofemoral junction. Such findings were consistent with a recurrent lesion. Following microscopic investigation, spindle- cell with atypical mitoses and nuclear pleomorphism, admixed with conventional GCTB, were identified. Sarcomatous changes in malignant GCT develop many years, or even decades, following the primary lesion's removal. Radiologic features are represented by large lesions with cortical destruction and prominent invasion into the soft tissue. Microscopically, the conventional GCTB is adjacent to, or intermixed with, the sarcomatous area. Based on such findings, we conclude this case is a secondary malignant GCTB.

[*] Corresponding Author's Email: fadhlinamuharmi@gmail.com.

Keywords: giant cell tumor of the bone, secondary malignant

INTRODUCTION

Giant cell tumor of bone (GCTB) is a primary bone neoplasm composed of mononuclear cells proliferating among numerous scattered macrophages and large, osteoclast-like giant cells [1]. It represents around 4% – 5% of all primary bone tumors. Its peak incidence is between the ages of 20 and 45, with a slight predominance in females. In terms of localization, GCTB generally arises at the ends of long bones (e.g., distal femur, proximal tibia, distal radius and proximal humerus). The lesion commonly involves epiphysis and adjacent metaphysis [1-3].

Malignant transformation in GCTB is a rare event. It is classified as primary and secondary [4-6]. Primary malignant GCTB is defined as GCTB composed of sarcomatous growth juxtaposed with zones of typical benign GCTB in an individual without a previous history of surgery or radiotherapy [4-7]. It occurs in 1% – 3% of all GCTB cases [6]. Secondary malignant GCTB is described as sarcomatous growth at the site of a previously documented benign GCT [4-7]. It occurs in 5% – 10% of all GCTB cases [6]. Most secondary malignant GCTBs have a history of irradiation treatment for the primary lesion. Therefore, malignant changes occurring after only surgical procedures represent an extremely rare phenomenon [5, 8].

Histologically, tumors are characterized by many osteoclast-like giant cells, uniformly scattered among numerous oval or plump, spindle- shaped mononuclear cells. The nuclei of mononuclear and giant cells are similar; specifically, they both have round or oval nuclei with regular outlines, evenly distributed fine chromatin, prominent nucleoli, and eosinophilic cytoplasm. Occasionally, a subset of giant cells may present with 50 – 100 or even more nuclei. Mitotic figures are typically observed [1, 9]. Sarcomas are identified based on the presence of atypical mitotic figures and cytological anaplasia in the round or spindle-shaped mononuclear cells associated with conventional GCTB [1, 10].

In the present case report, we describe a 32-year-old female patient with a recurrent bone tumor in the right distal femur. She had an earlier history of bone tumor (in 2009). Upon X-Ray examination, an epimetaphyseal mass in the right distal femur was identified. Histologically, the lesion presented as a high grade sarcoma, consistent with secondary malignant of GCTB.

Secondary malignant GCTB's diagnosis is based on several aspects, such as patient history (age, symptoms, and physical examinations), preferred location, radiographs and histopathology. Secondary malignant GCTB is a rare event. This case report aims to share the experience of diagnosing a rare case.

CASE REPORT

A 32-year-old female presented with right knee pain, which started about one year before evaluation. The patient had a medical history of bone tumor and underwent surgery six years ago. A histopathological examination was not performed. Physical examination of the right

knee showed deformity, shortening, a 2cm leg length discrepancy, external rotation, and a mass. The mass was 8 x 8 x 2cm in size, firm, tender and warm (Figure 1).

X- ray of the right knee showed a plate and screw internal fixation from distal to mid-diaphysis of the right femur in good condition. There was also swelling of the right distal femur soft tissue (Figure 2). An X- ray of the right femur showed a lytic lesion in distal femoral metadiaphysis with thickening of the surrounding soft tissues (Figure 3).

Figure 1. Tumor mass in the right femur (arrow).

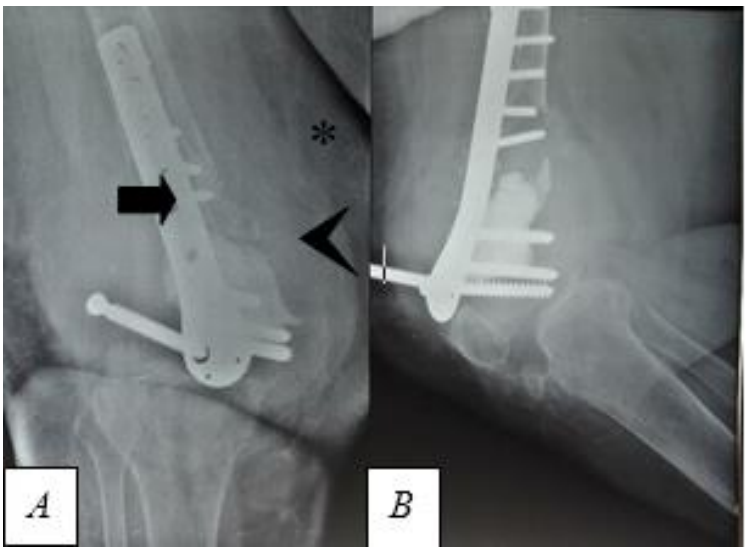

Figure 2. An X- ray of the right knee in (a) anteroposterior and (b) lateral views. Plate and screw internal fixation (arrow) and GCT (arrow head) with right distal femur soft tissue swelling (asterisk) are shown.

Figure 3. X- ray of the right femur in (a) anteroposterior and (b) lateral views. Lytic lesion (arrow head) with thickening of surrounding soft tissues (asterisk) are shown.

A CT scan of the right knee showed a right distal femur epimetaphyseal (6.1 × 10.2 × 11cm in size), extending into the tibiofemoral and patellofemoral junction, consistent with a recurrent lesion (Figure 4).

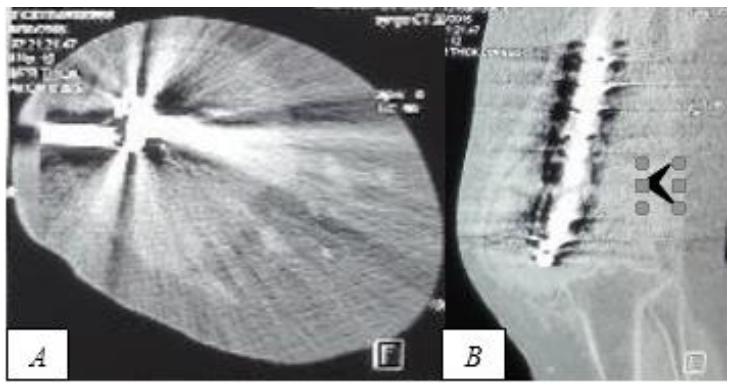

Figure 4. A CT scan of the right knee in (a) axial plane and (b) sagittal plane views. The right distal femur epimetaphyseal mass (arrow head), extending into the tibiofemoral and patellofemoral junction, are shown.

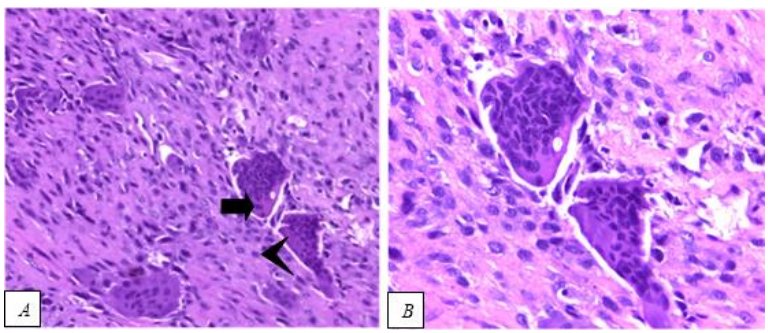

Figure 5. Core biopsy of the right distal femur. (a) Giant cells with >20 nuclei (arrow) resemble the stroma cell nuclei (arrow head) (HE 100X). (b) Round/oval nuclei, mild pleomorphic, hyperchromatic and often vesicular with conspicuous nucleoli (HE 400X).

Core biopsy sample revealed tissues contained giant cells with >20 nuclei resembling stroma cell nuclei. The nuclei were round/oval, mild pleomorphic, hyperchromatic, and often vesicular with conspicuous nucleoli. Histological findings were compatible with a giant cell containing lesion, which can be identified in GCTB (Figure 5).

The patient underwent a second surgery one month later. A surgical specimen sized 21 x 14 x 9cm was collected. The cut surface presented as well-circumscribed white mass with solid consistency (Figure 6).

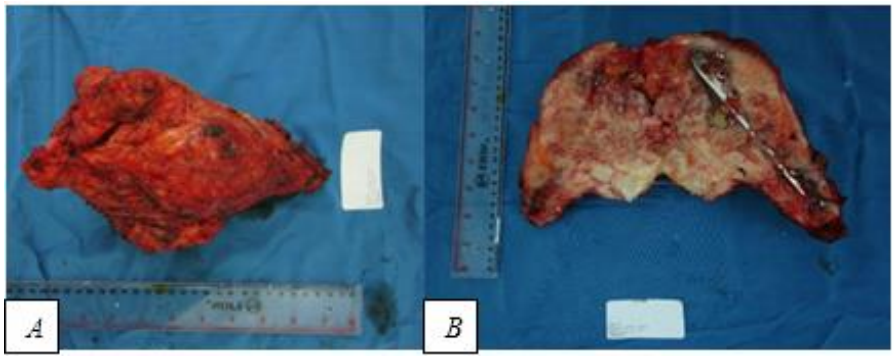

Figure 6. (a) Mass removed from the right knee. (b) The well-circumscribed white mass with solid consistency.

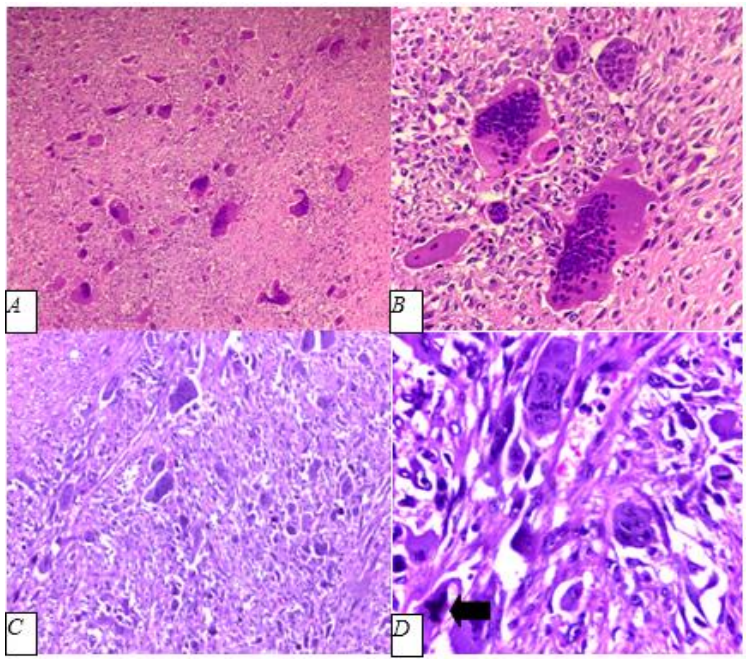

Figure 7. Histological sections of a surgery specimen. (A&B) Conventional GCT area (HE 40X & 400X). (C&D) Sarcomatous area with atypical mitosis (arrow) (HE 40X & 400X).

Representative sections were submitted in 11 cassettes. Histological evaluation revealed tumor tissues contained giant cells with >20 nuclei. There was a similarity among subsets of giant cells and stromal cells nuclei. Nuclei were round/oval, mild pleomorphic, vesicular,

eosinio philic cytoplasm. High cellular stroma were found and arranged in storiform pattern, sarcomatous with oval/spindle nuclei, pleomorphic to bizarre, hyperchromatic, eosinophilic cytoplasm. The mitotic count was 2/10 HPF. Giant cells with bizarre nuclei, lymphovascular invasion, and areas of necrosis were also identified (Figure 7). Histological findings were compatible with high grade sarcoma, which can be found in secondary malignant GCTB.

DISCUSSION

About 70% of GCTB cases are diagnosed in patients 20 – 40 years old, with a peak incidence in the third decade of life [9]. Women are affected about 1.5 times more frequently than men [1, 2, 9]. In line with current reports, the present case involved a 32-year-old female patient.

GCTB is commonly located in the epiphyseal ends of long tubular bones, usually in the distal end of the femur, the proximal end of the tibia, and the distal end of the radius. In the present case, the tumor was at the end of the long bone (right distal femur). Such a location was where the GCTB was previously diagnosed.

GCTB tends to progress to a high grade malignancy. Sarcomatous changes in malignant giant cell tumors can also develop for several years, or even decades, following removal of the primary lesion. Transformation to high grade sarcoma rarely occurs spontaneously. Specifically, it takes place with higher- frequency, post-irradiation therapy [8]. Alternatively, it can occur following a single local recurrence or multiple recurrences. [9] A histological or radiological differentiation between the two is impossible [6]. Clinically, the recurrence of pain and swelling many years post-GCT treatment is a clue of malignant transformation [1, 7]. In the present case, the patient was diagnosed with a bone tumor and underwent the first surgery six years ago, with no histopathological examination. The histopathologic findings from the second surgery, performed one year later, were consistent with high grade sarcoma, corresponding to secondary malignant GCTB. The patient did not have history of irradiation.

GCTB typically occurs as an eccentric, purely lytic lesion involving the end of the bone. It usually extends up to the subchondral bone plate. As a consequence of the tumor growth, the cortex is frequently destroyed. The lesion expands to soft tissues, where it is covered with a thin shell of reactive new bone [2]. Radiologically, a giant cell tumor with malignant change has the features of a large destructive lesion with cortical destruction and prominent invasion into soft tissues.

Plain X-rays of primary malignant GCTB demonstrate the presence of a lytic process extending to the end of the long bone. Imaging rarely shows typical GCT features and sclerotic destructive tumors juxtaposed with it. Plain X-rays of secondary malignant GCTB are characterized by a destructive process, with poor margination, situated at the site of a previously diagnosed GCTB [1]. In the case presented here, an X- ray showed lytic lesions in the distal femoral metadiaphysis, with thickening of the surrounding soft tissues. A CT scan showed a right distal femur epimetaphyseal mass 6.1 × 10.2 × 11 cm in size. The lesion appeared to extend into the tibiofemoral and patellofemoral junction, consistent with a recurrent lesion.

The gross appearance of malignancy in GCT is a large, fleshy tumor often with a soft tissue extension that is commonly seen in sarcomas [1, 2]. In the present case, the tumor's cut

surface showed a well-circumscribed white mass, of solid consistency, with soft tissue extension.

Secondary malignant GCT are a rare condition, defined as a sarcomatous growth that occurs at the site of a previously documented benign GCT [4-8]. Characterised histologically by atypical mitoses and pleomorphism spindle cell nuclear that is next to or intermixed with conventional GCT [9, 11, 12]. Of note, immunohistochemical studies are not required for the transformation's diagnosis [12]. In the present case, a histopathological examination from the first surgery was not available for our review. A core biopsy performed before the second surgery revealed a giant cell containing lesion consistent with GCTB. The histological sections from the second surgery revealed giant cells with >20 nuclei admixed with round and spindle mononuclear cells. Subsets of the giant cells and mononuclear cells' nuclei were similar. In some areas, the spindle stromal component predominated and proliferated. Cells were arranged in storiform pattern with hyperchromatic and pleomorphic to bizarre nuclei. Atypical mitotic, lymphovascular invasion, and necrotic areas were identified. Based on these findings, we conclude that there was a malignant change characterized by sarcomatous growth that occurred next to, or intermixed with, the conventional GCT.

Malignant changes in GCT may be in the form of fibrosarcoma, malignant fibrous histiocytoma, osteosarcoma, or undifferentiated high- grade pleomorphic sarcoma. In an earlier study, Gong et al. reported malignant components, including osteosarcoma (11 cases), undifferentiated, high grade pleomorphic sarcoma (two cases), and fibrosarcoma (four cases) [13]. Additionally, Rock et al. found three times more fibrosarcomas than osteosarcomas among secondary malignant GCTB cases [14]. Bertoni et al. reported osteosarcomas in primary malignant GCTB (four of five cases), osteosarcomas in secondary malignant GCTB (9 of 12 cases), fibrosarcomas (two postradiation secondary malignant GCTBs) and malignant fibrous histiocytomas (one primary malignant GCTB and one postsurgical secondary malignant GCTB) [15]. In the present case, the malignant change was in the form of an undifferentiated high-grade pleomorphic sarcoma.

Secondary malignant GCTB needs to be differentiated from giant cell-rich osteosarcoma. Osteosarcoma's diagnosis requires the presence of a malignant bone-forming tumor [9]. In the present case, no malignant bone-forming tumor was identified.

The prognosis for patients with secondary malignant GCTB is similar to high grade sarcomas. Reports have shown that, in such patients, the prognosis is worse than in those with primary malignant GCTB [1].

The present case report presents a limitation. Specifically, no histopathological examination was performed at the time of the first surgery. However, from the second surgery's microscopic examination, we identified areas of anaplastic pleomorphic tumor cells and atypical mitoses were intermixed with conventional GCT. Such findings were the key in diagnosing malignant changes in GCT [9, 11, 12].

SUMMARY

Malignancy in GCT is a sarcoma arising within the GCT or at the site where a GCT had been previously documented. Malignant transformation in GCTB is rare. Giant cell tumors with malignant changes have radiologic features of large, destructive lesions with cortical

destruction and prominent invasion into soft tissues. Key microscopic features in diagnosing malignant changes in GCT are atypical mitoses and pleomorphism spindle cell nuclear that is next to or intermixed with conventional GCT.

REFERENCES

[1] Athanasou, N. A.; Bansai, M.; Forsyth, R.; Reid, R. P.; Sapi, Z. Giant cell tumour of bone. In: Fletcher, C. D. M.; Bridge, J. A.; Hogendoorn, P.; Mertens, F.; editors. *WHO classification of tumours of soft tissue and bone.* 4th ed. Lyon: IARC. 2013. p. 321 - 324.

[2] Silverberg, S. G. Giant cell tumor. In: Silverberg, S. G.; editor. *AFIP atlas of tumor pathology: Tumors of the bones and joints.* Series 4. Washington: Armed forces institute of pathology. 2005. p. 282 - 295.

[3] Bacchini, P.; Bertoni, F. Giant cell tumor of bone. In: Folpe, A. L.; Inwards, C. Y.; editors. *Bone and soft tissue pathology*, p. 401 - 407.

[4] Saito, T.; Mitomi, H.; Suehara, Y.; Okubo, T.; Torigoe, T.; Takagi, T.; Kaneko, K.; Yao, T. A case of de novo secondary malignant giant- cell tumor of bone with loss of heterozygosity of p53 gene that transformed within a short - term follow- up. *Pathology-Research and Practice*, 2011 207, 664 - 669.

[5] Saito, T.; Mitomi, H.; Izumi, H.; Suehara, Y.; Okubo, T.; Torigoe, T.; Takagi, T.; Kaneko, K.; Sato, K.; Matsumoto, T.; Yao, T. A case of secondary malignant giant- cell tumor of bone with p53 mutation after longterm follow- up. *Human Pathology*, 2011 42, 727 - 733.

[6] Georgiev, G. P.; Slavchev, S.; Dimitrova, I. N.; Landzhov, B. Giant cell tumor of bone: current review of morphological; clinical; radiological; andtherapeutic characteristics. *Journal of Clinical and Experimental Investigations*, 2014 5,475 - 485.

[7] Grote, H. J.; Braun, M.; Kalinski, T.; Pomjanski, N.; Back, W.; Bleyl, U.; Böcking, A.; Roessner, A. Spontaneous malignant transformation of conventional giant cell tumor. *Skeletal Radiology*, 2004 33, 169 - 175.

[8] Oda,Y.; Sakamoto, A.; Saito, T.; Matsuda, S.; Tanaka, K.; Iwamoto, Y.; Tsuneyoshi, M. Secondary malignant giant- cell tumour of bone: molecular abnormalities of p53 and H- ras gene correlated with malignant transformation. *Histopathology*, 2001 39, 629 - 637.

[9] Czerniak, B. Giant cell lesion. In: Czerniak, B.; editor. *Dorfman and czerniak's bone tumors*. 2nd ed. Philadelphia: Saunders. 2016. p. 692 - 742.

[10] Zheng, M. H.; Robbins, P.; Xu, J.; Huang, L.; Wood, D. J.; Papadimitriou, J. M. The histogenesis of giant cell tumour of bone: a model of interaction between neoplastic cells and osteoclasts. *Histology and Histopathology*, 2001 16, 297 - 307.

[11] Bullough, P. G. Benign nonmatrix- producing bone tumors. In: Bullough, P. G.; editor. *Orthopaedic pathology*. 5th ed. Mosby elsevier: Missouri. 2010. p. 466 - 474

[12] Miller, I. J.; Blank, A.; Yin, S. M.; Mcnickle, A.; Gray, R.; Gitelis, S. A case of recurrent giant cell tumor of bone with malignant transformation and benign pulmonary metastases. *Diagnostic Pathology*, 2010 5, 62.

[13] Gong, L.; Liu, W.; Sun, X.; Sajdik, C.; Tian, X.; Niu, X.; Huang X. Histological and clinical characteristics of malignant giant cell tumor of bone. *Virchows Archiv.,* 2012 460, 327 - 334.

[14] Rock, M. G., Sim, F. H., Unni, K. K., et al. Secondary malignant giant-cell tumor of bone. Clinicopathological assessment of nineteen patients. *J. Bone Joint Surg. Am.,* 1986 68, 1073 - 1079.

[15] Bertoni, F.; Bacchini, P.; Staals, E. L. Malignancy in giant cell tumor of bone. *Cancer,* 2003 97, 2520 - 2529.

In: Encyclopedia of Surgery (22 Volume Set)
Editors: Andreas Lehrer and Kristin Mueller
ISBN: 978-1-53618-329-0
© 2020 Nova Science Publishers, Inc

Chapter 352

SEGMENTAL ABSENCE OF INTESTINAL MUSCULATURE: CASE REPORT OF A RARE CAUSE OF NEONATAL INTESTINAL OBSTRUCTION

Ignasia Andhini Retnowulan[1] and Nur Rahadiani[2,*]
[1]Anatomical Pathology Residency Program, Faculty of Medicine, Universitas Indonesia, Jakarta, Indonesia
[2]Department of Anatomical Pathology, Faculty of Medicine, Universitas Indonesia, Jakarta, Indonesia

ABSTRACT

Segmental absence of intestinal musculature is a distinct histopathological entity with rare occurrence. The condition typically presents in neonates, with the primary manifestation being intestinal obstruction or perforation. Here we present the case of a neonate who initially presented with a high lesion of anal atresia. In the first few days following colostomy, the infant exhibited signs of intestinal obstruction. An exploratory laparotomy revealed ileal stenosis. A resected ileum specimen showed a narrowed segment of the ileum. Histopathological examination showed focal hypoplasia to total absence of muscularis propria with intact mucosal, submucosal, and serosal layers. Histochemical and immunohistochemical studies confirmed the absence and hypoplasia of muscularis propria, presence of ganglion cells, and absence of Cajal cells in the pathological segment. In cases of neonatal intestinal obstruction due to segmental absence of intestinal musculature, the possibility of defects of intestinal musculature should be investigated, particularly in conjunction with other congenital diseases.

Keywords: congenital defect, segmental absence of intestinal musculature

* Corresponding Author's Email: nur.rahadiani@ui.ac.id.

INTRODUCTION

Segmental absence of intestinal musculature (SAIM) is a distinct histopathological entity with rare occurrence. The condition was reported for the first time in 1943 [1]. Since then, the number of reported cases has been increasing, reaching approximately 25 cases in the English and Asian relevant literature [2]. However, thus far, there have been no such cases reported in Indonesia.

Typically, the condition presents in the neonatal age group, although several cases have been reported in adults [3]. The main manifestation of the disease is intestinal obstruction or perforation, along with other congenital anomalies, such as intestinal atresia, biliary atresia, patent ductus arteriosus, and ventricular septal defect [2, 4, 5]. Patients are mainly admitted to the hospital with complaints of abdominal distention, hypoactive bowel, ileus, and failure to pass meconium [6]. The majority of SAIM cases are discovered through surgery; however, a definitive diagnosis is based on histopathological findings [6]. Following gross examination, several cases demonstrated a thin-walled resected bowel, consistent with wall atrophy with paper-like consistency. Studies have reported an almost translucent color of the resected bowel [1]. Histological findings showed segmental absence or atrophy of intestinal musculature, with normal remaining intestinal layers. Other less common findings include fibrosis, inflammatory infiltration in the pathologic segment, and an underdeveloped capillary network [1,4,7]. The condition may involve the stomach, small intestine, or colon [1].

The pathogenesis of SAIM remains uncertain. However, several theories have been proposed. Abnormality during embryogenesis is thought to lead to incomplete myogenesis. Other theories described an etiology of an ischemic process during pre- or post-natal life, or as part of the remnant of developmental diverticula [2, 8]. Nevertheless, whether the disease is primarily due to malformation, or an ischemic or inflammation process remains controversial [4].

Currently, the condition is not widely recognized among clinicians and pathologists; hence, it is thought that the disease may be underdiagnosed. The aim of this case report was to familiarize pathologists and clinicians with this rare disease.

CASE REPORT

Clinical Summary

A neonate was admitted to Cipto Mangunkusumo General Hospital 20h after birth due to congenital absence of the anal opening. The full-term infant was born through a spontaneous midwife-assisted labor from a mother who underwent irregular prenatal care. There was no record of the Appearance, Pulse, Grimace, Activity, Respiration (APGAR) score; however, the mother stated that the infant cried immediately after birth. The weight of the infant at birth was 3,000g. There were no other congenital anomalies identified at birth. In addition, there was no maternal illness or pregnancy complications reported. The 27-year-old mother denied consuming any medication or herbal drinks during pregnancy other than vitamins prescribed by the midwife. However, the mother revealed a history of untreated leukorrhea during pregnancy. Both parents did not report a family history of congenital anomalies. The older

sibling of the patient was aged 5 years and born without any congenital anomalies or complications during pregnancy and labor.

At the time of hospital admission, physical examination showed normal vital signs with pale acral. It was observed that the abdominal distention with an abdominal circumference of 34cm, exceeded the normal limit (Figure 1) [9]. Laboratory testing showed a slight increase in leucocyte count (24,400/μL) and prolonged prothrombin time/activated partial thromboplastin time (1.46×/1.57×). Abdominal X-ray and babygram examination confirmed the diagnosis of a highlesion of anal atresia.

Figure 1. The patient presented with abdominal distention 20h after birth.

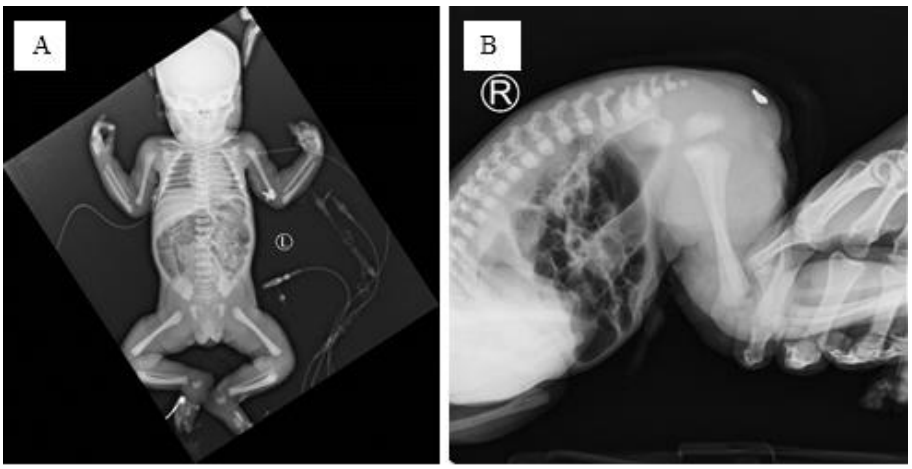

Figure 2. Radiological examination performed at the time of hospital admission. (a) Babygram imaging. (b) Abdominal X-ray examination in the knee-chest position.

The colon and small bowel were distended and filled with fecal mass (Figure 2a, 2b). The early babygram did not reveal ileal atresia. The initial diagnosis was anal atresia with suspicion of late-onset neonatal sepsis.

At the age of 2 days, the patient underwent colostomy. In the first few days following surgery, the patient developed signs and symptoms of intestinal obstruction, such as vomiting, abdominal distention, and decreased production of stoma. The intestinal obstruction became apparent on day 8. The patient was lethargic and serum markers of inflammation increased. The levels of C-reactive protein and procalcitonin were 16.4 and 0.44, respectively. Repeated abdominal X-ray examinations showed intestinal dilatation, indicating the presence of high intestinal obstruction. Subsequently, an exploratory re-laparotomy was performed. Intraoperative findings revealed ileal stenosis, located 120cm from the Treitz ligament. Evaluation of the colostomy stoma did not demonstrate obstruction or presence of pus. Adhesion between the ileum and sigmoid was found. A 2.5-cm specimen of the ileal stenosis was resected, and an ileo-ileal anastomosis and adhesiolysis were performed. Post-operative abdominal X-ray examination did not show signs of intestinal obstruction. Post-operative laboratory testing showed a decrease in the level of C-reactive protein from 16.4 to 10.9; however, the level of procalcitonin was slightly increased from 0.44 to 0.54. There was no vomiting reported, and the production of colostomy stoma was within normal limits. Several days following the surgery, an enteral diet was initiated. The patient was discharged from the hospital 19 days after surgery. During subsequent outpatient visits, the patient did not show signs of recurring intestinal obstruction. Moreover, the stoma output was within normal limits. Unfortunately, the patient was lost to follow-up after a few months.

Pathological Findings

Histopathological examination was performed using a resected specimen of the ileum (2.5cm in length and 1cm in diameter). The specimen revealed a narrowing segment of the ileum (Figure 3). Histopathological examination showed intact mucosa with a normal to shortened ileal villous. The lamina propria to serosal layers were mildly infiltrated with chronic inflammatory cells, neutrophils and eosinophils of 5–10 per high-power field. Muscularis propria showed focal hypoplasia to total absence of smooth muscle fibers. There were no vascular network abnormalities, vasculitis, or ischemic changes present (Figure 4).

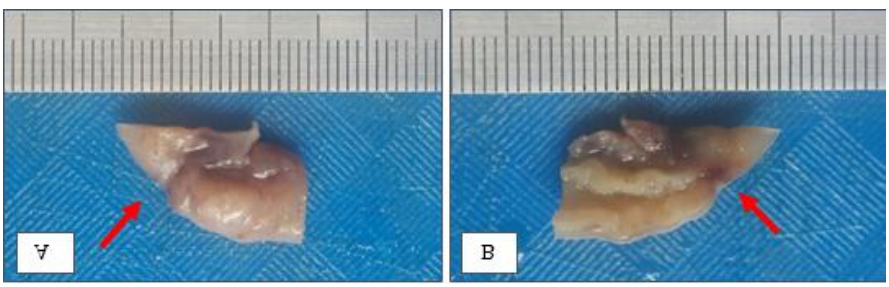

Figure 3. Gross examination showed a narrowing segment (red arrow) of the resected ileum. (a) Serosal surface and (b) Luminal surface.

Histochemical and immunohistochemical staining was performed for further assessment of both the muscle fibers and innervation of the ileum. Gomori trichrome staining showed normal connective tissue fibers in both the normal and stenotic segments of the bowel. Smooth muscle actin showed positivity in the smooth muscle, in terms of normal thickness

and hypoplastic muscle. CD117 immunostaining was non-reactive, thus revealing the absence of Cajal cells in both segments where the muscularis propia were hypoplastic and absent. Calretinin, which was positive in normal ganglion cells, showed normal submucosal and myenteric ganglion cells in the narrowed segment and revealed slightly hyperplastic ganglion cells in the normal segment (Figure 5, 6).

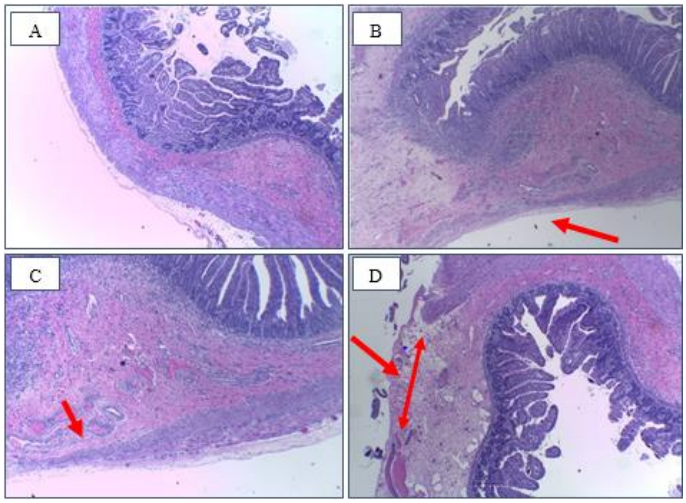

Figure 4. Histopathological examination. (a) Relatively normal segment of the ileum (HE, 40×). (b) Focal hypoplasia of the muscularis propria (hematoxylin & eosin [HE], 40×). (c) Focal hypoplasia of the muscularis propria (HE, 100×). (d) Total absence of the muscularis propria (HE, 40×). b-d. Intact mucosal, submucosal, and serosal layers.

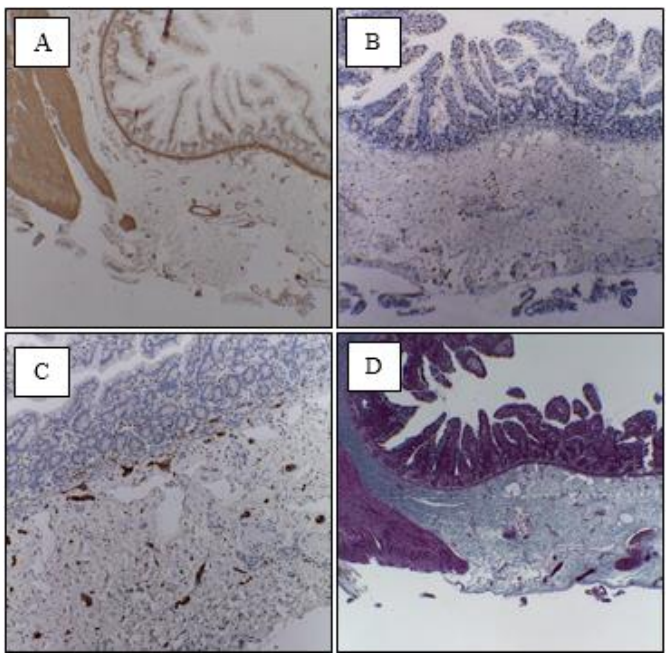

Figure 5. Histochemical and immunohistochemical staining in the total absence of muscularis propria. (a) SMA, 40×; (b) CD117, 40×; (c) Calretinin, 100× and (d) Gomori trichrome, 40×.

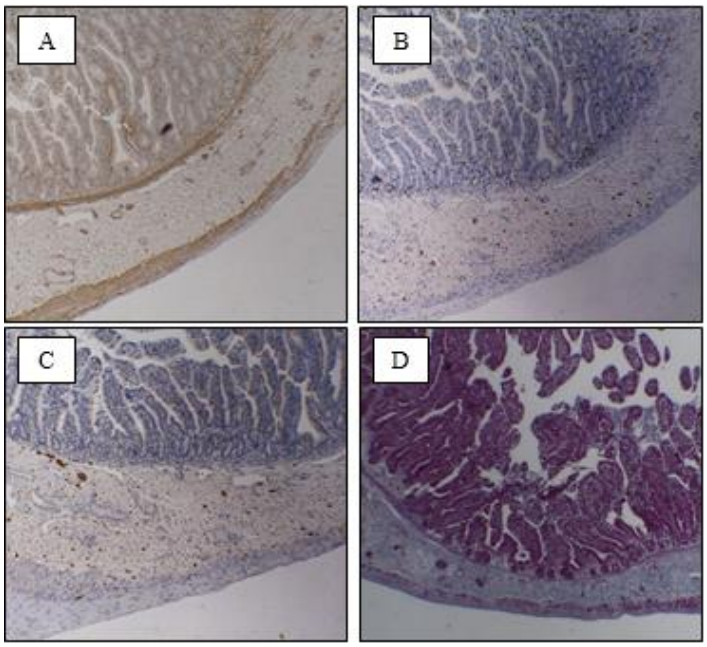

Figure 6. Histochemical and immunohistochemical staining of the hypoplastic muscularis propria. (a) SMA, 40×; (b) CD117, 40×; (c) Calretinin, 100× and (d) Gomori trichrome, 40×.

DISCUSSION

Neonatal intestinal obstruction commonly results in admission to the Neonatal Intensive Care Unit. The incidence rate is approximately 1 in 2,000 live births [10]. The cardinal signs of this condition are polyhydramnion, bilious emesis, failure to pass meconium in the first 24–48 hours of life, and abdominal distention [10, 11]. The blockage along the gastrointestinal tract may be structural or functional [11, 12]. Structural obstruction includes atresia, stenosis, intussusception, volvulus, intussusception, hernias, bands, and presence of masses [11]. In contrast, functional obstruction can be caused by Hirschsprung's disease, sepsis, electrolyte imbalance, meconium plug syndrome, and other secondary conditions that lead to loss of peristaltic activity [11, 13]. The most common cause of intestinal obstruction in newborns is intussusception (20.8%), followed by intestinal atresia (11.8%) [14]. Among intestinal atresias, jejunoileal and anal atresia are the most common conditions, with an incidence rate of 1 in 5,000 live births [10]. Initial treatment involves nasogastric decompression, fluid resuscitation, and administration of broad-spectrum antibiotics. Most cases usually require non-emergent operative repair, except for malrotation and volvulus. However, surgical management should proceed promptly [10].

On the other hand, gastrointestinal perforation in newborns exhibits a slightly higher incidence rate of approximately 0.6% in the neonatal intensive care unit [15]. However, the exact incidence rate is yet to be determined. The mortality rate remains high (30–50%), despite the development of antibiotics and surgical procedures [15, 16]. The leading cause of gastrointestinal perforation in newborns is necrotizing enterocolitis (NEC), which occurs in approximately 1–3 per 1,000 live births [12]. Other causes of perforations are sepsis,

intestinal obstruction, iatrogenic trauma, Hirschsprung's disease, and spontaneous intestinal perforations [15].

SAIM is a rare condition that mainly occurs in neonates and presents with other congenital anomalies, such as patent ductus arteriosus, ventricular septal defect, intestinal atresia, and biliary atresia [1, 2, 4]. The main manifestation of this disease is a progressively acute abdomen due to bowel obstruction or perforation. Patients are admitted to the hospital with complaints of moderate-to-severe abdominal distention, diminished bowel sounds, failure to pass meconium, and bilious vomiting [17]. The incidence of SAIM is difficult to determine due to its rarity. In the neonatal age group, the age of onset ranges from 1 to 99 days. Davis *et al.* reported five cases of SAIM, all of whom were born preterm through cesarean section, with very low-birth-weight ranging from 490g to 1166g [17]. The majority of preterm neonates with SAIM also present with respiratory distress syndrome [4]. Although typically present in neonates, studies have also reported the occurrence of SAIM in adults. There is no sex predilection of this defect in adults. The age of onset ranges from 26 to 64 years, with a higher incidence reported in the older age group [3]. Two studies reported a family history of congenital anomalies, such as congenital megacolon and osteogenesis imperfect [3, 18].

In the present case, the clinical presentation was similar to that observed in other reported cases, with regards to chief complaints, age of onset, and correlation with other congenital anomalies. The patient was admitted to the hospital primarily due to anal atresia. Abdominal distention was also reported at the time of admission. An initial diagnosis of bowel obstruction was considered due to the anal atresia. However, abdominal distention, vomiting, and the absence of stoma production persisted after colostomy. These signs and symptoms led to the diagnosis of intestinal obstruction, which was located proximally to the stoma. According to the history of pregnancy, the patient was born full term, with a birth weight within normal limits (3,000g). This may raise awareness among clinicians, as most reported neonatal cases occur in preterm, low-birth-weight infants. This case shows that full-term infants with a normal birth weight may also harbor a congenital defect.

Following gross examination, the resected SAIM showed a thin-walled bowel, with paper-like consistency [3]. Investigators have reported several cases exhibiting segments of intestine with an almost translucent color [1]. Therefore, intraoperative transillumination is recommended as part of the diagnostic process [1, 17]. In this case, intraoperative findings and gross examination of the resected small intestine showed a narrowing segment of the ileum that manifested as an intestinal obstruction. Macroscopically, the observed atrophic intestinal wall was consistent with findings reported in previous studies. Unfortunately, transillumination was not performed during surgery.

Nawar and Sawyer stated that all the cases they reviewed showed a gradual or abrupt loss of the muscularis propria of both the longitudinal and circular layers. Inflammation and mesenteric vessel thrombosis are uncommon findings. Approximately half of the cases demonstrated loss of nerve plexuses in affected segments [3, 19]. Our histopathological findings showed segmental hypoplasia to total absence of the muscularis propria, with remaining intact mucosal, submucosal, and serosal layers. There were mild inflammatory cell infiltrations within the lamina propria. However, vasculitis, thrombosis, or signs of vascular anomaly were not identified. Moreover, there was no fibrosis found in the area of the defect. Innervation was found to be normal. Submucosal and myenteric plexuses were observed in both normal and pathological segments. These findings are consistent with previous results

reported in the literature. The diagnosis of SAIM was reached solely based on pathological evaluation.

SAIM may mimic other conditions that manifest as obstruction or perforation. In the presence of obstruction, the closest differential diagnoses are Hirschsprung's disease and intestinal atresia. In the presence of perforation, SAIM may also mimic NEC and intestinal ischemia. Both Hirschsprung's disease and SAIM may cause delay in passing meconium and colonic dilatation. Hirschsprung's disease is diagnosed by the absence of ganglion cells and hypertrophied nerve fibers [12]. SAIM, on the other hand, involves the presence of ganglion cells and absence of muscularis propria. Intestinal atresia varies from a septum obstructing the bowel (i.e., membranous atresia) to a complete gap between the bowel ends with a mesenteric defect and apple-peel atresia [12,14]. However, SAIM may cause dilatation or stenosis of the bowel, while maintaining the continuity of the bowel. However, several articles reported cases of SAIM, which were found in close proximity to intestinal atresia [14, 20]. Therefore, it is possible that both entities share a similar etiology. NEC accounts for the majority of intestinal obstructions occurring in newborns. Therefore, it is the closest differential diagnosis for SAIM, which manifests as perforation. However, NEC shows signs of inflammation, bacterial overgrowth, epithelial regeneration, mucosal edema, and ischemic transmural necrosis [21]. Notably, SAIM shows limited signs of inflammation. The pathology of intestinal ischemia involves mucosal damage, neutrophil infiltration, neuronal damage, and degeneration of muscle, which includes clear cytoplasm, pyknotic nuclei, and apoptotic bodies [22]. In the present case, there was no mucosal damage or acute inflammatory cells identified. The remaining muscularis propria in the hypoplastic segment was normal.

Considering that the clinical presentation of SAIM may mimic other conditions, exploratory laparotomy is the gold standard, and the diagnosis is mainly dependent on histopathological findings. Resection of the affected intestines, ileostomy, and end-to-end anastomosis have been linked to favorable outcomes. Of note, most patients are not in good general condition at the time of diagnosis due to the presence of peritonitis. Therefore, they usually require initial enterostomy [17]. The incidence of SAIM is currently unknown; thus, determining the prognosis of this disease is challenging. Davis *et al.* did not report progression or secondary perforation in five cases of neonatal SAIM [17]. Additionally, Nawar and Sawyer did not report the recurrence of intestinal perforation in adults with SAIM [3]. However, Oyachi *et al.* reported the occurrence of multiple perforations after resection. This condition is caused by unstable mesenteric circulation, which leads to ischemic process and infarction at previously unresected SAIM lesions [5]. Considering that the diagnosis of SAIM lesions during surgery is occasionally challenging, a frozen section procedure may be a useful diagnostic modality to avoid misdiagnosis. Surgeons should ensure that the resection margins are free of lesions prior to performing an end-to-end anastomosis. Preoperative diagnosis of SAIM is not possible; therefore, it is important for surgeons to understand this condition in order to recognize the lesions during surgery and prevent secondary destruction of the muscle layer.

CONCLUSION

In cases of neonatal intestinal obstruction or perforation, the possibility of defects of intestinal musculature due to SAIM should be investigated, especially in conjunction with other congenital diseases.

CONFLICT OF INTEREST

None declared.

REFERENCES

[1] Pereira, S., Tortosa, F., Gonçalves, M. (2014). Segmental absence of intestinal musculature concerning a child with acute appendicitis. *J. Pediatr. Surg.*,3(5), 207-210.

[2] Nandedkar, S.S., Malukani, K., Patidar, E., Nayak, R. (2015). Segmental absence of intestinal musculature: A rare case report. *Int. J. Appl. Basic Med. Res.*, 5(3), 222-224.

[3] Nawar, N.A., Sawyer, P.R. (2016). Segmental absence of intestinal musculature in a 64-year-old female: Case report and literature review. *Am. J. Case Rep.*, 17, 749-54.

[4] Oretti, C., Bussani, R., Janes, A., Demarini, S. (2010). Multiple segmental absence of intestinal musculature presenting as spontaneous isolated perforation in an extremely low-birth-weight infant. *J. Pediatr. Surg.*, 45(8), E25-27.

[5] Oyachi, N., Suzuki, T., Emura, T., Obana, K., Nemoto, A., Naito, A., Oyama, T. (2017). Segmental absence of intestinal musculature with metachronous bowel perforations in an infant. *J. Pediatr. Surg. Case Rep.*, 30, 1-3.

[6] Tawfik, O., Newell, B., Lee, K.R. (1998). Segmental absence of intestinal musculature in an adult. *Dig. Dis. Sci.*, 43(2), 397-399.

[7] Ozguner, I.F., Savas, C., Ozguner, M., Candir, O. (2005). Intestinal atresia with segmental musculature and neural defect. *J. Pediatr. Surg.*, 40(8), 1232-1237.

[8] McCarthy, D., Qualman, S., Besner, G. (1994). Absent intestinal musculature: Anatomic evidence of an embryonic origin of the lesion. *J. Pediatr. Surg.*, 29(11), 1476-1478.

[9] Meldere, I., Urtans, V., Kruze, D., Petersons, A., Abola, Z. (2013). Neonatal anthropometry: Measurement of the abdominal circumference in newborns. *Acta Chir. Latviensis*, 1, 47-50.

[10] Juang, D., Snyder, C.L. (2012). Neonatal bowel obstruction. *Surg. Clin. North Am.*, 92(3), 685-711.

[11] de Silva, N.T., Young, J.A., Wales, P.W. (2006). Understanding neonatal bowel obstruction: Building knowledge to advance practice. *Neonatal Netw.*, 25(5), 303-318.

[12] de la Hunt, M.N. (2006). The acute abdomen in the newborn. *Semin. Fetal Neonat. Med.*, 11(3), 191-197.

[13] Kiho, T., L., Scheimberg, I., Phelps, S., Misra, D., Ward, H., Colmenero, I. (2011). Neonatal functional intestinal obstruction and the presence of severely immature ganglion cells on rectal biopsy: 6 year experience. *Pediatr. Surg. Int.*, 27(5), 487-490.

[14] Subbarayan, D., Singh, M., Khurana, N., Sathish, A. (2015). Histomorphological features of intestinal atresia and its clinical correlation. *J. Clin. Diagn. Res.,* 9(11), EC26-29.

[15] Sarac, M., Bakal, U., Aydin, M., Tartar, T., Orman, A., Taskin, E., Canpolat, Ş., Kazez, A. (2017). Neonatal gastrointestinal perforations: the 10-year experience of a reference hospital. *Indian J. Surg.*, 79(5), 431-436.

[16] Hakan, N., Aydin, M., Erdogan, D., Cavusoglu, Y.H., Dursun, A., Zenciroglu, A., Okumus, N., Ozguner, I.F., Karaman, A., Karaman, I. (2013). Neonatal gastrointestinal perforations: a 7-year single center experience at a tertiary neonatal intensive care unit in Turkey. *CIB. Tech. J. Surg.*, 3, 1-7.

[17] Davis, J.S., Ryan, M.L., Shields, J.M., Sola, J.E., Perez, E.A., Neville, H.L., Rodriguez, M.M. (2012). Segmental absence of intestinal musculature: an increasingly reported pathology. *J. Pediatr. Surg.,* 47(8), 1566-1571.

[18] Steiner, D.H., Maxwell, J.G., Rasmussen, B.L., Jones, R. (1969). Segmental absence of intestinal musculature. An unusual cause of intestinal obstruction in the neonate. *Am. J. Surg.,* 118(6), 964-967.

[19] Dzieniecka, M., Grzelak-Krzymianowska, A., Kulig, A.(2010). Segmental congenital defect of the intestinal musculature. *Pol. J.Pathol.*, 61(2), 94-96.

[20] Budhiraja, S., Jaiswal, T.S., Sen, R. (2004). Ileal atresia with segmental defect of intestinal musculature. *Indian J. Pediatr.*, 71(2), 177-179.

[21] Tanner, S.M., Berryhill, T.F., Ellenburg, J.L., Jilling, T., Cleveland, D.S., Lorenz, R.G., Martin, C.A. (2015). Pathogenesis of necrotizing enterocolitis: modeling the innate immune response. *Am. J. Pathol.,* 185(1), 4-16.

[22] Pontell, L., Sharma, P., Rivera, L.R., Thacker, M., Tan, Y.H., Brock, J.A., Furness, J.B. (2011). Damaging effects of ischemia/reperfusion on intestinal muscle. *Cell Tissue Res.,* 343,411-419.

In: Encyclopedia of Surgery (22 Volume Set)
Editors: Andreas Lehrer and Kristin Mueller
ISBN: 978-1-53618-329-0
© 2020 Nova Science Publishers, Inc

Chapter 353

HEMANGIOMA-LIKE VESSELS IN THE RESECTION MARGIN OF GIANT HEMANGIOMAS OF THE LIVER AS A POSSIBLE CAUSE OF RECURRENCE: A CASE SERIES AND LITERATURE REVIEW

Marini Stephanie*, Ening Krisnuhoni, Diah Rini Handjari and Nur Rahadiani
Department of Anatomical Pathology, Universitas Indonesia/
Cipto Mangunkusumo Hospital, Jakarta-Indonesia

ABSTRACT

Most liver hemangiomas are small and asymptomatic, but large, or giant, hemangiomas may be symptomatic and can occur with hemangioma-like vessels (HLVs) distant from the primary tumor. We report three cases of giant cavernous hemangioma of the liver in adults, with the hemangioma recurring in one of the three patients 8 months after surgical resection. All cases had clusters of HLVs located far from the primary tumor and in the resection margin.

Keywords: giant hemangioma, liver, recurrence, hemangioma-like vessels

INTRODUCTION

Cavernous hemangioma of the liver is the most common benign liver tumor with an estimated incidence ranging from <1% to 20%. It can occur at any age but is most frequently found in young adult women. Increased size may be related with sex hormones. Liver hemangiomas are generally solitary, with only about 10% being multiple. Cavernous hemangiomas can vary in size from a few millimeters to so large that they can replace most of

* Corresponding Author's Email: marini2sh@gmail.com.

the liver. However, the majority are <4 cm and are usually asymptomatic. Gross sections have a spongy appearance with a lot of blood. Cavernous hemangiomas rarely become malignant, and usually, surgical resection is indicated for large tumors or those that progress. Hemangiomas can have irregular margins that extend between liver cells at the edge of tumor. The presence of small clusters of hemangioma-like vessels (HLVs), located distant from the tumor mass associated with giant hemangioma may be the reason for post-resection recurrence. We report three cases of giant cavernous hemangioma of the liver in adults, one of which recurred after surgical resection [1, 2].

CASE REPORT

Case 1

A 46-year-old man came to the Cipto Mangunkusumo Hospital complaining of intermittent stomach pain for 3 weeks before admission. The patient had a 6-year history of stomach discomfort; however, he noted an enlargement of the stomach accompanied by nausea and fatigue 1 year ago. Enlargement of the abdomen without jaundice was found on physical examination. Abdominal computed tomography (CT) scan showed a hypodense 14 × 16 × 20-cm lesion involved segments V, VI, VII, and VIII, with enhancement in the arterial phase that increased in the venous and delayed phases, consistent with a hemangioma.

Gross examination following hepatectomy revealed a well-demarcated 15 × 14 × 8-cm tumor (Figure 1). The cut surface had a spongy appearance, and tissue sections contained a lot of dark blood, with some areas appearing yellow-white. Microscopic examination showed spaces and vascular channels of varying sizes that were separated by a fibrous matrix, lined by flattened endothelial cells. Organizing thrombi and wide fibrotic areas were observed. The interface between the lesion and the adjacent liver parenchyma was irregular, and many hemangioma-like vessels (HLVs) were seen in the resection margin.

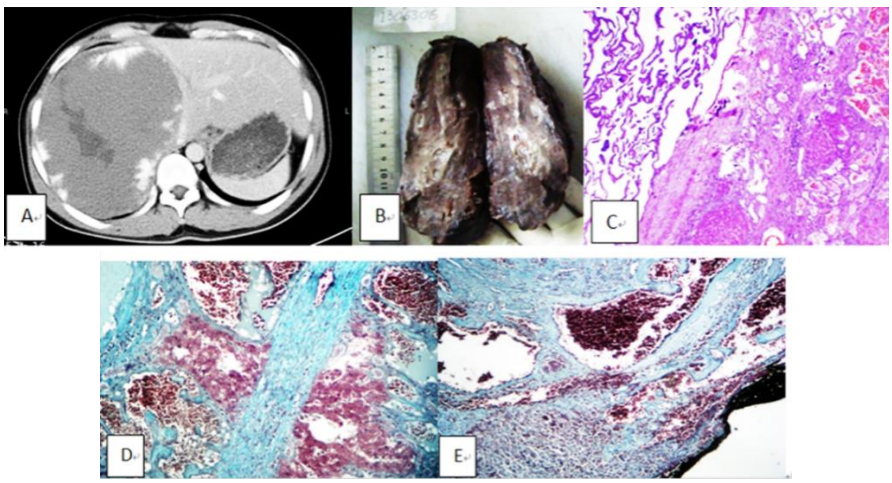

Figure 1. A. Abdominal CT scan, venous phase. B. Macroscopic appearance of the right lobe resection of case one. C. Microscopic appearance of the cavernous hemangioma of case one (HE, ×40); D. Irregular, spongy interface (Trichrome ×100); E. Resection margins with hemangioma-like vessels (HLVs) (Trichrome ×100).

A follow up abdominal CT scan performed 8 months after resection revealed a 5.4 × 5 × 5-cm nodule in the posteromedial right lobe segment VIII. Afterwards the second surgical resection was done to the patient. In intraoperation, a new growth was noted in the post-resection site, and gross examination revealed a 6 × 4 × 3-cm tumor with microscopic features similar to those of the previous tumor with hemangioma-like vessels (HLVs) in the resection margin. Trichrome staining of the interface border revealed a tumor margin with an irregular, spongy interface. Immunohistochemistry was negative for Ki-67.

Case 2

A 53-year-old woman came to the Cipto Mangunkusumo Hospital complaining of enlargement of the abdomen for 1 year before admission, accompanied by nausea, vomiting, and weight loss over the previous 6 months. Physical examination found no jaundice and a palpable mass with indistinct edges in the right hypochondria. An abdominal CT showed a 15.8 × 12.8 × 15.3-cm hypodense mass in the right lobe of the liver, segments IV, V, VII, and VIII with enhancement in the arterial, venous, and delayed phases, consistent with hemangioma. A follow-up CT scan 6 months after transarterial embolization found necrosis with no significant change in the size of the mass. Following hepatectomy, gross examination revealed a 20 × 13 × 9 cm tumor (Figure 2). The cut surface had a spongy appearance and tissue sections contained a lot of dark blood and some areas that were yellow-white in color. Microscopic examination showed spaces and vascular channels of varying sizes lined by flattened endothelial cells and separated by a fibrous network including dispersed thrombi. The interface between the lesion and adjacent live parenchyma was irregular and hemangioma-like vessels (HLVs) were seen in the resection margin. Trichrome staining of the interface border revealed a tumor margin with a predominantly irregular and spongy interface and an interdigitating pattern. Immunohistochemistry was negative for Ki 67.

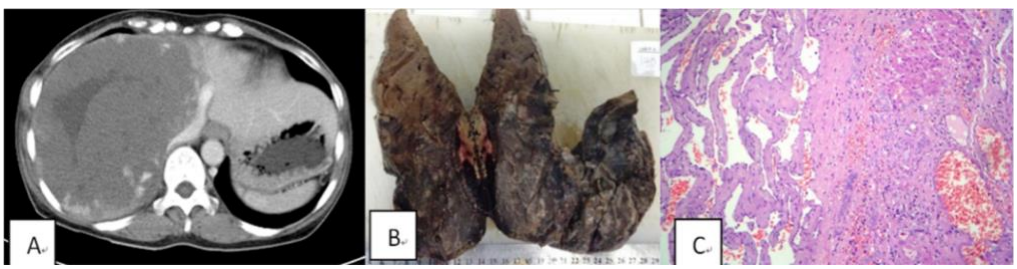

Figure 2. A. Abdominal CT scan, venous phase; B. Macroscopic appearance of right lobe resection of case two; C. Microscopic appearance of the cavernous hemangioma of case two (HE, ×100).

Case 3

A 41-year-old woman came to the Cipto Mangunkusumo Hospital complaining of stomach bloating for 2 months before admission. Physical examination found no jaundice and a solitary palpable mass with indistinct edges in the right hypochondria. An abdominal CT showed a 10.16 × 9.3 × 26.67-cm multilobulated mass with irregular edges involved liver

segments V, VI, VII, and VIII that displaced the intestine medially. There was contrast enhancement in the arterial and venous phases and patchy areas of enhancement within the mass, consistent with liver neoplasm and a differential diagnosis of hemangioma and hepatocellular carcinoma. The gross appearance of the hepatectomy specimen revealed a 22 × 16 × 9-cm tumor (Figure 3). The cut surface had a spongy appearance and tissue sections contained a lot of dark blood and some areas that were cystic or yellow-white in color. Microscopic examination showed spaces and vascular channels of varying sizes lined by flattened endothelial cells and separated by a fibrous network including dispersed thrombi. The interface between the lesion and adjacent live parenchyma was irregular and hemangioma-like vessels (HLVs) were seen in the resection margin. Trichrome staining of the interface border revealed an interdigitating pattern. Immunohistochemistry was negative for Ki 67.

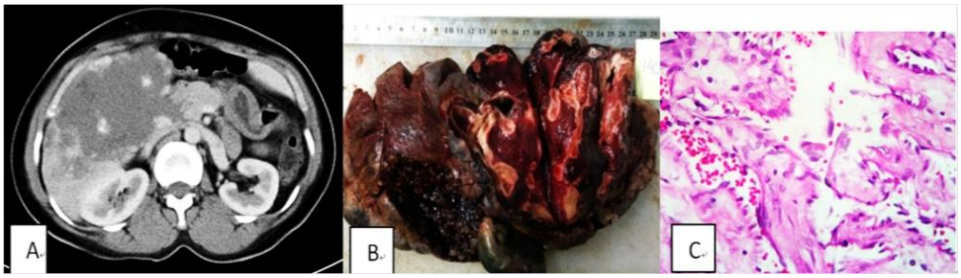

Figure 3. A. Abdominal CT scan, venous phase; B. Macroscopic appearance of right lobe resection of case three; C. Microscopic appearance of cavernous hemangioma of case three (HE, ×400).

DISCUSSION

The ages of these three patients with cavernous hemangiomas of the liver ranged from 41 to 53 yers old. Patients came in a state of advanced may have contributed to the large size of the tumors [2]. All three were found in the right lobe of the liver, and a size of more than 10 cm surpassed the 5 cm needed consideration as a giant hemangioma [1-3]. The ages of a series of 198 cases of hepatic hemangioma reported by Etemadi et al. ranged from 27–84 years. Most were located in the right lobe, and only 18,2% were from 5 to 25 cm in size. Of the 129 who could be followed-up, 7% were treated by surgical resection because of abdominal pain, large size, rupture, or bleeding [4]. The lack of response to arterial embolization in case two is consistent with a report by Koszka et al. that arterial embolization to restrict the growth of a 40 cm giant liver hemangioma was not effective and was followed by a worsening of symptoms [5].

The gross and microscopic appearance of the resected tumor was similar in all three cases and in line with a previous report of the pathological characteristics of the interface border of the tumor and liver parenchyma by Zimmermann et al. [6].

In a previous report, Zimmermann et al. have described four distinct interface patterns that were seen in cavernous liver hemangiomas [6]. Pattern A was characterized by a capsule-like fibrous lamella(fibrous interfaces). In pattern B, the peripheral component of the hemangioma interdigitated with the liver parenchyma, dilated vascular channels were associated with remnants of the portal tract, and a fibrous lamella was absent(interdigitating

interfaces). Pattern C included a compressed interface with a thin, vascular tissue layer that separated the tumor and liver parenchyma without the presence of a fibrous lamella or interdigitating vascular channels. Pattern D was a, irregular, spongy interface with a highly irregular border characterized by the presence of liver parenchyma located between dilated vascular channels. Of the 10 cases in their report, 7 showed predominantly pattern A, and with 5 of the 10 exhibiting a single pattern and the remaining 5 a mixed pattern. Only two hemangiomas had a predominant pattern D. Trichrome staining of tissue from our patients revealed that the interface border in case one and two had a predominant pattern D with a highly irregular border and lack of a clear separated of tumor and non tumor tissue. Case three had a pattern B interdigitating interface. Immunohistochemistry was done to exclude a diagnosis of low-grade angiosarcoma, with Ki67 staining of low- and high-grade angiosarcomas as controls.

Case one had the longest follow-up, with recurrence detected on CT at 8 months after hepatectomy. Previously, Conter et al. have reported four cases of recurrence of hepatic hemangiomas, with two of them recurring years after surgery in patients with histories of long-term hormonal therapy [7]. Romano et al. have described a case with three hepatic hemangioma recurrences in the years after surgery in a patient with no history of hormonal therapy [8]. The pathological evaluation of the resection margins or hemangioma-like vessels (HLVs) was not reported in either of those cases. Zhu et al. reported two cases of giant hepatic hemangiomas that recurred 4 and 5 years after resection. Both had irregular interfaces because of the presence of hemangioma-like vessels (HLVs). No hormonal therapy data were reported [9]. Etemadi et al. have reported post-surgical recurrences in three of 198 patients with hepatic hemangioma, but the time of recurrence, pathology data on the resection margin, and the presence of hemangioma-like vessels (HLVs) were not reported [4]. Our case had a short recurrence time, and the tumor, which occurred in the area of the original hepatectomy, had hemangioma-like vessels (HLVs) in the resection margin. The patient did not have a history of hormonal therapy. However, whether HLV in the resection margin or hormonal therapy contributed to the recurrence remained unclear. All three of our patients had hemangioma-like vessels (HLVs) in the margin but only one experienced a recurrence.

CONCLUSION

Three cases of giant liver hemangiomas had hemangioma-like vessels (HLVs) in the resection margin, two had highly irregular interfacesbut onlyone had a short recurrence time.. However, whether hemangioma-like vessels (HLVs) at the resection margins, an irregular interface, or hormonal therapy contribute to recurrence is not clear.

REFERENCES

[1] Goodman, ZD, Terracciano, LM, Wee A. Tumours and tumour-like lesions of the liver. In: Burt AD, Ferrel LD, Portmann BC, editors. *MacSween's pathology of the liver*. 7th ed. London: Churchill Livingstone, 2018, 835-37.

[2] Miettinen, M, Fletcher, CDM, Kindblom, LG, Zimmermann, A, Tsui, WMS. Mesenchymaltumours of the liver. In: Bosman FT, Carneiro F, Hruban RH, Theise ND, editors. *WHO classification of tumours of the digestive system*. 4th ed. Lyon: IARC, 2010, 243-4.

[3] Suriawinata, AA. Miscellaneous tumors and tumor-like lesions. In: Saxena R, editor. *Practical hepaticpathology*. 2nd ed. Philadelphia: Elsevier Saunders, 2011, 583-84.

[4] Etemadi, A, Golozar, A, Ghassabian, A, Zarei, M, Hashemi Taheri, AP, Dawsey, SM, Malekzadeh, R. Cavernous hemangioma of the liver: factors affecting disease progression in general hepatology practice. *Eur J Gastroenterol Hepatol*, 2011 23, 354-8.

[5] Koszka, AJM, Ferreira, FG, de Aquino, CG, Ribeiro, MA, Gallo, AS, Aranzana, EMC, Szutan, LA. Resection of a rapid-growing 40-cm giant liver hemangioma. *World J Hepatol*, 2010 27, 292-94.

[6] Zimmermann, A, Baer, HA. Fibrous tumor-liver interface in large hepaticneoplasms: its significance for tumor resection and enucleation. *Liver Transpl Surg*, 1996 2, 192-9.

[7] Conter, RL, Longmire, WP. Recurrent hepatichemangiomas. Possible association with estrogen therapy. *Ann Surg*, 1988 207, 115-19.

[8] Romano, F, Messinesi, G, Tana, F, Uggeri F. Recurrent giant hemangioma causing severe respiratory distress. *Dig Dis Sci*, 2007 52, 3526-9.

[9] Zhu, H, Obeidat, K, Ouyang, J, Roayaie, S, Schwartz, M, Thung, SN. Recurrent giant hemangiomas of liver: report of two rare cases with literature review. *World J Gastrointest Surg*, 2012 4, 262-66.

In: Encyclopedia of Surgery (22 Volume Set)
Editors: Andreas Lehrer and Kristin Mueller
ISBN: 978-1-53618-329-0
© 2020 Nova Science Publishers, Inc

Chapter 354

46, XX OVOTESTICULAR DISORDER OF SEX DEVELOPMENT, HISTOPATHOLOGICAL VIEW: REPORT OF A RARE CASE

Intan Nevita Oktamiya Bernanthos
and Budiana Tanurahardja*
Department of Anatomical Pathology, Faculty of Medicine,
Universtas Indonesia/Dr. Cipto Mangunkusumo Hospital, Jakarta, Indonesia

ABSTRACT

Ovotesticular disorder of sexual development (OT-DSD) is a rare congenital anomaly characterized by the simultaneous presence of ovarian tissue with mature ovarian follicles and testicular tissue with distinct seminiferous tubules in the same individual. The most common karyotype of OT-DSD is 46, XX. A 12-year-old boy was brought by his parents to our hospital because of a mass in his right groin area that had enlarged over the past 2 weeks. The patient's medical history included multiple surgeries due to hypospadias and unilateral right-side cryptorchidism. Histopathological analysis revealed the presence of ovarian tissue containing multilocular cysts and uterine tissue with an endometrium component, but no testicular component. Hormone analysis showed elevated levels of luteinizing hormone and follicle-stimulating hormone, with normal levels of testosterone and anti-Müllerian hormones. The patient was diagnosed with 46, XX OT-DSD and assigned as a male.

Keywords: ovotesticular disorder of sexual development, 46, XX DSD

* Corresponding Author's Email: budiana.t@gmail.com.

INTRODUCTION

Disorder of sex development (DSD) is a rare congenital condition associated with a disagreement between chromosomal, gonadal, and phenotypic sex [1]. Generally, DSD is divided into disorders of the sex chromosomes (such as Klinefelter and Turner syndrome), hormone synthesis or action (such as congenital adrenal hyperplasia), and gonadal development (such as XY gonadal dysgenesis, XX testicular DSD, and ovotesticular DSD (OT-DSD)) [2]. The incidence of DSD is reportedly 1:4500 in newborns with ovotesticular disorders accounting for less than 10% of cases [3]. Disorders of gonadal development with the 46 XX karyotype include testicular DSD, ovotesticular DSD, gonadal dysgenesis, and premature ovarian failure [4].

OT-DSD, formerly known as true hermaphroditism, is a rare congenital anomaly characterized by the simultaneous presence of ovarian tissue with mature ovarian follicles and testicular tissue with distinct seminiferous tubules in the same individual, which accounts for 3%-10% of all cases of DSD. The most common karyotype is 46, XX (60%), followed by chromosomal mosaicism/chimerism (33%), and the 46, XY karyotype (7%) [4-7]. OT-DSD most commonly occurs in XX and XX/XY, but rarely XY individuals, and typically presents in infancy as a range of atypical genitalia.

Generally, clinical manifestations of OT-DSD include ambiguous genitalia, isolated clitoromegaly, perineal hypospadias, and cryptorchidism. Phenotypical males complain of breast development, periodical hematuria, or cryptorchidism. Patients with the female phenotype present with menstrual disorders or clitoromegaly, and more rarely with cyclic pain emanating from a descended or undescended gonad [8].

Ovotesticular DSD is usually detected in infancy as underdeveloped genitalia. The etiology of 46, XX ovotesticular DSD is heterogeneous and may be related to mosaicism or genetic mutations. Most cases (65%) are negative for the sex determining region of the Y chromosome (SRY). XX ovotesticular DSD lies in the spectrum of testicular DSDs. Although the genetic etiology of 46, XX testicular and ovotesticular DSD may be the same, it is critical to detect the presence of ovarian tissue for optimal management [6].

Here, we report a rare case of 46, XX ovotesticular DSD with emphasis on its pathological aspects and clinical significance to increase the awareness of this entity.

CASE REPORT

In December 2016, a 12-year-old boy was brought by his parents to our hospital due to the presence of a mass in his right groin area that had enlarged over the past 2 weeks. The mass caused no pain, redness, or itching. The patient's medical history included multiple genital surgeries due to hypospadias (penoscrotal type) and unilateral cryptorchidism in his hometown and in a hospital in Malaysia, as well as repair urethroplasty due to abnormal erections and urine leakage. There was no remarkable family history or parental consanguinity. The patient was fully alert with stable vital signs. The patient's body weight was 33.5 kg, height of 140 cm, and body mass index of 17.09 kg/m^2 ($-1<z$ score<0). A physical examination showed bilateral breast enlargement. An examination of the external

genital examination revealed enlargement of the right testicle (6 ×4 cm), while the size of the left testicle was normal.

Laboratory results showed no elevation in either β-human chorionic gonadotropin or alpha-fetoprotein serum levels (0.100 IU/L and 0.8 IU/mL, respectively). A chromosomal examination using Giemsa banding showed that the karyotype of the patients was 46, XX (Figure 1). SRY gene detection was performed for this patient. Testicular ultrasound revealed multiple cystic lesions and septation of the enlarged right scrotum, but not the left (Figure 2).

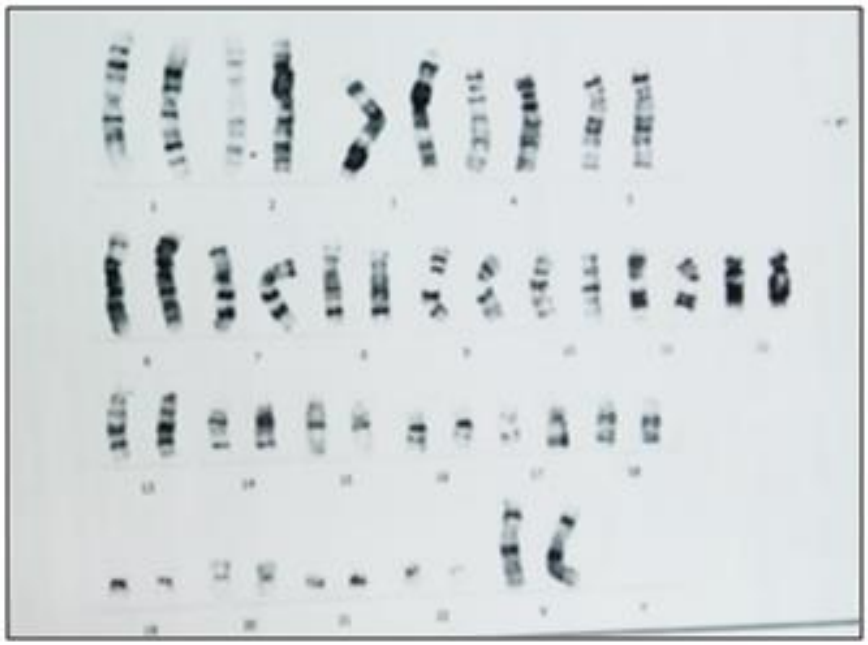

Figure 1. Chromosome analysis results. Giemsa banding of a peripheral blood sample revealed that the karyotype of the patients was 46, XX (46 chromosomes with XX sex chromosomes). There was no major structural abnormality.

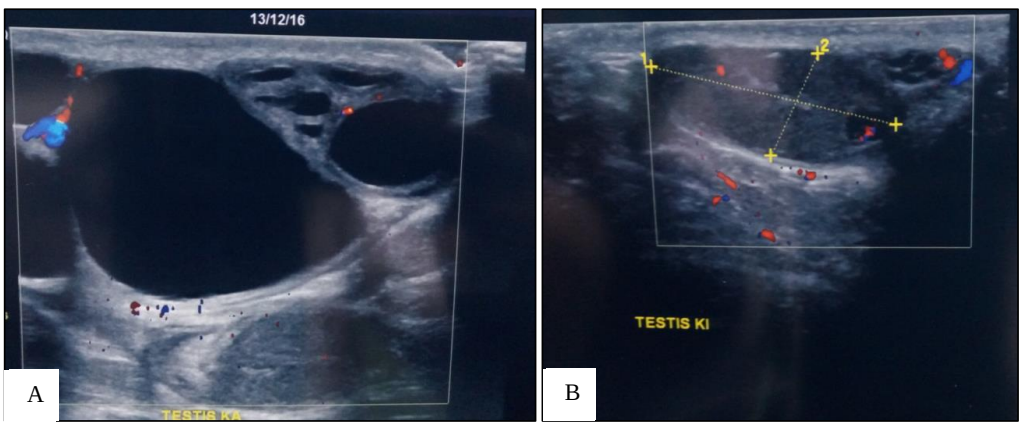

Figure 2. Testicular ultrasound. A. Multiple cystic lesions with septa of the right scrotum. B. The left testis appeared to be solid.

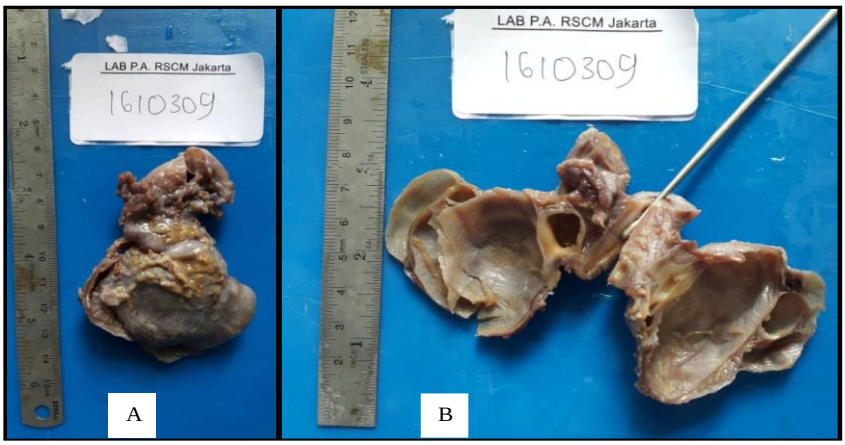

Figure 3. Gross appearance of the right testis. A. Mass with a smooth muscle surface. B. Cut section showing areas with multiple cysts.

The patient was scheduled for explorative surgery. Following identification of the right testicular mass, right orchiectomy was performed. Macroscopically, the tumor was encapsulated with a smooth external surface, measuring 8.5 ×5.0 ×3.5 cm, and gray in color. On a cut section, the tumor appeared to have multiple cysts containing serohemorrhagic fluid with diameters ranging from 0.1 to 4.5 cm. A histopathological examination revealed the presence of ovarian tissue containing multilocular cysts of various sizes, lined by granulosa cells, as well as uterine tissue with the endometrial component lined by ciliated columnar cells, accompanied by endometrial glands arranged in tubular patterns. There was no testicular component of the tissue. The histological findings were consistent with ovarian tissue with follicle cysts and uterine tissue with endometrial cells (Figure 4).

The results of a postoperative hormonal assay showed increased levels of luteinizing hormone (LH), 10,5 mIU/mL (normal 1.7-8.6 mIU/mL) and follicle-stimulating hormone (FSH), 19 mIU/mL (normal 1.5-12.4 mIU/mL), with normal levels of estradiol (5.00 pg/mL; normal range, 5-20 pg/mL), testosterone (159 ng/mL; normal range, 64.9-778 ng/mL), anti-Müllerian hormone (AMH) (26.37 ng/mL; normal range, 3.8-159.8 ng/mL), and dehydroepiandrosterone sulfate (34.7 µg/dL; normal range, 24.4-247 µg/dL). The postoperative serum levels of alpha-fetoprotein and β-human chorionic gonadotropin were within normal limits (0.8 IU/mL and 0.1 IU/L, respectively).

Follow-up visits were then scheduled. The urethrocutaneous fistula and webbed peniswere addressed by urethroplasty and penile reconstruction at 6 months after presentation. A tissue sample of the left testicle collected during surgery had a Müllerian duct remnant with extensive squamous metaplasia and ovarian tissue with primary follicles (Figure 5). A repeat urethroplasty was performed within 6 months for repair of recurrent urine leakage. After surgery, erections were normal with no more urine leakage. The patient also underwent breast reduction surgery. Histological analysis of the breast revealed that the tissue was consistent with gynecomastia (florid type) with ductal epithelial hyperplasia, tufting, micropapillary patterns, and increased periductal stromal cellularity (Figure 6).

After psychiatric consultation and evaluation, the patient and his parents decided that the patient was a boy. The patient then continued with hormonal therapy and was scheduled for a routine follow-up.

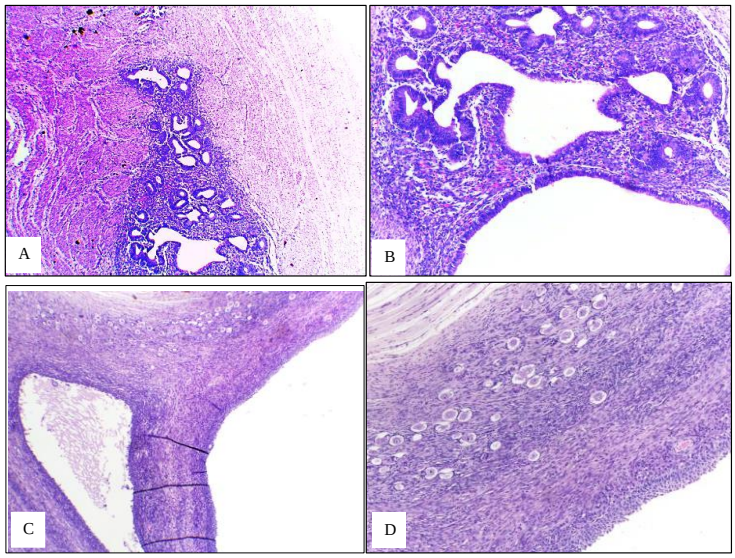

Figure 4. Histopathological examination of ovarian tissue with primary follicles and multilocular cysts, varying in size, lined by granulosa cells and uterine tissue with an endometrial component lined by ciliated columnar cells, with tubuluar ductus. No testicular tissue was observed. (A) Hematoxylin and eosin (H&E) staining, ×40. (B) H&E, ×100. (C) H&E, ×40. (D) H&E, ×100.

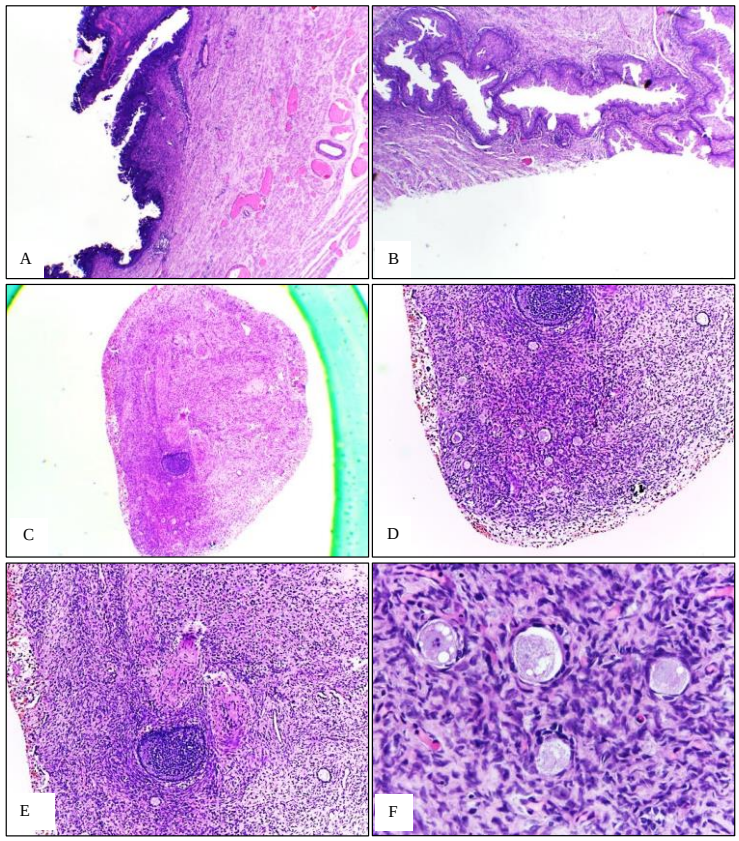

Figure 5. Histopathological features. (A and B) A remnant of a Müllerian duct with extensive squamous metaplasia (H&E, ×100). (C-F) Ovarian tissue with primary follicles (H&E, ×40, ×100, and ×400).

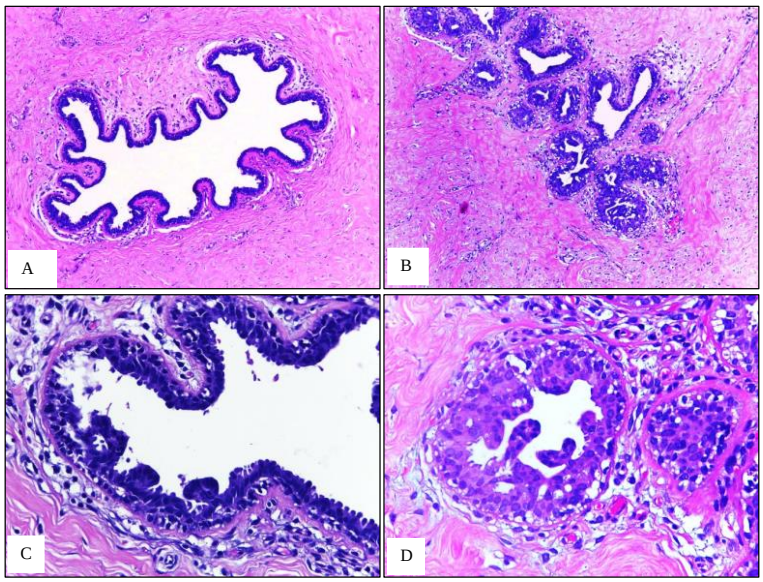

Figure 6. Gynecomastia (florid type). Ductal epithelial hyperplasia with tufting, micropapillary patterns, and increased periductal stromal cellularity (A and B) H&E, ×100. (C and D) H&E, ×400.

DISCUSSION

DSD is rare congenital condition associated with a disagreement between chromosomal, gonadal, and phenotypic sex with an incidence of 1:2000-5.500 live births due to multifactorial etiologies. The Chicago nomenclature divides the condition into six groups (Table 1). The current etiological classification of DSD according to the 2006 consensus of the Lawson Wilkins Pediatric Endocrine Society (LWPES) and the European Society for Pediatric Endocrinology (ESPE) is dependent on adrenal or gonadal involvement and karyotype analysis [1].

Table 1. DSD classification according to the 2006 LWPES/ESPE consensus

Cases	*Previous nomenclature*	*New nomenclature*
	Intersex	*DSD type*
1.	Congenital adrenal hyperplasia	46, XX DSD
Cases	*Previous nomenclature*	*New nomenclature*
	Intersex	*DSD type*
2.	Male pseudohermaphrodite	46, XY DSD
	Undervirilization of an XY male	
	Undermasculinization of an XY male	
3.	Female pseudohermaphrodite	46, XX DSD
	Overvirilization of an XX female	
	Masculinization of an XX female	
4	True hermaphrodite	Ovotesticular DSD
5.	XX male or XX sex reversal	46, XX testicular DSD
6.	XY sex reversal	46, XY, complete gonadal dysgenesis

Embryologically, the genital and urinary systems have the same origin. The development of the gonads (testes and ovaries) begins at around gestational week (GW) 4 by the formation of urogenital ridges originating from the intermediate mesoderm. From the urogenital ridge cells, two cellular masses evolve successively toward transitional embryonic kidneys (pronephros and mesonephros) and the definitive embryonic kidneys (metanephros). The mesonephros consists of the mesonephric (or Wolffian) ducts and the paramesonephrics (or Müllerian) ducts (Figure 7) [1].

Early gonadal differentiation is controlled by various genetic factors (Figure 7). At GW 7, the transcription factor SRY, mapped to Yp11.2 (with only one exon), is activated, while other genes (essentially SF-1, WT1, and CBX2) promote male gonadal development. SRY, also known as testis-determining factor, promotes the transformation of the primary sex cords to testes. Around GW 8, the male-specific hormones testosterone and AMH are produced. Testosterone secreted by Leydig cells promotes the development of the internal genital tract in the male, which consists of the epididymis, vas deferens, seminal vesicles, and ejaculatory ducts. On the other hand, AMH secreted by Sertoli cells induces regression of the paramesonephric ducts and inhibits development of the female internal genitalia [1].

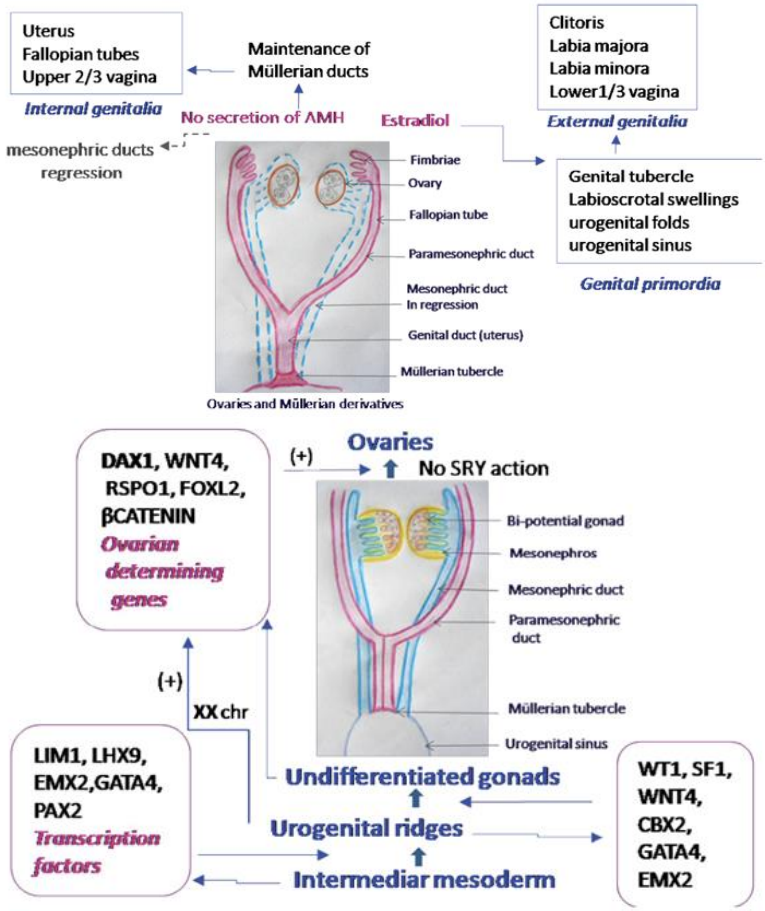

(A)

Figure 7. (Continued).

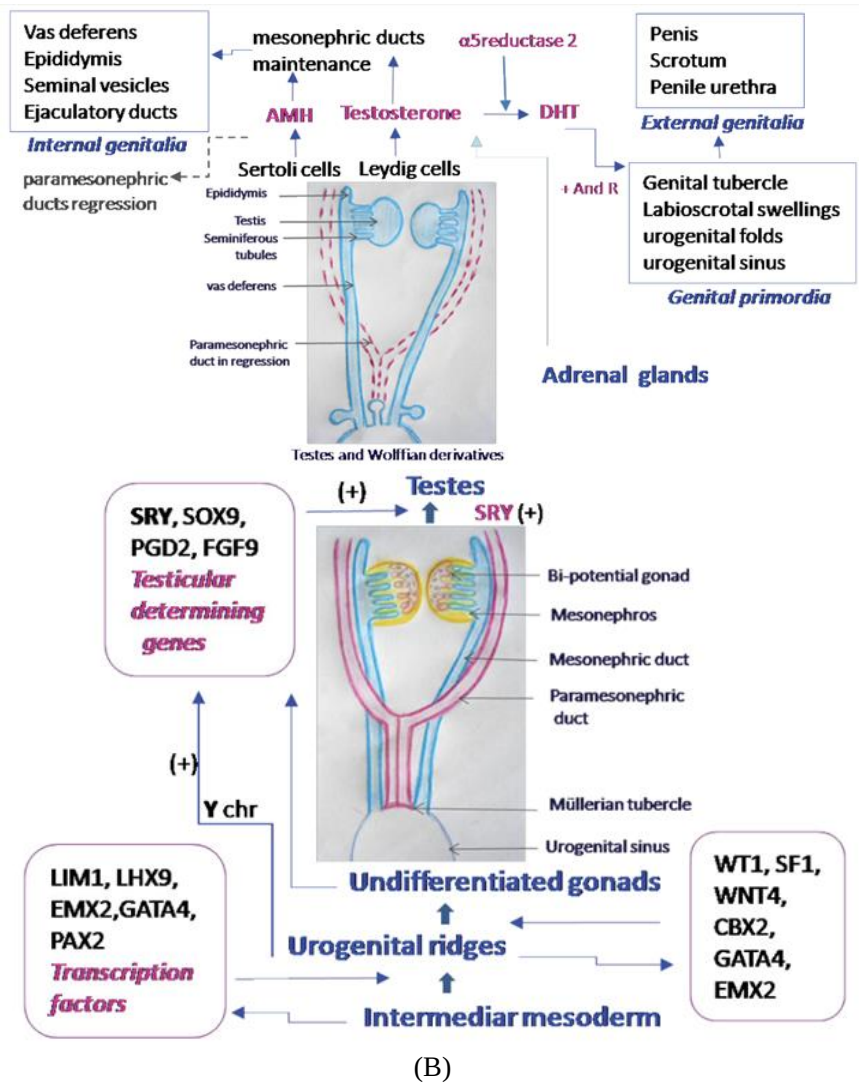

(B)

Figure 7. Genetic and hormonal factors involved in embryological genital development. (A) Male. (B) Female.

The molecular pathway of sex determination in the 46, XX individual include important genes for the initial formation of the genital ridge, such as Wilms tumor suppressor 1 (*WT1*) and steroidogenic factor 1 (*SF1*). The *WT1* gene is expressed in the urogenital ridge, mesonephros, kidney, gonads, and granulosa cells in females. Mutations to the *WT1* gene occurring in the XY genotype are associated with both gonadal dysgenesis and renal anomalies. *SF1* is also an important gene in early gonadal development. The phenotypic spectrum of genetic defects associated with the *SF1* gene is broad and dependent on the specific mutation. Such genetic defects range from complete testicular dysgenesis with maintenance of Müllerian structures to severe penoscrotal hypospadias with or without adrenal insufficiency. A heterozygous mutation to *SF1* was detected in a 46, XX prepubertal individual presenting with adrenal insufficiency, but apparently normal ovarian differentiation [2].

OT-DSD is a very rare sexual differentiation disorder in infants born with the internal reproductive organs (gonads) of both sexes and is characterized by the presence of ovarian tissue with mature ovarian follicles and testicular tissue with distinct seminiferous tubules in the same gonad (ovotestis) [5, 7, 8]. However, as time passes, the ovarian tissue usually becomes functional and the testicular tissue regresses becoming dysgenetic and showing interstitial fibrosis and lack of spermatogonia [2]. Our patient was diagnosed with suspected OT-DSD as an infant based on a gonadal biopsy that revealed the presence of ovarian tissue, but no testicular tissue. Even though there was no histopathological finding of testicular tissue, the elevated levels of testosterone and AMH supported the presence of functional testicular tissue in this patient.

The types of gonads observed in OT-DSD patients are ovotestis (44%), ovary (33%), and testis (22%). Depending on the type and laterality of the abnormal gonad, OT-DSD is classified into three types: unilateral (ovotestis on one side and a normal gonad on the other side), bilateral (both gonads are ovotestis), and lateral (one gonad is a testis and the other is an ovary) [8].In our patient, both gonads were composed of ovarian tissue.

Various types of chromosomal abnormalities have been described in OT-DSD, including 46, XX; 46, XY; 46, XX/46, XY, and 45, X/46, XY [5, 8-10].Most cases of ovotesticular DSD are sporadic [8]. Genetically, the karyotype of our patient was 46, XX and there was no remarkable family history.

Clinical features of OT-DSD include ambiguous genitalia, isolated clitoromegaly, perineal hypospadias, and cryptorchidism. Phenotypical males complain of breast development, periodical hematuria, or cryptorchidism. Patients with a female phenotype present with menstrual disorders or clitoromegaly, and more rarely with cyclic pain emanating from a descended or undescended gonad [8] (Figure 8), while hormonal levels are typically normal. Patients with OT-DSD have some degree of function and therefore normal levels of FSH, LH, estradiol, and DHT [11]. In the present case, all hormonal levels were normal. The clinical presentations of OT-DSD often go undetected until adolescence when phenotypic males are evaluated for gynecomastia or testicular cysts, which are treated surgically [13].

The diagnosis of OT-DSD is suggested by a mosaic karyotype, but is confirmed by the presence of ovarian and testicular tissue on biopsy [14]. Based on detection of the SRY gene, 46, XX DSD can be clinically classified as SRY-positive or -negative. SRY-positive individuals usually have normal male genitalia, small azoospermic testes, and hypergonadotropic hypogonadism. These characteristics have also been reported in some 46, XX males (testicular DSD). The SRY-negative group includes patients with OT-DSD, which is characterized by the presence of both testicular and ovarian tissues in the gonads of the same individual. Testicular DSD is characterized by the full development of both gonads as testis without any evidence of ovarian tissue [12]. The diagnosis of OT-DSD is based on the exclusion of other DSDs. The differential diagnosis include mixed gonadal dysgenesis, 46, XX testicular DSD, and premature ovarian failure (Table 2).

Microscopically, with OT-DSD, the ovary is usually normal (prepubertal ovary with primordial follicles and primary oocytes with a few primary or antral follicles, prepubertal testis with immature seminiferous tubules lined by immature Sertoli cells and primitive germ cells, usually without spermatogonia). Ovotestis is characterized by normal ovarian tissue with atrophic testicular tissue [15] (Figure 9).

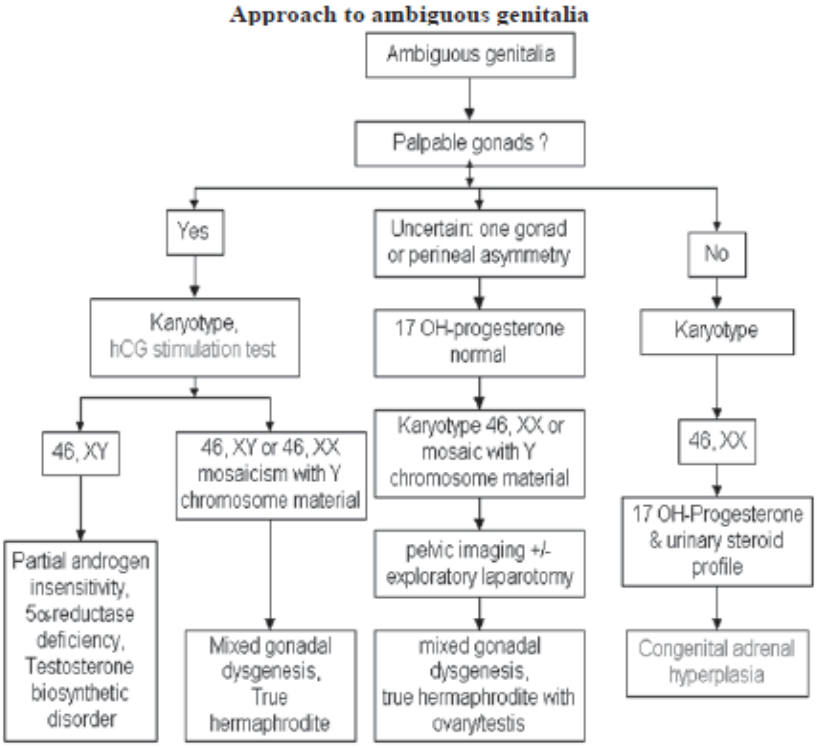

Figure 8. Approach for ambiguous genitalia.

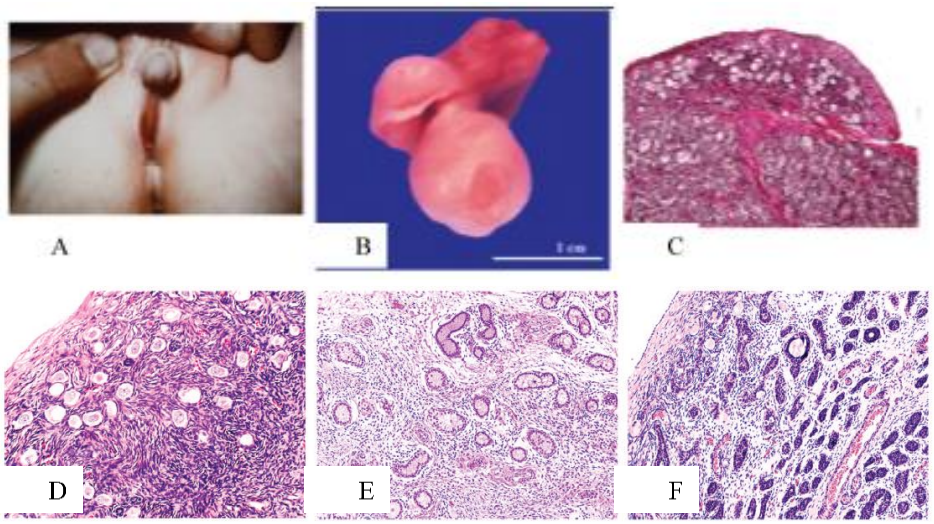

Figure 9. Clinical and pathological aspects of OT-DSD. (A) External male genitalia are hypoplastic with a penile clitoris, hypoplastic labia, and vaginal vestibule. (B) Ovotestis of a child. The ovarian parenchyma forms a cap over the testicle, which is attached by a pedicle. (C) Ovotestis of a child. A gonad with two parts separated by a connective septum. The upper zone shows the ovarian parenchyma overlying the testicular parenchyma. Among some seminiferous tubules, primordial follicles can be identified. (D) Numerous primordial follicles without maturation set in an abundance of spindle cell stroma. (E) Testicular parenchyma rich with cellular stroma similar to ovarian stroma. Some seminiferous tubules are markedly hypoplastic. (F) Epithelial cords with irregular shapes and microliths. Underneath the surface, these cords are embedded in ovarian-like stroma.

Table 2. Differential diagnosis of ovotesticular DSDs [10, 15]

No.	Diagnosis	Common features	Different features	Karyotype	Picture
1.	Mixed gonadal dysgenesis	Cryptorchidism, pubertal masculinization. Asymmetric gonadal differentiation	Ovarian tissue, if present, lacks primordial follicles; internal/external genitalia are not relevant to differentiate these two conditions. Elevated FSH	45, X/46, XY, 45, X/46, XX or 45, X/47, XXY; may also have 46, XX but missing part of one X chromosome	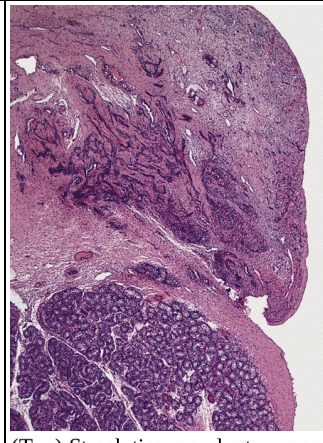 (Top) Streak tissue and rete are separated by the tunica albuginea of the testis. (Bottom) Prepubertal patients develop normal immature testis during puberty with tubules exhibiting mild hypospermatogenesis to total sclerosis. The streak gonad has ovarian stroma without primordial ovarian follicles. The streak ovary has primordial follicles and primitive sex cord-like structures with or without germ cell components within the ovarian type stroma, mimicking gonadoblastoma and tumors composed of granulosa or Sertoli cells.

Table 2. (Continued)

No.	Diagnosis	Common features	Different features	Karyotype	Picture
2.	46, XX testicular DSD	Gynecomastia, cryptorchidism, hypospadias ambiguous genitalia	No ovarian tissue	46, XX	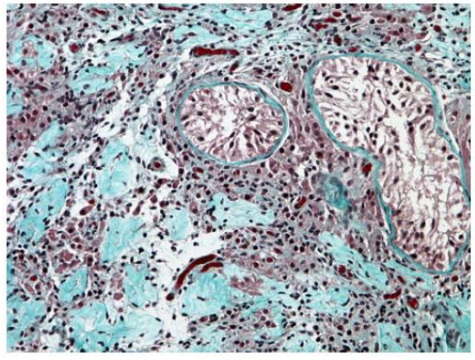 Testicular parenchyma with marked fibrosclerosis of most of the seminiferous tubules, alternating with other tubules lined only with Sertoli cells. Leydig cells are also present.
3.	Premature ovarian failure	46, XX	Sex steroid deficiency and elevated of serum gonadotropins before the age of 40 years [16]	46, XX	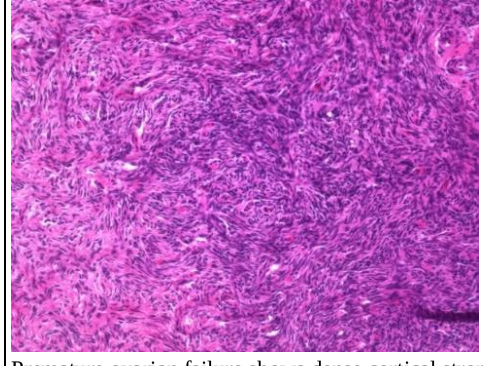 Premature ovarian failure shows dense cortical stroma lacking primordial or developing follicles. This appearance was seen throughout the ovary.

The extent of follicular maturation, the corpora lutea, and corpora albicantia varies with OT-DSD. The seminiferous tubules, which rarely contain developing sperm cells, often have Sertoli cells only with a dysgenetic appearance that frequently undergo hyalinization. Sertoli cells are positive for immunostaining of inhibin and maintain the expression of D2-40, which is indicative of immaturity. Many Sertoli cells are negative for the androgen receptor [8] (Figure 10).

Prognostic factors are important to assign gender as soon as possible (before the age of 2-4 years), since there are usually no other developmental anomalies and patients will have a better chance for normal psychological, sexual, and reproductive lives if the gonad inappropriate for gender assignment is removed. Dysplastic gonads are at risk for developing germ cell malignancy and an increased risk for gonadal malignancy if a Y chromosome is present [15].

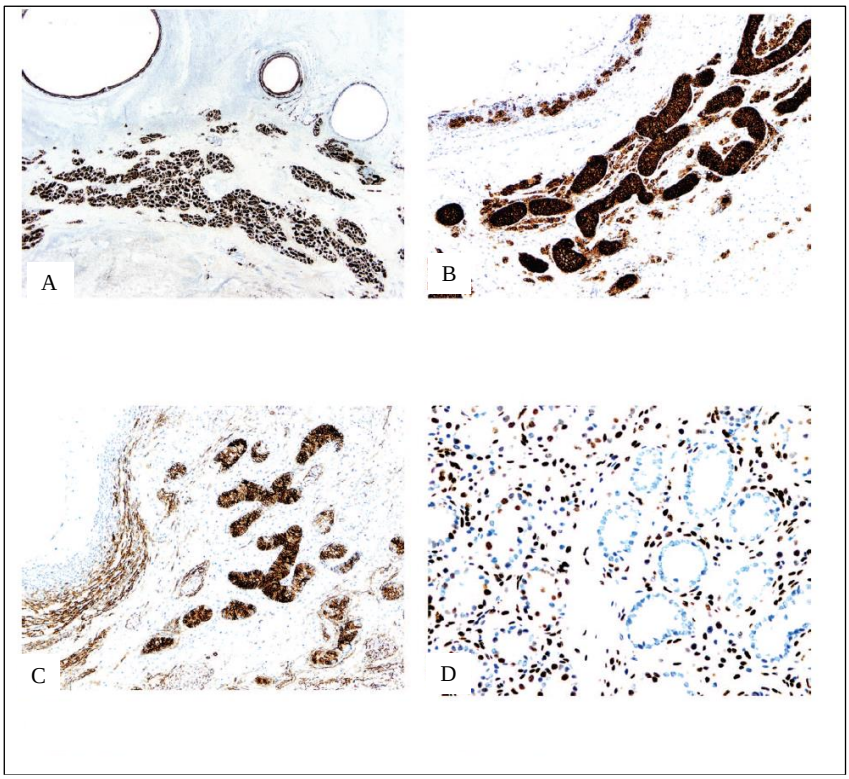

Figure 10. Immunostaining in OT-DSD. (A) Inhibin immunostaining of an ovotestis. Seminiferous tubules are highlighted by inhibin staining, which is also expressed by the immature ovarian follicles. (B) The seminiferous tubules and Leydig cells were positive for inhibin immunostaining. Seminiferous tubules are immature and malformed. (C) Immature and malformed seminiferous tubules as well as the perifollicullar stroma are positive for D240 immunostaining. (D) Androgen receptors are scarcely expressed in Sertoli cells or even absent in some seminiferous tubules, in contrast with the strong expression in peritubular and interstitial cells.

Treatment of OT-DSD is complex because it requires expertise in several subspecialized fields. Also gender assignment should be based on the functional potential of the phenotype. The discordant gonads should be removed as early as possible. In males, the testicular tissue

is preserved and orchiopexy is performed. The incidence of testicular tumors in males ranges from 1 to 10%, which are predominantly gonadoblastomas and dysgerminomas, thus long-term surveillance is needed. Hypospadia repair is also required for such males. Males also tend to require hormonal replacement therapy because of progressive testicular fibrosis [14]. The incidence of gonadal tumors is approximately 3% in 46, XY OT-DSD and rare in 46, XX OT-DSD [15].

REFERENCES

[1] Poaty, H. Ondima, I., Moyen, E., Demba Diop, J.P., Moukouma, C., & Ndiaye, R. (2017). Human genetics & embryology disorders of sex development in an infant (46, XX) - A Case Report and Review of Literature. *Hum. Gen. Embryol.*, 7, 3-7.

[2] Barseghyan, H. & Vilain, E. (2014). The genetics of ovotesticular disorders of sex development. *Genet. Steroid Disord.*, 261-263.

[3] Puji, H. T., Julia, M. & Prawirohartono, E. P. (2016). 46 XX ovotesticular disorder of sexual development with detected SRY (Sexdetermining Region Y) gene: A case report. *J. Clin. Case Rep.*, 6, 9-11.

[4] Kousta, E., Papathanasiou, A. & Skordis, N. (2010). Sex determination and disorders of sex development according to the revised nomenclature and classification in 46,XX individuals. *Hormones(Athens)*, 9, 218-231.

[5] Singh, R., Ahluwalia, C. & Mandal, A. K. (2016). Case report ovotesticular disorder of sexual development with rare karyotype. *Ann. Pathol. Lab. Med*., 3, 69-71.

[6] Vilain, E. (2011). The genetics of ovotesticular disorders of sex development. *Adv. Exp. Med. Biol.*, 707, 105-106.

[7] Scarpa, M.G. (2017). Ovotesticular differences of sex development: Surgery or not sugery? That is the question. *Front. Pediatr.*, 5, 231.

[8] Nistal, M., Paniagua, R., González-Peramato, P. & Reyes-Múgica, M. (2015). Perspectives in pediatric pathology, Chapter 7. Ovotesticular DSD (True Hermaphroditism). *Pediatr. Dev. Pathol.*,18, 345-352.

[9] Pleskacova, J., Hersmus, R., Oosterhuis, J.W., Setyawati, B.A., Faradz, S.M., Cools, M., Wolffenbuttel, K.P., Lebl, J., Drop, S.L., & Looijenga, L.H. (2010). Tumor risk in disorders of sex development. *New Concepts Hum. Disord. Sex Dev*.,5, 259-269.

[10] Nistal, M., Paniagua, R., González-Peramato, P. & Reyes-Múgica, M. (2015). Perspectives in Pediatric Pathology, Chapter 5. Gonadal Dysgenesis. *Pediatr. Dev. Pathol.*,18, 259-278.

[11] Délot, E. C. & Vilain, E. (2018). *Disorders of sex development. in Yen & Jaffe's reproductive endocrinology: physiology, pathophysiology, and clinical management (Eighth Edition)*.

[12] Alves, C., Braid, Z., Coeli, F. B. & Mello, M. P. De. (2010). 46,XX Male - Testicular disorder of sexual differentiation (DSD): hormonal, molecular and cytogenetic studies. *Arq. Bras. Endocrinol. Metabol.*, 54, 6-10.

[13] Gatti, J.M. (2014). *Ashcraft's Pediatric Surgery*: Chapter: Disorders of sexual differentiation. (6th edition, pp. 826-837). Philadelphia. Elsevier.

[14] Al-Hussain, T. *True hermaphroditism*. PathologyOutlines.com website. Available from: URL: https://www.pathologyoutlines.com/ topic/testistruehermaph.html.

[15] Ebrahimi, M. & Akbari Asbagh, F. (2011). Pathogenesis and causes of premature ovarian failure: an update. *Int. J. Fertil. Steril.*, 5, 54-65.

In: Encyclopedia of Surgery (22 Volume Set)
Editors: Andreas Lehrer and Kristin Mueller
ISBN: 978-1-53618-329-0
© 2020 Nova Science Publishers, Inc.

Chapter 355

A 56-YEAR-OLD WOMAN WITH AN ELEVATED PARATHORMONE LEVEL AFTER THE SURGERY FOR SECONDARY HYPERPARATHYROIDISM

Caglar Keskin and Mustafa Şahin
Ankara University School of Medicine, Ankara, Turkey

A 56-year-old women presented with generalized bone pain and itching. In laboratory test parathyroid hormone levels was found to be 1470 pg/ml. In the patient's past medical history she had been undergoing *hemodialysis since* 2000 for chronic kidney disease secondary to pyelonephritis. In 2006, she admitted to our hospital with multinodular goiter and high parathyroid hormone level (PTH: 1088 pg/ml) and then she had bilateral subtotal thyroidectomy for nodular goiter and parathyroidectomy. She has no history of neck irradiation. Pathological examination was consistent with 16 mm oncocytic variant papillary thyroid cancer and right parathyroid nodular hyperplasia. There was not thyroid capsular invasion. After the surgery radioiodine theraphy had not been given because of re-surgery plan. Serum thyroglobulin and antithyroglobulin antibody measurement was found 1.78 ng/ml and 1274 IU/ml respectively. Throid function tests were within the normal range and the patient was not using levothyroxine. During the follow-up parathyroid hormone levels has been remained high and calcium level was normal. In 2009 hypoechoic lesion with 05x06 mm diameter was seen in right thyroid bed in thyroid sonography. In the same ultrasonographic examination did not revealed parathyroid adenoma and parathyroid scintigraphy also revealed no pathological findings. At that time in laboratory tests, PTH, calcium and phosphate level was found 1440 pg/ml, 8.6 mg/dl and 6.4 mg/dl respectively. In 2011 the patient was treated with cinacalcet but after the three months treatment was discontinued because of continued epistaxis. Coagulation analyses were within normal ranges. Previously renal hemorrhage has been reported due to cinacalcet [1].

End stage renal disease (ESRD) patients with secondary hyperparathyroidism (HPT) are at greater risk of thyroid cancer [2]. It is not clear if thyroid cancer in these patients is more aggressive. Specific immunological functional defects may be responsible in part. In addition to relation between primary hyperparathyroidism and thyroid cancer. Secondary hyperparathyroidism may also be related to thyroid cancer.

DEXA scan results was consistent with osteoporosis (femur neck T-score:-4.8, lumbar spine total T-score:-3.7)

Recommended target values for serum PTH (150–300 pg/ml) in secondary hyperparathyroidism [3]. Parathyroidectomy is not required for patients with a mild form of secondary hyperparathyroidism. Parathyroidectomy is generally required for severe secondary hyperparathyroidism which are not controlled by medical therapy. Especially young patients with precisely localized lesion in sonography evaluation [4, 5, 6].

There is no consensus or guideline on the treatment and the radioactive iodine dosages that should be administered in end stage renal disease patients. Empirically 40-50 % of routine doses would be enough in such patients. It is better to perform dialysis sessions immediately before and at 48 hours after ^{131}I administration [7]. Also there is no specific recommendation for TSH suppression in these patients.

REFERENCES

[1] Wada K, Wada Y, Iino Y. Two cases of acute renal hemorrhage undergoing maintenance hemodialysis after concurrent administration of cinacalcet. *Clin. Exp. Nephrol*. 2011 Oct;15(5): 783-7.

[2] Lin SY[1], Lin WM[2], Lin CL[3], Yang TY[4], Sung FC[3], Wang YH[5], Kao CH[6].The relationship between secondary hyperparathyroidism and thyroid cancer in end stage renal disease: a population based cohort study. *Eur. J. Intern. Med.* 2014 Mar;25(3): 276-80.

[3] National Kidney Foundation (2003) K/DOQI clinical practice guidelines: bone metabolism and disease in chronic kidney disease. *Am. J. Kidney* 42: S1–S201.

[4] Messa P[1], Regalia A, Alfieri CM, Cresseri D, Forzenigo L, Gandolfo MT, Rastaldi MP. Current indications to parathyroidectomy in CKD patients before and after renal transplantation. *J. Nephrol.* 2013 Nov-Dec;26(6): 1025-32.

[5] Dewberry LK[1], Weber C, Sharma J. Near total parathyroidectomy is effective therapy for tertiary hyperparathyroidism. *Am. Surg.* 2014 Jul;80(7): 646-51.

[6] Blomme RA[1], Blomme AM, Rinkes IH, Meerwaldt R, van der Wal MB, Valk GD, Vriens MR. Surgical strategy in patients with secondary and tertiary hyperparathyroidism. A bi-institutional series. *Acta Chir. Belg.* 2010 Jan-Feb;110(1): 35-9.

[7] Alevizaki C, Molfetas M, Samartzis A, Vlassopoulou B, Vassilopoulos C, Rondogianni P, Kottou S, Hadjiconstantinou V, Alevizaki M. Iodine 131 treatment for differentiated thyroid carcinoma in patients with end stage renal failure: dosimetric, radiation safety, and practical considerations. *Hormones* (Athens). 2006 Oct-Dec;5(4): 276-87.

In: Encyclopedia of Surgery (22 Volume Set)
Editors: Andreas Lehrer and Kristin Mueller
ISBN: 978-1-53618-329-0
© 2020 Nova Science Publishers, Inc.

Chapter 356

EPILEPSY SURGERY AND TECHNICAL ASPECTS OF INVASIVE MONITORING

Jorge A. González-Martínez, MD, PhD
Epilepsy Center, Neuroscience Institute, Cleveland Clinic

KEY POINTS

- To discuss the clinical indications for invasive monitoring for medically intractable epilepsy.
- To understand the advantages and disadvantages of the subdural method
- To understand the advantages and disadvantages of the SEEG method
- To discuss specific indications for different methods of invasive monitoring

INTRODUCTION

Epilepsy surgery aims for the complete resection (or disconnection) of the cortical and subcortical brain areas responsible for the generation and primary organization of the epileptic clinical activities (epileptogenic zone). The epileptogenic zones (EZ) may eventually overlap with functional (eloquent) cortex, which must be preserved in most of the patients. In order to define the anatomical location of the EZ and its proximity with possible cortical and subcortical eloquent areas, an array of non-invasive tools are available: analysis of seizure semiology, video-scalp electroencephalographic recordings (ictal and interictal recordings), neuropsychological testing, magnetoencephalography (MEG) and MRI) [4, 22, 28]. In addition Neuroimaging techniques may provide functional (ictal single-photon-emission computed tomography [SPECT] and fMRI) as well as metabolic information (magnetic resonance spectroscopy [MRS] and positron emission tomography [PET]). These methods are usually complementary and will define hypothetical cortical zones of interest as the symptomatogenic, irritative, ictal and functional deficit zones, in addition to the EZ. When the non-invasive data is insufficient to precisely define the location of the hypothetical EZ,

when there is the suspicious for early involvement of eloquent cortical and subcortical areas or when there is the possibility for multi-focal seizures, invasive monitoring may be indicated [1, 16, 17, 38].

This chapter discusses the technical aspects, clinical indications and the role of invasive monitoring in medically refractory focal epilepsy, focusing on subdural electrodes and stereoelectroencephalopgraphy-(SEEG).

LOCALIZING THE EPILEPTOGENIC ZONE

In most cases of focal medically intractable epilepsy, data generated from non-invasive EEG recordings and other electrophysiologic/neuroimaging techniques are sufficient to approximate the location of the epileptogenic zone [9, 28, 32, 37]. Prolonged video-scalp EEG monitoring, in conjunction with analysis of clinical semiology, remains the gold standard for diagnosis and localization of epileptogenic zone [22]. This non-invasive sampling technique gives an excellent overview of the location and extent of the epileptogenic areas but quite often only approximates the boundaries of both the irritative and epileptogenic zones. Scalp EEG detects only epileptiform activity that results from EEG synchronization of large areas of cortex, estimated in some studies to be between 6 and 8 cm^2, and recordings are disturbed by the smearing effect of bone and other high-resistance structures (e.g., meninges and scalp) between the cortical generators and the recording electrodes [12, 22]. Magneto-encephalography (MEG) may overcome some of these problems, with better identification of the epileptic activity localized in a tangential orientation (as the interhemispheric fissure, opercular areas, etc.) but still providing limited information regarding the interictal epileptic activity [19]. In specific pathological groups as malformation of cortical development (MCD), between 85% and 100% of patients with MCD exhibit epileptiform discharges on interictal scalp EEG recordings ranging from lobar to lateralized, non-localizing to diffuse (including generalized spike-wave patterns in some cases of subependymal heterotopia [23, 29, 30]. The spatial distribution of interictal spikes is usually more extensive than the structural abnormality as assessed by intraoperative inspection or MRI visual analysis [20, 23]. For these reasons, when subtle forms of cortical dysplasia are suspected as the pathological subtract of medically intractable epilepsy, mainly in patients with extra-temporal epilepsy and non-lesional imaging, extra-operative monitoring is indicated [1, 13, 14, 24].

LOCALIZATION OF THE FUNCTIONAL/ELOQUENT ZONE

Localization of functional areas in the brain, and the anatomical boundaries of these areas with the EZ is an essential part in the process of developing an adequate and individualized surgical strategy [5, 22, 37]. In malformations of cortical development (MCD), because most the pathological subtract are often localized in the frontal lobe (therefore in potentially eloquent cortex), an understanding of the functional status of the involved region(s) and its anatomical and pathological correlations are essential [18, 21, 37]. Some focal MCD lesions characterized by significant FLAIR signal increase on MRI and located in anatomically

functional areas (e.g., primary motor, Broca area) are not functional on direct electrical stimulation, and the same lesions showed no evidence of intrinsic epileptogenicity as assessed through mapping of the ictal onset zones [36]. On the other hand, MCD lesions with mild or no FLAIR signal increase were functional and at times epileptogenic. These results agree with previous observations that eloquent function persisted in MCD devoid of balloon cells [24, 41]. Similar EcoG patterns were reported in patients with low-grade glial tumors (e.g., dysembryoplastic neuroepithelial tumor and ganglioglioma), whereas dysplastic and epileptic cortical areas were found immediately surrounding these lesions [6]. Functional cortex may therefore be displaced within the same hemisphere and have direct implications on the options for epilepsy surgery. Therefore, the precise anatomical location of eloquent cortex located in the vicinity or within the limits of the hypothetical EZ is essential information that will guide the surgeon in performing a safe and efficient surgical strategy, which has, as ultimate goal, a sustained seizure control status with no neurological deficits. Among the several invasive methods used for the diagnosis and treatment of medically intractable epilepsy, the subdural method likely provides the more precise and detailed functional mapping data from the superficial cortical areas.

THE SUBDURAL METHOD

Chronic intracranial recordings were initially reported in 1939 when Penfield and colleagues used epidural single contact electrodes in a patient with an old left temporal-parietal fracture and whose pneumoencephalography disclosed diffuse cerebral atrophy [2]. Subsequently, the use of subdural grid arrays became more popular after multiple publications during the 1980s demonstrated their safety and efficacy [11, 22, 40]. Before that time most invasive techniques involved epidural electrodes or intraoperative recordings.

Indications, Advantages and Disadvantages of Subdurals

The most common indications for intracranial electrodes include lateralization or localization of epilepsy and localization of functional/eloquent cortical information. In the first case, preoperative non-invasive studies and semiology often suggest focal epilepsy but scalp electroencephalography is unable to adequately localize or lateralize the epileptogenic zone. Subdural grids have particular advantages: they can be in place long enough to record both spontaneous seizures and interictal activity during various stages of arousal, and they have superb applicability for mapping of cerebral function extra-operatively. These characteristics allow tailored cortical resections around areas of higher function while minimizing the risk of permanent neurological deterioration. *Extra-operative mapping with the subdural method (which here includes subdural grids and strips) has the main advantage of allowing an optimal coverage of the subdural space adjacent cortex with adequate and continuous superficial functional mapping capabilities* [17, 24, 25, 26]. Intra-operative electrocorticography, as compared with chronically implanted subdural grids, is a limited option because it only provides information restricted to interictal activity. When used in patients under general anesthesia, it is believed that anesthetic agents may influence EEG

activity by altering the thresholds of after discharges and motor responses creating a misleading electroencephalographic picture [1]. Additionally, intraoperative functional mapping often requires a cooperative patient that can tolerate being awake during surgery under local anesthesia. This is particularly difficult in the pediatric population.

Subdural grids has many disadvantages, including surgical risks, financial costs, and limitations in the ability to access deep cortical regions. Because foreign bodies are inserted into the cranial vault, the risks of the procedure include wound infection, flap osteomyelitis, acute meningitis, cerebral edema, and hemorrhage [21, 27, 33]. Concerns about increased intracranial pressure may reduce the maximal number of electrodes that can be inserted and therefore produce incomplete epileptic mapping from large cortical areas. Other limitations may include the anatomic location of the proposed area of sampling (e.g., mesial orbitofrontal, anterior cingulate gyrus) and "re-do" surgeries with cortical adhesions. Other limitations of subdural grid implantation are the number of available channels for recording with the EEG system in the hospital. Some systems can handle only 64 channels unlike other systems, which can record up to 200 channels thus allowing the implantation of more electrodes over wider cortical areas. Despite this, only limited coverage of cortical regions can be sampled and preoperative surgical planning is necessary to maximize the chances of covering the ictal onset zone with the electrodes. *One of the main disadvantages of the subdural methodology is the incapacity of exploring deep cortical areas*, as the depths of sulci, opercular, interhemispheric, mesial temporal structures and insula [35]. Depth electrodes implanted using a non or semi-stereotactic technique can partially compensate these deficiencies [7].

Subdural Implantation Technique

Subdural electrodes (stainless steel or magnetic resonance–compatible platinum) electrodes, embedded in strips or sheets of polyurethane or other synthetic material, are implanted over the suspected epileptogenic or functional dysplastic regions. Variability in shape and size of the electrodes permits tailoring their use to the specific clinical situation. Custom designed arrays of subdural electrodes have been configured for placement in specific anatomical locations. For example, to record from interhemispheric brain regions, rows of electrodes arranged in curvilinear fashion were designed to follow the curvature of the corpus callosum. Subdural grids are inserted through either open craniotomy incisions or burrholes and registered stereotactically for extraoperative mapping. The cortical covering may extend beyond the visualized cortical area, as grids may be slid over the edges of the craniotomy to cover adjacent areas for better EcoG or functional sampling. Besides the EcoG recordings and direct electrical stimulation studies, grids can be used to record somatosensory evoked potentials after stimulation of the trigeminal (lip) or median nerves for central sulcus localization.

All patients that are offered subdural grid electrode implantation for monitoring have previously undergone the standard pre-operative evaluation. Decision for invasive monitoring is made during a multidisciplinary meeting, including neurologists, neurosurgeons, neuroradiologists and neurophycologists. Areas of coverage are determine based on pre-operative non-invasive studies including scalp EEG, ictal SPECT, PET, MEG, and at times, sphenoidal electrodes. Incision and craniotomy should allow for placement of electrodes in

addition to the anticipated area of resection. Positioning of the patient should allow for stereotactic guidance in the event that depth electrodes are to be placed during the same operation. As part of our surgical protocol, peri-operatively antibiotics, dexamethasone, and mannitol (0.25 g/kg) are given. The incision should be large enough to allow for a sizable craniotomy. Usually a T-shaped or large question mark incision is used. If basal temporal coverage is needed, the incision should extend down to the zygoma. Orbitofrontal coverage can be easily achieve as long as the incision allows for visualizing the key hole and turning a flap just above this level. Inter-hemispheric coverage necessitates an incision to midline. In order to facilitate placement of electrodes, the basal and mesial surfaces should be carefully inspected for cortical draining veins that will impede placement of electrodes. Using bayoneted forceps, and under a constant stream of irrigation, the grid electrodes can be slid into place. Any resistance likely indicates impedence from a draining vein and the trajectory of the grid should be adjusted.

Prior to covering lateral cortex, the depth electrodes are inserted using stereotactic guidance. The entry point should be in the middle of a gyrus, avoiding sulci, with a trajectory that is as perpendicular to the cortical surface as possible. The parenchyma serves to anchor the electrode in place. Using the wand to find the trajectory from the entry point, the pial surface is incised and the electrode inserted. Once the depth electrodes are in place, the grids for lateral coverage can be inserted. Again using bayoneted forceps, the larger grid electrodes are laid over the cortical surface, tucking the edges under the borders of the dural flap. Once in place, each electrode wire is secured to the nearest dural edge with a stitch. The remaining closure is performed using standard neurosurgical technique (Figure 1).

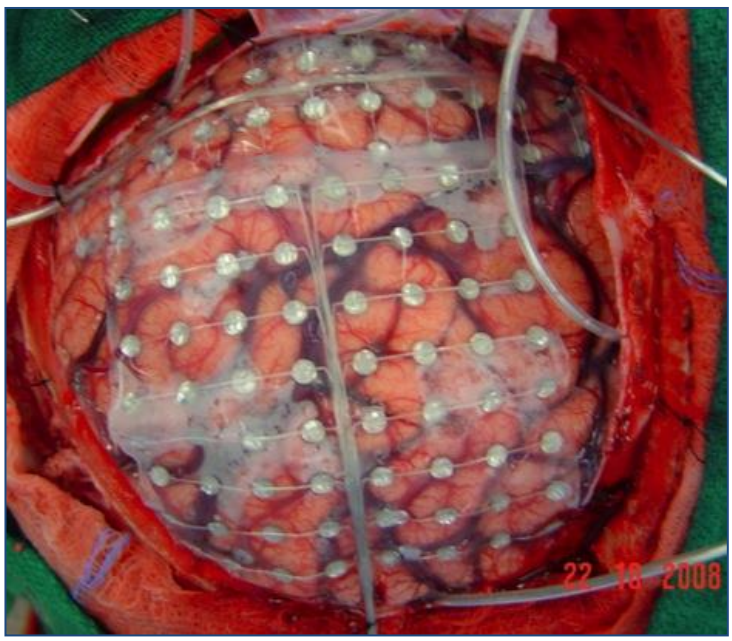

Figure 1. Intra-operative aspect of subdural grid implantation in patient with extra-temporal epilepsy and non-lesional MRI. The picture shows a large right side temporal-parietal occipital craniotomy with placement of large 8X8 subdural grid at the dorsal-lateral convexity of the posterior quadrant region and multiple strips in the subtemporal, frontal and mesial occipital areas. Depth electrodes were implanted in the temporal and frontal lobes.

The Stereo-Electroencephalography (SEEG) Method

The SEEG method was developed and popularized in France by Jean Tailarach and Jean Bancaud during the 50's and has been mostly used in France and Italy, as the method of choice for invasive mapping in refractory focal epilepsy [5, 10, 29]. The principle of SEEG is based on anatomo-electro-clinical correlations, which takes as the main principle, the 3-dimensional spatial-temporal organization of the epileptic discharge within the brain in correlation with seizure semiology. The implantation strategy is individualized, with electrode placement based on a pre-implantation hypothesis that takes into consideration the primary organization of the epileptiform activity and the hypothetical epileptic network involved in the propagation of seizures. For these reasons, the pre-implantation hypothesis has a paramount importance in the strategic placement of the electrodes. If the pre-implantation hypothesis is incorrect, the placement of the depth electrodes will be inadequate and the interpretation of the SEEG recordings misleading. According to several European and recent North-American reports, *SEEG methodology enables precise recordings from deep cortical and subcortical structures, multiple non-contiguous lobes, as well as bilateral explorations while avoiding the need for large craniotomies* [3, 9, 14, 35].

The SEEG technique was originally described as a multi-phase and complex method, using the Talairach stereotactic frame and the double grid system in association with teleangiography [34, 37]. Despite its long reported successful record, with almost 60 years of clinical use, the technical complexity regarding the placement of SEEG depth electrodes may have contributed to the limited widespread application of the technique in centers outside Europe. Taking advantage of new radiological and computational innovations, commonly available in many surgical centers, more modern and less cumbersome methods of stereotactic implantation of depth electrodes can be applied in routine basis.

Indications, Advantages and Disadvantages of SEEG

In addition to the general indications for invasive monitoring, specific indications can be considered to choose SEEG in detriment to other methods of invasive monitoring. These criteria included:

1. The possibility of a deep-seated or difficult to cover location of the EZ in areas such as the mesial structures of the temporal lobe, opercular areas, cingulate gyrus, interhemispheric regions, posterior orbito-frontal areas, insula and depths of sulci.
2. A failure of a previous subdural invasive study to clearly outline the exact location of the seizure onset zone.
3. The need for extensive bi-hemispheric explorations.
4. Presurgical evaluation suggestive of a functional network involvement (e.g. limbic system) in the setting of normal MRI.

In these scenarios, the SEEG methodology may be considered as a more efficient and safer option. As mentioned above, the SEEG methodology has the advantages of allowing extensive and precise deep brain recordings and stimulations with minimal associated morbidity. In re-operations, mainly in patients who underwent a previous subdural evaluation,

possibilities are that the majority of these patients failed epilepsy surgery because of difficulties in accurately localizing the EZ. These patients pose a significant dilemma for further management, having relatively few options available. Further open subdural grid evaluations may carry the risks associated with encountering scar formations, and still having limitations related to deep cortical structure recordings. A subsequent evaluation using the SEEG method may overcome these limitations, offering an additional opportunity for seizure localization and sustained seizure freedom [35]. *The main disadvantage of the SEEG method is the more restricted capability for performing functional mapping*. Due to limited number of contacts located in the superficial cortex, a contiguous mapping of eloquent brain areas cannot be obtained as in the subdural method mapping. In order to overcome this relative disadvantage, the functional mapping information extracted from the SEEG method is frequently complemented with other methods of mapping, as DTI images or awake craniotomies [14].

Technique of SEEG Implantation

The development of an SEEG implantation plan requires the clear formulation of a specific anatomo-electro-functional hypothesis to be tested. This hypothesis is typically generated during the patient management conference and is based on the results of the various non-invasive evaluation tests. In this decision-making process, the respective significance of pre-surgical evaluation testing may vary greatly, depending on each patient. After an anatomical and functional localizing hypothesis is formulated, a tailored implantation strategy is planned, with the goal of confirming or rejecting the pre-implantation hypothesis. In this phase, the exploration is focused to sample the anatomic lesion (if present), the more likely structure(s) of ictal onset and the possible pathway(s) of propagation of the seizures (functional networks). The desired targets are reached using commercially available depth electrodes in various lengths and number of contacts, depending on the specific brain region to be explored. The electrodes are implanted using conventional stereotactic technique through 2.5 mm diameter drill holes. Depth electrodes are inserted using orthogonal or oblique orientation, allowing intracranial recording from lateral, intermediate or deep cortical and subcortical structures in a three-dimensional arrangement, thus accounting for the dynamic, multidirectional spatiotemporal organization of the epileptic pathways.

As part of our routine practice, the patient are admitted to the hospital the day of surgery. The day before surgery, a stereo contrasted volumetric T1 sequence MRI is performed. Images are then transferred to our stereotactic neuronavigation software (iPlan Cranial 2.6, Brainlab AG, Feldkirchen, Germany) where trajectories are calculated the following day. The day of surgery, while the patient is under general anesthesia, the Leksell stereotactic frame (Elekta, Stockholm, Sweden) is applied using standard technique. Once the patient is attached to the operating table with the frame, a stereo dyna CT is performed. The pre-operative MR images and the stereo dyna CT are then digitally processed using a dedicated fusion software (syngo XWP, Siemens Healthcare, Forchheim, Germany). These fused images are used during the implantation procedure to confirm the accuracy of the final position of each electrode and to insure the absence of vascular structures along the electrode pathway, which weren't previously noted with the contrasted MRI. Following the planning phase using the stereotactic software, trajectories' coordinates are recorded and transmitted to the operating

room. Trajectories are in general planned in orthogonal orientation in relation to the skull's sagittal plane in order to facilitate implantation and later on interpretation of the electrode positions. Using the Leksell stereotactic system, coordinates for each trajectory are then adjusted in the stereotactic frame and a fluoroscopic image, in lateral view, is performed in each new position. If the specific trajectory is aligned correctly, the implantation is then continued, with skull perforation, dura opening, placement of the guiding bolt (AdTech, Racine, WI, USA; Integra, Plainsboro, NJ, USA) and final insertion of the electrode under fluoroscopic guidance. The electrode insertion progress is observed under live fluoroscopic control in a frontal view to confirm the straight trajectory of each electrode. For additional guidance a coronal MRI slice corresponding to the level of each electrode implantation is overlaid to the fluoroscopic image.

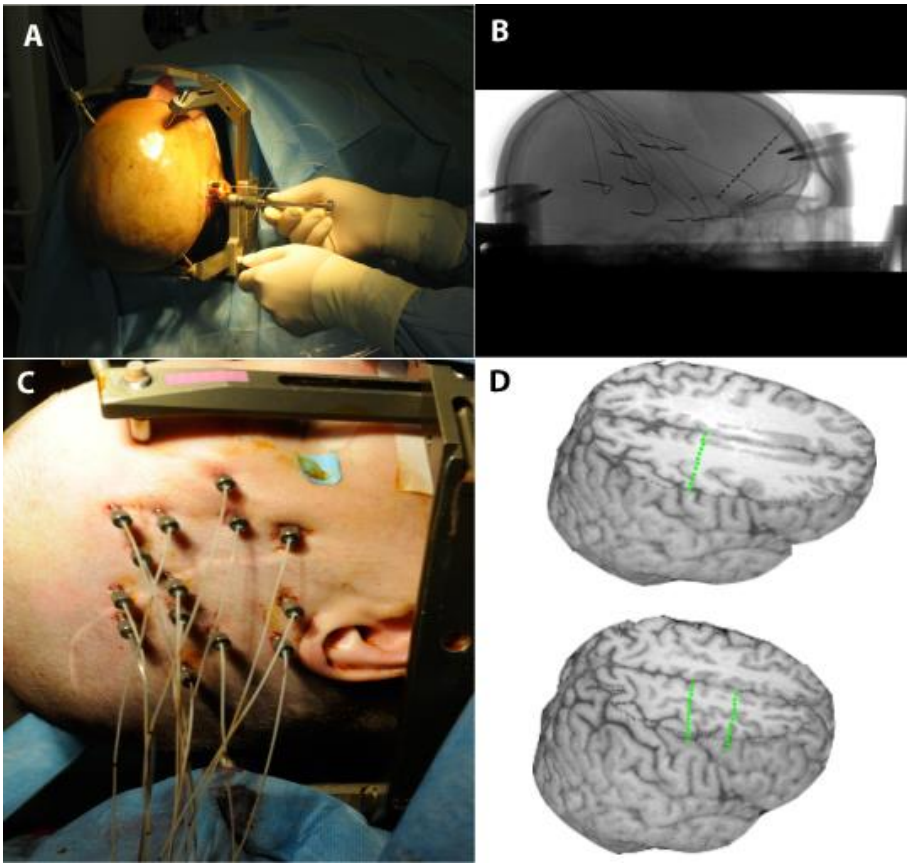

Figure 2. SEEG methodology. Picture showing the SEEG implantation technique with the stereotactic placement of depth electrodes (A); post-operative X-ray with electrodes placed in orthogonal and oblique fashion in the right temporal, parietal and insula regions (B); Final aspect of right side SEEG implantation (C); Post operative imaging processing with three dimensional representation of the brain anatomy and the implanted SEEG electrodes (D).

A post-implantation dynaCT scan is performed while the patient is still anesthetized and positioned in the operating table. The reconstructed images are then fused with the MRI dataset using the previously described fusion software. The resulting merged datasets are displayed and reviewed in axial, sagittal and coronal planes allowing the verification of the

correct placement of the electrodes [14]. After surgery, patients are transferred to the epilepsy monitoring unit (EMU). The duration of admission at the epilepsy monitoring unit varies from patient to patient, depending on several factors including number, quality and ictal and interictal patterns of recordings. The average, length of stay of patients in the EMU who underwent SEEG implantation is 7 days (range from 3 to 28 days). After obtaining the necessary information electrodes are removed in the operating room, in a procedure performed under local anesthesia and sedation. Patients are discharged next morning and resective surgery is scheduled 2-3 months following SEEG electrodes removal (Figure 2).

Invasive Monitoring Morbidity

In the recent SEEG series, the total complication rate varies from 3% to 5% [9, 14]. Other groups reported similar results. Cossu et al reported a morbidity rate of 5.6%, with severe permanent deficits from intracerebral hemorrhage in 2 patients (1%). In the Cleveland Clinic reported series, all 3 complications were hemorrhagic, which has been reported in several studies to be the most common complication in depth electrodes placement [14]. Other published series reporting complications across invasive monitoring procedures (subdural grids and depth electrodes) reported rates ranging from 0% to 26% [27, 21, 39]. Interestingly, subdural monitoring with grid electrodes has historically been shown to have low permanent morbidity (0 to 3%) compared with depth electrodes (3-6%) since there is no intraparenchymal passage. Although it is difficult to compare morbidity rates between subdural grids and SEEG due to the variability in patient selection, different institutions and variable number of implanted electrodes, it is our preliminary impression that the SEEG method provides at least a similar degree of safety when compared with subdural grids or strips. This impression is also shared by others [8, 10, 15].

CONCLUSION

The goals of invasive monitoring in refractory focal epilepsy may include (1) the need for better anatomical delineation of the hypothetical epileptogenic zone and (2) the need for the definition of cortical and subcortical functional brain areas. Extra-operative mapping with the subdural method (which here includes subdural grids and strips) has the advantage of allowing an optimal coverage of the subdural space adjacent cortex with adequate and continuous superficial functional mapping capabilities. In addition, from a surgical perspective, subdural implantations are open procedures, with better management of possible intracranial hemorrhagic complications. The disadvantages of the subdural method are related to the incapacity of recording and stimulating from deep cortical and subcortical areas, as the insula, posterior orbito-frontal, cingulate gyrus, depths of sulci, etc. In these scenarios, the SEEG methodology may be considered as a more efficient and safer option. SEEG has the advantages of allowing extensive and precise deep brain recordings and stimulations with minimal associated morbidity.

REFERENCES

[1] Adelson, P.D., O'Rourke, D.K. & Albright, A.L., 1995. Chronic invasive monitoring for identifying seizure foci in children. *Neurosurgery clinics of North America*, 6(3), pp.491–504.

[2] Almeida, A.N., Martinez, V. & Feindel, W., 2005. The first case of invasive EEG monitoring for the surgical treatment of epilepsy: historical significance and context. *Epilepsia*, 46(7), pp.1082–1085.

[3] Avanzini, G.G., 1994. Discussion of stereoelectroencephalography. *Acta Neurologica Scandinavica*, 152, pp.70–73.

[4] Baltuch, G.H., Baltuch, G. & Villemure, J.-G., 2008. *Operative Techniques in Epilepsy Surgery*, Thieme Medical Pub.

[5] Bancaud, J., 1970. [Epilepsy after 60 years of age. Experience in a functional neurosurgical department]. *La semaine des hôpitaux : organe fondé par l"Association d"enseignement médical des hôpitaux de Paris*, 46(48), pp.3138–3140.

[6] Battaglia, G. et al., 2006. Periventricular nodular heterotopia: classification, epileptic history, and genesis of epileptic discharges. *Epilepsia*, 47(1), pp.86–97.

[7] Bulacio, J.C. et al., 2012. Long-term seizure outcome after resective surgery in patients evaluated with intracranial electrodes. *Epilepsia*, 53(10), pp.1722–1730.

[8] Chabardès, S. et al., 2008. [Temporal disconnection as an alternative treatment for intractable temporal lobe epilepsy: techniques, complications and results]. *Neuro-Chirurgie*, 54(3), pp.297–302.

[9] Cossu, M., Chabardès, S., et al., 2008a. [Presurgical evaluation of intractable epilepsy using stereo-electro-encephalography methodology: principles, technique and morbidity]. *Neuro-Chirurgie*, 54(3), pp.367–373.

[10] Devaux, B. et al., 2008. [Epilepsy surgery in France]. *Neuro-Chirurgie*, 54(3), pp.453–465.

[11] Dinner, D.S., Lüders, H.O. & Klem, G., 1998. Chronic electrocorticography: Cleveland clinic experience. *Electroencephalography and clinical neurophysiology. Supplement*, 48, pp.58–69.

[12] Engel, J.J. et al., 1990. Presurgical evaluation for partial epilepsy: relative contributions of chronic depth-electrode recordings versus FDG-PET and scalp-sphenoidal ictal EEG. *Neurology*, 40(11), pp.1670–1677.

[13] Francione, S. et al., 2003. Intra-lesional stereo-EEG activity in Taylor's focal cortical dysplasia. *Epileptic disorders*.

[14] Gonzalez Martinez, J. et al., 2012. Stereoelectroencephalography in the "difficult to localize" refractory focal epilepsy: Early experience from a North American Epilepsy Center. *Epilepsia*.

[15] 15. Guénot, M. & Isnard, J., 2008. [Epilepsy and insula]. *Neuro-Chirurgie*, 54(3), pp.374–381.

[16] Jayakar, P., Duchowny, M. & Resnick, T.J., 1994. Subdural Monitoring in the Evaluation of Children for Epilepsy Surgery. *Journal of Child Neurology*, 9(2_suppl), pp.261–266.

[17] Jayakar, P.P., 1999. Invasive EEG monitoring in children: when, where, and what? *Journal of Clinical Neurophysiology*, 16(5), pp.408–418.

[18] Jeha, L.E. et al., 2007. Surgical outcome and prognostic factors of frontal lobe epilepsy surgery. *Brain*, 130(Pt 2), pp.574–584.

[19] Kakisaka, Y. et al., 2012. Use of simultaneous depth and MEG recording may provide complementary information regarding the epileptogenic region. *Epileptic disorders : international epilepsy journal with videotape*, 14(3), pp.298–303.

[20] Kellinghaus, C. et al., 2007. Dissociation between in vitro and in vivo epileptogenicity in a rat model of cortical dysplasia. *Epileptic disorders : international epilepsy journal with videotape*, 9(1), pp.11–19.

[21] Lee, W.S. et al., 2000. Complications and results of subdural grid electrode implantation in epilepsy surgery. *Surgical Neurology*, 54(5), pp.346–351.

[22] Lüders, H. & Comair, Y.G., 2001. *Epilepsy surgery*.

[23] Marnet, D. et al., 2008. [Surgical resection of focal cortical dysplasias in the central region]. *Neuro-Chirurgie*, 54(3), pp.399–408.

[24] Marusic, P. et al., 2002. Focal cortical dysplasias in eloquent cortex: functional characteristics and correlation with MRI and histopathologic changes. *Epilepsia*, 43(1), pp.27–32.

[25] Nair, D.R. et al., 2008. Chronic subdural electrodes in the management of epilepsy. *Clinical neurophysiology: official journal of the International Federation of Clinical Neurophysiology*, 119(1), pp.11–28.

[26] Najm, I.M., Bingaman, W.E. & Lüders, H.O., 2002. The use of subdural grids in the management of focal malformations due to abnormal cortical development. *Neurosurgery clinics of North America*, 13(1), pp.87–92– viii–ix.

[27] Onal, C. et al., 2003. Complications of invasive subdural grid monitoring in children with epilepsy. *Journal of neurosurgery*, 98(5), pp.1017–1026.

[28] Rosenow, F. & Lüders, H., 2001. Presurgical evaluation of epilepsy. *Brain*, 124(Pt 9), pp.1683–1700.

[29] Russo, G.L. et al., 2003. Focal cortical resection in malformations of cortical development. *Epileptic disorders*.

[30] Russo, Lo, G. et al., 2002. Focal cortical dysplasia: neuropathological subtypes, EEG, neuroimaging and surgical outcome. *Brain*.

[31] Rydenhag, B. & Hans, C., 2001. Complications of epilepsy surgery after 654 procedures in Sweden, September 1990-1995: a multicenter study based on the Swedish National Epilepsy Surgery …. *Neurosurgery*.

[32] Siegel, A.M., 2004. Presurgical evaluation and surgical treatment of medically refractory epilepsy. *Neurosurgical review*, 27(1), pp.1–18– discussion 19–21.

[33] Simon, S.L., Telfeian, A. & Duhaime, A.-C., 2003. Complications of invasive monitoring used in intractable pediatric epilepsy. *Pediatric neurosurgery*, 38(1), pp.47–52.

[34] Talairach, J. et al., 1992. Surgical therapy for frontal epilepsies. *Advances in neurology*, 57, pp.707–732.

[35] Vadera, S. et al., 2013. SEEG Following Subdural Grid Placement for Difficult to Localize Epilepsy. *Neurosurgery*.

[36] Widdess-Walsh, P. et al., 2007. Subdural electrode analysis in focal cortical dysplasia: Predictors of surgical outcome. *Neurology*, 69(7), pp.660–667.

[37] Wieser, H.G., 1996. Epilepsy surgery. *Baillière's clinical neurology*, 5(4), pp.849–875.

[38] Winkler, P.A. et al., 1999. [Noninvasive protocol for surgical treatment of focal epilepsies]. *Der Nervenarzt*, 70(12), pp.1088–1093.

[39] Wyler, A.R., Walker, G. & Somes, G., 1991. The morbidity of long-term seizure monitoring using subdural strip electrodes. *Journal of neurosurgery*.

[40] Wyllie, E. et al. eds., 2010. *Wyllie's Treatment of Epilepsy: Principles and Practice* (Wyllie, Treatment of Epilepsy) Fifth, Lippincott Williams & Wilkins.

[41] Ying, Z. & Najm, I.M., 2002. Mechanisms of epileptogenicity in focal malformations caused by abnormal cortical development. *Neurosurgery clinics of North America*, 13(1), pp.27–33– vii.

In: Encyclopedia of Surgery (22 Volume Set)
Editors: Andreas Lehrer and Kristin Mueller
ISBN: 978-1-53618-329-0
© 2020 Nova Science Publishers, Inc.

Chapter 357

PERIOPERATIVE VISUAL LOSS AFTER SPINE SURGERY

Mariel Manlapaz, MD and Sree Kolli, MD
Anesthesiology Institute, Cleveland Clinic, Cleveland, Ohio

KEY POINTS

- The post-operative vision loss (POVL) is rare but a very a devastating complication.
- The ischemic optic neuritis (ION) is the main cause of POVL
- Maintaining optimum ocular perfusion pressure and keeping the eyes free from pressure are the main factors to prevent POVL
- Avoidance hypotension and anemia are helpful to maintain ocular perfusion pressure.
- The use of colloids more than crystalloids solutions are helpful to reduce the increase in intraoculr pressure during spine in prone position.

INTRODUCTION

Perioperative visual loss (POVL) is a rare, unexpected, but devastating complication that can occur in patients undergoing spine surgery. The incidence of POVL is approximately 1/60,000 to 1/125,000 of all general anesthetics [1, 2] However the risk of POVL is believed to be significantly greater following cardiac surgery and spine surgery. First described by Hollenhorst in 1954 [3], there have been numerous reports since, establishing a clear link between spine surgery in the prone position and POVL. Research on POVL is limited due to its rare occurrence and consists largely of case reports [6-7]. A recent review by Shen and colleagues of 5.6 million patients from the National Inpatient sample (NIS) found the incidence of POVL to be 3.09/10,000(0.03%) after spinal fusion and 8.64/10,000 (0.09%) after cardiac surgery. The actual rate of POVL may be even higher after spine surgery, with incidence rates ranging from 0.094% [4] to 0.2% [8].

ETIOLOGY

Although the etiology of POVL is not properly understood, multiple risk factors have been proposed that includes decreased ocular perfusion pressure, excessive blood loss and anemia, hypotension, hypoxia, excessive fluid replacement, elevated venous pressure, head positioning and patient-specific vascular susceptibility [10]. POVL occurring with spine surgery may result from anterior ischemic optic neuropathy (AION), posterior ischemic optic neuropathy (PION), central retinal artery occlusion (CRAO), cortical blindness and posterior reversible encephalopathy (PRES). According to the American Society of Anesthesiologists (ASA) postoperative visual loss registry, the most common cause of POVL in spinal procedures are the two different forms of ischemic optic neuropathy: AION and PION, accounting for 89% of the cases. [9], of which 60% is due to PION and 11% due to CRAO.

Most recent NIS review suggests gender plays an important role with men being at higher risk of POVL after spinal fusion relative to women (odds ratio OR of 1.75). Age appears to be a risk factor too, with those aged 50-64 years displaying an increased risk (OR 1.75). Another unexplained finding was that children under 18 years age had the highest overall risk for POVL (OR 6.91), which was primarily attributed to cortical blindness rather than AION/PION and may represent a different etiology. POVL is also noted to be significantly increased in hip and femur operations (1.86/10,000 or 0.19%). These procedures share several features including large blood loss, hemodynamic perturbations, high embolic loads, and significant inflammation.

A recent multicenter case-control study by the Postoperative Visual Loss Study Group, explored the risk factors for ION after spinal fusion surgery in the prone position [11]. They compared 80 cases from the ASA Postoperative Visual Loss Registry to 315 controls from 17 institutions throughout the United States overcoming the limitations of the previous small studies. [4, 5, 49]. Obesity, male sex, Wilson Frame use, longer anesthetic duration, greater estimated blood loss, and decreased percent colloid administration were significantly and independently associated with ION after spinal fusion surgery [11].

ANATOMY

Basic knowledge of the blood supply to the optic nerve is important to understand POVL, especially ION. The Ophthalmic artery, originating from the internal carotid artery and its various branches is the principal blood supply to the retina, globe and optic nerve. The central retinal artery, a division of the ophthalmic artery supplies the inner retina.

The anterior part of the optic nerve has a rich arterial supply mainly from the posterior ciliary artery (PCA), except for the surface nerve fiber layer which is supplied by the retinal circulation. The blood supply in the optic nerve head has a sectorial distribution, which may explain the segmental vision loss seen in ischemic disorders [13]. The posterior part of the optic nerve is supplied by the pial vascular plexus that is supplied by pial branches originating from the peripapillary choroid, circle of Zinn-Haller, central retinal artery, ophthalmic artery and other orbital arteries. The circle of Zinn- Haller around the optic nerve is complete only in 77% of post-mortem human specimens. The PCA’s are end arteries without any anastomoses, allowing for the variations in the location of watershed zones in the optic nerve.

In contrast to the densely supplied anterior and posterior portions of the nerve, the central portion within the optic canal is supplied only by the pial vascular plexus derived from arterial extensions of the anterior and posterior blood supplies and intraneural branches of the central retinal artery. This comparatively sparse vascular supply to the mid portion of the optic nerve renders it most susceptible to ischemia and it is this portion of the nerve that is thought to or related to PION [14]. However, it is important to note that there is significant interindividual variability in the complex blood supply to the optic nerve, especially in terms of the location and pattern of watershed zones [12].

Venous drainage occurs mostly via the central retinal vein that is drained by the internal jugular vein. In the pre-laminar region of the eye, there are retinociliary collaterals to the peripapillary choroidal veins and the drainage through these collaterals can become significant in case of central retinal vein thrombosis [14].

ISCHEMIC OPTIC NEUROPATHY

ION is characterized by decreased blood flow and perfusion pressure to the optic nerve. Postoperative ION is a devastating complication that can occur after a variety of surgical procedures, most often following cardiothoracic surgery [15], instrumented spinal fusion [16, 17], and head and neck surgery [18]. ION can be categorized into anterior or posterior ION, based on whether the insult occurs in the anterior or posterior portion of the optic nerve. The type of ION seen varies depending on the type of surgery performed, with AION occurring most frequently after cardiac surgery and PION occurring most frequently after spine surgery in the prone position or radical neck dissection [9].

Anterior Ischemic Optic Neuropathy

AION is caused by occlusion or hypoperfusion of the anterior optic nerve head by the PCA's and typically presents with sudden onset of painless vision loss and a visual field defect. The fundoscopy shows diffuse or segmental disc edema with ensuing atrophy and occasionally splinter hemorrhage's around the optic disc [19, 20]. AION can be classified into arteritic and nonarteritic AION.

Arteritic AION is caused by temporal arteritis and is often seen in the elderly with an elevated erythrocyte sedimentation rate(ESR) and c-reactive protein (CRP), markers that are entirely non-specific in the post-operative period [21]. It is rarely found in the perioperative period.

Nonarteritic AION perioperatively is most often associated with cardiac surgery, especially CABG and generally presents immediately upon awakening from surgery. It occurs both spontaneously in the community and in the perioperative setting, often in patients with pre-existing vascular disease [23]. Although this can occur in healthy patients, risk factors include diabetes mellitus, arterial hypotension, arterial hypertension, blood loss, prone positioning during surgery, prolonged surgery, atherosclerosis, sleep apnea and migraine [13]. The pathophysiology is most likely a combination of these factors, together with abnormal autoregulation and other patient specific characteristics that predispose to ischemic injury

[23]. AION may rarely present as abrupt loss of vision after a delay or period of normal vision lasting hours to days [24].

Posterior Ischemic Optic Neuropathy

PION also manifests as sudden onset of painless loss of vision and visual field deficiencies and results from infarction of the optic nerve posterior to the lamina cribrosa. It is usually discovered on waking from the surgical procedure and tends to present with significant bilateral visual loss or complete blindness [13]. The fundoscopic examination initially reveals a completely normal appearing fundus, with optic nerve pallor and atrophy occurring only after approximately 4-6 wks [24]. In the ASA Registry of spine-related ION, 46% of the patients reported had no light perception [9], which is usually permanent. Similar to AION, POIN can be classified into arteritic and nonarteritic AION. The arteritic form is attributable to temporal arteritis while the nonarteritic form is seen most commonly following spine surgery.

Etiology in the development of postoperative PION include multiple hemodynamic derangements like hypotension, anemia, increased venous pressure, prone positioning during surgery, increased cerebrospinal fluid, and direct ocular compression [25]. Anemia and hypotension are almost always observed in patients that develop postoperative PION [26]. The pial vessels that supply the posterior optic nerve lack an autoregulatory mechanism, rendering them susceptible to ischemia during periods of hypotension and when the blood oxygen carrying capacity is decreased [27]. However, studies comparing patients with POVL after spine surgery with those of controls demonstrated no difference in perioperative hematocrit and blood pressure, suggesting a multifactorial cause [28, 49].

The prone position, a key element to spine surgery, is also the setting in which the majority of postoperative PION is observed. Prone positioning, especially when in the Trendelenburg position, leads to increased orbital venous pressure through an increase in abdominal venous pressure, thus increasing resistance to local blood flow [29]. Direct orbital pressure, often seen with face pillows/cushions or other positioning devices, has also been implicated in the pathogenesis of PION. However, with the resultant decreased perfusion pressure to the optic nerve head and central retinal artery, AION or CRAO would be more likely observed [26]. Avoidance of the prone position and direct ocular pressure is insufficient, however, to prevent postoperative PION, as cases have been documented following surgery in the supine position and with the use of head pins [7, 9, 30].

Pathophysiology of Ion in Prone Position

The theoretical mechanism most often described for ION post spine surgery in prone position is the elevation of venous pressure and development of interstitial edema [11]. Both these processes can cause damage to the optic nerve by compression of the vessels that feed the optic nerve, venous infarction or direct mechanical compression. A rise in central venous pressure can occur in obese patients when their abdomen is compressed during prone position. Similarly venous pressure may be elevated when the head position is lower than the heart, as seen in the Wilson frame. Lower oncotic pressure leading to a growing interstitial

edema can occur when there is significant inflammation and capillary leak such as in situations of major blood loss and/or prolonged cases. The same can occur when less colloid is used overall. All these explanations are simply theories that require further investigation. Why the male sex appears to be a risk factor for ischemic optic neuropathy during prone position is not understood, but it has been suggested that estrogen may serve a protective role [31].

RETINAL ISCHEMIA

Central retinal artery occlusion (CRAO) decreases blood supply to the entire retina, whereas occlusion of a retinal branch (BRAO) affects only a portion of the retina. Both are ophthalmic emergencies and analogous to an acute stroke of the eye. Retinal ischemia has been documented in both adults and children following ocular trauma [32], and also embolic [33] and vasospastic episodes [34].

In spine surgery, these conditions are mostly seen during the perioperative period from improper patient positioning and external compression on the eye [35]. Perioperative trauma was noted in 70% of the cases of CRAO from the ASA Visual Loss Registry, as evidenced by corneal abrasion, ipsilateral decreased supraorbital sensation, ophthalmoplegia, ptosis, or unilateral erythema [9].

Theoretical mechanisms that have been used to explain CRAO include thromboembolism, direct pressure to the globe, and increased intraocular pressure. Decreased oxygen carrying capacity and blood flow to optic nerve such as from hypovolemia, anemia, large blood loss, and peripheral vascular disease, have also been suggested etiologic factors for CRAO. The use of horseshoe-shaped headrest has been associated with this complication. Hollenhurst et al., [3] described CRAO in eight patients after prone spine surgery on horseshoe headrest. Increased risk is also observed in patients with altered facial anatomy, osteogenesis imperfecta, and exophthalmos, all of which can increase effects of external compression [36].

CRAO is often unilateral in presentation with severe visual loss in the affected eye. Pathological features include a cherry-red spot on the macula, a white ground-glass appearance of the retina, attenuated arterioles, and an afferent pupillary defect [37]. Visual loss from CRAO is almost always irreversible and there are no established effective treatment options.

CORTICAL BLINDNESS

Cortical blindness is due to decreased perfusion to the occipital cortex by the posterior cerebral artery. It is caused either by hypoperfusion or embolic phenomenon. Patients with cortical blindness have normal light reflex and fundoscopic examination as the optic tracts and radiations are unaffected. When one side is affected, the patient presents with contralateral homonymous hemianopsia. If both sides suffer ischemic insult, the patient may have peripheral vision loss or complete blindness. Cortical blindness may improve initially after the infarct, but total recovery is rare.

PRES

PRES is a neurologic syndrome that presents as a combination of seizures, visual changes, vomiting, headache, and decreased level of consciousness. It is associated with acute medical illnesses such hypertensive episodes, autoimmune disease, malignancy, chemotherapy, immunosuppressant therapy, infection, renal disease, vasculitis, eclampsia, and preeclampsia [38]. Although more closely identified with obstetric patients, PRES has also been reported after lumbar fusion [39], hysterectomy [40], and video-assisted-thoracoscopic wedge resection [41]. PRES has characteristic MRI findings. There are two leading theoretical explanations for PRES. One is acute increase in blood pressure above the brain's autoregulatory limit, thereby causing brain edema. The other pathophysiologic explanation is cytotoxic drugs or diseases causing endothelial injury and edema formation. Management is appropriate use of anti-seizure and anti-hypertensive agents and treatment of causative factors. Unlike ION and CRAO, PRES has a favorable recovery pattern.

TREATMENT AND PREVENTION OF POVL

When a patient reports any visual symptoms following surgery, an urgent ophthalmologic consultation should be obtained to determine its cause. If there is no evident ocular injury or central retinal artery occlusion, neuroimaging should be obtained. MRI with gadolinium is preferred to assess for intracranial pathologies, including occipital stroke or pituitary apoplexy [42]. If imaging is negative, the most likely etiology is ION. Patients have been treated with high dose steroids, mannitol or other agents to decrease intraocular pressure, and anti-platelet agents. However, none of these approaches have been shown to be effective [13, 24, 43].

A recent study examined the effect of crystalloid versus colloid and the use of the α-agonist Brimonidine on IOP during prone spine surgery [44]. The study found the mean rate of IOP rise in the prone position and mean IOP at the end of surgery was significantly greater in patients receiving crystalloid than those receiving colloid. Topical Brimonidine also led to a significant reduction in IOP, both intraoperative and postoperative. Ocular perfusion pressure, however, did not vary significantly between the groups as hypotension was aggressively treated, suggesting that maintenance of blood pressure may be a more important factor in determining perfusion pressure. Much larger studies are needed to determine whether maintaining appropriate ocular perfusion pressure reduces the risk of POVL after spine surgery.

Given the poor prognosis and lack of validated treatment options, it is essential to take prophylactic measures during surgery to prevent the development of POVL. The ASA Task Force on Perioperative Blindness, consisting of anesthesiologists, neuro-ophthalmologists, and spine surgeons, suggest periodically checking hemoglobin and hematocrit values, and avoidance of direct pressure on the globe to avoid CRAO injuries. Wide range of devices are available to help limit mechanical ocular compression during prone surgery, but these still require vigilance on the part of the surgeon and anesthesiologist as patient movement and shifting of the device may occur. In high risk patients, additional efforts directed towards

optimizing hemoglobin/hematocrit values, hemodynamic status, and systemic oxygenation may be appropriate [43].

PERIOPERATIVE VISUAL LOSS IN OTHER SURGERIES

Apart from spine and cardiac surgery, perioperative visual loss has also been associated with robotic and laparoscopic surgeries. Cases of visual impairment have been reported to occur in minimally invasive proctocolectomy, laparoscopic nephrectomy and robotic prostatectomy [45-48]. During robotic prostatectomy, increased intraocular pressure occurs due to prolonged duration in steep Trendelenburg position combined with CO2 insufflation of the abdomen. The central venous pressure within the thorax increases with Trendelenburg position, which may reduce drainage of blood flow from the head, thereby leading to elevation in IOP. During CO2 insufflation, the increase in intra-abdominal pressure will further augment the increase in intrathoracic pressure. Furthermore, insufflation of CO2 increases the carbon dioxide in the blood, which can lead to cerebral vasodilatation and increased cerebral blood volume. All these factors ultimately lead to elevation in venous pressure. It is unknown whether the same risk factors for POVL in spine surgery can be applied to laparoscopic and robotic surgeries, but it appears venous congestion and interstitial edema are commonalities among these surgeries.

SUMMARY

POVL after spine surgery is extremely rare, but remains a dreaded complication despite significant efforts to identify risk factors and a pathophysiological mechanism. Potential causes of POVL after spine surgery include anterior ischemic optic neuropathy, posterior ischemic optic neuropathy, cortical blindness, retinal ischemia, and posterior reversible encephalopathy syndrome. The vast majority of cases are related to ischemic optic neuropathy.

Many reports have attempted to link hypotension, anemia, and blood loss to the development of this disease; however, no single mechanism can entirely explain the varied circumstances in which it occurs. This suggests a multifactorial etiology and perhaps individual susceptibility related to varied optic nerve blood supply and anatomy. Postoperative Visual Loss Group, using data from the ASA Post-Operative Visual Loss Registry, identified obesity, male sex, Wilson frame use, longer anesthetic duration, greater estimated blood loss, and decreased percent colloid administration as significant independent risk factors for the development of ION. These risk factors, with the possible exception of male sex, are thought to promote a rise in venous pressure and interstitial edema limiting optic nerve perfusion. Prevention is crucial for limiting the incidence of POVL as there are no treatment modalities once the damage occurs. ASA guidelines listed in the table below are recommended, especially for patients identified as high risk, undergoing procedures that are known to result in visual loss.

Table 1. American Society of Anesthesiologists perioperative visual loss practice advisory consensus conclusions

There is a subset of patients who undergo spine procedures while they are positioned prone and receiving general anesthesia that has an increased risk for the development of POVL. This "high-risk" subset includes patients who are anticipated preoperatively to undergo procedures that are prolonged, have substantial blood loss, or both
Consider continuous blood pressure and central venous pressure monitoring in high-risk patients
Consider informing high-risk patients that there is a small, unpredictable risk of POVL
The use of deliberate hypotensive techniques during spine surgery has not been shown to be associated with the development of POVL
Colloids should be used along with crystalloids to maintain intravascular volume in patients who have substantial blood loss
At this time, there is no apparent transfusion threshold that would eliminate the risk of POVL related to anemia
High-risk patients should be positioned so that their heads are level with or higher than the heart, when possible. In addition, their heads should be maintained in a neutral forward position (without significant neck flexion, extension, lateral flexion, or rotation) when possible
Consideration should be given to the use of staged spine procedures in high-risk patients

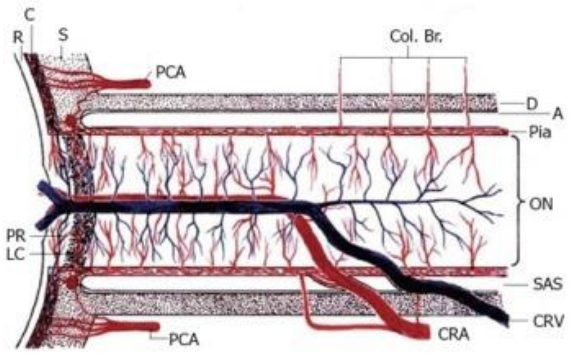

REFERENCES

[1] Warner ME, Warner MA, Garrity JA, MacKenzie RA, Warner DO. The frequency of perioperative vision loss. *Anesth. Analg*. 2001;93:1417–1421, table of contents. [PubMed].

[2] Roth S, Thisted RA, Erickson JP, Black S, Schreider BD. Eye injuries after nonocular surgery. A study of 60,965 anesthetics from 1988 to 1992. *Anesthesiology.* 1996;85:1020–1027. [PubMed].

[3] Hollenhorse RW, Svien HJ, Benoit CF. Unilateral blindness occurring during anesthesia for neurosurgical operations. *AMA Arch. Ophthalmol.* 1954;52:819–830. [PubMed].

[4] Patil CG, Lad EM, Lad SP, Ho C, Boakye M. Visual loss after spine surgery: a population-based study. *Spine (Phila Pa 1976)* 2008;33:1491–1496. [PubMed].

[5] Shen Y, Drum M, Roth S. The prevalence of perioperative visual loss in the United States: a 10-year study from 1996 to 2005 of spinal, orthopedic, cardiac, and general surgery. *Anesth. Analg*. 2009;109:1534–1545. [PubMed].

[6] Alexandrakis G, Lam BL. Bilateral posterior ischemic optic neuropathy after spinal surgery. *Am. J. Ophthalmol*. 1999;127:354–355. [PubMed].

[7] 7.Cheng MA, Todorov A, Tempelhoff R, McHugh T, Crowder CM, Lauryssen C. The effect of prone positioning on intraocular pressure in anesthetized patients. *Anesthesiology*. 2001;95:1351–1355. [PubMed].

[8] Stevens WR, Glazer PA, Kelley SD, Lietman TM, Bradford DS. Ophthalmic complications after spinal surgery. *Spine (Phila Pa 1976)* 1997;22:1319–1324. [PubMed].

[9] Lee LA, Roth S, Posner KL, Cheney FW, Caplan RA, Newman NJ, Domino KB. The American Society of Anesthesiologists Postoperative Visual Loss Registry: analysis of 93 spine surgery cases with postoperative visual loss. *Anesthesiology*. 2006;105:652–659; quiz 652-659. [PubMed].

[10] Kawaguchi M1, Hayashi H, Kurita N, Furuya H. Postoperative visual disturbances after non-ophthalmic surgery. *Masui.* 2009 Aug;58(8):952-61 [PubMed].

[11] Postoperative Visual Loss Study Group. Risk factors associated with ischemic optic neuropathy after spinal fusion surgery. *Anesthesiology*. 2012;116:15–24. [PubMed].

[12] Hayreh SS. The blood supply of the optic nerve head and the evaluation of it - myth and reality. *Prog. Retin Eye Res.* 2001;20:563–593. [PubMed].

[13] Hayreh SS. Ischemic optic neuropathies - where are we now? Graefes *Arch. Clin. Exp. Ophthalmol*. 2013;251:1873–1884. [PubMed].

[14] Goepfert CE, Ifune C, Tempelhoff R. Ischemic optic neuropathy: are we any further? *Curr. Opin. Anaesthesiol*. 2010;23:582–587. [PubMed].

[15] Tice DA. Ischemic optic neuropathy and cardiac surgery. *Ann. Thorac. Surg.* 1987;44:677. [PubMed].

[16] Gill B, Heavner JE. Postoperative visual loss associated with spine surgery. *Eur Spine J.* 2006;15:479–484. [PMC free article] [PubMed].

[17] Stambough JL, Dolan D, Werner R, Godfrey E. Ophthalmologic complications associated with prone positioning in spine surgery. *J. Am. Acad. Orthop. Surg*. 2007;15:156–165. [PubMed].

[18] Schobel GA, Schmidbauer M, Millesi W, Undt G. Posterior ischemic optic neuropathy following bilateral radical neck dissection. *Int. J. Oral. Maxillofac. Surg*. 1995;24:283–287. [PubMed].

[19] Miller NR. Current concepts in the diagnosis, pathogenesis, and management of nonarteritic anterior ischemic optic neuropathy. *J. Neuroophthalmol.* 2011;31:e1–e3. [PubMed].

[20] Hayreh SS. Management of ischemic optic neuropathies. *Indian J. Ophthalmol.* 2011;59:123–136. [PMC free article] [PubMed].

[21] Hayreh SS. Anterior ischemic optic neuropathy. VIII. Clinical features and pathogenesis of post-hemorrhagic amaurosis. *Ophthalmology.* 1987;94:1488–1502. [PubMed].

[22] Lee LA, Newman NJ, Wagner TA, Dettori JR, Dettori NJ. Postoperative ischemic optic neuropathy. *Spine (Phila Pa 1976)* 2010;35:S105–S116. [PubMed].

[23] Roth S. Perioperative visual loss: what do we know, what can we do? *Br J. Anaesth*. 2009;103 Suppl 1:i31–i40. [PMC free article] [PubMed].

[24] Newman NJ. Perioperative visual loss after nonocular surgeries. *Am. J. Ophthalmol.* 2008;145:604–610. [PMC free article] [PubMed].

[25] Berg KT, Harrison AR, Lee MS. Perioperative visual loss in ocular and nonocular surgery. *Clin. Ophthalmol*. 2010;4:531–546. [PMC free article] [PubMed].
[26] Buono LM, Foroozan R. Perioperative posterior ischemic optic neuropathy: review of the literature. *Surv. Ophthalmol*. 2005;50:15–26. [PubMed].
[27] Isayama Y, Takahashi T, Inoue M, Jimura T. Posterior ischemic optic neuropathy. III. Clinical diagnosis. *Ophthalmologica.* 1983;187:141–147. [PubMed].
[28] Myers MA, Hamilton SR, Bogosian AJ, Smith CH, Wagner TA. Visual loss as a complication of spine surgery. A review of 37 cases. *Spine (Phila Pa 1976)* 1997;22:1325–1329. [PubMed].
[29] Wollenberg B, Walz A, Kolbow K, Pauli C, Chaubal S, Andratschke M. Clinical relevance of circulating tumour cells in the bone marrow of patients with SCCHN. *Onkologie*. 2004;27:358–362. [PubMed].
[30] Cheng MA, Sigurdson W, Tempelhoff R, Lauryssen C. Visual loss after spine surgery: a survey. *Neurosurgery*. 2000;46:625–630; discussion 630-631. [PubMed].
[31] Giordano C, Montopoli M, Perli E, Orlandi M, Fantin M, Ross-Cisneros FN, Caparrotta L, Martinuzzi A, Ragazzi E, Ghelli A, et al. Oestrogens ameliorate mitochondrial dysfunction in Leber's hereditary optic neuropathy. *Brain*. 2011;134:220–234. [PMC free article] [PubMed].
[32] Noble MJ, Alvarez EV. Combined occlusion of the central retinal artery and central retinal vein following blunt ocular trauma: a case report. *Br. J. Ophthalmol.* 1987;71:834–836. [PMC free article] [PubMed].
[33] Kollarits CR, Lubow M, Hissong SL. Retinal strokes. I. Incidence of carotid atheromata. *JAMA.* 1972;222:1273–1275. [PubMed].
[34] Brown GC, Magargal LE, Shields JA, Goldberg RE, Walsh PN. Retinal arterial obstruction in children and young adults. *Ophthalmology.* 1981;88:18–25. [PubMed].
[35] Katz DA, Karlin LI. Visual field defect after posterior spine fusion. *Spine (Phila Pa 1976)* 2005;30:E83–E85. [PubMed].
[36] Bradish CF, Flowers M. Central retinal artery occlusion in association with osteogenesis imperfecta. *Spine (Phila Pa 1976)* 1987;12:193–194. [PubMed].
[37] Hayreh SS, Kolder HE, Weingeist TA. Central retinal artery occlusion and retinal tolerance time. *Ophthalmology*. 1980;87:75–78. [PubMed].
[38] Lee LA. Perioperative visual loss and anesthetic management. *Curr. Opin Anaesthesiol.* 2013;26:375–381. [PubMed].
[39] Yi JH, Ha SH, Kim YK, Choi EM. Posterior reversible encephalopathy syndrome in an untreated hypertensive patient after spinal surgery under general anesthesia -A case report- *Korean J. Anesthesiol*. 2011;60:369–372. [PMC free article] [PubMed].
[40] Kim TK, Yoon JU, Park SC, Lee HJ, Kim WS, Yoon JY. Postoperative blindness associated with posterior reversible encephalopathy syndrome: a case report. *J. Anesth*. 2010;24:783–785. [PubMed].
[41] Eran A, Barak M. Posterior reversible encephalopathy syndrome after combined general and spinal anesthesia with intrathecal morphine. *Anesth. Analg*. 2009;108:609–612. [PubMed].
[42] American Society of Anesthesiologists Task Force on Perioperative Blindness. Practice advisory for perioperative visual loss associated with spine surgery: a report by the American Society of Anesthesiologists Task Force on Perioperative Blindness. *Anesthesiology. 2006*;104:1319–1328. [PubMed].

[43] American Society of Anesthesiologists Task Force on Perioperative Visual Loss. Practice advisory for perioperative visual loss associated with spine surgery: an updated report by the American Society of Anesthesiologists Task Force on Perioperative Visual Loss. *Anesthesiology*. 2012;116:274–285. [PubMed].

[44] Farag E, Sessler DI, Kovaci B, Wang L, Mascha EJ, Bell G, Kalfas I, Rockwood E, Kurz A. Effects of crystalloid versus colloid and the α-2 agonist brimonidine versus placebo on intraocular pressure during prone spine surgery: a factorial randomized trial. *Anesthesiology*. 2012;116:807–815. [PubMed].

[45] Weber ED, Colyer MH, Lesser RL, Subramanian PS. Posterior ischemic optic neuropathy after minimally invasive prostatectomy. *J. Neuroophthalmol*. 2007;27:285–287. [PubMed].

[46] Mizrahi H, Hugkulstone CE, Vyakarnam P, Parker MC. Bilateral ischaemic optic neuropathy following laparoscopic proctocolectomy: a case report. *Ann. R. Coll. Surg. Engl*. 2011;93:e53–e54. [PubMed].

[47] Metwalli AR, Davis RG, Donovan JF. Visual impairment after laparoscopic donor nephrectomy. *J. Endourol*. 2004;18:888–890. [PubMed].

[48] Lee LA, Posner KL, Bruchas R, Roth S, Domino KB. Visual loss after prostatectomy. *Proceedings of the 2010 Annual Meeting of the American Society of Anesthesiologists*; 2010. p. A1132.

[49] Holy SE, Tsai JH, McAllister RK, Smith KH. Perioperative ischemic optic neuropathy: a case control analysis of 126,666 surgical procedures at a single institution. *Anesthesiology*. 2009;110:246–253. [PubMed].

In: Encyclopedia of Surgery (22 Volume Set)
Editors: Andreas Lehrer and Kristin Mueller
ISBN: 978-1-53618-329-0
© 2020 Nova Science Publishers, Inc.

Chapter 358

SURGERY FOR INTRAHEPATIC CHOLANGIOCARCINOMA

Kelly Olino, MD and Michael D'Angelica*, MD
Department of Surgery, Hepatopancreatobiliary Service,
Memorial Sloan Kettering Cancer Center, New York, NY, US

ABSTRACT

Surgical resection of intrahepatic cholangiocarcinoma is the only potentially curative treatment option. However, due to the natural history of the disease, most patients present at an advanced stage at which liver resection cannot be considered. As there has been little progress in the development of efficacious chemotherapy and other non-surgical treatments, patients with potentially resectable tumors are generally offered a surgical approach that should include removal of lymph nodes in the gastroduodenal ligament for adequate staging assessment despite no known impact on survival or local recurrence. The aim of this chapter is to present the actual indications for resection, the outcomes after surgery including assessment of prognostic factors and to discuss the role of re-resection, liver transplantation and implant of intraarterial pump for hepatic arterial infusion in unresectable ICC.

KEY POINTS

- The presence of a positive lymph node and multifocal liver disease are the most important prognostic factors effecting survival following surgical resection of intrahepatic cholangiocarcinoma.
- Consideration should be made for removal of lymph nodes in the gastroduodenal ligament for adequate staging assessment despite no known impact on survival or local recurrence.

* Corresponding Author's Email: dangelim@MSKCC.ORG; Fax: (212) 717-3218.

- Complete resection should only be attempted in patients without evidence of multifocal disease or gross lymphatic involvement. Patients with these high risk features should otherwise be considered for treatment with chemotherapy and decisions regarding resection made on a case by case basis.
- Resection of large and locally invasive tumors into biliary and major vascular structures can be undertaken with acceptable morbidity and mortality.
- The goal of any resection for ICC should be that of a margin negative resection.
- The use of liver transplantation should be considered experimental and warrants further investigation.
- The use of hepatic arterial infusion pump therapy has led to promising response rates and survival among unresectable patients compared to historic controls and continues to be the subject of clinical trials.

INTRODUCTION

Intrahepatic cholangiocarcinoma is the second most common type of primary liver tumor. These tumors are thought to arise from the biliary epithelium although there is more recent data supporting the supposition that these tumors may arise from hepatocyte dedifferentiation [1]. Cholangiocarcinoma is commonly classified based upon the location from which it arises. Intrahepatic cholangiocarcinoma arises from second order intrahepatic bile ducts and represents 10% of cholangiocarcinoma with most patients presenting with sporadic disease [2]. There are 3 gross subtypes of intrahepatic cholangiocarcinoma as defined by the Liver Cancer Study Group of Japan including the mass forming, periductal infiltrating and intraductal growth types. The mass forming type is the most frequent subtype representing 60-80% of all cases, with a propensity for intrahepatic metastases and lymph node involvement. The prognosis of the intraductal growth subtype is most favorable and that of the periductal infiltrating subtype is the worst [3].

The incidence and presence of risk factors for the development of intrahepatic cholangiocarcinoma varies widely by country with the highest rates approaching > 80/100,000 in Thailand due to endemic parasitic infection while much rarer in the US (1.67/100,000) and Europe representing less than 3% of malignant tumors [4]. However, numerous reports have indicated that the world-wide incidence is increasing, even in western countries [5]. A recently published analysis using data from the SEER database indicates that since 1983 the incidence of cholangiocarcinoma as well as the utilization of liver directed surgical intervention has increased over time calling for increased attention to this relatively rare disease [6].

PRESENTATION, DIAGNOSTIC WORKUP AND PRE-OPERATIVE STAGING

Patients who present with intrahepatic cholangiocarcinoma are usually asymptomatic at early stages but ultimately develop non-specific symptoms including right upper quadrant or epigastric pain, weight loss or night sweats with advanced stage of disease [7]. Jaundice is

uncommon and only develops in cases where masses are large enough to cause biliary obstruction by mass effect or by direct invasion into the hilum. Given the non-specific nature of presenting symptoms, care should be taken to identify patients who are at risk for developing the disease, particularly in endemic areas. In cases where a liver mass is incidentally found, radiographic imaging in combination with the clinical history makes the diagnosis.

Tri-phasic contrast-enhanced computed tomography imaging typically shows a hypointense liver tumor with ambiguous peripheral borders on non-contrast imaging, but with peripheral enhancement on arterial phase that continues to increase in attenuation during venous phase. It is thought this delay is due to increased stromal fibrosis resulting from the tumor. Findings also commonly include retraction of the liver capsule and distal biliary dilation around the periphery of the tumor [8-10].

CT imaging is also utilized for assessment of extrahepatic disease, satellite lesions within the liver and to determine involvement of vascular and biliary structures in order to determine resectability. Care should be taken to look for evidence of segmental liver atrophy as this is associated with biliary or portal involvement. As with any liver resection, evaluation of both vascular inflow (arterial and portal) and outflow (hepatic vein), as well as an estimation of the residual liver volume should be determined preoperatively. Accurate assessment of the perihepatic regional lymph nodes is limited. Studies typically demonstrate that the incidence of involved nodes is underestimated radiographically with sensitivity ranging from 22-43%, specificity 73-76% and accuracy 62-68%. Risk factors such as tumor size > 5cm and hilar invasion are predictive of having involved lymph nodes [11, 12]. However, even in the case of enlarged lymph nodes (> 1cm), it is difficult to predict metastatic involvement [13]. The conclusions of Grobmyer et al. [14] are frequently cited as evidence of the diagnostic accuracy of preoperative imaging studies in the prediction of involved perihepatic lymph nodes in patients with metastatic or primary liver cancer. Using CT assessment, the negative predictive value was 95% and the positive predictive value was 30%. Truly occult metastatic nodal disease was only found in 1 patient in the study group. However, 75 patients in the study cohort had colorectal metastases, while only 8 patients had intrahepatic cholangiocarcinoma. In fact, most studies addressing the accuracy of imaging in the detection of regional lymph node metastases for cholangiocarcinoma are limited by small case numbers and non-uniform performance of lymphadenectomy.

MRI is complementary to CT and reveals lesions that are usually hypointense on T1 weighted images and hyperintense on T2 weighted imaging with features on dynamic imaging indicative of central fibrosis. The hepatobiliary phase is particularly useful in characterizing the primary tumor and identifying intrahepatic metastases, where these tumors are hypointense and are well delineated. The addition of gadolinium enhanced images can show peripheral enhancement of the mass and provides accurate assessment of vascular involvement. Multi-phase MRI is useful in distinguishing intrahepatic cholangiocarcinoma from hepatocellular carcinoma [15, 16].

Tumor markers such as CA19-9 are not sensitive or specific for the diagnosis of cholangiocarcinoma given the overlap with other hepatobiliary malignancies. However, AFP, CEA, CA19-9 and hepatitis B and C serology should be sent to aid the workup of any patient who presents with a liver mass. AFP is not elevated in cholangiocarcinoma as compared to hepatocellular carcinoma, while CEA and CA19-9 are variably elevated. Markedly elevated CA19-9 >1000 U/ml is a marker for poorer survival [17] and may indicate metastatic disease.

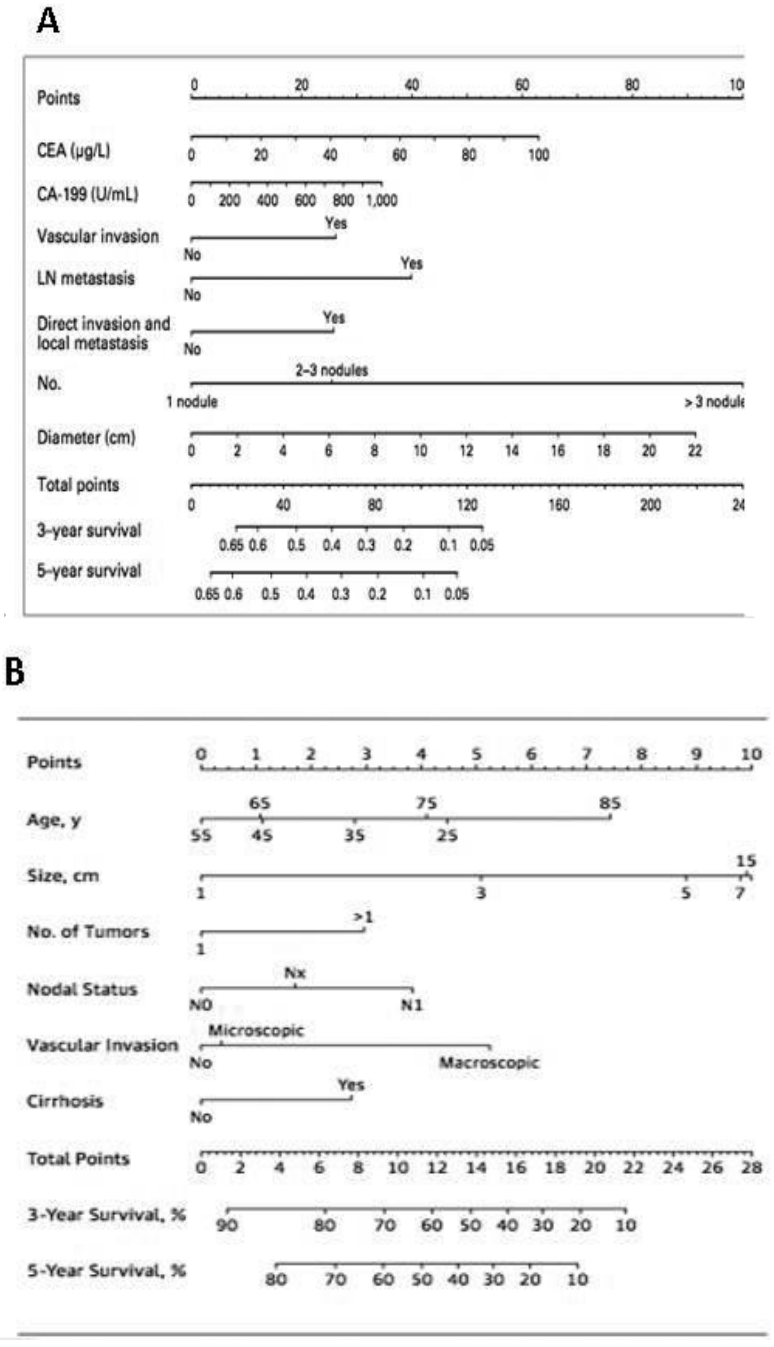

Figure 1. Nomograms for predicting survival following resection of intrahepatic cholangiocarcinoma. Total points are determined by looking at the appropriate value for a given patient variable and assigning points based upon the top axis. Individual points are then summed and a line is drawn down from the Total Points to determine 3- and 5-year survival. (From A) Wang Y. et al. [22] and B) Hyder O. et al. [21]).

Table 1. Clinicopathologic results of selected large retrospective case series for resected intrahepatic cholangiocarcinoma

Author	Year	Center	Patient Number Resected	R0 Resection Rate	Positive LN mets	% Patients with lymphadenectomy	Solitary Tumor	3yrOS	5 yr OS	Negative Prognostic Factors on Multivariate Analysis for Overall Survival
Luo et al. [17]	2014	Shanghai, China	1333	34.8%	28%	41%	64.1%	25.2%	17%	LN metastases, multiple intrahepatic tumors, R1 resection, vascular invasion, Elevated CA19-9 or CEA
De Jong et al. [23]	2011	Multicenter-US, Europe	449	81%	16.5%	55.2%	79%	44.3%	31%	LN metastases, multiple intrahepatic tumors, R1 resection
Farges et al. [19]	2011	Multicenter France	212	76%	40%	100%	41%	43%	28%	pTNM stage, LN metastases, R1 resection
Uenishi et al. [25]	2014	Multicenter Japan	233	100%	37.3%	79%		39.4%	31.1%	Tumor size > 2cm, LN metastases, multiple intrahepatic tumors
Ribero et al. [36]	2012	Multicenter Italy	434	84.6%	36.9%	62.2%	67.5%	47.1%	32.9%	Elevated CA19-9, LN metastases, multiple intrahepatic tumors, (margin not included in analysis)
Marubashi et al. [11]	2014	Osaka, Japan	111	65%	28%	78%	31.4%	41.8%	40.5%	Hilar invasion, multiple intrahepatic tumors, ALT, LN metastases, R1 resection
Uchiyama et al. [24]	2011	Multicenter Japan	341	85%	49.6%	67%	71%	36.4%	29.2%	Elevated CA19-9, multiple intrahepatic tumors, LN metastases, Tumor size > 5cm
Endo et al. [18]	2008	MSKCC	82	85.4%	8.5%	55%	70.7%	NR	NR	LN metastases, multiple intrahepatic tumors, tumor size > 5cm

Since most patients are referred to a surgeon with a liver mass and intrahepatic cholangiocarcinoma occurs less commonly than metastatic disease, workup including upper and lower endoscopy and cross sectional imaging of the chest, abdomen and pelvis is indicated to look for an occult primary tumor. A careful history reviewing any cancer history as well as routine surveillance for gynecologic and breast cancers should be sought. Core needle biopsy has a limited role in the diagnosis of ICC when the tumor is resectable, but is mandatory for patients who are not resectable and are being considered for non-surgical treatment. Histology of biopsy specimens are typically interpreted as adenocarcinoma, while morphology and immunohistochemical analysis can be suggestive of a pancreatobiliary tumor. Biopsy alone, however, is not accurate enough to diagnose intrahepatic cholangiocarcinoma and the above-mentioned workup is mandatory. At our center, we currently use pre-operative biopsy sparingly in cases of patients with resectable disease and instead rely on the clinical scenario and preoperative imaging. In cases where imaging reveals unresectable or multi-focal disease with inconclusive imaging, biopsy is obtained prior to beginning systemic therapy given the difference in treatment between HCC and ICC. Preoperative workup is completed with assessment of liver function and identification of major medical comorbidities that would preclude liver resection.

PATIENT SELECTION/SURGICAL OUTCOMES AND PROGNOSIS

Resection of intrahepatic cholangiocarcinoma is the treatment of choice for non-metastatic disease and is the only treatment associated with long-term survival and cure. Patients who are not amenable to resection have a median survival of 6-9 months with no five year survivors while those undergoing resection have an associated 5-year survival of up to 30% [17-19]. Since patients are asymptomatic at the early stages of the disease, most present with metastatic or locally advanced disease. As there has been little progress in the development of efficacious chemotherapy and other non-surgical treatments, patients with potentially resectable tumors are generally offered a surgical approach.

Recently, multiple case series have identified prognostic clinicopathologic variables that are now recognized to be important determinants to decide who should be considered for operative therapy. Surgeons and oncologists should understand these prognostic factors in order to best select patients who are most likely to benefit from resection. The role of surgery must also be interpreted in the context of the limited impact of systemic chemotherapy on survival [20]. Both recurrence free and overall survival have consistently been demonstrated to be negatively impacted by the presence of lymph node involvement, multifocal intrahepatic disease and the inability to perform a margin negative (R0) resection [11, 17]. The prognostic impact of tumor size and an elevated pre-operative serum CA19-9 on overall survival varies in different series (Table 1). Two recently developed nomograms (Figure 1) also included CEA, CA19-9, vascular invasion, older age and cirrhosis in addition to the clinicopathologic factors noted above in their prediction models [21, 22]. Unfortunately even when these factors are taken into account, a high risk of recurrence and overall poor prognosis exists even among those with the most favorable tumor characteristics.

THE IMPACT OF LYMPH NODE INVOLVEMENT AND THE ROLE FOR LYMPHADENECTOMY

Lymphadenectomy for intrahepatic cholangiocarcinoma is performed more commonly in Asia than in Western centers. Lymph node removal varies from sampling only radiographic or clinically suspicious nodes, to a formal lymphadenectomy based upon nodal drainage patterns. In centers where routine nodal assessment is performed, dissection includes the removal of all fatty tissue and associated nodes in the hepatoduodenal ligament. Some centers include the common hepatic and left gastric artery lymph nodes for left sided liver lesions due to a differing lymphatic drainage pattern for these tumors [26, 27]. Extended lymphadenectomy, although performed much less commonly, includes posterior pancreatic and para-aortic lymph nodes [11, 17, 24, 26, 28].

When lymphadenectomy or nodal sampling is performed, the overall incidence of positive lymph nodes during surgical resection for ICC ranges from 8.5-50% in case series. However, on balance, most series report approximately a 30% lymph node positivity rate [18, 23-25] (Table 1). Retrospective series have reported the importance of positive lymph nodes on patient prognosis and compared this to other important clinicopathologic features such as a positive surgical margins or the presence of multifocal hepatic disease. Luo et al. [17] reported in the subset of patients where a positive lymph node metastasis was found at the time of surgical resection, overall survival was equally poor regardless margin status with 5-year survival reported as 5.3% and 0% respectively. Farges et al. [19] also reported similar findings in their subset of node positive patients with median survival of 18 months in margin positive and 13 months in margin negative patients. De Jong et al. [23], in a multi-institutional western series, reported that a solitary lesion with lymph node metastases faired equally poorly to that of multifocal tumors (Figure 2).

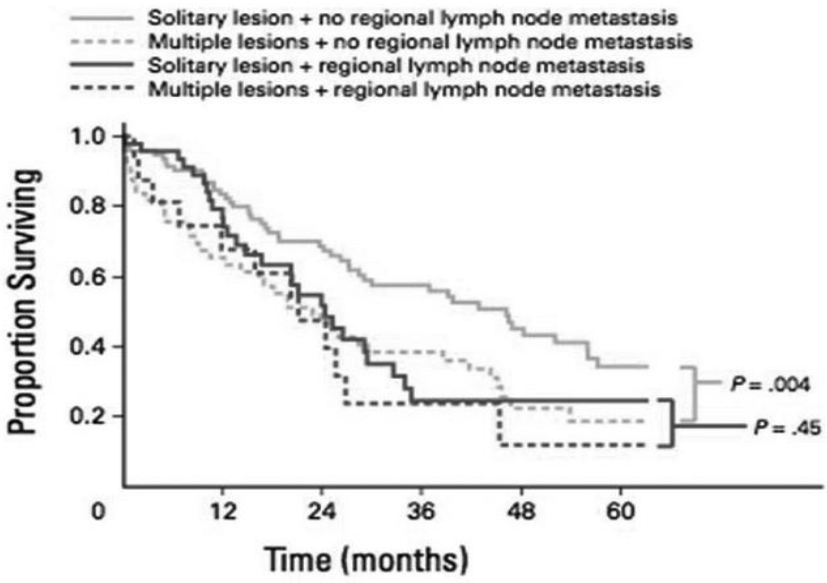

Figure 2. The effect of a positive lymph node on the presence of a solitary versus multifocal disease (From de Jong M. C. et al. [23]).

Although multiple retrospective case series demonstrate the presence of a positive lymph node to be an important prognostic factor correlated with worsened overall survival there are no prospective randomized studies to show an improvement in locoregional control or a survival benefit by performing a lymphadenectomy. It is also controversial whether performing a regional or an extended lymphadenectomy improves staging compared to sampling clinically suspicious lymph nodes.

The evidence supporting lymphadenectomy for appropriate staging is borne from retrospective case series. For example, in the largest case series reported for surgically resected intrahepatic cholangiocarcinoma, Luo et al. [17], reported that 5-year overall survival was lower for patients who were found to have positive lymph nodes on pathology (4.1%) compared to node negative patients (21.7%). The group also reported an association of improved overall survival when involved lymph nodes were limited to the hepatoduodenal ligament as compared to those with involvement of retropancreatic, celiac or para-aortic lymph nodes. On univariate analysis, patients who underwent formal dissection had an improved median survival of 13mo compared to patients who underwent lymph node sampling alone (6mo). Guglielmi et al. [26] analyzed the prognostic significance of performing a lymph node dissection in a subgroup of patients who underwent resection for ICC. The presence of a positive lymph node was again associated with poor outcomes with no five year survivors. As seen in other series [24, 29], the most common site of nodal metastases was in the hepatoduodenal ligament (Table 2). There were no patients in this series that were reported to have distant nodal disease that also did not have synchronous regional nodal disease. This would argue against the need for performing an extended lymph node dissection to ensure adequate staging. The results of the location and incidence of positive lymph nodes and the associated overall survival are shown in Table 3.

Uchiyama et al. [24] examined this further in a retrospective multicenter study in Japan. Patients who underwent an extended lymph node dissection (n = 228 out of 341) were compared to patients who underwent resection of the hepatoduodenal lymph nodes or nodal sampling alone. Patients who underwent extended lymph node dissection had a similar 5-year survival of 34.1% versus 32.9% (Figure 3). Loco-regional recurrence rates were not reported.

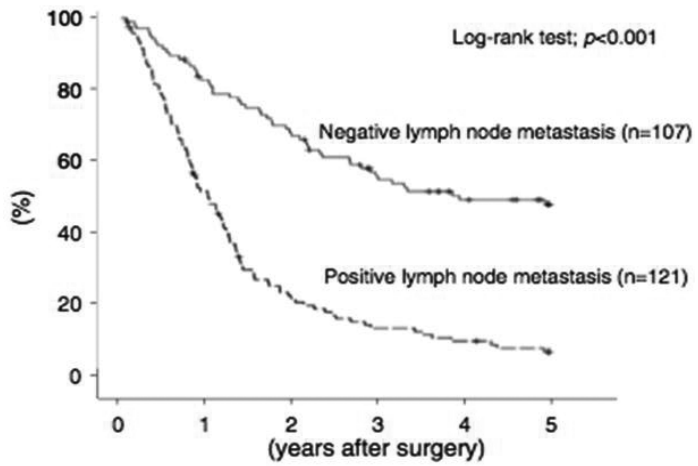

Figure 3. Overall survival of patients following extended lymphadenectomy beyond the hepatoduodenal ligament for intrahepatic cholangiocarcinoma. (from Uchiyama K et al. [24]).

Guglielmi et al. also analyzed the subgroup of patients who were found to be node negative after lymphadenectomy. Those patients who had > 3 LN removed had a longer median survival than patients who had 1-3 nodes removed (43mo v 18mo). However, Choi et al. [30] reported that the extent of lymph node dissection was not associated with differences in survival in node negative patients with 5-year survival of nearly 40% in both groups. These conflicting findings can be explained by stage migration as those with a smaller number of nodes resected may be harboring occult node positive disease. This is supported by the 60-70% diagnostic accuracy in identifying lymph node involvement based upon preoperative CT imaging in accurately assessing nodal involvement [30]. However, even if these nodes were not detected preoperatively, survival for this disease is dependent upon recurrent disease in the liver and not loco-regional recurrence. In fact, two retrospective studies report that elective lymphadenectomy for solitary clinically node negative tumors suggest that only 4-5% of these patients would derive any benefit [31, 32].

Table 2. Total number of positive and harvested lymph nodes per lymph node station harvested and percentage of patients with positive lymph nodes per station harvested (adapted from Guglielmi A. et al. [26])

Lymph Node Station	Total Number Positive/ Total Number LN Harvested	Percentage of patients with positive LN
Right cardiac region	5/8	1.8%
Left gastric artery	4/25	1.8%
Common hepatic artery	1/25	1.8%
Celiac artery	0/10	0%
Hepatoduodenal ligament	60/247	33.3%
Posterior pancreas head	7/34	7.4%
Superior mesenteric artery	0/6	0%
Paraaortic	5/43	5.5%
Total Number	69/398	

Table 3. Characteristics of lymph nodes and associated survival for resected intrahepatic cholangiocarcinoma in patient subgroup who underwent lymphadenectomy (adapted from Guglielmi A. et al. [26])

	N of patients	Median Survival (95%CI)	3-yr survival	5-yr survival	P value
Total LN retrieved					0.56
0	16	32 (13-50)	40	30	
1-3	17	38 (24-51)	56	10	
> 3	37	37 (0-83)	53	42	
LN status					0.05
N0	36	42(21-64)	64	36	
N +	18	19(11-26)	36	0	
No. negative LN retrieved					0.05
1-3	13	38 (17-58)	52	10	
> 3	23	69(27-110)	69	54	
No. positive LN retrieved					0.02
1-3	13	52 (-)	51	-	
> 3	5	12(3-20)	0	0	
Positive LN station					0.68
Hepatoduodenal	14	19(0-38)	40	-	
Hepatoduodenal + other	4	12(-)	0	0	

(Note: Median survival in months).

In summary, although the status of regional lymph nodes is an important prognostic factor, performing a regional or extended lymphadenectomy is not associated with a survival advantage. The role of routine regional lymphadectomy for staging for ICC has not been defined and two recent systematic reviews on the role of lymphadenectomy have failed to help to reach a consensus [28, 33]. Given the limited data, the NCCN currently recommends that a portal (regional) lymphadenectomy is "reasonable" and should be considered during operative intervention and that distant nodal disease should be regarded as a contraindication to surgical resection [34]. In the case of obvious, positive regional nodal disease diagnosed preoperatively, surgical judgment must be exercised to determine whether surgical resection should be undertaken given that a major resection may be truly more palliative than potentially curative.

MULTIFOCAL INTRAHEPATIC METASTASES

The presence of multifocal disease is one of the strongest negative prognostic factors found in multiple case series published in both Western and Eastern experiences (Table 1). Endo et al. [18] reported a median survival of 87 months for those with resected solitary disease versus 19 months in patients with multiple tumors (Figure 4). Two large multicenter, retrospective analyses, one from a Western series and the other from Japan analyzed the prognostic significance of multifocal liver disease [25]. De Jong et al. [23] reported that multifocal disease was associated with poor 5-survival regardless of nodal status (Figure 2). The multicenter analysis by the Study Group for Hepatic Surgery of the Japanese Society of Hepato-Biliary-Pancreatic Surgery reported 5-year overall survival of 49% for solitary liver tumors and 18% for multifocal liver tumors. They also reported that multifocal disease confined to one lobe of the liver had the same overall survival as bilobar disease. Endo et al. [18] reported that the median survival following resection of multifocal hepatic disease in their patient cohort was no different than those patients with liver only disease that were treated non-operatively. Despite the technical feasibility to resect such tumors, such a decision has to be approached with caution given the poor prognosis [25]. These patients are best treated with chemotherapy first. The NCCN guidelines consider multifocal intrahepatic cholangiocarcinoma to be a relative contraindication to resection and only to be considered in highly selected cases [34].

HEPATIC RESECTION AND MARGINS

The goal of any potentially curative operation for ICC is to achieve a margin negative resection even if this requires major vascular or biliary resection with reconstruction [35]. Case series report differences in 5-year survival in those who underwent an R0 or R1 resection of 28.7-50% versus 0-13.9% [11, 17, 18]. However, the impact of margin status on survival dissipates when factors such as the presence of positive lymph nodes, or multiple hepatic lesions are adjusted for on multivariate analyses. When Farges et al. [19] examined the impact of margin status on survival patients with pathologically involved lymph nodes had similar overall median survival with a R1 resection (18mo) or R0 resection (13mo).

However, in the subset of patients with pathologically proven node negative disease and a solitary tumor, a negative margin resection had a 70% survival, with no 5-year survivors in the presence of a positive margin. In node negative patients, on multivariate analysis, a margin width of < 5mm was associated with poorer survival. Of note there were no statistically significant differences between the extent of surgery performed, tumor size or tumor multifocality between groups.

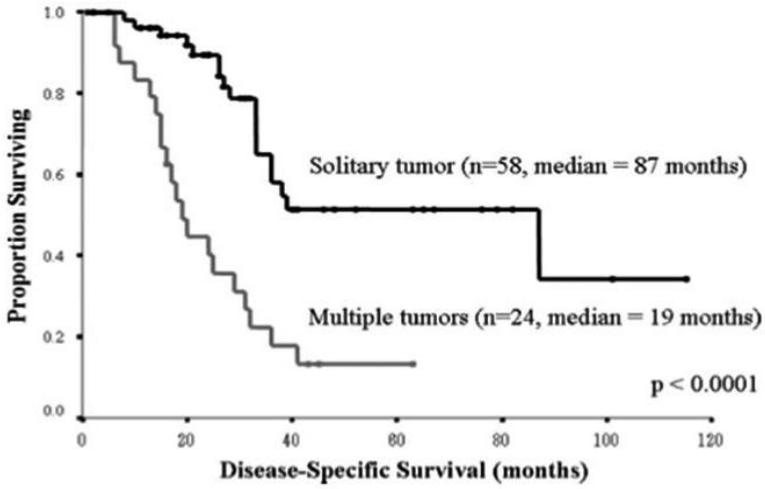

Figure 4. Disease specific survival after resection of intrahepatic cholangiocarcinoma stratified by number of tumors. (From Endo I. et al. [18]).

Ribero et al. [36] evaluated margin status and found a higher local recurrence rate of 74% with positive margins, but 54% of patients with negative margins still recurred locally. The width of that margin did not seem to impact survival or local recurrence. Based upon the reported data, obtaining a negative margin should be the goal for all resections and particular care should be undertaken in patients with solitary, node negative disease.

SIZE

Retrospective reviews have sought to analyze the relative prognostic value of tumor size with varying results (Table 1). The current AJCC 7th edition staging system [37] does not utilize size in determining the T stage as it was not found to be discriminatory in the analysis of the dataset used to formulate staging. However in both versions of the Liver Cancer Study Group of Japan staging system for ICC (LCSGJ) [25, 38], size was included as a discriminatory factor. Patients with a solitary tumor < 2cm in size in node negative patients had over 90% survival compared to 30-40% in tumors ≥ 2cm. Despite the exclusion of size in the 7th edition of the AJCC staging, two recently published nomograms (Figure 1), include tumor size as a continuous variable in determining prognosis following resection [21, 22]. Increasing size is associated with worsened pathologic variables such as tumor grade and microscopic vascular invasion [36, 39]. Large tumor size is also a surrogate for other factors impacting outcomes such as the need for major liver resection and R1 resection. Therefore, it

is difficult to determine an exact cutoff value for which tumor size becomes associated with a worse outcome given the variability in reporting other significant clinicopathologic variables. Given limited treatment options for this disease, for solitary tumors, particularly without gross nodal involvement aggressive surgical resection is warranted if an R0 resection can be achieved.

SURGICAL TECHNIQUE: RESECTION AND RECONSTRUCTION

Few studies have looked at the use of diagnostic laparoscopy in ICC. Laparoscopy can prevent a non-therapeutic laparotomy by detecting small volume metastatic peritoneal disease, multi-focal liver disease and even nodal disease. Improvements in cross sectional imaging have decreased the yield of finding metastatic disease at exploration but given the low morbidity of the procedure, this step should be considered to prevent the morbidity of a laparotomy.

Intraoperative ultrasound remains an important study to help guide resection. This can be performed laparoscopically or at the time of laparotomy to look for occult intrahepatic metastases and to confirm intrahepatic anatomy as related to the tumor. Following this, exploration of lymph node basins as described previously should be performed with either nodal sampling of suspicious lymph nodes or formal lymphadenectomy of periportal lymph nodes performed for staging.

Given the large size of tumors at the time of presentation, invasion of the hilum and major vascular structures is not uncommon and require radical resections, not only requiring a major hepatectomy but also vascular and biliary reconstruction. Uchiyama et al. [24] performed a major hepatectomy 76% of cases, with extrahepatic bile duct resection and reconstruction performed in 42.8% and combined vascular and biliary resection in 15.5% of cases. This was accomplished with mortality of 3.2% and morbidity of 34.3%. Ribero et al. [36] in another large multicenter study performed major liver resections in 50% of cases and performed bile duct resections in 55% of cases and major vascular resections in 14.5% of cases. Mortality was 5.3% and surgical morbidity was 35%, with 44% of complications related to the liver. Infectious complications comprised 20% of complications, similar to other published series [39]. Resection should be performed at expert, high volume centers not only to ensure an R0 resection but to safely manage the high rate of post operative complications [11, 35].

SURGICAL MANAGEMENT OF RECURRENT ICC

Recurrence, even amongst those patients who underwent R0 resection with node negative disease is common and usually occurs within the 3 years after surgery. The overall recurrence rate approaches 50% and the sites most commonly involved include the liver, peritoneum, lymph nodes and bone [3, 40]. Endo et al. [18] found that two thirds of patients recurred at a median follow up of 26 months and that over 60% of these recurrences involved the liver. For node negative, solitary tumors the recurrence rate was 47.3% while those with multifocal disease or lymphatic involvement at the time of initial surgery recurred in 92.6% of cases.

Recurrent disease is managed by chemotherapy in combination with other modalities such as radiation, radiofrequency ablation, hepatic arterial embolization and rarely repeat surgical resection. Ercolani et al. [41] reported a case series of 23 patients with recurrent disease. Six patients underwent hepatic re-resection and 8 patients underwent RFA for isolated liver recurrences and were treated concomitantly with chemotherapy. 5-year survival in this highly selected group reached 56%. Hyder et al. [40] reported that following recurrence, 33/161 patients underwent repeated operative intervention. Those that were resected had a median survival of 26 months, while those who received chemotherapy or supportive care alone had a median survival of 9.2 months.

Zhang et al. [42] reported a series of 109 patients with recurrent ICC treated with thermal ablative therapy (n = 77) or repeat hepatic resection (n = 32). Criteria for re-resection were less stringent in this series and included patients with both early and multifocal recurrence within the liver. Patients treated with ablation had a 94.7% rate of technical success but recurrent disease was common with 60% of patients recurring with a median disease free interval of 6.8 months and median overall survival of 21 months. The subgroup of patients who underwent repeat hepatic resection recurred 70% of the time with a mean disease free interval of 9 months and a median overall survival of 20months. Both groups had 3-year survival approaching 20% with no 5-year survivors from the time of repeat intervention. Multivariate analysis showed that a disease free interval of 1 year or greater and a solitary recurrence were associated with improved overall survival in this cohort. In summary, recurrences are common following resection of ICC and chemotherapy is the backbone for management. We feel that there is a very limited role for repeat surgical intervention and should be only be considered in patients with isolated, solitary recurrences within the liver who have a long initial disease free interval and who do not progress while on chemotherapy.

TRANSPLANTATION

Interest in liver transplantation for ICC was initially proposed for high risk patients, particularly those with large solitary tumors, where removal of the liver would result in a R0 resection, theoretically leading to improvement in disease control and survival. However, outcomes following transplantation for intrahepatic cholangiocarcinoma have been historically poor with 5-year survival rates ranging from 0-42% and 5-year disease free survival rates ranging from 0-30% (Table 4). The same factors associated with poor prognosis following hepatectomy are also seen for liver transplantation including multifocal disease, positive margins and lymph node metastases [43].

Hong et al. [44] reported the UCLA experience of 37 patients who underwent orthotopic liver transplantation for locally advanced (94%) and/or multifocal tumors (60%) that were not amenable to hepatectomy with biliary or vascular reconstruction. Fifty five percent of these patients were cirrhotic, with primary sclerosing cholangitis (67%) and hepatitis (19%) being the most common cause of chronic liver disease. In their retrospective review, the subset of transplanted patients with these very high risk tumors who were treated with both neoadjuvant and adjuvant chemotherapy experienced nearly 60% 5-year compared to those who received adjuvant or no therapy whose survival was 20%. However, treatment with neoadjuvant therapy may not have changed the true outcome, but rather likely allowed for

more specific patient selection. The authors do not indicate what the dropout rate is but as the study reviewed over 20 years of the centers experience, these patients were truly highly selected. Currently, given the scarcity of organs available for donation the International Liver Cancer Association does not recommend transplantation for these high risk patients, while UNOS does not have established guidelines [45].

There are conflicting reports related to outcomes after transplantation for early stage ICC incidentally noted in liver explant specimens from patients transplanted for hepatic cirrhosis or primary sclerosing cholangitis. One case series reported a 50% disease recurrence after a median time of 10months [46]. Another case series reported 3-year overall survival to be 30% with a median survival of 30 months [47]. In contrast to this, a multicenter study from Spain reported 5-year overall survival of 73% for solitary tumors less than 2cm in size [48]. These results are similar to rates expected with partial hepatectomy in patients with normal livers. Currently, known ICC is not an indication for transplantation so although patients with severe cirrhosis with a small, solitary tumor could theoretically benefit from such an intervention, it cannot be recommended at this time.

SURGICAL PLACEMENT AND OUTCOMES OF HEPATIC ARTERIAL INFUSION PUMP THERAPY FOR UNRESECTABLE ICC

The use of hepatic directed intra-arterial therapies including TACE with or without drug-eluding beads and Y-90 radioembolization are discussed in a separate chapter so will not be specifically reviewed here. The Memorial Sloan Kettering Cancer Center is currently studying the use of hepatic arterial infusion chemotherapy with floxuridine and dexamethasone utilizing a surgically implanted pump in combination with systemic chemotherapy. The placement is performed through a limited laparotomy. Typically, a separate subutaneous pocket for the pump is made laterally in the left lower quadrant of the abdomen. The pump catheter is brought down through the fascia and placed into the lumen of the gastroduodenal artery through a distal arteriotomy and secured with ties. The gastroduodenal artery is the most common site of pump catheter placement and has the best long term durability and complication rate [49]. The right gastric artery as well as all small branches leading to the stomach duodenum and pancreas are ligated and divided off of the GDA and hepatic artery to prevent extrahepatic perfusion. Methylene blue or fluorescein is injected into the pump intraoperatively in order to check liver perfusion.

Two phase II clinical trials [50, 51] totaling 44 patients with unresectable cholangiocarcinoma have been completed and reported thus far. The first trial included 26 patients with unresectable ICC who were treated with regional chemotherapy consisting of FUDR and dexamethasone, 50 while in the second phase II trial, 18 patients were treated with regional FUDR with dexamethasone in combination with systemic bevacizumab. Sixteen percent of patients were previously treated with systemic chemotherapy and over 60% had multifocal disease. Partial response rates for all patients ranged from 53.8% with over 90% experiencing stable disease at a median 2-year follow up. The addition of systemic bevacizumab in the second trial led to unacceptable biliary toxicity leading to the termination of the study. Updated follow up of these trials has shown 23% 3-year and 11% 5-year survival with a median overall survival of 29.3 months. Post trial treatment included systemic

chemotherapy in 95% of these patients and 82% received additional hepatic arterial infusional chemotherapy either alone or in combination with systemic chemotherapy [52]. Three patients were downstaged and underwent complete resection.

Table 4. Overall and disease free following transplantation for intrahepatic cholangiocarcinoma

Author	Year	Site	N	Overall Survival			Author	Year	Site	N
				1-Year	3-year	5-year				
Casavilla	1997	Pittsburgh	20	70	29	18	31	Adjuvant	Yes**	None
Meyer	2000	Cincinnati	207	72	NR	23	51	Adjuvant	Yes	43
Robles	2004	Spain	23	77	65	42	27	Adjuvant	Yes	10
Becker	2007	UNOS	280	74	NR	38	NR	NR	NR	77
Hong	2011	UCLA	38	NR	38	32	41	Neoadjuvant/ Adjuvant	Yes	None

* High risk features include large tumor size, multifocal lesions or positive lymph nodes.

** 9 patients underwent multi-visceral resection to achieve negative margin.

(Adapted from Rana and Hong. Orthotopic liver transplantation in combination with neoadjuvant therapy: A new paradigm in the treatment of unresectable intrahepatic cholangiocarcinoma. *Curr Opin Gastroenterol*, 2012; 28:258-265 and Guglielmi, Ruzzenente and Iacono *Surgical Treatment of Hilar and ICC*, Springer 2008: p. 230).

Table 5. Comparison of hepatic arterial outcomes for unresectable intrahepatic cholangiocarcinoma (modified from Boehm L. M. et al. [53])

Author	Year	Sample	Treatment Regimen	Type of System	Extra-hepatic disease	Multi-focal disease	Median Survival (mo)	Major Toxicity (= > III)
Tanaka et al.	2002	11	5-FU, Doxorubi-cin, MMC, Cisplatin*	Percuatneous Catheter-Port	36%	45%	26 (mean)	18%
Jarnagin et al.	2009	26	FUDR + Dexamethasone	Surgically placed Port	0%	61%	29.5	14.7%
Inaba et al.	2011	25	Gemcitabine	Percuatn-eous Catheter-Port	36%	NR	11.3	48%
Kemeny et al.	2011	18	FUDR+ Dexame-thasone + bevacizumab**	Surgically placed Port	0%	68%	31.1	27%

* multiple different regimens administered.

** systemically administered.

Although not currently defined, patient selection will be equally important when considering those patients with unresectable disease who will derive benefit from treatment with HAI therapy. The regimens used and results of hepatic arterial infusional treatment at other centers [53] (Table 5) is variable with the best results seen by the group at Memorial and by Tanaka et al. [54] despite using different regimens and drug delivery systems. Both groups excluded patients with evidence of extrahepatic disease were excluded and the majority of patients also had solitary tumors. Currently, although promising, the use of HAI therapy is still investigational and continued study will be required to determine its role in treatment.

CONCLUSION

Since surgery remains the only potentially curative therapy complete resection should be attempted in all fit patients with a resectable tumor. The presence of multifocal disease or gross lymphatic involvement should indicate the need for a treatment with chemotherapy with a secondary resection made on a case by case basis. The presence of large and locally invasive tumors into biliary and major vascular structures cannot be considered a contraindication to surgery. The use of liver transplantation is still experimental and warrants further investigation.

REFERENCES

[1] Rizvi, S., Gores, G. J. Pathogenesis, diagnosis and management of cholangiocarcinoma. *Gastroenterology*, 2013, 145(6):1215-1229.

[2] Dodson, R. M., Weiss, M. J., Cosgrove, D. et al., Intrahepatic cholangiocarcinoma: Management options and emerging therapies. *J Am Coll Surg*, 2013, 217(4):736-750.

[3] Guglielmi, A., Ruzzenente, A., Iacono, C., *Surgical Treatment of Hilar and Intrahepatic Cholangiocarcinoma*. Springer, 2008.

[4] Bridgewater, J., Galle, P. R., Khan, S. A. et al., Guidelines for the diagnosis and management of intrahepatic cholangiocarcinoma. *J Hepatol*, 2014, 60(6):1268-1289.

[5] Bertuccio, P., Bosetti, C., Levi, F., Decarli, A., Negri, E., La Vecchia, C. A comparison of trends in mortality from primary liver cancer and intrahepatic cholangiocarcinoma in Europe. *Ann Oncol*, 2013, 24(6): 1667-1674.

[6] Amini, N., Ejaz, A., Spolverato, G., Kim, Y., Herman, J. M., Pawlik, T. M., Temporal trends in liver-directed therapy of patients with intrahepatic cholangiocarcinoma in the United States: A population-based analysis. *J Surg Oncol*, 2014, 110(2):163-170.

[7] Carpizo, D. R., D'Angelica, M., Management and extent of resection for intrahepatic cholangiocarcinoma. *Surg Oncol Clin N Am*, 2009, 18(2): 289-305.

[8] Kim, S. A., Lee, J. M., Lee, K. B. et al., Intrahepatic mass-forming cholangiocarcinomas: Enhancement patterns at multiphasic CT, with special emphasis on arterial enhancement pattern: Correlation with clinicopathologic findings. *Radiology*, 2011, 260(1):148-157.

[9] Miller, G., Schwartz, L. H., D'Angelica, M. The use of imaging in the diagnosis and staging of hepatobiliary malignancies. *Surg Oncol Clin N Am*, 2007, 16(2):343-368.

[10] Valls, C., Gumà, A., Puig, I. et al., Intrahepatic peripheral cholangiocarcinoma: CT evaluation. *Abdom Imaging*, 2014, 25(5):490-496.

[11] Marubashi, S., Gotoh, K., Takahashi, H., et al., Prediction of the postoperative prognosis of intrahepatic cholangiocarcinoma (ICC): Importance of preoperatively-determined anatomic invasion level and number of tumors. *Dig Dis Sci*, 2014, 59(1):201-213.

[12] Seo, S., Hatano, E., Higashi, T. et al., Fluorine-18 fluorodeoxyglucose positron emission tomography predicts lymph node metastasis, P-glycoprotein expression and recurrence after resection in mass-forming intrahepatic cholangiocarcinoma. *Surgery*, 2008, 143(6):769-777.

[13] Vilgrain, V., Staging cholangiocarcinoma by imaging studies. *HPB* (Oxford), 2008, 10(2):106-109.

[14] Grobmyer, S. R., Wang, L., Gonen, M. et al., Perihepatic lymph node assessment in patients undergoing partial hepatectomy for malignancy. *Ann Surg*, 2006, 244(2):260-264.

[15] Kang, Y., Lee, J. M., Kim, S. H., Han, J. K., Choi, B. I., Intrahepatic mass-forming cholangiocarcinoma: Enhancement patterns on gadoxetic acid-enhanced MR images. *Radiology*, 2012, 264(3):751-760.

[16] Zhang, Y., Uchida, M., Abe, T., Nishimura, H., Hayabuchi, N., Nakashima, Y. Intrahepatic peripheral cholangiocarcinoma: Comparison of dynamic CT and dynamic MRI. *J Comput Assist Tomogr*, 2014, 23 (5):670-677.

[17] Luo, X., Yuan, L., Wang, Y., Ge, R., Sun, Y., Wei, G., Survival outcomes and prognostic factors of surgical therapy for all potentially resectable intrahepatic cholangiocarcinoma: A large single-center cohort study. *J Gastrointest Surg*, 2014, 18 (3):562-572.

[18] Endo, I., Gonen, M., Yopp, A. C. et al., Intrahepatic cholangiocarcinoma: Rising frequency, improved survival and determinants of outcome after resection. *Ann Surg*, 2008, 248(1):84-96.

[19] Farges, O., Fuks, D., Boleslawski, E. et al., Influence of surgical margins on outcome in patients with intrahepatic cholangiocarcinoma: A multicenter study by the AFC-IHCC-2009 study group. *Ann Surg*, 2011, 254(5):824-829., discussion 830.

[20] Park, J., Kim, M. H., Kim, K. P. et al., Natural History and Prognostic Factors of Advanced Cholangiocarcinoma without Surgery, Chemotherapy, or Radiotherapy: A Large-Scale Observational Study. *Gut Liver*, 2009, 3(4):298-305.

[21] Hyder, O., Marques, H., Pulitano, C. et al., A nomogram to predict long-term survival after resection for intrahepatic cholangiocarcinoma: An Eastern and Western experience. *JAMA Surg*, 2014, 149(5):432-438.

[22] Wang, Y., Li, J., Xia, Y. et al., Prognostic nomogram for intrahepatic cholangiocarcinoma after partial hepatectomy. *J Clin Oncol*, 2013, 31(9):1188-1195.

[23] De Jong, M. C., Nathan, H., Sotiropoulos, G. C. et al., Intrahepatic cholangiocarcinoma: An international multi-institutional analysis of prognostic factors and lymph node assessment. *J Clin Oncol*, 2011, 29(23):3140-3145.

[24] Uchiyama, K., Yamamoto, M., Yamaue, H. et al., Impact of nodal involvement on surgical outcomes of intrahepatic cholangiocarcinoma: A multicenter analysis by the Study Group for Hepatic Surgery of the Japanese Society of Hepato-Biliary-Pancreatic Surgery. *J Hepatobiliary Pancreat Sci*, 2011, 18(3):443-452.

[25] Uenishi, T., Ariizumi, S., Aoki, T. et al., Proposal of a new staging system for mass-forming intrahepatic cholangiocarcinoma: A multicenter analysis by the Study Group for Hepatic Surgery of the Japanese Society of Hepato-Biliary-Pancreatic Surgery. *J Hepatobiliary Pancreat Sci*, 2014, 21(7):499-508.

[26] Guglielmi, A., Ruzzenente, A., Campagnaro, T. et al., Patterns and prognostic significance of lymph node dissection for surgical treatment of perihilar and intrahepatic cholangiocarcinoma. *J Gastrointest Surg*, 2013, 17(11):1917-1928.

[27] Yamamoto, M., Takasaki, K., Yoshikawa, T., Lymph Node Metastasis in Intrahepatic Cholangiocarcinoma. *Jpn J Clin Oncol*, 1999, 29(3):147-150.

[28] Amini, N., Ejaz, A., Spolverato, G., Maithel, S. K., Kim, Y., Pawlik., T. M., Management of lymph nodes during resection of hepatocellular carcinoma and intrahepatic cholangiocarcinoma: A systematic review. *J Gastrointest Surg*, 2014, 18 (12):2136-2148.

[29] Shirabe, K., Mano, Y., Taketomi, A. et al., Clinicopathological Prognostic Factors After Hepatectomy for Patients with Mass-Forming Type Intrahepatic Cholangiocarcinoma: Relevance of the Lymphatic Invasion Index. *Ann Surg Oncol*, 2010, 17: 1816-1822.

[30] Choi, S. B., Kim, K. S., Choi, J. Y. et al., The prognosis and survival outcome of intrahepatic cholangiocarcinoma following surgical resection: Association of lymph node metastasis and lymph node dissection with survival. *Ann Surg Oncol*, 2009, 16(11):3048-3056.

[31] Shimada, K., Sano, T., Nara, S. et al., Therapeutic value of lymph node dissection during hepatectomy in patients with intrahepatic cholangiocellular carcinoma with negative lymph node involvement. *Surgery*, 2009, 145(4):411-416.

[32] Li, D. Y., Zhang, H. B., Yang, N., Quan, Y., Yang, G. S., Routine lymph node dissection may be not suitable for all intrahepatic cholangiocarcinoma patients: Results of a monocentric series. *W J Gastroenterol*, 2013, 19(47):9084-9091.

[33] Adachi, T., Eguchi, S. Lymph node dissection for intrahepatic cholangiocarcinoma: A critical review of the literature to date. *J Hepatobiliary Pancreat Sci*, 2014, 21(3):162-168.

[34] National Comprehensive Cancer Network. *Hepatobiliary Cancers* (Version 2.2014). Available from http://www.nccn.org/professionals/physician_gls/pdf/hepatobiliary. pdf. Accessed June 1, 2014.

[35] Ali, S. M., Clark, C. J., Zaydfudim, V. M. et al., Role of Major Vascular Resection in Patients with Intrahepatic Cholangiocarcinoma. *Ann Surg Oncol*, 2013, 20:2023-2028.

[36] Ribero, D., Pinna, A. D., Guglielmi, A. et al., Surgical Approach for Long-term Survival of Patients with Intrahepatic Cholangiocarcinoma: A Multi-institutional Analysis of 434 Patients. *Arch Surg*, 2012, 147(12):1107-1113.

[37] Nathan, H., Aloia, T. A., Vauthey, J. N. et al., A proposed staging system for intrahepatic cholangiocarcinoma. *Ann Surg Oncol*, 2009, 16(1):14-22.

[38] Farges, O., Fuks, D., Le Treut, Y. P. et al., AJCC 7th edition of TNM staging accurately discriminates outcomes of patients with resectable intrahepatic cholangiocarcinoma: By the AFC-IHCC-2009 study group. *Cancer*, 2011, 117(10):2170-2177.

[39] Spolverato, G., Kim, Y., Alexandrescu, S. et al., Is Hepatic Resection for Large or Multifocal Intrahepatic Cholangiocarcinoma Justified? Results from a Multi-Institutional Collaboration. *Ann Surg Oncol*, 2014 [Epub ahead of print].

[40] Hyder, O., Hatzaras, I., Sotiropoulos, G. C. et al., Recurrence after operative management of intrahepatic cholangiocarcinoma. *Surgery*, 2013, 153(6):811-818.

[41] Ercolani, G., Vetrone, G., Grazi, G. L. et al., Intrahepatic cholangiocarcinoma: Primary liver resection and aggressive multimodal treatment of recurrence significantly prolong survival. *Ann Surg*, 2010, 252(1):107-114.

[42] Zhang, S. J., Hu, P., Wang, N. et al., Thermal ablation versus repeated hepatic resection for recurrent intrahepatic cholangiocarcinoma. *Ann Surg Oncol*, 2013, 20(11):3596-3602.

[43] Casavilla, F. A., Marsh, J. W., Iwatsuki, S. et al., Hepatic resection and transplantation for peripheral cholangiocarcinoma. *J Am Coll Surg*, 1997, 185(5):429-436.

[44] Hong, J. C., Jones, C. M., Duffy, J. P. et al., Comparative analysis of resection and liver transplantation for intrahepatic and hilar cholangiocarcinoma: A 24-year experience in a single center. *Arch Surg*, 2011, 146(6):683-689.

[45] Fujita, T. Liver transplantation for intrahepatic cholangiocarcinoma. *Lancet*, 2014, 384(9949):1182.

[46] Vallin, M., Sturm, N., Lamblin, G. et al., Unrecognized intrahepatic cholangiocarcinoma: An analysis of 993 adult cirrhotic liver explants. *Clin Transplant*, 2013, 27(3):403-409.

[47] Ghali, P., Marotta, P. J., Yoshida, E. M. et al., Liver transplantation for incidental cholangiocarcinoma: Analysis of the Canadian experience. *Liver Transpl*, 2005, 11(11): 1412-1416.

[48] Sapisochin, G., Rodríguez de Lope, C., Gastaca, M., et al., "Very early" intrahepatic cholangiocarcinoma in cirrhotic patients: Should liver transplantation be reconsidered in these patients? *Am J Transplant*, 2014, 14(3):660-667.

[49] Allen, P. J., Nissan, A., Picon, A. I. et al., Technical complications and durability of hepatic artery infusion pumps for unresectable colorectal liver metastases: An institutional experience of 544 consecutive cases. *J Am Coll Surg*, 2005, 201(1):57-65.

[50] Jarnagin, W. R., Schwartz, L. H., Gultekin, D. H. et al., Regional chemotherapy for unresectable primary liver cancer: Results of a phase II clinical trial and assessment of DCE-MRI as a biomarker of survival. *Ann Oncol*, 2009, 20(9):1589-1595.

[51] Kemeny, N. E., Schwartz, L., Gönen, M. et al., Treating primary liver cancer with hepatic arterial infusion of floxuridine and dexamethasone: Does the addition of systemic bevacizumab improve results? *Oncology*, 2011, 80(3-4):153-159.

[52] Konstantinidis, I. T., Do, R. K. G., Gultekin, D. H. et al., Regional chemotherapy for unresectable intrahepatic cholangiocarcinoma: A potential role for dynamic magnetic resonance imaging as an imaging biomarker and a survival update from two prospective clinical trials. *Ann Surg Oncol*, 2014, 21(8):2675-2683.

[53] Boehm, L. M., Jayakrishnan, T. T., Miura, J. T. et al., Comparative effectiveness of hepatic artery based therapies for unresectable intrahepatic cholangiocarcinoma. *J Surg Oncol*, 2015, 111(2):213-220.

[54] Tanaka, N., Yamakado, K., Nakatsuka, A., et al., Arterial chemoinfusion therapy through an implanted port system for patients with unresectable intrahepatic cholangiocarcinoma: Initial experience. *Eur J of Rad*, 2002, 41:42-48.

In: Encyclopedia of Surgery (22 Volume Set)
Editors: Andreas Lehrer and Kristin Mueller
ISBN: 978-1-53618-329-0
© 2020 Nova Science Publishers, Inc.

Chapter 359

SURGERY FOR HILAR CHOLANGIOCARCINOMA

Daniel Seehofer*, MD, PhD and Peter Neuhaus, MD
Department of General-, Visceral- and Transplantation- Surgery,
Charité - Universitätsmedizin Berlin, Campus Virchow-Klinikum. Berlin, Germany

ABSTRACT

Resection of hilar cholangiocarcinama is the only potentially curative treatment option. However, to treat with a radical intent this tumor, along with the excision of the bile duct, major or extended liver resections, lymphadenectomy and often vascular resections are needed. Because of the complexity of the procedure, optimal patient selection and preparation, which include in many cases biliary drainage and portal vein embolization, are essential to ensure adequate short and long term results. The present chapter reviews the evidence for the optimal preoperative and intraoperative management of patients with a "Klatskin" tumor.

INTRODUCTION

Complete surgical resection represents the only curative treatment option for patents with hilar cholangiocarcinoma (hCCA). However, liver resection for hCCA is technically demanding and associated with a relatively high postoperative morbidity, compared to other liver resections (e.g. for colorectal metastases). This is based on the following risk factors, which are particularly relevant for patients with hCCA:

- A high loss of functional liver parenchyma, since a small extrahepatic tumor has to be removed with a high amount of functional, non-tumorous liver parenchyma.
- Simultaneous requirement of a complex bilioenteric reconstruction often with multiple, thin-walled intrahepatic second or third order biliary branches.
- Additional vascular resections and reconstructions are often required (mostly portal vein reconstruction).

* Corresponding Author's Email: daniel.seehofer@charite.de.

- Predominance of old aged patients, since the incidence of cholangiocarcinomas is increasing with age.

Therefore, most hCCA are operated in specialized centers, which ensure optimal conditioning of the future liver remnant (FLR) prior to surgery. This might include treatment of cholangitis, relief of cholestasis via ERC or PTC, testing of liver function in combination with volumetric assessment of the FLR and portal venous embolization. These measures help to assure an acceptable perioperative morbidity and a low mortality. However, the long term outcome largely depends on an adequate surgical technique and a selection of the most radical but still sustainable surgical approach for the individual patient. Due to the central location of hCCA with close proximity to paramount vascular structures, the achievable safety margin is generally lower, than in most other GI-Tumors. Hence, the rate of positive margins (R1) is around 20-30%, even in large series of experienced centers.

INDICATIONS AND CONTRAINDICATIONS FOR SURGERY

The two major goals of oncological surgery for hCCA are:

1) Curative resection: achievement of negative resection margins (R0 resection).
2) Avoidance of severe postoperative complications and especially of postoperative liver failure.

If it is upfront clear, that these two goals cannot be achieved, surgery is contra-indicated. However, in many cases one cannot decide clearly on the basis of preoperative staging investigations including CT, MRI and ERC, if an R0 resection is possible or not. This is caused by the typical growth pattern of hCCA. Radiological definition of the tumor extensions is difficult in the periductal infiltrating subtype, which has the highest prevalence. Tumor extensions of the nodular and the intraductal papillary subtype of hCCA can be better assessed on radiological investigations, however these growth patterns are rare.

For the periductal pattern, on the one hand, tumor extensions might be under-estimated, since tumor progression over the macroscopically visible biliary stenosis is often seen due to an additional periductal growth of the tumor. Therefore a safety margin of 5-10 mm over the visible tumor stenosis should be envisaged, although this often not possible. On the other hand, tumor extensions might also be over-estimated due to a concomitant inflammatory reaction, which is often associated with hCCA. Thus, in many cases the discrimination between R0 or R1 is obtained only intraoperatively by frozen section after severance of the intrahepatic bile duct. At this stage, a point of no return has already been reached. This explains the relatively high rate of R1 resections in the literature. However, there is some indication, that even R1-resection is beneficial for the patient, and 5-year survival rates of up to 20% haven been reported after R1-resection [1].

Therefore, one should progress to surgical exploration, if the tumor is deemed potentially resectable by an experienced hepatobiliary surgeon, obvious contraindications (see below) are absent and the perioperative risk for the patient is acceptable (patient age, liver function, concomitant diseases). Classification systems like the Bismuth type I to IV classification or

the Memorial Sloan Kettering (MSKCC) T1 to T4 stages are useful for the classification of the tumor and the complexity of the surgical procedure. However, in modern times neither Bismuth type IV nor MSKCC T4 generally preclude R0 resection. Accordingly, many recently published surgical series include a high rate of curatively resected Bismuth type IV tumors [e.g. 2].

Form the issues stated above, it becomes clear that contraindications for surgical resection based on local extension of the tumor can only be judged by an experienced hepatobiliary surgeon on the basis of high quality imaging. The same is true for liver function as relative contraindication. Therefore, nowadays all patients with loco-regionally limited hCCA should be discussed in a multidisciplinary tumor board before a final decision concerning resectability or irresectability is made. Potential contraindications for surgical resection of hCCA include:

- peritoneal carcinosis
- distant metastases (lung, liver)
- liver cirrhosis or poor liver function
- infiltration of vascular structures which cannot be reconstructed
- perioperative risk is deemed to high (individual consideration, e.g. due to reduced liver function, complex vascular reconstructions, etc.)

SURGICAL STRATEGY

Rationale for Major Hepatectomy

Hilar cholangiocarcinomas are mostly infiltrating along the biliary tree, in some cases in a discontinuous manner. During planning of the surgical strategy, a biliary safety margin of 5-10 mm should be envisaged if possible. Due to the almost absent muscular layer of the bile ducts, infiltration of the periductal tissue and the adjacent liver parenchyma is seen early and often. Moreover, due to the close vicinity of the biliary confluence to the portal vein bifurcation, occlusion of one main portal branch by tumor infiltration or tumor encasement is seen in around 30% of cases [3]. Based on these tumor characteristics, it can be recognized, that an isolated resection of the extrahepatic bile duct (“hilar resection”) does not meet the requirements of an radical oncological procedure. As a consequence, the risk of tumor recurrence after isolated hilar resection is higher than 90% and long term survival is rarely seen after this procedure [4]. Therefore, limited resections are reserved for very old patients or patients with liver cirrhosis or very poor liver function, who would not tolerate major liver surgery.

To gain an adequate safety margin a simultaneous en bloc resection of the adjacent liver segments without preparation or “lowering” of the hilar plate is inevitable. Moreover, locally more advanced tumors often approximate or even encase vital vascular structures of one or both lobes, which than necessitates (extended) hemihepatectomies. Even if vascular structures are not involved directly, for reasons of oncological radicality extended hepatectomies have evolved as the standard surgical procedure for hCCA - adequate liver function provided.

Accordingly, the rate of simultaneous major liver resection in most recent series is nowadays more than 95 % [5].

Predilection Sites for R1 Resection

The risk for incomplete or marginal tumor resection (R1) resection is highest at the longitudinal tumor extension within the biliary tree. Additionally, at the circumferential margin there are further predilection sites of R1-resection:

- the right hepatic artery, which normally traverses dorsal to the proximal common hepatic duct
- the portal vein bifurcation, which is situated immediately dorsal to the biliary confluence
- the transection margin of the liver parenchyma

As far as possible, these predilection sites for R1-resection should be avoided during surgical preparation. If however, "manifest" R1-resection is diagnosed at the biliary margin by frozen section, an additional resection should be considered, if technically feasible. If than a R0 resection can be achieved, this has been shown to improve the long term prognosis [6].

Planning of the Surgical Strategy: Right vs. Left Hepatectomy

Bilateral surgical exploration of the hepatoduodenal ligament to determine the type of liver resection intra-operatively increases the risk of tumor cell dissemination and therefore opposes the oncological principle of a no touch technique. Thus, it is recommendable to determine the general type of surgical procedure (i.e. right hepatectomy vs. left hepatectomy) early in the diagnostic workup and dissect the hepatoduodenal ligament accordingly (see below). In loco-regionally confined tumors, the surgical strategy is best defined before any invasive measures like ERC or PTC are performed. The ideal basis for the decision making his a high quality MRI with MRCP. Among others, the following information derived from MRI are mandatory for the further treatment strategy:

- the longitudinal tumor extension in the biliary tree (e.g. Bismuth classification)
- potential vascular involvement and/or atrophy of one lobe (e.g. MSKCC classification)
- the volume of the future liver remnant (FLR)

Based on these findings, the subsequent relief of cholestasis and eventual further preconditioning of the FLR can be planned specifically. The principal decision for a right sided or a left sided hepatectomy should be made at this point, however this decision might be demanding at that point and requires some experience with surgery for hCCA.

In about one third of patients, one lobe is severely atrophic (Figure 1), which is also easily seen on MRI. In those cases the atrophic side can be potentially removed, provided the

vascular supply to the contralateral lobe is free of tumor invasion (or the vascular supply can be reconstructed during surgery) and the contralateral biliary infiltration allows reasonable biliary reconstruction. This commonly requires at least tumor free second or third order biliary branches. However, especially after left hemihepatectomy the reconstruction of 4 to 8 orifices is often required due to the early branching of the right biliary tree.

If none of the lobes is atrophic, and the local tumor extension permits a right sided hepatectomy, this procedure is thought to be the most radical approach for hilar cholangiocarcinoma for several reasons:

- An adequate biliary safety margin is achieved more likely on the left side, since the left hepatic duct has a common course of 1 to 5 cm before ramification to the segmental ducts, whereas the right hepatic duct has only a short common course of 1 cm or less. By using a right trisectionectomy the biliary system can be divided in the umbilical fissure, which allows curative tumor resection in a high percentage of cases [7].
- The right hepatic artery has not to be separated from the bile duct (danger of tumor cell dissemination) and can be dissected only at its origin, distant from the tumor region. In contrast the left hepatic artery commonly runs away from the tumor region on the left margin of the hepatoduodenal ligament (Figure 2)
- The portal vein bifurcation can be resected en-bloc with the tumor region, which further increases the circumferential safety margin. The anastomosis of the main portal trunk to the left portal vein with its long common course is generally easier than to the right portal vein, due to the branching pattern of the right portal vein.

Figure 1. Severe atrophy of the left liver lobe due to occlusion of the left portal branch.

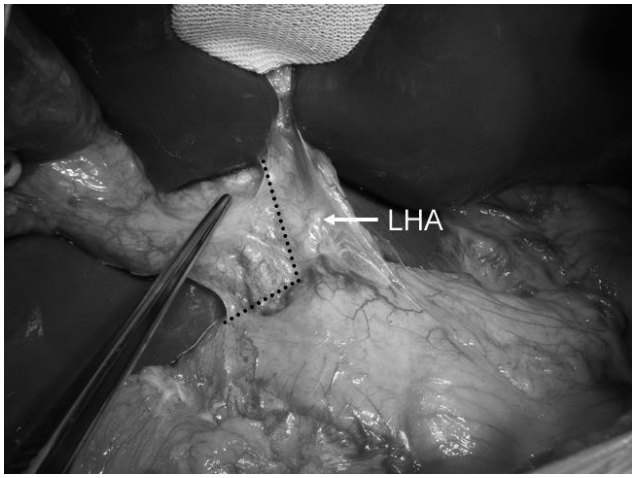

Figure 2. View of the hepatoduodenal ligament with the left hepatic artery (LHA) at its left border. The dotted line represents the dissection line during hilar en bloc resection for extended right hepatectomy. The dissection line proceeds at the upper duodenal border and along the LHA.

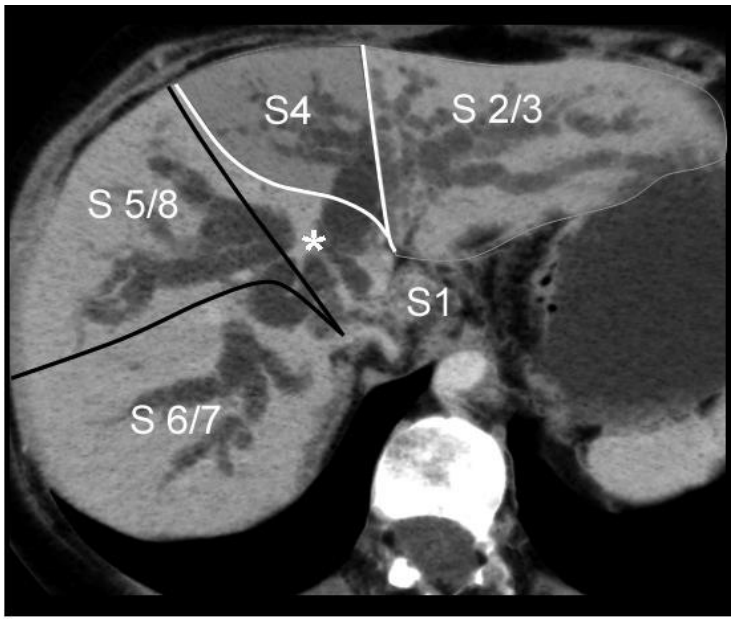

Figure 3. Future liver remnant (FLR) after right trisectionectomy (green), which constitutes about 25% of the total liver volume. To increase the FLR, partial preservation of segment 4 may be considered (red area).

The major drawback of extended right hepatectomies or right trisectionectomies for hCCA is the extensive loss of functional liver volume (Figure 3). This results in a relatively small future liver remnant. Therefore, this technique should be used cautiously in patients with markedly impaired liver function and in old-aged patients with a presumed reduced liver regeneration capacity. If permitted by the local tumor extensions, left hepatectomy might be the safer alternative for high risk patients (old aged, poor liver function). In contrast, for

young and fit patients extended right hepatectomies might increase the oncological radicality and improve the long term results [8].

Preconditioning of the Future Liver Remnant

Since both, right and left hepatectomies for hCCA represent high risk surgical procedures, an optimal preconditioning of the future liver remnant (FLR) is essential to reduce the postoperative morbidity. This includes:

- **Relief of cholestasis** by preoperative biliary drainage of the FLR (the contralateral side might be left un-drained) either internally (ERC) or percutaneously (PTC). Surgery is mostly performed after decrease of serum bilirubin to normal or close to normal.
- **Treatment of cholangitis** by biliary drainage and antibiotics (if present in the hemi-liver to be resected, biliary drainage of both sides is necessary)
- **Portal vein Embolization** of the right portal branch is recommendable prior to extended right hepatectomies, especially in older patients, in case of impaired liver function or if volumetry reveals a small FLR. Also before left trisectionectomies portal vein embolization of the left lobe is occasionally used, subject to the relative size of the FLR. In general, surgery is performed 2 to 6 weeks after embolization and consecutive hypertrophy of the FLR.

SURGERY

Surgery for hCCA starts with a uni- or bilateral transverse plus median upper abdominal laparotomy. Although laparoscopic or hybrid approaches to hCCA have been described [9], open surgery remains the standard of care. Initial staging laparoscopy might be considered, if there is a suspicion of peritoneal carcinosis or diffuse bilateral liver metastases, which is both relatively seldom in early stages of hCCA. Apart from that, in most cases no additional information about local tumor extension or operability is provided by laparoscopy [10]. Moreover, if required the parenchmal quality of the liver can be evaluated by laparoscopy and biopsy.

After laparotomy the abdomen is explored for conditions precluding curative tumor resection like peritoneal seeding, distant metastases, and lymph node metastases in the para-aortal region. Peritoneal implants are most often seen in the subphrenic and subhepatic region, but also in all other predilection sites of the abdominal cavity. Thereafter the local tumor extensions are roughly evaluated by palpating the intrahepatic bile duct in the region of planned division. For right sided hepatectomies, this is the region around the umbilical fissure, which can be palpated after dissection of parenchymal bridge between the segments 2 and 4. Palpation is more difficult during left sided hepatectomies at this stage, since especially the cranial parts of the tumor (right posterior sectoral duct) are difficult to palpate before further preparation of the right sided vascular structures and dissection of the liver parenchyma.

Hilar Preparation and Lymphadenectomy

The surgery commonly starts with the preparation of the hepatoduodenal ligament. Thereby it is envisaged to dissect as far as possible from the tumor region. In general the supplying vascular structures (portal vein, artery) to the FLR are freed of all lymphatic tissue. The preservable vessels are dissected until the region proximal to the tumor. If they are not infiltrated, tumor resection is possible and further lymph node dissection proceeds. A Kocher maneuver can be helpful for retropancreatic lymph node dissection (status after completed lymph node dissection for left hemihepatectomy is shown in Figure 4).The standard lymphadenctomy of hCCA includes:

- all lymph nodes of the hepatoduodenal ligament
- retropancreatic lymph nodes
- lymph nodes along the common hepatic artery
- eventually coeliac lymph nodes

Special Aspects of Right Hemihepatectomy

For extended right hemihepatecomy en bloc with extrahepatic bile duct resection and resection of the portal vein bifurcation ("hilar en bloc resection") the complete hilar dissection proceeds distant to the tumor region (Figure 2). Surgical preparation is performed only on the left side of the hepatoduodenal ligament and distally close to the duodenum. Thereby the tumor region is spared out in order to comply with the onco-surgical principle of a no-touch technique.

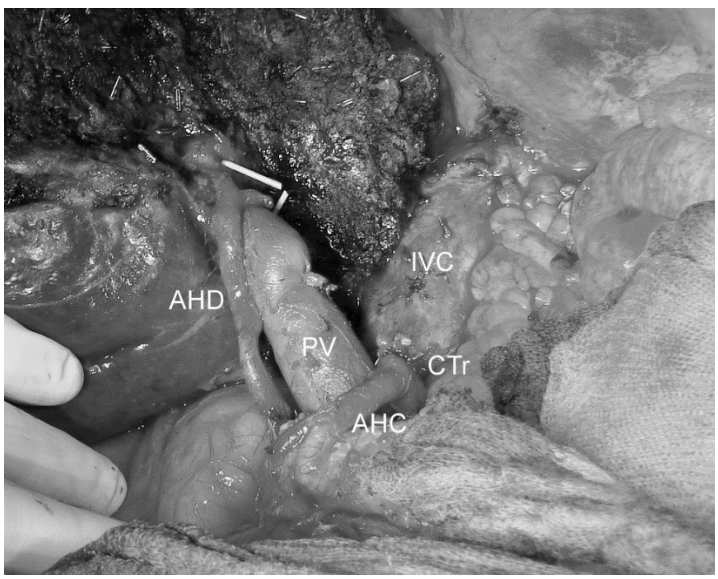

Figure 4. Status after lleft hemihepatectomy with lymph node dissection. All lymph regional nodes have been removed and the right hepatic artery (RHA) until the common hepatic artery (AHC) and the coeliac trunc (CTr) have been completly freed from the lymphatic tissue.

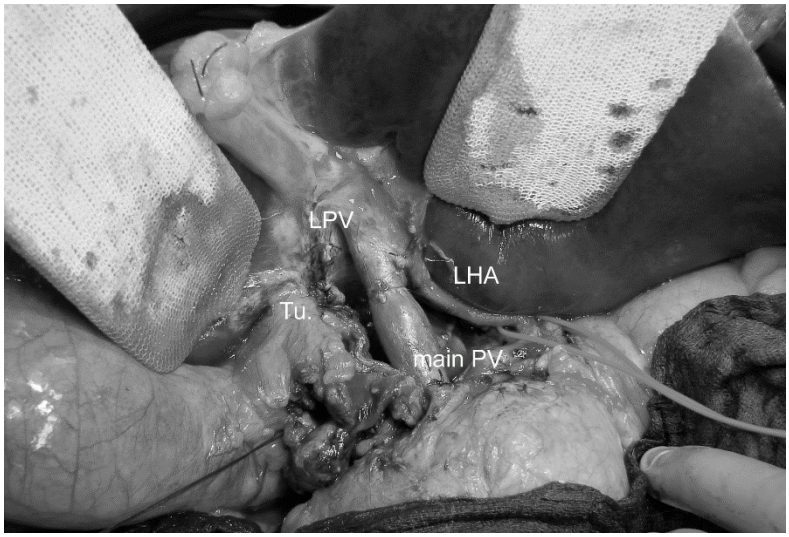

Figure 5. Situs after hilar preparation for right trisectionectomy after portal vein anastomosis of the main portal trunk (PV) with the let portal vein (LPV). The left hepatic artery (LHA) has been completely sceletonized. The whole preparation proceeded distant to the tumor region (Tu).

In brief, the left hepatic artery is skeletonised up to the umbilical fissure. The right hepatic artery is prepared and divided solely close to its origin. The further course behind the common bile duct is left untouched. The left portal branch is encircled in the umbilical fissure, the main trunk of the portal vein is encircled above the pancreas. The common bile duct is divided distally in a region which seems tumor free by palpation (frozen section). Spillage of bile is to be avoided, since it may contain tumor cells. Next, an end-to-end anastomosis of the main portal trunk and the left portal branch is performed (Figure 5). Thereby the portal vein bifurcation remains undissected at the tumor region. The hilar preparation is now finished. The right liver lobe and the caudate lobe are completely mobilized from the inferior caval vein by division of the short hepatic veins and the right hepatic vein. Afterwards the liver parenchyma is transsected along the falciform ligament (right trisectionectomy, Figure 6) or parts of segment 4 may be preserved if permitted by the local tumor extensions (Figure 3). Finally the left hepatic duct is divided intrahepatically after completion of the the parenchymal dissection and again the margin is sent for frozen section

Special Aspects of Left Hemihepatectomy

In contrast to the extended right hemihepatectomy with hilar en bloc resection, preparation of the right hepatic artery behind the common bile duct is mandatory for left hemihepatectomy. Afterwards the main portal trunk is dissected as well as the right portal branch. The left hepatic artery and the left portal vein are divided centrally. The common bile duct is divided distally above the duodenum. The left lobe and the caudate lobe are separated from the caval vein. Afterwards the parenchyma is transected and finally the right hepatic duct is divided in the parenchyma. Commonly, two or more bile duct orifices have to be reconstructed after left or extended left hemihepatectomy (Figure 7).

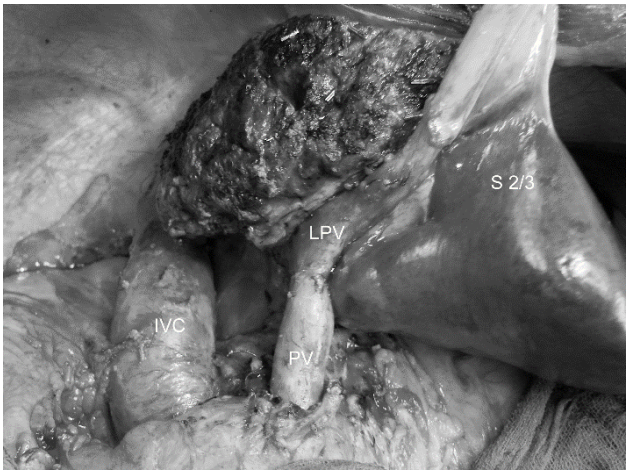

Figure 6. Situs after completion of right trisectionsectomy with portal vein anastomosis and regional lymph node dissection.

In case of tumor infiltration of the portal vein bifurcation the portal vein is now clamped above the pancreas and at the right portal branch using vascular clamps. Both vessels are divided and reconstructed end to end.

Vascular Resection

Portal vein resection and reconstruction - either in case of infiltration or to increase the oncological radicality ("hilar en bloc resection", [7]) can be regarded as a standard procedure nowadays, since no significantly increased complication rate is observed. The portal vein is reconstructed by direct suture (Figure 5 and Figure 6) in the majority of cases. Only occasionally, an interposition graft is necessary.

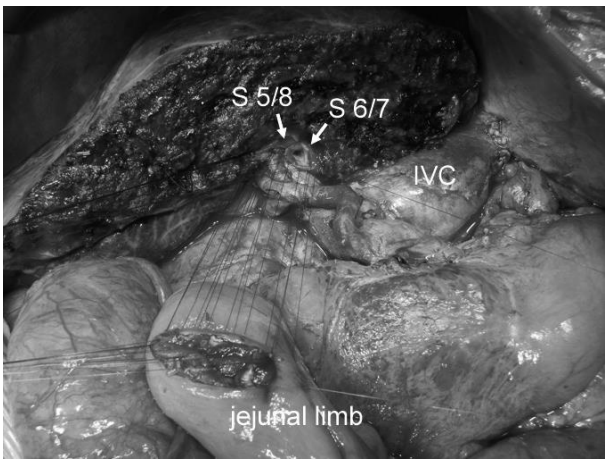

Figure 7. Creation of a bilioenteric anastomosis with the sectoral branches to the anterior (S 5/8) and the posterior (S 6/7) segmens using the parachute technique after left hemihepatectomy.

In contrast, arterial reconstruction is associated with an increased complication rate [11]. However, it might be considered in case of arterial infiltration in selected cases, mainly in younger patients and in lymph node negative cases. Different methods of arterial reconstruction have been described. Depending on the length of the defect, reconstruction is possible either by direct suture, by transposition of another artery or a by a vascular interposition graft [9].

Multivisceral Resection

If the distal bile duct margin is infiltrated by tumor cells (R1) in the frozen section investigation, a radical additional resection would require a resection of the pancreatic head in most cases. This might be considered in patients with an acceptable general risk for such an extended procedure, if the oncological risk is also moderate (e.g. negative lymph nodes or low lymph-node ratio). Adequate patient selection provided, promising long term results have been reported, e.g. by Ebata et al., who observed a 5 Year survival of 37% after en bloc hepatecomy and partial pancreatoduodenectomy [12].

Biliary Reconstruction

Biliary reconstruction can be technically demanding after liver resection for hCCA, since in many cases more than one orifice has to be reconstructed. Moreover, especially after left hepatectomies, in many cases segmental bile ducts have to be sutured, which occasionally can be very fragile and thin walled. Especially, if several orifices have to be reconstructed, it is important not to overlooked an orifice. If possible, orifices which are situated in close proximity are unified by sutures. For bilioenteric anastomosis a Roux-en-Y jejunal limb is prepared and placed next to the biliary orifices e.g. via the retrocolic route in a tension free fashion. Bilio-enteric anastomosis is performed be interrupted (Figure 7) or running suture. Many centers routinely place biliary drains, e.g. transhepatic drains to reduce the risk of anastomotic leakage.

POSTOPERATIVE COMPLICATIONS

Surgery for hCCA is technically demanding and the relevant loss of functional liver parenchyma is combined with a vulnerable bilioenteric anastomosis. Therefore, even in experienced centres, postoperative complications are to be expected in around every third patient and the in hospital mortality is about 5 to 8 %.

The commonest complications are insufficiencies of the bilioenteric anastomosis, bile leaks from the cut surface, infectious complications (mainly cholangitis), vascular complications (especially after vascular reconstructions) and hepatic failure. The latter is often triggered by one other, of the aforementioned complications. Known risk factors for postoperatively elevated bilirubin levels as one indicator of liver failure include preoperative total bilirubin values of more than 2 mg/dl, postoperative major complications and extended

hepatectomies [13]. Namely major postoperative complications, and especially severe infections, are thought to influence postoperative hepatic regeneration and liver function. Likewise a correlation between postoperative hepatic dysfunction and postoperative infectious complications has been described, especially in patients with a small residual liver volume of less than 27 % [14]. Vascular complications are the second major complication as cause of postoperative haepatic failure [15]. However, using modern peri-operative measures including optimal preconditioning of the FLR, the mortality is decreasing and therefore aggressive resection for hilar cholangiocarcinoma is justified despite the relatively high morbidity.

LONG TERM RESULTS

Disease recurrence is the commonest cause of death after resection of hCCA. Predilection sites of tumor recurrence include the peritoneum, the liver remant and the paraaortal lymph nodes. The 5-year overall survival rate of recent single center experiences, ranges between 20% and 40% ([16-23], Table 1). Beneath the depth of tumor invasion (T-category), also the macroscopic tumor type (papillary vs. diffuse infiltrating), vascular invasion and positive lymph node status are known major determinants of long term outcome.

In retrospective analyses, several other factors were found to be significantly associated with impaired long term survival. These include poor differentiation of the tumor (G3), irresectability, incomplete tumor resection (R1, R2) and distant metastases. The latter three factors are normally associated with a 5 year survival of 0%. However, after R1 resection long term survival seems to be achievable in a minority of patients. Whereas 5 year survival after R1 resection is 0% in several publications, others have observed a 5 year survival of 10 to 20% (Table 1).

Table 1. Long term results in exemplary large single center experiences within the recent years

author, study period	**Ref #**	**N=**	**R0 [%]**	**Mortality [%]**	**5yr-OS R0 [%]**	**5yr-OS R1 [%]**	**5yr-OS all pats. [%]**
Sano, 2000-2004	[16]	102	61	0			**44**
Cheng, 1997-2002	[17]	75		1			**12**
Yubin, 1990-2004	[18]	115					**25**
Lee, 2001-2008	[19]	302	71	2	47	8	**33**
Miyazaki, 2001-2008	[20]	107	59	2	33	21	**28**
Unno, 2001-2008	[21]	125	63	8	46	19	**35**
Hirano, 2001-2008	[22]	146	88	3			**36**
Igami, 2001-2008	[23]	298	74	2			**42**

CONCLUSION

Resection for hCCA is one of the most technically demanding procedures with high postoperative mortality rates of 5 to 8 %. Therefore, a precise preoperative staging, accurate patient selection and the optimization of the FLR that might include biliary drainage and portal vein embolization, are the key factors for a successful hepatectomy. Management in highly specialized centers is the only way to ensure the optimal conditioning to obtain the best outcomes

SUMMARY

- Resection of hilar cholangiocarcinama is a demanding procedure associated with substantial morbidity and mortality rates of 5-8%.
- Accurate staging and proper patients selection that must include testing of liver function in combination with volumetric assessment of the FLR, are essential step before surgery.
- Preoperative optimization of the liver with treatment of cholangitis, relief of cholestasis, and portal venous embolization in patients with an inadequate FLR volume might assure acceptable outcomes.
- An aggressive surgical approach is essential to reduce the rate of the rate of positive margins (R1) resection which is still around 20-30%.

REFERENCES

[1] Seehofer, D; Neuhaus, P. Strategies to Optimise R0 Resection for Hilar Cholangiocarcinoma. *Zentralbl Chir*, 2014.

[2] Ruys, AT; Busch, OR; Rauws, EA; Gouma, DJ; van Gulik, TM. Prognostic impact of preoperative imaging parameters on resectability of hilar cholangiocarcinoma. *HPB Surg*, 2013, 2013, 657309.

[3] Otani, K; Chijiiwa, K; Kai, M; et al. Outcome of surgical treatment of hilar cholangiocarcinoma. *J Gastrointest Surg*, 2008, 12, 1033-1040.

[4] Hirano, S; Kondo, S; Tanaka, E; et al. Outcome of surgical treatment of hilar cholangiocarcinoma: a special reference to postoperative morbidity and mortality. *J Hepatobiliary Pancreat Sci*, 2010, 17, 455-462.

[5] Nagino, M; Ebata, T; Yokoyama, Y; Igami, T; Sugawara, G; Takahashi, Y; Nimura, Y. Evolution of surgical treatment for perihilar cholangiocarcinoma: a single-center 34-year review of 574 consecutive resections. *Ann Surg*, 2013, 258, 129-40.

[6] Ribero, D; Amisano, M; Lo Tesoriere, R; Rosso, S; Ferrero, A; Capussotti, L. Additional resection of an intraoperative margin-positive proximal bile duct improves survival in patients with hilar cholangiocarcinoma. *Ann Surg*, 2011, 254, 776-83.

[7] Neuhaus, P; Jonas, S; Bechstein, WO; et al. Extended resections for hilar cholangiocarcinoma. *Ann Surg*, 1999, 230, 808–818.

[8] Neuhaus, P; Thelen, A; Jonas, S; Puhl, G; Denecke, T; Veltzke-Schlieker, W; Seehofer, D. Oncological superiority of hilar en bloc resection for the treatment of hilar cholangiocarcinoma. *Ann Surg Oncol*, 2012, 19(5), 1602-8.

[9] Machado, MA; Makdissi, FF; Surjan, RC; Mochizuki, M. Laparoscopic resection of hilar cholangiocarcinoma. *J Laparoendosc Adv Surg Tech A*, 2012, 22, 954-6.

[10] Ruys, AT; Busch, OR; Gouma, DJ; van Gulik, TM. Staging Laparoscopy for Hilar Cholangiocarcinoma: Is it Still Worthwhile? *Indian J Surg Oncol*, 2012, 3(2), 147-53.

[11] Nagino, M; Nimura, Y; Nishio, H; et al. Hepatectomy with simultaneous resection of the portal vein and hepatic artery for advanced perihilar cholangiocarcinoma: an audit of 50 consecutive cases. *Ann Surg*, 2010, 252, 115-123.

[12] Ebata, T; Yokoyama, Y; Igami, T; Sugawara, G; Takahashi, Y; Nimura, Y; Nagino, M. Hepatopancreatoduodenectomy for cholangiocarcinoma: a single-center review of 85 consecutive patients. *Ann Surg*, 2012, 256, 297-305.

[13] Hasegawa, S; Ikai, I; Fujii, H; Hatano, E; Shimahara, Y. Surgical resection of hilar cholangiocarcinoma: analysis of survival and postoperative complications. *W J Surg*, 2007, 31, 1256-1263.

[14] Schindl, MJ; Redhead, DN; Fearon, KCH; Garden, OJ; Wigmore, SJ. Edinburgh Liver Surgery and Transplantation Experimental Research Group (eLISTER). The value of residual liver volume as a predictor of hepatic dysfunction and infection after major liver resection. *Gut*, 2005, 54, 289–296.

[15] Hirano, S; Kondo, S; Tanaka, E; Shichinohe, T; Tsuchikawa, T; Kato, K; Matsumoto, J; Kawasaki, R. Outcome of surgical treatment of hilar cholangiocarcinoma: a special reference to postoperative morbidity and mortality. *J Hepatobiliary Pancreat Sci*, 2010, 17, 455-462.

[16] Sano, T; Shimada, K; Sakamoto, Y; et al. One hundred two consecutive hepatobiliary resections for perihilar cholangiocarcinoma with zero mortality. *Ann Surg*, 2006, 44, 240-247.

[17] Cheng, Q; Luo, X; Zhang, B; et al. Predictive factors for prognosis of hilar cholangiocarcinoma: postresection radiotherapy improves survival. *Eur J Surg Oncol*, 2007, 33, 202-207.

[18] Yubin, L; Chihua, F; Zhixiang, J; et al. Surgical management and prognostic factors of hilar cholangiocarcinoma: experience with 115 cases in China. *Ann Surg Oncol*, 2008, 15, 2113-2119.

[19] Lee, SG; Song, GW; Hwang, S; et al. Surgical treatment of hilar cholangiocarcinoma in the new era: the Asan experience. *J Hepatobiliary Pancreat Sci*, 2010, 17, 476-489.

[20] Miyazaki, M; Kimura, F; Shimizu, H; et al. One hundred seven consecutive surgical resections for hilar cholangiocarcinoma of Bismuth types II, III, IV between 2001 and 2008. *J Hepatobiliary Pancreat Sci*, 2010, 17, 470-475.

[21] Unno, M; Katayose, Y; Rikiyama, T; et al. Major hepatectomy for perihilar cholangiocarcinoma. *J Hepatobiliary Pancreat Sci*, 2010, 17, 463-469.

[22] Hirano, S; Kondo, S; Tanaka, E; et al. Outcome of surgical treatment of hilar cholangiocarcinoma: a special reference to postoperative morbidity and mortality. *J Hepatobiliary Pancreat Sci*, 2010, 17, 455-462.

[23] Igami, T; Nishio, H; Ebata, T; et al. Surgical treatment of hilar cholangiocarcinoma in the "new era": the Nagoya University experience. *J Hepatobiliary Pancreat Sci*, 2010, 17, 449-454.

In: Encyclopedia of Surgery (22 Volume Set)
Editors: Andreas Lehrer and Kristin Mueller
ISBN: 978-1-53618-329-0
© 2020 Nova Science Publishers, Inc.

Chapter 360

SURGERY FOR DISTAL CHOLANGIOCARCINOMA

Salvatore Paiella*, MD, Stefano Andrianello, MD, Giovanni Marchegiani, MD, Roberto Salvia, MD, PhD and Claudio Bassi, MD

Unit of Surgery B, Department of Surgery and Oncology,
The Pancreas Institute,
University of Verona Hospital Trust,
Verona, Italy

ABSTRACT

The occurrence of a distal cholangiocarcinomas is extremely uncommon.

However, due to early signs and symptoms, it can be diagnosed once surgical resection can still be achieved. The patients often present with a pancreatic head mass and obstructive jaundice. Rather than obtaining a preoperative histological diagnosis, clinicians should focus on cancer staging, assessment of "resectability" and the need to palliate the bile duct obstruction.

Pylorus-preserving pancreaticoduodenectomy (PPPD) represents the surgical procedure of choice in case of distal bile duct cancer. To achieve a "R0" resection, associated with proper lymphadenectomy, plays a key role in reaching long term survival. In particular lymphadenectomy serves as a staging procedure, and at least 11 lymph nodes must be collected during surgery.

With the improvement of standard of care and with the introduction of dedicated clinical pathways, patients undergoing major pancreatic resections for distal bile duct cancer (DBDC) can me managed following fast-track protocols, in order to reduce both surgical morbidity and the length of hospital stay. PPPD for DBDC is burdened by the same complication pattern of surgery for pancreatic ductal adenocarcinoma. However due to the low incidence of obstructive pancreatitis and consequent harder gland texture, post-operative pancreatic fistula (POPF) rate is higher.

Prognosis in case of DBDC is still poor, but an R0 PPPD performed at high volume center, allowing for an acceptable rate of morbidity and mortality, represents the best chance for cure.

* Corresponding Author's Email: Salvatore.paiella@ospedaleuniverona.it.

INTRODUCTION

Malignant neoplasms of the bile duct are relatively rare with an annual incidence rate in Western countries of 1-2 cases per 100,000 [1]. Incidence of bile duct cancer is related with ageing. It is a slow growing tumor, so that patients and physicians can be unaware of its presence. With growth, infiltration of adjacent vessels can occur and often the primary tumour becomes unresectable.

Cholangiocarcinomas are classified in intrahepatic, perihilar and distal (table 1).

Among them, DBDC is the second most frequent [2] and its prognosis is comparable to those of other two types [3-5]. When cancer arises in the distal part of the main bile duct it usually causes symptoms including early jaundice and cholangitis. This chance can lead to early diagnosis and surgically excision.

Table 1.

Classification of cholangiocarcinomas and relative distribution in Western countries [adapted from [6]]	
Intrahepatic	8%
Perihilar	50%
Distal bile duct	42%

PREOPERATIVE ASSESSMENT

To obtain a preoperative histological diagnosis of DBDC is not possible all cases, so that this is only presumed in several cases. The incidence of cholangiocarcinoma is often overestimated on the basis of preoperative clinical and radiological evaluation. In our series, on 74 cases (unpublished data) of highly suspected cholangiocarcinoma 39 cases (52,7%) resulted to be pancreatic ductal adenocarcinoma. On the contrary, only 9 cases (16,9%) of 53 histologically proven cholangiocarcinoma were interpreted with an alternative diagnosis (mostly pancreatic adenocarcinoma).

There is no evidence that a patient with a resectable pancreatic head mass should undergo histologic assessment of the diagnosis through a fine needle aspiration (FNA; US, CT scan or EUS guided) or biopsy. On the other hand, histologic confirmation is the first fundamental step in case of both unresectable and borderline resectable masses, since neoadjuvant chemotherapy should be at least considered.

Our Institutional diagnostic work-up for periampullary region masses generally includes clinical examination, laboratory tests with oncologic markers (i.e. serum levels of Ca19.9 and CEA) and abdominal contrast-enhanced CT-scan. We consider a lesion as resectable when it is confined to the distal bile duct, even in the presence of invasion of pancreas or duodenum, without evidence of metastatic disease to the liver, lungs, peritoneum, or any other distant site. Direct invasion of adjacent organs such as stomach or colon, as well as gross lymphadenopathy, may suggest the simultaneous presence of distant spread. When tumour extents to celiac trunk (very rare for distal cholangiocarcinomas), common hepatic artery, and superior mesenteric artery it can be classified as locally advanced. At our Institution, the

presence of an abutment of more than 180° and no longer than 2 cm in length of superior mesenteric vein or portal vein-superior mesenteric vein confluence also precludes surgical resection. Venous vascular resections can be carried out in order to obtain an R0 resection, however survival benefits represents still a matter of debate [7, 8].

Contrast-enhanced ultrasound (CEUS) may add some important information about locoregional spread of the disease through the dynamic evaluation of perfusion of periampullary region with a high accuracy in detecting vascular infiltration or encasement. CEUS can better define liver involvement in case of metastatic disease [9-11].

Magnetic Resonance with Cholangio Pancreatography (MRCP) is advocated to better define the presence of bile duct stenosis (such as for pancreatic head mass, cholangiocarcinoma, choledocolithiasis) [12-15]. This is particularly useful once CT-scan fails to show a mass growing in the periampullary region. Additional information can be retrieved by the use of Endoscopic Retrograde Cholangiopancreatography (ERCP), the procedure of choice to palliate obstructive jaundice. ERCP can be useful to perform fine-needle aspiration (FNA), transpapillary biopsy and brush cytology. Unfortunately, these sampling methods are poorly sensitive (30-70%) even if highly specific (90%) [14, 16-18].

Endoscopic ultrasound (EUS) findings (i.e. thickness of biliary wall, polipoid or non-polipoid cancer protrusion into the biliary lumen) in order to distinguish the nature and the site of distal bile duct obstructions and to evaluate the extent of the disease (i.e. nodal involvement) [19].

SURGERY

The treatment of choice for DBDC is represented by surgical resection. The reported resectability rates range between 22% and 89% [20]. Radical resection can only be achieved through pancreaticoduodenectomy (either pylorus-preserving or Kausch-Whipple procedure). Both procedures provide a comparable outcome for distal cholangiocarcinoma [21-24]. A meta-analysis demonstrated that the Kausch-Whipple procedure and the pylorus preserving procedure reach equal results in terms of perioperative morbidity and mortality [25]. PPPD can be considered as a safe procedure in high-volume centers, but still burdened by an overall 30% morbidity risk and a mortality rate of around 3% (26-28). In a series reported in literature including 11.559 pancreatic procedures, the Pancreatic Surgery Mortality Group reported an overall 30- and 90-day mortalities of 0.96% and 1.89%, respectively [26]. The vast majority of complications were referable to issues related to pancreatic anastomosis. At our Institution, we prefer to perform pylorus-preserving pancreaticoduodenectomy, with a non-stented end-to-side pancreaticojejunostomy.

Technique

At our institution, we historically prefer a xifo-umbilical incision. After a meticulous exploration of the abdominal cavity, to detect small metastases unrevealed by preoperative instrumental tools, a Kocher maneuver is then performed in order to palpate pancreatic head and to assess if eventually the tumor spread already involved the superior mesenteric vessels

(artery and vein). At this point intraoperative ultrasound could be useful to deeply investigate the cranial extension of the neoplasm along the bile tree, to deepen hepatic suspect nodules and to clarify doubtful vascular adhesions. If neither macroscopic, nor instrumental nor haptic signs of unresectability are identified, then we proceed with a pylorus-preserving pancreaticoduodenectomy (PP-PD) [29].

The noteworthy difference between the surgical strategy of a PP-PD (or PD) for a pancreatic cancer or for a biliary cancer is represented by the necessity to do first the frozen-section of the biliary duct stump. It is important to take into account the pattern of anatomic spread of cholangiocarcinoma.

Akamatsu et al. argued that it is possible to distinguish two types of spread: longitudinal spread and vertical spread [30]. The first aspect refers to the main feature of extrahepatic cholangiocarcinomas, that is the mucosal and submucosal infiltration trend, according to the tumor's growth pattern [31]. The latter concept, on the contrary, refers to direct involvement of the surrounding duodenum or pancreas, or hepatoduodenal ligament (distant metastases, including those to para-aortic lymph nodes it is considered as an extension of this idea).

Therefore, in a curative radical intent to remove all the possible invasive carcinoma cells spread within the biliary wall, a 20-mm margin beyond the macroscopically palpable one is required [31].

If the margin is positive then additional segmental resection of the hepatic duct is required to obtain a R0 procedure. It is important to note that, for distal cholangiocarcinomas arising from the cranial portion of the intrapancreatic bile duct, in case of superficial spread of the carcinoma along the bile duct (i.e. in a short biliary tree) toward the biliary hilum, then it is mandatory to perform a major hepatectomy (extended right- or left- hemihepatectomy) with pancreaticoduodenectomy to obtain R0 resection [32]. We routinely perform also frozen-section of the pancreatic resection margin and, obviously, cholecystectomy. End-to-side hepatico-jejunal anastomosis is our selected option for reconstruction of biliointestinal continuity, usually 15-20 cm distal to pancreatico-jejunostomy (or in the isolated loop in case of pancreatico-gastrostomy), with 3-0, 4-0 or 5-0 interrupted sutures according to the surgeon. Occasionally, we perform two half-continuous sutures when the diameter of common hepatic duct is greater than 1 cm.

Restoration of pancreatico-intestinal continuity is still a big challenge for pancreatobiliary surgeons.

Several studies have made huge efforts in order to solve this long-standing problem. However, none of them seems to be the cornerstone of the management of pancreatic anastomosis [33-35]. A recent multicenter randomized study stated that pancreatico-gastrostomy should be the preferred pancreaticoenterostomy, independently of pancreatic duct size and without the use of pancreatic stent [36]. Nevertheless, this study also contains several limitations that do not make us able to adopt this option as the definitive one [37].

At our Institution, pancreatico-jejunal anastomosis is the preferred option for pancreatic reconstruction. However, in selected cases (i.e. soft pancreatic tissue, small main pancreatic duct size) we adopt the reconstruction with pancreatico-gastrostomy [figure 1].

As reported in the literature, bile duct resection alone cannot reaches the appropriate lymph nodes collection and should be reserved for highly selected cases because only few patients obtain curative resection margins at the final pathology [30, 38, 39].

Figure 1. Open pancreaticogastrostomy technique [from [29]]. Legend: through a posterior gastrotomy the pancreatic stump is invaginated for 3-4 cm into the stomach, through an anterior gastrotomy a pancreatico-gastrostostomy is then performed.

Station	Name
1	Right cardial lymph nodes
2	Left cardial lymph nodes
3	Lymph nodes along the lesser curvature of the stomach
4	Lymph nodes along the greater curvature of the stomach
5	Suprapyloric lymph nodes
6	Infrapyloric lymph nodes
7	Lymph nodes along the left gastric artery
8a	Lymph nodes in the anterosuperior group along the common hepatic artery
8p	Lymph nodes in the posterior group along the common hepatic artery
9	Lymph nodes around the celiac artery
10	Lymph nodes at the splenic hilum
11p	Lymph nodes along the proxiaml splenic artery
11d	Lymph nodes along the distal splenic artery
12a	Lymph nodes along the hepatic artery
12p	Lymph nodes along the portal vein
12b	Lymph nodes along the bile duct
13a	Lymph nodes on the posterior aspect of the superior portion of the head of the pancreas
13b	Lymph nodes on the posterior aspect of the inferior portion of the head of the pancreas
14p	Lymph nodes on the proximal superior mesenteric artery
14d	Lymph nodes along the distal superior mesenteric artery
15	Lymph nodes along the middle colic artery
16	Lymph nodes around the abdominal aorta
16al	Lymph nodes around the aortic hiatus of the diaphragm
16a2	Lymph nodes around the abdominal aorta (from the superior margin of the celiac trunk to the inferior margin of the left renal vein)
16b1	Lymph nodes around the abdominal aorta (from the inferior margin of the left renal vein to the superior margin of the inferior mesenteric artery)
16b2	Lymph nodes around the abdominal arota (from the superior margin of the inferior mesenteric artery to the aortic bifuraction)
17a	Lymph nodes on the anterior sufrace of the superior portion of the head of the pancreas
17b	Lymph nodes on the anterior surface of the inferior portion of the head of the pancreas
18	Lymph nodes along the inferior margin of pancreas

Figure 2. Lymph Node Stations according to JPS [40].

Lymphadenectomy

We want to underline the importance of regional lymphadenectomy. Using the pancreatic cancer metastatic spread as a model, according to Japancese Pancreas Society (JPS) eighteen lymph-node stations can be defined. Consequently, 3 levels of nodal involvement can be identified according to lymphatic spread of pancreaticobiliary malignancies (figures 2-3; table 2).

It has been reported that the frequency of lymph node metastases in distal cholangiocarcinoma ranges between 22% and 58%, while the absence of lymph node metastases represents a predictor of outcome [41]. The 7th edition of AJCC recommendations suggested that at least 3 lymph nodes should be examined for accurate staging of extrahepatic cholangiocarcinomas. The rationale for this statement is unclear, in fact recent studies has identified that node negative (N0) patients with a total lymph nodes count greater than 11 show a better prognosis that N0 patients with lesser than 11 lymph nodes yielded [39]. Therefore, we can state that it is important to harvest at least 11 lymph nodes in order to avoid patients' understaging.

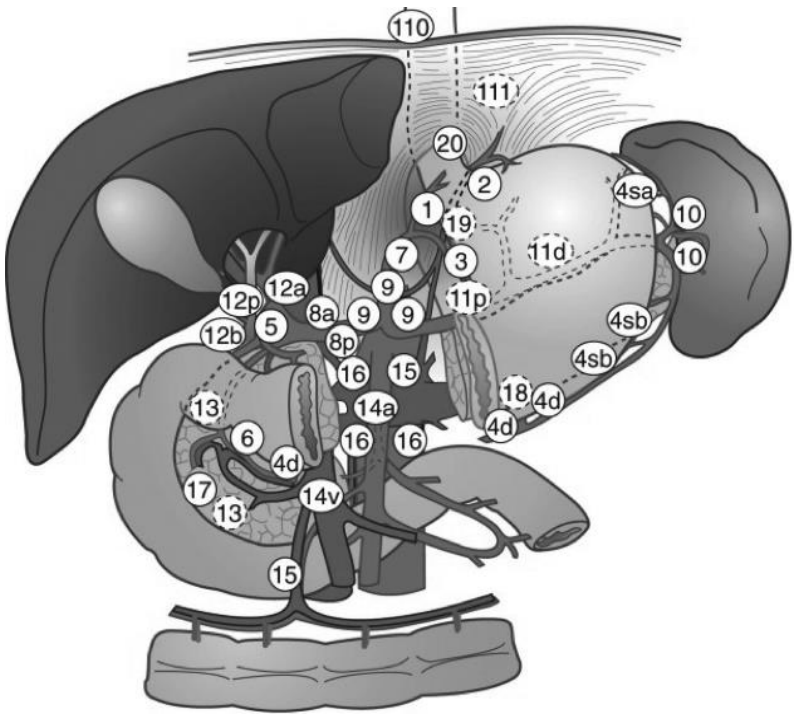

Figure 3. Schematic anatomic location of lymph-node stations (from Japan Pancreas Society - General rules for the study of pancreatic cancer - 5th Ed. Tokyo Kanehara 2002).

Table 2. JPS Lymph node group classification (adapted from [40])

Group 1 Lymph node stations	13a*, 13b*, 17a*, 17b*
Group 2 Lymph node stations	6*, 8a*, 8p*, 12a*, 12b*, 12p*, 14p*, 14d*
Group 3 Lymph Node stations	1, 2, 3, 4, 5, 7, 9*, 10, 11p*, 11d, 15, 16a2, 16b1, 18*

* Regional lymph nodes by the UICC.

Recently, as for pancreatic cancer, it has been reported that the ratio between the number of metastatic lymph nodes and the total number of harvested (Lymph Node Ratio, LNR) is an independent predictor of survival for patients with distal cholangiocarcinoma, being > 0.2 (or 20%) associated with a poorer prognosis [41].

Moreover, there is knowledge that and extended lymphadenectomy including para-aortic lymph nodes dissection has a mere staging role rather than a curative in pancreaticobiliary tumours. As for pancreatic cancer [42] the disease specific survival for patients with positive para-aortic lymph nodes, in fact, is similar to metastatic patients. This data suggest that survival is not influenced by an extended lymphadenectomy [43-45]. Instead, clinical and prognostic significance of nodal micrometastases in biliary cancer it is still unclear [46-48].

Vascular Resection

Advances in perioperative care and rising interest in long-term survival have led to an expansion of the resectability criteria for pancreaticobiliary tumors. Hence, the debate on vascular resections during pancreaticoduodenectomy has risen. However, this subject has always been described with controversial results in terms of survival, morbidity and mortality. The rationale for a vascular resection is to achieve the R0. Unfortunately the vast majority of original studies focused on vascular resection lack of a rigorous assessment of the R status. As for venous resections, a recent systematic review showed the results coming from 28 retrospective studies, all focused on resection of superior mesenteric-portal vein. The reported mortality rates ranged between 0% and 17%, the median rate of bleeding was 4%, the rate of vascular thrombosis was 0% and the reoperation rate was 9% [7]. The Authors did not find any correlation between microscopic neoplastic vascular infiltration and overall survival. Interestingly they anyway propose to change the surgical approach suggesting an end-to-end or graft reconstruction once a venous infiltration is present [7].

As for the arterial infiltration, a recent systematic review and meta-analysis took into account 26 studies. Perioperative morbidity rates of arterial resection associated to pancreatic resection ranged between 16.7% and 100%, reoperation rates ranged from 0% to 75%, median mortality rate was 11.8% and no benefits were reported in terms of survival. Hence, arterial resection should be avoided in every cases [8].

Our recommendation is to avoid R2 resections, while venous resection should be carried out only in case of macroscopic vascular infiltration of less than 180° and for less than 2 cm in length, in order to obtain an R0. Arterial resections should always be avoided.

Palliation

A relevant amount of patients affected by DBDC cannot be candidate for radical surgery. Since jaundice is the most common presenting symptom, endoscopic palliative procedures play an important role in patients suffering from DBDC [49], in order to improve patients' quality of life and to reduce the possible side effects due to the toxicity of bilirubin. If the patient it is not candidate for radical resection because of a locally advanced disease, the stenting of common bile duct should be carried out before neoadjuvant therapy. In particular, metallic stents should be preferred as for metastatic patients. Once the ERCP approach is not

capable to solve jaundice, it is preferable to proceed with percutaneous transhepatic biliary drainage (PTBD), possibly with metal self-expanding stent, because they have shown to be associated with more patency and less risk of obstruction than plastic ones [50]. Surgical bypass with hepaticojejunostomy or choledochojejunostomy should be considered as the last step only once less invasive techniques have eventually failed.

POSTOPERATIVE CARE

Postoperative management varies across Institutions and is greatly influenced by several economical and social aspects. According to the recent progress obtained in the field of enhanced recovery after surgery, a lot of validated fast-track protocols have been introduced also in the field of pancreaticobiliary procedures, with a consequent reduction in the length of hospital stay and the costs. It is still a matter of debate whether fast-track protocols can reduce post-operative morbidity after major pancreatic resections with the adoption of peculiar clinical pathways [51-54]. Our clinical management is continuously evolving thanks to the contribution of clinical studies and can be resumed as following. Post-operative analgesia is obtained by continuous intravenous opioid infusion or by epidural catheter metameric anesthesia. Nose-gastric tube (NGT) is removed on post-operative day (POD) 0 or POD1 on the basis of its output. Patient can drink clear fluids on POD1 and eat a light diet on POD2 with progressive increase of the amount of food until oral diet is completely tolerated. On POD1 the patient is mobilized on a chair and further mobilization is encouraged over the following days. On POD2 or POD3 urinary catheter is removed. Central venous catheter is removed on POD4 or POD5. Patient is discharged when is able to tolerate oral diet and when post-operative pain is easily controlled by oral medications.

We do not promote an excessive intravenous post-operative fluid overload, as it can lead to submucosal intestinal edema, decreased blood flow and decreased tissue oxygenation resulting in a possible eventual anastomotic failure. Our recommendation is to use a balanced fluid restricted intake guided by the body weight (usually 25-30 ml/kg) and fluids loss. The best way to obtain this goal is to stop intravenous fluid as soon as possible and shifting to oral intake of fluids and medications.

COMPLICATIONS

Regardless of the indication, PPPD results in a peculiar pattern of complications. The most common one is represented by POPF, with an incidence rate ranging from 10 to 30% [21, 23, 55-61].

POPF can be associated with intra-abdominal fluid collections/abscesses, sepsis, hemorrhage, and, sometimes, re-laparotomy. Successful management of a POPF depends on its early identification and effective external drainage. Our group has demonstrated that an amylase value in drains ≤5000 U/l on POD1 identifies a subset of patients who are not likely to develop POPF and in whom continued drain management beyond the early postoperative period may be detrimental [62]. As a result of a randomized controlled trial we have determined that removing drains on POD3 is associated with a significantly decreased rate of

POPF, abdominal complications, and pulmonary complications [63]. Considering current available evidence, we recommend the prophylactic use of somatostatin analogues in order to reduce the risk of POPF [64]. At our Institution, somatostatin analogues are administered by POD0 (at the dose of 0,1 mg 3 times a day) until drain removal in non-complicated pancreaticoduodenectomy. In case of POPF, somatostatin analogues can be administered in order to reduce the entity of a high output POPF only in cases where infected POPF can be ruled out. The use of somatostatin analogues in case of infected POPF is not recommended. Therapeutic use of somatostatin analogues is not considered as an evidence-based approach yet because they are neither able to reduce the incidence of POPF grade B or C nor able to reduce the associated mortality.

Other important surgical complications are widely described in the literature. These are represented by post-pancreatectomy hemorrhage (PPH) [65], postoperative biliary fistula, delayed gastric emptying [66].

Nevertheless, appropriate drains management, optimal pain care, correct fluid administration, early oral nutrition and patient mobilization, represent key factors in order to reduce postoperative morbidity and the length of in-hospital stay.

MORBIDITY AND MORTALITY

Compared with PD for PDAC, PD for DBDC is associated with a different distribution of post-surgery morbidity. Usually, in case of PDAC, PD has a relatively low incidence of POPF. There are a lot studies that explored this aspect. Overall morbidity reaches 50%, where POPF account for around 15%, DGE for 13%, intra-abdominal collections for 16%, biliary fistula for 5% and Post-Pancreatectomy Hemorrhage (PPH) for 7% [67].

Our series of resected DBDC shows an overall morbidity rate of 66%, with consequent POPF rate of 45%, DGE 9%, intra-abdominal collections 32%, biliary fistula 7% and PPH at 19% (table 3). We can speculate that the high incidence of PPH, biliary fistula and intra-abdominal collections is directly related to the higher incidence of POPF. Post-operative pancreatic fistula is found to be related to specific factors, such as intraoperative blood loss, pancreatic remnant texture, pancreatic duct diameter, and histology of the primitive tumor [68]. With the exception of intraoperative blood loss, all the other three factors are related to obstructive pancreatitis. In fact, PDAC often produce an obstructive pancreatitis that leads to pancreatic duct dilatation and pancreatic remnant hard texture. DBDC, on the contrary, is often diagnosed at an early stage, because of early symptoms. The higher incidence of POPF for PD for distal bile duct cancer is related to the lack of obstructive pancreatitis in most of cases. Despite the morbidity rate, in our experience we found no mortality out of 74 cases.

SURVIVAL

High-volume centres report an overall 3- and 5-years survival ranging between 33 and 63% and between 16 and 52% respectively [30]. Surgical margin status has been reported to be a significant independent prognostic factor [69]. Curative R0 resection is mandatory in order to achieve long-term survival in DBDC.

Curative resection rates for DBDC are relatively higher than those for perihilar cancer [3].

The reason for such a poor prognosis for resected DBDC might be its locoregional and distant metastatic spread, which can occur at various times after surgery. Local recurrence along the biliary tree has been reported to be more common than distant recurrences in DBDC [70]. Therefore resection margin and perineural invasion are found to be strong independent predictors of survival [30, 41, 49, 71, 72).

Table 3.

	PD for distal bile duct cancer*	PD for ductal adenocarcinoma [from [67]]
POPF	45%	15%
DGE	9%	13%
PPH	19%	7%
Intrabdominal collections	32%	16%
Overall morbidity rate	66%	50%

POPF: Post-Operative Pancreatic Fistula; DGE: Delayed Gastric Empty; PPH: Post-Pancreatectomy Haemorrage.
*Unpublished data (n=74) - General Surgery B - Institute of Pancreas, University of Verona

CONCLUSION

Although encouraging results have been reached in diagnostic imaging, surgical technique, perioperative care and pathological assessment, distal cholangiocarcinoma still remains a disease associated with a poor prognosis. Gold standard surgical treatment is represented by pancreaticoduodenectomy with achievement of an R0 resection. It should not be underestimated that pancreatic surgery is a high-risk surgery and that it should be managed only by high-volume centres.

Key Sentences

1. Distal cholangiocarcinoma is a rare malignancy, but thank to early symptoms, it must be diagnosed in early stages
2. When dealing with a resectable mass do not try to obtain an histological confirmation, preoperative work-up must focus on cancer staging and resectability assessment
3. In case of obstructive jaundice the select the patient for preoperative biliary drainage (endoscopic drainage is preferred; choose plastic stents unless you have ruled out surgical unresectability) on the basis of the correct indications (cholangitis, malnourishment, long-standing jaundice, renal insufficiency)
4. Fast-track protocols and clinical pathways should be adopted a safely used also in case of extensive surgical procedure to reduce hospitalization, morbidity and costs
5. Pancreaticoduodenectomy for distal bile duct cancer has a higher morbidity rate because of the presence of a “healthy” pancreatic remnant

6. Radical resection to obtain negative resection margin is a key point to increase chances of survival
7. Lymphadenectomy has a staging purpose and should be performed systematically by collecting at least 11 lymph nodes
8. Cholangio-Wirsung MR (CWMR), Contrast-Enhanced Ultrasound CEUS), CT-scan, Endoultrasonography (EUS) and Endoscopic retrograde cholangio-pancreatography (ERCP) are complementary techniques, sometimes all necessary for correct surgical assessment, according to different clinical situations
9. Surgery for distal cholangiocarcinoma should be performed only by high-volume centers or by well-trained surgeons

REFERENCES

[1] Welzel TM, McGlynn KA, Hsing AW, O'Brien TR, Pfeiffer RM. Impact of classification of hilar cholangiocarcinomas (Klatskin tumors) on the incidence of intra- and extrahepatic cholangiocarcinoma in the United States. *J Natl Cancer Inst. Oxford University Press*; 2006 Jun 21;98(12):873–5.

[2] Hepatobiliary cancers. *Clinical practice guidelines in oncology*. [Internet]. 2006. pp. 728–50. Available from: http://eutils.ncbi.nlm.nih.gov/entrez/eutils/elink.fcgi?dbfrom=pubmed&id=16948952&retmode=ref&cmd=prlinks

[3] Allen PJ, Reiner AS, Gonen M, Klimstra DK, Blumgart LH, Brennan MF, et al. *Extrahepatic cholangiocarcinoma: a comparison of patients with resected proximal and distal lesions*. 2008;10(5):341–6.

[4] *Cholangiocarcinoma: the impact of tumor location and treatment strategy on outcome*. 2003 Aug;26(4):422–8. Available from: http://content.wkhealth.com/linkback/openurl?sid=WKPTLP:landingpage&an=00000421-200308000-00024

[5] *Prognostic factors in bile duct carcinoma: analysis of 96 cases*. 1981 Oct;194(4):447–57. Available from: http://eutils.ncbi.nlm.nih.gov/entrez/eutils/elink.fcgi?dbfrom=pubmed&id=7283506&retmode=ref&cmd=prlinks

[6] DeOliveira ML, Cunningham SC, Cameron JL, Kamangar F, Winter JM, Lillemoe KD, et al. *Cholangiocarcinoma: thirty-one-year experience with 564 patients at a single institution*. 2007 May;245(5):755–62.

[7] *Extended Pancreaticoduodenectomy with Vascular Resection for Pancreatic Cancer: A Systematic Review*. 2010 Apr 9;14(9):1442–52. Available from: http://link.springer.com/10.1007/s11605-009-1129-7

[8] *Arterial Resection During Pancreatectomy for Pancreatic Cancer*. 2011 Dec;254(6):882–93. Available from: http://content.wkhealth.com/linkback/openurl?sid=WKPTLP:landingpage&an=00000658-201112000-00009.

[9] Faccioli N, Crippa S, Bassi C, D'Onofrio M. *Contrast-enhanced ultrasonography of the pancreas*. 2009;9(5):560–6.

[10] Faccioli N, D'Onofrio M, Malagò R, Zamboni G, Falconi M, Capelli P, et al. *Resectable pancreatic adenocarcinoma: depiction of tumoral margins at contrast-enhanced ultrasonography*. 2008 Oct;37(3):265–8.

[11] *Ultrasonography of the pancreas. 4. Contrast-enhanced imaging*. Springer-Verlag; 2007 Mar;32(2):171–81. Available from: http://link.springer.com/10.1007/s00261-006-9010-6.

[12] *Magnetic resonance cholangiography: past, present and future: a review*. 2010. Available from: http://www.europeanreview.org/wp/wp-content/uploads/808.pdf

[13] *Utility of magnetic resonance cholangiography in the evaluation of biliary obstruction*. 1999 Jul;189(1):63–71–discussion71–2. Available from: http://eutils.ncbi.nlm.nih.gov/entrez/eutils/elink.fcgi?dbfrom=pubmed&id=10401742&retmode=ref&cmd=prlinks

[14] *Diagnosis of cholangiocarcinoma*. 2008;10(2):87–93. Available from: http://doi.wiley.com/10.1080/13651820801992716

[15] *Magnetic Resonance Cholangiopancreatography: A Meta-Analysis of Test Performance in Suspected Biliary Disease*. American College of Physicians; 2003 Oct 7;139(7):547–57. Available from: http://annals.org/article.aspx?articleid=716818

[16] Biliary Brush Cytology and the Detection of Cholangiocarcinoma in Primary Sclerosing Cholangitis Evaluation of Specific Cytomorphologic Features and CA19-9 Levels. *American Society for Clinical Pathology*; 2005 Sep 1;124(3):355–60. Available from: http://ajcp.ascpjournals.org/content/124/3/355.abstract

[17] *Diagnostic accuracy of biliary brush cytology*. BMJ Publishing Group Ltd and British Society of Gastroenterology; 2011 Apr 1;60(Suppl 1):A55–5. Available from: http://gut.bmj.com/content/60/Suppl_1/A55.1.abstract

[18] Endoscopic transpapillary biopsies and intraductal ultrasonography in the diagnostics of bile duct strictures: a prospective study. *BMJ* Publishing Group Ltd and British Society of Gastroenterology; 2002 Aug 1;51(2):240–4. Available from: http://gut.bmj.com/content/51/2/240.full

[19] *The use of radial endosonography findings in the prediction of cholangiocarcinoma in cases with distal bile duct obstructions*. 2013 Jun;60(124):678–83. Available from: http://eutils.ncbi.nlm.nih.gov/entrez/eutils/elink.fcgi?dbfrom=pubmed&id=24046829&retmode=ref&cmd=prlinks

[20] Veillette G, Castillo CF-D. *Distal biliary malignancy*. 2008 Dec;88(6):1429–47–xi.

[21] Riall TS, Cameron JL, Lillemoe KD, Campbell KA, Sauter PK, Coleman J, et al. Pancreaticoduodenectomy with or without distal gastrectomy and extended retroperitoneal lymphadenectomy for periampullary adenocarcinoma--part 3: update on 5-year survival. *J Gastrointest Surg.* 2005 Dec;9(9):1191–204–discussion1204–6.

[22] Yeo CJ, Cameron JL, Lillemoe KD, Sohn TA, Campbell KA, Sauter PK, et al. Pancreaticoduodenectomy with or without distal gastrectomy and extended retroperitoneal lymphadenectomy for periampullary adenocarcinoma, part 2: randomized controlled trial evaluating survival, morbidity, and mortality. *Annals of Surgery*. 2002 Sep;236(3):355–66–discussion366–8.

[23] *One Thousand Consecutive Pancreaticoduodenectomies*. 2006 Jul;244(1):10–5. Available from: http://content.wkhealth.com/linkback/openurl?sid=WKPTLP:landingpage&an=00000658-200607000-00003.

[24] *Randomized clinical trial of pylorus-preserving duodenopancreatectomyversus classical Whipple resection? long term results*. 2005;92(5):547–56. Available from: http://doi. wiley.com/10.1002/bjs.4881.

[25] Michalski CW, Kleeff J, Wente MN, Diener MK, Büchler MW, Friess H. Systematic review and meta-analysis of standard and extended lymphadenectomy in pancreaticoduodenectomy for pancreatic cancer. *Br J Surg*. 2007 Mar;94(3):265–73.

[26] The Pancreatic Surgery Mortality Study Group, Vollmer CM, Sanchez N, Gondek S, McAuliffe J, Kent TS, et al. *A Root-Cause Analysis of Mortality Following Major Pancreatectomy*. 2011 Nov 8;16(1):89–103.

[27] Balzano G, Zerbi A, Capretti G, Rocchetti S, Capitanio V, Di Carlo V. Effect of hospital volume on outcome of pancreaticoduodenectomy in Italy. *Br J Surg.* John Wiley & Sons, Ltd; 2008 Mar;95(3):357–62.

[28] Pancreaticoduodenectomy. *Informa Healthcare*; 2013;49(4):000–0. Available from: http://dx.doi.org/10.3109/00365521.2013.847116

[29] Malleo G, Marchegiani G, Salvia R, Butturini G, Pederzoli P, Bassi C. *Pancreaticoduodenectomy for pancreatic cancer: the Verona experience*. Springer Japan; 2011 Apr;41(4):463–70.

[30] Akamatsu N, Sugawara Y, Hashimoto D. Surgical strategy for bile duct cancer: *Advances and current limitations*. 2011 Feb 10;2(2):94–107.

[31] *The pattern of infiltration at the proximal border of hilar bile duct carcinoma: a histologic analysis of 62 resected cases.* 1998 Mar;227(3):405–11. Available from: http://eutils.ncbi.nlm.nih.gov/entrez/eutils/elink.fcgi?dbfrom=pubmed&id=9527064&retmode=ref&cmd=prlinks

[32] *Evolution of Surgical Treatment for Perihilar Cholangiocarcinoma*. 2013 Jul;258(1): 129–40. Available from: http://content.wkhealth.com/linkback/openurl?sid=WKPTLP: landingpage&an=00000658-201307000-00019.

[33] Bassi C, Falconi M, Molinari E, Salvia R, Butturini G, Sartori N, et al. Reconstruction by Pancreaticojejunostomy Versus Pancreaticogastrostomy Following Pancreatectomy. *Annals of Surgery*. 2005 Dec;242(6):767–73.

[34] *Pancreatogastrostomy with Gastric Partition after Pylorus-Preserving Pancreatoduodenectomy Versus Conventional Pancreatojejunostomy*. 2008 Dec;248 (6):930–8. Available from: http://content.wkhealth.com/linkback/openurl?sid= WKPTLP: landingpage&an=00000658-200812000-00005.

[35] *A controlled randomized multicenter trial of pancreatogastrostomy or pancreatojejunostomy after pancreatoduodenectomy*. 2005 Jun;189(6):720–9. Available from: http://linkinghub.elsevier.com/retrieve/pii/S0002961005002266.

[36] Topal B, Fieuws S, Aerts R, Weerts J, Feryn T, Roeyen G, et al. Pancreaticojejunostomy versus pancreaticogastrostomy reconstruction after pancreaticoduodenectomy for pancreatic or periampullary tumours: a multicentre randomised trial. *Lancet Oncol.* Elsevier; 2013 Jun;14(7):655–62.

[37] *Pancreaticoduodenectomy: time to change our approach?* Elsevier Ltd; 2013 May 25;14(7):573–5. Available from: http://dx.doi.org/10.1016/S1470-2045(13)70159-1

[38] Murakami Y, Uemura K, Hayashidani Y, Sudo T, Hashimoto Y, Ohge H, et al. *Prognostic significance of lymph node metastasis and surgical margin status for distal cholangiocarcinoma*. Wiley Subscription Services, Inc., A Wiley Company; 2007 Mar 1;95(3):207–12.

[39] Ito K, Ito H, Allen PJ, Gonen M, Klimstra D, D'Angelica MI, et al. Adequate lymph node assessment for extrahepatic bile duct adenocarcinoma. *Annals of Surgery*. 2010 Apr;251(4):675–81.

[40] Kondo S. Japanese Pancreas Society Staging Systems for Pancreatic Cancer. *Pancreatic Cancer*. New York, NY: Springer New York; 2010. pp. 1035–50.

[41] Kawai M, Tani M, Kobayashi Y, Tsuji T, Tabuse K, Horiuchi T, et al. The ratio between metastatic and examined lymph nodes is an independent prognostic factor for patients with resectable middle and distal bile duct carcinoma. *Am J Surg. Elsevier*; 2010 Apr;199(4):447–52.

[42] Schwarz L, Lupinacci RM, Svrcek M, Lesurtel M, Bubenheim M, Vuarnesson H, et al. Para-aortic lymph node sampling in pancreatic head adenocarcinoma. *Br J Surg*. 2014 Apr;101(5):530–8.

[43] Kitagawa Y, Nagino M, Kamiya J, Uesaka K, Sano T, Yamamoto H, et al. *Lymph node metastasis from hilar cholangiocarcinoma: audit of 110 patients who underwent regional and paraaortic node dissection*. 2001 Mar;233(3):385–92.

[44] *Outcome of paraaortic node-positive pancreatic head and bile duct adenocarcinoma*. 2004 Jun;187(6):736–40. Available from: http://linkinghub.elsevier.com/retrieve/pii/S0002961004000601.

[45] *Regional and para-aortic lymphadenectomy in radical surgery for advanced gallbladder carcinoma*. Blackwell Science Ltd; 2000;87(4):418–22. Available from: http://www. blackwell-synergy.com/rd.asp?issn=1365-2168&vol=87&page=418&goto=abstract.

[46] *Clinical Significance of Lymph Node Micrometastasis in Ampullary Carcinoma*. 2006 May 10;30(6):985–91. Available from: http://link.springer.com/10.1007/s00268-005-7985-8.

[47] Yonemori A, Kondo S, Matsuno Y, Ito T, Nakanishi Y, Miyamoto M, et al. *Prognostic impact of regional lymph node micrometastasis in patients with node-negative biliary cancer*. 2010 Jul;252(1):99–106.

[48] *Prognostic impact of para-aortic lymph node micrometastasis in patients with regional node-positive biliary cancer*. 2009 May;96(5):509–16. Available from: http://doi.wiley.com/10.1002/bjs.6585.

[49] *Advances in diagnosis, treatment and palliation of cholangiocarcinoma: 1990-2009*. 2009. Available from: http://www.ncbi.nlm.nih.gov/pmc/articles/PMC2744180/

[50] *Percutaneous drainage and stenting for palliation of malignant bile duct obstruction*. 2007 Oct 25;18(3):448–56. Available from: http://link.springer.com/10.1007/s00330-007-0796-6.

[51] *Fast-track programmes for hepatopancreatic resections: where do we stand?* Blackwell Publishing Ltd; 2011;13(12):833–8. Available from: http://onlinelibrary.wiley.com/doi/10.1111/j.1477-2574.2011.00391.x/full

[52] Berberat PO, Ingold H, Gulbinas A, Kleeff J, Müller MW, Gutt C, et al. *Fast track--different implications in pancreatic surgery*. 2007 Jul;11(7):880–7.

[53] Balzano G, Zerbi A, Braga M, Rocchetti S, Beneduce AA, Di Carlo V. Fast-track recovery programme after pancreatico- duodenectomy reduces delayed gastric emptying. *Br J Surg*. John Wiley & Sons, Ltd; 2008 Nov;95(11):1387–93.

[54] Lassen K, Coolsen MME, Slim K, Carli F, de Aguilar-Nascimento JE, Schäfer M, et al. Guidelines for perioperative care for pancreaticoduodenectomy: Enhanced Recovery After Surgery (ERAS®) Society recommendations. *Clinical nutrition* (Edinburgh, Scotland). Elsevier; 2012. pp. 817–30.

[55] Bassi C, Dervenis C, Butturini G, Fingerhut A, Yeo C, Izbicki J, et al. *Postoperative pancreatic fistula: An international study group (ISGPF) definition*. 2005 Jul;138(1):8–13.

[56] *Assessment of Complications After Pancreatic Surgery*. Lippincott, Williams, and Wilkins; 2006 Dec;244(6):931–9. Available from: http://content.wkhealth.com/linkback/openurl?sid=WKPTLP:landingpage&an=00000658-200612000-00013.

[57] *Does pancreatic duct stenting decrease the rate of pancreatic fistula following pancreaticoduodenectomy? Results of a prospective randomized trial*. Springer-Verlag; 2006;10(9):1280–90. Available from: http://link.springer.com/article/10.1016/j.gassur.2006.07.020.

[58] *Does Type of Pancreaticojejunostomy after Pancreaticoduodenectomy Decrease Rate of Pancreatic Fistula? A Randomized, Prospective, Dual-Institution Trial*. 2009 May;208(5):738–47. Available from: http://linkinghub.elsevier.com/retrieve/pii/S1072751509001768.

[59] *Pancreatic fistula after pancreaticoduodenectomy: the conservative treatment of choice*. Blackwell Publishing Ltd; 2009;11(3):203–9. Available from: http://onlinelibrary. wiley.com/doi/10.1111/j.1477-2574.2009.00007.x/full.

[60] *Risk Prediction for Development of Pancreatic Fistula Using the ISGPF Classification Scheme*. Springer-Verlag; 2008;32(3):419–28. Available from: http://link.springer.com/article/10.1007/s00268-007-9388-5/fulltext.html.

[61] *Resected adenocarcinoma of the pancreas— 616 patients: Results, outcomes, and prognostic indicators*. Springer-Verlag; 2000;4(6):567–79. Available from: http://linkinghub.elsevier.com/retrieve/pii/S1091255X00801055.

[62] Molinari E, Bassi C, Salvia R, Butturini G, Crippa S, Talamini G, et al. *Amylase value in drains after pancreatic resection as predictive factor of postoperative pancreatic fistula: results of a prospective study in 137 patients*. 2007 Aug;246(2):281–7.

[63] Bassi C, Molinari E, Malleo G, Crippa S, Butturini G, Salvia R, et al. *Early versus late drain removal after standard pancreatic resections: results of a prospective randomized trial*. 2010 Aug;252(2):207–14.

[64] Webster J, Scuffham P, Sherriff KL. Negative pressure wound therapy for skin grafts and surgical wounds healing by primary intention. *Database Syst Rev*. 2012.

[65] Wente MN, Veit JA, Bassi C, Dervenis C, Fingerhut A, Gouma DJ, et al. *Postpancreatectomy hemorrhage (PPH*)–An International Study Group of Pancreatic Surgery (ISGPS) definition. 2007 Jul;142(1):20–5.

[66] Wente MN, Bassi C, Dervenis C, Fingerhut A, Gouma DJ, Izbicki JR, et al. *Delayed gastric emptying (DGE) after pancreatic surgery*: A suggested definition by the International Study Group of Pancreatic Surgery (ISGPS). 2007 Nov;142(5):761–8.

[67] Addeo P, Delpero JR, Paye F, Oussoultzoglou E, Fuchshuber PR, Sauvanet A, et al. Pancreatic fistula after a pancreaticoduodenectomy for ductal adenocarcinoma and its association with morbidity: *a multicentre study of the French Surgical Association*. 2014 Jan;16(1):46–55.

[68] Callery MP, Pratt WB, Kent TS, Chaikof EL, Vollmer CM. *A prospectively validated clinical risk score accurately predicts pancreatic fistula after pancreatoduodenectomy*. Elsevier; 2013 Jan;216(1):1–14.

[69] Murakami Y, Uemura K, Sudo T, Hashimoto Y, Nakashima A, Kondo N, et al. Prognostic factors after surgical resection for intrahepatic, hilar, and distal cholangiocarcinoma. *Ann Surg Oncol.* Springer-Verlag; 2011 Mar;18(3):651–8.

[70] Woo SM, Ryu JK, Lee SH, Yoo JW, Park JK, Kim Y-T, et al. *Recurrence and prognostic factors of ampullary carcinoma after radical resection: comparison with distal extrahepatic cholangiocarcinoma*. 2007 Nov;14(11):3195–201.

[71] *Evaluation of extra capsular lymph node involvement in patients with extra-hepatic bile duct cancer*. 2012;10:106. Available from: http://eutils.ncbi.nlm.nih.gov/entrez/eutils/elink.fcgi?dbfrom=pubmed&id=22681770&retmode=ref&cmd=prlinks.

[72] Kim HJ, Kim CY, Hur YH, Koh YS, Kim JC, Kim HJ, et al. The prognostic factors for survival after curative resection of distal cholangiocarcinoma: perineural invasion and lymphovascular invasion. *Surg Today*. Springer Japan; 2014 Oct;44(10):1879–86.

In: Encyclopedia of Surgery (22 Volume Set)
Editors: Andreas Lehrer and Kristin Mueller
ISBN: 978-1-53618-329-0
© 2020 Nova Science Publishers, Inc.

Chapter 361

INTRAOCULAR SURGERY IN KYPHOSIS

Mohannad Qasim Albdour[1], MD
and Karanjit S. Kooner[2,*], MD, PhD
[1]Department of Ophthalmology,
University of Texas Southwestern medical Center, Dallas, Texas, USA
[2]Currently at Department of Ophthalmology,
King Hussein Medical Center, Amman, Jordan

ABSTRACT

Kyphosis is a progressive, curvature of thoracic spine which results in rounding or bowing of the back . Curved spine accompanied by restricted neck motion and poor lung reserve present challenges for an ophthalmic surgeon who is used to patient's neck and head resting flat on the operating table and the eye in the horizontal position. Intraoperative difficulties include poor view, inability to maneuver surgical instruments properly and constant threat of elevated vitreous pressure. Several innovative solutions have been published including, maximal reverse Trendelenburg position with pillows under the head and neck, use of a donut and wedge shaped head positioner, allowing the patient to remain in upright sitting position while their head is positioned horizontally in a modified waiting room chair, performing surgery while standing, using 4-section orthopedic operating table, laying the patients on their sides, *side saddle* positioning, face-to-face positioning, parachute type harness inferior corneal retraction suture, or extreme patient positioning for retinal surgery. This chapter highlights various surgical options to facilitate surgeons pick the best course of action when dealing with intraocular surgery in patients with kyphosis.

Keywords: intraocular surgery, kyphosis

[*] Corresponding Author's Email: Karanjit.Kooner@UTSouthwestern.edu; Fax: (214) 648-2270.

INTRODUCTION

Intraocular microsurgery mandates comfortable seating of both the patient and the surgeon at the start of the surgery. If either of these pre requisites is compromised, the ensuing suboptimal view of the eye may result in a high chance of intraocular complications. Patients with kyphosis present multitude of challenges related to their physical disabilities including concomitant pulmonary and cardiovascular diseases [1]. Several practical solutions have been described by very experienced surgeons but complications may still occur [2].

Gordon et al were able to successfully complete cataract surgery on a patient with severe kyphosis by using three pillows under his head and neck and 11 pillows under patient's buttocks and legs with the operating table positioned in maximum reverse Trendelenburg position [3]. They stressed that pillows be securely taped to the operating table to prevent slippage. A wedge-shaped pillow with built-in donut for positioning of the head and back [Profex Medical Products, St. Louis, MO] has been used by some surgeons [4]. This allows patient's head to be extended forward thus making the eye more accessible for surgery. They recommended using more than one of these positioners in severe cases. The depth of the doughnut helps to fix as well as elevate the head.

Fine and associates modified a common waiting room chair, for less than $ 200, to accommodate patients with various back and head disabilities and enable these patients to remain in an upright seated position and tilt their head back [5]. The back cushion of the chair was placed on adjustable brackets. The legs of the chair were shortened to allow the patients to stretch their legs out in front to counterbalance the tilted position of the back and head. An adjustable head rest clamp was attached to the back of the chair to provide firm support. Extra stability was provided by a spindle attached to a strut between the front legs of the chair for counterbalance. Authors felt that their patients did not experience the cognitive and anoxia related symptoms in a supine position.

Another approach suggested performing cataract surgery standing up using loupes for magnification and fiber optic headlamp for coaxial illumination and making an infero-temporal scleral tunnel [6]. This surgery was complicated by posterior capsular tear requiring anterior vitrectomy. The surgeons were also unable to remove sub-incisional cortex because of shallow anterior chamber secondary to elevated posterior vitreous pressure. Poor visualization and unaccustomed standing position may have contributed to the complications. Hunter was able to remove cataract in an obese patient by performing phacoemulsification while standing but needed an ophthalmic technician to control focusing and side movements of the microscope [7]. A national survey of ophthalmic surgeons in United Kingdom reported that over 50% did perform cataract surgery while standing, if required [8]. A prospective study in England also showed that standing phacoemulsification was as safe as conventional surgery in the hands of experienced surgeons provided patient specific measures were taken [9].

Prasad et al recommended using a 4-section orthopedic operating table to enable an extreme reverse Trendelenburg position for cataract and glaucoma surgery [10]. However, because of blurred vision, they were unable to perform curvilinear capsulorehexis and had to resort to can-opener capsulotomy. Sambandam was able to complete cataract surgery on a patient with severe kyphosis by laying her on her side [11]. This patient was unable to lie on her back at all. A side saddle approach was described by Nair et al where in the surgeon sat

with his thighs parallel to the long axis of the operating table and facing the head end [12]. The optical axis of the microscope had to be inclined about 60° towards the horizontal. The globe was tilted superotemporally to optimize red reflex. They used intra cameral anesthesia and infero-temporal corneal incision which may increase incidence of endophthalmitis. When the patient can only be placed in a semi recumbent position, Ang et al have proposed a face-to-face sitting position and tilting the operating microscope 60° from the vertical [13]. Surgeon has to be aware and adjust for the unsteadiness caused by outstretched arms. Topical anesthesia allowed the patient to comply with requests to fixate on the microscope light. Some patients may need strong parachute-like support harness for secure positioning [14]. The surgeons used foam to support the head, neck, shoulders and knees and moved the table in extreme Trendelenburg position. They used Velcro surgical straps similar to straps in a parachute harness. Cataract was removed via a superotemporal corneal approach under retrobulbar anesthesia. Elevated legs may distend jugular veins and result in increased posterior pressure.

We described a 49- year-old obese male with controlled secondary glaucoma who needed cataract surgery in the right eye [15]. He had ankylosing spondylitis related extreme kyphosis and neck in fixed flexion (Figure 1). His pulmonary reserve was also very low. The past ocular history was positive for recurrent uveitis and glaucoma shunt surgery in the right eye. The pupil was small and fixed from posterior synechia. The cataract was +4 dense. The best corrected visual acuity was 20/200. The anterior chamber was shallow and glaucoma tube shunt was visible at 11 o'clock position. The pre-op plan included pupillary dilation with iris retraction hooks, corneal staining with trypan blue, and phacoemulsification with intra ocular implantation under local anesthesia. The anesthesiologist was reluctant to use general anesthesia because of patient's disability and poor health.

Figure 1. The patient with kyphosis and immobile neck in fixed flexion.

In the operating room, the patient could only recline to about 40° from the vertical axis despite maximal reverse Trendelenburg position and number of pillows under his back, neck, head and legs (Figure 2). With the surgeon at the temporal side of the patient, the eye was also seen reclining at 40° (Figure 3). While trying to focus the microscope, it became evident that by grasping the eye at the inferior limbus with a fine forceps, and pulling it upwards, the

eye could be moved to a more desirable horizontal position. A single 7/0 Vicryl (polyglactin) corneal retraction suture was placed at the limbus at 6 o'clock position to achieve the desired view (Figure 4). The assistant was able to rotate the eye to the desired positions during the whole procedure by relaxing or pulling on the suture (Figure 5). There were no intra-ocular complications and the post-operative recovery was uneventful. The final best corrected visual acuity was 20/30.

Figure 2. The position best tolerated by the patient during surgery.

Retinal surgeries are often more complex and require longer duration than cataract surgeries. You and associates [16] employed the head-down position with cushioning support in a man with severe 90 ◦ curvature of his spine. They used three large orthopedic cushions and several pillows to raise the patient's legs by approximately 48 ◦ and secured the patient with ample surgical tape and three straps. The operating microscope had to be tilted at 15 ◦ offset. The team was able to complete the very complex retinal procedure without any complications.

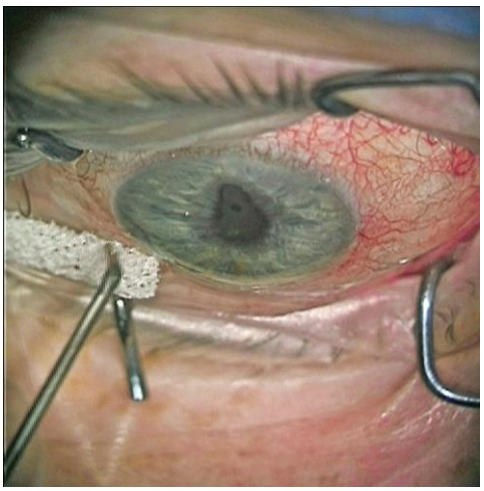

Figure 3. The virtual vertical position of the eye at the beginning of surgery.

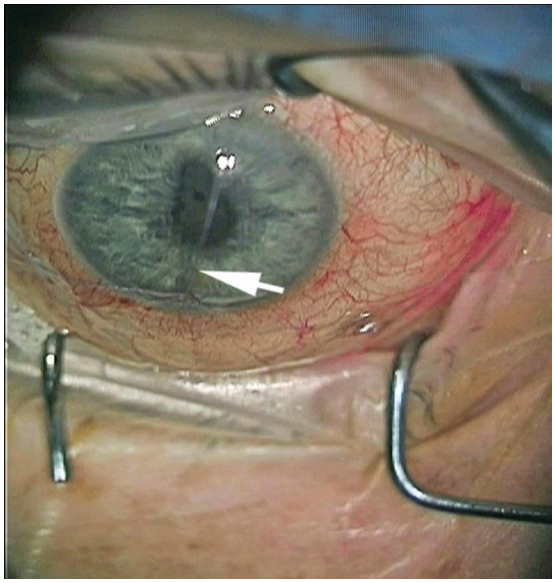

Figure 4. Pull on the corneal retraction suture (white arrow) allowed rotation of the eye more horizontally.

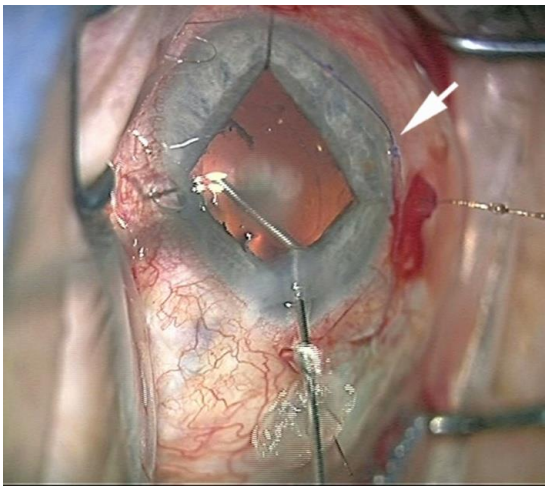

Figure 5. Cataract surgery was completed successfully. Iris retraction sutures kept the pupil dilated.

In a patient with severe thoracic kyphosis who was unable to lie flat on a table, Razeghinejad et al used a chair with adjustable top between an operating table and another small table [17]. The wheels of the table and the chair were secured with adhesive tape. The patient was laid with his head on the small table and his thorax fitting on the well-padded chair. The adjustable top of the chair allowed accommodating kyphotic thorax. The cataract surgery was performed successfully. Packer recommended making an extra paracentesis inferiorly to assist in capsulorehexis but the relatively vertical position of the eye still made this procedure difficult [18].

CONCLUSION

Patients with kyphosis may present several unique challenges to an eye surgeon. The foremost being the inability to lay the head and neck in the ideal horizontal position. The resulting poor view makes focusing and manipulation of tissues and instruments difficult. Tilting the head end of the operating table down and raising patient's legs may compromise venous return from the orbit causing venous engorgement and elevated posterior vitreous pressure during surgery. In addition, patient's poor pulmonary reserve itself may further impede orbital/jugular venous return resulting in increased posterior vitreous pressure [14, 5, 6, 9]. Afshar et al have proposed an in-office trial of Trendelenburg positioning by inclining an office examination chair to determine head position while supine [19]. Other features of kyphosis that may adversely affect intra ocular surgery are tenderness and stiffness of the back and difficulty breathing. It is imperative that the anesthesiology and nursing staff be alerted and consulted for team work. Most experts have recommended topical, intracameral anesthesia rather than general anesthesia in patients with kyphosis [12, 19, 20]. Topical anesthesia allows the patient to fixate on the operating light, keep the eye in the desired position and obtain the best red reflex. Other helpful maneuvers are, turning the patient's face and /or chin up, standing temporal approach and using straight instruments rather than curved to avoid damaging intraocular structures [20]. In short, there is no single solution for these groups of difficult patients. Careful pre-op evaluation, planning and a team approach with internist, anesthesiologist, nursing staff is paramount. A surgeon may use one or more proven ways to deal with the issues at hand. Besides kyphosis these suggestions may also be helpful in other conditions causing inability to recline such as torticollis [21], chronic obstructive pulmonary disease, chronic congestive heart failure, morbid obesity, myotonic dystrophy, ankylosing spondylitis, cerebral palsy, Meniere's disease or claustrophobia. Surgeons may consider operating on these patients earlier when the cataract is softer rather than later to avoid complications associated with advanced hard cataracts.

ACKNOWLEDGMET

Supported in part by unrestricted grant from the Society to Prevent Blindness New York, and Visual Science Core Grant EY 020799.

CONFLICT OF INTEREST

Authors have no financial or proprietary interest in the materials described in the article.

REFERENCES

[1] Freeman BL III. Scoliosis and kyphosis. In: Canale ST, Beaty JH, eds. *Campbell's Operative Orthopaedics*. 11th ed. Philadelphia, Pa: Mosby Elsevier; 2007: chap 38.

[2] Rogers GM and Goins KM. Cataract surgery in the patient that cannot lie flat. *Curr Opin Ophthalmol.* 2010; 21:71-74.

[3] Gordon ML, Rodriguez AA, Olson MD, Miller KM. Pillow case. *J Cataract Refract Surg* 2005; 31: 1824-1825.

[4] Livingston M and Mackool RJ. Donut wedge cataract positioner (letter). *J Cataract Refract Surg.* 1995; 21:5-6.

[5] Fine IH, Hoffman RS, Binstock S. Phacoemulsification performed in a modified waiting room chair. *J Cataract Refract Surg.* 1996; 22:1408-1410.

[6] Rimmer S and Miller KM. Phacoemulsification in the standing position with loupe magnification and headlamp illumination. *J Cataract Refract Surg.* 1994; 20:353-354.

[7] Hunter LH. Standing while performing phacoemulsification. *J Cataract Refract Surg*. 1995; 21:111.

[8] Chandradeva K, Hugkulstone CE. Standing phacoemulsification: a national survey. *Journal of Cataract and Refractive Surgery* 2007; 32(12):2155-6. DOI:10.1016/ j.jcrs.2006.06.038.

[9] Hugkulstone CE. Standing phacoemulsification: A prospective audit of 20 consecutive cases. *Journal of Cataract and Refractive Surgery* 2010; 36(10):1763-7. DOI: 10.1016/j.jcrs.2010.04.031.

[10] Prasad SP, Kamath GG and Philips RP. Phacoemulsification in a patient with marked cervical kyphosis. *J Cataract Refract Surg* 2000; 26: 1258-1260.98.

[11] Sambandam SPT. Cataract extraction in a humpback woman. *Indian J Ophthalmol*. 1974; 22:35, available from: http://www.ijo.in/text.asp? 1974/22/1/35/31381.

[12] Nair J and Rimmer T. Side saddle cataract surgery for patients unable to lie flat: learning from the past. *Eye* 2007; 21:1122-1123. DOI:10.1038/sj.eye.6702891.

[13] Ang GS, Ong JM, Eke T. Face-to-face seated positioning for phacoemulsification in patients unable to lie flat for cataract surgery. *Am J Ophthalmol. 2006*; 141(6):1151-2.

[14] Muthialu A, Rauen M, Newsom TH, Jensen L, Oetting TA. Parachute-like harness to position patients with severe kyphosis during cataract surgery. *J Cataract Refract Surg.* 2009; 35(8):1332-4. DOI: 10.1016 /j.jcrs.2009.03.027.

[15] Kooner KS and Barte FM: Intraocular surgery in kyphosis: an easier approach. *Case Rep Ophthalmol* 2013; 4:34-38. DOI: 10.1159 /000353227.

[16] You T, Huang CX, Chen S, Maggiano J, Rathod R, Chang E and Casiano M. Case report: extreme patient positioning for retinal surgery in advanced kyphosis. *Retin cases Brief Rep.* 2015 (Epub ahead of print).

[17] Razeghinejad M and Eghbal M. A simple way to achieve the routine position for phacoemulsification in a patient with marked thoracic kyphosis. *J Ophthalmic Vis Res* 2009; 4 (4): 253-255.

[18] Packer M. *Cataract surgery in severely kyphotic patient*. Video available at http://www.surgytec.com/video/cataract-surgerykyphotic-patient.

[19] Afshar AR, Pongsachareonnont P, Siegner SW, Stewart JM. Trendelenburg positioning with temporal approach for vitreoretinal surgery in a patient with severe kyphosis. *Eye* (2014) 28, 1261–1263; doi:10.1038/eye.2014.17.

[20] Eke T. Side-saddle cataract surgery for patients unable to lie flat: learning from the past (letter). *Eye* 2008; 22: 860. DOI:10.1038/sj.eye.6703032.

[21] Liu C. phacoemulsification in a patient with torticollis (letter). *J Cataract Refract Surg.* 1995; 21: 364.

In: Encyclopedia of Surgery (22 Volume Set)
Editors: Andreas Lehrer and Kristin Mueller
ISBN: 978-1-53618-329-0
© 2020 Nova Science Publishers, Inc.

Chapter 362

SURGERY OF THYMOMATOUS MYASTHENIA GRAVIS

Cameron D. Wright*
Division of Thoracic Surgery, Massachusetts General Hospital,
Boston, MA, US

ABSTRACT

About 21% of patients with myasthenia gravis have a thymoma and about 50% of patients with a thymoma have myasthenia gravis. Patients with thymoma-associated myasthenia gravis tend to be younger than thymoma-alone patients and tend to have World Health Organization type AB, B1 or B2 thymomas. Resection with an extended thymectomy is generally the treatment of choice. Whereas in the past myasthenia gravis was thought to lead to a worse prognosis, recent series suggest either a better or equivalent prognosis. The neurologic results tend to be worse than those reported for pure myasthenia gravis after extended thymectomy. Myasthenia gravis may appear late after resection of a thymoma not associated with myasthenia gravis, independent of any recurrence of the thymoma.

INTRODUCTION

The incidence of thymoma in patients with myasthenia gravis (MG) has been reported to vary between 11 and 60% in large case series [1]. A recent systematic review of 49 articles covering over 6000 patients reported an incidence of 21%, with population-based studies at 17%, hospital-based studies at 12% and surgical series at 25% [1]. Further analysis of these patients indicated that male gender (Odds ratio [OR] 1.78) and age > 40 (OR 5.74) were risk factors for myasthenia patients to present with a thymoma.

Given the well-known association of MG and thymoma it is standard practice to screen for a thymoma when MG is first diagnosed. The most commonly ordered exam is a contrast-

* Corresponding Author's Email: cdwright@partners.org.

enhanced CT. Alternatively, a mediastinal magnetic resonance (MR) exam can be ordered which has the advantage of no radiation exposure to the patient. This is especially useful for children and young woman. Furthermore, MR is very good at distinguishing thymic hyperplasia from an early thymoma which is an occasional clinical concern [2]. The disadvantages of an MR exam is that it is more costly and has a higher dissatisfaction rate with patients due to the length of the exam, noise and the close confines of the machine.

Large case series of thymoma patients report an incidence of MG at presentation of 40-50%. A recent large multicenter study of 537 patients with thymoma reported an incidence of MG in 51% of patients [3]. This study also reported that thymoma patients with MG were more likely to have an early stage tumor and have WHO type B histology compared to A histology [3].

PREOPERATIVE PREPARATION

The preoperative preparation for patients undergoing surgery for a thymoma associated with MG is the same as those without a thymoma. Close cooperation between the neurologist and thoracic surgeon is mandatory and the patient should be in optimal condition before operation to minimize the risk of postoperative complications related to poor myasthenic control. An operation is a stressful event and is a known risk factor for a myasthenic crisis. A recent study reported on the risk factors for myasthenic crisis after thymectomy in 178 patients [4]. Multivariate analysis indicated that preoperative myasthenic crisis (OR 2.8), presence of bulbar symptoms (OR 3.1) and longer operations (OR 1.1) were risk factors for a postoperative myasthenic crisis [4]. One recent intriguing study reported on the efficacy of high-dose prednisolone therapy perioperatively to reduce postoperative myasthenic crisis. This was an observational study that was not randomized. Seventy patients had steroids and 61 patients did not in a group of patients with MG, with and without thymoma. Patients who had steroids had a reduced rate of postoperative myasthenic crisis (12% vs 3%, p=0.045) [5].

SURGICAL TECHNIQUE

The standard operation for a thymoma associated with MG is a complete resection of both the thymus and the thymoma. Most surgical series report that an R0 resection is one of the most, if not the most important predictors of long-term survival after thymoma resection [3]. The surgeon must carefully review the preoperative imaging to determine the estimated clinical stage of the patient. Predictors of invasion include large size, edge characteristics that suggest invasion and a lobulated contour [6]. Induction chemotherapy should be administered for invasive tumors that appear marginally resectable. The operative approach depends on the stage, location and experience of the thoracic surgeon. Small early stage thymomas can be resected by essentially all operative approaches as described in other sections dealing with non-thymomatous MG.

The “standard” operation is a transsternal resection of both the thymus and the thymoma and has stood the test of time. Large tumors involving the lung are sometimes best resected with a hemi-clamshell approach. Minimally invasive approaches have been reported with

increasing frequency and enthusiasm with intermediate term results essentially equivalent to those of the standard trans-sternal approach [7,8].

Most recurrences of thymomas occur between years 5 and 10 and thus long-term follow-up is needed to ascertain the results of any surgical approach. Minimally invasive resection of invasive thymomas has been reported as well in more limited numbers [9]. One center reported an apparent advantage of robotic thymectomy over VATS thymectomy in terms of MG regression although it was a retrospective study [10]. In the end, as long as a complete resection of both the thymus and thymoma is accomplished the results should be the same between the 2 approaches.

Certainly there is increasing enthusiasm for minimally invasive resections of thymomas, regardless of whether myasthenia is present or not. In general, the early results suggest less blood loss, less pain, shorter hospital stays and earlier return of baseline physical status. These early results however must be tempered against the long-term results, especially the recurrence rate and the complete remission rate.

To date, I am unaware of any large series with reported 10 year results after minimally invasive resection of thymomas. I suspect they will be essentially the same as with open approaches but there will be the rare patient that had some inadvertent spillage during the resection that recurs unexpectantly late in the pleural space. I have seen 2 such patients in the past 10 years who were operated on by expert surgeons elsewhere by VATS for early stage I thymomas with early pleural recurrence. It is important not to grasp the tumor itself when attempting a minimally invasive resection to avoid inadvertent capsular disruption.

Consideration should be given to have either a trocar or a wound protector in all access sites to reduce the chance of a port recurrence. Of course a plastic bag should be used and closed before the specimen is removed. The surrounding mediastinal fat can be used as holder to facilitate resection. A recent case report of a port site recurrence after VATS resection of a stage I thymoma illustrates what can happen after a seemingly uncomplicated resection of an encapsulated thymoma [11]. A recent review article summarized the series reported as of 2011 comparing VATS and trans-sternal thymectomy for MG [12].

Tables 1 and 2 summarize this review. Table 1 reports the important metrics in nonthymomatous MG between VATS and trans-sternal thymectomy. Overall the operating time was a little longer, the remission rate was a little less (but the p was 0.16), while the blood loss and hospital stay were less. The complication rates and amount of thymic tissue resected were similar. Table 2 reports the outcomes in mixed thymomatous and non-thymomatous MG patients between VATS and transsternal resections. VATS patients had less need for an ICU, decreased length of stay and less need for pain medication. VATS patients had longer operations and the patients perceived a better cosmetic result along with improved symptoms of MG.

My overall thoughts are that many small clinically encapsulated thymomas can be removed safely by VATS, but if the surgeon has any concerns the resection should be done by an open approach. I still think that invasive tumors are generally best resected with an open approach. However it is clear this field is evolving and no universal consensus has been reached on the best technique.

Table 1. Outcomes in nonthymomatous myasthenia gravis between VATS and transsternal thymectomy based on 6 studies [12]

Approach	OR time (minutes)	EBL	LOS days	Complications	Remission	Thymic mass resected	Postop. mortality
VATS	268	74ml	5.6	23%	33%	37 g	0
Sternotomy	177	155 ml	8.1	19%	45%	34 g	0

VATS=Video-assisted thoracic surgery, OR=Operating room, EBL=Estimated blood loss, LOS=Length of stay.

Table 2. Outcomes in mixed thymomatous and nonthymomatous myasthenia gravis between VATS and transsternal resection based on 8 studies [12]

Approach	OR time (minutes)	ICU stay (days)	LOS (days)	Narcotic need (rate)	Cosmetic satisfaction	Symptom improvement	Postop. mortality
VATS	268	1.5	1.9	36%	100%	100%	0
Sternotomy	177	3.2	4.6	77%	83%	78%	0

VATS=video-assisted thoracic surgery, OR=Operating room, ICU=Intensive care unit, LOS=Length of stay.

Figures 1 and 2 demonstrate two early stage thymomas that were resected by a VATS technique. Figures 3 and 4 demonstrate two locally advanced thymomas that had induction chemotherapy followed by an open resection. These are easy cases to stratify between a minimally invasive and open approach. The many cases in between require a great deal of judgment and a consideration of the skill and philosophy of the surgeon to decide on a particular approach.

Figure 1. Small midline thymoma with sharp borders and a clear tissue plane between the thymoma and the aorta, clinically not invasive. Pathology revealed a Masaoka stage 1, WHO B2 thymoma. This was removed by VATS.

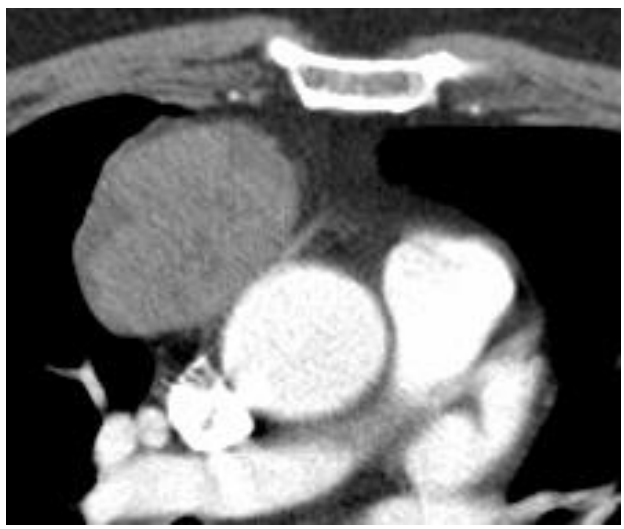

Figure 2. Small right sided thymoma with sharp borders, clinically not invasive. Pathology revealed a Masaoka stage I, WHO AB thymoma. This was removed by VATS.

Figure 3. Large lobulated heterogenous thymoma with areas of necrosis and calcification and invasive borders. Pathology revealed a Masaoka stage III, WHO B3 thymoma. This was removed by mediansternotomy after induction chemotherapy. The pericardium, phrenic nerve and lung were resected along with the thymoma.

Figure 4. Large invasive thymoma with encasement of the innominate vein and invasive borders. Pathology revealed a Masaoka stage II thymoma, WHO B3 thymoma. This was removed by mediansternotomy after induction therapy. The innominate vein was resected and a superior vena cava resection and reconstruction was required.

One particular issue frequently comes up during resection of thymomas associated with myasthenia gravis-that of preserving the phrenic nerve. Thymomas frequently abut the phrenic nerve as they enlarge and drop down into the affected pleural space. If the nerve is clearly invaded and the diaphragm is known to be paralyzed preoperatively the intraoperative decision is easy-cleanly resect the nerve to enhance the R0 resection. More difficult is when the nerve is abutted but not clearly invaded. Many surgeons will then skeletonize the nerve, mark it with clips for possible adjuvant radiation in an effort to maximize lung function and reduce the risk of respiratory failure.

Obviously when one nerve is significantly at risk every effort should be made to not put the other phrenic nerve at risk. One recent paper tried to address this important issue [13]. One-hundred fourteen patients with Stage III and IVA thymomas were studied. The phrenic nerve was either abutted or invaded in all. The phrenic nerve was spared in 73 patients and resected in 41. The indications for sparing the nerve were: both nerves involved, compromised lung function, severe MG, or severe comorbidities with close abutment. There was no difference in postoperative morbidity or mortality. A higher recurrence rate was observed in the phrenic nerve spared group (67% vs 54%) but there was no difference in overall or disease free mortality [13].

RESULTS

The perioperative results of thymoma resection in association with MG in the current era are essentially similar to patients without MG [3,14,15]. With current management strategies that emphasize close cooperation with a neurologist and optimal preoperative preparation myasthenic crises are rare after operation. A recent study reported on the predictors of a myasthenic crisis after thymectomy. Multivariate analysis suggested that a history of preoperative myasthenic crisis, presence of bulbar symptoms and longer operation duration were predictors of postoperative myasthenic crises [4].

The long-term results of surgery can be separated into 2 aspects-freedom from recurrence and survival related to the thymoma and the response of the MG to thymectomy. The important predictors of freedom from recurrence and long-term survival are well known in thymoma; an R0 resection, Masaoka stage and World Health Organization (WHO) histology [16]. A generation ago the thought was that thymoma associated with MG led to a worse prognosis, largely due to poor neurologic outcomes. However the medical care of myasthenic patients has significantly improved over the past 20 years. Several recent series suggest a slightly better survival of thymoma patients with MG than those without MG [17].

However a recent large multi-institutional series of 2,151 patients reported in a multivariate analysis that MG had no significant effect on overall or disease-free survival [16]. Many clinicians think that MG patients often have an earlier diagnosis of thymoma leading to slightly better results. However with proper statistical analysis after matching of all important covariates it seems likely that there is no significant survival difference in thymoma patients with and without MG.

In general, most series report that remission from MG associated with a thymoma is worse than patients without thymoma, generally with a complete remission rate of only 10-15% [17,18]. A relatively recent report on 123 patients with MG and thymoma resected with an extended thymectomy however reported a 43% complete remission rate at 5 years, similar to reports with MG alone [14]. This study also reported an intriguing result-that patients who achieved a complete remission had a better oncologic prognosis. It is hard to reconcile these disparate results though one could argue that careful attention to an extended thymectomy (in addition to an R0 resection of the thymoma) is likely to lead to better MG neurologic results and a less complete thymectomy could be the reason for suboptimal results.

MG symptoms may be exacerbated after resection of a thymoma (and thymectomy) and lead to a need for enhanced medical treatment of the MG and occasionally lead to a

myasthenic crisis [4,20]. MG may also appear in the late postoperative period after resection of a thymoma not associated with preoperative MG [4,20,21]. The incidence in larger series ranges from 5-10% [18,21]. There appears to be no association with the WHO histology of the thymoma and late postoperative MG. The majority of cases of late postoperative MG are not associated with a recurrence of the thymoma. Alternatively, a thymoma may develop late after thymectomy for nonthymomatous myasthenia gravis, despite a reported "complete" thymectomy [22]. Presumably this is due to thymic rests in the unresected mediastinal fat that later develop into a thymoma.

Patients with myasthenia gravis and thymoma need long-term follow-up, both for medical management of myasthenia and to monitor for a possible recurrence of the thymoma. The outlook is overall quite favorable and in large series the 5 year survival is 93% and the 10 year survival is 80% in patients with MG and thymoma [14].

CONCLUSION

About 21% of patients with MG have a thymoma and about 50% of patients with a thymoma have MG. Patients with thymoma-associated MG tend to be younger than thymoma-alone patients and tend to have WHO type AB, B1 or B2 thymomas. Resection with an extended thymectomy is generally the treatment of choice. Optimal preoperative preparation of the underlying MG is very important. Resection of early stage thymomas can be done by either VATS or an open approach depending on the details of the thymoma and the expertise of the surgeon. Locally advanced thymomas are usually resected by an open approach.

Whereas in the past MG was thought to lead to a worse prognosis, recent series suggest either a better or equivalent prognosis. The neurologic results tend to be worse than those reported for pure MG after extended thymectomy. MG may appear late after resection of a thymoma not associated with MG, independent of any recurrence of the thymoma. Long-term survival at 10 years approaches 80% in patients with combined MG and thymoma.

REFERENCES

[1] Mao ZF, Mo XA, Qin C, Lai YR, Hackett ML. Incidence of thymoma in myasthenia gravis: A systematic review. *J Clin Neurol* 2012;8:161-169.

[2] Ackman JB. A practical guide to nonvascular thoracic magnetic resonance imaging. *J Thorac Imaging* 2014;1:17-29.

[3] Filosso PL, Venuta F, Oliaro A, Ruffini E, Rendina EA, Margaritora S, Casadio C, Terzi A, Rena O, Lococo F, Guerrera F. Thymoma and inter-relationships between clinical variables: A multicenter study in 537 patients. *Eur J Cardiothorac Surg* 2014;45:1020-1027.

[4] Yu S, Lin J, Fu X, Li J, Li Y, Chen B, Yang M, Zhang M, Bu B. Risk factors of myasthenic crisis after thymectomy in 178 generalized myasthenia gravis patients in a five year follow-up study. *Int J Neurosci* 2014; 124: 792-798.

[5] Yamada Y, Yoshida S, Suzuki H, Tagawa T, Iwata T, Mizobuchi T, Kawaguchi N, Yoshino I. Efficacy of high-dose prednisolone therapy during thymectomy in myasthenia gravis patients. *J Cardiothorac Surg* 2013;8:226-31.

[6] Marom EM. Advances in thymoma imaging. *J Thorac Imaging* 2013;28:69-80.

[7] He Z, Zhu Q, Wen W, Chen L, Xu H, Li H. Surgical approaches for Stage I and II thymoma-associated myasthenia gravis: feasibility of complete video-assisted thoracoscopic surgery (VATS) thymectomy in comparison with trans-sternal resection. *J Biomed Res* 2013;27:62-70.

[8] Mineo TC, Pompeo E. Extended videothoracoscopic thymectomy in nonthymomatous myasthenia gravis. *Thorac Surg Clin* 2010;20:253-263.

[9] Ismail M, Swierzy M, Ruckert RI, Ruckert JC. Robotic thymectomy for myasthenia gravis. *Thorac Surg Clin* 2014;24:189-95.

[10] Ruckert JC, Swierzy M, Ismail M. Comparison of robotic and nonrobotic thoracoscopic thymectomy; a cohort study. *J Thorac Cardiovasc Surg* 2011;141:673-7.

[11] Ishibashi H, Takasaki C, Okubo K. Port-site recurrence after complete resection of a stage I thymoma by video-assisted thoracoscopic surgery: report of a case. *Surg Today* 2013 Nov 17 (Epub).

[12] Zahid I, Sharif S, Routledge T, Scarci M. Video-assisted thoracoscopic surgery or trans-sternal thymectomy in the treatment of myasthenia gravis. *Interactive Cardiovasc Thorac Surg* 2011;12:40-46.

[13] Hamdi S, Mercier O, Fadel E, Mussot S, Fabre D, Ghigna MR, de Montpreville V, Besse B, Le Pechoux C, Ladurie FL, Le Chevalier T, Dartevelle P. Is sacrifying the phrenic nerve during thymoma resection worthwhile? *Eur J Cardiothorac Surg* 2014;45:e151-56.

[14] Lucchi M, Ricciardi R, Melfi F, Duranti L, Basolo F, Palmiero G, Murri L, Mussi A. Association of thymoma and myasthenia gravis; oncological and neurological results of the surgical treatment. *Eur J Cardiothorac Surg* 2009;35:812-816.

[15] Ruffini E, Filosso PL, Mossetti C, Bruna MC, Novero D, Lista P, Casadio C, Oliaro A. Thymoma; inter-relationships among World Health Organization histology, Masaoka staging, and myasthenia gravis and their independent prognostic significance: a single centre experience. *Eur J Cardiothorac Surg* 2011;40:146-153.

[16] Ruffini E, Detterbeck F, Van Raemdonck D, Rocco G, Thomas P, Weder W, Brunelli A, Guerrera F, Keshavjee S, Altorki N, Schützner J, Arame A, Spaggiari L, Lim E, Toker A, Venuta F; European Society of Thoracic Surgeons Thymic Working Group. Tumors of the thymus: a cohort study of prognostic factors from the European Society of Thoracic Surgeons database. *Eur J Cardiothorac Surg* 2014; 46: 361-368.

[17] Kondo K, Monden Y. Thymoma and myasthenia gravis: A clinical study of 1,089 patients from Japan. *Ann Thorac Surg* 2005;79:219-24.

[18] Maggi L, Andreetta F, Antozzi C, Baggi F, Bernasconi P, Cavalcante P, Cornelio F, Muscolino G, Novellino L, Mantegazza R. Thymoma-associated myasthenia gravis: outcome, clinical and pathologic correlations in 197 patients on a 20-year experience. *J Neuroimmunol* 2008;201:237-244.

[19] Somnier F. Exacerbation of myasthenia gravis after removal of thymoma. *Acta Neurol Scand* 1994;90:56-66.

[20] Shaulov A, Rottenstreich M, Peleg H, Spiegel M, Shichman B, Argov Z. Myasthenia gravis appearing 18 years after resection of benign thymoma with subsequent limbic encephalitis. *J Neurol Sci* 2012;317:146-147.
[21] Sun XG, Wang YL, Liu YH, Zhang N, Yin XL, Zhang WJ. Myasthenia gravis appearing after thymectomy. *J Clin Neurosci* 2011;18:57-60.
[22] Vasiliki Z, Georgios V, Dimitra R, Charalambos Z. Appearance of thymoma 5 years after thymectomy for nonthymomatous myasthenia gravis. *J Clin Neuromuscul Dis* 2014;16:42-43.

In: Encyclopedia of Surgery (22 Volume Set)
Editors: Andreas Lehrer and Kristin Mueller
ISBN: 978-1-53618-329-0
© 2020 Nova Science Publishers, Inc.

Chapter 363

PALLIATIVE HIP SURGERY IN PATIENTS WITH CEREBRAL PALSY

Julio Duart-Clemente[1,*] and Serafín García-Mata[1]
[1]Paediatric Orthopaedic Dept., Navarra Hospital Complex,
Pamplona, Spain

ABSTRACT

The painful dislocated hip in cerebral palsy cases is a challenging problem. The incidence of hip subluxation or dislocation in CP is reported to be between 20% and 60% and is most common in the higher Gross Motor Function Classification System (GMFCS) levels. The cause of the dislocation is clearly multifactorial. Several changes have been described in patients with dislocation of the hip. The muscle forces combined with acetabular dysplasia lead to dislocation and degenerative changes in the femoral head. These degenerative changes can be painful and affect the patient's quality of life and levels of nursing care required. Dislocation of the hip usually produces changes in the position, represents a major nursing dilemma and can lead to ulceration. The treatment of hip dislocation in patients with CP remains controversial. Salvage procedures may be appropriate for hips that cannot be reconstructed; but, the key is to identify the most appropriate surgical technique for each patient. The most common procedures are: femoral head resection, femoral head resection and subtrochanteric valgus osteotomy, proximal femoral resection-interposition arthroplasty, total hip replacement and hip arthrodesis.

Keywords: hip, cerebral palsy, palliative surgery, dislocation, resection, arthroplasty

KEY POINTS

- The painful dislocated hip in cerebral palsy cases is a challenging problem**.**
- The cause of the dislocation is clearly multifactorial.

[*] Corresponding Author's Email: duart.julio@gmail.com.

- Surgical treatment should be placed in three main categories: resection procedures (proximal femoral resection arthroplasty, subtrochanteric valgus osteotomy, with femoral head resection and interposition arthroplasty), total hip arthroplasty and hip fusion.
- The most significant complications that we can present after palliative surgery we highlight persistent pain and chronic pain syndrome**.**
- There are many methodological difficulties in measuring the functional outcomes of these procedures.
- Although surgical treatment is mandatory in case of painful spastic hip, it is difficult to determine which is the best treatment.

1. INTRODUCTION

The incidence and spectrum of hip abnormalities in children with cerebral palsy vary greatly. The painful dislocated hip in cerebral palsy cases is a challenge. Dislocation can be painful because of hypertonia and may impair care-giving, seating, positioning and quality of life [1]. The cause of the dislocation is clearly multifactorial. Several changes have been described in patients with dislocation of the hip. Muscle forces combined with acetabular dysplasia, persistent femoral anteversion and increased neck-shaft angle lead to dislocation and degenerative changes in the femoral head. These degenerative changes can be painful and affect the patient's quality of life and levels of nursing care required. [2]

In the normal hip, balanced muscle use promotes the symbiotic development of the acetabulum and femoral head. Upright posture and ambulation promotes remodelling of neonatal femoral anteversion. Children with cerebral palsy are born with normal hips. However, these hips are soon subjected to abnormal muscle forces that lead to hip abnormalities. The combination of spastic muscle activity and altered sitting posture redirects the femoral head to the superolateral and posterior aspects of the acetabulum.

With progressive subluxation, the femoral head presses up to the lateral edge of the acetabulum. The lack of mobility and increased pressure on the medial aspect of the femoral head leads to flattening and a loss of sphericity. The upper portion of the femoral head remodels and the articular cartilage of the femoral head is worn away. Dislocation of the hip usually produces changes in position with the patient holding the lower limb in adduction and flexion. These changes may result in difficulty sitting in a good position.

Dislocation also represents a major nursing dilemma. Indeed it can make it difficult to ensure adequate perineal hygiene care due the limitation of the adduction of the hip. (Figure 1) The deformity can also cause overload in some areas of the skin (such as the isquium and sacrus) that can lead to ulceration. Patients with hip dislocation commonly have a tilted pelvis as well as scoliosis and a higher risk of femur fracture [3].

It is extremely difficult to appreciate if a dislocated hip is painful due to the usual lack of expression of patients with severe neuromuscular compromise (GMFCS IV and V). Often the opinion of parents and caregivers is very important, such as changes in facial expression or sounds of grievance can be very useful signs to determine if the dislocated hip is painful.

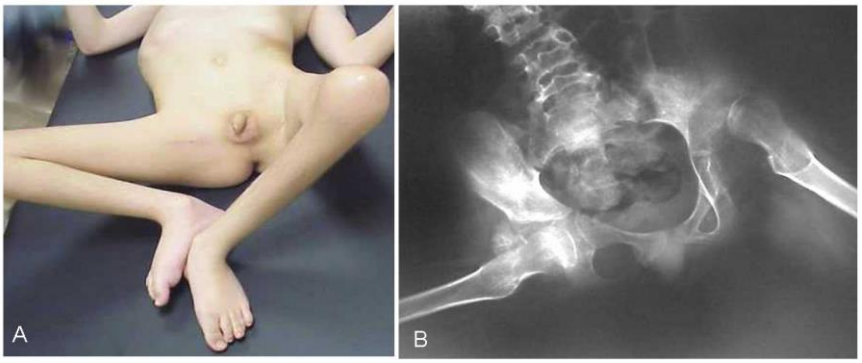

Figure 1. A. Male, age 11+6, spastic *quadriplegia*. He presents impossibility for abduction of the left hip and difficult for nursing and daily care. B. Initial pelvic radiograph Subluxation of the right hip and dislocation of the left hip.

The treatment of hip dislocation in patients with CP remains controversial [1]. The recommended treatment depends on the patient's hip function and somewhat on their size and general health. In young patients or adolescents who present with pain in the absence of degenerative signs on the hip, we can try conservative treatment including restricting physical activity, rehabilitation and pain-killers.

If the pain is not remedied rapidly, surgical treatment may be indicated. It's important to determine the goals of palliative treatment for the dislocation of hips. The main goal is to relieve pain resulting from dislocation of the hip. Having achieved the main goal, we can focus on secondary objectives related to the patient's functionality such as achieving a stable joint, increased range of motion attempting a better sitting position and walking if possible.

Surgical treatment should be placed in three main categories: resection procedures (proximal femoral resection arthroplasty, femoral head resection with subtrochanteric valgus osteotomy, and interposition arthroplasty), total hip arthroplasty and hip fusion.

2. RESECTION PROCEDURE

Proximal Femoral Resection Arthroplasty (PFRA)

Resection of the femoral head and neck has been recommended for the treatment of patients in whom a congruous hip reduction is impossible due to an incongruity of the femoral head and the acetabulum following prolonged dislocation. Castle and Schneider [4] described a procedure in 1978 when they performed a subtrochanteric resection of the femur in twelve severely mentally and physically disabled children with dislocated hips and severe adduction of the lower limbs. Usually this procedure is indicated in very young patients with poor health [4, 5].

The deformity often interferes with perineal hygiene, nursing care and positioning in bed and in a wheelchair. After surgery all patient have an improved sitting position and passive range of motion of the hip, which facilitates care and hygiene.

In the original paper they described the surgical technique. After an extraperiosteal dissection they removed the entire femur, including head, neck and 3 cm of femoral shaft

distal of the lesser trochanter. This wide resection also detaches the abductors, gluteus maximus, iliopsoas, quadriceps and the capsule. After that this soft tissue can be inserted between the femoral shaft and the acetabulum. Generally, the recommended aftercare is for these patients to be kept in distraction traction for six weeks with traction of the lower limbs, to limit the proximal migration, until the soft tissue healed and resection was stabilized (Figure 2).

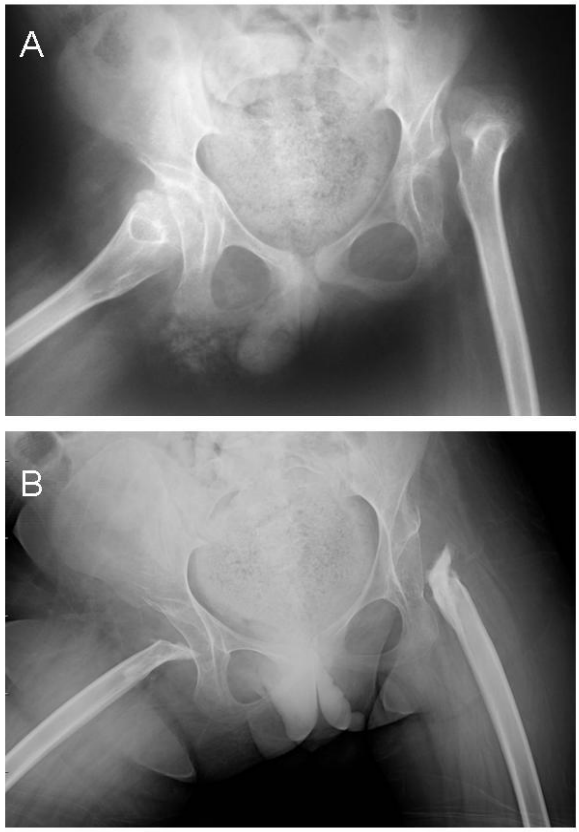

Figure 2. A. Male, age 15+2, spastic *quadriplegia*, Initial pelvic radiograph. B. Age 17+11, postoperative 2 +9years of Castle procedure both hip.

Baxter and D'Astous [5] published their experience with this technique in four patients with CP and painful spastic hip dislocations. They did not observe significant loss of motion, no bony ankylosis or impingement, no myositis ossificans, and no recurrence of pain. The postoperative results in terms of comfortable sitting were positive.

A variation of this technique was described by McCarthy [6] in 1988 for the treatment of adult patients. This variation was introduced with the intention of minimizing secondary complications due to the supine position needed for the traction in the Castle technique such as pressures sores, aspirations pneumonia, urinary stasis and gastrointestinasl hemorrhage. After the resection of the proximal femur, the abductors and iliopsoas were sutured to the hip capsule and the femoral stump was covered with the vastus lateralis. In the original study the

author reported an improvement in the sitting capacity and range of motion in 33 of the 34 patients treated with this resection, with a minimum of two years of follow-up.

In 1999 Widman [7] published the Hospital for Special Surgery experience on PFRA as a salvage procedure for intractable pain or seating difficulty, consisting in thirteen patients (18 hips). Eleven patients (14 hips) had prior unsuccessful soft-tissue or bone reconstructions. The average follow-up was 7.4 years. All patients/caregivers noted significant improvement in the subjective assessment of pain following surgery, but resolution of pain may not have been immediate. There was an improvement in upright sitting tolerance and the range of motion of the hips. They recommend the use of radiation to prevent heterotopic ossification.

The largest series reported in the literature was by Muthusamy [8], a retrospective case series with a follow-up questionnaire. A sample of 27 patients was used with an average follow-up time of 7.8 years. They found an improvement in hip pain, range of motion, daily activities, and quality of life after surgery. They compared age at surgery, type of immobilization and presence of heterotopic ossification or femoral migration and did not find a relationship with the long-term surgical outcome.

Postoperative complications of these techniques include persistent pain, infection, decubitus ulceration, pneumonia and heterotypic ossifications. Some authors emphasize the importance of informing the carers that this procedure takes six to nine months postoperatively to achieve relief of pain [7].

Femoral Head Resection

Resection of the femoral head alone is described as the Girdlestone procedure and has been used to treat severe degenerative arthritis, especially prior to a total hip replacement. It is disputable whether the use of this technique is adequate in spastic hips, with only one report comparing the results of the Girdlestone procedure with Castle's results [9]. They reviewed retrospectively their experience in patients with symptomatic subluxation or dislocation of the hip that underwent proximal femoral resection arthroplasty presented. The sample consisted of thirteen patients (19 hips). The resections were performed at the level of the neck in nine hips and in the subtrochanteric region in 10 hips. They observed poor clinical results with no correction of the pre-operative pelvic tilt, the postoperative adduction contracture, and bone contact between the pelvis femur and heterotopic ossification. These results demonstrate that the Girdlestone is not as effective at relieving pain as the subtrochanteric resection.

In 1990 MacHale [10] described a modification of the resection of the femoral head associating a subtrochanteric valgus osteotomy. They performed this procedure on six hips in five non-ambulatory adolescent patients with CP which presented painful and dislocated hips. The operative technique described in the paper includes adductor release in all cases. Through an anterolateral approach of the hip a resection of the neck and head was done, then a close wedge subtrochanterich osteotomy was performed, the valgus position was maintained by internal fixation. Subsequently, the lesser throchanter was rotated into the actabulum, and the capsulorraphy was performed. The aftercare included a spica cast for 3 weeks. All patients were able to sit for longer periods pain-free prior the surgery (Figure 3).

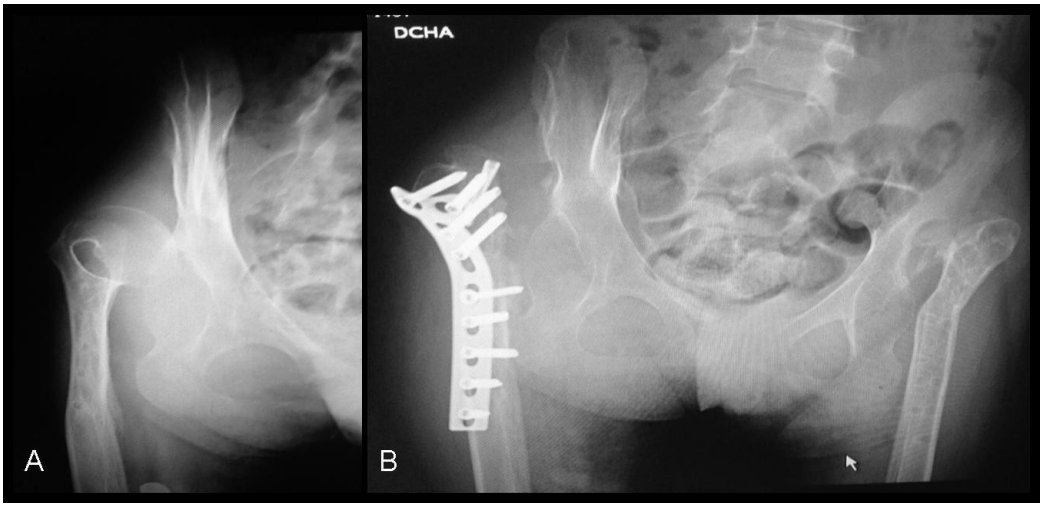

Figure 3. A. Female, spastic *quadriplegia*, Initial pelvic radiograph. B. Postoperative radiograph of McHale procedure both hip (courtesy Dr. Martinez Caballero).

In 2009 Van Riet and Moens [11] published their experience of this procedure; they conducted a retrospective study of adolescent and adult patients with cerebral palsy, affected by chronically painful and dislocated hips who underwent the McHale procedure between 1994 and 2004. They presented thirteen patients with seventeen procedures. All patients had pain at the time of the surgery, and most of them reported limitations in sitting and nursing care problems. All patients underwent clinical and radiological examination of the hips, and a questionnaire was answered by both parents and caretakers. The minimum follow-up was 23 months. They observed an improvement in all patients with respect to pain and higher sitting tolerance in 6 patients. Ten caregivers reported that it was easier to administer care. Although these results appear promising, they are not very optimistic about this procedure because of the high rate of complications, including heterotopic ossification, residual pain, hardware intolerance, fractures and pulmonary complications.

They concluded that procedure was successful because it led to pain relief, ease of perineal care, and facility of seating. The subtrochanteric valgus osteotomy is an excellent procedure for a hip that is pain-free but fixed in a poor position. There is however a high incidence of failure and complications.

Prosthetic Interposition Arthroplasty

One of the modifications after the proximal resection is the use of prosthesis. Prosthetic Interposition arthroplasty has been utilized in patients who have open growth plates, or patients who are non-weight-bearing. One noteworthy advantage of this technique when used in these patients is that traction was not needed after surgery. Descriptions in the literature are rare; in fact the only case series is that published by the DuPont Institute [12]. They have presented their experience in using a prosthetic arthroplasty for the treatment of painful degenerative arthritis in 11 non-ambulatory patients (14 hips) with CP. Clinical follow-up averaged 5 years. Ten patients (13 hips) had complete relief of hip pain. Carer satisfaction

was high for these patients, with all 10 carers stating that they would recommend the procedure. Only one patient continued to have persistent pain in the hip.

The implants prosthesis serves as a spacer between the bone ends. Different materials and devices have been used for interposition such as shoulder prosthesis, cement spacers, Poly methyl methacrylate (PMMA), silastic arthroplasty, etc. (Figure 4) Gabos recommended an interposition arthroplasty using a standard shoulder [12] or hip resurfacing implant.

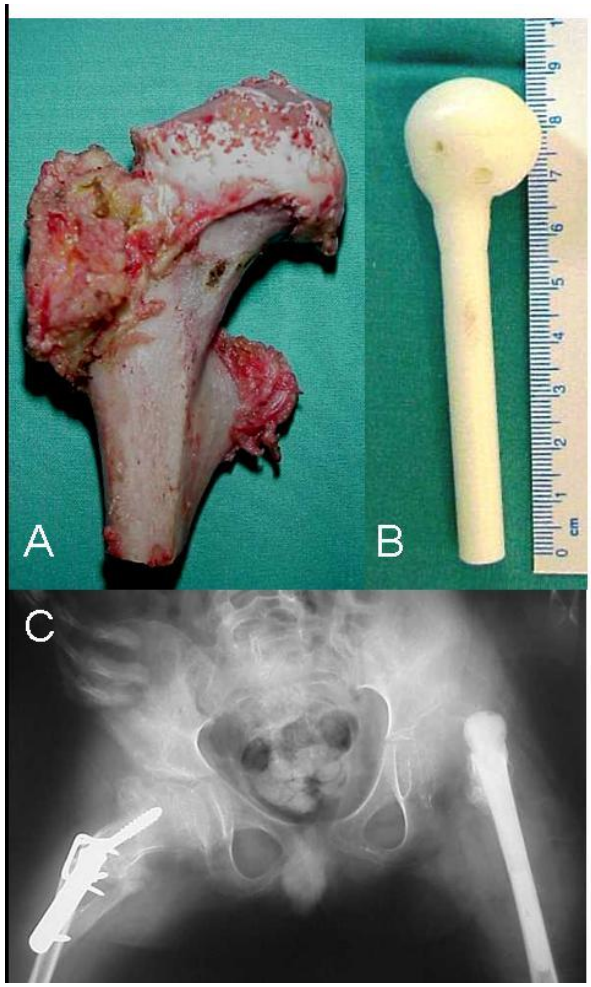

Figure 4. Patient of the Figure 1. A. Resected specimen of the proximal femur. Note the triangular shape of the femoral head and extensive loss of articular cartilage on the medial, lateral, and superior surfaces. B. The handmade interposition device manufactured in Polymethyl.-methacrylate (PMMA). C. Postoperative pelvic radiograph with a VRO of the right hip and a prosthetic interposition arthosplastly on the left hip.

One of the most important points about this treatment is that it is not crucial that the prosthesis remain in a reduced position, although an attempt is made during the operative procedure to suture soft tissue around it to hold it in the false acetabulum or real acetabulum. Gabos observed that ten of the hips remained located on the latest radiographs, and four of the hips dislocated within 4 months of the procedure. No patient exhibited migration or failure of

the implants, although one patient exhibited periprosthetic osteolysis, which remained unchanged over a 4-year period [12]. They presented intraoperative complications such as breakage of the tip of a femoral canal reamer inside the femoral shaft. And two patients sustained femoral fractures following the procedure, one patient on distal third of the femoral shaft and a second at the site of a previous midshaft femoral fracture.

The goal of surgery is to relieve pain and maintain some joint mobility. Some authors recommend placing a glenoid component when raw bone is observed. Following surgery patients should be kept with legs apart in order to place the joint in the correct position. For this we use an abduction pillow or the patient can be placed in the short broomstick leg cast with broomsticks. Usually these patients do not require traction. The results of this procedure have shown good pain relief that is more quickly effective than with the femoral resection [12].

Prosthetic interposition arthroplasty appears to be an effective surgical option for the treatment of a painful, subluxated or dislocated arthritic hip in non-ambulatory patients with severe spastic quadriplegic-pattern cerebral palsy.

Total Hip Arthroplasty

Total hip arthroplasty (THA) has changed the life of millions of people with painful hips since the early 1960s. As discussed by Root [13], orthopaedic surgeons have been reluctant to recommend the procedure for a CP person with a painful subluxed or dislocated hip. The questions were: would a hip replacement in a CP patient dislocate or loosen prematurely because of spasticity or athetosis? And would the procedure reduce pain and restore function in this group of patients?

THA is an alternative, but is an exceptional indication. The risks of dislocation, ectopic ossifications and infection often refute this indication. THA may be indicated for patients who are able to stand and bear weight for transfers or home care, and definitely for individuals who are community paramedics. This procedure provides the most stable joint, and in adults or young adults, it can be done with acceptable risk. The goal of THA for the paralytic hip is to obtain a painless joint which is as mobile as possible with recovery of the functional level prior to joint degeneration. It is however important to note that THA does not produce any improvement in the patients' functional capacity. As normal hip function is not the goal in patients with a paralytic joint, it is important to take into full account the patient's motor capacity (Figure 5).

Weber and Cabanela [14] reported on 16 patients with 16 hip replacements. Eighty-seven percent of the patients had pain relief, and ambulatory function improved in 79%. They had no dislocations, and complications were rare.

Root et al. [13] published results on THA in CP, the survivorship was 95% for 10 years, and preoperative pain was relieved in 94% of the patients. These studies confirm that THA is a safe and successful procedure for painful hips in the cerebral palsy population, even in younger age groups and even in those who function mainly in a wheelchair.

Recently, Schroeder et al. [15] reported eighteen THAs in 16 ambulatory patients with cerebral palsy. There was a significant postoperative reduction in pain on the NAS (narrative analogue scale), the mean follow-up was 10 years (range 2–18 years) and at follow-up no stem had been revised. Three cups were revised for aseptic loosening at two and six years,

and one cup was revised for recurrent dislocation of the hip. One hip was revised for infection 12 years after the index surgery. One hip dislocated (three months postoperatively) and was treated by closed reduction.

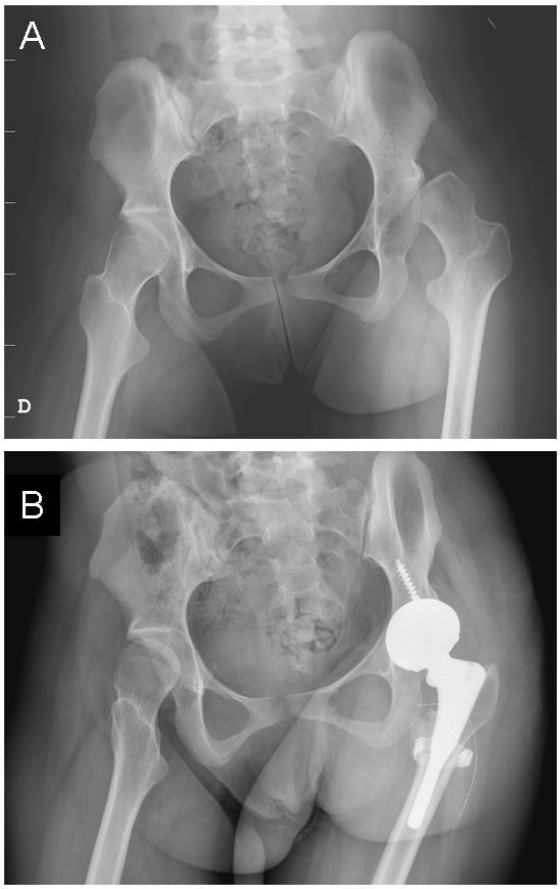

Figure 5. A. Female, age 16+6, spastic *quadriplegia*, Initial pelvic radiograph. B. Age 17+3, postoperative 6 month of left Total Hip Replacement.

The largest series published in the literature was in 2010 by Raphael et al. [16], relating to patients of the Hospital for Special Surgery (New York, USA), a retrospective study of 56 patients (59 hips) with CP who had THAs for painful hips, patients or caregivers completed a questionnaire, including a modified Gross Motor Function Classification System mobility scale and qualitative reports of pain and satisfaction. All patients have pain relief. Seven patients underwent acetabular component revisions, and two patients had a femoral stem component revision, the 10-year survivorship was 85%.

Prior to surgery is important to consider that the primary underlying pathological mechanism is muscle imbalance with the strong hip flexors and adductors overpowering the weaker abductors and extensors, resulting in contractures and bone abnormalities include excessive valgus of the femoral neck and persistence of fetal anteversion and acetabular dysplasia. These changes may affect the stability of the implant and and make necessary modifications to the standard surgical techniques including the use of custom-made femoral

implants, tenotomies, hip spicas and placing the acetabular component in anteversion for sitters.

Many reports in the literature [13, 14, 17] conclude that the major complication of THA replacement is the risk of dislocation. All the dislocations were probably secondary to motor disorders induced by the transient disruption of periarticular muscle activity due to surgery [13] and recurrent dislocation due to incorrect implant orientation that were successfully treated by changing the prosthetic components [17]. Several techniques have been attempted to prevent dislocation. Some authors have suggested the use of custom implants, but this proposal has not been widespread in the literature. Blake [18] recommends the use of constrained hybrid prosthesis, consisting of an uncemented acetabular component with acetabular screws, a constrained liner and a cemented femoral component. Some authors suggest routine use of postoperative spica cast immobilization. Transtrochanteric assess to the hip can help prevent dislocations because it preserves the integrity of the periarticular musculature and perhaps is a means of reducing motor phenomena as described above.

Other complications included heterotopic ossifications that were noted unless prophylactic nonsteroidal anti-inflammatory drugs are used, this complication occurs after THA in 53% [13] of the patients. Non-union of the greater trochanter is not exceptional. Infections of the implants, with late presentation [15] and with loosening [16], trochanteric Bursitis, and periprosthetic fracture [13, 17]

Hip Fusion

Hip arthrodesis is an option in the treatment of patients with spastic painful dislocation or subluxation of the hip where reconstruction is not possible due to femoral head deformity. Hip fusion is a relatively reasonable option for young, healthy walkers who have unilateral spastic hip disease and no scoliosis. Hip fusion should be considered as an alternative to total hip replacement in young, and functional individuals.

The fusion [19] is performed through a longitudinal lateral hip incision used to expose the hip joint, then capsulotomy is performed and we can observe the deformation of the femoral head and the loss of cartilage. After removing the soft tissue of the acetubulum (ligamentum teres and pulvinar), the articular cartilage is removed, the acetabular cavity is prepared to receive the femoral head. Then the hip is reduced and hip is fixed in the desired position. Usually the implants used to stabilize the arthrodesis are the *cobra head* compression *plate, with proximal screws in the iliacus and distal in the proximal femur.* After surgery, it is essential to perform regular clinical and radiographic check-ups at least once a year, to monitor the contralateral hip and the spine, especially in more severe patients, to detect any early changes and to treat the deformity before it is severe and fixed (Figure 6).

In 1986 Root [13] reported eight attempted hip fusions. Six of these attempts had a positive result, one needed a repeat procedure to obtain fusion secondary to a pseudarthrosis, and the other was converted to a total hip replacement. Technical aspects were recommended by the author such as the combination of intraarticular and extraarticular arthrodesis, the utilization of muscle pedicle –bone, the use of internal fixation that increases the fusion rate and the femoral osteotomy to correct the femoral anterversion (Root).

Recently Fucs and Cols [19] published a study abut 21 patients affected by spastic CP with painful chronic hip subluxation and dislocation treated with hip fusion with a mean

follow-up period of 14.5 years. All patients in this long-term review demonstrated bone union, pain relief, and postural improvement with patient or caregiver satisfaction.

Four patients developed a pseudoarthrosis and needed a repeat procedure to obtain fusion. The final results were considered satisfactory in all patients, although 4 patients needed a second procedure for bone union.

Surgical complications were observed. Root [13] found pseudoartrosois in two patients, one at eleven months and the other at three years. Both were treated with revision surgery and graft. One patient has supracondilar fracture, another pin intolerance which required pin removal, and two patients had superficial sacral pressure sores.

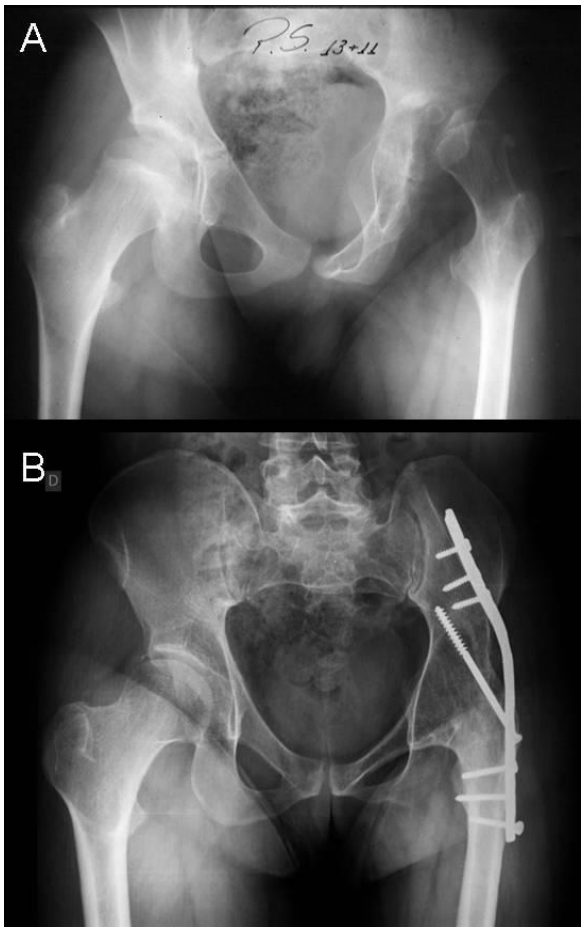

Figure 6. A. Male patient, age 13+11, spastic diplegic, community ambulator, initial pelvic radiograph. B. Age 29+11, postoperative 17 years of left hip arthrodesis (courtesy Dr. Fucs).

By the other hand, Fucs [19] described no superficial or deep wound infections. One patient's skin was broken in the sacral region due to a pressure sore in the cast period. In another patient an accidental femoral vein laceration occurred during the surgical release of the adductor muscles. This was repaired immediately and there were no further complications. There were 3 patients who presented with femoral fractures following surgery on the side of the arthrodesis.

Both authors concluded that hip arthrodesis is an option for patients with spastic CP with painful subluxation or dislocated hips with the goal of maintaining pain relief or improving functional status, and facilitating care. It is primarily useful if the patient is a young ambulatory with normal contralateral hip and normal spine.

3. COMPLICATIONS OF PALLIATIVE TREATMENT

Among the most significant complications that we can present after palliative surgery we highlight persistent pain and chronic pain syndrome. The continuation of pain after the resection arthroplasty, either the Girdlestone or the Castle procedure, is relatively common, up to 25% of cases. Refractory pain after resection osteotomies resection is frequently described in the literature. Indeed, Widman [7] warns that there may be pain for up to 6 months following the PFRA. Some authors do not recommend new revision surgeries for at least a year.

In cases of interposition arthroplasty or total hip arthoplasthy, pain may be secondary to implant loosening or infection. Detailed tests should be performed to determine possible causes of pain. When persistent pain occurs in patients who have undergone surgery for hip fusion the most frequent cause is the non-union of the arthrodesis

It seems reasonable that some of these patients who have long periods of persistent pain may precipitate chronic pain syndrome. Chronic pain in children and adolescents often results in considerable functional disability. Very little has been written regarding chronic pain as a secondary problem in persons who already have a physical disability, despite the potential for pain to increase the negative impact of what may already be a very disabling condition. Functional improvement can be achieved using a multidisciplinary approach to pain management in children.

4. OUTCOMES OF PALLIATIVE SURGERY

Few article in the literature compare different treatments for patients with spastic CP with painful subluxation or dislocated hips. Wright [20] reported a retrospective study which compares the outcomes of 3 different surgical procedures performed at same institution for pain relief in patients with spastic quadriplegic cerebral palsy and painful dislocated hips. The procedures identified were proximal femoral resection arthroplasty (PFRA); subtrochanteric valgus osteotomy (SVO) with femoral head resection; and (3) proximal femur prosthetic interposition arthroplasty (PFIA) using a humeral prosthesis. The outcomes were based on pain and range of motion. Forty-four surgeries in 33 patients, 12 hips were treated with a PFRA, 21 with a SVO, and 11 with a PFIA. An excellent or good result was noted in 67% of PFRAs, 67% of SVOs, and 73% of PFIAs. No statistical significance between these procedures was ascertained.

Boldingh and Cols [21] performed a systematic review of the results of palliative hip surgery in severe cerebral palsy. They reviewed articles on resection surgery of the femoral head, arthrodesis of the hip joint, and total hip replacement. They found 44 articles, all of which were observational studies. Finally they found only 8 articles on palliative surgery. The

aspects evaluated were pain relief, seating and nursing problems and complications of the procedures. The published literature does not clearly favor one procedure over the others. The resection arthroplasty technique developed by Castle is reported to yield the best results and fewer complications, and seems to eventually lead to a good outcome.

Graham and Narayanan [1] warn there are many methodological difficulties in measuring the functional outcomes of these procedures. We need improved reporting of pre- and post-operative pain and function, using valid, reliable and responsive outcome measures and health-related quality of life (HRQoL) tools. Although surgical treatment is mandatory in case of painful spastic hip, it is difficult to determine which is the best treatment.

REFERENCES

[1] Graham HK, Narayanan UG. Salvage hip surgery in severe cerebral palsy: some answers, more questions? *Bone Joint J.* 2014 ; 96-B:567-8.

[2] Samilson R, Tsou P, Gordon A, Green W. Dislocation and subluxation of the hip in CP: pathogenesis, natural history and management. *J Bone Joint Surg* 1972; 54-A: 863–73.

[3] Gamble JG, Rinsky LA, Bleck EE. Established hip dislocations in children with cerebral palsy. *Clin Orthop Relat Res.* 1990; 253:90-9.

[4] Castle M E, Schneider C. Proximal femoral resection-interposition arthroplasty. *J Bone Joint Surg.* 1978;60-A:1051-4.

[5] Baxter, M. P.; D'Astous, J. L. Proximal femoral resection-interposition arthroplasty: salvage hip surgery for the severely disabled child with cerebral palsy. *J Pediatr Orthop* 1986; 6:681-5.

[6] McCarthy R E, Simon S, Douglas B, Zawacki R, Reese N. Proximal femoral resection to allow adults who have severe cerebral palsy to sit. *J Bone Joint Surg* 1988;70-A:1011-6.

[7] Widmann RF, Do TT, Doyle SM, Burke SW, Root L. Resection arthroplasty of the hip for patients with cerebral palsy: an outcome study. *J Pediatr Orthop* 1999; 19:805-10.

[8] Muthusamy K, Chu HY, Friesen RM, Chou PC, Eilert RE, Chang FM. Femoral head resection as a salvage procedure for the severely dysplastic hip in nonambulatory children with cerebral palsy. *J Pediatr Orthop.* 2008 ;28:884-9.

[9] Perlmutter MN, Synder M, Miller F, Bisbal R. Proximal femoral resection for older children with spastic hip disease. *Dev Med Child Neurol* 1993; 35:525-31.

[10] McHale KA, Bagg M, Nason SS. Treatment of the chronically dislocated hip in adolescents with cerebral palsy with femoral head resection and subtrochanteric valgus osteotomy. *J Pediatr Orthop* 1990; 10:504-9.

[11] Van Riet A, Moens P. The McHale procedure in the treatment of the painful chronically dislocated hip in adolescents and adults with cerebral palsy. *Acta Orthop Belg.* 2009; 75(2):181-8.

[12] Gabos PG, Miller F, Galban MA, GuptaGG, Dabney K. Prosthetic interposition arthroplasty for the palliative treatment of end-stage spastic hip disease in nonambulatory patients with cerebral palsy. *J Pediatr Orthop* 1999; 19:796-804.

[13] Root L, Goss JR, Mendes J. The treatment of the painful hip in cerebral palsy by total hip replacement or hip arthrodesis. *J Bone Joint Surg* 1986; 68-A:590-8.

[14] Weber M, Cabanela ME. Total hip arthroplasty in patients with cerebral palsy. *Orthopedics* 1999; 22:425-7.

[15] Schroeder K, Hauck C,Wiedenhöfer B, Braatz F, Aldinger PR. Long-term results of hip arthroplasty in ambulatory patients with cerebral palsy. *Int Orthop.* 2010 ; 34: 335–339.

[16] Raphael BS, Dines JS, Akerman M, Root L. Long-term Followup of Total Hip Arthroplasty in Patients with Cerebral Palsy. *Clin Orthop Relat Res. 2010*; 468(7): 1845–1854.

[17] Buly RL, Huo M, Root L, Binzer T, Wilson PD Jr. Total hip arthroplasty in cerebral palsy. Long-term follow-up results. *Clin Orthop Relat Res.* 1993;296:148-53.

[18] Blake SM, Kitson J, Howell JR, Gie GA, Cox PJ. Constrained total hip arthroplasty in a paediatric patient with cerebral palsy and painful dislocation of the hip: a case report. *J Bone Joint Surg* 2006;88-B:655-7.

[19] Fucs PM, Yamada HH. Hip fusion as hip salvage procedure in cerebral palsy. *J Pediatr Orthop.* 2014 34 Suppl 1:S32-5.

[20] Boldingh EJ, Bouwhuis CB, van der Heijden-Maessen HC, Bos CF, Lankhorst GJ. Palliative hip surgery in severe cerebral palsy: a systematic review. *J Pediatr Orthop* B. 2014 ;23:86-92.

[21] Wright PB, Ruder J, Birnbaum MA, Phillips JH, Herrera-Soto JA, Knapp DR. Outcomes after salvage procedures for the painful dislocated hip in cerebral palsy. *J Pediatr Orthop.* 2013;33:505-10.

In: Encyclopedia of Surgery (22 Volume Set)
Editors: Andreas Lehrer and Kristin Mueller
ISBN: 978-1-53618-329-0
© 2020 Nova Science Publishers, Inc.

Chapter 364

APPLICATION TO CARDIOVASCULAR SURGERY

Shohei Miyazaki[1,*], Keiichi Itatani[1], Sachi Koyama[2], Kouki Nakashima[1], Tetsuya Horai[1], Norihiko Oka[1], Tadashi Kitamura[1,2] and Kagami Miyaji[1,2]

[1]Departments of Hemodynamic Analysis and Cardiovascular Surgery,
Kitasato University School of Medicine
[2]Department of Cardiac Surgery, The University of Tokyo

ABSTRACT

One of the goals of cardiovascular surgery is to obtain an optimal hemodynamic state. Cardiovascular surgery often drastically changes the geometric configuration of the heart valve and the structures of vessels; therefore, hemodynamic evaluation has gained popularity among cardiovascular surgeons.

Novel technologies related to imaging modalities are emerging that are capable of estimating blood flow dynamics. Computational fluid dynamics (CFD) has been used since the mid 1990's to reveal the complicated hemodynamics of patients with congenital heart disease. CFD in combination with 3D computer graphics has also been applied in virtual coronary artery bypass surgery. Flow measurement technologies such as 3D cine PC MRI (three-dimensional cine phase contrast magnetic resonance imaging) also known as 4D flow MRI, have recently been applied in patients with chronic aortic dissection or aortic valve disease to determine the optimal therapeutic intervention. Echocardiographic flow visualization has been used to elucidate intraventricular flow patterns after heart-valve replacement.

In this chapter, we summarize the reported hemodynamic evaluation results related to cardiovascular surgery, and introduce novel technologies with potential applications in cardiovascular surgery.

Keywords: computational fluid dynamics, virtual surgery, 3D Cine PC MRI, echocardiography, congenital heart disease, aortic dissection, coronary heart disease

* Corresponding Author's Email: keiichiitatani@gmail.com.

1. HEMODYNAMIC RESEARCH IN THE CARDIOVASCULAR SURGERY

Cardiovascular surgery is performed to avoid life threatening events caused by cardiovascular diseases. Moreover, it is performed to achieve long-term improved cardiac performances for the activities of daily living. Open heart surgery is performed in some patients with complicated congenital heart anomalies to improve cyanosis and ventricular load; heart valve surgery is undertaken to reduce the volume (preload) or pressure (afterload) on the ventricle, coronary artery bypass grafting is practiced to supply sufficient myocardial blood flow and to avoid sudden myocardial infarction, and aortic surgery is undertaken to avoid sudden death. Therefore, the goals of cardiovascular surgery can be said to obtain optimal hemodynamics. Thus, application of hemodynamic research to the cardiovascular surgery is one of the most challenging topics.

Despite recent advances in perioperative patient management, the reduction in morbidity and mortality rate of cardiovascular surgery have been limited; thus, the cardiovascular surgeons should be careful to avoid both oversurgery and mistiming the surgery. Moreover, because switching procedure is difficult after surgery, procedure selection is crucial when planning cardiovascular surgery. Although cardiovascular surgery often drastically alters the shape of the heart valve and vessels and changes the blood flow pathways, its goal is to achieve an optimal and efficient blood flow. However, both the traditional and current surgical indications are primarily dependent on geometric or anatomic information on cardiovascular structures or on the pressure gradient at the site of stenosis. The indications for treating volume overload heart valve disease are based on the size or dimensions of the ventricle; those for treating aortic disease are based on the site of the disease and diameter of the diseased aorta, those for coronary artery bypass surgery are based on the site of stenosis with severity based on the diameter change or pressure drop; and those for treating heart valve stenosis or coractation are based on pressure gradients.

Recently, it has been discussed that a detailed analysis of blood flow is a key to avoiding long-term complications. Observing the disturbed flow, calculating the shear stress exerted on the vessel wall by the blood flow, or calculating the flow energy loss (EL) caused by turbulent flow may permit the reliable prediction of the prognosis of cardiovascular diseases, and may help to evaluate the surgical procedures used to treat them. In this regard, blood flow visualization research results that were depicted by colorful flow streamline, contour distribution of wall shear stress (WSS) on the vessel wall and pressure drop using computer graphics have provided great insight in surgical procedures and their indications. In this chapter, we describe the blood flow visualization techniques suitable for various types of cardiovascular surgeries.

2. METHODOLOGIES IN FLOW EVALUATION

2.1. Overview of Tools for Hemodynamics Evaluation

As described in previous chapters, hemodynamic evaluation examinations include catheter measurements and flow visualization methods based on imaging modalities. Computer flow simulation is another powerful tool for hemodynamics evaluation, particularly

for cardiovascular surgery, because it can predict hemodynamics before performing surgery (Figure 1).

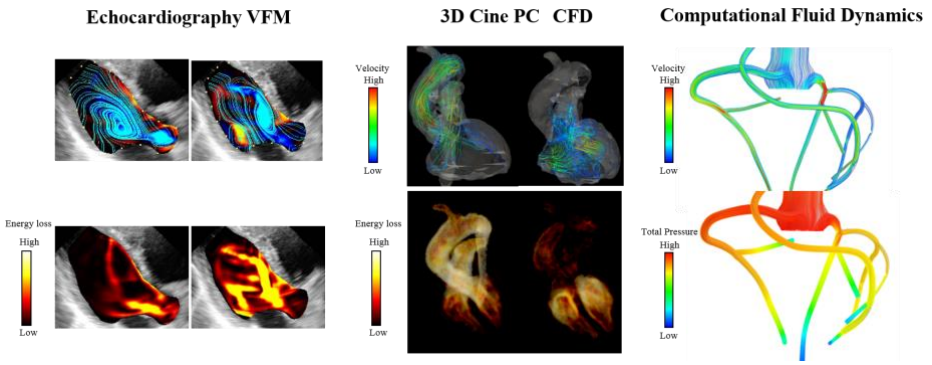

Figure 1. Flow visualization samples using echocardiography, 3D cine PC MRI (three-dimensional cine phase contrast magnetic resonance imaging), and CFD (computational fluid dynamics). These modalities can acquire the distribution of velocity and calculate energy loss. Energy loss based on echography and magnetic resonance imaging (MRI) is calculated based on the disturbance of flow and viscosity, whereas that based on CFD is calculated based on total pressure; however, both are mathematically equal.

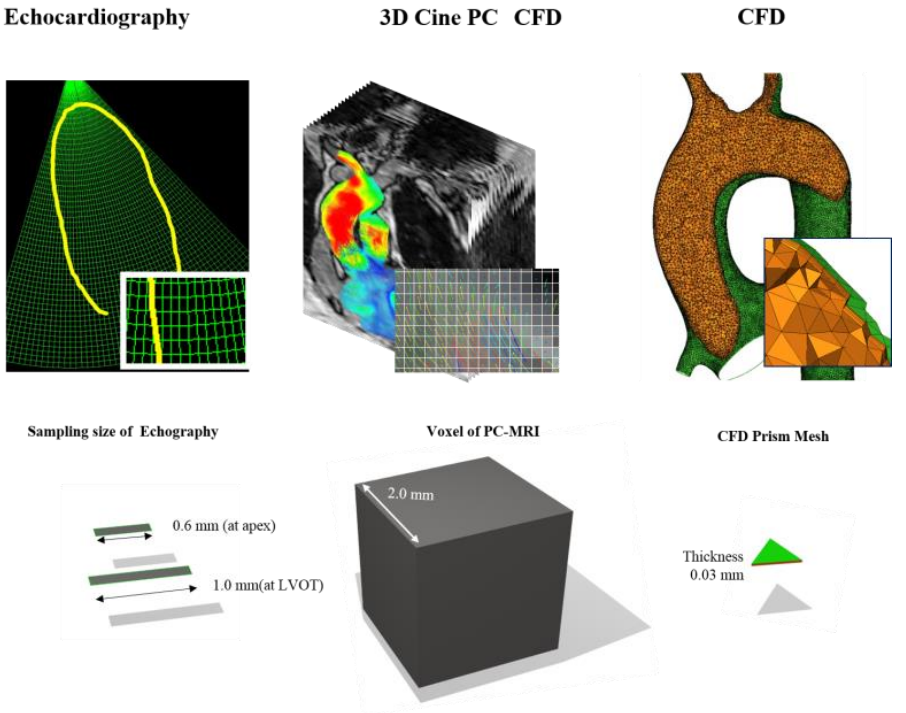

Figure 2. The near-wall spatial resolution of each modality. Spatial resolution is defined by sampling size in echography, voxel size in phase contrast magnetic resonance imaging (PC-MRI), and mesh size in CFD. Above: How the region is discretized in each modality. Echography using a sector probe samples the data in polar coordinates. PC-MRI outputs the data in voxels. CFD uses polyhedrons to discretize the space. Below: The size of each sampling are area/voxel/ mesh near the wall in the same scale, showing the effect on the accuracy and precision of wall shear stress calculations.

Table summarizes the characteristics of echocardiography and phase contrast magnetic resonance imaging (PC-MRI) flow visualization modalities and computer flow simulation based on computational fluid dynamics (CFD).

Flow-visualization modalities using echocardiography and MRI are based on actual flow measurements, and are available in daily clinical practice. Nevertheless, they have low resolution and are subject to noise and error, which could cause serious problems when calculating hemodynamic indices essential for the prognosis prediction (Spiegel et al., 2011). Conversely, numerical flow-simulation data based on CFD have sufficiently high resolution without noise.

Table 1. Feature of blood flow visualization modalities

	Echography	MRI	CFD
Labor Hour	10 minute	Few hours	1 day - Few days
2D or 3D	2D	2D and 3D	3D
Wall movement	Possible	Possible	Difficult
Temporal resolution	Coarse e.g. 20 - 30 Hz	Coarse e.g. 7-30 Hz	Fine e.g. 10000-200000 Hz
Spatial resolution	Moderate e.g. 0.1 – 1 mm	Coarse e.g., 1mm – 3mm	Fine e.g. 0.03 mm – 3 mm
Advantage	・Simple and easy.	・3D visualization in vivo	・Accurate hemodynamic parameters ・Virtual surgery / Simulation under virtual Condition ・Analysis using idealized model
Disadvantage	・2D Limitation	・Coarse resolution ・Unclear acquisition protocols ・Long acquisition time	・Unclear validity ・Technical difficulty ・Rigid wall assumption
Typical analysis region	・Ventricle and atrium	・Ventricle and atrium ・Large vessel	・Vessel

Table shows an example of the near-wall spatial resolution of each modality. In addition, numerical simulation can be applied to virtual surgery. Using this technique, it is possible to predict blood flow dynamics after surgery, or design new methods of surgery. However, despite the advantages of numerical simulation over other flow measurement modalities, it is technically difficult and time-consuming.

2.2. Hemodynamic Research Using Cardiac Catheterization

Cardiac catheterization is an invasive procedure to investigate the function of the heart. The catheter enters into the blood vessels and allows the direct measurement of the pressure/pressure gradient, measurement of O_2 saturation to evaluate blood flow, or visualization of the blood flow or shape of the cardiac vessels with the assistance of contrast medium. Above all, absolute pressure value measurement cannot be performed by any other

modality. Currently, cardiac catheterization is the gold standard for the diagnosis of coronary artery disease, and congenital heart disease; however, as an invasive examination, it carries the risk of vessel injury or stroke. Catheter angiography provides only 2D images, which can lead to the misinterpretation of complex anatomy (Kern et al., 2010). Pressure measurements by catheter is highly dependent on the characteristics of the flow at the measurement site, such as its direction or turbulence. Regarding its accuracy using a 0.014 mm pressure wire, which is currently considered the gold standard, the procedure demonstrated a 24 % overestimation in peak systolic pressure despite the low catheter vessel radius ratio (De Vecchi et al., 2014). Recently, use of digital measurement wires that simultaneously measure pressure and flow velocity has increased, particularly to evaluate coronary arterial flow, because they provide pressure and flow velocity at the point, they can even provide flow energy loss (EL) based on total pressure (TP) measurements (Honda et al., 2013).

2.3. Hemodynamic Research Using Echocardiography

Flow visualization with echocardiography is noninvasive and portable features that are useful in daily clinical practice for the estimation of myocardium or intraventricular flow. Currently, there are two major groups of flow visualization methods. The first is based on B mode image using contrast medium and is called echo PIV (particle image velocimery) (Hertzberg et al., 2004), or color Doppler Vector Flow Mapping (VFM) (Itatani et al., 2013, Mehregan et al., 2014). Compared with other flow-visualization techniques, flow visualization using echocardiography is noninvasive and portable and flow analysis can be performed even in patients in intensive care. Further the analysis requires just seconds or minutes. Thus, VFM flow analysis provides an almost real-time flow analysis, even during open heart surgery in operative room based on data acquired using transesophageal echocardiography (TEE). VFM requires a sufficient color Doppler window, which covers the ventricular wall for speckle tracking. Thus, the measurement plane is limited and should be carefully selected. The limitations of flow visualization using echocardiography include a 2D flow assumption and a velocity range far less than the jet flow in valvular diseases. Flow visualization based on color Doppler also has the limitation of aliasing over the Nyquist limit, and the accuracy of echo PIV is considered insufficient with a flow velocity of over 42 cm/s (Prinz et al., 2012); thus, jet flow around the valve or through wall defects cannot be accurately evaluated using this method.

In summary, flow visualization using echocardiography is suitable for daily use because of its portability and rapid analysis. Real-time flow evaluation even during surgery with TEE is possible. Its limitations are 2D flow visualization and a velocity range lower than the jet flow.

2.4. Hemodynamic Research Using MRI (Magnetic Resonance Imaging)

Phase Contrast MRI (PC-MRI) is alternative noninvasive method to visualize blood flow. As other modalities, blood flow is visualized as field of flow vector (Napel et al., 1992), which is called phase velocity mapping (Osinnski et al., 1995). Performing this technique in multislice mode allows the three-dimensional evaluation of blood flow dynamics (Wigström

al. 1996, and 1999), and is called 3D cine PC MRI (also termed 4D flow MRI). It is attracts attention because it is the only way to evaluate 3D flow in vivo. Thus, it enables the evaluation of blood flow in diseases with a complex 3D geometry such as aortic dissection. As in CFD, the blood flow field is visualized by animation of the 3D streamlines or pathline using 3D computer graphics. In addition, it has the potential to calculate WSS and its fluctuation: termed the oscillatory shear index (OSI) (Barker et al., 2013; Harloff et al., 2010, Papathanasopoulou et al., 2003, Cibis et al., 2014) which are considered important factors in endothelial dysfunction (Reneman et al., 2006).

One of the disadvantages of 3D cine PC MRI is its relatively long data-acquisition time approximately 10 - 30 min, compared with echocardiography or CT (computed tomography). Therefore, eligible patients are limited to those to lie motionless in MRI equipment and who can hold their breath for several seconds. Thus, infants or preschool children are suitable for this modality. Another limitation is its low spatial resolution which affects its ability to estimate the flow in small vessels. The approximate resolution of 3D Cine PC MRI is currently around 1.0 - 3.0 mm, which is not sufficient to evaluate vessels such as the peripheral coronary artery, which is around 2.0 mm in diameter. Furthermore, the low resolution affects the accuracy of WSS calculation (Cibis et al., 2014), even though, it is reported that the WSS distribution is similar to that of numerical simulation in aorta (Boussel et al., 2011). Furthermore, the unclear effects on hemodynamic parameters of data acquisition and processing methods such as spatial resolution or noise reduction are problematic and hinder the clinical applications of flow analysis.

In summary, flow visualization using MRI is useful to understand 3D blood flow in large vessels such as the aorta or in the ventricle. However, the current performance of these MRI machines is insufficient to evaluate small vessels such as the coronary arteries.

2.5. Blood Flow Simulation Using Numerical Models

The zero-dimensional model (Migliavacca et al., 2006) often referred to lumped parameter model (Figure 3), and the one-dimensional model (Hughes et al., 1973) often termed the distributed parameter model are the classical methods of modeling the circulation. These methods use electric circuit units including resistance, inheritance and compliance to simulate pressure and flow rate mimicking the vessel function. They are useful tools to simulate the flow and pressure changes after drastic circulatory system changes such as staged palliative changes in single-ventricular physiology in patients with congenital heart disease.

CFD is a fluid flow simulation based on the numerical solution of the *Navier-Stokes* equation (1.17) (1.18) (1.21)-(1.24) using computers. One of its advantages is that it has an extremely high resolution. The temporal and spatial resolutions are determined by the limits of the computer's memory. CFD detects small local flow that can never be measured *in vivo*, and such fine resolution enables precise evaluation of useful parameters such as WSS and EL. Another advantage is that it can simulate various virtual conditions such as exercise by changing flow rate and pressure boundary conditions.

Inlet and outlet boundary conditions, which regulate the flow in the domain, are crucial factors to obtain an accurate result. There are two ways to define boundary condition: first, using measured data, and second, modeling the outside of the boundary. The former is simple

and clear but requires additional measurement data, such as flow or pressure profiles based on Doppler echo or catheter measurements. The latter is powerful to estimate the amount of flow under the conditions of peripheral autoregulation; however, it adds calculation assumptions, and precise parameter settings are necessary to realize physiologic flow.

One of the disadvantages of CFD is that the analysis is a time consuming process. The preprocessing process, with geometry extraction and smoothing, is mainly performed manually and takes a couple of hours, whereas calculation of the *Navier-Stoles* equation for one cardiac cycle of 1.0 second, with a time step size around 50μsec, a one million element, and using a computer with a 4-6 core 3.5- 4.0 MHz CPU (central processing unit) takes several days. Thus, if surgeons wish to use CFD results preoperatively, elaborate preplanning is necessary.

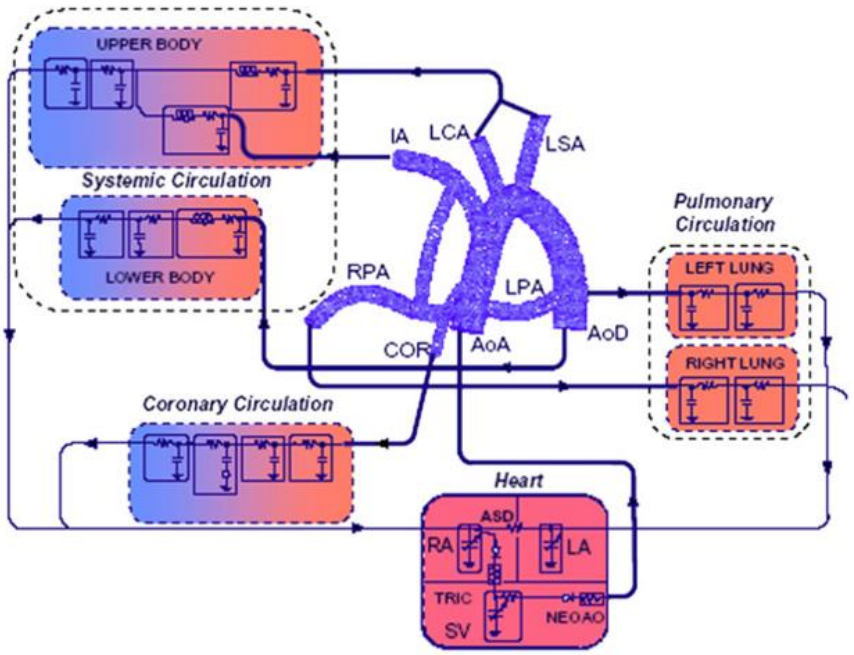

Figure 3. Boundary conditions using the lumped parameter model (Bove et al. 2008). CFD of Blalock-Taussig shunt using the lumped parameter model as the boundary conditions. The lumped parameter model was used to simulate the whole systemic circuit, coronary circuit, pulmonary circuit, and heart.

Moreover, simulating flow inside moving elastic structures is technically difficult. Fluid Structure Interaction (FSI) refers to simulation that computes both fluid flow and structure deformation. The difficulty of calculating the FSI of the circulatory system is associated with mesh deformation following structure movement. There are several algorithms for mesh deformation, such as the Arbitrary Lagrangian and Eulerian (ALE) and immersed boundary methods; however, in problems with large structure deformations such as heart valve opening/closure, these methods lose their robustness of computation. FSI solves structure equations in addition to fluid equations, not only related to the flow inside or around moving structures, but also related to the stress forces acting on structures including von Mises stress. However, the current cost of FSI is huge (it requires a supercomputer), and current studies on FSI contain too many simplified assumptions about vessel properties, such as uniform elastic

property constants; therefore, their validation is difficult, in vessels with non-uniform structural properties such as atherosclerotic aorta.

CFD can obtain wide-ranging, detailed information on hemodynamics; however, the various manual processes affect the simulation, which could yield inaccurate results. To compute valid results, accurate geometry, appropriate boundary conditions and proper computing algorithms are necessary. Moreover, it is important to compare with actual measurements to confirm the reliability of the CFD method, when planning cardiovascular surgery.

2.6. Computerized Virtual Surgery Based on Computational Fluid Dynamics

Virtual surgery is one of the most useful applications of CFD. It enables the non-invasive prediction of postoperative flow dynamics, and the trial of new surgical methods on a computer (Figure 4).

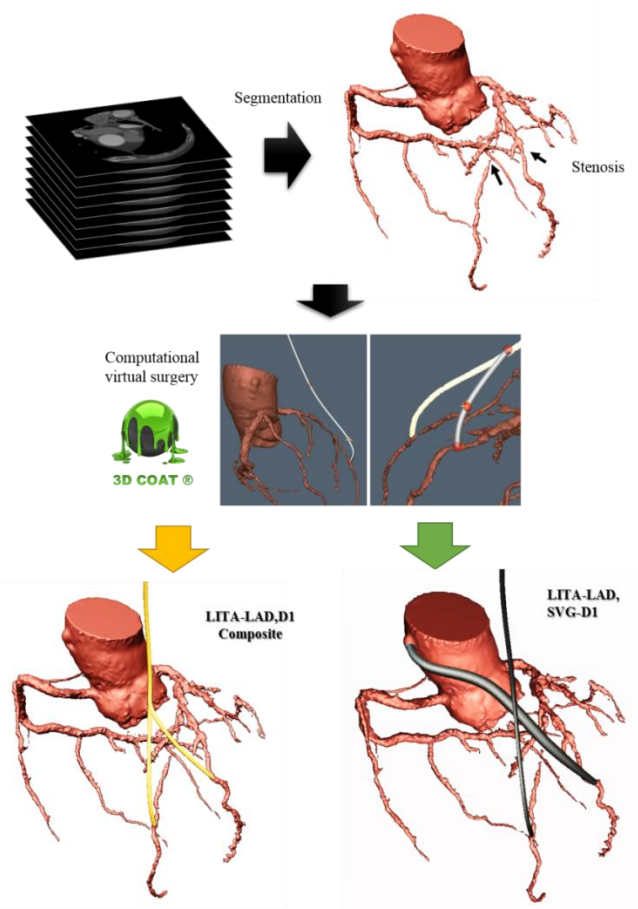

Figure 4. Computerized virtual surgery on coronary heart disease. Virtual surgery of coronary bypass grafting using computer-aided design (CAD).

Virtual surgery predicts postoperative hemodynamics using post-operative geometry which is generated by deforming the preoperative geometry obtained from patient data. Thus, the modification of geometry plays an important role in computerized virtual surgery. Recently, much sophisticated 3D modeling software for computer graphic has been developed, which offers free and intuitive geometry deformation and/or generation tools. Moreover, 3D computer aided design (CAD) software enables the deformation of geometry with fixed measurements.

Several geometric data description methods for geometry modification are shown in Figure 5. The surface polygon model is fundamental to 3D graphics. The surface of the geometry is described as triangular polygons. Most of the current rendering or 3D engines uses the surface polygon model to depict 3D images. Thus, this format can be used for almost all software, and the data can be transferred between different software. The deformation of the geometry is limited by the topology of the surface triangles. Deformation in uninform polygons causes geometric irregularities; thus, complicated geometry requires file format conversion and other methods. The voxel-based model is a convenient format for complex geometry.

A voxel represents a value on a regular grid in a 3D space in medical images. It is useful because of its ability to deform like clay. Voxel sculpting, which is available in 3D modeling software such as 3D-Coat (Pilgway Studio, Ukraine), allows users to deform geometries intuitively without worrying about any topological problem.

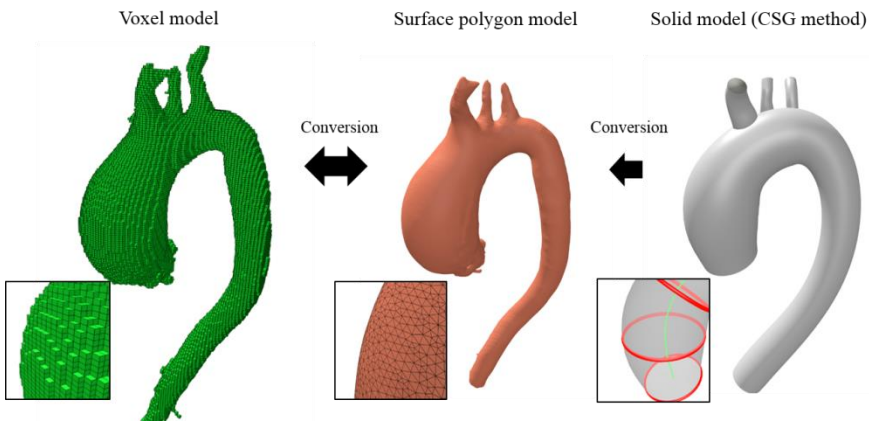

Figure 5. Description of the method for 3D geometry. There are several ways to keep geometric data. Left: Voxel format. Most 3D medical data are handled as voxels. Dynamic deformation of the geometry is capable in virtual surgery. Middle: Surface polygon geometry is fundamental to describe 3D geometry. It fits well with the curvature of complex anatomy; however, the deformation is limited by its topology. Right: Idealized solid geometry generated using constructive solid geometry (CSG) method. The geometry is defined using a centerline and diameters.

Thus, it facilitates the virtual deformation of complicated geometry such as a virtual bypass based on the original CT data (Figure 4). Voxel format is not common to all 3D modeling and meshing software, and voxel data should be converted to surface geometry data for transfer to computational mesh creating process.

These two methods are useful for intuitive deformation but have difficulty creating geometry with a precisely defined diameter or curvature. To generate geometry with

reproducibility and precise measurements, constructive solid geometry (CSG), which is commonly used in CAD software, is useful. The CSG method is a solid modeling method that combines simple geometry such as shares, cuboids, solids of revolution and tubes along spline curves. These simple geometries are united, differenced or multiplied to generate complex geometry. The biggest advantage of this method is that it can define complex geometry precisely using numerical values such as curvature, angle and length, and for these reasons, this method is often used in 3D mechanical CAD software. This method is also useful for generating idealized geometry generated from averaged measurements obtained by angiography excluding individual features. These three methods can be used in combination by exporting or importing data in a common format and combining those using Boolean calculations.

Any complex geometry, whether actual geometry extracted from CT or virtual geometry created on a computer can be generated and edited using these methods, and the flow calculated by CFD. Computerized virtual surgery enables flow analysis of any virtual geometry, even for geometries not realizable in actual human anatomy.

3. Applications of Hemodynamic Research in Cardiovascular Surgery

3.1. Hemodynamic Evaluation in Surgery for Congenital Heart Diseases

Following surgery for congenital heart disease, hemodynamics changes drastically. Recent advances in perioperative patient management have improved postoperative mortality rates even in patients with complex heart and after neonatal open heart surgery, and the long-term results are gaining attention. Long-term cardiac performance is considered to be associated with hemodynamics, and blood flow analysis is performed especially for palliative procedures in patients with a single-ventricular physiology (Figure 1.28). Particularly, CFD and 3D cine PC MRI have been used to study blood flow after the Fontan (Figure 6).

The Fontan operation is a final palliative procedure in patients with a single ventricle, in which venous blood is connected to the pulmonary arteries (PAs) without passing through the functional right ventricle. After Fontan et al., 1971 reported this procedure, various types of modifications have been reported including total cavopulmonary connections, the lateral tunnel procedure, extracardiac conduits and bifurcated Y-graft modifications, and long-term survival has greatly improved. (Khairy et al., 2008). However, several long-term complications remain, including thrombosis, ventricular failure and sudden death due to arrhythmia. These complications are partly associated with the hemodynamic features of the Fontan circulation in the absence of a functional right ventricle, and flow collision from the superior and inferior vena cava (SVC and IVC) flow. To avoid these complications, low central venous pressure with no flow stagnation is considered to be advantageous, and the anatomical features of Fontan geometry have become a focus of hemodynamic research in this field.

The first CFD Fontan study was performed by Haesdonck et al., 1995 and compared the energetic efficiency of the flow between the APC and cavopulmonary connection. More than

20 studies of Fontan hemodynamics based on CFD have been reported in the past two decades.

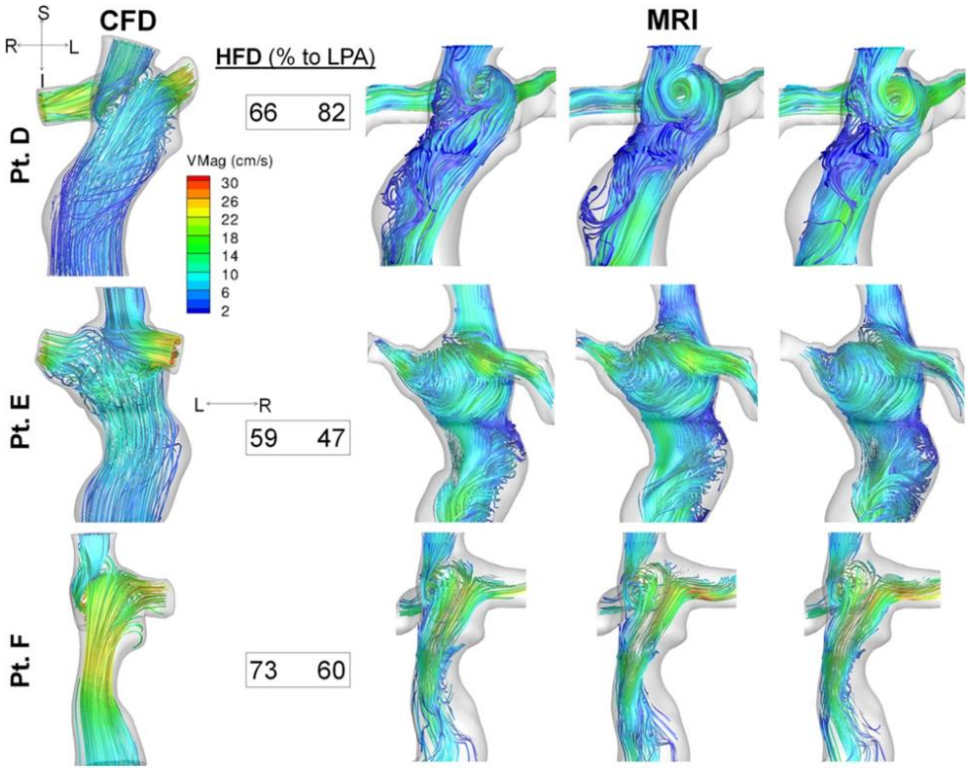

Figure 6. Comparison of the visualization of Fontan circulation using CFD and PC MRI (Haggerty et al. 2013). Flow visualization of Fontan circulation. The streamline and hepatic fluid factor (HFD) was compared between CFD and 3D cine PC MRI.

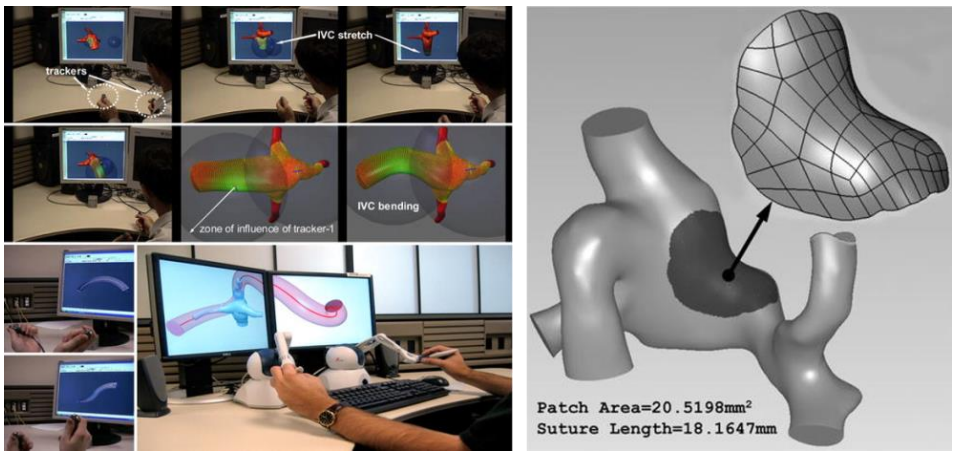

Figure 7. The application of virtual surgery on Fontan patient (Pekkan et al. 2008). Left: Virtual surgery using 6 DoF device enables intuitive deformation of vessel geometry. Right: Patch size is computed from virtual surgery.

There are several important metrics used to analyze postoperative Fontan flow. Flow contribution from the IVC to the left and right lungs is important because a “hepatic factor” is thought to be protective against the development of pulmonary arteriovenous malformations. Patients with left atrial isomerism, such as those with azygous continuations of an interrupted IVC, exhibit this phenomenon. Goksel et al., first described the application of Y-graft Fontan, the conduit of which was from the IVC bearing blood contains the “hepatic factor”, which ensured the equal separation of the IVC flow to the left and right lungs, CFD was used to evaluate the utility of this new surgical method.

Energy efficiency in the Fontan circulation, defined as EL is the outcomes measured by these hemodynamic studies. The reduction in EL based on TP (1.45), (1.A.20), (1.A.21) is used as the index for good hemodynamic performance of the Fontan procedure; also, reduced EL reportedly related to good ventricular diastolic function in the single systemic ventricle after the Fontan procedure. (Honda et al., 2013). Furthermore, the energy efficiency of Fontan hemodynamics is thought to affect the exercise tolerance of patients.

Whitehead et al., 2007 estimated Fontan hemodynamics during exercise using CFD, and concluded that a nonlinear relationship exists between cardiac output and EL, which is highly dependent on the geometry of the TCPC and the division of flow between the left and right PAs. They used the MRI data of 10 patients to generate the geometry and flow rate through the SVC, IVC, and right and left PAs as boundary conditions. The simulation of exercise was performed under the boundary conditions of twice and three times the baseline flow increase of the MRI acquired flow. Haggerty et al., 2013 used both CFD and 3D cine PC MRI to estimate the hemodynamics of 100 patients who underwent the Fontan procedure. They computed Fontan flow using the geometry extracted from MRI and flow rate boundary conditions acquired using 2D PC MRI, and calculated the energy efficiency of patients. Interpreting the EL value is difficult because it varies according to body size, and heart function. Haggerty et al., 2013 normalized EL calling it indexed power loss (iPL) by correcting it for body surface area (BSA) and systemic flow rate (Qs) as in the following equation.

$$iPL = \frac{EL}{\left(\frac{\rho Qs^3}{BSA^2}\right)} \tag{1}$$

iPL is correlated with cardiac index, indicating that high resistance in the TCPC is caused by irregularities in the shape of the PAs, such as narrowing, acute diameter differences, and bending in turn affecting heart function. They also used 3D cine PC MRI to visualize flow in the TCPC to validate the flow computed using CFD, as shown in Figure 6. The computed flow is largely dependent on the boundary conditions, use of a turbulence model, steady/ transient scheme and computing mesh quality. Combined use of numerical simulation and actual measurements is useful to compute physiological flow.

Other important hemodynamic information about the Fontan circulation includes flow stagnation, which contributes to the formation of thromboses. In the extracardiac Fontan circulation, SVC conduit size must be selected considering the growth of the patient, and a larger size is preferred. However, the larger the conduit, the more apparent flow stagnation and turbulence become, which could lead to long-term complications such as heart failure or thrombosis. Itatani et al 2009 determined the optimal size of the conduit for the extracardiac Fontan procedure based on energy efficiency and the volume of stagnation. The simulation

was performed based on the idealized geometry generated from the averaged size of angiographic data of 17 patients who underwent the extracardiac Fontan procedure under the transient boundary conditions of flow rate at the SVC and IVC and pressure at the left and right PA outlets which fluctuate with respiration. They concluded that 16 or 18 mm conduits are optimal for children aged 2 - 3 years. In this way, using averaged, idealized geometry for computation is a useful application of CFD that excludes individual differences and can estimate the general tendency of a surgical method.

Recently, CFD has been used not only to evaluate of postoperative hemodynamics but also to predict the postoperative hemodynamic state before surgery. Pekkan et al., 2008 developed the anatomy editing/surgical planning tool (SURGEM) and applied it to Fontan surgery. This software is based on a mathematic model for surface polygon deformation called free-form deformations (FFD) and enables freely intuitive deformation of patient-specific geometry. The deformation is performed using six degrees of freedom (6 DoF: 3 axis position and 3 axis rotation) trackers to control the parameters of FFD (Figure 7). Even though its deformation does not solve stress on the vessel, 6 DoF device and FFD enable pulling, pushing and twisting of the geometry vessels with simple and natural gestures of both hands.

There are several limitations of Fontan CFD studies. Many Fontan CFD studies use steady-state computation, and few compute pulsatile flow. However, regarding the fluctuation of flow in the Fontan circulation, the fluctuation caused by respiration is more dominant than that caused by heartbeat; in fluctuation caused by respiration, the lung sucks in blood flow as a result of a pressure drop in the Pas following expiration. This mechanism is called respiratory pump and is a power source of the Fontan circulation (Hsia et al., 2000). Although the respiratory pump regarded as an important factor in the Fontan circulation, few previous CFD simulations consider this mechanism in their boundary conditions. Therefore, Fontan CFD has the longest history in the applications of CFD in cardiovascular diseases; however, the method of computation, mainly regarding boundary conditions, is not completely established. For this reason, the combined use of numerical simulation and actual measurements such as those obtained using 3D cine PC MRI is important for the validation of the CFD flow analysis system.

3.2. Flow Evaluation in Coronary Artery Bypass Grafting (CABG)

Coronary heart disease is one of the most common cardiovascular diseases in elderly people. Angina pectoris or myocardial infarction is caused by the interruption of blood flow in the lumen of coronary arteries narrowed by the buildup of plaques along the inner wall. The current method of diagnosing coronary heart disease is based on function and morphology. Fractional flow reserve (FFR), Doppler wire assessment coronary flow reserve (CFR), and scintigraphy are proven techniques for functional evaluation. However, these catheter based measurement are invasive, and scintigraphy may underestimate severe multivessel disease. Regarding the evaluation of morphology, coronary angiography (CAG), coronary CT, and intravascular ultrasound (IVUS) are used to estimate the amount and vulnerability of the plaques, and the severity of the stenosis. The gold standard is CAG; however, it could underestimate the severity of stenotic lesion in arteries with complex irregularity or tortuous course (Kern et al., 2010).

Flow analysis is beneficial because the goal of treatments for coronary artery disease is sufficient blood flow to the myocardium. CFD is the only tool currently available to obtain a detailed picture of flow dynamics at diseased sites in the coronary artery; because the resolution of MRI and echocardiography is too low to detect detailed flow inside small coronary arteries. Recently, a technique called computation of fractional flow reserve from coronary computed tomography angiography (FFR_{CT}) was demonstrated to be capable of calculating FFR using CFD (Kim et al., 2010), and the FFR calculated correlated with actual measurement obtained by catheter (Koo et al., 2011). Based on its clinical utility, Heart Flow Inc. the first commercial application of CFD for clinical use was developed for the evaluation of ischemic heart disease with the advantages of reduced cost and noninvasiveness.

The advantages of the application of CFD for the assessment of coronary heart disease are not only the noninvasive FFR evaluation, but also that the technique can estimate stress on the intimal wall of coronary arteries, which may predict the progression or rupture of plaques. WSS and its fluctuation in the cardiac cycle termed oscillatory shear index (OSI) are thought to be important factors because they promote plaque progression or to elevate free radical levels in endothelial cells. (Samady et al., 2011, Harrison et al., 2003, Chatzizisis et al., 2007). Because WSS is calculated from a spatial differential of velocity, and because the size of coronary arteries is small at approximately 3 mm in diameter, it is very difficult to obtain actual measurements for WSS; thus, CFD, which can visualize flow at extremely high resolution, is the most useful and reliable modality to evaluate stress. The small diameter of the coronary artery also cause problem with actual measurement by catheter. Catheter which are 0.014 mm in diameter with a circular cross-sectional shape have a large resistance for blood flow, and are known to disturb arterial flow. Tori et al., 2007 studied the effect on flow of a catheter in an idealized model of a coronary artery with a diameter of 3 mm, and found that the presence of the catheter altered the flow patterns and increased the pressure drop. In addition, velocity measurements were underestimated during one cardiac cycle.

CFD is also useful when planning a surgical strategy for the treatment of coronary heart disease. Coronary artery bypass grafting (CABG) is commonly performed in coronary arteries with stenotic lesions to restore blood flow. The success of CABG is dependent on the long-term patency of the arterial and venous grafts, which is in turn dependent on the design of the coronary revascularization. However, the optimal bypass design is uncertain especially, particularly in cases with multivessel disease, because of flow competition between the graft and native vessels (Nakajima et al., 2007). Using virtual surgery, the shape of the CABG can be optimized to achieve an adequate flow rate and long-term patency. Dur et al., 2011 developed a surgical planning method using a combination of computer-aided design (CAD) and CFD. This method models the whole anatomy of the patient-specific aortic arch and coronary arteries and uses the lumped parameter model as the boundary conditions. Each outlet has resistance for the outlet boundary conditions. Virtual grafts are added to the 3D geometry generated from preoperative patient data, such as CT and MRI data using an in-house anatomic editing tool based on solid modeling. This system also provides automatic optimization of the graft shape based on the CFD evaluation of the cost function.

The optimization is performed in 2D CFD using the 2D projected geometry of the virtual graft. The shape of the graft, including the angle of anastomosis and curvature vectors of the proximal and distal portions is determined according to the cost function that evaluate the velocity gradient, pressure drop, mean WSS, flow deviation angle, and vorticity. Once the optimized 2D geometry is generated, it is converted into 3D geometry and 3D CFD is

performed using the geometry. This system is unique in that it divides the CFD process into two stages: first, 2D CFD, which has an adequately low computational cost, enabling a large number of iterations for optimization of the graft shape; and second, 3D CFD, which enables a detailed hemodynamic evaluation of the whole anatomy of the coronary arteries and grafts. The optimal bypass root is automatically defined with a practical computational cost.

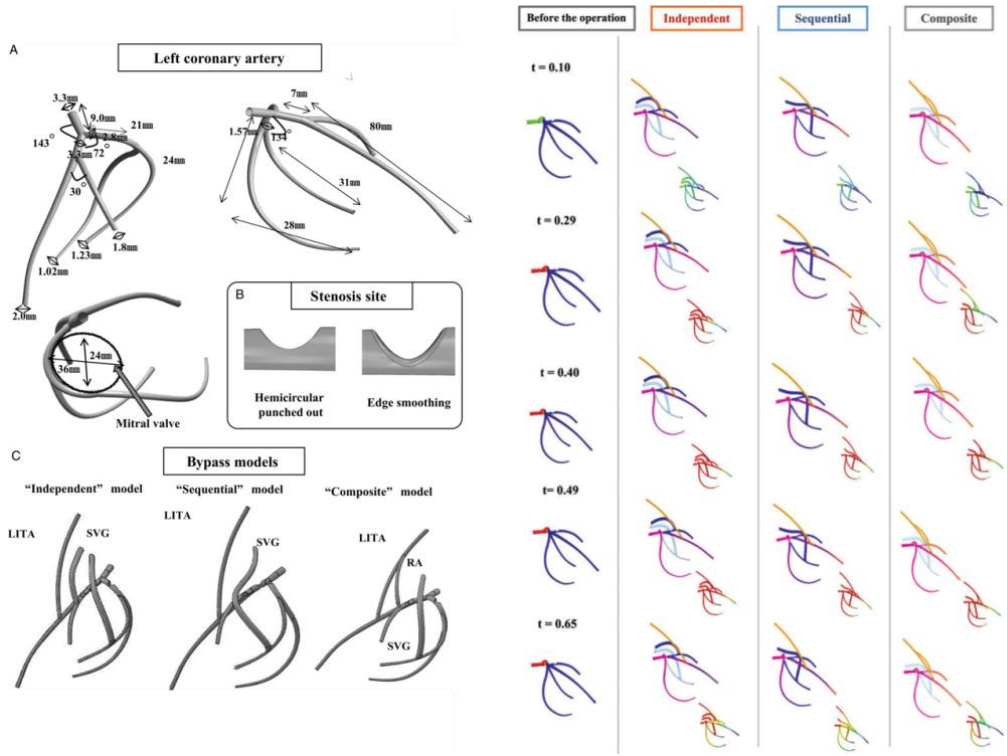

Figure 8. Idealized geometry CFD on coronary heart disease (Koyama et al 2014). Left: Coronary artery geometry was generated using solid modeling based on patients' average measurements. The general tendency of the flow was evaluated by comparing different bypass models. Right: The pressure distribution and streamline colored by origin of flow was visualized in several phases.

In addition to estimating patient specific hemodynamics, CFD also enables the evaluation of the general tendency of surgical methods. Koyama et al. 2014 used idealized coronary artery geometry to estimate the optimal bypass design for CABG for the left anterior descending and diagonal coronary arteries based on CFD idealized geometry created by using 3D mechanical CAD software as shown in Figure 8. They created a coronary artery model that reflected geometric features of coronary artery branches that include vessel diameter and the angles of the averaged data of 10 normal individuals. They revealed that the combination of graft design and the severity of native coronary stenosis affected the flow in each branch: reverse flow in the grafted vessels sometimes created disadvantageous flow collision; however, in some situations it acted as additional flow to another grafted vessel. (Figure 9). Patient-specific CFD is a substitute for actual measurements that can obtain much detailed information on blood flow less invasively. To estimate general tendencies using a patient-specific model, statistical analysis based on CFD calculations in a large cohort is necessary, which requires a lot of time and effort. However, CFD using idealized geometry can evaluate

general tendencies in only one analysis. Moreover, it is easy to perform controlled experiments using an idealized model by independently modifying the flow rate/pressure boundary conditions.

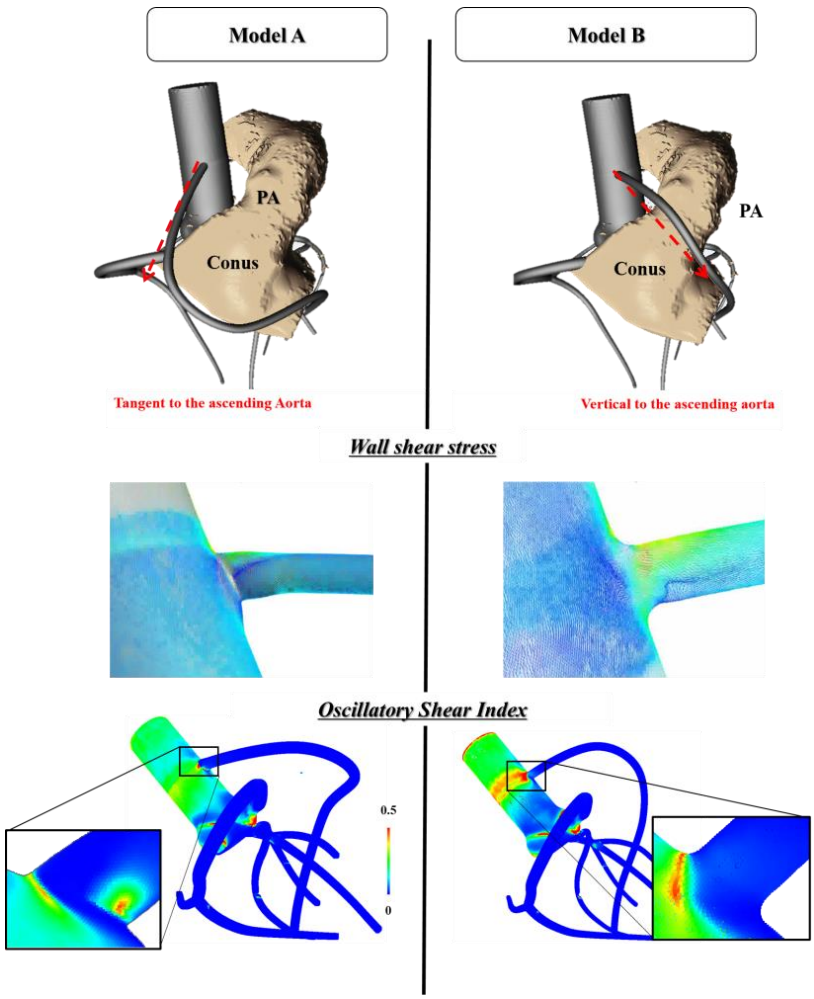

Figure 9. Two types of idealized coronary artery bypass model were created, and the impact of the top-end anastomosis design on patency and flow stability were evaluated based on wall shear stress (WSS) and oscillatory shear index (OSI) (Koyama et al. 2015). Model A: The top-end anastomosis is parallel to the long axis of the ascending aorta and the graft passes over the right ventricle. Model B: The top-end anastomosis is directed toward the shortest pathway, and forms at nearly a right angle to the long axis of the ascending aorta.

3.3. Prediction of the Prognosis of Aortic Disease

Ruptured aortic aneurysm is a life-threatening disease. There are no effective medications or therapies for aortic aneurysms, most patients postpone treatment until their aneurysm is enlarged. The indications for the surgical treatment of aortic aneurysms are determined based on their diameter (Brewster et al., 2003). However, predicting the progress of aneurysms is

difficult and rupture can occur even if the diameter is under the threshold (Davies et al., 2002, Dapunt et al., 1994). Several studies on features such as the geometry of the aortic curvature and mechanical properties of the aorta (Elefteriades et al., 2010, Poullis et al., 2008, and Koullias et al., 2005) have attempted to establish alternative criteria for the diagnosis of aortic aneurysm.

Several recent studies using numerical analysis have reported a relationship between hemodynamic parameters and rupture risk. Fillinger et al., 2002 studied differences in peak wall mechanical stress in patients with abdominal aortic aneurysm (AAA), and found that peak wall stress was significantly higher in the ruptured group (Fillinger et al., 2002). Truijers et al 2007 reported that AAA wall stress at peak systolic pressure was significantly higher in ruptured than asymptomatic aneurysms. In a patient-specific analysis, it is important to derive the accurate geometry of the lumen, thrombus, wall and calcifications: thrombi decrease wall stress, whereas calcifications increase the stress. They referred that geometry of lumen and calcifications can be obtained using 3D CTA or MRI; however, that of thrombi and the wall thickness is more difficult to derive because the boundary between thrombi and the wall is unclear. Thubrikar et al., 2001 showed that a wall thickness increase from 1.31 to 1.58 mm results in an increase in stress of up to 21 %. Xenos et al., 2011 emphasized the importance of advanced material properties for performing a reliable stress analysis (Figure 10): An anisotropic material model predicted higher principal axis stress than an isotropic material model. These studies, which use seismic analysis without considering the effect of fluid forces, can be performed to estimate mechanical wall stress based on the finite element method; however, several previous studies have shown that the influence of fluid force on wall stress is up to 25 % (Papaharilaou et al., 2007, Scotti et al., 2008). FSI enables a more detailed prediction in the interaction between aneurysmal wall and blood flow there. For example, a large iliac angle reportedly increases the von Mises stress in an AAA. Also, it was demonstrated that the use of FSI permitted the prediction of the location of rupture in several cases of ruptured AAA (Xenos et al., 2011). However, the FSI requires too much time and effort to perform on each patients, and it is difficult to examine in a large cohort study.

In addition to a rupture risk analysis, CFD flow analysis has been applied to predict aneurysm progression. 3D cine PC MRI (4D flow MRI) has also been used to assess the risk of progression of aneurysms. Although 4D flow MRI cannot provide information on the pressure inside the lumen or von Mises stress on the wall, WSS and OSI can be calculated and they are believed to play an important role in the prediction of aneurysm progression (Bieging et al., 2011, Boussel et al., 2011). The coarse spatial resolution of MRI is disadvantageous in the calculation of WSS, nevertheless, WSS derived using MRI is reportedly concordant with CFD results (Boussel et al., 2011) and other measurement studies (Bürk et al., 2012). Currently, there is insufficient evidence on these parameters because of a lack of follow-up.

Aortic dissection is one of the most catastrophic diseases in cardiovascular disease with a mortality rate increasing 1-2% per hour after symptom onset. It is classified into two types, Stanford Type A and B depending on the dissection site.

Stanford Type A aortic dissection, which involves the ascending aorta, requires primary surgical treatment. Stanford Type B aortic dissection, which does not involve the ascending aorta, is generally treated with medication as the initial treatment, and the majority of patients with Type B dissection survive the acute phase. However, the long-term prognosis is not always sufficient: the dissection develops aneurysmal dilatation within 1-5 years in

approximately 20-50% of patients (Khan et al 2002), which is considered a significant predictor of poor survival (Genoni et al., 2002). Recently, the relationship between the prognosis of patients with Type B dissection and blood flow abnormalities has been discussed. For example, it is known that patients with thrombosis of the false lumen have an improved outcome, whereas those with a patent false lumen have an increased risk of aortic expansion and death (Bernard et al., 2001, Pretre et al., 1997), and that flow abnormalities and stasis are factors that contribute to thrombus formation. Additionally, recent studies using computer simulations have shown that abnormal flow patterns in the dissected aorta play a role in false lumen expansion and aneurysm formation (Cheng et al., 2010).

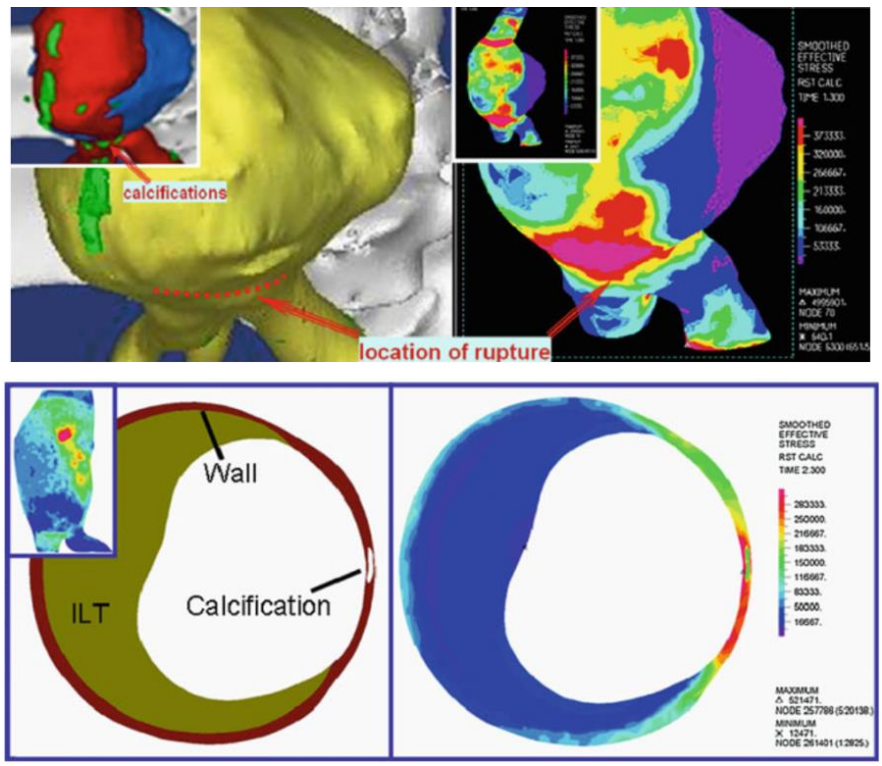

Figure 10. Analysis of stress on abdominal aorta aneurysm (AAA) using fluid structure interaction (FSI) analysis (Xenos et al. 2011). Fluid-structure interaction analysis of an abdominal aortic aneurysm. Thrombus decreases the von Mises stress on the wall, while calcification increase this stress.

Computational simulation and 3D cine PC MRI are the commonly-used modalities for flow evaluation of the dissected aorta. Computer simulation is capable of calculating hemodynamic parameters, including WSS and OSI, considered to have a key role in the development of aneurysms (Bürk et al., 2012). However, because computational simulation is dependent on the assumptions including medical image information, it is important to identify the entry and re-entry that dominates flow in the false lumen. Karmonik et al., 2011 simulated the hemodynamic effects of entry- and exit-tear coverage in a Type B dissection using CFD based on 4 geometries that differ in terms of entry and re-entry tears as shown in Figure 11.

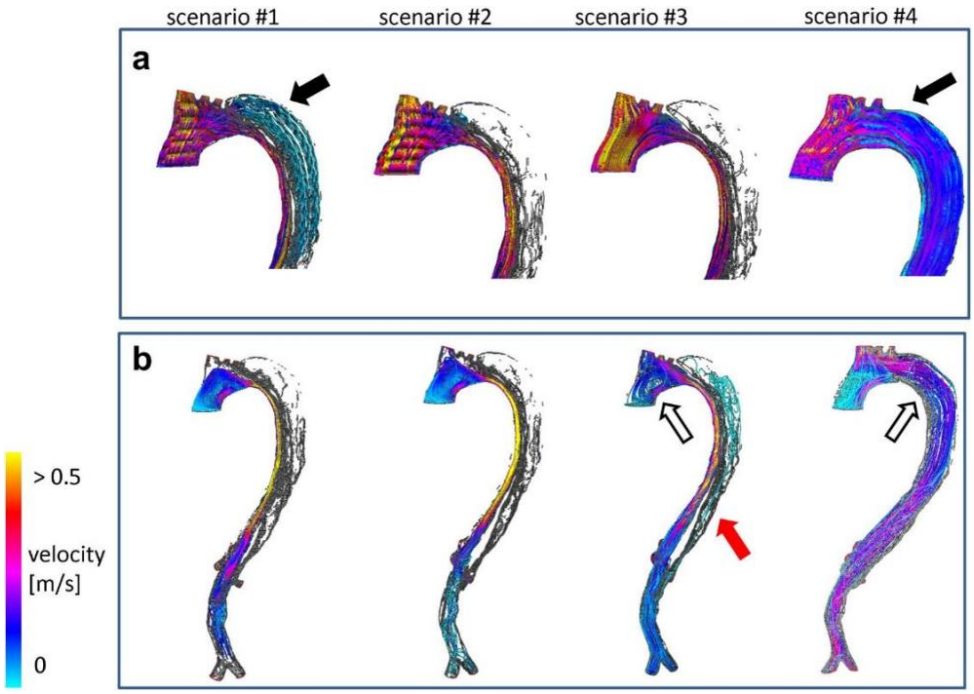

Figure 11. CFD analysis in aortic dissection (Karmonik et al. 2011). The existence of entry and re-entry was virtually changed: #1: Geometry at presentation, one entrance and one exit tear. #2: The exit tear was virtually removed, simulating thrombotic occlusion of the exit tear during disease progression. #3: The entrance tear virtually occluded mimicking endovascular intervention. #4: The flap was virtually removed, simulating surgical fenestration.

They found large variability in pressure and velocity in the false lumen pressures in 4 scenarios, and that the outflow restrictions may cause elevated false lumen pressures, promoting lumen expansion. Their results had the limitation that the information on entry or re-entry tears, despite the low spatial resolution, could greatly affect the calculated results.

One of the difficulty in CFD modeling of the dissected aorta is the control of movements in the dissected flap. The flaps dynamically move by the pressure difference between the true lumen and the false lumen, changing the shape and volume of the pathway of blood flow, and simple rigid flap assumption is unsuitable in these problems. However, there are several technical difficulty in modeling with FSI such as elastic property distribution in addition to the vast calculation costs.

3D cine PC MRI is useful to analyze the flow in patients with complex 3D anatomy, such as aortic dissection. The aorta has adequately large that even the low spatial resolution of MRI is considered to have a small effect on the flow measured. Clough et al., 2012 analyzed hemodynamics in dissected aorta of 12 patients with Stanford Type B by aortic dissection using 3D cine PC MRI (Figure 12), and found that relationships exist between the position of the dominant entry tear and the area of greatest false lumen expansion, and between the position of distal entry tears and the aortic expansion. François et al., 2012 analyzed hemodynamics in the true and the false lumina of 12 patients using 3D cine PC MRI, and visualized and analyzed the differences between flow in the false lumen and that in the true lumen. According to this study, the flow velocity in the false lumen is lower than that of true lumen, and flow reverse in systolic phase was observed in false lumen of some patients,

which thought to be caused by pulse wave reflection from the distal end of a false lumen with no re-entry. In addition, abnormal flow, including vortex flow, was observed in both the true and false lumina, which is thought be caused by the moving flap.

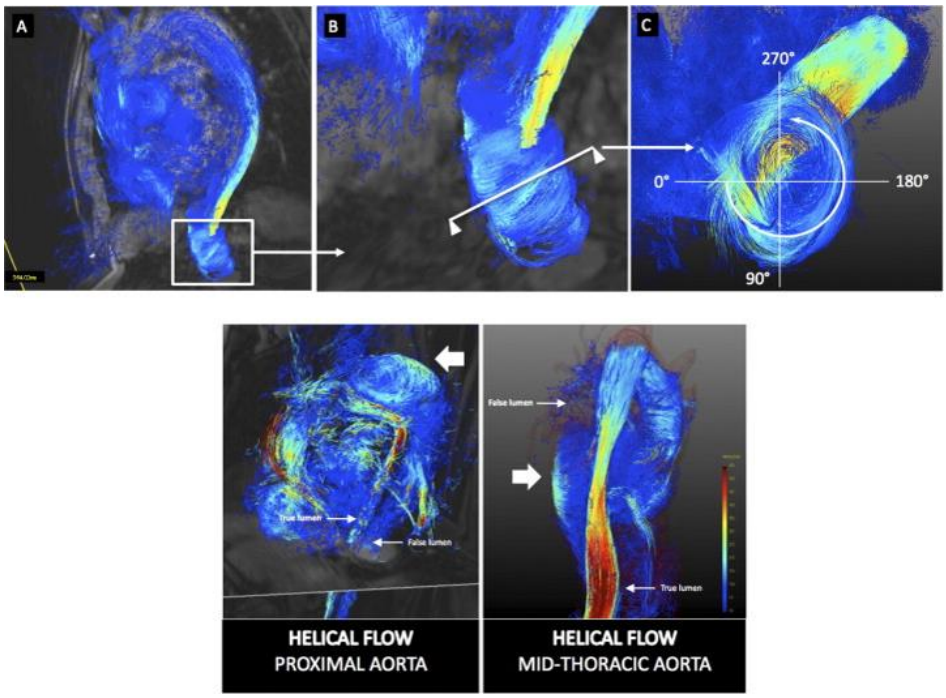

Figure 12. Flow analysis in a dissected aorta using 3D cine PC MRI (Clough et al. 2012). Identification and quantification of helical flow using 3D cine PC MRI. Helicity (degree/s) was quantified based on the amount of rotation in the plane shown in C.

Although 3D cine PC MRI is suited to the analysis of aortic dissection, research results obtained with 3D cine PC MRI related to the aortic dissection are only just being reported. Several technical limitations including the data acquisition process and post-processing, must be overcome to perform high volume multicenter studies. Thus, there is no statistical evidence regarding the hemodynamics of the dissected aorta. Larger prospective studies are required to determine a method of the prognosis of aortic dissection using 3D cine PC MRI.

3.4. Applications in Valve Surgery

Patients with heart-valve insufficiency or stenosis are typically evaluated by measurements of flow and/or pressure. The severity of aortic valve stenosis is classified into 3 groups according to the measured flow and pressure (Zoghbi et al., 2003). However, the primary indication for intervention is often symptom development (Vahanian et al., 2012). For early treatment, more reliable parameters for valvular heart disease are required. Currently, the transvalvular pressure gradient is the commonly- used parameter for the determination of treatment indication. However, several previous studies have emphasized the importance of pressure recovery that occurs on downstream of heart valves (Baumgartner et

al., 1990). Flow EL is well-established concept that evaluates not only pressure loss but also kinetic EL. Some studies have this parameter to evaluate heart valve performance. Bahlmann et al., 2013 reported the difference in survival rate between patients with aortic stenosis. It was also reported that EL in patients with dilated cardiomyopathy decreases with a decrease in size of the vortex after medication (Nabeta et al., 2014). Recently, Itatani et al., 2014 reported a method to evaluate EL based on viscosity and blood flow vector distribution. Using this method, EL can be calculated without pressure information, which enables EL evaluation using VFM and 3D cine PC MRI. Local EL is calculated and depicted as shown in Figure 1. It is useful to know the cause of the loss, and to interpret the variety of vortex flows formed in the ventricle/vessel. For example, Figure 14 shows the velocity and flow streamlines with vorticity after mitral valve replacement.

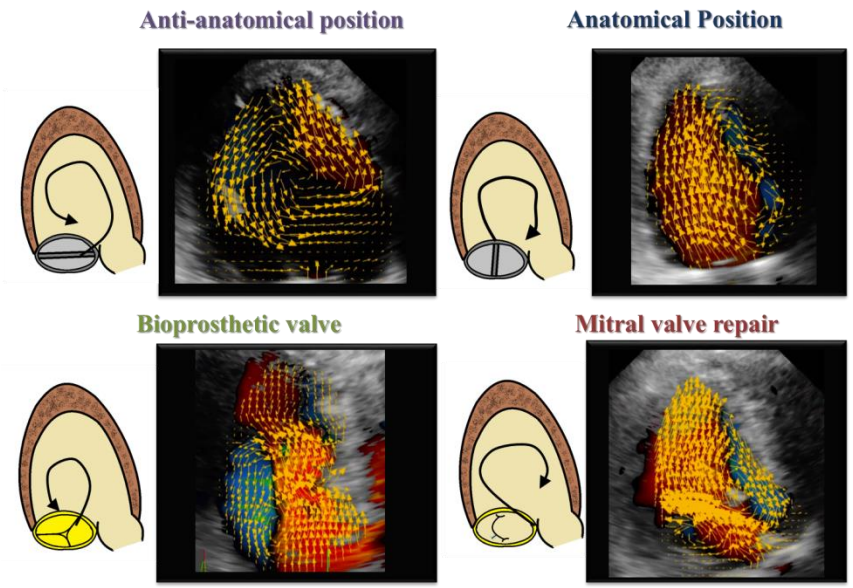

Figure 13. The intraventricular vortex after mitral valve surgery (Modified image from Itatani K. 2014).

Each case shows different-shaped vortices which are not seen in the normal ventricle. In the case of a mechanical valve fitted in an anti-anatomic position, transmitral flow collides with the anteroseptal wall, and, is directed to the apical and posterolateral walls, forming a large vortex filling the whole ventricle. In a case after mitral valve plasty, left ventricular vortex flow appeared as a physiological flow pattern with a large clockwise vortex. Conversely, in case of a mechanical valve fitted in an anatomical valve position and in a case of mitral valve plasty, transmitral flow formed a clockwise vortex as normal. These abnormal flow patterns have the possibility to decrease the efficiency of the flow and increase the EL. This information is useful when considering a treatment plan.

However, VFM has the limitation of 2D measurement. In some cases, disturbed flow or jet flow may not fit inside the single plane of echocardiography, which may lead to the underestimation of EL. Currently, the only way to visualize 3D in-vivo flow in actual measurements is using MRI. It is capable of calculating the EL of the disease (Barker et al., 2013). However, noise in the velocity distribution is problematic when calculating EL. As

shown in Figure 14 noise largely affects the EL. Thus, MRI data-acquisition conditions and noise reduction in post-processing directly change the EL value. Validation studies on spatial resolution and noise reduction, as well as clinical studies are required to examine these issues further.

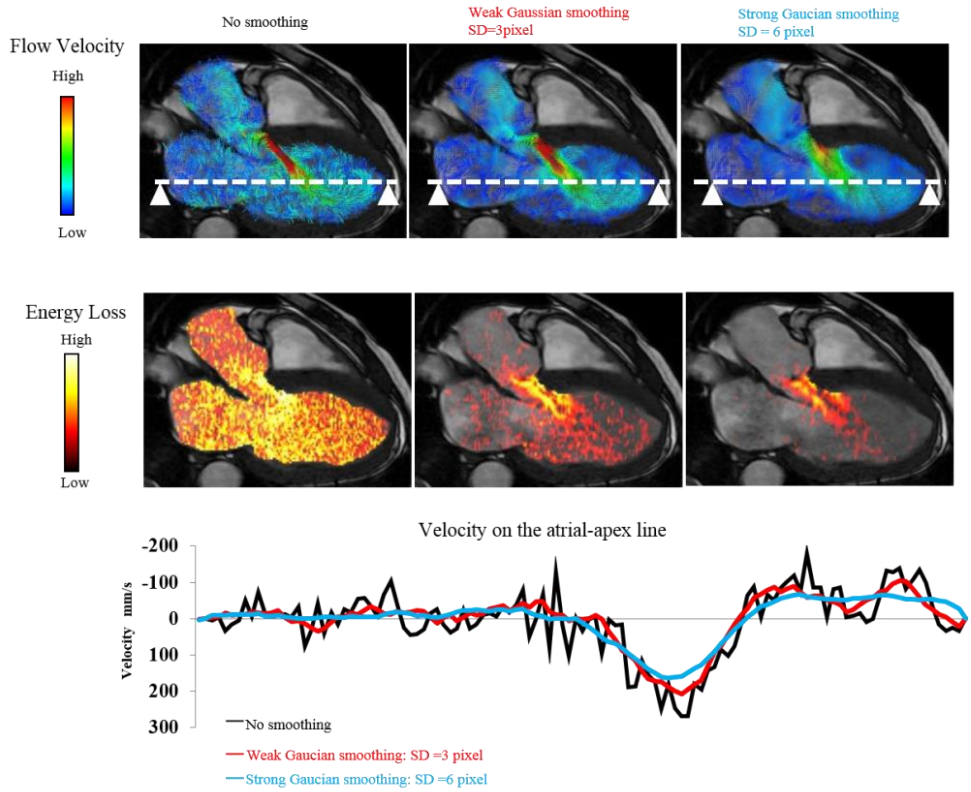

Figure 14. The impact of noise on energy loss calculation. Flow visualization using 2D phase-contrast MRI. Left: The visualization of flow and energy loss without the smoothing of velocity. Middle: Gaussian smoothing with 3 pixel standard deviation. Right: Gaussian smoothing with 6 pixel standard deviation. Energy loss is largely dependent on the noise in velocity distribution.

The computational simulation method has also been studied in some groups. Drastic movement of the valve makes it difficult to simulate on a computer because of the difficulty of computing mesh deformation. Katayama et al., 2013 developed an automatic mesh reconnecting algorithm to avoid this problem. They simulated blood flow and the motion of the aortic valve leaflets using FSI to examine the influence of the morphologic characteristics of the bicuspid aortic valve on disease progression by comparing the motion, stress/strain distribution, and blood flow of normal and stenotic tricuspid valves. They found that the characteristic morphology of the bicuspid valve creates excessive bending strain on the leaflets during ventricular ejection, and a greater increase was observed in the bicuspid valve. Valve analysis based on computer simulation is technically difficult because of mesh torsion caused by large movements of the aortic valve, and few studies have been conducted. However, numerical simulation enables the gathering of high resolution information about

valve movement and an understanding of the surrounding hemodynamics, which cannot be observed using actual measurements, can be obtained by numerical simulation.

FUTURE PERSPECTIVES AND CONCLUSIONS

Flow visualization enables the calculation of various hemodynamic parameters, which presents predictive indicators for the progression of cardiovascular diseases. These parameters and the visualized flow are helpful to understand the complex flow dynamics of cardiovascular diseases, which is in turn helpful for surgical planning. There are several modalities of flow visualization and each has advantages and disadvantages. The appropriate modality must be selected according to its purpose and the region for analysis. CFD is useful in virtual surgery, idealized geometry analysis and for small vessels. 3D cine PC MRI is useful in regions where structures have a large impact on blood flow such as around the valves and in the ventricle. Furthermore, it is useful to evaluate complex 3D flow. Echocardiography is simple and the time required for analysis is short, which is useful for routine clinical use.

Currently, clinical evidence for the utility of blood flow visualization is scarce because of a lack of large cohort studies. However, systems for analyzing blood flow have undergone rapidly development recently, and flow analysis will become the standard for the diagnosis of cardiovascular diseases.

Flow visualization using echocardiography is a powerful tool to evaluate the intraventricular blood flow; however, evaluation in 2D measurement plane is a big limitation especially in turbulent flow in valvular heart disease. In future, this kind of modality should be aiming toward 3D flow evaluation using 3D echocardiography. MRI is a powerful tool because it can acquire 3D flow distribution in actual measurement. This advantage is beneficial in evaluating the flow in the complex structure such as aortic dissection whose flap drastically moves in a cardiac cycle. Currently, target of MRI is limited to large vessel, but performance of MRI machine continues to improve with the development of technology; thus, small vessel flow will possibly be evaluated in future. The use of computational simulations will be much focus on virtual surgery combined with computer graphics or study based on idealized model to conclude general information such as indication of surgical treatment.

REFERENCES

Akins CW, Travis B, Yoganathan AP. Energy loss for evaluating heart valve performance. *J. Thorac. Cardiovasc. Surg*. 2008;136(4):820–33.

Bahlmann E, Gerdts E, Cramariuc D, Gohlke-Baerwolf C, Nienaber C a, Wachtell K, Seifert R, Chambers JB, Kuck KH, Ray S. Prognostic value of energy loss index in asymptomatic aortic stenosis. *Circulation.* 2013;127(10):1149–56.

Barker AJ, van Ooij P, Bandi K, Garcia J, Albaghdadi M, McCarthy P, Bonow RO, Carr J, Collins J, Malaisrie SC, Markl M. Viscous energy loss in the presence of abnormal aortic flow. *Magn. Reson. Med*. 2013;00(00):1–9.

Baumgartner H, Khan S, DeRobertis M, Czer L, Maurer G. Discrepancies between Doppler and catheter gradients in aortic prosthetic valves in vitro. A manifestation of localized gradients and pressure recovery. *Circulation.* 1990;82(4):1467–75.

Bernard Y, Zimmermann H, Chocron S, Litzler JF, Kastler B, Etievent JP, Meneveau N, Schiele F, Bassand JP. False lumen patency as a predictor of late outcome in aortic dissection. *Am. J. Cardiol*. 2001;87(01):1378–82.

Bieging ET, Frydrychowicz A, Wentland A, Landgraf BR, Johnson KM, Wieben O, François CJ. In vivo three-dimensional MR wall shear stress estimation in ascending aortic dilatation. *J. Magn. Reson. Imaging.* 2011;33(3):589–97.

Boussel L, Rayz V, Martin A, Acevedo-bolton G, Lawton MT, Higashida R, Smith WS, Young WL, Saloner D. *Phase-Contrast MRI measurements in intra-cranial aneurysms in-vivo of flow patterns, velocity fields and wall shear stress: A comparison with CFD*. 2011;61(2):409–17.

Breeuwer M, de Putter S, Kose U, Speelman L, Visser K, Gerritsen F, Hoogeveen R, Krams R, van den Bosch H, Buth J, Gunther T, Wolters B, van Dam E, van de Vosse F. Towards patient-specific risk assessment of abdominal aortic aneurysm. *Med. Biol. Eng. Comput*. 2008;46(11):1085–95.

Brewster DC, Cronenwett JL, Hallett JW, Johnston KW, Krupski WC, Matsumura JS. Guidelines for the treatment of abdominal aortic aneurysms: Report of a subcommittee of the Joint Council of the American Association for Vascular Surgery and Society for Vascular Surgery. *J. Vasc. Surg*. 2003;37(5):1106–17.

Bürk J, Blanke P, Stankovic Z, Barker A, Russe M, Geiger J, Frydrychowicz A, Langer M, Markl M. Evaluation of 3D blood flow patterns and wall shear stress in the normal and dilated thoracic aorta using flow-sensitive 4D CMR. *J. Cardiovasc. Magn. Reson.*. 2012;14(1):84.

Chatzizisis YS, Coskun AU, Jonas M, Edelman ER, Feldman CL, Stone PH. Role of endothelial shear stress in the natural history of coronary atherosclerosis and vascular remodeling: molecular, cellular, and vascular behavior. *J. Am. Coll. Cardiol*. 2007;49(25):2379–93.

Cheng Z, Tan FPP, Riga C V, Bicknell CD, Hamady MS, Gibbs RGJ, Wood NB, Xu XY. Analysis of flow patterns in a patient-specific aortic dissection model. *J. Biomech. Eng*. 2010;132(5):051007.

Cibis M, Potters W V, Gijsen FJH, Marquering H, vanBavel E, van der Steen AFW, Nederveen AJ, Wentzel JJ. Wall shear stress calculations based on 3D cine phase contrast MRI and computational fluid dynamics: a comparison study in healthy carotid arteries. *NMR Biomed.* 2014;27(7):826–34.

Clough RE, Waltham M, Giese D, Taylor PR, Schaeffter T. A new imaging method for assessment of aortic dissection using four-dimensional phase contrast magnetic resonance imaging. *J. Vasc. Surg*. 2012;55(4):914–23.

Dapunt OE, Galla JD, Sadeghi AM, Lansman SL, Mezrow CK, de Asla RA, Quintana C, Wallenstein S, Ergin AM, Griepp RB. The natural history of thoracic aortic aneurysms. *J. Thorac. Cardiovasc. Surg*. 1994;107(5):1323–32; discussion 1332–3.

Davies RR, Goldstein LJ, Coady MA, Tittle SL, Rizzo JA, Kopf GS, Elefteriades JA. Yearly rupture or dissection rates for thoracic aortic aneurysms: simple prediction based on size. *Ann. Thorac. Surg.* 2002;73(1):17–27; discussion 27–8.

De Vecchi A, Clough RE, Gaddum NR, Rutten MCM, Lamata P, Schaeffter T, Nordsletten D a., Smith NP. Catheter-induced errors in pressure measurements in vessels: An in-vitro and numerical study. *IEEE Trans. Biomed. Eng*. 2014;61(6):1844–50.

Dur O, Coskun ST, Coskun KO, Frakes D, Kara LB, Pekkan K. Computer-Aided Patient-Specific Coronary Artery Graft Design Improvements Using CFD Coupled Shape Optimizer. *Cardiovasc. Eng. Technol.* 2011;2(1):35–47.

Elefteriades J a., Farkas E a. Thoracic Aortic Aneurysm. Clinically Pertinent Controversies and Uncertainties. *J. Am. Coll. Cardiol*. 2010;55(9):841–57.

Fillinger MF, Raghavan ML, Marra SP, Cronenwett JL, Kennedy FE. In vivo analysis of mechanical wall stress and abdominal aortic aneurysm rupture risk. *J. Vasc. Surg*. 2002;36(3):589–97.

Fontan F, Baudet E. Surgical repair of tricuspid atresia. *Thorax.* 1971;26:240–8.

François CJ, Srinivasan S, Schiebler ML, Reeder SB, Niespodzany E, Landgraf BR, Wieben O, Frydrychowicz A. 4D cardiovascular magnetic resonance velocity mapping of alterations of right heart flow patterns and main pulmonary artery hemodynamics in tetralogy of Fallot. *J. Cardiovasc. Magn. Reson.*. 2012;14(1):16.

Genoni M, Paul M, Tavakoli R, Künzli A, Lachat M, Graves K, Seifert B, Turina M. Predictors of complications in acute type B aortic dissection. *Eur. J. Cardiothorac. Surg*. 2002;22(1):59–63.

Harloff A, Nussbaumer A, Bauer S, Stalder AF, Frydrychowicz A, Weiller C, Hennig J, Markl M. In vivo assessment of wall shear stress in the atherosclerotic aorta using flow-sensitive 4D MRI. *Magn. Reson. Med.* 2010;63(6):1529–36.

Harrison D, Griendling KK, Landmesser U. Role of Oxidative Stress in Atherosclerosis Regulation of Vascular. *Am. J. Cardiol.* 2003;9149(02):7–11.

Honda T, Itatani K, Takanashi M, Mineo E, Kitagawa A, Ando H, Kimura S, Nakahata Y, Oka N, Miyaji K, Ishii M. Quantitative Evaluation of Hemodynamics in the Fontan Circulation: A Cross-Sectional Study Measuring Energy Loss In Vivo. *Pediatr Cardiol*. 2013;35(2):361–7.

Hsia TY, Khambadkone S, Redington a N, Migliavacca F, Deanfield JE, de Leval MR. Effects of respiration and gravity on infradiaphragmatic venous flow in normal and Fontan patients. *Circulation.* 2000;102(19 Suppl 3):III148–53.

Hughes TJR, Lubliner J. On the one-dimensional theory of blood flow in the larger vessels. *Math Biosci*. 1973;18(1-2):161–70.

Itatani K. When the blood flow becomes bright. *Eur. Heart J*. 2014;35(12):747–8.

Itatani K, Miyaji K, Tomoyasu T, Nakahata Y, Ohara K, Takamoto S, Ishii M. Optimal Conduit Size of the Extracardiac Fontan Operation Based on Energy Loss and Flow Stagnation. *Ann. Thorac. Surg*. 2009;88(2):565–73.

Itatani K, Okada T, Uejima T, Tanaka T, Ono M, Miyaji K, Takenaka K. Intraventricular Flow Velocity Vector Visualization Based on the Continuity Equation and Measurements of Vorticity and Wall Shear Stress. *Jpn J. Appl. Phys*. 2013;52(7S):07HF16.

Karmonik C, Bismuth J, Shah DJ, Davies MG, Purdy D, Lumsden a. B. Computational study of haemodynamic effects of entry- and exit-tear coverage in a DeBakey type III aortic dissection: Technical report. *Eur. J. Vasc. Endovasc. Surg.* 2011;42(2):172–7.

Katayama S, Umetani N, Hisada T, Sugiura S. Bicuspid aortic valves undergo excessive strain during opening: A simulation study. *J. Thorac. Cardiovasc. Surg.* 2013;145(6):1570–6.

Kern MJ, Samady H. Current Concepts of Integrated Coronary Physiology in the Catheterization Laboratory. *J. Am. Coll. Cardiol*. 2010;55(3):173–85.

Khairy P, Fernandes SM, Mayer JE, Triedman JK, Walsh EP, Lock JE, Landzberg MJ. Long-term survival, modes of death, and predictors of mortality in patients with Fontan surgery. *Circulation.* 2008;117(1):85–92.

Kim HB, Hertzberg JR, Shandas R. Development and validation of echo PIV. *Exp. Fluids*. 2004;36(3):455–62.

Kim HJ, Vignon-Clementel IE, Coogan JS, Figueroa C a., Jansen KE, Taylor C a. Patient-specific modeling of blood flow and pressure in human coronary arteries. *Ann. Biomed. Eng*. 2010;38(10):3195–209.

Koo BK, Erglis A, Doh JH, Daniels D V., Jegere S, Kim HS, Dunning A, Defrance T, Lansky A, Leipsic J, Min JK. Diagnosis of ischemia-causing coronary stenoses by noninvasive fractional flow reserve computed from coronary computed tomographic angiograms: Results from the prospective multicenter Discover-Flow (Diagnosis of Ischemia-Causing Stenoses Obtained Via Noni. *J. Am. Coll. Cardiol.* 2011;58(19):1989–97.

Koullias G, Modak R, Tranquilli M, Korkolis DP, Barash P, Elefteriades J a. Mechanical deterioration underlies malignant behavior of aneurysmal human ascending aorta. *J. Thorac. Cardiovasc. Surg*. 2005;130(3):677.

Koyama S, Itatani K, Yamamoto T, Miyazaki S, Kitamura T, Taketani T, Ono M, Miyaji K. Optimal bypass graft design for left anterior descending and diagonal territory in multivessel coronary disease. *Interact Cardiovasc. Thorac. Surg*. 2014;19(3):406–13.

Koyama S, Kitamura T, Itatani K, Yamamoto T, Miyazaki S, Oka N, Nakashima K, Horai T, Ono M, Kagami M. Impact of Top End Anastomosis Design on Patency and Flow Stability in Coronary Artery Bypass Grafting. *Heart and Vessels*. 2015 In-Press.

Markl M, Frydrychowicz A, Kozerke S, Hope M, Wieben O. 4D flow MRI. *J. Magn. Reson. Imaging*. 2012;36(5):1015–36.

Mehregan F, Tournoux F, Muth S, Pibarot P, Rieu R, Cloutier G, Garcia D. Doppler vortography: a color Doppler approach to quantification of intraventricular blood flow vortices. *Ultrasound Med. Biol.* 2014;40(1):210–21.

Migliavacca F, Balossino R, Pennati G, Dubini G, Hsia T-Y, de Leval MR, Bove EL. Multiscale modelling in biofluidynamics: application to reconstructive paediatric cardiac surgery. *J. Biomech*. 2006;39(6):1010–20.

Nabeta T, Itatani K, Miyaji K, Ako J. Vortex flow energy loss reflects therapeutic effect in dilated cardiomyopathy. *Eur. Heart J.* 2014;36(11):637.

Nakajima H, Kobayashi J, Tagusari O, Niwaya K, Funatsu T, Brik A, Yagihara T, Kitamura S. Graft design strategies with optimum antegrade bypass flow in total arterial off-pump coronary artery bypass. *Eur. J. Cardio-thoracic. Surg*. 2007;31:276–82.

Napel S, Lee DH, Frayne R, Rutt BK. Visualizing three-dimensional flow with simulated streamlines and three-dimensional phase-contrast MR imaging. *J Magn. Reson. Imaging*. 1992;2(2):143–53.

Osinnski JN, Ku DN, Mukundan S, Loth F, Pettigrew RI. Determination of wall shear stress in the aorta with the use of MR phase velocity mapping. *J. Magn. Reson. Imaging*. 1995;5(6):640–7.

Papaharilaou Y, Ekaterinaris J a., Manousaki E, Katsamouris AN. A decoupled fluid structure approach for estimating wall stress in abdominal aortic aneurysms. *J. Biomech*. 2007;40(1):367–77.

Papathanasopoulou P, Zhao S, Köhler U, Robertson MB, Long Q, Hoskins P, Xu XY, Marshall I. MRI measurement of time-resolved wall shear stress vectors in a carotid bifurcation model, and comparison with CFD predictions. *J. Magn. Reson. Imaging*. 2003;17(2):153–62.

Pekkan K, Whited B, Kanter K, Sharma S, de Zelicourt D, Sundareswaran K, Frakes D, Rossignac J, Yoganathan AP. Patient-specific surgical planning and hemodynamic computational fluid dynamics optimization through free-form haptic anatomy editing tool (SURGEM). *Med. Biol. Eng. Comput.* 2008;46(11):1139–52.

Poullis MP, Warwick R, Oo A, Poole RJ. Ascending aortic curvature as an independent risk factor for type A dissection, and ascending aortic aneurysm formation: a mathematical model. *Eur. J. Cardio-thoracic Surg.* 2008;33(1):995–1001.

Pretre R, Vonsegesser L. Aortic dissection. *Lancet.* 1997;349(9063):1461–4.

Prinz C, Faludi R, Walker A, Amzulescu M, Gao H, Uejima T, Fraser AG, Voigt J-U. Can echocardiographic particle image velocimetry correctly detect motion patterns as they occur in blood inside heart chambers? A validation study using moving phantoms. *Cardiovasc Ultrasound.* 2012;10(1):1.

Reneman RS, Arts T, Hoeks APG. Wall shear stress - an important determinant of endothelial cell function and structure - in the arterial system in vivo. Discrepancies with theory. *J. Vasc. Res.* 2006;43(3):251–69.

Samady H, Eshtehardi P, McDaniel MC, Suo J, Dhawan SS, Maynard C, Timmins LH, Quyyumi A a, Giddens DP. Coronary artery wall shear stress is associated with progression and transformation of atherosclerotic plaque and arterial remodeling in patients with coronary artery disease. *Circulation.* 2011;124(7):779–88.

Scotti CM, Jimenez J, Muluk SC, Finol EA. Wall stress and flow dynamics in abdominal aortic aneurysms: finite element analysis vs. fluid-structure interaction. *Comput. Methods Biomech. Biomed. Engin*. 2008;11(3):301–22.

Spiegel M, Redel T, Zhang YJ, Struffert T, Hornegger J, Grossman RG, Doerfler A, Karmonik C. Tetrahedral vs. polyhedral mesh size evaluation on flow velocity and wall shear stress for cerebral hemodynamic simulation. *Comput. Methods Biomech. Biomed. Engin*. 2011;14(1):9–22.

Thubrikar MJ, al-Soudi J, Robicsek F. Wall stress studies of abdominal aortic aneurysm in a clinical model. *Ann. Vasc. Surg.* 2001;15(3):355–66.

Torii R, Wood NB, Hughes AD, Thom S a., Aguado-Sierra J, Davies JE, Francis DP, Parker KH, Xu XY. A computational study on the influence of catheter-delivered intravascular probes on blood flow in a coronary artery model. *J. Biomech.* 2007;40:2501–9.

Truijers M, Pol J a, Schultzekool LJ, van Sterkenburg SM, Fillinger MF, Blankensteijn JD. Wall stress analysis in small asymptomatic, symptomatic and ruptured abdominal aortic aneurysms. *Eur. J. Vasc. Endovasc Surg.* 2007;33(4):401–7.

Van Haesdonck J-M, Mertens L, Sizaire R, Montas G, Purnode B, Daenen W, Crochet M, Gewillig M. Comparison by Computerized Numeric Modeling of Energy Losses in Different Fontan Connections. *Circulation.* 1995;92(9):322–6.

Wigström L, Ebbers T, Fyrenius A, Karlsson M, Engvall J, Wranne B, Bolger a F. Particle trace visualization of intracardiac flow using time-resolved 3D phase contrast MRI. *Magn. Reson. Med*. 1999;41(4):793–9.

Wigström L, Sjöqvist L, Wranne B. Temporally resolved 3D phase-contrast imaging. *Magn. Reson. Med.* 1996;36(9):800–3.

Whitehead KK, Pekkan K, Kitajima HD, Paridon SM, Yoganathan AP, Fogel M a. Nonlinear power loss during exercise in single-ventricle patients after the Fontan: insights from computational fluid dynamics. *Circulation.* 2007;116(11 Suppl):I165–71.

Xenos M, Bluestein D. Biomechanical Aspects of Abdominal Aortic Aneurysm (AAA) and its Risk of Rupture : Fluid Structure Interaction (FSI) Studies. *Stud. Mechanobiol. Tissue Eng. Biomater*. 2011;7(1):181–220.

Zoghbi W a., Enriquez-Sarano M, Foster E, Grayburn P a., Kraft CD, Levine R a., Nihoyannopoulos P, Otto CM, Quinones M a., Rakowski H, Stewart WJ, Waggoner A, Weissman NJ. Recommendations for Evaluation of the Severity of Native Valvular Regurgitation with Two-dimensional and Doppler Echocardiography. *J. Am. Soc. Echocardiogr*. 2003;16(7):777–802.

In: Encyclopedia of Surgery (22 Volume Set)
Editors: Andreas Lehrer and Kristin Mueller
ISBN: 978-1-53618-329-0
© 2020 Nova Science Publishers, Inc.

Chapter 365

TRANSFUSION PRACTICES IN CARDIAC SURGERY

Surendra Kumar Agarwal*, Gauranga Majumdar, Shantanu Pande and Siddartha Churchigundi Rudrappa
Department of CVTS, SGPGIMS, Lucknow, India

ABSTRACT

Cardiac surgery is the main source of consumption of majority of blood products, and best practices are required to reduce the use of this scarce resource. Use of blood and blood products is also associated with increased morbidity and mortality in cardiac surgical patients. This should aim at reducing risks associated with transfusion while at the same time correcting anemia and reducing bleeding. Transfusion-related lung injury is an important complication associated with blood and products transfusion in cardiac surgery patients. The methods to achieve optimal utilization of blood products in cardiac surgery include preoperative, intraoperative as well as postoperative measures. Preoperative identification of risk factors using proper transfusion triggers and development of Maximum Blood Ordering Schedule (MSBOS) for various procedures in the hospital and judicious use/stoppage of medications help reduce bleeding associated with cardiac surgery. Intraoperative use of antifibrinolytic and other medications results in reduction of bleeding and transfusion requirements. Use of minimal invasive procedures, modifications in cardio-pulmonary bypass circuits, and various modes of salvage of shed mediastinal blood during the surgical procedure have been shown to reduce transfusion requirements. Autologous donation, both preoperatively along with erythropoietin (EPO) therapy and intraoperatively, just before going on cardiopulmonary bypass (CPB) may also be used in the select group of patients. Various types of hemostatic agents are used to reduce bleeding and need of transfusion and include topical agents used in the surgical field as well as systemic agents such as factor concentrates. In the postoperative period, use of positive end expiratory pressure and salvage of shed mediastinal blood are helpful in reducing use of blood products. There are special situations, which require specific management. These include hypothermia during surgery and issues related to cold agglutinins, special issues in cyanotic congenital heart disease patients, and management of heparin and protamine during CPB. Heparin resistance and heparin-induced thrombocytopenia also pose important challenge during

* Corresponding Author's Email:surendra2000_in@yahoo.com.

cardiac surgery and need special attention for diagnosis and management. Recent developments include use of various point-of-care devices for targeted management of heparin and protamine. These devices are also helpful in specific management of bleeding by diagnosing the deficiency of specific factors in a particular patient and using the required blood products. A team approach involving surgeon, anesthesiologist, perfusionist, transfusion medicine specialist, ICU care providers, cardiologists, nurses, and other personnel involved in care of patient undergoing cardiovascular surgery is required. This multidisciplinary team approach will be helpful in risk assessment, development, and use of best practice guidelines for transfusion for the institution. A rational use of various methods for individual patients will result in the best outcome at a reasonable cost.

Keywords: cardiac surgery, transfusion, hemostasis, point of care devices, cardiopulmonary bypass, transfusion triggers

INTRODUCTION

Cardiac surgical procedures account for 14–20% of the use of blood and blood products' pool available. [1–3] As blood is a scarce resource, it is imperative to adhere to best practices for transfusion and evidence-based strategies for reduction in use of blood and blood products in cardiac surgery. This is more important in view of the fact that most of the consumption of blood products in cardiac surgery is by a minority of patients [4] and also that transfusion is associated with an increase in morbidity and mortality. [4] The need of transfusion in cardiac surgery is required to correct anemia (red cells) and control non-surgical bleeding (blood products such as plasma, platelets, etc.). Acute anemia results in reduced oxygen delivery and tissue hypoxia, which may cause organ failure and death. The heart extracts 60–70% of delivered oxygen under normal conditions and therefore the only compensatory mechanism available to the heart for increasing oxygen delivery is to increase blood flow to myocardium through coronary vasodilatation. This is difficult in patients with coronary artery disease and myocardial hypertrophy, aortic valve disease, and other conditions. [5, 6] Acute hemodilution during cardiopulmonary bypass (CPB), along with non-physiological non-pulsatile flow results in increased risk of stroke, [7, 8] renal dysfunction, [9] and other organ dysfunction. [10] A retrospective study of 1188 adults undergoing cardiac surgery under CPB found that excessive postoperative bleeding was associated with increased risk of re-exploration for bleeding, stroke, prolonged ventilation time, and intensive care unit (ICU) stay and 30 day mortality. [11] Excessive bleeding also resulted in significantly increased cost.

RISKS ASSOCIATED WITH TRANSFUSION IN CARDIAC SURGERY

Most important and feared risk of blood transfusion is transmission of infections (human immunodeficiency virus, hepatitis B, hepatitis C and other viral, bacterial, and parasitic infections). [12–14] Although rare, [15] the risks are real in countries like India where modern blood banking practices are often not available and because of paid donors who

masquerade as relatives. The other problems include immunological reactions (febrile non-hemolytic transfusion reactions, anaphylactic reactions, ABO mismatch, hemolysis, leukocyte-related organ injury, post-transfusion purpura, acute lung injury (ALI), and sometimes death), screening-related errors like malaria, Creutzfeldt–Jacob disease, and other related disease transmission and mismatch-related errors. [4] Many studies in recent years have shown that allogeneic blood transfusion, especially with blood which has been stored for longer period, isan independent risk factor for increased morbidity as well as mortality including increased hospital stay and costs. [16–19] Although some of these results might have been associated with confounding bias of the inclusion, they cannot be ignored. Exact reasons for this are still unknown, but one of the causes of perioperative mortality in these patients has been ALI following blood transfusion.

Transfusion-Related Acute Lung Injury

Phillips and Fleischner described three patients with transient non-cardiogenic pulmonary edema along with fever, cough, and cyanosis following blood transfusion in 1966. [20] This reaction was initially termed pulmonary hypersensitivity reaction. In 1985, Popovsky and Moore described similar reaction in 36 cases and termed it transfusion-related acute lung injury (TRALI). [21] The entity was being recognized more and more commonly and in 2006, more than 50% of deaths related to transfusion were attributed to TRALI. [22] TRALI is defined as ALI, occurring within 6 h of transfusion of one or more plasma containing blood/blood products in patients without pre-existing risk factors for ALI or in patients with risk factors for ALI if ALI was not present before transfusion or if there is a temporal association between transfusion and ALI. ALI is defined as $PaO_2/FiO_2 < 300$ mmHg or $SpO_2 < 90\%$ on room air, clinical features of hypoxia and bilateral infiltrates on chest X-ray in the absence of increased left atrial pressure. [23] The pathophysiology of TRALI is being understood and is considered to be due to leukocyte antibodies present in donor blood. [24] TRALI is associated with 5–13% mortality. [25] Recent guidelines by the International Society for Blood Transfusion (ISBT) recommend screening of high-risk donors (parous women and individuals who have undergone transplantation and transfusions)for leukocyte antibodies for prevention of TRALI. [26] TRALI is more common in patients undergoing cardiac surgery. This may be due to additional inflammatory response to CPB, both systemic as well as pulmonary. [27, 28]

Risk Factors for Transfusion in Cardiac Surgery

Studies in the Society of Thoracic Surgeons (STS) Adult Cardiac Surgery database has revealed that only about 50% of patients undergoing cardiac surgery need blood transfusion [29] and patients receiving over 10 units of blood products fall in the 90th percentile of the patient transfusion profile. [4] This suggests that some patients are at a higher risk of bleeding or need blood transfusion after cardiac surgery. Preoperative recognition of these risk factors and appropriate intervention at various stages will help in minimizing the blood transfusion requirements. The 2007 STS guidelines on blood conservation [4] suggested three major risk factors: advanced age, decreased red blood cell volume before surgery due to anemia or

smaller body size, and complex or emergency surgeries like re-operations, aortic surgery, and non-coronary bypass grafting (CABG) operations. Table 1 gives a list of various risk factors associated with need for blood transfusion after cardiac surgery. Various studies, both observational as well as with multivariate analysis, have identified predictors of bleeding and blood transfusion after cardiac surgery but odds ratios are available in only a few reports. Although some of risk factors may be a spectrum of low to high intensity, it is not quantified by any robust study till date. Unfortunately, review of available literature failed to give a reliable method of assigning relative values to various risk factors or to provide evidence to stratify various interventions for blood conservation by risk factors. [30] Presence of these risk factors, especially those undergoing complex surgical procedures like combined valve and CABG, aortic surgery and surgical procedures requiring deep hypothermic circulatory arrest etc. should act as "red flag", and adequate measures should be taken for blood conservation in these patients.

Table 1. Factors that increase bleeding and use of blood products in cardiac surgery

Patient-related factors	Procedure related	Surgeon/unit related
Advanced age, especially >70 years	Prolonged cardio-pulmonary bypass time	Non-use of algorithm for transfusion
Female gender	Reoperation	Non-use of point of care testing
Smaller body surface area	Complex procedure (aortic surgery, combined valve, coronary procedure, etc.)	Use of bi-lateral internal mammary artery
Preoperative antithrombotic therapy (oral anticoagulants, unfractionated heparin, low molecular weight heparin, short- or long-acting direct thrombin inhibitors)	Increased dose of protamine after bypass to neutralize heparin	Use of lower dose of heparin
Preoperative use of low intensity antiplatelet agents (aspirin, clopidogrel, dipyridamole, tirofiban, etc.)	Increased volume in cell saver	Lower body temperature while the patient is in ICU
Preoperative use of high intensity antiplatelet therapy (abciximab, etc.)	Intraoperative autologous donation	
Preoperative thrombolysis	Need for transfusion during CPB	
Hereditary coagulopathy or platelet function disorders[9]von-Willebrand's disease, Hermansky–Pudlak syndrome, Bernard–Soulier syndrome, Glanzmann's syndrome, hemophilia, deficiency of clotting factors, etc.	Use of polymerized starch as volume replacement	
Acquired coagulopathy or platelet dysfunction (cirrhosis, polycythemiavera, chronic lymphoid leukemia, mylodysplastic syndrome, idiopathic thrombocytopenic purpura, thalassemia, etc.)		
Cardiogenic shock		
Congestive heart failure		
Renal dysfunction		
Liver dysfunction		
Adult onset insulin dependent diabetes		
Preoperative sepsis		
Peripheral vascular disease		

Patient-Related Factors

Thrombocytopenia (platelet count <50,000/cmm) [31–35] or thrombasthenia [4] (qualitative defect in platelet function) from any cause (Congenital viz. Von-Willebrand's disease, Bernard–Soulier syndrome, storage pool disease and acquired viz. liver disease, renal disease and drug induced) and hyper-responsivity to aspirin in association to preoperative use of antiplatelet agents, [36] which usually results from pharmacogenetics involving antiplatelet, anticoagulant, anti-inflammatory, and endothelial protecting properties of these drugs predisposes patients to increased risk of bleeding. [4] Anemia due to any cause also results in increased risk of transfusion, [37] and this risk is increased by antiplatelet drugs. [36]

Surgeon-Related Factors

Apart from transfusion practices used by a particular surgeon/unit [2] including triggers for transfusion (symptom based vs. based on level of hemoglobin), [38] variations in CPB practices, CPB time, use of hypothermia [39] and management practices for post-operative bleeding [40, 41] are important determinants of transfusion.

Procedure-Related Factors

Although surgery- and surgeon-related factors are usually inter-related, certain procedures are at unusually high risk of bleeding during and after cardiac surgery and in turn usage of blood products. These include but not limited to re-do surgical procedures, [42] use of CPB vs. Off-pump surgery, [43] use of bilateral mammary artery vs. use of saphenous veins for CABG, [44] Ross procedure [45] (replacement of aortic valve with pulmonary autograft), use of ventricular assist devices (VAD), and artificial heart [46–48] and aortic surgery.

INDICATION OF TRANSFUSION IN CARDIAC SURGERY

The basic indications for use of blood products in cardiac surgery remain correction of anemia and oxygen carrying capacity of blood and correction of coagulopathies. At this point of time, objective evidence is lacking regarding these decisions. Development of "transfusion trigger" which is a level of hemoglobin, hematocrit for red blood cell transfusion, and value of platelet count for platelet transfusion. Initially, hemoglobin level of <10 g/dL or hematocrit value of <30% was used as a trigger. However, there is no evidence supporting this practice. Similarly, there is no evidence for use of estimation of intravascular blood volume or blood loss for transfusion decisions. Measurement of oxygen consumption, whole body oxygen carrying capacity, oxygen extraction ratios, and oxygen delivery [49] may provide a better method to determine need of red cell transfusion, but these measurements are not routinely available and may not be cost-effective. The physiological threshold at which insufficient

oxygen delivery starts decreasing oxygen consumption in human beings is a hemoglobin level of <5 g/dL, oxygen extraction ratio of <0.44, mixed venous oxygen of <34 mmHg, and mixed venous saturation of <56% [50] and may be an absolute indication/trigger for red cell transfusion. But, in cardiac surgical patients, various factors such as coronary artery blood flow reserve and myocardial hypertrophy compound the situation and these patients may not tolerate these low values. A study [51] did not find any increase in mortality in cardiac surgery patients till perioperative hemoglobin fell below 5 g/dL. A group of patients, Jehovah's witnesses, refuse any blood/product transfusion and have provided some data on this issue. A review of literature of studies between 1983 and1990, involving over 1000 patients concluded that anemia and lack of transfusion influenced mortality only in 1.4% patients in this group, [52] which was also confirmed in a later review of over 4000 patients. [53]

Various organizations such as National Institute of Health, American Association of Blood Banks, American College of Physicians, and American Society of Anaesthesiology convened consensus meetings and task forces and reviewed literature extensively and published guidelines for evidence-based use of red cells, platelets, fresh frozen plasma(FFP), and cryoprecipitate, [54] which is given in Table 2.

Table 2. American Society of Anaesthesiology guidelines for transfusion of blood products

Hemoglobin level of <6 g/dL on cardio-pulmonary bypass
Hemoglobin level of <7 g/dL in patients aged >65 years or patients with chronic cardiovascular or respiratory disease
Acute blood loss of >1500 mL or .30% of blood volume
Evidence of acute blood loss without evidence of control of bleeding

Source: Adapted from Ferraris et al. [4]

During surgery, when the patient is on CPB, hemodilution is better tolerated and various studies found that hematocrit levels of <17–19% were associated with increased mortality. [51, 55] Karkouti et al. [56] found that each percent decrease in hematocrit during CPB was associated with a 10% increase in the odds of perioperative stroke after controlling of other confounding variable. Another study found that a hematocrit level of 22% was associated with increased risk of stroke, myocardial infarction, low cardiac output, cardiac arrest, renal failure, prolonged ventilation, pulmonary edema, reoperations due to bleeding, sepsis and multi-organ failure and consequent increased mortality, hospital stay, and cost. [57] But unfortunately these studies did not study the role of transfusions on the outcome. An observational study [58] concluded that although anemia due to hemodilution during CPB increased the risk of low cardiac output after surgery, transfusion of 1–2 units of packed red cells caused an additional 27% risk adjusted risk regardless of lowest hematocrit. Another study of about 2000 patients undergoing first time isolated CABG showed that only 34% of the patients received a transfusion in the hospital stay. [59] These patients were more likely to be older, smaller, female, and more likely to have other co-morbidities. The transfused patients had twice (15% vs. 7%) 5-year mortality. Another study found a correlation with postoperative infection and use of transfusion. [60]

One randomized controlled trial [59] conducted in patients undergoing cardiac surgery to assess transfusion strategies (<30% hematocrit; <10 g/dL hemoglobin vs. <24% hematocrit; <8 g/dL hemoglobin) concluded that there was no difference in combined mortality and morbidity outcome rate, mortality was increased in the low threshold group (hazard ratio 1.28) although it was not statistically significant. Another study [61] done on high-risk patients undergoing cardiac surgery with restrictive and liberal strategies for blood transfusion, based on hemoglobin levels during and after CPB of <7.5 and 8.5 g/dL vs. <9.5 and 10 g/dL, respectively, showed similar results. Another multicenter, international, randomized controlled study (TRICCS III) is enrolling patients to study the same in a larger number of patients and may be able to provide some guidelines in this regard.

The indications of other products are often more complicated due to difficulty in assessing the cause of bleeding and requirement of specific product. In recent years, these decisions have been made easy by use of point of care (POC) devices, which is discussed later in the chapter.

BEST PRACTICES FOR REDUCING TRANSFUSIONS IN CARDIAC SURGERY

Risk Assessment and Use of MSBOS

The first and foremost step for reducing the transfusion requirements in cardiac surgery is to identify the patients at high risk and device various strategies to modify the risk factors if possible or to take adequate measures during various phases before during and after surgery to reduce the risk of bleeding and consequent transfusion requirements. The major risk factors have been discussed above.

In addition, this also allows the surgeons and blood banks to device mechanisms to reduce the wastage of blood/products after cross matching. One such strategy is to use the MSBOS, which is a table of elective surgical procedures and lists the number of units of blood to be cross matched before surgery. The concept was first given by Friedman in 1976 to reduce the wastage of blood and blood products. [62] The lists need to be developed at individual centers for the procedures that are performed there and from their experience of usage of blood products. This acts only as a guide and requirement is modified according to the individual case if needed. The basis of MSBOS is to cross-match twice the median requirement for that procedure.

Preoperative Interventions

Of the above listed risk factors (Table 1), only two (anti-platelet therapy and anemia) are subject to modification in the preoperative period and are discussed in the below sections.

Antiplatelet Therapy

Antiplatelet drugs are used more and more commonly in patients undergoing cardiac surgery, especially CABG for prevention of stent/graft thrombo-occlusion. Continuation of

these drugs before surgery is associated with increased risk of bleeding and therefore transfusion of allogenic blood products. Therefore, one must manage the antiplatelet drugs before surgery to minimize bleeding while also not exposing the patient to unnecessary risk of acute coronary event. Patients with thrombocytopenia or with thrombasthenia are more sensitive to antiplatelet therapy and require various strategies to reduce bleeding and transfusion risks including preoperative stoppage of these drugs.

Low-intensity antiplatelet drugs like aspirin may be continued in patients with acute coronary syndromes but should be stopped 2–3 days before surgery in patients undergoing elective surgery. [4] Dipyridamole was shown to be associated with reduced risk of postoperative bleeding by preserving platelets during surgery initially, but later studies could not confirm this. Currently, there is no evidence to use this drug alone or in combination with aspirin in coronary artery disease patients.

Thienopyridines drugs, which inhibit platelet P2Y12 receptor (clopidogrel, prasugrel, and tricagrelor) and reduce adenosine diphosphate (ADP)-mediated activation of platelets, are commonly used in patients with coronary artery disease and peripheral vascular disease, especially in patients with acute coronary syndrome and after placement of drug-eluting stents either alone or more commonly as dual antiplatelet agents in addition to aspirin and are a cause of excessive bleeding in surgical procedures, both with and without use of CPB. [30, 63] Use of dual antiplatelet therapy (aspirin plus clopidogrel) before angiography in patients who later required CABG has been found to be associated with lower incidence of ischemic events without significantly increased bleeding as compared with withholding clopidogrel until after angiography, [64] but this was achieved by withholding clopidogrel for 5 days before surgery wherever it was possible. It is recommended that these drugs are stopped at least 3 days before surgery if possible. [30, 63] This recommendation is based on assumption that with ~30% clopidogrel resistance, addition of clopidogrel to aspirin exposes 70% of CABG patients to the risk of additional bleeding while reducing only 2–3% ischemic events. [30] Similarly, there is inadequate current evidence to support addition of another antiplatelet agent to aspirin after CABG for reducing graft occlusion and adverse ischemic events, but it unnecessarily exposes these patients to increased risk of bleeding if a reoperation is required. Dual antiplatelet therapy is only recommended currently in patients with drug-eluting stents or those presenting with acute coronary syndrome at the time of CABG. [30]

Another tricky situation is a patient who has a patent drug-eluting coronary stent and is on dual antiplatelet therapy and requires cardiac surgery. Stoppage of antiplatelet therapy may result in acute stent thrombosis and may not be advisable. In this situation, if the surgery is emergent, the drugs are continued and other precautions are taken to reduce perioperative bleeding including transfusion of platelets if required, with or without help of platelet count and function testing to guide platelet therapy. In an elective situation, the patient may be shifted to other short-acting antiplatelet agents like glycoprotein IIb/IIIa receptor inhibitors (tirofiban, eptifibatide) before surgery. [4] Another drug in this class, abciximab is a long-acting drug and should not be used for this purpose. If the patient requires urgent surgery following coronary stenting with drug-eluting stenting where the patient has received large doses of various antiplatelet agents including glycoprotein inhibitors, a cautious approach is required during surgery to limit bleeding and to judiciously use blood products including platelets. As there is variability in responsiveness to antiplatelet therapy due to compliance as well as pharmacogenetic factors, POC testing for platelet ADP responsiveness may be used to determine the continuation or discontinuation of antiplatelet agents before surgery.

Other Antithrombotic and Antiplatelet Drugs

Heparin is almost an universally used drug in patients with acute coronary syndrome and has been found to be safe in patients receiving thrombolysis. [4] As most patients undergoing cardiac surgery with or without CPB receive unfractionated heparin intraoperatively, and the fact that heparin action can be reversed with protamine, unfractionated heparin may not be associated with increased risk of bleeding and transfusions. Although concerns regarding heparin rebound, heparin resistance, and heparin-induced thrombocytopenia or platelet dysfunction remain. Low molecular weight heparins, on the other hand, have been associated with increased risk of perioperative bleeding and transfusion of blood products especially if the dose was given within 12 h before surgery. [65]

Direct acting thrombin inhibitors such ashirudin, bivalrudin, and argatroban are recently developed drugs to be used as antithrombotic agents in patients with cardiovascular disease. The advantage of these drugs that there is a predictable response is countered by the disadvantage of inability to monitor the effect and non-availability of any drug to reverse their effect. They find their use mainly in patients with heparin-induced thrombocytopenia. At this point, experience with these drugs in patients undergoing cardiac surgery is limited. [4] Oral anticoagulants should always be stopped in patients undergoing cardiac surgery, and patient should be switched over to intravenous heparin. The patient should be operated once the international normalized ratio (INR) becomes less than 1.5. If this is not possible, the effect may be minimized by using vitamin K along with FFP.

Erythropoietin

EPO is a glycoprotein hormone that stimulates red cell production and is usually excreted from kidneys in response to anemia and tissue hypoxia. Its production is severely reduced in patients with chronic renal failure. Now it is commercially available as recombinant human EPO as is primarily used in chronic renal failure patients to treat anemia. A meta-analysis of many studies found that its use in the preoperative period, especially following autologous donation in both adults as well as children undergoing cardiac surgery, helped in reducing preoperative anemia and also helped in reducing transfusion requirements in the perioperative period. [66] Its main side effect is hypertension, and adequate iron supplementation is required along with EPO to get the proper red cell production and desired hemoglobin levels. [30] But at this point of time, there is little evidence regarding cost-effectiveness of this strategy in routine patients and it is only recommended in special situations such as Jehovah's witnesses, chronic renal failure, and anemia as an "off-label" application. It needs to be given at least 1week before surgery as its effect takes 4–6 days.

Preoperative Autologous Donation

Although not routinely used due to various concerns in patients with cardiac disorders, preoperative autologous donation of up to 2 units of blood, few days to few weeks before surgery has been found to be safe and effective in reducing need of allogenic transfusions. It may be coupled with EPO and iron therapy for best results. [4, 67]

Intra-Operative Interventions

Intraoperative Autologous Donation

In this technique, 1–2 units of blood are removed from patient immediately before commencement of CPB which is replaced with crystalloid or colloid in 1:1 ratio. During CPB use, hematocrit values are used to guide transfusion (collected autologous blood followed by allogenic red cells if needed). The results of this technique have been equivocal with some studies showing benefits, while others failed to show any benefit. Also, there is a risk of hemodynamic compromise in sick high-risk patients like unstable angina, cardiogenic shock, etc. At present, it may be used in some selective patients as part of the multimodality approach. [4]

Pharmacological Agents

Antifibrinolytic Drugs

These drugs include Epsilon-aminocaproic acid (EACA), tranexamic acid, and aprotinin. The first two drugs are classified as lysine analogues [4] and act by inhibition of fibrinolysis through inhibition of plasminogen inhibitors and antiplasmin activity. These drugs bind to the lysine binding sites of the plasminogen molecule. Tranexamic acid is about 10 times more potent as compared with EACA. Aprotinin, a bovine protein, is a serine protease inhibitor, especially plasmin and acts by reducing fibrinolysis, inflammation, and thrombus generation. Aprotinin (low dose; 1 million KIU or high dose; 6 million KIU) and lysine analogs reduce the need for blood transfusion, total blood loss, and re-exploration for bleeding (high-dose aprotinin only). Although these drugs have been in use in cardiac surgery to reduce bleeding during and after cardiac surgery, especially the ones done using CPB for many years, there have been concerns regarding their safety and efficacy, especially after publication of blood conservation using antifibrinolytics trial (BART), [68] which showed that there was a significantly increased risk of 30 day mortality in the aprotinin group as compared with lysine analogs. There have been more randomized trials and meta-analyses after this study, showing risk as well as benefits of aprotinin and resulting in newer guidelines for their use. The current recommendations [30] suggest that as aprotinin significantly increases mortality, stroke, renal failure, and heart failure, its routine use in low- to moderate-risk cardiac surgeries is not recommended. However, it may be beneficial in infants and in patients at greatest risk of perioperative bleeding and is special group patients like Jehovah's Witness. Lysine analogs are indicated to reduce risk of bleeding in moderate-to high-risk patients as their efficacy is lesser as compared with aprotinin and their side effects are less well studied. An ongoing trial (aspirin and tranexamic acid for coronary artery surgery trial) is currently enrolling patients and will be able to provide more information.

Another use of antifibrinolytic drugs is to use them topically into the surgical field after cardiac surgery with CPB. Use of CPB is associated with activation of tissue factor, which combines with factor VII and forms a complex that activates other coagulation factors and then generates thrombin, which converts fibrinogen into fibrin. The normal control over this activity by antithrombin is not enough in cardiac surgery with CPB. This along with fibrinolysis caused by thrombin induced tissue type plasminogen activator results in

consumptive coagulopathy. Antifibrinolytic agents reduce bleeding after cardiac surgery and CPB by limiting this process. Aprotinin (1 million KIU in 100 mL saline) as well as tranexamic acid (1 g in 100 mL saline) is poured in the surgical field just before closure of sternum and clamping of chest drains during wound closure. A meta-analysis of 7 trials involving 525 first time cardiac surgical procedures with CPB found that use of topical antifibrinolytic agents was associated with significant reduction in 24 h chest drainage after surgery. [69]

Desmopressin Acetate

1-Deamino-8-D-arginine vasopressin (DDAVP) or desmopressin acetate acts to limit bleeding by releasing endogenous factor VII precursors, von Willebrand's factor and tissue-type plasminogen activator by acting on vascular endothelial cells and has been tried in cardiac surgery in an attempt to reduce post-operative bleeding transfusion requirements. At present, its use is not recommended routinely. It can be used preoperatively in patients with inherited or acquired platelet dysfunction, identified by using POC device PFA 100 to reverse platelet dysfunction to reduce bleeding and need for transfusion of blood and blood products. [70]

Salvage of Red Cells

Use of a cell saver system (collection of blood from the surgical site by suction, centrifugation of collected blood, and reinfusion of red cells collected after centrifugation) to salvage the red cells from shed blood in mediastinum is a useful technique in blood conservation strategy, especially in those operations where CPB is not used (off pump surgery, closed heart surgery, aortic surgery, etc.) and the blood cannot be returned to the CPB circuit. Initially, the technique was used for surgical procedures on CPB. The safety is well established with no adverse events such as central nervous system events, infections, hemolysis, air, or fat embolism along with lesser markers of inflammation. [4] There is a risk of loss of coagulation factors with resultant bleeding diathesis in patients with massive bleeding and use of cell saver to salvage the red cells. It is contraindicated in patients with infections and if the blood has been exposed to topical haemostatic agents. The current literature suggests that it is not cost-effective for routine cardiac surgery but may be useful adjunct to other methods in high-risk patients. [30]

Platelet Plasmapharesis

Use of platelet plasmapharesis results in selective removal of concentrated platelets (platelet rich plasma) from the patient, which then can be transfused to the patient after completion of the surgical procedure and CPB. This is based on the fact that CPB is associated with platelet destruction as well as dysfunction, and this strategy spares platelets from the effect of CPB. Many studies, done till date, [30] have shown variable results. In addition, there are cost and difficulties involved in the procedure and possibility of hemodynamic instability during the procedure and risk of contamination of harvested product. At present, it is only recommended in only high-risk patients if there is a reasonable chance of getting adequate platelet yield.

Concentrates of Factor IX, or Clotting Factor Complexes

Factor IX activation by tissue factor-activated factor VII complex is an important step in clot formation. Therefore, concentrates of factor IX or clotting factors in which factor IX was also present have been used in cardiac surgical procedures to reduce bleeding in patients with hemophilia B or as prophylaxis in some Jehovah's Witness patients who are ready to accept processed blood products such asthese concentrates, as a part of prothrombin complex concentrate (Beriplex) for reversal of effect of Coumadin analogs like warfarin before surgery and in patients with factor VII inhibitors to bypass factor VII inhibitor activity. [30] They are not recommended for routine use.

Use of Minimally Invasive Procedures

It is known that use of CPB and aortic surgery are associated with increased risk of bleeding and need for transfusion. Therefore, it is assumed that use of minimally invasive techniques and prevention of CPB use may be associated with reduced transfusion needs in cardiac surgical practice.

Off Pump Surgery

There has been increasing use of off pump surgery especially for coronary artery bypass surgery with standard sternotomy or using minimally invasive approaches with or without use of endoscopic tools or robot. One of the suggested benefits of off pump surgery was reduced risk of bleeding and transfusion requirements. [4, 30] A large, multi-centric, randomized trial [71] of off pump vs. on pump coronary artery surgery in high-risk patients (CORONARY trial) found that there was significant reduction in the rate of transfusion on off pump group (50.7% vs. 63.3%) despite significantly lesser use of anti-fibrinolytic agents (26.1% vs. 37.0%). There was also a significant lesser need for re-exploration for bleeding with off pump surgery (1.4% vs. 2.4%).

Endovascular Repair for Aortic Diseases

In recent years, more and more patients with thoracic aortic pathology, especially descending thoracic aortic aneurysm, are undergoing repair by placing endovascular stent grafts (thoracic endovascular aortic repair or TEVAR). A meta-analysis suggests that TEVAR is associated with reduced number of patients requiring transfusions (3.9% vs. 83.7%) and reoperation for bleeding (0.01% vs. 6.5%) along with other clinical outcomes including death and renal dysfunction as compared withopen aortic surgery. [72]

Type of Oxygenator and Blood Pump for CPB

Although there were many types of oxygenators used for CPB in the past, at present almost all centers use membrane oxygenators. Among other benefits, they are also associated with reduced need for blood transfusion. [4] There is no difference in terms of transfusion requirements in membrane oxygenators with closed or open venous systems.

The blood pump used for aortic return of oxygenated blood from CPB may be roller or centrifugal. Although there are theoretical advantages with centrifugal pumps (reduced complement activation and preservation of platelet function), there is no proven clinical benefit of use of centrifugal pump over roller pump in terms of bleeding or transfusion needs. [4] Another aspect of CPB is use of suction to retrieve the blood from operative field to oxygenator and to get a better view in the surgical field. If there is prolonged or high suction pressure use, there is increased risk of damage to blood components including red cells and platelets. This increases the need for transfusion and risk of bleeding. It is advisable to use the CPB suckers for keeping the operative field clean judiciously.

Biocompatible CPB Circuits, Microcircuits, and Vacuum-Assisted Venous Drainage

There is need for tubing and connectors to establish CPB for cardiac surgery. These tubing are made of medical grade PVC. When the blood comes in contact with these tubing and oxygenators, there is damage to the components of blood and activation of platelets, and coagulation and inflammatory proteins. Apart on other adverse clinical effects, these effects of contact of blood to artificial surface also lead to increased risk of bleeding and resultant transfusion requirements. Various types of heparin and heparin polymer bonded CPB circuits are available in market for clinical use. There is some evidence that use of these circuits; especially third-generation heparin polymer coated circuits may be associated with reduced blood loss, transfusion requirements, and re-exploration for bleeding. [73] Their use may be justified in high-risk patients.

Microcircuits using either minimized circuits or integrated centrifugal pump with oxygenator circuits reduce priming volume and resultant hemodilution and also reduce the surface area in contact with blood. They are particularly useful in patients with reduced body surface, preoperative anemia, and in children due to reduced hemodilution. The current evidence suggests that these circuits result in reduced bleeding and postoperative transfusion [74] along with reduction in release of inflammatory markers. The only problem with these circuits is that there is either no venous reservoir or a closed one. Closed reservoir may lead to air in the system and air lock while no reservoir carries risk of exsanguination if there is uncontrolled bleeding during CPB and surgery. A vacuum-assisted venous drainage (VAVD) has been proposed either alone or along with microcircuits in place of standard gravity-assisted drainage has been shown to help with reduced bleeding and chest drainage and thus reduced blood transfusion. [30] Again there is a risk of increased air microemboli and hemolysis with use of VAVD, and therefore this is not routinely used in cardiac surgery practice. However, it may be used with care in high-risk patients along with other measures.

Reduction of Loss of Blood in CPB Circuit

In standard CPB for cardiac surgery, priming is done with crystalloid and some of the extra volume of crystalloid is added during cardioplegia and suction of topically used saline.

This results in residual volume after completion of bypass and if this volume is discarded, there is risk of need for blood transfusion to correct anemia in the postoperative period. Various techniques may be used in isolation or in combination to reduce this loss of red cells. Retrograde autologous priming of the CPB circuit is a method to replace the crystalloid prime of the circuit with patient's blood just before starting bypass. It is first done through arterial route after placement of aortic cannula and then through venous system after placement of venous drainage cannula. Due to increased risk of air embolization, VAVD should not be used with this technique. This technique results in reduced need for blood transfusions. [4]

Hemofiltration or ultrafiltration devices may be used in parallel to the CPB circuits to filter out water and other low molecular weight substances from blood in circuit to reduce hemodilution. In the conventional technique, ultrafiltration is used during CPB while in modified ultrafiltration; it is done after completion of CPB. Although both techniques have been shown to reduce need for transfusion, modified ultrafiltration seems to be superior to conventional ultrafiltration. [30, 75] Another technique, called zero balance ultrafiltration, employs ultrafiltration with replacement of filtered volume with equal volume of balanced electrolyte solution during bypass may help reduce effects of inflammation but does not help with transfusion requirements. Microplegia is a technique in which instead of crystalloid cardioplegia or 4:1 blood–cardioplegia to arrest the heart for the cardiac surgical procedure, a mixed blood (from CPB circuit) with concentrated cardioplegia solution is used with use of a special pump in the CPB machine. At present, its effect on use of blood products is not known. Salvage of pump blood, either directly without any processing or after processing it by centrifugation or ultrafiltration, is often used in practice of cardiac surgery to limit loss of blood and to reduce need for transfusion. Although many studies have been done in recent years, mostly with small number of patients undergoing on pump coronary artery surgery, most fail to show any significant benefit in terms of reduction of transfusion, postoperative hemoglobin levels, or postoperative chest drainage. [30]

Topical Hemostatic Agents

Although there is no substitute for proper surgical hemostasis, in surgical practice, especially cardiovascular surgery, there is a need for topical haemostatic agents. These agents are useful to seal the anastomotic sites to reduce bleeding. These agents work either by compression or by sealing of anastomotic site by clot or synthetic agents. Table 3 lists various agents used for this purpose, their mechanism of action and disadvantages if any. At present, there is little evidence about efficacy or superiority of any one agent or one agent over another, limiting evidence-based use of these products. Based on individual reports, series, and some randomized studies, it may be advised that these agents can be used in high-risk patients to reduce risk of bleeding from anastomotic sites after adequate surgical hemostasis is achieved. [30]

Postoperative Interventions

Although management of bleeding and related blood conservation is similar in the perioperative period, management in the postoperative period involves reducing bleeding and utilization of shed mediastinal blood.

Use of Positive End Expiratory Pressure Ventilation

Increased Positive End Expiratory Pressure Ventilation (PEEP) when the patient is on mechanical ventilation after cardiac surgery may be effective in reducing excessive postoperative bleeding by mechanical compression of myocardium. The pressure of PEEP used ranges from 5 to 25 cm water. Available evidence suggests that it is not useful as prophylactic measure but may be effective in few patients with excessive bleeding in the postoperative period. [4] The disadvantage of excessive PEEP is effect on hemodynamics caused by cardiac compression, resulting in tamponade-like situation.

Reinfusion of Postoperative Shed Mediastinal Blood

There are many reports suggesting benefit of reinfusion of postoperative mediastinal shed blood to decrease blood transfusion. It is not recommended to re-infuse this blood directly because of the risk of infection, inflammation, and activation of extrinsic pathway of coagulation. However, it can be re-infused after treating it through a cell saver. This is useful especially in high-risk patients along with other interventions to limit transfusions. [4]

Table 3. Topical hemostatic agents

Hemostatic agent and its composition	Mechanism of action	Disadvantage
Bio-absorbable gauge of oxidizedcellulose in form of woven sheets of fibers	Compression, promotion of clotting by activation of platelets, also have bacteriostatic properties	Depend on normal clotting system, less effective in the presence of coagulopathy
Microfibrillar bovine collagen	Platelet activation to promote clot formation and wound sealing	May cause organ damage if returned to circulation
Bovine fibrillar collagen/gelatine with thrombin (bovine or recombinant human) and autologous plasma	Platelet activation and clot formation with compression	Risk of antibody formation
Fibrin glue (fibrinogen plus thrombin and aprotinin)	Fibrin matrix to seal the wound	Rare risk of anaphylactic reaction
Synthetic cyanoacrylate polymers (biodegradable)	Synthetic sealant without any need of clotting system	
Synthetic polymers of polyethylene glycol	Formation of matrix sealant by action of polymers with proteins	Limited efficacy in active bleeding, use limited to seal anastomosis before resumption of blood flow
Mixture of bovine albumin and gluteraldehyde	Clot sealant formation without need of intrinsic pathway by denaturated albumin	Risk of gluteraldehyde toxicity
Large surface area polysaccharide hemispheres (plant-based polysaccharide with large surface area)	Dehydration on the surface of contact to concentrate blood cells and proteins	
Chitin-based sealants (natural polysaccharide polymer)	Formation of clot by direct action on red cell membrane may induce local growth factors	

PROCEDURES AND PRACTICES IN POSTOPERATIVE ICU

As there are many practices in ICU requiring testing of blood for various investigations including blood gas analysis, it may be a significant source of blood loss, especially in patients with prolonged ICU stay. Therefore, methods have been devised to limit this part of blood loss by using small-volume tubes, not discarding blood in the arterial line and limiting use and frequency of laboratory investigations along with use of oxymetry in place of blood gas analysis. These measures have been shown to reduce need for transfusion without compromising on safety in a cost-effective manner. [4, 76]

Special Situations

There are some special situations which warrant specific management protocols during various stages of the cardiac surgical procedure (pre-, intra- and postoperative periods) and need to be discussed separately.

Role of Hypothermia

Hypothermia has been used in cardiac surgery as an adjunct to CPB since the inception of cardiac surgery. It may be used with or without total circulatory arrest. Hypothermia helps in protecting organs, most importantly brain, liver, and kidneys, during periods of circulatory arrest of reduced blood flow that is often required to perform exact surgical procedures in patients with complex cardiac defects like congenital heart disease and disease of ascending aorta, arch, or descending thoracic aorta. Hypothermia acts by decreasing metabolic rate and oxygen consumption, preserving high energy phosphates and reducing excitotoxic neurotransmitters. [77, 78] But these advantages come at the cost of increased postoperative bleeding and increased incidence of blood and blood products transfusion apart from the increased rate of wound infections and delayed recovery from the effect of anesthetic drugs. [79] Coagulopathy induced by hypothermia results from platelet dysfunction (due to reduced release of thromboxane A2) and inhibition of enzymatic reactions of coagulation pathway. Therefore, avoiding hypothermia if possible and maintaining normothermia in postoperative period help in reducing bleeding and transfusions. If hypothermia is inevitable, one must use plasma and platelets to restore clotting mechanism and reduce need for red cell transfusion. [77, 80]

Cold Agglutinins

Cold agglutinins are mostly IgM antibodies that react with surface antigens of red blood cells at cold temperatures, leading to hemagglutination followed by complement fixation and hemolysis on warming. They also result in myocardial dysfunction by blocking coronary microcirculation if cold blood cardioplegia is used for myocardial preservation during aortic cross clamp. [81] They may also result in intravascular thrombosis, embolization and tissue

ischemia or infarction of various organs. These antibodies may be primary (idiopathic) or secondary due to infections such as mycoplasma, infectious mononucleosis or other viral infections, or due to lymphoproliferative disorders. They rarely are clinically apparent due to activity at low temperature. It is recommended that routine cross matching for cardiac surgery should also include testing and estimation of titer of these antibodies along with their thermal amplitude (temperature below which antibody get activated). The incidence of cold agglutinins in cardiac surgery is 0.8–4%. [82] Although most patients are asymptomatic, some patients with high titers and or high thermal amplitude can show signs of hemagglutination (peripheral ischemia, hemolysis, etc.) at low temperatures. If the diagnosis is not made before, it can be suspected by the presence of visible agglutination in cardioplegia circuit, intracoronary thrombosis, and inadequate cardioplegia delivery with high line pressures in the CPB circuit.

The management plan includes preoperative detection. If the antibodies are present, one must test for the presence of autoimmune hemolytic anemia (AIHA). If AIHA is present, one must involve a hematologist and a transfusion medicine specialist in the management of these patients. If AIHA is absent, the management involves avoidance of CPB (off-pump surgery), hypothermia (normothermic CPB), and cold cardioplegia (use of warm cardioplegia). Sometimes preoperative plasmapharesis or immunoglobin G therapy may be required if hypothermia cannot be avoided for the surgical procedure. [81, 83] If intraoperative agglutination is detected, the patient should be re-warmed to normothermia and the coronaries should be flushed using warm crystalloid cardioplegia. Other measures are aimed at management of hemolysis and other organ damage if present.

SPECIAL ISSUES IN CHILDREN, ESPECIALLY WITH CYANOTIC CONGENITAL HEART DISEASE

Children cannot be treated like small adults and therefore, strategies used in adults should not be scaled down and used in children who undergo cardiac surgery. The most important factors to consider in children are their small circulating volume and tendency to develop hemodynamic instability with small changes. Therefore, important considerations are limiting priming volume and using drugs like tranexamic acid or aprotinin to decrease risk of bleeding and transfusion requirements. Role of best practices in ICU may not be overemphasized in children.

Other important consideration in children is the presence of cyanotic congenital heart disease, which is one of the most important causes of cardiac surgical procedures in children. These children have associated deficiencies of coagulation factors and thrombocytopenia. [77] Use of minicircuits, priming the pump circuit with colloid instead of crystalloid, avoidance of hypothermia, etc. are most important tolls to decrease the risk of bleeding in these children. One should use FFP and platelets as required, depending of laboratory values and hemodynamic status of the patient to decrease bleeding and limit use of red cells. [84]

VADS, Extra-Corporeal Membrane Oxygenation, and Heart/Heart–Lung Transplantation

These are the sickest patients in practice of cardiac surgery, requiring long-term circulatory/pulmonary support. Use of these circulatory support devices, in isolation for management of patients or in conjunction with heart transplantation (preoperatively till the heart is available or postoperatively if the organ is rejected), is associated with increased bleeding disorders and need careful management of blood resources. [85] Use of VAD and ECMO is associated with bleeding from cannulation site, surgical incision and gastro-intestinal or intracranial bleeding along with risk of clotting in circuit and thromboembolic complications. [30, 86] There are guidelines for VAD and ECMO management which include heparin use (activated clotting time between 180 and 240 s), use of heparin bonded circuits, use of non-heparin anticoagulants if HIT is present and use of antifibrinolytic agents. The role of POC testing to direct use of various blood products cannot be overemphasized in these patients. [77, 87] Anticoagulation management of long-term VAD support is beyond the scope of this chapter.

Role of Electrocautery and Harmonic Scalpel in Transfusion Management in Cardiovascular Surgery

Although the best method of dissection in surgical practice is sharp dissection using knife and scissors, it leads to bleeding and damage to cardiac structures. Electrocautery of bleeding vessels and for dissection may reduce bleeding, but it may also result in inadvertent damage to cardiac structures. A safer method of electrocautery is to use bi-polar cautery for bleeding vessels. A new method for dissection, cutting, and control of bleeding is harmonic scalpel, which works with ultrasonic energy. [88] It has been shown to be useful in decreasing bleeding as well as transfusion requirements in cardiac surgery, especially in patients undergoing re-do cardiac surgery or those undergoing pericardiectomy for constrictive pericarditis. [89]

Role of Perioperative Blood Testing

There is a role of use of conventional clotting tests (CCT) like bleeding time, clotting time, prothrombin, and activated partial thromboplastin time (PT and APTT), fibrinogen level, testing for D-dimer along with measurement of hemoglobin, hematocrit, and platelet count in patients undergoing cardiovascular surgery to determine high-risk patients for bleeding, correction of abnormalities in the preoperative period if feasible and taking adequate measures in the operating room and ICU to decrease risk of bleeding and need for transfusion of blood and blood products. The CCTs have limitations like measurement of only individual coagulation component/mechanism; no measurement of interplay between various parts of coagulation pathways and little correlation with clinically significant coagulopathy or bleeding. Furthermore, most of these cannot be used as POC tests resulting in delay in decision making. [4] POCs are the tests, which are available at the bedside (in

operation room or ICU) and have a turnaround time of 10–20 min. Most common tests are based on viscoelastic hemostatic assay and include thromboelastography (TEG; Hemoscope Corporation, Niles, IL, USA) and rotational thromboelastometry (ROTEM; Tem International, GmbH, Munich, Germany). Both these tests provide a graphic analysis of clot formation and subsequent lysis.

Various parts of the graph give information on initiation speed of clotting, thrombin generation and fibrinogen cleavage kinetics, clot strength, and clot lysis and indicate the component/s of the clotting mechanism that are dysfunctional thus providing goal-directed transfusion of prevention as well as therapy of bleeding. [90] A recent study showed that POC testing was superior to CCT in prediction of bleeding, need of re-exploration, and reduction of need for blood transfusion. [91] Other POC devices which are useful are platelet function analyzer 100 (PFA-100; Siemens Healthcare Diagnostics, GmbH, Eschborn, Germany) and whole blood impedance aggregometry (Multiplate) for platelet function analysis and FIBTEM (Tem International GmbH, Munich, Germany) for analyzing fibrin polymerization. There are also devices to measure isolated function of clotting pathway (EXTEM for extrinsic pathway, INTEM for intrinsic pathway, HEPTEM for heparin effect, ACATEM for direct thrombin inhibition, and APTEM for fibrinolysis; all from Tem International, GmbH, Munich, Germany). Although these POC devices are useful adjunct to management of transfusion and bleeding in patients with cardiovascular surgery, [87, 92, 93] they are expensive, not routinely available and the cost of each test is also high. Figures 1–3 show flow charts for transfusion practices in cardiovascular surgery. These should be used as suggestive only and exact patient management should be done by a multispeciality team and locally derived guidelines keeping in mind both the cost as well safety to the patient.

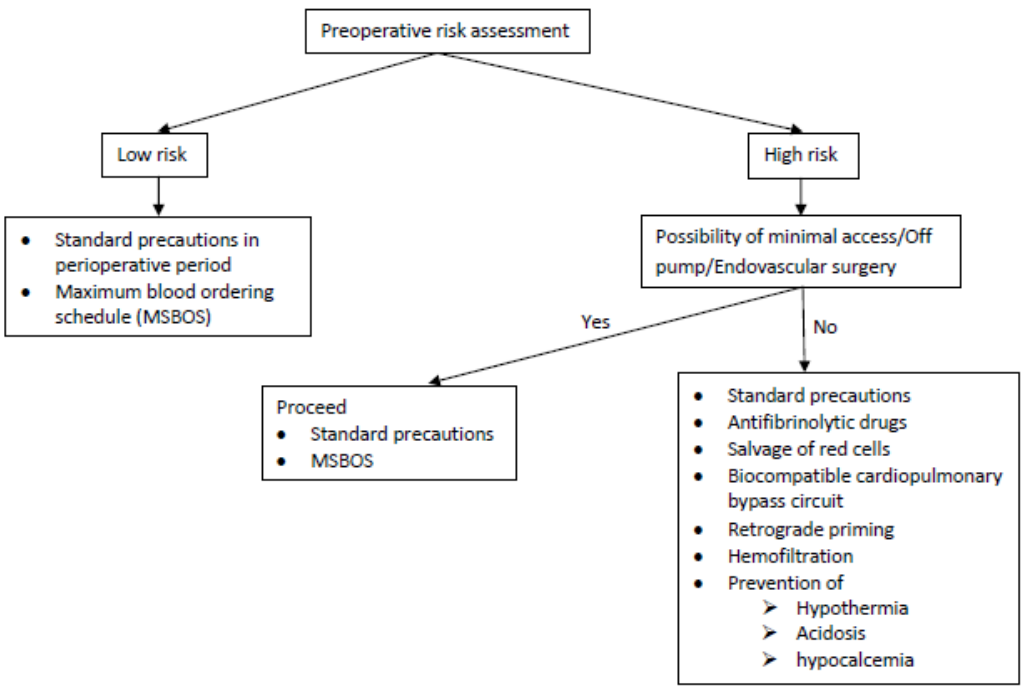

Figure 1. Pre-operative risk assessment as a strategy for best practices.

Management of Heparin and Protamine during Surgery, Heparin Resistance, and Heparin-Induced Thrombocytopenia

The most commonly used anticoagulation agent during cardiac surgery and for CPB is heparin, which is reversed after surgery with protamine. Heparin and protamine management during cardiac surgery needs to be understood to decrease bleeding problems and serious catastrophe. Heparin acts by binding with serine protease antithrombin III (AT), which in turn binds with thrombin and other coagulation factors including factor Xa and inhibits them. Heparin also reduces consumption of coagulation proteins and platelets and is also helpful in decreasing transfusion requirements. It also prevents clotting in the CPB circuit. [4, 30] It also helps by inhibiting many other sites in intrinsic and extrinsic pathways. Traditionally heparin dosing is either fixed or guided by activated clotting time (ACT) measurement, which has not been shown to consistently decrease bleeding and transfusion requirements in cardiovascular surgery. [4, 30] In comparison, use of a POC system (Hepcon; Medtronic Blood Management, Englewood, CO, USA) not only reduced total heparin and protamine dose, but also resulted in [94] reduced requirement of platelets, FFP and cryoprecipitate along with reduced postoperative bleeding.

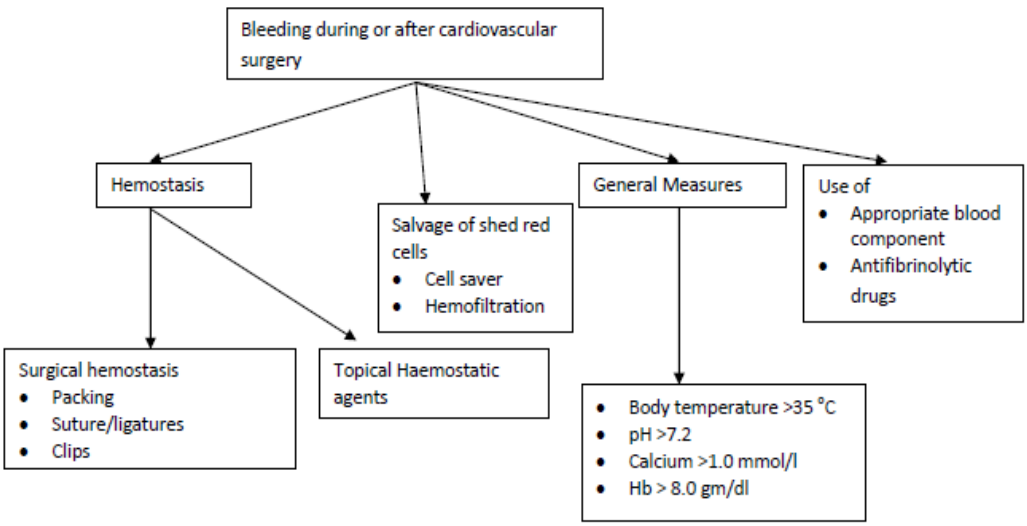

Figure 2. Best practices in management of bleeding in cardiovascular surgery.

Impaired heparin response or heparin resistance (HR) is most commonly due to AT deficiency but may also occur due to heparin binding to various cells and proteins. Other factors responsible for HR are its origin (intestinal vs. lung; bovine vs. porcine), method of preparation, and molecular weight distribution of various heparins in the prepared heparin. HR is defined as failure to achieve target ACT (400–480 s) after standard dose of heparin (400–1200 U/kg body weight). HR has been traditionally treated by FFP or AT concentrate (plasma derived or recombinant). [95] As compared withFFP, AT concentrates are advantageous in not only restoring heparin responsiveness but also in suppression of thrombin generation and fibrinolysis associated with use of CPB. [96] This results in less bleeding, blood transfusion as well as lesser incidence of thromboembolic complications. [30,

97] Protamine is the agent used to neutralize the effect of heparin after completion of CPB. It is usually used empirically (50% of total heparin dose used). As protamine itself is an anticoagulant, its over or under dose is associated with increased risk of bleeding. Recent evidence suggests that use of POC systems to titrate dose of protamine (for example, by RxDx system; International Technidyne, Edison, NJ, USA) results in use of lower dose of protamine, reduced postoperative bleeding, and need for blood transfusion. [98]

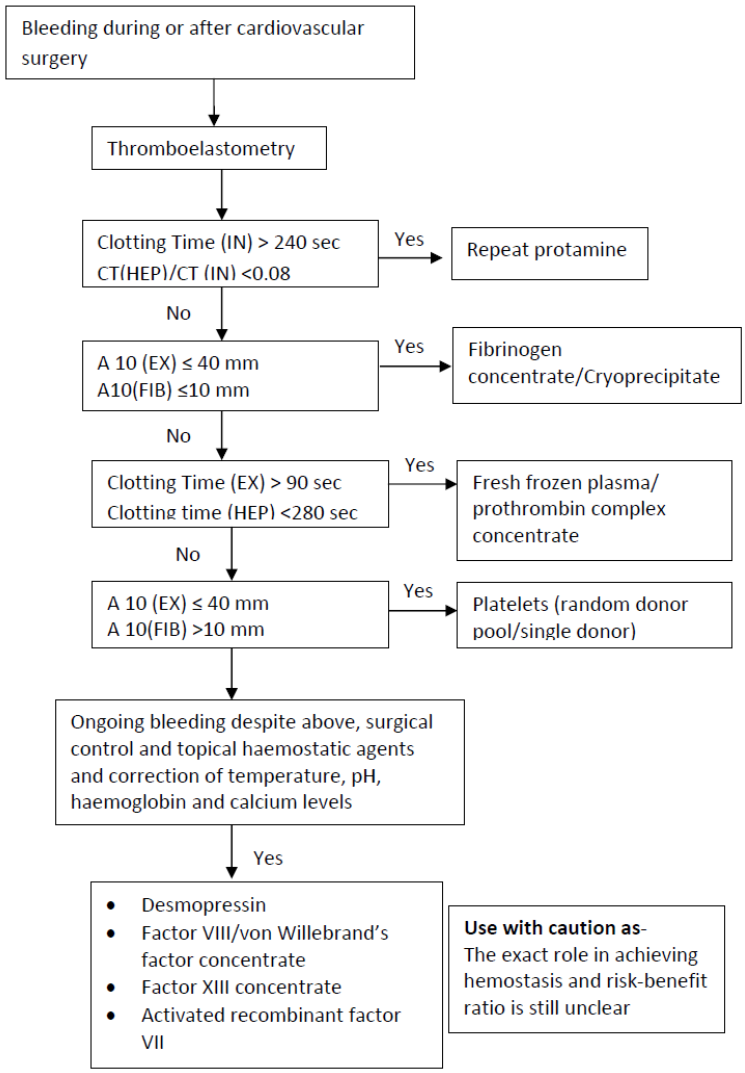

(A 10, amplitude of clot firmness 10 minutes after clotting time; CT, clotting time; EX, EXTEM; Tem international, Munich, Germany; ROTEM test activated by tissue factor; FIB, FIBTEM; Tem international, Munich, Germany; ROTEM test activated by tissue factor and block of platelet function by cytochalatin D; HEP, HEPTEM; Tem international, Munich, Germany; ROTEM test activated by ellagic acid and elimination of a potential heparin action by heparinise; IN, INTEM; Tem international, Munich, Germany; ROTEM test activated by ellagic acid)

Figure 3. Use of point of care devices (thromboelastometry; ROTEM; Tem international, Munich, Germany) for use of blood component therapy for bleeding during or after cardiovascular surgery.

Heparin-induced thrombocytopenia (HIT) is a reaction to heparin resulting in damage to platelets, thrombocytopenia, and complications like bleeding as well as thrombosis. It occurs in ~1.5–3% of all the patients exposed to heparin. It may be nonimmune-mediated (type I), which occurs early (<4 days) after intravenous heparin exposure, is dose dependent and is characterized by lower degree of thrombocytopenia and early recovery. It probably results from increased platelet aggregation and sequestration in spleen. Immune-mediated (type II) HIT occurs late (>4 days) after heparin exposure by any route, is not dose dependent, and results from formation of HIT antibodies. It is associated with >50% reduction in platelet count along with activation of coagulation cascade by activation and aggregation of platelets and thrombotic complications. The diagnosis is usually clinical and may be confirmed by platelet aggregation tests, C14 serotonin release assay, heparin-induced platelet aggregation, and various types of assays to detect HIT antibody. The treatment involves stopping any kind of heparin therapy, use of alternate anticoagulant use (bivalirudin, leuperidine, danaparoid, argotraban, etc.), and use of steroids and plasmapharesis for severe cases. [99]

CONCLUSION

Cardiovascular surgery remains to be one of the specialties requiring maximum demand on blood banks resulting in increased costs, difficulty in meeting demands due to limited supply of blood and blood products, and risks of various morbidities and increased mortality associated with blood transfusion. On the other hand, restricting use of blood and products may lead to increased bleeding and anemia with consequent effects on the outcome. Recent evidence suggests that there can be a scientific way to reduce transfusions with improved patient outcomes by team approach involving surgeon, anesthesiologist, perfusionist, transfusion medicine specialist, ICU care providers, cardiologists, nurses, and other personnel involved in care of patients undergoing cardiovascular surgery. This multidisciplinary team involving surgeons as well as non-surgeons should work together. Risk assessment, development, and use of best practice guidelines for transfusion for the institution and rational use of various methods described above for individual patients will ultimately lead to the best outcome at a reasonable cost.

REFERENCES

[1] Covin R, O'Brien M, Grunwald G, Brimhall B, Sethi G, Walczak S, et al. Factors affecting transfusion of fresh frozen plasma, platelets, and red blood cells during elective coronary artery bypass graft surgery. *Arch Pathol Lab Med.* 2003;127:415–23.

[2] Cobain TJ, Vamvakas EC, Wells A, Titlestad K. A survey of the demographics of blood use. *Transfus Med.* 2007;17:1–15.

[3] Josephson CD, Glynn SA, Kleinman SH, Blajchman MA; State-of-the Science Symposium Transfusion Medicine Committee. A multidisciplinary "think tank": the top 10 clinical trial opportunities in transfusion medicine from the National Heart, Lung, and Blood Institute-sponsored 2009 state-of-the-science symposium. *Transfusion.* 2011;51:828–41.

[4] Ferraris VA, Ferraris SP, Saha SP, Hessel EA 2nd, Haan CK, Royston BD, et al. for the Society of Thoracic Surgeons Blood Conservation Guideline Task Force and The Society of Cardiovascular Anesthesiologists Special task Force on Blood Transfusion. Perioperative blood transfusion and blood conservation in cardiac surgery: the society of thoracic surgeons and the society of cardiovascular anesthesiologis clinical practice guidelines. *Ann Thorac Surg.* 2007;83:S27–86.

[5] Geha AS, Baue AE. Graded coronary stenosis and coronary flow during acute normovolemic anemia. *World J Surg.* 1978;2:645–51.

[6] Jakobsen CJ. Transfusion strategy: impact of haemodynamics and the challenge of haemodilution. *J Blood Transfus.* 2014;(2014):627141.

[7] Karkouti K, Djaiani G, Borger MA, Beattie WS, Fedorko L, Wijeysundera D, et al. Low hematocrit during cardiopulmonary bypass is associated with increased risk of perioperative stroke in cardiac surgery. *Ann Thorac Surg.* 2005;80:1381–7.

[8] Spiegelstein D, Holmes SD, Pritchard G, Halpin L, Ad N. Preoperative hematocrit as a predictor of perioperative morbidities following nonemergent coronary artery bypass surgery. *J Card Surg.* 2015;30:20–6.

[9] Karkouti K. Transfusion and risk of acute kidney injury in cardiac surgery. *Br J Anaesth.* 2012;109(Suppl 1):i29–38.

[10] Loor G, Li L, Sabik JF 3rd, Rajeswaran J, Blackstone EH, Koch CG. Nadir hematocrit during cardiopulmonary bypass: end-organ dysfunction and mortality. *J Thorac Cardiovasc Surg.* 2012;144:654–62.

[11] Christensen MC, Dziewior F, Kempel A, von Heymann C. Increased chest tube drainage is independently associated with adverse outcome after cardiac surgery. *J Cardiothorac Vasc Anesth.* 2012;26:46–51.

[12] Goodnough LT, Shander A, Brecher ME. Transfusion medicine: looking to the future. *Lancet.* 2003;361:161–9.

[13] AuBuchon JP, Birkmeyer JD, Busch MP. Safety of the blood supply in the United States: opportunities and controversies. *Ann Intern Med.* 1997;127:904–9.

[14] Yomtovian R, Lazarus HM, Goodnough LT, Hirschler NV, Morrissey AM, Jacobs MR. A prospective microbiologic surveillance program to detect and prevent the transfusion of bacterially contaminated platelets. *Transfusion*. 1993;33:902–9.

[15] Horvath KA, Acker MA, Chang H, Bagiella E, Smith PK, Iribarne A, et al. Blood transfusion and infection after cardiac surgery. *Ann Thorac Surg.* 2013;95:2194–201.

[16] Surgenor SD, Kramer RS, Olmstead EM, Ross CS, Sellke FW, Likosky DS, et al; Northern New England Cardiovascular Disease Study Group. The association of perioperative red blood cell transfusions and decreased long-term survival after cardiac surgery. *Anesth Analg.* 2009;108:1741–6.

[17] Bhaskar B, Dulhunty J, Mullany DV, Fraser JF. Impact of blood product transfusion on short and long-term survival after cardiac surgery: more evidence. *Ann Thorac Surg.* 2012;94:460–7.

[18] Engoren MC, Habib RH, Zacharias A, Schwann TA, Riordan CJ, Durham SJ. Effect of blood transfusion on long-term survival after cardiac operation. *Ann Thorac Surg*. 2002;74:1180–6.

[19] Koch CG, Li L, Sessler DI, Figueroa P, Hoeltge GA, Mihaljevic T. Duration of red-cell storage and complications after cardiac surgery. *N Engl J Med.* 2008; 358:229–39.

[20] Philipps E, Fleischner FG. Pulmonary edema in the course of a blood transfusion without overloading the circulation. *Dis Chest.* 1966;50:619–23.
[21] Popovsky MA, Moore SB. Diagnostic and pathogenetic considerations in transfusion-related acute lung injury. *Transfusion.* 1985;25:573–7.
[22] Vamvakas EC, Blajchman MA. Transfusion-related mortality: the ongoing risks of allogenic blood transfusion and the available strategies for their prevention. *Blood.* 2009;113:3406–17.
[23] Toy P, Popovsky MA, Abraham E, Ambruso DR, Holness LG, Kopko PM, et al. Transfusion-related acute lung injury: definition and review. *Crit Care Med.* 2005;33:721–6.
[24] Triulzi DJ. Transfusion-related acute lung injury: current concepts for the clinician. *Anesth Analg.* 2009;108:770–6.
[25] Silliman CC, Fung YL, Ball JB, Khan SY. Transfusion-related acute lung injury (TRALI):current concepts and misconceptions. *Blood Rev.* 2009;23:245–55.
[26] Shaz BH, Stowell SR, Hillyer CD. Transfusion-related acute lung injury: from bedside to bench and back. *Blood.* 2011;117:1463–71.
[27] Vlaar AP, Hofstra JJ, Determann RM, Veelo DP, Paulus F, Levi M, et al. Transfusion-related acute lung injury in cardiac surgery patients is characterized by pulmonary inflammation and coagulopathy: a prospective nested case-control study. *Crit Care Med*. 2012;40:2813–20.
[28] Vlaar AP, Hofstra JJ, Determann RM, Veelo DP, Paulus F, Kulik W, et al. The incidence, risk factors, and outcome of transfusion-related acute lung injury in a cohort of cardiac surgery patients: a prospective nested case–control study. *Blood.* 2011;117:4218–25.
[29] Mehta RH, Sheng S, O'Brien SM, Grover FL, Gammie JS, Ferguson TB, et al. Reoperation for bleeding in patients undergoing coronary artery bypass surgery: incidence, risk factors, time trends and outcomes. *Circ Cardiovasc Qual Outcomes.* 2009;2:583–90.
[30] Ferraris VA, Brown JR, Despotis GJ, Hammon JW, Reece TB, Saha SP, et al. 2011 Update to The Society of Thoracic Surgeons and the Society of Cardiovascular Anesthesiologists. Blood conservation clinical practice guidelines. *Ann Thorac Surg*. 2011;91:944–82.
[31] Miyagi Y, Yamauchi S, Suzuki S, Kitagawa A, Masaki Y, Gomibuchi M, et al. Investigation ofcoronary artery bypass grafting for a patient with myelodysplasticsyndrome. *Ann Thorac Cardiovasc Surg.* 2001;7:250–3.
[32] Christiansen S, Rotker J, Roeder N, Jahn UR, Stypmann J, Scheld HH, et al. Are patients withWerlhof's disease at increased risk for bleeding complications when undergoing cardiac surgery? *Eur J Cardiothorac Surg.* 2000;18:353–6.
[33] Mathew TC, Vasudevan R, Leb L, Pezzella SM, Pezzella AT. Coronary artery bypasses grafting in immune thrombocytopenicpurpura. *Ann Thorac Surg.* 1997;64:1059–62.
[34] Boccara F, Michel M, Hermine O, Kaplan C, Aumont MC. Thrombocytopenia after cardiac surgery due to antiplateletallo-immunization. Apropos of a case. *Arch Mal Coeur Vaiss.* 1997;90:107–10.
[35] Jubelirer SJ. Coronary artery bypass in two patients withimmune thrombocytopenic purpura without preoperativesplenectomy. *WV Med J.* 1992;88:510–1.

[36] Ferraris VA, Ferraris SP, Joseph O, Wehner P, Mentzer RM Jr. Aspirin and postoperative bleeding after coronary artery bypass grafting. *Ann Surg.* 2002;235:820–7.

[37] IsilCT, Yazici P, Bakir I. Risk factors and outcome of increased red blood cell transfusion in cardiac surgical patients aged 65 years and older. *Thorac Cardiovasc Surg.* 2015;63:39–44.

[38] Johnson RG, Thurer RJ, Kruskall M, Sirois C, Gervino EV, Critchlow J, et al. Comparison of two transfusion strategies after elective operations for myocardial revascularization. *J Thorac Cardiovasc Surg.* 1992;104:307–14.

[39] Michelson AD, Barnard MR, Khuri SF, Rohrer MJ, MacGregor H, Valeri CR. The effects of aspirin and hypothermia on platelet function in vivo. *Br J Haematol.* 1999;104:64–8.

[40] Cote C, MacLeod JB, Yip AM, Ouzounian M, Brown CD, Forgie R, et al. Variation in transfusion rates within a single institution: exploring the effect of differing practice patterns on the likelihood of blood product transfusion in patients undergoing cardiac surgery. *J Thorac Cardiovasc Surg.* 2015;149:297–302.

[41] Munoz JJ, Birkmeyer NJ, Dacey LJ, Birkmeyer JD, Charlesworth DC, Johnson ER, et al. Trends in rates of reexploration for hemorrhage after coronary artery bypass surgery. Northern New England Cardiovascular Disease Study Group. *Ann Thorac Surg.* 1999;68:1321–5.

[42] Bracey AW, Radovancevic R, Radovancevic B, McAllister HA Jr, Vaughn WK, Cooley DA. Blood use in patients undergoing repeat coronary artery bypass graft procedures: multivariate analysis. *Transfusion.* 1995;35:850–4.

[43] Wijeysundera DN, Beattie WS, Djaiani G, Rao V, Borger MA, Karkouti K, et al. Off-pump coronary artery surgery for reducing mortality and morbidity: meta-analysis of randomized and observational studies. *J Am Coll Cardiol.* 2005;46:872–82.

[44] Davies MJ, Picken J, Buxton BF, Fuller JA. Blood conservation techniques for coronary-artery bypass surgery at a private hospital. *Med J Aust.* 1988;149:517–49.

[45] Stelzer P, Jones DJ, Elkins RC. Aortic root replacement with pulmonary autograft. *Circulation.* 1989;80:III209–213.

[46] Green K, Liska J, Egberg N, Koul B, Ljungberg B, Blombäck M, et al. Hemostatic disturbances associated with implantation of an artificial heart. *Thromb Res.* 1987;48:349–62.

[47] Wang IW, Kottke-Marchant K, Vargo RL, McCarthy PM. Hemostatic profiles of Heart Mate ventricular assist device recipients. *ASAIO J.* 1995;41:M782–7.

[48] Schmid C, Weyand M, Hammel D, Deng MC, Nabavi D, Scheld HH. Effect of platelet inhibitors on thromboembolism after implantation of a Novacor N100-preliminary results. *Thorac Cardiovasc Surg.* 1998;46:260–2.

[49] Jan KM, Chien S. Effect of hematocrit variations on coronary hemodynamics and oxygen utilization. *Am J Physiol.* 1977;233:H106–13.

[50] Weisel RD, Charlesworth DC, Mickleborough LL, Fremes SE, Ivanov J, Mickle DA, et al. Limitations of blood conservation. *J Thorac Cardiovasc Surg.* 1984;88:26–38.

[51] Fang WC, Helm RE, Krieger KH, Rosengart TK, DuBois WJ, Sason C, et al. Impact of minimum hematocrit during cardiopulmonary bypass on mortality in patients undergoing coronary artery surgery. *Circulation.* 1997;96(Suppl 2):194–9.

[52] Spence RK, Alexander JB, DelRossi AJ, Cernaianu AD, Cilley J Jr, Pello MJ, et al. Transfusion guidelines for cardiovascular surgery: lessons learned from operations in Jehovah's Witnesses. *J Vasc Surg.* 1992;16:825–31.

[53] Viele MK, Weiskopf RB. What can we learn about the need for transfusion from patients who refuse blood? The experience with Jehovah's Witnesses. *Transfusion.* 1994;34:396–401.

[54] American Society of Anesthesiologists Task Force on Blood Component Therapy. Practice guidelines for blood component therapy: a report by the American Society of Anesthesiologists task force on blood component therapy. *Anesthesiology.* 1996;84:732–4.

[55] DeFoe GR, Ross CS, Olmstead EM, Surgenor SD, Fillinger MP, Groom RC, et al. Lowest hematocrit on bypass and adverse outcomes associated with coronary artery bypass grafting. Northern New England Cardiovascular Disease Study Group. *Ann Thorac Surg.* 2001;71:769–76.

[56] Karkouti K, Djaiani G, Borger MA, Beattie WS, Fedorko L, Wijeysundera D, et al. Low hematocrit during cardiopulmonary bypass is associated with increased risk of perioperative stroke in cardiac surgery. *Ann Thorac Surg.* 2005;80:1381–7.

[57] Habib RH, Zacharias A, Schwann TA, Riordan CJ, Durham SJ, Shah A. Adverse effects of low hematocrit duringcardiopulmonary bypass in the adult: should current practicebe changed? *J Thorac Cardiovasc Surg.* 2003;125:1438–50.

[58] Surgenor SD, DeFoe GR, Fillinger MP, Likosky DS, Groom RC, Clark C, et al. Intraoperativered blood cell transfusion during coronary artery bypassgraft surgery increases the risk of postoperative low-outputheart failure. *Circulation.* 2006;114(Suppl 1):43–8.

[59] Engoren MC, Habib RH, Zacharias A, Schwann TA, Riordan CJ, Durham SJ. Effect of blood transfusion on long-term survival after cardiac operation. *Ann Thorac Surg.* 2002;74:1180–6.

[60] Banbury MK, Brizzio ME, Rajeswaran J, Lytle BW, Blackstone EH. Transfusion increases the risk of postoperative infection after cardiovascular surgery. *J Am Coll Surg.* 2006;202:131–8.

[61] *Transfusion Requirements in Cardiac Surgery II*. Available at http://clinicaltrials.gov/ct2/show/NCT01484639?term=red+cell+transfusion+and+cardiac+surgery&rank=1.

[62] Friedman BA, Oberman HA, Chadwick AR, Kingdom KI. The maximum surgical blood order schedule and surgical blood use in the United States. *Transfusion.* 1976;16:380–7.

[63] Berger JS, Frye CB, Harshaw Q, Edwards FH, Steinhubl SR, Becker RC. Impact of clopidogrel in patients with acute coronary syndromes requiring coronary artery bypass surgery: a multicenter analysis. *J Am Coll Cardiol.* 2008;52:1693–701.

[64] Ebrahimi R, Dyke C, Mehran R, Manoukian SV, Feit F, Cox DA, et al. Outcomes following pre-operative clopidogrel administration in patients with acute coronary syndromes undergoing coronary artery bypass surgery: the ACUITY (Acute Catheterization and Urgent Intervention Triage Strategy) trial. *J Am Coll Cardiol.* 2009;53:1965–72.

[65] Kincaid EH, Monroe ML, Saliba DL, Kon ND, Byerly WG, Reichert MG. Effects of preoperative enoxaparin versus unfractionated heparin on bleeding indices in patients undergoing coronary artery bypass grafting. *Ann Thorac Surg.* 2003;76:124–8.

[66] Alghamdi AA, Albanna MJ, Guru V, Brister SJ. Does the use of erythropoietin reduce the risk of exposure to allogenic blood transfusion in cardiac surgery? A systematic review and meta-analysis. *J Card Surg.* 2006;21:320–6.

[67] Dietrich W, Thuermel K, Heyde S, Busley R, Berger K. Autologous blood donation in cardiac surgery: reduction of allogenic blood transfusion and cost-effectiveness. *J Cardiothorac Vasc Anesth.* 2005;19:589–96.

[68] Dhir A. Antifibrinolytics in cardiac surgery. *Ann Card Anaesth.* 2013;16:117–25.

[69] Abrishami A, Chung F, Wong J. Topical application of antifibrinolytic drugs for on-pump cardiac surgery: a systematic review and meta-analysis. *Can J Anaesth.* 2009;56:202–12.

[70] Koscielny J, von Tempelhoff GF, Ziemer S, Radtke H, Schmutzler M, Sinha P, et al. A practical concept for preoperative management of patients with impaired primary hemostasis. *Clin Appl Thromb Hemost.* 2004;10:155–66.

[71] Lamy A, Devereaux PJ, Prabhakaran D, Taggart DP, Hu S, Paolasso E, et al. for the CORONARY investigators. Off-pump or on-pump coronary-artery bypass grafting at 30 days. *N Engl J Med.* 2012;366:1489–97.

[72] Cheng D, Martin J, Shennib H, Dunning J, Muneretto C, Schueler S, et al. Endovascular aortic repair versus open surgical repair for descending thoracic aortic disease: a systematic review and meta-analysis of comparative studies. *J Am Coll Cardiol.* 2010;55:986–001.

[73] Mahmood S, Bilal H, Zaman M, Tang A. Is a fully heparin-bonded cardiopulmonary bypass circuit superior to a standard cardiopulmonary bypass circuit? *Interact Cardiovasc Thorac Surg.* 2012;14:406–14.

[74] Benedetto U, Luciani R, Goracci M, Capuano F, Refice S, Angeloni E, et al. Miniaturized cardiopulmonary bypass and acute kidney injury in coronary artery bypass graft surgery. *Ann Thorac Surg.* 2009;88:529–35.

[75] Boodhwani M, Williams K, Babaev A, Gill G, Saleem N, Rubens FD. Ultrafiltration reduces blood transfusions following cardiac surgery: A meta-analysis. *Eur J Cardiothorac Surg.* 2006;30:892–7.

[76] Cannon MA, Beattie C, Speroff T, France D, Mistak B, Drinkwater D. The economic benefit of organizational restructuring of the cardiothoracic intensive care unit. *J Cardiothorac Vasc Anesth.* 2003;17:565–70.

[77] Kouchoukos NT, Blackstone EH, Hanley FL, Kirklin JK, editors. Hypothermia, circulatory arrest, and cardiopulmonary bypass. *Kirklin/Barrat Boyes Cardiac Surgery*. 4th ed. Philadelphia: Elsevier; 2013. p. 67–132.

[78] Swain JA, Mcdonald TJ, Griffith PK, Balaban RS, Clark RE, Ceckler T. Low flow hypothermic cardiopulmonary bypass protects the brain. *J Thorac Cardiovasc Surg.* 1991;102:76–84.

[79] Kurz A. Thermal care in the perioperative period. *Best Pract Res Clin Anaesthesiol.* 2008;22:39–62.

[80] Rajagopalan S1, Mascha E, Na J, Sessler DI. The effects of mild perioperative hypothermia on blood loss and transfusion requirement. *Anesthesiology.* 2008;108:71–7.

[81] Agarwal SK, Ghosh PK, Gupta D. Cardiac surgery and cold-reactive proteins. *Ann Thorac Surg.* 1995;60:1143–50.

[82] Hoffman JW, Gilbert TB, Hyder ML. Cold agglutinins complicating repair of aortic dissection using cardiopulmonary bypass and hypothermic circulatory arrest: case report and review. *Perfusion.* 2002;17:391–4.

[83] Kanemitsu S, Onoda K, Yamamoto K, Shimpo H. Simple preoperative management for cold agglutinins before cardiac surgery. *J Thorac Cardiovasc Surg.* 2010;140:73–4.

[84] Wilkinson KL, Brunskill SJ, Doree C, Trivella M, Gill R, Murphy MF. Red cell transfusion management for patients undergoing cardiac surgery for congenital heart disease. *Cochrane Database Syst Rev.* 2014 Feb 7;2 CD009752. doi: 10.1002/14651858.CD009752.pub2. Review.

[85] Voelker MT, Busch T, Bercker S, Fichtner F, Kaisers UX, Laudi S. Restrictive transfusion practice during extracorporeal membrane oxygenation therapy for severe acute respiratory distress syndrome. *Artif Organs.* 2015; 39: 374-8.

[86] Stone ML, LaPar DJ, Benrashid E, Scalzo DC, Ailawadi G, Kron IL, et al. Ventricular assist devices and increased blood product utilization for cardiac transplantation. *J Card Surg.* 2015;30:194–200.

[87] Sun W, Jeleniowski K, Zhao X, Shen P, Li D, Hammond JA. Thromboelastography (TEG)-based algorithm reduces blood product utilization in patients undergoing VAD implant. *J Card Surg.* 2014;29:238–43.

[88] Sankaranarayanan G, Resapu RR, Jones DB, Schwaitzberg S, De S. Common uses and cited complications of energy in surgery. *Surg Endosc.* 2013;27:3056–72.

[89] Luciani N, Anselmi A, Gaudino M, Nasso G, Glieca F, Martinelli L, et al. Harmonic scalpel reducesbleedingand postoperative complications in redocardiac surgery. *Ann Thorac Surg.* 2005;80:934–8.

[90] Yeung MC, Tong SY, Tong PY, Cheung BH, Ng JY, Leung GK. Use of viscoelastic haemostatic assay in emergency and elective surgery. *Hong Kong Med J.* 2015;21: 45-51.

[91] Johansson PI, Sølbeck S, Genet G, Stensballe J, Ostrowski SR. Coagulopathy and hemostatic monitoring in cardiac surgery: an update. *Scand Cardiovasc J.* 2012;46:194–202.

[92] Zubair MM, Bailly DK, Lantz G, Sunstrom RE, Saharan S, Boshkov LK, et al. Preoperative platelet dysfunction predicts blood product transfusion in children undergoing cardiac surgery. *Interact Cardiovasc Thorac Surg.* 2015;20:24–30.

[93] Görlinger K, Dirkmann D, Hanke AA. Potential value of transfusion protocols in cardiac surgery. *Curr Opin Anaesthesiol.* 2013;26:230–43.

[94] Despotis GJ, Joist JH, Hogue CW Jr, Alsoufiev A, Kater K, Goodnough LT, et al. The impact of heparin concentration and activated clotting time monitoring on blood conservation. A prospective, randomized evaluation in patients undergoing cardiac operation. *J Thorac Cardiovasc Surg.* 1995;110:46–54.

[95] Karkouti K, Wijeysundera DN, Yau TM, Callum JL, Meineri M, Wasowicz M, et al. Platelet transfusions are not associated with increased morbidity or mortality in cardiac surgery. *Can J Anaesth.* 2006;53:279–87.

[96] Levy JH, Despotis GJ, Szlam F, Olson P, Meeker D, Weisinger A. Recombinant human transgenic antithrombin in cardiac surgery: a dose-finding study. *Anesthesiology.* 2002;96:1095–102.

[97] Holcomb JB, Jenkins D, Rhee P, Johannigman J, Mahoney P, Mehta S, et al. Damage control resuscitation: directly addressing the early coagulopathy of trauma. *J Trauma. 2007*;62:307–10.

[98] Weber CF, Klages M, Zacharowski K. Perioperative coagulation management during cardiac surgery. *Curr Opin Anaesthesiol.* 2013;26:60–4.

[99] Linkins LA. Heparin induced thrombocytopenia. *BMJ.* 2015;350:g7566.

In: Encyclopedia of Surgery (22 Volume Set)
Editors: Andreas Lehrer and Kristin Mueller
ISBN: 978-1-53618-329-0
© 2020 Nova Science Publishers, Inc.

Chapter 366

FOREGUT SURGERY

Emily S. Reardon[1], MD, Daniel Mansour[1], MD and Stephen M. Kavic[2,*], MD

[1]University of Maryland Medical Center, Baltimore, MD, US
[2]University of Maryland School of Medicine, Baltimore, MD, US

ABSTRACT

Crohn's disease results in transmural inflammation involving any portion of the gastrointestinal tract from the mouth to the anus. However, Crohn's disease most commonly affects the lower gastrointestinal tract, often sparing the proximal portions. Here, we review the presentation and management of Crohn's disease of the esophagus, stomach, and duodenum. When Crohn's is referred to as a "spectrum of disease," the writer may indeed have foregut disease in mind. Like all forms of Crohn's disease, the initial management is typically medical. Unlike the remainder of the GI tract, however, bypass techniques are preferred to resection or strictureplasty techniques. Surgeons that often encounter Crohn's disease will inevitably face the patient with Crohn's of the foregut, either in isolation, or more commonly, in conjunction with ileal or colonic disease. This overview is intended to help with both the evaluation and management of foregut disease.

PREVALENCE

The prevalence of symptomatic Crohn's disease involving the esophagus, stomach, and/or duodenum has been reported to be between 0.5 and 4% [1-7]. With more liberal use of esophagogastroduodenoscopy (EGD), however, recent studies suggest that occult findings in the upper gastrointestinal tract are far more frequent, ranging from 16 to 51% [8-10]. In a retrospective review, published in 2014, endoscopic and pathologic changes of the upper GI tract in 138 patients with Crohn's disease were examined [8]. Seventy of 138 patients (51%)

* Corresponding Author's Email: skavic@smail.umaryland.edu.

demonstrated macroscopic disease-specific findings. The definition of disease-specific findings involving the upper GI tract and results of this study are detailed in Figure 1.

Location	Any findings (%)	CD specific findings* (%)	Granuloma detection (%)
Esophagus	14	7	0
Stomach: upper to mid	51	48	6
Stomach: lower	60	25	25
Duodenum: bulb	42	32	11
Duodenum: 2nd portion	19	18	0
Total	75	51	11

* Crohn's disease (CD) specific findings included: aphthae, longitudinal/irregular erosions and ulcers, Bamboo joint appearances, protruded or notch like appearances in the duodenum and fistula or stricture irrespective of location. Esophageal lesions were considered non-CD related when relation with reflux esophagitis was suspected. Gastroduodenal lesions were considered non-CD related when relation with *H. pylori* or NSAIDs was suspected.

Figure 1. Frequency of identification of characteristic findings and granulomas on EGD, based on a review of 138 patients [8].

Presently, upper endoscopic evaluation is recommended for use only in Crohn's disease patients with upper GI symptoms. However, given that there are frequent occult findings, some argue that EGD should be included as part of the routine diagnostic work-up [9, 10]. In a prospective analysis published in 2012, 119 patients with Crohn's disease underwent histologic and endoscopic examination before and after medical therapy [10]. All symptomatic patients showed relief of symptoms following treatment, and while 63% of patients were asymptomatic at presentation, nearly half of these patients (47%) demonstrated mucosal healing on post-treatment biopsy.

The prevalence of Crohn's disease involving the foregut does not seem to vary significantly with age. In children with Crohn's disease, histologic evidence by endoscopy of the upper GI tract is also frequently documented (30-80%) [11-13]. Nonetheless, symptomatic disease in this region is uncommon.

CLINICAL MANIFESTATIONS

Isolated involvement of the esophagus, stomach or duodenum is exceptionally rare. Patients are more commonly diagnosed with disease in the terminal ileum, and symptomatic involvement of the foregut is identified secondarily. Patients with Crohn's of the foregut, often present with the signs and symptoms of Crohn's disease.

In a study by Nugent and Roy, which examined 89 patients with gastroduodenal Crohn's disease, 46 of 89 patients (52%) had documented distal disease before the development of upper GI symptoms [4]. At a follow-up interval of 12 years, distal disease had developed in 82 of 89 patients (92%); 53 of 89 patients (60%) had contiguous gastroduodenal involvement, and two of 36 patients with duodenal disease also had involvement in the proximal jejunum.

Importantly, symptoms of Crohn's disease involving the foregut can be difficult to differentiate from other more common ailments of the upper gastrointestinal tract, such as gastroesophageal reflux and peptic ulcer disease. Esophageal symptoms might include epigastric or chest pain, dysphagia or weight loss, thereby mimicking symptoms of

gastroesophageal reflux. Some patients with involvement of the esophagus may also present with oral aphthous ulceration [14].

The presenting symptoms of patients with gastroduodenal Crohn's disease from several series are outlined in Figure 2 [1, 4, 15-17]. The most common symptoms of gastroduodenal involvement included postprandial pain, nausea, vomiting, and weight loss. Notably, the pain associated with gastroduodenal Crohn's disease was relieved by antacids or acid suppressive therapy, as is seen in peptic ulcer disease.

Much like Crohn's disease that involves any region of the gastrointestinal tract, advanced manifestations of Crohn's disease in the foregut include stricture, obstruction, fistulization, or bleeding. Of these complications in esophageal Crohn's disease, stricture presents most frequently. In Decker's review, the clinical course and outcome in twenty patients with symptoms of esophageal Crohn's disease is described well. Four of twenty patients (20%) presented with esophageal stricture [14]. The overwhelming majority presented with dysphagia, and these patients were found to have esophageal ulceration and/or erosion (90%) without complication. Obstruction is the most common presenting symptom in gastroduodenal Crohn's disease, and remains the most common indication for surgery in Crohn's disease involving the foregut, ranging from 70-90% [4, 7, 19].

Symptom	Nugent and Roy [4]	Worsey [15]	Farmer [16]	Poggioli [17]
Postprandial pain	79	71	100	100
Weight loss	64	65	72	55
Nausea and vomiting	61	32	72	55
Bloating	NR	68	NR	NR
Bleeding and anemia	17	NR	9	33

NR = not recorded.

Figure 2. Presenting symptoms of gastroduodenal Crohn's disease.

Fistulization of the esophagus in Crohn's disease can also occur, involving communication with the proximal and/or distal airway, however this is much more rare [18]. Fistulas involving the stomach and/or duodenum are also infrequent, and if they arise, are more often attributed to primary colonic or distal small bowel disease. Fistulization to the pancreatic gland, although vanishingly rare, has also been described in gastroduodenal Crohn's disease [20-24]. Likewise, granulomatous involvement of the gallbladder, and common bile duct obstruction, have both been reported [23-26].

Studies examining surgical patients who present with complications of Crohn's disease involving the esophagus, stomach or duodenum, suggest that the patient population should be considered high risk. Crohn's disease of the upper gastrointestinal tract has been associated with increased recurrence, need for surgery and length of hospitalization [27, 28]. Interestingly, in a recent cross-sectional query of the National Institute of Diabetes and Digestive and Kidney Diseases Inflammatory Bowel Disease Genetics Consortium (IBDGC), published by Lazarev in 2014, 175 of 1,759 patients (10%) with Crohn's disease involving the esophagus, stomach or duodenum (EGD) were compared to patients with isolated jejunal disease, 115 of 1,759 patients (7%) [29]. In this study, while patients with EGD involvement seemed to present at an earlier age, they were less likely to have stricturing and undergo multiple surgeries. Instead, independent predictors of structuring behavior and multiple abdominal surgeries included ileal involvement, longer duration of disease and isolated

jejunal disease. Current classification schemes do not reflect a difference between Crohn's disease of the duodenum and jejunum.

DIAGNOSIS AND CLASSIFICATION

A diagnosis of subtle disease involving the esophagus, stomach or duodenum can be done endoscopically, and reported prevalence varies dramatically based on clinical presentation. This variance is further complicated by non-specific gross and/or histologic findings identified on endoscopy, as universal criteria for Crohn's disease involving the upper gastrointestinal tract have yet to be defined. While findings of macroscopic ulceration or aphthous lesions are frequently seen in Crohn's disease of the upper GI tract, erythema, edema and other inflammatory changes cannot exclusively be attributed to Crohn's disease.

The histology of gastric Crohn's disease in particular is difficult to interpret. The occurrence of epithelioid granulomas is considered a histological hallmark of the disease, however this finding is detected infrequently [1, 8, 9]. A list of commonly accepted Crohn's disease-specific findings in the upper GI tract is included in Figure 1.

Upper GI studies with contrast (typically barium) are best utilized to characterize fistulas or obstructive lesions. Although these findings are uncommon, they have been well described in the literature. The shape of the distended stomach and a rigid stenotic antrum and duodenum has been described as the "ram's horn deformity", seen in gastroduodenal Crohn's disease [30]. Similarly, a tube-like appearance of the antrum, pylorus and duodenum has been termed, the "pseudo-Billroth I", characterizing Crohn's disease which involves the stomach and duodenum as similar in appearance to a surgical end-to-end gastro-duodenostomy [31].

Current systems used to classify Crohn's disease include the Vienna and Montreal classifications. The Montreal classification system is the most recently updated version [32]. Note that this classification scheme may be revised to further subclassify L4 disease into two categories, esophageal-gastric-duodenal, and jejunal, reflecting increasing evidence that supports clinically distinct differences between the two [29].

MEDICAL TREATMENT

The current therapeutic approach to Crohn's disease accounts for the broad spectrum of disease involvement. Most clinicians, however, assume that the entire GI tract is at risk for the subsequent manifestation of Crohn's disease. As a result, patients with Crohn's disease of the foregut are treated with standard therapy, including 5-aminosalicylic acid and steroids. The efficacy of more recent immunosuppressive treatments has not been specifically evaluated in Crohn's disease of the upper GI tract, but has been reported to be successful [33, 34]. Other modalities that have been used, but have not been widely adopted, include endoscopic dilation and local steroid injection for obstructive lesions [14, 35-37].

SURGICAL MANAGEMENT

Esophageal Crohn's Disease

In general, an anastomosis to the esophagus within the chest has a significant risk of complications. This risk is amplified in patients with Crohn's disease, making resection with anastomosis particularly unappealing. Therefore Crohn's disease of the esophagus, when presenting with severe complications, requires esophagectomy.

Fortunately, esophageal disease is infrequent. Unfortunately, the consequence for surgeons is that there is a paucity of quality literature to guide management. Early case reports, from the 1960's to the 1980's, often documented very poor outcomes [38, 39]. More recent literature on the topic has focused on endoscopic and medical therapies for strictures and obstruction, as alternatives to esophagectomy [14, 35-37]. The most common endoluminal therapies include dilation, steroid injection, and topical application of other immunosuppressive regimens. Despite modern advancements in surgical technique and post-operative care, which have likely improved associated morbidity and mortality, the use of esophagectomy for surgical management of esophageal Crohn's disease should be reserved for severe cases. It is worrisome to replace the native esophagus with intestinal conduit, as a replacement with colon may lead to recurrent disease within the chest if Crohn's develops within the colon. Given the morbidity of both medical immunosuppression as well as surgical complications, it is also essential to consider first and eliminate the more common causes of chronic esophageal inflammation, such as gastroesophageal reflux.

Gastroduodenal Crohn's Disease

The most common indications for surgery in gastroduodenal Crohn's disease include obstruction and refractory painful ulceration. Isolated gastric disease is extremely rare [40, 41]. Options for surgical management of complicated gastroduodenal Crohn's disease include bypass, resection, or strictureplasty. Unlike the management of Crohn's disease involving the distal small bowel and colon, bypass is more commonly used than resection, as resection in this region is associated with significant morbidity [42]. Bypass techniques most frequently used include gastro-jejunostomy, gastro-duodenostomy, and Roux-en-Y gastro-jejunostomy.

In one of the largest and most recent studies performed on surgical management of patients with gastroduodenal Crohn's disease, Shapiro retrospectively examined 30 patients who underwent surgical intervention between 1995 and 2006 at Mount Sinai Medical Center [19]. Eleven patients underwent open bypass, thirteen had laparoscopic bypass, two underwent strictureplasty, and four had fistula takedown. The average length of follow-up was 58 months, 27% (n = 7) experienced major complications, including five patients in the open bypass group and one patient in the laparoscopic bypass group, and there was one death. The authors concluded that surgery is a viable and safe option for patients with intractable gastroduodenal Crohn's disease. Furthermore, in the era of widespread use of proton pump inhibitors, vagotomy is no longer considered necessary to prevent marginal ulceration post-operatively. Results of this study in comparison to other published series are listed in Figure 3. These studies report significant complication rates, yet serious morbidity (such as

anastomotic leak and sepsis) is uncommon, and mortality rates are also very low. A comparison between bypass and strictureplasty has not been prospectively evaluated in Crohn's disease of the upper GI tract. Initial analysis in the early 1990s, suggested that strictureplasty may be associated with a significant complication rate. In one analysis, 9 of 13 patients (69%) required reoperation for complication and/or recurrent disease. However, a more recent report from the same surgical group published a surgical recurrence rate of only 25% (2 of 8 patients) in this patient population [7, 43, 44]. Although these results represent small sample sizes, they suggest that refinements in technique can result in improved outcomes. Currently, strictureplasty remains an acceptable alternative to bypass for Crohn's disease involving the duodenum and is used according to surgeon preference.

Study (Sample Size)	Open Bypass	Laparoscopic Bypass	Strictureplasty	Vagotomy	Morbidity	Mortality
Worsey [15] (n = 34)	21	0	15	21	6 (18%)*	NR
Nugent and Roy [4] (n = 33)	32	0	0	18	8 (24%)*	NR
Yamamoto [7] (n = 23)	13	0	10	4	13 (57%)	NR
Shapiro [19] (n = 30)	11	13	2	1	14 (47%)	1 (3%)

*Morbidity in these series was recorded as recurrence requiring surgical revision.

Figure 3. Surgical management and outcomes in patients with Crohn's disease of the foregut.

Current recommendations include strictureplasty for short segment disease within a segment of small bowel when the segment is surgically accessible and the procedure may be accomplished with minimal risk to adjacent structures. Therefore, patients with stricturing disease in the second and fourth portions of the duodenum may be better served by bypass techniques (gastro-duodenal or gastro-jejunal). Disease in the first portion or third portion may be amenable to Heineke-Mikulicz strictureplasty.

Cancer Risk and Management

Small-intestinal adenocarcinoma associated with preexisting Crohn's disease has been rarely reported and requires complete oncologic resection [45-52]. Cancer of the small intestine, arising in Crohn's disease patients, has been associated with younger age at presentation and has a male predilection. There is a poor prognosis due to delay in diagnosis, often attributed to difficulty in differentiating underlying Crohn's disease and early signs of invasive carcinoma. These cases emphasize the need to perform a careful and thorough endoscopic evaluation, with the use of biopsy of any concerning lesions, to rule out malignancy in patients with Crohn's disease.

CONCLUSION

Crohn's disease isolated to the foregut is a rare condition, which more commonly manifests in association with contiguous involvement in the distal gastrointestinal tract. Crohn's disease-specific lesions are increasingly being identified with the use of upper endoscopy, and practitioners still debate when best to perform an endoscopic exam. Medical therapy continues to be the mainstay of management in the majority of patients who present with Crohn's disease involving the stomach, esophagus and/or duodenum; however surgeons still have a vital role. Surgical intervention for Crohn's disease of the foregut can be performed safely and with good outcomes, yet should be reserved for patients with severe complications and/or disease that is refractory to medical treatment.

REFERENCES

[1] Reynolds HL, Stellato TA. Crohn's disease of the foregut. *Surg. Clin. N. Am.* 2001; 81: 117-135.

[2] Farmer RG, Whelan G, Fazio VW. Long-term follow-up of patients with Crohn's disease: relationship between the clinical pattern and prognosis. *Gastroenterology* 1985; 88: 1818-1825.

[3] Legge DA, Carlson HC, Judd ES. Roentgenologic features of regional enteritis of the upper gastrointestinal tract. *Am. J. Roentgenol.* 1970; 110: 355-360.

[4] Nugent FW, Roy MA. Duodenal Crohn's disease: an analysis of 89 cases. *Am. J. Gastroenterol.* 1989; 84: 861-862.

[5] Sandler RS, Golden AL. Epidemiology of Crohn's disease. *J. Clin. Gastroenterol* 1986; 8: 160-165.

[6] Tootla F, Lucas RJ, Bernacki EG, et al. Gastroduodenal Crohn's disease. *Arch. Surg.* 1980; 111: 855-857.

[7] Yamamoto T, Bain IM, Connolly AB, et al. Outcome of strictureplasty for duodenal Crohn's disease. *Br. J. Surg.* 1999; 86: 259-262.

[8] Sakuraba A, Iwao Y, Matsuoka K, Naganuma M, Ogata H, Kanai T, Hibi T. Endoscopic and pathologic changes of the upper gastrointestinal tract in Crohn's disease. *BioMed. Res. Int.* 2014; 1-6.

[9] Turner D, Griffiths AM. Esophageal, gastric, and duodenal manifestations of IBD and the role of upper endoscopy in IBD diagnosis. *Curr. Gastroenterol. Rep.* 2007; 9: 475-478.

[10] Annunziata ML, Caviglia R, Papparella LG, Cicala M. Upper gastrointestinal involvement of Crohn's disease: a prospective study on the role of upper endoscopy in the diagnostic work-up. *Dig. Dis. Sci.* 2012; 57: 1618-1623.

[11] Dolgin SE. Surgical management of upper gastrointestinal and small bowel Crohn's disease. *Sem. Ped. Surg.* 2007; 16: 172-177.

[12] Ruushka T, Vaajalahti P, Arajarvi P, et al. Prospective evaluation of upper gastrointestinal mucosal lesions in children with ulcerative colitis and Crohn's disease. *J. Pediatr Gastrointest. Nutr.* 1994; 19: 181-186.

[13] Lenaerts C, Roy CC, Vaillancourt M, et al. High incidence of upper gastrointestinal tract involvement in children with Crohn disease. *Pediatrics* 1989; 83: 777-781.
[14] Anton G, Decker G, Loftus EV, Pasha TM, Tremaine WJ, Sandborn WJ. Crohn's disease of the esophagus: clinical features and outcomes. *Inflam Bowel Dis.* 2001; 7: 113-119.
[15] Worsey MJ, Hull T, Ryland L, et al. Strictureplasty is an effective option in the operative management of duodenal Crohn's disease. *Dis. Colon Rectum* 1999; 42: 596-600.
[16] Farmer RG, Hawk WA, Turnbull RB. Crohn's disease of the duodenum (transmural duodenitits): clinical manifestations, report of 11 cases. *Am. J. Dig. Dis.* 1972; 17: 191-198.
[17] Poggioli G, Stocchi L, Laureti S, et al. Duodenal involvement of Crohn's disease: three different clinicopathologic patterns. *Dis. Colon Rectum.* 1997; 40: 179-183.
[18] Clarke BW, Cassara JE, Morgan DR. Crohn's disease of the esophagus with esophagobronchial fistula formation: a case report and review of the literature. *Gastrointest Endosc.* 2010; 71: 207-209.
[19] Shapiro M, Greenstein AJ, Bryn J, Corona J, Greenstein AJ, Salky B, Harris MT, Divino CM. Surgical management and outcomes of patients with duodenal Crohn's disease. *J. Am. Coll Surg.* 2008; 207: 36-42.
[20] Jacobson IM, Schapiro RH, Warshaw AL. Gastric and duodenal fistulas in Crohn's disease. *Gastroenterology* 1985; 89: 1347-1352.
[21] Gschwantler M, Kogelbauer G, Klose W, et al. The pancreas as a site of granulomatous inflammation in Crohn's disease. *Gastroenterology* 1995; 108: 1246-1249.
[22] Omata F, Arakawa S, Takahashi H, et al. Crohn's disease associated with pancreatitis of unknown etiology: a case report. *Gastroenterol. Jpn* 1993; 28: 420-423.
[23] Spiess SE, Braun M, Vogelzang RL, et al. Crohn's disease of the duodenum complicated by pancreatitis and common bile duct obstruction. *Am. J. Gastroenterol.* 1992; 87: 1033-1036.
[24] Guellouz S, Pariente B, Benet C, Baudry C, Lourenco N, Kraemer A, Allez M, Gornet JM. Cephalic duodenopancreatectomy for hyperalgic duodenal Crohn's disease fistulized in the pancreatic gland. *Case Rep. Gastroenterol.* 2014; 8: 72-76.
[25] Foutch PG, Ferguson DR. Duodenal Crohn's disease complicated by common bile duct obstruction: report of a case and review of the literature. *Am. J. Gastroenterol.* 1984; 79: 520-524.
[26] Post AB, van Stolk R, Broughan TA, et al. Crohn's disease of the gallbladder. *J. Clin. Gastroenterol.* 1993; 139-142.
[27] Wolters FL, Russel MG, Sijbrandij J, et al. Phenotype at diagnosis predicts recurrence rates in Crohn's disease. *Gut* 2006; 55: 1124-1130.
[28] Chow DK, Sung J, Yu JC, et al. Upper gastrointestinal tract phenotype of Crohn's disease is associated with early surgery and further hospitalization. *Inflamm Bowel Dis.* 2009; 15: 551-557.
[29] Lazarev M, Huang C, Bitton A, Cho JH, Duerr RH, McGovern DP, Proctor DD, Regueiro M, Rioux JD, Schumm PP, Taylor KD, Silverberg MS, Steinhart AH, Hutfless S, Brant SR. Relationship between proximal Crohn's disease location and disease behavior and surgery: a cross-sectional study of the IBD genetics consortium. *Am. J. Gastroenterol.* 2013; 108: 106-112.

[30] Farman J, FAegenburg D, Dallemand S, et al. Crohn's disease of the stomach: the "ram's horn" sign. *Am. J. Roentgenol.* 1975; 123: 242-251.
[31] Thompson WM, Cockrill H, Rice RP. Regional enteritis of the duodenum. *Am. J. Roentgenol.* 1975; 123: 252-261.
[32] Silverberg MS, Satsangi J, Ahmad T, et al. Toward an integrated clinical, molecular and serological classification of inflammatory bowel disease: report of a working party of the 2005 Montreal World Congress of Gastroenterology. *Can. J. Gastroenterology* 2005; 19: 5-36.
[33] Odashima M, Otaka M, Jin M, Horikawa Y, Matsuhashi T, Ohba R, Koizumi S, Kinoshita N, Takahashi T, Watanabe S. Successful treatment of refractory duodenal Crohn's disease with infliximab. *Dig. Dis. Sci.* 2007; 52: 31-32.
[34] Karaoglu AO, Yukselen V. Obstructing Crohn's disease of the duodenum: is surgery always mandatory? *Int. J. Clin. Pract.* 2004; 58: 221-223.
[35] Anderson JM. Treatment of espophageal strictures with intralesional steroids. *Gastrointest Endosc.* 1995; 41: 333.
[36] Tamboer C, Verhamme M, Dhondt E, et al. Endoscopic treatment of stenosis in recurrent Crohn's disease with balloon dilation combined with local corticosteroid injection. *Gastrointest Endosc.* 1995; 42: 252-255.
[37] Rupp T, Earle D, Dick P, et al. Randomized trial of dilation plus intralesional steroids vs dilation alone for benign gastroesophageal strictures. *Gastrointes Endosc.* 1993; 39: 287.
[38] Howden FM, Mills LR, Rubin J. Crohn's disease of the esophagus. *Am. Surg.* 1994; 60: 656-660.
[39] Dyer NH, Cook PL, Harper RA. Oesophageal stricture associated with Crohn'd disease. *Gut* 1969; 10: 549-554.
[40] Ingle SB, Pujari GP, Patle YG, Nagoba BS. An unusual case of Crohn's disease with isolated gastric involvement. *J. Crohn's Colitis* 2011; 5: 69-70.
[41] Ingle SB, Hinge CR, Dakhure S, Bhosale SS. Isolated gastric Crohn's disease. *World J. Clin. Cases* 2013; 1: 71-73.
[42] Ghahremani GG, Gore RM, Breuer RI, et al. Esophageal manifestations of Crohn's disease. *Gastrointest Radiol* 1982; 7: 199-203.
[43] Yamamamoto T. The role of strictureplasty in the surgical management of duodenal Crohn'd disease. *J. Crohn's Colitis* 2013; 7: 237.
[44] Yamamoto T, Fazio VW, Tekkis PP. Safety and efficacy of stritureplasty for Crohn's disease: a systematic review and meta-analysis. *Dis. Colon Rectum* 2007; 50: 1968-1986.
[45] Collier PE, Turowski P, Diamond DL. Small intestinal adenocarcinoma complicating regional enteritis. *Cancer* 1985; 55: 516-521.
[46] Fresko D, Lazarus S, Dotan J, et al. Early presentation of carcinoma of the small bowel in Crohn's disease: case reports and review of the literature. *Gastroenterology* 1982; 7: 199-203.
[47] Greenstein AJ, Sachar DB, Smith H, et al. A comparison of cancer risk in Crohn's disease and ulcerative colitis. *Cancer* 1980; 46: 403-407.
[48] Greenstein AJ, Sachar DB, Smith H, et al. A comparison of cancer risk in Crohn's disease and ulcerative colitis. *Cancer* 1981; 48: 2742-2745

[49] Guye SN, Prior P, McCartney JL, et al. Malignancy in Crohn's disease. *Gut* 1980; 21: 1024-1029.
[50] Hawker PC, Guge SN, Thompson H, et al. Adenocarcinoma of the small intestine complicating Crohn's disease. *Gut* 1982; 23: 188-193.
[51] Meiselman MS, Ghahremani GG, Kaufman MW. Crohn's disease of the duodenum complicated by adenocarcinoma. *Gastrointest Radiol.* 1987; 12: 333-336.
[52] Traube J, Simpson S, Riddel RH, et al. Crohn's disease and adenocarcinoma of the bowel. *Dig. Dis. Sci.* 1980; 25: 939-944.

In: Encyclopedia of Surgery (22 Volume Set)
Editors: Andreas Lehrer and Kristin Mueller
ISBN: 978-1-53618-329-0
© 2020 Nova Science Publishers, Inc.

Chapter 367

SMALL BOWEL SURGERY

Eric Wise[1], MD, Stephen P. Gadomski[2], II and Stephen M. Kavic[3,*], MD

[1]University of Maryland Medical Center, Baltimore, MD, US
[2]Vanderbilt University School of Medicine, Nashville, TN, US
[3]University of Maryland School of Medicine, Baltimore, MD, US

ABSTRACT

The terminal ileum is clearly the most frequently involved portion of the intestine in patients with Crohn's disease. However, it is more difficult to discern the relative frequency of isolated small bowel involvement in this population. Stricturing disease is commonly encountered, and we review both the pathophysiology as well as the major techniques of resection and strictureplasty. An algorithm for perforating disease is also presented, as well as strategies for the management of fistulizing disease. As with other portions of the GI tract, multi-disciplinary care is the key to optimal outcomes. However, the surgeon plays a central role in the management of complicated small bowel disease, especially in cases of obstruction, perforation, and fistulization.

INTRODUCTION

It is well-known that an estimated 75-80% of Crohn's patients ultimately require surgery, with numbers as high as 50% within ten years of their diagnosis. [1] However, the precise data concerning small intestinal disease specifically are harder to discern. As the terminal ileum is the single most commonly involved segment of disease, and resection necessarily involves the cecum, there is some overlap between colectomy and small intestinal resection that increases the difficulty of interpreting the literature. In this chapter, we will examine the disease patterns that may necessitate small bowel surgery in Crohn's disease, discuss major surgical techniques of strictureplasty, and discuss preoperative and postoperative considerations.

* Corresponding Author's Email: skavic@smail.umaryland.edu.

LOCATION

Approximately 30% of patients have isolated small bowel involvement. Within the small bowel, the terminal ileum is the most common site of active disease. In fact, terminal ileal stricture causing obstruction is the classical presentation for surgically managed Crohn's disease. [2] The terminal ileal predominance of Crohn's disease extends to a variety of pathologies, including obstruction, fistula, stricture and neoplasm.

Duodenal involvement is the least common small bowel location, found in fewer than 3% of patients. Duodenal disease generally manifests with gastric outlet obstruction. Unlike terminal ileal disease, which often requires resection, the primary treatment remains immunosuppressive into the late stages of disease. [3] Once the symptoms can no longer be controlled, a bypass (gastro-jejunostomy or duodeno-jejunostomy) should be considered.

PREOPERATIVE CONSIDERATIONS

Prior to an elective operation for Crohn's disease, the first consideration is the determination of medical management of the patient. Current medical therapy provides most patients with symptomatic control, and may be preferred over surgical intervention. However, those with fibrostenotic disease may have minimal response to anti-inflammatory medications. In addition, some patients with localized disease may opt for primary surgical intervention over systemic therapies. Increasingly, the management of Crohn's disease is multi-disciplinary, and the surgeon should not hesitate to be involved early in the discussions of management options for these patients.

Once the decision to operate has been made, each patient should be optimized for surgery. Most patients will require general anesthesia, and guidelines for cardiac workup before invasive procedures have been well established. [4] Routine assessment includes basic laboratory studies (CBC, CMP, and coagulation studies), chest radiograph and EKG in most patients. It is our practice to type and screen all patients undergoing intestinal resection.

Most patients with Crohn's disease have a thorough history of localizing studies. Indeed, it is rare to find a patient requiring operation without a dossier of endoscopy, CT scans, or other contrast-based studies. It is mandatory that the surgeon review the preoperative imaging, and to repeat studies if there has been a substantial interval between imaging and operation. A CT scan is probably the most useful single test to assist in localization and the diagnosis of complex Crohn's disease. [2]

Perhaps the most important factor specific to Crohn's patients is overall nutrition status. Often, patients with Crohn's disease have poor nutrition, due to poor intake, malabsorption, systemic inflammation and medication side effects. Optimizing preoperative nutrition is critical for postoperative wound healing, particularly if a primary bowel anastomosis is constructed. It has been demonstrated in elective colorectal resections that anastomotic dehiscence is associated with hypoalbuminemia (<3.5 g/dL). [5, 6] Enteral nutritional support is preferred to optimize preoperative nutrition.

Though Crohn's disease patients may have a broad spectrum of nutritional deficiencies, components including an elemental diet and omega-3 fatty acids have been advocated by some to promote ease of digestion and prevent proinflammatory leukotriene and

prostaglandin generation, respectively. [5, 7-9] A course of total parenteral nutrition prior to surgery of at least 18-30 days is also recommended by some for nutritional repletion prior to elective surgery, though the risk/benefit ratio of this intervention has not been demonstrated. [10, 11]

The most difficult preoperative task is management of immunosuppressive therapy perioperatively. Generally, non-steroidal immunosuppressive regimens can be safely stopped just before surgery or not at all, while chronic steroid use necessitates continued perioperative use, occasionally requiring a stress dose to prevent adrenal insufficiency. [2] In the past, almost all patients received "stress doses" of corticosteroids; currently, this dogma has been challenged by the clinical experience that many patients do not require supplemental exogenous steroids. Finally, in the elective setting, a standard preoperative antibiotic regimen of intravenous cefoxitin, or ciprofloxacin and metronidazole should be administered. In the setting of an emergent operation, generally for perforating disease, a broader regimen should be considered perioperatively.

In small bowel surgery for Crohn's disease, a bowel preparation regimen is not recommended. There is no evidence to suggest a bowel preparation mitigates postoperative complications. However, in elective colon resections for patients with any pathology, a bowel preparation has been recognized as a risk factor for anastomotic leak. [12, 13]

DISEASE PATTERNS

Obstructing Disease of the Small Bowel

The most frequent indication for surgery in Crohn's disease patients is obstructing disease. [14] Obstructing disease in Crohn's disease patients is thought to develop from the progressive wall thickening subsequent to recurrent bouts of inflammation. Fibrostenotic disease does not respond well to medical management as the benefits of minimizing inflammation dwindle as mural thickening stenoses the luminal diameter (Figure 1).

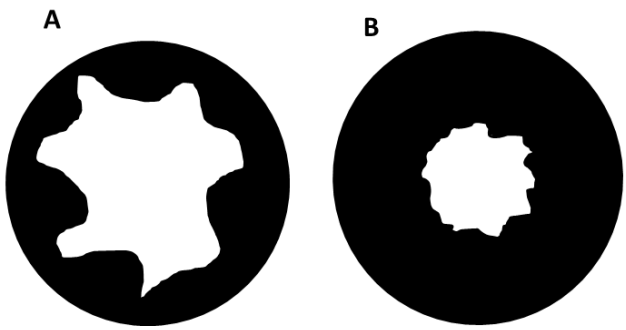

Figure 1. Inflammation of the intestine, in cross-section. A: Normal wall, moderate inflammation. In this setting, anti-inflammatory management will restore the luminal diameter of the intestine. B: Thickened wall, minimal inflammation. In the advanced state, medical management will have minimal effect on the lumen, and the patient will require surgical intervention for clinical relief.

Stricturing disease is quite common, and can be repaired with segmental resection or strictureplasty. In addition, an inflammatory mass such as a phlegmon or abscess, or a neoplasm, can cause bowel compression and obstruction. [15] These can be addressed medically, or via percutaneous or open surgical intervention.

The transmural inflammation of Crohn's disease also promotes fistulizaton between inflamed bowel and another organ, such as another segment of small bowel, large bowel, bladder or the skin, among others. Fistulizing disease often requires operative intervention when obstructive or septic complications develop. Perforating disease of inflamed small bowel can lead to peritonitis, requiring acute surgical intervention in Crohn's disease patients. Here, we will summarize the management of obstructing Crohn's disease of the small bowel.

Duodenal Obstruction

Duodenal involvement in Crohn's disease is relatively rare, occurring in 1-5% of patients. [16] The proximal duodenum is the most common location for duodenal Crohn's disease, followed by the descending portion. [17] Obstruction, generally due to structuring disease, is its most frequent presentation. The most common obstructive symptoms are abdominal pain, nausea, vomiting and early satiety. [18]

In principle, diagnosis of small bowel disease is made by upper gastrointestinal series. Early stenotic disease may show thickening and blunting of mucosal folds, cobblestoning and erosions. Progression of stenotic disease may lead to healing, scarring and fibrosis of the bowel segment.

More characteristically, deep linear ulcerations with opposing wall sacculations are seen. [19-21] More commonly, however, the diagnosis of duodenal obstruction is suggested on a CT scan, and confirmed on EGD. CT findings may include signs of gastric outlet obstruction, duodenal mural thickening, hyperemia of the mucosa, soft tissue stranding as well as sites of extra-duodenal inflammation. [20]

Although initial management is generally with antacid and anti-inflammatory medications including steroids and infliximab,[16] surgical intervention may be eventually required in up to 91% of these patients. [17] In the face of duodenal obstruction, the surgeon is faced with two options: bypass or strictureplasty. Resection of the duodenum is no longer considered a routinely viable option, as it is associated with very high morbidity and mortality; in rare cases, partial duodenectomy or even a formal pancreaticoduodenectomy may be required. [21]

Unfortunately, due to the low prevalence of duodenal Crohn's disease, the best surgical approach between duodenal bypass and duodenal strictureplasty has only been studied in small case series, and neither approach is supported with high-level evidence. Therefore, both procedures are currently considered equivalent surgical options.

Both duodenal strictureplasty and bypass often necessitate reoperation for further obstruction/re-stricturing disease, while anastomotic leak and postoperative hemorrhage have also been described as complications from both procedures. [16] For patients who receive duodenal bypass, surgical options include gastrojejunostomy, gastroduodenostomy and Roux-en-Y-gastrojejunostomy. Strictureplasty, on the other hand, allows for restoration of the constricted lumen throughout the affected portion of bowel. The operative technique is based on the length of strictured segment, and is described in detail in this chapter.

Duodenal strictureplasty is often quite difficult, however, as extensive mobilization of the duodenum is required, made difficult by extensive inflammation. The complexity is further increased due to the retroperitoneal location and proximity to sensitive vascular and pancreaticobiliary structures. [21]

Jejunoileal Obstruction

Up to 3-10% of Crohn's disease patients are affected by diffuse jejunoileal disease, with obstruction the most common indication for surgical intervention. Generally, several strictures develop, and the series of strictures leads to chronic, high-grade obstruction that presents as postprandial cramping, nausea and vomiting. [22] This condition can progress to complete obstruction (a closed loop) a case in which surgery is mandatory. In jejunoileal obstruction, multiple tight strictures are often present, transforming the bowel into alternating saccular segments and tight strictures. This pathology does not simply cause classic obstructive symptoms. The stagnation that occurs in these saccular segments can lead to bacterial overgrowth, leading to diarrhea, malabsorption and nutrient deficiency as well. [22]

Surgical intervention is warranted when medical management fails, when the obstruction becomes complete, or when acute sepsis develops. Historically, resection was the mainstay of treatment, but strictureplasty is now the preferred operative approach for jejunoileal obstruction in non-emergent operations. In fact, recent data demonstrates that strictureplasty is safe even for grossly diseased intestine. While there remains a risk of necessity for reoperation, recurrent disease is most often away from the site of strictureplasty. [16, 22-24] Furthermore, relative to resection, patients treated with strictureplasty have fewer complications. [25] Therefore, when feasible, strictureplasty should be performed in jejunoileal stricturing Crohn's disease. The surgical approach to strictureplasty is discussed in detail in this chapter.

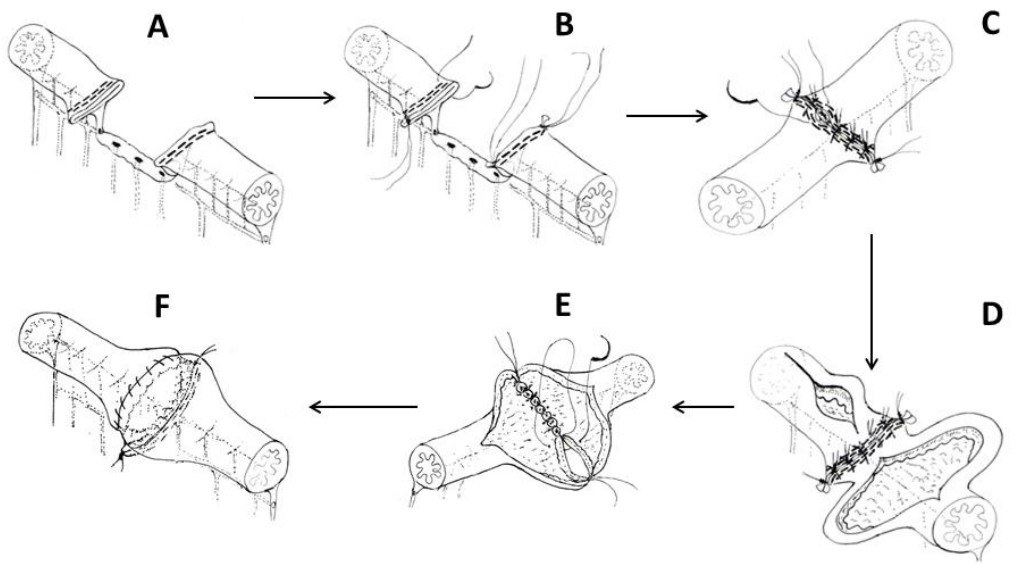

Figure 2. Construction Kono-S anastomosis. Adapted from Fichera A, et al., (2012) *Journal of gastrointestinal surgery*: official journal of the Society for Surgery of the Alimentary Tract 16:1412-1416.

Stirctureplasty is not always feasible in the elective treatment of obstructive disease. If there is excessive tension due to rigid thickened bowel segments, multiple strictures within a short segment, or suspicion of cancer at the stricture, a segmental resection is indicated. [16] While primary re-anastomosis may be indicated for jejunoileal obstructive disease, the superiority of anastomotic configuration (i.e., end-to-side, side-to-side, end-to-end,) has not been well established. Many surgeons opt to create a generous anastomosis, with the belief that a larger initial lumen may lengthen the interval to clinical symptoms should further stricturing occur.

Kono and colleagues have recently proposed a novel technique for primary re-anastomosis after resection for Crohn's disease. [26] To attempt to reduce anastomotic recurrence of Crohn's disease after resection, a functional end-to-end handsewn anastomosis has been proposed, called the Kono-S anastomosis for small or large bowel (Figure 2). Once the bowel to be resected has been identified, that segment is divided transversely with a GIA stapler device, dividing the associated mesentery close to the bowel. Then, the corners of the staple lines are sutured together, and the staple lines are re-approximated in an interrupted fashion. On both sides of the newly re-apposed suture line, an anti-mesenteric longitudinal enterotomy is made. These two enterotomies are then re-approximated in two layers, allowing a large transverse lumen of 7-8 cm. [26, 27] Prospective data regarding recurrence rates of obstruction and active disease at the anastomotic site, however, is not yet sufficiently available, though this technique presents a promising alternative anastomosis that may prove more resistant to further obstruction due to a luminal widening. [26]

Terminal Ileal Obstruction

Chronic obstruction in the terminal ileal and ileocecal region is the primary indication for ileocecal operative intervention. [28] Traditionally, ileocecectomy with ileal-ascending colon anastomosis was performed for this condition, as many surgeons felt the intestinal walls in this region were not suitable for strictureplasty. The terminal ileum is often the most aggressive site of Crohn's disease. Bowel walls are often highly inflamed, with friable hemorrhagic mucosa and deep ulcerations. [29] As such, there has been a hesitancy to preserve the ileocecal region in these patients. In addition, the ileocecal valve itself may be involved in the inflammatory process, complicating local repair options.

However, strictureplasty of the terminal ileal and ileocecal region is possible. Strictureplasty, primarily of the Finney type (see section on Strictureplasty), has demonstrated no difference relative to ileocecectomy with respect to ten-year outcomes and clinical relapse of terminal ileitis. [29] Terminal ileal strictureplasty is becoming recognized as a viable alternative to segmental resection. Nonetheless, resection remains the technique of choice for many surgeons in the treatment of terminal ileal and ileocecal Crohn's disease.

For bowel resection, the primary considerations are the margin resection and anastomotic technique. In ileocecal resection for Crohn's disease, randomized controlled data have demonstrated no benefit with respect to recurrent rates between a limited resection (2cm margins from macroscopic disease) and an extended resection (12cm margins from macroscopic disease), several years postoperatively. [30] Therefore, radical resection is currently not recommended, particularly as bowel conservation is a fundamental component of small bowel surgery in these patients. [16]

There is limited data examining the superiority of stapled vs. hand-sewn, and end-to-end or side-to-side anastomosis after ileocecectomy in Crohn's disease. [31] Reports from the late

1990s retrospectively examined whether there was a difference in outcomes in stapled vs. sutured end-to-end anastomoses. These studies suggested that a stapled technique was associated with fewer complications and less recurrent disease at the anastomotic site. [32, 33] A 2004 study suggested that recurrent disease was less frequent in patients with stapled and hand-sewn side-to-side anastomoses relative to those constructed using stapled end-to-side technique. [34] McLeod, in 2009, published the first multicenter randomized controlled data assessing the influence of anastomotic type on recurrence of disease. It was found that disease recurrence rates were similar between end-to-end and side-to-side ileocolic anastomoses in patients who underwent ileocecectomy for Crohn's disease. [35] Overall, the literature appears to favor stapling anastomoses over hand-sewing them. [36] However, until the emergence of high level, validated evidence, it is recommended that ileocolic anastomosis be constructed in a manner by which the surgeon is most comfortable.

Management of the Mesentery

In addition to anastomotic technique, consideration must be made of the surgical approach to the pathological changes in the mesentery. These include mesenteric fat growth (frequently encompassing the circumference of the bowel), diffuse inflammation with enlarged lymph nodes, and friable tissue. Energy devices often have difficulty forming a proper seal in this setting, as the vessels may fracture while the energy dissipates into the surrounding fatty coat.

Caution must be taken when clamping the inflamed mesentery of Crohn's disease patients. The surgeon should always be aware of the "corkscrew" vessels that penetrate near the bowel wall, as well as the presence of excess adipose tissue and pathologically enlarged lymph nodes, which still maintain their relationship to the underlying vasculature. [2] Mesentery can be managed by obtaining proximal control with atraumatic clamps, followed by ligation and control of remaining areas of bleeding. [31] Alternatively, serial, overlapping clamps can be used with a particular goal to prevent hematoma formation. [2]

Fistulizing Disease of the Small Bowel

A Crohn's disease fistula is an abnormal epithelialized connection between two organs. The interested reader is directed to an excellent review on the process of fistula formation in Crohn's disease, reported by Scharl and Rogler in 2014. [37] In active Crohn's disease, full thickness inflammation promotes the creation of pathologic fistulae either completely within the alimentary tract, or between a portion of the alimentary tract and an organ such as the skin, bladder or vagina. [38] Fistulae often develop at sites of active disease, however, one-fourth of fistulae in Crohn's patients form at anastomotic sites from previous bowel resection. [38] One of the most common complications of Crohn's disease, fistula formation occurs in 30-40% of patients. Over half of Crohn's fistulae are located in the perianal region. Approximately 24% of Crohn's fistulae are entero-enteric, while enterocutaneous fistulae account for approximately 6%. [38, 39] Internal fistulae, those that form between two internal organs, can often remain subclinical. External fistulae, in which there is a fistulous tract with the skin, are easier to identify.

Enterocutaneous Fistulae

Enterocutaneous fistulae (ECF) in Crohn's disease can be a significant management challenge. These fistulae generally develop after a previous bowel resection, and are classically ileocutaneous. In the early postoperative setting, ECF can present 7-10 days postoperatively due to anastomotic breakdown. If an ECF presents in a delayed fashion, typically after two weeks postoperatively, it may be attributed to a previously contained anastomotic leak. [40] They are initially managed with skin care, as well as nutritional support. Sepsis is the most common cause of mortality from ECF.

A fistula is considered high-output if it expels over 500 mLs per 24 hours, and in these cases, supplemental parenteral nutrition is often needed to avoid malnutrition. Multiple methods are used to reduce fistula output, including restriction of hypo-osmolar fluids, consumption of electrolytes with high concentrations of glucose and sodium, anti-secretory agents (*e.g.*, proton pump inhibitors, octreotide) and anti-motility agents (*e.g.*, loperamide). [38] ECF may close spontaneously or with the assistance of anti-secretory medications, however, treatment is often surgical. If spontaneous closure is not observed two months from diagnosis, surgical planning is then considered for a formal ECF resection.

Prior to surgical treatment of ECF, it is imperative that the patient is nutritionally optimized, managed with skin care and has intestinal anatomy defined. Classically, the best preoperative study performed prior to ECF resection was an upper GI contrast study with small bowel follow-through. However, this has largely been supplanted by CT imaging. With concerns over malignancy due to cumulative doses of radiation, some centers have moved to magnetic resonance enterography as the imaging of choice. The cost and lack of universal availability of this modality have limited its widespread adoption.

While not a complication of Crohn's disease *per se*, peri-ileostomy cutaneous fistulae can form after the initial ECF resection. Early postoperative peri-stomal fistulae develop due to excess tension placed on sutures between the abdominal fascia and bowel serosa, leading to bowel injury and subsequent fistulization with the skin. This complication begets another operation in which the ileostomy must be further exteriorized and a second stoma allowed to mature. [40] Fistulizing Crohn's disease may develop in the stoma; however, a fistula that develops may represent disease relapse rather than a technical misadventure. In contrast to perianal fistulae removal, in which there are multiple surgical techniques, ECF are generally removed via an abdominal incision, and excision of the fistulized segments of the small intestine. Often, temporary fecal diversion is performed with an ileostomy. [40]

Internal Fistulae

In Crohn's disease, a segment of the small bowel, upon becoming inflamed, can form an inflammatory adhesion and ultimately fistulize with another segment of bowel. The ileum is the most common site of active inflammation in the small bowel, and it is therefore by far the most common segment of small bowel involved in internal fistulae formation. Most frequently, the target organ for fistulization is the sigmoid colon, however, ileocecal fistulae and ileoenteric fistulae are common as well. Small bowel fistula formation can occur without ileal involvement as well, although this is far more rare. Gastrocolic and duodenocolic fistulae have been reported in small case series. [41]

Enteroenteric fistula, in which an inflamed portion of small bowel (generally ileum) fistulizes with additional small bowel, is often observed as well, as it was the most frequent fistula observed in a recently reported cohort of Japanese Crohn's disease patients. [42] In

addition, the small bowel can internally fistulize with a solid organ outside of the alimentary tract. In up to 8% of Crohn's disease patients, fistulae between bowel and the urinary system (ureter and bladder) can form spontaneously. With involvement in 64% of cases, the ileum is the most common segment of bowel involved in these fistulae. [41, 43]

Diagnosis of Small Bowel Fistula

Since they are often subclinical, internal fistulae of the small bowel can develop and progress without overt signs and symptoms. Typically, it is only late in the process when septic or obstructive symptoms necessitate diagnostic imaging. [40] The most common presenting symptoms for internal fistulae involving the small bowel are abdominal pain and diarrhea, although fever from abscess formation is seen as well. In one classic series of patients with fistulizing Crohn's disease, while most fistulae are diagnosed radiographically, up to ¼ of them are diagnosed intraoperatively, or on pathologic examination of the resected specimen. [44] In principle, fistulae can be diagnosed through a variety of means. Cross-sectional imaging (CT or MRI) or contrast studies will illustrate a fistula. In practice, the severe inflammation present often masks the small aperture of the fistula, and it may only be diagnosed intraoperatively.

Enterovesical fistulae in Crohn's disease are almost always ileovesical. Both urinary and gastrointestinal symptoms may bring attention to the diagnosis, perhaps even as the first clinical manifestation of the patient's Crohn's disease. Reported in 50-70% of patients with enterovesical fistulae, pneumaturia is the most common presenting symptom. Although pneumaturia may be an uncommon clinical sign, it is pathognomonic for this disorder.

Dysuria, fecaluria, suprapubic pain and recurrent urinary tract infections (UTI), generally due to *Escherichia coli*, are common symptoms as well. When suspected, diagnostic confirmation of the fistula is necessary, particularly for surgical planning. There are a variety of imaging techniques used in the case of a suspected enterovesical fistula. [45] These include cystoscopy, colonoscopy, the "poppy seed" test, transabdominal ultrasonography, computerized tomography, magnetic resonance imaging, barium enema, and a cystogram. In the poppy seed test, a few grams of poppy seeds are ingested orally. If there is a significant fistula, then the seeds pass through and are visible in the urine.

Although each modality has its own advantages and disadvantages, Golabek proposed an optimized diagnostic imaging algorithm after a best evidence examination of the literature. Once clinically suspected, both transabdominal ultrasound and the "Poppy seed" test are performed. If still suspected, CT/MRI imaging and cystoscopy with biopsy are undertaken. [46] Sigmoidoscopy may demonstrate the enteral side of the fistula; cystoscopy can show the bladder side. If the presence of an enterovesical fistula is confirmed after this workup, a management plan can then be initiated.

Management of Small Bowel Fistula

An Internal fistula involving the ileum or other small bowel region does not represent an indication for surgery; rather, a deleterious sequela from the fistula must be present.

The first indication is the creation of a bypass between segments of bowel due to the fistulous tract. If large enough, the disuse of that segment of bowel can lead to malabsorption, diarrhea, malnutrition and bacterial overgrowth. [39] Second, an internal fistula can exteriorize, becoming enterocutaneous in nature. Due to the high risk of malnutrition and septic complications, this is an indication for eventual surgical treatment. [40] Finally, the

development of a fistula can lead to abscesses in the abdomen which have the potential to cause obstruction.

Medical therapy can be used as a first line treatment of non-acute small bowel fistulous Crohn's disease, however, its failure to control the development of symptoms or abscess development from the fistula represents an indication for surgery. [39] While isolated enteroenteric fistulae can generally be managed nonsurgically, 40% of patients require surgery by one year, and an additional 33% within 9 years. [2] In surgical repair of internal fistulae involving the small bowel, the inflamed segment (usually ileal) is excised with either diversion or primary re-anastomosis. When the small bowel segment fistulizes with the sigmoid, it is often the practice of surgeons to close the fistulous opening in the sigmoid rather than resecting it. [45] Primary repair of the sigmoid is indicated if there is minimal inflammation of the colon. It is worth paying scrupulous attention to the character of the sigmoid colon, as suturing inflamed bowel may lead to a high rate of failure with subsequent leak, abscess, or sepsis.

Enterovesical fistulae due to Crohn's disease require prompt evaluation and management, due to the potential development of recurrent UTI and urosepsis. Once recognized, the first line of management is often medical. Consistent with general management of Crohn's disease, treatment with sulfasalazine, corticosteroids, 6-mercaptopurine and antibiotics such as metronizadole is often used. [47] In addition, bowel rest with total parenteral nutrition as well as ureteral catheter drainage is recommended for conservative management.

As there is scarce data on its efficacy, agents including TNF-alpha monoclonal antibodies should be reserved for second line medical treatment of enterovesical fistulae. [46] The goal of medical therapy is to reduce inflammation while preventing recurrent UTIs, allowing for the fistula tract to heal. Often, symptoms persist or recur, necessitating a surgical repair of the enterovesical fistula.

The goal of operative management of enterovesical fistulae is to resect the involved small bowel segment, and then performing an enteroenteric re-anastomosis. In addition, the hole in the bladder is closed. This repair may be endoscopic, open, or laparoscopic.

Laparoscopic repair of ileovesical fistula is currently the most frequent approach. [45] In the majority of cases, the resection can be done with a primary re-anastomosis of bowel segments. The bowel is bluntly dissected of the bladder wall. The bladder is then infused with a methylene blue solution via a Foley catheter if the hole is not clearly visible. Once identified, the vesical injury is then oversewed in one or two layers. Although some cystotomies have been left to heal spontaneously once divided from the fistula, it is our practice to attempt primary closure. [46] Some authors have advocated interposing an omental flap between the bladder and bowel, as the high vascularity may promote healing, however, high-level evidence for this technique still lacks. [46, 48]

In turning the attention to the bowel, the fistulous segment should be resected. If deemed feasible, primary reanastomosis should be attempted. A two-stage procedure is recommended in cases where the pathology or operation led to gross contamination of the abdomen with bowel contents, or a large abdominopelvic abscess was noted. [46] A temporary diverting ileostomy can be constructed, with closure of the colon (Hartmann's pouch), and re-anastomosis can be undertaken at a later date. While definitive surgical management of enterovesical fistulae is often quite successful, there is a risk of recurrence, in addition to other postoperative complications including abscess formation, enterocutaneous fistula development at the anastomotic site and anastomotic failure.

Anti-TNF Alpha Biologic Therapy

An integral component of the medical treatment of fistulizing Crohn's disease is the use of chimeric monoclonal antibodies, or human monoclonal antibodies against tumor necrosis factor alpha (TNF-alpha). The best known in this class are infliximab or adalimumab, and are reviewed. Briefly, TNF-alpha is a proinflammatory cytokine implicated in the pathogenesis of Crohn's disease.

In 2002, the ACCENT I trial demonstrated that intermittent infliximab infusion therapy maintained remission of Crohn's disease for the duration of the study (54 weeks), and allowed patients to discontinue corticosteroid use. [49] In 2004, the ACCENT II trial showed that infliximab infusion promoted and maintained closure of externally draining fistulae in Crohn's disease, with an acceptable safety profile. [50] This led to FDA approval of infliximab for the treatment of fistulizing Crohn's disease, and its clinical use has since been extended to treat various other manifestations.

The formation of fistulae is a consequence of the transmural inflammation unique to Crohn's disease. It is most prevalent and symptomatic in the perianal region. However, the small bowel is often involved as well. These fistulae require prompt management when they are cutaneous, or with another solid organ such as the bladder. However, fistulae between two segments of bowel, especially when in close proximity, can often be clinically monitored for symptomatology before surgical management.

There is little evidence that supports the use of anti-TNF therapy to treat fistulae involving the small bowel. Its use as a maintenance agent after a bowel resection is not clear as well; recent data demonstrates that infliximab therapy reduces the tensile strength of small bowel anastomoses in a rabbit model. [51] Generally, in fistulizing disease involving an internal fistula in the bowel, the first line treatment is surgery once it becomes symptomatic, while no specific treatment is indicated in asymptomatic cases. [45] In the case of enterovesical fistulae, there is no consensus on the use of anti-TNF therapy at this time.

Perforating Disease of the Small Bowel

Perforating Crohn's disease represents one of the primary phenotypes seen at diagnosis. The perforating phenotype includes symptomatic sequelae of bowel microperforations due to chronic inflammation, including fistulae or abscess. [52] Crohn's disease most often presents as obstruction, however, 50-60% of these patients are noted to have concomitant perforating disease at the time of surgery, and can add additional morbidity to the operation. [14] Notably, a 2013 study by Bellolio, reported that in patients undergoing ileocolic resection for Crohn's disease, those with perforating disease documented either preoperatively or intraoperatively required a more complex procedure, had a longer inpatient stay and were more likely to require a temporary ileostomy. [53]

The presence of perforating disease as the presenting phenotype has been shown to portend more frequent future abdominal operations, faster clinical symptomatic recurrence, and a higher immunosuppression requirement. [52] A suggested algorithm for the management of perforating Crohn's disease is illustrated in Figure 3.

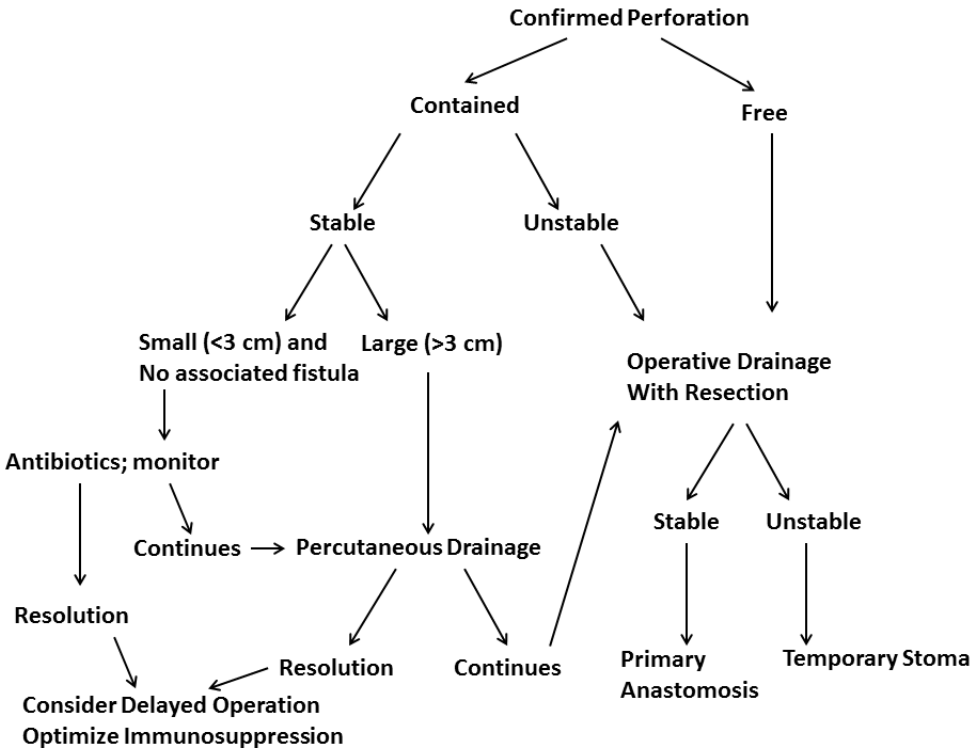

Figure 3. A suggested management algorithm for perforation of the small bowel, adapted in part from Feagins LA, et al., (2011) *Clinical gastroenterology and hepatology*: the official clinical practice journal of the American Gastroenterological Association 9:842-850.

Abscess

Due to the transmural nature of Crohn's disease, one of the most common complications is development of intraabdominal abscess. Abscesses occur in 10-30% of Crohn's disease patients, and are most common between the ages of 20-30. [54, 55] Often, abscesses in Crohn's disease are formed at sites of prior bowel anastomoses. However, as many as 50% of abscesses in Crohn's patients are spontaneous, and form due to microperforations in diseased segments of bowel, usually in the ileocecal region. [55]

Several mechanisms have been proposed for abscess development. The first, and most common, involves transmural inflammation with fistulization to contiguous tissues, allowing for the direct spread of pathogenic bacteria. Second, diseased bowel can disseminate bacteria hematogenously, leading to intra-abdominal seeding. Finally, at the time of operation, peritoneal contamination of the bowel can lead to a complicating postoperative abscess. [56] The complex interactions between the bacteria and host lead to accumulation of neutrophils and the fibrin encasement of the abscess. The abscesses are generally polymicrobial, with *Escherichia coli* and *Enterococcus* as the most commonly isolated aerobes, and *Bacteroidis fragilis* and *Peptostreptococcus* as the most common anaerobes. [57]

The diagnosis of abscess is generally suspected in a patient with Crohn's disease who presents with fever or a new abdominal mass. Radiologic diagnosis is often confirmed with CT or MRI, though ultrasound is a reasonable diagnostic modality for superficial abscesses. Associated complications such as fistulae and stricture are often present, and can be assessed

by using an enterography protocol with the imaging, requiring the patient to consume oral contrast. MR enterography has been shown to be superior to CT enterography in one study, however, either modality provides valuable diagnostic information that can be used to guide management. Nonetheless, approximately 10% of abscesses remain clinically unsuspected, and are diagnosed at laparotomy for refractory disease. [54]

Classically, these abscesses required surgical drainage; however, trends in management have shifted toward the use of medical management alone, or percutaneous drainage. [57, 58] Over the past two decades, multiple studies have been performed examining the success of the several strategies of management of abscesses due to Crohn's disease. In addition to the abscess, the management of immunosuppressive therapy in the face of a septic complication presents a challenge. In theory, the clinician wants to pursue mutually exclusive goals: to preserve immune function to deal with infection, but also suppress the immune response to minimize intestinal inflammation. Usually, in the acute setting, the management of infection trumps the management of inflammation.

After assessment of studies examining the success of percutaneous drainage, Feagins proposed an algorithm for the management of intra-abdominal abscesses in patients with Crohn's disease (Figure 3). [57] Initial management of a spontaneous abscess, regardless of size, location, immunosuppression regimen or associated fistula, involves treatment with a broad-spectrum antibiotic regimen. Appropriate regimens include ticarcillin-clavulanate, ertapenem or moxifloxacin as monotherapy, or dual therapy with metronizadole and a fluoroquinolone (ciprofloxacin or levofloxacin) or an appropriate cephalosporin (i.e. cefazolin, ceftriaxone or cefuroxime). After institution of treatment with antibiotics, an abscess <3 cm can be observed for a short course, with a recommended repeat imaging study 4-6 weeks after initial diagnosis assuming no clinical deterioration. For abscesses >3 cm, or those with an associated fistula or on steroids, percutaneous drainage under radiologic guidance is indicated. If the abscess persists, a resection of the offending bowel region is indicated. If the abscess resolves, immunosuppression therapy can be safely resumed, though a surgical procedure will eventually be required for most patients. [57] There are few simple risk factors that predict the eventual need for operative intervention, but the duration and severity of symptoms typically give some indication of the success of purely medical management.

According to a recent report from the Nationwide Inpatient Sample, of 3,296 hospitalizations for intraabdominal abscesses in patients with Crohn's Disease in 2007, approximately 39% were treated medically, 29% with percutaneous drainage and 32% with surgery, representing a greater than fourfold increase in the use of percutaneous drainage since 1998. [58] Percutaneous abscess drainage is typically performed by interventional radiologists, and can be done under ultrasonographic, CT or fluoroscopic guidance. For typical abscesses, catheter sizes placed in the cavity are between 8 and 16 French, and generally require daily flushing with saline for maintain patency. In clinically improving patients, catheters can be removed when drainage is between 10-20 mL/d, however, if there are persistent signs and symptoms of infection, reimaging may be indicated to assess the placement of the catheter while looking for another potential focus of infection. Conversely, persistently high-output (>50 mL/day) from a percutaneous drain may indicate a contrast study through the catheter. Upon injection of the catheter with contrast, the small bowel can then be assessed for fistulization using X-ray technology. [59]

Percutaneous drainage has a very high success rate, particularly when there is not an associated fistula. Although delayed interval resection of the diseased segment is often required, an initial percutaneous approach is more successful is allowing for a primary re-anastomosis at the time of surgery, rather than temporary diversion, often required in open surgical drainage due to the presence of an infected field or need for perioperative steroids, compromising an anastomosis. [5, 57] Repeated studies have demonstrated that an interval resection following percutaneous drainage allows for an easier operation, with increased likelihood of primary re-anastomosis. [60, 61] Furthermore, Gutierrez demonstrated that two-thirds of abscesses treated percutaneously may not require surgery for at least one year. [56] Though typically reserved for cases not amenable or refractory to percutaneous drainage, an abscess still may be drained surgically. This operation involves thorough irrigation and debridement of the abscess cavity, followed by an en-bloc bowel resection. [57] However, if the abscess is recurrent and the patient is relatively well, a repeated attempt at percutaneous drainage is often performed, although studies assessing optimal management of recurrent spontaneous abscess in Crohn's disease are lacking.

Free Perforation

The most morbid presentation of perforating disease is due to a free perforation into the abdominal cavity. Spontaneous free perforations of the small intestine can be caused by many conditions, including trauma, infections, neoplasms, drugs, vascular disease or, as with Crohn's disease, immune-mediated or inflammatory conditions. [62] Unlike an abscess, which is walled off or contained due to a retroperitoneal location or a closed space, a free perforation usually presents with generalized peritonitis and requires emergent surgical intervention. Fortunately, in Crohn's disease, free perforation is quite rare, estimated to be less than 2%, though higher in Asian populations. [62, 63] The most common location for free perforation is in the ileum, though jejunal and duodenal perforations are also seen. Importantly, they may herald the presence of a Crohn's disease-induced neoplasm such as an adenocarcinoma or lymphoma. [62]

In a stable patient with suspected free perforation, obtaining a plain film of the abdomen is performed concomitantly with resuscitation and initiation of broad spectrum antibiosis. However, the lack of pneumoperitoneum on plain film should not exclude free perforation. Free air is only present in 20% of perforations in Crohn's disease patients, and this percentage may be even lower in ileal disease. [64] The patient is then promptly taken to the operating room for emergent exploration. After thorough examination of the small bowel, resection is performed in almost all cases of perforated jejunoileal disease, followed by primary re-anastomosis or construction of a temporary ileostomy, and thorough irrigation of the abdomen. [62, 65] In the rarer case of a gastroduodenal perforation, debridement and primary repair is recommended. [64]

The choice of diversion has traditionally been a function of the location of perforation, the stability of the patient, and the length of time since presentation. Specifically, the lower in the GI tract toward the rectum, the worse hemodynamic parameters, and the longer the timeline, should all prompt the surgeon to consider diverting ileostomy. In extreme cases, resection without anastomosis, leaving the GI tract in discontinuity with temporary abdominal closure, may be prudent. In these cases, return to the operating room for definitive anastomosis or stoma formation should follow the index operation within 48 hours.

OPERATIVE CONSIDERATIONS AND TECHNIQUE

General

In any Crohn's operation, the full length of the small bowel should be examined and described in the operative note. As it is a transmural process, the extent of Crohn's disease is defined by visual inspection of the bowel. Palpation of the mesenteric margin of the bowel wall is another key indicator of the extent of disease: once the margin is easily palpable, normal intestine has been reached. [2]

Resection

The first step to resection is to identify the extent of disease using radiographic and tactile guidance. It is unnecessary to remove bowel to negative micro- or macroscopic margins. For example, there is no need to resect areas of aphthous ulcers on otherwise healthy mucosa. [2] As alluded to previously, following the resection, a stapled anastomosis has a slightly less recurrence rate than a hand-sewn approach. [36] A paper by He supports this approach, and also advocates for a side-to-side anastomosis based on results from their meta-analysis. [66] The side-to-side anastomosis results in greater luminal width of the bowel. Finally, because of the recurrent nature of the disease, the surgeon should measure and document the extent of small intestine resected.

Not all patients benefit from an immediate anastomosis; as many as 20% will require a temporary ileostomy following ileocecal resection. [2] Common scenarios that require this approach include patients with poor nutritional status, chronic steroid therapy, sepsis, and the presence of an enterocutaneous fistula. [2] There is no literature to suggest any benefit to choosing either a loop or end ileostomy in these cases, however recent data suggests that anastomotic complications can be reduced by performance of a split-stoma in these "high-risk" patients that have at least two of the aforementioned factors. [67] A split-stoma involves exteriorization of both free ends of bowel after resection, with delayed re-anastomosis. Diversion is beneficial because it allows time for treatment of the underlying nutritional deficiency or heightened state of inflammation. Additionally, there is a growing body of evidence to suggest that fecal diversion, in and of itself, is associated with a lower risk of recurrence. [35] The mechanism is not entirely understood but is thought to be related to the integrity (or lack thereof in active Crohn's patients) of the intestinal mucosa as well as through a lack of fecal stasis in a narrow anastomosis. [35, 68-70]

Strictureplasty

The majority of patients (70-90%) with small bowel Crohn's Disease will require an operation at some point in their clinical course. [71] Patients with acute perforation, or those with focal disease, are primarily candidates for segmental resection. Generally, 40-50% resection of small bowel length is well tolerated, less if the ileocecal valve is not left intact.

[72] However, it may be those with medically refractory disease, or those with poor compliance, who are at risk for short gut syndrome.

Short gut syndrome is a functional entity, and there is no specific length of bowel that serves as a reliable threshold to predict the need for supplemental parenteral nutrition. However, short gut syndrome typically occurs in adults with fewer than 200 cm of intestine, and can be a significant problem in the Crohn's population. [73] When there is too little small bowel, malabsorption of both micronutrients and macronutrients can result. Ileal resection can rapidly lead to large fluid losses, and inability to absorb certain nutrients such as vitamin B_{12}. Jejunal resections, while generally better tolerated, can also lead to nutrient deficiencies. [72]

Additionally, extensive loss of small bowel length can cause a hormonal imbalance. Notably, the negative feedback mechanism for gastrin generation is removed leading to hypergastrinemic peptic ulcer disease and gastroesophageal reflux. [74] Short gut syndrome, therefore, necessitates close monitoring of nutritional status, frequent supplementation and carries the potential for harmful systemic sequelae, including a decreased life expectancy. [75] As such, when feasible, minimization of small bowel resection is advantageous. The strictureplasty is such a surgical technique, one in which one or multiple small bowel strictures are surgically opened, rather than resected, presenting an alternative, bowel-preserving operation for patients with a history of segmental resection. [76]

For non-phlegmanous small bowel Crohn's disease causing fibrotic strictures with symptomatic obstruction, the strictureplasty is the current treatment of choice. [77] The strictureplasty was first described by Katariya in 1977, in which a small case series of nine patients with obstructing tubercular strictures who underwent the procedure was described. [78] Within the next several years, the procedure was adapted to patients with Crohn's Disease, and early results of patients with strictureplasty as an alternative to bowel resection in small bowel disease were promising. The first report of strictureplasty for Crohn's Disease of the small bowel, reported by Lee, examined nine patients with chronic intestinal obstruction, as diagnosed by barium enema or enteroclysis. Using strictureplasty as one of three methods of relief of obstruction (minimal resections and short-segment bypasses were also used), no major complications were observed yet a lasting benefit was realized in terms of weight gain up to three years postoperatively. [79] Suddenly, the strictureplasty for small bowel Crohn's Disease gained favor as a safe and effective alternative for obstructing small bowel lesions. The procedure has developed such that there are several variations in surgical technique, dependent primarily on stricture length. These techniques are the Heineke-Mikulicz, Finney, Jaboulay and Michelassi, and will be described further.

Indications for Strictureplasty

The use of strictureplasty has expanded throughout the last two decades. Initially, the technique was used in only fibrotic structures. It is now a recognized procedure in patients with active disease. In 2006, Roy retrospectively examined 73 strictureplasties in 14 patients, in active, obstructive jejunoileal Crohn's disease, and found no worse recurrence and complication rates relative to limited resection. Despite the limited sample size and low level of evidence, the increased experience with, and improvement of the strictureplasty technique combined with the reported safety and efficacy profile, expanded the use of strictureplasty to patients with active, obliterative disease in addition to fibrotic lesions. [80]

In the 1980s, the strictureplasty technique was applied conservatively, as small (<10cm) strictures incised longitudinally and re-apposed transversely, a method analogous to the

Heinecke-Mikulicz technique for pyloroplasty. [81] However, the ability to successfully open longer strictures developed over the next 20 years, further expanding the indications for strictureplasty over resection in obstructive Crohn's disease. Not long after the Heinecke-Mikulicz technique was used, longer strictures (~12cm-25cm) were opened with the Finney procedure, a side-to-side anastomosis also previously used for pyloroplasty, with good results and few complications. Subsequently, in 1996, Michelassi described a side-to-side isoperistaltic strictureplasty method that is currently recommended for long-segment strictures (>25cm) or multiple closely-grouped short strictures. [82] In describing this technique, for which multiple modifications have since been made, the feasibility of strictureplasty as an alternative to segmental resection greatly increased. [77] Now, strictureplasty presents a viable option for patients with even long segment strictures and may thus prolong or prevent the necessity of enterectomy and subsequent development of symptomatic short gut syndrome.

There are several current indications for small bowel strictureplasty in Crohn's disease. Primarily, its use is indicated in patients with multiple strictures over a long segment of bowel, especially critical in patients with a history of prior bowel resections over >100 cm, or with short gut syndrome. In addition, patients with rapid recurrence of disease with obstruction, or strictures at previous anastomotic sites, particularly ileorectal or ileocolic, are also candidates for strictureplasty. [83, 84] Currently, evidence supports the use of strictureplasty primarily in the jejunal and ileal regions, as treatment of duodenal strictures has yet to be sufficiently investigated to recommend strictureplasty over bypass or resection, primarily due to the low prevalence of duodenal stricturing disease. [17, 84-86]

Contraindications

Performance of strictureplasty is contraindicated in certain instances. Preoperative malnutrition is a contraindication to strictureplasty, as it is with any procedure involving intestinal anastomoses. A serum albumin level <2.0 g/dL is reported as a cutoff for prohibitive malnutrition. [83] The presence of focal pathology such as phlegmon, fistula or perforation is a contraindication to strictureplasty throughout the length of the small bowel. Sepsis due to acute inflammation of the bowel is a sign that portends a poor ability of the bowel to hold suture, and strictureplasty in such a systemic inflammatory setting is highly likely to fail. Additional contraindications to strictureplasty include a stricture next to a site of planned resection and likelihood of tension on closure of strictureplasty. [83, 84]

Techniques of Strictureplasty

Heinecke-Mikulicz

The Heineke-Mikulicz technique, described in 1888, was initially used for pyloroplasty. It popularized the concept of increasing the luminal diameter without resection, and remains a tenet of pyloroplasty in adults, primarily as a component of an acid-reducing operation. [87, 88] The procedure is most useful and safe for strictures under ten centimeters in length, and begins with determination of the location of stricture. This is generally done by palpation of the full length of small bowel, often with radiologic guidance. Once the operative site is identified, a full-thickness longitudinal incision through the bowel wall is made overlying the

strictured region, on the anti-mesenteric border (Figure 4). The incision is then closed transversely, generally using interrupted absorbable sutures. As the bowel wall is often edematous, stapling is not generally used for the transverse re-apposition. [83]

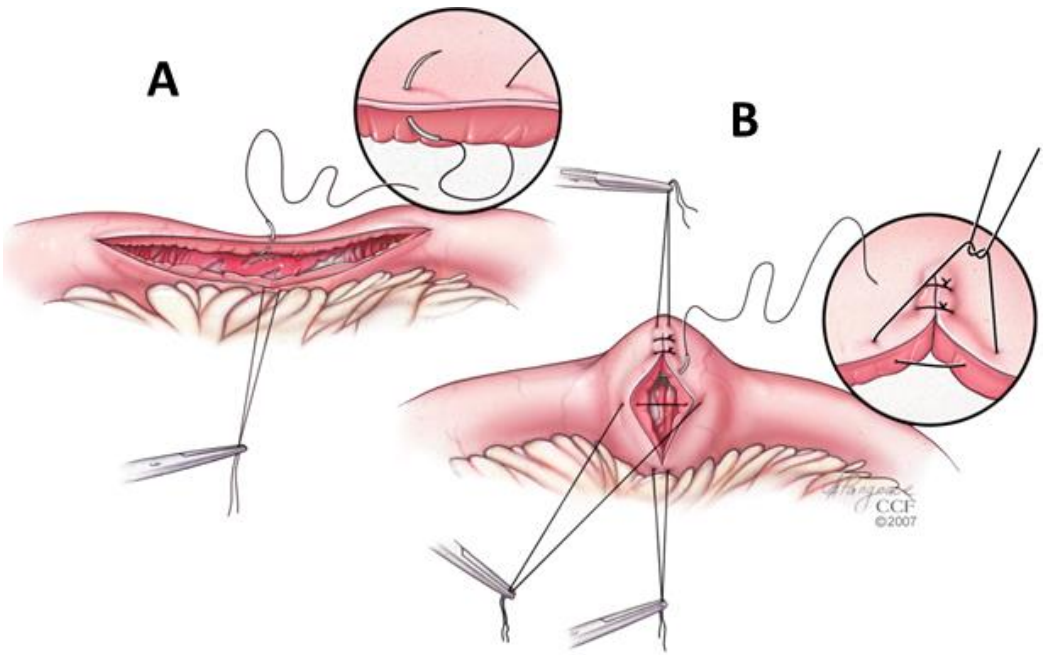

Figure 4. Heineke-Mikulicz strictureplasty. A: The stricture site is identified and a longitudinal incision made at the site. B: Stay sutures are used to distract the incision, and the incision is closed transversely in one or two layers. (Reprinted with permission from Cleveland Clinic Center for Medical Art and Photopgraphy; initially found in Hesham W, Kann BR (2013) *Clinics in colon and rectal surgery* 26:80-83).

Finney and Jaboulay

The Finney strictureplasty is the approach of choice for small bowel strictures between 10cm-25cm in length. In this approach, the strictured segment is folded in a U-configuration with a stay suture placed at the base of the "U" (Figure 5). An enterotomy is made, again on the antimesenteric aspect of bowel. Finally, the afferent and efferent limbs of the segment are sewn together in a side-to-side fashion using a full-thickness running absorbable suture for reapproximation of the posterior aspect, and an interrupted closure of the anterior aspect. [84] Alternatively, the anastomosis can be stapled. [89] The Jaboulay strictureplasty technique is similar to the Finney strictureplasty. In the Jaboulay technique, the "U" shape is created, but two separate longitudinal incisions are made. The enteroenterostomy is then fashioned in a side-to-side fashion effectively bypassing the primary strictured region. [83] There have been multiple techniques reported that include variations of the Finney and Jaboulay strictureplasties as well, however, for Crohn's disease strictures under <25 cm, these two operations are the fundamental.

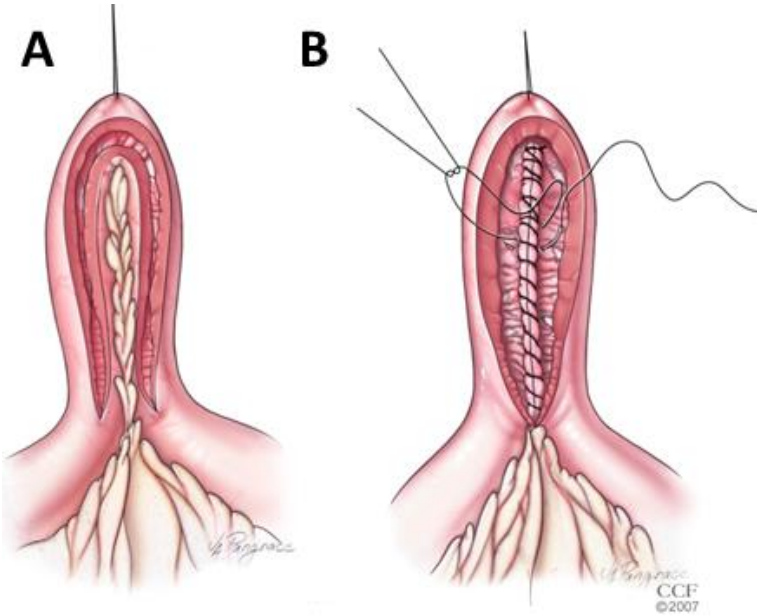

Figure 5. Finney type strictureplasty. A: The bowel is folded on itself at the region of the stricture. B: The side walls may be divided using a stapling device or via hand-sewn techniques. The enterotomy is closed via suture. (Reprinted with permission from Cleveland Clinic Center for Medical Art and Photography; initially found in Hesham W, Kann BR (2013) *Clinics in colon and rectal surgery* 26:80-83).

Michelassi

In 1996, Michelassi reported a technique for longer-segment (>25cm) strictureplasty in patients with stricturing disease of the small bowel due to Crohn's disease (Figure 6).

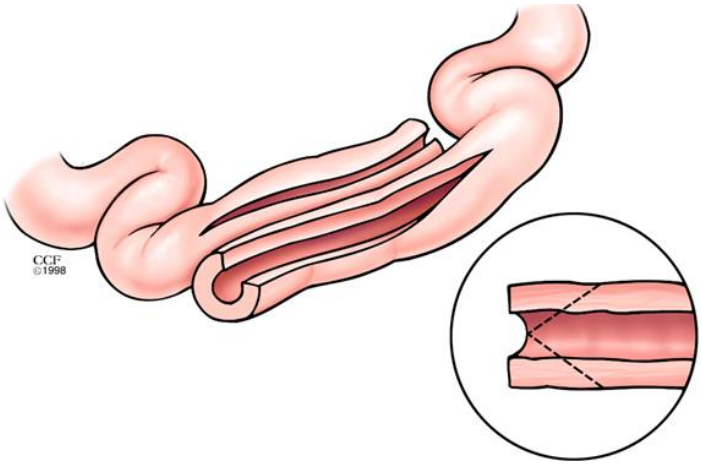

Figure 6. Michelassi (isoperistaltic, side-to-side) strictureplasty. (Reprinted with permission from Cleveland Clinic Center for Medical Art and Photography; initially found in Hesham W, Kann BR (2013) *Clinics in colon and rectal surgery* 26:80-83).

The eponymous technique can be used for a long continuous stricture, or for multiple strictures in close proximity, as an alternative to the Heinecke-Mikulicz, Finney and Jaboulay approaches. In this technique, the portion of diseased bowel is isolated with atraumatic bowel clamps, first dividing the associated mesentery at its midpoint. The proximal and distal loops are apposed in a side-to-side fashion, and a formal enteroenterostomy is made. At this step, stenotic areas of one loop should be opposed to dilated areas of the other loop to avoid persistent narrowing. Two layer closures of the enteroenterostomy and the blind ends are then made with non-absorbable sutures, in an interrupted fashion. This technique, or its variations, yields a side-to-side isoperistaltic strictureplasty. [77]

Modifications have been made to these conventional approaches to strictureplasty. These techniques have recently been summarized by Campbell. [90]

THE ROLE OF LAPAROSCOPY

Laparoscopic techniques have been used successfully in all aspects of management of Crohn's disease. Although they are reviewed extensively in other chapters, in skilled hands laparoscopic resection offers at least equivalent intestinal outcomes while minimizing trauma to the abdominal wall. Laparoscopic techniques have been applied to the small bowel since the 1990s, and several centers offer these advanced procedures to patients.

It should be noted that minimally invasive techniques represent a potential trap for the inexperienced surgeon. To begin with, the mesentery is deceptively thickened in many patients, and requires subtle changes in technique to ensure adequate hemostasis. Secondly, identification of inflamed segments of bowel becomes a visual exercise instead of a tactile one. Further, it is remarkably easy to traumatize the bowel while running the length laparoscopically, so that enterotomies may occur distant from the line of transection. Last, estimation of the length of bowel may be inaccurate in the laparoscopic setting due to the well-known phenomenon of errors inherent in the magnification afforded by the laparoscope.

A recent Cochrane review analyzed laparoscopic surgery for small bowel Crohn's disease. [91] Although only two randomized controlled trials were included, the reviewers found that there was a significant decrease in wound infection, intra-abdominal abscess, length of stay, and postoperative ileus with laparoscopic techniques. In addition, there was the suggestion that the risk of herniation was smaller in the laparoscopic group.

The safety of laparoscopic ileocecectomy, the most common laparoscopic small bowel operation in Crohn's disease patients,[92] was very recently evaluated by Antoniou as a best evidence topic. Five observational studies, three follow-up studies, two randomized trials and a meta-analysis were considered. [93] The report found that perioperative outcomes were similar to open surgery, and that the laparoscopic approach was safe for uncomplicated disease, assuming appropriate expertise of the surgeon. [93] On the other hand, leak rates of laparoscopic anastomoses may be higher, and there is little evidence that laparoscopic techniques lead to superior outcomes in the long-term.

There are other tangible benefits to the laparoscopic approach. For instance, some studies have shown that laparoscopy offered improved pulmonary function perioperatively. [94] There is potential for improved cosmesis and improved abdominal wall function that may restore the patient psychologically more than a generous midline laparotomy. In addition,

many patients will require multiple operations over their lifetimes, and it is advantageous to minimize trauma to the abdominal wall during each incursion. There is also decrease in the extent of adhesion formation, which is of critical importance to these patients who often face multiple operations. [95]

While laparoscopy for Crohn's disease offers is associated with decreased costs and hospital stay,[96] it comes at the expense of longer operative times. [97] Furthermore, patients with palpable masses or fistulizing disease are more likely to require intraoperative conversion, and may benefit from an initial open approach. [98] Laparoscopy is also feasible in patients with recurrent Crohn's disease, particularly so in non-fistulizing recurrent disease. [36, 99] In fact, single port laparoscopy is increasingly becoming a viable option for Crohn's disease operations. [100] It may be that the outcomes are dependent on surgeon experience, which we are often reluctant to admit as a specialty. Nonetheless, at this time, then, we advocate minimally invasive surgery as an initial approach for even patients with complex disease.

POSTOPERATIVE CONSIDERATIONS

There are few clear guidelines regarding the medical management of patients with Crohn's in the immediate postoperative period with exception to the use of immunosuppressive medication. Regarding general care, we advocate for the prompt resumption of enteral/parenteral nutrition as soon as the patient can tolerate. Because some patients may have lost a significant portion of their terminal ileum, they may be at risk for vitamin B_{12} deficiency and bile malabsorption. B_{12} stores are readily treated with oral supplementation, whereas bile-acids may necessitate sequestrants to prevent diarrhea. Fluid balance should also be attended to appropriately.

There is some general consensus concerning the administration of immunomodulatory medication. This can be subdivided into the use of these medications in the immediate perioperative period and over the long term as recurrence prevention. The latter will be discussed later in the chapter. 5-Aminosalicylic acid (5-ASA) drugs are eliminated renally with a short half-life and can be stopped a day before surgery and restarted postoperative day two. [101] Resumption of thiopurine therapy can commence on the second postoperative day providing that renal function is within normal limits. [101] There is mixed data regarding the use of biologics in the perioperative setting, however, it is notable that infliximab has a long half-life of 8-9.5 days. [101] Thus, it is reasonable to stop biologicals a month in advance of a planned surgery.

Postoperative surveillance is essential to monitor for either endoscopic or clinical recurrence, both of which will be outlined in the following section. The current paradigm is that endoscopic recurrence is the first manifestation of recurrent Crohn's disease, though not all endoscopic disease manifests clinically. [102] To monitor for endoscopic recurrence, the standard of care is to perform follow-up endoscopy one-year postoperatively. De Cruz showed that "endoscopically targeted therapy," with appropriate escalation of treatment if there were identifiable areas of recurrence at 6 month endoscopy, resulted in superior outcomes to the standard of care. [102-104]

OUTCOMES AND RECURRENT DISEASE

Recurrent Crohn's disease can be stratified into endoscopic recurrence or clinical recurrence. Endoscopic recurrence is disappointingly common on routine follow-up endoscopy, most often occurs within one year postoperatively, and is a risk factor for clinical recurrence. [105] Endoscopic recurrence after ileocecal surgery has been reported to be 79% at 1-3 years post-ileocecectomy, and can be characterized the Rutgeerts scoring system, a measure of severity of endoscopic lesions. [106, 107] A score of 0 reflects no lesions, 1 reflects <5 apthuous ulcers, and a spectrum of inflammatory lesions continues up to a score of 4, reflecting diffuse inflammation with large ulcers, nodules and narrowing. Generally, a score of 1 of greater indicates endoscopic recurrence. [108, 109]

Clinical recurrence can be broadly defined as the recrudescence of severe symptoms after a primary operation, generally a resection. It can also be quantified by the Crohn's disease activity index (CDAI), the most popular of the scores used to quantify clinical severity of disease. This index is calculated from eight patient variables, including stool number and quality, abdominal pain severity, daily well-being scores, extraintestinal symptoms, antidiarrheal regimen, presence of an abnormal mass, hematocrit and body weight. [110] A CDAI>150 is taken to indicate recurrent disease. [109, 110] Clinical recurrence rates in the absence of treatment are estimated at 10-30% during the first year postoperatively, and in excess of 60% in the first decade postoperatively. [105]

Reoperations for recurrence have been approximated to be 10%-30% at 5 years, 20%-40% at 10 years and up to 60% at 20 years postoperatively. [16, 111] Reoperation, however, requires endoscopic confirmation, as the CDAI may be high in patients with symptoms or very low in patients with a severe recurrence, making postoperative endoscopy mandatory. Patients undergoing a first or second reoperation tend to have similar long-term clinical courses as those without an additional procedure. However, postoperative complications are increased, and length of stay is longer in reoperative surgery. [112] Patients with multiple reoperations will continue to experience more frequent recurrences of active disease, and have a shorter time until a permanent ileostomy is required. [36, 113] For obstructive disease, strictureplasties are often performed at the time of reoperation, if not the first operation, to preserve bowel. Cumulative reoperative rates after small bowel strictureplasty are between 22-45%, with a rate of re-stricture at the strictureplasty site estimated at 5-9%, higher at sites of ileocecal strictureplasties. [23, 36, 114-116]

There has been substantial research directed towards identifying risk factors that predispose one to recurrent disease in an attempt to stratify patients into either high or low risk categories. The most consistent risk factor in the literature is cigarette smoking, which consistently has demonstrated a significant association with recurrence. [102, 109, 117] In addition, evidence suggests that a history of prior resection, perforating disease, and myenteric plexitis are independent risk factors for recurrence. [102, 109, 117] Many other risk factors have been identified to predict recurrence in small studies, however, the results have either been ambiguous, or without external validation. These factors include gender, a positive family history of inflammatory bowel disease, a younger age of onset, a history of prior resection and the presence of small bowel or ileocecal disease over other locations. [104, 117]

With the identification of risk factors and the advent of stratification, patients are able to receive more tailored therapy. The first step for prevention of recurrent disease is smoking cessation. Medical therapies to prevent recurrence include drugs typically used in the treatment of Crohn's disease. However mesalamine and other similar 5-aminosalicylic (5-ASA) compounds provide only minor benefit in prevention across all risk categories. [102, 109, 117] Domenech suggested this benefit may be due to a delay in clinical symptoms, and not actually prevention of endoscopic recurrence. [117] It is generally accepted, however, that 5-ASA compounds are relatively well-tolerated and inexpensive, thus their use has been widespread. Thiopurines, including azathioprine and 6-mercaptopurine, are generally accepted to be first line therapy for low-risk patients. They exhibited a relative risk reduction for clinical recurrence vs. placebo of 0.59 (95% CI: 0.38-0.92) and endoscopic recurrence vs. placebo of 0.64 (95% CI: 0.44-0.92). [102] For high risk patients, anti-TNF agents are recommended as they had a greater relative risk reduction compared to placebo, with the recommendation to start them two to three weeks after surgery. [109, 117].

Not surprisingly, the most recent research suggests that anti-TNF agents are more efficacious than thiopruines in the prevention of recurrence. [103] Probiotics, interleukin-10, and steroids have all proven ineffective for postoperative prophylaxis. [102, 103, 117] There is some evidence that suggests nitroimidazole antibiotics, e.g. metronidazole, will decrease risk in the immediate postoperative setting when given for one month following the surgery, but side-effects and compliance prevent the widespread use of these as an adjunctive therapy. [102]

CONCLUSION

Crohn's disease is highly variable in its location and severity of presentation. Most patients, however, will require operative intervention during their clinical course. Small bowel involvement is quite common, particularly in the terminal ileum and cecum. While there are a variety of disease phenotypes and surgical indications, there remain guiding principles of surgical management of small bowel Crohn's disease. First, the goal of surgery is to make the operation as safe as possible. This involves directed preoperative imaging and optimization, as well as appropriate postoperative care and endoscopic followup. [16] Next, as serial operations are often necessary, conservation of bowel is paramount. [16] This can be accomplished by minimization of resection margins, or performance of strictureplasty for obstructing disease, a technique that can be accomplished in a variety of ways. Finally, the surgeon must recognize that unlike ulcerative colitis, Crohn's disease can not be treated with excision, rather, only complications and severe symptoms should be pursued operatively. As with any surgical procedure, the surgeon should be certain an operation will truly benefit the patient, and also consider whether a laparoscopic approach may be beneficial. [16]

REFERENCES

[1] Wagner IJ, Rombeau JL (2011) Nutritional support of surgical patients with inflammatory bowel disease. *The Surgical clinics of North America* 91:787-803, viii.

[2] Delaney CP, Fazio VW (2001) Crohn's disease of the small bowel. *The Surgical clinics of North America* 81:137-158, ix.

[3] Kim YL, Park YS, Park EK, Park DR, Choi GS, Ahn SB, Kim SH, Jo YJ (2014) Refractory duodenal Crohn's disease successfully treated with infliximab. *Intestinal research* 12:66-69.

[4] Poldermans D, Bax JJ, Boersma E, De Hert S, Eeckhout E, Fowkes G, Gorenek B, Hennerici MG, Iung B, Kelm M, Kjeldsen KP, Kristensen SD, Lopez-Sendon J, Pelosi P, Philippe F, Pierard L, Ponikowski P, Schmid JP, Sellevold OF, Sicari R, Van den Berghe G, Vermassen F, Hoeks SE, Vanhorebeek I, Vahanian A, Auricchio A, Bax JJ, Ceconi C, Dean V, Filippatos G, Funck-Brentano C, Hobbs R, Kearn P, McDonag T, McGregor K, Popescu BA, Reiner Z, Sechtem U, Sirnes PA, Tendera M, Vardas P, Widimsky P, De Caterina R, Agewall S, Al Attar N, Andreotti F, Anker SD, Baron-Esquivias G, Berkenboom G, Chapoutot L, Cifkova R, Faggiano P, Gibbs S, Hansen HS, Iserin L, Israel CW, Kornowski R, Eizagaechevarria NM, Pepi M, Piepoli M, Priebe HJ, Scherer M, Stepinska J, Taggart D, Tubaro M, Task Force for Preoperative Cardiac Risk A, Perioperative Cardiac Management in Non-cardiac Surgery of European Society of C, European Society of A (2010) Guidelines for pre-operative cardiac risk assessment and perioperative cardiac management in non-cardiac surgery: the Task Force for Preoperative Cardiac Risk Assessment and Perioperative Cardiac Management in Non-cardiac Surgery of the European Society of Cardiology (ESC) and endorsed by the European Society of Anaesthesiology (ESA). *European journal of anaesthesiology* 27:92-137.

[5] Sharma A, Chinn BT (2013) Preoperative optimization of crohn disease. *Clinics in colon and rectal surgery* 26:75-79.

[6] Makela JT, Kiviniemi H, Laitinen S (2003) Risk factors for anastomotic leakage after left-sided colorectal resection with rectal anastomosis. *Diseases of the colon and rectum* 46:653-660.

[7] Zoli G, Care M, Parazza M, Spano C, Biagi PL, Bernardi M, Gasbarrini G (1997) A randomized controlled study comparing elemental diet and steroid treatment in Crohn's disease. *Alimentary pharmacology & therapeutics* 11:735-740.

[8] Takahashi H, Ando T, Watanabe O, Maeda O, Ishiguro K, Ohmiya N, Niwa Y, Goto H (2007) Usefulness of an elemental diet in Crohn's disease. *Inflammopharmacology* 15:15-17.

[9] Macdonald A (2006) Omega-3 fatty acids as adjunctive therapy in Crohns disease. *Gastroenterology nursing : the official journal of the Society of Gastroenterology Nurses and Associates* 29:295-301; quiz 302-293.

[10] Jacobson S (2012) Early postoperative complications in patients with Crohn's disease given and not given preoperative total parenteral nutrition. *Scandinavian journal of gastroenterology* 47:170-177.

[11] Tsujikawa T, Andoh A, Fujiyama Y (2003) Enteral and parenteral nutrition therapy for Crohn's disease. *Current pharmaceutical design* 9:323-332.

[12] Wille-Jorgensen P, Guenaga KF, Matos D, Castro AA (2005) Pre-operative mechanical bowel cleansing or not? an updated meta-analysis. *Colorectal disease : the official journal of the Association of Coloproctology of Great Britain and Ireland* 7:304-310.

[13] Efron JE, Young-Fadok TM (2007) Preoperative optimization of Crohn's disease. *Clinics in colon and rectal surgery* 20:303-308.

[14] Sampietro GM, Casiraghi S, Foschi D (2013) Perforating Crohn's disease: conservative and surgical treatment. *Digestive diseases* 31:218-221.

[15] Ripolles T, Martinez-Perez MJ, Paredes JM, Vizuete J, Garcia-Martinez E, Jimenez-Restrepo DH (2013) Contrast-enhanced ultrasound in the differentiation between phlegmon and abscess in Crohn's disease and other abdominal conditions. *European journal of radiology* 82:e525-531.

[16] Yamamoto T, Watanabe T (2014) Surgery for luminal Crohn's disease. *World journal of gastroenterology*: WJG 20:78-90.

[17] Shapiro M, Greenstein AJ, Byrn J, Corona J, Greenstein AJ, Salky B, Harris MT, Divino CM (2008) Surgical management and outcomes of patients with duodenal Crohn's disease. *Journal of the American College* of Surgeons 207:36-42.

[18] Murray JJ, Schoetz DJ, Jr., Nugent FW, Coller JA, Veidenheimer MC (1984) Surgical management of Crohn's disease involving the duodenum. *American journal of surgery* 147:58-65.

[19] Fix OK, Soto JA, Andrews CW, Farraye FA (2004) Gastroduodenal Crohn's disease. *Gastrointestinal endoscopy* 60:985.

[20] Carbo AI, Sangster GP, Caraway J, Heldmann MG, Thomas J, Takalkar A (2014) Acquired constricting and restricting lesions of the descending duodenum. *Radiographics : a review publication of the Radiological Society of North America*, Inc 34:1196-1217.

[21] Racz JM, Davies W (2012) Severe stricturing Crohn's disease of the duodenum: A case report and review of surgical options. *International journal of surgery case reports* 3:242-245.

[22] Fichera A, Michelassi F (2007) Surgical treatment of Crohn's disease. *Journal of gastrointestinal surgery : official journal of the Society for Surgery of the Alimentary Tract* 11:791-803.

[23] Dietz DW, Laureti S, Strong SA, Hull TL, Church J, Remzi FH, Lavery IC, Fazio VW (2001) Safety and longterm efficacy of strictureplasty in 314 patients with obstructing small bowel Crohn's disease. *Journal of the American College of Surgeons* 192:330-337; discussion 337-338.

[24] Tichansky D, Cagir B, Yoo E, Marcus SM, Fry RD (2000) Strictureplasty for Crohn's disease: meta-analysis. *Diseases of the colon and rectum* 43:911-919.

[25] Reese GE, Purkayastha S, Tilney HS, von Roon A, Yamamoto T, Tekkis PP (2007) Strictureplasty vs resection in small bowel Crohn's disease: an evaluation of short-term outcomes and recurrence. *Colorectal disease : the official journal of the Association of Coloproctology of Great Britain and Ireland* 9:686-694.

[26] Fichera A, Zoccali M, Kono T (2012) Antimesenteric functional end-to-end handsewn (Kono-S) anastomosis. *Journal of gastrointestinal surgery : official journal of the Society for Surgery of the Alimentary Tract* 16:1412-1416.

[27] Kono T, Fichera A (2014) Kono-S anastomosis for Crohn's disease: narrative - a video vignette. *Colorectal disease : the official journal of the Association of Coloproctology of Great Britain and Ireland* 16:833.

[28] Benoist S, Panis Y, Beaufour A, Bouhnik Y, Matuchansky C, Valleur P (2003) Laparoscopic ileocecal resection in Crohn's disease: a case-matched comparison with open resection. *Surgical endoscopy* 17:814-818.

[29] Tonelli F, Fazi M, Di Martino C (2010) Ileocecal strictureplasty for Crohn's disease: long-term results and comparison with ileocecal resection. *World journal of surgery* 34:2860-2866.

[30] Fazio VW, Marchetti F, Church M, Goldblum JR, Lavery C, Hull TL, Milsom JW, Strong SA, Oakley JR, Secic M (1996) Effect of resection margins on the recurrence of Crohn's disease in the small bowel. A randomized controlled trial. *Annals of surgery 224*:563-571; discussion 571-563.

[31] Michelassi F, Sultan S (2014) Surgical treatment of complex small bowel Crohn disease. *Annals of surgery* 260:230-235.

[32] Hashemi M, Novell JR, Lewis AA (1998) Side-to-side stapled anastomosis may delay recurrence in Crohn's disease. *Diseases of the colon and rectum* 41:1293-1296.

[33] Yamamoto T, Bain IM, Mylonakis E, Allan RN, Keighley MR (1999) Stapled functional end-to-end anastomosis versus sutured end-to-end anastomosis after ileocolonic resection in Crohn disease. *Scandinavian journal of gastroenterology* 34:708-713.

[34] Scarpa M, Angriman I, Barollo M, Polese L, Ruffolo C, Bertin M, D'Amico DF (2004) Role of stapled and hand-sewn anastomoses in recurrence of Crohn's disease. *Hepato-gastroenterology* 51:1053-1057.

[35] McLeod RS, Wolff BG, Ross S, Parkes R, McKenzie M, Investigators of the CT (2009) Recurrence of Crohn's disease after ileocolic resection is not affected by anastomotic type: results of a multicenter, randomized, controlled trial. *Diseases of the colon and rectum* 52:919-927.

[36] Ramirez RL, Fleshner P (2006) Reoperative inflammatory bowel disease surgery. *Clinics in colon and rectal surgery* 19:195-206.

[37] Scharl M, Rogler G (2014) Pathophysiology of fistula formation in Crohn's disease. *World journal of gastrointestinal pathophysiology* 5:205-212.

[38] Gecse K, Khanna R, Stoker J, Jenkins JT, Gabe S, Hahnloser D, D'Haens G (2013) Fistulizing Crohn's disease: Diagnosis and management. *United European gastroenterology journal* 1:206-213.

[39] Bouhnik Y, Panis Y (2003) [Therapeutic strategies of fistulous Crohn's disease: medical or surgical treatment?]. *Gastroenterologie clinique et biologique* 27:S98-103.

[40] Lichtenstein GR (2000) Treatment of fistulizing Crohn's disease. *Gastroenterology* 119:1132-1147.

[41] Levy C, Tremaine WJ (2002) Management of internal fistulas in Crohn's disease. *Inflammatory bowel diseases* 8:106-111.

[42] Yoon YS, Yu CS, Yang SK, Yoon SN, Lim SB, Kim JC (2010) Intra-abdominal fistulas in surgically treated Crohn's disease patients. *World journal of surgery* 34:1924-1929.

[43] Solem CA, Loftus EV, Jr., Tremaine WJ, Pemberton JH, Wolff BG, Sandborn WJ (2002) Fistulas to the urinary system in Crohn's disease: clinical features and outcomes. *The American journal of gastroenterology* 97:2300-2305.

[44] Broe PJ, Bayless TM, Cameron JL (1982) Crohn's disease: are enteroenteral fistulas an indication for surgery? *Surgery* 91:249-253.

[45] Bouhnik Y (2003) [Medical management of inflammatory bowel disease: consensus and controversies]. *Gastroenterologie clinique et biologique* 27:S87-91.

[46] Golabek T, Szymanska A, Szopinski T, Bukowczan J, Furmanek M, Powroznik J, Chlosta P (2013) Enterovesical fistulae: aetiology, imaging, and management. *Gastroenterology research and practice* 2013:617967.

[47] Su YR, Shih IL, Tai HC, Wei SC, Lin BR, Yu HJ, Huang CY (2014) Surgical management in enterovesical fistula in Crohn disease at a single medical center. *International surgery* 99:120-125.

[48] O'Leary DP (1999) Use of the greater omentum in colorectal surgery. *Diseases of the colon and rectum* 42:533-539.

[49] Hanauer SB, Feagan BG, Lichtenstein GR, Mayer LF, Schreiber S, Colombel JF, Rachmilewitz D, Wolf DC, Olson A, Bao W, Rutgeerts P, Group AIS (2002) Maintenance infliximab for Crohn's disease: the ACCENT I randomised trial. *Lancet* 359:1541-1549.

[50] Sands BE, Anderson FH, Bernstein CN, Chey WY, Feagan BG, Fedorak RN, Kamm MA, Korzenik JR, Lashner BA, Onken JE, Rachmilewitz D, Rutgeerts P, Wild G, Wolf DC, Marsters PA, Travers SB, Blank MA, van Deventer SJ (2004) Infliximab maintenance therapy for fistulizing Crohn's disease. *The New England journal of medicine* 350:876-885.

[51] Jensen JS, Petersen NB, Biagini M, Bollen P, Qvist N (2014) Infliximab treatment reduces tensile strength in intestinal anastomosis. *The Journal of surgical research*.

[52] Louis E, Reenaers C, Belaiche J (2008) Does the phenotype at diagnosis (e.g., fibrostenosing, inflammatory, perforating) predict the course of Crohn's disease? *Inflammatory bowel diseases* 14 Suppl 2:S59-60.

[53] Bellolio F, Cohen Z, Macrae HM, O'Connor BI, Huang H, Victor JC, McLeod RS (2013) Outcomes following surgery for perforating Crohn's disease. *The British journal of surgery* 100:1344-1348.

[54] Jawhari A, Kamm MA, Ong C, Forbes A, Bartram CI, Hawley PR (1998) Intra-abdominal and pelvic abscess in Crohn's disease: results of noninvasive and surgical management. *The British journal of surgery* 85:367-371.

[55] Yamaguchi A, Matsui T, Sakurai T, Ueki T, Nakabayashi S, Yao T, Futami K, Arima S, Ono H (2004) The clinical characteristics and outcome of intraabdominal abscess in Crohn's disease. *Journal of gastroenterology* 39:441-448.

[56] Gutierrez A, Lee H, Sands BE (2006) Outcome of surgical versus percutaneous drainage of abdominal and pelvic abscesses in Crohn's disease. *The American journal of gastroenterology* 101:2283-2289.

[57] Feagins LA, Holubar SD, Kane SV, Spechler SJ (2011) Current strategies in the management of intra-abdominal abscesses in Crohn's disease. *Clinical gastroenterology and hepatology : the official clinical practice journal of the American Gastroenterological Association* 9:842-850.

[58] Ananthakrishnan AN, McGinley EL (2013) Treatment of intra-abdominal abscesses in Crohn's disease: a nationwide analysis of patterns and outcomes of care. *Digestive diseases and sciences* 58:2013-2018.

[59] Gervais DA, Hahn PF, O'Neill MJ, Mueller PR (2002) Percutaneous abscess drainage in Crohn disease: technical success and short- and long-term outcomes during 14 years. *Radiology* 222:645-651.

[60] Xie Y, Zhu W, Li N, Li J (2012) The outcome of initial percutaneous drainage versus surgical drainage for intra-abdominal abscesses in Crohn's disease. *International journal of colorectal disease* 27:199-206.

[61] Rypens F, Dubois J, Garel L, Deslandres C, Saint-Vil D (2007) Percutaneous drainage of abdominal abscesses in pediatric Crohn's disease. *AJR American journal of roentgenology* 188:579-585.

[62] Freeman HJ (2014) Spontaneous free perforation of the small intestine in adults. *World journal of gastroenterology : WJG* 20:9990-9997.

[63] Ikeuchi H, Yamamura T (2002) Free perforation in Crohn's disease: review of the Japanese literature. *Journal of gastroenterology* 37:1020-1027.

[64] Berg DF, Bahadursingh AM, Kaminski DL, Longo WE (2002) Acute surgical emergencies in inflammatory bowel disease. *American journal of surgery* 184:45-51.

[65] Chirantan B, Niladri S, Madhumita M, Sabyasachi S, Sibaji D, Jay K (2013) Crohn's Perforation: Not so Uncommon in the Indian Population. *The Indian journal of surgery* 75:28-30.

[66] He X, Chen Z, Huang J, Lian L, Rouniyar S, Wu X, Lan P (2014) Stapled side-to-side anastomosis might be better than handsewn end-to-end anastomosis in ileocolic resection for Crohn's disease: a meta-analysis. *Digestive diseases and sciences* 59:1544-1551.

[67] Myrelid P, Soderholm JD, Olaison G, Sjodahl R, Andersson P (2012) Split stoma in resectional surgery of high-risk patients with ileocolonic Crohn's disease. *Colorectal disease : the official journal of the Association of Coloproctology of Great Britain and Ireland* 14:188-193.

[68] D'Haens GR, Geboes K, Peeters M, Baert F, Penninckx F, Rutgeerts P (1998) Early lesions of recurrent Crohn's disease caused by infusion of intestinal contents in excluded ileum. *Gastroenterology* 114:262-267.

[69] Winslet MC, Allan A, Poxon V, Youngs D, Keighley MR (1994) Faecal diversion for Crohn's colitis: a model to study the role of the faecal stream in the inflammatory process. *Gut* 35:236-242.

[70] Antoni L, Nuding S, Wehkamp J, Stange EF (2014) Intestinal barrier in inflammatory bowel disease. *World journal of gastroenterology* : WJG 20:1165-1179.

[71] Gardiner KR, Dasari BV (2007) Operative management of small bowel Crohn's disease. *The Surgical clinics of North America* 87:587-610.

[72] Vanderhoof JA, Langnas AN (1997) Short-bowel syndrome in children and adults. *Gastroenterology* 113:1767-1778.

[73] Buchman AL (2006) Etiology and initial management of short bowel syndrome. *Gastroenterology* 130:S5-S15.

[74] Williams NS, Evans P, King RF (1985) Gastric acid secretion and gastrin production in the short bowel syndrome. *Gut* 26:914-919.

[75] Schalamon J, Mayr JM, Hollwarth ME (2003) Mortality and economics in short bowel syndrome. *Best practice & research Clinical gastroenterology* 17:931-942.

[76] Schwartz SI, Brunicardi FC (2010) Schwartz's principles of surgery, 9th edn, McGraw-Hill, Medical Pub. Division, New York.

[77] Maggiori L, Michelassi F (2012) How I do it: Side-to-side isoperistaltic strictureplasty for extensive Crohn's disease. *Journal of gastrointestinal surgery : official journal of the Society for Surgery of the Alimentary Tract* 16:1976-1980.

[78] Katariya RN, Sood S, Rao PG, Rao PL (1977) Stricture-plasty for tubercular strictures of the gastro-intestinal tract. *The British journal of surgery* 64:496-498.

[79] Lee EC, Papaioannou N (1982) Minimal surgery for chronic obstruction in patients with extensive or universal Crohn's disease. *Annals of the Royal College of Surgeons of England* 64:229-233.

[80] Roy P, Kumar D (2006) Strictureplasty for active Crohn's disease. *International journal of colorectal disease* 21:427-432.

[81] Brunicardi FC, Schwartz SI (2005) *Schwartz's principles of surgery*, 8th edn, McGraw-Hill, Health Pub. Division, New York.

[82] Michelassi F (1996) Side-to-side isoperistaltic strictureplasty for multiple Crohn's strictures. *Diseases of the colon and rectum* 39:345-349.

[83] Roy P, Kumar D (2004) Strictureplasty. *The British journal of surgery* 91:1428-1437.

[84] Hesham W, Kann BR (2013) Strictureplasty. *Clinics in colon and rectal surgery* 26:80-83.

[85] Yamamoto T (2013) The role of strictureplasty in the surgical management of duodenal Crohn's disease. *Journal of Crohn's & colitis* 7:e237.

[86] Tonelli F, Alemanno G, Bellucci F, Focardi A, Sturiale A, Giudici F (2013) Symptomatic duodenal Crohn's disease: is strictureplasty the right choice? *Journal of Crohn's & colitis* 7:791-796.

[87] Fazio VW, Galandiuk S, Jagelman DG, Lavery IC (1989) Strictureplasty in Crohn's disease. *Annals of surgery* 210:621-625.

[88] Wilkins FB (1953) Pyloroplasty for gastric drainage with vagotomy. *California medicine* 78:513-514.

[89] Keighley MR (1991) Stapled strictureplasty for Crohn's disease. *Diseases of the colon and rectum* 34:945-947.

[90] Campbell L, Ambe R, Weaver J, Marcus SM, Cagir B (2012) Comparison of conventional and nonconventional strictureplasties in Crohn's disease: a systematic review and meta-analysis. *Diseases of the colon and rectum* 55:714-726.

[91] Dasari BV, McKay D, Gardiner K (2011) Laparoscopic versus Open surgery for small bowel Crohn's disease. *The Cochrane database of systematic reviews*:CD006956.

[92] Schmidt CM, Talamini MA, Kaufman HS, Lilliemoe KD, Learn P, Bayless T (2001) Laparoscopic surgery for Crohn's disease: reasons for conversion. *Annals of surgery* 233:733-739.

[93] Antoniou SA, Antoniou GA, Koch OO, Pointner R, Granderath FA (2014) Is laparoscopic ileocecal resection a safe option for Crohn's disease? Best evidence topic. *International journal of surgery* 12:22-25.

[94] Milsom JW, Hammerhofer KA, Bohm B, Marcello P, Elson P, Fazio VW (2001) Prospective, randomized trial comparing laparoscopic vs. conventional surgery for refractory ileocolic Crohn's disease. *Diseases of the colon and rectum* 44:1-8; discussion 8-9.

[95] Riss S, Schuster I, Papay P, Mittlbock M, Stift A (2013) Repeat intestinal resections increase the risk of recurrence of Crohn's disease. *Diseases of the colon and rectum* 56:881-887.

[96] Naidu MN, Trang AC, Salky BA (2007) Laparoscopy in Crohn's disease. *Clinics in colon and rectal surgery* 20:329-335.

[97] Aarons CB (2013) Laparoscopic surgery for crohn disease: a brief review of the literature. *Clinics in colon and rectal surgery* 26:122-127.

[98] Bauer JJ, Harris MT, Grumbach NM, Gorfine SR (1996) Laparoscopic-assisted intestinal resection for Crohn's disease. Which patients are good candidates? *Journal of clinical gastroenterology* 23:44-46.

[99] Hasegawa H, Watanabe M, Nishibori H, Okabayashi K, Hibi T, Kitajima M (2003) Laparoscopic surgery for recurrent Crohn's disease. *The British journal of surgery* 90:970-973.

[100] Moftah M, Nazour F, Cunningham M, Cahill RA (2014) Single port laparoscopic surgery for patients with complex and recurrent Crohn's disease. *Journal of Crohn's & colitis* 8:1055-1061.

[101] Kumar A, Auron M, Aneja A, Mohr F, Jain A, Shen B (2011) Inflammatory bowel disease: perioperative pharmacological considerations. *Mayo Clinic proceedings* 86:748-757.

[102] Vaughn BP, Moss AC (2014) Prevention of post-operative recurrence of Crohn's disease. *World journal of gastroenterology* : WJG 20:1147-1154.

[103] De Cruz P, Kamm MA, Hamilton AL, Ritchie KJ, Krejany EO, Gorelik A, Liew D, Prideaux L, Lawrance IC, Andrews JM, Bampton PA, Gibson PR, Sparrow M, Leong RW, Florin TH, Gearry RB, Radford-Smith G, Macrae FA, Debinski H, Selby W, Kronborg I, Johnston MJ, Woods R, Elliott PR, Bell SJ, Brown SJ, Connell WR, Desmond PV (2014) *Crohn's disease management after intestinal resection: a randomised trial. Lancet* .

[104] De Cruz P, Kamm MA, Prideaux L, Allen PB, Desmond PV (2012) Postoperative recurrent luminal Crohn's disease: a systematic review. *Inflammatory bowel diseases* 18:758-777.

[105] Lee YW, Lee KM, Chung WC, Paik CN, Sung HJ, Oh YS (2014) Clinical and endoscopic recurrence after surgical resection in patients with Crohn's disease. *Intestinal research* 12:117-123.

[106] Rutgeerts P, Geboes K, Vantrappen G, Beyls J, Kerremans R, Hiele M (1990) Predictability of the postoperative course of Crohn's disease. *Gastroenterology* 99:956-963.

[107] Rutgeerts P, Geboes K, Vantrappen G, Kerremans R, Coenegrachts JL, Coremans G (1984) Natural history of recurrent Crohn's disease at the ileocolonic anastomosis after curative surgery. *Gut 2*5:665-672.

[108] Vantrappen G, Rutgeerts P (1990) Recurrence of Crohn's lesions in the neoterminal ileum after ileal resection and ileocolonic anastomosis. *Verhandelingen - Koninklijke Academie voor Geneeskunde van Belgie* 52:373-382; discussion 383-375.

[109] Spinelli A, Sacchi M, Fiorino G, Danese S, Montorsi M (2011) Risk of postoperative recurrence and postoperative management of Crohn's disease. *World journal of gastroenterology : WJG* 17:3213-3219.

[110] Best WR, Becktel JM, Singleton JW, Kern F, Jr. (1976) Development of a Crohn's disease activity index. National Cooperative Crohn's Disease Study. *Gastroenterology 7*0:439-444.

[111] Yamamoto T (2005) Factors affecting recurrence after surgery for Crohn's disease. *World journal of gastroenterology* : WJG 11:3971-3979.

[112] Brouquet A, Blanc B, Bretagnol F, Valleur P, Bouhnik Y, Panis Y (2010) Surgery for intestinal Crohn's disease recurrence. *Surgery* 148:936-946.

[113] Heimann TM, Greenstein AJ, Lewis B, Kaufman D, Heimann DM, Aufses AH, Jr. (1998) Comparison of primary and reoperative surgery in patients with Crohns disease. *Annals of surgery* 227:492-495.

[114] Ozuner G, Fazio VW, Lavery IC, Milsom JW, Strong SA (1996) Reoperative rates for Crohn's disease following strictureplasty. Long-term analysis. *Diseases of the colon and rectum* 39:1199-1203.

[115] Hurst RD, Michelassi F (1998) Strictureplasty for Crohn's disease: techniques and long-term results. *World journal of surgery* 22:359-363.

[116] Futami K, Arima S (2005) Role of strictureplasty in surgical treatment of Crohn's disease. *Journal of gastroenterology* 40 Suppl 16:35-39.

[117] Domenech E, Manosa M, Lobaton T, Cabre E (2014) Optimizing post-operative Crohn's disease treatment. *Annals of gastroenterology: quarterly publication of the Hellenic Society of Gastroenterology* 27:313-319.

In: Encyclopedia of Surgery (22 Volume Set)
Editors: Andreas Lehrer and Kristin Mueller
ISBN: 978-1-53618-329-0
© 2020 Nova Science Publishers, Inc.

Chapter 368

COLON SURGERY

William A. Teeter[1], MD and Andrea C. Bafford[2,*], MD
[1]University of Maryland Medical Center, Baltimore, MD, US
[2]University of Maryland School of Medicine, Baltimore, MD, US

ABSTRACT

Crohn's disease frequently involves the colon. The majority of patients with colonic Crohn's disease will require surgical intervention at some point. The management of Crohn's colitis includes a careful assessment of the patient's response to medical therapy and the anatomy involved. Selection of treatment is based on preserving as much function and quality of life as possible. While surgery cannot cure Crohn's colitis, it can remove life-threatening complications and provide excellent symptom relief. Surgical options include proximal diversion, ileocecetomy, segmental colectomy, total colectomy, proctocolectomy, and in select patients, ileal pouch-anal anastomosis. The choice of surgical treatment requires a thorough knowledge of currently evolving literature. This section will discuss the current state of evidence-based clinical practice in the surgical management of Crohn's colitis.

INTRODUCTION

Crohn's disease is an ulcerogenic, transmural, inflammatory bowel disease that can affect any portion of the gastrointestinal tract. Crohn's disease is most frequently found in the terminal ileum or ileocolic region (55%), with an additional approximately 20-30% of patients presenting with isolated colonic disease[1,2]. Colonic disease typically presents with abdominal pain, perianal complications, rectal bleeding, or extraintestinal manifestations.[3] As with Crohn's disease in general, the foundation of current treatment for colonic Crohn's disease is medical therapy with aminosalicylates, immunomodulators, biologic agents, and steroids, with surgery reserved for complications of the disease and failure of medical management.

* Corresponding Author's Email: abafford@smail.umaryland.edu.

As a whole, greater than 75% of Crohn's patients require surgery during their lifetime.[4,5] Symptomatic recurrence of Crohn's disease will occur within the first five years postoperatively in approximately 30 to 50% of patients, and in 50 to 80% within 10 years.[6] Reoperation can be expected in 40 to 50% of patients within 10 to 15 years.[7] Anatomic distribution of disease affects the rates of surgical intervention. Right-sided colonic disease or disease involving the terminal ileum accounts for 40% of patients undergoing surgery.[3]

The failure of medical management remains the leading indication for surgery in Crohn's patients.[4,5] Reasons for failure vary widely in patients from noncompliance, to intolerable side effects, to lack of response to the medical regimen. It is important that clinicians realize that surgical intervention is not a "failure", but rather, an opportunity to offer many patients a demonstrable improvement in their quality of life.[8-10] Surgery for Crohn's disease of the colon includes ileocolic resection, segmental colon resection, total colectomy, proctocolectomy, and proximal diversion. Complications of Crohn's disease and their associated surgical indications can be separated into acute and chronic categories.

INDICATIONS FOR SURGERY

Acute

Obstruction

Colonic obstruction in Crohn's disease is not uncommon, occurring in almost 17% of patients.[11] Strictures can occur throughout the colon and are due to fibrosis associated with repeated episodes of transmural inflammation. Over time, the wall thickens and becomes irreversibly scarred and fibrotic, with a progressively decreasing luminal diameter. Many strictures, including those at previous anastomotic sites, are responsive to endoscopic dilation.[12] However, up to 7% of colonic strictures in Crohn's patients may contain malignancy and should always be biopsied.[11,13] In the event of a positive biopsy, resection should follow established oncologic guidelines. In the absence of malignancy, many strictures can be treated conservatively, however frequent or severe obstructions should be managed with surgical intervention.

Hemorrhage

Hemorrhage occurs infrequently in Crohn's disease as compared to ulcerative colitis.[14] Patients may develop lower gastrointestinal bleeding, but it is usually associated with a separate complication, such as neoplasia or toxic megacolon. Initial management includes resuscitation with intravenous fluids, blood transfusion, correction of any coagulopathy, and attempts to identify the source of hemorrhage within the GI tract. Colonoscopy can be used if the hemorrhage is from a suspected colonic source. Angiography and nuclear medicine imaging may also play a role. The extent of resection is determined by successful identification of the bleeding source. In general, grossly affected colon should be resected, preserving as much future colorectal function as possible. In all, nearly 40% of patients with inflammatory bowel disease will require surgical resection to correct the hemorrhage.[15]

Abscess

Contained perforation leading to abscess or fistula complicates colonic Crohn's disease much more frequently than free perforation. Following initial resuscitation, additional treatment depends on the patient's response and clinical stability. Hemodynamically unstable patients and those with generalized peritonitis should undergo immediate surgery. For stable patients, percutaneous abscess drainage is typically undertaken.[16] In the past, most patients went on to receive surgical resection of the involved segment. However, a recent study showed similar rates of complications and abscess recurrence when medical and surgical treatment of Crohn's-related abdominal abscesses were compared.[17] The management of intra-abdominal septic complications of Crohn's disease will be discussed further in Section III.

Perforation

Although rare, perforation can occur in patients with Crohn's colitis and is an emergent indication for surgical intervention.[18] Perforation is most associated with small bowel disease with obstruction or abscess. In patients with colonic disease, perforation is usually seen complicating toxic colitis.[19,20] Toxic megacolon, or toxic colitis, is a life threatening complication of Crohn's disease. Diagnosis is made during a disease flare with the presence of colonic dilatation as well as two of the following: leukocytosis, tachycardia, or temperature greater than 38.6.[21] Initial management includes aggressive resuscitation, bowel rest and decompression, immunosuppressants, such as intravenous steroids, broad-spectrum antibiotics, and possibly nutritional support. Perforation or impending perforation, lack of improvement within 2-3 days of conservative management, clinical deterioration, and shock/sepsis are indications for immediate operative intervention. Surgery for toxic colitis usually consists of total abdominal colectomy with end ileostomy.

Chronic

Failure of Medical Therapy

Some complications that lead to the failure of medical management occur due to adverse effects of the immunosuppressive medications themselves. Long-term corticosteroid use can result in suppression of adrenal function, hypertension, osteoporosis, infections, including increased rates of abdominopelvic abscesses, hypokalemia, and hyperglycemia.[22] Corticosteroids should therefore never be used for maintenance of disease remission. Of the patients who receive corticosteroids for acute symptoms, 50% will develop steroid "dependent" or "resistant" Crohn's disease,[23] with higher rates of resistance seen in smokers and patients with colonic involvement.[24] Half of these patients will progress to resistance and require surgery within one year.[25] Other patients have continued or worsening symptoms despite escalation of medical therapy, which may include aminosalicylates, immunomodulators, and biologic agents.

Growth Retardation in Children

The metabolic consequences of Crohn's disease can be especially severe in the pediatric population. Growth retardation occurs in 15%-40% of children affected and may precede the

clinical diagnosis of Crohn's by several years.[26-28] Failure of growth is due to malabsorption, decreased caloric intake, and increased nutrient loss as a result of the disease's effect on the GI tract. Surgical intervention has been shown in retrospective series to improve growth velocity and pubertal development in patients with growth retardation.[29-31]

Malignant Transformation

As a pro-inflammatory disease, it is not surprising that patients with Crohn's disease have a higher incidence of several types of malignancy,[32] especially colorectal cancer.[33] When discovered, resectable malignancy remains an indication for surgical intervention. The extent of colonic resection required for Crohn's colitis patients with colorectal dysplasia or cancer is somewhat controversial and will be discussed later is this chapter.

Fistula

In patients with Crohn's disease, the colon is sometimes affected by fistula formation (Figure 1).[34] Overall, fistulization is predictive of higher lifetime relative risk (1.7) of receiving surgical treatment[3] and is independently associated with decreased time to surgery (HR, 3.44, 95% CI 2.33 to 5.08 vs inflammatory disease).[35] Given the transmural nature of Crohn's disease, fistulous communication with other bowel,[36] lung,[37] vagina,[38] bladder,[39] or skin[40] have been reported in patients where the colon is the primary site of inflammation. The colon may also be involved secondarily with fistulous communication arising from the stomach, duodenum, or small bowel.[40] Fistulizing disease is associated with increased postoperative complications, higher rate of conversion to open procedure, and higher incidence of postoperative fistula formation, of which enteroenteric is the most common.[41,42] Even with the development of anti-TNF agents, 75% of patients being treated for fistulizing Crohn's disease still require surgical intervention.[43]

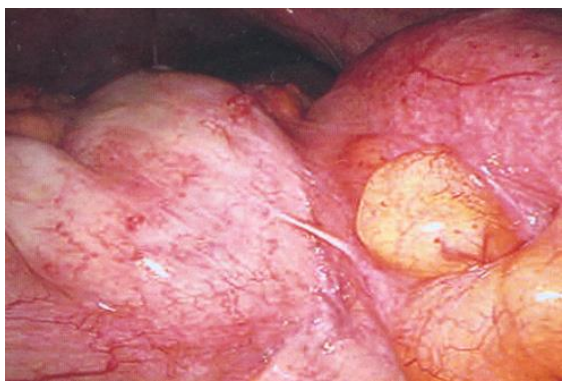

Figure 1. Ileal-sigmoid fistula secondary to Crohn's disease.

SURGICAL ILEOCOLONIC DISEASE

Indications for Surgery

Ileocolonic disease is the most common presentation in Crohn's disease and the leading cause of surgical intervention. The preferred method of surgical treatment is resection of the

diseased bowel. Operation for ileocolonic Crohn's disease is indicated in any of the complications discussed above. The majority of patients with ileocolonic disease undergo surgery for either penetrating disease, which leads to fistula or abscess, or stricturing disease, which causes partial or complete obstruction and possibly perforation. Penetrating and stricturing disease can be a continuum of disease pathogenesis, where perforation arises in areas of transmural inflammation due to increased pressure produced by downstream stricture, especially at the ileocecal junction.[44]

Between 10%-30% of patients with Crohn's disease will develop an abdominal or pelvic abscess.[45] Microperforation of transmural ulcerations with or without fistula formation is the accepted pathogenesis of perforating Crohn's disease. Abscesses most frequently occur due to disease within the terminal ileum and cecum.[45,46] The preferred treatment of Crohn's-related abdominopelvic abscesses is with antibiotics and percutaneous drainage.[47,48] The timing of and need for definitive surgery has been debated in the literature. Most authors recommend controlling sepsis with the methods discussed above followed by subsequent elective surgery to resect the affected bowel. Gutierrez showed that one-third of patients who underwent successful percutaneous abscess drainage ultimately required surgery within one year's time.[16] When managing Crohn's patients with intra-abdominal septic complications, a holistic review of the individual's disease course and a multidisciplinary approach to therapy is advocated.[46,49]

Stricturing disease is caused by chronic and severe inflammation of the bowel wall with up-regulation of extracellular matrix component deposition, including collagen and fibronectins, and mesenchymal cell expansion.[50] As with penetrating disease, the most common location for stricturing disease is the terminal ileum and ileocecal junction.[51] Despite improvement in most Crohn's disease metrics over the past few decades, stricturing disease has not decreased in incidence with the advancement of medical therapy.[52]

Minimally Invasive Ileocolic Resection

The last fifteen years have witnessed an increase in the use of laparoscopy following the publication of the first prospective randomized controlled trial comparing laparoscopic versus open surgical intervention.[53] Initial results indicated that laparoscopy results in fewer complications, a shorter length of hospital stay, and reduced time to pulmonary recovery. In 2006, a multi-institutional prospective randomized controlled trial by Maartense, showed a reduction in hospital stay and hospital costs, with similar results in quality of life and return to normal diet.[54] Both studies found no significant difference in rates of anastomotic leak, intra-abdominal abscess, and reoperation in the first 30 days. Although limited in their power, these initial studies provided the first evidence that the safety and efficacy of laparoscopy was comparable to that of open surgery.[2]

Further studies have replicated these initial results. Several meta-analyses comparing laparoscopic to open ileocolic resection found benefit to laparoscopy with respect to postoperative complications and morbidity,[55-57] length of hospital stay,[55,56,58] and return of bowel function[56-58] in the short term. These studies also demonstrated a significant increase in operative time for laparoscopy versus open surgery. Longer-term follow-up of these patients showed similar or lower rates of disease recurrence[56,57,59-61] and overall morbidity [56,57,60,62]. Bergamaschi also found a lower rate of bowel

obstruction at 5 years of follow-up after laparoscopic versus open ileocolic resection.[61] These authors concluded that experienced surgeons may offer the majority of patients laparoscopic intervention for ileocolic Crohn's disease.

More recently, several series have been published on the use of single incision laparoscopic surgery (SILS). Stewart published a series of six patients who underwent SILS for complicated ileocolic disease. These authors demonstrated no conversion to open, return of bowel function in 1.6 days, and hospital stay of 4.8 days, which all compares favorably to traditional laparoscopic techniques. A larger retrospective series of 20 patients who underwent SILS as compared to 20 individually matched traditional laparoscopy patients showed no difference in length of stay, postoperative pain, morbidity (ileus, wound infection, intrabdominal abscess), or conversion to open surgery.[63] The SILS group had a shorter operative time.

Methods of Anastomosis

Outcomes in laparoscopic bowel resection appear to be influenced by several factors. Smoking, perianal disease, presence of perforation, and surgical technique have all been associated with worse outcomes.[64] As a modifiable risk, interest in surgical technique has gained attention in the literature. McLeod found that anastomotic type (side-to-side versus end-to-end) did not affect disease recurrence in their multi-center randomized trial.[65] Ikeuchi found that stapled anastomosis delayed recurrence when compared to hand-sewn anastomosis.[66] A meta-analysis by Guo comparing the differences between side-to-side and end-to-end anastomoses demonstrated no significant difference between the two with respect to short-term complications or recurrence.[67] Their analysis did suggest that the stapled side-to-side anastomotic technique might improve outcome.

A recent meta-analysis looking at this question demonstrated that stapled side-to-side techniques do carry a lower risk of overall postoperative complications, anastomotic leak, recurrence, and reoperation for recurrence, when compared to hand sewn end-to-end anastomosis. Length of stay, mortality, and complications other than anastomotic leak were not significantly different. However, a variance in follow-up between the two groups, 34 months for the stapled anastomosis versus 92 months in the hand-sewn anastomosis, is a limitation.[68] A novel anti-mesenteric functional end-to-end anastomosis, or Kono-S anastomosis, has shown low rates of complications in short-term follow-up.[69,70] These studies suggest that side-to-side stapled anastomosis may provide a short-term benefit in complications and recurrence, however long-term comparative trials are needed.

CROHN'S DISEASE OF THE COLON

Isolated involvement of the colon in Crohn's is seen in one third of patients (Figure 2).[2] The common anatomic distributions within the colon are pancolonic involvement in about 30% of patients, left-sided disease in approximately 30% of patients, and segmental disease in 40% of patients.[3,71] Patients may present with abdominal pain, malnutrition, and hip or pelvic pain from abscess or fistula.[3,71] Indications for colonic resection include fulminant

colitis non-responsive to medical therapy, intolerable side effects of medical therapy, hemorrhage, obstruction, and abscess or fistula. Surgical options include subtotal colectomy with ileorectal anastomosis, total proctocolectomy, and segmental colectomy.

Recent literature suggests that isolated colonic Crohn's disease presents with pathologic and clinical characteristics, which differ from patients with other anatomic distributions of the disease. One study demonstrated that 81% of patients presenting with pancolitis suffered from isolated colonic disease. This study also showed a higher rate of extracolonic disease in patients undergoing segmental colonic resection.[72]

Hancock published results showing that patients with isolated colonic disease were more commonly female, non-smokers, and carriers of the DRB1*0103 allelic polymorphism as compared to patients without colonic involvement.[73] Recently, Soucy found that patients with isolated colonic Crohn's disease present later in life. Reproducing results of Hancock, they also demonstrated a shorter mean time before surgical intervention in these patients.[74] Interestingly, Soucy also described a subpopulation within the isolated colonic involvement group with 'ulcerative colitis-like Crohn's colitis', a disease entity which has been sparsely reported in the literature.[75,76] Patients with ulcerative colitis-like Crohn's colitis present at an earlier age, however have a less severe phenotype and fewer histologic characteristics of Crohn's disease compared to their standard Crohn's colitis counterparts. Outcomes appear otherwise similar.[74]

Toxic Colitis

Toxic colitis or toxic megacolon is the most severe form of Crohn's colitis, and a frequent cause of urgen surgical intervention. Similar to the more common toxic megacolon seen in ulcerative colitis, toxic megacolon due to Crohn's disease is initially treated with medical management, including aggressive resuscitation, antibiotics, and possibly immunosuppressive agents. Following adequate resuscitation, patients with perforation, uncontrolled bleeding, and those who clinically deteriorate should receive emergent surgical intervention.[77]

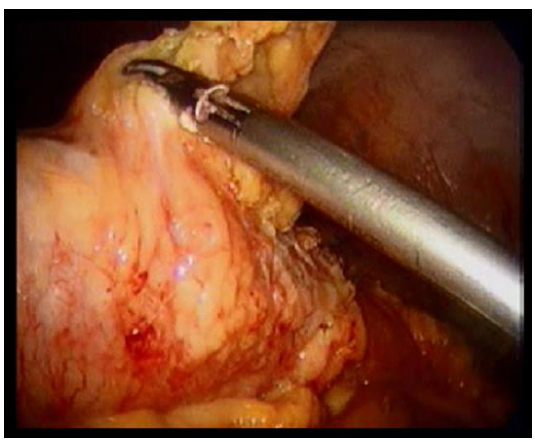

Figure 2. Severely inflamed transverse colon in a patient with Crohn's colitis.

Early operative management was with a loop ileostomy and "blowhole" transverse colostomy, as reported in 1970 by Turnbull.[78] However, this procedure was associated with high rates of mortality (71%) and complications, including ongoing severe bleeding.[79] The Turnbull procedure is therefore rarely performed presently, except in the most severely ill patients who are unable to tolerate longer operations.

Total proctocolectomy and subtotal colectomy with end ileostomy are the remaining options for surgical intervention. One study showed that in patients who received total proctocolectomy for toxic megacolon, complication and mortality rates were both 21%, whereas in those treated with subtotal colectomy with end ileostomy, the complication rate was 8% and the mortality rate was 6%[79]. The use of subtotal colectomy with end-ileostomy has greatly reduced the mortality of toxic colitis and remains the procedure of choice.

Segmental versus Subtotal Colectomy

Similar to that for small bowel disease, maintenance of colon function with bowel sparing techniques is the goal of current surgical treatment of colonic Crohn's disease. Despite the eventual choice of procedure, the literature is clear that segmental colectomy only requires resection to grossly normal bowel.[80] The choice of surgical procedure is governed largely by the anatomical presentation of the disease. Fichera published a prospective series of patients comparing the surgical outcomes of segmental colectomy, total abdominal colectomy, and total proctocolectomy.[81] Clinical characteristics were the same for all groups, except the segmental colectomy patients were significantly younger. The authors found that patients with diffuse colonic involvement, distal colonic involvement, or multiple involved segments were significantly less likely to receive segmental colectomy. The literature has conflicting data regarding the rate of recurrence following the surgical options mentioned above. In Fichera's study, segmental colectomy patients had a greater risk of recurrence than patients who received proctocolectomy, but not subtotal colectomy.[81] These results were confirmed in a large meta-analysis that compared segmental resection to subtotal colectomy with ileorectal anastomosis; no significant difference in incidence of surgical recurrence was found between groups.[82] A more recent single institution series also demonstrated that segmental colectomy was not an independent predictor of disease recurrence.[83]

There is some consensus that the speed of recurrence differs between surgical techniques. Fichera reported a significant difference in time to first recurrence between the three surgical groups, especially between segmental colectomy and total proctocolectomy. Tekkis similarly found that the segmental resection group presented with recurrence approximately 4 years earlier.

One important consideration concerning patient quality of life is the need for a permanent stoma following colectomy. In Fischera's study, the need for permanent stoma was significantly higher in patients presenting with isolated distal colonic disease versus isolated proximal disease.[81] Kiran found no difference in stoma free survival between segmental colectomy (76.8%) and subtotal colectomy (84.2%) groups. Past perianal sepsis and the presence of multiple comorbidities did reduce stoma-free survival.[83] These studies support the conclusion that both segmental and subtotal colectomies are reasonable options for

treatment of Crohn's colitis when used in conjunction with careful patient selection and thorough review of patient disease course.

Colectomy for Dysplasia or Cancer

Proctocolectomy is the standard therapy for ulcerative colitis patients with colorectal dysplasia or cancer, based on literature demonstrating high rates of synchronous and metachronous disease.[84,85] The surgical management of dysplasia in patients with Crohn's colitis is largely extrapolated from ulcerative colitis data, given a lack of similar studies in patients with Crohn's disease. However, the presence of segmental disease as well as the lack of an ideal reconstructive option makes protocolectomy a less obvious treatment choice in patients with Crohn's colitis.

Kiran et al. evaluated 50 patients who underwent colectomy for Crohn's colitis-associated dysplasia. 44% of patients who underwent total proctocolectomy or subtotal colectomy had multifocal dysplasia. Of those patients who had a colorectal cancer, 40% had dysplasia remote from the cancer site. The authors therefore recommended total proctocolectomy as the treatment of choice in good-risk patients.[86] Maser et al. found that 40% of patients who underwent segmental resection for colon cancer and 35% of patients who underwent subtotal colectomy for colon cancer developed metachronous cancer. 43% of patients who underwent segmental colectomy and 50% of patients who underwent subtotal colectomy for dysplasia developed a new dysplasia. They similarly concluded that total proctocolectomy should be considered in Crohn's patients with dysplasia or cancer due to high rates of metachronous disease.[87]

Based upon limited data, total proctocolectomy rather than subtotal or segmental colectomy should be strongly considered in Crohn's colitis patients with colorectal dysplasia or cancer.

DISTAL COLONIC DISEASE

The management of Crohn's disease affecting the distal colon is challenging. Patients with isolated distal disease are significantly more likely to require a permanent stoma than those with isolated proximal disease (54% vs 11%).[81] Patients with distal involvement are also significantly more likely to undergo a more extensive resection than those with more proximal disease patterns.

Surgical indications for distal resection are dependent on the extent of inflammation and anatomy involved. Total proctocolectomy and end ileostomy is indicated when patients present with diffuse and extensive colorectal disease. In those patients with rectal sparing (40%[88]), both total abdominal colectomy with ileorectal anastomosis and segmental resection can be considered. For patients with concomitant distal colonic and perianal Crohn's disease, surgical options include proctectomy with end-colostomy, proctocolectomy, and proximal diversion with or without segmental or subtotal colectomy.

Techniques in Crohn's Colitis with Rectal Sparing

Total Proctocolectomy

The management of Crohn's colitis with relative rectal sparing is a current area of controversy in the literature. In patients with Crohn's colitis, concomitant involvement of the rectum and anal canal must be considered when choosing treatment. Total proctocolectomy is the most appropriate option for patients with extensive colitis and refractory perianal disease, despite the presence of rectal sparing. This procedure involves the removal of all colonic, rectal and perianal disease and therefore affords the lowest rates of recurrence, reoperation, and need for medical therapy postoperatively.[81,89,90]

On the other hand, many patients undergoing surgery for Crohn's disease are relatively young, and the risk of pelvic nerve injury, including impact on sexual function and fertility, may not be considered acceptable.[89,91] Further, total proctocolectomy results in a permanent end ileostomy, which can negatively impact patient satisfaction and quality of life. As a result, high levels of patient resistance to this procedure are frequently encountered. In recent years, intersphincteric proctectomy is being used to avoid sexual dysfunction related to dissection near the hypogastric nerve plexus and also to reduce the rate of perineal wound complications.[92]

Total Abdominal Colectomy with Ileorectal Anastomosis

Total abdominal colectomy with ileorectal anastomosis is a further option in patients with rectal sparing. It is preferred for patients without perianal disease and for those whose perianal disease is mild. A series of 833 patients with Crohn's colitis demonstrated fairly high rates of symptomatic recurrence when subtotal colectomy with ileorectal anastomosis and segmental colon resection were compared with subtotal colectomy and proctocolectomy with ileostomy (58% and 47% versus 24% and 37%, respectively). On multivariate analyis, perianal disease, ileorectal anastomosis, and segment resection were independent risk factors for recurrence.[93] Andersson also found similar rates of re-resection following segmental versus subtotal colectomy for Crohn's colitis. However, segmental colectomy patients had the advantages of fewer loose stools, better anorectal function, and fewer symptoms overall.[94]

In contrast, a large meta-analysis examining 488 patients undergoing ileorectal anastomosis versus segmental colectomy showed that ileorectal anastomosis lead to lower rates of postoperative complications and permanent stoma creation. Those patients with multiple affected colonic segments were less likely to need re-operation when they underwent ileorectal anastomosis.[95]

Ileal Pouch-anal Anastomosis (IPAA)

Ileal pouch-anal anastomosis (IPAA) may be an option for very select patients with both ileal and anal sparing Crohn's disease. The more common setting for this procedure is in patients who carry a preoperative diagnosis of ulcerative colitis, and are subsequently diagnosed with Crohn's disease on final pathology. A study of 60 patients in this situation found that 35% developed disease recurrence, 40% reported issues with continence, and 12% ultimately required pouch excision.[96] Another study of 41 patients with ileal and rectal-sparing inflammation including 26 patients with a preoperative diagnosis of Crohn's disease, demonstrated a 10% rate of pouch excision, and a 35% incidence of serious complication,

including pouchitis, abscess, and fistula formation.[97] Many of these patients had improvement in symptoms with medical management, and therefore the authors concluded that IPAA is warranted in Crohn's patients meeting the criteria of ileal and anal sparing disease.

Several contemporaneous studies found that the outcomes of IPAA in Crohn's disease were not as favorable. One study published results showing that 56% of patients who underwent restorative proctocolectomy for Crohn's colitis required diversion or pouch excision compared to only 6% who had the procedure performed for ulcerative colitis.[98] Further, Bravemen found that of 32 patients diagnosed with Crohn's disease postoperatively from IPAA, 93% had significant complications, including fistula (63%), pouchitis (50%), and anal stricture (38%). Pouch excision or permanent diversion was required in 29% of patients.[99]

Finally, a meta-analysis of 10 studies, including 3103 patients who underwent restorative proctocolectomy for inflammatory colitis, Crohn's disease patients (n=225) had higher rates of incontinence, anastomotic strictures, and pouch failure.[100] In summary, ileoanal pouch construction remains controversial due to significant variance in the rate of complications (35% to 93%[96-100]) reported in the literature. Some studies have suggested better outcomes in those Crohn's colitis patients without perianal disease or small bowel involvement. Other investigators have not found any features predictive of outcome after an IPAA procedure.[99]

LAPAROSCOPIC TECHNIQUES IN CROHN'S COLITIS

Laparoscopic techniques have significantly improved the outcomes of patients undergoing colorectal surgery. There is an abundance of evidence showing advantages of laparoscopic colorectal surgery over open technique, including reduced length of hospital stay, decreased postoperative narcotic use, reduced wound complications, and earlier return of postoperative bowel function.[101-103] Laparoscopic colectomy was first reported in 1991.[104] Soon after, interest arose in the use of laparoscopy for the treatment of Crohn's disease, given the young age of Crohn's patients requiring surgery, the recurrent nature of the disease and therefore the high likelihood of subsequent reoperation, the high rates of complications, in particular wound infections, seen following traditional Crohn's surgery, and the debilitated state patients with Crohn's disease often present in. Laparoscopic colectomy followed behind laparoscopic ileocolic resection and early comparisons were favorable.[105]

One of the earliest studies examining the use of laparocopy in Crohn's colitis was published in 2007. In this study, the authors compared 27 patients who underwent laparoscopic colectomy with matched controls.[106] They found significantly higher median operative times, comparable rates of blood loss, and similar postoperative complications. However, they also demonstrated shorter median length of stay and time to first bowel movement. When 30-day readmissions were included, laparoscopic surgery also led to significantly shorter overall length of stay.

One review of a prospectively collected database from a single institution evaluated 92 patients who underwent laparoscopy and hand-assisted laparoscopic surgery (HALS) for total, subtotal, or segmental colectomy. The authors reported a median operative time of 248

minutes and a mean postoperative length of stay of 5 days. The rate of any complication was 34%, and was predicted by perianal disease. The overall conversion rate was 16%, which was predicted by presence of small bowel disease. When the study patients were further subdivided into segmental colectomy and either total or subtotal colectomy, the segmental colectomy group was significantly less likely to have a complication. The authors concluded that laparoscopy was safe with "reasonable operative times, conversion rates, and excellent postoperative outcomes".[107] A second prospective study of patients undergoing laparoscopic versus open colectomy demonstrated a shorter length of stay, earlier return of bowel function, less intraoperative blood loss, and fewer complications in the laparoscopic group. The conversion rate was 10.9%.[108] The literature-to-date supports these authors' conclusion that laparoscopy is a safe and effective surgical option for patients with colonic Crohn's disease.

Recurrent disease is a noteworthy challenge in the management of patients with Crohn's. As the indications for laparoscopic intervention in colonic Crohn's disease grow, its use in difficult recrudescent cases is expected. There are several studies available which have investigated the use of laparoscopy in recurrent disease with favorable results.[42,109] In a study of 26 patients who underwent mixed small and large bowel procedures, laparoscopic and open techniques were compared. The authors found similar rates of blood loss, operative time, need for reoperation, time to return of bowel function, length of hospital stay, and readmission. They also found that laparoscopy was associated with a significantly lower rate of wound infection.[110] They concluded that while laparoscopy may have lower rates of wound infection, the similarity in surgical outcomes between laparoscopy and open procedures does not show an advantage to either approach.

The advancement of laparoscopic techniques for the management of Crohn's disease has been augmented by the use of alternative methods, including robotic-assisted laparoscopy, HALS, and SILS. Robotic-assisted laparoscopic surgery has gained significant attention in the treatment of colorectal disease. A meta-analysis of 39 studies including 13 ileocecal resections, 220 right colectomies, 190 left and sigmoid resections, 440 anterior resections, 149 abdominoperineal resections, and 11 total or subtotal colectomies, demonstrated acceptable rates of conversion and morbidity.[111] Recently, a study of 17 robot-assisted proctectomies and ileal pouch-anal anastomosis procedures in patients with Crohn's colitis demonstrated similar rates of operative blood loss, postoperative complications, and impact on bowel and sexual function, compared to their laparoscopic counterparts.[112] While the evidence in the colorectal literature is growing, the use of robotic-assisted laparoscopy remains experimental and should only be used by experienced robotic surgeons in selected patients at the present time.

CONCLUSION

Crohn's disease is a complicated disease that affects the entire gastrointestinal tract and significantly impacts the health and quality of life of patients who suffer from it. Medical management has greatly improved the treatment options and outcomes of patients, and remains an active frontier of research. However, despite improvements in medical therapy, the majority of Crohn's disease patients still require surgical intervention in their lifetimes.

Although surgery cannot cure Crohn's disease, it continues to play a significant role in managing what can be life-threatening complications and improving disease symptomatology and patient quality of life. As discussed in this chapter, the management of Crohn's colitis is complicated, and therefore treating surgeons must remain abreast of the relevant literature, comprehensive in their knowledge of the disease, and current in surgical technique. Minimization of morbidity, preservation of gastrointestinal function, and improvement in quality of life are all of priority when caring for patients with Crohn's disease.

REFERENCES

[1] Loftus, EV; Jr. Clinical epidemiology of inflammatory bowel disease: Incidence, prevalence, and environmental influences. *Gastroenterology*, 2004, 126, 1504-17.

[2] Dasari, BV; McKay, D; Gardiner, K. Laparoscopic versus Open surgery for small bowel Crohn's disease. *Cochrane Database Syst Rev*, 2011, CD006956.

[3] Lapidus, A; Bernell, O; Hellers, G; Lofberg, R. Clinical course of colorectal Crohn's disease: a 35-year follow-up study of 507 patients. *Gastroenterology*, 1998, 114, 1151-60.

[4] Penner, RM; Madsen, KL; Fedorak, RN. Postoperative Crohn's disease. *Inflamm Bowel Dis*, 2005, 11, 765-77.

[5] Hancock, L; Windsor, AC; Mortensen, NJ. Inflammatory bowel disease: the view of the surgeon. *Colorectal Dis*, 2006, 8 Suppl 1, 10-4.

[6] Gordon, PH; Nivatvongs, S. *Principles and practice of surgery for the colon, rectum, and anus*. 2nd ed. St. Louis, Mo.: Quality Medical Pub., 2007.

[7] Spinelli, A; Sacchi, M; Bazzi, P; Leone, N; Danese, S; Montorsi, M. Laparoscopic surgery for recurrent Crohn's disease. *Gastroenterol Res Pract*, 2012, 2012, 381017.

[8] Thirlby, RC; Land, JC; Fenster, LF; Lonborg, R. Effect of surgery on health-related quality of life in patients with inflammatory bowel disease: a prospective study. *Arch Surg*, 1998, 133, 826-32.

[9] Silverstein, MD; Loftus, EV; Sandborn, WJ; et al. Clinical course and costs of care for Crohn's disease: Markov model analysis of a population-based cohort. *Gastroenterology*, 1999, 117, 49-57.

[10] McLeod, RS. Surgery for inflammatory bowel diseases. *Dig Dis*, 2003, 21, 168-79.

[11] Yamazaki, Y; Ribeiro, MB; Sachar, DB; Aufses, AH; Jr. Greenstein, AJ. Malignant colorectal strictures in Crohn's disease. *Am J Gastroenterol*, 1991, 86, 882-5.

[12] Chutkan, RK; Scherl, E; Waye, JD. Colonoscopy in inflammatory bowel disease. *Gastrointest Endosc Clin N Am*, 2002, 12, 463-83, viii.

[13] Itzkowitz, SH; Present, DH. Consensus conference: Colorectal cancer screening and surveillance in inflammatory bowel disease. *Inflamm Bowel Dis*, 2005, 11, 314-21.

[14] Kostka, R; Lukas, M. Massive, life-threatening bleeding in Crohn's disease. *Acta Chir Belg*, 2005, 105, 168-74.

[15] Pardi, DS; Loftus, EV; Jr. Tremaine, WJ; et al. Acute major gastrointestinal hemorrhage in inflammatory bowel disease. *Gastrointest Endosc*, 1999, 49, 153-7.

[16] Gutierrez, A; Lee, H; Sands, BE. Outcome of surgical versus percutaneous drainage of abdominal and pelvic abscesses in Crohn's disease. *Am J Gastroenterol*, 2006, 101, 2283-9.

[17] Nguyen, DL; Sandborn, WJ; Loftus, EV; Jr. et al. Similar outcomes of surgical and medical treatment of intra-abdominal abscesses in patients with Crohn's disease. *Clin Gastroenterol Hepatol*, 2012, 10, 400-4.

[18] Gardiner, KR; Dasari, BV. Operative management of small bowel Crohn's disease. *Surg Clin North Am*, 2007, 87, 587-610.

[19] Werbin, N; Haddad, R; Greenberg, R; Karin, E; Skornick, Y. Free perforation in Crohn's disease. *Isr Med Assoc J*, 2003, 5, 175-7.

[20] Greenstein, AJ; Sachar, DB; Mann, D; Lachman, P; Heimann, T; Aufses, AH; Jr. Spontaneous free perforation and perforated abscess in 30 patients with Crohn's disease. *Ann Surg*, 1987, 205, 72-6.

[21] Strong, S; ed. Surgery for Crohn's Disease: Springer Science; 2007.

[22] Vavricka, SR; Schoepfer, AM; Scharl, M; Rogler, G. Steroid use in Crohn's disease. *Drugs*, 2014, 74, 313-24.

[23] Munkholm, P; Langholz, E; Davidsen, M; Binder, V. Frequency of glucocorticoid resistance and dependency in Crohn's disease. *Gut*, 1994, 35, 360-2.

[24] Franchimont, DP; Louis, E; Croes, F; Belaiche, J. Clinical pattern of corticosteroid dependent Crohn's disease. *Eur J Gastroenterol Hepatol*, 1998, 10, 821-5.

[25] Faubion, WA; Jr. Loftus, EV Jr; Harmsen, WS; Zinsmeister, AR; Sandborn, WJ. The natural history of corticosteroid therapy for inflammatory bowel disease: a population-based study. *Gastroenterology*, 2001, 121, 255-60.

[26] Shamir, R; Phillip, M; Levine, A. Growth retardation in pediatric Crohn's disease: pathogenesis and interventions. *Inflamm Bowel Dis*, 2007, 13, 620-8.

[27] Newby, E, SA; Thomas, A; et al. Interventions for growth failure in childhood Crohn's disease. In: *Cochrane Database Syst Rev*, 2005.

[28] Cezard, JP; Touati, G; Alberti, C; Hugot, JP; Brinon, C; Czernichow, P. Growth in paediatric Crohn's disease. *Horm Res*, 2002, 58 Suppl 1, 11-5.

[29] McLain, BI; Davidson, PM; Stokes, KB; Beasley, SW. Growth after *gut* resection for Crohn's disease. *Arch Dis Child*, 1990, 65, 760-2.

[30] Griffiths, AM; Wesson, DE; Shandling, B; Corey, M; Sherman, PM. Factors influencing postoperative recurrence of Crohn's disease in childhood. *Gut*, 1991, 32, 491-5.

[31] Dokucu, AI; Sarnacki, S; Michel, JL; et al. Indications and results of surgery in patients with Crohn's disease with onset under 10 years of age: a series of 18 patients. *Eur J Pediatr Surg*, 2002, 12, 180-5.

[32] Hemminki, K; Li, X; Sundquist, J; Sundquist, K. Cancer risks in Crohn disease patients. *Ann Oncol*, 2009, 20, 574-80.

[33] Grivennikov, SI. Inflammation and colorectal cancer: colitis-associated neoplasia. *Semin Immunopathol*, 2013, 35, 229-44.

[34] Steele, SR. Operative management of Crohn's disease of the colon including anorectal disease. *Surg Clin North Am*, 2007, 87, 611-31.

[35] Lakatos, PL; Golovics, PA; David, G; et al. Has there been a change in the natural history of Crohn's disease? Surgical rates and medical management in a population-

based inception cohort from Western Hungary between, 1977-2009. *Am J Gastroenterol*, 2012, 107, 579-88.

[36] El, H; II. Abdul-Baki, H; El-Zahabi, LM; Barada, KA. Primary coloduodenal fistula in Crohn's disease. *Dig Dis Sci*, 2007, 52, 59-63.

[37] Barisiae, G; Krivokapiae, Z; Adziae, T; Pavloviae, A; Popoviae, M; Gojniae, M. Fecopneumothorax and colopleural fistula - uncommon complications of Crohn's disease. *BMC Gastroenterol*, 2006, 6, 17.

[38] Bahadursingh, AM; Longo, WE. Colovaginal fistulas. Etiology and management. *J Reprod Med*, 2003, 48, 489-95.

[39] Garcea, G; Majid, I; Sutton, CD; Pattenden, CJ; Thomas, WM. Diagnosis and management of colovesical fistulae; six-year experience of 90 consecutive cases. *Colorectal Dis*, 2006, 8, 347-52.

[40] Poritz, LS; Gagliano, GA; McLeod, RS; MacRae, H; Cohen, Z. Surgical management of entero and colocutaneous fistulae in Crohn's disease: 17 year's experience. *Int J Colorectal Dis*, 2004, 19, 481-5, discussion 6.

[41] Pinto, RA; Shawki, S; Narita, K; Weiss, EG; Wexner, SD. Laparoscopy for recurrent Crohn's disease: how do the results compare with the results for primary Crohn's disease? *Colorectal Dis*, 2011, 13, 302-7.

[42] Brouquet, A; Bretagnol, F; Soprani, A; Valleur, P; Bouhnik, Y; Panis, Y. A laparoscopic approach to iterative ileocolonic resection for the recurrence of Crohn's disease. *Surg Endosc*, 2010, 24, 879-87.

[43] Poritz, LS; Rowe, WA; Koltun, WA. Remicade does not abolish the need for surgery in fistulizing Crohn's disease. *Dis Colon Rectum*, 2002, 45, 771-5.

[44] Oberhuber, G; Stangl, PC; Vogelsang, H; Schober, E; Herbst, F; Gasche, C. Significant association of strictures and internal fistula formation in Crohn's disease. *Virchows Arch*, 2000, 437, 293-7.

[45] Yamaguchi, A; Matsui, T; Sakurai, T; et al. The clinical characteristics and outcome of intraabdominal abscess in Crohn's disease. *J Gastroenterol*, 2004, 39, 441-8.

[46] Alos, R; Hinojosa, J. Timing of surgery in Crohn's disease: a key issue in the management. *World J Gastroenterol*, 2008, 14, 5532-9.

[47] Richards, RJ. Management of abdominal and pelvic abscess in Crohn's disease. *World J Gastrointest Endosc*, 2011, 3, 209-12.

[48] Sahai, A; Bélair, M; Gianfelice, D; Coté, S; Gratton, J; Lahaie, R. Percutaneous drainage of intra-abdominal abscesses in Crohn's disease: short and long-term outcome. *Am J Gastroenterol*., 1997 Feb, 92(2), 275-8.

[49] Fleshman, JW. Pyogenic complications of Crohn's disease, evaluation, and management. *J Gastrointest Surg*, 2008, 12, 2160-3.

[50] Rieder, F; Zimmermann, EM; Remzi, FH; Sandborn, WJ. Crohn's disease complicated by strictures: a systematic review. *Gut*, 2013, 62, 1072-84.

[51] Gasche, C; Scholmerich, J; Brynskov, J; et al. A simple classification of Crohn's disease: report of the Working Party for the World Congresses of Gastroenterology, Vienna, 1998. *Inflamm Bowel Dis*, 2000, 6, 8-15.

[52] Cosnes, J; Nion-Larmurier, I; Beaugerie, L; Afchain, P; Tiret, E; Gendre, JP. Impact of the increasing use of immunosuppressants in Crohn's disease on the need for intestinal surgery. *Gut*, 2005, 54, 237-41.

[53] Milsom, JW; Lavery, IC; Bohm, B; Fazio, VW. Laparoscopically assisted ileocolectomy in Crohn's disease. *Surg Laparosc Endosc*, 1993, 3, 77-80.

[54] Maartense, S; Dunker, MS; Slors, JF; et al. Laparoscopic-assisted versus open ileocolic resection for Crohn's disease: a randomized trial. *Ann Surg*, 2006, 243, 143-9, discussion 50-3.

[55] Lee, Y; Fleming, FJ; Deeb, AP; Gunzler, D; Messing, S; Monson, JR. A laparoscopic approach reduces short-term complications and length of stay following ileocolic resection in Crohn's disease: an analysis of outcomes from the NSQIP database. *Colorectal Dis*, 2012, 14, 572-7.

[56] Tan, JJ; Tjandra, JJ. Laparoscopic surgery for Crohn's disease: a meta-analysis. *Dis Colon Rectum*, 2007, 50, 576-85.

[57] Rosman, AS; Melis, M; Fichera, A. Metaanalysis of trials comparing laparoscopic and open surgery for Crohn's disease. *Surg Endosc*, 2005, 19, 1549-55.

[58] Tilney, HS; Constantinides, VA; Heriot, AG; et al. Comparison of laparoscopic and open ileocecal resection for Crohn's disease: a metaanalysis. *Surg Endosc*, 2006, 20, 1036-44.

[59] Lowney, JK; Dietz, DW; Birnbaum, EH; Kodner, IJ; Mutch, MG; Fleshman, JW. Is there any difference in recurrence rates in laparoscopic ileocolic resection for Crohn's disease compared with conventional surgery? A long-term, follow-up study. *Dis Colon Rectum*, 2006, 49, 58-63.

[60] Stocchi, L; Milsom, JW; Fazio, VW. Long-term outcomes of laparoscopic versus open ileocolic resection for Crohn's disease: follow-up of a prospective randomized trial. *Surgery*, 2008, 144, 622-7, discussion 7-8.

[61] Bergamaschi, R; Pessaux, P; Arnaud, JP. Comparison of conventional and laparoscopic ileocolic resection for Crohn's disease. *Dis Colon Rectum*, 2003, 46, 1129-33.

[62] Eshuis, EJ; Slors, JF; Stokkers, PC; et al. Long-term outcomes following laparoscopically assisted versus open ileocolic resection for Crohn's disease. *Br J Surg*, 2010, 97, 563-8.

[63] Rijcken, E; Mennigen, R; Argyris, I; Senninger, N; Bruewer, M. Single-incision laparoscopic *surgery* for ileocolic resection in Crohn's disease. *Dis Colon Rectum*, 2012, 55, 140-6.

[64] Li, Y; Zhu, W; Zuo, L; et al. Frequency and risk factors of postoperative recurrence of Crohn's disease after intestinal resection in the Chinese population. *J Gastrointest Surg*, 2012, 16, 1539-47.

[65] McLeod, RS; Wolff, BG; Ross, S; Parkes, R; McKenzie, M. Recurrence of Crohn's disease after ileocolic resection is not affected by anastomotic type: results of a multicenter, randomized, controlled trial. *Dis Colon Rectum*, 2009, 52, 919-27.

[66] Ikeuchi, H; Kusunoki, M; Yamamura, T. Long-term results of stapled and hand-sewn anastomoses in patients with Crohn's disease. *Dig Surg*, 2000, 17, 493-6.

[67] Guo, Z; Li, Y; Zhu, W; Gong, J; Li, N; Li, J. Comparing outcomes between side-to-side anastomosis and other anastomotic configurations after intestinal resection for patients with Crohn's disease: a meta-analysis. *World J Surg*, 2013, 37, 893-901.

[68] He, X; Chen, Z; Huang, J; et al. Stapled side-to-side anastomosis might be better than handsewn end-to-end anastomosis in ileocolic resection for Crohn's disease: a meta-analysis. *Dig Dis Sci*, 2014, 59, 1544-51.

[69] Kono, T; Ashida, T; Ebisawa, Y; et al. A new antimesenteric functional end-to-end handsewn anastomosis: surgical prevention of anastomotic recurrence in Crohn's disease. *Dis Colon Rectum*, 2011, 54, 586-92.

[70] Fichera, A; Zoccali, M; Kono, T. Antimesenteric functional end-to-end handsewn (Kono-S) anastomosis. *J Gastrointest Surg*, 2012, 16, 1412-6.

[71] Renison, DM; Forouhar, FA; Levine, JB; Breiter, JR. Filiform polyposis of the colon presenting as massive hemorrhage: an uncommon complication of Crohn's disease. *Am J Gastroenterol*, 1983, 78, 413-6.

[72] Morpurgo, E; Petras, R; Kimberling, J; Ziegler, C; Galandiuk, S. Characterization and clinical behavior of Crohn's disease initially presenting predominantly as colitis. *Dis Colon Rectum*, 2003, 46, 918-24.

[73] Hancock, L; Beckly, J; Geremia, A; et al. Clinical and molecular characteristics of isolated colonic Crohn's disease. *Inflamm Bowel Dis*, 2008, 14, 1667-77.

[74] Soucy, G; Wang, HH; Farraye, FA; et al. Clinical and pathological analysis of colonic Crohn's disease, including a subgroup with ulcerative colitis-like features. *Mod Pathol*, 2012, 25, 295-307.

[75] McQuillan, AC, AH. Superficial Crohn's disease: a study of 10 patients. *Surg Pathol*, 1989, 2, 231-9.

[76] Harpaz, N, FS; George, J. Superficial Crohn's colitis: pathological and clinical features including long-term follow up. *Mod Pathol*, 2001, 14, 86A.

[77] Autenrieth, DM; Baumgart, DC. Toxic megacolon. *Inflamm Bowel Dis*, 2012, 18, 584-91.

[78] Turnbull, RB; Jr. Weakley, FL; Hawk, WA; Schofield, P. Choice of operation for the toxic megacolon phase of nonspecific ulcerative colitis. *Surg Clin North Am*, 1970, 50, 1151-69.

[79] Ausch, C; Madoff, RD; Gnant, M; et al. Aetiology and surgical management of toxic megacolon. *Colorectal Dis*, 2006, 8, 195-201.

[80] Pennington, L; Hamilton, SR; Bayless, TM; Cameron, JL. Surgical management of Crohn's disease. Influence of disease at margin of resection. *Ann Surg*, 1980, 192, 311-8.

[81] Fichera, A; McCormack, R; Rubin, MA; Hurst, RD; Michelassi, F. Long-term outcome of surgically treated Crohn's colitis: a prospective study. *Dis Colon Rectum*, 2005, 48, 963-9.

[82] Tekkis, PP; Heriot, AG; Smith, O; Smith, JJ; Windsor, AC; Nicholls, RJ. Long-term outcomes of restorative proctocolectomy for Crohn's disease and indeterminate colitis. *Colorectal Dis*, 2005, 7, 218-23.

[83] Kiran, RP; Nisar, PJ; Church, JM; Fazio, VW. The role of primary surgical procedure in maintaining intestinal continuity for patients with Crohn's colitis. *Ann Surg*, 2011, 253, 1130-5.

[84] Bernstein, CN; Shanahan, F; Weinstein, WM. Are we telling patients the truth about surveillance colonoscopy in ulcerative colitis? *Lancet*, 1994, 343, 71-4.

[85] Rutter, MD; Saunders, BP; Wilkinson, KH; et al. Thirty-year analysis of a colonoscopic surveillance program for neoplasia in ulcerative colitis. *Gastroenterology*, 2006, 130, 1030-8.

[86] Kiran, RP; Nisar, PJ; Goldblum, JR; et al. Dysplasia associated with Crohn's colitis: segmental colectomy or more extended resection? *Ann Surg*, 2012, 256, 221-6.

[87] Maser, EA; Sachar, DB; Kruse, D; Harpaz, N; Ullman, T; Bauer, JJ. High rates of metachronous colon cancer or dysplasia after segmental resection or subtotal colectomy in Crohn's colitis. *Inflamm Bowel Dis*, 2013, 19, 1827-32.

[88] Mills, S; Stamos, MJ. Colonic Crohn's disease. *Clin Colon Rectal Surg*, 2007, 20, 309-13.

[89] Yamamoto, T; Bain, IM; Allan, RN; Keighley, MR. Persistent perineal sinus after proctocolectomy for Crohn's disease. *Dis Colon Rectum*, 1999, 42, 96-101.

[90] Ritchie, JK. The results of *surgery* for large bowel Crohn's disease. *Ann R Coll Surg Engl*, 1990, 72, 155-7.

[91] Yamamoto, T; Keighley, MR. Proctocolectomy is associated with a higher complication rate but carries a lower recurrence rate than total colectomy and ileorectal anastomosis in Crohn colitis. *Scand J Gastroenterol*, 1999, 34, 1212-5.

[92] Leicester, RJ; Ritchie, JK; Wadsworth, J; Thomson, JP; Hawley, PR. Sexual function and perineal wound healing after intersphincteric excision of the rectum for inflammatory bowel disease. *Dis Colon Rectum*, 1984, 27, 244-8.

[93] Bernell, O; Lapidus, A; Hellers, G. Recurrence after colectomy in Crohn's colitis. *Dis Colon Rectum*, 2001, 44, 647-54, discussion 54.

[94] Andersson, P; Olaison, G; Hallbook, O; Sjodahl, R. Segmental resection or subtotal colectomy in Crohn's colitis? *Dis Colon Rectum*, 2002, 45, 47-53.

[95] Tekkis, PP; Purkayastha, S; Lanitis, S; et al. A comparison of segmental vs subtotal/total colectomy for colonic Crohn's disease: a meta-analysis. *Colorectal Dis*, 2006, 8, 82-90.

[96] Hartley, JE; Fazio, VW; Remzi, FH; et al. Analysis of the outcome of ileal pouch-anal anastomosis in patients with Crohn's disease. *Dis Colon Rectum*, 2004, 47, 1808-15.

[97] Regimbeau, JM; Panis, Y; Pocard, M; et al. Long-term results of ileal pouch-anal anastomosis for colorectal Crohn's disease. *Dis Colon Rectum*, 2001, 44, 769-78.

[98] Brown, CJ; Maclean, AR; Cohen, Z; Macrae, HM; O'Connor, BI; McLeod, RS. Crohn's disease and indeterminate colitis and the ileal pouch-anal anastomosis: outcomes and patterns of failure. *Dis Colon Rectum*, 2005, 48, 1542-9.

[99] Braveman, JM; Schoetz, DJ, Jr.; Marcello, PW, et al. The fate of the ileal pouch in patients developing Crohn's disease. *Dis Colon Rectum*, 2004, 47, 1613-9.

[100] Reese, GE; Lovegrove, RE; Tilney, HS; et al. The effect of Crohn's disease on outcomes after restorative proctocolectomy. *Dis Colon Rectum*, 2007, 50, 239-50.

[101] A comparison of laparoscopically assisted and open colectomy for colon cancer. *N Engl J Med*, 2004, 350, 2050-9.

[102] Guillou, PJ; Quirke, P; Thorpe, H; et al. Short-term endpoints of conventional versus laparoscopic-assisted *surgery* in patients with colorectal cancer (MRC CLASICC trial): multicentre, randomised controlled trial. *Lancet*, 2005, 365, 1718-26.

[103] Schwenk, W; Bohm, B; Haase, O; Junghans, T; Muller, JM. Laparoscopic versus conventional colorectal resection: a prospective randomised study of postoperative ileus and early postoperative feeding. Langenbecks *Arch Surg*, 1998, 383, 49-55.

[104] Schlinkert, RT. Laparoscopic-assisted right hemicolectomy. *Dis Colon Rectum*, 1991, 34, 1030-1.

[105] Hamel, CT; Hildebrandt, U; Weiss, EG; Feifelz, G; Wexner, SD. Laparoscopic *surgery* for inflammatory bowel disease. *Surg Endosc*, 2001, 15, 642-5.

[106] da Luz, Moreira, A; Stocchi, L; Remzi, FH; Geisler, D; Hammel, J; Fazio, VW. Laparoscopic *surgery* for patients with Crohn's colitis: a case-matched study. *J Gastrointest Surg*, 2007, 11, 1529-33.

[107] Holubar, SD; Dozois, EJ; Privitera, A; Pemberton, JH; Cima, RR; Larson, DW. Minimally invasive colectomy for Crohn's colitis: a single institution experience. *Inflamm Bowel Dis*, 2010, 16, 1940-6.

[108] Umanskiy, K; Malhotra, G; Chase, A; Rubin, MA; Hurst, RD; Fichera, A. Laparoscopic colectomy for Crohn's colitis. A large prospective comparative study. *J Gastrointest Surg*, 2010, 14, 658-63.

[109] Chaudhary, B; Glancy, D; Dixon, AR. Laparoscopic *surgery* for recurrent ileocolic Crohn's disease is as safe and effective as primary resection. *Colorectal Dis*, 2011, 13, 1413-6.

[110] Aytac, E; Stocchi, L; Remzi, FH; Kiran, RP. Is laparoscopic *surgery* for recurrent Crohn's disease beneficial in patients with previous primary resection through midline laparotomy? A case-matched study. *Surg Endosc*, 2012, 26, 3552-6.

[111] Antoniou, SA; Antoniou, GA; Koch, OO; Pointner, R; Granderath, FA. Robot-assisted laparoscopic *surgery* of the colon and rectum. *Surg Endosc*, 2012, 26, 1-11.

[112] Miller, AT; Berian, JR; Rubin, M; Hurst, RD; Fichera, A; Umanskiy, K. Robotic-assisted proctectomy for inflammatory bowel disease: a case-matched comparison of laparoscopic and robotic technique. *J Gastrointest Surg*, 2012, 16, 587-94.

In: Encyclopedia of Surgery (22 Volume Set)
Editors: Andreas Lehrer and Kristin Mueller
ISBN: 978-1-53618-329-0
© 2020 Nova Science Publishers, Inc.

Chapter 369

COMPLICATIONS OF SURGERY

Sarwat Ahmad[1], MD and Stephen M. Kavic[2,*], MD
[1]University of Maryland Medical Center, Baltimore, MD, US
[2]University of Maryland School of Medicine, Baltimore, MD, US

ABSTRACT

The majority of patients with Crohn's disease eventually require surgery within ten years of diagnosis, most often due to failure of medical therapy or obstruction secondary to ileocolic stenosis. Because of the transmural, chronic, inflammatory nature of the disease as well as the inherent characteristics of the Crohn's patient population (young, malnourished, high percentage of smokers, etc.), there are a number of common and often difficult to manage complications associated particularly with surgery for Crohn's disease. These include surgical site infection, intra-abdominal septic complications, anastomotic complications such as stenosis and leak, enterocutaneous fistula, surgical recurrence, and development of venous thromboembolism. Patients with septic complications, penetrating disease, and number of other risk factors such as smoking, weight loss, and steroid use, tend to require multiple reoperations and intestinal resections, putting them at risk for short gut syndrome and ultimately, intestinal failure. One must be able to identify high-risk patients and be aware of the current diagnostic and management principles of Crohn's disease complications in order to prevent progression to these devastating outcomes and minimize morbidity and mortality.

INTRODUCTION

Crohn's disease (CD) is a complex, incurable, chronic condition with significant morbidity. Its natural history includes many complications such as progression to strictures, fistulae, perianal disease, abscesses, and/or colorectal cancer. Almost half of CD patients develop at least one of these complications [1], and the risk is even higher in males and

* Corresponding Author's Email: skavic@smail.umaryand.edu.

smokers [1, 2]. Complications of CD lead to surgery in approximately 80% of patients within ten years of diagnosis [3].

Complications may follow any surgical procedure, and may involve any organ system. For instance, tooth dislodgement may occur with endotracheal intubation, but has little to do with the specific operative procedure. Further, these complications may range from the mild to the life-threatening in severity. Rather than provide an exhaustive list of all potential surgical complications, in this chapter we will attempt to focus on the complications specific to intestinal surgery for CD.

In CD, 40-50% of patients present with disease of the terminal ileum and cecum, while 20-30% present with primarily colonic disease. The most common indications for surgery are failure of medical therapy and/or intestinal obstruction secondary to stricture, but can also include fistula, abscess formation, hemorrhage, cancer, or growth retardation in children. More than half of patients need a second operation or procedure within 20 years after ileocolic resection and anastomosis[4]. The most common surgery for primary disease is ileocecal resection, and the most common surgery for recurrent disease is ileocolic resection. Repeat surgical interventions further increase risk of complications, which accumulate and lead to debilitating disease.

Postoperative surgical complication rates are higher for CD than for other benign diseases and occur in about 5-13% cases [3,5] with a readmission rate of about 3.7% [3]. Rate of medical relapse or recurrence after surgery is even higher – up to 25% in the immediate postoperative period, and up to 100% ultimately. Clearly, early recurrence will further complicate the post-operative course. Given the high degree of morbidity and complexity associated with this disease, it is important to recognize the common complications to which the Crohn's surgical patient is most susceptible and gain a current understanding of their risk factors, diagnosis, and management.

GENERAL RISK FACTORS

Complications usually occur over a short time frame, typically within four years of operation [3]. Short-term complications are infection (surgical site infections and intra-abdominal sepsis), anastomotic complications, bleeding, venous thromboembolus (VTE), and fistula. Many of these –such as anastomotic leak, enterocutaneous fistula, and infection— overlap, and subject the patient to a cycle of readmissions and interventions. VTE and recurrence can occur in the short or long term. Short gut syndrome and intestinal failure are chronic complications of large resections, repeated resections, recurrent complications, and severe, unremitting disease activity. The overall incidences and risk factors reported for each type of complication are summarized in Figure 1.

In general, risk factors for the development of post-operative complications in Crohn's disease and poor outcome are significant pre-operative weight loss (>5 kg or 10% TBW), pre-operative albumin level <3.0 g/dL, prolonged refractory symptoms, young age at diagnosis, primarily small bowel disease, steroid use, presence of two or more co-morbidities, and penetrating disease behavior [6,7,8]. Risk may be reduced by optimization of nutrition [9], use of antibiotics, and percutaneous drainage of abscesses, among other strategies that will be discussed in this chapter.

List of Complications		
	Incidence	Risk Factors
Wound dehiscence	4%	
Surgical Site Infection	9-30%	Steroid use, proximal small bowel disease, smoking, weight loss prior to surgery, obesity
Superficial surgical site infection	9-19%	Poor nutrition, disease type, extended OR time, blood loss during surgery, transfusions, serum CRP level, serum albumin level, serum lymphocyte count
Deep surgical site infection	2%-10%	Crohn's disease diagnosis
Organ Space infection	3-10%	Pre-operative weight loss, extended OR time, open procedures, contaminated dirty wounds
Intra-abdominal Septic Complication	5-30%	Poor nutrition, albumin <3 g/dL, steroids, presence of abscess or fistula at time of surgery, Less common: penetrating disease, extended OR time, hand-sewn anastomosis, articular disease manifestation, disease duration >10 years before surgery, weight loss, thiopurine therapy, colo-colonic anastomosis, recurrent clinical episodes of CD
GI Bleeding	0.5-4.2%	Thickened mesentery, inadequate clearing of the mesentery prior to division, coagulopathy or bleeding dyscrasia
Anastomotic leak	0.5-7%	Steroid use, pre-operative abscess formation, extensive LOA, extended OR time, proximal small bowel disease, low anterior resection, obesity and male gender (extraperitoneal) Less common: ASA class III-IV, emergent surgery, stapled anastomosis
Anastomotic stricture	Up to 50%	Ischemia at anastomosis, anastomotic leak, recurrent disease, inflammation
Enterocutaneous fistula	Up to 33%	Extensive lysis of adhesions, anastomotic leak, recurrent disease, open surgery
Venous thromboembolism	1.4%	Age <40 years, steroid use, anemia, malnutrition, prolonged anesthesia time, complicated IBD, active disease, recent hospitalizations for IBD, smoking
Short gut Syndrome	5-10%	Earlier age at diagnosis, family history of IBD, stricturing disease, younger age at first surgery, surgical complications, aggressive resections, errors in initial diagnosis
Surgical recurrence	3-8 30% at 5 years, 40% at 10 years and 55% at 20 years	Smoking, presence of fistula or intra-abdominal sepsis as the indication for the primary surgery, short duration of disease prior to surgery, perforating disease Less common: steroids, perianal disease, younger age, primarily small bowel disease, primarily large bowel disease, small bowel wall thickening 1 year post-op, structuring disease,

Figure 1. Possible complications of surgery for Crohn's disease, along with incidence and risk factors.

Pre-operative steroid use has been linked to higher risk of postoperative complications [6]. In a large prospective trial of 8000+ patients with Crohn's disease followed over seven years, there was a higher rate of wound dehiscence, need for blood transfusion, infection, VTE, 30-day reoperation rate, and longer hospital length of stay and post-operative length of stay for patients with pre-operative steroid use [10]. Unfortunately, those contemplating

surgery often have some degree of acute illness that is treated with corticosteroids, making their use common in the surgical population.

Immunomodulators [azathioprine, mesalamines, 6-MP, methotrexate, etc] and *biologic agents* such as anti-tumor necrosis factor α (anti-TNF) agents (infliximab, adalimumab, certolizumab pegol) are steroid-sparing and should theoretically reduce the negative effects of steroid use described above. However, anti-TNF agents have inconsistently been linked to risk for post-operative complications [11-14]. A systematic review and meta-analysis of 18 studies found a moderately increased risk of total early complications with infliximab use, particularly infectious complications [13]. Appau found that infliximab was associated with postoperative sepsis but not anastomotic dehiscence [14].

In contrast, another meta-analysis of six studies found no difference in major or minor complication rate, re-operation rate, or 30-day mortality for patients taking infliximab [12]. In a comparative, multicenter trial of 111 CD patients undergoing surgery with anastomosis treated with biologics within two months perioperatively versus 187 control patients, there was no difference in rate or severity of post-operative complications [11]. A small, randomized controlled trial suggested that infliximab was protective for post-operative maintenance therapy compared to other immunomodulators [15,16]. The effect of biologics in addition to that of other immunosuppressive drugs will be further explored as they relate to each complication described below.

INFECTIOUS COMPLICATIONS

Surgical Site Infection

A surgical site infection (SSI) can be superficial or deep incisional or in the organ/space. SSI usually occurs within 30 days of the operation and displays at least one of the following: 1) purulent discharge from the incision or from a drain placed into the organ space; 2) isolation of organisms from the culture of fluid or tissue obtained from the incision or organ/space; 3) the presence of an open wound with signs and symptoms of infection; 4) abscess formation or other evidence of infection on examinations of the incision or organ/space [17]. As one of the most common post-surgical complications, SSI increases medical costs and length of hospital stay.

Colorectal surgery in general predisposes patients to development of SSI due to increased bacterial contamination, creation of ostomies and intestinal anastomoses. This risk is especially pronounced in CD, which is inflammatory in nature and frequently involves an immunosuppressed host at risk for anemia and malnutrition.

According to NSQIP data comparing 35,557 segmental colectomies from 2006-2011, the incidence of post-operative SSI for CD is higher (17-30%) than for other indications, such as diverticulitis (13%) and colon cancer (10%). A diagnosis of CD is an independent risk factor for developing any post-operative infection. CD is an independent predictor of deep incisional SSI and deep organ space SSI, but not superficial incisional SSI. CD patients who develop SSI were more likely to be smokers, have taken steroids, and lost significant weight prior to surgery [18,19].

Compared to colon cancer patients, CD and diverticulitis patients are more likely to have contaminated or dirty wounds (34%). There was no difference in rate of wound dehiscence (1%). CD group had the highest rate of postoperative infectious complications in general– 21% - with twice the rate of deep organ space SSI (7%) than for other indications. Laparoscopic procedure lowered the risk of infection. Diabetes was not associated with increased SSI risk [18].

Another large study of 270 patients with CD had a 19% incidence of any septic complication, 10% incidence of wound infection, and 2% incidence of intra-abdominal abscess [20]. Incisional but not organ/space SSI has been correlated with disease type (perforating or fistulizing), length of operation, estimated blood loss during operation, perioperative transfusion, and inclusion of a proctectomy [21, 14]. The type of ileocolic anastomosis (hand-sewn vs. stapled) seems to have no effect on incidence of intra-abdominal abscess or wound infection [22].

There is no current consensus on whether creating a diverting stoma increases or decreases risk of infective complications. Syed found that ostomy creation was associated with increased risk of postoperative wound infection [23]. This may be because most of these ostomies were unplanned and the patients did not undergo proper pre-operative siting. Other studies observed that ostomy creation decreased risk of postoperative infection, potentially due to lack of anastomosis or diversion of stool from a new anastomosis.

There is no difference in incidence of organ space infection after laparoscopic or open ileocolectomy [24,25]. A large retrospective study of 2618 patients evaluated the risk factors for organ space infection after open or laparoscopic ileocectomy and found that increased risk of organ space infection was seen with preoperative weight loss >10% of total body weight, extended operating room time, open procedures, and contaminated or dirty wounds. Rates of stoma creation and steroid use did not affect organ/space infection rate, although they did not know about pre-existing fistulizing or abscessing disease behavior or the use of biologics [19].

Nutritional and inflammatory statuses are also risk factors for postoperative infection. One should perform an adequate preoperative nutrition assessment of the patient prior to CD surgery. Several validated assessment tools exist, such as the Malnutrition Universal Screening Tool (MUST), the Nutritional Risk Scoring 2002 (NRS2002), the Mini- Nutritional Assessment, and Onodera's Prognostic Nutritional Index (OPNI). The OPNI is calculated by taking into account serum albumin and total lymphocyte count, thus also reflecting the patient's inflammatory status, and is inversely correlated with rate of postoperative incisional SSI in CD [21]. Lower OPNI and lower serum albumin are associated with higher SSI risk, as are higher lymphocyte count and CRP level. Additional clinical parameters that can be used to gauge nutritional response are body weight, BMI, and serum albumin. Inflammatory disease activity can also be monitored by measurement of serum haptoglobin, CRP, and white blood cell count.

Potential risk of incurring surgical site complications in patients on other immunomodulating drugs and/or anti-TNF agents should also be discussed pre-operatively. There is significant debate on whether these agents affect postoperative infection risk, with some conflicting information in the literature. Several groups have reported that immunomodulators and/or infliximab are not associated with higher rates of infection, reoperation, or anastomotic leak in patients having surgery for CD [21, 26, 27, 28].

Beyond mere equivalency, it is possible that there is a protective effect at work. The anti-inflammatory nature of infliximab may actually reduce incisional SSI, especially in fistulizing disease. One multi-institutional study of 217 patients found that combined steroids and anti-TNFα therapy did increase risk of postoperative intra-abdominal infection while anti-TNFα alone did not [29].

Other studies, including a recent systematic review, did find an increased postoperative infection risk with anti-TNF agents [13, 14, 23, 30], and these studies recommended avoiding surgery within 8-12 weeks of initiating anti-TNF therapy in patients at higher risk for post-operative infectious and surgical site complications, if possible. At present, it may be prudent to maintain biologic therapy, and not routinely change the timing of biologic agents administered to those undergoing surgery, but to minimize infusion within one month of operation.

Additionally, higher doses of infliximab in CD patients may correlate with postoperative infection risk, overall postoperative morbidity, and hospital readmissions [31]. It is important to keep in mind, however, that the patients on anti-TNF agents in these studies are more likely to display aggressive disease behavior, be treated with immunomodulators, and have other risk factors such as anemia, malnutrition, fistulae, and past surgeries. Overall, the trend is towards continuing use of pre-operative infliximab in patients with penetrating or fistulizing disease, and maintaining close observation of the wound in these patients since they may be at higher risk.

INTRA-ABDOMINAL SEPTIC COMPLICATIONS

Intra-abdominal septic complications (IASC) encompass anastomotic leaks, intra-abdominal abscesses, or enterocutaneous fistula (ECF). The incidence of post-operative intra-abdominal septic complications exceeds that for other benign diseases, and is estimated to occur between 5-30% [6, 32, 33, 34]. IASC prolong hospital stay, affect quality of life, and increase the risk of surgical recurrence [6]. Even more importantly, IASC accounts for about half of postoperative deaths in CD [33]. Therefore, it is critical to identify both pre- and post-operative clinical risk factors in order to understand how to prevent and optimally manage IASC in CD.

Several studies have examined risk factors for IASC. The *independent risk factors* that have been most consistently identified are listed in Figure 2, and represent a combination of patient disease and treatment factors. These factors are poor nutritional status or low albumin level <3.0 g/dL [11, 23, 33, 35] steroid use [32, 33, 34] presence of abscess, and presence of fistula at time of surgery [11, 32, 33, 34]. According to Yamamoto, the risk of post-operative IASC was 50% if all four of these risk factors were present and 29% if three of four were present [33]. To confound this relationship, it is unclear whether steroid-related infectious complications are a result of its immunosuppressive side effects, or simply reflective of the severity of disease activity.

Other *less commonly reported risk factors* for IASC are: recurrent clinical episodes of CD [32], penetrating disease, operation time >180 minutes [34, 35], hand-sewn anastomosis [35], articular disease manifestation, duration of symptoms before surgery, disease duration of more than 10 years, weight loss, thiopurine therapy [11], colo-colonic anastomoses [11, 34].



Figure 2. Independent risk factors for postoperative intra-abdominal septic complications.

Some researchers have found that the number, site or method of anastomoses does not affect septic complications [33]. In general, surgical teaching has been that affected bowel only needs to be resected to grossly normal margins, assessed intraoperatively by visual means alone. However, one study found that positive histological margins in patients undergoing ileocolic resection are a risk factor for postoperative IASC. Thus, some have suggested that if an anastomosis is constructed in a patient at high risk for infection, one might send frozen sections of the margins to assist the decision to make a temporary diverting ileostomy.

Penetrating or perforating disease (i.e., presents with abscess, fistula, or free perforation with peritonitis) has been identified by several studies as an independent risk factor for postoperative IASC, surgical recurrence, and overall complication rate. Compared to patients with non-perforating indications for ileocolic resection (i.e., fibrostenotic), patients with perforating disease have longer, more complex operations, are less likely to be performed laparoscopically, and more likely to require preoperative TPN, an ileostomy, and a longer postoperative stay [36]. These patients should be managed with thorough preoperative evaluation including optimization of nutrition and cessation of smoking, combined with percutaneous drainage and antibiotics when appropriate.

ABSCESSES

Abdominal and/or pelvic abscess develop as complications of the disease itself. In surgical patients, abscess develops post-operatively after Crohn's surgery in up to 9% of patients in ten years [37], especially in those with anastomotic leaks or postoperative fistulae. Those with penetrating or perforating disease behavior are more likely to develop abscess than those with stricturing or inflammatory disease [36]. Most abscesses develop near the anastomotic site [37], and almost all require intervention. However, abscesses can develop in almost any location, and have been reported in the abdominal wall, peritoneal cavity, retroperitoneum, iliopsoas, and subphrenic region [37].

There are three conceptual approaches to treating an abscess: medical management with antibiotics; percutaneous drainage; or surgical drainage, with or without resection of involved segments. About 25% of abscesses will recur after treatment [37], although this rate is lower with surgical drainage than with those treated medically or via percutaneous drainage.

Medical management and percutaneous drainage can be used to delay or prevent re-operation if better suited for the patient's clinical condition. Regardless of approach, earlier intervention to drain abdominal or pelvic abscesses is associated with shorter time to resolution [38].

There is no difference between anastomotic technique (stapled or hand-sewn) on the incidence of postoperative abscess [22]. Interestingly, patients who present with abscesses are less likely to undergo laparoscopic surgery [36], although it is not a contraindication to laparoscopic surgery. Ideally, pyogenic complications should be managed electively and after nutritional repletion to prevent long-term complications [39]. Of course, this is not always possible in the setting of acute illness or sepsis.

STRATEGIES FOR PERIOPERATIVE INFECTION CONTROL

Presence of intra-abdominal abscess at time of laparotomy increases risk of post-operative IASC by five-fold [32]. Accordingly, percutaneous abscess drainage should be utilized before definitive surgery, and has been shown to significantly reduce the occurrence of severe postoperative IASC in CD as well as hospital length of stay [40]. Percutaneous drainage allows time for medical optimization with parenteral hyperalimentation, bowel rest, and antibiotics before surgery, as well as reduces pus contamination at time of surgery to enable anastomosis and avoid stoma. Timing of surgery after percutaneous drainage is variable, with most surgeons recommending a 4-6 week interval to allow for resolution.

As with any elective procedure, the patient should be medically optimized prior to planned surgery. This includes correction of anemia, fluid deficits, electrolyte and acid-base disorders, and malnutrition. Preoperative TPN for at least 18 days is recommended for patients with moderate to severe CD to minimize risk of early postoperative complications [9]. For those who can tolerate it, exclusively enteral nutrition may be appropriate, as one study found it reduces the risk of postoperative intra-abdominal septic complications after operation for ECFs in CD [41].

Preoperative imaging with CT enterography or MR enterography may assist in adequate planning and identification of extraluminal complications. In theory, this identification before operation should reduce operative duration and infectious risk. However, CT imaging should be ordered with discretion in CD patients, since they may require repeated scans over time and accumulate radiation risks [42]. Mechanical or chemical bowel preparations are not required to safely perform intestinal surgery in CD patients. Intravenous second-generation cephalosporin or ciprofloxacin plus metronidazole for prophylaxis should be given 30 minutes before surgery and every 3 hours during the procedure.

ANASTOMOTIC COMPLICATIONS

The most common anastomotic complications are bleeding, dehiscence and leaks, strictures, and fistulas.

Bleeding can be minor or major and is thought to occur due to inadequate clearance of the mesentery prior to division and/or stapling of the bowel. There may be an increased tendency to bleed due to the inherent friability of the blood vessels, coupled with the inflammatory

process that surrounds the vessels in a thick, fatty coat. Minor bleeding from the staple or suture line manifests as passage of blood or dark stool with the patient's first bowel movement. This bleeding is self-limited and resolves within 24 hours.

Major bleeding occurs in 0.5-4.2% of patients undergoing anastomosis following all cause colorectal surgery [43, 44]. In the colorectal literature, there is no difference in incidence of postoperative bleeding between benign versus malignant indications. Further, the technique of anastomosis (stapled vs. hand-sewn) does not have an effect on the incidence of bleeding [44].

Management of post-operative bleeding in CD patients follows the same principles of managing lower gastrointestinal bleed in any surgical patient. Specifically, the initial measures are aimed at preserving intravascular volume by administering resuscitative intravenous fluids, blood transfusions, and correction of any underlying coagulopathy. Surgery, angiography, and/or endoscopy are reserved for those who are unstable or have failed conservative management. Early endoscopy, however, may carry a risk for anastomotic dehiscence and disruption of friable tissue, thus should be performed with great care. Persistent bleeding from a low anastomosis may be assessed transanally with a proctoscope and managed with suture ligation. Higher anastomoses need endoscopy, angiography, or re-operation. Angiography is particularly important to identify and possibly treat the bleeding source either without surgery or before surgery. Intraoperative enteroscopy can also be used, but may be difficult to perform in the presence of many strictures.

Major bleeding can also occur intraoperatively if the patient has a very thickened, friable mesentery. The associated diseased bowel loop must be handled and resected with extreme caution, as tearing the friable mesentery can result in profuse and rapid bleeding. It is advisable that patients with thickened mesenteries on pre-operative evaluation undergo open laparotomy in case the surgeon needs to control hemorrhage quickly. In the event of mesenteric tearing or difficult-to-perform vascular control of a thick mesentery, the surgeon should obtain proximal control of the root of the mesentery with large, non-crushing non-traumatizing clamps to minimize further blood loss. Upon release of the clamp, bleeding areas can be controlled with hemostats, suture ligatures, or an energy device [45]. In general, the mesenteric division should occur with clamps and ties rather than relying on energy devices, which may not have the same efficacy in the thickened mesentery of CD.

ANASTOMOTIC LEAK

Anastomotic leak is perhaps the most feared surgical complication of CD surgery, as it can lead to difficult-to-treat enterocutaneous fistulae and/or intestinal failure. Anastomotic leaks are associated with prolonged hospital stay and increased risk of in-hospital mortality.

Like other surgery of the lower GI tract, the risk of anastomotic leak seems to increase with an increasingly distal location of the anastomosis. The reported leak rate for an ileocolic anastomosis is 0.5-7.0% with a mortality rate of up to 20%. Ileocolic anastomoses are different from other colonic anastomoses with regard to bacterial characteristics, bowel caliber, wall structure, location in abdomen, staple technique, and anastomotic leak rate [46]. However, coloanal anastomoses tend to have a higher leak rate (10-20%) [47].

Risk factors for anastomotic leak depend on whether the anastomosis is extraperitoneal or intraperitoneal. Low anterior resection with an extraperitoneal anastomosis is not the most common surgery in CD, but it does carry the highest anastomotic dehiscence rate (8%). The risk is inversely correlated with distance of anastomosis from the anal verge and blood flow to the anastomotic site. Obesity and male gender are also risk factors for extraperitoneal anastomoses due to the more difficult dissection encountered in the deep pelvis.

Intraperitoneal anastomoses—such as jejunoileal, ileoileal, and ileocolic—are at higher risk for leak in patients with significant comorbidity (ASA class III to V), prolonged operative time, extensive lysis of adhesions [11], proximal small bowel disease [11], steroid use, presence of pre-operative abscess, and perhaps, emergent surgery. In one series, the risk of anastomotic complications and overall infectious complications doubles in patients with either steroid use or pre-operative abscess, and is nearly 40% if both risk factors were present [48].

Corticosteroids impair anastomotic healing through a number of mechanisms: they decrease activation and infiltration of inflammatory cells (macrophages and neutrophils) that are critical in the first phase of wound healing; and they inhibit growth factors, matrix proteins, and collagen synthesis. There is no consistent evidence describing dose or duration of steroids that cause anastomotic complications. Arbitrarily, one study defined steroid use as 10 mg or more of prednisone or equivalent for at least 4 weeks and within 2 weeks of surgery [48]. Most clinical experience suggests that steroid doses exceeding 20mg a day confer a significant additional risk.

The incidence of postoperative leak is not affected by laparoscopic versus open surgical approach (2.6% vs. 2.1%) [49]. However, there is substantial variability in technique that makes interpreting the literature difficult. Many surgeons that offer a laparoscopic technique will perform the anastomosis extra-corporeally, via the extraction incision. Others perform the surgery completely laparoscopically. The use of specific energy devices, stapling technology, anastomotic arrangement, and the level of training all serve to leave the practitioner scanning the literature with the sense that there are as many techniques as there are authors.

The data is truly inconclusive as to which anastomotic technique is best for CD surgery. In a meta-analysis of six randomized controlled trials and 955 patients undergoing ileocolic anastomosis for both benign and malignant disease, hand-sewn anastomoses were associated with a significantly higher leak (6% vs. 1.4%) in cancer patients, but there was no difference between hand-sewn and stapled on the incidence of anastomotic leak for non-malignant disease [22]. Besides being faster to perform and requiring less handling of the bowel, stapled anastomosis may lead to less spillage and a more uniform closure, potentially explaining why fewer anastomotic leaks were seen in the overall group of patients included in the meta-analysis [22]. There does not appear to be a benefit for stapled over hand-sewn anastomosis for leak rate after colorectal anastomosis, and it may actually lead to higher chance of stenosis in colon anastomoses.

Again, for CD patients specifically, there is significant variation in the literature on this topic. Representative of this discussion is one Italian study from 2005, where a 7 fold reduction in anastomotic complications was observed when stapled techniques were used instead of hand-sewn anastomoses [50]. On the other hand, another group clearly demonstrated intestinal complications and early reoperation were significantly reduced by use

of a hand-sewn anastomosis [51]. At present, many surgeons prefer the convenience of stapled anastomoses, and the most common configuration is side-to-side.

To avoid complication, one should keep in mind the following standard requirements of an intestinal anastomosis: maintenance of adequate blood flow, freedom from tension, and presence of minimal to no contamination and infectious disease in the abdomen. The decision to avoid anastomosis and resort to an ostomy in CD surgery should also take into account degree of malnutrition, dose of steroids, and severity of co-existing septic issues. Other strategies that have been explored to reduce leak rate are application of fibrin glue and mechanical bowel preparation, although no randomized controlled trials support these tactics as of yet.

Anastomotic leaks usually manifest clinically between postoperative days five and seven, although up to 12 percent occur after postoperative day 30 [52]. Leaks are diagnosed by the presence of fecal discharge from the drain or wound, development of postoperative enterocutaneous fistula originating from the anastomotic site, or evidence of peritonitis on physical exam. Most patients present with signs of sepsis or peritonitis, such as pain, fever, and tachycardia.

In the unstable patient with generalized peritonitis or high-grade sepsis, emergent exploratory laparotomy should be undertaken immediately. If a stable patient shows signs of a clinical leak and low-grade sepsis, management begins with timely initiation of supportive care: fluid resuscitation and broad spectrum antibiotics. If the patient is hemodynamically stable, a CT scan with oral, intravenous, and rectal contrast or a water-soluble enema is obtained. The findings of fluid collections or gas containing collections on CT scan are highly suggestive of anastomotic leak. Imaging is used to determine location of leak, severity, and whether fluid collections are in continuity with the leak.

A subclinical leak is apparent radiographically, but the patient may be asymptomatic, and this can be managed with observation. A free intraperitoneal leak should be taken to the operating room for exploration and repair. If the patient is stable and there are small (<3 cm), contained abscesses on imaging, the patient can be treated conservatively with bowel rest and broad spectrum antibiotics. Larger abscesses (>3 cm) should be drained percutaneously if feasible, with surgery reserved for abscesses not amenable to drainage or if patient's clinical condition does not improve. Intraoperatively, if the primary finding is an inoperable phlegmon, drains can be placed by the anastomosis and a proximal loop ileostomy or colostomy created for temporary fecal diversion. A small anastomotic defect may be repaired primarily with placement of drains and proximal diversion. An anastomotic defect >1 cm or greater than 1/3 of the circumference can be resected with creation of a stoma, re-anastomosis and proximal diversion, or exteriorization of both ends of the stoma. Recurrence rate is lower in those whose anastomosis is taken down and end-ileostomy created [6].

STRICTURE

Anastomotic strictures are another common and unfortunate complication of CD surgery. Colorectal strictures are defined as the inability to pass a scope at least 12 mm in diameter through the stenosis. Clinically, the patient may be asymptomatic or present with partial or complete bowel obstruction. Recurrent disease at the site of anastomosis eventually causes

transmural inflammatory edema and fibrosis, leading to stricture in about half of patients three years after ileocolic resection. Stricture at the site of ileocolic or colorectal anastomosis may also result from tissue ischemia, anastomotic leak, and inflammation. Recurrent strictures lead to re-operation and further resections, potentially leading to short gut syndrome. Sites of inflammation may be identified at operation, and even marked with a metal clip to aid in future radiographic identification.

If presenting with obstruction, strictures in CD should first be treated conservatively with intravenous hydration, nasogastric suction, and parenteral nutrition if necessary. Surgery and is no longer the only intervention available to open the stricture. Ileocolic, colocolic, or higher colorectal strictures may be managed with endoluminal therapy, in addition to stricturoplasty, or conservative resection and anastomosis. Lower colorectal anastomoses can also be dilated digitally or with serial dilators.

Endoluminal therapy may delay the need for surgery or avoid it altogether. In a meta-analysis of 13 studies and 347 patients, endoscopic balloon dilation was feasible in 86% of cases and had minimal complications [53]. It is effective for short strictures (<4 cm), but relapse rate is high, requiring repeat dilation in up to 50% of patients. Limited case series and datasets describe the utility of self-expandable metal stents to treat anastomotic and other intestinal stenoses in CD patients, but there are several complications (migration, restenosis, perforation, and fistulization) that can occur. Some argue that stents should not be placed into sites of active inflammation and should be used primarily as a short-term bridge to definitive management. The durability and efficacy of endoluminal stents has not yet been adequately studied.

FISTULA

Most fistulae associated with CD are internal and spontaneous as a result of transmural inflammatory disease activity. These fistulae can form between any two loops of bowel or between bowel and adjacent structure, such as bladder, ureter, or vagina. Fistulizing Crohn's is best treated medically with infliximab, azathioprine, or 6-MP, but sometimes surgical resection is required. This section will not focus on these spontaneous fistulae, but rather, will discuss enterocutaneous fistula (ECF) as a result of intestinal surgery for CD.

In fact, about 20% of all ECF are related to CD. Following colorectal surgery, the most common causes of enterocutaneous fistula are anastomotic leak and failure to recognize an inadvertent enterotomy. CD is an especially potent risk factor (4.68 times higher than other causes) for development of early postoperative enterocutaneous fistula, which is associated with 2.5 fold higher in-hospital mortality compared to patients without early postoperative ECF [54]. As expected, lysis of adhesions is associated with higher postoperative ECF rate, and laparoscopic surgery is associated with a lower rate of ECF; however, these associations were described for all-cause colorectal surgery and not specifically for CD [54].

Postoperative ECF clinically present as a patient who fails to do well immediately after surgery. A protracted clinical course may include development of fever, prolonged ileus, malaise, and/or abdominal distension and tenderness. On postoperative day 5-10, a wound infection may appear followed by drainage of enteric contents from the wound [55].

Management of ECFs in this setting is complex, multidisciplinary, and depends on surgeon experience and judgment. Along with initial resuscitation and treatment of any associated sepsis with antibiotics, the drainage should be contained to minimize skin irritation and further wound contamination. It is important to identify the fistula either clinically or radiologically with CT scan or fistulogram to determine where it occurs and whether it arises spontaneously from healthy bowel after a resection, from diseased bowel, or from an anastomotic breakdown. If arisen from healthier bowel, it has a high likelihood of spontaneous closure, and can be treated non-operatively with bowel rest and parenteral nutrition. Patients with ECF from diseased bowel may benefit from early resection due to lower likelihood of spontaneous closure and higher tendency to re-open. If an abdominal wall abscess is present, it should be drained immediately to resolve the local sepsis.

Though not always possible, the ideal timing of surgical repair of a spontaneous ECF is best when inflammation has subsided as much as possible and the abdominal wall has become soft [45]. Timing of repair of an early post-operative ECF is more controversial. Some studies found that re-operation within 9-10 days avoids a higher mortality associated with operating at a later time [55]. However, some surgeons advocate conservative management, if possible, since the patient is still in an inflammatory, immunosuppressed, and potentially undernourished state, making it likely that another fistula will form. Reoperation can be attempted in 4 or 5 months, if the patient is cooperative and the clinical condition is otherwise stable.

Common principles of fistulae repair apply: 1) transection of the fistulous tract; 2) resection of the diseased segment; and 3) primary closure of the fistulous opening on the target organ [56]. If the ECF is chronic and the surrounding tissue is inflamed, the incision can be made away from the fistulous tract. This will not only simplify dissection, but also reduce the chance of postoperative wound healing problems.

Laparoscopic surgery for fistulous complications is feasible and safe [57]. In twenty patients with CD and fistulae treated with surgery, hospital length of stay was eight days and oral intake resumed on postoperative day one. Other studies have echoed that laparoscopic surgery is safe and feasible, although, of course, with proper training [58].

Fluid, electrolyte, and nutritional support are key factors in the management of post-operative ECF. Intravascular volume is usually depleted due to third spacing from bowel distension and/or fistula output, and the patient must be resuscitated to normal levels in a timely fashion. Patients with ECF tend to have deficiencies in sodium, phosphate, potassium, and magnesium. These electrolytes should be monitored closely and repleted. Poor perioperative nutrition has been linked to poor surgical outcome including higher mortality in several studies. Total parenteral nutrition is indicated to meet the metabolic demand, and it is associated with both disease remission and higher spontaneous ECF closure rates. If the patient has sufficient small bowel for absorption (typically greater than 100 cm), a combination of parenteral and enteral feeds is desirable. Enteral feeds may increase fistula output and should be given with great caution to avoid hyperosmolar concentrations and intestinal necrosis.

Recently, exclusive enteral nutrition (EEN) has been proposed as a strategy to induce remission and combat surgical complications. EEN modifies intestinal microbiota and has purported anti-inflammatory and pro-mucosal healing effects [59]. Li showed retrospectively that EEN for at least three months before operation for ECF reduced the risk of anastomotic complications after bowel resections [41]. These patients achieved an albumin level of <

4g/dL and lower CRP (thus lower inflammatory activity) at time of operation than the non-EEN patients.

COMPLICATION RATES AFTER SPECIFIC TYPES OF SURGICAL PROCEDURES

Depending on the location and severity of the disease, colonic CD can be treated by either segmental resection, subtotal colectomy with ileorectal anastomosis, or total proctocolectomy. The complications for each of these surgical approaches have been compared. A meta-analysis comparing outcomes for segmental resection vs. subtotal/total colectomy with ileorectal anastomosis in six different studies (488 patients, 265 segmental resection vs. 223 ileorectal anastomosis) found no significant difference in the incidence of surgical recurrence between the two types of operations, but the segmental resection group recurred 4.43 years earlier than the ileorectal anastomosis group. There was no difference in incidence of other postoperative complications. [60] Recent reviews advocate use of segmental colectomy whenever possible, as the 5 year recurrence-free survival, need for stoma, and quality of life were not significantly different compared to subtotal colectomy [61]. The likelihood of requiring stoma depends on presence of current or past perianal sepsis at time of resection and presence of more than one co-morbidity [61].

In another study of CD patients with primary colonic disease, there was an earlier recurrence interval for those treated with segmental resection than those treated with total proctocolectomy. Patients with distal colonic involvement were more likely to require a permanent stoma than those with isolated proximal colonic involvement. [62].

LAPAROSCOPIC AND OPEN TECHNIQUES

Recent meta-analyses of non-randomized trials report that laparoscopic ileocolic resection leads to reduced perioperative complications, incisional hernia, length of stay, and postoperative ileus compared with open surgery. However, in a meta-analysis of two randomized trials, there was no significant difference in incidence of wound infections, pneumonia, length of stay, postoperative narcotic use, reoperation rates of CD recurrence, or reoperation for non-CD related complications between patients in the open and laparoscopic groups [63]. The data for laparoscopic colectomy are similar, showing no effect on the complication rate. Taken together, these data suggest that laparoscopic surgery for CD is feasible, safe, and associated with good outcomes [64, 65, 66] but does not show a clear advantage over open surgery based on the relatively few and small randomized controlled trials we have so far.

In experienced hands, laparoscopy can be performed safely even for complicated CD [64, 67]. In one series of a single surgeon, despite increasing complexity of cases, there was a significant decrease in hospital length of stay after laparoscopic ileal resection with time [67]. Another group found no difference in minor or major complications of laparoscopic colorectal surgery during the learning curve, and the mean operative time did not decrease over time [8].

Conversion from laparoscopic to open surgery is associated with higher rates of both minor and major complications [8]. Common reasons for conversion include encountering complex masses, dense adhesions, abscesses, fistulae, or other complications of previous resections [67]. The complication rate for elective laparoscopic surgery for CD in one series was 8.7% for minor and 5.4% for major complications [8]. This particular study originally reviewed complications for all indications for colorectal surgery, and observed that overall, low anterior resection and male gender were risk factors for conversion. Low rectal pathology is generally considered a risk factor for high-grade complications such as intra-operative bleeding, ureteral injury, and anastomosis-related complications, most likely due to the extensive pelvic dissection in these cases.

Another prospective study reported a conversion rate of 30% in CD patients undergoing ileocolic resection, and identified two independent risk factors for conversion: recurrent medical acute episodes of CD and unexpected intraperitoneal abscess or fistula [68]. Age is not considered a risk factor for complications after laparoscopic surgery; in fact, laparoscopic approach for colorectal resections is generally considered lower risk than open surgery in older patients [69]. Together, these data suggest that patients who present with low rectal pathology, especially male patients, should be approached with an open or modified hybrid approach (such as laparoscopic vessel ligation, splenic flexure mobilization, and open pelvic dissection through a lower midline incision), and one should maintain a low threshold for conversion in a patients with both recurrent flares of CD and finding of intraabdominal sepsis at initial laparoscopy.

To reduce risk of conversion, decrease operative time, and enable tactile feedback as a tool to assess diseased bowel, the hand-assisted laparoscopic surgery (HALS) is a viable alternative to laparoscopic or laparoscopic-assisted surgery. HALS has been reported to be safe and feasible in complex Crohn's colitis with no increase in postoperative complications [70].

Single-port laparoscopic surgery (SILS) is another available minimally invasive approach. So far, limited data exists on SILS in the Crohn's population. One study reviewed single-port ileocectomy for terminal ileum stenosis reported it as safe and feasible, with similar rates of conversion (1/20) and overall complication rate (20%) as the laparoscopic-assisted controls in that study [71]. The single-port approach did not decrease post-operative pain scores or hospital duration. Again, those that practice SILS recommend thorough familiarity with the laparoscopic approach before adopting SILS [72].

RECURRENCE

Recurrence after resection is another common complication in CD patients. Indeed, without proper medical therapy, all patients with CD can be expected to experience disease recurrence ultimately. Recurrent disease carries significant economic burden and is an independent predictor of lower patient quality of life scores, regardless of surgical approach and cosmesis outcome [61].

Recurrence can be discovered during endoscopic follow-up (histologic or endoscopic recurrence). When symptomatic, recurrence can be clinical (requiring medical intervention)

or surgical (requiring re-operation). The usual location for disease recurrence is the anastomosis region, and is surprisingly common.

Endoscopic recurrence is evident in 70-90% of patients at one year after surgery [73] and manifests as aphthous and serpinginous ulceration. Endoscopic recurrence correlates with the likelihood of needing future intervention, thus it is important to perform endoscopic follow-up evaluation 6-12 months after surgery [74] to identify those patients at risk for recurrence. It is not yet clear whether severity of endoscopic recurrence correlates with clinical severity.

The risk of recurrent clinical disease after a primary operation for Crohn's disease is approximately 17-55% at 5 years, 32-76% at 10 years, and 72-73% at 20 years [2, 4, 75]. The risk of surgical disease increases over time as well, occurring in up to 30% at 5 years, 40% at 10 years and 55% at 20 years [76]. Recurrent operations are associated with higher complication rates than primary procedures (17% versus 6.52%).

Several risk factors for recurrence have been examined. Cigarette smoking is consistently associated with all levels of recurrent disease, increasing the risk by two-fold. Additionally, quitting smoking reduces post-operative recurrence [4[. Education and encouragement are crucial in the management of these patients. Recent studies have noted that perforating disease, presence of fistula and/or post-operative intra-abdominal sepsis at time of primary surgery are risks for early recurrence [6].

A 2005 review of all studies describing risk factors for recurrence concluded that the following do NOT consistently increase recurrence, though may have been cited as risk factors in individual studies: age at onset of disease, sex, family history of Crohn's disease, anatomical site of disease, length of resected bowel, presence of granuloma in the specimen, blood transfusions, and post-operative complications [4]. Short duration of disease prior to first operation was a risk for recurrence, but it is not recommended to delay surgery simply based on this prognosticator. Risk of recurrence was higher in patients with small bowel disease in some studies, especially proximal (duodenal or upper jejunoileal) disease, but other studies found that recurrence was higher for predominantly large bowel disease; therefore, "anatomical site" is not a reliable parameter for prognosis. Presence of perianal disease is an independent risk factor for recurrence [76, 77].

In one prospective trial, the authors also saw more recurrence in patients who presented with younger age, small bowel wall thickening 12 months after surgery, and stricturing disease behavior [5]. Typically, perforating disease has been linked to higher rates of and earlier recurrences (1.7 years versus 13 years) and overall worse prognosis, thus the data for differing recurrence rates based on disease type is also inconclusive.

Although intuitively it would seem that recurrence rate may be lower in CD colitis patients who undergo total colectomy and ileostomy rather than ileal resection with anastomosis, there are several recent studies that suggest that surgical approach does not affect recurrence rate. This applies to laparoscopic versus open surgery, as well as radical versus non-radical resection. Thus, limited resection techniques such as stricturoplasty and segmental resection are still justified.

Anastomosis configuration may also affect recurrence rate, although there is conflicting data for this modifiable risk factor as well, as previously discussed. Most retrospective studies found that stapled functional end-to-end anastomosis is the method of choice to reduce recurrence and complications [4]. In another series, hand-sewn side-to-side anastomoses led to lower recurrence rates in the long term than stapled end-to-end or end-to-side [51].

PROPHYLAXIS

The high rate of recurrence after CD surgery has spurred significant research in the area of prophylactic therapy. The mechanisms of action and drug profiles of the various medical therapies available are beyond the scope of this chapter, but we will briefly discuss the current literature regarding their efficacy in preventing surgical recurrence. A target of prophylactic therapy is observation of mucosal healing (MH), or the absence of ulcers on endoscopic visualization. Mucosal healing has been associated with fewer complications and recurrences after surgery [78].

Prophylactic corticosteroid therapy does not seem to reduce recurrence rate [4]. A number of earlier randomized controlled trials and a 2009 Cochrane systematic review suggest that nitroimidazole antibiotics (metronidazole, ornidazole), 5-ASA (mesalamine), 6-mercaptopurine, and azathioprine are all effective in reducing post-operative clinical and endoscopic recurrence. Efficacy of sulfasalazine is not yet clear. Utility of these agents should take into consideration their risk of adverse events, which was higher with nitroimidazoles (metallic taste, GI upset, or neuropathy) and azathioprine/6-MP than with meselamine [79]. The authors recommend considering these agents in the first 3 months after surgery in high-risk patients. Combination therapy with AZA and metronidazole in this short-term period enhances the benefit of AZA by approximately 20%. Azathioprine and 6-MP, in particular, may be more effective at maintaining remission in patients who have undergone intestinal resection (not colectomy) for CD complications and are left with minimally involved areas not yet requiring resection but rather ongoing immunosuppressive therapy.

Chemoprevention with biologics has been gaining momentum, as anti-TNF agents have shown success in reducing long-term recurrence. In a small, randomized placebo-controlled study of 24 adult patients, administration of infliximab after intestinal resection (at 0, 2, and 6 weeks, then every 8 weeks for 54 weeks) successfully prevented endoscopic, histological, and clinical recurrence of CD at one year follow-up (9.1% recurrence vs. 84.6% in placebo group) [80] without an increase in adverse events. In this study, the infliximab treatment group had a significantly higher number of smokers. This suggests that patients who are at high risk for post-operative recurrence of CD (such as smokers, or those with post-operative sepsis, ileal penetrating disease, or recurrent resections) should be considered for postoperative infliximab prophylaxis.

The role of enteric microflora in the pathophysiology of inflammatory bowel disease is another topic of recent interest, since recurrence seems to occur more in bowel exposed to enteric contents compared with bypassed intestinal segments. Probiotics such as *Lactobacillus johnsonii* , *Lactobacillus rhamnosus*, or cocktails of several probiotics have shown promising results in the prevention of pouchitis; however, meta-analysis of the few randomized controlled trials available show no significant difference in their effect on clinical recurrence [79].

Poor nutrition may also contribute to recurrence. Preoperative parenteral and enteric nutrition have both shown to reduce postoperative complications, potentially then reducing risk of repeat operations [9, 41]. Postoperative long-term elemental enteral nutrition (low fat diet supplemented with nocturnal elemental nasogastric feeds) prevented endoscopic and clinical recurrence in a small non-randomized trial, although patient compliance was an obstacle in maintaining the nutritional regimen [81].

In summary, strategies that may reduce risk of recurrence in high risk CD patients include: smoking cessation, control of intra-abdominal sepsis prior to operation, possibly anastomosis configuration, use of prophylactic antibiotics and immunomodulating or biologic agents, and nutritional supplementation. Clinical parameters that may identify patients at risk are: younger age (<30) at presentation, duration of disease, disease behavior, repeat resection, and proximal disease. Endoscopic follow-up within the first year of operation should be performed. Active disease should prompt intensification of immunosuppression.

SHORT GUT SYNDROME AND INTESTINAL FAILURE

Though less frequent than in earlier eras, short gut syndrome (SGS) after bowel resection is still a relatively common and debilitating complication of recurrent surgery for Crohn's disease. SGS can occur after a single large resection or as a result of repeated resections. SGS leads to intestinal failure if the remaining small intestine lacks the surface area and capacity to digest and absorb nutrients. SGS is usually defined as <200 cm of small intestine remaining, and signs of malabsorption usually present at <110-130 cm or <70-90 cm of small bowel with intact colon. Very short gut syndrome has been defined as <50 cm of small intestine and associated malabsorption.

Risk factors for SGS include early age at CD diagnosis (before age 16), family history of CD, early age at first surgery, penetrating disease, aggressive resections, surgical complications, and errors in initial diagnosis [82, 83, 84]. In a retrospective review of 82 patients with intestinal failure, the median duration of CD before intestinal failure was 26 years, median time from disease onset to diagnosis of intestinal failure was 18 years, and patients had a median of five intestinal resections. 47% had SGS due to primary active CD requiring resections, and 29% had SGS due to operative complications, such as leaks, fistulas, or ischemia as a result of surgery; 24% had both.

Symptoms of SGS are dehydration, diarrhea, weight loss, and nutritional deficiencies. Clinical severity and approach to therapy depend on SGS type (three types) based on the level of the intestinal anastomosis: Type I) end-jejunostomy; II) jejuno-colic anastomosis; and III) jejuno-ileal anastomosis. Depending on the type of SGS, adaptation of the remaining bowel occurs over time, which involves intestinal lengthening and dilation, growth of villi, deepening of crypts, hyperplasia of enterocytes, and enlargement of folds, in order to enhance surface area for absorption [85].

Intestinal adaptation is poorest in Type I, in which there is chronic, severe fluid and electrolyte losses. Type II has a slower intestinal transit than Type 1, higher degree of adaptation, and preservation of colon that aids in fiber digestion and fatty acid absorption. Type II clinically presents with chronic under-nutrition. Type III rarely presents with malnutrition, as these patients are more able to tolerate enteral feeds. Loss of ileum is the most perilous, as the jejunum is less able to adapt, and there is loss of the ileal brake mechanism, which appropriately slows intestinal transit to maximize reabsorption. Additionally, loss of the ileocecal valve allows colonic flora to colonize the small bowel, increasing risk of small intestinal bacterial overgrowth and its associated symptoms and malabsorption.

Prevention of SGS is a priority for the IBD surgeon. In patients requiring repeat operations, bowel-sparing techniques and minimally invasive resection should be used whenever possible. While one retrospective study claimed that positive margins predicted post-operative intraabdominal septic complications, a randomized controlled trial showed that absence or presence of negative margins does not have an effect on recurrence rate [86]. Therefore, resection should be limited to the most diseased portions to avoid development of short gut syndrome. In addition, the surgeon should liberally consider use of stricturoplasty in CD.

Management of short gut syndrome is complex and may require consultation with a nutrition specialist. Fluid and electrolyte replacement is essential with care taken to avoid hypotonic hypo-osmolar liquids, hyperosmolar liquids, or liquids with diuretic effects such alcohol and caffeine. Small frequent meals with high caloric intake comprised mostly of carbohydrates and protein is an ideal dietary plan. Most patients are also on some regimen of antidiarrheal/antimotility medication, antisecretory medication, and/or growth factors. If patients continue to fail medical management, they may be considered for intestinal transplantation.

VENOUS THROMBOEMBOLISM

Venous thromboembolism (VTE) including deep venous thrombosis (DVT) and pulmonary embolus (PE) are known complications in patients with inflammatory bowel disease. For both CD and ulcerative colitis (UC), the annual risk for VTE is 0.26%-0.3% [87], increased by two-fold over the general population [88]. The risk is higher in hospitalized IBD patients versus non-hospitalized, and about 2/3 of VTE cases occur in patients who have had an intestinal resection.

Compared to non-IBD patients, IBD patients are at higher risk for postoperative VTE (1.4% for CD and 3.3% for UC) [89] within 30 days of colorectal surgery. The thromboembolic episodes tend to occur around 10 days postoperatively. The overall risk of VTE is equal for UC and CD patients, but higher in hospitalized UC patients compared to hospitalized CD patients. Patients under 40 years of age are at the greatest risk, which is earlier in life than occurrence of VTE in non-IBD patients.

Risk factors for postoperative VTE in IBD patients are steroid use, anemia, malnutrition, and prolonged anesthesia time [89], as well as complicated CD (fistula, stenosis, abscess), active disease, and recent hospitalizations for CD for overall VTE risk. Traditional risk factors such as smoking may also play a role. VTE recurs in 10-13%. It is associated with higher morbidity (longer length of stay, more in-hospital complications) and mortality (4% vs. 0.9%) [89].

A meta-analysis of 33 studies showed that in addition to DVT and PE, CD patients also had a higher risk of ischemic heart disease and mesenteric ischemia, although these were not necessarily post-operative occurrences and there was no increased risk of cardiovascular mortality. [88]. Tight control of inflammation with immunosuppressives and biologic agents may help reduce risk of thrombovascular disease in CD patients, but currently there are no studies that measure impact of CD medications on this particular complication.

In a retrospective review of IBD patients with VTE, 50% of the patients who developed VTE during the hospital stay were not receiving pharmaceutical DVT prophylaxis. Despite clinical practice guidelines recommending that hospitalized IBD patients receive dual prevention with mechanical and pharmaceutical prophylaxis given that there are no contraindications to unfractionated or low molecular weight heparin, up to 35% of physicians do not follow these guidelines [90], perhaps due to a perceived risk of bleeding. There is no consensus for a standardized agent or approach to anticoagulation tailored to type of IBD (Crohn's or UC), severity, surgical procedure, or length of hospitalization.

OTHER COMPLICATIONS

Other rare complications of Crohn's disease surgery are small intestine adenocarcinoma or colorectal cancer, free intestinal perforation (2.4%), enteroenteric intussusception, and urinary tract infection (UTI). Free perforation has been reported in about 100 cases and should be managed with resection and anastomosis instead of simple suture repair. Enteroenteric intussusception presents as upper abdominal distension in patients who have had ileocecal resection. It is thought to be most likely due to dilated ileal segments from prior obstructions. Differential diagnosis includes small bowel obstruction or stricturing disease. In the few case reports that describe this complication, no Crohn's disease segments were found in the resected areas [91]. CD was found to be an independent predictor of UTI in one broad series for patients who had underwent segmental colectomy and may be related to prolonged hospital stay [18].

GRADING SYSTEMS

Grading post-operative complications serves as a useful comparative tool for quality control and predicting surgical risk in patients for whom surgical consequences would dramatically affect quality of life. There are several grading systems that have been shown to be useful in predicting 30-day morbidity and mortality, although there is not yet an IBD-specific grading system available. The POSSUM score (Physiological and Operative Severity Score for the enUmeration of Mortality and Morbidity) is one such validated tool that has been found to be precise in predicting 30-day morbidity in patients with abdominal Crohn's disease [92].

Mazeh prospectively validated a grading system that introduced a severity scale of 1-5 for complications of colorectal surgery in 2114 patients. They found that complication grade correlated with length of stay and identified a number of factors that predicted postoperative complications [93]. Asa validated the use of a grading system for complications associated with elective laparoscopic colorectal surgery in 501 patients and found that conversion to open was associated with both minor and major postoperative complications. Complication grade was again directly related to length of stay. In this study, CD was the indication for surgery in 5.6%, cancer in 56.5%, polyps in 20%, diverticular disease in 9.2%, and "other" for 9% [8].

CONCLUSION

The main complications of surgery for Crohn's disease are related to the inherent inflammatory nature of the disease and clinical features of the patient population. They include an increased rate of wound infections, intra-abdominal abscesses, anastomotic complications, enterocutaneous fistulae and venous thromboembolic events than the general surgical population. Complications are even higher in patients who smoke tobacco, are diagnosed or operated on earlier in life, have penetrating disease behavior, malnutrition and weight loss, chronic steroid use, and/or intra-abdominal sepsis at the time of operation. Complications lead to re-operation in about half of patients. Patients with multiple resections are at risk for short gut syndrome. Strategies to reduce post-operative complications are cessation of smoking, optimization of preoperative nutrition, preoperative antibiotics and percutaneous drainage of abscesses, limited resection techniques, routine endoscopic follow-up, use of standard postoperative VTE prophylaxis, and judicious use of steroid-sparing immunomodulating and biologic agents.

REFERENCES

[1] Mazor, Y; Maza, I; Kaufman, E; Ben-Horin, S; Karban, A; Chowers, Y; Eliakim, R. Prediction of disease complication occurrence in Crohn's disease using phenotype and genotype parameters at diagnosis. *J Crohn's and Colitis*., 2011, 5(6)592-597.

[2] Bergamaschi, R; Haughn, C; Reed, JF; Arnaud, JP. Laparoscopic intracorporeal ileocolic resection for Crohn's disease: is it safe? *Dis Colon Rectum*., 2009. 52(4), 651-6.

[3] Hancock, L; Mortensen, NJ. How often do IBD patients require resection of the intestine? *Inflamm Bowel Dis*., 2008, (14) Suppl2, S68-9.

[4] Yamamoto, T. Factors affecting recurrence after surgery for Crohn's disease. *R World J Gastroenterol*., 2005, 11(26), 3971-3979.

[5] Sampietro, GM; Corsi, F; Maconi, G; Ardizzone, S; Frontali, A; Corona, A; Porro, GB; Foschi, D. Prospective study of long-term results and prognostic factors after conservative surgery for small bowel Crohn's disease. *Clin Gastroenterol Hepatol*., 2009, 7(2), 183-91.

[6] Iesalnieks, I; Dederichs, F; Kilger, A; Schlitt, HJ; Agha, A. Postoperative morbidity after bowel resections in patients with Crohn's disease: risk, management strategies, prevention. *Z Gastroenterol*., 2012, 50(6), 595-600.

[7] Mazeh, H; Samet, Y; Abu-Wasel, B; Beglaibter, N; Grinbaum, R; Cohen, T; Pinto, M; Hamburger, T; Freund, HR; Nissan, A. Application of a novel severity grading system for surgical complications after colorectal resection. *J Am Coll Surg*., 2009, 208:355–361.

[8] Asa, Z; Greenberg, R; Ghinea, R; Inbar, R; Wasserberg, N; Avital, S. Grading of complications and risk factor evaluation in laparoscopic colorectal surgery. *Surg Endosc*., 2013 Oct, 27(10), 3748-53.

[9] Jacobson, S. Early postoperative complications in patients with Crohn's disease given and not given preoperative total parenteral nutrition. *Scand J Gastroenterol*., 2012, 47(2), 170-7.

[10] Nyugen, GC; Elnahas, A; Jackson, TD. The impact of preoperative steroid use on short-term outcomes following surgery for inflammatory bowel disease. *J Crohns Colitis*., 2014, 8, 1661-1667.

[11] Myrelid, P; Marti-Gallostra, M; Ashraf, S; Sunde, ML; Tholin, M; Oresland, T; Lovegrove, RE; Tøttrup, A; Kjaer, DW; George, BD. Complications in surgery for Crohn's disease after preoperative antitumour necrosis factor therapy. *Br J Surg*., 2014, 101(5), 539-45.

[12] Rosenfeld, G; Qian, H; Bressler, B. The risks of post-operative complications following pre-operative infliximab therapy for Crohn's disease in patients undergoing abdominal surgery: a systematic review and meta-analysis. *J Crohns Colitis*., 2013, 7(11), 868-77.

[13] Yang, ZP; Hong, L; Wu, Q; Wu, KC; Fan, DM. Preoperative infliximab use and postoperative complications in Crohn's disease: a systematic review and meta-analysis. *Surg*., 2014, 12(3), 224-30.

[14] Appau, KA; Fazio, VW; Shen, B; Church, JM; Lashner, B; Remzi, F; Brzezinski, A; Strong, SA; Hammel, J; Kiran, RP. Use of infliximab within 3 months of ileocolonic resection is associated with adverse postoperative outcomes in Crohn's patients. *J Gastrointest Surg*., 2008, 12(10), 1738-44.

[15] Yoshida, K; Fukunaga, K; Ikeuchi, H; Kamikozuru, K; Hida, N; Ohda, Y; Yokoyama, Y; Iimuro, M; Takeda, N; Kato, K; Kikuyama, R; Nagase, K; Hori, K; Nakamura, S; Miwa, H; Matsumoto, T. Scheduled infliximab monotherapy to prevent recurrence of Crohn's disease following ileocolic or ileal resection: A 3-year prospective randomized open trial. *Inflammatory Bowel Diseases*, 2012, 18(9), 1617-1623.

[16] Regueiro, M; Kip, KE; Baidoo, L; Swoger, JM; Schraut, W. Postoperative therapy with infliximab prevents long-term Crohn's disease recurrence. *Clin Gastroenterol Hepatol*., 2014, 12(9), 1494-502.

[17] Garner, JS; Jarvis, WR; Emori, TG; Horan, TC; Hughes, JM. CDC definitions for nosocomial infections, 1988. *Am J Infect Control*., 1988, 16:128–140.

[18] Wideroff, M; Xing, Y; Liao, J; Byrn, JC. Crohn's Disease but not Diverticulitis Is an Independent Risk Factor for Surgical Site Infections in Colectomy. *J Gastrointest Surg*, 2014, 18(10), 1817-1823.

[19] Wilson, MZ; Connelly, TM; Hollenbeak, CS; Messaris, E. Organ space infection following ileocolectomy for Crohn's disease: a National Surgical Quality Improvement Project study. *Am J Surg*., 2014, 208(5), 749-55.

[20] Colombel, JF; Loftus, EV; Tremaine, WJ; Pemberton, JH; Wolff, BG; Young-Fadok, T; Harmsen, WS; Schleck, CD; Sandborn, WJ. Early Postoperative Complications are not Increased in Patients with Crohn's Disease Treated Perioperatively with Infliximab or Immunosuppressive Therapy. *Am J Gastroenterol*., 2004, 99, 878–883.

[21] Maeda, K; Nagahara, H; Shibutani, M; Otani, H; Sakurai, K; Toyokawa, T; Tanaka, H; Kubo, N; Muguruma, K; Kamata, N; Yamagami, H; Hirakawa, K. A preoperative low nutritional prognostic index correlates with the incidence of incisional surgical site infections after bowel resection in patients with Crohn's disease. *Surg Today*., 2014 Oct 16. [Epub ahead of print].

[22] Choy, PY; Bissett, IP; Docherty, JG; Parry, BR; Merrie, A; Fitzgerald, A. Stapled versus handsewn methods for ileocolic anastomoses. *Cochrane Database Syst Rev*., 2011, (9), CD004320.

[23] Syed, A; Cross, RK; Flasar, MH. Anti-Tumor Necrosis Factor Therapy Is Associated With Infections after Abdominal Surgery in Crohn's Disease Patients. *Am J Gastroenterol*., 2013, 108(4), 583-93.

[24] Tilney, HS; Constantinides, VA; Heriot, AG; et al. Comparison of laparoscopic and open ileocecal resection for Crohn's disease: a meta-analysis. *Surg Endosc*, 2006, 20, 1036–44.

[25] Lee, Y; Fleming, FJ; Deeb, AP; et al. A laparoscopic approach reduces short-term complications and length of stay following ileocolic resec- tion in Crohn's disease: an analysis of outcomes from the NSQIP data- base. *Colorectal Dis* 2012, 14, 572–7. Canedo 2010.

[26] Uchino, M; Ikeuchi, H; Matsuoka, H; Bando, T; Ichiki, K; Nakajima, K; Tomita, N; Takesue, Y. Risk factors for surgical site infection and association with infliximab administration during surgery for Crohn's disease. *Dis Colon Rectum*., 2013, 56(10), 1156-65.

[27] Canedo, J; Pinto, RA; Regadas, S; Regadas, FS; Rosen, L; Wexner, SD. Laparoscopic surgery for inflammatory bowel disease: does weight matter? *Surg Endosc*., 2010, 24, 1274-1279.

[28] Nasir, BS; Dozois, EJ; Cima, RR; Pemberton, JH; Wolff, BG; Sandborn, WJ; Loftus, EV; Larson, DW. Perioperative anti-tumor necrosis factor therapy does not increase the rate of early postoperative complications in Crohn's disease. *J Gastrointest Surg*., 2010, 14(12), 1859-65.

[29] Serradori, T; Germain, A; Scherrer, ML; Ayav, C; Perez, M; Romain, B; Palot, JP; Rohr, S; Peyrin-Biroulet, L; Bresler, L. The effect of immune therapy on surgical site infection following Crohn's Disease resection. *Br J Surg*., 2013, 100(8), 1089-93.

[30] Samimi, R; Flasar, MH; Kavic, SM; Tracy, K; Cross, RC. Outcome of medical treatment of stricturing and penetrating Crohn's disease: a retrospective study. *Inflamm Bowel Dis*., 2010, 16(7), 1187-1194.

[31] Lau; C; Dubinsky, M; Melmed, G; Vasiliauskas, E; Berel, D; McGovern, D; Ippoliti, A; Shih, D; Targan, S; Fleshner, P. The Impact of Preoperative Serum Anti-TNF[alpha] Therapy Levels on Early Postoperative Outcomes in Inflammatory Bowel Disease Surgery. *Ann Surg*., 2014, Epub ahead of print as of 12-22-14.

[32] Alves, A1; Panis, Y; Bouhnik, Y; Pocard, M; Vicaut, E; Valleur, P. Risk factors for intra-abdominal septic complications after a first ileocecal resection for Crohn's disease: a multivariate analysis in 161 consecutive patients. *Dis Colon Rectum*., 2007, 50(3), 331-6.

[33] Yamamoto, T; Allan, RN; Keighley, MRB. Risk Factors for Intra-Abdominal Sepsis After Surgery in Crohn's Disease. *Dis Colon Rectum*., 2000, 43(8), 1141-5.

[34] El-Hussuna, A; Krag, A; Olaison, G; Bendtsen, F; Gluud, LL. The effect of anti-tumor necrosis factor alpha agents on postoperative anastomotic complications in Crohn's disease: a systematic review. *Dis Colon Rectum*., 2013, 56(12), 1423-33.

[35] Kanazawa, A; Yamana, T; Okamoto, K; Sahara, R. Risk factors for postoperative intra-abdominal septic complications after bowel resection in patients with Crohn's disease. *Dis Colon Rectum*., 2012, 55(9), 957-62.

[36] Bellolio, F; Cohen, Z; Macrae, HM; et al. Outcomes following surgery for perforating Crohn's disease. *Br J Surg* 2013, 100, 1344–8.

[37] Yamaguchi, A; Matsui, T; Sakurai, T; Ueki, T; Nakabayashi, S; Yao, T; Futami, K; Arima, S; Ono, H. The clinical characteristics and outcome of intraabdominal abscess in Crohn's disease. *J Gastroenterol*., 2004, 39(5), 441-8.

[38] Gutierrez, A; Lee, H; Sands, BE. Outcome of surgical versus percutaneous drainage of abdominal and pelvic abscesses in Crohn's disease. *Am J Gastroenterol*., 2006, 101(10), 2283-9.

[39] Fleshman, JW. Pyogenic complications of Crohn's disease, evaluation, and management. *strointest Surg*., 2008, 12(12), 2160-3.

[40] Müller-Wille, R; Iesalnieks, I; Dornia, C; Ott, C; Jung, EM; Friedrich, C; Schill, G; Hoffstetter, P; Zorger, N; Schreyer, AG. Influence of percutaneous abscess drainage on severe postoperative septic complications in patients with Crohn's disease. *Colorectal Dis*., 2011 Jun, 26(6), 769-74.

[41] Li, G; Ren, J; Wang, G; Hu, D; Gu, G; Liu, S; Ren, H; Wu, X; Li, J. Preoperative exclusive enteral nutrition reduces the postoperative septic complications of fistulizing Crohn's disease. *Eur J Clin Nutr*., 2014, 68(4), 441-6.

[42] Swanson, G; Behara, R; Braun, R; Keshavarzian, A. Diagnostic medical radiation in inflammatory bowel disease: how to limit risk and maximize benefit. *Inflamm Bowel Dis*., 2013, 19(11), 2501-2508.

[43] Martínez-Serrano, MA; Parés, D; Pera, M; Pascual, M; Courtier, R; Egea, MJ; Grande, L. Management of lower gastrointestinal bleeding after colorectal resection and stapled anastomosis. *Tech Coloproctol*., 2009, 13(1), 49.

[44] Matos, D; Atallah, ÁN; Castro, AA; Silva, Lustosa, SA. Stapled versus handsewn methods for colorectal anastomosis surgery. *Cochrane Database Syst Rev*, 2008, CD003144.

[45] Michelassi; Fabrizio, MD; Sultan; Samuel, MD. Surgical Treatment of Complex Small Bowel Crohn Disease. *Ann Surg*., 2014, 260(2), 230-5.

[46] Kracht, M; Hay, J-M; Fagniez, P-L; Fingerhut, A. Ileocolonic anastomosis after right hemicolectomy for carcinoma: stapled or hand-sewn? *Int J Colorectal Disease*, 1993, 8, 29–33.

[47] Dietz; DW; Bailey; HR. Postoperative complications. In: *ASCRS Textbook of Colon and Rectal Surgery*, Church, JM, Beck, DE, Wolff, BG, Fleshman, JW, Pemberton, JH, (Eds), Springer-Verlag New York, LLC, New York 2006. p., 141.

[48] Tzivanakis, A; Singh, JC; Guy, RJ; Travis, SP; Mortensen, NJ; George, BD. Influence of risk factors on the safety of ileocolic anastomosis in Crohn's disease surgery. *Dis Colon Rectum*., 2012, 55(5), 558-62.

[49] El-Gazzaz, G; Geisler, D; Hull, T. Risk of clinical leak after laparoscopic versus open bowel anastomosis. *Surg Endosc*., 2010 Aug, 24(8), 1898-903.

[50] Resegotti, A; Astegiano, M; Farina, EC; et al. Side-to-side stapled anastomosis strongly reduces anastomotic leak rates in Crohn's disease surgery. *Dis Colon Rectum*., 2005, 48(3), 464-468.

[51] Scarpa, M; Ruffolo, C; Bertin, E; Polese, L; Filosa, T; Prando, D; Pagano, D; Norberto, L; Frego, M; D'Amico, DF; Angriman, I. Surgical predictors of recurrence of Crohn's disease after ileocolonic resection. *Int J Colorectal Dis*., 2007, 22(9), 1061.

[52] Hyman, N; Manchester, TL; Osler, T; Burns, B; Cataldo, PA. Anastomotic leaks after intestinal anastomosis: it's later than you think. *Ann Surg*., 2007, 245(2), 254-8.

[53] Hassan, C; Zullo, A; De, Francesco, V; Ierardi, E; Giustini, M; Pitidis, A; Taggi, F; Winn, S; Morini, S. Systematic review: endoscopic dilatation in Crohn's disease. *Alimentary Pharmacology & Therapeutics* 2007, 26(11/12), 1457-1464.

[54] Masoomi, H; Carmichael, JC; Mills, S; Pigazzi, A; Stamos, MJ. Predictive Risk Factors of Early Postoperative Enteric Fistula in Colon and Rectal Surgery. *Am Surg*., 2013, 79(10), 1058-63.

[55] Fischer, JE; Evenson, AR. Chapter 146: Gastrointestinal-Cutaneous Fistulas, *Fischer's Mastery of Surgery*, 6e. Fischer, JE; Jones, DB; Pomposelli, FB; Upchurch, GR; Klimberg, VS; Schwaitzberg, SD; Bland, KI. Lippincott Williams & Wilkins. 2012, Philadelphia, PA USA. ISBN-13: 978-1608317400, ISBN-10: 1608317404.

[56] Poritz, LS; Gagliano, GA; McLeod, RS; et al. Surgical management of entero and colocutaneous fistulae in Crohn's disease: 17 year's experience. *Int J Colorectal Dis*., 2004, 19, 481–485.

[57] Watanabe, M; Hasegawa, H; Yamamoto, S; Hibi, T; Kitajima, M. Successful application of laparoscopic surgery to the treatment of Crohn's disease with fistulas. *Dis Colon Rectum*., 2002, 45(8), 1057-61.

[58] Beyer-Berjot, L; Mancini, J; Bege, T; et al. Laparoscopic approach is feasible in Crohn's complex enterovisceral fistulas: a case-match review. *Dis Colon Rectum*., 2013, 56(2), 191-197.

[59] Alhagamhmad, MH; Day, AS; Lemberg, DA; Leach, ST. An update of the role of nutritional therapy in the management of Crohn's disease. *J Gastroenterol*., 2012, 47(8), 872-82.

[60] Tekkis, PP; Purkayastha, S; Lanitis, S; Athanasiou, T; Heriot, AG; Orchard, TR; Nicholls, RJ; Darzi, AW. A comparison of segmental vs. subtotal/total colectomy for colonic Crohn's disease: a meta-analysis. *Colorectal Dis*., 2006, 8(2), 82–90.

[61] Kiran, RP; Nisar, PJ; Church, JM; Fazio, VW. The role of primary surgical procedure in maintaining intestinal continuity for patients with Crohn's colitis. *Ann Surg*., 2011, 253(6), 1130–1135.

[62] Fichera, A; McCormack, R; Rubin, MA; Hurst, RD; Michelassi, F. Long-term outcome of surgically treated Crohn's colitis: a prospective study. *Dis Colon Rectum*., 2005, 48(5), 963–969.

[63] Patel, SV; Patel, SV; Ramagopalan, SV; Ott, MC. Laparoscopic surgery for Crohn's disease: a meta-analysis of perioperative complications and long term outcomes compared with open surgery. *BMC Surg*., 2013, 13:14.

[64] Goyer, P; Alves, A; Bretagnol, F; Bouhnik, Y; Valleur, P; Panis, Y. Impact of complex Crohn's disease on the outcome of laparoscopic ileocecal resection: a comparative clinical study in 124 patients. *Dis Colon Rectum*., 2009, 52(2), 205-10.

[65] Vangeenberghe, N1; De, Vogelaere, K; Haentjens, P; Delvaux, G. Laparoscopically assisted ileocolectomy in patients with Crohn's disease: a study of 50 consecutive patients. *Surg Endosc*., 2009, 8, 1797-801.

[66] Pokala, N; Delaney, CP; Brady, KM; Senagore, AJ. Elective laparoscopic surgery for benign internal enteric fistulas: a review of 43 cases. *Surg Endosc*., 2005, 19(2), 222-5.

[67] Evans, J; Poritz, L; MacRae, H. Influence of experience on laparoscopic ileocolic resection for Crohn's disease. *Dis Colon Rectum*., 2002 Dec, 45(12), 1595-600.

[68] Alves, A; Panis, Y; Bouhnik, Y; Marceau, C; Rouach, Y; Lavergne-Slove, A; Vicaut, E; Valleur, P. Factors that predict conversion in 69 consecutive patients undergoing laparoscopic ileocecal resection for Crohn's disease: a prospective study. *Dis Colon Rectum*., 2005, 48(12), 2302–2308.

[69] Person, B; Cera, SM; Sands, DR; Weiss, EG; Vernava, AM; Nogueras, JJ; Wexner, SD. Do elderly patients benefit from laparoscopic colorectal surgery? *Surg Endosc*, 2008, 22, 401–405.

[70] Nakajima, K; Nezu, R; Hirota, M; Nishida, T. The role of hand-assisted laparoscopic surgery in subtotal and total colectomy for Crohn's colitis. *Surg Endosc*., 2010, 24(11), 2713–2717.

[71] Rijcken, E; Mennigan, R; Senninger, N; Bruewer, M. Single-port laparoscopic surgery for inflammatory bowel disease. *Minim Invasive Surg*., 2012, 106878.

[72] Vestweber, B; Galetin, T; Lammertinq, K; et al. Single-incision laparoscopic surgery: outcomes of 224 colonic resections performed at a single center using SILS. *Surg Endosc*., 2013, 27(2), 434-442.

[73] Olaison, G; Smedh, K; Sjodahl, R. Natural course of Crohn's disease after ileocolic resection: endoscopically visualized ileal ulcers preceding symptoms. *Gut*, 1992, 33, 331–335.

[74] Terdiman, JP. Prevention of postoperative recurrence in Crohn's disease. *Clin Gastroenterol Hepatol*, 2008, (6), 616–620.

[75] Mirow, L; Hauenschild, L; Hildebrand, P; Kleemann, M; Keller, R; Franke, C; Roblick, UJ; Bruch, HP; Kujath, P. Recurrence of Crohn's disease after surgery—causes and risks. *Zentralbi Chir*., 2008, 133(2), 182-7.

[76] Bernell, O; Lapidus, A; Hellers, G. Risk Factors for Surgery and Postoperative Recurrence in Crohn's Disease. *Ann Surg*., 2000, 231(1), 38.

[77] Sandborn WJ, Fazio VW, Feagan BG, Hanauer SB. AGA technical review on perianal Crohn's disease. *Gastroenterology*., 2003, 125(5), 1508.

[78] Baert, F; Moortgat, L; Van, Assche, G; Caenepeel, P; Vergauwe, P; De, Vos, M; Stokkers, P; Hommes, D; Rutgeerts, P; Vermeire, S; D'Haens, G. Mucosal Healing Predicts Sustained Clinical Remission in Patients With Early-Stage Crohn's Disease. *Gastroenterology*, 2010, 138(2), e10-e11.

[79] Doherty, G; Bennett, G; Patil, S; Cheifetz, A; Moss, AC. Interventions for prevention of post-operative recurrence of Crohn's disease. *Cochrane Database Syst Rev*., 2009, (4), CD006873.

[80] Regueiro, M; Schraut, W; Baidoo, L; Kip, KE; Sepulveda, AR; Pesci, M; Harrison, J; Plevy, SE. Infliximab prevents Crohn's recurrence after ileal resection. *Gastroenterology*., 2009, 136: 441-450.

[81] Yamamoto, T; Nakahigashi, M; Umegae, S; Kitagawa, T; Matsumoto, K. Impact of long-term enteral nutrition on clinical and endoscopic recurrence after resection for Crohn's disease: A prospective, non-randomized, parallel, controlled study. *Aliment Pharmacol Ther*., 2007, 25(1), 67.

[82] Thompson, JS; Iyer, KR; DiBaise, JK; Young, RL; Brown, CR; Langnas, AN. Short bowel syndrome and Crohn's disease. *J Gastrointest Surg*., 2003 Dec, 7(8), 1069-72.

[83] Keller, J; Panter, H; Layer, P. Management of the short bowel syndrome after extensive small bowel resection. *Best Pract Res Clin Gastroenterol*., 2004 Oct, 18(5), 977-92.

[84] Gearry, RB; Kamm, MA; Hart, AL; Bassett, P; Gabe, SM; Nightingale, JM. Predictors for developing intestinal failure in patients with Crohn's disease. *J Gastroenterol Hepatol*., 2013 May, 28(5), 801-7.

[85] Bechtold, ML; McClave, SA; Palmer, LB; Nguyen, DL; Urben, LM; Martindale, RG; Hurt, RT. The pharmacologic treatment of short bowel syndrome: new tricks and novel agents. *Curr Gastroenterol Rep*., 2014, 16(7), 392.

[86] Fazio, VW; Marchetti, F; Church, M; Goldblum, JR; Lavery, C; Hull, TL; Milsom, JW; Strong, SA; Oakley, JR; Secic, M. Effect of resection margins on the recurrence of Crohn's disease in the small bowel. A randomized controlled trial. *Ann Surg*., 2004, 224(4), 563–571.

[87] Dwyer, JP; Javed, A; Hair, CS; Moore, GT. Venous thromboembolism and underutilisation of anticoagulant thromboprophylaxis in hospitalised patients with inflammatory bowel disease. *Intern Med J*., 2014, 44(8), 779-84.

[88] Fumerya, M; Xiaocang, C; Dauchet, L; Gower-Rousseaud, C; Peyrin-Biroulet, L; Colombel, J. Thromboembolic events and cardiovascular mortality in inflammatory bowel diseases: A meta-analysis of observational studies. *J Crohn's and Colitis*, 2014, 8, 469–479.

[89] Wallaert, JB; De, Martino, RR; Marsicovetere, PS; Goodney, PP; Finlayson, SR; Murray, JJ; Holubar, SD. Venous thromboembolism after surgery for inflammatory bowel disease: are there modifiable risk factors? Data from ACS NSQIP. *Dis Colon Rectum*., 2012, 55(11), 1138-44.

[90] Tinsley, A; Naymagon, S; Trindade, AJ; Sachar, DB; Sands, BE; Ullman, TA. A survey of current practice of venous thromboembolism prophylaxis in hospitalized inflammatory bowel disease patients in the United States. *J Clin Gastroenterol*, 2013, 47, e1–6.

[91] Uchino, M; Ikeuchi, H; Matsuoka, H; Tanaka, K; Kuno, T; Oshima, T; Tsukamoto, K; Nakamura, M; Gega, M; Yagyu, T; Nakano, H; Noda, M; Tomita, N. Postoperative enteroenteric intussusception in patients with Crohn's disease: report of two cases. *Surg Today*, 2008, 38(4), 366-70.

[92] Ugolini, G; Montroni, I; Rosati, G; Ghignone, F; Bacchi-Reggiani, ML; Belluzzi, A; Castellani, L; Taffurelli, M. Can POSSUM accurately predict post-operative complications risk in patients with abdominal Crohn's disease? *ANZ J Surg*., 2014, 84(1-2), 78-84.

[93] Mazeh, H; Cohen, O; Mizrahi, I; Hamburger, T; Stojadinovic, A; Abu-Wasel, B; Alaiyan, B; Freund, H; Eid, A; Nissan, A. Prospective validation of a surgical complications grading system in a cohort of 2114 patients. *J Surg Res*., 2014, 188(1), 30-6.

In: Encyclopedia of Surgery (22 Volume Set)
Editors: Andreas Lehrer and Kristin Mueller
ISBN: 978-1-53618-329-0
© 2020 Nova Science Publishers, Inc.

Chapter 370

ASSESSMENT OF OVARIAN RESERVE BEFORE AND AFTER GYNECOLOGIC SURGERY

Akira Iwase*
Department of Maternal and Perinatal Medicine,
Nagoya University Hospital, Japan

ABSTRACT

Anti-Müllerian hormone (AMH) serum levels have been recently applied to the assessment of ovarian reserve apart from infertility treatments due to the advantages in clinical use, such as intra- and inter-cycle consistency. Surgical interventions for benign gynecologic conditions as well as diseases themselves possibly affect ovarian reserve. Such gynecologic conditions and interventions include endometriosis/endometriomas, benign ovarian tumor, hydrosalpinx, ovarian cystectomy, salpingectomy, and hysterectomy. Most studies demonstrate a decline in serum AMH levels after cystectomy for endometriomas, especially in bilateral cases. It is not conclusive whether electrocoagulation or suturing as a surgical method for hemostasis after cystectomy is preferable for ovarian reserve. The effects of other gynecologic diseases including benign ovarian cysts/tumors and interventions, such as hysterectomy and salpingectomy, on ovarian reserve are controversial. Ovarian reserve is severely decreased following unilateral oophorectomy with/without chemotherapy, in patients with ovarian malignancies who desire future fertility. Serum AMH levels allow quantitative evaluation of ovarian reserve, and should be considered as a marker in determining the indication and selection of operative methods for benign gynecologic conditions. However, there is little available information regarding the correlation between the probabilities of live births and serum AMH levels before and after surgical interventions.

* Corresponding Author's Email: akiwase@med.nagoya-u.ac.jp; Fax: +81-52-744-2268.

INTRODUCTION

Benign gynecologic diseases are often implicated in fertility problems, and therefore, interventions are required to improve fertility in such conditions. Gynecologic diseases without any concomitant fertility problems, such as endometriosis with severe dysmenorrhea, are indications for fertility-preserving interventions in women who desire future fertility. However, surgical interventions involving the uterus, fallopian tubes and ovaries, have been demonstrated to potentially affect ovarian function, as these interventions might decrease ovarian cortical tissues and blood supply to ovaries [1-3]. In some cases, benign gynecologic diseases themselves may affect ovarian function and ovarian reserve. Therefore, interventions for benign gynecologic conditions aiming to preserve fertility as well as benign gynecologic diseases themselves prior to interventions must be assessed from the point of view of ovarian reserve.

Malignant gynecologic conditions are different from benign ones in fertility preservation. Preserving fertility following treatment for malignant ovarian tumors is particularly challenging. With proper and careful selection of patients, more conservative surgery to preserve the uterus or ovaries may be feasible in patients with early-stage epithelial ovarian cancers, low malignant potential ovarian tumors, or malignant germ cell ovarian tumors [4-6]. However, in these patients, maintaining ovarian function following treatment can be a serious issue if unilateral oophorectomy, possibly followed by chemotherapy, is performed.

The clinical utility of measuring serum anti-Müllerian hormone (AMH) levels has been evaluated in a wide range of health-care issues in women. Apart from infertility treatments, in the last decade, other possible clinical uses for ovarian reserve tests have been explored [7, 8]. Such uses include assessment of ovarian damage caused by chemotherapy, radiation, and surgery, as a marker of ovarian insufficiency, and possible predictive marker for menopause [9]. For these purposes, AMH has some advantages in clinical use, such as its sensitivity for decline with advancing age and intra-cycle consistency, which can make blood tests possible independent of the menstrual cycle [10].

This chapter focuses on the assessment of ovarian reserve after gynecologic interventions. Also included is an assessment of the influence of gynecologic diseases, such as endometriosis and endometriomas, on ovarian reserve and discuss what mechanisms are associated with the disturbance of ovarian reserve prior to surgical interventions. Other ovarian toxic interventions, such as chemotherapy and radiotherapy, are not included in this chapter. In addition, there will be particular reference to post-surgical ovarian reserve in women with fertility-preserving surgery for malignant ovarian tumors.

OVARY

Surgical interventions involving the ovaries can potentially cause damage to ovarian function because of the loss of ovarian cortex and/or detrimental effects on blood supply to the ovaries [11]. Post-surgical changes, such as inflammation, might affect ovarian follicle pool and therefore, be involved in the post-surgical decrease in ovarian reserve. Surgical procedures include cystectomy for endometriomas and other ovarian tumors, which are often performed as part of infertility treatments. Therefore, a decline in ovarian reserve after these

interventions must be kept to a minimum. Serum AMH levels allow for the quantitative evaluation of ovarian reserve. Assessments of a surgical procedure's influence on ovarian reserve using serum AMH levels as a marker may be helpful for improving these surgical indications and interventions.

On the contrary, ovarian cysts/tumors themselves might affect ovarian reserve. Thinning and fibrosis of the ovarian cortex is a potential mechanism involved in the decrease in ovarian reserve in affected ovaries. Hence, the indication, timing, and modalities of surgical interventions must be evaluated, and compared from the standpoint of the influence of ovarian cysts/tumors themselves and the surgical procedure on ovarian reserve.

Endometrioma and Endometriosis

Excision of the endometrioma capsule is superior to drainage and electrocoagulation of the endometrioma wall to increase spontaneous pregnancy rates in infertile women with ovarian endometrioma undergoing surgery [12]. On the other hand, there is no evidence that cystectomy for endometriomas prior to treatment with assisted reproductive technologies improves pregnancy rates [12-14]. Taken together, the significance of ovarian reserve after surgery for endometriomas is dependent on post-surgical infertility treatment. Serum AMH levels prior to surgery also should be assessed from this standpoint.

The ovarian cortex surrounding endometriomas has been reported to potentially cause a reduction in the volume of healthy tissue, to lower follicular density, and cause a loss of cortex-specific stroma [15-17]. These results suggest that endometriomas might result in diminished ovarian reserve. Lemos et al. reported that infertile patients with minimal/mild endometriosis without endometriomas, categorized as stage I/II according to the revised American Society for Reproductive Medicine (rASRM) classification [18], have decreased serum AMH levels compared to those in a control group with tubal obstruction without endometriosis [19]. With regards to endometriomas, Kim et al. demonstrated that patients with stage IV endometriosis with endometriomas displayed significantly lower AMH levels than age- and body mass index (BMI)-matched controls [20]. Similarly, it has been reported that AMH levels are lower in patients with stage III/IV endometriosis without prior ovarian surgery than in controls [21]. Uncu et al. also reported lower AMH levels in patients with endometrioma than in age-matched controls [22]. In this study, the unilateral endometrioma group exhibited lower AMH levels than the bilateral endometrioma group. However, a cross-sectional study including 313 women with a diagnosis of endometriosis and 413 women without endometriosis (controls) identified no difference in serum AMH levels correlated to the type of endometriosis excluding women who had a past history of surgery for endometriomas [23].

It is still inconclusive whether and how endometriosis and endometriomas affect serum AMH levels, although several studies have reported decreased levels of serum AMH in endometriosis patients (Table 1). Inflammation surrounding ovaries might have some influence on ovarian reserve, if serum AMH levels are altered by endometriosis without endometriomas. Moreover, endometriosis and endometriomas might affect not only the quantitative aspects of ovarian reserve, but also the quality of oocytes.

Table 1. Serum anti-Müllerian hormone (AMH) levels in endometriosis and endometrioma surgery

Author (Year)	Ref	Comparison	Serum AMH level (ng/mL)	P
Control vs. Endometriosis				
Lemo et al. (2008)	19	Control vs. Stage I/II endometriosis	2.02 ± 0.72 vs. 1.26 ± 0.7 [a]	0.004
Kim et al. (2013)	20	Control vs. Stage IV endometriosis	3.1 ± 0.4 vs. 2.1 ± 0.3 [b]	0.02
Pacchiarotti et al. (2014)	21	Control vs. Stage III/IV endometriosis	1.72 ± 0.63 vs. 0.97 ± 0.59 [a]	0.001
Uncu et al. (2013)	22	Control vs. Endometrioma	4.20 ± 2.26 vs. 2.81 ± 2.15 [a]	0.002
Streuli et al. (2012)	23	Control vs. SUP vs. EMA vs. DIE	4.1 ± 3.4 vs. 4.5 ± 3.6 vs. 3.8 ± 2.9 vs. 3.4 ± 3.0 [a]	0.06
Post-surgical changes after cystectomy				
Ercan et al. (2011)	27	Pre vs. 3 months (unilateral 36 cases)	2.03 ± 0.41 vs. 1.95 ± 0.62 [a]	NS
Hirokawa et al. (2011)	29	Pre vs. 1 month (unilateral 20 cases)	4.1 ± 2.3 vs. 2.9 ± 1.6 [a]	<0.001
		Pre vs. 1 month (bilateral 18 cases)	3.6 ± 2.7 vs. 1.2 ± 1.0 [a]	<0.001
Kitajima et al. (2011)	30	Pre vs. 2 months (unilateral 19 cases)	4.27 ± 3.00 vs. 24.6% decrease	Not specified
Lee et al. (2011)	31	Pre vs. 1 month (unilateral 13 cases)	4.69 ± 2.50 vs. 2.77 ± 1.46 [a]	0.002
Tsolakidis et al. (2010)	32	Pre vs. 6 months (unilateral 7/bilateral 3 cases)	3.9 ± 0.4 vs. 2.9 ± 0.2 [b]	0.026
Surgical methods				
Tsolakidis et al. (2010)	32	3-step method vs. Stripping (baseline)	4.5 ± 0.4 vs. 3.9 ± 0.4 [b]	Not specified
		3-step method vs. Stripping (6 months)	3.99 ± 0.6 vs. 2.9 ± 0.2 [b]	Not specified
Sonmezer et al. (2013)	37	Hemostatic matrix vs. Bipolar (baseline)	3.73 ± 1.50 vs. 3.66 ± 1.20 [a]	NS
		Hemostatic matrix vs. Bipolar (1 month)	2.72 ± 1.49 vs. 1.64 ± 0.93 [a]	0.001
		Hemostatic matrix vs. Bipolar (3 months)	3.07 ± 1.43 vs. 2.84 ± 1.12 [a]	0.467
Zaitoun et al. (2013)	38	Laparotomic suture vs. Laparoscopic bipolar (baseline)	4.6 ± 0.9 vs. 4.5 ± 0.8 [a]	0.8
		Laparotomic suture vs. Laparoscopic bipolar (6 months)	4.5 ± 0.9 vs. 2.4 ± 0.5 [a]	<0.005
		Laparotomic suture vs. Laparoscopic bipolar (12 months)	4.4 ± 0.9 vs. 2.7 ± 0.5 [a]	<0.005
		Laparotomic suture vs. Laparoscopic bipolar (18 months)	4.5 ± 0.9 vs. 2.5 ± 0.4 [a]	<0.005

[a] mean ± SD; [b] mean ± SEM; SUP, superficial lesion; EMA, endometrioma; DIE, deep infiltrating endometriosis; NS, not significant.

Surgery for Endometrioma

Busacca et al. reported 3 cases of post-surgical ovarian failure in a total of 126 patients who underwent bilateral endometriomas [24]. Surgeons should keep ovarian reserve in mind particularly when considering surgical intervention for bilateral endometriomas.

Unlike the controversy regarding the influence of an endometrioma itself on ovarian reserve, warnings that cystectomy for endometriomas diminishes ovarian reserve has been supported by data regarding the number of oocytes retrieved in *in vitro* fertilization (IVF) procedures [11]. Chang et al. and Iwase et al. first reported that cystectomy for endometriomas leads to a greater decrease in serum AMH levels than cystectomy compared to other benign ovarian tumors [25, 26]. Among the subsequently published pioneer studies, one study demonstrated that cystectomy for endometriomas did not cause significant changes in serum AMH levels (Table 1) [27-32]. These studies have already been reviewed and a meta-analysis has led to the conclusion that cystectomy for endometriomas may cause a decline of ovarian reserve [33, 34]. A cross-sectional study also demonstrated that AMH levels were significantly lower in women who previously underwent endometrioma surgery, irrespective of whether endometriomas were present at the time of the study ($P < 0.05$) [23].

Factors Affecting Ovarian Reserve in Endometrioma Surgery

Several issues have emerged regarding surgery for endometrioma and ovarian reserve. The first issue concerns the factors causing post-surgical decreases in ovarian reserve. One such factor is bilateral surgery. It has been reported that laparoscopic cystectomy for bilateral endometriomas caused a greater decline of serum AMH levels compared to unilateral cystectomy [25, 26]. Hirokawa et al. reported a greater rate of decline in serum AMH levels 1 month after surgery for bilateral endometriomas compared with unilateral tumors ($24.7 \pm 32.5\%$ in the unilateral surgery vs. $62.8 \pm 29.6\%$ in the bilateral surgery, mean ± SD of the decline rates; $P < 0.001$) [29]. The Authors also found that higher rASRM scores tended to cause greater reduction in serum AMH levels after surgery. Kitajima et al. compared the decline of serum AMH levels within 3 months after surgery in women with an excised cyst wall that contained normal ovarian tissue and women without healthy ovarian tissue in the excised cyst wall ($42.0 \pm 32.9\%$ vs. $8.9 \pm 13.4\%$; $P = 0.01$) [30]. Recently, a study of 193 patients who underwent laparoscopic cystectomy for endometrioma demonstrated that postoperative AMH levels significantly decreased after surgery irrespective of age (≤38 years, $P < 0.001$; >38 years, $P < 0.001$), cyst size (>3 cm, $P = 0.018$; ≤3 cm, $P = 0.022$), and laterality (unilateral, $P < 0.001$; bilateral, $P < 0.001$) [35].

The second issue concerns the determination of which surgical methods are optimal from the standpoint of postoperative AMH levels (Table 1). Although excision of the endometrioma capsule is superior to drainage and electrocoagulation of the endometrioma wall in spontaneous pregnancy rates [12], most gynecologists believe that cauterization and vaporization of the cyst wall is ovarian reserve-friendly. The "three-step technique," consisting of irrigation during the first laparoscopy, followed by treatment with a gonadotropin-releasing hormone agonist, and vaporization in the second laparoscopy, resulted in a lower post-surgical decline in AMH levels compared to endometrioma stripping [32]. Bipolar electrocoagulation may potentially damage the cortex of ovaries. Several studies have

compared different hemostasis methods in ovarian cystectomy for endometriomas. Ferrero et al. compared serum AMH levels following hemostasis by bipolar coagulation versus suturing after laparoscopic cystectomy for bilateral endometriomas [36]. They found no significant difference in the mean percentage decrease in AMH levels in the two groups after 3, 6, and 12 months of follow-up. Another randomized controlled trial (RCT) compared the effects of hemostatic matrix with bipolar electrocoagulation in unilateral cystectomy for endometrioma [37]. Serum AMH levels in the bipolar coagulation group were significantly lower at 1 month after surgery and were similar at 3 months after surgery compared to AMH levels in the hemostatic matrix group. Zaitoun et al. prospectively compared laparoscopic cystectomy with bipolar coagulation and laparotomic cystectomy with sutures. Only the laparoscopic cystectomy group displayed a significant decrease in AMH levels [38].

The third issue to be addressed is the recovery of serum AMH levels after surgery for endometriomas. AMH is produced by primary, preantral, small antral follicles but not by primordial follicles [39]. If rearrangements of follicle cohorts from a healthy primordial follicle pool occur, then serum AMH levels that decrease because of surgery could be expected to recover. Two early studies indicated that serum AMH levels could be restored to some extent by 1 week, 1 month, and 3 months after cystectomy for endometriomas [25, 31]. In the aforementioned RCT, AMH levels, especially in the bipolar coagulation group, tended to recover at 3 months after surgery compared with 1 month after surgery [37]. On the contrary, several studies have demonstrated that serum AMH levels gradually decreased or remained low [22, 36, 40, 41]. Celik et al. assessed serum AMH levels preoperatively and at 6 weeks and 6 months after surgery and reported that AMH levels gradually decreased in patients with bilateral tumors or in those with cyst diameters ≥5 cm [40]. Sugita et al. reported that serum AMH levels could be higher or lower 12 months after surgery compared to those observed 1 month after surgery [42]. They indicated and speculated that the immediate postsurgical decline of serum AMH levels was possibly related to the reduction of cortex volume from the excision, and that the medium/long-term decrease might be caused by other factors, including reduced blood supply to the ovaries.

Benign Ovarian Cysts

Matsuzaki et al. demonstrated that the surgically excised cyst wall contained a detectable number of follicles found in normal ovarian tissue following endometrioma surgery, while the cyst wall of other benign ovarian tumors did not contain any accidentally removed ovarian cortex [43]. Therefore, from the standpoint of the influence of cystectomy on ovarian reserve, one must distinguish benign ovarian cysts/tumors from endometriomas.

No significant difference was observed in preoperative serum AMH levels between the mature cystic teratoma group and age- and BMI-matched controls (Table 2) [20]. Iwase et al. reported that laparoscopic cystectomy for non-endometriomas (15 cases of unilateral tumors and 5 cases of bilateral tumors) caused a lesser, but significant, decline in AMH levels (Table 2) [26]. Similarly, Chang et al. reported that serum AMH levels were lower 1 week after laparoscopic cystectomy for non-endometriotic cysts (69.2% of the preoperative AMH levels; $P < 0.05$) [25]. Jang et al. recently reconfirmed the results from Iwase and Chang [44]. The decline in serum AMH levels after cystectomy for benign ovarian tumors have been reported to be lower than those after cystectomy for endometriomas. Chang et al. reported that the

decline in serum AMH levels at 1 week after laparoscopic cystectomy was smaller for non-endometriotic cysts than for endometrioma (69.2% vs. 33.9% of preoperative AMH levels; P = 0.028) [25]. A similar tendency was reported by Iwase et al. with a degree of decline of AMH levels compared to preoperative levels of 16.1% in the benign ovarian tumor group vs. 24.9% in the endometrioma group [26].

Table 2. Serum anti-Müllerian hormone (AMH) levels in benign gynecologic conditions except for endometriosis

Author (Year)	Ref	Comparison	Serum AMH level (ng/mL)	P
Benign ovarian cysts/tumors				
Kim et al. (2013)	20	Control vs. MCT	4.0 ± 0.5 vs. 4.0 ± 0.5 [b]	NS
Iwase et al. (2010)	26	Pre vs. 1 month after cystectomy (unilateral 15/bilateral 5 cases)	3.92 vs. 3.29 [c]	0.044
Mohamed et al. (2011)	45	Laparotomy vs. Laparoscopy (baseline)	4.6 vs. 4.2 [d]	0.18
		Laparotomy vs. Laparoscopy (1 month)	3.7 vs. 3.2 [d]	0.004
		Laparotomy vs. Laparoscopy (3 months)	3.5 vs. 2.6 [d]	<0.001
		Laparotomy vs. Laparoscopy (6 months)	3.6 vs. 2.4 [d]	<0.001
Fallopian tubes				
Gynnerup et al. (2013)	51	Non-salpingectomy vs. Salpingectomy	3.28 vs. 2.25 [c,e]	0.04
Uterus				
Atabekoglu et al. (2012)	56	Control vs. Hysterectomy (baseline)	1.53 ± 1.82 vs. 1.46 ± 2.02 [a]	0.73
		Control vs. Hysterectomy (4 months)	1.26 ± 1.78 vs. 0.62 ± 0.9 [a]	0.262
Lee et al. (2010)	57	Pre vs. 3 months after hysterectomy	1.80 ± 1.81 vs. 1.52 ± 1.72 [a]	0.805
Wang et al. (2013)	58	Pre vs. 3 months after hysterectomy	1.08 ± 0.77 vs. 0.81 ± 0.55 [a]	<0.01
Findley et al. (2013)	60	Hysterectomy with vs. without salpingectomy (baseline)	2.26 ± 2.72 vs. 2.25 ± 2.57 [a]	0.99
		Hysterectomy with vs. without salpingectomy (3 months)	1.86 ± 1.99 vs. 1.82 ± 3.12 [a]	0.97
Iwase et al. (2010)	26	Pre vs. 1 month after myomectomy	4.64 vs. 4.16 [c]	0.012
Wang et al. (2013)	58	Pre vs. 3 months after myomectomy	1.54 ± 0.95 vs. 1.50 ± 0.58 [a]	0.07

[a] mean ± SD; [b] mean ± SEM; [c] median; [d] mean; [e] originally reported in pmol/L; MCT, mature cystic teratoma; NS, not significant.

To date, only one prospective randomized study has compared serum AMH levels after cystectomy for unilateral non-endometriotic cysts using laparoscopy and laparotomy [45]. Significant differences have been found in AMH levels between the laparoscopy and laparotomy groups at 1, 3, and 6 cycles after cystectomy (Table 2).

Ovarian Malignancies

Iwase et al. compared postoperative levels of AMH in women with ovarian malignancies and AMH levels post-cystectomy for benign ovarian tumors as a control to assess the impact of the fertility-preserving surgery with or without chemotherapy on ovarian reserve. They found that the mean AMH level in the treatment group measured 0.9 ng/mL, which was significantly lower than the levels measured in the control group (4.70 ± 3.77 ng/mL, mean ± SD) [46].

FALLOPIAN TUBE

A hydrosalpinx can reduce the likelihood of pregnancy after IVF. Therefore, salpingectomy of diseased fallopian tubes before IVF should be considered [47]. Salpingectomy might result in decreased blood supply to the ovaries. However, the ovarian response after salpingectomy has been inconsistent [48, 49]. Of course, it is not clear whether the hydrosalpinx itself may affect ovarian reserve. Only one cross-sectional study has assessed serum AMH levels in different tubal surgical procedures. No significant differences were found in serum AMH levels among patients undergoing different tubal surgical procedures, including 26, 34, 23, and 51 patients who underwent bilateral salpingectomy, unilateral salpingectomy, bilateral interruption in the proximal oviducts, and bilateral oviduct obstruction, respectively [50]. On the contrary, Grynnerup et al. reported that AMH levels were significantly lower in the salpingectomy group than in the non-salpingectomy group (Table 2) [51]. Sequential assessments of serum AMH levels did not reveal statistically significant differences before and after laparoscopic coagulation and dissection of the proximal tubes (1.548 ng/mL preoperatively vs. 1.481 ng/mL 3 months after surgery, median; P = 0.079) [52]. Similarly, a study also illustrated that serum AMH levels were not affected by tubal ligation (1.43 ng/mL preoperatively vs. 1.30 ng/mL 12 months after surgery, median; P = 0.23) [53].

UTERUS

Hysterectomy

Hysterectomy is not an option in women who desire future fertility. However, ovarian sex steroid hormones are necessary for relatively younger women even after hysterectomy. Therefore, simultaneous oophorectomy in hysterectomy for benign uterine diseases should be avoided in women aged less than 45 years. Hysterectomy, even if the ovaries are preserved, can possibly cause adverse effects on ovarian function. Subsequently, it might shorten the time to menopause [54, 55]. Serum AMH levels showed tendency to decline more at 4 months after hysterectomy compared to those in controls who did not undergo hysterectomy, although this was not statistically significant (Table 2) [56]. The authors concluded that the decrease in ovarian reserve after hysterectomy is possibly caused by low blood supply because of the interruption of the uterine arteries. On the contrary, Lee et al. revealed that

hysterectomy did not affect ovarian artery blood flow or serum AMH levels (Table 2) [57]. However, Wang et al. demonstrated that serum AMH levels significantly declined 3 months following hysterectomy, whereas AMH levels 3 months after myomectomy were similar to the preoperative levels (Table 2) [58].

Simple hysterectomy for benign diseases is performed with or without salpingectomy. The mesosalpinx plays a role in blood supply to ovaries. Therefore, prophylactic salpingectomy with hysterectomy should be reconsidered. Salpingectomy with total laparoscopic hysterectomy (TLH) did not cause a significant decrease in AMH levels compared to those observed after standard TLH without adnexectomy (-0.06 ± 0.1 ng/mL vs. -0.08 ± 0.1 ng/mL ΔAMH for TLH with vs. without salpingectomy, mean ± SD; $P = 0.35$; where ΔAMH refers to the change in post-operative and pre-operative values of AMH) [59]. This result was confirmed in an RCT by Findley et al. (Table 2) [60].

Myomectomy

Leiomyoma of the uterus is one of the most frequently observed benign gynecologic conditions affecting fertility. Abdominal or laparoscopic myomectomy is performed for leiomyoma patients who desire future fertility. A small, but statistically significant, decrease in postoperative serum AMH levels was found in the myomectomy group [26]. On the contrary, Wang et al. demonstrated that serum AMH levels 3 months after myomectomy were similar to the preoperative levels [58]. Myomectomy is a procedure in which severe hemorrhage can occur. Therefore, a decrease in blood supply during surgery might affect ovarian reserve. However, serum AMH levels greatly differed in the above two studies, and therefore, it would be difficult to draw a definitive interpretation.

CONCLUSION

It can be concluded that the current status of pre- and post-gynecologic surgery as follows: 1) the influence on ovarian reserve with endometriosis/endometrioma itself is still controversial and this influence might not reach clinical significance as far as serum AMH levels are concerned; 2) cystectomy for endometriomas tends to reduce AMH levels more than cystectomy for other types of benign ovarian tumors, especially in bilateral endometriomas; 3) cystectomy and bipolar coagulation in endometrioma surgery could be factors that decrease ovarian reserve; however, no definitive conclusions can be made about which surgical method is preferable from the standpoint of ovarian reserve; and 4) although hysterectomy, salpingectomy, and myomectomy might affect ovarian reserve, conclusions remain speculative since evidence is insufficient. Tables 1 and 2 show the representative results available to date regarding serum AMH levels and gynecologic conditions and surgeries.

This chapter focused on the clinical utility of AMH levels as a marker for the evaluation of ovarian damage caused by gynecologic diseases and surgery. A meta-analysis using two randomized studies has shown that stripping was superior to vaporization or coagulation of the cyst wall in terms of rates of spontaneous pregnancy and disease recurrences [61-63].

However, vaporization or coagulation has been demonstrated to be more favorable in terms of ovarian reserve [11]. Most studies have evaluated ovarian reserve in terms of the numbers of oocytes retrieved in IVF procedures. However, all women who underwent surgery for endometriosis did not necessarily require IVF treatment. Not surprisingly, the increasingly widespread use of AMH measurement has boosted research to identify the most appropriate indication and surgical methods for treatment of endometriomas. As mentioned above, several studies have revealed that cystectomy for endometriomas causes a decrease in ovarian reserve especially in bilateral cases. The loss of ovarian cortex removed accidentally and/or by electrocoagulation for hemostasis is the primary reason for a decrease in ovarian reserve. A small number of studies show that suturing or using hemostatic materials without bipolar electrocoagulation might be preferable in the preservation of ovarian reserve. Disturbance of the blood supply has been considered another cause affecting ovarian reserve in endometrioma cystectomy. Adhesiolysis is one of the main components of endometriosis surgery. Anatomical corrections including excessive adhesiolysis might cause the diminished blood supply to the mesosalpinx. Surgical methods for endometriomas including cystectomy or vaporization/coagulation, suture or electrocoagulation as a hemostasis method, should be reevaluated from the standpoint of ovarian reserve. However, further studies, including rates of pregnancy and recurrences after surgery, are required in order to evaluate the true usability of serum AMH levels as a marker in endometrioma surgery.

In addition to endometrioma surgery, surgical interventions for other gynecologic conditions that might cause ovarian damage should be evaluated in terms of ovarian reserve. It is controversial whether cystectomy for benign ovarian tumors, with the exception of endometriomas, negatively affects ovarian reserve. The decline in ovarian reserve possibly caused by salpingectomy, which is occasionally performed for ectopic pregnancy or hydrosalpinx, is also an issue that should be addressed. There is a possibility that other surgical procedures for removal of fallopian tubes besides salpingectomy, such as dissection of the tubes may be preferred, although the available evidence is too limited to draw a conclusion. Sex steroid hormones secreted by the ovary, such as estrogen, are important for women's healthcare even if patients do not foresee a future pregnancy. Therefore, when considering ovarian life after hysterectomy, the assessment for ovarian reserve using AMH has an important role. The studies performed so far have not reported a huge influence, although the impacts on ovarian reserve by such interventions are not conclusive.

Ovarian reserve is severely reduced following unilateral oophorectomy with/without chemotherapy, in patients with ovarian malignancies. Assessment of ovarian reserve using serum AMH levels as a marker of ovarian reserve would be valuable for fertility planning in patients with ovarian malignancies.

In conclusion, measurement of serum AMH levels is helpful for counseling patients who desire future fertility but have benign and malignant gynecologic conditions that may require surgical interventions. Serum AMH levels may be preferred in helping to determine the indication and selection of surgical methods for benign gynecologic conditions, especially endometriomas. However, there is little available information regarding the correlation between the possibility of eventual live births and serum AMH levels pre- and post-operative procedures. Further studies are required to investigate whether and to what degree serum AMH levels in patients with gynecologic conditions, including fertility-preserving interventions for ovarian malignancies, are relevant to prospective live births.

QUESTIONS FOR FURTHER RESEARCH

What surgical procedure including hemostatic method for endometriomas is the most appropriate to maintain ovarian reserve?

Can pre- and post-surgical AMH levels in gynecologic diseases predict future live births?

Is ovarian reserve affected by non-ovarian gynecological diseases, such as uterine leiomyomas and hydrosalpinx, and its surgical procedures?

REFERENCES

[1] La Torre R, Montanino-Oliva M, Marchiani E, Boninfante M, Montanino G, Cosmi EV: Ovarian blood flow before and after conservative laparoscopic treatment for endometrioma. *Clin. Exp. Obstet. Gynecol.* 1998, 25:12-14.

[2] Marconi G, Vilela M, Quintana R, Sueldo C: Laparoscopic ovarian cystectomy of endometriomas does not affect the ovarian response to gonadotropin stimulation. *Fertil Steril* 2002, 78:876-878.

[3] Muzii L, Bianchi A, Croce C, Manci N, Panici PB: Laparoscopic excision of ovarian cysts: is the stripping technique a tissue-sparing procedure? *Fertil Steril* 2002, 77:609-614.

[4] Lee MM, Donahoe PK, Hasegawa T, Silverman B, Crist GB, Best S, Hasegawa Y, Noto RA, Schoenfeld D, MacLaughlin DT: Mullerian inhibiting substance in humans: normal levels from infancy to adulthood. *J. Clin. Endocrinol. Metab.* 1996, 81:571-576.

[5] Rasool N, Rose PG: Fertility-preserving surgical procedures for patients with gynecologic malignancies. *Clin. Obstet. Gynecol.* 2010, 53:804-814.

[6] Wright JD, Shah M, Mathew L, Burke WM, Culhane J, Goldman N, Schiff PB, Herzog TJ: Fertility preservation in young women with epithelial ovarian cancer. *Cancer* 2009, 115:4118-4126.

[7] Loh JS, Maheshwari A: Anti-Mullerian hormone--is it a crystal ball for predicting ovarian ageing? *Hum. Reprod.* 2011, 26:2925-2932.

[8] Nelson SM: Biomarkers of ovarian response: current and future applications. *Fertil Steril* 2013, 99:963-969.

[9] Lambalk CB, van Disseldorp J, de Koning CH, Broekmans FJ: Testing ovarian reserve to predict age at menopause. *Maturitas* 2009, 63:280-291.

[10] van Disseldorp J, Lambalk CB, Kwee J, Looman CW, Eijkemans MJ, Fauser BC, Broekmans FJ: Comparison of inter- and intra-cycle variability of anti-Mullerian hormone and antral follicle counts. *Hum. Reprod.* 2010, 25:221-227.

[11] Somigliana E, Vercellini P, Vigano P, Ragni G, Crosignani PG: Should endometriomas be treated before IVF-ICSI cycles? *Hum. Reprod. Update* 2006, 12:57-64.

[12] Hart RJ, Hickey M, Maouris P, Buckett W: Excisional surgery versus ablative surgery for ovarian endometriomata. *Cochrane Database Syst. Rev.* 2008:CD004992.

[13] Benschop L, Farquhar C, van der Poel N, Heineman MJ: Interventions for women with endometrioma prior to assisted reproductive technology. *Cochrane Database Syst. Rev.* 2010:CD008571.

[14] Donnez J, Wyns C, Nisolle M: Does ovarian surgery for endometriomas impair the ovarian response to gonadotropin? *Fertil Steril* 2001, 76:662-665.
[15] Kitajima M, Defrere S, Dolmans MM, Colette S, Squifflet J, Van Langendonckt A, Donnez J: Endometriomas as a possible cause of reduced ovarian reserve in women with endometriosis. *Fertil Steril* 2011, 96:685-691.
[16] Maneschi F, Marasa L, Incandela S, Mazzarese M, Zupi E: Ovarian cortex surrounding benign neoplasms: a histologic study. *Am. J. Obstet. Gynecol.* 1993, 169:388-393.
[17] Schubert B, Canis M, Darcha C, Artonne C, Pouly JL, Dechelotte P, Boucher D, Grizard G: Human ovarian tissue from cortex surrounding benign cysts: a model to study ovarian tissue cryopreservation. *Hum. Reprod.* 2005, 20:1786-1792.
[18] Revised American Fertility Society classification of endometriosis: 1985. *Fertil Steril* 1985, 43:351-352.
[19] Lemos NA, Arbo E, Scalco R, Weiler E, Rosa V, Cunha-Filho JS: Decreased anti-Mullerian hormone and altered ovarian follicular cohort in infertile patients with mild/minimal endometriosis. *Fertil Steril* 2008, 89:1064-1068.
[20] Kim JY, Jee BC, Suh CS, Kim SH: Preoperative serum anti-mullerian hormone level in women with ovarian endometrioma and mature cystic teratoma. *Yonsei Med. J.* 2013, 54:921-926.
[21] Pacchiarotti A, Frati P, Milazzo GN, Catalano A, Gentile V, Moscarini M: Evaluation of serum anti-Mullerian hormone levels to assess the ovarian reserve in women with severe endometriosis. *Eur. J. Obstet. Gynecol. Reprod. Biol.* 2014, 172:62-64.
[22] Uncu G, Kasapoglu I, Ozerkan K, Seyhan A, Oral Yilmaztepe A, Ata B: Prospective assessment of the impact of endometriomas and their removal on ovarian reserve and determinants of the rate of decline in ovarian reserve. *Hum. Reprod.* 2013, 28:2140-2145.
[23] Streuli I, de Ziegler D, Gayet V, Santulli P, Bijaoui G, de Mouzon J, Chapron C: In women with endometriosis anti-Mullerian hormone levels are decreased only in those with previous endometrioma surgery. *Hum. Reprod.* 2012, 27:3294-3303.
[24] Busacca M, Riparini J, Somigliana E, Oggioni G, Izzo S, Vignali M, Candiani M: Postsurgical ovarian failure after laparoscopic excision of bilateral endometriomas. *Am. J. Obstet. Gynecol.* 2006, 195:421-425.
[25] Chang HJ, Han SH, Lee JR, Jee BC, Lee BI, Suh CS, Kim SH: Impact of laparoscopic cystectomy on ovarian reserve: serial changes of serum anti-Mullerian hormone levels. *Fertil Steril* 2010, 94:343-349.
[26] Iwase A, Hirokawa W, Goto M, Takikawa S, Nagatomo Y, Nakahara T, Manabe S, Kikkawa F: Serum anti-Mullerian hormone level is a useful marker for evaluating the impact of laparoscopic cystectomy on ovarian reserve. *Fertil Steril* 2010, 94:2846-2849.
[27] Ercan CM, Duru NK, Karasahin KE, Coksuer H, Dede M, Baser I: Ultrasonographic evaluation and anti-mullerian hormone levels after laparoscopic stripping of unilateral endometriomas. *Eur. J. Obstet. Gynecol. Reprod. Biol.* 2011, 158:280-284.
[28] Ercan CM, Sakinci M, Duru NK, Alanbay I, Karasahin KE, Baser I: Antimullerian hormone levels after laparoscopic endometrioma stripping surgery. *Gynecol. Endocrinol.* 2010, 26:468-472.
[29] Hirokawa W, Iwase A, Goto M, Takikawa S, Nagatomo Y, Nakahara T, Bayasula B, Nakamura T, Manabe S, Kikkawa F: The post-operative decline in serum anti-

Mullerian hormone correlates with the bilaterality and severity of endometriosis. *Hum. Reprod.* 2011, 26:904-910.

[30] Kitajima M, Khan KN, Hiraki K, Inoue T, Fujishita A, Masuzaki H: Changes in serum anti-Mullerian hormone levels may predict damage to residual normal ovarian tissue after laparoscopic surgery for women with ovarian endometrioma. *Fertil Steril* 2011, 95:2589-2591 e2581.

[31] Lee DY, Young Kim N, Jae Kim M, Yoon BK, Choi D: Effects of laparoscopic surgery on serum anti-Mullerian hormone levels in reproductive-aged women with endometrioma. *Gynecol. Endocrinol.* 2011, 27:733-736.

[32] Tsolakidis D, Pados G, Vavilis D, Athanatos D, Tsalikis T, Giannakou A, Tarlatzis BC: The impact on ovarian reserve after laparoscopic ovarian cystectomy versus three-stage management in patients with endometriomas: a prospective randomized study. *Fertil Steril* 2010, 94:71-77.

[33] Raffi F, Metwally M, Amer S: The impact of excision of ovarian endometrioma on ovarian reserve: a systematic review and meta-analysis. *J. Clin. Endocrinol. Metab.* 2012, 97:3146-3154.

[34] Somigliana E, Berlanda N, Benaglia L, Vigano P, Vercellini P, Fedele L: Surgical excision of endometriomas and ovarian reserve: a systematic review on serum antimullerian hormone level modifications. *Fertil Steril* 2012, 98:1531-1538.

[35] Alborzi S, Keramati P, Younesi M, Samsami A, Dadras N: The impact of laparoscopic cystectomy on ovarian reserve in patients with unilateral and bilateral endometriomas. *Fertil Steril* 2014, 101:427-434.

[36] Ferrero S, Venturini PL, Gillott DJ, Remorgida V, Leone Roberti Maggiore U: Hemostasis by bipolar coagulation versus suture after surgical stripping of bilateral ovarian endometriomas: a randomized controlled trial. *J. Minim Invasive Gynecol.* 2012, 19:722-730.

[37] Sonmezer M, Taskin S, Gemici A, Kahraman K, Ozmen B, Berker B, Atabekoglu C: Can ovarian damage be reduced using hemostatic matrix during laparoscopic endometrioma surgery? A prospective, randomized study. *Arch. Gynecol. Obstet.* 2013, 287:1251-1257.

[38] Zaitoun MM, El Behery MM: Comparing long term impact on ovarian reserve between laparoscopic ovarian cystectomy and open laprotomy for ovarian endometrioma. *J. Ovarian Res.* 2013, 6:76.

[39] Weenen C, Laven JS, Von Bergh AR, Cranfield M, Groome NP, Visser JA, Kramer P, Fauser BC, Themmen AP: Anti-Mullerian hormone expression pattern in the human ovary: potential implications for initial and cyclic follicle recruitment. *Mol. Hum. Reprod.* 2004, 10:77-83.

[40] Celik HG, Dogan E, Okyay E, Ulukus C, Saatli B, Uysal S, Koyuncuoglu M: Effect of laparoscopic excision of endometriomas on ovarian reserve: serial changes in the serum antimullerian hormone levels. *Fertil Steril* 2012, 97:1472-1478.

[41] Urman B, Alper E, Yakin K, Oktem O, Aksoy S, Alatas C, Mercan R, Ata B: Removal of unilateral endometriomas is associated with immediate and sustained reduction in ovarian reserve. *Reprod. Biomed. Online* 2013, 27:212-216.

[42] Sugita A, Iwase A, Goto M, Nakahara T, Nakamura T, Kondo M, Osuka S, Mori M, Saito A, Kikkawa F: One-year follow-up of serum antimullerian hormone levels in

patients with cystectomy: are different sequential changes due to different mechanisms causing damage to the ovarian reserve? *Fertil Steril* 2013, 100:516-522 e513.

[43] Matsuzaki S, Houlle C, Darcha C, Pouly JL, Mage G, Canis M: Analysis of risk factors for the removal of normal ovarian tissue during laparoscopic cystectomy for ovarian endometriosis. *Hum. Reprod.* 2009, 24:1402-1406.

[44] Jang WK, Lim SY, Park JC, Lee KR, Lee A, Rhee JH: Surgical impact on serum anti-Mullerian hormone in women with benign ovarian cyst: A prospective study. *Obstet. Gynecol. Sci.* 2014, 57:121-127.

[45] Mohamed ML, Nouh AA, El-Behery MM, Mansour SA: Effect on ovarian reserve of laparoscopic bipolar electrocoagulation versus laparotomic hemostatic sutures during unilateral ovarian cystectomy. *Int. J. Gynaecol. Obstet.* 2011, 114:69-72.

[46] Iwase A, Sugita A, Hirokawa W, Goto M, Nakahara T, Bayasula, Kajiyama H, Shibata K, Nagatomo Y, Kikkawa F: Anti-Mullerian hormone as a marker of ovarian reserve in patients with ovarian malignancies who have undergone fertility-preserving surgery and chemotherapy. *Gynecol. Endocrinol.* 2013, 29:357-360.

[47] Johnson N, van Voorst S, Sowter MC, Strandell A, Mol BW: Surgical treatment for tubal disease in women due to undergo in vitro fertilisation. *Cochrane Database Syst. Rev.* 2010:CD002125.

[48] Orvieto R, Saar-Ryss B, Morgante G, Gemer O, Anteby EY, Meltcer S: Does salpingectomy affect the ipsilateral ovarian response to gonadotropin during in vitro fertilization-embryo transfer cycles? *Fertil Steril* 2011, 95:1842-1844.

[49] Strandell A, Lindhard A, Waldenstrom U, Thorburn J: Prophylactic salpingectomy does not impair the ovarian response in IVF treatment. *Hum. Reprod.* 2001, 16:1135-1139.

[50] Ni L, Sadiq S, Mao Y, Cui Y, Wang W, Liu J: Influence of various tubal surgeries to serum antimullerian hormone level and outcome of the subsequent IVF-ET treatment. *Gynecol. Endocrinol.* 2013, 29:345-349.

[51] Grynnerup AG, Lindhard A, Sorensen S: Anti-Mullerian hormone levels in salpingectomized compared with nonsalpingectomized women with tubal factor infertility and women with unexplained infertility. *Acta Obstet. Gynecol. Scand.* 2013, 92:1297-1303.

[52] Ercan CM, Sakinci M, Coksuer H, Keskin U, Tapan S, Ergun A: Ovarian reserve testing before and after laparoscopic tubal bipolar electrodesiccation and transection. *Eur. J. Obstet. Gynecol. Reprod. Biol.* 2013, 166:56-60.

[53] Silva AL, Re C, Dietrich C, Fuhrmeister IP, Pimentel A, Corleta HV: Impact of tubal ligation on ovarian reserve as measured by anti-Mullerian hormone levels: a prospective cohort study. *Contraception* 2013, 88:700-705.

[54] Duhan N, Sirohiwal D: Uterine myomas revisited. *Eur. J. Obstet. Gynecol. Reprod. Biol.* 2010, 152:119-125.

[55] Siddle N, Sarrel P, Whitehead M: The effect of hysterectomy on the age at ovarian failure: identification of a subgroup of women with premature loss of ovarian function and literature review. *Fertil Steril* 1987, 47:94-100.

[56] Atabekoglu C, Taskin S, Kahraman K, Gemici A, Taskin EA, Ozmen B, Berker B, Sonmezer M: The effect of total abdominal hysterectomy on serum anti-Mullerian hormone levels: a pilot study. *Climacteric* 2012, 15:393-397.

[57] Lee DY, Park HJ, Kim BG, Bae DS, Yoon BK, Choi D: Change in the ovarian environment after hysterectomy as assessed by ovarian arterial blood flow indices and

serum anti-Mullerian hormone levels. *Eur. J. Obstet. Gynecol. Reprod. Biol.* 2010, 151:82-85.

[58] Wang HY, Quan S, Zhang RL, Ye HY, Bi YL, Jiang ZM, Ng EH: Comparison of serum anti-Mullerian hormone levels following hysterectomy and myomectomy for benign gynaecological conditions. *Eur. J. Obstet. Gynecol. Reprod. Biol.* 2013, 171:368-371.

[59] Morelli M, Venturella R, Mocciaro R, Di Cello A, Rania E, Lico D, D'Alessandro P, Zullo F: Prophylactic salpingectomy in premenopausal low-risk women for ovarian cancer: primum non nocere. *Gynecol. Oncol.* 2013, 129:448-451.

[60] Findley AD, Siedhoff MT, Hobbs KA, Steege JF, Carey ET, McCall CA, Steiner AZ: Short-term effects of salpingectomy during laparoscopic hysterectomy on ovarian reserve: a pilot randomized controlled trial. *Fertil Steril* 2013, 100:1704-1708.

[61] Alborzi S, Momtahan M, Parsanezhad ME, Dehbashi S, Zolghadri J: A prospective, randomized study comparing laparoscopic ovarian cystectomy versus fenestration and coagulation in patients with endometriomas. *Fertil Steril* 2004, 82:1633-1637.

[62] Beretta P, Franchi M, Ghezzi F, Busacca M, Zupi E, Bolis P: Randomized clinical trial of two laparoscopic treatments of endometriomas: cystectomy versus drainage and coagulation. *Fertil Steril* 1998, 70:1176-1180.

[63] Hart R, Hickey M, Maouris P, Buckett W, Garry R: Excisional surgery versus ablative surgery for ovarian endometriomata: a Cochrane Review. *Hum. Reprod.* 2005, 20:3000-3007.

In: Encyclopedia of Surgery (22 Volume Set)
Editors: Andreas Lehrer and Kristin Mueller
ISBN: 978-1-53618-329-0
© 2020 Nova Science Publishers, Inc.

Chapter 371

FOLLOW-UP AFTER TREATMENT OF LOCALIZED RENAL TUMOR (SURGERY, SURVEILLANCE, ABLATIVE THERAPIES)

Francisco Javier Perez Garcia*, PhD
Department of Urology, Hospital San Agustin, Aviles, Asturias, Spain

ABSTRACT

Renal cell carcinoma (RCC) comprises approximately 2%-3% of all adult malignancies, representing the seventh most common cancer in men and nine commonest cancers in women. Surgical resection (radical or partial nephrectomy) remains the only effective therapy for clinically localized RCC. Other treatment options like Active Surveillance and Ablation therapies can be used in selected patients.

Follow-up after surgery, active surveillance and ablation treatment allows the urologist to monitor for postoperative complications, renal function, local recurrence, recurrence in the contralateral kidney and development of metastasis.

A review of the most important and relevant guidelines was conducted to summarize the necessity and the studies to do for surveillance in these patients.

INTRODUCTION

Renal cell carcinoma (RCC) comprises approximately 2%-3% of all adult malignancies, representing the seventh most common cancer in men and nine commonest cancers in women. It is the tenth most common cause of cancer-related deaths among men [1,2]. Risk factors for RCC include active and passive smoking, obesity, end-stage renal failure, acquired renal cystic disease and hereditary conditions associated with a mutation in the von-Hippel-Lindau gene [3,4]. Surgical resection (radical or partial nephrectomy) remains the only effective therapy for clinically localized RCC. Other treatment options like Active Surveillance and Ablation therapies can be used in selected patients.

* Corresponding Author's Email: franjapg@yahoo.es.

Surgical management with resection of the primary tumor provides for immediate local control of renal tumors and valuable pathologic data that may aid in understanding prognosis and guide patient follow-up.

Indications for active surveillance include elderly patients, those with decreased life expectancy or those with medical comorbidities that would be associated with increased risk if a therapeutic intervention were to be undertaken. Alternatively, a strategy of observation with delayed intervention as indicated may be elected in order to determine the growth rate or to obtain alternative diagnostic imaging. Ablative techniques may be performed by a variety of approaches (open/laparoscopic/percutaneous) and operators (urologic surgeons/ interventional radiologists). The majority of neoplasms selected for ablative procedures are less than 4 cm and exophytic, as markedly higher incomplete ablation rates have been noted for endophytic, central and larger neoplasms.

Staging

The Union for International Cancer Control tumour–node–metastasis staging system should be used (Table 1).

Risk Assessment

RCC is recognised as having a very variable natural history. Risk assessment models have been developed to provide prognostic information for patients and to inform the eligibility and risk stratification designs of clinical trials. [5]

Table 1. The Union for International Cancer Control tumour–node–metastasis staging system

T	Primary tumour
Tx	Primary tumour cannot be assessed
T0	No evidence of primary tumour
T1	Tumour of < or = 7cm in greatest dimension limited to the kidney
T1a	Tumour < or = 4 cm
T1b	Tumour > 4 cm but < or = 7 cm
T2	Tumour >7cm in greatest dimension limited to the kidney
T2a	Tumour > 7 cm but < or = 10 cm
T2b	Tumour > 10 cm limited to the kidney
T3	Tumour extends to major veins or perinephric tissues but not into the ipsilateral adrenal gland and not beyond Gerota´s fascia
T3a	Tumour grossly extends into the renal vein or its segmental (muscle-containing) branches, or tumour invades peri-renal or renal sinus fat (peripelvic) but not beyond Gerota´s fascia

T	Primary tumour
T3b	Tumour grossly extends into the vena cava below the diaphragm
T3c	Tumour grossly extends into the vena cava above the diaphragm or invades the wall of the vena cava
T4	Tumour invades beyond Gerota´s fascia (including contiguous extension into the ipsilateral adrenal gland)
N	Regional lymph nodes
Nx	Regional lymph nodes cannot be assessed
N0	No regional lymph node metastasis
N1	Metastasis in regional lymph node(s)
M	Distant metastasis
CM0	Clinically no distant metastasis
CM1	Clinically distant metastasis
PM1	Pathologically proven distant metastasis e.g. needle biopsy
Stage Grouping	
Stage I	T1 N0 M0
Stage II	T2 N0 M0 T3 Any N M0
Stage III	T1-3 N1 M0 T4 Any N M0
Stage IV	Any T Any N M1

Localised disease. Two systems can be used to assess the risk of progression in localised tumors: the stage, size grade and necrosis (SSIGN) score [6] and the University of California Los Angeles Integrated Staging System (UISS) [7]. These systems are described in Tables 2 and 3. In SSIGN, risk points are accumulated as noted in Table 2 and added up to provide a risk score.

Table 2. Stage, size grade and necrosis (SSIGN) score for localized RCC

Feature		Score
Pathological T category of primary tumour (TNM 2002)	pT1a	0
	pT1b	2
	pT2	3
	pT3a-4	4
Regional lymph node status	pNx or pN0	0
	pN1 or pN2	2

Table 2. (Continued)

Feature		Score
Tumour size (cm)	<10	0
	>10	1
Nuclear grade	1 or 2	0
	3	1
	4	3
Histological tumour necrosis	No	0
	Yes	1
Scores	Group	5-year metastasis free survival (%)
0-2	Low risk	97.1
3-5	Intermediate risk	73.8
> or = 6	High risk	31.2

Table 3. University of California Los Angeles Integrated Staging System (UISS) risk groups and 5-year disease-specific survival

Patient group		Pronostic group			
		T stage	Fuhrman´s grade	ECOG status	5-year disease-specific survival (%)
Localised disease (N0, M0)	Low risk	1	1-2	0	91.1
	Intermediate risk	1	1-2	1 or more	80.4
		1	3-4	Any	
		2	Any	Any	
		3	1	Any	
		3	2-4	Any	
	High	3	2-4	1 or more	54.7
		4	Any	Any	
Metastatc disease	Low risk	N1 M0	Any	Any	32
		N2M0/M1	1-2	0	
	Intermediate risk	N2M0/M1	1-2	1 or more	19.5
			3	0, 1 or more	
			4	0	
	High	N2M0/m1	4	1 or more	0

The SSIGN score compared favourably with the UISS score in predictive accuracy in a series of patients who had surgically resected clear-cell RCC. On the other hand, the UISS provides prognostic predictions for both localised and metastatic disease.

Advanced disease. Prognostic models were first built when immunotherapy was the standard therapy. The Memorial Sloane Kettering Cancer Centre (MSKCC) or Motzer score was the standard system. The MSKCC score has now been validated and updated for use in

the current era of targeted therapies as the Heng or International Metastatic RCC Database Consortium (IMDC) criteria [8]. Patients are stratified according to the presence of six risk factors:

- Karnofsky performance status (PS) <80%.
- Haemoglobin <lower limit of normal.
- Time from diagnosis to treatment of <1 year.
- Corrected calcium above the upper limit of normal.
- Platelets greater than the upper limit of normal.
- Neutrophils greater than the upper limit of normal.

The number of risk factors present is added up and the risk is stratified as can be seen in table 4.

Table 4. The Memorial Sloane Kettering Cancer Centre (MSKCC) score

Number of Risk factors	Risk group	Median overall Survival (OS) months	2-year OS (%)
0	Favourable	43	75
1-2	Intermediate	27	53
3-6	Poor	8.8	7

RATIONALE FOR SURVEILLANCE

There is no evidence that any particular follow-up protocol influences the outcome in early RCC. No standard recommendation can be given for the follow-up in advanced RCC either. The follow-up scheme for localized RCC following surgery should be dependent on the therapeutic possibilities upon recurrence. CT scans of thorax and abdomen are routinely performed, with time intervals dependent on risk factors. Long term follow-up is proposed in some institutions, due to the possibility of late relapse, but its benefit has never been demonstrated. [5]

A review of the most important and relevant guidelines was conducted to summarize the necessity and the studies to do for surveillance in these patients.

According to NCCN guidelines, [9] after surgical excision, 20% to 30% of patients with localized tumors experience relapse. Lung metastasis is the most common site of distant recurrence, occurring in 50% to 60% of patients. The median time to relapse after surgery is 1 to 2 years, with most relapses occurring within 3 years. [10]

When it comes to AUA guidelines, [11] follow-up for adult cancer survivors has traditionally focused on the early detection of a cancer recurrence based on the presumption that treatment of a lower tumor burden would result in better patient outcomes, although the evidentiary data supporting this presumption is limited [12]. The recommended essential elements of adult cancer survivorship care now include not only monitoring for cancer recurrence, secondary cancers and treatment effects, but also the prevention of recurrences or new tumors, medical interventions for the consequences of cancer and its treatment effects

and the coordination between specialists and primary care physicians to meet survivors' needs [13]. Treatment "effects" include those related to the sequelae of surgery, systemic therapies, ablative therapy and radiation.

There is now an increasing rate of detection and subsequent treatment of small renal masses of uncertain biological potential as well as a widening spectrum of contemporary treatment options with varied treatment related effects. Such options include observation/surveillance, ablative therapies and minimally-invasive as well as open approaches to partial and radical nephrectomy. The advent of a new generation of targeted systematic therapy now holds the promise of prolonged survival of patients with metastatic disease. Additionally, patients with renal cell cancer tend to be older and have a greater incidence of pre-existing kidney disease, which places them at an increased risk for either the development or progression of chronic kidney disease following therapy [14-15]. Since effective treatment strategies are available to slow the progression of chronic kidney disease and reduce cardiovascular risks, it would seem prudent to include renal function monitoring in the follow-up of renal cancer patients to facilitate early interventions or referral to nephrology.

Surveillance after surgery allows the urologist to monitor for postoperative complications, renal function, local recurrence, recurrence in the contralateral kidney and development of metastasis. [16]

Renal function and postoperative complications are commonly assessed by history, physical examination, and measurement of serum creatinine and haemoglobin at 4–6 weeks postsurgery. Long-term monitoring of serum creatinine is recommended particularly in patients with compromised renal function prior to surgery or significant increase in creatinine after surgery.

Early diagnosis of local and contralateral kidney recurrence (incidence < 2%) is useful since the most effective treatment is surgical resection. Recurrence in the kidney is associated with positive surgical margins, multifocality and grade. Tumors that develop in the contralateral kidney can be treated with nephron-sparing surgery when detected at a small size. Patients who underwent surgery when local recurrences became symptomatic have a higher rate of incomplete resection of recurrence, positive surgical margins and poorer survival.

Extensive tumor recurrence reduces the possibility of complete surgical resection, which is standard therapy for patients with local recurrence or resectable solitary metastasis.

Furthermore, an early diagnosis of disease relapse may enhance efficacy of systemic therapy if the tumour burden is low. Hence, this supports the rationale for surveillance of patients to detect recurrences and metastases early.

According to the EAU guidelines, there is no consensus on surveillance after treatment for RCC, and there is no evidence that early vs later diagnosis of recurrences improves survival. [17]

It is reasonable to stratify the follow-up, taking into account the risk of a recurrence or metastases developing. There have been large studies examining prognostic factors with long follow-up periods, from which some conclusions can be drawn:

- The sensitivity of chest radiography for small metastases is poor and US has limitations. [18]

- When the risk of relapse is intermediate or high, CT of the chest and abdomen is the investigation of choice. Findings using CT can clearly reveal metastatic lesions from RCC. [19]
- Surveillance should also include clinical evaluation of renal function and cardiovascular risk factors.
- Positron-emission tomography (PET) and PET-CT as well as bone scintigraphy are not the standard of care in RCC surveillance, due to their limited specificity and sensitivity.
- More strict follow-up schedules may be required after cryotherapy and RFA due to the higher local recurrence rate after these modality of treatment.
- There is controversy over the optimal duration of follow-up. Some argue that follow-up with imaging is not cost-effective after 5 years; however, late metastases are more likely to be solitary and justify more aggressive therapy with curative intent. In addition, patients with tumors that develop in the contralateral kidney can be treated with nephron-sparing surgery if the tumors are detected when small. In addition, for tumors < 4 cm in size, there is no difference between partial and radical nephrectomy with regard to recurrences during the follow-up. [20]

The American Urological Association published in the year 2013 the guideline for follow-up for clinically localized renal neoplasms and established several guideline statements [11]. Patients undergoing follow-up for treated or observed renal masses should undergo a history and physical examination directed at detecting signs and symptoms of metastatic spread or local recurrence. They should undergo basic laboratory testing to include blood urea nitrogen (BUN)/creatinine, urine analysis (UA) and estimated glomerular filtration rate (eGFR). Other laboratory evaluations, including complete blood count (CBC), lactate dehydrogenase (LDH), liver function tests (LFTs), alkaline phosphatase (ALP) and calcium level, may be used at the discretion of the clinician. Patients with progressive renal insufficiency on follow-up laboratory evaluation should be referred to nephrology.

The guideline recommends a bone scan in patients with an elevated alkaline phosphatase (ALP), clinical symptoms such as bone pain, and/or if radiographic findings are suggestive of a bony neoplasm.

Patients with a history of a renal neoplasm presenting with acute neurological signs or symptoms must undergo prompt neurologic cross-sectional CT or MRI scanning of the head or spine based on localization of symptomatology.

FOLLOW UP AFTER SURGICAL TREATMENT BASED IN NCCN AND AUA RECOMMENDATIONS (TABLE 5)

Low Risk Patients (pT1, N0, Nx)

Patients should undergo a baseline abdominal scan (CT or MRI) for nephron sparing surgery and abdominal imaging (US, CT or MRI) for radical nephrectomy within three to twelve months following renal surgery.

Additional abdominal imaging (US, CT or MRI) may be performed in patients with low risk (pT1, N0, Nx) disease following a radical nephrectomy if the initial postoperative baseline image is negative at the discretion of the clinician.

Abdominal imaging (US, CT, or MRI) may be performed yearly for three years in patients with low risk (pT1, N0, Nx) disease following a partial nephrectomy based on individual risk factors if the initial postoperative scan is negative.

Patients with a history of low risk (pT1, N0, Nx) renal cell carcinoma should undergo yearly chest x-ray (CXR) to assess for pulmonary metastases for three years and only as clinically indicated beyond that time period.

Table 5. Follow up after surgical treatment. Radical or partial nephrectomy

Follow-up Measure	Radical or Partial Nephrectomy	
Physical Exam and History	History and physical examination directed at detecting signs and symptoms of metastatic spread or local recurrence	
Laboratory Testing	– blood urea nitrogen (BUN)/creatinine, urine analysis (UA) and estimated glomerular filtration rate (eGFR). – complete blood count (CBC), lactate dehydrogenase (LDH), liver function tests (LFTs), alkaline phosphatase (ALP) and calcium level, may be used at the discretion of the clinician. – Patients with progressive renal insufficiency on follow-up laboratory evaluation should be referred to nephrology.	
CNS Scan	Acute neurological signs or symptoms must undergo prompt neurologic cross-sectional CT or MRI scanning of the head or spine based on localization of symptomatology	
Bone scan	Elevated alkaline phosphatase (ALP), clinical symptoms such as bone pain, and/or if radiographic findings are suggestive of a bony neoplasm.	
Follow-up Measure	Low Risk	Moderate to High Risk
Abdominal Scan/Imaging	Partial Nephrectomy - Baseline abdominal scan (CT or MRI) within 3 to 12 months following surgery: - If the initial postoperative scan is negative, abdominal imaging (US,CT or MRI) may be performed yearly for 3 years based on individual risk factors Radical Nephrectomy - Patients should undergo abdominal imaging (US,CT,MRI) within 3 to 12 months following renal surgery. - If the initial postoperative imaging is negative , abdominal imaging beyond 12 months may be performed at the discretion of the clinician	– A baseline abdominal scan (CT or MRI) within 3 to 6 months following surgery with continued imaging (US,CT, MRI) every six months for at least three years and annually thereafter to year five – Imaging beyond 5 years may be performed at the discretion of the clinician – Perform site specific imaging as symptoms warrants
Chest Imaging/Scan	Obtain a yearly chest x-ray for 3 years and only as clinical indicated beyond that time period	Obtain a baseline chest scan (CT) within 3 to 6 months following surgery with continued imaging (CXR or CT) every 6 months for at least 3 years and annually thereafter to year five. Imaging beyond 5 years is optional and should be based on individual patient characteristics and tumour risk factors

Moderate to High Risk Patients (pT2-4N0 Nx or Any Stage N+)

Moderate to high risk patients should undergo baseline chest and abdominal scan (CT or MRI) within three to six months following surgery with continued imaging (US, CXR, CT or MRI) every six months for at least three years and annually thereafter to year five.

It is recommended site-specific imaging as warranted by clinical symptoms suggestive of recurrence or metastatic spread.

Imaging (US, CXR, CT or MRI) beyond five years may be performed at the discretion of the clinician for moderate to high risk patients.

Routine FDG-PET scan is not indicated in the follow-up for renal cancer.

FOLLOW-UP IN ACTIVE SURVEILLANCE (TABLE 6)

Indications for active surveillance include elderly patients, those with decreased life expectancy or those with significant medical comorbidities that would be associated with increased risk if a therapeutic intervention were to be undertaken. Alternatively, a strategy of observation with delayed intervention as indicated may be elected in order to determine the growth rate or to obtain alternative diagnostic imaging.

It is assumed that the patient who has been chosen for active surveillance is one who would undergo intervention if, in the course of active surveillance, changes occur in the primary tumor for which intervention would normally be indicated. In the patient for whom no surgical or minimally invasive intervention (i.e., surgery or percutaneous ablative procedure) would ever be considered due to comorbidities, no imaging is necessary.

Follow-up protocols may vary depending on whether the patient has undergone a biopsy of the renal mass. The AUA guidelines considered clinical scenarios including biopsy-proven, untreated, clinically localized renal cancers; biopsies yielding low-malignant potential neoplasms or normal renal parenchyma; and renal lesions radiographically suspicious for neoplasm that either have not been biopsied or have indeterminate biopsy results.

Physicians should counsel patients on their other therapeutic options, as addressed in the AUA Treatment of T1 Renal Mass Guidelines [21]. Specifically, the patient should be counselled about the small but potential risk of cancer progression while on active surveillance, the potential loss of a window of opportunity for nephron-sparing surgery, the lack of curative salvage therapies if metastases develop and the deficiencies of the current data used to support this approach. Potential triggers for intervention while on active surveillance primarily involve absolute tumor size, tumor growth rate or a change in patient preference.

The precise growth rate or absolute tumor size that would trigger intervention is controversial given the limited available data. Some would propose that because the normal growth rate is approximately 0.3 cm/year, a persistent tumor growth rate of greater than 0.3-0.5 cm per year, and/or an absolute tumor size of greater than 3cm would justify intervention. The intervention would primarily involve local treatment, although a biopsy (in the case of biopsy-unproven renal masses) or a change to more frequent imaging could also be incorporated.

Table 6. Follow-up in active surveillance

Follow-up Measure	Active Surveillance
Physical Exam and History	History and physical examination directed at detecting signs and symptoms of metastatic or local progression
Laboratory Testing	Basic laboratory testing to include BUN/creatinine. UA and eGFR; CBC, LDH, LFTs. ALP and calcium level test may be used at the discretion of the physician; Progressive renal insufficiency should prompt a nephrology referral
CNS Scan	Acute neurological signs should undergo prompt cross sectional (CT or MRI) scan of the head or spine based on localized symptomatology
Bone Scan	Elevated ALP, clinical symptoms such as bone pain, and/or radiographic findings suggestive of a bony neoplasm should prompt a bone scan; A bone scan should not be performed in the absence of these symptoms
Percutaneous Biopsy	Percutaneous biopsy may be considered prior to active surveillance
Abdominal Scan/Imaging	Cross-sectional abdominal scanning (CT or MRI) within six months of active surveillance initiation to establish a growth rate with continued imaging (US, CT or MRI) at least annually thereafter
Chest X-ray	Patients with biopsy proven RCC or a tumour with oncocytic features on active surveillance should undergo an annual chest x-ray to assess for pulmonary metastases

Percutaneous biopsy may be considered in patients planning to undergo active surveillance.

The Panel of the AUA guidelines recommends that patients undergo cross-sectional abdominal scanning (CT or MRI) within six months of active surveillance initiation to establish a growth rate. They also recommend continued imaging (US, CT or MRI) at least annually thereafter. CT and MRI tend to be used more often for surveillance because they provides higher quality information over US, especially for neoplasms under 3cm; however, there may be benefits in reducing the risks of contrast and radiation exposure by employing alternative imaging. Alternative methods for limiting the amount of radiation and contrast exposure, include limiting CT use to once yearly unless otherwise clinically indicated, using a low dose radiation CT protocol for imaging, using MRI, and/or alternating the use of CT or MRI with US for surveillance. Importantly, with respect to tumor size measurements, differences of < 3.1 mm for inter-observer or < 2.3 mm for intra-observer evaluations are within the variability of measurement and should, therefore, not be attributed to tumor growth [20], unless in the case where there are persistent increases over two or more interval exams**.** Although it has been shown that the growth rate of a renal mass does not necessarily predict the presence of cancer and no robust method exists for distinguishing benign/indolent versus malignant/aggressive tumors based purely on radiologic features, more rapid rates and larger size trend towards association with true cancer and aggressive disease.

Patients on active surveillance with biopsy proven renal cell carcinoma or a tumor with oncocytic features should undergo an annual chest x-ray (CXR) to assess for pulmonary metastases.

FOLLOW-UP AFTER ABLATION THERAPY (TABLE 7)

Thermal ablative modalities, specifically cryoablation and radiofrequency ablation (RFA), currently represent accepted minimally invasive treatment options for clinical T1a renal masses in select patients with appropriate informed consent and counselling. Ablative techniques may be performed by a variety of approaches (open/laparoscopic/percutaneous) and operators (urologic surgeons/interventional radiologists). The majority of neoplasms selected for ablative procedures are less than 4 cm and exophytic, as markedly higher incomplete ablation rates have been noted for endophytic, central and larger neoplasms.

A urologist should be involved in the clinical management of all patients undergoing renal ablative procedures including percutaneous ablation. All patients undergoing ablation procedures for a renal mass should undergo a pretreatment diagnostic biopsy.

A standardized definition of treatment failure or local recurrence should be adopted by clinicians. This should be further clarified to include a visually enlarging neoplasm or new nodularity in the same area of treatment whether determined by enhancement of the neoplasm on post-treatment contrast imaging, or failure of regression in size of the treated lesion over time, new satellite or port site soft tissue nodules or biopsy proven recurrence.

Table 7. Follow-up after Ablation Therapy

Follow-up Measure	Renal Ablation
Physical Exam and History	History and physical examination directed at detecting signs and symptoms of metastatic spread or local recurrence
Laboratory Testing	Basic laboratory testing to include BUN/creatinine. UA and eGFR; CBC, LDH, LFTs. ALP and calcium level test may be used at the discretion of the physician; Progressive renal insufficiency should prompt a nephrology referral
CNS Scan	Acute neurological signs should undergo prompt cross sectional (CT or MRI) scan of the head or spine based on localized symptomatology
Bone Scan	Elevated ALP, clinical symptoms such as bone pain, and/or radiographic findings suggestive of a bony neoplasm should prompt a bone scan; A bone scan should not be performed in the absence of these symptoms
Percutaneous Biopsy	Patients should undergo a pre-treatment diagnosis biopsy
Abdominal Scan	Cross-sectional abdominal scanning (CT or MRI) with and without IV contrast unless otherwise contraindicated at three and six months following ablative therapy with continued scanning annually thereafter for five years; Scanning beyond five years is optional based on individual risk factors
Chest X-ray	Patients who have either biopsy proven low risk RCC, oncocytoma, a tumour with oncocytic features, non-diagnostic biopsies or no prior biopsy should undergo annual chest x-ray to assess for pulmonary metastases for five years; Imaging CXR or CT beyond five years is optional based on individual patient risk factors and the determination of treatment success; Radiologic scanning is not recommended with pathological confirmation of benign disease at or before treatment and post treatment radiographic confirmation of treatment success and no evidence or treatment-related complications.
Repeat Biopsy	New enhancement, a progressive increase in size of an ablated neoplasm with or without contrast enhancement, new nodularity in or around the treated zone, failure of the treated lesion to regress over time, satellite or port side lesions, should prompt a repeat lesion biopsy. Observation, repeat treatment and surgical intervention should be discussed.

Patients should undergo cross-sectional scanning (CT or MRI) with and without intravenous (IV) contrast unless otherwise contraindicated at three and six months following ablative therapy to assess treatment success. This should be followed by annual abdominal scans (CT or MRI) thereafter for five years.

Patients may undergo further scanning (CT or MRI) beyond five years based on individual patient risk factors.

Patients undergoing ablative procedures who have either biopsy proven low risk renal cell carcinoma, oncocytoma, a tumor with oncocytic features, non-diagnostic biopsies or no prior biopsy should undergo annual chest x-ray (CXR) to assess for pulmonary metastases for five years. Imaging beyond five years is optional based on individual patient risk factors and the determination of treatment success.

Patients who underwent an ablative procedure with pathological confirmation of benign histology at or before treatment and who have radiographic confirmation of treatment success and no evidence of treatment related complications don't need further imaging studies.

The alternatives of observation, repeat treatment and surgical intervention should be discussed, and repeat biopsy should be performed if there is radiographic evidence of treatment failure within six months if the patient is a treatment candidate. A progressive increase in size of an ablated neoplasm, with or without contrast enhancement, new nodularity in or around the treated zone, failure of the treated lesion to regress in size over time, satellite or port side lesions, should prompt lesion biopsy.

EVALUATION OF THE GUIDELINES AND FUTURE DIRECTIONS

In November 2014 an evaluation of the National Comprehensive Cancer Network and American Urological Association Renal Cell Carcinoma Surveillance Guidelines was presented at the American Society of Clinical Oncology 2014 Genitourinary Cancers Symposium, San Francisco, CA, January 31-February 1, 2014, and the 2014 Annual Meeting of the American Urological Association, Orlando, FL, May 16-21, 2014, and published in the Journal of Clinical Oncology [22]. 3,651 patients who underwent surgery for M0 RCC between 1970 and 2008 were stratified as AUA low risk (pT1Nx-0) after partial (LR-partial) or radical nephrectomy (LR-radical) or as moderate/high risk (M/HR; pT2-4Nx-0/pTanyN1). Guidelines were assessed by calculating the percentage of recurrences detected when following the 2013 and 2014 NCCN and AUA recommendations, and associated Medicare costs were compared. At a median follow-up of 9.0 years a total of 1,088 patients (29.8%) experienced a recurrence.

Surprisingly, nearly one third of recurrences were missed when following American Urological Association or National Comprehensive Cancer Network guidelines, with a need for significantly longer follow-up (up to 21 years) to capture 95% of these recurrences. In an editorial that accompanied that article, Angela B. Smith, MD, and Matthew I. Milowsky, MD, of the University Of North Carolina Lineberger Comprehensive Cancer Center, called the results striking, but added a few additional points to help put the results in perspective. [23]

First, they noted that the results were taken from a single center making it difficult to generalize more widely. Next, because the researchers found higher recurrence rates among

low-risk radical nephrectomy patients, physicians may lack an accurate system for characterizing low- and high-risk RCC.

Gaining a better understanding of tumor biology may improve risk stratification and translate to a surveillance regimen that more accurately captures meaningful recurrences (ie, those that require treatment, affect survival outcomes, or diminish quality of life). Without stronger data associating surveillance with survival and quality of life, justification for extending surveillance guidelines and incurring the additional cost cannot be recommended at this time.

There is a critical need for high quality, prospectively defined cohort studies to better define the prognosis of various renal masses and to establish prognosticators of important patient outcomes, such as overall survival, disease specific survival, cardiovascular and metabolic sequelae and quality of life. Given the potential burden of long-term follow-up of renal masses, randomized trials of different surveillance regimens should be conducted in order to better tailor follow-up to the patients' needs. There is a need for better prospectively designed studies to define the diagnostic accuracy of renal biopsies to define the underlying pathology, natural history and need for treatment, and also renal biopsies following ablative therapies to define the treatment response, natural history and need for further treatment. In light of the expanding use of ablative therapies for renal masses there is need for a uniform definition of treatment success and failure. There is a essential for better prospectively designed studies to examine the utility of tissue, plasma, or tumor markers or existing markers of systemic inflammation/immune response, in predicting survival, recurrence or metabolic sequelae. [11]

CONCLUSION

Follow-up after surgery, active surveillance and ablation treatment allows the urologist to monitor for postoperative complications, renal function, local recurrence, recurrence in the contralateral kidney and development of metastasis. No single follow-up plan is appropriate for all patients. There is no evidence that any particular follow-up protocol influences the outcome in early RCC. No standard recommendation can be given for the follow-up in advanced RCC either. The follow-up scheme for localised RCC following surgery should be dependent on the therapeutic possibilities upon recurrence. CT scans of thorax and abdomen are routinely performed, with time intervals dependent on risk factors. Long-term follow-up is proposed in some institutions, due to the possibility of late relapse, but its benefit has never been demonstrated. Most follow-up test after ablative therapy are similar to the test included during active surveillance. All the guidelines and recommendations should be modified for the individual patient using clinical judgment.

Current guidelines misses a significant proportion of RCC recurrences. Further research remains necessary to identify an optimal surveillance approach that balances patient benefit and health care costs.

REFERENCES

[1] Jemal A, Siegel R, Ward E, et al. Cancer statistics, 2006. *CA Cancer J. Clin.* 2006; 56:106-30.

[2] Rini BI, Campbell SC, Escudier B. Renal cell carcinoma. *Lancet* 2009;373:1119-1132.

[3] Bergstrom A, Hsieh CC, Lindblad P, et al. Obesity and renal cell cancer — a quantitative review. *Br. J. Cancer* 2001;85:984-90.

[4] Lindblad P. Epidemiology of renal cell carcinoma. *Scand. J. Surg.* 2004;93:88-96.

[5] Renal cell carcinoma: ESMO Clinical Practice Guidelines for diagnosis, treatment and follow-up. B. Escudier, C. Porta, M. Schmidinger, F. Algaba, J. J. Patard, V. Khoo, T. Eisen & A. Horwich on behalf of the ESMO Guidelines Working Group *Annals of Oncology* 25 (Supplement 3): iii49–iii56, 2014. doi:10.1093/annonc/mdu25.

[6] Leibovich BC, Blute M, Cheville JC et al. Prediction of progression after radical nephrectomy for patients with clear cell renal cell carcinoma: a stratification tool for prospective clinical trials. *Cancer* 2003; 97: 1663–1671.

[7] Patard JJ, Kim HL, Lam JS et al. Use of the University of California Los Angeles integrated staging system to predict survival in renal cell carcinoma: an international multicenter study. *J. Clin. Oncol.* 2004; 22: 3316–3322.

[8] Heng DY, Xie W, Regan MM et al. Prognostic factors for overall survival in patients with metastatic renal cell carcinoma treated with vascular endothelial growth factor-targeted agents: results from a large, multicenter study. *J. Clin. Oncol.* 2009; 27: 5794–5799.

[9] *NCCN guidelines*. http://www.nccn.org/professionals/physiccian_ gls/ pdf/kidney.pdf

[10] Eggener SE, Yossepowitch O, Pettus JA et al. Renal cell carcinoma recurrence after nephrectomy for localized disease: predicting survival from time of recurrence. *J. Clin. Oncol.* 2006;24:3101-3106.

[11] *Follow-up for clinically localized renal neoplasms: AUA Guideline*. American Urological Association Education and Research, Inc. April 2013.

[12] Brennan MF: Follow up is valuable and effective: true, true and unrelated? *Ann. Surg. Oncol.* 2000; 7: 2.

[13] Jacobs LA, Palmer SC, Schwartz LA et al: Adult cancer survivorship: evolution, research and planning care. *CA Cancer J. Clin.* 2009; 59: 391.

[14] Huang WC, Levey AS, Serio AM et al: Chronic kidney disease after nephrectomy in patients with renal cortical tumors: a retrospective cohort study. *Lancet Oncol.* 2006; 7: 735.

[15] Lane BR, Poggio ED, Herts BR et al: Renal function assessment in the era of chronic kidney disease: renewed emphasis on renal function centered patient care. *J. Urol.* 2009; 182: 435.

[16] Follow-up guidelines after radial or partial nephrectomy for localized and locally advanced renal cell carcinoma. *Can. Urol. Assoc. J.*, 2009;3(1):73.76.

[17] Follow-up after radical or partial nephrectomy or ablative therapies for RCC. EAU guidelines. *Renal Cell Carcinoma*. Update April 2014; 65-68.

[18] Doornweerd BH, de Jong IJ, Bergman LM, et al. Chest X-ray in the follow-up of renal cell carcinoma. *World J. Urol.* 2013 Oct 6. http://www.ncbi.nlm.nih.gov /pubmed/ 24096433.

[19] Coquia SF, Johnson PT, Ahmed S, et al. MDCT imaging following nephrectomy for renal cell carcinoma: Protocol optimization and patterns of tumor recurrence. *World J. Radiol.* 2013 Nov; 5(11):436-45.

[20] Patard JJ, Shvarts O, Lam JS, et al. Safety and efficacy of partial nephrectomy for all T1 tumors based on an international multicenter experience. *J Urol* 2004 Jun;171(6 Pt 1):2181-5; quiz 2435. http://www. ncbi.nlm.nih.gov/pubmed/15126781.

[21] Novick AC, Campbell SC, Belldegrun A et al: *Guideline for Management of the Clinical Stage 1 Renal Mass*. American Urological Association 2009.

[22] Suzanne B. Stewart, R. Houston Thompson, Sarah P. Psutka, John C. Cheville, Christine M. Lohse, Stephen A. Boorjian, and Bradley C. Leibovich Evaluation of the National Comprehensive Cancer Network and American Urological Association Renal Cell Carcinoma Surveillance Guidelines. *J. Clin. Oncol. 32*:4059-4065,2014

[23] Is Extending Surveillance Guidelines for Renal Cell Carcinoma Without Understanding PatientOutcomes Putting the Cart Before the Horse? *Journal of Clinical Oncology*, Vol 32, No 36 (December 20), 2014: pp 4031-4032.

In: Encyclopedia of Surgery (22 Volume Set)
Editors: Andreas Lehrer and Kristin Mueller
ISBN: 978-1-53618-329-0
© 2020 Nova Science Publishers, Inc.

Chapter 372

VIDEO-ASSISTED THORACIC SURGERY

Hirochika Matsubara[1], MD, PhD
and Diego Marquez-Medina[2], MD, PhD
[1]Thoracic Surgery Division, SurgeryDepartment, University of Yamanashi, Japan
[2]Medical Oncology Department, Arnau de Vilanova University Hospital of Lleida, Spain

ABSTRACT

The development of minimally invasive surgery has made a dramatic impact on all fields of surgery. Video-assisted thoracic surgery (VATS) lobectomy for early-stage non-small cell lung cancer was first described in the early 1990's and has become widely accepted for its safety and effectiveness. In addition, numerous reports have suggested favorable perioperative outcomes for this procedure, including lower morbidity, equivalent or reduced mortality, a shorter hospital stay, and an improved lung function. In carefully selected patients with early-stage lung cancer, VATS is a promising technique that reduces morbidity and promotes recovery without sacrificing the oncologic prognosis. Principle procedures, indications, short- and long-term benefit and complications of VATS lobectomy will be reviewed by comparison with conventional open lobectomy.

1. GENERAL DEFINITION OF THE PROCEDURE

The definition of video-assisted thoracic surgery (VATS) lobectomy for early-stage non-small cell lung cancer (NSCLC) is often confused with what is called Hybrid VATS, in which 'mini-thoracotomy lobectomy' is assisted by an endoscope. We prefer to standardize the definition of VATS lobectomy to encompass true anatomic lobectomy with individual ligation of the lobar vessels and bronchus as well as hilar lymph node dissection or sampling using only the video screen for guidance, with three or four ports and no retractor or rib spreading.

International standards differentiate thoracoscopic surgery and open surgery according to whether the operation is performed using a video-image system or direct visualization and not based on whether an endoscope is used for assistance.

Historically, the use of surgery with thoracoscopic procedures to treat lung diseases goes back to Sweden, 1910 when Jacobeus first reported ability to lyse tuberculous adhesions using a cystoscope. For many years, thoracoscopic procedures were chiefly used to perform biopsies and/or for diagnostic purposes, while open thoracotomy was the standard procedure to treat more extensive lesions. The first VATS lobectomy was reported by Lewis in 1992 [1]. However, the procedure was not widely accepted at that time due to a lack of evidence concerning both short- and long-term results. Lobectomy or anatomical segmentectomy is especially challenging and technically demanding, with a steep learning curve, which may discourage surgeons in smaller centers. Nevertheless, the VATS procedure has become increasingly accepted in the last two decades following advances in thoracoscopic equipment, particularly high-definition cameras and monitors. A recent meta-analysis also confirmed its validity, and VATS lobectomy is gradually becoming accepted as a standard procedure for early-stage lung cancer. Unfortunately, only 45% of lobectomies registered in the Society of Thoracic Surgeons database are performed thoracoscopically [2].

Currently, this percentage is increasing, and due to the benefits of the procedure, we feel that VATS surgery may be a valid treatment option in carefully selected patients.

The most recent guidelines on NSCLC from the National Comprehensive Cancer Network indicate that VATS lobectomy is a reasonable surgical approach for early-stage NSCLC [3]. A new section of the document states that, "in high-volume centers with significant VATS experience, VATS lobectomy in selected patients results in improved early outcomes (pain, hospital length of stay, return to function) without compromise of cancer outcomes". The guidelines of the American College of Chest Physicians (ACCP) also recommend minimally invasive approaches over thoracotomy for clinical stage I NSCLC at experienced centers [4]. Meanwhile, the European Society for Medical Oncology (ESMO) guidelines state that “either open thoracotomy or VATS access can thus be utilized as appropriate to the expertise of the surgeon”.

However, caution should be taken in that there is not enough evidence from randomized controlled trials to detect important differences between the two techniques [5]. Nonetheless, the number of studies favoring VATS resection has increased in the past decade, and most guidelines accept this technique as being a reasonable procedure for treating early-stage NSCLC (Table 1).

2. INDICATIONS AND CONTRAINDICATIONS

Although the VATS procedure is beneficial as a result of minimal invasiveness, some patients may not be candidates for VATS lobectomy. The indications for VATS lobectomy as well as rules for conversion to thoracotomy vary among surgeons, readily changing over time as the surgeon gains more experience with the procedure.

The stage and minimal physiological requirements for lobectomy must be determined carefully preoperatively. This usually requires lung function testing, positron emission computed tomography scanning and bronchoscopy.

Table 1. Guidelines for video-assisted thoracic surgery in early stage non-small cell lung cancer

Guideline	Year	VATS	Grade of recommendation
NCCN	2013	VATS is a reasonable and acceptable approach for patients with no anatomic or surgical contraindications, as long as there is no compromise of standard oncologic and dissection principles of thoracic surgery	2A: Based upon lower-level evidence, there is uniform NCCn consensus that the intervention is appropriate
ACCP	2013	For patients with clinical stage I NSCLC, a minimally invasive approach such as VATS is preferred over a thoracotomy for anatomic pulmonary resection and is suggested in experienced centers	2C
ESMO	2013	Either open thoracotomy or VATS access can be utilised as appropriate to the expertise of the surgeon	3C 3: prospective cohort studies. A: Strong evidence for efficacy with a substantial clinical benefit, strongly recommended

ACCP American College of Chest Physicians; ESMO European Society of Medical Oncology; NCCN National Comprehensive Cancer Network.

The best candidates for VATS lobectomy are patients with early-stage NSCLC. The indications do not differ too much from those for open lobectomy, as the procedure inevitably involves the risk of conversion to open surgery. Therefore, peripherally located T1-2 tumors (clinical stage I) should be first considered for VATS procedures.

Although the tumor size may vary, the lesions must be small enough to be removed without having to enlarge the 3-5 cm incision for instrumentation or cause trauma to the ribs. We consider tumors up to 3 cm in size to constitute the general criterion.

T3 (chest wall) or T4 tumors, active N2-3 disease, intolerance to single-lung ventilation and the inability to achieve complete resection with lobectomy are considered to be contraindications for VATS surgery [6]. Tumors found to be visible on bronchoscopy within 2 cm of the lobar orifice should be evaluated carefully considering possible sleeve resection. Relative contraindications include tumors centrally located near the hilum or major blood vessels, involving complicated or severely calcified areas of hilar lymphadenopathy, or history of a prior irradiation. Although much attention is required in patients with prior tuberculosis infection, or subjected to cardiothoracic surgery or chemoradiotherapy, they are not necessarily contraindicated for VATS surgery. Successful VATS procedures have been reported in patients with a prior history of surgery, T3 tumors involving the pericardium or mediastinal pleura, incomplete fissures, and non-calcified adenopathy [7-9]. The procedure should be attempted in borderline cases based on the surgeon's experience.

Age is usually not a limitation for VATS surgery. Rather, reports have been published favoring VATS lobectomy in elderly patients. For example, a retrospective, matched case-control study evaluating perioperative outcomes after open surgery versus VATS lobectomy for clinical stage I NSCLC in patients over 70 years of age showed that the VATS group had a significantly lower rate of complications (28% vs. 45%), shorter length of hospital stay (5 vs. 6 days) and overall reduced severity of complications [10]. This opens the door for the use of this technique in patients previously rejected for surgical therapy due to their overall

physical status. However, aggressive attempts to continue the VATS procedure after encountering complications may be hazardous, and resection without a negative margin is not acceptable; thus, the surgeon must always keep in mind the need to convert to open surgery without delay.

3. LIGHTS AND SHADOWS

A great benefit of VATS is that the operation can be visualized by assisting doctors or nurses with the same high-quality view experienced by the surgeon. Sharing visual information of the surgical site is advantageous for teamwork and allows for better communication. This set-up is also helpful for providing education to students and residents.

Furthermore, the use of high-definition monitors is also superior to direct vision, especially in cases of thoracic surgery, where the operation is performed deep within the thoracic cavity, where light sources may have difficulty reaching.

On the other hand, a major disadvantage of VATS surgery is that neither hands-on procedures nor palpation of the diseased lesions can be performed.

As for the patient, the benefits of minimal invasive surgery are primarily based on quality of life measurements. Such factors include the postsurgical pulmonary function, pain, length of stay, overall wellbeing, and discharge independence. Table 2 summarizes complication rates from several meta-analyses. Most authors agree that complication rates are lower or equivalent to those of open lobectomy and that this advantage results in a decreased length of hospital stay. Persistent air leakage is a troublesome complication for both the patient and surgeon. In most institutions, chest tubes are removed within a few days, and data suggest a tendency toward a shorter duration to removal and lower risk of prolonged air leaks [11, 12].

Table 2. Comparison of postoperative morbidity and mortality in prior meta-analyses

Author	Publication year	Literature search	Survival rate	Perioperative mortality	Perioperative morbidity	Local recurrence	Prolomged air leakage	Arrhythmia	Pneumonia
Yan [18]	2009	21 studies (2RCT, 19RC)	VATS higher	No difference	VATS lower	VATS lower	No difference	No difference	No difference
Cao [20]	2012	4studies	NR	No difference	VATS lower	NR	VATS lower	VATS lower	VATS lower
Cai [19]	2013	23 studies (2RCT, 21RC)	VATS higher	NR	VATS lower	VATS higher	No difference	No difference	No difference
Zhang [27]	2013	21 studies (2RCT,19RC)	VATS higher	NR	NR	VATS lower	NR	NR	NR
Taioli [28]	2013	20 studies (all RC)	VATS higher	NR	NR	NR	NR	NR	NR

NR not reported; RC retrospective cohort; RCT randomized controlled trial.

Although this complication is not necessarily life threatening, reducing the number of chest tube days shortens the hospital stay and decreases and costs and stress on the patient.

Postoperative pain, usually related to the use of rib spreading during open surgery is inevitable. Proper management of persistent and substantial pain has a significant effect on the patient's recovery. Several previous groups have shown that VATS lobectomy reduces postoperative pain compared to open surgery [11, 13-16] as Cheng et al. [14] reported in their meta-analysis and systemic review of controlled trials. VATS surgery promoted a significant decrease in the dose of pain medicine and duration of intake, as evidenced by lower scores on the Visual Analog Scale.

Significant improvements in the arm and shoulder function and postoperative forced vital capacity have also been reported [14, 17]. Li et al. [17] performed a prospective study of the shoulder function, as assessed by physiotherapists using the American Shoulder and Elbow Surgeons Standardized Shoulder Assessment Form, in 29 patients undergoing either VATS or open surgery. The results showed that shoulder strength was preserved in 92% of the VATS group, compared to 81% in the open surgery group, with a better range of motion.

A recent report evaluating the Society of Thoracic Surgeons (STS) Database showed that open surgery and decreased FEV1% and DLCO% values are independent predictors of pulmonary complications. Furthermore, VATS surgery results in fewer pulmonary complications in patients with a FEV below 60% of the predicted value compared to open surgery [2]. Pneumonia is a life-threatening complication after lung surgery. Several meta-analyses have demonstrated a reduced risk of pneumonia in patients treated with VATS surgery [18-20]. Whitson et al. [11] reported a significantly fewer cases of postoperative pneumonia in clinical stage I NSCLC treated with VATS lobectomy than with open surgery, and attributed the results to a decreased acute inflammatory response and reduced sputum production. Indeed, the levels of inflammatory markers are known to be lower or not persistently elevated after VATS surgery. It has also been demonstrated that the VATS procedure induces a lower stress response than conventional surgery.

Many groups have studied inflammatory markers and immune responses after VATS surgery. Notably, Yim et al. [21] reported significantly low levels of interleukin-6 and -8 in patients undergoing thoracoscopic surgery [21]. Moreover, a study by Craig et al. showed lower levels of C-reactive protein and interleukin-6 [22].

In terms of tumor immunosurveillance, the cytotoxic function of natural killer cells plays an important role in this process. In general, the greater the surgical stress, the greater the impact on cell-mediated immunity. In one study, Ng et al. [23] found higher circulating levels of insulin-like growth factor binding protein 3 (IGFBP-3) and lower levels of matrix metalloproteinase-9 (MMP-9) and tissue inhibitor of metalloproteinase-1 (TIMP-1: antagonist of MMP-9) in the VATS group. Studies of low levels of IGFBP-3, known to be a p53-regulated apoptotic factor, have linked this finding to the advancement of various cancers and development of colon cancer in particular. Surgical trauma has also been reported to be associated with increased levels of MMP-9, which can deactivate IGFBP-3.

Taken together, the immune status and autologous tumor killing ability is better preserved with thoracoscopic surgery. These immunological benefits may also aid the smooth delivery of postoperative chemotherapy when required. Furthermore, preserving the postoperative immune function may result in a lower rate of recurrence and better prognosis.

One must not forget that the primary objective of any surgery for cancer is to perform safe, as well as complete, resection.

The Cancer and Leukemia Group B 39802 trial was performed to assess whether the use of VATS in cases of early NSCLC using a standard definition for VATS lobectomy is

reasonable, although this was a prospective, multi-institutional study [8]. In that trial, the authors defined feasibility as "the ability to successfully perform lobectomy without significant morbidity or perioperative mortality." The consequent low rates of complications and favorable outcomes regarding the secondary survival endpoints at early follow-up demonstrated that VATS lobectomy is indeed feasible.

In addition, there are three prospective randomized trials comparing VATS lobectomy with the open approach [24-26]. The earliest study by Kirby confirmed that VATS lobectomy is not inferior to open surgery [25]. That is, the authors reported no significant differences in perioperative morbidity. More recent studies by Sugi or Palade have not only shown comparable morbidity, but also acceptable 5-year survival [24, 26].

Table 3 shows a summary of the four prospective randomized trials. There has been debate as to whether mediastinal lymphadenectomy is as effective in VATS surgery as in open surgery. A study by Palade focused on the number of lymph nodes that could be removed with each procedure and concluded that there were no significant differences regarding the overall number of lymph nodes or number of lymph nodes in each zone [26].

Oncologic effectiveness is an indispensable factor for assessing the feasibility of any treatment. Several meta-analyses comparing the efficacy of VATS lobectomy and open surgery for early-stage NSCLC have been reported [18, 19, 27, 28], and a number of comparative studies have found no significant differences in local or systemic recurrence rates [24, 29, 30]. There appears to be argument in terms of local regional recurrence rates, in which some studies have reported higher incidences [19] and others have shown either significant decreases [27] or no significant differences [18]. However, there is a consensus as to long-term mortality, as most studies provide data in favor of VATS lobectomy or show equivalent outcomes for stage I NSCLC [18, 19, 27, 28]. A meta-analysis by Taioli including 20 observational studies (2,106 VATS and 2,661 thoracotomy patients) showed an advantage in long-term mortality for patients undergoing VATS and a higher as 5-year OS when compared with subjects undergoing thoracotomy (62-97% vs. 58-97%) [28].

Table 3. Prospective randomized trials with VATS lobectomy

Author	Publication year	Purpose	Stage	N	Operative time	Number of dissected LNs	Perioperative complication	Hospital stay	Survival
Swanson [8]	2007	VATS feasibility	stage I	111	VATS feasible	VATS feasible	VATS feasible	NR	NR
Kirby [25]	1995	VATS vs. Open surgery	stage I	55	No difference	NR	No difference	No difference	NR
Sugi [24]	2000	VATS vs. Open surgery	stage I	100	NR	No difference	NR	NR	No difference
Palade [26]	2013	VATS vs. Open surgery	stage I	66	VATS longer	No difference	No difference	No difference	No difference

Furthermore, Yan reported a reduced systemic recurrence rate [18], and Cai showed similar distant recurrence rates [19]. Owing to its lower morbidity rates, VATS resection allows for more patients to receive proper doses of adjuvant chemotherapy, which maximizes curability, even in those patients treated with incomplete resection [31, 32].

This implies that VATS surgery could provide to elderly patients or fragile patients the chance of surgical curability and/or mass reduction, which may result in better results in association with adjuvant chemotherapy. In terms of medical economics, the cost of disposable instruments, such as endoscopic staplers, is often associated with increased expenses for minimally invasive surgeries. However, some authors have argued that the overall hospital charge for VATS surgery may be lower due to the shorter length of hospital stay and, although not always applicable, reduced number of days in the intensive care unit [33]. Swanson et al. [34] performed a retrospective multi-institutional database analysis of 3,961 patients (including 2,907 open resections and 1,054 VATS) undergoing lobectomy for cancer [34] and found that hospital costs were higher in the open surgery group than in the VATS group ($21,016 vs. $20,316).

More interestingly, adjusting for the surgeon's experience revealed the average cost for surgery performed by experienced surgeons to be significantly lower.

4. PROCEDURE

A preoperative evaluation of the lung tumor and workup of the patient's physical status must be conducted, similar to conventional resection. A major disadvantage of VATS surgery is that the surgeon cannot palpate the tumor. Therefore, performing imaging of the lesion preoperatively is crucial for successfully completing the procedure. Three-dimensional computed tomography can be applied to evaluate the tumor location and pulmonary vessel branching pattern, increasing the safety of VATS surgery [35].

A typical operating room set-up is shown in Figure 1. The anesthetic technique for VATS lobectomy is similar to that applied in other cases of pulmonary resection, and the use of a double lumen endotracheal tube or bronchial blocker is routine to obtain single lung ventilation. The patient is placed in the lateral decubitus position, which helps to spread the intercostal space and provides a good operative field. The number and placement of port incisions vary according to the preference and experience of the surgeon.

In general, the port positions are the same whether upper, lower or middle lobectomy is performed. The placement of the camera and working ports is crucial for successfully completing the procedure. In our facility, the location of the port differs between operations involving the right and left lung.

The position of the port during the operation for the right and left lungs is shown in Figure 2. The surgeon is positioned on the right side of the patient, while the scopist and the assistant are positioned on the left side of the patient.

Two video monitors are positioned cranially on both sides of the patient. All thoracoscopic surgeries are performed with a 10- or 5-mm 30-degree angled thoracoscope. Instrumentation is important when performing thoracoscopic pulmonary resection, and the selection of fine instruments with an appropriate reach is mandatory for retraction and dissection.

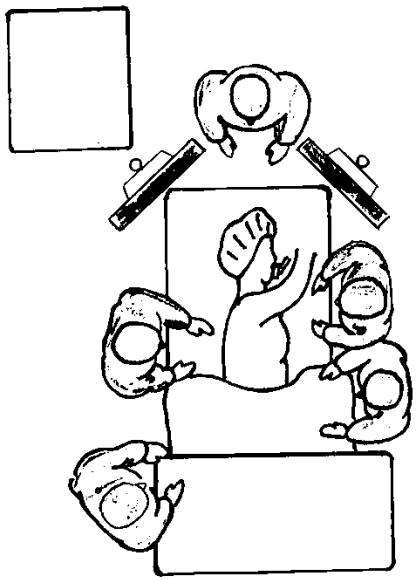

Figure 1. A typical operating room set-up.

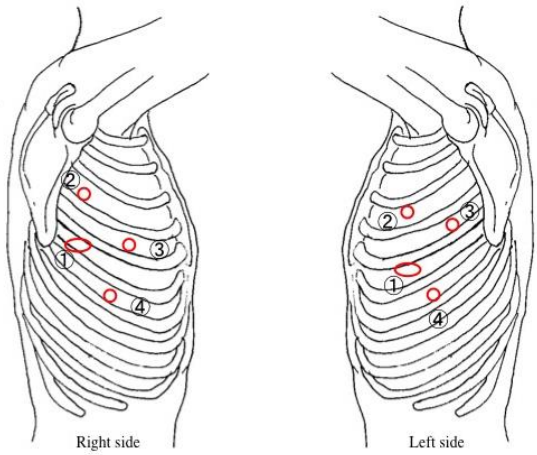

[1]3-5 cm incision with the wound protector for surgeon's hand instrument.
[2]10 mm working port for the surgeon's left instrument.
[3]10 mm camera port.
[4]15 mm port for the assistant's instrument.

Figure 2. Typical positioning of incisions for VATS surgery.

High-definition video equipment improves visualization in cases of difficult dissection. The pulmonary vessels and bronchi are dissected as in open thoracotomy. The vessels, bronchus and fissures are divided sequentially using appropriate endo-staplers. Sometimes, the vessel sealing system is applied for small vessels measuring 3-4 mm in diameter.

This is very useful for lymphadenectomy, where the system facilitates "en bloc" dissection. The resected lobe is placed in a protective plastic bag and removed through the incision at which the ribs are widest. Finally, a single chest tube is placed intercostally towards the apex through the assistant's instrument incision.

5. SAFETY AND COMPLICATIONS

The safety and efficacy of VATS lobectomy has been demonstrated in several reviews worldwide. However, in order to perform VATS surgery safely, the surgeon must always keep a watchful eye on the potential for complications and be ready for conversion to open surgery. In a series of 1,806 patients planned to undergo VATS lobectomy, Yang reported major complications in 129 patients (7.3%), with a mortality rate of 0.3%. The authors found that pulmonary complications, including prolonged air leaks, atelectasis and pleural effusion, contributed to more than 90% of the major complications and 80% of mortality. Furthermore, a multivariate logistic regression analysis showed that co-morbidity and a long operative time longer than 240 minutes were independent risk factors for major adverse events [36]. However, this is not to say that the complication rates are high compared to open surgery. A retrospective study by Whitson et al. 37 analyzed 147 patients with clinical stage I NSCLC, including 88 cases of thoracotomy and 59 cases of VATS surgery, reporting that no significant differences in terms of perioperative complications such as the operative time, amount of blood loss, incidence of atrial fibrillation, or number of ventilator days between both two groups. Meta-analyses comparing the two procedures have also provided data showing lower or at least equivalent morbidity, as mentioned earlier.

The rate of conversion to open surgery is reported to be 0-17% [18]. According to Hanna et al. [6], the causes of conversion to open thoracotomy can be classified into four categories: intraoperative complications, technical problems, anatomical problems, and the oncological condition. Some reported reasons for conversion include the tumor location, bleeding, dense lymphadenopathy, presence of calcified nodes adhering to the pulmonary arteries and bronchus, history of tuberculosis, intolerance to single-lung ventilation, an abnormal bronchial anatomy, the inability to identify pathological areas, difficulty in safely dissecting the interlobular pulmonary artery or the detection of incomplete fissures. Converted VATS procedures have been reported to result in an increased risk of postoperative atrial fibrillation, length of stay, duration of chest tube drainage, operative time and amount of intraoperative blood loss [38], and, although the VATS procedure is primarily indicated for most early-stage NSCLC lesions, cases involving calcification near the hilum should only be considered by surgeons with adequate experience. Haraguchi used receiver-operator characteristic curves to analyze risk factors for VATS and found that an operative time lasting for more than 297 minutes cancels out the advantages of VATS surgery [39]. This implies that the initial judgment as to the indication for VATS is vital and that any delays in the decision regarding conversion to open surgery may compromise patient outcomes.

CONCLUSION

The safety and efficacy of thoracoscopic lobectomy have been gradually recognized and are becoming widely accepted. Many studies have reported findings showing reduced chest wall trauma, an improved pulmonary function and lower levels of cytokine dysfunction.

Furthermore, patients who require chemotherapy after VATS surgery are more likely to succeed in completing the prescribed course of chemotherapy. From the standpoint of medical economics, these better outcomes are thought to contribute to significant hospital

savings. Unfortunately, randomized trials comparing the oncologic efficacy of VATS and open approaches remain insufficient, and the further accumulation of evidence supporting the advantages of VATS is expected to advance the rate of adoption of VATS procedures for early-stage NSCLC.

REFERENCES

[1] Lewis, R. J., Caccavale, R. J., Sisler, G. E., et al. Video-assisted thoracic surgical resection of malignant lung tumors. *J. Thorac. Cardiovasc. Surg*. 1992; 104:1679-85.

[2] Ceppa, D. P., Kosinski, A. S., Berry, M. F., et al. Thoracoscopic lobectomy has increasing benefit in patients with poor pulmonary function: a Society of Thoracic Surgeons Database analysis. *Ann. Surg*. 2012; 256: 487-93.

[3] NCCN Guidelines(R) Updates. *J. Natl. Compr. Canc. Netw*. 2013; 11: xxxii-xxxvi.

[4] Howington, J. A., Blum, M. G., Chang, A. C., et al. Treatment of stage I and II non-small cell lung cancer: Diagnosis and management of lung cancer, 3rd ed.: American College of Chest Physicians evidence-based clinical practice guidelines. *Chest*. 2013; 143: e278S-313S.

[5] Vansteenkiste, J., De Ruysscher, D., Eberhardt, W. E., et al. Early and locally advanced non-small-cell lung cancer (NSCLC): ESMO Clinical Practice Guidelines for diagnosis, treatment and follow-up. *Ann. Oncol*. 2013; 24: vi89-98.

[6] Hanna, J. M., Berry, M. F., D'Amico, T. A. Contraindications of video-assisted thoracoscopic surgical lobectomy and determinants of conversion to open. *J. Thorac. Dis*. 2013; 5: S182-189.

[7] Onaitis, M. W., Petersen, R. P., Balderson, S. S., et al. Thoracoscopic lobectomy is a safe and versatile procedure: experience with 500 consecutive patients. *Ann. Surg*. 2006; 244: 420-25.

[8] Swanson, S. J., Herndon, J. E., 2nd, D'Amico, T. A., et al. Video-assisted thoracic surgery lobectomy: report of CALGB 39802--a prospective, multi-institution feasibility study. *J. Clin. Oncol*. 2007; 25: 4993-7.

[9] Yim, A. P., Liu, H. P., Hazelrigg, S. R., Izzat, M. B., et al. Thoracoscopic operations on reoperated chests. *Ann. Thorac. Surg*. 1998; 65 (2): 328-30.

[10] Cattaneo, S. M., Park, B. J., Wilton, A. S., et al. Use of video-assisted thoracic surgery for lobectomy in the elderly results in fewer complications. *Ann. Thorac. Surg*. 2008; 85 (1): 231-5.

[11] Whitson, B. A., D'Cunha, J., Andrade, R. S., et al. Thoracoscopic versus thoracotomy approaches to lobectomy: differential impairment of cellular immunity. *Ann. Thorac. Surg*. 2008; 86: 1735-44.

[12] Villamizar, N. R., Darrabie, M. D., Burfeind, W. R., et al. Thoracoscopic lobectomy is associated with lower morbidity compared with thoracotomy. *J. Thorac. Cardiovasc. Surg*. 2009; 138: 419-25.

[13] Downey, R. J., Cheng, D., Kernstine, K., et al. Video-Assisted Thoracic Surgery for Lung Cancer Resection: A Consensus Statement of the International Society of Minimally Invasive Cardiothoracic Surgery (ISMICS) 2007. *Innovations* (Phila.). 2007; 2: 293-302.

[14] Cheng, D., Downey, R. J., Kernstine, K., et al. Video-assisted thoracic surgery in lung cancer resection: a meta-analysis and systematic review of controlled trials. *Innovations* (Phila.). 2007; 2: 261-92.

[15] Handy, J. R. Jr, Asaph, J. W., Douville, E. C., et al. Does video-assisted thoracoscopic lobectomy for lung cancer provide improved functional outcomes compared with open lobectomy? *Eur. J. Cardiothorac. Surg*. 2010; 37: 451-5.

[16] Paul, S., Altorki, N. K., Sheng, S., et al. Thoracoscopic lobectomy is associated with lower morbidity than open lobectomy: a propensity-matched analysis from the STS database. *J. Thorac. Cardiovasc. Surg*. 2010; 139: 366-78.

[17] Li, W. W., Lee, R. L., Lee, T. W., et al. The impact of thoracic surgical access on early shoulder function: video-assisted thoracic surgery versus posterolateral thoracotomy. *Eur. J. Cardiothorac. Surg*. 2003; 23: 390-6.

[18] Yan, T. D., Black, D., Bannon, P. G., et al. Systematic review and meta-analysis of randomized and nonrandomized trials on safety and efficacy of video-assisted thoracic surgery lobectomy for early-stage non-small-cell lung cancer. *J. Clin. Oncol*. 2009; 27: 2553-62.

[19] Cai, Y. X., Fu, X. N., Xu, Q. Z., et al. Thoracoscopic lobectomy versus open lobectomy in stage I non-small cell lung cancer: a meta-analysis. *PLoS One*. 2013; 8: e82366.

[20] Cao, C., Manganas, C., Ang, S. C., Yan, T. D. A meta-analysis of unmatched and matched patients comparing video-assisted thoracoscopic lobectomy and conventional open lobectomy. *Ann. Cardiothorac. Surg.* 2012; 1: 16-23.

[21] Yim, A. P., Wan, S., Lee, T. W., Arifi, A. A. VATS lobectomy reduces cytokine responses compared with conventional surgery. *Ann. Thorac. Surg*. 2000; 70: 243-7.

[22] Craig, S. R., Leaver, H. A., Yap, P. L., et al. Acute phase responses following minimal access and conventional thoracic surgery. *Eur. J. Cardiothorac. Surg*. 2001; 20: 455-63.

[23] Ng, C. S., Wan, S., Hui, C. W., et al. Video-assisted thoracic surgery lobectomy for lung cancer is associated with less immunochemokine disturbances than thoracotomy. *Eur. J. Cardiothorac. Surg*. 2007; 31: 83-7.

[24] Sugi, K., Kaneda, Y., Esato, K. Video-assisted thoracoscopic lobectomy achieves a satisfactory long-term prognosis in patients with clinical stage IA lung cancer. *World J. Surg*. 2000; 24: 27-30.

[25] Kirby, T. J., Mack, M. J., Landreneau, R. J., et al. Lobectomy--video-assisted thoracic surgery versus muscle-sparing thoracotomy. A randomized trial. *J. Thorac. Cardiovasc. Surg*. 1995; 109: 997-1001.

[26] Palade, E., Passlick, B., Osei-Agyemang, T., et al. Video-assisted vs open mediastinal lymphadenectomy for Stage I non-small-cell lung cancer: results of a prospective randomized trial. *Eur. J. Cardiothorac. Surg.* 2013; 44: 244-9.

[27] Zhang, Z., Zhang, Y., Feng, H., et al. Is video-assisted thoracic surgery lobectomy better than thoracotomy for early-stage non-small-cell lung cancer? A systematic review and meta-analysis. *Eur. J. Cardiothorac. Surg*. 2013; 44 (3): 407-14.

[28] Taioli, E., Lee, D. S., Lesser, M., et al. Long-term survival in video-assisted thoracoscopic lobectomy vs open lobectomy in lung-cancer patients: a meta-analysis. *Eur. J. Cardiothorac. Surg*. 2013; 44: 591-7.

[29] Koizumi, K., Haraguchi, S., Hirata, T., et al. Video-assisted lobectomy in elderly lung cancer patients. *Jpn. J. Thorac. Cardiovasc. Surg*. 2002; 50: 15-22.

[30] Sakuraba, M., Miyamoto, H., Oh, S., et al. Video-assisted thoracoscopic lobectomy vs. conventional lobectomy via open thoracotomy in patients with clinical stage IA non-small cell lung carcinoma. *Interact. Cardiovasc. Thorac. Surg*. 2007; 6: 614-7.

[31] Petersen, R. P., Pham, D., Burfeind, W. R., Hanish, S. I., Toloza, E. M., Harpole, D. H., Jr., D'Amico, T. A. Thoracoscopic lobectomy facilitates the delivery of chemotherapy after resection for lung cancer. *Ann. Thorac. Surg*. 2007; 83: 1245-9.

[32] Nicastri, D. G., Wisnivesky, J. P., Litle, V. R., Yun, J., Chin, C., Dembitzer, F. R., Swanson, S. J. Thoracoscopic lobectomy: report on safety, discharge independence, pain, and chemotherapy tolerance. *J. Thorac. Cardiovasc. Surg*. 2008; 135: 642-7.

[33] Nakajima, J., Takamoto, S., Kohno, T., et al. Costs of videothoracoscopic surgery versus open resection for patients with of lung carcinoma. *Cancer*. 2000; 89: 2497-501.

[34] Swanson, S. J., Meyers, B. F., Gunnarsson, C. L., et al. Video-assisted thoracoscopic lobectomy is less costly and morbid than open lobectomy: a retrospective multiinstitutional database analysis. *Ann. Thorac. Surg*. 2012; 93: 1027-32.

[35] Hagiwara, M., Shimada, Y., Kato, Y., et al. High-quality 3-dimensional image simulation for pulmonary lobectomy and segmentectomy: results of preoperative assessment of pulmonary vessels and short-term surgical outcomes in consecutive patients undergoing video-assisted thoracic surgery dagger. *Eur. J. Cardiothorac. Surg*. 2014; 46: e120-6.

[36] Yang, J., Xia, Y., Yang, Y., et al. Risk factors for major adverse events of video-assisted thoracic surgery lobectomy for lung cancer. *Int. J. Med*.

[37] Whitson, B. A., Andrade, R. S., Boettcher, A., et al. Video-assisted thoracoscopic surgery is more favorable than thoracotomy for resection of clinical stage I non-small cell lung cancer. *Ann. Thorac. Surg*. 2007; 83: 1965-70.

[38] Samson, P., Guitron, J., Reed, M. F., Hanseman, D. J., Starnes, S. L. Predictors of conversion to thoracotomy for video-assisted thoracoscopic lobectomy: a retrospective analysis and the influence of computed tomography-based calcification assessment. *J. Thorac. Cardiovasc. Surg*. 2013; 145: 1512-8.

[39] Haraguchi, S., Koizumi, K., Hatori, N., et al. Postoperative respiratory complications of video-assisted thoracic surgery for lung cancer. *J. Nippon Med. Sch*. 2004; 71: 30-4.

In: Encyclopedia of Surgery (22 Volume Set)
Editors: Andreas Lehrer and Kristin Mueller
ISBN: 978-1-53618-329-0
© 2020 Nova Science Publishers, Inc.

Chapter 373

SURGERY FOR EARLY NON-SMALL CELL LUNG CANCER

Masafumi Yamaguchi[1], MD, PhD
and Diego Marquez-Medina[2], MD, PhD
[1]Department of Thoracic Oncology,
National Kyusyu Cancer Center of Fukuoka City, Japan
[2]Medical Oncology Department, Arnau de Vilanova University Hospital of Lleida, Spain

ABSTRACT

At present, the standard treatment modality for early-stage non-small cell lung cancer (NSCLC) is lobectomy or any other form of resection of the affected pulmonary parenchyma and mediastinal lymph node removal. The recent progress in the diagnostic modalities including high-resolution computed tomography or fluorodeoxyglucose positron emission tomography have enabled oncologists to obtain a more accurate clinical diagnosis at the time of treatment. Simultaneously, a greater number of small-sized lung cancers are also being detected. The presence of ground-glass opacity nodules in the lung cancer has suggested a prognostic factor for post-operative survival, especially for tumors greater than 2 cm.

Subsequently, arguments for the surgical procedure of choice for such small-sized lung cancers, i.e. sublobar resection or lobectomy, have emerged. Based on the results of the phase III trial conducted in 1995, lobectomy and mediastinal lymph node dissection is the standard procedure for early-stage NSCLC. On the contrary, many articles support or oppose the benefits of sublobar resection over lobectomy on post-operative pulmonary function and equivalent post-operative survival. There has not been any conclusive evidence to resolve this issue, as there is no phase III trial directly comparing sublobar resection with lobar resection for early-stage NSCLC, except for the one carried out during the 1980's and reported in 1995.

Two ongoing randomized phase III trials by the Japanese Clinical Oncology Group and the West Japan Oncology Group (JCOG0802/WJOG4607L) and by Cancer and Leukemia Group B of the United States (CALGB 140503) will compare sublobar resection with lobectomy, which will hopefully provide the answers. Stage II NSCLC include a more heterogeneous group of tumors with aspects such as the more frequent hilar lymph node metastasis and a more aggressive nature of the primary tumor.

Therefore, lobectomy or another form of resection with removal of mediastinal lymph node is often appropriate for treating them. The large-size of primary tumor involvement or the central bronchus or hilar node metastasis sometimes requires pneumonectomy. Plasty of bronchus and/or pulmonary artery is selected to preserve the post-operative pulmonary function. Adjuvant chemotherapy is currently standard treatment of choice following resection.

1. HISTORY OF PULMONARY RESECTION

Surgical treatments for lung cancer have greatly improved and become widespread during the last five decades. The first ever successful pulmonary lobectomy was performed in 1912 by Davies [1] in a patient with pulmonary tumor, the patient survived for eight years after the operation. Subsequently, the first successful one-stage pneumonectomy for a lung cancer patient was reported by Graham in 1933 [2]. The first successful anatomical segmentectomy for a patient with bronchiectasis was performed by Churchill and Belsey in 1939 [3]. In 1960, Cahan [4] established lobectomy with mediastinal lymph node dissection as the standard surgical procedure for lung cancer treatment.

2. CLINICAL FEATURE OF EARLY-STAGE NON-SMALL CELL LUNG CANCER: THE SEVENTH TNM STAGING VERSION

Lung cancer is the leading cause of death among adults worldwide. The estimated numbers of new cases and deaths due to lung cancer in the United States in 2014 were 224,210 and 159,260 respectively. The five-year survival rate was 17% for patients in all stages and 54% for localized disease only [5].

The definition of stage I-II lung cancer in tumor, node, metastasis (TNM) 7th staging version is summarized in Table 1 [6]. Briefly, stage I cancer can be defined as lung cancer without lymph node involvement. They are sub-classified according to tumor size into stage IA (less than 3 cm) and stage IB (3-5 cm). Stage II includes T2 tumor involving the main bronchus $\geq$2 cm distal to the carina, invading the visceral pleura, or associated with atelectasis or obstructive pneumonitis that extends to the hilar region, but not involving the entire lung. Stage II cancer is also sub-classified into stage IIA and Stage IIB. Stage IIA cancer includes smaller than 5 cm tumors (T1-2a) with hilar lymph node involvement (N1) or tumor sized 5-7 cm (T2b) without lymph node metastases. Stage IIB includes T2b tumors with hilar lymph node metastases or tumor longer than 7 cm or directly invading any of the following: 1) chest wall (including superior sulcus tumors), diaphragm, phrenic nerve, mediastinal pleura, and parietal pericardium; 2) tumor in the main bronchus closer than 2 cm distal to the carina but not involving it; 3) associated atelectasis or obstructive pneumonitis of the entire lung, or; 4) separate tumor nodule(s) in the same lobe (T3).

Table 1. Features of Stage I-II lung cancer defined by Seventh tumor, node, metastasis classification of lung cancer

Stage	
IA	T1a-bN0
IB	T2aN0
IIA	T1a-T2aN1
	T2bN0
IIB	T2bN1
	T3N0 (any T3)
Definitions	
T: Tumor	
T1	Tumor < 3 cm in greatest dimension, surrounded by lung or visceral pleura, without bronchoscopic evidence of invasion more proximal than the lobar bronchus (i.e., not in the main bronchus)
T1a	Tumor < 2 cm in greatest dimension
T1b	Tumor > 2 cm but < 3 cm in greatest dimension
T2	Tumor > 3 cm but < 7 cm or tumor with any of the following features (T2 tumors with these features are classified T2a if < 5 cm):
	Involves main bronchus, > 2 cm distal to the carina
	Invades visceral pleura
	Associated with atelectasis or obstructive pneumonitis that extends to the hilar region but does not involve the entire lung
T2a	Tumor > 3 cm but < 5 cm in greatest dimension
T2b	Tumor > 5 cm but < 7 cm in greatest dimension
T3	Tumor > 7 cm or one that directly invades any of the following:
	Chest wall (including superior sulcus tumors), diaphragm, phrenic nerve, mediastinal pleura, parietal pericardium
	Tumor in the main bronchus < 2 cm distal to the carina but without involvement of the carina
	Associated atelectasis or obstructive pneumonitis of the entire lung
	Separate tumor nodule(s) in the same lobe
N: Nodes	
NX	Regional lymph nodes cannot be assessed
N0	No regional lymph node metastasis
N1	Metastasis in ipsilateral peribronchial and/or ipsilateral hilar lymph nodes and intrapulmonary nodes, including involvement by direct extension

3. CURRENT STANDARD TREATMENT FOR CLINICAL STAGE I-II NON-SMALL CELL LUNG CANCER

To date, the standard clinical guideline for patients with clinical stage cI-II NSCLC is surgery with curative intent and lobectomy or pneumonectomy with mediastinal lymph node dissection is the recommendation (Table 2) [7-10]. The guidelines also recommend a limited lung resection only for cI-II NSCLC patients with poor pulmonary function.

This surgical strategy is based on the results of phase III trial reported by the Lung Cancer Study Group (LCSG) [11] in 1995. The primary endpoint was 5-year overall survival (OS), and the secondary endpoints were disease-free survival (DFS), post-operative pulmonary function, and patterns of recurrence. Out of the 771 patients included in the trial, 495 were found to be ineligible. Of the 276 patients found eligible, 122 patients were

randomized to limited resection group (82 patients underwent segmentectomy and 40 patients underwent partial resection), and 125 patients were allocated to the lobectomy group. Limited resection was associated with 30% increase in the overall death rate and 75% increase in recurrence rate.

Table 2. Guideline recommendations for treating early-stage lung cancer

Guideline Year		cStage	Surgery	Adjuvant CTx	
				pStage	Recommendation
NCCN7	2013	I-II	-anatomical resection (2A)	IA	-Observation (2A)
			-Segmentectomy or wedge	IB	-Observation, or CTx
			resection is appropriate in		for high risk cases (2A)
			selected patients	II	-CTx (P-based) (2A)
				IIIA	-CRT (2A)
ACCP8	2013	I-II	-Lobectomy (1B)	IA-B	-No CTx (1B)
			-LN dissection (1B)	IIA-B	-CTx (P-based) (1A)
			-Sleeve over Pneu (2C)		
ESMO9	2013	I-III	-Lobectomy (I, A)	IA	-Observation (II, B)
			-LN dissection (III, A)	II-III	-CTx (P-based) (1A)
Thorax10	2010	NS	-Sublobar resection for	IB	-CTx (B)
			limited function (B)	II-IIIA	-CTx (A)
			-Systemic dissection (A)		

CTx: chemotherapy, P-based: platinum based, CRT: chemoradiotherapy, Pneu: pneumonectomy, NS: not stated, Categories of evidence and consensus of each guidelines in parenthesis.

4. Recurrence Pattern of Resected Early-Stage Non-Small Cell Lung Cancer

Even completely resected pathological stage pI NSCLC present a 15-40% distant and 5-32% local relapse rate [12, 13]. The Lung Adjuvant Cisplatin Evaluation (LACE) meta-analysis reviewed the outcome of curatively resected pII-III NSCLC receiving adjuvant cisplatin plus vinorelbine in major phase III clinical trials (Adjuvant Navelbine International Trialist Association [14], BIG Lung Trial [15], International Adjuvant Lung Cancer Trial [16], and National Cancer Institute of Canada Clinical Trials Group JBR.10 [17]). Adjuvant chemotherapy achieved 8.9% benefit on 5-year OS compared to observation alone, and was established as standard treatment for curatively resected pII-III NSCLC patients [18].

4.1. Survival Outcome of Early Non-Small Cell Lung Cancer

In 2007, the International Staging Committee and Participating Institutions and International Association for the Study of Lung Cancer (IASLC) reported the post-operative outcome of 67,725 NSCLC treated between 1990 and 2000. Stratified by clinical stage, the 5-year OS was 50% for cIA, 43% for cIB, 36% for cIIA, and 25% for cIIB. Stratified by

pathologic stage, post-operative 5-year OS was 73% for pIA, 58% for pIB, 46% for pIIA, and 36% for pIIB [6] (Table 3).

Table 3. Improvement of post-operative 5-year survival of Stage I-II NSCLC by era

	IASLC[5]	JJCLCR[11]		
Patients accrued	1999-2000	1994	1999	2004
TNM staging system	(ver. 7)	(ver. 6)	(ver.6)	(ver.7)
Clinical stage				
IA	50%	72%	77%	82%
IB	43%	50%	60%	66%
IIA	36%	48%	54%	55%
IIB	25%	40%	44%	46%
Pathological Stage				
IA	73%	79%	83%	87%
IB	58%	60%	66%	74%
IIA	46%	59%	60%	62%
IIB	31%	42%	47%	60%

IASLC: International Association for the Study of Lung Cancer, JJCLCR: the Japanese Joint Committee of Lung Cancer Registry.

The remarkable progression and spread of current diagnostic tools such as high resolution computed tomography (CT-scan), positron emission tomography (PET/CT-scan) or magnetic resonance imaging (MRI) for lung cancer diagnosis provided an accurate baseline staging of NSCLC.

Recently data reported by the Japanese Joint Committee of Lung Cancer (JJCLCR) analyzed 11,663 resected NSCLC patients [19] (Table 3). The 5-year post-operative OS improved over time from 1994 to 2004, being 82% for cStage IA, 66% for cIB, 55% for cIIA, and 46% for cIIB tumors. The 5-year OS stratified by pathological stage was 87% for pIA, 74% for pIB, 62% for pIIA, and 60% for pIIB tumors.

4.2. Prognostic Risk Factors in Completely Resected Early-Stage Non-Small Cell Lung Cancer

Several prognostic factors have been retrospectively examined for completely resected early-stage NSCLC. Pre-operative adverse prognostic included poor performance status [20], presence of clinical symptoms [20], older age [13], pre-operative smoking history [21, 22], high serum carcinoembryonic antigen level [23], higher standardized uptake value (SUV) on PET/CT-Scan [24], tumor size [6, 23] or consolidation or tumor ratio on high resolution CT-scan [25, 26].

Surgical prognostic factors include the eventual adverse impact of positive pleural lavage fluid cytology for the lung cancer cells at the time of thoracotomy [27, 28]. No prospective clinical trial exploring this issue has been reported. However, a meta-analysis by the International Pleural Lavage Cytology Collaborators (IPLCC) including 8,763 NSCLC patients from 11 centers reported that the positive pleural lavage fluid cytology was an independent predictor of poor survival (HR 1.46; $p< 0.001$) for lung cancer patients [29]. The

role of the systemic mediastinal lymph node dissection is under discussion. In general, systemic mediastinal lymph node dissection was considered to be a favorable prognostic factor [30]. However, a recent prospective phase III clinical trial comparing the systemic mediastinal lymph node dissection with sampling alone did not revealed any differences on OS [31]. The survival benefits of lobar resection or sublobar resection including segmentectomy, especially for small-sized peripheral lung cancer, will be described below.

Pathological prognostic adverse factors included poor or moderate histological differentiation [23] or solid-predominant adenocarcinoma as per the current classification system of the International Association for the Study of Lung Cancer, American Thoracic Society (ATS) or European Respiratory Society (ERS) [32].

The so-called type A and B , less than 2 cm adenocarcinoma *in situ* in Noguchi's classification have a 5-year OS of 100% [33]. Lymphovascular invasion in the pathological specimen is not reflected in the current TNM staging. However, it has been extensively reported as a poor prognostic factor [13, 23, 34-36]. A recent meta-analysis of 20 published reports reported that lymphovascular invasion in cI NSCLC was significantly associated with a worse DFS (HR 3.63) and OS (HR 2.38) [37].

5. INTENTIONAL LIMITED RESECTION FOR EARLY-STAGE NON-SMALL CELL LUNG CANCER

As mentioned above, lobectomy has been the standard surgical procedure for the treatment of early-stage lung cancer since Lung Cancer Study Group phase III trial was published. This trial is the only randomized clinical trial directly comparing limited resection with lobectomy. Sublobar resection including segmentectomy or non-anatomical wedge resection was considered appropriate procedures for patients with insufficient pulmonary reserve for lobectomy or with any other major comorbidity. With the current developments and use of high resolution CT-scans for diagnosis, there has been an increase in the detection of small-sized NSCLC. Nevertheless, many currently detected nodules with or without ground-glass opacity (GGO) should not be detected on the plain chest roentgenography or in the Lung Cancer Study Group trial. The re-evaluation of the role of sublobar resection over lobectomy is becoming necessary. In the last two decades, numerous works have compared sublobar resection and lobectomy for early-stage NSCLC, mainly with regard to the post-operative prognosis or pulmonary function.

Segmentectomy is expected to preserve post-operative pulmonary function with lesser incidence of post-operative complications than lobectomy. Moreover, the post-operative local recurrence and survival rates have to be evaluated. Non-anatomical wedge resections are not able to evaluate hilar lymph node involvement. In segmentectomy, intraoperative frozen section is mandatory to evaluate presence of hilar lymph node metastases that warrant to convert segmentectomy to lobectomy.

Table 4 summarizes some reported articles assessing the similar prognosis and disease recurrence rate of sublobar resection when compared to lobectomy in cI NSCLC [38-42], especially in the local site. However, Okada et al. [38] compared 305 segmentectomy with 262 lobectomy cases in smaller than 2 cm peripheral cT1aN0M0 NSCLC in a non-randomized multicenter study. The 5-year local recurrence rate trended to benefit the

segmentectomy arm (4.9% vs. 6.9%), but OS was similar in both groups (89.6% vs. 89.1%). Carr et al. [39] retrospectively analyzed 178 segmentectomy and 251 lobectomy cases for cIA NSCLC. The cancer-specific 5-year OS was similar in the two arms for T1a (90% vs. 91%) and T1b tumors (82% vs. 78%). Moreover, no statistical difference was observed in the recurrence rate and operative mortality. Altorki et al. [40] compared 53 sublobar resection cases (16 segmentectomy and 37 non-anatomical wedge resection cases) with 294 lobectomy cases for mainly smaller than 2 cm cIA NSCLC. The 10-year OS was similar in both two groups (86% vs. 85%).

Table 4. Results of retrospective analysis of limited vs. lobar resection for clinical Stage I non-small cell lung cancer

Author	Year	T	Procedure	No	Rec (local/dis) (%)	5-y OS (%)
Okada M[38]	2005	T1a	Sublobar	305	4.9 / 9.2 ^{NS}	89.6 ^{NS}
			Lobectomy	262	6.9 / 10.3	89.1
El-Shelif A[42]	2006	T1	Sublobar	207	29 (NS) NS	40 (p<0.0038)
			Lobectomy	577	28 (NS)	54
Carr SR[39]	2012	T1	Seg	178	5.6 / 10.0^{NS}	90 (T1a) ^{NS}
			Lobectomy	251	6.0 / 13.9	91 (T1a)
Altorki NK40	2014	T1	Sublobar	53	NA	86 (10-y) ^{NS}
			Lobectomy	294	NA	85 (10-y)
Landreneau RJ[41]	2014	T1-2a	Seg	392	5.5 / 14.8 ^{NS}	54 ^{NS}
			Lobectomy	800	5.1 /11.6	60

Rec: recurrence, dis: distant, OS: overall survival, NS: not significant, NA: not available.

Landreneau et al. [41] also reported no significant differences in the 5-year local recurrence rate (5.5% vs. 5.1%) or OS (54% vs. 60%), even including 22% of cIB NSCLC. On the contrary, El-Sherif et al. [42] analyzed 207 sublobar (85 segmentectomy cases and 122 non-anatomical wedge resection cases) and 577 lobectomy cases for cI NSCLC including 50% of cIB patients. There was no statistical difference in DFS (HR 1.51; p= 0.0023). However, the 5-year OS was worse in segmentectomy group (40% vs. 54%; p< 0.0038). Similarly, the Surveillance Epidemiology and End Results (SEER) [43] compared the sublobar resection with lobectomy in 13,892 NSCLC. The 581 patients undergoing segmentectomy for stage IA adenocarcinoma or squamous cell carcinoma had a worse 5-year OS than those undergoing lobectomy (HR 0.73). From the same database, Yendamuri et al. [44] analyzed 2,161 patients who underwent sublobar resection and 6,636 patients who underwent lobectomy or other forms of resection, grouping the patients into three groups according to the era: 1) early, from 1987 to 1997); 2) intermediate, from 1998 to 2004), and; 3) late, from 2005 to 2008. Despite the worse prognosis in patients undergoing sublobar resection in the early period (HR 1.41), no significant difference on survival between sublobar resection and lobectomy was reported in the intermediate or late period (HR 1.04 and HR 0.83, respectively).

Despite on data supporting sublobar resection for cI NSCLC, conclusions have yet to be drawn. Causes to explain the dearth of non-randomized studies analyzing this issue included the heterogeneity of cohort groups even in the cI NSCLC (tumor size, histological subtype,

presence of adenocarcinoma *in situ*, minimally invasive adenocarcinoma [32], or GGO), and the detection of really early lesions with high resolution CT-scan or PET/CT-scan.

6. MANAGEMENT OF PULMONARY NODULES WITH GROUND-GLASS OPACITY LESIONS

With the progress and spread of CT-scan screening for lung cancer detection and the development of high resolution CT-scans, small-sized lung cancers, especially adenocarcinoma presenting GGO, are becoming more common to diagnose [45, 46]. Radiologically, GGO is defined as lesions showing hazy increased attenuation that does not obliterate the underlying bronchial or vascular structures on high resolution CT-scan [47].

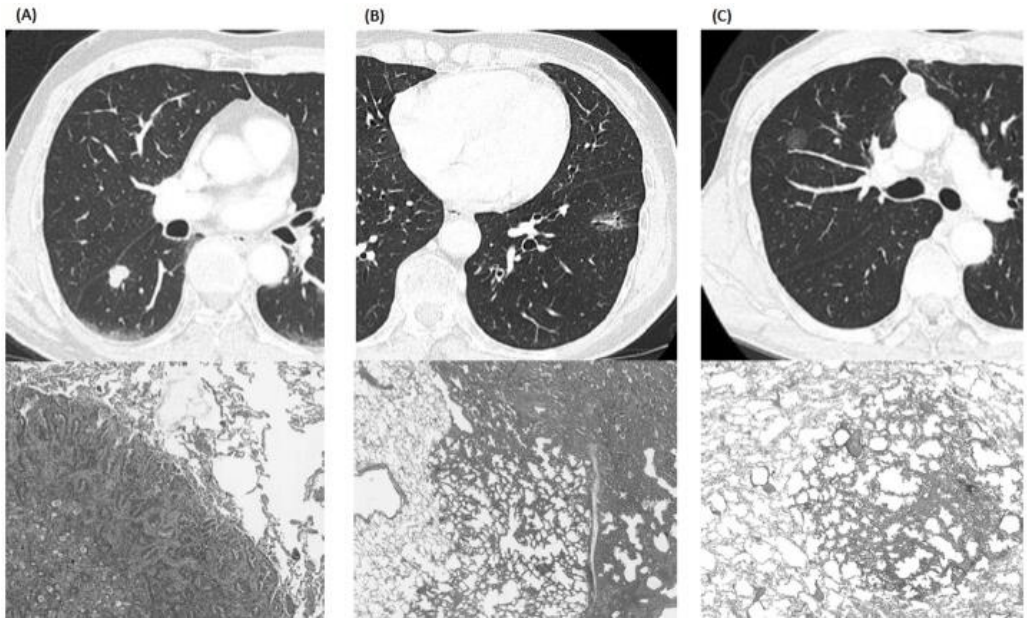

Figure 1. Features of small-sized lung nodules of ground-glass opacity. (a) small-sized lung adenocarcinoma with consolidation in high resolution CT-scan. (b) mixed ground-glass opacity (c) pure ground-glass opacity.

Figure 1 shows the typical features of small-sized lung nodules of GGO with or without any consolidation detected on high resolution CT-scan and pathological specimens. Figure 1(a) shows a small-sized lung adenocarcinoma with consolidation, so-called solid nodules viewed in high resolution CT-scan. These nodules are generally defined as pathologically invasive lung cancer with a higher possibility to be detected by the plain chest roentgenogram. On the contrary, the small-sized lung nodules with solid part surrounded by GGO (mixed-GGO) or pure GGO are presented in Figures 1(b) and (c) respectively, and are often detected only by high resolution CT-scans.

6.1. Management of Focal Pure Ground-Glass Opacity Lesions

The incidence of focal pure GGO nodules has been reported to range from 6 to 12% of all CT-scan detected pulmonary nodules in the screening setting [45, 46]. Many clinicians face difficulty in treating patients with asymptomatic pulmonary nodules. The reasons for this are as follows: 1) The clinical course of focal pure GGO nodules is generally thought to be indolent [48] 2) obtaining a radiological diagnosis of these lesions is quite difficult; PET/CT-scan fails to distinguish focal pure GGO nodules from malignant tumors [49, 50], 3) the small size of focal pure GGO makes it difficult for fiberoptic bronchoscopy- or CT-scan-guided biopsies, and surgical resection alone provides the eventual diagnosis [51], and 4) the radiological-pathological concordance of focal pure GGO nodules is non-specific [52, 53].

No such definitive strategy for the management of focal pure GGO nodules exists. One possible recommendation would be the careful observation by high resolution CT-scan. The indications for surgical resection should include a tumor size greater than 10 mm and/or the development of a solid pattern in the tumor while on the follow-up [52]. Nevertheless, the adequate surgical procedure has not been clearly defined too.

6.2. Stage I Non-Small Cell Lung Cancers Presenting Part-Solid or Solid Lesions on High Resolution CT-Scan

The ratio of GGO in small-sized CT-scan detected lung cancer has been reported to predict the histological invasiveness of lung adenocarcinomas [54, 55], even in small-sized lung cancer. Figure 2 shows a mixed GGO on high resolution CT-scan. Figure 2(a) indicates the maximal diameter of the tumor, and (b) Indicates maximal diameter of the consolidation portions, thus (b)/(a) = consolidation/tumor ratio (C/T). For small-sized lung cancer, especially adenocarcinoma, C/T $\leq$ 0.5 is a predictor of pathologically non-invasive adenocarcinoma. A prospective analysis by the Japanese Clinical Oncology Group, the JCOG 0201 trial, analyzed the concordance between radiological findings in high resolution CT-scan and pathological non-invasiveness in 545 peripheral cIA NSCLC undergoing lobectomy along with lymph node dissection. Specificity and sensitivity were recorded to be 96.4% and 30.4%, respectively. Concordance was found to be within the specificity of 98.7% for the smaller than 2 cm tumors and C/T <0.25. Thus, the non-invasive adenocarcinoma could be defined radiographically in this cohort of patients [56]. Consecutively, prognosis was evaluated in the same cohort of 545 patients from the JCOG 0201 trial revealing an significantly higher 5-year OS in cT1a-b cIA adenocarcinomas with consolidation/tumor ratio $\leq$0.5 than in those with the C/T >0.5 (96.7% vs. 88.9%; p< 0.001). Patients with smaller than 2 cm tumors did not present any statistical difference in the 5-year OS stratified with the cut-off value $\leq$0.25 (97.1% vs. 92.4%; p= 0.259). Patients with C/T <0.25 and smaller than 2 cm tumors and C/T $\leq$0.5 and smaller than 3 cm tumors were considered as a homogeneous cohort with a similar 5-year OS of 97% [25].

Two ongoing prospective randomized phase III trials will assess the role of sublobar resection versus lobectomy for peripheral cIA NSCLC in Japan and the United States (Table 5). One is being conducted as an intergroup study by the Japanese Clinical Oncology Group and West Japan Oncology Group (WJOG) (JCOG0802/WJOG4607L), and the other one is being conducted by the Cancer and Leukemia Group B (CALGB 140503). The Japanese trial

plan to accrue 1,100 patients with smaller than 2 cm tumors and C/T ≥0.5. OS is considered to be the primary endpoint. CALGB 140503 plan to accrue 908 patients with smaller than 2 cm tumors. These trials could shift the paradigm for the treatment strategy in cT1a IA NSCLC.

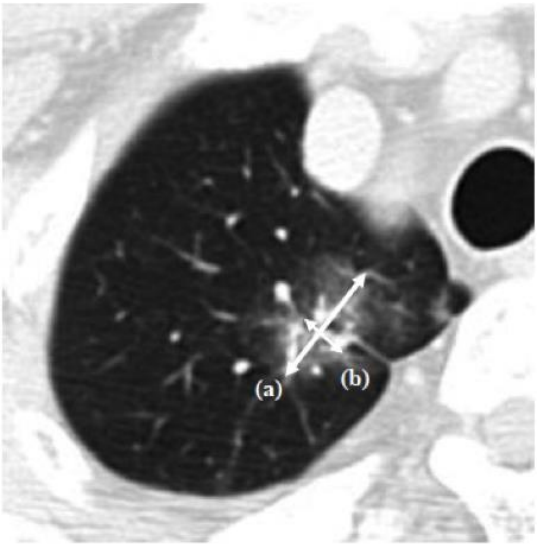

Figure 2. Mixed ground-glass opacity on high resolution CT-scan. (a) maximal diameter of the tumor. (b) maximal diameter of the consolidation portions, thus (b)/(a) = consolidation/tumor ratio.

Table 5. Ongoing prospective randomized phase III trials comparing sublobar resection vs. lobectomy

	JCOG0802/WJOG4607L	CALGB 140503
Target accrual	1,100	908
Design	Phase III, non-inferiority	Phase III, non-inferiority
Surgical procedure		
Control arm	Lobectomy	Lobectomy
Study arm	Segmentectomy	Segmentectomy or Wedge
Eligibility criteria		
T factor	peripheral, <2 cm	peripheral, <2 cm
	Part-solid (C/T ratio > 50%)	
	Single lesion	
N factor	N0	N0
Primary endpoint	OS	DFS
Secondary endpoints	Pulmonary function at 6m and 1y, DFS, LRR, AE completion rate of segmentectomy others	OS, LRR, SRR
		Pulmonary function at 6m others
Follow-up	Chest CT every 6m for 2y,	Chest CT 6m and 1y,
	then yearly until 5y	then yearly until 5y

Wedge: wedge resection, C/G: consolidation/ground-glass opacity ratio, OS: overall survival, DFS: disease free survival, LRR: local recurrence rate, SRR: systemic recurrence rate, AE: adverse event.

7. SURGERY FOR CT2-3N1M0 STAGE II NON-SMALL CELL LUNG CANCER

Surgical options for cII NSCLC are more limited due to common the hilar lymph node involvement and oncological aggressiveness. There is relative consensus for lobectomy or other resection procedures with mediastinal lymph node removal as a curative-intent resection. The extent of surgical resection is not defined. The extra-nodal invasion of the hilar lymph node to the proximal or main stem of the bronchus or segmental pulmonary artery or larger tumor > 7cm that crosses the fissure between the upper and lower lobes often requires pneumonectomy for complete resection. In selected cases, pneumonectomy with resection of carina is indicated for cT3N0 tumors invading the main bronchus within <2 cm from the carina and no lymph node invasion. The sleeve bronchial and/or pulmonary artery resection is often considered for normal pulmonary parenchyma preservation if the tumor or hilar metastatic lymph nodes invades the adjacent main bronchi or central branch of pulmonary artery. The benefit of sleeve resection over pneumonectomy is unclear. However, several articles reported equivalent post-operative survival of sleeve resection as compared to pnemunectomy [57-59] with a similar incidence morbidity or mortality [60] and better post-operative quality of life [61].

REFERENCES

[1] Naef AP. Hugh Morriston Davies: first dissection lobectomy in 1912. *Ann. Thorac. Surg.* 1993; 56: 988-9.

[2] Horn L, Johnson DH. Evarts A. Graham and the first pneumonectomy for lung cancer. *J. Clin. Oncol*. 2008; 26: 3268-75.

[3] Churchill ED, Belsey R. Segmental Pneumonectomy in Bronchiectasis: The Lingula Segment of the Left Upper Lobe. *Ann Surg*. 1939; 109: 481-99.

[4] Cahan WG. Radical lobectomy. *J. Thorac. Cardiovasc. Surg*. 1960; 39: 555-72.

[5] Siegel R, Ma J, Zou Z, Jemal A. Cancer statistics, 2014. *CA Cancer J. Clin*. 2014; 64: 9-29.

[6] Goldstraw P, Crowley J, Chansky K, et al. The IASLC Lung Cancer Staging Project: proposals for the revision of the TNM stage groupings in the forthcoming (seventh) edition of the TNM Classification of malignant tumours. *J. Thorac. Oncol*. 2007; 2: 706-14.

[7] National Comprehensive Cancer Network. Clinical Practice Guidelines in Oncology (NCCN Guidelines) *Non-Small Cell Lung Cancer version* 2.2013. In: www.nccn.com.

[8] Howington JA, Blum MG, Chang AC, et al. Treatment of stage I and II non-small cell lung cancer: Diagnosis and management of lung cancer, 3rd ed: American College of Chest Physicians evidence-based clinical practice guidelines. *Chest*. 2013; 143: e278S-313S.

[9] Vansteenkiste J, De Ruysscher D, Eberhardt WE, et al. Early and locally advanced non-small-cell lung cancer (NSCLC): ESMO Clinical Practice Guidelines for diagnosis, treatment and follow-up. *Ann. Oncol*. 2013; 24: vi89-98.

[10] Lim E, Baldwin D, Beckles M, et al. Guidelines on the radical management of patients with lung cancer. *Thorax*. 2010; 65: iii1-27.
[11] Ginsberg RJ, Rubinstein LV. Randomized trial of lobectomy versus limited resection for T1 N0 non-small cell lung cancer. Lung Cancer Study Group. *Ann. Thorac. Surg*. 1995; 60: 615-22.
[12] Kato H, Tsuboi M, Kato Y, et al. Postoperative adjuvant therapy for completely resected early-stage non-small cell lung cancer. *Int. J. Clin. Oncol.* 2005; 10: 157-64.
[13] Kiankhooy A, Taylor MD, LaPar DJ, et al. Predictors of early recurrence for node-negative t1 to t2b non-small cell lung cancer. *Ann. Thorac. Surg.* 2014; 98: 1175-83.
[14] Douillard JY, Rosell R, De Lena M, et al. Adjuvant vinorelbine plus cisplatin versus observation in patients with completely resected stage IB-IIIA non-small-cell lung cancer (Adjuvant Navelbine International Trialist Association [ANITA]): a randomised controlled trial. *Lancet Oncol.* 2006; 7: 719-27.
[15] Waller D, Peake MD, Stephens RJ, et al. Chemotherapy for patients with non-small cell lung cancer: the surgical setting of the Big Lung Trial. *Eur. J. Cardiothorac. Surg*. 2004; 26: 173-82.
[16] Arriagada R, Bergman B, Dunant A, et al. Cisplatin-based adjuvant chemotherapy in patients with completely resected non-small-cell lung cancer. *N. Engl. J. Med*. 2004; 350: 351-60.
[17] Winton T, Livingston R, Johnson D, et al. Vinorelbine plus cisplatin vs. observation in resected non-small-cell lung cancer. *N. Engl. J. Med*. 2005; 352: 2589-97.
[18] Douillard JY, Tribodet H, Aubert D, et al. Adjuvant cisplatin and vinorelbine for completely resected non-small cell lung cancer: subgroup analysis of the Lung Adjuvant Cisplatin Evaluation. *J. Thorac. Oncol.* 2010; 5: 220-8.
[19] Sawabata N. Prognosis of lung cancer patients in Japan according to data from the Japanese Joint Committee of Lung Cancer Registry. *Respir Investig.* 2014; 52: 317-21.
[20] Graziano SL. Non-small cell lung cancer: clinical value of new biological predictors. *Lung Cancer*. 1997; 17: S37-58.
[21] Kawai H, Tada A, Kawahara M, et al. Smoking history before surgery and prognosis in patients with stage IA non-small-cell lung cancer--a multicenter study. *Lung Cancer*. 2005; 49: 63-70.
[22] Yoshino I, Kawano D, Oba T, et al. Smoking status as a prognostic factor in patients with stage I pulmonary adenocarcinoma. *Ann. Thorac. Surg.* 2006; 81: 1189-93.
[23] Kuo SW, Chen JS, Huang PM, et al. Prognostic significance of histologic differentiation, carcinoembryonic antigen value, and lymphovascular invasion in stage I non-small cell lung cancer. *J. Thorac. Cardiovasc. Surg. 2014*; 148: 1200-7.
[24] Sasaki R, Komaki R, Macapinlac H, et al. [18F]fluorodeoxyglucose uptake by positron emission tomography predicts outcome of non-small-cell lung cancer. *J. Clin. Oncol*. 2005; 23: 1136-43.
[25] Asamura H, Hishida T, Suzuki K, et al. Radiographically determined noninvasive adenocarcinoma of the lung: survival outcomes of Japan Clinical Oncology Group 0201. *J. Thorac. Cardiovasc. Surg*. 2013; 146: 24-30.
[26] Matsuguma H, Oki I, Nakahara R, et al. Comparison of three measurements on computed tomography for the prediction of less invasiveness in patients with clinical stage I non-small cell lung cancer. *Ann. Thorac. Surg*. 2013; 95: 1878-84.

[27] Nakagawa T, Okumura N, Kokado Y, et al. Clinical relevance of intraoperative pleural lavage cytology in non-small cell lung cancer. *Ann. Thorac. Surg*. 2007; 83: 204-8.

[28] Okada M, Sakamoto T, Nishio W, et al. Pleural lavage cytology in non-small cell lung cancer: lessons from 1000 consecutive resections. *J. Thorac. Cardiovasc. Surg.* 2003; 126: 1911-5.

[29] Lim E, Clough R, Goldstraw P, et al. Impact of positive pleural lavage cytology on survival in patients having lung resection for non-small-cell lung cancer: An international individual patient data meta-analysis. *J. Thorac. Cardiovasc. Surg.* 2010; 139: 1441-6.

[30] Takizawa T, Terashima M, Koike T, et al. Mediastinal lymph node metastasis in patients with clinical stage I peripheral non-small-cell lung cancer. *J. Thorac. Cardiovasc. Surg*. 1997; 113: 248-52.

[31] Darling GE, Allen MS, Decker PA, et al. Randomized trial of mediastinal lymph node sampling versus complete lymphadenectomy during pulmonary resection in the patient with N0 or N1 (less than hilar) non-small cell carcinoma: results of the American College of Surgery Oncology Group Z0030 Trial. *J. Thorac. Cardiovasc. Surg*. 2011; 141: 662-70.

[32] Hung JJ, Yeh YC, Jeng WJ, et al. Predictive value of the international association for the study of lung cancer/American Thoracic Society/European Respiratory Society classification of lung adenocarcinoma in tumor recurrence and patient survival. *J. Clin. Oncol.* 2014; 32: 2357-64.

[33] Noguchi M, Morikawa A, Kawasaki M, et al. Small adenocarcinoma of the lung. Histologic characteristics and prognosis. *Cancer*. 1995; 75: 2844-52.

[34] Kudo Y, Saji H, Shimada Y, et al. Impact of visceral pleural invasion on the survival of patients with non-small cell lung cancer. *Lung Cancer.* 2012; 78: 153-60.

[35] Tao H, Hayashi T, Sano F, et al. Prognostic impact of lymphovascular invasion compared with that of visceral pleural invasion in patients with pN0 non-small-cell lung cancer and a tumor diameter of 2 cm or smaller. *J. Surg. Res.* 2013; 185: 250-4.

[36] Shim HS, Park IK, Lee CY, et al. Prognostic significance of visceral pleural invasion in the forthcoming (seventh) edition of TNM classification for lung cancer. *Lung Cancer*. 2009; 65: 161-5.

[37] Mollberg NM, Bennette C, Howell E, et al. Lymphovascular invasion as a prognostic indicator in stage I non-small cell lung cancer: a systematic review and meta-analysis. *Ann. Thorac. Surg*. 2014; 97: 965-71.

[38] Okada M, Koike T, Higashiyama M, et al. Radical sublobar resection for small-sized non-small cell lung cancer: a multicenter study. *J. Thorac. Cardiovasc. Surg*. 2006; 132: 769-75.

[39] Carr SR, Schuchert MJ, Pennathur A, et al. Impact of tumor size on outcomes after anatomic lung resection for stage 1A non-small cell lung cancer based on the current staging system. *J. Thorac. Cardiovasc. Surg.* 2012; 143: 390-7.

[40] Altorki NK, Yip R, Hanaoka T, et al. Sublobar resection is equivalent to lobectomy for clinical stage 1A lung cancer in solid nodules. *J. Thorac. Cardiovasc. Surg*. 2014; 147: 754-62.

[41] Landreneau RJ, Normolle DP, Christie NA, et al. Recurrence and survival outcomes after anatomic segmentectomy versus lobectomy for clinical stage I non-small-cell lung cancer: a propensity-matched analysis. *J. Clin. Oncol*. 2014; 32: 2449-55.

[42] El-Sherif A, Gooding WE, Santos R, et al. Outcomes of sublobar resection versus lobectomy for stage I non-small cell lung cancer: a 13-year analysis. *Ann. Thorac. Surg*. 2006; 82: 408-15.

[43] Whitson BA, Groth SS, Andrade RS, et al. Survival after lobectomy versus segmentectomy for stage I non-small cell lung cancer: a population-based analysis. *Ann. Thorac. Surg*. 2011; 92: 1943-50.

[44] Yendamuri S, Sharma R, Demmy M, et al. Temporal trends in outcomes following sublobar and lobar resections for small (</= 2 cm) non-small cell lung cancers--a Surveillance Epidemiology End Results database analysis. *J. Surg. Res*. 2013; 183: 27-32.

[45] CT Screening for lung cancer: diagnoses resulting from the New York Early Lung Cancer Action Project. *Radiology*. 2007; 243: 239-49.

[46] Sone S, Takashima S, Li F, et al. Mass screening for lung cancer with mobile spiral computed tomography scanner. *Lancet*. 1998; 351: 1242-5.

[47] Hansell DM, Bankier AA, MacMahon H, et al. Fleischner Society: glossary of terms for thoracic imaging. *Radiology*. 2008; 246: 697-722.

[48] Kim HK, Choi YS, Kim K, et al. Management of ground-glass opacity lesions detected in patients with otherwise operable non-small cell lung cancer. *J. Thorac. Oncol*. 2009; 4: 1242-6.

[49] Yap CS, Schiepers C, Fishbein MC, et al. FDG-PET imaging in lung cancer: how sensitive is it for bronchioloalveolar carcinoma? *Eur. J. Nucl. Med. Mol. Imaging*. 2002; 29: 1166-73.

[50] Tsunezuka Y, Shimizu Y, Tanaka N, et al. Positron emission tomography in relation to Noguchi's classification for diagnosis of peripheral non-small-cell lung cancer 2 cm or less in size. *World J. Surg*. 2007; 31: 314-7.

[51] Shimizu K, Ikeda N, Tsuboi M, et al. Percutaneous CT-guided fine needle aspiration for lung cancer smaller than 2 cm and revealed by ground-glass opacity at CT. *Lung Cancer*. 2006; 51: 173-9.

[52] Chang B, Hwang JH, Choi YH, et al. Natural history of pure ground-glass opacity lung nodules detected by low-dose CT scan. *Chest*. 2013; 143: 172-8.

[53] Kodama K, Higashiyama M, Yokouchi H, et al. Natural history of pure ground-glass opacity after long-term follow-up of more than 2 years. *Ann. Thorac. Surg*. 2002; 73: 386-92.

[54] Suzuki K, Kusumoto M, Watanabe S, Tsuchiya R, Asamura H. Radiologic classification of small adenocarcinoma of the lung: radiologic-pathologic correlation and its prognostic impact. *Ann. Thorac. Surg*. 2006; 81: 413-9.

[55] Okada M, Nishio W, Sakamoto T, et al. Discrepancy of computed tomographic image between lung and mediastinal windows as a prognostic implication in small lung adenocarcinoma. *Ann. Thorac. Surg*. 2003; 76: 1828-32.

[56] Suzuki K, Koike T, Asakawa T, et al. A prospective radiological study of thin-section computed tomography to predict pathological noninvasiveness in peripheral clinical IA lung cancer (Japan Clinical Oncology Group 0201). *J. Thorac. Oncol*. 2011; 6: 751-6.

[57] Park JS, Yang HC, Kim HK, et al. Sleeve lobectomy as an alternative procedure to pneumonectomy for non-small cell lung cancer. *J. Thorac. Oncol*. 2010; 5: 517-20.

[58] Takeda S, Maeda H, Koma M, et al. Comparison of surgical results after pneumonectomy and sleeve lobectomy for non-small cell lung cancer: trends over time and 20-year institutional experience. *Eur. J. Cardiothorac* Surg. 2006; 29: 276-80.

[59] Yamamoto K, Miyamoto Y, Ohsumi A, et al. Sleeve lung resection for lung cancer: analysis according to the type of procedure. *J. Thorac. Cardiovasc. Surg.* 2008; 136: 1349-56.

[60] Yildizeli B, Fadel E, Mussot S, et al. Morbidity, mortality, and long-term survival after sleeve lobectomy for non-small cell lung cancer. *Eur. J. Cardiothorac. Surg*. 2007; 31: 95-102.

[61] Balduyck B, Hendriks J, Lauwers P, et al. Quality of life after lung cancer surgery: a prospective pilot study comparing bronchial sleeve lobectomy with pneumonectomy. *J. Thorac. Oncol*. 2008; 3: 604-8.

In: Encyclopedia of Surgery (22 Volume Set)
Editors: Andreas Lehrer and Kristin Mueller
ISBN: 978-1-53618-329-0
© 2020 Nova Science Publishers, Inc.

Chapter 374

VASCULAR ANATOMY OF THE SELLAR REGION AND COMPLICATIONS DURING ENDOSCOPIC ENDONASAL TRANSSPHENOIDAL SURGERY FOR PITUITARY ADENOMAS

Yasuhiko Hayashi*[*]*, MD, PhD
Department of Neurosurgery, Graduate School of Medical Science,
Kanazawa University, Kanazawa, Japan

ABSTRACT

In general, transsphenoidal surgery has been considered to have a low rate of complication and mortality. Among the postoperative complications associated with transsphenoidal surgery (TSS), such as cerebrospinal fluid leakage, hypopituitarism, diabetes insipidus, vascular injury, meningitis, cranial nerve neuropathy, and nasal bleeding, vascular injury is unusual, but most possibly fatal complication. Therefore, the pituitary neurosurgeons need to have the knowledge about the possible incidence during the intra- and post-operative phase. Vascular injuries during the TSS described in the literature include fatal hemorrhage from internal carotid artery (ICA), ICA occlusion, pseudoaneurysm formation, carotid cavernous fistula, subarachnoid hemorrhage, vasospasm, and distal embolism with cerebral infarction. It is important to understand the patient's vascular anatomy at the sella and its surrounding structures, during the preoperative examination of the TSS, to avoid the vascular complications. Although recent advancement of the operative techniques and instruments of transsphenoidal approach enable the neurosurgeons to dissect arteries derived from the ICA and external carotid artery (ECA) during the surgery, it remains a difficult problem to preserve intact vessels even for the expert pituitary neurosurgeons. In particular, the introduction of endoscope into the TSS dramatically improved intraoperative visualization and diminished traumatization. Subsequently, the operative indication for performing TSS gradually developed to include the suprasellar, parasellar, clival, and cervicomedullary junction (extended transsphenoidal surgery). However, since the indications for the use of TSS have grown, this fact can lead to increasing chances of intraoperative vascular

[*] Corresponding Author's Email: yahayashi@med.kanazawa-u.ac.jp; Fax: +81-076-234-4262.

injuries, and till now has not been reached a definite conclusion, whether TSS has a significant difference in the complication rate between endoscope and microscope techniques. Another advancement of preoperative neuroradiological investigation to detect such arteries derived from the ICA and the ECA is also useful for their precise localization and avoidance of fatal complications. Especially, the role of digital subtraction angiography in the operating room is significant, because, once the arterial injury during TSS happens, the emergent detection of affected vessel(s) and the management of the trauma is required. In addition, the development of endovascular surgery both in the techniques and the instruments remarkably changed the principles of treatment for intraoperative vascular injury during the TSS. Especially, in cases of ICA injury, the endovascular treatment with parent artery occlusion can be performed with acceptable morbidity and mortality rates. This technique can be also applied to the pseudoaneurysm, which arises from the injury site of the ICA at the postoperative delayed period, and causes fatal and massive epistaxis. However, vascular injury during endoscopic endonasal TSS is not well studied or reported, despite it is still a feared complication. The anatomic substrate for such complication in each stage of the TSS (naso-sphenoidal, spheno-planum, dural, intrasellar, and suprasellar phase) is discussed with respect to operative and neuroradiological aspects, identification of risk factors, management strategies for avoidance of such serious vascular complications, and their outcomes.

Keywords: transsphenoidal surgery, pituitary, vascular, complication, endoscope

1. INTRODUCTION

Pituitary adenomas constitute approximately 10-22.5% of all primary intracranial tumors, and surgical removal is the first optional management except for prolactinoma [1-4]. The transsphenoidal surgery (TSS) for removal of pituitary tumors has been originally applied due to its effectiveness and safety, with serious morbidity and mortality rates typically less than 1% [5, 6]. Recent advancement in operative and neuroradiological technologies has had a major impact on the treatment strategies for pituitary tumors, and TSS has become increasingly popular all over the world. In particular, the introduction of endoscope into the TSS has made a great progress not only on the resection rate of the tumor but also on the preservation of normal endocrinological function and the remission rate for the functioning adenoma [1, 7-9]. Moreover, the indication for the use of TSS has grown for the suprasellar, parasellar, clival, and craniocervical junction, since it has been regarded as extended TSS, and many surgeons reported its effectiveness in the management of craniopharyngioma, clival chordoma, and pituitary adenoma with invasion into the cavernous sinus [10-12].

Historically, the TSS was originally introduced by Schloffer and Cushing during the first decade of the 20th Century [13-15]. The adaptation of the transsphenoidal route as a surgical corridor is based on the concept that this surgery is significantly less dangerous for the patients with pituitary tumors compared to the craniotomy, which was considered to be extraordinary difficult on the contrary, because the instrumentation, lightning, cautery, anesthesia, and medication were not available in those days [13, 14]. This revolutionary introduction was followed by the addition of the radiofluoroscopy by Guiot, as well as the operating microscope and specialized instruments by Hardy 60 years later [16, 17]. Therefore, concerning TSS, safety should be secured both through the operation by the surgical

techniques and the anatomical knowledge of the pituitary region. However, many authors have reported various complications associated with the TSS including cerebrospinal fluid leakage, hypopituitarism, diabetes insipidus, meningitis, cranial nerve neuropathy, nasal bleeding, and vascular injury [1-7, 16, 18].

Despite the advancement of TSS, one of the most serious problems during this approach is vascular complications, in which injury to the cavernous ICA most commonly occurs at the sellar dural incision, and has been reported tooccur in 0-3.8% of cases [5, 18-22]. Even expert pituitary neurosurgeons experienced a 0.6-0.8% incidence of vascular injuries [23-25]. Therefore, all neurosurgeons trying to perform TSS should try to avoid the ICA injury and prepare to manage its risk with the appropriate preoperative evaluation, such as digital subtraction angiography (DSA) or 3-dimensional computed tomographic angiography (3D-CTA), fusion images with magnetic resonance imaging (MRI) and 3D-CTA, and computer graphics. The overall incidence of ICA injury was reported to be 1.1%, and the rate of ICA injury was inversely proportional to the surgeon's transsphenoidal experience, being 1.4% for the least experienced surgeons, 0.6% for those with intermediate experience, and 0.4% for the most experienced [19].

Anatomical studies of the sphenoid sinus and sellar region are relevant, because they can improve spatial orientation to the landmarks. Injury to ICA is the most feared complication leading to the catastrophic clinical deterioration of the patients [3, 11, 26, 27]. Historically, emergency surgical ligation of the ICA, to cease massive bleeding during pituitary surgery, has been required. However, this treatment was associated with an unacceptable high incidence of major clinical neurological deficit [20, 21]. Therefore, the development of endovascular treatment, combined with bypass surgery can provide dramatic changes on the aspect of control of the bleeding, embolization of carotid cavernous fistula and pseudoaneurysm, and cerebral revascularization to maintain good clinical outcomes [28-31]. In addition, the cavernous sinuses on both sides, which exist on the boundaries of the sella turcica, are vulnerable to injury during the TSS [21, 32]. The vascular complications should be discussed in each stage of the TSS (naso-sphenoidal, spheno-planum, dural, intrasellar, and suprasellar phase) with respect to the operative and neuroradiological aspects, identification of risk factors, management strategies for the avoidance of such serious vascular complications, and their outcomes.

2. VASCULAR ANATOMY OF THE TRANSSPHENOIDAL SURGERY

The process of the TSS was divided into five phases including naso-sphenoidal, sphenoid-planum, dural, intrasellar, and suprasellar. Vascular anatomic aspects of each stage are described.

2.1. Naso-Sphenoid Phase

Vascular injury can be frequently encountered on removal of the base of middle turbinate. The sphenopalatine arteries, branches of the internal maxillary artery, emerge through the sphenopalatine foramen (the height of lower margin of superior turbinate), run under the nasal mucosa, and supply the nasal structures, including nasal septum (anterior ~

posterior part: posterior septal nasal artery, inferior part: descending palatine artery) and middle turbinate (posterior lateral nasal artery). Posterior septal nasal artery, distributing nasal septum, has anastomoses with the posterior ethmoidal artery (PEA) [26]. Endoscopic observation sometimes reveals the pulsation of the artery. All the above mentioned arteries are important and should be kept in mind not to be injured. Careful attention should be paid at the procedure for dissection of mucosa at the nasal septum from the anterior wall of the sphenoid sinus. The sphenopalatine artery can be caught at the sphenopalatine foramen, through which the artery emerges, so as not to cause massive bleeding when removal of the anterior wall of the sphenoid sinus is widely required (Figure 1A) [34]. Law reported that the bleeding from the sphenopalatine artery could occur from the bone directly, from the venous diploic space or from the blood supply to stout bony structure, particularly in patients with acromegaly [20]. If the bleeding from the sphenopalatine artery is difficult to control, endovascular management, coil embolization of the maxillary artery, can be indicated. Although the midline approach would not disturb the main trunks of the sphenopalatine arteries, hemostasis of the posterior attachment of the middle turbinate, containing a branch of the sphenopalatine artery, is achieved with a suction electrocautery [34]. However, when nasoseptal pedicled flap, which is used for reconstruction of the skull base, should be made intraoperatively from the nasal septal mucosa, it is important to keep the sphenopalatine artery intact within the nasoseptal flap, whose base is required to be narrow in order to be adhered to the skull base. Therefore, the sphenopalatine artery should be stored within the narrow base of the pedicled flap [35].

Maxillary artery is the largest terminal branch of the ECA. It arises at the level of the neck of the condylar process and passes medial to it. Then, it ascends to the posterior part of the pterygopalatine fossa, and sphenopalatine artery is divided from it and run into the sphenopalatine foramen (Figure 1B). When exploring tumors, extending into the pterygoid fossa such as pituitary adenoma, adenocystic carcinoma and neurinoma, the course of the maxillary artery, which is buried in the adipose tissue at the pterygoid fossa, needs to be recognized in order to avoid an injury. Therefore, preoperative evaluation of the maxillary artery, such as 3D-CTA, is important.

2.2. Spheno-Planum Phase

Vascular injury can be frequently encountered on removal of the planum sphenoidale and the posterior base of superior turbinate, especially in the case of extended TSS for the suprasellar lesion, an unusual TSS targeting for the pituitary adenoma. PEA, which has a smaller diameter than the anterior ethmoidal artery, diverges from the ophthalmic artery and passes between the medial rectal muscle and the superior oblique muscle. Afterwards, it runs through a thin, bony channel at the medial wall of the orbit along the ethmoidal roof, seen after submucosal dissection in the posterior ethmoidal sinus [12, 33].

Although the distribution of PEA has been reported to be variable, mainly it perfuses into the superior turbinate, the posterior ethmoid sinus, the posterior part of the lamina cribrosa, and the planum sphenoidale [33]. Neurosurgeons can find the unexpected hemorrhage from PEA, if the dissection around the superior turbinate and the posterior ethmoidal sinus is carried out [11]. Although the injury of PEA is considered as an extremely rare complication

during TSS, the pituitary neurosurgeon should always have in mind the possibility of PEA injury.

In order to expose suprasellar lesions in the extended TSS approach, the superior and/or supreme turbinates should be removed along their base, taking care not to damage the turbinate lamina. During such maneuvers, it is important to avoid damaging the PEA, which frequently arises from the first segment of the ophthalmic artery and passes medially from the dura of the planum sphenoidale, to the posterior lamina cribrosa and then to the posterior ethmoidal cells [12]. Cavallo et al. reported that wide sphenoidectomy and bilateral posterior ethmoidectomy, to obtain a wider view of the planum sphenoidale, enable surgeons to clearly identify both PEAs, which are considered as "dangerous" landmarks and represent the anterior limit when opening the planum sphenoidale [10, 36]. Because the PEA branches the proximal portion of the ophthalmic artery with high blood pressure, injury of the PEA can cause massive and severe bleeding that should be avoided as much as possible.

As the PEA is a large branch stemming from the ophthalmic artery, it can be detected at the planum sphenoidale or posterior ethmoidal sinus on preoperative examinations, such as CTA. If this is the case performing the extended TSS, more attention should be paid in order to avoid unexpected severe arterial bleeding during submucosal dissection of the superior and lateral nasal cavity.

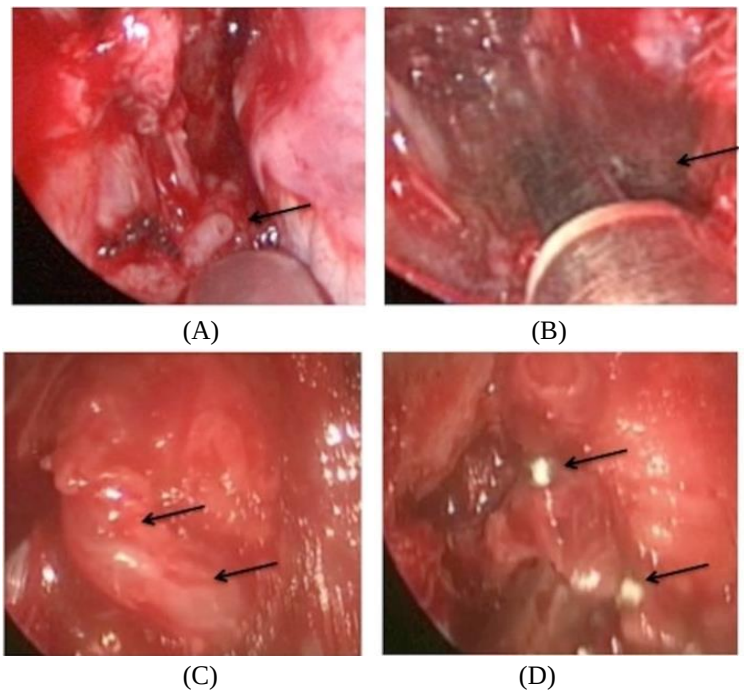

Figure 1. A. Intraoperative endoscopic view shows the bleeding from the branch of sphenopalatine artery (posterior lateral nasal artery; A, arrow) B. is successfully coagulated with single-shaft bipolar coagulator (B, arrow) C. Intraoperative endoscopic view shows the maxillary artery (arrows) running in the pterygopalatine fossa after removal of the posterior wall of the maxillary sinus D. Hemoclips (arrows) were applied to resect the maxillary artery in the pterygopalatine fossa.

(A) (B) (C)

Figure 2. A. Magnetic resonance imaging of pituitary adenoma extending into the suprasellar region and compressing the optic nerves, with further invasion into the right cavernous sinus B. Intraoperatively, a massive hemorrhage suddenly appeared during mucosa dissection just above the sellar floor, suggesting the posterior ethmoidal artery (PEA) as the origin of the bleeding (white arrow) C. Digital subtraction angiography performed after the operation showed left PEA (arrow) to be responsible for this hemorrhage.

3. ILLUSTRATIVE CASE 1

A 69-year-old man presented with a 6-month history of activity loss and visual field disturbance. MRI identified a pituitary tumor extending into the suprasellar region, compressing the optic nerves and invading the right cavernous sinus (Figure 2A). Neuro-ophthalmological investigation showed bitemporal hemianopsia, and endocrinological evaluation showed a decline of adrenocorticotrophic hormone (ACTH).

During the routine endoscopic TSS, a massive hemorrhage was suddenly encountered in the sphenoidal phase during mucosa dissection just above the sellar floor (Figure 2B). It was difficult to control this arterial bleeding, and the massive hemorrhage obstructed our endoscopic view, with the total amount of blood rising up to 2280ml. The bleeding point was found to originate from the left PEA was captured under the direct endoscopic view and was controlled with the single shaft bipolar coagulator (Karl Storz Endoscopy, Tuttlingen, Germany). Partial resection of the hard adenoma was performed, and the visual field defect and decline of ACTH level were restored. DSA performed after the operation showed left PEA, stemming from the ipsilateral ophthalmic artery, to be responsible for this hemorrhage (Figure 2C). Postoperative course was uneventful, and the residual tumor has been unchanged for four years.

3.1. Dural Phase

Vascular injury can be frequently encountered on opening of the dura mater of sellar floor, especially in the case of extended TSS for a suprasellar lesion, such as craniopharyngioma. Pituitary adenomas, further manifest with ballooning of the sellar floor, and compression of the intercavernous sinus for a long period and thus leading even to its complete occlusion.

The cavernous sinuses on either side of the sella are vascular structures filled with venous blood under venous pressure. The two cavernous sinuses frequently connect through dural channels, most commonly superior and inferior intercavernous sinus. These connecting channels can be injured during the opening of the dura mater. The dura itself consists of two layers, and between them, vascular channels commonly proliferate and are diminished by compression of macroadenoma for a long period. In particular, superior intercavernous sinus usually locates between the sellar floor and the tuberculum sellae (tuberculum recessus), and coagulation and cut off of the superior intercavernous sinus is required, to advance into the suprasellar lesion during the extended TSS (trans-tuberculum sellae approach). The size and location of the superior intercavernous sinus can also influence the bone removal of the tuberculum sellae [20]. If bleeding once occurs in the cutting of the sinus, the surgical procedure will be slow and more difficult. Therefore, the incisions are made in the dura mater anteriorly and inferiorly to the superior intercavernous sinus, and the sinus is coagulated and then divided to obtain a direct view of the suprasellar cistern without disturbance by the pituitary gland [37]. In order to coagulate this sinus, the low-profile, single shaft bipolar coagulator is very useful (Figure 3).

The capsular artery, which feeds the capsule (dura mater) of the pituitary, usually is clinically insignificant and arises from the distal and medial portion of the cavernous ICA, commonly supply the sellar dura, and can also proliferate to feed any possible pituitary lesion [20, 21]. These vessels have anastomosis with the contralateral ones at the midline, and have the potential of causing technical difficulty, when dealing with the lesion directly. Zada et al. reported the midline dural filum at the sellar floor, in half of the cases examined. This filum is identified as a strand-like dural extension or as a small vascular dural structure [38]. From our intraoperative observation, active bleeding was identified from the dural filum in many of the cases, which was thought as a result of the blood supply from the anastomosis of the capsular arteries (Figure 4).

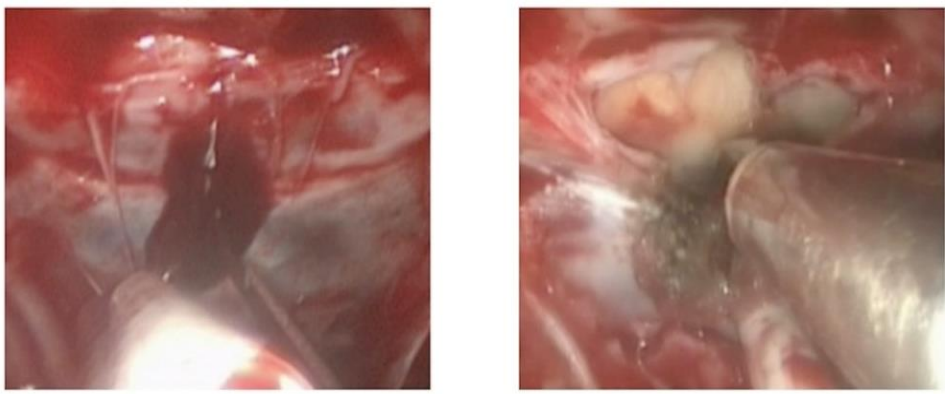

(A) (B)

Figure 3. A. Bleeding from the superior intercavernous sinus is detected when cutting with a micro-knife and B. Coagulating with the single-shaft bipolar coagulator, in order to obtain a direct view of the suprasellar cistern without disturbing the pituitary gland.

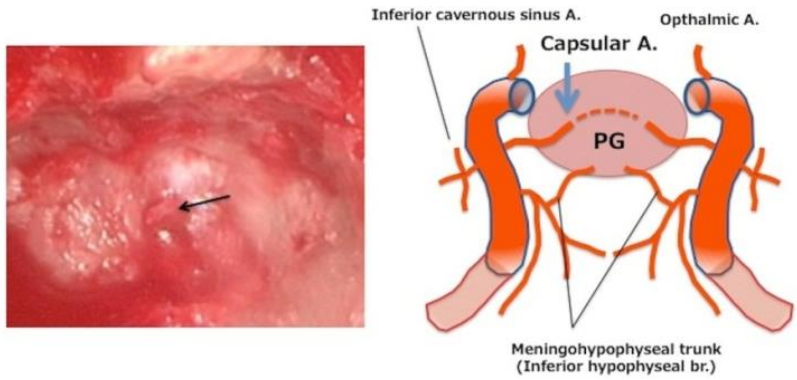

Figure 4. A. Intraoperative endoscopic observation identifies the dural filum and the bleeding from it (arrow), which was thought to originate from the capsular arteries B. A scheme of the arterial supply over the dura mater of the sella.

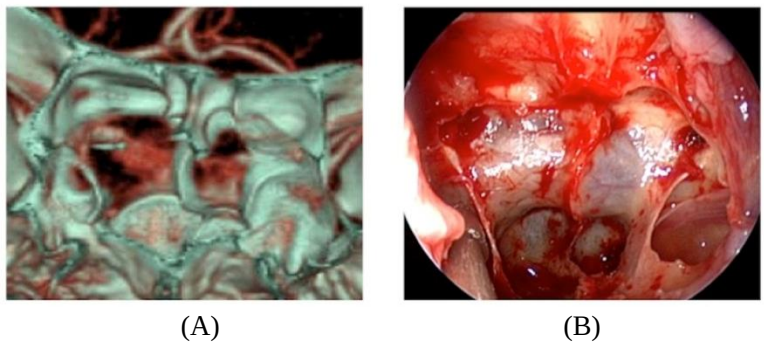

Figure 5. A. 3D-CT reconstruction of oblique-coronal image (sections perpendicular to the line, from lower margin of the nostril to the top of the posterior clinoid process) as “transsphenoidal view”, is obtained as a routine preoperative evaluation of the transsphenoidal surgery for the pituitary tumors B. Intraoperative endoscopic view for the sellar floor and its surroundings after wide sphenoidectomy.

The carotid artery frequently produces a bony prominence into the sphenoid sinus wall, below the floor and along the anterior margin of the sella bilaterally (carotid prominence). Moreover, usually the optic canals protrude into the superolateral portion of the sinus, and the carotid prominence, a diverticulum of the sinus, often projects laterally between the optic canal and the carotid prominence. The dura mater over the medial surface of the cavernous sinus is exposed after removing the mucosa and bone at the lateral wall of the sphenoid sinus. Subsequently, the cavernous ICA is exposed after dural opening of the sella. Rhoton reported that there is an area between optic nerves and carotid arteries where bone thickness less than 0.5 mm from the mucosa of the sphenoid sinus in some of the cases, and meanwhile, no bony thickness is found between these structures in a few cases. The absence of such bony protection over the wall of the cavernous sinus may lead to a serious injury of the cranial nerves and the ICA during the TSS. The bone of the calvaria is often thinner over the carotid arteries than over the anterior margin of the pituitary gland [39]. Pituitary neurosurgeons are required to recognize these bony structures, related to the ICA, in order to avoid unnecessary ICA injury. 3D-CTA with thin slices of bone images is useful as a preoperative evaluation. In

our institute, oblique-coronal image (sections perpendicular to the line from lower margin of the nostril to the top of the posterior clinoid process) as "transsphenoidal view" is taken routinely in the preoperative evaluation of the TSS (Figure 5).

During the TSS approach to the sella, complete midline orientation should be maintained all the time to avoid the injury of the ICAs. Besides, the cavernous portion of the ICA is vulnerable to damage during the exposure of the sella. In the dural phase, in most cases, the injury of ICA can be encountered with the dural opening of the sellar floor. Therefore, careful preoperative evaluation of bony structure in the sphenoid sinus as well as measurement of intercarotid distance is essential to avoid the serious ICA injury [20]. Perdoni et al. reported that the mean intercarotid distances found at the level of tuberculum sellae, sellar floor and clivus were 13.32, 18.00 and 18.90 mm respectively. The distance between ICAs at the tuberculum sellae is narrower than that at the sellar floor. The mean distance found between the ICAs at the level of the 18 mm sellar floor can be considered a "safe zone" to access the hypophysis, and other researchers reported similar value [40]. However, endoscopy is very useful in providing a panoramic view of the depth in the sphenoid sinus, including bilateral carotid prominence and opticocarotid recessus. Fujii et al. reported an interesting study, showing the various parts regarding bony thickness of the posterior wall of the sphenoid sinus. In this chapter, the thickness of the bone of the sphenoid sinus together with the intracranial ICAs was described as follows; the thickness of the bone separated the ICA and sinus is less than 0.5 mm in 88% of cases, and areas of bone defect were present in 8% of them [41]. Therefore, fine maneuvers are required and easy cautery should be avoided as much as possible. In this connection, the vidian canal can be a critical landmark for the petrous and parasellar ICA [12]. Identification of this landmark and the parasellar and paraclival carotid prominence is also critical in staying oriented to the petrous ICA [42]. The bone over these prominences can be carefully and safely removed to have the ICA in view [43].

4. ILLUSTRATIVE CASE 2

A 38-year-old man presented with activity loss and visual field deficits that had been ongoing for the last two months. He had consulted previously another clinic, where a large-sized suprasellar extended tumor was detected with MRI, and was referred to our department where neurological evaluation revealed bitemporal hemianopsia, and endocrinological evaluation showed reduced levels of baseline cortisol, ACTH, and thyroid hormones. MRI showed a calcified solid mass with remarkable suprasellar extension compressing both optic nerves upward (Figure 6A). Extended endoscopic endonasal TSS was performed, and gross total removal of the tumor was achieved and subsequently visual function was remarkably improved. Pathological diagnosis of the surgical specimen was non-functioning pituitary adenoma.

Intraoperatively, during right-sided dissection of the dural phase of the TSS, arterial bleeding emerged from the right ICA, during the removal of the bone at the carotid prominence (Figure 6B). Hemostasis was immediately carried out with continuous aspiration of the hemorrhage without leading to catastrophic hemorrhage. Tumor was successfully removed via extended TSS, and the patient was discharged without any neurological deficit.

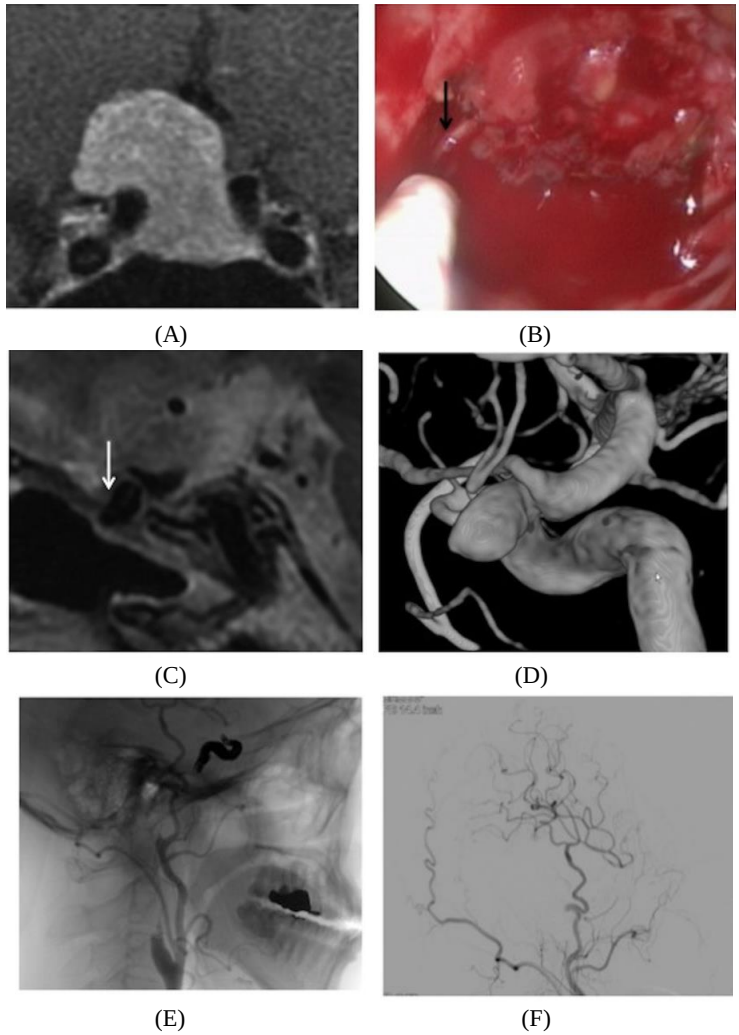

Figure 6. A. Magnetic resonance imaging (MRI) reveals the non-functioning pituitary adenoma extending into the suprasellar cistern B. During right-sided dissection of the dural phase of the transsphenoidal surgery, arterial bleeding emerged from the small branch of the right ICA (arrow) during the removal of the bone at the carotid prominence C. MRI obtained one month later revealed de novo flow void mass with anterior protrusion at the right cavernous ICA D. DSA demonstrated aneurysm formation at the right cavernous ICA, suggesting pseudoaneurysm E. Endovascular embolization of parent ICA to occlude pseudoaneurysm and superficial temporal artery-middle cerebral artery anastomosis for cerebral revascularization was successfully performed. Postoperative DSA revealed disappearance of the aneurysm and F. excellent restoration of the blood supply from the ECA to the ICA.

However, one month later, follow-up MRI revealed de novo flow void mass at the cavernous ICA (Figure 6C). DSA was performed to demonstrate aneurysm formation at the right cavernous ICA, and it was most suspected to be pseudoaneurysm (Figure 6D). The risk of aneurysm rupture is considered to be quite high. Therefore, in order to prevent rupture the aneurysm, endovascular embolization of parent ICA to occlude pseudoaneurysm and superficial temporal artery-middle cerebral artery anastomosis for cerebral revascularization was successfully performed. Postoperative DSA revealed disappearance of aneurysm and

restoration of the blood supply from the ECA to the ICA (Figure 6E, 6F). Cerebral blood flow measurement showed no perfusion defect and MRI showed no ischemic changes on the right hemisphere. The patient left the hospital with no neurological deficit. In a later time-point, residual tumor was managed with conservative treatment.

4.1. Intrasellar Phase

Vascular injury of ICA and its perforator can be encountered on removal of tumor invading into the cavernous sinus or incision of cavernous sinus wall. The ICA sometimes can be tortuous and protrude to the midline [32]. Therefore, ICA injury in this phase frequently leads to the fatal neurological and systemic complications, with published rates, occurring by the use of traditional open approaches ranging from 3% to 8%. [44, 45], whereas for standard microscopic TSS for pituitary tumors ranging from 0.2% to 1.4% [5, 18, 20]. On the other hand, cases in which endoscopic endonasal surgery was used, a limited number of ICA injuries were reported, suggesting that these were indeed rare [37, 46, 47]. Moreover, increased use of the endoscopic endonasal approach for skull base lesions can provide wide exposure and visualization of its surroundings with remarkable advancement of the specialized instrumentation [8, 9]. It can allow improved localization and control of the ICAs. However, increased chances of dissection due to endoscopic wide visualization around the ICAs may result in a higher rate of ICA injury [26]. In some cases, the parasellar ICA protrudes inside the adenoma with remarkably tortuosity. Cautious preoperative evaluation is required to prevent fatal ICA injury and remove the tumor efficiently (Figure 7).

Because little or no separation exists between the medial portion of the ICA and the lateral surface of the pituitary gland, blunt instrument should be used for the dissection of the tumor periphery inside the sella. Perforation or laceration of the ICAs in the cavernous sinus represents a very serious problem and unfortunately is a common type of injury in the TSS [21]. In the cases of large invasive pituitary adenomas eroding the skull base, tumors may actually surround the ICAs and, occasionally, may invade the adventitial wall of the vessels, which causes injury to the integrity of the ICAs, when the tumor is removed radically. Dissection of tumors away from the ICAs or displacement of the ICAs in the cavernous sinus during an attempt to achieve hemostasis can lead to thrombosis of the ICAs, resulting in occlusion and occasionally embolization.

Important branches of the ICA, supplying the pituitary gland with blood, arise from the meningohypophyseal trunk, which arises between the carotid segment C4 and C5 and supplies the pituitary gland and the pituitary stalk [20]. This trunk can also proliferate to provide blood supply to pituitary tumors. It divides into three branches, inferior hypophyseal branch, dorsal meningeal branch, and tentorial branch. Inferior hypophyseal branch is the largest of these three, and runs medially to supply the posterior pituitary lobe, appearing as the latter's net of terminal vessels [12, 44].

Direct injury to the carotid artery frequently leads to formation of a pseudoaneurysm, like in our case described above, even if the artery appears to be intact up to the point of maintaining its flow inside the ICAs without further bleeding. According to some authors' reports, the rates of pseudoaneurysm formation after ICA injury are generally very high, and carotid cavernous fistula and thrombosis can occur either [26, 48]. Kai et al. reported a case of a patient who suffered a pseudo ICA aneurysm following TSS, and cerebral angiograms

showed a pseudoaneurysm arising from the C4 portion of the left ICA. It was successfully treated with bypass surgery and ICA occlusion involving the pseudoaneurysm using coil embolization. Postoperative angiograms showed that the pseudoaneurysm was completely occluded and the bypass was fully patent. Authors addressed that massive arterial bleeding is encountered during TSS, therefore the patient should be carefully monitored to detect early the development of a pseudoaneurysm. When such an aneurysm is found to have ruptured, interventional surgery has proved effective in the management of this complication [49].

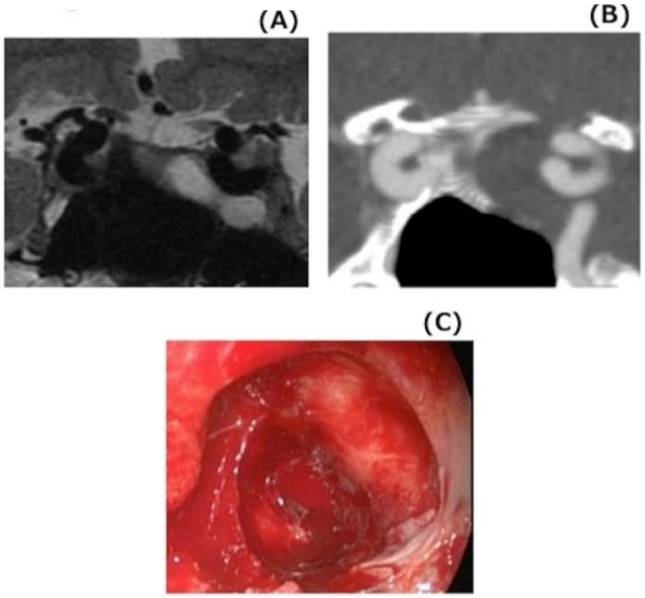

Figure 7. In a representative case was shown the ICA protrusion into pituitary adenoma, the latter invading into the cavernous sinus. A. Preoperative MRI revealed that the cavernous ICA was involved in the adenoma. An intratumoral cyst was identified B. Preoperative CTA revealed tortuous cavernous ICA protruding into the adenoma C. Intraoperative endoscopic view after opening of the intratumoral cyst clearly showing the tortuous ICA to be adjacent to the cyst.

The ICA can be placed into mechanical spasm by causing dissection around the ICAs or injury to them. TSS complicated by peritumoral hemorrhage is associated with a significant rate of neurological deterioration, due to delayed cerebral vasospasm, and this spasm can clearly cause arterial insufficiency and stroke [26]. Therefore, early recognition and proper management, according to guidelines used for postaneurysmal subarachnoid hemorrhage (SAH), may help to prevent deterioration of outcomes in those patients [19, 50]. Puri et al. reported three cases of developed vasospasm of the intracranial vessels after TSS, with extension of peritumoral hemorrhage into the subarachnoid space, starting as early as postoperative day 5 and continued as late as postoperative day 10. The outcomes of these three cases were not excellent; therefore, they concluded that the vasospasm after TSS associates with the significant risk of neurological morbidity [50]. The timing and distribution of cerebral vasospasm after TSS is similar to that observed in the patients after SAH due to aneurysmal rupture. Therefore, the management of the vasospasm including early vascular imaging evaluation, aggressive hyperdynamic therapy, and neurointerventional procedures should be applied to prevent upcoming ischemic complications [50-52].

4.2. Suprasellar Phase

Pituitary adenoma with remarkable suprasellar extension, in particular, in the case with significant anterior skull base extension, the extended transtuberculum sellae-transplanum sphenoidale approach is required to remove the pituitary adenoma. With this approach, the suprasellar cistern is fully exposed during and after the surgery [53, 54]. Vascular injury, at the level of supraclinoid ICAs and their branches, can be encountered on dissection between the tumor and the vessels involved or adhered to the tumors at the suprasellar, the interpeduncular, and the prepontine cisterns. Thus, ICA, superior hypophyseal artery, anterior and posterior communicating arteries, posterior cerebral artery, basilar artery and its perforators, and superior cerebellar artery, are the vessels affected during the extended endoscopic TSS (Figure 8). Therefore, during the manipulation of the vessels in the suprasellar phase, neurosurgeons should take into consideration the anatomy of the Circle of Willis and its integrity with respect to its collateral flow [48]. Concerning their branches and perforators, special attention should be paid to the injuries of the hypothalamic arteries, but also prevention of a direct hypothalamic trauma, which could cause recent memory disturbance [25]. Once the pituitary stalk can be seen in the subchiasmal spaces, the superior hypophyseal artery and the perforating branches for the inferior surface of the chiasm are apparent, and the posterior communicating artery and its perforator are also detected in the deeper parts of the operative field [10]. During the removal and dissection of the tumors at the TSS, the vascular anatomy around the suprasellar cistern turns to be very complex and is frequently distorted in the cases of large tumors. Besides, above the diaphragm sellae, a circuminfundibular venous plexus exists and can elaborate to feed pituitary lesions. As mentioned above, more expanded approach to obtain wide operative field and excellent visualization, with greater ICAs manipulations and subsequent ICAs' exposure, could increase the risk of vascular injuries [12, 27]. However, in some series, it was indicated that lateral exposure of pituitary tumors enable wider range of endoscope access than microscope and does not lead to a remarkable incidence of injuries overall of for tumors. In the cases of vascular injuries described above, massive bleedings flow into the sphenoid sinus and nasal cavity. However, in this phase, massive bleeding due to the vascular injuries "attacks" hypothalamus, intraventricle and brainstem, causing fatal neurological deteriorations. Besides, once the vascular injury occurs, it is very difficult to control the bleeding, so as to maintain visualization at the deep and narrow operative field, thus higher techniques are required to find the bleeding point [27].

Needless to say, the best strategy for managing ICA injuries during the TSS is prevention. Therefore, considerable preoperative neuroradiological assessment of the course of the ICAs at the suprasellar cistern is essential, as well as tumor and patient risk factors (e.g., ICA involvement with tumor, atherosclerosis in patients with acromegaly or Cushing disease) [27].

When exploring a suprasellar lesion below the optic chiasm such as craniopharyngioma, preservation of chiasm vascularization, fed from the superior hypophyseal artery is partially important, and extended transsphenoidal approach with endoscope offers an excellent visualization, in order to avoid any vascular injury resulting during the dissection between the tumor and the vessels [11]. An avulsion of perforator arising from the P1 portion of posterior cerebral artery during the resection of the part of suprasellar extension of pituitary adenoma

may occur, and Kassam et al. used a topical hemostatic agent to control the bleeding, but as a result of this forcible tearing, the patient suffered from severe transient dysphagia [36].

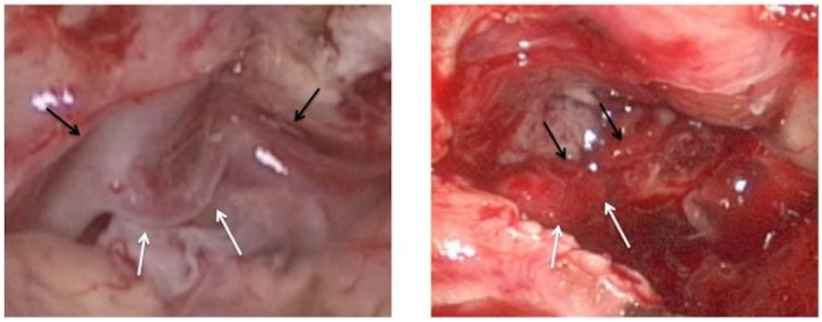

Figure 8. A. Intraoperative endoscopic view clearly revealed the anterior communicating artery (white arrows) and anterior cerebral arteries (black arrows) and B. the ICA (white arrows) and the superior hypophyseal artery (black arrows) after removal of pituitary adenoma via the extended transtuberculum sellae approach.

5. Procedures and Instrumentations for the Prevention and Control of Bleeding

As mentioned above, the first problem related to this approach concerns the control and prevention of bleeding, especially in the procedures of intra- and supra-sellar phases. Because it is difficult to control massive bleeding coming from the main vessels, as many neurosurgeons addressed, it is important to make all surgical maneuvers under the direct endoscopic view [16].

In particular, in the suprasellar phase, angled 30° or 45° 4 mm rigid endoscope was used to assess the completeness of tumor removal and to help observe the tumor-neurovascular interface clearly [1, 9, 37]. Dusick et al. reported that the use of the micro-Doppler probe for carotid localization before dural opening and angled hook blades for lateral dural opening are potentially simple and effective surgical adjuncts that can help minimize the risk of ICA injury, and recommended for all TSS as routine intraoperative examination (Figure 9)[19, 22]. Kitano and Taneda reported the use of the micro-Doppler probe later during tumor resection within the cavernous sinus, in order to confirm the ICA course, as a technique that they strongly recommended [55]. In addition, the Doppler is more reliable than neuronavigation systems, because it gives real time feedback, whereas the latter are prone to varying degrees of inaccuracy even for fixed cranial-base landmark [2, 56]. Indocyanine green fluorescence shows promise as an intraoperative marker in differentiating pituitary tumors from normal gland, and virtually identifying areas of dural invasion without development of any adverse events [57]. Yano et al. clearly demonstrated intraoperative visualization of the intercavernous sinus before dural incision and the cavernous ICA in the intrasellar phase, and encouraged the improvement of the tumor resection with more safety and effectiveness [35]. Although the indocyanine green fluorescence has not yet become popular in the TSS, these results support the further development of fluorescence-guided tumor resection techniques, since these can lead to improved outcomes, from the aspect of

preservation of normal gland, extent of tumor resection, and avoidance of vascular injury. Dusick et al. also addressed that the use of low-profile hook blades for dural opening can reduce the risk of the ICA and other vascular injuries because the blade angle allows the cutting force to be directed away from the intradural surface and back toward the surgeon instead [19]. Rhoton proposed that angled piston-gripped dural scissors could be used for this purpose [58].

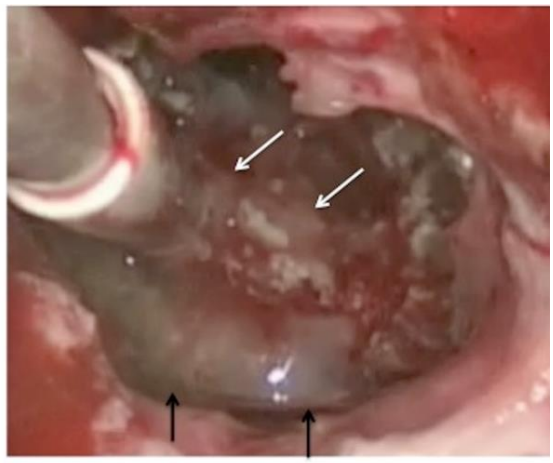

Figure 9. Micro-Doppler probe (black arrow) for localizing carotid artery (white arrow) during the removal of pituitary adenoma, to prevent the ICA injury. The procedure is recommended for every kind of transsphenoidal surgery as routine intraoperative examination.

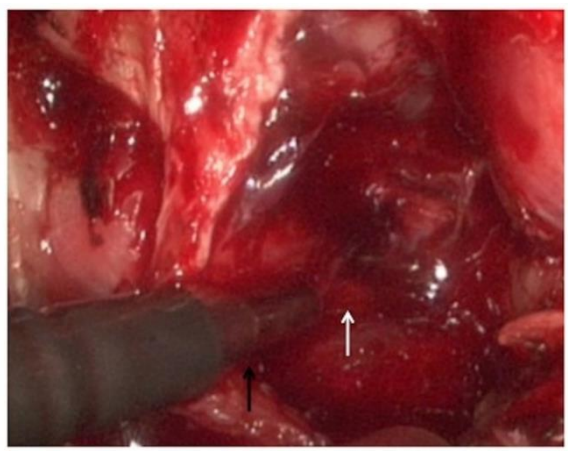

Figure 10. Low-profile bipolar coagulator for the coagulation of vessels of the tumor capsule, making possible the bipolar coagulation of arterial bleeding in narrow spaces.

Low-profile bipolar coagulator, specially designed to work through the nose, with tips up to 0.3 mm and single shaft, are now available for the coagulation of vessels of the tumor capsule, making possible the bipolar coagulation of arterial bleeding in narrow spaces (Figure 10). Vascular clips with an applicator designed for endonasal use can be useful for the bleeding control of the vascular injuries in the naso-sphenoid and sphenoid-planum phase

[20]. However, these devices are not practical for the ICA injury for the fear of enlarging the hemorrhage point.

Although the bleeding due to the ICA injury during the TSS is so massive and difficult to control in the operative field, most ICA injuries originated from small puncture wounds that can be fortunately controlled in an initial phase with Gelform and cottonoids. Therefore, when the neurosurgeons encounter the ICA injury during the TSS, they must detect the accurate bleeding point of the ICA injury despite of the difficulty in controlling a massive bleeding at first moment [30]. Following the initial care, the next steps include a two-layered muslin gauze patch or collagen sponge immersed in fibrin glue or BioGlue, and then a fat graft put over the puncture point accurately. Harvested fascia with fibrin glue is strong and adhesive material, which can be applied to the puncture point for the control of the bleeding [59]. But neurosurgeons need to prepare the fascia and fat graft from abdomen or thigh in advance intraoperatively. However, overpacking the repair of injured site should be refrained, because it could result in carotid occlusion and subsequent cerebral infarction. The use of the clip to control the bleeding and preservation of the vessel patency is reported in some cases [20]. Direct suturing repair for the larger laceration of the vessel is basically not practical, because suturing technique is quite difficult and time consuming at that serious situation.

Unfortunately, if the arterial bleeding from the injured vessels is not controlled finally, trapping of the vessels with aneurysm clip is applied to the injured site or the parent artery, thus “sacrificing” the vessels. However, recent advancement of endovascular surgery has changed the methods to repair the vascular injuries [28]. As some authors have already described and vascular group of our institute performs, urgent cerebral angiography should be carried out in the operating room. After the detection of the extravasation and presentation of a pseudoaneurysm or carotid cavernous fistula, balloon is approached to the injured site and inflated to occlude the parent vessels [28, 29, 48]. After the repair of the injured site, ICAs are supposed to be involved in most of the cases, it is needed to confirm that the injured site is successfully repaired after deflation of the balloon and collateral circulation via the Circle of Willis in the case of ICA occlusion should be assessed [30]. With the appearance of pseudoaneurysm or carotid cavernous fistula, endovascular treatment, involving ICA embolization, should be immediately achieved [31, 60, 61]. In this case, since the collateral circulation is not excellent via anterior communicating artery or posterior communicating artery, the ECA-ICA bypass surgery, including superficial temporal artery-middle cerebral artery anastomosis, high flow bypass using arterial graft, should be immediately performed to prevent the subsequent ischemic complication due to the ICA embolization [49]. Even if the result of the angiography is normal after the vascular injury, it is strongly recommended to repeat DSA or 3D-CTA within five days to detect the delayed occurrence of any possible pseudoaneurysm. MRI should be also carried out and evaluated, whether cerebral infarction emerges in the case of the ICA embolization, and CT scan should be also obtained immediately after endovascular procedure, whether SAH occurred, which can lead to clinically significant cerebral vasospasm [50, 62].

REFERENCES

[1] Halvorsen, H; Ramm-Pettersen, J; Josefesen, R; Ronning, P; Reinlie, S; Meling, T; et al. Surgical complications after transsphenoidal microscopic and endoscopic surgery for pituitary adenoma: a consecutive series of 506 procedures. *Acta Neurochir (Wien)*, 2014, 156, 441-449.

[2] Central Brain Tumor Registry of the United States: *Primary Brain Tumors in the United States Statistical Report 1998-2002*. Hinsdale II; CBTRUS, 2005 (http://www. cbtrus.org/reports/2005-2006/ 2006report. pdf).

[3] Ramakrishman, VR; Suh, JD; Lee, JY; O'Malley, BW; Grady, MS; Palmer, JN. Sphenoid sinus anatomy and suprasellar extension of pituitary tumors. *J Neurosurg*, 2013, 119, 669-674.

[4] Surawicz, TS; McCarthy, BJ; Kupelian, V; Jukich, PJ; Bruner, JM; Davis. FG. Descriptive epidemiology of primary brain and CNS tumors: results from the Central Brain Tumor Registry of the United States, 1990-1994. *Neuro Oncol*, 1999, 1, 14-25.

[5] Ciric, I; Ragin, A; Baumgartner, C; Pierce, D. Complications of transsphenoidal surgery: results of a national survey, review of the literature; and personal experience. *Neurosurgery*, 1997, 40, 225-236.

[6] Gondim, JA; Almeida, JP; Albuquerque, LA; Schops, M; Gomes, E; Ferraz, T; et al. Endoscopic endonasal approach for pituitary adenoma: surgical complications in 301 patients. *Pituitary*, 2011, 14, 174-183.

[7] Berker, M; Hazer, DB; Yücel, T; Gürlek, A; Cila, A; Aldur, M; Onerci, M. Complications of endoscopic surgery of the pituitary adenomas: analysis of 570 patients and review of the literature. *Pituitary*, 2012, 15, 288-300.

[8] Schwartz, TH; Stieg, PE; Anand, VK. Endoscopic transsphenoidal pituitary surgery with intraoperative magnetic resonance imaging. *Neurosurgery*, 2006, 58(Suppl 1), ONS44-51.

[9] Saeki, N; Murai, H; Hasegawa, Y; Horiguchi, K; Hanazawa, T. Endoscopic endonasal transsphenoidal surgery for pituitary adenomas. *No Shinkei Geka*, 2007, 35, 971-985.

[10] Cavallo, LM; de Divitiis, O; Aydin, S; Messina, A; Esposito, F; Iaconetta, G; et al. Extended endoscopic endonasal transsphenoidal approach to the suprasellar area: anatomic considerations--part 1. *Neurosurgery*, 2007, 61(Suppl 3), 24-33.

[11] de Divitiis, E; Cavallo, LM; Cappabianca, P; Esposito, F. Extended endoscopic endonasal transsphenoidal approach for the removal of suprasellar tumors: Part 2. *Neurosurgery*, 2007, 60, 46-58.

[12] Kassam, A; Snyderman, CH; Mintz, A; Gardner, P; Carrau, RL. Expanded endonasal approach, the rostrocaudal axis. Part I. Crista galli to the sella turcica. *Neurosurg Focus*, 2005, 19, E3.

[13] Cohen-Gadol, AA; Laws, ER; Spencer, DD; De Salles, AA. The evolution of Harvey Cushing's surgical approach to pituitary tumors from transsphenoidal to transfrontal. *J Neurosurg*, 2005, 103, 372-377.

[14] Cushing, H. *Papers relating to the pituitary body; hypothalamus and parasympathetic nervous system*. Charles C. Thomas. Springfield: IL, 1932.

[15] Schloffer, H. Erfolgreiche Operation eines Hypophysentumors auf nasalem Wege (In German). *Wien Klin Wochenschr*, 1907, 20, 621-624.

[16] Guiot, G. Transsphenoidal approach in surgical treatment of pituitary adenomas: General principals and indications in non-functioning adenomas. In Kohler PO, Ross GT (editors): Diagnosis and Treatment of pituitary tumors: Proceedings of a conference. International Congress Series. *Excerpta Medica*, Amsterdam, 1973, pp. 159-179.

[17] Hardy, J. Transsphenoidal hypophysectomy. *J Neurosurg*, 1971, 34, 582-594.

[18] Fatami, N; Dusick, JR; de Paiva Neto, MA; Kelly, DF. The endonasal microscopic approach for pituitary adenomas and other parasellar tumors: a 10-year experience. *Neurosurgery*, 2008, 63(Suppl 2), 244-256.

[19] Dusick, JR; Esposito, F; Malkasian, D; Kelly, DF. Avoidance of carotid artery injuries in transsphenoidal surgery with the Doppler probe and micro-hook blades. *Neurosurgery*, 2007, 60(Suppl 2), 322-328.

[20] Laws, ER. Jr. Vascular complications of transsphenoidal surgery. *Pituitary*, 1999, 2, 163-170.

[21] Oskouian, RJ; Kelly, DF; Laws, ER. Jr. Vascular injury and transsphenoidal surgery. *Front Horm Res*, 2006, 34, 256-278.

[22] Yamasaki, T; Moritake, K; Hatta, J; Nagai, H. Intraoperative monitoring with pulse Doppler ultrasonography in transsphenoidal surgery: technique application. *Neurosurgery*, 1996, 38, 95-98.

[23] Mortini, P; Losa, M; Bazaghi, R; Boari, N; Giovanelli, M. Results of transsphenoidal surgery in a large series of patients with pituitary adenoma. *Neurosurgery*, 2005, 56, 1222-1233.

[24] Oskoulan, RJ; Laws, ER. Vascular complications in transsphenoidal surgery. Presented at the annual meeting of the American Association of Neurological Surgeons, May 1-6. *J Neurosurg*, 2004, 100, 806.

[25] Raymond, J; Hardy, J; Czepko, R; Roy, D. Arterial injuries in transsphenoidal surgery for pituitary adenoma: the role of angiography and endovascular treatment. *AJNR Am J Neuroradiol*, 1997, 18, 655-665.

[26] Gadhinglajkar, SV; Sreedhar, R; Bhattacharya, RN. Carotid artery injury during transsphenoidal resection of pituitary tumor: anesthesia perspective. *J Neurosurg Anesthesiol*, 2003, 15, 323-326.

[27] Gardner, PA; Tormenti, MJ; Pant, H; Fernandes-Miranda, JC; Snyderman, CH; Horowitz, MB. Carotid artery injury during endoscopic endonasal skull base surgery: incidence and outcomes. *Neurosurgery*, 2013, 73(Suppl 2), 261-270.

[28] Cinar, C; Bozkaya, H; Parildar, M; Oran, I. Endovascular management of vascular Injury during transsphenoidal surgery. *Interv Neuroradiol*, 2013, 19, 102-109.

[29] Dolenc, VV; Lipovsek, M; Slokan, S. Traumatic aneurysm and carotid-cavernous fistula following transsphenoidal approach to a pituitary adenoma: treatment by transcranial operation. *Br J Neurosurg*, 1999, 13, 185-188.

[30] Ghatge, SB; Modi, DB. Treatment of ruptured ICA during transsphenoidal surgery. Two different endovascular strategies in two cases. *Interv Neuroradiol*, 2010, 16, 31-37.

[31] Kim, BM; Jeon, P; Kim, DJ; Kim, DI; Suh, SH; Park, KY. Jostent covered stent placement for emergency reconstruction of a ruptured internal carotid artery during or after transsphenoidal surgery. *J Neurosurg*, 2015, 122, 1223-1228.

[32] Harris, FS; Rhoton, AL. Anatomy of the cavernous sinus. A microsurgical study. *J Neurosurg*, 1976, 45, 169-180.

[33] Nagatani, T; Wakabayashi, T. Endoscopic endonasal transsphenoidal approach for the removal of pituitary adenomas based on basis of microsurgical anatomy. *Jpn J Neurosurg (Tokyo)*, 2013, 22, 362-369.

[34] Rejas Ugena, E; Trinidad Ruiz, G; Alvarez Domínguez, J; Carrasco Claver, F; Pino Rivero, V; Blasco Huelva, A. Utility of the surgical treatment for severe epistaxis by endoscopic approach of sphenopalatine and ethmoidal arteries. *Acta Otorrinolaringol Esp*, 2006, 57, 228-234.

[35] Yano, S; Hide, S; Shinoshima, N; Kuratsu, J. Usefulness of indocyanin green fluorescence endoscopy in endoscopic skull base surgery. *Jpn J Neurosurg (Tokyo)*, 2015, 24, 85-91.

[36] Kassam, AB; Prevedello, DM; Carrau, RL; Snyderman, CH; Thomas, A; Gardner, P; et al. Endoscopic endonasal skull base surgery: analysis of complications in the authors' initial 800 patients. *J Neurosurg*, 2011, 114, 1544-1568.

[37] Dusick, JR; Esposito, F; Kelly, DF; Cohan, P; de Salles, A; Becker, DP; et al. The extended direct endonasal transsphenoidal approach for nonadenomatous suprasellar tumors. *J Neurosurg*, 2005, 102, 832-841.

[38] Zada, G; Kim, AH; Governale, LS; Laws, ER. Midline filum of the sellar dura; a useful landmark during endoscopic transsphenoidal pituitary surgery. *Neurosurgery*, 2010, 67(Suppl 2), 391-394.

[39] Rhoton, AL. Diagnosis and management of pituitary tumors: Anatomy of the pituitary gland and sellar region. In Thapar K, Kovacs K, Scheithauer B, Lloyd RV (editors): *Diagnosis and Management of Pituitary Tumors*. Springer Science+Business Media New York 2001, pp 13-40.

[40] Perondi, GE; Isolan, GR; de Aguiar, PH; Stefani, MA; Falcetta, EF. Endoscopic anatomy of sellar region. *Pituitary*, 2013, 16, 251-259.

[41] Fujii, K; Chanmbers, SM; Rhoton, AL Jr. Neurovascular relationships of the sphenoid sinus. A microsurgical study. *J Neurosurg*, 1979, 50, 31-39.

[42] Vescan, AD; Snyderman, CH; Carrau, RL; Mintz, A; Gardner, P; Branstetter, B 4th; et al. Vidian canal: analysis and relationship to the internal carotid artery. *Laryngoscope*, 2007, 117, 1338-1342.

[43] Kassam, AB; Vescan, AD; Carrau, RL; Prevedello, DM; Gardner, P; Mintz, AH; et al. Expanded endonasal approach: vidian canal as a landmark to the petrous internal carotid artery. *J Neurosurg*, 2008, 108, 177-183.

[44] Banerji, D; Behari, S; Tyagi, I; Pandey, T; Jain, VK; Chhabra, DK. Extended frontobasal approach to the skull base. *Neurol India*, 2001, 49, 253-261.

[45] Inamasu, J; Guiot, BH. Iatrogenic carotid artery injury in neurosurgery. *Neurosurg Rev*, 2005, 28, 239-247.

[46] Cavallo, LM; Messina, A; Esposito, F; de Divitiis, O; Dal Fabbro, M; de Divitiis, E; et al. Skull base reconstruction in the extended endoscopic transsphenoidal approach for suprasellar lesions. *J Neurosurg*, 2007, 107, 713-720.

[47] Dehdashti, AR; Ganna, A; Witterick, I; Gentili, F. Expanded endoscopic endonasal approach for anterior cranial base and suprasellar lesions: indications and limitations. *Neurosurgery*, 2009, 64, 677-689.

[48] Vanninen, RL; Manninen, HI; Rinne, J. Intrasellar iatrogenic carotid pseudoaneurysm, endovascular treatment with a polytetrafluoroethylene-covered stent. *Cardiovasc Intervent Radiol*, 2003, 26, 298-301.

[49] Kai, Y; Hamada, J; Nishi, T; Ushio, Y. Successful treatment with bypass and interventional surgery for a ruptured pseudo carotid artery aneurysm after transsphenoidal surgery: a case report. *No Shinkei Geka*, 2001, 29, 241-245.

[50] Puri, AS; Zada, G; Zarzour, H; Laws, E; Frerichs, K. Cerebral vasospasm after transsphenoidal resection of pituitary macroadenomas: report of 3 cases and review of the literature. *Neurosurgery*, 2012, 71(Suppl 1), 173-181.

[51] Kasliwal, MK; Srivastava, R; Sinha, S; Kale, SS; Sharma, BS. Vasospasm after transsphenoidal pituitary surgery: a case report and review of the literature. *Neurol India*, 2008, 56, 81-83.

[52] Nishioka, H; Ito, H; Haraoka, J. Cerebral vasospasm following transsphenoidal removal of a pituitary adenoma. *Br J Neurosurg*, 2001, 15, 41-47.

[53] Cappabianca, P; Cavallo, LM; Esposito, F; De Divitiis, O; Messina, A; De Divitiis, E. Extended endoscopic endonasal approach to the midline skull base: the evolving role of transsphenoidal surgery. *Adv Tech Stand Neurosurg*, 2008, 33, 151-199.

[54] Kitano, M; Taneda, M; Shimono, T; Nakao, Y. Extended transsphenoidal approach for surgical management of pituitary adenomas invading the cavernous sinus. *J Neurosurg*, 2008, 108, 26-36.

[55] Kitano, M; Taneda, M. Extended transsphenoidal approach with submucosal posterior ethmoidectomy for parasellar tumors. Technical note. *J Neurosurg*, 2001, 94, 999-1004.

[56] Yamasaki, T; Moritake, K; Nagai, H; Kimura Y. Integration of ultrasonography and endoscopy into transsphenoidal surgery with a “picture-in-picture” viewing system--Technical note. *Neurol Med Chir (Tokyo)*, 2002, 42, 275-278.

[57] Litvack, ZN; Zada, G; Laws, ER. Indocyanine green fluorescence endoscopy for visual differentiation of pituitary tumor surrounding structures. *J Neurosurg*, 2012, 116, 935-941.

[58] Rhoton, AL. Jr. The sellar region. *Neurosurgery*, 2002, 51(Suppl 4), S335-374.

[59] Couldwell, WT; Weiss, MH; Rabb, C; Liu, JK; Apfelbaum, RI; Fukushima, T. Variations on the standard transsphenoidal approach to the sellar region, with emphasis on the extended approaches and parasellar approaches: surgical experience in 105 cases. *Neurosurgery*, 2004, 55, 539-550.

[60] Dolenc, VV; Lipovsek, M; Slokan, S. Traumatic aneurysm and carotid-cavernous fistula following transsphenoidal approach to a pituitary adenoma: treatment by transcranial operation. *Br J Neurosurg*, 1999, 13, 185-188.

[61] Fukushima, T; Maroon, JC. Repair of carotid artery perforations during transsphenoidal surgery. *Surg Neurol*, 1998, 50, 174-177.

[62] Matsuno, A; Yoshida, S; Basugi, N; Itoh, S; Tanaka, J. Severe subarachnoid hemorrhage during transsphenoidal surgery for pituitary adenoma. *Surg Neurol*, 1993, 39, 276-278.

In: Encyclopedia of Surgery (22 Volume Set)
Editors: Andreas Lehrer and Kristin Mueller
ISBN: 978-1-53618-329-0
© 2020 Nova Science Publishers, Inc.

Chapter 375

TRANSSPHENOIDAL SURGERY FOR PITUITARY ADENOMAS GUIDED BY INTRAOPERATIVE MAGNETIC RESONANCE IMAGING (IMRI)

Sven Berkmann*, MD and Javier Fandino, MD
Department of Neurosurgery, Kantonsspital Aarau, Tellstrasse, Aarau/Switzerland

ABSTRACT

Transsphenoidal surgery is the first-line treatment in the majority of symptomatic sellar tumors. The goals are cure of endocrinological syndromes (e.g., acromegaly), neurological deficits (e.g., optic chiasm compression syndrome), restoration of pituitary function and long-term tumor control. With the evolution of the transsphenoidal approach, several tools like the X-ray intensifier, cisternography, sonography, computed tomography, the endoscope, and the intraoperative MRI (iMRI) have been used to increase visualization of the tumor and thereby to make surgery safer and to increase the extent of resection.

The iMRI has been used since 20 years in combination with a microscopic or endoscopic approach and numerous studies have shown the efficacy of iMRI-controlled transsphenoidal surgery, as well as identified the indications and drawbacks of the various setups and subtypes. Based on our own peer-reviewed clinical studies and by reviewing the literature we will present critical insights in the use of this fascinating technology for transsphenoidal pituitary adenoma surgery.

Keywords: pituitary adenoma, transsphenoidal surgery, intraoperative MRI

1. INTRODUCTION

Transsphenoidal surgery is the first-line treatment in the majority of symptomatic sellar tumors. The goals are cure of endocrinological syndromes (e.g., acromegaly), relief of neurological deficits (e.g., optic chiasm compression syndrome), restoration of pituitary

* Corresponding Author's Email: sven.berkmann@ksa.ch.

function and long-term remission. Nevertheless, due to the narrow access to the *sella turcica* and its adjacent compartments, the rate of unsuspected – and further resectable - tumor remnants after surgery may be high. While gross total resection (GTR) of hormonally active pituitary adenomas is mandatory for cure of endocrinological syndromes, most remnants of hormonally inactive tumors may regrow within 5 years after resection and eventually cause local compression symptoms again [1]. Nevertheless, aggressive probing for tumor remnants may lead to severe complications due to the proximity of the optic nerves, the internal carotid arteries and the cavernous sinus. Visualization of the tumor and safe exploration of the surgical site is therefore the key to successful transsphenoidal surgery.

Lars Leksell advocated the philosophy that no technique in neurosurgery could be too refined, particularly in reference to the ability to localize lesions [2]. This is especially true for pituitary surgery. The first transsphenoidal tumor resection was performed by Hermann Schloffer (1886-1937) on March 16th 1907 in Innsbruck, Austria [3]. After a number of modifications culminating in the description of the oronasal rhinoseptal approach with a sublabial gingival incision by Albert Edward Halstead (1869-1926), Harvey Cushing (1869-1939) adopted this technique and performed 231 such procedures from 1910 to 1925. Ultimately Cushing abandoned the transsphenoidal approach. He reverted to the transcranial technique because he believed that the optical structures may thereby be more readily decompressed. Ultimately, this was a direct consequence of the non-existing possibility to sufficiently visualize the surgical site by the transsphenoidal approach. Due to Cushing's influence at the time, many surgeons followed his example. The transsphenoidal approach to the pituitary was mostly neglected for 40 years and it was only in the middle of the 60s with the birth of micro-neurosurgery and the introduction of the operating microscope when the renaissance of the transsphenoidal approach began.

Various tools for a better visualization of the tumor and its adjacent structures and for tailoring the transsphenoidal approach have been introduced during the subsequent 50 years. Principally, the further evolution of pituitary surgery was paralleled by the improvement of intraoperative imaging [4, 5]. In 1965 Hardy introduced the use of radiofluoroscopy in combination with the operating microscope [6]. Nevertheless, as the X-ray intensifier only allowed depiction of the skull base and the metal instruments introduced, there were further attempts in conjunction with cisternography to assess the suprasellar extension of the tumor [7]. In 1993 intraoperative computerized tomography was proposed as a more progressive tool to appraise the extent of tumor resection. At this time it was suggested that intraoperative CT scanning would probably remain the preeminent modality for conventional intraoperative image-guided surgery because of the enhanced access to the operating field and its instrument compatibility as compared to the iMRI, which almost evolved at the same time [8]. Nevertheless, use of radiation, fixed slice orientation, and especially the poor soft-tissue contrast limited the benefit [9]. Other attempts [10-12] to further localize the surrounding anatomical structures included ultrasonography and the color Doppler system; however, none of these tools reached a high level of acceptance as an independent method to assess the extent of resection [13-15].

During the past 15 years the evolution of image-guided neuronavigation based on preoperative datasets referenced to the patient's head began to replace intraoperative fluoroscopy for orientation in the surgical site more and more [16-21]. Because one of the main reasons for incomplete tumor resection is poor exposure of the sellar space, neuronavigation facilitated the optimal tailoring of the approach. In conjunction with

intraoperative imaging, real-time assessment of the grade of resection became possible because the neuronavigation datasets could be immediately updated with the new footage.

The intraoperative MRI (iMRI) has been used since 1994 [22]. In the subsequent years a growing number of departments all over the world adapted MRI systems to their operating theaters. In transsphenoidal surgery it allows a quick evaluation of the extent of tumor resection, an update of images for intraoperative navigation, and the exclusion of imminent complications (e.g., hemorrhage or ischemia), before the site is closed. Numerous studies have shown the efficacy of iMRI-controlled transsphenoidal surgery, as well as identified indications and drawbacks. In the first part of this chapter an overview of the different setups and subtypes of iMRI with respect to their pros and cons will be given. In the second part, today's experience in iMRI-controlled transsphenoidal surgery for pituitary adenomas with respect to the different pathological entities will be reviewed, before a critical review of the arguments in favor of and against the use of iMRI is finally given.

2. TECHNICAL SYSTEMS AND OPERATING ROOM SETUPS

The basic problems to be solved when using an iMRI are the following:

1. Electromagnetic interaction and compatibility of electrical devices used by the surgeon and the anesthesiologist
2. Ferromagnetic interaction between the surgical instruments and the scanner, which may not only influence image quality, but also the microsurgical handling of the devices and the safety of the patient and the operation personnel
3. Electromagnetic shielding to avoid loss of image quality caused by exogenous fields
4. Access to the operating field and possibilities for patient positioning. All these problems are directly correlated with the field-strength of the MR-scanner.

Therefore, two basic concepts for the use of iMRI have evolved: operating within the magnet and its associated field or moving the patient to the magnet only for scanning (i.e., "two room concept"). Commonly, the setups which make it possible to operate within the field are using field strengths up to 0.5 Tesla (T). These so-called 'low-field setups' are markedly different from 'high-field setups', which use magnetic fields from 1.5 to 3 T.

The first truly incorporated MR scanner within an operating room was the Magnetic Resonance Therapy Unit at Brigham and Women's Hospital in Boston, Massachusetts, introduced in 1994 [22]. It was a collaborative project between Peter Black as Head of the Neurosurgical Department, Marvin Fried, Director of the Department of Otorhinolaryngology, and Ferenc Jolesz of the Department of Radiology, and engineers at General Electric Medical Systems (Milwaukee, Wisconsin). In the late 1980s, the closed-configuration of conventional MRI systems prohibited access to the patient; therefore, fundamental changes in magnet and coil design and display methods were necessary. This resulted in a "double donut"-shaped scanner, with a magnetic field of 0.5 T in the space between the two "donut" rings (GE 0.5-T Signa SP). The surgeon was standing in the limited space between the two superconductive magnet coils. Along with the design of the iMRI, many commonly used tools had to be adapted: ferromagnetic surgical instruments were

replaced by titanium; the Mayfield head holder device was remodeled from high performance plastic; the power-drill used for e.g., modeling the craniotomy flap was redesigned by the Midas Rex Corporation (Medtronic, Minneapolis, Minnesota) as a non-ferromagnetic tool; the ferromagnetic joints of the operating microscope were replaced by plastic; and finally a bipolar coagulator not interfering with the magnetic field was introduced. Anesthesia and patient monitoring devices that did not emit electronic noise were at that time already in use for performing pediatric MR imaging under anesthesia and could be installed in the iMRI suite.

After the potential of the iMRI and its benefits became obvious, the next step was to optimize its availability and to develop cost-effective units. In Erlangen, Germany, Rudolf Fahlbusch, Michael Buchfelder, and Christopher Nimsky from the neurosurgical Department first developed together with their colleagues from Heidelberg and Siemens Medical (Siemens AG, Erlangen, Germany) a 0.2 T scanner (0.2-T Magnetom Open™; Siemens Medical solutions) in 1996, before moving on to a 1.5 T scanner (Magnetom Sonata Maestro Class™; Siemens Medical Solutions) in 2002. Integral to the new high-field concept was the possibility of simultaneous intraoperative imaging and neuronavigation. The setup was based on a rotatable surgical table (Trumpf, Saalfeld, Germany), which could be locked into various positions and adapted to the scanner to allow for a special surgical MR tabletop. MR-compatible monitoring was installed for control of anesthesia and for wireless 2.4 GHz data transfer from the radiofrequency-shielded cabin. For intraoperative navigation, the patient's head was fixed in a 5-pin head holder (Noras MRI products, Hoechberg, Germany) with an integrated 8-channel coil. This allowed to directly update the intraoperatively acquired datasets for neuronavigation without additional referencing. One shortcoming of this system is that patients can only be positioned in the prone or supine position. The neuronavigation datasets were used in conjunction with a navigation microscope placed inside the 0.5 mT zone. As opposed to the image quality generated by low-field-iMR systems, the quality obtained by high-field-strength scanners compared well to regular diagnostic MR-images. In addition, functional MRI, MR spectroscopy and fiber tracking became possible during surgery. For a regular T1- or T2-scan including the draping the scanning time amounts to about 10 to 15 minutes.

While various other low-field settings have been described [23, 24], one of the most widely used units are the PoleStar™ systems (Medtronic Navigation, Louisville, Colorado). This low-field setup was driven by the Israeli surgeon Moshe Hadani and his group and introduced in 2001 [25]. The initial model PoleStar™ N-10 iMRI consisted of a 0.12 T magnet that required only modest remodeling of the operating room. The actual model, PoleStar™ N20, comes with a 0.15 T-magnet (Figure 1).

The portable device is stored within a small garage next to the operating room and at need installed beneath the operating table. Thus, in contrary to a permanently installed scanner, the use of the operating theater is not dominated by the iMRI. A neuronavigation system (StealthStation TREON™, Medtronic) is integrated in the system, which detects not only the position of the patient but also of the iMR-scanner. During the scans radiofrequency shielding is maintained by a foldable tent (StarShield™, Medtronic), which encloses the magnet and the whole operating table. Although the surgical field is directly above the scanner, the use of ferromagnetic tools is still possible due to the comparably low field strength. Nevertheless, the power drill and the patient monitoring devices still have to be MR-compatible. The titanium head clamp and the space within the magnet allow prone, supine

and lateral positioning. As in the high field-setup, the scanning time including the draping amounts to about 15 minutes. One of the major drawbacks compared to the high field-iMRI is the low contrast and resolution of the images when used for pituitary surgery. The optic chiasm, the pituitary stalk and the internal carotid arteries may be readily identified, while invasive tumor in the cavernous sinus may be difficult to differentiate from the venous caverns [26, 27].

3. OUTCOME OF iMRI-CONTROLLED TRANSSPHENOIDAL SURGERY

Since 1994 a growing number of studies addressing the outcome of iMRI-controlled transsphenoidal surgery have been published [1, 26-56]. An overview of the literature is given in *Tables 1* and *2*. While earlier studies mostly aimed at feasibility and technical issues and presented patient groups with mixed pathologies [28, 46], the end points of recent studies have become more specific in reporting the outcome of the individual pituitary tumor pathologies, and in assessing the course of symptoms and the long-term outcome [1, 26, 47].

Figure 1. The PoleStar™ N20 unit with integrated neuronavigation system S7. (picture provided by courtesy of Medtronic Switzerland).

3.1. Nonfunctioning Pituitary Adenoma

Transsphenoidal surgery is the first-line treatment in symptomatic hormonally inactive pituitary tumors and histological specimens will show nonfunctioning or so-called silent secreting pituitary adenomas (NFA) in most cases. Serial imaging by MRI is mandatory as a postoperative follow-up routine, as there are no other markers (such as serum hormone levels) to hint for regrowth of tumor remnants or recurrence after GTR before local compression symptoms occur. Roelfsema et al. [57] found a recurrence rate for NFA after transsphenoidal surgery of 0.022 patients/year by analyzing 31 studies. Kaplan-Meier analyses show relapse rates of 23, 47 and 68% at 5, 10 and 15 years, respectively [58].

Therefore, GTR is the highest goal of surgery for NFA. Nevertheless, due to invasive or expansive tumor growth or lack of intraoperative visualization of unsuspected remnants, the final GTR rate may not be as high as could be preoperatively expected. The main reason for a reoperation in these patients is regrowth of tumor remnants [56. 58]. While residual tumors may shrink spontaneously during the first months after surgery, virtually all of the visible remnants do grow during long-term follow-up [1, 59]. The majority of regrowths is detected within 5 years after surgery; however, compared to hormonally active adenomas, up to 50% of these tumors may recur later [1, 57]. Because of invasive growth into the cavernous sinus or the clivus and because of abundant supra- and retrosellar tumor masses surgical resection is sometimes intended to remain incomplete; however if a complete resection seems possible, it is very unfortunate for the patient if tumor is left behind due to limited visualization during surgery. Consequently, this may provoke the discussion whether to re-operate in a patient who has possibly become asymptomatic, or whether to embark for lifelong high-frequent screening for regrowth.

This is the place for using the iMRI in NFA because, as will be shown, it significantly reduces the rate of unexpected remnants. While there was a tendency in the earlier phase to treat as many patients as possible with iMRI-control to gather further experience, latter studies are based on the thereby evolved indications for its use. These criteria include e.g., invasive tumor growth, history of previous transsphenoidal surgery and awkwardly irregular (e.g., dumbbell) shaped tumors. A selection for the use of iMRI in pituitary surgery is often necessary, because of the eventually high caseload of pituitary patients in large centers compared to the operating time capacity in the iMRI, which may also be used, for example, for glioma and epilepsy surgery.

Generally, acquisition of iMRI controls is decided in case GTR is supposed or if incomplete resection is suspected but no further removal seems safely possible. As with several study-designs on the use of intraoperative diagnostics, one may argue that the possibility of visualizing the tumor with iMRI may have weakened the effort to probe for occult remnants. Nevertheless, as control scans are generally time consuming and a final scan before the site is closed is mandatory, most surgeons may avoid supplementary scans. In most cases 2 to 3 scans are needed: the first scan before resection is started as a baseline benchmark for comparison, the second to look for remnants and an eventual third to ensure removal of these remnants.

Table 1. Results of iMRI-controlled pituitary surgery with low-field setups

Author	Ref.	Year	Diagnosis	n	iMRI setup	Field strength (T)	Remnant on 1st iMRI (n)	Additional resection (n)	GTR (n)	Increase of GTR rate by iMRI
Steinmeier et al.	109	1998	misc	16	Siemens Magnetom	0.2	6 (38%)	5 (83%)	13 (81%)	19%, p = NS
Martin et al.	75	1999	misc adenoma	5	General Electric Signa SP	0.5	2 (40%)	2 (100%)	4 (80%)	20%; p = NS
Bohinski et al.	26	2001	misc adenoma	29	Hitachi AIRIS II vertical-field	0.3	19 (66%)	19 (100%)	25 (86%)	52%, p < 0.0001
Fahlbusch et al.	41	2001	misc adenoma	44	Siemens Magnetom	0.2	25 (57%)	15 (60%)	31 (70%)	27%, p = 0.0087
Schwartz et al.	100	2006	misc adenoma	15	Polestar N-10	0.12	3 (20%)	3 (100%)	15 (100%)	20%; p = NS
Ahn et al.	3	2008	misc adenoma	51	Polestar N-20	0.15	13 (25%)	13 (100%)	48 (94%)	20%; p = 0.0062
Gerlach et al.	46	2008	misc adenoma	40	Polestar N-20	0.15	26 (65%)	7 (27%)	15 (38%)	3%; p = NS
Wu et al.	121	2009	misc adenoma	55	Polestar N-20	0.15	23 (42%)	23 (100%)	46 (84%)	26%; p = 0.0029
Baumann et al.	11	2010	giant adenoma	6	Polestar N-20	0.15	5 (83%)	5 (100%)	3 (50%)	33%; p = NS
Bellut et al.	14	2010	acromegaly	37	Polestar N-20	0.15	8 (21%)	8 (100%)	38 (97%)	18%; p = 0.0141
Theodosopoulos et al.	115	2010	misc adenoma	27	Hitachi AIRIS II vertical-field	0.3	9 (33%)	4 (44%)	19 (70%)	7%; p = NS
Vitaz et al.	118	2011	misc	100	General Electric Signa SP	0.5	41 (41%)	41 (41%)	76 (76%)	35%; 0.0077
Ramm-Pettersen	91	2011	misc adenoma	20	General Electric Signa SP	0.5	12 (60%)	11 (92%)	12 (60%)	20%; p = NS
Berkmann et al.	19	2011	misc adenoma	32	Polestar N-20	0.15	15 (47%)	9 (60%)	25 (78%)	25%; p = 0.0321
Berkmann et al.	18	2012	NFA	60	Polestar N-20	0.15	23 (38%)	20 (87%)	51 (85%)	23%; p = 0.0034
Berkmann et al.	17	2012	misc	115	Polestar N-20	0.15	45 (39%)	36 (80%)	94 (82%)	21%; p = 0.0004
Bellut et al.	13	2012	misc adenoma	148	Polestar N-20	0.15	56 (38%)	44 (79%)	106 (72%)	10%; p = NS
Tabakow et al.	113	2012	misc adenoma	18	Polestar N-20	0.15	9 (50%)	6 (67%)	15 (83%)	33%; p = 0.0375
Kim et al.	57	2013	misc adenoma	198	Polestar N-20	0.15	44 (22%)	37 (84%)	184 (93%)	15%; p < 0.0001
Hlavica et al.	51	2013	NFA	104	Polestar N-20	0.15	48 (46%)	44 (92%)	70 (67%)	21%; p = 0.0324

Abbreviations: misc sellar, miscellaneous sellar tumors; misc adenoma, miscellaneous pituitary adenomas; NFA, nonfunctioning pituitary adenoma; GTR, gross total resection; NS, not significant

Table 2. Results of iMRI-controlled pituitary surgery with high-field setups

Author	Ref.	Year	Diagnosis	n	iMRI setup	Field strength (T)	Remnant on 1st iMRI (n)	Additional resection (n)	GTR (n)	Increase of GTR rate by iMRI
Dort et al.	39	2001	misc adenoma	15	Magnex Scientific IMRIS	1.5	9 (60%)	9 (100%)	14 (93%)	33%; p = 0.0026
Fahlbusch et al.	42	2005	acromegaly	23	Siemens Magnetom Sonata Maestro	1.5	13 (57%)	5 (38%)	14 (61%)	18%; p = NS
Nimsky et al.	82	2006	NFA	129	Siemens Magnetom Sonata Maestro	1.5	61 (47%)	47 (77%)	83 (64%)	17%; p = 0.0383
Pamir et al.	87	2011	NFA	42	Siemens Magnetom Trio	3	22 (52%)	10 (45%)	24 (57%)	9%; p = NS
Meng et al.	77	2011	misc adenoma	30	Calgary Crane System, IMRIS	1.5	12 (40%)	10 (83%)	26 (87%)	27%; p = 0.0195
Lang et al.	62	2011	misc	9	Siemens Magnetom Verio IMRIS	3	1 (11%)	1 (100%)	9 (100%)	11%; p=NS
Netuka et al.	81	2011	misc	86	Signa HDx General Electric	3	51 (59%)	31 (61%)	45 (52%)	11%; p = NS
Szerlip et al.	112	2011	misc adenoma	53	Siemens Magnetom Espree	1.5	34 (64%)	28 (82%)	33 (62%)	26%; p = 0.0056
Tanei et al.	114	2013	misc adenoma	14	Siemens Magnetom Symphony	1.5	7 (50%)	5 (71%)	11 (79%)	29%; p = NS
Fomekong et al.	45	2014	misc adenoma	73	Philips Achieve	3	30 (41%)	8 (27%)	53 (73%)	14%; p = 0.05
Berkmann et al.	21	2014	NFA	85	Siemens Magnetom Sonata Maestro	1.5	48 (56%)	40 (83%)	56 (66%)	22%; p = 0.0027
Berkmann et al.	22	2014	NFA recurr	111	Siemens Magnetom Sonata Maestro	1.5	92 (83%)	62 (67%)	54 (49%)	32%; p < 0.0001
Sylvester et al.	111	2014	misc adenoma	156	Siemens Magnetom Espree	1.5	112 (72%)	56 (50%)	59 (38%)	10%; p = 0.0458
Paterno et al.	89	2014	misc adenoma	72	Siemens Magnetom Espree	1.5	42 (58%)	26 (56%)	53 (74%)	32%; p < 0.0001
Coburger et al.	31	2014	misc adenoma	76	Siemens Magnetom Espree	1.5	NA	NA	40 (53%)	NA

Abbreviations: misc sellar, miscellaneous sellar tumors; misc adenoma, miscellaneous pituitary adenomas; NFA, nonfunctioning pituitary adenoma; reop, reoperated; GTR, gross total resection; NS, not significant

The use of iMRI facilitates GTR. This is the common conclusion in studies on iMRI-controlled transsphenoidal surgery. For the pathologies operated with low-field iMRI (Table 1) the mean increase of GTR rates was 22% (range 3-52%). Additional resections based on iMR images were performed in 27-100% (mean 81%) of the patients. For high-field iMRI studies (Table 2) the mean increase of GTR was 21% (range 9-33%) and additional resections were possible in 27-100% (mean 67%) of the patients. The broad range of these results is characterized by the variability of types, sizes and grades of infiltration of pathologies included in these various studies. As mentioned above, some NFA are deemed for intended incomplete resection. The mean GTR rate in the low-field studies (*Table 1*) was 57% (range 17-80%) in the first intraoperative scan and 77% (38-100%) in the postoperative scan. In high-field studies, the initial mean GTR rate was 47% (range 17-89%) and 67% (38-100%) after additional resection. It is noteworthy that a meta-analysis of 5.022 patients with NFA operated without the use of iMRI reported a mean GTR rate of 44% [57]. This reflects nicely the GTR rate detected by the iMRI scans before further resections based on these images were made.

To assure a good outcome, long-term follow-up is the key in NFA; however, there are only few studies with mean follow-ups over 1 year. In a recent series on transsphenoidal surgery for NFA assisted by ultra-low-field MRI, an initial GTR rate of 85% was reported for 60 NFA with a mean volume of 6.8 cm^3. No recurrences were seen during a mean follow-up of 3.2 years (0.5-4.3 years) [27]. Another study with a follow-up of 2.8 years in 104 patients with NFA, who were operated in a PoleStar™-unit, detected recurrences in 3% of the patients [44]. For high-field iMRI, the study [1]. with the currently longest mean follow-up (5.6 years) reported recurrences in 7% of the patients resulting in a comparably low recurrence rate of 0.013 patients/year (as compared to the quoted meta-analysis which reported a rate of 0.022 patients/year) [57]. In the same study, regrowth of known remnants after incomplete resection was noted by follow-up imaging in 64 % of the patients. The regrowth rate was 0.114 patients/year. Seventy-nine percent of these patients showed further growth within 5 years after surgery.

In the case of recurrence of NFA after GTR or regrowth of tumor remnants, treatment options include observation, radiotherapy, stereotactic radiosurgery, and transsphenoidal reoperation or craniotomy. Transsphenoidal reoperations for tumor resection may be challenging, due to the varying operative anatomy, frequently invasive growth of these recurring tumors, loss of anatomical landmarks, the effects of radiotherapy and the presence of scarring. While various studies on the use of iMRI also included patients with reoperations in their mixed study groups, a recent study explicitly reports on this subject [56]. The initial GTR rate in these patients was 17%, which correlates well with the rates reported in the literature on transsphenoidal reoperations without iMRI [60]. Further resection based on the updated iMRI sequences was possible in 67% of these patients, resulting in a final GTR rate of 49%. In patients with noninvasive tumors the GTR rate could even be increased from 31% to 75%. Nevertheless, the GTR rate of 49% is still low compared with data from iMRI studies on first-time procedures (*Tables 1 & 2*). The complication rate for reoperations was reported to be significantly higher than for primary surgery [61]. Diabetes insipidus, meningitis and cerebrospinal fluid (CSF) fistulas, as a sequelae that need to be repaired, may be present in up to 25%, 5% and 9% of these patients, respectively. The reported rates for iMRI-controlled resections did not exceed the incidence reported in the literature for primary procedures [62,

63]. Persistent diabetes insipidus was found in 3%, reoperations for CSF leaks were indicated in 4% of these cases and 2% of the patients suffered from postoperative meningitis [56].

Even if not completely resectable and as stated, this may be e.g., more often the case in reoperations of recurrent tumors or in invasive tumors the iMRI may facilitate remnant volume reduction [1, 56]. This is essential if further therapy options like conventional or stereotactic irradiation have to be indicated. Tumor control rates of 90% were reported for fractionated radiotherapy [64, 65], as well as for stereotactic irradiation such as Gamma Knife radiosurgery [66-69]. The peak of tumor size reduction is seen about 3 years after radiotherapy, and volume reductions of 50% have been described within 5 years [70, 71]. Additionally, radiosurgery may be an option for local control in patients with pituitary adenomas who have already undergone radiotherapy [72]. Tumor volume is one of the most important issues for indicating radiosurgery. The main factor influencing the incidence of tumor regrowth or the induction of neurological deficits by radiosurgery is a tumor volume greater than 5 cm^3 [68, 73]. Therefore, even if complete resection may not be possible, additional iMRI guided reduction may achieve smaller remnant volumes and thereby enhance the efficiency and at the same time reduce the morbidity of radiotherapy.

3.2. Outcome of Compression Syndromes

If not detected incidentally by MRI or CT imaging, indicated for non-pituitary related disorders, pituitary adenomas and typically NFA may grow extensively. With time they lead to damage of the anterior visual pathway, such as visual field (VF) defects or decline of visual acuity (VA) as described by Harvey Cushing in 1935 [74, 75]. Oculomotor and facial sensibility disturbances may be seen in the case of parasellar extension to the cavernous sinus, and even obstructive hydrocephalus may occur when the third ventricle is compressed. For ophthalmological symptoms, early decompression of the chiasm and the optic nerves significantly improves visual outcomes [76, 77]. In the case of rapid VA decline caused by pituitary tumor apoplexy transsphenoidal decompression may even be indicated as an emergency procedure [78]. Nevertheless, in case of abundant suprasellar extension of macro- or giant-adenomas, the risk for leaving behind remnants is high. These residual masses may prolong symptoms and thereby reduce the possibility of the optic fibers to recover. Remnants may typically be hidden in descending folds of the sellar diaphragm and visualization by the microscope or the endoscope may be difficult [11]. Furthermore, possibly unnecessary manipulations of the diaphragm, which is often thinned due to the distension caused by the tumor, may lead to CSF leaks. Ultimately, blind probing into the suprasellar space may directly harm the optic nerves.

Through the use of iMRI these limitations in visualizing remnants which compress the optic nerves may be overcome. Generally, the suprasellar structures are more distinctively depicted, while primarily in low-field imaging intra- and parasellar remnants may be more difficult to detect. The specificity for low-field iMRI to detect remnants was reported to be about 90% and the sensitivity 100% [26, 27]. For high-field iMRI, a specificity and a sensitivity as high as 100% was reported [1]. In a study explicitly addressing the issue of early visual recovery after iMRI-controlled tumor resection in a low-field setting, 60% of the patients with residual tumors had persistent optic nerve compression on the first iMRI control scans [26]. An additional resection was possible in 56% of these patients. Ultimately the optic

apparatus was decompressed in 84% of the patients. The positive predictive values for VF and for VA recoveries if a decompressed optic chiasm was depicted by iMRI were both as high as 96%. For high-field settings, long-term data show improvement of VF and VA in up to 100% of the patients [1]. In iMRI-controlled reoperations VF and VA recovery were 86% and 74%, respectively [56]. One of the reasons for the lower rate in reoperated patients may be the longer duration of symptoms caused by persistent compression of the optic nerve structures; however, until now there is no controlled data supporting this thesis. Basically, a randomized trial may be able to compare the differences in the ophthalmological outcome caused by the use of iMR imaging; however, it may be questionable to which extent this could withhold the overt benefit of iMR imaging to these patients.

Deterioration of vision is one of the severe complications of transsphenoidal surgery. It was described by different authors, also after procedures guided by iMR imaging [30, 35, 48, 56]. Based on the reported rates in the studies summarized in Tables 1 and 2, the apparent incidence of postoperative decline of visual function may be below 1%; however, the comparison with study groups not using iMRI imaging remains difficult. It may be biased due to the different techniques applied and the variability of factors such as size, consistency and invasiveness of the tumors and duration of symptoms of the patients included. Nevertheless, while an incidence for ophthalmic function decline of 3% has been reported in a study using iMRI [79], the incidence in other studies without iMRI seems to be similar to those using iMRI [16, 20, 80-82].

3.3. Outcome of Hormonal Function

The dominant mechanisms of hypopituitarism are interruption of the hypophyseal portal vessels, compression of the pituitary stalk, and increased intrasellar pressure caused by tumor growth [83-87]. Therefore, surgical decompression of the pituitary gland and its stalk may lead to recovery of hypopituitarism. Predictive factors for better recovery rates include younger age, absence of arterial hypertension, lack of intraoperative CSF leak, pre-operative hyperprolactinemia and smaller tumor size [83, 88, 89]. The detection of gross total resection on postoperative imaging is a significant factor for postoperative hormonal recovery [90]. On the other hand, loss of pituitary function may be a complication of pituitary surgery. The rate of postoperative hypopituitarism in series on transsphenoidal tumor resections is commonly below 20% [63, 88, 89, 91-94]. Nevertheless, higher rates have been described [95-97]; especially in the case of larger or hormonally inactive tumors [88-90, 98] or pituitary apoplexy [99, 100].

Series of transsphenoidal surgery for pituitary adenomas with iMRI controls report an incidence of new hypopituitarism of 0-29% [27, 34, 36, 47, 48]. When comparing patients with NFA, who were operated in the iMRI to matched controls, the benefit in increasing GTR again becomes obvious. In a study focusing on endocrinological outcome, the first low-field iMRI scan showed GTR in 62% of the patients, which corresponds well to the results of postoperative MRI in the control group showing a GTR rate of 69% [27]. Additional tumor resection significantly increased the GTR rate in the iMRI-group to 85%. The question whether a possibly aggressive additional resection based on iMRI controls puts pituitary function at harm could be denied in this and in subsequent studies [1, 27, 56]. While the differences of new hormonal deficits (iMRI-group 29%, control group 45%), which was

generally high in this study, including mainly large and invasive NFA, did not reach statistical significance, there was however a tendency towards a smaller hormonal complication rate of iMRI-controlled surgery. Considering the recovery rates of tumor-induced hypopituitarism, a similar tendency towards a beneficial effect of iMRI was reported. As 59% of the patients in the iMRI-group showed some restoration of pituitary axis function, this was only detected in 45% of the controls. Predictive factors for a lower risk of pituitary function loss when the iMRI was used were age below 65 years, absence of cardiovascular risk factors (e.g., arterial hypertension and tobacco smoking) and pre-existing partial hypopituitarism [27]. Additionally, long-term data of patients operated in a high-field setting show quite dynamic results of the endocrinological outcome in those with NFA [1]. The development of hypopituitarism was detected in 11% of the patients 1 week after surgery; however, further loss was diagnosed in another 15% during a mean follow-up time of 5.6 ± 1.9 years. On the other hand, hormonal recovery was seen in 29% of the patients 1 week postoperatively and in another 48% of the patients at the end of follow-up. Radiotherapy-induced pituitary damage [101] may have influenced these results to some extent as 27% of the patients with late onset hypopituitarism were irradiated. This points out to the conclusion that repetitive testing of hormonal function is mandatory not only in iMRI-controlled, but in all NFA patients possibly suffering from hypopituitarism, as recovery or loss of function may happen not only in the initial but also in the later course after surgery [1, 102].

While reoperations may be a risk factor for loss of pituitary axes function, the reported rates for iMRI-controlled surgery do not exceed this range [56, 61]. In reoperated NFA with use of iMRI, endocrinological follow-up testing showed postoperative loss and recovery of hormonal axes in 12% and 15% of patients, respectively [56]. This recovery rate seems comparably low to series on primary surgeries; however, this may correlate with the lower GTR rate in reoperations as previously discussed [90].

In patients with intraoperative CSF leaks, craniopharyngiomas or Rathke's cleft cysts as well as transient or permanent diabetes insipidus may be detected more often [103]. The use of iMRI did not significantly influence the incidence of postoperative diabetes insipidus or syndrome of inadequate antidiuretic hormone secretion in a comparative cohort study including patients with NFA [27]. Nevertheless, the reported rates of diabetes insipidus (8%) and SIADH (5%) were comparably small when compared to the incidence in the general literature (18-30%) [62, 103-107].

3.4. Functioning Pituitary Adenoma

Acromegaly is caused by a growth hormone (GH)-producing pituitary adenoma. If excessive output of GH is not normalized, cardiovascular and metabolic disturbances as well as cosmetic and orthopedic deformities will result. Depending on the criteria for remission, transsphenoidal surgery in acromegaly leads to cure of the condition in 50-60% of the patients [41, 108-115]. Indeed, the size matters, as 75-95% of the patients with microadenomas, but only 40-70% of the patients with macroadenomas will show normalization of growth hormone excess. High preoperative growth hormone levels and invasive tumor growth configuration are two other significant predictors of an incomplete resection [108]. Persistent postoperative acromegaly may be accompanied by larger visible, either resectable or unresectable tumor remnants. Re-operations are reasonable only when tumor remnants that

seem to be resectable are detected. Nevertheless, due to postoperative changes in early MR-imaging, the sensitivity for detecting remnants is low during the first 3 months after surgery. While early imaging within 3 days postoperatively may still prove helpful [116], later images may become difficult to "read" due to scarring, fluid retention and changes of grafts applied for closure [117]. While growth hormone levels decrease rather rapidly within days, if surgery was successful, IGF-1 may decrease only after 1-2 weeks. That is why normally at the time when persisting acromegaly becomes probable, an immediate MRI to indicate an early reoperation before scarring takes place may not be helpful. Therefore, the results of iMRI scans, performed before the site is closed, may be valuable.

Intraoperative image quality is crucial for the evaluation of the intrasellar structures, and it was therefore postulated that the high-field setup would have definitive advantages over the low-field setups [47]. The only study, exclusively focusing on the outcome of growth hormone excess after transsphenoidal resection in a high-field setting, included 23 patients [47]. In 78% of the patients, complete tumor removal was intended; however, iMRI scans revealed tumor remnants in 44% of the operated cases, leading to an extended resection in 28% of them. This increased the rate of complete tumor removal and endocrine normalization from 33% to 44% using the consensus criteria [118], and improved endocrine outcome in another 17%. The comparability between postoperative MRI after three months and iMRI was excellent as none of the patients with remnants depicted on iMRI met the criteria for remission. In all cases with suspected cavernous sinus infiltration on iMRI, postoperative imaging after 3 months confirmed the parasellar remnants. If iMRI showed complete removal and no full endocrine remission was achieved, postoperative MRI after 3 months neither showed a remnant.

Surgery for GH-producing pituitary adenoma, applying an ultra-low-field iMR imaging modality, showed an overall remission rate of 67% [37]. In patients with primary surgery the remission rate was 74%; however, in previously operated patients the rate dropped to 20%. The remission rate was increased by 5% by additional resections based on iMRI scans. The patients' characteristics of the already performed studies using high-field [47] or low-field iMRI [37] do not seem to be well comparable; thus, deductions which modality may be superior cannot be drawn from these results.

While there are studies including miscellaneous subtypes of functioning pituitary adenomas [41, 54], there is no study up to now reporting results on iMRI-controlled transsphenoidal surgery exclusively for Cushing's disease or prolactinoma in a reasonable large patient group.

3.5. iMRI in Combination with Endoscopy

As stated above, visualization of the tumor and the related anatomy of the operating field is the key to successful transsphenoidal surgery. While the results of iMRI-controlled operations have been presented in this chapter, other techniques which may be used as a sole modality or in conjunction with iMRI have to be mentioned. As an additional tool for transsphenoidal surgery, the endoscope has been used more and more during the past decade. Numerous studies reported technical details, surgical results and its value in tumor visualization. In this context, several reports of endoscopicaly-assisted procedures, as an adjunct to low-field and to high-field iMRI-guidance for resection control, have been

published [1, 32, 38, 52, 56]. Considering tumor visualization, sensitivity and specificity for detection of remnants by high-field iMRI were reported to be 100% compared to postoperative MRI [1]. The endoscopical assessment of the resection rate before an iMRI-control scan was acquired in the same patients yielded a sensitivity of only 21% and a specificity of 78%. The remnants depicted by iMRI were found in the following localizations: lateral of the sella/cavernous sinus, 48%; suprasellar space, 28%; retrosellar space/clivus, 12%; in the sella, 12%. An additional resection based on the iMR images was made in 73% of these patients. Thereby the difference between the GTR rate (66%) on the postoperative MRI and the GTR rate (35%) detected by iMRI after endoscopicaly-assisted resection became very significant ($p < 0.0001$; OR 5.4, 95% CI 2.3-13.0).

In transsphenoidal reoperations the endoscopic assessment of GTR may even be more difficult, e.g., due to scarring and lack of anatomical landmarks. A study on transsphenoidal reoperations, which included a small subgroup of patients operated with endoscopical assistance used in a high-field iMRI-setting, reported that GTR was assumed in 40% of the patients based on the endoscopic assessment [56]. In another 40% of the patients partial resection was detected by the endoscope but further tumor removal did not seem possible. In the remaining 20% no definite statement about the extent of resection could be given. All of these patients showed tumor remnants on the subsequent iMRI control scans even those who were thought to be without remnants based on the endoscopic visualization. The localization of the remnants on the iMRI scans was as follows: lateral/in the cavernous sinus, 60%; suprasellar, 50%; intrasellar, 10%. Notably, an additional iMRI-guided resection was possible in 80% of these cases.

Previous studies raised similar points concerning false negative endoscopical findings, and uniformly reported an increase of GTR rates after further tumor visualization by iMRI [32, 38]. In contrast to the direct inspection by the endoscope, iMRI allows the evaluation of hidden structures which are not accessible by direct visualization (e.g., by being hidden in invaginations of the descending diaphragm or in the suprasellar space). The identification of tumor remnants may be even more facilitated by the possibility of comparing pre- and intraoperative images that are acquired in the same position of the device. Compared to the iMRI, the endoscope may be less cost intensive. Nevertheless, the benefit of a complete resection in these mostly benign tumors weakens arguments about costs. While most studies on iMRI were not weighed towards the analysis of cost efficiency, the significantly higher GTR rate made possible by iMRI controlled surgery resulting in a lower rate of reoperations or additional therapies (e.g., radiotherapy) is indeed noteworthy.

4. PROS AND CONS

4.1. Specificity and Sensitivity of Tumor Detection

Visualization is the key; however, the surgeon has to remind himself that not everything that he detects with whatever tool used to visualize tumor remnants is really what it seems to be. False-positive iMRI findings may provoke unnecessary probing for remnants and increase the risk of hypopituitarism and CSF leakage. Both the specificity and sensitivity of iMRI for

detection of residual sellar lesions were subject of debate in several studies [1, 26, 27, 30, 31, 35, 56, 119]. The following reasons for misinterpretations have been reported:

1. The iMRI fails to give sufficient imaging results due to "noise"
2. Gadolinium enhancement is poor
3. Image layering misses the tumor
4. Poor resolution due to low field strength
5. There is difficulty in differentiating remnants of sellar tumor from intrasellar blood products and blood within the venous sinus. Specificity and sensitivity reported for both low- and high-field iMRI are commonly in the range of 90-100% and 75-100%, respectively.

It seems that most often coagula may be misinterpreted as residual tumor. In low-field settings pituitary adenoma and blood products often have an isointense aspect in non-enhanced T1- and T2-weighed images. If gadolinium is administered a difference may be observed during the first control scan. Nevertheless, in the case of repeat imaging the accumulated blood may be mixed with contrast agent and reliable differentiation may not be possible anymore. There are several technical tricks to facilitate image interpretation. Pooling of blood may be prevented by applying bone wax as a temporary reconstruction of the sellar floor [31]. In small adenomas the resection cavity may be filled with a small wax ball and the localization and extent of the ball may be compared to the tumor localization on the scans acquired before resection. Another technique to enhance the contrast is packing of the tumor resection cavity with contrast-soaked cotton pledgets and filling the remainder of the space with gauze [45].

4.2. Time and Cost Efficiency

One of the common arguments used by sceptics against iMRI-controls in transsphenoidal surgery is the additional time needed for the scans. Nevertheless, the duration of the control scans is often overestimated. Most devices provide short scanning sequences to verify the scanner's correct position before a longer sequence is started. For the Medtronic PoleStar™-unit there is e.g., the eSteady sequence, which is acquired in 24 seconds. The Siemens Magnetom Sonata™ provides a shortcut via the HASTE sequence, which takes 20 seconds. In case of a remnant already depicted by these sequences, surgery may be continued without further detailed time-consuming imaging. More detailed scan sequences (e.g., the T1-weighed contrast enhanced 3mm scan of the Medtronic PoleStar™unit or the T2-scan of the Siemens Magnetom Sonata™) will take about 10 minutes and may be immediately transferred to the neuronavigation sequences without further referencing. Thus, the mean duration for draping, scanning and return to the surgical field is about 15 minutes. Depending on the number of intraoperative scans needed, the use of an iMRI will prolong the procedure by 15-30 minutes in most cases [36, 56]. Nevertheless, the operating time will also be prolonged by the consecutive additional resections, which obviously would not have been made without the use of iMRI. Thus, the operating times of procedures with and without iMRI may not be well comparable. Until now, no tendency of an increased complication rate caused by the prolonged operation time was detected [12]. Ultimately the surgeon has to ask the question

whether the goal is to increase the chances for a GTR during the first procedure which will take some extra time or whether the operating time is better used for the reoperation if a resectable remnant keeps on growing.

Due to the additional time needed, in case this technology is used, it may be reasonable to use selection criteria for indicating the use of iMRI in transsphenoidal pituitary surgery. This may even be mandatory in high-impact centers, as operative capacity in the iMRI may be lower than the number of patients asking for treatment. A proposal which patients benefit from iMRI-controlled procedures has been made and includes the following points [1]:

1. History of previous transsphenoidal surgery (e.g., with presence of massive scarring and loss of anatomical landmarks)
2. Invasive tumor growth pattern (e.g., into the clivus or the cavernous sinus, Knosp grades 3 or 4)
3. Abundant suprasellar or retrosellar tumor growth (modified Hardy's grades 3 or 4) [6, 120] with consecutive high probability of incomplete resection and/or persisting symptomatic remnants (e.g., dumbbell-shaped tumors)
4. Tumors that need extended transsphenoidal approaches (e.g., subfrontal, transclival).

An additional drawback for the use of iMRI is the considerable equipment cost. This may be an issue more dominated by medico-economic arguments, than influenced by the results of the individual operative procedures which, as has been shown in the previous pages, are significantly enhanced by the use of iMRI. Of course the iMRI suites are not exclusively used for transsphenoidal surgery. Concurrent with the quoted results of its use for pituitary tumors, numerous studies have reported the benefit in several other cranial procedures. Promising results have e.g., been reported for iMRI-controlled resection of low and high grade glioma [121-123] and in epilepsy surgery [124, 125]. Depending on the case load and case mix of a department, the concept of an iMRI may be very reasonable. Given by the fact that informed patients often seek treatment in specialized departments with availability of intraoperative imaging techniques, the thereby provoked increase in cases may once more improve the affordability of such a device.

The true value of iMRI in transsphenoidal pituitary surgery may ultimately only be determined by randomized studies. Ironically, due to the excellent results provided by the studies presented above, this will be difficult to accomplish. Surgeons as well as patients with tumors suitable for iMRI-controlled procedures will want to use this technology and artificially withholding an obvious benefit is simply not justifiable.

REFERENCES

[1] Berkmann, S; Schlaffer, S; Nimsky, C; Fahlbusch, R; Buchfelder, M. Follow-up and long-term outcome of nonfunctioning pituitary adenoma operated by transsphenoidal surgery with intraoperative high-field magnetic resonance imaging. *Acta Neurochir (Wien)*, 2014, 156, 2233-2243.

[2] Lunsford, LD; Kondziolka, D; Bissonette, DJ. Intraoperative imaging of the brain. *Stereotact Funct Neurosurg*, 1996, 66, 58-64.

[3] Schloffer, H. Erfolgreiche Operation eines Hypophysentumors auf nasalem Wege (In German). *Wien Klin Wochenschr*, 1907, 20, 621-624.

[4] Buchfelder, M. Treatment of pituitary tumors: surgery. *Endocrine*, 2005, 28, 67-75.

[5] Maartens, NF. The history of the treatment of pituitary adenomas. *Endocrine*, 2005, 28, 9-26.

[6] Hardy, J; Wigser, SM. Trans-sphenoidal surgery of pituitary fossa tumors with televised radiofluoroscopic control. *J Neurosurg*, 1965, 23, 612-619.

[7] Nesbakken, R; Reinlie, S; Eldevik, OP. Intraoperative gas cisternography and gas dissection in the operative treatment of pituitary tumors. A methodological description. *Eur Surg Res*, 1984, 16 Suppl 2, 73-79.

[8] Lunsford, LD; Kondziolka, D; Maitz, A; Flickinger, JC. Black holes; white dwarfs and supernovas: imaging after radiosurgery. *Stereotact Funct Neurosurg*, 1998, 70 Suppl 1, 2-10.

[9] Okudera, H; Takemae, T; Kobayashi, S. Intraoperative computed tomographic scanning during transsphenoidal surgery: technical note. *Neurosurgery*, 1993, 32, 1041-1043.

[10] Sylvester, PT; Evans, JA; Zipfel, GJ; Chole, RA; Uppaluri, R; Haughey, BH; et al. Combined high-field intraoperative magnetic resonance imaging and endoscopy increase extent of resection and progression-free survival for pituitary adenomas. *Pituitary*, 2015, 18, 72-85.

[11] Paterno, V; Fahlbusch, R. High-Field iMRI in transsphenoidal pituitary adenoma surgery with special respect to typical localization of residual tumor. *Acta Neurochir (Wien)*, 2014, 156, 463-74.

[12] Coburger, J; Konig, R; Seitz, K; Bazner, U; Wirtz, CR; Hlavac, M. Determining the utility of intraoperative magnetic resonance imaging for transsphenoidal surgery: a retrospective study. *J Neurosurg*, 2014, 120, 346-356.

[13] Arita, K; Kurisu, K; Tominaga, A; Kawamoto, H; Iida, K; Mizoue, T; et al. Trans-sellar color Doppler ultrasonography during transsphenoidal surgery. *Neurosurgery*, 1998, 42, 81-86.

[14] Atkinson, JL; Kasperbauer, JL; James, EM; Lane, JI; Nippoldt, TB. Transcranial-transdural real-time ultrasonography during transsphenoidal resection of a large pituitary tumor. Case report. *J Neurosurg*, 2000, 93, 129-131.

[15] Doppman, JL; Ram, Z; Shawker, TH; Oldfield, EH. Intraoperative US of the pituitary gland. Work in progress. *Radiology*, 1994, 192, 111-115.

[16] Elias, WJ; Chadduck, JB; Alden, TD; Laws, ER; Jr. Frameless stereotaxy for transsphenoidal surgery. *Neurosurgery*, 1999, 45, 271-277.

[17] Jane, JA; Jr, Thapar, K; Alden, TD; Laws, ER. Jr. Fluoroscopic frameless stereotaxy for transsphenoidal surgery. *Neurosurgery*, 2001, 48, 1302-1308.

[18] Kacker, A; Komisar, A; Huo, J; Mangiardi, J. Transsphenoidal surgery utilizing computer-assisted stereotactic guidance. *Rhinology*, 2001, 39, 207-210.

[19] Lasio, G; Ferroli, P; Felisati, G; Broggi, G. Image-guided endoscopic transnasal removal of recurrent pituitary adenomas. *Neurosurgery*, 2002, 51, 132-137.

[20] Thomale, UW; Stover, JF; Unterberg, AW. The use of neuronavigation in transnasal transsphenoidal pituitary surgery. *Zentralbl Neurochir*, 2005, 66, 126-132.

[21] Walker DG, Ohaegbulam C, Black PM. Frameless stereotaxy as an alternative to fluoroscopy for transsphenoidal surgery: use of the InstaTrak-3000 and a novel headset. *J Clin Neurosci* 2002;9:294-297.

[22] Black, PM; Moriarty, T; Alexander, E; 3rd, Stieg, P; Woodard, EJ; Gleason, PL; et al. Development and implementation of intraoperative magnetic resonance imaging and its neurosurgical applications. *Neurosurgery*, 1997, 41, 831-845.

[23] Lewin, JS; Nour, SG; Meyers, ML; Metzger, AK; Maciunas, RJ; Wendt, M; et al. Intraoperative MRI with a rotating; tiltable surgical table: a time use study and clinical results in 122 patients. *AJR Am J Roentgenol*, 2007, 189, 1096-1103.

[24] Darakchiev, BJ; Tew, JM; Jr, Bohinski, RJ; Warnick, RE. Adaptation of a standard low-field (0.3-T) system to the operating room: focus on pituitary adenomas. *Neurosurg Clin N Am*, 2005, 16, 155-164.

[25] Hadani, M; Spiegelman, R; Feldman, Z; Berkenstadt, H; Ram, Z. Novel, compact, intraoperative magnetic resonance imaging-guided system for conventional neurosurgical operating rooms. *Neurosurgery*, 2001, 48, 799-809.

[26] Berkmann, S; Fandino, J; Zosso, S; Killer, HE; Remonda, L; Landolt, H. Intraoperative magnetic resonance imaging and early prognosis for vision after transsphenoidal surgery for sellar lesions. *J Neurosurg*, 2011, 115, 518-527.

[27] Berkmann, S; Fandino, J; Muller, B; Remonda, L; Landolt, H. Intraoperative MRI and endocrinological outcome of transsphenoidal surgery for non-functioning pituitary adenoma. *Acta Neurochir (Wien)*, 2012, 154, 639-647.

[28] Steinmeier, R; Fahlbusch, R; Ganslandt, O; Nimsky, C; Buchfelder, M; Klaus, M; et al. Intraoperative magnetic resonance imaging with the magnetom open scanner: concepts, neurosurgical indications, and procedures: a preliminary report. *Neurosurgery*, 1998, 43, 739-748.

[29] Martin, CH; Schwartz, R; Jolesz, F; Black, PM. Transsphenoidal resection of pituitary adenomas in an intraoperative MRI unit. *Pituitary*, 1999, 2, 155-162.

[30] Bohinski, RJ; Warnick, RE; Gaskill-Shipley, MF; Zuccarello, M; van Loveren, HR; Kormos, DW; et al. Intraoperative magnetic resonance imaging to determine the extent of resection of pituitary macroadenomas during transsphenoidal microsurgery. *Neurosurgery*, 2001, 49, 1133-1144.

[31] Fahlbusch, R; Ganslandt, O; Buchfelder, M; Schott, W; Nimsky, C. Intraoperative magnetic resonance imaging during transsphenoidal surgery. *J Neurosurg*, 2001, 95, 381-390.

[32] Schwartz, TH; Stieg, PE; Anand, VK. Endoscopic transsphenoidal pituitary surgery with intraoperative magnetic resonance imaging. *Neurosurgery*, 2006, 58(Suppl 1), ONS44-51.

[33] Ahn, JY; Jung, JY; Kim, J; Lee, KS; Kim, SH. How to overcome the limitations to determine the resection margin of pituitary tumours with low-field intra-operative MRI during trans-sphenoidal surgery: usefulness of Gadolinium-soaked cotton pledgets. *Acta Neurochir (Wien)*, 2008, 150, 763-771.

[34] Gerlach, R; du Mesnil de Rochemont, R; Gasser, T; Marquardt, G; Reusch, J; Imoehl, L; et al. Feasibility of Polestar N20, an ultra-low-field intraoperative magnetic resonance imaging system in resection control of pituitary macroadenomas: lessons learned from the first 40 cases. *Neurosurgery*, 2008, 63, 272-285.

[35] Wu, JS; Shou, XF; Yao, CJ; Wang, YF; Zhuang, DX; Mao, Y; et al. Transsphenoidal pituitary macroadenomas resection guided by PoleStar N20 low-field intraoperative magnetic resonance imaging: comparison with early postoperative high-field magnetic resonance imaging. *Neurosurgery*, 2009, 65, 63-71.

[36] Baumann, F; Schmid, C; Bernays, RL. Intraoperative magnetic resonance imaging-guided transsphenoidal surgery for giant pituitary adenomas. *Neurosurg Rev*, 2010, 33, 83-90.

[37] Bellut, D; Hlavica, M; Schmid, C; Bernays, RL. Intraoperative magnetic resonance imaging-assisted transsphenoidal pituitary surgery in patients with acromegaly. *Neurosurg Focus*, 2010, 29, E9.

[38] Theodosopoulos, PV; Leach, J; Kerr, RG; Zimmer, LA; Denny, AM; Guthikonda, B; et al. Maximizing the extent of tumor resection during transsphenoidal surgery for pituitary macroadenomas: can endoscopy replace intraoperative magnetic resonance imaging? *J Neurosurg*, 2010, 112, 736-743.

[39] Vitaz, TW; Inkabi, KE; Carrubba, CJ. Intraoperative MRI for transphenoidal procedures: short-term outcome for 100 consecutive cases. *Clin Neurol Neurosurg*, 2011, 113, 731-735.

[40] Ramm-Pettersen, J; Berg-Johnsen, J; Hol, PK; Roy, S; Bollerslev, J; Schreiner, T; et al. Intra-operative MRI facilitates tumour resection during trans-sphenoidal surgery for pituitary adenomas. *Acta Neurochir (Wien)*, 2011, 153, 1367-1373.

[41] Berkmann, S; Fandino, J; Muller, B; Kothbauer, K; Henzen, C; Landolt, H. Pituitary surgery: experience from a large network in Central Switzerland. *Swiss Med Wkly*, 2012, 142, w13680.

[42] Bellut, D; Hlavica, M; Muroi, C; Woernle, CM; Schmid, C; Bernays, RL. Impact of intraoperative MRI-guided transsphenoidal surgery on endocrine function and hormone substitution therapy in patients with pituitary adenoma. *Swiss Med Wkly*, 2012, 142, w13699.

[43] Tabakow, P; Czyz, M; Jarmundowicz, W; Lechowicz-Glogowska, E. Surgical treatment of pituitary adenomas using low-field intraoperative magnetic resonance imaging. *Adv Clin Exp Med*, 2012, 21, 495-503.

[44] Hlavica, M; Bellut, D; Lemm, D; Schmid, C; Bernays, RL. Impact of ultra-low-field intraoperative magnetic resonance imaging on extent of resection and frequency of tumor recurrence in 104 surgically treated nonfunctioning pituitary adenomas. *World Neurosurg*, 2013, 79, 99-109.

[45] Kim, EH; Oh, MC; Kim, SH. Application of low-field intraoperative magnetic resonance imaging in transsphenoidal surgery for pituitary adenomas: technical points to improve the visibility of the tumor resection margin. *Acta Neurochir (Wien)*, 2013, 155, 485-493.

[46] Dort, JC; Sutherland, GR. Intraoperative magnetic resonance imaging for skull base surgery. *Laryngoscope*, 2001, 111, 1570-1575.

[47] Fahlbusch, R; Keller, B; Ganslandt, O; Kreutzer, J; Nimsky, C. Transsphenoidal surgery in acromegaly investigated by intraoperative high-field magnetic resonance imaging. *Eur J Endocrinol*, 2005, 153, 239-248.

[48] Nimsky, C; von Keller, B; Ganslandt, O; Fahlbusch, R. Intraoperative high-field magnetic resonance imaging in transsphenoidal surgery of hormonally inactive pituitary macroadenomas. *Neurosurgery*, 2006, 59, 105-114.

[49] Pamir, MN. 3 T ioMRI: the Istanbul experience. *Acta Neurochir Suppl*, 2011, 109, 131-137.

[50] Meng, XH; Xu, BN; Wei, SB; Zhou, T; Chen, XL; Yu, XG; et al. [High-field intraoperative magnetic resonance imaging suite with neuronavigation system: implementation and preliminary experience in the pituitary adenoma operation with transsphenoidal approach] *Zhonghua Wai Ke Za Zhi*, 2011, 49, 703-706.

[51] Lang, MJ; Kelly, JJ; Sutherland, GR. A moveable 3-Tesla intraoperative magnetic resonance imaging system. *Neurosurgery*, 2011, 68, 168-179.

[52] Netuka, D; Masopust, V; Belsan, T; Kramar, F; Benes, V. One year experience with 3.0 T intraoperative MRI in pituitary surgery. *Acta Neurochir Suppl*, 2011, 109, 157-159.

[53] Szerlip, NJ; Zhang, YC; Placantonakis, DG; Goldman, M; Colevas, KB; Rubin, DG; et al. Transsphenoidal resection of sellar tumors using high-field intraoperative magnetic resonance imaging. *Skull Base*, 2011, 21, 223-232.

[54] Tanei, T; Nagatani, T; Nakahara, N; Watanabe, T; Nishihata, T; Nielsen, ML; et al. Use of high-field intraoperative magnetic resonance imaging during endoscopic transsphenoidal surgery for functioning pituitary microadenomas and small adenomas located in the intrasellar region. *Neurol Med Chir (Tokyo)*, 2013, 53, 501-510.

[55] Fomekong, E; Duprez, T; Docquier, MA; Ntsambi, G; Maiter, D; Raftopoulos, C. Intraoperative 3T MRI for pituitary macroadenoma resection: Initial experience in 73 consecutive patients. *Clin Neurol Neurosurg*, 2014, 126, 143-149.

[56] Berkmann, S; Schlaffer, S; Nimsky, C; Fahlbusch, R; Buchfelder, M. Intraoperative high-field MRI for transsphenoidal reoperations of nonfunctioning pituitary adenoma. *J Neurosurg*, 2014, 121, 1166-1175.

[57] Roelfsema, F; Biermasz, NR; Pereira, AM. Clinical factors involved in the recurrence of pituitary adenomas after surgical remission: a structured review and meta-analysis. *Pituitary*, 2012, 15, 71-83.

[58] Reddy, R; Cudlip, S; Byrne, JV; Karavitaki, N; Wass, JA. Can we ever stop imaging in surgically treated and radiotherapy-naive patients with non-functioning pituitary adenoma? *Eur J Endocrinol*, 2011, 165, 739-744.

[59] Berkmann, S; Schlaffer, S; Buchfelder, M. Tumor shrinkage after transsphenoidal surgery for nonfunctioning pituitary adenoma. *J Neurosurg*, 2013, 119, 1447-1452.

[60] Benveniste, RJ; King, WA; Walsh, J; Lee, JS; Delman, BN; Post, KD. Repeated transsphenoidal surgery to treat recurrent or residual pituitary adenoma. *J Neurosurg*, 2005, 102, 1004-1012.

[61] Jahangiri, A; Wagner, J; Han, SW; Zygourakis, CC; Han, SJ; Tran, MT; et al. Morbidity of repeat transsphenoidal surgery assessed in more than 1000 operations. *J Neurosurg*, 2014, 121, 67-74.

[62] Black, PM; Zervas, NT; Candia, GL. Incidence and management of complications of transsphenoidal operation for pituitary adenomas. *Neurosurgery*, 1987, 20, 920-924.

[63] Ciric, I; Ragin, A; Baumgartner, C; Pierce, D. Complications of transsphenoidal surgery: results of a national survey, review of the literature, and personal experience. *Neurosurgery*, 1997, 40, 225-237.

[64] Boelaert, K; Gittoes, NJ. Radiotherapy for non-functioning pituitary adenomas. *Eur J Endocrinol*, 2001, 144, 569-575.

[65] Zierhut, D; Flentje, M; Adolph, J; Erdmann, J; Raue, F; Wannenmacher, M. External radiotherapy of pituitary adenomas. *Int J Radiat Oncol Biol Phys*, 1995, 33, 307-314.

[66] Losa, M; Valle, M; Mortini, P; Franzin, A; da Passano, CF; Cenzato, M; et al. Gamma knife surgery for treatment of residual nonfunctioning pituitary adenomas after surgical debulking. *J Neurosurg*, 2004, 100, 438-444.

[67] Sheehan, JP; Kondziolka, D; Flickinger, J; Lunsford, LD. Radiosurgery for residual or recurrent nonfunctioning pituitary adenoma. *J Neurosurg*, 2002, 97, 408-414.

[68] Sheehan, JP; Starke, RM; Mathieu, D; Young, B; Sneed, PK; Chiang, VL; et al. Gamma Knife radiosurgery for the management of nonfunctioning pituitary adenomas: a multicenter study. *J Neurosurg*, 2013, 119, 446-456.

[69] Pollock, BE; Carpenter PC. Stereotactic radiosurgery as an alternative to fractionated radiotherapy for patients with recurrent or residual nonfunctioning pituitary adenomas. *Neurosurgery*, 2003, 53, 1086-1094.

[70] Kopp, C; Theodorou, M; Poullos, N; Jacob, V; Astner, ST; Geinitz, H; et al. Tumor shrinkage assessed by volumetric MRI in long-term follow-up after fractionated stereotactic radiotherapy of nonfunctioning pituitary adenoma. *Int J Radiat Oncol Biol Phys*, 2012, 82, 1262-1267.

[71] Sasaki, R; Murakami, M; Okamoto, Y; Kono, K; Yoden, E; Nakajima, T; et al. The efficacy of conventional radiation therapy in the management of pituitary adenoma. *Int J Radiat Oncol Biol Phys*, 2000, 47, 1337-1345.

[72] Verma, J; McCutcheon, IE; Waguespack, SG; Mahajan, A. Feasibility and outcome of re-irradiation in the treatment of multiply recurrent pituitary adenomas. *Pituitary*, 2014, 17, 539-545.

[73] Starke, RM; Williams, BJ; Jane, JA; Sheehan, JP. Gamma Knife surgery for patients with nonfunctioning pituitary macroadenomas: predictors of tumor control; neurological deficits; and hypopituitarism. *J Neurosurg*, 2012, 117, 129-135.

[74] Losa, M; Donofrio, CA; Barzaghi, R; Mortini, P. Presentation and surgical results of incidentally discovered nonfunctioning pituitary adenomas: evidence for a better outcome independently of other patients' characteristics. *Eur J Endocrinol*, 2013, 169, 735-742.

[75] Cushing, H. The chiasmal syndrome of primary optic atrophy and bitemporal field defects in adults with a normal sella turcica. *Arch Ophthalmol*, 1935, 3, 505-551.

[76] Cohen, AR; Cooper, PR; Kupersmith, MJ; Flamm, ES; Ransohoff, J. Visual recovery after transsphenoidal removal of pituitary adenomas. *Neurosurgery*, 1985, 17, 446-452.

[77] Suri, A; Narang, KS; Sharma, BS; Mahapatra, AK. Visual outcome after surgery in patients with suprasellar tumors and preoperative blindness. *J Neurosurg*, 2008, 108, 19-25.

[78] Muthukumar, N; Rossette, D; Soundaram, M; Senthilbabu, S; Badrinarayanan, T. Blindness following pituitary apoplexy: timing of surgery and neuro-ophthalmic outcome. *J Clin Neurosci*, 2008, 15, 873-879.

[79] Sandeman, D; Moufid, A. Interactive image-guided pituitary surgery. An experience of 101 procedures. *Neurochirurgie*, 1998, 44, 331-338.

[80] Burkey, BB; Speyer, MT; Maciunas, RJ; Fitzpatrick, JM; Galloway, RL; Jr, Allen GS. Sublabial, transseptal, transsphenoidal approach to the pituitary region guided by the ACUSTAR I system. *Otolaryngol Head Neck Surg*, 1998, 118, 191-194.

[81] Jagannathan, J; Prevedello, DM; Ayer, VS; Dumont, AS; Jane, JA; Jr, Laws, ER. Computer-assisted frameless stereotaxy in transsphenoidal surgery at a single institution: review of 176 cases. *Neurosurg Focus*, 2006, 20, E9.

[82] Zhao, Y; Yu, S; Wang, R; Zhao, J. Clinical application of a neuronavigation system in transsphenoidal surgery of pituitary macroadenoma. *Neurosurg Rev*, 2006, 29, 306-312.

[83] Arafah, BM. Reversible hypopituitarism in patients with large nonfunctioning pituitary adenomas. *J Clin Endocrinol Metab*, 1986, 62, 1173-1179.

[84] Arafah, BM; Kailani, SH; Nekl, KE; Gold, RS; Selman, WR. Immediate recovery of pituitary function after transsphenoidal resection of pituitary macroadenomas. *J Clin Endocrinol Metab*, 1994, 79, 348-354.

[85] Arafah, BM; Prunty, D; Ybarra, J; Hlavin, ML; Selman, WR. The dominant role of increased intrasellar pressure in the pathogenesis of hypopituitarism; hyperprolactinemia; and headaches in patients with pituitary adenomas. *J Clin Endocrinol Metab*, 2000, 85, 1789-1793.

[86] Randall, RV; Scheithauer, BW; Laws, ER; Jr, Abbound CF; Ebersold, MJ; Kao, PC. Pituitary adenomas associated with hyperprolactinemia: a clinical and immunohistochemical study of 97 patients operated on transsphenoidally. *Mayo Clin Proc*, 1985, 60, 753-762.

[87] Zayour, DH; Selman, WR; Arafah, BM. Extreme elevation of intrasellar pressure in patients with pituitary tumor apoplexy: relation to pituitary function. *J Clin Endocrinol Metab*, 2004, 89, 5649-5654.

[88] Fatemi, N; Dusick, JR; Mattozo, C; McArthur, DL; Cohan, P; Boscardin, J; et al. Pituitary hormonal loss and recovery after transsphenoidal adenoma removal. *Neurosurgery*, 2008, 63, 709-719.

[89] Nomikos, P; Ladar, C; Fahlbusch, R; Buchfelder, M. Impact of primary surgery on pituitary function in patients with non-functioning pituitary adenomas - a study on 721 patients. *Acta Neurochir (Wien)*, 2004, 146, 27-35.

[90] Webb, SM; Rigla, M; Wagner, A; Oliver, B; Bartumeus, F. Recovery of hypopituitarism after neurosurgical treatment of pituitary adenomas. *J Clin Endocrinol Metab*, 1999, 84, 3696-3700.

[91] Abosch, A; Tyrrell, JB; Lamborn, KR; Hannegan, LT; Applebury, CB; Wilson, CB. Transsphenoidal microsurgery for growth hormone-secreting pituitary adenomas: initial outcome and long-term results. *J Clin Endocrinol Metab*, 1998, 83, 3411-3418.

[92] Barker, FG; 2nd, Klibanski, A; Swearingen, B. Transsphenoidal surgery for pituitary tumors in the United States, 1996-2000: mortality, morbidity, and the effects of hospital and surgeon volume. *J Clin Endocrinol Metab*, 2003, 88, 4709-4719.

[93] Cappabianca, P; Cavallo, LM; Colao, A; de Divitiis, E. Surgical complications associated with the endoscopic endonasal transsphenoidal approach for pituitary adenomas. *J Neurosurg*, 2002, 97, 293-298.

[94] Comtois, R; Beauregard, H; Somma, M; Serri, O; Aris-Jilwan, N; Hardy, J. The clinical and endocrine outcome to trans-sphenoidal microsurgery of nonsecreting pituitary adenomas. *Cancer*, 1991, 68, 860-866.

[95] Baskin, DS; Boggan, JE; Wilson, CB. Transsphenoidal microsurgical removal of growth hormone-secreting pituitary adenomas. A review of 137 cases. *J Neurosurg*, 1982, 56, 634-641.

[96] Faria, MA; Jr. Tindall, GT. Transsphenoidal microsurgery for prolactin-secreting pituitary adenomas. *J Neurosurg*, 1982, 56, 33-43.

[97] McPherson, CM; Bohinski, RJ; Dagnew, E; Warnick, RE; Tew, JM. Tumor resection in a shared-resource magnetic resonance operating room: experience at the University of Cincinnati. *Acta Neurochir Suppl*, 2003, 85, 39-44.

[98] Colao, A; Cerbone, G; Cappabianca, P; Ferone, D; Alfieri, A; Di Salle, F; et al. Effect of surgery and radiotherapy on visual and endocrine function in nonfunctioning pituitary adenomas. *J Endocrinol Invest*, 1998, 21, 284-290.

[99] Randeva, HS; Schoebel, J; Byrne, J; Esiri, M; Adams, CB; Wass, JA. Classical pituitary apoplexy: clinical features; management and outcome. *Clin Endocrinol (Oxf)*, 1999, 51, 181-188.

[100] Semple, PL; Webb, MK; de Villiers, JC; Laws, ER; Jr. Pituitary apoplexy. *Neurosurgery*, 2005, 56, 65-73.

[101] Littley, MD; Shalet, SM; Beardwell, CG; Ahmed, SR; Applegate, G; Sutton, ML. Hypopituitarism following external radiotherapy for pituitary tumours in adults. *Q J Med*, 1989, 70, 145-160.

[102] Berg, C; Meinel, T; Lahner, H; Mann, K; Petersenn, S. Recovery of pituitary function in the late-postoperative phase after pituitary surgery: results of dynamic testing in patients with pituitary disease by insulin tolerance test 3 and 12 months after surgery. *Eur J Endocrinol*, 2010, 162, 853-859.

[103] Nemergut, EC; Zuo, Z; Jane, JA; Jr. Laws, ER; Jr. Predictors of diabetes insipidus after transsphenoidal surgery: a review of 881 patients. *J Neurosurg*, 2005, 103, 448-454.

[104] Adams, JR; Blevins, LS; Jr. Allen, GS; Verity, DK; Devin, JK. Disorders of water metabolism following transsphenoidal pituitary surgery: a single institution's experience. *Pituitary*, 2006, 9, 93-99.

[105] Olson, BR; Gumowski, J; Rubino, D; Oldfield, EH. Pathophysiology of hyponatremia after transsphenoidal pituitary surgery. *J Neurosurg*, 1997, 87, 499-507.

[106] Robinson, AG; Verbalis, JG. Diabetes insipidus. *Curr Ther Endocrinol Metab*, 1994, 5, 1-6.

[107] Singer, PA; Sevilla, LJ. Postoperative endocrine management of pituitary tumors. *Neurosurg Clin N Am*, 2003, 14, 123-138.

[108] Nomikos, P; Buchfelder, M; Fahlbusch, R. The outcome of surgery in 668 patients with acromegaly using current criteria of biochemical ‘cure’. *Eur J Endocrinol*, 2005, 152, 379-387.

[109] Shimon, I; Cohen, ZR; Ram, Z; Hadani, M. Transsphenoidal surgery for acromegaly: endocrinological follow-up of 98 patients. *Neurosurgery*, 2001, 48, 1239-1245.

[110] Beauregard, C; Truong, U; Hardy, J; Serri, O. Long-term outcome and mortality after transsphenoidal adenomectomy for acromegaly. *Clin Endocrinol (Oxf)*, 2003, 58, 86-91.

[111] Laws, ER; Vance, ML; Thapar, K. Pituitary surgery for the management of acromegaly. *Horm Res*, 2000, 53(Suppl 3), 71-75.

[112] Kreutzer, J; Vance, ML; Lopes, MB; Laws, ER. Jr. Surgical management of GH-secreting pituitary adenomas: an outcome study using modern remission criteria. *J Clin Endocrinol Metab*, 2001, 86, 4072-4077.

[113] Kaltsas, GA; Isidori, AM; Florakis, D; Trainer, PJ; Camacho-Hubner, C; Afshar, F; et al. Predictors of the outcome of surgical treatment in acromegaly and the value of the mean growth hormone day curve in assessing postoperative disease activity. *J Clin Endocrinol Metab*, 2001, 86, 1645-1652.

[114] De, P; Rees, DA; Davies, N; John, R; Neal, J; Mills, RG; et al. Transsphenoidal surgery for acromegaly in wales: results based on stringent criteria of remission. *J Clin Endocrinol Metab*, 2003, 88, 3567-3572.

[115] Ludecke, DK; Abe, T. Transsphenoidal microsurgery for newly diagnosed acromegaly: a personal view after more than 1,000 operations. *Neuroendocrinology*, 2006, 83, 230-239.

[116] Yoon, PH; Kim, DI; Jeon, P; Lee, SI; Lee, SK; Kim, SH. Pituitary adenomas: early postoperative MR imaging after transsphenoidal resection. *AJNR Am J Neuroradiol*, 2001, 22, 1097-1104.

[117] Kremer, P; Forsting, M; Ranaei, G; Wüster C; Hamer J; Sartor K; et al. Magnetic resonance imaging after transsphenoidal surgery of clinically non-functional pituitary macroadenomas and its impact on detecting residual adenoma. *Acta Neurochir (Wien)*, 2002, 144, 433-443.

[118] Giustina, A; Barkan, A; Casanueva, FF; Cavagnini, F; Frohman, L; Ho, K; et al. Criteria for cure of acromegaly: a consensus statement. *J Clin Endocrinol Metab*, 2000, 85, 526-529.

[119] Hirschl, RA; Wilson, J; Miller, B; Bergese, S; Chiocca, E. The predictive value of low-field strength magnetic resonance imaging for intraoperative residual tumor detection. Clinical article. *J Neurosurg*, 2009, 111, 252-257.

[120] Shou, XF; Li, SQ; Wang, YF; Zhao, Y; Jia, PF; Zhou, LF. Treatment of pituitary adenomas with a transsphenoidal approach. *Neurosurgery*, 2005, 56, 249-256.

[121] Kubben, PL; ter Meulen, KJ; Schijns, OE; ter Laak-Poort, MP; van Overbeeke, JJ; van Santbrink, H. Intraoperative MRI-guided resection of glioblastoma multiforme: a systematic review. *Lancet Oncol*, 2011, 12, 1062-1070.

[122] Livne, O; Harel, R; Hadani, M; Spiegelmann, R; Feldman, Z; Cohen, ZR. Intraoperative magnetic resonance imaging for resection of intra-axial brain lesions: a decade of experience using low-field magnetic resonance imaging, Polestar N-10, 20, 30 systems. *World Neurosurg*, 2014, 82, 770-776.

[123] Pamir, MN; Özduman, K; Yıldız, E; Sav, A; Dinçer, A. Intraoperative magnetic resonance spectroscopy for identification of residual tumor during low-grade glioma surgery: clinical article. *J Neurosurg*, 2013, 118, 1191-1198.

[124] Levivier, M; Wikler, D; Massager, N; Legros, B; Van Bogaert, P; Brotchi, J. [Intraoperative MRI and epilepsy surgery] *Neurochirurgie*, 2008, 54, 448-452.

[125] Sommer, B; Grummich, P; Coras, R; Kasper, BS; Blumcke, I; Hamer, HM; et al. Integration of functional neuronavigation and intraoperative MRI in surgery for drug-resistant extratemporal epilepsy close to eloquent brain areas. *Neurosurg Focus*, 2013, 34, E4.

In: Encyclopedia of Surgery (22 Volume Set)
Editors: Andreas Lehrer and Kristin Mueller
ISBN: 978-1-53618-329-0
© 2020 Nova Science Publishers, Inc.

Chapter 376

INGUINAL HERNIA SURGERY IN PATIENTS WITH LIVER CIRRHOSIS

Roberto De la Plaza-Llamas*, MD,
José M. Ramia, MD, PhD,
Vladimir Arteaga-Peralta, MD, PhD,
Jhonny D. Gonzales-Aguilar, MD,
Cristina García-Amador, MD
and Aylhin J. López-Marcano, MD
Department of Surgery, Hospital Universitario de Guadalajara, Guadalajara, Spain

ABSTRACT

The optimal management of inguinal hernia (IH) in patients with liver cirrhosis (LC) with or without ascites remains a matter of debate. There are very few references to the incidence and natural history of IH in patients in this setting. In this chapter, we present a review of the current literature.

In the seven reports of the repair of IH in patients with LC published to date, the best level of evidence observed is IIb. In the light of the results we stress the importance of preoperative optimization, including management of ascites, hemostatic disorders and infections. If possible, procedures should be performed under local anesthesia. Herniorraphy and hernioplasty obtain good results. It is important not to open the hernia sac; if it is necessary to do so, suturing is essential.

Morbidity and mortality rates after IH repair are worse in cirrhotic than in non-cirrhotic patients. Mortality ranges from 0 to 2.7%, and occurs mainly in emergency procedures, while morbidity ranges from 6.2 to 36.4%. Several authors have postulated that morbidity is not related to the Child-Turcotte-Pugh (CTP) score or to the presence of ascites. The recurrence rate described is between 0 and 11%. The repair of symptomatic IH in patients with LC improves their quality of life, especially in the case of CTP class C patients and in patients with refractory ascites who often present severe symptoms

* Corresponding Author's Email: rdplazal@sescam.jccm.es.

associated with their IH. Elective repair of IH in patients with LC requires careful surgical technique and perioperative care.

1. INTRODUCTION

The prevalence of chronic liver disease and liver cirrhosis (LC) has risen in recent years, due to the global obesity epidemic, alcohol abuse, and viral hepatitis [1]. Regarding hernias of the abdominal wall, the most common types in cirrhotic patients are umbilical and incisional, followed by inguinal [2]. The main problems facing surgeons in these patients are coagulation, infection and delayed wound healing [2]. As a result, cirrhotic patients present a higher surgical risk and surgeons are often reluctant to operate.

The optimal management of LC patients with IH with or without ascites remains a matter of debate. The incidence and the natural history of IH in patients with LC have not been clearly documented [3], and in fact there are very few references to this problem in the literature.

2. METHODS

We performed a search of articles published in PubMed until December 1, 2014 in all languages, with keywords (MeSH): hernia, inguinal and liver cirrhosis. All types of study were included. The search details were: ("hernia, inguinal" [MeSH Terms] OR ("hernia" [All Fields] AND "inguinal" [All Fields]) OR "inguinal hernia" [All Fields] OR ("hernia" [All Fields] AND "inguinal" [All Fields]) OR "hernia, inguinal" [All Fields]) AND ("liver cirrhosis" [MeSH Terms] OR ("liver" [All Fields] AND "cirrhosis" [All Fields]) OR "liver cirrhosis" [All Fields]). Our first search identified 31 papers. References of these 31 papers were also investigated. All the papers related to the topic of this chapter were used. Finally, only 30 papers were included in the study.

3. INGUINAL HERNIA INCIDENCE IN PATIENTS WITH LIVER CIRRHOSIS

The incidence of IH in patients with LC has not been established, but it appears to be higher than in the general population, especially in patients who also present severe ascites [3,4]. It has been postulated that the increased intra-abdominal pressure due to ascites distends the peritoneum in sites that support the abdominal wall, thus producing hernia [5].

In Denmark (a country with a population of 5.2 million) Hansen et al carried out a follow-up study of patients treated from 1993 to 1997 identified from the Danish National Hospital Register, which contains information on all hospital admissions since 1977. These authors recorded 22,840 patients with a diagnosis of LC, of whom 741 (3.24%) had an IH [6].

4. PATHOGENESIS AND EVOLUTION

The formation of abdominal hernias in patients with LC is linked to an increase in intra-abdominal pressure due to several factors: ascites [7,8], the weakness of the abdominal wall due to changes in protein metabolism, and vascular changes associated with decompensated portal hypertension [8]. However, some authors claim that, with the exception of umbilical hernias, IH are not markedly influenced by the presence of ascites [2,9,10]. Furthermore, it appears that ascites may prevent strangulation, which may occur when large volumes of ascites fluid are extracted quickly. An incarcerated IH is rare in patients with ascites [9,10].

This opinion, presented in Hurst et al's paper [11], has received support from other authors [5,9]. In Hurst et al's study, three of the 11 patients were operated on urgently. Two of the three incarcerated hernias were diagnosed in patients with well-controlled ascites; the third patient suffered a femoral hernia, and so no relationship between ascites and complications was seen [11]. In the series of Gillet et al (26 patients with LC and IH) incarceration occurred in three [12]. None of these patients required intestinal resection, and none of the patients with LC and IH had uncontrolled ascites [9].

If left untreated, defects of the abdominal wall in LC patients can grow to an immense size and may be associated with necrosis of the overlying skin due to pressure, skin rupture, leakage of ascites, and bacterial peritonitis [7].

The IH may lead to a clear deterioration in the quality of life of patients with LC, but repair improves it markedly [13,14]. Patients with decompensated cirrhosis often have severe symptoms, because ascites enters the hernia sac, and the hernia enlarges progressively, often becoming painful. It may hinder deambulation and often forces the patient to stay in bed [14].

5. PREOPERATIVE MANAGEMENT

Several preoperative measures have been recommended in these patients.

1. Doppler Ultrasound: In the preoperative study Doppler ultrasound has been recommended to avoid the possibility of a mistaken diagnosis. Sometimes, massive venous dilations entering the spermatic cord at the internal inguinal ring can simulate a hernia. Doppler ultrasound is mandatory when diagnosis is doubtful, in order to avoid an unnecessary surgical intervention [15].
2. Medical history: Extensive preoperative evaluation is essential to improve management of ascites, coagulopathy and platelets.
3. Ascites: Many authors have stressed the need to provide intensive treatment for ascites before IH surgery, especially in cases of refractory ascites [3,9,11,14]. Refractory ascites is defined as lack of body weight response (loss of body weight less than 200 g/day after 4 days) to sodium restriction (50 mEq/day) and high doses of diuretics (400 mg spironolactone per day plus 160 mg furosemide per day) or the development of diuretic-induced complications that preclude the use of effective diuretic dosage [16].

Belghiti et al. initiated medical treatment including a low-sodium diet and diuretics. When this is effective, surgical herniorrhaphy can be performed electively after ascites has been controlled; the procedure is associated with low mortality and morbidity. These authors also stressed that abdominal ultrasound examination should always be performed in order to confirm the elimination of ascites [9]. In Hurst et al.'s series of 18 patients, the treatment of ascites included fluid restriction (n=16 patients), diuretics (n=16), large-volume paracentesis (n=5), and peritoneovenous shunt (n=2). Only one of the patients requiring large-volume paracentesis and none of those that underwent peritoneovenous shunting required surgery [11]. Patti et al. all treated all patients with ascites with higher doses of diuretics, (spironolactone 400 mg per day and, 160 mg per day of furosemide), and sodium restriction (50 mEq/d). This medical management was continued until the disappearance of ascites, and then patients were operated [14]. Oh et al. controlled ascites with diuretics or intermittent tapping [3].

4. Hemostasia: Abnormalities of hemostasis in the LC are complex and multifactorial and may predispose to prolonged bleeding after invasive procedures. Therefore, LC patients should undergo elective surgery after completing medical optimization, and rapid evaluation and correction of hemostatic abnormalities are recommended [7]. However the correction of the platelet count and INR before surgery is controversial; there are no specific guidelines regarding surgical procedures such as inguinal hernia repair. Furthermore, at many centers that perform liver transplantation, it is standard practice not to administer blood products before or during the procedure except in the case of active bleeding [17]. The American Association for the Study of Liver Diseases (AASLD) guidelines for liver biopsy (transcutaneous or transvenous) state that platelet transfusion should be considered when levels are less than 50,000-60,000/μL. The use of prophylactic measures or rescue strategy such as plasma, fibrinolysis inhibitors, or recombinant factors should be considered only in specific situations, and in fact their effectiveness remains to be established [18]. The Society of Interventional Radiology guidelines recommend correcting an INR greater than 1.5 and a platelet count less than 50,000/μL [19]. Weeder et al proposed abandoning the old practice of prothrombin time and platelet count-guided prophylactic transfusion and to adopt the following guidelines, which are now increasingly accepted in liver transplantation care [17]:
    - Pre-procedural phase: no prophylactic correction of hemostasis; treat existing infections and optimize renal status.
    - Intra-procedural phase: treat only active hemostatic bleeding with transfusion or antifibrinolytics; maintain low central venous pressure and normothermia, calcium and pH.
    - Post-procedural phase: restore central venous pressure to normal values, detect and treat thrombotic or bleeding complications.
    - Apply thrombosis prophylaxis during these three phases.

Desmopressin (vasopressin 1-desamino-8-D-arginine (DDAVP)), has been shown to be safe and effective for the prevention and treatment of bleeding in cirrhotic patients [20]. In a prospective study by Koscielny et al. of 13 patients with LC, platelet dysfunction was

corrected in 11 cases (84.6%). Bleeding time after DDAVP administration was corrected in nine [21]. Prophylactic treatment with DDAVP should be administered approximately one hour before the scheduled surgery. Postoperative treatment with repeated doses of 12-24 hours after the procedure should be considered until wound healing [22].

5. Antibiotics: Few authors report the use of prophylactic antibiotics one hour before the operation. Several antibiotics have been used: ceftazidime 2 g intravenously [14] or cefazolin 1 g intravenously [3,13]. Gubitosi et al. used ceftriaxone in 39 patients and amoxicillin/clavulanic in 13 others just before surgery [2]. The prophylactic administration of antibiotics to patients with LC is known to reduce mortality and increase hemostatic function, but the exact mechanism is unknown. The adequate surveillance for and treatment of infections before invasive procedures is therefore recommended [17].

6. ANESTHETIC AND SURGICAL TECHNIQUES

Local anesthesia has been widely advocated and used in the surgical repair of IH in patients with LC [2,13,14,23,24]. Pere et al. noted the risks of spinal and epidural anesthesia: 1) spinal or epidural anesthetics should not be given to patients with severe coagulation disorders, because of the risk of epidural hemorrhage. 2) Vasodilation and relative hypovolemia, typically found in LC patients, worsen with spinal or epidural anesthesia. Pere et al. reported two cases of LC with controlled ascites whose condition deteriorated severely after elective inguinal herniorrhaphy in which spinal anesthesia was performed, and one exitus in whom epidural anesthesia was used [5]. If a central block is chosen, adequate monitoring, volume loading, and inotropic support are essential to maintain adequate blood pressure and visceral perfusion [5].

Few authors have included hernia repair technical details in their papers. Here we summarize the most relevant tips and tricks:

Gubitosi et al. [2]: a series of 52 LC patients with IH. Minor complications occurred in five patients. They used the following technical measures:

- Cross-matched platelet transfusions were given to 19 patients (36.53%) preoperatively (except in one case), and intra- and postoperatively.
- The hernia sac was not opened.
- Surgical Technique: Prolene Hernia System (PHS) Gilbert (6 cases), Trabucco (37), and Lichtenstein (9).
- After inserting the mesh and performing adequate hemostasis, 2-5 ml of human fibrin glue (Tissucol®) was applied in 42 patients. The application of fibrin-glue significantly reduced the rate of complications.
- The aponeurosis of the external oblique muscle under the funicular structures was closed when repair is finished.
- Elastic adhesive bandages from the pubis across to the anterior superior iliac spine were applied at the end of the operation (Thensoplast®).

Patti et al. [14]: 32 LC patients undergoing IH repair. During the in-hospital postoperative time, two inguinoscrotal hematomas were diagnosed (6.25%). The technical details were:

- The hernia sac was carefully isolated from the related structures in order to avoid perforation and, subsequently, it was invaginated without opening the abdominal cavity. Large hernia sacs were cut, sutured and invaginated at the internal inguinal ring to avoid the risk of ascitic leak.
- All patients were operated with a Lichtenstein hernioplasty using a polypropylene mesh.
- The fascia was closed with a running suture using a nonabsorbable monofilament.
- A suction drainage was inserted if the dead space was large and if refractory ascites was present. No ascites leakage from the surgical wound or wound infection was observed in postoperative period.

7. MORBIDITY AND MORTALITY

Surgery in patients with LC is classically associated with increased mortality and morbidity. A large study in the United States (1999-2004) assessed the results of repair of abdominal wall hernias (excluding IH) in cirrhotic versus non-cirrhotic patients. Data from 30,836 cirrhotic patients were included and compared to 1,197 non-cirrhotic patients [7]. LC patients had significantly longer hospital stay, and higher morbidity (16.5% vs. 13.8%) and mortality (2.5% vs 0.2%) than non-cirrhotic patients. Moreover, patients with LC underwent emergency surgery more often (58.9% vs. 29.5%) and associated morbidity rates were also higher (17.3% vs. 14.5%). Differences in elective surgical mortality in patients with cirrhosis approached statistical significance (0.6% vs 0.1%), and mortality was seven times higher in emergency procedures (3.8% vs. 0.5%). Several associated comorbidities increased mortality in patients with LC: functional impairment, congestive heart failure, renal failure, nutritional deficiencies, and peripheral vascular disease. The study concluded that, ideally, patients with cirrhosis should undergo elective hernia repair after medical optimization.

In a systematic review of morbidity and mortality after non-hepatic surgery in patients with and without LC, de Goede et al. found a higher postoperative morbidity and mortality in cirrhotic patients. Cholecystectomy and umbilical and inguinal hernia correction were associated with the lowest increases in morbidity and mortality, while pancreatic surgery, cardiovascular and trauma surgery presented the highest differences between groups. The preoperative model for end stage liver disease (MELD) and CTP scores appeared to be predictive of postoperative risks. Portal hypertension and emergency surgery were associated with increased mortality and morbidity rates [25].

There is no consensus regarding morbidity and mortality rates in patients with IH and LC. Classically, it was believed that hernia repair in this population is plagued with wound complications such as persistent ascitic fluid leakage through the incision and the wound infection and mesh, and recurrence of the hernia [6,9, 10,11].

Belghiti et al. stated that patients with IH and LC without ascites or with moderate ascites were candidates for elective surgical repair and that mortality and morbidity rates were low.

Moreover, in patients with refractory ascites, surgical repair is associated with high mortality and morbidity. Ascites may cause postoperative infection, thus delaying healing. Besides, severe complications such as strangulation are uncommon in patients with IH and LC; therefore, these authors did not recommend surgical repair in patients with refractory ascites and without hernia symptoms [9].

In the study by Hansen et al. [6], 256 patients with IH and LC underwent surgery. The control group consisted of a sample of 741 Danish patients over 20 years of age who underwent the same operative procedure as the IH/LC patients on the same day. Seven patients (2.7%) died within 30 days, compared with five (0.7%) in the control group. The adjusted odds ratio for 30-day mortality was 4.4. However, very few clinical data (reason for surgical indications, details about the operation, anesthetic procedures, stage of LC, ascites, smoking habits, alcohol consumption or cause of death) were reported and so no firm conclusions can be drawn from the results.

Morbidity and Mortality, and Results of published series:

The literature search revealed seven series of IH repair in patients with LC (Table 1).

Hurst et al.: Hurst et al retrospectively reviewed the records of 18 cirrhotic patients with ascites and groin hernias (20 inguinal and one femoral). Eleven patients underwent repair of their groin hernias (13 repairs). Ten herniorrhaphies were performed electively; two were performed urgently for recent difficult reduction, and one was performed urgently for incarceration without strangulation. There were four minor postoperative complications: two minor wound complications, one episode of readily correctable prerenal azotemia, and one case of mild and reversible postoperative hepatic encephalopathy. There were no ascites leaks, and no perioperative mortality. Twelve groin hernia repairs were followed for 25 months (mean). One recurrence (8%) occurred 11 months after surgical repair. In eight patients, herniorrhaphy was performed when ascites was well controlled. Although five hernias were repaired in the presence of clinically significant ascites, the ascites either persisted or recurred at some time in the postoperative course in all but two cases. The results of this retrospective study suggest that serious complications from groin hernias in LC are uncommon, and that elective repair can usually await control of ascites. Additionally, for selected patients with ascites, elective inguinal hernia repair can be performed safely with an acceptable rate of recurrence [11].

Park et al: In Park et al.'s series, 53 patients underwent surgery for abdominal wall hernias (42 IH, seven umbilical hernias and two incisional hernias). Seventeen patients were Child–Turcotte–Pugh (CTP) A, 27 patients CTP B, and nine CTP C. The median follow-up was 24 months. There was only one 30-day postoperative death in a CTP C patient, and no CTP deterioration after 30 days of operation. There was no mortality or recurrence in 17 patients with medically refractory ascites. The difference in 30-day mortality according to CTP class and the presence of refractory ascites was not statistically significant [13]. The authors concluded that IH operation was safe in CTP A and B, with low rate of recurrences, and that there was no clear increase in the operative risk in class C. In addition, refractory ascites did not increase the operative risk or the recurrence rate. Therefore, surgical repair may be recommended even in patients with refractory ascites and poor hepatic function in order to prevent life-threatening complications or severe pain. However, others have reported high mortality and morbidity with surgical repair of inguinal hernia in patients with refractory ascites this procedure [9,11].

Table 1. Reported series of inguinal hernia repair in patients with liver cirrhosis

Author Year	Inguinal Hernia/ Patients	Child Score	Technique	Type Of Anesthesia	30 Days Morbidity N/%	Mortality	Post-Operative Stay (Days)	Recurrence	Follow-Up Months
Hurst et al. 1992 [11]	13 / 11 (urgently: 2 emergently: 1)	A: 6 B:2 C:3 OA: 5	Bassini or McVay herniorrhaphy	-	4 minor (36.4%)	0	-	1 (8%)	25
Park et al. 2006 [13]	42 / 53	A: 17 B:27 C:9 RA: 17	Polyester o proly-propylene mesh	SA: 26 GA: 25 LA:2	-	1 CTP C (2.38%) (emergent)	-	-	Median: 24
Patti et al.2008 [14]	32/32	A: 10 B:14 C:8 RA: 10	Lichtenstein hernioplasty	GA: 24 LA:8	2 minor (6.2%)	0	2.9 (± 1.5)	0	6
Lawson et al. 2009 [23]	20 / 18 (bilateral: 2 incarcerated:4)	A: 3 B:12 C:3 Ascites: 8	Tissular 12 (8 Bassini, 3 McVay, 1 preperitoneal) and 6 mesh	GA: 13 LA: 5	3 minor (16.7%)	0	5: outpatient 13: 2.6 (1-6)	2 (11%)	30 (4-124)
Oh et al. 2011 [3]	141 / 129 (bilateral:12 emergent: 2)	A: 45 B:66 C:18 OA: 81	McVay hernia repair	GA: 53 SA: 76	14 minor (10.9%)	2 CTP C (1.55%) 1 emergent / 1 elective	-	3 (2.3%)	Median: 22.9 (0.6-129.5)
Gubitosi et al. 2011 [2]	52 / 52	A: 37 B: 12 C: 3 Ascites: 14	Prolypropylene prosthesis: Gilbert 6, Trabucco 37, Lichtenstein 9	LA: 50 SA: 2	5 minor 9,6%	0	25: day surgery 27: 3,1 (2-7)	-	-
Hur et al. 2011 [24]	22 / 22	A: 0 B:15 C:7 OA: 22 RA: 0	Mesh plug hernia repair	LA: 22	3 minor (13.6%)	0	1.8 ±2 (1-10)	0	-

RA: refractory ascites; OA: ascites at the moment of operation; CTP: Child-Turcotte-Pugh scores; SA: spinal anesthesia; GA: general anesthesia; LA: local anesthesia.

Patti et al: Thirty-two cirrhotic patients undergoing inguinal hernioplasty were evaluated. The same surgeon performed all hernioplasties. In eight patients, hernioplasty was performed under local anesthesia and the remaining 24 were treated under general anesthesia. All patients received a tension-free Lichtenstein hernioplasty. During the postoperative in-hospital course, two inguinoscrotal hematomas appeared, both in a CTP B patient without ascites [14].

Lawson et al.: Lawson et al. conducted a retrospective review comparing patients with LC who underwent groin herniorrhaphy and patients who underwent inguinal herniorrhaphy after liver transplantation. They reported 43 inguinal herniorrhaphy procedures, 18 in 18 documented LC and 25 in 24 patients after liver transplantation. The mean follow up was 33 months. Two IH recurred in the LC group, at 15 months and at 7 years after repair (relapse: 11%), and none after liver transplantation. Both patients had undergone repair without a mesh. There were no deaths, major complications, reoperations, ascitic leaks, or infections in either group. Minor complications in the LC group included hematomas in two patients and seroma in one (17%); one hematoma was the only complication in the liver transplantation group (4%). The authors concluded that groin herniorrhaphy with or without a mesh is a safe and durable procedure in patients with LC and after liver transplantation [23].

Oh et al*:* The retrospective study performed by Oh et al. [3] compared 129 symptomatic patients with IH and LC who underwent surgical IH repair (McVay) performed by the same surgeon with 760 non-LC patients. Complications occurred in 14/129 (10.9%) patients with LC, but all these complications were resolved conservatively. Complications also developed in 44 (6.8%) of the non-LC controls. The complication rate for patients with LC was not significantly higher than for non-LC controls (P = 0.11). In the LC group, complication rates were not related to CTP class. LC patients with ascites at the time of the operation developed more postoperative complications than those without ascites, but the difference was not significant (LC-ascites: 10/81, 12.3% vs. LC-non-ascites: 4/48, 8.3%; P = 0.57). There was no leakage of ascites. Two CTP class C patients (1.55%) died in the postoperative period due to liver failure. For patients with LC, the median follow-up was 22.9 months (mean: 38.1 months; range 0.6 to 129.5 months) and recurrence occurred in three patients (2.3%) (two CTP B and one CTP C). Although all recurrent hernias developed in patients who had ascites at the time of the initial operation, no significant differences in recurrence rates were found between patients with and without ascites (3.7% vs. 0%; P = 0.29). The median time to recurrence was 30.9 months (range, 26.7 to 37.2 months), and all recurrent hernias were repaired successfully. For non-LC controls, the median follow-up was 30.1 months (mean: 39.4; range: 0.5 to 134.6 months), and there were no significant differences in the duration of follow-up with regard to the LC group (P = 0.68).

The recurrence rate was 2.3% (n = 15), and cumulative recurrence rates did not differ significantly between LC patients and controls (0 vs. 1.2% at 1 year, 3.6 versus 2, 2% at 3 years, and 5.7 vs. 3.6% at 5 years; P = 0.87). This study shows that IH repair carries a higher risk of postoperative complications and recurrence in cirrhotic than in non-cirrhotic patients. In addition, complications and recurrence rates were independent of CTP class. The authors suggested that patients with symptomatic IH LC should be considered for elective surgical repair.

Gubitosi et al: Gubitosi et al. [2] studied 52 LC patients undergoing IH repair between January 2007 and January 2009. Repair was performed by the same surgeon: the main end-point was to assess the effectiveness and safety of surgical treatment with certain

perioperative measures. Day-surgery was performed in 25 patients. Average hospital stay was 3.1 days (2-7). There was no mortality, no intraoperative complications and no surgical infection. The postoperative complication rate was 9.6%: seromas/serohematomas, serohematic congestion spermatic cord, and postoperative neuralgia (one patient).

There were no statistically significant associations with ascites, the number of hernias, or the type of defect; only hernia size was associated with complications. Patients with CTP C had a higher rate of complications, but as in other series [7,14,26] the difference was not statistically significant. The application of fibrin-glue significantly reduced the rate of complications and need for platelet transfusion. The type of admission (regular inpatient or day surgery) had no significant effect on the complication rate [2].

Hur et al. These authors retrospectively reviewed the medical records of 22 patients with LC and ascites (no cases of refractory ascites) who underwent IH repair with mesh plug performed by the same surgeon under local anesthesia. Minor complications occurred in only three patients (13.6%): two hematomas, and one case of swelling of the scrotum. These complications resolved spontaneously without blood transfusion or reoperation [24].

8. Quality of Life

IH and LC impair quality of life (QOL). QOL is reduced by the presence of IH in patients without LC [27] and improves after repair [28,29]. LC also reduces QOL [30], and surgical repair of IH in patients with LC improves it [13,14].

The study by Patti et al. [14], of 32 LC patients undergoing inguinal hernioplasty showed that the scores on all eight domains of SF-36 and two comprehensive indexes of SF-36 – Physical Component Summary (PCS) and Mental Component Summary (MCS) – improved notably after hernioplasty, especially in CTP class C patients and/or with refractory ascites. This improvement was most evident for bodily pain, physical role, social functioning, and overall health. The improvement in the PCS was more notable in patients with refractory ascites compared to those with the treatable form (40.2% versus 17.7%). The results for the MCS were even more striking (61.1% vs 6.8%) in all Child's classes, and CTP C patients presented a particularly high increase of 61.3% between preoperative and postoperative score.

In Park et al's series, in the follow-up interview all 53 patients (100%) reported that hernia operation increased their QOL [13].

Conclusion

The ideal management of IH in patients with LC is not clearly established. After this review of seven published series we draw the following conclusions:

- Optimal preoperative management of ascites, hemostasis disorders and infections is required.
- Use of local anesthesia is recommended.
- Free-tension techniques should be performed.

- In principle, the hernia sac should not be opened; if it has to be opened, or if it is opened accidentally, it must be repaired.
- Morbidity and mortality of IH repair are higher in patients with LC:
  - Morbidity: 6.2 to 36.4%. Several authors affirm that morbidity is independent of CTP [3,6,14] and is unaffected by the presence of ascites [7,9].
  - Mortality: 0 to 2.7%. One study reported an overall mortality of 2.7% after inguinal hernia repair compared to 0.7% for non-cirrhotic patients (OR 4.4) [6]. Mortality occurs mainly in emergency procedures.
- Recurrence is between 0 to 11%.
- Repair of symptomatic IH in patients with LC improves their quality of life [13,14] particularly in patients with CTP C and in patients with refractory ascites [14]. In patients with high MELD scores and awaiting liver transplantation, hernia repair should be delayed until after transplantation, or during this procedure in some selected cases [23].

Elective repair of IH in patients with LC requires careful technique and intensive perioperative care.

REFERENCES

[1] Rahimi RS, Rockey DC. Complications and outcomes in chronic liver disease. *Curr. Opin. Gastroenterol.* 2011;27:204–209.

[2] Gubitosi A, Ruggiero R, Docimo G, Avenia N, Villaccio G, Esposito A, Foroni F, Agresti M. Hepatic cirrhosis and groin hernia: binomial or dichotomy? Our experience with a safe surgical treatment protocol. *Ann. Ital. Chir*. 2011;82:197-204

[3] Oh HK, Kim H, Ryoo S, Choe EK, Park KJ. Inguinal hernia repair in patients with cirrhosis is not associated with increased risk of complications and recurrence. *World J. Surg.* 2011;35:1229–33

[4] McIntyre N. Symptoms and signs of liver disease. In: McIntyre N, Benhamou J-P, eds. *Oxford textbook of clinical hepatology*. Oxford: Oxford University Press, 1991:271–290.

[5] Pere P, Höckerstedt K, Lindgren L. Life-threatening liver failure after inguinal herniorrhaphy in patients with cirrhosis. *Eur. J. Surg.* 1999;165:1000-2.

[6] Hansen JB, Thulstrup AM, Vilstup H, Sorensen HT. Danish nationwide cohort study of postoperative death in patients with liver cirrhosis undergoing hernia repair. *Br. J. Surg.* 2002;89:805–6.

[7] Carbonell AM, Wolfe LG, DeMaria EJ. Poor outcomes in cirrhosis-associated hernia repair: a nationwide cohort study of 32,033 patients. *Hernia* 2005;9:353–7.

[8] Ozden I, Emre A, Bilge O, Tekant Y, Acarli K, Alper A, Aryogul O. Elective repair of abdominal wall hernias in decompensated cirrhosis. *Hepatogastroenterology* 1998;45:1516-8.

[9] Belghiti J, Durand F. Abdominal wall hernias in the setting of cirrhosis. *Semin. Liver Dis* 1997;17:219–26.

[10] Mansour A, Watson W, Shayani V, Pickleman J. Abdominal operations in patients with cirrhosis: still a major surgical challenge. *Surgery* 1997;122:730–6.

[11] Hurst RD, Butler BN, Soybel DI, Wright HK. Management of groin hernias in patients with ascites. *Ann. Surg.* 1992;216:696–700.

[12] Guillet M. Chirugie de la paroi chez le cirrhotique. In: Belghiti J, Guillet M, eds. *La chirugie digestive chez le cirrhotique*. Paris, Springer-Verlag, 1993:53-60.

[13] Park JK, Lee SH, Yoon WJ, Lee JK, Park SC, Park BJ, Jung YJ, Kim BG, Yoon JH, Kim CY, Ha J, Park KJ, Kim YJ. Evaluation of hernia repair operation in Child-Turcotte-Pugh class C cirrhosis and refractory ascites. *J. Gastroenterol. Hepatol*. 2007;22:377-82.

[14] Patti R, Almasio PL, Buscemi S, Famà F, Craxì A, Di Vita G. Inguinal hernioplasty improves the quality of life in patients with cirrhosis. *Am. J. Surg.* 2008;196:373-8.

[15] Horn TW, Harris JA, Martindale R, Gadacz T. When a hernia is not a hernia: the evaluation of inguinal hernias in the cirrhotic patient. *Am. Surg.* 2001;67:1093-5.

[16] Gines P, Cardenas A, Arroyo V, Rodes J. Management of cirrhosis and ascites. *N. Engl. J. Med.* 2004;350: 1646–54.

[17] Weeder PD, Porte RJ, Lisman T. Hemostasis in liver disease: implications of new concepts for perioperative management. *Transfus Med. Rev.* 2014;28:107-13.

[18] Rockey D, Caldwell S, Goodman Z, Nelson R, Smith A. Liver biopsy. *Hepatology* 2009;49:1017–44.

[19] Patel I, Davidson J, Nikolic B, Salazar G, Schwartzberg M, Walker TG, Saad WA; Standards of Practice Committee, with Cardiovascular and Interventional Radiological Society of Europe (CIRSE) Endorsement. Consensus guidelines for periprocedural management of coagulation status and hemostasis risk in percutaneous image-guided interventions. *J. Vasc. Interv. Radiol.*, 2012;23:727–36.

[20] Vucelić D, Golubović M, Bjelović M. PFA-100 test in the detection of platelet dysfunction and monitoring DDAVP in a patient with liver cirrhosis undergoing inguinal hernia repair. *Srp. Arh. Celok Lek.* 2012;140:782-5.

[21] Koscielny J, von Tempelhoff GF, Ziemer S, Radtke H, Schmutzler M, Sinha P, Salama A, Kiesewetter H, Latza R. A practical concept for preoperative management of patients with impaired primary haemostasis. *Clin. Appl. Thromb. Haemost*. 2004; 10:155-66.

[22] Sadler JE, Blinder M. Von Willebrand disease: diagnosis, classification, and treatment. In: Colman RW, Hirsh J, Morer VJ, Clowes AW, George JN, editors. *Hemostasis and Thrombosis. Basic Principles and Clinical Practice*. Philadelphia: Lippincott Williams & Wilkins; 2001:825-37.

[23] Lawson EH, Benjamin E, Busuttil RW, Hiatt JR. Groin herniorrhaphy in patients with cirrhosis and after liver transplantation. *Am. Surg.* 2009;75:962-5.

[24] Hur YH, Kim JC, Kim DY, Kim SK, Park CY. Inguinal hernia repair in patients with liver cirrhosis accompanied by ascites. *J. Korean Surg. Soc.* 2011;80:420-5.

[25] de Goede B, Klitsie PJ, Lange JF, Metselaar HJ, Kazemier G. Morbidity and mortality related to non-hepatic surgery in patients with liver cirrhosis: a systematic review. *Best Pract. Res. Clin. Gastroenterol.* 2012;26:47-59.

[26] Ginsburg BY, Sharma AN. Spontaneous rupture of an umbilical hernia with evisceration. *J. Emerg. Med.* 2006;30:155-7.

[27] Mathur S, Bartlett AS, Gilkison W, Krishna G. Quality of life assessment in patients with inguinal hernia. *ANZ J. Surg.* 2006;76:491–3.

[28] Lawrence K, McWhinnie D, Jenkinson C, Coulter A. Quality of life in patients undergoing inguinal hernia repair. *Ann. R. Coll Surg. Engl.* 1997;79:40 –5.

[29] Zieren J, Küpper F, Paul M, Neuss H, Müller JM. Inguinal hernia: obligatory indication for elective surgery? A prospective assessment of quality of life before and after plug and patch inguinal hernia repair. *Langenbecks Arch. Surg.* 2003;387:417–20.

[30] Marchesini G, Bianchi G, Amodio P, Salerno F, Merli M, Panella C, Loguercio C, Apolone G, Niero M, Abbiati R; Italian Study Group for quality of life in cirrhosis. Factors associated with poor health-related quality of life of patients with cirrhosis. *Gastroenterology* 2001;120:170–8.

In: Encyclopedia of Surgery (22 Volume Set)
Editors: Andreas Lehrer and Kristin Mueller
ISBN: 978-1-53618-329-0
© 2020 Nova Science Publishers, Inc.

Chapter 377

ERECTILE FUNCTION AFTER FEMALE-TO-MALE TRANSSEXUAL SURGERY

Borko Stojanovic, Marta R. Bizic and Miroslav L. Djordjevic*
School of Medicine, University of Belgrade, Serbia

ABSTRACT

Neophalloplasty is one of the most difficult surgical procedures in genital reconstructive surgery. Many different tissues have been applied such as local vascularized flaps or microvascular free transfer grafts. The main goal of the neophalloplasty is to construct the functional and cosmetically acceptable penis. Although voiding while standing is a priority for most female-to-male transgenders, most patients want to use the neophallus for sexual experience. Erectile function in male transgenders is based on erogenous sensitivity and possibility to achieve erection. In transgenders who underwent metoidioplasty, erogenous sensation is fully preserved while the erectile size of the reconstructed clitoris is not enough for penetration. In patients with total phalloplasty, erectile dysfunction is occurred due to the lack of erectile tissue and penile prosthesis implantation presents a suitable option. Two types of penile prostheses, semi-rigid and inflatable, are usually used after total phalloplasty. Different techniques have been described to enable insertion of both types of prosthesis, but they often resulted in complications and failure. The main limiting factor is presented by the fact that there is no adequate substitute for the penile erectile tissue after phalloplasty. In contrary to serious complications reported in the past, new techniques and modifications for penile prosthesis implantation into the neophallus seem to be safe in experienced hands.

Keywords: neophalloplasty, radial forearm free flap, musculocutaneous latissimus dorsi flap, erectile function, penile prosthesis, complications

* Corresponding Author's Email: djordjevic@uromiros.com.

INTRODUCTION

The term transsexual came into professional and public usage in the 1950's as defining a person who aspired to or actually lived in the anatomically contrary gender role, whether or not hormones had been administered or surgery had been performed. In recent years, there has been an increase in the awareness and acceptance of the transsexuals. In the International Classification of Diseases (ICD-10) *'transsexualism'* is described as a desire to live and be accepted as a member of the opposite sex, usually accompanied by a sense of discomfort with, or inappropriateness of, one's anatomic sex, and a wish to have surgery and hormonal treatment to make one's body as congruent as possible with one's preferred sex. Therefore, genital sexual reassignment requires the combined team efforts of a psychiatrist, an endocrinologist, a plastic surgeon, a gynecologist and an urologist. Sex reassignment surgery (SRS), either male to female or female to male, is the last step in an individual's transition and includes surgical procedures that will reshape the individual's body into a body with the appearance of the desired gender [1, 2].

Prior to SRS, all patients need to have complete psychiatrist evaluation for the further hormonal and surgical treatment and documents called Standards of Care for Gender Identity Disorders (SOC). The most widespread SOC in this field is published by the World Professional Association for Transgender Health (WPATH) [3]. All patients have to have undergone medically supervised hormonal treatments before commencing the surgical procedures. Female to male transsexuals need to start with testosterone use to enlarge the clitoris, deepen the voice and produce facial and body hair. In female to male transsexuals definitive sex reassignment surgery involves chest reconstruction, removal of female reproductive organs and creation of a neophallus.

Bilateral mastectomy is very often the first, and in many cases the only surgical procedure that female to male transsexual patients undergo. Breasts are one of the mostly visible symbols of the female body, and therefore represent the main psychological problem of these patients. Removal of female reproductive organs (hysterectomy and bilateral salpingoophorectomy) can be performed either before or at the same time with phalloplasty. It can be performed using either abdominal, transvaginal or laparoscopically assisted approach. Removal of the vagina is presented by destruction of mucosal and submucosal part of the vagina so called colpocleisys and followed with reconstruction of the perineum to be as in males [4, 5].

Reconstruction of the neophallus is one of the most difficult elements in surgical treatment of female transsexuals. While there are a variety of available surgical techniques, their results are not equally acceptable to all patients. The preference for a specific surgical technique mostly depends on the patient's desires and expectations [6]. Nevertheless, it is the surgeon's duty to fully inform the patient about all advantages and disadvantages, as well as all complications that might occur after surgical procedure and their potential severity and even to talk them out of a desired surgical technique if there are contraindications. Although voiding while standing is a priority for most female-to-male transgenders, most patients want to use the neophallus for sexual experience. The main limiting factor is presented by the fact that there is no adequate substitute for the penile erectile tissue after phalloplasty. Different techniques have been described to enable neophallic rigidity, but they often resulted in complications and failure [7].

TECHNIQUES OF PHALLOPLASTY

Metoidioplasty

This is a technically demanding and challenging surgical procedure used in female to male transsexuals who want a gender reassignment surgery without undergoing a complex, multi-staged surgical creation of an adult size phallus. It represents a technique for creating a neophallus from a hormonally hypertrophied clitoris in female to male transsexuals who do not wish to have sexual intercourse (Figure 1) [8]. The clitoris and penis are homologues, like the labia majora and the scrotum, even though sited in a different position. Durfee and Rowland were the first to report surgical penile substitution using the clitoris in female transsexuals [9]. The techniques have been refined since then, and Laub et al. defined this surgical transformation as metoidioplasty derived from the Greek words 'meta', 'toward' and 'oidion', 'male genitalia' [10]. Selecting metoidioplasty as a surgical procedure will limit scarring to the external genital region. Hage reported that even though metoidioplasty represents an essentially one-stage procedure, even with this technique, phalloplasty for female to male transsexuals can hardly be completed in one step. Therefore, metoidioplasty is a method of choice in all cases where the clitoris is large enough to provide a neophallus with all functions of a penis [11]. We have published the results of metoidioplasty in 22 patients, with a mean follow-up of 3.9 years, during which 3 urethral fistulas and two strictures were encountered [12]. Therefore, a continual challenge in the search for new and better solutions resulted in many modifications of our original technique with the aim of changing the feminine appearance of the external genitalia to a more masculine morphology and of allowing voiding while standing.

Figure 1. Appearance of genitalia in female to male transgender. Clitoris is hormonally enlarged.

Advancement of the clitoris begins with circular incision beneath the clitoral glans, at the border between the inner and outer layer of the clitoral prepuce and continues around the urethral plate and native urethral orifice. After total degloving, fundiform and suspensory clitoral ligaments were detached from the pubic bone to advance the clitoris, so it would become mobile to enable the new fixation at the base of the neophallus. Urethral

reconstruction begins with the reconstruction of the bulbar part of the urethra. Remaining part of the anterior vaginal wall is anastomosed with the remaining urethral plate, forming the bulbar part of the urethra. Further urethral reconstruction includes using of all available genital tissue, both labia minora, and hairless clitoral skin. The inner surface of both labia minora is dissected to create a flap with appropriate dimensions without detachment from the outer labial surface. This way, excellent vascularization of the flap is enabled. Flaps are joined to create a tube and to lengthen urethra from its bulbar part. More length of the urethra is achieved using available clitoral skin. Both varieties of flaps, clitoral and labial, have fine supportive tissue that prevents fistula formation and give satisfactory aesthetical results. Finally, new urethral meatus is placed at the base of the neophallus. At the end, vaginal space is closed and perineum is created to be as in males. Both labia maiora are joined in the midline over the neourethra creating the one-sac scrotum. Silicone testicle prostheses are inserted in both labia maiora completing scrotoplasty (Figures 2-4).

Figure 2. Appearance of genitalia after metoidioplasty.

Figure 3. Good relationship between neophallus and scrotum with implants is visible.

Figure 4. Voiding while standing is achieved.

Radial Forearm Free Flap Phalloplasty

In patients who desire a larger phallus, many different surgical techniques were reported using available local vascularized tissues or microvascular tissue transfers. The most widely used flap for total neophalloplasty is the radial forearm flap [13-17]. However, it has many drawbacks, e.g., an unsightly donor site scar, very frequent urethral complications, and a small penis that does not allow for a safe insertion of penile prosthesis in the majority of cases.

In the classic surgical procedure, three surgical teams operate at the same time: 1) the vascular surgeon prepares recipient blood vessels, 2) the urologist is operating in perineal area and prepares recipient site for neophallus, and 3) plastic/genital surgeon is dissecting the free vascularized flap of the forearm for tubularization and creation of the neophallus. Neophallus is transferred to the pubic area and fixed at the proper position. The radial artery is miscrosurgically connected to the common femoral artery in an end to side fashion. The venous anastomosis is performed between cephalic vein and the greater saphenous vein. One forearm nerve is connected to the ilioinguinal nerve for tactile sensation and another nerve is anastomosed to the dorsal clitoral nerve for erogenous sensation. The defect of the donor area is covered either by full-thickness or split-thickness skin grafts [18, 19].

Musculocutaneous Latissimus Dorsi Free Flap Phalloplasty

Since genitals have an important role in creating body image and, without any doubt, determine future mental image, we assumed that phalloplasty with normal-looking external genitalia and physical plays a main role in female to male gender reassignment surgery. This was the main reason behind our development of a new technique using the musculocutaneous latissimus dorsi free transfer flap, based on favorable experimental and clinical experience. It has a reliable and suitable anatomy to meet the esthetic and functional needs for phallic

reconstruction. Due to its workable size, ease of identification, long neurovascular pedicle and minimal functional loss after removal, the latissimus dorsi flap has been used for a variety of reconstructions.[20-24]. The main advantage of this flap is its large surface area, allowing for an excellent penile size (length and circumference), large enough to allow urethroplasty and implantation of a penile prosthesis. Moreover, the penis can be constructed to the size desired by the patient. Neophallus retraction seems less likely with muscle-based grafts than with fasciocutaneous forearm flaps, since denervated well-vascularized muscle is less prone to contraction than connective tissue. Sexual function of this neophallus remains problematic, as the flap lacks orgasmic sensitivity; it is restricted to the glans with a preserved dorsal nerve bundle incorporated at the base of the neophallus. Strong motivation and excellent cooperation of the partner are mandatory for a successful sexual intercourse [22, 23].

Figure 5. Design of the latissimus dorsi musculocutaneous flap.

A latissimus dorsi musculocutaneous flap of the non-dominant side is designed and harvested with thoracodorsal artery, vein and nerve. The surface of the flap is templated in two parts: 1) a rectangular part for neophallic shaft to be approximately 15X14cm and 2) additional, circular or semilunar component for glans reconstruction (Figure 5). The flap is completely elevated except for the neurovascular bundle, which was not transected until the recipient vessels and nerve had been prepared for microanastomosis. The neophallus is created while the flap is still perfusing on its vascular pedicle; the flap is tubularized in the midline and the neoglans formed by folding over and approximating to the penile shaft. The new constructed phallus is detached from the axilla after clamping dividing neurovascular pedicle with aim to achieve maximal pedicle length. The donor site defect is closed by direct skin approximation. If it is impossible, remaining donor site defect is grafted with split-thickness skin graft. Simultaneously, another team dissects the recipient area together with femoral artery, saphenous vein and ilioinguinal nerve. Additional “Y” incision is made in the pubic area and a wide tunnel is created to place the flap pedicle. The neophallus is transferred to the recipient area and microsurgical anastomoses are created between thoracodorsal and femoral artery, thoracodorsal and saphenous vein and thoracodorsal and ilioinguinal nerve (Figure 6). Specially constructed dressing is used to keep the neophallus in an elevated position for approximately 2 weeks.

Figure 6. Neophallus is created and fixed at the proper space above the new created scrotum. Microvascular anastomosis between neophallus and recipient blood vessels is done.

Figure 7. Neourethra is created from all available vascularized hairless tissue: urethral plate, labia minora and clitoral skin. Scrotum is formed by joining of both labia maiora. Perineum is fashioned as in male.

The principles of the reconstruction of the neophallus urethra are previously described [25-27]. In female-to-male transsexuals gap between the neourethra and female urethral meatus is always more than 10 cm. The principle of the reconstruction is the same as in metoidioplasty. Recently, we started to use all available vascularized hairless tissue to lengthen the neourethra maximally preventing the postoperative complications (Figure 7). For this reason, both labia minora and available clitoral skin are used for urethral tubularization. This way, new urethral opening is placed in first half of neophallus, minimizing the requests for longer neophallus urethroplasty. Further reconstruction is based on two-staged procedure. This principle introduced by Johanson in the 1950 is still in use today, directly or indirectly [28]. The first stage includes creation of the new ”urethral plate” using buccal mucosa graft. Buccal mucosa grafts (either pairs or single, depending on the

width and length of neourethra needed) are placed on the ventral side of the penis. When the healed grafts are ready for final stage tubularization and closure, it is important to incise the underlying tissue that will support the neourethra and avoid ischemia at the neourethral suture line. It is recommended to create second layer from surrounding tissue to cover and support the new created urethra. The key for successful repair is waiting long enough until the skin is supple. Second stage should be performed when the "urethral plate" has matured enough to be supple and thus more easily mobilized for a tubularization. If it is necessary, additional buccal mucosa grafts can be used for urethral plate augmentation and easier tubularization.

ERECTILE FUNCTION

Erectile function in male transgenders is based on erogenous sensitivity and possibility to achieve erection. In transgenders who underwent metoidioplasty, erogenous sensation is fully preserved while the erectile size of the reconstructed clitoris is not enough for penetration. [29] In patients with total phalloplasty, erectile dysfunction is occurred due to the lack of erectile tissue and penile prosthesis implantation presents a suitable option. Its usage has frequently been associated with complications, sometimes in as many as 50% of cases [30].

The penile prosthesis is recognized as a most effective option to obtain an artificial erection satisfactory for sexual intercourse with penetration. These devices are subject to continuous development and they are achieving even better mechanical reliability and safety. Despite the fact that the penile prosthesis surgery represents the gold standard in patients with erectile dysfunction, they are also used to obtain rigidity in cases of phalloplasty performed for gender dysphoria [31].

Two types of penile prostheses, semi-rigid and inflatable, are usually used after total phalloplasty. The semi-rigid (malleable and mechanical) prostheses are characterized by two silicone cylinders and an internal twisted stainless steel wire core. Simple surgical procedure and easy usage present the main advantages. These devices have the disadvantage that the neophallus is always erect. However, it can be oriented in different ways depending on the need to urinate, to have sexual intercourse or to cover it with clothes. Inflatable prostheses may have two or three components. Two-component prostheses are composed of two flexible cylinders with a reservoir at the base connected to the pump. In three-component prostheses, reservoir is inserted in Rezius space or into the peritoneum and connected with pump and cylinders. The main advantages are that they feel softer than semi-rigid with better esthetical appearance and possibility to ensure more natural erection. The disadvantages are the possibility of malfunction and more postoperative complications (infection, erosion, etc.) [32, 33].

Only two surgical approaches, the infrapubic or/and the penoscrotal, are suitable for penile prosthesis implantation into the neophallus [34]. A longitudinal or a transverse incision is made below the pubis, just above the base of the neophallus. Hegar dilators are used to create the space for insertion of the prosthesis (Figure 8). The prosthesis is covered with vascular grafts imitating tunica albuginea to prevent protrusion through the glans. The prosthesis is additionally fixed to the periostium of the inferior pubic rami. Disadvantages of the infrapubic approach include possible damage of the neurovascular bundle of the neophallus and limited exposure for prosthesis insertion. Also, it is impossible to transfer the

tubes between cylinders and the pump located in the scrotum. The pump of the inflatable prosthesis is inserted into the scrotum using a small incision above the scrotum (Figures 9 and 10).

Figure 8. Second stage: dorsal approach is used for insertion of penile implants. Hegar dilators are used for creation of the proper spaces for cylinders.

Figure 9. Three-component inflatable prosthesis is inserted: both cylinders into the neophallus, pump into the left hemiscrotum and reservoir retrovesically.

With the penoscrotal approach, a vertical or a transverse incision is made ventrally at the penoscrotal junction. Initially, there was concern that this approach might be associated with a higher infection rate than the infrapubic approach, however, it has been shown not to be the case. Advantages of the penoscrotal approach include avoidance of injury of vascular supply, better exposure for prosthesis insertion, insertion of the pump without an additional incision and the ability to anchor the prosthesis to the pubic bones. Fixation of the cylinder bases to

the periostium of the inferior pubic rami stabilizes the prosthesis and discourages cylinder protrusion through the neoglans. With the vertical penoscrotal approach, all layers are opened longitudinally allowing good visualization of all structures, especially the urethra. The scar produced by this incision is barely visible and hidden between two hemiscrotums [35].

Figure 10. Appearance after closure of all incisions.

For a long time, conventional wisdom has dictated that if penile prosthesis revision surgery is necessary, it should be performed by the same approach that was used for the initial implant. When a patient presents for the explant of a semi-rigid prosthesis that was implanted via the infrapubic approach and reimplant of a three-piece inflatable prosthesis in its place, we go through the infrapubic scar and remove the malleable implants. The new prosthesis is then implanted using the described technique.

A major concern regarding erectile function in female to male transgenders is long-term follow-up. However, only a few reports with small numbers of patients have been published. Puckett and Montie firstly reported implantation of hydraulic prostheses after phalloplasty [36]. In two separated studies, Levine and Jordan reported low success rate in 4 and 8 cases, respectively [37, 30]. Two largest series of penile prostheses in male transgenders were published by Ghent group in 2003 and 2010 [38, 39]. Hoebeke et al, in the larger series to date, reported long-term follow-up in 129 patients who underwent female to male surgery. Inflatable prostheses were used in all cases with average follow up of 44.3 months. Since their data was only available on this subject, they compared results with studies on the subject of prosthesis implantation in males with erectile dysfunction and found some differences. First, higher risk of malposition in transsexuals is occurred due to missing of crura of corpora cavernosa. Second, tissue of the neophalus is totally different from natural cavernosal tissue and tunica albuginea and makes higher risk for protrusion and infections. Third, female to male transsexuals are usually younger and sexually more active than older males with erectile dysfunction. This fact may lead in more mechanical failures of prostheses.

CONCLUSION

Erectile function in female to male transsexuals is limited after phalloplasty. Metoidioplasty presents a good variant for patients who are interested to have small phallus with possibility to void while standing. They should be informed that the sexual intercourse will not be possible. However, it is always possible to perform some of regular procedures for total phalloplasty at a later stage, and with less risk of complications and operation time.

In total phalloplasty, insertion of penile prosthesis is required for penetrating sexual intercourse. In the past, attempts have been made to use part of bone or cartilage, but without satisfactory long-term results. Recently, two different models of penile implants are available, semi-rigid and inflatable. These prostheses are subject to continuous development and they are achieving ever better mechanical reliability and safety. Despite these high complication rates, penile prostheses implantation remains the best option for sexual intercourse after phalloplasty in female to male transgenders.

REFERENCES

[1] WHO *International Statistical Classification of Diseases and Related Problems*, 10th revision, 2nd ed., Geneva, 2005.

[2] Monstrey S, Hoebeke P, Dhont M et al. Surgical therapy in transsexual patients: a multi-disciplinary approach. *Acta Chir Belg*. 2001;101(5):200–9.

[3] Coleman E, Bockting W, Botzer M et al. 7th version of WPATH Standards of Care. *Int J Transgenderism*. 2011;13:165–232.

[4] Eicher W. Surgical Treatment of Female-to-Male Transsexuals. In: Echer W, editor. *Plastic Surgery in the Sexually Handicapped*. Berlin: Springer; 11989. pp. 106–12.

[5] Selvaggi G, Bellringer J. Gender reassignment surgery: an overview. *Nat Rev Urol.* 2011;8(5):274-82.

[6] Hage JJ, Bloem JJAM, Suliman HM. Review of the literature on techniques for phalloplasty with emphasis on the applicability in female-to-male transsexuals. *J Urol*. 1993;150:1093–8.

[7] Hage JJ, Bloem JJ, Bouman FG. Obtaining rigidity in the neophallus of FTM transsexuals: a review of literature. *Ann Plast Surg* 1993; 30:327-33.

[8] Bouman FG. The first step in phalloplasty in female transsexuals. *Plast Reconstr Sur*g. 1987;79:662–4.

[9] Durfee R, and Rowland W. Penile Substitution with Clitoral Enlargement and Urethral Transfer. In: Laub DR. and Gandy P, editors. *Proceedings of the Second Interdisciplinary Symposium on Gender Dysphoria Syndrome*. Palo Alto: Stanford University Press; 1973. pp. 181-3.

[10] Laub DR, Eicher W, Laub DR II, Hentz VR. Penis construction in female-to-male transsexuals. In: Eicher W, Kubli F, and Herms V, editors. *Plastic Surgery in the Sexually Handicapped*. Berlin: Springer; 1989. pp. 113-28.

[11] Hage JJ. Metoidioplasty: an alternative phalloplasty technique in transsexuals. *Plast Reconstr Surg*. 1996; 97:161-7.

[12] Djordjevic ML, Stanojevic D, Bizic M, et al. Metoidioplasty as a single stage sex reassignment surgery in female transsexuals: Belgrade experience. *J Sex Med*. 2009; 6:1306-13.
[13] Khouri RK, Young VL, Casoli VM. Long-term results of total penile reconstruction with a prefabricated lateral arm free flap. *J Urol*. 1998; 160:383–8.
[14] Santanelli F, Scuderi N. Neophalloplasty in female-to male transsexuals with the island tensor fasciae latae flap. *Plast Reconstr Surg*. 2000; 105:1990–6.
[15] Fang RH, Kao YS, Ma S, et al. Phalloplasty in female-to male transsexuals using free radial osteocutaneous flap: a series of 22 cases. *Br J Plast Surg.* 1999; 52:217–22.
[16] Bettocchi C, Ralph DJ, Pryor JP. Pedicled pubic phalloplasty in females with gender dysphoria. *BJU Int*. 2005; 95:120-4.
[17] Chang TS and Hwang WY. Forearm flap in one stage reconstruction of the penis. *Plast Reconstr Surg*. 1984; 74:251-8.
[18] Monstrey S, Hoebeke P, Dhont M et al. Radial forearm phalloplasty: a review of 81 cases. *Eur J Plast Surg* 2005;28:206-12.
[19] Lumen N, Monstrey S, Selvaggi G et al. Phalloplasty: A valuable treatment for males with penile insufficiency. *Urology* 2008;71:272-6.
[20] Ninkovic M, Stenzl A, Schwabegger A et al. Free neurovascular transfer of latissimus dorsi muscle for the treatment of bladder contractility: II Clinical results. *J Urol.* 2003; 169:1379-83.
[21] Baudet J, Guimberteau J, Nascimento E. Successful clinical transfer of two free thoraco dorsal axillary flaps. *Plast Reconstr Surg*. 1976;58:680–8.
[22] Djordjevic ML, Bumbasirevic MZ, Vukovic PM, Sansalone S, Perovic SV. Musculocutaneous latissimus dorsi free transfer flap for total phalloplasty in children. *J Pediatr Urol*. 2006;2:333-9.
[23] Perovic SV, Djinovic R, Bumbasirevic M, Djordjevic M, Vukovic P. Total phalloplasty using a musculocutaneous latissimus dorsi flap. *BJU Int.* 2007;100:899-905.
[24] Lassen M, Krag C, Nielsen I. The latissimus dorsi flap. An overview. *Scand J Plast Reconstr Surg*. 1985;19:41-51.
[25] Rohrmann D, Jakse G. Urethroplasty in female-to-male transsexuals. *Eur Urol* 2003; 44:611-4.
[26] Dabernig J, Shelley OP, Cuccia G, Schaff J. Urethral reconstruction using the radial forearm free flap: experience in oncology cases and gender reassignment. *Eur Urol* 2007; 52:547-54.
[27] Djordjevic ML, Bizic M, Stanojevic D et al. Urethral lengthening in metoidioplasty (female-to-male sex reassignment surgery) by combined buccal mucosa graft and labia minora flap. *Urology* 2009;74:349-53.
[28] Johanson B. Reconstruction of the male urethra in strictures. Application of the buried intact epithelium tube. *Acta Chir Scand*. 1953;176:1.
[29] Stojanovic B, Djordjevic ML. Anatomy of the clitoris and its impact on neophalloplasty (metoidioplasty) in female transgenders. *Clin Anat*. 2015;28(3):368-75.
[30] Jordan GH, Alter GJ, Gilbert DA, Horton CE, Devine Jr CJ. Penile prosthesis implantation in total phalloplasty. *J Urol*. 1994;152:410-4.
[31] Moncada I, Martinez-Salamanca JI, Allona A, Hernandez C. Current role of penile implants for erectile dysfunction. *Curr Opin Urol*. 2004;14:375-80.

[32] Bettocchi C, Palumbo F, Spilotros M et al. Penile prostheses. *Ther Adv Urol.* 2010;2(1):35-40.
[33] Bettocchi C, Palumbo F, Spilotros M et al. Patient and partner satisfaction after AMS inflatable penile prosthesis implant. *J Sex Med*. 2010;7:304-9.
[34] Sadeghi-Nejad H. Penile prosthesis surgery: a review of prosthetic devices and associated complications. *J Sex Med*. 2007;4:296-309.
[35] Simmons M, Montague DK. Penile prosthesis implantation: past, present and future. *Int J Impot Res*. 2008;20:437-44.
[36] Puckett CL, Montie JE. Construction of male genitalia in the transsexual, using a tubed groin flap for the penis and a hydraulic inflation device. *Plast Reconstr Surg*. 1978;61:523-30.
[37] Levine LA, Zachary LS, Gottlieb LJ. Prosthesis placement after total phallic reconstruction. *J Urol.* 1993;149:593-8.
[38] Hoebeke P, de Cuypere G, Ceulemans P, Monstrey S. Obtaining rigidity in total phalloplasty: experience with 35 patients. *J Urol*. 2003;169:221-3.
[39] Hoebeke PB, Decaestecker K, Beysens M et al. Erectile implants in female-to-male transsexuals: our experience in 129 patients. *Eur Urol*. 2010;57:334-40.

In: Encyclopedia of Surgery (22 Volume Set)
Editors: Andreas Lehrer and Kristin Mueller
ISBN: 978-1-53618-329-0
© 2020 Nova Science Publishers, Inc.

Chapter 378

FAILED BACK SURGERY SYNDROME AND SPINAL CORD STIMULATION

Ferdinand Iannaccone[1], MD, Neil Majmundar[2,*], MD and Vanny Le[1], MD
[1]Department of Anesthesiology,
[2]Department of Neurological Surgery, Rutgers New Jersey Medical School,
Newark, NJ, US

Keywords: failed back surgery syndrome; spinal cord stimulation; back pain; radiculopathy

INTRODUCTION

Spinal cord stimulation (SCS) continues to aid in the successful treatment of chronic pain conditions, namely those that are neuropathic in nature. There is no more common chronic pain ailment than back pain. A 2007 U.S. survey found that upwards of 17% of patients had experienced primarily lower back pain over the previous 3 months, roughly 34 million people [3]. It has long been questioned if back surgery is beneficial for these patients. Surgical interventions can be geared towards decompression, discectomy, laminectomy, or limiting painful vertebral movement with fusions or interbody cages. In 2001, hospitalizations for lumbar surgery totaled 356,638. Of those, over 122,000 were lumbar fusions for degenerative conditions, a 220% increase from 10 years prior [6]. With no concrete indications for surgical intervention due to chronic back pain, patients often times undergo surgery and are left with continued pain.

Multiple studies suggest at best a 70-75% success rate in regards to reduction of Visual Analog Scale (VAS) pain scores at 4 weeks post lumbar fusion [28]. This correlates with surgical modalities outside of fusions as well. However, upwards of 1 out of 4 patients will still experience notable pain postoperatively and there is no clear data describing long-term outcomes. Unsurprisingly, this embarks serious healthcare costs as a result. A retrospective

* Corresponding Author's Email: majmunne@njms.rutgers.edu.

review in 2010 of 111 patients who underwent single level discectomy for lumbar pain and radiculopathy showed that the 36 patients diagnosed with postoperative mechanical back pain were billed a total of $547,655.00 for workup, conservative therapy and subsequent fusion [27].

Table 1. Factors leading to failed back surgery syndrome

Preoperative Factors
Improper selection criteria
Premorbid psychological risk factors
Litigation
Improper communication of goals
Unrealistic expectations
Intra-operative Factors
Misdiagnosis
Wrong spinal level
Inadequate decompression
Residual disc material
Improper screw placement
Fusion instability
Postoperative Factors
Stenosis (residual or new)
Epidural fibrosis
Herniated disc (residual or new)
Worsening degenerative disc

As the number of patients undergoing back surgery continues to grow so does the prospective number of patients suffering from continued pain. Failed back surgery syndrome (FBSS) has been described as persistent back pain that may or may not include pain radiating to the leg after one or more back surgeries. That definition has evolved to also include pain that may be *post-surgical* in onset and may be referred or radiating pain. The etiology of FBSS can be approached temporally as related to surgery: preoperative factors, intraoperative factors and postoperative factors (Table 1) [9].

Preoperative factors describe conditions that apply to patient selection for surgery and can be a significant contributing factor to poor post-surgical outcomes. These conditions can frequently be elucidated with effective communication. Use of psychometric tests like Minnesota Multiphasic Personality Inventory (MMPI) can help identify some of the more predictive personality traits associated with poor outcomes, such as hysteria, hypochondriasis, and depression [8]. Understanding patient motives or secondary gains associated with worker's compensation cases may also be predictive of poor outcomes. Management of postsurgical expectations also plays a great role; a decrease of 3 or more units in VAS is considered an extremely positive outcome [32].

Intraoperative factors involve circumstances such as correct surgical diagnosis, surgical approach or operative events. For example, although spinal canal stenosis can be most evident from herniated disc material, its excision my not result in alleviating neuropathic pain due to

undiagnosed ligamentum flavum hypertrophy. A cautious approach must also be taken in the immediate postoperative phase where pain, increased pain or new pain may require surgical evaluation. Complications such as improper screw placement or fusion instability may result in permanent neurologic injury if not diagnosed quickly.

Postoperative factors relate to events that take place shortly after surgery or slowly develop over time as a result of back surgery. Structural changes due to surgical manipulation are unavoidable. Epidural fibrosis, internal disc disruption or residual disc material are frequently sited causes of continued pain after back surgery. It is also likely that the degenerative changes that prompted surgical correction develop on the contralateral side years later.

Just as with any other disease or ailment, history and physical examination are the starting point for patient evaluation. FBSS is defined as persistent back pain that may or may not include pain radiating to the leg after one or more back surgeries; it is therefore necessary to rule out surgical complications. Nerve root damage, although rare, may present as a focal neurologic deficit or bowel and bladder incontinence. Other complications such as cerebrospinal fluid leak, infection, bleeding or operative level instability should also be considered. Initial diagnostic imaging should include a basic standing X-ray in both flexion and extension to evaluate alignment, stability or degeneration.

Table 2. Imaging modalities

X-ray Bony structures, alignment, and stability
MRI- Modality of choice Effective in diagnosing most etiologies Image quality may be effected by artifact if surgical hardware present Contrast-enhanced imaging may be required if previous surgery for HNP
CT Myelogram Alternative to MRI if surgical hardware causes artifact
CT w/Multiplanar Reconstructions Optimal in patients who have had previous fusion and/or pedicle screws
Discography Evaluate discogenic pain
Diagnostic injections Useful for confirming etiology, particularly if the physical examination and imaging modalities do not match

Most frequently employed advanced imaging for diagnostic purposes in FBSS is MRI. (Table 2) [9]. Many, but not all, etiologies of FBSS can be found on MRI: spinal stenosis, degenerative disc disease, inadequate nerve root decompression, facet join arthropathy, fibrosis or arachnoiditis. Interventional testing can supply more specific testing such as epiduroscopy, which will describe the degree of epidural fibrosis, as well as diagnostic injections can aide in confirming or localizing the spinal level acting as the pain generator.

Studies have shown that the use of SCS improves pain, quality of life, functional capacity and patient overall satisfaction in treating neuropathic pain secondary to FBBS [13, 14]. However, as with most chronic back pain a conservative initial approach is warranted. Physical therapy and pharmacologic management are mainstays of conservative management. Commonly, patients who have undergone back surgery and who now present with FBSS have already attempted physical therapy and may be on an intensive medical regimen for their pain. A retrospective review of 50 patients who underwent surgical treatment for FBSS showed significant improvement in pain and function in only 66% of patients, suggesting a low success rate [10]. In these situations, minimally invasive interventional procedures driven at the likely etiology of FBSS are a good choice.

Based on history and physical exam, assessing if pain is radicular in nature versus axial/musculoskeletal aids in generating targets of treatment. Radicular pain may be secondary to inflammatory processes originating from herniated nucleus pulposus, annular tears or nerve compression. Epidural steroid injections treat radicular pain by interrupting the inflammatory cascade initiated by the production of arachidonic acid from cell membrane phospholipases. Interlaminar, transforaminal or caudal approaches have all been described; data thus far displays mixed conclusions to the exact duration of pain relief expected. In the case of FBSS, anatomical changes from surgical hardware or manipulation make exact needle placement at times challenging.

Axial pain may present in a number of different ways: sharp, dull, throbbing, constant or intermittent. It is confined to a local anatomical region and thus pain is non-radiating. Muscle strain or facet joint arthropathy are common causes of axial pain. Medial branch block and radiofrequency ablation achieve zygapophyseal joint denervation resulting in decreased sensation of pain.

Epidural fibrosis secondary to surgical manipulation and trauma can be the causative etiology in FBSS in upwards of 8-14% of cases [4]. An MRI may show evidence of fibrosis but not accurately describe the quality and severity, therefore epiduroscopy under direct visualization will aide in identifying the severity and location of fibrosis. Adhesiolysis with lidocaine, hypertonic saline, non-particulate betamethasone or a less conservative approach, endoscopic under direct visualization may give pain relief in patients who are seemingly unresponsive to epidural steroid injections.

INDICATIONS FOR SCS IMPLANTATION IN FBSS

Over the years, the indications for spinal cord stimulator implantation have increased in order to treat a variety of pathologies that cause chronic pain. These indications include but are not limited to FBSS, complex regional pain syndrome (CRPS), refractory angina pectoris, peripheral vascular disease, phantom limb pain, and spinal stenosis [3, 12]. The success of

SCS in each of these indications varies. In addition to the treatment options mentioned earlier in this chapter, the use of SCS for FBSS continues to evolve with the development of better-designed electrodes, improvements in surgical techniques, and most importantly, with the implementation of evidence-based trials in order to support this indication. FBSS is by far the most common indication for SCS, with FBSS patients making up 70% of the patients treated with SCS implantation [12].

Spinal cord stimulator implantation has historically been the last resort treatment of neuropathic pain, following pharmacotherapy, physical therapy, and interventional modalities. Once these modes of treatment have all been exhausted, a psychiatric history has been performed, and imaging (MRI, flexion/extension radiographs, CT myelogram) has not show any surgically correctable factors, the clinician must move towards exploring surgical options which include spinal cord stimulator implantation, intrathecal drug delivery system, or reoperation [5]. Patients with predominantly neuropathic radicular pain are better candidates for SCS, as relief of axial pain is usually considered a secondary benefit [2]. Patients with predominantly axial back pain, even with improved electrode coverage, may not necessarily report a positive response to spinal cord stimulator implantation [7]. Furthermore, when considering surgical options, SCS has been shown to be more effective, cost effective, and safer [12, 23, 33].

Prior to permanent implantation, the patient must first undergo a period of trial stimulation with an external generator and percutaneous leads. If the patient is unable to obtain >50% pain relief from the temporary leads, the patient is not considered a good candidate for SCS as temporary pain relief is the greatest predictor of a negative outcome [36]. If the patient is able to achieve >50% pain relief along with the several other criteria mentioned earlier, the patient is then thought to be a good candidate for SCS. After the risks are discussed with the patient, the stimulator can be implanted and its effectiveness can be determined.

As more evidenced based studies portray the benefits and positive outcomes in SCS patients, the challenge for clinicians has slowly shifted from deciding whether or not SCS is a safe and effective treatment for FBSS, to deciding which patient spinal cord stimulator implantation will be most effective in and how soon to reach that decision. Two randomized clinical trials, which will be more closely examined in the following section, have already demonstrated that patients implanted with SCS report better pain relief, than those treated with repeat surgery or conventional medical management (CMM) [13, 14, 24].

EVIDENCE BASED OUTCOMES FOR SCS

In the past SCS has been thought of as the last resort, mainly due to a lack of evidence illustrating its effectiveness over conventional medical management and other treatments, dangerous potential complications, and prohibitive cost of implantation and maintenance. More recently, a number of studies have been conducted in order to examine the clinical effectiveness of SCS in FBSS patients.

A systematic review conducted by Frey et al. in 2009, demonstrated that only 9 of 25 observational studies and 2 of 6 randomized controlled trials regarding SCS and FBSS met the authors' inclusion criteria (methodologic quality assessment of 50 or higher) [7]. From

these 11 studies, Frey et al. found that the 2 randomized clinical trials, and 8 of the 9 observational studies showed positive results for short- and long-term relief after spinal cord stimulator implantation [7]. In the lone observational study, which did not show positive results, only 48% of the 182 patients included experienced 50% or greater long-term relief after spinal cord stimulator implantation [15].

The first of the two randomized controlled trials discussed was conducted by North et al. in 2005 [24]. In two separate studies performed in 1991, North et al. had demonstrated better outcomes in patients treated with SCS than those treated with reoperation at 5 years [19, 20]. In the randomized controlled trial, 50 patients with FBSS characterized by radicular pain were randomized to a reoperation or SCS group and were followed for an average of 3 years. Among the 45 patients available follow-up, 9 of the 19 SCS patients (47%) compared with 3 of the 26 reoperation patients (12%) reported at least 50% pain relief ($P < 0.01$). Patients in the SCS group were also less likely to cross over ($P = 0.02$) than those in the reoperation group. The reoperation group also required increased amounts of opiate analgesics when compared to the SCS group ($P < 0.025$).

The second randomized controlled trial, The Prospective Randomized Controlled Multicenter Trial of the Effectiveness of Spinal Cord Stimulation (i.e., PROCESS) trial followed 100 patients with neuropathic radicular leg pain for 24 months [13, 14]. From the 214 patients initially assessed for the study, 100 were selected; 52 were randomized to the SCS group and 48 to the CMM group. At 6-months, the primary outcome of 50% leg pain relief was achieved in 24 patients (48%) from the SCS group and 4 patients (9%) from the CMM group ($p < 0.001$) [14]. In addition to the primary outcomes, Kumar et al., also reported that the SCS group experienced lower levels of leg and back pain, higher health-related quality of life on 7 of the 8 SF-36 dimensions, better function, and greater satisfaction with treatment ($p < / = 0.02$ for all secondary outcome analyses). Along with these primary and secondary outcomes, SCS implantation also let to decreased analgesic drug intake and non-drug therapy use [14]. At 24 months, 17 of the 46 patients (37%) originally in the SCS group and 1 of the 41 patients originally in the CMM group achieved primary outcome ($p = 0.003$) [13]. At the conclusion of the study, 34 of the 72 patients (47%) who received SCS as the final treatment achieved the primary outcome, while 1 of the 15 patients in the CMM group achieved the primary outcome ($p = 0.02$).

These two randomized controlled trials supported the clinical effectiveness of SCS in patients with predominantly radicular leg pain, over CMM and reoperation. More importantly, they were paramount in establishing that SCS is an effective treatment for patients with FBSS.

A number of more recent studies have also attempted to support the use of SCS in patients with FBSS characterized by both radicular leg and low back pain. In a prospective multicenter trial in Europe, Van Buyten et al. notably showed pain relief achieved without paresthesia by using high frequency stimulation [34]. Seventy-four percent of the patients treated with high frequency (up to 10khz) waveforms reported greater than 50% lower back pain relief at 6 months. At long term follow-up of 24 months, patients reported significant reductions in back and leg pain, decreased opioid use, and improved sleep and function [1]. This study, although having its limitations in its lack of a control group, was important in developing a modality within SCS to treat lower back pain along with the radicular leg pain symptoms found in FBSS.

At the time of this publication, several other trials examining SCS for FBSS are being conducted. North et al. are conducting the EVIDENCE study, which is an international multicenter randomized controlled trial assessing both the effectiveness and cost-effectiveness of SCS (implanted with a rechargeable pulse generator) versus reoperation through a 3 year follow-up in FBSS patients [26]. Rigoard et al. initiated recruitment for the PROMISE study, an international multicenter randomized controlled trial, in January 2013. This study will recruit patients with FBSS and predominant low back pain to compare the clinical effectiveness of SCS and optimal medical management versus medical management alone [30].

SCS has also been shown to be a more cost-effective treatment modality than reoperation and CMM [23, 33]. Kumar et al. added that even failed-SCS is more cost-effective than CMM alone [12]. Kunal and Wilson further stated that an argument can be made to implant patients earlier in the patient-selection and operation algorithm, as many patients are unable to obtain positive outcomes after SCS due to the delay in treatment [17]. Several studies have been conducted regarding the relationship between delay in treatment and implantation success, and the causes behind it [12]. These cost-effectiveness and time-to-treatment studies will help further support the notion that SCS should not be considered a last resort treatment, instead, an effective treatment modality which should be considered earlier for the "right patient." In order to further develop this treatment algorithm for FBSS patients, additional studies must strive to create a more a precise picture of which patient SCS will be most effective in earlier along in the treatment selection process.

SPINAL CORD STIMULATOR LEAD PLACEMENT

Spinal cord stimulator technology has significantly progressed over the past decades as newer leads, pulse generators, and targets have emerged. In this section, we will briefly discuss lead placement as it pertains to FBSS.

As discussed earlier, percutaneous cylindrical leads have generally been used in trial stimulation, while a paddle lead is typically placed via laminectomy. Although percutaneous leads provided a less invasive approach for lead placement and can be done under local anesthesia, they have historically been associated with poor outcomes possibly due to high rates of lead migration [22, 29]. The often-referenced randomized control trial study by North et al. from 2005 demonstrated that laminectomy electrode placement produced better results than percutaneous placed electrodes in FBSS patients at a mean of 1.9 years follow-up, though this statistical significance was lost at 2.9 years of follow-up in their small sample size [22]. A study performed a few years prior by Villavicencio et al., also found better outcomes long-term in patients with laminectomy placed electrodes. These studies, along with lower reported rates of migration, less lead breakage, lower output parameters, and better results in FBSS patients strengthened the perception that implantation of plate type electrodes under direct vision via laminectomy was superior [16, 21, 25].

More recently, a number of studies regarding percutaneous-placed electrodes have shown equal or better long-term outcomes in FBSS patients [11, 18, 35]. These studies regarding percutaneous methods of implantation have demonstrated improved migration rates and patient satisfaction when compared with studies performed in the past. While these

percutaneous implantation methods can be sufficient in less complex cases, FBSS patients at times can present a much more complex problem requiring multicolumn lead placement. Rigoard et al., in a recent nonrandomized observational study, suggested the efficacy of multicolumn surgically implanted leads, and importantly noted the millions of potential programming combinations available to optimize stimulation [31].These leads which include, Medtronic 5-6-5 and Penta, St. Jude Medical, may require a more stable spatial relationship among the multiple columns so that they can provide adequate coverage [12]. Both these leads are designed to improve lateral coverage, which may assist in treating axial back pain along with the radicular symptoms found in FBSS patients [30].

CONCLUSION

Failed back surgery syndrome represents one of the most common indications for spinal cord stimulation. Candidates must be carefully selected, and must have realistic treatment goals. In the well-selected patient, spinal cord stimulation has been shown to be safe, efficacious, and cost-effective. With advances in technology and surgical technique, patient satisfaction has been improving. Moving forward, long term outcomes studies and studies of functional outcome and return to work will be of importance.

REFERENCES

[1] Al-Kaisy A, Van Buyten JP, Smet I, Palmisani S, Pang D, Smith T: Sustained effectiveness of 10 kHz high-frequency spinal cord stimulation for patients with chronic, low back pain: 24-month results of a prospective multicenter study. *Pain Med 15:*347-354, 2014.

[2] Atkinson L, Sundaraj SR, Brooker C, O'Callaghan J, Teddy P, Salmon J, et al: Recommendations for patient selection in spinal cord stimulation. *J Clin Neurosci 18:*1295-1302, 2011.

[3] Bendersky D, Yampolsky C: Is spinal cord stimulation safe? A review of its complications. *World Neurosurg 82:*1359-1368, 2014.

[4] Burton CV: Causes of failure of surgery on the lumbar spine: ten-year follow-up. *Mt Sinai J Med 58:*183-187, 1991.

[5] Chan CW, Peng P: Failed back surgery syndrome. *Pain Med 12:*577-606, 2011.

[6] Deyo RA, Gray DT, Kreuter W, Mirza S, Martin BI: United States trends in lumbar fusion surgery for degenerative conditions. *Spine (Phila Pa 1976) 30:*1441-1445; discussion 1446-1447, 2005.

[7] Frey ME, Manchikanti L, Benyamin RM, Schultz DM, Smith HS, Cohen SP: Spinal cord stimulation for patients with failed back surgery syndrome: a systematic review. *Pain Physician 12:*379-397, 2009.

[8] Guyer RD, Patterson M, Ohnmeiss DD: Failed back surgery syndrome: diagnostic evaluation. *J Am Acad Orthop Surg 14:*534-543, 2006.

[9] Hussain A, Erdek M: Interventional pain management for failed back surgery syndrome. *Pain Pract 14:*64-78, 2014.

[10] Kim SS, Michelsen CB: Revision surgery for failed back surgery syndrome. *Spine (Phila Pa 1976) 17:*957-960, 1992.

[11] Kinfe TM, Schu S, Quack FJ, Wille C, Vesper J: Percutaneous implanted paddle lead for spinal cord stimulation: technical considerations and long-term follow-up. *Neuromodulation 15:*402-407, 2012.

[12] Kumar K, Caraway DL, Rizvi S, Bishop S: Current challenges in spinal cord stimulation. *Neuromodulation 17 Suppl 1:*22-35, 2014.

[13] Kumar K, Taylor RS, Jacques L, Eldabe S, Meglio M, Molet J, et al: The effects of spinal cord stimulation in neuropathic pain are sustained: a 24-month follow-up of the prospective randomized controlled multicenter trial of the effectiveness of spinal cord stimulation. *Neurosurgery 63:*762-770; discussion 770, 2008.

[14] Kumar K, Taylor RS, Jacques L, Eldabe S, Meglio M, Molet J, et al: Spinal cord stimulation versus conventional medical management for neuropathic pain: a multicentre randomised controlled trial in patients with failed back surgery syndrome. *Pain 132:*179-188, 2007.

[15] Kumar K, Toth C: The role of spinal cord stimulation in the treatment of chronic pain postlaminectomy. *Curr Rev Pain 2:*85-92, 1998.

[16] Kumar K, Toth C, Nath RK, Laing P: Epidural spinal cord stimulation for treatment of chronic pain--some predictors of success. A 15-year experience. *Surg Neurol 50:*110-120; discussion 120-111, 1998.

[17] Kumar K, Wilson JR: Factors affecting spinal cord stimulation outcome in chronic benign pain with suggestions to improve success rate. *Acta Neurochir Suppl 97:*91-99, 2007.

[18] Loge D, Vanneste S, Vancamp T, Rijckaert D: Long-term outcomes of spinal cord stimulation with percutaneously introduced paddle leads in the treatment of failed back surgery syndrome and lumboischialgia. *Neuromodulation 16:*537-545; discussion 545, 2013.

[19] North RB, Campbell JN, James CS, Conover-Walker MK, Wang H, Piantadosi S, et al: Failed back surgery syndrome: 5-year follow-up in 102 patients undergoing repeated operation. *Neurosurgery 28:*685-690; discussion 690-681, 1991.

[20] North RB, Ewend MG, Lawton MT, Kidd DH, Piantadosi S: Failed back surgery syndrome: 5-year follow-up after spinal cord stimulator implantation. *Neurosurgery 28:*692-699, 1991.

[21] North RB, Ewend MG, Lawton MT, Piantadosi S: Spinal cord stimulation for chronic, intractable pain: superiority of "multi-channel" devices. *Pain 44:*119-130, 1991.

[22] North RB, Fischell TA, Long DM: Chronic stimulation via percutaneously inserted epidural electrodes. *Neurosurgery 1:*215-218, 1977.

[23] North RB, Kidd D, Shipley J, Taylor RS: Spinal cord stimulation versus reoperation for failed back surgery syndrome: a cost effectiveness and cost utility analysis based on a randomized, controlled trial. *Neurosurgery 61:*361-368; discussion 368-369, 2007.

[24] North RB, Kidd DH, Farrokhi F, Piantadosi SA: Spinal cord stimulation versus repeated lumbosacral spine surgery for chronic pain: a randomized, controlled trial. *Neurosurgery 56:*98-106; discussion 106-107, 2005.

[25] North RB, Kidd DH, Zahurak M, James CS, Long DM: Spinal cord stimulation for chronic, intractable pain: experience over two decades. *Neurosurgery 32:*384-394; discussion 394-385, 1993.

[26] North RB, Kumar K, Wallace MS, Henderson JM, Shipley J, Hernandez J, et al: Spinal cord stimulation versus re-operation in patients with failed back surgery syndrome: an international multicenter randomized controlled trial (EVIDENCE study). *Neuromodulation 14:*330-335; discussion 335-336, 2011.

[27] Parker SL, Xu R, McGirt MJ, Witham TF, Long DM, Bydon A: Long-term back pain after a single-level discectomy for radiculopathy: incidence and health care cost analysis. *J Neurosurg Spine 12:*178-182, 2010.

[28] Pereira P, Buzek D, Franke J, Senker W, Kosmala A, Hubbe U, et al: Surgical data and early postoperative outcomes after minimally invasive lumbar interbody fusion: results of a prospective, multicenter, observational data-monitored study. *PLoS One 10:*e0122312, 2015.

[29] Racz GB, McCarron RF, Talboys P: Percutaneous dorsal column stimulator for chronic pain control. *Spine (Phila Pa 1976) 14:*1-4, 1989.

[30] Rigoard P, Desai MJ, North RB, Taylor RS, Annemans L, Greening C, et al: Spinal cord stimulation for predominant low back pain in failed back surgery syndrome: study protocol for an international multicenter randomized controlled trial (PROMISE study). *Trials 14:*376, 2013.

[31] Rigoard P, Jacques L, Delmotte A, Poon K, Munson R, Monlezun O, et al: An algorithmic programming approach for back pain symptoms in failed back surgery syndrome using spinal cord stimulation with a multicolumn surgically implanted epidural lead: a multicenter international prospective study. *Pain Pract 15:*195-207, 2015.

[32] Schofferman J, Reynolds J, Herzog R, Covington E, Dreyfuss P, O'Neill C: Failed back surgery: etiology and diagnostic evaluation. *Spine J 3:*400-403, 2003.

[33] Taylor RS, Ryan J, O'Donnell R, Eldabe S, Kumar K, North RB: The cost-effectiveness of spinal cord stimulation in the treatment of failed back surgery syndrome. *Clin J Pain 26:*463-469, 2010.

[34] Van Buyten JP, Al-Kaisy A, Smet I, Palmisani S, Smith T: High-frequency spinal cord stimulation for the treatment of chronic back pain patients: results of a prospective multicenter European clinical study. *Neuromodulation 16:*59-65; discussion 65-56, 2013.

[35] Vonhogen LH, Vancamp T, Vanneste S, Pollet W, Dirksen R, Bakker P, et al: Percutaneously implanted plates in failed back surgery syndrome (FBSS). *Neuromodulation 14:*319-324; discussion 324-315, 2011.

[36] Williams KA, Gonzalez-Fernandez M, Hamzehzadeh S, Wilkinson I, Erdek MA, Plunkett A, et al: A multi-center analysis evaluating factors associated with spinal cord stimulation outcome in chronic pain patients. *Pain Med 12:*1142-1153, 2011.

In: Encyclopedia of Surgery (22 Volume Set)
Editors: Andreas Lehrer and Kristin Mueller
ISBN: 978-1-53618-329-0
© 2020 Nova Science Publishers, Inc.

Chapter 379

COMPLICATION AVOIDANCE AND REVISION SURGERY

Sameah A. Haider, Meghan E. Wilock and Julie G. Pilitsis*, MD, PhD
Department of Neurosurgery, Albany Medical College, Albany, NY, US

ABSTRACT

Neuromodulation offers a reversible, low risk, and cost-effective treatment modality for select patients with chronic neuropathic pain refractory to conservative management and surgical approaches. While the indications for neuromodulation are broadening, spinal cord stimulation (SCS) for failed back surgery syndrome (FBSS) or complex regional pain syndrome (CRPS) remains the most well-established and most utilized modality of neuromodulation. Nearly four decades since its inception, the burgeoning arena of spinal cord stimulation (SCS) has been met with iterative advances in technique, technology, and efficacy. The authors describe the incidence, clinical manifestation, therapeutic approach, and avoidance of complications related to spinal cord stimulation. Understanding the complications of SCS is important not only for evaluating postoperative patients but also essential for avoiding therapy failure, advancing operative techniques, maximizing outcomes, and improving quality of life for patients.

Keywords: adverse events, complications, neuromodulation, spinal cord stimulation, chronic pain, hardware, biologic, biopsychosocial

INTRODUCTION

Since its advent in the late 1960s, spinal cord stimulation (SCS) has made considerable advances in the treatment of chronic pain refractory to conservative medical management or surgery. This modality has gained traction in recent decades, owing to its minimally-invasive

* Corresponding Author's Email: Pilitsj@mail.amc.edu.

nature, safety, efficacy, and reversibility [1]. Originally based on the gate control theory of pain [2], modern day SCS stemmed from the idea that electrical currents applied along the spinal cord could moderate pain perception by modulating small and large diameter afferent pain fibers [1, 3, 4]. Although the precise mechanism by which SCS exerts its therapeutic effects remains elusive, we now appreciate other pathways may be involved (i.e., supraspinal centers, neurotransmitters, autonomic nervous system) [4, 5, 6].

Candidates for SCS are screened on the basis of their underlying pathology, thereby reserving SCS for patients deemed to reap the greatest benefit. FDA-approved indications for SCS include chronic neuropathic pain of the trunk and limbs, failed back surgery syndrome (FBSS) and complex regional pain syndrome (CRPS) [7]. Literature to date suggests the best outcomes of SCS have been reported for FBSS, CRPS, refractory angina pectoris, and critical limb ischemia secondary to peripheral vascular disease [3, 6, 8].

SCS has long been plagued by a high complication rate—between 30-40% of patients report complications [3] while 23.1-34.3% require revision [9]. Although the rate is high, the majority of complications are relatively reversible without any permanent sequelae [10, 11]. SCS complications are predominately hardware-related, with lead migration, lead fracture, and need for lead repositioning representing the most common complications. While hardware-related complications typically occur within the first 2-years, biologic complications predominate within the first 3 postoperative months [3, 9].

We conducted a literature review using PubMed, Web of Science, and Google Scholar databases. Keywords used include “SCS”, “complications”, “adverse effects”, “allergy”, “foreign body”, “mental health”, “biopsychosocial”, and “psychological”. Applicable English sources were selected for retrieval with additional cross-reference search of cited literature. Our investigation of SCS-related complications is organized into distinct classifications: 1) hardware-related, 2) biologic, 3) stimulation-related, and 4) cognitive/behavioral considerations.

HARDWARE COMPLICATIONS

Lead Migration

Hardware-related issues comprise the majority of SCS-related complications, but adverse events have decreased substantially with evolving technology, technique, and device improvements seen in recent decades [1, 12]. The most frequent cause for surgical revision of SCS is lead migration [5, 13] (Figure 1). Occurring in 11.3-22.6% of patients treated, not only is lead migration the most common cause of revision but it is also the most common complication of SCS overall [3, 11, 12, 14, 15, 16]. When the electrodes shift from their original site of placement within the epidural space, the patient may experience 1) a change in paresthesia coverage, 2) acute changes in amplitude requirements to sustain the same level of coverage, 3) loss of pain control, or 4) other clinical manifestations [12]. Lead migration most commonly occurs within the first four weeks after implantation; after this period there is a greater degree of fibrosis. Anatomic location within the spinal canal is related to incidence of lead migration due to relative differences in mobility within the cervical, thoracic, and lumbar spines. Hence cervical and lumbar placements have greater migration rates than their thoracic

counterparts [3, 12, 16, 17]. Lead migration occurs more commonly in the axial plane (cephalocaudad direction), rather than transversely (laterally within the epidural space) [3, 5].

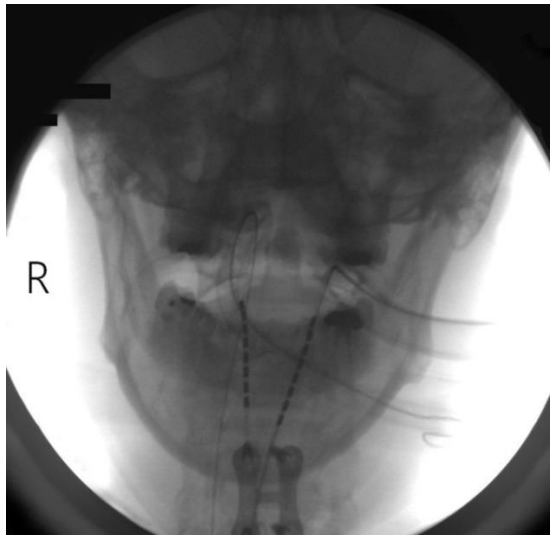

(a)

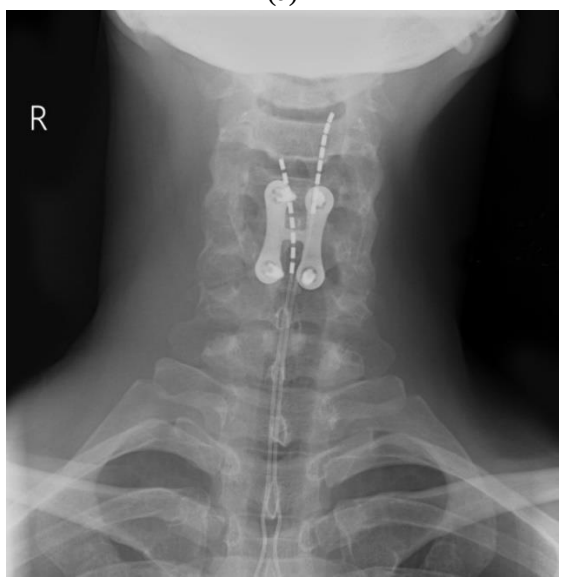

(b)

Figure 1a. Intraoperative anterior-posterior Xray of two octrode percutaneous leads spanning from mid C2 to the upper level of C4. 1b. Anterior-Posterior Xray demonstrating bilateral lead migration in the caudal direction. Patient presented with loss of therapeutic stimulation on her right side.

In recent decades, improvements in electrode design and surgical technique have lessened the burden of electrode migration. Over a period of 22 years and 410 patients, Kumar et al. noted a lead migration incidence of 21.5%-- however, when the latter decade of that study period was analyzed separately the incidence dropped down to 11.3% [16,18]. During this same period, there was also a decline in surgical revision rates [18] (Kumar et al. 2006a). The

use of more electrodes per paddle has allowed strategic reprogramming of the stimulation pattern along the spinal cord to appropriately recapture target areas when leads inappropriately migrate. A greater number of contacts on the leads promotes a greater degree of flexibility in reprogramming (Figure 2); ultimately this translates to a greater likelihood of reestablishing therapeutic paresthesia coverage [3, 12]. In one study the revision rate for bipolar leads was 23%, whereas the same was 16% in multichannel leads and 3.8% in octopolar leads [11, 16].

(a)

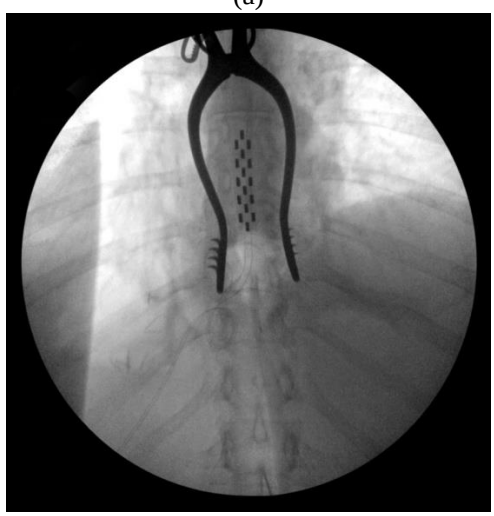

(b)

Figure 2a. Older quadrapolar lead which was similar to leads used in studies of SCS in the past. 2b. Newer lead allowing more flexibility and directionality of programming.

Lead Migration: Recommendations

Proper patient education regarding activity restrictions will help limit the occurrence of lead migration. Namely, patients should avoid excessive twisting, bending, and lifting during the first six weeks postoperatively [3,9]. If a patient has a prior history of lead migration or difficulties with placing percutaneous electrodes during trial, surgical placement of paddle

electrodes via laminotomy is preferred since long-term reoperation rates are lower for paddle electrodes [5, 6, 12].

Surgical approaches that may affect lead migration include appropriate use of anchoring techniques, anchoring points, and anchor types. Electrodes should be anchored to the fascia [3, 9]. The incorporation of strain-relief loops between the anchor and implantable pulse generator (IPG) provides slack and limits traction forces on the lead [9, 18]. Permanent implantation of percutaneous leads requires a suture between the supraspinous ligament and anchor with an additional suture between the anchor and fascia. The anchor/lead interface can be additionally secured using a silicone elastomer adhesive between the inner sleeve of the anchor and outer diameter of the passing lead [19, 20]. For paddle leads, anchors, when used, should be secured to the fascia with strain relief loops in the epifascial plane [9, 21, 22]. Additional strain relief is provided by coiling redundant loops of lead beneath the IPG [19]. For a more comprehensive account of anchoring mechanisms, please refer to the Neuromodulation Appropriateness Concensus Committee publication on Avoidance and Treatment of Complications of Neurostimulation [3].

In face of the clinical picture of lead migration, initial management should include repeat X-rays to compare the current location of electrodes to the post-implantation location [3]. Given most contemporary leads employ multichannel arrays; the best course of action is to attempt recapturing pain control through reprogramming. If alternative programming fails to correct the issue, a surgical revision is necessary [12].

The location of the IPG pocket also has a role in the tendency of lead displacement. Implantations in the gluteal area were associated with double the rate of lead migration when compared to those placed in abdominal pockets, 21% and 10% respectively. Implantation in the gluteal region, however, confers several advantages over IPG placement in the abdominal pocket; Scheepens et al. report a reduction in operative time, fewer incisions, lower infection rate, and decreased incidence of pain over the IPG site. Positioning the IPG in an abdominal pocket requires repositioning the patient from prone to lateral decubitus, as well as prepping and draping the patient once again [23].

Lead Fracture

The incidence of lead fracture ranges from 3-9.1% in the literature [11, 12, 13, 14, 16]. A recent account on the present state of neuromodulation by Kumar et al. supports the notion that the incidence of lead fracture is on the decline as a result of improved manufacturing methods [1]. One should suspect the possibility of lead fracture if there is a sudden decrease in pain relief, a loss of induced paresthesia, or a burning sensation [12]. Anchoring may play a role; when the nose of the anchor was pushed through, and circumferentially invested by, the deep fascia the cylindrical electrode was able to withstand 200,000 bend cycles before failure. When the anchor was located a distance of 1cm or greater from the lead exit-point the electrode only withstood 5,500 bend cycles until failure [16].

Lead Fracture: Recommendations

Methods used to reduce the risk of lead migration are similarly employed to decrease the likelihood of fracture. For instance, appropriate anchoring techniques, use of strain-relief loops, and consideration of IPG locations [12]. Initial management of suspected fractures involves x-ray of the entire SCS system and an impedance check.

Abnormal impedance values are reflective of an open circuit and will require replacement of the broken lead(s) [12, 18].

Miscellaneous Hardware Complications

Implantable pulse generators are either rechargeable or nonrechargeable [12]. The operational lifespan of a battery is dependent on the usage characteristics of the SCS system. Patients that require stimulation at greater amplitudes, higher pulse widths, and for longer durations of stimulation have a shortened battery life [9]. Additionally, the characteristics of the leads used also impact energy consumption. For instance, when compared to paddle electrodes, cylindrical percutaneous electrodes are less efficient due to their higher impedances and radially-directed energy dispersion [12].

The complication of unexpected battery failure occurs when an IPG battery requires replacement before the estimated date—the expected date of depletion is approximated using the patient-specific usage characteristics [3]. The incidence of unexpected battery failure was reported as 1.6% in a meta-analysis by Cameron and 1.5% in a retrospective analysis by Kumar et al. [11, 18]. If a patient is expected to be a high-energy utilizer of the IPG or if the battery is estimated to last less than 4.25 years, then a rechargeable IPG unit is recommended [9, 17]. With the aforementioned scenario, the patient is spared from lapses in SCS performance, reoperation for new battery placement, and the rechargeable unit becomes the more cost-effective alternative [17].

Device interference is a concern when considering the use of MRI in patients with older SCS. Complications include infarct, paresthesia, pain, and complete dysfunction of the SCS apparatus [5]. In a case report by Simopoulos and Gill, the authors recount the experience of a 50-year old patient with thoracic SCS who underwent lumbar MRI; the SCS apparatus was turned off prior to the imaging study. During the MRI, the patient experienced a sensation of heat from the IPG pocket and multiple jolting dysesthesias along his back. Any future attempts to turn the SCS back on resulted in similar sensations, despite unaffected paresthesia coverage. Radiography, reprogramming, and interrogation of the system did not yield any abnormalities or improvements. The patient required surgical revision with replacement of the IPG and subsequently returned to baseline at follow-up [24]. There are a number of indications for which MRI is considered the benchmark for diagnosis and surveillance; thus the inability to utilize this modality is a point that must be discussed with patients prior to implantation. Recently, a new device has been FDA approved for use with full-body MRI, up to 1.5T. [3, 5, 25].

BIOLOGIC COMPLICATIONS

Infection

The possibility of infection is an inherent risk associated with any surgical procedure. This complication can be particularly costly in the setting of SCS; an infection that fails to resolve with conservative treatment often necessitates reoperation and explantation of the hardware (Figure 3). The incidence of infection in SCS ranges from 3.4-4.6%, commensurate with surgical-site infection (SSI) rates for spine surgery overall [3, 5, 10, 11, 12, 14, 18]. The three main presentations of infection include superficial SSI, deep SSI, and abscess formation [3]. With the latter two presentations being exceedingly rare, the risk of life threatening infection and permanent sequelae is outstandingly low. In a retrospective series of 707 cases with an infection rate of 4.5%, all infections resolved with antibiotics alone and produced no permanent morbidity [14]. In our experience, we have been able to treat a number of superficial issues with antibiotics alone. When this was not possible, we removed some or all of the hardware. A systematic review of complications among 21 SCS studies suggested that the rate of SSIs was 4.5% for superficial SSI and 0.1% for deep SSI—the former usually occurred within 30 days while the latter is conceivable up to 1 year post-implantation [3, 15]. The literature to date reports only one case of death due to infection and one case of paralysis secondary to epidural abscess [9, 11, 12]. The most commonly cultured organisms are staphylococcus aureus and staphylococcus epidermidis [3].

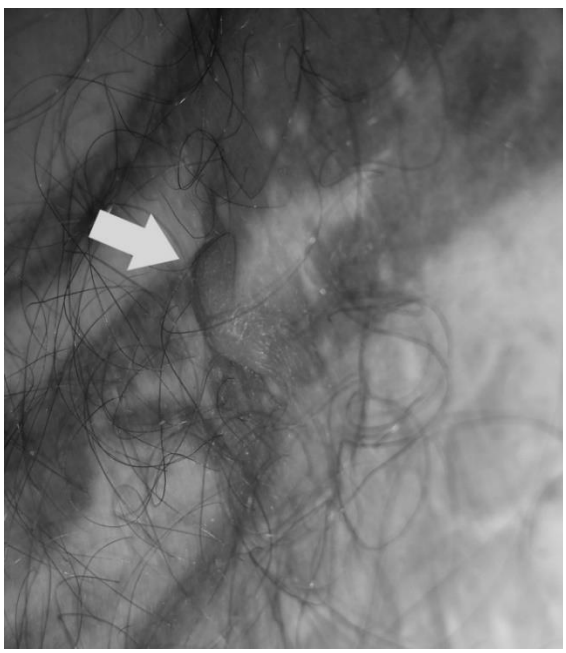

Figure 3. White arrow denotes vesicular outpouching of skin due to indolent infection with staphylococcus epidermidis. Surrounding pigmented area depicts an old tattoo.

Infection: Recommendations

Prevention of surgical site infections in neurosurgery is a well characterized topic hence our discussion will be limited to recommendations specific to SCS. With respect to the trial period of stimulation, there appears to be a positive association between trial length and risk of infection [12]. In the interest of decreasing the infection incidence, the authors suggest judicious choice of trial length [12].

Given the potential morbidity associated with infection and the costly nature of surgical explantation, vigilance for postoperative signs of infection is of utmost prudence. The clinician should initiate the appropriate work up for infectious etiologies should clinical symptoms of wound infection present; this includes, and is not limited to, complete blood count, culture specimens from the surgical site and implant site, blood cultures, erythrocyte sedimentation rate, C-reactive protein, and contrasted computed tomography scan. Empiric antibiotics should be promptly initiated after a culture is taken with appropriate amendments once culture and sensitivities return. During conservative management of a SSI, one must be watchful for signs of advancing infection, deeper infection, or neurologic involvement. Surgical revision with removal of the device is then required. Explant is also indicated if the infection is in close proximity to hardware; in most instances this is limited to the IPG and extension wire with sparing of the epidural constituents [3, 12].

Pain at IPG Site

Postoperative pain at the IPG implantation pocket may be disconcerting to patients; however, the pain is typically transient in nature and resolves within 7-14 days. The pivotal PROCESS study by Kumar et al. demonstrated a 12% incidence (5 of 42 patients) of pain at the IPG site [26] with a similar incidence of 10% demonstrated in our series (unpublished data). In a larger sample of patients from 1995-2004 from the same authors, the incidence of discomfort over the IPG dropped down to 2.5% [18]. Later studies with larger sample sizes reported zero cases pain related to device components [14,19] while a meta-analysis of the literature reported a 0.9% incidence. Of note, it is speculated that the abnormally high incidence of pain over device components observed during the PROCESS trial may be attributable to the larger size of IPGs utilized [3].

Pain at IPG Site: Recommendations

Discomfort related to the site of device components is a transient symptom that is nonetheless a true nuisance to the patient; it is best managed with empathy and reassurance. Although reductions in device size may have helped decrease the incidence of this complication, the implanter may additionally reduce this occurrence by avoiding placement of the IPG pocket in close proximity to the ribcage or inguinal ligament [18]. Local pain may be an early sign of infection or burning discomfort can be indicative of a damaged connection with the extension wire [12]. At our center we often employ a local injection of triamcinolone and lidocaine. With the injection and/or lidocaine patches, we offer to move the battery. If an electrical leak is suspected, the battery is replaced. By choosing a lead of appropriate length,

we may avoid the use of an extension wire and directly connect lead to IPG—this technique minimizes the number of components and reduces potential failure modes.

CSF Leak and Dural Puncture

CSF leak is an iatrogenic complication that infrequently occurs after percutaneous lead placement (incidence 0-0.3%) and surgical paddle lead placement (incidence 0.05%) [3]. Levy and colleagues similarly report that dural puncture is more common with percutaneous electrodes (0.3%) than with paddle electrodes (0.2%) [10]. The clinical presentation includes positional headaches, neck pain, hearing loss, tinnitus, diplopia, and/or vertigo occurring 1-3 days postoperatively. Risk factors include anatomic changes that make technique or visualization more onerous, such as: calcified ligamentum flavum, spinal stenosis, or previous surgery/puncture at the needle entry point [3].

CSF Leak and Dural Puncture: Recommendations

The clinical manifestation of PDPH within the first few postoperative days should increase suspicion of a CSF leak. The incision sites must be examined for evidence of clear fluid seepage. Conservative management includes several days of flat bedrest, use of abdominal binder, caffeine, and/or butalbital/acetaminophen/caffeine combination pill [12]. If symptoms are severe or conservative management fails, an autologous blood patch or saline can be employed into the epidural space [12, 18]. While evidence suggests that epidural blood patch should be offered within 24-48 hours of dural puncture [27], the literature also describes successful use within five days [28]. During application of the epidural blood patch, the use of fluoroscopy and a slow infusion rate is instrumental in avoiding manipulation of the epidural electrodes [28]. As the mechanism of action of a blood patch is thought to be a compressive one, injecting preservative free saline is another option if autologous blood is not readily available [27, 29].

An intraoperative dural puncture may become evident when CSF is visible in the surgical field. While some surgeons may choose to continue lead placement at the same level or a different level, others recommend aborting the SCS trial/implantation attempt, placing an autologous blood patch, and rescheduling the procedure in 3 weeks at minimum [3, 12, 18].

Subcutaneous Hematoma and Seroma

A collection of blood or serous fluid beneath the skin, most commonly located at the IPG site, may develop within the weeks following surgery. This complication may occur when dead space is left [3]. The reported incidence in the literature ranges from 0-9%; a series of 160 consecutive SCS patients presented a 3.1% incidence [18]. Patients may present with swelling, redness, or pain at the site therefore infectious etiologies often need to be ruled out. Risk factors for hematoma/seroma development include smoking, diabetes, and patients with poor wound healing [3].

Subcutaneous Hematoma and Seroma: Recommendations

The majority of seromas resolve spontaneously and expeditiously if not infected. We only recommend aspiration and compression with a dressing/binder if there is a high concern for infection [12]. The Neuromodulation Appropriateness Consensus Committee recommends several techniques to minimize the risk of hematoma/seroma formation: minimal cautery, meticulous attention to hemostasis, layered closure, and gentle pressure via the use of an abdominal binder [3, 10]. Additionally, creating an IPG pocket that is as small as possible further decreases the likelihood of seroma formation [12].

Symptomatic Epidural Hematoma

Bleeding in the epidural space, with or without expansion of a developing clot, is recognized as an epidural hematoma. The source of bleeding is usually within the epidural space itself, though it may be from paraspinal vasculature. Although exceedingly rare, a symptomatic epidural hematoma (EDH) is a feared complication due to its potential for cord compression and permanent neurological deficit [10]. An EDH generally presents within the first 24 hours, though this time frame may be longer in patients restarting blood thinners. A systematic review of 2,972 cases revealed no occurrences while a separate series of 2,000 patients revealed two occurrences of EDH [12]. In a meta-analysis of 68 studies spanning 20 years of data, Cameron reports the incidence to be 0.3% with the incidence of secondary paralysis as 0.03% [11].

Using the FDA MAUDE (Manufacturer and User Facility Device Experience) database of 44,587 SCS patients, Levy et al. report the incidence of epidural hematoma to be 0.19% (83 cases). Of the 83 cases, 68 experienced some degree of motor deficit. Intrinsic limitations of the MAUDE data set make it difficult to extrapolate a true rate of recovery for patients who suffered from EDH [10].

While the preoperative evaluation may uncover coagulopathies, it is important to note that platelet dysfunction due to aspirin and/or newer anti-coagulants use may go undetected. It is thus prudent to advise patients to avoid all blood thinners, fish oil, vitamin E, aspirin and aspirin containing products (i.e., popular over-the-counter headache remedies containing acetaminophen, aspirin, and caffeine) 7 days before and up to 7 days after operation. Exact recommendations should be made by the surgeon and the doctor prescribing the anti-coagulant.

Symptomatic Epidural Hematomas: Recommendations

Operative techniques to minimize the risk of EDH include the use of: 1) meticulous attention to hemostasis, 2) hemostatic agents such as bone wax, Gelfoam, thrombin, Flo-seal, etc., and 3) multi-layered closure. As with other spinal procedures, the routine use of a drain is not recommended due to increased risk of infection [10, 12].

Any SCS patient that develops progressive motor, sensory, or autonomic deficits at the commencement of postoperative recovery should be evaluated for an epidural hematoma with

an urgent noncontrast CT [3]. Symptomatic epidural hematomas, regardless of size, should be surgically evacuated due to risk of permanent neurological damage.

Direct Neuraxial Injury

The early pioneers of neuromodulation encountered greater morbidity and adverse neurological outcomes than currently experienced. Over the past 4 decades, evolving technology, technique, and understanding have made permanent neurologic sequelae the rare exception [10,30,31]. Prior to 1980, SCS was achieved using subdural and intradural electrodes; this approach of 'dorsal column stimulation' was inherently riskier than later approaches that did not violate the dura [5].

In a 1967 series of 90 patients undergoing dorsal column stimulation (DCS), 6 out of 90 patients experienced paraparesis or paraplegia [10]. A subsequent analysis of DCS in 1978 reported delayed paraparesis in 2 out of 92 implants [30]. A 2010 analysis of 44,587 cases yielded a considerably lower rate of neurologic injury; 0.13% of patients experienced major motor deficit without epidural hematoma and 0.10% experienced limited motor deficit without epidural hematoma. The presence of postoperative motor deficit in the absence of epidural hematoma was inferred to be a result of direct spinal cord injury [10], however, transient cord ischemia or vasospasm are also possible.

To decrease the risk of spinal cord injury, preoperative imaging is mandatory as it may reveal evidence of spinal stenosis, spondylosis, disc herniation, vascular anomalies, or general anatomic morphology for operative planning. Spinal stenosis is not an absolute contraindication to SCS, granted there is adequate decompression prior to implantation [10].

In a recent series of 172 patients undergoing paddle-electrode SCS, 8.7% of patients suffered new-onset thoracic radiculopathy that was refractory to medical and conservative management. Surgical revision with a more extensive laminectomy or dorsal decompression produced immediate resolution of symptoms [32]. In our experience, we have been able to place a smaller lead in revisions of these cases to maintain the therapy but relieve the radiculopathy.

Miscellaneous Biologic Complications

Despite the reported biocompatibility of SCS devices, several case reports have described allergic reactions attributable to device components. Contact dermatitis is a local T-cell mediated delayed-hypersensitivity reaction in response to immunogenic antigens. Device constituents/components that been implicated in the development of hypersensitivity reactions include: silicone, polyurethane, titanium, platinum, iridium, nickel, and epoxy [33, 34, 35]. The patient with an allergy to device components typically presents within 8-days to 1-month, although a delayed hypersensitivity is conceivable several months after implant. Symptoms include rash with or without pain, erythema, pruritus, or delayed wound healing [33, 34, 35].

Although a very rare occurrence, appreciating the clinical presentation of a local immunologic reaction and including it in the differential diagnosis of cutaneous inflammation may help avoid unnecessary device removal. Upon suspicion of an allergic reaction, it

remains prudent to rule out infectious etiologies with tissue cultures or biopsy. Features that make infection less likely include 1) a well demarcated, non-advancing area of inflammation, 2) absence of fever, 3) absence of purulence.

Initial workup should include cutaneous patch testing of the various allergens that may be responsible—a model-specific patch testing kit may be available directly from the device manufacturer [34,36]. A negative patch test does not exclude the possibility of allergic reactivity, thus excision with histological analysis may be required [33]. A trial of topical steroids may be employed; however, we caution that there exists at least one reported case where this modality may have contributed to poor wound healing and dehiscence [33, 35]. While management generally calls for removal of the device [11, 33, 37], Gadgil and colleagues report successfully treating IPG-related contact dermatitis by encasing the device in an expandable polytetrafluoroethylene (ePTFE) sheath and reimplanting it within the subcutaneous pocket [34].

A foreign body reaction is a non-allergic, inflammatory process that may present similarly to allergic contact dermatitis, however, may take months or years to develop. A foreign body reaction occurs due to the body's persistent efforts, and failure, to remove non-self-particles. Failure to digest the foreign particles results in the body's attempt to wall-off the offending area with granuloma formation. Diagnosis is made histologically, with the presence of fused-macrophages—so called 'giant cells' [33]. A review of the literature uncovers three case reports of foreign body reactions occurring at the site of epidural electrode placement. All three presentations resulted in compression of the spinal cord with symptomatic resolution status-post surgical removal and lysis of epidural adhesions [38, 39, 40]. We recommend that foreign body reaction be included in the differential for etiologies of late-onset cord compression.

The complication of skin erosion in areas overlying hardware is a rare event (0.2% incidence) [11]. Skin erosion increases the risk of infection, epidural abscess, and wound dehiscence. Appropriate measures to help limit this complication include a) multi-layered closure, 2) avoiding placement of suture lines directly over the implanted device, 3) and implanting the IPG away from bony elements. Any presentation of skin erosion should include an appropriate workup for superimposed infection [3].

STIMULATION-RELATED COMPLICATIONS

Positional Dependence

The thickness of the dorsal CSF layer varies between patients and makes the greatest contribution to the overall distance between electrode and spinal cord. In addition, the dorsal CSF layer is the most variable constituent with a degree of thickness that is dependent on a) spinal level, b) body position/posture, and c) spinal canal morphology [5, 11, 41, 42]. While the SCS electrode is relatively fixed in position within the epidural space, the spinal cord is mobile.

With a fixed intensity of electrical stimulation, changes in thickness of the dorsal CSF layer contribute to understimulation and overstimulation [42]. In the supine position the spinal cord is shifted dorsally with a dorsal CSF layer of 2.0-6.0mm at T11. In the prone

position the spinal cord is shifted ventrally, increasing the dorsal CSF layer by approximately 2.2mm [42]. It becomes no surprise that the supine position, with a smaller electrode-to-spinal cord distance, results in overstimulation of target spinal tissue. Conversely, the prone position, with a larger dorsal CSF layer, is associated with subtherapeutic paresthesia [5]. While understimulation is associated with decreased paresthesia and a reduction in pain relief, overstimulation has been described as a dysesthesia of uncomfortable jolts, surges, and pain [3, 42].

Positional Dependence: Recommendations

SCS systems include a handheld programmer for the patient to manually adjust stimulation settings on an as-needed basis. Nonetheless, patients may find that changing stimulation parameters throughout the day is inconvenient and unnecessarily repetitive. Over and understimulation induced by positional changes can disrupt pain relief and cause frustration, worsening health-related quality of life. Additionally, the need to frequently reprogram a SCS with position changes imposes a gratuitous burden on patients and may contribute to therapy failure and dissatisfaction.

The problem of positional dependence has compelled the development of SCS devices with built-in position-sensing capabilities. Sensor-driven devices embrace integrated accelerometers to detect positional changes and automatically adjust stimulation intensity to individually-preset parameters. The use of this novel SCS in a multicenter, randomized, open-label trial with 15 patients revealed improved patient satisfaction with automatic sensor-driven stimulators versus manually adjustable stimulators with respect to position changes and physical activity [43]. A larger prospective, randomized crossover study with 79 patients reported comparable positive outcomes: 1) 86.5% experienced improved pain relief with no loss of convenience or no loss of pain relief with improved convenience, 2) 80.3% improved comfort during position changes, 3) 69% improved physical activity, and 4) 47.9% improved sleep [42]. The position-sensing SCS group and the manually-adjustable SCS group showed no statistical difference with respect to incidence of adverse events and unpleasant sensations. In addition, 90.1% of patients wished to keep the sensor-driven SCS in the automated mode all, or most, of the time [42]. In a prospective cohort of 62 patients at the authors' home institution, patients with position-adaptive devices achieved greater reductions in VAS scores at short-term follow-up than their counterparts fitted with standard devices [44].

Aberrant Stimulation: Autonomic Dysfunction

A handful of reports depict variable manifestations of gastrointestinal symptoms after SCS implantation. The precise mechanism by which SCS affects gastrointestinal function is unclear; current hypotheses postulate induced imbalances between sympathetic and parasympathetic tone [3, 45, 46, 47]. La Grua describes an occasion in which thoracic SCS for FBSS produced persistent constipation, distension, and abdominal pain refractory to pharmacologic treatment. Subtherapeutic levels, or complete cessation, of stimulation resulted in symptomatic alleviation or resolution, respectively [46]. A similar effect of decreased intestinal motility was observed as an unintended side effect in a patient treated with thoracic

SCS for refractory pain secondary to IBS; the frequency of diarrheal episodes was dramatically reduced from multiple daily episodes to less than once a month [48]. Thakkar et al. describe two patients who suffered persistent nausea, vomiting, diarrhea, and worsening reflux after SCS; the first patient with CRPSII became symptomatic during multiple SCS trials while the second patient with FBSS achieved a successful trial and developed symptoms immediately after permanent implantation of the device [3, 49]. Symptoms did not resolve despite efforts to reprogram stimulation parameters and both patients inevitably required device removal [49]. Gastrointestinal side effects of SCS are not uniformly predictable; however, they appear to be refractory to medical management and reversible upon cessation of stimulation.

Case reports of urologic dysfunction after SCS include urethral sphincter spasm, urge incontinence, and micturition inhibition. In a patient with spinal cord injury at T12-L1, thoracic SCS for neuropathic pain resulted in urethral sphincter spasm that impeded successful self-catheterization [3]. La Grua and Michelagnoli report of a patient with pre-existing T11-L1 spinal cord injury, secondary to cord compression from an angioma, who underwent thoracic SCS with resolution of neuropathic pain but new onset micturition inhibition [50]. Although urologic complications appear to be a rare, reversible occurrence, it may prove beneficial to perform urologic function testing during the SCS trial period for patients with a history of spinal cord injury or genitourinary pathology [3].

Stimulation Tolerance

The phenomenon of stimulation tolerance is best described as the gradual loss of therapeutic pain relief or the increase in stimulation requirements to achieve the same level of analgesia [3, 16]. Stimulation tolerance occurs in the absence of hardware-related complications, as evidenced by an unchanging paresthesia distribution overlying painful areas. Theorized etiologies include: neuroplasticity (local or supraspinal pathways), disease progression, or psychological factors. Autopsy and surgical inspection fail to support the theory of peri-electrode fibrosis as a potential mechanism of stimulation tolerance [16].

Several studies have suggested that SCS becomes less efficacious after a period of 2-3 years; reported incidence of stimulation tolerance varies from 21-30% [3, 15, 16]. Despite a trend towards gradually diminishing efficacy with time, studies to date nearly unanimously report patient willingness to undergo SCS again [15, 51, 52, 53]. Thus, patient inclination to repeat SCS in order to achieve identical results is a testament to the perceived benefit provided by treatment. The intrinsic purpose of SCS is not the complete elimination of pain, but rather symptomatic relief, pain control, and improvement in quality of life.

Since our understanding of stimulation tolerance is still cursory, recommendations regarding its prevention do not exist. Kumar and colleagues have attempted adjuvant medications and stimulation-free intervals to address the issue—both attempts were met without success, but are still commonly used. SCS has traditionally relied on low frequency tonic stimulation to deliver paresthesia over the target region of pain. A burgeoning frontier of SCS involves the use of high frequency stimulation and burst stimulation—both of which have been reported to provide paresthesia-free pain relief [3, 5, 54]. While initial reports depict efficacy in pain control [7, 54], we pose the question of whether these novel stimulation paradigms are susceptible to stimulation tolerance.

COGNITIVE AND BEHAVIORAL CONSIDERATIONS

Psychological Testing

A significant proportion of patients suffering from chronic pain also live with mental health illnesses. Before a trial of SCS is initiated, we mandate patients to undergo psychological testing [3]. Psychological assessment is regarded as indispensable based on associations drawn from retrospective studies [55, 56, 57]. Furthermore, many insurance companies throughout the United States mandate psychological screening before surgery [57]. Psychological risk factors identified as predictors for poorer outcome in SCS include somatization, anxiety, depression, and poor coping skills. The association of these risk factors with poorer outcomes is not unique to SCS, but is similarly shared with outcomes of other surgical procedures [3]. While some studies have demonstrated an improvement in depression scores following SCS therapy [58], others have failed to show a consistent correlation between level of depression and efficacy of SCS [5, 56].

Psychological Testing: Recommendations

According to the principle of beneficence, clinicians endorse the modality that is expected to provide the greatest good while minimizing the likelihood of harm. To this effect, psychosocial screening for surgical candidates can prevent high risk patients from undergoing invasive procedures from which they are likely to derive little benefit. Additionally, such screening creates the foundation for proper postoperative management and support. Stephens and Ward suggest a three-pronged approach to evaluate patient candidacy for surgical neuromodulation; 1) recognition of psychological risk factors, 2) patient education (regarding surgery, living with implanted hardware, maintenance of therapy), and 3) managing expectations for pain reduction [55].

Recognition of psychological risk factors begins with evaluation by psychologist with experience in chronic pain management. The clinical interview should be supplemented with standardized assessment tools [55]. Although there remains a lack of consensus regarding which screening tools to use, assessments that have gained traction in the neuromodulation community include: the McGill Pain Questionnaire, Beck Depression Inventory, modified Zung Depression Scale for back pain, Minnesota Multiphasic Personality Inventory, Distress and Risk Assessment Method, Patient Health Questionaire-9, and the Generalized Anxiety Disorder 7-item scale [55, 56, 57]. We find MMPI to be of greatest value.

Psychological assessments should not be the sole basis for exclusion from SCS therapy. Rather, biopsychosocial issues that arise during screening may be factors that are amenable to treatment—thereby improving patient selection. Thus, identification of psychiatric risk factors may help improve post-operative management of mental health or facilitate more suitable, alternative treatment modalities [55, 59]. Psychiatric treatment and surgical management need not be mutually exclusive. Furthermore, literature suggests that improvements in coping skills are associated with reductions in patient-reported pain and disability [60].

CONCLUSION

Spinal cord stimulation continues to grow as one of the most promising modalities of neuromodulation for chronic neuropathic pain. While the morbidity and mortality after SCS are rare, appreciating the vast array of complications—both common and uncommon—will aid clinicians with device implantation, complication recognition, and avoidance of sequelae. Our continued improvement in SCS technology and technique will guide the development of unique applications of neuromodulation.

REFERENCES

[1] Kumar, K; Rizvi, S. Historical and Present State of Neuromodulation in Chronic Pain. *Curr Pain Headache Rep*., 2014, 18, 387.

[2] Melzack, R; Wall, PD. Pain mechanisms: a new theory. *Science*., 1965, 150, 971-979.

[3] Deer, TR; Mekhail, N; Provenzano, D; Pope, J; Krames, E ; et al. The Appropriate Use of Neurostimulation: Avoidance and Treatment of Complications of Neurostimulation Therapies for the Treatment of Chronic Pain. *Neuromodulation*., 2014, 17, 571-598.

[4] Krabbenbos, IP; van Dongen, EPA; Nijhuis, HJA; Liem, L. Mechanisms of Spinal Cord Stimulation in Neuropathic Pain. *Topics in Neuromodulation Treatment*, Dr. Carrillo-Ruiz (Ed.). Rijeka: Intech Open Access Publisher.

[5] Wolter, T. Spinal Cord Stimulation for neuropathic pain: current perspectives. *J Pain Res*., 2014, 7, 651-663.

[6] Jeon, YH. Spinal Cord Stimulation in Pain Management: A Review. *Korean J Pain*., 2012, 25, 143-150.

[7] Song, JJ; Popescu, A; Bell, RL. Present and Potential Use of Spinal Cord Stimulation to Control Chronic Pain. *Pain Physician*., 2014, 17, 235-246.

[8] Lee, AW; Pilitsis, JG. Spinal Cord Stimulation: indications and outcome. *Neurosurg Focus*., 2006, 6, E3.

[9] Kumar, K; Buchser, E; Linderoth, B; Meglio, M; Van Buyten, JP. Avoiding Complications from Spinal Cord Stimulation: Practical Recommendations from an International Panel of Experts. *Neuromodulation*., 2007, 10, 24-44.

[10] Levy, R; Henderson, J; Slavin, K; Simpson, BA; Barolat, G; et al. Incidence and Avoidance of Neurologic Complications with Paddle Type Spinal Cord Stimulation Leads. *Neuromodulation*., 2011, 14, 412-422.

[11] Cameron, T. Safety and efficacy of spinal cord stimulation for the treatment of chronic pain: a 20-year literature review. *J Neurosurg*., 2004. (Spine 3). 254-267.

[12] Bendersky, D; Yampolsky, C. Is Spinal Cord Stimulation Safe? A Review of its Complications. *World Neurosurg*., 2014, 82(6), 1359-1368.

[13] Rosenow, JM; Stanton-Hicks, M; Rezai, AR; Henderson, JM. Failure modes of spinal cord stimulation hardware. *J Neurosurg*., 2006, (Spine 5), 183-190.

[14] Mekhail, NA; Mathews, M; Nageeb, F; Guirguis, M; Mekhail, MN; et al. Retrospective Review of 707 Cases of Spinal Cord Stimulation: Indications and Complications. *Pain Practice*., 2010, 11, 148-153.

[15] Turner, JA; Loeser, JD; Deyo, RA; Sanders, SB. Spinal cord stimulation for patients with failed back surgery syndrome or complex regional pain syndrome: a systematic review of effectiveness and complications. *Pain*., 2004, 108, 137-147.

[16] Kumar, K; Hunter, G; Demeria, D. Spinal Cord Stimulation in Treatment of Chronic Benign Pain: Challenges in Treatment Planning and Present Status, a 22-Year Experience. *Neurosurg*., 2006, 58, 481-496.

[17] Deer, TR; Mekhail, N; Provenzano, D; Pope, J; Krames, E; et al. The Appropriate Use of Neurostimulation of the Spinal Cord and Peripheral Nervous System for the Treatment of Chronic Pain and Ischemic Diseases: The Neuromodulation Appropriateness Consensus Committee. *Neuromodulation*, 2014, 17, 515-550.

[18] Kumar, K; Wilson, JR; Taylor, RS; Gupta, S. Complications of spinal cord stimulation, suggestions to improve outcome, and financial impact. *J Neurosurg*., 2006, (Spine 5), 191-203.

[19] North, RB; Recinos, VR; Attenello, FJ; Shipley, J; Long, DM. Prevention of Percutaneous Spinal Cord Stimulation Electrode Migration: A 15-Year Experience. *Neuromodulation*., 2014, 17, 670-677.

[20] Renard, VM; North, RB. Prevention of percutaneous electrode migration in spinal cord sitmulation by modification of the standard implantation technique. *J Neurosurg*., 2006, (Spine 4), 300-303.

[21] Oakley, JC. (2004). Spinal Cord Stimulation for the Treatment of Chronic Pain. In *Neurosurgical Pain Management*, (131-143). KA Follett. Saunders.

[22] Henderson, JM; Schade, CM; Sasaki, J; Caraway, DL; Oakley, JC. Prevention of Mechanical Failures in Implanted Spinal Cord Stimulation Systems. *Neuromodulation*., 2006, 9, 183-191.

[23] Scheepens, WA; Weil, EH; van Koeveringe, GA; Rohrmann, D; Schurch, B; et al. Buttock placement of the implantable pulse generator: a new implantation technique for sacral neuromodulation—a multicenter study. *Eur Urol*., 2001, 4, 424-428.

[24] Simopoulos, TT; Gill, JS. Magnetic Resonance imaging of the Lumbar Spine in a Patient with a Spinal Cord Stimulator. *Pain Physician*., 2013, 16, E295-E300.

[25] Moeschler, SM; Sanders, RA; Hooten, WM; Hoelzer, BC. Spinal Cord Stimulator Explantation for Magnetic Resonance Imaging: A Case Series. *Neuromodulation*., 2014, E-pub ahead of print.

[26] Kumar, K; Taylor, RS; Jacques, L; Eldabe, S; Meglio, M; et al. Spinal cord stimulation versus conventional medical management for neuropathic pain: A multicentre randomised controlled trial in patients with failed back surgery syndrome. *Pain*., 2007, 132, 179-188.

[27] Candido, KD; Stevens, RA. Post-dural puncture headache: pathophysiology, prevention and treatment. *Best Practice & Research Clin Anes*., 2003, 17, 451-469.

[28] Eldridge, JS; Weingarten, TN; Rho, RH. Management of Cerebrospinal Fluid Leak Complicating Spinal Cord Stimulator Implantation. *Pain Practice*., 2006, 6, 285-288.

[29] Morewood, GH. A rational approach to the cause, prevention, and treatment of postdural puncture headache. *Can Med Assoc J*., 1993, 149(8), 1087-1093.

[30] Pineda, A. Complications of dorsal column stimulation. *J Neurosurg*., 1978, 48, 64-68.

[31] Taub, A; Collins, WF; Venes, J. Partial, Reversible, Functional Spinal Cord Transection. *Arch Neurol*, 1974, 30, 107-108.

[32] Mammis, A; Bonsignore, C; Mogilner, AY. Thoracic Radiculopathy Following Spinal Cord Stimulator Placement: Case Series. *Neuromodulation*., 2013, 16, 443-448.

[33] Chaudhry, ZA; Najib, U; Jacobs, WC; Sheikh, J; Simopoulos, TT. Detailed analysis of allergic cutaneous reactions to spinal cord stimulator devices. *J Pain Research*., 2013, 6, 617-623.

[34] Gadgil, N; Burton, AW; Viswanathan, A. Treatment of Contact Dermatitis Associated with Spinal Cord Stimulator Pulse Generator – Technical Note. *Neuromodulation*., 2013, 16, 600-602.

[35] McKenna, KE; McCleane, G. Dermatitis induced by a spinal cord stimulator implant. *Contact Dermatitis*., 1999, 41, 229.

[36] Taverner, MG. A Case of an Allergic Reaction to a Spinal Cord Stimulator: Identification of the Antigen with Epicutaneous Patch Testing, Allowing Successful Reimplantation. *Neuromodulation*., 2013, 16, 595-599.

[37] Ochani, TD; Almirante, J; Siddiqui, A; Kaplan, R. Allergic Reaction to Spinal Cord Stimulator. *Clin J of Pain*., 2000, 16, 178-180.

[38] Scranton, RA; Skaribas, IM; Simpson, RK. Spinal stimulator peri-electrode masses: case report. *J Neurosurg*., 2015, (Spine 22), 70-74.

[39] Lennarson, PJ; Guillen, FT. Spinal Cord Compression from a Foreign Body Reaction to Spinal Cord Stimulation: A Previously Unreported Complication. *Spine*., 2010, 35, E1516-1519.

[40] Wada, E; Kawai, H. Late onset cervical myelopathy secondary to fibrous scar tissue formation around the spinal cord stimulation electrode. *Spinal Cord*., 2010, 48, 646-648.

[41] Kapural, L. Spinal Cord Stimulation for Intractable Chronic Pain. *Curr Pain Headache Rep.*, 2014, 18(4), 406.

[42] Schultz, DM; Webster, L; Kosek, P; Dar, U; Tan, Y; Sun, M. Sensor-Driven Position-Adaptive Spinal Cord Stimulation for Chronic Pain. *Pain Physician*., 2012, 15, 1-12.

[43] Schade, CM; Schultz, DM; Tamayo, N; Iyer, S; Panken, E. Automatic Adaptation of Neurostimulation Therapy in Response to Changes in Patient Position: Results of the Posture Responsive Spinal Cord Stimulation (PRS) Research Study. *Pain Physician*., 2011, 14, 407-417.

[44] Roth, SG; Haller, J; Heran, M; Lange, S; Campbell, JC; De La Cruz, P; Pilitsis, JG. Do Advanced Programming Options Make a Difference in Spinal Cord Stimulation? *Neurosurgery*., *CNS Oral Presentation* Aug 2014, 61 Suppl 1, 216.

[45] Vorenkamp, KE; Baker, NE. Spontaneous Resolution of Nausea Induced by Spinal Cord Stimulation for Failed Back Surgery Syndrome. *Neuromodulation*., 2010, 13, 292-295.

[46] La Grua, M. Rare Side-effects during Spinal Cord Stimulation: Gastrointesitnal Symptoms. *Neuromodulation*., 2009, 12, 161-163.

[47] Eliasson, T; Augustinsson, LE; Mannheimer, C. Spinal cord stimulation in severe angina pectoris – presentation of current studies, indications and clinical experience. *Pain*., 1996, 65, 169-179.

[48] Krames, E; Mousad, DG. Spinal Cord Stimulation Reverses Pain and Diarrheal Episodes of Irritable Bowel Syndrome: A Case Report. *Neuromodulation*., 2004, 2, 82-88.

[49] Thakkar, N; Connelly, NR; Vieira, P. Gastrointestinal Symptoms Secondary to Implanted Spinal Cord Stimulators. *Anesth Analg*., 2003, 97, 547-549.

[50] La Grua, M; Michelangnoli, G. Rare Adverse Effect of Spinal Cord Stimulaiton: Micturation Inhibition. *Clin J Pain*., 2010, 26, 433-434.

[51] Sears, NC; Machado, AG; Nagel, SJ; Deogaonkar, M; Stanton-Hicks, M; et al. Long-Term Outcomes of Spinal Cord Stimulation with Paddle Leads in the Treatment of Complex Regional Pain Syndrome and Failed Back Surgery Syndrome. *Neuromodulation*., 2011, 14, 312-318.

[52] Kemler, MA; De Vet, HCW; Barendse, GAM; Van Den Wildenberg, FAJM; Van Kleef, M. Effect of spinal cord stimulation for chronic complex regional pain syndrome Type I: five-year final follow-up of patients in a randomized controlled trial. *J Neurosurg*., 2008, 108, 292-298.

[53] Kumar, K; Taylor, RS; Jacques, L; Eldabe, S; Meglio, M; et al. The Effects of Spinal Cord Stimulation in Neuropathic Pain Are Sustained: A 24-Month Follow-up of the Prospective Randomized Controlled Multicenter Trial of the Effectiveness of Spinal Cord Stimulation. *Neurosurg*., 2008, 63, 762-770.

[54] De Ridder, D; Vanneste, S; Plazier, M; van der Loo, E; Menovsky, T. Burst Spinal Cord Stimulation: Toward Paresthesia-Free Pain Suppression. *Neurosurg.*, 2010, 66, 986-990.

[55] Stephens, KA; Ward, A. Patient Selection for Spinal Cord Stimulators: Mental Health Perspective. *Curr Pain Headache Rep*., 2014, 18, 398.

[56] Kumar, K; Caraway, DL; Rizvi, S; Bishop, S. Current Challenges in Spinal Cord Stimulation. *Neuromodulation.*, 2014, 17(Suppl. 1), 22-35.

[57] Celestin, J; Edwards, RR; Jamison, RN. Pretreatment Psychosocial Variables as Predictors of Outcomes Following Lumbar Surgery and Spinal Cord Stimulation: A Systematic Review and Literature Synthesis. *Pain Med*., 2009, 10:639-653.

[58] Wolter, T; Fauler, I; Kieselbach, K. The Impact of Psychological Factors on Outcomes for Spinal Cord Stimulation: An Analysis with Long-term Follow-up. *Pain Physician*., 2013, 16, 265-275.

[59] Doleys, DM. Psychological factors in spinal cord stimulation therapy: brief review and discussion. *Neurosurg Focus*., 2006, 21(6), E1.

[60] Davis, CE; Kyle, BN; Thorp, J; Wu, Q; Firnhaber, J. Comparison of Pain, Functioning, Coping, and Psychological Distress in Patients with Chronic Low Back Pain Evaluated for Spinal Cord Stimulator Implant or Behavioral Pain Management. *Pain Medicine*., 2014, E-pub ahead of print. PMID: 25087848.

In: Encyclopedia of Surgery (22 Volume Set)
Editors: Andreas Lehrer and Kristin Mueller
ISBN: 978-1-53618-329-0
© 2020 Nova Science Publishers, Inc.

Chapter 380

EFFICACY OF POST-OPERATIVE ORAL TRAMADOL AND DICLOFENAC SODIUM ON PAIN RELIEF FOLLOWING MANDIBULAR THIRD MOLAR SURGERY: A DOUBLE BLIND, RANDOMIZED CONTROLLED TRIAL

M. Nabeel Nazar [*] ***and Ashok K. Ramadorai*** [†]
Department of Oral and Maxillofacial Surgery, Saveetha Dental College,
Saveetha University, Chennai, India

ABSTRACT

Surgical removal of impacted third molar results in pain, trismus and swelling. Non-steroidal anti-inflammatory drugs (NSAIDs) routinely used for the control of pain may be associated with severe gastric and bleeding related side effects. The use of centrally acting analgesics may be more useful in this regard. Not many studies have compared Diclofenac sodium with Tramadol. The aim of this study is to compare the efficacy of diclofenac sodium and tramadol in offering pain relief in patients following surgical removal of the third molar. The present study included 98 patients, who presented with impacted mandibular third molar. They were stratified and randomly allocated to one of the 2 groups (Tramadol 50mg and Diclofenac sodium 75mg). Patients recorded their pain intensity after intake of the drugs, in study diaries for a three day period. Patients also noted the global assessments of study medication on a 5-point scale. Comparing the two drugs there was no significant difference in the pain scores or global assessment scores for both the drugs ($P>0.05$). Within the limitations of this study, the pain relief offered by Tramadol was similar to that of Diclofenac sodium. Tramadol may be considered a viable alternative to Non-steroidal anti-inflammatory drugs, for surgical removal of mandibular third molar.

[*] Corresponding Author's Email: nabeel_nazar@yahoo.com. M. Nabeel Nazar[*], BDS, MDS, MOMS RCPS(Glasgow).
[†] Ashok K. Ramadorai, BDS, FFDSRCS.

Keywords: diclofenac sodium, impaction, NSAID, opioid, pain, third molar, tramadol hydrochloride

INTRODUCTION

Impaction of the mandibular third molar is a common condition giving rise to symptoms which necessitate its removal. Prophylactic extraction of third molars poses little surgical risk and may be beneficial in preventing disease [1]. Pain, trismus and swelling are the common complications occurring post-operatively. Post-operative pain after third molar surgery is a localized inflammatory pain of varying intensity.

The more prolonged periods of pain and inflammation appear to be integrally involved with the formation and function of the prostaglandins, which are a group of biologically active fatty acids derived from arachidonic acid and linoleic acid. Trauma, heat, anoxia or any stimulus which will result in deformation of the cell membrane or activation of lipolysis will elicit hydrolysis of phospholipids and triglycerides to release arachidonic acid metabolites via cyclooxygenase and lipooxygenase pathways the free fatty acid precursors of prostaglandins. These fatty acids are transformed into prostaglandin endoperoxides, PGD2, PGE2, prostacylin and thromboxanes. Arachidonic acid is also a substrate for lipoxygenase enzymes: Lipoxygenases generate a number of open-chain mono or dihydroxy acids from arachidonic acid via the corresponding unstable hydroperoxy acids, Hydroperoxy Eicosa Tetra Enoic acid (HPETE). 5-HPETE is also the precursor of the recently described leukotrienes. Leukotriene A is identical to a slow-reacting substance released in anaphylaxis and leukotriene B is a very potent chemotactic substance. It is possible therefore, that lipoxygenase products, as well as cyclooxygenase products may contribute to the development of pain and edema in the inflammatory response.

Pain resulting from the surgical removal of impacted third molars is a frequent problem and may affect the patient's post-operative quality of life. Pain reaches maximum intensity within 3–5 hours of surgery. For pain, trismus and swelling control after lower third molar surgery, several non-steroidal anti-inflammatory drugs (NSAIDs) have been used [2-6]. These medications have their therapeutic effect by means of the inhibition of cyclooxygenase (COX), which determines an inhibition of prostaglandin production. Three isoforms of COX are known: COX-1, a constitutive form expressed in almost all tissues, COX-2, predominantly induced and constitutively expressed in a limited number of tissues (renal medulla, prostate, brain and endothelium), and COX-3, a COX-1-derived protein, most abundant in the cerebral cortex and heart. It is believed that COX-2 is the main isoenzyme for pro-inflammatory prostaglandin production, and that the inhibition of COX-3 could represent a primary central mechanism by which NSAIDs like acetaminophen and dipyrone decrease pain and possibly fever. According to their relative inhibition of COX isoenzymes, NSAIDs can be classified as non-selective, COX-2 preferential or COX-2 selective. Acetaminophen has analgesic and antipyretic effects similar to aspirin. However, it has only weak anti-inflammatory effects and is thought to have a generally poor ability to inhibit the activity of the COX enzyme system in the presence of high concentrations of peroxidases, as are found at sites of inflammation.

The side effects associated with the use of NSAIDs are numerous, but primarily they are related to gastrointestinal (GI), hematologic, and renal disorders, as well as the propensity to cause skin and mucosal reactions. It should be noted that most of the manifestations of these adverse effects occur with chronic dosing of NSAIDs. Therefore, over a long period of time, the continuous inhibition of the COX enzymes becomes increasingly significant. The most profound adverse effect of the prolonged use of traditional NSAIDs is GI disturbance. Because this class of drugs blocks both COX enzymes, the gastric protective functions produced from prostaglandins produced by the COX-1 enzyme are not present. This makes the GI tract susceptible to GI ulcers, dyspepsia, and gastric bleeding. It has been found that gastric and duodenal ulcers are prevalent (15%-30% of patients) at endoscopy in patients taking NSAIDs on a regular basis [7]. Another adverse effect of NSAID use is increased bleeding risk intra-operatively and postoperatively. The inhibition of COX-1 in platelets by conventional NSAIDs results in modulation of platelet function leading to prolonged bleeding [8]. The renal side effects of NSAIDs are also well known and equally concerning.

Diclofenac is a NSAID that is available in an oral immediate-release potassium salt tablet form and a sodium salt delayed-release and extended-release tablet form. Diclofenac has potent inhibitory control of cyclo-oxygenase 1 and 2 sites. In pharmacokinetic studies diclofenac is rapidly and efficiently absorbed from the gastrointestinal (GI) tract.

Tramadol Hydrochloride (1RS, 2RS)-2-[(dimethyl amino)-methyl]-1-(3-methoxyphenyl)-cyclohexanol Hydrochloride, is a centrally-acting synthetic analgesic of the amino-cyclohexanol group with opioid-like effects. It is not derived from natural sources, nor is it chemically related to opiates. It is clinically effective in the treatment of moderate to moderately severe pain with a relative low addiction potential. In acute therapeutic use, Tramadol Hydrochloride produces analgesia against multiple pain conditions, such as post-surgical pain, obstetric pain, terminal cancer pain, and pain of coronary origin, and it has been used as adjuvant therapy in anesthesia. It acts at opioid receptors and also seems to modify transmission of pain impulses by inhibition of mono-amine reuptake. Tramadol Hydrochloride is administered as a racemic mixture of 2 enantiomers that are metabolized by the liver. While the (+) enantiomer has a moderate affinity for the opioid receptors, and inhibits serotonin reuptake, the other enantiomer (-) is a norepinephrine reuptake inhibitor. Although pre-clinical testing has not completely explained the mode of action, at least two complementary mechanisms appear applicable: binding to ?-opioid receptors and inhibition of re-uptake of noradrenaline and serotonin. The opioid-like activity of Tramadol Hydrochloride derives from low affinity binding of the parent compound to ?-opioid receptors and higher affinity binding of the principal active metabolite, O-desmethyl Tramadol, denoted M1, to ?-opioid receptors. The analgesic and anesthetic properties of tramadol in different oral surgical procedures have been studied [9-13].

An extensive review of literature showed us that there were no comparisons of Diclofenac sodium with Tramadol Hydrochloride in offering pain relief following surgical removal of impacted third molars.

METHODS

This is a randomized, double-blind, controlled study. A power calculation showed that a sample size of 80 subjects would detect a 30 % difference in the success rate of the two test groups at a power of 90% (α-- type I error of 0.05 and β - type II error of 0.10). Hence a total number of 120 subjects were screened considering a 10% attrition during follow-up to achieve the required sample size. The protocol was approved by the institutional review board, ethical committee and the study was conducted in accordance with the ethical standards for human experimentation established by the Declaration of Helsinki. All patients provided written informed consent before study participation.

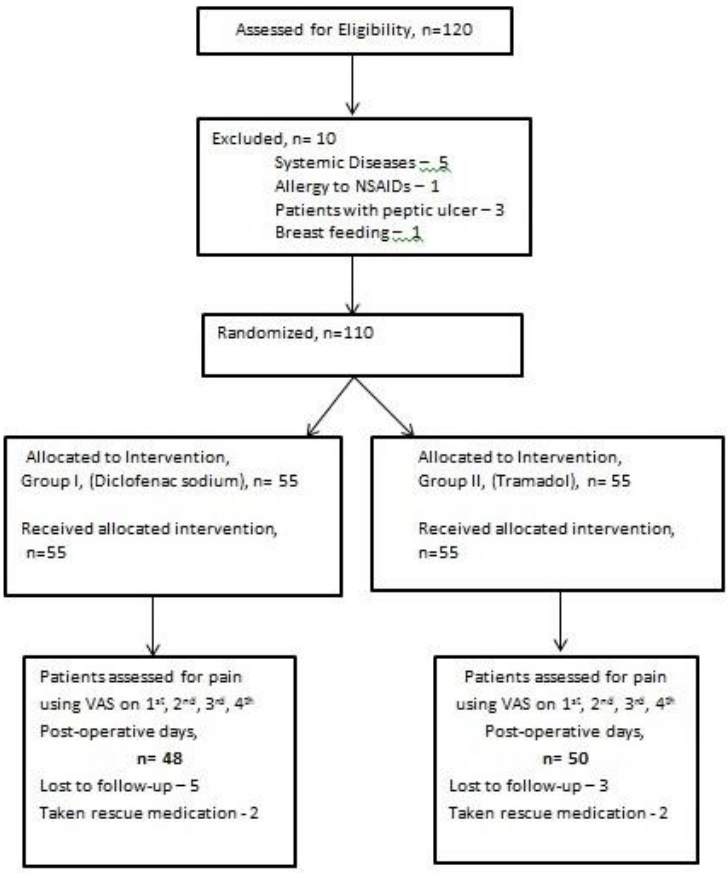

Figure 1. Consort flowchart.

Healthy male and female patients aged 18 to 45 years who required removal of impacted mandibular third molar were included in the study. Reasons for exclusion from the study were: known allergy to NSAIDs, hepatic, renal or heart diseases, asthma, diabetes mellitus, hypertension, epileptics, concurrent treatment with immunosuppressants, corticosteroids, history of peptic ulceration, gastrointestinal hemorrhage, pregnancy, use of oral contraceptives, history of NSAIDs use in the past 10 days and evidence of infection at the surgical site.

The study consisted of a pre-study screening visit, a treatment visit (dental surgery, followed by randomization to study drug), and a post-study visit 4 days and 7 days after surgery. Patients who met the inclusion criteria at the screening visit returned after 2 days for surgical extraction of third molars, for which local anesthesia (epinephrine with lidocaine) was administered. One partial or full bony impacted mandibular third molar was extracted under local anesthesia. At the time of surgery, the investigator noted the tooth removed, the duration of surgery, and the impaction score for each tooth (Based on Pederson's difficulty index) [14].

Allocation of patients to treatment was stratified by impaction score (mild or moderate or severe). Patients fulfilling the criteria were randomly allocated from a computer-generated list of random numbers into one of the 2 groups to receive treatment two times a day with Tramadol 50 mg or diclofenac sodium 75 mg (see figure 1). The study drugs were dispensed as identical capsules by an unblinded staff member. Patients were advised to take all the medications orally after meals. The first dose was administered 1 h after surgery. The procedure was described to the patients and written informed consent was obtained. The same surgeon operated on all the patients to avoid any variation in the surgical technique. The operation was carried out under local anesthesia. Anesthesia was by nerve block of the inferior alveolar and buccal nerves with 1.8 ml of 2% lignocaine containing 1:2,00,000 epinephrine. The surgical procedure consisted of a 3–4 cm long buccal incision, elevation of the mucoperiosteal flap, removal of buccal bone using bur, splitting and elevation of the impacted tooth, followed by debridement, achievement of hemostasis and closure of wound by interrupted suture using 3/0 braided silk. Metronidazole 400mg was prescribed to the patients in both groups.

The patients who did not achieve adequate pain relief with study medication were asked to take acetaminophen 500 mg as rescue medication. Patients who had consumed rescue medication were excluded from the final analysis.

Efficacy Assessments

Patients recorded their pain intensity after intake of the drugs, in study diaries at specified time intervals. In addition, they provided a global assessment of study medication at the end of 24 hours post-dose. Each patient was given a copy of the Visual Analog Scale (VAS) with readings from 0 to 10 with a gradation of 1(from 0 = none to 10 = severe). The patients were asked to use this scale to note their pain intensity after intake of medication and to record it on the pain diary. The global assessments of study medication used a 5-point scale (from 0 = poor to 4 = excellent).

Data Presentation and Analysis

Three parameters were assessed to determine the overall analgesic effect of the drugs : pain relief at the end of 24 hours (TOPAR 24), pain relief at the end of everyday for 4 days (TOPAR 1, 2, 3, 4), patient's global assessment score at 24 hours (GLOBAL24). The data were recorded on a microsoft excel sheet for statistical evaluation using a commercial program (SPSS 19). Age and post medication scores were tabulated and compared using

multiple comparison analysis of variance and post-hoc test. Equality of variances was assessed using Leven statistics, if an equality of variances existed, t-test was employed to identify significant differences between groups. The gender of the patients, type of tooth, the difficulty level of the impaction and the global assessment of functions were compared by chi-square test. The alpha type error (significance level) was set at P=0.05 for these analyses.

Table 1. Distribution of patients in Groups I & II based on difficulty scores

Difficulty Score	Group I	Group II	Total
‹5	12(30%)	10(25%)	22(27.5%)
5-7	20(50%)	20(50%)	40(50%)
›7	8(20%)	10(25%)	18(22.5%)
Total	48(100%)	50(100%)	98(100%)

RESULTS

All data were analyzed using SPSS 19 software. The total of 98 randomized patients comprised of 58.8% male (n=58) and 41.3% females (n=40). Chi-square test showed no significant difference between the sexes and ages for both treatment groups. There was no significant difference between the 2 groups in terms of distribution of patients based on the difficulty of impaction (see table 1).

Both the medications brought about a significant pain relief over the four day period (P<0.05). There was no significant difference in pain scores between the two groups (P>0.05)(see table 2). With regards to global assessment of function, there was no significant difference between the two groups, (P>0.05) (see table 3).

Table 2. Pain scores for Groups I & II

Group I (mean±SD)	Group II (mean±SD)	
Day 1	38.42 ± 11.059[a]	37.67 ± 14.285 [a]
Day 2	22.05 ± 10.246 [b]	26.58 ± 12 [b]
Day 3	14.53 ± 7.686 [c]	16.55 ± 10.51 [c]
Day 4	3.38 ± 2.227 [d]	4.05 ± 5.702 [d]

Within the same group different superscripts indicate statistical significance (P<0.05), between groups same superscripts indicate no statistical significance (P>0.05).

Table 3. Global Assessment of function for Groups I & II

Global Assessment	Group I No.(%)	Group II No.(%)	Total No.(%)
Very Poor	5(10.4%)	8(16%)	13(13.2%)
Poor	22(45.9%)	22(44%)	44(44.9%)
Fair	12(25%)	9(18%)	21(21.4%)
Good	7(15%)	7(14%)	14(14.2%)
Excellent	2(4.1%)	4(8%)	6(6.1%)

DISCUSSION

Post-operative pain after third molar surgery is a localised inflammatory pain of varying intensity. The initial pain includes the release of various mediators into the local environment, such as arachidonic acid metabolites, 5-HT and bradykinin. These mediators increase the responsiveness of local nociceptors. The afferent activity is relayed to the dorsal horn neurons in the spinal cord, which relay to higher centers where pain is perceived. The two other pathways that may be important to pain control are the descending inhibitory pathway and the sympathetic nervous system, which is implicated in the maintenance of pain states [15]. The problem of dental pain can be tackled using peripherally acting drugs or a centrally acting analgesic.

The most prevalent methods to prevent peripheral sensitization include administration of: NSAIDs [2-6], which prevent peripheral sensitization by reducing prostaglandin synthesis at the site of surgery; regional anaesthetics [16], which block afferent nociceptive impulses prior to incision; opioids [17], which modulate afferent input by blocking the postsynaptic receptors and decreasing neurotransmitter release or by activating inhibitory pathways; and NMDA-receptor antagonists [18], which inhibit activation of N-methyl-Daspartate (NMDA) receptors in the human spinal cord, thus preventing the main mechanism of central sensitization.

Results of clinical trials reported in the literature about pain after removal of third molars compare the analgesic effect of NSAID with placebos [19], or other NSAIDs [3, 6, 20-22] or test regimens only before or after the surgery [5]. There are also reports of NSAIDs compared with tramadol [4], however they used the intra-venous route for the administration of the drugs. Although placebo controlled clinical trials are considered the norm and gold standard for evaluation, this study did not utilize a placebo for comparison because of ethical reasons. Some studies which have utilized a placebo for comparison also placed the patients on rescue medication, however patients consuming the rescue medications were excluded from the study. This will induce a confounding factor. In the present study patients were advised to take a rescue medication of acetaminophen 500mg, if they had persisting pain after intake of the test drugs. Two patients in both the groups had taken rescue medications and therefore were excluded from the study. This study utilized a stratified random sampling method based on the severity of impaction as determined by Pederson's difficulty score. This was done to ensure that patients were equally distributed between the two study groups based on the difficulty level. However an attempt was not made to correlate the difficulty level with the pain relief. This needs further investigations.

The results of this study showed that the pain scores, and hence indirectly the pain relief, were not significantly different when either Diclofenac sodium 75mg or Tramadol Hydrochloride 50mg were prescribed as post-operative medications. Comparing the pain scores between the two treatment groups at the end of 24 hours, although Tramadol Hydrochloride brought about a marginal increase in the pain relief, this difference was not statistically significant when compared with Diclofenac sodium. Both the medications brought about a significant pain relief over the four day period. Furthermore both the drugs did not bring about any adverse effects and there was no significant difference in the global assessment score of both the drugs. Similar results have been reported comparing these two study drugs in pain control following bimaxillary osteotomy as well as osteoarthritis [23, 24].

However such a comparison has not been made for pain management following surgical removal of impacted third molars. Studies have reported that intra-muscular (IM) administration of tramadol pre-emptively offered better pain relief than post-operative administration via the same route [9]. It is also been shown that intra-venous (IV) tramadol provides better pain relief than oral tramadol, but administration of tramadol via the IM or IV routes could result in side effects like depression and sedation [10].

The possible mechanism by which tramadol brings about pain relief as effective as NSAIDs is an interesting factor which warrants discussion. Opening of potassium channels located in the primary afferent nerve endings produces anti-nociception and represents an important step in the peripheral anti-nociceptive effect of several NSAIDs. Activation of the NO-cyclic guanosine monophosphate (GMP) pathway could also induce anti-nociception through the opening of potassium channels. Such a mechanism has been implicated for the anti-nociceptive action of rofecoxib and lornoxicam [25, 26] both of which are NSAIDs. It is possible that both Tramadol Hydrochloride (in addition to its centrally acting mechanism) and Diclofenac sodium could share the above mentioned mechanism. Another probable reason is the involvement of transient receptor potential vanilloid channels (TRPV-1), which have been implicated in pain signaling. TRPV-1 plays a major role in hyperalgesia and allodynia, and is expressed in both the parasympathetic nervous system and central nervous system [27]. TRPV-1 is sensitized by prostaglandins and other inflammatory mediators leading to a potentiation of currents through the channel. Activation of TRPV-4 channel does not occur by the action of a single inflammatory mediator but rather through the concerted action of multiple mediators [28]. It could be hypothesized that Tramadol Hydrochloride brings about inhibition of TRPV channels more effectively than Diclofenac. However further research is required in this direction.

Apart from analgesia, Tramadol Hydrochloride may produce other symptoms similar to that of opioids including: dizziness, somnolence, nausea, constipation, sweating and pruritus. However, Tramadol Hydrochloride causes significantly less respiratory depression than morphine. In contrast to morphine, Tramadol Hydrochloride has not been shown to cause histamine release. At therapeutic doses, Tramadol Hydrochloride has no clinically significant effect on heart rate, left ventricular function or cardiac index. Orthostatic changes in blood pressure have been observed. Several studies indicated that unlike other opioids, Tramadol Hydrochloride was not associated with clinically relevant side effects. Drowsiness, nausea, and dizziness are the most common adverse effects[29]. In a study of the effects of Tramadol Hydrochloride on dentoalveolar surgical pain by Collins et al., 39% of patients on high doses of Tramadol Hydrochloride (100 mg four times a day orally), 12% on moderate doses (50 mg 4 times a day), and 6% on low dose (50 mg 2 times a day) withdrew from the study owing to nausea, vomiting, dizziness, or drowsiness [30] and in another study [9], seven of 40 patients reported drowsiness and three reported nausea. In our study, Global assessment of function was used to assess the side effects and 10% of 48 patients showed very poor compliance, of which 3 patients had nausea and 1 had vomiting, however none of the patients discontinued the medication.

The clinical application of the results of this study should be exercised with caution. This study evaluated only one type of NSAID i.e., Diclofenac sodium and hence, generalization or applicability of the results to the entire category of NSAIDs may not be possible. This warrants further inspection. Therefore Tramadol Hydrochloride may be considered as a viable alternative to Diclofenac sodium in patients where NSAIDs are contraindicated.

CONCLUSION

This study suggests that Tramadol Hydrochloride is a safe and effective alternate to NSAIDs, for mandibular third molar surgery.

REFERENCES

[1] Waite PD, Reynolds RR. Surgical management of impacted third molars. *Semin Orthod* 1998;4(2):113-23.

[2] Calvo AM, Sakai VT, Giglio FP, Modena KC, Colombini BL, Benetello V, et al. Analgesic and anti-inflammatory dose response relationship of 7.5 and 15 mg meloxicam after lower third molar removal: a double-blind, randomized, crossover study. *Int J Oral Maxillofac Surg* 2007;36:26-31.

[3] Daniels SE, Desjardins PJ, Bird SR, Smugar SS, Tershakovec AM. Rofecoxib 50 mg mg and Valdecoxib 20 or 40 mg in adults and adolescents with postoperative pain after third molar extraction: results of two randomized, double-blind, placebo-controlled, single-dose studies. *Clin Ther* 2006;28(7):1022-34.

[4] Ong KS, Tan JML. Preoperative intravenous tramadol versus ketorolac for preventing postoperative pain after third molar surgery. *Int J Oral Maxillofac Surg* 2004;33:274-8.

[5] Lima PVP, Fontanella V. Analgesic efficacy of aceclofenac after surgical extraction of impacted lower third molars. *Int J Oral Maxillofac Surg* 2006;35:518-21.

[6] Kara SM, Polat S, Inci MF, Gümüş C. Analgesic and anti-inflammatory effects of oxaprozin and naproxen sodium after removal of impacted lower third molars: A randomized, double-blind, placebo-controlled crossover study. *J Oral Maxillofac Surg* 2010;68:1018-24.

[7] Laine L. Gastrointestinal effects of NSAIDs and coxibs. *J Pain Symptom Manage* 2003;25(2 Suppl):32-40.

[8] Isakson P, Hubbard R. Analgesics: nonsteroidal anti-inflammatory drugs. In: Evers AS, Maze M, eds. *Anesthetic pharmacology: physiologic principles and clinical practice*. London: Churchill Livingstone, 2004:435-55.

[9] Pozos-Guillen A, Martinez-Rider R, Aguirre-Banuelos P, Perez-Urizar J. Pre-emptive analgesic effect of tramadol hydrochloride after mandibular third molar extraction: A Pilot Study. *J Oral Maxillofac Surg* 2007;65(7): 1315-20.

[10] Pozos AJ, Martinez R, Aguirre P, Perez J. Tramadol administered in a combination of routes for reducing pain after removal of an impacted mandibular third molar. *J Oral Maxillofac Surg* 2007;65(8):1633-9.

[11] Ong CK, Lirk P, Tan JM, Sow BW. The Analgesic efficacy of intravenous versus oral tramadol for preventing postoperative pain after third molar surgery. *J Oral Maxillofac Surg* 2005;63(8):1162-8.

[12] Altunkaya H, Ozer Y, Kargi E, Babuccu O. Comparison of local anaesthetic effects of Tramadol Hydrochloride with prilocaine for minor surgical procedures. *Br J Anaesth* 2003;90(3):320.

[13] Altunkaya H, Ozer Y, Kargi E, Ozkocak I, Hosnuter M, Demirel CB, Babuccu O. The postoperative analgesic effect of Tramadol Hydrochloride when used as subcutaneous local anesthetic. *Anesth Analg* 2004; 99(5):1461.

[14] Koerner KR. The removal of impacted third molars. Principles and procedures. *Dent Clin North Am* 1994;38(2):261.

[15] Urquhart E. Analgesic agents and strategies in the dental pain model. *J Dent* 1994;22(6): 336–41.

[16] Campbell WI, Kendrick RW, Fee JP. Balanced pre-emptive analgesia: does it work? A double-blind, controlled study in bilaterally symmetrical oral surgery. *Br J Anaesth* 1998; 81(5): 727-30.

[17] Lebrun T, Van Elstraete AC, Sandefo I, Polin B, Pierre-Louis L. Lack of pre-emptive effect of low-dose ketamine on postoperative pain following oral surgery. *Can J Anesth* 2006;53:146-52.

[18] Helmy SA, Bali A. The effect of the preemptive use of the NMDA receptor antagonist dextromethorphan on postoperative analgesic requirements. *Anesth Analg* 2001;92(3): 739-44.

[19] Petersen JK. Anti-inflammatory and analgesic effects of indomethacin following removal of impacted mandibular third molars. *Int J Oral Surg* 1975;4(6):267-76.

[20] Cooper SA, Gelb S, Goldman E, Cohn P, Dyer C. Comparative efficacy of fenoprofen calcium and zomepirac sodium in postsurgical dental pain. *Oral Surg Oral Med Oral Pathol* 1984;57:485-9.

[21] Daniels SE, Desjardins PJ, Talwalker S, Recker DP, Verburg KM. The analgesic efficacy of valdecoxib vs. oxycodone/acetaminophen after oral surgery. *J Am Dent Assoc* 2002;133:611-21.

[22] Seymour RA, Frame J, Negus TW, Hawkesford JE, Marsden J, Matthew IR. The comparative efficacy of aceclofenac and ibuprofen in postoperative pain after third molar surgery. *Br J Oral Maxillofac Surg* 1998;36:375-9.

[23] Beaulieu AD, Peloso PM, Haraoui B, Bensen W, Thomson G, Wade J, et al. Once-daily, controlled-release tramadol and sustained-release diclofenac relieve chronic pain due to osteoarthritis: a randomized controlled trial. *Pain Res Manage* 2008;13(2):103-10.

[24] Tuzuner AM, Ucok C, Kucukyavuz Z, Alkis N, Alanoglu Z. Preoperative diclofenac sodium and tramadol for pain relief after bimaxillary osteotomy. *J Oral Maxillofac Surg* 2007;65(12): 2453-8.

[25] Déciga-Campos M, López-Muñoz FJ. Participation of the L-arginine-nitric oxide-cyclic GMP-ATP-sensitive K+ channel cascade in the antinociceptive effect of rofecoxib. *Eur J Pharmacol* 2004;484(2-3):193-9.

[26] Prasanna N, Subbarao CV, Gutmann JL. The efficacy of pre-operative oral medication of lornoxicam and Diclofenac potassium on the success of inferior alveolar nerve block in patients with irreversible pulpitis: a double-blind, randomised controlled clinical trial. *Int Endod J* 2011; 44(4): 330-6.

[27] Patwardhan AM, Scotland PE, Akopian AN, Hargreaves KM. Activation of TRPV1 in the spinal cord by oxidized linoleic acid metabolites contributes to inflammatory hyperalgesia. *Proc Natl Acad Sci USA* 2009; 106(44):1820-4.

[28] Simmons DL, Botting RM, Hla T. Cyclooxygenase isozymes: the biology of prostaglandin synthesis and inhibition. *Pharmacol Rev* 2004; 56(3):387-437.

[29] Scott LJ, Perry CM. Tramadol. A review of its use in perioperative pain. *Drugs* 2000;60(1):139.

[30] Collins M, Young I, Sweeney P, Fenn GC, Stratford ME, Wilson A, Harris M. The effect of tramadol on dento-alveolar surgical pain. *Br J Oral Maxillofac Surg* 1997;35(1):54-8.

In: Encyclopedia of Surgery (22 Volume Set)
Editors: Andreas Lehrer and Kristin Mueller
ISBN: 978-1-53618-329-0
© 2020 Nova Science Publishers, Inc.

Chapter 381

MANAGEMENT OF FAILED BACK SURGERY SYNDROME AND RELATED DISORDERS

Angelo Rafael Cunha de Azevedo*, MD
and William Omar Contreras Lopez, PhD, MD
University of São Paulo, São Paulo, Brazil

ABSTRACT

Fail Back Surgery Syndrome (FBSS) and post laminectomy syndrome are commonly associated with spinal adhesive arachnoditis and Complex Regional Pain Syndrome (CRPS). Post laminectomy and FBSS have common symptoms and their treatment by spinal cord surgery is typically unsuccessful, with subsequent development of lumbar and radicular pain, despite the use of modern physiatrics techniques and pharmacological approaches. Spinal arachnoiditis is an inflammatory process involving all three meningeal layers or the nerve roots and commonly produces persistent pain. Patients with inappropriately long post-surgery immobility periods are at risk of CRPS, which is characterized by functional limitations in walking, neuropathic pain, edema and colors changes in the affected limb. Among drugs for the treatment of neuropatic chronic pain established are Gabapentin, Tramadol, Venlafaxine or Duloxetine being most commonly applied as a multi-therapy approach. Physical therapy often helps with pain relief and gain of movement. Here we performed spinal cord stimulation (SCS) to treat FBSS. When well indicated, SCS can achieve up to 50% pain relief in VAS (visual analogic scale). Alternative treatment options include continuous intratechal morphine delivery and ozone therapy by spinal epidural endoscopy, which have been reported to reduce pain by more than 40%.

Keywords: lumbar pain, fail back surgery syndrome, complex regional pain syndrome, spinal cord stimulation

* Corresponding Author's Email: angelo.azevedo@hc.fm.usp.br.

INTRODUCTION

The term Fail Back Surgery Syndrome (FBSS) describes cases in which therapy has failed because of structural abnormalities in the back and/or psychosocial influences. FBSS is typically assessed by resonance imaging techniques, together with physical examination and an evaluation of the patient's medical history. Concomitant evaluation of psychosocial issues is mandatory and should include a reasonable attempt at physical rehabilitation, giving attention to both local factors and general functioning. If intensive conservative rehabilitation efforts fail, those patients principally suffering from physical abnormalities can be treated by reparative surgery or pain-relieving procedures. Although reparative surgery can successfully address initial surgical failures, some patients fail to benefit and have their conditions worsened by such procedures. Most patients suffering from FBSS are incapacitated by psychiatric, psychologic and social/vocational factors, which are only indirectly related their back complaint. Decisions concerning the most appropriate treatment are often made by patients, attorneys, disability determination systems, employers and judges, which can be influenced by extraneous motives, including financial gain and personal bias, and often reflect the current dearth of available information about FBSS [1].

Back surgery can fail if patients are erroneously selected for intervention, in cases of lumbar disc protrusion and if lateral recess stenosis goes undiagnosed. Patient motivation levels also affect surgical outcome. The ideal candidate FBSS patient for surgical intervention would have sciatica that is more severe than backache, a recurrent or residual disc protrusion associated with the stenosis and high levels of motivation that are not affected by workers' compensation (WC) or other insurance claims or benefits [2]. Vik et al. compared the patient outcomes of 211 patients with unilateral sciatica operated on for lumbar disc herniation that were either reoperated or operated on only once. Eight years after operation, the reoperated patients had a significantly worse outcome than the operated once patients. In addition, reoperated patients with preoperatively confirmed recurrence of the same disc had a better outcome than reoperated patients without preoperative signs of a recurrence [3].

FBSS is a relatively frequent (5–10% of patients) complication of lumbosacral spine surgery [4]. In a study evaluating trends associated with surgery for lumbar spinal stenosis in older adults, the authors identified a 15-fold increase in the rates of complex fusion procedures from 2002 to 2007, with higher rates of life-threatening complications (5.6%) compared to simple decompression (2.3%). A higher rate for rehospitalization within 30 days was also noted with complex fusion (13%) compared to decompression (7.8) [5]. In ~11% of FBSS patients, low sacral arachnoiditis adhesive is the primarily responsible for incapacitation. Data from the 1990 indicate that about 25% of the patients that underwent back surgery in the United States were either not improved or made worse [6].

Currently, the number of FBSS patients is growing. This is partly due to a growing number of young patients undergoing lumbar fusion, which is surprisingly rarely discussed among physicians. The term *fusion*, which implies rigid fixation, has been replaced with *arthrodesis* (from the Greek: arthro—joint, desis—to bind) and applied to many pathologies of lumbar instability or misdiagnosed chronic lumbar pain. We propose that, among spine surgeons, there is a widespread need for the recognition that motion-preserving stabilizations often represent a better surgical option than multilevel pedicle screw and rod rigid approaches for patients with multilevel degenerative disease [7].

PATHOLOGY

Spinal arachnoiditis is an insidious disease caused by an inflammatory process of the arachnoid membrane and can arise from myelograms with oil-based radiographic contract agents and multiple back surgeries [8]. Spinal arachnoiditis involves all three meningeal layers or the nerve roots and causes persistent pain in 6–16% of postsurgical cases [9]. During the initial phase of this process, the roots in the intrathecal trajectory present swelling, with the hyperemia and an important fibrinous exudate, completely filling the subarachnoid space. In the absence of the cell fibrinolytic liberating enzyme, fibrin is deposited, covering the nerve roots and arachnoid, ultimately resulting in adhesions between cellular components. Nevertheless, fibroblast proliferation continues throughout this phase. The second phase is characterized by collagen deposition leading to adhesion between the nerve roots and the meninges. In the second phases, autoimmune factors determine the order of the procedure, as well as its progression. In some instances, the inflammatory reaction is so pronounced that the scar tissue completely occupies the sub-arachnoid space, progressing from a focal to totally blockage. Calcification of the fibrous bands may also occur [10]. The patient usually describes a continuous burning sensation at the sacral area, severe pain down the back of one or both legs, without sciatic distribution, tingling pain when walking, burning at the knees, while tingling and pain in the feet, calves and ankles is usually ameliorated. The pain is normally reduced when the patient lies flat [11]. Lumbar adhesive arachnoiditis can be subdivided into three injury types: (1) the roots clustering in the center of the thecal sac; (2) the roots are adhering to the periphery of the thecal sac - aspect of "empty bag"; and (3) conglomerates root and scar tissue that fills the subarachnoid space - pseudo-tumoral aspect.

Complex regional pain syndrome (CRPS) is used by the International Association for the Study of Pain (IASP) to describe disorders characterized by spontaneous or stimulus-induced pain that is disproportionate to the inciting event and accompanied by a wide variety of autonomic and motor disturbances in highly variable combinations. The term CRPS has been subdivided into type I and type II. CRPS I is intended to encompass reflex sympathetic dystrophy and similar disorders, without a nerve injury, while CRPS II occurs after damage to a peripheral nerve [12].

	CRPS I	CRPS II
Etiology	No lesion	Nerve lesion
Localization	Distal extremity Independent to nerve's distribution	Any peripheral site Confined to nerve's distribution
Spreading of Symptoms	Obligatory	Rare
Spontaneous Pain	Eventual Mostly deep Orthostatic component	Several Superficial No orthostatic component
Mechanical Allodynea	Most Patients With Spreading Tendency	Obligatory in Nerve Distribution
Autonomic Symptoms	Distally Generalized With Spreading Tendency	Related To Nerve Lesion
Motor Symptoms	Distally Generalized	Related To Nerve Lesion
Sensory Symptoms	Distally Generalized With Spreading Tendency	Related To Nerve Lesion

CRPS-I is more commonly associated with FBSS than CRPS-II. Although it has long been hypothesized that CRPS is mediated by the sympathetic nervous system, its pathophysiology is not yet fully understood. The most popular theory is that there is a mismatch between the sensory input and motor output, leading to a disorganization of motor programming in cortical structures. Motor control studies have suggested that this mismatch could be corrected using a proprioceptive feedback mechanism [13, 14].

Traditionally, CRPS was considered a progressive condition, described in three stages: (1) the "acute stage," characterized by a painful, swollen, warm, red limb; (2) the "dystrophic stage," the limb was said to cool and appear cyanotic, with changes to hair and nail growth, osteoporosis, stiffness, and muscle wasting; (3) the "atrophic stage," irreversible atrophy of bones, muscles and nails [15].

EVALUATION

Iophendylato (Pantopaque), a liposoluble dye used during myelography, was identified as a cause of arachnoiditis adesiva and its use banned in Scandinavia and rest of Europe in (1948) and only much later (in 1980) in the US.

Dyes are useful during myelography, helping with diagnosis and treatment. The lesions associated with arachnoiditis are usually discovered at myelography and/or operation. When the myelographic defects do not conform to the classical lumbar disc condition, then arachnoiditis is probably the presenting pathological condition. Among etiologic agents, water-based contrast agents are less commonly applied. The closer the contrast material is to isomolarity, the less likely adhesions are to develop. The current dye in use, Iohexol-300 Parenteral (phenterminehydrochloride), is a water-soluble isomolaric compound that is reabsorbed by the cerebrospinal fluid, requiring no special removal steps [16].

The CT myelography better defines intradural injuries of arachnoiditis. It allows opacification of certain areas of the sub-arachnoid space, which are invisible during myelography, allowing better diagnosis. In most cases, arachnoiditis is demonstrated by plain-film and CT myelography, although abnormally configured nerve roots can also be detected by magnetic resonance imaging (MRI). For the diagnosis of moderate to severe arachnoiditis, MRI data typically correlate with the findings of CT myelographic and plain-film myelography [17].

MRI can be used to distinguish between arachnoiditis subtypes. T2-weighted sequences offer the same signal as axial view CT myelography, with the roots as hyposignals within the hyperintense CSF. This sequence is useful for defining the distribution of the intrathecal roots. However, the pathology may be masked by a hyperintense signal during fibrosis, which can simulate the hyperintense CSF. The T1-weighted sequences are the most sensitive, both in sagittal and axial sections, with the roots having an intermediate signal within the hypointense CSF.

Evaluation by MRI is critical because it provides evidence for continued pain and functional incapacitation in 19% of cases. The causes of delayed recurrence of lower back and sciatic pain are multiple and include arachnoiditis, epidural fibrosis, facet osteoarthritic degenerative change, instability, new intervertebral disc herniation, spinal stenosis (lateral or central, from postoperative bony overgrowth) and vertebral osteomyelitis [18]. FBSS can

arise from both successful and unsuccessful osseous fusions. Successful lumbar spinal surgery with osseous fusion results in altered biomechanics, with hypermobility of the adjacent levels, causing accelerated degenerative changes. Unsuccessful osseous fusion can result in pseudoarthrosis. Findings of T1 hypointensity and T2 hyperintensity persisting between the vertebral body and bone graft for more than 6 months are suggestive of pseudoarthrosis [19].

Thermography has an 80% sensitivity and 60% specificity for CRPS patients that have undergone the procedure [20]. The cold stress test can also be used in CRPS evaluations. The patient is acclimated for 15 min unclothed in an isolated room maintained at a mean temperature of 23 ± 2°C and a relative humidity of 50%. A temperature asymmetry between the affected and unaffected extremities greater than 1.00°C is considered a positive finding [21].

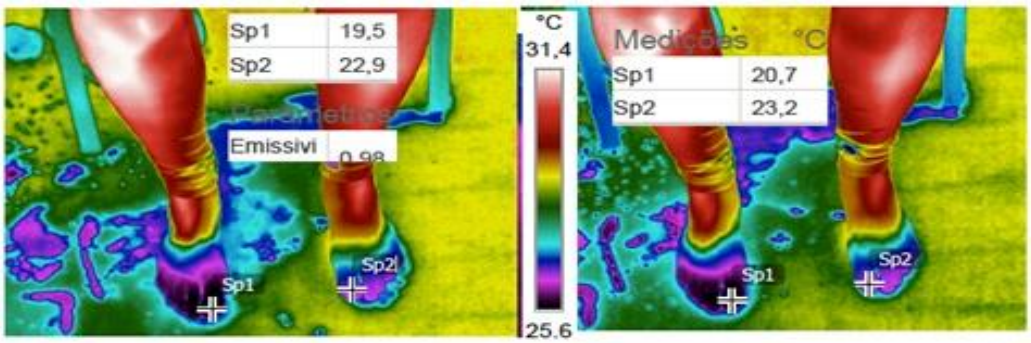

Figure 1. Termography data. The initial measurements in lower limbs were 19.5ºC and 22.9ºC. After 10 min, these values have changed to 20.7ºC and 23.2ºC respectively, indicating that the Sp1 (right leg) is positive for CRPS-I. Image courtesy of Dr. Gilberto de Paula.

TREATMENT

CRPS treatment options usually include a range of physical, psychological, medical and surgical therapies. In our center, we subscribe opioids, anticonvulsants and antidepressants to control secondary back pain. Table summarizes the drugs typically used to treat CRPS.

Amongst the invasive pain treatments available for FBSS, we usually offer: (1) spinal cord stimulation (SCS); (2) epiduroscopy and (3) continuous morphine intrathecal pump.

SCS is less expensive and more effective than reoperation in selected FBSS patients. North et al., found that patients who crossed over to another therapy had less successful outcomes than patients who did not cross over; 2 of 8 patients who did not crossover from reoperation were successes, whereas none of the 5 who crossed over to reoperation and 7 of 14 who did not crossover from SCS were successes, versus 5 of 13 who crossed over to SCS [22].

In our experience, SCS is advantageous for the treatment of FBSS, which is in line with the findings of international studies. Boswell et al. (2005 and 2007) have recommended SCS to treat CRPS and FBSS [23, 24] In 2007, the European Federation of Neurological Societies (EFNS) launched a task force to evaluate the evidence for the use of these techniques and to produce relevant recommendations [25]. Using literature data from 1968 to 2006, SCS was

shown to be efficacious in FBSS and Type I CRPS (level B recommendation) [26]. A Dutch Multidisciplinary Guideline for Invasive Treatment of Pain Syndromes of the Lumbosacral Spine Task force has proposed that SCS is recommended for patients with FBSS who have pronounced leg pain and for whom conservative therapy has failed [27].

	Class	Dose/day	Action	Common Side-effect
Venlafaxine	antidepressant	75-150mg	Dual (Noradrenaline and Sertraline)	Vomit
Duloxetine	antidepressant	60-120mg	Dual (Noradrenaline and Sertraline)	Not reported
Pregabalin	anticonvulsant	150-600mg	Ca+ channel blocker	Drowseness
Gabapentin	anticonvulsant	600-2400mg	Ca+ channel blocker	Not reported
Oxycodone	Opioid	30 – 120mg	Sintetic agonist	Itch
Codeine	Opioid	120mg - up	agonist	Itch
Tramadol	Opioid	200-400mg	Sintetic agonist	Itch
Morphine	Opioid	40mg - up	agonist	Itch, constipation

There are two types of electrode that can be used during SCS implantation: a single tubular lead (4–8 contacts) or paddle lead (2 or more columns and 8–20 contacts). The surgery techniques depend on the type of electrode to be implanted. To treat pain in lower limbs and lumbar pain, electrodes are usually implanted on the epidural space of the D9 intervertebral disc spaces.

The patient is positioned in the prone position with a pillow under their hips and sedated with dexmedetomidine hydrochloride. The procedure is performed under aseptic conditions with antibiotic (prophylaxis) and requires the use of fluoroscopy. With the tubular lead, the puncture is made with a Tuohy needle held laterally to L3-L4 levels on a peduncular line, with the needle positioned toward the midline using C-arch fluoroscopy. After withdraw of the guide thread, the electrode is carefully introduced through the needle and the tip of the lead is sliped up to T8-9 intervertebral disc spaces.

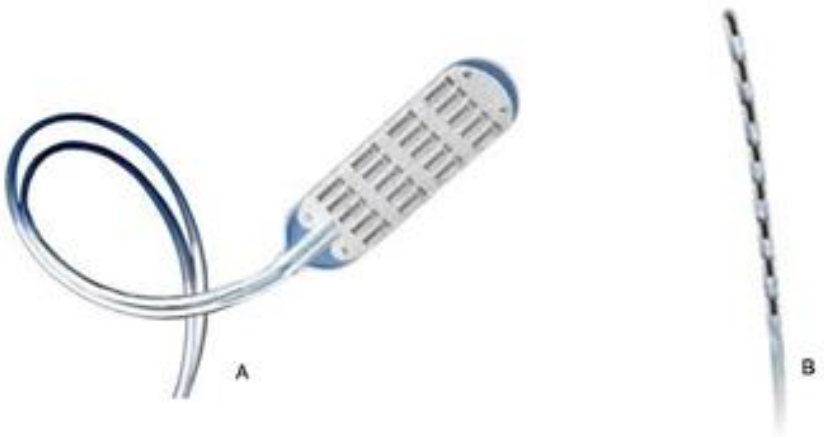

Figure 2. An ANS Penta™ paddle lead 5-column with 20 contacts (A) and tubular lead with 8 contacts (B). Drawing courtesy by St. Jude, Brazil.

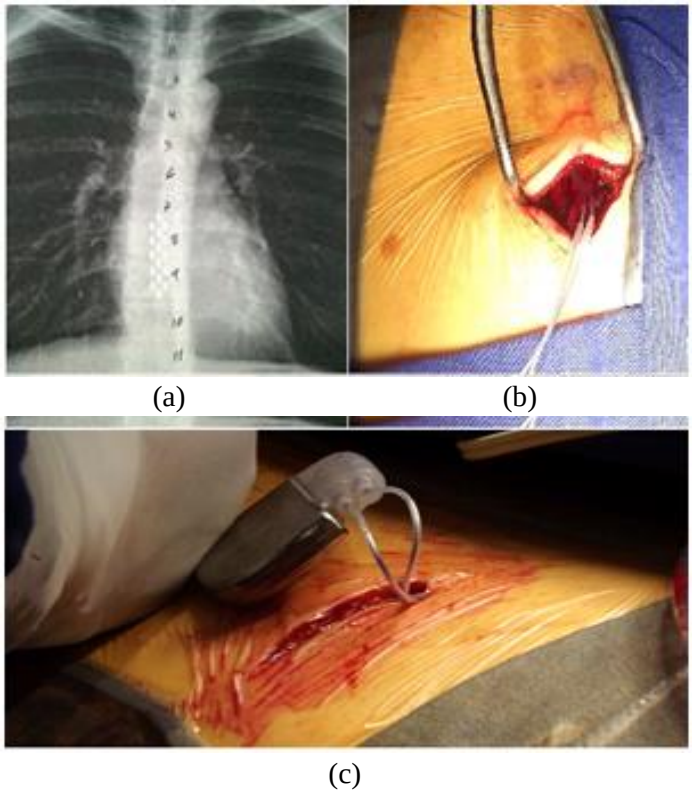

Figure 3. (A) Preview by arc-C fluoroscopy of 3–column lead positioned. (B) Small incision and flavectomy, showing the electrode on the epidural space. (C) After the extensions transposed, the lead is connected to a pulse generator.

When using the paddle lead, the procedure is performed with the patient in the prone position, following a protocol similar to the puncture method but on fully endovenous anesthesya. The T9–T10 spinal process level, which will be open, is marked on the skin after visualizing by C-arch fluoroscopy. A sharp dissection is performed to the point of the spinal posterior ligaments and flavectomy is performed. The epidural space is then examined and tested by probe before passing the paddle electrode, which will be positioned on the T8–9 intervetebral disc spaces and stimulate to test the sensitivity level. Also, the stimulation can be performed through an external disposable extension during 7 days for a test. The pulse generator is implanted and the external disposable extension removed, after these 7 days during a second surgery.

Patients that have undergone a stimulation test appear to have a better predictive value (in almost 90% of cases) than those that did not undergo a stimulation trial. Furthermore, the success of SCS depends on the selection of patients based on extensive interdisciplinary examinations following a combination of physical, psychological and medical therapies. Pain relief is rated as good reduced by more than 50%. The important advantages and disadvantages of the electrode types are shown in the table below.

The programing parameters generally begin at an amplitude of 3–10 mA, frequency 50 Hz and pulse width of 90–250 μsec. Most patients recover function and improve at low

stimulation, however, high-frequency SCS (1–10 kHz) is sometimes required difficult-to-treat patients with chronic back pain [28].

	Tubular lead	Paddle lead
Implantation	Easy to do by puncture	Need open the skin and muscles
Migration/displacement	Common	Rare
Programing	Until 8 contacts	More than 8 contacts option
Fracture	Common	Rare
Side-effects	Multidirections, may stimulate posterior areas to electrode	One steering, stimulate anterior area to electrode

Epidural fibrosis or arachnoiditis may account for as much as 20–36% of all cases of FBSS. Based on the U.S. Preventive Services Task Force (USPSTF) criteria, the required evidence level for endoscopic adhesiolysis is Level II-1 or II-2 for short- and long-term relief respectively [29]. Although serious complications can arise from the pressure increase in the epidural space during epiduroscopy, patients have an average reduction of lumbar pain of 44% and a 61% reduction in leg pain, with 44% improvement within the first 6 months [30].

In our service, endoscopic adhesiolysis is carried out under local anesthesia with the patient awake, thus avoiding potential unrecognized pressure effects in the epidural canal. Light sedation and analgesia are sometimes required to ensure total patient cooperation while maintaining verbal contact. The patient is positioned in a prone position with a pillow under their hips. The procedure is performed under aseptic conditions with antibiotic (prophylaxis) and requires the use of fluoroscopy. A puncture is then made using a 17G Tuohy needle through the sacrococcygeal ligament, followed by a caudal epidurogram to confirm needle placement. The Seldinger technique is then performed by a dilator placement and inserted sheaths through a small incision. Next, a fiber-optic microendoscope (Flexible Fiber Optic Endoscope - Model 3000E; Myelotec®, Roswell, GA, USA) is introduced into the epidural space through the appropriate introducer to obtain video images. Slow irrigation with saline allows visualization of the epidural space by gentle distension. Blunt dissection coupled with hydrostatic distension of the epidural space create a pocket, through which the injected drug can access the symptomatic nerve roots. After adhesiolysis, the patient receives 20 mL of oxygen–ozone mixture at a concentration of 30 μg/mL, obtained from an ozone generator (Medplus Philozon®, Balneário Camboriu, SC, Brazil). After the procedure, the patient is left at rest for 2–4 h in the supine position before being released from the hospital [30].

Intrathecal opioid therapy in general indicated for pain sensitive to opioid medication. However, due to increasing systemic side-effects such as nausea, vomiting, constipation or central nervous system depression, oral or intravenous opioid therapy alone is no longer acceptable.

The targets of intrathecal drug application are the pre- and post-synaptic receptors in the dorsal horn of the spinal cord [31]. After direct intrathecal application, very high concentrations of morphine can reach the receptor sites. Approximately 79% of morphine glucuronation is assumed to take place in the liver [32]. Recently, glucuronide formation was also detected in human brain tissue samples [33]. Because of the proximity of the opioid receptors, even minute amounts of metabolites may have significant pharmacological effects.

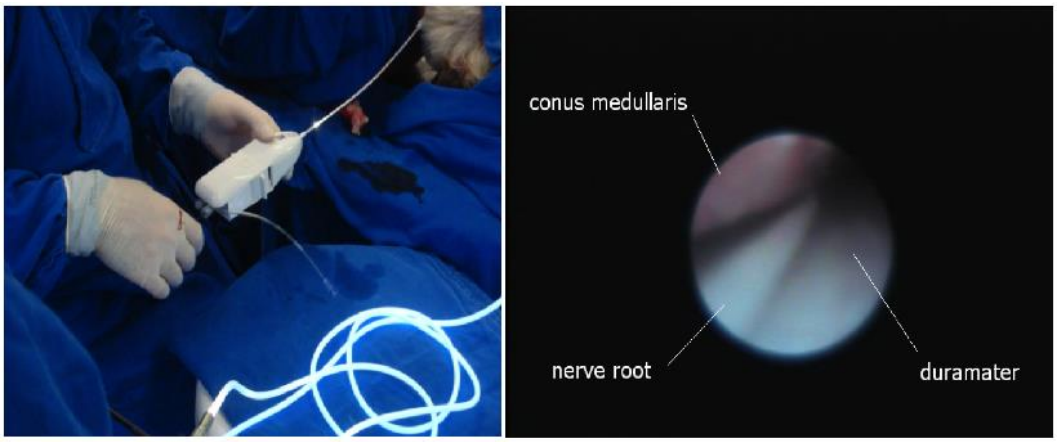

Figure 4. Flexible fiber optic endoscope and irrigation with saline solution (left). Intradural view after puncture of the dural sac at the D12 level (right).

In a study conducted in our hospital, the mean intensity of pain was reduced from 9.5 to 4.6 according to VAS (a 48.5% reduction). The mean daily dose of morphine necessary for pain control became constant after the sixth month of treatment and there was improvement in the quality of life. Side effects inherent to drug treatment may occur, although these are more frequent at the beginning of the treatment and become more tolerable after the first month of treatment [34].

There are currently two treatment modalities for pumps: (1) constant infusion and; (2) bolus infusion. There are also two pump types: programmable and non-programmable. In general, pumps have a maximum capacity and infusion time according to the dose to be used. Prior to the use of intrathecal morphine, patients are typically receiving high doses of oral opioids and have already experienced side effects. Before pump implantation, patients undergo an epidural morphine bolus trial by external catheter and receive up to 10 mg/day. Those showing good results (improvement of at least 50% on VAS) proceed to pump implant.

Infection, distal catheter obstruction, catheter migration, catheter disconnection, leakage and persistent side effects (vomit, drowsiness, itch, taquicardia) are complications associated with pump implant. In a study of 122 patients, approximately 30% of complications associated with implants were mostly pharmacological and transient [35]. In the case of infections, we recommend full implant removal because of the risk of meningitis and granulomas.

Technically, the procedure is performed by puncture and the catheter guided to the desired level by fluoroscopy. We usually perform the puncture with a Tuohy needle on the back midline (L3–L4) intradiscal space and pass the catheter through the needle, sliding gently toward the T6 vertebral level. Then, after insertion and fixation, the catheter is transposed by a cannula from the back of the abdomen and connected to a pump.

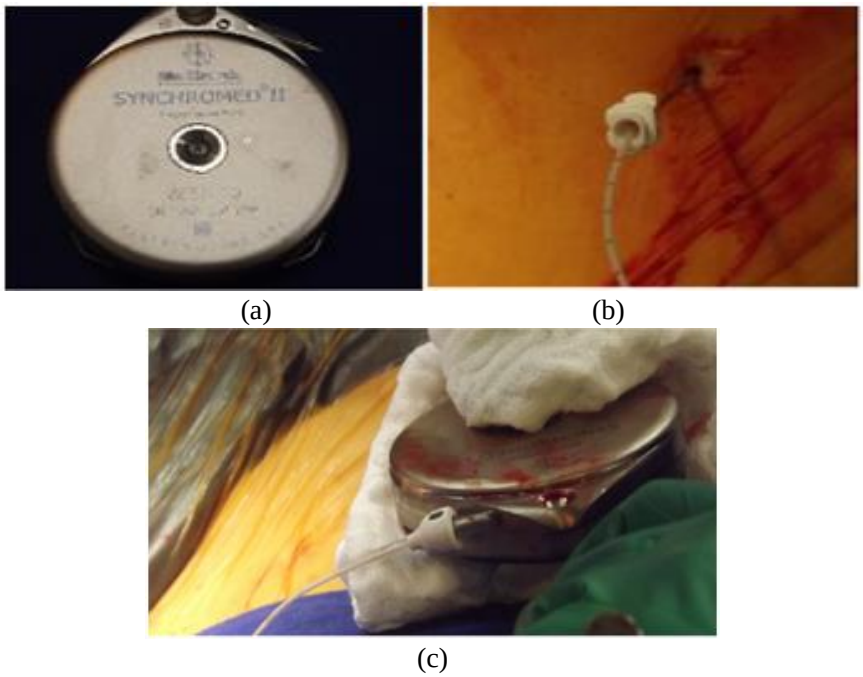

(a) (b)

(c)

Figure 5. (A) Synchromed® II pump by Medtronic™, 20 ml capacity. (B) Tuohy Needle positioned intrathecal and catheter passed by needle. (C) Synchromed® pump connected to intrathecal catether.

CONCLUSION

Fail Back Surgery Syndrome is an ensemble of pathologies involving unwieldy pain induced by drugs and physiotherapy, often leading to disability. The causative factors of FBSS should be identified in order to direct treatment. In our department, we discourage reoperations for fusions. Here, we describe three FBSS treatment options (Spinal cord stimulation, epiduroscopy and continuous intrathecal morphine pump) and report patient outcome results comparable to those typically found in the literature.

ACKNOWLEDGMENT

For PhD., MD Erich Talamoni Fonoff, whom I acquired knowledge and taught me functional treatment for pain.

REFERENCES

[1] Long DM. Failed back surgery syndrome. *Neurosurg Clin N Am.* 1991 Oct;2(4):899–919.

[2] Yaksich I. Failed back surgery syndrome: problems, pitfalls and prevention. *Ann Acad Med Singapore.* 1993 May;22(3 Suppl):414–7.

[3] Vik A, Zwart JA, Hulleberg G, Nygaard OP. Eight year outcome after surgery for lumbar disc herniation: a comparison of reoperated and not reoperated patients. *Acta Neurochir* (Wien). 2001;143(6):607–10; discussion 610–1.

[4] Fiume D, Sherkat S, Callovini GM, Parziale G, Gazzeri G. Treatment of the failed back surgery syndrome due to lumbo-sacral epidural fibrosis. *Acta Neurochir Suppl.* 1995;64:116–8.

[5] Deyo RA, Mirza SK, Martin BI, Kreuter W, Goodman DC, Jarvik JG. Trends, major medical complications, and charges associated with surgery for lumbar spinal stenosis in older adults. *JAMA.* 2010 Apr 7;303(13):1259–65.

[6] Burton CV, Kirkaldy-Willis WH, Yong-Hing K, Heithoff KB. Causes of failure of surgery on the lumbar spine. *Clin Orthop.* 1981 Jun;(157):191–9.

[7] Heithoff KB, Gundry CR, Burton CV, Winter RB. Juvenile discogenic disease. *Spine.* 1994 Feb 1;19(3):335–40.

[8] Burton CV. Failed back surgery patients: the alarm bells are ringing. *Surg Neurol*. 2006 Jan;65(1):5–6.

[9] Wright MH, Denney LC. A comprehensive review of spinal arachnoiditis. *Orthop Nurs.* 2003 Jun;22(3):215–9; quiz 220–1.

[10] Van Goethem JWM, Parizel PM, Jinkins JR. Review article: MRI of the postoperative lumbar spine. *Neuroradiology*. 2002 Sep;44(9):723–39.

[11] Bourne IH. Lumbo-sacral adhesive arachnoiditis: a review. *J R Soc Med*. 1990 Apr;83(4):262–5.

[12] Quiles M, Marchisello PJ, Tsairis P. Lumbar adhesive arachnoiditis. Etiologic and pathologic aspects. *Spine.* 1978 Mar;3(1):45–50.

[13] Borchers AT, Gershwin ME. Complex regional pain syndrome: a comprehensive and critical review. *Autoimmun Rev.* 2014 Mar;13(3):242–65.

[14] Gay A, Parratte S, Salazard B, Guinard D, Pham T, Legré R, et al. Proprioceptive feedback enhancement induced by vibratory stimulation in complex regional pain syndrome type I: an open comparative pilot study in 11 patients. *Jt Bone Spine Rev Rhum*. 2007 Oct;74(5):461–6.

[15] Bank PJM, Peper CLE, Marinus J, Beek PJ, van Hilten JJ. Motor dysfunction of complex regional pain syndrome is related to impaired central processing of proprioceptive information. *J Pain Off J Am Pain Soc.* 2013 Nov;14(11):1460–74.

[16] Bonica JJ. Causalgia and other reflex sympathetic dystrophies. In: *Management of Pain.* Philadelphia: Lea & Feibiger; 1990. p. 220–43.

[17] Dolan RA. Spinal adhesive arachnoiditis. *Surg Neurol*. 1993 Jun;39(6):479–84.

[18] Ross JS, Masaryk TJ, Modic MT, Delamater R, Bohlman H, Wilbur G, et al. MR imaging of lumbar arachnoiditis. *AJR Am J Roentgenol*. 1987 Nov;149(5):1025–32.

[19] Ross JS. MR imaging of the postoperative lumbar spine. *Magn Reson Imaging Clin N Am*. 1999 Aug;7(3):513–24, viii.

[20] Malhotra A, Kalra VB, Wu X, Grant R, Bronen RA, Abbed KM. Imaging of lumbar spinal surgery complications. *Insights Imaging.* 2015 Oct 2.

[21] Kim HJ, Yang HE, Kim DH, Park YG. Predictive value of sympathetic skin response in diagnosing complex regional pain syndrome: a case-control study. *Ann Rehabil Med.* 2015 Feb;39(1):116–21.

[22] Niehof SP, Huygen FJ, van der Weerd RW, Westra M, Zijlstra FJ. Thermography imaging during static and controlled thermoregulation in complex regional pain

syndrome type 1: diagnostic value and involvement of the central sympathetic system. *Biomed Eng OnLine.* 2006 May 12;5:30.

[23] North RB, Kidd D, Shipley J, Taylor RS. Spinal cord stimulation versus reoperation for failed back surgery syndrome: a cost effectiveness and cost utility analysis based on a randomized, controlled trial. *Neurosurgery.* 2007 Aug;61(2):361–8; discussion 368–9.

[24] Boswell MV, Shah RV, Everett CR, Sehgal N, McKenzie Brown AM, Abdi S, et al. Interventional techniques in the management of chronic spinal pain: evidence-based practice guidelines. *Pain Physician.* 2005 Jan;8(1):1–47.

[25] Boswell MV, Trescot AM, Datta S, Schultz DM, Hansen HC, Abdi S, et al. Interventional techniques: evidence-based practice guidelines in the management of chronic spinal pain. *Pain Physician.* 2007 Jan;10(1):7–111.

[26] Deer TR, Thomson S, Pope JE, Russo M, Luscombe F, Levy R. International neuromodulation society critical assessment: guideline review of implantable neurostimulation devices. *Neuromodulation J Int Neuromodulation Soc.* 2014 Oct;17(7):678–85; discussion 685.

[27] Cruccu G, Aziz TZ, Garcia-Larrea L, Hansson P, Jensen TS, Lefaucheur J-P, et al. EFNS guidelines on neurostimulation therapy for neuropathic pain. *Eur J Neurol.* 2007 Sep;14(9):952–70.

[28] Itz CJ, Willems PC, Zeilstra DJ, Huygen FJ. Dutch Multidisciplinary Guideline for Invasive Treatment of Pain Syndromes of the Lumbosacral Spine. *Pain Pract Off J World Inst Pain.* 2015 Jun 1;

[29] Van Buyten J-P, Al-Kaisy A, Smet I, Palmisani S, Smith T. High-frequency spinal cord stimulation for the treatment of chronic back pain patients: results of a prospective multicenter European clinical study. Neuromodulation *J Int Neuromodulation Soc*. 2013 Feb;16(1):59–65; discussion 65–6.

[30] Hayek SM, Helm S, Benyamin RM, Singh V, Bryce DA, Smith HS. Effectiveness of spinal endoscopic adhesiolysis in post lumbar surgery syndrome: a systematic review. *Pain Physician.* 2009 Apr;12(2):419–35.

[31] Magalhães FN de O, Soares SC, Torres JM, Ungaretti A, Cacciacarro MF, Teixeira MJ, et al. Effects of ozone applied by spinal endoscopy in patients with chronic pain related to failed back surgery syndrome: a pilot study. *Neuropsychiatr Dis Treat.* 2013;9:1759–66.

[32] Koulousakis A, Kuchta J, Bayarassou A, Sturm V. Intrathecal opioids for intractable pain syndromes. *Acta Neurochir Suppl.* 2007;97(Pt 1):43–8.

[33] Osborne R, Joel S, Trew D, Slevin M. Morphine and metabolite behavior after different routes of morphine administration: demonstration of the importance of the active metabolite morphine-6-glucuronide. *Clin Pharmacol Ther.* 1990 Jan;47(1):12–9.

[34] Wahlström A, Winblad B, Bixo M, Rane A. Human brain metabolism of morphine and naloxone. *Pain.* 1988 Nov;35(2):121–7.

[35] Lara NA, Teixeira MJ, Fonoff ET. Long term intrathecal infusion of opiates for treatment of failed back surgery syndrome. *Acta Neurochir Suppl.* 2011;108:41–7.

[36] Kamran S, Wright BD. Complications of intrathecal drug delivery systems. *Neuromodulation J Int Neuromodulation Soc.* 2001 Jul;4(3):111–5.

In: Encyclopedia of Surgery (22 Volume Set)
Editors: Andreas Lehrer and Kristin Mueller
ISBN: 978-1-53618-329-0
© 2020 Nova Science Publishers, Inc.

Chapter 382

HEMODYNAMIC COMPLICATIONS ASSOCIATED WITH PRONE POSITIONING IN LUMBAR SPINAL SURGERY

Alessandra D'Ambrosi*, MD and Francesco Fedele†, PhD
Department of Cardiovascular Science "Sapienza" University of Rome, Rome, Italy

ABSTRACT

Prone positioning is required in operations such as spinal surgery. Changes in cardiac function in the prone position have been studied with various methodologies. Several studies have investigated changes in term of cardiovascular complications and hemodynamic abnormalities. The aim of this chapter is analyzed the pathophysiology, comorbidities and preventive methods of cardiovascular complication during spinal surgery. A literature review utilizing PubMed was performed identifying relevant articles that addressed cardiovascular complications associated with prone surgical positioning in spine surgery.

Keywords: spinal surgery, prone position, cardiovascular

INTRODUCTION

The neurosurgical procedures are often very long lead times. Some postoperative complications may be related to incorrect positioning. Patient positioning on the operating table is an important moment of perioperative nursing care. The importance of this procedure should never be underestimated because several factors as immobility, time of surgery and synergistic effect of mechanical pressure and anesthesia, may be cause of complications [1].

In particular, the prone surgical positioning is adopted in spine surgery and in some operations performed in the posterior fossa. The transition from supine to prone position is a very delicate phase and is associated with several important cardiovascular complications

* Corresponding Author's Email: alessandra.dambrosi@gmail.com.
† Corresponding Author's Email: francesco.fedele@uniroma1.it.

(e.g., Bradycardia and hypotension). In this positioning, the ECG monitoring and invasive pressure and check that there are no alterations or kinking of the endotracheal tube is very important.

METHODS

Pathophisiology

In prone position it is possible to find a reduced cardiac filling pressures with reductions in stroke volume in relation to any excessive lowering of the legs or femoral vein or the vena cava compression. The decrease in cardiac output seen on turning prone is considered to be a result of reduced stroke volume. The resulting decrease in arterial pressure is countered by a compensatory sympathetic tachycardia and an increase in peripheral resistance [2].

A decrease in pre-load is thought to be responsible for the reduced stroke volume that is seen. Many factors contribute to a decrease in pre-load and include [7]:

- caval compression;
- blood sequestration;
- increased intra-thoracic pressure with poor positioning and chest wall compression;
- positive pressure ventilation and PEEP.

Because of baseline postural hypotension and decreased cardiac function in the prone position, hypovolemia in the prone patient can exacerbate hypoperfusion to multiple organ systems and may increase the likelihood of acute kidney injury, especially during procedures with high blood loss [2, 3].

The abdomen should be free from crushing, so as not to congest the vertebral venous plexus through the anastomotic circle that connects them to the inferior vena cava, with increased intraoperative bleeding. The mechanical ventilation may be compromised by incorrect positioning in pronation, in fact, if the abdomen is compressed viscera push the diaphragm, resulting in an increase of the ventilation pressures (peak and plateau) resulting in increased risk of barotrauma and reduced venous return to increase central venous pressure. The positioning of cushioned under the shoulders and on the iliac crests, allow to obviate to these occurrences [2].

Table 1. Hemodynamic effects after prone positioning

BPm	↓
BPs	↓
HR	↑
Stoke Volume Index	↓
Cardiac Index	↓
Wedge Pressure	↓

Comorbidities

The history for heart failure or ischemic coronary disease represents the relative complication at prone positioning. Shimizu M et al. evaluated cardiac function in the supine and prone positions in 90 patients without atrial fibrillation who underwent (99m) Tc-tetrofosmin quantitative gated single-photon emission computed tomography. Three groups of 30 patients each were classified as "no history of myocardial ischemia or cardiomyopathy" (Group A), "history of myocardial infarction" (Group B), and "ischemic heart disease without myocardial infarction history" (Group C). Ejection fraction changes occurred only in Group B, and diastolic function changes occurred in Groups B and C, but not in Group A. The changes caused by prone positioning were more severe in the patients with low cardiac function [3].

The aorta injuries are rare during posterior spinal surgery, but can result in catastrophic complications. Qiu XS et al. analyzed that there are not prior studies that have used MRI images obtained with patients in the prone position for the purpose of systematically evaluating the potential risks of aorta injury due to thoracic pedicle screw misplacement (TPS). Qiu XS et al. evaluated the potential risks of aorta injury from thoracic pedicle screw (TPS) misplacement in right thoracic adolescent idiopathic scoliosis (RT-AIS) patients who are in the prone position. In conclusions prone positioning may increase the risk of aorta injury in RT-AIS patients, particularly at T5-T6 and T11 even if a left TPS just barely touches the anteriolateral or lateral cortex of the vertebrae [5].

The susceptibility to thromboembolism represents one of comorbidity in the prone positioning, however, can be easily prevented with the use of anticoagulants. Where there is a contraindication to the use of anticoagulants, you can place an Inferior Vena Cava (IVC) filter. Chalhoub V. et al. reported a case of a case of an IVC filter migration to the right ventricle occurring while a trauma patient was undergoing spinal surgery in the prone position. The prone position during surgery can induce anatomic and hemodynamic changes in the IVC. This may contribute to the migration of IVC filters. Careful handling and positioning of patients with IVC filters is recommended to avoid a sudden increase in IVC pressure that may predispose to IVC filter migration [8].

Prone positioning for spine surgery has also been associated with rare airway and vascular complications. Airway obstruction has also been reported in a patient with Duchenne muscular dystrophy and lordoscoliosis with concomitant airway malacia who underwent spine surgery in the prone position. Vascular complications including femoral artery ischemia and avascular necrosis of the femoral head are other rarely-described complications of prone positioning. Pressure on the arteries and inguinal area combined with reduced venous outflow and hypotension from anesthesia has been implicated in cases of avascular necrosis of the femoral head [9].

Preventing Cardiovascular Complications

A study using transoesophageal ECHO compared changes in hemodynamic and cardiac function after prone positioning using different prone positioners. Dharmavaram et al. measured cardiac index, stroke volume, and cardiac output in patients placed on the differing

supports. The effect on all cardiovascular parameters was seen with the Jackson table, whereas the cardiac index was decreased when prone on the Wilson table and the Andrews support (knee-chest position) [6, 7].

The jack-knife prone position has been shown to cause a decrease in cardiac index, a bradycardia, and raised mean arterial pressure that returned to supine values when the patients were placed in the Trendelenburg position.

Variabilities in pulse pressure and stroke volume are greater in the prone position, compared with the supine position, and both can be used to predict whether the anaesthetized ventilated prone patient will respond to a fluid challenge. Adequate fluid replacement reduced hypotension and hemodynamic instability after prone positioning. The Jackson spine table and longitudinal bolsters had minimal effects on cardiac function, and should be considered in patients with cardiac dysfunction.

CONCLUSION

Prone positioning complications associated with spine surgery can cause patient morbidity. These complications, careful patient positioning, efficient use of anesthesia time and avoidance of intraoperative hypotension may help reduce the incidence of prone positioning related complications.

REFERENCES

[1] Landi A, Corradetti E, Mancarella C, Delfini R. Prevention of complications related to patient prone positioning during spinal neurosurgical care: a nursing point of view. *J Spine Neurosurg* 2013, 2:2 http://dx.doi.org/10.4172/2325-9701.1000109.

[2] DePasse JM, Palumbo MA, Haque M, Eberson CP, Daniels AH1. Complications associated with prone positioning in elective spinal surgery. *World J Orthop*. 2015 Apr 18;6(3):351-9. doi: 10.5312/wjo. v6.i3.351.eCollection 2015.

[3] Shimizu M , Fujii H, Yamawake N, Nishizaki M. Cardiac function changes with switching from the supine to prone position: analysis by quantitative semiconductor gated single-photon emission computed tomography. *J Nucl Cardiol.* 2015 Apr;22(2): 301-7. doi:10.1007/s12350-014-0058-3. Epub 2015 Jan 23.

[4] Yang SY, Shim JK, Song Y, Seo SJ, Kwak YL. Validation of pulse pressure variation and corrected flow time as predictors of fluid responsiveness in patients in the prone position. *Br J Anaesth* 2013; 110: 713-20.

[5] Qiu XS1, Jiang H, Qian BP, Wang WJ, Zhu F, Zhu ZZ, Qiu Y. Influence of prone positioning on potential risk of aorta injury from pedicle screw misplacement in adolescent idiopathic scoliosis patients. *J Spinal Disord Tech.* 2014 Jul;27(5):E162-7. doi:10.1097/BSD.0000000000000075.

[6] Dharmavaram S, Jellish WS, Nockels RP et al. Effect of prone positioning systems on hemodynamic and cardiac function during lumbar spine surgery: an echocardiographic study. *Spine* 2006; 31: 1388-93.

[7] Birte Feix, PhD MB BChir FRCA Anaesthesia in the prone position *Oxford Journal* 2014.

[8] Chalhoub V, Tohmé J, Richa F, Dagher C, Yazbeck P. Inferior vena cava filter migration during prone position during the prone position for spinal surgery: a case report. *Can J Anaesth*. 2015 Oct;62(10):1114-8. doi:10.1007/s12630-015-0438-4. Epub 2015 Aug 4.

[9] Yang JH, Bhandarkar AW, Lim BG, Modi HN, Suh SW. Intraoperative airway obstruction in a Duchenne muscular dystrophy patient. *Eur Spine J* 2013; 22 Suppl 3: S491-S496 [PMID: 23503897 DOI: 10.1007/s00586-013-2696-6].

In: Encyclopedia of Surgery (22 Volume Set)
Editors: Andreas Lehrer and Kristin Mueller
ISBN: 978-1-53618-329-0
© 2020 Nova Science Publishers, Inc.

Chapter 383

OPEN SURGERY IN THE OSTEOPOROTIC SPINE

Demo Eugenio Dugoni, MD
Department of Neurology and Psychiatry, Neurosurgery,
"Sapienza" University of Rome, Italy

ABSTRACT

Open surgery in the osteoporotic spine is a great challenge. The poor quality of the bone, the age of the patients and comorbidity make surgical strategy very difficult. Open surgery is the only possible treatment in case of neurological symptomps due to spinal stenosis secondary to vertebral compression fracture and subsequent deformity. When the treatment is open surgery, the main difficult is the failure of the implant. Over the years, very different technique has been developed in order to reduce the risk of this complication. To date the best strategy seems to be multiple points fixation with vertebral body augmentation. It is very important to choose the length of the instrumentation respecting the biomechanic of the spine avoiding excessive corrections. Vertebroplasty and kyphopalsty are the important tools to increase the strenght of the bone. Different kinds of pedicle screws are today available in order to increase the risck of pullout.

Keywords: osteoporosis, compression fractures, open surgery, vertebral body augmentation

INTRODUCTION

Osteoporosis is a pathological condition predisposing to the occurrence of fractures through the decreased bone strength. In the United States, 10 million people suffer from osteoporosis, and an additional 34% of people (including more than 55% of the population over age 50) is at risk of developing osteoporosis. 700,000 vertebral compression fractures occur among this group of people affected by osteoporosis. A vertebral compression fracture occurs in about 25% of American women who reach menopause. Although osteoporosis considered a disease of the female gender, 33% of men over the age of 75 are affected by this pathology. It represents, in the elderly population, a significant cause of mortality and morbidity. In spinal pathology osteoporosis is an important condition predisposing to the

development of progressive deformities potentially cause of neurological disability. A compression fracture, in an osteoporotic patient, may produce several changes in local and global structure of the spine such as kyphosis, secondary stenosis to deformity and sagittal imbalance. The main symptom in the early stage of an osteoporotic vertebral collapse is pain. About one third of patients with a vertebral osteoporotic fracture continues to complain of pain despite medical therapy. Similarly, the several different medical treatments with calcium, vitamin D, bisphosphonates, raloxifene, hormone therapy, although very effective, not completely protect patients from the risk of an osteoporotic vertebral fracture, which occurs in about 15% of clients in treatment. In addition, there are the patients non-responders and non-compliants. The number of elderly patients with severe osteoporosis observed by the spinal surgeon is increasing. Surgical treatment of these patients has some peculiar difficulties. In the presence of neurological deficits, the only possible treatment is spinal decompression and stabilization but the procedure, in particular if performed with pedicle screws, has a very high risk of failure because of the loss of bone strength.

PHYSIOPATHOLOGY

Osteoporosis is a disease characterized by a decrease in bone mass which leads to a reduction of the structural support capacity of the spine. Primary osteoporosis is classified into two types: type 1 affects women in post-menopausal age and type 2 affects individuals over 70 years old and configure as a bone loss associated with aging. Secondary osteoporosis is defined as the reduction in bone mass due to pathological or iatrogenic conditions such as endocrine disorders, chronic inflammatory conditions or prolonged corticosteroid therapy. Primary osteoporosis can be further framed as osteoporosis with high turnover in which the excessive osteoclast activity is not balanced by the osteoblasts activity, resulting in bone loss (osteoporosis type 1 primary, post-menopausal); osteoporosis with low turnover in which osteoblastic activity decreases progressively (type 2 osteoporosis, aging). This classification of the pathology allowed to establish therapeutic protocols more and more specific and tailored.

Figure 1. Multiple osteoporotic non-traumatic fractures (CT scan).

DIAGNOSIS

Only one non-traumatic spinal fracture can be significant for diagnosis of osteoporosis (Figure 1). The National Osteoporosis Foundation determined that a non-traumatic spinal fracture is compatible with the diagnosis of osteoporosis and constitutes a valid indication for introducing a medical treatment in order to prevent further vertebral collapses.

PRINCIPLES OF TREATMENT IN OPEN SURGERY

Very different spinal pathological conditions may affect the osteoporotic spine. They consist mainly of: acute and subacute single or multiple fractures, permanent spinal instability, postural abnormalities and sagittal imbalance, spinal stenosis and/or radicular due to deformity. In presence of neurological symptoms, caused by spinal cord or radicular compression, open surgery is the only treatment able to solve the symptomatology. No percutaneous treatment is indicated for the resolution of neurological symptoms. In presence of deformity and in case of severe osteoporosis, the only open decompression is not the treatment of choice, because of the risk of further progression of the deformity and the consequent non-resolution of the symptoms. For these reasons stabilization and fusion with pedicle screws is often necessary. However, in case of severe osteoporosis, the risk of implant failure and new fractures of adjacent segments is very high. Bone quality is a crucial question when you practice a stabilization with pedicle screws and, in cases of severely osteoporotic spine, the overall failure rate of the implants reaches 12%. A further problem is that osteoporotic patients may be very old and affected by different pathologies and for this reason, hardly amenable to surgery. Several studies have analyzed the reasons for such a high failure rate of surgical treatment, seeking the causes and proposing solutions. The most frequent complications were divided into early: pull-out of the pedicle screws and pedicle fractures of stabilized levels and delayed: degeneration of adjacent segments and pseudoartrosis. In particular, non-fusion occurs because the excessive osteoclast activity, in the osteoporotic patient, leading to a delay in the fusion. In this way the system undergoes too prolonged stresses over time, waiting for the fusion, greatly increasing the chances of failure. These problems concern the whole instrumented surgery. It is very important to know that, in the osteoporotic patient, revision surgery, performed in case of implant failure, presents even greater difficulties than the first surgery.

SURGICAL TREATMENT

Internal Fixation – Points of Fixation

The multiple points of fixation is a valuable strategy in case of patients with severe osteoporosis. In presence of kyphosis is recommended three levels cranial and three levels caudal fixation from the center of the deformity. It is mandatory never stop the fixation inside the kyphotic segment of the spine because the sagittal imbalance would overload the implant and would produce excessive stress in a bone with very low mineral density, leading

unavoidably to failure. For this reason, it is very important that: the apex point of fixation of each implant should be below the dorsal kyphosis or at the beginning of the thoracic kyphotic curve, at the level of the first dorsal vertebrae. Regarding the low lumbar spine stabilization, several authors recommend the extension of the construct at the level of the sacrum and the ileum, in order to reduce the risk of failure of the implant. In case of severe deformity, we should not look for the ideal correction of the deformity, as in non-osteoporotic patient, in order to reduce the stress on the system. Multiple points fixation may be performed with some different instrumentations: hooks, sublaminar wires and, more frequently, with pedicle screws. Such techniques can be combined; several studies in the literature demonstrate how the combination of hooks or sublaminar wires with pedicle screws, increase the pullout resistance of the screws up to the 100%. Similarly, the use of the cement is a valid option in order to increase the pullout resistance of the pedicle screws. Under clinical view there is no difference between the use of hooks/wires or the cement. However, under a biomechanical point of view, the cement would seem to increase the stress on the implant during rotation while hooks/wires during the translation.

Pedicle Screws Fixation and Augmentation Tecnhiques

The insertion of cement to increase the strength of the pedicle screws inside the osteoporotic bone, is a very well described technique in the literature (Figure 2). However, the debate on the best strategy of the pedicle screws augmentation is still open. Probably, the combination of cemented pedicle screws and hooks or wires (to protect the adjacent segments) is today the best technique. Some authors state that is not possible to perform a very long fixation using the cement for each level, as in case of severe deformity, where it is possible to cement only the apical screws of the construct. The most widely used material is the polymethylmethacrylate (PMMA); other possibilities are bioactive ceramics and calcium phosphate. Several studies demonstrate that vertebral body augmentation by PMMA or other material, increase the pullout resistance of the screw (from 119% to 250%), in case of first surgery and/or revision.

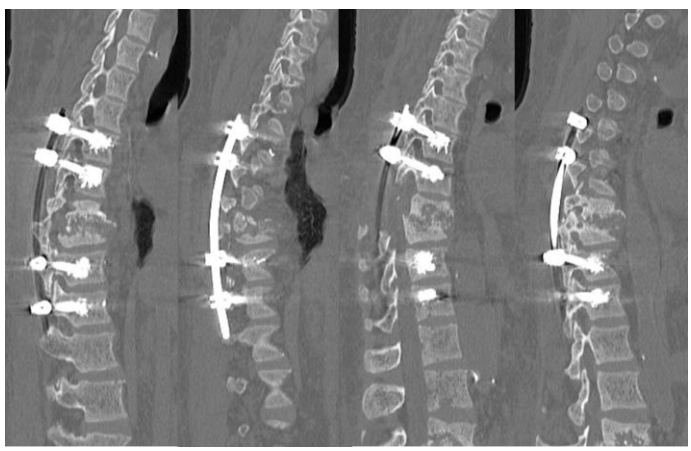

Figure 2. Cemented fenestrated pedicle screws (xray).

Vertebropalsty may be also very useful to cement the adjacent vertebrae to the implant, in order to reduce the risk of junctional fractures. This procedure can be also performed after open surgery as a second percutaneous step. Some authors describe the vertebral body augmentation by kyphoplasty. Burval shows the superiority of this technique compared to the insertion of the cement through the pedicle screw. The main trouble in the vertebral body augmentation with cement is the difficult to remove and replace the implant in case of infection or any other complication.

Pedicle Screws

In case of severe osteoporosis, it is very important to choose the screws with the maximum allowed diameter. It has been demonstrated that screws with diameter greater than 7 mm reduce the risk of pullout. However, because of the poor quality of the bone, it is very easy to break the pedicle during screw insertion. This complication occurs in a percentage from 24% to 40% of cases. In order to solve this problem, Cook created the expandable screws. This screw keeps its diameter inside the pedicle and expands inside the vertebral body. However, in case of very elderly patients with severe osteoporosis, the strength of the screws is inevitably compromise by the bad quality of the bone, mainly in case of compression fractures.

One other typology of screw, available today, is the fenestrated screw with dual and quad thread. This screw has some peculiar proprieties very useful in case of severe osteoporosis. In particular, the characteristics of the thread double the number of contact points with the cortical wall of the pedicle, increases the resistance with axial pullout forces. The presence of fenestration only in the distal portion of the screw, allows for cement injection directly into the vertebral body and ensures that the cement does not flow back into the pedicle. The peculiarities of this screw allow to avoid the use of oversized screws that increase the risk of pedicle fractures.

REFERENCES

Brantley AG, Mayfield JK, Koeneman JB, et al. The effects of pedicle screw fit. An in vitro study. *Spine* 1994;19:1752.

Burkus JK, Foley K, Haid R, et al. Radiographic assessment of interbody fusion devices: Fusion criteria for anterior interbody surgery. *Neurosurg Focus* 2001;10:1.

Burval DJ, McLain RF, Milks R, et al. Primary pedicle screw augmentation in osteoporotic lumbar vertebrae: Biomechanical analysis of pedicle fixation strength. *Spine* 2007;32:1077.

Childers JC Jr. Cardiovascular collapse and death during vertebroplasty. *Radiology* 2003;228:902.

Coe JD, Warden KE, Herzig MA, et al. Influence of bone mineral density on the fixation of thoracolumbar implants. A comparative study of transpedicular screws, laminar hooks, and spinous process wires. *Spine* 1990;15:902.

Cook SD, Barbera J, Rubi M, et al. Lumbosacral fixation using expandable pedicle screws: An alternative in reoperation and osteoporosis. *Spine J* 2001;1:109.

Cook SD, Salkeld SL, Whitecloud TS, et al. Biomechanical evaluation and preliminary clinical experience with an expansive pedicle screw design. *J Spinal Disord* 2000;13:230.

Frankel BM, Jones T, Wang C. Segmental polymethylmethacrylate-augmented pedicle screw fixation in patients with bone softening caused by osteoporosis and metastatic tumor involvement: A clinical evaluation. *Neurosurgery* 2007; 61:531.

Garfin SR, Yuan HA, Reiley MA. New technologies in spine: Kyphoplasty and vertebroplasty for the treatment of painful osteoporotic compression fractures. *Spine* 2001;26:1511.

Grados F, Depriester C, Cayrolle G, et al. Long-term observations of vertebral osteoporotic fractures treated by percutaneous vertebroplasty. *Rheumatology* 2000;39:1410.

Halvorson TL, Kelley LA, Thomas KA, et al. Effects of bone mineral density on pedicle screw fixation. *Spine* 1994;21:2415.

Harrington KD. Major neurologic complications following percutaneous vertebroplasty with polymethylmethacrylate: A case report. *J Bone Joint* Surg Am 2001;83:1070

Hilibrand AS, Moore DC, Graziano GP. The role of pediculolaminar fixation in compromised pedicle bone. *Spine* 1996; 21:445.

Jang JS, Lee SH, Jung SK. Pulmonary embolism of polymethylmethacrylate after percutaneous vertebroplasty: A report of three cases. *Spine* 2002;27:416.

Law M, Tencer AF, Anderson PA. Caudo-cephalad loading of pedicle screws: Mechanisms of loosening and methods of augmentation. *Spine* 1993;18:2438.

Lee BJ, Lee SR, Yoo TY. Paraplegia as a complication of percutaneous vertebroplasty with polymethylmethacrylate: A case report. *Spine* 2002;27:419.

Lei W,WuZX. Biomechanical evaluation of an expansive pedicle screw in calf vertebrae. *Eur Spine J* 2006;15:321.

Lonstein JE, Denis F, Perra JH, et al. Complications associated with pedicle screws. *J Bone Joint Surg Am* 1999;81:1519.

Maestretti G, Cremer C, Otten P, et al. Prospective study of standalone balloon kyphoplasty with calcium phosphate cement augmentation in traumatic fractures. *Eur Spine J* 2007;16:601.

Mathis JM, Wong W. Percutaneous vertebroplasty: Technical considerations. *J Vasc Interv Radiol* 2003;14:953.

Moore DC, Maitra RS, Farjo LA, et al. Restoration of pedicle screw fixation with an in situ setting calcium phosphate cement. *Spine* 1997;22:1696.

Okuyama K, Abe E, Suzuki T, et al. Influence of bone mineral density on pedicle screw fixation: A study of pedicle screw fixation augmenting posterior lumbar interbody fusion in elderly patients. *Spine J* 2001;1:402.

Padovani B, Kasriel O, Brunner P, et al. Pulmonary embolism caused by acrylic cement: A rare complication of percutaneous vertebroplasty. *Am J Neuroradiol* 1999;20:375.

Patel V, Issever AS, Burghardt A. Micro CT evaluation of normal and osteoarthritic bone structure in human knee specimens. *J Orthop Res* 2003;21:6.

Pfeifer BA, Krag MH, Johnson C. Repair of failed transpedicle screw fixation.A biomechanical study comparing polymethylmethacrylate, milled bone, and matchstick bone reconstruction. *Spine* 1994;19:350.

Polly DW, Orchowski JR, Ellenbogen RG. Revision pedicle screws: Bigger, longer shims-what is best? *Spine* 1998;12:1374.

Ratliff J, Nguyen T, Heiss J. Root and spinal cord compression from methylmethacrylate vertebroplasty. *Spine* 2001;26:300.

Sapkas GS, Papadakis SA, Stathakopoulos DP, et al. Evaluation of pedicle screw position in thoracic and lumbar fixation using plain radiographs and computed tomography. A prospective study of 35 patients. *Spine* 1999;24:1926.

Sarzier JS, Evans AJ, Cahill DW. Increased pedicle screw pullout strength with vertebroplasty augmentation in osteoporotic spines. *Neurosurg* 2002;96(3 Suppl):309.

Schmidt R, CakirB,Mattes T, et al. Cement leakage during vertebroplasty:An underestimated problem? *Eur Spine J* 2005;14:466.

Scroop R, Eskridge J, Britz GW. Paradoxical cerebral arterial embolization of cement during intraoperative vertebroplasty: Case report. *Am J Neuroradiol* 2002;23:868.

Shapiro S, Abel T, Purvines S. Surgical removal of epidural and intradural polymethylmethacrylate extravasation complicating percutaneous vertebroplasty for an osteoporotic lumbar compression fracture. *J Neurosurg* 2003;98:90.

Skinner R, Maybee J, Transfeldt E, et al. Experimental pullout testing and comparison of variables in transpedicular screw fixation. A biomechanical study. *Spine* 1990;15:195.

Soshi S, Shiba R, Kondo H, et al. An experimental study on transpedicular screw fixation in relation to osteoporosis of the lumbar spine. *Spine* 1991;16:1335.

Taylor RS, Taylor RJ, Fritzell P. Balloon kyphoplasty and vertebroplasty for vertebral compression fractures: A comparative systematic review of efficacy and safety. *Spine* 2006;31:2747.

Watts NB, Harris ST, Genant HK. Treatment of painful osteoporotic vertebral fractures with percutaneous vertebroplasty or kyphoplasty. *Osteoporos Int* 2001;12:429.

Wittenberg RH, Lee KS, Shea M, et al. Effect of screw diameter, insertion technique, and bone cement augmentation of pedicular screw fixation strength. *Clin Orthop Relat Res* 1993;296:278.

Yerby SA, Toh E, McLain RF. Revision of failed pedicle screws using hydroxyapatite cement. A biomechanical analysis. *Spine* 1998;23:1657.

Zindrick MR, Wiltse LL, Widell EH, et al. A biomechanical study of intrapeduncular screw fixation in the lumbosacral spine. *Clin Orthop Relat Res* 1986;203:99.

In: Encyclopedia of Surgery (22 Volume Set)
Editors: Andreas Lehrer and Kristin Mueller
ISBN: 978-1-53618-329-0
© 2020 Nova Science Publishers, Inc.

Chapter 384

PRINCIPLES OF FRACTURE FIXATION IN ORTHOPAEDIC TRAUMA SURGERY

Wasim Khan[1,*], Mamun Al-Rashid[2] and Kishan Vemulapalli[2]
[1]University College London Institute of Orthopaedic and Musculoskeletal Sciences,
Royal National Orthopaedic Hospital, Stanmore, Middlesex, UK
[2]Barking, Havering and Redbridge NHS Trust, Queen's Hospital,
Rom Valley Way, Romford, Essex, UK

ABSTRACT

Fractures are common injuries, and their management has evolved over the last 30 years with a greater propensity to treat fractures surgically. There have also been accompanying advances with a better understanding of the principles of bone healing and their implications on implant choice. The purpose of this chapter is to highlight the various surgical fixation devices available for the management of fractures and their underlying principles.

Keywords: fracture, healing, fixation, devices

INTRODUCTION

This chapter deals with the principles of fracture fixation in trauma and orthopaedics (Al-Rashid et al. 2010). Fractures are common injuries with an incidence of 3.6 fractures per 100 people per year. The lifetime fracture prevalence exceeds 50% in middle-aged men, and 40% in women over the age of 75 years (Donaldson et al. 2008). The management of fractures takes up the more time and resources in emergency theatres than any other type of injury (Tambe et al. 2005). This chapter aims to describe the principles of successful fracture management and how fractures heal. This is followed by a description of commonly used implants used for fracture repair and the biomechanical principles that guide their use.

* Corresponding Author's Email: wasimkhan@doctors.org.uk; Fax: +44 (0) 1707 655059.

SUCCESSFUL FRACTURE MANAGEMENT

Successful fracture management aims to achieve early fracture union without significant complications. It is important to restore patients to a pre-fracture level of function. Fractures need to be reduced to a satisfactory position if they are displaced significantly. Following this the fractures need to be held or stabilised in a satisfactory position to allow fracture healing. In most cases, fracture stabilisation could be achieved using non-operative measures e.g. plaster casts, slings or straps. In some cases however surgical fixation or prolonged periods of traction is needed to stabilise a fracture till union is achieved.

Surgical fixation of fracture fragments can give sufficient stability permitting immediate joint movement, earlier weight-bearing, shorter hospital stay and early return to work and other activities. Early active pain-free mobilisation enhances articular cartilage nutrition by the synovial fluid. It also allows a rapid return of normal blood supply to bone and soft tissues. Early weight-bearing decreases post-traumatic osteoporosis by restoring the equilibrium between bone resorption and bone formation. Surgical fixation prevents many of the disastrous sequelea associated with non-operative management of fractures with traction and its associated prolonged periods of immobility including pressure sores, infections and deep vein thromboses. It is these principles and findings that have shaped fracture fixation surgery over the last 30 years and seen a shift from non-operative management of these fractures to a greater propensity for surgical fixation (Broos & Sermon 2004). This has been promoted by a higher patient expectation and a desire for earlier return to activities of daily living, and facilitated by the design of better surgical devices for fracture fixation.

BONE HEALING

Depending on the biological and mechanical environment, potentially contributed to by the surgical fixation devices, bone can heal in two ways (Rahn 1987). The first is indirect bone healing, afforded by relative stability of the fixation device. This begins with haematoma and inflammation followed by callus formation that remodels into woven or lamellar bone. This is achieved by any device which holds the bone sufficiently to maintain length and prevent rotation and angular deformity, but still allowing a low level of displacement or micro-movement between fracture fragments thus providing a mechanical signal that stimulates the biological repair processes. Gross motion between fracture fragments leads to non-union and fibrocartilage tissue formation and should be avoided. Examples of fixation devices that provide relatively stable fixation include locked intra-medullary nails, plates used as bridging plates and external fixators as discussed below.

The second method is direct bone healing, and is facilitated in an environment of absolute stability provided by the fixation device. This results from internal remodelling that bypasses callus formation and allows contact healing between two vascular bone surfaces. This can be achieved by a device that prevents fracture surfaces displacing under physiological load. This requires anatomical reduction and inter-fragmentary compression. Inter-fragmentary compression is best achieved by a lag screw, or for large, dense bones, compression plate fixation as discussed below. The design and use of various surgical fixation devices relies on an understanding of bone healing and the loads and forces they are subjected to.

DIFFERENT IMPLANTS USED IN FRACTURE FIXATION SURGERY

Fractures vary in their pattern, and bones vary in their size, structure and strength. As a result, a wide variety of fixation devices has been developed and continues to be developed. More recent implants are made of biocompatible materials and have a low profile resulting in reduced rates of soft tissue irritation. They can also be contoured to suit individual anatomy. The successful application of these fixation devices lies in a thorough understanding of the individual fracture personality, its biology and the underpinning biomechanics of the fixation device.

In addition to the understanding of how the mechanical environment of fracture fixation shapes fracture healing, it is crucial to recognise how the type of implant affects the biology of the fracture healing. It is thought that adequate blood supply to bony fragments of the fracture through the soft tissues is of utmost importance for fracture healing to progress (Rüedi & Murphy 2000). Hence any fracture fixation surgery which further violates this blood supply in already tenuous devascularised bony fragments will adversely affect healing. This is one of the main reasons why external fixation is preferred where there is significant soft tissue damage, rather than internal fixation and its associated soft tissue dissection.

Any fixation device used in trauma surgery must be biologically inert, and not give rise to toxic reactions or local inflammatory changes (Gotman 1997). It is also important to avoid any electrolytic degradation and corrosion by avoiding implant of different materials at the same site. Metals currently used include stainless steel (316L), alloys of chromium, cobalt and molybdenum, and titanium (Ti-6Al-4V). Corrosion resistance of these materials relies on their passivation by a thin surface layer of oxide. Stainless steel is the least corrosion resistant and less inert, but easier to machine and cheaper. The cobalt chrome alloys are biologically very inert but are difficult to machine adding to their cost. Titanium has the favourable combination of high strength, light weight, high fatigue strength and low modulus of elasticity, and is biomechanically closer to bone than 316L stainless steel. This allows production of thinner plates and stronger intra-medullary nails.

More recently there has been interest in the use of biodegradable polymers e.g. polylactic acid (Hughes 2006). These have the advantage of being more flexible resulting in greater weight-bearing by the bone thus avoiding stress shielding, and they do not need to be removed. Their disadvantages include limited strength and risk of adverse biological response, and these have hindered the more widespread use of these materials.

Numerous devices are available for the fixation of fractures and these include wires, pins, screws, plates, intra-medullary nails and external fixators (Malik et al. 2009, Khan et al. 2010, Dheerendra et al. 2011, Haughton et al. 2012).

1. Pins

There is a variety of pins used in trauma surgery for the fixation of fractures (Kurup et al. 2008, Yosri et al. 2012). The pins may be smooth or threaded, and are available in a number of sizes. Threaded pins provide additional stability, as they minimise sliding of bone fragments, but are also more difficult to take out. Among the most commonly used are Kirschner wires, commonly called K-wires, and Steinman pins.

K-wires can be used to hold fragments of bone prior to rigid fixation, and for percutaneous pinning of small bone fractures. They are commonly used in hand and wrist fractures (Malik et al. 2009). At least two wires should be used and they should not be parallel (Figure 1).

Figure 1. Antero-posterior and lateral radiograph of a distal radial fracture at the wrist stabilised with two Kirschner wires and a back-slab plaster.

They lack sufficient mechanical stability for use as the primary fixation device in long weight bearing bones. Steinman pins, are commonly used to apply skeletal traction, and are attached to traction devices.

2. Wires

In combination with pins or screws, wires can be used to create a tension band that converts distractive muscular forces to compressive forces at the fracture site. Wires are frequently used for the fixation of olecranon (Figure 2) and patella fractures. They are also used to reattach bone fragments e.g. greater trochanter or olecranon after elective osteotomies (Nork et al. 2001). The use of tension band wires requires tightening to achieve equal tension, and this can result in wire breakage or cut-through of bone. Many companies now manufacture wire tensioning and twisting instruments. The use of wires also relies on the making of holes for passing the wires that can be associated with complications. Wires in the form of cerclage wires, are also used to deal with periprosthetic fractures, for fixation of bone fragments and plate onto bone.

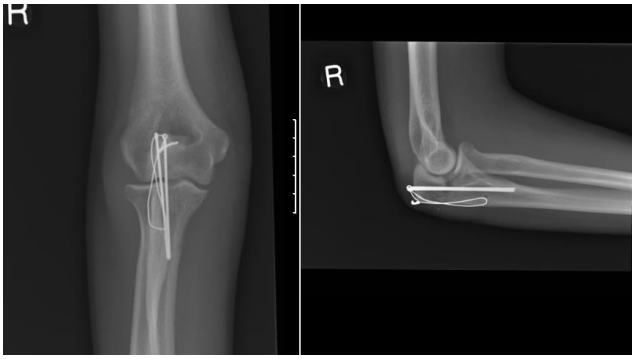

Figure 2. Antero-posterior and lateral radiograph of an olecranon fracture at the elbow fixed with tension band wiring.

3. Screws

A variety of screws are used in trauma surgery (Mudgal & Jupiter 2006). It is a device which converts rotational or torsional forces to compressive forces. Screws can be cancellous or cortical, self tapping or non-tapping, partial or fully threaded, locking or non-locking. They can be of different sizes from 1.5mm to 8.0 mm, based on the site of their application. The screw essentially consists of the screw head, the bulbous end and the part engaged by the screwdriver, and the shank or core, which can be of variable diameter and sizes. The distance between the threads is called the pitch. The factors that affect the holding power of the screw are its outer thread diameter, thread configuration and thread length. The choice of screw depends on the type of bone, fracture configuration, associated implant used and surgeon's preference.

They can be used in isolation to hold two fragments of bone together. If screws are used in isolation, an attempt should be made to insert them perpendicular to the fracture line to avoid shear forces (Figure 3). If the fixation relies on the lag principle, the hole in the proximal bone fragment is over-drilled to avoid engagement of the threads and this allows compression between the distal fragment engaging the screw threads and the screw head on the proximal fragment. Screws are commonly used in combination with plates (Figure 4) and nails or rods (Figure 5). Screw can be inserted using a torque screwdriver that allows a controlled and constant force to be applied.

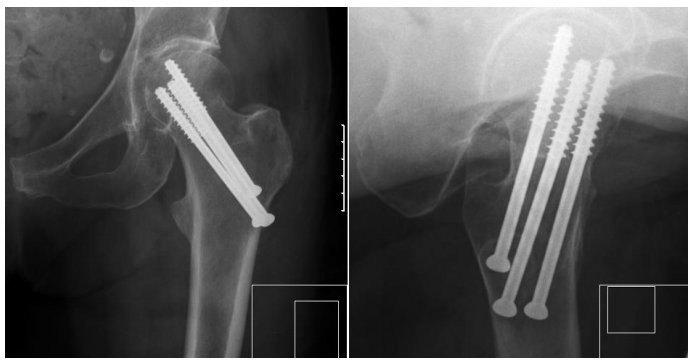

Figure 3. Antero-posterior and lateral radiograph of an intra-capsular fracture of the hip fixed with three cannulated screws.

Figure 4. Antero-posterior and lateral radiograph of a radial and ulnar fracture of the forearm fixed with plates and screws.

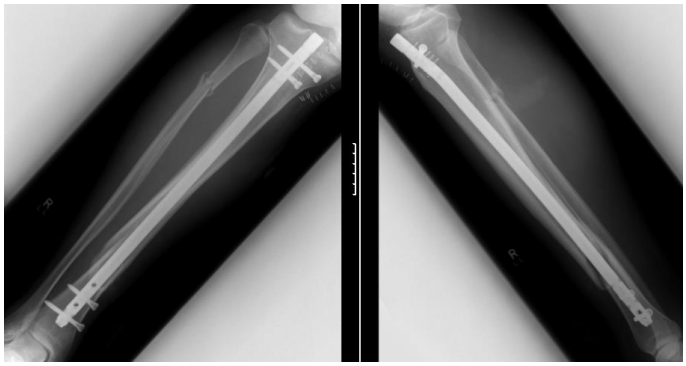

Figure 5. Antero-posterior and lateral radiograph of a tibial fracture of the lower leg fixed with an intra-medullary nail and locked with proximal and distal screws for rotary and axial stability.

4. Plates

Plates have screw holes that are counter-sunk to avoid prominence of the screw head. A variety of plates is available that can be used for fracture fixation to provide both relative stability and absolute stability (Egol et al. 2004). The way a plate is used determines its mechanical function. In the neutralisation mode, the plate functions to reduce the forces on an inter-fragmentary compression or lag screw. In the buttress mode, the plate acts to support the fracture fragment preventing displacement from forces. Plates can be used as bridging plates to span gaps where bone has been lost due to trauma or disease. In the compression mode, the screws are inserted offset from the centre and on tightening the bone fragments move closer together providing inter-fragmentary compression. Locking plates have threaded holes for the screw head to engage in and provide more durable fixation that is better for osteoporotic bone (Cornell et al. 2003). These locking plate systems avoid the need for bicortical fixation. The majority of these plates are made of stainless steel or titanium.

A plate is considered to provide relative stability if it allows appreciable inter-fragmentary movement under functional load. Fracture healing under conditions of relative stability takes place by callus formation. Bridging of the fracture with a stiff splint reduces mobility of the fracture fragments, which allows minimal displacement under functional load. A plate that provides rigid fixation, e.g. with inter-fragmentary compression, provides absolute stability of the fracture fragments diminishes the strain at the fracture site and allows direct healing without callus formation.

Rigid fracture fixation with plates and screws still has an important place and is desirable for fractures that involve an articular surface. Articular fractures require exact anatomic reduction and stable fixation to avoid development of abundant callus. This is important because incongruity of the joint surface and presence of callus formation at the articular surface lead to patient discomfort and often development of early and progressive osteoarthritis (Dirschl et al. 2004).

The use of plates does rely on a significant exposure that can compromise blood supply that is already disrupted from the fracture and possible associated soft tissue injury. If a plate is in total contact with a bone surface, it can act like a plug and stop radial perfusion, leading to necrosis of the bone. If the bone plate contact is reduced, as is increasingly the case with

the newly developed plates, there will be less disruption to this radial perfusion of the bony fragment (Miclau & Martin 1997).

5. Intra-Medullary Nails

Intra-medullary devices act as an internal splint to stabilise long bone fractures (Hohaus et al. 2008) as shown in Figure 5. They neutralise varus and valgus forces, and allow axial compression. This can result in shortening in comminuted fracture if the nail is not locked. The locking option of a nail allows better rotational control. Nails can be solid or hollow, slotted or non-slotted. Solid nails are stiffer in bending, although these properties may be altered by changing the wall thickness. Reaming of bone allows better fixation of the nail and improves the transfer of load from the bone to the nail and stability (Pape & Giannoudis 2007). Slotted nails have less torsional stiffness than non-slotted ones.

Stiffness and strength are related to the diameter of the nail, and the strength of a nail determines its resistance to fatigue failure. The bending rigidity of the nail is proportional to the radius to the fourth power thus one large nail is stiffer than multiple smaller nails.

6. External Fixation

Another method of fracture stabilisation is with an external fixation (Ziran et al. 2008) as shown in Figure 6. This involves percutaneously placed transosseus pins and/or wires secured to external scaffolding in the form of bars and rings providing support and stabilising a fractured bone. There are a large number of variables that determine the stability provided by the external fixator construct and these include the number, location and diameter of the pins and connecting rods as well as the orientation of the construct.

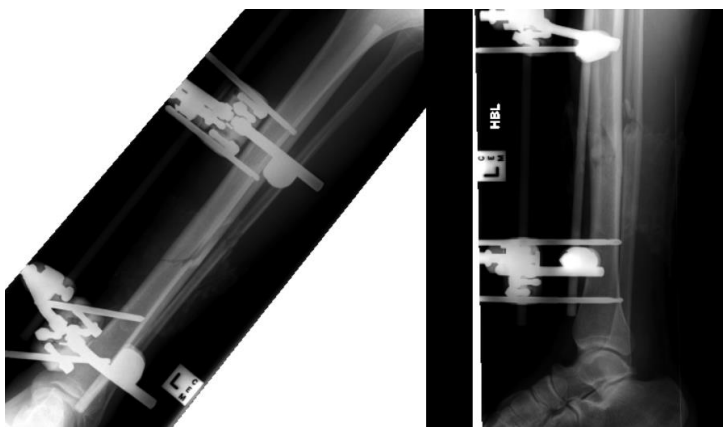

Figure 6. Antero-posterior and lateral radiograph of a tibial fracture of the lower leg fixed with an external-fixator.

External fixators cause less disruption to the soft tissues, and better preserve the blood supply to bone and periosteum (Claes et al. 1999). This makes fixators a useful tool in open fractures enabling satisfactory soft tissue management in the acute trauma setting with skin

contusions and open wounds. They are also useful in peri-articular fractures as they allow restoration of the articular surface by ligamentotaxis and early mobilisation (Khan & Fahmy 2006, Bhamra et al. 2012). One major complication with the use external fixators is associated pin site infections. External fixators have a wide scope of use in trauma surgery as quick, life saving temporary fracture stabilisation devices in the multiple trauma patients.

CONCLUSION

Fractures are common injuries and there has been a greater trend over the last few years from non-operative management with traction to early surgical fixation. There are a number of fracture fixation devices available for the fixation of fractures and these devices could be used in a number of different ways depending on the nature of the fracture and associated injuries. Bone can heal in two ways; the first is indirect bone healing afforded by relative stability of locked intra-medullary nails, bridging plates and external fixators. The second method of bone healing is direct bone healing, and is facilitated in an environment of absolute stability provided by lag screws and compression plating.

REFERENCES

Al-Rashid M, Khan WS, Vermulapali K (2010). Principles of Fracture Fixation in Orthopaedic Trauma Surgery. *J. Perioper. Pract.* 20(3): 113-7.

Bhamra JS, Khan WS, Pastides P (2012). The use of the S-Quattro dynamic external fixator for the treatment of intra-articular phalangeal fractures: a review of the literature. *Open. Orthop. J*. 6(1): 54-59.

Broos PL, Sermon A 2004 From unstable internal fixation to biological osteosynthesis. A historical overview of operative fracture treatment. *Acta. Chirurgica Belgica* 104 396-400.

Claes L, Heitemeyer U, Krischak G, Braun H, Hierholzer G 1999 Fixation technique influences osteogenesis of comminuted fractures. *Clinical Orthopaedics & Related Research* 365 221-229.

Cornell CN, Lane JM, Poynton AR 2003 Orthopedic management of vertebral and long bone fractures in patients with osteoporosis. *Clinics in Geriatric Medicine* 19 433-455.

Dheerendra S, Khan WS, Barber J, Goddard N, Ahrens P (2011). Outcomes of locking plates in proximal humeral fractures: a systematic review. *Shoulder & Elbow*. 3: 74-84.

Dirschl DR, Marsh JL, Buckwalter JA et al. 2004 Articular fractures. *Journal of American Academy of Orthopaedic Surgeons* 12 416-423.

Donaldson LJ, Reckless IP, Scholes S, Mindell JS, Shelton NJ 2008 The epidemiology of fractures in England. *Journal of Epidemiology & Community Health* 62 174-180.

Egol KA, Kubiak EN, Fulkerson E, Kummer FJ, Koval KJ 2004 Biomechanics of locked plates and screws. *Journal of Orthopaedic Trauma* 18 488-493.

Gotman I 1997 Characteristics of metals used in implants. *Journal of Endourology* 11 383-389.

Haughton DN, Jordan D, Malahias M, Hindocha S, Khan WS (2012). Principles of hand fracture management. *Open Orthop*. J. 6(1): 43-53.

Hohaus T, Bula P, Bonnaire F 2008 Intramedullary osteosynthesis in the treatment of lower extremity fractures. *Acta Chirurgiae Orthopaedicae et Traumatologiae Cechoslovaca* 75 52-60.

Hughes TB 2006 Bioabsorbable implants in the treatment of hand fractures: an update. *Clinical Orthopaedics & Related Research* 445 169-174.

Khan WS, Fahmy NRM 2006 The S-Quattro in the management of intra-articular fractures of the fingers. *Journal of Hand Surgery* 31B 79-92.

Khan WS, Oragui E, Akagha E (2010). Common Fractures and Injuries of the Ankle and Foot: Functional Anatomy, Imaging, Classification and Management. *J. Perioper Pract*. 20(7): 249-58.

Kurup HV, Mandalia VM, Shaju KA, Singh B, Beaumont AR 2008 Late collapse of distal radius fractures after K-wire removal: is it significant? *Journal of Orthopaedic Traumatology* 9 69-72.

Malik AA, Yousaf N, Khan WS, Ihsan M, Ravenscroft M 2009 Common fractures of the wrist and hand, and their management. *Journal of Perioperative Practice* (in press).

Miclau T, Martin RE 1997 The evolution of modern plate osteosynthesis. *Injury* 28 3-6.

Mudgal CS, Jupiter JB 2006 Plate and screw design in fractures of the hand and wrist. *Clinical Orthopaedics & Related Research* 445 68-80.

Nork SE, Jones CB, Henley MB 2001 Surgical treatment of olecranon fractures. *American Journal of Orthopaedics* 30 577-586.

Pape HC, Giannoudis P 2007 The biological and physiological effects of intramedullary reaming. *Journal of Bone & Joint Surgery* 89B 1421-1426.

Rahn BA 1987 Direct and indirect bone healing after operative fracture treatment Otolaryngologic. *Clinics of North America* 20 425-440.

Rüedi TP, Murphy WM 2000 AO principles of fracture management. Stuttgart, Germany: Thieme.

Tambe A, Rodriguez JC, Monk J, Chen C, Calthorpe D 2005 Orthopaedic trauma care: a two-tier system? *Injury* 36 771-774.

Yousri T, Tarassoli P, Whitehouse M, Khan WS, Monsell F (2012). Systematic Review of Randomized Controlled Trials Comparing Efficacy of Crossed Versus Lateral K-wire fixation in Extension type Gartland type III Supracondylar Fractures of the Humerus in Children. *Orthop. Trauma Rehab.* 14(5):397-405.

Ziran BH, Smith WR, Anglen JO, Tornetta III P 2008 External fixation: how to make it work. *Instructional Course Lectures* 57 37-49.

In: Encyclopedia of Surgery (22 Volume Set)
Editors: Andreas Lehrer and Kristin Mueller
ISBN: 978-1-53618-329-0
© 2020 Nova Science Publishers, Inc.

Chapter 385

SURGERY IN ELDERLY PATIENTS WITH HIP FRACTURES

J. White, P. Smitham and W. S. Khan*
University College London Institute of Orthopaedic and Musculoskeletal Sciences,
Royal National Orthopaedic Hospital, Stanmore, Middlesex, UK

ABSTRACT

Hip fracture is a major cause of morbidity, mortality and loss of independence for the elderly. Surgical fixation of the fractured hip remains the standard of care to allow for early mobilisation and a return to independence. Operative management in this population carries its own set of problems. The altered physiological state of the older person, often coupled with significant co-morbidity, can present challenges for the anaesthetist, the surgeon and the rest of the perioperative team. This chapter provides an evidence-based review of these important perioperative factors associated with hip fractures in the older person and their management.

Keywords: hip fractures, elderly, co-morbidity, pain, venous thromboemboli

INTRODUCTION

This chapter discusses the evidence for managing hip fractures in elderly patients (White et al. 2011). Hip fractures are frequent injuries amongst older patients with osteoporosis and account for about 76,000 cases in the UK per year according to the National Hip Fracture Database (NHFD 2010). A review that examined the extensive hip fracture literature published in the English language between 1980 and 2009 concerning hip fracture prevalence trends suggested that hip fractures will remain a serious global health issue (Marks 2010). Hip fractures are a major cause of morbidity, mortality and loss of independence in the elderly.

* Corresponding Author's Email: wasimkhan@doctors.org.uk.

These fractures pose a major public healthcare burden and continue to consume large portions of healthcare resources.

Surgical fixation of fractured hips remains the standard of care to allow early mobilisation and a return to independence. Timely surgery limits the period of recumbence and helps to prevent pressure sores, urinary tract infections, deep vein thrombosis and pulmonary complications including atelectases, pneumonia and pulmonary emboli. Surgical intervention is considered superior in medically-fit elderly patients (Parker et al. 2000, Beaupre et al. 2005), and ideally this should be completed within 48 hours for the majority of patients with hip fracture (Egol & Strauss 2009). Even in the absence of co-morbidity, the altered physiological state of the older person can present challenges for the anaesthetist and the rest of the perioperative team. Operative management in this population carries its own set of problems and implications, and these are discussed below.

Fractures of the neck of femur could be divided into extracapsular and intracpsular fractures. Extracapsular fractures are generally treated with fixation using a dynamic hip screw or intramedullary nailing. Although undisplaced intracapsular fractures are also generally treated with fixation using cannulated screws, there is controversy regarding the optimal management of displaced intraarticular fractures. Although most elderly patients with displaced intraarticular fractures are managed with a hemiarthroplasty and do well, there is increasing evidence to suggest that a total hip replacement improves patient functional outcomes for healthy, independent, elderly patients compared with hemiarthroplasty and should be considered as the treatment of choice for these patients as it is more predictable, durable and cost-effective in the longer-term (Schmidt et al. 2005, Malik et al. 2009, Dheerendra et al. 2010, Lowe et al. 2010). A detailed discussion on the surgical management of these fractures is beyond the scope of this chapter.

PREOPERATIVE MEDICAL CONSIDERATIONS

The key difference between elderly patients and their younger contemporaries is a loss of functional reserve and a general decline in organ function (Muravchick 2000). Although age is not an independent risk factor for post-operative complications, the perioperative period is filled with increased risk secondary to the higher incidence of co-existing disease in the elderly. Older patients may present with an array of co-morbidities involving any organ system and these must be evaluated and optimised prior to surgery to improve the post-operative outcome. This highlights the crucial roles played by both anaesthetists and geriatricians in the perioperative management of this challenging patient population.

The risk of postoperative complications in the elderly hip fracture patient is proportional to the number of co-morbidities present. Roche et al. (2005), in a prospective cohort study of 2,448 geriatric patients with hip fracture, evaluated the relationship between preoperative co-morbidity and the risk of postoperative complications and mortality. The authors found that the presence of three or more preoperative co-morbidities is the strongest predictor of increased mortality at 30 days postoperatively, followed by respiratory disease and malignancy. The most common postoperative complications were chest infection (9%) and cardiac failure (5%). These findings underline the importance of effective medical assessment and optimisation in the perioperative period.

A number of studies have sought to identify specific co-morbidities predictive of increased postoperative mortality. Mortality data at 30 days (Nettleman et al. 1996), six months (de Luise et al. 2008) and one year post-injury (Penrod et al. 2008) have identified a history of congestive cardiac failure (CCF), chronic obstructive pulmonary disease (COPD) and and/or malignancy as strong positive predictors. Nettleman et al. (1996), in a retrospective analysis of 390 elderly patients with hip fracture, found that 63% of inpatient mortalities were cardiovascular in nature.

THE AMERICAN ASSOCIATION OF ANAESTHETISTS GRADING

The American Society of Anaesthetists (ASA) developed a grading system (I to V) to classify patients according to their physical status, thus serving as an indicator of anaesthetic and surgical risk. A normal, healthy individual with minimal risk is deemed ASA class I, whereas a moribund patient who is not expected to survive 24 hours regardless of surgery is designated ASA class V. The majority of elderly patients will be ASA class II or greater (AAGBI 2001).

The ASA score is a useful predictor of long term mortality after hip fracture (Michel et al. 2002, Richmond et al. 2003, Bjorgul et al. 2010). In a prospective study of 1,635 patients with hip fracture, Bjorgul et al. (2010) demonstrated that survival rates vary significantly between ASA classes. Over a five to ten year period postoperatively, survival for ASA I was 8.5 years versus only 1.6 years for ASA IV. Use of the ASA classification to predict postoperative mortality risk can be further enhanced by complementing it with the Short Potable Mental Status Questionnaire (SPMSQ) for assessing cognitive function. Soderqvist et al. (2009) , in a prospective cohort study of 1,944 patients aged 66 or older, revealed that the combination of ASA score and SPMSQ provides greater information about survival times compared with the ASA score alone.

In addition to mortality the risk of medical complications can be predicted using the ASA class. In a retrospective analysis of 197 elderly patients with hip fracture, Donegan et al. (2010) reported that medical complications were more common in those with ASA classes III and IV compared with ASA class II. Furthermore, patients classed as ASA IV were over seven times more likely to have medical complications compared with those in class II. These complications are numerous, and in a retrospective study of 8,930 patients aged 60 or over with hip fracture, Lawrence et al. (2002) listed cardiac and pulmonary complications as most frequent (8% and 4% respectively). Other complications included gastrointestinal bleeding (2%), venous thromboembolism (1%), and transient ischaemic attack or stroke (1%). In another series of 1,010 patients evaluated by Ranhoff et al. (2010), the most common complications were anaemia requiring transfusion, delirium and urinary tract infections.

SURGICAL COMPLICATIONS

Surgical complications include superficial wound infections, deep joint infections, hip dislocations, periprosthetic fractures, failure of fracture fixation, neurovascular injuries and leg length discrepancies (Hall et al. 2009). Most of these complications will need further surgical interventions. Although no study has determined a link between age and

complications, the number of co-morbidities is proportional to the risk of postoperative complications (Roche et al. 2005) and elderly hip fracture patients are more likely to have co-morbidities. The reduced functional reserve and general decline in organ function seen in the elderly patients (Muravchick 2000) makes it more difficult for them to cope with the increased physiological demands of the complication and the possible surgical intervention that it may require.

POSTOPERATIVE PAIN CONTROL

The provision of adequate analgesia for hip fracture patients is essential, not only to allow for effective ambulation postoperatively, but also to help prevent complications. The pain induced by trauma and surgery leads to decreased mobility, and this in turn leads to reduced respiratory effort causing atelectasis and pneumonia. Decreased mobility also predisposes to urinary tract infections, deep vein thromboses and pulmonary emboli. Poor postoperative pain control can lead to a vicious cycle in which the pain itself is compounded by the patient's own anxieties, thus limiting progress even further.

Although some evidence exists regarding the most appropriate analgesia for patients with hip fracture, better analgesic control for the elderly need to be discovered (Beaupre et al. 2005). Poorly controlled pain however, increases the length of hospital stay, delays mobilisation, and reduces long-term functional ability (Morrison et al. 2003). It is likely that complications arise secondary to impaired cognition, medical co-morbidities, and altered drug metabolism and pharmacokinetics. These factors make effective pain control in the older population far more complex than their younger counterparts.

Acutely, postoperative pain management with intravenous morphine can be safely achieved using the same protocol as for younger patients. There appears to be no difference in the incidence of morphine-related complications or sedation (Aubrun et al. 2002). Several days postoperatively however, opioid requirements amongst elderly patients drop in comparison (Gagliese et al. 2000). It is important that regular pain assessments are made to allow for adequate dosing adjustments, in addition to a baseline assessment upon arrival to hospital. Furthermore, special consideration must be given to cognitively-impaired patients, whose pain control is often suboptimal due to self-reporting of less pain. Behavioural pain indicators do not however differ between congnitively-impaired and cognitively-intact patients, supporting the use of behavioural assessments in the cognitively-impaired (Horgas et al. 2009). Another strategy to ameliorate this may be the adoption a standardised protocol for pain management (Adunsky et al. 2002).

Regional analgesia via the epidural route may provide a novel technique for managing acute postoperative pain in elderly hip fracture patients, although more research is needed. Foss et al. (2005) examined the effect of four days postoperative epidural infusion of bupivacaine and morphine versus placebo in 60 elderly hip fracture patients. Epidural analgesia was found to be significantly superior in managing postoperative pain during all basic physical functions compared with controls. Despite the improved pain relief, there was no significant difference in scores for recovery of physical independence. These findings demonstrate that epidural analgesia provides enhanced pain control over standard regimens,

but further studies are needed to elicit whether this improvement translates into enhanced recovery.

PRESSURE ULCER PREVENTION

The development of pressure sores after hip surgery is a common occurrence, with a reported incidence ranging from 9% to 55% (Gunningsberg et al. 2000, Baumgarten et al. 2003). It carries a great burden of morbidity as patients that develop pressure ulcers are at increased risk of developing nosocomial infections and other hospital complications, as well as enduring a significantly longer hospital stay (Allman et al. 1999). The assessment and management of a pressure ulcer requires a systematic, comprehensive and multidisciplinary approach. Assessment of an elderly hip fracture patient includes the patient's comorbidities, functional state, nutritional status, and degree of social and emotional support (Jaul 2010). Vigilant nursing care can reduce this risk, through visual inspection, frequent turning, and the application of topical preparations. Furthermore, the implementation of heel protection and pressure-relieving mattresses can provide additional benefit. In a prospective randomised controlled trial assessing the benefits of an interface pressure-decreasing mattress, Hofman et al. (1994) found that the incidence and severity of pressure ulcers were significantly reduced compared with a standard hospital mattress (24% versus 68%).

Currently there is no research evidence that high-tech pressure-relieving mattresses are more effective than low-tech foam mattresses for the prevention of pressure ulcers. There is also a lack of evidence regarding the benefit of heel protection devices. Professional consensus recommends their use, but further research is needed.

VENOUS THROMBOEMBOLISM PREVENTION

Hip fracture is a major risk factor for venous thromboembolism (VTE) throughout the perioperative period. Other significant risk factors include malignancy, coagulopathy, immobility, previous VTE, obesity, stroke, atherosclerosis, and ASA grade ≥ 3 (Beksac et al. 2006). Advanced age is weakly associated with the development of VTE (Abad Rico et al. 2010). Incidence rates for deep vein thromboses range from 36% to 60% (Ennis 2003), whilst those of pulmonary embolism range from 4% to 24% (Egol and Strauss 2009). Fatal pulmonary emboli occur in 1% to 13% of cases (Ennis 2003).

Despite extensive research on an optimal thromboprophylaxis strategy, there remains no agreement on a standard protocol (Chahal et al. 2013). The Pulmonary Embolism Prevention (PEP) trial (2000) assessed the effect of aspirin versus placebo for VTE prophylaxis in 13,365 patients with hip fracture. Treatment with aspirin reduced the risk of both symptomatic deep vein thromboses and pulmonary emboli when compared with placebo (29% and 43% respectively). There was an increased transfusion requirement in patients assigned aspirin, however mortalities due to bleeding were comparable between study groups. Based on the findings, the authors concluded that treatment with aspirin decreases the incidence of deep vein thromboses and pulmonary emboli by a third perioperatively and should be used routinely in patients with hip fracture.

A retrospective study by Ennis (2003) of 1,000 consecutive hip fractures compared the use of aspirin with the low-molecular-weight heparin (LMWH), enoxaparin. Although there was no significant difference in deep vein thrombosis rates between the treatment groups, there was one case of fatal pulmonary embolism in those treated with aspirin and no pulmonary emboli recorded with enoxaparin. Considering its short half-life, predictability and favourable safety profile, the author concluded that enoxaparin, and thus LMWH, was an ideal form of thromboprophylaxis.

A total of 32 trials covering 3,614 adult hip fracture cases have shown that unfractionated heparin and LMWH protect against VTE (Handoll et al. 2002, Eriksson & Lassen 2003). In a Cochrane review by Handoll et al. (2002) however, there was insufficient data to confirm a protective effect against pulmonary emboli. No significant differences were established between unfractionated heparin and LMWH. Eriksson & Lassen (2003) found that fondaparinux (factor Xa inhibitor) conferred a relative reduction in the risk of VTE (including pulmonary emboli) of 96% when compared with placebo. The incidence of symptomatic VTE was also found to be significantly lower in patients treated with fondaparinux and there was no increase in the incidence of clinically significant bleeding.

Turpie et al. (2002) reported a meta-analysis of four randomised, double-blind trials comparing the prophylactic effects of fondaparinux and enoxaparin in 7,344 cases of hip fracture. Fondaparinux was shown to confer a significantly greater protective effect against VTE than enoxaparin, with an odds reduction of 55%. It was also shown to significantly reduce the incidence of proximal deep vein thromboses with a reduction of 57%. The risk of clinically relevant bleeding was low and did not differ significantly between the treatment groups. In a retrospective study by Shorr et al. (2007) of 144,806 patients who had undergone major orthopaedic surgery, including that for hip fracture, the benefits of fondaparinux were further clarified. Patients receiving fondaparinux experienced fewer VTE events (1.5%) compared to enoxaparin (2.1%), dalteparin (2.1%) and unfractionated heparin (4.2%).

Post-discharge, there remains a risk of delayed thromboembolic events, thus justifying the need for extended thromboprophylaxis (Anand & Buch 2007). Prolonged treatment with fondaparinux over a 4-week period can reduce the risk of DVT by 96% and the risk of symptomatic VTE by 89% compared with perioperative (1-week) treatment (Kwong 2004). The American College of Chest Physicians recommends the routine use of fondaparinux, LMWH, or unfractionated heparin for patients undergoing hip fracture surgery. Their guidelines also recommend against the use of aspirin alone for thromboprophylaxis and encourage the use of physical methods of anticoagulation for patients with a high bleeding risk or as an adjunct to chemoprophylaxis (Geerts et al. 2008).

POSTOPERATIVE CONFUSION/DELIRIUM

Postoperative delirium is characterised by a disturbance of consciousness and temporary abnormalities in cognition and perception. It is a common problem in the elderly hip fracture patient with a postoperative incidence ranging from 5% to 61% (Edelstein et al. 2004, Gustafson et al. 1988). Risk factors for delirium include advanced age, pre-fracture cognitive and functional impairment, pre-existing cerebrovascular and other brain diseases, indoor injury, communication difficulties and social isolation (Duppils & Wikblad 2001, Juliebo et

al. 2009). Precipitating factors for delirium comprise perioperative falls in blood pressure, postoperative infections and malnutrition (Edlund et al. 2001). Perioperative risk factors associated with postoperative delirium include intraoperative blood loss, electrolyte abnormalities and a postoperative haematocrit <30% (Mercantonio et al. 1998). Neither intraoperative haemodynamic instability nor route of anaesthesia is associated with increased postoperative delirium (Mercantonio et al. 1998). A randomised controlled trial by Sieber (2009) did demonstrate however that the depth of sedation achieved with propofol during spinal anaesthesia does influence the subsequent development of delirium. In the trial, 114 individuals were randomised and the results showed that there were far fewer cases of delirium in the light sedation group versus the deep group (19% versus 40% respectively). The authors concluded that limiting the depth of sedation during spinal anaesthesia is a safe, effective and economical and should be widely instituted.

Unfortunately, postoperative delirium has received little attention in the perioperative literature, despite its considerable morbidity and mortality. Over two decades ago, it had shown to significantly increase the length of hospital stay and postoperative complications such as urinary incontinence, feeding difficulties and pressure sores (Gustafson et al. 1988). Patients experience reduced ambulation and rehabilitation, with a decline in their activities of daily living, prefracture walking level and ultimately their independence. Finally, patients suffer an increased rate of mortality or are placed into a nursing home (Gustafson et al. 1988, Mercantonio et al. 2001, Edelstein et al. 2004).

Management strategies towards postoperative delirium are therefore necessary to prevent and/or lessen the impact on patient outcomes. Careful and frequent assessment of a patient's mental status and cognitive function are important as is addressing any risk factors present. Precipitating factors need to be avoided and if delirium does present itself, treatment needs to focus on supportive care and identifying the underlying causes. Specific measures include adequate postoperative analgesia, careful drug selection and management within a multidisciplinary framework. Mercantonio et al. (2001) conducted a randomised controlled trial assessing the effects of regular geriatrics input on postoperative delirium in 126 elderly hip fracture patients. Geriatrics consultation was shown to significantly decrease the incidence of postoperative delirium by a third, with a relative risk of 0.64. There was an even greater reduction in cases of severe delirium, although length of stay did not vary significantly between intervention groups. In a similar study by Lundstrom et al. (2007), postoperative care on either an orthopaedic ward or geriatric ward was compared in 199 patients. Less patients treated on the geriatric ward developed delirium, and if so, their delirium lasted for a shorter period of time. Furthermore, intervention patients developed fewer complications such as pressure ulcers, nutritional deficits, urinary tract infections, sleeping problems and falls.

CONCLUSION

Based on the literature we have reviewed, hip fractures are common injuries and are a major cause of morbidity, mortality and loss of independence for the elderly. Although surgical fixation of the fractured hips remains the standard of care, operative management carries its own set of problems. The altered physiological state of the older person, often

coupled with significant co-morbidity, can present challenges for the anaesthetist and the rest of the perioperative team. It is important that an evidence-based approach is utilised to help ensure the patient, who has been optimised perioperatively, has appropriate management of pain, pressure ulcers, venous thromboemboli, delirium and confusion. The appropriate assessment and evidence-based management of these patients should lead to an improved outcome.

REFERENCES

Abad Rico JI, Llau Pitarch JV, Rocha E 2010. *Overview of Venous Thromboembolism Drugs* 2010 70 (S2) 3-10.

Allman RM, Goode PS, Burst N, Bartolucci AA, Thomas DR 1999 Pressure ulcers, hospital complications, disease severity: impact on hospital costs and length of stay Advances in Wound Care: *The Journal for Prevention and Healing* 12 (1) 22-30.

Anaesthesia and Perioperative care of the Elderly 2001 [online] Available from: http://www.aagbi.org/publications/guidelines/docs/careelderly01.pdf [Accessed September 2010].

Anand S, Buch K 2007 Post-discharge symptomatic thromboembolic events in hip fracture patients. *Annals of the Royal College of Surgeons of England* 89 (5) 517-520.

Baumgarten M, Margolis D, Berlin JA, Strom BL, Garino J, Kagan SH, Kavesh SH, Carson JL 2003 Risk factors for pressure ulcer among elderly hip fracture patients. *Wound Repair and Regeneration* 11 (2) 96-103.

Beaupre LA, Jones CA, Saunders LD, Johnston DW, Buckingham J, Majumdar SR 2005 Best practices for elderly hip fracture patients. A systematic overview of the evidence. *Journal of General Internal Medicine* 20 (11) 1019-1025.

Beksac B, Gonzalez Della Valle A, Salvati EA 2006 Thromboembolic disease after total hip arthroplasty: who is at risk? *Clinical Orthopaedics and Related Research* 453 211-224.

Bjorgul K, Novicoff WM, Saleh KJ 2010 American Society of Anaesthesiologist Physical Status score may be used as a comorbidity index in hip fracture surgery. *Journal of Arthroplasty* 25 (6 Suppl) 134-137.

Chahal GS, Saithna A, Brewster M, Gilbody J, Lever S, Khan WS, Foguet P (2013). A Comparison of Complications Requiring Return to Theatre in Hip and Knee Arthroplasty Patients Taking Enoxaparin versus Rivaroxaban for Thromboprophylaxis. *Orthop. Trauma Rehab*. 15(2): 125-9.

de Luise C, Brimacombe M, Pedersen L, Sorensen HT 2008 Comorbidity and mortality following hip fracture: a population-based cohort study. *Aging Clinical and Experimental Research* 20 (5) 412-418.

Dheerendra S, Khan WS, Saeed MZ, Goddard NJ (2010). Recent Developments in Total Hip Replacements: Cementation, Articulation, Minimal-Invasion and Navigation. *J. Perioper Pract*. 20(4): 133-8.

Donegan DJ, Gay AN, Baldwin K, Morales EE, Esterhai JL Jr, Mehta S 2010 Use of medical comorbidities to predict complications after hip fracture surgery in the elderly. *Journal of Bone and Joint Surgery* (American Volume) 92 (4) 807-813.

Duppils GS, Wikblad K 2000 Acute confusional states in patients undergoing hip surgery: a prospective observational study *Gerontology* 46 (1) 36-43.

Edelstein DM, Aharonoff GB, Karp A, Capla EL, Zuckerman JD, Koval KJ 2004 Effect of postoperative delirium on outcome after hip fracture *Clinical Orthopaedics and Related Research* (422) 195-200.

Edlund A, Lundstrom M, Brannstrom B, Bucht G, Gustafson Y 2001 Delirium before and after operation for femoral neck fracture. *Journal of the American Geriatrics Society* 49 (10) 1335-1340.

Egol KA, Strauss EJ 2009 Perioperative considerations in geriatric patients with hip fracture: what is the evidence? *Journal of Orthopaedic* Trauma 23 (6) 386-394.

Ennis RS 2003 Postoperative deep vein thrombosis prophylaxis: a retrospective analysis in 1000 consecutive hip fracture patients treated in a community hospital setting. *Journal of the Southern Orthopaedic Association* 12 (1) 10-17.

Eriksson BI, Lassen MR 2003 Duration of prophylaxis against venous thromboembolism with fondaparinux after hip fracture surgery: a multi-center, randomized, placebo-controlled, double-blind study. *Archives of Internal Medicine* 163 (11) 1337-1342.

Foss NB, Kristensen MT, Kristensen BB, Jensen PS, Kehlet H 2005 Effect of postoperative analgesia on rehabilitation and pain after hip fracture surgery: a randomised, double-blind, placebo-controlled trial. *Anaesthesiology* 102 (6) 1197-1204.

Gagliese L, Jackson M, Ritvo P, Wowk A, Katz J 2000 Age is not an impediment to effective use of patient-controlled analgesia by surgical patients. *Anaesthesiology* 93 (3) 601-610.

Geerts WH, Bergqvist D, Pineo GF, Heit JA, Samama CM, Lassen MR, Colwell CW; American College of Chest Physicians 2008 Prevention of venous thromboembolism: American College of Chest Physicians Evidence-Based Clinical Practice Guidelines (8th Edition). *Chest* 133 (6 suppl) 381S-453S.

Gunningsberg L, Lindholm C, Carlsson M, Sjoden PO 2000 The development of pressure ulcers in patients with hip fractures: inadequate nursing documentation is still a problem. *Journal of Advanced Nursing* 31 (5) 1155-1164.

Gustafson Y, Berggren D, Brannstrom B, Bucht G, Norberg A, Hansson LI, Winblad B 1988 Acute confusional states in elderly patients treated for femoral neck fracture. *Journal of the American Geriatrics Society* 36 (6) 525-530.

Hall C, Khan WS, Ahmed SI, Sochart DH (2009). A rare case of arterial avulsion presenting with occult blood loss in a patient following total hip arthroplasty: A case report. *J. Med. Case Rep*. 3: 9320.

Handoll HH, FTytherleigh-Strong G, Milne AA, Gillespie WJ 2002 Heparin, low molecular weight heparin and physical methods for preventing deep vein thrombosis and pulmonary embolism following surgery for hip fractures. *Cochrane Database of Systematic Reviews* (4):CD000305.

Hofman A, Geelkerken RH, Willie J, Hamming JJ, Hermans J, Breslau PJ 1994 Pressure sores and pressure-decreasing mattresses: controlled clinical trial. *Lancet* 343 (8897) 568-571.

Horgas AL, Elliott AF, Marsiske M 2009 Pain assessment in persons with dementia: relationship between self-report and behavioral observation *Journal of the American Geriatrics Society* 57 (1) 126-132.

Jaul E 2010 Assessment and management of pressure ulcers in the elderly: current strategies. *Drugs Aging* 27 (4) 311-325.

Juliebo V, Bjoro K, Krogseth M, Skovlund E, Ranhoff AH, Wyller TB 2009 Risk factors for preoperative and postoperative delirium in elderly patients with hip fracture. *Journal of the American Geriatrics Association* 57 (8) 1354-1361.

Kwong LM 2004 Hip fracture and venous thromboembolism in the elderly *Journal of Surgical Orthopaedic Advances* 13 (3) 139-148.

Lawrence VA, Hilsenbeck SG, Noveck H, Poses RM, Carson JL 2002 Medical complications and outcomes after hip fracture surgery. *Archives of Internal Medicine* 162 (18) 2053-2057.

Lowe JA, Crist BD, Bhandari M, Ferguson TA 2010 Optimal treatment of femoral neck fractures according to patient's physiologic age: an evidence-based review. *Orthopaedic Clinics of North America* 41 (2) 157-166.

Lundstrom M, Olofsson B, Stenvall M, Nyberg L, Englund U, Borssen B, Svensson O, Gustafson Y 2007 Postoperative delirium in old patients with femoral neck fracture: a randomised intervention study. *Ageing Clinical and Experimental Research* 19 (3) 178-186.

Malik AA, Kell P, Khan WS, Ihsan KM, Dunkow P 2009 Surgical management of fractured neck of femur. *Journal of Perioperative Practice* 19 (3) 100-104.

Marks R 2010 Hip fracture epidemiological trends, outcomes, and risk factors, 1970-2009. *International Journal of General Medicine* 8 (3) 1-17.

Mercantonio ER, Goldman L, Orav EJ, Cook EF, Lee TH 1998 The association of intraoperative factors with the development of postoperative delirium. *The American Journal of Medicine* 105 (5) 380-384.

Mercantonio ER, Flacker JM, Wright RJ, Resnick NM 2001 Reducing delirium after hip fracture: a randomised trial. *Journal of the American Geriatrics Society* 49 (5) 516-522.

Michel J, Klopfenstein C, Hoffmeyer P, Stern R, Grab B 2002 Hip fracture surgery: is the pre-operative American Society of Anaesthesiologists (ASA) score a predictor of functional outcome? *Ageing Clinical and Experimental Research* 14 (5) 389-394.

Morrison RS, Magaziner J, McLaughlin MA, Orosz G, Silberzweig SB, Koval KJ, Siu AL 2003 The impact of post-operative pain on outcomes following hip fracture. *Pain* 103 (3) 303-311.

Muravchick S 2000 Preoperative assessment of the elderly patient. *Anesthesiology Clinics of North America* 18 (1) 71-89.

Nettleman MD, Alsip J, Schrader M, Schulte M 1996 Predictors of mortality after acute hip fracture. *Journal of General Internal Medicine* 11 (2) 765-777.

Paqueron X, Lumbroso A, Mergoni P, Aubrun F, Langeron O, Coriat P, Riou B 2002 Is morphine-induced sedation synonymous with analgesia during intravenous morphine titration? *British Journal of Anaesthesia* 89 (5) 697-701.

Parker MJ, Handoll HHG, Bhargara A 2000 Conservative versus operative treatment for hip fractures. *Cochrane Database Systematic* Reviews Issue 4.

Penrod JD, Litke A, Hawke WG, Magaziner J, Doucette JT, Koval KJ, Silberzweig SB, Egol KA, Siu AL 2008 The association of race, gender, and co-morbidity with mortality and function after hip fracture. *The Journals of Gerontology* 63 (8) 867-872.

Prevention of pulmonary embolism and deep vein thrombosis with low dose aspirin: Pulmonary Embolism Prevention (PEP) trial 2000. *Lancet* 355 (9212) 1295-1302.

Ranhoff AH, Holvik K, Martinsen MI, Domaas K, Solheim LF 2010 Older hip fracture patients: three groups with different needs. *BMC Geriatrics* 10 (1) 65.

Richmond J, Aharonoff GB, Zuckerman JD, Koval KJ 2003 Mortality risk after hip fracture. *Journal of Orthopaedic Trauma* 17 (1) 53-56.

Roche JJ, Wenn RT, Sahota O, Moran CG 2005 Effect of comorbidities and postoperative complications on mortality after hip fracture in elderly people: prospective observational cohort study. *British Medical Journal* 331 (7529) 1374-1379.

Schmidt AH, Asnis SE, Haidukewych G, Koval KJ, Thorngren KG 2005 Femoral neck fractures. *Instructional Course Lectures* 54 417-445.

Shorr AF, Kwong LM, Sarnes M, Happe L, Farelly E, Mody-Patel N 2007 Venous thromboembolism after orthopaedic surgery: implications of the choice for prophylaxis. *Thrombosis Research* 121 (1) 17-24.

Sieber FE 2009 Postoperative delirium in the elderly surgical patient. *Anaesthesiology Clinics* 27 (3) 451-464.

Soderqvist A, Ekstrom W, Ponzer S, Petterson H, Cederholm T, Dalen N, Hedstrom M, Tidermark J 2009 Prediction of mortality in elderly patients with hip fractures: a two-year prospective study of 1944 patients. *Gerontology* 55 (5) 496-504.

The National Hip Fracture Database National Report 2010 [online] Available from: http://www.ccad.org.uk/nhfd.nsf/NHFD%20National%20Report%202010.pdf [Accessed September 2010]

Turpie AG, Eriksson BI, Lassen MR, Bauer KA 2002 A meta-analysis of fondaparinux versus enoxaparin in the prevention of venous thromboembolism after major orthopaedic surgery. *Journal of the Southern Orthopaedic Association* 11 (4) 182-188.

In: Encyclopedia of Surgery (22 Volume Set)
Editors: Andreas Lehrer and Kristin Mueller
ISBN: 978-1-53618-329-0
© 2020 Nova Science Publishers, Inc.

Chapter 386

ARTHROSCOPIC KNEE SURGERY: AN EVIDENCE-BASED PRACTICE

Christopher Onyema, Emeka Oragui, Jonathan White and Wasim S. Khan*

University College London Institute of Orthopaedics and Musculoskeletal Sciences, Royal National Orthopaedic Hospital, Stanmore, London, UK

ABSTRACT

Knee arthroscopy is a minimally-invasive technique that allows intra-articular assessment and treatment of knee joint pathology. It has proven benefits of reduced patient morbidity, earlier recovery and mobilisation, and it is cost-effective. In this chapter we review the anatomy of the knee joint, indications and contra-indications to knee arthroscopic use, and consider the main techniques of knee arthroscopy including types of anaesthetic, prophylactic antibiotics, theatre setup and arthroscopic portals, and post-operative care.

Keywords: Knee; arthroscopy; evidence-based practice; minimally invasive surgery (MIS)

In this chapter we review the evidence base behind arthroscopic knee surgery (Onyema et al 2011). Arthroscopy of the knee is the most common operative procedure in orthopaedic surgery today. Like all arthroscopic procedures, it delivers a minimally invasive approach to orthopaedic operations that previously necessitated open surgery. The basic principle involves the insertion of a camera and associated equipment through small portals in the skin to allow intra-articular evaluation and treatment of pathology. Professor Kenji Takagi of Tokyo has traditionally been cited as having performed the first arthroscopic assessment of the knee in 1919 although it may be that the Danish physician Severin Nordentoft actually pioneered the technique seven years earlier. The technique became an established feature of orthopaedic practice during the 1970s, and today surgeons can perform an array of complex intra-articular

* Corresponding Author's Email: wasimkhan@doctors.org.uk; Fax: +44 (0) 1707 655059.

operations through small incisions (Katz & Gomoll 2007). Knee arthroscopy is used to perform many procedures that previously necessitated an open procedure such as simple meniscectomies, ligament reconstruction and cartilage restoration.

There are many advantages of arthroscopic surgery over traditional open surgery. The minimally invasive technique results in less trauma to the patient, less post-operative pain and less blood loss. Patients recover faster and can quickly return to their normal daily activities. A day surgery arthroscopic procedure is more readily accepted by patients than an in-patient arthrotomy and may facilitate earlier intervention. Cosmetically-speaking, smaller skin scars are more appealing. An economic benefit is provided as patients spend less time in hospital, can quickly return to work, and overall, the procedure is less expensive compared to open operations.

ARTHROSCOPIC KNEE ANATOMY

The knee joint comprises articulations between the medial and lateral compartments of the distal femur and proximal tibia as well as an articulation between the patella and the anterior aspect of the distal femur, which forms the third, patellofemoral compartment. The surfaces of these bones are lined with articular cartilage and in addition two crescent-shaped fibro-cartilaginous pads called menisci lie between the femoral and tibial compartments and are joined by a transverse inter-meniscal ligament that connects them anteriorly. These menisci protect articular surfaces by providing lubrication and reducing friction. They may also have a role in providing nutrition to tissues (Katz 2007).

The peripheral part of the meniscus is vascular and DeHaven (1990) suggested that tears in the peripheral 3 mm are amenable to repair (Koval & Zuckerman 2004), whereas tears more than 5 mm from the menisco-capsular aspect are avascular with little or no potential for healing or repair.

The knee joint is stabilised by ligaments around the knee. These include the medial and lateral collateral ligaments which can be palpated at the joint line and resist varus and valgus strain respectively. The anterior cruciate ligaments (ACL) and posterior cruciate ligaments (PCL) lie within the joint and resist displacement of the tibia on the femur in an anterior or posterior direction respectively. The fibrous capsule contributes to the stability of the joint. The knee is also supported by several muscles that include the quadriceps and the hamstrings (Koval & Zuckerman 2004).

INDICATIONS AND CONTRA-INDICATIONS TO KNEE ARTHROSCOPY

Knee arthroscopy may be diagnostic or therapeutic, and is indicated when there is no other way to confirm the diagnosis, or the lesion is amenable to arthroscopic surgery and no easier technique to treat the pathology exists. The final decision on whether to perform an elective knee arthroscopy or not usually relies upon symptoms and disabilities that negatively impact on the quality of a patient's life but may be hard to quantify (DeHaven 1990). The use of knee arthroscopy has been demonstrated for diagnosis and treatment of intra-articular

lesions, loose bodies, meniscal tears, osteoarthritis, cartilage repair, ACL reconstruction, synovectomy and plicectomy, unexplained knee pain, intra-articular tumours, painful knee after total knee replacement, pyogenic arthritis, and arthro-fibrosis (Marx 2008).

Only a few contraindications for knee arthroscopy exist. These include localised soft tissue infection where the insertion of the equipment into the knee joint may introduce infection into the joint and cause overt sepsis. Infection in the joint itself is not a contraindication, and in such cases arthroscopic techniques may be employed for debridement and drainage.

Severe degenerative joint diseases resulting in stiffness or ankylosis of the knee may prohibit manoeuvring of the arthroscope within the various compartments and access may be difficult. It may also be difficult to operate on any patient with a recent haemarthrosis as visualisation may be compromised. Training and technical ability also limits the procedures that may be performed by any knee surgeon (Noble 1992).

A thorough evaluation of the patient before the procedure is mandatory and should include a relevant history, examination and appropriate imaging. Magnetic resonance imaging (MRI) is useful as it has been shown to be reliable for the exclusion of intraarticular lesions, thus reducing the number of unnecessary arthroscopies (Friemert 2004). During the operation, all necessary imaging should be made available (Jackson 1972).

ANAESTHESIA

Arthroscopic knee surgery can be performed with general, regional or local anaesthesia, each having its own advantages and disadvantages. The anaesthetic technique(s) used will depend on the preferences of the anaesthetist, patient and operating surgeon, as well as local guidelines.

1. General Anaesthetic

General anaesthesia has remained the most common modality for knee arthroscopy. This technique puts the patient to sleep, allowing complete muscle relaxation for the entire procedure and is a good choice for very young or anxious patients. However, there are associated risks of allergic/ anaphylactic reactions to the anaesthetic agents and the risk associated with intubation and ventilation during general anaesthesia (Dandy 1997). In the anaesthetic room, a laryngeal mask airway is commonly used. Before starting the procedure the portal sites may be injected with a local anaesthetic as this has been shown to reduce post-operative pain and opioid requirements (Buckenmaier 2002).

2. Spinal Anaesthetic

Spinal anaesthesia provides good single-injection anaesthesia for knee arthroscopy. It is preferred for lower limb orthopaedic surgery because of its reliability and simplicity. It

permits the patient to be awake during the procedure if desired. Other advantages include a rapid onset, high reliability, and a reduction in the time that the patient spends in post-anaesthesia recovery and facilitates early hospital discharge. Low dose, short-acting agents such as lidocaine have considerable benefits over long-acting agents in terms of recovery and home discharge. Disadvantages include the small risk of spinal headache despite using newer spinal needles, and the possibility of a difficult spinal puncture (McKeon et al 2009).

3. Local Anaesthetic

Although not commonly practiced in the UK or US, knee arthroscopy under local anaesthesia has been shown to be reliable and safe with appropriate case selection by an experienced anaesthetist. Evidence for its efficacy has been demonstrated in Hong Kong, Japan and Sweden (Law et al 2009, Jacobsen et al 2000, Yoshiya et al 1988). The disadvantages are that this method of anaesthesia may limit tourniquet use, and the patient's tolerance to movement of the limb may limit the amount of forceful manipulation that can be achieved.

In some cases, conversion to general anaesthesia is required. Local anaesthesia is cost-effective, allows for a quicker recovery and shorter hospital stay (O'Donnell BD & Iohom 2008). Nevertheless, the use of arthroscopy under local anaesthesia will depend on surgeon preference and local practice.

The local anaesthetic should be injected into the portal sites and joint itself, with most of the agent being injected into the subcutaneous layer. Successful intra-articular injection can be confirmed by a positive patellar tap and bulging from the medial gutter. Introduction of the agent into the subcapsular layer should be avoided as this will push the fat pad into the joint, hindering visualisation in the initial stages. A twenty minute waiting interval should be given after the injection to allow for onset of action of the agent. Sedatives can also be given for anxious or apprehensive patients.

PROPHYLACTIC ANTIBIOTICS

Prophylactic antibiotics are not routinely used for knee arthroscopy because the procedure is considered clean. This is supported by the low rate of post-operative infection reported in the literature. The use of antibiotics also increases costs and introduces a risk of allergic reactions and the development of antibiotic resistant organisms (Law et al 2009, Allum 2002). In a study of 2,780 arthroscopic meniscectomies Bert et al (2007) showed that there was no value in administering antibiotics. They reported infection rates of 0.15% when prophylactic antibiotics were administered compared to 0.16% in patients who received no antibiotics ($P = 0.59$).

Complex procedures of long duration or those that involve the use of implants may require antibiotics. Patients who have a high risk of infection and those with conditions such as diabetes, skin and immunological disorders should also be considered for prophylactic antibiotics (Allum 2002).

THEATRE SETUP

1. Skin Preparation

Full aseptic precautions must be taken and the skin should be prepped and draped. A standard antiseptic solution such as a chlorhexidine-based one should be used to prepare the skin from ankle to groin. Special precautions should be taken when dealing with the skin around the foot as the bacterial load is high and the risk of cross contamination of the operative site greater (Bert et al 2007).

2. Tourniquet

A tourniquet may be used to produce a bloodless field during the procedure although some surgeons may prefer not to. It may be sensible to apply the tourniquet before the operation, reserving inflation for cases where unexpected bleeding has occurred and sufficient visibility cannot be maintained. Tourniquet pressure is determined by the anaesthetist based on the patient's blood pressure; a pressure of 300 mm Hg has been shown to be safe in the lower limb (Wu and Richmond 2003). Using a wide and padded tourniquet minimises the incidence of complications such as compression neurapraxia and temporary paresis (Dandy 1986, Wakai et al 2001, Oragui et al in press).

3. Equipment Setup

In the operating room careful planning and communication is essential in setting up the operating room to allow the anaesthetist to provide a safe anaesthetic and the surgeon to make best use of all the necessary equipment. Special consideration should be placed upon the position of video equipment, the arthroscope, light source, shaving and cauterising systems, the irrigation pump, and an array of arthroscopic hand instruments.

4. Patient Positioning

The patient is positioned supine on the operating table. The operative limb may be placed in a leg holder, so that the joint can be adequately manipulated and opened. If a leg holder is used it should be well-padded and placed high on the thigh and snug. Some surgeons prefer to use a lateral side post and choose to leave the limb on the table, adjusting the patient's knee during the procedure. A lateral side post should be carefully set up to ensure that it will be at the correct level. Incorrect use of the leg holder or unpadded leg holders will increase the risk of pressure injury (Buckenmaier 2002, Malik et al 2009). Adequate light source is essential for placement of the portals (Marx 2000).

ARTHROSCOPIC PORTALS

Accurate placement of portals is essential to optimise visualisation and manipulation of the joint. Palpating and drawing bony landmarks, joint lines and soft tissue structures can help to identify correct sites of entry. The inflow cannula is usually inserted into the supero-medial supra-patella pouch once landmarks have been marked out. The irrigation fluid bag should be raised 1.5 metres higher than the patient and the fluid outflow regulated to ensure distension of the knee joint. This will remove soft tissue such as the synovium and fat pad from view (Aiello 1986). Most procedures require only two portals, however a third portal may be needed for fluid flow with certain irrigation systems.

1. Antero-Lateral Portal

The antero-lateral portal is most commonly employed for diagnostic arthroscopy as it offers superior visualisation of most parts of the knee joint. A 4 mm incision is made approximately 1 cm lateral to the border of the patellar tendon and about 1 cm above the lateral joint line (Aiello 1986). To avoid damaging the meniscus, the cutting edge of the blade should be pointing up when extended through the capsule and synovium, and the scalpel should not plunge too deep as to damage the articular cartilage. A blunt trocar in an arthroscope sheath is then introduced through the portal, directed toward the medial wall of the intercondylar notch, with the knee in approximately 30 degrees of flexion. The arthroscope is then inserted into the sheath, replacing the blunt trocar (Katx & Gomoll 2007, Aiello 1986).

2. Antero-Medial Portal

The antero-medial portal is used for additional visualisation of the lateral compartment, and instrumentation of the medial or lateral compartment structures. It is created with the knee in 30 degrees of flexion, where the soft spot is palpated, 1 cm medial to the border of the patellar tendon and about 1 cm above the medial joint line (Aiello 1986).

3. Postero-Medial Portal

The postero-medial portal is placed in a small triangular soft spot about 1 cm posterior to the postero-medial edge of the femoral condyle, and about 1 cm above the postero-medial joint line. For best results with creating this portal, the knee should be fully distended, with 90 degrees of flexion, external rotation, and abduction. With the arthroscope angled at 30 degrees, it should be possible to view and inspect all the structures in the postero-medial compartment including the PCL, posterior horn of the medial meniscus, and the postero-medial aspect of the femoral condyle and synovial lining (Katx & Gomoll 2007, Buckenmaier 2002).

4. Supero-Lateral Portal

The supero-lateral portal is the best approach for viewing the articulation between the patella and femur diagnostically, with a 70 degree arthroscope. The surgeon should be able to track the patella and assess congruity. The portal should be established as close to the lateral margin of the quadriceps tendon as possible, and about 2.5 cm superior to the supero-lateral edge of the patella (Katx & Gomoll 2007, Aiello 1986).

5. Additional Portals

Other portals exist, and their placement depends on the pathology that is expected or encountered. These include postero-lateral, medial and lateral proximal mid-patellar, and the central trans-patellar tendon portals (Buckenmaier 2002, Aiello 1986).

SOME COMMON ARTHROSCOPIC PROCEDURES

1. Diagnostic Arthroscopy

The most common use for knee arthroscopy has been that of a diagnostic tool and includes staging osteoathritic degenerative disease, assessing osteochondritis dessicans defects, obtaining biopsies for diagnosis confirmation e.g. rhuematoid arthritis, managing septic arthritis and haemoarthrosis, and assessing tibial plateau fractures. The method should be conducted in the same sequence each time, dividing the knee into individual compartments (suprapatellar pouch and patellofemoral joint; medial gutter; medial compartment; intercondylar notch; posteromedial compartment; lateral compartment; and lateral gutter). This allows for a thorough evaluation and diagnosis of knee joint pathology with the option of intervention if required.

In the current economic climate, the role of diagnostic knee arthroscopy is under review. Although arthroscopy remains the gold standard for the investigation of intra-articular abnormalities, MRI provides a less invasive and more cost-effective alternative (Vincken et al 2007). It is a highly accurate modality for diagnosing meniscal and ACL lesions, although for PCL lesions the sensitivity and accuracy is low (Crawford et al 2007). Its high specificity and negative predictive value confirm its use as the most accurate screening tool prior to therapeutic arthroscopy. In the non-acute setting, when used in combination with a full history and clinical examination, MRI can obviate the need for arthroscopy, saving costs and preventing unnecessary risk.

2. Meniscal lesions

Meniscal injury is the most common indication for the therapeutic application of knee arthroscopy. Meniscal tears are classified intra-operatively according to macroscopic appearance. They may be classified as longitudinal, horizontal, oblique and radial tears, as

well as flap, basket handle, complex and degenerative tears (Aiello 1986). When the meniscus is torn the site will determine whether the lesion is amenable to healing and whether arthroscopic surgery is required to either repair or to excise a portion of the meniscus (Koval & Zuckerman 2004). Excisions can be performed with a basket-punch or a motorised shaver, although the use of radiofrequency ablation has also been demonstrated. It is always preferable to save as much of the meniscus as possible by performing a partial meniscectomy, where only loose fragments are excised (Marx 2000, Pasa & Visna 2005).

3. Loose Body Extraction

Removing loose bodies from the knee arthroscopically is a relatively common procedure and surgeons should select the correct portal depending on the site of the lesion (Gold et al 1995). Due to gravity, intra-articular loose bodies are often found in the posterior compartment and an appropriate portal should be selected (Dandy & O'Carroll 1982). The loose body should then be immobilised, grasped and removed. The smallest should be removed first and then the knee re-examined before closure.

4. Focal Articular Cartilage Lesions

A number of options for the repair or replacement of focal cartilaginous lesions have been used arthrosopically including abrasive chondroplasty, subchondral drilling, micro-fracture, cartilage transplantation and Autologous Chondrocyte Implantation (ACI) (Spahn et al 2008, Jaiswal et al 2010, 2011). A promising new approach is the use of tissue engineering applications for the arthroscopic replacement of articular cartilage defects using stem cells (Khan et al 2010, Ong et al 2013).

5. ACL Reconstruction

Ligament reconstruction of both the ACL and PCL can be achieved using arthroscopic techniques. A minimally invasive, arthroscopic approach has several advantages: smaller incisions, fewer adhesions, less disruption to the extensor mechanism, less pain, faster rehabilitation and enhanced visualisation of the ligament insertion points. Graft selection is surgeon and patient-dependent and options include autograft (patellar tendon or hamstrings) or allograft (patellar tendon or Achilles' tendon).

6. Osteoarthritis

Techniques such as joint lavage and debridement, loose body extraction, partial synovectomy, and meniscectomy are currently being utilised for treatment of osteoarthritis of the knee (Khan & Hardingham 2010). Arthroscopy may not be beneficial to all patients with

knee osteoarthritis and controversy exists as to whether it provides any additional benefit over conventional treatment (Siparsky et al 2007, Minocha & Khan 2014).

During arthroscopy the severity of osteoarthritis can be graded using the Outerbridge scale grading system. This may help determine the specific arthroscopic technique to be use when treating osteoarthritis. Grade I refers to softening of articular cartilage; grades II and III refer to fragmentation of an area of articular cartilage less than 1 cm and greater than 1 cm respectively; in grade IV there is erosion of articular cartilage through to the underlying bone (Nutton 2009).

DRESSINGS AND POST-OPERATIVE CARE

Once the case is finished, excess irrigation fluid is removed and long acting local anaesthetic may be injected into the joint to help reduce post-operative pain. The wound may be closed with appropriate sutures or steri-stips. Before a compressive wrap is applied, the wound should ideally be covered with absorbable pads and sterile dressing (Buckenmaier 2002, Stuart & Lubowitz 2006). The regime will vary depending on the surgeon's preference and local practice.

Specific post-operative rehabilitation will depend upon findings and procedures undertaken. For basic arthroscopy the patient should be instructed in the use of crutches and exercises, and should continue to use crutches for one to three days. Early exercise is usually allowed however the weight bearing status varies with the procedure performed. Patients may remove dressings for simple arthroscopy after forty-eight hours and maintain hygienic wound care (Buckenmaier 2002, Stuart & Lubowitz 2006). The patient may have a brace applied for up to six weeks if they have undergone a focal cartilage repair procedure (Burkhart 2003).

COMPLICATIONS

Although knee arthroscopy is a relatively safe procedure, complications can and do occur and may depend upon the exact procedure being carried out. Intra-operative complications such as nerve compression injury may result from leg holders or prolonged tourniquet use (Khan et al 2007). Other operative complications include compartment syndrome and vascular injury (Kim et al 2002). Penetrating injuries to the popliteal artery have also been reported (Law et al 2009).

Post-operative complications include pain, haemarthrosis, complex regional pain syndrome, synovial fistula, infection and thrombo-embolism. Most arthroscopic procedures are of short duration and early post-operative mobilisation reduces the risk of thrombo-embolism. For this reason thrombo-prophylaxis is not routinely given in arthroscopic surgery. However, thrombo-prophylaxis is indicated for high risk patients such as those with a previous history of thrombo-embolic disease, morbidly obese patients and procedures that have involved prolonged tourniquet use (Ramos et al 2007).

CONCLUSION

The advantages of arthroscopic surgery are clear when compared to traditional open surgery. Patients recover faster and can quickly resume their normal daily activities. Procedures can be done on a day case basis, and in general are more readily accepted by patients than an in-patient arthrotomy, thus facilitating earlier intervention. Day surgery is also more economical as patients spend less time in hospital and return to work sooner.

In the current economic climate, the role of diagnostic knee arthroscopy is under review. Although arthroscopy remains the gold standard for the investigation of intra-articular abnormalities with the potential benefit of intervention, MRI provides a less invasive, highly accurate and more cost-effective alternative and has a role as a screening tool prior to therapeutic arthroscopy. In the non-acute setting, when used in combination with a full history and clinical examination, MRI can obviate the need for arthroscopy, saving costs and preventing unnecessary risk.

Knee arthroscopy is indicated in the diagnosis and treatment of a variety of knee pathology. A thorough understanding of the principles and techniques of knee arthroscopy and evidence-base is crucial to a successful outcome and low complication rate.

REFERENCES

Ahn JH, Yoo JC, Lee SH 2007, Arthroscopic loose-body removal in posterior compartment of the knee joint: a technical note. Knee Surgery, Sports Traumatology, *Arthroscopy* 15 (1) 100-106.

Aiello D 1986. Arthroscopy of the knee, A perioperative nursing challenge. *AORN Journal* 43 (4) 824-827

Allum R 2002. Complications of arthroscopy of the knee, Journal of Bone and Joint Surgery. *British Volume* 84 (7) 937-945.

Bert J, Giannini D, Nace L 2007, Antibiotic prophylaxis for arthroscopy of the knee: is it necessary? *Arthroscopy* 23 (1) 4-6.

Buckenmaier C 3rd 2002 Anaesthesia for outpatient knee surgery Best Practice & Research. *Clinical Anaesthesi,ology* 16 (2) 255-270.

Burkhart SS 2003, *Operative arthroscopy 3rd ed*. Philadelphia, Lippincott Williams & Wilkins.

Campbell W, Canale S 2003, *Campbell's operative orthopaedics 10th ed*. St Louis, Mosby.

Crawford R, Walley G, Bridgman S, Maffulli N 2007, Magnetic resonance imaging versus arthroscopy in the diagnosis of knee pathology, concentrating on meniscal lesions and ACL tears: systematic review. *British Medical Bulletin* 84 5-23.

Dandy D, O'Carroll P 1982, The removal of loose bodies from the knee under arthroscopic control. Journal of Bone and Joint Surgery. *British Volume* 64 (4)473-474.

Dandy D 1986, Arthroscopy: the endoscopy of joints. *British Medical Bulletin* 42 (3) 301-306.

Dandy D 1997, Arthroscopy and MRI for the knee Journal of Bone and Joint Surgery. *British Volume* 79 (4) 520.

DeHaven K 1990, Decision-making factors in the treatment of meniscus lesions. *Clinical Orthopaedics and Related Research* 252 49-54.

Friemert B, Oberlander Y, Schwarz W, Haberle HJ, Bahren W, Gerngross H, Danz B 2004, Diagnosis of chondral lesions of the knee joint: can MRI replace arthroscopy? A prospective study Knee Surgery, Sports Traumatology, *Arthroscopy* 12 (1) 58-64.

Gold D, Schaner P, Sapega A 1995, The posteromedial portal in knee arthroscopy: an analysis of diagnostic and surgical utility. *Arthroscopy* 11 (2) 139-145.

Jackson R, Abe I 1972, The role of arthroscopy in the management of disorders of the knee. An analysis of 200 consecutive examinations Journal of Bone and Joint Surgery. *British Volume* 54 (2) 310-322.

Jacobsen E, Forssblad M, Rosenberg J, Westman L, Weidenhielm L 2000, Can local anaesthesia be recommended for routine use in elective knee arthroscopy? A comparison between local, spinal, and general anaesthesia. *Arthroscopy* 16 (2) 183-190.

Jaiswal PK, Wong K, Khan WS (2010). Current cell based strategies for knee cartilage injuries. *J Stem Cells*. 5(4):177-85.

Jaiswal PK, Wong K, Khan WS (2011). Operative Treatment of Knee Cartilage Injuries: A Review of the Current Literature on Non-Cell-Based and Cell-Based Therapies. *Br J Med Med Res*. 1(4): 516-537.

Katz J, Gomoll A 2007, Advances in arthroscopic surgery: indications and outcomes. *Current Opinion in Rheumatology* 19 (2) 106-110.

Khan WS, Jones RK, Nokes L, Johnson DS 2007, How accurate are lockable orthotic knee braces? An objective study with the use of gait analysis. *The Knee* 14 (6) 497-499.

Khan WS, Hardingham TE 2010, *Stem Cell Applications and Cartilage Tissue Engineering Approaches in Orthopaedic Surgery*. New York, Nova Science Publishers.

Khan WS, Johnson DS, Hardingham TE 2010, The potential use of stem cells for knee articular cartilage repair. *The Knee* 17 (6) 369-374.

Kim TK, Savino RM, McFarland EG, Cosgarea HJ 2002, Neurovascular complications of knee arthroscopy. *The American Journal of Sports Medicine* 30 (4) 619-629.

Koval K, Zuckerman J 2004, *Atlas of orthopaedic surgery: a multimedia reference* Philadelphia, Lippincott Williams & Wilkins.

Kurzweil P 2006, *Antibiotic prophylaxis for arthroscopic surgery Arthroscopy* 22 (4) 452-454.

Law BK, Yung PS, Ho EP, Chang JJ, Kwok GK, Fung KY, Chan KM 2009, Review of knee arthroscopy performed under local anesthesia. *Sports Medicine, Arthroscopy, Rehabilitation, Therapy & Technology* 1 (1) 3.

Malik AA, Khan WS, Chaudhry A, Ihsan M, Cullen NP 2009, Acute Compartment Syndrome- A Life and Limb Threatening Surgical Emergency. *Journal of Perioperative Practice* 19 (5) 137-142.

Marx RG 2000, Tourniquet use during arthroscopy did not adversely affect patient outcomes. *Journal of Bone and Joint Surgery*. American Volume 82 (9) 1325.

Marx RG 2008, Arthroscopic surgery for osteoarthritis of the knee? *The New England Journal of Medicine* 359 (11) 1169-1170.

McKeon B, Bono JV, Richmond JC 2009, Knee Arthroscopy New York, Springer Noble J 1992 Unnecessary arthroscopy. *Journal of Bone and Joint Surgery*. British Volume 74 (6) 797-798.

Minocha A, Khan WS (2014). *Knee osteoarthritis: review of treatment options*. GM: Midlife & Beyond. 44(9): 88-91.

Nutton RW 2009, Is arthroscopic surgery a beneficial treatment for knee osteoarthritis? Nature Clinical Practice. *Rheumatology* 5 (3) 122-123.

O'Donnell B, Iohom G 2008, Regional anesthesia techniques for ambulatory orthopedic surgery. *Current Opinion in Anaesthesiology* 21 (6) 723-728.

Ong E, Chimutengwende-Gordon M, Khan W (2013). Stem cell therapy for knee ligament, articular cartilage and meniscal injuries. *Curr Stem Cell Res Ther*. 8(6): 422-8.

Onyema C, Oragui E, White J, Khan WS (2011). Evidence-based practice in arthroscopic knee surgery. *J Perioper Pract.* 21(4): 128-134.

Oragui E, Parsons A, White T, Khan WS, Longo UG. Tourniquet Use in Upper Limb Surgery. *Hand* (NY) (in press).

Pasa L, Visna P 2005, Suture of meniscus. *Scripta Medica* 78 (3) 135-150.

Ramos J, Perrotta C, Badariotti G, Berenstein G 2007, Interventions for preventing venous thromboembolism in adults undergoing knee arthroscopy. *Cochrane Database of Systematic Reviews* (online) 18 (2):CD005259.

Siparsky P, Ryzewicz M, Peterson B, Bartz R 2007, Arthroscopic treatment of osteoarthritis of the knee: are there any evidence-based indications? *Clinical Orthopaedics and Related Research* 455 107-112.

Spahn G, Kahl E, Mückley T, Hoffman GO, Klinger HM 2008, Arthroscopic knee chondroplasty using a bipolar radiofrequency-based device compared to mechanical shaver: results of a prospective, randomized, controlled study. *Knee Surgery, Sports Traumatology, Arthroscopy* 16 (6) 565-573.

Stuart MJ, Lubowitz JH 2006, What, if any, are the indications for arthroscopic debridement of the osteoarthritic knee? *Arthroscopy* 22 (3) 238-239.

Vincken PW, ter Braak AP, van Erkel AR et al 2007, MR imaging: effectiveness and costs at triage of patients with nonacute knee symptoms. *Radiology* 242 (1) 85-93.

Wakai A, Winter DC, Street JT, Redmond PH 2001, Pneumatic tourniquets in extremity surgery. *The Journal of the American Academy of Orthopaedic Surgeons* 9 (5) 345-351.

In: Encyclopedia of Surgery (22 Volume Set)
Editors: Andreas Lehrer and Kristin Mueller
ISBN: 978-1-53618-329-0
© 2020 Nova Science Publishers, Inc.

Chapter 387

THE ROLE OF NAVIGATION IN TOTAL KNEE REPLACEMENT SURGERY

James Min-Leong Wong, Wasim S. Khan* and Joyti Saksena
Department of Trauma and Orthopaedics, Chase Farm Hospital,
Royal Free Hospitals NHS Trust, Enfield, Middlesex, UK

ABSTRACT

Since the introduction of modern implants in the 1970's, Total Knee Replacement surgery has been a great clinical and commercial success. Implants and techniques have continued to evolve, driven by the desire for improved function and longevity. However, inaccurate insertion of these implants may cause them to loosen and fail. Computer navigation has been introduced as a modification to existing surgical techniques to improve the accuracy with which the bones are cut prior to inserting the knee replacement implants. Research continues to see if this potentially costly and time consuming technique can contribute to improved longevity of knee replacements.

Keywords: total knee replacement; navigation; implants; accuracy; longevity; computer

INTRODUCTION

This chapter deals with the role of navigation in Total Knee Arthroplasty, or Replacement (TKR) surgery (Wong et al 2012). Over the past 20 years TKR surgery has enjoyed great clinical and commercial success. Modern implants have been shown to have excellent long term results (Berger 2001, Rodriguez 2001, Laskin 2001) with a high level of patient satisfaction (Ethgen 2004, Noble 2006, Bourne 2010). The most recent published National Joint Registry figures show almost 80,000 TKR's were performed in the UK alone in 2009/10

* Corresponding Author's Email: wasimkhan@doctors.org.uk.

(NJR 2010). This figure is expected to rise, with some estimates projecting a 673% increase from 2005 levels by the year 2030 (Kurtz 2007).

Although better implant designs, materials and patient education has improved the longevity of implants, some knee replacements, due to a combination of surgical, patient and implant factors, do fail. The most common cause for a TKR requiring revision is infection, followed by aseptic loosening and wear (Hossain 2010). Although some of these causative factors for failure are out of the surgeon's control, malpositioning of implants, which can lead to aseptic loosening and early failure (Lotke 1977, Tew 1985, Ritter 1994), is. The final position of the tibial and femoral components of a knee replacement are strongly influenced by the cuts the surgeon makes in these bones, resecting the arthritic articular surfaces and preparing them to accept the knee prosthesis. The accuracy of these cuts will affect the ultimate alignment and stability of the prosthetic joint, in addition to soft tissue and ligament balancing.

Computer assisted surgery, or navigation, has been developed to improve the accuracy of these cuts. An increasing number of navigation options are now commercially available, usually designed by implant manufacturers to be used solely with a specific knee implant system. Despite ongoing advances, the use of these systems has thus far been limited as they are cumbersome and time consuming to use, as well as costly.

The vast majority of TKR implants in use today are versions of the "condylar" knee replacements developed in the 1970's. The introduction of this design resulted in not only a marked improvement in results and longevity, but also reproducibility. Jigs and guides were introduced to enable the surgeon to reliably determine the orientation and alignment of the tibia and femur, and use this to guide his subsequent bony cuts. Most knee systems utilise a combination of intramedullary and extramedullary instrumentation, together with extensive visual referencing, to guide appropriate resection of bone.

Figure 1. A modern knee replacement prosthesis. (Picture reproduced courtesy of Zimmer Inc., Warsaw, Indiana USA).

Condylar knee replacements incorporate an anatomically shaped femoral component, with an anterior flange to articulate with the patella. The cobalt chrome femoral component articulates with a polyethylene tibial insert, which is usually attached to a titanium tibial component (Fig 1). Inserting these implants involves resection of the bone ends to create parallel and equal spaces in flexion and extension, and then balancing the soft tissues to convey stability.

These implants are usually cemented in place using acrylic polymethylmethacrylate cement, but can be coated in materials which enable an uncemented, biological fixation.

The majority of surgeons are guided in cutting the femur with the aid of intramedullary guide. A rod is inserted up the femoral canal, thus defining its anatomical axis. A cutting jig is then applied to this rod, enabling the distal femur to be cut in at the desired angle relative to the anatomical axis of the femur.

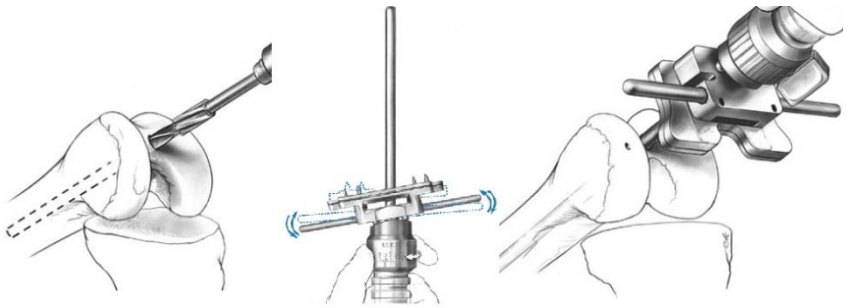

Figure 2. Intramedullary femoral instrumentation. A drill is passed up the intramedullary femoral canal, approximating the anatomical axis. Cutting the distal femur is guided by a rod passed up the drill hole and a cutting jig set to resect bone. This is usually set at 5-7 degrees from the estimated anatomical axis (Images courtesy of Zimmer Inc. Warsaw, Indiana).

Cutting guides are then applied to allow further bone cuts to be made to accommodate the anatomically shaped femoral component, with the majority of surgeon's using a guide which enables them to place these cuts in 3 degrees of external rotation relative to the posterior femoral condyles.

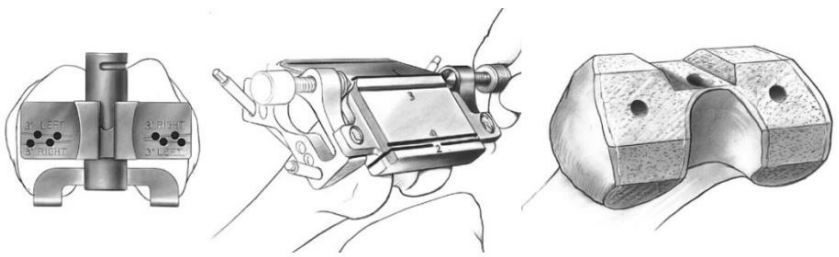

Figure 3. Further femoral instrumentation determine the size and rotation of the femoral component and then guide further bone cuts (Images courtesy of Zimmer Inc. Warsaw, Indiana).

When cutting the tibial component, many surgeons use extramedullary instrumentation, placing an alignment guide parallel to the tibia, and cutting the tibia in a plane perpendicular to this.

Once these cuts have been made to the surgeon's satisfaction, the gap between the cut femoral and tibial surfaces is checked to ensure a symmetrical gap in flexion and extension. If the gap is found to be asymmetrical, it is corrected by a combination of soft tissue releases or further bony cuts. Only after the soft tissues have been appropriately balanced are the implants inserted and secured in place.

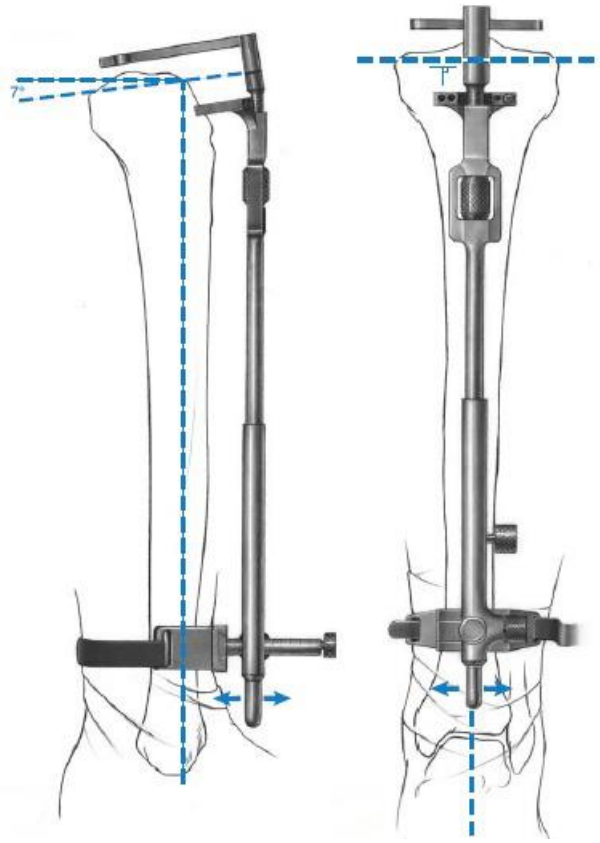

Figure 4. Extramedullary tibial instrumentation. This guide is placed on the anterior surface of the tibia. The mechanical axis is estimated by placing this guide over anatomical landmarks and a cutting jig is then applied to guide bone cuts perpendicular to this (Images courtesy of Zimmer Inc. Warsaw, Indiana).

The Need for Navigation

The conventional instrumentation described above is largely similar amongst manufacturers and has not changed significantly over the past 20 years. Even in experienced hands, using conventional instrumentation to guide bone resection can still result in component malposition. It is estimated that up to 10% of total knee replacements have significant (> 3 degrees) errors in mechanical alignment (Stulberg 2002). Mechanical axis malalignment has been proven to adversely affect implant function and survival (Jeffery 1991, Ritter 1994, Wasielewski 1994), particularly if the erroneous bony cuts result in a significant varus deformity (Jeffery).

Figure 5. Preoperative long leg and lateral xrays of a patient previously affected by rickets and previous bilateral total hip replacements. The bowed femurs and hip replacements make femoral intramedullary instrumentation difficult.

Furthermore, the use of conventional instrumentation to accurately resect bone can be technically very difficult in the presence of abnormal patient anatomy, poor exposure and preoperative bone loss. There are occasions when using intramedullary instrumentation is not possible at all. For example patients with previous trauma and residual bony deformity, or with pre-existing metal implants such as a total hip replacement, which may prevent the use of an intramedullary guide.

At a time when TKR's are now being performed in ever younger and more demanding patients, there is a need to improve the accuracy of existing surgical techniques, in the hope this will maximise the longevity and function of these implants. Computer assisted, or navigated, surgery is a technique previously well known in neurosurgery to guide precise surgery. It has now been adapted to aid the accurate implantation of total knee replacements.

Navigation Systems

Various types of navigated surgical systems are now available. Most are produced by manufacturers of total knee replacement implant systems and are generally recommended to be used with specific TKR implants. All these systems develop a three dimensional model of

the patient's knee and maps the position of the surgeon's instruments in relation to this model. This can then be used to guide the surgeon to make accurate bony cuts.

Image-guided navigated systems utilise data obtained preoperatively or intraoperatively to build a three dimensional model of the knee which is then used to guide bony cuts. Most of these systems utilise preoperative imaging, usually in the form of CT scans, but some also use intraoperative fluoroscopy to map anatomical landmarks.

(A)

(B)

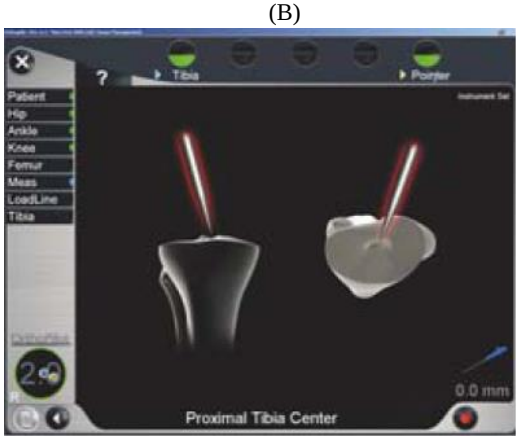

(C)

Figure 6. (Continued).

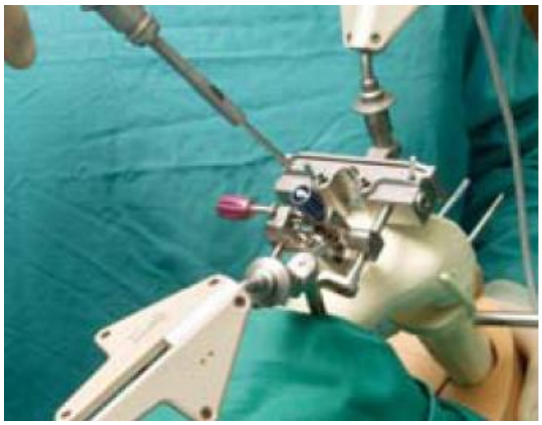

(D)

(E)

Figure 6. A. An example of an imageless navigation system. Reflective markers are drilled into the femur and tibia (3), and their location is detected by an infrared (2) camera attached to a computer (1). B,C. A stylus with another reflective marker attached is then used to register multiple anatomical landmarks to enable the computer to develop a three-dimensional model of the knee D. Cutting guides with a further reflective marker attached are then placed on the knee. E. The monitor display is used to guide the positioning, angulation and rotation of the cutting guide to ensure that the bone is accurately cut. (Images courtesy of B Braun Inc, Tuttlengen, Germany).

Once the computer has developed a three dimensional model of the patient's lower limb, bone cuts can then be accurately planned. Navigation systems can then use this information intraoperatively. The position of the patient's knee is registered into the navigation system, which then correlates this with the three dimensional model. The most common means of doing this is the use of reflective markers which are drilled into the femur and tibia, and a further marker which can be placed on surgical instruments and cutting jigs. Infrared cameras which are coupled to an emitter and the navigation computer can track the movements of the markers drilled into bone and marked surgical instruments relative to each other. The computer can thus guide the surgeon to ensure that the cutting jigs are deployed in exactly the correct position.

A variation of this approach is an imageless navigation system. This is also called morphing surface navigation and utilizes a large database of knee CT scans. Once the markers have been drilled into the femur and tibia, a marked stylus is used to register multiple

anatomical landmarks (figure 6). The computer system then uses the information on its database to build or morph a three dimensional model of the patient's knee which fits the registered anatomical landmarks.

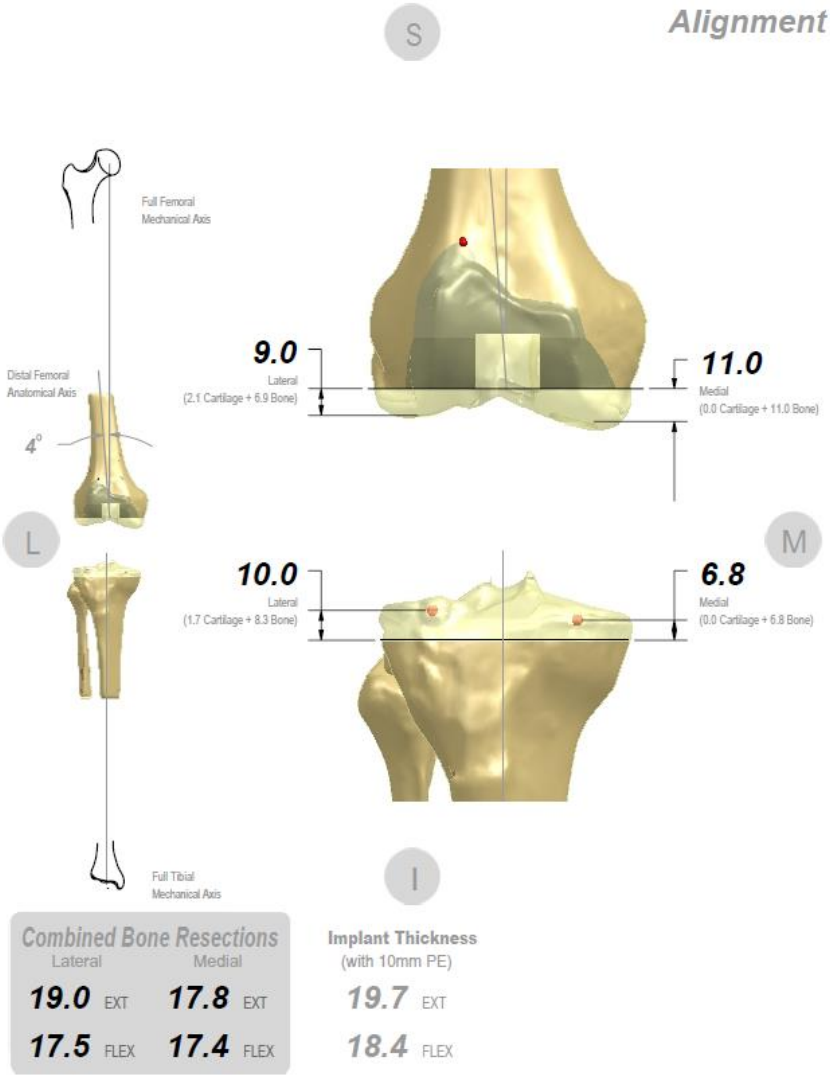

Figure 7. A three-dimensional model of the knee has been produced based on a patient's CT scan, allowing the desired cuts to be planned by the surgeon prior to surgery. (Image courtesy of Depuy Orthopaedics Inc., Warsaw, Indiana).

It should be recognised that all of these systems increase the operative time required to perform a knee replacement (Weng 2009). Furthermore, in the current health economy the cost of installing and maintaining these systems may prove prohibitive, with one author estimating the cost of purchasing the computer system and software approaches $150,000, with a further $20,000 a year spent on maintenance. These factors have limited the use of navigated systems, particularly at a time when the need for increased efficiencies and cost reduction in operating theatres is being stressed.

Customised Patient Instrumentation

The next evolution of navigated knee surgery is the manufacture of instrumentation or cutting guides to specifically fit an individual patient. These systems involve building a model of the knee based on preoperative CT or MRI scans and taking images of the hip and ankle to determine mechanical alignment. The ideal cuts are planned by the surgeon based on this model (Figure 7) and then custom designed cutting blocks are manufactured using three-dimensional printing techniques to fit that individual patient's knee and produce the planned cuts. Some of these systems produce patient specific cutting guides that fit directly onto a patient without the need for any conventional instrumentation, others guide the placement of pins into the bone, and conventional cutting blocks are then passed over these pins (Figure 8).

Figure 8. Customised patient specific instruments are manufactured to fit over the patient's bone and guide a saw blade to accurately.

This strategy has the advantage of being a faster procedure, with reduced tourniquet times when compared with conventional knee replacement surgery (Hafez 2006). There is no need to drill markers into the tibia and femur, as the time consuming anatomical landmark registration is no longer necessary and, unlike conventional knee replacements, no intra- or extra-medullary guides are required. All patients will however, need to undergo a preoperative CT or MRI, and this, combined with the need to manufacture cutting guides for each procedure, does mean that there is a lead time for each surgery and an added cost.

RESULTS

Multiple prospective randomised controlled trials have now been performed comparing various navigated systems with conventional total knee replacements. Many have shown significant improvements in coronal alignment (Mullaji 2007, Dutton 2008), with better restoration of the mechanical axis of the limb on post operative radiographs. CT scans have

also been used to assess postoperative implant position showing improved accuracy in the coronal (Mizu-uchi 2008, Hernandez-Vacquero 2010) and sagittal planes (Chauhan 2004, Matziolis 2007).

Two of these trials also showed significantly improved rotational alignment of implanted prostheses (Chauhan 2004, Mizu-uchi 2008). Other trials, however, have showed no difference in alignment and rotation (Kim 2007, Lutzner 2008), although one of these did show a reduction in large deviations of mechanical axis in the navigated group. It should be noted that errors in alignment have not been completely eradicated by navigation, and errors in inserting and cementing implants in place has been shown to cause malpositioning despite perfect bony cuts (Catani 2008)

Studies have also investigated the potential improved accuracy of navigation in the presence of significant deformity.

When used in the presence of significant femoral bowing in a Taiwanese population, navigated TKR's were found to be significantly better at reproducing a normal mechanical axis than conventional TKR (Huang 2011). A further study also showed improved leg alignment when performing navigated TKR's in the presence of large frontal plane deformities (Hernandez-Vacquero 2010).

With an increasing number of trials available, two META-analyses have now been published, with mixed results. Whilst one has shown significantly improved alignment and rotational orientation when compared to conventional TKR (Mason 2007), another showed no overall difference in alignment, but a decrease in critical deviations from the mechanical axis in excess of 3 degrees (Bauwens 2007).

Whether these improvements in accuracy will translate to improved function and implant survival, however, remains to be seen. A functional analysis of patients at two years post surgery has shown no difference in clinical outcome between navigated and conventional TKR's (Spencer 2007). As yet, no studies have been able to demonstrate a survival benefit for Navigated TKR's.

A further study has investigated whether the added cost of navigation (an estimated $1500 per operation) is justified (Novak 2007). The argument was made that the improved alignment will reduce the need for a potentially very costly early revision procedure, and this study concluded that navigated surgery was a cost-saving and cost-effective modification to conventional total knee replacement.

CONCLUSION

Whilst excellent results continue to be reported for the vast majority of total knee replacement implants, even the best implants can fail due to malpositioning. Using conventional instrumentation, significant errors in position can occur in up to 10% of patients. Navigated knee replacement systems have been devised to reduce the amount of error in implant positioning.

Despite advances in navigation technology, however, many surgeons still find these systems cumbersome and time-consuming to use. They are, of course, also expensive to acquire and may require additional CT or MRI scans. As a result, navigated knee replacement systems have not entered widespread use.

Customised patient instrumentation may achieve more widespread acceptance, although these systems are still in their infancy and long term results are yet to be published.

It should also be remembered that TKR is not just a procedure on bony abnormality, but also a procedure to correct soft tissue imbalances. Despite many studies showing improved alignment none have as yet shown a functional improvement or improved implant survival.

As navigation continues to improve, its role in future knee replacement will become clearer. Whether this role is its involvement in all total knee replacements, or limited to difficult patients with distorted anatomy, is dependent on future clinical results, improvements to navigated systems and of course the long term health economy.

REFERENCES

Bauwens K, Matthes G, Wich M, Gebhard F, Hanson B, Ekkernkamp A, Stengel D. Navigated total knee replacement. A meta-analysis. *Journal of Bone and Joint Surgery* [Am]. 2007; 89:261-9.

Berger RA, Rosenberg AG, Barden RM, Sheinkop MB, Jacobs JJ, Galante JO. Long-term followup of the Miller-Galante total knee replacement. *Clin Orthop Relat Res*. 2001;388:58–67.

Bourne RB, Chesworth BM, Davis, AM, Mahed NN, Charon KDJ. Patient Satisfaction after Total Knee Arthroplasty. *Clinical Orthopaedics & Related Research*. 2010; 468:57–63.

Catani F, Biasca N, Ensini A, Leardini A, Bianchi L, Digennaro V, Giannini S. Alignment deviation between bone resection and final implant positioning in computer-navigated total knee arthroplasty. *Journal of Bone and Joint Surgery* [Am]. 2008;90:765-71.

Chauhan SK, Scott RG, Breidahl W, Beaver RJ. Computer-assisted knee arthroplasty versus a conventional jig-based technique: a randomised, prospective trial. *J Bone Joint Surg Br*. 2004;86: 372–377.

Dutton AQ, Yeo S-J, Yang K-Y, Lo N-N, Chia K-U, Chong H-C. Computer-Assisted Minimally Invasive Total Knee Arthroplasty Compared with Standard Total Knee Arthroplasty A Prospective, Randomized Study. *Journal of Bone and Joint Surgery* [Am]. 2008;90:2-9.

Erik J. Novak, Marc D. Silverstein and Kevin J. Bozic The Cost-Effectiveness of Computer-Assisted Navigation in Total Knee Arthroplasty. *J Bone Joint Surg Am.* 2007;89:2389-2397 156.

Ethgen O, Bruyère O, Richy F, Dardennes C, Reginster JY. Health-related quality of life in total hip and total knee arthroplasty. A qualitative and systematic review of the literature. *J Bone Joint Surg Am*. 2004;86:963-74.

Hafez MA, Chelule KL, Seedhom BB and Sherman KP. Computer-assisted Total Knee Arthroplasty Using Patient-specific Templating. *Clinical Orthopaedics and Related Research* 2006; 444: 184–192.

Hernandez-Vaquero MD, Suarez-Vazquez A , Sandoval-Garcia M, Noriega-Fernandez A. Computer Assistance Increases Precision of Component Placement in Total Knee Arthroplasty with Articular Deformity. *Clin Orthop Relat Res* (2010) 468:1237–1241.

Hossain F, Patel S, Haddad FS. Midterm Assessment of Causes and Results of Revision Total Knee Arthroplasty. *Clin Orthop Relat Res*. 2010 468:1221–1228.

Huang TW, Hsu WH, Peng KT, Hsu RWW Total knee replacement in patients with significant femoral bowing in the coronal plane. *J Bone Joint Surg* [Br] 2011;93B:345-50.

Jeffery RS, Morris RW, Denham RA. Coronal alignment after Total Knee Replacement. JBJS [Br] 1991 73B: 709-14

Kim YH, Kim JS, Yoon SH. Alignment and orientation of the components in total knee replacement with and without navigation support *J Bone Joint Surg* [Br] 2007;89-B:471-6.

Kurtz S, Ong K, Lau E, Mowat F, Halpern M. Projections of primary and revision hip and knee arthroplasty in the United States from 2005 to 2030. *Journal of Bone and Joint Surgery [Am]*. 2007;89:780-5.

Laskin RS. The Genesis total knee prosthesis: a 10-year followup study. *Clin Orthop Relat Res*. 2001;388:95–102.

Lotke PA, Ecker ML. Influence of positioning of prosthesis in total knee replacement. *J Bone Joint Surg Am*. 1977;59:77-

Lützner J, Krummenauer F, Wolf C, Günther P, Kirschner S. Computer-assisted and conventional total knee replacement. *J Bone Joint Surg* [Br] 2008;90-B:1039-44.

Mason JB, Fehring TK, Estok R, Banel D, Fahrbach K. Meta-analysis of alignment outcomes in computer-assisted total knee arthroplasty surgery. *J Arthroplasty*.2007;22:1097-106.

Matziolis G, Krocker D, Weiss U, Tohtz S, Perka C. A prospective, randomized study of computer-assisted and conventional total knee arthroplasty. Three dimensional evaluation of implant alignment and rotation. *Journal of Bone and Joint Surgery* [Am]. 2007;89:236-43.

Mizu-uchi H., Matsuda S., Miura H., Okazaki K., Akasaki Y., Iwamoto Y. The evaluation of post-operative alignment in total knee replacement using a CT-based navigation system. *J Bone Joint Surg* [Br] 2008;90-B:1025-31

Mullaji A, Kanna R, Marawar S, Kohli A, Sharma A. Comparison of limb and component alignment using computer-assisted navigation versus image intensifier guided conventional total knee arthroplasty: a prospective, randomized, single surgeon study of 467 knees. *J Arthroplasty*. 2007;22:953-9.

No authors listed. *National Joint Registry for England and Wales: Summary Report the 7th Annual Report*. 2010. http://www. njrcentre.org.uk (date last accessed 20 October 2010).

Noble PC, Conditt MA, Cook KF, Mathis KB. The John Insall Award: Patient expectations affect satisfaction with total knee arthroplasty. *Clinical Orthopaedics & Related Research.* 2006; 452:35-43.

Ritter MA, Faris PM, Keating EM et al. Postoperative alignment of total knee replacement. Its effect on survival. *Clinical Orthopaedics & Related Research*.1994;299:153.

Ritter MA, Faris PM, Keating EM et al. Postoperative alignment of total knee replacement. Its effect on survival. *Clinical Orthopaedics & Related Research*.1994;299:153.

Rodriguez JA, Bhende H, Ranawat CS. Total condylar knee replacement: a 20-year followup study. *Clin Orthop Relat Res*. 2001; 388:10–17.

Spencer JM, Chauhan SK, Sloan K, Taylor A, Beaver RJ Computer navigation *versus* conventional total knee replacement. *J Bone Joint Surg* [Br] 2007;89-B:477-80.

Stulberg SD, Loan P, Sarin V (2002) Computer-assisted navigation in total knee replacement: results of an initial experience in thirty-five patients. *J Bone Joint Surg Am* 84-A(Suppl 2):90–98.

Tew M, Waugh W. Tibiofemoral alignment and the results of knee replacement. *J Bone Joint Surg Br*. 1985;67:551-6.

Wasielewski RC, Galante JO, Leighty R, et al. Wearpatterns on retrieved polyethylene inserts and their relationship to technical considerations during total knee arthroplasty. *Clin Orthop Relat Res* 1994;299:31.

Weng YJ, Hsu RW, Hsu WH. Comparison of computer-assisted navigation and conventional instrumentation for bilateral total knee arthroplasty. *J Arthroplasty*. 2009;24(5):668-673.

Wong JM, Khan WS, Saksena J (2013). The Role of Navigation in Total Knee Replacement Surgery. *J Periop Pract*. 23(9): 202-7.

In: Encyclopedia of Surgery (22 Volume Set)
Editors: Andreas Lehrer and Kristin Mueller
ISBN: 978-1-53618-329-0
© 2020 Nova Science Publishers, Inc.

Chapter 388

SPLENECTOMY AS PART OF CYTOREDUCTIVE SURGERY FOR ADVANCED STAGE AND RELAPSED OVARIAN CANCER

N. Bacalbasa[1,*] and Irina Balescu[2]
[1]"Carol Davila" University of Medicine and Pharmacy, Bucharest
[2]Ponderas Hospital, Bucharest, Romania

ABSTRACT

Ovarian cancer is the second most common gynecologic malignancy among women worldwide after endometrial cancer and the most common cause of death in women with gynecologic malignancies. Because of the increasing life expectancy experienced worldwide it is estimated that the incidence of this aggressive disease will significantly increase in the next few decades. Among all cases diagnosed with ovarian cancer the histopathological subtype consisting of epithelial tumors represents the largest part and has been widely studied. However, there is still an important number of patients who are diagnosed in an advanced stage of the disease, when disseminated bulky tumors are already present. It has been demonstrated that the most frequent patterns of spread are represented by the peritoneal, hematogenous and lymphatic route, all of them being responsible in different proportions for the presence of upper abdominal burden which sometimes is present from the moment of initial diagnosis. In all these cases the therapeutic mainstay remains cytoreductive surgery, followed by taxanes and platinum based adjuvant chemotherapy. When it comes to long term outcomes, among various prognostic factors such as age, stage at diagnosis, histopathological subtype, differentiation grade and residual disease, only residual disease has been widely demonstrated to strongly impact survival; at the same time, the amount of residual tumor burden at the end of debulking surgery is the only parameter which is influenced by the treating physician's experience. The presence of upper abdominal disseminations has been considered for a long period of time to be the sign of a tumor with a more aggressive biology and was considered as a poor prognostic factor. The main invaded organs in the upper abdomen consist of liver and porta hepatis, diaphragm, and less

* Corresponding Author's Email: nicolae_bacalbasa@yahoo.ro.

common, the spleen. While in cases presenting hepatic involvement the presence of hematogenous disease has been accepted as a poor prognosis factor and was classified the disease as FIGO stage IV, there was no explicit specification whether parenchimatous splenic involvement should be classified as part of the same FIGO stage. Initially a poorer outcome was reported for patients submitted to splenectomy as part of debulking surgery for advanced stage epithelial ovarian cancer, this fact being related to a more aggressive biological behaviour of the tumor. Other studies have stipulated the fact that the presence of splenic metastases is an independent poor prognosis factor but they could not distinguish whether the poorer outcome is related to the presence of hematogenous involvement of the upper abdominal parenchimatous viscera or to the co-existence of bulky left quadrant upper abdominal tumoral burden.

However, the initial results were strongly influenced by the small number of cases included and by the different characteristics of the included patients. For example patients submitted to splenectomy as part of primary and secondary cytoreduction were included in the same study so the results were also influenced by the moment of performing the surgery.

More recently, a significant difference in terms of survival was reported for hematogenous versus peritoneal splenic metastases and concluded that their presence should be considered as an explicit criterion for FIGO stage IV disease. Although it is a safe and effective surgical procedure, performing a splenectomy as part of cytoreductive surgery for advanced stage or relapsed ovarian cancer might associate a higher rate of postoperative morbidity rather due to the fact that in these cases ovarian cancer becomes a systemic disease with multiple visceral involvements, imposing multiple visceral resections in order to achieve an R0 resection; in all these cases the postoperative outcomes are influenced by a cumulative postoperative risk related to each performed resection in part.

However, since splenectomy can be safely performed with acceptable rates of postoperative complications it should be routinely performed in cases presenting splenic tumoral involvement in order to increase the rate of complete cytoreduction. This chapter focuses on the patterns of spread, prognostic factors of patients with splenic involvement, safety and effectiveness of splenectomy as part of cytoreductive surgery for advanced stage and relapsed epithelial ovarian cancer.

INTRODUCTION

Splenic tumors usually develop in the context of lymphoreticular malignancies, while most commonly splenic involvement from solid tumors occurs in breast, lung, melanoma, colorectal, gastric and ovarian cancer [1, 2, 3]. In the majority of cases splenic metastases from solid tumors occur in the context of disseminated hematogenous spread and are associated with other visceral tumoral lesions [1]. The prevalence of splenic metastases from solid tumors is mainly obtained from large autopsy studies and range between 2.3-7.4%, the largest investigated series being conducted by Berge who reported 312 splenic metastases among 7165 autopsies for cancer [1]. In the last decades large studies on living patients have been conducted and reported that the splenic tumoral involvement (determined by histopathological studies of the splenectomy specimen) occurs in 1.1-1.3% of cases while the incidence of splenic metastases at preoperative imagistic studies is up to 0.15% (in a Japanese study conducted on 24761 patients 37 cases were diagnosed ultrasonographically with splenic involvement) [4, 5]. The rarity of splenic tumoral involvement is explained through multiple mechanisms: inhibitory influence of the splenic microenvironment on neoplastic cells, the

sharp angle and tortuosity of the splenic artery which associates a modified blood flow through the splenic vasculature, the lack of splenic lymphatic afferents, the rhythmic contractility and the role of barrier of the splenic capsule [2, 3, 6-8].

When it comes to splenic involvement in advanced stage ovarian cancer, three patterns of spread have been advocated: hematogenous, peritoneal and lymphatic way. However, tumor cell metastasis involves multiple mechanisms including disconnection of the tumor cell from the solid tumor, invasion of the malignant cells into the blood, lymphatic flow or ascites, escape from the immunological filters, adhesion to endothelial cells, extravasation from the blood or lymphatic flow and angiogenesis induction [9].

PATHWAYS OF SPLENIC INVOLVEMENT

Ovarian cancer metastasizes more likely via intraperitoneal dissemination followed by the hematogenous and lymphatic route. Intraperitoneal spread is influenced by growth factors and cytokines which will induce the epithelial – mesenchymal transition, responsible for the increased motility and invasion ability of the tumoral cells [9]. This transition consists of dramatic phenotypic changes which will provide epithelial to mesenchymal cell conversion. Once malignant cells acquire mesenchymal properties, they will express a higher capacity of adhesion and an increased motility leading to a higher capacity of inducing distant metastases [9]. Recently the epithelial-mesenchymal transition was classified into three distinct categories, only type 3 of transition being considered as part of tumor progression; the other two types are considered to be part of embryogenesis (type 1) and inflammation and tissue damage repair respectively (type 2) [10]. Once a type 3 epithelial-mesenchymal transition occurs, distant metastases are expected. After evading from the ovarian capsule, the malignant cells will become part of the peritoneal fluid and will follow its' normal route into the peritoneal cavity [11]. In the study conducted by Carmingani et al. it has been demonstrated that the malignant cells will be transported by the peritoneal fluid according to physical forces such as intraperitoneal fluid hydrodynamics and gravity; according to this study, preferential tumor seeding will develop in the pelvic space, near the ileocecal valve, along the right paracolic gutter, diaphragm and greater omentum. The diaphragmatic and omental involvement were explained by the presence at this level of lymphatic lacunae on the diaphragmatic peritoneal surface and lymphoid tissue of the greater omentum respectively [12]. In contrast, if the intraperitoneal fluid is reduced, malignant cells are restricted in motion and will implant nearby the primary tumor leading to rectal or urinary bladder invasion [13]. Although it is not a common site of involvement, the spleen can be interested by the development of isolated peritoneal nodules or by contiguity from the greater omentum. In the latter situation involvement occurs by contiguous spread to the attached colon, spleen, gastroc-colic ligament, stomach and even pancreas and necessitates performing of extended left upper quadrant resections in order to provide a local control of the disease [14].

Another pattern of spread is the lymphatic route; however it has been demonstrated that this pathway is rather a secondary route which develops later in the evolution of the disease leading to pelvic and para-aortic lymph node metastases. When it comes to the upper abdomen lymphatic involvement, Feki et al. demonstrated that once the malignant cells disseminate into the greater omentum and diaphragmatic peritoneum, they will migrate

through the milky spots which are mainly found at these levels, pass through the mesothelial barrier and get into the lymphatic flow. The authors also hypothesized that ovarian malignant cells migrate primarily via lymphatics and block the lymphatic clearance of the peritoneum [11]. However the presence of distant lymphatic metastases has been considered as a poor prognostic factor and cases diagnosed with lymph node metastases have been classified as FIGO stage IIIC [15].

As for the hematogenous route of dissemination, although it is less frequently seen, it is associated with the poorest prognostic. Hematogenous route is incriminated whenever parenchymal organ involvement is encountered and has been widely studied in patients with ovarian cancer liver metastases. Hematogenous liver metastases are usually associated with decreased survival even if the principles of radical surgery are applied; these findings enabled the International Federation of Gynecology and Obstetrics to classify these cases as stage IV disease status [16, 17]. When it comes to splenic hematogenous involvement, initially there was no explicit mention whether these patients should be classified as FIGO stage IV, especially due to the low number of cases diagnosed with parenchimatous splenic involvement [18], the reported incidence of splenic metastases at the time of primary cytoreduction ranging between 0 and 41% [19-22].However, FIGO classification presented in 2014 clearly distinghuished between parenchymatous and peritoneal seeding and classified capsular splenic lesions as stage IIIC of the disease while the parenchymatous lesions were classified as FIGO stage IV.

Splenectomy as Part of Debulking Surgery in Advanced Stage Ovarian Cancer with Bulky Upper Abdominal Involvement

It has been widely demonstrated that the best therapeutic option to achieve an increased long term survival in advanced stage ovarian cancer is obtaining a complete cytoreduction with no residual disease. In Bristow's meta-analysis involving 6885 patients diagnosed with advanced stage ovarian cancer each 10% increase in the proportion of patients undergoing maximal cytoreduction was associated with a concomitant 5.5% increase in median cohort survival time [23]. The same study reported that the percentage of patients submitted to optimal cytoreduction widely varies in the literature reported data from 15% to 85%; these differences are mostly related to the presence of extended upper abdominal disease at the time of diagnosis [23]. According to the study conducted by Eisenkop in 2001, the disease sites which are usually associated with incomplete cytoreduction are the diaphragm (in 76.3% of cases), portal triad (in 77.1% of cases), mesentery (in up to 82% of cases) and omentum, spleen and pancreas (in 13% of cases) [24]. The authors included in their study 393 physicians and questioned them regarding the therapeutic strategy and the number of performed procedures in order to achieve complete cytoreduction; in the meantime the responders were asked to define the notion of optimal cytoreduction. A median of 95% of patients were reported to be submitted directly to cytoreductive surgery while in the other 5% of cases neoadjuvant chemotherapy followed by surgery was the treatment of choice. At the question regarding the number of performed procedures as part of debulking surgery, a median value of nine procedures (range 0-15) was reported. When it comes to the definition of optimal cytoreduction, 12% of the responders defined it as no residual disease, 13.7% used a 5 mm threshold, and 60.8% used a 1 cm threshold while 12.6% used a 1.5 – 2 cm threshold.

When questioned about the possibility of performing upper abdominal resections in order to maximize the cytoreductive effort, 60.1% of respondents declared that they excise the omentum en bloc with splenectomy and distal pancreatectomy if necessary, 16.2% do not perform this type of surgery due to the lack of experience and 23.7% do not perform it due to an unacceptable risk of postoperative complications or due to the lack of data establishing the efficacy of the procedure. In the meantime 83.9% of the respondents favoured the development of post-fellowship training in debulking surgery. Those who voted against post-fellowship training also invoked concerns related to the efficacy of multiple resections (p = 0.01) [24].

However, due to the improvement achieved in surgical techniques regarding the upper abdominal resections and in the postoperative management of the patients submitted to extended hepato-bilio-pancreatic surgery, these type of surgical procedures were successfully implemented in the armamentarium of the oncologic surgeon. It has been widely demonstrated that addition of upper abdominal resection provides a significant increase of the rate of complete resection to no residual disease cytoreduction with acceptable rates of postoperative morbidity, so radical surgery in the upper abdomen is widely performed nowadays [25-28].

In the study conducted by Oliver Zivanovic between 1989 and 2005, 490 patients submitted to surgery for FIGO stage IIIC ovarian cancer at Memorial Sloan Kettering Center were introduced [29]. The patients were classified according to the presence of upper abdominal disease in three groups: group 1 – no upper abdominal disease and included 116 cases, group 2 – upper abdominal disease < 1cm and included 161 cases and group 3 – bulky upper abdominal disease and included 197 cases. Optimal cytoreduction was considered whether residual disease was < 1cm and was achieved in 81%, 63% and 39% of cases in groups 1, 2, and 3 respectively ($p < 0.001$). The patients were also stratified according to the time of surgery: before 2001 and after 2001. The distribution of the upper abdominal involvement was similar for both time periods ($p = 0.289$); however the majority of surgical procedures involving upper abdomen resections were performed after 2001 (66 cases were submitted to upper abdominal resections after 2001 compared to 12 cases submitted to upper abdominal procedures before 2001, $p < 0.001$). The rate of optimal cytoreduction was significantly higher after 2001 (40% before 2001 versus 78% after 2001, $p < 0.001$), this effect being more pronounced in patients with bulky upper abdominal disease (11% before 2001 versus 70% after 2001, $p < 0.001$) [29]. In another study conducted by the same author involving 526 patients with stage IIIC ovarian cancer 158 cases had minimal upper abdominal involvement, 243 cases had bulky abdominal involvement while the other 125 cases had no upper abdominal involvement [30]. The authors demonstrated that the long term outcomes were not influenced by the location of the tumoral burden; the most important predictor for an improved outcome remained the completion of the resectional process: patients submitted to suboptimal cytoreductive surgery reported comparable low median progression free survivals (14 months for cases with no upper abdominal disease, 11 months for cases with minimal upper abdominal disease and 13 months for patients with bulky abdominal disease respectively). Although in cases submitted to complete cytoreduction to no residual disease patients with bulky upper abdominal involvement had a poorer outcome when compared to those with no upper abdomen involvement, the benefits of radical surgery were still present, underlining the necessity to maximize the debulking effort whenever is possible [30].

Initially large studies have been conducted on the issue of upper abdominal surgery in advanced stage ovarian cancer and discussed about the benefits of multiple visceral resections including hepatic, diaphragmatic, splenic, pancreatic and upper abdomen lymph node dissection; it has been demonstrated that all these surgical procedures can be safely performed, with acceptable rates of postoperative complications and in the meantime with increased rates of long term survivors [14, 16, 28].

The necessity to perform splenectomy in order to achieve an R0 resection and the complications related to this surgical procedure widely vary between the existing studies. The largest studies which include splenectomy as part of upper abdominal resections are summarized in Table 1.

These data come to suggest that splenectomy was increasingly associated as part of debulking surgery in the last two decades leading to an increased rate of cytoreduction to no residual disease; in the meantime association of splenectomy does not seem to increase the postoperative complications. For example, in the study conducted by Pierluigi Beneditti Panici regarding the predictors of postoperative morbidity after cytoreduction for advanced stage ovarian cancer 121 patients were included, submitted to 212 surgical procedures [33]. At diagnosis 96 patients were diagnosed with FIGO stage IIIC disease while the other 25 cases had FIGO stage IV disease. Upper abdominal metastatic sites included diaphragmatic involvement in 62 cases, liver involvement in 43 cases, stomach in 16 cases, biliary tract and porta hepatis in 24 cases, spleen in 53 cases and pancreatic tail in 14 cases. The main associated resections were diaphragmatic peritonectomies in 28.9% of cases, diaphragmatic resections in 31.4% of cases, glissonian resections in 15.7% cases, liver resections in 13.2% of cases, partial gastrectomies in 9.9% of cases, distal pancreatectomies in 13.2% of cases and splenectomies in 39.6% of cases. When it comes to the extent of cytoreduction, an R0 resection was achieved in 75.1% of cases, while in other 20.7% of cases a residual disease < 1 cm; in the other 4.1% of cases an R2 resection (defined as residual disease > 1 cm) was performed. At univariate analysis diaphragmatic, pancreatic, gastric and splenic resections were associated to a prolonged hospital in stay while in multivariate analysis only diaphragmatic resections and pancreatic resections were associated with a longer hospitalization. Intraoperative and postoperative complications occurred in 29.7% of cases. Intraoperatively the main complication consisted of severe blood loss and was observed after multiple liver resections for disseminated hepatic lesions while postoperatively the complication rate was influenced by the number of associated resections. In multivariate analysis diaphragmatic resections, diaphragmatic peritonectomies, pancreatectomies and hepatic surgery were associated with an overall increased risk of postoperative complications while diaphragmatic, hepatic, pancreatic and biliary tract resections were independent predictors of severe complications. When studying the risk of developing a pleural effusion it was significantly influenced by performing diaphragmatic surgery, hepatic and pancreatic surgery. Although splenectomy was associated with an increased postoperative hospitalization, splenic resection did not predispose to a higher rate of postoperative complications; moreover, the authors also concluded that the surgical procedure with the most severe postoperative complications remains pancreatic resections [33].

Based on the observation that a significant number of patients present bulky upper abdominal disease at the time of diagnosis and necessitate multivisceral en bloc resections, Hoffman et al. conducted a study on six patients submitted to en bloc resection in the left upper abdominal quadrant [14].

Table 1. Studies in which splenectomy was included as part of upper abdomen debulking surgery

Author	Period of the study	Year of publishing the study	No. of cases	No. of performed splenectomies (%)	R0 definition	R0 resection (%)	Postoperative complications	Splenectomy related complications	30 days postoperative mortality
Cliby et al. [31]	1998-2001	2004	41	7 (17%)	Largest residual tumor <1cm	90%	19.6%	NR	2.4%
Chi et al. [27]	1998-2002	2004	140	9 (6.4%)	Residual tumor <1cm	62.8%	5% (Clavien Dindo grade 3-5 complications)	NR	0.71%
Eisenhauer et al. [16]	1998-2003, splenectomy was performed after May 2000	2006	262	17 (6.4%)	No visible residual disease	19.08%	12%	NR	NR
Hoffman et al. [14]	2002-2004	2007	6	6 (100%)	No residual disease	33%	50%	NR	0
Chi et al. [32]	January 2001-December 2006	2010	141	45 (32%)	No gross residual disease	30%	22%	NR	1.4%
Panici et al. [33]	September 2006-May 2014	2015	121	53 (43.8%)	No visible residual disease	75%	29.7%	NR; however splenectomy was not a predictor of severe complications	0

Starting from the hypothesis that almost all women with advanced stage ovarian cancer already have omentum tumor burden which might spread via the ligaments to the surrounding viscera, the authors proposed a en bloc technique of the involved organs in order to achieve an R0 resection: after an initial phase of exploration of the peritoneal cavity mobilization of the involved colic segment is required in order to determine which is the length of bowel which will be resected and how many anastomoses will by necessary. If the splenic flexure is involved by contiguous spread, it will be not mobilized. Than the gastrocolic ligament is dissected close to the stomach providing a good access in the omental bursa; the anterior surface of the pancreas and the splenic vessel are explored. Bulky left abdominal tumor will be removed en bloc with the spleen, pancreatic tail, splenic flexure and parcelar gastrectomy if the stomach is involved. Postoperative complications were described in three patients and consisted of pulmonary embolism associated with a small anastomotic leak in one case, left quadrant abscess in one case and gastric leak requiring re-operation in the third case. The reported disease free survival ranged between 2-12 months, one patient refusing adjuvant chemotherapy. The authors demonstrated the efficacy of en bloc resection in these cases underlining the advantage of a more complete apparent clearance of the tumor compared to piecemeal resection and secondarily a benefit in terms of survival [14].

However, although surgical technique continued to improve in the last decades, there are still cases in which a complete resection to no residual tumor cannot be reached. In the study conducted by Francesco Raspagliesi, 37 patients with advanced stage ovarian cancer with upper abdominal dissemination were included. In 67% of cases omental bursa was involved, consisting of anterior pancreatic surface, caudate lobe, supra-gastric lesser sac, porta hepatis or celiac trunk involvement [28]. Debulking surgery consisted of omental removal en bloc with the lesser omentum, gastro-colic ligament, surface of the pancreas, caudate lobe, celiac lymph nodes and portal nodes. Other associated procedures consisted of splenectomy in 35% of cases, diaphragmatic resections in 21.6% of cases, large bowel resections in 54% of cases or small bowel resections in 18.9% of patients. Splenic spread was present in 12 of the 25 cases presenting omental bursa involvement. In three cases residual disease < 5 mm was present at the end of debulking surgery due to the presence of deep infiltration of porta hepatis or celiac trunk. No postoperative complication was related to the association of splenic resection. The authors demonstrated the importance of omental bursa exploration at the time of cytoreductive surgery in order to achieve a complete resection and concluded that this region could be the „sanctuary" of residual disease which might be responsible to splenic hylum tumoral spread [28].

In a similar study conducted by A. Martinez involving 28 patients with upper abdominal tumor burden complete cytoreduction to no residual disease was achieved in all but one patient who was cytoreduced to millimetric residual disease. Splenectomy was safely associated in 10 cases; major postoperative complications occurred in 35,7% of cases, none of them being related to the association of splenic resection [34].

Other reported factors associated with an improved outcome after cytoreductive surgery for stage IIIC ovarian malignancies with splenic involvement were the histological grade and the adjuvant chemotherapic treatment. In the study conducted by Zheng et al. on 32 patients with epithelial ovarian cancer submitted to splenectomy as part of debulking surgery at Zhejiang Cancer Hospital between 1998 and 2006 the univariate analysis revealed the influence of the histological grade, residual tumor and cycles of chemotherapy on the overall survival ($p < 0.05$) while in multivariate analysis only residual tumor and association of

adjuvant chemotherapy impacted on survival. After a median follow up of 38 months the estimated 2 year and 5 year survival were 70% and 36% enabling the authors to consider that splenectomy can be successfully associated as part of debulking surgery [35].

Splenectomy as Part of Cytoreductive Surgery in Advanced Stage and Relapsed Ovarian Cancer

Once the benefits of extended upper abdominal resections in advanced stage ovarian cancer were widely demonstrated, further studies were conducted on the issue of splenectomy as part of cytoreductive surgery. However, due to the fact that splenic involvement is not such a frequent situation, initially only case reports or case series have been described, leading to conflicting results regarding the benefits and postoperative complications [36-38]. One of the first series reported on this subject was conducted by Paul Matigbay and involved 112 patients submitted to splenic resections during primary and secondary cytoreductive surgery for advanced stage and relapsed ovarian cancer at Mayo Clinic between 1983 and 2003 [39]. At the time of the study 66 patients were submitted to primary cytoreduction while the other 46 cases underwent secondary cytoreduction for recurrent disease. Splenectomy was performed for direct splenic involvement in 46% of cases, while an en-bloc resection to facilitate the removal of peri-splenic disease was performed in 41% of cases; in other 13 per cents splenectomy was imposed by the intraoperative trauma leading to an uncontrollable haemorrhage. Other associated visceral resections consisted in intestinal resections (performed in 52% of cases at the time of primary cytoreduction and in 48% of cases at the time of secondary cytoreduction) and urinary tract resections (performed in 3% of patients at the moment of primary cytoreduction and 7% of patients at the moment of secondary cytoreduction). Intraoperatively the median number of units of packed red blood cells was 2 units while on the whole in stay period the median number of transfused red blood cells was 4. Reoperation due to postoperative bleeding was needed in two cases: one case developed a severe intravascular coagulopathy with diffuse bleeding areas including the splenic bed while in the second case the bleeding originated from the pelvic sidewall. Postoperatively 6,3% of cases developed wound infection, 4.5% developed postoperative pneumonias, 8% experienced thromboembolic events and 4.5% developed a septic status due to fungal infection (in two cases), anastomotic leak (in one case) and of unknown origin (in other two cases). However none of these septic complications could be directly attributed to the splenectomy; the 30-days postoperative mortality rate was 5% and was associated to septic shock due to an anastomotic leak in one case and due to respiratory failure secondary to pneumonia in other two cases. Other causes of early postoperative mortality were thromboembolic events in two cases while in another case the death cause remained unknown. No postoperative pancreatic leakage was reported. When it comes to the long term outcomes, the primary cytoreduction group reported an overall median survival time of 21.6 months with an estimated 2-year survival of 46.2% while the median overall survival and the estimated 2 year survival in the secondary cytoreduction group were 20.3 months and 42.3% respectively. The strongest predictor for long term survival remained the completion of the resection; when it comes to the various patterns of spread, no difference in terms of survival was obtained in parenchimatous versus peritoneal seeding of the spleen. This was the largest reported series regarding the safety of splenectomy as part of debulking surgery for advanced

and relapsed ovarian cancer; however the study failed to identify other prognostic factors and which patients could mostly benefit from splenectomy as part of debulking surgery in advanced stage and recurrent ovarian cancer. This fact could be explained by the heterogeneity of the studied cohort, which included patients at different moments of disease evolution. Moreover, the study also included a number of 15 cases in which splenectomy was necessary for haemostatic purpose due to an intraoperative uncontrollable haemorrhage [39].

In a similar study conducted by Gemignani et al. and published in 1997 the authors included six patients submitted to splenectomy during cytoreductive surgery for isolated parenchymal splenic metastasis [40]. The study retrospectively reviewed data of patients submitted to surgery between 1991 and 1997. The single reported complication was a diaphragmatic tear which necessitated chest tube placement. At a median follow-up of 25.5 months all patients were alive and free of recurrent disease [40].

In order to determine if the presence of splenic metastases is the reflection of a more biologically aggressive disease and if performing a splenic resection could increase survival, Scott Eisenkop et al. conducted a study on 356 patients submitted to complete cytoreduction for stage IIIC ovarian cancer; in 49 cases splenectomy was required in order to maximize the cytoreductive effort while in the other 307 patients an R0 resection was feasible without requiring splenectomy [41]. Patients requiring splenectomy were older ($p = 0.05$), had a poorer general status ($p < 0.001$), a higher volume of ascites ($p < 0.001$) and a larger maximal diameter of metastatic disease ($p = 0.004$); in the meantime cases in which splenectomy was required necessitated more often other extended resections such as pelvic exenteration ($p < 0.001$), diaphragm stripping ($p < 0.001$), diaphragm resection ($p < 0.001$) and gross pelvic or para-aortic lymph nodes ($p = 0.006$) when compared to cases in which splenectomy was not required. Regarding the intraoperative and postoperative outcomes, patients in whom splenectomy was performed had a significantly longer operative time (238 minutes versus 192 minutes, $p = 0.004$), a higher blood loss (1663 ml versus 1167 ml, $p = 0.001$), a higher number of transfused red blood cells (5.3 units versus 3.2 units, $p = 0.002$) and a longer hospitalization (16.1 days versus 12.2 days, $p = 0.001$). However the rates of postoperative complications and 30 days mortality were similar between the two groups. When it comes to the long term outcomes, patients requiring splenectomy had a median overall survival rate of 56.4 months and an estimated 5 year survival of 48% while cases in which splenectomy was not necessary had a median survival rate of 76.8 months and an estimated 5 year survival rate of 58%. However these data did not reach statistical significance ($p = 0.4$). The authors underlined that, although a less favourable outcome was observed among patients submitted to splenectomy when compared to those who did not necessitate it, the presence of splenic involvement should not be considered an indicator of a biologically aggressive disease which could contraindicate the surgical approach. The authors also considered that a stratification of the overall survival according to the type of splenic involvement (contiguous spread of the omental disease, confluent metastases, parenchimatous or lymphatic hylar involvement) could not be feasible due to the small number of cases in each subgroup and suggested that a large multi-institutional prospective observational study is needed to determine whether there are prognostic differences between the hematogenous, peritoneal and lymphatic pattern of spread [41].

DIFFERENCES IN TERMS OF PROGNOSIS ACCORDING TO THE PATTERN OF SPREAD

Once it has been demonstrated that the presence of parenchimatous liver metastases is a poor prognostic factor compared to peritoneal seeding and was considered as an inclusion criteria of FIGO stage IV disease, attention was focused to determine if the presence of other parenchimatous lesions should also be considered as a criterion of FIGO stage IV disease. One of the first authors which suggested that FIGO stage IV should be extended in order to include parenchimatous splenic lesions was J. L. Nicklin in 1995. The author conducted a study on 18 patients submitted to splenectomy as part of primary cytoreduction for advanced stage ovarian cancer between 1989 and 1994; among these cases, three patients were found to have splenic parenchimatous lesions. Due to the poorer outcome of these patients, the authors proposed an extension of FIGO classification in order to include splenic parenchimatous metastases as a criterion for stage IV disease. In the meantime the reported rates of postoperative complications enabled the authors to consider that splenectomy should be performed only in selected cases [42].

Another study in which the authors investigated if a difference in terms of survival should be expected according to the pattern of splenic involvement was conducted by Ayhan et al. The authors reported a series of 34 patients submitted to cytoreductive surgery to < 1 cm residual disease over 12 years in whom splenectomy was performed as part of primary debulking effort [20]. Among these cases the hematogenous pattern of spread was incriminated in 18 cases. Although patients with splenic metastases reported a trend to a poorer prognosis when compared to those who did not have splenic involvement this fact did not reach statistical significance ($p > 0.05$) and the authors concluded that splenectomy should be performed whenever is needed in order to maximize the cytoreductive effort even if parenchimatous lesions are present. The authors reported a postoperative morbidity rate of 29.4% and a 30-days postoperative mortality rate of 8.8%, none of the complications being directly related to the splenectomy procedure [20].

The first study which came to demonstrate that parenchimatous splenic metastases is an independent poor prognostic factor and should be considered as a criterion for FIGO stage IV of disease is the one conducted by Eduard Tanner and published in 2013 [18]. The study involved 576 patients submitted to cytoreductive surgery for FIGO stage IIIB-IV at Memorial Sloan Kettering Cancer Center between 2001 and 2010. Splenectomy was performed in 97 patients while optimal cytoreduction (defined as residual disease as less than or equal to 1 cm) was achieved in 87.6% of them. The histopathological studies of the specimens revealed the presence of parenchimatous lesions in 20.8% of cases, capsular lesions in 67% of cases, splenic hylum in in 47.4% of cases and attached fat in 69.1% of cases. Among the patients with parenchimatous lesions, six of them had other evidence of stage IV disease: hepatic parenchimatous metastases in three cases, supradiaphragmatic adenopathy in two cases and malignant pleural effusion in one case. Patients requiring splenectomy were more likely to be diagnosed in an advanced stage of the disease ($p = 0,014$), including bulky upper abdominal tumors ($p < 0.0001$). In the meantime patients in whom splenectomy was performed were more likely to necessitate other visceral resection such as: rectal resections ($p < 0.0001$), colic resections ($p < 0.0001$), distal pancreatectomies ($p < 0.0001$), hepatic resections ($p < 0.0001$), or diaphragmatic resections ($p < 0.0001$). In order to quantify the complexity of the surgical

procedure the authors used the Surgical Complexity Score introduced by Aletti; according to this score, the patients were classified into low (≤ 3), intermediate (4-7) and high (> 7) complexity scores. Based on this classification, patients submitted to splenectomy were more likely to be considered as having a high complexity score ($p < 0.0001$). When studying the long term outcomes, cases in which a complete cytoreduction was achieved had a significantly better outcome (with a reported progression free survival of 26.3 months and an overall survival of 69.7 months) when compared to those with residual disease < 1 mm (with a reported progression free survival of 16.5 months and an overall survival of 45.7 months) and to those with residual disease >1 mm (with a reported progression free survival of 12.7 months and an overall survival of 35.3 months). The presence of parenchimatous splenic metastases was another poor prognostic factor, inducing a 21 months decrease in overall survival (the reported overall survival was 28.5 months for patients with parenchimatous lesions versus 49.9 months for cases in which the hematogenous splenic involvement was not present). Other prognostic factors which reached statistical influence in univariate analysis were the age at diagnosis ($p < 0.0001$), preoperative albumin levels ($p < 0.0001$), FIGO stage ($p = 0.001$), histopathological subtype ($p = 0.028$), presence of bulky upper abdominal disease ($p < 0.0001$), the absence of residual disease ($p < 0.0001$), and association of intraperitoneal chemotherapy ($p < 0.0001$). In multivariate analysis the presence of parenchimatous splenic lesions maintained a significant association with a decreased overall survival (OR=0.506; 95% CI, 0.272–0.944) [18].

Another study conducted on this issue involved patients with advanced stage ovarian cancer submitted to splenectomy at the moment of primary cytoreduction in „Dan Setlacec" Center of Gatrointestinal Disease and Liver Transplantation, Fundeni Clinical Institute, Bucharest [43]. Sixty-six patients were eligible for the study, in 55 cases the upper abdominal tumor burden being limited to the spleen while in the other 11 cases bulky abdominal disease being reported. Preoperatively 47 patients were diagnosed in FIGO stage IIIC while the other 19 cases were diagnosed in FIGO stage IV. The most often associated visceral resections included colorectal resections (37 cases), diaphragmatic resections (9 cases), gastric resections (9 cases), distal pancreatectomies (3 cases) and atypical hepatectomies (1 case). The histopathological studies of the specimens described a hematogenous pattern of spread in 19 cases, capsular involvement in 35 cases and hilar involvement in 12 cases. The median hospital in stay was 12 days while the main postoperative complications were pancreatic leakage (in four cases), abdominal abscess (in four cases, two of them necessitating re-operation), pleural effusion (three cases), bronchopneumonia (three cases) and neurologic disorders (three cases). The overall morbidity rate was 30% while the 30-day postoperative mortality rate was 7%; death occurred in five cases: two due to abdominal abscess (originating from an enteral anastomosis in one case and pancreatic leakage in the other case), one case due to a severe bronco-pneumonia, one patient developed a cerebral ischemic stroke, while the fifth patient (with important preoperative cardiac and respiratory dysfunctions) developed a severe uncontrollable metabolic acidosis leading to a multiple organ failure. The authors compared the results to a control group including 272 patients with advanced stage ovarian cancer submitted to cytoreductive surgery in the same period of time and by the same surgical teams but in whom splenectomy was not necessary. The rates of postoperative morbidity and 30 days mortality were similar between the two subgroups: while the postoperative morbidity was 30% among patients submitted to splenectomy and the 30 days postoperative mortality rate was 7%, in the control group which did not necessitate

performing a splenectomy, complications developed in 27% of cases and the early postoperative mortality rate was 5%. Similarly to Tanner's study, a significant difference in terms of survival was obtained between the three patterns of spread: while patients diagnosed with peritoneal seeding reported an overall survival of 58.4 months, patients with parenchimatous lesions had a median overall survival of 24.5 months ($p = 0.0126$); in the meantime the overall survival of cases diagnosed with hylar involvement was 40.6 months. When studying the differences in terms of survival between hylar and parenchimatous lesions and respectively hylar versus peritoneal seeding no significant difference was obtained ($p = 0.362$ and respectively $p = 0.457$). However the study demonstrated the feasibility of the procedure and demonstrated that the presence of hematogenous splenic involvement is an independent negative prognosis factor [43].

SPLENECTOMY AS PART OF CYTOREDUCTION FOR RELAPSE OVARIAN CANCER

After demonstrating the benefits in terms of survival after splenectomy at the time of primary cytoreduction for advanced stage ovarian cancer, studies went even further and tried to demonstrate the feasibility of the procedure as part of secondary and even tertiary cytoreduction. The main studies investigating this issue are summarized in Table 2.

In the study conducted by Hanprasertpong et al. six patients were submitted to splenectomy as part of interval debulking surgery and secondary cytoreduction respectively [49]. Among the three patients submitted to splenectomy as part of secondary cytoreduction in two cases an isolated splenic recurrence was diagnosed while in the third case the splenic lesion was associated to an inguinal lymph node metastasis.

The postoperative course was uneventful in all cases, splenectomy being well tolerated. The histopathological findings revealed the presence of parenchimatous splenic lesions in two cases and a capsular lesion in the third case. When it comes to the long term survival, none of the patients presented evidence of recurrent disease at the moment of ending the study [49].

In a more recent study, twenty-eight patients submitted to splenectomy at the time of secondary, tertiary and even quaternary cytoreduction were introduced [50]. All cases were submitted to surgery in the same center ("Dan Setlacec" Center of Gastrointestinal Disease and Liver Transplantation, Fundeni Clinical Institute, Bucharest) between 2002 and 2014. Splenectomy was performed at the time of secondary cytoreduction in 21 cases, at tertiary cytoreduction in six cases and at quaternary cytoreduction in one case. In all cases the specimen of splenectomy was sent to histopathological study in order to determine if the splenic involvement had a peritoneal, hematogenous or lymphatic origin. At the time of secondary cytoreduction the main associated visceral resections consisted of colic resections (42.86% of cases), rectosigmoidian resections (33.33% of cases), distal pancreatectomy (19.05% of cases), atypical hepatectomy (14.29% of cases) and partial frenectomy (14.29% of cases). The histopathological studies revealed a hematogenous pattern of spread in 42.85% of cases and peritoneal lesions in 52.38% of cases, while the hilar involvement was reported in a single case.

Table 2. Splenectomy as part of debulking surgery in relapsed ovarian cancer

Author	Period of the study	Year of publishing the study	Type of cytoreduction	No. of cases	No. of performed splenectomies (%)	R0 definition	R0 resection (%)	Postoperative complications	Splenectomy related complications	30 days post-operative mortality
Fagotti et al.[44]	May 2005-September 2008	2009	secondary	25	8 (32%)	No visible residual disease	92%	Overall: 44%; severe complications: 28%	NR	0
Schorge et al.[45]	January 1998-January 2008	2010	secondary	40	4(10%)	No residual disease	55%	23% - severe complications	NR	0
Petrillo et al.[46]	January 1995-December 2010	2013	secondary	73	4(5.4%)	1 cm	100%	NR	NR	NR
Tang et al. [47]	May 1999-November 2010	2013	tertiary	83	2 (2.4%)	Microscopic residual disease	34.9%	15%	NR	0
Magrina et al. [48]	January 2006-December 2010	2013	secondary	52	5 (9.6%)	No visible residual disease	75%	36.5% (overall complication rate)	NR	0

The median duration of hospitalization was 14 days (range 2-89 days). Early postoperative complications were reported in six cases, in half of them re-operation being needed; in one case re-operation was imposed by a high-flow enteral fistula, in the second case the indication of re-operation was given by an unresponsive to conservative treatment pancreatic fistula while in the third case early postoperative hemoperitoneum occurred. The early postoperative mortality rate was 9.5%; death occurred in two cases, due to uncontrolled septic shock in one case and haemorrhagic shock with disseminated intravascular coagulopathy in the second case. Although it did not reach statistical significance, the median overall survival of patients with peritoneal seeding was longer when compared to cases with parenchimatous lesions (35 months versus 12 months, $p = 0.2$). When it comes to patients submitted to splenectomy in the setting of tertiary cytoreduction, the main associated visceral resections were: colic resections (in 3 cases), rectosigmoidian resections (in two cases), distal pancreatectomy (in one case) and atypical hepatectomy (in one case).

The histopathological studies revealed a peritoneal pattern of spread in four cases while in the other two cases the hematogenous route was incriminated, the splenic metastases being entirely surrounded by normal parenchyma. Postoperatively two patients developed complications – an abdominal abscess and a biliary fistula, both cases being successfully managed conservatively. The long term outcomes revealed an improved survival for patients with peritoneal seeding (21 month) versus parenchimatous lesions (4 months). However, the results were not statistically significant ($p = 0.08$). As for the patient submitted to splenectomy as the time of the third relapse, quaternary cytoreduction was performed at 102 months after the initial diagnosis and also associated an atypical hepatectomy, partial gastrectomy and extended pelvic resections for a large pelvic recurrence. The histopathological studies revealed a hematogenous liver lesion associated with a peritoneal splenic seeding. The postoperative outcome was uneventful; however the patient died of disease 20 months after quaternary cytoreduction.

This study came to underline that also not statistically significant, a poorer outcome should be expected in patients with parenchimatous lesions at secondary and even tertiary cytoreduction. However, splenectomy was safely associated whenever it was needed in order to maximize the debulking effort [50].

THE ROLE OF LAPAROSCOPIC SPLENECTOMY IN ADVANCED STAGE AND RELAPSED OVARIAN CANCER

In order to improve the early postoperative outcome, to provide a faster recovering and secondarily a more rapid association of adjuvant chemotherapy, attention was focused in performing laparoscopic resections for advanced stage and recurrent ovarian cancer. The first hand-assisted splenectomy for isolated splenic metastases was first reported in 1998 by Klinger demonstrating the feasibility of the procedure [51].

In the study conducted by Dennis Chi et al. the authors included six patients submitted to laparoscopic or hand assisted splenectomy between 1996 and 2005; in five of the six cases laparoscopic or hand assisted resection was performed while in the sixth case conversion to laparotomy was imposed by the presence of peritoneal carcinomatosis [52]. In four of the six cases the histopathological examinations confirmed the presence of splenic tumoral

involvement while in the other case a benign splenic cyst was found. In one of the cases residual tumor < 1 cm was reported, all the other cases being cytoreduced to no residual disease. The estimated blood loss ranged between 50 and 300 ml while the postoperative hospitalization ranged between 3 and 5 days. Postoperatively all five cases in which recurrent disease was diagnosed were submitted to adjuvant therapy with platinum based salts and taxanes (in four cases) while the fifth patient underwent aromatase inhibitor therapy. At 2084 months after surgery all patients were free of any recurrent disease. The study came to demonstrate the effectiveness of the procedure and underlined the fast recovery of the patient; however the authors considered that this procedure should be performed only by specialized surgeons and in selected cases [52].

In the meantime, Pedro Ramirez published a paper focusing on the technique of open versus totally laparoscopic splenectomy in cases with advanced or recurrent ovarian cancer. The author demonstrated the feasibility of total laparoscopic splenectomy by a lateral approach using a four ports technique. After complete mobilization, the specimen of splenectomy is placed in an Endobag and extracted through the 12 mm trocar after extending the incision line. According to the same author after laparoscopic splenectomy a pancreatic leak rate of 6% is expected while the thromboembolic events occur in up to 10% of cases [53].

In another similar study Fagotti introduced 10 patients with relapsed ovarian cancer who were submitted to laparoscopic or robotic surgery associated with intraperitoneal hypertemic chemotherapy (HIPEC) for isolated recurrences [54]. In seven cases debulking was performed on the laparoscopic route while in the other three cases a robotic approach was chosen. As for the chosen chemotherapic agent for HIPEC, nine patients received cisplatin while the tenth patient received oxaliplatin. In two cases splenectomy was needed while in the other eight cases location of the recurrence necessitated radical omentectomy or selective splenectomy. The operative time ranged between 95 and 140 minutes while the estimated blood loss ranged between 50 and 100 ml. All patients were discharged after 3-7 days while systemic chemotherapy was administrated after a median interval of 21 days (19-32 days). A single patient developed postoperative complications consisting of a low frequency atrial fibrillation. When it comes to long term outcomes, no recurrence or death was reported after 10 months (range 6-37 months). The authors demonstrated the safety and efficacy of laparoscopic surgery for isolated relapse from ovarian cancer in association with HIPEC, a shorter convalescence interval and a faster administration of systemic chemotherapy being achieved [54].

One of the most suggestive studies regarding the benefits of minimally invasive surgery in relapsed ovarian cancer comes from Javier Magrina et al. and involved a retrospective analysis of 52 patients submitted to secondary cytoreduction for relapsed ovarian cancer at Mayo Clinic Arizona between January 2006 and December 2010 [48]. Among these cases laparoscopic resection was performed in 9 cases, robotics in 10 cases, while the other 33 patients were benefited from a classic approach. Splenectomy was performed in 11.1% of patients submitted to laparoscopy and 12.1% of patients submitted to laparotomy. The perioperative outcomes were similar between the three subgroups in terms of operating time, rate of complete debulking surgery, intra- and postoperative complications, while the estimated blood loss and postoperative hospital in stay were significantly lower in the minimally invasive subgroup. In the meantime there was no significant difference in regard to

the long term outcomes, the reported overall survival being similar among the three subgroups [48].

Association of Pancreatic Resections to Splenectomy as Part of Cytoreductive Surgery in Advanced Stage and Relapsed Ovarian Cancer

In a significant number of cases the presence of the bulky left quadrant abdominal disease will force the surgeon to perform multiple visceral resections en bloc with the tumor in order to achieve negative resection margins and an R0 resection. One of the most frequent associated visceral resection to splenectomy remains distal pancreatectomy [14]. Although initially it has been considered that a pancreatic resection predisposes to an unacceptable risk regarding the postoperative morbidity rate, progression achieved in hepat-bilio-pancreatic surgery offered the possibility to safely include pancreatic resection as part of debulking surgery for advanced and relapsed ovarian cancer. However, at this moment the reported experience regarding pancreatic surgery as part of debulking is still limited, most of the reported cases including small series of patients.

In the study conducted by Pieluigi Benediti Panici involving 121 patients with advanced stage ovarian cancer distal pancreatectomy was associated in 16 cases while splenectomy was performed in 48 cases. After performing an aggressive surgical approach the rate of complete cytoreduction (defined as no residual disease) was 75.1%. When studying the short term outcomes, the authors reported that performing pancreatic resection was associated with a longer length of hospitalization in both univariate and multivariate analysis. In the meantime pancreatic surgery was associated with the higher rate of postoperative complications, with a reported rate of pancreatitis and abscess formation secondary to a pancreatic leak of 13% among cases submitted to pancreatic resections [33].

Most often complications related to pancreatic surgery are related to the exocrine pancreatic secretion as pancreatic leaks and their rate ranges between 30-60% while the mortality rate is up to 5% [55-57]. However, the rate of reported pancreatic leaks widely varies in literature data due to the absence of a standard definition of the pancreatic leak. While Rodriguez *et al.* defined pancreatic fistula as a daily output of at least 30ml/day with amylase levels three times higher compared to amylase serum levels after the fifth postoperative day [57], Grobmyer defined it as clinical signs or radiological confirmation of a collection with increased levels of amylase (more than 50 ml/day) beyond the fifth postoperative day [58]. The first standardized definition came from the International Study Group of Pancreatic Fistula: according to their opinion, pancreatic leak was defined as a left upper quadrant fluid collection present after the third postoperative day with a fluid amylase level>3 times the level of serum amylase [59].

In order to determine the incidence and management of pancreatic leaks after splenectomy en bloc with distal pancreatectomy during primary cytoreduction Siobhan Kehoe et al. conducted a study on 17 patients; all cases were submitted to splenectomy en bloc with distal pancreatectomy as part of primary cytoreduction between January 2001 and December 2006 [60]. In the meantime splenectomy without pancreatic resection was performed in other 24 cases. Pancreatic leaks were defined accordingly to the International Study Group of Pancreatic Fistula. Optimal cytoreduction was defined as residual tumor of less than 1 cm. In all cases distal pancreatectomy was performed for left quadrant bulky disease invading the

spleen and the splenic hylum, inseparable from the pancreatic tail. In all cases the pancreatic tail was transsected using a vascular stapler while the reinforcement of the stapler line by oversewing remained at the surgeon's discretion In 53% of cases resection to no gross residual disease was achieved while in other 41% of cases optimal cytoreduction was performed; in a single case the remnant tumoral volume was larger than 1 cm. Postoperatively 24% of the patients developed pancreatic leaks at a median time of 9 days after resection. In three cases pancreatic leaks developed in the early postoperative period (within the first 10 days postoperatively) while in the fourth case the pancreatic leak was diagnosed in the 66th postoperative day, after re-admission for abdominal pain; the biological tests showed an increased number of leukocytes while the imagistic studies revealed the presence of a multiloculated collection surrounding the pancreas which was successfully drained by percutaneous route; a therapy with somatostatin, bowel rest and total parenteral nutrition were also instituted with good outcomes, the patient being able to retake the oral diet two weeks after drainage. In regard to the histopathological studies, the authors reported parenchimatous splenic metastases in six cases, parenchimatous pancreatic lesions in one case and peripancreatic tumoral involvement in 12 cases; however all patients in whom pancreatic leak was found had a peri-pancreatic tumoral involvement. The authors concluded that spleno-pancreatectomy should be performed in metastatic gynaecological cancers although pancreatic leaks represent a relative complication after distal pancreatectomy [60].

In the study conducted by Bacalbasa et al. at "Dan Setlacec" Center of Gastrointestinal Diseases and Liver Transplantation, Fundeni Clinical Institute, Bucharest six patients submitted to spleno-pancreatectomy were included. The patients were submitted to pancreatic resections at the moment of primary cytoreduction (one case), secondary cytoreduction (four cases) and tertiary cytoreduction (one case). During the early postoperative period two patients developed pancreatic fistulas; both cases were submitted to pancreatic resections at the moment of secondary cytoreduction. In one case the pancreatic fistula was successfully treated by conservative approach, while in the second case reoperation was needed. There was no complication related to splenectomy. In all cases complete cytoreduction to no visible residual disease was achieved. The 30-days postoperative mortality was 0. The patient submitted to spleno-pancreatectomy during primary cytoreduction was diagnosed with relapsed ovarian cancer at 54 months follow up and was proposed for secondary cytoreduction at the time of ending the study; the median overall survival for patients submitted to distal pancreatectomy was 36.38 months while the patient submitted to spleno-pancreatectomy at the moment of tertiary cytoreduction died of disease 10 months later. The study came to demonstrate the benefits of extended upper abdominal resections including splenopancreatectomy in advanced and relapsed ovarian cancer in order to achieve a complete resection and secondarily, a benefit in terms of survival [61].

CONCLUSION

Although splenic involvement is not a common situation in the setting of advanced stage and relapsed ovarian cancer, large studies came to demonstrate the safety and effectiveness of splenectomy as part of debulking surgery. Moreover, a difference in terms of survival between the different patterns of spread has been recently demonstrated, suggesting the

possibility to include hematogenous splenic metastases among the inclusion criteria for FIGO stage IV. When it comes to the benefit of multiple visceral resections, distal pancreatectomy was successfully associated to maximize the debulking effort.

REFERENCES

[1] Berge T (1974). Splenic metastases. Frequencies and patterns, *Acta Pathol. Microbiol. Scand.A* 82: 499-506.

[2] van den BW, Tascilar M, Offerhaus GJ, Albores-Saavedra J, Wenig BM, Hruban RH, Gabrielson E (2000). Pancreatic mucinous cystic neoplasms with sarcomatous stroma: molecular evidence for monoclonal origin with subsequent divergence of the epithelial and sarcomatous components, *Mod. Pathol.* 13: 86-91.

[3] Comperat E, Bardier-Dupas A, Camparo P, Capron F, Charlotte F (2007). Splenic metastases: clinicopathologic presentation, differential diagnosis, and pathogenesis, *Arch. Pathol. Lab Med.* 131: 965-969.

[4] Kraus MD, Fleming MD, Vonderheide RH (2001). The spleen as a diagnostic specimen: a review of 10 years' experience at two tertiary care institutions, *Cancer* 91: 2001-2009.

[5] Ishida H, Konno K, Ishida J, Shirayama K, Naganuma H, Komatsuda T, Hamashima Y, Masamune O (1997). Isolated splenic metastases, *J. Ultrasound Med.* 16: 743-749.

[6] Lee SS, Morgenstern L, Phillips EH, Hiatt JR, Margulies DR (2000). Splenectomy for splenic metastases: a changing clinical spectrum, *Am. Surg.* 66: 837-840.

[7] Lam KY, Tang V (2000). Metastatic tumors to the spleen: a 25-year clinicopathologic study, *Arch. Pathol. Lab Med.* 124: 526-530.

[8] Kochar K, Vijayasekar C, Pandey U, Bhogal R, Brown L, Mathew G (2009). Primary carcinosarcoma of the spleen: case report of a rare tumor and review of the literature, *Int. J. Surg. Pathol.* 17: 72-77.

[9] Nakayama K, Nakayama N, Katagiri H, Miyazaki K (2012). Mechanisms of ovarian cancer metastasis: biochemical pathways, *Int. J. Mol. Sci.* 13: 11705-11717.

[10] Kalluri R, Weinberg RA (2009). The basics of epithelial-mesenchymal transition, *J. Clin. Invest* 119: 1420-1428.

[11] Feki A, Berardi P, Bellingan G, Major A, Krause KH, Petignat P, Zehra R, Pervaiz S, Irminger-Finger I (2009). Dissemination of intraperitoneal ovarian cancer: Discussion of mechanisms and demonstration of lymphatic spreading in ovarian cancer model, *Crit Rev.Oncol.Hematol.* 72: 1-9.

[12] Carmignani CP, Sugarbaker TA, Bromley CM, Sugarbaker PH (2003). Intraperitoneal cancer dissemination: mechanisms of the patterns of spread, *Cancer Metastasis Rev.* 22: 465-472.

[13] Sugarbaker, Paul H. "Observations concerning cancer spread within the peritoneal cavity and concepts supporting an ordered pathophysiology."*Peritoneal carcinomatosis: principles of management*. Springer US, 1996. 79-100.

[14] Hoffman MS, Tebes SJ, Sayer RA, Lockhart J (2007). Extended cytoreduction of intraabdominal metastatic ovarian cancer in the left upper quadrant utilizing en bloc resection, *Am. J. Obstet. Gynecol.* 197: 209-4.

[15] FIGO Cancer Committee (1986). Staging announcement, *Gynecol Oncol* 25: 5.
[16] Eisenhauer EL, Abu-Rustum NR, Sonoda Y, Levine DA, Poynor EA, Aghajanian C, Jarnagin WR, DeMatteo RP, D'Angelica MI, Barakat RR, Chi DS (2006). The addition of extensive upper abdominal surgery to achieve optimal cytoreduction improves survival in patients with stages IIIC-IV epithelial ovarian cancer, *Gynecol Oncol* 103: 1083-1090.
[17] Elattar A, Bryant A, Winter-Roach BA, Hatem M, Naik R (2011). Optimal primary surgical treatment for advanced epithelial ovarian cancer, *Cochrane. Database. Syst. Rev.* CD007565.
[18] Tanner EJ, Long KC, Feffer JB, Leitao MM, Jr., Abu-Rustum NR, Barakat RR, Chi DS, Gardner GJ (2013). Parenchymal splenic metastasis is an independent negative predictor of overall survival in advanced ovarian, fallopian tube, and primary peritoneal cancer, *Gynecol Oncol* 128: 28-33.
[19] Chen LM, Leuchter RS, Lagasse LD, Karlan BY (2000). Splenectomy and surgical cytoreduction for ovarian cancer, *Gynecol Oncol* 77: 362-368.
[20] Ayhan A, Al RA, Baykal C, Demirtas E, Ayhan A, Yuce K (2004). The influence of splenic metastases on survival in FIGO stage IIIC epithelial ovarian cancer, *Int. J. Gynecol Cancer* 14: 51-56.
[21] McCann CK, Growdon WB, Munro EG, Del Carmen MG, Boruta DM, Schorge JO, Goodman A (2011). Prognostic significance of splenectomy as part of initial cytoreductive surgery in ovarian cancer, *Ann. Surg. Oncol* 18: 2912-2918.
[22] Bilgin T, Ozerkan K, Ozan H (2005). Splenectomy in cytoreductive surgery for advanced ovarian cancer, *Arch. Gynecol Obstet.* 271: 329-331.
[23] Bristow RE, Tomacruz RS, Armstrong DK, Trimble EL, Montz FJ (2002). Survival effect of maximal cytoreductive surgery for advanced ovarian carcinoma during the platinum era: a meta-analysis, *J. Clin. Oncol* 20: 1248-1259.
[24] Eisenkop SM, Spirtos NM (2001). What are the current surgical objectives, strategies, and technical capabilities of gynecologic oncologists treating advanced epithelial ovarian cancer?, *Gynecol Oncol* 82: 489-497.
[25] Lim MC, Kang S, Lee KS, Han SS, Park SJ, Seo SS, Park SY (2009). The clinical significance of hepatic parenchymal metastasis in patients with primary epithelial ovarian cancer, *Gynecol Oncol* 112: 28-34.
[26] Song YJ, Lim MC, Kang S, Seo SS, Park JW, Choi HS, Park SY (2009). Total colectomy as part of primary cytoreductive surgery in advanced Mullerian cancer, *Gynecol Oncol* 114: 183-187.
[27] Chi DS, Franklin CC, Levine DA, Akselrod F, Sabbatini P, Jarnagin WR, DeMatteo R, Poynor EA, Abu-Rustum NR, Barakat RR (2004). Improved optimal cytoreduction rates for stages IIIC and IV epithelial ovarian, fallopian tube, and primary peritoneal cancer: a change in surgical approach, *Gynecol Oncol* 94: 650-654.
[28] Raspagliesi F, Ditto A, Martinelli F, Haeusler E, Lorusso D (2013). Advanced ovarian cancer: omental bursa, lesser omentum, celiac, portal and triad nodes spread as cause of inaccurate evaluation of residual tumor, *Gynecol Oncol* 129: 92-96.
[29] Zivanovic O, Eisenhauer EL, Zhou Q, Iasonos A, Sabbatini P, Sonoda Y, Abu-Rustum NR, Barakat RR, Chi DS (2008). The impact of bulky upper abdominal disease cephalad to the greater omentum on surgical outcome for stage IIIC epithelial ovarian, fallopian tube, and primary peritoneal cancer, *Gynecol Oncol* 108: 287-292.

[30] Zivanovic O, Sima CS, Iasonos A, Hoskins WJ, Pingle PR, Leitao MM, Jr., Sonoda Y, Abu-Rustum NR, Barakat RR, Chi DS (2010). The effect of primary cytoreduction on outcomes of patients with FIGO stage IIIC ovarian cancer stratified by the initial tumor burden in the upper abdomen cephalad to the greater omentum, *Gynecol Oncol* 116: 351-357.

[31] Cliby W, Dowdy S, Feitoza SS, Gostout BS, Podratz KC (2004). Diaphragm resection for ovarian cancer: technique and short-term complications, *Gynecol Oncol* 94: 655-660.

[32] Chi DS, Zivanovic O, Levinson KL, Kolev V, Huh J, Dottino J, Gardner GJ, Leitao MM, Jr., Levine DA, Sonoda Y, Abu-Rustum NR, Brown CL, Barakat RR (2010). The incidence of major complications after the performance of extensive upper abdominal surgical procedures during primary cytoreduction of advanced ovarian, tubal, and peritoneal carcinomas, *Gynecol Oncol* 119: 38-42.

[33] Benedetti PP, Di D, V, Fischetti M, Casorelli A, Perniola G, Musella A, Marchetti C, Palaia I, Berloco P, Muzii L (2015). Predictors of postoperative morbidity after cytoreduction for advanced ovarian cancer: Analysis and management of complications in upper abdominal surgery, *Gynecol Oncol* 137: 406-411.

[34] Martinez A, Pomel C, Mery E, Querleu D, Gladieff L, Ferron G (2011). Celiac lymph node resection and porta hepatis disease resection in advanced or recurrent epithelial ovarian, fallopian tube, and primary peritoneal cancer, *Gynecol Oncol* 121: 258-263.

[35] Zheng AW, Zheng F, Chen YQ, Zhu HN, Qian JH (2008). [Splenectomy in epithelial ovarian cancer: analysis of 32 cases], *Zhonghua Fu Chan Ke.Za Zhi.* 43: 197-200.

[36] Koh YS, Kim JC, Cho CK (2004). Splenectomy for solitary splenic metastasis of ovarian cancer, *BMC. Cancer* 4: 96.

[37] Lauro S, Trasatti L, Capalbo C, Conti A, Ricci F, Mingazzini PL, Vecchione A (2002). Solitary splenic recurrence of epithelial ovarian cancer: a case report and review, *Anticancer Res.* 22: 3643-3645.

[38] Minagawa Y, Kanamori Y, Ishihara H, Morishita K, Kigawa J, Ito T, Maeda K, Saito S (1991). Solitary metastatic ovarian carcinoma of the spleen: a case report, *Asia Oceania J.Obstet.Gynaecol.* 17: 45-48.

[39] Magtibay PM, Adams PB, Silverman MB, Cha SS, Podratz KC (2006). Splenectomy as part of cytoreductive surgery in ovarian cancer, *Gynecol Oncol* 102: 369-374.

[40] Gemignani ML, Chi DS, Gurin CC, Curtin JP, Barakat RR (1999). Splenectomy in recurrent epithelial ovarian cancer, *Gynecol Oncol* 72: 407-410.

[41] Eisenkop SM, Spirtos NM, Lin WC (2006). Splenectomy in the context of primary cytoreductive operations for advanced epithelial ovarian cancer, *Gynecol Oncol* 100: 344-348.

[42] Nicklin JL, Copeland LJ, O'Toole RV, Lewandowski GS, Vaccarello L, Havenar LP (1995). Splenectomy as part of cytoreductive surgery for ovarian carcinoma, *Gynecol Oncol* 58: 244-247.

[43] Bacalbasa N, Balescu I, Dima S, Brasoveanu V, Popescu I. Hematogenous Splenic Metastases as an Independent Negative Prognosis Factor at the Moment of Primary Cytoreduction in Advanced Stage Epithelial Ovarian Cancer – A Single Center Experience. *Anticancer Research 35*: xxx-xxx (2015).

[44] Fagotti A, Paris I, Grimolizzi F, Fanfani F, Vizzielli G, Naldini A, Scambia G (2009). Secondary cytoreduction plus oxaliplatin-based HIPEC in platinum-sensitive recurrent ovarian cancer patients: a pilot study, *Gynecol Oncol* 113: 335-340.

[45] Schorge JO, Wingo SN, Bhore R, Heffernan TP, Lea JS (2010). Secondary cytoreductive surgery for recurrent platinum-sensitive ovarian cancer, *Int. J. Gynaecol. Obstet.* 108: 123-127.

[46] Petrillo M, Fagotti A, Ferrandina G, Fanfani F, Costantini B, Vizzielli G, Pedone AL, Nero C, Margariti PA, Scambia G (2013). Ovarian cancer patients with localized relapse: clinical outcome and prognostic factors, *Gynecol Oncol* 131: 36-41.

[47] Tang J, Liu DL, Shu S, Tian WJ, Liu Y, Zang RY (2013). Outcomes and patterns of secondary relapse in platinum-sensitive ovarian cancer: implications for tertiary cytoreductive surgery, *Eur. J. Surg. Oncol* 39: 786-791.

[48] Magrina JF, Cetta RL, Chang YH, Guevara G, Magtibay PM (2013). Analysis of secondary cytoreduction for recurrent ovarian cancer by robotics, laparoscopy and laparotomy, *Gynecol Oncol* 129: 336-340.

[49] Hanprasertpong J, Ohishi R, Iwasa N, Nagao S, Okamoto K, Fujiwara K (2010). Splenectomy during secondary cytoreductive surgery for epithelial ovarian cancer, *Asian Pac. J. Cancer Prev.* 11: 413-416.

[50] Bacalbasa N, Balescu I, Dima S, Brasoveanu V, Popescu I. Splenectomy as Part of Cytoreductive Surgery in Recurrent Epithelial Ovarian Cancer. Anticancer Research *35*: xxx-xxx (2015).

[51] Klingler PJ, Hinder RA, Menke DM, Smith SL (1998). Hand-assisted laparoscopic distal pancreatectomy for pancreatic cystadenoma, *Surg. Laparosc. Endosc.* 8: 180-184.

[52] Chi DS, Abu-Rustum NR, Sonoda Y, Im HB, Jhamb N, D'Angelica M, Rim M, Dupont J, Barakat RR (2006). Laparoscopic and hand-assisted laparoscopic splenectomy for recurrent and persistent ovarian cancer, *Gynecol Oncol* 101: 224-227.

[53] Ramirez PT, Dos RR (2007). Splenectomy in patients with advanced or recurrent ovarian cancer: open and laparoscopic surgical techniques and clinical outcomes, *Gynecol Oncol* 104: 29-32.

[54] Fagotti A, Petrillo M, Costantini B, Fanfani F, Gallotta V, Chiantera V, Turco LC, Bottoni C, Scambia G (2014). Minimally invasive secondary cytoreduction plus HIPEC for recurrent ovarian cancer: a case series, *Gynecol Oncol* 132: 303-306.

[55] Gouma DJ, van Geenen RC, van Gulik TM, de Haan RJ, de Wit LT, Busch OR, Obertop H (2000). Rates of complications and death after pancreaticoduodenectomy: risk factors and the impact of hospital volume, *Ann. Surg.* 232: 786-795.

[56] Connor S, Raraty MG, Howes N, Evans J, Ghaneh P, Sutton R, Neoptolemos JP (2005). Surgery in the treatment of acute pancreatitis--minimal access pancreatic necrosectomy, *Scand. J. Surg.* 94: 135-142.

[57] Rodriguez JR, Germes SS, Pandharipande PV, Gazelle GS, Thayer SP, Warshaw AL, Fernandez-del Castillo C (2006). Implications and cost of pancreatic leak following distal pancreatic resection, *Arch. Surg.* 141: 361-365.

[58] Grobmyer SR, Pieracci FM, Allen PJ, Brennan MF, Jaques DP (2007). Defining morbidity after pancreaticoduodenectomy: use of a prospective complication grading system, *J. Am. Coll. Surg.* 204: 356-364.

[59] Pratt WB, Maithel SK, Vanounou T, Huang ZS, Callery MP, Vollmer CM, Jr. (2007). Clinical and economic validation of the International Study Group of Pancreatic Fistula (ISGPF) classification scheme, *Ann. Surg.* 245: 443-451.

[60] Kehoe SM, Eisenhauer EL, Abu-Rustum NR, Sonoda Y, D'Angelica M, Jarnagin WR, Barakat RR, Chi DS (2009). Incidence and management of pancreatic leaks after splenectomy with distal pancreatectomy performed during primary cytoreductive surgery for advanced ovarian, peritoneal and fallopian tube cancer, *Gynecol Oncol* 112: 496-500.

[61] Bacalbasa N, Balescu I, Dima S, Brasoveanu V, Popescu I (2015). Pancreatic Resection as Part of Cytoreductive Surgery in Advanced-stage and Recurrent Epithelial Ovarian Cancer - A Single-center Experience, *Anticancer Res.* 35: 4125-4129.

In: Encyclopedia of Surgery (22 Volume Set)
Editors: Andreas Lehrer and Kristin Mueller
ISBN: 978-1-53618-329-0
© 2020 Nova Science Publishers, Inc.

Chapter 389

LIVER SURGERY IN OVARIAN CANCER LIVER METASTASES

N. Bacalbasa[1,*] and Irina Balescu[2]
[1]"Carol Davila" University of Medicine and Pharmacy, Bucharest
[2]Ponderas Hospital, Bucharest, Romania

ABSTRACT

Ovarian cancer is one of the most aggressive gynecologic malignancies and represents a major cause of death for women worldwide. This aggressive behavior is especially related to the fact that most patients are diagnosed in an advanced stage of the disease when disseminated tumoral burden is already present. Although the intraperitoneal route seems to be the most common pattern of spread, ovarian cancer can also develop distant metastases by hematogenous route and throughout lymphatic channels, the most commonly affected sites by hematogenous spread including the lungs and liver. Historically, patients with liver involvement have been considered as having a systemic, uncontrollable disease and were considered as candidates for supportive care or palliative chemotherapy.

Although the presence of liver metastases at the moment of diagnosis is usually associated with an altered tumor biology and aggressive disease, there was no convincing evidence that cytoreduction in the presence of liver metastases is less efficacious. Starting from this hypothesis, hepatic resection for ovarian cancer liver metastases has been proposed.

However, at this moment it is estimated that the number of patients submitted to liver resection for hepatic metastases from gynecological cancer represent less than 1% of the total resected liver metastases, the role of surgery in patients with ovarian cancer liver metastases being still in question. The main reason for this paucity of hepatectomies in ovarian cancer liver metastases is related to the fact that usually these kinds of tumors develop liver metastases in the settings of obvious systemic or regional dissemination which is not suitable for a complete macroscopic resection. Patients presenting resectable, isolated and limited to liver metastases are rather an exception than a rule in

* Corresponding Author's Email: nicolae_bacalbasa@yahoo.ro.

the setting of ovarian cancer. However this small subgroup of patients with isolated hepatic lesions has been initially considered to suit best to liver resection.

According to this principle, initially the main indication for resection in ovarian cancer liver metastases was the presence of solitary liver lesions with no extrahepatic tumoral burden as the best results in terms of survival had been obtained in such cases. More recently, it has been demonstrated that the presence of extrahepatic tumoral burden does not represent a significant prognostic factor for a poorer outcome in all patients and allowed to identify the subsets of patients with extrahepatic tumor burden who could benefit most from liver resections.

A crucial step in studying the long term outcomes after liver resection for ovarian cancer hepatic metastases was demonstrating the different outcomes between the two distinct patterns of hepatic involvement: peritoneal and hematogenous spread. Metastases originating from peritoneal seeding with parenchimatous invasion of at least 2 cm were classified as peritoneal lesions while lesions entirely surrounded by liver parenchyma were considered to have hematogenous origins. Significant differences in terms of survival between patients with peritoneal versus hematogenous lesions submitted to complete resections were observed. Based on these findings, it has been largely accepted that the presence of peritoneal seeding involving the liver included the case in FIGO stage IIIC while the presence of hematogenous liver involvement should be classified as FIGO stage IV.

When it comes to the role of liver resection as part of secondary or even tertiary cytoreduction, literature data is even scarcer, the presence of liver metastases being considered for long time as an exclusion criterion when establishing whether a patient is a candidate for optimal cytoreduction at the moment of surgery for recurrent disease. In time, improved understating of hepatic anatomy in association with the improvement of surgical techniques and postoperative care transformed hepatic resection in a more frequent associated surgical procedure in serial resections for ovarian cancer relapse. Once liver resection has been successfully associated as part of cytoreduction for relapsed ovarian cancer, attention was focused on determining other potential prognostic factors which might influence survival such as initial FIGO stage, disease free survival or histopatologic subtype of the tumor.

This chapter focuses on the subject of liver resection as part of cytoreductive surgery for advanced stage or relapsed ovarian cancer. The influence of different patterns of spread, the safety and effectiveness of performing anatomical or extended liver resections are also presented.

INTRODUCTION

Ovarian cancer remains one of the most common and aggressive malignancies worldwide, with an estimated incidence of 225,500 new cases per year and a reported mortality of 140,200 deaths per year [1]. Unfortunately, the majority of patients are diagnosed in an advanced stage of the disease when disseminated lesions are already present; most of these cases will experience recurrent disease; only 20-25% of patients being expected to experience a long term survival despite an initial good response to primary therapeutic strategy [2-4]. However, in the last decades the reported survival even in patients diagnosed in an advanced stage of the disease significantly increased due to the progressive incorporation of more extended surgical resections in order to maximize the debulking effort [5]. When it comes to the optimal residual disease, the definition of optimal cytoreduction has modified from remnant tumor < 1cm to no gross residual disease [5]. The redefinition of

optimal residual disease was proposed by Chang and Bristow and was based on the results of Bristow's meta-analysis conducted on 6885 patients with advanced stage ovarian cancer. The author demonstrated that each 10% increase in the proportion of patients undergoing maximal cytoreduction was associated with a 5.5% increase of the median cohort survival time. The authors concluded that one of the strongest factors influencing the long terms outcomes was performing a maximal cytoreductive surgery [6]. However, in patients diagnosed in an advanced stage of the disease, presenting disseminated lesions multiple visceral resections might be needed. In cases with pelvic extension association of surgical procedures such as pelvic peritonectomy, rectosigmoidian resection, colic or enteral resections or even urinary tract resections have been successfully implemented in the armamentarium of the oncologic gynecologist increasing the rate of resection to no visible residual disease [7-10]. Although these procedures have been introduced as part of the standard surgical procedures which might be needed in order to achieve a complete cytoreduction, the percentage of patients benefiting from a maximal debulking effort widely varies in the literature data from 15% to 85% [6]. It has been advocated that studies in which the reported rate of optimal cytoreduction surpasses 50% usually incorporate extensive upper abdominal resections [11-13]. Chi et al. demonstrated that association of upper abdominal extended resections leads to a significant improvement of disease free survival and overall survival, so they recommended that surgeons should consider including these therapeutic gestures as part of the standard treatment in patients presenting upper abdominal involvement [14].

When it comes to hepatic metastases in ovarian cancer, the presence of liver involvement at the time of diagnosis or during the evolution of the disease is usually considered as a poor prognosis factor with devastating effects on the long term outcomes [15].

MECHANISMS OF LIVER INVOLVEMENT IN ADVANCED STAGE AND RELAPSED OVARIAN CANCER

When it comes to the most common patterns of spread in advanced stage ovarian cancer, it has been widely demonstrated that the main pathways of spread are represented by the peritoneal route, followed by lymphatic and hematogenous route. While the presence of peritoneal spread is usually conditioned by the apparition of the epithelial –to – mesenchymal transition in association with the presence of growth factors and cytokines, the hepatic involvement via hematogenous route usually occurs via portal flow [16, 17]. However, the presence of ovarian cancer liver metastases is common events since Rose et al. reported in their study that nearly one half of the patients with ovarian cancer have liver metastases at the time of death. The study presenting the autopsy findings in 428 patients with various histological subtypes of ovarian cancer also reported that while the peritoneum was most commonly involved (in up to 100% of cases), lymph node metastases were reported in up to 60% of cases [17]. In the study conducted by Cormio et al. the liver was reported as the most common site of distant metastases [15]. The different outcomes reported after liver resections of peritoneal versus hematogenous liver metastases is also suggested by the inclusion of the two patterns of spread as two separate criteria in FIGO classification: while the presence of capsular hepatic lesions is considered as IIIC stage of the disease while the presence of hematogenous lesions (defined as hepatic parenchymatous lesions) is considered as an

inclusion criteria for FIGO stage IV of disease [18]. In conclusion, a clear distinction between the different pathways of liver involvement needs to be made in all cases.

SAFETY AND EFFECTIVENESS OF HEPATIC RESECTIONS IN OVARIAN CANCER LIVER METASTASES

Initially it has been considered that liver resection is not justified due to the fact the hepatic involvement usually develops in the context of a systemic disease and therefore, systemic chemotherapy should be the treatment of choice [19-21]. However, the reported success after hepatic resections in colorectal and neuroendocrine malignancies quantified by increasing the rate of long term survivors up to 25% at ten year follow up encouraged the surgeons worldwide to study the effectiveness and benefits in long term outcomes for liver resection in non-colorectal non-neuroendocrine liver metastases [19-23]. Although the groups of patients involved in these studies are small in number and heterogeneous in regard to the primary tumor, the general conclusion is that hepatic resection could improve the long term outcomes [21-23]. Among cases included in these studies, patients with advanced stage or relapsed ovarian cancer were involved and a benefit in terms of survival was achieved. The most important studies focused on this issue are summarized in Table 1.

All these reported results showing increased rates of survival after resection of liver metastases enabled the surgeons worldwide to include it in the standard treatment for hepatic metastases from other primaries including gynecological cancers.

In the study conducted by Sarah Kamel et al. the authors introduced 87 patients diagnosed with liver metastases from gynecological malignancies submitted to hepatic resections at John Hopkins Hospital between 1990 and 2010. Most patients included in the study had a primary tumor located in the ovary (67 cases, 77%) and were classified with FIGO stage III disease. Other involved primaries were uterus/endometrium (in 17% of patients), cervix (in 4% of cases) and fallopian tube (in 2% of cases). The main surgical procedure consisted of total hysterectomy with bilateral adnexectomy (81%), concurrent lymph node dissection (61%) and peritoneal debulking (81%). Up to 34% of cases were found to have positive lymph nodes.

Synchronous liver involvement was reported in 30 patients (34% of cases) while in the other 57 patients metachronous lesions were found after a median disease free interval of 25 months.

Among patients with synchronous liver metastases 24 cases (80%) were submitted to concomitant liver resections. Among patients diagnosed with metachronous liver lesions 45 patients had been submitted to neoadjuvant chemotherapy; furthermore, 23 patients were submitted to liver resections. When studying the completeness of resection, negative resections margins were seen in 63% of cases, while 15% of specimens revealed microscopic disease on the specimen's margins; in a single case macroscopic residual disease was reported. The postoperative mortality rate was 0. Recurrence was found in 39 cases after a median follow up of 13 months: in six cases the recurrence was limited to the liver, in 13 cases only an extrahepatic recurrent disease was found, while in the other 18 cases both intrahepatic and extrahepatic recurrences were reported; in other two cases the site of recurrence remained unknown.

Table 1. Studies conducted on the issue of hepatic resections in non-colorectal non-neuroendocrine liver metastases including subjects with ovarian cancer

Author, year of the study	Period of the study	No. of cases	No of patients with ovarian cancer (%)	5-year overall survival of the entire cohort	Median survival after resection of cases with ovarian primaries (months)
Slotta et al. 2014 [21]	7 years	101	5 (15.84%)	30%	15.84
Reddy et al. 2007 [22]	1995-2005	82	11 (13.4%)	37%	NR
Martel et al. 2105 [24]	1990-2012	52	3 (5.7%)	58%	89.9
Lendoire et al. 2007 [25]	1989-2006	106	14(13.2%)	19%	NR, 5-year OS for genitor-urinary tumors (renal, ovarian) 30%
Adam et al. 2006 [26]	1983-2004	1452	65 (4.47%)	36%	98

Of the six patients diagnosed with intrahepatic recurrent disease three cases were submitted to re-operation. The median overall survival after resection of liver metastases with ovarian origin was similar to the other non-ovarian primaries (21 versus 22 months respectively, $p = 0.53$). Although patients diagnosed with parenchimatous lesions had a poorer outcome, this fact did not reach statistical significance ($p = 0.12$) [27].

One year later Jose Ramia et al. published a literature review suggestively entitled: "Liver Metastases from Gynecological cancers: Time to Resection?" in which the author included the published articles between 1990 and 2011 based on a PubMed Search. A total of 20 articles including case-reports were reviewed; however the authors referred only to hematogenous metastases. When it came to ovarian cancer, liver resection was mainly proposed for isolated lesions, the presence of concomitant extra-hepatic burden being even considered as an absolute contraindication by some authors [28, 29]. However, most studies considered that primary debulking surgery followed by adjuvant chemotherapy is the treatment of choice, although relapse might occur [30-32]. Moreover, a second debulking surgery has been proposed, especially in patients with a reported disease free survival of at least 12 months. Although an important percentage of patients is expected to be submitted to secondary cytoreduction, liver resection is performed only in a low percentage of cases ranging between 0 and 9%. When it comes to prognostic factors, negative resection margins, the absence of extrahepatic burden, slow-growing tumors, a longer disease free survival (> 12 months) and a good clinical status were associated with improved survival [33].

LIVER RESECTION AS PART OF UPPER ABDOMINAL SURGERY IN ADVANCED STAGE AND RELAPSED OVARIAN CANCER

In an attempt to improve the rates of complete cytoreductive surgery Dennis Chi et al. introduced in the therapeutic armamentarium extensive upper abdominal surgical procedures as part of primary cytoreduction for advanced stage ovarian cancer from 2001. In order to demonstrate the feasibility and safety of these procedures, the authors compared the results with those obtained before the year of 2001 in the same hospital. The first study group consisted of 168 patients submitted to cytoreductive surgery between 1996-1999 while the second group consisted of 210 patients submitted to cytoreductive surgery between 2001 and 2004. Both study groups included patients with FIGO stage IIIC and IV; however, upper abdominal surgery was performed only in the second group. Extended upper abdominal surgery included diaphragmatic peritonectomy and/or resection, splenectomy, distal pancreatectomy, cholecistectomy, hepatectomy and porta hepatis tumor resection. Optimal residual disease was defined as no residual tumor larger than 1 cm. The two subgroups were similar in regard to age at diagnosis, tumor stage, tumor grade or clinical status according to the American Society of Anesthesiologists class. Among the patients submitted to extended upper abdominal resections, hepatectomy was performed in 13 patients (6% of cases) while resection of porta hepatis lesions was performed in 11 patients (5% of cases). The rate of complete cytoreduction was significantly higher among the second group (80% versus 46% in the first group, $p < 0.01$). In the meantime the estimated blood loss, intraoperative transfusion rates, operative time and major complications were more frequently present in the second group. However none of these aspects influenced the administration of adjuvant

chemotherapy while the mortality rate was similar between the two groups (0.6% in the first group versus 0.6% in the second group). When it comes to long term outcomes, the 5 year overall survival rate was 31% in the second group, significantly higher when compared to the first group (with a 5 year overall survival rate of 14%, $p = 0.001$). The reported median overall survival was 54 months for the second group and only 43 months for the first group ($p = 0.03$) [14].

In another similar study focused on the issue of extended upper abdominal resections in patients with stage IIIC and IV ovarian cancer, Eisenhauer et al. introduced 262 patients divided in three groups: the first group included 57 patients who required extended upper abdominal resection to achieve complete cytoreduction, the second group included 122 patients in which upper abdominal procedures were not necessary while the third group included 83 patients with advanced stage disease but who were submitted to incomplete cytoreduction. Among cases submitted to extended upper abdominal procedures liver resection was performed in 9 cases (16%) while porta hepatis tumor was resected in 8 cases (14%). The first group reported a longer operative time and a higher median blood loss while the complication rate was similar between the different groups. In the meantime, although patients from the first group were submitted to the adjuvant chemotherapy later on when compared to the other two groups, similar doses of chemotherapic agents were administrated and the response to chemotherapy was significantly improved. As for the long term outcomes, comparable rates of survival were obtained for the first two groups and were significantly higher when compared to the third group (at the end of the study the median overall survival was not yet reached for group 1, was 84 months for group 2 and 37 months for group 3). The similar reported outcomes between the first two groups come to demonstrate the efficiency of extended resections. In the meantime comparable rates of postoperative complications enabled the surgeons to consider that addition of upper abdominal resections is a safe procedure [34].

Once it has been widely demonstrated that completion of the resection is one of the strongest predictors for long term survival, few authors focused on determining the specific involvement sites which could predict the presence of unresectable disease. For example, Francesco Raspagliesli studied the influence of upper abdominal tumor burden involving the omental bursa, lesser omentum, celiac, portal and triad nodes spread as cause of incomplete cytoreduction. A total of 37 consecutive patients with advanced stage ovarian cancer and upper abdomen involvement were introduced in the study: 29 cases were diagnosed with FIGO stage IIIC disease while the other 8 patients were classified as FIGO stage IV. Cytoreduction to no residual disease was achieved in 34 cases, while in the other 3 cases residual disease of 5 mm was reported. The main location of the residual nodules was at the level of hepatic pedicle, demonstrating that the involvement of the areas surrounding the vital anatomic structures in the upper abdomen might still be a reason for incomplete cytoreduction [35].

While most studies focus on the possibility of obtaining a complete cytoreduction and an improved long term survival, only few studies have been conducted on the issue of the early postoperative complications and their predictors. One of the largest studies regarding this subject was conducted by Pierluigi Beneditti Panici and involved 121 patients submitted to 212 surgical procedures including upper abdominal resections. Upper abdominal sites of involvement included: diaphragm (51.2%), the liver (33.5%), the stomach (13.3%), the biliary tract and porta hepatis (19.8%), the spleen (43.8%) and the pancreatic tail (11.6%). The main

performed upper abdominal procedures included diaphragmatic peritonectomies (28.9%), diaphragmatic resections (31.4%), glissonian resections (15.7%), liver resections (13.2%), gastric resections (9.9%), distal pancreatectomies (13.2%), splenectomy (39.6%) and biliary tract surgery (19.8%). In univariate analysis performing diaphragmatic, pancreatic, gastric and splenic resections was associated with longer postoperative hospital in stay. Hepatic surgery was associated with a minimal increase of the length of hospitalization (9.2 days for patients submitted to liver resections versus 8.8 days for cases in which liver resection was not necessary, $p = 0.757$).

Despite this fact, liver surgery was associated with a higher rate of complications. In two cases a severe blood loss was observed after resection of nine and seven respectively liver metastases, while postoperatively hepatic surgery was significantly associated with an increased rate of both overall and severe complications ($p = 0.037$ and $p = 0.004$ respectively). The reported 90 days mortality rate was 0.8%. The authors concluded that extended upper abdominal resections should be performed in selected cases and by selected surgical teams, in centers with a high capacity to manage life-threatening complications [36].

LIVER RESECTION AT THE MOMENT OF PRIMARY CYTOREDUCTION FOR ADVANCED STAGE OVARIAN CANCER

At the time of primary cytoreduction, liver resection for ovarian cancer is most often presented as integrative part of the maximal cytoreductive effort in association with other extrahepatic resections.

In order to evaluate the role of debulking surgery in patients with stage IV ovarian cancer, Bristow et al. conducted a study on 84 patients with a median age at diagnosis of 61 years. Forty-four percents were diagnosed with parenchymal liver metastases while 38% had malignant pleural effusion. Optimal cytoreduction (defined as residual disease < 1 cm) was achieved in 30% of cases and was associated with a median overall survival of 38.4 months, while patients with suboptimal residual disease reported an overall survival of 10.3 months ($p = 0.0004$).

Optimal resection of both intrahepatic and extrahepatic disease was achieved in 16% of cases and reported an overall survival of 50.1 months, significantly higher when compared to patients with optimal extrahepatic disease but suboptimal residual hepatic tumor (with a median survival rate of 27 months) and with those with suboptimal extrahepatic and hepatic disease who had a median overall survival rate of 7.6 months [37].

The benefits of multiple visceral resections in the setting of FIGO stage IIIC and IV ovarian cancer were also reported in the study conducted by Heinz Scholz over a five year period, on 101 patients in Nurnberg, Germany. Among these cases, 54% of patients were submitted to surgery as primary therapeutic option while the other 46% of cases had been previously submitted to neoadjuvant chemotherapy. In all cases cytoreduction to no gross residual disease was attempted and was achieved in 82% of cases submitted to surgery as first therapeutic option and in 85% of cases in which neoadjuvant chemotherapy had been performed ($p = 0.793$).

Partial hepatectomy was performed in 11% of cases while Glisson capsule resection was performed in 39% of cases; the 30 days postoperative mortality rate was 0. Long term

outcomes revealed a median survival of 47 months while the five year survival rate was 33% for the entire group. Patients submitted directly to surgery reported a better outcome in terms of survival comparatively to those submitted to neoadjuvant chemotherapy and interval debulking surgery ($p = 0.046$). The authors demonstrated the effectiveness of debulking surgery even if hepatic metastases are present and revealed the superiority of primary surgical treatment comparatively to interval debulking surgery [38].

Another German study comes from Ulf Neumann and discusses the benefits of liver resections as part of primary cytoreductive surgery in advanced stage ovarian cancer. The study was conducted between 1991 and 2007 and included 70 patients with advanced stage disease submitted to surgery in Charite, Virchow Clinic. Liver resection was performed in 41 out of the 70 patients, the other 29 cases presenting unresectable disease. Additional surgical procedures included total hysterectomy (in 14.3% of cases), bilateral adnexectomy (in 24.3% of cases), omentectomy (in 32.9% of cases), partial colectomy (in 51.4% of cases), partial small bowel resection (in 32.9% of cases), partial gastrectomies (in 5.7% of cases) and partial pancreatectomies (in 4.3% of cases).

In all cases submitted to liver resection a residual tumor volume < 5 mm was achieved. The 3- months postoperative mortality rate was 14.6% in the subgroup submitted to liver resection and 41% in the subgroup in which liver resection was not feasible ($p = 0.025$), while the morbidity rate was similar between the two groups. Regarding the long term outcomes, the median survival rate was significantly higher among patients submitted to liver resection: patients submitted to an R0 resection reported a median survival rate of 42 months while cases in which liver resection was not feasible reported a median overall survival of 4 months ($p < 0.001$).

Other poor prognostic factors were represented by the presence of ascites and bilobular liver metastases. When it came to establishing the predictors of resecability of hepatic metastases, only the presence of ascites was associated with a poorer resecability rate. The authors concluded that liver resection should be part of the standard therapeutic protocol whenever a residual disease of less than 5 mm can be achieved and demonstrated that performing hepatic resections in ovarian cancer liver metastases does not increase the early postoperative mortality rate [39].

THE SIGNIFICANCE OF HEMATOGENOUS HEPATIC METASTASES IN THE SETTING OF ADVANCED STAGE OVARIAN CANCER

Based on the postoperative outcome, liver involvement in advanced stage ovarian cancer is classified as FIGO stage IIIC when peritoneal seeding involving the liver parenchyma is diagnosed and stage IV respectively when hematogemous spread is the pathogenic mechanism. Thus, hepatic hematogenous involvement is based on the postoperative pathologic diagnosis. In an attempt to determine if there is a survival difference between parenchimatous and peritoneal hepatic involvement in cases in which an R0 resection is achieved large studies have been conducted.

In the study conducted by Lim et al. data of 117 patients submitted to primary cytoreduction for advanced stage ovarian cancer with liver involvement were retrospectively reviewed. Sixteen of the 117 patients were diagnosed with parenchimatous lesions and were

included in FIGO stage IV group; however, in two cases the tumors proved to be unresectable and liver surgery consisted only in liver biopsy, confirming the ovarian origin. The remaining 14 cases were underwent hepatic resections and the histopathological studies confirmed the presence of hematogenous liver involvement. In all cases negative resection margins were achieved. The remnant 101 patients were diagnosed with FIGO stage IIIC disease. In the two cases in which liver resection could not be performed, although 3rd line chemotherapy was initiated, the reported survival was of inly 9 and 10 months respectively. Among patients diagnosed with FIGO stage IIIC disease 44 cases were submitted to neo-adjuvant chemotherapy. When it comes to the preoperative and intraoperative findings, there were no significant differences regarding the age, histology or grade, median CA 125 levels or the administration of neo-adjuvant chemotherapy. Optimal cytoreduction was achieved in 94% and 93% respectively in patients diagnosed in FIGO stage IIIC and IV while no visible residual disease was reported in 47 and 43% of patients with FIGO stage IIIC and IV respectively. The main types of liver resection included wedge resections in 50% of cases, segmentectomies in 36% of cases and hemi-hepatectomies in 14% of cases. There was no significant difference regarding the operative time, estimated blood loss, transfusion, postoperative hospital stay, largest residual disease or time to adjuvant chemotherapy. No liver-related surgery complication such as bile leakage or bleeding occurred. The most common complications in the both group were febrile morbidity, ileus, pancreatic fistula and pleural effusion. In regard to the long term outcomes, the 5-year overall survival rates were 55% and respectively 51% for the two subgroups $p = 0.5671$). The authors concluded that if an R0 resection is achieved in cases with parenchimatous lesions, a similar overall survival to cases with peritoneal lesions should be expected and suggested that a possible revision of FIGO classification might be taken in consideration [40].

In a similar study conducted at "Dan Setlacec" Center of Gastrointestinal Disease and Liver Transplantation, Fundeni Clinical Institute, Bucharest 11 patients submitted to liver resection at the time of primary cytoreduction were included. Neoadjuvant chemotherapy was administrated in two cases. Postoperatively the rate of severe complications in 25% patients, all of them being diagnosed with stage IV disease; however, the 30 days postoperative mortality was 0. Although it did not reach statistical significance the overall survival was consistently higher among patients with peritoneal seeding (34.33 months versus 15.63 months, $p = 0.702$) [41].

LIVER RESECTION AS PART OF SECONDARY CYTOREDUCTIVE SURGERY

The benefits of secondary cytoreduction in the setting of relapsed ovarian cancer have been widely demonstrated with maximal effects in cases with a long disease free interval after completion of the primary therapeutic protocol and if isolated recurrences are found at the time of relapse [42]. However, even if multiple recurrences are found at the time of diagnosis, an aggressive surgical approach in order to maximize the debulking effort is perfectly justified in order to improve survival [43-46]. In the study conducted by Niu et al. the authors included both patients with no history of extrahepatic disease as well as patients with extrahepatic burden. Although patients with liver confined disease had an improved outcome

(median overall survival of 41.42 months) when compared to those with both intrahepatic and extrahepatic disease (median overall survival of 36.99 months), the benefit in terms of survival was consistent when compared to the results of the patients submitted to chemotherapy alone [46]. In a similar study conducted by Roh et al. the outcomes of 18 patients submitted to hepatic resections for ovarian cancer liver metastases with the reported results of 25 cases with unresectable liver metastases; although extrahepatic resections were similar between the two groups, in the second subgroup no liver procedure (including surgery, radiofrequency ablation or ethanol injection) was performed. The overall survival rate was significantly improved in the hepatectomy group - 38 months, comparatively to the non-hepatectomy group - 10 months ($p = 0.0232$) [47]. The largest studies conducted on the issue of liver resection at the moment of secondary resection are summarized in Table 2. As for the early postoperative outcomes, improvement of surgical technique of hepatic resections has led to acceptable postoperative rates of liver related surgery complications and an early postoperative mortality rate almost null [51,52]. In the meantime the actual surgical techniques in association with the postoperative management provided the possibility of resecting up to 70% of the liver parenchyma with mortality rates of up to 5% [53]. All these aspects encouraged surgeons to perform more extended resections for liver metastatic disease. When it comes to the long term outcomes, association of liver resection as part of cytoreductive surgery has significantly improved the overall survival. The most suggestive results in regard to the short and long term outcomes are summarized in Table 3.

PROGNOSTIC FACTORS AFTER LIVER RESECTION AT THE MOMENT OF SECONDARY CYTOREDUCTION

Association of Extrahepatic Tumor Burden and Diameter of the Residual Tumor

The strongest predictor for long term survival remains the completeness of the resection. In Bosquet's study optimal cytoreduction was defined as hepatic or extra-hepatic residual disease < 1cm in the greatest diameter was consistently associated with improved survival: the median disease specific survival was significantly higher in patients submitted to optimal cytoreduction when compared to those in which optimal cytoreduction was not feasible: 41,3 months versus 5,7 months, $p < 0.0001$) [42].

Similar results were reported by Kolev et al. at the same cut-off of 1 cm [49]. In the study conducted by Niu et al. involving 60 patients submitted to liver resection for metachronous liver metastases the completion of the resection was achieved by studying the resection margins of the specimen. The absence of tumor involvement on the resection margins was defined as R0 resection and associated a significantly improved outcome when compared to patients with R1 resection (defined as microscopic involvement of the resection margins of the specimen) (51.9 months versus 22,01 months, $p = 0.039$) [46]. Although not statistical significant, extrahepatic tumor burden was associated with a poorer outcome in Niu's study (41.42 months for patients with liver confined disease versus 36.99 months for cases with both intra- and extrahepatic lesions ($p = 0.290$).

Table 2. Studies regarding the role of hepatic resections as part of secondary cytoreduction in relapsed ovarian cancer

Author, year	Period of the study	No. of cases	Median DFI from initial diagnosis to liver rmetastases (months)	Extent of liver resection	Type of resection(definition of optimal cytoreduction)	Residual disease	Associated visceral resections
Bosquet et al., 2006 [42]	1976-2003	35	NR	NR	Residual disease< 1cm	< 1cm: 29pts > 1cm: 6 pts	Bowel resection: 34.3% Other associated resections: 80%
Niu et al., 2012 [46]	2000-2011	60	34	Wedge resection: 46.7% Lobectomy: 11.7% Trisegmentectomy: 11.7% -Bisegmentectomy:20% -RFA:10%	R0= negative resection margins on the specimen of liver resection R1= microscopic involvement of the margins	Negative resection margins: 54 pts Microscopic disease at margins: 6 pts	0
Abood et al., 2008 [48]	1998-2006	10	48	Trisegmentectomy: 40% Lobectomy: 50% Bisegmentectomy: 10%	R0= negative resection margins on the specimen of liver resection R1= microscopic involvement of the margins	Negative resection margins:5 pts Microscopic disease at margins: 5 pts	Diaphragmatic resection: 60% Bowel resection: 30% Adrenalectomy: 10%
Kolev et al., 2014 [49]	1988-2012	27	27	Multisegmentectomy: 11.1% Lobectomy: 14.8% Segmentectomy:40.7% Wedge resections: 33.3%	Residual disease < 1cm	< 1cm: 25pts > 1cm: 2 pts	Diaphragmatic resections: 33.3% Bowel resection: 7.4% Splenectomy: 7.4%
Yoon et al., 2003 [30]	1988-2001	24	68.5	Trisegmentectomy: 8.3% Lobectomy: 8.3% Segmentectomy: 70.8% Wedge resection:12.5%	Residual disease < 1cm	R0: 88% of cases R1: 12% of cases	

Author, year	Period of the study	No. of cases	Median DFI from initial diagnosis to liver rmetastases (months)	Extent of liver resection	Type of resection (definition of optimal cytoreduction)	Residual disease	Associated visceral resections
							Resection of extrahepatic disease: 66% Diaphragmatic resections: 50%, Cholecystectomy: 54.16% Colectomy: 16.6% Lung resection: 12.5% Nephrectomy: 8.3% Pericardial resection: 8.3% Adrenalectomy: 4.16% Splenectomy: 4.16% Pancreatectomy: 4.16% Gastrectomy: 4.16%
Roh et al., 2011 [47]	1991-2008	18	33	Bisegmentectomy: 5.5% Segmentectomy:72.2% Wedge resections: 22.2%	Residual disease < 1cm	< 1cm: 12pts >1cm: 6 pts	Resection of extrahepatic disease, multiple sites: 100%
Pekmezci et al., 2010 [50]	2003-2008	8	64.5 (5.38 years)	Right hepatectomy: 12.5% Left lateral sectorectomy: 25% Segmentectomy: 37.5% Wedge resection: 25%	Macroscopic residual disease	No macroscopic residual disease and no microscopic invasion of the resection margins were achieved in all cases	Upper abdomen lymph node dissection: 25% Resection of intra-abdominal peritoneal nodules: 25%
Merideth et al., 2003 [32]	1976-1999	26	29.4	Right hepatectomy: 15.4% Left hepatectomy: 3.8% Segmentectomy: 69.2% Trisegmentectomy: 11.5%	Intra- and extrahepatic residual disease < 1cm	R0: 21 pts R1: 5 pts	Bowel resection: 42.3% Diaphragmatic resection: 50% Splenectomy: 7.7% Lung resection: 7.7% Lymph node dissection:15.4% Cholecystectomy: 9.2%

DFI: disease free interval; RFA: radiofrequency ablation.

Table 3. Early postoperative outcomes and long term results after liver resection for ovarian cancer liver metastases as part of secondary cytoreduction

Author, year	Period of the study	No. of cases	Postoperative complications	Hepatic surgery related complications	30 days postop. mortality rate	Median overall survival (months)
Bosquet et al. 2006 [42]	1976-2003	35	2.9% of patients required reoperation (small bowel fistula)	0	0	27.4
Niu et al. 2012 [46]	2000-2011	60	10% (pulmonary complications, wound infections)	0	0	39
Abood et al. 2008 [48]	1998-2006	10	10% (anemia requiring transfusion occurred in one case)	10%	0	33
Kolev et al. 2014 [49]	1988-2012	27	11% (two anastomotic leaks requiring reoperation and one postoperative sepsis)	NR	0	56 months – from the time of the diagnosis
Yoon et al. 2003 [30]	1988-2001	24	21% (two bilomas, one case of ileus, one case of urinary tract infection, one case of pneumonia	8.3%	0	62
Roh et al. 2011 [47]	1991-2008	18	The rate of major complication was 5.6% (one case of transverse colon perforation). Five other patients experienced minor complications (ileus, wound infection, bile leakage, transient abnormality liver function or pleural effusion)	NR	0	38
Pekmezci et al. 2010 [50]	2003-2008	8	0	0	0	NR, disease free survival after liver resection=39 months
Merideth et al., 2003 [32]	1976-1999	26	7.6% (wound infection in one case and small bowel perforation requiring reoperation in the second case	0	0	26.3

In the study conducted by Roh et al. including 18 patients resection margins of the hepatectomy specimen and residual disease were both associated with an improved survival.

Patients presenting negative resection margins experienced a significantly improved survival when compared to those with positive resection margins (40 months versus 9 months, $p = 0.0196$) while patients submitted to an optimal cytoreduction (defined as residual disease < 1cm) reported a median overall survival of 40 months, significantly higher when compared to those with suboptimal cytoreduction (median overall survival of 9 months, $p = 0.0004$) [47]. Optimal cytoreduction (defined as extrahepatic and intrahepatic residual disease < 1 cm) was also associated with an improved survival (27.3 months versus 8.6 months, $p = 0.031$) in Melissa Meredith's study conducted at Mayo Clinic, Rochester between 1976 and 1999 [32].

Based on these findings, the authors concluded that hepatic resection should only be considered if optimal cytoreduction is feasible [32, 47]. Similar results were also obtained by other studies, demonstrating that the tumoral burden as well as the diameter of the metastatic tumor are important prognostic factors and patients submitted to cytoreduction in the presence of extrahepatic disease should be carefully selected [47, 48].

Disease Free Survival

It has been advocated that patients with an increased disease specific survival from the primary surgery for ovarian cancer to the moment of liver resection have an improved outcome. In Bosquet's study patients with disease specific survival longer than one year also experienced an improved survival after liver resection (31.7 months versus 15.1 months, $p = 0.01$) [42]. Similar results were also reported by Niu's study, with a significantly improved median overall survival for patients with disease free survival of more than 12 months between ovarian cancer surgery and diagnosis of liver metastases (50.96 months versus 30.94 months, $p = 0.018$). The same authors stated that the improved results obtained after liver resections in patients with an initial linger disease free survival might be a reflection of a biologically indolent tumor [46]. In Kolev's study involving 27 patients a disease free survival after the initial treatment of 24 months was found to be statistically significant ($p = 0.044$) [49].One of the most suggestive studies which demonstrates that the patient selection is crucial comes from S.S. Yoon et al. and was conducted at Memorial Sloan Kettering Cancer Center between June 1988 and December 2001. All patients included in this study had a relatively slow tumor progression and initially chemosensitive disease; this fact is demonstrated by the long disease free survival between the diagnosis of ovarian cancer and the apparition of liver metastases (with a median reported disease free interval of 68.5 months). In the meantime, the reported median overall survival was 62 months, although 75% of patients had extrahepatic tumoral burden [30]. Pekmezci et al. also considered that a longer disease free survival after the initial surgery for ovarian cancer is the mark of a good biological tumor behavior and considered these cases as the ideal candidates for secondary cytoreduction; the authors included in their study eight patients who developed liver metastases after a median disease free survival of 5.38 years; in the meantime the authors reported a secondary disease free survival after liver resection of 39 months which also favors the hypothesis of a less aggressive biology of the tumor [50]. Mayo Clinic reported similar results with a median overall survival of 27.3 months for patients with initial disease free

survival longer than 12 months versus 5.7 months for patients with a shorter initial disease free survival (p = 0.004) [32]. Oppositely to these results, in Hyun Jin Roh's study conducted on18 patients, time from initial diagnosis to liver resection did not significantly impacted on survival [47].

Number and Distribution of the Hepatic Lesions

The benefits of liver resection in patients presenting multiple lesions have been widely studied in colon cancer. In a study conducted by Bolton et al. patients submitted to liver resection for colorectal hepatic metastases were divided in to subgroups: cases with fewer than three liver metastases and cases with more lesions. The authors demonstrated that if all the lesions were resected, there was no difference in terms of survival between the two groups [54]. More recently, in order to find out if there is any limit regarding the maximum number of metastases which could be resected in liver metastases from colorectal cancer, an international panel of multidisciplinary experts decided that there is no limitation in regard to the number of excised lesions [55].

When it comes to ovarian cancer, although a higher number of hepatic lesions and a bilobar distribution might be considered as a poor prognosis factor, the reported results are inconstant. In Bosquet's study neither the number nor the distribution of the hepatic metastases presented statistically significance in terms of survival [42]; similar results were also reported by Kolev et al., and Merideth et al. respectively, no significant difference being revealed between cases with solitary liver masses and multiple lesions [32, 49]. Oppositely to these studies, Niu et al. reported an improved survival for patients diagnosed with a single metastases versus those with multiple lesions (55.4 months versus 26.06 months, p = 0.018). However, this fact did not reach statistical significance in multivariate analysis (p = 0.085) [46]. The diameter of the largest liver metastasis was proven to have a significant importance in Gerard Abood's study, conducted at Loloya University Medical Center, in which 10 patients were included. According to this study, tumor size larger than 5 cm was associated with a significantly increased survival (with a reported median survival of 17.2 months versus 11.2 months in patients with smaller tumors, p = 0.046); the authors explained this surprising aspect by the fact that cases with larger tumors have in fact less hepatic tumor burden due to the smaller number of lesions [48].

Other Prognostic Factors

When it comes to other possible prognostic factors such as the tumor histology and degree of differentiation, no significant influence in terms of survival has been demonstrated [32, 42, 46]. In the study conducted by Yoon et al. a favorable tumor biology (reflected in a slow growing pattern, limited to liver disease and long disease free interval) associated with a good biological status of the patient represents the ideal scenario for performing liver resection for ovarian cancer metachrnous hepatic metastases [30]. An interesting aspect was revealed by Roh's study which demonstrated that a higher upper abdominal burden is significantly associated with a decreased survival (patients with a higher pelvic tumor burden

reported a median overall survival of 38 months while with those with a higher upper abdominal burden reported a median overall survival of 11 months, $p = 0.032$) [47].

The Significance of Hematogenous Hepatic Metastases in the Setting of Relapsed Stage Ovarian Cancer

In order to determine if a difference in terms of survival is maintained at the moment of secondary cytoreduction for peritoneal versus hematogenous lesions, a study involving 15 patients was conducted in Fundeni Clinical Institute, Bucharest. Disease free interval between surgery for ovarian cancer and diagnosis of liver metastases was 30 months. An R0 resection (defined as no residual tumor) was achieved in 12 patients. The histopathological findings revealed the presence of peritoneal lesions in six patients while in the other nine patients entirely parenchimatous lesions have been found. When it came to the type of liver resection, minor hepatectomies (defined as liver resection of less than two segments) were performed in 14 cases while in the fifteenth case a major hepatectomy was performed. In order to maximize the cytoreductive effort, associated visceral resections were performed: splenectomy (in four cases), bowel resection (in four cases), diaphragmatic resections (in three cases) and subtotal gastrectomy (in a single case).

The postoperative morbidity arte was 27% while the liver surgery related complication rate was 13% and consisted of biliary leak and a hepatic abscess respectively. Although it did not present statistical significance, patients with liver metastases with peritoneal origin had a better outcome when compared to those with hematogenous lesions (14.51 months versus 6.16 months, $p = 0.197$). However, liver resection proved to be a safe and effective method as part of secondary cytoreduction [41].

In conclusion, hepatic resection for metachronous liver metastases from ovarian cancer can be safely performed at the time of secondary cytoreduction with acceptable rates of postoperative liver related complications and almost zero mortality. However, mixed surgical teams including hepato-bilio-pancreatic surgeons, visceral surgeons and gynecologic oncologist should be created in order to maximize the effects of this aggressive surgical approach and to minimize the postoperative complication rates [42-45].

LIVER RESECTION BEYOND SECONDARY CYTOREDUCTION FOR RELAPSED OVARIAN CARCINOMA

Data regarding the place of liver resection beyond tertiary cytoreduction are even scarcer, limited number of cases being reported. In the same study conducted in Fundeni Clinical Hospital, liver resection was performed in three cases as part of tertiary cytoreduction and in two patients submitted to quaternary cytoreduction. Liver resection at the moment of tertiary cytoreduction was performed after a mean interval of 54 months after the initial diagnosis. In two cases minor hepatectomies (defined as resection of less than 2 segments) was performed while in the third cases a major hepatectomy was performed. Postoperatively death occurred in a single case due to the development of a urinary fistula after synchronous resection of a pelvic recurrence. The postoperative course uneventful in the other two cases; the long term

outcomes revealed a survival of 63 months for one case and 70 months for the second patient, the latter being alive at the moment of ending the study. As for the patients submitted to liver resection as part of quaternary cytoreduction,, the interval between the primary and quaternary cytoreduction was 40 and 33 months respectively. None of the patients experienced postoperative complications while the reported survival after quaternary cytoreduction was 16 and 20 months, both patients being dead of disease by the end of the study [41].

In another similar study conducted by Mario Leitao in which 26 patients submitted to tertiary cytoreduction liver resection was necessary in three cases: in two cases wedge resections were performed while in the third case a segmentectomy was necessary to resect the hepatic lesions with negative margins. The postoperative morbidity rate was 27% while the overall mortality rate was zero. However liver surgery related complications were not reported [56].

In the study conducted by K.K. Shih et al. regarding the role of cytoreductive surgery beyond tertiary cytoreduction, a single patient submitted to quaternary cytoreduction had recurrent disease in the liver at the preoperative imagistic studies [57].

LAPAROSCOPIC AND ROBOTIC APPROACH FOR OVARIAN CANCER LIVER METASTASES

Once the safety and effectiveness of laparoscopic and robotic techniques have been widely demonstrated, these minimally invasive techniques became more frequently used in liver surgery too. The main advantages consist of implementing a minimally invasive procedure which assures a rapid postoperative rehabilitation without compromising the oncologic outcomes. The first robotic procedure performed in a patient with liver recurrence after ovarian cancer came from Robert Holloway and was performed in Florida in 2010. It was the case of a 60-year-old patient diagnosed with a 3.4 cm liver metastasis developed on the dome of the right liver, invading the diaphragm which was successfully resected robotically, after a console time of 82 minutes; the estimated blood loss was 100 ml. Postoperatively she developed a pleural effusion which was punctioned, the patient being discharged on the fifth postoperative day. She was submitted to adjuvant chemotherapy 4 weeks postoperatively [58].

Utility of Radiofrequency Ablation in Association with Liver Resection for Ovarian Cancer Hepatic Metastases

In an attempt to increase the rate of complete cytoreduction and in the meantime to decrease even more the rate of postoperative liver surgery related complications some studies focused on the possibility of association of radiofrequency ablation in the setting of advanced stage and relapsed ovarian cancer with liver involvement [59-61]. However, the utility of radiofrequency ablation was initially proved in patients with liver metastases from colorectal cancer, data regarding the utility of the method in ovarian cancer liver metastases still being scarce [60-64]. Although in cases with liver metastases from colorectal cancer radiofrequency

ablation seems to be unjustified in the presence of extrahepatic disease, when it comes to ovarian cancer, it is perfectly justified in order to maximize the cytoreductive effort [59-61].

The main benefit in radiofrequency ablation is the fact that it provides a rapid, bloodless destruction of the hepatic lesion; in the meantime this method creates a circumferential coagulative necrosis of the surrounding liver parenchyma decreasing in this way the blood loss in cases in which hepatectomy is intentioned as the second step procedure. However, the method is still limited in cases presenting centro-hilar lesions: in these cases the close proximity of the large blood vessels will induce a "heat sink" effect, decreasing in this way the likelihood of complete ablation and secondarily increasing the risk of recurrence. In the meantime it can increase the risk of biliary fistula [28,65]. Another limitative factor remains the dimension of the lesions, lesions larger than 5 cm being associated with a higher risk of recurrence; however this risk can be decreased if radiofrequency ablation is followed by liver resection [28]. The method of radiofrequency ablation of liver metastases seems to be especially effective in patients with disseminated, bilobar parenchimatous lesions, in an attempt to spare as much as possible the healthy parenchyma without compromising the oncological outcomes. In the meantime peritoneal lesions seem to be best treated by classic surgical approach. In this way combining the two methods might maximize the cytoreductive effort [60].

In one of the most recent published series, Petrou et al. included 145 consecutive patients diagnosed with liver metastases from various primaries submitted to radiofrequency ablation assite liver resection in order to decrease the blood lost during surgery. The standard technique in these cases consists of applying the radiofrequency ablation needle along the line of parenchymal transsection in order to create at this level an area of bloodless coagulative necrosis. By applying this principle, it is estimated that liver ischemia-reperfusion injury which usually develop after partial or total vascular occlusion could be safely minimized. Among the 145 patients submitted to radiofrequency ablation followed by liver resection, ovarian primaries were reported in two cases; in one case radiofrequency ablation was followed by a minor hepatic resection while in the latter case a major hepatectomy was associated. After performing these maneuvers, liver tests were slightly elevate during the early postoperative period and were normalized within seven days after surgery. When it comes to the completeness of resection, an R0 resection was achieved in 114 patients while in the other 13 cases an R1 resection was performed, the remnant 18 patients being submitted to liver resection for benign conditions. Regarding the postoperative outcomes, morbidity developed in 47 cases, no-one requiring re-operation. The most common complication remained transient liver insufficiency, which was completely recovered in all cases. Postoperative bile-leaks developed in ten patients, the mean duration of the leak being 17 days (range 5-32 days). However the postoperative complication rates were similar between cases submitted to major versus minor resections, demonstrating the safety and efficacy of the method [66].

In the case series reported by Mateo et al. three patients submitted to liver resection and radiofrequency ablation were included. The first reported case was a 59-year-old woman initially diagnosed with a stage IV ovarian cancer for which she was submitted to neoadjuvant chemotherapy followed by optimal debulking surgery. Five years later the patient was diagnosed with isolated hepatic recurrence (located in segment VI according to Couinaud's classification). Intraoperatively the lesions were successfully resected; however the intraoperative ultrasound revealed the presence of other two lesions located in the caudate

lobe, each one measuring less than 2 cm which were successfully ablated. Several peritoneal nodules were also found and resected, achieving a complete resection. At 13 months follow up the patient had no recurrent disease. The second reported case was the one of a 51-year-old patient initially diagnosed with stage III ovarian cancer for which she was submitted to debulking surgery followed by other two cytoreductive procedures for relapsed disease. Seven years after the initial diagnosis the patient was diagnosed with two liver metastases: the first one was developed on the right hepatic dome invading the diaphragm which was successfully resected while the second one measuring 2.8 cm was located in the proximity of the right hepatic vein and of the anterior branch of the right portal vein and was treated by radiofrequency ablation. At nine months follow up there was no sign of recurrent disease. In the third case radiofrequency ablation was the treatment of choice for a late recurrence after a stage III ovarian granulosa cell tumor. The patient had been previously submitted to surgery 19 years before, followed by adjuvant chemotherapy. At the time of recurrence she was diagnosed with an 18 cm tumor developed in the right hemiliver associated with a 2.5 cm lesion located in segment IV. The largest lesion was resected by an extended hepatectomy was the segment IV lesion, which was ablated by radiofrequency. Although the patient refused any adjuvant chemotherapy, she was free of any recurrent disease at 39 months follow up [60].

All of these encouraging results come to underline the benefits of association between radiofrequency ablation and liver resection for advanced stage or relapsed ovarian cancer with liver involvement.

REFERENCES

[1] Jemal A, Bray F, Center MM, Ferlay J, Ward E, Forman D (2011), Global cancer statistics, *CA Cancer J. Clin.* 61: 69-90.

[2] Kim HS, Kim JW, Shouten LJ, Larsson SC, Chung HH, Kim YB, Ju W, Park NH, Song YS, Kim SC, Kang SB (2010), Wine drinking and epithelial ovarian cancer risk: a meta-analysis, *J. Gynecol Oncol* 21: 112-118.

[3] Shih KK, Chi DS (2010), Maximal cytoreductive effort in epithelial ovarian cancer surgery, *J. Gynecol Oncol* 21: 75-80.

[4] Ozols RF (2005), Treatment goals in ovarian cancer, *Int. J. Gynecol Cancer* 15 Suppl 1: 3-11.

[5] Chang SJ, Bristow RE (2012), Evolution of surgical treatment paradigms for advanced-stage ovarian cancer: redefining 'optimal' residual disease, *Gynecol Oncol* 125: 483-492.

[6] Bristow RE, Tomacruz RS, Armstrong DK, Trimble EL, Montz FJ (2002), Survival effect of maximal cytoreductive surgery for advanced ovarian carcinoma during the platinum era: a meta-analysis, *J. Clin. Oncol* 20: 1248-1259.

[7] Salani R, Zahurak ML, Santillan A, Giuntoli RL, Bristow RE (2007), Survival impact of multiple bowel resections in patients undergoing primary cytoreductive surgery for advanced ovarian cancer: a case-control study, *Gynecol Oncol* 107: 495-499.

[8] Houvenaeghel G, Gutowski M, Buttarelli M, Cuisenier J, Narducci F, Dalle C, Ferron G, Morice P, Meeus P, Stockle E, Bannier M, Lambaudie E, Rouanet P, Fraisse J,

Leblanc E, Dauplat J, Querleu D, Martel P, Castaigne D (2009), Modified posterior pelvic exenteration for ovarian cancer, *Int. J. Gynecol Cancer* 19: 968-973.

[9] Tixier H, Fraisse J, Chauffert B, Mayer F, Causeret S, Loustalot C, Deville C, Bonnetain F, Sagot P, Douvier S, Cuisenier J (2010), Evaluation of pelvic posterior exenteration in the management of advanced-stage ovarian cancer, *Arch. Gynecol Obstet.* 281: 505-510.

[10] Estes JM, Leath CA, III, Straughn JM, Jr., Rocconi RP, Kirby TO, Huh WK, Barnes MN, III (2006), Bowel resection at the time of primary debulking for epithelial ovarian carcinoma: outcomes in patients treated with platinum and taxane-based chemotherapy, *J. Am. Coll. Surg.* 203: 527-532.

[11] Kuhn W, Glorack G, Roder J, Schmalfeldt B, Pache L, Rust M, et al. (1998), The influence of upper abdominal surgery on perioperative morbidity and mortality in patients with advanced ovarian cancer FIGO III and IV. *Int J Gynecol Cancer*. 8:56–63.

[12] Eisenkop SM, Spirtos NM, Friedman RL, Lin WC, Pisani AL, Perticucci S (2003), Relative influences of tumor volume before surgery and the cytoreductive outcome on survival for patients with advanced ovarian cancer: a prospective study, *Gynecol Oncol* 90: 390-396.

[13] Aletti GD, Dowdy SC, Gostout BS, Jones MB, Stanhope CR, Wilson TO, Podratz KC, Cliby WA (2006), Aggressive surgical effort and improved survival in advanced-stage ovarian cancer, *Obstet. Gynecol* 107: 77-85.

[14] Chi DS, Eisenhauer EL, Zivanovic O, Sonoda Y, Abu-Rustum NR, Levine DA, Guile MW, Bristow RE, Aghajanian C, Barakat RR (2009), Improved progression-free and overall survival in advanced ovarian cancer as a result of a change in surgical paradigm, *Gynecol Oncol* 114: 26-31.

[15] Cormio G, Rossi C, Cazzolla A, Resta L, Loverro G, Greco P, Selvaggi L (2003), Distant metastases in ovarian carcinoma, *Int. J. Gynecol Cancer* 13: 125-129.

[16] Nakayama K, Nakayama N, Katagiri H, Miyazaki K (2012), Mechanisms of ovarian cancer metastasis: biochemical pathways, *Int.J.Mol.Sci.* 13: 11705-11717.

[17] Rose PG, Piver MS, Tsukada Y, Lau TS (1989), Metastatic patterns in histologic variants of ovarian cancer. An autopsy study, *Cancer* 64: 1508-1513.

[18] FIGO Cancer Committee (1986). Staging announcement, *Gynecol Oncol* 25: 5.

[19] Rees M, Tekkis PP, Welsh FK, O'Rourke T, John TG (2008), Evaluation of long-term survival after hepatic resection for metastatic colorectal cancer: a multifactorial model of 929 patients, *Ann. Surg.* 247: 125-135.

[20] Sutcliffe R, Maguire D, Ramage J, Rela M, Heaton N (2004), Management of neuroendocrine liver metastases, *Am. J. Surg.* 187: 39-46.

[21] Slotta JE, Schuld J, Distler S, Richter S, Schilling MK, Kollmar O (2014), Hepatic resection of non-colorectal and non-neuroendocrine liver metastases - survival benefit for patients with non-gastrointestinal primary cancers - a case-controlled study, *Int. J. Surg.* 12: 163-168.

[22] Reddy SK, Barbas AS, Marroquin CE, Morse MA, Kuo PC, Clary BM (2007), Resection of noncolorectal nonneuroendocrine liver metastases: a comparative analysis, *J. Am. Coll. Surg.* 204: 372-382.

[23] Earle SA, Perez EA, Gutierrez JC, Sleeman D, Livingstone AS, Franceschi D, Levi JU, Robbins C, Koniaris LG (2006), Hepatectomy enables prolonged survival in select patients with isolated noncolorectal liver metastasis, *J. Am. Coll. Surg.* 203: 436-446.

[24] Martel G, Hawel J, Rekman J, Croome KP, Bertens K, Balaa FK, Hernandez-Alejandro R (2015), Liver resection for non-colorectal, non-carcinoid, non-sarcoma metastases: a multicenter study, *PLoS. One.* 10: e0120569.

[25] Lendoire J, Moro M, Andriani O, Grondona J, Gil O, Raffin G, Silva J, Bracco R, Podesta G, Valenzuela C, Imventarza O, Pekolj J, De Santibanes E (2007), Liver resection for non-colorectal, non-neuroendocrine metastases: analysis of a multicenter study from Argentina, *HPB (Oxford)* 9: 435-439.

[26] Adam R, Chiche L, Aloia T, Elias D, Salmon R, Rivoire M, Jaeck D, Saric J, Le Treut YP, Belghiti J, Mantion G, Mentha G (2006), Hepatic resection for noncolorectal nonendocrine liver metastases: analysis of 1,452 patients and development of a prognostic model, *Ann. Surg.* 244: 524-535.

[27] Kamel SI, de Jong MC, Schulick RD, Diaz-Montes TP, Wolfgang CL, Hirose K, Edil BH, Choti MA, Anders RA, Pawlik TM (2011), The role of liver-directed surgery in patients with hepatic metastasis from a gynecologic primary carcinoma, *World J. Surg.* 35: 1345-1354.

[28] Chi DS, Fong Y, Venkatraman ES, Barakat RR (1997), Hepatic resection for metastatic gynecologic carcinomas, *Gynecol Oncol* 66: 45-51.

[29] Chalkiadakis GE, Lasithiotakis KG, Petrakis I, Kourousis C, Georgoulias V (2005), Major hepatectomy and right hemicolectomy at the time of primary cytoreductive surgery for advanced ovarian cancer: report of a case, *Int. J. Gynecol Cancer* 15: 1115-1119.

[30] Yoon SS, Jarnagin WR, Fong Y, DeMatteo RP, Barakat RR, Blumgart LH, Chi DS (2003), Resection of recurrent ovarian or fallopian tube carcinoma involving the liver, *Gynecol Oncol* 91: 383-388.

[31] Tangjitgamol S, Levenback CF, Beller U, Kavanagh JJ (2004), Role of surgical resection for lung, liver, and central nervous system metastases in patients with gynecological cancer: a literature review, *Int. J. Gynecol Cancer* 14: 399-422.

[32] Merideth MA, Cliby WA, Keeney GL, Lesnick TG, Nagorney DM, Podratz KC (2003), Hepatic resection for metachronous metastases from ovarian carcinoma, *Gynecol Oncol* 89: 16-21.

[33] Ramia JM, De La Plaza R, Quiñones J, Veguillas P, Adel F, García-Parreño J (2012), Liver Metastases from Gynecological Cancers: Time to Resection?. *Surgical Science* 3, 120-125.

[34] Eisenhauer EL, Abu-Rustum NR, Sonoda Y, Levine DA, Poynor EA, Aghajanian C, Jarnagin WR, DeMatteo RP, D'Angelica MI, Barakat RR, Chi DS (2006), The addition of extensive upper abdominal surgery to achieve optimal cytoreduction improves survival in patients with stages IIIC-IV epithelial ovarian cancer, *Gynecol Oncol* 103: 1083-1090.

[35] Raspagliesi F, Ditto A, Martinelli F, Haeusler E, Lorusso D (2013), Advanced ovarian cancer: omental bursa, lesser omentum, celiac, portal and triad nodes spread as cause of inaccurate evaluation of residual tumor, *Gynecol Oncol* 129: 92-96.

[36] Benedetti PP, Di D, V, Fischetti M, Casorelli A, Perniola G, Musella A, Marchetti C, Palaia I, Berloco P, Muzii L (2015), Predictors of postoperative morbidity after cytoreduction for advanced ovarian cancer: Analysis and management of complications in upper abdominal surgery, *Gynecol Oncol* 137: 406-411.

[37] Bristow RE, Montz FJ, Lagasse LD, Leuchter RS, Karlan BY (1999), Survival impact of surgical cytoreduction in stage IV epithelial ovarian cancer, *Gynecol Oncol* 72: 278-287.

[38] Scholz HS, Tasdemir H, Hunlich T, Turnwald W, Both A, Egger H (2007), Multivisceral cytoreductive surgery in FIGO stages IIIC and IV epithelial ovarian cancer: results and 5-year follow-up, *Gynecol Oncol* 106: 591-595.

[39] Neumann UP, Fotopoulou C, Schmeding M, Thelen A, Papanikolaou G, Braicu EI, Neuhaus P, Sehouli J (2012), Clinical outcome of patients with advanced ovarian cancer after resection of liver metastases, *Anticancer Res.* 32: 4517-4521.

[40] Lim MC, Kang S, Lee KS, Han SS, Park SJ, Seo SS, Park SY (2009), The clinical significance of hepatic parenchymal metastasis in patients with primary epithelial ovarian cancer, *Gynecol Oncol* 112: 28-34.

[41] Bacalbasa N, Dima S, Brasoveanu V, David L , Balescu I, Purnichescu-Purtan R, Popescu I. Liver resection for ovarian cancer liver metastases as part of cytoreductive surgery is safe and may bring survival benefit. Bacalbasa et al. *World Journal of Surgical Oncology* DOI 10.1186/s12957-015-0652-0, in press.

[42] Bosquet JG, Merideth MA, Podratz KC, Nagorney DM (2006), Hepatic resection for metachronous metastases from ovarian carcinoma, *HPB (Oxford)* 8: 93-96.

[43] Scarabelli C, Gallo A, Carbone A (2001), Secondary cytoreductive surgery for patients with recurrent epithelial ovarian carcinoma, *Gynecol Oncol* 83: 504-512.

[44] Zang RY, Li ZT, Tang J, Cheng X, Cai SM, Zhang ZY, Teng NN (2004), Secondary cytoreductive surgery for patients with relapsed epithelial ovarian carcinoma: who benefits?, *Cancer* 100: 1152-1161.

[45] Eisenkop SM, Friedman RL, Spirtos NM (2000), The role of secondary cytoreductive surgery in the treatment of patients with recurrent epithelial ovarian carcinoma, *Cancer* 88: 144-153.

[46] Niu GC, Shen CM, Cui W, Li Q (2012), Hepatic Resection is Safe for Metachronous Hepatic Metastases from Ovarian Cancer, *Cancer Biol. Med.* 9: 182-187.

[47] Roh HJ, Kim DY, Joo WD, Yoo HJ, Kim JH, Kim YM, Kim YT, Nam JH (2011), Hepatic resection as part of secondary cytoreductive surgery for recurrent ovarian cancer involving the liver, *Arch. Gynecol Obstet.* 284: 1223-1229.

[48] Abood G, Bowen M, Potkul R, Aranha G, Shoup M (2008), Hepatic resection for recurrent metastatic ovarian cancer, *Am. J. Surg.* 195: 370-373.

[49] Kolev V, Pereira EB, Schwartz M, Sarpel U, Roayaie S, Labow D, Momeni M, Chuang L, Dottino P, Rahaman J, Zakashansky K (2014), The role of liver resection at the time of secondary cytoreduction in patients with recurrent ovarian cancer, *Int. J. Gynecol Cancer* 24: 70-74.

[50] Pekmezci S, Saribeyoglu K, Aytac E, Arvas M, Demirkiran F, Ozguroglu M (2010), Surgery for isolated liver metastasis of ovarian cancer, *Asian J. Surg.* 33: 83-88.

[51] Gold JS, Are C, Kornprat P, Jarnagin WR, Gonen M, Fong Y, DeMatteo RP, Blumgart LH, D'Angelica M (2008), Increased use of parenchymal-sparing surgery for bilateral liver metastases from colorectal cancer is associated with improved mortality without change in oncologic outcome: trends in treatment over time in 440 patients, *Ann. Surg.* 247: 109-117.

[52] Shah SA, Bromberg R, Coates A, Rempel E, Simunovic M, Gallinger S (2007), Survival after liver resection for metastatic colorectal carcinoma in a large population, *J. Am. Coll. Surg.* 205: 676-683.
[53] Chang YC (2004), Low mortality major hepatectomy, *Hepatogastroenterology* 51: 1766-1770.
[54] Bolton JS, Fuhrman GM (2000), Survival after resection of multiple bilobar hepatic metastases from colorectal carcinoma, *Ann. Surg.* 231: 743-751.
[55] Adam R, De Gramont A, Figueras J, Guthrie A, Kokudo N, Kunstlinger F, Loyer E, Poston G, Rougier P, Rubbia-Brandt L, Sobrero A, Tabernero J, Teh C, Van Cutsem E (2012), The oncosurgery approach to managing liver metastases from colorectal cancer: a multidisciplinary international consensus, *Oncologist.* 17: 1225-1239.
[56] Leitao MM, Jr., Kardos S, Barakat RR, Chi DS (2004), Tertiary cytoreduction in patients with recurrent ovarian carcinoma, *Gynecol Oncol* 95: 181-188.
[57] Shih KK, Chi DS, Barakat RR, Leitao MM, Jr. (2010), Beyond tertiary cytoreduction in patients with recurrent epithelial ovarian, fallopian tube, or primary peritoneal cancer, *Gynecol Oncol* 116: 364-369.
[58] Holloway RW, Brudie LA, Rakowski JA, Ahmad S (2011), Robotic-assisted resection of liver and diaphragm recurrent ovarian carcinoma: description of technique, *Gynecol Oncol* 120: 419-422.
[59] Fleury AC, Spirtos N, Eisenkop SM, Kirgan D, Silver DF, Futoran R (2008), The Use of Radiofrequency Ablation in Advanced Ovarian Cancer: Resection and Ablation of Liver Metastases. *Clinical Ovarian Cancer* 1(2): 135-138; DOI: 10.3816/COC. 2008.n.015.
[60] Mateo R, Singh G, Jabbour N, Palmer S, Genyk Y, Roman L (2005), Optimal cytoreduction after combined resection and radiofrequency ablation of hepatic metastases from recurrent malignant ovarian tumors, *Gynecol Oncol* 97: 266-270.
[61] Bojalian MO, Machado GR, Swensen R, Reeves ME (2004), Radiofrequency ablation of liver metastasis from ovarian adenocarcinoma: case report and literature review, *Gynecol Oncol* 93: 557-560.
[62] Jacobs IA, Chang CK, Salti G (2003), Hepatic radiofrequency ablation of metastatic ovarian granulosa cell tumors, *Am. Surg.* 69: 416-418.
[63] Bleicher RJ, Allegra DP, Nora DT, Wood TF, Foshag LJ, Bilchik AJ (2003), Radiofrequency ablation in 447 complex unresectable liver tumors: lessons learned, *Ann. Surg. Oncol* 10: 52-58.
[64] Navarra G, Ayav A, Weber JC, Jensen SL, Smadga C, Nicholls JP, Habib NA, Jiao LR (2005), Short- and-long term results of intraoperative radiofrequency ablation of liver metastases, *Int. J. Colorectal Dis.* 20: 521-528.
[65] Bachellier P, Ayav A, Pai M, Weber JC, Rosso E, Jaeck D, Habib NA, Jiao LR (2007), Laparoscopic liver resection assisted with radiofrequency, *Am. J. Surg.* 193: 427-430.
[66] Petrou A, Neofytou K, Mihas C, Bagenal J, Kontos M, Griniatsos J, Felekouras E (2015), Radiofrequency ablation-assisted liver resection: a step toward bloodless liver resection, *Hepatobiliary. Pancreat. Dis. Int.* 14: 69-74.

In: Encyclopedia of Surgery (22 Volume Set)
Editors: Andreas Lehrer and Kristin Mueller
ISBN: 978-1-53618-329-0
© 2020 Nova Science Publishers, Inc.

Chapter 390

BEST PRACTICE IN INFORMED CONSENT IN ORAL SURGERY

Aida Gutiérrez-Corrales, Gonzalo Ruiz-de-León-Hernández, Rand Alsheikh, Marisa Heras-Meseguer, Concepción Recio-Lora, Esther Hernández-Pacheco, Daniel Torres-Lagares and José-Luis Gutiérrez-Pérez*

Master in Oral Surgery, University of Seville, Seville, Spain

ABSTRACT

Introduction and aim: The aim of the informed consent cannot only be to comply with what is established by the law. It must be a process of communication between the doctor and the patient which is the basis of a relationship based on trust. This will improve the quality of the assistance that the patient receives by diminishing his anxiety through the information provided. The aim of the research described in this chapter is to evaluate the effect of informed consent format on preoperative anxiety of patients. Besides, we are attempt to analyze the influence of anxiety (both state and trait) in postoperative recovery of the patient submitted to the extraction of mandibular third molar, and also to establish the role of each types of anxiety in the results obtained in an independent and complementary way.

Material and methods: We carried out two prospective studies. The first one was performed in 91 patients undergoing lower third molar extraction. Patients were distributed in three groups and informed consent was provided through a written document, a verbal interview and a video recording. Then, patients were asked about their anxiety level and the effect that the informed consent have had on it. The second study included 88 patients, the intervention performed was the extraction of the third molars and subjects were asked to complete the Spielberger State-Trait Anxiety Inventory - Trait and State before receiving any information about the surgical procedure. The study evaluated postoperative swelling and pain.

Then patients were asked to fill out a 10-point visual analog scale (VAS) at home every day, 8 days after the surgery, until sutures were removed.

* Corresponding Author's Email: jlgp@ us.es; Fax: 95.448.11.11.

Results and discussion: While the results showed that the information provided to patients in oral and written formats were useful to relieve their anxiety (in a scale of -3 to +3) 0.97 ± 1.21 and 0.29 ± 0.97, respectively), the video recording increased patient's anxiety in a statistically significant way (in a scale of -3 to +3, -0.57 ± 1.43). The difference obtained between the values obtained in oral and written information was not statistically significant. Regarding postoperative outcomes between positive and negative trait anxiety groups, results showed that the consumption of analgesics was higher in positive trait anxiety group, while differences between both groups regarding pain and swelling were detected only on specific moments. The relation between the informed consent format, the level of anxiety, and the postoperative outcomes, can provide new lines for future research to improve the clinical assistance and the best use of informed consent.

1. INFORMED CONSENT

One of the most important responsibilities of a healthcare provider is to ensure that before any clinical procedure is undertaken the patient has been provided with all the information concerning the surgery. Mainly, this implies explaining to the patient the reason why it is necessary to undergo this procedure, also giving him relative information such as associated complications, risks and benefits, without forgetting any possible alternative treatment. Normally, the consent of a patient undergoing a surgical procedure must be obtained. Because, even though the goal of the procedure is to improve their health, a risk of an injury or any other negative outcome or complications could also be encountered.

This process, based on patient-doctor communication, is known as 'informed consent' whose main purpose is providing enough information to allowing the patients to understand their treatment and to be voluntarily submitted to the intervention. Nevertheless, although the doctor tries his best, sometimes patients are not able to retain all the information received or to express their questions for a better understanding. That is the reason why nowadays, there is a growing interest in improving the quality of informed consent given to the patients, including not only oral or written communication, but also the availability of videos and websites. To protect human rights, some organizations such as General Medical Council or American Medical Association, among others, have reached consensus concerning the information that healthcare community should give to patients during the informed consent. For that, scientific community has created international guidelines such as Declaration of Helsinki (DoH 2001, 2009) of the World Medical Association. Referring to informed consent, the requirements to be considered it valid are the following [1, 2]:

- The patient has to understand the information provided by the healthcare professional.
- The individual must be able to retain the information long enough to make a decision.
- The patient must be capable to ponder the information as part of the decision-making process.
- The individual can communicate openly his decision.

In some cases, problems with informed consent can appear when doctors underestimate or undervalue the information that patients need [4]. It could be due to that the clinicians may overestimate the amount of information they explain [5], they could have a lack of skills in passing this information [6] or use specific technical language. The UK Department of Health emphasizes that when all the relevant information has not been given adequately to patients, when individuals are not capable to understand correctly or they have had not the chance to ask doubts, the consent may not be valid although the patient has signed it. Furthermore, with a proper verbal informed consent, even if the consent form is not signed, is not considered a barrier to proceed the treatment. Moreover, some doctors usually focus on communicating technical risks or negative outcomes relative to surgical procedure, for example, a wound infection, nerve injury or other specific complications [7].

These possible risks could be of concern to patients, but this approach overrides the awareness about other problems of greater importance. These complications can include pain or more days of inability at work [8]. Ideal circumstances would be that doctors could talk to patients at least two or three times before the surgical procedure. This gives the patient the time to think about the given information and to make the right decision about undergoing an operation. Nevertheless, when the consent form has been signed and thus, the formal consent discussion is considered understood, the patient usually has no more interviews until the intervention. That is the reason why informed consent procedure has become a routine process that does not allow enough time to the patients for considering their decision [9]. One of the reasons for this problem regarding the informed consent routine, can be due to a standardized consent form which makes the process seems repetitive to doctors. This can also affect the clinician making him more desensitized to patient's fears and concerns, because doctor can view the surgical procedure commonplace and routine [10]. However, any standardization of this procedure could have the problem of not promoting patient autonomy [11]. Particularly, only a percentage of 41% of patients believe that informed consent is useful to clear their doubts and the 46% believe that the main purpose of the consent form is to protect the hospital [12]. Ensuring a quality consent form presents challenges for both doctors and healthcare organizations. It has been reported that patients who received enough information were more likely to undergo conservative treatment with the consequence of declining surgical procedures, thus reducing overall health costs [13]. On the one hand, one of the main causes of formal complaints and costly litigation is due to a failure regarding the informed consent. On the other hand, satisfactory information provides extra benefits for patients, such as greater satisfaction, more rapid recovery, reduction of anxiety, and thus, a decrease in the use of analgesics and other drugs [14, 15].

2. INFORMED CONSENT IN ORAL SURGERY

Informed consent is one of the basic principles of the current surgery. It is considered a result of a satisfactory communication between doctor and patient, and the basis on which the clinical setting is established. It's not only a fundamental right of patients, but also an ethical and legal requirement for clinicians. As it was explained, this legal document must be submitted and signed before surgery and allows that patient authorizes the intervention recognizing that he has been informed sufficiently about benefits, risks and possible treatment

options. In the consent form, the consequences of the intervention should be exposed as well as typical, atypical and exceptional risks which must be included due to its severity or its relationship with the personal circumstances of the patient. In short, informed consent must cover four key areas: need of treatment, its risks, benefits and alternatives [16].

- Informed consent must include the following information:
  - Patient's name and name and number of clinician.
  - Treatment that will be carried out detailing the procedure and the purpose that is expected.
  - Information relative to consequences, possible discomfort, typical and atypical risks to which the patient is exposed.
  - Alternative treatments.
  - Declaration that patient has understood the information provided.
  - Expression of consent.
  - Date and signature of patient and doctor.
  - Section for withdrawal of consent.

Informing the patient can not only be a legal requirement, it is also one of the techniques used to reduce preoperative anxiety of patients. Many studies have reached consensus that providing quality information about intervention is beneficial because patients feel they have more control over the situation so his psychological stress is reduced and his preoperative anxiety decreases [17, 18]. Besides, this offers benefits in both objective and subjective improvement of patient recovery process [19]. In other words, not receiving information increases the feeling of anxiety [20] but also the level of satisfaction [21].

Unlike other interventions of general surgery, dental surgery, in most cases, are performed with the patient awake and under local anesthesia, hence, informing the patient previously before the intervention helps to decrease his fears and anxiety which also positively influences in the postoperative outcomes [22].

It has been proposed that patients who did not receive adequate medical information showed high levels of state anxiety in STAI test [23] and patients with high levels of anxiety-state usually demand more information [24, 25]. From this topic, health community is shrouded in controversy. While some authors ensure that medical information can increase levels of anxiety and also influence in the number of postoperative complications [26], from another point of view, several publications reported that providing detailed information can increase levels of anxiety and stress [27].

There is an interesting study with objective results about how information can influence in physiological changes of patients submitted to third molar extraction surgery. To measure the increase of anxiety, they analyzed the pulse of the patient [28].

- Informed consent formats

Unfortunately, the best methodology of informed consent is not legally defined, neither the quality nor the quantity of the information that must be given to the patient [29]. What we must be sure of is that the patient has understood the information provided using a simple language, avoiding jargon and adapting it to their individual and personal characteristics [30]. The informed consent information can be offered in different formats [16].

- Detailed / Brief format:

Regarding to the amount of information, there is no consensus about the maximum or the minimum information that must be given to the patient. In general, protocols must be generic and, for each patient the doctor may complete it by adding specific risks and complications of the procedure. Studies show that patients suffer less preoperative anxiety if the information provided is extensive and detailed than if it is too brief [31].

However, giving too much information can produce an increment of anxiety and restlessness. According to wisdom teeth removal, it is essential to highlight in the preoperative information two possible complications that may have relevant consequences for the patient and therefore, important legal implications: damage to the inferior alveolar nerve or to the lingual nerve with loss of sensitivity or paresthesia [29].

Those are the most feared complications for patients and should be specified in the informed consent of third mandibular molars extraction. Detailed information that oral and maxillofacial surgeons provide their patients makes them feel more comfortable with the third molar surgery [32].

- Oral / Written Format:

The oral form to provide information is the most used and relevant, but it is also the easier one to forget and it is considered insufficient [29]. In addition, the stress generated while the patient is waiting for the surgery interferes in his ability to retain the information provided in the oral form.

Some authors confirm that verbal communication with the patient is interactive and more efficient than the written format in explaining the information [31]. The best option would be the combination of both formats; explaining everything about the procedure to the patient and providing him with written information so he can read it as long as he needs. This will lead to a better understanding and higher patient satisfaction [34, 35].

- Audiovisual format:

Nowadays, information may need alternative formats to written documents or oral consents. The audiovisual format is considered an acceptable method for being very illustrative.

Besides, its application it may be interesting in populations with low education [36]. Many studies confirm that the understanding of information from patients is poor and inadequate [29, 31] so this assessment can be improved by using audio-visual formats [16]. Several authors have reported the benefit of using multimedia technology due to they improve the understanding of informed consent. These are considered to be a direct communication complementary between the doctor and the patient [37, 38].

There is still controversy about the effect of audiovisual informed consent in aspects related to patients. It seems to help in understanding the information as they improve satisfaction of patients with the information provided but there is no sufficient evidence to draw conclusions about the anxiety caused by audiovisual informed consent [39].

3. Oral Surgery

The most common surgical procedure carried out in the oral cavity is the third molar extraction. Some indications for this surgery are: caries impossible to be restorable, cyst development due to a fracture, damage to second molar, recurrent infection because the molar has not totally erupted or it is impacted in soft tissues, a need of space for orthodontic treatments and preventive removal, which is considered an extraction of a third molar without symptoms before the development of anticipated problems, among other indications. Furthermore, a very frequent indication is a repetitive episode of pericoronitis associated to pain, bad taste and swelling [40, 41]. According to this kind of operation, the extraction of impacted lower third molar is usually accompanied by pain in the operated area, soft tissue swelling and sometimes restricted mouth opening and in a small percentage, the possibility of suffering from complications such as alveolar osteitis, infections, nerve injuries and abscess or mandible fractures. These consequences are so uncomfortable for daily life of patients, and several factors may influence in their intensity, such as the complexity and duration of surgery [43], the surgeon's technique or patients´ mood [42, 44]. Apart from that, there are other factors that also influence in the results of the intervention, for example, it has been reported that the most common range of age is from 18 to 30 years old. Young patients have better circulation, more elasticity and their jaw bone is more resilient than in old patients. Hence, bone removal is more difficult with consequences such as more pain and inflammation and less healing potential of jawbone [46]. Likewise, other characteristics have been studied to stablish an association with postoperative recovery such as the position and localization of the third molar in relation with jawbone, distance to alveolar nerve, previous caries with recurrent infection, etc. [47].

The latest advances in surgical techniques, the increase of knowledge about symptoms and possible risks of surgery, and the awareness about postoperative outcomes have permitted to improve surgical techniques using less traumatic methods. This is important because the decrease of symptoms may influence in patients´ satisfaction helping them to improve their quality of life and it also minimizes fear of future surgical interventions [45].

Once surgery has been carried out, it has been recognized that postoperative swelling and pain appear as physiological responds of the organism. Postoperative orofacial pain is a direct consequence of the injury caused by the surgery and how the body responses to it. It is important to remember that pain perception varies with each individual and it is based on different factors. The importance of anxiety and the degree of stress that patient suffers before the intervention is crucial in the postoperative pain perception. This has been widely studied by different authors, who defined that anxiety can increase the intensity of postoperative symptoms and also induce greater pain perception by reducing the threshold of pain tolerance.

4. The Meaning of Anxiety

In recent years, anxiety is increasingly associated with several diseases as well as it has been recognized it has some influence on the daily life of patients. Due to the importance that anxiety is taking nowadays, many researchers attempt to find the right definition, although it is not easy due to the fact it is considered a complex concept.

It has been reported an average of 5-7% of population who hardly ever go to dentist due to having fear of dental treatment [48, 50]. In accordance with the International Classification System of Psychiatric Disorders (DSM-IV), when some criteria are present such as avoidance, negative effect on daily life, fear, among others, we can consider that anxiety has reached a clinically significant level [51].

On the one hand, some authors declared that anxiety can be understood as a natural human emotion that resembles other emotional reactions such as joy, anger, fear, sadness, etc. Particularly, anxiety is experienced as an unpleasant emotion that arises in a situation in which the individual perceives a threat with possible negative consequences [49]. On the other hand, other authors proposed that anxiety is a phenomenon that can normally occur in everyone and, under normal conditions, it improves performance and adaptation to social, laboral or academic environment. It has a significant role in mobilizing the individual against threatening or disturbing situations, so it is useful to do what is necessary to avoid the risk, neutralize it or face it [52].

❖ Evolution of anxiety meaning

According to scientific literature, anxiety is considered a relatively modern concept, thus, it would be useful to do a review of its meaning for a better understanding.

During the fifties and later in the sixties, psychological research was focused on schizophrenia recognized as a mental disorder, whereas in the seventies, the interest turned to the evaluation of moods, specifically depression. However, in 1985, two American psychologists called Husain and Jack Maser [53] claimed that the decade of the eighties would be considered in the history as the decade of anxiety, and thereafter it would occupy a special place which still prevails nowadays. Existential philosophy believes that anxiety is a response of human character that is facing the threat of moral values and it appears when the system of values that gives meaning to human life is being threatened. Existentialist psychiatrists give a notable importance to the fact that anxiety is an ontological characteristic of humans. This philosophical current maintains that it is not an attitude among many others, as it could be pleasure or sadness [54].

Nonetheless, from a psychopathological point of view, the concept of anxiety has not always been evenly used. Several Latin words contain the Germanic root *"angh"* but, despite this, the term that has prevailed throughout the Western culture to define that feeling of restlessness has been "anxiety."

This is due to the influence of Freud who defined anxiety as an unpleasant emotional state characterized by apprehension, combination of feelings and disturbing thoughts for the individual [55]. In 1968, Lang [56] set a theory of anxiety defined in three domains, according to which, it is considered a physiological emotional response that includes: behavior, such as displeasure, tension, apprehension, concern; physiological, in which the autonomic nervous system is highly active; and cognitive domains such as the escape in a dangerous situation. Hence, a person could show an intense reaction in subjective category, moderated in the physiological and even mild in the cognitive, whereas another person could experiment just the opposite, concluding that individual reactions are highly variable [57]. The concept of anxiety has evolved into a multitude dimensions considered as a temporary emotional and physiological state, as a personality trait and an explanation of behavior.

Likewise, anxiety not always varies in direct proportion to perceived risk; it can also appear of an irrational manner, which means, in situations without authentic danger [58]. Since the decade of eighties until today, anxiety occupies a relevant place in the field of psychological research. Anxiety is a state of physical and psychological emotion characterized by feelings such as distress, restlessness and insecurity facing to what seems as an imminent threat. From the nineties, it is proposed that anxiety is an emotional response that can be provoked by inner stimuli of the subject as ideas and thoughts or associated to external stimuli like situations in which the subject has to face, to confirm his adaptation to environment. The type of stimulus able to provoke an anxiety response is largely determined by the characteristics of the individual.

In short, anxiety has been seen as a consistent emotional reaction to feelings of tension, apprehension, nervousness and concern accompanying the activation of the sympathetic autonomic nervous system.

❖ Anxiety in surgical procedures

Surgery is perceived as important stress agent. When a surgical intervention is going to be carried out, a feeling of anxiety appears with more or less intensity. Some emotions that usually are felt previously to a surgical procedure are [59]:

- Intense apprehension, fear and anguish to something understood as threatening.
- A state of irritability that can produce loss of concentration.
- A set of somatic symptoms as sweating, palpitations, tightness, fatigue, etc.

Preoperative anxiety is being studied for its consequences attributed to physical and emotional recovery of patients and also because it provides a natural framework for research on coping with stressful events. Several publications confirm that patients with high levels of trait anxiety are associated with greater levels of state anxiety before and after surgery. There is an evolution of anxiety from the moment patient is submitted to the intervention until the recovery has finished. This has significant practical applications in the attempt to reduce anxiety or in developing methods to control this anxiety. Programmed surgeries let clinicians carry out preparatory techniques to reduce preoperative anxiety. When a patient assimilates that he needs to be operated, he realizes his illness, recovery, and possible sequels. Moreover, in the imminent moment before intervention, anxiety is mainly influenced by factors related to the surgery procedure. Overall, from all anxiety-inducing factors, pain stands out from the others. The fact that the individual confronts surgery with high levels of anxiety can have negative influences on his physical and psychological recovery, including more analgesics consumption. For that reason, it would be convenient to evaluate the anxiety before anxiety to indicate the application of psychological techniques for premedication with the objective of minimizing levels of anxiety [60].

Anxiety experienced in a dental office or hospital can be due to various reasons: fear of suffering pain or injury, fear of losing self-control or fear of not being well treated. These fears are usually due to previous personal experiences (specifically in childhood) or opinions from people around. Past traumatic experiences increase significantly pain and anxiety to surgical procedures.

There are studies which support that anxiety decreases tolerance threshold of pain, thereby there is a possibility that non-noxious stimuli can be interpreted by the patient as painful. The first negative effect of dental anxiety and fear would be avoidance of dental treatment. This avoidance will only leads to worsening and deterioration of the case, which will end up by making the patient feels guilty. Moreover, as the time passes, the anxiety level will be increased, the patient´s self-esteem will be reduced and quality of life can be compromised and limited [61].

❖ Factors that influence anxiety

The degree of dental anxiety that patients may present is determined by different factors:

- Gender: women generally present higher dental anxiety than men as happens with other anxiety disorders [62, 63]. One the one hand, some studies have found no significant differences in relation to this variable [64], on the other hand, trait and dental anxiety of women seem to be related to the possibility of suffering from a dental phobia accompanied with other psychopathology [65].
- Age: The majority of negative attitudes to dental treatment arise in childhood, as a result of the influence of parents' fears, fear to feel pain and fear to the unknown [65]. Dental anxiety usually decreases with age, which is mainly due to the development of the responsibility to accept the need of treatment and because with age other general or specific phobias are also reduced [62].
- Oral health: when a patient is aware that his oral health status is not appropriate and he needs a treatment, higher levels of dental anxiety are generated [66]. As well as people who have never visit a dentist, their level of dental anxiety is also higher [67].
- Socioeconomic and cultural level: according to some authors a low socioeconomic and educational level is associated with poor oral health, greater difficulty in accessing oral treatments and as a result, higher levels of dental anxiety [69, 70]. Not all studies that investigated this factors influencing dental anxiety have reached the same conclusion [71].
- Factors related the dental treatment: in relation to the procedure itself, the procedures that evoke the highest anxiety levels are surgery and injection of local anesthetic [72]. The quality of treatment that the patient receives is strongly associated with the loss of self-control and vulnerability. Short waiting times are positively valued because if the appointment is delayed, the patient perceives it as a lack of organization and efficiency and it gives him more time to think negatively about the treatment and outcomes. Anxiety experienced by the patient affects not only itself but also affects the professional team. Therefore, oral health professionals must acquire the necessary skills to manage and control the anxiety of their patients [73].

❖ Types of anxiety

There are several classifications to describe different types of anxiety, but the most common is the one that classifies anxiety based on the reason provoking it, whether it’s general or specific. Since the seventies, the two types of anxiety recognized from the point of view of psychology of the personality are trait anxiety and state anxiety.

Trait anxiety is defined as an individual tendency to respond anxiously, to interpret many everyday situations as threatening. It is usually accompanied by a neurotic personality. Moreover, state anxiety is perceived by the subject as a transient unpleasant emotion with variable intensity and duration to some situation perceived as threatening [74].

Both anxiety levels are evaluated on a list of 40 items that make up the *"Questionnaire state anxiety trait" (State Trait Anxiety Inventory, STAIE-R)* of Spielberger, first described in 1970 and revised in 1983. It is used to assess the level of anxiety and the ability of people to respond to stress [75].

The test consists of two parts with 20 questions each one. The first part, state anxiety, assesses a transitory emotional state characterized by attention, apprehension and subjective feelings consciously perceived. This is caused due to hyperactivity of autonomic nervous system. The other part evaluates trait anxiety with a tendency to anxiety, relatively stable, which characterizes individuals to perceive situations as threatening. Depending on sex and age of subjects who undergo the test, there are reference values that determine if there is trait anxiety, state anxiety or both. If the marks are above the reference values, the patient has anxiety, if the marks are lower, the patient has no anxiety. Several studies have confirmed the reliability and validity of this questionnaire [76].

5. How Anxiety Influences in Third Molar Surgery

Dental extractions are the most stressful procedures in dentistry and wisdom teeth extraction is considered one of the interventions that generate the highest levels of anxiety [77-80]. One of the basic principles of general and oral surgery is doing the proper diagnosis with a detailed anamnesis thereby anxious patients can be identified directly. Establishing a psychological assessment to identify specifically the patient´s level of anxiety, fear to the intervention, and possible depressive symptoms is crucial at this step. An increment of anxiety when patient realizes he is going to be operated is considered normal but the goal is to recognize patients with an excessive level of anxiety and to clarify if it is trait anxiety or fundamentally due to the fact of surgery (state anxiety) [81, 82].

Several studies affirm that when a patient is submitted to a third molar extraction, the anxiety experienced provokes a decrease in the threshold of pain tolerance. This increases the time of intervention, producing higher levels of pain and inflammation [83].

In addition, preoperative anxiety may influence in the development of psychosomatic pathology [as xerostomia and higher blood pressure], which can also adversely affect the postoperative period [24, 69].

Some authors declared that trait anxiety is a good predictor of dental anxiety and patients with high levels of trait anxiety suffer more pain as a sequel to lower third molar extraction [22, 47]. Other authors affirmed that there is a lack in the association between trait anxiety and postoperative pain in this type of intervention [82, 86] and with dental anxiety in general [87]. Some current publications showed that state anxiety and fear to pain are the best predictors of preoperative anxiety before the extraction of impacted lower molars [31]. It has been reported that the state anxiety is more sensitive than trait anxiety before wisdom teeth removal. In postoperative days, the state anxiety decreases while trait anxiety remains stable [88].

Preoperative anxiety is mainly determined by the fear of feeling pain during dental procedure. A bad experience can provoke anxiety and postoperative dental trauma [79].

Fortunately, the pain felt during the intervention is less than the expected but not knowing that generates preoperative anxiety. The level of anxiety during surgery is greater than after it and preoperative anxiety is the one that reaches highest intensity. In fact, some studies show that anxiety decreases in lower third molar extraction when patient has been submitted to similar previous experience [84, 88].

The degree of the satisfaction with the surgery is determined by the preoperative anxiety suffered and whether there are complications or not [89]. For this reason, it is important that oral surgeon to find out if the patient has predisposition to anxiety and in that case, and to apply appropriate preventive and therapeutic methods [47].

On the one hand, conducting a study, aimed to evaluate the effect of informed consent format on anxiety before the extraction of third molars is very interesting due to the importance and prevalence of this surgical intervention. The results of this study are also of importance for the oral health community in order to improve the awareness about the importance of a correct informed consent and how it can influence in the preoperative anxiety. On the other hand, current publications are shrouded in controversy about the association of anxiety before oral surgery and postoperative complications. For that reason, we carried out a second study aimed to analyze the influence of anxiety (both state and trait) in postoperative recovery of the patient submitted to the extraction of mandibular third molar, and also to establish the role of each types of anxiety in the results obtained in an independent and complementary way.

6. A Prospective Study to Evaluate the Effect of Informed Consent Format on Preoperative Anxiety in Patients Undergoing Inferior Third Molar Surgery

Once the objectives of the study have been developed, the proposed hypothesis was: One informed consent format is more effective than the others reducing preoperative anxiety of the patient to be subjected of third molar extraction.

We present an experimental, longitudinal, prospective study that was carried out in the Department of Stomatology of the University of Seville, within the Master of Oral Surgery at the University of Seville, and in the Service of Oral and Maxillofacial Surgery of the University Hospital Virgen del Rocío, Seville, Spain. In this research, a total of 91 patients, (35 male and 56 female) aged between 14 and 64 years were voluntary submitted to third molar extraction with the following inclusion criteria:

- ✓ Patients who required extraction of lower third molars under local anesthesia.
- ✓ Patients who agreed to enter the study and did not meet any of the exclusion criteria.
- ✓ Only patients with ASA I and II types were accepted.

These exclusion criteria were:

- ✓ Patients under 12 and over 70.
- ✓ Patients suffering pain due to the third molar at operating day.
- ✓ Patients with a physical or mental impairment that affect cognitive or communication skills.
- ✓ Patients undergoing treatment with anxiolytics.
- ✓ Patients who had previously undergone other oral surgery procedures.
- ✓ Patients who did not correctly complete the questionnaires.
- ✓ Patients who were suffering Trait Anxiety.

Before surgery, patients were asked to complete the test Spielberger State-Trait Anxiety Inventory, also known as STAI test. With it, in order to assess whether the patient had trait anxiety and / or state anxiety at that moment. This test consists of a 40 items questionnaire designed to evaluate two independent concepts of anxiety: anxiety as state (transient emotional condition) and trait anxiety [propensity anxious relatively stable]. Each question has a 4 options response system depending on the intensity (0 = almost never / no, 1 = something / sometimes 2 = very / often, 3 = much / almost always). The total score varies between 0 and 60 points with a direct/positive answer with another reverse/negative one. The total score is the sum of each positive and negative answer of each type of anxiety responses. There were some reference values to determine the type of anxiety (trait anxiety, state anxiety or both) depending on patient's sex and age.

After the completion of the consent, the clinician provided the patient with detailed information about the surgery. Patients were randomly divided into three groups according to the consent format they have been given. Thus, the first group (30 patients) was provided with the information verbally, the second group (31 patients) was provided with the information by written form and. The third group (30 patients) was provided with the information using a video (audiovisual format).

The information provided was the same in all three formats:

- ✓ Oral Format: the surgeon verbally explained to the patient the information written in the consent format.
- ✓ Written Format: the patient read the information.
- ✓ Audiovisual Format: the patient watched a video that contains images and verbal explanations of the intervention.

After receiving the information, patients filled out another test to record their state of anxiety at that moment before surgery. This assessment was performed by two simple items that allowed us to evaluate the situation of the patient after informed consent process.

The first question, "At this moment, do you feel nervous?" helped us to confirm the patient's condition at that moment. The second question was "The information provided before the intervention, helped you to be calm or made you feel more nervous?" This question was referenced to the information received. Once the second questionnaire has been collected, each patient signed the informed consent document and the surgery was carried out.

The STAI test determined that 70% of the patients did not have state anxiety before the surgery. Analyzing the informed consent format associated with state anxiety, the results showed that the third group recorded the highest level of anxiety (audiovisual format: 1.50 ±

0.82) compared with the first group (verbal format) (1.23 ± 0.89) and the second group recorded the lowest levels of anxiety (1.12 ± 0.80).

The average of state anxiety in each group of the study was similar and the p-value (0.535) did not reveal significant differences so the results in the three groups were not statistically significant. Nonetheless, it is important to state that the oral and written information provided to the patients (0.97 ± 1.21 and 0.29 ± 0.97, respectively) had different effects on anxiety levels compared to the video recording, which increased patients' anxiety (0.57 ± 1.43) with statistically significant differences. The difference between values corresponding to the written and the oral information was not statistically significant.

Regarding to the relationship between sex and state anxiety, we observed that men have an average of state anxiety of 13.26 ± 7.13 and women of 18.75 ± 11.07. Data revealed that statistically significant differences were obtained, so the value of state anxiety for men and women in our sample has differences to consider (Figure 1).

7. Influence of State Anxiety and Trait Anxiety on Postoperative Recovery in Oral Surgery

It has been widely studied how anxiety can influence postoperative outcomes of oral surgery, specifically pain experience. Several researchers concluded that facing a surgical procedure with high levels of stress and anxiety may be worsening both physical and psychological recovery [90]. This means a higher consumption of analgesics and a longer hospitalization, which may also affect the budget of the health care system [91, 92].

As explained earlier, anxiety can be classified as trait anxiety or as state anxiety.

The current study revealed that both trait anxiety and state anxiety are independent, which means that having one of these types of anxiety does not imply nor prevent having the other [22]. Nonetheless, scientific community is shrouded in controversy about this topic because the results were obtained with different scales what makes it difficult to compare their results [93].

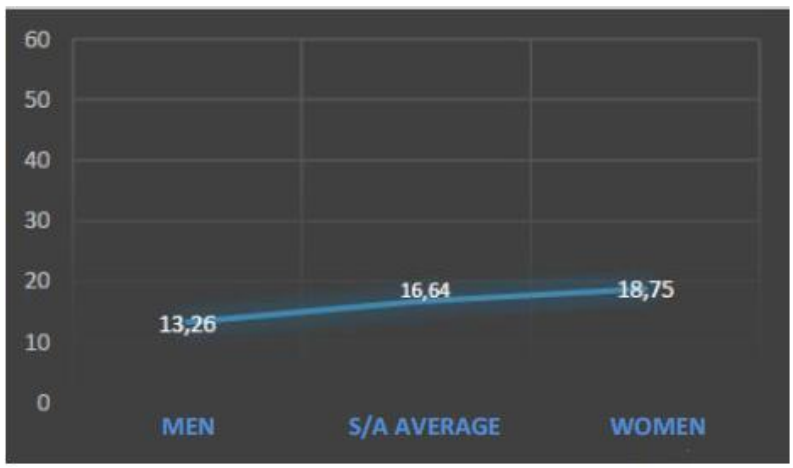

S/A: state anxiety average of the sample.

Figure 1. State anxiety value in men and women of the sample.

A prospective study was carried out to analyze the influence of state and trait anxiety in postoperative recovery after third molar extraction, with the aim of establishing the role of each types of anxiety in an independent and complementary way.

A total of 88 patient underwent lower third molar extraction for the first time, 31 (35,2%) men and 57 (64,8%) women. The age average was 30,4 years ± 10,1.

The exclusion criteria were:

- ✓ To not complete all the requirements criteria of the study.
- ✓ To have been submitted to a previous third molar surgery.
- ✓ Not participating voluntarily
- ✓ Cognitive and communication impaired abilities.
- ✓ Under anxiolytic treatment or suffering anxiety attacks.
- ✓ Surgery duration of more than 30 minutes.
- ✓ Patients with medical conditions.
- ✓ Patients with acute pericoronitis or severe periodontal disease at the time of surgery.

To evaluate the anxiety, an hour before the surgery, patients were asked to fill out the Spielberger State-Trait Anxiety Inventory - Trait (STAI-T). This questionnaire is composed of 20 items with a 4 levels frequency scale ranging from "almost never" to "almost always" to record the degree of anxiety in some situations that patients perceived as threatening. After this, subjects were informed about the surgery and postoperative recovery. Thirty minutes before the surgery has been carried out, patients were asked to complete the Spielberger State-Trait Anxiety Inventory - State (STAI-S). This is a 20 items questionnaire using a 4 levels frequency scale, but in this case, the range was from 0 to 3.

The results obtained from both STAI-T and STAI-S, were between 0 and 60, considering valid from 20 for young men (percentile 50 in validation) and from 22 for young women (percentile 50 in validation studies).

Regarding the surgical procedure, all the molar extractions were performed by eight postgraduate students at the University of Seville (Spain) with the same experience level. In all cases, nerve-block local anesthesia was performed for the inferior dental nerve, lingual nerve, and buccal nerve. After raising a mucoperiosteal flap and removing the bone, coronal section, or root section was performed when it was necessary. Adequate instructions and recommendations about postoperative recovery period were explained to every patient and antibiotic (amoxicillin 500 mg/8 h for 7 days) and an anti-inflammatory (ibuprofen 600 mg for 7 days) were prescribed. The data showed that 30 (37,5%) of 88 patients included in the study presented trait anxiety and 41 patients (45,4%) presented state anxiety. Statistically significant results showed that the consumption of analgesics was higher in positive trait anxiety group, while differences between both groups regarding pain were detected only on specific moments (at the end of the study procedure) and regarding swelling at the beginning. Only the influence of state anxiety has been previously studied in publications, so the clinical results of this research are useful in two ways.

On the one hand, the influence of the state and trait anxiety in the postoperative period has been objectively demonstrated. On the other hand, our study also supports the administration of tranquilizers before surgery, although this should be evaluated together with the costs and possible risks of medication. Therefore, some activities that decrease anxiety must be promoted.

CONCLUSION AND FUTURE LINE OF RESEARCH

- In the sample studied, the state anxiety is more common in women.
- The information provided to patients about the surgical procedure of the third molar before the intervention slightly decreases preoperative anxiety.
- There are significant differences in the preoperative anxiety level depending on the format in which the information is explained. The audiovisual format increases significantly the anxiety compared to the written and verbal format which decrease the level of anxiety.

The anxiety that a patient suffers from extracting third molars is mainly determined by his personality and previous experiences in the field of dentistry and oral surgery. The patient that is going to be submitted to the surgical removal of lower third molar must be properly informed about the procedure, predictable and possible postoperative complications, risks of surgery, etc. Informing patients can influence their anxiety but this is mandatory before asking them to sign the informed consent. It would be interesting to develop new studies about the best moment to provide the patient with the information, and if there are differences between informing the patient immediately before surgery or on the day of the diagnosis. It would be also carrying out a study with the objective of measuring the influence of different factures on patient's anxiety level. Therefore, clinicians should be able to determine whether the patient is anxious, the necessary amount of information to be explained, and the best moment and format to deliver this information.

REFERENCES

[1] Kinnersley, P., Phillips, K. Interventions to promote informed consent for patients undergoing surgical and other invasive healthcare procedures. *Cochrane Database Syst. Rev*. 2013 Jul. 6;7: CD009445.

[2] Pitak-Arnnop, P., Sader, R. Reporting of ethical protection in recent oral and maxillofacial surgery research involving human subjects. *Int. J. Oral Maxillofac. Surg.* 2009 Jul;38(7):707-12.

[3] Ferrus Torres, E., Valmaseda Castellon, E. Informed consent in oral surgery: The value of written information. *J. Oral Maxillofac. Surg*. 2011; 69(1):54-8.

[4] Beisecker, A. E., Beisecker, T. D. Patient information-seeking behaviors when communicating with doctors. *Med. Care*. 1990 Jan;28(1):19-28.

[5] Makoul, G., Arntson, P. Health promotion in primary care: physician-patient communication and decision making about prescription medications. *Soc. Sci. Med*. 1995 Nov;41(9):1241-54.

[6] Jenkins, D. H., Reilly, P. M. Improving the approach to organ donation: a review. *World J. Surg*. 1999 Jul;23(7):644-9.

[7] Ergina, P. L., Cook, J. A. Challenges in evaluating surgical innovation. *Lancet*. 2009 Sep. 26;374(9695):1097-104.

[8] Jefford, M. J., Clancy, J. L. A quality use of medicines program for continuity of care in therapeutics from hospital to community. *Med. J. Aust.* 2002 Nov. 18;177(10):574-5.

[9] Elwyn, G. Patient consent--decision or assumption? *BMJ*. 2008 Jun. 7; 336(7656): 1259-60.

[10] Picano, E. Informed consent and communication of risk from radiological and nuclear medicine examinations: how to escape from a communication inferno. *BMJ*. 2004 Oct. 9;329(7470):849-51.

[11] Habiba, M., Jackson, C. Women's accounts of consenting to surgery: is consent a quality problem? *Qual. Saf. Health Care*. 2004 Dec;13(6):422-7.

[12] Akkad, A., Jackson, C. Patients' perceptions of written consent: questionnaire study. *BMJ*. 2006 Sep. 9;333(7567):528. Beh, H. G. The role of institutional review boards in protecting human subjects: are we really ready to fix a broken system? *Law Psychol. Rev*. 2002 Spring;26 (1):1-47.

[13] Beh, H. G. The role of institutional review boards in protecting human subjects: are we really ready to fix a broken system? *Law Psychol. Rev*. 2002 Spring;26(1):1-47.

[14] Egbert, L. D., Battit, G. E. Reduction of postoperative pain by encouragement and instruction of patients. A study of doctor-patient rapport. *N. Engl. J. Med*. 1964 Apr. 16; 270:825-7.

[15] Roter, D. L., Frankel, R. M. The expression of emotion through nonverbal behavior in medical visits. Mechanisms and outcomes. *J. Gen. Intern. Med*. 2006 Jan;21 Suppl. 1: S28-34.

[16] Cabrales-Vega, R. A., Calvachi-Jiménez, J. V. Informed consent is for whom? *Rev. Salud. Pública* (Bogota). 2012 Jun;14(3):502-11.

[17] Warner, E. Should you tell your patients the truth? *Can. Med. Assoc. J*. 1983; 129(3): 278-80.

[18] Muglali, M., Komerik, N. Factors related to patients' anxiety before and after oral surgery. *J. Oral Maxillofac. Surg*. 2008; 66(5):870-7.

[19] Webber, G. C. Patient education. A review of the issues. *Med. Care*. 1990; 28(11): 1089-103.

[20] Johnson, B. R., Schwartz, A. A chairside aid for shared decision making in dentistry: A randomized controlled trial. *J. Dent. Educ*. 2006; 70(2): 133-41.

[21] Vallerand, W. P., Vallerand, A. H. The effects of postoperative preparatory information on the clinical course following third molar extraction. *J. Oral Maxillofac. Surg*. 1994; 52(11):1165,70.

[22] Lago Méndez, L., Diniz Freitas, M. Postoperative recovery after removal of a lower third molar: Role of trait and dental anxiety. *Oral Surg. Oral Med. Oral Pathol. Oral Radiol. Endod*. 2009; 108(6):855-60.

[23] Antrobus, J. H. Anxiety and informed consent. Does anxiety influence consent for inclusion in a study of anxiolytic premedication? *Anaesthesia*. 1988; 43(4):267-9.

[24] Garip, H., Abali, O. Anxiety and extraction of third molars in Turkish patients. *Br. J. Oral Maxillofac. Surg*. 2004; 42(6):551-4.

[25] Moerman, N., van Dam, F. S. The Amsterdam preoperative anxiety and information scale (APAIS). *Anesth. Analg*. 1996; 82(3):445-51.

[26] Spring, D. B., Akin, J. R. Informed consent for intravenous contrast-enhanced radiography: A national survey of practice and opinion. *Radiology*. 1984; 152(3):609-13.

[27] Erten, H., Akarslan, Z. Z. Dental fear and anxiety levels of patients attending a dental clinic. *Quintessence Int*. 2006; 37(4):304-10.

[28] Casap, N., Alterman, M. The effect of informed consent on stress levels associated with extraction of impacted mandibular third molars. *J. Oral Maxillofac. Surg*. 2008; 66(5): 878-81.

[29] Ferrus Torres, E., Valmaseda Castellon, E. Informed consent in oral surgery: The value of written information. *J. Oral Maxillofac. Surg*. 2011; 69(1):54-8.

[30] Iglesias Lepine, M. L., Pedro-Botet Montoya, J. Informed consent: opinions of health care personnel from a teaching hospital. *Rev. Clin. Esp.* 2007 Nov;207(10):483-8.

[31] van Wijk, A. J., Buchanan, H. Preparatory information for third molar extraction: Does preference for information and behavioral involvement matter? *Patient Educ. Couns*. 2010; 79(1):94-9.

[32] Brasileiro, B. F., de Braganca, R. M. An evaluation of patients' knowledge about perioperative information for third molar removal. *J. Oral Maxillofac. Surg*. 2012; 70 (1):12-8.

[33] Atchison, K. A., Black, E. E. A qualitative report of patient problems and postoperative instructions. *J. Oral Maxillofac. Surg.* 2005; 63(4): 449-56.

[34] Layton, S., Korsen, J. Informed consent in oral and maxillofacial surgery: A study of the value of written warnings. *Br. J. Oral Maxillofac. Surg*. 1994; 32(1):34-6.

[35] O'Neill, P., Humphris, G. M. The use of an information leaflet for patients undergoing wisdom tooth removal. *Br. J. Oral Maxillofac. Surg.* 1996; 34(4):331-4.

[36] Montenegro Suris, A., Monreal Aguero, M. E. The informed consent in international clinical trials including developing countries. *Cuad. Bioet*. 2008; 19(65):67-79.

[37] Bollschweiler, E., Apitzsch, J. Improving informed consent of surgical patients using a multimedia-based program? Results of a prospective randomized multicenter study of patients before cholecystectomy. *Ann. Surg*. 2008; 248(2):205-11.

[38] Inwald, A. C., Hippisley Cox, J. Competency, consent, and the duty of care: Ethical dilemma. *BMJ*. 1998; 317(7161):809-10.

[39] Synnot, A., Ryan, R. Audio-visual presentation of information for informed consent for participation in clinical trials. *Cochrane Database Syst. Rev.* 2014; 5: CD003717.

[40] Ventä, I. Current care guidelines for third molar teeth. *J. Oral Maxillofac. Surg*. 2015 May;73(5):804-5.

[41] Campbell, J. H. Pathology associated with the third molar. *Oral Maxillofac. Surg. Clin. North Am*. 2013 Feb;25(1):1-10.

[42] de Santana-Santos, T., de Souza-Santos, A. A. Prediction of postoperative facial swelling, pain and trismus following third molar surgery based on preoperative variables. *Med. Oral Patol. Oral Cir. Bucal*. 2013;18(1):e65-70.

[43] Laskin, D. M., Abubaker, A. O. Accuracy of predicting the duration of a surgical operation. *J. Oral Maxillofac. Surg*. 2013;71(2):446-7.

[44] Seymour, R., Meechan, J. G. An investigation into post-operative pain after third molar surgery under local analgesia. *Br. J. Oral Maxillofac. Surg*. 1985; 23: 410-8.

[45] Coulthard, P., Bailey, E. Surgical techniques for the removal of mandibular wisdom teeth. *Cochrane Database Syst. Rev*. 2014 Jul. 29;7: CD004345.

[46] Haug, R. H., Abdul-Majid, J. Evidenced-based decision making: the third molar. *Dent. Clin. North Am*. 2009 Jan;53(1):77-96.

[47] Lago-Méndez, L., Diniz-Freitas, M. Relationships between surgical difficulty and postoperative pain in lower third molar extractions. *J. Oral Maxillofac. Surg*. 2007 May;65(5):979-83.

[48] De Jongh, A., Adair, P. Clinical management of dental anxiety: what works for whom? *Int. Dent. J*. 2005 Apr;55(2):73-80.
[49] Lazarus, R. S. From psychological stress to the emotions: A history of changing outlooks. *Annu. Rev. Psychol*. 1993; 44:1-21.
[50] Milgrom, P., Fiset, L. The prevalence and practice management consequences of dental fear in a major US city. *J. Am. Dent. Assoc*. 1988 May;116(6):641-7.
[51] Kvale, G., Raadal, M. Treatment of dental anxiety disorders. Outcome related to DSM-IV diagnoses. *Eur. J. Oral Sci*. 2002 Apr;110(2):69-74.
[52] Cano-Vindel, A., Miguel-Tobal, J. J. Arousal versus threat when inducing an anxiety reaction. *Psicothema*. 2009 May;21(2):177-82.
[53] Tuma, A. H., Maser, J. D. *Anxiety and the anxiety disorders*. Hillsdale, N.J.: L. Erlbaum Associates; 1985.
[54] Malmo, R. B. Anxiety and behavioral arousal. *Psychol. Rev*. 1957; 64(5):276-87.
[55] Lewis, A. Problems presented by the ambiguous word "anxiety" as used in psychopathology. *Isr. Ann. Psychiatr. Relat. Discip*. 1967 5(2):105-21.
[56] Lang, P. J. Fear reduction and fear behavior: Problems in treating a construct. In: Shlien, John M., ed. *Research in psychotherapy*. Washington, DC, US: American Psychological Association; 1968. pp. 90-102.
[57] Lipp, O. V. Human fear learning: contemporary procedures and measurement. In: Craske, M. G., Hermans, D., Vansteenwegen, D., editors. *Fear and Learning: from basic processes to clinical implications*. Washington, DC: American Psychological Association; 2006. pp. 37-52.
[58] Mowrer, O. H. A stimulus-response analysis of anxiety and its role as a reinforcing agent. *Psychol. Rev*. 1939; 46(6):553-65.
[59] Armfield, J. M., Heaton, L. J. Management of fear and anxiety in the dental clinic: a review. *Aust. Dent. J*. 2013 Dec;58(4):390-407; quiz 531.
[60] Moix Queraltó, J. The assessment of anxiety in the surgical anteroom. *Med. Clin*. 1997 Feb. 1;108(4):157-8.
[61] Armfield, J. M. Towards a better understanding of dental anxiety and fear: cognitions vs. experiences. *Eur. J. Oral Sci*. 2010;118:259-264.
[62] Hagglin, C., Berggren, U. Variations in dental anxiety among middle-aged and elderly women in sweden: A longitudinal study between 1968 and 1996. *J. Dent. Res*. 1999; 78 (10):1655-61.
[63] Smyth, J. S. Some problems of dental treatment. Part 1. Patient anxiety: Some correlates and sex differences. *Aust. Dent. J*. 1993; 38(5):354-9.
[64] Elter, J. R., Strauss, R. P. Assessing dental anxiety, dental care use and oral status in older adults. *J. Am. Dent. Assoc*. 1997; 128(5):591-7.
[65] Locker, D., Thomson, W. M. Psychological disorder, conditioning experiences and the onset of dental anxiety in early adulthood. *J. Dent. Res.* 2001; 80(6):1588-92.
[66] Aguilera, F., Osorio, R. Causas, factores y consecuencias implicados en la aparición de la ansiedad en la consulta dental. *Rev. Andal. Odontol. Estomatol.* 2002; 12:21-4.
[67] Hmud, R., Walsh, L. J. Dental anxiety: causes, complications and management approaches. *J. Minim. Interv. Dent*. 2009; 2(1):67-78.
[68] Thomson, W. M., Locker, D., Poulton, R. Incidence of dental anxiety in young adults in relation to dental treatment experience. *Community Dent. Oral Epidemiol.* 2000; 28(4): 289-94.

[69] Hagglin, C., Hakeberg, M. Factors associated with dental anxiety and attendance in middle-aged and elderly women. *Community Dent. Oral Epidemiol*. 2000; 28(6):451-60.

[70] Goettems, M. L., Schuch, H. S. Impact of dental anxiety and fear on dental care use in brazilian women. *J. Public Health Dent*. 2014; 74(4): 310-6.

[71] Locker, D., Liddell, A. Diagnostic categories of dental anxiety: A population-based study. *Behav. Res. Ther*. 1999; 37(1):25-37.

[72] Quteish Taani, D. S. Dental anxiety and regularity of dental attendance in younger adults. *J. Oral Rehabil*. 2002; 29(6):604-8.

[73] Eitner, S., Wichmann, M. Dental anxiety-and epidemiological study on its clinical correlation and effects on oral health. *J. Oral Rehabil*. 2006; 33(8):588-93.

[74] Endler, N. S., Kocovski, N. L. State and trait anxiety revisited. *J. Anxiety Disord*. 2001; 15(3):231-45.

[75] Spielberg, C. D., Gorsuch, R. L. *Manual for the state-trait anxiety inventory*. Palo Alto, CA: Consulting Psychologists Press; 1983.

[76] Oei, T. P., Evans, L. Utility and validity of the STAI with anxiety disorder patients. *Br. J. Clin. Psychol*. 1990; 29:429-32.

[77] Shepherd, J. P., Brickley, M. Surgical removal of third molars. *BMJ*. 1994; 309(6955): 620-1.

[78] de Jongh, A., Olff, M. Anxiety and post-traumatic stress symptoms following wisdom tooth removal. *Behav. Res. Ther*. 2008; 46(12):1305-10.

[79] van Wijk, A., Lindeboom, J. The effect of a separate consultation on anxiety levels before third molar surgery. *Oral Surg. Oral Med. Oral Pathol. Oral Radiol. Endod*. 2008; 105(3):303-7.

[80] de Jongh, A., van Wijk, A. J. Psychological impact of third molar surgery: A 1-month prospective study. *J. Oral Maxillofac. Surg*. 2011; 69(1):59-65.

[81] Desjardins, P. J. Patient pain and anxiety: The medical and psychologic challenges facing oral and maxillofacial surgery. *J. Oral Maxillofac. Surg*. 2000; 58(10 Suppl. 2): 1-3.

[82] Earl, P. Patients' anxieties with third molar surgery. *Br. J. Oral Maxillofac. Surg*. 1994; 32(5):293-7.

[83] Frazer, M., Hampson, S. Some personality factors related to dental anxiety and fear of pain. *Br. Dent. J*. 1988; 165(12):436-9.

[84] Garip, H., Abali, O. Anxiety and extraction of third molars in Turkish patients. *Br. J. Oral Maxillofac. Surg*. 2004; 42(6):551-4.

[85] Tsuchihashi, T., Takata, Y. Blood pressure response during dental surgery. *Hypertens. Res*. 1996; 19(3):189-94.

[86] Taenzer, P., Melzack, R. Influence of psychological factors on postoperative pain, mood and analgesic requirements. *Pain*. 1986; 24(3): 331-42.

[87] Fuentes, D., Gorenstein, C. Dental anxiety and trait anxiety: An investigation of their relationship. *Br. Dent. J*. 2009; 206(8):E17.

[88] Yusa, H., Onizawa, K. Anxiety measurements in university students undergoing third molar extraction. *Oral Surg. Oral Med. Oral Pathol. Oral Radiol. Endod*. 2004; 98(1): 23-7.

[89] Kim, Y., Kim, S. Independent predictors of satisfaction in impacted third molar surgery patients. *Community Dent. Oral Epidemiol*. 2010; 38(3): 274-86.

[90] Janssen, K. J., Kalkman, C. J. The risk of severe postoperative pain: Modification and validation of a clinical prediction rule. *Anesth. Analg*. 2008;107:1330-9.
[91] Devine, E. C., Cook, T. D. Clinical and cost-saving effects of psycho-educational interventions with surgical patients: a meta-analysis. *Res. Nurs. Health*. 1986;9:89-105.
[92] Sobel, D. S. Rethinking medicine: improving health outcomes with cost-effective psychosocial interventions. *Psychosom. Med*. 1995;57:234-44.
[93] Mobilio, N., Gremigni, P. Explaining Pain After Lower Third Molar Extraction by Preoperative Pain Assessment. *J. Oral Maxillofac. Surg*. 2011;69:2731-8.

In: Encyclopedia of Surgery (22 Volume Set)
Editors: Andreas Lehrer and Kristin Mueller
ISBN: 978-1-53618-329-0
© 2020 Nova Science Publishers, Inc.

Chapter 391

ZINC DEFICIENCY AFTER BARIATRIC SURGERY: ETIOLOGY, HEALTH IMPLICATIONS AND MANAGEMENT

Jaime Ruiz-Tovar[1,*], MD, PhD and Carolina Llavero[2]
[1]Department of Surgery, University Hospital Rey Juan Carlos, Madrid, Spain
[2]Department of Surgical Nursery, Sureste Hospital, Madrid, Spain

ABSTRACT

Bariatric surgery leads to a significant body weight reduction, and improvement of obesity-related comorbidities. However, it is associated with a higher risk of presenting some nutritional deficiencies. These deficiencies are especially relevant after mixed or malabsorptive procedures.

Deficiencies in micronutrients after bariatric procedures are a known threat if not corrected appropriately.

Though zinc deficiency is not considered among the most frequent deficiencies after bariatric surgery, several studies have shown that its frequency might overcome 10%, even after restrictive procedures and in patients with multivitamin supplements intake.

Zinc is the second most prevalent trace found in the human body after iron. It is essential for normal cell function and metabolism, playing a central role in over 300 enzymatic reactions, and protects cells from free radical damage. The central role of zinc in cell growth and differentiation explains the dramatic effect of zinc deficiency in tissues with a rapid cell turnover such as hair growth.

In recent years much interest has been generated by the possibility that subclinical zinc deficiency may significantly increase the incidence of and morbidity and mortality from diarrhea and upper respiratory tract infections. Clinical manifestations of zinc deficiency include delayed sexual maturation, impotence, hypogonadism, oligospermia, alopecia, dysgeusia, immune dysfunction, night blindness, impaired wound healing, and various skin lesions.

After bariatric surgery, zinc deficiency is often associated with other micronutrients deficiencies, mainly iron. It has been demonstrated that zinc and iron levels, both within

* Corresponding Author's Email: jruiztovar@gmail.com.

the normal range, but close to the minimum level of the range, can be associated with hair loss, mainly between the 6th and 9th postoperative month.

For the evaluation of zinc status, plasma levels are generally a good index of zinc status in healthy individuals.

Zinc supplements are usually indicated for patients with low zinc levels, depending upon the clinical context. In obese patients after bariatric surgery, zinc supplementation can be considered even in patients with serum levels within the normal range, when iron levels are also close to the minimum value of normality and the patient complain of alopecia.

INTRODUCTION

Zinc is the second most prevalent trace found in the human body after iron. Along with iron, iodine, and vitamin A, zinc deficiency is one of the most important micronutrient deficiencies globally. Serum zinc deficiency can determine the appearance of several diseases. Most of these deficiencies are caused by inadequate nutrition. Meats, nuts and lentils are excellent sources of zinc. However, it has been estimated that nearly 45% of adults may have inadequate zinc intakes. Mild zinc deficiency appears to be common, especially in developing countries. Individuals in developing countries are at risk of zinc deficiency because the diet is relatively low in zinc and contain significant amounts of phytates (which reduce zinc absorption) [1, 2]. The Food and Nutrition Board of the Institute of Medicine and the World Health Organization (WHO) have published standard recommendations for daily zinc intake. Requirements vary by age and gender, rising from 3 mg daily in early childhood to 8 mg daily for adult women, and 11 mg daily for adult men. Requirements are slightly higher during pregnancy and lactation [3].

ZINC METABOLISM

Around 60% of total body zinc is in bone and muscle pools with slow turnover. Zinc is absorbed mainly in the duodenum and jejunum, and to a lesser extent in the ileum and colon. Typically, zinc absorption is 20 to 40% efficient, and may be related to zinc status [4].

During digestion, dietary zinc is released and forms complexes with different ligands, namely amino acids, phosphates, organic acids, and histidines. Zinc-ligand complexes are then absorbed through the intestinal mucosa. Pancreatic enzymes are necessary for release of dietary zinc, and pancreatic juices may contain zinc-complexing ligands. Once absorbed, the portal circulation carries zinc to the liver. There is an intricate homeostatic control of zinc absorption, regulated by metallothionein, a metalloprotein that binds copper and other divalent cations [5].

The major route of zinc excretion is via the gastrointestinal tract. Up to 10% of the circulating zinc is also excreted through urine. Zinc homeostasis is probably maintained by a combination of changes in fractional absorption and endogenous fecal zinc excretion [1].

BIOLOGICAL ROLE OF ZINC

The biological role of zinc mainly depends on the ability to form tight bonds with certain amino acids, especially histidine and cysteine. When zinc binds four amino acids (tetradentate configuration), it serves a structural role maintaining protein structure (such as the beta-pleated sheet), and maintains nuclear stability and histone structure. When zinc binds three amino acids, the fourth site is temporarily taken by a water molecule; in this form, zinc can play a role in the metabolic activity of many proteins. Approximately 250 proteins contain zinc. These include enzymes such as angiotensin converting enzyme, alkaline phosphatase, carbonic anhydrase, DNA and RNA polymerases, copper-zinc superoxide dismutase, and metallothionein, as well as a large family of zinc proteins involved in gene transcription (such as the zinc finger proteins). Zinc has important roles both in cell division as well as apoptosis (programmed cell death) [1]. Zinc plays a central role in over 300 enzymatic reactions, and protects cells from free radical damage [6, 7].

ZINC DEFICIENCY

Mild dietary zinc deficiency impairs growth velocity while severe depletion of zinc leads to growth retardation. Other clinical manifestations of zinc deficiency include delayed sexual maturation, impotence, hypogonadism, oligospermia, alopecia, dysgeusia, immune dysfunction, nictalopia, impaired wound healing, and various skin lesions. Other signs and symptoms of zinc deficiency include loss of taste, change in hair color, impaired appetite and decreased sperm counts [8].

Findings such as these, suggesting zinc deficiency, have been described in chronic diseases such as malnutrition, malabsorption syndromes (such as chronic inflammatory bowel disease), prolonged breast feeding, cirrhotic patients and elderly individuals with poor diet quality. In the latter cases, the dietary zinc deficiency may have been exacerbated by medications that increase urinary losses of zinc, including thiazides, loop diuretics, and angiotensin receptor blockers [9].

In recent years much interest has been generated by the possibility that subclinical zinc deficiency may significantly increase the incidence of and morbidity and mortality from diarrhea and upper respiratory tract infections [8].

ZINC DEFICIENCY AFTER BARIATRIC SURGERY

In the recent decades, reduced zinc absorption and stores have been demonstrated in patients who have undergone bariatric surgery, mainly malabsorptive procedures [6]. Though zinc deficiency is not considered among the most frequent deficiencies after bariatric surgery, several studies have shown that its frequency might overcome 10%, even after restrictive procedures and in patients with multivitamin supplements intake. In malabsorptive procedures, as it has been previously explained, zinc is absorbed in duodenum and jejunum, which are the main parts of small bowel that are bypassed in malabsorptive techniques. Similar to zinc, other minerals are also absorbed in these locations of the small bowel (iron,

calcium,…). Therefore, deficiencies in micronutrients after bariatric procedures are a known threat if not corrected appropriately [9-11]. Another factor that might contribute to an impairment of zinc levels, is a reduced stomach production of hydrochloric acid required for zinc bioavailability and absorption [12, 13]. The reduction of gastric acid segregation is probably the main explanation for zinc deficiencies after restrictive procedures, such as sleeve gastrectomy, as there is no malabsorption associated with this procedure. Absorption is also related to zinc concentration in food and red meat is the richest common source of readily available zinc, providing about 50% of dietary intake [14]. Some studies which evaluated food records found that zinc intake was not enough in almost all patients in the first months after bariatric surgery, based on a limited quantity of red meat intake. In patients undergoing any type of bariatric surgery, solid food intake begins 1 month after surgery, but chicken is the main meat included in this first solid diet. Red meat is progressively introduced, but most patients complained of difficult digestions with this red meat and they decide to reduce the ingestion. It is around the 3rd postoperative month, when they can ingest red meat without problems.

EVALUATION OF ZINC STATUS

Serum levels of zinc are often the only method performed to evaluate zinc status. After bariatric surgery, serum levels of zinc are included in the routinary blood analysis performed for monitoring the nutritional status in the postoperative course. However, it has been demonstrated that serum levels do not necessarily correlate with tissue levels and do not reliably identify individuals with zinc deficiency. Although plasma levels can be a good index of zinc status in healthy individuals, these levels are depressed during inflammatory disease states. It is important to remember that obesity is considered as a pro-inflammatory entity, and the rapid weight loss after surgery is identified by the organism as an aggression, associating an inflammatory response, that ends once a weight stability is achieved [15]. Thus, the accuracy of serum zinc levels for the diagnosis of zinc deficiency is low.

Erythrocyte concentrations of zinc may provide a more useful measure of zinc status during acute or chronic inflammation. Serum superoxide dismutase and erythrocyte alkaline phosphatase activities are functional indices that can also be used to indirectly assess zinc status [16]. The main limit of these tests is that they are not widely available.

ALOPECIA AND MILD ZINC DEFICIENCY AFTER BARIATRIC SURGERY

The central role of zinc in cell growth and differentiation explains the dramatic effect of zinc deficiency in tissues with a rapid cell turnover, such as the hair growth [12]. The phenomenon of postoperative hair loss is multifactorial. Though hair loss is mainly due to a rapid weight loss, micronutrient deficiencies must be discarded. Zinc is the most frequently suspected deficiency with rapid clinical responses reported from therapy [6]. A recent study of our group showed that zinc levels within the normal range, but close to the minimum value, can be associated with hair loss in females between the 3rd and the 9th postoperative months, especially when iron levels are also close to the minimum limit. We proposed to

study a new variable, called Addition (serum zinc + serum iron). When Addition levels are below 115, these values are associated with alopecia, that disappeared with zinc supplementation [17]. These findings support the fact that serum levels of zinc within the normal range in the postoperative course of bariatric surgery, are not a good marker for zinc status.

MANAGEMENT OF ZINC DEFICIENCY

The fact that after zinc supplement intake hair loss stopped in most patients of our study, even in those with zinc levels within normal range, reveals that there is a mild zinc deficiency after sleeve gastrectomy, that probably alone is not enough to produce hair loss, but associated with iron mild deficiency (also with levels within normal range) it can appear. There are currently no guidelines for zinc supplementation and optimal dose and rules of prescription after bariatric surgery are still to be determined. In our series, just a small dose of 12.5mg/day (125% RDA) during 2 months was enough to slightly increase the serum zinc levels and to stop hair loss. As prophylactic measure against hair loss after bariatric surgery, it could be hypothesized a routinely supplementation with low doses of zinc [17].

During zinc supplementation, it is recommended to monitor periodically the serum concentrations in order to avoid the appearance of adverse effects associated with overload. Anyway, humans are very tolerant of high zinc intakes up to 100 mg/day (1000% RDA). Mega-dose supplementation or high zinc intake from contaminated food has been associated with nonspecific gastrointestinal symptoms, including abdominal pain, diarrhea, nausea, and vomiting. Zinc overload may interfere with copper absorption, and high zinc intakes (> 150 mg/day) can lead to copper deficiency. Treatment for zinc toxicity is primarily supportive, although chelation with calcium disodium ethylenediaminetetraacetate (CaNa2EDTA) has been used in some cases of severe toxicity [18].

REFERENCES

[1] King, JC; Klein, CL. Zinc. In: Shils ME, Olson JA, Shike M, et al. *Modern nutrition in health and disease*. Philadelphia, Lippincott, 2000, 223.

[2] Briefel, RR; Bialostosky, K; Kennedy-Stephenson, J; et al. Zinc intake of the U.S. population: findings from the third National Health and Nutrition Examination Survey, 1988-1994. *J Nutr*, 2000, 130, 1367S-1373S.

[3] World Health Organization. *Vitamin and mineral requirements in human nutrition* (2e), 2004 http://www.who.int/vmnis/en/ (Accessed on January 27, 2009).

[4] Sandström, B. Bioavailability of zinc. *Eur J Clin Nutr*, 1997, 51, S17-19.

[5] Cousins, RJ; Lee-Ambrose, LM. Nuclear zinc uptake and interactions and metallothionein gene expression are influenced by dietary zinc in rats. *J Nutr*, 1992, 122, 56-64.

[6] Daniells, S; Hardy, G. Hair loss in long-term or home parenteral nutrition: are micronutrient deficiencies to blame? *Curr Opin Clin Nutr Metab care*, 2010, 13, 690-697.

[7] Chimenti, F; Aouffen, M; Favier, A; et al. Zinc homeostasis-regulating proteins: new drug target for triggering cell fate. *Curr Drug Targets*, 2003, 4, 323-338.
[8] Ruz, M; Carrasco, F; Rojas, P; et al. Zinc absorption and zinc status are reduced after Roux-en-Y gastric bypass: a randomized study using 2 supplements. *Am J Clin Nutr*, 2011, 94, 1004-1011.
[9] Rojas, P; Gosch, M; Basfi-fer, K; Carrasco, F; et al. Alopecia en mujeres con obesidad mórbida severa sometidas a cirugía bariátrica. *Nutr Hosp*, 2011, 26, 856-862.
[10] Bloomberg, RD; Fleishman, A; et al. Nutritional deficiencies following bariatric surgery: what have we learned? *Obes Surg*, 2005, 15, 145-154.
[11] Mason, ME; Jalagani, H; et al. Metabolic complications of bariatric surgery: diagnosis and treatment issues. *Gastroenterol Clin North Am*, 2005, 34, 25-33.
[12] Salle, A; Demarsy, D; Poirier, AL; et al. Zinc deficiency: A frequent and underestimated complication after bariatric surgery. *Obes Surg*, 2010, 20, 1660-1670.
[13] Schweitzer, DH; Posthuma, EF. Prevention of vitamin and mineral deficiencies after bariatric surgery:evidence and algorithms. *Obes Surg*, 2008, 18, 1485-1488.
[14] Maret, W; Sandstead, HH. Zinc requirements and the risks and benefits of zinc supplementation. *J Trace Elem Med Biol*, 2006, 20, 3-18.
[15] Ruiz-Tovar, J; Oller, I; Galindo, I; et al. Change in levels of C reactive protein (CRP) and serum cortisol in morbidly obese patients after laparoscopic sleeve gastrectomu. *Obes Surg*, 2013, 23, 764-769.
[16] Oakes, EJ; Lyon, TD; Duncan, A; et al. Acute inflammatory response does not affect erythrocyte concentrations of copper, zinc and selenium. *Clin Nutr*, 2008, 27, 115-120.
[17] Ruiz-Tovar, J; Oller, I; Llavero, C; et al. Hair loss in females after sleeve gastrectomy: Predictive value of serum zinc and iron levels. *Am Surg*, 2014, 80, 466-71.
[18] Wastney, ME; Ahmed, S; Henkin, RI. Changes in regulation of human zinc metabolism with age. *Am J Physiol*, 1992, 263, R1162-1168.

In: Encyclopedia of Surgery (22 Volume Set)
Editors: Andreas Lehrer and Kristin Mueller
ISBN: 978-1-53618-329-0
© 2020 Nova Science Publishers, Inc.

Chapter 392

MECHANISMS OF ZINC DEFICIENCY AND ITS CLINICAL SIGNIFICANCE AFTER BARIATRIC SURGERY

Anand Nath[1], MD, Hiral Shah[3], MD, Bikram S. Bal[4], MD, Timothy R. Shope[2], MD and Timothy R. Koch[*,2], MD

[1]Department of Medicine and
[2]Center for Advanced Laparoscopic
and Bariatric Surgery, Department of Surgery,
MedStar-Washington Hospital Center and
Georgetown University School of Medicine, Washington, DC, US
[3]EPGI, Lehigh Valley Hospital, Allentown, PA, US
[4]Center for Gastrointestinal and Liver Diseases, Centra Southside, Farmville, VA, US

ABSTRACT

The rising prevalence of obesity (body mass index of >/= 30 kg/m^2) in more than 100 countries has been described as a global pandemic. Studies have found that surgery results in more significant and sustained weight loss, when compared to dietary and lifestyle interventions, in individuals with medically-complicated obesity.

Zinc is an essential component of the catalytic site of hundreds of different metalloenzymes where it functions as a Lewis acid.

The small intestine is the main site of zinc absorption via transporter expression which is regulated in part by dietary zinc intake. Zinc deficiency is a clinical concern since it may result in multiple clinical symptoms.

After bariatric surgery, the prevalence of biochemical zinc deficiency has been reported to range from 5% to 83%. It has been suggested that bariatric procedures that result in restriction may have lower rates of zinc deficiency compared to bariatric procedures that produce restriction as well as malabsorption.

The mechanisms for zinc deficiency after bariatric surgery have not been fully delineated but may include decreased intake, poor food tolerability, decreased surface

[*] Corresponding Author's Email: timothy.r.koch@medstar.net; Fax: +1-877 680-8198.

area for absorption, rapid oral-cecal transit, altered compensatory mechanisms, and/or small intestinal bacterial overgrowth.

Elevated serum folic acid levels, a marker for small intestinal bacterial overgrowth, is common after gastric bypass surgery, and small bowel bacterial overgrowth is associated with decreased zinc absorption. We evaluated 230 patients after gastric bypass surgery and 145 patients had elevated serum folate levels, supporting 63% prevalence for small intestinal bacterial overgrowth. In 54 patients with normal serum folate levels, 43 had normal zinc levels, while among 118 patients with elevated serum folate, 78 had low serum zinc (Chi-squared 2X2: $P < 0.001$), supporting upper gut bacterial overgrowth as a mechanism for biochemical zinc deficiency.

We have evaluated 43 patients who underwent upper endoscopy after gastric bypass surgery. In 17 out of 43 (40%) of these patients, there was an abnormal finding at upper endoscopy: gastrojejunal anastomotic stricture (obstruction) or gastrojejunal anastomotic ulcer. In 8 patients with gastrojejunal ulceration, 66% of the patients had low serum zinc levels. In patients who had elevated serum folate levels, there was no increased risk of gastrojejunal ulceration (Chi-squared 2X2: $P = 0.53$).

Currently, recommendations regarding routine screening for zinc deficiency or the use of daily oral zinc supplementation in individuals after bariatric surgery are not based on clinical trials. Gaps that exist in our understanding of this clinical disorder are summarized in this chapter. Since present physiological evidence supports zinc absorption primarily in the jejunum by a transcellular route involving a zinc-specific transporter, Zip4, proposed studies should examine potential post-operative changes in zinc transport and the potential for reversibility with antibiotic treatment of small intestinal bacterial overgrowth.

INTRODUCTION

The Pandemic of Obesity

As shown in Table 1, obesity is consistent with a Body Mass Index (BMI) >/= 30 kg/m^2 while overweight people have a BMI >/= 25 kg/m^2 [1]. Over the past decades, the rising prevalence of overweight and obesity in more than 100 countries has been described as a global pandemic [2-4].

Table 1. Obesity can be defined by body mass index or BMI

BMI (kg/m^2)	Definition	Obesity Class
18.5-24.9	Normal	
25-29.9	Overweight	
30-34.9	Obesity	I
35-39.9	Obesity	II
40.0-	Obesity	III

There is a universal concern about health risks associated with increased obesity.

According to a recent study, the conditions overweight and obesity were estimated to cause 3.4 million deaths, 4% of life years lost and 4% of disability adjusted life years across the globe in 2010 [5]. Worldwide, the combined prevalence of overweight and obesity rose by 27.5% for adults and 47.1% for children between 1980 and 2013 (see Figure 1). The

worldwide number of overweight and obese adults increased from 857 million in 1980 to 2.1 billion in 2013.

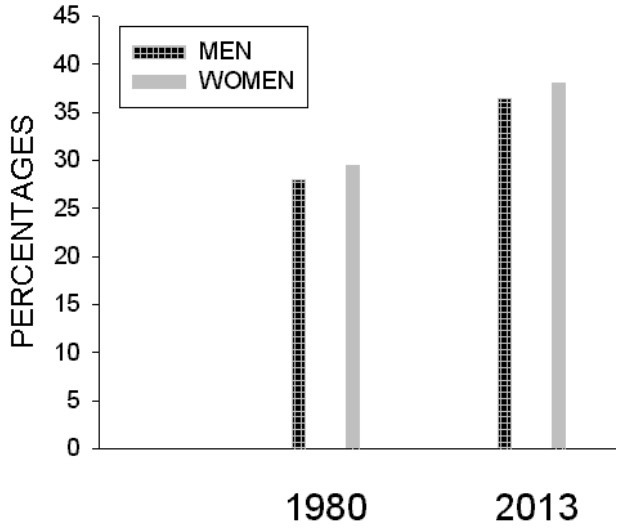

Figure 1. There was a rise in the worldwide prevalence (in percentages) of men and women who were overweight or obesity in 1980 and in 2013.

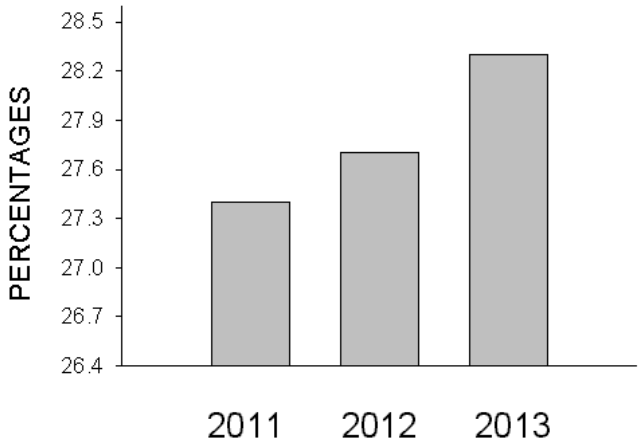

Figure 2. There was a rise in percentages of adults aged 18 years and older who were obese in the United States in 2011, 2012, and 2013.

Data from studies in the United States have suggested that during the past 20 years, there has been a dramatic increase in obesity and therefore rates remain high (see Figure 2). More than one-third of U.S. adults (34.9%) and approximately 17% (or 12.7 million) of children and adolescents aged 2 to 19 years-old are obese [6, 7].

The connection between the rising rates of obesity and rising medical spending is also clear. In 1998 the medical costs of obesity were estimated to be as high as $78.5 billion and these costs increased to $147 billion by 2008 (see Figure 3). In 2006, obese individuals had medical spending that was $1,429 greater than spending for normal-weight individuals [8].

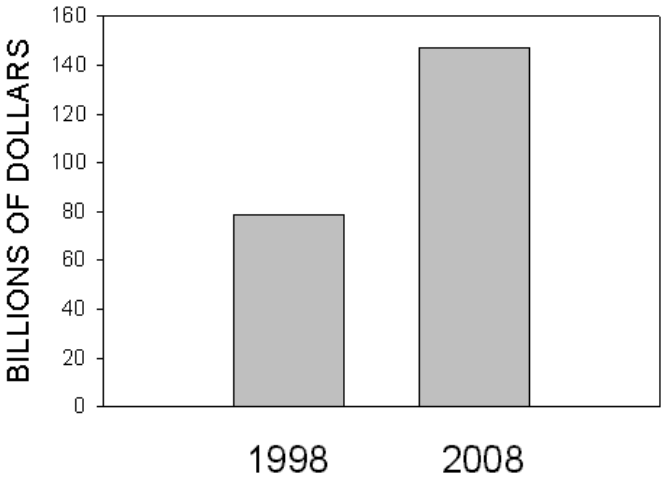

Figure 3. There were increased estimates of the medical costs (in billions of dollars) related to obesity in the United States in 1998 and in 2008.

Surgical Management of Obesity

Morbid obesity has been directly associated with an extensive list of significant co-morbid conditions, including the metabolic syndrome, cardiovascular diseases, obstructive sleep apnea, certain carcinomas (i.e., endometrial, breast, colon), osteoarthritis and non-alcoholic steatohepatitis. Childhood obesity is associated with a higher chance of obesity and disability when reaching adulthood.

In addition to increased future risks, obese children experience breathing difficulties, increased risk of fractures, hypertension, insulin resistance, and psychological disorders.

Management options for obesity include dietary and activity program, pharmacological therapy, endoscopic interventions, and surgical procedures. The initial management of obesity includes dietary and lifestyle interventions. Recent studies have showed that more focus on healthy eating and physical activity have led to a potential decline in obesity rates in school children in a school based program [9].

However dietary and activity program, and pharmacological therapy, have resulted in poor weight loss and/or poor maintenance of weight loss especially in individuals with severe obesity [10, 11]. Controlled studies and cohort studies have found that bariatric surgery results in more dramatic and sustained weight loss as compared to nonsurgical interventions [12-14].

Bariatric surgical procedures (see Figure 4) are considered for individuals with a body mass index > 39.9 kg/m^2 or a body mass index of >34.9 kg/m^2 with an associated significant co-morbidity, e.g., diabetes mellitus, obstructive sleep apnea, Pickwickian syndrome, obesity-related cardiomyopathy, or disabling osteoarthritis. Currently, only about 1% of the morbidly obese population is being evaluated for this surgical strategy. Clinical outcome studies have shown significant reductions in long term mortality after gastric bypass surgery, including mortality caused by cardiovascular events, diabetes, and cancer [15-18]. These data support the current indications of bariatric surgery for the treatment of medically-complicated obesity.

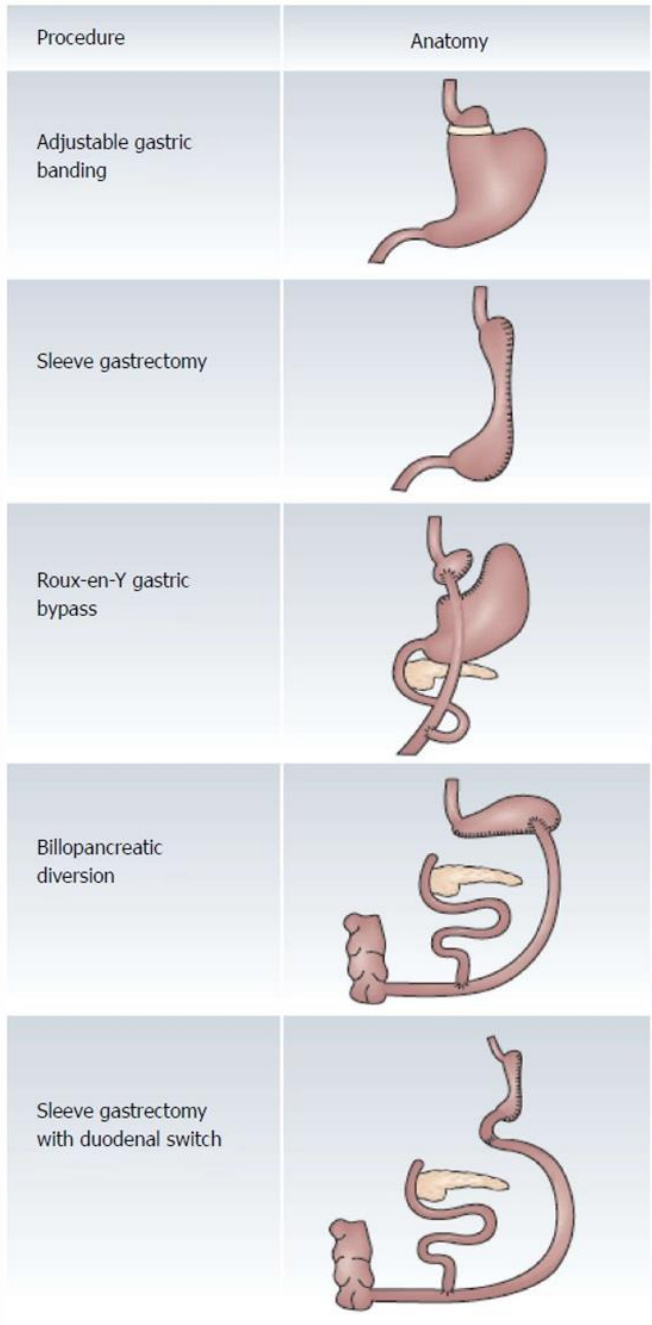

Figure 4. Representations of major bariatric surgical procedures. Restrictive bariatric surgical procedures include the adjustable gastric band and the vertical sleeve gastrectomy. Bariatric surgical procedures that result in both restriction as well as in some malabsorption include the Roux-en-Y gastric bypass, the biliopancreatic diversion, and the duodenal switch. In gastric bypass surgery and in biliopancreatic diversion, the length of the biliopancreatic limb (e.g., bypassed small intestine) is related to the distance from the pylorus to the jejuno-jejunal anastomosis. In gastric bypass surgery and in biliopancreatic diversion, small intestine distal to the jejuno-jejunal anastomosis (e.g., the common channel) is required to allow mixing of micronutrients with bile and pancreatic secretions. (Reproduced with permission from Bal, BS; et al. Nature Rev Endocrinol 2012; 8: 544-556.).

Data from a global survey shows that the total number of bariatric procedures performed worldwide in 2013 was 468,609, in which 95.7% were completed laparoscopically. The highest number (n = 154,276) were performed in the USA/Canada region. The most commonly performed procedure in the world was Roux-en-Y gastric bypass (RYGB), at 45%, followed by the vertical sleeve gastrectomy (SG), at 37%, and then the adjustable gastric banding (AGB), at 10%. The most significant changes were the worldwide rise in utilization of SG from 0% in 2003 to 37% of bariatric surgical procedures in 2013, with a related decline in the performance of AGB after its peak in 2008 [19]. The number of procedures performed in the USA/Canada has increased over time, with the number being 179000 in 2013 [23], which results in approximately 40% of the global total.

Bariatric surgeries involving the stomach are restrictive in general, while surgery involving the small intestine can also result in malabsorption. Vertical sleeve gastrectomy and adjustable gastric band are the commonly performed restrictive procedures, while Roux-en-Y gastric bypass and biliopancreatic diversion (more rarely performed due to the risks of malnutrition) result in malabsorption in addition to restriction. Procedures designed to include a malabsorptive component produce greater nutritional deficiencies than restrictive surgeries.

In Roux-en-Y gastric bypass, a small gastric pouch is created by complete division of the stomach, and then the proximal gastric pouch is directly connected to jejunum that was divided commonly 40 to 50 cm distal to the ligament of Treitz. The location of the jejuno-jejunal anastomosis is important because a long proximal alimentary limb (which is distal to the proximal gastric pouch) results in a short common channel (e.g., the small intestine distal to the jejuno-jejunostomy). Patients with a short common channel are more at risk for developing malabsorption and malnutrition, compared to patients with longer common channels, due to decreased surface area of small intestine available for the absorption of micronutrients and possible alteration of bacterial flora [24].

The vertical sleeve gastrectomy is gaining popularity worldwide and is now commonly performed in the USA. The gastric fundus and body are surgically excised, leaving a narrow, tubular stomach along the lesser curvature of the stomach. It allows for an immediate restriction of caloric intake without an intestinal anastomosis, placement of an extrinsic foreign body, or the need for adjustments [24].

The adjustable gastric band is primarily a restrictive strategy that does not bypass any part of the gastrointestinal tract. A plastic latch is used to hold a soft, silicone ring circumferentially around the upper stomach just distal to the gastroesophageal junction, leaving a very small pouch available for food. A subcutaneous access port is connected via tubing to the silicone ring or band. Sterile fluid added to the port induces extrinsic compression of the proximal gastric lumen by inflating the balloon positioned around the proximal stomach [24]. Biliopancreatic diversion involves a distal gastrectomy with closure of the duodenal stump. The jejunum is divided and the distal limb is anastomosed to the proximal stomach, while the proximal limb (termed the biliopancreatic limb) is anastomosed to the ileum. A variation of this procedure, termed biliopancreatic diversion with duodenal switch, was developed to decrease the adverse effects of dumping syndrome. In this procedure restrictive component is maintained by a partial gastrectomy of 70% to 80% of the greater curvature of the stomach in a gastric sleeve configuration [25].

Vertical-banded gastroplasty is another bariatric procedure that was developed to be restrictive in nature and was designed to decrease morbidity. Due to an unacceptably high failure to maintain long term weight loss, this procedure is now rarely performed [26].

PHYSIOLOGY OF ZINC

Zinc is the second most abundant trace element in the body after iron. The average adult stores a total of 2 to 3 grams of zinc, mainly present in muscle and bone. In clinical research studies of zinc metabolism, an exchangeable zinc pool mathematically estimates compartments in the body in which zinc can rapidly exchange with serum zinc. The exchangeable zinc pool in adults has been correlated with dietary zinc intake. Therefore, this concept may provide a useful measure in studies of zinc metabolism. Zinc is required as a cofactor for more than 100 metalloenzymes where it functions as a Lewis acid. These enzymes are involved in synthesis of DNA and RNA, release of vitamin A from liver, metabolism of carbohydrates, disposal of free radicals, biosynthesis of heme and essential fatty acids, and transport of carbon dioxide. In addition, zinc appears to stabilize cell membranes, assists in immune function, and is involved in the synthesis, storage and release of insulin from the pancreas. Zinc is physiologically important for normal taste perception, wound healing, production of sperm, and fetal development.

Zinc is principally absorbed in the small intestine. The rate of the zinc absorption varies from 15-40% depending on the zinc status in the body: if more zinc is needed, more is absorbed. Dietary factors also influence its absorption, and zinc is better absorbed when the stomach is empty. Meat, shellfish, and nuts are good sources of bioavailable zinc, whereas zinc in grains and legumes is less bioavailable. Absorption of dietary zinc may be inhibited by dietary phytate, fiber, oxalate, iron, and copper.

Zinc is absorbed into intestinal mucosal cells by passive carrier-mediated diffusion. A portion of absorbed zinc is utilized in the metabolic functions of the cell itself. Alternatively, zinc may be retained within mucosal cells by interaction with metallothionein, a binding protein. By this mechanism, metallothionein in intestinal cells may be involved in the regulation of zinc absorption. This step is mediated by an energy dependent process, is regulated by body stores of zinc, and is potentially altered by the presence of iron cations [28, 29].

The level of zinc supplementation does not have a significant differential effect on the magnitude of its absorption. Recent advances have shown that zinc absorption is a complex process involving the participation of several transporters from both the ZIP (solute linked carrier SLC39) and the ZnT (solute-linked carrier SLC30) families. ZIP4 is considered the primary regulator of zinc uptake in the intestinal cells, and ZnT1 is pivotal for the zinc efflux from the enterocyte into the blood [30-33]. The expression of these zinc transporters is regulated by cytokines, hormones, and zinc levels in the body [30]. It is believed that surgery on the small intestine can cause changes in the expression of zinc transporters, resulting in important effects on zinc homeostasis [31].

Zinc's main transport vehicle in the blood is albumin. Some zinc also binds to transferrin. In conditions of iron overload, transferrin is saturated hence leaving too few sites available for zinc binding. The converse is also true: large doses of zinc inhibit iron absorption. A proportion of the circulating zinc is taken up by the pancreas, where it is incorporated into digestive enzymes that are released at mealtime. This recycling of zinc in the body from small intestine to the pancreas and back to the small intestine is known as enteropancreatic circulation. As zinc circulates through the small intestine, it may not be absorbed by intestinal mucosal cells. Zinc is also excreted in intestinal cells shed into the intestinal lumen. The

primary excretion of zinc from the body is within feces. The body also loses small amounts of zinc in urine, hair, skin cells that are sloughed, sweat, menstrual fluid, and semen.

PREOPERATIVE AND POSTOPERATIVE ZINC METABOLISM

Zinc and Obesity

An estimated 17.3% of the world's population is at risk of inadequate zinc intake [34]. Preoperative determination of zinc levels in obese individuals considering bariatric surgery suggests that biochemical zinc deficiency (e.g., low serum levels of zinc) is common in this population. Multiple studies evaluating morbidly obese individuals preoperatively have found that the prevalence of zinc deficiency ranges from 15% to 73.9% [35-39]. Such wide differences in results may be attributable to poor dietary habits in the studied population, socioeconomic factors, gastrointestinal pathologies, and/or the use of different cutoff points for defining biochemical zinc deficiency.

Sanchez et al evaluated 103 morbidly obese women for micronutrient deficiencies before proceeding to gastric bypass surgery. The mean BMI of these individuals was 43.1 ± 5.3 kg/m^2 and the mean age was 36.0 ± 9.6 years-old in the study group. Low hair zinc concentrations were detected in about 15% of the patients [35]. In a second study by Gobato at al, biochemical zinc deficiency was found in 20 (55.5%) of 36 morbidly obese patients presenting for preoperative evaluation for gastric bypass surgery [36].

Although the exact mechanism to explain zinc deficiency in the obese patient population is not clear, several mechanisms have been hypothesized. Dietary intake may be both an origin for obesity as well as an origin for the development of micronutrient deficiencies. The obese patient usually has a high intake of calorie dense food rich in large amounts of carbohydrate and fat, but poor in vitamins and minerals [40-44]. A substantial proportion of these patients also have problematic eating behaviors such as loss of control eating, night eating syndrome, binge eating disorder, and bulimia nervosa [45]. Additionally, these individuals have altered bioavailability of micronutrients, due to "high calorie malnutrition", which is a state of excess intake of calories with concurrent nutrient deficiencies resulting in inadequate ability to utilize these calories efficiently; the toxic by-products of incomplete biochemical reactions create a vicious cycle resulting in further weight gain, eating disorders, metabolic syndrome, and fatigue [41]. Another potential explanation for biochemical zinc deficiency could be dilution effects of extracellular concentrations due to elevated quantities of total body water in individuals with obesity, since the extracellular compartment is relatively larger than the intracellular compartment, causing imbalances in the vitamin status [46]. It has also been postulated that there is decreased levels of bioavailable zinc in the obese patients due to sequestration of a majority of zinc in increased body fat [47, 48]. Small intestinal bacterial overgrowth (SIBO), especially in diabetic patients with concurrent malabsorption is another potential explanation for the development of zinc deficiency.

Zinc and Bariatric Surgery

Although bariatric surgical procedures have shown promising results in sustained extensive weight loss, chronic complications including macronutrient and micronutrient deficiencies occur. Micronutrient disorders including biochemical zinc deficiency are commonly found in individuals before bariatric surgery and have been shown to persist or worsen after bariatric surgery.

Clinical zinc deficiency is a major clinical concern in bariatric surgery patients because of the important function of this mineral and the co-morbidities related to its deficiency, such as growth retardation, hypogonadism, dermatitis, alopecia, poor immunity, acrodermatitis, poor healing, and impaired neuropsychological performance [49-51]. The potential role of zinc in development of diarrhea is not as clear since many individuals with diarrhea can develop biochemical zinc deficiency. Many bariatric surgery patients are women in child bearing age, and zinc deficiency has been associated with adverse effects on maternal health and pregnancy outcomes, including hypertension [52, 53].

Biochemical zinc deficiency after bariatric surgery has been supported by multiple studies (see Table 2). There are wide variations reported in the post-operative prevalence of reduced serum zinc levels possibly due to the type of hospital involved in bariatric surgery, the length of postoperative follow-up, patients' socioeconomic factors, and the use of different cutoff levels in defining a biochemical nutritional deficiency.

Table 2. Prevalence of zinc deficiency after specific bariatric procedures

Surgery*	Post-op period	No. of patients	Zinc deficiency	Reference
RYGB	6 months	36	61.11%	[55]
RYGB	12 months	100	36%	[54]
RYGB	12 months	86	34.88%	[56]
SG	12 months	50	30%	[56]
SG	12 months	200	5 %	[57]
SG	12 months	28	10.7%	[58]
BPD/DS	6 months	24	83%	[66]
BPD/DS	18 months	180	38.3%	[65]

*RYGB: Roux-en-Y Gastric Bypass; VSG: Vertical Sleeve Gastrectomy; BPD/DS: Biliopancreatic Diversion/Duodenal Switch.

In a study from University Hospital in Memphis, TN [54], 100 individuals had serum zinc levels examined at 1 year after surgery. In this study the prevalence of zinc deficiency was 36%. In a more recent study [36], 36 individuals had serum zinc levels measured six months after Roux-en-Y gastric bypass. The prevalence of zinc deficiency in this long term study was 61.11%. In an additional study from Switzerland, Gehrer et al found that 34.9% of patients were zinc deficient after Roux-en-Y gastric bypass, compared to 30% after vertical sleeve gastrectomy, in postoperative follow up at 1 year [55].

Due to its restrictive nature, vertical sleeve gastrectomy is thought to result in less frequent and less severe postoperative nutritional deficiencies compared to gastric bypass surgery. Despite the absence of surgically induced malabsorption in individuals undergoing vertical sleeve gastrectomy, there is emerging literature suggesting that zinc deficiency is common after sleeve gastrectomy. This is important due to the worldwide rise in the utilization of vertical sleeve gastrectomy, as mentioned above. There have been short term as well as long term studies of the prevalence of zinc deficiency after vertical sleeve gastrectomy. In a one year follow up of 200 individuals after vertical sleeve gastrectomy, van Rutte et al reported a 5% prevalence of zinc deficiency [40]. In a similar study, Saif et al. reported a 10.7% prevalence of zinc deficiency at one year follow up of 28 individuals after vertical sleeve gastrectomy. These results were confirmed by an additional 4 year follow up that showed a 14.3% prevalence of zinc deficiency in these patients [56].

In contrast to vertical sleeve gastrectomy, the worldwide performance of adjustable gastric banding has rapidly declined in recent years. Studies evaluating zinc deficiency after this bariatric procedure are scarce. In 30 patients who underwent laparoscopic adjustable gastric banding, at 6 months after the surgery Boyuk et al found that the postoperative zinc levels (500 ± 130 ng/ml) were statistically significantly lower than the preoperative zinc levels (740 ± 230 ng/ml) [59], but this decline did not result in clinical zinc deficiency.

Biliopancreatic diversion with duodenal switch may be superior to other bariatric procedures in terms of weight loss, as supported by recent meta-analyses [58-60]. However, biliopancreatic diversion is also associated with more frequent postoperative nutritional disorders due to increased malabsorption, and so this bariatric procedure is generally restricted to super-morbidly obese patients (body mass index of ≥ 50 kg/m^2) for whom greater weight loss is required [61, 62]. An increased risk of zinc deficiency has been reported in individuals after BPD/DS by Botella and associates [63]. The authors report results from 180 patients with BMI decreasing from a preoperative value of 52.9 ± 7.7 kg/m^2 to 30.8 ± 5.2kg/m^2 after surgery. In this group, 38.3% of the patients were found to have low serum zinc levels at 18 months follow up. In a similar study, when evaluating 24 patients after BPD/DS, Salle et al reported that 83% and 91.7% of the patients had biochemical zinc deficiency at 6 months and at 12 months postoperatively [64].

MECHANISMS OF ZINC DEFICIENCY

Postoperative Bariatric Surgery

Despite multiple studies describing low zinc levels and its outcome, the exact underlying mechanisms involved in the development of postoperative zinc deficiency are not well understood (see Table 3). Three major factors can influence zinc status in humans: reduced zinc intake, reduced zinc absorption, and increased losses.

An important factor associated with zinc deficiency early after bariatric surgery is reduction in dietary nutrient intake due to decreased gastric capacity. Studies that evaluated food records found that zinc intake was inadequate in almost all patients presenting for follow up after bariatric surgery [65-67]. In addition to this decrease in total zinc intake, zinc

ingestion related to use of meat products (beef, lamb, and oysters) can also be decreased due to low tolerance [68-70] or the use of a low fat, high protein sources in the postoperative diet.

Table 3. Proposed mechanisms for development of zinc deficiency after bariatric surgery

• Reduction in total food intake due to decreased gastric capacity
• Poor tolerability of food with high zinc contents
• Post-operative vomiting
• Substantial reduction in intestinal absorption surface
• Dumping syndrome with rapid oral-cecal transit
• Altered bioavailability of zinc in obesity
• Small intestinal bacterial overgrowth
• Concomitant administration of iron and copper
• Altered compensatory mechanisms post-operatively

Zinc absorption takes place mainly in the duodenum and initial portions of the jejunum. These portions of the intestine are bypassed during Roux-en-Y gastric bypass which may result in a substantial reduction in intestinal absorption surface and, in turn, less absorption capacity. In a recent study evaluating the patients who underwent Roux-en-Y gastric bypass surgery, percentage zinc absorption from a standard diet decreased significantly from 32.3% to 13.6% at 6 months and to 21% at 18 months after surgery [71]. Although vertical sleeve gastrectomy restricts the volume of the stomach without bypass of the small intestine, it also leads to accelerated gastric emptying. Subsequently, rapid gastric emptying might promote nutrient deficiencies [72], as observed in a recent study describing increased fecal excretion of fatty acids which induced moderate malabsorption [73]. Due to the high frequency of postoperative iron deficiency, frequent administration of iron supplements may also increase a patient's risk of zinc deficiency due to competitive interactions for uptake of these minerals [74].

Post-surgery zinc deficiency could also be due to a defect in compensatory mechanisms. Zinc is subject to strong homeostatic regulation via the gut and liver. Zinc absorption is affected by zinc status and absorption efficiency is inversely correlated with the zinc level in the body [75]. Zinc is mainly excreted by the intestine through intestinal and pancreatic secretions. It is believed that zinc homeostasis can be altered by malabsorptive surgery. This result may be partly due to excessive loss of zinc arising from secondary diarrhea after these surgeries [76]. A major compensatory mechanism in the presence of biochemical zinc deficiency (e.g., greater intestinal absorption and reduced excretion of zinc) can therefore be reduced [77].

Zinc and Small Intestinal Bacterial Overgrowth

Small intestinal bacterial overgrowth after gastrointestinal surgery has long been known to lead to cyanocobalamin or vitamin B12 deficiency. Our group has further examined the role of small intestinal bacterial overgrowth in development of thiamine or vitamin B1 deficiency. The results of our studies support small intestinal bacterial overgrowth as a potential mechanism to explain postoperative micronutrient deficiencies [78]. These studies have also expanded upon prior reports of increased serum levels of folate (which is produced by upper intestinal bacteria and then absorbed into the serum) in individuals with small intestinal bacterial overgrowth [79] by comparing elevated serum folate levels with abnormal breath hydrogen levels in individuals examined by glucose-hydrogen breath testing after Roux-en-Y gastric bypass surgery.

Small intestinal bacterial overgrowth can result in malabsorption as a result of the effect of gut flora on intestinal absorptive functions. In normal individuals, colonization of bacteria in the proximal gastrointestinal tract is in low concentrations. However, in individuals with small intestinal bacterial overgrowth, the flora of the proximal gut can be changed toward higher concentrations of colonic-type anaerobic bacteria that can induce fermentation.

Small intestinal motility and the migrating motor complex are important defense mechanisms against upper gut bacterial overgrowth, likely due to passage of bacteria into the colon [80]. Bariatric surgery may disrupt these defense mechanisms. The creation of a shorter small intestine may result in less time and less intestinal surface area for absorption of bile acids, gastric acid, and pancreatic enzymes.

These post-procedural disruptions may alter small intestinal motility and could permit bacteria to have prolonged access to intestinal chyme further promoting bacterial overgrowth [81].

A clinical diagnosis of upper gut bacterial overgrowth can be difficult since patients can present after bariatric surgery with non-specific abdominal symptoms including cramping abdominal pain, abdominal bloating or distension, increased flatulence, or diarrhea. These abdominal symptoms can overlap with symptoms of malabsorption caused by lactose intolerance, fructose intolerance, or surgical bypass of small intestine.

Based upon prior reports of B vitamin deficiencies induced by small intestinal bacterial overgrowth, our group examined the association between zinc absorption and small intestinal bacterial overgrowth [82].

This study was a retrospective review of 452 patients who underwent Roux-en-Y gastric bypass surgery from 1999 to 2005. As a marker of small intestinal bacterial overgrowth, an elevated serum folate level (a serum level above the upper limit of normal for the serum folate assay) has a reported specificity of 79%.

All patients were identified who had measurement of serum folate levels. Levels of serum folate were available in 230 patients, while 172 patients had determination of both serum folate and serum zinc levels. This study involved 199 females and 31 male patients with an average age of 46 years-old (range was 21 to 68 years old). The mean body mass index was 53 kg/m^2 with a range of 40 to 100 kg/m^2.

For results involving the total 230 patients, 145 had elevated serum folate levels supporting 63% prevalence for upper gut bacterial overgrowth. As shown in Table 4, among the 172 patients who had measurement of both serum folate and serum zinc levels, in 54 patients with normal serum folate levels, 43 had normal serum zinc; among 118 patients with

elevated serum folate, 78 had low serum zinc (Chi-squared 2x2: P < .001), supporting upper gut bacterial overgrowth as a mechanism for biochemical zinc deficiency.

While these results support upper gut bacterial overgrowth as a mechanism for the development of zinc deficiency after bariatric surgery, in previous studies we showed that treatment of Vitamin B1 deficiency with oral Vitamin B1 supplements requires concomitant antibiotic therapy for small intestinal bacterial overgrowth [78].

This finding suggests that oral zinc supplements may not be fully effective for the treatment of zinc deficiency in individuals who have upper gut bacterial overgrowth after bariatric surgery. Further studies need to be performed to evaluate treatment of small intestinal bacterial overgrowth with antibiotics and the subsequent absorption of dietary zinc.

Table 4. Relationship between serum folate levels and serum zinc levels after gastric bypass surgery*

		SERUM FOLATE LEVELS		
		NORMAL	ELEVATED	TOTALS
SERUM ZINC LEVELS	NORMAL	43	40	83
	LOW	11	78	89
TOTALS		54	118	172

*Chi-squared 2X2: P < .001.

The high prevalence (52%) of biochemical zinc deficiency in our above study of patients after gastric bypass surgery raised the question of the clinical importance of this finding.

We evaluated 43 patients who underwent upper endoscopy for vomiting, abdominal pain, or bleeding after gastric bypass surgery from May 2007 to May 2008 [83].

There were 40 female and 3 male patients with an average age of 46 years-old (range was 21 to 63 years). In 17 out of 43 (40%) of these patients, there was an abnormal finding at upper endoscopy: gastrojejunal anastomotic stricture (obstruction) or gastrojejunal anastomotic ulcer. In 8 patients with gastrojejunal ulceration, 66% of the patients had low serum zinc levels. In patients who had elevated serum folate levels, there was no increased risk of gastrojejunal ulceration (Chi-squared 2X2: P=0.53), but there was a strong trend toward decreased serum zinc levels (P = .16) supporting a role of upper gut bacterial overgrowth in developing zinc deficiency. Based on these results, in this subset of patients after Roux-en-Y gastric bypass surgery, zinc deficiency was associated with formation of marginal gastrojejunal ulceration. Since zinc in an important component in the biosynthesis of Cu-Zinc superoxide dismutase, these findings support the importance of bioavailable zinc in tissue homeostasis. There was no evidence to support the notion that marginal gastrojejunal ulceration was caused by small intestinal bacterial overgrowth.

CLINICAL MANIFESTATIONS AND PREVENTION OF ZINC DEFICIENCY

Potential Clinical Screening Methods

Due to its high prevalence after bariatric surgery, clinicians should be aware of the risk of zinc deficiency and the need to monitor bariatric patients closely. Regular follow-up and clinical recognition could be important for preventing the development of zinc deficiency in this susceptible postoperative group.

The pivotal role of zinc in cell growth and differentiation can explain the substantial effect of zinc deficiency in tissues with a rapid cell turnover, particularly the skin, gastrointestinal tract mucosa, gonads and immune system. As summarized in Table 5, numerous signs and symptoms have been associated with zinc deficiency. Mild zinc deficiency is associated with depressed immunity, dysgeusia (loss of taste), anosmia (loss of smell), impaired wound healing and decreased spermatogenesis. Severe zinc deficiency may be characterized by growth retardation, alopecia, acrodermatitis, severe infections due to altered immune function, and cognitive decline [51, 84-91].

Ongoing clinical and biochemical assessment of zinc status poses many challenges because, despite the large number of methods proposed, all of the available methods have problems that alter their validity. The search for a reliable indicator of zinc deficiency has been problematic because the effective regulation of zinc homeostasis buffers the functional response to dietary deficiency and excess.

Table 5. Common clinical manifestations of zinc deficiency

• Alopecia	• Stomatitis
• Delayed wound healing	• Dysarthria
• Acrodermatitis	• Nystagmus
• Growth retardation	• Hypogonadism
• Anorexia	• Dysgeusia
• Anosmia	• Immune dysfunction
• Impaired concentration	

According to a recent systematic analysis by Lowe et al, plasma zinc concentration is the only biomarker that can be used to measure zinc status in individuals and reflects zinc intake [92, 93]. However, there are various confounders of plasma zinc concentrations and clinical interpretation should be made while keeping in mind these limitations and constraints. Measurement of 24-hour urinary zinc excretion may be useful in monitoring response to zinc supplements, but their role in detecting low zinc levels is not clearly validated. Lowe and associates concluded that zinc concentration in erythrocytes, polymorphonuclear cells, and mononuclear cells and platelets, as well as plasma alkaline phosphatase levels, do not appear to be useful biomarkers of zinc status according to the current evidence. Other bioactive measures such as the exchangeable zinc pool [94] and endogenous zinc measurement with the

use of stable isotopes [73] are potential biomarkers. Clearly, there is a clinical need to develop reliable biomarker of zinc status, and more high quality studies are required to assess the effects of the current indices in a variety of populations included postoperative bariatric patients.

Zinc Deficiency after Bariatric Surgery

As described above, there is a high prevalence of micronutrient deficiencies after gastric bypass surgeries. The extent of and severity of micronutrient undernutrition is related to the extent and severity of disruption of normal gastrointestinal anatomy and physiology [95]. Post-operatively, it is presently recommended that all individuals who have undergone Roux-en-Y gastric bypass or vertical sleeve gastrectomy receive daily micronutrient supplementation consisting of two multivitamin supplements (to include iron, folic acid, thiamine, and Vitamin B12), 1500 mg of elemental calcium, and at least 3000 international units or 75 mcg of daily vitamin D for minimally the first 3 to 6 months after surgery [96]. Currently, there are no recommendations with regards to oral zinc supplementation in this susceptible postoperative population due to insufficient data, although multivitamins containing mineral supplements routinely include zinc. There is some evidence to support routine screening for zinc deficiency after malabsorptive bariatric surgical procedures and to support the use of routine supplementation following biliopancreatic diversion with duodenal switch [65, 97]. Again, the dosage of zinc in such patients needs to be further studied.

The high rates of zinc deficiency are concerning and this diagnosis should be considered in all post-operative patients who present with the signs and symptoms summarized in Table 4. The recommended "optimal" dose of oral zinc supplementation for individuals with symptomatic zinc deficiency has varied in the available literature and there is no present consensus. The concentration of zinc in oral multivitamins used in supplementation programs after bariatric surgery may not be sufficient as described above. While treating with oral supplements, potential risks of interactions with other trace minerals such as iron must be considered. The timing of the zinc in relation to the meals is also important as its absorption is 60% during fasting but decreases to 20 to 30% when taken with a meal [98]; indeed many patients take their multivitamin supplements with a meal after bariatric surgery. The Recommended Dietary Allowances for zinc is 11 mg/day for male and 8 mg/day for female in healthy, non-operative adults who are 19 years or older according to the Institute of Medicine of the National Academy [99]. However, the doses of zinc needed to replete zinc in patients with zinc deficiency, when zinc intake and absorption are reduced by significant alterations in the anatomy and physiology of the gastrointestinal tract, are unknown.

Ruz et al studied the effects of zinc supplement in 56 morbidly obese patients undergoing bariatric surgery [73]. These patients were divided into two groups of 27 and 19 patients respectively. One group received standard supplement with daily dose of 7.5 mg/day while the other group received double the dose, e.g., 15 mg/day. Despite supplementation, the mean zinc levels decreased from 87.2 μg/dL to 80.3 μg/dL in the group receiving standard zinc supplements and from 87.2 μg/dL to 80.5 μg/dL in the group receiving double zinc supplements. Based on their data, the investigators suggested routine supplementation of the zinc, but at a higher dose of 40 to 60 mg/day. Zinc absorption can plateau at a dose of about 20 mg/day [100], but in situations of zinc malabsorption, doses as high as 60 mg/day of zinc

are advised. There is a need for additional studies to determine the appropriate dose and monitoring of the patients with varied levels of biochemical zinc deficiency after different types of bariatric surgery.

CONCLUSION

The prevalence of obesity is rising worldwide. Bariatric surgical procedures remain a major option for treatment of medically-complicated obesity. Currently, only about 1% of the morbidly obese population is being evaluated for this surgical strategy. With an expected future rise in the prevalence of obesity and the popularity of bariatric surgeries, the worldwide total number of bariatric surgeries will likely rise. These bariatric surgical procedures are not without complications and nutritional deficiencies including zinc deficiency remain significant clinical concerns. Bariatric patients who have zinc deficiency are at risk for developing a myriad of symptoms.

The most common symptoms of zinc deficiency include delayed wound healing, dermatitis, cognitive impairment, hypogonadism and recurrent infections. This susceptible postoperative population has a high prevalence of biochemical zinc deficiency, even prior to bariatric surgery. These risks further increases after bariatric surgical procedures especially if there has been insufficient screening for and treatment of zinc deficiency, both pre-operatively and long-term post-operatively. Bariatric surgical procedures that include a restrictive component with less malabsorptive component may develop lower rates of zinc deficiency in the short term period.

However, long term follow up of postoperative bariatric patients show that other mechanisms may be important for the persistence of zinc deficiency, sometimes overwhelming the use of oral zinc supplements. Our studies support the concern that small intestinal bacterial overgrowth may induce malabsorption of oral zinc. This is a potential mechanism for persistent zinc deficiency in patients after bariatric surgery receiving oral zinc supplements. Clinicians should maintain increased suspicion for the presence of small intestinal bacterial overgrowth in those patients with persistent zinc deficiency following bariatric surgery.

To date, there are no recommendations based on high quality clinical studies either for postoperative screening of serum zinc or for the routine daily supplementation of zinc after bariatric surgery.

Doses of oral zinc supplements higher than the RDAs are required to supplement those individuals who develop zinc deficiency after bariatric surgery. Currently, there are many gaps in our understanding including the exact mechanisms involved in pre-operative and post-operative zinc deficiency, the potential need for screening and routine supplementation after different bariatric procedures, and to what extent low serum zinc levels can be normalized in postoperative patients. It will be important in this field of research to find the answers to these questions by completing high quality translational studies.

REFERENCES

[1] "*Obesity and overweight*." World Health Organization website. http://www.who.int/mediacentre/factsheets/fs311/en/. Updated January 2015. Accessed September 12, 2015.

[2] Roth, J, Qiang, X, Marbán, SL, Redelt, H, Lowell, BC. 2004. "The obesity pandemic: Where have we been and where are we going?" *Obes Res* 12 (suppl 2):88S-101S.

[3] Popkin, BM, Adair, LS, Ng, SW. 2012. "Global nutrition transition and the pandemic of obesity in developing countries." *Nutr Rev* 70:3-21.

[4] Swinburn, BA, Sacks, G, Hall, KD, et al. 2011. "The global obesity pandemic: Shaped by global drivers and local environments." *Lancet* 378:804-814.

[5] Ng, M, Fleming, T, Robinson, M, et al. 2013. "Global, regional, and national prevalence of overweight and obesity in children and adults during 1980–2013: A systematic analysis for the Global Burden of Disease Study 2013." *Lancet* 384(9945):766–781.

[6] Ogden, CL, Carroll, MD, Kit, BK, Flegal, KM. 2014. "Prevalence of childhood and adult obesity in the United States, 2011-2012." *JAMA* 311(8):806-814.

[7] "*Adult Obesity Facts*." Center for Disease Control and Prevention website. <http://www.cdc.gov/obesity/data/adult.html>. Updated September 21, 2015. Accessed September 24, 2015.

[8] Finkelstein, Eric A, Trogdon, Justin G, Cohen, Joel W, Dietz, William. 2009. "Annual medical spending attributable to obesity: Payer-and service-specific Estimates." *Health Affairs* 28(5):w822-w831.

[9] "Decline in Student Obesity Rate Linked With School-Based Program." 2014. *JAMA* 311(14):1390.

[10] Svetkey, LP, Stevens, VJ, Brantley, PJ, et al. 2008. "Comparison of strategies for sustaining weight loss: The weight loss maintenance randomized controlled trial." *JAMA* 299:1139–48.

[11] Clifton, PM. "Dietary treatment for obesity." 2008. *Nat Clin Pract Gastroenterol Hepatol* 5:672–81.

[12] O'Brien, PE, Dixon, JB, Laurie, C, et al. 2006. "Treatment of mild to moderate obesity with laparoscopic adjustable gastric banding or an intensive medical program: A randomized trial." *Ann Intern Med* 144(9): 625-633.

[13] Dixon, JB, O'Brien, PE, Playfair, J, et al. 2008. "Adjustable gastric banding and conventional therapy for type 2 diabetes: A randomized controlled trial." *JAMA* 299(3):316-323.

[14] Adams, TD, Pendleton, RC, Strong, MB, et al. 2010. "Health outcomes of gastric bypass patients compared to nonsurgical, nonintervened severely obese." *Obesity (Silver Spring)* 18(1): 121-30.

[15] Sjostrom, L, Lindroos, AK, Peltonen, M, et al. 2004. "Lifestyle, diabetes, and cardiovascular risk factors 10 years after bariatric surgery." *N Engl J Med* 351(26): 2683-2693.

[16] Adams, TD, Davidson, LE, Litwin, SE, Hunt, SC. 2012. "Gastrointestinal surgery: Cardiovascular risk reduction and improved long-term survival in patients with obesity and diabetes." *Curr Atheroscler Rep* 14(6):606-615.

[17] Sjöström, L, Narbro, K, Sjöström, CD. 2007. "Effects of bariatric surgery on mortality in Swedish obese subjects." *N Engl J Med* 357(8): 741-52.

[18] Adams, TD, Gress, RE, Smith, SC. 2007. "Long-term mortality after gastric bypass surgery." *N Engl J Med* 357(8):753-61.

[19] Angrisani, L, Santonicola, A, Iovino, P, Formisano, G, Buchwald, H, Scopinaro, N. 2015. "Bariatric surgery worldwide 2013." *Obes Surg* 25(10):1822-32.

[20] Buchwald, H, Oien, DM. 2013. "Metabolic/bariatric surgery worldwide 2011." *Obes Surg* 23(4):427-36.

[21] Buchwald, H, Oien, DM. 2009. "Metabolic/bariatric surgery worldwide 2008." *Obes Surg* 19(12):1605-11.

[22] Buchwald, H, Williams, SE. 2004. "Bariatric surgery worldwide 2003." *Obes Surg* 14(9):1157-64.

[23] "Estimate of Bariatric Surgery Numbers." *American Society for Metabolic and Bariatric Surgery* website. https://asmbs.org/resources/estimate-of-bariatric-surgery-numbers. Published July 2015. Accessed September 20, 2015.

[24] Rashti, F, Gupta, E, Ebrahimi, S, Shope, TR, Koch, TR, Gostout, CJ. 2014. "Development of minimally invasive techniques for management of medically-complicated obesity." *World J Gastroenterol* 20(37):13424-45.

[25] Sudan, R, Jacobs, DO. 2011. "Biliopancreatic diversion with duodenal switch." *Surg Clin North Am* 91:1281–1293, ix.

[26] Baker, MT. 2011. "The history and evolution of bariatric surgical procedures." *Surg Clin North Am* 91:1181–2001, viii.

[27] Bal, BS, Finelli, FC, Shope, TR, Koch, TR. 2012. "Nutritional deficiencies after bariatric surgery." *Nat Rev Endocrinol* 8:544–556.

[28] Whitney, E, Rolfes, SR. 2005. *Understanding Nutrition*. 10th ed. Belmont, CA: Wadsworth.

[29] Linder, Maria, et al. 1991. *Nutritional Biochemistry and Metabolism with Clinical Applications*. 2nd ed. New York: Elsevier Science Publishing Co.

[30] Cousins, RJ, Liuzzi, JP, Lichten, LA. 2006. "Mammalian zinc transport, trafficking, and signals." *J Biol Chem* 281(34):24085-9.

[31] Cragg, RA, Phillips, SR, Piper, JM, Varma, JS, Campbell, FC, Mathers, JC, Ford, D. 2005. "Homeostatic regulation of zinc transporters in the human small intestine by dietary zinc supplementation." *Gut* 54:469–78.

[32] Lichten, LA, Cousins, RJ. 2009. "Mammalian zinc transporters: nutritional and physiologic regulation." *Annu Rev Nutr* 29:153–76.

[33] Wang, K, Zhou, B, Kuo, YM, Zemansky, J, Gitschier, J. 2002. "A novel member of a zinc transporter family is defective in acrodermatitis enteropathica." *Am J Hum Genet* 71:66–73.

[34] Wessells, KR, Brown, KH. 2012. "Estimating the global prevalence of zinc deficiency: Results based on zinc availability in national food supplies and the prevalence of stunting." *PLoS One* 7(11):e50568.

[35] Sánchez, A, Rojas, P, Basfi-Fer, K, Carrasco, F, Inostroza, J, Codoceo, J, Valencia, A, Papapietro, K, Csendes, A, Ruz, M. 2015. "Micronutrient deficiencies in morbidly obese women prior to bariatric surgery." *Obes Surg* [Epub ahead of print] PubMed PMID: 26108638.

[36] Gobato, RC, Seixas, Chaves, DF, Chaim, EA. 2014. "Micronutrient and physiologic parameters before and 6 months after RYGB." *Surg Obes Relat Dis* 10(5):944-51.

[37] Chen, MD, Lin, PY, Lin, WH, Cheng, V. 1988. "Zinc in hair and serum of obese individuals in Taiwan." *Am J Clin Nutr* 48(5):1307–9.

[38] de Luis, DA, Pacheco, D, Izaola, O, Terroba, MC, Cuellar, L, Cabezas, G. 2013. "Micronutrient status in morbidly obese women before bariatric surgery." *Surg Obes Relat Dis* 9(2):323-7.

[39] Moizé, V, Deulofeu, R, Torres, F, de Osaba, JM, Vidal, J. 2011. "Nutritional intake and prevalence of nutritional deficiencies prior to surgery in a Spanish morbidly obese population." *Obes Surg* 21(9):1382-8.

[40] van Rutte, PW, Aarts, EO, Smulders, JF, Nienhuijs, SW. 2014. "Nutrient deficiencies before and after sleeve gastrectomy." *Obes Surg* 24(10):1639-46.

[41] Kaidar-Person, O, Person, B, Szomstein, S, Rosenthal, RJ. 2008. "Nutritional deficiencies in morbidly obese patients: A new form of malnutrition? Part A: Vitamins." *Obes Surg* 18(7):870–876.

[42] Kaidar-Person, O, Person, B, Szomstein, S, Rosenthal, RJ. 2008. "Nutritional deficiencies in morbidly obese patients: A new form of malnutrition? Part B: Minerals." *Obes Surg* 18(8):1028-34.

[43] Damms-Machado, A, Friedrich, A, Kramer, KM, Stingel, K, Meile, T, Küper, MA, Königsrainer, A, Bischoff, SC. 2012. "Pre- and postoperative nutritional deficiencies in obese patients undergoing laparoscopic sleeve gastrectomy." *Obes Surg* 22(6):881-9.

[44] Schweiger, C, Weiss, R, Berry, E, Keidar, A. 2010. "Nutritional deficiencies in bariatric surgery candidates." *Obes Surg* 20(2):193-7.

[45] Mitchell, JE, King, WC, Courcoulas, A, et al. 2015. "Eating behavior and eating disorders in adults before bariatric surgery." *Int J Eat Disord* 48(2):215-22.

[46] Waki, M, Kral, JG, Mazariegos, M, Wang, J, Pierson, RN Jr, Heymsfield, SG. 1991. "Relative expansion of extracellular fluid in obese vs. non-obese women." *Am J Physiol Endocrinol Metab* 261:199–203.

[47] Schweitzer, DH, Posthuma, EF. 2008. "Prevention of vitamin and mineral deficiencies after bariatric surgery: Evidence and algorithms." *Obes Surg* 18:1485–8.

[48] Peronne, LGG, Moro, R, Feng, SL, et al. 1998. "Zinc, copper, and iron in obese children and adolescents." *Nutrition Res* 18:183–9.

[49] Andriollo-Sanchez, M, Hininger-Favier, I, Meunier, N, et al. 2005. "Zinc intake and status in middle-aged and older European subjects: the ZENITH study." *Eur J Clin Nutr* 59 Suppl 2:S37–41.

[50] Bhatnagar, S, Taneja, S. 2001. "Zinc and cognitive development." *Br J Nutr* 85 Suppl 2:S139–45.

[51] Prasad, A. 2000. "Effects of zinc deficiency on immune functions." *J Trace Elem Exp Med* 13:1–20.

[52] Gibson, RS. 1994. "Zinc nutrition in developing countries." *Nutr Res Rev* 7:151–73.

[53] Castillo-Durán, C, Weisstaub, G. 2003. "Zinc supplementation and growth of the fetus and low birth weight infant." *J Nutr* 133(5 Suppl 1):1494S-7S.

[54] Madan, AK, Orth, WS, Tichansky, DS, Ternovits, CA. 2006. "Vitamin and trace mineral levels after laparoscopic gastric bypass." *Obes Surg* 16(5):603-6.

[55] Gehrer, S, Kern, B, Peters, T, Christoffel-Courtin, C, Peterli, R. 2010. "Fewer nutrient deficiencies after laparoscopic sleeve gastrectomy (LSG) than after laparoscopic Roux-Y-gastric bypass (LRYGB)-A prospective study." *Obes Surg* 20: 447-53.

[56] Saif, T, Strain, GW, Dakin, G, Gagner, M, Costa, R, Pomp, A. 2012. "Evaluation of nutrient status after laparoscopic sleeve gastrectomy 1, 3, and 5 years after surgery." *Surg Obes Relat Dis* 8:542-7.

[57] Böyük, A, Banli, O, Gümüş, M, Evliyaoğlu, O, Demirelli, S. 2011. "Plasma levels of zinc, copper, and ceruloplasmin in patients after undergoing laparoscopic adjustable gastric banding." *Biol Trace Elem Res* 143(3):1282-8.

[58] Maggard, MA, Shugarman, LR, Suttorp, M, et al. 2005. "Meta-analysis: Surgical treatment of obesity." *Ann Intern Med* 142:547–559.

[59] National Institutes of Health Consensus Development Panel. 1991. "Gastrointestinal surgery for severe obesity." *Ann Intern Med* 115:956–961.

[60] Buchwald, H, Avidor, Y, Braunwald, E, et al. 2004. "Bariatric surgery: A systematic review and meta-analysis." *JAMA* 292:1724–1737.

[61] Dolan, K, Hatzifotis, M, Newbury, L, et al. 2004. "A clinical and nutritional comparison of biliopancreatic diversion with and without duodenal switch." *Ann Surg* 240:51–56.

[62] Carlin, AM, Rao, DS, Meslemani, AM, et al. 2006. "Prevalence of vitamin D depletion among morbidly obese patients seeking gastric bypass surgery." *Surg Obes Relat Dis* 2:98–103.

[63] Botella Romero, F, Milla Tobarra, M, Alfaro Martínez, JJ, et al. 2011. "Bariatric surgery in duodenal switch procedure: weight changes and associated nutritional deficiencies." *Endocrinol Nutr* 58(5):214-8.

[64] Sallé, A, Demarsy, D, Poirier, AL, et al. 2010. "Zinc deficiency: A frequent and underestimated complication after bariatric surgery." *Obes Surg* 20(12):1660-70.

[65] Cominetti, C, Garrido, AB Jr, Cozzolino, SM. 2006. "Zinc nutritional status of morbidly obese patients before and after Roux-en-Y gastric bypass: A preliminary report." *Obes Surg* 16:448–53.

[66] Andersen, T, Larsen, U. 1989. "Dietary outcome in obese patients treated with a gastroplasty program." *Am J Clin Nutr* 50:1328–40.

[67] Cooper, PL, Brearley, LK, Jamieson, AC, et al. 1999. "Nutritional consequences of modified vertical gastroplasty in obese subjects." *Int J Obes Relat Metab Disord* 23:382–8.

[68] Mares-Perlman, JA, Subar, AF, Block, G, et al. 1995. "Zinc intake and sources in the US adult population: 1976–1980." *J Am Coll Nutr* 14:349–57.

[69] Ruz, M, Carrasco, F, Rojas, P, et al. 2009. "Iron absorption and iron status are reduced after Roux-en-Y gastric bypass." *Am J Clin Nutr* 90:527–32.

[70] Kushner, RF. 2006. "Micronutrient deficiencies and bariatric surgery." *Curr Opin Endocrinol Diabetes* 13:405–11.

[71] Ruz M, Carrasco F, Rojas P, et al. 2011. "Zinc absorption and zinc status are reduced after Roux-en-Y gastric bypass: a randomized study using 2 supplements." *Am J Clin Nutr* 94(4):1004-11.

[72] Melissas, J, Daskalakis, M, Koukouraki, S, et al. 2008. "Sleeve gastrectomy-a "food limiting" operation. *Obes Surg* 18(10):1251–6.

[73] Damms-Machado, A, Mitra, S, Schollenberger, AE, et al. 2015. "Effects of surgical and dietary weight loss therapy for obesity on gut microbiota composition and nutrient absorption." *BioMed Res Int* 2015:806248. doi: 10.1155/2015/806248.

[74] Yamaji, S, Tennant, J, Tandy, S, et al. 2001. "Zinc regulates the function and expression of the iron transporters DMT1 and IREG1 in human intestinal Caco-2 cells." *FEBS Lett* 507:137–41.

[75] Lee, DY, Prasad, AS, Hydrick-Adair, C, et al. 1993. "Homeostasis of zinc in marginal human zinc deficiency: role of absorption and endogenous excretion of zinc." *J Lab Clin Med* 122:549–56.

[76] Castillo-Duran, C, Weisstaub, G. 2003. "Zinc supplementation and growth of the fetus and low birth weight infant." *J Nutr* 133:1494S-1497S.

[77] Johnson, PE, Hunt, JR, Ralston, NV. 1988. "The effect of past and current dietary Zn intake on Zn absorption and endogenous excretion in the rat." *J Nutr* 118:1205–9.

[78] Lakhani, SV, Shah, HN, Alexander, K, Finellli, FC, Kirkpatrick, JR, Koch, TR. 2008. "Small intestinal bacterial overgrowth and thiamine deficiency after Roux-en-Y gastric bypass surgery in obese patients." *Nutrition Res* 28(5):293-298.

[79] Camilo, E, Zimmerman, J, Mason, JB, et al. 1996. "Folate synthesized by bacteria in the human upper small intestine is assimilated by the host." *Gastroenterology* 110(4):991-8.

[80] Singh, VV, Toskes, PP. 2003. "Small bowel bacterial overgrowth: Presentation, diagnosis, and treatment." *Curr Gastro Rep* 5:365-372.

[81] Bal, BS, Shah, HN, Finelli, FC, Kirkpatrick, JR, Koch, TR. 2008. "Risk factors associated with small intestinal bacterial overgrowth after Roux-en-Y gastric bypass surgery." *Am J Gastroenterol* 103(S1):S97-8.

[82] Shah, H, Bal, B, Finelli, FC, Carroll, NM, Kirkpatrick, JR, Koch, TR. 2007. "Mechanisms of zinc deficiency in patients with Roux-en-Y Gastric Bypass Surgery." *Am J Gastroenterol* 102(S2):S201.

[83] Shah, HN, Bal, B, Finelli, FC, Kirkpatrick, JR, Koch, TR. 2008. "Relationship between zinc deficiency and marginal ulcer formation following Roux-en-Y gastric bypass surgery". *Am J Gastroenterol* 103(S1):S104.

[84] Shankar, AH, Prasad, AS. 1998. "Zinc and immune function: the biological basis of altered resistance to infection." *Am J Clin Nutr* 68(2 Suppl):447S-463S.

[85] Prasad, AS. 1998. "Zinc and immunity." *Mol Cell Biochem* 188(1-2):63-9.

[86] Kay, RG, Tasman-Jones, C. 1975. "Acute zinc deficiency in man during intravenous alimentation." *Aust N Z J Surg* 45(4):325-30.

[87] Prasad, AS. 2009. "Zinc: Role in immunity, oxidative stress and chronic inflammation." *Curr Opin Clin Nutr Metab Care* 12(6):646-52.

[88] Haase, H, Overbeck, S, Rink, L. 2008. "Zinc supplementation for the treatment or prevention of disease: Current status and future perspectives." *Exp Gerontol* 43(5):394-408.

[89] Tupe, RP, Chiplonkar, SA. 2009. "Zinc supplementation improved cognitive performance and taste acuity in Indian adolescent girls." *J Am Coll Nutr* 28(4):388-96.

[90] Andriollo-Sanchez, M, Hininger-Favier, I, Meunier N, et al. 2005. "Zinc intake and status in middle-aged and older European subjects: the ZENITH study." *Eur J Clin Nutr* 59 Suppl 2:S37–41.

[91] Bhatnagar, S, Taneja, S. 2001. "Zinc and cognitive development." *Br J Nutr* 85 Suppl 2:S139–45.

[92] Ruz, M, Cavan, KR, Bettger, WJ, Thompson, L, Berry, M, Gibson, RS. 1991. "Development of a dietary model for the study of mild zinc deficiency in humans and evaluation of some biochemical and functional indices of zinc status." *Am J Clin Nutr* 53(5):1295-303.

[93] Lowe, NM, Fekete, K, Decsi, T. 2009. "Methods of assessment of zinc status in humans: A systematic review." *Am J Clin Nutr* 89(6):2040S-2051S.

[94] Griffin, IJ, Abrams, SA. 1999. "The exchangeable zinc pool as a measure of zinc nutritional status in children." *Pediatric Res* 45:111A–111A.

[95] Malone, M. 2008. "Recommended nutritional supplements for bariatric surgery patients." *Ann Pharmacother* 42:1851–1858.

[96] Mechanick, JI, Youdim, A, Jones, DB, et al. 2013. "Clinical practice guidelines for the perioperative nutritional, metabolic, and nonsurgical support of the bariatric surgery patients—2013 update: Cosponsored by American Association of Clinical Endocrinologists, The Obesity Society, and American Society for Metabolic & Bariatric Surgery." *Obesity* 21:S1–S27

[97] Balsa, JA, Botella-Carretero, JI, Gómez-Martín, JM, Peromingo, R, Arrieta, F, Santiuste, C, Zamarrón, I, Vázquez, C. 2011. "Copper and zinc serum levels after derivative bariatric surgery: Differences between Roux-en-Y Gastric bypass and biliopancreatic diversion." *Obes Surg* 21(6):744-50.

[98] Solomons, NW. 1982. "Factors affecting the bioavailability of zinc." *J Am Diet Assoc* 80(2):115-21.

[99] Institute of Medicine (US) *Standing Committee on the Scientific Evaluation of Dietary Reference Intakes*. 1997. "Dietary reference intakes for calcium, phosphorus, magnesium, vitamin D, and fluoride." Washington (DC): National Academies Press (US).

[100] Tran, CD, Miller, LV, Krebs, NF, et al. 2004. "Zinc absorption as a function of the dose of zinc sulfate in aqueous solution." *Am J Clin Nutr* 80:1570–3.

In: Encyclopedia of Surgery (22 Volume Set)
Editors: Andreas Lehrer and Kristin Mueller
ISBN: 978-1-53618-329-0
© 2020 Nova Science Publishers, Inc.

Chapter 393

THE PERCEPTION OF THE BODY: QUANTITATIVE METHODS FOR SELF-EVALUATION OF THE BODY IN PLASTIC, RECONSTRUCTIVE AND AESTHETIC SURGERY

Paolo Persichetti, Annalisa Cogliandro and Mauro Barone*
Department of Plastic Surgery,
Campus Bio-Medico University of Rome, Italy

ABSTRACT

The human search for beauty is to be conceived both as an aesthetical attitude and as an expression of personal satisfaction and balance between self and external appearance. The body image can be mainly understood in two ways: how our body is seen by others, and how our body is seen by ourselves. The perception of our body as an external entity represents an objective point of view, while the perception of our body as we see it deals more with a subjective point of view. Cosmetic surgery should address only the objective dimension of body image, and therefore should correct the imperfections that actually exist as well as underlie any relational or social difficulty of the patient. The patient's point of view must be made scientifically valid and provable. The only means to achieve this goal are questionnaires which can filter patients' perception about their own bodies. In conclusion, we believe that every surgical technique and medical action which ground on patient requests need to be combined with a specific questionnaire which can assess the actual result and success rate on that specific patient.

Keywords: beauty, plastic surgery, BREAST-Q, FACE-Q, DAS59

* Corresponding Author's Email: m.barone@unicampus.it.

INTRODUCTION

Aesthetic Surgery is the surgical specialty that aims to correct or improve imperfections, whether congenital, acquired by illness, traumatic or paraphysiological events such as aging, including, even, those surgical procedures requested by normal patients, who need to improve their self "exterior." [1] Therefore it differs from Reconstructive surgery, however, it deals with the treatment of morphological alterations that underlie a pathological condition; in the specificity of their respective areas, cosmetic surgery and Reconstructive surgery both belong to Plastic Surgery. There has been an increase in cosmetic surgeries performed in recent years, in line with the orientation of modern society in which the wellbeing of the individual is strongly based on one's physical appearance. There is continual research on beauty, which is not only intended as an aesthetic ideal but also as an expression of personal satisfaction and a balance between personality and external appearance. [2] While the value of plastic surgery has never been doubted, the same cannot be said for cosmetic surgery. Hostility toward cosmetic surgery has been lessened by a new concept of health. Previously, health was considered an absence of illness, but the World Health Organization later defined health as physical, psychological, and social well being. Therefore, the reformed concept of health acquires a subjective value that individuals place on themselves and their bodies [3].

Medicine and cosmetic surgery are developed in the wake of a philosophical and literary reflection. Medical discipline deals with the search for the aesthetic body through exalting and correction of the human form in order to reach a corporeality that respects the standards of beauty, classically or commonly understood.

The search for beauty and its value has always been a topic of discussion. Modern and safer plastic surgery techniques as well as aesthetic medicine have brought back the question, making beauty possible, accessible and democratic. Being beautiful will end up becoming an imperative from which a new and subtle discrimination comes out: natural beauty is more precious than artificial beauty. Concerning the clinical practice, a relevant question is whether an objective indication exists for cosmetic surgery [4].

In the context of a world dominated by the image, physicality plays an important role, medicine and cosmetic surgery procedures are performed in order to improve the patient subjective perception of physical appearance and often personal self-esteem.

The body image can be understood in two ways: our body seen by others and our body seen by ourselves. The perception of our body from the outside is an objective point of view, while the perception of our body seen by ourselves is a subjective point of view [5].

Cosmetic surgery should address the objective component and then correct the defects that are actually existing as well as possible underlying relationship problems of the patient.

The patient's point of view must be made scientifically valid and provable. To achieve this the only means are questionnaires which can filter the patient's perception about their own bodies.

Plastic Surgery in Modern Society

Depending on the ages and historical moments society develops ideas and patterns in relation to the body, influencing individuals. The social-anthropological interpretation,

therefore, will vary with the context in which the analysis is expected to lie, as you may be faced with the implementation of interventions that, at first glance, are technically quite similar but which, however, have different meanings depending on the patient who suffers them, and the expectation of the meaning given to the surgical procedure.

It is certainly possible to find in patients undergoing cosmetic surgery different individual motivations, however, they are always related to appearance conformed to a certain social model or to a vision of the same.

The appearance of the body responds to the staging, by social actors, of all the investments that they bear in order to make the body presentable, and at the same time represented. [6] These two aspects are inseparable and in this sense the body, understood as an individual product, embodies the dynamics of the incorporation process by which the individual organizes the symbolic mode of the society in which he lives.

Cosmetic surgery can be interpreted as a genuine care where the body becomes a complex of desires and modular, replaceable, affordable parts.

Behind the appearance of the cure lies the birth of a new non-ethics of the parties, to which the body is not only divided and subdivided, but is also driven to a real marketing that responds to the demands of a global market. [7] In this sense, the anthropological discipline is called into question once again with the purpose of its social reassignment towards which it cannot escape.

Surgical procedures on the buttocks, abdomen, thighs or on the face would give answers to the anxieties associated with aging and thus promise a body that remains or becomes imperishable, young in appearance, and ultimately, healthy-looking. These needs cannot be compared to social needs, they are wishes of individuals which take on a collective dimension and conformist aspects; people are absolutely convinced of the fact that plastic surgery makes possible what seemed impossible before, that is to "re-construct" a body that is free and fulfilled. In this idea of an embodiment by means of a surgical intervention there are paradoxical aspects on how to complete something, or better conclude a route of a body that is considered to be incomplete, because perceived as deficient or otherwise forced by some limitations and for which a real life comes at the cost of a "counter-life" [8].

In cosmetic surgery with its "beauty industry professionals", [9] you can guess a dual corrective purpose: that of the outer body, but also that of the spirit. The correction of body parts through surgery can become an absolutely essential condition for those social actors, investing on a narcissistic desire of self, who seek and find (they say) in the "new" body a renewed sense of well being and reconciliation with the world. Not surprisingly, once the surgery is performed, patients generally report feeling better and perceiving an improvement in their quality of life.

From the analytical point of view this desire relies on a model of corporeality that can be properly defined as "up to standard", [10] that is a realization of conformity; This conforming to socially accepted norms is proposed by contemporary societies in relation to a state of psychological well-being, that combined with the notions of "being better" and "healthy" can actually be realized through the exploitation of cosmetic surgery [11].

It necessarily finds the forefront of those who truly "correct" the body, because this task is ultimately delegated to a "social caste of specialists", cosmetic surgeons, who are in charge to "repair" the bodies, and then to ensure an adjustment to the stereotypes of beauty through surgery, which itself becomes a "surgery of conformity." Retrofitting by the hand of the

surgeon in charge, is creating a "corrected body" in the sense of an act that is lawful and legitimate in terms of the powers of a social space.

The bodies appear to have become the privileged places of realization of the idea of "taking care" of themselves, an encouragement towards the fulfillment of self and others. Today, the body appears as the only possible anchor, dream of liberation and freedom, a way to be able to plan and invest in ourselves; it becomes an expression of will, the drive of desire, the search for renewed identity, a young and healthy appearance. The body is renewed and transformed in step with technological innovation: this is a neo-positivist image where achievement of perfection is a reassuring goal.

Quantitative Methods for Self-Assessment of the Body

The use of questionnaires is the only way to analyze scientifically and objectively the perception that the patient's own body and how he would like to see it changed.

The BREAST-Q, [12] a new patient-reported outcome instrument, was developed with strict adherence to recommended international guidelines to address the lack of instruments for breast surgery patients. There are currently four modules (breast reduction, augmentation, reconstruction, and mastectomy without reconstruction), each of which includes a core of independent scales assessing six domains (satisfaction with breasts, satisfaction with overall outcome, psychosocial well-being, sexual well-being, physical well-being, and satisfaction with care). In the original development study, all scales were found to fulfill criteria for good measurement.

For women, breast cancer remains a common and dreaded experience; it is normal for a diagnosis of breast cancer to evoke grief, anger, and intense fear. The options of breast conservation and reconstruction give women a new sense of control over their treatment and are quite successful in helping women feel comfortable with their bodies again [13].

In our experience we deal with two types of women with breast cancer: young women (aged less than 40 years) and older women (aged over 60 years). Our dialogue with these patients is radically different, in fact, younger women not only want to heal from the disease, but their concern is also paid to the aesthetic postoperative consequences, expecting that the plastic surgeon should be giving due attention to the reconstruction in order to maintain the outward appearance of the breast as much as possible unchanged. Healing for a woman of young age can only be achieved when the appearance of the breast is the most aesthetically satisfactory. For older aged women healing consists principally in cancer eradication, while reconstruction is something that some patients still refuse. Currently we are conducting a study on our breast unit and we are analyzing the results of the last ten years of heterologous reconstruction in patients with breast cancer. Patients who underwent breast reconstruction after demolition procedures have a much higher quality of life than patients who have not completed their breast reconstruction [14].

The assessment of quality of life before and after surgery cannot be based on personal considerations of the attending physician, but must necessarily be expressed through objective studies, such as evaluating through the BREAST-Q.

The surgery should be chosen not only based on the anatomical part to be rebuilt but also according to what the patient expects. [15] The concept of modern surgery is no longer the sake of science that deals with a "disease to treat" rather than a "patient to be cured," but it is

a psycho-surgery, by which we aim to make the most satisfied patients in the shortest possible time; this concept is achievable only if the satisfaction of the patient and the improvement of quality of life can be assessed from a scientific and objective point of view.

We agree with Coriddi M. et. al. [16] saying that there is increasing pressure to use validated survey instruments to demonstrate patient-reported outcomes, as the implementation of evidence-based medicine continues to grow in everyday practice. We think that the use of the BREAST-Q questionnaires should become part of the routine in the management of candidates for an intervention of mammary and reconstructive surgical procedures, they should be discussed and compared according to the needs of the patient [17].

This new set of FACE-Q [18] instruments can be smoothly incorporated into research and/or clinical routine practice to better understand the recovery process and quality of life impact of facial aesthetics procedures as well as what patients think about their decision to have surgery. [19] Plastic surgeons seek to continually improve aesthetic outcomes alongside the patient experience.

Every man is born with specific physical features that make him unique, especially the face, which more than anything else defines the person. We like to divide the face into three anatomical planes that correspond to three different aspects of the patient: the upper or brain, which includes the forehead and eyes, corresponds to the function of thought and imagination and translates to the degree of our rational understanding of the world. The mid-plane or social-emotional, with cheekbones and nose, is linked to the feelings and values and expresses our intuitive perception of the world. The lower or instinctive, jaw and mouth, corresponds to the functions of nutrition and indicates our interest in the concrete.

When the patient wants to change one of these three parts, he wants to change a specific part of himself.

Many people feel a deep psychological malaise which they try to overcome or at least lessen with surgery, which acquires therefore also a therapeutic value. Of course, these arguments are not valid for all patients because the considerations vary from person to person and it is difficult to answer them in absolute terms. In any case, the therapeutic indication of a correction considered “aesthetic” and also the same lawfulness of the procedure from a legal point of view, always starts from the idea of improving the physical and mental well being of the patient and to accept the freedom of the people who want to “change” their appearance.

The representation and the objectification of the body becomes almost an obsessive and prominent part of society today, increasing attention towards plastic surgery, identified as the most powerful tool that corrects dimorphism, alterations in body perception, improves irregularities and may even intervene in exaggerated attitudes, such as hyper-correction of aging, making the dream of eternal youth come true. It is not so uncommon, then, that the patient desires a correspondence between the image of the body “exterior” and of the body “interior”, which in his mind is still young. The problem occurs, however, with the awareness that this process of “change” and the natural aging and as such must be accepted [20].

If it is true that these considerations can be applied to all areas of the body and the face, which is obviously something more than an anatomical area, because the face characterizes the individual and profoundly affects social relations. Therefore it is common to request a change mainly as a result of the progressive changes that aging causes, but are these discomforts and proper framing issues exclusively aesthetic issues?

All these points must be objectified and evaluated and the FACE-Q is a good way to get answer, [21] like other questionnaires used for other parts of the body. [22] We already use

the BREAST-Q to objectify the perception that our patients have of their body before and after surgery. The FACE-Q should therefore be applied both in aesthetic medicine practices and in those of cosmetic surgery [23].

The DAS59 has been designed and developed to meet the need for an objective measure of the spectrum of psychological distress and dysfunction that is characteristic of disfigurements, deformities and aesthetic problems of appearance. The DAS59 is highly sensitive as a measure of change following treatment with large and significant preoperative-postoperative reductions in full-scale and factorial scores of patients treated for facial features or body/sexual features. The DAS59 offers benefits for patient selection in both cosmetic and reconstructive plastic surgery and in the evaluation of outcome. [24] As the global population grows, the percentage of those over 60 will escalate disproportionately. Their needs will become an ever more dominant feature of public policy and healthcare provision. Older adults' appearance is often removed from cultural ideals and stereotypes of beauty, often seen as synonymous with "youth." This has seen older adults' concerns about appearance and body image somewhat sidelined in practice and in research. This study investigates the extent to which self-consciousness of appearance is associated with distress and dysfunction in those over 60 years old. Furthermore, we contrast the extent of this phenomenon in two European nations, UK and Italy, and consider the direct impact and interaction of cultural context and participant gender. The Italian translation was sound, with acceptability in the Italian-speaking sample and acceptable internal consistency scores for full-scale and subscales. ANOVA analysis demonstrated that for overall adjustment, and all subscale scores, the Italians were more distressed about their appearance than UK comparators. Moreover, there were significant differences between Italian women and men, with Italian women more distressed than Italian men overall, and also general self-consciousness, sexual self-consciousness, and social self-consciousness subscales [25].

Currently we are carrying out a protocol subjecting all patients who undergo a cosmetic surgery of any anatomical region to our original Italian questionnaire. [26] This study aims to analyze the levels of information and awareness of patients requesting cosmetic surgery using a questionnaire completed by patients before surgery. The questionnaire is the original result of a collaboration between the Department of Plastic, reconstructive and cosmetic surgery and the Institute of Philosophy of Scientific and Technological Activity of the Campus Bio-Medico University of Rome. We analyze the quality of the information given, the expectations and motivation of the patients who decided to undergo surgery, the degree of patient awareness about the proposed operation, and the aim of the required consent for cosmetic surgery. [27] We published a pilot study that defines the results of the questionnaires obtained from patients only preoperatively. We propose to apply the questionnaire preoperatively and postoperatively in all patients who undergo cosmetic surgery at our institution, and we would like to translate our questionnaire in multiple languages.

CONCLUSION

The only way to evaluate from an objectively valid point of view of the patient, his motivation for surgery, the level of awareness before the surgery, the degree of satisfaction after surgery, improving the quality of view and change in the perception of his body, is the

quantitative analysis of responses obtained through a questionnaire. We believe that any surgical technique and any medical action which is made on a patient needs to be combined with a specific questionnaire which can assess the actual result on the patient. All scientific work on plastic surgery requires a questionnaire on quality of life and the perception of the body, to be considered valid by any magazine of international impact.

REFERENCES

[1] Persichetti P, Simone P, Tambone V. About beauty, *Plast. Reconstr Surg.* 2004; 114(1):270-1.

[2] Fusaschi M. (2008), *Corporalmente corretto*, Meltelmi.

[3] Benicasa M., "Liceità e fondamento dell'attività medico chirurgica a scopo terapeutico," in *Riv. it. proc.pen*., 1980, p. 713.

[4] Sezgin B, Findikcioglu K, Kaya B, Sibar S, Yavuzer R. Mirror on the Wall: A Study of Women's Perception of Facial Features as They Age. *Aesthet Surg. J*. 2012: 32(4):421-5.

[5] Persichetti P., Russo M. ,Tambone V. (2012) *Cosm-Etica. Chirurgia estetica, corpo e bellezza*. McGraw-Hill.

[6] Bordieu P. (1977), Remarques provisoires sur la perception sociale du corps, *Actes de la recherche en sciences sociales*, 14, (14), 51-54.

[7] Scheper-Hughes N., Wacquant L. (Eds) (2003), *Commodifying Bodies*. London: Sage Publications.

[8] Remaury B. (2006). *Il gentil sesso debole. Le immagini del corpo femminile tra cosmetica e salute*, Meltemi, p. 15.

[9] Ibid. p. 132.

[10] Liotard P. (2003), Corps en kit, *Quasimodo*, 7-20.

[11] Fusaschi M. (2008), *Corporalmente corretto*, Meltelmi Ed.

[12] Cano S.J., Klassen A.F., Scott A.M., Cordeiro P.G., Pusic A.L. The BREAST-Q: further validation in independent clinical samples, *Plast Reconstr Surg.* 2012 Feb;129(2):293-302.

[13] Schover L.R. The impact of breast cancer on sexuality, body image, and intimate relationships. *CA Cancer J. Clin*. 1991 Mar-Apr;41(2):112-20.

[14] Persichetti P, Cagli B, Simone P, Cogliandro A, Fortunato L, Altomare V, Trodella L. Implant breast reconstruction after salvage mastectomy in previously irradiated patients. *Ann. Plast. Surg.* 2009 Apr; 62(4):350-4.

[15] Barone M, Cogliandro A, Persichetti P. Role of aesthetic surgery in improving the quality of life: only vanity or a solution to physical and psychorelational problems? *Plast Reconstr. Surg.* 2013 Sep; 132(3):477e-8e.

[16] Coriddi M, Nadeau M, Taghizadeh M, Taylor A. Analysis of Satisfaction and Well-Being following Breast Reduction Using a Validated Survey Instrument: The BREAST-Q. *Plast Reconstr. Surg.* 2013 Aug;132(2):285-90.

[17] Cagli B., Cogliandro A., Barone M., Persichetti P. Quality-of- life outcomes between mastectomy alone and breast reconstruction: comparison of patient-reported BREAST-

Q and other health-related quality-of-life measures. *Plast Reconstr. Surg*. 2014 Apr;133(4):594e-5e.

[18] Klassen A.F., Cano S.J., Schwitzer J., Scott A., Pusic A.L. FACE-Q Scales for Health-Related Quality of Life, Early Life Impact and Satisfaction with Outcomes and Decision to Have Treatment: Development and Validation, *Plast Reconstr Surg*. 2014 Oct 29.

[19] Klassen A.F., Cano S.J., Scott A.M., Pusic A.L. Measuring outcomes that matter to face-lift patients: development and validation of FACE-Q appearance appraisal scales and adverse effects checklist for the lower face and neck. *Plast Reconstr. Surg*. 2014 Jan;133(1):21-30.

[20] Barone M., Cagli B., Cogliandro A., Persichetti P. FACE-Q Scales for Health-Related Quality of Life, Early Life Impact, Satisfaction with Outcomes, and Decision to Have Treatment: Development and Validation. *Plast Reconstr. Surg*, 2015, 136(2), 272e-3e.

[21] Panchapakesan V., Klassen A.F., Cano S.J., Scott A.M., Pusic A.L. Development and psychometric evaluation of the FACE-Q Aging Appraisal Scale and Patient-Perceived Age Visual Analog Scale. *Aesthet. Surg. J*. 2013 Nov 1;33(8):1099-109.

[22] Swanson E. The FACE-Q: the importance of full disclosure and sound methodology in outcome studies. *Aesthet. Surg. J. 2014* May 1;34(4):626-7.

[23] Pusic A.L., Klassen A.F., Scott A.M., Cano S.J. Development and psychometric evaluation of the FACE-Q satisfaction with appearance scale: a new patient-reported outcome instrument for facial aesthetics patients. *Clin. Plast Surg*. 2013 Apr;40(2):249-60.

[24] Harris D.L., Carr A.T. The Derriford Appearance Scale (DAS59): a new psychometric scale for the evaluation of patients with disfigurements and aesthetic problems of appearance. *Br. J. Plast. Surg*. 2001 Apr;54(3):216-22.

[25] Moss T.P., Cogliandro A., Pennacchini M., Tambone V., Persichetti P. Appearance distress and dysfunction in the elderly: international contrasts across Italy and the UK using DAS59. *Aesthetic Plast. Surg*. 2013 Dec;37(6):1187-93.

[26] Barone M., Cogliandro A., La Monaca G., Tambone V., Persichetti P. Cognitive investigation study of patients admitted for cosmetic surgery: information, expectations, and consent for treatment. *Arch. Plast. Surg.* 2015 Jan;42(1):46-51.

[27] Barone M., Cogliandro A., Persichetti P. Role of Aesthetic Surgery in improving the quality of life: only vanity or a solution to physical and psycho-relational problems? *Plast Reconstr. Surg*. 2013 Sep;132(3):477e-8e.

In: Encyclopedia of Surgery (22 Volume Set)
Editors: Andreas Lehrer and Kristin Mueller
ISBN: 978-1-53618-329-0
© 2020 Nova Science Publishers, Inc.

Chapter 394

LEADERSHIP, ETHICS, AND THE ADOPTION OF EVIDENCE BASED MEDICINE AMONG LEADERS OF INTERNAL MEDICINE AND SURGERY

Ronald Bogdasarian*
The Commonwealth Medical College, Scranton, PA, US

ABSTRACT

Background: Leadership, ethics and the adoption of evidence-based medicine (EBM) are interrelated components of modern medical care. In today's medical world, cost-effectiveness, patient safety and outcomes are paramount. EBM is at the forefront while engrained medical traditions are scrutinized at an increasing rate. This shift in paradigm requires strong leadership. With this complicated arrangement, exploration and comparison of the concepts of leadership, ethics, and EBM in two prominent areas of healthcare, general internal medicine and surgery, is a valuable exercise.

Objective: The primary objective of this work is to review the literature on leadership and ethics in the field of internal medicine compared to surgery and examine how they affect the adoption of EBM. The secondary objective is to identify aspects of leadership, ethics, and the implementation of EBM within internal medicine and surgery that may serve to improve the other discipline.

Design: A review of the literature using Pubmed and Embase was performed. Keywords included leadership in internal medicine, leadership in surgery, ethics in internal medicine, ethics in surgery, evidence-based medicine in internal medicine, and evidence-based medicine in surgery.

Setting: The Commonwealth Medical College, Scranton, PA.

Results/Conclusion: The study identifies multiple similar qualities of leadership in internal medicine and surgery, especially the broad use of transformational leadership. While the less tangible qualities of charisma and personality are recognized, leaders who are willing to educate colleagues and work to solve problems with the healthcare system are required to generate acceptance of EBM by a healthcare team. Differences in leadership style that might affect the adoption of EBM exist between internal medicine and surgery. Internal medicine depends more on the culture of the team, while surgery

* Corresponding Author's Email: RBogdasarian@tcmc.edu.

depends more on the influence of powerful individual leaders. Other differences included internal medicine's greater appreciation for patient participation in care while surgical leaders are acknowledged most for technical skill and the ability to teach. Notably, both internal medicine and surgery ethical leaders refrain from conflicts of interest, especially regarding increasing financial responsibilities, in order to maintain personal morals and the trust and respect of their healthcare teams. Ethical leaders in internal medicine place the patient's autonomy above the decisions of the medical team. Ethical leaders in surgery make appropriate decisions regarding heroic and end-of-life care. There are inherent differences between internal medicine and surgery that challenge the cross-over of leadership qualities from one discipline to the other. However, the differences in leadership style that do exist provide potential areas of improvement for each.

Keywords: leadership, medicine, surgery, ethics, evidence based

BACKGROUND

In this review of the literature we explore the differences between internal medicine and surgery with regard to leadership and leadership's interface with ethics and the adoption of evidence-based medicine (EBM). We examine our findings and search for lessons that may benefit the art and practice of each discipline, particularly regarding the adoption of EBM. Today, a large portion of the leadership in healthcare is derived from non-physician, organizational management. This chapter will focus on physician leadership and ethics and their roles in the adoption of EBM.

A large body of literature describes two major systems of leadership—transformational and transactional leadership. Transformational leadership results in an environment in which team members feel personally connected to the goal. This system is often utilized in situations requiring broad change [1]. Transactional leadership is suited for use in emergency situations in which grand change is not necessary. It relies on rewards and punishments [2].

Much of the literature on leadership in medicine and surgery focuses on the team and a stepwise process, conforming more with the transformational system [3,4,5].

First, the leader, utilizing qualities such as charisma, confidence, wisdom, and inspirational communication, instills a common goal and culture within the team [6].

Second, while an active member of the clinical team, the physician leader is an excellent delegator and ensures that all members feel comfortable and important.

Third, the leader properly assesses performance and ensures completion of tasks.

Fourth, he or she constantly reflects in order to improve performance. These are the basics of medical leadership and are generally shared by internal medicine and surgery leaders. How, though, do leaders of medicine and surgery differ? Can these qualities cross over to improve leadership in the opposite discipline, and can these improvements lead to better implementation of EBM?

Strong ethics are essential for proper healthcare and leadership. Physicians are often presented with challenging ethical dilemmas which require familiarity with the fundaments of ethics. Both internal medicine and surgery leaders have a strong grasp on the principles of autonomy, beneficence, nonmaleficence, justice, the intricacies of informed consent, durable power of attorney and healthcare proxies [7,8]. Are there other emphasized areas of ethics in

healthcare today? How do ethics, cost-effective medicine, and EBM interrelate in the practice of healthcare leaders?

Today, EBM has a permanent place in medical practice and increasingly directs medical care. Many healthcare practitioners lament the loss of control over their abilities to make their own healthcare decisions. For this reason, knowledge of physician leadership and how it differs between internal medicine and surgery should prove valuable to improve the art and practice of medicine, healthcare professional satisfaction and patient outcomes.

MATERIALS AND METHODS

Pubmed and Embase were used to review the literature. Keywords included leadership in internal medicine, leadership in surgery, ethics in internal medicine, ethics in surgery, evidence-based medicine in internal medicine and evidence-based medicine in surgery.

RESULTS

Leadership in Internal Medicine:

In addition to the transformational stepwise process of goal oriented leadership within the team environment, the literature presents multiple qualities of the strong internal medicine leader. Heavily emphasized is acceptance of change which has clear implications for the adoption of EBM over non-evidence supported traditional practices [9,10,11].

Further highlighted is teamwork, especially in interdisciplinary teams with emphasis on the patient as a team member [12,13]. Two 2014 articles from the *Journal of General Internal Medicine* state that internal medicine leaders are inspired by their patients [14,15]. Another 2014 article from the *Journal of General Internal Medicine* indicates that shared decision-making by the physician and patient, when evidence-based options and uncertainty are discussed, can lead to improved patient satisfaction [16].

A 2007 article from the *American Journal of Medical Quality* asserted that great internal medicine leaders direct attention to problems with the system, rather than with individual employees when an error causes harm to a patient [17]. This indicates that when a leader is dissatisfied with the implementation of EBM by a co-worker, he or she should examine the system in place meant to ensure the proper practice of EBM. This re-evaluation of the system, rather than a reprimand of a single employee or colleague, may help to improve the overall adoption of EBM.

Ethics in Internal Medicine

The literature expands upon the basic ethical principles mentioned in the background section. In a world where clinical leaders are becoming members of administration, conflict of interest and issues regarding financial honesty and fraud are paramount for the ethical leaders of internal medicine [18,19,20]. A 2013 article from the *Journal of Taibah University*

of Medical Science notes multiple qualities of the internal medicine ethical leader, including "altruism, accountability, excellence, duty, honor and integrity, and respect for others." These leaders resist "abuse of power, sexual harassment, conflicts of interest, professional arrogance, physician impairment, and fraud in research" [21].

In order to accomplish the implementation of EBM through transformational leadership, in which a healthcare team becomes personally connected to the goal, the leader in internal medicine must be ethically sound. Conflicts of interest and fraud in research may undermine a healthcare team's trust in the evidence behind EBM and lead to reduced acceptance of new medical practices.

As explained previously, including the patient in decision making leads to increased patient satisfaction. Including the patient as an active member of the team was considered to be ethically essential for the internal medicine leader [14,15]. Likewise, transparency and honestly with patients are also indispensable qualities of the internal medicine ethical leader [22].

Evidence Based Medicine in Internal Medicine

Much of the literature agrees that, in order for an internal medicine team to accept EBM, a culture of acceptance of change is paramount. This culture of change, resulting in the adoption of evidence-based practices, occurs in locations with strong hierarchal leadership and strong opinion leaders [23,24]. These leaders are often seniors with time to reflect and learn. In other words, in order to be a leader, one cannot be overwhelmed by the daily routine such that he or she cannot engage in novel medical learning [25]. These individuals must also be willing to "do what it takes to remove obstacles" to quality improvement such as poorly supported traditional beliefs and approaches. These leaders must be willing to take the time to share information and new knowledge on EBM and do so in a clear, concise manner [26].

Leadership in Surgery

Much of the literature on leadership in surgery states that confidence and speed pertaining to technical skill is essential for the leader in surgery [27,28]. A surgeon who proves the worth of EBM through his or her own practice is more likely to convince others to train using similar practices.

The abilities to teach and mentor are highly regarded qualities of the surgical leader. A 2013 paper from the *International Journal of Surgery* takes this a step further, explicitly differentiating surgery from internal medicine. The authors comment that great surgical leaders take routine processes, such as check lists, and transform them into rich learning experiences [29]. In surgery, leaders who are able to employ this strategy in their support of EBM should be more successful.

The literature also highlights the ability to communicate in a democratic fashion in order to accomplish tasks with those with different ideals, personalities, and even goals [30,31]. A 2014 study from *Health Affairs* states that humility is a key trait of the most respected surgical leaders. These leaders, while maintaining goals, are able to accept failure and are willing to communicate and cooperate with others to correct errors [32,33]. Surgical leaders

are also respected for "incisive, imaginative, [and] innovative scientific minds" [34]. One 1997 article from *Acta Neurochirurgica* discusses at length the importance of awareness to one's surroundings, objectives, and problems [35]. Interestingly, a 2013 article from the *Canadian Journal of Surgery* discusses the importance of personal development, especially in personal health and exercise in surgical leaders [36]. While not as prominent in the literature as technical skill and the ability to teach, these additional qualities may add to the recognition of the surgical leader and his or her ability to engage co-workers in the adoption of EBM.

In a glimpse into the minds of what influences surgical residents, a paper from *Aesthetic Plastic Surgery* describes "informal leadership". This concept refers to respect that is earned through consistent success in difficult situations, and can only be bestowed by peers. This "informal leadership" is distinct from one's title, or "formal leadership", which can be acquired by a surgeon who does not possess innate leadership qualities [37]. Surgical residents often gravitate to these surgeons who describe personal anecdotes of exciting, heroic experiences. While some may argue that these anecdotal experiences are exciting because they inherently diverge from the common, algorithmic EBM, these leaders are in a position to reaffirm the importance of EBM in everyday practice.

Ethics in Surgery

As in internal medicine, the literature on ethics in surgery recognizes the good leader's resistance to conflicts of interest [38,39]. Leaders in surgery are becoming more involved in administration, the financial aspects of care, and funding for research. The literature indicates that leaders in surgery must also avoid unethical practices in order to maintain co-workers trust for the implementation of EBM.

The literature on ethics in surgery also emphasizes the leader's ability to decide when heroic care is appropriate [40,41]. End-of-life care and heroic care are often technically difficult, expensive, and controversial. An in depth discussion on the specifics of EBM in this area of medicine is beyond the scope of this chapter. However, surgeons who are experienced and are capable of making difficult medical decisions, while remaining sensitive to the families of patients, are in a strong position to lead the adoption of EBM in this area.

Evidence Based Medicine in Surgery

Much literature focuses on the surgical leader's acceptance of EBM, which indicates that there is greater resistance to change and the adoption of EBM in surgery than in internal medicine, at least regarding engrained, everyday practices [42]. Again, the ability to teach is one of the most highly regarded qualities of leaders in surgery and is essential for the propagation of evidence-based practices. The literature emphasized the open-mindedness of surgical opinion leaders who are called upon to accept EBM and show expertise and technical skill in its delivery. The literature suggests that opinion leaders are the driving force in a hierarchical system that is the structure in which attending and resident surgeons continue to learn. Thus, highly respected local opinion leaders as advocates for EBM is of utmost importance in surgery [43,44,45].

DISCUSSION

As discussed in the background, the key components of leadership and ethics and their connection to the adoption of EBM are similar between internal medicine and surgery. There are, however, many notable differences.

Leadership

The literature indicates that leaders of both internal medicine and surgery tend to utilize a transformational, structured approach. Leaders generate a clear goal that members of the team identify with which supports a culture of agreement and productivity. Leaders put team members in positions to succeed and feel important. Leaders evaluate success as the team progresses. Once a goal is achieved, leaders reflect in order to improve for the future. This transformational method of leadership is well suited for the movement towards the EBM model.

Differences in leadership qualities between internal medicine and surgery include the following. Leaders of internal medicine accept the patient as a member of the team and are even "inspired" by their patients more often than their surgical counterparts. An essential quality of leadership in surgery is technical skill which can only be said for a small subset of internal medical physicians who perform a large volume of procedures [46]. Notably, the ability to teach is more commonly emphasized in the literature on surgical leaders than on internal medicine leaders.

These differences likely arise from the inherent differences between internal medicine and surgery. Internal medicine physicians traditionally spend more time conversing with patients in order to gather large volumes of information for management of multiple problems. These physicians receive praise as leaders for their ability to educate, comfort, and include patients in decision making. In surgery, much of the time spent with a patient is in the operating room where technical skill and outcomes are regarded as most important. While surgeons are still respected for good communication with patients, the emphasis is on the operative result. It is important to stress that discussions with patients should include education about evidence-based options for care. This results in the greatest patient satisfaction.

Due to the inherent differences between medicine and surgery, it is difficult to identify many areas of leadership that could cross over to the other discipline and improve the acceptance of EBM specifically. That said, possibilities areas for improvement include the following. In surgery, the technically savvy opinion leader has great potential for generating a more powerful culture change and should not be satisfied with simply providing an example of EBM to his or her peers. In internal medicine, while educating his or her colleagues and residents, the internal medicine leader should strive to create rich learning experiences from the repetitive daily routines that are part of EBM. Ultimately, all leaders should work to enhance the acknowledged strengths of their discipline's leadership style if they wish to increase the adoption of EBM.

Ethics

Many similarities exist regarding the ethics of internal medicine and surgery leaders. Both leaders have a strong grasp of the core principles of ethics, including autonomy, beneficence, nonmaleficence, justice, the proper use of informed consent, durable power of attorney and healthcare proxies.

Increasingly, both medical and surgical leaders are more involved in administration, finances, and funding for research. Recent literature focuses on the leader's refrainment from conflicts of interest that are possible in these positions. Internal medicine and surgery leaders must embrace this ethical pillar. Trust and respect from the healthcare team are necessary for change and the acceptance of EBM.

An important area of consideration regarding ethics is end-of-life care and heroic care. The literature indicates that internal medicine leaders focus more on the physician-patient relationship, while surgery leaders focus on when and when not to operate. While many surgical leaders do enjoy strong relationships with their patients during end-of-life care, the literature indicates that this is an area where surgeons could learn from their medical counterparts in order to strengthen this relationship. It is unclear, however, if this could enhance the adoption of EBM in surgery with regard to this area of healthcare. Alternatively, a focus on the willingness to make difficult decisions in end-of-life care is acknowledged as an important, albeit controversial, area in need of change toward EBM for both internal medicine and surgery leaders.

Evidence Based Medicine

The literature agrees that leaders in both internal medicine and surgery are at the forefront of the adoption of EBM. The manner in which EBM is encouraged differs, however.

The literature indicates that internal medicine leaders must create culture changes within their teams. Strong opinion leaders who are not overwhelmed by daily practice are required to generate these changes. Surgery is similar in that respected opinion leaders are essential, but there is less emphasis on culture change as a process.

The difference is subtle. Opinion leaders in internal medicine are important, but it is the cultural environment of the team that is most crucial. The literature indicates that surgery employs a powerful hierarchal system. In this system, the leaders have earned high regard due to their skills and ability to teach. These surgical leaders are able to influence the practice of their followers more so than the surgical culture does. As described previously, the surgical opinion leader may enjoy increased success in his followers' implementation of EBM if he works to generate culture change.

CONCLUSION

Most leaders in both internal medicine and surgery rely on the transformational form of leadership. The adoption of EBM by a team fits this leadership model well and is utilized by both groups of leaders. While the basics of leadership are similar, many of the differences

between internal medicine and surgery leaders are due to the inherent differences in the respective disciplines. Even so, many leaders in each field bridge the gap and look to their colleagues in the other field for areas of potential improvement.

Key to the success of these physician and surgeon leaders is the sense of teamwork. They are confident and capable within their own realms of practice to the extent that they are able to diversify and enjoy aspects of the other group. While there are many specifics of leadership that can be improved upon by each group of leaders, such as patient centeredness for surgeons, teaching style, and technical skills for physicians and decisions regarding end-of-life care, it is most important to recall that physicians and surgeons are all members of the same team. All physicians and surgeons should share a common culture of teamwork so that colleagues may practice the most proven forms of medicine and patients may enjoy the best outcomes possible.

It is important to repeat that the material from this chapter comes from a literature review. The differences in leadership style, ethics and use of EBM between internal medicine and surgery were retrieved based on their relative presence in the literature. Although the literature may emphasize certain areas of leadership more in one discipline, this does not mean that leaders in the other discipline are not strong in that area.

Weaknesses of this review include the following. We did not differentiate among leadership in practice size or style or academic or community environment. We did not explore the topics of gender or race. We did not discuss non-physician leadership or the relationship between clinical leaders and administration. Healthcare costs, patient safety and outcomes are among the pre-eminent issues of healthcare today. The strongest of clinical leaders should have the ability to connect administrative leadership with the clinical work force in order to facilitate a relationship that benefits the three parties involved: the healthcare organization, clinicians, and patients. In this light, clinical leaders are more frequently assuming administrative rolls [47,48]. In this review of the literature, the author attempted to withhold opinion.

ACKNOWLEDGMENT

I would like to acknowledge Bridget Conlogue of The Commonwealth Medical College Library for her vital contributions to this chapter.

FUNDING

We received no funding for the production of this work.

REFERENCES

[1] *Transformational leadership*. Wikipedia. http://en.wikipedia.org/wiki/Transformational_leadership. Accessed 8/14/14.

[2] *Transactional leadership*. Wikipedia. http://en.wikipedia.org/wiki/Transactional_leadership. Accessed 8/14/14.

[3] Richard MJ, Bohmer MB, Ch, B. Leading Clinicians and Clinicians Leading. *N. Engl. J. Med*. 2013; 368:1468-1470. doi: 10.1056/NEJMp1301814.

[4] Duda, RB. Physician and scientist leadership in academic medicine: strategic planning for a successful academic leadership career. *Current Surg*. 2004; 61:175-177.

[5] Oza, SK, Miao, E, Pierce, R, Kuo, A, Van Schaik, S. Development of a leadership observation and feedback tool (LOFT). *Journ. of Gen. Intern Med.* 2013; 28(1): 459.

[6] Dine CJ, Khan JM, Abella BS, Asch DA, Shea JA. Key elements of clinical physician leadership at an academic medical center. *Journ. Grad. Med. Edu*. 2011; 3(1): 31–36. doi: 10.4300/JGME-D-10-00017.1.

[7] Ethical Decision Making in Obstetrics and Gynecology*. ACOG Committee Opinion no. 390. American College of Obstetricians and Gynecologists. *Obstet. Gynecol* 2007;110:1479-87.

[8] Mayer DM, Nurmohamed S, Trevino LK, Shapiro DL, Schminke M. Encouraging employees to report unethical conduct internally: it takes a village. *Org. Behav. and Hum. Decis Proc*. 2013; 89-103.

[9] Williams BC, Fisseha S, Williams J, Mullan P. Educating for change: Medical students develop organizational leadership skills through student-driven community based field projects. *Journ of Gen Intern Med*. 2014; 29(1): 516-517.

[10] Paryizi N, Shahaney S, Martin G, Ahmad A, Moghu M l. Instigating change: trainee doctors' perspective. *Postgrad Med. J*. 2013; 89:572-577. doi:10.1136/postgradmedj-2011-000370rep.

[11] Ball M, Lindberg D, Masic I. Special Tribute on Morris F. Collen: Charismatic leader of medical informatics. *Acta Inform Med*. 2014; 22(1): 4-5. doi:10.5455/aim.2014.22.4-5

[12] Rose SA, Jackson N, Fenner BP, Capel B, Rudy D. Promoting positive change in the residency experience through discovery of resident values. *Journ of Gen. Intern Med.* 2014; 185-186.

[13] Kim CS, King E, Stein J, Robinson E, Salameh M, O'Leary KJ. Unit-based interprofessional leadership models in six US hospitals. *J. Hosp. Med*. 2014; 9(8):545-50. doi: 10.1002/jhm.2200.

[14] Jackson N, Fenner B, Capel BJ, Rudy D. Promoting positive change in the residency experience through discovery of resident values. *Journ. of Gen. Intern Med.* 2014; 62(2): 582.

[15] Radhakrishnan P, Thorn P. Story telling: my most memorable patient – lessons in humanism, reflection, and the development of expertise. *Journ. of Gen. Intern Med.* 2014; 29(1): 534.

[16] Berger Z. Navigating the unknown: shared decision-making in the face of uncertainty. *Journ of Gen. Intern Med.* 2014: In press,

[17] Clarke JR, Lerner JC, Marella W. The role for leaders of healthcare organizations in patient safety. *Am. J. Med. Qual.* 2007; 22: 311-318.

[18] Pisano ED, Golden RN, Schweitzer L. Conflict of interest policies for academic health system leaders who work with outside corporations. *JAMA.* 2014; 311(11): 1111-1112. doi:10.1001/jama.2014.788.

[19] Campbell C, Wolf D, Hoover N, Rees T, Smith S. Incomplete conflict of interest (COI) disclosures-analysis of recent publications. *Cur. Med. Resear and Opin.* 2013; 29(1): 9-19. doi:10.1185/03007995.2013.780866.

[20] DeCamp M, Farber NJ, Torke AM, George M, Berger Z, Keirns CC, Kaldjian LC. Ethical challenges for accountable care organizations: a structured review. *J. Gen. Intern Med.* 2014. Ahead of Press.

[21] Kasule OH. Medical professionalism and professional organizations. *Journ Taibah Univ. Med. Sci.* 2013; 8(3): 137–141. doi: 10.1016/j.jtumed.2013.09.003.

[22] Chervenak FA, McCullough LB. An ethical framework for identifying, preventing, and managing conflicts confronting leaders of academic health centers. *Aca Med*. 2004; 79(11):1056-61.

[23] Shahzad S, Zareen H. Perception of leadership among health managers working in tertiary level hospitals. *Journ Ayub. Med. Coll*. 2012; 24(1): 96-100.

[24] Curran GM, Thrush CR, Smith JL, Owen RR, Ritchie M, Chadwick D. Implementing research findings into practice using clinical opinion leaders: barriers and lessons learned. *Jt Comm J. Qual Patient Saf.* 2005; 31(12):700-7.

[25] Swennen MHJ, Van Der Heijden GJ, Blijham GH, Kalkman CJ. Career stage and work setting create different barriers for evidence-based medicine. *J. Eval. Clin. Pract.* 2011; 17(4): 775-85.

[26] Davidow SL. Physicians taking the lead to improve patient care. *Jt Comm J. Qual. Improv*. 1999; 25(3):145-52.

[27] Briggs A, Raja AS, Joyce MF, Yule SJ, Jian W, Lipsitz SR, Havens JM. The impact of trauma team training on team leaders' non-technical skills during simulated trauma scenarios. *J. Surg. Res.* 2014; 186(2): 671-672. doi:10.1016/j.jss.2013.11.747.

[28] Jernigan AM, Stephens JP, Knight J. Surgeons as active leaders in the operating room: potential cost-saving behaviors. *Gynecologic Oncology*. 2014; 133(1): 35. doi:10.1016/j.ygyno.2014.03.107.

[29] Suliman A, Klaber RE, Warren OJ. Exploiting opportunities for leadership development of surgeons within the operating theatre. *Int. J. Surg.* 2013; 11(1): 6-11. doi: 10.1016/j.ijsu.2012.11.002.

[30] Robinson M, Macneily A, Afshar K, McInnes C, Lennox P, Carr N, Skarlicki D, Masterson J, Arneja J. Leadership in Canadian urology: what is the right stuff? *J. Surg. Edu*. 2013; 70(5): 606-612. doi: 10.1016/j.jsurg.2013.04.013.

[31] Souba WW. New ways of understanding and accomplishing leadership in academic medicine. *J. Surg. Res.* 2004; 117(2):177-86.

[32] Mello MM, Senecal SK, Kuznetsov Y, Cohn JS. Implementing hospital-based communication-and-resolution programs: lessons learned in New York City. *Health Aff.* 2014; 33(1): 30-38. doi: 10.1377/hlthaff.2013.0849.

[33] Hu Y, Parker SH, Arriaga AF, Peyre SE, Corso KA, Roth EM, Yule SJ, Greenberg CC. Follow the leader? The impact of leadership style on team performance in the OR. *J. Surg. Res.* 2013; 179(2).

[34] Shields CB. Leadership in neurosurgery. *Neurosurg*. 1989; 25(1): 1-5.

[35] Brock M. Leadership qualities in prominent neurosurgeons. *Acta Neurochir Suppl.* 1997; 69: 8-11.

[36] Klein G, Hussain N, Sprague S, Mehlman CT, Dogbey G, Bhandari M. Characteristics of highly successful orthopedic surgeons: a survey of orthopedic chairs and editors. *Can J. Surg.* 2013; 56(3):192–198. doi: 10.1503/cjs.017511.

[37] Prado A, Parada F. Leadership in plastic surgery today. *Aesthet Plas Surg*. 2010; 1-3.

[38] Minter RM, Angelos P, Coimbra R, Dale P, De Vera ME, Hardacre J, Hawkins W, Kirkwood K, Matthews JB, McLoughlin J, Peralta E, Schmidt M, Zhou W, Schwarze ML. Ethical management of conflict of interest: proposed standards for academic surgical societies. *J. Am. Coll. Surg.* 2011; 213(5): 677-82. doi: 10.1016/j.jamcollsurg. 2011.08.003.

[39] Elliot BM. Conflict of interest and the society for vascular surgery. *J. Vasc. Surg.* 2011; 54(3): 3-11.

[40] Roberts DJ, Zygun DA, Kirkpatrick AW, Ball CG, Faris PD, Bobrovitz N, Robertson HL, Stelfox HT. A protocol for a scoping and qualitative study to identify and evaluate indications for damage control surgery and damage control interventions in civilian trauma patients. *BMJ Open.* 2014; 4(7): doi:10.1136/bmjopen-2014-005634.

[41] Civetta JM. Critical care: how should we evaluate our progress? *Crit Care Med.* 1992; 20(12): 1714-20.

[42] Escobar MA, McCullough LB. Responsibly managing ethical challenges of residency training: a guide for surgery residents, educators, and residency program directors. *J. Am. Coll. Surg.* 2006; 202: 531-535.

[43] Callahan CD, Adair D, Bozic KJ, Manning BT, Saleh JK, Saleh KJ. Orthopaedic surgery under national health reform: an analysis of power, process, adaptation, and leadership: AOA critical issues. *J. Bone Joint Surg. Am.* 2014; 96(13): 111.

[44] Stijntjes F, Obertop H. Evidence-based surgery. *Nederland Tijdschrift voor Geneeskunde*. 2008; 152(38): 2065-70.

[45] Young JM, Hollands MJ, Ward J, Holman CD. Role for opinion leaders in promoting evidence-based surgery. *Arch. Surg.* 2003; 138(7): 785-91.

[46] Chonde M, Intaphan J, Killu C. ACLS leadership training in medical residents and its effect on confidence. *Critic Care Med*. 2013; 41(12): 128-129.

[47] Mostashari F, Sanghavi D, McClellan M. Health Reform and Physician-Led Accountable Care: The Paradox of Primary Care Physician Leadership. *JAMA.* 2014; 311(18):1855-1856. doi:10.1001/jama.2014.4086.

[48] Satiani B, Sena J, Ruberg R, Ellison EC. Talent management and physician leadership training is essential for preparing tomorrow's physician leaders. *J. Vasc. Surg.* 2014; 59(2): 542-6. doi: 10.1016/j.jvs.2013.10.074.

In: Encyclopedia of Surgery (22 Volume Set)
Editors: Andreas Lehrer and Kristin Mueller
ISBN: 978-1-53618-329-0
© 2020 Nova Science Publishers, Inc.

Chapter 395

APPLICATION OF DA VINCI® ROBOT IN GENERAL SURGERY: A COST ASSESSMENT

Ioannis D. Gkegkes[1] and Christos Iavazzo[2]
[1]First Department of Surgery, General Hospital of Attica "KAT", Athens, Greece
[2]Gynaecological Oncology Department, Christie Hospital, Manchester, United Kingdom

ABSTRACT

The utilization of robotic assisted surgical techniques represents a novelty in the field of general surgery. Moreover, the development of robotic technology facilitated the realization of complex operations both in hepatopancreatic and in colorectal surgery. However, the elevated costs of the robotic assisted surgery, in comparison to the other minimally invasive procedures, mainly the laparoscopic ones, make the application of robotics in general surgery expensive and not an everyday surgical technique. The present evidence reveals that robotic surgery, under specific conditions, has the potential to become cost-effective. Large number of cases, presence of industry competition and multidisciplinary team utilization are some of the factors that could make more reasonable and cost-effective the robotic assisted technique.

The evolution of robotic technology applications in surgery during the last decade has facilitated the realization of a great variety of operations in various surgical fields [1]. The robotic assisted technique has an important position among the other minimally invasive methods in general surgery. Several are the main advantages of robotic assisted surgery, such as three dimensional view of the operating field, low intraoperative blood loss, precision of movements due to elimination of surgeon tremor, utilization of wristed instruments that improve dexterity and facilitate suturing, have made possible even the most complicate operations such as robotic pancreaticoduodenectomy [2-4]. In contrast to the above mentioned advantages, the absence of tactile feedback of the surgeon and the cost are the main weak points of the robotic technique.

Nowadays, the only commercially available robotic equipment (da Vinci® Surgical System) is characterized by elevated cost, including cost of acquisition, training and

equipment-instrument cost, as well as that of maintenance of the robotic system (with an annual service contract, over 100,000 US dollars). This high cost can explain the reasons that decreased the widespread use of robotic assisted surgery [4]. According to van Dam et al., in order to amortize the initial capital for the acquisition of robotic devices, the technique should be applied on more than 300 surgical procedures per year for a period longer of 7 years, equivalent to an amount of over 1,000 Euros per patient [4]. As a result, it can be easily understood that the robotic technology refers exclusively to surgical centers with large volume of patients in order to achieve the per case charges as low as possible. The robotic instrumentation that has increased cost of acquisition (almost over 1,500 Euros per instrument) as well as a limited number of uses (10 lives per instrument) represents another financial burden [5]. Moreover, the reimbursement to the hospital for utilization of the robot is in direct correlation with the type of health insurance and the health system itself, favoring the countries without universal health coverage

The introduction of innovative and less invasive technologies in surgical fields has been adopted with great difficulty from the health care systems as a consequence of the lack of data and of the high costs (acquisition and maintenance) of every novel equipment [6]. In the current finance situation, where the major part of the European economies and a portion of the rest of the world are facing difficulties to sustain the already present health structures, doubts could be raised in the attempts to introduce new and highly expensive technique such as robotics as the new standard of care without the presence of strong evidence of significant cost effectiveness and the comparison of minimally invasive methods to standard surgical techniques. Though cost related studies are complicated to be organized, it is essential that all parts involved, society and doctors, should comprehend the impact of the cost of robotics.

Robotic assisted surgery specifically requires equipment of elevated cost as result of the novelty and the high specialization of the utilized devices [5, 7]. The high cost of acquisition (over 1 million Euros) as well the expensive maintenance costs (almost 150,000 Euros /year) are obstacles that should be overcome. Van Dam et al. has suggested that the costs of robotic equipment could be amortized, if the health care systems permit the application of robotic equipment on elevated number of patients [4]. Furthermore, the absence of competition in the market of robotic equipment, especially after 2003, is one of the most important factors that maintain high the costs of robotic instrumentation [8]. More specifically, in 2003, the merge of the only two existed companies in the market of robotic devices was achieved, creating monopoly conditions.

The operating time is another essential reason that may cause great variations on the total surgical costs. Even though for private health structures the length of the operating time is not an issue, for public health systems, which are financed by the government's budget, every penny must be carefully spent. The setup of the robotic equipment, which is significantly longer compared to either the laparoscopic or the open one can increase the cost, however, it was shown that this time can be substantially improved when the surgical team is well trained [6]. Furthermore, the operative time is related to the experience of the surgical team. The type of surgical operation, as well as the surgeon's capability and experience are factors that influence considerably the learning curve [4]. In addition, the costs are in correlation with the learning curve and are considered as an additional cost caused by the fact that surgeons already went through a training program for both laparoscopic and open technique [9]. Nevertheless, it should be mentioned that an effective way to decrease the costs related to

learning curve is the presence of great volume of patients and the necessity of virtual reality simulators [10, 11].

Minimal invasive techniques have revealed to have an edge over laparotomy for the management of patients in a wide spectrum of pathologies [12, 13]. Keyhole incisions offer various advantages over the open surgical method, such as decrease of both post-operative pain and recovery time, less post operative complications, reduced blood loss, better cosmetic result. In particular, robotic techniques have a positive impact on specific patients' categories, such as the reduction of operative costs and of hospital stay in elderly or morbidly obese patients. According to some studies, the total cost between both open and laparoscopic technique do not present statistically significant difference [14, 15].

The extent of hospital stay has an important influence on the total charges of hospitalization. The limited hospital stay is a principal characteristic of both robotic and laparoscopic approach as it is expected in comparison to the open method [5]. Therefore, the decreased number of hospital days can amortize part of the increased operative costs of the minimal invasive techniques. Besides, the expenses of hospitalization are also in strait correlation with the category of health care system and the type of health care structure [4, 16]. Differences between countries, private or public sectors render complex any approach in order to evaluate those cost data. Regarding the comparison of robotic procedures to laparoscopy, several studies claim that over hospital stay the robotic surgery seems to have a slight financial advantage over the standard laparoscopy [17]. Nevertheless, currently, it appears that laparoscopy is a most economic approach among the other minimal invasive methods.

As presented in Table 1, the greater part of the studies referred to gastric fundoplication and showed that robotic is more expensive in comparison to laparoscopic technique. Despite the cost of acquisiting the robotic devices, professional charges, operating room costs, surgical equipment costs present great variation in the included studies. Such a cost could be minimized if we also take into consideration the decrease of the hospital stay, the sooner return to normal patient's activities, the reduction of blood loss and the decrease on conversion rates to laparotomy. Also, by improving the robotic training of all personnel, the surgical time could be further reduced and as consequence favor the use of minimal invasive techniques.

The utilization of robotics in almost every surgical field could be thought, in the future, as a valuable tool in common surgical practice. In order to realize this fact, both operative costs and unnecessary charges should be eliminated. The formation of specialized robotic units operating on great number of cases per year, the reduction of operating time per procedure by specialized training on robotic approach, the decision for early discharge of the patients when that is possible and the minimization of the number of instruments used per operation are some of the first steps that could be done in this direction. An additional proposal to minimize the cost is the multiple-use of the robotic equipment by multiple surgical specialties, good training of all the team members implicated while the acquisition of the robotic devices could be made through research funding or even charities.

Table 1. Robotics in general surgery: costs related to equipment and peri-operative outcomes[†]

First author, Year [ref]	Type of operation	Number of patients (%)	Total costs	Operative charges	Non-operative charges	Robot cost included (Y/N)	Surgical equipment costs	Operating room costs	Length of hospital stay (days)	Conversion to laparotomy (%)	Duration of surgery (min)	Blood loss (mL)
Adhesiolysis												
Salman, 2013 [18]	OP	165,078/226,445 (16.3)	median[‡]: 32,020	NR	NR	NR	NR	NR	median[‡]: 5.7	NR	NR	NR
	LA	205,813/1,162,790 (17.7)	median[‡]: 30,318	NR	NR		NR	NR	median[‡]: 4.7	NR	NR	NR
	RO	34,177/37,270 (91.7)	median[‡]: 21,995 p < 0.05	NR	NR		NR	NR	median[‡]: 4.9 p <0 .05	NR	NR	NR
Adrenalectomy												
Salman, 2013 [18]	OP	16,530/226,445 (7.3)	median[‡]: 39,692	NR	NR	NR	NR	NR	median[‡]: 6.7	NR	NR	NR
	LA	3,488/1,162,790 (0.3)	median[‡]: 31,207	NR	NR		NR	NR	median[‡]: 6.2	NR	NR	NR
	RO	447/37,270 (1.2)	median[‡]: 32,712 p < 0.05	NR	NR		NR	NR	median[‡]: 6.7 p < 0.05	NR	NR	NR
Brunaud, 2008 [19]	LA	-	mean: 1,799	NR	NR	NR	NR	NR	NR	NR	NR	NR
	RO	100	mean: 4,102	NR	NR		NR	NR	mean (SD): 6.4 (3)	5/100 (5)	mean (SD) (range): 99 (35) (40-275)	NR
Prewitt, 2008 [20]	OP	-	NR	NR	NR	NR	NR	NR	-	NR	NR	NR
	RO	16	NR	mean: 6,942	NR		NR	NR	mean: 1.8	NR	NR	NR
Winter, 2006 [21]	OP	20/95 (21)	median: 13,383	median: 2,686	median: 10,697	NR	NR	NR	-	NR	NR	NR
	LA	45/95 (47)	median: 13,197	median: 4,699	median: 8,498		NR	NR	median: 2	4/45 (9)	NR	NR

First author, Year [ref]	Type of operation	Number of patients (%)	Total costs	Operative charges	Non-operative charges	Robot cost included (Y/N)	Surgical equipment costs	Operating room costs	Length of hospital stay (days)	Conversion to laparotomy (%)	Duration of surgery (min)	Blood loss (mL)
	RO	30/95 (32)	median: 15,842	median: 6,334	median: 9,508		NR	NR	median: 2	0/30	median (range): 185 (130-295)	NR
Morino, 2004 [22]	LA	10/20 (50)	mean: 2,005	mean: 1,027	mean: 991	N	mean: 598	mean: 428	mean (range): 5.4 (4-8)	0/10	mean (range): 115.3 (95-155)	NR
	RO	10/20 (50)	mean: 2,539 p < 0.01	mean: 1,510	mean: 1,046		mean: 873	mean: 636	mean (range): 5.7 (4-9) p = NS	4/10 (40)	mean (range): 169 (136-215) p < 0.01	NR
Adjustable gastric banding												
Muehlmann, 2003 [23]	LA	10/20 (50)	NR	mean: 4,587	NR	NR	NR	NR	mean (range): 3 (2-4)	NR	mean (range): 97 (60-140)	NR
	RO	10/20 (50)	NR	mean: 6,964 p<0.001	NR		mean: 1,089	NR	mean (range): 3 (2-4)	NR	mean (range): 137 (110-175) p = 0.04	NR
Cholecystectomy												
Buzat, 2013 [24]	LA	10/30 (33)	NR	NR	NR	N	mean: 945	NR	NR	0/10	mean (SD): 85.5 (11.8)	mean (SD): 12 (7.5)
	RO	20/30 (67)	NR	NR	NR		mean: 935	NR	NR	0/20	mean (SD): 84.6 (20.5) p = 0.8737	mean (SD): 8.4 (7.3) p=0.2289

Table 1. (Continued)

First author, Year [ref]	Type of operation	Number of patients (%)	Total costs	Operative charges	Non-operative charges	Robot cost included (Y/N)	Surgical equipment costs	Operating room costs	Length of hospital stay (days)	Conversion to laparotomy (%)	Duration of surgery (min)	Blood loss (mL)
Salman, 2013 [18]	OP	NA	NA	NR	NR	NR	NR	NR	NA	NR	NR	NR
	LA	731,395/1,162,790 (62.9)	median‡: 23,561	NR	NR		NR	NR	median‡: 4.1	NR	NR	NR
	RO	484/37,270 (1.3)	median‡: 23,307	NR	NR		NR	NR	median‡: 4.4	NR	NR	NR
Breitenstein, 2008 [25]	LA	50/100 (50)	mean (SD): 4,583 (1,433)	mean: 1,223	mean: 3,390	Y	NR	NR	mean (SD): 4.84 (2.2)	0/50	mean (SD): 50.2 (29.2)	NR
	RO	50/100 (50)	mean (SD): 5,851 (1,290)	mean: 1,291	mean: 4,598		NR	NR	mean (SD): 4.58 (1.9) p = 0.4	0/50	mean (SD): 54.6 (31.6) p = 0.54	NR
Heemskerk, 2005 [26]	LA	12/24 (50)	mean: 2,148.45	mean: 273.74	mean: 1,874.71	Y	-	NR	mean: 2.3	0/12	mean: 1.30 ††	NR
	RO	12/24 (50)	mean: 3,329.07 p < 0.001	mean: 1,163.75	mean: 2,165.32		mean: 889.18 p < 0.001	NR	mean: 2.7 p = 0.208	0/12	mean: 1.55 †† p = 0.17	NR
Colectomy												
Keller, 2013 [27]	LA	17,265/18,009 (95.9)	mean: 31,970	mean: 2,571	mean: 29,399	Y	mean: 2,252	NR	mean: 6.13	0/17,265	mean: 201	NR
	RO	744//18,009 (4.1)	mean: 39,160	mean: 3,572 p < 0.001	mean: 35,588		mean: 3,777 p < 0.001	NR	mean: 7.46 p < 0.001	0/744	mean: 261 p < 0.001	NR
Park, 2012 [28]	LA	35/70 (50)	mean (SD): 7,561 (1,178)	mean: 5,014	mean: 2,596	Y	mean (SD): 4,468 (4,091)	NR	mean (SD): 8.3 (4.2)	0/35	mean (SD): 130 (43)	mean (SD): 56.8 (31.3)

First author, Year [ref]	Type of operation	Number of patients (%)	Total costs	Operative charges	Non-operative charges	Robot cost included (Y/N)	Surgical equipment costs	Operating room costs	Length of hospital stay (days)	Conversion to laparotomy (%)	Duration of surgery (min)	Blood loss (mL)
	RO	35/70 (50)	mean (SD): 8,964 (1,398) p = 0.013	mean: 7,451	mean: 1,572		mean (SD): 6,639 (979) p < 0.001	NR	mean (SD): 7.9 (4.1) p = 0.13	0/35	mean (SD): 195 (41) p < 0.001	mean (SD): 35.8 (26.3) p = 0.211
Bertani, 2011 [29]	OP	45/109 (41.3)	mean: 7,888	NR	NR	Y	mean: 1,694	mean: 795	median (range): 6 (5-32)	-	median (range): 133 (55-210)	median (range): 150 (50-500)
	LA	30/109 (27.5)	mean: 7,968	NR	NR		mean: 2,066	mean: 1,128	median (range): 5 (3-12) p < 0.001**	2/30 (6.7)	median (range): 210 (150-360) p < 0.001**	median (range): 110 (50-300)
	RO	34/109 (31.2)	mean: 10,027	NR	NR		mean: 3,166	mean: 1,011	median (range): 5 (4-17)	2/34 (5.9)	median (range): 194 (130-301) p < 0.001*	median (range): 170 (80-1,000)
de Souza, 2010 [30]	LA	135/175 (77.1)	median (range): 9,057 (5,712-58,203)	median (range): 5,458 (3,109-33,865)	median (range): 3,739 (2,248-24,339)	NR	NR	NR	median (range): 5 (2-16)	1/135 (0.74)	mean (SD): 118.08 (38.11)	median (range): 50 (100-600)
	RO	40/175 (22.9)	median (range): 11,131 (7,181-28,173) p = 0.003	median (range): 6,816 (3,739-17,080) p = 0.004	median (range): 4,556 (3,442-11,093) p = 0.003		NR	NR	median (range): 5 (3-10) p=0.861	1/40 (2.5) p=0.402	mean (SD): 158.93 (36.69) p<0.001	median (range): 50 (10-240) p=0.52

Table 1. (Continued)

First author, Year [ref]	Type of operation	Number of patients (%)	Total costs	Operative charges	Non-operative charges	Robot cost included (Y/N)	Surgical equipment costs	Operating room costs	Length of hospital stay (days)	Conversion to laparotomy (%)	Duration of surgery (min)	Blood loss (mL)
Rawlings, 2007 [31]	LA	15/32 (46.9)	mean (SD): 5,954 (2,069)	NR	NR	NR	mean (SD): 1,358 (382)	mean (SD): 3,200 (639)	mean (SD): 5.5 (3.4)	2/15 (13.3)	mean (SD): 169.2 (37.5)	mean (SD): 66.3 (50.7)
	RO	17/32 (53.1)	mean (SD): 6,825 (3,743) p = 0.43	NR	NR		mean (SD): 2,176 (350) p < 0.0001	mean (SD): 4,294 (669) p < 0.0001	mean (SD): 5.2 (5.8) p = 0.862	0/17	mean (SD): 218.9 (44.6) p = 0.002	mean (SD): 40 (24.9) p = 0.067
Sigmoidectomy												
Rawlings, 2007 [31]	LA	12/25 (48)	mean (SD): 7,889 (8,642)	NR	NR	NR	mean (SD): 1,650 (698)	mean (SD): 3,668 (1,177)	mean (SD): 6.6 (8.3)	0/12	mean (SD): 199.4 (44.5)	mean (SD): 65.4 (52.1)
	RO	13/25 (52)	mean (SD): 9,097 (8,969) p=0.735	NR	NR		mean (SD): 2,330 (470) p=0.003	mean (SD): 4,468 (903) p=0.068	mean (SD): 6.0 (7.3) p=0.854	2/13 (15.4)	mean (SD): 225.2 (37.1) p=0.128	mean (SD): 90.4 (60) p=0.28
Rectal resection												
Baek, 2012 [32]	LA	150/304 (49.3)	mean (SD): 7,311 (2,600)	mean (SD): 1,677 (430)	mean: 5,634	Y	mean (SD): 2,457 (544)	NR	mean (SD): 10.8 (8.6)	NR	mean (SD): 219.7 (71.2)	mean (SD): 126.2 (267.7)
	RO	154/304 (50.7)	mean (SD): 10,731 (2,800) p = 0.001	mean (SD): 6,483 (1,167) p < 0.001	mean: 4,248		mean (SD): 644 (7,194) p < 0.001	NR	mean (SD): 11.1 (7.0) p = 0.819	NR	mean (SD): 285.2 (69.1) p = 0.018	mean (SD): 167.8 (26.1) p = 0.2

First author, Year [ref]	Type of operation	Number of patients (%)	Total costs	Operative charges	Non-operative charges	Robot cost included (Y/N)	Surgical equipment costs	Operating room costs	Length of hospital stay (days)	Conversion to laparotomy (%)	Duration of surgery (min)	Blood loss (mL)
Bertani, 2011 [29]	OP	34/86 (39.5)	mean: 9,858	NR	NR	Y	mean: 2,511	mean: 954	median (range): 7 (4-24)	0/34	median (range): 164 (100-350)	median (range): 120 (50-2,000)
	RO	52/86 (60.5)	mean: 11,214	NR	NR		mean: 3,140	mean: 1,417	median (range): 6 (4-51) p = 0.004	2/52 (4)	median (range): 260 (190-370) p = 0.001	median (range): 100 (50-1,000) p = 0.146
Gastroenterostomy												
Wormer, 2013 [33]	LA	29,677/29,959 (99.1)	mean (SD): 31,317 (17,120)	NR	NR	NR	NR	NR	mean (SD): 2.2 (1.5)	NR	NR	NR
	RO	282/29,959 (0.9)	mean (SD): 44,574 (21,165) p < 0.05	NR	NR		NR	NR	mean (SD): 2.5 (2.4) p < 0.05	NR	NR	NR
Fundoplication												
Owen, 2014 [34]	OP	2,168/ 12,079 (18)	mean (SD): 9,353 (10,244) p < 0.05**	NR	NR	NR	NR	NR	mean (SD): 6.1 (7.2) p < 0.05**	NR	NR	NR
	LA	9,572/12,079 (79.2)	mean (SD): 5,838 (5106) p < 0.05***	NR	NR		NR	NR	mean (SD): 2.8 (3.6) p = NS***	NR	NR	NR
	RO	339/12,079 (2.8)	mean (SD): 7,799 (4,426) p < 0.05*	NR	NR		NR	NR	mean (SD): 3 (3.5) p < 0.05*	NR	NR	NR

Table 1. (Continued)

First author, Year [ref]	Type of operation	Number of patients (%)	Total costs	Operative charges	Non-operative charges	Robot cost included (Y/N)	Surgical equipment costs	Operating room costs	Length of hospital stay (days)	Conversion to laparotomy (%)	Duration of surgery (min)	Blood loss (mL)
Wormer, 2013 [33]	LA	7,484/7,756 (96.5)	mean (SD): 24,139 (17,622)	NR	NR	NR	NR	NR	mean (SD): 2.3 (2)	NR	NR	NR
	RO	272/7,756 (3.5)	mean (SD): 27,576 (15,484) p < 0.05	NR	NR		NR	NR	mean (SD): 2.3 (2)	NR	NR	NR
Nakadi, 2010 [35]	LA	11/20 (55)	mean (SEM):5,907 (168)	mean (SEM): 1,525 (35)	mean: 4,382	N	mean: 76	NR	mean (SEM): 4.1 (0.3)	0/11	mean (SEM): 96 (5)	NR
	RO	9/20 (45)	mean (SEM): 27,561 (99) p < 0.001	mean (SEM): 1,553 (40) p = 0.601	mean: 26,008		mean: 1,214 p < 0.001	NR	mean (SEM): 4.4 (0.2) p = 0.284	1/9 (11.1)	mean (SEM): 137 (12) p = 0.01	NR
Andeberg, 2009 [36]	OP	10/34 (29.4)	mean: 10,521	NR	mean: 8,347	N	NR	NR	mean (SD): 7.9 (2.8)	NR	mean (SD): 129 (43)	NR
	LA	10/34 (29.4)	mean: 8,982	NR	mean: 5,494		NR	NR	mean (SD): 5.2 (3.0)	2/10 (20)	mean (SD): 207 (52)	NR
	RO	14/34 (41.2)	mean: 9,584	NR	mean: 4,015		mean: 2,081	NR	mean (SD): 3.8 (1.9) p=0.002	NR	mean (SD): 207 (47) p=0.003	NR
Heemskerk, 2007 [37]	LA	11/22 (50)	mean: 3,376.35	NR	NR	NR	NR	NR	mean: 4	0/11	mean: 135	NR
	RO	11/22 (50)	mean: 4,363.82 p = 0.033	NR	NR		NR	NR	mean: 4 p=0.928	0/11	mean: 176 p=0.094	NR

First author, Year [ref]	Type of operation	Number of patients (%)	Total costs	Operative charges	Non-operative charges	Robot cost included (Y/N)	Surgical equipment costs	Operating room costs	Length of hospital stay (days)	Conversion to laparotomy (%)	Duration of surgery (min)	Blood loss (mL)
Mueller-Stich, 2007 [38]	LA	20/40 (50)	mean (SD): 2,743 (483)	mean (SD): 763 (115)	NR	NR	NR	NR	mean (SD): 3.3 (0.8)	0/40	mean (SD): 102 (19)	NR
	RO	20/40 (50)	mean (SD): 3,244 (512) p = 0.03	mean (SD): 1,534 (111) p=0.001	NR		NR	NR	mean (SD): 2.9 (0.8) p=0.086	0/40	mean (SD): 88 (18) p=0.033	NR
Morino, 2006 [39]	LA	25/50 (50)	mean: 1,527	mean: 657	mean: 870	N	mean: 100	mean: 557	mean (range): 2.9 (2-6)	0/25	mean (SEM): 91.1 (10.6)	NR
	RO	25/50 (50)	mean: 3,157 p<0.001	mean: 2,257	mean: 900		mean: 1,454	mean: 803	mean (range): 3 (2-7) p=0.588	1/25 (4)	mean (SEM): 131.3 (18.3) p<0.001	NR
Pancreatectomy												
Kang, 2011 [40]	LA	25/45 (55.6)	mean (SD): 2,829 (1,263)	mean (SD): 1,628 (460)	NR	Y	NR	NR	mean (SD): 7.3 (3.0)	NR	mean (SD): 258.2 (118.6)	mean (SD): 420.2 (445.5)
	RO	20/45 (44.4)	mean (SD): 6,085 (637) p < 0.001	mean (SD): 4,215 (279) p < 0.001	NR		NR	NR	mean (SD): 7.1 (2.2) p = NS	NR	mean (SD): 328.7 (121.8) p = 0.024	mean (SD): 372 (341.5) p = NS
Waters, 2010 [41]	OP	22/57 (38.6)	mean: 11,372	mean: 2,572	mean: 8,800	Y	NR	NR	mean (range): 8 (3-25)	-	mean (range): 234 (136-437)	mean (range): 681 (50-3,300)

Table 1. (Continued)

First author, Year [ref]	Type of operation	Number of patients (%)	Total costs	Operative charges	Non-operative charges	Robot cost included (Y/N)	Surgical equipment costs	Operating room costs	Length of hospital stay (days)	Conversion to laparotomy (%)	Duration of surgery (min)	Blood loss (mL)
	LA	18/57 (31.6)	mean: 9,451	mean: 2,251	mean: 7,201		NR	NR	mean (range): 6 (3-34)	2/18 (11.1)	mean (range): 224 (100-346)	mean (range): 667 (50-7,000)
	RO	17/57 (29.8)	mean: 7,758	mean: 3,589 p = 0.04	mean: 4,169 p = 0.01		NR	NR	mean (range): 4 (2-6) p=0.04	2/17 (11.7)	mean (range): 298 (191-418) p=0.01	mean (range): 279 (20-1,200) p=0.17
Rectopexy												
Heemskerk, 2007 [42]	LA	14/33 (42.4)	mean: 3,115.55	NR	NR	Y	mean: 780	NR	mean: 4.3	0/19	mean: 113	NR
	RO	19/33 (57.6)	mean: 3,672.84 p = 0.012	NR	NR		mean: 780 p=1	NR	mean: 3.5 p=0.527	1/19 (5) p=0.383	mean: 152 p=0.04	NR
Roux-en-Y gastric bypass												
Hagen, 2012 [43]	OP	524/990 (52.9)	mean: 16,851	NR	NR	NR	mean: 1,869	NR	mean (range): 10.9 (5-220)	-	NR	NR
	LA	323/990 (32.6)	mean: 15,897	NR	NR		mean: 4,025	NR	mean (range): 11 (5-249)	16/323 (4.9)	NR	NR
	RO	143/990 (14.5)	mean: 14,187	NR	NR		mean: 3,845	NR	mean (range): 7.4 (4-24)	2/143 (1.4) p=0.038	NR	NR
Scozzari, 2011 [44]	LA	423/533 (79.4)	mean: 4,658.28	mean: 2,318.28	mean: 2,340	Y	mean: 765.78	mean: 1,402.5	mean (range): 8.3 (3-99)	0/423	mean (range): 187 (75-360)	NR

First author, Year [ref]	Type of operation	Number of patients (%)	Total costs	Operative charges	Non-operative charges	Robot cost included (Y/N)	Surgical equipment costs	Operating room costs	Length of hospital stay (days)	Conversion to laparotomy (%)	Duration of surgery (min)	Blood loss (mL)
	RO	110/533 (20.6)	mean: 5,777.76 p<0.001	mean: 3287.76	mean: 2,490		mean: 1,581.51	mean: 1,856.25	mean (range): 7.8 (3-65) p=NS	0/110	mean (range): 247.5 (90-405) p<0.001	NR
Curet, 2009 [45]	LAH	36/135 (26.7)	mean: 50,408	NR	mean: 42,055	NR	NR	NR	mean: 3.3	NR	mean: 183.3	NR
	LAS	78/135 (57.8)	mean: 48,503	NR	mean: 39,418		NR	NR	mean: 3.6	NR	mean: 185.6	NR
	RO	21/135 (15.5)	mean: 57,002 p = 0.047	NR	mean: 48,796 p = 0.015		NR	NR	mean: 3 p = 0.13	NR	mean: 181.7 p = 0.92	NR
Sleeve Gastrectomy												
Schraibman, 2014 [46]	LA	32/48 (66.7)	mean (range): 9,972 (23,518-54,645)	mean (range): 7,138 (17,299-46,725)	NR	Y	NR	NR	median (1st-3rd quartile): 3 (2-4)	NR	median (1st-3rd quartile): 138 (115-170)	NR
	RO	16/48 (33.3)	mean (range): 15,521 (11,433-98,668) p < 0.001	mean (range): 13,670 (8,532-20,144) p < 0.001	NR		NR	NR	median (1st-3rd quartile): 3 (2-4) p = 0.766	NR	median (1st-3rd quartile): 148 (133-168) p = 0.211	NR
Splenectomy												
Gelmini, 2011 [47]	LA	45/90 (50)	median: 1,898	NR	NR	NR	NR	NR	median: 5.3	5/45 (11.1)	median: 125	NR
	RO	45/90 (50)	median: 5,077 p < 0.05	NR	NR		NR	NR	median: 5.1 p=NS	4/45 (8.9) p=NS	median: 153 p<0.05	NR

Table 1. (Continued)

First author, Year [ref]	Type of operation	Number of patients (%)	Total costs	Operative charges	Non-operative charges	Robot cost included (Y/N)	Surgical equipment costs	Operating room costs	Length of hospital stay (days)	Conversion to laparotomy (%)	Duration of surgery (min)	Blood loss (mL)
Bodner, 2005 [48]	LA	6/12 (50)	NR	mean: 2,992	NR	Y	NR	NR	mean (range): 6 (4-7)	0/12	mean (range): 127 (95-174)	mean: <50
	RO	6/12 (50)	NR	mean: 5,075 $p < 0.05$	NR		mean: 957	NR	mean (range): 7 (5-11) $p < 0.05$	0/12	mean (range): 154 (115-292) $p < 0.05$	mean: <50

Abbreviations: OP = open, LA = laparoscopic, RO = robotic, NR = not referred, NA= not applicable, Y = Yes, N =No, hr = hour, SD = standard deviation, SEM=standard error of mean, NS= not statistically significant, LAH = laparoscopic handsewn technique, LAS = laparoscopic stapled technique.

†All costs are estimated in Euros.

††Expressed in hours.

*Comparison between open and robotic.

**Comparison between open and laparoscopy.

***Comparison between laparoscopy and robotics.

‡Adjusted median.

The implement of robotic technology in operations of general surgery represent a novelty that may influence both the surgical treatment of numerous pathologies and the post operative outcomes. The robotic assisted surgery has serious possibilities to evolve in a cost-effective technique especially in centers with large number of cases, in spite of the undeniable elevated costs of acquisition and maintenance. Having as intention to increase the use of this surgical technique, it should be utilized not only on clinical treatment of patients but as well for the surgical training of all residents. The possible future industry competition in correlation with the technological development may steadily reduce the cost of the robotic equipment, making robotics a more cost-effective and affordable technique.

REFERENCES

[1] Yu, HY; Friedlander, DF; Patel, S; Hu, JC. The current status of robotic oncologic surgery. *CA Cancer J Clin*., 2013, 63, 45-56.

[2] Boggi, U; Signori, S; De Lio, N; et al. Feasibility of robotic pancreaticoduodenectomy. *Br J Surg*., 2013, 100, 917-25.

[3] Smith, JA; Jr. Herrell, SD. Robotic-assisted laparoscopic prostatectomy: do minimally invasive approaches offer significant advantages? *J Clin Oncol*., 2005, 23, 8170-5.

[4] van Dam, P; Hauspy, J; Verkinderen, L; et al. Are costs of robot-assisted surgery warranted for gynecological procedures? *Obstet Gynecol Int*., 2011, 2011, 973830.

[5] Lotan, Y. Is robotic surgery cost-effective: no. *Curr Opin Urol*., 2012, 22, 66-9.

[6] Heemskerk, J; Bouvy, ND; Baeten, CG. The end of robot-assisted laparoscopy? A critical appraisal of scientific evidence on the use of robot-assisted laparoscopic surgery. *Surg Endosc*., 2014, 28, 1388-98.

[7] Turchetti, G; Palla, I; Pierotti, F; Cuschieri, A. Economic evaluation of da Vinci-assisted robotic surgery: a systematic review. *Surg Endosc*., 2012, 26, 598-606.

[8] Intuitive, Surgical. In: *Wikipedia*, the free encyclopedia. http:// en.wikipedia.org/ wiki/ Intuitive_Surgical Accessed on 11 Nov 2015.

[9] Steinberg, PL; Merguerian, PA; Bihrle, W; 3rd, Seigne, JD. The cost of learning robotic-assisted prostatectomy. *Urology*., 2008, 72, 1068-72.

[10] Albani, JM; Lee, DI. Virtual reality-assisted robotic surgery simulation. *J Endourol*., 2007, 21, 285-7.

[11] Iavazzo, C; Papadopoulou, EK; Gkegkes, ID. Cost assessment of robotics in gynecologic surgery: A systematic review. *J Obstet Gynaecol Res*., 2014, 40, 2125-34.

[12] Blackmore, AE; Wong, MT; Tang, CL. Evolution of laparoscopy in colorectal surgery: an evidence-based review. *World J Gastroenterol*., 2014, 20, 4926-33.

[13] Ng, AT; Tam, PC. Current status of robot-assisted surgery. *Hong Kong Med J*., 2014, 20, 241-50.

[14] Gorter, RR; Heij, HA; Eker, HH; Kazemier, G. Laparoscopic appendectomy: State of the art. Tailored approach to the application of laparoscopic appendectomy? *Best Pract Res Clin Gastroenterol*., 2014, 28, 211-24.

[15] Magrina, JF. Outcomes of laparoscopic treatment for endometrial cancer. *Curr Opin Obstet Gynecol*., 2005, 17, 343-6.

[16] Schreuder, HW; Verheijen, RH. Robotic surgery. *BJOG*., 2009, 116, 198-213.

[17] Seamon, LG; Cohn, DE; Henretta, MS; et al. Minimally invasive comprehensive surgical staging for endometrial cancer: Robotics or laparoscopy? *Gynecol Oncol*., 2009, 113, 36-41.

[18] Salman, M; Bell, T; Martin, J; Bhuva, K; Grim, R; Ahuja, V. Use, cost, complications, and mortality of robotic versus nonrobotic general surgery procedures based on a nationwide database. *Am Surg*., 2013, 79, 553-60.

[19] Brunaud, L; Ayav, A; Zarnegar, R; et al. Prospective evaluation of 100 robotic-assisted unilateral adrenalectomies. *Surgery*., 2008, 144, 995-1001.

[20] Prewitt, R; Bochkarev V; McBride, CL; et al. The patterns and costs of the Da Vinci robotic surgery system in a large academic institution, *J Robotic Surg*., 2008, 2, 17-20.

[21] Winter, JM; Talamini, MA; Stanfield, CL; et al. Thirty robotic adrenalectomies: a single institution's experience. *Surg Endosc*., 2006, 20, 119-24.

[22] Morino, M; Beninca, G; Giraudo, G; Del Genio, GM; Rebecchi, F; Garrone, C. Robot-assisted vs laparoscopic adrenalectomy: a prospective randomized controlled trial. *Surg Endosc*., 2004, 18, 1742-6.

[23] Muhlmann, G; Klaus, A; Kirchmayr, W; et al. DaVinci robotic-assisted laparoscopic bariatric surgery: is it justified in a routine setting? *Obes Surg*., 2003, 13, 848-54.

[24] Buzad, FA; Corne, LM; Brown, TC; et al. Single-site robotic cholecystectomy: efficiency and cost analysis. *Int J Med Robot*., 2013, 9, 365-70.

[25] Breitenstein, S; Nocito, A; Puhan, M; Held, U; Weber, M; Clavien, PA. Robotic-assisted versus laparoscopic cholecystectomy: outcome and cost analyses of a case-matched control study. *Ann Surg*., 2008, 247, 987-93.

[26] Heemskerk, J; van Dam, R; van Gemert, WG; et al. First results after introduction of the four-armed da Vinci Surgical System in fully robotic laparoscopic cholecystectomy. *Dig Surg*., 2005, 22, 426-31.

[27] Keller, DS; Senagore, AJ; Lawrence, JK; Champagne, BJ; Delaney, CP. Comparative effectiveness of laparoscopic versus robot-assisted colorectal resection. *Surg Endosc*., 2014, 28, 212-21.

[28] Park, JS; Choi, GS; Park, SY; Kim, HJ; Ryuk, JP. Randomized clinical trial of robot-assisted versus standard laparoscopic right colectomy. *Br J Surg*., 2012, 99, 1219-26.

[29] Bertani, E; Chiappa, A; Biffi, R; et al. Assessing appropriateness for elective colorectal cancer surgery: clinical, oncological, and quality-of-life short-term outcomes employing different treatment approaches. *Int J Colorectal Dis*., 2011, 26, 1317-27.

[30] deSouza, AL; Prasad, LM; Park, JJ; Marecik, SJ; Blumetti, J; Abcarian, H. Robotic assistance in right hemicolectomy: is there a role? *Dis Colon Rectum*., 2010, 53, 1000-6.

[31] Rawlings, AL; Woodland, JH; Vegunta, RK; Crawford, DL. Robotic versus laparoscopic colectomy. *Surg Endosc*., 2007, 21, 1701-8.

[32] Baek, SJ; Kim, SH; Cho, JS; Shin, JW; Kim, J. Robotic versus conventional laparoscopic surgery for rectal cancer: a cost analysis from a single institute in Korea. *World J Surg*., 2012, 36, 2722-9.

[33] Wormer, BA; Dacey, KT; Williams, KB; et al. The first nationwide evaluation of robotic general surgery: a regionalized, small but safe start. *Surg Endosc*., 2014, 28, 767-76.

[34] Owen, B; Simorov, A; Siref, A; Shostrom, V; Oleynikov, D. How does robotic anti-reflux surgery compare with traditional open and laparoscopic techniques: a cost and outcomes analysis. *Surg Endosc*., 2014, 28, 1686-90.

[35] Nakadi, IE; Melot, C; Closset, J; et al. Evaluation of da Vinci Nissen fundoplication clinical results and cost minimization. *World J Surg*., 2006, 30, 1050-4.

[36] Anderberg, M; Kockum, CC; Arnbjornsson, E. Paediatric robotic surgery in clinical practice: a cost analysis. *Eur J Pediatr Surg*., 2009, 19, 311-5.

[37] Heemskerk, J; van Gemert, WG; Greve, JW; Bouvy, ND. Robot-assisted versus conventional laparoscopic Nissen fundoplication: a comparative retrospective study on costs and time consumption. *Surg Laparosc Endosc Percutan Tech*., 2007, 17, 1-4.

[38] Muller-Stich, BP; Reiter, MA; Wente, MN; et al. Robot-assisted versus conventional laparoscopic fundoplication: short-term outcome of a pilot randomized controlled trial. *Surg Endosc*., 2007, 21, 1800-5.

[39] Morino, M; Pellegrino, L; Giaccone, C; Garrone, C; Rebecchi, F. Randomized clinical trial of robot-assisted versus laparoscopic Nissen fundoplication. *Br J Surg*., 2006, 93, 553-8.

[40] Kang, CM; Kim, DH; Lee, WJ; Chi, HS. Conventional laparoscopic and robot-assisted spleen-preserving pancreatectomy: does da Vinci have clinical advantages? *Surg Endosc*., 2011, 25, 2004-9.

[41] Waters, JA; Canal, DF; Wiebke, EA; et al. Robotic distal pancreatectomy: cost effective? *Surgery*., 2010, 148, 814-23.

[42] Heemskerk, J; de Hoog, DE; van Gemert, WG; Baeten, CG; Greve, JW; Bouvy, ND. Robot-assisted vs. conventional laparoscopic rectopexy for rectal prolapse: a comparative study on costs and time. *Dis Colon Rectum*., 2007, 50, 1825-30.

[43] Hagen, ME; Pugin, F; Chassot, G; et al. Reducing cost of surgery by avoiding complications: the model of robotic Roux-en-Y gastric bypass. *Obes Surg*., 2012, 22, 52-61.

[44] Scozzari, G; Rebecchi, F; Millo, P; Rocchietto, S; Allieta, R; Morino, M. Robot-assisted gastrojejunal anastomosis does not improve the results of the laparoscopic Roux-en-Y gastric bypass. *Surg Endosc*., 2011, 25, 597-603.

[45] Curet, MJ; Curet M; Solomon, H; et al. Comparison of hospital charges between robotic, laparoscopic stapled, and laparoscopic handsewn Roux-en-Y gastric bypass, *J Robotic Surg*., 2009, 3, 75-78.

[46] Schraibman, V; Macedo, AL; Epstein, MG; et al. Comparison of the morbidity, weight loss, and relative costs between robotic and laparoscopic sleeve gastrectomy for the treatment of obesity in Brazil. *Obes Surg*., 2014, 24, 1420-4.

[47] Gelmini, R; Franzoni, C; Spaziani, A; Patriti, A; Casciola, L; Saviano, M. Laparoscopic splenectomy: conventional versus robotic approach--a comparative study. *J Laparoendosc Adv Surg Tech A*., 2011, 21, 393-8.

[48] Bodner, J; Kafka-Ritsch, R; Lucciarini, P; Fish, JH; 3rd, Schmid, T. A critical comparison of robotic versus conventional laparoscopic splenectomies. *World J Surg*., 2005, 29, 982-5, discussion 5-6.

In: Encyclopedia of Surgery (22 Volume Set)
Editors: Andreas Lehrer and Kristin Mueller
ISBN: 978-1-53618-329-0
© 2020 Nova Science Publishers, Inc.

Chapter 396

THERAPEUTIC POTENTIAL OF ADIPOSE-DERIVED STROMAL CELLS IN WOUND HEALING, ANTI-AGING, AND PLASTIC SURGERY

Changyue Xue and Guo Li*

The State Key Laboratory of Oral Diseases,
National Clinical Research Center for Oral Diseases,
West China Hospital of Stomatology, Sichuan University, Chengdu, China

ABSTRACT

Stem cells are undifferentiated cells with important properties for self-renewal and differentiation. Adipose-derived stem cells (ASCs) have many advantages, such as accessibility and abundance, compared to other kinds of stem cells. Regeneration therapies using ASCs have received much attention in the treatment of various dermatological diseases. In previous studies, ASCs were shown to have antioxidant, whitening, and wound-healing effects in the skin through secretion of various growth factors and by activating fibroblasts. There is an abundance of literature supporting the efficacy of ASCs in both aesthetic and reconstructive cases. In dermatology, there are also many studies on the effective application of ASCs, such as improved retention in autologous fat transplantation, antioxidant action, and whitening effects. In this chapter, we will summarize the therapeutic potential and clinical applications of ASCs in wound healing, anti-aging, and plastic surgery.

Keywords: adipose-derived stem cells, wound healing, anti-aging, plastic surgery

INTRODUCTION

The ability of stem cells to self-renew, to secrete trophic factors, and to differentiate into a multitude of cell types has allowed for the development of more flexible cell therapies to

* Corresponding Author's Email: vicentguoli@hotmail.com; Fax: +86-28-85582167.

redefine the classic "autologous tissue transplant" and offer more customizable treatment options. Recent advances in regenerative medicine, in particular the discovery of multipotent, easily accessible stem cells such as adipose-derived stem cells (ASCs), have provided opportunities for using autologous stem cell transplants in regenerative therapies. Compared with bone marrow-derived mesenchymal stem cells, ASCs are particularly useful, as they can be easily harvested with minimal donor site morbidity and have broad differentiation potential. In addition, ASCs have higher yields and greater proliferative rates in culture. ASCs are not only precursors to adipocytes, but also multipotent progenitors to a variety of cells including osteoblasts, chondrocytes, myocytes, epithelial cells, and neuronal cells. This discovery has created the potential to treat a variety of tissue defects from a single, easily accessible autologous cell source.

ASCs have been shown to play a significant role in anti-aging and skin regeneration by forming tissue consisting of hypodermis, dermis, and epidermis. Recent studies also have shown the utility of ASCs in improving wound healing, describing their ability to regenerate soft tissues and their remodeling capacity provided by their unique cytokine and growth factor profiles (Figure 1). There have been many clinical applications about ASCs for compensation of skin defects, wound healing, and plastic surgery. The purpose of this chapter is to summarize the utilization of ASCs in wound healing, anti-aging, and plastic surgery, and to describe the current limitations of ASC treatments with regard to developing translatable clinical therapies. Understanding the current status of clinical ASCs treatments and defining the challenges ahead may bring us closer to achieving desired outcome while minimizing unwanted side effects with these therapies.

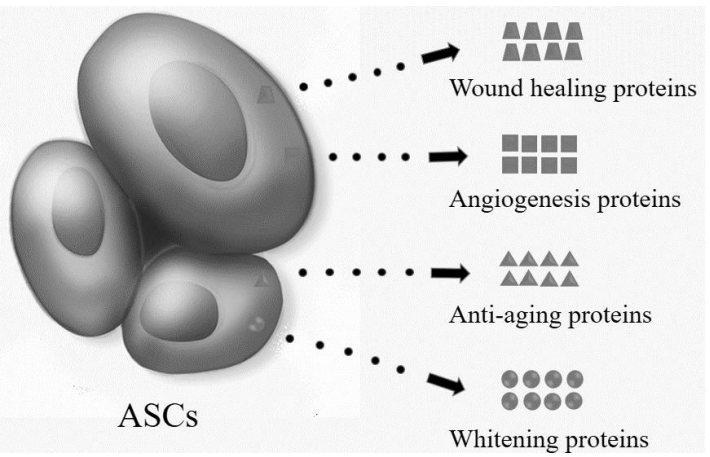

Figure 1. Paracrine effect of ASCs in anti-aging and skin regeneration.

APPLICATIONS OF ASCS IN WOUND HEALING

Background

Wound healing is a complex chain of events involving interactions between different cells and tissues, and tissue repair is a lengthy process. The ultimate goal for tissue

engineering is to regenerate skin so that the complete structural and functional properties of a wounded area can be restored to the levels before injury [1]. To accelerate skin regeneration, many skin tissue engineering techniques such as the use of various scaffolds, cells, and growth factors, have been researched [2]. However, only a subset of tissue functions can be restored with existing tissue engineering techniques.

The purpose of tissue engineering is to heal and regenerate injured organs using a combination of cells, cytokines, and biomaterials. The limited availability of human cells capable of self-renewal and differentiation into multiple cells is a barrier for expansion and development of regenerative medicine. Stem cells and progenitor cells provide a potential approach to this dilemma.

In Vitro Studies and Murine Studies

Mesenchymal stem cells (MSCs) are an attractive cell therapy source for the regeneration of damaged tissues, as they are capable of self-renewal and can differentiate into various cell lineages [3]. In cutaneous repair, MSCs can significantly accelerate wound closure, exhibiting increased re-epithelialization, neovascularization, and regeneration of skin appendages [4]. However, several studies have claimed that the effects of MSC therapy are unremarkable in the absence of scaffolds or stimulators [5]. Interestingly, ASCs have surface markers and gene profiles similar to MSCs, and their soluble factors are more sufficient [6]. Because they are conveniently isolated compared with MSCs and show extensive proliferative capacities ex vivo, ASCs hold great promise for use in wound repair and regeneration.

The most abundant and accessible source of adult stem cells come from adipose tissue; ASCs are available in liposuction aspirate [7-9]. Despite its rapid translation to clinical practice, the mechanism of its function is not well characterized. It was initially hypothesized that immature stem cells can migrate to the damaged area, differentiate into the cell type of the injured tissue, repopulate the diseased organ with new healthy cells, and subsequently repair the tissue (building-block function). However, the levels of grafted cells and their survival rates are too low, i.e., < 5%, to be therapeutically relevant [10-12]. Importantly, much of the functional improvement and inhibition of injury afforded by stem cells can be achieved by treatment with cell-free conditioned media derived from ASCs [13]. Thus, it can be deduced that ASCs may exert their beneficial effects not only by direct cell-to-cell contact, but also by complex paracrine actions (manager function) in addition to building-block functions.

Earlier studies have already shown that ASCs have a positive influence on wound healing, as they are attracted to the wound site and influence wound healing process via paracrine mechanisms as well as fusion and differentiation; for example, into keratinocytes, fibroblasts, endothelial cells, sweat glands, sebaceous glands, and hair follicles [14-17]. Additionally, some basic fibroblast growth factor (bFGF), vascular endothelial growth factor (VEGF), and human growth factor (HGF)-positive ASCs were detected in the wound bed. bFGF is one of the most important growth factors in wound healing because it affects cell proliferation, matrix deposition, and angiogenesis [18]. VEGF is one of the key factors that promotes vasculogenesis and angiogenesis [19], and is considered to play an indispensable role in myogenic differentiation [20], wound healing [21], and many other processes [22]. HGF is another potent proangiogenic factor that induces cell migration and proliferation and

inhibits apoptotic cell death of endothelial cells [23]. Prior studies also suggested that transplanting ASCs induces neovascularization and improves blood flow to ischemic tissue in animal models [24,25]. Furthermore, ASC-conditioned media (ASC-CM) increased the secretion of type I collagen from dermal fibroblasts as well as stimulating fibroblast migration in in vitro wound-healing models. In addition to the in vitro evidence, ASCs have also been shown to be effective in wound healing in animal models. Topical administration of ASCs prominently reduced the wound size by 34% and accelerated the re-epithelialization at the wound edge. Similar to ASC treatment, ASC-CM treatment also accelerated wound healing in laser-induced burn animal models.

Shokrgozar et al. supplemented collagen scaffolds with ASCs and showed improved epidermal regeneration in burn wounds compared with the control group in ten rats [26]. The surface area of the wound and histopathological findings regarding the formation of dermis and epidermis on the scaffolds supplemented with ASCs were reported. Loder et al. studied the effects of isolated autologous ASCs, fat, ASCs and fat, and phosphate-buffered saline grafts on burns of twenty mice [27]. There was a significant decrease in wound surface area in all groups compared with controls, but not when compared with each other. Groups with ASC treatment and mixed groups showed a significant decrease in wound depth apoptosis. Karimi et al. reported significant increases in fibroplasia and collagen remodeling and a decrease in the surface area of wounds after treatment with ASCs compared with fat grafts in thirty mice [28]. The differences in eschar thickness, inflammatory cell counts, epithelialization, and angiogenesis, however, were not significant.

Murine studies have shown histologic improvements in angiogenesis, collagen organization, and neuropathic pain. There is a lack of randomized controlled trials and quantitative analysis supporting the efficacy of ASCs in burn healing. However, this emerging therapy shows great potential.

Clinical Studies

Human ASC (hASC) therapy has also been successfully applied to wound injury treatments. In 2012, Collawn et al. confirmed that ASCs accelerated wound healing in an organotypic graft culture model [29]. Park et al. showed that spheroid grafting of hASCs treated with low-level light irradiation can enhance ischemic wound healing [30]. Furthermore, Song et al. generated v-myc-expressing hASCs as a long-term sustainable stem cell model for promoting wound healing [31]. Other studies have also found that transplantation of ASCs can promote regeneration of expanded skin, which confirms the effectiveness of ASCs in treating wounds in human models. The applications of ASCs for wound healing are widely recognized as a promising tactic in the future [32]. Existing evidence suggests that ASCs may be useful for improving the survival of diabetic skin flaps [21, 33]. Recently, the effectiveness of ASCs in improving the viability of skin flaps in non-diabetic mice was demonstrated in a study by Lu et al. [34], in which they injected ASCs locally at the flap pedicle and found a nearly two-fold increase in the surviving area compared with a flap without ASC administration. Furthermore, emerging works [35] have shown that the healing of diabetic wounds can also be improved by implantation of ASCs. However, it is still unclear whether topical applications of ASCs could improve the viability of diabetic skin flaps, which represent a more complicated pathophysiological condition and lacks an

effective clinical intervention. Hypoxia amplifies the paracrine effects of ASCs by enhancing the secretion of growth factors [33, 36]. For example, ASCs improved the perfusion in hindlimb ischemia induced by the ligation of femoral arteries, and hypoxic culture conditions enhanced the function of ASCs [37]. Because inflammation and oxidative stress near the wound area in the skin evokes an oxygen deficit, the wound-healing effects of ASCs were investigated in relation to hypoxia. As expected, the secretomes of ASCs cultured under hypoxic conditions shrunk the wound area considerably compared with those cultured under normoxic conditions. Furthermore, analysis of mRNA and protein expression levels revealed that hypoxia up-regulated several growth factors such as VEGF and bFGF. An inhibition study using neutralizing antibodies of VEGF and bFGF induced delayed wound healing, indicating that VEGF and bFGF at least partially account for the hypoxia-enhanced functionality of ASCs. These results suggest that the wound-healing effects of ASCs are at least partially regulated by secretory factors and are amplified by hypoxia.

Currently, chronic wounds represent a major problem in medical field, as their incidence is continuously increasing because of an aging population and a rise in the incidence of underlying diseases [38]. It is estimated that approximately 2% of the population in industrialized countries may be affected by chronic wounds in their lifetime [39]. Physiological wound healing is a complex biological process proceeding from inflammation through proliferation to maturation. It requires well-orchestrated interactions between mediators, resident cells, and infiltrating cells. Basal keratinocytes and fibroblasts play a key role in this process, as they proliferate and migrate, eventually leading to complete wound closure. ASCs can also contribute to the regeneration process for chronic wounds, as they have the ability to replace damaged tissues [40]. With regard to the treatment of burn scars, histological analysis in human studies revealed that ASCs can increase vascularity, new collagen deposition, and reorganization [41-43]. Studies also reported improvements in mimic features, skin texture, thickness, color [44], and patient satisfaction [45]. The utility of lipofilling as a secondary measure to improve previous treatments is also considered to be feasible. Although the regenerative capacity of ASCs is an alluring concept [46], relatively few human studies detailed the use of ASC-supplemented grafts in burns [47]. Two human studies investigated wound healing in the acute phase. A study by Piccolo et al. [48] showed improved wound healing and fibrosis in some acute and subacute wounds. Although there was a lack of controls, the study had sufficient detail regarding the procedures and adequate follow-up. The case study using ASCs from discarded burn tissue was a small case study that was too difficult to assess, but the cells were shown to possess the same adipogenic, osteogenic, and chondrogenic potential as their abdominally derived counterparts [49-51]. Therefore, they may represent a source of multipotent cells in patients with extensive burns for whom there may not be enough viable tissue to perform subcutaneous liposuction to obtain such cells from non-injured sites. Indeed, as the percentage of total surface area affected by burn injury increases, so does the availability of these ASCs from discarded burn tissue.

Although limited in number, studies detailing the use of ASCs on burn wounds and scars had positive results. Murine studies have suggested that ASC therapy may improve outcomes when applied on a newly acquired burn wound. Although some studies had conflicting results regarding the effects of ASCs on the wound surface area, most concluded that early use of ASC therapy can alter the course of the remodeling phase of healing by decreasing apoptosis and increasing fibroplasias [27, 28].

APPLICATIONS OF ASCS IN ANTI-AGING

Background

As individuals age, the skin undergoes some changes, including anomalous pigmentation, thinning, and loss of elasticity, owing to both genetic and environmental factors. These changes may worsen, turning into precancerous and cancerous diseases. Skin aging, which is mostly characterized by loss of elasticity and generation of wrinkles, has preoccupied human for centuries and inspired us to make great efforts to prevent it, yet it still remains a conundrum. A variety of medical treatments and topical cosmeceuticals have been used to treat some symptoms of photoaging; however, the outcomes have been less than satisfactory. ASCs display multi-lineage developmental plasticity and secrete various growth factors that control and manage damaged neighboring cells. Recently, the production and secretion of these growth factors has been reported to be an indispensable function of ASCs, and diverse regenerative features of ASCs have been reported in the skin. Therefore, ASCs and their soluble factors demonstrated promise for the treatment of photoaging.

As skin is exposed directly to the outside environment, it undergoes not only intrinsic aging, but also extrinsic aging; both are associated with structural and functional changes in cutaneous tissue [52, 53]. Aging damage gives rise to a decline in the amount, lifespan, and function of fibroblasts in the dermis, leading to the appearance of aging; this indicates the significance of fibroblasts in researching mechanisms and further therapies to prevent skin aging. In in vitro studies, fibroblasts can be serially passaged until they reach replicative senescence to simulate intrinsic aging [54, 55]. On the other hand, it is widely perceived that ultraviolet rays serve as a major extrinsic factor (approximately 80%) for skin aging; ultraviolet radiation B (UVB)-irradiated fibroblasts have been established as an experimental model in many studies related to skin aging [56, 57].

Biological Basis for Soft Tissue Therapy Using ASCs

ASCs stand out as an upstart in the field of anti-aging, owing to their secretome, which has been identified through proteomics, including transforming growth factor-beta (TGF-β), platelet derived growth factor (PDGF), hepatocyte growth factor (HGF), pigment epithelium-derived factor (PEDF), interleukins, and many antioxidants such as insulin-like growth factor-binding proteins (IGFBPs) and superoxide dismutase 2 (SOD2) [58-60]. ASCs have been proven to communicate with and regulate surrounding cells through a paracrine mechanism; thus, ASC-CM, which not only contains all bioactive components provided by ASCs but also has the advantages of easier storage and safer application over ASCs, has recently drawn much attention. Numerous studies have confirmed that the secretome of ASCs can attenuate the symptoms of photoaging. Kim et al. demonstrated that subcutaneous injection of ASCs can improve UVB-induced wrinkles and increase dermal thickness in mice [61]. Song et al. reported that ASC-CM performed better than ASC co-culture in improving proliferation and converting necrotic or late apoptotic cells to early apoptotic cells in UVB-irradiated HDFs [62]. These results were consistent with that of the present study: ASC-CM increased the proliferative activity and decreased the apoptotic cell ratio of UVB-irradiated HDFs. As

shown in the studies by Xu and Kim et al., ASC-CM prevented HDFs from reaching UVB-induced G1 phase arrest [63], a condition in which proliferation stops, senescence occurs, and apoptosis is triggered through repressing p16 expression [62, 64]. However, further investigation of this and more related markers are required to explain these results. Very few studies have reported on the impact of ASCs on intrinsic aging damage, as Shen et al. demonstrated in a recent study that ASCs can increase SA-β-Gal mRNA expression in co-cultured HDFs from young and old volunteers. As we know, SA-β-Gal has been confirmed to be a reliable biomarker of cellular senescence, expression of both its mRNA and protein increase significantly in senescent cells, as does its enzymatic activity. Shen et al. hypothesized that co-culture of ASCs may accelerate fibroblast senescence [65]; to some extent, this deviated from our results: ASC-CM treatment had no impact on SA-β-Gal activity in serially passaged HDFs in vitro; this may indicate that existing and accumulated damages at the genetic level cannot be easily reversed. The inconsistency in these results may indicate that ASCs do not simply act on HDFs via paracrine growth factors; there may exist a feedback loop between HDFs and ASCs through cell-to-cell crosstalk.

The production and secretion of growth factors is considered an essential function of ASCs; various rejuvenating effects of ASCs on the skin have been revealed61. For example, it was confirmed that ASCs and ASC-CM stimulated both collagen synthesis and migration of dermal fibroblasts during the wound-healing process [66]. ASC-CM also inhibited melanogenesis by down-regulating tyrosinase and tyrosinase-related protein-1 (TRP-1) expression in B16 melanoma cells [67]. In addition, ASCs and their secretory factors protected dermal fibroblasts from oxidative stress induced by chemicals and UVB irradiation [68]. In a clinical setting, intradermal injection of processed lipoaspirate cells (approximately 20–30% ASCs) induced an increase in dermal thickness and a reduction of wrinkles [69]. This evidence supports the important role of ASCs and their secretory factors in protecting the skin against photodamage. Chronic UV radiation harms human skin, affecting skin tone as well as its resiliency and results in premature aging (photoaging), the symptoms of which include wrinkles, laxity, sallowness, mottled pigmentation, leathery texture, and, in the long run, precancerous (lentigo maligna, actinic keratoses) and cancerous changes. Besides, ASCs may promote collagen synthesis and angiogenesis as well as exhibit protective effects against D-galactose-induced skin aging in mice [70, 71]. These reports indicate the wealth of potential applications of ASCs in the anti-aging industry.

Several studies into the pathophysiology of photoaging have uncovered similarities with certain aspects of chronic wounds [72, 73]. Histologically, photo-aged skin shows significant changes in ECM composition [74]. The collagen component of dermal ECM is responsible for the strength and resiliency of skin and is deeply involved in the pathology of photoaging and wounds.

Antioxidant Effects of ASCs

Currently, a popular topic in dermatology is the exploration of any possible means to counteract the injurious effects of anatomical-functional skin damage. Substances that prevent free radical-induced skin damage are of great interest. Although there are few reports on the antioxidant capabilities of ASCs, some evidence shows that the secretomes of ASCs may have a protective effect during oxidative injury. For instance, interleukin-6 (IL-6) attenuates

epithelial cell death induced by hydrogen peroxide [75]. This evidence suggests that ASCs exhibit an antioxidant effect. However, the underlying mechanism of this protective effect is yet to be determined.

As ASCs are located under the skin, specifically beneath dermal fibroblasts, they may play key roles in skin damage involving oxidative stress. Consequently, the antioxidant effects of ASC-CM on dermal fibroblasts were investigated in an oxidative injury model. In ASC-CM, various antioxidant proteins such as IGF binding proteins, IL-6, PEDF, SOD2, and HGF were examined using proteomic analysis and an enzyme-linked immunosorbent assay (ELISA). A cell-survival assay demonstrated that incubation in ASC-CM protected dermal fibroblasts from free radicals produced by tbOOH and induced morphological changes. Furthermore, activities of both SOD and glutathione peroxidase were enhanced in dermal fibroblasts after treatment with ASC-CM. Cell cycle analysis revealed that ASC-CM treatment reversed apoptotic cell death induced by reactive oxygen species (ROS), as shown by a notable decrease of sub-G1 phase dermal fibroblasts. Recent studies have revealed that ASC-CM inhibited the proliferation of B16 melanoma cells without inducing apoptosis. Even though the mechanisms responsible for the anticancer effects of ASC-CM are yet to be fully characterized, secretory factors of ASCs prolonged the G1 phase in B16 cells (G1 arrest), delaying the progression of cancer. Considering the antioxidant and anticancer effects of ASC-CM, it is reasonable to assume that ASCs play an important defensive role against oxidative stress in the skin.

Potential Applications of ASCs in Photoaging

Sun exposure harms the skin due to the effects of UV radiation. UVA and UVB reportedly alter particular cellular pathways, resulting in several developments. UVB radiation leads to redness of the skin, whereas UVA can penetrate deeper into the dermis where it causes more DNA damage. Exposure to UV radiation has a notable effect on collagen production as well as pigmentation, and is responsible for skin thickening, mottled pigmentation, and wrinkling [76]. However, ASCs protect the skin from UV irradiation, improve wrinkling, and reduce pigmentation.

Anti-Wrinkling Effects of ASCs

Topical application of several growth factors stimulates the repair of photo-damaged skin, leading to new collagen synthesis, epidermal thickening, as well as a clinical appearance of smoother skin with less visible wrinkling [77]. A cell-based treatment using autologous cultured dermal fibroblasts was developed to promote skin texture; the treatment showed relatively optimistic results in clinical applications [78]. Because several growth factors involved in skin repair are secreted by ASCs, and ASCs have characteristics that are similar to fibroblasts, it was hypothesized that ASCs may improve UVB-induced wrinkling. The use of soft tissue fillers containing ASCs to restore volume to depressed areas of skin to maintain a youthful appearance has gained popularity in recent years. Such applications are very popular because of their simplicity, low invasiveness, procedure reversibility, and relatively safe profile. However, as the use of fillers has increased, so has the number of reported

complications. These complications, including vascular compromise and skin necrosis, are mostly significant and permanent.

Whitening Effects of ASCs

Clinically, photo-aged skin is coarsely wrinkled and exhibits associated dyspigmentation and telangiectasia. In Asians, the principal manifestation of photodamage is pigmentary change, rather than wrinkling [79, 80]. Antioxidants inhibit chemical reactions that result in melanin formation, change the type of melanin formed, and interfere with the distribution of pigment and melanosome transfer. Therefore, they are ideal candidates for skin whitening agents. In addition, several growth factors reportedly modulate melanogenesis and are also major regulators of tyrosinase and TRPs [81-83]. Because ASC-CM has potent antioxidant capabilities and contains several whitening growth factors, the whitening effects of ASCs were investigated. ASC-CM was harvested and its inhibitory effects were studied in melanoma B16 cells. ASC-CM treatment attenuated both the synthesis of melanin as well as tyrosinase activity in a dose-dependent manner. To further clarify the underlying mechanisms of the whitening effects of ASC-CM, melanogenic proteins were qualified using western blot analysis. Although expression of microphthalmia-associated transcription factor (MITF) and TRP2 remained unchanged, ASC-CM treatment reduced the expression of tyrosinase and TRP1. TGF-1, a potent regulator of melanogenic proteins, was neutralized by adding a blocking antibody to ASC-CM, and the down-regulation of tyrosinase and TRP1 was almost reversed. Although the exact mechanism responsible for the whitening action of ASCs has not been fully characterized, secretory factors may down-regulate the expression of melanogenic enzymes; TGF-1 plays a key role.

APPLICATIONS OF ASCS IN PLASTIC SURGERY

Background

Recent advances in tissue engineering, especially the discovery of multipotent, easily accessible stem cells such as ASCs, have provided the potential to use autologous stem cell transplants in regenerative therapies. The field of plastic surgery is centered on the restoration and enhancement of the body, and is logically positioned to utilize such new technologies focused on the repair and replacement of diseased cells and tissues [84]. The ability of stem cells to self-renew, to secrete trophic factors, and to differentiate into different cell types has made it possible for the development of more flexible therapies to redefine the classic "autologous tissue transplant" and to offer more customizable treatment options. ASCs are being utilized in a variety of different applications in plastic surgery [85-89], and as our understanding of the basic science of stem cells continues to develop, plastic surgeons should be better prepared for the translational and clinical implications of this progress.

The Biological Basis for Soft-Tissue Therapy Using ASCs

Early work suggests that injecting ASCs into soft tissue or into a defect will not alone produce a soft-tissue fill. A therapeutic strategy must be used to leverage the unique aspects of these cells. One strategy is to use a tissue engineering approach, combining cells stimulated with certain chemical compounds with a matrix or scaffold to "manufacture" an implantable neoadipose construct. Several potential scaffolds combined with cells have been investigated for their utility in soft-tissue treatment. In one example, preadipocyte cells, which are similar—if not identical—to ASCs, were combined with the resorbable material poly (lactide-co-glycolide acid) (PLGA). In this study, although initial results were promising, analysis after 5 to 12 months showed a complete absence of fat and PLGA [90, 91]. A similar study compared the hyaluronic acid sponge, HYAFF 11, with collagen sponges augmented with ASCs. They found that HYAFF 11 was superior to collagen in supporting the differentiation and expansion of ASCs [92].

Clinical Applications

The regenerative potential of ASCs has been confirmed for many years, which has resulted in the advent of techniques such as fat grafting for replacement of soft tissue. The autologous tissue utilized in fat grafting contains a variety of cells, including ASCs [93], which support tissue neo-vascularization [94] and regeneration through the secretion of various growth factors [95]. Cell-assisted lipotransfer (CAL), a technique first described by Matsumoto et al. in 2006, combines aspirated fat with concentrated ASCs to create stem cell-rich fat grafts [96]. This approach resulted in considerable improvements in the survival rates of transplanted fat, with less fat resorption [97] and a decrease in the adverse effects of lipoinjection such as cyst formation and fibrosis (Figure 2). In breast tissue, fat grafting has also been connected with fat necrosis and calcifications, which can complicate breast imaging and breast cancer surveillance [98, 99]. Coincidentally, Yoshimura et al. used CAL in 2008 for cosmetic breast augmentation in forty patients and reported a favorable aesthetic outcome with no major complications [100]. Thereafter, CAL has been used in other studies involving breast augmentation [101-103] as well as for facial lipoatrophy [104, 105] and augmentation during facelifts and facial contouring surgeries, among others [106].

Very recently, a clinical multicenter trial on breast reconstruction with stem cell-enhanced fat grafting after a partial mastectomy was published. Processed ASCs were utilized to enrich the fat graft. Autologous ASC-enriched fat grafting for breast augmentations in a prospective series of twenty patients was also reported by a Japanese group without conclusions about oncological concerns with 9 months of follow-up [101]. Kolle et al. demonstrated significant fat graft survival in human cases after ex vivo expansion of collagenase-processed ASCs used for CAL when compared to traditional methods of fat grafting [107]. Alternative ASC therapies have also been explored, including techniques such as stem cell-enriched tissue injections that combine traditional fat grafts and subsequent ASC injections [108, 109]. These preliminary studies showed that ASCs might allow for improvements in the retention and volume-restoration capabilities of transplanted fat, though the applicability of these studies in the United States is limited because of the methods used (enzymatic isolation). A Spanish group's report showed promising results from combining

ASCs with fibrin glue for treatment of fistulas in Crohn's patients [110]; this study stands in the vanguard as a report on the application of ASCs in clinical practice. Thus, as a feasibility study, this investigation warrants the attention of plastic and reconstructive surgeons. Since the early reports describing a population of ASCs with multi-lineage differentiation potential by Zuk et al. [111] in 2001, our understanding of the molecular biology of ASCs and their potential functional benefits has rapidly gained pace. In 2006, Moseley et al. [112] reported on preliminary results from Japan indicating that combining ASC seeding with conventional adipose transfer for soft tissue fill is beneficial. Studies from their laboratory and ours have begun to uncover the molecular and cell biology underlying this potentially advantageous approach. In essence, early data suggested that ASCs enhance local microvascular establishment when introduced in the therapeutic milieu, providing support to the adipose graft. As such, this early boost in vascular support would buttress the initial take of the graft and minimize long-term atrophy, thereby providing superior maintenance of graft volume fill over time.

Concerns have been raised over the application of ASCs in the form of CAL for breast augmentation after breast cancer treatment. For example, studies have revealed that MSCs increase the risk of metastatic potency in breast cancer cells when the two were mixed and re-implanted [113-115]. While there is little evidence in terms of CAL therapy for breast augmentation post-mastectomy, the American Society of Plastic Surgeons has concluded that fat grafting does not increase the risk of breast cancer recurrence. It appears that ASCs may enhance the growth of active cells without affecting dormant cells, but because more research is needed, the current recommendations are such that CAL therapy should be delayed for reconstructive purposes in breast cancer treatment until there is no evidence of active disease for a period of 7 years [116].

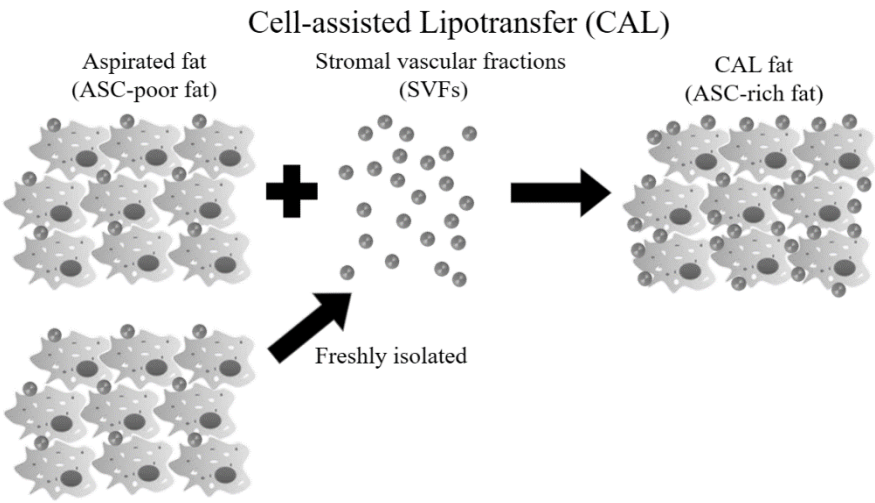

Figure 2. Scheme of cell-assisted lipotransfer. Relatively ASC-poor aspirated fat is converted to ASC-rich fat by supplementing ASCs isolated from the other half of the aspirated fat. The ASCs are attached to the aspirated fat, which is used as a scaffold in this strategy.

Barriers to Clinical Entry

In 2006, Yoshimura et al. described a cell population in the liposuction aspirate fluid; these cells exhibited phenotypic properties similar to those of ASCs harvested in the traditional manner (collagenase) from processed lipoaspirate cells. However, the yield was reduced by a third when comparing to the two approaches [117]. Thereafter, additional studies have been published touting the benefits of non-enzymatic ASC isolation. In 2010, Francis et al. described a method of ASC "Rapid Isolation" in 30 min, which excluded the use of collagenase; however, an obvious disadvantage of this study was the low yield of less than 250,000 cells from a starting volume of about 250 ml liposuction aspirate fluid [118]. Zeng et al. investigated a "rapid and efficient" form of non-enzymatic ASC isolation in which adipose tissue is cut into small pieces and placed in culture flasks with 100% FBS, where the plastic-adherent cells were allowed to grow for several days [119]. One significant disadvantage to this method is the requirement to expand the cell population using calf serum. Most recently, Shah et al. described a form of non-enzymatic ASC isolation by combining the cells of the liposuction aspirate fluid with cells captured from the processed lipoaspirate tissue wash, which is typically discarded prior to collagenase digestion [120]. They observed a significant improvement in MSC-related phenotypic markers and similar adipogenic and osteogenic differentiation characteristics. While their isolation time was cut by one-third, they observed a 19-fold decrease in ASC isolation when compared to the traditional method.

Most convincingly, Kolle et al. showed a clear benefit to CAL over lipotransfer alone. They isolated and expanded ASCs ex vivo from human patients, followed by lipotransfer to the arms of the patients with or without ASC supplementation. They demonstrated a 65% improvement in fat graft survival after 4 months in the group with ASC treatment. The major drawback to their experimental model was that in order to achieve these results, 34 ml lipotransfer was supplemented with 6.5×10^8 ASCs, or 2,000 times the physiological level [107]. The approaches of "rapid isolation," as previously mentioned, demonstrated the ability to isolate ASCs without the aid of enzymatic digestion, but at a cost of greatly reduced yields.

There is promise in capitalizing on the plastic-adherent properties of ASCs as a form of non-enzymatic isolation. Doi et al, The same group that first described the isolation of cells from the LAF, has reported that an adherent column of rayon-polyethylene non-woven fabrics may also be useful for isolating ASCs, though at a lower yield than traditional methods [121]. Further advances in harnessing the plastic-adherent properties of these cells are obviously needed, as Buschmann et al. demonstrated that 30-50% of ASCs remain in suspension after 24 h of primary culture [122].

PERSPECTIVES

Participants

The pharmacology of ASCs and ASC-derived secretory factors that are involved in wound healing, anti-aging, and plastic surgery have been reviewed in this paper. To date, applications of ASCs and their secretory factors have been investigated mainly in vitro and in animal models; more clinical trials in humans are needed. Because ASCs and ASC-derived

secretory factors have anti-wrinkling, antioxidant, and skin-whitening effects, they are regarded as promising agents. However, ASCs are difficult both to handle and to commercialize, approaches to overcome these barriers are needed, but many questions remain unanswered. The long-term safety of CAL in previously cancerous areas remains unknown. While we are still uncovering the exact mechanism of stem cell function, whether paracrine or differentiation induced, the discovery of the very abundant ASCs will allow for major advancements in tissue engineering, particularly pertaining to therapeutics. In addition, it may become clear that these therapies will need to be individually tailored if it is found that patients vary in their responses to these cells or the trophic factors they produce. The ultimate answer will likely be achieved by the combined efforts of basic scientists, clinicians, and biomedical engineers.

REFERENCES

[1] Chen M, Przyborowski M, Berthiaume F. 2009. "Stem cells for skin tissue engineering and wound healing." *Critical Reviews in Biomedical Engineering* 37:399-421.

[2] Metcalfe AD, Ferguson MW. 2007. "Bioengineering skin using mechanisms of regeneration and repair." *Biomaterials* 28:5100-5113.

[3] Kern S, Eichler H, Stoeve J, Kluter H, Bieback K. 2006. "Comparative analysis of mesenchymal stem cells from bone marrow, umbilical cord blood, or adipose tissue." *Stem cells* 24:1294-1301.

[4] Wu Y, Zhao RC, Tredget EE. 2010. "Concise review: bone marrow-derived stem/progenitor cells in cutaneous repair and regeneration." *Stem cells* 28:905-915.

[5] Cha J, Falanga V. 2007. "Stem cells in cutaneous wound healing." *Clinics in dermatology* 25:73-78.

[6] Izadpanah R, Trygg C, Patel B. 2006. "Biologic properties of mesenchymal stem cells derived from bone marrow and adipose tissue." *Journal of cellular biochemistry* 99:1285-1297.

[7] Huang T, He D, Kleiner G, Kuluz J. 2007. "Neuron-like differentiation of adipose-derived stem cells from infant piglets in vitro." *The journal of spinal cord medicine* 30 Suppl 1:S35-40.

[8] Schachinger V, Erbs S, Elsasser A. 2006. "Intracoronary bone marrow-derived progenitor cells in acute myocardial infarction." *The New England journal of medicine* 355:1210-1221.

[9] Marenzi G, Bartorelli AL. 2007. "Improved clinical outcome after intracoronary administration of bone marrow-derived progenitor cells in acute myocardial infarction: final 1-year results of the REPAIR-AMI trial." *European heart journal* 28:2172-2173.

[10] Crisostomo PR, Markel TA, Wang M, Lahm T, Lillemoe KD, Meldrum DR. 2007. "In the adult mesenchymal stem cell population, source gender is a biologically relevant aspect of protective power." *Surgery* 142:215-221.

[11] Uemura R, Xu M, Ahmad N, Ashraf M. 2006. "Bone marrow stem cells prevent left ventricular remodeling of ischemic heart through paracrine signaling." *Circ Res* 98:1414-1421.

[12] Wang M, Tsai BM, Crisostomo PR, Meldrum DR. 2006. "Pretreatment with adult progenitor cells improves recovery and decreases native myocardial proinflammatory signaling after ischemia." *Shock* 25:454-459.

[13] Patel KM, Crisostomo P, Lahm T. 2007. "Mesenchymal stem cells attenuate hypoxic pulmonary vasoconstriction by a paracrine mechanism." *The Journal of surgical research* 143:281-285.

[14] Cho HH, Kyoung KM, Seo MJ, Kim YJ, Bae YC, Jung JS. 2006. "Overexpression of CXCR4 increases migration and proliferation of human adipose tissue stromal cells." *Stem cells and development* 15:853-864.

[15] Kataoka K, Medina RJ, Kageyama T. 2003. "Participation of adult mouse bone marrow cells in reconstitution of skin." *The American journal of pathology* 163:1227-1231.

[16] Nie C, Yang D, Xu J, Si Z, Jin X, Zhang J. 2011. "Locally administered adipose-derived stem cells accelerate wound healing through differentiation and vasculogenesis." *Cell transplantation* 20:205-216.

[17] Wu Y, Chen L, Scott PG, Tredget EE. 2007. "Mesenchymal stem cells enhance wound healing through differentiation and angiogenesis." *Stem cells* 25:2648-2659.

[18] Heydarkhan-Hagvall S, Schenke-Layland K, Yang JQ. 2008. "Human adipose stem cells: a potential cell source for cardiovascular tissue engineering." *Cells, tissues, organs* 187:263-274.

[19] Millauer B, Wizigmann-Voos S, Schnurch H. 1993. "High affinity VEGF binding and developmental expression suggest Flk-1 as a major regulator of vasculogenesis and angiogenesis." *Cell* 72:835-846.

[20] Kim MH, Hong HN, Hong JP. 2010. "The effect of VEGF on the myogenic differentiation of adipose tissue derived stem cells within thermosensitive hydrogel matrices." *Biomaterials* 31:1213-1218.

[21] Lee EY, Xia Y, Kim WS. 2009. "Hypoxia-enhanced wound-healing function of adipose-derived stem cells: increase in stem cell proliferation and up-regulation of VEGF and bFGF." *Wound repair and regeneration: official publication of the Wound Healing Society [and] the European Tissue Repair Society* 17:540-547.

[22] Song SY, Chung HM, Sung JH. 2010. "The pivotal role of VEGF in adipose-derived-stem-cell-mediated regeneration." *Expert opinion on biological therapy* 10:1529-1537.

[23] Lee EJ, Park HW, Jeon HJ, Kim HS, Chang MS. 2013. "Potentiated therapeutic angiogenesis by primed human mesenchymal stem cells in a mouse model of hindlimb ischemia." *Regenerative medicine* 8:283-293.

[24] Sumi M, Sata M, Toya N, Yanaga K, Ohki T, Nagai R. 2007. "Transplantation of adipose stromal cells, but not mature adipocytes, augments ischemia-induced angiogenesis." *Life sciences* 80:559-565.

[25] Harada Y, Yamamoto Y, Tsujimoto S, Matsugami H, Yoshida A, Hisatome I. 2013. "Transplantation of freshly isolated adipose tissue-derived regenerative cells enhances angiogenesis in a murine model of hind limb ischemia." *Biomedical research* 34:23-29.

[26] Shokrgozar MA, Fattahi M, Bonakdar S. 2012. "Healing potential of mesenchymal stem cells cultured on a collagen-based scaffold for skin regeneration." *Iranian biomedical journal* 16:68-76.

[27] Loder S, Peterson JR, Agarwal S. 2015. "Wound healing after thermal injury is improved by fat and adipose-derived stem cell isografts." *Journal of burn care & research: official publication of the American Burn Association* 36:70-76.

[28] Karimi H, Soudmand A, Orouji Z, Taghiabadi E, Mousavi SJ. 2014. "Burn wound healing with injection of adipose-derived stem cells: a mouse model study." *Annals of burns and fire disasters* 27:44-49.

[29] Collawn SS, Banerjee NS, de la Torre J, Vasconez L, Chow LT. 2012. "Adipose-derived stromal cells accelerate wound healing in an organotypic raft culture model." *Annals of plastic surgery* 68:501-504.

[30] Park IS, Chung PS, Ahn JC. 2015. "Enhancement of Ischemic Wound Healing by Spheroid Grafting of Human Adipose-Derived Stem Cells Treated with Low-Level Light Irradiation." *PLoS One* 10:e0122776.

[31] Song SH, Lee MO, Lee JS. 2012. "Genetic modification of human adipose-derived stem cells for promoting wound healing." *Journal of dermatological science* 66:98-107.

[32] Sheng L, Yang M, Liang Y, Li Q. 2013. "Adipose tissue-derived stem cells (ADSCs) transplantation promotes regeneration of expanded skin using a tissue expansion model." *Wound repair and regeneration: official publication of the Wound Healing Society [and] the European Tissue Repair Society* 21:746-754.

[33] Rehman J, Traktuev D, Li J. 2004. "Secretion of angiogenic and antiapoptotic factors by human adipose stromal cells." *Circulation* 109:1292-1298.

[34] Lu F, Mizuno H, Uysal CA, Cai X, Ogawa R, Hyakusoku H. 2008. "Improved viability of random pattern skin flaps through the use of adipose-derived stem cells." *Plastic and reconstructive surgery* 121:50-58.

[35] Amos PJ, Kapur SK, Stapor PC. 2010. "Human adipose-derived stromal cells accelerate diabetic wound healing: impact of cell formulation and delivery." *Tissue engineering. Part A* 16:1595-1606.

[36] Lee JH, Kemp DM. 2006. "Human adipose-derived stem cells display myogenic potential and perturbed function in hypoxic conditions." *Biochemical and biophysical research communications* 341:882-888.

[37] Kinnaird T, Stabile E, Burnett MS. 2004. "Local delivery of marrow-derived stromal cells augments collateral perfusion through paracrine mechanisms." *Circulation* 30:1543-1549.

[38] Sen CK, Gordillo GM, Roy S. 2009. "Human skin wounds: a major and snowballing threat to public health and the economy." *Wound repair and regeneration: official publication of the Wound Healing Society [and] the European Tissue Repair Society* 17:763-771.

[39] Gottrup F. 2004. "A specialized wound-healing center concept: importance of a multidisciplinary department structure and surgical treatment facilities in the treatment of chronic wounds." *American journal of surgery* 187:38s-43s.

[40] Nambu M, Kishimoto S, Nakamura S. 2009. "Accelerated wound healing in healing-impaired db/db mice by autologous adipose tissue-derived stromal cells combined with atelocollagen matrix." *Annals of plastic surgery* 62:317-321.

[41] Bruno A, Delli Santi G, Fasciani L, Cempanari M, Palombo M, Palombo P. 2013. "Burn scar lipofilling: immunohistochemical and clinical outcomes." *The Journal of craniofacial surgery* 24:1806-1814.

[42] Klinger M, Marazzi M, Vigo D, Torre M. 2008. “Fat injection for cases of severe burn outcomes: a new perspective of scar remodeling and reduction.” *Aesthetic plastic surgery* 32:465-469.

[43] Brongo S, Nicoletti GF, La Padula S, Mele CM, D'Andrea F. 2012. “Use of lipofilling for the treatment of severe burn outcomes.” *Plastic and reconstructive surgery* 130:374e-376e.

[44] Viard R, Bouguila J, Voulliaume D, Comparin JP, Dionyssopoulos A, Foyatier JL. 2012. “Fat grafting in facial burns sequelae.” *Annales de chirurgie plastique et esthetique* 57:217-229.

[45] Caviggioli F, Villani F, Forcellini D, Vinci V, Klinger F. 2010. “Nipple resuscitation by lipostructure in burn sequelae and scar retraction.” *Plastic and reconstructive surgery* 125:174e-176e.

[46] Conde-Green A, Wu I, Graham I. 2013. “Comparison of 3 techniques of fat grafting and cell-supplemented lipotransfer in athymic rats: a pilot study.” *Aesthetic surgery journal* 33:713-721.

[47] Gentile P, De Angelis B, Pasin M. 2014. “Adipose-derived stromal vascular fraction cells and platelet-rich plasma: basic and clinical evaluation for cell-based therapies in patients with scars on the face.” *The Journal of craniofacial surgery* 25:267-272.

[48] Piccolo NS, Piccolo MS, Piccolo MT. 2015. “Fat grafting for treatment of burns, burn scars, and other difficult wounds.” *Clinics in plastic surgery* 42:263-283.

[49] van der Veen VC, Vlig M, van Milligen FJ, de Vries SI, Middelkoop E, Ulrich MM. 2012. “Stem cells in burn eschar.” *Cell transplantation* 21:933-942.

[50] Chan RK, Zamora DO, Wrice NL. 2012. “Development of a vascularized skin construct using adipose-derived stem cells from debrided burned skin.” *Stem cells international* 841203.

[51] Natesan S, Zamora DO, Wrice NL, Baer DG, Christy RJ. 2013. “Bilayer hydrogel with autologous stem cells derived from debrided human burn skin for improved skin regeneration.” *Journal of burn care & research: official publication of the American Burn Association* 34:18-30.

[52] Montagna W, Kirchner S, Carlisle K. 1989. “Histology of sun-damaged human skin.” *Journal of the American Academy of Dermatology* 21:907-918.

[53] Warren R, Gartstein V, Kligman AM, Montagna W, Allendorf RA, Ridder GM. 1991. “Age, sunlight, and facial skin: a histologic and quantitative study.” *Journal of the American Academy of Dermatology* 25:751-760.

[54] Yeo EJ, Jang IS, Lim HK, Ha KS, Park SC. 2002. “Agonist-specific differential changes of cellular signal transduction pathways in senescent human diploid fibroblasts.” *Experimental gerontology* 37:871-883.

[55] Wang E. 1995. “Senescent human fibroblasts resist programmed cell death, and failure to suppress bcl2 is involved.” *Cancer research* 55:2284-2292.

[56] Straface E, Vona R, Ascione B. 2007. “Single exposure of human fibroblasts (WI-38) to a sub-cytotoxic dose of UVB induces premature senescence.” *FEBS letters* 581:4342-4348.

[57] Debacq-Chainiaux F, Borlon C, Pascal T. 2005. “Repeated exposure of human skin fibroblasts to UVB at subcytotoxic level triggers premature senescence through the TGF-beta1 signaling pathway.” *Journal of cell science* 118:743-758.

[58] Skalnikova H, Motlik J, Gadher SJ, Kovarova H. 2011. "Mapping of the secretome of primary isolates of mammalian cells, stem cells and derived cell lines." *Proteomics* 11:691-708.

[59] Kilroy GE, Foster SJ, Wu X. 2007. "Cytokine profile of human adipose-derived stem cells: expression of angiogenic, hematopoietic, and pro-inflammatory factors." *J Cell Physiol* 212:702-709.

[60] Peinado JR, Pardo M, de la Rosa O, Malagon MM. 2012. "Proteomic characterization of adipose tissue constituents, a necessary step for understanding adipose tissue complexity." *Proteomics* 12:607-620.

[61] Kim WS, Park BS, Park SH, Kim HK, Sung JH. 2009. "Antiwrinkle effect of adipose-derived stem cell: activation of dermal fibroblast by secretory factors." *Journal of dermatological science* 53:96-102.

[62] Song SY, Jung JE, Jeon YR, Tark KC, Lew DH. 2011. "Determination of adipose-derived stem cell application on photo-aged fibroblasts, based on paracrine function." *Cytotherapy* 13:378-384.

[63] Xu X, Wang HY, Zhang Y. 2014. "Adipose-derived stem cells cooperate with fractional carbon dioxide laser in antagonizing photoaging: a potential role of Wnt and beta-catenin signaling." *Cell & bioscience* 4:24.

[64] Ressler S, Bartkova J, Niederegger H. 2006. "p16INK4A is a robust in vivo biomarker of cellular aging in human skin." *Aging cell* 5:379-389.

[65] Shen X, Du Y, Shen W, Xue B, Zhao Y. 2014. "Adipose-derived stem cells promote human dermal fibroblast function and increase senescence-associated betagalactosidase mRNA expression through paracrine effects." *Molecular medicine reports* 10:3068-3072.

[66] Kim WS, Park BS, Sung JH. 2007. "Wound healing effect of adipose-derived stem cells: a critical role of secretory factors on human dermal fibroblasts." *Journal of dermatological science* 48:15-24.

[67] Kim WS, Park SH, Ahn SJ. 2008. "Whitening effect of adipose-derived stem cells: a critical role of TGF-beta 1." *Biological & pharmaceutical bulletin* 31:606-610.

[68] Kim WS, Park BS, Kim HK. 2008. "Evidence supporting antioxidant action of adipose-derived stem cells: protection of human dermal fibroblasts from oxidative stress." *Journal of dermatological science* 49:133-142.

[69] Park BS, Jang KA, Sung JH. 2008. "Adipose-derived stem cells and their secretory factors as a promising therapy for skin aging." *Dermatologic surgery: official publication for American Society for Dermatologic Surgery* 34:1323-1326.

[70] Kim JH, Jung M, Kim HS, Kim YM, Choi EH. 2011. "Adipose-derived stem cells as a new therapeutic modality for ageing skin." *Experimental dermatology* 20:383-387.

[71] Zhang S, Dong Z, Peng Z, Lu F. 2014. "Anti-aging effect of adipose-derived stem cells in a mouse model of skin aging induced by D-galactose." *PLoS One* 9:e97573.

[72] Grether-Beck S, Wlaschek M, Krutmann J, Scharffetter-Kochanek K. 2005. "Photodamage and photoaging--prevention and treatment." *Journal of the German Society of Dermatology* 3:S19-25.

[73] Vaughan MB, Ramirez RD, Brown SA, Yang JC, Wright WE, Shay JW. 2004 "A reproducible laser-wounded skin equivalent model to study the effects of aging in vitro." *Rejuvenation research* 7:99-110.

[74] Tanaka H, Yamaba H, Kosugi N, Mizutani H, Nakata S. 2008. "Fermentable metabolite of Zymomonas mobilis controls collagen reduction in photoaging skin by improving TGF-beta/Smad signaling suppression." *Archives of dermatological research.* 300:S57-64.

[75] Kida H, Yoshida M, Hoshino S. 2005. "Protective effect of IL-6 on alveolar epithelial cell death induced by hydrogen peroxide." *American journal of physiology. Lung cellular and molecular physiology* 288:L342-349.

[76] Cameron K. 2005. "Review: chemotherapy plus supportive care improves survival and quality of life in advanced or metastatic gastrointestinal cancer more than supportive care alone." *Evidence-based nursing* 8:18.

[77] Fitzpatrick RE, Rostan EF. 2003. "Reversal of photodamage with topical growth factors: a pilot study." *Journal of cosmetic and laser therapy: official publication of the European Society for Laser Dermatology* 5:25-34.

[78] Watson D, Keller GS, Lacombe V, Fodor PB, Rawnsley J, Lask GP. 1999. "Autologous fibroblasts for treatment of facial rhytids and dermal depressions. A pilot study." *Archives of facial plastic surgery* 1:165-170.

[79] Chung JH, Lee SH, Youn CS. 2001. "Cutaneous photodamage in Koreans: influence of sex, sun exposure, smoking, and skin color." *Archives of dermatology* 137:1043-1051.

[80] Chung JH. 2003. "Photoaging in Asians." *Photodermatology, photoimmunology & photomedicine* 19:109-121.

[81] Kim DS, Park SH, Park KC. 2004. "Transforming growth factor-beta1 decreases melanin synthesis via delayed extracellular signal-regulated kinase activation." *The international journal of biochemistry & cell biology* 36:1482-1491.

[82] Martinez-Esparza M, Jimenez-Cervantes C, Beermann F, Aparicio P, Lozano JA, Garcia-Borron JC. 1997. "Transforming growth factor-beta1 inhibits basal melanogenesis in B16/F10 mouse melanoma cells by increasing the rate of degradation of tyrosinase and tyrosinase-related protein-1." *The Journal of biological chemistry* 272:3967-3972.

[83] Martinez-Esparza M, Solano F, Garcia-Borron JC. 1999. "Independent regulation of tyrosinase by the hypopigmenting cytokines TGF beta1 and TNF alpha and the melanogenic hormone alpha-MSH in B16 mouse melanocytes." *Cellular and molecular biology* 45:991-1000.

[84] Walia B, Satija N, Tripathi RP, Gangenahalli GU. 2012. "Induced pluripotent stem cells: fundamentals and applications of the reprogramming process and its ramifications on regenerative medicine." *Stem cell reviews* 8:100-115.

[85] Lee HC, An SG, Lee HW. 2012. "Safety and effect of adipose tissue-derived stem cell implantation in patients with critical limb ischemia: a pilot study." *Circulation journal: official journal of the Japanese Circulation Society* 76:1750-1760.

[86] Lendeckel S, Jodicke A, Christophis P. 2004. "Autologous stem cells (adipose) and fibrin glue used to treat widespread traumatic calvarial defects: case report." *Journal of cranio-maxillo-facial surgery: official publication of the European Association for Cranio-Maxillo-Facial Surgery* 32:370-373.

[87] Shen CC, Yang YC, Liu BS. 2012. "Peripheral nerve repair of transplanted undifferentiated adipose tissue-derived stem cells in a biodegradable reinforced nerve conduit." *Journal of biomedical materials research. Part A* 100:48-63.

[88] Thesleff T, Lehtimaki K, Niskakangas T. 2011. "Cranioplasty with adipose-derived stem cells and biomaterial: a novel method for cranial reconstruction." *Neurosurgery* 68:1535-1540.

[89] Warnke PH, Springer IN, Wiltfang J. 2004. "Growth and transplantation of a custom vascularised bone graft in a man." *Lancet* 364:766-770.

[90] Patrick CW, Jr., Chauvin PB, Hobley J, Reece GP. 1999. "Preadipocyte seeded PLGA scaffolds for adipose tissue engineering." *Tissue engineering* 5:139-151.

[91] Patrick CW, Jr., Zheng B, Johnston C, Reece GP. 2002. "Long-term implantation of preadipocyte-seeded PLGA scaffolds." *Tissue engineering* 8:283-293.

[92] von Heimburg D, Zachariah S, Low A, Pallua N. 2001. "Influence of different biodegradable carriers on the in vivo behavior of human adipose precursor cells." *Plastic and reconstructive surgery* 108:411-420.

[93] Brown SA, Levi B, Lequeux C, Wong VW, Mojallal A, Longaker MT. 2010. "Basic science review on adipose tissue for clinicians." *Plastic and reconstructive surgery* 126:1936-1946.

[94] Sheng L, Yang M, Li H, Du Z, Yang Y, Li Q. 2011. "Transplantation of adipose stromal cells promotes neovascularization of random skin flaps." *The Tohoku journal of experimental medicine* 224:229-234.

[95] Salgado AJ, Reis RL, Sousa NJ, Gimble JM. 2010. "Adipose tissue derived stem cells secretome: soluble factors and their roles in regenerative medicine." *Current stem cell research & therapy* 5:103-110.

[96] Matsumoto D, Sato K, Gonda K. 2006. "Cell-assisted lipotransfer: supportive use of human adipose-derived cells for soft tissue augmentation with lipoinjection." *Tissue engineering* 12:3375-3382.

[97] Koh KS, Oh TS, Kim H. 2012. "Clinical application of human adipose tissue-derived mesenchymal stem cells in progressive hemifacial atrophy (Parry-Romberg disease) with microfat grafting techniques using 3-dimensional computed tomography and 3-dimensional camera." *Annals of plastic surgery* 69:331-337.

[98] Coleman SR, Saboeiro AP. 2007. "Fat grafting to the breast revisited: safety and efficacy." *Plastic and reconstructive surgery* 119:775-785.

[99] Zheng DN, Li QF, Lei H. 2008. "Autologous fat grafting to the breast for cosmetic enhancement: experience in 66 patients with long-term follow up." *Journal of plastic, reconstructive & aesthetic surgery* 61:792-798.

[100] Yoshimura K, Sato K, Aoi N, Kurita M, Hirohi T, Harii K. 2008. "Cell-assisted lipotransfer for cosmetic breast augmentation: supportive use of adipose-derived stem/stromal cells." *Aesthetic plastic surgery* 32:48-55.

[101] Kamakura T, Ito K. 2011. "Autologous cell-enriched fat grafting for breast augmentation." *Aesthetic plastic surgery* 35:1022-1030.

[102] Wang L, Lu Y, Luo X. 2012. "Cell-assisted lipotransfer for breast augmentation: a report of 18 patients." *Chinese journal of plastic surgery* 28:1-6.

[103] Yoshimura K, Asano Y, Aoi N. 2010. "Progenitor-enriched adipose tissue transplantation as rescue for breast implant complications." *The breast journal* 16:169-175.

[104] Yoshimura K, Sato K, Aoi N. 2008. "Cell-assisted lipotransfer for facial lipoatrophy: efficacy of clinical use of adipose-derived stem cells." *Dermatologic surgery: official publication for American Society for Dermatologic Surgery* 34:1178-1185.

[105] Castro-Govea Y, De La Garza-Pineda O, Lara-Arias J. 2012. "Cell-assisted lipotransfer for the treatment of parry-romberg syndrome." *Archives of plastic surgery* 39:659-662.

[106] Lee SK, Kim DW, Dhong ES, Park SH, Yoon ES. 2012. "Facial Soft Tissue Augmentation using Autologous Fat Mixed with Stromal Vascular Fraction." *Archives of plastic surgery* 39:534-539.

[107] Kolle SF, Fischer-Nielsen A, Mathiasen AB. 2013. "Enrichment of autologous fat grafts with ex-vivo expanded adipose tissue-derived stem cells for graft survival: a randomised placebo-controlled trial." *Lancet* 82:1113-1120.

[108] Zhu M, Zhou Z, Chen Y. 2010. "Supplementation of fat grafts with adipose-derived regenerative cells improves long-term graft retention." *Annals of plastic surgery* 64:222-228.

[109] Tiryaki T, Findikli N, Tiryaki D. 2011. "Staged stem cell-enriched tissue (SET) injections for soft tissue augmentation in hostile recipient areas: a preliminary report." *Aesthetic plastic surgery* 35:965-971.

[110] Garcia-Olmo D, Garcia-Arranz M, Herreros D, Pascual I, Peiro C, Rodriguez-Montes JA. 2005. "A phase I clinical trial of the treatment of Crohn's fistula by adipose mesenchymal stem cell transplantation." *Diseases of the colon and rectum* 48:1416-1423.

[111] Zuk PA, Zhu M, Mizuno H. 2001. "Multilineage cells from human adipose tissue: implications for cell-based therapies." *Tissue engineering* 7:211-228.

[112] Moseley TA, Zhu M, Hedrick MH. 2006. "Adipose-derived stem and progenitor cells as fillers in plastic and reconstructive surgery." *Plastic and reconstructive surgery* 118:121s-128s.

[113] Eterno V, Zambelli A, Pavesi L. 2014. "Adipose-derived Mesenchymal Stem Cells (ASCs) may favour breast cancer recurrence via HGF/c-Met signaling." *Oncotarget* 5:613-633.

[114] Karnoub AE, Dash AB, Vo AP. 2007. "Mesenchymal stem cells within tumour stroma promote breast cancer metastasis." *Nature* 449:557-563.

[115] Rowan BG, Gimble JM, Sheng M. 2014. "Human adipose tissue-derived stromal/stem cells promote migration and early metastasis of triple negative breast cancer xenografts." *PLoS One* 9:e89595.

[116] Zimmerlin L, Donnenberg AD, Rubin JP, Basse P, Landreneau RJ, Donnenberg VS. 2011. "Regenerative therapy and cancer: in vitro and in vivo studies of the interaction between adipose-derived stem cells and breast cancer cells from clinical isolates." *Tissue engineering. Part A* 17:93-106.

[117] Yoshimura K, Shigeura T, Matsumoto D. 2006. "Characterization of freshly isolated and cultured cells derived from the fatty and fluid portions of liposuction aspirates." *J Cell Physiol* 208:64-76.

[118] Francis MP, Sachs PC, Elmore LW, Holt SE. 2010. "Isolating adipose-derived mesenchymal stem cells from lipoaspirate blood and saline fraction." *Organogenesis* 6:11-14.

[119] Zeng G, Lai K, Li J. 2013. "A rapid and efficient method for primary culture of human adipose-derived stem cells." *Organogenesis* 9:287-295.

[120] Shah FS, Wu X, Dietrich M, Rood J, Gimble JM. 2013. "A non-enzymatic method for isolating human adipose tissue-derived stromal stem cells." *Cytotherapy* 15:979-985.

[121] Doi K, Kuno S, Kobayashi A. 2014. "Enrichment isolation of adipose-derived stem/stromal cells from the liquid portion of liposuction aspirates with the use of an adherent column." *Cytotherapy* 16:381-391.

[122] Buschmann J, Gao S, Harter L. 2013. "Yield and proliferation rate of adipose-derived stromal cells as a function of age, body mass index and harvest site-increasing the yield by use of adherent and supernatant fractions?" *Cytotherapy* 15:1098-1105.

In: Encyclopedia of Surgery (22 Volume Set)
Editors: Andreas Lehrer and Kristin Mueller
ISBN: 978-1-53618-329-0
© 2020 Nova Science Publishers, Inc.

Chapter 397

SPEEDY AND EASY TECHNIQUES IN FACIAL PALSY SURGERY

A. Di Stadio*
Otophatology Lab, Otolaryngology Department, Mass Eye and Ear,
Harvard Medical School, Boston, MA, US

ABSTRACT

Several techniques are used to treat facial palsy. Some of these techniques show very good results but take a long time to execute or are very invasive.

In our opinion, it's important to first identify the problem, understand what is necessary, and find a solution that is easy and rapid for both patient and surgeon.

In this chapter, the author will discuss the association between the different techniques for achieving symmetry recovery in facial palsy patients.

Presented are the techniques most used in recent years. The author will show in detail their personal surgical technique for the treatment of eye disease and the results in terms of improvement in recovery time. Based on the author's experience, the association between the eye technique and the reanimation of the middle and inferior face is the best option.

In this chapter, the author will show techniques that are simpler and faster to perform in the belief that facility and velocity are advantages for both surgeon and patient. The techniques will be described in a didactic and detailed way, starting from surgical anatomy and covering all surgical technical details. It is the goal for these techniques to be easily reproducible after this primary study.

The goal of this chapter is to show how fast and simple techniques can provide results as satisfactory as, if not better than, more complex techniques.

* Corresponding Author's Emails: ariannadistadio@hotmail.com; arianna_distadio@meei.harvard.edu.

INTRODUCTION

In history, several methods have been discussed and used to treat the asymmetry of permanent or irreversible facial palsy [1]. Surgical rehabilitation techniques are divided into three categories: physiological, dynamic, and static [2-3]. The physiological method is represented by direct anastomosis and nerve transfer, cross-face, and free-flap re-anastomosis. These techniques were performed with the goal of restoration of the damaged nerve with creation of a "new" nerve. The dynamic method uses muscle transposition. Muscles, innerved to normal functional nerve and deputies of another movement, are transposed to restore movement; examples of this are temporalis and masseter muscle transfer. Static techniques, in contrast to the first two methods, are surgery methods able to correct the asymmetry in static positions only, without a real correction in dynamic movements [4]. Examples include fascia lata suspension or selective myotomies on the face [6].

In this chapter we propose an association with different techniques to obtain facial symmetry. We will explain how to treat the paralyzed eye and smile with fast techniques.

PREOPERATIVE EVALUATIONS

Understanding the problem is the first step to solving it. In a paralyzed face, it is important to focus attention on the eye and smile. For the eye, analyzing the area of scleral exposure (ASE) in sick and healthy eyes is necessary to understand which procedures are useful to treat superior and inferior eyelids. This is a photographic method of evaluation with millimeter paper to capture the sclera in static (open eye) and dynamic (closed eye) action. The normal distance between the upper and lower eyelids in an open eye is 10-12 mm. The ASE system also considers the position of eyelid relative to pupil, which is useful to understand which procedure to use on the eyelid and whether it is necessary to use two different techniques [7].



Figure 1. Example of ASE system. The white portion uses mill metric paper to evaluate the sclera's exposition.

In smile analysis, it is important to consider the "three smile classification". In terms of how many muscles are involved during the action of smiling, we can identify three different types of smiles: the zygomatic or Mona Lisa smile, the canine smile, and the full teeth smile. Understanding the patient's smile helps in choosing a surgery technique and its details [8, 9, 10].

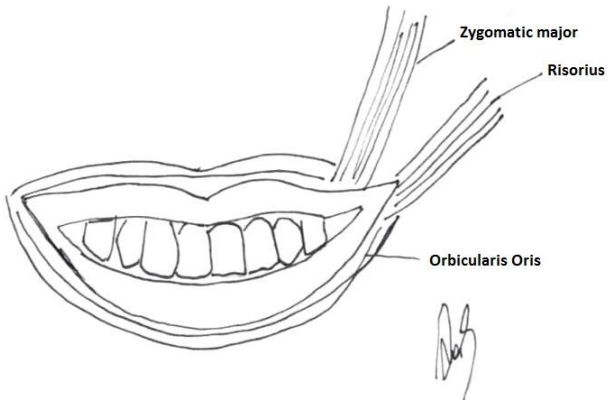

Figure 2. Mona Lisa smile.

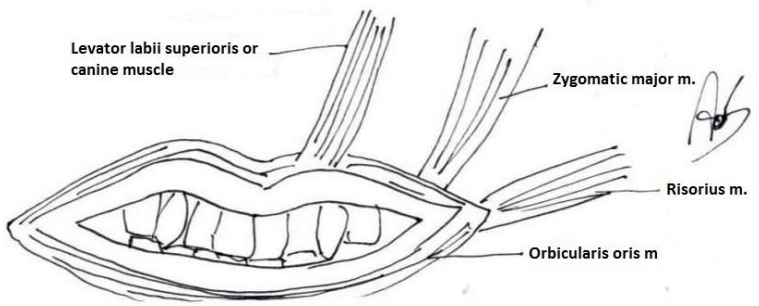

Figure 3. Canine smile.

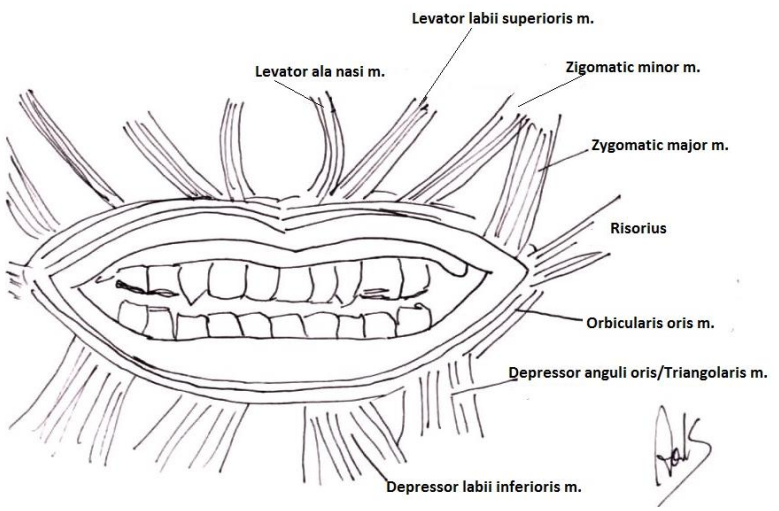

Figure 4. Full teeth smile.

Anatomy per Images

Eyelid: anatomy of the orbicularis oculi muscle (Figure 5a, 5b and 6).
Temporal muscle: Image 7 and 8
Masseter muscle: Image 9a
“Subzygomatic triangle”: Image 9b
Masseter nerve: Image 10

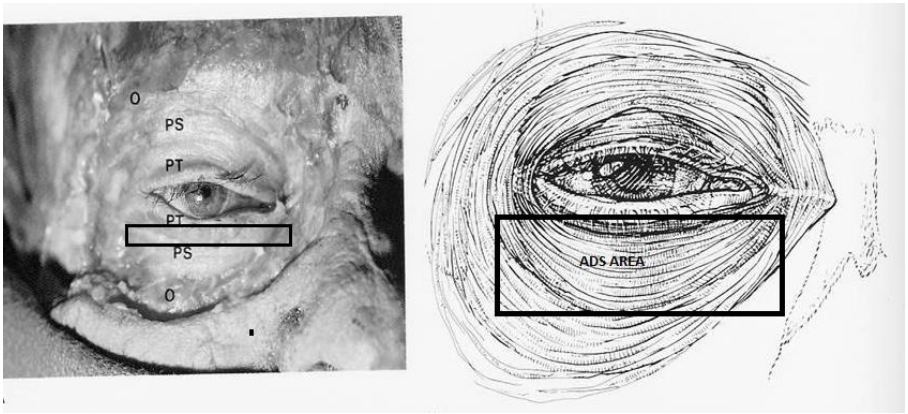

(a) (b)

Figure 5a. Eye anatomy frontal view. This muscle is divided into two regions: the orbital and palpebral areas. The palpebral area is further subdivided into the pretarsal (PT) and preseptal (PS) regions.
Figure 5b. ADS (acronimus of author’s name) palpebral area within the PS and PT regions. The exact position of this muscular structure is easy to establish during surgery because the PT portion of the muscle is directly adherent to the inferior tarsal structure and is immobile with respect to the plane.

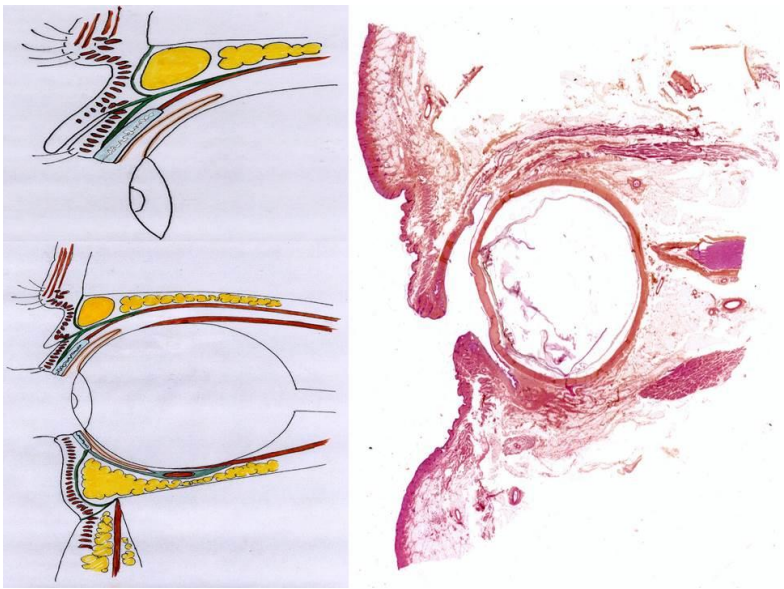

Figure 6. Eye anatomy lateral view.

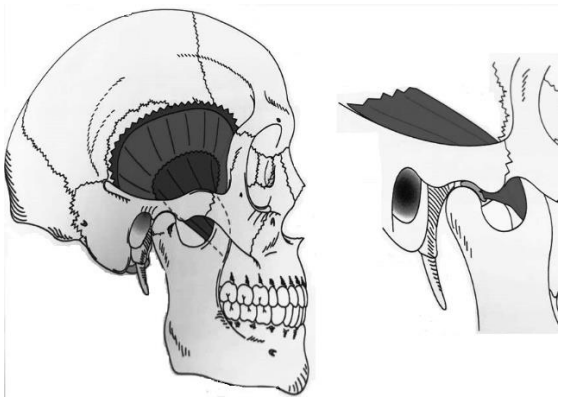

Figure 7. Anatomy of the temporal muscle and insertion on coronoid process, lateral view.

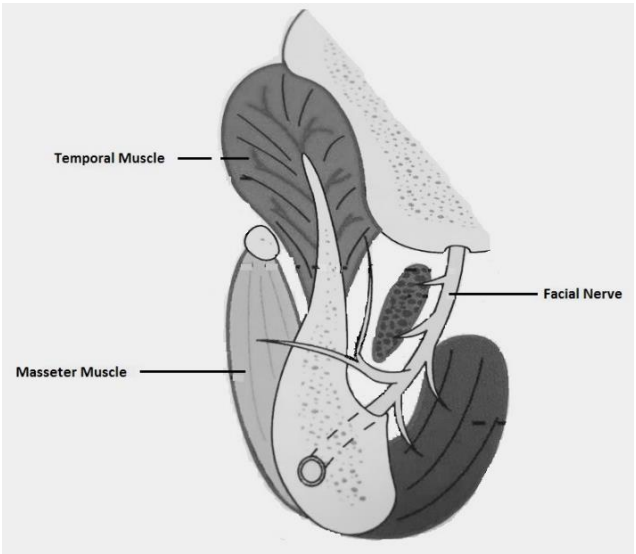

Figure 8. Anatomy of the temporal muscle, masseter muscle, and facial nerve, coronal view.

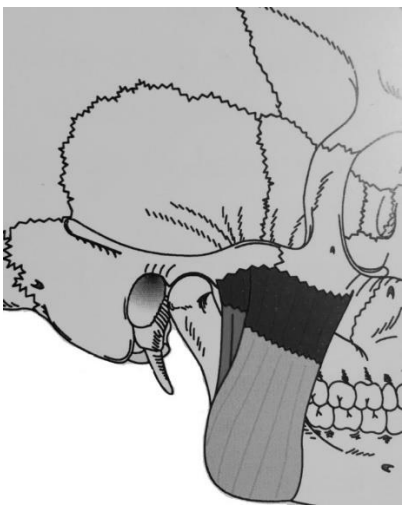

Figure 9a. Anatomy of the masseter muscle superficial and profond, lateral view.

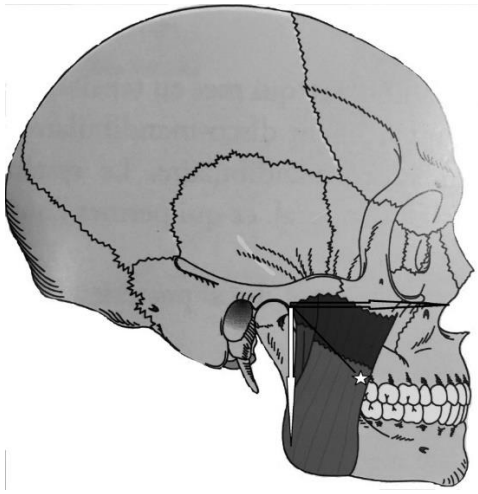

Figure 9b. Subzygomatic triangle. This triangle is formed by the inferior border of zygomatic arch superiorly, a vertical line through the anterior border of temporomandibular joint posteriorly, and the frontal branch of the facial nerve inferiorly and anteriorly. The masseteric nerve follows a line that begins at the angle of subzygomatic triangle and crosses the midpoint of triangle's base. The nerve is located in the deep muscle belly below a white fibrous fascia. The dominant branch of masseter nerve's course is obliquely within the substance of the muscle for 2 to 3 cm in an anterio-posterior direction [27].

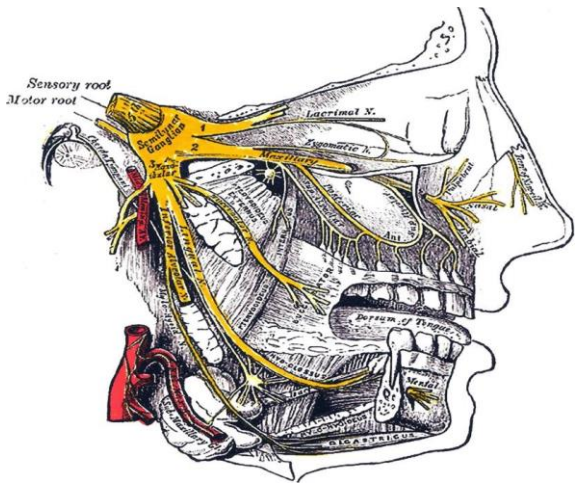

Figure 10. Anatomy of the masseter nerve lateral view.

EYE TREATMENT

Superior Eyelid

Indication to Use

Tessier's technique is useful in addition to Labbé's technique because this practice takes temporal fascia during the surgery. A weight implant can be used in single treatment for eye

disease in association with ADS technique and anastomosis. This technique has more risks than Tessier's technique because is an allograft, with more risk of rejection and extrusion.

Upper Eyelid Titanium Weight Implant

(on youtube:www.youtube.com/watch?v=ti2GYGF1sRc)

It is necessary to test different weights before starting the surgery. This procedure is very important to obtain the best result.

An incision is made in the lid crease followed by sharp dissection through the orbicularis muscle to the surface of the tarsal plate. The pocket, where the weight implantation will be placed, is then prepared. This pocket will be the same length as the implant, as in this way is possible to reduce the number of sutures. The pocket will be created at the juncture of the medial and central third of the lid, as in this way we can obtain a completely symmetric eye closure. The prosthesis will be placed over the tarsal plate a few millimeters above the lid margin. The implant will be attached on the tarsal plate with a 6/0 nylon suture in the medial and lateral portion. The reposition of orbicular muscle and suture should be done with 6/0 Vicryl and the eyelid is closed with continue suture [11, 12].

Tessier's Technique

This alternative technique is used to lengthen the elevator muscle of upper eyelid. This technique is a good choice associate to temporal myoplasty because we use temporal fascia to perform the graft. The calculation of the graft's dimension is evaluated with a preliminary eye test. Normally its width is double the palpebral retraction. On times that the graft is token, using an incision in the lid crease performs the same passage of weight implant until reach the tarsus, in upper portion, where the aponeurosis is present we dissect it from the elevator muscle. The aponeurosis is sectioned with a cold scalpel and removed from the muscle. The graft is positioned between the superior edge of the tarsal plate and the inferior edge of elevator muscle and sutured with 6-8 points of 6/0 Vicryl. Suture of the orbicular muscle should be done with separate suture and the skin suture with continue suture [13].

ADS TECHNIQUE

Inferior Eyelid

Indication to Use

If the patient presents ectropion (exposure of the conjunctiva due to a reduction in tension of the anterior compartment of the eye muscle) and lagophthalmus, we perform lateral lower eyelid lifting surgery. For cases with epiphora (eversion of the lachrymal point) and lagophthalmus, we perform medial lower eyelid lifting surgery [7].

These surgical techniques happen at the level of the eyelid. Here, two different techniques are evaluated for specific eye diseases.

Surgery is always performed under local anesthesia.

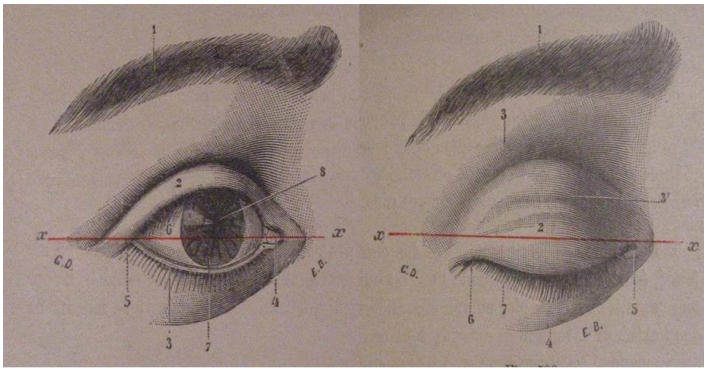

(a)

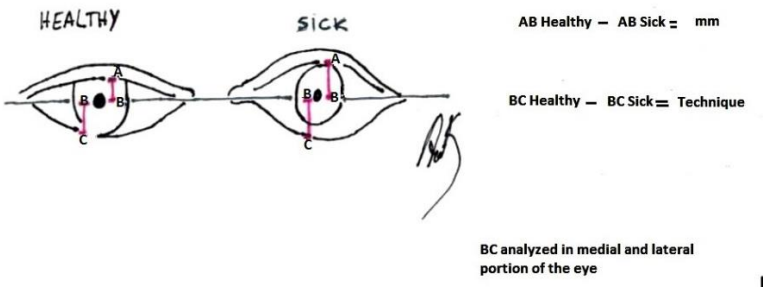

(b)

Figure 11a and b. Evaluation method for identifying the correct surgical technique. This method is useful for Tessier's technique but also for identifying which of the ADS are better to treat the eye disease. We analyze in sick and healthy eyes the distance between the superior eyelid and an imaginary line beginning at the lateral cantus, passing through the pupil, and ending at the level of the medial cantus. The same measure will be used for the inferior eyelid. We identify two different measures, one defined as AB between the superior eyelid and the imaginary line, and a second one defined as BC between the imaginary line and the inferior eyelid. We will analyze the BC measurement in the medial and lateral portion of the eye to identify the correct ADS to use. We will take the AB measurement in the central portion of the eye. The resulting difference between healthy and sick eyes will determine, in the AB measurement, the millimeter for the graft, and in case of BC, which ADS technique is the best to treat the disease.

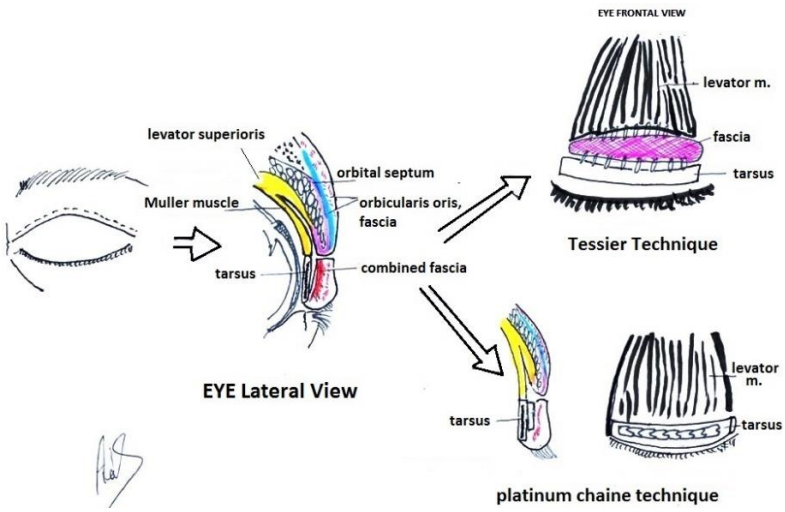

Figure 12. Eye surgery: Tessier's technique and platinum chain technique.

Lateral Lower Eyelid Lifting Surgery

4 stages: [1] a transcutaneous subciliary incision is made, moving from the lateral canthus down to half of the lower eyelid, [2] a small triangle of skin is resectioned, a maximum of 3 mm to avoid possible retraction, and [3] a lateral micromuscular PT advanced flap is established, including dissecting the muscle for 6–8 mm, starting 2 mm under the PT portion; lateralizing and elevating the flap; repositioning the PS portion of the muscle with some tension; and suturing at the level of the lateral portion of the PT muscle with 2/3-point 6/0-resorbable sutures. It is necessary to suture the PT muscle to the tarsal portion; specifically, the suture point is on the tarsal cartilage (point 1) in the lateral portion, and points 2 and 3 are attached at the level of the periosteum. At the periosteum, it is necessary to maintain the tension of the lateral part of the muscle, and it is the gold standard to preserve the lower eyelid's correct position in older patients. [4] The suture points are separated by 6/0 polypropylene sutures

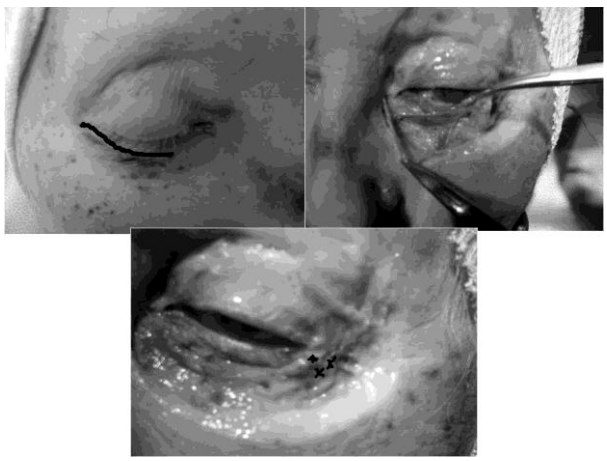

Figure 13, 14, 15. ADS technique lateral: line of incision starting from the middle of the inferior eyelid, elevation of the micromuscolar flap orbicular muscle, and lateral fixation of the flap with 3 separated points.

Figure 16, 17, 18. ADS technique medial incision in inverted Y shape: in the medial portion of the inferior eyelid, preparation of the micromuscular flap with the orbicular muscle, fixation of the flap at the medial cantus with 4 separated points.

Medial Lower Eyelid Lifting Surgery

3 stages: [1] a transcutaneous subciliary incision is made in the shape of an inverted Y, moving down one third from the medial canthus to the anterior region of the lower eyelid and moving up within 2 mm from the upper eyelid. This incision is necessary to expose the line on the medial cantus. The micromuscular advanced flap will in fact be sutured 1 mm above this line to obtain good suspension of the medial portion of the eyelid (figure 6). [2] A micromuscular advanced flap is made the same way as described for the lateral eyelid technique. Then the PS muscular flap is elevated at the level of the PT portion of the orbicularis oculi muscle and sutured with 3- to 4-point 6/0-resorbable sutures, starting from the medial cantus and working toward the middle tarsal portion of the lower eyelid. [3] Suturing at the level of the medial canthus with polypropylene 6/0 sutures is performed

Smile Treatment

Indication to Use

The choice of temporal myoplasty or masseter/facial anastomosis is based on the surgeon's preference. In this case, in fact, both techniques are valid and offer very good results. General anesthesia is necessary.

Lengthening Temporal Myoplasty (Dynamic Technique)

(on youtube:www.youtube.com/watch/v=fzCi4Het7Q)

Two different approaches are available; the choice is in the function of the necessary lengthening of muscle to join the orbicular muscle.

Upper Head Dissection

Coronal or Monocoronal Lifting approach. The local anesthesia is performed because is also useful to help the dissection. The subgaleal dissection is necessary up to 2 cm above the eyebrows, dissection starts above the deep temporal fascia and then passes to superficial temporal fascia, where fat is present (about 1 cm above the zygomatic arch). It's important to preserve this fat to avoid muscle displacement. To put the two dissection areas in contact, make an incision in a superficial fascia, 15-20 mm up the zygomatic arch. Perform medial temporal muscle dissection in contact with the frontal bone and a large subperiostal dissection in the orbit and cheekbone area. The zygomatic arch should be dissected in the anterior and posterior part. The zygomatic arch osteotomy leaves the masseter muscle inserted. Perform zygomatic arch displacement before and, dissect the masseter muscle deep fibers to arrive at the prolongation temporal muscle in the buccal fat pad. Subperiostal dissection should be performed forward and obliquely up to ascending mandible ramus. Oblique section of coronoid apophysis, in higher position possible, without temporalis muscle shutdown (this move is used to take advantage of the entire muscle length). For temporal muscle release, make an incision of 5 mm 1 cm above the temporal crest in the anterior muscle portion to leave an aponeurosis portion inserted on the bone. Complete disconnection of the posterior muscle portion until temporal crest. Take care during inferior dissection of the temporal muscle at the spheno-temporal crest where we find the vascular nervous package.

Difference in the Monocoronal approach: avoids superficial undermining of the anterior part of the temporal muscle (see pictures); performs osteotomy of coronoid process with a nasolabial approach, avoiding Zygoma's osteotomy. Presents a damage risk for main vascular pedicles if you aren't practiced with the anatomy [14, 15, 16].

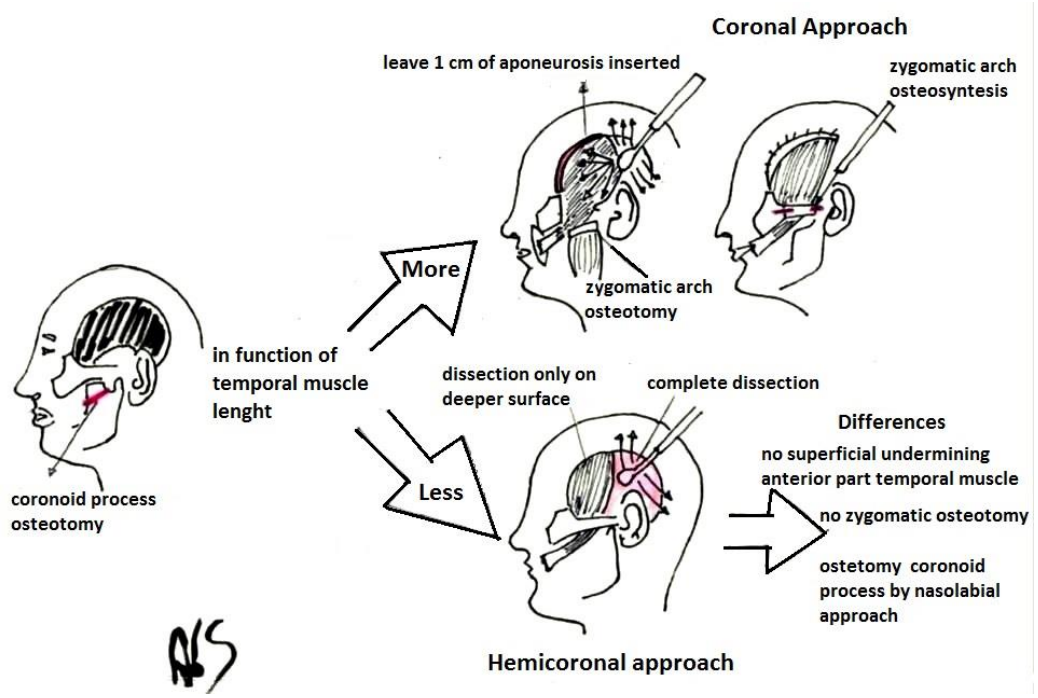

Figure 19. Lengthening temporalis myoplasty: the images show two different approaches, coronal and hemicoranal, and their differences in surgical terms.

Lower Approach Dissection

Face dissection is performed on the nasal fold starting from alar nose. Subcutaneous antero-posterior dissection is performed from the nasal fold toward the cheekbone to recreate the zygomatic major and minor muscles' path. You have to identify and prepare orbicular muscle and modiolus before suturing the temporal muscle with three points at these structures. These points will be placed in order to reproduce the three different types of smile. The subcutaneous dissection becomes deeper at the level of the buccal fat pad in contact with the maxilla-malar junction to join the temporal muscle, still attached to coronoid process before osteotomies. Using the subcutaneous path previously prepared, catch the coronal bone using an Ellis, and with linear and continuous traction the bone fragment is pulled down to reach the orbicular muscle. With dissection of the muscle tendon temporal from choroid process with a scalpel, we obtain a 4 cm width tendon. We attach the temporal muscle at the three points previously prepared on the orbicular muscle with a U suture. The position of the temporal tendon on the orbicular muscle at the modiolus level, was defined based on smile types. The suture will be completed at the level of the orbicularis muscle with 5-10 non-absorbable points, with a light overcorrection. Taking the upper portion of the temporal muscle with two pliers, make an upward traction to test the position of the future smile [17, 18, 19].

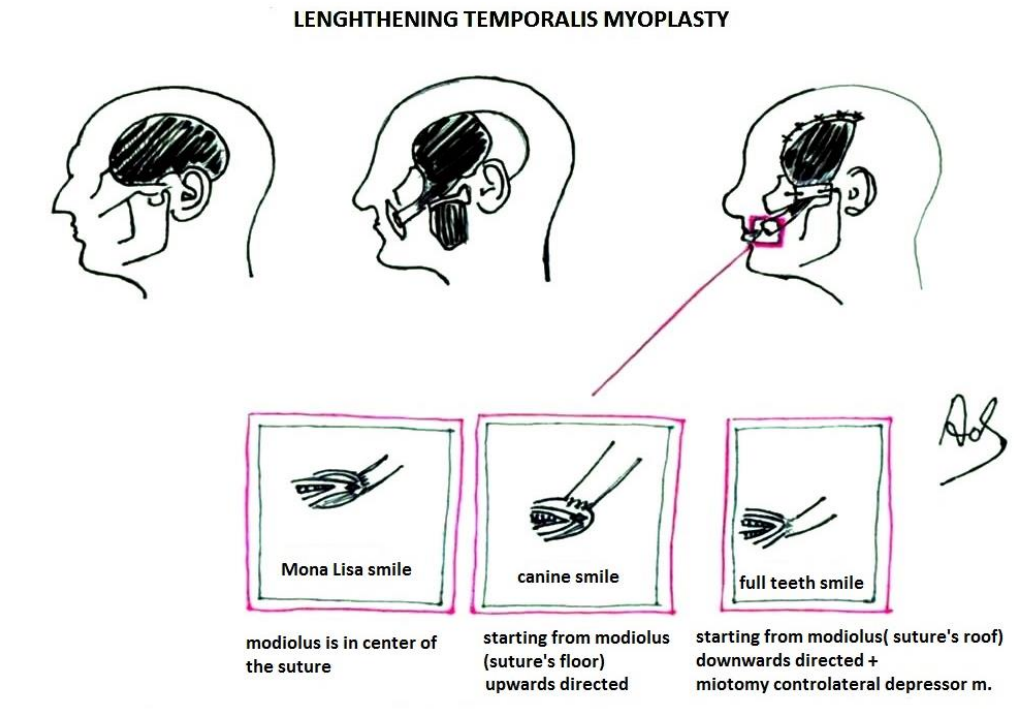

Figure 20. This image shows in detail the different ways suture in function of the smile.

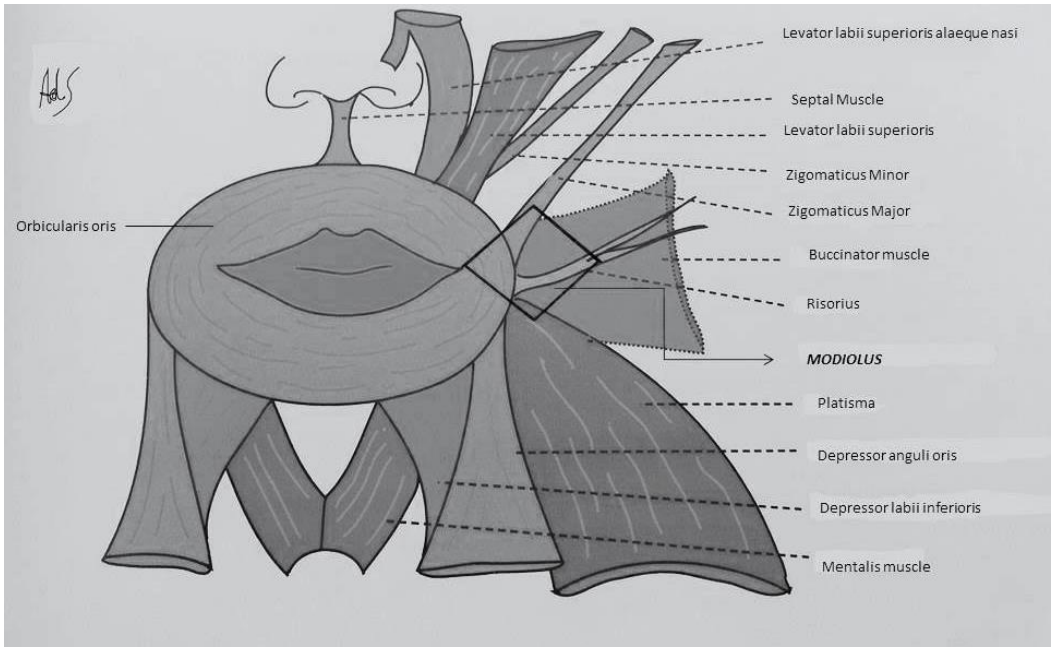

Figure 21. Anatomy of the modiolus, this is the convergence area of the smile's muscles zigomaticus major, risorius, buccinator and platisma.

Suturing and Closure

Suture temporal muscle on the aponeurosis, previously left attached at the bone, with 3-5 non-absorbable points. Perform osteosynthesis of the zygomatic arch. Place sutures at the level of the nose labial fold and on the coronal approach. Put in place two drainages: one in the frontal position, one under the zygomatic arch.

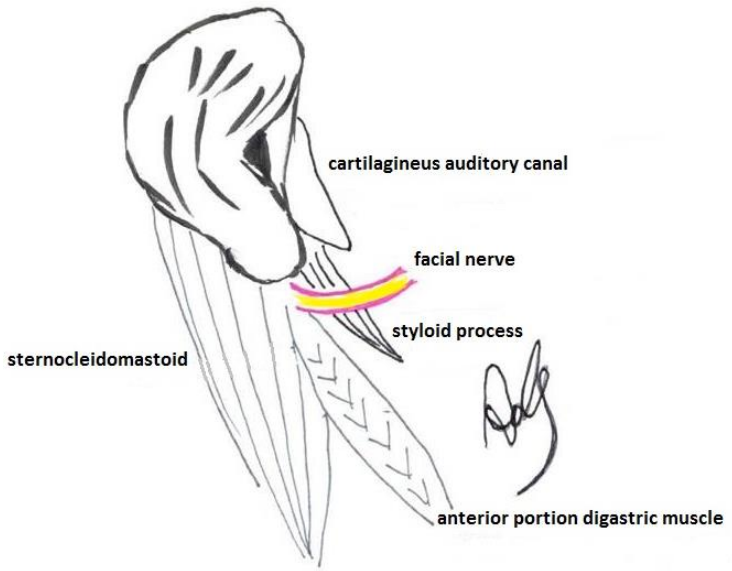

Figure 22. Exit of the facial nerve from the foramen stilomastoideum.

Anastomosis of Masseteric/Inferior Branch Facial Nerve (Physiologic Technique)

(on youtube: www.youtube.com/watch?v=GdzYbSoneuo)

Classic Technique

Under General anesthesia and previous local ansthesia too, a facelift-type incision is performed beginning in the temporal region, passing hidden behind the tragus, continuing under the earlobe, and extending into the mastoid region. An anterior-inferior skin flap is elevated in order to access the parotid-masseter region. We identify the facial nerve's exit from the styloid foramen by the standard extra cranial antegrade technique (see Figure 22). The zygomatic arch is exposed and the posterior half of masseter muscle is carefully dissected off the bony arch [20, 21, 22, 23]. We identify the masseter nerve and dissect it into the muscle to secure adequate length. We continue the facial nerve dissection started earlier with identification, until its bifurcation in the principal upper and lower division. The lower division is cut off the main trunk and mobilized sufficiently to permit its anastomosis, without tension, to previously dissected masseteric nerve. This suture will be performed under the microscope with 4 points 10/0 nylon suture in position time 12, 3, 6, 9 [24, 25, 26].

Mini-Lifting Approach Technique

This technique is based on the "subzygomatic triangle" area (see earlier) [27, 28]. Anatomic landmarks of this area are the temporo mandibular joint, the zigomatic arch, the sigmoid notch, and the malar eminence. A modified mini-facelift-type incision is performed

with an extension into the temporal hair tuft. The vertical incision extendes to the preauricular crease and stops just before the ear lobule. The musculocutaneous flap is prepared and the parotid fascia is exposed. Blunt dissection through the parotid-masseteric fascia is used to identify the buccal branch of the facial nerve. The facial nerve is safely retracted. Blunt dissection is carried out within the subzygomatic triangle into the substance of the masseter muscle. Once identified, the masseter nerve is traced inferiorly for approximately 2 to 3 cm until it arborized. It is divided and transposed on the buccal facial trunk and a tension free neurorrhaphy is performed (see Figure 23).

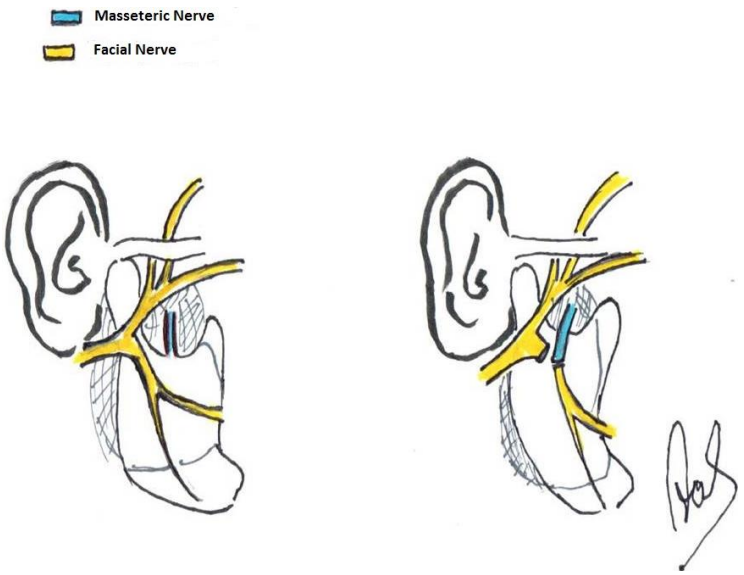

Figure 23. Masseteric anastomosis: in yellow, the facial nerve; in blue, the masseter nerve. A termino-terminal anastomosis will be effectuated between the two nerves.

Suturing and Closure

Suture planes with resorbable suture. Continue skin suture with prolene 4/0.

Ancillary Technique Eyebrow

Indication to Use

The choice of technique is dependent on patient's general conditions. In the case of coagulation disorders or treatment of small eyebrow asymmetry, the double needle technique is better because it is less invasive. If general conditions are good and the patient presents a large asymmetry or risk of sensibility to the suture, frontal lifting is the best option.

Frontal Lifting

(on youtube:www.youtube.com/watch?v=KT4XZMwbWbE)

Under general anesthesia, we can perform this technique easily and quickly. We can combine this to all other procedures described before. We also use local anesthesia to prepare our dissection zone.

An irregular incision of 4-6 cm is performed inside the temporal hairline; we respect the oblique cut line to preserve hair follicles. We identify the deep temporal fascia and with a smooth periosteal dissector we make our posterior dissection to the eyebrow tail, in the lateral cantal skin as well, and to the head of the eyebrow anteriorly.

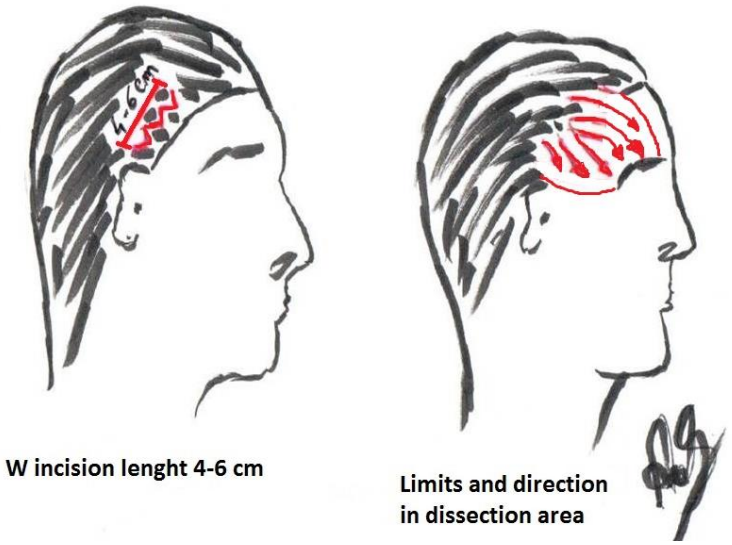

Figure 24. Frontal Lifting. The images show the incision and limits of the area and method of dissection.

This is a not risky dissection if performed tight to the temporal deep fascia, because facial nerves run superficially in this. After total detachment of the area of interest, the temporal skin is elevated. The suture to stabilize the eyebrow will perform securing the points to deep fascia. 4-6 point non-absorbable sutures are sufficient to give the desired lifting effect.

The excess skin is cut following the irregular line and sutured with 4-0 Vicryl and stainless steel skin clips.

Do not use any drainage, but a compressive bandage is requested for 48 hours to avoid surgical sequel [29, 30, 31].

Static Suspension with Non-Absorbable Suture Double Needle

This is a very quick and easy procedure to perform. You can perform this technique almost without risks.

Perform local anesthesia at the needle insertion point, in the zone of entry and exit of the needle. Two double-needle sutures are necessary to lift the eyebrow, one at the level of the eyebrow's head and another at its tail. The smooth portion of the suture is 'the traction point'. Keeping 3-4 cm at the level of the head and 3-4 cm at the tail level is sufficient to obtain a very good result. This is a bidirectional convergent suture, so you can obtain 4-point traction with only two sutures [33, 34, 35].

Figure 25. Double needle suture.

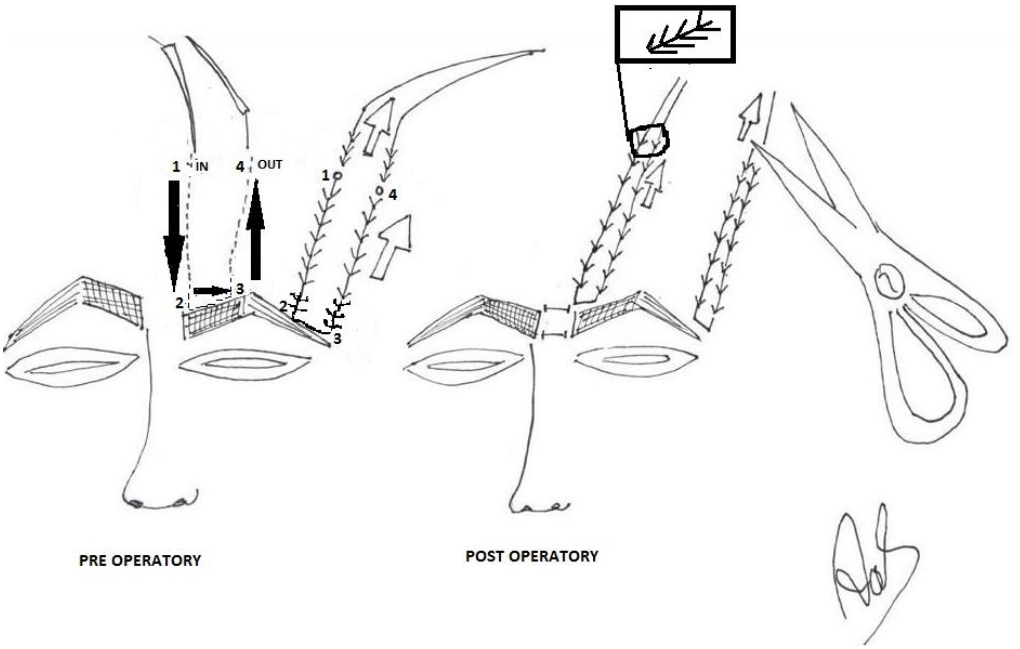

Figure 26. Static suspension with double needle suture at the level of the head and tail of eyebrow. Insertion of the needle starting at point 1; at the level of point 2, turn the needle directly to point 3 in a horizontal line, then turn the needle in a vertical line directly to point 4 until exiting to the skin. The black arrows show the direction of needle during the three passages. The empty arrows show the direction of the traction of the suture. After the needle's passage from point 1 to point 4, cut the needle. It will simply make a symmetrical traction on two threads for the suspension of the area of interest. The threads possess some bidirectional spines able to engage and support the tissue without making suture to subcutaneous tissue or the fascia a necessity.

CONCLUSION

As shown in this chapter, the choice of technique has the goal of achieving good results with less invasive surgery.

REFERENCES

[1] Sir Charles Ballance, KCMG; LLD; FRCS; Arthur B. Duel, MD. The operative treatment of facial palsy by the introduction of nerve grafts into the fallopian canal and by other intratemporal methods *Arch Otolaryngol*., 1932, 15(1), 1-70. doi:10.1001/archotol. 1932. 03570030 008001.

[2] Alan Bienstock, MD; Mark S Granick, MD. FACS Dynamic Reconstruction for Facial Nerve Paralysis. *Medscape*, 1289133, 1-14.

[3] Ritvik, P. Mehta Surgical Treatment of Facial Paralysis *Clin Exp Otorhinolaryngol*., 2009 Mar, 2(1), 1–5.

[4] Jowett, N[1]; Hadlock, TA[1].Contemporary Approach to Facial Reanimation. *JAMA Facial Plast Surg.*, 2015 Jul-Aug, 17(4), 293-300. doi: 10. 1001/ jamafacial.2015.0399.

[5] May, M; Barry, M. Schaitkin, Facial Paralysis Rehabilitation technique, *Book Hardcover Thieme*, 2003.

[6] Niklison, J. Facial paralysis: moderation of non-paralysed muscles. *Br J Plast Surg.*, 1965 Oct, 18(4), 397-405.

[7] Di Stadio, A. Eyelid lifting for ectropion and scleral show in facial palsy disease. *ORL J Otorhinolaryngol Relat Spec*., 2014, 76(6), 329-35. doi: 10.1159/000369623. Epub 2015 Jan 8.

[8] Rubin, LR. The anatomy of a smile: its importance in the treatment of facial paralysis. *Plast Reconstr Surg*., 1974 Apr, 53(4), 384-7.

[9] Rubin, LR, Mishriki, Y; Lee, G. Anatomy of the nasolabial fold: the keystone of the smiling mechanism. *Plast Reconstr Surg*., 1989 Jan, 83(1), 1-10.

[10] Rubin, LR. The anatomy of the nasolabial fold: the keystone of the smiling mechanism. *Plast Reconstr Surg*., 1999 Feb, 103(2), 687-91, discussion 692-4.

[11] Bianchi, B; Ferri, A; Leporati, M; Ferrari, S; Lanfranco, D; Ferri, T; Sesenna, E. Upper eyelid platinum chain placement for treating paralytic lagophthalmos. *J Craniomaxillofac Surg*., 2014 Dec, 42(8), 2045-8. doi: 10.1016/j.jcms.2014.09.012. Epub 2014 Oct 7.

[12] Wambier, SP; Garcia, DM; Cruz, AA; Messias, A. Spontaneous Blinking Kinetics on Paralytic Lagophthalmos After Lid Load with Gold Weight or Autogenous Temporalis Fascia Sling. *Curr Eye Res*., 2015 Aug 19, 1-8.

[13] Guerreschi, P; Labbe, D. Lengthening temporalis myoplasty: a surgical tool for dynamic labial commissure reanimation. *Facial Plast Surg*., 2015 Apr, 31(2), 123-7. doi: 10.1055/s-0035-1549039. Epub 2015 May 8.

[14] Labbè, D, Bussu, F; Iodice, A. A comprehensive approach to long-standing facial paralysis based on lengthening temporalis myoplasty. *Acta Otorhinolaryngol Ital.*, 2012 Jun, 32(3), 145-53.

[15] Labbé, D. [Lengthening of temporalis myoplasty and reanimation of lips. Technical notes]. *Ann Chir Plast Esthet*., 1997 Feb, 42(1), 44-7.

[16] Labbé, D; Hamel, M; Bénateau, H. [Lengthening temporalis myoplasty and transfacial nerve graft (VII-V). Technical note]. *Ann Chir Plast Esthet*., 2003 Feb, 48(1), 31-5.

[17] Labbé, D; Huault, M. Lengthening temporalis myoplasty and lip reanimation. *Plast Reconstr Surg*., 2000 Apr, 105(4), 1289-97; discussion 1298.

[18] Moubayed, SP; Labbé, D; Rahal, A. Lengthening temporalis myoplasty for facial paralysis reanimation: an objective analysis of each surgical step. *JAMA Facial Plast Surg*., 2015 May-Jun, 17(3), 179-82. doi: 10.1001/jamafacial.2015.46.

[19] Bénateau, H; Labbé, D; Elissalde, JM; Salamé, E. [Anatomical study of the temporalis tendon. Value in temporalis lengthening myoplasty]. *Ann Chir Plast Esthet*., 2001 Dec, 46(6), 611-6.

[20] Annamaneni, RC; Reddy, MD; Srikanth, R; Moturi, S; Komuravelly, A; Sadam, SR; Kanth, VS; Rao, VB. To evaluate the feasibility of neurotisation of facial nerve branches with ipsilateral masseteric nerve: an anatomic study. *J Clin Diagn Res*., 2014 Apr, 8(4), NC04-7. doi: 10.7860/JCDR/2014/7708.4302. Epub 2014 Apr 15.

[21] Yoshioka, N; Tominaga, S. Masseteric nerve transfer for short-term facial paralysis following skull base surgery. *J Plast Reconstr Aesthet Surg*., 2015 Jun, 68(6), 764-70. doi: 10.1016/j.bjps.2015.02.031. Epub 2015 Mar 19.

[22] Hontanilla, B; Marre, D; Cabello, A. Masseteric nerve for reanimation of the smile in short-term facial paralysis. *Br J Oral Maxillofac Surg*., 2014 Feb, 52(2), 118-23. doi: 10.1016/j.bjoms.2013.09.017. Epub 2013 Oct 19.

[23] Henstrom, DK. Masseteric nerve use in facial reanimation. *Curr Opin Otolaryngol Head Neck Surg.*, 2014 Aug, 22(4), 284-90. doi: 10.1097/ MOO.0000000000000070.

[24] Borschel, GH; Kawamura, DH; Kasukurthi, R; Hunter, DA; Zuker, RM; Woo, AS. The motor nerve to the masseter muscle: an anatomic and histomorphometric study to facilitate its use in facial reanimation. *J Plast Reconstr Aesthet Surg*., 2012 Mar, 65(3), 363-6. doi: 10.1016/ j. bjps.2011.09.026. Epub 2011 Oct 10.

[25] Biglioli, F; Frigerio, A; Colombo, V; Colletti, G; Rabbiosi, D; Mortini, P; Dalla Toffola, E; Lozza, A; Brusati, R. Masseteric-facial nerve anastomosis for early facial reanimation. *J Craniomaxillofac Surg*., 2012 Feb, 40(2), 149-55. doi: 10.1016/ j.jcms.2011.03.005. Epub 2011 Apr.

[26] Spira, M. Anastomosis of masseteric nerve to lower division of facial nerve for correction of lower facial paralysis. Preliminary report. *Plast Reconstr Surg*., 1978 Mar, 61(3), 330-4.

[27] Collar, RM; Byrne, PJ; Boahene, KD. The subzygomatic triangle: rapid, minimally invasive identification of the masseteric nerve for facial reanimation. *Plast Reconstr Surg*., 2013 Jul, 132(1), 183-8. doi: 10.1097/ PRS.0b013e318290f6dc.

[28] Cotrufo, S; Hart, A; Payne, AP; Sjogren, A; Lorenzo, A; Morley, S. Topographic anatomy of the nerve to masseter: an anatomical and clinical study. *J Plast Reconstr Aesthet Surg*., 2011 Nov, 64(11), 1424-9. doi: 10.1016/j.bjps.2011.05.026. Epub 2011 Jul 23.

[29] Emerson, W. *Ralph Facial aesthetic and lifting procedure*. Hardcover 196-206.

[30] Paul, MD. Subperiosteal transblepharoplasty forehead lift. *Aesthetic Plast Surg*., 1996 Mar-Apr, 20(2), 129-34.

[31] Jean Pierre Bessede *Chirurgie Plastique de la face et du cou* Volume 1 Elsevier Masson 10/2011.

[32] Savoia, A[1]; Accardo, C; Vannini, F; Di Pasquale, B; Baldi, A. Outcomes in thread lift for facial rejuvenation: a study performed with happy lift™ revitalizing. *Dermatol Ther (Heidelb)*., 2014 Jun, 4(1), 103-14. doi: 10.1007/s13555-014-0041-6. Epub 2014 Jan 17.

[33] Park, DM[1]. Total facelift: forehead lift, midface lift, and neck lift. *Arch Plast Surg*., 2015 Ma, 42(2), 111-25. doi: 10.5999/aps.2015.42.2.111. Epub 2015 Mar 16.
[34] Jean Pierre Bessede *Chirurgie Plastique de la face et du cou* Volume 2 Elsevier Masson 10/2012.
[35] Caix, P., *Anatomie tete et Cou Edition Arfa*, 2013.

BIOGRAPHICAL SKETCH

Arianna Di Stadio MD, PhD
Specialist in ENT, Microsurgery and Facial Plastic and Reconstructive Surgery

Affiliation: Harvard Medical School/Mass Eye and Ear Infirmary Otolaryngology Department

Research experiences: Research assistant at the University La Sapienza of Rome since 1999, she becomes PI in 2006.She worked like ENT and Clinical Researcher at the Pitie Salpetriere Hospital (Paris) in France and now she is Senior Research Fellow at MEEI/Harvard Medical School. Her research is addressed in several topics starting from facial palsy surgery to speech and hearing disorders. Now her researcher is focused in disorders of Internal Auditory Canal link to different disease.

Publications Last 3 Years:

1. A.Di Stadio, D.Lazzaro "DAAR: New Software for Studying Voice Parameters in People with Cochlear Implant" *CMNSEM*, Vol 3 No 4: 103-109 May 2012
2. Di Stadio A. "New scale for the assessment of facial paralysis: ADS scale" *Italian Journal of Maxillofacial Surgery* 2013 Agosto;24(2):81-7
3. Di Stadio A. "Combination of rehabilitation and eye soft surgery thought to reduce eye disease and the incidence of syncinesia" *Italian Journal of Maxillofacial Surgery* 2013 Agosto; 24(2): 69-75
4. Di Stadio A. "Eyelid lifting for ectropion and scleral show in facial palsy disease" *ORL* 2014; 76:329-335
5. A.Di Stadio, D.Lazzaro "DAAR®: New Digital software for prosody's study in subject with monolateral cochlear implant" *Prevention and research Journal* 2015; 4(3): 84-90
6. Di Stadio A. "another scale for the assessment of Facial Paralysis? ADS Scale:our preposition, How to use it." *Journal of Clinical and Diagnostic Research* accepted October 2015, in progress

Patents and Designs:

2015 Research Look on line Platform in progress

2013 OTOAGE and MY FACE COMPLEX oral supplement, Creator of the formulation and holder of the registration.

August 2007 Patent holder of “DAAR: New Digital software for the studies of vocal parameters in implanted children” (0001379177) Italy.

Clinical Guidelines and Reports

Authorization of clinical protocols addressed to “Receivers human body products” and to “Innovative therapies” like ***member*** of France National Agency for Health safe (***ANSM***).

In: Encyclopedia of Surgery (22 Volume Set)
Editors: Andreas Lehrer and Kristin Mueller
ISBN: 978-1-53618-329-0
© 2020 Nova Science Publishers, Inc.

Chapter 398

SETTING UP A MINIMALLY INVASIVE AORTIC VALVE SURGERY PROGRAM

Hunaid A. Vohra[1,*] and Christopher P. Young[2]
[1]Department of Cardiac Surgery, Bristol Heart Institute, Bristol, UK
[2]St. Thomas' Hospital, London, UK

ABSTRACT

Here we describe in detail the logical procedure and philosophical approach to establish a minimally invasive aortic valve replacement programme in the current era. The philosophical lessons learnt from the experiences are highlighted. It is hoped that this chapter will act as a template for newly established surgeons to embark onto a minimally invasive aortic valve surgery program. Although some technical fallacies are highlighted, the main aim is to focus on the non-surgical factors that could have a huge impact on the success of such an endeavour.

Keywords: valve, aortic, program, minimally invasive

INTRODUCTION

Clinical effectiveness and patient safety is paramount when introducing a new procedure or technique in the current National Health Service (NHS) climate. Here we describe in detail the logical procedure and philosophical approach to establish a minimally invasive aortic valve replacement program in the current era. A real example of a NHS Trust in the United Kingdom has been described in a step-wise manner. The outcomes of the new procedure established in this fashion are reported and the philosophical lessons learnt from the experiences are highlighted. It is hoped that this paper will act as a template for newly established surgeons to embark onto a minimally invasive aortic valve replacement (MIAVR) programme.

* Corresponding Author's Email: Hunaid.Vohra@UHBristol.nhs.uk.

ESTABLISHING THE NEED

MIAVR is now an established procedure. The first parasternal approach for MIAVR was reported by Cosgrove and Sabik [1] in 1996 following the minimally invasive revolution in general surgery in the late 1980's. Further evolution has resulted in the upper hemi-sternotomy (UHS) and the anterior right thoracotomy (ART) approaches to be currently the most popular ones. UHS provides a window through which the aortic root is freely accessible. Without additional risk to the patient, the surgeon applies slight modification to already established familiar techniques. This offers the patients the benefit of prompt recovery in appropriately selected patients and enhances patient choice and patient experience. Although suited for isolated AVR in patients of all ages, MIAVR is particularly applicable to the elderly, obese, recent smokers and those with impaired respiratory function. As compared to a conventional sternotomy, UHS leaves the sternum more stable and is particularly suitable for patients who may have a higher risk of sternal dehiscence but otherwise suitable for conventional AVR. Hence these are not patients who would be considered for trans-catheter aortic valve replacement (TAVR). Some studies have demonstrated reduction in hospital stay with MIAVR. With an increasingly elderly population in a tight fiscal climate, reducing the length of hospital stay after AVR, even by 1-2 days, could translate into better overall clinical outcomes and huge savings. Applying this argument would be a key selling point when trying to set up a MIAVR service in a cardiac surgical unit. A smaller scar, less pain and blood loss are other potential benefits. In centres where this procedure is well-established, the referral base has significantly increased as MIAVR is requested both by the patients as well as the cardiologists.

TRAINING

It is also important to establish any training needs, not only for the surgeon, but the whole team including anesthetists, perfusionists and the scrub team. Before the first cases are performed, local departmental teaching should be organised (lectures, evidence, videos, etc.) where all disciplines are invited. We used a combination of theoretical information as well as operative footage in order to familiarise the team with the procedure and its potential pitfalls. Visits to 'MIAVR centers' and attendance at courses targeted at new centres are strongly advised. From the surgical perspective, at least 2 surgeons are required with an interest in minimal access surgery. An experienced aortic valve surgeon teaming up with a newly appointed surgeon would be the ideal combination. Enthusiasm and wisdom are the 2 key elements that are required to set up such a programme. In our experience, a senior Consultant had performed hundreds of conventional AVRs and had visited a UK centre to observe MIAVR. On the other hand, a junior Consultant had performed >100 conventional AVRs but had spent time in fellowships, first learning minimally invasive surgery in another European center and then returning to another fellowship at St. Thomas' Hospital, UK focusing on MIAVR, TAVR and rapid deployment valves.

NEW PROCEDURE APPROVAL BY THE HOSPITAL

NIPAG Application

In most UK hospitals, all new procedures need prior approval from a committee, for example, 'New Interventions and Procedures Advisory Group (NIPAG).' It is crucial that the team endeavours to gain approval from such committees, if they exist in other countries, before embarking onto a MIAVR programme. This ensures patient safety, highlights clinical governance and maintains quality control. The NIPAG application requires description and indications of the proposed procedure, intended benefits, possible complications, summary of evidence base, estimated number of annual procedures to be performed, names of supporting colleagues, names of performing colleagues and letter of support from lead clinician.

Support from Colleagues

Ideally, the proposed procedure should be discussed with all Consultant surgical colleagues formally and their support sought, even if all of them would not be performing the new procedure. The names of the surgeons performing the operation in the 'setting-up' phase should be specified. Once this phase has passed and the final approval from NIPAG granted, other surgeons may also be able to embark onto the programme with appropriate in-house training.

Proctor

It should be considered compulsory to have a named proctor with considerable experience and reputation in the field to provide training and supervision in the first cases performed. The ideal proctor is one with whom at least one of the operating surgeons has worked or trained with before.

Patient Information Leaflet

NIPAG also requires that a patient information leaflet is devised in a language easily understood by patients where it is clearly stated that this is a new procedure to the trust but the surgeons involved are adequately trained and will be initially supervised to perform this. The leaflet informs the patient of the potential benefits and that this operation would not put the patients at higher risk of harm as compared to conventional surgery. Reassurance should also be provided that in case of a serious complication the incision will be made bigger to control the situation. The leaflet is intended to educate the patient with respect to the 'new technique' and provides them with an option they may wish to consider.

Audit

NIPAG also requires that individual patient audit and a summative audit is provided after the first 20 cases are performed. Any untoward serious event must be reported and copied to NIPAG. This provides the foundation for the final Trust approval. Regardless, once the procedure becomes well-established, 6-12 monthly audit with morbidity and mortality figures would be recommended best practice.

Cost

Although new additional costs can be involved, MIAVR by the UHS technique can generally be performed without the requirement for any special equipment. The Hospital Management should be reassured that extra funding would not be required for starting a MIAVR programme, at least in the initial phase, when UHS would be employed.

TAKE-OFF

Communicate

Before the programme commences, every effort must be made to encourage open discussion in a relaxed environment, to exploit every opportunity to highlight concerns regarding equipment and training and to facilitate team-work and boost morale. This becomes paramount if previous experiences have not been positive. Frequent informal dialogues in corridors and coffee rooms as well as formal discussions at regular Consultant, Monthly Audit and other Clinical Governance meeting should not be under-estimated.

Patient Selection

In the initial period (first 20 cases), patient selection is the key. Avoid very elderly, grossly obese, current smokers and high-risk patients. Once the programme is ‘up and running’, it is these very patients who might benefit from MIAVR. At the outset, the skin incision can be made slightly longer as it is the mini-sternotomy and not the skin incision which provides clinical benefit. A flow chart of patient selection for MIAVR is provided (Figure 1).

Proctor Contract

As the proctor is likely to be working in another hospital, he will require an honorary contract to be able to visit the center where the new procedure is envisaged. To avoid last minute disappointment, ensure that this is organised beforehand. Although sounds tedious,

but this can be easily and quickly done by communication between the two Human Resources Departments, especially if they are within the same country.

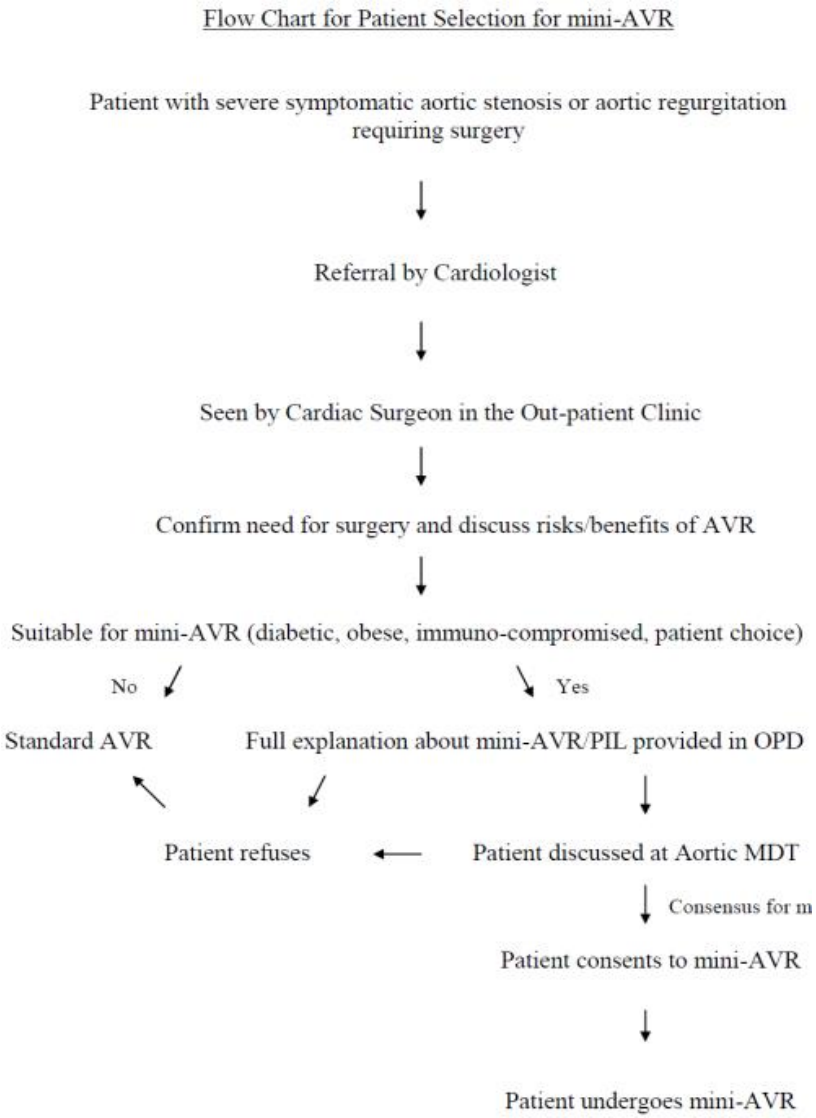

Key: AVR - aortic valve replacement, PIL - patient information leaflet, OPD - out-patient department, MDT - multi-disciplinary team.

Figure 1. Patient selection flow chart.

Team Briefing

Prior to the first case, the whole team must be extensively debriefed (with the proctor present) and ensure that all equipment required is available. It is important that all members of the team are encouraged to ask questions at this point to provide further opportunity to highlight issues and promote team involvement.

First 20 Cases

The first case in our programme was performed by the senior Consultant with the proctor as the first assistant and the junior Consultant as the second assistant. The second case was again performed by the senior Consultant with the junior Consultant as the first assistant and the proctor observing unscrubbed. During these cases, there were frequent technical points discussed which helped enormously. Thereafter, another 3 cases (unproctored) were performed by the 2 surgeons scrubbed together and then the rest of the first 20 cases were performed by one surgeon individually with the other surgeon on back-up within the hospital, if required. After the first 20 cases, the audit should be submitted to NIPAG and final approval sought. Initially, the cross-clamp time and total procedure is longer than conventional AVR but this reduces rapidly once the learning-curve is overcome.

Examples of Technical Difficulties

Although not the subject of this chapter, nevertheless below are some examples of technical difficulties that were experienced in the initial phase of the program with a brief explanation of how they were solved.

Difficult Access

By increasing the length of the skin incision and/or changing from a J to a T hemi-sternotomy or sternotomy into the 5th intercostal space instead of the 3rd or 4th space.

Right Atrial Venous Pipe 'in the Way'

Use a flat venous cannula and pass it under the retractor before connecting to cardio-pulmonary bypass circuit.

Blocked Drain

Using 2 drains of two sizes smaller instead of one big drain.

Difficulty in Placing Ventricular Pacing Wires

Insert while the heart is still before removing the cross-clamp.

Key Lessons Learnt

- Work together with an experienced surgeon
- Proctor essential
- Always have back up
- Do not be afraid to convert
- It is not as difficult as it sounds

CONCLUSION

The universal adoption of MIAVR in contemporary cardiac surgery seems inevitable in the foreseeable future. It is a safe and logical option from the data provided so far from studies and registries. An open-minded and enthusiastic team will undoubtedly be able to facilitate the introduction of this 'new service.' The 'starting-up' period can be daunting for a newly appointed surgeon. However, a sensible approach will provide safe and sustainable outcomes.

REFERENCE

[1] Cosgrove DM, 3rd, Sabik JF. Minimally invasive approach for aortic valve operations. *Ann Thorac Surg* 1996;62(2):596-7.

In: Encyclopedia of Surgery (22 Volume Set)
Editors: Andreas Lehrer and Kristin Mueller
ISBN: 978-1-53618-329-0
© 2020 Nova Science Publishers, Inc.

Chapter 399

CT IMAGING AND ECHOCARDIOGRAPHY FOR MINIMALLY INVASIVE AORTIC VALVE SURGERY

Gabriel Loor[1], MD and Eric E. Roselli[2,*], MD
[1]University of Minnesota, Department of Surgery, Division of Cardiothoracic Surgery, Minneapolis, MN, US
[2]Cleveland Clinic, Department of Thoracic and Cardiovascular Surgery and Center for Minimally Invasive Cardiothoracic Surgery, Heart and Vascular Institute, Cleveland, OH, US

ABSTRACT

Minimally invasive aortic valve replacement (MIAVR) compared with conventional AVR offers the potential for less pain, blood transfusions and resource utilization. Yet none of these benefits are realized if an adverse event occurs due to compromised exposure. Preoperative imaging levels the playing field; MIAVR becomes as feasible as a conventional AVR when the right exposure is chosen for the right patient. Here we review the use of preoperative imaging technology to select the appropriate candidates for MIAVR. We review our operative technique and the role of high resolution 3D reconstruction and echocardiography in the choice of surgical exposure and intraoperative management.

Keywords: minimally invasive, aortic valve replacement, computed tomography, echocardiography

INTRODUCTION

Surgical aortic valve replacement (AVR) including excision of the native valve and hand-sewn fixation remains the gold standard treatment for aortic valve disease with the longest data on freedom from reoperation and survival [1, 2]. Minimally invasive aortic valve

* Corresponding Author's Email: roselle@ccf.org.

replacement (MIAVR) has come a long way from the days of it being a highly specialised procedure offered only by a few surgeons. With appropriate use of preoperative imaging, careful patient selection, and experience, mortality rates for MIAVR can remain below 1% even with concomitant procedures [3]. It has now become the method of choice for isolated AVR at many centres. There is little tolerance in the current era for complications associated with exposure. The current chapter highlights our surgical approach to MIAVR and the role of imaging in determining patient selection and operative exposure.

OPERATIVE TECHNIQUE

Before we discuss the role of imaging, we will briefly review our technique for minimally invasive exposure which has evolved slightly from the original descriptions in the mid 90's by Drs. Cosgrove and Sabik [4]. The most commonly used exposure remains the mini-upper hemisternotomy (UHS). Typically a 6-10 cm skin incision is made starting 2 finger breaths above the angle of Louise (Figure 1A) [5]. A modest subcutaneous flap is raised at the upper and lower borders of the incision to allow access to the sternal notch and 4th intercostal space (ICS), respectively. Cosmesis is an important feature of this technique, hence the value of a smaller incision. On the other hand, the sternotomy portion remains the same no matter how big the skin incision and we believe the real benefit from a minimally invasive incision comes from the maintenance of chest wall respiratory physiology. Making the skin incision 8 cm or bigger may allow better visualization of the aorta for cannulation which is important for safety in the beginning of the operator's experience.

The 4th ICS is carefully dissected out so that the right lateral edge of the sternum is visible and accessible. Electrocautery is used to score a line in the sternum from the sternal notch, down the midline to just above the 4th ICS. This mark is slanted down towards the right lateral edge of the 4th ICS in a so called "J" configuration. The lungs are disconnected from the ventilator and the saw is engaged in the sternal notch. The sternum is divided along the outlined mark and slanted into the 4th ICS (Figure 1B). We prefer the J incision made with one saw over the so called "reverse L" configuration made with two saw blades at a right angle because the bone comes together more regularly with the former. We also prefer either of the former sternotomies to a full "inverted T" incision where the partial sternotomy includes a transverse sternotomy because the integrity of the chest wall is better preserved with the lesser incisions. Care is taken to avoid injuring the skin and the right internal thoracic artery during these manoeuvres.

Once the sternotomy is complete, hemostasis is obtained above and below the sternal edge and the 4th ICS is carefully inspected to ensure that the mammary artery and vein are not injured. If they are, they should be clipped and divided to prevent bleeding. Now a mini-sternal retractor is inserted and gradually opened. Care is taken to avoid excessive traction injury on the skin. The thymus is divided down the midline and the pericardium is entered. Hemostasis needs to be excellent since any bleeding will be magnified through minimally invasive exposure. The pericardium is opened inferiorly as far as possible and superiorly towards the innominate vein. Three stay sutures are placed on either side of the pericardium. Anesthesia is advised that the pressure may drop with pericardial elevation. Intravenous fluids and pressors are used as needed. The lungs are disconnected from the ventilator, the retractor

is removed, and the stay sutures are elevated and tightly secured to the sterile towels or sutured to the skin edge. The retractor is then re-inserted within the pericardium and the exposure is complete (Figure 1C).

For the mini anterior right thoracotomy (ART) approach, we make a 6 cm incision over the right 2nd ICS. The third intercostal rib head is transected close to its attachment to the sternum to improve exposure taking care to avoid periosteal or perichondral injury. A soft tissue retractor is inserted into the wound, and the mini-sternal retractor is inserted and gradually opened. The pericardium is entered and retracted with stay sutures to pull the aorta into the operative field. Certain adjuncts such as lighted retractors, auto suture devices like the Cor-knot (LSI solutions, Victor, NY), or the use of newer sutureless bioprosthetic valves can facilitate minimally invasive approaches. The rib is usually reattached to the sternum with a plate.

Peripheral cannulation is always an option but we prefer central cannulation due to the atherosclerotic burden that is common in these patients with calcific aortic valve disease and the associated risk of stroke. Retrograde cardioplegia is our preferred approach for protecting the heart during most conventional cardiac operations, but it is not completely reliable during MIAVR. The consequences of inadequate cardioplegia during an AVR can be devastating. Thus, we typically rely on antegrade induction with modified Buckberg cardioplegia followed by intermittent doses with direct infusion into the right and left coronary ostia. More recently, we have used single dose Del Nido cardioplegia to ensure an uninterrupted 1-1.5 hour cardiac arrest interval. A recent study by Mick and colleagues showed decreased operating times, no hospital deaths, similar troponin T levels and no change in left ventricular ejection fraction with Del Nido solution compared to modified Buckberg [6].

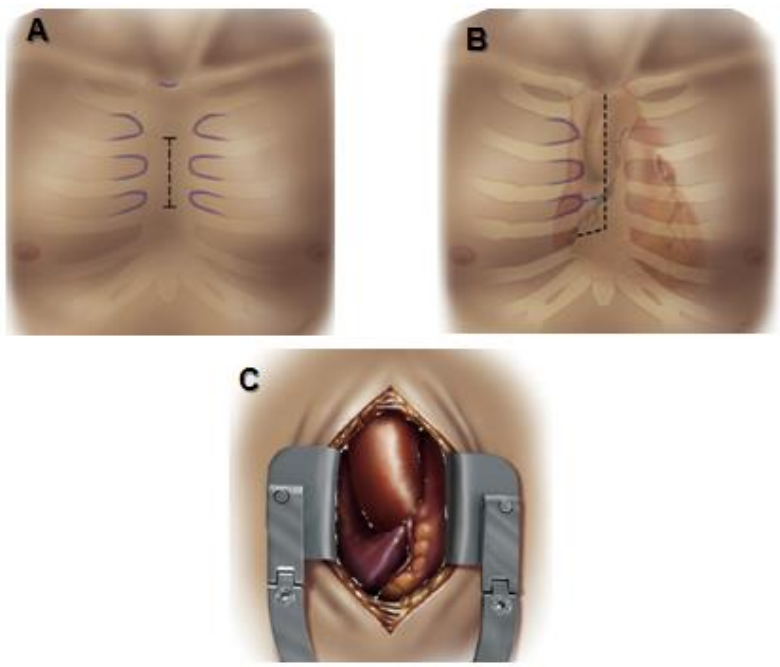

Figure 1. Operative technique. A). Skin incision B). Sternotomy (“J”) C). Final exposure (reprinted with permission Malaisrie et al. *JTCVS* 2014 [30]).

The AVR proceeds as usual. Any aortotomy of choice can be used and root enlargements are sometimes required. Stay sutures at the commissures may be helpful for elevating the annulus in the operative field. Complete valve excision and debridement is performed and we double check that all calcium debris has been irrigated and suctioned. Meticulous technique is required to ensure proper suture placement and symmetry. We do not typically use a superior pulmonary vein vent, so exposure to the right superior pulmonary vein is not mandatory but feasible. We use a drop in flexible suction catheter in the left ventricular outflow tract instead. With experience operating times through a mini incision approach those through a conventional incision.

BENEFITS OF MIAVR

There is a greater time and financial investment involved with preoperative imaging so there has to be a gain to MIAVR that justifies this. Here we highlight some of the data comparing outcomes for MIAVR compared with conventional AVR.

Tabata and colleagues reviewed 1000 minimally invasive aortic valve procedures and showed an operative mortality of 1.9% with 10 year survival of 88% [7]. Incidence of deep sternal wound infection, pneumonia and reoperation for bleeding were 0.5%, 1.3%, and 2.4%, respectively. The Cleveland Clinic experience recently showed an operative mortality below 1% even with adjunctive procedures [1]. Bakir and colleagues noted decreased blood use and decreased hospital stay with MIAVR compared with conventional AVR [8]. A recent review of the Brigham and Women's Hospital experience showed decreased blood use, ICU and hospital stays [9]. Ghanta and colleagues reviewed 289 propensity matched patients and showed decreased blood use, ventilator time, hospital stay and a cost reduction of approximately $1,891 with MIAVR [10]. Gilmanov and colleagues' analysis of 182 propensity matched pairs demonstrated a lower incidence of atrial fibrillation and blood use with MIAVR compared with conventional AVR [11]. Similar benefits have been reported by several additional investigators [12-15].

Not all studies have found a resounding benefit for MIAVR. Phan and colleagues utilized a Bayesian meta-analysis of 6 databases. They found that clamp duration and bypass times were longer with the ART approach but equivalent with the UHS approach [16]. Other short-term outcomes were equivalent. A larger meta-analysis by Phan and colleagues showed that overall quality of evidence for trials comparing MIAVR and conventional AVR is poor [17]. Yet they concluded that MIAVR was associated with similar mortality, and trends towards reduced ICU stay (by about half a day), hospitalization (by about a day), renal failure, transfusions, and pain. Stamou and colleagues reviewed 500 AVRs and showed no difference in blood transfusions after controlling for patient risk factors [18]. Detter and colleagues compared 70 MIAVR and conventional AVRs and showed no difference in any of 8 quality of life categories, in patient satisfaction, or in judgment of the cosmetic aspect. The lack of superiority found in these studies should caution the surgeon to reduce morbidity as much as possible by optimizing preoperative planning. It is hard to justify a complication related to exposure.

An appreciation for the use of preoperative imaging should allow for further development of even less invasive minimal access approaches. This will become increasing apparent as

other AVR technologies evolve. A collapsible sutureless aortic prosthesis like the Perceval valve (LivaNova, Milano, Italy) can be delivered into the mediastinum through a port sized incision [19-22]. Miceli and colleagues showed that MIAVR compared favorably with transcatheter AVR (TAVR) for high risk candidates [23]. They noted zero strokes for the sutureless valve compared with 5.4% for TAVR, zero deaths compared with 8% for TAVR, no paravalvular leaks compared with 27% for TAVR, and a 91% 2-year survival compared with 66% for TAVR. In addition, Gosev and colleagues recently showed that patients who require a redo AVR after a MIAVR do better than those who require a redo AVR following a standard sternotomy [24]. They noted shorter operating times, shorter vent times, and better long-term survival (100% 5-year survival for prior MIAVR compared with 85% 5-year survival for prior standard sternotomy). There are several potential benefits to minimally invasive exposure, but none of these are realized if the exposure is poor or circulatory support techniques are compromised.

Potential Pitfalls Related to Exposure

Conversions to standard sternotomy are required 1-8% of the time even in experienced hands [25, 26]. While conversions are necessary and warranted in the setting of poor exposure, it was associated with as high as 33% mortality in one series [27]. The most common reason for conversion involves issues with inadequate exposure although ventricular arrhythmias, myocardial dysfunction and bleeding are other reasons.

The aortic cannulation site may be prohibitively far from reach or calcified. The atrial cannulation site may also be far from reach. Typically cannulation issues do not preclude a MIAVR as there are several alternative cannulation strategies, but it is ideal to predict these scenarios ahead of time. An aortic annulus that is far from the operator's field can compromise complete and safe calcium debridement, suture placement and seating of the valve. Paravalvular leaks and coronary occlusion are complications that can occur as a consequence of poor exposure. One series found that up to 6% of MIAVR required revision or alteration of the operation in the same operative setting.

Preoperative Imaging with Computed Tomography

Achieving safe exposure is directed at two elements of the operation: (1) visualisation and access to the distal ascending aorta and right atrium for central cannulation and (2) visualization and access to the aortic annulus after cross clamping and arrest. Since 2006 we have increasingly adopted computed tomography (CT) to predict the most optimal exposure for an individual patient who is otherwise deemed a candidate for minimally invasive valve surgery. We have noticed that patient anatomy is variable; an exposure that works for one individual may not work for another. Preoperative planning has reduced our rate of unanticipated conversions to full sternotomy. The correct exposure allows for MIAVR to proceed with little difficulty or risk as compared to conventional AVR. This is true for patients at all levels of risk and variations in body habitus including the morbidly obese and those with chest wall deformities like pectus excavatum.

As mentioned above, there are several options for exposure including the following: (1) conventional upper hemisternotomy (UHS; J sternotomy) into the right 4th ICS, (2) extended upper hemisternotomy into the right 5th ICS, (3) lower hemisternotomy (inverted J) into the right 2nd or 3rd ICS, anterior right thoracotomy (ART) into the 2nd ICS, (4) mini-skin (11 cm) full sternotomy, and (5) conventional sternotomy. Ongoing investigations are focused on developing a robotically-assisted port approach. The main point is to select an exposure that is conducive to a safe operation while harnessing the benefits of a minimally invasive approach.

Ammar and colleagues first described the use of non-contrast CT for surgical planning of MIAVR in 1998 [28]. They identified intraoperative variations in patient anatomy and aortic annular location easily predicted by the preoperative CT scans. They tailored their incisions to the patients' anatomy and no patient required an extension or deviation from the anticipated exposure. Others have since advocated for the use of preoperative CT as standard of care for operative planning in MIAVR [29-33].

The advent of off-line three dimensional CT processing has simplified our ability to plan a cardiac operation. The bone removal function and soft tissue slab techniques allow the surgeon to fade from the skin level to the aortic annulus on any given scan (Figure 2A-C). For 3D reconstructions, the resolution of the aorta and its surrounding structures are enhanced with the use of IV contrast. Most AVR patients will require a contrast coronary angiogram prior to surgery which should be taken into account when scheduling the CT scan to avoid excessive dye boluses. Alternatively, cardiac MRI, while more expensive, can be used to plan surgical incisions and provide substantial granular detail.

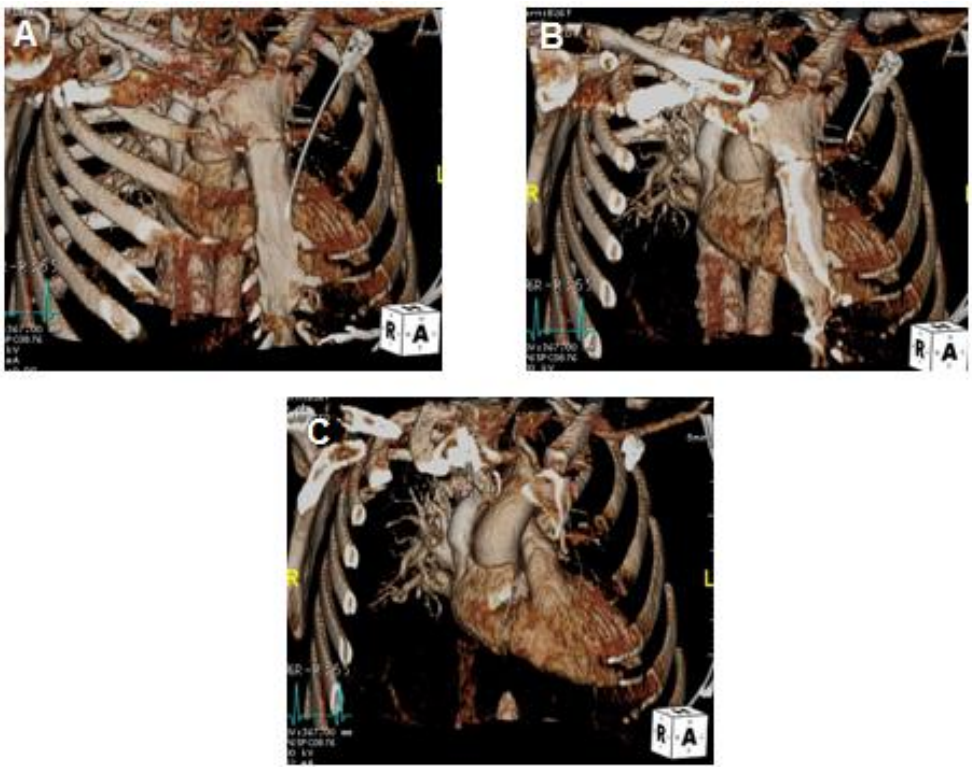

Figure 2. Advanced off line 3D reconstructions allow gradual removal of bone and soft tissue (A→C). This provides a road map from skin to annulus to guide the operative approach.

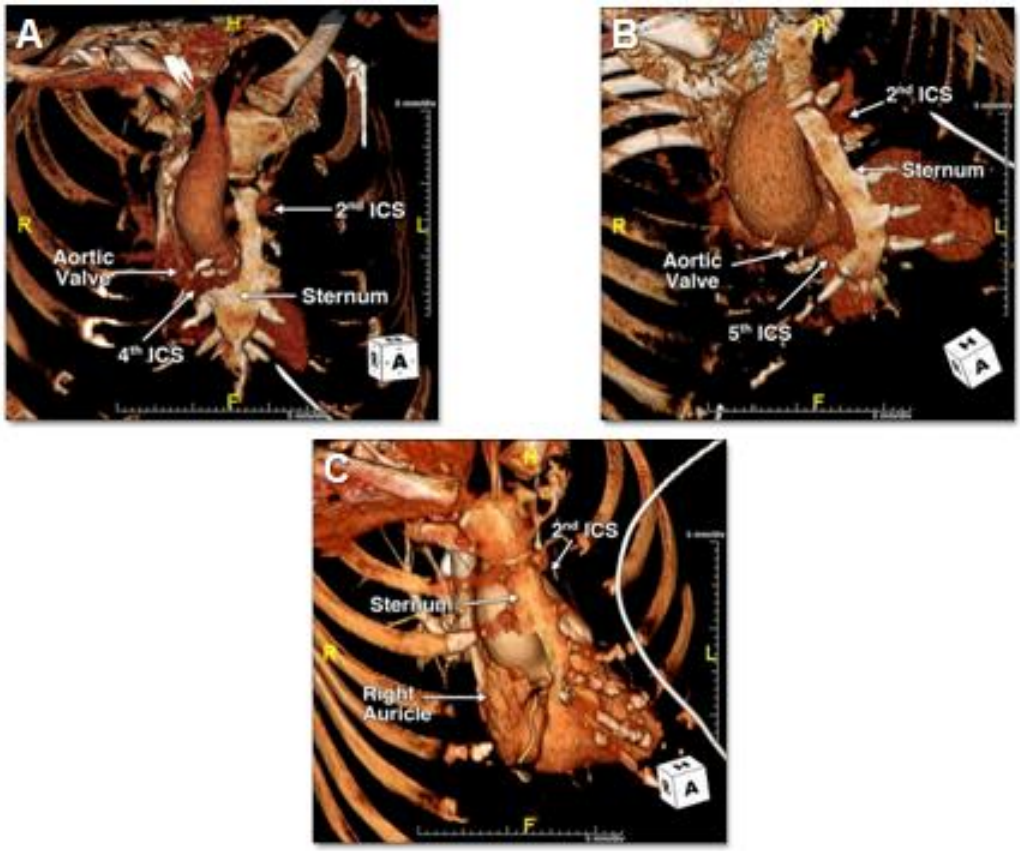

Figure 3. 3D high resolution reconstructions depict variations in human anatomy. A). The aortic annulus is in the expected position, midline, 4th ICS. A standard mini-AVR into the 4th ICS provides optimal exposure B). The annulus is slightly lower than expected. Bone fragmentation suggests that extension of the sternotomy to the 5th ICS would provide optimal exposure. C). The annulus is extremely low and near the xiphoid. Bone fragmentation suggests that an inverted lower hemisternotomy extended into the right 2nd or 3rd ICS would provide adequate exposure. (Reprinted with permis-sion Loor G and Roselli E, *JACC*: Imaging 2013 [32]).

For illustration, we will review 4 cases depicting anatomical variations detected with preoperative CT [32]. We utilize 3D reconstructed contrast-enhanced multi-detector computed tomography (MDCT). All cases employ MDCT technology using an iCT256-slice scanner (Phillips, Andover, Massachussetts) to acquire prospectively triggered axial images. Low osmolar iodinated contrast optimizes visualization of the vasculature in relation to the bony thorax. Multi-planar reconstruction, maximum intensity projections, volume rendered reconstructions and advanced 3D off-line post-processing is performed on a dedicated stand-alone workstation (AcquariusNET, TeraRecon, Inc, San Mateo, California) that is available on each surgeons desktop, in the outpatient clinic, and in each operating room.

In the first scenario (Figure 3A) CT showed an aortic annulus slightly above the 4th ICS and at the middle of the sternum. This is ideal for the standard UHS. The exposure to the annulus and cannulating areas was no different than a conventional AVR. Note that the aorta did sway towards the right at the level of the 2nd ICS. Thus, ART could have been considered.

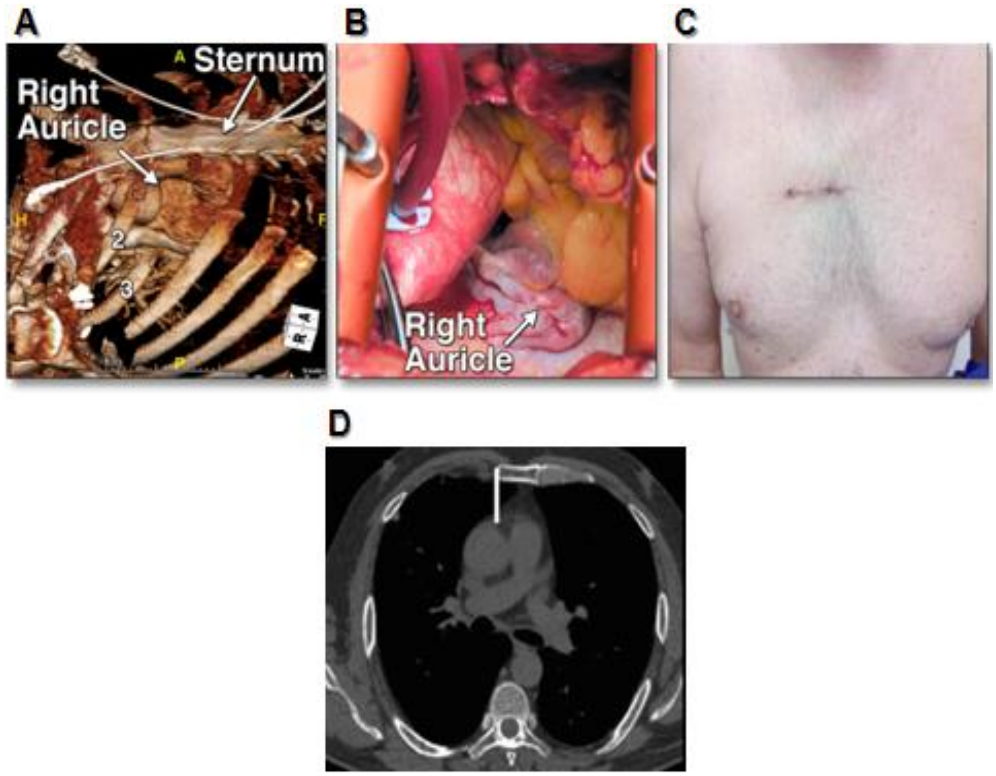

Figure 4. The right lateral thoracotomy exposure A-C). 3D reconstruction and virtual planning suggests the right thoracotomy approach would be ideal for this patient with the aorta deviated to the right (Reprinted with permission Loor G and Roselli E, *JACC* 2013 [32]). D). A vertical line from the right sternal border to the aorta shows >50% of the aorta to the right of this mark. This suggests optimal exposure via right anterior thoracotomy. (Reprinted with permission Glauber et al. *JTCVS* 2011 [34]).

The next example (Figure 3B) shows an aortic annulus closer to the 5th ICS. The choices include a conventional median sternotomy, a mini-incision (11 cm) full sternotomy, or a MIAVR through the 5th ICS. The latter extends the sternotomy slightly more than the 4th ICS standard UHS but spares the complete sternotomy and allows for a smaller skin incision (8cm). While this is not common, the 5th ICS extension is much better than struggling through the 4th ICS. The valve anatomy was very comfortable to see and dissect. The third example (Figure 3C) is a patient with an annulus nearly at the level of the xiphoid due to an aneurysmal ascending aorta. In this case an inverted sternotomy with extension into the right 3rd ICS was used. The exposure was excellent.

The final example shows a patient with the aorta and annulus shifted up and towards the right 3rd rib head (Figure 4A-C). This is ideal for an ART approach. We had easy access to the ascending aorta for clamping and the delivery of antegrade cardioplegia. Additional imaging through the chest, abdomen and pelvis can be included to assess the feasibility for femoral bypass if central access cannot be achieved safely.

When using preoperative imaging it is helpful to have certain standard measurements to make your decisions about exposure. For instance, if the aortic annulus is above the 4th ICS and in midline or to the left then a standard UHS is indicated, if the annulus is to the right of midline then a right lateral thoracotomy can be safely considered, if the annulus is lower than

the 5th ICS then an extended right upper hemisternotomy will facilitate exposure, and if the ascending aorta is below the 2nd ICS then an inverted hemisternotomy will work. There are no published standards to guide these decisions and they serve as general guidelines. As one gains experience using CT to guide the decision-making process and with the intraoperative manipulations available to assist exposure, a better understanding will be gained about tailoring the various incision options to each patient. Manipulation of the 3D images by removing soft tissue and bone allows you to position the patient as one would for surgery and mimic the operative exposure. In these cases it becomes evident whether a specific exposure will work.

Even without reconstructions, rough measurements based on trial and error can guide the surgeon towards the correct exposure. For example, Glauber and colleagues suggest that if more than half of the ascending aorta is to the right of a vertical line drawn from the right sternal border to the ascending aorta on an axial cut (Figure 4D) then the ART approach is reasonable [34].

There are other benefits gained from having a preoperative CT scan for operative planning. It can show the extent of calcium or extension of such into the outflow tract, coronary ostial location in relation to the annulus, and annular size [35]. Understanding the size of the annulus may assist with device choice such as whether a root enlargement may be anticipated. CT can guide cardiopulmonary bypass strategies by clarifying plaque burden and distance to the cannulation sites. For redo operations, the CT is indispensable in clarifying the proximity of vital structures to the posterior sternum [36]. Thus, preoperative planning with 3D reconstructions of a contrast chest CT reveals potential pitfalls prior to the operation.

ECHOCARDIOGRAPHY AND MIAVR

Echocardiography also plays an important role in the preoperative planning and intraoperative management for MIAVR. Transthoracic echocardiography (TTE) allows confirmation of the presence and severity of valvular disease. It provides details related to the valvular and subvalvular apparatus. It reveals significant subvalvular gradients and hypertrophy which may alter the operative approach. It demonstrates the extent of aortic insufficiency that may have implications for myocardial protection during MIAVR. For instance, Del Nido cardioplegia solution delivered via a cannula in the proximal ascending in a patient with moderate or more aortic insufficiency may be interrupted after the heart becomes bradycardic enough, and then followed by direct delivery into the coronary ostia.

If retrograde cardioplegia into the coronary sinus is the preferred method of cardiac protection, trans-oesophageal echocardiography (TOE) has been helpful for retrograde cannula placement and confirmation of positioning into the coronary sinus. Infusion of air through the sinus port and use of cannulae with radio-opaque tips can also assist with TOE-guided positioning. Demirsoy and colleagues reported a success rate of 85% with TOE-guided retrograde cardioplegia cannula placement [37].

Echocardiography can clarify the details of preoperative myocardial function. A patient with a very low ejection fraction may be best approached through a conventional sternotomy depending on the details of the patient's disease and the surgeon's experience. Cross-clamp and bypass times tend to be longer with MIAVR and the quality of cardiac protection may not

be as reliable as when the entire heart is exposed. Low EF patients typically do not tolerate increased operative times or deviations in myocardial protection.

It has long been know that intra-operative echocardiography is useful for evaluating post bypass cardiac function and de-airing techniques during MIAVR, and was recently demonstrated to be the case in a study by Secknus and colleagues [38]. Echocardiography also revealed a problem with the valve requiring additional intervention to correct it in 6% of cases. Epicardial echocardiography can influence the location of aortic cannulation by revealing aortic plaque [39]. Thus, the preoperative and intra-operative echocardiogra- phy is helpful in documenting valve pathology, cardiac function, retrograde coronary sinus catheter placement, safe cannulation and de-airing. Echocardiography has limited role in planning the specific surgical incision site for MIAVR.

MIAVR AND BEYOND

Preoperative imaging also clarifies the potential for performing adjunctive procedures safely. Repair of ascending aortic aneurysm, for instance, is feasible through a minimally invasive exposure if preoperative CT scanning suggests that the aorta and valve are within the operative field of view (http://www.ctsnet.org/article/mini-sternotomy-hemiarch-and-bicuspid-aortic-valve-bav-repair) [40]. Operations requiring circulatory arrest are feasible through minimally invasive approaches with no compromise in safety by using preoperative CT to plan the approach. Re-operative AVR can also be carried out through UHS. The imaging should support a location of the annulus near or above the fourth ICS. Other features of the CT will be relevant for a redo-sternotomy such as the location of the innominate vein and other vital structures [41, 42]. Even redo-sternotomy on patients with a prior heart transplant for MIAVR has been described [43]. In an early series of 54 patients, Svensson and colleagues performed re-operations in 33%, composite valve grafts in 28%, and elephant trunk type procedures in 6% of patients. The survival rate was 96%, stroke 3.7%, mean circulatory arrest time was 20 min, and mean units of blood transfused were 1.3 [44].

Even concomitant aortic valve and mitral valve procedures can be performed in patients with reasonable anatomy. The UHS approach to double valve disease has been used successfully in Cleveland for over twenty years. Additionally, Lamelas published his experience with the “Miami Method” for performing concomitant aortic valve and mitral valve surgery via ART [45]. Preoperative imaging is used to clarify patients who are suitable for this approach. Interventions on the leaflets for moderate mitral regurgitation such as an Alfieri stitch are feasible if the exposure to the annulus and subannular apparatus are good [46]. Patients with severe mitral annular calcification or leaflet calcification should be excluded from this approach.

A variety of other adjunctive procedures have been described through the MIAVR exposure. Minimally invasive resections of fibroelastomas [47], root replacement and repairs [7], and a modified maze procedure can be safely performed if the exposure is adequate [8]. For these types of multi-component procedures, the anatomical exposure needs to be adequate and the means for myocardial protection need to suitable. If there is any concern about protecting the heart during a longer operation, it is preferable to use a conventional sternotomy.

CONCLUSION

In conclusion, MIAVR may offer an advantage over conventional AVR in terms of decreased blood transfusions, length of hospital stay, ventilator time, recovery time and pain. These benefits are most pronounced in small series performed by very experienced surgeons. With conventional sternotomy as a competitive alternative, there is no room for compromise in the exposure. Current technology allows for readily available processing of preoperative CT imaging providing exquisite three-dimensional detail that should be used to decide if a patient is a candidate for MIAVR and how best to perform it. In addition to the details of valve morphology and pathology, echocardiography provides adjunctive information to guide cardioplegia and cannulation strategies. Preoperative imaging is mandatory to provide the safest application of minimally invasive techniques for patients undergoing MIAVR.

REFERENCES

[1] Johnston DR, Soltesz EG, Vakil N, Rajeswaran J, Roselli EE, Sabik JF 3rd, Smedira NG, Svensson LG, Lytle BW, Blackstone EH. Long-term durability of bioprosthetic aortic valves: implications from 12,569 implants. *The Annals of thoracic surgery* 2015;99(4):1239-1247.

[2] McClure RS, Narayanasamy N, Wiegerinck E, Lipsitz S, Maloney A, Byrne JG, Aranki SF, Couper GS, Cohn LH. Late outcomes for aortic valve replacement with the Carpentier-Edwards pericardial bioprosthesis: up to 17-year follow-up in 1,000 patients. *The Annals of thoracic surgery* 2010;89(5):1410-1416.

[3] Johnston DR, Roselli EE. Minimally invasive aortic valve surgery: Cleveland Clinic experience. *Annals of cardiothoracic surgery* 2015; 4(2):140-147.

[4] Cosgrove DM, 3rd, Sabik JF. Minimally invasive approach for aortic valve operations. *The Annals of thoracic surgery* 1996;62(2):596-597.

[5] Mihaljevic T, Gillinov MA, Cosgrove DM. Minimally invasive aortic valve replacement. *Multimedia manual of cardiothoracic surgery: MMCTS/European Association for Cardio-Thoracic Surgery* 2006;2006 (315):mmcts 2005 001131.

[6] Mick SL, Robich MP, Houghtaling PL, Gillinov AM, Soltesz EG, Johnston DR, Blackstone EH, Sabik JF 3rd. Del Nido versus Buckberg cardioplegia in adult isolated valve surgery. *The Journal of thoracic and cardiovascular surgery* 2015;149(2):626-634.

[7] Tabata M, Umakanthan R, Cohn LH, Bolman RM 3rd, Shekar PS, Chen FY, Couper GS, Aranki SF. Early and late outcomes of 1000 minimally invasive aortic valve operations. *European journal of cardio-thoracic surgery* 2008;33(4):537-541.

[8] Bakir I, Casselman FP, Wellens F, Jeanmart H, De Geest R, Degrieck I, Van Praet F, Vermeulen Y, Vanermen H. Minimally invasive versus standard approach aortic valve replacement: a study in 506 patients. *The Annals of thoracic surgery* 2006;81(5):1599-1604.

[9] Neely RC, Boskovski MT, Gosev I, Kaneko T, McGurk S, Leacche M, Cohn LH. Minimally invasive aortic valve replacement versus aortic valve replacement through

full sternotomy: the Brigham and Women's Hospital experience. *Annals of cardiothoracic surgery*. 2015;4(1):38-48.

[10] Ghanta RK, Lapar DJ, Kern JA, Kron IL, Speir AM, Fonner E Jr, Quader M, Ailawadi G. Minimally invasive aortic valve replacement provides equivalent outcomes at reduced cost compared with conventional aortic valve replacement: A real-world multi-institutional analysis. *The Journal of thoracic and cardiovascular surgery* 2015; 149(4):1060-1065.

[11] Gilmanov D, Bevilacqua S, Murzi M, Cerillo AG, Gasbarri T, Kallushi E, Miceli A, Glauber M. Minimally invasive and conventional aortic valve replacement: a propensity score analysis. *The Annals of thoracic surgery* 2013;96(3):837-843.

[12] Hiraoka A, Totsugawa T, Kuinose M, Nakajima K, Chikazawa G, Tamura K, Yoshitaka H, Sakaguchi T. Propensity Score-Matched Analysis of Minimally Invasive Aortic Valve Replacement. *Circ J* 2014; 78(12):2876-81.

[13] Sharony R, Grossi EA, Saunders PC, Schwartz CF, Ribakove GH, Culliford AT, Ursomanno P, Baumann FG, Galloway AC, Colvin SB. Minimally invasive aortic valve surgery in the elderly: a case-control study. *Circulation* 2003;108 Suppl 1:II43-47.

[14] Liu J, Sidiropoulos A, Konertz W. Minimally invasive aortic valve replacement (AVR) compared to standard AVR. *European journal of cardio-thoracic surgery* 1999;16 Suppl 2:S80-83.

[15] Svensson LG, D'Agostino RS. Minimal-access aortic and valvular operations, including the "J/j" incision. *The Annals of thoracic surgery* 1998;66(2):431-435.

[16] Phan K, Xie A, Tsai YC, Black D, Di Eusanio M, Yan TD. Ministernotomy or minithoracotomy for minimally invasive aortic valve replacement: a Bayesian network meta-analysis. *Annals of cardiothora- cic surgery* 2015;4(1):3-14.

[17] Phan K, Xie A, Di Eusanio M, Yan TD. A meta-analysis of minimally invasive versus conventional sternotomy for aortic valve replacement. *The Annals of thoracic surgery*. 2014;98(4):1499-1511.

[18] Stamou SC, Kapetanakis EI, Lowery R, Jablonski KA, Frankel TL, Corso PJ. Allogeneic blood transfusion requirements after minimally invasive versus conventional aortic valve replacement: a risk-adjusted analysis. *The Annals of thoracic surgery*. 2003;76(4):1101-1106.

[19] Santarpino G, Pfeiffer S, Sirch J, Vogt F, Concistre G, Fischlein T. Minimally invasive aortic valve replacement with Perceval valves: first clinical experience. *J Cardiovasc Med (Hagerstown)* 2014;15(3):230-234.

[20] Miceli A, Santarpino G, Pfeiffer S, Murzi M, Gilmanov D, Concistré G, Quaini E, Solinas M, Fischlein T, Glauber M. Minimally invasive aortic valve replacement with Perceval S sutureless valve: early outcomes and one-year survival from two European centers. *The Journal of thoracic and cardiovascular surgery* 2014;148(6):2838-2843.

[21] Shrestha M, Timm R, Höffler K, Koigeldiyev N, Khaladj N, Hagl C, Haverich A, Sarikouch S. Minimally invasive aortic valve replacement with self-anchoring Perceval valve. *The Journal of heart valve disease.* 2013;22(2):230-235.

[22] Santarpino G, Pfeiffer S, Vogt F, Hinzmann M, Concistre G, Fischlein T. Advanced age per se should not be an exclusion criterion for minimally invasive aortic valve replacement. *The Journal of heart valve disease.* 2013;22(4):455-459.

[23] Miceli A, Gilmanov D, Murzi M, Marchi F, Ferrarini M, Cerillo AG, Quaini E, Solinas M, Berti S, Glauber M. Minimally invasive aortic valve replacement with a sutureless

valve through a right anterior mini-thoracotomy versus transcatheter aortic valve implantation in high-risk patients. *European journal of cardio-thoracic surgery* 2015 Jun 25. pii: ezv210. [Epub ahead of print].

[24] Gosev I, Neely RC, Leacche M, McGurk S, Kaneko T, Zeljko D, Loberman D, Javed Q, Cohn LH, Aranki SF.. The impact of a minimally invasive approach on reoperative aortic valve replacement. *The Journal of heart valve disease* 2015;24(2):181-186.

[25] Moscoso Luduena M, Rastan AJ. Complications and conversions in minimally invasive aortic valve surgery. *Annals of cardiothoracic surgery* 2015;4(1):94-98.

[26] Borger MA, Moustafine V, Conradi L, Knosalla C, Richter M, Merk DR, Doenst T, Hammerschmidt R, Treede H, Dohmen P, Strauch JT. A randomized multicenter trial of minimally invasive rapid deployment versus conventional full sternotomy aortic valve replacement. *The Annals of thoracic surgery* 2015;99(1):17-25.

[27] Tabata M, Aranki SF, Fox JA, Couper GS, Cohn LH, Shekar PS. Minimally invasive aortic valve replacement in left ventricular dysfunction. *Asian cardiovascular & thoracic annals* 2007;15(3):225-228.

[28] Ammar R, Porat E, Eisenberg DS, Uretzky G. Utility of spiral CT in minimally invasive approach for aortic valve replacement. *European journal of cardio-thoracic surgery* 1998;14 Suppl 1:S130-133.

[29] Baumgartner WA, Burrows S, Del Nido PJ, Gardner TJ, Goldberg S, Gorman RC, Letsou GV, Mascette A, Michler RE, Puskas JD, Rose EA, Rosengart TK, Sellke FW, Shumway SJ, Wilke N; National Heart, Lung, and Blood Institute Working Group on Future Direction in Cardiac Surgery. Recommendations of the National Heart, Lung, and Blood Institute Working Group on Future Direction in Cardiac Surgery. *Circulation* 2005;111(22):3007-3013.

[30] Malaisrie SC, Barnhart GR, Farivar RS, Mehall J, Hummel B, Rodriguez E, Anderson M, Lewis C, Hargrove C, Ailawadi G, Goldman S, Khan J, Moront M, Grossi E, Roselli EE, Agnihotri A, Mack MJ, Smith JM, Thourani VH, Duhay FG, Kocis MT, Ryan WH. Current era minimally invasive aortic valve replacement: techniques and practice. *The Journal of thoracic and cardiovascular surgery* 2014;147(1):6-14.

[31] Plass A, Scheffel H, Alkadhi H, Kaufmann P, Genoni M, Falk V, Grünenfelder J. Aortic valve replacement through a minimally invasive approach: preoperative planning, surgical technique, and outcome. *The Annals of thoracic surgery* 2009;88(6):1851-1856.

[32] Loor G, Desai MY, Roselli EE. Pre-operative 3D CT imaging for virtual planning of minimally invasive aortic valve surgery. *JACC: Cardio- vascular Imaging*. 2013;6(2):269-71.

[33] Loor G, Roselli EE. Imaging and minimally invasive aortic valve replacement. *Annals of cardiothoracic surgery*. 2015;4(1):62-66.

[34] Glauber M, Miceli A, Bevilacqua S, Farneti PA. Minimally invasive aortic valve replacement via right anterior minithoracotomy: early outcomes and midterm follow-up. *The Journal of thoracic and cardio- vascular surgery*. 2011;142(6):1577-1579.

[35] Schoenhagen P, Tuzcu EM, Kapadia SR, Desai MY, Svensson LG. Three-dimensional imaging of the aortic valve and aortic root with computed tomography: new standards in an era of transcatheter valve repair/implantation. *European heart journal*. 2009;30(17):2079-2086.

[36] Roselli EE, Pettersson GB, Blackstone EH, Brizzio ME, Houghtaling PL, Hauck R, Burke JM, Lytle BW. Adverse events during reoperative cardiac surgery: frequency, characterization, and rescue. *J Thorac Cardiovasc Surg* 2008;135(2):316-23, 323.e1-6.

[37] Demirsoy E, Ozbek U, Bayindir O, Sonmez B. Clinical experience with coronary sinus catheterization in minimally invasive aortic valve surgery under transesophageal echocardiography guidance. *Int J Cardiovasc Imaging* 2002;18(6):453-455.

[38] Secknus MA, Asher CR, Scalia GM, Cosgrove DM, 3rd, Stewart WJ. Intraoperative transesophageal echocardiography in minimally invasive cardiac valve surgery. *J Am Soc Echocardiogr* 1999;12(4):231-236.

[39] Davila-Roman VG, Phillips KJ, Daily BB, Davila RM, Kouchoukos NT, Barzilai B. Intraoperative transesophageal echocardiography and epiaortic ultrasound for assessment of atherosclerosis of the thoracic aorta. *Journal of the American College of Cardiology* 1996;28(4):942-947.

[40] Roselli EE. Interventions on the aortic valve and proximal thoracic aorta through a minimally invasive approach. *Annals of cardiothoracic surgery.* 2015;4(1):81-84.

[41] Mikus E, Calvi S, Tripodi A, Dozza L, Lamarra M, Del Giglio M. Minimally invasive reoperative aortic valve replacement. *Annals of cardiothoracic surgery* 2015;4(1):67-70.

[42] Pineda AM, Santana O, Lamas GA, Lamelas J. Is a minimally invasive approach for re-operative aortic valve replacement superior to standard full resternotomy? *Interactive cardiovascular and thoracic surgery.* 2012;15(2):248-252.

[43] Vistarini N, D'Armini AM, Pellegrini C, Aiello M, Toscano M, Minzioni G, Viganò M. Minimally invasive aortic valve replacement in a transplanted heart. *The Annals of thoracic surgery* 2010;90(5):1688-1690.

[44] Svensson LG, Nadolny EM, Kimmel WA. Minimal access aortic surgery including re-operations. *European journal of cardio-thoracic surgery* 2001;19(1):30-33.

[45] Lamelas J. Minimally invasive concomitant aortic and mitral valve surgery: the "Miami Method." *Annals of cardiothoracic surgery* 2015; 4(1):33-37.

[46] Mihos CG, Santana O, Brenes JC, Lamelas J. Outcomes of transaortic edge-to-edge repair of the mitral valve in patients undergoing minimally invasive aortic valve replacement. *The Journal of thoracic and cardiovascular surgery* 2013;145(5):1412-1413.

[47] Hsu VM, Atluri P, Keane MG, Woo YJ. Minimally invasive aortic valve papillary fibroelastoma resection. *Interactive cardiovascular and thoracic surgery* 2006;5(6): 779-781.

In: Encyclopedia of Surgery (22 Volume Set)
Editors: Andreas Lehrer and Kristin Mueller
ISBN: 978-1-53618-329-0
© 2020 Nova Science Publishers, Inc.

Chapter 400

ANAESTHESIA AND FAST-TRACKING IN MINIMALLY INVASIVE AORTIC VALVE SURGERY

Ben Gibbison*
Department of Cardiac Anaesthesia, Bristol Heart Institute/University of Bristol, Bristol, UK

ABSTRACT

The main drive behind minimally invasive surgery is to reduce tissue damage. This is likely to translate into a smaller inflammatory response and faster recovery. Primarily, this aims to improve patient experience - meaning that patients have less pain, feel better and can return to their normal life sooner. However, this also aligns with incentives for healthcare providers to reduce hospital stays and improve efficiency. Inherent within the process for minimally invasive surgery should be a move towards improving recovery as measured by reduced intensive care and hospital stays. This chapter discusses anaesthesia for minimally invasive aortic valve surgery and measures to enhance fast-tracking post-surgery.

Keywords: anaesthesia, fast-tracking, minimally invasive, aortic, valve

INTRODUCTION

Lesser tissue destruction, change to respiratory mechanics and ultimately inflammatory activation, the fewer the post-operative problems. This is evidenced by trans-femoral transcatheter aortic valve implantation patients who, without the inflammatory response of bypass and sternotomy, are routinely discharged on the second post-operative day.

Traditionally, high dose opiates were given to cardiac surgical patients to abolish the neuro-hormonal responses to surgical insult. The trade-off of this approach is that patients need to be ventilated overnight in an intensive care unit. During the 1990s, fast-track cardiac

* Corresponding Author's Email: Ben.Gibbison@UHBristol.nhs.uk.

surgery emerged as a way to address increasing demand with limited resources. The drive to faster extubation means that in some cardiac surgical units, patients are now extubated "on table" at the end of the case and post-operative care provided in a dedicated post-anaesthetic care unit outside the main intensive care unit [1].

ANAESTHESIA FOR MINIMALLY INVASIVE AORTIC VALVE SURGERY

Patient Selection

Patient selection is critical to success in moving patients rapidly through the peri-operative care pathway. In theory, all elective patients should be considered as eligible for a fast-track programme - high risk patients may benefit from optimal preparation, reduced stays in the ICU, and increased mobilisation, although re-admission to the ICU is associated with a poor outcome. Predictors of failure in fast-track surgery are shown below and these criteria should be applied rigorously. i.e., if a patient meets any of these criteria at any stage, they should be removed from the fast-track pathway.

- Severely impaired LV function (<30%) [5]
- Long operative time (>4hrs 30min) [6]
- Long cardiopulmonary bypass time (>2hrs) [6]
- Impaired renal function (GFR < 65) [7]
- Non-elective surgery [5]
- Pre-operative intra-aortic balloon pump [5]
- 'Redo' surgery

It should be noted that when considering impaired renal function, it is the Glomerular filtration rate (GFR) that is the important value, not just the creatinine. Wide variance in GFR can be seen between individuals for the same serum creatinine level due to differences in sex, race, muscularity and other inherited and acquired differences [7].

Pre-Operative Assessment

Pre-operative assessment for minimally invasive aortic valve replacement (MIAVR) should be the same as any other cardiac surgical operation. That is that the severity and symptoms of the lesion should be established, as well as its consequences of the rest of the heart. The presence and severity of all co-morbidities must also be known.

When assessing patients for MIAVR, several pre-existing health conditions warrant further investigation:

- Cerebrovascular and peripheral vascular disease: Peripheral vascular disease is associated with an increased risk of stroke or systemic embolization with retrograde arterial perfusion. A CT of the chest and abdomen will delineate the anatomy of the vascular tree and a contrast angiogram will show potentially hazardous plaques

within the lumen. Knowledge of the size and tortuosity of the ilio-femoral vessels helps in correct cannula size selection.

- Previous cardiac surgery, lung conditions and chest wall deformity/irradiation: Chest wall deformity, irradiation and pre-existing cardiac surgery are all associated with adhesions and previous coronary surgery may mean that grafts cross the operative field. These can all be characterised by means of a CT chest. Airway assessment and pulmonary function tests to assess suitability for one lung ventilation should be assessed in those undergoing surgery via a thoracotomy approach.
- Co-existent coronary artery disease: If possible, evaluation of this should be carried out before CT angiography of the arterial tree due to the risk of iatrogenic dissection of the iliac artery during cardiac catheterisation. This could be catastrophic if unrecognised when the iliac vessels are cannulated at the time of MIAVR. A single, anterior graft can be carried out the time of MIAVR, although more usually treatment of coronary artery disease is by percutaneous stents.
- Trans-oesophageal echocardiography (TOE): is essential for safe conduct of minimally invasive surgery. Therefore, contra-indication to TOE should also be assessed. These include oesophageal carcinoma, stricture, varices or prior oesophagectomy.

Preoperative Preparations

Numerous methods have been attempted to help patients adequately prepare for cardiac surgery and ensure patients are in optimal condition prior to surgery. However, few of them have any real evidence-base to recommend them. Pre-operative physiotherapy [8] and respiratory exercises [9] have been shown to improve rates of post-operative pulmonary complications (atelectasis and pneumonia) after elective cardiac surgery. Pre-operative carbohydrate drinks close to surgery also have shown benefits in terms of reduced stays, but the Cochrane meta-analysis cautioned against the high risk of bias in these studies [10], although the risk of harm is low.

Perioperative Anaesthetic Considerations

Anaesthetic considerations for MIAVR should be as for any other cardiac surgical procedure. It should be remembered that conduct in the operating theatre affects post-operative care. Sedative pre-medication should be avoided and prophylactic antibiotics should be administered prior to urinary catheterisation. Large bore venous access and arterial monitoring should be established prior to induction of anaesthesia. To facilitate rapid extubation and recovery, moderate doses of short acting opiates, hypnotics and muscle relaxants are used. Despite multiple attempts comparing volatile with intravenous anaesthesia and different types and doses of opiates - no one type of anaesthesia has been shown to be beneficial in terms of meaningful clinical outcomes [11, 12]. Studies of remifentanil, an ultra-short acting opiate, which does not accumulate, have shown reduced mechanical ventilation and hospital stay times without changes in mortality, although virtually all of these studies

were carried out in coronary artery surgery [13]. If using remifentanil, care must be taken to give post-operative opioids 30 minutes prior to waking due to its short half-life. There is some evidence that remifentanil has such profound effects on opioid receptors, that increased doses of post-operative analgesics are needed to overcome 'rebound' hyperalgesia [14].

A multi-lumen central venous catheter is placed and in some centres, a 9Fr pulmonary artery vent is inserted at the same site to minimise the number of cannulae arising from the incision (this is essential in the thoracotomy approach). Because of limited access to the heart for internal defibrillation during surgery, external pads should be both placed and connected to the defibrillator prior to the start of surgery. Careful attention to temperature maintenance is required after weaning from cardio-pulmonary bypass (CPB) to prevent falls in temperature. Heated mattresses, heated blankets, fluid warmers and head covering should be should all be employed. These methods should mean that complete rewarming is complete in most patients by the time of leaving the operating theatre. Similarly, conducting normothermic, or at least only mild hypothermic bypass is essential to maintain the post-CPB temperature.

Postoperative Considerations

Post-operative pain usually peaks within the first 48 hours after surgery, but usually declines from the second and third post-operative day - both from upper hemi-sternotomy and anterior right thoracotomy (ART). Limited rib retraction at ART and early drain removal shorten the period of peak pain. Patients under 60 years old have higher pain scores and so steps should be taken to pre-empt this [15, 16].

Evidence to support any one type of analgesia after cardiac valve surgery is missing. In principle, central neuraxial analgesia should be ideal for all surgical approaches to the heart. However, concerns still exist around bleeding in anti-coagulated patients near the spinal cord. A Cochrane review of thoracic epidurals in cardiac surgery showed no difference in terms of mortality, stroke or cardiovascular outcomes, but did show improved pulmonary outcomes and lower rates of dysrhythmias. The authors still counselled that these results should still be interpreted with caution and that there was still insufficient evidence to recommend this form of analgesia [17].

Opiates form the mainstay of analgesia, but regional adjuncts such as intercostal nerve blocks and paravertebral infusions can be useful for the ART approach and direct delivery of local anaesthetic to the wound using reservoir devices has also been used. Judicious use of non-steroidal anti-inflammatory drugs is also useful after the second post-operative day and ensuring that the renal function has returned to normal.

To assist with mobilisation, all intravenous catheters should be removed on the morning of the second post-operative day, along with the urinary catheter if the renal function is normal or returning to normal. Mobilisation assists with bowel habit, but prophylactic laxatives should be prescribed for all patients.

Trans-Oesophageal Echocardiography

Aortic valve replacement is a class II indication for TOE. However, as the surgeon's view of the heart decreases, reliance on the perioperative TOE increases. Thus, TOE is essential for minimally invasive aortic valve surgery. A complete perioperative TOE examination [18] should be completed in every case, but the key roles of TOE in minimally invasive aortic valve surgery are:

- Pre CPB
  - Confirmation of diagnosis
  - Ensure competence of the aortic valve for ante-grade cardioplegia delivery
  - Assessment of left and right ventricular function
  - Exclusion of an intra-cardiac shunt
  - Exclusion of aortic pathology
    - Mobile plaques
    - Aneurysmal disease
    - Dissection/intramural haematoma
    - Penetrative ulceration
- Peri CPB
  - Correct placement of the percutaneous venous cannula in the right atrium/vena cava
    - Exclusion of large Eustachian/Thebesian valves
    - Exclusion of prominent and obstructive Chiari network
  - Correct placement of the retrograde cardioplegia cannula in the coronary sinus
    - Exclusion of persistent left sided-SVC
  - Adequacy of de-airing
- Post CPB
  - Assessment of valve repair/replacement
  - Assessment of non-valvular complications
  - Exclusion of concealed bleeding
    - Pericardial
    - Pleural
    - Retroperitoneal

Placement of the Venous Drainage Catheter

Optimal surgical conditions are achieved by maintaining a still, flaccid, decompressed heart. Reducing venous return to the right side of the heart is accomplished by the venous CPB cannula. To reduce the risk of this large cannula when it is placed percutaneously, both the wire and then the cannula must be seen in right atrium. This is best visualised in the mid-oesophgeal bicaval view at 90° with the probe turned to the right.

Placement of the Coronary Sinus Catheter

The coronary sinus catheter enables delivery of retrograde cardioplegia. The risks of misplacement are failure of delivery of cardioplegia and coronary sinus perforation. The

catheter can either be placed through the mini-sternotomy or percutaneously via a 9Fr sheath placed in the right internal jugular vein. A modified mid-oesophgeal bicaval view (at 110-130°) is the optimal view for percutaneous catheter placement, as the whole catheter can be visualised at all times. In this view, the coronary sinus is seen in the centre of the view - appearing just below the left atrium. The catheter is placed in the sinus and confirmed by pressure monitoring. It is advanced as distally as possible to maintain stability. The balloon should then be inflated under direct vision. To ensure correct positioning - a ventricularised pressure trace should be seen and on injecting agitated saline, no bubbles should escape via the coronary sinus ostium. These two conditions must be met, even if the catheter looks adequately placed on echocardiography. New onset pericardial effusion during catheter manipulation should be treated as coronary sinus perforation until proven otherwise.

Placement of the Pulmonary Artery Vent

The pulmonary artery vent can be used as part of a complete venous drainage strategy and particularly if there is only one venous cannula in the right atrium. For optimal position, this should be placed exactly at the bifurcation of the main pulmonary artery (MPA) into its left and right branches. The catheter can be followed through the right ventricle and into the main pulmonary artery by viewing the right ventricular inflow-outflow view at 30-60°. The probe is then withdrawn and the angle of the array decreased to 0-20^{0} to view the MPA bifurcation.

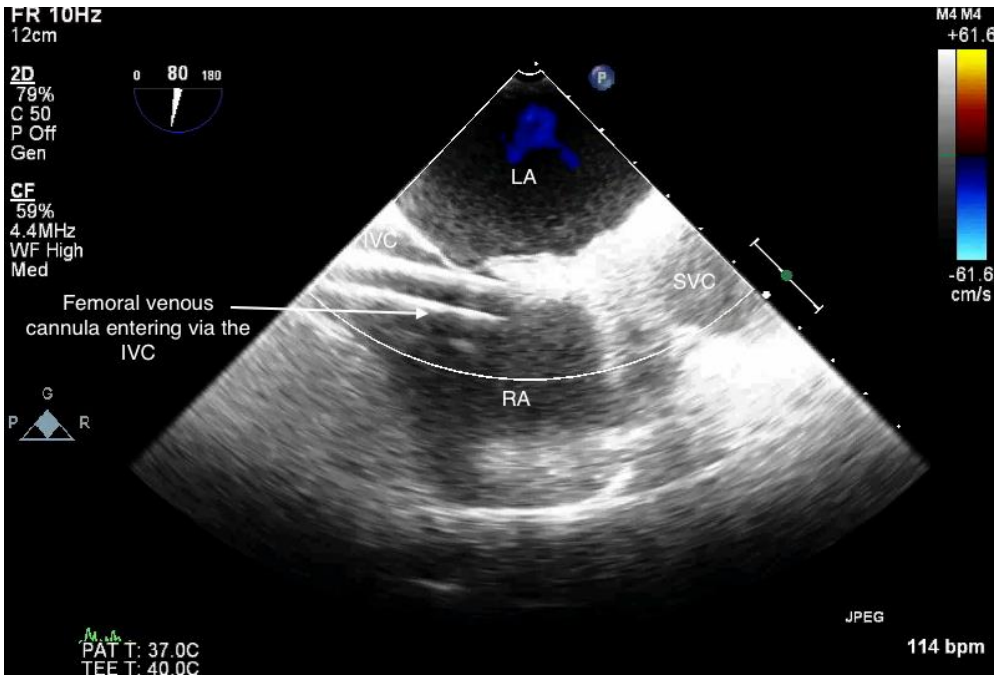

Figure 1. TOE image of femoral venous drainage catheter in the bicaval view. The cannula can be seen to enter the RA via the IVC. LA - left atrium. RA - Right atrium. SVC - Superior vena cava. IVC - inferior vena cava.

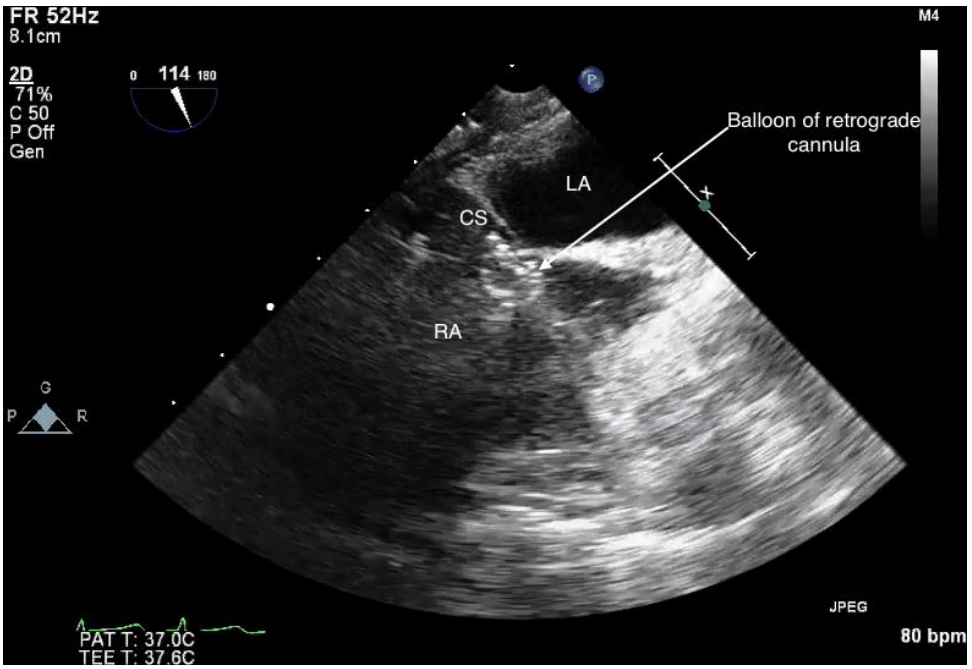

Figure 2. TOE image of the placement of the coronary sinus catheter in a modified bicaval view. The coronary sinus catheter balloon can be seen in the entrance to the coronary sinus. LA - left atrium. RA - right atrium. CS - coronary sinus.

FAST-TRACKING IN MINIMALLY INVASIVE AORTIC VALVE SURGERY

A fast-track approach has been shown to be equally safe and effective compared to 'standard' care in terms of morbidity and mortality, but with shorter extubation times and intensive care unit stays [2]. These shorter ICU stays have not yet led to a shorter hospital stay [3] showing that extubation *per se* is not the rate limiting step of intensive care discharge. Indeed patients who fail the fast-track stream may have longer stays than if they were in a 'standard' stream [3].

There is currently no level I evidence as yet pertaining to fast-track minimal invasive aortic valve surgery. However, when designing a fast-track protocol for minimally invasive aortic valve surgery, the same empiric principles will apply.

There is no standard definition of what constitutes fast-track aortic valve surgery [2], but it is this authors opinion that the drive should be towards improving patient care and experience; efficiencies to the healthcare system will come as a by-product of providing this high-quality care. A fast-track system should address the whole peri-operative pathway, from patient selection and pre-admission to hospital discharge and follow-up.

Enhanced Recovery

The stage beyond fast-track aortic valve surgery is enhanced recovery (ER). ER is a programme of high quality surgical care that returns patients back to normal function sooner.

ER and minimally invasive surgery are inter-dependent: ER cannot occur without less tissue damage and a smaller and shorter inflammatory response. Similarly, the benefits of minimally invasive aortic valve surgery will fail to be realised without a system change that moves patients through that system faster.

ER works on the principle of "the aggregation of marginal gains" [4]. This means making every part of the peri-operative care pathway as good as it possibly can be for as many patients as possible. The higher the rate of compliance with the elements of the ER, the lower the rate of later than expected discharges (Joshi et al. ACTA Manchester 2015 In press).

There are four elements to an enhanced recovery programme:

1. Pre-operative assessment, planning and preparation before admission: It is important to involve the patient, their family and their careers in the operation, as well as the patient's General Practitioner. This means that that the dates for admission, operation AND expected discharge are in everyone's diary. Planning and maintaining a date for operation and discharge makes sure that staff identify and co-ordinate all essential resources. Pre-operative assessment should be made as soon as the decision to operate has been made. This allows all relevant investigations and consultations to be complete by the time of surgery.
2. Reducing the physical stress of the operation: Using minimally invasive surgery, maintaining adequate temperature and optimal fluid management.
3. A structured approach to immediate post-operative and peri-operative management, including pain relief. Structured and protocol driven post-operative care is essential, not only as it ensures that patients are getting the right care, but will identify patients who are failing the pathway. This will allow early intervention to treat these problems.
4. Early mobilisation: This is dependent on high quality analgesia and structured physiotherapy. Patients should be ambulated at the earliest opportunity.

Key factors that help implement an enhanced recovery programme are:

- Staff training: The multi-disciplinary team must be trained so that they understand the evidence about speeding up recovery after surgery and thus develop a mind-set which allows patients to be active in their recovery. Operating theatre staff needs to be formally trained in minimally invasive aortic valve techniques to ensure smooth process of the operation and keeping operating and cross-clamp times to a minimum.
- Improved processes: The workflow should be planned and scheduled. This means everybody knows what to expect and when to expect it.
- Procedure specific care plans: A generic 'cardiac surgery' care plan is no longer appropriate. MIAVR care plans should be separate from mitral valve repairs and coronary artery surgery. The pre-, peri- and post-operative goals are different and therefore should be treated differently. This not only allows early identification of those who are failing, but also allows advanced planning (e.g., pre-discharge echo, optimal anti-coagulation) to ensure discharges are timely.

CONCLUSION

Meticulous attention must be given by the anaesthetist and/or the intesivist to anaesthetic methods, analgesic techniques and anatomical/echocardiographic considerations before, during and after minimally invasive aortic valve surgery to avoid complications, enhance quicker recovery, avoid pain and earlier discharge from the hospital. Fast-track protocols should be devised and followed for suitable patients.

REFERENCES

[1] Probst S, Cech C, Haentschel D, Scholz M, Ender J. A specialized post anaesthetic care unit improves fast-track management in cardiac surgery: a prospective randomized trial. *Crit Care* 2014;**18:** 468.

[2] Zhu F, Lee A, Chee Y. Fast-track cardiac care for adult cardiac surgical patients. *Cochrane Database Syst Rev* 2012;**10,** Cd003587.

[3] Svircevic V, Nierich AP, Moons KG, Brandon Bravo Bruinsma GJ, Kalkman CJ, van Dijk D. Fast-track anesthesia and cardiac surgery: a retrospective cohort study of 7989 patients. *Anesth Analg* 2009;**108:** 727-733.

[4] Sport, B. *Dave Brailsford BBC Interview*. at <http://www.bbc.co.uk/sport/olympics/19174302>.

[5] Constantinides VA, Tekkis PP, Fazil A, Kaur K, Leonard R, Platt M, Casula R, Stanbridge R, Darzi A, Athanasiou T. Fast-track failure after cardiac surgery: development of a prediction model. *Crit Care Med* 2006;**34:** 2875-2882.

[6] Kiessling AH, Huneke P, Reyher C, Bingold T, Zierer A, Moritz A. Risk factor analysis for fast track protocol failure. *J Cardiothorac Surg* 2013:**8:**47.

[7] Youssefi P, Timbrell D, Valencia O, Gregory P, Vlachou C, Jahangiri M, Edsell M. Predictors of Failure in Fast-Track Cardiac Surgery. *J Cardiothorac Vasc Anesth* 2015 doi:10.1053/j.jvca.2015.07.002.

[8] Hulzebos EH, Smit Y, Helders PP, van Meeteren NL. Preoperative physical therapy for elective cardiac surgery patients. *Cochrane Database Syst Rev* 2012;**11:** Cd010118.

[9] Katsura M, Kuriyama A, Takeshima T, Fukuhara S, Furukawa TA. Preoperative inspiratory muscle training for postoperative pulmonary complications in adults undergoing cardiac and major abdominal surgery. *Cochrane Database Syst Rev* 2015; **10:** Cd010356.

[10] Smith MD, McCall J, Plank L, Herbison GP, Soop M, Nygren J. Preoperative carbohydrate treatment for enhancing recovery after elective surgery. *Cochrane Database Syst Rev* 2014;**8:**Cd009161.

[11] Landoni G, Guarracino F, Cariello C, Franco A, Baldassarri R, Borghi G, Covello RD, Gerli C, Crivellari M, Zangrillo A. Volatile compared with total intravenous anaesthesia in patients undergoing high-risk cardiac surgery: a randomized multicentre study. *Br J Anaesth* 2014**;113 (6):**955-963.

[12] Módolo NSP, Módolo MP, Marton MA, Volpato E, Arantes VM, Nascimento P Junior, El Dib R. Intravenous versus inhalation anaesthesia for one-lung ventilation. *Cochrane Database Syst Rev* 2013;**7:**Cd006313.

[13] Greco M, Landoni G, Biondi-Zoccai G, Cabrini L, Ruggeri L, Pasculli N, Giacchi V, Sayeg J, Greco T, Zangrillo A. Remifentanil in Cardiac Surgery: A Meta-analysis of Randomized Controlled Trials. *J Cardiothorac Vasc Anesth* 2012;**26:**110-116.

[14] Joly V, Richebe P, Guignard B, Fletcher D, Maurette P, Sessler DI, Chauvin M Remifentanil-induced postoperative hyperalgesia and its prevention with small-dose ketamine. *Anesthesiology* 2005;**103:**147-155.

[15] Meehan DA, McRae ME, Rourke DA, Eisenring C, Imperial FA. Analgesic administration, pain intensity, and patient satisfaction in cardiac surgical patients. *American journal of critical care: an official publication, American Association of Critical-Care Nurses* 1995;**4:**435-442.

[16] Mueller XM, Tinguely F, Tevaearai HT, Revelly JP, Chioléro R, von Segesser LK. Pain location, distribution, and intensity after cardiac surgery. *Chest* 2000;**118:**391-396.

[17] Svircevic V, Passier MM, Nierich AP, van Dijk D, Kalkman CJ, van der Heijden GJ. Epidural analgesia for cardiac surgery. *Cochrane Database Syst Rev* 2013;**6:**Cd006715.

[18] Hahn RT, Abraham T, Adams MS, Bruce CJ, Glas KE, Lang RM, Reeves ST, Shanewise JS, Siu SC, Stewart W, Picard MH. Guidelines for performing a comprehensive transesophageal echocardiographic examination: recommendations from the American Society of Echocardiography and the Society of Cardiovascular Anesthesiologists. *Anesth Analg* 2014;**118:** 21-68.

In: Encyclopedia of Surgery (22 Volume Set)
Editors: Andreas Lehrer and Kristin Mueller
ISBN: 978-1-53618-329-0
© 2020 Nova Science Publishers, Inc.

Chapter 401

CANNULATION AND CARDIO-PULMONARY BYPASS FOR MINIMALLY INVASIVE AORTIC VALVE SURGERY

Martin Andreas, Guenther Laufer and Alfred Kocher*
Department of Cardiac Surgery, Medical University of Vienna,
Vienna, Austria

ABSTRACT

Cannulation and cardio-pulmonary bypass deserves distinct attention in patients undergoing minimally invasive aortic valve surgery. Meticulous care and attention has to be paid to every detail from pre-operative planing througout the surgical procedure until post-operative care. This chapter provides several practical tips and a step-by-step guide to successful and minimal-risk cannulation for optimal conduct of cardio-pulmonary bypass. The pros and cons of different techniques are discussed to provide the reader relevant background information for clinical decision making.

Keywords: cannulation, hemi-sternotomy, anterior right thoracotomy, minimally invasive

INTRODUCTION

The cannulation strategy – which is the topic of the current chapter - may differ depending on access for valve surgery. This book chapter focuses on the two most commonly applied minimally invasive strategies for aortic valve replacement (AVR), namely anterior right thoracotomy (ART) and upper hemisternotomy (UHS) [1]. UHS is less complex regarding cannulation and cardio-pulmonary bypass (CPB) compared to ART. The most commonly performed UHS is the reversed-L-shaped (or 'J' shaped) into the right 3rd or 4th intercostal space [2]. While UHS can be performed with a routine set of cannulas, ART requires different arterial and venous cannulae. Furthermore, aortic cross-clamping, venting, cardioplegic arrest and de-airing may undergo significant adaptations from UHS to ART.

* Corresponding Author's Email: Alfred.Kocher@meduniwien.ac.at; Fax: +43 1 404005640.

This chapter describes current techniques for cannulation and CPB applied at the Medical University of Vienna. Most techniques for direct cannulation via ART were implemented at our department by Prof. Guenther Laufer (Head of Department).

Stable CPB is an absolute requirement for a safe and successful surgical procedure. The calculated flow must be achieved and optimal drainage is crucial to optimise exposure in these surgical procedures. Literally every millimeter is essential in minimally invasive aortic valve surgery. A stepwise approach may be selected during the implementation of a minimally invasive program at a department or during the training of younger surgeons. This could include cannulation via the groin or the axillary artery during the early period of ART aortic valve surgery to optimise exposure through limited access. A switch to intra-thoracic cannulation may be performed after more surgical experience is achieved.

PATIENT SELECTION

Patients have to fulfill distinct criteria to be eligible for minimally invasive aortic valve surgery. Some of the criteria are also related to cannulation.

Indication for Aortic Valve Surgery

The underlying aortic valve disease may influence the decision regarding the surgical access. Aortic stenosis without other co-morbidities may be ideal for minimally invasive AVR. On the contrary, pure aortic regurgitation (AR) may add complexity to the procedure. Here, the aorta may be dilated and highly pulsatile prior to cross-clamping, which may make suture placement and aortic clamping more challenging. Furthermore, administration of cardioplegia will lead to regurgitation into the ventricle and may cause ventricular dilatation and impaired cardio-protection. Direct coronary intubation and administration of cardioplegia will be necessary in these patients. Furthermore, rapid-deployment valves are not always suitable in these patients.

Patients suffering from active endocarditis of the aortic valve should not be approached by ART due to the potential additional procedures that may be required to reconstruct the left ventricular outflow tract. However, UHS could be chosen after intense review of the trans-oesophageal echocardiogram showing no abscess formation in the aortic root and no involvement of other valves in these patients.

Additional attention should also be paid to younger patients with AR. They may benefit from aortic valve reconstruction or a Ross procedure [3]. Although aortic valve reconstruction has also been performed via ART previously, we do not recommend this approach in patients who have a planned aortic valve reconstruction.

Concomitant Procedures

Patients selected for minimally invasive aortic valve surgery should not have an indication for additional procedures. However, an aortic reduction plasty or even a Bentall procedure may be performed via UHS in selected patients.

Patients with an untreated significant coronary artery disease should not undergo minimally invasive aortic valve surgery. A coronary bypass should be performed during the same procedure. Furthermore, we do not recommend to treat coronary artery stenosis by stenting to enable minimally invasive valve surgery. However, other authors may accept low risk stenosis for prior stenting in selected patients [1]. In addition, Lewis at al reported two cases with significant stenosis of the proximal right coronary artery who underwent bypass surgery via ART in addition to minimally invasive aortic valve surgery[4].

Patients who require a MAZE procedure or an additional valve procedure are not suitable for minimally invasive surgery.

Re-Operative Aortic Valve Surgery

Minimally invasive surgery for AVR has been applied in re-operative surgery in patients with previous bypass or valve surgery [5]. Potential advantages are less invasiveness with reduced blood loss. However, several technical modifications are required for this approach. The margin for surgical error is small and we do not recommend this during the early phases of a minimally invasive program.

Previous Non-Cardiac Procedures

All previously performed non-cardiac procedures have to be recorded for procedural planning and screened for a potential influence on the surgical strategy and the preferred cannulation technique. Previous ilio-femoral bypass surgery, stenting of the abdominal aorta or an abdominal aortic aneurysm may prohibit femoral arterial cannulation. A previously implanted cava umbrella may likewise represent a contraindication for femoral venous cannulation.

Thoracic Anatomy

Patients with a funnel – chest or other deformities should not undergo minimally invasive aortic valve surgery (distinct exceptions should be evaluated with special prudence) [1].

PREOPERATIVE PLANNING

Patients selected for minimally invasive aortic valve surgery require intense pre-operative planning to provide optimal access and avoid adverse events. Some prohibitive patient

characteristics have been described in the previous section. It is essential to obtain a detailed medical history by a surgical experienced fellow or consultant to gather all information relevant for the planning of a minimally invasive procedure. Furthermore, we recommend a preoperative ECG-gated computed tomography (CT) scan with contrast dye in every patient without a contraindication [6].

The pre-operative CT scan provides several relevant information for minimally invasive aortic valve surgery. The thoracic anatomy and the relation of the aorta and the aortic valve to the thoracic bone structures should be assessed [1]. Furthermore, optimal cannulation and cardio-protection strategies can be planned with a pre-operative CT scan [7]. This may influence the intercostal space approached for ART or UHS. We perform the L-shaped incision to the right thoracic side (reversed-L). However, some surgeons recommend performing the L-shaped incision to the left thoracic side for better exposure. This may be true in selected patients and a CT scan can identify these specific patients. There are a few patients where an inverse T is necessary to gain optimal exposure.

The distance from the intercostal space opened during ART and the aorta for cannulation and the aortic valve for AVR should also be evaluated with a pre-operative CT scan. Glauber at al [8] defined patients eligible for ART if ‘more than half of the ascending aorta is located on the right in respect to a vertical line drawn from the right sternal border to the ascending aorta’ and if ‘the distance from the ascending aorta to the sternum does not exceed 10 cm’. However, patients not fulfilling these criteria may be approached via ART according to surgeons’ choice with adapted procedural steps. We recommend switching the intercostal space to the third intercostal space with a transection of the third rib in patients with a caudal aortic valve.

A detailed analysis of the aorta and the great vessels should be performed in every patient. This should include the screening for severe calcification in the ascending aorta, which may represent a contraindication for cross–clamping and also calcification of the groin vessels in patients with planned cannulation through the femoral artery. Furthermore, relevant stenosis should be detected and also addressed prior to surgery whenever possible. The application of contrast dye during an ECG gated CT scan enables the detection of soft plaques and potential other sources of emboli. Soft plaques or mobile thrombotic structures may be a contraindication for clamping of the ascending aorta depending on their localisation. The ascending aorta is not a routine spot of severe calcification. The aortic arch and the descending thoracic aorta are more commonly affected by severe calcifications, soft-plaques and mobile thrombotic structures. These may be dislodged with a cannulation of the aorta by an arterial cannula via Seldinger technique in patients undergoing minimally invasive aortic valve surgery via ART.

CANNULAE FOR MINIMALLY INVASIVE AORTIC VALVE SURGERY

We have provided a short-list of available cannulas in Table 1-3. These are recommendations retrieved from relevant literature and our own experience. However, this list is not considered complete and should only be used for reference purposes only.

Table 1. Arterial cannulae for minimally invasive aortic valve surgery

Name	Sizes in French	Company	Access	Reference
OptiSite	18, 20, 22	Edwards Lifesciences, Irvine, CA, USA	UHS	(Malaisrie et al.)
Sarns Soft-Flow	21, 24	Terumo Cardiovascular Systems, Ann Arbor, MI, USA	UHS	(Malaisrie et al.)
Curved tip	22	Medtronic, Minneapolis, MN, USA	UHS	Vienna
Fem-Flex II	14, 16, 18, 20	Edwards Lifesciences, Irvine, CA, USA	ART	(Malaisrie et al.)
Bio-Medicus	17, 19, 21	Medtronic, Minneapolis, MN, USA	ART	(Malaisrie et al.), Vienna

Table 2. Venous cannulae for minimally invasive aortic valve surgery

Name	Size in French	Company	Access	Reference
Thin-Flex	-	Edwards Lifesciences, Irvine, CA, USA	UHS	(Malaisrie et al.)
MC2X	29/46/37	Medtronic, Minneapolis, MN, USA	UHS	(Malaisrie et al.)
Three-stage	-	Terumo Cardiovascular Systems, Ann Arbor, MI, USA	UHS	(Malaisrie et al.)
Single Stage Venous Cannula (Ref 67536)	36	Medtronic, Minneapolis, MN, USA	ART (thoracic)/ UHS	Vienna
QuickDraw	22, 25	Edwards Lifesciences, Irvine, CA, USA	ART (groin)	(Malaisrie et al.)
Bio-Medicus Multi-Stage	19, 21, 25	Medtronic, Minneapolis, MN, USA	ART (groin)	(Malaisrie et al.)
Remote Access Perfusion Femoral Venous cannula, RAP FV	-	Estech Inc, San Ramon, CA, USA	ART (groin)	(Schachner et al.; Murzi et al.)
Smart cannula	-	Smart- canula LLC, Lausanne, Switzerland	ART (groin)	(von Segesser et al.)

Upper Hemi-Sternotomy

Standard arterial and venous cannulae can be applied for AVR via UHS. However, a bulky venous cannula should be avoided to provide maximal space for the surgical procedure. Vaughan at al [9] report good drainage with a low-profile three-stage venous cannula (Medtronic MC2X, Medtronic Inc, USA). A straight arterial cannula may be used to cannulate the aortic arch in Seldinger technique for patients requiring an additional procedure of the ascending aorta in selected cases. A list of recommended cannulae is presented in Table 1 for arterial cannulation and in Table 2 for venous cannulation. The venous cannula should be fixated with a pericardial stay suture at the right lower corner of the operative field to optimise surgical exposure and drainage.

Anterior Right Thoracotomy

Cannulation for aortic valve surgery via ART requires special cannulae (Table 1-3). Arterial cannulae are rather uniform. Standard multiside-hole cannulas may be used for femoral cannulation. Non-heparinized cannulae are available in addition to ECMO cannulae at a lower price and can be used without restrain in this case.

Table 3. Vents and cardioplegia cannulae

Name	Type	Company	Access	Reference
ProPlege peripheral retrograde cardioplegia device	Peripheral retrograde cardioplegia device	Edwards Lifesciences, Irvine, CA, USA	UHS/ART	(Malaisrie et al.)
EndoVent pulmonary catheter	Peripheral pulmonary vent	Edwards Lifesciences, Irvine, CA, USA	UHS/ART	(Malaisrie et al.)
Aortic Root Cannula	Aortic root cannula with vent line (Ref: 20012)	Medtronic, Minneapolis, MN, USA	UHS	Vienna
Left heart vent catheter	Soft and flexible vent (Ref 12016)	Medtronic, Minneapolis, MN, USA	UHS/ART	Vienna
Tourniquet Kit	(Ref 79006)	Medtronic, Minneapolis, MN, USA	UHS/ART	Vienna

Venous cannulae are available in different sizes and shapes (Table 2). Some cannulae have special design elements for optimal drainage. The Estech RAP cannula (Remote Access Perfusion Femoral Venous cannula, RAP FV; Estech Inc, USA) has two areas of venous inflow providing venting directly from the superior and inferior venous system [10-11]. Other similar approaches are available with a multi-stage cannula (Bio-Medicus Multi-Stage Venous Cannula, Medtronic Inc, USA) or a self-expanding venous cannula, providing optimal drainage of all venous vessels due to “stenting” of the venous system [12].

A vent should be used to provide optimal visualisation of the surgical field (Table 3). The vent may be applied directly through the aortic valve, through the pulmonary artery or through the right upper pulmonary vein. The latter allows the venting of the left ventricle, if the vent was advanced through the mitral valve. This may be of importance during administration of cardioplegia, for de-airing and after removal of the aortic cross clamp in cases of ventricular fibrillation.

Cardioplegia may be applied through a plastic aortic cannula or a longer metal cannula (Table 3). A single-shot Bretschneider’s solution is highly recommended in routine cases of minimally invasive aortic valve surgery. Direct application into the coronary ostia is possible in cases of relevant AR. However, an application through the aortic root should be the primary approach. The aorta has to be opened rapidly in cases of ventricular distension and a direct coronary administration is then continued.

Retrograde cardioplegia can also by applied in selected patients undergoing AVR for AR via UHS. However, the administration of the retrograde catheter may not always be possible and needs echocardiographic guidance.

SPECIAL REQUIREMENTS DURING CARDIO-PULMONARY BYPASS

Additional monitoring may be required due to the cannulation technique. An arterial cannulation via the common femoral artery should prompt a pulse oxygenation monitoring of the limb [1]. An axillary arterial cannulation requires an additional pressure line for the right arm. Although not described in detail in this chapter, introduction of a cannula for retrograde cardioplegia and a second cannula for venting via the pulmonary artery is possible through the jugular vein (Table 3).

The required pump flow is calculated according to the patient's body surface area. Although several components influence the maximum flow achieved by the perfusion system, venous drainage has the most significant impact [13]. Minimally invasive cardiac surgery includes cannulation techniques with miniaturised cannulae. Therefore, specific details have to be followed to provide sufficient pump flow. Bad drainage is one of the big obstacles in minimally invasive aortic valve surgery due to the impaired exposure of the surgical field. The meticulous placement of venous cannulae is of major importance to optimise drainage. Therefore, we recommend re-arrangement of cannulae prior to aortic clamping in cases of insufficient drainage to save time during the main parts of the surgical procedure. In addition, vacuum-assisted drainage is at least required in patients with a higher body surface area despite optimal cannulation [9]. Low vacuum may improve drainage in every patient, but high vacuum suction causes air embolism and haemolysis [13].

A further relevant detail is the temperature management during minimally invasive aortic valve surgery. The arrested heart has increased contact to the adjacent organs compared to full sternotomy. Furthermore, topical cooling by cold saline cannot be applied as easy as in patients with full sternotomy. Therefore, cooling of the patient during the surgical procedure may improve cardio-protection. Due to the lack of retrograde repetitive cardioplegia, which can be applied more easily during aortic valve procedures in patients with full sternotomy, the myocardial cooling is additionally impaired. Although institutional protocols should be adapted to the current practice, we recommend a cooling towards 34°C body temperature in UHS and to 32°C in ART cases. The difference in the recommended target temperature is mainly due to the duration of aortic cross-clamping, which is longer in ART.

CARDIOPLEGIC SOLUTIONS FOR MINIMALLY INVASIVE AORTIC VALVE SURGERY

Bretschneider's HTK cardioplegic solution (HTK – histidine-tryptophan-ketoglutarate) is the preferred cardioplegic approach in patients undergoing minimally invasive aortic valve surgery at our centre. HTK removes Na^+ and Ca^{2+} from the extracellular tissue and thereby avoids an action potential without changing the resting membrane potential. It has a low K^+ concentration, which permits the administration of a higher amount (about 2 litres) only once during surgery directly after aortic cross-clamping. Therefore, repetitive dosing and retrograde application are not required with this approach. However, the high amount of administered additional fluid during a short period of time may cause volume overload. Therefore, we recommend haemofiltration during CPB to remove the administered fluid whenever possible prior to discontinuation of CPB.

Routine cold blood cardioplegia is applied by other groups in patients undergoing aortic valve surgery via UHS after placement of a retrograde cardioplegic catheter. The repeated application of blood cardioplegia is also possible via direct cannulation of the coronary ostia. However, this may significantly prolong the surgical procedure.

CANNULATION VIA UPPER HEMI-STERNOTOMY

Cannulation for patients undergoing aortic valve surgery via UHS can be performed in a rather comparable way to full sternotomy. The pericardium is opened after reversed-L-shaped UHS. The pre-pericardial fat should be resected in patients with limited exposure without injuring the innominate vein or opening a pleural space. The pericardial sac is opened and stay sutures are placed. To improve the exposure at this step, the sternal spreader could be removed, the stay sutures re-fixated with clamps at the surgical dressing and the spreader is replaced thereafter [1]. Two diamond – shaped purse-string sutures are then placed over the distal ascending aorta. The surgeon should feel for aortic calcifications prior to the selection of the cannulation site. A pre-operative CT scan is of major importance to identify soft plaques. Alternatively, an epi-aortic ultrasound can be applied to search for aortic soft plaques or calcifications. Cannulation of the aorta is performed after heparin administration and the minimum required period of activated-clotting-time has been achieved. The limited exposure may add some difficulties to direct cannulation. A set of sterile Hegar dilators should be available on the table in the case of complicated cannulation.

Two different strategies are favoured for venous cannulation in patients operated via UHS. Some authors favour the optimal visualisation with percutaneous femoral venous cannulation [14,15], whereas others rely on direct atrial cannulation without the need of femoral cannulation [16,17]. We also recommend the latter approach. One purse-string suture is placed in the right atrium close to or in the right atrial appendage for venous cannulation. Some surgeons prefer to clamp the right atrial appendage prior to suture placement, cut the tip to the appendage and place the suture thereafter. This provides a better and more stable exposure, especially in cases with a deep right atrium. The surgeons hold both sides of the cut edge with forceps and venous cannula is placed. One has to be aware of the fact that correct placement of the cannula into the inferior caval vein cannot be verified by palpation.

A vent is applied through the right upper pulmonary vein and advanced in the left ventricle. The CO_2 inflation should be started prior to vent placement with 2 litres/minute to avoid air embolism. A simple U-stitch with a 4-0 prolene suture is sufficient. The vein is incised with an 11 blade and the hole is widened with instrument. The vent is placed using a forceps for guidance.

The aorta is separated from the pulmonary artery after CPB is established. The Y-shaped cannula for cardioplegia and venting is placed at a position rather distal at the highest point of the ascending aorta to allow de-airing after AVR through the vent line.

CANNULATION VIA THE GROIN FOR ANTERIOR RIGHT THORACOTOMY

Several surgical details have to be taken into account for safe cannulation of the groin. Potential adverse events are bleeding, local dissection, traumatic vessel injury, retrograde aortic dissection, seroma, lymph fistula, pseudo-aneurysm and infection [18]. Aortic dissection has an incidence of 0.9% in a large retrospective study and is a major drawback of this approach [18]. However, this study applied aortic endo-clamping, which has the potential to cause either direct aortic dissection or retrograde aortic dissection due to jet lesions at the inflow cannula. Therefore, we do not recommend the use of an endoclamp system. In general, a number of complications can be avoided by direct cannulation via ART. However, some anatomical settings and early phases in a minimally invasive program require cannulation in the groin. A pre-operative CT scan including the femoral vessels helps to select the left or the right side for cannulation and the optimal shape and size of cannulae [18]. If both sides are available for cannulation, the right side should be used.

The skin incision should be performed after palpation of the arterial pulse. We align the direction of the skin incision along the direction of the inguinal ligament. The incision should be performed about 1-2 cm cranial to the groin crease to reduce the likelihood of infection. Reduce the length of the incision to 4 cm. The vessels are revealed right below the inguinal ligament. However, only the frontal plane of the vessels is prepared. We do not recommend placing vessel loops around the vessels, as this increases the risk of lymph fistula. A double 5-0 prolene purse-string suture is placed on both vessels in a quadrangular longitudinal shape to avoid vessel stenosis. At this step, the thoracic incision is performed and the thorax is opened prior to heparin administration. The femoral artery is punctured at the caudal end of the purse-sting suture after heparin administration and a J-tipped guidewire is advanced into the aorta under echocardiographic control. The cannula is inserted by Seldinger technique after confirmation of the correct guidewire position. Thereafter, the venous cannula is inserted in the same way. The arterial cannula is secured with three silk sutures. Consider a second 14-gauge arterial cannula for limb perfusion in patients with a drop of oxygen saturation measured at the limb during CPB. The venous cannula should not be secured directly after cannulation. This enables the re-adjustment of the cannula position in patients with insufficient venous drainage.

A vent can be placed in the right upper pulmonary vein through the thoracotomy or through an extra thoracic incision. Alternatively, an endo-vent can be placed via the jugular vein into the pulmonary artery.

DIRECT CANNULATION VIA ANTERIOR RIGHT THORACOTOMY

Direct cannulation in patients undergoing ART is possible for experienced surgeons and should be favoured whenever possible. The cannulation process starts directly after the thoracotomy is performed. A second incision about 1.5 cm is performed in the sub-mammary fold. A tunnel is prepared through the 4th or 5th intercostal space. Thereafter, a 36 French angled venous cannula is cut at the connection end to create a rather pointed tip (Figure 1, Table 2). Thereafter, the cannula is brought through the thorax, the tip is cut straight again

and any foreign material is removed from the inside of the cannula. After that, the soft-tissue retractor can be placed and the pericardium is opened after heparin administration. The aortic pressure should be directed to a mean pressure of about 80 mmHg at this step of cannulation. This enables some mobility of the ascending aorta during arterial cannulation but provides the necessary counter-pressure for cannula insertion. We use a standard multiside-hole arterial cannula although direct straight arterial cannulas without a soft part at the end are available (Figure 2, Table 1).

Figure 1. Preparation of the venous cannula for anterior right thoracotomy. Caption: The tip of the cannula is cut to ease transthoracic placement in patients undergoing aortic valve replacement via anterior right thoracotomy and intrathoracic cannulation.

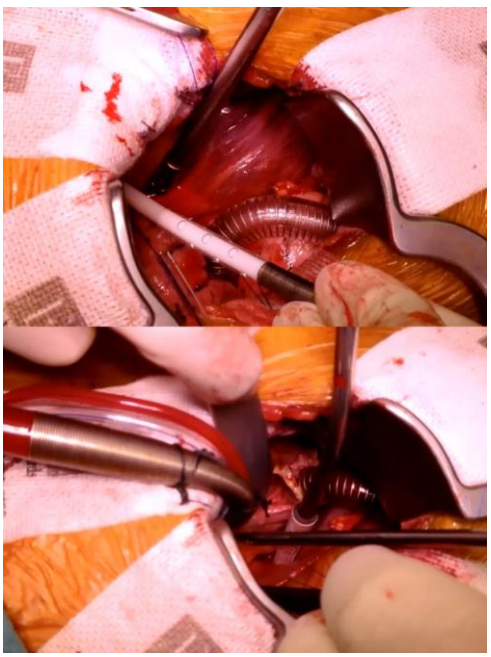

Figure 2. Cannula – placement for intrathoracic cannulation via anterior right thoracotomy. Caption: The first figure shows the cannula prior to placement. The venous cannula should be placed through the thorax prior to arterial cannulation.

We suggest that the cannulation is safer if the arterial cannula can be advanced some centimetres into the thoracic aorta to avoid unintended dislodgement. Two 3-0 prolene purse string sutures are inserted on the ascending aorta for cannulation. It is important to avoid transmural stiches, as any bleeding will increase the difficulty of the whole procedure. A guide-wire is advanced through a puncture needle. The correct placement of the guide-wire in the descending aorta is confirmed by trans-oesophageal echocardiography. The tip of the cannula should be inserted until is passes the origin of the left subclavian artery to avoid any unintended dislodgement into a branch vessel. The cannula is secured with a heavy silk suture to the left upper margin of the incision. Thereafter, a purse-string suture is placed at the right atrial appendage. A clamp should be used to stabilise the appendage and optimise visualisation. The atrial appendage is cut and a purse-string suture is placed. Two forceps hold the appendage, the clamp is released and the angled 36 French cannula is advanced into the right atrium. The tourniquet for the purse-string suture is secured with clips and brought into the thorax (Figure 2, Table 3). Slight tension on the cannula optimises the surgical field and opens the space between atrial appendage and aorta. A vent is placed thereafter through the right upper pulmonary vein with a pledgeted prolene suture (Figure 3). The aorta is clamped with a Chitwood clamp [19]. The correct position of the clamp in the Transverse sinus has to be confirmed prior to clamping. The final valve exposure is shown in Figure 4.

Figure 3. Vent for placement through the right upper pulmonary vein. Caption: The vent should be bent in this form to facilitate intra-ventricular placement.

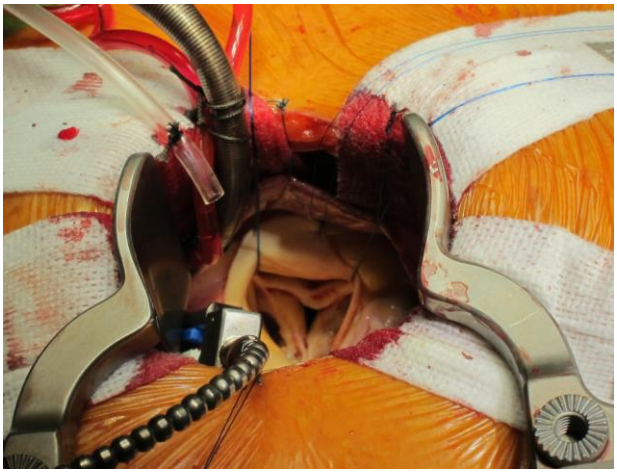

Figure 4. Exposure of the aortic valve via anterior right thoracotomy. Caption: The aortic cross clamp is placed through the transverse sinus. Optimal exposure includes the placement of three commissural sutures.

DECANNULATION – EVERY STEP IS RELEVANT

The aorta is closed by prolene sutures according to the preference of the surgeon. However, de-airing should be performed prior to the tying of the aortic suture to remove air and potential debris originating from the decalcification process. The vent is stopped for de-airing, venous drainage is reduced and the heart is filled. The lungs should be ventilated at higher pressure. The patient's chest is compressed repeatedly to compress the heart. The aortic suture is finished thereafter. Now, chest tubes and pacemaker wires should be placed. Then, the de-airing process should be repeated via the Y – shaped arterial cardioplegic cannula in UHS patients or via the hole left after cardioplegia application via the metal needle in ART patients. The aortic cross – clamp is removed thereafter. The hole should be closed thereafter with a pledgeted prolene suture.

It is important to place external defibrillator pads in every patient undergoing minimally invasive aortic valve surgery. The lungs should be ventilated prior to external defibrillation after aortic de-clamping.

The vent can be removed after the heart is beating in sinus rhythm and the venous cannula can be removed after CPB is stopped and the patient is stable. A chest tube can be placed in patients operated via ART via the 36 French cannula. Every cannulation site should be secured with an additional suture after removal of the cannula. The aortic cannula is removed after full protamine administration in a stable patient.

CONCLUSION

Cannulation for minimally invasive aortic valve surgery requires detailed preparation and meticulous conduct to avoid complications and provide optimal exposure for valve surgery. A stepwise approach from UHS to direct cannulation via ART should be followed during the

training period of every surgeon willing to conduct the full spectrum of minimally invasive aortic valve surgery.

REFERENCES

[1] Malaisrie SC, Barnhart GR, Farivar RS, Mehall J, Hummel B, Rodriguez E, Anderson M, Lewis C, Hargrove C, Ailawadi G, Goldman S, Khan J, Moront M, Grossi E, Roselli EE, Agnihotri A, Mack MJ, Smith JM, Thourani VH, Duhay FG, Kocis MT, Ryan WH. Current Era Minimally Invasive Aortic Valve Replacement: Techniques and Practice. *J Thorac Cardiovasc Surg 2014;*147(1): 6-14.

[2] Iribarne A, Easterwood R, Chan EY, Yang J, Soni L, Russo MJ, Smith CR, Argenziano M. The Golden Age of Minimally Invasive Cardiothoracic Surgery: Current and Future Perspectives. *Future Cardiol 2011;*7(3): 333-46.

[3] Andreas M, Wiedemann D, Seebacher G, Rath C, Aref T, Rosenhek R, Heinze G, Eigenbauer E, Simon P, Ruetzler K, Hiesmayr JM, Moritz A, Laufer G, Kocher A. The Ross Procedure Offers Excellent Survival Compared with Mechanical Aortic Valve Replacement in a Real-World Setting. *Eur J Cardiothorac Surg 2014;*46(3): 409-13.

[4] Lewis CT, Stephens RL, Cline JL, Tyndal CM. Concurrent Minimally Invasive Aortic Valve Replacement and Coronary Artery Bypass Via Limited Right Anterior Thoracotomy. *Innovations (Phila) 2015;*10(4): 273-5.

[5] Kaneko T, Leacche M, Byrne J, Cohn L. Reoperative Minimal Access Aortic Valve Replacement. *J Thorac Dis 2013;*5(6): S669-72.

[6] Kurra V, Schoenhagen P, Roselli EE, Kapadia SR, Tuzcu EM, Greenberg R, Akhtar M, Desai MY, Flamm SD, Halliburton SS, Svensson LG, Sola S. Prevalence of Significant Peripheral Artery Disease in Patients Evaluated for Percutaneous Aortic Valve Insertion: Preprocedural Assessment with Multidetector Computed Tomography. *J Thorac Cardiovasc Surg 2009;*137(5): 1258-64.

[7] Loor G, Roselli EE. Imaging and Minimally Invasive Aortic Valve Replacement. *Ann Cardiothorac Surg 2015;*4(1): 62-6.

[8] Glauber M, Miceli A, Bevilacqua S, Farneti PA. Minimally Invasive Aortic Valve Replacement Via Right Anterior Minithoracotomy: Early Outcomes and Midterm Follow-Up. *J Thorac Cardiovasc Surg 2011;*142(6):1577-9.

[9] Vaughan P, Fenwick N, Kumar P. Assisted Venous Drainage on Cardiopulmonary Bypass for Minimally Invasive Aortic Valve Replacement: Is It Necessary, Useful or Desirable? *Interact Cardiovasc Thorac Surg 2010;*10(6):868-71.

[10] Schachner T, Bonaros N, Laufer G, Bonatti J. The Estech Remote Access Perfusion Cannula in Minimally Invasive Cardiac Surgery. *Heart Surg Forum 2004;*7(6): E632-5.

[11] Murzi M, Kallushi E, Solinas M, Glauber M. Video-Assisted Right Atrial Surgery with a Single Two-Stage Femoral Venous Cannula. *Interact Cardiovasc Thorac Surg 2009;*9(1): 9-10.

[12] von Segesser LK, Ferrari E, Delay D, Maunz O, Horisberger J, Tozzi P. Routine Use of Self-Expanding Venous Cannulas for Cardiopulmonary Bypass: Benefits and Pitfalls in 100 Consecutive Cases. *Eur J Cardiothorac Surg 2008;*4(3):635-40.

[13] Corno AF. Systemic Venous Drainage: Can We Help Newton? *Eur J Cardiothorac Surg 2007;*31(6):1044-51.

[14] Tabata M, Umakanthan R, Cohn LH, Bolman RM 3rd, Shekar PS, Chen FY, Couper GS, Aranki SF. Early and Late Outcomes of 1000 Minimally Invasive Aortic Valve Operations. *Eur J Cardiothorac Surg 2008;*33(4): 537-41.

[15] Cosgrove DM 3rd, Sabik JF. Minimally Invasive Approach for Aortic Valve Operations. *Ann Thorac Surg 1996;*62(2): 596-7.

[16] Murai N, Cho M, Okada S, Chiba T, Saito M, Shioguchi S, Gon S, Hata I, Yamauchi N, Imazeki T. Venous Drainage Method for Cardiopulmonary Bypass in Single-Access Minimally Invasive Cardiac Surgery: Siphon and Vacuum-Assisted Drainage. *J Artif Organs 2005;*8(2): 91-4.

[17] Doll N, Borger MA, Hain J, Bucerius J, Walther T, Gummert JF, Mohr FW. Minimal Access Aortic Valve Replacement: Effects on Morbidity and Resource Utilization. *Ann Thorac Surg 2002;*74(4): S1318-22.

[18] Jeanmart H, Casselman FP, De Grieck Y, Bakir I, Coddens J, Foubert L, Van Vaerenbergh G, Vermeulen Y, Vanermen H. Avoiding Vascular Complications During Minimally Invasive, Totally Endoscopic Intracardiac Surgery. *J Thorac Cardiovasc Surg 2007;*133(4): 1066-70.

[19] Chitwood WR Jr, Elbeery JR, Chapman WH, Moran JM, Lust RL, Wooden WA, Deaton DH. Video-Assisted Minimally Invasive Mitral Valve Surgery: The "Micro-Mitral" Operation. *J Thorac Cardiovasc Surg 1997;*113(2): 413-4.

In: Encyclopedia of Surgery (22 Volume Set)
Editors: Andreas Lehrer and Kristin Mueller
ISBN: 978-1-53618-329-0
© 2020 Nova Science Publishers, Inc.

Chapter 402

MINI-STERNOTOMY AORTIC VALVE SURGERY

Jared P. Beller[1], MD and Gorav Ailawadi[1,2,*], MD
[1]Department of Cardiovascular Surgery
[2]Department of Biomedical Engineering
University of Virginia Health System,
Charlottesville, VA, US

ABSTRACT

There has been increasing interest in minimally invasive approaches to cardiac surgery, specifically with regard to the management of aortic valve disease. There are various minimally invasive surgical options, of which, an upper hemi-sternotomy has emerged as one of the most reliable approaches. Patients benefit from this operation with shorter hospital and intensive care unit stays, reduced surgical trauma and the potential for reduced total cost. More recently, the synergism of minimal surgical access with rapidly deployable valves has leveraged the potential benefits of these innovations. In this chapter our approach to, and technical considerations for minimally invasive aortic valve replacement through an upper hemi-sternotomy are outlined. Further, a brief history of the development of these techniques, the outcomes for minimally invasive aortic valve replacement surgery, and future directions are discussed.

Keywords: aortic valve, minimally invasive, hemisternotomy, sutureless cardiac valves

INTRODUCTION

Open surgical aortic valve replacement (AVR) through a sternotomy has been the standard of care for the treatment of aortic valve pathology for decades. Although there is a long history of both its safety and efficacy, the recovery period is substantial and patients require many weeks of restriction prior to returning to full physical activity and work.

* Corresponding Author's Email: gorav@virginia.edu; Fax: 434-244-7588.

The advent of novel surgical approaches with smaller incisions in the 1990s, was met with tempered enthusiasm due to concerns over wound healing and vascular complications. More recently, there has been growing interest in less invasive approaches to valve replacement. Two main approaches have emerged as the operations of choice: anterior right mini-thoracotomy (ART) and upper hemisternotomy (UHS). The preferred approach is often surgeon specific, but there are advantages and disadvantages for each operation, as well as patient characteristics that influence the ideal surgical approach. Despite nearly 20-year experience with these techniques, widespread adoption has not been realised. Technical challenges and concerns about longer operative times still remain. The introduction of rapidly deployable, sutureless bioprosthetic valves may be ideally suited for less invasive approaches. When combined with a minimally invasive surgical approach, these novel valves may negate the concerns surrounding longer operative and ischemic times. Interest in minimally invasive surgical options has seen resurgence, both with the development of time saving devices, and as an alternative to the expanding indications for percutaneous catheter based intervention.

In this chapter, we will discuss both the technical aspects and clinical results of the UHS approach to minimally invasive AVR (MIAVR).

HEMISTERNOTOMY FOR MINIMALLY INVASIVE AORTIC VALVE REPLACEMENT

Preoperative Evaluation

The preoperative evaluation for patients that will undergo AVR via an UHS is similar to the evaluation for those that will undergo conventional full sternotomy. However, there are some notable points of emphasis that will be highlighted here. Evaluation for concomitant cerebrovascular and coronary artery disease should begin with appropriate risk stratification and completed with carotid artery duplex and cardiac catheterization if indicated. Significant coronary artery disease would preclude the feasibility of UHS as coronary artery bypass grafting cannot be readily performed through this approach. A non-contrast computed tomography (CT) scan of the chest is particularly important to aid in operative planning. This provides the surgeon with the precise anatomical location of the aortic valve in relation to the bony anatomy, which aids in the decision of which interspace (3rd vs. 4th) to extend the UHS. Moreover, this study will reveal areas of significant aortic atheromatous or calcific disease facilitating the formulation of cannulation and cross clamp strategies. Although central arterial cannulation is preferred, if peripheral arterial cannulation with retrograde perfusion is required, CT angiography of the aorta, iliac, and femoral vessels should be performed to evaluate for peripheral vascular disease.

Initial Operative Steps

The 3rd or 4th interspace is chosen based on preoperative CT imaging and proximity to the valve. A 5-6 cm skin incision is made, beginning just inferior to the sterno-manubrial junction and extended caudally. The subcutaneous tissue is dissected and skin undermined, exposing

the sternal notch and interspace, carefully dissecting off the internal thoracic pedicle. A sternal saw is used to create a J-sternotomy, beginning at the sternal notch and completed in the 3rd or 4th interspace typically to the patient's right (Figure 1). Rarely, an inverted "T" or "L" sternotomy is required if the aortic valve is positioned to the patient's left as assessed by CT scan. A small Finochietto type retractor is inserted and enables excellent visualisation for both surgeon and assistant (Figure 2).

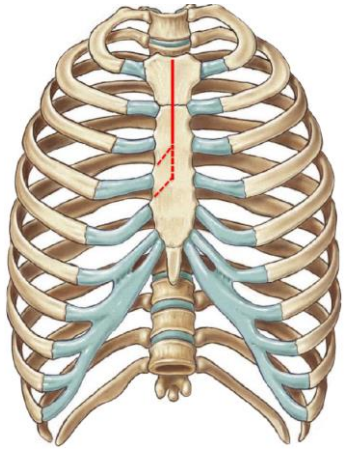

Figure 1. Sternal incision for minimally invasive hemisternotomy (J-Sternotomy) extended through the 3rd or 4th interspace.

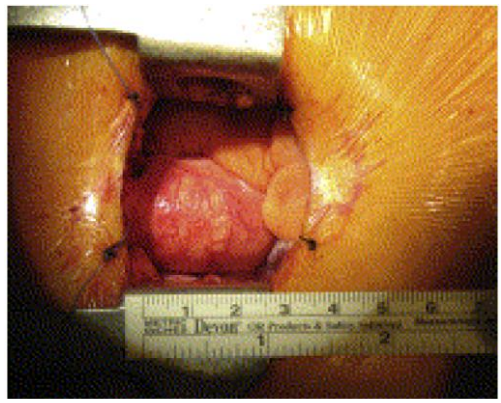

Figure 2. Operative view of ascending aorta through hemisternotomy.

The thymic fat is excised completely to ease in visualisation. The pericardium is opened and multiple pericardial sutures are placed on both sides and secured to the drapes with tension cradling the heart into the wound. Direct arterial cannulation of the distal ascending aorta is achieved in the standard fashion. The two major tenets of minimally invasive surgery are: 1) complete venous drainage, and 2) myocardial protection. Venous cannulation is established with a long, multi-stage venous cannula inserted in the femoral vein percutaneously using the Seldinger technique and trans-oesophogeal echocardiography (TEE) guidance. Ideally, the tip of the cannula is placed into the SVC and can be retracted if

necessary. The size of the venous cannula is typically a 25F to optimize drainage. Carbon dioxide is used to flood the operative field to reduce the risk of air embolization.

Myocardial Protection

Myocardial protection is typically achieved by moderate hypothermia (33-35°C), delivery of antegrade cardioplegia using del Nido solution, and the application of topical ice. In cases where moderate or severe aortic valve insufficiency is present, a retrograde cardioplegia cannula is inserted into the coronary sinus via the right atrium, or more commonly, percutaneously via the right internal jugular vein by the anesthesiologist. Correct placement within the coronary sinus is confirmed with TEE. After initiation of bypass, a 13F left ventricular vent with a stylet is inserted through the right superior pulmonary vein. The aorta is cross-clamped directly and the clamp can be used to gently retract the heart superiorly. Topical ice is applied to the heart using a sterile teaspoon. In general, we utilize 1200-1500cc antegrade del Nido cardioplegia dependent upon the rapidity of arrest and redose every 60 minutes if required. If significant aortic insufficiency exists, retrograde cardioplegia or direct infusion with a hand-held catheter into both the left and right coronary systems is performed after opening the aorta.



Figure 3. Following aortotomy, three sutures are placed at the commissures and the valve is elevated to aid in exposure and excision.

Exposure and Valve Implantation

Once adequate arrest has been obtained, a transverse aortotomy is created with a curve cranially toward the left away from the pulmonary artery and the distal aortotomy is tacked to the superior extent of the pericardium. Stay sutures are placed at the commissures to aid in visualisation (Figure 3). The diseased native valve is excised with meticulous care given to the removal of debris from the operative field. Interrupted non-pledgeted horizontal mattress 2-0 sutures are placed in the annulus and then passed through the sewing ring of the prosthetic valve. Care is taken to properly seat the new valve within the annulus. The Cor-Knot system

(LSI Solutions, Victor, NY) is used to secure the valve in place often tacking the 3 commissure sutures first to ensure the valve seats properly. Although not commercially available in the U.S. and only in clinical trial, a sutureless bioprosthetic valve (3F (Medtronic, Minneapolis, MI), Perceval (LivaNova, London, UK) or INTUITY (Edwards, Irvina, CA)) may be employed. Following excision of the native tissue, the valve is placed into correct position, orientation and deployed.

Weaning from Cardiopulmonary Bypass

After the valve is sutured or secured in place, the aortotomy is closed, warm blood is administered into the aortic root with amiodarone, and pacing wires are placed on the RV prior to cross clamp removal. Warm blood can be administered for several minutes until return of sustainable native or paced cardiac rhythm prior to clamp removal. Due to limited access to the left ventricle for decompression, a particular concern is ventricular defibrillation. While pediatric paddles can be utilized, due to the small incision, we find that transcutaneous defibrillation is technically easier and should be performed with lung inflation. Ventricular distension should be a concern for paravalvular leak which occurs with similar infrequency as with conventional sternotomy. With rhythm achieved and cardiac and valvular function verified, the heart is de-aired through the aortic root with TOE guidance and various patient positions on the table. After weaning of bypass, the femoral venous cannula is removed and a simple silk stitch is used to aid in hemostasis. Manual compression is held until 10 minutes following the completion of protamine. The arterial cannula is removed following partial protamine administration.

Closure and Postoperative Management

Two silastic flexible drains are placed in the pericardium from the right chest. The pacing wires are passed though one of the chest tubes and separated outside of the skin. The UHS is re-approximated using stainless steel wires starting from inferiorly to superiorly. The first wire is placed one interspace lower on the patient's left hemisternum to the interspace above on the right. The second wire is placed across the same insterspace one above the extent of the sternotomy. A sterile spoon is used to protect the right ventricle (RV) from the closing needle. Next, the soft tissue is closed in layers per usual. Patients are transported to the intensive care unit intubated. Freedom from mechanical ventilation is usually achieved in 2-4 hours and patients can often be transferred to the telemetry unit on post-operative day one. Although conventional sternal restrictions are employed, it is common that patients begin driving by 3 weeks postoperatively with return to work soon after.

TECHNICAL DEVELOPMENT AND CLINICAL OUTCOMES

The initial experience with MIAVR was via a right paramedian incision through the 3rd and 4th costal cartilages by Cosgrove and Sabik in 1996 [1]. Over the subsequent years,

interest in alternative access to the aortic valve burgeoned. Techniques were trialed across the world with no consensus on the ideal approach. At the World Congress on Minimally Invasive Cardiac Surgery in May of 1997 five different incisions were presented: 1) transverse sternotomy, 2) superior hemi-sternotomy, 3) inverted T, 4) J sternotomy and 5) parasternal (Figure 4) [2]. Despite dissention on the ideal approach, by the late 1990s, minimally invasive access was lauded as the future of cardiac surgery, citing improvement in patient satisfaction, more rapid improvement to normal function and reduced resource utilization [3-6]. In 1998, Cosgrove published the results of their initial 100 patients, and although major clinical outcomes were favorable, concern was raised at the instability that arose from the costo-sternal dissociation, the need for femoral arterial cannulation, and sacrifice of the right internal mammary artery [7]. As a result, their preferred approach shifted to an UHS. Since then, the UHS and ART have emerged as the two lasting alternatives to a traditional full sternotomy.

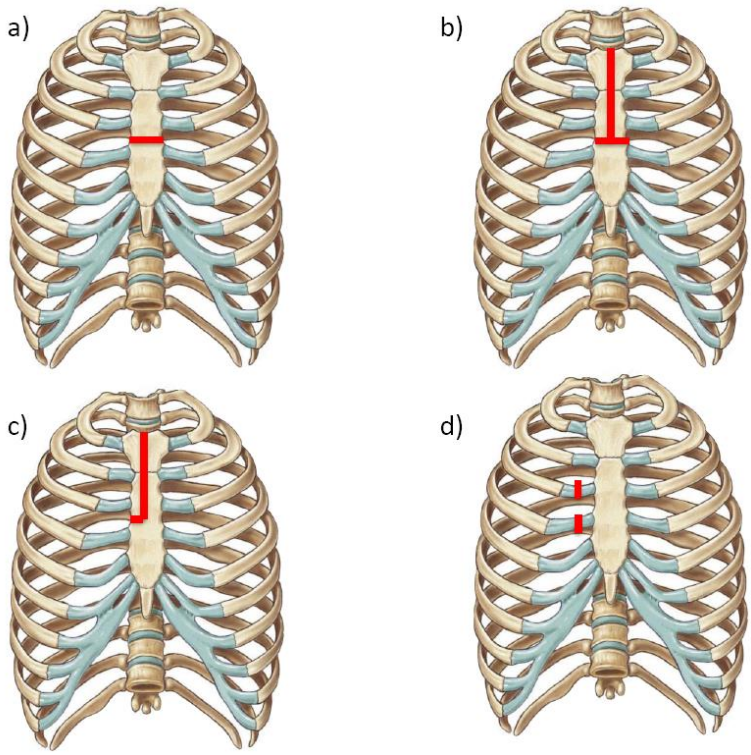

Figure 4. Minimally invasive approaches in use in the late 1990s: a) transverse sternotomy b) inverted T c) reversed L d) parasternal.

Although the UHS and ART are currently utilised as minimally invasive options, significant differences exist between the two approaches. The ART has the benefit of preserving the entirety of the sternum thus enabling potentially more rapid recovery and reducing wound complications, but it is not without its own limitations. Exposure is often more difficult and peripheral arterial cannulation is required. In a 2015 single intuition propensity matched study comparing 160 pairs, no difference was found in 90-day mortality between ART and UHS [8]. However, ART when compared to UHS, resulted in significantly

longer operative times (median cross clamp time 93 vs. 75 minutes; $p < 0.0001$, median cardiopulmonary bypass time 137 vs. 113 minutes; $p < 0.0001$), and significantly higher rates of conversion to full sternotomy, groin complications, and requirement for repeated cross clamping. At our institution, UHS is the approach of choice as the exposure affords both the attending surgeon and trainee an excellent operative view.

Clinical studies over the two decades have demonstrated excellent results when utilizing an UHS for isolated MIAVR. Specifically, similar operative mortality and long-term outcomes have been shown when compared to conventional sternotomy for AVR [9-12]. Moreover, there is the benefit of shorter intensive care and hospital stays despite the potential for longer operative times [6, 13-14]. Further, a higher percentage of patients are discharged home following MIAVR [15]. Rates of transfusion are decreased and post-operative pulmonary function is improved [13, 16]. Finally, it has been proven to be a reliable and versatile approach with safety demonstrated even in re-operative situations [17]. These clinical advantages of a mini sternotomy for AVR also result in financial benefit, with reduced total hospital costs [18].

In a 2009 systematic review and meta-analysis including 26 randomized and observational studies comparing UHS vs. conventional sternotomy, the benefits of UHS were highlighted [19]. Comparing a total of 2,054 UHS and 2,532 conventional AVR procedures, there was no difference in operative mortality despite longer cross clamp and cardiopulmonary bypass times (mean difference of 7.9 and 11.5 minutes respectively). The operative approach did not seem to influence rates of post-operative complications, including rates of atrial fibrillation, stroke and wound complications. However, ventilator time (2.1 hours), ICU length of stay (0.5 days), and hospital length of stay (0.9 days) were shorter with the UHS approach.

There have been a number of previous randomised trials comparing UHS to conventional sternotomy, which confirmed its safety and efficacy [10, 16, 21]. The initial randomized data was published in 1999 and included 120 patients that either underwent MIAVR by a surgeon who regularly performed this procedure or AVR through a conventional sternotomy [10]. A meaningful reduction in ventilator time, blood loss and analgesia use was seen. These results were confirmed by two later randomized trials, both demonstrated the ability to perform UHS without extending operative times [16, 21]. Collectively, these randomized trials were able to show the benefit of UHS, namely in the reduction in blood loss, post-operative pain and improvements in pulmonary function.

In recent years, the introduction of sutureless valves has emerged as a technology that may have synergistic benefits when combined with AVR through an UHS. Currently, there are three valves that are either available commercially (in Europe) or on an experimental protocol (in the U.S.) – INTUITY (Edwards, Irvine, CA), 3F Enable (Medtronic, Minneapolis, MN) and Perceval (LivaNova, London, UK) (Figure 5).

The INTUITY valve is based on the Magna Ease bioprosthetic, and is similarly constructed of bovine pericardium, but seated in a cloth-covered balloon expandable stainless steel frame. The 3F Enable aortic bioprosthesis is composed of a balloon expandable nitinol frame with three equal sections of equine pericardium [22]. The Perceval aortic valve is a self-expanding sutureless valve constructed of bovine pericardium mounted in a nitinol stent [23]. The feasibility of combining each of these valve with a minimally invasive approach has already been demonstrated and may resolve the concern for prolonged ischemic times. In 2015, the results of a randomized trial (CADENCE-MIS) comparing UHS utilizing the

INTUITY valve to a full sternotomy with standard bioprosthetic were published [20]. A total of 100 patients were randomized and their main findings were shorter cross clamp times (41.3 vs. 54.0 minutes; $p < 0.001$) and improved hemodynamic parameters (reduced mean transvalvular gradient 8.5 vs 10.3 mm Hg; $p = 0.044$) in the UHS arm. In 2010, the results of 22 patients implanted with the 3F Enable prosthesis through a UHS were reported with favorable and consistent outcomes [24]. Finally, a multicenter, prospective trial (CAVALIER) enrolled 658 patients to undergo implantation of the Perceval valve. In this cohort, 219 (33.3%) patients underwent a minimally invasive approach – the overwhelming majority (98.6%) through an UHS. This large trial demonstrated both the safety and efficacy of the Perceval valve when combined with a minimally invasive strategy [25]

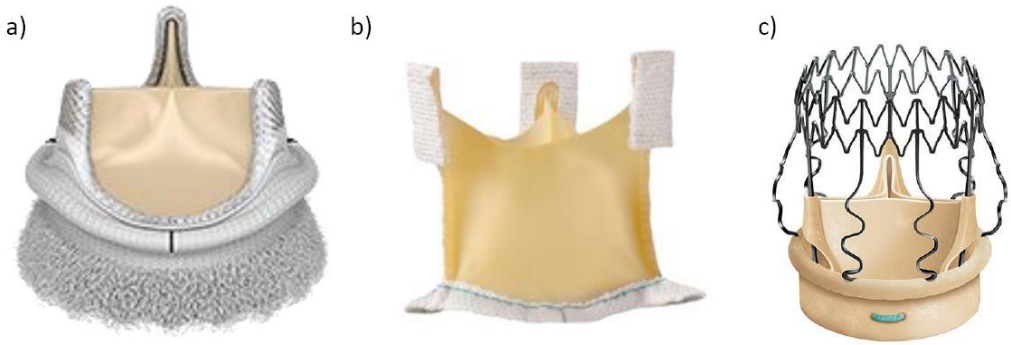

Figure 5. Suturelss Aortic Valves: a) Edwards INTUITY b) Medtronic 3F and c) Sorin Perceval.

Since a minimally invasive approach to AVR was first introduced, there have been a number of technical advancements and innovative devices that continue to make this surgical option increasingly relevant and widely applicable. All patients that undergo isolated AVR should be considered for a minimally invasive option with careful attention to the relative contraindications of such a procedure including right ventricular dysfunction, significant aortic calcification, the need for concomitant coronary bypass surgery, reoperative situations with live bypass grafts and morbid obesity. Although a MIAVR may be the standard of care, there should be requirements for surgeons who wish to begin such a program. A consensus panel of experts has recently provided recommendations for its development [26]. It is prudent to have a significant volume of aortic valve disease and to simulate the exposure and set-up one would require for a minimally invasive operation. This ensures that the entire team, surgeon, anesthesiologist, perfusion and nursing are comfortable with the procedure and necessary adjuncts prior to initiation.

CONCLUSION

MIAVR provides excellent short-term and long-term results. There is reduced surgical trauma resulting in lower rates of blood loss, rates of transfusion and post-operative pain. Moreover, recovery is expedited with shorter intensive care stay, total hospital length of stay, and a more rapid return to baseline function. Respiratory function is improved with shorter requirements of mechanical ventilation, improved respiratory mechanics, and avoidance of

the disruption of diaphgram attachments to the lower sternum. Lingering concerns of longer operative appear to be well tolerated. Moreover, the recent advent of sutureless valves may mitigate this final concern.

REFERENCES

[1] Cosgrove DM, 3rd, Sabik JF. Minimally invasive approach for aortic valve operations. *The Annals of thoracic surgery* 1996;62:596-7.

[2] Aris A, Camara ML, Montiel J, Delgado LJ, Galan J, Litvan H. Ministernotomy versus median sternotomy for aortic valve replacement: a prospective, randomized study. *The Annals of thoracic surgery* 1999;67:1583-7;d7-8.

[3] Svensson LG. Minimal-access "J" or "j" sternotomy for valvular, aortic, and coronary operations or reoperations. *The Annals of thoracic surgery* 1997;64:1501-3.

[4] Massetti M, Babatasi G, Lotti A, Bhoyroo S, Le Page O, Khayat A. Less-invasive heart surgery: the preservation of median approach. *Eur J Cariothoracic* 1998;14S1:S138-42.

[5] Tam RK, Almeida AA. Minimally invasive aortic valve replacement via hemi-sternotomy: a preliminary report. *Eur J Cardiothoracic Surg* 1998;14S1:S134-

[6] Cohn LH, Adams DH, Couper GS, Bichell DP, Rosborough DM, Sears SP, Aranki SF Minimally invasive cardiac valve surgery improves patient satisfaction while reducing costs of cardiac valve replacement and repair. *Ann Surg* 1997;226:421-6;d7-8.

[7] Cosgrove DM, 3rd, Sabik JF, Navia JL. Minimally invasive valve operations. *The Annals of thoracic surgery* 1998;65:1535-8;d8-9.

[8] Semsroth S, Matteucci-Gothe R, Heinz A, Dal Capello T, Kilo J, Müller L, Grimm M, Ruttman-Ulmer E. Comparison of Anterolateral Minithoracotomy Versus Partial Upper Hemisternotomy in Aortic Valve Replacement. *The Annals of thoracic surgery* 2015;100:868-73.

[9] Liu J, Sidiropoulos A, Konertz W. Minimally invasive aortic valve replacement (AVR) compared to standard AVR. *Eur J Cardiothoracic* Surg 1999;16:S80-3.

[10] Mächler HE, Bergmann P, Anelli-Monti M, Dacar D, Rehak P, Knez I, Salaymeh L, Mahla E, Rigler B. Minimally invasive versus conventional aortic valve operations: a prospective study in 120 patients. *The Annals of thoracic surgery* 1999;67:1001-5.

[11] Gosev I, Kaneko T, McGurk S, McClure SR, Maloney A, Cohn LH. A 16-year experience in minimally invasive aortic valve replacement: context for the changing management of aortic valve disease. *Innovations* (Philadelphia, Pa) 2014;9:104-10; d10.

[12] Merk DR, Lehmann S, Holzhey DM, Dohmen P, Candolfi P, Misfeld M, Mohr FW, Borger MA. Minimal invasive aortic valve replacement surgery is associated with improved survival: a propensity-matched comparison. *Eur J Cardiothoracic Surg* 2015;47:11-7;d7.

[13] Mihaljevic T, Cohn LH, Unic D, Aranki SF, Couper GS, Byrne JG. One thousand minimally invasive valve operations: early and late results. *Annals of surgery* 2004;240:529-534;d534.

[14] Estrera AL, Reardon MJ. Current approaches to minimally invasive aortic valve surgery. *Curr Opin Cardiolog* 2000;15:91-95.

[15] Sharony R, Grossi EA, Saunders PC, Schwartz CF, Ribakove GH, Culliford AT, Ursomanno P. Minimally invasive aortic valve surgery in the elderly: a case-control study. *Circulation* 2003;108:S43-7.

[16] Bonacchi M, Prifti E, Giunti G, Frati G, Sani G. Does ministernotomy improve postoperative outcome in aortic valve operation? A prospective randomized study. *The Ann Thorac Surg* 2002;73:460-5;d5-6.

[17] Gosev I, Yammine M, Leacche M, Ivkovic V, McGurk S, Cohn LH. Reoperative aortic valve replacement through upper hemisternotomy. Annals of Cardiothoracic *Surgery* 2015;4:88-90.

[18] Ghanta RK, Lapar DJ, Kern JA, Kron IL, Speir AM, Fonner E Jr, Quader M, Ailawadi G. Minimally invasive aortic valve replacement provides equivalent outcomes at reduced cost compared with conventional aortic valve replacement: A real-wrold multi-institutional analysis. *J Thorac Cardiovasc Surg* 2015;149:1060-5.

[19] Brown ML, McKellar SH, Sundt TM, Schaff HV. Ministernotomy versus conventional sternotomy for aortic valve replacement: a systematic review and meta-analysis. *J Thorac Cardiovasc Surg* 2009;137:670-9.e5.

[20] Borger MA, Moustafine V, Conradi L, Knosalla C, Richter M, Merk DR, Doenst T, Hammerschmidt R, Treede H, Dohmen P, Strauch JT. A randomized multicenter trial of minimally invasive rapid deployment versus conventional full sternotomy aortic valve replacement. *Ann Thorac Surg* 2015;99:17-25.

[21] Dogan S, Dzemali O, Wimmer-Greinecker G, Derra P, Doss M, Khan MF, Aybek T, Kleine P, Moritz A. Minimally invasive versus conventional aortic valve replacement: a prospective randomized trial. *J Heart Valve Disease* 2003;12:76-80.

[22] Martens S, Sadowski J, Eckstein FS, Bartus K, Kapelak B, Sievers HH, Schlensak C, Carrel T. Clinical experience with the ATS 3f Enable(R) Sutureless Bioprosthesis. *Eur J Cardiothoracic Surg* 2011;40:749-55.

[23] Folliguet TA, Laborde F, Zannis K, Ghorayeb G, Haverich A, Shrestha M. Sutureless perceval aortic valve replacement: results of two European centers. *The Annals of thoracic surgery* 2012;93:1483-8.

[24] Martens S, Zierer A, Ploss A, Sirat S, Miskovic A, Moritz A, Doss M. Sutureless aortic valve replacement via partial sternotomy. *Innovations* 2010;5:12-5.

[25] Laborde F, Fischlein T, Hakim-Meibodi K, Misfeld M, Carrel T, Zembala M, Madonna F, Meuris B, Haverich A, Shrestha M; Cavalier Trial Investigators. Clinical and haemodynamic outcomes in 658 patients receiving the Perceval sutureless aortic valves: early results from a prospective European multicenter study (the Cavalier Trial). Eur *J Cardiothoracic Surg* 2015 Aug 4. pii: ezv257. [Epub ahead of print].

[26] Malaisrie SC, Barnhart GR, Farivar RS, Mehall J, Hummel B, Rodriguez E, Anderson M, Lewis C, Hargrove C, Ailawadi G, Goldman S, Khan J, Moront M, Grossi E, Roselli EE, Agnihotri A, Mack MJ, Smith JM, Thourani VH, Duhay FG, Kocis MT, Ryan WH. Current era minimally invasive aortic valve replacement: techniques and practice. *J Thorac Cardiovasc Surg* 2014;147:6-14.

In: Encyclopedia of Surgery (22 Volume Set)
Editors: Andreas Lehrer and Kristin Mueller
ISBN: 978-1-53618-329-0
© 2020 Nova Science Publishers, Inc.

Chapter 403

MINI-THORACOTOMY AORTIC VALVE SURGERY

Mattia Glauber, Antonio Miceli and Antonio Lio*
Cardiothoracic Center, Istituto Clinico Sant'Ambrogio,
Gruppo Ospedaliero San Donato, Milan, Italy

ABSTRACT

Although aortic valve replacement (AVR) via complete median sternotomy continues to be the 'gold standard' treatment for patients with aortic valve disease, several minimally invasive approaches have been recently developed. This chapter report technical details and postoperative outcomes of AVR through a right anterior mini-thoracotomy (ART). ART is associated with excellent results, reducing mortality and morbidity and allowing faster recovery, less blood transfusion, atrial fibrillation, shorter hospital stay and better cosmetics results. The introduction of sutureless prostheses has expanded indications for ART minimally invasive AVR and it has reduced the long operative times associated with these minimally invasive procedures.

Keywords: minimally invasive aortic valve replacement, right minithoracotomy, sutureless valve

INTRODUCTION

Aortic valve disease is a prevalent disorder that affects approximately 2% of the adult general population [1]; it is the most common valvular heart disease in developed countries and its incidence is likely to increase with age [2].

Aortic valve replacement (AVR) through a full sternotomy (FS) continues to be the conventional approach for the treatment of aortic valve disease with excellent short- and long-term outcomes. Data from the Society of Thoracic Surgeon (STS) database show a dramatically in-hospital mortality reduction from 3.4% in 1997 to 2.6% in 2006 for isolated AVR, although an increase in patients' profile risk [3]. Despite these excellent results, in

* Corresponding Author's Email: antoniolio@hotmail.it.

recent years, minimally invasive AVR (MIAVR) has gained consensus among surgeons; since 1993 several minimally invasive approaches (right parasternal approach, upper and lower ministernotomy, V-shaped, inverse-T, J- and reverse-L partial mini-sternotomy, transverse sternotomy, and right mini-thoracotomy) have been developed and have been associated with better outcomes and lower perioperative morbidity compared with FS [4-7]. Compared with conventional surgery, MIAVR has been shown to provide faster recovery, shorter hospital stay, improved cosmesis and less wound infection. In addition, MIAVR has shown to improve post-operative respiratory function due to the preservation of sternum, and reduction of post-operative pain, blood loss and blood transfusions related to the reduction of surgical dissection, as well as facilitating reoperation at a later date, as part of pericardium remains closed [8-12].

The most common minimally invasive technique for AVR has been the upper mini-sternotomy (UHS) approach, and the outcomes reported from several meta-analyses have focused mainly on this procedure [9, 10], although anterior right mini-thoracotomy (ART) has the potential to offer better outcomes.

The aim of this chapter is to report our experience with MIAVR through ART: our right thoracotomy program started in 2004 and now, after the introduction of the sutureless technology, it has become our first MIAVR access for approaching a patient with an aortic valve disease.

PATIENTS SELECTION AND PREOPERATIVE PLANNING

All patients planned for aortic valve surgery undergo imaging with a 64-slice computed tomography (CT) scanner without contrast enhancement. It is important that during the CT scanning, patient' arms are adducted, recreating the normal patient position on operative table. Images are elaborated in the coronal and sagittal planes and then reconstructed in a 3D format to evaluate the relationship among the intercostal spaces, ribs, sternum, ascending aorta and aortic valve.

Patients are considered suitable for ART if the following CT scan criteria were met: (1) at the level of the main pulmonary artery, the ascending aorta was rightward (more than one-half located on the right in respect to the right sternal border); (2) the distance from the ascending aorta to the sternum did not exceed 10 cm; (3) the angle between the ascending aorta and the patient's midline should be more than 45°.

The retrosternal position of the ascending aorta and the deep thorax were considered unfavourable anatomic conditions for the ART approach. However, in the sutureless era (since April 2011), these CT criteria have only relative importance for the choice of surgical approach, and not every patient meet them.

The exclusion criteria for ART are: previous right-side chest surgery; a history of right pleurisy or previous right-side pleural effusion with adhesion formation; severe chest wall deformities; severe pulmonary bullous disease; and the presence of an ascending aorta aneurysm or the technical impossibility of obtaining peripheral percutaneous venous cannulation.

SURGICAL TECHNIQUE

Anaesthesia is provided according the standard protocol for conventional AVR. The patient is positioned in a supine position and two defibrillator pads are placed across the chest wall for electrical conduction. A single lumen for intubation and a neckline for drugs infusion are used.

The minimally invasive procedure is performed through a skin incision of 5 cm placed at the level of the second intercostal space without rib resection. The right internal thoracic artery (RITA) is in older patients often sacrified in order to achieve a better valve exposition and avoid bleeding complications; preservation of RITA is reserved for young patients with risk factors for coronary artery disease. A soft tissue is inserted into the thoracotomy and a small rib retractor is often used.

Once the lungs are off, the phrenic nerve is identified and the residual thymic tissue is removed up to the left innominate vein. The pericardium is usually opened 4-5 cm upper the phrenic nerve and above the ascending aorta. It is very important to retract the pericardium to allow the ascending aorta to come right forward and to obtain a better exposure. Once the pericardium is open, two concentric 2-0 polyester purse-string sutures for direct arterial cannulation are placed on the anterolateral portion of the distal ascending aorta with the second purse string reinforced with two pledgets. During the purse-string suture placement, the aorta can be kept steady using locking forceps to reduce physiological motion.

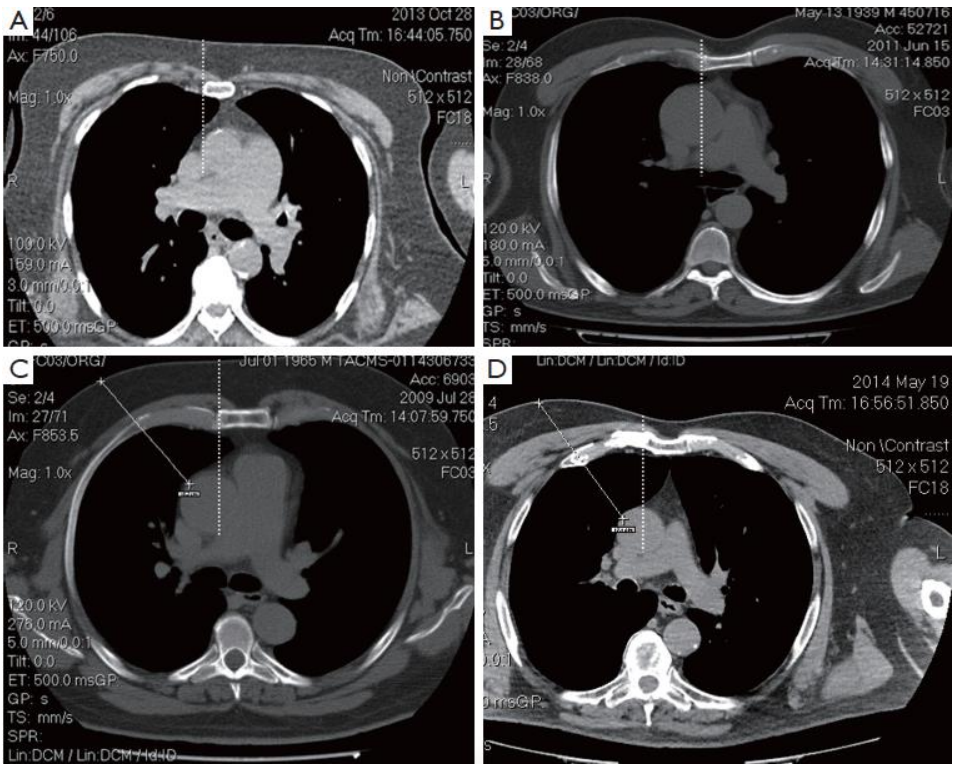

Figure 1. Preoperative chest computed tomography showing position of the ascending aorta in relation to the sternum. (A) retrosternal position of the ascending aorta (non suitable for ART); (B) right-sided ascending aorta (suitable for ART); (C, D) examples of deep thorax.

After heparin administration, venous cannulation is achieved using a BioMedicus Multistage (Medtronic, Inc., Minneapolis, MN, USA) or, in alternative, a RAP double stage 23-25 Fr (Sorin Group, Saluggia, Italy) inserted through the femoral vein into the right atrium with the Seldinger technique and under transoesophageal echocardiographic guidance. Thereafter, direct aortic cannulation is performed using a flexible cannula (Easyflow, Sorin Group, Saluggia, Italy).

On bypass a left ventricular vent is placed through the right superior pulmonary vein and a Y-shaped vent/cardioplegia positioned into the ascending aorta. Then, aorta is clamped with the aortic Glauber clamp (Cardiomedical GmbH, Langenhagen, Germany, distributed by Sorin, Saluggia, Italy). Antegrade cardioplegic solution is instilled into the aortic root or selectively into the coronary ostia using warm blood cardioplegia. Once the heart is arrested, aortotomy is performed and the operative field is flooded with carbon dioxide at a flow of 0.5 l/min. Aortotomy is performed differently depending on the type of prosthesis- sutured or sutureless/fast deployment valve- used.

In case of sutured valve implantation, a transverse aortotomy or an oblique aortomy toward the non coronary sinus is performed. The disease valve is removed and decalcification of the aortic annulus performed. Once the annulus is sized with appropriate valve sizer, stiches are passed through the aortic annulus in the following order: left coronary sinus, non coronary sinus and right coronary sinus. This because the right coronary sinus is more difficult to expose and we recommend passing the stiches after extending the aortic annulus. Once the stiches are passed through the bioprosthesis, the valve is parachuted down into the aortic root and then tied to the aortic annulus. If possible, we do not advise to tie the stiches with knot pusher as the fingers give a better sensation in control the knots.

In cases of sutureless valve implantation, Perceval S valve (Sorin Group) is the bioprosthesis of choice in our clinical practice, because it is a collapsible device. A collapsible profile, in ART AVR, seems to be the most useful and effective concept, enhancing visualisation in a reduced surgical exposure site and allowing the surgeon to secure correct position of the prosthesis under direct visual control before deployment.

In sutureless AVR, a smaller transverse aortotomy is performed at least 2 cm higher than conventional aortotomy, taking the inferior margin of Concato preaortic bundle as the reference point. The aortic annulus is sized with an ad hoc sizer, and then, three guiding 4/0 polypropilene sutures are placed at the nadir point of each valve sinus. The stitches are passed through the aortic annulus in the following order: right coronary sinus, non coronary sinus and the left coronary sinus. The Perceval S valve is collapsed and connected to the guiding sutures through the bottom holes placed on the inflow ring of the valve. Once the valve is parachuted into the aortic root, it is deployed and expanded with warm saline solution. Afterwards, the guiding sutures are removed and the valve is inspected; a correct position is achieved if the inflow ring of the sutureless valve covers the whole annulus and the coaptation of the three new leaflets figures a simmetrical Mercedes-Benz sign.

Rapid Deployment Edwards Intuity valve (Edwards Lifesciences, Irvie, CA, USA) can also be implanted via ART. A conventional aortotomy is performed, due to the non-collapsible profile of the device. After valve removal, the cylindrical end of an ad-hoc sizer is insterted through the annulus: the proper valve size is chosen when the flange of the sizer is not able to pass the aortic annulus. Then, three braided, non-pledgeted sutures are inserted as a figure-of-eight at the nadir of each aortic sinus. The sutures are passed through the sewing ring of the prosthesis and snared with a tourniquet and the valve is lowered into the annulus.

Therefore, it is mandatory to confirm that the valve stents lie completely within the aortic annulus; in minimally invasive procedures, due to the reduced visibility, a 5 mm-30° thoracoscope should be inserted through the holding device to confirm the correct position. Then, the valve is secured with the suture tourniquets and deployed. Finally, the three guiding sutures are tied and cut.

Figure 2. Final aesthetic result.

After an accurate aortotomy closure, before filling the heart and declamping the aorta a pace-maker wires should be placed before the heart starts to beat.

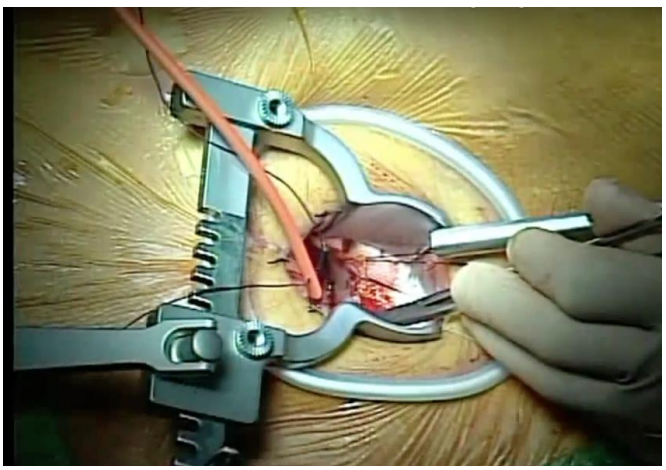

Figure 3. Surgical field of an ART AVR.

After dearing patient is weaned from cardiopulmonary bypass (CPB) and CPB is stopped. Trans-oesophageal echocardiography is performed to asses valve performance and correct position. For cannula removal, our protocol provides that the arterial cannula is removed first. At this time it is mandatory to induce systemic hypotension for closing the purse-strings. In case of need, like bleeding or haemodynamic instability, the venous cannula represents a rapid way to fill the patient. The femoral vein cannula is left in place to fill patients with residual blood in the cardiotomy. Once the reservoir is empty and for safety reason the venous

cannula needs to stay still in place, the mandrin can be reintroduced to avoid intralumen clotting. After protamine administration, the venous cannula is finally removed.

COMMENTS

MIAVR has become an alternative to standard sternotomy and it is increasingly performed in last years; compared to conventional surgery, MIAVR reduces postoperative morbidity and provides better cosmetic results [8-12].

Despite these positive results, the data reported from most of studies have focused on UHS. Few studies have evaluated the potential advantages of MIAVR using the ART approach.

We have described our first experience in 2011, reporting 192 consecutive patients who underwent isolate MIAVR through ART using stented valves from January 2005 to June 2010. Overall mortality was 1.6% and the rate of intraoperative conversion was 1.6%. The median of the length of stay was 5 days and discharge home was 90%. Interestingly, a low incidence of postoperative atrial fibrillation (AF) and blood transfusion were found (18% and 16%, respectively), nevertheless cross-clamp and CPB times were longer than in the standard approach [13].

Longer surgical times are considered an important drawback of ART, because of the negative impact on very old and fragile patients [14]. To overcome the technical challenges of MIAVR, and to shorten implantation time, a new generation of sutureless aortic valve prostheses have been introduced in clinical practice [15].

Since 2011, which is the year that clinical application of sutureless technology began at our Institution, there was a substantial increase in the number of patients that underwent ART AVR. Recently, we have reported a ten-year experience on 593 patients treated through a ART, showing a surgical mortality of 1.0% and an overall actuarial survival at 8-years of 93.3% ± 2%. Moreover, we showed that sutureless prostheses significantly reduce operative times and provide at least comparable clinical outcomes than conventional valves [16].

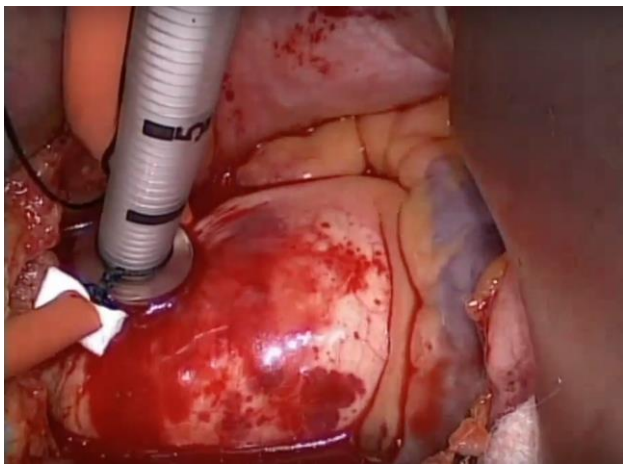

Figure 4. Intra-operative image showing central cannulation of the ascending aorta.

Advantages of ART approach over standard sternotomy were demonstrated by our group by a comparision with patients undergoing conventional surgery [17]. Specifically, 138 patients undergoing ART were matched to a full sternotomy group using propensity score analysis. The overall in-hospital mortality was 0.7%, with no difference between the two groups. MIAVR via ART was associated with a lower incidence of postoperative AF and blood transfusions compared to conventional surgery. In addition, patients in the ART group had a shorter mechanical ventilation time and postoperative length of stay.

Moreover, among patients undergoing MIAVR, the less surgical trauma induced by a minithoracotomy with sternal preservation might translate in lower postoperative morbidity. In a retrospective observational study, we have found that patients receiving a ART approach have better outcomes than those receiving mini-sternotomy, in terms of lower AF (19.5% vs 34.2%, P = 0.01), shorter ventilation time (median, 7 hours vs median, 8 hours, P = 0.003) and hospital stay (median, 5 days vs median, 6 days, P = 0.0001) [18].

Interestingly in all our studies, a low rate of atrial fibrillation was found to be associated with the ART approach. This might be related to a smaller pericardial incision and exposed area, as well as anatomical and electrical integrity of the percutaneously cannulated right atrium, which reduces the inflammatory response. In addition, an intact sternum would result in less postoperative pain, reducing the likelihood of AF.

Another criticism related to MIAVR regards the costs of surgical instrumentations. Although all the instruments and devices used for MIAVR are more expensive, we strongly believe that the less rate of postoperative complications, the shorter hospital stay and the faster recovery translate in less resources in the healthy system and therefore lower costs. However, this hypothesis should be evaluated with a well-designed study.

In the light of outstanding results that we have obtained in our 10-year experience with the ART AVR, MIAVR with sutureless prosthesis might be considered the real “alternative” to transcatheter aortic valve replacement (TAVR) procedure for high-risk patients judged still operable by a Heart Team.

Although TAVR represents the real MIAVR because it is performed without CPB, the main limitation of TAVR is that the native stenotic valve is left in place, resulting in a high degree of stroke and paravalvular leakage (PVL). We have recently demonstrated that high-risk patients undergoing MIAVR through ART using sutureless valves is associated with a trend of better early outcomes and mid-term survival with TAVR [19]. Specifically, in a small but matched population, the in-hospital mortality rate was 8.1% in the TAVI group and 0% in the ART group (p = 0.25), the incidence rate of stroke was 5.4% versus 0% in the TAVI and ART groups (p = 0.3). In the TAVR group, 37.8% and 27% had mild and moderate paravalvular leakage, whereas 2.7% had mild PVL in the ART group (P < 0.001). Finally, one- and 2-year survival rates were 91.6 vs 78.6% and 91.6 vs 66.2% in patients undergoing ART with the Perceval S sutureless valve compared with those undergoing TAVR (p = 0.1).

CONCLUSION

MIAVR performed through ART is a safe procedure associated with excellent postoperative outcomes, in terms of mortality, morbidity, shorter hospital stay and faster recovery. Sutureless technology have a potential to increase the adoption of MIAVR;

furthermore, the idea of minimal invasiveness regarding the surgical incision is complemented by reduced manipulation inside the aortic root, compared with a conventional sutured valve prosthesis implantation. The combination of MIAVR and sutureless prostheses may further improve postoperative outcomes, becoming the real alternative to TAVR procedure in the treatment of high operable risk patients affected by an aortic valve stenosis.

REFERENCES

[1] Nkomo VT, Gardin JM, Skelton TN, Gottdiener JS, Scott CG, Enriquez-Sarano M. Burden of valvular heart diseases: a population-based study. *Lancet* 2006;368:1005-11.

[2] Carabello BA, Paulus WJ. Aortic stenosis. *Lancet* 2009;373:956-66.

[3] Brown JM, O'Brien SM, Wu C, Sikora JA, Griffith BP, Gammie JS. Isolated aortic valve replacement in North America comprising 108,687 patients in 10 years: changes in risks, valve types, and outcomes in the Society of Thoracic Surgeons National Database. *J Thorac Cardiovasc Surg* 2009;137:82-90.

[4] Rao PN, Kumar AS. Aortic valve replacement through right thoracotomy. *Tex Heart Inst J* 1993;20:307-8.

[5] Cosgrove DM, Sabik JF. Minimally invasive approach for aortic valve operations. *Ann Thorac Surg* 1996;62:596-7.

[6] von Segesser LK, Westaby S, Pomar J, Loisance D, Groscurth P, Turina M. Less invasive aortic valve surgery: rationale and technique. *Eur J Cardiothorac Surg* 1999;15:781-5.

[7] Ruttmann E, Gilhofer TS, Ulmer H, Chevtchik O, Kocher A, Schistek R, Laufert G, Mueller LC. Propensity score-matched analysis of aortic valve replacement by mini-thoracotomy. *J Heart Valve Dis* 2010;19:606-14.

[8] Shekar PS, Cohn LH. Minimally invasive aortic valve surgery. In: Cohn LH. eds. *Cardiac surgery in the Adult,* 3rd ed. New York: McGraw-Hill Professional;2007:957-62.

[9] Brown ML, McKellar SH, Sundt TM, Schaff HV. Ministernotomy versus conventional sternotomy for aortic valve replacement: a systematic review and meta-analysis. *J Thorac Cardiovasc Surg* 2009;137:670-9.e5.

[10] Murtuza B, Pepper JR, Stanbridge RD, Jones C, Rao C, Darzi A, Athanasiou T. Minimal access aortic valve replacement: is it worth it? *Ann Thorac Surg* 2008;85:1121-31.

[11] Phan K, Xie A, Di Eusanio M, Yan TD. A meta-analysis of minimally invasive versus conventional sternotomy for aortic valve replacement. *Ann Thorac Surg* 2014;98:1499-511.

[12] Khoshbin E, Prayaga S, Kinsella J, Sutherland FW. Mini-sternotomy for aortic valve replacement reduces the length of stay in the cardiac intensive care unit: meta-analysis of randomised controlled trials. *BMJ Open* 2011;1:e000266.

[13] Glauber M, Miceli A, Bevilacqua S, Farneti PA. Minimally invasive aortic valvge replacement via right anterior minithoracotomy:early and midterm follow-up. *J Thorac Cardiovasc Surg* 2011;142:1577-9.

[14] Ranucci M, Frigiola A, Menicanti L, Castelvecchio S, de Vincentiis C, Pistuddi V. Aortic cross-clamp time, new prostheses, and outcome in aortic valve replacement. *J Heart Valve Dis* 2012;21:732–9.

[15] Shrestha M, Timm R, Höffler K, Koigeldiyev N, Khaladj N, Hagl C, Haverich A, Sarikouch S. Minimally invasive aortic valve replacement with self-anchoring Perceval valve. *J Heart Valve Dis* 2013;22:230-5.

[16] Glauber M, Gilmanov D, Farneti PA, Kallushi E, Miceli A, Chiaramonti F, Murzi M, Solinas M.Right anterior minithoracotomy for aortic valve replacement: 10-year experience of a single center. *J Thorac Cardiovasc Surg* 2015;150:548-56.

[17] Glauber M, Miceli A, Gilmanov D, Ferrarini M, Bevilacqua S, Farneti PA, Solinas M. Right anterior minithoracotomy versus conventional aortic valve replacement: a propensity score matched study. *J Thorac Cardiovasc Surg* 2013;145:1222-6.

[18] Miceli A, Murzi M, Gilmanov D, Fugà R, Ferrarini M, Solinas M, Glauber M. Minimally invasive aortic valve replacement using right minithoracotomy is associated with better outcomes than ministernotomy. *J Thorac Cardiovasc Surg* 2014;148:133-7.

[19] Miceli A, Gilmanov D, Murzi M, Marchi F, Ferrarini M, Cerillo AG, Quaini E, Solinas M, Berti S, Glauber M. Minimally invasive aortic valve replacement with a sutureless valve through a right anterior minithoracotomy versus transcatheter aortic valve implantation in high risk patients. *Eur J Cardiothorac Surg* 2015 Jun 25. pii: ezv210.

In: Encyclopedia of Surgery (22 Volume Set)
Editors: Andreas Lehrer and Kristin Mueller
ISBN: 978-1-53618-329-0
© 2020 Nova Science Publishers, Inc.

Chapter 404

RE-OPERATIVE MINIMALLY INVASIVE AORTIC VALVE SURGERY

Mauro Del Giglio and Elisa Mikus*, MD
Department of Cardiothoracic and Vascular Surgery,
Maria Cecilia Hospital, GVM Care and Research,
Cotignola (RA) GVM Care and Research, Italy

ABSTRACT

Minimally invasive surgery through an upper "J" ministernotomy (or upper hemi-sternotomy) for aortic valve replacement has become the routine approach in many centers with excellent results. However, the potential benefits of minimally invasive surgery in case of aortic valve re-operations remains questionable, especially in case of patent bypass grafts. All cardiac re-operations are associated with an increased peri-operative risk of morbidity and mortality when compared to the first operation. For this reason, the standard approach still utilises a full sternotomy and peripheral cannulation. On the other hand, employment of minimally invasive approaches in this situation, will result in minimal dissection of adhesions which may lead to reduced risk of bleeding and damage to a patent left internal mammary artery graft. This study compares the advantages and disadvantages of a minimally invasive approach in repeat aortic valve replacement compared to the standard approach, highlighting difficulties and potential solutions.

Keywords: aortic valve replacement, re-operative surgery, minimally invasive approach, upper "J" hemi-sternotomy, central cannulation.

INTRODUCTION

In 1962, Dr. Donald Ross in England reported the first successful aortic valve homograft implant [1]. Actually, aortic valve disease, especially stenotic calcific one, is the most

* Corresponding Author's Email: elisamikus@yahoo.it; Fax: +39 (545) 217135.

common valvular heart disease in the aging population of the developed world. The conventional treatment of severe aortic valve disease is still surgical aortic valve replacement (AVR) through a median sternotomy, with complications and mortality decreasing in recent years [2]. However, in an era transformed by an aging population, the presenting patient is increasingly older and sicker [3, 4]. This is the reason why, a modern surgical challenge has triggered the development of less invasive procedures, assumed to diminish the operative risk.

Since the first report by Dr. Delos Cosgrove of the Cleveland Clinic Foundation in 1996, [5] the belief that minimally invasive aortic valve surgery could be performed with similar hospital mortality but more advantages (less blood transfusion, earlier recovery of daily activities, and higher patient satisfaction) compare to the standard approach, has driven its diffusion in most centers worldwide. Various techniques exist for minimally invasive aortic valve surgery: upper partial or hemi-sternotomy (UHS; J shaped or inverse-T, reverse C incision) and mini-thoracotomy in the right 2nd or 3rd intercostal space (anterior right thoracotomy; ART) [5-10]. In addition transcatheter aortic valve replacement has been developed in the last years.

Although a large volume of literature on primary minimally invasive AVR (MIAVR) is available, only a few studies have been reported on the use of this technique in patients who have undergone a previous cardiac surgical procedure [11]. In addition, the increasing life expectancy coupled with an ageing population is creating an increased need for cardiovascular disease treatment in very elderly patients and also in those who have already been subjected to cardiac surgery. The frequent use of biological prostheses may cause an additional enhancement in the number of aortic valve re-operations. This creates problems, given the need to reduce health system expenses through shorter hospital stays, less blood transfusions, and better postoperative outcomes by avoiding prolonged ventilation time and wound infections. To reach this goal, minimally invasive approach, through a upper "J" hemi-sternotomy (UHS), has been proposed also in case of re-operative AVR (rAVR) [12-14]. The surgical indications for surgery are the same of standard full sternotomy based on current guidelines [15] and no real contraindication exists for this kind of surgical approach except for the inability to perform minimally invasive valve surgery. Many advantages were reported for this technique attributable to the lesser dissection of mediastinal tissues, especially in cases of patent bypass grafts [16-19]. However, actually, the benchmark for rAVR is still the full sternotomy, often associated with a peripheral cannulation [15].

TECHNIQUE

During each surgical procedure, the operative technique and the surgeon's expertise are most important in guiding the choices of materials, prosthesis and stitches to obtain the best clinical outcome. This is why appropriate training and adequate learning curve are essential. Minimally invasive rAVR (MIrAVR) is composed of many little steps, extracted from many clinical aspects and technical problems. Investing in surgeons' technical abilities and in adequate training in minimally invasive field of young surgeons is the key to improve the clinical outcome. Here, advantages and disadvantages of minimally invasive approach are discussed elaborating some tricks to overcome difficulties.

The surgical technique adopted in our unit [15] consists of a small (5-7 cm) "J" shaped partial upper re-sternotomy performed in the 3rd right intercostal space through a 6 cm skin incision. A trans-oesophageal echocardiographic probe is placed in every patient.

Surgical dissection is mainly performed only on the right side of the surgical incision. Minimal dissection around the aorta and the right atrium is performed to allow cannulation for cardiopulmonary bypass (CPB) and aortic cross-clamp placement.

The exposure of femoral artery (or alternatively the axillary artery) for CPB access is the safer approach, but it is not free from potential complications [13, 21]. In addition, based on the principle that antegrade perfusion has advantages over retrograde flow, [22, 23] it is better to adopt total central (aortic) cannulation, whenever possible. Under direct visualisation, the aorta is exposed up to the origin of the innominate artery after which two concentric purse string sutures for direct arterial cannulation are placed in a standard fashion. The cannulation site is generally chosen by identifying the transverse sinus as the orientation where the aortic cross-clamp will be placed. It is advisable that cannulation site is at some distance above the crossclamp level. Ascending aorta cannulation is performed under direct vision as routinely.

Venous drainage is achieved through the right atrium. The left ventricle is vented through the right upper pulmonary vein. Continuous carbon dioxide insufflation is used during the operation at a flow of 2 litres/minute. The ascending aorta is cross-clamped at the origin of the innominate artery and hypothermic 4°C blood cardioplegia (St Thomas with procaine) is administered in an antegrade fashion into the aortic root to stop the heart and then directly into the coronary ostia in case of aortic regurgitation.

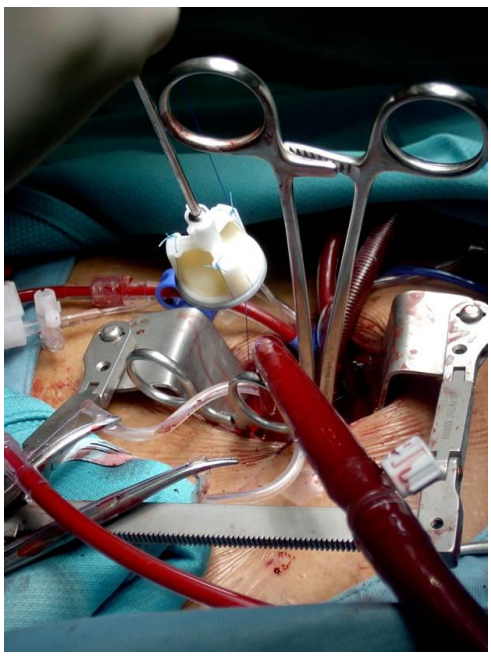

Figure 1.

Myocardial protection is crucial, especially in patients undergoing AVR who have undergone previous coronary artery bypass graft surgery (CABG) and a patent left internal mammary graft (LIMA). Usually temporary occlusion of LIMA pedicle is adopted during

cardioplegic arrest to avoid myocardial regional warming and cardioplegic solution "washout." Nevertheless, sometimes, the isolation of LIMA is not easy as it may be difficult to access and there is risk of LIMA injury. For these reasons, it is possible to maintain LIMA unclamped and to adopt a blood normothermic antegrade repeated each 20 minutes. The aim of the initial dose of cardioplegia is to arrest the heart to open the aorta and to explore the aortic valve; if the heart restarts to contract the main goal is to keep the left heart well vented without cooling down the patient. Our results, in addition to data from the literature, do not show an increased incidence in perioperative morbidity and mortality in the case of an unclamped LIMA graft [17, 20, 24]. In 1999, Byrne and colleagues left the LIMA graft unclamped while performing the AVR under hypothermia (20°C) and cardioplegic arrest [15]. Kaneko proposed to cool the patients to 25°C to 30°C and to adopt both antegrade and retrograde cardioplegia. When cardiac activity was observed because of a patent LIMA graft, additional systemic potassium was given through the pump (40 mEq) to a dosage of 6.0 to 7.0 mEq [18, 19].

A transverse incision of the ascending aorta is performed and the native valve is excised. The prosthetic valve is implanted using three running 2-0 (120 cm long) polypropylene sutures as we do routinely in conventional AVRs (Fig 1). Ascending aorta incision is closed using a 4-0 double suture.

The ventricular pacing wire must be placed on the right ventricle when aorta is still clamped and the heart is still and empty. Sometimes, this manoeuvre can be challenging due to the adhesions and the limited surgical field. In this case, temporary endocardial pacing leads through the right internal jugular vein can be placed [17-19].

Deairing the heart is achieved using a 2-stage procedure. First, the table is lifted head up, the heart is filled, both lungs are ventilated, and air is removed from the left atrium through the vent. The bed is then placed head down, the aortic clamp is released, and air is removed via the transmitral vent and the aortic vent. In addition, correct de-airing is ensured with continuous carbon dioxide insufflation and trans-oesophageal echocardiography is always used to monitor it and to assess prosthesis function [17-19]. The patient is then weaned from CPB. Cannulae are removed and protamine is administered at a 1:1 ratio with heparin. Sternum is closed with steel wires and subcutaneous sutures are employed for wound closure.

RESULTS

Between October 2007 and October 2015, a total of 2788 consecutive adult patients underwent isolated AVR at our institution. This included 153 patients who had had previously undergone previous cardiac surgery. In this chapter, we present the results of 59 patients in whom UHS approach was chosen instead of conventional full sternotomy, which was employed in the remaining 94 patients.

Patients' demographic and operative data are expressed as mean ± standard deviation, medians (interquartile range, IQR, 25th-75th percentiles) or as prevalence percentages, as appropriate. All statistical analysis was performed with SPSS software, version 23.0 (SPSS Inc, Chicago, IL, USA).

Table 1. Baseline characteristics of the patients

Age (years)	75 (66-78)
Male sex	35 (59.3%)
Hypertension	49 (83.1%)
Diabetes	14 (23.7%)
Smoking status	
Current	12 (20.3%)
Former	14 (23.8%)
Chronic lung disease	11 (18.3%)
Atrial fibrillation	12 (20.3%)
Ejection fraction (%)	55 (48-60)
Prior Coronary Artery Bypass graft	31 (52.5%)
Euro SCORE ♦	10 (8-12)

Counts are presented as number of patients and percentage of total series. Continuous data are presented as median (25 percentile to 75 percentile).

♦ EuroSCORE= European system for cardiac operative risk evaluation.

Table 2. Early postoperative outcome

Tracheostomy	3 (5.1%)
Sepsis	1 (1.7%)
Re-exploration for bleeding	5 (8.5%)
Post-operative Pacemaker	5 (8.5%)
Atrial fibrillation	11 (18.6%)
Blood transfusions	41 (69.5%)
Red blood cell units	2 (1.7-5)
Ventilation time (hours)	6.5 (5-13.3)
Intensive Care Unit stay (hours)	47.5 (38-72)
Discharged alive	58 (98.3%)

Counts are presented as number of patients and percentage of total series. Continuous data are presented as median (25 percentile to 75 percentile).

The median age of patients was 75 years (interquartile range (IR): 66-78 years) and 35 were male (59.3%). Previous cardiac surgery procedures included CABG in 31 pts (2 had LIMA-right internal mammary graft patent "Y" grafts). Demographic, intraoperative and short-term outcome data of all patients were collected and analysed. Patients baseline characteristics are described in Table 1. Overall median CPB time was 65 minutes (IR 55-79 minutes) and median aortic cross clamp time was 49 minutes (IR 42-64 minutes). In 44 patients (74.5%), a biological prosthesis was implanted because of the patient's age or preference; in the remaining 15 patients, a mechanical valve was used. Median intensive care and hospital stay were 47.5 hours (IR: 38-72 hours) and 8 days (IR: 7-11days), respectively. Hospital mortality was 1.7% (1/59). All postoperative outcomes are reported in Table 2.

CONCLUSION

We believe that, in contrast to some already described disadvantages, the minimally invasive surgical option offers various benefits. Firstly, it reduces surgical trauma due to

lesser dissection of pericardial adhesions and the mediastinal dissection is limited to the ascending aorta and a small portion of the right atrium. The right ventricle does not need to be dissected completely. This avoids bleeding and risk of injury, especially in cases of patent bypass grafts [26-27]. The UHS for MIrAVR offers an adequate surgical and aortic valve exposure and an easy conversion to full sternotomy if required. The minimally invasive alternative approach is the ART [28], but this is more technically challenging in re-operative cases. Secondly, the aesthetic result is worst due to the presence of a second scar in the thorax.

The available data suggests a favourable effect of MIrAVR without compromising the efficacy of the entire operative procedure. The reported operative mortality and morbidity figures are very encouraging [11, 14, 18, 20, 29-31], despite including results from the surgeons' learning curve. The authors of this chapter believe that MIrAVR reduces biological invasiveness, which may result into shorter duration of surgery, hospital stay and lower risk for sternal instability and/or infection.

REFERENCES

[1] Ross DN. Homograft replacement of the aortic valve. *Lancet.* 19628;2(7254):487.

[2] Aikawa E, Schoen FJ. In: Calcific and degenerative heart valve disease, in *Cellular and molecular pathobiology of cardiovascular disease*. Stone J, Homeister JM, Willis MS, editors. Elsevier; 2014. pp. 161–181.

[3] Brown JM, O'Brien SM, Wu C, Sikora JA, Griffith BP, Gammie JS. Isolated aortic valve replacement in North America comprising 108,687 patients in 10 years: changes in risks, valve types, and outcomes in the Society of Thoracic Surgeons National Database. *J Thorac Cardiovasc Surg* 2009;137:82-9.

[4] Frilling B, von Renteln-Kruse W, Riess FC. Evaluation of operative risk in elderly patients undergoing aortic valve replacement: the predictive value of operative risk scores. *Cardiology* 2010;116:213-8.

[5] Cosgrove DM3rd, Sabik JF. Minimally invasive approach for aortic valve operations. *Ann Thorac Surg* 1996;62:596-7.

[6] Benetti FJ, Mariani MA, Rizzardi JL, Benetti I. Minimally invasive aortic valve replacement. *J Thorac Cardiovasc Surg* 1997;113:806-7.

[7] Gundry SR, Shattuck OH, Razzouk AJ, del Rio MJ, Sardari FF, Bailey LL. Facile minimally invasive cardiac surgery via ministernotomy. *Ann Thorac Surg* 1998;65:1100-4.

[8] Kim BS, Soltesz EG, Cohn LH. Minimally invasive approaches to aortic valve surgery: Brigham experience. *Semin Thorac Cardiovasc Surg* 2006;18:148-53.

[9] Svensson LG, D'Agostino RS. "J" incision minimal-access valve operations. *Ann Thorac Surg* 1998;66:1110-2.

[10] von Segesser LK, Westaby S, Pomar J, Loisance D, Groscurth P, Turina M. Less invasive aortic valve surgery: rationale and technique. *Eur J Cardiothorac Surg* 1999;15:781-5.

[11] Phan K, Xie A, Di Eusanio M., Yan T. A Meta-analysis of minimally invasive versus conventional sternotomy for aortic valve replacement. *Ann Thorac Surg* 2014; 98:1499-544.

[12] Tam RK, Garlick RB, Almeida AA. Minimally invasive redo aortic valve replacement. *J Thorac Cardiovasc Surg* 1997; 114:682-3.

[13] Cohn LH, Adams DH, Couper GS, Bichell DP, Rosborough DM, Sears SP, Aranki SF. Minimally invasive cardiac valve surgery improves patient satisfaction while reducing cost of cardiac valve replacement and repair. *Ann Surg* 1997;226:421-6.

[14] Pineda AM, Santana O, Lamas G, Lamelas J. Is a minimally invasive approach for re-operative aortic valve replacement superior to standard full resternotomy? *Interact Cardiovasc Thorac Surg* 2012;15(2):248-52.

[15] Onorati F1, Biancari F, De Feo M, Mariscalco G, Messina A, Santarpino G, Santini F, Beghi C, Nappi G, Troise G, Fischlein T, Passerone G, Heikkinen J, Faggian G. Mid-term results of aortic valve surgery in redo scenarios in the current practice: results from the multicentre European RECORD (REdo Cardiac Operation Research Database) initiative. *Eur J Cardiothorac Surg* 2015;47(2):269-80.

[16] Byrne JG, Karavas AN, Filsoufi F, Mihaljevic T, Aklog L, Adams DH, Cohn LH, Aranki SF. Aortic valve surgery after coronary artery bypassn grafting with functioning internal mammary artery patent grafts. *Ann Thorac Cardiovasc Surg* 2002;73:779–784.

[17] Gaeta R, Lentini S, Raffa G, Pellegrini C, Zattera G, Viganò M. Aortic valve replacement by ministernotomy in redo patients with previous left internal mammary artery patent grafts. *Ann Thorac Cardiovasc Surg* 2010;16:181–86.

[18] Kaneko T, Leacche M, Byrne J, Cohn L. Reoperative minimal access aortic valve replacement. *J Thorac Dis* 2013;5(Suppl 6):S669-S672.

[19] Kaneko T, Loberman D, Gosev I, Rassam F, McGurk S, Leacche M, Cohn L. Reoperative aortic valve replacement in the octogenarians-minimally invasive technique in the era of transcatheter valve replacement. *J Thorac Cardiovasc Surg* 2014;147(1):155-62.

[20] Mikus E, Calvi S, Tripodi A, Lamarra M, Del Giglio M. Upper 'J' ministernotomy versus full sternotomy: an easier approach for aortic valve reoperation. *J Heart Valve Dis* 2013;22(3):295-300.

[21] Ruttmann E, Gilhofer TS, Ulmer H, Chevtchik O, Kocher A, Schistek R, Laufert G, Mueller LC. Propensity score-matched analysis of aortic valve replacement by mini-thoracotomy. *J Heart Valve Dis* 2010;19:606-14.

[22] Crooke GA, Schwartz CF, Ribakove GH, Ursomanno P, Gogoladze G, Culliford AT, Galloway AC, Grossi EA. Retrograde arterial perfusion, not incision location, significantly increases the risk of stroke in reoperative mitral valve procedures. *Ann Thorac Surg* 2010;89:723-30.

[23] Grossi EA, Loulmet DF, Schwartz CF, Solomon B, Dellis SL, Culliford AT, Zias E, Galloway AC. Minimally invasive valve surgery with antegrade perfusion strategy is not associated with increased neurologic complications. *Ann Thorac Surg* 2011;92:1346-50.

[24] Smith RL, Ellman PI, Thompson PW, Girotti ME, Mettler BA, Ailawadi G, Peeler BB, Kern JA, Kron IL. Do you need to clamp a patent left internal thoracic artery left anterior descending graft in reoperative cardiac surgery? *Ann Thorac Surg* 2009;87:742–747.

[25] Byrne JG, Aranki SF, Couper GS, Adams DH, Allred EN, Cohn LH. Reoperative aortic valve replacement: partial upper hemisternotomy versus conventional full sternotomy. *J Thorac Cardiovasc Surg* 1999 Dec;118(6):991-7.

[26] Dobrilovic N, Fingleton JG, Maslow A, Machan J, Feng W, Casey P, Sellke FW, Singh AK. Midterm outcomes of patients undergoing aortic valve replacement after previous coronary artery bypass grafting. *Eur J Cardiothorac Surg* 2012;42(5):819-25.

[27] Follis FM, Pett SB, Jr, Miller KB, Wong RS, Temes RT, Wernly JA. Catastrophic hemorrhage on sternal reentry: still a dreaded complication? *Ann Thorac Surg* 1999; 68: 2215–9.

[28] Pineda AM, Santana O, Reyna J, Sarria A, Lamas GA, Lamelas J. Outcomes of aortic valve replacement via right minithoracotomy versus median sternotomy after prior cardiac surgery. *J Heart Valve Dis* 2013;22(1):50-5.

[29] Murtuza B, Pepper JR, Stanbridge RD, Jones C, Rao C, Darzi A, Athanasiou T. Minimal access aortic valve replacement: is it worth it. *Ann Thorac Surg* 2008;85:1121–31.

[30] Brown ML, McKellar SH, Sundt TM, Schaff HV. Ministernotomy versus conventional sternotomy for aortic valve replacement: a systematic review and meta-analysis. *J Thorac Cardiovasc Surg* 2009;137:670-9.

[31] Phan K, Zhou JJ, Niranjan N, Di Eusanio M, Yan TD. Minimally invasive reoperative aortic valve replacement—A systematic review and meta-analysis. *Ann Cardiothorac Surg* 2015;4(1):15-25.

In: Encyclopedia of Surgery (22 Volume Set)
Editors: Andreas Lehrer and Kristin Mueller
ISBN: 978-1-53618-329-0
© 2020 Nova Science Publishers, Inc.

Chapter 405

TOTALLY ENDOSCOPIC AND ROBOTICALLY-ENHANCED MINIMALLY INVASIVE AORTIC VALVE SURGERY

Marco Vola, MD, PhD and Antoine Gerbay*, MD
Department of Cardiovascular Surgery
University Hospital of Saint-Etienne Saint-Etienne, France

ABSTRACT

Totally endoscopic aortic valve replacement (TEAVR) is not opposed but complementary to trans-catheter aortic valve replacement, since as a surgical therapy TEAVR still provides the removal of the underlying pathology prior to the insertion of a valvular substitute. TEAVR could become the surgical approach of reference in terms of early recovery post-aortic valve replacement. The approach has proven to be feasible with use of the sutureless prostheses. It is our challenge to safely increase the procedural reproducibility.

Keywords: endoscopic, minimal, aortic, valve, robotic

INTRODUCTION

Several minimally invasive approaches have already proven to provide advantages over full sternotomy in terms of blood transfusion and reduction of postoperative discomfort. Totally endoscopic cardiac surgery has showed excellent results in terms of post-operative life quality [1, 2]. The perspective to perform surgical aortic valve replacement (AVR) in a closed chest setting also is our forthcoming challenge.

* Corresponding Author: Antoine Gerbay MD Department of Cardiovascular Surgery, University Hospital of Saint-Etienne, Saint-Etienne, France.

RATIONALE OF TOTALLY ENDOSCOPIC AORTIC VALVE SURGERY

Totally endoscopic aortic valve replacement (TEAVR) aims maximal reduction of surgical wall chest trauma necessary for a biologic AVR. However, such technical effort may question part of the scientific community, since trans-catheter aortic valve replacement (TAVR) with reported excellent results of third generation devices, could be soon extended into lower risk patients. On the other hand, surgery facilitates the removal of calcified aortic valvular tissues, that contribute to a considerable incidence to transcatheter paravalvular regurgitation responsible, for the reported lower 5 year life expectancy [3] after TAVR. The asymmetric distribution of aortic valve calcifications contributes to the elliptic expansion of transcatheter stents, with an asymmetric leaflet valve opening and a supposed lower prosthetic durability. Finally, the role of a delayed chronic micro embolisation, from the aortic anfractuous calcified tissues acting as a nidus for micro thrombi, is actually under investigation [4]. These elements, associated with a fairly high incidence of pace maker implantation in some third generation TAVR models (e.g., the Sapien III, [5]), fuels ongoing discussion to invest energy in the refinement of an evolved surgical setting aimed primarily at intermediate and low risk patients with a high calcium score. The objective is to provide the removal of calcium before the implantation of a valvular substitute, an extremely low grade of invasiveness and an improved quality of life. Moreover, intermediate risk patients compared to high risk aged patients can tolerate longer cross clamp times and benefit from a quick return to an active lifestyle. These are the patients who are the ideal target for TEAVR.

The widely available stented valves are incompressible and still need a mini-thoracotomy to be inserted into the thorax since they cannot be compressed into trocars. But with the introduction of sutureless Nitinol stented prosthesis, this issue was resolved, and the first human totally endoscopic valve replacement was performed in 2013 [6].

COMPRESSIBLE SUTURELESS VALVES AS A CONDITION FOR A TOTALLY ENDOSCOPIC APPROACH

The primary aim of sutureless bioprosthesis is to avoid the passage of stiches into the aortic annulus and knot-tying. Several reports [7-10] are focused on the ischaemic time that is supposed to be saved with this technology. Nevertheless, it appears that the reduction of the cross-clamp time, as compared to the sutured valves, is less marked in the full sternotomy procedures as compared to minimally invasive. This is true, especially with the anterior right mini-thoracotomy, which is more challenging than its upper hemi-sternotomy counterpart [11]. Beyond this time-saving logic, there is a technical advantage in use of sutureless valves. This is the avoidance of sutures in settings where their placement is technically challenging or impossible (e.g., hypercalcified aortic roots, re-operative aortic stentless valve procedures, etc. [12-15]).

Concerning the totally endoscopic approach, a further property of the Nitonol sutureless valves becomes pivotal: the possibility to fold/compress the bioprostheses in order to introduce them into a thoracoscopic trocar. Since the existing commercially available thoracoscopic largest trocars measure 20mm (internal diameter), it is mandatory that all sizes

of sutureless valves selected for the endoscopic approach can be reduced at this diameter when folded, before the re-expansion into the aortic root. These compression ratios have been studied for the 3f Enable and Perceval sutureless models, that both fulfill the criterion [16]. But it not excluded that, in the future, second generation sutureless valve would not be able to fit into lower diameter trocars. In fact, the industry is actually moving towards a common valve which could be adaptable into a Nitinol stented sutureless like valve when surgical decalcification is indicated prior to implantation or into a TAVR like valve, if decalcification is not needed and a simple implantation of a prosthesis is sufficient.

SURGICAL SET-UP

The procedure is performed under selective pulmonary ventilation. Purse strings are placed onto the common femoral artery and vein in order to establish femoro-femoral bypass. Cardio-protection is performed with Custodiol solution (histidine-tryptophanketoglutarate cardioplegic solution; Kohler Chemie, Alsbach-Hahnlein, Germany).The main working trocar (20mm, Flexipath; Ethicon, Inc, Somerville, NJ) is placed in the second intercostal space, a second operative trocar (15mm) is in the third, a percutaneous transthoracic aortic clamp is in the first, a 5-mm30 optic is in the second (7mmtrocar), and a right pulmonary vein venting line and purse-string with carbon dioxide insufflation line are in the fifth (with a 7mmtrocar) Figure 1). A complete video of the procedure with use of the 3f Enable valve is available at the following link: http://www.annalscts.com/article/view/4990/6716).

Figure 1. Operative setting. The aorta is cross clamped (Chitwood clamp, first intercostal space). Note the vent and the corresponding purse string throughout the trocar in the fifth space.

PATIENT SELECTION

Patients should be selected considering that TEAVR is a procedure in phase of clinical development, with longer cross clamping times as compared to open surgery: thus it is reasonable to avoid patients with significant ventricular or renal dysfunction. Moreover,

patients have to fulfill criteria for safe retrograde cardio-pulmonary bypass. It is recommended to avoid patients with insufficient peri-aortic working space (<2 cm between the inferior margin of the sternum and the aortic anterior wall). To keep comfortable distance between the aortic clamp, the cardioplegia needle, and the aortotomy, and consequently safe placement of the aortic closing sutures, very short aortas should also be excluded (the central line of the ascending aorta should be longer than 5 cm). Vertical aortas without physiologic curvature should be avoided. The central axis of the proximal aortic root together with the operative axis of the third intercostal space should be ascertained. A CT scan is performed to assess these anatomic criteria. A 3D reconstruction can be helpful in planning the ideal position of the trocars for each patient (Figure 2).

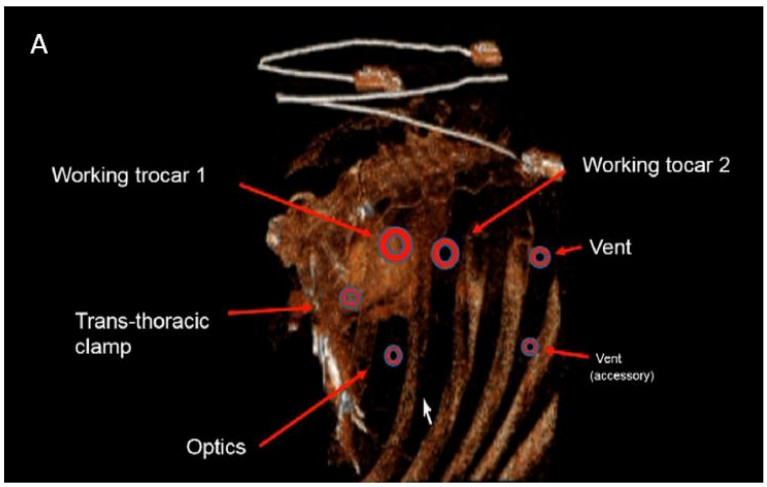

(A)

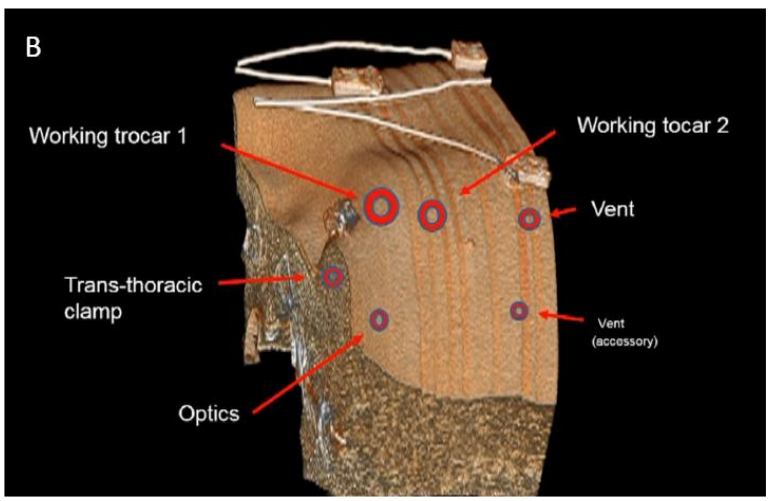

(B)

Figure 2. CT scan 3D reconstruction. (A) trocar position planning in consideration of the aortic root anatomy; (B) Cutaneous projection of the same trocar position in order to simulate the localisation of the patient's micro- incisions on the skin.

MANAGEMENT OF THE SUTURELESS VALVE INTO THE AORTIC ROOT

The 3f Enable valve, now withdrawn from the market, was the first model implanted experimentally (cadaver) and clinically in a totally endoscopic setting. This prosthesis is manually folded and is not provided with a real holder but just with a simple grasper keeping the stent folded. But once descended into the thorax immediately after the passage into the trocar, the lower part of the stent tended to expand making further approach into the aortic root problematic. Thus the technique of implantation was modified, adding two 4/0 prolene stitches sutured one at the flange and one higher, at the level of the Nitinol stent. This ensured that the prosthesis remained collapsed and facilitated control, by cutting the stitches when the flange was perfectly aligned with the native annulus (Figure 3).

The Perceval is managed with a holder that keeps the valve folded. Moreover, the release of the prosthesis is performed with three guiding sutures facilitating the alignment of the prosthetic flange with the native annulus. The implantation of the Perceval prosthesis has already reported to be safe and reproducible via a mini-thoracotomy [11]. In our recent clinical experience it was shown that it was implantable throughout a 20 mm trocar within cross clamp times lower than the mean value of our previous 3f Enable TEAVR experience (112 ± 18 minutes, 14 patients). In the Perceval TEAVR approach, use of three tourniquets preventing any prolene twist around the holder has been necessary (Figure 4), but the rest of the implantation technique is not different as compared to open access.

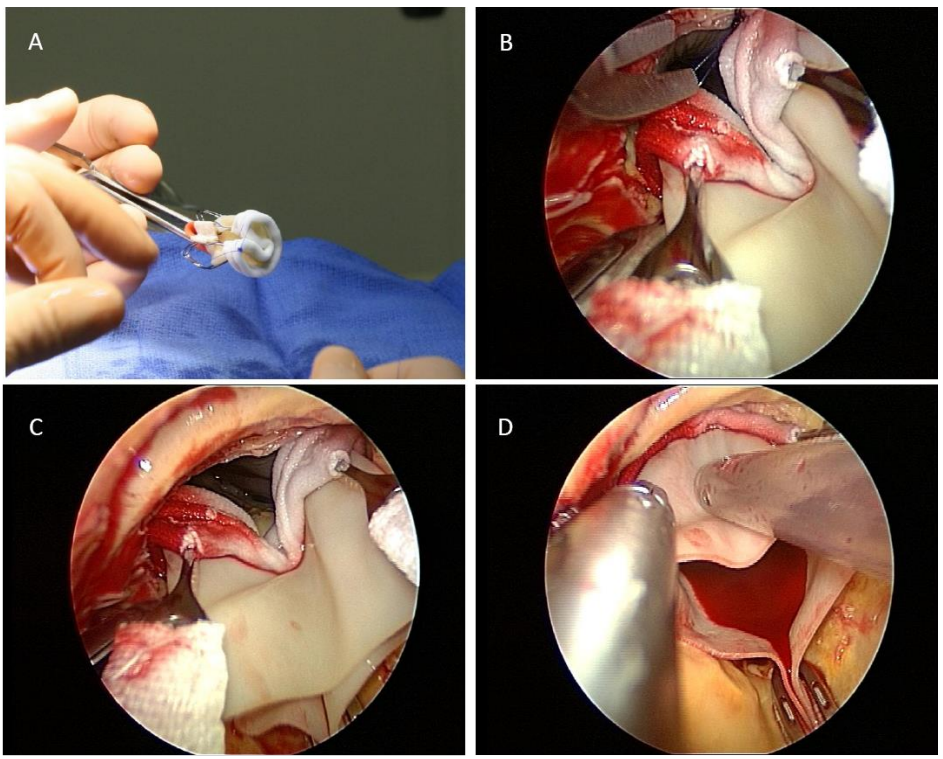

Figure 3. A. 3f Enable valve kept folded by a prolene stitch at the flange. B: Cutting of the prolene stitch end valve expansion (C and D).

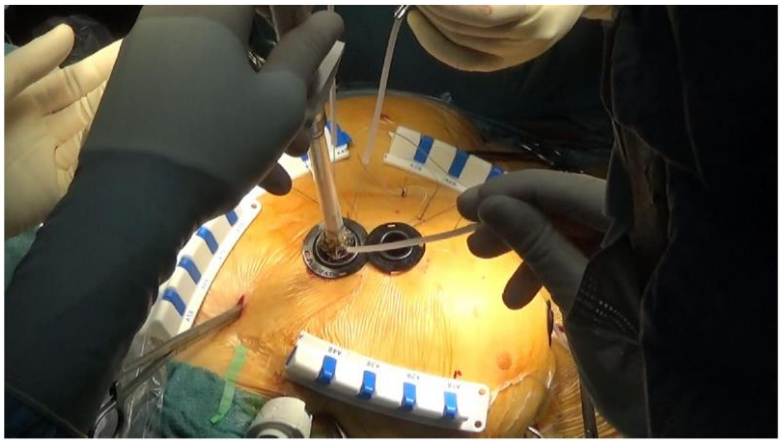

Figure 4. Perceval TEAVR: note the use of tourniquets that will follow the descent of the valve into the aortic root in order to facilitate the management of the guiding suture.

CHALLENGES AND PERSPECTIVES

Robotic Assisted Aortic Valve Replacement via a Right Minithoracotomy

Use of the da Vinci tele manipulation system is reported by several authors in mitral repair and replacement [17, 18]. Concerning aortic valve surgery, few robotic assisted procedures via a right mini-thoracotomy have been published by Folliguet and colleagues [19]: 10 patients were successfully operated on with 98.2±30.4 min of cross clamp time. Two robotic arms were placed, one in the second intercostal space mid axillary and one in the fifth or fourth intercostal. In 2010, Suri and collaborators reported, in a cadaveric study [20], the replacement of the aortic valve with the sutureless Perceval prosthesis through a 4cm right mini-thoracotomy.

Robotic TEAVR

No clinical reports have been published with a totally thoracoscopic procedure, as intended exclusively through thoracoscopic trocars.

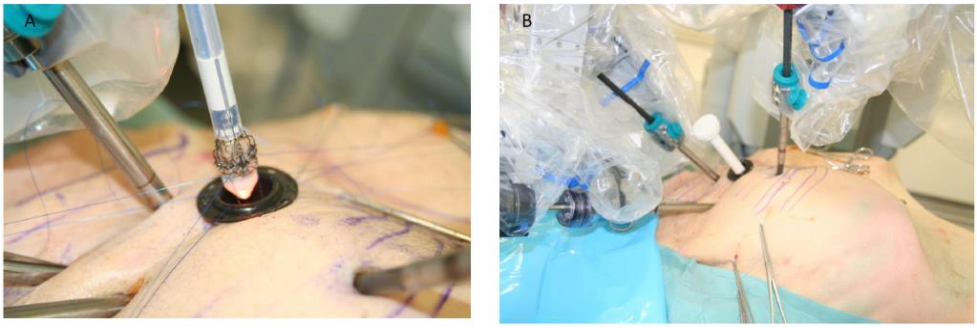

Figure 5. A) Robotic Perceval TEAVR (Da Vinci Robot, Cadaveric study). B) endoscopic sizing with use of the Vola endoscopic sizer.

Some technical reasons may explain the poverty of application of the robotic surgery in the aortic valve field as compared to the mitral. As per the non-robotic totally endoscopic approach, the ideal setting of the operating arms, with use of the actual sutureless Nitinol stented valves (the Perceval), must be adapted to operate in the aortic root in consideration of a high aortotomy. In fact, during the aortotomy, sufficient margin of aortic tissue should remain at the proximal aortic margin, from the Nitonol stent, in order to enable a safe and quick closure. It follows that the aortic root is a more difficult working space as compared to the left atrium. Specifically, the discardment between the robotic arms is reduced, and the triangulation between the optics and the two operative arms is also very limited. In a cadaveric report of totally endoscopic aortic valve replacement with the da Vinci System S*i* (Intuitive Surgical, Sunnivale, CA, USA) model conducted by our group and implantation either of the 3F Enable and Perceval sutureless prostheses [21] (Figure 5), the arms had to be specifically adapted to avoid any conflict. The Surgical setting adopted in this report included positioning of a 20mm main working port into the second intercostal space for the introduction of the valve into the thorax; a second working port is positioned into the first intercostal space (left robotic arm), a second robotic arm in the third or fourth intercostal space (right robotic arm). Laterally (anterior axillary line) optics (30°) are positioned in the second intercostal space, and a transthoracic percutaneous clamp (Chitwood clamp) in the first intercostal space. The new model of the Da Vinci X*i* telemanipulator (Intuitive Surgical, Sunnivale, CA, USA) could be of interest for this aortic valve application since the arms are thinner and the conflict external to the thorax can be reduced. Experimental studies in this are area still awaited.

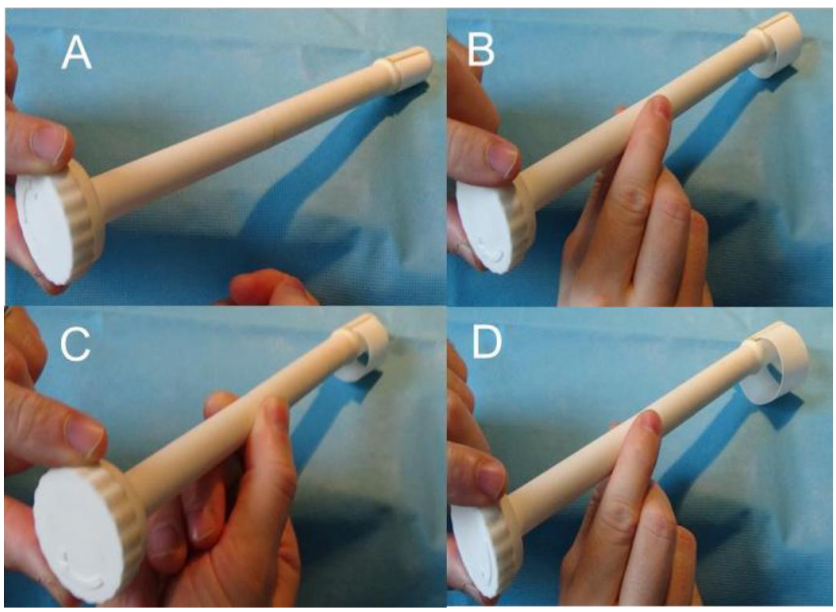

Figure 6. A-D. Progressive expansion of the plastic tape at the extremity of the Vola's endoscopic expandable sizer.

Robot advantages in sutureless TEAVR are potentially focused on the native calcified aortic valve removal and the ascending aorta closure. On the other hand, no cadaveric studies have been conducted in presence of selected calcified or heavily calcified leaflets.

Additionally, the actual surgical instruments of the da Vinci system are not conceived specifically to decalcify a stenotic aortic valve apparatus. The da Vinci system could also be helpful in enhancing the reproducibility of the running suture of the ascending aorta. Nevertheless, the lack of tactile feedback has to be taken in account when tissues are fragile.

Endoscopic Sizing

Although in our previous TEAVR experience with in the 3F Enable valve, annular sizing was image-based, physical annular sizing remains fundamental in current and future use of sutureless valves. Unless the skin of the main trocar cutaneous incision is stretched, passage of Perceval sizers greater than the "small" one is actually impossible throughout that limited incision (20mm length). The problem can be overcome only with the development of dedicated endoscopic expandable sizers (Figure 5b and 6). These devices are not yet CE marked and will be clinically tested with an institutional pilot study.

Venous Percutaneous Retrograde Cardioplegia and Endoventing

Pulmonary vein venting requires the preparation of purse string that requires careful surgical training. The future solution seems to be interestingly overcome by using a trans-jugular pulmonary artery vent. Only one device labelled for this use is actually available (Edwards Endovent (Edwards, Irvine CA) and further literature is awaited in this area. More generally, in a closed-chest context, the trans-jugular access also seems promising for the insertion of trans-jugular pacing catheter and retrograde cardioplegia delivery.

CONCLUSION

Overall, the TEAVR development process should lead to a four step "closed chest" rapid and reproducible procedure: this is an ambitious target needing further technical development. The affirmation of such a technique as a surgical reference in the future will be function of the capacity to set a device-assisted procedure rather than investing in a very intensive endoscopic training enabling only highly specialised surgeons and high volume centers. Ideally, this latter condition may be acceptable only in a transitional phase of the technique, as it is at present.

ACKNOWLEDGMENTS

We thank Professor Thierry Folliguet and Jean-françois Fuzellier, and Doctor Salvatore Campisi, for the support in the redaction of this chapter.

REFERENCES

[1] Morgan JA, Peacock JC, Kohmoto T, Garrido MJ, Schanzer BM, Kherani AR, Vigilance DW, Cheema FH, Kaplan S, Smith CR, Oz MC, Argenziano M. Robotic techniques improve quality of life in patients undergoing atrial septal defect repair. *Ann Thorac Surg* 2004;77:1328-33.

[2] Bonaros N, Schachner T, Wiedemann D, Oehlinger A, Ruetzler E, Feuchtner G, Kolbitsch C, Velik-Salchner C, Friedrich G, Pachinger O, Laufer G, Bonatti J. Quality of life improvement after robotically assisted coronary artery bypass grafting. *Cardiology* 2009;114:59-66.

[3] Mack MJ, Leon MB, Smith CR, Miller DC, Moses JW, Tuzcu EM, Webb JG, Douglas PS, Anderson WN, Blackstone EH, Kodali SK, Makkar RR, Fontana GP, Kapadia S, Bavaria J, Hahn RT, Thourani VH, Babaliaros V, Pichard A, Herrmann HC, Brown DL, Williams M, Akin J, Davidson MJ, Svensson LG; PARTNER 1 trial investigators. 5-year outcomes of transcatheter aortic valve replacement or surgical aortic valve replacement for high surgical risk patients with aortic stenosis (PARTNER 1): a randomised controlled trial. *Lancet* 2015;385:2477-84.

[4] Fanning JP, Wesley AJ, Platts DG, Walters DL, Eeles EM, Seco M, Tronstad O, Strugnell W, Barnett AG, Clarke AJ, Bellapart J, Vallely MP, Tesar PJ, Fraser JF. The silent and apparent neurological injury in transcatheter aortic valve implantation study (SANITY): concept, design and rationale. *BMC cardiovascular disorders* 2014;14:45.

[5] Webb J, Gerosa G, Lefèvre T, Leipsic J, Spence M, Thomas M, Thielmann M, Treede H, Wendler O, Walther T. Multicenter evaluation of a next-generation balloon-expandable transcatheter aortic valve. *Journal of the American College of Cardiology* 2014;64:2235-43.

[6] Vola M, Fuzellier JF, Chavent B, Duprey A. First human totally endoscopic aortic valve replacement: an early report. *The Journal of thoracic and cardiovascular surgery* 2014;147:1091-3.

[7] Gilmanov D, Miceli A, Bevilacqua S, Farneti P, Solinas M, Ferrarini M, Glauber M. Sutureless implantation of the perceval s aortic valve prosthesis through right anterior minithoracotomy. *Ann Thorac Surg* 2013;96:2101-8.

[8] Dalén M, Biancari F, Rubino AS, Santarpino G, Glaser N, De Praetere H, Kasama K, Juvonen T, Deste W, Pollari F, Meuris B, Fischlein T, Mignosa C, Gatti G, Pappalardo A, Svenarud P, Sartipy U. Aortic valve replacement through full sternotomy with a stented bioprosthesis versus minimally invasive sternotomy with a sutureless bioprosthesis. *EJCTS* 2016;49(1):220-7.

[9] Shrestha M, Timm R, Höffler K, Koigeldiyev N, Khaladj N, Hagl C, Haverich A, Sarikouch S. Minimally invasive aortic valve replacement with self-anchoring Perceval valve. *The Journal of Heart Valve Disease* 2013;22:230-5.

[10] Zannis K, Folliguet T, Laborde F. New sutureless aortic valve prosthesis: another tool in less invasive aortic valve replacement. *Curr Opin Cardiol* 2012;27:125-9.

[11] Miceli A, Santarpino G, Pfeiffer S, Murzi M, Gilmanov D, Concistré G, Quaini E, Solinas M, Fischlein T, Glauber M. Minimally invasive aortic valve replacement with Perceval S sutureless valve: Early outcomes and one-year survival from two European centers. *The Journal of thoracic and cardiovascular surgery* 2014;148(6):2838-43.

[12] Concistre G, Farneti P, Miceli A, Glauber M. Sutureless aortic bioprosthesis in severe aortic root calcification: an innovative approach. *Interactive cardiovascular and thoracic surgery* 2012;14:670-2.

[13] Gariboldi V, Grisoli D, Devin A, Nee L, Theron A, Hubert S, Jaussaud N, Morera P, Collart F. Reoperation for failure of freestyle bioprosthesis using an Edwards intuity valve. *Ann Thorac Surg* 2013;96:e47-8.

[14] Gatti G, Benussi B, Camerini F, Pappalardo A. Aortic valve replacement within an unexpected porcelain aorta: the sutureless valve option. *Interactive cardiovascular and thoracic surgery* 2013.

[15] Villa E, Messina A, Cirillo M, Brunelli F, Mhagna Z, Dalla Tomba M, Troise G. Perceval Sutureless Valve in Freestyle Root: New Surgical Valve-in-Valve Therapy. *Ann Thorac Surg* 2013;96:e155-7.

[16] Vola M, Fuzellier JF, Campisi S, Grinberg D, Albertini JN, Morel J, Gerbay A. Total endoscopic sutureless aortic valve replacement: rationale, development, perspectives. *Annals of cardiothoracic surgery* 2015;4:170-4.

[17] Murphy DA, Moss E, Binongo J, Miller JS, Macheers SK, Sarin EL, Herzog AM, Thourani VH, Guyton RA, Halkos ME. The Expanding Role of Endoscopic Robotics in Mitral Valve Surgery: 1,257 Consecutive Procedures. *Ann Thorac Surg* 2015;100:1675-82.

[18] Bush B, Nifong LW, Alwair H, Chitwood WR, Jr. Robotic mitral valve surgery-current status and future directions. *Annals of cardiothoracic surgery* 2013;2:814-7.

[19] Folliguet TA, Vanhuyse F, Konstantinos Z, Laborde F. Early experience with robotic aortic valve replacement. European journal of cardio-thoracic surgery : *official journal of the European Association for Cardio-thoracic Surgery* 2005;28:172-3.

[20] Suri RM, Burkhart HM, Schaff HV. Robot-assisted aortic valve replacement using a novel sutureless bovine pericardial prosthesis: proof of concept as an alternative to percutaneous implantation. *Innovations* 2010;5:419-23.

[21] Vola M, Maureira P, Kassir R, Fuzellier JF, Campisi S, Doguet F, Albertini JN, Ruggieri VG, Folliguet T. Robotic total endoscopic sutureless aortic valve replacement: proof of concept for a future surgical setting. *Int J Med Robot* 2015 Aug 18. doi: 10.1002/rcs.1694. [Epub ahead of print].

In: Encyclopedia of Surgery (22 Volume Set)
Editors: Andreas Lehrer and Kristin Mueller
ISBN: 978-1-53618-329-0
© 2020 Nova Science Publishers, Inc.

Chapter 406

RAPID DEPLOYMENT AORTIC VALVES AND MINIMALLY INVASIVE SURGERY

Kevin Phan and Tristan D. Yan*, MD, PhD
University of Sydney, Sydney Adventist Hospital, Sydney, NSW, Australia
University of Sydney, Royal Prince Alfred Hospital,
Sydney, Australia

ABSTRACT

Early clinical evidence suggests that the sutureless aortic valve prosthesis is suitable for both traditional and minimally invasive approaches to minimize cross-clamp and bypass time, which may reduce perioperative risk. This chapter will overview the history, rational, current evidence and future directions for sutureless or rapid deployment aortic prostheses.

Keywords: rapid deployment, aortic valve, minimally invasive

INTRODUCTION

Aortic stenosis (AS) is the most frequent type of valvular cardiac disease [1]. With increasing prevalence in elderly population more than 65 years, clinicians are frequently facing the challenging of treating or managing elderly patients with complex cardiac comorbidities and advanced valvular disease [2]. Particularly in a burgeoning era of increased healthcare costs, there is a continued need to re-evaluate surgical procedures and interventions performed in this population, whether such interventions are justified, and how can patients and procedures be selected to achieve optimal patient outcomes and associated costs. In the context of cardiac surgery, in recent decades there has been a massive emphasis on minimally invasive surgical techniques, to minimize the burden of surgical trauma to the

* Corresponding Author's Email: tristanyan@annalscts.com.

patient. Such strategies have aimed at reducing incision sizes, reducing cardio-pulmonary bypass (CPB) [3, 4] and cross-clamp times (AoX) [5], and the use of percutaneous catheter based technologies [6, 7].

Aortic valvular surgery is still undergoing a transformation from a traditional open approach to minimally invasive approaches. The traditional approach for aortic valve stenosis was an aortic valve replacement (AVR) via median sternotomy, with implantation using either a biological or mechanical prosthesis. There are many follow-up studies which have demonstrated safe and long-term efficacy for the standard AVR for AS treatment. Following this, minimally invasive aortic valve replacement (MIAVR) was introduced to minimize surgical trauma [4, 8, 9]. To further improve an effective treatment, the focus has shifted to minimising the invasiveness of the procedure and to expand the boundaries of operability to elderly patients who are at higher surgical risk with multiple comorbidities.

Transcatheter aortic valve replacement (TAVR) via a transfemoral or transapical approach has emerged in the past 10 years as an alternative to sternotomy and extracorporeal circulation as well as ischemia associated with aortic cross-clamping [6, 7, 10, 11]. TAVR has expanded the realm of interventions to carefully selected high risk inoperable elderly patients. Despite tremendous implications of this technology, ultimately the diseased native valve is left in place, resulting in drawbacks including paravalvular leak, increased pacemaker requirements, and the potential for strokes, vascular complications and implant migration [10]. Furthermore, the TAVR prosthesis is based on a crimping technique, which may affect the durability of the TAVR prosthesis [12]. As such, whilst TAVR produces an excellent opportunity to replace the valve in high-risk or inoperable patients, there is no definitive evidence supporting the use of TAVR for patients in the "intermediate grey zone" of intermediate to high-risk operability.

The natural progression of technological advancement have led to the development of an approach which may indicated specifically for such patients in the "intermediate" range – the progression from conventional "sutured" valves to "sutureless" or rapid deployed aortic valves. Modern sutureless aortic valves have been introduced and used in practice since early 2007 in Europe and 2009 in North America. This technology avoids or minimizes the requirement for placement and tying of sutures following annular decalcification, and can revolutionize AVR by reducing cross-clamp and cardiopulmonary bypass durations as well as facilitate minimally invasive approaches. Overall, this has the potential to reduce postoperative mortality, morbidity, postoperative stay, and improve cost-effectiveness. Furthermore in contrast to transcatheter techniques, sutureless AVR may offer a "curative" procedure since the native diseased valve is excised.

Early clinical evidence suggests that the sutureless aortic prosthesis is suitable for both traditional and minimally invasive approaches to minimize AoX and CPB time, which may reduce perioperative risk.

This chapter will overview the history, rational, current evidence and future directions for sutureless or rapid deployment aortic prostheses.

HISTORY OF SUTURELESS VALVES

Despite the recent focus on sutureless technology on the latter half of the past decade, the concept was first introduced in the early 1960s. The earliest model of sutureless valve fixation

was developed by Magovern and Cromie [13]. This consisted of a valve Belfixation ring combined with mechanical ball-cage aortic valve prosthesis. There were two mechanisms of valve replacement that was developed: (1) circular base with upper and lower plates, and 9 L-shaped pins which eject laterally and driven into the aortic wall for fixation; and (2) central cylinder with grooved surface, with 2 rings threaded and 24 curve pins to eject laterally and fixate on the aortic wall. The purported advantages of their design was that it could be implanted faster and had an increased valvular diameter and aortic valve area when compared to equal sized conventional vales.

The first Magovern-Cromie valve was implanted in 1962, and Mogovern continued to implant this valve for several more years. In their initial cohort study which included 7 aortic and 3 mitral sutureless implantations by Magovern, the mean AoX time was 30 minutes [13]. From 10 patients, there was 3 hospital deaths and 1 late death caused by cerebral embolism. Data from a further 52 patients of the same group and prosthesis demonstrated an AoX time of 18 minutes, however, this was offset by increased complications of thromboembolism, ball variance, paravalvular leak, endocarditis and insufficient anticoagulation [14]. Magovern did note that many pitfalls of the procedure could be minimised by changing the design of the valve. He also stated that none of the hospital deaths within the aortic patients were likely related to common issues in cardiac surgery such as renal failure, bleeding, arrhythmias, pulmonary emboli or endocarditis. Over 7300 Magovern-Cromie prostheses were implanted, however, production ceased in 1980 [15]. However, the initial sutureless prosthesis remains a significant milestone in cardiac surgery which was way ahead of its time, with the first valve implantation performed by Harken only two years previously [16].

After this period, the concept of sutureless implantation of valvular prostheses was forgotten, whilst transcatheter based technologies started to develop and flourish. The percutaneous technique was first introduced via the concept of balloon valvuloplasty, introduced in 1985. Alain Cribier performed the first percutaneous valve implantation in 2002 [17], based on the concept of mounting a biological aortic valve into a metal or Nitinol stent, compressing it into a catheter and balloon the Nitinol-stent based valve into position. Whilst the percutaneous approach was initially performed via transfemoral access, in patients presenting with severe peripheral vascular disease, the transapical approach represented an alternative option. These developments have spurred the resurgence of sutureless technology in the surgical community, as a surgical alternative to TAVR in high risk operable patients. There are currently three sutureless prostheses that have been approved (Figure1): (A) 3F Enable (Medtronic, Minneapolis, USA); (B) Perceval S (Sorin, Saluggia, Italy); (C) Intuity (Edward Lifesciences, Irvine, USA).

There are several similarities and differences between sutureless/rapid deployment aortic valves and transcatheter prostheses. Whilst sutureless prostheses are based on a similar technology and concept to TAVR prostheses, the sutureless approach does not require crimping of the pericardium. The sutureless surgical approach allows direct visualization of the diseased native valve and target orifice, and facilitates remove of the diseased valve and annulus decalcification prior to deployment of the replacement prosthesis. In contrast, TAVR relies on visualization of the prosthesis and deployment indirectly via fluoroscopy. Current TAVR protocols do not involve removal of the native diseased valve, which in some cases is responsible for post-operative paravalvular leak. In comparison with standard conventional AVR, sutureless valves do not require extensive placement or tying of sutures. Both

procedures involve excision of the diseased valve, require CPB and AoX. Both procedures can be approached using standard median sternotomy, ministernotomy or minithoracotomy.

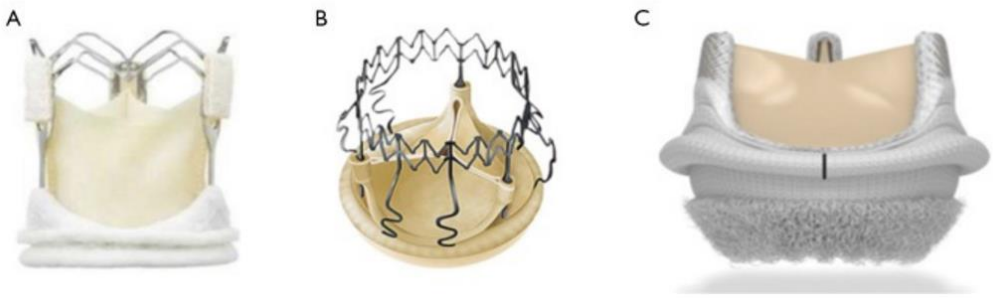

Figure 1. Commercially available sutureless aortic valves. (A) 3F Enable (Medtronic, Minneapolis, USA); (B) Perceval S (Sorin, Saluggia, Italy); (C) Intuity Elite (Edward Lifesciences, Irvine, USA).

TYPES OF RAPID DEPLOYMENT AORTIC VALVES

The 3F Enable Sutureless aortic valve, CE mark approved in 2009, was designed to mimic the function of the native valve. It consists of the 3F aortic bioprosthesis model 1000 assembled from three equal sections of equine pericardial material, fixed with glutaraldehyde and mounted on a self-expanding Nitinol frame. A polyester fabric covers the inflow flange/skirt. The expanding Nitinol frame allows fixation of the device in the native annulus via outward radial forces. The first implantation was in 2005 on a 76-year old male by Sadowski. Early results were promising, with deployment time of 148 ± 173 seconds and cross-clamp time of 55 minutes. Postoperatively, the mean aortic valve area was 3.18 ± 0.41 cm^2. However, mild paravalvular leak was detected and attributed to insufficient nitinol-based stent radial forces. In 2006, an expanded valve cuff was added to the 3F Enable design as well as a change to a double flange design, in an effort to reduce paravalvular leak.

Implantation of the 3F Enable valve can be performed under full sternotomy or mini-sternotomy. Standard CPB is established by cannulation of the ascending aorta and right atrium. As per conventional AVR, transverse aortotomy is performed, with the native diseased valve excised and annulus decalcified. Particularly for sutureless valves, the sizing of the prosthesis is crucial – it is not possible to expand an oversized Enable valve in a smaller annulus. The advantage of the nitinol frame and flexibility of the pericardial leaflets is that the device can be folded in chilled water intraoperatively and positioned in the root. After deployment, the Nitinol stent shape and size return to preset dimensions. Its inherent outward radial forces will allow fixation of the position. Whilst no sutures are required for implantation, it is recommended that two permanent sutures put in to support the prosthesis at the annulus.

The Perceval sutureless valve was CE approved in 2011. This prosthesis consists of bovine pericardium tissue attached of self-expandable elastic Ni-Ti alloy stent made of two rings and nine vertical struts, with the dual task of supporting the valve and holding it in place without any permanent suture. It also has a thin coating of Carbofilm™ to improve biocompatibility. For implantation, the valve is collapsed with an atraumatic device. The

valve remains collapsed until it is positioned correctly, which enables direct visualization. Once in the appropriate position, it can be self-expanded back to its original diameter.

The design of the Edwards Intuity valve, CE approved in 2012, is based on the Perimount valve family. The Edwards Intuity valve is a stented trileaflet bovine pericardial bioprosthesis, with a balloon-expandable, cloth-covered skirt frame at the inflow aspect. For implantation, three equidistant guiding sutures are placed through the annulus at the nadir of each sinus. This is then passed through corresponding black marks on the nadir portion of the valve suture ring. These three set of guide sutures are used to position the valve in the aortic annulus. The balloon-expandable frame is then deployed via short balloon inflation, followed by tying of the guide sutures.

RATIONALE

The introduction of sutureless or rapid deployment aortic valves has the potential to revolutionize minimally invasive aortic valve surgery. First from a technical perspective, sutureless AVR involves excision and removal of the native diseased valve – a curative approach – which contrasts with current TAVR procedures where the diseased native valve is not removed. The main advantage offered by these technologies is a reduction in AoX and CPB duration, given that there is easier placement and less tying of sutures required [18]. In the context of the cardiothoracic surgical literature, extended AoX and CPB durations have been linked with cardiovascular morbidity [19]. Particularly in patients with poorer left ventricular ejection fraction or with diabetes, a reduction in AoX or CPB duration has the potential to decrease complications risk and long-term mortality, even in the face of the most modern cardio-protective techniques and methods.

A systematic review and meta-analysis conducted by the International Valvular Surgery Study Group (IVSSG) identified 12 studies, which when pooled showed a pooled AoX and CPB duration for isolated AVR using a sutureless prosthesis of 56.7 and 33 min, respectively, half of that compared to values reported by the Society of Thoracic Surgeons (STS) National Database for conventional sutured AVR. Cross-clamp times in minimally invasive surgery were comparable to full sternotomy. Thus, the reduction of AoX and CPB time with sutureless or rapid deployment aortic valves may improve results in all patients, but may particularly be beneficial in patients with significant underlying comorbidities and high surgical risk profiles. As such, the sutureless approach may also be reasonable in complex operations with multiple interventions, to reduce operative duration and improve outcomes.

Another advantage of sutureless technology is its potential to facilitate minimally invasive aortic valve surgery. Prior studies have demonstrated similar outcomes between MIAVR and conventional AVR, including decreased hospital stay, reduced sternal wound complications, surgical trauma and improved cosmesis. However, the MIAVR approach also has its limitations including a difficult learning curve, longer AoX and CPB durations, which has limited its dissemination into the wide cardiothoracic community. The technical difficulty and longer durations involved is partly due to the challenging placement and tying of sutureless down a narrow surgical corridor. As such, the use of rapid deployment technology can help overcome this barrier, by simplifying the MIAVR procedure and avoiding the need to suture the aortic valve to the annulus via this limited surgical field. With reduced operation

complexity and duration, the use of sutureless prostheses in the setting of mini access surgery may facilitated further improvements in outcomes, as well as facilitate this operation in more elderly and higher risk operable patients.

Sutureless prostheses may also be more superior to its transcatheter counterpart by means of paravalvular leak rates. Paravalvular leak has been previously associated with poorer outcomes following TAVR, predicting 1-year mortality even after multivariate adjustment in a meta-analysis by Athappan et al. Paravalvular leak rates are expected to be lower in sutureless AVR. From a procedural standpoint, sutureless AVR involves excision of the calcified valve and prosthesis under direct visualization, with pooled leak rates of 2-4% at latest follow-up. This is significantly lower than reported rates of 12% following TAVR.

Additionally, sutureless AVR is associated with excellent hemodynamic outcomes, with very low transvalvular gradients and reduced risk of patient-prosthesis mismatch (PPM). As such, high risk subset patients will more likely than others to benefit from sutureless AVR, a promising alternative with excellent hemodynamic performance that facilitates minimally invasive and less traumatic approaches while minimizing CPB and AoX durations.

INDICATIONS

Currently, the indications and contraindications for sutureless and rapid deployment aortic prostheses follow the recommendations and guidelines for biological stented aortic prostheses [2, 20]. Since current recommendations suggest patients 65 years and older to be potential candidates for biological valve replacement, it is also recommended to consider sutureless and rapid deployment valves for patients of the same age group. Sutureless and rapid deployment valves may be a suitable alternative to stented valves in isolated procedures in patients with comorbidities, delicate aortic wall conditions as calcified root, porcelain aorta or prior implantation of aortic homograft and stentless valves as well as for concomitant procedures and small aortic roots.

For concomitant procedures, sutureless valves may be considered as the prosthesis of first choice to reduce complications and morbidity associated with the duration of extracorporeal circulation and cross-clamp time [20-23]. For reoperative procedures, there may be extensive adhesions which could distort cardiac structures. As such, limited access surgery may be difficult and challenging [24-26]. In this setting, sutureless and rapid deployment valves may facilitate redo operations due to prior AVR, coronary artery bypass grafting (CABG) or delicate aortic wall conditions as calcified root and porcelain aorta [27, 28].

In terms of annulus size, 19 mm is considered too small for the implantation of sutureless and rapid deployment valves. Annulus enlargement procedures would be necessary, due to size limits of the current available prostheses. However, since these procedures may be time-consuming and the implantation of patch material in the aortic annulus may result in less stability to anchor a self-expanding valve. It is recommended that root enlargement procedures should be avoided if sutureless or rapid deployment valves are considered [29]. The use of sutureless and rapid deployment valves is currently limited to annular sizes of 19–27 mm [29].

DISCUSSION AND CLINICAL EVIDENCE

Several systematic reviews and meta-analyses have explored outcomes of sutureless aortic valve surgery [18, 30, 31]. From 12 studies identified for inclusion, the minimally invasive approach was used in 40.4% of included patients, while 22.8% underwent concomitant CABG. Pooled AoX and CPB duration for isolated AVR was 56.7 and 46.5 minutes, respectively. Pooled 30-day and 1-year mortality rates were 2.1% and 4.9%, respectively, while the incidences of strokes (1.5%), valve degenerations (0.4%) and paravalvular leaks (PVL) (3.0%) were acceptable. The authors concluded that sutureless aortic valve implantation is a safe procedure associated with shorter AoX and CPB duration.

Sutureless vs Conventional Aortic Valve Replacement

There have been several comparative studies investigating outcomes of sutureless versus conventional AVR. In 2013, D'Onofrio et al. [32, 33] reported a comparison between conventional surgery, sutureless valves and transapical TAVR for AVR. From 2009-2012, 566 TAVR, 349 AVR and 38 sutureless AVR patients were treated. There was 0 deaths in the sutureless AVR group compared to 1 death in the AVR group. There were no strokes in either group, both groups had one case each of permanent pacemaker required. There were 6 cases (19.4%) of postoperative aortic regurgitation (AR) in the sutureless AVR group compared to 2 cases (1.8%) in the AVR group. After matching and multivariate analysis, there were no differences between the groups in terms of postoperative outcomes. The authors concluded that similar outcomes were achieved with matched sutureless and conventional AVR surgery.

Shrestha et al. [34] compared 70 AVRs versus 50 sutureless AVR elderly patients >75 years old with small aortic roots (<22 mm). The sutureless technique was associated with shorter CPB time (58.7 vs 75.3 minutes) and AoX time (30.1 vs 50.3 minutes). There were 3 deaths (4.3%) in the conventional group versus no deaths in the sutureless group. The authors concluded that sutureless surgery may be advantageous by facilitating minimally invasive surgery in elderly patients with small aortic roots.

In the first randomized study comparing minimally invasive rapid deployment versus conventional AVR, Borger et al. [5] demonstrated that the sutureless approach involved significantly reduced AoX times (41.3 vs 54 minutes) but similar CPB times (68.8 vs 74.4 minutes). There were also similar early clinical outcomes. The sutureless approach was associated with lower mean transvalvular gradients (8.5 vs 10.3 mmHg) and lower patient-prosthesis mismatch (0 vs 15%). The authors concluded that rapid deployment aortic prosthesis may result in reduced AoX time and improved valvular hemodynamics in comparison to conventional stented bioprostheses.

Similar conclusions were reached by Dalen et al. [35], who matched 133 conventional AVR and 133 sutureless AVR patients. The sutureless approach was associated with significantly reduced CPB and AoX times. Similar in-hospital mortality was reported for the two groups, similar incidence of postoperative strokes and pacemaker implantations, but shorter duration of mechanical ventilation was required in the sutureless group. Despite the limits of its retrospective design, the study confirms that sutureless AVR significantly reduces operative and mechanically assisted ventilation times compared with sutured prostheses, and

is associated with low mortality and morbidity, leading to excellent surgical and hemodynamic results.

Several systematic reviews and meta-analyses have explored outcomes between sutureless and conventional AVR as well as sutureless and TAVR. Hurley et al. [30] performed a meta-analysis to compare outcomes of 832 sutureless patients versus 3740 conventional AVR patients. AoX (39.8 vs 62.4 minutes; $P < 0.001$) and CPB (64.9 vs 86.7 minutes) times were shorter in the sutureless group. Permanent pacemaker implantation rate was higher in the sutureless cohort (9.1% vs 2.4%).

Sutureless vs Transcatheter Aortic Valve Replacement

Santarpino et al. [36] studied 37 matched pairs of patients who underwent TAVR and sutureless AVR. Preoperative characteristics and risk scores were comparable. The authors found that permanent pacemakers were required in 4 patients in the sutureless group (10.8%) and 1 patient in the TAVR group (2.7%). Neurological events occurred in 2 patients in each group. Higher paravalvular leak rates occurred in the TAVR group compared to sutureless group (13.5% vs 0%). At mean follow-up of 18.9 months, survival was significantly higher in the sutureless group (97.3% vs 86.5%). The authors suggested that AVR may be the first-line treatment for high-risk patients considered in the "gray zone" between TAVR and conventional surgery.

Biancari et al. [37] also compared the immediate outcomes of sutureless versus TAVR. There were 394 patients who underwent TAVR compared to 379 patients who underwent sutureless AVR. In-hospital mortality was 2.6% after sutureless AVR and 5.3% after TAVR. There was significantly higher mild paravalvular regurgitation (44% vs 2.1%) as well as moderate-severe paravalvular regurgitation (14.1% vs 0.3%). TAVR was also associated with higher pacemaker requirement (17.3% vs 9.8%).

Kamperidis et al. [38] evaluated 258 patients undergoing TAVR or sutureless AVR. Compared with the 3f Enable valve, TAVR prostheses (Edwards SAPIEN XT [Edwards Lifesciences, Irvine, California] and CoreValve [Medtronic]) had larger effective orifice area index, lower pressure gradient, less frequent prosthesis-patient mismatch, but more frequent AR. However, the survival of the 2 groups was comparable after 1.5-year follow-up. TAVR prostheses demonstrated better hemodynamics than the 3f Enable valve but a higher incidence of AR. However, these differences did not influence mid-term survival of patients.

Most recently, Miceli et al. [39] reported early and mid-term outcomes of MIAVR via anterior right mini-thoracotomy (ART) with sutureless valves versus TAVR for severe AS. From October 2008 to March 2013, 269 patients with severe aortic stenosis underwent either RT with perceval S sutureless valves (n = 178 patients, 66.2%) or TAVR (n = 91, 33.8%: 44 transapical and 47 trans-femoral). In the matched group, the in-hospital mortality rate was 8.1% in the TAVR group and 0% in the ART group. In the TAVR group, 37.8% had mild paravalvular leakage (PVL) and 27% had moderate PVL, whereas 2.7% had mild PVL in the ART group. One- and 2-year survival rates were 91.6 vs 78.6% and 91.6 vs 66.2% in patients undergoing ART with the perceval S sutureless valve compared with those undergoing TAVR. The authors concluded that MIAVR with Perceval S sutureless valves is associated with a trend of better early outcomes and mid-term survival compared with TAVR.

Takagi et al. [31] performed a meta-analysis of 7 observational comparative studies. The first pooled analysis demonstrated a statistically significant reduction in mortality with sutureless AVR over TAVR [2.5% versus 7.3%]. The second pooled analyses demonstrated no statistically significant difference in bleeding complications, acute kidney injury, and conduction disturbance between sutureless AVR and TAVR. The third pooled analysis demonstrated a statistically significant reduction in paravalvular AR with sutureless AVR over TAVR (3.5% versus 33.2%), consistent with prior studies. It was concluded that sutureless AVR may be associated with a reduction in early mortality and postoperative paravalvular AR.

CONCLUSION AND FUTURE RESEARCH

The implantation procedure for sutureless valves is different to conventional AVR, and requires proctoring for the surgeon to traverse the learning curve. Sizing the valve is absolutely important, and if the size is not ideal, paravalvular leaks, valve migration, and root dehiscence will be the catastrophic resulting complications. Given that sutureless AVR is still surgical procedure with AoX and CPB, associated complications may still occur.

Like other valves, sutureless aortic valves is also susceptible to "stent creep," a permanent inward deflection of stent posts which may lead to valvular leak [40]. Therefore, sizing is still a critical assessment step during the use of sutureless aortic valves.

Furthermore, there is a still a lack of long-term follow-up data available for sutureless valves and limited worldwide experience. Mid-term durability data for sutureless valves have been reported for 3-5 years follow-up, which is considerably less compared to the 20-25 years follow-up reported for some stented prostheses. Recently, the IVSSG has formulated to conduct the Sutureless Projects, a large international collaborative group to investigate this technology [18, 41, 42]. An international collaborative effort led by the IVSSG will hopefully set up to provide clinical robust evidence for the safety, efficacy and long-term complications profile for sutureless aortic valve technology.

REFERENCES

[1] Nkomo VT, Gardin JM, Skelton TN, Gottdiener JS, Scott CG, Enriquez-Sarano M. Burden of valvular heart diseases: a population-based study. *Lancet* 2006:368:1005-1011.

[2] Vahanian A, Otto CM. Risk stratification of patients with aortic stenosis. *European Heart Journal* 2010:31:416-423.

[3] Cosgrove DM, 3rd, Sabik JF. Minimally invasive approach for aortic valve operations. *Annals Thorac Surg* 1996:62:596-597.

[4] Phan K, Xie A, Di Eusanio M, Yan TD. A meta-analysis of minimally invasive versus conventional sternotomy for aortic valve replacement. *Annals Thorac Surg* 2014:98:1499-1511.

[5] Borger MA, Moustafine V, Conradi L, Knosalla C, Richter M, Merk DR, Doenst T, Hammerschmidt R, Treede H, Dohmen P, Strauch JT. A Randomized Multicenter Trial

of Minimally Invasive Rapid Deployment Versus Conventional Full Sternotomy Aortic Valve Replacement. *The Annals Thorac Surg* 2015;99(1):17-25.

[6] Kapadia SR, Tuzcu EM, Makkar RR, Svensson LG, Agarwal S, Kodali S, Fontana GP, Webb JG, Mack M, Thourani VH, Babaliaros VC, Herrmann HC, Szeto W, Pichard AD, Williams MR, Anderson WN, Akin JJ, Miller DC, Smith CR, Leon MB. Long-Term Outcomes of Inoperable Patients with Aortic Stenosis Randomized to Transcatheter Aortic Valve Replacement or Standard Therapy. *Circulation* 2014;130(17):1483-927.

[7] Leon MB, Smith CR, Mack M, Miller DC, Moses JW, Svensson LG, Tuzcu EM, Webb JG, Fontana GP, Makkar RR, Brown DL, Block PC, Guyton RA, Pichard AD, Bavaria JE, Herrmann HC, Douglas PS, Petersen JL, Akin JJ, Anderson WN, Wang D, Pocock S, Investigators PT. Transcatheter aortic-valve implantation for aortic stenosis in patients who cannot undergo surgery. *The New England Journal of Medicine* 2010;363:1597-1607.

[8] Phan K, Zhou JJ, Niranjan N, Di Eusanio M, Yan TD. Minimally invasive reoperative aortic valve replacement: a systematic review and meta-analysis. *Annals of Cardiothoracic Surgery* 2014;4:15-25.

[9] Phan K, Xie A, Tsai Y-C, Black D, Di Eusanio M, Yan TD. Ministernotomy or minithoracotomy for minimally invasive aortic valve replacement: a Bayesian network meta-analysis. *Annals of cardiothoracic surgery* 2014;4:3-14.

[10] Zahn R, Gerckens U, Grube E, Linke A, Sievert H, Eggebrecht H, Hambrecht R, Sack S, Hauptmann KE, Richardt G, Figulla HR, Senges J, German Transcatheter Aortic Valve Interventions-Registry I. Transcatheter aortic valve implantation: first results from a multi-centre real-world registry. *European Heart Journal* 2011;32:198-204.

[11] Genereux P, Webb JG, Svensson LG, Kodali SK, Satler LF, Fearon WF, Davidson CJ, Eisenhauer AC, Makkar RR, Bergman GW, Babaliaros V, Bavaria JE, Velazquez OC, Williams MR, Hueter I, Xu K, Leon MB, Investigators PT. Vascular complications after transcatheter aortic valve replacement: insights from the PARTNER (Placement of AoRTic TraNscathetER Valve) trial. *Journal of the American College of Cardiology* 2012;60:1043-1052.

[12] Kiefer P, Gruenwald F, Kempfert J, Aupperle H, Seeburger J, Mohr FW, Walther T. Crimping may affect the durability of transcatheter valves: an experimental analysis. *Annals Thorac Surg* 2011;92:155-160.

[13] Magovern GJ, Cromie HW. Sutureless Prosthetic Heart Valves. *JTCVS* 1963;46:726-736.

[14] Magovern GJ, Kent EM, Cromie HW, Cushing WB, Scott S. Sutureless Aortic and Mitral Prosthetic Valves. Clinical Results and Operative Technique in 60 patients. *JTCVS* 1964;48:346-361.

[15] Magovern GJ, Liebler GA, Park SB, Burkholder JA, Sakert T, Simpson KA. Twenty-five-year review of the Magovern-Cromie sutureless aortic valve. *Annals Thoracic Surgery* 1989;48:S33-34.

[16] Gott VL, Alejo DE, Cameron DE. Mechanical heart valves: 50 years of evolution. *Annals Thorac Surg* 2003;76:S2230-2239.

[17] Cribier A, Savin T, Saoudi N, Rocha P, Berland J, Letac B. Percutaneous transluminal valvuloplasty of acquired aortic stenosis in elderly patients: an alternative to valve replacement? *Lancet* 1986;1:63-67.

[18] Phan K, Tsai Y-C, Niranjan N, Di Eusanio M, Yan TD. Sutureless aortic valve replacement: a systematic review and meta-analysis. *Annals of cardiothoracic surgery* 2015;4(2):100-11.

[19] Al-Sarraf N, Thalib L, Hughes A, Houlihan M, Tolan M, Young V, McGovern E. Cross-clamp time is an independent predictor of mortality and morbidity in low- and high-risk cardiac patients. *International journal of surgery (*London) 2011;9:104-109.

[20] Chandola R, Teoh K, Elhenawy A, Christakis G. Perceval Sutureless Valve - are Sutureless Valves Here? *Current Cardiology Reviews* 2015;11:220-228.

[21] Martens S, Zierer A, Ploss A, Sirat S, Miskovic A, Moritz A, Doss M. Sutureless Aortic Valve Replacement via Partial Sternotomy. *Innovations* (Philadelphia, Pa) 2010;5:12-15.

[22] Eichstaedt HC, Easo J, Harle T, Dapunt OE. Early single-center experience in sutureless aortic valve implantation in 120 patients. *JTCVS* 2014;147:370-375.

[23] Shrestha M, Folliguet TA, Pfeiffer S, Meuris B, Carrel T, Bechtel M, Flameng WJ, Fischlein T, Laborde F, Haverich A. Aortic valve replacement and concomitant procedures with the Perceval valve: results of European trials. *Annals Thorac Surg* 2014;98:1294-1300.

[24] Christiansen S, Schmid M, Autschbach R. Perioperative risk of redo aortic valve replacement. *Ann Thorac Cardiovasc Surg* 2009:15:105-110.

[25] Christiansen S, Autschbach R. Perioperative risk of aortic valve replacement after coronary artery bypass grafting. *The Thoracic and Cardiovascular Surgeon* 2006;54:157-161.

[26] Jones JM, O'Kane H, Gladstone DJ, Sarsam MA, Campalani G, MacGowan SW, Cleland J, Cran GW. Repeat heart valve surgery: risk factors for operative mortality. *The Journal of thoracic and cardiovascular surgery* 2001;122:913-918.

[27] Santarpino G, Pfeiffer S, Fischlein T. Perceval sutureless approach in a patient with porcelain aorta unsuitable for transcatheter aortic valve implantation. *International Journal of Cardiology* 2012;155:168-170.

[28] Plass A, Scheffel H, Alkadhi H, Kaufmann P, Genoni M, Falk V, Grunenfelder J. Aortic valve replacement through a minimally invasive approach: preoperative planning, surgical technique, and outcome. *Annals Thorac Surg* 2009;88:1851-1856.

[29] Gersak B, Fischlein T, Folliguet TA, Meuris B, Teoh KH, Moten SC, Solinas M, Miceli A, Oberwalder PJ, Rambaldini M, Bhatnagar G, Borger MA, Bouchard D, Bouchot O, Clark SC, Dapunt OE, Ferrarini M, Laufer G, Mignosa C, Millner R, Noirhomme P, Pfeiffer S, Ruyra-Baliarda X, Shrestha M, Suri RM, Troise G, Diegeler A, Laborde F, Laskar M, Najm HK, Glauber M. Sutureless, rapid deployment valves and stented bioprosthesis in aortic valve replacement: recommendations of an International Expert Consensus Panel. *EJCTS* 2016;49:709-718.

[30] Hurley ET, O'Sullivan KE, Segurado R, Hurley JP. A Meta-Analysis Examining Differences in Short-Term Outcomes Between Sutureless and Conventional Aortic Valve Prostheses. *Innovations* (Philadelphia, Pa) 2015;10:375-382.

[31] Takagi H, Umemoto T. Sutureless aortic valve replacement may improve early mortality compared with transcatheter aortic valve implantation: A meta-analysis of comparative studies. *Journal of cardiology*. 2015 Oct 23 doi: 10.1016/ j.jjcc.2015.09.009.

[32] D'Onofrio A, Messina A, Lorusso R, Alfieri OR, Fusari M, Rubino P, Rinaldi M, Di Bartolomeo R, Glauber M, Troise G, Gerosa G. Sutureless aortic valve replacement as an alternative treatment for patients belonging to the "gray zone" between transcatheter aortic valve implantation and conventional surgery: a propensity-matched, multicenter analysis. *JTCVS* 2012:144:1010-1016.

[33] D'Onofrio A, Rizzoli G, Messina A, Alfieri O, Lorusso R, Salizzoni S, Glauber M, Di Bartolomeo R, Besola L, Rinaldi M, Troise G, Gerosa G. Conventional surgery, sutureless valves, and transapical aortic valve replacement: what is the best option for patients with aortic valve stenosis? A multicenter, propensity-matched analysis. *The Journal of thoracic and cardiovascular surgery* 2013;146:1065-1070.

[34] Shrestha M, Maeding I, Hoffler K, Koigeldiyev N, Marsch G, Siemeni T, Fleissner F, Haverich A. Aortic valve replacement in geriatric patients with small aortic roots: are sutureless valves the future? *Interactive cardiovascular and thoracic surgery* 2013;17:778-782.

[35] Dalén M, Biancari F, Rubino AS, Santarpino G, Glaser N, De Praetere H, Kasama K, Juvonen T, Deste W, Pollari F, Meuris B, Fischlein T, Mignosa C, Gatti G, Pappalardo A, Svenarud P, Sartipy U. Aortic valve replacement through full sternotomy with a stented bioprosthesis versus minimally invasive sternotomy with a sutureless bioprosthesis. *EJCTS* 2016;49(1):220-7.

[36] 36.Santarpino G, Pfeiffer S, Jessl J, Dell'Aquila A, Vogt F, von Wardenburg C, Schwab J, Sirch J, Pauschinger M, Fischlein T. Clinical Outcome and Cost Analysis of Sutureless Versus Transcatheter Aortic Valve Implantation With Propensity Score Matching Analysis. *American J Cardiol* 2015;116:1737-1743.

[37] Biancari F, Barbanti M, Santarpino G, Deste W, Tamburino C, Gulino S, Imme S, Di Simone E, Todaro D, Pollari F, Fischlein T, Kasama K, Meuris B, Dalen M, Sartipy U, Svenarud P, Lahtinen J, Heikkinen J, Juvonen T, Gatti G, Pappalardo A, Mignosa C, Rubino AS. Immediate outcome after sutureless versus transcatheter aortic valve replacement. *Heart and Vessels* 2015 doi: 10.1007/s00380-014-0623-3.

[38] Kamperidis V, van Rosendael PJ, de Weger A, Katsanos S, Regeer M, van der Kley F, Mertens B, Sianos G, Ajmone Marsan N, Bax JJ, Delgado V. Surgical sutureless and transcatheter aortic valves: hemodynamic performance and clinical outcomes in propensity score-matched high-risk populations with severe aortic stenosis. *JACC Cardiovascular Interventions* 2015;8:670-677.

[39] Miceli A, Gilmanov D, Murzi M, Marchi F, Ferrarini M, Cerillo AG, Quaini E, Solinas M, Berti S, Glauber M. Minimally invasive aortic valve replacement with a sutureless valve through a right anterior mini-thoracotomy versus transcatheter aortic valve implantation in high-risk patients. *EJCTS* 2016;49:960-965.

[40] Fleissner F, Molitoris U, Shrestha M, Martens A. Stent distortion after sutureless aortic valve implantation: a new complication seen with a novel surgical technique. *Interactive cardiovascular and thoracic surgery* 2015;20(3):436-8.

[41] Di Eusanio M, Phan K, Bouchard D, Carrel TP, Dapunt OE, Di Bartolomeo R, Eichstaedt HC, Fischlein T, Folliguet T, Gersak B, Glauber M, Haverich A, Misfeld M, Oberwalder PJ, Santarpino G, Shrestha ML, Solinas M, Vola M, Alamanni F, Albertini A, Bhatnagar G, Carrier M, Clark S, Collart F, Kappert U, Kocher A, Meuris B, Mignosa C, Ouda A, Pelletier M, Rahmanian PB, Reineke D, Teoh K, Troise G, Villa E, Wahlers T, Yan TD. Sutureless Aortic Valve Replacement International Registry

(SU-AVR-IR): design and rationale from the International Valvular Surgery Study Group (IVSSG). *Annals of cardiothoracic surgery* 2015;4:131-139.

[42] Di Eusanio M, Phan K. Sutureless aortic valve replacement. *Annals Cardiothorac Surg* 2015;4:123-130.

In: Encyclopedia of Surgery (22 Volume Set)
Editors: Andreas Lehrer and Kristin Mueller
ISBN: 978-1-53618-329-0
© 2020 Nova Science Publishers, Inc.

Chapter 407

MINIMALLY INVASIVE AORTIC SURGERY

Tristan D. Yan*, MD, PhD
University of Sydney, Sydney Adventist Hospital, Sydney, NSW, Australia
University of Sydney, Royal Prince Alfred Hospital, Sydney, Australia

ABSTRACT

Thoracic aortic aneurysm (TAA) poses a silent and potentially deadly threat to those who harbor them. Clinicians ought to maintain a high index of clinical suspicion for patients with a possible TAA and offer prompt preemptive surgical intervention before devastating complications occur. An important objective in surgery is to reduce surgical trauma and achieve faster recovery for our patients. This chapter describes the technical details on how I perform *minimally invasive aortic surgery* via a mini-sternotomy access. The operation consists of 6 major steps: 1) mini-sternotomy, 2) cannulation, 3) aortic root exposition, 4) 'French Cuff' technique or double layer anastomosis, 5) coronary buttons re-implantation and 6) hemi-arch replacement. The success of the operation is a direct result of careful completion of these steps. The details of the '*French Cuff*' technique are described in this chapter to show how to improve the hemostasis along the proximal annular anastomosis.

Keywords: aortic surgery, Bentall procedure, minimal access, minimally invasive, mini-Bentall

INTRODUCTION

The incidence of thoracic aortic aneurysm (TAA) is approximately 10 in 100,000 people [1]. It is a common aortic pathology requiring careful and prompt surgical evaluation. The symptoms associated with TAA can often be subtle, including those related to aneurysm expansion (e.g., chest pain or hoarseness) and compression (e.g., stridor). It is fair to say that that TAA is the '*Great Masquerader*' (Figure 1), as many patients may be undiagnosed or

* Corresponding Author's Email: tristanyan@annalscts.com.

misdiagnosed, until they present with death or catastrophic complications that threaten their lives, such as acute aortic dissection, aortic rupture, cardiovascular collapse and malperfusion syndrome. The first section of this chapter provides a general overview on TAA that highlights an important message: we, as clinicians, ought to maintain a high index of clinical suspicion for patients with a possible TAA and offer prompt preemptive surgical intervention before devastating complications occur.

A complete surgical repair of proximal TAA was first described by Hugh Bentall and Antony De Bono in 1968, using an inclusion technique [2]. This classic Bentall operation has undergone technical modifications over the years, mainly in an attempt to improve hemostasis. The modified Bentall operation, including composite graft replacement of the aortic valve, aortic root and ascending aorta, with re-implantation of the coronary buttons is now more widely performed. In recent years, several traditional cardiac procedures have been challenged by minimally invasive techniques. Mini-sternotomy or mini-thoracotomy approaches are increasingly used in our specialty to minimize surgical trauma and enhance patient recovery [3-7]. The second section of this chapter describes the details of my technique on how to perform minimally invasive aortic surgery via a mini-sternotomy approach, depicting six major surgical steps: 1) mini-sternotomy, 2) cannulation, 3) aortic root exposition, 4) 'French Cuff' technique, 5) coronary button re-implantation and 6) hemi-arch replacement. In particular, technical elements of "*French-cuff*' technique is highlighted. It cannot be emphasized enough that a meticulous surgical technique to ensure an absolute hemostasis is utmost important in minimally invasive aortic surgery.

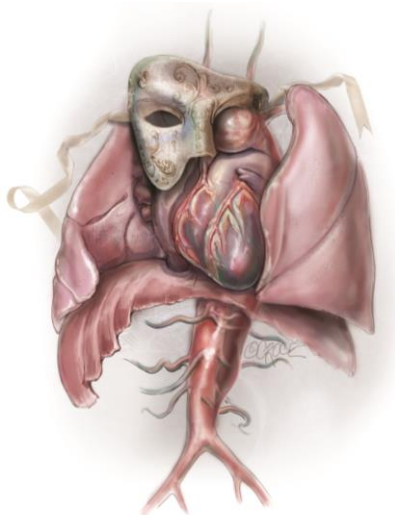

Figure 1. Thoracic aortic aneurysm – a "Great Masquerader."

THORACIC AORTIC ANEURYSM

Clinical Genetics of Thoracic Aortic Aneurysm

The genetic forms of thoracic aneurysms can be broadly divided into two categories: syndromic, which are typically associated with extra-aortic manifestations or the disease, and

non-syndromic, which lacks phenotypical features of body-wide syndromes. In recent years, greater understanding of specific mutations has permitted precise identification of affected patients, which in turn has further elaborated our understanding of the subtle differences in disease progression. Numerous genetic syndromes predispose individuals to TAA, accounting for 5% of all cases. Most prominent among these is Marfan syndrome, which causes progressive aortic root dilatation, necessitating surgery in 80% of patients by the age of 40, and almost all patients by the age of 60 [8]. Clinical diagnosis is based on the revised Ghent Nosology, incorporating family history, molecular testing, and clinical features [9]. Other syndromic forms of thoracic aortic aneurysms include Ehlers-Danlos syndrome, Loeys-Dietz syndrome, aneurysm osteoarthritis syndrome, and arterial tortuosity syndrome, which are similarly diagnosed by genetic testing and characteristic dysmorphic features.

Thoracic aneurysms not accompanied with phenotypical features of body-wide syndromes are classified as non-syndromic TAAs. This form is inherited in an autosomal dominant fashion with decreased penetrance and variable expression, exhibiting significant clinical and genetic heterogeneity. Non-syndromic TAAs can be further subdivided into sporadic TAA or familial TAA, depending on whether only one family member or if multiple family members are affected. Sporadic TAAs typically presents later in life than familial TAAs (mid-60s vs mid-50s), have a lower annual growth rate, and accounts for a greater majority of all TAA cases (80% vs 20%)[10]. In such patients, their aortic tissue can be extremely fragile, and prompt preemptive intervention is warranted.

BICUSPID AORTIC VALVE ASSOCIATED THORACIC AORTIC ANEURYSM

Bicuspid aortic valve (BAV) is the most common congenital heart condition, affecting 2% of the general population (Figure 2). BAV is a clinically heterogeneous disorder with a high rate of surgically relevant aortic valve and ascending aortic complications, which occur in over 35% of those affected [11]. As such, BAV confers a greater burden of disease than all other congenital heart diseases combined. Familial clustering and genetic studies have established that BAV has a heritable trait, with approximately 10% prevalence amongst first-degree relatives, and up to 25% in families with more than one affected family member [11].

TAA is common in BAV, reported in up to 50-60% of affected individuals [11, 12], predisposing them to aortic dissection or rupture. The histologic changes observed in bicuspid aortopathy are the end result of abnormal regulatory pathways of vascular smooth-muscle cells within the aortic media, leading to the release of matrix metalloproteinases, resulting disruption of the media layer, adversely affecting the structural integrity and flexibility of the aorta (Figure 3) [12]. Indeed, BAV conveys an eight-fold increased risk of aortic dissection, with a 26% risk for aneurysm formation at 25 years and 25% risk for aortic surgery [13]. As such, according to Class I recommendations by the American College of Cardiology Foundation (ACCF) and the American Heart Association (AHA) guidelines [14]:

1. First-degree relatives of patients with a BAV and/or a familial form of TAA and dissection should be evaluated for the presence of a BAV and asymptomatic thoracic aortic disease.

2. All patients with a BAV should have both the aortic root and ascending thoracic aorta evaluated for evidence of aneurysm.

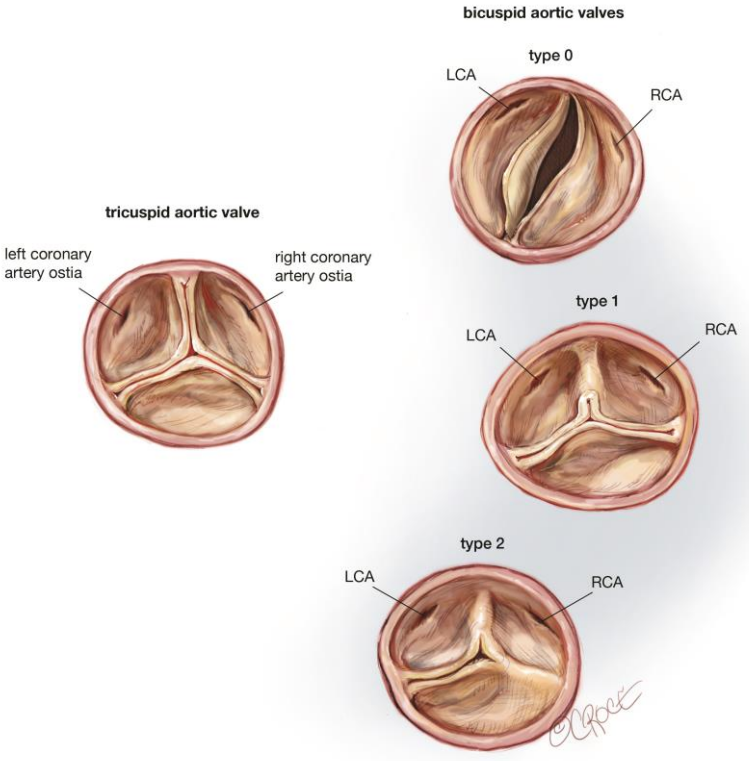

Figure 2. Schematic drawings comparing tricuspid aortic valve morphology with three types of bicuspid aortic valve morphologies (Type 0 - no raphe; Type 1 - one raphe and Type 2 - two raphes).

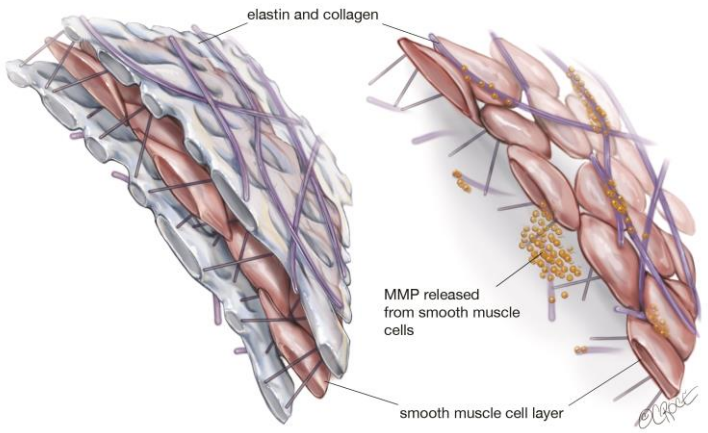

Figure 3. Pathophysiological features of bicuspid aortopathy: A) in a healthy individual with tricuspid aortic valve, the smooth-muscle cells in the aorta are connected to the adjacent elastin and collagen matrix by fibrillin 1 microfibrils; B) in an individual with BAV, deficiency of fibrillin 1 initiates detachment of vascular smooth-muscle cells from the extracellular matrix, leading to the release of matrix metalloproteinases (MMPs), resulting elastin and lamellar fragmentation and disruption of the media layer, adversely affecting the structural integrity and flexibility of the aorta.

SURGICAL INDICATION

The timing for surgery is largely based on presenting symptoms and the size of the aneurysm. The risks of aortic dissection, rupture and/or death increase exponentially if a TAA reaches 6 cm or bigger [14]. However, most of these complications can be forestalled by prompt preemptive surgical intervention when a TAA reaches 5.5 cm. Surgery should be considered even earlier if patients have a connective tissue disorders. Therefore, it is recommended that:

1. Patients with symptoms suggestive of expansion of a TAA should be evaluated for prompt surgical intervention unless life expectancy from comorbid conditions is limited or quality of life is substantially impaired
2. Asymptomatic patients with TAA, who are otherwise suitable candidates and for whom the ascending aortic aneurysm reaches 5.5 cm should be evaluated for surgical repair
3. Patients with connective tissue disorders (Marfan syndrome, vascular Ehlers-Danlos syndrome, Turner syndrome, or familial thoracic aortic aneurysm and dissection) should undergo elective operation at smaller diameters (4.0 to 5.0 cm) to avoid acute dissection or rupture
4. Patients with a growth rate of >0.5 cm/year in an aorta that is <5.5 cm in diameter should be considered for operation

PATIENT SELECTION CRITERIA

Patients with thoracic aortic aneurysms, affecting the aortic root, ascending aorta and/or aortic arch, may be considered for inclusion. Exclusion criteria in my practice included: redo cardiac procedure, emergency surgery, salvage surgery, infective endocarditis, concomitant coronary artery bypass surgery or valvular surgery (other than aortic valve) requiring full sternotomy access, and/or patient's refusal.

PREOPERATIVE ASSESSMENT

Initial assessment is performed using transthoracic echocardiography to evaluate proximal aorta and valvular pathology. To visualize distal ascending aorta, aortic arch and descending thoracic aorta, computed tomography (CT) thoracic aortogram is the most commonly used imaging modality as it provides detailed information regarding the size, location, and extent of the disease. The other imaging techniques include: chest X-ray, magnetic resonance imaging, trans-oesophageal echocardiography (TOE) and aortography.

A careful review of three-dimensional reconstructed images of the thoracic aorta in relation to the sternum and the rib cage is necessary, as this will greatly facilitate the planning for the mini-sternotomy. The degree of aortic wall calcification and evidence of atheromatous disease are evaluated in both contrast and non-contrast phases. A decision regarding the most appropriate cannulation strategy is sought with the aim to minimize potential embolic risks.

OPERATIVE STEPS

Following induction of anaesthesia, a radial arterial pressure monitor line with or without a femoral arterial pressure monitor line, central venous line, pulmonary arterial sheath/catheter and urinary catheter are inserted. The patient is placed in the supine position and the body surface anatomy is clearly marked with a permanent marking pen depicting the positions of supra-sternal notch, sterno-manubrial junction, 2nd to 4th intercostal spaces, the inferior extent of xiphoid cartilage and bilateral femoral arteries. The body is painted with an antiseptic solution, followed by positioning of the sterile drapes to expose the precordium laterally to the mid-clavicular lines and bilateral groin regions.

Mini-Sternotomy

A midline skin incision is performed from the manubrio-sternal junction to the level of the third intercostal space. This is usually 5-7 cm in length depending on the body size of the patient. The incision is developed through the subcutaneous fat onto the body of the sternum using diathermy, followed by the development of a cutaneous flap with a diathermy hand-piece along the prepectoral fascia. This flap is then extended superiorly above the supra-sternal notch and laterally to the limits of the sternum. A Kocker retractor is used to elevate the skin flap superiorly to expose the bridging vein over the manubrium and inferiorly to the 4th intercostal space. The bridging vein is clipped and cut. A 14 Fr Jackson Pratt drain (Cardinal Health, McGaw Park, IL, USA) is inserted through the skin at the level of 4th parasternal space on the left side and positioned in the subcutaneous space. This is used for CO_2 inflow during the case to prevent air embolism and as a subcutaneous drain at the completion of the operation.

A mini-sternotomy is performed using a hand-held electrical saw from the superior extent of the manubrium. The division is terminated either to the left or right para-sternal space. In this illustrated article, a left-sided, reversed "J" hemi-sternotomy is demonstrated (Figure 4). Hemostasis is achieved by applying a small amount of wax to the bone marrow. The thymic fat pad is completely mobilized to the innominate vein superiorly. The pericardium is opened longitudinally to the pericardial reflection superiorly and the level of 4th intercostal space inferiorly. Three pericardial traction sutures are placed on each side; hitched up and tied securely to the edges of the skin incision.

A minimally invasive sternal retractor is placed over the pericardial edges and opened up gradually. In doing so, the sternum is spread open, together with the pericardium, which anteriorizes the ascending aorta. A Semb clamp is passed around the ascending aorta by bluntly developing a plane between the mid-ascending aorta and the right pulmonary artery posteriorly and pulmonary artery trunk medially. The mid-ascending aorta is slung with a nylon tape and subsequent downward traction is applied to provide additional exposure of distal ascending aorta to facilitate aortic cannulation. This access would adequately expose the aorta from the level of sinotubular junction to that of the distal ascending aorta (Figure 5).

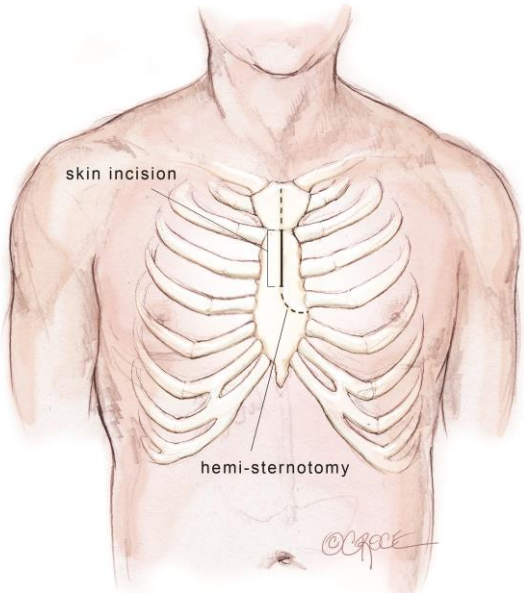

Figure 4. A midline skin incision is performed from the manubrio-sternal junction to the level of the third intercostal space. A reversed "J" upper hemi-sternotomy is terminated to the left fourth intercostal space.

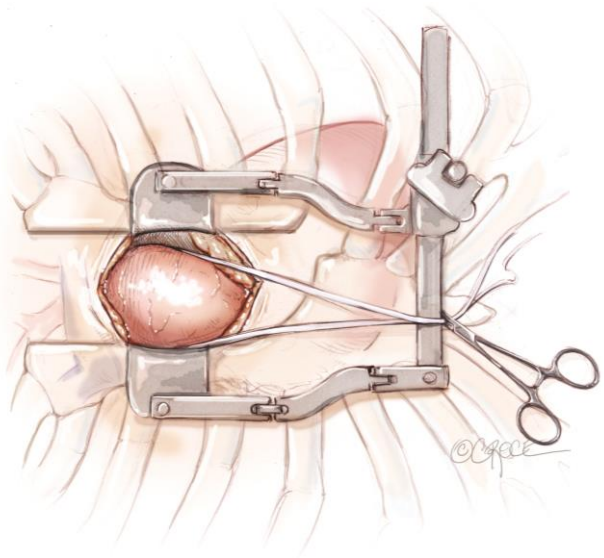

Figure 5. The mid-ascending aorta is slung with a Nylon tape. The access should adequately expose the aorta from the level of sinotubular junction to that of the distal ascending aorta.

Cannulation Strategy

A vacuum-assist device is built in the cardiopulmonary bypass (CBP) circuit to maximize venous drainage. Full systemic heparinization is achieved with activated clotting time (ACT) greater than 450 seconds. Peripheral venous cannulation is established first, using a Seldinger

technique. After puncture of a femoral vein, a guide wire is passed up to the superior vena cava. The position of the wire is confirmed with TOE through a bicaval view. The femoral vein puncture site is then progressively dilated. A 23 or 25 Fr multi-stage venous cannula (Maquet Getinge Group, Rastatt, Germany) is introduced. The pointy-tipped insert is not advanced further once it enters the right atrium. Only the venous cannula itself is now advanced forward over the insert under strict TOE guidance. It is essential that the cannula tip be placed in the superior vena cava to ensure satisfactory bicaval venous return. The venous cannula is subsequently connected to the CPB circuit.

Arterial cannulation can be established via either the distal ascending aorta or the femoral artery. In this chapter, a distal ascending aortic cannulation is depicted. The nylon tape slung around the mid-ascending aorta is retracted inferiorly. The superior edge of the skin incision is elevated cephalad using a Kocker tractor. Two 2-0 Ti-Cron purstrings for the aortic cannula are placed in the distal ascending aorta at the level of pericardial reflection. The aorta is carefully cannulated with an Elongated One-Piece Arterial (EOPA) cannula (Medtronic Inc, Minneapolis, MN, USA), which is secured in position and connected to the CPB circuit.

A 16 Fr DLP pulmonary artery vent cannula (Medtronic Inc, Minneapolis, MN, USA) is inserted in the main pulmonary trunk (Figure 6). Once CPB is established, the heart is off-loaded. Systemic temperature is maintained at 32 degrees centigrade for aortic root replacement or 25 degrees if hemi-arch replacement is anticipated. In the latter, splitting the arterial line is necessary beforehand to provide additional cerebral perfusion.

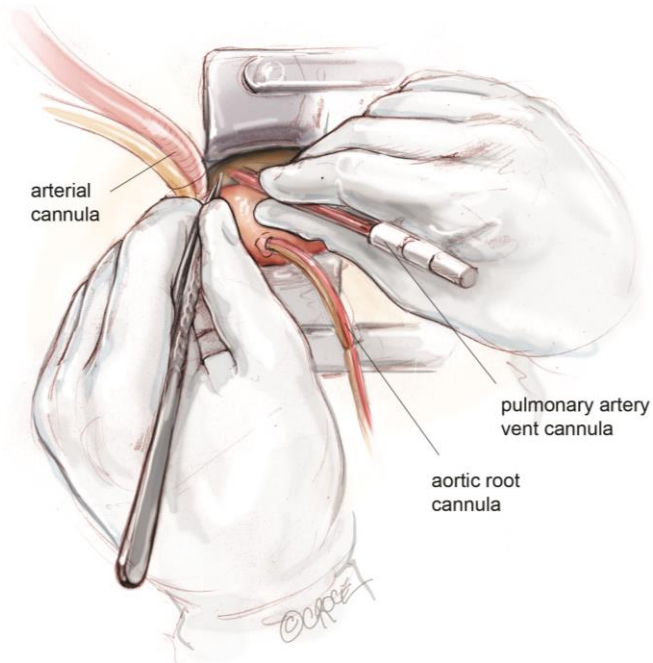

Figure 6. Cardiopulmonary bypass is established via central aortic cannulation and femoral venous cannulation. A 16 Fr DLP pulmonary artery vent cannula (Medtronic Inc, Minneapolis, MN, USA) is inserted in the main pulmonary trunk.

Aortic Root Exposition

Under a low-flow condition, an atraumatic aortic cross-clamp is applied across the distal ascending aorta. Diastolic arrest is achieved with antegrade cardioplegia delivered via a DLP aortic root cannula (Medtronic Inc, Minneapolis, MN, USA) or direct coronary ostial balloon tip cannula (Maquet Getinge Group, Rastatt, Germany) in the presence of aortic regurgitation. Either cold-blood cardioplegia solution or Custodiol cardioplegia solution (Koehler Chemi, Alsbach-Haenlien, Germany) is suitable.

After aortotomy, the blood in the aortic root is salvaged. The aneurysmal segment of the ascending aorta is resected, leaving 1 cm cuff of aortic tissue proximal to the cross-clamp and 1 cm above the sinotubular junction (Figure 7). The inside of the aortic root is assessed and the positions of the coronary arteries are visualized. The aortic root is carefully mobilized circumferentially. Subsequently, the non-coronary sinus is resected, leaving an 8 mm rim of aortic wall just above the non-coronary annulus. Then, the right coronary button flap is prepared. Two vertical incisions are made from the sinotubular junction down along both sides of the right coronary ostium and connected inferiorly (Figure 8). A 4-0 polypropylene suture is passed through the top end of the right coronary button flap to provide gentle traction when required. Similarly, the left coronary button flap is also fashioned. Often only limited mobilization of the coronary buttons from the surrounding connective tissue is required.

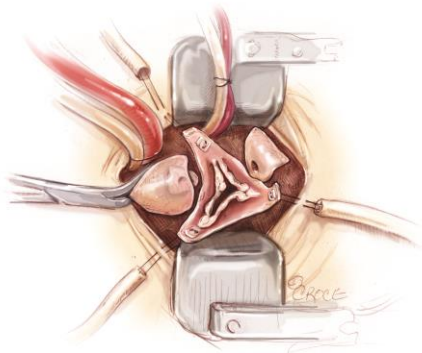

Figure 7. The ascending aortic aneurysm is resected, leaving 1 cm cuff of aortic tissue proximal to the cross-clamp and 1 cm above the sinotubular junction.

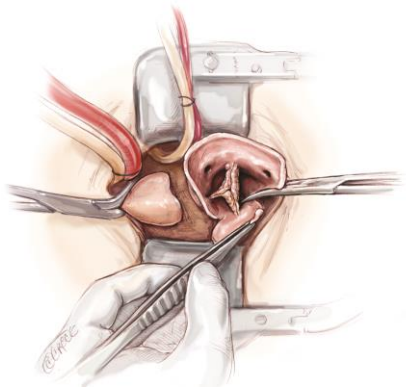

Figure 8. The aortic root is carefully mobilized circumferentially and resected, leaving a rim of aortic wall just above the aortic annulus. The coronary buttons are prepared.

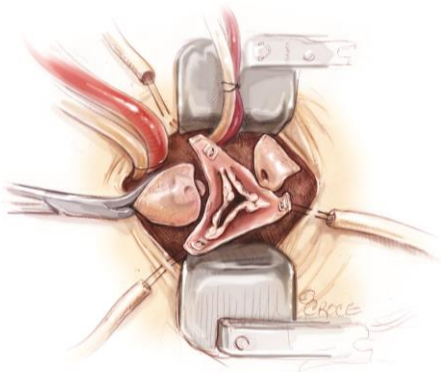

Figure 9. To provide an excellent exposure, the aortic root is brought in the cephalad direction by pulling on three commissural traction sutures.

In order to provide an excellent exposure, the aortic root is brought in a cephalad direction. This is achieved by putting the first pledgeted 2-0 Ti-Cron horizontal mattress suture above the non-/left-coronary commissure. The needles are then passed through the edge of the skin incision on the right side, at the 10 o'clock position. The traction suture is snared and clipped. The needles of the next pledgeted 2-0 Ti-Cron suture are passed through just above the left-/right-coronary commissure and the skin edge on the left side at the 2 o'clock position. The third pledgeted 2-0 Ti-Cron traction suture is used to elevate the right-/non-coronary commissure and attached to the skin edge on the right side at the 7 o'clock position. These three commissural traction sutures are hitched up and snared in position. This simple manoeuvre provides an excellent exposure of the aortic valve for the minimal access surgical approach (Figure 9). The aortic leaflets are resected and the aortic annulus is decalcified (Figure 10). Horizontal mattress sutures are placed neatly below the aortic annulus, using 2-0 Ethibond *Excel* annular sutures with or without pledgets. Pledgets can help to reduce the tension created by the sutures when the valve conduit is tied down, especially at the nadirs. The placement of these sub-annular sutures needs to be precise, both in terms of the spacing and whether or not the needle is passed through the annulus at a perpendicular angle (Figure 11). The sutures are evenly distributed.

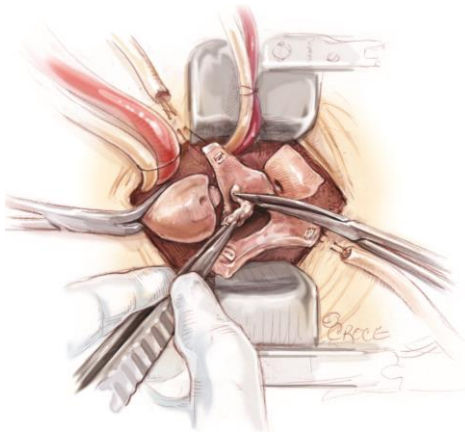

Figure 10. The aortic leaflets are resected and the aortic annulus is decalcified.

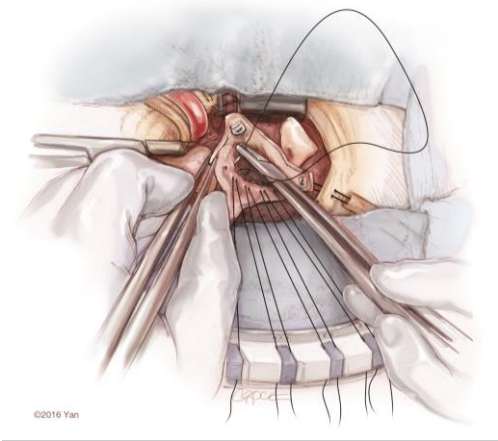

Figure 11. Horizontal mattress sutures are used, with pledgets placed neatly below the aortic annulus.

'French Cuff' Technique

The annulus is sized for its intra-annular and supra-annular dimensions. An appropriate prosthetic valve is selected, as one would do for routine aortic valve replacement, although it is advisable not to oversize the valve. A Valsalva graft (Vascutek Ltd, Renfrewshire, Scotland) is selected according to this formula: *Valsalva Graft Size = Aortic Valve Size + 5mm* (at least 3mm). Subsequently, the following steps are followed for the 'French Cuff' technique. The details of the French Cuff Technique are published elsewhere [15].

Step 1: The proximal cuff of the Valsalva graft is trimmed down to 8mm. This cuff is folded back over the outside of Valsalva portion of the graft to make a double cuff, the eponymous 'French Cuff'.

Step 2: The prosthetic valve is positioned inside of the Valsalva graft. The annular sutures are passed through the sewing ring of the prosthesis first and then the folded proximal edge of the Valsalva graft. Once all the sutures are passed through, the valve and the graft are parachuted down onto the annulus (Figure 12). The sutures are tied and cut sequentially around the sewing cuff. This completes the first proximal layer anastomosis.

Step 3: The second 'hemostatic' layer is performed using a 4-0 running Polypropylene suture, starting from the commissure between the left and right annulus and progressing clock-wise circumferentially. It is important to ensure that this layer of running suture incorporates the remnant of aortic wall and the everted 'French Cuff' edge. In addition, constant tension on the suture needs to be maintained by the assistant when following the suture.

If a mechanical valve conduit (St. Jude Medical, St. Paul, MN, USA) is used and there are any concerns regarding the hemostasis along the annulus (due to suture spacing or severely calcified annulus), a second 'hemostatic' layer can be achieved by using a continuous 4-0 running polypropylene suture that incorporates the 8 mm remnant of the aortic wall and the sewing cuff of the valve conduit. This '*double layer*' anastomosis technique works well for a mechanical valve conduit, as the sewing cuff is big enough to accommodate two rows of anastomoses.

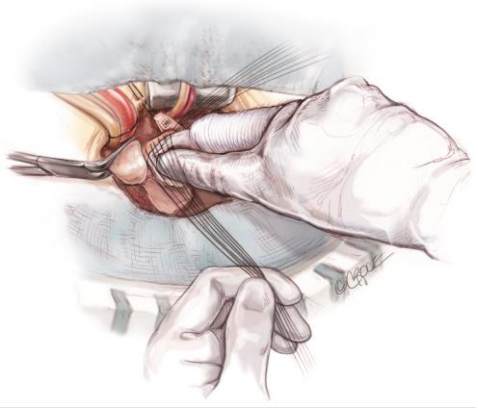

Figure 12. The valve and the conduit are parachuted down by gently pulling the sutures vertically upwards with one hand and firmly pushing the valve conduit down onto the annulus with the other.

Coronary Button Re-Implantation

The left coronary artery button is rested in its anatomical position. The appropriate site on the valsalva graft (Vascutek Ltd, Renfrewshire, Scotland) for left coronary button re-implantation is determined with the heart fully loaded, so that there is no tension or rotation of the left coronary button anastomosis. Once the position of the anastomosis is marked, the heart is off-loaded. A Bovie electrocautery (Bovie Medical Corporation, Clearwater, FL, USA) is used to create a circular hole for receiving the left coronary button. The coronary button is trimmed to a 3 mm circumferential cuff and re-implanted using a 5-0 running polypropylene suture. The cuff of the coronary button needs to be attached snuggly to the outside of Valsalva graft (Figure 13). The right coronary button is prepared and re-implanted in a similar fashion (Figure 14). It is imperative to ensure that a full thickness bite with each stitch is achieved. Failing to do so may cause bleeding in a very difficult site to access once the cross-clamp is taken off. The aortic root is pressurized and the anastomoses are tested by delivering a full dose of antegrade cardioplegia. Systemic rewarming is subsequently initiated.

The distal aortic anastomosis is reconstructed with the aortic cross-clamp on. The length of the graft is determined by filling the heart up and pulling the graft upwards on a stretch to meet distal ascending aorta. The graft is trimmed and anastomosed to the distal ascending aortic cuff by using a 3-0 running polypropylene suture. The anastomosis is started from the point furthest away from the operating surgeon. The posterior wall is completed first from 4 o'clock to 11 o'clock position on the aorta (Figure 15). A nerve hook is used to tighten the posterior wall suture progressively towards the operating surgeon. The anterior half of the anastomosis is completed by picking up the other end of the suture and sewing towards the operator. An aortic root vent is inserted before the two ends of the suture are tied. The table is then put in a Trendelenburg position, the heart is filled and lungs are inflated, the arterial flow is turned down, aortic cross-clamp is release and the graft is de-aired from the aortic root vent.

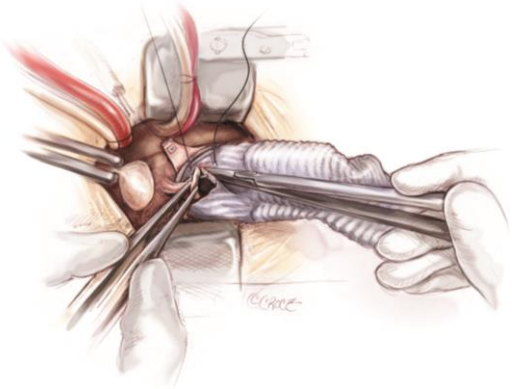

Figure 13. The left coronary button is trimmed, leaving a 3 mm circumferential cuff and re-implanted using a 5-0 running polypropylene suture.

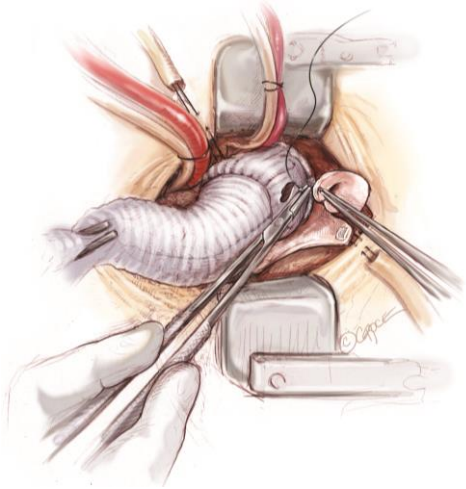

Figure 14. The right coronary button is prepared and re-implanted using a 5-0 running polypropylene suture.

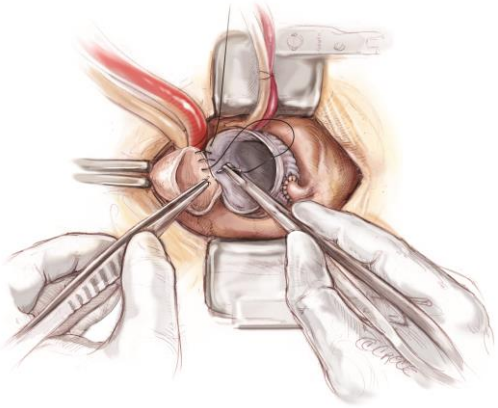

Figure 15. The graft is trimmed and anastomosed to the distal ascending aortic cuff by using a 3-0 running polypropylene suture.

Hemi-Arch Replacement

If the distal ascending and/or proximal arch is aneurysmal, a hemi-arch replacement with an open distal anastomosis is performed. Two cerebral perfusion cannulae are prepared at the beginning of the case in readiness for antegrade cerebral perfusion. Systemic cooling down to 25 degrees is initiated.

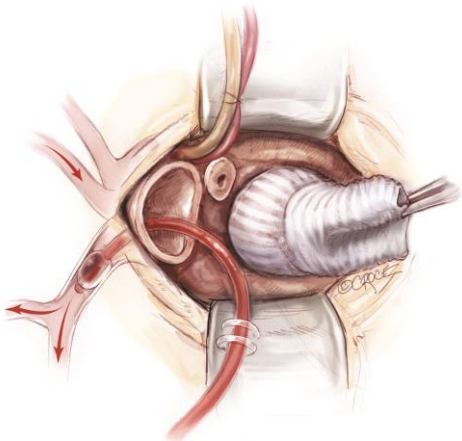

Figure 16. The mid to distal ascending aorta is resected completely, together with the cannulation site. Selective antegrade cerebral perfusion is achieved by cannulating the innominate artery with or without left common carotid artery.

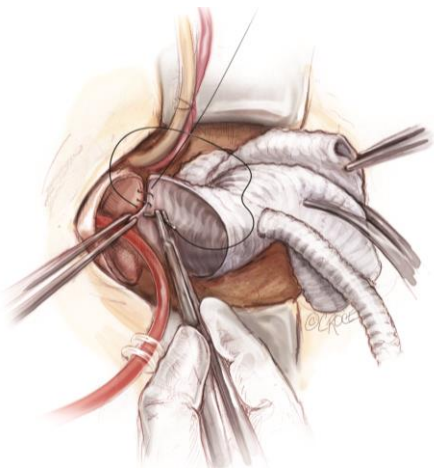

Figure 17. The open distal anastomosis is performed with a separate Ante-Flo graft with a single side arm (Vascutek Ltd, Renfrewshire, Scotland), using a continuous 3-0 running polypropylene suture.

As soon as the systemic temperature reaches 25 degrees, attention is then turned to the distal hemi-arch replacement. At this stage, the head is packed in ice, the antegrade flow is ceased, the aortic cannula is clamped, the aortic cross clamp is removed and the patient's blood is drained into the reservoir. The mid to distal ascending aorta is resected completely, together with the cannulation site, and the under surface of the proximal aortic arch is beveled. The inside of the aortic arch and the origins of epi-aortic vessels are inspected for

any evidence of atheromatous disease. Selective antegrade cerebral perfusion is achieved by cannulating the innominate artery with or without left common carotid artery (Figure 16). The open distal anastomosis is performed using a separate Ante-Flo graft with a single side arm (Vascutek Ltd, Renfrewshire, Scotland). A continuous 3-0 running polypropylene suture is used, starting from the point furthest away from the operating surgeon and completing the posterior aortic wall first (Figure 17). A nerve hook is used to tighten the suture along the posterior wall. The anterior half of the anastomosis is completed by picking up the other end of the suture and sewing towards the operator. This distal anastomosis is reinforced with pledgeted 4-0 prolene sutures where necessary to ensure absolute hemostasis. After completion of the open distal anastomosis, antegrade systemic perfusion is resumed via the side-arm perfusion limb of the Ante-Flo graft. The patient is rewarmed towards 37 degrees centigrade.

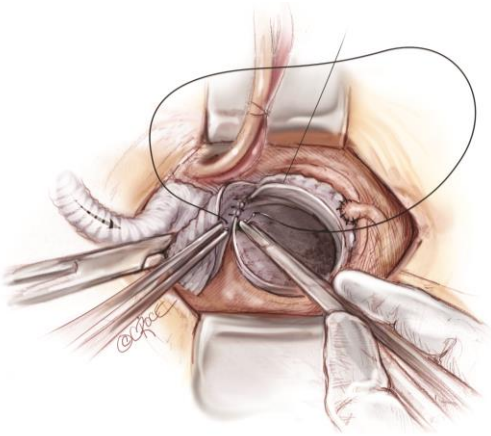

Figure 18. A graft-to-graft anastomosis is performed using a continuous 3-0 running polypropylene suture and reinforced using pledgeted 4-0 polypropylene sutures where necessary.

Once the root procedure is completed, the proximal valve conduit is trimmed just above the Valsalva portion of the graft. The distal Ante-Flo graft is put under a stretch and cut to an appropriate length. A graft-to-graft anastomosis is performed using a continuous 3-0 running prolene suture (Figure 18). The spacing between the adjacent stitches needs to be narrow and precise when doing a graft-to-graft anastomosis, usually a couple of millimeters apart. Finally, the aortic root vent is inserted, the aortic cross clamp is slowly released and a 21-gauge needle is used to de-air the graft. In order to ensure an absolute hemostasis, pledgeted 4-0 prolene sutures are applied to reinforce the proximal anastomosis when necessary.

Completion

A bi-polar temporary pacing wire is inserted in the epicardium over the right ventricular outflow tract. One 28 Fr soft drain is inserted and brought out below the xiphoid cartilage. Hemostasis is carefully checked and the patient is weaned from CPB. Protamine is given to reverse the heparin effect. Topical Floseal Hemostatatic Matrix (Baxter Healthcare, Zurich, Switzerland) is applied around the anastomotic sites. The surgical site is packed with small

gauze sponges for a period of 10-minute hemostatic pause. Once the hemostasis is deemed satisfactory, four stainless steel wires are used to approximate the sternum. No. 1 Vicryl suture is used to close the fascia and the subcutaneous fat. The skin is closed with a 5-0 Monocryl subcuticular suture. This completes the minimally invasive aortic surgery.

DISCUSSION

An important goal in modern cardiovascular surgery is reducing surgical trauma to achieve faster recovery for our patients. The benefits of minimally invasive surgery are evident [3-7]. Surgeons are comfortable with aortic valve replacement via upper hemi-sternotomy or right mini-thoracotomy, and thus naturally there is a growing interest in performing aortic surgery via a minimal access incision. The present chapter described my technique on how to perform Mini-Bentall Procedure and hemi-arch replacement for elective surgical patients with aortic root and ascending aortic aneurysms.

The mini-sternotomy is performed using a hand-held electrical saw from the superior extent of the manubrium, with the division terminated either to the left or right para-sternal space. One advantage to the right (a "J" mini-sternotomy) is avoiding any potential injury to the left internal mammary artery, should it be used for coronary bypass surgery in the future. In addition, access to the right superior pulmonary vein for venting is made easier. The main advantage of performing a mini-sternotomy to the left (a reverse "J") is increasing the exposure of proximal arch, especially if a concomitant hemi-arch replacement is anticipated. Under this circumstance, a pulmonary artery vent is used instead of right superior pulmonary vein vent. It should be cautioned that when inserting a pulmonary artery vent, the heart needs to be kept full or even before going on cardiopulmonary bypass. This will avoid injury to the posterior wall of the pulmonary trunk with the tip of the pulmonary artery cannula.

Arterial cannulation can be established either via distal ascending aorta or femoral artery. It is preferable to employ central arterial cannulation whenever possible to provide adequate antegrade systemic perfusion and avoid potential retrograde embolization and vascular complications that may be associated with peripheral cannulation [16]. Should femoral arterial cannulation be used, a 2.5 cm oblique incision is performed in the groin, exposing the anterior aspect of the common femoral artery. A 5-0 polypropylene purstring suture is placed in the anterior aspect of the common femoral artery. The artery is cannulated using a Seldinger technique. A guide wire is passed up in the descending thoracic aorta. Its presence within the descending aorta is confirmed with TOE. After progressive manual dilatation of the femoral artery puncture site, a wire-reinforced femoral arterial cannula should be inserted without any resistance.

In order to provide adequate exposure and surgical accessibility, it is important to anteriorize the aortic root, as well as bring the aortic annulus cephalad. This is achieved by placing three pledgeted 2-0 Ti-Cron horizontal mattress sutures above the commissures and hitching them up to the skin edges. This simple manoeuvre provides an excellent exposure of the aortic valve for the minimal access surgical approach. Even though the mini-sternotomy terminating at the level of sinotubular junction, this manoeuvre can bring the aortic annulus forward in the cephalad direction by 2 to 3 cm.

Composite graft replacement of the ascending aorta and aortic valve was first introduced by Bentall and De Bono in 1968 [2]. According to this technique, the aortic tissue surrounding the coronary ostia is directly sutured to the openings in the composite graft. These anastomoses were all made within the ascending aorta, and then the aortic wall is tightly wrapped over the conduit. This technique has been known as the wrap/inclusion technique [2]. Coronary artery dehiscence and coronary false aneurysms may result from tension created by bleeding into the space between the graft and the wrap [17]. A few technical modifications have been implemented, including the use of a reinforcement suture joining the cut edge of the aortic wall and the prosthetic sewing ring [18]. This technique described two separate proximal suture lines, an interrupted one between the most proximal part of the valve sewing ring and the aortic valve annulus, and a continuous one between the more distal portion of the sewing ring and the cut edge of the proximal aorta. In a Mini-Bentall Procedure, absolute hemostasis must be achieved. If there are any concerns regarding the hemostasis along the annulus (due to suture spacing or severely calcified annulus), a second 'hemostatic' layer is achieved by using a continuous 4-0 running polypropylene suture that incorporates the 8 mm remnant of the aortic wall and the sewing cuff of the valve conduit. This technique works well for a mechanical valve conduit as the sewing cuff is large enough to accommodate two rows of anastomoses. However, when a bioprosthetic valve is used inside of a valsalva graft, whereby the sewing ring of the tissue valve is narrow and the second 'hemostatic' layer is difficult to achieve, a 'French Cuff' technique can be used [15].

In the strategy presented, the fundamental principles of a traditional aortic root replacement are respected and it cannot be emphasized enough that a meticulous surgical technique to ensure absolute hemostasis is of the utmost importance in minimally invasive surgery. This results in a complete aortic repair via a minimal access incision and successful treatment in selected patients with aortic root, ascending aortic aneurysm and/or proximal arch aneurysms.

REFERENCES

[1] Elefteriades JA, Olin JW, Halperin JL. *Diseases of the Aorta*. In: Fuster V, ed. Hurst's the heart. 13th edn. New York: McGraw Hill, 2011:2261–89.

[2] Bentall H, De Bono A. A technique for complete replacement of the ascending aorta. *Thorax* 1968;23:338-9.

[3] Navia JL, Cosgrove DM, 3rd. Minimally invasive mitral valve operations. *Ann Thorac Surg*. 1996;62(5):1542-4.

[4] Cohn LH, Adams DH, Couper GS, et al. Minimally invasive cardiac valve surgery improves patient satisfaction while reducing costs of cardiac valve replacement and repair. *Ann Surg*. 1997;226(4):421-6; discussion 7-8.

[5] Phan K, Xie A, Di Eusanio M, Yan TD. A meta-analysis of minimally invasive versus conventional sternotomy for aortic valve replacement. *The Ann Thorac Surg.* 2014;98(4):1499-511.

[6] Phan K, Xie A, Tsai YC, Black D, Di Eusanio M, Yan TD. Ministernotomy or minithoracotomy for minimally invasive aortic valve replacement: a Bayesian network meta-analysis. *Ann Cardiothorac Surg.* 2015;4(1):3-14.

[7] Borger MA, Moustafine V, Conradi L, et al. A randomized multicenter trial of minimally invasive rapid deployment versus conventional full sternotomy aortic valve replacement. *Ann Thorac Surg*. 2015;99(1):17-25.

[8] Samadi A, Detaint D, Roy C, et al. Surgical management of patients with Marfan syndrome: evolution throughout the years. *Arch Cardiovasc* Dis 2012;105:84–90.

[9] Loeys, B.L., Dietz, H.C., Braverman, A.C., Callewaert, B.L., De Backer, J., Devereux, R.B., Hilhorst-Hofstee, Y., Jondeau, G., Faivre, L., Milewicz, D.M. and Pyeritz, R.E., 2010. The revised Ghent nosology for the Marfan syndrome. *Journal of medical genetics*, 47(7), pp.476-485.

[10] Luyckx, I. and Loeys, B.L., 2015. The genetic architecture of non-syndromic thoracic aortic aneurysm. *Heart*, pp.heartjnl-2014.

[11] Padang R, Bannon PG, Jeremy R, Richmond DR, Semsarian C, Vallely M, Wilson M, Yan TD. The genetic and molecular basis of bicuspid aortic valve associated thoracic aortopathy: a link to phenotype heterogeneity. *Ann Cardiothorac Surg* 2013;2(1):83-91.

[12] Verma S, Siu SC. Aortic dilatation in patients with bicuspid aortic valve. *N Engl J Med* 2014;370:1920-9.

[13] Michelena HI, Khanna AD, Mahoney D, et al. Incidence of aortic complications in patients with bicuspid aortic valves. *JAMA* 2011;306:1104-12.

[14] ACCF/AHA/AATS/ACR/ASA/SCA/SCAI/SIR/STS/SVM Guidelines for the Diagnosis and Management of Patients With Thoracic Aortic Disease: Executive Summary. J Am Coll Cardiol. 2010;55(14):1509-44.

[15] Yan TD. Min-Bentall Procedure - 'French Cuff' technique. *Ann Thorac Surg.* 2016 Feb;101(2):780-2.

[16] Benedetto U, Raja SG, Amrani M, et al. The impact of arterial cannulation strategy on operative outcomes in aortic surgery: evidence from a comprehensive meta-analysis of comparative studies on 4476 patients. *J Thorac Cardiovasc Surg.* 2014;148(6):2936-43.

[17] Nezic D, Cirkovic M, Knezevic A, Jovic M. Modified Bentall procedure – 'a collar technique' to control bleeding from coronary ostia anastomoses. *Interactive Cardiovasc Thorac Surg*. 2008;7(4):709-11

[18] Copeland JG, 3rd, Rosado LJ, Snyder SL. New technique for improving hemostasis in aortic root replacement with composite graft. *Ann Thorac Surg.* 1993;55(4):1027-9.

In: Encyclopedia of Surgery (22 Volume Set)
Editors: Andreas Lehrer and Kristin Mueller
ISBN: 978-1-53618-329-0
© 2020 Nova Science Publishers, Inc.

Chapter 408

THE EFFECTS OF DEXAMETHASONE IN PRE AND POST OPERATIVE SURGERY

Jun-Beom Park*, DDS, PhD
Department of Periodontics, College of Medicine, The Catholic University of Korea, Seoul, Republic of Korea

ABSTRACT

Dexamethasone is reported to be a potent synthetic member of the glucocorticoid class of steroid drugs. It acts as an anti-inflammatory and immunosuppressant. Dexamethasone has been used before, during and after surgery.

In this paper, extensive review of the role of dexamethasone before, during and after the surgery will be performed using in vivo and clinisal studies. Clinical implications of dexamethasone will be also conduced.

Keywords: analgesia, dexamethasone, nausea, pain, pain management, vomiting

INTRODUCTION

Dexamethasone is a potent synthetic member of the glucocorticoid class of steroid hormones [1]. Dexamethasone is a steroidal anti-inflammatory drug that induces annexing, a protein that, among other actions, is capable of inhibiting phospholipase A2 (i.e., the enzyme responsible for the induction of arachidonic acid) [2, 3]. The arachidonic-acid cascade initiation culminates in the expression of prostaglandins, prostacyclins, thromboxanes, and leukotrienes, which are related to pain [4]. It also suppresses the production of free oxygen radicals and nitric oxide by endothelial cells [5].

Dexamethasone has been used before, during and after surgery. In this paper, extensive review of the role of dexamethasone before, during and after the surgery will be performed

* Corresponding Author's Email: jbassoonis@yahoo.co.kr; Fax: +82-2-537-2374.

using in vivo and clinisal studies. Clinical implications of dexamethasone will be also conduced.

EFFECTS OF DEXAMETHASONE

Post-operative assessment of pain and discomfort showed that persistent discomfort and pain were found to be more in the placebo group compared to dexamethasone group [3]. The adoption of a preemptive medication protocol using dexamethasone may be considered effective for pain and discomfort prevention after open-flap debridement surgeries [3]. Co-therapy with non-steroidal anti-inflammatory drugs and steroids was suggested to provide beneficial inflammatory and pain relief in the absence of side effects [6]. It was seen that co-administration of dexamethasone and diclofenac potassium (non-steroidal anti-inflammatory drug) was significantly superior to diclofenac potassium alone for the relief of pain in third molar surgery [6].

The results previous study indicated that the use of intraoperative dexamethasone is an effective therapeutic strategy for limiting trismus following surgical removal of impacted third molars [7]. Postoperative swelling and edema may be due in part to the conversion of phospholipids into arachidonic acid [7].

Dexamethasone, plus a 5-HT3 receptor antagonist and an NK-1 receptor antagonist are recommended for controlling the chemotherapy-induced nausea and vomiting of highly emetogenic chemotherapy [8]. Moreover, previous report showed that continuous dexamethasone treatment facilitated osteogenic, adipogenic and chondrogenic differentiation [9].

DOSAGE

Application of dexamethasone was performed with 8 mg of dexamethasone parenterally 30 minutes before operation and 4 mg of dexamethasone intravenously, 6 hours postoperatively [6]. In other report, 8 mg dexamethasone was given orally 1 hour prior to surgery or immediately before induction of anesthesia [3, 10]. In other study, dexamethasone 10 mg was applied intravenously during the operation [7].

Dexamethasone 12 mg was administered intravenously on day 1, and then 8 mg of dexamethasone was applied intravenously on day 2 and 3 for controlling nausea and vomiting [8].

MECHANISM

The conversion of phospholipids into arachidonic acid is done by phospholipase A2 and the resultant production of leukotrienes, prostacyclins, prostaglandins, and thromboxane A2 act as mediators of the inflammatory response [7]. And the use of dexamethasone is reported to inhibit the initial step in this process.

META-ANALYSIS OF PAIN RELIEF

Differences in relief of pain between dexamethasone and placebo from meta-analysis are shown in Figure 1. The results showed that the additional use of dexamethasone was found to be associated with enhanced pain relief (odds ratio=8.981, 95% confidence of interval=5.454, 14.790).

CONSIDERATION

The time needed for dexamethasone to reach a plasmatic-concentration peak varies from 1 to 2 hours, and there were favorable results with its use 1 or 2 hours before surgery [4]. After an 8-mg dose of dexamethasone, elimination half life (t1/2) and volume of distribution (Vd) are 3 hours and 1.0 liter x kg-1, respectively [5, 11].

Study name	Statistics for each study					Sample size		
	Odds ratio	Lower limit	Upper limit	Z-Value	p-Value	Treated	Control	Relative weight
Bamgbose, 2005	11.233	5.118	24.654	6.031	0.000	50	50	40.27
Steffens, 2010	3.599	0.944	13.714	1.876	0.061	15	15	13.90
Pilatti, 2006	1.531	0.496	4.731	0.740	0.459	20	20	19.55
Moore, 2005	16.147	2.265	115.119	2.776	0.006	9	8	6.45
Asad, 2015	51.189	16.700	156.906	6.886	0.000	32	32	19.83
	8.981	5.454	14.790	8.625	0.000			

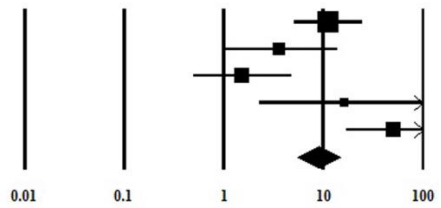

Figure 1. Differences in relief of pain between dexamethasone and placebo from meta-analysis.

CONCLUSION

A number of studies have demonstrated the various effects of dexamethasone on surgical procedures. Relatively abundant information about dexamethasone indicates their possible beneficial effects on relief of pain and postoperative complications.

ACKNOWLEDGMENT

This research was supported by Basic Science Research Program through the National Research Foundation of Korea (NRF) funded by the Ministry of Science, Information and Communication Technology & Future Planning (NRF-2014R1A1A1003106).

REFERENCES

[1] P. N. Naik, S. A. Chimatadar and S. T. Nandibewoor, *J. Photochem. Photobiol. B.* 100, 147 (2010).

[2] L. Parente and E. Solito, *Inflammation research : official journal of the European Histamine Research Society ... [*et al.*]*. 53, 125 (2004).
[3] K. Konuganti, M. Rangaraj and A. Elizabeth, *Journal of Indian Society of Periodontology*. 19, 474 (2015).
[4] J. P. Steffens, F. A. Santos, R. Sartori and G. L. Pilatti, *Journal of periodontology*. 81, 1153 (2010).
[5] G. L. Pilatti, F. Andre dos Santos, A. Bianchi, R. Cavassim and C. W. Tozetto, *Journal of periodontology*. 77, 1809 (2006).
[6] B. O. Bamgbose, J. A. Akinwande, W. L. Adeyemo, A. L. Ladeinde, G. T. Arotiba and M. O. Ogunlewe, *Head & face medicine*. 1, 11 (2005).
[7] P. A. Moore, P. Brar, E. R. Smiga and B. J. Costello, *Oral surgery, oral medicine, oral pathology, oral radiology, and endodontics*. 99, E1 (2005).
[8] Y. Kosaka, H. Tanino, N. Sengoku, et al., *Supportive care in cancer : official journal of the Multinational Association of Supportive Care in Cancer*. (2015).
[9] H. Oshina, S. Sotome, T. Yoshii, et al., *Bone*. 41, 575 (2007).
[10] M. V. Asad and F. A. Khan, *Journal of anaesthesiology, clinical pharmacology*. 31, 339 (2015).
[11] S. E. Tsuei, R. G. Moore, J. J. Ashley and W. G. McBride, *Journal of pharmacokinetics and biopharmaceutics*. **7**, 249 (1979).

In: Encyclopedia of Surgery (22 Volume Set)
Editors: Andreas Lehrer and Kristin Mueller
ISBN: 978-1-53618-329-0
© 2020 Nova Science Publishers, Inc.

Chapter 409

QUALITY OF LIFE CHANGES RELEVANT TO EXTENT OF THYROID SURGERY

Fatima Z. Syed*, MD
Division of endocrinology, Thomas Jefferson University Hospital,
Philadelphia, PA, US

ABSTRACT

One of the most frustrating facets of clinical thyroidology is to deal with the unhappy patients who have iatrogenic post-surgical hypothyroidism. These patients frequently have complaints of brain fog, weight gain and fatigue without any easy "fix".

These symptoms predominate frequently in the post-operative patient and are obviously real because they occur so frequently! "Prevention is better than cure" so we need to, where appropriate, minimize the extent of thyroid surgery as it would appear that some endogenous remaining thyroid hormone minimizes these symptoms as opposed to no endogenous thyroid function where these symptoms predominate. Future efforts need to be directed to more adequately defining appropriate thyroid hormone replacement and which compounds fare best? Finally perhaps the future rests on stem cell or related technique to retain endogenous thyroid hormone function?

Dr Syed addresses these issues in her narrative and provides some guide in minimizing extent of thyroid surgery where appropriate as well as attempts to appropriately replace physiological thyroid hormones and which compounds to use?

CASE REPORT ONE

Mrs. DS is a 65 year-old Caucasian female with history of well-controlled hypertension. Four years ago, she presented with a left sided two-centimeter thyroid nodule. Biopsy was consistent with papillary thyroid cancer, classical variant. She underwent a total thyroidectomy. Pathology was consistent with papillary cancer classic type 2cm in size. She did not have vascular invasion nor did she have any lymph node involvement. She did not

* Corresponding Author's Email: Fatima.syed@jefferson.edu.

receive radioactive iodine. Today, she presents to you for follow-up. At each visit in the last four years, she complains of fatigue, which did not exist prior to her surgery. Utilizing the Brief Fatigue Inventory, she states that she is fatigued at a score of 7/10 currently. At her worst, her fatigue is 10/10. Most of the time, she lives near a fatigue score of 8/10. She states that the fatigue affects her mood, her ability to exercise, and has interfered with work. She had planned on working into her 70s but states she feels so tired, she retired from her work as an accountant last year. She attributes the fatigue beginning after her thyroidectomy. She has been on a steady dose of levothyroxine 112 mcg for many years and has been biochemically euthyroid at your last five visits together. She ends the appointment by stating, "I wish I had never gotten my thyroid removed."

CASE REPORT TWO

Ms. Y is a 33 year-old East Asian female with history of papillary thyroid cancer status post total thyroidectomy here for follow-up. Three years ago, during a routine GYN visit, she was noted to have a right-sided thyroid nodule. She had no history of radiation in the past and she had no family history of thyroid cancer or other malignancies. She underwent a biopsy of the nodule, which came back as papillary thyroid cancer. She underwent total thyroidectomy and had a 3 cm nodule with classical PTC showing lymphovascular invasion. She received radioactive iodine as well. She comes today for follow-up. She is on levothyroxine at 100 mcg daily. She has been biochemically euthyroid for over one year. She complained of having low energy. She feels she is not functioning as well as she should and sleeps poorly at night. She screens negative for depression and has no other medical issues or stressors. She does have an eight month old daughter. However, her daughter is sleeping through the night and she does not believe motherhood is the source of her fatigue. She states that since her thyroidectomy and starting thyroid replacement, she has never felt the same.

CASE REPORT THREE

Mr. W is a 46 year-old who was diagnosed with papillary thyroid cancer, classic variant seven years ago upon discovering a palpable nodule on the right side of his thyroid whilst shaving one morning. He underwent biopsy, which showed the results as stated. He has no exposure to radiation. His mother also had papillary thyroid cancer and underwent total thyroidectomy. He was referred for surgery. It was ultimately decided that patient would undergo a right lobectomy as the nodule was only 2cm in size. Pathologically the right lobe showed 18mm papillary thyroid cancer without lymphovascular invasion. Post-operatively his thyroid function remained within normal range without the need for thyroid hormone replacement. He did however have minimal weight gain and complaint of fatigue in follow up.

INTRODUCTION

"I haven't been the same since my thyroid was removed." This is a common complaint endocrinologists hear from patients who have undergone total thyroidectomy. Before examining symptoms associated with thyroidectomy, it is first important to understand the role of the thyroid and the effects and treatment of hypothyroidism. The most common cause of hypothyroidism globally is iodine deficiency [1]. However, in the United States and other developed nations, the most common cause of hypothyroidism is autoimmune thyroid disease [2]. Amongst leadership in clinical guidelines, screening for hypothyroidism is not generally recommended. However, in cases of other autoimmune disease, family history, history of radiation, or personal history of thyroid surgery, screening of thyroid function is recommended. Of course, if a patient has symptoms of hypothyroidism, he or she should be screened [2, 3].

Patients who have their thyroid gland surgically or radioactively removed require lifelong thyroid replacement [2]. Typically, thyroid replacement involves replacing levothyroxine at 1.6 micrograms/kilogram for all patients [4], regardless of the etiology of hypothyroidism. However, according to the American Thyroid Association, patients who have had surgical thyroidectomies may require more replacement [2]. This can be adjusted based on symptoms of the patient. Thyroid replacement is therefore based on both qualitative and quantitative measures.

Traditionally, patients that are status post thyroidectomies TSH are initially suppressed and then are maintained to be biochemically euthyroid [5]. However, in our case reports above, we find a common complaint amongst these patients is that they may not feel as they did before thyroidectomy, despite effective treatment of thyroid hormone replacement. The aim of this chapter is as follows:

1. Examine quality of life for patients who have undergone thyroidectomies
2. Understand the objective measurement tools of quality of life
3. Review treatment options of PTC and examine morbidity and mortality associated with PTC
4. Understand the perceptions of lobectomy versus thyroidectomy

OBJECTIVE MEASUREMENTS OF QUALITY OF LIFE

In evaluating patients with history of thyroidectomies, it is important to ask the symptoms the patient experiences as well as if those symptoms are tolerable or not. This can help guide supportive care for the patient. Several objective measures on quality of life can be applied to patients who have had total thyroidectomies.

Massolt et al. describe the following quality of life measures [5].

Thyroid Specific Patient Reported Outcome Measures (ThyPRO)

This is a qualitative survey containing eighty-five questions summarized in 13 scales. It accounts for cross-cultural [6, 7] and socio-economic validity [5].

Multidimensional Fatigue Index (MFI-20)

This is a twenty-question survey which evaluates generalized fatigue, physical fatigue, mental fatigue, reduced motivation and reduced activity [5, 8].

RAND-36

This is a validated Dutch survey on evaluating overall health in the prior thirty days [9]. It consists of nine subclasses, including physical health problems, limitations of emotional and general health care needs.

Cancer Quality of Life Survey

This is a survey typically for patients before and after chemotherapy, however it is also helpful in evaluating depression and fatigue in patients with history of cancer [5].

THYROIDECTOMY PATIENTS PERCEPTIONS OF QUALITY OF LIFE VERSUS AGE NORMATIVE POPULATIONS

In a study by Husson et al, quality of life of patients with thyroidectomy is compared to age normative populations [10]. Consistently, it is found that patients with thyroidectomy have decreased quality of life compared to age normative populations. Patients with thyroid cancer have comparable life expectancies as patients without thyroid cancer [11]. Given the length of life expected by these patients, according to the study, any impacts to quality of life become concerning. The study aims to "assess [thyroid cancer specific] Health Related Quality of Life (HRQoL) among long-term thyroid cancer survivors and to compare this with the HRQoL of an age- and sex-matched normative population. Secondly, our aim was to investigate which clinical and socio-demographic characteristics and thyroid cancer specific problems were associated with HRQoL" [10].

The study surveyed patients over a twenty-year period of new patients diagnosed with thyroid cancer. It used objective surveys to assess disease specific symptoms. These scores were then compared with age and sex matched disease free controls. Confounding factors such as socio-economic status were addressed [10].

The study found that "Thyroid cancer survivors had significantly lower scores on physical, role, emotional, cognitive and social functioning ($p < 0.001$) compared to the normative population after adjusting for comorbidities. Sympathetic problems [feeling chilly

(52%), hot flushes (40%)], neuromuscular problems [cramp legs (43%) and pain joints/muscles (64%)] and abrupt attacks of fatigue (50%) were the most often reported thyroid cancer specific complaints. Thyroid cancer specific neuromuscular, concentration, sympathetic and psychological problems explained 41–58% of the variance in HRQoL. Clinical and socio-demographic factors explained a small part of the variance in (thyroid cancer specific) HRQoL (1–27%)" [10].

Further studies have shown that patients with thyroid cancer who have undergone thyroidectomy are at higher risk of unemployment [12]. Patients report fatigue as reasons for unemployment. It is difficult to correlate fatigue alone as reason for unemployment, which is a complicated issue. However, the correlation with thyroid cancer survivorship does indeed exist [12].

Overall, patients who have thyroid cancer and survived will likely have worse quality of life had they never had thyroid cancer and required a thyroidectomy [13]. There is not objective data as to why patients with thyroidectomy have worsened quality of life. Obvious thought is that the thyroid is produces some endogenous substance [5], which contributes to energy that is beyond thyroid hormone alone. Additionally, many with PTC have some component of autoimmune thyroid disease [2]. Autoimmunity itself may not disappear after surgery, and it is possible, this is causing the residual fatigue and impairment to perceived quality of life [5, 14].

THYROIDECTOMY VERSUS LOBECTOMY IN TREATMENT OF THYROID CANCER AND EFFECTS ON QUALITY OF LIFE

According to a study done at Memorial Sloan Kettering over a twenty- year period, there was no difference in mortality in patients who received a total versus partial lobectomy for non-invasive thyroid cancer [15]. This study only included patients with thyroid cancers that were less than or equal to 4 cm in size and with no known invasion of lymph nodes or spread outside the neck. "A total of 361 patients were treated with lobectomy and 528 were treated with total thyroidectomy. As expected, the survival at 10 years was high in both groups of patients (93% in the lobectomy and 91% in the total thyroidectomy group). There were no significant differences in 10 year survival or thyroid cancer recurrence between the two groups of patients. Both age greater than 45 and male gender were predictive of a worse overall survival, while the type of surgery had no effect on survival" [15].

According to Husson et al. and other studies, patients with lobectomy still report worse quality of life in comparison to those without thyroid cancer [10].

CONCLUSION

In all three cases, the commonality was that patients felt worse after thyroidectomy than before. There are many reasons this could be the case. In those with cancer survivorship in general, quality of life is perceived worse after cancer than before even decades after cure [16]. Therefore, thyroid cancer, although mostly has high levels of long term survivorship, is not different than other cancers. Perhaps evaluating patients' quality of life before and after

would be helpful in evaluating their perceptions of symptoms. Also in low risk thyroid cancer perhaps minimalistic surgery (lobectomy),leaving patients with some functioning thyroid tissue of their own, may alleviate some of the fatigue and weight gain attendant with total thyroidectomies without compromising longevity nor recurrence risk?

REFERENCES

[1] Vanderpump MP. The epidemiology of thyroid disease. *Br Med Bull.* 2011;99(1):39-51.

[2] Haugen BR, Alexander EK, Bible KC, Doherty GM, Mandel SJ, Nikiforov YE, . . . Wartofsky L. 2015 American Thyroid Association management guidelines for adult patients with thyroid nodules and differentiated thyroid cancer: the American Thyroid Association guidelines task force on thyroid nodules and differentiated thyroid cancer. *Thyroid.* 2015;26(1):1-133.

[3] Garber JR, Cobin RH, Gharib H, Hennessey,JV, Klein I, Mechanick JI, . . . Woeber KA. Clinical practice guidelines for hypothyroidism in adults: Cosponsored by the American Association of Clinical Endocrinologists and the American Thyroid Association. *Thyroid.* 2015;22(12):1200-1235.

[4] Devdhar M, Drooger R, Pehlivanova M, Singh G, Jonklaas J. Levothyroxine replacement doses are affected by gender and weight, but not age. *Thyroid*. 2011;21:821–827.

[5] Massolt ET, van der Windt M, Korevaar TI, Kam BL, Burger JW, Lehmphul I, …, Peeters RP. Thyroid hormone and its metabolites in relation to quality of life in patients treated for differentiated thyroid cancer. *Clin Endocrinol (Oxf).* 2016;5(13).

[6] Bukvić B, Živaljević V, Šipetić S, Diklić A, Taušanović K, Paunović I. Validation and cross-cultural adaptation of the questionnaire ThyPRO in thyroid patients in Serbia. *Vojnosanlt Pregl.* Jul 2015;72(7):583-8.

[7] Watt T, Barbesino G, Bjorner JB, Bonnema SJ, Bukvic B, Drummond R, …, Feldt-Rassmussen U. Cross-cultural validity of thyroid-specific quality-of-life patient-reported outcome measure, ThyPRO. *Qual Life Res.* Mar 2015;24(3):769-80.

[8] Smets EM, Garssen B, Cull A, de Haes JC. Application of multidimensional fatigue inventory (MFI-20) in cancer patients receiving radiotherapy. *Br J Cancer*. Jan 1996;73(2):241-5.

[9] VanderZee KI, Sanderman R, Heyink JW, de Haes H. Psychometric qualities of the RAND 36-Item Health Survey 1.0: a multidimensional measure of general health status. *Int J Behav Med.* 1996;3(2):104-22.

[10] Husson O, Haak HR, Bufart LM, Nieuwlaat WA, Oranje WA, Mols F, … van de Poll-Franse LV. Health-related quality of life and disease specific symptoms in long-term thyroid cancer survivors: a study from the population-based PROFILES registry. *Acta Oncol.* Feb 2013;52(2):249-58.

[11] Links TP, van TOL KM, Jager PL, Plukker TM, Piers DA, Boezen HM, … Sluiter WJ. Life expectancy in differentiated thyroid cancer: a novel approach to survival analysis. *Endocr Relat Cancer*. Jun 2005;12(2):273-80.

[12] Ratzon NZ, Uziely B, de Boear AG, Rottenberg Y. Unemployment risk and decreased income two and four years after thyroid cancer diagnosis: a population-based study. *Thyroid.* Sept 2016;26(9):1251-8.

[13] JI Lee, Kim SH, Tan AH, Kim HK, Jang HW, Hur KY, …, Kim SW. Decreased health-related quality of life in disease-free survivors of differentiated thyroid cancer in Korea. *Health Qual Life Outcomes.* 2010;8:101.

[14] Hirsch D, Ginat M, Levy S, Benbassat C, Weinstein R, Tsvetov G, …, Reicher-Atir R. Illness perception in patients with differentiated epithelial cell thyroid cancer. *Thyroid.* May 2009;19(5)459-65.

[15] Nixon IJ, Ganly I, Patel SG, Palmer FL, Whitcher MM, Tuttle RM, …, Shah JP. Thyroid Lobectomy for treatment of well differentiated intrathyroid malignancy. *Surgery.* Apr 2012;151(4):571-9.

[16] Schlumberger MJ. Diagnostic follow up of well differentiated thyroid carcinoma: historical perspectives and current status. *J Endocrinol Invest.* 1999;22(11 Suppl):3–7.

In: Encyclopedia of Surgery (22 Volume Set)
Editors: Andreas Lehrer and Kristin Mueller
ISBN: 978-1-53618-329-0
© 2020 Nova Science Publishers, Inc.

Chapter 410

BIOLOGICAL CHARACTERISTICS, CLINICAL CLASSIFICATION, AND SPASM OF ARTERIAL GRAFTS AND ANTISPASTIC MANAGEMENT IN CORONARY ARTERY BYPASS GRAFTING SURGERY

Guo-Wei He*, MD, PhD
TEDA International Cardiovascular Hospital, Chinese Academy of Medical Sciences & Peking Union Medical College, Tianjin & The Affiliated Hospital of Hangzhou Normal University & Zhejiang University, Hangzhou, China,
Department of Surgery, Oregon Health and Science University,
Portland, OR, US

ABSTRACT

CABG surgery has been the standard treatment for patients with coronary artery disease, particularly for three-vessel disease, although PCI has become the preferred method in one- or two-vessel disease. Arterial grafting using autologous arteries as the bypass grafts has been demonstrated to have superior long-term results. Arterial grafts can be classified Type I, II, and III for clinical consideration according to their biological characteristics. Use of the left internal mammary artery to graft the diseased LAD has become the standard method for almost all CABG surgery and bilateral IMA grafts may further enhance survival over the long-term. The radial artery is also commonly used as a bypass graft, and occasionally the right gastroepiploic artery, and inferior epigastric artery. However, in comparison to vein grafts, arterial grafts have a tendency to develop vasospasm that can lead to potentially life-threatening complications. Various antispastic pharmacologicals have been used during surgery but the rationale and efficacy are sometimes unclear and there is still controversy as to what is the most effective regimen. This is partially due to the pathophysiological complexity of the mechanism of vascular spasm and, consequently, the evolution of several pharmacological vasodilators. Better understanding of the mechanism of vascular spasm, development of new pharmacological vasodilators, and the adequate evaluation of non-pharmacological

* Corresponding Author's Email: gwhezj@163.com; Fax: 86-22-6520 8732.

methods may lead to a more unanimous opinion as to the best method to prevent and treat arterial spasm in contemporary clinical practice.

1. INTRODUCTION

CABG surgery has been the standard treatment for patients with coronary artery disease (CAD), particularly for three-vessel disease, although over the past decade, percutaneous coronary intervention (PCI) has gradually become the preferred method of revascularization in patients with one-vessel or two-vessel disease [1, 2]. Arterial grafting, i.e., using autologous arteries rather than veins as the grafts, has been demonstrated to have superior long-term results compared to vein grafts [3]. In particular, use of the left internal mammary artery (IMA) to graft the diseased LAD has become the standard method for almost all CABG surgery [4, 5]. In addition, other arteries such as the radial artery (RA) [6, 7], and less commonly the right gastroepiploic artery (GEA) [8-10], and the inferior epigastric artery (IEA) [11-12] are used as bypass grafts. However, arterial grafts are relatively small arteries with a varying muscular component in the vessel wall and have a tendency to develop vasospasm during surgery, as discussed below in details.

Antispastic therapy therefore has been and remains an important issue through the history of development of CABG particularly in arterial grafting. Studies of the pathophysiology of spasm and the development of antispastic pharmacological management have paralled the employment of arterial grafts in CABG [13-61]. This has included a large number of pharmacological and some non-pharmacological methods to prevent or treat vasospasm. Due to the complexity of the antispastic drugs and other methods involved, no single technique for antispastic management has been uniformly accepted or adopted. In this Review, we discuss the evidence base for the existence and incidence of vasospasm in CABG surgery using arterial grafts, the clinically available potential antispastic methods, and their possible advantages and disadvantages with a view to help elucidate mechanisms of vasospasm of arterial grafts and the decision making in choice of the potential antispastic methods.

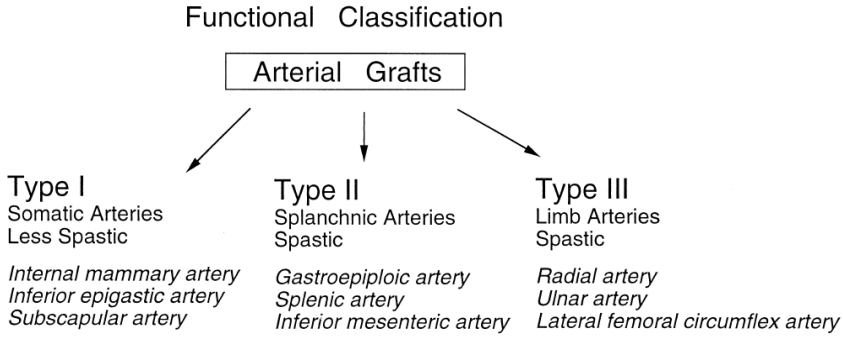

Figure 1. The functional classification for arterial grafts, often referred as “HE classification” (From He GW: Arterial grafts for coronary artery bypass grafting: biological characteristics, functional classification, and clinical choice. *Ann Thorac Surg.* 1999;67:277-84. With permission).

1.1. Biological Characteristics and Clinical Classification of Arterial Grafts

The biological characteristics of arterial grafts are the basis of the behavior when they are grafted on the coronary artery system. A clinical classification is useful for a practicing surgeon. Based on our own experimental studies on the vasoreactivity combined with anatomical, physiological, and embryological considerations of the arterial grafts, I have proposed a functional classification for the grafts, suggesting that there are three types of arterial grafts: Type I- somatic arteries; Type II- splanchnic arteries; and Type III- limb arteries [29, 62]. The Type I arteries have better endothelial function and release more nitric oxide and other vasorelaxing factors [63, 64]; the Type II arteries, such as the gastro-epiploic artery, and the Type III arteries, such as the radial artery, have higher pharmacological reactivity to vasoconstrictors. The Type III arteries were later demonstrated to have higher contractility [65] and less eNOS expression [66]. This classification explains why the IMA has the best long-term patency. Because Type II and III arteries are prone to spasms due to higher contractility, they require more active pharmacological interventions.

2. PATHOPHYSIOLOGY OF SPASM

2.1. Existence and Incidence of Spasm of Arterial Grafts

Prevalence of Spasm of IMA

Spasm of IMA was first reported in 1987 [48]. Spasm could be a localized phenomenon or a diffuse process, referred to as a "string sign"[49], could cause hypoperfusion, typically occurring 30 to 40 minutes after discontinuation of cardiopulmonary bypass but also seen subsequently in the intensive care unit [50] when it may also be confused with coronary artery spasm. IMA spasm may also occur years after bypass grafting [51].

Based on these clinical observations, a large body of studies has been reported on the physiological and pharmacological characteristics of the IMA to understand the nature of spasm. In an early study, I demonstrated that the contractility of the distal section of the IMA is inversely correlated to its diameter; that is, the smaller the diameter, the greater the tendency for spasm to develop. This suggests that trimming off the distal end of the IMA as much as possible may be the best way to prevent graft spasm [52]. Nevertheless, since 1980s, a large body of literature has demonstrated the existence of spasm in IMA even in current practice [53-60].

The exact incidence of spasm of arterial grafts is unknown. This is particularly due to the fact that when it is mild, it may be asymptomatic; or, if responsible to vasodilator treatment, it is usually not reported. However, when spasm is severe and has little response to the usual pharmacological management, it can be lethal [53-57, 59]. A recent report indicated that among 5,762 patients who underwent isolated CABG, 7 patients (0.12%) experienced refractory spasm of coronary arteries and grafted conduits including the left IMA and 18 patients experienced perioperative vasospasm of a single coronary artery or of a grafted conduit [59]. This suggests that the confirmed severe perioperative vasospasm in coronary artery of grafts is about 0.43% in all CABG surgery. It is possible that the incidence of

vasospasm could be underestimated because there could be some patients who have vasospasm responsible to early use of vasodilator agents and not counted as vasospasm.

The Incidence of Spasm in Other Arterial Grafts

The RA and GEA have been demonstrated as prone to spasm. Dramatically, the revival of the use of RA was due to the use of successful antispastic management [6]. Since the more widespread use of the RA, spasm has been reported more frequently by cardiac surgeons [67], physicians [68] and cardiologists during catheterization [69]. Gabe and colleagues reported an unusual case of CABG, complicated by vasospasm of a grafted RA leading to postoperative ventricular fibrillation. RA graft spasm was demonstrated by angiography and was successfully resolved by intravenous nitroglycerin administration [70]. In addition, focal RA graft stenosis may be difficult to differentiate from spasm and can be treated by percutaneous intervention [71].

GEA spasm is also a well-recognized complication. Spasm can occur during or soon after harvesting of these vasoreactive grafts [72-74] or a few months or years postoperatively, as demonstrated by angiography [75].

There are fewer reports on IEA spasm. This is probably due to the fact that first, anatomically and functionally, IEA belongs to the Type I artery that may be less spastic [29, 62, 76] and second, use of IEA is not as frequent as IMA, RA, or GEA. However, occasionally, IEA graft is reported to have spasm even at 5-year angiographic follow-up [61].

2.2. Mechanisms of Spasm of Arterial Grafts

Despite of the efforts to try to understand the mechanism(s) of vascular spasm, it is still not fully understood owing to the complex nature at molecular levels. However, it is understood that spasm is an extreme form of vasoconstriction. In general, vasoconstriction may be evoked by a number of stimulants. Mechanical stimulation, nerve stimulation, as well as vasoconstrictor substances are common stimulants of vasoconstriction [17, 77]. These vasoconstrictor substances are therefore referred to as spasmogens. The possible spasmogens in arterial grafts have been well studied. These include: endothelium-derived contracting factors such as endothelin-1 [77, 78], prostaglandins such as TX_{A2} or mimetics and $PGF_{2\alpha}$, α-adrenoceptor agonists such as norepinephrine, methoxamine and phenylephrine, platelet-derived substances such as 5-HT, and cellular membrane depolarizing agent potassium [77], mast cells and histamine [79]. It should be noted that studies have been performed in the human vessels since there are marked differences between human and animal vessels in response to these spasmogens [15, 17]. In addition, there are differences in responses between the IMA and coronary artery to vasoconstrictors [29]. In general, arterial grafts have higher responsiveness to norepinephrine because the coronary artery is α- and β-adrenoceptor-balanced vessel. However, IMA [19, 21, 80] and RA [37] are α-adrenoceptor predominant vessels. On the other hand, however, it has also been demonstrated that IMA graft is unresponsive to ergonovine at least in the amount required to produce coronary artery spasm in patients with variant angina [81]. In comparison to the IMA and IEA, the GEA has been demonstrated to have highest responsiveness to endothelin, TXA_2 mimetic, and potassium [29]. Subsequently, RA was demonstrated to have higher receptor-mediated contractility to endothelin and angiotensin II [65], vasopressin [82], 5-HT [83], and TXA_2 [84].

Other causes for vasospasm in arterial grafts may be related to certain pathways of vascular contractility or endothelial dysfunction. For example, autologous neutrophils release a stable non-protein small molecule that disturbs internal mammary artery endothelial function [85]. In addition, it was demonstrated that RhoA/Rho kinase pathway may be one mechanism by which RA is more susceptible to spasm than IMA [86] and that isoprostane responses in radial arteries are found to be mediated by prostanoid receptors selective for TXA_2 with activation of Rho-kinase and release of Ca^{2+} [87].

Recently, it has been recognized that fat cells or adipocytes produce large numbers of metabolically active substances with both endocrine and paracrine actions. Perivascular adipose tissue may play a role in the mechanism of vascular spasm [88].

Apart from vasoconstrictor spasmogens, other stimulants such as hypothermia [89] have also been demonstrated to be related to spasm of the grafts. Metabolic diseases such as diabetes mellitus have been demonstrated to increase the risk of radial artery spasm [67].

It must be indicated that the intact endothelium plays an extremely important role to prevent vascular spasm. The endothelium releases a number of endothelium-derived relaxing factors such as nitric oxide (NO), endothelium-derived hyperpolarizing factor, and PGI_2 [33, 34, 36] that keeps the adequate vascular tone in the arterial grafts. This is why it is ultimately important to prevent endothelial damage when using arterial grafts.

3. PHARMACOLOGICAL MANAGEMENT FOR SPASM (PHARMACOLOGICAL ANTISPASTIC METHODS)

Pharmacological studies have paralleled the development of the arterial grafts in CABG [17-28] owing to the fact that arterial grafts are relatively small arteries and there is a tendency to develop spasm in these arteries during surgery, as described above. Pharmacological studies on CABG grafts were initially focused on the IMA. Along with the increased use of other arterial grafts, studies have been also extended to these arteries. Pharmacological management in CABG is a complex topic. It should actually include two aspects. This may involve firstly, systematic use of pharmacological agents in order to maintain cardiac output and graft function during the pre-, intra-, and post-operative period, and secondly, specific pharmacological management for arterial conduits by using both systematic and topical methods.

Adequate understanding of the mechanism of vasoconstriction and the effect of vasodilators is essential to design any protocols to use vasodilators. Such understanding should be based on 1). the nature of vasoconstriction and the mechanism of the vasodilators [77]; 2). the status of the contraction that refers to prevent or to reverse existing contraction/spasm [17]; 3). duration of the use of a vasodilator agent, which refers to single or long-term use; the latter may develop tolerance such as to nitrates [90]. The role of mitochondrial aldehyde dehydrogenase was discovered [90], which specifically generates 1,2-glyceryl dinitrate from nitroglycerin, in the bioactivation of nitroglycerin to elicit vasorelaxation and in the development of tolerance to nitroglycerin; 4). the concentration of vasodilator that should be correlated to the plasma concentrations if used systematically but could be much higher if used topically [17]; and 5). the rapidity of onset of effect that may maximally relief spasm [14, 24].

3.1. The Vasodilator Agents Used for Arterial Grafts

Papaverine

Papaverine is a traditional topical vasodilator and is probably a pharmacological vasodilator used earlier than most others. The satisfactory results were reported in early studies [91]. Papaverine is an opioid-derivative and a non-specific vasodilator substance, which relaxes blood vessels through multiple mechanisms. It is a phosphodiesterase inhibitor and therefore may raise cGMP level in smooth muscle cells [92]. Papaverine-induced relaxation is also due to other actions such as decreased calcium influx [93], or inhibition of release of intracellularly stored calcium [94]. It usually relaxes vessels (such as human IMA) at high concentrations regardless of the nature of the contraction. It has been suggested that papaverine has a satisfactory vasorelaxant effect in IMA [91, 95-100] and other arterial grafts [101]. However, papaverine is not recommended for systemic use. The major concern of the topical use of papaverine is its acidic nature (pH 4.4 at -2.6 log M and pH 4.8 at -4.5 log M [23], which may damage the endothelial function. These concentrations are related to the solutions used for surgery as demonstrated in the human RA [36]. A common clinical protocol to topically use papaverine is to mix papaverine with blood. This may reduce its acidity due to the buffering effect of blood. On the other hand, papaverine hydrochloride is relatively unstable in non-acidic solutions and a white precipitate sometimes formed when papaverine is added to plasmalyte solution (pH approximately 7.4) [13] and the effect of this phenomenon in papaverine-blood mixture is unknown. In addition, the onset of vasodilation effect of papaverine is slower than other vasodilators such as NTG and verapamil although once reaches the plateau, the effect of papaverine is sustained [23, 34]. Papaverine was also shown to be inferior to nitroglycerin in GEA [102].

Nitrovasodilators

Organic nitrates (nitrovasodilators) such as nitroglycerin (NTG, i.e., glyceryl trinitrate [GTN]), sodium nitroprusside (SNP), or isosorbide dinitrate are widely used in CABG patients. The mechanism of vasorelaxation of these vasodilators is that they release NO, a powerful stimulant for guanylate cyclase which raises cGMP in the smooth muscle cell [103]. This subsequently reduces intracellular calcium concentrations and leads to relaxation of the smooth muscle cell.

Nitrovasodilators (NTG or SNP) have been demonstrated to be potent vasodilators in the human IMA [17, 20, 23, 25, 33, 41, 42, 44, 45, 47, 104-109], RA [36, 38, 41, 42, 44, 45, 106-108, 110], GEA [40, 105], and IEA [30, 106]. It was demonstrated that NTG is effective for either topical [19, 42, 102, 109, 110] or systemic [42, 44, 107] use. Nitrates are slightly more effective in blocking receptor-operated channels than blocking depolarizing agent-mediated contraction [17]. Early studies focusing on NTG and nitroprusside showed different effects of these drugs in vitro and in vivo [104]. Another group of NO donors thionitrites such as S-nitrosothiol RIG200 has been demonstrated to have prolonged, NO-mediated relaxation [111].

Importantly, nitrates are effective in treating established vascular spasm, regardless of the nature of the contraction; i.e., they are effective in reversing either receptor-mediated (TXA_2 receptors, adrenoceptors, or ET receptors) contraction or depolarizing agent (K^+)-mediated contraction [17]. However, they are less potent in prevention of vasospasm [17, 19, 20, 38].

This is probably related to the tolerance of a vessel to these nitrovasodilators [19, 25, 90, 103], as demonstrated later that mitochondrial aldehyde dehydrogenase plays a role in the mechanism of the development of tolerance to nitroglycerin [90]. Compared each other, NTG is more potent than SNP in the vasorelaxing effect but SNP is more effective in preventing ANGII and α-adrenoceptor-mediated contraction in the IMA [35].

Calcium Antagonists

Classical calcium antagonists were three chemically divergent groups - dihydropyridine (nifedipine, exc.), phenylalkylamines (verapamil, exc.), and benzothiazepines (diltiazem, exc.). The new generations of these drugs, particularly the new dihydropyridines such as nisoldipine [112], nicardipine [113-116], amlodipine [117], cilnidipine [118], and azalnidipine [119], have been developed in the past decades and their effect on arterial grafts have been investigated. In general, they all express vasodilatory effect in arterial grafts. In addition to the calcium channel blockage, some of these new generations of calcium antagonists such as amlodipine [117], cilnidipine [118], and azalnidipine [119] may also stimulate the vascular endothelium to release NO that may further enhance the vasorelaxant effect in arterial grafts. It is possible that these new vasodilators may be proved to be usefeul in the prevention of spasm in arterial grafts.

In fact, calcium antagonists have been used as antispastic drugs in arterial grafting either alone [6, 120] or in combination to NTG [23, 34, 36, 39, 121]. Among the first generation of the three calcium antagonists, it was reported that diltiazem is the least potent one and nifedipine is 15-fold more potent than diltiazem in IMA [17]. However, diltiazem contributed to the successful revival of the RA after this graft was abandoned for almost 20-years due to serious spasm problems [6]. In contrast, diltiazem was reported to have little effect on human RA contractions [38, 43]. Further, verapamil is more potent than diltiazem in the human vessels [17] and this drug was available in injection form, therefore it was reconmmended to be included in the antispastic protocols [23, 34, 36]. As discussed before, in arterial grafts the effects of vasodilators depend on the nature of the vasoconstriction and this is particularly important for calcium antagonists. When IMA contracts with depolarizing agent potassium (K^+), nifedipine or other calcium antagonists are very effective in both preventing and reversing IMA contraction through inhibition of L-type calcium channel [17]. This is due to the fact that calcium antagonists relax blood vessels through a specific mechanism. Calcium antagonists reduce Ca^{2+} influx by blocking voltage-operated calcium channels, which is the major mechanism for the depolarizing agent K^+ to contract vessels. Therefore, calcium antagonists are particularly effective in preventing or treating K^+-induced contraction and this has been demonstrated in either IMA [17, 39] or RA [38, 43]. However, calcium antagonists such as nifedipine are less effective in contraction mediated by receptors such as TXA_2 receptors [17], α-adrenoceptors [27 122], ET [25, 123], or vasopressin (VP1 receptors) - mediated contraction [124].

Phosphodiesterase (PDE) Inhibitors

As modulators of vascular smooth muscle tone, intracellular cAMP and cGMP are controlled through synthesis by cyclases and through hydrolysis by PDEs that are classified to at least five types. PDE III inhibitors such as amrinone or milrinone are known to inhibit cGMP-inhibitable low Km cAMP PDE [125]. The cardiac and vascular smooth muscle

actions are favorable in postoperative management of patients who undergo open heart surgery, particularly in patients who present ventricular dysfunction and receive arterial grafts for CABG. The effect of PDEIII inhibitor milrinone on the IMA [33, 126, 127] or RA [82, 128, 129], and PDEIIIA inhibitor olprinone on the GEA and RA [130] has been studied and shown effective. It is noticed that the effect of milrinone on the IMA is superior to that on RA [82]. Further, in the systemic use, after cardiopulmonary bypass, milrinone dilates the IMA [131] and perioperative continuous infusion of milrinone, compared with nifedipine, results in a significantly lower incidence of myocardial ischaemia and myocardial cell damage after elective CABG [132]. In opposite, another PDEIII inhibitor enoximone is a potent in vitro vasodilator but exerts weak relaxant effects in IMA and GEA at concentrations in the therapeutic range [133].

α-adrenoceptor Antagonists

It has been demonstrated that both IMA [21, 134] and RA [37, 134] are α_1-adrenoceptor-predominant artery. However, IMA has little α_2-adrenoceptor [21] whereas the RA has significant α_2-adrenoceptor [37] function, although the RA is also α_1-adrenoceptor predominant. This is the rationale to use α-adrenoceptor antagonists such as phenoxybenzamine as antispastic drug in CABG as an effective agent to prevent catecholamine-mediated spasm of RA [135, 136].

Phenoxybenzamine is reported more effective and less harmful than papaverine in the prevention of radial artery vasospasm [137, 138]. On the other hand, however, theoretically, α-adrenoceptor antagonists are only effective in reversing the contraction evoked by α-adrenoceptor but not to other vasoconstrictors as may be predicted from the pharmacological mechanism of α-adrenoceptor antagonists, i.e., α-adrenoceptor antagonists may only be effective in one specific mechanism of spasm and could be insufficient when the spasm is due to other mechanisms such as due to other receptor-mechanisms or due to the mechanism related to the L-type calcium channels. The nature of vasoconstriction and spasm is complex and may involve many other vasoconstrictors [77]. In fact, Conant and colleagues [139] reported that phenoxybenzamine-treated radial artery failed to respond to noradrenaline but did respond to vasopressin, angiotensin II, endothelin-1, and KCl and therefore is insufficient to prevent spasm in the radial artery. In this regard, new calcium antagonists with α_1-adrenergic receptor blocking activity such as AJ-2615 may overcome the shortage of pure α-adrenoceptor antagonists [140] but this requires more clinical studies.

Beta-Receptor Agonists

It has been reported that β-adrenoceptor function is weak in both IMA [80] and RA [37], despite of the coexistence of at least three distinct beta-adrenoceptors in IMA [141]. Therefore, theoretically, use of β-adrenoceptor agonists such as dobutamine unlikely relaxes the IMA and RA to a significant degree and this was demonstrated to be true in IMA and GEA [133].

Dopamine Receptor Agonists

The effect for these agonists is more complicated. Due to the complexity of the interaction between dopamine and dopamine receptors as well as α_1-adrenoceptors, dopamine-induced responses are complex and dose-dependent [142]. In RA, dopamine

enhanced the norepinephrine-induced contraction. In GEA, low concentrations (<10(-7) mol/L) of dopamine attenuated the norepinephrine-induced contraction but higher concentrations did not. In IMA, dopamine induced a vasorelaxation on the norepinephrine-contraction only at higher concentrations (10(-6)-10(-5) mol/L) [142] and the selective dopamine-1 (D1) receptor partial agonist fenoldopam, 0.1 microg/kg/min, did not influence coronary conduit blood flow to a clinically significant extent [143]. Most likely, dopamine is not suitable to be used primarily for the vasorelaxant effect in the arterial grafts but its effect on the graft should be aware of when it is used primarily for its inotropic effect.

Prostacyclin PGI2 Analogue

Synthetic analogue of prostacyclin PGI_2 iloprost was recommended to be an antispastic drug for RA [144, 145] and IMA [145]. Iloprost, when the infusion was initiated 5 days before surgery, was shown to have superior efficacy over diltiazem in preventing RA spasm in the early period and the 2-year angiographic patency [146].

Rho-Kinase Inhibitor

Rho kinase inhibitors may be effective drug candidates to prevent and treat spasm [147]. Intraluminal injection of rho kinase inhibitor fasudil (1.5 mg/min for 15 minutes) into the spastic arteries (both coronary and graft arteries) successfully resolved the spasm and improved myocardial ischemia in all patients without any systemic adverse effects [148]. In addition, recently, fasudil is shown to be useful for dilating RA grafts [149].

Angiotensin Receptor Antagonist

Due to the fact that angiotensin has been shown to be a spasmogen in arterial grafts [65, 67, 83, 113]. Angiotensin receptor antagonists were therefore tested for the possible antispastic effectiveness [150]. However, there are no clinical reports yet.

Heme Oxygenase 1

Heme oxygenase plays a role in the control of arterial vasoreactivity [151]. Hemin caused in vitro induction of heme oxygenase 1 in human IMA and RA and resulted in a reduced contractility to norepinephrine, partially through the cyclic guanosine monophosphate-dependent pathway [151]. It is possible that activation of heme oxygenase may become one of the antispastic methods.

C-Type Natriuretic Peptide

C-type natriuretic peptide relaxes IMA and RA preconstricted by endothelin-1 and therefore may have therapeutic potential of antispastic therapy [152].

TXA2 Antagonists

Because of the well-known importance of TXA_2 in vasoconstriction and thrombosis, specific TXA_2 antagonists may be useful in the antispastic therapy of arterial grafts. One of TXA_2 antagonists GR32191 has been found to be a potent vasodilator for TXA_2-mediated contraction in either IMA [153] or RA [154]. Further clinical trials are necessary to confirm this.

Vascular Endothelial Growth Factor (VEGF)

As an endothelium-dependent relaxing agent, VEGF may not be considered as the primary drug for antispastic therapy in arterial grafts. However, the potent hypotensive effect of VEGF due to its systemic vasorelaxation through endothelium-dependent mechanism is demonstrated in the IMA [155]. Most likely, the relaxing effect is related to the NO and PGI_2 mechanisms through the KDR-receptor [156].

Potassium (K+) Channel Openers (KCOs)

ATP-sensitive potassium channels (KATP) exist in a wide range of cells, particularly in endocrine cells, smooth muscle, skeletal muscle, neurons, and cardiac cells [157]. Potassium (K+) channel openers (KCOs) are considered to comprise a heterogeneous group of organic compounds [158]. KCOs repolarize or hyperpolarize the cell membrane. They therefore decrease the opening probability of voltage-dependent L- and T-type Ca^{2+}-channels and restrain agonist-induced Ca^{2+} release from intracellular sources through inhibition of inositol trisphosphate (IP3) formation, and lower the efficiency of calcium as an activator of contractile proteins [158]. In addition, KCOs may accelerate the clearance of intracellular free Ca^{2+} via the $Na^{+}/Ca2^{+}$ exchange pathway. The effects drive the vascular smooth muscle cells into a relaxed state and reduce membrane excitability and the reactivity of the cell [158]. It has been suggested that vascular smooth muscle is particularly sensitive to KCOs [157]. Considering these characteristics, KCOs are of great value as therapeutical agents. Aprikalim [159, 160], levcromakalim [161, 162], KRN4884 [163], and rilmakalim [162] have been studied in the human IMA and found to be potent vasodilators in a number of receptor-mediated contraction and therefore, these KCOs may become a clinically useful antispastic drug in arterial grafts.

Antiplatelet Drugs

Activated platelets induce pronounced contraction of the gastroepiploic artery that may contribute to postoperative spasm. Therefore vasodilators that prevent the effects of TXA_2 and serotonin may be beneficial to gastroepiploic artery graft function [164].

Vasodilators through Other Mechanisms Potentially Useful for Antispastic Protocols

A few of other substances have been investigated in the human arterial grafts and suggested be potential antispastic agents. Nutritional supplement L-carnitine Carnitine, a quaternary ammonium compound biosynthesized from the amino acids lysine and methionine, is widely available as a nutritional supplement. L-carnitine is a potential vasodilatory drug for internal mammary artery and saphenous vein grafts [165]. Botulinum toxin inhibits muscle contraction for about three months and is shown to prevented arterial graft spasm in vitro and had a longer lasting effect than papaverine, with no toxic effect on the artery of rats [166] but there were no human artery studies. Finally, NO-independent soluble guanylate cyclase (sGC) activator YC-1, and DEA/NO (diethylamine/nitric oxide), a NO-nucleophile adduct may be effective as vasodilator for the short-term treatment of perioperative spasm of coronary bypass grafts [167]. Most likely, those vasodilator substances would unlikely be primarily chosen as clinical antispastic agents.

Combination of Vasodilators

It must be emphasized that all vasodilators have their own limitations in some aspect because each of them has a specific mechanism or mechanisms to relax vessels. These mechanisms have been discussed above. Combination of these vasodilators may overcome these disadvantages and therefore produce a better effect. Some of the combinations have been studied in the IMA and RA. For example, as an intraluminal or topical solution for the preparation of the grafts, calcium antagonists and NTG may have synergistic effect in IMA [23, 39, 112, 168] and in RA [34, 36 22, 23; 121, 169]. Yoshizaki and associates have demonstrated that combination of verapamil and nitroglycerin improves the patency rate of radial artery grafts [169]. Even in the critical situation with lethal spasm problems, the combination of NTG and verapamil has been reported to successfully release the spasm in arterial grafts through intraluminal injection that was a life salvage procedure [54]. The method is used successfully by others to relieve the coronary spasm as well [170] and is now used in catheterization laboratory for preventing RA spasm with success [171].

Other combination of vasodilators may also be clinically useful. The more than additive effect of milrinone and NTG has also been demonstrated [33] although such in vivo effect is to be demonstrated [46]. In addition, combined use of enoximone (a PDEIII inhibitor) and dobutamine (a beta-receptor agonist) at concentrations in the therapeutic range exerts a greater than additive vasorelaxant effect in IMA and GEA [133]. However, the role of such combination of vasodilator drugs in preparation of arterial grafts is to be established.

Taken together, from literature, the effect of a particular vasodilator in prevention or treatment of spasm in arterial grafts is often contradictory. We may conclude that there is no "perfect" vasodilator for dilating the IMA or other arterial grafts. This is due to the fact that spasm of arterial grafts may involve many mechanisms and each particular vasodilator may only relax the vessel through one mechanism or sometimes more than one mechanisms but no vasodilator may relax the vessel through all mechanisms. Under some circumstances, combination of vasodilators may be preferable.

3.2. Existing Pharmacological Methods (Antispastic Protocols) to Overcome Spasm

There are various antispastic protocols available in different units around the world.

Pharmacological methods are the most common antispastic protocols used in clinical practice world-widely.

Table 1 gives summary of the pharmacological antispastic protocols used in the practice of arterial grafting. Some of the protocols were designed based on the pharmacological studies on arterial grafts, as detailed in Table 1. However, other protocols are rather empirical.

Table 1. Summary of the antispastic protocols and existing techniques used in arterial grafting in CABG (from reference 202 with permission)

Authors	Topical	IMA	GEA	RA	Systemic	Postoperative oral
Mills 1989 [91]	papaverine	+				
Acar 1992 [6]	papaverine + blood			+	Diltiazem	Diltiazem
Suma 1991 [101]	papaverine		+			
Dietl 1995 [25]	papaverine			+	Diltiazem	Diltiazem "if spasm is noted"
Dregelid1995 [95]	papaverine	+				
Reyes 1995 [27]	papaverine 60 mg + 60 ml blood			+	Diltiazem	
Sasson 1995 [96]	papaverine	+				
Bilgen 1996 [97]	papaverine	+				
Yavuz 2001 [98]	papaverine	+				
Girard 2004 [99]	papaverine	+				
Tatoulis 2004 [22]	Papaverine			+	Nitroglycerin	amlodipine
Bahcivan 2007 [100]	papaverine	+				
Kiessling 2013 [32]	Papaverine					
He GW 1994 [23]	VG	+				
He GW 1996 [34, 36]	VG			+#	Nicardipine*	one calcium antagonist**
Esmore 2000 [28]	VG			+	Nitroglycerin	
Yoshizaki 2008 [169]	VG			+#		
Mussa 2003 [135]	Phenoxy-benzamine			+		
Corvera 2003 [136]	Phenoxy-benzamine			+		
Gurevitch 1997 [106]	isosorbide dinitrate #	+	+	+		
Shapira 2000 [107]				+#	Nitroglycerin	
Chavanon 1999 [40]	Nitroglycerin		+			
García-Rinaldi 1999 [128]	milrinone			+		
Halpenny 2001 [143]		+			fenoldopam (D1 agonist)	
Zabeeda 2001 [44]		+#		+#	Nitroglycerin	
Möllhoff 2002 [132]				+#	milrinone	
Inokuchi 2004 [148]		+			Fasudil (through catheter)	
Tabel 2004 [120]		+			Diltiazem	
Nisanoglu 2006 [110]	Nitroglycerin			+		
Yamaguchi 2006 [130]	PDEIII inhibitor (olprinone)			+		
He 2008 [114]; Zheng 2012 [115]	NG	+			Nicardipine*	one calcium antagonist**
Ustunsoy 2009 [146]				+#	iloprost (5 days preop)	
Watanabe 2013 [149]	fasudil			+#		

4. NON-PHARMACOLOGICAL THERAPY TO OVERCOME SPASM

4.1. Denervation or Skeletonization or En-Bloc Harvesting?

It has been suggested that skeletonized arterial grafting may reduce the risk of graft spasm and may improve graft patency [172] and the removal of the periarterial sympathetic nerve from the human gastroepiploic artery reduced vascular contraction, elicited by peripheral nerve stimulation, without disturbing endothelial and smooth muscle contractile functions. This reduction may contribute to the prevention of vasospasms [10].

Similarly, it was reported that the results of using skeletonized radial artery grafts are excellent [130, 173-175] and this is often done with the ultrasonic scalpel **[**173, 174]. Kucukarslan and colleagues [176] used long fasciotomy of the posterior aspect of the RA for the purpose of sympathectomy to prepare the RA graft and believed this technique provides a satisfactory increase in the blood flow index and reduces the manipulation time as well as the risk of injury to the graft.

On the other hand, a study from Germany compared the skeletonization technique with pedicle preparation using either an ultrasonic scalpel or scissors and analyzed endothelial morphology by scanning electron microscopy and the conclusion is that skeletonization with an ultrasonic scalpel did not result in additional length and was more frequently associated with severe endothelial damage. Pedicle preparation using scissors or an ultrasonic scalpel is much simpler and faster, and does not jeopardize endothelial integrity [177]. Therefore, whether the skeletonization technique gives better results is still in debate.

In support of the above study, en-bloc free gastroepiploic artery graft, which has the gastroepiploic vein anastomosed to the right atrial appendage to prevent graft spasm [178] is proposed. They believed that the free gastroepiploic artery grafting with venous drainage technique can prevent graft spasm, leading to improved patency rate.

A retrospective review [179] in 57 patients who received en-bloc grafts and 29 who had skeletonized grafts reveals that 80-month patency rates of 100% for en-bloc grafts and 60% for skeletonized grafts. The observation, however, requires further clinical trials to be confirmed.

4.2. Carbon Dioxide Insufflation

Carbon dioxide insufflation of the internal thoracic artery was suggested to be an efficient technique to increase the flow and prevent vasospasm [180]. The reactivity of the human internal mammary artery grafts harvested by either classical or carbon dioxide insufflation technique was compared; carbon dioxide insufflation technique does seem not only to protect the integrity of the endothelium and the whole vessel, but also prevent the possible vasospasm of the internal mammary artery segments [181].

4.3. Normothermia or Heat Therapy or No Need for Vasodilators

Normothermia

It is possible that hypothermia plays an important role in radial artery vasospasm. It was even proposed that after harvesting the graft, regaining physiological normothermic state is enough for vasodilatation [182]. It has been suggested by the same group that preserving internal thoracic artery pedicles in normothermic conditions can be the preferred treatment for spasms [183] and that store of the radial artery graft in normothermic bath may relieve spasm of radial artery and the effect is similar to the use of verapamil-nitroglycerin solution [184]. On opposite, it was also proposed to treat radial artery grafts thermally in situ (45°C to 65°C; up to 120 s), so-called thermal ablation with effective anti-spastic effect [185].

However, the concept in those sporadic reports has not been widely accepted.

As mentioned above, the causes and mechanisms of vasospasm involve multiple factors, unlikely the temperature is the only factor affecting the vascular contraction/relaxation balance and therefore it is unlikely true that to use normothermia as the anti-spastic method would be effective under all situations.

4.4. Injection of Room Air Beneath the Endothoracic Fascia Before IMA Dissection

Occasionally, injection of room air beneath the endothoracic fascia before IMA dissection is used to prevent spasm and shorten harvest time [186] but the practice is not widely accepted.

4.5. Harmonic Scalpel

Since causes of vasospasm of the grafts may involve thermal injury caused by electrocautery and traumatic harvesting technique, the harmonic scalpel was proposed to decrease the harvesting time, frequency of spasm, and excessive use of hemostatic clips [187].

This technique was rapidly spread out and was demonstrated to be effective in harvesting of the RA associated with decreased RA spasm, good hemostasis, no additional harvest time, and has become standard technique in a number of units [188-193]. In addition, it was demonstrated that the optical coherence tomographic findings suggest that the harmonic scalpel induces less spasm and intimal injury compared with electrocautery [194].

4.6. Intraoperative Detection of Intimal Lipid in the Radial Artery Predicts Degree of Postoperative Spasm

In two reports from one group [195, 196], optical coherence tomography imaging was used as a quality assurance tool for evaluating endoscopic harvest of the radial artery and the authors imaged RA conduits before and after CABG in order to characterize intimal

abnormalities that might be related to the risk of spasm. They reported that the degree of attenuation of the optical coherence tomography (OCT) signal produced by the RA was strongly correlated with percentage diameter change and was significantly more pronounced in grafts with spasm versus no spasm. Histology confirmed lipid deposits in areas of RA with strong attenuation. RA conduits were often found by OCT imaging to have a substantial amount of lipid, which in turn strongly relates to the risk of postoperative spasm. Screening conduits based on characteristics of intimal quality may improve results following RA grafting [195] and catheter-based OCT provide an important quality assurance tool for RA harvest [196].

4.7. Careful Dissection and Preparation of the IMA Pedicle to Prevent Injury and Spasm

Tector and colleagues [197] emphasize that initial flow in the IMA immediately after grafting is critical to the success of the operation. Careful dissection and preparation of the IMA pedicle to prevent injury and spasm, constructing parallel and perpendicular anastomoses so the most proximal portion of the IMA is used for anastomosis and the use of the free right IMA to increase length of graft available are measures employed to increase critical flow.

4.8. Intractable LIMA Spasm in the Postoperative Period Treated by Placement of 'Bridging' Stent - A “Hybrid Procedure”

Pratt and colleagues [57] reported that a woman with critical left main stenosis suffered intractable left internal mammary artery (LIMA) spasm post-coronary artery bypass grafting. This was managed with a left main stent and the patient stabilized. A 3-month follow-up angiogram showed a patent graft and a blocked stent. This “hybrid” method may be the choice of the patients under such circumstances.

4.9. Pre-Emptive Stellate Ganglion Block

Pre-emptive stellate ganglion block (SGB) was suggested to be an effective method for increasing radial artery blood flow and preventing radial artery spasm [198].

4.10. Extrafascially Harvested Radial Artery

It was suggested that when the radial artery is harvested extrafascially, with diltiazem infusion, the RA may be used with improve the early and long-term results [199].

4.11. Injection of Vasodilators into Arterial Grafts through Cardiac Catheter to Relieve Spasm

When the grafts or the coronary artery develop spasm perioperatively, injection of vasodilators such as verapamil plus nitroglycerin into arterial grafts as well as the native coronary artery through cardiac catheter may relieve spasm and this could a life-saving procedure [54]. The method is used successfully by others to relieve the coronary spasm as well [170]. Due to the fact that radial artery spasm is a frequent complication of the transradial approach for coronary angiography and angioplasty, this method is now used in catheterization laboratory. Administration of an intra-arterial vasodilating cocktail composed of verapamil plus nitroglycerine prior to sheath insertion reduces the occurrence and severity of radial artery spasm [171].

4.12. Balloon Calibration to Relieve IMA Spasm

This technique allows full IMA distention without the devascularizing effects of full skeletonization and was applied in more than 793 patients over five years. Postcalibration flow rates increased 3- to 18-fold over precalibration flow rates [200].

4.13. Adenoviral Transfer of NOS

Adenoviral transfer of NOS suggests that future clinical application of gene therapy may play an important role in prevention of RA vasospasm [38].

4.14. Extracorporeal Membrane Oxygenation (ECMO)

For diffuse refractory vascular spasm after CABG, a rare but lethal condition, an aggressive treatment, that is, prompt ECMO institution and controlled cardiocirculatory assistance, represents the preferred solution to face such a dramatic event and may save patient lives [59].

The above pharmacological and non-pharmacological antispastic methods have been summarized with detailed illustrations and tables in the two most recent review articles [201,202].

SUMMARY AND CONCLUSION

CABG surgery has been the standard treatment for patients with coronary artery disease particularly for three-vessel disease, although PCI has become the preferred method in one- or two-vessel disease. Arterial grafting using autologous arteries as the grafts has been demonstrated to have superior long-term results. Use of the left IMA to graft the diseased LAD has become the standard method for almost all CABG surgery and bilateral IMA grafts

may further enhance survival over the long-term. Other arteries such as radial artery, right gastroepiploic artery, and inferior epigastric artery are commonly used arterial grafts. However, in comparison to vein grafts, arterial grafts have a tendency to develop vasospasm that can lead to potentially life-threatening complications. This is a long-recognized clinical problem and occurs even in the current practice. There have been various antispastic protocols, either pharmacological or non-pharmacological, but the rationale and efficacy are sometimes unclear. The multiple methods used in CABG to prevent and treat spasm of arterial grafts are effective in the current practice but it is still controversial as to what is the most effective regimen. This is partially due to the pathophysiological complexity of the mechanism of vascular spasm and the evolution of pharmacological vasodilators and non-pharmacological methods. Better understanding of the mechanism of vascular spasm, development of new pharmacological vasodilators, and the adequate evaluation of non-pharmacological methods may lead to a more unanimous opinion as to the best method to prevent and treat arterial spasm in contemporary clinical practice.

FUNDING SOURCES

The work described in this paper was fully supported by grants from the National Natural Science Foundation of China (81170148), Zhejiang Provincial Natural Science Foundation (LY15H020008), Hangzhou Science and Technology Projects (20140633B12), & Tianjin Binhai Key Platform for Creative Research Program (2012-BH110004), Binhai New Area Health Bureau (2012BWKZ 008).

DISCLOSURES

None.

REFERENCES

[1] Loop FD, Lytle BW, Cosgrove DM, Stewart RW, Goormastic M, Williams GW, Golding LA, Gill CC, Taylor PC, Sheldon WC. Influence of the internal- mammary-artery graft on 10-year survival and other cardiac events. *N Engl J Med* 1986; 314:1-6.

[2] Taggart DP. CABG or stents in coronary artery disease: end of the debate? *Lancet.* 2013 Feb 23;381:605-7.

[3] Sabik JF 3rd, Stockins A, Nowicki ER, Blackstone EH, Houghtaling PL, Lytle BW, Loop FD. Does location of the second internal thoracic artery graft influence outcome of coronary artery bypass grafting? *Circulation.* 2008;118:S210-5.

[4] Leacche M, Gosev I. Hybrid coronary revascularization: the future of coronary artery bypass surgery or an unfulfilled promise? *Circulation.* 2014 Jul 23. pii: CIRCULATION AHA.114.011857.

[5] Yi G, Shine B, Rehman SM, Altman DG, Taggart DP. Effect of bilateral internal mammary artery on long-term survival: a meta-analysis approach. *Circulation.* 2014 Jun 10. pii: CIRCULATION AHA.113.004255.

[6] Acar C, Jebara VA, Portoghese M, et al.: Revival of the radial artery for coronary bypass grafting. *Ann Thorac Surg* 1992;54:652-60.

[7] Rehman SM, Yi G, Taggart DP. The radial artery: current concepts on its use in coronary artery revascularization. *Ann Thorac Surg.* 2013;96:1900-9.

[8] Pym J, Brown PM, Charrette EJP, Parker JO, West RO. Gastroepiploic-coronary anastomosis: a viable alternative bypass graft. *J Thorac Cardiovasc Surg* 1987;94:256-9.

[9] Suma H, Wanibuchi Y, Furuta S, Isshiki T, Yamaguchi T, Takanashi R. Comparative study between the gastroepiploic and the internal thoracic artery as a coronary bypass graft. Size, flow, patency, histology. *Eur J Cardiothorac Surg.* 1991;5:244-7.

[10] Yokoyama Y, Matsushita S, Iesaki T, Yamamoto T, Inaba H, Okada T, Amano A. Denervation of gastroepiploic artery graft can reduce vasospasm. *J Thorac Cardiovasc Surg.* 2014;147:951-5.

[11] Puig LB, Ciongolli W, Cividanes GV, Dontos A, Kopel L, Bittencourt D, Assis RV, Jatene AD. Inferior epigastric artery as a free graft for myocardial revascularization. *J Thorac Cardiovasc Surg* 1990;99:251-5.

[12] Buche M, Schoevaerdts JC, Louagie Y, Schroeder E, Marchandise B, Chenu P, Dion R, Verhelst R, Deloos M, Gonzales E. Use of the inferior epigastric artery for coronary bypass. *J Thorac Cardiovasc Surg* 1992;103:665-70.

[13] Cunningham JN: Papaverine hydrochloride preservation of vein grafts. *J Thorac Cardiovasc Surg* 1982; 84:933-4.

[14] He GW, Rosenfeldt FL, Angus JA. Pharmacological relaxation of the saphenous vein during harvesting for coronary artery bypass grafting. *Ann Thorac Surg.* 1993;55:1210-7.

[15] He GW, Angus JA, Rosenfeldt FL: Reactivity of the canine isolated internal mammary artery, saphenous vein, and coronary artery to constrictor and dilator substances: Relevance to coronary bypass graft surgery. *J Cardiovasc Pharmacol* 1988;12:12-22.

[16] Luscher TF, Diederich D, Siebenmann R, et al. Difference between endothlium-dependent relaxation in arterial and in venous coronary bypass grafts. *N Engl J Med* 1988;319:462-7.

[17] He GW, Rosenfeldt F, Buxton B, Angus JA: Reactivity of human isolated internal mammary artery to constrictor and dilator agents. Implications for treatment of internal mammary artery spasm. *Circulation* 1989;80:I-141-50.

[18] Jett GK, Guyton RA, Hatcher CR, Abel PW: Inhibition of human internal mammary artery contractions. An in vitro study of vasodilators. *J Thorac Cardiovasc Surg* 1992;104:977-82.

[19] He GW, Shaw J, Yang CQ, et al. Inhibitory effects of glyceryl trinitrate on α-adrenoceptor mediated contraction in the internal mammary artery. *Br J Clin Pharmacol* 1992;34:236-43.

[20] Cooper GJ, Wilkinson GAL, Angilini GD: Overcoming perioperative spasm of the internal mammary artery: which is the best vasodilator? *J Thorac Cardiovasc Surg* 1992;104:465-8.

[21] He GW, Shaw J, Hughes C.F, et al. Predominant α1-adrenoceptor mediated contraction in the human internal mammary artery. *J Cardiovasc Pharmacol* 1993;21:256-63.

[22] Tatoulis J, Buxton BF, Fuller JA. Patencies of 2127 arterial to coronary conduits over 15 years. *Ann Thorac Surg.* 2004;77:93-101.

[23] He GW, Rosenfeldt FL, Angus JA, and Buxton, BF: Pharmacological dilatation of internal mammary artery during surgery. *J Thorac Cardiovasc Surg* 1994;107:1440-4.

[24] Cooper GJ, Locke TJ: The in vitro response of human internal mammary artery to vasodilators. *J Thorac Cadiovasc Surg* 1994;107:1155-6.

[25] Dietle CA, Benoit CH: Radial artery graft for coronary revascularization: Technical considerations. *Ann Thorac Surg* 1995;60:102-10.

[26] Seo B, Oemar BS, Siebenmann R, von Segesser L, Luscher TF: Both ETA and ETB receptors mediate contraction to endothelin-1 in human blood vessels. *Circulation* 1994;89:1203-8.

[27] Reyes AT, Frame R, Brodman RF. Technique for harvesting the radial artery as a coronary artery bypass graft. *Ann Thorac Surg* 1995;59:118-26.

[28] Esmore DS, Burton PR, Smith JA, Rabinov M, Pick A, McMahon J, Rosenfeldt FL. A simplified method of harvesting and dilating the radial artery achieves acceptable clinical outcomes. *Aust N Z J Surg. 2000*;70:366-70.

[29] He GW, Yang CQ: Comparison among arterial grafts and coronary artery. An attempt at functional classification. *J Thorac Cardiovasc Surg* 1995;109:707-15.

[30] He GW, Acuff TE, Yang CQ, Ryan WH, Mack MJ: Functional comparison between the human inferior epigastric artery and internal mammary artery: Similarities and differences. *J Thorac Cardiovasc Surg* 1995;109:13-20.

[31] He GW, Yang CQ: Effects of thromboxane A2 antagonist GR32191B on prostanoid and nonprostanoid receptors in the human internal mammary artery. *J Cardiovasc Pharmacol* 1995;26:13-9.

[32] Kiessling AH, Romasku D, Beiras-Fernandez A, Ferreirós N, Labocha S, Moritz A, Rastan AJ. Pharmacokinetics of intraluminally administered serum papaverine for spasm prophylaxis of the internal mammary artery. *Heart Surg Forum.* 2013;16:E266-70.

[33] He GW, Yang CQ, Gately H, et al: Potential greater than additive vasorelaxant actions of milrinone and nitroglycerin on human conduit arteries. *Br J Clin Pharmacol* 1996;41:101-7.

[34] He GW, Yang CQ: Use of verapamil and nitroglycerin solution in preparation of radial artery for coronary grafting. *Ann Thorac Surg* 1996;61:610-4.

[35] He GW, Yang CQ: Comparison of nitroprusside and nitroglycerin in inhibition of angiotensin II and other vasoconstrictor-mediated contraction in human coronary bypass conduits. *Br J Clin Pharmacol* 1997;44:361-7.

[36] He GW: Verapamil plus nitroglycerin solution maximally preserves endothelial function of the radial artery: comparison to papaverine solution. *J Thorac Cardiovasc Surg* 1998;115:1321-7.

[37] He GW, Yang CQ: Characteristics of adrenoceptors in the human radial artery: clinical implications. *J Thorac Cardiovasc Surg* 1998;115:1136-41.

[38] Cable DG, Caccitolo JA, Pearson PJ, O'Brien T, Mullany CJ, Daly RC, Orszulak TA, Schaff HV: New approaches to prevention and treatment of radial artery graft vasospasm. *Circulation* 1998; 98:II15-21; discussion II21-2.

[39] Rosenfeldt FL, He GW, Buxton BF, Angus JA: Pharmacology of coronary artery bypass grafts. *Ann Thorac Surg* 1999;67:878-88.

[40] Chavanon O, Cracowski JL, Hacini R, Stanke F, Durand M, Noirclerc M, Blin D: Effect of topical vasodilators on gastroepiploic artery graft. *Ann Thorac Surg* 1999;67:1295-8.

[41] He GW, Yang CQ: Comparison of vasorelaxant effect of nitroprusside and nitroglycerin in the human radial artery. *Br J Clin Pharmacol* 1999;48:99-104.

[42] Shapira OM, Xu A, Vita JA, Aldea GS, Shah N, Shemin RJ, Keaney JF Jr: Nitroglycerin is superior to diltiazem as a coronary bypass conduit vasodilator. *J Thorac Cardiovasc Surg* 1999;117:906-11.

[43] He GW, Yang CQ: Comparative study on calcium channel antagonists in the human radial artery: clinical implications. *J Thorac Cardiovasc Surg* 2000;119:94-100.

[44] Zabeeda D, Medalion B, Jackobshvilli S, Ezra S, Schachner A, Cohen AJ: Comparison of systemic vasodilators: effects on flow in internal mammary and radial arteries. *Ann Thorac Surg* 2001;71:138-41.

[45] Gabe ED, Figal JC, Wisner JN, Laguens R: Radial artery graft vasospasm. *Eur J Cardiothorac Surg* 2001;19:102-4.

[46] Lobato EB, Janelle GM, Urdaneta F, Martin TD: Comparison of milrinone versus nitroglycerin, alone and in combination, on grafted internal mammary artery flow after cardiopulmonary bypass: effects of alpha-adrenergic stimulation. *J Cardiothorac Vasc Anesth* 2001;15:723-7.

[47] Wei W, H. Storm Floten, He GW: Interaction between vasodilators and vasopressin in internal mammary artery and clinical significance. *Ann Thorac Surg* 2002;73:516-22.

[48] Sarabu MR, McClung JA, Fass A, Reed GE. Early postoperative spasm in left internal mammary artery bypass grafts. *Ann Thorac Surg.* 1987;44:199-200.

[49] Hata M, Shiono M, Orime Y, Hata H, Yagi S, Tsukamoto S, Kimura S, Sezai A, Kashiwawzaki S, Choh S, Negishi N, Sezai Y. Spontaneous recanalization of postoperative severe graft stenosis. What is the cause and prognosis of the "string sign" in the internal thoracic artery? *Ann Thorac Cardiovasc Surg.* 1999;5:52-5.

[50] Jones EL, Lattouf OM, Weintraub WS. Catastrophic consequences of internal mammary artery hypoperfusion. *J Thorac Cardiovasc Surg.* 1989;98:902-7.

[51] Fakiolas CN1, Adamopoulou EN, Kouvaras GA, Olympios CD, Foussas SG. Systolic segmental disappearance of internal mammary artery graft. Correlation with prolonged spasm of the graft. *Acta Cardiol.* 1995;50(1):71-7.

[52] He GW. Contractility of the human internal mammary artery at the distal section increases toward the end. Emphasis on not using the end of the internal mammary artery for grafting. *J Thorac Cardiovasc Surg.* 1993;106:406-11.

[53] Vogt PR, Hess O, Turina MI. Internal mammary artery spasm immediately after grafting to the left anterior descending artery: diagnosis and treatment. *Eur Heart J.* 1996;17:804.

[54] He GW, Fan KY, Chiu SW, Chow WH. Injection of vasodilators into arterial grafts through cardiac catheter to relieve spasm. *Ann Thorac Surg.* 2000;69:625-8.

[55] Sanders LH, Newman MA. Intractable postoperative internal thoracic artery spasm managed with angiographic intraluminal papaverine. *J Thorac Cardiovasc Surg.* 2005;130:938-40.

[56] Harskamp RE, McNeil JD, van Ginkel MW, Bastos RB, Baisden CE, Calhoon JH. Postoperative internal thoracic artery spasm after coronary artery bypass grafting. *Ann Thorac Surg.* 2008;85:647-9.

[57] Pratt GF, Erickson M, Provenzano S, Mews G, Edwards M. Intractable LIMA spasm in the postoperative period treated by placement of 'bridging' stent. *Ann Thorac Surg.* 2008;86:1985-7.

[58] Baek JH1, Han SS, Lee DH. Native coronary artery and grafted artery spasm just after coronary artery bypass grafting: a case report. *J Korean Med Sci.* 2010 ;25:641-3.

[59] Lorusso R, Crudeli E, Lucà F, De Cicco G, Vizzardi E, D'Aloia A, Gelsomino S. Refractory spasm of coronary arteries and grafted conduits after isolated coronary artery bypass surgery. *Ann Thorac Surg.* 2012;93:545-51.

[60] Nakazawa H, Moriyama K, Motoyasu A, Endo H, Kubota H, Yorozu T. Prompt institution of percutaneous cardiopulmonary support managed perioperative refractory vascular spasm after isolated coronary artery bypass grafting surgery. *Gen Thorac Cardiovasc Surg.* 2013;61:711-5.

[61] Ichikawa Y1, Kajiwara H, Hamada T, Yamazaki I, Jin Y, Sato S. Late vasospasm of the inferior epigastric artery graft. *Ann Thorac Surg.* 1999;67:1800-1.

[62] He GW. Arterial grafts for coronary artery bypass grafting: biological characteristics, functional classification, and clinical choice. *Ann Thorac Surg.* 1999;67:277-84.

[63] Liu ZG, Ge ZD, He GW. Difference in endothelium-derived hyperpolarizing factor-mediated hyperpolarization and nitric oxide release between human internal mammary artery and saphenous vein. *Circulation.* 2000;102:III296-301.

[64] He GW, Liu ZG. Comparison of nitric oxide release and endothelium-derived hyperpolarizing factor-mediated hyperpolarization between human radial and internal mammary arteries. *Circulation.* 2001;104:I344-9.

[65] He GW, Yang CQ. Radial artery has higher receptor-mediated contractility but similar endothelial function compared with mammary artery. *Ann Thorac Surg* 1997;63:1346-52.

[66] He GW, Fan L, Grove KL, Furnary A, Yang Q. Expression and function of endothelial nitric oxide synthase messenger RNA and protein are higher in internal mammary than in radial arteries. *Ann Thorac Surg.* 2011;92:845-50.

[67] Choudhary BP, Antoniades C, Brading AF, Galione A, Channon K, Taggart DP. Diabetes mellitus as a predictor for radial artery vasoreactivity in patients undergoing coronary artery bypass grafting. *J Am Coll Cardiol.* 2007;50:1047-53.

[68] Yaqub Y, Suarez J, Perez-Verdia A, Arvandi A, Nugent KM. Klippel-Trenaunay syndrome and radial artery coronary graft spasm. *J Coll Physicians Surg Pak.* 2009;19:658-60.

[69] Kulkarni NM, Thomas MR. Severe spasm of a radial artery coronary bypass graft during coronary intervention. *Catheter Cardiovasc Interv.* 1999;47:331-5.

[70] Gabe ED, Figal JC, Wisner JN, Laguens R. Radial artery graft vasospasm. *Eur J Cardiothorac Surg.* 2001;19:102-4.

[71] Goube P, Hammoudi N, Pagny JY, Boutekadjirt R, Toledano D, Achouh P, Acar C. Radial artery graft stenosis treated by percutaneous intervention. *Eur J Cardiothorac Surg.* 2010;37:697-703.

[72] Suma H. Spasm of the gastroepiploic artery graft. *Ann Thorac Surg* 1990;49:168-9.

[73] Mills NL, Hockmuth DR, Everson CT, Robart CC. Right gastroepiploic artery used for coronary artery bypass grafting. Evaluation of flow characteristics and size. *J Thorac Cardiovasc Surg.* 1993;106:579-85.

[74] Cate CM, Gitter R, Jett K. Spasm of the gastroepiploic artery used for coronary artery bypass grafting. *Am J Cardiol.* 1996 ;77:1022-3.

[75] Hara K, Kashida M, Tamura T, Saeki F, Ikari Y, Suma H. Diffuse spasm of a free gastroepiploic artery graft during percutaneous balloon angioplasty. *Cathet Cardiovasc Diagn.* 1994;33:136-8.

[76] Van Son JAM, Smedts F, Vincent JG, Van Lier HJ, Kubat K. Comparative anatomic studies of various arterial conduits for myocardial revascularization. *J Thorac Cardiovasc Surg* 1990;99:703-7.

[77] He GW, Yang CQ, Starr A: An overview of the nature of vasoconstriction in arterial grafts for coronary surgery. *Ann Thorac Surg* 1995;59:676-83.

[78] Lockowandt U, Ritchie A, Grossebener M, Franco-Cereceda A. Endothelin and effects of endothelin-receptor activation in the mammary and radial artery. *Scand Cardiovasc J.* 2004;38:240-4.

[79] Cross KS, el-Sanadiki MN, Murray JJ, Mikat EM, McCann RL, Hagen PO. Mast cell infiltration: a possible mechanism for vein graft vasospasm. *Surgery.* 1988;104:171-7.

[80] He GW, Buxton B, Rosenfeldt FL, Wilson AC, Angus JA. Weak beta-adrenoceptor-mediated relaxation in the human internal mammary artery. *J Thorac Cardiovasc Surg.* 1989;97:259-66.

[81] Kitamura S1, Morita R, Kawachi K, Iioka S, Seki T, Inoue K, Taniguchi S. Different responses of coronary artery and internal mammary artery bypass grafts to ergonovine and nitroglycerin in variant angina. *Ann Thorac Surg.* 1989;47:756-60.

[82] Wei W, Yang CQ, Furnary A, He GW: Greater vasopressin-induced vasoconstriction and inferior effects of nitrovasodilators and milrinone in the radial artery than in the internal thoracic artery. *J Thorac Cardiovasc Surg* 2005;129:33-40.

[83] Stojnic N, Bukarica LG, Peric M, Bumbasirevic M, Lesic A, Lipkovski JM, Heinle H. Analysis of vasoreactivity of isolated human radial artery. *J Pharmacol Sci.* 2006;100:34-40.

[84] Arshad M, Vijay V, Floyd BC, Marks B, Sarabu MR, Wolin MS, Gupte SA. Thromboxane receptor stimulation suppresses guanylate cyclase-mediated relaxation of radial arteries. *Ann Thorac Surg.* 2006;81:2147-54.

[85] Liu JJ, Chen JR, Bradley CJ, Xie B, Johnston CI, Buxton BF. Autologous neutrophil derived supernatants inhibit endothelium dependent relaxation in human coronary bypass graft. *Cardiovasc Res.* 1994 ;28:1353-9.

[86] Kun X, Lefeng W, Rongjing D, Xincun Y. RhoA/ROK pathway related to the mechanism of higher susceptibility to spasm in RA than in IMA. *J Card Surg.* 2009;24:766-71.

[87] Mueed I, Tazzeo T, Liu C, Pertens E, Zhang Y, Cybulski I, Semelhago L, Noora J, Lamy A, Teoh K, Chu V, Janssen LJ. Isoprostanes constrict human radial artery by

stimulation of thromboxane receptors, Ca2+ release, and RhoA activation. *J Thorac Cardiovasc Surg.* 2008;135:131-8.

[88] Aghamohammadzadeh R, Withers S, Lynch F, Greenstein A, Malik R, Heagerty A. Perivascular adipose tissue from human systemic and coronary vessels: the emergence of a new pharmacotherapeutic target. *Br J Pharmacol.* 2012;165:670-82.

[89] Bodelsson M, Arneklo-Nobin B, Chester AH, Tadjkarimi S, Törnebrandt K, Yacoub M. Differential effect of hypothermia on the vascular tone and reactivity of the human coronary artery and graft vessels. *J Cardiovasc Surg (Torino).* 1991 ;32:288-94.

[90] Chen Z, Zhang J, Stamler JS. Identification of the enzymatic mechanism of nitroglycerin bioactivation. *Proc Natl Acad Sci U S A.* 2002;99:8306-11.

[91] Mills NL, Bringaze WL 3rd.Preparation of the internal mammary artery graft. Which is the best method? *J Thorac Cardiovasc Surg.* 1989;98:73-7; discussion 78-9.

[92] Martin W, Furchgott RF, Villani GM, Jothianandan: Phosphodiesterase inhibitors induce endothelium-dependent relaxation of rat and rabbit aorta by potentiating the effects of spontaneously released endothelium-derived relaxing factor. *J Pharmacol Exp Ther* 1986;237:539-47.

[93] Fujioka M. Lack of a causal relationship between the vasodilator effect of papaverine and cyclic AMP production in the dog basilar artery. *Br J Pharmoc* 1984;83:113-24.

[94] Brading AF, Burdyga TV, Scripnyuk ZD. The effects of papaverine on the electrical and mechanical activity of the guinea-pig ureter. *J Physiol* 1983;334:79-89.

[95] Dregelid E, Heldal K, Resch F, Stangeland L, Breivik K, Svendsen E. Dilation of the internal mammary artery by external and intraluminal papaverine application. *J Thorac Cardiovasc Surg.* 1995;110:697-703.

[96] Sasson L, Cohen AJ, Hauptman E, Schachner A. Effect of topical vasodilators on internal mammary arteries. *Ann Thorac Surg.* 1995;59:494-6.

[97] Bilgen F, Yapici MF, Serbetçioğlu A, Tarhan IA, Coruh T, Ozler A. Effect of normothermic papaverine to relieve intraoperative spasm of the internal thoracic artery. *Ann Thorac Surg.* 1996;62:769-71.

[98] Yavuz S, Celkan A, Göncü T, Türk T, Ozdemir IA. Effect of papaverine applications on blood flow of the internal mammary artery. *Ann Thorac Cardiovasc Surg.* 2001;7:84-8.

[99] Girard DS, Sutton JP 3rd, Williams TH, Crumbley AJ 3rd, Zellner JL, Kratz JM, Crawford FA. Papaverine delivery to the internal mammary artery pedicle effectively treats spasm. *Ann Thorac Surg.* 2004;78:1295-8.

[100] Bahcivan M, Kolbakir F, Karamustafa H, Keceligil HT. Endothoracic papaverine application for internal thoracic artery harvest. *Asian Cardiovasc Thorac Ann.* 2007;15:234-7.

[101] Suma H, Wanibuchi Y, Furuta S, Isshiki T, Yamaguchi T, Takanashi R. Comparative study between the gastroepiploic and the internal thoracic artery as a coronary bypass graft. Size, flow, patency, histology. *Eur J Cardiothorac Surg.* 1991;5:244-7.

[102] Chavanon O, Cracowski JL, Hacini R, Stanke F, Durand M, Noirclerc M, Blin D. Effect of topical vasodilators on gastroepiploic artery graft. *Ann Thorac Surg.* 1999;67:1295-8.

[103] Ignarro LJ. After 130 years, the molecular mechanism of action of nitroglycerin is revealed. *Proc Natl Acad Sci U S A.* 2002; 99: 7816–7817.

[104] Jett GK, Arcici JM Jr, Hatcher CR Jr, Abel PW, Guyton RA. Vasodilator drug effects on internal mammary artery and saphenous vein grafts. *J Am Coll Cardiol.* 1988;11:1317-24.

[105] Uydeş-Doğan BS, Nebigil M, Aslamaci S, Onuk E, Kanzik I, Akar F. The comparison of vascular reactivities of arterial and venous grafts to vasodilators: management of graft spasm. *Int J Cardiol.* 1996;53:137-45.

[106] Gurevitch J, Miller HI, Shapira I, Kramer A, Paz Y, Matsa M, Mohr R, Yakirevich V. High-dose isosorbide dinitrate for myocardial revascularization with composite arterial grafts. *Ann Thorac Surg.* 1997;63:382-7.

[107] Shapira OM, Alkon JD, Macron DS, Keaney JF Jr, Vita JA, Aldea GS, Shemin RJ. Nitroglycerin is preferable to diltiazem for prevention of coronary bypass conduit spasm. *Ann Thorac Surg.* 2000 ;70:883-8; discussion 888-9.

[108] Ding R, Feng W, Li H, Wang L, Li D, Cheng Z, Guo J, Hu D. A comparative study on in vitro and in vivo effects of topical vasodilators in human internal mammary, radial artery and great saphenous vein. *Eur J Cardiothorac Surg.* 2008;34:536-41.

[109] Kiss L, Benko R, Kovács E, Szerafin T, Módis K, Szabó C, Lacza Z. Human internal thoracic artery grafts exhibit severe morphological and functional damage and spasmic vasomotion due to oxidative stress. *Med Sci Monit.* 2011;17:CR411-6.

[110] Nisanoglu V, Battaloglu B, Ozgur B, Eroglu T, Erdil N. Topical vasodilators for preventing radial artery spasm during harvesting for coronary revascularization: comparison of 4 agents. *Heart Surg Forum.* 2006;9:E807-12.

[111] Sogo N, Campanella C, Webb DJ, Megson IL. S-nitrosothiols cause prolonged, nitric oxide-mediated relaxation in human saphenous vein and internal mammary artery: therapeutic potential in bypass surgery. *Br J Pharmacol.* 2000;131:1236-44.

[112] Liu JJ, Johnston CI, Buxton BF: Synergistic effect of nisoldipine and nitroglycerin on human internal mammary artery. *J Pharmacol Exp Therap* 1994;268:434-40.

[113] Chanda J, Canver CC. Reversal of preexisting vasospasm in coronary artery conduits. *Ann Thorac Surg*. 2001;72:476-80.

[114] He GW, Fan L, Furnary A, Yang Q. A new antispastic solution for arterial grafting: nicardipine and nitroglycerin cocktail in preparation of internal thoracic and radial arteries for coronary surgery. *J Thorac Cardiovasc Surg.* 2008;136:673-80, 680.e1-2.

[115] Zheng SY, Wu M, Huang JS, Mai MJ, Chen TB, He GW. Use of antispastic nicardipine and nitroglycerin (NG) cocktail solution increases graft flow during off-pump coronary artery bypass grafting. *J Cardiovasc Surg (Torino).* 2012;53:783-8.

[116] He GW. Aterial grafts: clinical classification and pharmacological management. *Ann Cardiothorac Surg.* 2013 Jul;2(4):507-18.

[117] Bai XY, Liu XC, Jing WB, Yang Q, Tang XD, He GW. Effect of amlodipine in human internal mammary artery and clinical implications. *Ann Thorac Surg.* 2010;90:1952-7.

[118] Fan L, Yang Q, Xiao XQ, Grove KL, Huang Y, Chen ZW, Furnary A, He GW. Dual actions of cilnidipine in human internal thoracic artery: inhibition of calcium channels and enhancement of endothelial nitric oxide synthase. *J Thorac Cardiovasc Surg.* 2011;141:1063-9.

[119] Gao G, Liu XC, Jing WB, Yang Q, He GW. Vasorelaxation induced by new third-generation dihydropyridine calcium antagonist azelnidipine in human internal mammary artery. *Ann Thorac Surg.* 2013;96:1316-21.

[120] Tabel Y, Hepağuşlar H, Erdal C, Catalyürek H, Acikel U, Elar Z, Aslan O. Diltiazem provides higher internal mammary artery flow than nitroglycerin during coronary artery bypass grafting surgery. *Eur J Cardiothorac Surg.* 2004;25:553-9.

[121] Chanda J, Brichkov I, Canver CC. Prevention of radial artery graft vasospasm after coronary bypass. *Ann Thorac Surg.* 2000;70:2070-4.

[122] He GW, Acuff TE, Ryan WH, Yang CQ, Douthit MB, Bowman RT, Mack MJ. Inhibitory effects of calcium antagonists on alpha-adrenoceptor-mediated contraction in the human internal mammary artery. *Br J Clin Pharmacol.* 1994;37:173-9.

[123] He GW, Yang CQ, Mack MJ, Acuff TE, Ryan WH, Starr A. Interaction between endothelin and vasodilators in the human internal mammary artery. *Br J Clin Pharmacol.* 1994;38:505-12.

[124] Wei W, Floten HS, He GW: Interaction between vasodilators and vasopressin in internal mammary artery and clinical significance. *Ann Thorac Surg* 2002;73:516-22.

[125] Beavo JA, Reifsnyder DH: Primary sequences of cyclic nucleotide phosphodiesterases isozymes and the design of selective inhibitors. *Trends Pharmacol Sci* 1990;11:150-5.

[126] He G-W and Yang C-Q: Inhibition of vasoconstriction by phosphodiesterase III inhibitor milrinone in human conduit arteries used as coronary bypass grafts. *J Cardiovasc Pharmacol* 1996;28:208-14.

[127] Liu JJ, Doolan LA, Xie B, Chen JR, Buxton BF. Direct vasodilator effect of milrinone, an inotropic dgug, on arterial coronary bypass grafts. *J Thorac Cardiovasc Surg* 1997;113:3108-13.

[128] García-Rinaldi R, Soltero ER, Carballido J, Mojica J. Intraluminal milrinone for dilation of the radial artery graft. *Tex Heart Inst J.* 1999;26:189-91.

[129] He GW, Yang CQ: Vasorelaxant effect of phosphodiesterase-inhibitor milrinone in the human radial artery used as coronary bypass graft. *J Thorac Cardiovasc Surg* 2000;119:1039-45.

[130] Yamaguchi S, Watanabe G, Higasidani K, Tomita S, Iino K, Ujiie T, Yamamoto S. Skeletonized radial artery graft prepared with phosphodiesterase-III inhibitors indicates favorable results compared with pedicled radial artery graft in angiographic studies. *Innovations* (Phila). 2006;1:251-4.

[131] Lobato EB, Janelle GM, Urdaneta F, Martin TD: Comparison of milrinone versus nitroglycerin, alone and in combination, on grafted internal mammary artery flow after cardiopulmonary bypass: effects of alpha-adrenergic stimulation. *J Cardiothorac Vasc Anesth* 2001;15:723-7.

[132] Möllhoff T, Schmidt C, Van Aken H, Berendes E, Buerkle H, Marmann P, Reinbold T, Prenger-Berninghoff R, Tjan TD, Scheld HH, Deng MC. Myocardial ischaemia in patients with impaired left ventricular function undergoing coronary artery bypass grafting--milrinone versus nifedipin. *Eur J Anaesthesiol.* 2002;19:796-802.

[133] Cracowski JL, Stanke-Labesque F, Chavanon O, Blin D, Mallion JM, Bessard G, Devillier P: Vasorelaxant actions of enoximone, dobutamine, and the combination on human arterial coronary bypass grafts. *J Cardiovasc Pharmacol* 1999;34:741-8.

[134] Yan M, Liu DL, Chua YL, Chen C, Lim YL. Tyrosine kinase inhibitors suppress alpha1-adrenoceptor mediated contraction in human radial, internal mammary arteries and saphenous vein. *Neurosci Lett.* 2002;333:171-4.

[135] Mussa S, Guzik TJ, Black E, Dipp MA, Channon KM, Taggart DP. Comparative efficacies and durations of action of phenoxybenzamine, verapamil/nitroglycerin

solution, and papaverine as topical antispasmodics for radial artery coronary bypass grafting. *J Thorac Cardiovasc Surg* 2003;126:1798-805.

[136] Corvera JS, Morris CD, Budde JM, Velez DA, Puskas JD, Lattouf OM, Cooper WA, Guyton RA, Vinten-Johansen J. Pretreatment with phenoxybenzamine attenuates the radial artery's vasoconstrictor response to alpha-adrenergic stimuli. *J Thorac Cardiovasc Surg* 2003;126:1549-54.

[137] Dipp MA, Nye PC, Taggart DP. Phenoxybenzamine is more effective and less harmful than papaverine in the prevention of radial artery vasospasm. *Eur J Cardiothorac Surg.* 2001;19:482-6.

[138] Harrison WE, Mellor AJ, Clark J, Singer DR. Vasodilator pre-treatment of human radial arteries; comparison of effects of phenoxybenzamine vs papaverine on norepinephrine-induced contraction in vitro. *Eur Heart J.* 2001;22:2209-16.

[139] Conant AR, Shackcloth MJ, Oo AY, Chester MR, Simpson AW, Dihmis WC: Phenoxybenzamine treatment is insufficient to prevent spasm in the radial artery: the effect of other vasodilators. *J Thorac Cardiovasc Surg* 2003;126:448-54.

[140] Liu MH, Floten HS, Yang Q, He GW. Inhibition of vasoconstriction by AJ-2615, a novel calcium antagonist with α1-adrenergic receptor blocking activity in human conduit arteries used as bypass grafts. *Br J Clin Pharmacol* 2001;52:279-87.

[141] Shafiei M, Omrani G, Mahmoudian M: Coexistence of at least three distinct beta-adrenoceptors in human internal mammary artery. *Acta Physiol Hung* 2000;87:275-86.

[142] Katai R, Tsuneyoshi I, Hamasaki J, Onomoto M, Suehiro S, Sakata R, Kanmura Y: The variable effects of dopamine among human isolated arteries commonly used for coronary bypass grafts. *Anesth Analg* 2004;98:915-20.

[143] Halpenny M, Lakshmi S, O'Donnell A, O'Callaghan-Enright S, O'Connell D, Shorten G. The effects of fenoldopam on coronary conduit blood flow after coronary artery bypass graft surgery. *J Cardiothorac Vasc Anesth.* 2001;15:72-6.

[144] Ozdemir C, Ikizler M, Besogul Y, Karakaya A, Sirmagul B. An alternative agent for radial arterial graft spasm: application of topical iloprost. *Scand Cardiovasc J.* 2007;41:201-6.

[145] Ege T, Gur O, Karadag CH, Duran E. Evaluation of iloprost to prevent vasospasm in coronary artery bypass grafts. *J Int Med Res.* 2010 ;38:1759-63.

[146] Ustunsoy H, Kazaz H, Celkan MA, Deniz H, Davutoglu V, Bakir K, Cine N, Burma O. Randomized comparison of vasodilator effects of iloprost versus diltiazem on flow and pathologic changes in radial arteries: mid-term angiographic control study of the comparison of vasodilators on radial artery vasospasm. *Heart Surg Forum.* 2009;12:E202-7.

[147] Kun X, Lefeng W, Rongjing D, Xincun Y. RhoA/ROK pathway related to the mechanism of higher susceptibility to spasm in RA than in IMA. *J Card Surg.* 2009;24:766-71.

[148] Inokuchi K, Ito A, Fukumoto Y, Matoba T, Shiose A, Nishida T, Masuda M, Morita S, Shimokawa H. Usefulness of fasudil, a Rho-kinase inhibitor, to treat intractable severe coronary spasm after coronary artery bypass surgery. *J Cardiovasc Pharmacol.* 2004;44:275-7.

[149] Watanabe G, Yamaguchi S, Takagi T, Tomita S, Tuan PM. Potent Vasodilatory Effect of Fasudil on Radial Artery Graft in Coronary Artery Bypass Operations. *Ann Thorac Surg.* 2013. pii: S0003-4975(13)02341-2.

[150] Liu MH, Floten HS, Furnary A, He GW: Inhibition of vasoconstriction by angiotensin receptor antagonist GR117289C in arteries grafts. *Ann Thorac Surg* 2000;70:2064-9.

[151] Achouh P, Simonet S, Badier-Commander C, Chardigny C, Vayssettes-Courchay C, Zegdi R, Khabbaz Z, Fabiani JN, Verbeuren TJ. The induction of heme oxygenase 1 decreases contractility in human internal thoracic artery and radial artery grafts. *J Thorac Cardiovasc Surg.* 2005;130:1573-80.

[152] Kelsall CJ, Chester AH, Amrani M, Singer DR. C-type natriuretic peptide relaxes human coronary artery bypass grafts preconstricted by endothelin-1. *Ann Thorac Surg.* 2005;80:1347-51.

[153] He GW, Yang CQ. Effect of thromboxane A2 antagonist GR32191B on prostanoid and nonprostanoid receptors in the human internal mammary artery. *J Cardiovasc Pharmacol.* 1995;26:13-9.

[154] He GW, Yang CQ. Inhibition of vasoconstriction by thromboxane A2 antagonist GR32191B in the human radial artery. *Br J Clin Pharmacol* 1999;48:207-15.

[155] Liu MH, Jin HK, Floten HS, Ren Z, Yim APC, He GW: Vascular endothelial growth factor-mediated, endothelium-dependent relaxation in human internal mammary artery. *Ann Thorac Surg* 2002;73:819-24.

[156] Wei W, Jin H, Chen ZW, Zioncheck TF, Yim APC, He GW: Vascular endothelial growth factor-induced nitric oxide- and PGI2-dependent relaxation in human internal mammary arteries: a comparative study with KDR and Flt-1 selective mutants. *J Cardiovasc Pharmacol* 2004;44:615-21.

[157] Lazdunski M: ATP-sensitive potassium channels: an overview. *J Cardiovasc Pharmacol* 1994;24:S1-5.

[158] Atwal KS: Pharmacology and structure-active relationships for KATP modulators: tissue-selective KATP openers. *J Cardiovasc Pharmacol* 1994;24:S12-7.

[159] He GW and Yang CQ: Inhibition of vasoconstriction by potassium channel opener aprikalim in human conduit arteries. *Br J Clin Pharmacol* 1997;44:353-9.

[160] Liu MH, Floten HS, Furnary A, Yim APC, He GW: Effect of potassium channel opener (KCO) aprikalim on the receptor-mediated vasoconstriction in the human internal mammary artery (IMA). *Ann Thorac Surg* 2001;71:636-41.

[161] Akar F, Uydeş-Dogan BS, Tufan H, Aşlamaci S, Köksoy C, Kanzik I. The comparison of the responsiveness of human isolated internal mammary and gastroepiploic arteries to levcromakalim: an alternative approach to the management of graft spasm. *Br J Clin Pharmacol* 1997;44:49-56.

[162] Novaković A, Gojković-Bukarica L, Beleslin-Cokić B, Japundzić-Zigon N, Sajić Z, Nezić D, Perić M, Djukanović B, Kazić T. Differential antivasoconstrictor effects of levcromakalim and rilmakalim on the isolated human mammary artery and saphenous vein. *J Pharmacol Sci.* 2003;92:108-14.

[163] Ren Z, Floten HS, Furnary A, Liu MH, Gately H, Swanson J, Ahmad A, Yim APC, He GW: Effects of potassium channel opener KRN4884 on human conduit arteries used as coronary bypass grafts. *Br J Clin Pharmacol* 2000;50:154-60.

[164] Li XN, Stulz P, Siebenmann RP, Yang Z, Lüscher TF. Different effects of activated platelets in the right gastroepiploic and internal mammary arteries. Implications for coronary artery grafting. *J Thorac Cardiovasc Surg.* 1992;104:1294-302.

[165] Güçlü O, Yüksel V, Hüseyin S, Ege T, Canbaz S, Süngün M. In vitro effects of L-carnitine on coronary artery bypass grafts. *Exp Clin Cardiol.* 2013 Spring;18:118-20.

[166] Murakami E, Iwata H, Imaizumi M, Takemura H. Prevention of arterial graft spasm by botulinum toxin: an in-vitro experiment. *Interact Cardiovasc Thorac Surg.* 2009;9:395-8.

[167] Berkan O, Bagcivan I, Kaya T, Yildirim K, Yildirim S, Doğan K. Investigation of the vasorelaxant effects of 3-(5'-hydroxymethyl-2'-furyl)-1-benzyl indazole (YC-1) and diethylamine/nitric oxide (DEA/NO) on the human radial artery used as coronary bypass graft. *Can J Physiol Pharmacol.* 2007;85:521-6.

[168] Formica F, Ferro O, Brustia M, Corti F, Colagrande L, Bosisio E, Paolini G. Effects of papaverine and glycerylnitrate-verapamil solution as topical and intraluminal vasodilators for internal thoracic artery. *Ann Thorac Surg.* 2006 ;81:120-4.

[169] Yoshizaki T, Tabuchi N, Toyama M. Verapamil and nitroglycerin improves the patency rate of radial artery grafts. *Asian Cardiovasc Thorac Ann. 2008*;16:396-400.

[170] Caputo M, Nicolini F, Franciosi G, Gallotti R: Coronary artery spasm after coronary artery bypass grafting. *Eur J Cardiothorac Surg* 1999;15:545-8.

[171] Kiemeneij F, Vajifdar BU, Eccleshall SC, Laarman G, Slagboom T, van der Wieken R: Evaluation of a spasmolytic cocktail to prevent radial artery spasm during coronary procedures. *Catheter Cardiovasc Interv* 2003;58:281-4.

[172] Li R, Amano A, Miyagawa H, Dohi S, Hayashi I, Kajimoto K, Shimada A, Hirose H. Skeletonized gastroepiploic artery for off-pump coronary artery bypass grafting. *Heart Surg Forum.* 2004;7:E164-9.

[173] Asai T, Tabata S. Skeletonization of the right gastroepiploic artery using an ultrasonic scalpel. *Ann Thorac Surg.* 2002;74:1715-7.

[174] Amano A, Takahashi A, Hirose H. Skeletonized radial artery grafting: improved angiographic results. *Ann Thorac Surg.* 2002;73:1880-7.

[175] Hirose H, Amano A. Skeletonized radial artery grafting: one-year patency rate. *Heart Surg Forum.* 2004;7:E277-82.

[176] Kucukarslan N, Kirilmaz A, Sungun M, Ozal E, Ulusoy RE, Sanisoglu Y, Tatar H. Harvesting of the radial artery: subfasciotomy or full skeletonization: a comparative study. *J Card Surg.* 2008;23:341-5.

[177] Rukosujew A, Reichelt R, Fabricius AM, Drees G, Tjan TD, Rothenburger M, Hoffmeier A, Scheld HH, Schmid C. Skeletonization versus pedicle preparation of the radial artery with and without the ultrasonic scalpel. *Ann Thorac Surg.* 2004;77:120-5.

[178] Matsuura A, Yasuura K, Yoshida K, Oshima H, Tomari S, Ishida H, Mori S, Fujii G, Iwata K. Transplantation of the en bloc vascular system for coronary revascularization. *J Thorac Cardiovasc Surg.* 2001;121:520-5.

[179] Eda T, Miyahara K, Oshima H, Usui A, Matsuura A, Ueda Y. En-bloc free gastroepiploic artery graft provides a good long-term patency rate. *Asian Cardiovasc Thorac Ann.* 2010;18:244-9.

[180] Ozkan M, Koramaz I, Ulus AT, Tavil Y, Filizlioglu H, Baykan EC, Eryilmaz S, Inan B, Katircioglu SF, Ozyurda U. Effect of carbon dioxide insufflation on free internal thoracic artery flows: is it a vasodilator? *J Thorac Cardiovasc Surg.* 2004;128:354-6.

[181] Koramaz I, Ozkan M, Kesim M, Güven KY, Kadioglu M, Ulku C, Cobanoglu U, Yaris E, Kalyoncu NI, Ozcan F. The contracting and relaxing responses of human internal mammary artery grafts harvested by two different methods. *Pharmacol Res.* 2005;51:567-73.

[182] Tarhan A, Kehlibar T, Yapici F, Yilmaz M, Arslan Y, Yapici N, Ozler A. Role of physiological state 'normothermia' in internal thoracic artery spasm after harvesting. *Eur J Cardiothorac Surg.* 2006;30:749-52.

[183] Tarhan IA, Kehlibar T, Yilmaz M, Arslan Y, Dumantepe M, Berkoz K, Pancaroglu C, Ozler A. Normothermia is the key for the treatment of internal thoracic artery spasm. *Heart Surg Forum.* 2007;10:E180-5.

[184] Tarhan IA, Kehlibar T, Arslan Y, Yilmaz M, Dumantepe M, Berkoz K, Pancaroglu C, Ozler A. Effects of normothermic organ bath and verapamil-nitroglycerin solution alone or in combination on the blood flow of radial artery. *Eur J Cardiothorac Surg.* 2007;32:617-22.

[185] Mueed I, Tazzeo T, Doharris L, Aziz T, Chu V, Janssen LJ. Reduction of arterial graft smooth muscle mass by moderate heat therapy. *Transl Res.* 2011;157:128-38.

[186] Beşoğul Y. Endothoracic injection of room air for internal mammary artery harvest. *J Card Surg.* 2009n;24:309-11.

[187] Psacioğlu H, Atay Y, Cetindağ B, Saribülbül O, Buket S, Hamulu A. Easy harvesting of radial artery with ultrasonically activated scalpel. *Ann Thorac Surg.* 1998 ;65:984-5.].

[188] Ronan JW, Perry LA, Barner HB, Sundt TM 3rd. Radial artery harvest: comparison of ultrasonic dissection with standard technique. *Ann Thorac* Surg. 2000;69:113-4;

[189] Georghiou GP, Stamler A, Berman M, Sharoni E, Vidne BA, Sahar G. Advantages of the ultrasonic harmonic scalpel for radial artery harvesting. *Asian Cardiovasc Thorac Ann.* 2005;13:58-60;

[190] Canosa C, Nasso G, De Filippo CM, Modugno P, Spatuzza P, Calvo E, Testa N, Alessandrini F. Open clip-free radial artery harvesting with the harmonic shears. *J Card Surg.* 2007;22:139-41;

[191] Erkut B, Unlu Y, Karapolat S, Ugur Kocogullari C, Ceviz M, Becit N, Kocak H. Comparison of harmonic scalpel and high-frequency electrocautery in radial artery harvesting. *J Cardiovasc Surg (Torino).* 2008;49:371-9;

[192] Oz BS, Mataraci I, Iyem H, Kuralay E, Doganci S, Demirkilic U, Yokusoglu M, Tatar H. Comparison of ultrasonically activated scalpel and traditional technique in radial artery harvesting: clinical research. *Thorac Cardiovasc Surg.* 2007;55:104-7;

[193] Fawzy HF. Harvesting of the radial artery for coronary artery bypass grafting: comparison of ultrasonic harmonic scalpel dissector with the conventional technique. *J Card Surg.* 2009;24:285-9.

[194] Brazio PS, Laird PC, Xu C, Gu J, Burris NS, Brown EN, Kon ZN, Poston RS. Harmonic scalpel versus electrocautery for harvest of radial artery conduits: reduced risk of spasm and intimal injury on optical coherence tomography. *J Thorac Cardiovasc Surg.* 2008;136:1302-8.

[195] Brown EN, Burris NS, Kon ZN, Grant MC, Brazio PS, Xu C, Laird P, Gu J, Kallam S, Desai P, Poston RS. Intraoperative detection of intimal lipid in the radial artery predicts degree of postoperative spasm. *Atherosclerosis.* 2009;205:466-71.

[196] Burris NS, Brown EN, Grant M, Kon ZN, Gibber M, Gu J, Schwartz K, Kallam S, Joshi A, Vitali R, Poston RS. Optical coherence tomography imaging as a quality assurance tool for evaluating endoscopic harvest of the radial artery. *Ann Thorac Surg.* 2008;85:1271-7.

[197] Tector AJ, Schmahl TM, Crouch JD, Canino VR, Heckel RC. Sequential, free and Y internal thoracic artery grafts. *Eur Heart J.* 1989;10 Suppl H:71-7.
[198] Yildirim V, Akay HT, Bingol H, Bolcal C, Iyem H, Doğanci S, Demirkilic U, Tatar H. Pre-emptive stellate ganglion block increases the patency of radial artery grafts in coronary artery bypass surgery. *Acta Anaesthesiol Scand.* 2007;51:434-40.
[199] Kulshrestha P, Rao L, Garb JL, Rousou JA, Engelman RM, Wait RB. Use of extrafascially harvested radial artery for coronary artery revascularization: technical considerations. *J Card Surg.* 1999;14:26-31.
[200] Gaudiani VA, Buch WS, Chin AK, Ayres LJ, Fogarty TJ. An improved technique for the internal mammary artery coronary bypass graft procedure. *J Card Surg.* 1988;3:467-73.
[201] He GW, Taggart DP. Spasm in arterial grafts in coronary artery bypass grafting surgery. *Ann Thorac Surg.* 2016;101(3):1222-9. Epub 2015 Nov 14.
[202] He GW, Taggart DP. Antispastic management in arterial grafts in coronary artery bypass grafting surgery. *Ann Thorac Surg.* 2016 (in press).

In: Encyclopedia of Surgery (22 Volume Set)
Editors: Andreas Lehrer and Kristin Mueller
ISBN: 978-1-53618-329-0
© 2020 Nova Science Publishers, Inc.

Chapter 411

CARDIO THORACIC SURGERY APPROACH TO CARDIAC RESYNCHRONIZATION THERAPY: IMPLANT TECHNIQUES, ADVANTAGES AND LIMITATIONS

Nicola Testa[1], MD, Paola Spatuzza[1], MD,
Carlo Maria De Filippo[1], MD and Celestino Sardu[1,2,*], MD, PhD
[1]Cardiovascular Department, John Paul II,
Research and Care Foundation, Campobasso, Italy
[2]Department of Medical, Surgical, Neurological,
Metabolic and Aging Sciences, University of Naples, Naples, Italy

ABSTRACT

The transvenous route is the choice treatment for Cardiac resynchronization therapy (CRT). The success of implant technique during ventricular resynchronization therapy is related to the better left ventricle (LV) lead placement, such as pacing lead performance and stability, and in absence of phrenic nerve stimulation. The cardiac venous anatomy may still limit implantation of transvenous LV leads. Limitations to reach the best LV target area by percutaneous catheterization, and all cases of transvenous lead implantation failure, may be surmounted by direct surgic epicardial LV implant on the lateral or posterolateral wall. Surgical implantation of the LV electrode takes shorter time and involves no radiation as compared to transvenous route. During last decades, surgical approach has become more and more less invasive and evoluted, with shorter implant duration time and important reduction in peri-operative complications. In this chapter we will discuss about surgical approach techniques and peri operative complication rate. More over in this chapter, we summarized the most utilized surgical approaches to LV pacing lead implant.

Keywords: cardiac resynchronization therapy, sternotomy, thoracotomy, video assisted thoracoscopic techniques and robotic surgery

[*] Corresponding Author's Email: drsarducele@gmail.com; Fax: +390815095303.

INTRODUCTION

Cardiac resynchronization therapy (CRT) is a choice treatment for patients with severe cardiac failure refractory to medical drug therapy and with evidence of electromechanical dyssynchrony [1].

Several multicentre trials have shown that CRT via the transvenous route is the choice treatment to have significant improvements in exercise capacity, functional class, peak VO_2, and mortality [2].

The coronary venous anatomy has great interpersonal variation, which may result in the inability to reach an acceptable and stable left ventricle (LV) lead position [3]. The final position of the LV pacing lead depends on coronary sinus anatomy, pacing lead performance and stability, and on the absence of phrenic nerve stimulation [4]. An optimal left ventricle lead position may theoretically be defined by the positioning of the LV pacing lead coincident with the latest activated LV areas [2, 3]. In clinical practice, the standard first-line approach is the trans venous epicardial LV lead placement through a side lateral, postero-lateral (and/or antero-lateral) branch of the coronary sinus (CS) [4]. Successful implantation, may depend on the inclusion criteria, as mechanical dyssynchrony and latest mechanical activation by TDI measurements [5].

The success of implant technique during cardiac resynchronization therapy, is related to the better LV lead placement, such as pacing lead performance and stability, in absence of phrenic nerve stimulation [4]. Therefore the postero-basal LV wall pacing provides more effective hemodynamic augmentation (than either lateral or anterior positioned leads) [6], but it is related to a rate of unsuccessful transvenous LV lead implantation about 8% - 12% [7]. In fact, despite technological and procedural improvement, cardiac venous anatomy may still limit implantation of transvenous LV leads [8]. After a successful CRT implant, the left ventricular lead dislodgment (about 6% to 14%), and the increased pacing threshold, may require an re- intervention in a percentage of 13% to 18% of patients [9]. Sometimes, there are no tributes found in the CS, just a small part of the entry of the target vein , and too small side branches or complete absence of the side branches, requiring a coronary venoplasty or stenting [10]. Limitations to reach the best LV target area by percutaneous catheterization, and all cases of transvenous lead implantation failure, may be surmounted by direct surgic epicardial LV implant on the lateral or posterolateral wall [11]. Surgical implantation of the LV electrode takes shorter time and involves no radiation when compared to transvenous route [11].

The surger approach is related to the direct visualization and positioning of the lead at the obtuse marginal branch area [11]. Concerns persist regarding peri-operative morbidity and long recovery times, related to higher rates of post-operative respiratory tract infections, transient renal dysfunction, and pericardial effusions [12]. This higher complication rate combined with the recovery from a general anaesthetic, led to an increased length of hospitalization as compared to the transvenous group [12]. In this chapter we will describe the CRT surgical indications and techniques.

METHODS

In this chapter we report surgical techniques to perform surgical CRT. The open chest access remains secondary choice to standard endovascular lead placement failure [12]. Surgically epicardial LV implant leaves operators free to choose the optimal LV stimulation site [12]. Surgical CRT approaches may be classified on the basis of the LV pacing site (epicardial versus endocardial), and on the basis of operative access used (open chest orthoracoscopic/robotic access) [13-16], table 1. Surgical approaches shown the direct visual of target LV wall, giving the opportunity to choose the lead-tip position [13-16]. These approaches are combined to a low risk of lead dislodgement and phrenic nerve stimulation, and there is not the limitation of the coronary sinus anatomy [13-16]. Less fluoroscopy and avoidance of intravenous contrast material are also benefits over conventional percutaneous CRT [11-16]. Surgical epicardial left ventricular lead placement has several disadvantages, as the need for general anesthesia, the presence of poor vision due to epicardial fat or the presence of adhesions, and it is more invasive than the transvenous approaches [11-16].

The surgical trauma requires higher recovery time, compared with the transvenous left ventricular lead implantation, and surgical implanted epicardial leads have a significantly higher failure rate [11-16]. Epicardial pacing lead implantation is the currently preferred surgical alternative for left ventricular lead placement [11-16]. In table 1, we summarized the most utilized surgical approaches to LV pacing lead implant (m*edian sternotomy, lower ministernotomy*, f*ull left thoracotomy, minimal thoracotomy (minithoracotomy), video assisted thoracoscopic techniques* and *robotic surgery*).

Median Sternotomy

This surgical approach gives to operators a full access to cardiac left ventricle epicardial anatomy, selecting the target LV area to reach the optimal LV segment to pace [11-16]. On other hand, today this surgical access is used only whenever another cardiac surgery procedure is planned in a patient with reduced left ventricular function and with indication to CRT therapy [11-16]. For this reason we report a short description about this technique, and a representation in figure 1.

Table 1. In this table representation of surgical pacing site, surgical approach, and technique

Pacing site	Surgical approach	Mini invasive surgical approach	Surgical technique
Epicardial	Thoracotomy, Sternotomy	Mini thoracotomy	VAT
Endocardial	Trans-septal	Transapical Endocardial LV Lead Implantation	Transarterial Endocardial LV Lead Implantation

VAT is for video-assisted thoraco scopic; LV: left ventricle.

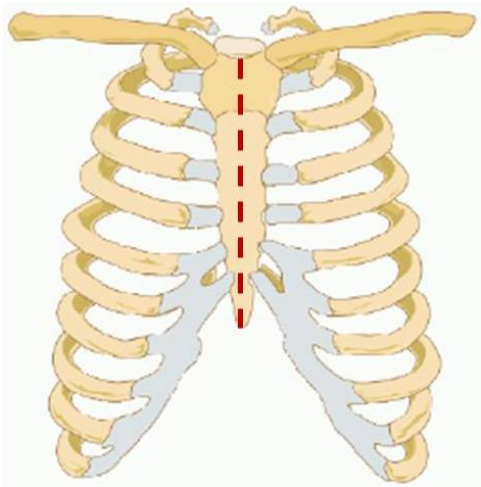

Figure 1. Median sternotomy representation. In this figure the chest, with ribs and sternum. The red discontinuous line is indicating the surgical approach to have a full median sternotomy.

Lateral Thoracotomy

Lateral thoracotomy allows direct visualization of the anterior and lateral segments of the left ventricle epicardium, thereby enabling a perfect selection of a pacing site free from coronary vessels and distant from the phrenic nerve [16].

This approach achieves relatively anterior lead placement that may be ineffective in ventricular resynchronization [12, 16]. A small thoracic size, the presence of a severe cardiomegaly, and/or the presence of adhesions may restrict the safe manipulation of surgical instruments [16]. After standard single-lumen intubation, with the left lung excluded from ventilation and the right lung selectively ventilated, the patient is placed in supine position with the leftchest elevated 30–40° [16]. About the operative technique, a large lateral thoracotomy between intercostal space 4–5 is performed [16], and the pericardium is opened anterior to the phrenic nerve and fixed with traction-sutures to the skin, rotating the heart to the right and creatingoptimal exposure of the lateral surface.

Unipolar or bipolar epicardial can this way easily be attached to the target area and secured with two polypropylene 5-0 or 6-0 sutures [16]. The connector of the lead can be brought through the third intercostal space and submuscularly tunneled to the device pocket and the pacemaker [16]. After this, the pericardium can be partially closed, and the insertion of a pleural drain and the standard wound closure complete the procedure [16].

Left Mini-Thoracotomy

The procedure is performed following a 4-5 cm long mini-thoracotomy in left lateral, mid axillary position at the site of the fourth intercostal space, the left lung is pushed back with a wet towel [16], figure 2. The pericardium is opened anterior to the phrenic nerve, and fixed with hang sutures to the skin with the heart rotated to the right to create optimal exposure to the lateral surface [16].

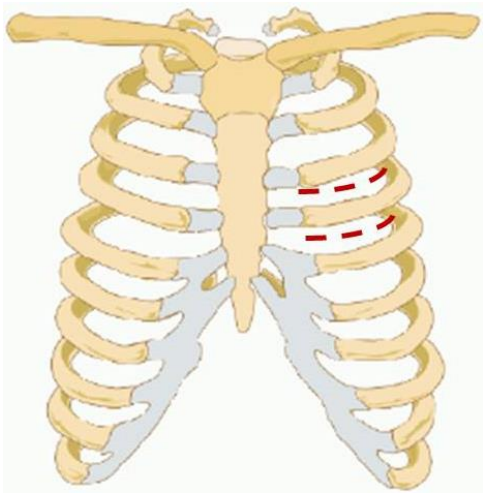

Figure 2. In this figure representation of lateral mini- thoracotomy. As indicated by red discontinuous line, the approach is by 3rd and 4rt intercostal space. In this position, an epicardial lead can be easily attached to the left ventricle target area.

In this position, an epicardial lead can be easily attached to the target area [16]. Completing the threshold measurements, the lead is secured with two sutures [16]. The connector is sub muscularly tunneled to the device pocket and connected to the pacemaker [16]. The pericardium can be approximated, and a pleural drain is placed and the wounds are closed as usual in layers with absorbable sutures [16].

Video-Assisted Thoracoscopic Left Ventricular Pacing

Video assisted thoracoscopic technique for lead implantation is less invasive than standard thoracotomy, and can allow more posterior lead placement [16]. The use of thoracoscopy can allow a safer procedure than left mini-thoracotomy, warranting better exposure and perfect control of the pacing site and reduced surgical trauma [17]. This approach is practiced under general anesthesia, and the patient is intubated with a double-lumen endotracheal tube, with the left lung excluded from ventilationandand the right lung selectively ventilated [16, 17]. The patient is placed supine on the operative table, with a longitudinal support under the left side of the back and somedegree of table tilt to the right [16, 17]. Three ports are used as standard access to the left ventricle [16, 17].

Figure 3. The first is positioned in the mid-axillary line, in the third or fourth intercostal space, for the insertion of thethoracoscope, a second port is placed inferior to this in the fourth or fifth intercostal space, and a third port is placed anteriorly in the fourth or fifth intercostal space [16, 17], figure 3. After visualization of the pericardium in the camera and his freeing from fat, the pericardium is longitudinally opened, anterior to the phrenic nerve, to expose the left ventricular free wall [16, 17]. An epicardial lead is placed into an unscarred area of myocardium as far posterior to the obtuse marginal arteriesas possible [16, 17, 18]. Pacing sensitivity and thresholds are checked, and if measures are satisfactory, the lead is passed through the anterior port site, tunneled fromthere to a prepectoral pocket, and connected to the generator [16, 17, 18].

After another check of pacing thresholds, the wounds are closed in layers with absorbable sutures, and a pleural drain is placed through one of the port accesses [16, 17, 18]. This technique represents a valid alternative to standard thoracotomy, is less invasive for the patient, shows good aesthetical results, and requires shortest times of Intensive Care Unit and hospitalization [16, 17, 18].

Robotically Assisted LV Lead Placement

Robotically enhanced manipulation systems can be helpful in managing difficult anatomical conditions, such as in re-do operations; however, the equipment is prohibitively expensive for most institutions [19].

The da Vinci robotic surgical system is the device used for surgical approach [19], figure 4. General anesthesia with selective right lung ventilation is used with patients positioned in the full posterolateral thoracotomy position, and a camera port is placed in the seventh intercostal space along the posterior axillary line [19]. The left and right arms of the robot are positioned in the ninth and fifth intercostals spaces, and a working port is inserted posteriorly to the camera port, for the introduction of leads and sutures [19].

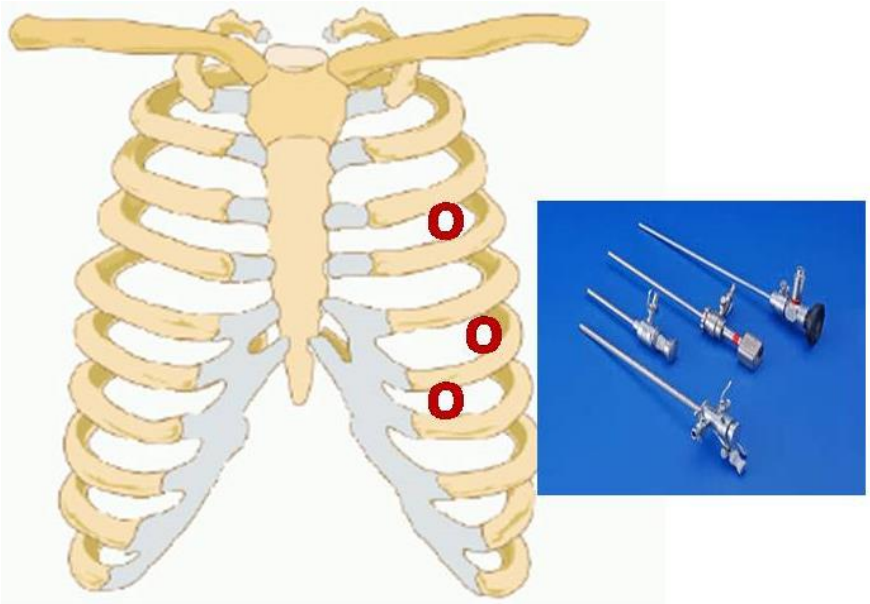

Figure 3. Port and instrument positioning for thoracoscopic approach to left ventricle. Three ports are used as standard access to the left ventricle, and are indicated by red circles. The first is positioned in the mid-axillary line, in the third or fourth intercostal space, for the insertion of thethoracoscope, a second port is placed inferior to this in the fourth or fifth intercostal space, and a third port is placed anteriorly in the fourth or fifth intercostal space. On the right part of figure representation of ports and instruments for thoracoscopy.The use of thoracoscopy can allow a safer procedure than left mini-thoracotomy, warranting better exposure and perfect control of the pacing site and reduced surgical trauma.

Figure 4. In this figure the robotic approach. This system can be helpful in managing difficult anatomical conditions, such as in re-do operations; however, the equipment is prohibitively expensive for most institutions. The da Vinci robotic surgical system is the device used for surgical approach.

Leads can be placed along the posterolateral left ventricle surface using the robotic arms [19]. Pericardial closure is performed, and the leads are tunneled to the left subpectoral pocket and connected to the device [19].

Trans-Apical Epicardial Left Ventricular Pacing via Left Minithoracotomy

This procedure is performed by hybrid and/or by transthoracic echocardiography, used to locate the LV apex [13].

After marking the access site, a left minithoracotomy is performed in the better position to reach the left ventricular apex [13]. After reaching the pericardial surface, a small pericardiotomy is performed above the LV apex and stay sutures are positioned [13]. A standard active fixation endocardial pacing lead (bipolar electrode) can be positioned in the LV cavity through the apex [13] .Hemorrhaging from the LV can be easily prevented with one or two 5/0 or 4/0 monofilament purse-string sutures at the puncture point [13]. The leads are inserted using Seldinger technique utilizing a peel-away sheath, and the apex is punctured with a needle and a guidewire is inserted [13]. The needle is removed from the apex and a dilatation of the apex hole is performed, using the peel-away sheath inserted over the guide [13]. After removal of the guidewire, the pacing electrode is positioned into the LV cavity through the sheath, and peelaway sheath is removed [13]. After effective endocardial fixation of the lead tip, the pacing and sensing parameters are measured [13, 20]. Purse-string sutures in the apex are tied to restrict the movement of the electrode through the apex and they are ligated to the body of the electrode to stabilize position [13, 20].The pericardium can be partially closed and a pleural drain is inserted, and followed by a standard minithoracotomy closure [13, 20]. The proximal body of the electrode is tunneled to an infra clavicular pocket [13, 20]. Lifelong anticoagulation is mandatory for these patients (similarly to transseptal CRT) [13, 20]. The trans-apical endocardial CRT has potential advantages, such as shorter procedure times, and decreased post operative burden [13, 20].

CONCLUSION

Cardiac surgery approach is efficient to reach the target LV epicardial area [11-20]. The continuous technical and procedural innovations have led this technique to be an important and resolutive approach in CRT pacing. In fact, starting from median thoracotomy, the first surgical LV lead positioning approach, the surgic technique has come to video-assisted and robotic approaches, representing important ameliorating in implant technique [11-20]. The surgical techniques result in low radiation exposure time, and high success percentage rate [11-20].

Therefore, surgical approach remains a consolidate and resolutive technique in selected and challenging CRT cases. In these cases, percutaneous approach may be not at all successful. In our opinion, it is relevant do not abandon failing heart patients, trying to perform in anyway a CRT. These remain the cases to treat by a surgical approach, to get an epicardial CRT. We think that peri operative complications may limit the clinicians enthusiasm, but this should not scare us in solving the problems in the best way. We have not to abandon this approach, trying to improve the surgical techniques, and lowering the peri operative complications rate, rendering more safe the surgery approach.

REFERENCES

[1] McAlister F. A., Ezekowitz J., Hooton N., et al. Cardiac Resynchronization Therapy for Patients With Left Ventricular Systolic Dysfunction A Systematic Review. *JAMA*, 2007; 297(22):2502-2514.

[2] Morgan J. M., Degaldo V. Lead positioning for cardiac resynchronization therapy: Techniques and priorities. *Europace,* 2009; 11:22–28.

[3] Bristow M. R., Saxon L. A., Boehmer J., et al. Comparison of Medical Therapy, Pacing, Defibrillation in Heart Failure (COMPA- NION) Investigators. Cardiac-resynchronization therapy with or without an implantable defibrillator in advanced chronic heart failure. *N. Eng. J. Med.*, 2004; 350:2140 – 50.

[4] Cleland J. G., Daubert J. C., Erdmann E., et al. Cardiac Resynchronization-Heart Failure (CARE-HF) Study Investigators. The effect of cardiac resynchronization on morbidity and mortality in heart failure. *N. Eng. J. Med.*, 2005; 352:1539–49.

[5] Butter C., Auricchio A., Stellbrink C., et al. Effect of resynchronization therapy stimulation site on the systolic function of heart failure patients. *Circulation,* 2001; 104:3026 –9.

[6] Ansalone G., Giannantoni P., Ricci R., Trambaiolo P., Fedele F., Santini M. Doppler myocardial imaging to evaluate the effectiveness of pacing sites in patients receiving biventricular pacing. *J. Am. Coll. Cardiol.*, 2002; 39:489 –99.

[7] C. Alonso, C. Leclercq, F. R. d'Allonnes, et al., "Six Year Experience of Transvenous Left Ventricular Lead Implantation for Permanent Left Biventricular Pacing in Patients with Advanced Heart Failure: *Technical Aspects," Heart,* Vol. 86, No. 4, 2001, pp. 405-410.

[8] Gras D., Bocker D., Lunati M., et al. Implantation of cardiac resynchronization therapy systems in the CARE-HF trial: Procedural success rate and safety. *Europace*, 2007; 9:516–522.

[9] Alonso C., Leclercq C., d'Allonnes F. R., et al. Six year experience of transvenous left ventricular lead implantation for permanent biventricular pacing in patients with advanced heart failure: technical aspects. *Heart*, 2001; 86:405-10.

[10] Van Gelder B. M., Meijer A., Basting P., Hendrix G., Bracke F. A. Successful implantation of a coronary sinus lead after stenting of a coronary vein stenosis. *Pacing Clin. Electrophysiol.*, 2003 Sep; 26(9):1904-6.

[11] H. Mair, J. Sachweh, B. Meuris, et al., "Surgical Epicar- dial Left Ventricular Lead Versus Coronary Sinus Lead Placement in Biventricular Pacing," *European Journal of Cardio-Thoracic Surgery*, Vol. 27, No. 2, 2005, pp. 235- 242.

[12] Doll N., Piorkowski C., Czesla M., et al. Epicardial versus transvenous left ventricular lead placement in patients receiving cardiac resynchronization therapy: results from a Randomized Prospective Study. *Thorac. Cardiovasc. Surg.*, 2008;56:256–61.

[13] Mihalcz A., Kassai I., Geller L., Szili-Torok T. Alternative Techniques for Left Ventricular Pacing in Cardiac Resynchronization Therapy. *PACE*, 2014; 37:255–26.

[14] Ven Gelder B. M., Scheffer M. G., Meijer A., Bracke F. A. Transeptal endocardial left ventricular pacing: an alternative technique for coronary sinus lead placement in cardiac resynchronization therapy. *Heart Rhythm*, 2007; 4:454-460.

[15] Kassai I., Szili-Torok T. concerns about the long term outcome of trans septal cardiac resynchronization therapy: what we have learned from surgical experience. *Europace*, 2008;1:121-122.

[16] Mair H., Jansens J. L., Lattouf O. M., Reichart B., Dabritz S. epicardial lead implantation techniques for biventricular pacing via left lateral mini-thoracotomy, video-assisted thoracoscopy, and robotic approach. *Heart Surg. Forum*, 2003; 6:412-7.

[17] Navia J. L., Atik F. A., Grimm R. A., et al. Minimally invasive left ventricular epicardial lead placement: surgical techniques for heart failure resynchronization therapy. *Ann. Thorac. Surg*., 2005; 79:1536–44.

[18] Nelson K. E., Bates M. G. D., Turley A. J., Linker N. J., Owens W. A. Video-Assisted Thoracoscopic Left VentricularPacing in Patients With and Without Previous Sternotomy *Ann. Thorac. Surg.*, 2013; 95:907–13.

[19] DeRose J. J., Ashton R. C., Belsley S., et al. Robotically assisted left ventricular epicardial lead implantation for biventricular pacing. *J. Am. Coll. Cardiol.*, 2003; 41:1414 –9.

[20] Mihalcz A., Kassai I., Kardos A., Foldesi C., Theuns D., Szili-Torok T. Comparison of the Efficacy of Two Surgical Alternatives for Cardiac Resynchronization Therapy: Trans-Apical versus Epicardial Left Ventricular Pacing, *PACE*, 2012; 35:124–130.

In: Encyclopedia of Surgery (22 Volume Set)
Editors: Andreas Lehrer and Kristin Mueller
ISBN: 978-1-53618-329-0
© 2020 Nova Science Publishers, Inc.

Chapter 412

SURGICAL STRATEGIES TO PUSH UP RESECTION LIMITS IN LIVER DISEASE AND LIVER FAILURE AFTER SURGERY

F. Romano[1], MD, S. Famularo[1], MD, R. A. Pellegrino[1], MD, L. V. Gianotti[1], MD, ScD, F. Uggeri[1], MD, E. Pinotti[1], MD, R. Corso[2], MD, D. Ippolito[2], MD, C. Talei[2], MD and D. Fior[2], MD

[1]School of Medicine and Surgery, Milano-Bicocca University andm Department of Surgery, San Gerardo Hospital, Monza, Italy

[2]Department of Radiology, San Gerardo Hospital, Monza (MB), Italy

ABSTRACT

In oncological surgery, the liver still remain a challenge for surgeons. From the seventies, when liver surgery spread, techniques and strategies to approach parenchymal resection are very changed: from a radical surgery, to the finding of liver regeneration capacity and the concept of minimum remnant size, until now, where new liver regeneration theories and new physiological data are changing our approach. In case of HCC, or in case of metastatic disease, when resection is indicated, there are several diagnostic feature to perform before candidate a patient to surgery. How could be safe a liver resection? Which is the phatophysiological etiology of post-hepatectomy liver failure? How could we expand the safe limits for surgery? All these questions are key-points to better understand liver disease, and, moreover, their treatments. From the first meeting with patient affected by liver cancer, we would like to describe how to manage patients, which kinds of imaging we should prefer, how to assess safe limits for resections, and, in case, how to expand this limit. Then, we will focus on interventional radiologic and surgical strategies to approach liver cancer, and how and why post-hepatectomy liver failure could be prevented and diagnosed correctly. Particularly, we would focus on portal vein embolization, two-staged hepatectomy, and ALPPS, always with physiological explanation, from the most up-to-date clinical evidence. Particular attention will be made for liver surgery's sequel and risks. Comparing the newest data available in literature, we will focus on diagnosing, staging and surgical planning to approach liver resections correctly.

INTRODUCTION

In the latest decades an important change was registered in liver surgery, related to the progress of surgical techniques, anesthesiology and postoperative treatment, allowing a sharp decrease in mortality and morbidity. However, management of liver cirrhosis or small size hepatic remnant still remains a challenge [1].

The liver presents regenerative capacity, allowing performance of repeated resections. In certain cases, when this capacity is impaired, or where extensive resections were performed with small remnant liver, these patients may develop small for size syndrome (SFSS) with the presence of reduced liver mass insufficient to maintain normal liver function. Surgeons continue to push the envelope of what can be defined as "resectable" disease by performing extensive liver resections that challenge both the oncologic and technical definition of respectability [2]. Within this context of extended resection, postoperative liver failure, because of an insufficient functional liver remnant, remains a real concern, especially in patients who have received extensive preoperative chemotherapy. The term SFSS was first employed in liver transplantation to describe the development of acute liver failure (ALF) (hyperbilirubinemia, coagulopathy, encephalopathy and refractory ascites) resulted from the transplantation of a donor liver that was too small for a given recipient [3]. A similar syndrome, called "post-hepatectomy liver failure (PHLF)" was also described in hepatic surgery involving extended resections of liver mass. The last one is characterized by postoperative liver dysfunction, with clinical signs of prolonged cholestasis, coagulopathy with reduced synthetic liver function, ascites and portal hypertension with progressive encephalophaty, renal failure SIRS and death. PHLF is the major cause of death after liver resection often associated with sepsis and ischemia- reperfusion injury (IRI) [4] and remains one of the most serious complications of major liver resection, with an incidence up to 10% of cases [5].

The patho-physiological mechanisms of the SFSS and PHLF are very similar, both presenting reduction of liver mass and portal hyper flow beyond a certain threshold [4]. The pathophisiology of PHLF is described by the following four major factors that influence each others: 1) volumetry (i.e., FRL), 2) quality of liver parenchyma, 3) liver function and 4) liver haemodynamics (i.e., arterial and portal inflow as well as hepatic outflow). Among them FRL remains the major factor influencing the risk of PHLF. Preoperative augmentation of the FRL may represent a possible resolution to the problem. The liver possesses the specific competence to return to a constant size within a short period after injury [7-8]. We can observe this clinically in the form of regeneration after liver resection or liver transplantation, and after toxic liver injury. Liver regeneration involves hyperplasia of all the cell types of the liver. In humans, hepatocyte replication generally starts within a day of major hepatectomy, and replication of non-parenchymal cells, such as endothelial cells, Kupffer cells, and biliary cells begins somewhat later [9]. **L**iver regeneration is triggered by altered hemodynamic factors. After liver resection, the increased portal vein flow past hepatocytes or sinusoidal endothelial cells initiates regeneration and regulates the size of the liver. Shear stress on the endothelial cells is the powerful impetus for regeneration, liver volume regulation, and growth, as well as atrophy [10]. Hemodynamic factors increase the shear stress in the liver, and nitric oxide (NO) is secreted. NO then initiates the liver regeneration cascade.

R0 resection with zero mortality is the ultimate goal for hepatobiliary surgeons, especially for the treatment of extensive hepatobiliary malignancies. The safety of liver resection is dependent on the function of the future liver remnant (FLR), and an inadequate FLR volume is related to a significant increase in postoperative mortality and morbidity due to the incidence of PHLF. Therefore, various criteria for the FLR volume have been proposed to secure the safety of major hepatectomies according to the extent of underlying injury in the liver [11-12]. However, these criteria for FLR volume often cause clinical dilemmas for surgeons in determining the surgical indications for patients with small FLR volumes because the safety of surgery and oncological radicality are, by nature, conflicting factors. Multiple strategies to increase the size of the future liver remnant (FLR) and thereby decrease the risk postoperative liver failure have been applied.

In the history of hepatobiliary surgery, there have been two outstanding approaches for the safe management of patients with very small FLR volumes. The first was the development of techniques that manipulate the portal blood flow to induce hypertrophy of the FLR.

Makuuchi et al., first described the use of portal vein embolization (PVE) to induce hypertrophy of the FLR before extensive liver resections [13]. Embolization of the right portal vein with inclusion of segment IV was shown to induce up to 70% volume increase within the standardized FLR (sFLR) 6 weeks Increasing evidence has suggested that hypertrophy of the FLR induced by portal flow modulation is associated with an improved safety of major hepatectomies [14-15]. In addition, dynamic volume parameters, such as the degree of hypertrophy or the kinetic growth rate, are also very informative for estimating the histologic quality and functional reserve of the underlying liver. The second noteworthy approach was the "two stage surgery" for the resection of multiple bilobar hepatic lesions. This sequential procedure was initially proposed by surgeons at the Hoˆpital Paul Brousse in Paris, France, with the expectation of allowing interim liver regeneration between the two sequential hepatic resections [16]. An oncological advantage of the two-stage approach has been reported in patients with extensive colorectal liver metastases [17], and this procedure used in conjunction with (as first described by Jaek et Al) [18] or without PVE has been adopted by numerous hepatobiliary centers. These two evolutional approaches have expanded the indications for surgery, and many patients with extensive liver tumors have benefited from surgery using these approaches. However, a remaining issue is that these approaches require at least several weeks to complete the entire clearance of the tumor burden within the liver. Some authors have suggested a risk of tumor progression during the waiting time after PVE [19-20]. Therefore, the time lag between the preoperative intervention and resection can be critical, especially for the treatment of patients with borderline resectable tumors and/or oncologically highly aggressive tumors.

Furthermore, 19–33% of patients who undergo PVE fail to undergo the second-stage operation due to insufficient hypertrophy and/or progression of disease during the time between PVE and the planned resection [21, 22]. More recent publications have described the ALPPS technique (i.e., the associating liver partition with portal vein ligation for staged hepatectomy) as a strategy for accelerated and extensive hypertrophy in the FLR [23-25]. Initial experience suggested that the volume increase after ALPPS is more rapid compared with previous techniques, allowing removal of the diseased hemiliver or extended hemiliver within 6–20 days [26]. The ALPPS technique has demonstrated encouraging results in terms of the degree of liver hypertrophy and the greater proportion of patients who make it to completion of the second stage. ALPPS, however, remains highly controversial, and

substantive concerns have been raised due to the paucity of long-term oncologic results as well as the high morbidity and mortality described in initial reports. Previous reports have described morbidity as great as 40% and inpatient mortality as great as 22% after the ALPPS procedure [27].

The size concept has been demonstrated to be useful in liver surgery management. Otherwise some recent studies conclude that the development of SFSS or PhLF are not strictly determined by the "size" of the liver graft or remnant. It is determined by the hemodynamic parameters of the hepatic circulation and, specifically, by a portal blood flow that, when excessive for the volume of the liver parenchyma leads to over-pressure, sinusoidal endothelial denudation and hemorrhage. Perisinusoidal and periportal hemorrhage occurs in the first minutes after an extended hepatic resection as well as after the reperfusion of a small graft, while arterial vasoconstriction and ischemic cholangitis are observed at later stages [28]. Also, experimental and clinical studies consistently show that an increased portal blood flow relative to the weight of the liver results in an inverse relationship between portal and arterial blood flows that is known as the arterio-portal buffer [29]. The arterio-portal buffer occurs when the portal blood flow increases, the adenosine concentration in the space of mall decreases leading to arterial vasoconstriction and decrease of arterial blood flow, which is responsible for the late damage. Several studies indicate that additionally to blood flow, portal pressure can also be considered a go higher values of hepatocyte growth factor (HGF) and diminished levels of vascular epithelial growth factor (VEGF), suggesting that an increased portal pressure also influences liver regeneration [30]. Studies involving extended hepatic resections also indicate that the increased portal blood flow with diminished residual parenchyma are a critical factor determining the development of PHLF [31, 32]. This lead to the development of a new paradigma: small for flow liver failure (SFFLF) [33]. The aim of this review is to discuss applicable peri-operative methods to prevent the SFSS or PHLF and highlight the main treatment types introducing the new concept of SFFLF.

References

[1] van den Broek MA, Olde Damink SW, Dejong CH, et al. Liver failure after partial hepatic resection: definition, pathophysiology, risk factors and treatment. *Liver Int* 2008;28:767-80.

[2] Pawlik TM[1], Schulick RD, Choti MA.Expanding criteria for resectability of colorectal liver metastases. *Oncologist* 2008 Jan;13(1):51-64.

[3] Ikegami T, Shimada M, Imura S, et al. Current concept of small-for-size grafts in living donor liver transplantation. *Surg Today* 2008;38:971-82.

[4] Balzan S, Belghiti J, Farges O, et al. The 50-50 Criteria on Postoperative Day 5. *Ann Surg* 2005;242:824-8, discussion 828-9.

[5] Schroeder RA, Marroquin CE, Bute BP, Khuri S, Henderson WG, Kuo PC: Predictive indices of morbidity and mortality after liver resection. *Ann Surg* 2006; 243: 373–379.

[6] Eshkenazy R, Dreznik y, Lahat E, Zakai B, Zendel A, Ariche A. Small for size liver remnant following resection: prevention and management *Hepatobiliary Surg Nutr* 2014;3(5):303-312.

[7] Fausto N, Campbell JS, Riehle KJ. Liver regeneration. *Hepatology* 2006;43:S45-53.

[8] Michalopoulos GK. Liver regeneration. *J Cell Physiol* 2007;213:286- 300.

[9] Clavien PA, Petrowsky H, DeOliveira ML, Graf R. Strategies for safer liver surgery and partial liver transplantation. *N Engl J Med* 2007;356:1545-1559.

[10] Sato Y, Tsukada K, Hatakeyama K. Role of shear stress and immune responses in liver regeneration after a partial hepatectomy. *Surg Today* 1999;29:1-9.

[11] Clavien PA, Oberkofler CE, Raptis DA, Lehmann K, Rickenbacher A, El-Badry AM. What is critical for liver surgery and partial liver transplantation: size or quality?. *Hepatology* 2010;52:715–729.

[12] Tsai S, Marques HP, de Jong MC et al., (2010) Two-stage strategy for patients with extensive bilateral colorectal liver metastases. *HPB* 12:262–269.

[13] Makuuchi M, Thai BL, Takayasu K, Takayama T, Kosuge T, Gunvén P, Yamazaki S, Hasegawa H, Ozaki H. Preoperative portal embolization to increase safety of major hepatectomy for hilar bile duct carcinoma: a preliminary report. *Surgery* 1990;107:521–527.

[14] Wicherts DA, Miller R, de Haas RJ et al., Long-term results of two-stage hepatectomy for irresectable colorectal cancer liver metastases. *Ann Surg* 2008;248:994–1005.

[15] Brouquet A, Abdalla EK, Kopetz S et al., (2011) High survival rate after two-stage resection of advanced colorectal liver metastases:response-based selection and complete resection define outcome. *J Clin Oncol* 29:1083–1090.

[16] Adam R, Laurent A, Azoulay D et al., Two-stage hepatectomy: a planned strategy to treat irresectable liver tumors. *Ann Surg* 2000;232:777–785.

[17] Narita M, Oussoultzoglou E, Jaeck D, et al.: Two-stage hepatectomy for multiple bilobar colorectal liver metastases. *Br J Surg* 2011;98:1463–1475.

[18] Jaeck D, Oussoultzoglou E, Rosso E, et al: A two-stage hepatectomy procedure combined with portal vein embolization to achieve curative resection for initially unresectable multiple and bilobar colorectal liver metastases. *Ann Surg* 2004;240:1037-1049.

[19] Muratore A, Zimmitti G, Ribero D, et al.: Chemotherapy between the first and second stages of a two-stage hepatectomy for colorectal liver metastases: Should we routinely recommend it? *Ann Surg Oncol* 2012;19:1310–1315.

[20] Lam VW, Laurence JM, Johnston E, Hollands MJ, Pleass HC, Richardson AJ. A systematic review of two-stage hepatectomy in patients with initially unresectable colorectal liver metastases. *HPB.* 2013;15:483–91.

[21] Giuliante F, Ardito F, Ferrero A, et al. Tumor progression during preoperative chemotherapy predicts failure to complete two-stage hepatectomy for colorectal liver metastases: results of an Italian multicenter analysis of 130 patients. *J Am Coll Surg*. 2014; 219:285–94.

[22] Turrini O, Ewald J, Viret F, et al. Two-stage hepatectomy: who will not jump over the second hurdle? *Eur J Surg Oncol* 2012;38:266-73.

[23] Schnitzbauer AA, Lang SA, Goessmann H, et al. Right portal vein ligation combined with in situ splitting induces rapid left lateral liver lobe hypertrophy enabling 2-staged extended right hepatic resection in small-for-size settings. *Ann Surg* 2012;255:405-14.

[24] Schadde E, Ardiles V, Slankamenac K, Tschuor C, Sergeant G, Amacker N, et al. ALPPS offers a better chance of complete resection in patients with primarily unresectable liver tumors compared with conventional-staged hepatectomies: results of a multicenter analysis. *World J Surg* 2014;38: 1510-9.

[25] Schadde E, Ardiles V, Robles-Campos R, Malago M, Machado M, Hernandez-Alejandro R, Soubrane O, Schnitzbauer AA, Raptis D, Tschuor C, Petrowsky H, De Santibanes E, Clavien PA. Early survival and safety of ALPPS: first report of the International ALPPS Registry. *Ann Surg* 2014; 260: 829-836.

[26] Truant S, Scatton O, Dokmak S, Regimbeau JM, Lucidi V, Laurent A, Gauzolino R, Castro Benitez C, Pequignot A, Donckier V, Lim C, Blanleuil ML, Brustia R, Le Treut YP, Soubrane O, Azoulay D, Farges O, Adam R, Pruvot FR. Associating liver partition and portal vein ligation for staged hepatectomy (ALPPS): impact of the interstages course on morbi-mortality and implications for management. *Eur J Surg Oncol* 2015; 41: 674-682.

[27] Bertens KA, Hawel J, Lung K, Buac S, Pineda-Solis K, Hernandez-Alejandro R. ALPPS: challenging the concept of unresectability--a systematic review. *Int J Surg*. 2015 Jan;13:280-7.

[28] Demetris AJ, Kelly DM, Eghtesad B, Fontes P, Wallis Marsh J, et al. (2006) Pathophysiologic observations and histopathologic recognition of the portal hyperperfusion or small-for-size syndrome. *Am J Surg Pathol* 30: 986-993.

[29] Eipel C, Abshagen K and Vollmar B. Regulation of hepatic blood flow: The hepatic arterial buffer response revisited World *J Gastroenterol.* 2010 Dec 28; 16: 6046–6057.

[30] Allard MA, Adam R, Bucur PO, Termos S, Cunha AS, et al. (2013) Posthepatectomy portal vein pressure predicts liver failure and mortality after major liver resection on noncirrhotic liver. *Ann Surg* 258: 822-829.

[31] Schreckenbach T, J Wolf J, Bechstein O, Moench C. *Posthepatectomy Liver Failure Dig Surg* 2012;29:79-85.

[32] Kauffmann R, Fong Y. Post-hepatectomy liver failure. *Hepatobiliary Surg Nutr* 2014;3:238-246.

[33] Asencio JM[1], Vaquero J, Olmedilla L, García Sabrido JL "Small-for-flow" syndrome: shifting the "size" paradigm. *Med Hypotheses.* 2013 May; 80:573-7.

SECTION 1. POST-HEPATECTOMY LIVER FAILURE (PHLF)

From Transplantation Experience to Oncological Surgery Environment

Liver function impairment is the most feared complication of liver surgery. It consist in a wide pattern of clinical manifestations that can range from mild hepatic dysfunction with isolated hyperbilirubinemia, to irreversible liver failure, which could lead to the death of the patient. This condition can arise in patients undergoing both hepatic resection and liver transplantation. This days, it is still difficult to provide uniform definition of it, because over time each of the many authors who have been confronted with it, provided a definition based on his personal working experience. In 1996 Emond et al., [1] first described this clinical manifestation following transplantation of small graft in living donor liver transplantation (LDLT), introducing the concept of Small For Size Syndrome (SFSS). SFSS is a consequence of size mismatch between graft and recipient, an event occurring especially in the setting of LDLT. When the liver volume is too small to provide to the metabolic demand, the liver loses

his peculiar ability, resulting in delayed synthetic dysfunction, coagulopathy, prolonged cholestasis and intractable ascites. Those factors can lead to septic complication and/or gastrointestinal upper bleeding that results in high mortality rate. Emond showed that early function of the graft significantly decreases if the graft is smaller than 50% of the expected liver volume, concluding that clinical recovery after a small-for- size transplant is characterized by significant functional impairment associated with paradoxical histologic changes typical of ischemia. These changes apparently are due to graft injury, which can only be the result of small graft size. Few years later, in 2005 Dahm et al., [2] proposed a more systematic definition. According to this author, SFSS was the result of graft-dysfunction after partial liver transplantation, and it was defined as the presence of two of the following criteria recorded on three consecutive postoperative days: serum bilirubin > 100 μmol/L (6mg/dL), international normalized ratio (INR) > 2 and presence of encephalopathy grade III or IV. Diagnosis is possible only after the exclusion of other causes leading to similar clinical pattern, such as technical complications (e.g., arterial or portal thrombosis; outflow congestion, bile leak), immunological (e.g., rejection) or infectious (e.g., cholangitis, sepsis). In Dahm's analysis, SFSS usually occurs within 7 day after surgery.

Table 1. Consensus definition and severity grading of PHLF by ISGLS

Grade	
A	abnormal laboratory parameters, but requiring no change in the clinical management of the patient
B	deviation from the regular clinical management but manageable without invasive treatment
C	deviation from the regular clinical management and requiring invasive treatment

Patient related	Male gender Age > 65 years Malnutrition Comorbidity ASA score elevated	!
Liver related	Cirrhosis Steatosis Fibrosis Cholangitis Chemotherapy-associated steatohepatitis	
Surgery related	Small remnant liver volume Blood loss > 1,250 ml Prolonged operation time	

Meanwhile in the field of hepatic resection, technical improvements during last two decades have provided extension of indications for major hepatectomies, and so the risk of post-hepatectomy liver failure (PHLF) has gained important concerns. As SFSS in liver transplantation, PHLF is a postoperative clinical manifestation that occurs when the volume

of remnant liver is not sufficient to provide for metabolic demanding. In order to standardize the definition of PHLF for prediction of early mortality after hepatectomy, in 2005 Balzan et al., [3] proposed the "50-50 criteria". The authors stated that the persistence of either PT < 50% or a serum bilirubin > 50 μmol/L (3mg/dL) on 5 postoperative days proved important for predicting mortality and might be considered as indicator of PHLF. The main result of the study was to demonstrate that the conjunction of these two values on 5 postoperative days, the so called "50-50 criteria", could predict nearly 100% morbidity rate and 50% mortality rate.

Recently the International Study Group of Liver Surgery (ISGLS) [4], considering the normal postoperative course of serum bilirubin concentration and International Normalized Ratio (INR), has proposed defining PHLF as a "postoperatively acquired deterioration in the ability of the liver (in patients with normal and abnormal liver function) to maintain its synthetic, excretory, and detoxifying functions, characterized by an increased INR (or need of clotting factors to maintain normal INR) and concomitant hyperbilirubinemia (according to the normal limits of the local laboratory) on or after postoperative day 5". The ISGLS differentiated also the severity of PHLF in 3 grades from A to C. The classification is shown in Table 1. Even if SFSS and PHLF recognize the same pathophysiology, and can be viewed as the same manifestation of liver function impairment, the two terms remains currently separated.

Epidemiology

Selecting the recent series incorporating a modern definition of PHLF, the incidence varies from 0% to 2% after resection on healthy liver parenchyma, but can reach 7% after major hepatectomy [5]. In cirrhotic liver PHLF ranges to 10% after limited resections, and reaches over 30% after major resections [5]. PHLF represents the leading cause of mortality after liver resection (>60%) [6], which varies from 0% to 8% depending on the extension of the resection and the status of underlying liver parenchyma [7, 8] (up to 32% in cirrhotic patients) [9]. Because death may occur beyond the 30th postoperative days, mortality at 3 months should be considered [10].

Risk Factors

In order to better select patients suitable for surgery, several risk factors to PHLF have been identified, (Table 2). The right selection of the patients and the improvement in surgical technique can prevent PHLF. Appropriate postoperative management may decrease the risk of PHLF.

Considering patient-related risk factors, age > 65 years old, male gender, malnutrition, presence of co- morbidities (lung disease, renal insufficiency) and the American Society of Anesthesiology Score (ASA score) are major predictors of PHLF [11]. This patient-related risk factors limit the ability of the liver regeneration and favor postoperative morbidity. Also diabetes is considered a major risk factor, since insulin play a central role in hepatocyte function regulation [12]. Experimental studies showed that even if this hormone is not a mitogen factor of hepatocytes, the lack of insulin results in atrophic liver [13]. Obesity is not an independent risk factor for PHLF, but non-alcoholic fatty liver disease have been proved to

be responsable for increasing rates of non-viral related liver cirrhosis, which is strongly related with PFLF [14]. Others risk factors regarding the remnant liver, for which it is intended both the parenchyma status and the future liver remnant (FLR) volume.

The assessment of FLR is made by imaging-technique, usually requiring CT-scan. Different rates of FLR are allowed, depending on underlying liver parenchyma status [15]. With a normal function, FLR should range between 20% and 30% of total liver volume [16]. In "injured" livers, resulting from steatosis, cholestasis, fibrosis or chemotherapy, the FLR should be greater than 30%-40%. Cirrhotic patients require more than 40% of FLR [16]. Therefore, an accurate preoperative assessment of liver function is needed. Cirrhosis is a major limitation to hepatic resection. The increased risk is explained by a frequent association with other risk factors and by a reduction of both liver functional reserves [17] and regenerative capacities [18].

The Child-Turcotte-Pugh (CTP), is the most used score system for the preoperatory assessment of liver functional status. It is evaluated by considering five different variables: serum albumin and bilirubin, INR, presence of ascites and encephalopathy. Three different functional classes are identified: class A (score 5- 6), class B (7-9) and C (10-15). Patients with CTP B or C are considered at high risk for PHLF [19]. Even if it was considered the gold standard for the risk stratification of patients undergoing hepatic surgery, CTP score alone has proved to be inadequate for the correct stratification of PHLF risk in patients with compensated cirrhosis (CTP score A). In those patients PHLF can happen because of low functional liver reserve [20, 21].

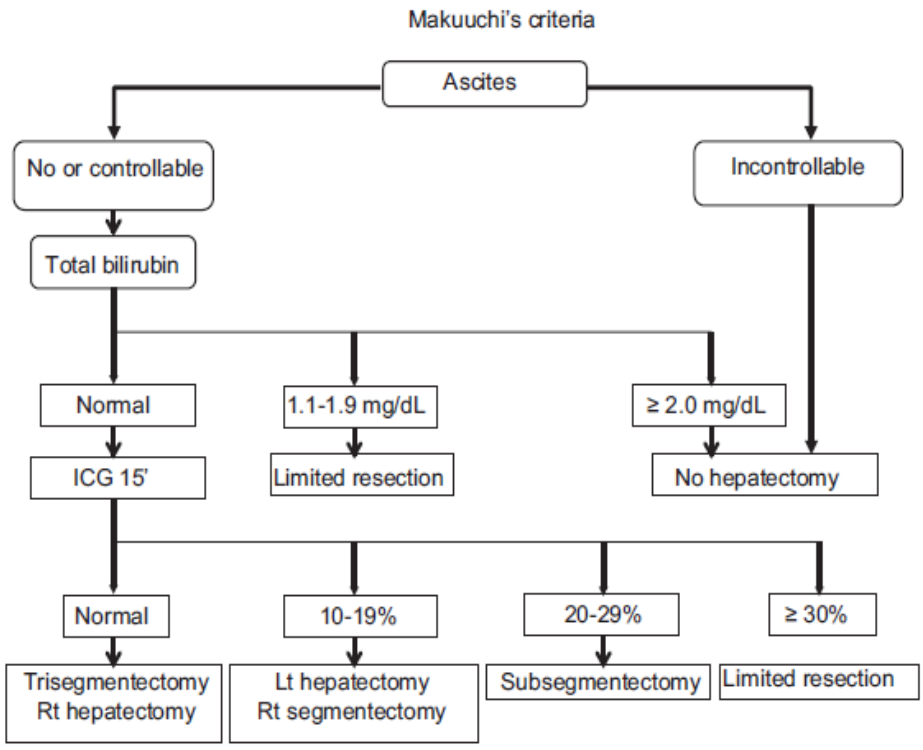

Figure 1. Selection criteria for patients undergoing liver resection according. to Makuuchi.

Other methods have been developed for evaluating liver function. The Model for End Stage Liver Disease (MELD) score was initially developed to predict the mortality of cirrhotic patients receiving transjugular intrahepatic porto-systemic shunts, and subsequently used as a disease severity index for priority on the waiting list for liver transplantation. It considers the following parameters: INR, serum bilirubin and creatinine. It was recently shown by several evidence-based studies that a save resection was possible if MELD score < 12 (82% sensitivity and 89% specificity for PHLF incidence) [22]. When MELD score > 12, morbidity rate raises to more than 50%, with PHLF risk rate > 15%, and associated mortality rate > 29% [22, 23]. In Eastern countries measurement of plasmatic clearance of indocyanine green (ICG) is a popular and largely used test to assess the functional liver reserves [24]. ICG is an injectable organic anion that binds to albumin. Its hepatocyte uptake is followed by its biliary excretion without entero-hepatic circulation. ICG clearance is a reflection of liver function, hepatic energy status, cardiac and arterio-portal blood flows. The ICG test evaluates the percentage of retention at 15 min (ICG 15') after administration of 0,5 mg IGC/Kg. Reference ICG 15' value is estimated around 10%. Patients suitable for major liver resection must have ICG 15' < 14-17%; for minor liver resection ICG 15' < 22% is allowed [24]. Portal hypertension (PHT) is a well known risk factor for PHLF, and is often a contraindication to major liver resection [25], especially without preoperative portal vein embolization (PVE) [26, 27]. PHT is usually related to a mild-moderate liver disease with minor functional liver reserve, and associated with poor outcome. According to BCLC staging system for the management of hepatocellular carcinoma [28], the presence of clinical signs of PHT, such as splenomegaly, esophageal varices or hypersplenism (with platelets count < 100000 U/μL), is a contraindication to liver resection. The reliable quantification of the portal gradient requires a central venous catheterization and measurement of wedged and free hepatic venous pressure. The presence of hepatic portal vein gradient (HPVG) > 10 mmHg is considered a contraindication to liver resection [19, 28]. However some authors state that PHT should not be considered as an absolute contraindication to liver resection, especially in patients with well compensated liver cirrhosis (CTP A and/or MELD score ≤ 10). In those patients postoperative complications related with PHT, such as bleeding from the rupture of esophageal varices or coagulopathy and or low platelets count, can be safely managed with adequate pre, peri and postoperative treatments [29, 30].

In the context of PHT, the decision tree developed by Makuuchi et al. [31] (Figure 1) may be used. It includes presence of ascites, bilirubin level and ICG clearance. A more than four segment resection requires a normal ICG 15' value, a two to three segment resection can be performed if the rate is < 20%, in case of ICG 15' > 30% only limited resection is safely feasible [32]. Also Cholestasis is associated with increased morbidity [33] and PHLF. The interruption in the enterohepatic bile circulation increases the risk of portal bacteremia [34], and it's also associated with a limited hepatocyte regeneration due to reduced secretion of hepatocyte growth factor (HGF) [35] and the braking of hepatocyte proliferation pathways (C-Myc and cyclin E)[36]. In animals, supplementation with bile salts or internal drainage [37] improves liver regeneration, unlike external drainage [38]. Fatty liver, and more widely non-alcoholic steatosis hepatitis, predisposes to PHLF by impaired microcirculation [39], by a greater susceptibility to ischemia–reperfusion lesions and an increased oxidative stress [40]. Preoperative chemotherapy in management of liver metastases of colorectal cancers is a well-defined risk factor for PHLF as well. Two types of chemotherapy-induced lesions are described: (1) the "Sinusoidal Obstruction Syndrome" after oxaliplatin [41] which can lead to

nodular regenerative hyperplasia, and (2) the "Chemo-Associated Steato-Hepatitis" (CASH) after irinotecan [42] which corresponds to a macro-vacuolar steatosis associated with lobular inflammation and hepatocytes ballooning. This toxicity causes significant morbidity, [43] but the accountability of chemotherapy on the PHLF remains debated, particularly for oxaliplatin. Karoui et al. [44] have shown that neoadjuvant chemotherapy was associated with increased postoperative morbidity (38% vs. 14%) and with an increased incidence of PHLF (11% vs. 0%). Soriano et al. [45] have shown that oxaliplatin alters post-PHx proliferation in animal models. This alteration does not affect post-PVE hypertrophy [46]. To date, no increased postoperative mortality in humans has been shown after oxaliplatin, unlike irinotecan which increases the morbidity/mortality and the incidence of PHLF [47]. The impact of targeted therapies has been less evaluated, but it appears that morbidity and mortality are not increased, if stopped 6 to 8 weeks before surgery [48, 49]. Bevacizumab does not appear to alter the volume gain after PVE [50] 52 and perhaps prevents vascular lesions induced by oxaliplatin [51]. In murine experimental models, sorafenib does not impair liver regeneration if stopped before surgery [48].

References

[1] Emond JC, et al. Functional analysis of grafts from living donors. Implications for the treatment of older recipients. *Ann Surg*, 1996; 224: 544-552; discussion 552-554.

[2] Dahm F, et al. Small-for-size syndrome after partial liver transplantation: definition, mechanisms of disease and clinical implications. *Am J Transplant*, 2005; 5: 2605-2610.

[3] Balzan S., et al. The 50-50 criteria on postoperative day 5. An accurate predictor of liver failure and death after hepatectomy. *Ann Surg*, 2005; 242 (6): 824-829.

[4] Nuh N. Rahbari, et al. Posthepatectomy liver failure: A definition and grading by the International Study Group of Liver Surgery (ISGLS). *Surgery*, 2011 May;149(5):713-24.

[5] Golse N., et al. New paradigms in post-hepatectomy liver failure. *J Gastrointest Surg*, 2013; 17:593-605.

[6] Sun H-C, et al. Risk factors for postoperative complications after liver resection. *HBPD Int.*, 2005; 4(3): 370-374.

[7] Virani S., et al. Morbidity and mortality after liver resection: results of the patient safety in surgery study. *J Am Coll Surg*, 2007; 204(6): 1284-1292.

[8] House MG, et al. Survival after hepatic resection for metastatic colorectalcancer: trends in outcomes fro 1600 patients during two decades at a single institution. *J Am Coll Surg*, 2010;210(5):744-52, 752-5.

[9] Broering DC, et al. Portal vein embolisation VS portal vein ligation for induction of hypertrophy of the future liver remnant. *J Gastrointest Surg* 2002;6: 905-913.

[10] Mullen JT, et al. Hepatic insufficiency and mortality in 1059 non cirrhotic patients undergoing major hepatectomy. *J Am Coll surg*, 2007;204(5):854-862.

[11] Hammonds JS, et al. Prediction, prevention and management of postresection liver failure. *Br J Surg*, 2011;98(9):1188-1200.

[12] Little SA, et al. Diabetes is associated with increased perioperative mortality but equivalent long-term outcomes after hepatic resection for colorectal cancer. *J Gastointest Surg 2002*;6(1):88-94.

[13] Bucher NL, et al. Insulin, glucagon, and the liver. *Adv. Enzyme Regul.,* 1976;15:221-230.
[14] Cucchetti A, et al. Safety of hepatic resection in overweight and obese patients with cirrhosis. *Br J Surg,* 2011;98(8):1147-1154.
[15] Breitenstein S., et al. State of the art in liver resection and living donor liver transplantation: a worldwide survey of 100 liver centers. *World J Surg,* 2009;33(4):797-803.
[16] Santibanes E., et al. How to avoid postoperative liver failure: a novel method. *World J Surg,* 2011;36(1):125-128.
[17] Hemming AW, et al. Indocyanine green clearance as a predictor of successful hepatic resection in cirrhotic patients. *Am J Surg,* 1992;163(5):515-518.
[18] Yamanaka N, et al. Dynamics of normal and injured liver regeneration after hepatectomy as assessed on the basis of computer tomography and liver function. *Hepatology,* 1993;18(1):79-85.
[19] EASL-EORTC Clinical Practice Guidelins: management of hepatocellular carcinoma. *Journal of Hepatology* 2012;56:908-943.
[20] Farges O, et al. Risk of major liver resection in patients with underlying chronic liver disease: a reappraisal. *Ann Surg,* 1999;229: 210-215.
[21] Belghiti J, et al. Seven hundred forty-seven hepatectomies in the 1990s: an update to evaluate the actual risk of liver resection. *J Am Coll Surg,* 2000; 191: 38-46.
[22] Cucchetti A., et al. Impact of model for end stage liver disease (MELD) score on prognosis after hepatectomy for hepatocellular carcinoma on cirrhosis. *Liver Transpl.,* 2006;12(6):966-971.
[23] Teh SH, et al. Hepatic resection of hepatocellular carcinoma in patients with cirrhosis: Model of End-Stage Liver Disease (MELD) score predicts perioperative mortality. *J Gastrointest Surg* 2005; 9:1207-1215.
[24] Kudo M, et al. Management of hepatocellular carcinoma in Japan: Consensus-Based Clinical Practice Guidelines proposed by the Japan Society of Hepatology (JSH) 2010 updated version. *Dig Dis* 2011; 29: 339-364.
[25] Bruix J, et al. Surgical resection of hepatocellular carcinoma in cirrhotic patients: prognostic value of preoperative portal pressure. *Gastroenterology* 1996;111(4):1018-1022.
[26] Lim C., et al. Portal vein occlusion before major hepatectomy in patients with colorectal liver metastases: rationale, indications, technical aspects, complications and outcome. *J Visc Surg,* 2012.
[27] Farges O., et al. Portal vein embolization before right hepatectomy: prospective clinical trial. *Ann Surg* 2003;237(2):208-217.
[28] Llovet JM, et al. Prognosis of hepatocellular carcinoma: the BCLC staging classification. *Semin Liver Dis.* 1999;19:329–338
[29] Kawano Y, et al. Short- and long-term outcomes after hepatic resection for hepatocellular carcinoma with concomitant esophageal varices in patients with cirrhosis. *Ann Surg Oncol* 2008; 15: 1670-1676
[30] Sugimachi K, et al., Appraisal of hepatic resection in the treatment of hepatocellular carcinoma with severe thrombocytopenia. *World J Surg* 2008; 32: 1077-1081,
[31] Makuuchi M, et al. Surgery for small liver cancers. *Semin Surg Oncol,* 1993;9(4):298-304.

[32] Seyama Y, et al. Assessment of liver function for safe hepatic resection. *Hepatology Research*, 2009;39(2):107-116.
[33] Das BC, et al. Analysis of 100 consecutive hepatectomies: risk factors in patients with liver cirrhosis or obstructive jaundice. *World J Surg.* 2001;25(3):266–273.
[34] Sano T, et al. Internal biliary drainage improves decreased number of gut mucosal T lymphocytes and MAdCAM-1 expression in jaundiced rats. *Surgery.* 2004;136(3):693–699.
[35] Makino H, et al. Changes in growth factor and cytokine expression in biliary obstructed rat liver and their relationship with delayed liver regeneration after partial hepatectomy. *World J Gastroenterol.* 2006;12(13):2053–2059.
[36] Nakano K, et al. Lower activity of CCAAT/enhancer-binding protein and expression of cyclin E, but not cyclin D1, activating protein-1 and p21(WAF1), after partial hepatectomy in obstructive jaundice. *Biochemical and Biophysical Research Communications.* 2001;280(3):640–645.
[37] Kamiya S, et al. The value of bile replacement during external biliary drainage: an analysis of intestinal permeability, integrity, and microflora. *Ann Surg.* 2004;239(4):510–517.
[38] 36. Iyomasa S, Terasaki M, Kuriki H, et al. Decrease in regeneration capacity of rat liver after external biliary drainage. *Eur Surg Res.*1992;24(5):265–272
[39] Seifalian AM, et al. The effect of graded steatosis on flow in the hepatic parenchymal microcirculation. *Transplantation.* 1999;68(6):780–784.
[40] Serafín A, et al. Ischemic preconditioning increases the tolerance of Fatty liver to hepatic ischemia–reperfusion injury in the rat. *Am J Pathol.* 2002;161(2):587–601.
[41] Rubbia-Brandt L, et al. Sinusoidal obstruction syndrome is a major feature of hepatic lesions associated with oxaliplatin neoadjuvant chemotherapy for liver colorectal metastases. *J Am Coll Surg.* 2006;202(1):199–200.
[42] Fong Y, et al. CASH (Chemotherapy-Associated Steatohepatitis) costs. *Ann Surg.* 2006;243(1):8–9.
[43] Aloia et al. Liver histology and surgical outcomes after preoperative chemotherapy with fluorouracil plus oxaliplatin in colorectal cancer liver metastases. *J Clin Oncol.* 2006;24(31):4983–4990.
[44] Karoui M, et al. Influence of preoperative chemotherapy on the risk of major hepatectomy for colorectal liver metastases. *Ann Surg.* 2006;243(1):1–7.T.
[45] Soriano PA, et al. Oxaliplatin but not irinotecan impairs posthepatectomy liver regeneration in a murine model. *International Journal of Hepatology.* 2011;2011:1–6.
[46] Nafidi O, et al. *Hypertrophy of the nonembolized liver after chemotherapy.* HPB (Oxford). 2009;11(2):103–107
[47] Vauthey JN. et al. Chemotherapy regimen predicts steatohepatitis and an increase in 90-day mortality after surgery for hepatic colorectal metastases. *Journal of Clinical Oncology.* 2006;24(13):2065–2072.
[48] Hora C, et al. Effect of sorafenib on murine liver regeneration. *Hepatology.* 2011;53(2):577–586.
[49] Van Cutsem E, et al. Cetuximab and chemotherapy as initial treatment for metastatic colorectal cancer. *N Engl J Med.* 2009;360(14):1408–1417.

[50] Zorzi D, et al. Chemotherapy with bevacizumab does not affect liver regeneration after portal vein embolization in the treatment of colorectal liver metastases. *Ann Surg Oncol.* 2008;15(10):2765–2772.
[51] Klinger M, et al. Bevacizumab protects against sinusoidal obstruction syndrome and does not increase response rate in neoadjuvant XELOX/FOLFOX therapy of colorectal cancer liver metastases. *Eur J Surg Oncol.* 2009;35(5):515–520.

SECTION 2. CLASSICAL APPROACH: THE CONCEPT OF SIZE

TLV and FLRV: How to Calculate?

In the last decade, in order to achieve microscopically radical resection margins in primary and secondary liver malignancies and thus better survival, surgical treatment has become more aggressive, resulting in an increased rate of complex and extended liver resections [1, 2]. Postoperative outcomes mainly depend on the size and quality of the future remnant liver (FRL). Liver resection, when performed in the absence of sufficient FRL, leads to post-resection liver failure, or "small for size syndrome" with an incidence ranges from 0.7 to 9.1% and a mortality of 80% [1-3].

Therefore an accurate methods to assess function of the FRL in the workup of candidates for major resection, has become an important issue, for hepato-biliary surgery [1, 4-7].

In a young and otherwise healthy patient with normal underlying liver parenchyma, commonly has reported a FLR cut-off values of 20–30% of the patient's total liver volume (TLV), while in patients with underlying hepatic disease (cirrhosis, cholestasis, steatosis) the critical FLR cut-off value rise up to 30%-40% [2, 3, 8-11].

In order to correctly and precisely determine an optimal FRL, different imaging modalities (i.e., CT, MRI, US) were employed in clinical practice. Mainly the measurements of liver volumes were performed directly on cross-sectional imaging, computing the remnant to TLV ratio using only functional nontumoral liver as representative of TLV. Alternatively, the technique described by Vauthey's group [12], that consists of estimating TLV, based on a patient's body surface area (BSA), measuring the future liver volume on cross-sectional imaging, and then calculating the percentage of the FLR that can now be considered to be standardized to the patient's BSA [2]. In this setting the computed tomography (CT) volumetry (CTV) has been widely used as a method for the preoperative volumetric assessment of the liver. The use of other imaging methods, such as magnetic resonance imaging (MRI) and ultrasound, have also been explored and have shown reliable organ volume measurements when the appropriate scanning protocols are employed [13]. The current gold standard, in the preoperative assessment of FRL volume, is computed tomography (CT) volumetry, as initially described by Heymsfield et al. [14]. With this technique, FRL volume can be calculated by manually tracing the liver contour in each sectional image and summing up the volume of all slices. The three-dimensional reconstruction is then used to calculate the non-tumorous liver volume, tumor volume, and FRL volume [1]. But should be considered that the manual tracing of the liver contour represents a time-consuming process. Moreover, tumor characteristics, such as small tumor size, multiple lesions, and liver characteristics (e.g., small or large liver due to compromised

liver parenchyma) make CT volumetry an error-sensitive imaging technique [1, 15, 16]. Attempts to use other imaging methods, such as ultra- sound and MRI, for liver volumetry have also been made, and several studies in literature have demonstrated that there exists a strong positive correlation in the virtual liver volume measurement using CT or MRI [13, 17, 18].

MRI has the additional advantage of superior soft-tissue contrast, this may theoretically allow for more accurate segmentation of the liver margins, as well as delineation of any focal hepatic tumours. A good knowledge of the appropriate sequences is important for optimal assessment. However, MRI is more expensive and is unsuitable for patients who are claustrophobic. Moreover, the quality of MRI images is easily degraded by motion artefacts, which may preclude in some cases the precise assessment.

Recently Kitajima et al. [19] reported the possibility of performing liver volumetry by means of conventional ultrasound, with good correlation with the volume of the actual specimen; Xu et al., [20] reported the usefulness of the three- dimensional ultrasound (3DUS) volumetric evaluation: the measured volumes all significantly correlated with the true volumes, with significant intraobserver and interobserver reproducibility [4].

Good concordance has been found between 3D ultra- sound and 3D CTV; however, the use of conventional 2D ultrasound has shown to be less precise compared to 3D ultrasound and 3D CTV [13].

Despite the relative widespread availability of 3DUS probes and a considerable refinement of this technique in recent years, ultrasound has not universally proven to be successful for 3D evaluation of the liver, because of well-known limits, both physical and related to a variable reproducibility of the exam, which mainly depends on the skill of the examiner [4, 13, 21-23].

A factor that may affect the accuracy of volumetric assessment is the scan phase. There are significant differences in the total liver volume and graft-liver volume calculations performed in the different contrastographic phases (i.e., unenhanced, arterial or portal venous phase). CTV based on portal venous phase computed analysis is associated with considerable overestimation, whereas volumetry based on the unenhanced CT phase yields the least significant overestimation. However, even though CTV based on the unhenanced CT phase most accurately matches the actual intraoperative findings, in clinical practice the portal venous phase is typically preferred, because it better delineates the vascular anatomy (hepatic veins, main portal trunk and side branch portal vein) and the margins of any tumour than unenhanced CT of the liver.

Manual, Semi-Automated and Automated Methods of CTV

The CTV has traditionally been performed by manual contour tracing of the hepatic contours and summation of the liver area on each axial section, by a radiologist; however, such manual methods depends on operator expertise, requiring considerable time-analysis. Therefore to speed up the process and avoid useless operations, several automated or semi-automated CT-application method have been proposed to perform the volumetric analysis of the liver. Various techniques and algorithms have been described and employed for the automated methods of volumetry, including three-dimensional (3D) active contour segmentation with geodesic active contour segmentation, also coupled with level set algorithms. This technique mainly based on involves the estimation of the mean CT

attenuation value of the liver, permit to select the initial candidate regions of the liver on each section by using the estimated CT cut-off value of the liver. The liver is then separated from other adjacent organs via the analysis of edge information inside the initially estimated liver. A 3D image of the liver is subsequently reproduced for the calculation of liver volume [13, 24-26].

Automatic segmentation sometimes fails in the analysis of CT images due to the low in contrast or to the missing edges (i.e., similar intensity of liver and adjacent organs or machine noise); therefore several semi-automated methods are proposed to include the user in the "processing work" in order to guide the automated segmentation. This approach provides more flexibility and control over the volumetric determination. Semi-automatic segmentation introduced by Wimmer et al. obtained the highest average performance score of 84.6 as stated in the "2007 proceedings of the Medical Image Computing and Computer-Assisted Intervention workshop" focused on segmentation of the liver. Basically, the described algorithm can be divided into three steps. The first step is manual delineation. Manual delineation works on two-dimensional (2D) multiplanar reconstruction views. It captures the cross-section of the liver by user input control points or live wire (Experiments show that typically six to eight contours can achieve good results). The second step is 3D surface reconstruction, which works by using radial basis function based on the manual delineation. The last step is surface evolution, which evolves the reconstructed 3D surface using a level set framework comprising both image and shape information. In general, semi-automatic methods have been show to outperform automatic methods [13, 27-29].

In terms of duration of examination, the average user time for automated volumetry is around 0.57 ` 0.06 min/case, whereas those for semi-automated and manual volumetry are around 27.3 ` 4.6 and 39.4 ` 5.5 min/case, respectively. This implies a highly effective time-saving measure of >30 min/case if one switched from manual to automated means of volumetric assessment [13, 30].

As accurate liver volume estimation relies on precise segmentation of the liver, theoretically it should expect more accurate results when using CT images with smaller section thicknesses. An inverse relationship between the section thickness and the final obtained liver volumes has been described, being liver volumes obtained from analysis of submillimetre thick CT sections larger than volume calculated from thicker images. A maximum error of 5% in the calculated graft volume should be expected if 6 mm thick sections are used [13, 31].

However, the use of thinner sections translates to a greater number of axial sections needed for segmentation, hence more time required for volumetric analysis. This approach represents a more time consuming process when a manual method of contour tracing is utilized. Supposing that a typical adult liver span is 12 cm, the use of 6 mm or 0.625 mm sections requires segmentation of approximately 20 images and 192 images, respectively. The balance between accuracy of volume estimation and time required for image analysis should be carefully weighed.

With regard to the use of volumetry in MRI, the source data are derived from dynamic 3D Gradient echo images, such as volumetric interpolated breath-hold examination and liver acquisition with volume acquisition. Reiner et al. suggested the use of 6 mm and 8 mm section thicknesses for CT and MRI, respectively, for a good balance between accuracy of calculated volume and time efficiency [32].

Volumetric measurements of the liver have been described beyond the use of dedicated professional soft- ware, also by using those software packages on a personal computer. Various authors have used more accessible and generic image processing software to measure hepatic volumes, and these have been found to well correlate with conventional CTV as well as with intra-operative graft volume [33, 34]. They represent a useful and reliable diagnostic tools in routinely work-up, offering a small interobserver variability (up to 5%) in the determination of total liver volumes, resection volumes, and tumour volumes especially when compared to those results obtained from CT scanner-linked software [13, 35].

References

[1] Cieslak KP, Runge JH, Heger M, Stoker J, Bennink RJ, van Gulik TM. New perspectives in the assessment of future remnant liver. *Dig Surg* 2014;31(4-5):255-68.

[2] Martel G, Cieslak KP, Huang R, van Lienden KP, Wiggers JK, Belblidia A, Dagenais M, Lapointe R, van Gulik TM, Vandenbroucke-Menu F. Comparison of techniques for volumetric analysis of the future liver remnant: implications for major hepatic resections. *HPB* (Oxford) 2015;17(12):1051-7.

[3] van den Broek MA, Olde Damink SW, Dejong CH, Lang H, Malago M, Jalan R, Saner FH: Liver failure after partial hepatic resection: definition, pathophysiology, risk factors and treatment. *Liver Int* 2008;28:767–780.

[4] D'Onofrio M, De Robertis R, Demozzi E, Crosara S, Canestrini S, Pozzi Mucelli R. Liver volumetry: Is imaging reliable? Personal experience and review of the literature. *World J Radiol* 2014; 28;6(4):62-71.

[5] Okamoto E, Kyo A, Yamanaka N, Tanaka N, Kuwata K. Prediction of the safe limits of hepatectomy by combined volumetric and functional measurements in patients with impaired hepatic function. *Surgery* 1984;95:586-592

[6] Cohnert TU, Rau HG, Buttler E, Hernandez-Richter T, Sauter G, Reuter C, Schildberg FW. Preoperative risk assessment of hepatic resection for malignant disease. *World J Surg* 1997;21:396-400

[7] Rau HG, Schauer R, Helmberger T, Holzknecht N, von Rückmann B, Meyer L, Buttler E, Kessler M, Zahlmann G, Schuhmann D, Schildberg FW. Impact of virtual reality imaging on hepatic liver tumor resection: calculation of risk. *Langenbecks Arch Surg* 2000;385:162-170

[8] Schindl MJ, Redhead DN, Fearon KCH, Garden OJ, Wigmore SJ. The value of residual liver volume as a predictor of hepatic dysfunction and infection after major liver resection. *Gut* 2005;54:289–296.

[9] Shoup M, Gonen M, D'Angelica M, Jarnagin WR, DeMatteo RP, Schwartz LH. Volumetric analysis predicts hepatic dysfunction in patients undergoing major liver resection. *J Gastrointest Surg* 2003;7:325–330.

[10] Breitenstein S, Apestegui C, Petrowsky H, Clavien PA. 'State of the art' in liver resection and living donor liver transplantation: a worldwide survey of 100 liver centers.*World J Surg* 2009;33:797–803.

[11] Abdalla EK, Barnett CC, Doherty D, Curley SA, Vauthey JN. Extended hepatectomy in patients with hepatobiliary malignancies with and without preoperative portal vein embolization. *Arch Surg* 2002;137:675–681.

[12] Vauthey JN, Abdalla EK, Doherty DA, Gertsch P, Fenstermacher MJ, Loyer EMet al. Body surface area and body weight predict total liver volume in Western adults. *Liver Transpl* 2002;8:233–240.

[13] Lim MC, Tan CH, Cai J, Zheng J, Kow AW. CT volumetry of the liver: where does it stand in clinical practice? *Clin Radiol.* 2014;69(9):887-95.

[14] Heymsfield SB, Fulenwider T, Nordlinger B, Barlow R, Sones P, Kutner M. Accurate measurement of liver, kidney, and spleen volume and mass by computerized axial tomography. *Ann Intern Med* 1979;90: 185–187.

[15] Kubota K, Makuuchi M, Kusaka K, Kobayashi T, Miki K, Hasegawa K, Harihara Y, Takayama T. Measurement of liver volume and hepatic functional reserve as a guide to decision making in resectional surgery for hepatic tumors. *Hepatology* 1997;26:1176–1181.

[16] Vauthey JN, Chaoui A, Do KA, Bilimoria MM, Fenstermacher MJ, Charnsangavej C, Hicks M, Alsfasser G, Lauwers G, Hawkins IF, Caridi J: Standardized measurement of the future liver remnant prior to extended liver resection: methodology and clinical associations. *Surgery* 2000;127:512–519.

[17] Karlo C, Reiner CS, Stolzmann P, Breitenstein S, Marincek B, Weishaupt D, Frauenfelder T. CT- and MRI-based volumetry of resected liver specimen: comparison to intraoperative volume and weight measurements and calculation of conversion factors. *Eur J Radiol* 2010;75:107-11.

[18] Muggli D, Muller MA, Karlo C, Fornaro J, Marincek B, Frauenfelder T. A simple method to approximate liver size on cross-sectional images using living liver models. *Clin Radiol* 2009;64:682e9.

[19] Kitajima K, Taboury J, Boleslawski E, Savier E, Vaillant JC, Hannoun L. Sonographic preoperative assessment of liver volume before major liver resection. *Gastroenterol Clin Biol* 2008;32:382-389.

[20] Xu HX, Yin XY, Lu MD, Liu GJ, Xu ZF. Estimation of liver tumor volume using a three-dimensional ultrasound volumetric system. *Ultrasound Med Biol* 2003;29:839-846.

[21] Oldhafer KJ, Högemann D, Stamm G, Raab R, Peitgen HO, Galanski M. 3-dimensional (3-D) visualization of the liver for planning extensive liver resections. *Chirurg* 1999;70:233-238.

[22] Lang H, Wolf GK, Prokop M, Weimann A, Pichlmayr R, Zoller WG. Volumetry of circumscribed liver changes with 3-D ultrasound in comparison with 3-D computerized tomography. *Langenbecks Arch Chir Suppl Kongressbd* 1998;115:1478-1480.

[23] Marescaux J, Clément JM, Tassetti V, Koehl C, Cotin S, Russier Y, Mutter D, Delingette H, Ayache N. Virtual reality applied to hepatic surgery simulation: the next revolution. *Ann Surg* 1998;228:627-634.

[24] Nakayama Y, Li Q, Katsuragawa S, Ikeda R, Hiai Y, Awai K, Kusunoki S, Yamashita Y, Okajima H, Inomata Y, Doi K. Automated hepatic volumetry for living related liver transplantation at multisection CT. *Radiology* 2006;240:743-8.

[25] Suzuki K, Epstein ML, Kohlbrenner R, Garg S, Hori M, Oto A, Baron RL. Quantitative radiology: automated CT liver volumetry compared with interactive volumetry and manual volumetry. *AJR Am J Roentgenol* 2011;197:706-12.

[26] Frericks BB, Kiene T, Stamm G, Shin H, Galanski M. CT-based liver volumetry in a porcine model: impact on clinical volumetry prior to living donated liver transplantation. *Rofo* 2004;176:252-7.

[27] Wimmer A, Soza G, Hornegger J. Two-stage semi-automatic organ segmentation framework using radial basis functions and level sets. In: Heimann T, Styner M, van Ginneken B, editors. *3D segmentation in the clinic: a grand challenge. Springer Berlin, Heidelberg: LNCS* 2007. pp. 179-88.

[28] Falcao AX, Udupa JK, Samarasekera S, Samarasekera S, Sharma S, Hirsch BE, de A. Lotufo R. User-steered image segmentation paradigms: live wire and live lane. *J Graph Models Imaging Proc* 1998;60:233-60.

[29] Sethian JA. *Level set methods and fast marching methods.* Cambridge: Cambridge University Press; 1999.

[30] Perandini S, Faccioli N, Inama M, Pozzi Mucelli R. Freehand liver volumetry by using an electromagnetic pen tablet: accuracy, precision, and rapidity. *J Digit Imaging* 2011;24:360-5.

[31] Hori M, Suzuki K, Epstein ML, Baron RL. Computed tomography liver volumetry using 3-dimensional image data in living donor liver transplantation: effects of the slice thickness on the volume calculation. *Liver Transpl* 2011;17:1427-36.

[32] Reiner CS, Karlo C, Petrowsky H, Marincek B, Weishaupt D, Frauenfelder T. Preoperative liver volumetry: how does the slice thickness influence the multidetector computed tomography and magnetic resonance liver volume measurements? *J Comput Assist Tomogr* 2009;33:390-7.

[33] Lu Y, Wu Z, Liu C, Wang HH. Hepatic volumetry with Photo Shop in personal computer. *Hepatobiliary Pancreat Dis Int* 2004;3:82-5.

[34] Dello SA, van Dam RM, Slangen JJ. Liver volumetry plug and play: do it yourself with Image. *World J Surg* 2007;31:2215-21.

[35] van der Vorst JR, van Dam RM, van Stiphout RS, van den Broek MA, Hollander IH, Kessels AG, Dejong CH. Virtual liver resection and volumetric analysis of the future liver remnant using open source image processing software. *World J Surg* 2010;34:2426-33.

Rationale and Historical Perspectives of Strategies to Push up Liver Resection's Limits

The liver is characterized by a unique and extraordinary capacity for self-renewal; it is the only internal solid organ in the mammal that can fully regenerate after injury or loss. This occurs through organized proliferation of all resident cell types resulting in restored function. The tremendous regenerative potential of the liver has been recognized since ancient times. In classical Greek mythology, Prometheus, after stealing the secret of fire and introducing it to earthlings, was punished by having an eagle of Zeus feast daily on his liver. His punishment was the ultimate torture, as his liver regenerated eternally while the eagle continued his perpetual daily feeding sessions from a constantly replenished source. This myth show how the extraordinary regenerative ability of the liver was known thousands of years ago. Today, the amazing regenerative capacity of the liver is no longer inspiration for mystical tales but is the basis for modern hepatobiliary surgery [16].

Liver surgery with curative intent has been recognized as the gold standard for the management of primary and secondary liver tumours. A careful selection of patients together with advances in both surgical technique and perioperative management has recently improved results of liver surgery. Most series from centers with extensive experience show an overall operative mortality of less than 5% and a mortality rate of about 1% when considering only patients without underlying cirrhosis [17-18]. Nevertheless, major and extended liver resections are still associated with high morbidity and mortality [19-20]. The most severe postoperative complication is liver failure, due to an inadequate amount of hepatic parenchyma after resection. Adults who have more than 75% of the functional liver resected usually are considered at higher risk for postoperative liver failure (30-35% if chirrosis is present). It has been demonstrated that the increase of the portal flow into a part of the liver can induce hypertrophy of the same part. A significantly higher volume of FLR correlates with improved metabolic liver function and reduced risk of postoperative liver failure. The redirection of portal flow can be obtained by surgical ligation (PVL), percutaneous embolization (PVE) or by surgical ligation associated with in situ liver partition (ALPPS). The human body responds to partial hepatectomy not by regenerating lost segments, but by inducing hyperplasia in the liver remnant. The process of restoration of liver volume in humans is initiated by the replication of various types of intrahepatic cells (such as hepatocites and stromal cells), followed by an increase in cell size. PVE, PVL and ALPPS are based on experimental observations reported by Rous and Larimore in 1920 [21] (Figure 2). These authors studied the consequences of segmental portal vein ligation in rabbits and found progressive atrophy of segments with occluded portal veins and hypertrophy of segments with portal vein flow. It has also been clinically observed that segments in which tumors were invading or occluding portal veins spontaneously atrophied while the contralateral lobes hypertrophied. Makuuchi et al. first used the selective occlusion strategy in patients in order to extend the limits of liver resection [22].

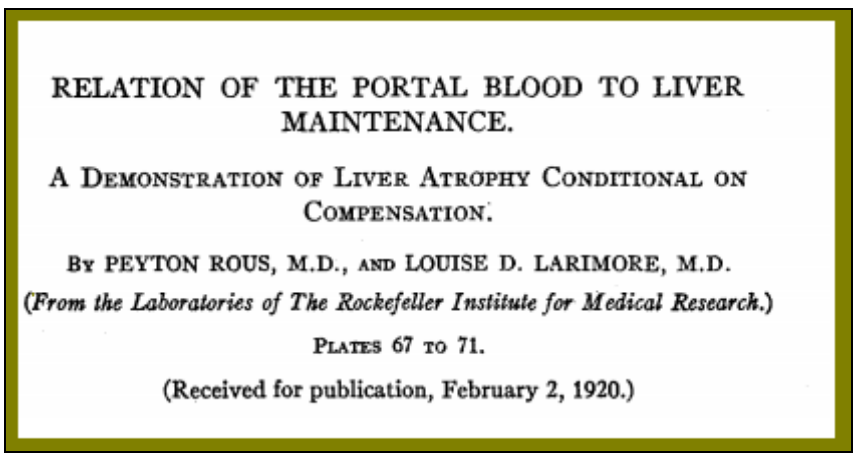

RELATION OF THE PORTAL BLOOD TO LIVER MAINTENANCE.

A DEMONSTRATION OF LIVER ATROPHY CONDITIONAL ON COMPENSATION.

BY PEYTON ROUS, M.D., AND LOUISE D. LARIMORE, M.D.

(*From the Laboratories of The Rockefeller Institute for Medical Research.*)

PLATES 67 TO 71.

(Received for publication, February 2, 1920.)

Figure 2. Header of the first manuscript published about the role of portal flow in liver maintenance.

Portal Vein Embolization (PVE)

Introduction

Preoperative portal vein embolization (PVE) is a procedure that was first described by Kinoshita [23] and used by Makuuchi in the context of the liver resection for Klatskin tumours in order to increase the size of the future liver remnant [22].

Technique

The goal of PVE is to redistribute portal flow toward the segments of liver that will remain after surgery. Embolization of portal branches must be as complete as possible and should result in occlusion of the entire portal tree to prevent the development of intrahepatic portoportal collaterals.

Ultrasound (US) of the liver is performed to determine the best access route into the portal venous system. Under sterile conditions, access into the portal venous system is gained with US or fluoroscopic guidance or both. The ipsilateral approach (access through the portion of the liver to be resected) is recommended as not to injure the FLR. It was found that the contralateral approach may result in iatrogenic lesions of the future liver remnant [24]. Many embolic materials have been used for PVE (gelatin sponge, nonspherical polyvinyl alcohol particles, alcohol, mixture of n-Butyl-cyanoacrylate and iodized oil and spherical microparticles). Small particles used in PVE can embolize capillary liver system eliminating the problematic of the presence of any shunt with healthy liver that can reduce the ipertrophization FLR frequently present in portal vein ligation [25].

Clinical Course after PVE

Postembolization syndrome, including pain, fever, nausea and vomiting, are usually minimal after PVE [26]. Most patients experience a mild fever following PVE, which subsides within 2-3 days. Likewise, changes in liver function (reflected by an increased total bilirubin value and prolonged prothrombin time) are mild and transient, returning to their baseline values 2-3 days after PVE. The serum AST and ALT values are stable in most of patients.

Histological Changes after PVE

Harada et al. have reported histological changes after PVE [27]. In the nonembolized part there are numerous small or binuclear hepatocytes, proliferative hepatocytes, occasionally mitotic figures but apoptotic hepatocytes were rare. In the embolized part, hepatocyte atrophy was observed, the cytoplasm was more eosinophilic than normal apoptotic cells were detected, predominantly in the perivenular area. Based on these findings, Harada concluded that PVE induces hepatocyte apoptosis leading to the atrophy of the embolized part; the cells in the nonembolized part enter a highly active phase of proliferation within two weeks after PVE.

Results

After a month from PVE, the volume of the FLR is evaluated using imaging and later the patient is subjected to major hepatectomy. Resection rate is around 85%. Reasons for non resection are tumor progression, peritoneal metastases or unsuspected metastases discovered

at laparotomy. Absence of hypertrophy is rare (less than 10% in metastatic liver) but can reach 20% in cirrhotic patients [28]. Manty studies have demonstrated that hypertrophy is inversely proportional to the FRL ratio before PVE, meaning that the smaller FRL before PVE will have the larger hypertrophy [28]. In a recent systematic review of a TSH series, (vedi lavoro aldrighetti) despite impressive OS and DFS rates and acceptable complication and mortality rates, a consistent proportion of patients (8–31%) did not progress to stage 2. The common reasons for this "dropout" were interval disease progression (88% of the dropout) and inadequate FLR hypertrophy (4% of the dropout).

(A)

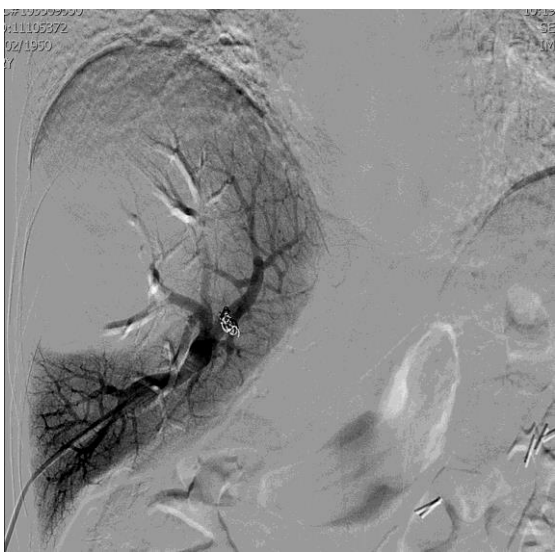

(B)

Figure 3. A-Percutaneous transhepatic angiographic catheter in introduced through the right portal branch into the main portal vein. B-Selective right angiogram following embolization of the subsegmental right branches with placement of coils and glue.

Portal Vein Ligation (PVL) and Two-Stage Hepatectomy

Introduction

PVE is usually preferred to PVL, because less invasive, but there are some cases in which PVL can be used to induce liver hypertrophy. The main ones are:

- Impossibility to perform PVE due to technical reasons.
- The need to evaluate the patient with an exploratory laparoscopy to exclude the presence of peritoneal carcinomatosis and to assess the resectability of the disease. The surgeon may submit the patient to a ligation of the right branch of the portal vein during this procedure [29]
- Bilobar liver metastases that require a two-staged hepatectomy or synchronous liver metastasis. In this case PVL may be associated with the resection of primitive tumor in the first stage. The higher invasiveness of surgical closure of the portal vein is offset by the need for surgery prior to liver resection.

Technique

Two-stage hepatectomy utilizes the regenerative capacity of the liver, aiming to perform a safe, curative hepatic resection for initially irresectable tumours [30]. This tecnique has been developed as a surgical strategy for extremely difficult cases of bilobar multinodular metastatic liver disease. It is applied when it is impossible to resect all malignant lesions in a single procedure, the main principle of this approach is sequential resection by a two-staged hepatectomy. Its goal is to achieve a complete metastasectomy in those cases in which a complete resection with a single hepatectomy would have left a remnant postresection liver too small for patient survival. The objective of the first hepatectomy is to render the final future remnant liver free from disease so that the second liver resection becomes feasible and potentially curative. The success of this method relies on liver regeneration between the two interventions, allowing the second hepatectomy to be performed with a lower risk of serious complications, including postoperative liver failure.

Results

Clinical and experimental studies show opposite results on the embolization technique. One prospective study in patients concluded that PVE is superior to PVL in terms of volume gained, lesser time to hypertrophy, lesser hospital stay, and fewer adhesions during major hepatectomy [25, 31] Another retrospective clinical study shown that PVL is as effective as PVE in inducing hypertrophy of the future liver remnant [32].

Associating Liver Partition and Portal Vein Ligation for Staged Hepatectomy (ALPPS)

Introduction

Recently, a new approach to prevent the onset of postoperative hepatic failure in patients with small FLR has been proposed with the acronym ALPPS (Associating Liver Partition and Portal Vein Ligation for Staged Hepatectomy) and represents an evolution of two-staged

hepatectomy. Patients are candidated for a program of two-stage hepatectomy. During the first stage portal vein ligation and parenchymal transection in situ are performed. After a week, the volume of the FLR is evaluated using imaging and later the patient is subjected to the second stage with major hepatectomy. ALPPS was first described in a publication in the Annals of Surgery in 2012 by Schnitzbauer [33]; he described the first series of 25 cases: the study reports an increased percentage of FLR of 74% in 9 days, so more rapid and more effective than normally occurs with the techniques of vascular occlusion (mean time with PVE and PVL: 25-35 days with an hypertrophy of 10-50% [25, 34]). The dramatic effect on liver regeneration can be explained thanks to the interruption of possible collateral vessels between the two portions of the parenchyma, which amplifies the effect of the portal overflow to FLR hindering recanalization of embolized portal branches. The parenchyma to be resected works as auxiliary liver until its removal. Knoefel et al.[35] compare the rate of parenchymal hypertrophy in a series of 22 patients undergoing PVE (12 pts), ALPPS (7 pts). He shows that after PVE the mean FLR volume increased was 37% after a mean of 27 days; After ALPPS rapid growth of a mean of 63% of the FLR was observed within 3 days.

This new approach might also involve a preconditioning phenomenon for the FLR, in which the diseased hemiliver acts as a transitory auxiliary liver that assists the growing FLR in metabolic, synthetic, and detoxifying functions during the critical first week after resection [36].

Even the problem of neoplastic progression in the interval between PVE and surgery, remarkable in the non-embolized liver is partially solved with ALPPS approach because the interval before the curative resection is greatly reduced (mean 7-10 days vs 25-35). Another good reason to emphasize the value of this approach is that it avoids the infiltration of FLR by tumor, especially when the tumor is located close to vascular structures [37]. The main problem with this approach is the high rate of morbidity and mortality. Schnitzbauer refers a morbidity of 64% and a mortality rate of 12%, while Knoefel shows that only two of 7 patients had a course free of complications [33, 35].

Technique

The procedure is performed in two steps. The first stage consists of exploratory laparotomy, assessment of resectability with intraoperative ultrasound and positioning the tumor in relation with vessels. If ALPPS is performed for bilobar liver metastases small metastases in left hemiliver can be resected, if is performed for synchronous liver metastases primitive tumors should be resected. The liver is mobilized and hilar structures are exposed; after the right portal vein branch is identified, it is sectioned. Total or nearly total parenchymal dissection is performed. The raw surface of the diseased liver, being partially ischemic after the first step, might be associated with a higher risk of biliary leaks. The second step is usually performed after an interval of 6-12 days. A computed tomography is performed to demonstrate liver hypertrophy and the procedure is completed by relaparotomy. The right artery, right bile duct and the right hepatic vein are ligated; remaining parenchymal bridges of liver tissue with vena cava and diaphragm is divided, if present.

Results

In ALPPS approach, the portal vein ligation associated with in situ splitting is able to induce enormously accelerated hypertrophy. The neovascularization and persistence of

interlobar perfusion are prevented by performing parenchymal dissection. The nearly total parenchymal dissection induced a median hypertrophy of 74%, which is markedly above the range that can be achieved by portal vein ligation or portal vein embolization alone [33, 35-38]. The median time interval to have hypertrophic effect is nine days. De Santibanes [36] observed a rapid growth of the future liver remnant up to 83% in only six days. In contrast, hypertrophy using portal vein ligation or portal vein embolization is generally after four weeks and achieved a much lower degree of hypertrophy (10-50%) [25-34]. An important point to promote accelerated hypertrophy must be attributed to the in situ splitting procedure. This technique prevents formation of vascular collaterals between the left and the right hemiliver. This combination of portal vein ligation and in situ splitting is able to induce a much stronger stimulus leading to rapid and marked hypertrophy of the left hemiliver or left lateral lobe. The in situ splitting causes disruption on intrahepatic portal collaterals leading to a portal flow deprivation to the excluded segments and redistribution of hepatotrophic factors. Since the publication of the article that first described this procedure (Schnitzbauer et al. [35]) great enthusiasm has surrounded this technique because it offers the possibility to treat otherwise inoperable patients. However, it is important to recall that the high rate of morbidity and mortality must confine this procedure only in selected patients and should only be undertaken by experienced hepatobiliary surgeons in a high-volume center.

Actual gold standard indication for ALPPS are colorectal liver metastases in patients younger than 60 years [37]. Pringle's manouvres, primitive liver disease, previously systemic chemo or radio-therapy, cholestasis, primary biliary tumors (Klatskin tumor's) are risk factor for a worse prognosis after operation for a reduced liver regeneration [37]. The main problem with this approach is the high rate of morbidity and mortality. Schnitzbauer refers a morbidity of 64% and a mortality rate of 12% [33] The promising short-term results obtained so far are difficult to interpret oncologically, because of the heterogeneous group of patients with different underlying pathologies, variable chemotherapy use, and technical variations applied. In conclusion ALPPS is a technique that opens revolutionary perspectives in hepatobiliary surgery, however, the high rate of complications and the lack of a long-term follow-up should limit this procedure in selected patients.

Conclusion

PVE and PVL are associated with comparable results in inducing future liver remnant hypertrophy, but PVE is a radiologic procedure performed under local anaesthesia that exposes patients to fewer risks in terms of comorbidities. PVE is preferable to PVL in all cases do not require a two stage hepatectomy to avoid additional surgery. ALPPS assures the possibility to obtain a higher rate of hypertrophy in a shorter time compared to the traditional techniques even if the complication rate of this procedure is higher. ALPPS should not be considered as substitute for PVE or PVL. ALPPS should be considered to expand the pool of resectable patients and should be indicated in patients with a small FLR who have contraindications to be subjected to PVE or PVL or needing a high growth in a short time of FLR due to high risk of neoplastic progression and tumor dissemination.

References

[1] Benzoni E, Lorenzin D, Baccarani U, Et all. Resective surgery for liver tumor: a multivariate analysis of causes and risk factors linked to postoperative complications. *Hepatobiliary Pancreat Dis Int* 2006; 5: 526–533

[2] Schindl MJ, Redhead DN, Fearon KC, Garden OJ, Wigmore SJ. The value of residual liver volume as a predictor of hepatic dysfunction and infection after major liver resection. *Gut* 2005; 54: 289–96.

[3] Behrns KE, Tsiotos GG, DeSouza NF, Krishna MK, Ludwig J, Nagorney DM: Hepatic steatosis as a potential risk factor for major hepatic resection. *J Gastrointest Surg* 1998; 2:292–298.

[4] Cherqui D, Benoist S, Malassagne B, Humeres R, Rodriguez V, Fagniez PL: Major liver resection for carcinoma in jaundiced patients without preoperative biliary drainage. *Arch Surg* 2000; 135: 302–308.

[5] Yang T, Zhang J, Lu JH, Yang GS, Wu MC, Yu WF: Risk factors influencing postoperative outcomes of major hepatic resection of hepatocellular carcinoma for patients with underlying liver diseases. *World J Surg* 2011; 35: 2073–2082

[6] Nakano H, Oussoultzoglou E, Rosso E, et al. Sinusoidal injury increases morbidity after major hepatectomy in patients with colorectal liver metastases receiving preoperative chemotherapy. *Ann Surg* 2008; 247: 118–24.

[7] Shirabe K, Shimada M, Gion T, Hasegawa H, Takenaka K, Utsunomiya T, Sugimachi K: Postoperative liver failure after major hepatic resection for hepatocellular carcinoma in the modern era with special reference to remnant liver volume. *J Am Coll Surg* 1999; 188: 304–309.

[8] Silva MA, Muralidharan V, Mirza DF. The management of coagulopathy and blood loss in liver surgery. *Semin Hematol* 2004; 41: 132–9.

[9] Van den Broek MA, Olde Damink SW, Dejong CH, Lang H, Malagó M, Jalan R, Saner FH: Liver failure after partial hepatic resection: definition, pathophysiology, risk factors and treatment. *Liver Int* 2008; 28: 767– 780.

[10] Kimura F, Shimizu H, Yoshidome H, et al. Circulating cytokines, chemokines, and stress hormones are increased in patients with organ dysfunction following liver resection. *J Surg Res* 2006; 133: 102–12.

[11] Thasler WE, Bein T, Jauch KW. Perioperative effects of hepatic resection surgery on hemodynamics, pulmonary fluid balance, and indocyanine green clearance. *Langenbecks Arch Surg* 2002; 387: 271–5.

[12] Dixon E, Vollmer CM Jr, Bathe OF, Sutherland F. Vascular occlusion to decrease blood loss during hepatic resection. *Am J Surg* 2005; 190: 75–86.

[13] Belghiti J, Noun R, Zante E, Ballet T, Sauvanet A. Portal triad clamping or hepatic vascular exclusion for major liver resection. *A controlled study. Ann Surg* 1996; 224: 155–61.

[14] Fan ST, Lo CM, Lai EC, Chu KM, Liu CL, Wong J. Perioperative nutritional support in patients undergoing hepatectomy for hepatocellular carcinoma. *N Engl J Med* 1994; 331: 1547–52.

[15] Hatfield AR, Tobias R, Terblanche J, et al. Preoperative external biliary drainage in obstructive jaundice. A prospective controlled clinical trial. *Lancet* 1982; 2: 896–9.

[16] Lehmann K, Clavien PA.History of hepatic surgery. *Surg Clin North Am.* 2010 Aug;90(4):655-64. doi: 10.1016/j.suc.2010.04.018.

[17] Jarnagin WR, Gonen M, Fong Y et al., (2002) Improvement in perioperative outcome after hepatic resection: analysis of 1,803 consecutive cases over the past decade. *Ann Surg* 236:397–407.

[18] Arru M, Aldrighetti L, Castoldi R, Di Palo S, Orsenigo E, Stella M, Pulitano` C, Gavazzi F, Ferla G, Di Carlo V, Staudacher C (2008) Analysis of prognostic factors influencing long-term survival after hepatic resection for metastatic colorectal cancer. *World J Surg* 32:93–103.

[19] Belghiti J, Hiramatsu K, Benoist S et al., (2000) Seven hundred forty-seven hepatectomies in the 1990s: an update to evaluate the actual risk of liver resection. *J Am Coll Surg* 191:38–46.

[20] Melendez J, Ferri E, Zwillman M et al., (2001) Extended hepatic resection: a 6-year retrospective study of risk factors for perioperative mortality. *J Am Coll Surg* 192:47–53.

[21] Rous P, Larimore LD. Relation of the portal blood to liver maintenance: a demonstration of liver atrophy conditional on compensation. *J Exp Med.* 1920;31:609–632.

[22] Makuuchi M, Thai BL, Takayasu K, et al. Preoperative portal embolization to increase safety of major hepatectomy for hilar bile duct carcinoma: a preliminary report. *Surgery* 1990 ; 107 : 521 – 7.

[23] Kinoshita H, Sakai K, Hirohashi K et al., (1986) Preoperative portal vein embolization for hepatocellular carcinoma. *World J Surg* 10:803–808.

[24] Di Stefano D, Bartoli J, De Baere T, et al. Incidents and complications after percutaneous portal vein embolization. *J Radiol* 2000;81:1488–9.

[25] Ratti F, Soldati C, Catena M, Paganelli M, Ferla G, Aldrighetti L. Role of portal vein embolization in liver surgery: single centre experience in sixty-two patients. *Updates Surg.* 2010 Dec;62(3-4):153-9.

[26] Feng TL, Zhu DZ, YU CQ, Ling B *Ginsenosides combined with dexamethasone in preventing and treating postembolization syndrome following transcatheter arterial chemoembolization: a randomized, controlled and double-blinded prospective trial.* 2005 Mar;3(2):99-102.

[27] Harada H, Imamura H, Miyagawa S et al. Fate of human liver aft er hemihepatic portal vein embolization: cell kinetics and morphometric study. *Hepatology* 1997; 26:1162-1170.

[28] Abulkhir A, Limongelli P, Healey AJ, et al. (2008) Preoperative portal vein embolization for major liver resection: a meta-analysis. *Ann Surg* 247(1):49-57.

[29] Georgios D. Ayiomamitis, Jee K. Low, Bassam Alkari, Stephen H. Lee Role of Laparoscopic Right Portal Vein Ligation in Planning Staged or Major Liver Resection. *Journal of Laparoendoscopic & Advanced Surgical Techniques.* June 2009, 19(3): 409-413. doi:10.1089/ lap.2008.0238.

[30] Adam R, Laurent A, Azoulay D, Castaing D, Bismuth H. Two-stage hepatectomy: A planned strategy to treat irresectable liver tumours. *Ann Surg.* 2000 Dec;232(6):777-85.

[31] Broering DC, Hillert C, Krupski G, Fischer L, Mueller L, Achilles EG, et al. Portal vein embolization vs. portal vein ligation for induction of hypertrophy of the future liver remnant. *J Gastrointest Surg* 2002;6:905-13.

[32] Aussilhou B, Lesurtel M, Sauvanet A, Farges O, Dokmak S, Goasguen N, et al. Right portal vein ligation is as efficient as portal vein embolization to induce hypertrophy of the left liver remnant. *J Gastrointest Surg* 2008;12:297-303.
[33] SchnitzbauerAA, Lang SA, Goessman H, Nadalin S, Baumgart S et al. Right portal vein ligation combined with in situ splitting induces rapid left lateral liver lobe hypertrophy enabling 2-staged extended right hepatic resection in small-for-size settings. *Ann Surg* 2012; 255:405-414.
[34] Abulkhir A, Limongelli P, Healey AJ, Damrah O, Tait P, Jackson J, Habib N, Jiao L (2008) Preoperative portal vein embolization for major liver resection. A meta-analysis. *Ann Surg* 247:49–57.
[35] Knoefel WT, Gabor I, Rehders A, Alexander A In situ liver transection with portal vein ligation for rapid growth of the future liver remnant in two-stage liver resection. *Br J Surg* 2013 Feb;100(3):388-94. doi: 10.1002/bjs.8955. Epub 2012 Nov 2.
[36] De Santibañes E, Alvarez FA, Ardiles V. How to avoid postoperative liver failure: a novel method. *World J Surg.* 2012;36:125–8.
[37] Ratti F, Cipriani F, Gagliano A, Catena M, Paganelli M, Aldrighetti L. Defining indications to ALPPS procedure: technical aspects and open issues. *Updates Surg.* 2014 Mar;66(1):41-9. doi: 10.1007/s13304-013-0243-y. Epub 2013 Dec 17.
[38] Baumgart J, Lang S, Lang H. A new method for induction of liver hypertrophy prior to righttrisectionectomy: a report of three cases. *HPB* (Oxford). 2011;13 suppl 2:1–145.

SECTION 3. NEW APPROACH: THE CONCEPT OF FLOW

A New Concept: Small for Flow Liver Failure (SFFLF)

The size concept has been demonstrated to be useful in liver surgery management [1] [2] [3] [4], pointing the predominant role of liver remnant respect the number of tumours or their diameter. Nevertheless, recently has been noticed that some patients undergoing major liver resection with supposed safe resection limits can develop post-hepatectomy liver failure as well [5]. This evidence leaded physician to perfection the physiological comprehension of post-hepatectomy liver failure, according to histological findings. In fact, it becomes clear that portal flow and pressure are key points in disease development, regardless the future liver remnant size. Liver function is not dependent only from size, but more from the delicate interrelation between parenchyma and liver vascular system. From this point of view, liver regeneration depends on how much we preserve liver functionality, comprehending how many live cells we leave, and how their physiological blood supply is guaranteed.

Even if imaging shows complete restoration of liver volume after few weeks from surgery, there is no evidence of complete restoration of liver's parenchymal microarchitecture when looking at the liver biopsy of the same patients taken soon after extended resection or transplantation [6] [7]. In the field of oncological surgery, liver regeneration is a very complex problem when it's approaching a malignancy. In fact, liver volume regeneration is not always accompanied by a quick and complete restoration of liver function [1]. Often, it has been noticed a distortion in micro and macro architecture of liver cells [8], with hyper-proliferation of hepatocytes, and lack of proper interaction with other types of hepatic cells.

Over portal flow and pressure are pointed as the "primum movens" in the pathophysiology of the syndrome. These phenomenon has been studied by Asencio et al. [9], proposing a new approach to post-hepatectomy liver failure, leading to a predominant role of flow and pressure in the etiophatogenesis, and, consequently, a new management approach for liver surgery and related safe limits.

Because of its small size, liver remnant after major hepatectomy is suddenly submitted to a hyperperfusion induced by the whole-maintained portal vein flow. This acute portal hypertension leads to endothelial damage, that explains liver dysfunction [10]. This hypothesis came out from living donor liver transplantation's experience, where it has been noticed the good outcome of portal flow and pressure modulation strategies to avoid small-for-size syndrome. In fact, in transplantation context, reducing portal vein pressure (PVP) by portocaval shunt [11], or by splenic artery embolization [12], or by splenectomy [13] had been showed to be very effective as prevention treatments. Ogura et al. [14] strongly showed that LDLT using small-grafts was feasible provided that Portal Vein Pressure was maintained below 15mmHg. In an oncological context, some experimental studies have showed how low PVP after surgery is a protective factor against histological damage, leading to a better functional regeneration of liver [15] [16] [17]. Recently, Allard MA and colleagues [18] observed a significantly higher post-hepatectomy PVP in patients who develop post-hepatectomy liver failure (all definitions considered) compared to those who did not. He suggested an intra-operative PVP cut off of 22mmHg, that is associated with 18.4%-21.1% (depending on definitions considered) of likelihood to develop a Small for flow liver failure, and a 90-days mortality of 12,7%. Several other studies indicate that portal pressure higher than 20mmHg show a decrease from 85% to 38% in their 6-months survival [11].

These new evidences lead different authors to change the approach to post-hepatectomy liver failure, and to the pre-operative management. In fact, it seems as it's not the size the key point to take under control, but the disproportion between the remnant size and its portal flow, reflected by the values of portal blood flow and pressure. A disproportionate increase of portal blood flow and pressure would lead to a sinusoidal injury, to ischemic injury due to a compensatory reduction of blood flow in hepatic artery, and to impairment of liver regeneration [19]. This could also explain why is required a bigger volume remnant in cirrhotic patients, who have an hyperdinamic splancnic circulation [20].

Shifting the paradigm, from size to flow, means an important change in pre-operative management of patients candidate for elective major hepatectomy, even for early surveillance strategies after surgery.

According to this, a new definition of post-hepatectomy liver failure could be assessed: *Small-for-Flow-Liver-Failure (SFFLF), a postoperative acquired deterioration in the ability of the liver to maintain its synthetic, excretory and detoxifying functions, which is characterized by serum bilirubin concentration above 50 μmol/L, HVPG > 10mmHg, Doppler evidences of portal overflow, on or after post-operative day five. This condition, if it's not correctly treated, could lead to liver failure and exitus.*

The diagnosis is based on the evidence of liver failure after an extended hepatectomy. Any other factor that could lead to liver failure such as anesthesia, iatrogenic damages or biliary structures injuries should be excluded. Thus, high bilirubin levels should be associated to a reduced liver synthetic capacity. INR (if plasma transfusion during or after surgery doesn't occur) is probably the most suitable parameter, but the serum levels of other proteins synthetized by the liver such as albumin or pseudocholinesterase can be useful. Extra-hepatic

cholestasis should be excluded and, according to small-for-flow theory, portal hypertension should be demonstrated by evaluating portal vein dimension and flow velocity by doppler ultrasound. If this condition is seen, then it became important to measure pressure to plan next therapies (read above). Summing up, SFFLF is a post-hepatectomy liver failure not explained by other causes: to assess it, we need to evaluate Bilirubin and INR levels, and perform a Liver UltraSound Doppler Scan to check portal vein condition. When the condition is diagnosed, we should proceed to perform pressure measurement (HVPG) to decide the best treatment to avoid the latest stage of disease.

After surgery, it is very important to perform a strict control of operated patients. In 48-72 hours after hepatectomy, a raise of bilirubin and INR it's very common due to liver injuries caused by surgery [21] [22]. Currently, a raise of bilirubin > 50 μmol/L (3mg/dl) and INR > 1.7 after 5th day post-op is commonly accepted as early markers of liver dysfunction. These criteria are called "50-50 criteria", as we have described before. Despite this, INR is not a very suitable parameter, because of blood and platelet infusion that are often administrated during or immediately after extended hepatectomy.

According to flow-theory, if a raise of bilirubin is recognized after day 5, different strategies can be adopted. Even if there are lack of evidence tested in SFFLF context, portal hyper pressure is usually diagnosed by Doppler US, through biliary system ectasia (according to AISF's guidelines [23], a diameter threshold > 13mm has a sensibility of 50% and specificity of 95%). Doppler US scan could be used to assess portal overflow, and a threshold of 250ml/min/100g of liver parenchyma has been indicated as risk factor for SFFLF development [24] [25]. When bilirubin raises, a simply Doppler US could develop the suspect of disease, leading to invasive diagnostic strategies (HVPG measurement) and therapeutic choices, as well as avoiding any other iatrogenic causes. After this indication, portal pressure with HVPG could be measured to develop therapies. Indeed, as previously stated a HVPG > 10mmHg is associated with functional liver regeneration's impairment (in Tab.1 cut-offs are summarized). As different authors suggest, if a raise in bilirubin > 50μmol/L and HVPG > 10mmHg is recognized, then we should refer the patient to an interventional radiologist to perform a Splenic Artery Embolization (SAE), to reduce flow and pressure in portal system [26] [27]. In case this strategy is not suitable, we could consider a TIPS, even if this last procedure is affected by higher morbidity than SAE. One of the authors of this article has suggested, in parallel with SAE, daily infusion of Terlipressine or Octeotride (50mcg/hour) until bilirubin falls [28], but this strategy is not confirmed by prospective randomized clinical trials. Even if in pre-operative work-up liver functional test are often taken into account, after hepatectomy these are unsuitable to estimate liver failure's risk, because of vascular changing in the remnant, the same changes that are at the base of syndrome's development. Several studies assessed the role of ICGR15 to predict post-hepatectomy liver failure, but its value diminished once liver failure is established, since the changes in hepatic blood flow impacts the test [29].

Pathophysiology

Although all clinical guidelines are focused on liver remnant size to prevent SFFLF, histopathological findings in patients who received a small graft, as well patients undergoing hepatic resections (comprising more than 70% of the parenchyma), point to a predominant

role of over-flow and high pressure through the portal system in the mechanism underlying the development of the syndrome and, consequently, the hepatic damage [30]. A review of literature, and our experience, support the hypothesis that post-hepatectomy liver failure is due to an excessive portal blood flow for the remnant liver parenchyma, causing over-pressure, and sinusoidal endothelial denudation and hemorrhage.

Few minutes after hepatectomy, perisinusoidal and periportal hemorrhage occurs. Later, arterial vasoconstriction, and ischemic cholangitis are observed [31]. According to several experimental and clinical studies, it has been shown that when there is a portal over-flow in liver remnant, it is possible to observe a fall of arterial flow to the liver, in a sort of inverse relationship, called "arterial portal buffer" [32] [33]. This phenomenon is characterized by decreasing concentration of Adenosine in the Space of Mall after a portal-over-flow, that leads to arterial vasoconstriction and decrease of arterial blood flow, which is responsible for the late damage [19]. The portal vein lacks an intrinsic autoregulation system, so when the liver volume is reduced due to major hepatectomy, it reaches the same portal flow first destined to the whole liver parenchyma. This portal over-flow causes the arterio-portal buffer response. After a period of ischemia, the complement cascade is triggered, leading to the activation of Kuppfer's cells, appearance of reactive oxygen species (ROS), and endothelial cell lesion. During reperfusion a release of cytokines, cell adhesion, activation and recruitment of T-cells and polymorphonuclear cell occurs, resulting in microvascular lesion, inflammation and cell death [21].

In addition, the number of Kupffer's cells after hepatic resections decreased and the liver's ability to react to infection also decreased, explaining the high risk of infections (above 50%). A relative increase in the production of endotoxins in the remnant liver is beneficial, once it activates the Kupffer's cells, triggering the liver regeneration; but if this state is prolonged, it may cause Kupffer's cellular dysfunction, resulting in difficulty of regeneration and even liver necrosis [21].

As already discussed, our knowledge is mainly based on transplant experimental studies [34]. Jiang et al. had established that portal blood flow of 300 ml/min/100g is the threshold above which the incidence of SFFLF increases significantly [35]. In pigs models, Fondevila et al. have indicated that an increased portal blood flow is both an early stimulus for regeneration and a pathogenetic factor of the sinusoidal damage [19], and they have proposed a porto-caval anastomosis to avoid SFFLF development by preventing a portal blood flow over double of its baseline [36]. Other studies have also confirmed the role of portal pressure. Yagi et al. showed that a portal pressure above 20 mmHg was associated with the development of ascites, coagulopathy, and hyperbilirubinemia as well as with an early hypertrophy of the graft, higher values of hepatocyte growth factor (HGF) and diminished levels of vascular epithelial growth factor (VEGF), suggesting that an increased portal pressure also influences liver regeneration [37].

References

[1] S. Balzan, J. Belghiti, O. Farges et al., The "50-50" criteria on postoperative day 5: an accurate predictor of liver failure and death after hepatectomy, *Ann Surg*, vol. 242, pp. 824-829, 2005.

[2] N. Rahbari, O. Garden, R. Padbury et al., Posthepatectomy liver failure: a definition and grading by the international study group of liver surgery (ISGL), *Surgery,* vol. 145, pp. 713-724, 2011.

[3] O. Tucker e N. Heaton, The 'small for size ' liver syndrome, *Current Opinion in critical care,* vol. 11, pp. 150-155, 2005.

[4] A. Guglielmi, A. Ruzzenente, S. Conci, A. Valdegamberi e C. Iacono, How much remnant is enough in liver resection?, *Dig Surg,* vol. 29, pp. 6-17, 2012.

[5] C. Li, K. Mi, T. Wen et al., Safety of patients with a graft to body weight ratio less than 0.8% in living donor liver transplantation using right hepatic lobe without middle hepatic vein, *Hepatogastro-enterology,* vol. 59, n. 114, pp. 469-472, 2012.

[6] Y. Panis, M. DM e J. Emond, Progressive necrosis after hepatectomy and the pathophysiology of liver failure after massive resection, *Surgery,* vol. 121, n. 2, pp. 142-149, 1997.

[7] R. Huang, T. Schiano, M. Amolat et al., Hepatocellular proliferation and changes in microarchitecture of right lobe allografts in adult transplant recipients, *Liver transpl,* vol. 10, n. 12, pp. 1461-1467, 2004.

[8] N. Golse, P. Bucur, R. Adam et al., new paradigms in post-hepatectomy liver failure, *J Gastrointest Surg,* vol. 17, n. 3, pp. 593-605, 2013.

[9] J. Asencio, J. Vaquero, L. Olmedilla e J. Garcia Sabrido, Small for flow syndrome: shifting the “size” paradigm, *Medical Hypothesis,* vol. 80, pp. 573-577, 2013.

[10] P. Clavien, C. Oberkofler, D. Raptis et al., What is critical for liver surgery and partial liver transplantation: size or quality?, *Hepatology,* vol. 52, pp. 715-729, 2010.

[11] O. Boillot, B. Delafosse, I. Mechet, C. Boucaud e M. Pouyet, Small-for-size partial liver graft in an adult recipient; a new transplant technique, *Lancet,* vol. 359, pp. 406-407, 2002.

[12] T. Ito, T. Kiuchi, H. Yamamoto, F. Oike, Y. Ogura e Y. e. a. Fujimoto, Changes in portal venous pressure in the early phase after living donor liver transplantation: pathogenesis and clinical implications, *Transplantation,* vol. 75, pp. 1313-1317, 2003.

[13] T. Hori, Y. Ogura, K. Ogawa et al., How transplant surgeons can overcome the inevitable insufficiency of allograft size during adult living donor liver transplantation: strategy for donor safety with a smaller-size graft and excellent recipient results, *Clin Transplant,* vol. 26, pp. E324-E334, 2012.

[14] Y. Ogura, T. Hori, W. El Moghazy et al., Portal pressure < 15mmHg is a key for successful adult living donor liver transplantation utilizing smaller grafts than before, *Liver transplant,* vol. 16, pp. 718-728, 2010.

[15] T. Asakura, N. Ohkohchi, T. Orii et al., Portal vein pressure is the key for successful liver transplantation of an extremely small graft in the pig model, *Transpl Int,* vol. 16, pp. 376-382, 2003.

[16] T. Iida, S. Yagi, K. Taniguchi et al., Improvement of morphological changes after 70% hepatectomy with portocaval shunt: preclinical study in porcine model, *J Surg Res,* vol. 143, pp. 238-246, 2007.

[17] T. Fukuchi, H. Hirose, A. Onitsuka et al., Effects of portal-systemic shunt following 90% partial hepatectomy in rats, *J Surg Res,* vol. 89, pp. 126-131, 2000.

[18] M. Allard, R. Adam, P. Bucur, S. Termos, A. Sa Cunha, H. Bismuth, D. Castaing e E. Vibert, Posthepatectomy portal vein pressure predicts liver failure and mortality after

major liver resection on noncirrhotic liver, *Annals of Surgery*, vol. 258, n. 5, pp. 822-830, 2013.

[19] C. Fondevila, A. Hessheimer, P. Taura, O. Sanchez, D. Calatayud, N. de Riva et al., Portal hyperperfusion: mechanism of injury and stimulus for regeneration in porcine small-for-size transplantation, *Liver transpl*, vol. 9, pp. 364-374, 2010.

[20] S. Imura, M. Shimada, T. Ikegami, Y. Morine e H. Kanemura, Strategies for improving the outcomes of small-for-size grafts in adult-to-adult living donor liver transplantation, *J Hepatobiliary Pancreat Surg*, vol. 15, pp. 102-110, 2008.

[21] R. Eshkenazy, Y. Dreznik, E. Lahat, B. Zakai, A. Zendel e A. Ariche, Small for size liver remnant following resection: prevention and management, *Hepatobiliary surg nutr*, vol. 3, n. 5, pp. 303-312, 2014.

[22] J. Hammond, I. Guha e I. e. a. Beckingam, Prediction, prevention and management of postresection liver failure, *Br J Surg*, vol. 98, pp. 1188-1200, 2011.

[23] I. A. f. t. s. o. t. L. -. P. h. committee, AISF guidelines for portal hypertension, *Digestive and liver disease*, 2006.

[24] R. Troisi e B. de Hemptinne, CLinical relevance of adapting portal vein flow in living donor liver transplantation in adult patients., *Liver Transpl*, vol. 9, pp. 36-41, 2003.

[25] R. Troisi, S. Ricciardi, P. Smeets, M. Petrovic, G. Van Maele, I. Colle et al., Effects of hemi-portocaval shunts for inflow modulation on the outcome of small-for-size grafts in living donor liver transplantation, *Am J Transplant*, vol. 5, pp. 1397-1404, 2005.

[26] T. Kaido, A. Mori, Y. Ogura, K. Hata, A. Yoshizawa, T. Lida et al., Lower limit of the graft-to-recipient weight ratio can be safely reduced to 0.6% in adult-to-adult living donor liver transplantation in combination with portal pressure control, *Transplant Proc*, vol. 34, pp. 2391-2393, 2011.

[27] T. Ikegami, K. Shirabe, Y. Soejima, T. Yoshizumi, H. Uchiyama, Y. Yamashita et al., Strategies for successful left-lobe living donor liver transplantation in 250 consecutive adult cases in a single center, *J Am Coll Surg*, vol. 216, pp. 356-362, 2013.

[28] S. Famularo, K. Nefotyou, N. Fotiadis, N. Khan, M. Foxton e AZ. Khan, Small for size liver syndrome: a case series with a proposal for management based on portal flow modulation, *Journal of Gastrointestinal Cancer*, 2015.

[29] C. de Liguori, D. O'Reilly, K. Dajani et al., Perioperative use of the LiMON method of indocyanine green elimination measurement for the prediction and early detection of post-hepatectomy liver failure, *Eur J Surg Oncol*, vol. 35, pp. 957-962, 2009.

[30] A. Demetris, D. Kelly, B. Eghtesad, P. Fontes, J. Wallis Marsh, K. Tom et al., Pathosysiologic observations and histopathologic recognition of the portal hyperperfusion or small-for-size syndrome., *Am J Surg Pathol*, vol. 30, pp. 986-983, 2006.

[31] D. Kelly, A. Demetris, J. Fung, A. Marcos, Y. Zhu, V. Subbotin et al., Porcine partial liver transplantation: a novel model of the “small-for-size” liver graft., *Liver Transpl*, vol. 10, pp. 253-263, 2004.

[32] W. Lautt, The 1995 Ciba-Geigy Award Lecture. Intrisic regulation of hepatic blood flow., *Can J Physiol Pharmacol*, vol. 74, pp. 223-233, 1996.

[33] C. Eipel, K. Abshagen e B. Vollmar, Regulation of hepatic blood flow: the hepatic arterial buffer response revisited., *World J Gastroenterol*, vol. 16, pp. 6046-6057, 2010.

[34] R. Troisi e B. de Hemptinne, Clinical relevance of adapting portal vein flow in living donor liver transplantation in adult patients, *Liver transpl*, vol. 9, pp. 36-41, 2003.

[35] S. Jiang, G. Zhou, R. Zhang, C. Peng, J. Yan, L. Wan et al., Role of splanchnic hemodynamics in liver regeneration after living donor liver transplantation, *Liver transpl*, vol. 15, pp. 1043-1049, 2009.
[36] A. Hessheimer, C. Fondevila, P. Taura, J. Munoz, O. Sanchez, J. Fuster et al., Decompression of the portal bed and twice-baseline portal inflow are necessary for the functional recovery of a "small-for-size" graft, *Ann Surg*, vol. 253, pp. 1201-1210, 2011.
[37] S. Yagi, T. Iida, T. Hori, K. Taniguchi, C. Yamamoto, K. Yamagiwa et al., Optimal portal venous circulation for liver graft function after living-donor liver transplantation, *Transplantation*, vol. 81, pp. 373-378, 2006.

Utility of Portal Pressure and Flow Measurements

The liver is a richly vascularized organ with a high blood flow of approximately 1.5 l/min of which 80% comes from the venous spleno-mesenteric-portal system. This significant amount of blood, once filtered through the liver parenchyma, flows into the hepatic veins that are tributaries of the inferior vena cava and thus the systemic circulation.

The normal pressure in the portal vein is 7-10 mmHg and 2-6 mmHg in the hepatic veins: physiologically between the portal system and the systemic circulation there is a small pressure gradient (≤5 mmHg) which allows the smooth flow of blood in the liver. A gradient between 6 and 10 mmHg defines a preclinical condition of portal hypertension (PH). When this gradient increases above 10 mmHg this is considered clinically significant portal hypertension and ≥12 mmHg values define a severe and complicated portal hypertension.

The main underlying causes of PH are due to an increased blood flow to the liver, as an increase in vascular resistance in the portal circulation or intrahepatic at the sinusoidal or post-sinusoidal level, for changes in liver microarchitecture from diseases spread directly involving the liver parenchyma as it can occur in cirrhosis. Portal hypertension and its consequences are considered the main factors aggravating liver cirrhosis, and therefore the presence of PH significantly worsens the prognosis [1].

The portal hypertension complications are mainly due to:

- the stagnation of blood in the venous spleno-mesenteric-portal district that contributes to the development of splenomegaly and hypersplenism, congestive gastropathy, spontaneous bacterial peritonitis, ascites;
- the opening of portoystemic collaterals both superficial and deep. In these cases, the blood from the portal system tends to make its way through normally virtual anastomotic ways with the caval vein system, resulting in increased pressure and variable development of dilated veins of varicose type. The most important venous ectasia are gastroesophageal varices from the rupture of which may result in bleeding with hematemesis and melena which are the main causes of death in portal hypertension [2].

In the presence of significant PH cirrhotic patients compared to non-cirrhotic patients, who underwent surgical resection for hepatocellular carcinoma (HCC), have an increased

incidence of intraoperative complications and also an increased risk of liver decompensation after surgery (appearance of ascites, encephalopathy, jaundice) with a consequent increase in mortality rates and therefore in these patients, surgery should be contraindicated [3, 4].

However in cirrhotic patients different levels of portal hypertension may exist that could not absolutely preclude surgery since of the improvement in recent years in surgical techniques, to better pre-operative assessment and progress in the field of anesthesia and medical care [5, 6].

For these reasons it is important to preliminarily diagnose the existence and severity degree of portal hypertension in cirrhotic patients to be subjected to surgical resection in order to assess the risk.

Hepatic Venous Pressure Gradient

A reliable PH diagnosis is obtained by measurement of portal venous pressure and the evaluation of the porto-systemic pressure gradient. However normally the diagnosis of PH is based on indirect criteria in a clinical-laboratory kind, of diagnostic imaging and endoscopic techniques: the presence of ascites and esophageal varices are strongly indicative of portal hypertension.

There are subclinical forms, clinically not significant or not manifest of PH: the occurrence and the severity of PH is possible to confirm through direct measurement, with very invasive techniques such as catheterization of the portal vein percutaneous transhepatic, transvenous, or during laparotomy through cannulation of the mesenteric or umbilical vein [7], or indirectly through evaluation of the portosystemic pressure gradient (*HVPG - Hepatic Venous Pressure gradient*) [8].

HVPG is the difference between the pressure in the portal vein and the intraabdominal vena cava pressure and currently represents the gold-standard in the evaluation of the presence and the level of portal hypertension.

The measurement of HVPG is performed percutaneously in the angiography suite under fluoroscopy through ultrasound-guided puncture and catheterization of the internal jugular, the common femoral or brachial vein under local anesthesia, deep sedation is required for pediatric patients. The angiographic catheter on a guidewire is advanced into the vena cava (superior or inferior depending on the access route), in the right atrium where a hepatic vein is catheterizing (right or medium) 2-4 cm from the opening into the inferior vena cava. At this point an occlusion balloon or Swan-Ganz catheter is positioned and connected to a calibrated transducer to execute a series of three blood pressure measurements with a free catheter into the non-blocked hepatic vein (*Free Hepatic Venous Pressure - FHVP*) which reflects the systemic venous pressure (normally there is a 1 mmHg difference between the inferior vena cava and hepatic veins) and is recorded on a track. In the same position a balloon placed at the end of the catheter is inflated causing a catheter blockage in the hepatic vein and a complete occlusion to the blood outflow that determines an ideal column of continuous blood from the hepatic vein to the portal vein system. The pressure in the blocked area is quickly balanced between the two systems and its measurement indirectly expresses the sinusoidal portal pressure by determining the so-called wedge pressure (*Wedged Hepatic Venous Pressure - WHVP*).

Subtracting FHVP from WHVP you will get the HVPG as a portal hypertension index:

HVPG = WHVP ─ FHVP

All measurements are to be repeated in two different hepatic veins, and the average should be calculated out of three measurements for each vein following the international guidelines [9].

The determination the HVPG is a safe and reliable technique to measure the degree of PH, with a low percentage of complications (<1%), but requires a rigorous technique to obtain correct and reproducible values [9, 10, 11]. Although not very employed, more authors recommend HVPG as an important clinical tool in both the classification and in stratification of risk in patients with cirrhosis since to reproducible information that couldn't be obtained in other ways [12, 13, 14]. In the evaluation of the response to drug therapy the variation in HVPG proved to be an excellent predictor of efficacy in the course of chronic liver disease or as a predictor of clinical events such as the appearance of variceal bleeding, HCC development and survival in particularly elevated HVPG values [15, 16, 17, 18].

Hemodynamic correlation studies have confirmed that in compensated cirrhosis the presence of clinically significant portal hypertension (HVPG ≥10 mmHg) is the main independent risk factor associated with the development of esophageal varices and first decompensation of cirrhosis [19].

The assessment of PH is controversial in the selection of cirrhotic patients to be underwent to major liver resection for HCC and in particular the systematic measurement of the HVPG [5, 20].

The guidelines report that in patients with HCC the presence of portal hypertension can be considered a negative prognostic factor and significantly influence the different treatment options [21] or even the type of surgery to be practiced [22].

In literature there are several studies that have analyzed the impact of HVPG measurement correlating with the severity of liver disease and the evaluation and risk stratification in cirrhotic patients to be subjected to surgery.

Bruix et al., reported in the multivariate analysis how the HVPG was the only independent preoperative value of the development of irreversible liver failure in the three months following surgery in cirrhotic patients with HVPG > 10 mmHg [3].

Hidaka et al., [23] in a group of 177 patients with HCC have detected how high portal vein pressure values measured directly in the course of surgery correlated with a worse prognosis both on the results (recurrence-free survival rate 52.5 vs 12%, $p < 0.001$) than on the long-term survival (5-year overall survival rate 63.7 vs 31%, $p < 0.001$).

Llovet et al., [24] have shown that 5-year survival after resection for HCC in cirrhotic patients is 74% in case of HVPG < 10 mmHg, 50% in the case of HVPG of 10 but with normal serum total bilirubin, and just 24% in patients with HVPG > 10 mmHg and total bilirubin ≥1 mg/dL.

Other authors have found that the increase of HVPG is associated with postoperative liver failure and mortality after liver resection for HCC in cirrhotic patients, and therefore recommend that the preoperative measure of HVPG must be systematically calculated in these patients in order to predict the risk of liver failure even in Child A patients and therefore the surgery should be restricted only to patients without PH [25, 4].

Stremitzer et al., [26] in a retrospective analysis of 132 cirrhotic patients resected for HCC have already recognized how a preoperative value of HVPG > 5 mmHg introduces possible postoperative complications, suggesting that the 10 mmHg was considered too high for the evaluation of these patients. On the contrary, some authors have recently reported how

a HVPG cut-off of 10 mmHg can be excluded from the benefit of a curative surgery in a substantial portion of patients [27].

This data indicates that patients with compensated liver cirrhosis with HCC should be evaluated for surgery not only through conventional parameters of liver function but also undergoing to liver catheterization and measurement of HVPG [3].

The measurement of HVPG ≥10 mmHg defines a clinically significant PH as a target to properly address portal hypertensive patients with chronic hepatitis to a drug treatment or cirrhotic patients with HCC to surgery if the HVPG is <10 mmHg [28]. In Child A patients with cirrhosis the HVPG has been proposed as a criteria to estimate the extent of liver damage and 'tolerance' in hepatic resection for HCC. This is based on the concept that a liver resection will determinate a reduction in the hepatic vascular bed, an increase in vascular resistance and a consequent increase of the HVPG value. It is generally accepted that patients whose HVPG > 10 mm Hg have greater susceptibility to liver failure with jaundice, ascites and encephalopathy after hepatic resection. This risk is maintained even after a long time and can affect a reduced survival rate and increase the risk of complications after liver resection. However, this concept has not yet integrate into the surgical routine and clinical practice and the HVPG is currently not generally used to decide whether a resection should or should not be performed.

Some disadvantages limit the routine use of the HVPG like the relative invasiveness of the technique, the need for trained physicians to obtain reliable and reproducible measurements and finally the costs associated with the procedure [9]. For these reasons new alternative instrumental methods have been proposed to assess and monitor non-invasively the presence of portal hypertension or quantify the degree of associated hepatic fibrosis which well correlated with HVPG. These include the B-mode ultrasound and Doppler and spectral-US, the transient US-elastography or MR-elastography for assessment of liver or splenic stiffness or the latest application shear wave-US: however the level of the operator's skill, the difficult standardization of these methods, the cut-off varying values and the heterogeneity results obtained in different studies do not allow currently to replace the measure of HVPG in the instrumental assessment of the PH [29, 30].

In conclusion, in the cirrhotic patients with resectable liver tumor suitable for surgery, HVPG have a central prognostic relevance can detect an increased risk of postoperative complications if they have subclinical PH (HVPG > 5mmHg), a greater risk for persistent liver decompensation if they have clinical and significant PH (HVPG > 10 mmHg) or contraindication to surgery if they have severe PH (HVPG ≥ 12 mmHg).

Doppler US

Diagnostic imaging in portal hypertension, such ultrasound techniques as B-mode, spectral Doppler, color Doppler, power Doppler or the contrast-enhanced ultrasonography (CEUS) are instrumental methods which are non-invasive, fast, highly sensitive and specific to studying the hemodynamic state of the liver in various conditions. For these reasons such methods have been proposed and widely adopted in evaluating the severity of PH in patients with chronic liver disease.

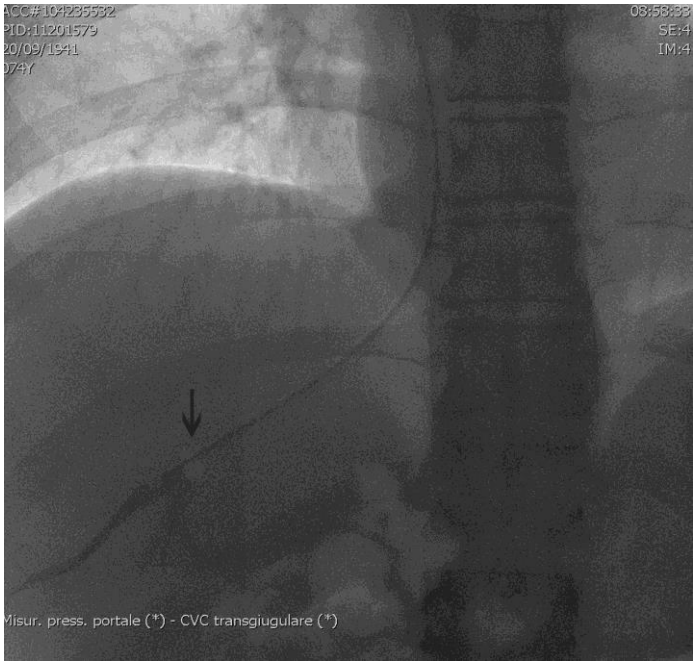

Figure 4. Hepatic Venous Pressure Gradient (HVPG) measurement into the hepatic vein with a catheter in the occluded position (black arrow indicates an inflated balloon).

The knowledge of vascular flow patterns in patients with cirrhosis and PH provides valuable information and therefore hepatic Doppler-US has for many years been considered the most important examination for the diagnosis of cirrhosis and portal hypertension, taking into consideration the repeatability and reliability in expert hands.

There are many B-mode ultrasound parameters associated with the presence of portal hypertension.

The observation of ascites and furthermore the detection of portosystemic collateral pathways in a patient with cirrhosis are considered accurate ultrasound signs of portal hypertension, which are highly specific, as for example is the presence of a recanalized paraumbilical vein, dilation of the coronary- left gastric venous collateral, existence of spontaneous splenorenal shunt, peripancreatic, periportal and pericholecystic varicose dilatations.

Among the peculiar two-dimensional US parameters of PH are: splenomegaly (spleen longitudinal diameter > 12 cm); portal vein diameter of >14 mm; no diameter variation on breath of the splenic and superior mesenteric vein.

As for the spectral and color-Doppler ultrasonography we can detect many qualitative and quantitative parameters [31]. Among the qualitative parameters color-Doppler images demonstrates within the main portal vein the presence or absence of portal flow and in the spectral analysis the flow direction (hepatopetal, reversal hepatofugal or alternating). The most important parameters detectable with the spectral Doppler examination are those quantitative and semi-quantitative. The study of the main portal vein allows the acquisition of measurements correlated to PH, such as: the increase of the cross sectional area in mm^2 (A); the reduction of the average portal velocity as peak systolic velocities range < 12-16 cm/s

(V); the increase in the congestion index (A/V); the reduction of blood volume (ml/min); the increase in the pulsatility index or peak systolic velocity.

Other parameters but subject to greater variability are: replaced with a monophasic hepatic veins pattern of the typical triphasic waveform; the change in the impedance and resistance index in hepatic, splenic, renal and superior mesenteric arteries.

The limit of Doppler ultrasound techniques lies in poor reproducibility of Doppler data, especially if monitored over time and with different equipment, related to the poor standardization of measurements without clear threshold values and significant intra- and interobserver variability on the accuracy of quantitative assessments that can only improve within of an intensive training programs and through strict application of well-defined guidelines [32].

The contrast-enhanced ultrasonography (CEUS) is a type of ultrasound perfusion imaging technique widely used in the hemodynamic evaluation and characterization of focal liver lesions. Some researchers have also tried to extend the CEUS indication to the evaluation of chronic liver diseases. In fact, some perfusion parameters obtainable with CEUS were correlated with the degree of hepatic fibrosis or PH, such as: hepatic vein arrival time (HVAT), intrahepatic transit time (ITT), peak signal intensity (PSI), time-to-peak (TTP), hepatic artery arrival time (HAAT), hepatic vein arrival time (HVAT).

Intrahepatic transit time (ITT) is the difference of arrival between the arterial and the venous flow (HAAT/HVAT), detectable to the time delay from the arrival of the microbubbles (coming from the contrast medium injected intravenous) at the hepatic artery to the hepatic vein. Now ITT is the only parameter reproducible which able to diagnose and assess the severity of PH and potentially can replace the measurement of HVPG [33].

Splenic Artery Embolization

General Consideration

The non-pharmacological or medical reduction of splenomegaly and hypersplenism consequences in cirrhotic subjects suffering from PH can be obtained effectively with surgical splenectomy, which however, can impair the body's ability to deal with infections or difficult situations in case of further abdominal surgery interventions.

The splenic artery embolization is a minimally invasive endovascular technique that through the catheterization of the splenic artery with a standard angiographic catheter or microcatheter inside proximal (a source downstream of pancreatic vessels) or distal (splenic hilum, branches of lobar or intraparenchymal division) splenic artery: through the catheter it’s possible to place a mechanical occlusion system (coils, plugs) or inject liquid or particulate embolic agents (microspheres of varying diameter 300-1000 μ, polyvinyl alcohol particles PVA, gelfoam, glue) with the objective to occlude partially the splenic artery and achieve a volume of infarcted splenic tissue of at least 50%.

Therefore the partial splenic artery embolization is a technique that has been proposed and used in selected cases, alone or in combination with other treatments, to limit in the long term the effects of hypersplenism in cirrhotic patients. The technique allows the reduction in volume of the vital and functioning splenic parenchyma below 30-50% resulting in an effective increase of altered haematological indices such as trombocytopenia and leukopenia, [34, 35], in particular if the volume of infarcted spleen is large [36].

(A)

(B)

Figure 5. **(**A)- Celiac axis angiogram demonstrates a tortuous and lengthened splenic artery.
(B) Proximal splenic artery embolization (white arrow) prior to the origin of the pancreatic and short gastric arteries (black arrow).

The splenic artery occlusion and reduction of spleen volume in the short term leads to significant changes in pressure values [37] such as the reduction of splenic venous pressure and WHVP (Wedged Hepatic Venous Pressure), which impact favourably on portal hemodynamics in cirrhotic patients by decreasing the clinical and subclinical PH and consequently reducing the risk of its complications, especially bleeding from esophageal varices.

Patients with least extensive splenic infarct will have a mild to moderate complication such as the embolization syndrome with fever, nausea and pain in the left upper quadrant [38]. These symptoms can usually be easily controlled with narcotics and antiemetic drugs. Fever is secondary to the release of pyrogens from infarcted spleen parenchyma and can be treated with steroids. Ascites and left pleural effusion may also appear.

Major complications could especially happen in cases of extensive embolization from 70-100% of the splenic parenchyma and include formation of splenic abscesses, pneumonia, atelectasia and empyema, pulmonary embolism, portal thrombosis, and death [39].

Although not frequently used as primary therapy for patients with portal hypertension, partial splenic artery embolization can be considered as a useful alternative or additional procedure [40].

The Role of Sae in Small-for-Flow Treatment

Splenic artery embolization has been proposed as a strategy to manage SFFLF due to the patophisiology of this syndrome. Akamatsu et al. [41] have showed the effect of splenic artery embolization in an in vivo human experimental model: when the splenic artery was clamped, the hepatic artery velocity immediately and significantly increased (16% $P < 0,001$), while in the meantime the portal venous flow also decreased significantly (10% $P = 0,03$). Fifteen minutes after clamping, the hepatic artery velocity remained increased at the level of the initial clamping, whereas the portal flow continued to decrease (16% $P < 0,001$ versus the control group). In transplant recipients, Troisi et al. [42] obtained a 33% portal flow decrease and a 74% hepatic arterial flow increase intraoperatively via splenic artery ligation. These results point on a major role of arterio-portal-buffer response as the main cause of liver hemodynamic changes after major hepatectomy. Most of this experience come from transplantation environment, where the risk of small-for-size syndrome, in living-donor, forces physician to avoid any risk for donor-patients. Intraoperative porto-caval shunts, as well splenectomy or splenic artery ligation/embolization spread to avoid liver failure's risk. Not so much data are described in the context of extended hepatectomy, where the risk to leave a small remnant is high, and could justified a similar approach to transplantation. Other authors [43] [44] have described the results in reducing portal flow and pressure by splenectomy. They have reported intraoperative portal flow measurements, demonstrating 43% and 30% portal flow decreases achieved by splenectomy in 8 and 13 living donor liver transplant recipients. In transplantation's experience, splenectomy could achieve the best reduction of portal flow: in Akamatsu's case series [41], maximal reduction of portal flow was 28%, with an increase of hepatic arterial flow of 31%. Thus, in oncological surgery context, splenectomy, a part when is indicated for other pathological reason, doesn't seem justified, because of SAE's safety, compared to surgical approach.

References

[1] D'Amico G, Garcia-Tsao G, Pagliaro L. Natural history and prognostic indicators of survival in cirrhosis: a systematic review of 118 studies. *J Hepatol* 2006;44:217-231.

[2] Sanyal AJ, Bosch J, Blei A, Arroio V. Portal Hypertension and Its Complications. *Gastroenterology* 2008;134:1715-1728.

[3] Bruix J, Castells A, Bosch J et al. Surgical resection of hepatocellular carcinoma in cirrhotic patients: prognostic value of preoperative portal pressure. *Gastroenterology* 1996;111:1018-1022.

[4] Chen X, Zhai J, Cai X et al. Severity of portal hypertension and prediction of postoperative liver failure after liver resection in patients Child-Pugh grade A cirrhosis. *British Journal of Surgery* 2012;99:1701-1710.

[5] Capussotti L, Ferrero A, Viganò L, Muratore A, Polastri R, Bouzari H. Portal hypertension: contraindication to liver surgery? *World J Surg.* 2006;30:992-999.

[6] Cucchetti A, Ercolani G, Vivarelli M et al. Is portal hypertension a contraindication to hepatic resection? *Ann Surg.* 2009;250:922-928.
[7] Bosch J, Mastai R, Kravetz D, Navasa M, Rodes J. Hemodynamic evaluation of the patient with portal hypertension. *Semin Liver Dis* 1986;6:309-317.
[8] Bosch J, Garcia-Pagán JC, Berzigotti A, Abraldes JG. Measurement of portal pressure and its role in the management of chronic liver disease. *Semin Liver Dis* 2006;26:348-362.
[9] Groszmann RJ, Wongcharatrawee S. The hepatic venous pressure gradient: anything worth doing should be done right. *Hepatology* 2004;39:280-282.
[10] Groszmann R, Vorobioff JD, Gao H. Measurement of Portal Pressure: When, How, and Why to Do It. *Clin Liver Dis* 2006;10:499-512.
[11] Kumar A, Sharma P, Kumar Sarin S. Hepatic venous pressure gradient measurement: Time to learn! *Indian J Gastroenterol* 2008;27:74-80.
[12] Albilllosa A, Garcia-Tsaob G. Classification of cirrhosis: The clinical use of HVPG measurements. *Disease Markers* 2011;31:121-128.
[13] Merkel C, Montagnese S. Hepatic venous pressure gradient measurement in clinical hepatology. *Digestive and Liver Disease* 2011;43:762-767.
[14] La Mura V, Nicolini A, Tosetti G, Primignani M. Cirrhosis and portal hypertension: The importance of risk stratification, the role of hepatic venous pressure gradient measurement. *World J Hepatol* 2015;7:688-695.
[15] Boyer TD. Changing clinical practice with measurements of portal pressure. *Hepatology* 2004;39:283-285.
[16] Tae Suk K. Hepatic venous pressure gradient: clinical use in chronic liver disease. *Clinical and Molecular Hepatology* 2014;20:6-14.
[17] Tae Yeob K, Jae Gon L, Joo Hyun S. Hepatic venous pressure gradient predicts long-term mortality in patients with decompensated cirrhosis. *Yonsei Med J* 2016;57:138-145.
[18] Ripoll C, Groszmann RJ, Garcia-Tsao G. Hepatic venous pressure gradient predicts development of hepatocellular carcinoma independently of severity of cirrhosis. *J Hepatol.* 2009; 50:923-928.
[19] Silva MF, Strasser SI, Carrilho FJ. Is hepatic venous pressure gradient assessment required before liver resection in patients with cirrhosis and hepatocellular carcinoma? *Clinics* 2013;68:437-440.
[20] EASL–EORTC Clinical Practice Guidelines: Management of hepatocellular carcinoma. *Journal of Hepatology* 2012;56:908-943.
[21] Kanematsu T, Furui J, Yanaga K, Okudaira S, Kamohara Y, Eguchi S. Measurement of portal venous pressure is useful for selecting the optimal type of resection in cirrhotic patients with hepatocellular carcinoma. *Hepatogastroenterology.* 2005;52:1828-1831.
[22] Ripoll C, Groszmann R, Garcia-Tsao G, Grace N, Burroughs A, Planas R, Escorsell A, Garcia-Pagan JC, Makuch R, Patch D, Matloff DS, Bosch J. Hepatic venous pressure gradient predicts clinical decompensation in patients with compensated cirrhosis. *Gastroenterology* 2007;133:481-488.
[23] Hidaka M, Takatsuki M, Soyama A et al. Intraoperative portal venous pressure and long-term outcome after curative resection for hepatocellular carcinoma. *Br J Surg.* 2012;99:1284-1289.

[24] Llovet JM, Fuster J, Bruix J. Intention-to-treat analysis of surgical treatment for early hepatocellular carcinoma: resection versus transplantation. *Hepatology*. 1999;30:1434–1430 12.

[25] Boleslawski E, Petrovai G, Truant S et al. Hepatic venous pressure gradient in the assessment of portal hypertension before liver resection in patients with cirrhosis. *Br J Surg*. 2012;99:855-863.

[26] Stremitzer S, Tamandl D, Kaczirek K et al. Value of hepatic venous pressure gradient measurement before liver resection for hepatocellular carcinoma. *Br J Surg*. 2011;98:1752-1758.

[27] Cucchetti A, Cescon M, Golfieri R et al. Hepatic venous pressure gradient in the preoperative assessment of patients with resectable hepatocellular carcinoma. *J Hepatol*. 2016;64:79-86.

[28] Vorobioff JD. Hepatic Venous Pressure in Practice How, When, and Why. *J Clin Gastroenterol* 2007;41:336-343.

[29] Procopet B, Tantau M, Bureau C. Are there any alternative methods to hepatic venous pressure gradient in portal hypertension assessment? *J Gastrointestin Liver Dis*, March 2013;22:73-78.

[30] Castera L, Pinzani M, Bosch J. Non invasive evaluation of portal hypertension using transient elastography. *Journal of Hepatology* 2012;56:696-703.

[31] Iranpour P, Lall C, Houshyar R et al. Altered Doppler flow patterns in cirrhosis patients: an overview. *Ultrasonography* 2016;35:3-12.

[32] Sabbà C, Merkel C, Zoli M et al: Interobserver and interequipment variability of echo-Doppler examination of the portal vein: effect of a comparative training program. *Hepatology* 1995;21:428-433.

[33] Jeong WK, Kim TY, Sohn JH, Kim Y, Kim J. Severe Portal Hypertension in Cirrhosis: Evaluation of Perfusion Parameters with Contrast-Enhanced Ultrasonography. *PLoS ONE* 2015;10:1-14.

[34] Hidaka H, Kokubu S, Saigenji K, Isobe Y, Maeda T. Restoration of thrombopoietin production after partial splenic embolization leads to resolution of thrombocytopenia in liver cirrhosis. *Hepatol Res* 2002;23:265-273.

[35] Zhu K, Meng X, Gian J et al. Partial splenic embolization for hypersplenism in cirrhosis: a long-term outcome in 62 patients. *Dig Liver Dis.* 2009;41:411-416.

[36] Hayashi H, Beppu T, Masuda T et al. Large splenic volume may be a useful predictor for partial splenic embolization-induced liver functional improvement in cirrhotic patients. *J Hepatobiliary Pancreat Sci.* 2014;21:51-57.

[37] Chikamori F, Kuniyoshi N, Kawashima T, Takase Y. Short-term portal hemodynamic effects of partial splenic embolization for hypersplenism. *Hepatogastroenterology*. 2007;54:1847-184913.

[38] Hadduck TA, McWilliams JP: Partial splenic artery embolization in cirrhotic patients. *World J Radiol* 2014;28; 6:160-168.

[39] N'Kontchou G, Seror O, Bourcier V et al. Partial splenic embolization in patients with cirrhosis: efficacy, tolerance and long-term outcome in 32 patients. *Eur J Gastroenterol Hepatol.* 2005;17:179-184.

[40] Smith M, Ray CE, M.D. Splenic Artery Embolization as an Adjunctive Procedure for Portal Hypertension. *Semin Intervent Radiol* 2012;29:135-139.

[41] N. Akamatsu, Y. Sugawara, S. Satou, T. Mitsui, R. Ninomiya, M. Komagome, F. Ozawa e Y. Beck, Hemodynamic changes in the hepatic circulation after the modulation of the splenic circulation in an in vivo human experimental model, *Liver Transplant*, vol. 20, pp. 116-121, 2014.

[42] R. Troisi, G. Cammu, G. Militerno, L. De Baerdemaeker, J. Decruyenaere, E. Hoste et al., Modulation of portal graft inflow: a necessity in adult living-donor liver transplantation?, *Ann Surg*, vol. 237, pp. 429-436, 2003.

[43] Y. Cheng, T. Huang, T. Chen, A. Concejero, L. Tsang, C. Wang et al., Liver graft-to-recipient spleen size ratio as a novel predictor of portal hyperperfusion syndrome in living donor liver transplantation, *Am J Transplant*, vol. 86, pp. 2994-2999, 2006.

[44] T. Yoshizumi, A. Taketomi, Y. Soejima, T. Ikegami, H. Uchiyama, H. Kayashima et al., The beneficial role of simultaneous splenectomy in living donor liver transplantation in patients with small-for-size graft, *Transpl Int*, vol. 21, pp. 833-842, 2008.

In: Encyclopedia of Surgery (22 Volume Set)
Editors: Andreas Lehrer and Kristin Mueller
ISBN: 978-1-53618-329-0
© 2020 Nova Science Publishers, Inc.

Chapter 413

MINIMALLY INVASIVE CRANIOSYNOSTOSIS SURGERY

Jordan A. Magarik and Christopher M. Bonfield*
Department of Neurosurgery, Vanderbilt University Medical Center, Nashville, TN, US

ABSTRACT

Craniosynostosis is the premature fusion of one or more of the cranial sutures. Commonly, it results in abnormal skull shapes, and may also lead to growth restriction of the underlying brain if left untreated. Therefore, treatment is undertaken primarily for two goals: to restore a more normal head shape for aesthetic reasons and secondarily to mitigate the risk posed by elevated intracranial pressure. Traditionally, the optimal time for surgical intervention is before one year of age as the bones are more malleable, bone re-growth is quicker and more likely to occur, and rapid brain growth benefits from skull remodeling. Extensive open operations, such as cranial vault reconstructions for sagittal, lambdoid, and multisuture synostoses and fronto-orbital advancements in coronal and metopic synostoses, have classically been performed with good results. However, these surgeries can result in substantial blood loss, high rates of blood transfusion, concern for hypothermia, lengthy ICU and hospital stays, significant swelling, and considerable recovery time. Jimenez and Barone first described endoscopic synostosis repair in 1998. Similarly, Lauritzen has promoted the use of springs to enhance skull reshaping. Minimally invasive procedures have resulted in smaller incisions, less blood loss and transfusions, shorter ICU and hospital stays, quicker recovery, and decreased costs. In this chapter, we will present surgical options for minimally invasive craniosynostosis surgery and review the published outcomes of these procedures.

INTRODUCTION

Craniosynostosis is a condition in which one or more of the calvarial sutures fuse prematurely. It occurs in approximately 1/2500 births, with sagittal synostosis comprising the

* Corresponding Author's Email: chris.bonfield@vanderbilt.edu.

majority of nonsyndromic cases. Our understanding of the biomechanics of craniosynostosis can be traced to the work of Virchow in the mid-19th century. Virchow's law states that cranial growth occurs in a perpendicular plane to a fused suture resulting in elongation of the skull in parallel with the fused suture line. In most cases, compensatory skull growth is adequate to accommodate concurrent brain growth and maturation, and the child is simply left with an abnormal head shape and facial features. However, in some cases, the restricted skull may not provide enough space for the growing brain, resulting in clinical manifestations of increased intracranial pressure (ICP), such as visual impairment, headaches, or an impairment of mental development. Options for treatment of craniosynostosis include traditional cranial vault reconstruction (CVR) or more recently developed treatment modalities such as spring-mediated cranioplasty (SMC) or endoscopic-assisted minimally-invasive craniectomy (EAC). The goal of this chapter is to introduce these modalities from a historical context, to discuss the technical details of EAC, and to review the clinical outcomes of EAC and SMC.

HISTORICAL OVERVIEW

Surgical correction of craniosynostosis dates back to the 19th century with the efforts of Lannelongue in 1890, followed by Lane in 1892. These approaches focused on strip craniectomies. While Lannelongue performed bilateral parasagittal strip craniectomies to release the affected suture, Lane preferred to resect the stenosed suture [1]. Strip craniectomies were performed throughout the next century, with mixed results, and it was not until the mid-20th century that the techniques pioneered by Lannelongue were transformed into the modern era cranial vault reconstruction. It was Tessier and Rougerie in the 1960's who began to focus on the cosmetic results of craniofacial repairs. Out of their work arose more expansive approaches, including large bicoronal incisions, and exposures with fronto-orbital advancement techniques that drove the field for decades [2-4]. Tessier's initial paper describes the technique for Crouzon's and Apert's diseases. His technique included dissection of the periobitum and pericranium as well as multiple osteotomies along the frontal bone, orbits, and nasal bone. Of importance was his emphasis on the flexibility of the approach to allow for correction of one or more craniofacial dysmorphisms including hypertolerism, orbitofacial clefts, orbital malposition, and craniosynostosis [2]. Early efforts by Tessier and Rougerie were quite successful; however the risks of surgery were high. Even in its inception, complications, not too dissimilar from modern complications, included large volume blood losses, dural tears, long hospital stays, and lengthy surgical times with its inherent complications of longer periods under general anesthesia.

In the modern era, cranial vault reconstruction (CVR) is the veritable workhorse for craniofacial surgeons. These techniques are based on Jane and colleagues' introduction of the "Pi" procedure in 1978, which not only addressed the primary suture fusion, but also the global cranial deformity and provided immediate correction [5]. Through a large exposure, the Pi procedure provides the flexibility to remodel the frontal, temporal, zygomatic, and nasal bones, along with orbital reconstruction allowing for a wide array of treatment options for both syndromic and non-syndromic causes of craniosynostosis. Yet, it is the nature of that large exposure and reconstruction that results in longer operative times, higher estimated

blood losses (EBL), increased transfusion rates, longer ICU and hospital stays, and increased costs.

The work of Jimenez and Barone in the 1990's on endoscopic-assisted minimally invasive craniectomy (EAC) laid the foundation for more minimally invasive approaches of craniosynostosis repair. Their technique for correction of sagittal synostosis (discussed later in this chapter), involving two small incisions, strip craniectomy, bilateral osteotomies, and post-operative helmeting, helped define a new era in craniofacial surgery. This approach offered good cosmetic results with less blood loss, decreased transfusion rates, and decreased hospital stays. These patients all went on to approximately one year of helmet therapy as part of their treatment [6], which was introduced about a decade prior to Jimenez and Barone's work by Persing. His work demonstrated both the effectiveness and economy of external orthosis [7].

Concomitantly, Lauritzen et al. developed spring-mediated cranioplasty (SMC) an alternative minimally invasive approach that requires two surgeries: one for the application of the springs and another for their removal. In his case report in a 5-year-old child with Apert's syndrome he describes the technique of strip craniectomy with application of springs applying a varying degree of force along the opened suture. The patient returned three months later for spring removal. No external orthoses were required post-operatively. He reported no exorbitism or midface retrusion at follow-up with good facial advancement and improved sleep apnea [8]. The use of spring-mediated cranioplasty continues at many institutions in the US and abroad and has been applied to a wide variety of craniosynostosis conditions. However, of the three available techniques, it is the least utilized. Later in the chapter, we will discuss how this approach compares with both the endoscopic approach and open cranial vault approach.

Technical Overview of Endoscopic-Assisted Minimally-Invasive Craniectomy (EAC)

In order to understand the benefits of a procedure, one must be familiar with the surgical technique. The technique described is how an endoscopic-assisted minimally-invasive craniectomy (EAC) for sagittal synostosis is performed at our institution. It is based on the original techniques first described by Jimenez and Barone [6]. The patient is placed under general anesthesia and positioned in the sphinx position on a beanbag [Figure 1]. The hair in the areas posterior to the coronal suture and anterior to the patient's lambdoid suture is clipped. The coronal and lambdoid sutures are confirmed with ultrasound. Two 4 cm coronal incisions are marked 2 cm posterior to the coronal suture and 2 cm anterior to lambda [Figure 2]. Incisions are opened with a needle tip electrocautery and dissection is carried out in a subgaleal plane to the anterior fontanelle from the anterior incision, and to the lambdoid sutures from the posterior incision. Bilateral parasagittal burr holes are placed 1 cm lateral to midline under the anterior incision and a craniectomy is performed with cuts parallel to the sagittal suture to the coronal suture. In similar fashion, burr holes are placed under the posterior incision and craniectomy performed posteriorly to the lambdoid sutures. Next, bone scissors are used to make para-sagittal cuts extending from the anterior craniectomy, posteriorly about 1.5 cm to allow easier access to the epidural space with the endoscope. A 30 degree rigid endoscope is then used to visualize the dural surface and adjacent bone. Under

direct visualization the dura was dissected off of the bone in the epidural plane with a suction. Any dural-based veins or bleeding points can be coagulated to avoid large volume blood loss. Subsequently, bone shears are used to complete a vertex strip craniectomy. Dural bleeding is addressed with the bipolar cautery or gel foam. The cut bone edges are coagulated completely with a bovie-suction on high power. Next, bilateral wedge osteotomies are made posterior to the coronal sutures and anterior to the lambdoid suture [Figure 3]. Again, a combination of bovie-suction cautery and bone wax is used to coagulate any bony bleeding. The wound is irrigated and closed in layers using Monocryl on the skin surface.

Postoperatively, the patient is sent to post-anesthesia recovery unit and then to the pediatric intensive care unit. A post-operative CBC is performed the next morning. Generally, the patient spends one night in the hospital and is discharged home. Prior to discharge, the patient is measured for helmet fabrication and helmet therapy is initiated as soon as possible.

Figure 1. The patient is placed in the “sphinx” position, with the head in extension.

Figure 2. Two 4cm coronal incisions are marked 2cm posterior to the coronal suture and 2cm anterior to lambda.

Figure 3. Bony removal includes a sagittal strip craniectomy from the anterior fontanelle to lambda and bilateral wedge osteotomies.

Post-Operative Metrics in Craniosynostosis Repair

The major objective measures used to evaluate and compare outcomes for different craniosynostosis treatment modalities focus on cosmesis, peri-operative care, and cost. Many studies have been published over the last twenty years looking at the advantages and disadvantages for each treatment type. More specifically these studies evaluate cosmesis through measures of cranial index pre- and post-operatively, age of treatment, duration of surgery, blood loss, length of hospital stay, and cost.

Throughout the remainder of this chapter we will take a closer look at the minimally invasive approaches to craniosynostosis repair including EAC and SMC as they compare to one another and to the more traditional open reconstructions.

Endoscopic-Assisted Craniectomy (EAC)

The EAC is the most widely utilized method for minimally invasive synostosis repair. Numerous studies evaluating the technique published over the last two decades can be seen in Table 1 [9, 10]. In his original paper, Jimenez et al. described the EAC technique applied in four patients with sagittal synostosis with a mean age of 1.75 months. All patients did well with no complications. The mean operative time was 1.68 hours, mean blood loss was 54.2 mL, and all were discharged within 24 hours of surgery. All patients went on to be fitted with helmet orthoses [6] In an early follow-up study by Barone et al. a year later, treated twelve patients were treated with EAC ranging from 0.4-7.8 months of age for sagittal, lambdoid, coronal, or metopic synostosis. Estimated blood loss ranged from 5-150 mL and only one patient requiring a blood transfusion. All patients were discharged from the hospital by day 2 [11]. Two years later in 2000, Jimenez et al. published on a much larger cohort of patients including 59 patients with sagittal synostosis who underwent EAC. His results again demonstrated decreased operative times, excellent cosmetic results, low blood loss, short hospital stays, and low complications rates [12].

Table 1. Endoscopically-assisted craniectomy (EAC) studies

Author	Year	Suture	n	Mean age (mo)	Pre-op CI	Post-op CI	Mean Surgery Time (Min)	Mean EBL (mL)	Mean LOS (days)	Cost ($)	Notes
Jimenez	1998	Sag	4	1.6	.67	.78	100	54	1.3	14300	Initial case series demonstrating safety and efficacy of EAC
Barone	1999	Sag, Cor, Lam, Multi	12	3.6			96	35	1.2	11700	EAC with decreased operative times, EBL, cost, and LOS, compared to open repair
Jimenez	2000	Sag	59	3.7	.64	.77	50	32	1.1		Follow-up case cohort of 59 patients showing safety and efficacy using cranial indices, however, must be performed on younger patients
Cohen	2002	Sag	5					60-150	2-3		Use of bioresorbable plates instead of post-operative helmet therapy is as safe with similar results when used with EAC
Baumgartner	2003	Sag, Met, Cor, Lam	14	2.5	.67 (Sag)	.78 (Sag)	108 (Sag), 55 (Other)	131 (Sag), 72 (Other)	2.9 (Sag), 2.2 (Other)		Technical overview using the microscope instead of endoscope for visualization of craniectomy, with good results
Jimenez	2004	Sag	139	3.6		>.75 in 87%	60	39	1.1		Good cosmetic results using cranial index, anthropometric, and post-operative radiographic analyses after EAC with low morbidity
Murad	2005	Sag, Met, Cor	19				97	74			Patients treated early with EAC have good cosmetic results with similar safety profile and improved peri-operative metrics compared to CVR
Jimenez	2007	Met, Cor	100	3.9			56	34	1.0		EAC can be applied to coronal and metopic synostosis safely and efficaciously

Author	Year	Suture	n	Mean age (mo)	Pre-op CI	Post-op CI	Mean Surgery Time (Min)	Mean EBL (mL)	Mean LOS (days)	Cost ($)	Notes
Keshavarzi	2009	Met	16	4.9			101	57	2.5		A review of important patient factors when deciding whether to use open versus EAC
Jimenez	2010	Multi	21	3.2			83	42	1.1		EAC is versatile and can be more widely applied to multi-suture craniosynostosis
Meier	2011	Sag, Met, Cor, Lam, Multi	100	3.1			48	25			Anesthesia experience with EAC in young infants demonstrates the technique can be safely performed in small infants with a low incidence of complications and blood transfusions
Ridgway	2011	Sag	56	3.2	.69	.76	45		1.4		Long-term benefits of EAC are durable and continue to show excellent safety profile
Berry-Candelario	2011	Sag, Cor, Lam, Multi	173	2.9	.69 (Sag)	.77 (Sag)	46		1.4		EAC continues to be safe and effective treatments of multiple forms of craniosynostosis
Shah	2011	Sag	47	3.6	.68	.76	88	29	1.2		EAC is equally effective to CVR with similar safety profiles and shorter LOS
Gociman	2012	Sag	46	3.1	.70	.80	75	56	2.2	12400	EAC is associated with shorter operative durations, shorter LOS, lower EBL, and excellent cosmetic results
Rivero-Garvia	2012	Multi	7	2.1				36	2.3		EAC in young infants less than 4 months of age with multi-suture synostosis is safe and effective with good cosmetic results

Table 1. (Continued)

Author	Year	Suture	n	Mean age (mo)	Pre-op CI	Post-op CI	Mean Surgery Time (Min)	Mean EBL (mL)	Mean LOS (days)	Cost ($)	Notes
Wong	2012	Sag, Met, Cor	76				83	50	2.1		For properly selected patients, EAC offers a valid alternative to the open traditional approaches
Jimenez	2012	Cor	100				54	20	1.0		The benefits of treatment of coronal synostosis with EAC are durable and safe
Jimenez	2012	Sag	256	3.9		>.80 in 87%	57	27	1.1		The benefits of treatment of sagittal synostosis with EAC are durable and safe
Ersahin	2013	Met	19	3.8			43				EAC is safe and effective and infants under 6 months with metopic synostosis
Gociman	2013	Met	16	2.9			79	83	1.6	12400	EAC metopic craniosynostosis showed improved metopic angle measurements with less blood loss, shorter LOS , and less costs
Jimenez	2013	Cor	115	3.1			55	20	1.0		EAC leads to significant correction in vertical dystopia, nasal deviation, sagittal misalignment, and ipsilateral proptosis in patients with coronal synostosis
Chan	2013	Sag	36	4.7			133	75	1.2	24400	EAC is a cost-effective procedure with less operative risk and minimal postoperative morbidity, however, compliance with post-operative helmet therapy present challenges to treatment

Author	Year	Suture	n	Mean age (mo)	Pre-op CI	Post-op CI	Mean Surgery Time (Min)	Mean EBL (mL)	Mean LOS (days)	Cost ($)	Notes
Tan	2013	Cor	11	2.0							Early EAC results in similar brow symmetry and better overall facial symmetry in midline deviation than fronto-orbital advancement done later in infancy
Vogel	2014	Sag	21	3.1			81	29	1.1	37300	EAC is far more cost-effective with lower utilization of peri-operative resources than CVR
Han	2015	Sag, Met,	140	3.4			71	36	1.1		Rates of intraoperative
		Cor, Lam, Multi									durotomies and surgical and medical complications were comparable between EAC and open techniques
Zubovic	2015	Lam	4	5.1			59	15			EAC under 6 months of age with orthotic therapy obtained comparable cranial base asymmetry outcomes to open reconstruction
Ghenbot	2015	Sag	16	1.8	.69	.77					Both EAC and CVR resulted in similar cranial vault volumes and cranial indices one year post-op when compared to control subjects
Nguyen	2015	Met	13	3.3							EAC and open repairs of metopic craniosynostosis show equivalent improvements in hypertolerism and trigonocephaly at one year post-op

CI = Cranial Index; Cor = Coronal; CVR = Cranial Vault Reconstruction; EAC = Endoscopically-assisted Craniectomy; EBL = Estimated Blood Loss; Lam = Lambdoid; LOS = Length of Stay; Met = Metopic; Multi = Multi-suture; Sag = Sagittal

The general technical aspect described by Jimenez has remained relatively fixed with slight variations adopted in the years since its development through the use of bio-resorbable plates and slightly variations on the wedge osteotomies [13, 14]. At the author's institution, our technique is similar to that initially described by Jimenez. Jimenez has published widely since 1998 and shown that endoscopic repair can be applied successfully and safely to not only sagittal synostosis, but to syndromic, metopic, and coronal synostosis as well [15-22].

Over the 18 years since its publication, numerous studies have looked at both replicating and improving upon these early metrics with tremendous success. Many reports continue to prove the safety and efficacy of EAC with post-operative helmet therapy. These include larger patient cohorts and various types of craniosynostosis [10, 23-28]. Some of these directly compare EAC to more traditional CVR. Chan et al. evaluated 21 patients who underwent open CVR versus 36 who underwent EAC. The mean age was much younger in the endoscopic group (4.7 months versus 10.6 months in the open group, $p = 0.001$), operating room times were significantly shorter (2.2 hours versus 5.7 hours, $p = 0.001$), EBL was lower (74 mL versus 280 mL, $p = 0.001$) and costs were far less as well in the endoscopic group ($24,404 versus $42,744, $p = 0.008$). The endoscopic cohort was also associated with significantly shorter hospital stays. These metrics of shorter hospital stay, lower blood loss, shorter operating room times, cheaper costs have also been repeated in several other studies [29-34].

When looking at efficacy from a cosmetic standpoint the endoscopic technique also proved to be as efficacious as open repair [30, 35-37]. A study in 2011 by Shah et al. retrospectively compared the open CVR against the EAC technique. They used the cranial index (CI) as their cosmetic endpoint. Forty-seven patients were treated with EAC versus 42 with open CVR. The mean pre- and post-operative CI at 13 months in the endoscopic group was 68% and 76% respectively, as opposed to 68% and 77% in the open group ($p = 0.35$) [30]. Another study from St. Louis Children's hospital in 2014 looked at 15 open versus 12 EAC repairs and similarly found no difference in outcome CI. The pre- and post-operative CI were 70.4% and 78.4% in the open group versus 68.7% and 76.6% ($p = 0.18$) [29].

Several more studies have reported alternative cosmetic results with the EAC. Nguyen et al. reviewed hypertelorism correction in metopic synostosis correction. Their group found no significant difference in interzygomaticofrontal distance and intercanthal distance between EAC and open CVR cohorts [35]. Tan et al. reviewed supraorbital symmetry in EAC versus open repair in 22 patients with unilateral coronal synostosis. Similarly, they found no significant difference in the two groups with regard to supraorbital symmetry ($p = 0.54$). The EAC group showed improved facial symmetry in midline deviation when compared to the open group (3.6 degrees versus 1.4 degrees, $p = 0.018$), as well as nasal tip deviation (5.6 degrees versus 2.3 degrees, $p = 0.006$) [10]. Another study by MacKinnon et al. examined ophthalmologic outcomes in EAC versus open repair of unilateral coronal synostosis. They reported no difference in V-pattern strabismus or aniso-astigmatism between the two groups at early follow-up, but a trend toward greater severity V-pattern strabismus and statistically significant increase in aniso-astigmatism in children treated with fronto-orbital advancement at late follow-up (14-45 months of age) [38].

While cosmetic and peri-operative metrics are critical, one other important consideration is parental stress when considering surgical options. Kim et al. examined parental stress in children undergoing open versus endoscopic-assisted repair. They utilized the Parenting Stress Index – Short Form to measure parental stress. Parents were grouped into open or

minimally invasive treatment cohorts and controlled for age, sex, ethnicity, and marital status. They demonstrated a statistically significant reduction in peri-operative stress in parents of children undergoing minimally invasive treatment options [39].

In all major studies utilizing the endoscopic approach, patients are generally less than six months of age. One of the major limitations to the endoscopic method is that it must be performed in young infants when the skull and sutures are malleable enough to be molded in post-operative helmet orthoses. The other major limitation of the endoscopic method is socioeconomic. Post-operatively, these patients must be near a center where their external orthoses can be modified over the course of the first post-operative year. The success of this approach is dependent on reliable caretakers who ensure the infant wears the helmet and will be able to follow-up with the craniofacial clinic for helmet modifications. Over the course of the year, these patients may require 1-3 helmets as their cranial vault reshapes and the brain grows. Other complications reported have included small case series of venous air embolisms during EAC cases and a development of leptomeningeal cysts post-operatively [40, 41]. Other reported limitations include the need for reoperation due to the development of pancraniosynostosis and lower rates of cosmetic success [42, 43].

Spring-Mediated Cranioplasty (SMC)

Spring-mediated cranioplasty (SMC) was developed around the same time as the endoscopic approach however its adoption has not been as widespread. A summary of published studies evaluating SMC is seen in Table 2. In an internet based survey by Doumit et al. in 2014 of 102 craniofacial surgeons in four countries, only 10% of the respondents used SMC as their first-line approach for treatment. CVR was the preferred method used 37% of the time and 35% of those surveyed performed EAC when a patient presented at younger than 4 months of age [44]. Since its inception, many studies looking at age of intervention, efficacy (cosmesis), and safety have shown the SMC can be performed at a younger age, with lower blood loss, and shorter hospital stays than CVR [45-56]. One of the largest retrospective studies performed by Lauritzen et al. in 2008 reviewed the group's first 96 cases using SMC on a cohort of patients with sagittal, metopic, bicoronal, and multiple synostoses. Spring dislodgement occurred in 5% of patients; otherwise, there were no major complications. The mean post-operative CI was 74.0 and significantly increased from 67 pre-operatively in the sagittal synostosis cohort. Mean surgical times and blood loss were 97 minutes and 143 mL, respectively [57]. Another large scale retrospective study of 80 patients by Mackenzie et al. compared cranial vault remodeling in 71 patients versus SMC in 9 patients of their cohort. Their early experience had similar findings with comparable cosmetic gains and safety profile when comparing the two techniques [58]. Recently, Arko et al. published their experience at the Children's Hospital of Philadelphia using SMC in twenty-two patients. Their cohort had an average age of 4.2 months and a mean blood loss of 56.3 mL. The mean hospital stay was just over two days at 2.2 days. The cranial index (CI) was corrected to a mean of 73.7, which was a statistically significant improvement over pre-operative CI [45]. Similarly, David et al. in another single-center experience, reported both statistically significant improvements in blood loss, cranial indices, operative times, and length of hospital stay with treatment of sagittal craniosynostosis [46, 47].

Table 2. Spring-mediated cranioplasty (SMC) studies

Author	Year	Suture	n	Mean age (mo)	Pre-op CI	Post-op CI	Surgery Time (Min)	EBL (mL)	LOS (days)	Cost ($)	Summary
Ririe	2003	Sag	9	3.9			141	48	3.1		SMC shows similar safety profile with shorter operative times, shorter LOS, and lower rates of blood transfusion when compared to CVR in sagittal synostosis
Guimaraes-Ferreira	2003	Sag	10	3.2	.65	.71	100		6.4		SMC is more effective than the modified pi-plasty procedure with less blood transfusion needed and shorter duration of hospital stay.
David	2004	Sag	15	3.9	.64	.78	32	22	2.2		SMC shows improved peri-operative variables when compared to CVR, with a similar rate of cranial index improvement
Lauritzen	2008	Sag, Met, Cor, Multi	96	3.8 (Sag)	.67 (Sag)	.74 (Sag)	97 (Sag)	143	5.0		A review of the first 100 cases of SMC in craniosynostosis demonstrates the safety and effectiveness of the technique
Mackenzie	2008	Sag	9	7.0			66		4.4		SMC is associated with shorter operative times and excellent safety profiles
Windh	2008	Sag	20	3.5	.67	.71	104	170	6.0		SMC had similar morphologic outcomes as patients undergoing pi-plasty treatment for sagittal synostosis
Pyle	2009	Sag	90	4.4							Long-term experience with spring-assisted surgery has facilitated the development of standardized, reproducible techniques allowing spring design modifications to optimize clinical outcome.
David	2010	Sag	75	5.7	.69	.75		25	1.0	21000	SMC is safe and effective in the treatment of scaphocephaly with low morbidity

Author	Year	Suture	n	Mean age (mo)	Pre-op CI	Post-op CI	Surgery Time (Min)	EBL (mL)	LOS (days)	Cost ($)	Summary
David	2010	Post	3	6.2			45	35			SMC of the patent lambdoid suture is an alternative technique to expand the posterior cranial fossa with low morbidity
Ririe	2011	Sag	100	4.4			31	15	1.6		Anesthesia peri-operative profiles in one hundred cases of SMC for sagittal synostosis reports facility and comfort with the surgical procedure increase with time and number of procedures performed
Taylor	2011	Sag	7	3.7	.65	.79	46	24	1.4		SMC versus minimally invasive strip craniectomy with parietal barrel staving show similar safety profile, however, SMC was associated with lower EBL and shorter length of stay
Tovetjarn	2012	Cor	18	5.0	.94	.82	155	237	6.3		SMC for syndromic bicoronal synostosis can be safely performed with short LOS, short surgical times, and minimal perioperative bleeding
Tuncbilek	2012	Multi	3	7.0							SMC in patients with cloverleaf skull deformity show good decompression with loss of lacunae, cosmetic outcome, and post-operative calvarial bone ossification
van Veelen	2012	Sag	41	5.8	.67	.75		54			SMC is effective in improving CI with less EBL, operative time, and complication rates. The primary disadvantages of SMC are the need for a second surgery for spring removal and inability to control spring tensile force

Table 2. (Continued)

Author	Year	Suture	n	Mean age (mo)	Pre-op CI	Post-op CI	Surgery Time (Min)	EBL (mL)	LOS (days)	Cost ($)	Summary
Arnaud	2012	Post	19								SMC can be performed safely and effectively without osteotomies for posterior skull distraction
de Jong	2013	Post	15	26.4			164		4.1		SMC has a superior safety profile over open cranial vault surgery for posterior distraction, however, certain drawbacks such as spring dislodgement and spring skin perforations should be recognized
Arko	2015	Sag	22	4.2	.70	.74	94	56	2.2		SMC is effective and safe in correcting CI, and have lower morbidity than CVR

CI = Cranial Index; Cor = Coronal; CVR = Cranial Vault Reconstruction; EBL = Estimated Blood Loss; LOS = Length of Stay; Met = Metopic; Multi = Multi-suture; Post = Posterior distraction; Sag = Sagittal; SMC = Spring-Mediated Cranioplasty

SMC has also been used not only in the treatment of sagittal craniosynostosis, but also posterior skull expansion in patients with turricephaly. Arnaud et al. reported their experience in posterior skull remodeling using SMC. They successfully applied springs to an already opened lambdoid suture in 19 patients. They showed dramatic cosmetic improvement with post-operative three-dimensional CT imaging without major complications. The major limitations included spring displacement, spring exposure, and difficulty in post-operative positioning as these patients cannot be supine during this period [59].

In order to utilize SMC one must understand the amount of spring force needed for proper correction of the respective synostosis. In a study of 90 patients, Pyle et al. described the varying degree of force need for surgical correction. In their study of sagittal synostosis correction, the range of force applied for the anterior spring was 5.5-9.5 Newtons and 5.5-9.5 Newtons for the posterior spring. The mean post-treatment expansion was 6.65 cm. They demonstrated that spring force was dependent on age, type of deformity, and severity of deformity [60].

The major drawbacks of SMC include the need to perform a second operation in order to remove the springs. This is typically performed 3-4 months post-operatively. Additionally, spring-scalp erosion has occurred, and inability to control the force of the spring has resulted in cosmetic problems. With regards to the latter, more modern techniques are using spring specific forces based on age, type and severity of deformity to mitigate these influences. However, these dynamic forces are subject to occasionally unpredictable cranial and suture movement [1, 55, 61]. Also, several centers reported spring dislodgment in a few patients, as well as a delayed tear in the sagittal sinus and small dural tears [48, 62]. Despite these drawbacks, the short operative times, minimal scalp incisions, and low volume blood losses make this approach a favorable one in the correct patient population.

Other Minimally Invasive Techniques

While endoscopic repair as described earlier in the chapter is the predominant minimally invasive technique other forms have been utilized. Massimi et al. in 2007 described a technique where 4-6 incisions are placed on or near sites of osteotomy cuts to allow for craniectomy and greater access to suture lines for skull remodeling. When compared to open bicoronal exposures for cranial vault reconstruction, the authors reported shorter operative lengths, lower blood loss, short hospital stays and comparable cosmetic results [63]. Other techniques, including the minimally-invasive CVR as described by Mutchnick, and Teichgraeber who utilizes a microscope when performing the craniectomies, have shown both safety and efficacy [32, 33, 64].

Other minimally invasive approaches include distraction osteogenesis (DO). In this technique, a craniotomy is performed with limited dural dissection, and internal distraction devices are applied. Distraction starts typically 2-5 days post-operatively with a goal distraction of 1mm/day. The devices are removed 3-5 weeks after complete distraction. The application of this technique has shown excellent improvements in cranial vault volume, fronto-orbital advancement, shorter operative length, and several case series has a similar safety profile when compared to the other minimally invasive techniques. However, this technique requires a second operation for removal of distraction devices [65-67].

CONCLUSION

Since its development in the 19th century, surgical correction for craniosynostosis has evolved into an effective and safe method of treatment of a multitude of craniofacial deformities. As outlined above, several techniques exist for treatment, each with a unique set of risks and benefits. The goal of this chapter was to highlight each techniques' differences, with an emphasis on the EAC and SMC. The decision on which modality to use depends on a given institutions craniofacial expertise and patient selection. While open CVR continues to be effectively utilized at many institutions, in the appropriate patient population, minimally-invasive approaches have been shown to be safer, equally successful, and more cost effective. Future studies will continue to evaluate these techniques in larger patient populations, increased indications, and also further evaluate outcomes, not only based on cranial shape, but also in neurological development.

REFERENCES

[1] Clayman, MA; Murad, GJ; Steele, MH; Seagle, MB; Pincus, DW. History of craniosynostosis surgery and the evolution of minimally invasive endoscopic techniques: the University of Florida experience. *Annals of plastic surgery*, 2007, 58, 285-287.

[2] Milestones in modern plastic surgery. The definitive plastic surgical treatment of the severe facial deformities of craniofacial dysostosis: Crouzon's and Apert's diseases. By Paul Tessier 1971. *Annals of plastic surgery*, 1987, 18, 330-351.

[3] Vaandrager, JM; van der Meulen, JC. [Fifty years of plastic surgery in the Netherlands. VIII. Craniofacial surgery]. *Nederlands tijdschrift voor geneeskunde*, 2000, 144, 1110-1118.

[4] Tessier, P. The definitive plastic surgical treatment of the severe facial deformities of craniofacial dysostosis. Crouzon's and Apert's diseases. *Plastic and reconstructive surgery*, 1971, 48, 419-442.

[5] Boulos, PT; Lin, KY; Jane, JA; Jr. Jane, JA. Sr. Correction of sagittal synostosis using a modified Pi method. *Clinics in plastic surgery*, 2004, 31, 489-498, vii.

[6] Jimenez, DF; Barone, CM. Endoscopic craniectomy for early surgical correction of sagittal craniosynostosis. *Journal of neurosurgery*, 1998, 88, 77-81.

[7] Persing, JA; Nichter, LS; Jane, JA; Edgerton, MT. Jr. External cranial vault molding after craniofacial surgery. *Annals of plastic surgery*, 1986, 17, 274-283.

[8] Lauritzen, C; Sugawara, Y; Kocabalkan, O; Olsson, R. Spring mediated dynamic craniofacial reshaping. Case report. *Scandinavian journal of plastic and reconstructive surgery and hand surgery/Nordisk plastikkirurgisk forening [and] Nordisk klubb for handkirurgi*, 1998, 32, 331-338.

[9] Jimenez, DF; Barone, CM; McGee, ME; Cartwright, CC; Baker, CL. Endoscopy-assisted wide-vertex craniectomy, barrel stave osteotomies, and postoperative helmet molding therapy in the management of sagittal suture craniosynostosis. *Journal of neurosurgery*, 2004, 100, 407-417.

[10] Tan, SP; Proctor, MR; Mulliken, JB; Rogers, GF. Early frontofacial symmetry after correction of unilateral coronal synostosis: frontoorbital advancement vs endoscopic strip craniectomy and helmet therapy. *The Journal of craniofacial surgery*, 2013, 24, 1190-1194.

[11] Barone, CM; Jimenez, DF. Endoscopic craniectomy for early correction of craniosynostosis. *Plastic and reconstructive surgery*, 1999, 104, 1965-1973, discussion 1974-1965.

[12] Jimenez, DF; Barone, CM. Endoscopy-assisted wide-vertex craniectomy, "barrel-stave" osteotomies, and postoperative helmet molding therapy in the early management of sagittal suture craniosynostosis. *Neurosurgical focus*, 2000, 9, e2.

[13] Cohen, SR; Holmes, RE; Meltzer, HS; Nakaji, P. Immediate cranial vault reconstruction with bioresorbable plates following endoscopically assisted sagittal synostectomy. *The Journal of craniofacial surgery*, 2002, 13, 578-582, discussion 583-574.

[14] Baumgartner, JE; Teichgraeber, JF; Waller, AL; Grantcherova, E; Gateno, J; Xia, JJ. Microscopic approach to craniosynostosis. *The Journal of craniofacial surgery*, 2005, 16, 997-1005.

[15] Jimenez, DF; Barone, CM. Early treatment of coronal synostosis with endoscopy-assisted craniectomy and postoperative cranial orthosis therapy: 16-year experience. *Journal of neurosurgery Pediatrics*, 2013, 12, 207-219.

[16] Jimenez, DF; Barone, CM. Bilateral endoscopic craniectomies in the treatment of an infant with Apert syndrome. *Journal of neurosurgery Pediatrics*, 2012, 10, 310-314.

[17] Jimenez, DF; Barone, CM. Endoscopic technique for coronal synostosis. *Child's nervous system:ChNS:official journal of the International Society for Pediatric Neurosurgery*, 2012, 28, 1429-1432.

[18] Jimenez, DF; Barone, CM. Multiple-suture nonsyndromic craniosynostosis: early and effective management using endoscopic techniques. *Journal of neurosurgery Pediatrics*, 2010, 5, 223-231.

[19] Jimenez, DF; Barone, CM. Early treatment of anterior calvarial craniosynostosis using endoscopic-assisted minimally invasive techniques. *Child's nervous system: ChNS: official journal of the International Society for Pediatric Neurosurgery*, 2007, 23, 1411-1419.

[20] Murad, GJ; Clayman, M; Seagle, MB; White, S; Perkins, LA; Pincus, DW. Endoscopic-assisted repair of craniosynostosis. *Neurosurgical focus*, 2005, 19, E6.

[21] Meier, PM; Goobie, SM; DiNardo, JA; Proctor, MR; Zurakowski, D; Soriano, SG. Endoscopic strip craniectomy in early infancy: the initial five years of anesthesia experience. *Anesthesia and analgesia*, 2011, 112, 407-414.

[22] Wong, RK; Emelin, JK; Meltzer, HS; Levy, ML; Cohen, SR. Nonsyndromic craniosynostosis: the Rady Children's Hospital approach. *The Journal of craniofacial surgery*, 2012, 23, 2061-2065.

[23] Berry-Candelario, J; Ridgway, EB; Grondin, RT; Rogers, GF; Proctor, MR. Endoscope-assisted strip craniectomy and postoperative helmet therapy for treatment of craniosynostosis. *Neurosurgical focus*, 2011, 31, E5.

[24] Ersahin, Y. Endoscope-assisted repair of metopic synostosis. *Child's nervous system: ChNS: official journal of the International Society for Pediatric Neurosurgery*, 2013, 29, 2195-2199.

[25] Gociman, B; Marengo, J; Ying, J; Kestle, JR; Siddiqi, F. Minimally invasive strip craniectomy for sagittal synostosis. *The Journal of craniofacial surgery*, 2012, 23, 825-828.

[26] Gociman, B; Agko, M; Blagg, R; Garlick, J; Kestle, JR; Siddiqi, F. Endoscopic-assisted correction of metopic synostosis. *The Journal of craniofacial surgery*, 2013, 24, 763-768.

[27] Han, RH; Nguyen, DC; Bruck, BS; et al. Characterization of complications associated with open and endoscopic craniosynostosis surgery at a single institution. *Journal of neurosurgery Pediatrics*, 2016, 17, 361-370.

[28] Rivero-Garvia, M; Marquez-Rivas, J; Rueda-Torres, AB; Ollero-Ortiz, A. Early endoscopy-assisted treatment of multiple-suture craniosynostosis. *Child's nervous system: ChNS: official journal of the International Society for Pediatric Neurosurgery*, 2012, 28, 427-431.

[29] Ghenbot, RG; Patel, KB; Skolnick, GB; Naidoo, SD; Smyth, MD; Woo, AS. Effects of open and endoscopic surgery on skull growth and calvarial vault volumes in sagittal synostosis. *The Journal of craniofacial surgery*, 2015, 26, 161-164.

[30] Shah, MN; Kane, AA; Petersen, JD; Woo, AS; Naidoo, SD; Smyth, MD. Endoscopically assisted versus open repair of sagittal craniosynostosis: the St. Louis Children's Hospital experience. *Journal of neurosurgery Pediatrics*, 2011, 8, 165-170.

[31] Vogel, TW; Woo, AS; Kane, AA; Patel, KB; Naidoo, SD; Smyth, MD. A comparison of costs associated with endoscope-assisted craniectomy versus open cranial vault repair for infants with sagittal synostosis. *Journal of neurosurgery Pediatrics*, 2014, 13, 324-331.

[32] Teichgraeber, JF; Baumgartner, JE; Waller, AL; et al. Microscopic minimally invasive approach to nonsyndromic craniosynostosis. *The Journal of craniofacial surgery*, 2009, 20, 1492-1500.

[33] Teichgraeber, JF; Baumgartner, JE; Viviano, SL; Gateno, J; Xia, JJ. Microscopic versus open approach to craniosynostosis: a long-term outcomes comparison. *The Journal of craniofacial surgery*, 2014, 25, 1245-1248.

[34] Chan, JW; Stewart, CL; Stalder, MW; St Hilaire, H; McBride, L; Moses, MH. Endoscope-assisted versus open repair of craniosynostosis: a comparison of perioperative cost and risk. *The Journal of craniofacial surgery*, 2013, 24, 170-174.

[35] Nguyen, DC; Patel, KB; Skolnick, GB; et al. Are endoscopic and open treatments of metopic synostosis equivalent in treating trigonocephaly and hypotelorism? *The Journal of craniofacial surgery*, 2015, 26, 129-134.

[36] Zubovic, E; Woo, AS; Skolnick, GB; Naidoo, SD; Smyth, MD; Patel, KB. Cranial Base and Posterior Cranial Vault Asymmetry After Open and Endoscopic Repair of Isolated Lambdoid Craniosynostosis. *The Journal of craniofacial surgery*, 2015, 26, 1568-1573.

[37] Ridgway, EB; Berry-Candelario, J; Grondin, RT; Rogers, GF; Proctor, MR. The management of sagittal synostosis using endoscopic suturectomy and postoperative helmet therapy. *Journal of neurosurgery Pediatrics*, 2011, 7, 620-626.

[38] MacKinnon, S; Rogers, GF; Gregas, M; Proctor, MR; Mulliken, JB; Dagi, LR. Treatment of unilateral coronal synostosis by endoscopic strip craniectomy or fronto-orbital advancement: Ophthalmologic findings. *Journal of AAPOS:the official publication of the American Association for Pediatric Ophthalmology and Strabismus/American Association for Pediatric Ophthalmology and Strabismus* 2009, 13, 155-160.

[39] Kim, D; Pryor, LS; Broder, K; et al. Comparison of open versus minimally invasive craniosynostosis procedures from the perspective of the parent. *The Journal of craniofacial surgery*, 2008, 19, 128-131.

[40] Tobias, JD; Johnson, JO; Jimenez, DF; Barone, CM; McBride, DS. Jr. Venous air embolism during endoscopic strip craniectomy for repair of craniosynostosis in infants. *Anesthesiology*, 2001, 95, 340-342.

[41] Aryan, HE; Meltzer, HS; Gerras, GG; Jandial, R; Levy, ML. Leptomeningeal cyst development after endoscopic craniosynostosis repair: case report. *Neurosurgery*, 2004, 55, 235-237, discussion 237-238.

[42] Jenkins, GH; Smith, NR; McNeely, PD. Pancraniosynostosis following endoscope-assisted strip craniectomy and helmet orthosis for sagittal suture craniosynostosis in a nonsyndromic patient. *Journal of neurosurgery Pediatrics*, 2013, 12, 77-79.

[43] Sivakumar, W; Goodwin, I; Blagg, R; et al. Pancraniosynostosis following endoscopic-assisted strip craniectomy for sagittal suture craniosynostosis in the setting of poor compliance with follow-up: a case report. *Journal of medical case reports*, 2015, 9, 64.

[44] Doumit, GD; Papay, FA; Moores, N; Zins, JE. Management of sagittal synostosis: a solution to equipoise. *The Journal of craniofacial surgery*, 2014, 25, 1260-1265.

[45] Arko, Lt; Swanson, JW; Fierst, TM; et al. Spring-mediated sagittal craniosynostosis treatment at the Children's Hospital of Philadelphia: technical notes and literature review. *Neurosurgical focus*, 2015, 38, E7.

[46] David, LR; Plikaitis, CM; Couture, D; Glazier, SS; Argenta, LC. Outcome analysis of our first 75 spring-assisted surgeries for scaphocephaly. *The Journal of craniofacial surgery*, 2010, 21, 3-9.

[47] David, LR; Proffer, P; Hurst, WJ; Glazier, S; Argenta, L. C. Spring-mediated cranial reshaping for craniosynostosis. *The Journal of craniofacial surgery*, 2004, 15, 810-816, discussion 817-818.

[48] de Jong, T; van Veelen, ML; Mathijssen, IM. Spring-assisted posterior vault expansion in multisuture craniosynostosis. *Child's nervous system: ChNS:official journal of the International Society for Pediatric Neurosurgery*, 2013, 29, 815-820.

[49] Tovetjarn, R; Maltese, G; Kolby, L; Kreiborg, S; Tarnow, P. Spring-assisted cranioplasty for bicoronal synostosis. *The Journal of craniofacial surgery*, 2012, 23, 977-981.

[50] Tuncbilek, G; Kaykcoglu, A; Bozkurt, G; Akalan, N. Spring-mediated cranioplasty in patients with multiple-suture synostosis and cloverleaf skull deformity. *The Journal of craniofacial surgery*, 2012, 23, 374-377.

[51] Shen, W; Cui, J; Chen, J; et al. Correction of craniosynostosis using modified spring-assisted surgery. *The Journal of craniofacial surgery*, 2015, 26, 522-525.

[52] Ririe, DG; David, LR; Glazier, SS; Smith, TE; Argenta, LC. Surgical advancement influences perioperative care: a comparison of two surgical techniques for sagittal craniosynostosis repair. *Anesthesia and analgesia*, 2003, 97, 699-703.

[53] Ririe, DG; Smith, TE; Wood, BC; et al. Time-dependent perioperative anesthetic management and outcomes of the first 100 consecutive cases of spring-assisted surgery for sagittal craniosynostosis. *Paediatric anaesthesia*, 2011, 21, 1015-1019.

[54] Windh, P; Davis, C; Sanger, C; Sahlin, P; Lauritzen, C. Spring-assisted cranioplasty vs pi-plasty for sagittal synostosis--a long term follow-up study. *The Journal of craniofacial surgery*, 2008, 19, 59-64.

[55] van Veelen, ML; Mathijssen, IM. Spring-assisted correction of sagittal suture synostosis. *Child's nervous system:ChNS:official journal of the International Society for Pediatric Neurosurgery*, 2012, 28, 1347-1351.

[56] Guimaraes-Ferreira, J; Gewalli, F; David, L; Olsson, R; Friede, H; Lauritzen, CG. Spring-mediated cranioplasty compared with the modified pi-plasty for sagittal synostosis. *Scandinavian journal of plastic and reconstructive surgery and hand surgery/Nordisk plastikkirurgisk forening [and] Nordisk klubb for handkirurgi*, 2003, 37, 208-215.

[57] Lauritzen, CG; Davis, C; Ivarsson, A; Sanger, C; Hewitt, T. D. The evolving role of springs in craniofacial surgery: the first 100 clinical cases. *Plastic and reconstructive surgery*, 2008, 121, 545-554.

[58] Mackenzie, KA; Davis, C; Yang, A; MacFarlane, MR. Evolution of surgery for sagittal synostosis: the role of new technologies. *The Journal of craniofacial surgery*, 2009, 20, 129-133.

[59] Arnaud, E; Marchac, A; Jeblaoui, Y; Renier, D; Di Rocco, F. Spring-assisted posterior skull expansion without osteotomies. *Child's nervous system:ChNS:official journal of the International Society for Pediatric Neurosurgery*, 2012, 28, 1545-1549.

[60] Pyle, J; Glazier, S; Couture, D; Sanger, C; Gordon, S; David, L. Spring-assisted surgery-a surgeon's manual for the manufacture and utilization of springs in craniofacial surgery. *The Journal of craniofacial surgery*, 2009, 20, 1962-1968.

[61] Sanger, C; David, L; Argenta, L. Latest trends in minimally invasive synostosis surgery: a review. *Current opinion in otolaryngology & head and neck surgery*, 2014, 22, 316-321.

[62] Lin, F; Wong, VH; Ekanayake, G; et al. Delayed sagittal sinus tear: a complication of spring cranioplasty for sagittal craniosynostosis. *The Journal of craniofacial surgery*, 2012, 23, 1382-1384.

[63] Massimi, L; Tamburrini, G; Caldarelli, M; Di Rocco, C. Effectiveness of a limited invasive scalp approach in the correction of sagittal craniosynostosis. *Child's nervous system: ChNS: official journal of the International Society for Pediatric Neurosurgery*, 2007, 23, 1389-1401.

[64] Mutchnick, IS; Maugans, TA. Nonendoscopic, minimally invasive calvarial vault remodeling without postoperative helmeting for sagittal synostosis. *Journal of neurosurgery Pediatrics*, 2012, 9, 222-227.

[65] Cho, BC; Hwang, SK; Uhm, KI. Distraction osteogenesis of the cranial vault for the treatment of craniofacial synostosis. *The Journal of craniofacial surgery*, 2004, 15, 135-144.

[66] Park, DH; Chung, J; Yoon, SH. Rotating distraction osteogenesis in 23 cases of craniosynostosis: comparison with the classical method of craniotomy and remodeling. *Pediatric neurosurgery*, 2010, 46, 89-100.

[67] Tellado, MG; Lema, A. Coronal suturectomy through minimal incisions and distraction osteogenesis are enough without other craniotomies for the treatment of plagiocephaly due to coronal synostosis. *The Journal of craniofacial surgery*, 2009, 20, 1975-1977.

In: Encyclopedia of Surgery (22 Volume Set)
Editors: Andreas Lehrer and Kristin Mueller
ISBN: 978-1-53618-329-0
© 2020 Nova Science Publishers, Inc.

Chapter 414

RAISING THE BAR ON PTERYGIUM SURGERY

Arun C. Gulani, MD and Parth G. Patel
Gulani Vision Institute, Jacksonville, FL, US

- The 'No Stitch, No Patch, No Red' Approach.

ABSTRACT

Pterygia and pingueculae are intriguing and some of the oldest pathologies that ophthalmologists confront. Presentations vary in various tissue distributions and vascular patterns from small atrophic lesions to large aggressive vision-compromising fibrovascular growths advanced cases.

Raising the bar

What started over a decade ago with celebrities, news anchors, and models seeking services for cosmetic outcomes of their pterygium, pterygium surgery has become a common demand of men and women from all walks of life. It is seen in a fair number of professional golfers, surfers, and avid outdoor enthusiasts. Although prolonged sun exposure is thought to cause pterygium and pinguecula formation, a genetic predilection has also been observed.

While cosmetic symptoms can seem trivial to ophthalmologists, patient concerns are genuine and range from self-consciousness, low self-esteem, and embarrassment to depression as a result of their ocular appearance. This realization has fueled a desire to continuously raise the bar on ocular surface surgery to a cosmetic outcome.

As in LASIK and cataract surgeries in which we aim for spectacle-free vision with a flawless looking eye, during every step in ocular surface surgery we should constantly think of how we want this patient to look immediately postoperatively and years later. Removing the lesion is one goal and beautifying the eye (with minimal visual impact) is the other goal, but both are essential. Considering the consistent outcomes of our pterygial surgery, patients have been actively seeking pinguecula correction.

The part of the pterygium that is visible is only the tip of the iceberg (Gulani Iceberg Concept). By removing only this visible portion, the main pathology with its tentacles is not addressed and remains hidden under the conjunctiva.

We have continuously studied the presentations and outcomes in improving the surgical approach and outcomes over the years to add an additional way to classify the pterygium based on the adhesion of the head locally, vascularity and surrounding tissue involvement.

Thus our surgical steps involve a lamellar approach along with atraumatic pterygium removal as a conjunctival scar with full dissection right up to the roots, including all arising heads followed by subconjunctival mitomycin-C application and Amniotic graft layering on the sclera with glue and reconstructing the fornix in many cases.

Patients are made to walk up to a mirror One day post-op, to appreciate that their eye looks like it has had no surgery.

The cosmetic appeal of the outcome with the no stitch, no patch and no red approach along with absence of visual deficit is raising the bar in patients now seeking this approach for related ocular surface conditions like pinguecula and conjunctivochalasis.

While the average pterygium recurrence rate is commonly considered to hover around the 39 percent mark, the recurrence rate with his technique is less than 0.5 percent (12 yr follow up).

INTRODUCTION

Pterygium is a fibrovascular growth arising from the conjunctiva of the eye that grows over the cornea. It is one of the most common pathologies seen by ophthalmologists. Factors implicated of causing pterygium include ultraviolet light exposure, chronic stimulation, inflammation, climate, and genetics. Surgical excision is the only treatment available and despite the different techniques tried world over, recurrence rates remain high. Bare sclera resection is a relatively straightforward procedure, but a recurrence rate between 24% to 89% is reported. Multiple strategies have been tried to decrease the high rate of pterygium recurrence including conjunctival autograft, amniotic membrane or stem cell transplantation. Various modalities used to inhibit regrowth are thiotepa, radiation, or mitomycin C (MMC).

MMC is an alkylating compound derived from Streptomyces caespitosus. It is used primarily as a chemotherapeutic agent because of its cytotoxic effects in inducing apoptosis. Using MMC following resection has been shown to reduce the rate of recurrence, in part because it can suppress neovascularization. However, attention to detail and meticulous maneuvers are important while using MMC because the apoptotic effects of MMC can potentially lead to other complications such as scleral thinning and ischemia.

In this chapter, we describe a ‘No stitch (sutureless), No patch, No red (painless and aesthetically pleasing)’ technique for pterygium surgery which gives best results both visually and cosmetically.

Raising the Bar

Pterygium surgery with cosmetic outcomes is no longer something that only celebrities, news anchors, and models seek. It has become a common demand of men and women from all walks of life. While cosmetic symptoms can seem trivial to ophthalmologists, patient concerns are genuine and range from self-consciousness, low self-esteem, and embarrassment to depression as a result of their ocular appearance. This realization has fueled a desire to continuously raise the bar on ocular surface surgery to a

cosmetic outcome. As in LASIK and cataract surgeries, there is today, little room for error in pterygium surgery. Beautifying the eye is just as important as removing the lesion and if possible enhancing vision simultaneously.

Anatomy of the Pterygium

The part of the pterygium that is visible is only the tip of the iceberg (Gulani Iceberg Concept). By removing only this visible portion, the main pathology with its tentacles is not addressed and remains hidden under the conjunctiva (Figure 1).

We have classified pterygium into categories based on the adhesion of the head locally, vascularity and draw test for surrounding tissue involvement.

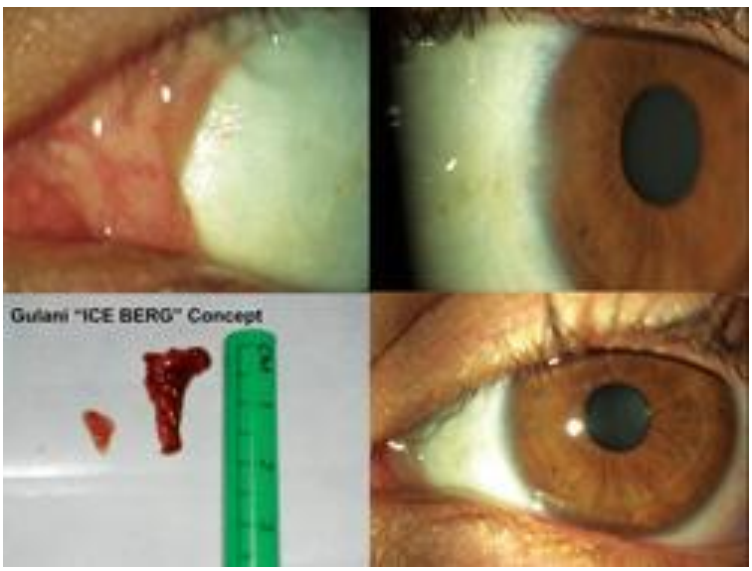

Figure 1. The Gulani "Iceberg" concept, in which the entire mass—not just the visible portion of the pterygium—is removed. Next day postop appearance is clear with no inflammation.

Pterygiums in the Gulani Classification (pictures included):

Head/Neck Adhesion: The adhesion may be Peripheral or Central (this can further be classified into diffuse, focal and density based). In cases of peripheral adhesion the pterygium easily peels off the cornea.

Vascularity: Engorged, tortuous vessels and simultaneous conjunctival fold contracture signifies a more aggressive pterygium.

Draw test: On tugging on the cornea some pterygia may be small in size but outright gritty and deep into the cornea resulting in thin cornea when removed. Also removal of these pterygia is more difficult from the corneal surface. Preparation for this before surgery helps plan a smooth outcome (Amniotic graft itself can be used as a lamellar fill).

Recent techniques have used amniotic membrane, the innermost layer of the fetal membrane, for the treatment of pterygium wherein after the removal of proliferative tissue, amniotic membrane is placed on the sclera and adhered to the sclera with glue.

In this surgical approach, we describe a non-traumatic, "No-Stitch" technique using the criteria below and treat the pterygium as if it were a corneal scar. We should plan for every surgery to leave the vision untouched or improved (corneoplastique principles).

The surgical steps involve a lamellar approach along with atraumatic pterygium removal as a conjunctival scar with full dissection right up to the roots, including all arising heads followed by subconjunctival mitomycin-C application and Amniotic graft layering on the sclera with glue and reconstructing the fornix in many cases.

Criteria for surgical plan:

- Determine the Extent of the pterygium.
- Examine the Density of the pterygium.
- Check for Involvement of adjacent structures.
- Draw test
- Head/Neck adhesion
- Vascularity

Technique

In a typical case, anesthesia is induced with topical tetracaine hydrochloride (Tetravisc Forte, Sigma Pharmaceuticals) applied preoperatively with topical antibiotics. Intralesional anesthesia in the form of lidocaine with epinephrine is used 1-2cc. This also delineates the extent of the pterygium in obscure or recurrent cases (Figure 2). Recently a trend has been noticed among patients seeking Pinguecula surgery requesting for LMA anesthesia. Given that most of these patients are young and healthy and also that sometimes the surgery may be extensive, this does allow for a comfortable experience for the patient with a safe recovery.

Depending on the appearance and draw test, decide to approach the pterygium at the contracted medial conjunctival fold and proceed medial to limbal (Gulani Centripetal approach) or from the head towards the medial conjunctival fold (Gulani Centrifugal approach).

At the start of the procedure, the head of the pterygium is delineated from the cornea underneath. This can be done with posterior-to anterior sweep using the Gulani Pterygium cross-action spreader (Storz ™).

In cases of mild adhesions the pterygium can be easily separated from the cornea (mostly peripheral pterygia) or effectively peeled in a single centrifugal/centripetal movement (Figure 3).

After smoothing the cornea with a specially designed blunt blade, remnant tissue (especially in the gritty kind of pterygium) is meticulously removed with toothed forceps medial to limbal directions always. The blade is used again to smoothen the limbus (Figure 4). A weck cell sponge soaked in 1:1000 epinephrine is used during this time tucked away into the nasal crevice where the cut pterygium is pressured into hemostasis (In this way by the time this step is done, we approach a bloodless field again for dissection. Also as added benefit we have created space for tucking the future amniotic graft).

Figure 2. Intralesional lidocaine with epinephrine to delineate the extent of the pterygium.

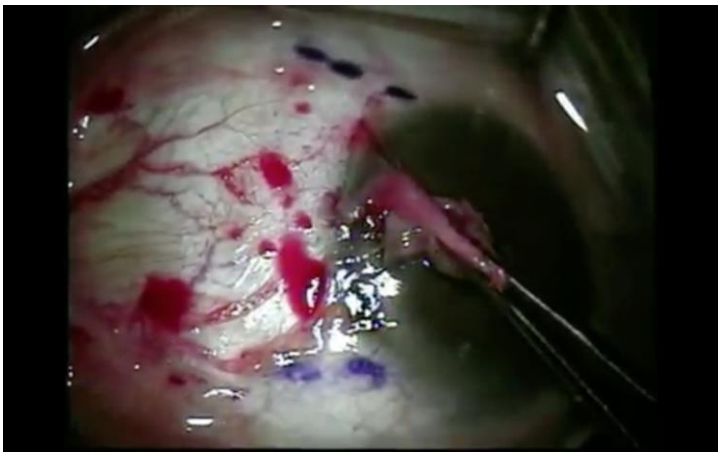

Figure 3. Centripetal peeling of pterygium from cornea.

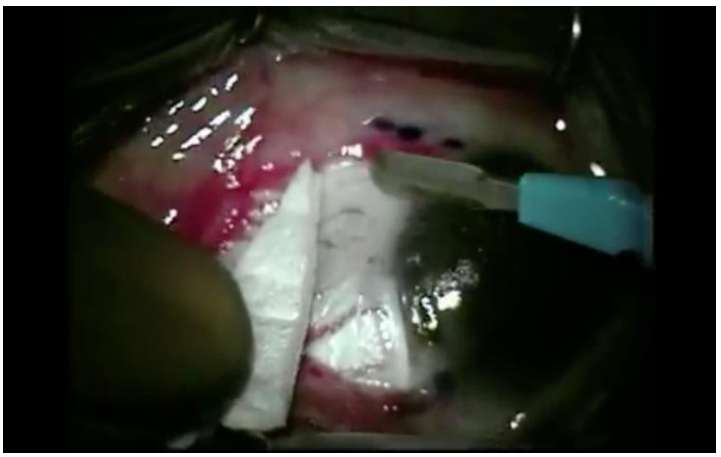

Figure 4. Blade being used to smoothen the limbus.

The most important stage is dissecting the pterygium. The whole plane of the pterygium is delineated subconjunctivally as if separating a fan shaped scar with tentacles into the fornices and medial angle. Keep the pull superior and vertical (to avoid damage to the underlying medial rectus. By cutting vertically instead of horizontally, you can avoid unnecessary involvement of orbital fat, bleeding and accidental damage to medial rectus. (In cases of recurrent pterygium, I habitually use a modified muscle hook-Gulani muscle manipulator to ascertain the anatomy by hooking the medial rectus). When the pterygium mass is removed, it resembles a spreading mass of tentacles. It is important to remove the entire mass to avoid recurrence. The pterygium is dissected carefully superiorly, to avoid buttonholing the conjunctiva and invading the orbital septum, and inferiorly, to avoid cutting the underlying muscles, which is rechecked after the pterygium is removed. There is none to very minimal bleeding during surgery (The cautery is to be used sparingly and then only for cosmetic reasons). Make it a point to patiently pick at the episcleral remnants to clear the underlying sclera in an attempt to remove all pterygium tissue from the area of impact.

Weck cell sponge pieces are soaked in mitomycin-C 0.04% and placed under the conjunctiva (rolled over these pieces) in the area of the dissection and left in place for 30 seconds (Figure 5). Avoid application to sclera (infact dry the sclera with a clean wekcel sponge). After removing the sponges to a full count, the area is flushed with copious balanced salt solution.

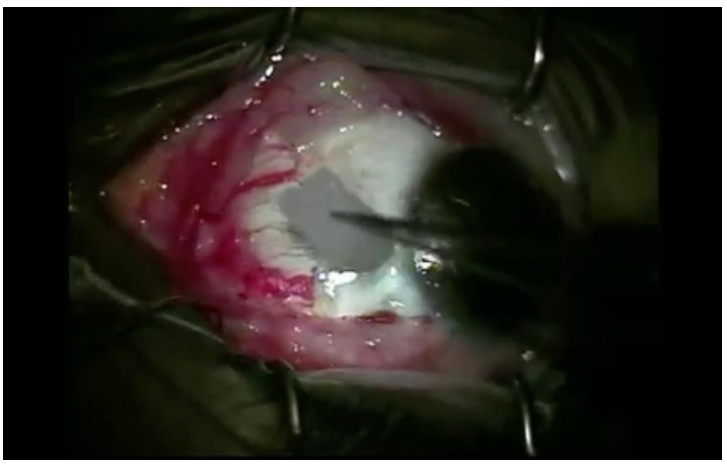

Figure 5. Weck cell sponge pieces soaked in mitomycin-C 0.04% are placed under the conjunctiva.

Use the cornea as an illuminated *receiving table* to drape the amniotic membrane which is then placed on the raw area and accepted with a Tyre-Tool technique (To avoid touching the membrane with any instrument) so it slips under the surrounding cut edge of the conjunctiva medially, superiorly and inferiorly (Figure 6).This is then milked to adhere to the globe contour using a specially designed forceps that literally squeegees the graft as it lays on the sclera.

Tisseel glue is now applied under the membrane (Sub-Amniotic, controlled delivery) as two separate components and the membrane squeegeed milked again in two quick sweeps to a pearly white and smooth appearance (Figure 7).

Now turn to the medial fornix and glue the conjunctiva and underlying tenons (Cut as a “C” with medial facing convexity) to ensure closure of any potential space in between. Check

the fornices for excessive glue and clear with a forceps sweep. Too much glue may cause irritation and keratitis next day if left behind.

Figure 6. Amniotic membrane being placed on the raw area.

Figure 7. Tisseel glue is applied sub-amniotically under the membrane.

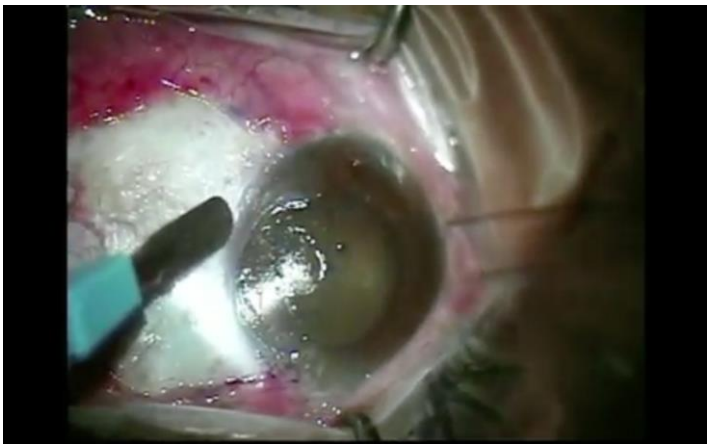

Figure 8. Blade is used in a single, sweep action to cut the excess graft at the limbus.

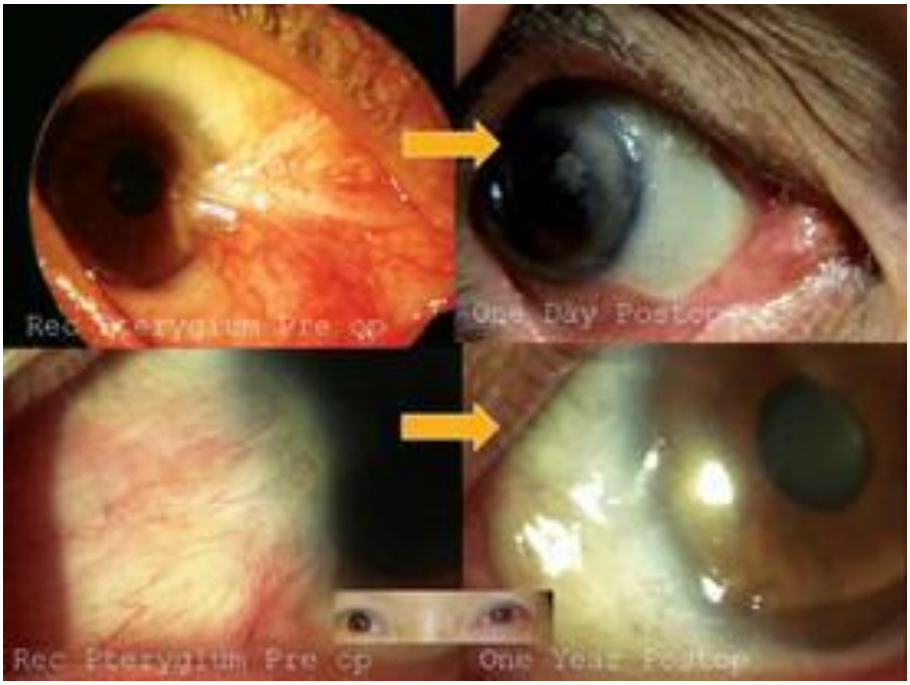

Figure 9. Recurrent Pterygia looking clear on day 1 (top) and 1 year post op (bottom).

At this time, take the same 64 blade and in a single sweep action cut the excess graft at the limbus (Figure 8). That excess graft is then peeled away as it clears the cornea and also confirms adhesion of the remaining graft (This allows for no bumpy anatomy at the limbus and patients can resume contact lens wear early)

In Recurrent Pterygia:

The surgery is exactly the same no matter how aggressive and recurrent (Figure 9) the pterygium is.

The bleeding is again very minimal if you follow these pearls in recurrent cases:

Select an area which is more amenable to approach and dissect down into this area until you reach the scleral bed (Most usually the previous ophthalmologist must have done a meticulous job of clearing the sclera). Once you reach sclera, dissect from behind forwards and the whole pterygium mass will lift up very much like a thick plate of armor ("*Armor plate Technique*"). Once again bleeding will be minimal (People try to cut and vigorously dissect. That will lead to bleeding and losing the plane of easy dissection).

In cases of simultaneous, nasal and temporal pterygium surgery, we have seen a case of irregular pupil and a case of strabismus that was corrected. Always insist on patient education including need for informed consent about seriousness of surgery despite the results that we can aim for.

Patients are made to walk up to a mirror next day (One day post-op) to appreciate what their eye looks like. (Tables 1-4).

Description: Subjective Grading: The day after the procedure patients walk up to a mirror, examined the operative site and give a verbal subjective exclamation which is documented as the postoperative patient subjective assessment of appearance. The verbal subjective response is graded on a scale of 1-4. This exclamation is based on the flawless,

clear appearance of the operated eye with equal lid openings. Subjective responses recorded the day after the procedure to measure patient discomfort upon eye movements is also recorded and titled patient subjective assessment of symptoms and is graded on a scale of 1 to 3.

Table 1. Grading of the amniotic graft placement post operatively on day one

Gulani Objective grading of the Post Operative Amniotic Graft Area	Examination Findings on the Amniotic Graft Area
Grade 1 Clear with good placement.	
Grade 2 Good placement but with bubble-wrap appearance.	
Grade 3 Displaced Graft.	
Grade 4 Sub-amniotic blood.	

Table 2. Post operative grading of the cornea on the basis of slit lamp examination

Gulani Objective Grading of the Post Operative Cornea	Examination Findings of the Post Operative Cornea
Grade 1 Clear.	
Grade 2 Mild Keratitis.	
Grade 3 Clouding at Surgical Site.	
Grade 4 Lamellar Fill.	

Table 3. Subjective grading of the post operative appearance day one (Slide 25)

Gulani Day One Post-OP Patient Subjective response scale	Appearance
GRADE 1	Cannot tell which eye had surgery.
GRADE 2	Can tell which eye had surgery but looks untouched.
GRADE 3	Operated eye looks red but acceptable.
GRADE 4	Operated eye looks beefy red and unacceptable.

Table 4. Subjective grading of discomfort day one post operative

Gulani Day One Post-Op Patient Subjective Symptom Scale	Level of Discomfort
GRADE 1	No Discomfort
GRADE 2	Some Discomfort
GRADE 3	Uncomfortable

Pterygium surgery has led itself to an increase in the requests for cosmetic pinguecula removal (Figure 10) for patients in whom their appearance may be troubling to the patient or threatens their livelihood itself (models, sales personnel etc.). Here again, since the bar has been raised on outcomes, pinguecula removal follows the same principle as pterygium surgery.

Additionally, these patients may undergo Laser Vision Surgery and or cataract surgery with Premium lens technologies very soon in succession since the cornea is basically cleared (for Laser PRK) with excellent globe contour or for the suction ring during Lasik and even INTACS. The concept of *Look Good, See Good!*

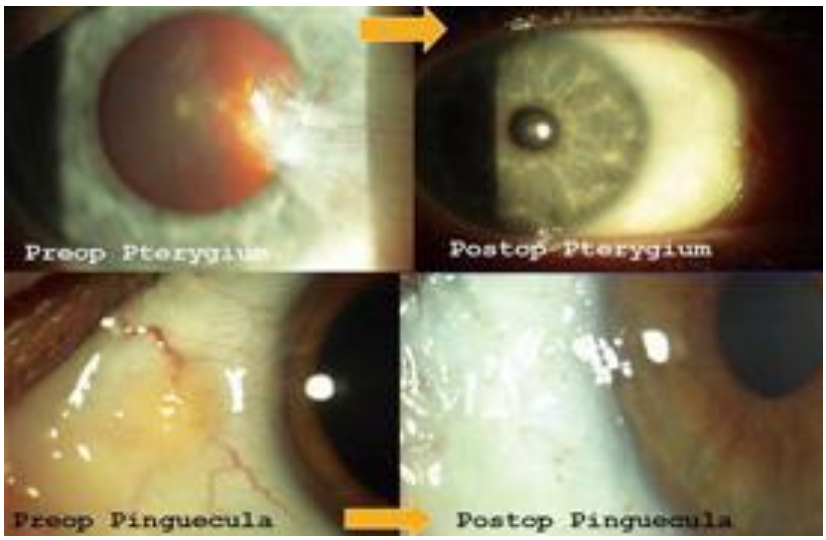

Figure 10. Next day postop of pterygium and pingecula surgery.

CONCLUSION

We have follow up of over 500 cases of amniotic graft surgery using the above mentioned technique with a recurrence rate of less than 0.5 % with upto 14 years follow up (Figure 11). It is thus safe to conclude that, the pterygium and pinguecula surgery outcomes (the very next day postoperative) have made aesthetic outcomes a reality, with methods described above.

The important thing to remember is that, no eye surgery is complete without addressing the patient's vision. It is our responsibility to also ensure that we are not jeopardizing vision in any form and in fact provide options for vision correction using modalities like Lasik, PRK, Premium cataract surgery, INTACS etc using Corneoplastique™ principles for an early visual rehabilitation of the operated eye (Figure 12). Also, with numerous patients having undergone Lasik and cataract surgery all over the world, we are seeing patients who need surgery for pterygium / pingueculas after these vision correcting surgeries. Here, it is vital not to affect the vision in any way as these patients shall not tolerate a drop in their excellent 20/20 outcomes.

Thus, the importance of this procedure goes beyond successfully treating pterygium and pinguecula patients with a procedure that offers the opportunity for sparkling white eyes one day postoperatively with a less than 0.5 percent recurrence rate. It also offers a vehicle to maintain the integrity of the ocular surface—or further improve the ocular surface—thereby raising the bar on refractive surgery outcomes. For instance, the elegance of this no-stitch amniotic graft technique enables many patients who were initially non-candidates for laser

refractive surgery or premium lens refractive surgery (due to tissue-induced irregular astigmatism, corneal scars, tear film instability or higher order aberrations) to be safely prepared for vision corrective surgery, such as surface ablation and even premium IOL cataract surgery. The removal of corneal scars and pterygium tissue, and the resultant clear and measurable optical system, in essence safely and elegantly converts patients from non-refractive surgery candidates into refractive surgery candidacy.

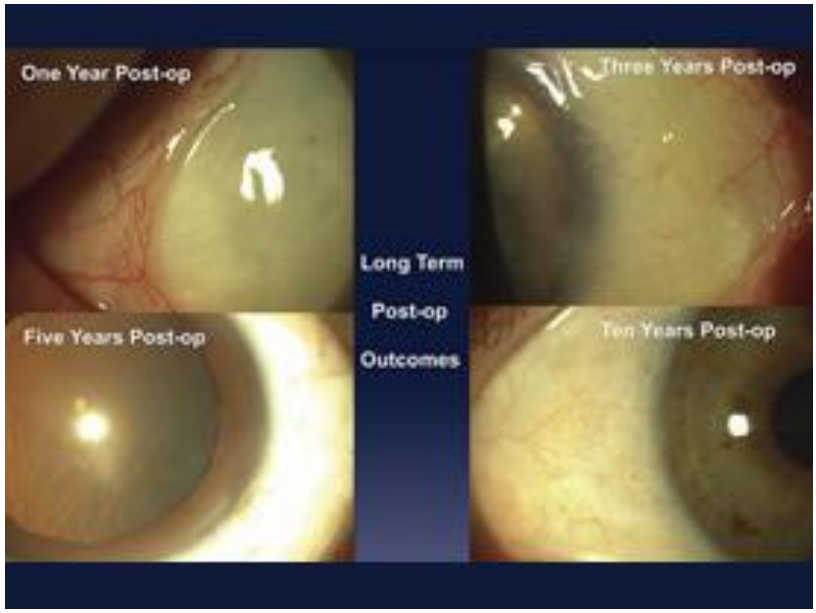

Figure 11. Follow up over 14 years.

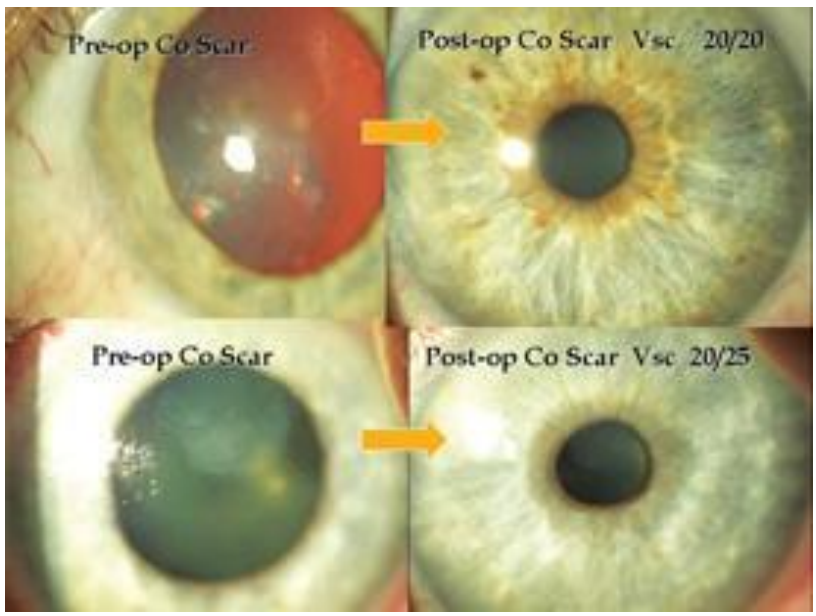

Figure 12. Corneoplastique techniques to remove pterygium scars and achieve 20/20 vision.

We request all eye surgeons to raise the bar on ocular surface surgery outcomes to those of cosmetic surgery given the capabilities of this procedure.

REFERENCES

Gulani AC. Pterygium and Pinguecula surgery: *Future of Ocular Surface Surgery*.

Gulani AC. Simultaneous Pterygium and Cataract Surgery. *J. Postgrad. Med.* 1995; 41: 8-11.

Gulani AC. Amniotic Membrane Lowers Chance of Pterygium Recurrence- *Ophthalmology Times*. Sept 15th. 2003.

Gulani AC. "*Corneoplastique*™" SASRCS – Durban. Aug 2005.

Gulani AC. *Advanced Corneal Surgery Course*: *AAO*, California, Oct 2006.

Gulani AC. "A New Concept for Refractive Surgery." *Ophthalmology Management* 2006; 10 (4). 57-63.

Gulani AC. "Corneoplastique" *Video Journal of Cataract and Refractive Surgery.* Vol XXII. Issue 3, 2006.

Gulani AC. Vision Corrective Surgeries: Past Techniques, Present Trends and Future Technologies. *NEFM Journal of Medicine*. 2007; 2 (58) 41-44.

Gulani AC. Principles of Surgical Treatment of Irregular Astigmatism in Unstable Corneas. *TextBook of Irregular Astigmatism*. Diagnosis and Treatment. Thorofare, NJ: SLACK Incorporated; 2007: 251-261.

Gulani AC. Corneoplastique. *Techniques in Ophthalmology* 5(1):11-20, 2007.

Gulani, AC. Sutureless Amniotic Surgery for Pterygium: Cosmetic Outcomes for Ocular Surface Surgery. *Techniques in Ophthalmology*. 6(2): 41-44, 2008.

Gulani AC. Surgical method sets higher standard for managing pterygium. *Ocular Surgery News.* Consultation Section, Aug. 2008.

Gulani AC. Combined Corneal Scar Excision, PRK Surgery Seeks Unaided Emmetropia. *Ocular Surgery News*. Cornea & External disease section, June 2008.

Gulani AC. "Corneoplastique: Art of Laser Vision Surgery"-Corneal Refractive *Surgery in Video Atlas of Ophthalmic Surgery*. XXXVIII. (2) 2008.

Gulani AC. "Dry Eye Matrix." Innovator's Lecture, ASCRS, 2002. *Video Journal of Ophthalmology*. 2009.

Kim JC, Tseng SCG. Transplantation of Preserved Human Amniotic Membrane for Surface Reconstruction in Severely Damaged Rabbit Corneas. *Cornea* 1995; 14: 472-484.

Tayyar M, Turan R, Ayata D. The Use of Amniotic Membrane Plus Heparin to Prevent Postoperative Adhesions in the Rabbit. Tokai *J. Exp. Clin. Med.* 1993; 18: 57-60.

Trelford JD, Trelford-Sauder M. The Amnion in Surgery, Past and Present. *Am. J. Obstet. Gynecol*. 1979; 134: 833-845.

In: Encyclopedia of Surgery (22 Volume Set)
Editors: Andreas Lehrer and Kristin Mueller
ISBN: 978-1-53618-329-0
© 2020 Nova Science Publishers, Inc.

Chapter 415

RELEVANCE OF C REACTIVE PROTEIN LEVELS IN MORBIDLY OBESE PATIENTS AND AFTER BARIATRIC SURGERY

Jaime Ruiz-Tovar*[1,*]*, MD, PhD
***and Carolina Llavero*[2,†]**
[1]Department of Surgery, University Hospital Rey Juan Carlos, Madrid, Spain
[2]Department of Surgical Nursery, Hospital del Sureste, Madrid, Spain

ABSTRACT

The measurement of CRP levels is useful because abnormalities generally reflect the presence and intensity of an inflammatory process. However, CRP measurements in clinical use are not specific to any particular disease, nor can they distinguish infection from other causes of acute and chronic inflammation. Elevations of the CRP occur in association with acute and chronic inflammation due to a range of causes, including infectious diseases and noninfectious inflammatory disorders. Small changes in CRP levels may also occur in association with metabolic stresses in the absence of acute or chronic inflammatory states.

Increased CRP levels have been related with the macro- and microvascular disorders, associating with cardiovascular risk, hypertension, diabetes mellitus, and dyslipidemia. Furthermore, increased CRP levels have also been related with central obesity and secondarily with atherosclerosis and other macrovascular disorders. There is a general consensus that obesity is an eminently inflammatory process. This is justified by alterations observed in obese patients, which affect the secretion of certain cytokines such as CRP, ceruloplasmin, leptin, adiponectin, and interleukin-6 (IL-6), among others. In a parallel way, other researchers have also pointed out alterations in the composition of fatty acids in the erythrocyte membrane of overweight adults. These changes lead to a more frequent status of atheromatosis and arteriosclerosis and finally to a higher cardiovascular risk. Therefore, it has been already described that some inflammatory markers (i.e., CRP, IL-6) are predictors of cardiovascular events.

[*] Corresponding Author's Email: jruiztovar@gmail.com.
[†] Carolina Llavero, RN.

A recent study of our group has demonstrated that CRP levels are increased preoperatively, but in the postoperative course, a significant reduction was observed at the 12- month postoperative determination; at this moment, all the patients presented CRP values under normal range. Therefore, normalization of CRP values could probably be useful to predict weight stabilization.

INTRODUCTION

C Reactive Protein (CRP) is an acute-phase reactant, synthesized by the liver, mainly in response to IL-6, which is produced not only during infection but also in many types of inflammation. The protein consists of five identical, non-covalently associated subunits, each with a molecular weight of approximately 23 kD, which are arranged symmetrically around a central pore [1-3].

CRP and related proteins with this structure are termed pentraxins, which are a family of pattern recognition molecules involved in the innate immune response. CRP can promote the recognition and elimination of pathogens and enhance the clearance of necrotic and apoptotic cells [4-6].

CRP has both proinflammatory and antiinflammatory actions, although the primary effect may be anti-inflammatory. A major function of CRP is its ability to bind phosphocholine, thereby permitting recognition of foreign pathogens and phospholipid constituents of damaged cells. CRP can also activate the complement system and bind to phagocytic cells, suggesting that it can initiate elimination of pathogens and targeted cells by interaction with humoral and cellular effector systems of inflammation [2, 7]. Proinflammatory effects of CRP include the induction in monocytes of inflammatory cytokines and tissue factor and shedding of the IL-6 receptor. As a result, the CRP response to tissue injury may worsen tissue damage in some settings [8, 9].

CLINICAL USE OF CRP DETERMINATIONS

CRP levels are useful because abnormalities generally reflect the presence and intensity of an inflammatory process. However, CRP measurements in clinical use are not specific to any particular disease, nor can distinguish infection from other causes of acute and chronic inflammation. Elevations of the CRP occur in association with acute and chronic inflammation due to a range of causes, including infectious diseases and noninfectious inflammatory disorders. Small changes in CRP levels may also occur, in association with metabolic stresses, in the absence of acute or chronic inflammatory states. In most inflammatory conditions, CRP becomes elevated as part of the acute phase response. Markedly elevated levels of CRP are strongly associated with infection. Levels of CRP may also be elevated in patients with viral infections, although often not to the degree seen in patients with bacterial infection [10].

RELEVANCE OF CRP VALUES IN THE POSTOPERATIVE COURSE

Infections contribute to significant postoperative morbidity, increased mortality, prolonged hospital stay and additional sanitary costs. An early diagnosis of complications after surgery is still a challenge for surgeons, but it is essential for a better outcome of the patient. Furthermore, this is more important when the patient is planned to undergo an early discharge, because a minimally invasive surgery has been performed, as happens in laparoscopic approaches. In these cases, to have a marker that may alert the surgeon to the development of a septic complication that may not have been clinically evident until then, would be essential to decide whether the patient can left the hospital or should remain hospitalized for further investigations to discard a possible postoperative complication. This is crucial and could change the management for many patients [11, 12].

Among several markers of inflammation and sepsis, CRP has been widely studied to investigate their accuracy for the diagnosis of bacterial infections. CRP is a useful marker for monitoring the postoperative course and diagnose severe preoperative bacterial infections. These studies have been conducted in gastrointestinal surgeries, most of them performed for malignancies, mainly in colorectal cancer surgery [13, 14]. Increased levels of CRP have already been established for signalling an unfavourable outcome. Furthermore, it is considered an indicator of postoperative surgical and nonsurgical complications. Recently, it has been shown that CRP elevation is predictive of infectious postoperative complications including anastomotic leakage. Though CRP levels are usually increased after surgery, it has been shown that in patients developing complications this elevation is significantly higher [11].

Little is known about the postoperative value of CRP after bariatric surgery. A recently published paper of our group demonstrated that CRP levels 24 hours after surgery is a predictive factor for septic complications after laparoscopic sleeve gastrectomy. A cut-off value was established in 100 mg/dl. Those patients overcoming this level have a 10-fold higher risk of developing postoperative septic complications [16].

Actually, many authors defend the monitoring of postoperative values of CRP rather than establishing a single cut-off point for many gastrointestinal surgeries, based on the dynamics of the molecule. It has been described a correlation between persistent CRP elevation as predictive of septic postoperative complications. Serum CRP levels show a peak 48-96 hours after surgery. In patients with an uneventful postoperative course decreased the peak after 2 days, while a prolonged increased in its levels has been described as an indicator of impending complications [11, 15]. Monitoring the CRP levels after a sleeve gastrectomy seems to be of no benefit, thus it is expected that the patient can be discharged 24- 48 hours after surgery, just coinciding with the CRP peak, so that the decrease of CRP levels cannot be determined [16].

CRP AND CARDIOVASCULAR RISK

Minor CRP elevation (concentrations between 3 and 10 mg/L) has been generally regarded as a marker of what has been called low-grade inflammation. The low-grade inflammatory state differs in several important ways from the acute inflammation that occurs

in response to infection or tissue injury. The acute inflammatory state is associated with the classic signs of inflammation (swelling, erythema, warmth, and pain), while low-grade inflammation is not. Acute inflammation generally shows a marked CRP response while low-grade inflammation shows only minor CRP elevation. The inflammatory response to infection and tissue injury supports host defense, clearance of necrotic tissue, adaptation, and repair, while the purpose of low-grade inflammation appears to be restoration of metabolic homeostasis [17].

Inflammation is a known factor in the development of atherosclerosis and subsequent cardiovascular events. Ongoing inflammation increases the vulnerability of an atherosclerotic lesion to erosion or rupture. CRP is the most extensively studied of numerous inflammatory biomarkers potentially linked to underlying atherosclerosis. When considered alone or in combination with traditional cardiovascular risk factors, elevated CRP levels have been associated with a higher risk of future cardiovascular events [18-21].

Minor degrees of inflammation may reflect obesity, cigarette smoking, diabetes mellitus and insulin resistance, hypertension and different degrees of metabolic dysfunction [10]. C-Reactive protein (CRP) has been associated with the macro- and microvascular effects of hypertension, diabetes mellitus, and coronary artery disease [22-24].

There is a general consensus that obesity is an eminently inflammatory process. This is justified by alterations observed in obese patients, which affect the secretion of certain cytokines such as CRP, ceruloplasmin, leptin, adiponectin, and interleukin-6 (IL-6), among others. In a parallel way, other researchers have also pointed out alterations in the composition of fatty acids in the erythrocyte membrane of overweight adults. These changes lead to a more frequent status of atheromatosis and arteriosclerosis and finally to a higher cardiovascular risk. Therefore, it has been already described that some inflammatory markers (i.e., CRP, IL-6) are predictors of cardiovascular events [25, 26].

According to this, a previous study conducted by our group, revealed that the patients of our sample presented elevated preoperative CRP levels, secondary to morbid obesity status and, in some of them, additionally to Metabolic Syndrome (MetS). However, a significant difference in preoperative CRP values could not be observed between the group of patients with and without MetS. An association between preoperative CRP levels and BMI score could not be either established. It may be that some lower level of obesity predisposes patients to elevated CRP levels. Notwithstanding, there is not a linear relationship between BMI and CRP levels [27].

An interesting finding of our study was the universal normalization CRP levels 1 year after surgery, and in posterior analytical determinations, CRP values remained under normal range in all the patients. Referring to weight loss, it was observed that after 1 year, weight did not present important modifications (increase or decrease over 3 kg). Several authors have affirmed that weight loss after bariatric surgery represents a catabolic state, and CRP has been described as a catabolic biomarker [28, 29]. In our patients, after 1 year, when important weight modifications were not observed any more, catabolism probably stopped, and therefore, CRP levels reached the normal range. Regarding these data, normalization of CRP values could probably be useful to predict weight stabilization [27].

CONCLUSION

In the postoperative course of bariatric surgery, CRP is a relevant marker for detecting postoperative complications. An elevation of CRP > 100 mg/l the first postoperative day, should alert the surgeon the possibility of occurrence of postoperative septic complications, even before it becomes clinically apparent. In these situations, the surgeon must be careful with early discharges of the patients.

CRP levels are mildly increased in obese patients, reflecting that obesity is a pro-inflammatory disorder. After bariatric surgery, when the weight stability is achieved, CRP values normalize as a sign of disappearance of the inflammatory status. Thus, this normalization of CRP values could probably be useful to predict weight stabilization.

REFERENCES

[1] Cid MC, Grant DS, Hoffman GS, et al. Identification of haptoglobin as an angiogenic factor in sera from patients with systemic vasculitis. *J Clin Invest* 1993; 91:977-985.

[2] Malle E, De Beer FC. Human serum amyloid A (SAA) protein: a prominent acute-phase reactant for clinical practice. *Eur J Clin Invest* 1996; 26:427-435.

[3] Yudkin JS, Stehouwer CD, Emeis JJ, Coppack SW. C-reactive protein in healthy subjects: associations with obesity, insulin resistance, and endothelial dysfunction: a potential role for cytokines originating from adipose tissue? *Arterioscler Thromb Vasc Biol* 1999; 19:972-978.

[4] Wullstein C, Drognitz O, Woeste G, et al. High levels of C-reactive proteína alter simultaneous páncreas-kidney transplantation predict pancreas graft-related complications and graft survival. *Transplantation* 2004;77:60-64.

[5] Matthiessen P, Henriksson M, Hallbook O, et al. Increase of serum C-reactive protein is an early indicator of subsequent symptomatic anastomotic leakage after anterior resection. *Colorectal Dis* 2008;10:75-80.

[6] Welsch T, Muller SA, Ulrich A, et al. C-reactive protein as early predictor for infectious postoperative complications in rectal surgery. *Int J Colorectal Dis* 2007;22:1499-1507.

[7] Fincher RM, Page MI. Clinical significance of extreme elevation of the erythrocyte sedimentation rate. *Arch Intern Med* 1986; 146:1581-1583.

[8] Woloshin S, Schwartz LM. Distribution of C-reactive protein values in the United States. *N Engl J Med* 2005; 352:1611-1613.

[9] Wener MH, Daum PR, McQuillan GM. The influence of age, sex, and race on the upper reference limit of serum C-reactive protein concentration. *J Rheumatol* 2000; 27:2351-2359.

[10] Kushner I. C-reactive protein elevation can be caused by conditions other than inflammation and may reflect biologic aging. *Cleve Clin J Med* 2001; 68:535-537.

[11] Woeste G, Muller C, Bechstein Wo, Wullstein C. Increased serum levels of C-Reactive Protein precede anastomotic leakage in colorectal surgery. *World J Surg* 2010;34:140-146.

[12] Pompilio E, Casigliani R, Sommariva S, Saggese MP. Acute phase proteins as markers of septic risk in surgical patients. *Minerva Chir* 1989;44:2185-2190.
[13] Simon L, Gauvin F, Amre DK, et al. Serum procalcitonin and C-reactive protein levels as markers of bacterial infection: a systematic review and meta-analysis. *CID* 2004;39:206-217.
[14] Montagnana M, Minicozzi AM, Salvagno GL, et al. Postoperative variation of C-reactive protein and procalcitonin in patients with gastrointestinal cancer. *Clin Lab* 2009;55:187-192.
[15] Matthiessen P, Henriksson M, Hallbook O, et al. Increase of serum C-reactive protein is an early indicator of subsequent symptomatic anastomotic leakage after anterior resection. *Colorectal Dis* 2008;10:75-80.
[16] Ruiz-Tovar J, Muñoz JL, Llavero C, et al. Serum C-reactive protein and fibrinogen levels as early markers of septic complications after sleeve gastrectomy in morbidly obese patients. *Surg Chronicles* 2014;19:32-36.
[17] Ockene IS, Matthews CE, Rifai N, et al. Variability and classification accuracy of serial high-sensitivity C-reactive protein measurements in healthy adults. *Clin Chem* 2001; 47:444-450.
[18] Kervinen H, Palosuo T, Manninen V, et al. Joint effects of C-reactive protein and other risk factors on acute coronary events. *Am Heart J* 2001; 141:580-585.
[19] Ridker PM. High-sensitivity C-reactive protein: potential adjunct for global risk assessment in the primary prevention of cardiovascular disease. *Circulation* 2001; 103:1813-1818.
[20] Koenig W, Löwel H, Baumert J, Meisinger C. C-reactive protein modulates risk prediction based on the Framingham Score: implications for future risk assessment: results from a large cohort study in southern Germany. *Circulation* 2004; 109:1349-1353.
[21] Ridker PM, Wilson PW, Grundy SM. Should C-reactive protein be added to metabolic syndrome and to assessment of global cardiovascular risk? *Circulation* 2004; 109:2818-2825.
[22] Gomez-Marcos MA, Recio-Rodriguez JI, Patino-Alonso MC, et al. Relationships between high-sensitive C-reactive protein and markers of arterial stiffness in hypertensive patients. Differences by sex. *BMC Cardiovasc Disord.* 2012;12:37. doi: 10.1186/1471-2261-12-37.
[23] Klempfner R, Leor J, Tenenbaum A, et al. Effects of a vildagliptin/ metformin combination on markers of atherosclerosis, thrombosis and inflammation in diabetic patients with coronary artery disease. *Cardiovasc Diabetol.* 2012;6:60-63.
[24] Varghese B, Swamy S, Srilakshmi MA, et al. Visceral adiposity in young patients with coronary artery disease—a case control study. *Indian Heart J.* 2012;64:284–289.
[25] Ridker PM. Clinical application of C-reactive protein for cardiovascular disease detection and prevention. *Circulation.* 2003;107:363–369.
[26] Chen JY, Chou CH, Tsai WC, et al. Effects of increased systemic inflammation and central obesity on arterial stiffness in patients with nonalcoholic fatty liver disease. *J Am Soc Hypertens.* 2012;6:253–260.
[27] Ruiz-Tovar J, Oller I, Galindo I, et al. Change of levels in C-reactive protein and serum cortisol in morbidly obese patients after laparoscopic sleeve gastrectomy. *Obes Surg* 2013;23:764-769.

[28] Stenholm S, Maggio M, Lauretani F, et al. Anabolic and catabolic biomarkers as predictors of muscle strength decline: the InCHIANT study. *Rejuvenation Res.* 2010;13:3–11.

[29] Schaap LA, Pluijm SM, Deeg DJ, et al. Higher inflammatory marker levels in older persons: associations with 5-year change in muscle mass and muscle strength. *J Gerontol A Biol Sci Med Sci.* 2009;64:1183–1189.

In: Encyclopedia of Surgery (22 Volume Set)
Editors: Andreas Lehrer and Kristin Mueller
ISBN: 978-1-53618-329-0
© 2020 Nova Science Publishers, Inc.

Chapter 416

POLYTETRAFLUOROETHYLENE PATCHES FOR SHOULDER SURGERY

Michael Nagra[1] and Manit Arora[2]
[1]Mayne Medical School, University of Queensland, Queensland, Australia
[2]St. George Clinical School, University of New South Wales, Sydney, Australia

ABSTRACT

Polytetrafluorothylene (PTFE) patches is an undissolvable material that has been used widely in surgical fields for vascular surgeries, abdominal surgeries, and some orthopaedic surgeries related to the knee and nasal bone. Due to PTFE high tensile strength and compatible to human tissue, it is also considered a prime augmentation material for a repair of a massive rotator cuff tear. Studies have shown PTFE patches provide better outcomes in returning to baseline function and tensile strength than in a non-augmented (tendon to bone) repair. It has low infection and adhesion rates, excellent properties to allow for shoulder healing during the "off-load" (rest) period. The use of PTFE augmentation for massive rotator cuff tears is recommended.

INTRODUCTION

Shoulder surgery has progressed rapidly in the last two decades. With these advances, innovations and inventions have become part and parcel of care. One such intervention is the use of Polytetrafluoroethylene (PTFE) patches for the treatment of rotator cuff (muscles and tendons around the shoulder) problems. With small tears we usually can bring the tendon to attach the bone directly, but with larger tears it becomes increasingly difficult. PTFE helps by acting as a scaffold or bridge between the torn tendon and the bone.

The rationale is to "off-load" the torn tendons by mechanical augmentation from the time of injury to some period post surgery. The "off-load" allows the injured tendons to rest while the scaffold material carries the weight and functions of the injured tendons. The "off loading" period produces faster and better healing outcome. It does so by stabilizing the tissue until healing is occurred. This method has also been shown to reduce pain after the shoulder

is healed, as well as producing a higher satisfaction and function compare to non-augmented repairs [1-3].

The ideal synthetic scaffold material should have low to none infection and adhesion rates, as well as being able to provide a good mechanical strength. The material should be able to maintain its mechanical properties over time to help stabilize and to prevent recurrence of the tear. The material used can either be dissolvable in human body, or undissolvable. A concern in an undissolvable material is it may increases risk of infection, which often leads to another surgery to remove the material. Multiple surgeries can subsequently lead to a loss of shoulder strength and function in a long term.

PTFE is an undissolvable synthetic material that can be used as a scaffold patch for massive rotator cuff tears. PTFE has a strong tensile strength and compatible to human tissues, which makes it excellent for biological healing [4]. It is able to provide mechanical support permanently. Its use is similar to abdominal hernia repair that it provides strength and support to abdominal muscles.

The usefulness of PTFE patch is well known, especially in abdominal and vascular surgeries. In hernia operations, PTFE is used to replace musculo-fascial tissue to approximate the abdominal wall [4]. Its benefit in abdominal wall surgery includes low rate of infection [5], low adhesion rate [6], support fibrous tissue corporation [7]. PTFE patch has been experimented for use as a prosthetic placement of an esophageal wall fragment in rats [8]. In vascular surgery, PTFE patch is used for coarctation repair [9], popliteal bypass [10], vascular graft [11, 12], etc.

In orthopedics, PTFE patch has shown a potential value in restoring knee joints in people with osteochondral defect (defects in knee bone and cartilage) as it allows for growth of tissue through the patch [13]. PTFE patch also shows excellent outcomes when used for Anterior Cruciate Ligament reconstruction in chronic unstable knee with an 83% satisfactory rate [14]. In plastic surgery, PTFE patch has been used successfully to treat small defect of the nasal bone and cartilage [15].

SURGICAL METHOD

The method of using patch augmentation for massive rotator cuff tears is performed via arthroscopic technique. The cuff tears are identified while patient is lying on the lateral side on the uninjured shoulder. Two portals are inserted to the injured shoulder; a lateral viewing portal is used as a cannula for PTFE patch insertion and posterior portal as surgical scope. The PTFE patch is placed as a scaffold into subacromial space (a space in a shoulder) through the lateral surgical portal cannula. The PTFE patch is then secured to the torn tissue via mattress sutures at the anterior and posterior portions of the rotator cuff. The patch is sized via a ruled probe or similar instrument prior to insertion. A pre-operative MRI is helpful for sizing of the patch. The optimal thickness for PTFE patch was estimated between 3-5 mm. There is minor difference in post-operative satisfaction between using small (less than 2 cm anterior to posterior dimension) or large patch size. Patients who received smaller patch size, compare to larger patch size group, have higher abduction strength post-operatively. Thus, the use of PTFE patch thickness 3-5mm and small patch size is recommended. A post-operative rehabilitation is essential for best outcomes.

RESULT

A systematic review for using PTFE patch as a treatment of massive rotator cuff tears found a total of eleven studies (four animals and seven clinical) [16]. A study on 31 beagle dog showed that when a PTFE augmentation is performed on host tissues, it increases tensile strength; but it also causes stiffness of the shoulder after the surgery [17]. Another study showed that weave suture technique, in comparison to multiple mattress suture technique, has a higher success in securing the PTFE patch in animal hosts [18]; and inverted mattress repair provides a higher footprint contact pressure than vertical mattress suture [19]. On sheep experiments, researchers found that interposition surgical repair using PTFE provided a significantly stronger massive rotator cuff tears than direct tendon to bone repair [20].

PTFE patches for massive rotator cuff tears have showed good outcomes in human trials, with as much as 90% patient's satisfactions in return of function post-operatively [21]. A study on 30 patients with irreparable massive rotator cuff tears over 5 years period showed significant improvement on pain score and lack of new development of bone destruction or inflammation [22]. However 30% of patients developed an enlargement of the bone gutter of the greater tuberosity after the surgery, this is believed to be attributed by the patients' biological reaction to PTFE [22]. It hasn't been shown that the use of PTFE is directly related to bone loss, so this phenomenon needed to be studied in the long term. The use of PTFE augmentation repair still needed to be compared with other repair or augmentation technique.

CONCLUSION

PTFE patches for treatment of rotator cuff tear has been found to be effective as it has a high post-operative satisfaction in returning to shoulder function, improved pain score, and lack of bone destruction. It has a high tensile strength and low complications rate related to adhesion and infection. Complications related to enlargement of bone gutter, bone loss, and comparison to other patch materials still needed to be studied in a long term. The use of PTFE patch for massive rotator cuff tears is recommended.

REFERENCES

[1] Badhe SP, Lawrence TM, Smith FD, Lunn PG. An assessment of porcine dermal xenograft as an augmentation graft in the treatment of extensive rotator cuff tears. *Journal of shoulder and elbow surgery/American Shoulder and Elbow Surgeons* [et al]. 2008; 17(1 Suppl): 35S-9S.

[2] Encalada-Diaz I, Cole BJ, Macgillivray JD, Ruiz-Suarez M, Kercher JS, Friel NA, et al. Rotator cuff repair augmentation using a novel polycarbonate polyurethane patch: preliminary results at 12 months' follow-up. *Journal of shoulder and elbow surgery/American Shoulder and Elbow Surgeons* [et al]. 2011;20(5):788-94.

[3] Metcalf MH, Savoie Iii FH, Kellum B. Surgical technique for xenograft (SIS) augmentation of rotator-cuff repairs. *Operative Techniques in Orthopaedics*. 2002;12(3):204-8.

[4] Hakimi O, Mouthuy PA, Carr A. Synthetic and degradable patches: an emerging solution for rotator cuff repair. *International journal of experimental pathology*. 2013;94(4):287-92.

[5] Rosenman JE, Pearce WH, Kempczinski RF. Bacterial adherence to vascular grafts after in vitro bacteremia. *The Journal of surgical research.* 1985;38(6):648-55.

[6] Brown GL, Richardson JD, Malangoni MA, Tobin GR, Ackerman D, Polk HC, Jr. Comparison of prosthetic materials for abdominal wall reconstruction in the presence of contamination and infection. *Annals of surgery.* 1985;201(6):705-11.

[7] Lamb JP, Vitale T, Kaminski DL. Comparative evaluation of synthetic meshes used for abdominal wall replacement. *Surgery*. 1983;93(5):643-8.

[8] González Sáez LA, Arnal Monreal F, Pita Fernández S, Machuca Santa Cruz J. Experimental Study Using PTFE (Goretex) Patches for Replacement of the Oesophageal Wall. *European Surgical Research.* 2003;35(4):372-6.

[9] DeSanto A, Bills RG, King H, Waller B, Brown JW. Pathogenesis of aneurysm formation opposite prosthetic patches used for coarctation repair. An experimental study. *The Journal of thoracic and cardiovascular surgery*. 1987;94(5):720-3.

[10] Klinkert P, Post PN, Breslau PJ, van Bockel JH. Saphenous Vein Versus PTFE for Above-Knee Femoropopliteal Bypass. A Review of the Literature. *European Journal of Vascular and Endovascular Surgery.* 2004;27(4):357-62.

[11] Taylor MRS, Loh A, McFarland RJ, Cox M, Chester JF. Improved technique for polytetrafluoroethylene bypass grafting: Long-term results using anastomotic vein patches. *British Journal of Surgery*. 1992;79(4):348-54.

[12] Lentz DJ, Henderson J, Dormier EJ, Zdrahala RJ. *PTFE vascular graft*. Google Patents; 1998.

[13] Hanff G, Sollerman C, Abrahamsson S-O, Lundborg G. Repair of Osteochondral Defects in the Rabbit Knee with Goretex™ (Expanded Polytetrafluoroethylene). *Scandinavian Journal of Plastic and Reconstructive Surgery and Hand Surgery.* 1990;24(3):217-23.

[14] Ahlfeld SK, Larson RL, Collins HR. Anterior cruciate reconstruction in the chronically unstable knee using an expanded polytetrafluoroethylene (PTFE) prosthetic ligament. *The American journal of sports medicine.* 1987;15(4):326-30.

[15] Stoll W. The use of polytetrafluoroethylene for particular augmentation of the nasal dorsum. *Aesthetic Plastic Surgery*. 15(1):233-6.

[16] Arora M, Khedekar RG, Shetty SH, Parikh M. Polytetrafluoroethylene patches for massive rotator cuff tears: An update of current concepts. *Journal of Arthroscopy and Joint Surgery*. 2015;2(1):12-5.

[17] Kimura A, Aoki M, Fukushima S, Ishii S, Yamakoshi K. Reconstruction of a defect of the rotator cuff with polytetrafluoroethylene felt graft. *Recovery of Tensile Strength and Histocompatibility in an Animal Model*. 2003;85-B(2):282-7.

[18] Ronquillo JC, Lam P, Murrell GAC. Arthroscopic ePTFE Patch Repair for Irreparable Rotator Cuff Tears: Part I: Surgical Technique and Biomechanical Comparison of 2-Suture Techniques at the Patch to Tendon Interface. *Techniques in Shoulder & Elbow Surgery.* 2013;14(2):29-32.

[19] Shepherd HM, Lam PH, Murrell GAC. Biomechanics of Synthetic Patch Rotator Cuff Repairs. *Techniques in Shoulder & Elbow Surgery*. 2011;12(4):94-100.

[20] McKeown AD, Beattie RF, Murrell GA, Lam PH. Biomechanical comparison of expanded polytetrafluoroethylene (ePTFE) and PTFE interpositional patches and direct tendon-to-bone repair for massive rotator cuff tears in an ovine model. *Shoulder & Elbow*. 2015.

[21] Ozaki J, Fujimoto S, Masuhara K, Tamai S, Yoshimoto S. Reconstruction of chronic massive rotator cuff tears with synthetic materials. *Clinical orthopaedics and related research*. 1986(202):173-83.

[22] Kimura A OK, Fukushima S, Ishii S, Aoki M. Clinical results of rotator cuff reconstruction with PTFE felt augmentation for irreparable massive rotator cuff tears. *Should Jt.* 2000;24:485-8.

In: Encyclopedia of Surgery (22 Volume Set)
Editors: Andreas Lehrer and Kristin Mueller
ISBN: 978-1-53618-329-0
© 2020 Nova Science Publishers, Inc.

Chapter 417

ANAESTHESIA FOR MINIMALLY INVASIVE MITRAL VALVE SURGERY

Ben Gibbison*[*]*, MD and Amit Ranjan
Department of Cardiac Anaesthesia, Bristol Heart Institute/University of Bristol, Bristol, UK

ABSTRACT

Minimally invasive mitral surgery is a part of the spectrum of minimal access cardiac surgery and fast tracking, which essentially aim to increase patient satisfaction by accelerated recovery and decrease pain, while maintaining overall surgical efficacy. The altered surgical approaches require changes to the anaesthetic technique and equipment. The restricted view of the heart also increases the reliance on trans-oesophageal echocardiography (TOE). This chapter discusses anaesthesia for minimally invasive mitral valve surgery (MIMVS) as well as TOE guided assessment of the mitral valve and placement of cardiopulmonary bypass equipment.

Keywords: anaesthesia, mitral, minimally invasive

INTRODUCTION

First video-assisted mitral valve (MV) repair through a mini-thoracotomy was performed by Carpentier in 1996. Since then minimally invasive mitral valve surgery (MIMVS) has come a long way and with better understanding of mitral valve patho-physiology and state of art surgical kits to operate, it is becoming an established practice for elective isolated MV surgery.

The main drive behind MIMVS is to reduce tissue damage. This leads to a smaller inflammatory response and a faster recovery. Primarily, this is aimed at improving the patient experience – meaning that patients have less pain, feel better and can return to their normal

[*] Corresponding Author's Email: ben.gibbison@bristol.ac.uk.

life sooner. However, this also aligns with incentives for healthcare providers to reduce hospital stays and improve efficiency. Whilst much of the literature in MIMVS is concentrated on operative techniques, within the process for minimally invasive surgery should be a move towards improving recovery as measured by reduced intensive care and hospital stays [1]. This must be implemented as a "package" of care alongside the minimally invasive approach to surgery. This is a multi-disciplinary effort encompassing pre-, peri- and post-operative interventions.

FAST-TRACKING MINIMALLY INVASIVE MITRAL VALVE SURGERY

The less tissue destruction, change to respiratory mechanics and ultimately inflammatory activation, the fewer the post-operative problems. This is evidenced by trans-femoral TAVIs (trans-catheter aortic valve implants) and Mitraclips© where, without the inflammatory response of cardio-pulmonary bypass (CPB) and sternotomy, are routinely discharged on the second or third post-operative day. Traditionally, high dose opiates are given to cardiac surgical patients to abolish the neuro-hormonal responses to surgical insult. The trade-off of this approach is that patients often needed to be ventilated overnight in an intensive care unit. During the 1990s, fast track cardiac surgery became a way to deal with increasing demand for limited resources. The drive to faster extubation means that in some cardiac surgical units, patients are now extubated "on table" at the end of the case and post-operative care provided in a dedicated post-anaesthetic care unit outside the main intensive care unit [2].

A fast-track approach has been shown to be equally safe and effective compared to 'standard' care in terms of morbidity and mortality, but with shorter extubation times and intensive care unit stays [3]. These shorter ICU stays have not yet led to a shorter hospital stay [4] showing that extubation *per se* is not the rate limiting step of intensive care discharge. Indeed patients who fail the fast-track stream may have longer stays than if they were in a 'standard' stream [4].

There is currently no level I evidence as yet pertaining to fast-track MIMVS. However, when designing a fast-track protocol for this specific intervention, the same empiric principles apply. Standard definitions of what constitutes fast-track cardiac surgery [3] vary in the literature and between centres, but it is the authors' opinion that the drive should be towards improving patient care and experience and that efficiencies to the healthcare system are a by-product of providing this high-quality care. A fast-track system should address the whole peri-operative pathway, from patient selection and pre-admission to hospital discharge and follow-up. This is a multi-disciplinary activity comprising the *co-ordinated* efforts of both clinical and administrative staff.

Enhanced Recovery

The stage beyond fast-track cardiac surgery is enhanced recovery (ER). Enhanced recovery is a programme of high quality surgical care that returns patients back to normal function sooner. Enhanced recovery and minimally invasive surgery are inter-dependent: The

benefits of enhanced recovery cannot be realised without less tissue damage and a smaller and shorter inflammatory response. Similarly, the benefits of minimally invasive surgery will not be realised without a systems based approach that moves patients through that system faster. Enhanced recovery works on the principle of "the aggregation of marginal gain" [5]. This means making every part of the peri-operative care pathway as good as it possibly can be for as many patients as possible. The higher the rate of compliance with the elements of the ER, the lower the rate of later than expected discharges. It should be remembered that many of these benefits, whilst small to the individual, amount to large improvements across a population.

There are four elements to an enhanced recovery programme:

1. Pre-operative assessment, planning and preparation before admission:

It is important to involve the patient, their family and their carers in the operation, as well as the patient's general practitioner. This means that that the dates for admission, operation AND expected discharge are in everyone's diary. Planning and maintaining a date for operation and discharge makes sure that staff identify and co-ordinate all essential resources. Discharge planning is particularly important prior to admission; having a discharge-ready patient in hospital for more days than is required is a waste of resources and an impact on the patient's life. Pre-operative assessment should be made as soon as the decision to operate has been made. This allows all relevant investigations and consultations to be complete by the time of surgery.

2. Reducing the physical stress of the operation:

This part comprises minimally invasive surgery, maintaining adequate temperature and optimal fluid management.

3. A structured approach to immediate post-operative and peri-operative management, including pain relief:

Structured and protocol driven post-operative care is essential, not only as it ensures that patients are getting the right care, but will identify patients who are failing the pathway. This allows early intervention to manage these problems and return the patients to the fast-track.

4. Early mobilisation:

This is dependent on high quality analgesia and structured physiotherapy. Patients should be ambulated at the *earliest* opportunity.

Key factors that help implement an enhanced recovery programme are:

- Staff training

The multi-disciplinary team must be trained so that they understand the evidence about speeding up recovery after surgery and thus develop a mind-set that allows patients to be active in their recovery. Operating theatre staff need to be formally trained in minimally invasive techniques to ensure smooth process of the operation and keeping operating and cross-clamp times to a minimum.

- Improved processes

The workflow should be planned and scheduled. This means everybody knows what to expect and when to expect it.

- Procedure specific care plans

A generic 'cardiac surgery' care plan is no longer appropriate. MIMVS care plans should be separate from aortic valve and coronary artery surgery. The pre-, peri- and post-operative goals are different and therefore should be treated differently. This not only allows early identification of those who are failing, but also allows advanced planning (eg pre-discharge echo, optimal anti-coagulation) to ensure timely discharges.

Once a MIMVS programme is in place, continuous audit of outcomes, including intensive care and hospital stays should be undertaken.

Patient Selection

Patient selection is critical to success in moving patients rapidly through the peri-operative care pathway. In theory, all elective patients should be considered as eligible for a fast-track programme – high risk patients may benefit from optimal preparation, reduced stays in the ICU, and increased mobilisation, although re-admission to the ICU is associated with a poor outcome. Predictors of failure in fast-track surgery are shown below and these criteria should be applied rigorously i.e., if a patient meets any of these criteria at any stage, they should be removed from the fast-track pathway:

- Severely impaired left ventricular (LV) function (<30%) [6]
- Long operative time (>4hrs 30min) [7]
- Long CPB time (>2hrs) [7]
- Impaired renal function (GFR < 65) [8]
- Non-elective surgery [6]
- Pre-operative intra-aortic balloon pump [6]
- 'Redo' surgery

It should be noted that when considering impaired renal function, it is the Glomerular filtration rate (GFR) that is the important value, not just the creatinine. Wide variance in GFR can be seen between individuals for the same serum creatinine level due to differences in sex, race, muscle bulk and other inherited and acquired differences [8].

Essentially suitability of MIMVS rest on surgeons, nevertheless, anaesthetists should be aware of pertinent issues. Following group of patients is considered not suitable for MIMVS:

1. Combined Aortic valve surgery with MV surgery
2. Coronary re-vascularisation with MV surgery
3. Ascending Aorta surgery in past
4. Severe peripheral vascular disease
5. Previous surgery in right thoracic cavity, a relative contraindication.

PRE-OPERATIVE ASSESSMENT FOR MIMVS

Pre-operative assessment for MIMV surgery should be the same as any other cardiac surgical operation. That is that the severity and symptoms of the lesion should be established, as well as its consequences of the rest of the heart. The presence and severity of all co-morbidities must also be known. When assessing patients for MIMVS several pre-existing health conditions warrant further investigation:

- Cerebrovascular and peripheral vascular disease.

Peripheral vascular disease is associated with an increased risk of stroke or systemic embolization with retrograde arterial perfusion. A CT of the chest and abdomen will delineate the anatomy of the vascular tree and a contrast angiogram will show potentially hazardous plaques within the lumen. Knowledge of the size and tortuosity of the ilio-femoral vessels helps in correct cannula size selection.

- Previous cardiac surgery, lung conditions and chest wall deformity/irradiation.

Chest wall deformity, irradiation and pre-existing cardiac surgery are all associated with adhesions and previous coronary surgery may mean that grafts cross the operative field. These can all be characterised by means of a CT chest. Airway assessment and pulmonary function tests to assess suitability for one lung ventilation should be assessed in those undergoing surgery via a thoracotomy approach.

- Co-existent coronary artery disease.

If possible, evaluation of this should be carried out before CT angiography of the arterial tree due to the risk of iatrogenic dissection of the iliac artery during cardiac catheterisation. This could be catastrophic if unrecognised when the iliac vessels are cannulated at the time of MIMVS.

- Trans-oesophageal echocardiography (TOE)

TOE is essential for safe conduct of minimally invasive surgery. Therefore, contra-indication to TOE should also be assessed. These include oesophageal carcinoma, stricture, varices or prior oesophagectomy. This is discussed in more detail below.

Preoperative Preparation

Numerous methods have been attempted to help patients adequately prepare for cardiac surgery and ensure patients are in optimal condition prior to surgery. However, few of them have any real evidence-base to recommend them. Pre-operative physiotherapy [9] and respiratory exercises [10] have been shown to improve rates of post-operative pulmonary complications (atelectasis and pneumonia) after elective cardiac surgery. Pre-operative carbohydrate drinks close to surgery also have shown benefits in terms of reduced stays, but the Cochrane meta-analysis cautioned against the high risk of bias in these studies [11], although the risk of harm is low.

Perioperative Anaesthetic Considerations

MIMVS requires general anaesthesia. The choice of anaesthetic agent is individual and institute dependent. Sedative pre-medications should be avoided where possible and the anaesthetic agents should have as few 'hang over' effects as possible. The principles of the anaesthetic technique for MIMVS are similar to conventional MV surgery. There are, however, some differences:

1. Positioning: The patient is usually placed in a supine position with the right chest elevated (Figure 1). The right arm is moved slightly away from body to allow improved surgical access. External defibrillator pads are applied because the internal 'paddles' are too large to fit through the smaller access sites. It should be noted that if the defibrillator pads are applied through the deflated lung there won't be effective electric conduction. They should therefore be applied in the antero-posterior orientation on the left chest wall.

Figure 1. Positioning of the patient for MIMVS (with permission of Dr. Solinas).

2. Airway: One lung ventilation (OLV) is not essential for MIMVS. However, a non-ventilated right lung allows surgeons better operating conditions. Lung isolation techniques are individual and institute dependent and each technique has its own advantages and disadvantages. It is the opinion of the authors that a left sided double lumen tracheal tube facilitates isolation and independent drainage of both lungs. Lung protective ventilation strategies using limited tidal volumes and positive end-expiratory pressure should be used where possible. Care should be taken to avoid hypoxia and / or hypercarbia as this may increase the pulmonary vascular resistance as well as the raised pulmonary pressures present in mitral regurgitation (MR). This can precipitate right heart failure which can be diagnosed with the TOE.
3. Cannulation for CPB: Both arterial and venous cannulation for CPB can be achieved peripherally – usually via the femoral vessels. However, axillary as well as ascending aortic arterial cannulation and jugular venous cannulation can be employed. Adequate venous drainage can be obtained with the tip of the venous cannula lying in the superior vena cava and the multi-orificed side ports in right atrium (See TOE section for details). Suction-assisted venous drainage may be needed. Troubleshooting cannulation and the maintenance of CPB is discussed in Chapter XX.
4. Aortic cross clamping: This is achieved either in a conventional manner by a long external clamp (introduced via either the operative or separate incision) or via an endo-aortic balloon clamp (inserted via the femoral or subclavian artery). The endo-aortic balloon clamp is inflated in the proximal ascending aorta under TOE guidance (best seen in the mid-esophageal ascending aorta LAX view). Anterograde cardioplegia can then either be delivered via the distal port of the balloon clamp or via a separate aortic root cannula.
5. Weaning from CPB is no different than conventional MV repair. However, as CPB times for MIMVS are slightly longer than conventional MV surgery, this should be considered in the decision making about post-CPB cardiovascular support.

TOE FOR MINIMALLY INVASIVE MITRAL VALVE SURGERY

Peri-operative TOE is recommended by for all MV repair surgery [12, 13]. TOE is particularly important in MIMVS as the smaller the access sites for cardiac surgery, the more the surgeon becomes reliant on the TOE. Use of the TOE for MIMVS falls into two stages:

- Pre-operative
  - Severity of MR
  - Function of the mitral valve leaflets, apparatus and assessment of pathological segments
  - Risk factors for surgical repair
  - Correct placement of CPB cannulae and apparatus
- Post-operative
  - Ensure sufficient de-airing of the LV
  - Identify residual MR / stenosis and mechanism

- Identify potential complications of MV repair
  - Circumflex artery ligation / distortion
  - Systolic anterior motion (SAM)
  - Aortic dissection

Pre-Operative TOE

Severity of Mitral Regurgitation

Assessment of the severity of MR under general anaesthesia is problematic as the loading conditions of the heart are different to that of the awake, upright person. With this caveat, there are essentially three ways to judge the severity of MR and the overall weight of the evidence used to classify the severity of the MR. These methods are:

- Estimation of Effective Regurgitant Orifice Area (EROA) using proximal iso-velocity surface area (PISA). This is done at a Nyquist limit of 40cm/s (NL40). See Box 1.
- Measurement of the Vena Contracta

The vena contracta is the narrowest point (and therefore the highest velocity) of a colour flow doppler jet measured on the atrial side of the leaflet tips. Less than 3mm is classified as mild and over 7mm is classified as severe. It should be measured with the Nyquist limit between 50 – 60cm/s. This is very useful for single-orifice regurgitant jets, but less useful for multiple orifice jets.

- Assessment of pulmonary vein flow

A normal pulmonary vein flow (Figure 2) has a systolic and a diastolic wave in the same direction from the baseline, with the systolic wave larger than the diastolic wave. As the severity of the MR increases, the systolic wave gets smaller and in severe regurgitation can be retrograde (i.e., in the opposite direction to that of the diastolic wave). In the presence of eccentric jets of MR, both left and right sided pulmonary veins should be interrogated.

Box 1. Severity categories of mitral regurgitation [13]

Mitral Regurgitation	Mild	Moderate	Severe
EROA	<0.20cm^2	0.21 – 0.39cm^2	≥0.40cm^2
Vena Contracta	<0.30cm	0.31 – 0.69cm	≥0.70cm
PISA Radius (NL40cm/s)	<0.40cm	0.41 – 1.00cm	>1.0cm

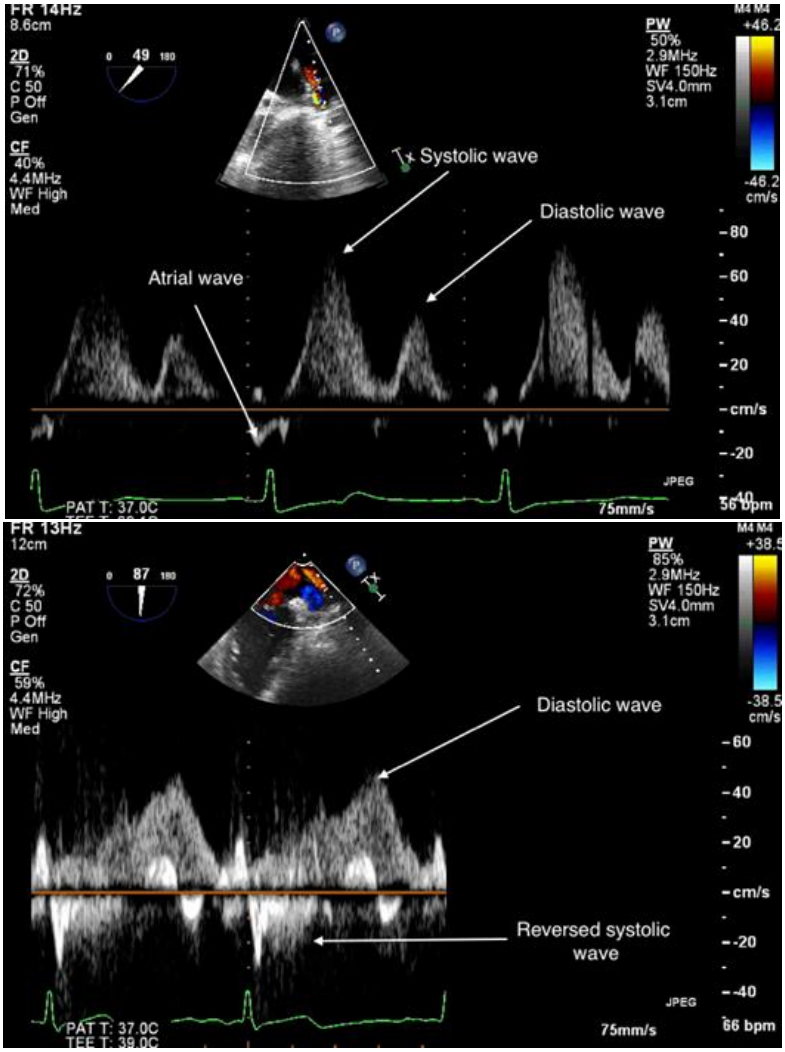

Figure 2. Pulsed wave Doppler flow of the left upper pulmonary vein flow. Left – normal. Right – the systolic flow reversal seen in severe MR. Note the S and D waves are timed from the ECG.

Function of the Mitral Valve Leaflets, Apparatus and Assessment of Pathological Segments

The LV and the MV are inter-related and therefore assessment of one incorporates assessment of the other. Assessment of LV dimensions and function are required, along with assessment of the papillary muscles, chordae and leaflets. Trans-gastric short axis views at both the mid papillary and basal levels are supplemented with segmental analysis in the mid-oesophageal views. Live, real-time 3-Dimensional (3D) TOE helps in both diagnosis and communication of the lesion to the surgeon and may be superior in detecting some pathologies [14, 15], particularly those around the commissures.

Risk Factors for Surgical Repair

The two complications particular to MV surgery that peri-operative TOE can influence are those of SAM and distortion/damage to the circumflex artery. SAM occurs in around 10% of cases of MV surgery and can vary in severity from mild protrusion of chordae to left ventricular outflow tract obstruction (LVOTO). Several pre-operative factors have been suggested as markers of risk for post-repair SAM [16]. These are:

- Posterior leaflet height > 15mm
- Anterior-posterior leaflet height ratio <1.4
  - These heights should be measured in the mid-esophageal AV 5C view
- Coaptation point to septal distance (C-sept) <25mm

Distortion or damage to the circumflex artery occurs in around 1% of MV surgery and is more likely to happen in those with a left dominant circulation due to the proximity of the circumflex artery to the MV annulus. The circumflex artery can usually be visualised with colour flow doppler as it branches from the left main stem and followed as it runs posteriorly around the lateral side of the mitral valve annulus [17]. To document post-operative change, a pre-operative image is required.

Correct Placement of Cardiopulmonary Bypass (CPB) Cannulas and Apparatus

The correct placement of the arterial and venous CPB cannulae is of paramount importance to avoid complications. The guidewire for femoral placed arterial cannulae is best seen in both long and short axis views of the descending aorta. The wire must be seen in the lumen of the aorta before placement of the cannula itself. The guidewire for the femorally inserted venous cannula should be seen in the right atrium (RA) and is best seen in the bicaval view. The optimal position for a femorally inserted 2-stage venous cannula is with 2-3cm of cannula in the superior vena cava (SVC – See Figure 3). If an SVC cannula is inserted from the right internal jugular vein, then then the femorally placed single stage venous cannula should be entirely within the inferior vena cava. To ensure endovascular positioning of the venous cannulae, some units inject agitated saline that can be seen in the RA. For port-access MV surgery, an endo-aortic balloon is used instead of an aortic clamp. This must be in the ascending aorta and is best seen in the mid-esophageal AV LAX view.

Box 2. Severity of mitral stenosis graded by mean trans-mitral pressure pressure gradient [18]

Mitral Stenosis	Mild	Moderate	Severe
Mean Pressure Drop	<5mmHg	6 – 10mmHg	>10mmHg
Pressure Half Time	<139ms	140 – 219ms	≥220ms

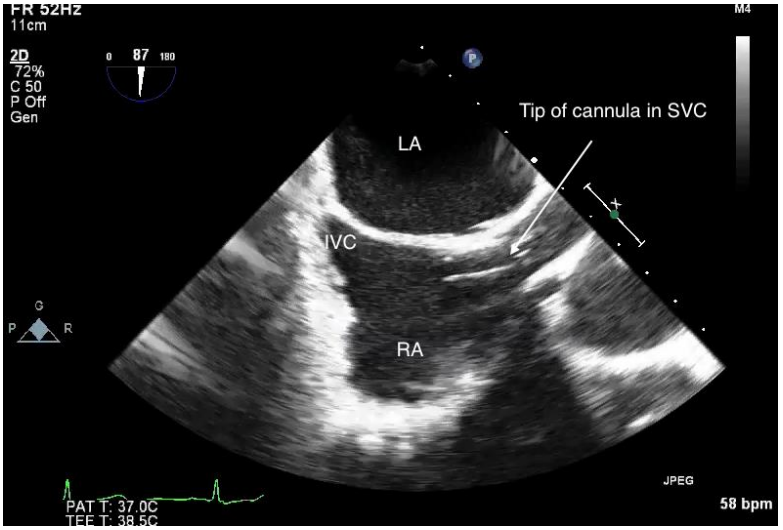

Figure 3. ME Bicaval view of Femoral CPB cannula inserted with tip correctly positioned just inside the superior vena cava. RA – Right atrium. LA – Left atrium. IVC – Inferior vena cava. SVC – superior vena cava.

Post-Operative TOE

Pre-Weaning from CPB

After removal of the aortic cross-clamp (of deflation of the endo-aortic balloon) the circumflex artery should be examined to establish that there is no distortion or damage to the vessel. The heart should be checked for residual intra-cavity air before removal of the surgical vents.

Post-Weaning from CPB

After weaning from CPB the adequacy of the repair should be assessed, along with heart function.

Mitral regurgitation – residual MR should be assessed in the same way as pre-bypass and only after complete weaning. Attempts should be made to assess the adequacy of MV repair under as a close to physiological conditions as possible. This usually requires small boluses of vasoconstrictor.

Mitral stenosis – mitral stenosis after MV repair occurs in around 2% of surgeries. The pressure drop across the repaired mitral valve is Mitral stenosis is graded as in Box 2. Planimetry of the repaired MV can be done in the trans-gastric basal SAX view, or using real-time 3D TOE imaging.

Dynamic left ventricular outflow tract obstruction (LVOT) due to SAM is best seen in the mid-esophageal 5C LAX view and mid-esophageal LAX views. The characteristic findings of MR and a pressure gradient measured in the LVOT are seen. There is a characteristic "dagger" shaped velocity profile in the LVOT seen on continuous wave doppler due the peak gradient occurring in late systole. Other complications that occur after MV surgery that should be sought out by TOE examination are aortic dissection and tethering of the non-coronary cusp of the aortic valve leading to aortic regurgitation.

PAIN MANAGEMENT AFTER MIMVS

One of the advantages of MIMVS is *overall* less pain in the post-operative period. However, the first 24 – 36 hours after thoracotomy may be associated with increased pain when compared to sternotomy. Adequate pain relief during this time is essential [19]. Regional analgesia plays an important role after thoracotomy in addition to regular paracetamol and patient controlled opioids. The following nerve blocks are useful and can be effective adjuncts:

- Thoracic epidural
- Paravetebral continuous infusion with surgically placed catheter under direct vision.
- Intercostal nerve blockade
- Continuous intercostal nerve blockade
- Extra-pleural catheter and continuous local anaesthetic infusion

CONCLUSION

MIMVS presents a change in approach for the anaesthetist. As well as different surgical equipment and technique, an alteration in the equipment and approach for the anaesthetist is required. The two main differences are the instigation of one lung ventilation before and after CPB and the increased reliance on the TOE for both MV assessment and placement of CPB equipment. To yield maximum gain from MIMVS, the anaesthesia and surgery itself must form part of a comprehensive package of peri-operative care that delivers high standards throughout the patient care pathway.

REFERENCES

[1] Downs EA, Johnston LE, LaPar DJ, Ghanta RK, Kron IL, Speir AM, Fonner CE, Kern JA, Ailawadi G. Minimally Invasive Mitral Valve Surgery Provides Excellent Outcomes Without Increased Cost: A Multi-Institutional Analysis. *Ann Thorac Surg* 2016; 102(1):14-21.

[2] Probst S, Cech C, Haentschel D, Scholz M, Ender J. A specialized post anaesthetic care unit improves fast-track management in cardiac surgery: a prospective randomized trial. *Crit Care* 2014; 18:468.

[3] Zhu F, Lee A, Chee YE. Fast-track cardiac care for adult cardiac surgical patients. *Cochrane Database Syst Rev* 2012; 10:Cd003587.

[4] Svircevic V, Nierich AP, Moons KG, Brandon Bravo Bruinsma GJ, Kalkman CJ, van Dijk D. Fast-track anesthesia and cardiac surgery: a retrospective cohort study of 7989 patients. *Anesth Analg* 2009; 108:727–33.

[5] *Olympics cycling: Marginal gains underpin Team GB dominance*. Available from: http://www.bbc.co.uk/sport/olympics/19174302.

[6] Constantinides VA1, Tekkis PP, Fazil A, Kaur K, Leonard R, Platt M, Casula R, Stanbridge R, Darzi A, Athanasiou T. Fast-track failure after cardiac surgery: development of a prediction model. *Crit Care Med* 2006; 34:2875–82.

[7] Kiessling AH, Huneke P, Reyher C, Bingold T, Zierer A, Moritz A. Risk factor analysis for fast track protocol failure. *J Cardiothorac Surg* 2013; 8:47.

[8] Youssefi P, Timbrell D, Valencia O, Gregory P, Vlachou C, Jahangiri M, Edsell M. Predictors of Failure in Fast-Track Cardiac Surgery. *J Cardiothorac Vasc Anesth* 2015; 29(6):1466-71.

[9] Hulzebos EH, Smit Y, Helders PP, van Meeteren NL. Preoperative physical therapy for elective cardiac surgery patients. *Cochrane Database Syst Rev* 2012; 11:Cd010118.

[10] Katsura M, Kuriyama A, Takeshima T, Fukuhara S, Furukawa TA. Preoperative inspiratory muscle training for postoperative pulmonary complications in adults undergoing cardiac and major abdominal surgery. *Cochrane Database Syst Rev* 2015; 10:Cd010356.

[11] Smith MD, McCall J, Plank L, Herbison GP, Soop M, Nygren J. Preoperative carbohydrate treatment for enhancing recovery after elective surgery. *Cochrane Database Syst Rev* 2014; 8:Cd009161.

[12] Joint Task Force on the Management of Valvular Heart Disease of the European Society of Cardiology (ESC).; European Association for Cardio-Thoracic Surgery (EACTS). Vahanian A, Alfieri O, Andreotti F, Antunes MJ, Barón-Esquivias G, Baumgartner H, Borger MA, Carrel TP, De Bonis M, Evangelista A, Falk V, Iung B, Lancellotti P, Pierard L, Price S, Schäfers HJ, Schuler G, Stepinska J, Swedberg K, Takkenberg J, Von Oppell UO, Windecker S, Zamorano JL, Zembala M. Guidelines on the management of valvular heart disease (version 2012). *Eur Heart J* 2012; 33(19):2451-96.

[13] Lancellotti P, Moura L, Pierard LA, Agricola E, Popescu BA, Tribouilloy C, Hagendorff A, Monin JL, Badano L, Zamorano JL; European Association of Echocardiography. European Association of Echocardiography recommendations for the assessment of valvular regurgitation. Part 2: mitral and tricuspid regurgitation (native valve disease). *Eur J Echocardiogr* 2010; 11:307–32.

[14] Manda J, Kesanolla SK, Hsuing MC, Nanda NC, Abo-Salem E, Dutta R, Laney CA, Wei J, Chang CY, Tsai SK, Hansalia S, Yin WH, Young MS. Comparison of real time two-dimensional with live/real time three-dimensional transesophageal echocardiography in the evaluation of mitral valve prolapse and chordae rupture. *Echocardiography* 2008; 25:1131–7.

[15] Grewal J, Mankad S, Freeman WK, Click RL, Suri RM, Abel MD, Oh JK, Pellikka PA, Nesbitt GC, Syed I, Mulvagh SL, Miller FA. Real-time three-dimensional transesophageal echocardiography in the intraoperative assessment of mitral valve disease. *J Am Soc Echocardiogr* 2009; 22:34–41.

[16] Maslow AD, Regan MM, Haering JM, Johnson RG, Levine RA. Echocardiographic predictors of left ventricular outflow tract obstruction and systolic anterior motion of the mitral valve after mitral valve reconstruction for myxomatous valve disease. *J Am Coll Cardiol* 1999; 34:2096–104.

[17] Ender J, Singh R, Nakahira J, Subramanian S, Thiele H, Mukherjee C. Echo didactic: visualization of the circumflex artery in the perioperative setting with transesophageal echocardiography. *Anesth Analg* 2012; 115:22–6.

[18] Zoghbi WA, Enriquez-Sarano M, Foster E. Recommendations for evaluation of the severity of native valvular regurgitation with two-dimensional and Doppler echocardiography. *Journal of the American Society of Echocardiography* 2003; 16:777–802.

[19] Sostaric M, Gersak B, Novak-Jankovic V. Early extubation and fast-track anesthetic technique for endoscopic cardiac surgery. *Heart Surg Forum* 2010; 13:E190–4.

In: Encyclopedia of Surgery (22 Volume Set)
Editors: Andreas Lehrer and Kristin Mueller
ISBN: 978-1-53618-329-0
© 2020 Nova Science Publishers, Inc.

Chapter 418

MINIMALLY INVASIVE APPROACHES TO MITRAL VALVE SURGERY

Kasra Shaikhrezai and Steven Hunter*
Chesterman wing, Northern General Hospital, Sheffield, UK

ABSTRACT

The emerging technology and the advent of the endoscopic camera revolutionised cardiac surgery introducing a novel and less invasive approach. Minimally invasive mitral valve surgery is now performed via mini-thoracotomy or port access, limited sternotomy and robotic surgery. The minimal invasive approach starts in the anaesthetic room and continues throughout the procedure. Exposure, cannulation, myocardial protection and the mitral valve are the cardinal targets of this approach. A rehearsed and well-planned approach at each stage will facilitate the smooth conduct of the operation and its progress from one stage to another. This shortens the learning curve and brings most of the procedure into the surgeon's comfort zone. The evolving technology is constantly changing and improving the current minimal invasive practice to create much less invasive approaches. Surgeons need to remain updated at all time and adopt new technology in favour of patient care and better outcomes. There are several ways of performing minimally invasive mitral valve surgery and it is the surgeon's task to set out a road map and strategy for each operation, which is always different from the last one.

Keywords: surgical approach, minimal invasive surgery, mitral valve surgery

INTRODUCTION

In Germany Eric Muhe and his colleagues performed the first laparoscopic cholecystectomy more than 30 years ago [1]. The described procedure revolutionised cholecystectomy however it took a fairly long-time to adopt the approach as the gold standard procedure. The evolving technology shortened the dormant period and new surgeon-friendly

* Corresponding Author's Email: steven.hunter@sth.nhs.uk.

instruments brought the approach into the surgeons' comfort zone. In our day laparoscopic cholecystectomy, which was once deemed as a fictional fantasy, is performed safely as a day-case operation. More than a decade later, Alain Carpentier performed the first successful minimal invasive mitral valve (MV) operation in man [2], which surgically and anaesthetically was a more demanding operation [3]. Twenty years on the minimal invasive approach has yet to become the gold standard for MV surgery in many institutions. In the United Kingdom since 2009, the number of isolated MV surgery has significantly increased to more than 2,300 cases per year in 2013 [4]. Although the outcome of MV surgery has improved nationwide during the past decade, a minimal invasive MV program is only run in a small number of institutions across the UK. In fact, the practice is quite skewed in Europe; in Germany alone the minimal invasive approach is considered as the first choice for nearly half of the isolated MV procedures [5]. The discrepancy is a multifactorial with a wide spectrum of confounding factors from logistical and technological setback to complex learning curve and adaptation problems. In many experiences a prolonged tortuous learning curve has been considered to be detrimental to the development of young programs. Centralisation of minimal invasive practice, which leads to the creation of high volume centres, has been proven to be a solution to this problem [6]. The difficulty in using single shafted instruments for minimal invasive mitral valve surgery (MIMVS) can be lessened by frequent handling of these instruments in cases via a median sternotomy approach [7]. Program failure may be largely attributed to a breakdown in the axis of team working – communication – performance. Young programs are vulnerable to demise at an early stage if the program is not set up and governed prudently. Teamed surgeons, full interaction with the anaesthesiology team and constant equipment check facilitate the smooth progress of the program. More importantly the surgical team should be aware of their limitations and overcome their ego at all stages of the program. The surgeon can start with a 10 to 12cm incision and consider staged reduction of the incision size as the program moves forward with good results. It is imperative to start the program with straightforward MV repairs (MVr) which allows the team to familiarise themselves with the set up. In addition, easy cases may create more comfort zones for the surgeon who is at the beginning of his learning curve. "Approach" terminology in minimal invasive surgery has a broad definition, which ultimately mandates the medical and surgical strategies from bed to table. There are multiple approaches at different levels of MIMVS, which need to be adopted as per individual cases of MV disease. A wisely chosen approach will shorten the learning curve and is pivotal to the survival of the program in providing the best treatment and care for the patients.

APPROACH

A comprehensive approach embraces crucial domains of a minimal invasive mitral valve surgery program, which can be categorised as: Exposure, Cannulation, Myocardial protection and Mitral valve.

Exposure

Positioning

Surgeons should not underestimate the importance of positioning in anaesthetic room. This obviously has already been confirmed at the briefing and all members of the team should familiarise themselves with the positioning of patient. The patient's right chest needs to be tilted up at a 30 degree angle with the table. The right arm should be extended at 45 degree with the elbow flexed at 90 degree resting on an arm board. This manoeuvre is the first important step for a desirable surgical exposure. At this stage the inguinal area (usually on the right side) needs to be scanned by ultrasound to make sure the femoral vessels are of good quality and acceptable calibre for cannulation, irrespective of pre-operative CT scans. Our minimum cut-off for femoral artery is 8 mm in diameter. Obviously any abnormality of femoral vessels such as localised dissection or calcified plaques will be a contraindication for femoral cannulation.

Thoracic Surgical Exposure

There are two main surgical minimal invasive approaches to MV surgery: limited incision on the sternum and limited incision on the right thoracic wall known as port access surgery. There are numerous concepts on how to establish the exposure as least invasive as possible. The sternotomy approach includes an upper limited sternotomy, which usually requires a trans-septal approach to the left atrium [8] and lower limited sternotomy, which is accompanied by an incision through the Sondergaard groove [9]. Although both approaches have succeeded to provide a good exposure as well as an acceptable cosmesis, the port access approach gained popularity as a standard approach in the field of MIMVS [10]. Therefore, in this chapter, we will be more focused on port access approach. As per our definition a port access approach includes a 4 – 5 cm right sub-mammary mini-thoracotomy with soft tissue retraction only. Rib spreading and using of a rib retractor will automatically disqualify an operation to be registered as port access MV surgery, however it is recommended to start the program with larger than 5 cm incision and occasional use of a mechanical rib retractor [7]. The incision size and abandoning the rib spreading techniques can be optimised when a surgeon is fully comfortable with the exposure. Generally, the chest exposure is categorised into external and internal exposure. For external exposure the incision is usually in the 4th intercostal space (ICS), however it may vary between patients with different chest anatomy. After performing the incision and applying the soft tissue retractor surgeon needs to use his index finger to check the distance from diaphragm, which may require the extension of initial incision for another 1 – 2 cm in lateral or medial direction. We usually use a 10 mm, 30 degree, 3D camera, which is inserted through a port with CO_2 connection in the same intercostal space as the main incision and 2 – 3 cm lateral to it. The camera holder is attached to top right-hand side of the table and will keep the camera steady throughout the procedure. A Sump sucker is inserted through a 4mm stab incision two to three spaces below the incision, which will be one of the drain locations at the conclusion of the operation. The left atrium (LA) retractor is inserted through a 3 mm stab incision in same intercostal space as the main incision 4 – 5 cm away from sternum. The surgeon should take extra care during the insertion of the LA retractor as this may injure the right internal thoracic artery. This is achieved by using the thoracoscope to visualise the inside of the chest wall and the course of

the internal thoracic vessels. A sternal wire is passed through a large bore needle above the main incision and is brought through the main incision and clipped. This is a crucial step as the mitral annular stitches at A_1 and P_1 location will be in front of the camera and hamper the view. If aortic occlusion is to be performed by a transthoracic aortic cross-clamp (AoX), this needs to be inserted one ICS above the camera port. At this stage the clamp must be tested to make sure that the grip and occlusion is satisfactory. All the above steps are demonstrated in Figure 1.

For internal exposure initially the pericardium is opened transversely between inferior vena cava (IVC) and superior vena cava (SVC). Pericardial retraction plays an important role in a desirable exposure. Sometimes it is inevitable to look through the incision rather than using the camera, for example in pericardiotomy and applying traction sutures; however, it is recommended to use the camera and the front screen as much as possible. The pericardial traction sutures are usually three and the sutures are taken out and affixed to the chest through the following holes: 1- Sump sucker hole (below the incision) which retracts the psterior border of pericardiotomy inferiorly 2- Camera port (below the incision) which retracts the posterior border of pericardiotomy superiorly. The third traction suture is placed in the anterior border of pericardiotomy and is brought through the main incision without cutting the needles. The latter traction suture will be used, following the left atriotomy, to retract the anterior border of atriotomy. Following institution of cardiopulmonary bypass (CPB) and administration of cardioplegia the final stage of internal exposure is the left atriotomy through the Sondergaard groove (Figures 2 and 3) and retracting the atriotomy (Figure 4).

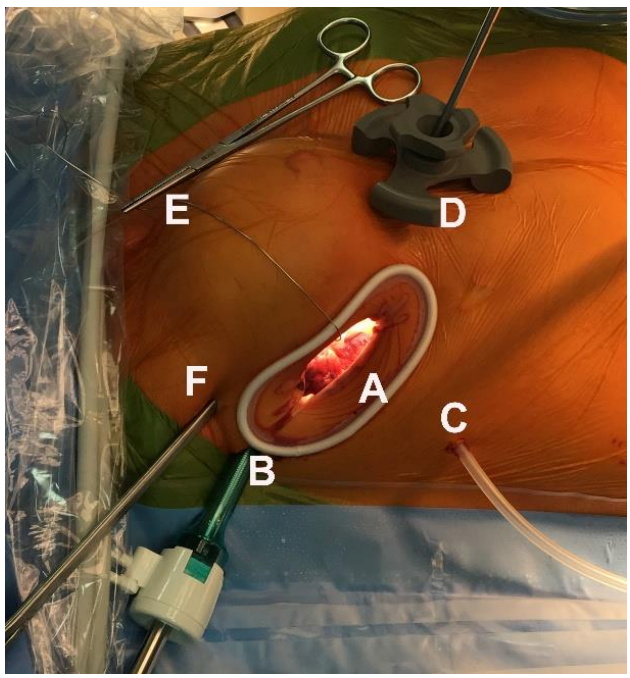

Figure 1. External thoracic exposure, A: Incision and soft tissue retractor B: Camera and the port with CO_2 entry valve C: Sump sucker (future drain location) D: Left atrium retractor E: Sternal wire as annular stitch retractor F: Transthoracic clamp known as the Chitwood clamp.

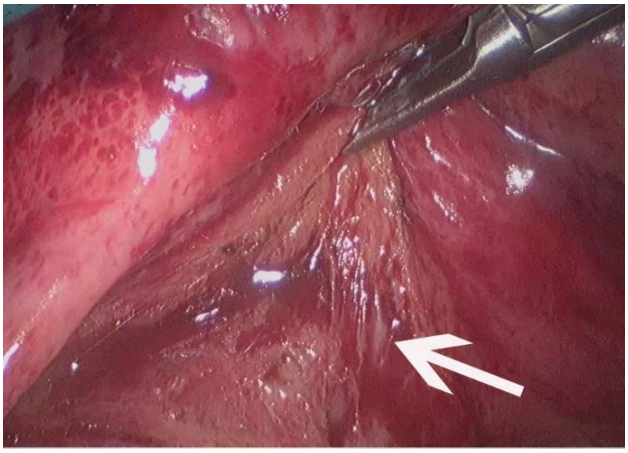

Figure 2. The Sondergaard groove (arrow).

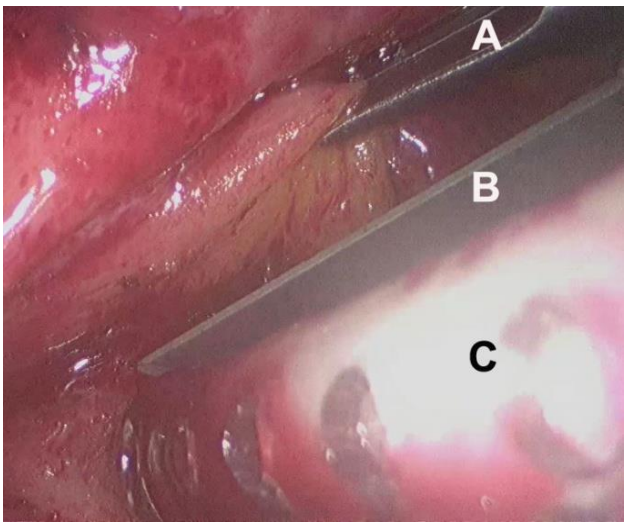

Figure 3. A: Forceps holding the upper border of the groove B: size 11 blade C: Sump sucker ready to be inserted into the atriotomy.

Inguinal Surgical Exposure

We believe that if the MV surgery is straightforward with no concomitant procedure prolonging the operation, femoral artery cannulation is less invasive with acceptable flow during the CPB. It is imperative to scan the inguinal area prior to operation and mark the incision site.

There are two approaches to femoral vessels cannulation: percutaneous and incisional. In percutaneous approach the cannulation of femoral vein and artery is performed contralaterally. The key instrument to cannulate the femoral artery is The Prostar (Abbott Vascular, Abbott Park, IL, USA) which is a closure device. Following venous decannulation and administration of protamine, temporary manual pressure would suffice to stop the bleeding. Femoral artery decannulation and application of Prostar requires a minimum of 24 hours compression on the cannulation site with pneumatic compression devices.

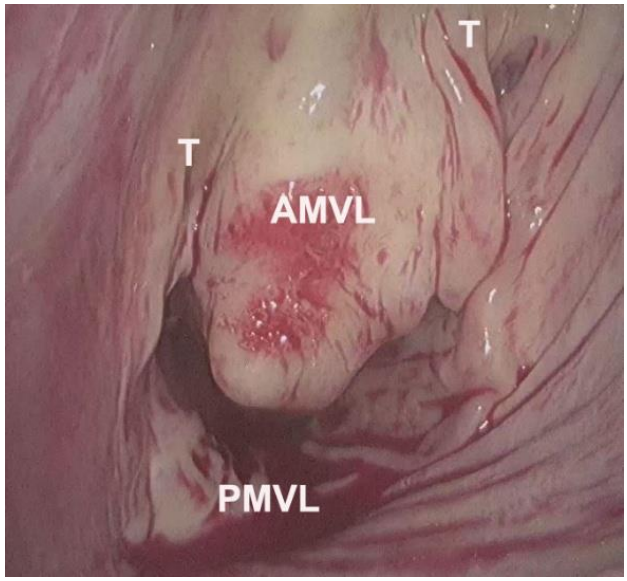

Figure 4. Final internal thoracic exposure: T: Trigone, AMVL: Anterior Mitral Valve Leaflet, PMVL: Posterior Mitral Valve Leaflet.

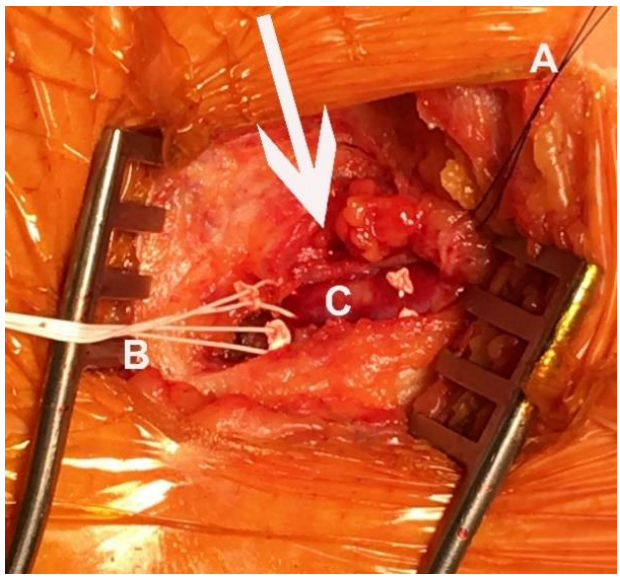

Figure 5. Surgeon's view of inguinal incision: A: Femoral vein purse string, B: Femoral artery purse string, C: Femoral artery and the cannulation site surrounded by four pledgets. The femoral vein should not be denuded and a small area of dark blue would suffice to insert the needle, guide wire and cannula (arrow).

The percutaneous cannulation has been proven to be safe with less inguinal wound complication [12]. During incisional approach it is imperative to expose the femoral sheath. Therefore the 3cm incision should not be on the inguinal crease, which may limit the exposure and miss the femoral sheath. The incision should be on the inguinal ligament, which is invariably superior to the crease. After fat dissection the retractor is positioned then and the

index finger is used in a sweeping manoeuvre is to clearly expose the inguinal ligament superiorly as well as femoral sheath inferiorly. Following a T incision on the femoral sheath the vessels will be sufficiently exposed underneath. It is recommended not to denude the femoral vein as the tissue surrounding the vein plays a role in haemostasis after femoral vein decannulation (Figure 5.). As mentioned previously we believe that not all diameters are suitable for femoral artery cannulation therefore our threshold is 8mm of the internal diameter. Sometimes the arteries are constricted masking the true size of the lumen in these cases we use a swab soaked in nitroglycerin, which will be packed into the inguinal wound for few minutes while the operation is progressing at the chest. We use two pledgeted CV5 GORE-TEX (W.L. Gore, AZ, USA) sutures as the femoral artery purse strings. The sutures are placed longitudinally with four pledgets defining the cannulation area (Figure 5). This minimal dissection of the femoral vessels decreases the chance of post-operative lymphocoele formation.

Cannulation

Although in many minimal invasive programs, the inguinal approach for both arterial and venous cannulation has been adopted as a routine practice, there are different approaches for cannulation and institution of CPB. Arterial cannulation can be performed directly on the ascending aorta with antegrade flow or on femoral artery with retrograde flow. Femoral artery cannulation is considered a less invasive approach with good control of cannulation site following decannulation. Direct cannulation of ascending aorta requires an extra hole in the chest or it may hamper the exposure. Large bruises on a fragile aorta are another shortcoming of direct ascending aorta cannulation, which may cause a some difficulty following decannulation and repair of the cannulation site. On the other hand, prolonged operation with femoral artery cannula and retrograde flow may cause ischaemia of the lower limb and deleterious shear stress and sand blasting effect on the arterial wall. Although there is no randomised trial comparing these two cannulation techniques, large cohorts have demonstrated that both approaches are acceptable with good results [11, 12]. Cannulation of the ascending aorta should be performed with extra care and usage of pledgeted sutures. During decannulation the inner purse string is best secured by Cor-Knot (LSI Solutions, NY, USA) and the outer purse string can be tied with a knot pusher. A routine over-and-over stitching of the cannulation site is also recommended to reduce the risk of dissection.

As a general rule, with the inguinal approach, the femoral vein is cannulated first followed by femoral artery. The venous cannula is a standard two-stage cannula which must be positioned carefully with the holes in the IVC, right atrium (RA) and SVC. Femoral vein cannulation can be disastrous and the surgical team should have a clear routine for cannulation with the help of the surgical scrub nurse. This requires pre-operative rehearsal and equipment check. If the needle after insertion into the dark blue area (Figure 5) did not aspirate enough blood do not be discouraged as patient might be hypovolaemic. Transoesophageal echocardiography (TOE) is an important adjunct to the operation by which the correct position of the wire in IVC – SVC view is confirmed. Cannula insertion does not always require pre-dilatation therefore surgeons should be cautious not to push the cannula in over the guide wire if there is any resistance. Always wet the cannula with a swab as this facilitates the insertion through the vessel wall. With the IVC – SVC view the cannula

location can be confirmed by TOE, at this stage the surgeon withdraws the trocar and the guide wire; the cannula holes in SVC and the RA can be clearly counted. This manoeuvre is our gold standard for confirmation of desirable cannula position (Figure 6).

Surgeons need to aware that while the LA is retracted after the atriotomy, the tip of the venous cannula if not in the right position or not well-advanced, may be pulled out of SVC. The mitral retractor occludes the SVC impeding the venous drainage. This manifests itself by a sudden rise in central venous pressure. Femoral artery cannulation requires 3-4 incremental dilators. It is recommended to insert the cannula with wrist rotating similar to handling a screw driver. In the event of using an endoballoon, the insertion of an antegrade cardioplegia cannula into the ascending aorta would not be necessary. In this situation the femoral artery cannula has a side arm, which allows the insertion of the endoballoon following cannulation of femoral artery (Figure 7). The surgeon should make sure that the side arm stays towards the surgeon (the right side of the artery).

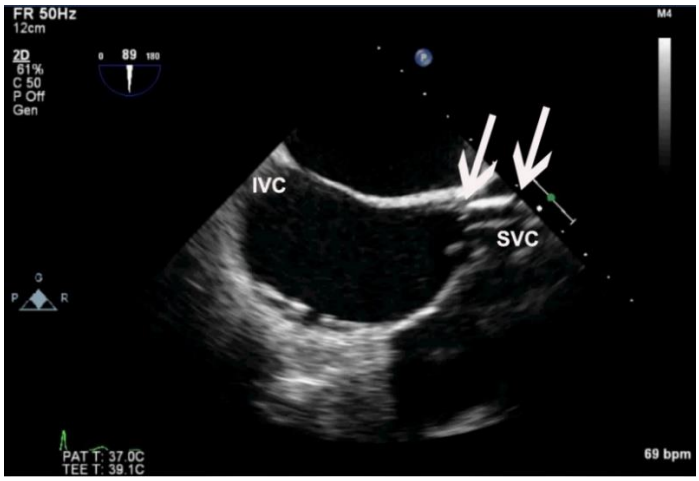

Figure 6. Femoral vein cannulation demonstrated by SVC (Superior Vena Cava) – IVC (inferior Vena Cava) TOE (Transoesophageal echocardiography) view. The distal cannula holes are demonstrated (arrows).

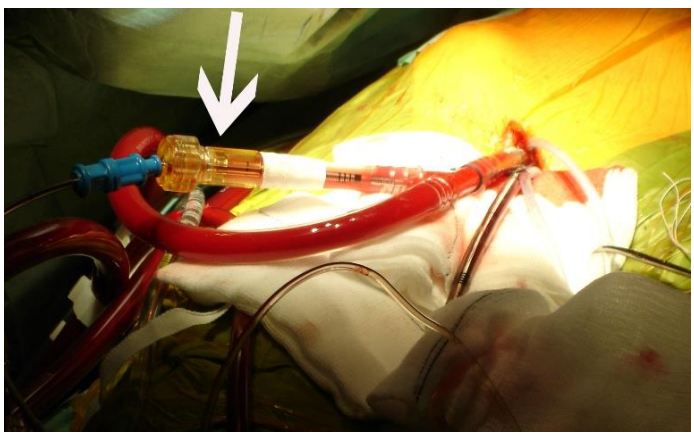

Figure 7. The side arm of the femoral artery cannula (arrow) containing the endoballoon with the blue locker cap visible at the tip of the side arm.

Figure 8. SVC cannula.

If there are concomitant procedures requiring access to RA (tricuspid valve surgery, atrial septal defect, cardiac tumors and Cox Maze IV) the cannulation strategy needs to be on the basis of separate cannulation of SVC and IVC. For these procedures the anaesthetist will cannulate the SVC before draping the patient (Figure 8).

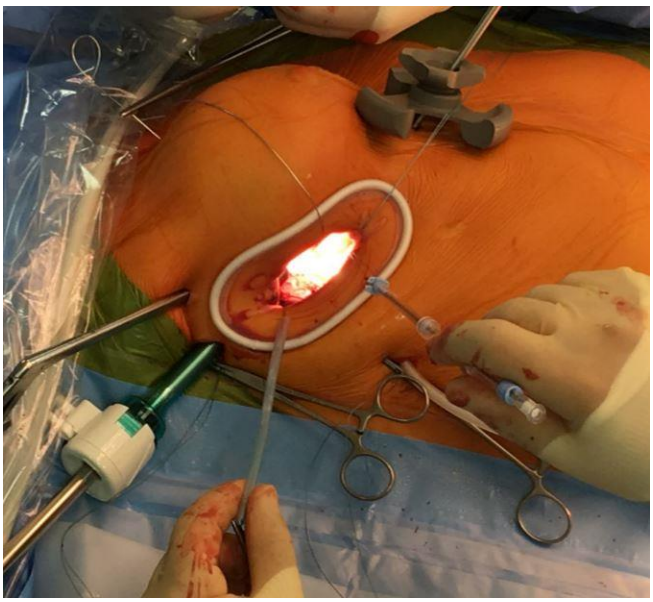

Figure 9. Insertion of a long antegrade cardioplegia cannula into the ascending aorta.

If a transthoracic clamp is used with femoral vessels cannulation, a long antegrade cardioplegia cannula needs to be inserted into the ascending aorta for the delivery of the cardioplegia (Figure 9).

Because the cardioplegia cannula is thin it is possible to pass it through the main incision without the need to create a new hole in the chest wall. It does not affect the view or exposure. As explained previously for direct ascending aorta cannulation it is safe to use pledgeted sutures and secure the first purse string with Cor-Knot after removing the antegrade

cardioplegia cannula. This decannulation needs to be done prior to femoral decannulation while patient is still on CPB. Femoral decannulation must be performed when all checks with the perfusionist and anaesthetist are done including TOE images confirming a good mitral valve repair. Decannulation always starts with the femoral vein cannula followed by the femoral artery cannula after administration of protamine. Femoral vein cannulation site usually does not require over-sewing particularly if the vein is not denuded. Following femoral artery decannulation, the CV5 sutures are tied and the ridge of the cannulation site is over sewn with a running suture. Groin compression following this technique, is not required.

Myocardial Protection

MIMVS and in particular the port access approach has been recognised as an operation with longer CPB and AoX times compared to conventional surgery via a median sternotomy [13]. Despite the longer ischaemic time, there are several studies confirming that port access approach is associated with favourable results and satisfactory post-operative course [14, 15, 16, 17, 18, 19, 20]. As a general principle all protection strategies such as beating heart and ventricular fibrillation used in sternotomy cases can be deployed in port access surgery. It has been demonstrated that ventricular fibrillation with cooling and beating heart surgery have provided satisfactory myocardial protection in complex redo cases of MIMVS where conventional approaches to myocardial protection were too difficult or not possible [21]. At present there is a consensus to use cardioplegia solution in order to achieve diastolic myocardial arrest as the gold standard approach [22]. The cardioplegia solutions have significantly evolved through time providing a better myocardial protection in the modern era of cardiac surgery [23]. There is no consensus on the type of cardioplegia used for port access approach. Because in the United Kingdom some solutions are not yet licensed, we use hyperkalaemic cold blood cardioplegia with a loading dose followed by maintenance doses every 20 minutes. In Germany, crystalloid Bretschneider solution has gained popularity and is used in MIMVS which provides the surgeons with 120 minutes window period between the loading dose and the next maintenance dose [17, 24]. The current practice of hypothermia is also quite skewed where the hypothermic protection varies from a simple temperature drift to run the CPB at 30-32 degrees C [17, 22]. Delivery of cardioplegia in port access MV surgery is antegrade with two main routes of administration; cardioplegia cannula inserted into the ascending aorta or cardioplegia delivered through the lumen of an endoballoon. Either of these can be combined with retrograde coronary sinus cardioplegia. The latter is administered through a cannula that can be place via the right internal jugular vein using TOE guidance. The deployment of the endoballoon requires specific consideration. The endoballoon is a multi-purpose device, which provides aortic occlusion as well as delivery of cardioplegia and venting of the aortic root. The design of the endoballoon started before the first MIMVS was performed in humans [25] but soon became a less invasive and safe method for administration of cardioplegia and aortic occlusion [26, 27, 28]. A pre-operative contrast chest and abdomen CT-scan is advised, especially, if an endoballoon is to be used. The large diameter of ascending aorta more than 38 mm would be in favour of transthoracic occlusion and not using the endoballoon. It is also safer not to use endoballoon if the patient has large calcified plaques in the aorta, pulmonary hypertension, right ventricle failure or poor ejection fraction. The device needs to be de-aired and prepared while patient is still in the anaesthetic room. All

the staff should receive training on how to prepare the endoballoon. The device contains multiple channels, which need to be monitored by the perfusionist, the anaesthetist and the surgeon (Figure 10). The perfusionist's end will be used for monitoring the balloon pressure (around 400 mmHg), running cardioplegia and venting the aortic root. The anaesthetist monitors the aortic root pressure and both right and left radial pressures. The surgeon with the help of the scrub nurse has control over handling the built-in guide wire for positioning the balloon and balloon inflation for aortic occlusion.

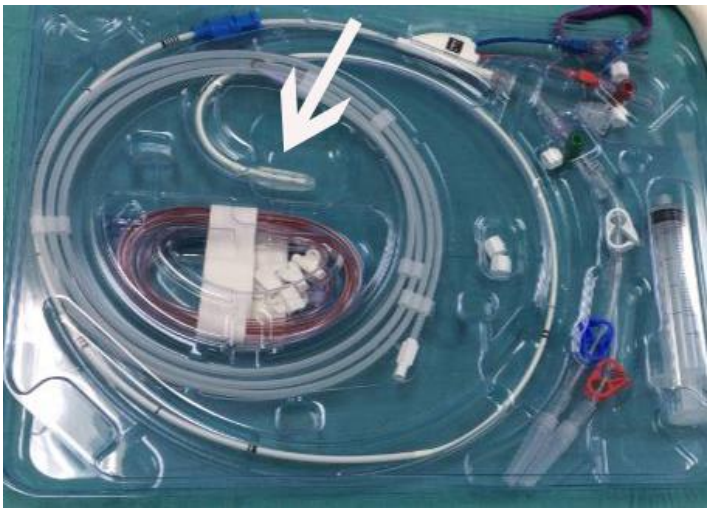

Figure 10. Endoballoon kit and the balloon occluding aortic (arrow).

The endoballoon is inserted through a side arm on the femoral artery cannula. When the balloon is still in the femoral artery cannula the guide wire is advanced and the location is confirmed by TOE with a descending aorta view. The guide wire with the appropriate TOE window is positioned in the ascending aorta. Then the device is driven over the wire until it reaches the ascending aorta, which is confirmed by TOE. The guide wire is withdrawn. The balloon is inflated with TOE guidance to optimise the position (1cm distal to the sinotubular junction). The device is locked when the desirable location is achieved. It is important to monitor the cardioplegia delivery on TOE images, which provides conformation of the safe delivery with no balloon displacement. All patients with the endoballoon should have an arterial line placed in right and left radial arteries. Migration of the balloon during cardioplegia delivery may occlude the right brachiocephalic artery. This occlusion is confirmed by damping in the right radial artery trace which requires TOE-guided repositioning of endoballoon. In some cases, the LA retractor may tent up the right coronary artery with temporary occlusion and also may cause aortic regurgitation. It is recommended to loosen the retractor while delivering the cardioplegia. In the event of mild aortic regurgitation we advocate a manoeuvre to overcome this problem in our practice. The manoeuvre constitutes the placement of a curved clamp through the transverse sinus with a gentle pressure towards the posterior aortic annulus. In our experience this manoeuvre significantly reduces the regurgitation, which can be easily observed through the mitral valve or by TOE images. Moderate aortic regurgitation is a relative contra-indication for MIMVS. Balloon rupture is a rare complication but the surgeon and his team should be prepared to deal with

this complication. Hard, calcified plaques or deep annular suturing at A1 area may rupture the balloon. The perfusionist reports a sudden drop in balloon pressure and the surgical field will be flooded with blood. In this situation particularly when LA is open, heart contractility may lead to catastrophic air emboli if the mitral valve is competent. Therefore, in all endoballoon cases, a transthoracic clamp and fibrillator must be available in theatre at all time. The best course of action following balloon rupture when LA is open would be ventricular fibrillation. This manoeuvre provides more time to establish a proper transthoracic occlusion.

Mitral Valve

The principles of approach to MV surgery remain similar to those of the conventional median sternotomy approach and are beyond the focus of this chapter. Surgeons should not try to change the MVr techniques that they have already adopted in conventional surgery while embarking on minimal invasive program [7]. All valve repair techniques such as triangular resection, neo-chordae attachment (Figure 11), chordal transfer and commissuroplasty are reproducible in minimal invasive setting with satisfactory outcomes [15, 17, 29]. It also has been demonstrated that port access MVr in complex cases such as Barlow's MV disease in large volume centres is associated with satisfactory results [30].

We believe that the foundation of a desirable MVr is proper annular plication. The plication requires an accurate suturing without damaging the adjacent structures. Proximity of coronary sinus and circumflex artery to the annulus may result in damage these structures during the annuloplasty or interrupted sutures for MV replacement. In order to avoid these complications and to optimise the visualisation we advocate switching to 3D mode of camera while suturing the annulus. One of the critical approaches to annular suturing with single shafted instrument is needle positioning. Fine hand movements tend to be exaggerated at the tip of the instrument because of the long shaft, which may create jerky needle shots. We have adopted an all-backhand approach to mitral annulus suturing. In this technique nearly all shots are performed by a needle, which is mounted backhand on the needle holder (Figure 12). The needle insertion site should be on the annulus however the backhand shot will drive the needle towards the LV and then back through the annulus into the LA. This manoeuvre almost guarantees the structures adjacent to the annulus will not be damaged. We usually use incomplete rings for annular plication and the sutures will be secured using Cor-Knot.

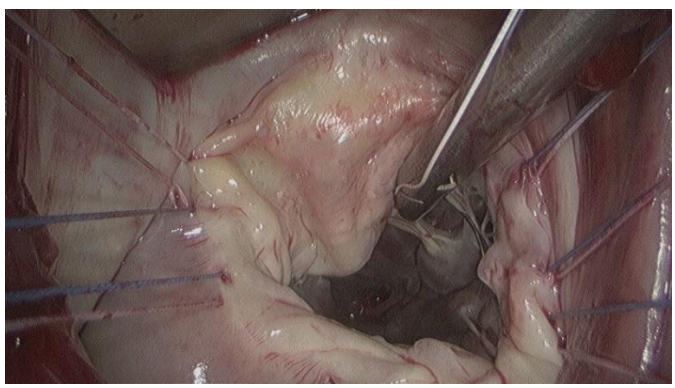

Figure 11. Attachment of neo-chordae to posteromedial papillary muscle.

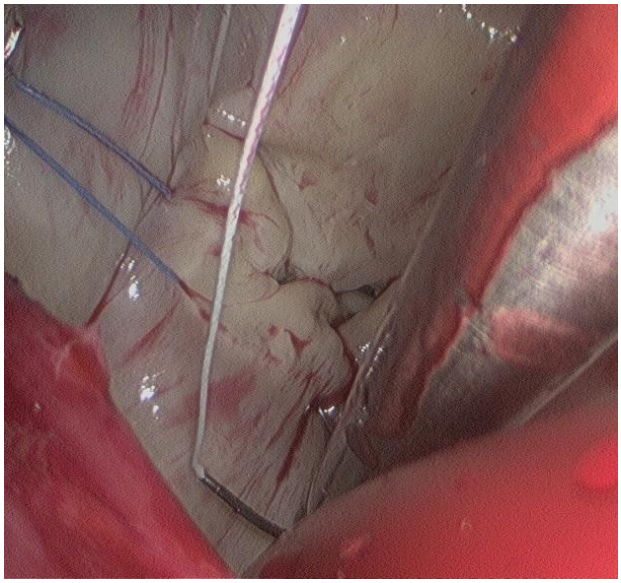

Figure 12. Backhand needle shot for annuloplasty suturing.

We have recently moved on from saline test to check the valve competency prior to atriotomy closure. For this a fine rubber catheter is attached to the cardioplegia line and placed in the left ventricle through the MV. The perfusionist starts to administer the blood cardioplegia while the root vent is stopped until the left ventricle is full. Usually the LV is well pressurised with 120 to 150 ml cardioplegia demonstrating a desirable repair (Figure 13). This manoeuvre also plays a role in final de-airing prior to closure of the atriotomy.

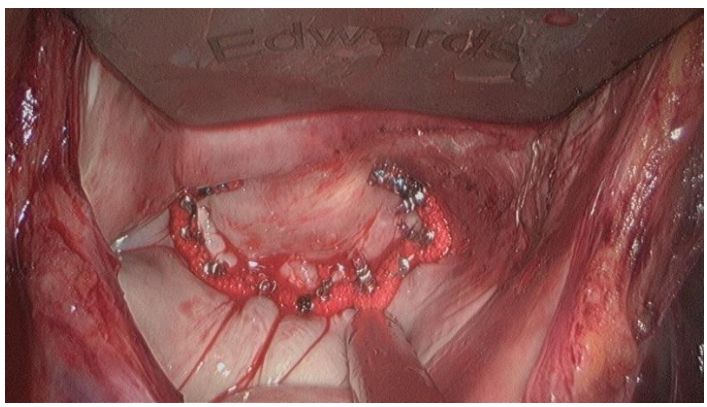

Figure 13. Mitral valve repair tested by blood cardioplegia. The sutures clipped down by Cor-Knot are visible across the incomplete ring.

Robotic Technology

The robotic approach to MVr started to evolve in late 1990s just a few years after the first minimally invasive MV operation [31]. Satisfactory results have been reported for the robotic approach, which in practice uses the port access approach principles [32, 33]. The robotic

approach requires more time to gain popularity as the primary approach to MV surgery. This is probably due to the costs, availability and training. This is discussed in more detail in another chapter.

CONCLUSION

MIMVS has rapidly progressed to become a safe modern operation offering one of the best treatments for MV disease. Port access surgery as one of the most recognised approaches constitutes several steps and phases. There are multiple instruments for each phase of the operation, which necessitates training for all the surgical and non-surgical team members prior to starting a program. On the other hand there are multiple approaches at different levels of the operation, which have been proven to be safe and reproducible in large published cohorts. The surgical team should be familiarised with all of these alternative approaches, as this would provide more options when the usual approach is not possible. TOE is a precious adjunct and surgeons need to master the interpretation of the images, which have a profound effect on planning and choosing the right approach. This also facilitates the learning curve while having more options on board automatically creates peace of mind. The rapid advance of technology is introducing new horizons and approaches to perform the operation as least invasive as possible. In the world of minimal invasive cardiac surgery the future is everyday!

REFERENCES

[1] Reynolds W Jr. *The first laparoscopic cholecystectomy*. JSLS 2001; 5 (1): 89-94.

[2] Carpentier A, Loulmet D, Carpentier A, Le Bret E, Haugades B, Dassier P, Guibourt P. *Open heart operation under videosurgery and minithoracotomy.* First case (mitral valvuloplasty) operated with success. C R Acad Sci III 1996;319(3):219-23. [Article in French].

[3] Rylski B, Beyersdorf F. Current concept for minimally invasive mitral valve repair. *Heart Lung Vessel* 2013; 5(4):207-212.

[4] SCTS Blue Book Online – "*Cardiac Surgery Audit Data*." Bluebook.scts.org. N.p., 2016. Web. Accessed [26 July 2016].

[5] Beckmann A, Funkat AK, Lewandowski J, Frie M, Ernst M, Hekmat K, Schiller W, Gummert JF, Cremer JT. Cardiac Surgery in Germany during 2014: A Report on Behalf of the German Society for Thoracic and Cardiovascular Surgery. *Thorac Cardiovasc Surg* 2015;63(4):258-69.

[6] Holzhey DM, Seeburger J, Misfeld M, Borger MA, Mohr FW. Learning minimally invasive mitral valve surgery: a cumulative sum sequential probability analysis of 3895 operations from a single high-volume center. *Circulation* 2013;128(5):483-91.

[7] Hunter S. How to start a minimal access mitral valve program. *Ann Cardiothorac Surg* 2013;2(6):774-8.

[8] Gillinov AM, Cosgrove DM. Minimally invasive mitral valve surgery: mini-sternotomy with extended transseptal approach. *Semin Thorac Cardiovasc Surg.* 1999;11(3):206-11.

[9] Nair RU, Sharpe DA. Limited lower sternotomy for minimally invasive mitral valve replacement. *Ann Thorac Surg* 1998;65(1):273-4.

[10] Casselman FP, Van Slycke S, Wellens F, De Geest R, Degrieck I, Van Praet, F, Vermeulen Y, Vanermen H. Mitral valve surgery can now routinely be performed endoscopically. *Circulation* 2003;108(1):II48-54.

[11] Grossi EA, Galloway AC, LaPietra A, Ribakove GH, Ursomanno P, Delianides J, Culliford AT, Bizekis C, Esposito RA, Baumann FG, Kanchuger MS, Colvin SB. Minimally invasive mitral valve surgery: a 6-year experience with 714 patients. *Ann Thorac Surg* 2002;74(3):660-3.

[12] Pozzi M, Henaine R, Grinberg D, Robin J, Saroul C, Delannoy B, Desebbe O, Obadia JF. Total percutaneous femoral vessels cannulation for minimally invasive mitral valve surgery. *Ann Cardiothorac Surg* 2013;2(6):739 – 743.

[13] Cao C, Gupta S, Chandrakumar D, Nienaber TA, Indraratna P, Ang SC, Phan K, Yan TD. A meta-analysis of minimally invasive versus conventional mitral valve repair for patients with degenerative mitral disease. *Ann Cardiothorac Surg* 2013;2(6):693 – 703.

[14] Modi P, Rodriguez E, Hargrove WC 3rd, Hassan A, Szeto WY, Chitwood WR Jr. Minimally invasive video-assisted mitral valve surgery: a 12-year, 2-center experience in 1178 patients. *J Thorac Cardiovasc Surg* 2009;137(6):1481-7.

[15] Davierwala PM, Seeburger J, Pfannmueller B, Garbade J, Misfeld M, Borger MA, Mohr FW. Minimally invasive mitral valve surgery: "The Leipzig experience." *Ann Cardiothorac Surg* 2013;2 (6):744-50.

[16] Holzhey DM, Shi W, Borger MA, Seeburger J, Garbade J, Pfannmüller B, Mohr, FW. Minimally invasive versus sternotomy approach for mitral valve surgery in patients greater than 70 years old: a propensity-matched comparison. *Ann Thorac Surg* 2011;91(2):401-5.

[17] Perier P, Hohenberger W, Lakew F, Batz G, Diegeler A. Rate of repair in minimally invasive mitral valve surgery. *Ann Cardiothorac Surg* 2013;2(6):751-7.

[18] Suri RM, Schaff HV, Meyer SR, Hargrove WC 3rd. Thoracoscopic versus open mitral valve repair: a propensity score analysis of early outcomes. *Ann Thorac Surg* 2009;88(4):1185-90.

[19] Goldstone AB, Atluri P, Szeto WY, Trubelja A, Howard JL, MacArthur JW Jr, Newcomb C, Donnelly JP, Kobrin DM, Sheridan MA, Powers C, Gorman RC,Gorman JH 3rd, Pochettino A, Bavaria JE, Acker MA, Hargrove WC 3rd, Woo YJ. Minimally invasive approach provides at least equivalent results for surgical correction of mitral regurgitation: a propensity-matched comparison. *J Thorac Cardiovasc Surg* 2013;145(3):748-56.

[20] Grossi EA, Galloway AC, Ribakove GH, Buttenheim PM, Esposito R, Baumann FG, Colvin SB. Minimally invasive port access surgery reduces operative morbidity for valve replacement in the elderly. *Heart Surg Forum* 1999;2(3):212-5.

[21] Romano MA, Haft JW, Pagani FD, Bolling SF. Beating heart surgery via right thoracotomy for reoperative mitral valve surgery: a safe and effective operative alternative. *J Thorac Cardiovasc Surg*. 2012;144(2):334-9.

[22] Garbade J, Davierwala P, Seeburger J, Pfannmueller B, Misfeld M, Borger MA, Mohr FW. Myocardial protection during minimally invasive mitral valve surgery: strategies and cardioplegia solutions. *Ann Cardiothorac Surg* 2013;2 6):803-8.

[23] Chambers DJ, Fallouh HB. Cardioplegia and cardiac surgery: pharmacological arrest and cardioprotection during global ischemia and reperfusion. *Pharmacol Ther.* 2010;127(1):41-52.

[24] Beyersdorf F, Krause E, Sarai K, Sieber B, Deutschländer N, Zimmer G, Mainka L, Probst S, Zegelman M, Schneider W .Clinical evaluation of hypothermic ventricular fibrillation, multi-dose blood cardioplegia, and single-dose Bretschneider cardioplegia in coronary surgery. *Thorac Cardiovasc Surg* 1990;38(1):20-9.

[25] Pompili MF, Stevens JH, Burdon TA, Siegel LC, Peters WS, Ribakove GH, Reitz BA. Port-access mitral valve replacement in dogs. *J Thorac Cardiovasc Surg* 1996;112(5):1268-74.

[26] Mohr FW, Falk V, Diegeler A, Walther T, van Son JA, Autschbach R. Minimally invasive port-access mitral valve surgery. *J Thorac Cardiovasc Surg* 1998;115(3):567-74.

[27] Mazine A, Pellerin M, Lebon JS, Dionne PO, Jeanmart H, Bouchard D. Minimally invasive mitral valve surgery: influence of aortic clamping technique on early outcomes. *Ann Thorac Surg* 2013;96(6):2116-22.

[28] Casselman F, Aramendi J, Bentala M, Candolfi P, Coppoolse R, Gersak B, Greco E, Herijgers P, Hunter S, Krakor R, Rinaldi M, Van Praet F ,Van Vaerenbergh G, Zacharias J. Endoaortic Clamping Does Not Increase the Risk of Stroke in Minimal Access Mitral Valve Surgery: A Multicenter Experience. *Ann Thorac Surg* 2015; 100(4):1334-9.

[29] Holubec T, Sündermann SH, Jacobs S, Falk V. Chordae replacement versus leaflet resection in minimally invasive mitral valve repair. *Ann Cardiothorac Surg* 2013;2(6):809-13.

[30] Melnitchouk SI, Seeburger J, Kaeding AF, Misfeld M, Mohr FW, Borger MA. Barlow's mitral valve disease: results of conventional and minimally invasive repair approaches. *Ann Cardiothorac Surg* 2013;2(6):768-73.

[31] Carpentier A, Loulmet D, Aupècle B, Kieffer JP, Tournay D, Guibourt P, Fiemeyer A, Méléard D, Richomme P, Cardon C. Computer assisted open heart surgery. First case operated on with success. *C R Acad Sci III* 1998;321(5):437-42.

[32] Mihaljevic T, Jarrett CM, Gillinov AM, Williams SJ, DeVilliers PA, Stewart WJ, Svensson LG, Sabik JF 3rd, Blackstone EH. Robotic repair of posterior mitral valve prolapse versus conventional approaches: potential realized. *J Thorac Cardiovasc Surg* 2011;141(1):72-80.

[33] Nifong LW, Chitwood WR, Pappas PS, Smith CR, Argenziano M, Starnes VA, Shah PM. Robotic mitral valve surgery: a United States multicenter trial. *J Thorac Cardiovasc Surg* 2005;129(6):1395-404.

In: Encyclopedia of Surgery (22 Volume Set)
Editors: Andreas Lehrer and Kristin Mueller
ISBN: 978-1-53618-329-0
© 2020 Nova Science Publishers, Inc.

Chapter 419

CANNULATION AND CARDIO-PULMONARY BYPASS FOR MINIMALLY INVASIVE MITRAL VALVE SURGERY

M. Pozzi [*] ***and J. F. Obadia***
Department of Cardiac Surgery, "Louis Pradel" Cardiologic Hospital,
"Claude Bernard" University, Lyon, France

ABSTRACT

A growing number of technological improvements have made minimally invasive mitral valve surgery (MIMVS) safe, easier and routinely performed in several experienced centers. Different cannulation techniques have been used over time in the specific setting of MIMVS. Direct aortic cannulation could represent a possible option to institute cardiopulmonary bypass. Moreover, femoral vessel cannulation has been progressively performed through smaller incisions and minimal dissection limited to the anterior face of the vessels. More recently, percutaneous femoral vessels cannulation became possible using closure devices with several potential advantages. Myocardial protection is of utmost importance in the outcome of MIMVS patients but the optimal cardioplegic solution remains still controversial. Some authors also suggested to perform MIMVS on a beating or fibrillating heart when aortic cross clamping is not technically feasible. So, the aim of the present chapter is to offer a description of our cannulation technique in MIMVS.

Keywords: complications, femoral artery, mitral valve, minimally invasive, percutaneous

INTRODUCTION

Minimally invasive mitral valve surgery (MIMVS) using various approaches was first performed in the second half of the 1990s by different surgical teams [1-3]. Then, a growing

[*] Corresponding Author's Email: mpozzi1979@gmail.com; Fax: +33472357383.

number of technological improvements have made MIMVS safe, easier and routinely performed in several experienced centers. Moreover, it has become the first-line surgical approach to treat mitral valve (MV) diseases in various centers [4, 5].

Different cannulation techniques have been used over time in the specific setting of MIMVS. Direct aortic cannulation could represent a possible option to institute cardiopulmonary bypass (CPB). Moreover, femoral vessel cannulation has been progressively performed through smaller incisions and minimal dissection limited to the anterior face of the vessels. More recently, percutaneous femoral vessels cannulation became possible using closure devices with several potential advantages. Percutaneous femoral vein cannulation is technically easy and already widely used in many surgical and interventional procedures. On the arterial side, the closure of the vessel is more difficult, requiring a specific closing device. Prostar (Abbott Vascular, Abbott Park, IL, USA), a percutaneous arterial access closure device, consists of a sheath containing four needles connected to two braided sutures. It has proven to be safe and effective in the setting of endovascular treatment of thoracic and abdominal aortic aneurysms [6-8] and transcatheter aortic valve implantation [9-11]. Our surgical team has already reported its application in the setting of MIMVS [12].

Myocardial protection is of utmost importance in the outcome of MIMVS patients but the optimal cardioplegic solution remains still controversial. Some authors also suggested to perform MIMVS on a beating or fibrillating heart when aortic cross clamping (AoX) is not technically feasible [13, 14]. The primary aim of the present chapter is to offer a description of our cannulation technique in MIMVS.

PREOPERATIVE EVALUATION

Preoperative evaluation starts with a meticulous history and a careful physical examination (in particular femoral arterial pulse). The history of the patient and chest x-ray evaluation should search for the presence of right pleural adhesions. Doppler ultrasound evaluation of the femoral vessels is no more performed on a routine basis but only if indicated by the physical examination. The presence of lower limb arteriopathy represents a formal contraindication to peripheral CPB. Preoperative echocardiography should detect possible aortic regurgitation, which could undermine myocardial protection with anterograde cardioplegia. Finally, diagnostic coronary angiography must be ideally performed through the radial artery in order to preserve femoral approaches. In young patients a non-invasive assessment of the coronary arteries by computed tomography (CT) is also an excellent option. Patients with MV disease are so operated in accordance with the current recommendations [15].

PATIENT PRERPARATION AND POSITIONING

After conventional anaesthesia, a single-lumen intubation is introduced. Double-lumen intubation was systematically performed at the beginning of our experience but now it is used only in case of concomitant atrial fibrillation (AF) ablation in order to reduce CPB duration. The patient is positioned in supine decubitus with a gel bolster under the shoulders. The right

arm is slightly folded with the palm of the hand looking at the table (figure 1). Defibrillation paddles are placed on the back of the patient.

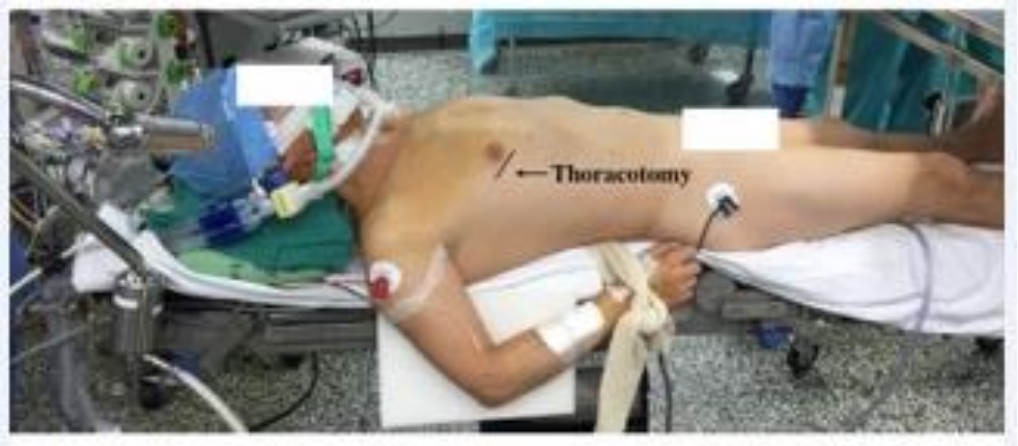

Figure 1. Patient positioning.

Asepsis is aimed to expose two surgical zones: the groins and the right chest with the sternum. The sternum must always be kept in the sterile zone in order to allow for conversion to a full sternotomy if needed. The sterile adhesive films are settled in order to pull up the breast and so to lift the inframammary groove in front of the fourth intercostal space (ICS). A 10mm 30° endoscope is installed and connected to the self-retaining Endoboy arm.

FEMORAL VESSEL CANNULATION

CPB is instituted through the cannulation of the femoral vessels with total percutaneous approach. This cannulation technique has been previously described [16]. Our technique begins with arterial cannulation. Infra-inguinal puncture carefully targets the anterior wall of the mid-common femoral artery before venous cannulation to avoid arterial puncture under systemic heparinization. In our opinion ultrasound-guided femoral artery puncture could be helpful in complex cases like severe obesity but is not necessary on a daily basis.

A guidewire is introduced and the correct position verified in the descending aorta with transesophageal echocardiography (TEE). Heparin is administered into the patient. Blunt dissection of the subcutaneous tissue all the way down to the femoral artery with a mosquito clamp is of utmost importance to allow a perfect introduction of the Prostar (Abbott Vascular, Abbott Park, IL, USA; figure 2).

Subsequently, an arterial cannula (usually 17 Fr; Maquet, Orleans, France) is inserted. The percutaneous venous cannulation is performed on the contralateral side (usually the right) to reduce the risk of arterio-venous fistula (figure 3).

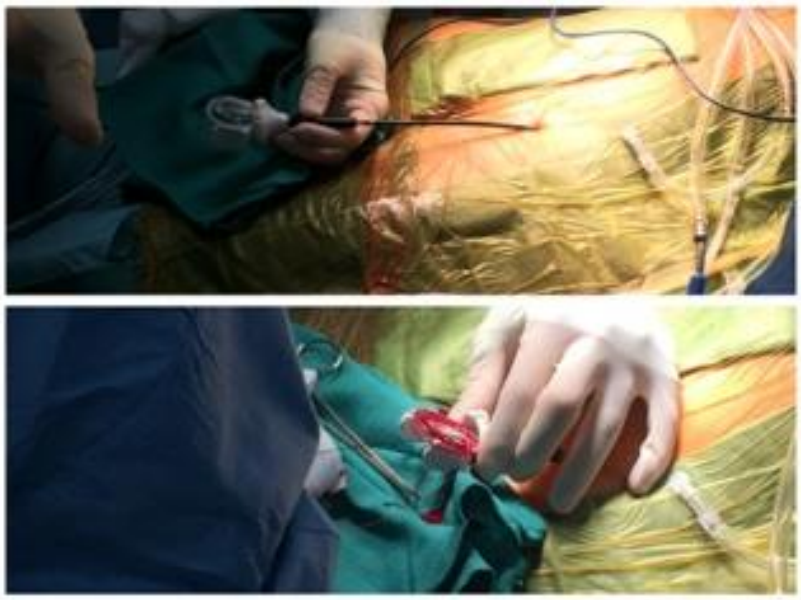

Figure 2. Introduction of Prostar.

We utilize a 23/25 Fr two-stage single cannula (Estech Inc., Danville, CA, USA) placed up to the superior vena cava (SVC) using TEE guidance, with satisfactory venous drainage achieved using a centrifugal pump (Medtronic Biomedicus, Eden Prairie, MN, USA). The percutaneous cannulation of the right internal jugular vein was performed only at the beginning of our experience.

Figure 3. Total percutaneous femoral vessels cannulation with the arterial cannula on the left side of the patient and the venous cannula on the right side.

SURGICAL TECHNIQUE

The surgical access is represented by an anterolateral right minithoracotomy (3-5 cm) at the fourth ICS. The optic is introduced in the same ICS at the level of the mid-axillary line. The soft tissue retractor is inserted over the insufflating CO_2 line (flow of approximately 2 l/min without pleural pressure control) (figure 4). CPB is commenced before opening the pericardium at the theoretical flow according to patient's body surface area. The ventilation is then stopped. The pericardium is so opened and exposed by two or three stitches while a transparietal stitch retracting the diaphragm is used only if necessary. The SVC and inferior vena cavae (IVC) are mobilized in order to facilitate the atriotomy subsequently and, if needed, to place the radiofrequency belt necessary for the AF ablation. A 3/0 polypropylene U-shaped purse string is realised on the ascending aorta.

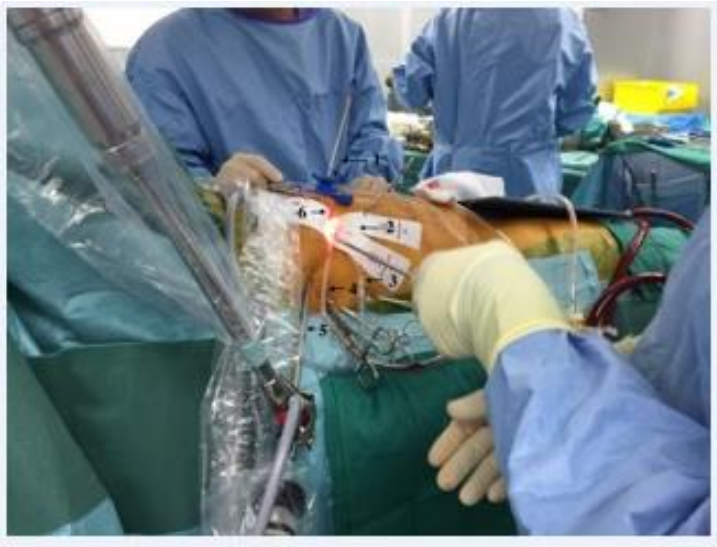

Figure 4. Right anterolateral minithoracothomy (3-5 cm) in the fourth intercostal space.
1 = percutaneous left atrium retractor, 2 = soft tissue retractor, 3 = CO_2 line, 4 = left ventricular vent line, 5 = optic, 6 = cardioplegia cannula.

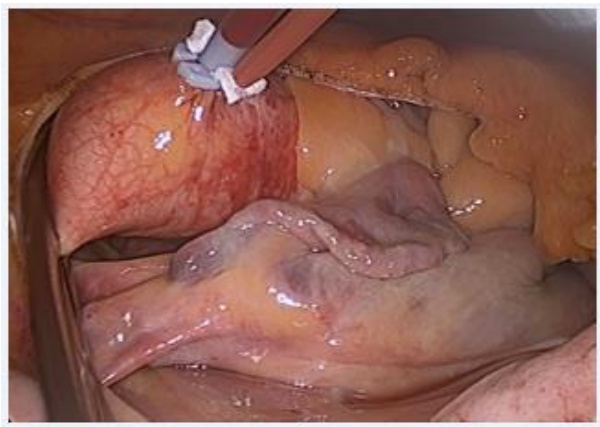

Figure 5. Aortic cross-clamping.

The cardioplegia cannula is placed on the ascending aorta and connected to the cardioplegia line. In our institution we utilize cold crystalloid cardioplegia for every type of minimally invasive MV operation. A transthoracic clamp is inserted through the fifth ICS in the mid-axillary line and directed toward the transverse sinus (figure 5). It is of paramount importance to check that the distal part of the transthoracic clamp does not engage the left atrial appendage. Specific, long-shaft surgical instruments are introduced through the soft tissue retractor. The left atrium (LA) is opened through the interatrial groove during the administration of the cardioplegia in order to unload the left ventricle (LV). One or two Ethibond 2/0 stitches are used to pull the upper portion of the atriotomy. A left atrium retractor is placed through the fourth ICS in the mid-clavicular line and then the left ventricular vent is positioned in the superior right pulmonary vein. The quality of this video-assisted approach allows performing either different repair techniques specifically addressed to the anterior and posterior leaflet or MV replacement. At the end of the MV operation, the LA retractor is removed and the LA is closed by two 3/0 polypropylene running sutures. The AoX is also removed after purge manoeuvres and deairing is accomplished though the cardioplegia cannula which is now an aortic root suction line. Epicardial pacing wires are placed on the anterior face of the right ventricle (RV) and it is strongly suggested to place them on CPB with an unloaded RV. TEE finally checks the quality of the dearing, optimal filling conditions, RV and LV function and the result of MV operation.

DECANNULATION

After weaning from CPB, the venous cannula is removed first. Local haemostasis is obtained with a simple skin stitch and manual compression on the right groin.

On the other side, after protamine administration, the left femoral cannula is removed and artery closure is assured by pulling down the two braided sutures of the Prostar (figure 6).

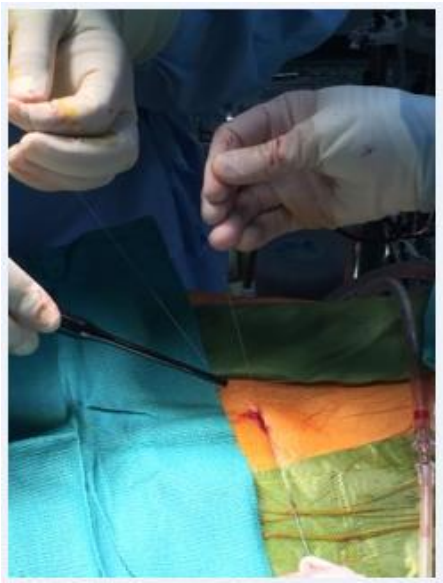

Figure 6. Percutaneous arterial hemostasis assured by Prostar device.

During this manoeuvre, it is very important to irrigate the sutures in order to help slide the knot down. A 24-hour compression was applied on both sides. Intrathoracic haemostasis is carefully controlled before removing the endoscope. Two 24 French thoracic drains are positioned through two different ports: the pleural drain through the optic port and directed to the posterior and lower part of the right pleural cavity and the pericardial drain through the AoX port towards the lateral face of the LV. Finally, the pericardium is closed, the ICS is approximated, superficial planes are closed in routine manner and local, long-acting anaesthesia is infiltrated before wound dressing.

CONCLUSION

Total percutaneous femoral vessels cannulation technique is particularly suitable for MIMVS with a high success rate and few complications after a short learning curve. With the advent of this percutaneous approach, the traditional complications of the groin incision have completely disappeared in modern operations with no groin infection, haematoma or lymphocele.

REFERENCES

[1] Navia, J. L., Cosgrove, D. M. 3rd. Minimally invasive mitral valve operations. *Ann. Thorac. Surg.*, 1996; 62(5):1542 - 4.

[2] Carpentier, A., Loulmet, D., Carpentier, A., Le Bret, E., Haugades, B., Dassier, P., Guibourt, P. Open heart operation under videosurgery and minithoracotomy. First case (mitral valvuloplasty) operated with success. *C R Acad. Sci. III,* 1996; 319(3):219 - 23.

[3] Cohn, L. H., Adams, D. H., Couper, G. S., Bichell, D. P., Rosborough, D. M., Sears, S. P., Aranki, S. F. Minimally invasive cardiac valve surgery improves patient satisfaction while reducing costs of cardiac valve replacement and repair. *Ann. Surg.,* 1997; 226(4):427 - 8.

[4] Cheng, D. C. 1., Martin, J., Lal, A., Diegeler, A., Folliguet, T. A., Nifong, L. W., Perier, P., Raanani, E., Smith, J. M., Seeburger, J., Falk, V. Minimally invasive versus conventional open mitral valve surgery: a meta-analysis and systematic review. *Innovations (Phila),* 2011; 6(2):84 - 103.

[5] Cao, C., Gupta, S., Chandrakumar, D., Nienaber, T. A., Indraratna, P., Ang, S. C., Phan, K., Yan, T. D. A meta-analysis of minimally invasive versus conventional mitral valve repair for patients with degenerative mitral disease. *Ann. Cardiothorac. Surg.,* 2013; 2(6): 693 - 703.

[6] Haulon, S., Hassen Khodja, R., Proudfoot, C. W., Samuels, E. A Systematic Literature Review of the Efficacy and Safety of the Prostar XL Device for the Closure of Large Femoral Arterial Access Sites in Patients Undergoing Percutaneous Endovascular Aortic Procedures. *Eur. J. Vasc. Endovasc. Surg*., 2011; 41(2):201 - 13.

[7] Krajcer, Z., Strickman, N., Mortazavi, A., Dougherty, K. Single-center experience of percutaneous abdominal aortic aneurysm repair with local anesthesia and conscious sedation: technique and results. *J. Cardiovasc. Surg. (Torino),* 2012; 53(6):695 - 706.

[8] Bechara, C. F. 1., Barshes, N. R., Pisimisis, G., Chen, H., Pak, T., Lin, P. H., Kougias, P. Predicting the learning curve and failures of total percutaneous endovascular aortic aneurysm repair. *J. Vasc. Surg.*, 2013; 57(1):72 - 6.

[9] Cockburn, J., de Belder, A., Brooks, M., Hutchinson, N., Hill, A., Trivedi, U., Hildick-Smith, D. Large calibre arterial access device closure for percutaneous aortic valve interventions: use of the Prostar system in 118 cases. *Catheter Cardiovasc. Interv.*, 2012; 79(1): 143 - 9.

[10] Hayashida, K., Lefèvre, T., Chevalier, B., Hovasse, T., Romano, M., Garot, P., Mylotte, D., Uribe, J., Farge, A., Donzeau-Gouge, P., Bouvier, E., Cormier, B., Morice, M. C. True percutaneous approach for transfemoral aortic valve implantation using the Prostar XL device: impact of learning curve on vascular complications. *JACC Cardiovasc. Interv.*, 2012; 5(2):207 - 14.

[11] Durand, E., Borz, B., Godin, M., Tron, C., Litzler, P. Y., Bessou, J. P., Bejar, K., Fraccaro, C., Sanchez-Giron, C., Dacher, J. N., Bauer, F., Cribier, A., Eltchaninoff, H. Transfemoral aortic valve replacement with the Edwards SAPIEN and Edwards SAPIEN XT prosthesis using exclusively local anesthesia and fluoroscopic guidance: feasibility and 30-day outcomes. *JACC Cardiovasc. Interv.*, 2012; 5(5):461 - 7.

[12] Vergnat, M., Finet, G., Rioufol, G., Obadia, J. F. Percutaneous femoral artery access with Prostar device for innovative mitral and aortic interventions. *Eur. J. Cardiothorac. Surg.*, 2011; 39(4):600 - 2.

[13] Grossi, E. A., Loulmet, D. F., Schwartz, C. F., Ursomanno, P., Zias, E. A., Dellis, S. L., Galloway, A. C. Evolution of operative techniques and perfusion strategies for minimally invasive mitral valve repair. *J. Thorac. Cardiovasc. Surg.*, 2012; 143(4):S68 - 70.

[14] Seeburger, J., Borger, M. A., Falk, V., Passage, J., Walther, T., Doll, N., Mohr, F. W. Minimally invasive mitral valve surgery after previous sternotomy: experience in 181 patients. *Ann. Thorac. Surg.*, 2009; 87(3):709 - 14.

[15] Joint Task Force on the Management of Valvular Heart Disease of the European Society of Cardiology (ESC); European Association for Cardio-Thoracic Surgery (EACTS), Vahanian, A., Alfieri, O., Andreotti, F., Antunes, M. J., Barón-Esquivias, G., Baumgartner, H., Borger, M. A., Carrel, T. P., De Bonis, M., Evangelista, A., Falk, V., Iung, B., Lancellotti, P., Pierard, L., Price, S., Schäfers, H. J., Schuler, G., Stepinska, J., Swedberg, K., Takkenberg, J., Von Oppell, U. O., Windecker, S., Zamorano, J. L., Zembala, M. Guidelines on the management of valvular heart disease (version 2012). *Eur. Heart J.*, 2012; 33(19):2451 - 96.

[16] Pozzi, M., Henaine, R., Grinberg, D., Robin, J., Saroul, C., Delannoy, B., Desebbe, O., Obadia, J. F. Total percutaneous femoral vessels cannulation for minimally invasive mitral valve surgery. *Ann. Cardiothorac. Surg.*, 2013; 2(6):739 - 43.

In: Encyclopedia of Surgery (22 Volume Set)
Editors: Andreas Lehrer and Kristin Mueller
ISBN: 978-1-53618-329-0
© 2020 Nova Science Publishers, Inc.

Chapter 420

MINI-STERNOTOMY MITRAL VALVE SURGERY

Ludwig C. Müller*
Department of Cardiac Surgery, Medical University,
Innsbruck, Austria

ABSTRACT

A minimally invasive approach to the mitral valve nowadays is increasingly becoming the procedure of choice for mitral valve surgery. If, however, a right mini-thoracotomy and video assisted mitral valve surgery is contraindicated or in cases when simultaneous aortic valve replacement (± tricuspid surgery) is necessary, upper hemisternotomy is a valuable and safe alternative. Indications, technique and results are delineated in this chapter.

Keywords: mitral, ministernotomy

INTRODUCTION

Since introduction of video-assisted surgery for mitral valve (MV) operations, right mini-thoracotomy has evolved as the most used access route by surgeons and in centers interested to reduce incisional size and thereby surgical trauma. In 2014 in Germany, 45% of isolated MV surgeries were performed through this approach [1]. However, these numbers were treated mainly in few high volume centers. As the intricate technical aspects of this technique may not be solved properly in lower volume centers and/or by lower volume surgeons, many still rely on full sternotomy to operate on the MV. Furthermore, there are patients in whom the mini-thoracotomy approach may be contraindicated or at least not recommendable. Finally there are still well renowned surgeons with excellent technique and results who find the mini-thoracotomy approach not well suited for their surgical requirements [2]. In all of these situations there ist still an option for reduced surgical trauma by avoiding full median

* Corresponding Author's Email: ludwig.mueller@i-med.ac.at.

sternotomy with the promise of shorter recovery and of course better cosmesis which should be preferably addressed as superior preservation of body integrity. Upper hemisternotomy (UHS) provides excellent access to the MV and of course also to the aortic (AoV) and tricuspid valves (TV) as well as to the main stem of the right coronary artery in case a single bypass to this vessel is required.

TECHNIQUE

The patient is positioned in a supine position as for median sternotomy and a longitudinal skin incision usually 8-10 cm long originating from two centimeters below the sternal notch to the level of the 4th intercostal space is performed (figure 1). Attention must be given to identification of the correct intercostal space (ICS). Then a midline sternotomy is performed from the sternal notch downwards into the left ICS using a common jigsaw like in full sternotomy. To avoid sternal fracture, it helps to softly curve the sternotomy into the 4th ICS (figure 2). After insertion of a small thoracotomy retractor, the procedure is continued as usual. Pericardiotomy is performed as an inversed T and multiple - usually 6 - pericardial stitches are used to fix the pericardium to the skin. The thoracotomy retractor is repositioned within the pericardium. Exposure is still very limited and concern may arise if the MV would be approached properly. It will!

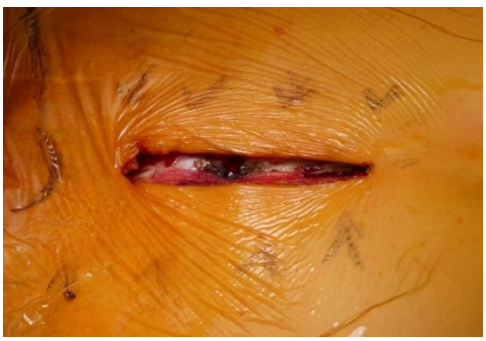

Figure 1. Skin incision.

Figure 2. Upper hemi-sternotomy.

After full heparinisation the ascending aorta is cannulated in standard fashion and the superior vena cava (SVC) is cannulated using a 22 Fr right angled venous cannula with a short leg. After connection to the tubing ECC can be started. IVC cannulation may be performed at this time using a 24 Fr straight cannula through the right atrium (RA). Alternatively (our preferred practice) femoral venous cannulation is employed. The right femoral vein is cannulated using Seldinger's technique with a 21-25 Fr femoral venous cannula. A two-staged femoral venous cannula (Livanova RAP cannula) may also be used to avoid any venous cannulae in the limited working space. When the heart is fully emptied and the lungs are deflated, exposure now inspires much more confidence to address the MV properly. A soft venting catheter is inserted into the left atrium (LA) via the right superior pulmonary vein. The caval veins can be encircled easily using vessel loops and the aorta is crossclamped and antegrade cardioplegia is given. After installation of total CPB, the RA is opened longitudinally and kept open with two stay sutures (4-0 polyethylene). If required, a coronary sinus catheter for retrograde application of cardioplegia is inserted and fixed with a 4-0 purse string suture within the coronary sinus ostium. The interatrial septum is incised at the level of the fossa ovalis and the incision extended into the roof of the LA to the desired level (figure 3). Care should be taken not to hit the posterior left atrial wall since due to suction the LA is collapsed. Most times division of the sinus node artery is not avoidable. At this point one must care to incise the LA not too close to the MV, otherwise exposure will be difficult. A 2 cm distance should be respected. Pledgeted mattress sutures right at the junction of the right and left atrial wall with the interatrial septum keep the LA open and later help at reconstruction of the septum and the LA. While the table is elevated head up and slightly rotated to the left, the MV is exposed by the assistant using two small (peanut) sponge sticks (figure 4). Up to now, no suitable mountable retractor for valve exposure is know to the author. Alternatively, the trans-septal approach through the roof of the LA is a viable solution. This may be the preferred access when simultaneous aortic valve replacement is needed. The ascending aorta is transected immediately above the sinotubular junction and the LA is entered without opening the RA and/or damaging the sinus node artery. Exposure of the MV is accomplished by the use of two sponge sticks.

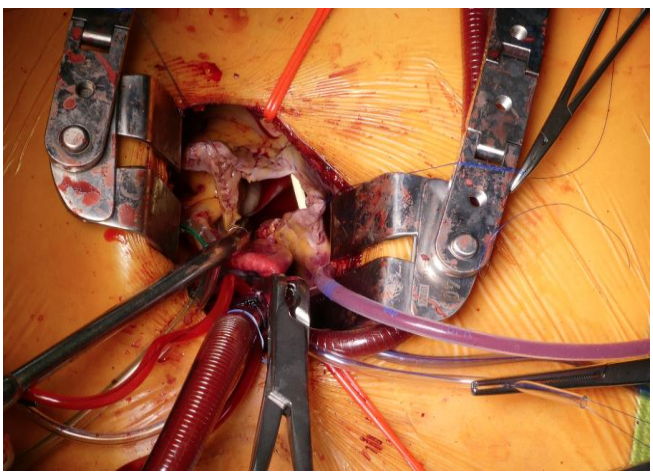

Figure 3. Trans-septal incision extended into the left atrial roof.

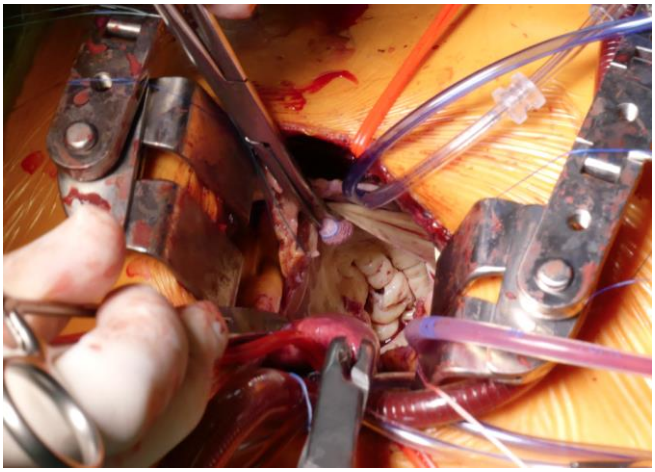

Figure 4. Exposure of the mitral valve using sponge sticks.

The operation is continued in a standard fashion using conventional instruments. Repair techniques or valve replacement can be performed as usual. In certain cases (as in full sternotomy also) use of long shafted instruments can be helpful if manipulation of the subvalvular apparatus is required. Of course, left atrial ablation using cryo or radiofrequency energy can be achieved if required. After the mitral valve repair (MVr) or replacement, the interatrial septum and the roof of the LA are reconstructed using two layers of running 4-0 polypropylen suture. Procedures on the AoV and/or TV can be accomplished now. Surgery of the TV can be performed on the beating heart after releasing the aortic cross clamp (AoX) if regarded helpful. However, attention should be paid to the aortic root. The aortic root may well impinge onto the RA and make TV surgery on the beating heart very challenging. The RA is closed in a standard fashion. A subxyphoidal pericardial drain should be inserted before releasing the AoX to minimize the risk of laceration of the heart.

As the sinus node artery is divided in most cases bradycardia may occur and temporary dual chamber pacing leads are mandatory in patients with sinus rhythm (SR). Normal SR usually is reestablished within a few days. Weaning off CPB is completed and the operation finished. The sternum is fixed by conventional methods.

INDICATIONS

As mentioned above, indications for the UHS approach depend on patient and surgeon/center related factors:

1) If the surgeons feels uneasy with the video assisted or totally endoscopic lateral mini-thoracotomy approach for any reason or if there is simply no such equipment available, a UHS is a valuable alternative.
2) Patients with a (relative) contraindication for lateral thoracotomy like severe bullous emphysema, expected severe pleural adhesions or fibrosis may definitely benefit from a limited sternotomy approach. The same is true if retrograde perfusion through the femoral artery should be avoided in patients with severe aorto-iliac

atherosclerosis and when axillary artery or direct aortic cannulation is not desired (figure 5). Other conditions like pulmonary hypertension or restricted renal function are not regarded as a contraindication to video assisted MV surgery. Also concomitant ablation for atrial fibrillation (AF) or TV repair can be performed through the mini-thoracotomy approach. However, if AoV replacement has to be performed simultaneouly upper partial sternotomy is ideal. Also coronary artery bypass grafting to the RCA is possible. Patients in SR bear a certain risk of postoperative rhythm disturbances so the indication for an extended transseptal approach should be considered seriously. If chronic AF is present, the choice of this approach is more obvious.

3) Contraindications: Patients who have had already cardiac surgery in the past are not ideal candidates for UHS redo surgery since isolation and encircling of the caval veins may be tricky. If very extensive annular calcium has to be resected and annular repair is planned, a full sternotomy will be the safer approach.

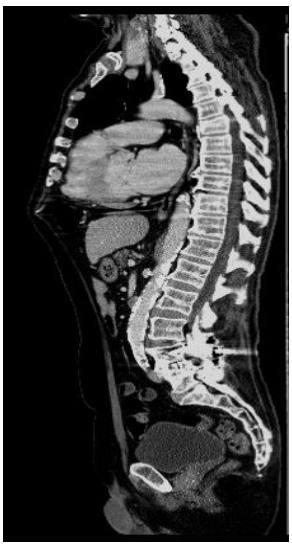

Figure 5. Calcified abdominal aorta.

SPECIAL CONSIDERATIONS

Choice of UHS length and shape: Using a J-incision into the 3rd ICS may do sufficiently, especially in women, however, the procedure can become really demanding and will need much more time. Even conversion to full sternotomy may become necessary. Therefore, the 4th ICS is the level of choice and we have not needed conversion due to inadequate access to and exposure of the MV. A sofly curved ’J’ shaped incision usually does fine and fracture of the sternal bone is no big issue. Although division of fibrous structures in the ICS close to the sternum is necessary, injury to the internal thoracic vessels is rare and division of these vessels usually is not required. The sternal incision is always carried to the left side since it gives better access to the MV and the left side of the sternum is elevated somewhat by the sternal retractor which gives even better exposure. As always in a UHS (also for AoV) before

institution of full CPB, emptying of the heart and deflation of the lungs, surgery of the MV virtually appears impossible. The contrary is true: due to the extended transseptal approach and dedicated exposure of the valve by the assistant, access is excellent and all procedures can be performed comfortably, except extensive resection of annular calcium and the following annulus reconstruction. Advantages of the UHS approach, of course, include the application of conventional techniques: no video, no screen, no long shafted instruments, no limited angulation of the instruments due to a very limited, few centimeters measuring hole in the thorax and finally no learning curve of a new surgical technique.

In our practice video assisted minimally invasive surgery is the technique of choice for MV repair and outnumbers the UHS cases by far. However, in certain situations, we are glad to have an alternative to full sternotomy and have not seen any disadvantages. Of course a limited approach makes surgery not easier but with dedication to surgical improvement and reduction of surgical trauma it can be achieved very well.

RESULTS

Since the introduction of UHS for MV surgery from May 2011 until June 2016, 71 (18.3 %) of 387 minimally invasive mitral valve procedures have been performed with this approach including 42 MVr and 29 MVR with additional 15 AoV replacements and 22 TV repairs. No mortality was observed and no conversions to full sternotomy were required. The high proportion of MV replacements (40.8%) reflects the underlying severe pathology of this patient cohort. No conversions to MV replacement for a failed repair was necessary.

CONCLUSION

UHS is a valuable minimally invasive approach for mitral and tricuspid valve surgery if contraindications for a lateral mini-thoracotomy with video assistance are present. Except a certain familiarity with limited access to the heart and a clear concept of the procedure, neither specialized training nor equipment are required. Definite indications for full sternotomy for isolated MV surgery have become rare.

REFERENCES

[1] Beckmann, A., Funkat, A. K., Lewandowski, J., Frie, M., Ernst, M., Hekmat, K., Schiller, W., Gummert, J. F., Cremer, J. T. Cardiac Surgery in Germany during 2014: A Report on Behalf of the German Society for Thoracic and Cardiovascular Surgery. *Thorac Cardiovasc Surg.* 2015; 63(4): 258-69.

[2] Castillo, J. G., Milla, F., Anyanwu, A. C., Adams, D. H. Video-atlas on minimally invasive mitral valve surgery - The David Adams technique. *Ann. Cardiothorac. Surg.* 2013; 2(6): 828-32.

In: Encyclopedia of Surgery (22 Volume Set)
Editors: Andreas Lehrer and Kristin Mueller
ISBN: 978-1-53618-329-0
© 2020 Nova Science Publishers, Inc.

Chapter 421

TOTALLY ENDOSCOPIC MITRAL VALVE SURGERY

Martin Misfeld*, MD, PhD and Friedrich W. Mohr
Heart Center, University of Leipzig,
Leipzig, Germany

ABSTRACT

Totally endoscopic mitral valve surgery (TE-MVS) represents a technique, which is part of the armamentarium of innovative minimally-invasive procedures. These procedures have gained increasing popularity over the last decade, not only due to the high patient demand and satisfaction, but also because of the proven safety and efficacy of this technique that is comparable to conventional procedures. It is associated with a lower risk of morbidity, improved patient comfort, shorter hospital stay and excellent cosmetic results. The totally endoscopic approach requires specific surgical skills, which involves the use of modified surgical instruments. In addition, establishment of extrathoracic cardio-pulmonary bypass and use of videoscopic guidance shifts direct vision of the heart, which the surgeon has during conventional mitral valve surgery through a standard median sternotomy to more indirect tools such as intra-operative transesophageal echocardiography. Standardization of the technique in TE-MVS increases the safety of this approach and results in excellent patient outcomes.

Keywords: minimally-invasive cardiac surgery, mitral valve surgery, endoscopic-surgery

INTRODUCTION

Mitral valve (MV) disease is the second most prevalent valve disorder in western countries [1]. Increasing lifespan of the general population is expected to escalate the number of patients with MV disease, which will further increase morbidity and mortality. In 2006, an age and sex-adjusted analysis reported a prevalence of 0.1% of mitral valve stenosis and 1.7% of mitral valve regurgitation (MR) in North America. It is estimated that the prevalence of

* Corresponding Author's Email: martinmisfeld@yahoo.com; Fax: +49 341 8651452c.

severe primary MR will increase up to 6.4% in the age group between 65 to 75 years and up to 9.3% in the age group older than 75 years [2]. MV surgery offers excellent results for various pathologies of the MV. The commonest surgical approach for MV surgery is still median sternotomy, as minimally-invasive techniques have not yet been adopted by the majority of cardiac surgeons so far. This chapter describes totally endoscopic mitral valve surgery (TE-MVS) in the context of minimally-invasive techniques. Following an overview of the history of MV surgery and the evolution of TE-MVS, the surgical techniques will be described in detail. Information on clinical outcomes of TE-MVS in comparison to conventional MV surgery through a median sternotomy will be followed by the description of potential pitfalls of this technique and the role of transesophageal echocardiography (TEE) in TE-MVS.

DEFINITION

'Minimally-invasive cardiac surgery' has been defined by the Society of Thoracic Surgeons (STS) database as 'any procedure not performed with a full sternotomy and cardio-pulmonary bypass support' [3]. As cardiopulmonary bypass (CPB) is mandatory for the performance of MV surgery today, minimally-invasive mitral valve surgery can be defined as any procedure performed without a full sternotomy as per this STS definition. Alternative surgical accesses and approaches are listed in Table 1.

Table 1. Surgical accesses and approaches in minimally-invasive mitral valve surgery

Partial sternotomy
transsternal incision
V incision
upper sternotomy
inverted T mini-sternotomy, J incision, L incision, inverted J incision, interved L incision
T mini-sternotomy, inverse L incision
Thoracotomy
right anterior mini-thoracotomy (forth to fifth intercostal space)
right parasternal incision
Video-assisted (endoscopic = videoscopic = thoracoscopic)
direct vision
via monitoring
2D, 3D
Robot-assisted
Da Vinci (Intuitive Surgical, Inc., Sunnyvale, California, USA)
Zeus (Computer Motion, Goleta, California, USA)
Telemanipulator (voice-activated) assistance
Aesop 3000 (Computer Motion, Goleta, California, USA)

HISTORY

Sir Lauder Brunton was probably the first physician to publish about the possibility of surgical treatment of MV stenosis in 1902. Following his experimental work, Elliot Carr Cutler performed the first successful MV operation in 1923. Together with the cardiology colleague Samuel Levine, a closed transventricular MV commissurotomy was performed on a 12-year-old patient with rheumatic MV stenosis at the Peter Bent Brigham Hospital [5]. Two years later, on May 6, Sir Henry Souttar was the first surgeon to dilate a stenotic MV by a digital maneuvre through the left atrial appendage [6].

In the mid 1990s the success of laparoscopic operations in general surgery transferred this concept into the field of cardiac surgery. J. L. Navia and D.M. Cosgrove reported their results of minimally-invasive MV surgery through the right parasternal incision in 1996 [7], followed by L.H. Cohn, who performed MV surgery through the same access [8]. The first video-assisted mitral valve repair (MVr) through a mini-thoracotomy using ventricular fibrillation was described by Carpentier in 1996 [9]. Two years later, Carpentier also performed the first successful computer assisted MV surgery using the Da Vinci Surgical System [10].

Several important developments have faciliated TE-MVS. This includes periphereal CPB, endo-aortic clamping, introduction of retrograde cardioplegia catheter under echocardiographic guidance and the use of carbon dioxide (CO_2) in the operating field. In addition, developments of minimally-invasive valve surgery instruments, progress in perfusion technology and the importance of routine TEE participated to the growth of TE-MVS [11].

SPECIAL EQUIPMENT FOR TE-MVS

Various manufacturers have designed and developed instruments to meet the specific demands of TE-MVS. These instruments may also be used in conventional surgeries, when the lengths of standard instruments fall short in some patients. Soft tissue retractors, longer cannulae or catheters for cardioplegia delivery into the aortic root or the coronary sinus (retrograde cardioplegia) respectively are examples how developments in TE-MVS have improved patient safety and surgeon comfort. Advances in extrathoracic CPB with port-access systems, smaller and non-kinking arterial and venous cannulae and the routine use of CO_2 have further improved outcomes and safety of TE-MVS.

The introduction of 3-D systems into TE-MVS has enabled the surgeon to have a three-dimensional view of the operative field and a better perception of depth through the viewing monitor, resulting in enhanced tissue handling.

PATIENT SELECTION

Appropriate patient selection is a key factor for successful TE-MVS. In specific scenarios, TE-MVS can even be more beneficial than a complete sternotomy to reduce the

risk of operative complications. However, absolute and relative contraindications do exist for this technique (Table 2).

Table 2. Indications for TE-MVS

Absolute contraindications	Relative contraindications	Potential advantages of TE-MVS in specific co-morbidities
Significant untreated coronary artery disease	Obese patients	Reoperations following • Valve surgery • Coronary artery • bypass surgery • without grafts to the • right coronary artery previous • reconstructive • surgery of an • infected sternum
Concomittant aortic or aortic valve pathology requiring surgical intervention	Reoperations	Obese patients
Prior right chest surgery	Mitral valve endocarditis	
Severe right lung adhesions	Pathologies of the descending aorta	
Aortic valve regurgitation > I°	Unsuitable femoral arteries to initiate CPB	
Severe mitral valve calcification or abscess formation requiring extensive mitral annulus remodeling		
Severe chest deformities with shifting of the heart to the left side		

Patients suitable for TE-MVS undergo isolated MV replacement or repair. Complexity of the underlying MV pathology should not be a contraindication for TE-MVS as all repair techniques can be performed through this approach. However, it is advisable that complex cases (i.e., Barlow's disease, combined mitral and tricuspid valve procedures) should be performed by experienced surgeons.

The following procedures can be performed in addition to MV surgery: tricuspid valve surgery, ablation therapy for atrial fibrillation, ligation/ closure of the left atrial appendage, PFO/ASD- closure and myectomy for hypertrophic obstructive cardiomyopathy.

SURGICAL TECHNIQUE

The most common surgical access in TE-MVS is a right lateral mini-thoracotomy. This technique will be described in detail. It is important to note, that a sternal saw be available at all times in case of an emergent conversion to a sternotomy approach.

Patient Preparation

The preparation of the patient for TE-MVS is the same as for a conventional MV operation performed through a sternotomy incision. However, due to the establishment of peripheral CPB, assessment of the femoral vessels is important. In cases in which port-access technology is used, further assessment of the descending aorta by computer tomography (CT) is routinely performed in some centers. It is also advisable to monitor the arterial pressure in both radial arteries to facilitate the proper position of the endo-balloon.

Depending on the surgical strategy, single or double lumen endo-tracheal tube can be are used. The latter enables preparation of the situs without early initiation of CPB and, therefore, helps reducing CPB time. If the ascending aorta is cannulated directly, a double lumen tube is mandatory. On the other hand, a single lumen tube and initiation CPB before thoracotomy, simplifies the procedure.

An example of an operation room set-up for TE-MVS is shown in Figure 1. Besides standard monitoring used during cardiac operations, additional monitors used for viewing images transmitted by the thoracoscopes are positioned opposite the operating table for the surgeon and behind the surgeon for the assistant surgeon. The anesthetist, perfusionist and scrub nurse are also able to follow the steps of the procedure. Training of residents and medical students in MV repair and replacement is much superior with this set-up as compared to the limited view observers/assistants have of the MV through a median sternotomy during conventional MV procedures.

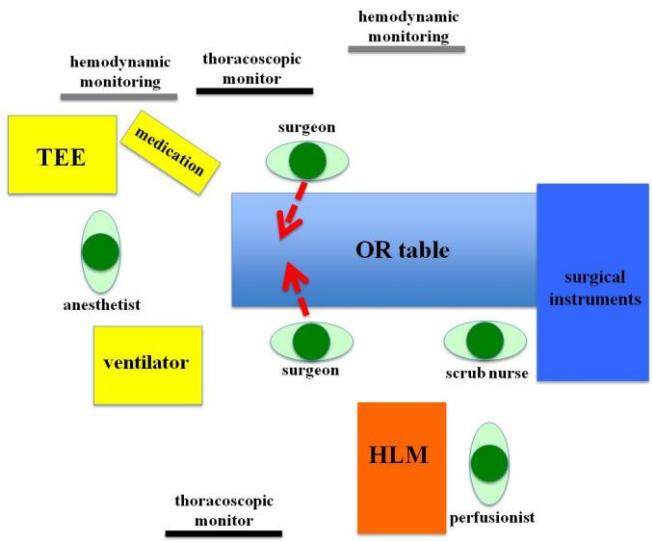

Figure 1. Operation room set-up for TE-MVS.

Patient Positioning

The patient is placed in a supine position with slight anterior-rotation of the right chest (30°). This can be achieved by placing a bolster under the right scapula of the patient,

enabling improved exposure for right mini-thoracotomy and adequate space for placement of the TE-MVS instruments and equipment.

It is advisable to mark out the desired location of the skin incision for the mini-thoracotomy and the sternal midline before application of the incise drapes, which should be used to further improve surgical field exposure, especially in women. Marking the submammary fold and pushing the breast cranially and to the left with the incise drape aids in achieving optimum cosmetic results. The marked sternal midline will also enable the surgeon perform a straight skin incision in rare cases in which the patient requires conversion to a sternotomy approach.

Initiation of Cardiopulmonary Bypass

Femoro-femoral CPB through the right groin is the commonest access site in patients undergoing TE-MVS (Figure 2). Therefore, coronary angiograms through the right groin should be avoided if performed immediately prior to surgery. Following a small, oblique skin incision (2–3 cm), the femoral vessels are dissected free of the surrounding tissues. Following heparinisation, a purse-string or pledgeted 4.0 monofilament U-stitch is passed through the anterior wall of each vessel. It is often easier to insert the venous cannula first, due to the anatomical position of the vessels. The guide wire is passed through the right femoral vein into the right atrium and superior vena cava (SVC) under TEE guidance using the Seldinger's technique. Following pre-dilatation of the opening in the femoralvein, the venous cannula is also passed cranially through the femoral vein so that its tip lies in the superior vena cava. Thereafter, femoral artery cannulation is similarly performed. In single lung ventilation, CPB is initiated at this stage in patients with a single-lumen endotracheal tube. In patients with a double lumen endotracheal tube, CPB can be initiated after opening the pericardium.

Vacuum suction will improve venous drainage. An additional jugular venous cannula can be inserted into the SVC under TEE guidance in obese patients or in those requiring additional right atrial interventions, either in the induction room after induction of anesthesia or in the operating room after prepping and draping the patients. As a bailout maneuver in patients with insufficient venous drainage via femoral canulation, direct cannulation of the SVC through the mini-thoracotomy or a separate incision may be an option.

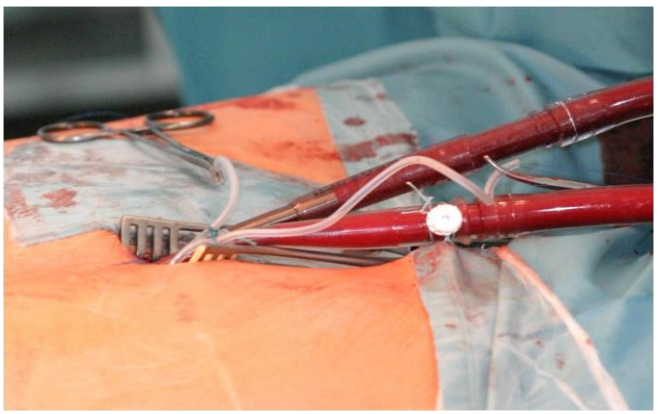

Figure 2. Femoro-femoral cardiopulmonary bypass for TE-MVS.

Operations are performed under mild hypothermia. Crystalloid or blood cardioplegia can be used. However, repeated delivery of blood cardioplegia interferes with the surgical set-up and work flow, thereby prolonging aortic cross-clamp (AoX) and CPB time.

MV reoperations can be performed under mild-moderate hypothermia (30^0C) and ventricular fibrillation without aortic clamping, thus avoiding dissection of the ascending aorta. A competent aortic valve and preserved left ventricular function are the prerequisites for safe execution of this technique.

Mini-Thoracotomy

The skin incision should be made to faciliate the best cosmetic results after the operation. This is particularly important in women. An antero-lateral small thoracotomy is performed, following skin incision and dissection of the subcutanous tissue. The 4th intercostal space (ICS) is the commonest entry site into the chest. Some surgeons use the areolar margin to enter the chest for cosmetic reasons. If additional right atrial procedures have to be performed, the incision should be slightly more anterior compared to an incision for isolated MV surgery.

It is advisable, at first, to make a small opening (finger's breadth) in the ICS and palpate the diaphragm through it with a finger. The distance of the diaphragm from the opening gives the surgeon a very good idea of whether the ICS is appropriate for entry into the thorax. Once the desired site of entry is confirmed the appropriate ICS is widely opened. The use of a soft tissue retractor provides adequate space through which the sureon can work comfortably. The endoscope is inserted through a 5 to 10 mm portone intercostal space superior to the mini-thoracotomy. A small incision (3-4 mm) medial to the thoracotomy can be used to exteriorise the cardioplegia cannula and insert the left atrial retractor.

The pericardium is opened parallel and preferably 3-4 cm anterior to the phrenic nerve to avoid too much traction on the latter in case of using pericardial stay sutures. If necessary, excessive pericardial fat pads should be excised for better visualization. Additional retraction sutures may be used to pull the diaphragm inferiorly. These sutures can be brought out directly through the lateral edge of the skin incision. Cardioplegia can be delivered either through a metallic needle or a standard long plastic cannula inserted into the aortic root or through a retrograde cardioplegia cannula inserted under TEE guidance.

An additional retraction suture is placed in the interatrial groove at the level of the right superior pulmonary vein and is brought out of the thorax through the same incision through which the cardioplegia cannula is exteriorized. Gentle traction on this suture facilitates the opening and closure of the left atrium.

The aorta can be clamped with a transthoracic clamp, which is inserted posteroinferior to the thoracoscope. Interference between both instruments should be avoided. Another option is the use of an endo-balloon, the placement and position of which is facilitated by TEE. CO_2 can be insufflated of 3-5 L/min into the thorax via the cannula through which the endoscope is inserted or via an additional tube.

An example of the access to the chest and positioning of additional TE-MVS equipment is depicted in Figure 3.

1. mini-thoracotomy, 2. incision for left atrial retractor, 3. position of thoracoscops, 4. insertion of X-clamp, 5. access to the femoral vessels for CPB

Figure 3. Example of the access to the chest and positioning of equipment for TE-MVS.

Following aortic clamping and delivery of cardioplegia, left atrium is open and the MV is exposed and assessed. Appropriate techniques for MVr such as neochordal replacement or resection techniques are performed according to the type of valve pathology, when the valve is deemed repairable. If not repairable, MV replacement can be performed in standard fashion. The left atrium is closed in 2 layers following repair or replacement of the MV. The pacemaker wire inserted preferably before removal of the AoX. The heart is then deaired and the AoX is removed. The patient is then weaned from CPB to assess the MVr or replacement on TEE. Once the findings are as desired, CPB is resumed so that the cardioplegia cannula can be removed. The needle vent site should be securely oversewn with a pledgeted monofilament suture. Hemostasis is confirmed. The pericardium may be closed before or after weaning from CPB. One or two drains are inserted according to surgeon's preference. The femoral vessels are decannulated followed by protamine. The chest and groin wounds are then closed in layers.

CLINICAL OUTCOMES

In 2014, 47.3% of the 5913 isolated MV procedures were performed with the minimally-invasive approach in Germany [12]. Data is still limited. However, systematic reviews have shown, that minimally invasive MV surgery is safe and effective and shows no differences in outcomes when compared to conventional MV surgery via median sternotomy [13-15]. Although the minimally-invasive approach and especially TE-MVS requires longer CPB and AoX times, this technique has shown to have significant advantages with regard to decreased postoperative pain, reduced surgical trauma, better respiratory function, fewer transfusions, and, therefore, greater patient satisfaction [16-18].

The quality of valve surgery, especially repair has been at par with standard MV surgery. Depending on the complexity of MVr, repair rates greater the 90% can be achieved in experienced centers [16, 19-22]. TE-MVS is associated with low morbidity and mortality similar to the conventional approach. Long-term survival and freedom from valve-related complications and reoperations are also comparable to standard MV surgery.

Table 3. Concepts of TE-MVS

Endoscopy	Initiation of CPB	Cardioplegia	Aortic clamping	Varia
5 or 10mm camera system with various camera angles	Femoral vein with/without additional jugular vein cannulation	Cristalloid or blood cardioplegia	External clamping (transthoracic, endothoracic)	CO_2-application into the operative field
2D-videoscope	Femoral artery	Administration via aortic root	Port Access technology with endo-aortic clamp	Bi-radial artery line when endo-aortic clamp system is used
3D-videoscope	Ascending aorta	Retrograde cardioplegia (TEE guided insertion)		Single or double lumen ventilation
Computer guided videoscope (AESOP 3000, voice controlled robotic arm)	Axillary artery	Cardioplegia administered via endo-aortic clamp system		Soft tissue retractor with/ without metal retractor

Even procedures requiring complex MVR, (i.e., Barlow's mitral valve disease), can be performed with TE-MVS [23]. With the introduction of simplified techniques such as the 'Leipzig Loop Technique', complex MVr has been made feasible with this approach [20].

It has been demonstrated that TE-MVS may be advantageous and lead to better outcomes especially in higher risk patients. This is true for selected cases of reoperations and elderly patients [24, 25].

POTENTIAL PITFALLS

TE-MVS has become the standard technique for MV surgery in some centers. There is still a lack of adopting this approach in other institutions. Reports published so far represent high volume centers with a broad experience with this technique. It has been shown that TE-MVS requires a learning curve, which varies between individual surgeons [26]. Awareness of potential pitfalls and avoidance of complications helps to increase the adoption of TE-MVS in more centers.

Potential pitfalls include improper patient selection and preparation, mistakes during establishment of CPB, insufficient patient set-up and complications associated with MV surgery per se. A list of potential pitfalls, their detection and avoidance are listed in Table 4.

Table 4. Potential pitfalls, complications and how to avoid them

Potential pitfalls	Possible complications	Potential solutions
Improper patient selection	Too complex mitral valve pathology or reoperation	Every mitral valve pathology can be repair with TE-MVS. Depending on the surgeons expertise, pathology may be too complex or reoperation may be too challenging for the minimally approach See also relative/absolute contraindications (table 2)
	Right chest adhesions	
	Thorax deformations	
	Severe obese patients	
	Severe calcification or abscess formation of the mitral valve annulus	
Inadequate patient preparation	Insufficient patient positioning	Adequate elevation of the right chest and positioning of the right arm to ensure enough space for the set-up of TE-MVS
	Bad cosmetic result	Mark skin incision line and use foil for proper retraction of the breast, especially in women In obese patients (especially women) pushing the breast downwards and performing a thoracotomy anterior to the breast may be an alternative
Wrong establishing of CPB	Complications of arterial/venous vessels during cannulation (e.g., aortic dissections, retroperitoneal hematoma, local dissections of femoral artery)	Control of adequate guiding wire position by TEE in the vena cava superior during venous cannulation and in the descending aorta during aortic cannulation Avoid oversizing of arterial cannula
	Insufficient venous drainage	Use of vacuum suction, additional venous neck cannula in obese patients

Potential pitfalls	Possible complications	Potential solutions
		If necessary insert an additional venous line through the TE-MVS access
		Stop CBP during application and release of X-clamp
	Aortic dissection during X-clamping	TEE control of adequate endo-balloon positioning and bilateral arterial pressure control
	Malpositioning of endo-clamp	Apply an additional reinforced suture, applied with X-clamp is still on on or under short run of low flow perfusion
	Complications from cardioplegia line	Avoid TE-MVS access in patient with aortic valve regurgitation > I°
	Improper administration of cardioplegia via the aortic root	
Insufficient set-up	Wrong intercostal space entered	Check chest X-ray for position of right diaphragm
		Enter chest with left index finger first an check for position of diaphragm
		"Enter the chest in women always one intercostal space higher than you think"
	Elevated right diaphragm interfering with access to the pericardium	retraction suture placed in the center of the diaphragm (pledged reinforced or pure-string suture, should be knotted to avoid bleeding), beware of liver damage
		incise pericardium at least 2 cm above the phrenic nerve
	Damage of phrenic nerve	check with thoracoscope for position of IMA before entering the chest
		Change angle/access of intercostal space for thoracoscope
	Damage of internal mammary artery by left atrial retractor	Avoid interference with thoracoscope and change position if necessary

Table 4. (Continued)

Potential pitfalls	Possible complications	Potential solutions
	Wrong position of throracoscope Wrong position of X-clamp	
Complications associated with mitral valve surgery	Improper presentation of the mitral valve by left atrial retractor Damage of circumflex artery Damage of conduction system Damage of aortic valve or aortic root	Retract left atrial appendage (LAA) to avoid damage by the X-clamp If the LAA is damaged, repair may be performed with the X-clamp still on through the transverse sinus. Use of special external closure devices for the LAA may be helpful Special devices are available to push the inferior part of the left atrium downwards Place annuloplasty suture in the posterior part for improved mitral valve exposure Use temporary retraction sutures on mitral valve leaflet or insert sizer for mitral valve replacement placed in the annulus to explore subvalvular apparatus Still on CPB: Check circumflex artery for flow before and after mitral valve surgery by TEE, check for wall motion abnormalities with TEE after mitral valve surgery Place pace maker wire with X-clamp still on Check for aortic valve competence and exclude aortic root hematoma with TEE

Potential pitfalls	Possible complications	Potential solutions
Varia	Re-expansion pulmonary edema	*Remark: Mechanism is unclear. Long CPB time, pulmonary hypertension, use of fresh frozen plasma, diabetes and chronic obstructive lung disease may be risk factors* Steroids may be used
	Air embolism	De-air via a separate line connected to a three-way cock of the cardioplegia root line. Change position of the table during de-airing maneuvers of the heart with the X-clamp still on Use Carbon dioxide insufflation into the chest with a flow of 3 L/min.
	Bleeding from the chest wall	Inspect every stab wound for hemostasis with thoracoscope, before chest is closed

LEARNING TE-MVS

To overcome the learning curve of TE-MVS, it is advisible to become aware of the potential pitfalls of this technique. The minimally invasive instruments should be used in the wet-lab to gain familiarity. They may also be beneficial in certain cases of median sternotomy, when standard instruments fall short due to inadequate length.

Practicing in a wet-lab on cadavers and attending wet-lab courses should be followed by visiting experienced centers in TE-MVS. It is also advisable to have a proctor while performing the first few cases. It is important to carefully select the first patients. Simple MV pathologies, ASD-closure, left atrial ablation procedures or left atrial myxomas may be cases to be chosen in the initial phase.

ROLE OF TRANSESOPHAGEAL ECHOCARDIOGRAPHY IN TE-MVS

TEE plays an important role in TE-MVS. It is mandatory for the evaluation of MV pathology and to assess the final operative result. In addition, verification of appropriate position of guide wires during venous and arterial cannulation and detection and exclusion of potential pitfalls should be routinely performed. This includes demonstration of the circumflex artery and its flow, evaluation of biventricular contractility, assessment of the aortic valve function, especially for its competency and the aorta and aortic root (see also table 4).

Adequate deairing should be performed under TEE control. Weaning from CPB and volume management in the initial phase after coming off pump is dependent on TEE, as cardiac filling cannot be judged by direct vision.

CONCLUSION

TE-MVS has grown significantly over the last decade. It has been shown to be equivalent to conventional MV surgery through a median sternotomy, whilst reducing ventilation and hospitalization time, decreasing blood loss and postoperative pain. The cosmetic results are excellent. This is why TE-MVS is frequently demanded by patients.

As specific surgical skills and the use of modified instruments and surgical equipment is necessary to perform TE-MVS, a learning curve still exists. To shorten the learning curve and to decrease the risk, surgeons should be aware of potential pitfalls associated with this procedure. It is hoped that with increasing expertise in a larger surgical community, TE-MVS will become the standard of care for MV surgery in selected patients within the next few years.

REFERENCES

[1] Nkomo, V.T., Gardin, J.M., Skelton, T.N., Gottdiener, J. S., Scott, C. G., Enriquez-Sarano, M., 2006. Burden of valvular heart diseases: a population-based study. *Lancet* 368:1005-1011.

[2] Lung, B., Vahanian, A., 2001. Epidemiology of valvular heart disease in the adult. *Nat Rev Cardiol* 8:162-172.

[3] STS National Database. Spring 2003, Executive Summary. Durham, NC: Duke Clinical Research Institute, 2003.

[4] Brunton, L. 1902. Preliminary note on the possibility of treating mitral valve stenosis by surgical methods. *Lancet* 159:352.

[5] Cutler, E.C., Levine, S.A., 1923. Cardiotomy and valvulotomy for mitral valve stenosis. *Boston Med Surg J* 188:1023.

[6] Souttar, H., 1925. The surgical treatment of mitral stenosis. *Brit Med J* 2:603.

[7] Navia, J. L., Cosgrove, D.M., 1996. "Minimally invasive mitral valve operations". *Ann Thorac Surg* 62:1542-1544.

[8] Cohn, L. H., Adams, D. A., Couper, G.S., Bichell, D. P., Rosborough, D. M., Sears, S. P., Aranki, S. F. 1997. Minimally invasive cardiac valve surgery improves patient satisfaction while reducing costs of cardiac valve replacement and repair. *Ann Surg* 226:421-428.

[9] Carpentier, A., Loulmet, D., Carpentier, A., Le Bret, E., Haugades, B., Dassier, P., Guibourt, P., 1996. Open heart operation under videosurgery and minithoracotomy. First case (mitral valvuloplasty) operated with success. *Comptes Rendus de l'Academie des Sciences III* 319:219-223.

[10] Carpentier, A., Loulmet, D., Aupècle, B., Kieffer, J. P., Tournay, D., Guibourt, P., Fiemeyer, A., Méléard, D., Richomme, P., Cardon, C. 1998. Computer assisted open heart surgery. First case operated on with success. *Comptes Rendus de l'Academie des Sciences* 321:437-442.

[11] Ritwick, B., Chaudhuri, K., Crouch, G., Edwards, J. R. M., Worthington, M., Stuklis, R. G. 2013. Minimally invasive mitral valve procedures: The current state. *Minimally Invasive Surg*, Article ID 679276, http://dx.doi.org/10.1155/2013/679276.

[12] Beckmann, A., Funkat, A. K., Lewandowski, J., Frie, M., Ernst, M., Hekmat, K., Schiller, W., Gummert, J. F., Cremer, J. T. 2015. Cardiac Surgery in Germany during 2014: A report on behalf of the German Society for Thoracic and Cardiovascular Surgery. *Thorac Cardiovasc Surg* 63;258-269.

[13] Luca, F., van Garsse, L., Rao, C. M., Parise, O., La Meir, M., Puntrello, C., Rubino, G., Carella, R., Lorusso, R., Gensini, G. F., Maessen, J. G. Gelsomino, S. 2013. Minimally invasive mitral valve surgery: a systematic review. *Minimally invasive Surg*, Article ID 179569, http://dx.doi.org/10.1155/2013/179569.

[14] Cao, C., Gupta, S., Chandrakumar, D., Nienaber, T. A., Indraratna, P., Ang, S. C., Phan, K., Yan, T. D. 2013. A meta-analysis of minimally invasive versus conventional mitral valve repair for patients with degenerative mitral disease. *Ann Cardiothorac Surg* 2:693-703.

[15] Ding,C., Jiang, D., Tao, K., Duan, Q., Li, J., Kong, M., Shen, Z., Dong, A. 2014. Anterolateral minithoracotomy versus median sternotomy for mitral valve disease: a meta-analysis. *J Zhejiang Univ-Sci B* 15:522-532.

[16] Schmitto, J. D., Mokashi, S. A., Cohn, L. H. 2010. Minimally-invasive valve surgery. *J Am Coll Cardiol* 56:455-462.

[17] Chirichilli, I., DÀscoli, R., Rose, D., Frati, G., Greco, E. 2013. Port access (Thru-Port System) video-assisted mitral valve surgery. *J Thorac Dis* 5:S680-S685.

[18] Woo, Y. J., Seeburger, J., Mohr, F. W. 2007. Minimally invasive valve surgery. *Semin Thorac Cardiovasc Surg* 19:289-298.

[19] Modi, P., Rodriguez, E., Hargrove III, W. C., Hassan, A., Szeto, W. Y., Chitwood, W. R. 2009. Minimally invasive video-assisted mitral valve surgery: a 12-year, 2-center experience in 1178 patients. *J Thorac Cardiovasc Surg* 137:1481-1487.

[20] Davierwala, P., Seeburger, J., Pfannmueller, B. Garbade, J., Misfeld, M., Borger, M. A., Mohr, F. W. 2013. Minimally invasive mitral valve surgery: "The Leipzig experience". *Ann Cardiothorac Surg* 2:744-750.

[21] Glauber, M., Miceli, A., Canarutto, D., Lio, A., Murzi, M., Gilmanov, D., Ferrarini, M., Farneti, P. A., Quaini, E. L., Solinas, M. 2015. Early and long-term outcomes of minimally invasive mitral valve surgery through right minithoracotomy: a 10-year experience in 1604 patients. *J Cardiothoracic Surg* 10:181-190.

[22] Downs, E. A., Johnston, L. E., LaPar, D. J., Ghanta, R. K., Kron, I. L., Speir, A. M., Fonner, C. E., Kern, J. A., Ailawadi, G., 2016. Minimally invasive mitral valve surgery provides excellent outcomes without increased cost: a multi-institutional analysis. *Ann Thorac Surg* 102:14-21.

[23] Melnitchouk, S. I., Seeburger, J., Kaeding, A. F., Miusfeld, M., Mohr, F. W., Borger, M. A. 2013. Barlow's mitral valve disease: results of conventional and minimally invasive repair approaches. *Ann Cardiothorac Surg* 2:768-773.

[24] Vallabhajosyula, P., Wallen, T., Pulsipher, A., Pitkin, E., Solometo, L. P., Musthaq, S., Fox, J., Acker, M., Hargrove III, W. C. 2015. Minimally invasive port access approach for reoperations on the mitral valve. *Ann Thorac Surg* 100:68-73.

[25] Moscarelli, M., Cerillo, A., Athanasiou, T., Farneti, P., Bianchi, G., Margaryan, R., Solinas, M. 2016. Minimally invasive mitral valve surgery in high-risk patients: operating outside the boxplot. *Interactive Cardiovasc Thorac Surg* 22:756-761.

[26] Holzhey, D. M., Seeburger, J., Misfeld, M., Borger, M. A., Mohr, F. W. 2013. Learning minimally invasive mitral valve surgery. A cumulative sum sequential probability analysis of 3895 operation from a single high-volume center. C*irculation* 128:483-491.

In: Encyclopedia of Surgery (22 Volume Set)
Editors: Andreas Lehrer and Kristin Mueller
ISBN: 978-1-53618-329-0
© 2020 Nova Science Publishers, Inc.

Chapter 422

ROBOTIC ASSISTED MITRAL VALVE SURGERY

Arman Arghami, Richard C. Daly*, Simon Maltais and Joseph A. Dearani
Cardiovascular Surgery Department of Mayo Clinic,
Rochester, MN, US

ABSTRACT

Robotic mitral valve (MV) repair is now routinely and safely performed for complete anatomic correction of all categories of MV leaflet prolapse, regardless of complexity. Robotic repair can be undertaken with or without concomitant tricuspid valve repair and atrial fibrillation ablation procedures, or even mitral valve replacement. The approach can been used to excilse benign tumors from the mitral valve or left atrium. Compared with conventional sternotomy, this procedure offers patients the advantages of reduced blood loss, lower risk of incisional infection and atrial fibrillation, shorter hospital length of stay, quicker return to normal activities, and a superior cosmetic result. Midterm quality outcomes after robotic MV repair are excellent, and thus the procedure may be particularly appealing in asymptomatic patients with preserved LV function undergoing correction of severe MR according to ACC/AHA class IIa Guideline recommendations to optimize long-term survival and decrease late heart failure risk.

Keywords: robotic surgery, minimally invasive, mitral valve, mitral regurgitation, mitral valve prolapse

INTRODUCTION AND HISTORY

Although it was one of the first intracardiac procedures to be performed (valvotomy in 1925), mitral valve (MV) surgery has evolved significantly in the last century. Since the invent of cardiopulmonary bypass (CPB) in the 1950s, MV procedures have been done routinely through median sternotomy. In 1995, surgeons started focusing on benefits of

* Corresponding Author's Email: rdaly@mayo.edu.

smaller sternal incisions and short CPB time. Soon thereafter mini-thoracotomy and video assisted minimally invasive operations were introduced. Special instruments were made to assist with the newly emerging field including the transthoracic aortic cross clamp (AoX) [1].

Robot-assisted MV repair (MVr) was introduced in the late 1990s with the goal of improving the technical precision of less-invasive surgical MV reconstruction. In 1998, Carpentier [2] in France and Mohr [3] in Gerrmany serially performed the first cardiac surgical procedures using the da Vinci Surgical System (Intuitive Surgical, Inc, Sunnyvale, Calif). Later, Lange's group in Munich [4] performed the first closed chest endoscopic MVr. In May 2000, under the first Food and Drug Administration (FDA) robotic investigational device protocol (G000023), Dr. Chitwood and Dr. Nifong and colleagues performed the first Robotic Assisted repair of MV using the da Vinci surgical system in the United States [1]. Their team then completed the the first FDA trial involving 20 patients to investigate the safety and efficacy of robotic MV procedures [1]. Ever since the utilization of this new tchnique has been increasing. Among 8814 MVr procedures reported to the Society of Thoracic Surgeon Database in 2013, 1132 (12.84%) were performed using robotic assistance [1, 5].

Recently, new information supporting the advantages of prompt surgical correction of primary severe mitral regurgitation (MR) to both prevent excess long-term mortality and diminish heart failure risks [6, 7] has led to a further evolution in thinking regarding the ideal timing for MVr. Further, MVr is now reproducible with approximately 99%certainty; it is effective, durable, and safe with very low risks of postoperative mortality and morbidity, particularly in high-volume centers [8, 9]. This has placed pressure on procedures providing better cosmetic results and pain and discomfort, and shorted hospital stay and recuperation, while maintaining benefits and results of a more traditional open approach.

There are several potential advantages of robotic MVr versus standard thoracoscopic approaches. First, enhanced surgical dexterity is allowed, facilitating precise movements of instruments in the closed chest and avoiding the fulcrum effect characteristic of long shafted endoscopic instruments experienced during minimally invasive procedures. Second, high-definition 3-dimensional visualization places the surgeon inside the left atrium with the line of vision parallel to the flow of blood into the valve. Visualization of the subvalvular apparatus is superior to that obtained using other approaches, so that any type of myxomatous pathology including fibroelastic deficiency and Barlow's disease can be treated with the standard techniques of triangular resection, insertion of artificial chordae, edge-to-edge repair or commissural plication. Third, the cosmetic results are appreciated by both female and male patients, particularly in patients with prior breast reconstruction Because of the reduced surgical trauma and avoidance of the median sternotomy, the requirement of heterologous blood products (7%) and the incidence of atrial fibrillation (AF) (odds ratio, 0.79) and postoperative pain have been reported to be lower in minimally invasive mitral procedures [5, 10, 11].

In this chapter we review (1) indication and contraindication for robotic MVr, (2) the surgical technique, and (3) describe the early postoperative and long-term outcomes and advantages of this technology.

EVALUATION

Workup

All patients undergo an ECG gated computed tomography (CT) angiography of the chest, abdomen and pelvis. This screens out significant coronary artery disease and also allows the surgeon to determine the left or right dominance coronary system which would be of great importance inregards to suturing around the mitral annulus. The CT angiogram also screens for and assesses the extent of aortoiliac atherosclerosis for peripheral cannulation. These findings along with cardiac multidetector CT looking for MV annular calcification could potentially change the recommended surgical approach from minimally invasive robotic surgery to standard sternotomy-based surgery [12]. The CT scan is also helpful in patients with sternal or thoracic deformities to help determine whether robotic instrument trajectories will be compromised. Patients with significant risk factors for carotid/peripheral vascular disease should be screened by CT/ultrasound/Magnetic Resonance Imaging (MRI). If there is any concern about significant coronary artery disease on the CT scan, formal coronary angiography is performed. A right heart catheterization may be indicated in patients who have significant pulmonary hypertension, especially with depressed right ventricular (RV) function. An excellent transthoracic echocardiography or transesophageal echocardiography (TEE) study should be performed to evaluate valve anatomy, pathology, suitability for repair, left ventricular (LV) function, ascending aortic size, aortic valve disease and competency, tricuspid valve (TV) competence and presence of patent foramel ovale. A TEE would be nescessary if there are questions regarding the mechanism of mitral insufficiency and ability to repair. In the operating room, TEE to delineate MV anatomy and pathology as well as postoperative evaluation of the repair is essential [5].

Indications

As for many other surgical procedures, robotic MVr was initially reserved for a very selective group of patients. The selection criteria has widened as surgeons have refined the techniques and gained confidence. Robotic MVr is appropriate for both degenerative and functional MV disease. Furthermore, MV replacement, concomitant Cox-Maze IV procedures using cryoablation, TV repair rand tumor resection (papillary fibroelastoma) all have been reported and can be performed with relative ease [5, 13-15].

Although we won't discuss the indications for MVr in this chapter, it's worth noting that there is a recent interest in early referral for MVr. Large series have shown excellent late outcomes of MVr using standardized surgical techniuqes [7, 8] along with reduction annuloplasty support [16, 17]. There may be a few contraindications to performing robotic assited MV surgery. Patient selection involves assesment of operative risks and mitral anatomy/pathology. Minimally invasive appraches, including robot assisted approaches, inherently involve less access to the heart. Factors such as signifcant aortic insufficiency, LV dilatation, reduced LV and/or RV function may increase the risk for LV distension or difficulty with cardioversion and may have a more profound impact on risk than these conditions would have in an open procedure.

It should be kept in mind that the goal of patient evaluation and selection, as well as preparation for and conduct of the operation should all be done with the intention to keep surgical risk as low as it is for a standard open procedure. Attention to detail throughout the process is critical.

The contraindications for robotic MV surgery can be broken down into four categories; (1) Difficulty with access through the right chest: this can include previous right thoracotomy, poor lung function with intolerance to single lung ventilation, chest wall deformity and body habitus including severe obesity (2) Need for concomitant operation: such as CABG or other valve surgeries excluding TV repair (3) Difficulties with cannulation or retrograde aortic perfusion: significant aortoiliac atherosclerotic disease. The cannulation site of the proximal ascending aorta for cardioplegia and venting is more risky and can be more difficult to repair if there is significant aortic root/ascending aortic dilation (4) General contraindication for MVr.

Table 1. Contraindications to robotic mitral valve repair

Right chest access	Contraindication
Previous right thoracotomy	Strong
Severe pulmonary dysfunction	Strong
Moderate pulmonary dysfunction	Relative
Chest wall deformity and body habitus	Relative
Previous sternotomy	Relative
Need for concomitant operation	
Coronary artery bypass	Strong
Severe aortic valve insufficiency	Strong
Mild to moderate aortic valve insufficiency	Relative
Additional heart valve disease	Relative
Cannulation	
Sever peripheral arterial disease	Strong
Limited peripheral vascular disease	Relative
Significant aortic root/ascending aortic dilation	Strong
Calcification of aortic root/ascending aorta	Strong
MV repair	
Mitral annular calcification	Strong
General	
Myocardial infarction or ischemia < 30d	Strong
Symptomatic cerebrovascular disease or stroke < 30d	Strong
Right ventricular dysfunction	Strong
Pulmonary hypertention (fixed >60 torr)	Strong
Severe liver or renal dysfunction	Strong
Significant bleeding disorder	Strong
Asymptomatic cerebrovascular disease	Relative
Poor LV function (EF<50%)	Relative
Pulmonary hypertention (variable >50 mmHg)	Relative

TECHNIQUE

Although a few variations exist in robotic MV surgery technique, such as totally endoscopic technique, herein we describe the robotic techniuqe that is used in our institution.

Patient Positioning

The patient is placed in a supine position with a roll under the right scapula, elevating the right chest to approximately 30-45 degrees above the horizontal plane in order to achieve optimal exposure of the right anterolateral hemithorax for direct access to the MV. The right arm is allowed to drape posteriorly and secured at a level below the posterior axillary line to allow the shoulder to fall back and expose the right axilla [18] (Figure 1).

Figure 1. Patient positioning: A roll is placed under the right shoulder and right arm is allowed to drape posteriorly and secured at a level below the posterior axillary line to allow the shoulder to fall back and expose the right axilla.

Port Placement

With single left lung ventilation the right lung is deflated and right thoracic access ports are fashioned. A 2-3 cm working port is created lateral to the right nipple in the fourth intercostal space (ICS) (Figure 2 and 3). A camera port is placed between the working port and the nipple areaola in the same (fourth) ICS. Alternatively, the working port can be extended anteriorly a short distance and the camera placed through the working port. If the right hemidiaphragm is interfering with the exposure, a pledgeted 2-0 silk suture is passed through the central fibrous portion of the diaphragm medial and posterior to the dome of the diaphragm and exteriorized using a laparoscopic suture passer, through the right chest anteriorly about the 6th ICS under tension.

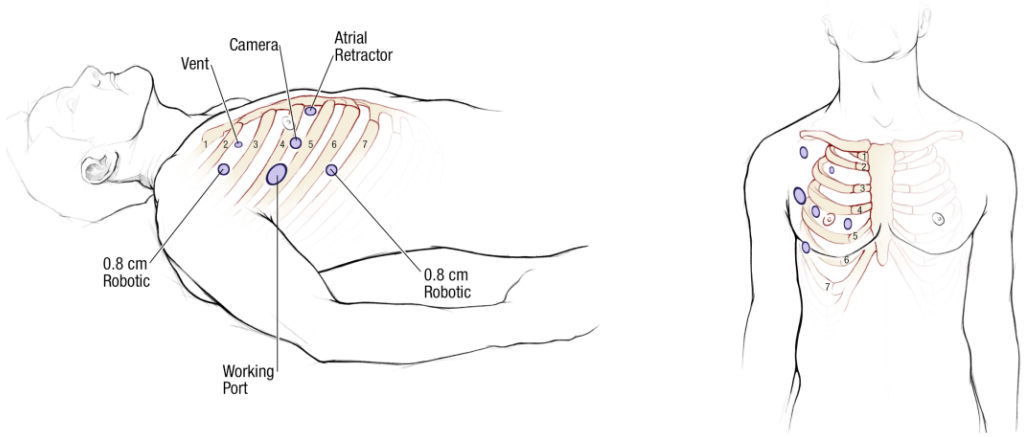

Figure 2. Schematic drawing of the port placement and their relation to the chet wall.

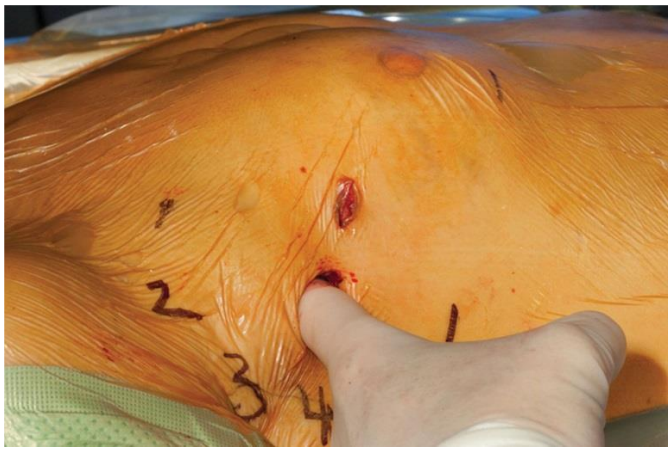

Figure 3. Working port placement, lateral to the nipple (rib numbers have been marked).

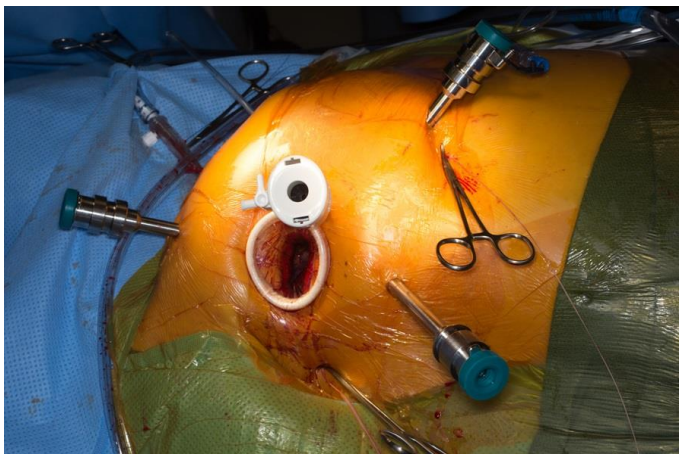

Figure 4. Intraoperative photo with all ports in place prior to docking of the robot. Note the location of the diaphragm (anterior) and pericardial (posterior) retraction sutures.

The pericardium is opened longitudinally under direct vision 4 cm anterior to the phrenic nerve and its posterior edge is suspended on stay sutures, which are exteriorized through the fourth ICS posterior to the working port. A site is selected in the right third ICS lateral to the right internal thoracic vessels to allow direct trajectory of a long cardioplegia/vent catheter to the ascending aorta. A grasper is passed through this site and a long vent catheter (Medtronic, Minneapolis, MN, USA) is pulled through the chest wall. The catheter is then flushed in a retrograde manner to clear fat or soft tissue debris. We also employ a cap over the cannula to further minimize chances of fat and debris getting into the tubing. The position of this catheter is important. The ideal location should allow for a perpendicular position to the desired aortic vent site. A common mistake is to have the cannula come in from further cephalad which may direct the cannula insertion needle toward the aortic valve. This is a concern because the cardioplegia/vent cannula is placed low on the ascending aorta because the cephalad space for placing the AoX is limited by the right pulmonry artery in the transverse sinus. The snare for the cardioplegia/vent catheter is brought out through the working port. With direct palpation through the working port, a 0.8-cm port for the left robotic arm is placed two interspaces above the working port and about 3 cm anterior to the anterior axillary line. Another 0.8-cm port for the right robotic arm is placed two interspaces below the working port (6th intercostal space) at the anterior axillary line. The left atrial retractor port is placed about 4 cm medially to the camera port in the fourth interspace, in a manner that avoids injury to the internal mammary artery/vein, usually in the inframammary crease. The Alexis soft tissue retractor (AppliedMedical, Rancho Santa Margarita, CA) (size XX-Small, 1–3 cm) is then positioned inside the working port (Figure 4). This facilitates repetitive movements of instruments into and out of chest also prevents tissue debris from entering the heart [18].

Cannulation, Cardiopulmonary Bypass and Myocardial Protection

The right common femoral vessels are exposed through a 1- to 2-cm oblique incision 2 cm cranial and parallel to the inguinal crease. The incision should not extend lateral to the femoral artery to avoid injury to the superficial cutaneous nerve which can affect sensation in the medial thigh territory. Two purse-string sutures are placed in the right common femoral artery and a single purse-string in the right common femoral vein.

A 22-F or 25-F multistage venous cannula is inserted using the Seldinger technique with echocardiographic guidance and advanced 4 cm superior to the junction between the superior vena cava (SVC) and right atrium. Another 16-F or 18-F cannula is percutaneously exchanged over a wire inserted through the previously placed 8.5-F right internal jugular sheath into the SVC. TEE is used to confirm the final position and ensure the absence of overlap between the two venous cannulae. A 17- or 19-F femoral arterial cannula is placed via the right common femoral artery. Echocardiographic guidance assures position of the arterial guidewire in the descending aorta before full femoral artery cannulation. Once the activated clotting time is adequate and the robot is docked (Figure 5), CPB is initiated while monitoring the descending thoracic aorta by TEE to confirm normal flow and the absence of a dissection flap. Patient temperature is allowed to drift to 34°C. With the right atrium empty, the pericardiotomy is extended cranially over the ascending aorta. A 3-0 polypropylene purse-

string suture with a felt pledget is placed in the ascending aorta. The previously placed cardioplegia tack vent is inserted through the purse-string and snared into place.

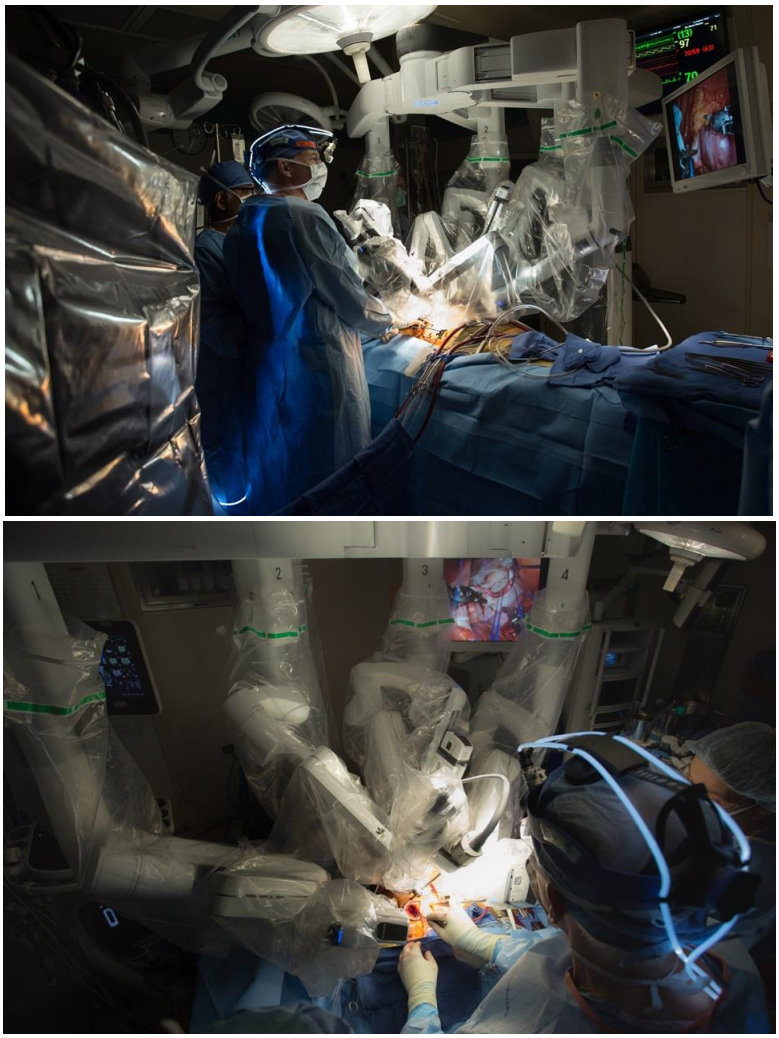

Figure 5. Intraoperative photo with robotic arms docked in place.

The transthoracic AoX is inserted through a small stab wound in the right axilla. A superior and posterior position of the croos clamp will help to avoid conflict with the left robotic arm. The AoX is positioned through the transverse sinus, taking care to avoid injury of the right pulmonary artery and left atrial appendage. The heart is arrested with 1 liter of cold blood high potassium cardioplegia, which is repeated every 20 min throughout the AoX time. Recently, we have used a single dose of del Nido cardioplegia solution.

The left atriotomy is carried out at the interatrial groove allowing a sufficient cuff on the anterior surface of the right pulmonary veins to permit closure. The oblique sinus is opened posterior to the inferior vena cava to reduce blood pooling and help with exposure. The robotic left atrial retractor is positioned and the MV is analysed [18].

Leaflet Repair and Annuloplasty Band

Our philosophy is that the highest quality MVr techniques with proven durability should not be altered to facilitate performance of the operation through small incisions. We therefore employ exactly the same standard techniques of MVr regardless of the surgical approach as previously published [19, 20]. For posterior leaflet disease, we typically perform standard triangular resection with two-layer running polypropylene reconstruction. For anterior leaflet prolapse, we use artificial chords with polytetrafluoroethylene (Gore-Tex; W.L. Gore & Associates, Inc., Flagstaff, AZ, USA). Patients with bileaflet prolapse undergo prolapse correction utilizing a combination of these techniques. Repair adjuncts include commissural or leaflet plication, leaflet shortening/ ventricularisation and posterior leaflet neochord placement - all of which are employed as indicated. All repairs are supported with a standard length 63 mm posterior annuloplasty band inserted in the standard manner with 2.0 Ethibond or Prolene interrupted sutures, anchored at the left and right fibrous trigones, that are tied by the bedside surgeon. Once the repair is tested with saline insufflation and found to be perfect, the left atrium is closed with running 3.0 prolene sutures starting at both ends of the left atriotomy and the sutures are tied in the middle. After deairing of the left heart, the AoX is removed. The patient is separated from CPB and TEE is performed to assess the adequacy of the repair and atrial suture line is inspected for hemostasis. CPB is temporarily resumed for safe removal of the cardioplegia/vent tack, tying of the stitch and placement of a reinforcing stitch. Decannulation and reversal of heparin are then performed following which, meticulous haemostasis is ensured. A 19-F soft silicone (Blake; Ethicon) pericardial drain inserted through the oblique sinus after which the pericardium is closed, and a 32-F right pleural chest tube is positioned in the posterior thorax is and secured in place. Incisions are closed in the standard manner [18].

OUTCOMES

Recent data point to increasing number of MV procedures being done by minimally invasive and robotic techniques. In a recent report amongst 8,814 MVr operations in USA, 1,132 (12.84%) were done using robotic assistance in 2013; similar to a previously reported trend [21, 22]. There is an abundance of published literature on outcomes of robotic MV surgery. Although a randomized clinical trial is missing, the outcomes are undeniable.

In 2015, outcomes were published from our institution of 487 robotic MV procedures. We reported a 99.5% 5 year survival, 94.6% 5 year freedom from MR and 97.7% freedom from reoperation at 5 years. The stroke risk was 0.8%. The complexity of technical repair did not appear to influence MR recurrence or MV reoperation risk [17]. In 2015, Murphy and colleagues [23], reported their exxperience with 1257 robotic mitral valve procedures. Their operative mortality was 0.9% and at a mean of 50 months followup, overall survival was 97.2%, and stroke risk of 0.7%. In their series 3.9% required reoperation. They commented that with increasing experience, the reoperation rate dropped to 0.9% in the second half of the study period with mean followup of 29 months. More than half of the recurrence and reoperations were due to prolapse or ring dehiscence. The latter decreased after abandoning the nitinol clips.

In earlier studies as in the report by Chittwood and colleagues in 2008 of 300 consecutive robotic MV operations, outcomes reported were 30-day mortality of 0.7%, 5 year survival of 96.6% and 93.8% freedom from reoperation at 5 years. Stroke risk was 0.7% and transient ischemic attack of 1%. Myocardial infarction (MI) occurred in 2.3% [24]. In 2014 Ramsey and colleagues [25] reported on their 300 consecutive robotic MV procedures. Thirty day mortality was 0.3%, risk of stroke 1.7%, reversible neurologic injury 0.7%, and MI occurred in 0.3%. All of their results improve in the second half of their cohort as the operative experience increased [25].

Several studies have demonstrated that although initial AoX, CPB and total operative times were longer as programs began, there were no differences between groups undergoing robotic versus non robotic MVr as the program gained experience [8]. The overall median AoX time of 53-82 minutes, and perfusion time was 76-114 minutes. Ramsey and colleagues demostrated that implementing a vigrous regimented stepwise approach of training new surgeons, resulted in shorted learning cruve with added benefit of preventing complications that are seen with novice surgeons. Their results reduced operating time by 25% and CPB time by 40% compared to first case of each surgeon [25].

Other than the discussed complications, there are few other less common complications, some specifically related to robotic MV operations. These include CPB access complications such as iliofemoral artery dissection, aortic dissection, groin hematoma, infection or nerve damage during dissection. Each of these complications has been reported in less than 1% in the reported literature [23, 26]. MI with involvement of the circumflex artery especially in left coronary dominant system patient has been reported 0-3% [8]. Another unique complication reported in some series is unilateral pulmonary edema up to 1.4%. Moss and colleague suggested a modification to patient positioning and perfusion and ventilation and have significantly limited this complication [27].

Comparison with Open Mitral Repair

Recent landmark open MVr outcomes published by David et al. [28] detailed long-term outcomes of 840 patients undergoing MVr for MR attributable to degenerative disease with 10.4-year median follow-up. Freedom from recurrent moderate or severe MR at 20 years was 69.2%. The risk of mitral reoperation was 5.9%. As mentioned before, robotic outcomes at least until 5 years followup in recent publications are similar [17]. In 2011, Mihaljevic et al. [29], in their series of 759 patient with MV procedures, compared robotic MVr to sternotomy, mini sternotomy and mini thoracotomy. Their repair results were similar between the groups and overal complication rates were also similar. CPB time was longer (42 min longer) for robotic compared to sternotomy, and AoX time was 26 minutes longer. The complication rate was mostly the same. Robotic MV surgery patients had the lowest incidence of AF and had shorter hospital stay. They concluded that longer procedure time is compensated by less invasive approach and shorter hospital stay [29].

Besides obvious cosmetic benefit and perhaps less discomfort, robotic MVr has been shown to be associated with a shorter hospital length of stay (3-4 days) and quicker return to work and perhaps improved quality of life [8, 10, 17, 23].

LIMITATIONS AND RISKS

Surgery using robotic instruments has 2 notable limitations. First, the robotic surgeon has no sense of proprioception. Robotic surgeons must be highly disciplined to avoid moving a robotic instrument unless it is in the endoscopic visual field to avoid inadvertent injuries to intra-thoracic structures with unwanted movements of robotic arms especially outside of the visual field. Newer model robotic systems have visual aids to allow the surgeon to locate instruments outside the endoscopic field without invoking the help of the patient-side assistant. Second, the robotic instruments have no tactile feedback. In practice, this has not been a practical limitation. Robotic surgeons also develop an "ocular tactility" as they learn to use visual cues to guide their tissue handling, similar to that used by professors in the training of younger surgeons [5]. Limitations related to minimal incisions and reduced cardiac access have been discussed above.

Reduced tactile feedback is especially important during annular suturing and avoidance of circumflex artery injury or kinking which have been reported. So special attention should be made to ECG changes post-op and cardiac catheter should be performed immediately if there is any hint of coronary artery injury. Kinking and not a complete blockage is common and this is usually amenable to stenting. As is always the subject of debate, robotic surgery has some upfront expenses but studies have shown that by reduction of ICU stay and hospital stay and efficiency of the high volume centers, robotic surgery has reduced the cost to similar levels of open operations ($30,606 vs $31,310). In addition these patients return to work sooner which resutls in overal better economic sense [5, 9, 30].

REFERENCES

[1] Nifong, LW; Chu, VF; Bailey, BM; Maziarz, DM; Sorrell, VL; Holbert, D; Chitwood, WR. Jr. Robotic mitral valve repair: experience with the da Vinci system. *Ann Thorac Surg*, 2003, 75(2), 438-42.

[2] Carpentier, A; Loulmet, D; Aupècle, B; Kieffer, JP; Tournay, D; Guibourt, P; Fiemeyer, A; Méléard, D; Richomme, P; Cardon, C. [Computer assisted open heart surgery. First case operated on with success]. *C R Acad Sci III*, 1998, 321(5), 437-42.

[3] Mohr, FW1; Falk, V; Diegeler, A; Walther, T; Gummert, JF; Bucerius, J; Jacobs, S; Autschbach, R. Computer-enhanced "robotic" cardiac surgery: experience in 148 patients. *J Thorac Cardiovasc Surg*, 2001, 121(5), 842-53.

[4] Mehmanesh, H; Henze, R; Lange, R. Totally endoscopic mitral valve repair. *J Thorac Cardiovasc Surg*, 2002, 123(1), 96-7.

[5] Suri, RM; Dearani, JA; Mihaljevic, T; Chitwood, WR; Jr. Murphy, DA; Trento, A; Javadikasgari, H; Burkhart, HM; Nifong, WL; Daly, RC; Gillinov, AM. Mitral valve repair using robotic technology: Safe, effective, and durable. *J Thorac Cardiovasc Surg*, 2016, 151(6), 1450-4.

[6] Nishimura, RA; Otto, CM; Bonow, RO; Carabello, BA; Erwin, JP; 3rd, Guyton, RA; O'Gara, PT; Ruiz, CE; Skubas, NJ; Sorajja, P; Sundt, TM; 3rd, Thomas, JD; Anderson, JL; Halperin, JL; Albert, NM; Bozkurt, B; Brindis, RG; Creager, MA; Curtis, LH; DeMets, D; Guyton, RA; Hochman, JS; Kovacs, RJ; Ohman, EM; Pressler, SJ; Sellke,

FW; Shen, WK; Stevenson, WG; Yancy, CW. American College of Cardiology.; American College of Cardiology/American Heart Association.; American Heart Association. 2014 AHA/ACC guideline for the management of patients with valvular heart disease: executive summary: a report of the American College of Cardiology/American Heart Association Task Force on Practice Guidelines. *J Am Coll Cardiol*, 2014, 63(22), 2438-88.

[7] Suri, RM; Vanoverschelde, JL; Grigioni, F; Schaff, HV; Tribouilloy, C; Avierinos, JF; Barbieri, A; Pasquet, A; Huebner, M; Rusinaru, D; Russo, A; Michelena, HI; Enriquez-Sarano, M. Association between early surgical intervention vs watchful waiting and outcomes for mitral regurgitation due to flail mitral valve leaflets. *JAMA*, 2013, 310(6), 609-16.

[8] Suri, RM; Burkhart, HM; Daly, RC; Dearani, JA; Park, SJ; Sundt, TM; 3rd, Li, Z; Enriquez-Sarano, M; Schaff, HV. Robotic mitral valve repair for all prolapse subsets using techniques identical to open valvuloplasty: establishing the benchmark against which percutaneous interventions should be judged. *J Thorac Cardiovasc Surg*, 2011, 142(5), 970-9.

[9] Suri, RM; Thompson, JE; Burkhart, HM; Huebner, M; Borah, BJ; Li, Z; Michelena, HI; Visscher, SL; Roger, VL; Daly, RC; Cook, DJ; Enriquez-Sarano, M; Schaff, HV. Improving affordability through innovation in the surgical treatment of mitral valve disease. *Mayo Clin Proc*, 2013, 88(10), 1075-84.

[10] Suri, RM; Antiel, RM; Burkhart, HM; Huebner, M; Li, Z; Eton, DT; Topilsky, T; Sarano, ME; Schaff, HV. Quality of life after early mitral valve repair using conventional and robotic approaches. *Ann Thorac Surg*, 2012, 93(3), 761-9.

[11] Ryan, WH; Brinkman, WT; Dewey, TM; Mack, MJ; Prince, SL; Herbert, MA. Mitral valve surgery: comparison of outcomes in matched sternotomy and port access groups. *J Heart Valve Dis*, 2010, 19(1), 51-8.

[12] Moodley, S; Schoenhagen, P; Gillinov, AM; Mihaljevic, T; Flamm, SD; Griffin, BP; Desai, MY. Preoperative multidetector computed tomography angiography for planning of minimally invasive robotic mitral valve surgery: impact on decision making. *J Thorac Cardiovasc Surg*, 2013, 146(2), 262-8.

[13] Arsalan, M; Smith, RL; Squiers, JJ; Wang, A; DiMaio, JM; Mack, MJ. Robotic Excision of a Papillary Fibroelastoma of the Mitral Chordae. *Ann Thorac Surg*, 2016, 101(6), 187-8.

[14] Nifong, LW; Rodriguez, E; Chitwood, WR. Jr. 540 consecutive robotic mitral valve repairs including concomitant atrial fibrillation cryoablation. *Ann Thorac Surg*, 2012, 94(1), 38-42.

[15] Lewis, CT; Stephens, RL; Tyndal, CM; Cline, JL. Concomitant robotic mitral and tricuspid valve repair: technique and early experience. *Ann Thorac Surg*, 2014, 97(3), 782-7.

[16] Chatterjee, S; Rankin, JS; Gammie, JS; Sheng, S; O'Brien, SM; Brennan, JM; Alexander, JC; Thourani, VH; Pearson, PJ; Suri, RM. Isolated mitral valve surgery risk in 77,836 patients from the Society of Thoracic Surgeons database. *Ann Thorac Surg*, 2013, 96(5), 1587-94.

[17] Suri, RM; Taggarse, A; Burkhart, HM; Daly, RC; Mauermann, W; Nishimura, RA; Li, Z; Dearani, JA; Michelena, HI; Enriquez-Sarano, M. Robotic Mitral Valve Repair for

Simple and Complex Degenerative Disease: Midterm Clinical and Echocardiographic Quality Outcomes. *Circulation*, 2015, 132(21), 1961-8.

[18] Algarni, KD; Suri, RM; Daly, RC. Robotic-assisted mitral valve repair: surgical technique. *Multimed Man Cardiothorac Surg*., 2014 Nov 1, 2014, pii: mmu022. doi: 10.1093/mmcts/mmu022. Print 2014.

[19] Suri, RM; Schaff, HV; Dearani, JA; Sundt, TM; 3rd, Daly, RC; Mullany, CJ; Enriquez-Sarano, M; Orszulak, TA. Survival advantage and improved durability of mitral repair for leaflet prolapse subsets in the current era. *Ann Thorac Surg*, 2006, 82(3), 819-26.

[20] Brown, ML; Schaff, HV; Li, Z; Suri, RM; Daly, RC; Orszulak, TA. Results of mitral valve annuloplasty with a standard-sized posterior band: is measuring important? *J Thorac Cardiovasc Surg*, 2009, 138(4), 886-91.

[21] Gammie, JS; Zhao, Y; Peterson, ED; O'Brien, SM; Rankin, JS; Griffith, BP. J. Maxwell Chamberlain Memorial Paper for adult cardiac surgery. Less-invasive mitral valve operations: trends and outcomes from the Society of Thoracic Surgeons Adult Cardiac Surgery Database. *Ann Thorac Surg*, 2010, 90(5), 1401-8.

[22] Taggarse, AK; Suri, RM; Daly, RC. How has robotic repair changed the landscape of mitral valve surgery? *Ann Cardiothorac Surg*, 2015, 4(4), 358-63.

[23] Murphy, DA; Moss, E; Binongo, J; Miller, JS; Macheers, SK; Sarin, EL; Herzog, AM; Thourani, VH; Guyton, RA; Halkos, ME. The Expanding Role of Endoscopic Robotics in Mitral Valve Surgery: 1,257 Consecutive Procedures. *Ann Thorac Surg*, 2015, 100(5), 1675-81.

[24] Chitwood, WR; Jr, Rodriguez, E; Chu, MW; Hassan, A; Ferguson, TB; Vos, PW; Nifong, LW. Robotic mitral valve repairs in 300 patients: a single-center experience. *J Thorac Cardiovasc Surg*, 2008, 136(2), 436-41.

[25] Ramzy, D; Trento, A; Cheng, W; De Robertis, MA; Mirocha, J; Ruzza, A; Kass, RM. Three hundred robotic-assisted mitral valve repairs: the Cedars-Sinai experience. *J Thorac Cardiovasc Surg*, 2014, 147(1), 228-35.

[26] Ward, AF; Loulmet, DF; Neuburger, PJ; Grossi, EA. Outcomes of peripheral perfusion with balloon aortic clamping for totally endoscopic robotic mitral valve repair. *J Thorac Cardiovasc Surg*, 2014, 148(6), 2769-72.

[27] Moss, E; Halkos, ME; Binongo, JN; Murphy, DA. Prevention of Unilateral Pulmonary Edema Complicating Robotic Mitral Valve Operations. *Ann Thorac Surg*, 2017, 103(1), 98-104.

[28] David, TE; Armstrong, S; McCrindle, BW; Manlhiot, C. Late outcomes of mitral valve repair for mitral regurgitation due to degenerative disease. *Circulation*, 2013, 127(14), 1485-92.

[29] Mihaljevic, T; Jarrett, CM; Gillinov, AM; Williams, SJ; DeVilliers, PA; Stewart, WJ; Svensson, LG; Sabik, JF. 3rd, Blackstone EH. Robotic repair of posterior mitral valve prolapse versus conventional approaches: potential realized. *J Thorac Cardiovasc Surg*, 2011, 141(1), 72-80.

[30] Mihaljevic, T; Koprivanac, M; Kelava, M; Goodman, A; Jarrett, C; Williams, SJ; Gillinov, AM; Bajwa, G; Mick, SL; Bonatti, J; Blackstone, EH. Value of robotically assisted surgery for mitral valve disease. *JAMA Surg*, 2014, 149(7), 679-86.

In: Encyclopedia of Surgery (22 Volume Set)
Editors: Andreas Lehrer and Kristin Mueller
ISBN: 978-1-53618-329-0
© 2020 Nova Science Publishers, Inc.

Chapter 423

REDO MINIMALLY INVASIVE MITRAL VALVE SURGERY

Marco Solinas, MD and Michele Murzi*, PhD
Adult Cardiac Surgery Department,
Fondazione Toscana Gabriele Monasterio,
Massa, Italy

ABSTRACT

In recent years, less invasive procedures have emerged as the new trend in mitral valve surgery. The conviction that minimally invasive mitral valve surgery (MIMVS) could be performed with similar hospital mortality versus standard approach, but with less blood transfusion, earlier recovery of daily activities and with higher patient satisfaction, have driven its diffusion in most centers worldwide. In 2003, we started our minimally invasive mitral valve surgery program and from the beginning of our experience a video-assisted right thoracotomy approach has become our first choice for re-operative mitral valve surgery. In the present chapter we review and discuss potential advantage and pitfall of minimally invasive approaches for re-operation on the mitral valve.

Keywords: mitral valve, minimally invasive cardiac surgery, re-operation

INTRODUCTION

An increasing number of patients require redo-mitral valve surgery because patients continue to live longer post-operatively and bioprosthetic valves have become increasingly popular. Furthermore, a large proportion of patients treated with restrictive annuloplasty for functional mitral valve disease, develop recurrence of mitral regurgitation (MR) requiring

* Corresponding Author's Email: michele.murzi@fgm.it.

surgery. Re-operative mitral valve (MV) operations can be particularly difficult in patients with patent coronary bypass grafts, where the risk of graft injury is a significant concern, or previous aortic valve replacement, where exposure of the MV through a sternotomy can be very challenging. Redo sternotomy may also be difficult in patients with vascular structures (brachiocephalic vein, ascending aorta, RV) that lie directly behind the sternum or in patients who had previous sternal wound infections or chest radiotherapy. To improve patient care and reduce the perioperative and intraoperative risk of resternotomy, new treatment strategies may be required for such patients. At our center, a video-assisted right mini-thoracotomy (MIMVS) has become the approach of choice for redo MV operations, since 2003 [1]. Early in our experience, we recognized the advantages of this technique in re-operative procedures. Indeed, with this access, the heart, great vessels, and patent bypass grafts are far away from the working field. Less need for surgical dissection can prevent post-operative bleeding, transfusion requirements and need for re-exploration. Furthermore, this approach produces less tissue trauma, less post-operative pain and greater stability of the bony thorax that usually translates in an early mobilization and recovery of the daily activities [2, 3].

PATIENT SELECTION

Contraindication to Redo MIMVS

Clinical evaluation of candidates for redo MIMVS should start with a careful clinical history and assessment of patients. Despite the fact that MIMVS approach can be offered to the vast majority of the patients requiring redo-MV intervention, surgeons embracing this technique should be aware of few conditions that must be considered as potential contra-indications:

1. Chest wall abnormalities such as pectus excavatum, or pronounced scoliosis: in these cases exposure of the MV can be extremelly difficult.
2. Patients with osteogenic disorders, i.e., osteogenesis imperfecta, should be avoided.
3. Known disease of the pleura or the lung, such as previous pleuritis, pleural calcifications or moderate-severe chronic obstructive pulmonary disease (COPD),
4. Previous right chest surgery.
5. Previous right chest radiotherapy.

All these cases should be evaluated on an individual basis.

PRE-OPERATIVE IMAGING

Chest X-Ray

Chest radiography is a simple yet informative tool for patients' evaluation. In the postero-anterior projection, along with classical radiological signs, we evaluate the ascending aorta

profile, calcification of the aorta, size of the intercostal spaces, pleural calcifications or adhesions, hilar congestion, diffuse lung disease or elevated hemidiaphragm; also abnormalities of ribs or severe deformations of the spine are evident. In lateral projection, the antero-posterior diameter of the thorax and the height of the diaphragm are assessed and it is important to correlate the actual location of abnormalities seen on the postero-anterior view.

Computed Tomography

Computed tomography (CT scan) is a foundamental tool for preoperative planning of the surgical access. In our institution, all the patients scheduled for a redo MIMVS routinely undergo contrast enhanched 64-slice CT scan (Toshiba Aquilon ONE; Toshiba Medical System, Tokio, Japan) to evaluate the anatomic relationship between the intercostal spaces (ICS), sternum, ascending aorta and MV. Three-dimensional reconstruction of contrast-enhanced CT scan can easily give the surgeon an idea of the operative field. Furthermore it allows to better understand the course of patent bypass grafts and their relationship to the heart.

Ascending aorta calcification is not considered an absolute contraindication for redo MIVMS, but it should be dealt with, with special caution. The CT should visualize the entire vascular tree upto the femoral artery and/or a femoral arterial duplex may be obtained to elucidate the quality of the femoral vessels. Lung and pleural imaging are of utmost importance; CT scan can identify pleural adhesions, plaques, lung bullae, blebs and also lung parenchymal disease; all these features must be taken into account and not overlooked by the surgeon planning redo-MIMVS.

Echocardiography

Standard preoperative trans-thoracic echocardiogram is obtained for all patients, according to the current guidelines [4]. Taking in mind that in a large proportion of this subset of patients, myocardial protection is obtained with hypothermic ventricular fibrillation (VF), information on the status of the aortic valve is crucial. The presence of more than moderate aortic regurgitation (AR) is considered a relative contra-indication for redo MIMVS because of the risk of inadequate cardioplegia delivery and left ventricular distension. Hence, accurate assessment of AR is mandatory to avoid unplanned conversion to a sternotomy during the procedure.

Lung Anatomy and Pulmonary Function

In our experiencec, the majority of redo MIMVS operations have been carried out without single lung ventilation; mainly to avoid potential complications from lung reperfusion, atelectasis and laryngo-tracheal trauma. Severe COPD, bullous emphysema, adhesions, pleural plaques or parenchymal disease, are considered as contraindication for redo MIMVS. During screening of patients as potential candidate for redo MIMVS, we

recommend CT scan with lung window and pulmonary function tests, due to the fact that breach of pleura is associated with an early decrease in lung function, but with significant improvement after three months.

Angiography

All the patients undergo standard coronary catheterization to visualize the anatomy of the native coronary arteries. In case of disease of one or more coronary arteries, a hybrid treatment strategy consisting of percutaneous treatment for coronary lesions followed a month later, by MIMVS may be performed. The exact timing would depend on clinical, anatomical and angiographic factors. In case of previous CABG, all the grafts are injected during angiography to determine their patency.

SURGICAL TECHNIQUE

Anesthesia and Patient Preparation

The procedure is performed in a standard operating room with each team member positioned according to existing protocols for conventional surgery. General anesthesia is provided according standard protocol for MV surgery. Blood pressure monitoring is obtained through cannulation of radial artery; a standard 4-lumen IV catheter is placed in the right internal jugular vein and a percutaneous sheath (8.5 Fr) introducer is placed to secure an access for endo-cavitary pacemaker lead, if needed. We usually use a single lumen normal tube for intubation. A double lumen endotracheal tube can be used for single (left) lung ventilation if some difficulties during preparation are expected. Transoesoephageal echocardiography (TOE) probe is positioned to obtain a clear anatomic image of the MV and its functional morphology, monitor the venous cannula correct insertion/placement, de-airing manouveres and to evaluate the valve function pre- and postoperatively. Two defibrillator pads are placed across the chest wall with the right pad placed under the patients' right shoulder and left pad over the anterior left chest wall to guarantee effective electrical conduction. The patient is placed in a supine position and an air sack is placed under the right scapulae, to allow the patient's right chest to be elevated slightly according to the need of the surgeon for a better working field exposure (Figure 1). This can be useful, particularly in patients with deep chest. This sack can be inflated/deflated enough to lift the right chest upwards/downwards, if required. Patient's right arm should be deviated slightly from the body by shoulder extension and elbow flexion to permit enough space for the placement of the working ports.

The patient's skin is prepared with antiseptic solutions according to the local intra-operative protocol. Draping is accomplished with care to expose: (a) superiorly the right clavicular edge and the pectoral muscle (b) laterally the right anterior axillary line (c) towards the right limb to expose the anterior superior iliac spine and the groin (d) on the left side the sternal notch is exposed and draping continues parallel to the left sternal edge, then laterally

to include the anterior superior iliac spine and the groin. An adhesive aseptic strip is then applied to the exposed areas, thus, minimizing the possible risk of contamination.

Figure 1. Patient position: the right chest is slightly elevated with the use of an air suck.

The Right Minithoracotomy

The procedure is carried out through a mini-thoracotomy in the 3rd or 4th ICS. The decision to pass through the 3rd or the 4th ICS is based on 3D CT scan reconstruction. Access through the fourth ICS usually allows a better exposure of the MV while an incision in the 3rd ICS gives more control on the ascending aorta. The subcutaneous tissue is divided with electrocautery towards the pectoralis major fascia that is incised; careful spread of tissue allows respect for the muscle, less post-operative pain, ease of reconstruction and better functional recovery. The intercostal muscle is then divided in the lateral part of the incision; the surgeon asks for lung deflation and the pleural space is entered gently, taking care to avoid lung injury. At this time, limited adhesion release is performed in an effort to gain enough space to insert a soft tissue retractor and two auxilliary working ports. One 5.5-mm working port is used for a video assistance and for passing the pericardial stay sutures. We prefer to use the same port to avoid further risk of intercostal arteries injury. The port is placed in the same ICS in the mid-axillary line where the thoracotomy incision is made. Another 10.5 mm port is placed two intercostal spaces lower in the mid-axillary line. This port is used for the cardiotomy vent, CO_2 insufflation and for other pericardial stay sutures. Consecutively in order to enhance direct vision, a surgical metallic multi-use retractor (Estech, San Ramon, CA, USA) is inserted and rib spreading is accomplished in a gradated manner. At this time, if pleuro-pericardial adhesions are not excessively dense, we prefer to continue surgical dissection before going on cardio-pulmonary bypass (CPB). However, in the event of severe lung adhesions, any attempt to dissect away the lung and the pleura from the thoracic wall may be very cumbersome time-consuming. In these cases, we immediately establish CPB through the femoral vessels, the lungs are deflated and surgical dissection is continued on pump.

Cardiopulmonary Bypass

Based on the conviction that antegrade perfusion is associated with less incidence of neurological complications [5, 6], we prefer to cannulate the ascending aorta directly, whenever possible. In case of a contraindication for ascending aorta cannulation (ascending aorta calcification, ascending aorta far from the incision, patent saphenous vein grafts, severe aorto-pulmonary adhesions, giant right atrium covering the ascending aorta), femoral artery cannulation is choosen as the second alternative. Cannulation of the femoral vessels eliminates issues relating to exposure of the aorta and right atrium and allows CPB to be initiated before the chest is opened. If the ascending aorta as well as the femoral artery are not suitable for cannulation, axillary artery or common carotid artery are used.

Central Aortic Cannulation

Direct aortic cannulation is accomplished using an Easy-flow™ cannula (LivaNova Biomedica Cardio Srl, Sallugia, Italy). Two concentric 2-0 polyester purse string sutures for direct arterial cannulation are placed in a standard fashion into the ascending aorta. The purse string may be reinforced with pledgets, if needed. During the purse-string suture placement, the aorta can be kept steady using locking forceps to reduce the physiological motion. The cannulation site is generally chosen proximal to the transverse sinus, which is the level where the aortic cross-clamp is placed. It is preferable to choose the cannulation site at some distance above the cross-clamp level. After medical induced hypotension, the aortic adventitia is opened progressively with a number 11 blade until intimal layer is exposed; at that point a small incision is made and the cannula is inserted. The Easy-flow™ cannula has an obturator that allows stiffening during insertion and the cannula becomes pliable once the obturator is removed; also a stop ring is available to control the depth of aortic cannulation. This is placed at the marker nearest the tip. After cannula deployment, whilst the assistant still holding the cannula, the first operator secures the cannula with two tourniquets using a silk suture. However, this can be difficult in cases of a deep chest and distant cannulation sites. In these cases, a silk suture previously placed through the tourniquet can facilitate knot-tying inside the chest.

Femoral Artery Cannulation

Exposure of the femoral artery is gained trough a 1.5 cm incision placed in the right groin crease. Minimal dissection of the femoral vessels is performed without encircling the vessels. This usually translate in a less probability of groin seroma. A 5/0 prolene purstring is performed on the superior aspect of the femoral artery and cannulation is performed with Seldinger's technique under TOE guidance. We prefer to cannulate femoral artery employing small wire-wound Bio-Medicus® arterial cannula (17 fr to 19 Fr), (Medtronic, Minneapolis, MN, USA).

Percoutaneus Venous Cannulation

Femoral vein is usually percutaneously cannulated with a 7 Fr sheath for later CPB. In our center, this maneuver is done before skin incision and heparin administration in order to minimize bleeding in the event of femoral artery puncture. Femoral vein should be punctured at 4-5 cm lower than inguinal ligament line. This permits a straighter introduction of the

venous cannula into the right femoral vein. A 260 cm guidewire is placed through the venous introducer sheath and is advanced to the right atrium and over the superior cavo-atrial junction under visualization with the TOE probe adjusted to a bicaval view (90–120°). In this particular view, the superior vena cava is on the right and the inferior on the left of the screen; at the top of the screen near the probe is the interatrial septum and left atrium. With the guidewire held in place, the introducer sheath is removed. With a number 11 blade, the puncture site is enlarged and progressive dilators passed to ensure adequate space for venous cannula insertion. It is then advanced into the femoral vein and its tip should be 3-4 cm beyond the superior cavo-atrial junction. The guidewire is slowly withdrawn while holding the cannula in place. The venous cannula sheath is then removed and de-airing accomplished by partially unclamping and expelling blood and any residual air from the lumen before connecting to the venous line of the CPB circuit. One silk stay suture is placed on the skin as a tourniquet over the cannula body to fix it in place and prevent dislodgement. This tourniquet may be easily released and refixed if we need to adjust (push or pull) the cannula during the procedure. The choice of venous cannula gauge is based on patients' weight and surgeons' preference; in our institution we use a range of 22-25 Fr depending on patient's specific nomogram; rarely 19 Fr is used for small patients. Our cannula of choice is the Bio-Medicus® multistage cannula (Medtronic, Minneapolis, MN, USA).

In patients who require additional tricuspid valve or atrial septal defect closure surgery, we use a specifically designed venous cannula. The Remote Access Perfusion Femoral Venous™ cannula (LivaNova Biomedica Cardio Srl, Sallugia, Italy), is a wire-reinforced polymer venous cannula which has two perforated distal sections, separated by a non-perforated segment of 15 cm in length (Figure 2). The two distal sections have multiple holes at multiple stage to allow increased fluid flow and to drain simultaneously both the superior and inferior vena cavae. Appropriate positioning of the perforated sections into both the caval veins is confirmed under TOE guidance [7]. This cannula achieves satisfactory bloodless working field also without occluding the venae cavae and this is of particular importance in redo patients, where placement of caval snares may be particulary challenging through a very small incision. If backflow from the unsnared caval veins is present, a small increase in negative pressure usually results in a relatively bloodless operative field.

Myocardial Protection

Myocardial preservation techniques are key elements for the success of these operations. Frequently, these patients present a variable degree of left ventricular impairment and assuring good myocardial protection is mandatory. At the beginning of our experience we used endo-aortic ballon occlusion but we have gradually abandoned this strategy and use mainly two strategies for myocardial preservation. If the ascending aorta can be safely dissected and clamped, we prefer to do this with a flexible trans-thoracic clampfollowed by delivery of antegrade cold crystalloid cardioplegia. In case of patent left internal mammary artery (LIMA) and spahenous vein grafts, ascending aorta calcification, previous ascending aorta replacement and severe adhesions around the ascending aorta, hypothermic ventricular fibrillation (VF) or beating heart is used. A diagram of our operative set-up is showed in Figure 3.

Figure 2. The Remote Access Perfusion Femoral Venous™ cannula (LivaNova Biomedica Cardio Srl, Sallugia, Italy), with two perforated distal section.

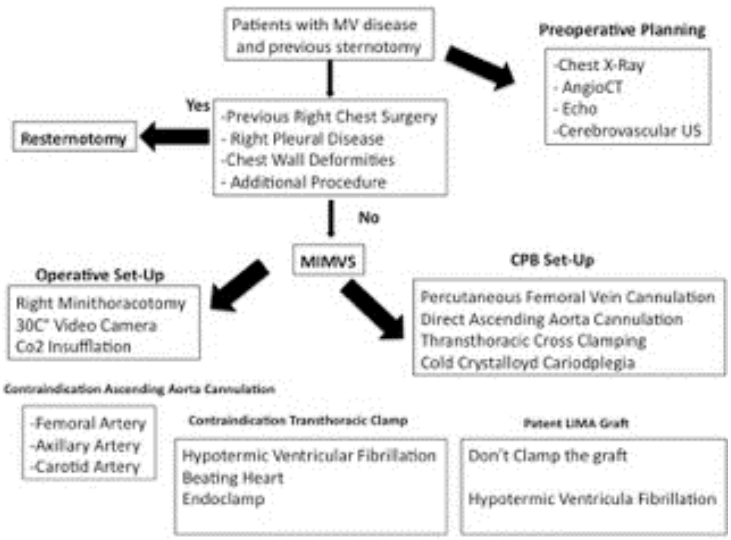

Figure 3. Diagram of our favored operative setup.

Endoartic Balloon

Early in our experience, endoaortic balloon occlusion with antegrade cardioplegia delivery was our preferred strategy for redo MIMVS. If this strategy is chosen, the femoral artery is cannulated with a dedicated "Y" shaped cannula that allows the insertion of the balloon through an additional branch. The ballon is advanced into the ascending aorta and inflated 2 cm above the sinotubular junction under TOE control. Cold crystalloid cardioplegia is delivered through the tip of the ballon. Currently, in our practice, the endoclamp is used only in those cases where the aorta cannot be clamped and moderate AR is present. Achieving aortic occlusion with the endo-balloon still represents a challenge. The occlusive balloon must be positioned under TOE guidance just above the sinotubular junction and the cathehter tip must be controlled continuously. Balloon dislodgment can cause innominate artery occlusion, potentially causing neurologic injury or prolapse into the left ventricle (LV) with suboptimal myocardial reservation. In addition when stitching on the mitro-aortic continuity, inadvertent balloon injury is possible.

Direct Aortic Cross-Clamping with Cold Crystalloid Cardioplegia

For most redo MIMVS, myocardial protection is obtained with direct transthoracic clamping and antegrade cold crystalloid cardioplegia. We use the Cygnet® flexible aortic clamp (Novare Surgical Systems, Inc., Cupertino, CA). The rigid shaft of the clamp enables tunnelling and accurate clamp jaws placement. Once properly placed, the rigid shaft retracts

leaving a flexible neck, which can be manouevred to a place ir remote from the surgeon's working field. After reducing the pump flow, the transverse sinus is gently dissected and with the aid of an external sucker, the aorta is gently elevated and the inferior jaw of the clamp is advanced. It is of particular importance to avoid inadvertent injury to the left atrial appendage and pulmonary artery during this step. Once the correct position of the jaws is verified, the aorta is clamped and full CPB flow is restablished. Cardioplegia is delivered antegradelly with a long dedicated catheter placed in the ascending aorta.

Hypotermic Ventricular Fibrillation

If VF heart surgery is used instead of aortic cross-clamping, the patient is cooled down to 28 C°. If the heart does not fibrillate spontaneously, when the target bladder temperature is reached, VF is induced with an electrical fibrillator. The left atrium is opened and an additional pump sucker is inserted into the LV to prevent distension and inadvertent ejection. In patients with mild AR or previous mechanical aortic valve replacement, a variable volume of blood can return from the aorta, obstructing the surgical view. In these case additional cooling with reduction of pump flow represents a succesful strategy to reduce blood return and speed up the procedure. The main risk associated with VF is represented by inadvertent air embolization. For this reason we vent the aorta whenever possible.

In patients with impaired ejection fraction, a beating heart strategy is employed. The patient is cooled to 32C°, aorta is vented and after pharmacologically-induced bradycardia the left atrium is opened. A second trans-mitral vent is immediatly inserted into the LV to avoid inadvertent ventricular distension and air embolization.

Management of Patent LIMA to LAD Graft

Redo MIMVS in the presence of patent LIMA graft, represents a particular challenge because these cannot be isolated through a right mini-thoracotomy. In this subset of patients, we routinely use systemic cooling and VF and we are satisfied with this strategy. However in few cases we have used cross-clamping with cold crystalloid cardioplegia and moderate systemic cooling to 32C°, leaving the mammary graft patent. As reported by other authors, we have not experienced significant problems with this strategy [8].

Mitral Valve Exposure

The MV is exposed through a standard left paraseptal atriotomy, with the aid of an atrial retractor supported by an external mechanical arm. The arm is inserted in the thorax through a right parasternal hole performed in the fourth ICS. After left atrial retraction, it is important to monitor the central venous pressure and the postion of the venous cannula, to detect inadvertent cannula obstruction or dislodgement. In presence of an aortic valve prosthesis, exposure of the MV can be difficult. In these cases we prefer to insert the arm of the atrial retractor through a parasternal hole in the fifth or sixth ICS. This allows to retract the left atrium more caudally and to avoid conflict between the atrial retractor blade and the aortic prosthesis.

Mitral Procedure

The right mini-thoracotomy permits to obtain a straight access to the MV and guarantees safe and excellent view of all the valve apparatus allowing all types of repair techniques such as neochordal placement and anterior leaflet repair (Figure 4). The right chest approach does not impede the replacement of a mitral prosthesis or the repair of paravalvular leak.

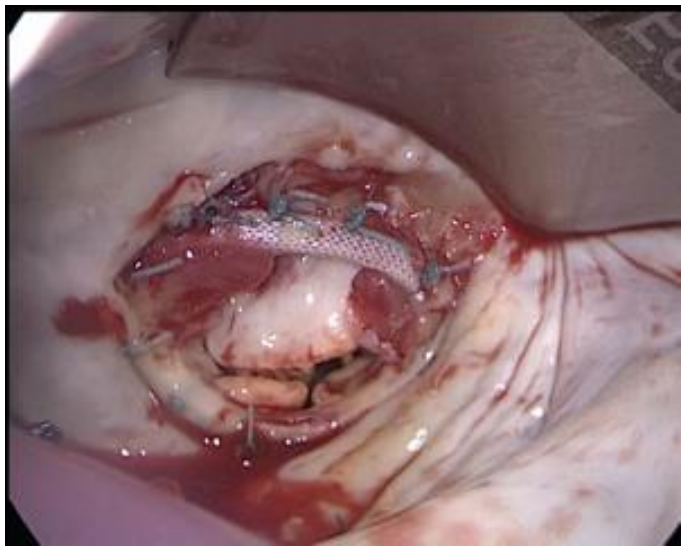

Figure 4. Surgeon's view of the mitral vave.

In our center, this technique has been employed routinely in patients with active endocarditis. However, in this subset of patients, it is extremely important to confirm the absence of any trigone or aortic valve involvement pre-operatively.

De-Airing the Heart

Meticolous cardiac air removal is extremely important in redo MIMVS, because the heart can not be manipulated and frequently the apex is attached to the thoracic wall by adhesions. Frequently the air tends to be retained into the cardiac apex and along the ventricular septum. In effort to reduce the amount of cardiac air, we routinely use CO2 insufflation into the thorax through a small cathether inserted via the 10.5 mm thoracic port. The CO2 released is started before the opening of the left atrium. The volume of CO2 insufflation is 1 liter/m.

At the end of the mitral procedure, a cathether vent is placed into the LV through the MV. Deairing the heart is obtained with a two-stage procedure. First, the table is lifted head up, the heart is filled, both lungs are ventilated and air is removed from the left atrium with a small forceps inserted through the suture line. Consecutively the bed is then placed head down, the aortic calmp is released and air is removed with suction on the tran-smitral vent and the aortic vent. The trans-mitral and aortic root vent are left in place until the heart is fully beating and no more air is seen on TOE.

Pacing Wires

In all patients, a preoperative percutaneous sheath (8.5 Fr) introducer is placed through the jugular vein, to secure access for endo-cavitary pacemaker lead. However, if needed, epicardial pacing wires can be positioned on the right ventricle (RV), with the heart empty on full CPB. The wires are then exteriorized through the parasternal hole, used for left atrail retractor stabilization. In case of tricuspid valve procedure, an endocardial wire can be positioned into the RV through the tricuspid valve and exteriorized through the right atriotomy suture line.

Institutional Experience

Between 2003 and 2016, 197 patients underwent a reoperative MIMVS at our institution. Mean time to redo surgery was 7.2 ± 3.6 years. For 24 patients this was the third intervention, in 6 was the fourth and in 1 the seventh. Mean preoperative Euroscore was was 12.4 ± 4.2. The operation was performed with direct ascending aorta cannulation in 74 patients, femoral artery cannulation in 121 and axillary artery in 2. Myocardial protection was achieved with aortic clamping (transthoracic clamp in 61 patients and endo-aortic balloon occluder in 73) and cold crystalloid cardioplegia. The remaining patients underwent operations during hypothermic VF (n = 41; 13.2%) or beating heart (n = 22; 11.5%). Mean cardiopulmonary bypass and aortic cross-clamp times were 160±48 min. and 82 ± 49 min. Conversion to sternotomy was required in 3 patients during the procedure: in one patient due to atrioventricular disruption and in 2 due to extensive adhesions on the chest wall. A MV repair was performed in 66 patients and MV replacement in 131. The 30-day mortality rate was 5% (n = 10). Causes of death were low cardiac output syndrome in 3 patients, multiorgan failure in 1, neurologic complication in 2 and sepsis in 1. Stroke was observed in 13 patients (6.5%). This was transient in 10 and permanent in 3. Early reoperation (<30 days) was necessary in one patient due to valve repair failure. The operation was re-performed through the right mini-thoracotomy and the valve was re-repaired. Blood transfusions were required in 79 patients (40%) and the mean unit transfusion/patient was 1.3 ± 1.1 Mean follow-up was 3.8 ± 2.4 years and 100% complete. Late death occurred in 21 patients. There were 2 late re-interventions at for mitral prosthesis endocarditis. Survivals at 1, 5 and 10 years was 92.8 ± 1.8%, 85.3 ± 2.1%, and 77.3 ± 3.2%, respectively.

CONCLUSION

A right mini-thoracotomy permits direct access to the MV without the need of extensive cardiac mobilization which is required in conventional redo procedures. The minimally invasive approach guarantees safe and excellent view of the entire valve apparatus allowing all types of repair techniques such as neochordal placement and anterior leaflet repair. The avoidance of extensive surgical dissection, good exposure of the valve, low requirement of blood transfusion and low hospital stay are the main advantages of this technique.

REFERENCES

[1] Murzi M, Cerillo AG, Bevilacqua S, Gasbarri T, Kallushi E, Farneti P, Solinas M, Glauber M. Enhancing departmental quality control in minimally invasive mitral valve surgery: a single-institution experience. *Eur J Cardiothorac Surg* 2012;42:500-6.

[2] Botta L, Cannata A, Bruschi G, Fratto P, Taglieri C, Russo CF, Martinelli L. Minimally invasive approach for redo mitral valve surgery. *J Thorac Dis* 2012;5:S686-93.

[3] Murzi M, Solinas M, Glauber M. Is a minimally invasive approach for re-operative mitral valve surgery superior to standard resternotomy? *Interact Cardiovasc Thorac Surg* 2009:9:327-32.

[4] Wharton G, Steeds R, Allen J, Phillips H, Jones R, Kanagala P, Lloyd G, Masani N, Mathew T, Oxborough D, Rana B, Sandoval J, Wheeler R, O'Gallagher K, Sharma V. A minimum dataset for a standard adult transthoracic echocardiogram: a guideline protocol *Echo Res Prac* 2015;2:G9-G24.

[5] Grossi EA, Loulmet DF, Schwartz CF, Solomon B, Dellis SL, Culliford AT, Zias E, Galloway AC. Minimally invasive valve surgery with antegrade perfusion strategy is not associated with increased neurologic complications. *Ann Thorac Surg* 2011;92:1346–50.

[6] Glauber M, Murzi M, Solinas M. Central aortic cannulation for minimally invasive mitral valve surgery through right minithoracotomy. *Ann Cardiothorac Surg* 2013;2:839-840.

[7] Murzi M, Kallushi E, Solinas M, Glauber M. Video-Assisted right atrial surgery with a single two stage femoral venous cannula. *Interact CardioVasc Thorac Surg* 2009;9:9-10.

[8] Smith RL, Ellman PI, Thompson PW, Girotti ME, Mettler BA, Ailawadi G, Peeler BB, Kern JA, Kron IL. Do you need to clamp a patent left internal thoracic artery-left anterior descending graft in reoperative cardiac surgery? *Ann Thorac Surg* 2009;87:742-7.

In: Encyclopedia of Surgery (22 Volume Set)
Editors: Andreas Lehrer and Kristin Mueller
ISBN: 978-1-53618-329-0
© 2020 Nova Science Publishers, Inc.

Chapter 424

VALVE REPAIR TECHNIQUES IN MINIMALLY INVASIVE MITRAL SURGERY

Loris Salvador, MD and Tommaso Hinna Danesi*, MD
Cardiac Surgery Unit, San Bortolo Hospital,
Vicenza, Italy

ABSTRACT

Over the past 15 years, minimally invasive cardiac surgery (MICS) has been increasingly adopted, especially with mitral valve (MV) surgery. A variety of different surgical approaches are described as minimally invasive, but may be substantially different one from another. More recently, the trend of surgical wound reduction requires surgery performed with indirect vision techniques where the application of the thoracoscope has become pivotal. This is the era of endoscopic minimally invasive cardiac surgery (endoscopic MICS). This surgery requires specific surgical skills and a complete knowledge of the mitral valve apparatus, pathology and repair techniques. All aspects of cardiac surgery are involved in this innovative procedure, including the anesthesiological and cardiopulmonary by-pass setups. Performing surgery using videoscopy with long shafted instruments requires reassessment of and adaptation to the different MV repair techniques aimed at approaching the mitral apparatus in a simpler way. Good experience in MV repair using e-PTFE artificial chordae with an associated annuloplasty may facilitate the developing of an endoscopic MICS program in MV repair and can be the optimal solution in about 90% of patients with degenerative mitral regurgitation.

Keywords: MICS, minimally invasive mitral valve surgery, port access, endoscopic MICS, cardiac endoscopy, mitral valve repair techniques

* Corresponding Author's Email: tommasohinnadanesi@gmail.com.

INTRODUCTION

Over the past 15 years, minimally invasive cardiac surgery (MICS) has been increasingly used, especially for mitral valve (MV) surgery. This growth has been driven by a desire to translate the benefits observed in other types of minimally invasive surgery, such as decreased pain, reduced surgical trauma, faster recovery and meeting the patient's needs, to cardiac surgery. The initial enthusiasm was tempered by the difficulties of performing complex operations through a small incision, a reduced operating field with no dedicated technology, rudimentary minimally invasive instruments and the compelling need of avoiding longer cross clamp time. However, innovation in perfusion techniques and devices and the development of dedicated instruments has made way to establish minimally invasive valve surgery (mitral, aortic and tricuspid) the standard of care in high volume centers in the current era.

MICS has undergone several changes with regards to techniques and philosophy. Surgical incisions, valve repair techniques including cardio-pulmonary bypass (CPB) and surgical instruments have been continually evolving, making MICS easier and reproducible, with surgical results comparable to the conventional surgical approach. In this chapter, MV repair (MVr) techniques in minimally invasive surgery will be explored. In the context of this chapter, minimally invasive mitral valve repair refers to surgery that is performed totally endoscopic under indirect vision where the use of a thoracoscope is mandatory; we define this surgery as Endoscopic MICS.

MINIMALLY INVASIVE CONCEPT: MICS AND ENDOSCOPIC MICS

There are several interpretations of the minimally invasive concept (Figure 1, Figure 2 and Figure 3).

Figure 1 shows a right anterior thoracotomy (RAT), in which the divarication of the ribs provides a larger operative field and surgery can be performed under direct vision. Figures 2 and 3 show a minimally invasive right anterior mini-thoracotomy (MRAT). Both approaches are intended as minimally invasive but there are several differences. First of all in the MRAT, the thoracoscope is mandatory to perform surgery, otherwise the reduced incision size does not allow to preserve the natural stereo-vision and often the MV itself cannot be directly visualized. This chapter will discuss only surgery performed under MRAT in which the small skin incision serves only to introduce endoscopic surgical instruments and cardiac devices as annuloplasty rings or prosthetic valves. This is done without any excessive rib spreading with the aid of a soft tissue retractor. The use of thoracoscope with indirect vision, the minimal skin incision, and no rib spreading are characteristics of endoscopic minimally invasive mitral valve repair (MIMVr). Rib spreading leads to post-operative pain ignoring one of the key principles of MIMVr which is pain avoidance.

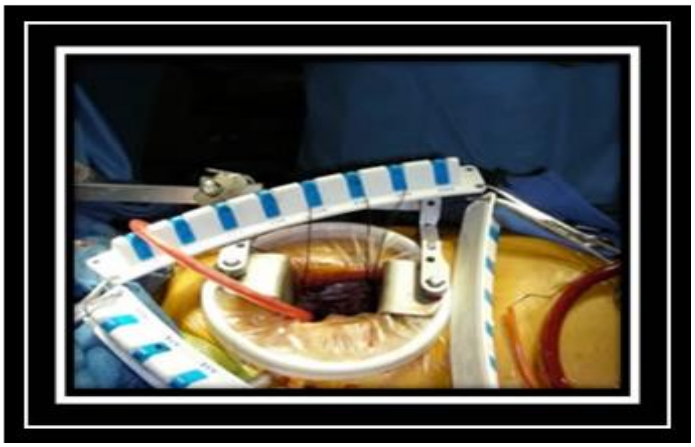

Figure 1.

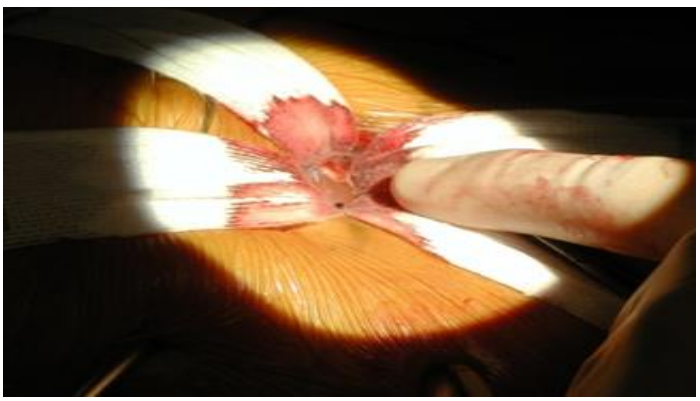

Figure 2.

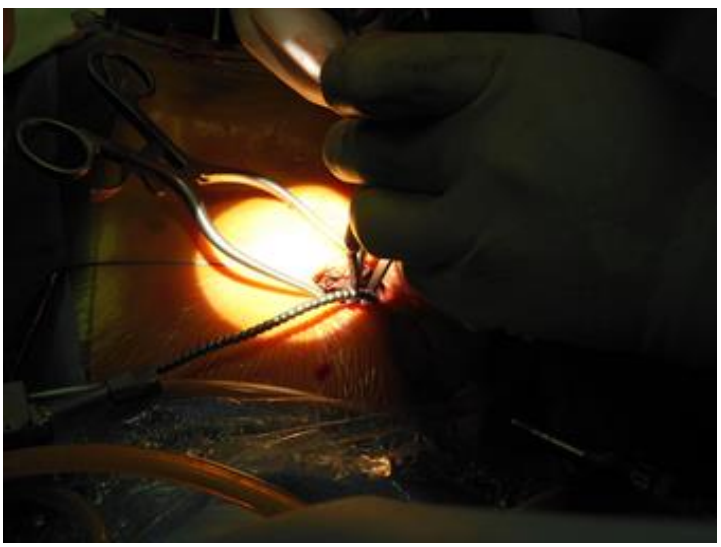

Figure 3.

GENERAL CONSIDERATIONS

From the Society of Thoracic Surgeons database, a minimally invasive valve surgery approach is defined as "any procedure not performed with a full sternotomy and CPB support" [1]. According to Chitwood et al. [2], MICS should not be defined in terms of a specific procedure, but rather a "philosophy" that requires an operation-specific strategy. Each minimally-invasive strategy introduces alternatives for CPB cannulation (central or peripheral), aortic occlusion (endovascular or transthoracic), and cardioplegia delivery (antegrade, atrial retrograde or transjugular retro-retrograde) [2, 3]. The concept of surgical access avoiding full sternotomy or a "philosophy" that requires specific surgical strategy translates into a wide range of surgical procedures in which a partial sternotomy and a full right thoracotomy are both considered minimally invasive surgery.

Preoperative assessment of MIMVr patients is still debated i.e., several centers consider a full aortic CT scan mandatory to assess the feasibility of femoro-femoral cannulation, the possibility to change surgical strategy or consider other options than surgery [4, 5]. Considering the risk factors of the population undergoing MIMVr and that 60-70% of mitral regurgitation (MR) is due to degenerative disease in a relatively younger age group, a preoperative CT scan could be considered useful to detect ascending aortic calcification affecting aortic cross-clamping as well as prediction of peripheral cannulation-related complications [6]. To establish a new surgical procedure as routine all non-surgical and surgical steps must be standardized to achieve consistent outcomes.

Anesthesiological set-up is not very different from conventional cardiac surgery. Although double lumen endo-tracheal intubation is widespread, this is often not mandatory. A retrospective review on 96 pts who underwent MICS using a single lumen tube or double lumen tube did not show any difference in intensive care unit stay or failure in fast track protocols [7]. Double lumen endo-tracheal intubation should be considered in patients with previous sternotomy and is mandatory in redo patients with a previous right thoracotomy. Central venous cannulation can be achieved through either the right or the left internal jugular veins. The right subclavian vein should be generally spared in order to avoid any interference with the thoracoscope which may be placed at the 2nd intercostal space (ICS). The right internal jugular vein may need to be avoided if percutaneous superior vena cava venous drainage is needed for CPB. Cannulation techniques for MIMVr have constantly evolved over the last few years. Until 2010, cannulation strategy evolved in our experience to favor central ascending aortic over peripheral femoral cannulation, percutaneous dual-stage bicaval venous drainage over percutaneous neck access and direct external aortic cross-clamp (AoX) over the endo-aortic balloon occlusion [8]. To have a clear consensus on the exact cannulation approach to CPB and aortic occlusion is not simple because there are not clinical randomized trials and the retrospective series published to date include a large variety of surgical approaches defined generically as minimally invasive. Currently, the commonest MIMVr approach is port-access, performed through a RAT or a MRAT depending on the center preference or experience (direct vs indirect vision). Because the endoscopic MIMVr is more attractive for both patients and surgeons, CPB institution through peripheral cannulation with the utilization of the endo-aortic balloon occlude is a growing-option.

MITRAL VALVE ACCESS IN ENDOSCOPIC MIMVr

In MIMVr, the choice of the skin incision and the ICS in the RAT is crucial, in order to achieve comfortable surgical procedure. In port-access surgery the 4th or 5th ICS is usually entered through a submammary skin incision performed laterally and posteriorly from the anterior axillary line (Figure 4). This approach allows direct vision surgery in which the thoracoscope serves mainly as light source and assists with the surgical procedure. Typically, this is known as *video-assisted mitral valve surgery*. The incorrect ICS or a very medial mini-thoracotomy can result in an uncomfortable setup and may lead to conversion into a median sternotomy. In male patients undergoing endoscopic MIMVr, the skin incision is performed following the lateral half of the areola of the nipple and the ICS used to enter the pleural space is immediately under the pectoralis and intercostal muscles (Figure 5). Usually this is the 3rd or the 4th ICS and if the diaphragm is not too high, this is the best approach to the MV. A soft tissue retractor is enough to obtain an adequate separation of the ribs needed in order to handle surgical instruments and insert an annuloplasty ring or valve prosthesis.

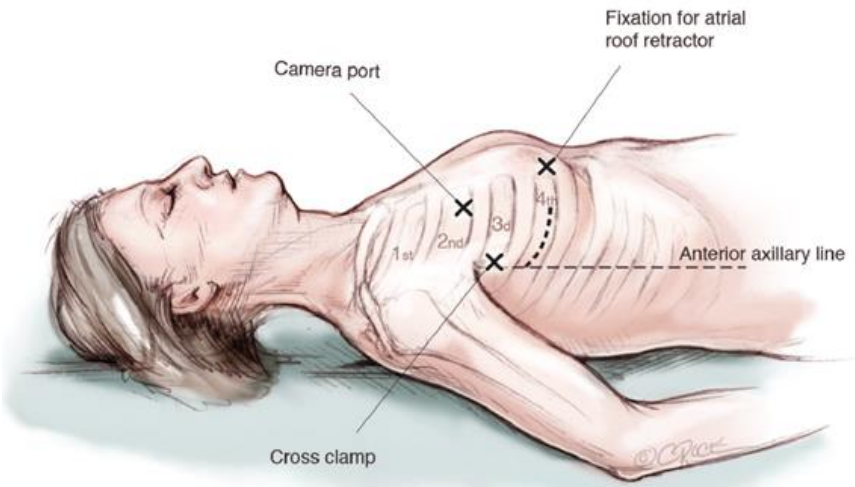

Figure 4. PortAccess MV surgery landmarks. From Jacobs S., Sündermann S. H. *Ann Cardiothorac Surg* 2013;2(6):818-824.

In female patients, the skin incision is performed in the right submammary line and the glandular tissue is gently dissected at its base to enter in the right ICS that usually lies 5-6 cm cephalad to the skin incision. It is preferable to enter the ICS lateral to the mid-axillary line, to achieve a straight trajectory to the MV annulus. Here, the 30° thoracoscope is essential which provides a magnified surgical view (Figure 6) and allows to "navigate the mediastinum" and access cardiac structures which are sometimes hard to display in conventional surgery i.e., pulmonary veins and the Sondergaard groove. The thoracoscope is very useful in left atrial access; in endoscopic MIMVr, the MV is accessible through a left atriotomy performed on the Sondergaard groove at the conjunction between the right upper pulmonary vein with the left atrial wall just below the interatrial septum. The atriotomy should be cranially extended just below the superior vena cava (SVC), and downwards 1 or 2 cm from the origin of the inferior vena cava (IVC). Once the left atrium (LA) has been

opened an atrial retractor can be inserted and the MV is exposed. Careful attention must be paid to avoid any injury to the right internal mammary artery during insertion of the trans-thoracic shaft to which the atrial retractor is fixed. When retracting the LA, it is important to check that the venous drainage is satisfactory, as the venous cannula could dislodge during this maneuver.

Figure 5. Periareolar skin incision.

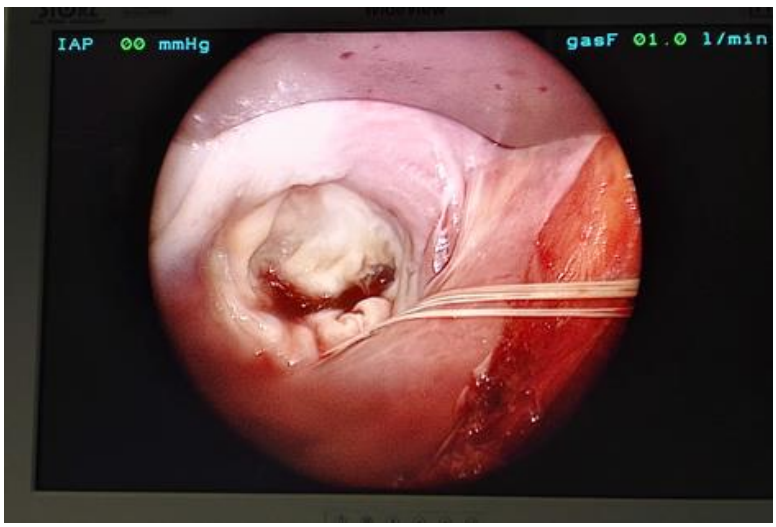

Figure 6. Magnified intra-operative mitral valve view.

VALVE REPAIR TECHNIQUES IN MIMVr

MV repair (MVr) has become the procedure of choice for degenerative MR, with superior results compared to MV replacement (MVR) [9-10]. MVr is feasible in as many as 95-99% of cases of degenerative MR, [11-14] despite the presence of complex lesions. The aim of MVr is to restore sufficient coaptation surface. This is the essence of Carpentier's lesson from his "French Correction" article [12]. The Carpentier quadrangular resection, with or without concomitant sliding plasty has been considered the standard surgical technique to correct posterior leaflet prolapse (Figure 7). New paradigms have risen for the reconstruction of the posterior leaflet: the "respect rather than resect" approach in which the MV apparatus is respected and any resection is avoided, is now frequently adopted. As leaflet tissue is the basic component of the coaptation surface, the logical corrective approach is to preserve the valve tissue and transform it into a large, regular and smooth coaptation surface [15]. Various types of reconstructive procedures, including triangular resection, chordal transfer, chordal shortening, edge-to-edge technique and papillary muscle repositioning have been used to repair anterior leaflet prolapse [13, 14-23].

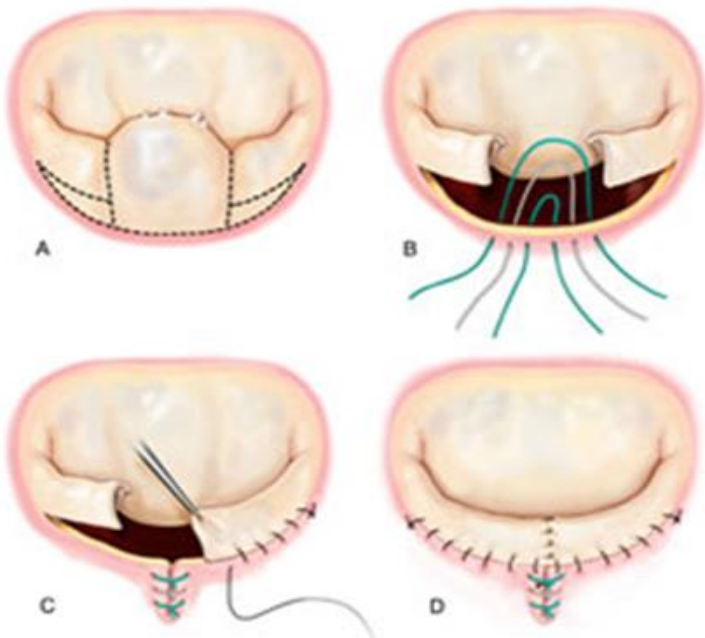

Figure 7. Carpentier's Quandrangular resection of P2 with sliding annuloplasty.
From www.mitralvalverepair.org.

Posterior Leaflet Prolapse Management

In the setting of posterior leaflet prolapse (PLP), the repair techniques proposed by Carpentier are the classical quadrangular resection of the prolapsing P2 segment with annular plication [16] or the sliding leaflet plasty [17]; several variations of this technique have been

adopted to answer questions arising from the complex world of MVr, such as 'how large should the resection be?' 'what if the prolapse involves the entire P2 in a very large P2?' 'what about two tiny leaflets remnants after P2 resection?' 'what if the prolapse involves an additional scallop?' 'should the annular plication give a risk of circumflex artery kinking?' The results were a variety of complex resection patterns from a simplified triangular resection of prolapsing P2 to a "The Fleur De Lys" technique for PLP. This technique has been designed to repair only the pathological components of the typical "floppy" mitral valve which include a thinning of the belly of the prolapsing scallop, whereas the basal region of the leaflet is thick and normal. the technique is founded on the ascertainment that there is typically an absence of secondary chords in the prolapse belly and the neighboring primary chords are either ruptured or thin and elongated and thus failing to control the affected leaflet edge. The technique is a variation of the "triangular resection." The fleur De Lys concept, visualizing each scallop as a "Fleur De Lys," does give the surgeon the sense of the curves rather than straight-line V resection to be performed as well as the areas of more normal tissue as represented by the right and left fronds (Figure 8) [18].

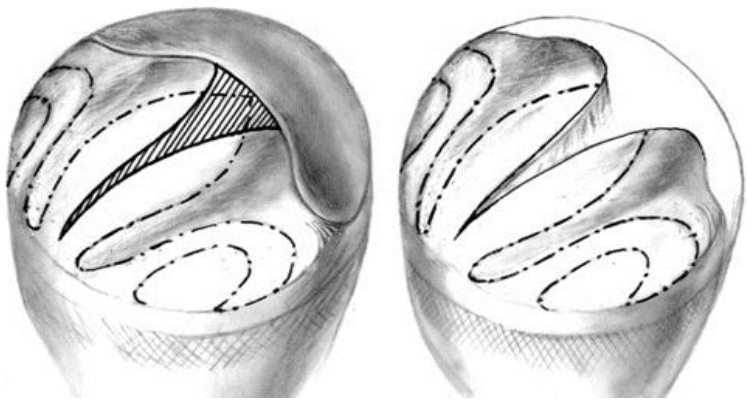

Figure 8. Conceptually each scallop can be visualized as a Fleur de Lys. The resection of the abnormal middle component of the middle scallop is curvilinear and the obverse to the middle Fleur de Lys frond. In actuality, the resection does not come to a point but is really more trumpet-shaped.

While the resecting technique excises the redundant valve tissue, the conservative technique employs expanded polytetrafluoroethylene (ePTFE) sutures (GORE-TEX sutures; W.L. Gore & Associates, Inc, Flagstaff, Ariz) to replace ruptured or elongated native chordae reducing the prolapsing segments. e-PTFE was introduced experimentally by Frater and colleagues in the early 1980s. Current use in clinical practice has permitted repair of complex mitral lesions, including anterior leaflet or bi-leaflet prolapse. This has now been widely adopted in clinical practice [21-22]. The commonest caliber of artificial chordae used is to replace the native MV chordae is the 5/0 CV Gore-Tex suture. Long term results of MVr with artificial chordae are excellent and this has become the standard repair technique in many experienced centers. Figure 9 and 10 show 15 year survival and freedom from re-operation of patients treated with e-PTFE neochord implantation [84% (95% CI 75-90%) and 92% (95% CI 87-95%), respectively]. The freedom from moderate MR recurrence was 85% (95% CI 78-91%) (Figure 11). At 12 years from first operation the artificial e-PTFE chordae are seen to be similar to the native chords in Figure 12 [23]. This efficient technique is particularly

suitable for the endoscopic MIMVr approach. After many years of MVr with artificial chordae implant, the number of implanted neochords have been progressively reduced in our experience. In the study from Salvador et al. [23], which included patients from 1986 to 2006, an average of 6 pairs (4-8) of e-PTFE neochords were placed. Nowadays perform MVr routinely using 2 or 3 pair of neochords. This number is able to reduce prolapsing segments and give a smooth and regular coaptation surface, allowing the anterior leaflet to evenly release the forces along the coaptation rim.

The length of the implanted e-PTFE neochords is still a matter of concern for some surgeons. Many published papers have proposed a variety of instruments and techniques in order to assess the adequate length of the artificial chordae. This can be estimated pre-operatively on echocardiographic basis with the healthy natural chordae as the reference point and/or intraoperatively with specific calipers [24-25].

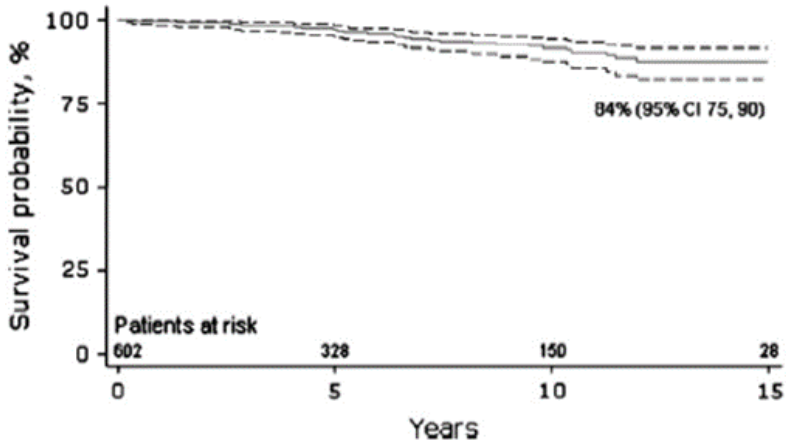

Figure 9. Long-term survival of patients with mitral valve repair with GORE-TEX CV-5 expanded polytetrafluoroethylene suture.

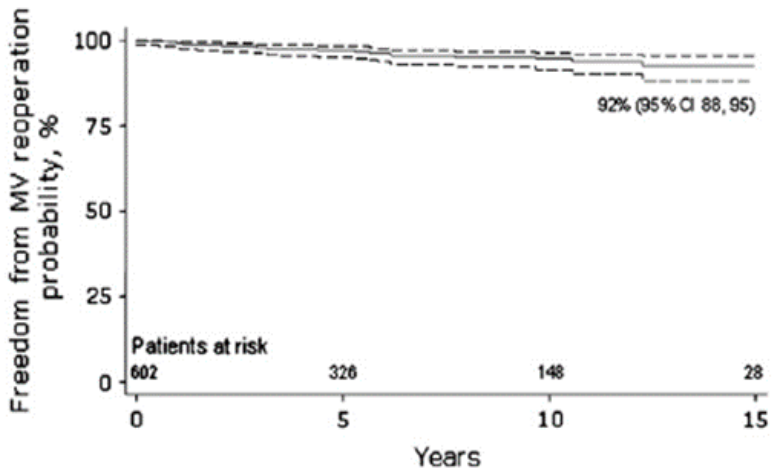

Figure 10. Freedom from reoperation for all patients after neochord insertion.

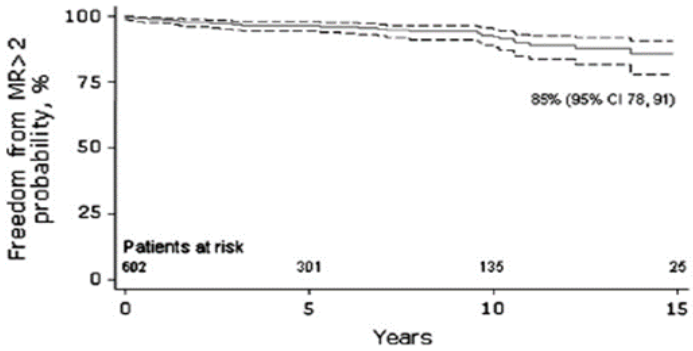

Figure 11. Freedom from MR>2 for all patients.

Table 1 shows several methods of posterior leaflet repair with e-PTFE implantation.

Table 1. Techniques for the repair of the posterior (or both) mitral leaflets

Study	Method of anchor to papillary muscle	Method of anchor to leaflet	Method of adjusting length	Knot tying	Annuloplasty ring	Special features
David 2004 [26]	3	B1	1	0	1	The length of each chordae loop varies with the stress pattern
Cimen et al. 2006 [27]	1	A1	1	2	0	Knots are tied under LV filling conditions
Tam et al. 2006 [28]	1	A2	3	0	1	Callipers are used to make loops of predetermined length, which are attached to leaflet and PM Not adjustable
Kudo et al. 2009 [29]	1	A4	3	1	0	After standard loop technique, a reduction 4-0 polyester suture is used to reduce prolapse of the leaflet in Barlow's disease
Isoda et al. 2012 [30]	3	3	1	0	0	This involves an anchor loop fixed to the papillary muscle A series of loops to the approximate length required is made and tied to the papillary anchor point The loop is fixed to the leaflet using additional small anchoring loops If the length need to be adjusted, additional anchor sutures are placed to shorten the loop

Method of anchor to papillary muscle: 0: not defined; 1: pledgetted support; 2: figure-of-eight conventional suture; 3: neither 0, 1, 2, e.g., fixation device.

Method of anchor to leaflet: 0: not defined; A: chordae tied permanently before or without length adjustment; B: chordae are left untied or are only partially tied until competence testing; 1: at the site of anatomical chordae attachment; 2: at the site of maximal prolapse; 3: use of special device used.

Method of adjusting length: 0: not defined; 1: adjusted after testing; 2: pre-determined by echo; 3: pre-determined by direct measurement; 4: other.

Knot tying: 0: not defined; 1: reverse knotting so that final length is not affected by tying; 2: surgeon's knot (reef knot with an extra throw); 3: slip-knots; 4: continuous suture.

Annuloplasty ring: 0: not defined; 1: before chordae placement; 2: after chordae placement.

From M. Ibrahim et al. / Interactive CardioVascular and Thoracic Surgery [25].

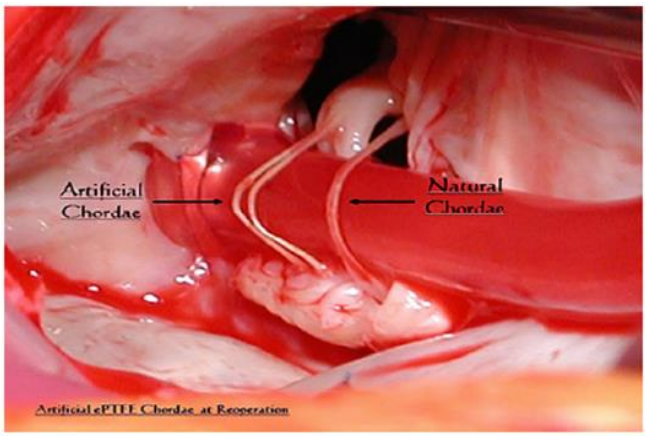

Figure 12. Comparison of artificial and native chordae, seen at reoperation after 12 years.

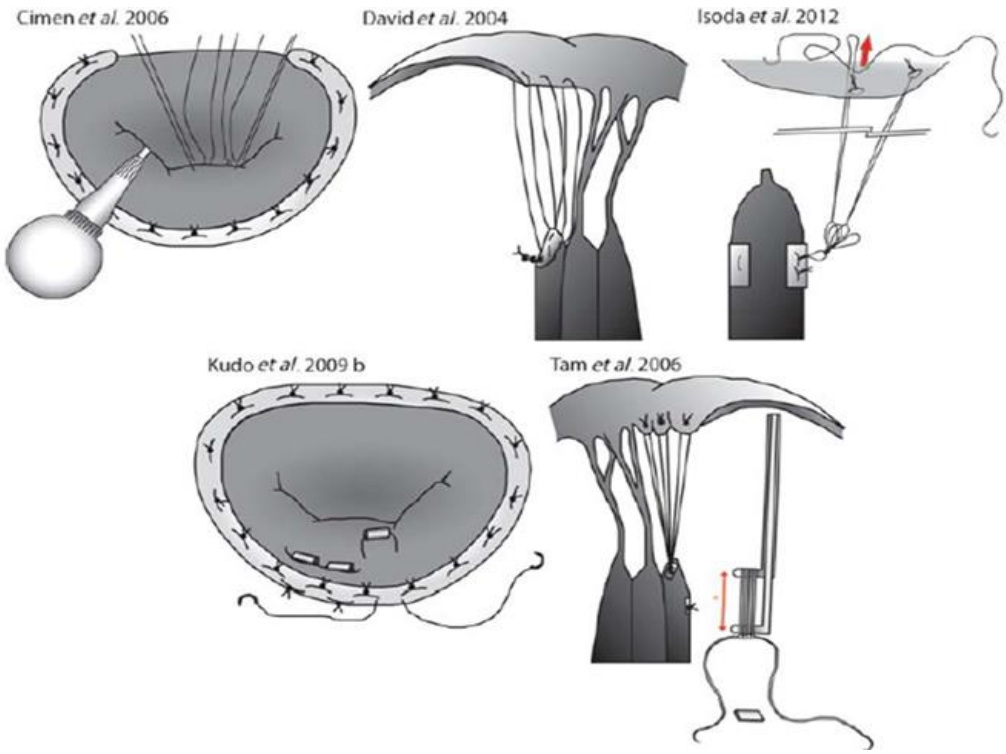

Figure 13. Techniques for the repair of the posterior or both mitral leaflets. The figure panel shows the essential steps of the techniques detailed in TABLE 1 for the repair of the posterior (or both) MV leaflet(s). From M. Ibrahim et al. / *Interactive CardioVascular and Thoracic Surgery* [25].

Figure 13 shows the essential steps in posterior or bileaflet MV repair detailed in Table 1. It is immediately apparent as many of the aforementioned techniques are may not be easily reproducible in an endoscopic MIMVr setting. Our experience in conventional MVr lead us to adopt a simplified technique, in which only 2 or 3 pairs of e-PTFE artificial chordae are placed to reduce the PLP segment. The artificial chordae are passed through the papillary muscle with an e-PTFE pledget parallel to the long axis of the muscle itself (Figure 17 and

18) in order to avoid any injury to the vascular system of the papillary muscle. The two tips of the neochord are passed twice at the level of the free edge of the prolapsing segment to obtain a modifiable but stable provisional fixation of the neochord. In this way the length of the e-PTFE chord can be easily modified during the saline test (Figure 19-20). Once the valve repair has been completed and the saline test is satisfactory, the artificial chordae are tied. If the P2 segment is too long and there is a real risk of systolic anterior motion (SAM) of the anterior MV leaflet, the free edge of the prolapsing segment of P2 is excised. In this way the posterior leaflet will be lower in height. The e-PTFE neochordae are then implanted at the resected zone of P2.

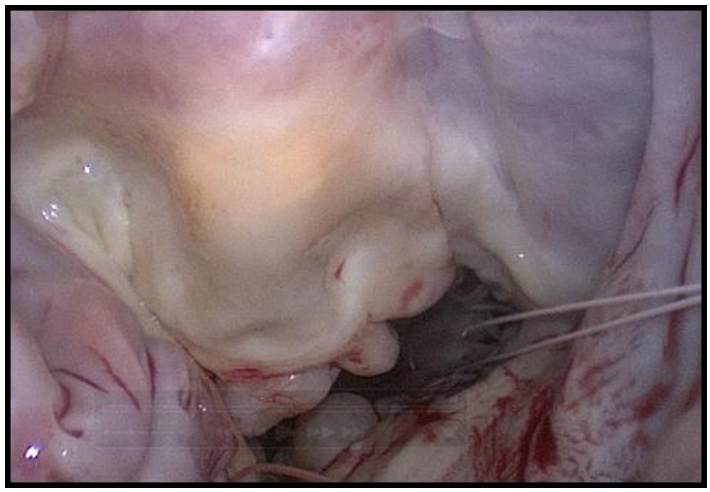

Figure 14. Implantation of the e-PTFE artificial chord deep on the fibrous edge of the posterior papillary muscle.

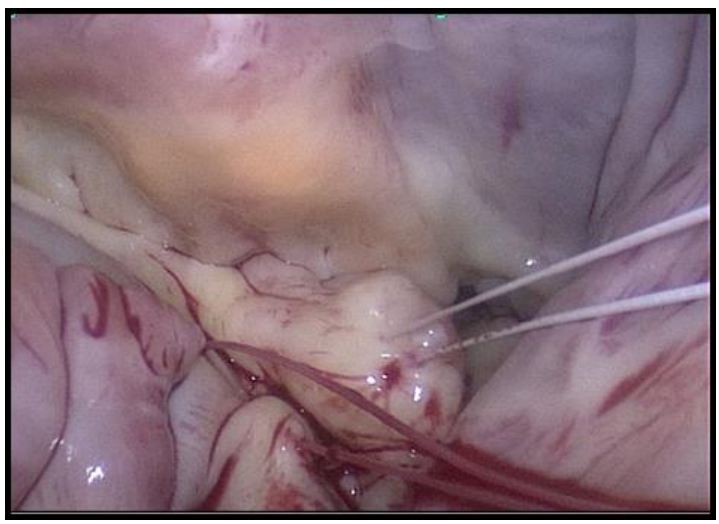

Figure 15. Implantation of the e-PTFE artificial chord on the free margin of the prolapsing segment of P2. two passages are made through the leaflet in order to achieve a stable but modifiable position of the segment itself.

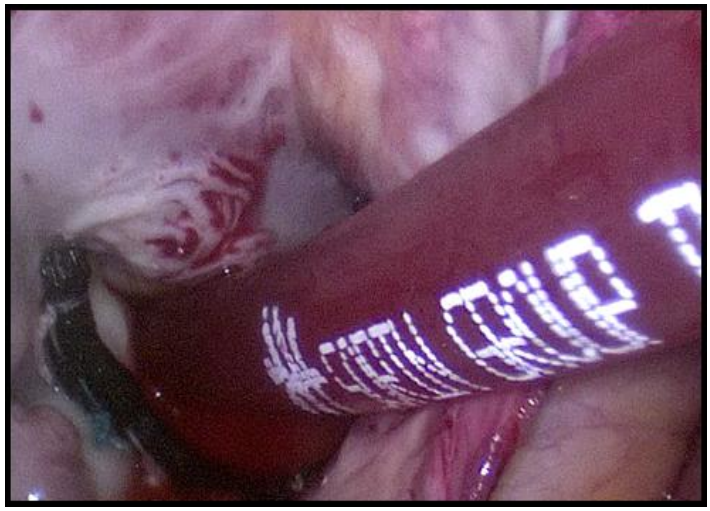

Figure 16. Once the annuloplasty has been performed the saline test is performed.

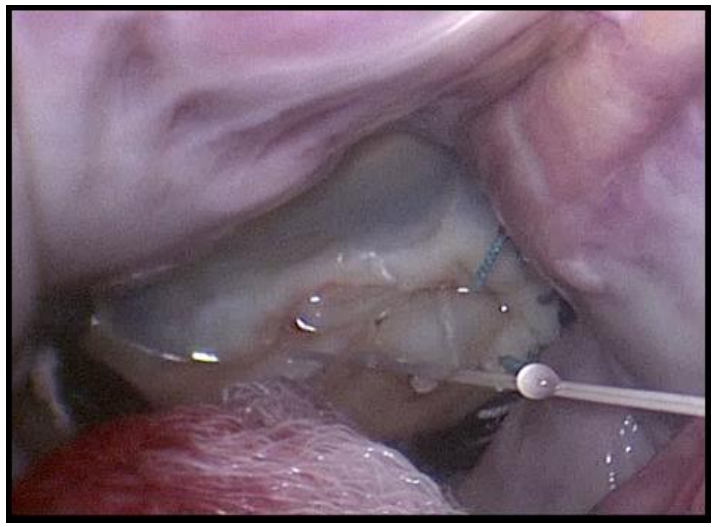

Figure 17. Under filled left ventricle the length of the e-PTFE neochord can be easily adjusted.

Anterior Leaflet or Bileaflets Prolapse Management

Anterior leaflet (ALP) or bileaflet prolapse (BLP) are deemed to require a more complex correction in comparison with PLP which is reflected in the associated valve repair durability in the long term [11-31]. A large armamentarium of surgical techniques is available for repairing these lesions, such as chordal transfer or shortening, e-PTFE neo-chordae implantation, papillary muscle repositioning, leflets resection and edge-to-edge technique. The choice of the right "height" of the anterior leaflet remains the crucial discussion point-of ALP repair to the extent that trans-aortic approaches have been proposed to correct this [32]. Due to the difficulties in its management, the use of e-PTFE neochordae was first studied in the treatment of the PLP and its application was then extended to ALP and BLP [33]. We

know that isolated ALP or BLP are independent predictors of MR recurrence [19]. Hence, to solve the complexity of treatment of these type of lesions, a large number of operative techniques, instruments and calipers have been purposed. Table 2 show several methods of anterior leaflet repair.

Table 2. Techniques for the repair of the anterior mitral leaflet

Study	Method of anchor to papillary muscle	Method of anchor to leaflet	Method of Adjusting length	Knot tying	Annuloplasty ring	Special features
Kasegawa et al. 1994 [34]	1	B1,3	1	0	1,2	Tourniquets used to secure neochordae at target length during testing
von Oppell and Mohr 2000 [35]	1	A4	3	1	0	Vernier callipers used to measure the PM–leaflet distance. Loops of neochordae are constructed to a predetermined length
Adams et al. 2001 [36]	3	B1	1	2	2	Leaflet is resected prior to chordae Construction
Duran and Pekar 2003 [37]	1	B2	4	1	1	Temporary Alfieri stitch is used to coapt the leaflets before tying
Matsui et al. 2005 [38]	1	B3	3	0	2	Specialized device measures target chordae length using surrounding normal chordae
Pretre et al. 2006 [32]	0	B2	1	0	1	Requires aortotomy
Shudo et al. 2006 [39]	0	B1	1	0	0	Continuous knot tying and number of knots are adjusted after knot tying
Rankin et al. 2006 [40]	1	B2	1	3	1	Clip holds sutures in place over slip-knot, while competency is tested The chordae is woven through the prolapsing segment, so may be particularly useful in Barlow's disease
Chocron 2007 [41]	0	B2	1	0	1	Knots are tied over clips which initially hold the chordae to prevent slipping
Mandegar et al. 2007 [42]	1	A1	2	1	0	A series of tight reverse knots made according to required length, which is determined by preoperative echoTied over a patch of pericardium

Study	Method of anchor to papillary muscle	Method of anchor to leaflet	Method of Adjusting length	Knot tying	Annuloplasty ring	Special features
Scorsin et al. 2007 [43]	0	A2	2	4	2	System of pre-manufactured chordae
Fattouch et al. 2007 [44]	1	B2	1	0	1	Knots are tied under conditions of LV loading Temporary Alfieri stitch is placed to oppose the leaflets
Maselli et al. 2007 [45]	3	B3	1	2	0	Two systems of Gore-Tex sutures, one papillary and the other leaflet Sutures interact and together form the neochordae
Smith and Stein 2008 [46]	0	B3	1	0	0	Knots are tied leaving a little room to avoid damage to the PM U-clips are used to attach the loop to the leaflet segment
Calafiore et al. 2008 [47]	0	A1	3	0	0	Addition of 5 mm extra when a nerve hook is used to extend the AML that maximally avoids under-sizing the chordae
Doi et al. 2009 [49]	1	A1,2	2,3	0	1	Involves the construction of callipers for the measurement of the length of AML chordae
Brunsting et al. 2009 [50]	1	B2,3	1	0	1	Robotic technique
Moorjani et al. 2009 [51]	2	B2	1	1	2	Chordae length sets under LV loading conditions
Ruyra-Baliarda 2010 [52]	0	A1	1	0	1	T-shaped no prolapse system ensures that the leaflets and annulus are at the same length
Cagli 2010 [53]	1	A2,3	2,3	3	1	Hegar Dilator is used to construct the neochordae
Garcia-Fuster et al. 2010 [54]	1	B2	0	2	0	Temporary stitch is used to bring the prolapsing segment to the level of the annulus, ensuring the correct chordae length is achieved
Maselli et al. 2010 [55]	1	B1	1	-	-	This system involves a suture with a loop attached to the end The suture contains a series of knots at a constant interval and by forming a slip noose-lace this can be adjusted

Table 2. (Continued)

Study	Method of anchor to papillary muscle	Method of anchor to leaflet	Method of Adjusting length	Knot tying	Annuloplasty ring	Special features
Maisano et al. 2011 [56]	1	A2,3	1	1	0	A simplified device was tested in dogs to allow combination of minimally invasive, beating heart and tuneable chordae implantation
Chang and Kao 2011 [57]	0	0	3	0	0	Slit plastic tube maintains length during knot tying
Iida et al. 2010 [58]	0	1/3	3	0	0	A system pulls chordae to the correct tension at the site of the opposing leaflet to ensure correct length of the chordae Points of tension are the leaflet and the apillary muscle
Matsui et al. 2011 [59]	1	3	3	0	2	Chordae are passed through tubes of predetermined length which are then cut after tying
Seeburger et al. 2012 [60]	1	3	1	0	0	Neochord DS 1000 device Beating heart, minimally-invasive technique with custom device Animal study
Chan et al. 2008 [61]	1	1	0	2	0	Clips are used to maintain the length of the chordae at the desired location, tied and cut

PM: papillary muscle; *AML*: anterior mitral valve leaflet.

Method of anchor to papillary muscle: 0: not defined; 1: pledgetted support; 2: figure-of-eight conventional suture; 3: neither 0, 1, 2, e.g., fixation device.

Method of anchor to leaflet: 0: not defined; A: chordae tied permanently before or without length adjustment; B: chordae are left untied or are only partially tied until competence testing; 1: at the site of anatomical chordae attachment; 2: at the site of maximal prolapse; 3: use of special device used.

Method of adjusting length: 0: not defined; 1: adjusted after testing; 2: pre-determined by echo; 3: pre-determined by direct measurement; 4: other

Knot tying: 0: not defined; 1: reverse knotting so that final length is not affected by tying; 2: surgeon's knot (reef knot with an extra throw); 3: slip-knots; 4: continuous suture.

Annuloplasty ring: 0: not defined; 1: before chordae placement; 2: after chordae placement.

From M. Ibrahim et al. / Interactive CardioVascular and Thoracic Surgery [25].

In Figures 18A, B, C are shown the essential steps of the techniques detailed in Table 2 for repair of the anterior mitral valve leaflet. In our experience of MVr, isolated ALP is quite rare. BLP is more common, consisting of around 30% of degenerative MR [33]. Usually precise reduction of PLP with e-PTFE neochordae implantation completed with a posterior annuloplasty can yield a perfectly competent MV without any intervention on the prolapsing anterior leaflet. This is due to the realization of a large and smooth coaptation surface after the "repositioning" of the posterior leaflet with artificial chordae and to the shifting forward the septum of the coaptation line that does not allow the anterior leaflet to prolapse again. If the native chordae relative to the anterior leaflet are elongated, reduced in number or too thin, a sentinel pair of e-PTFE neochord can be placed. The height is determined by referring to the native annulus.

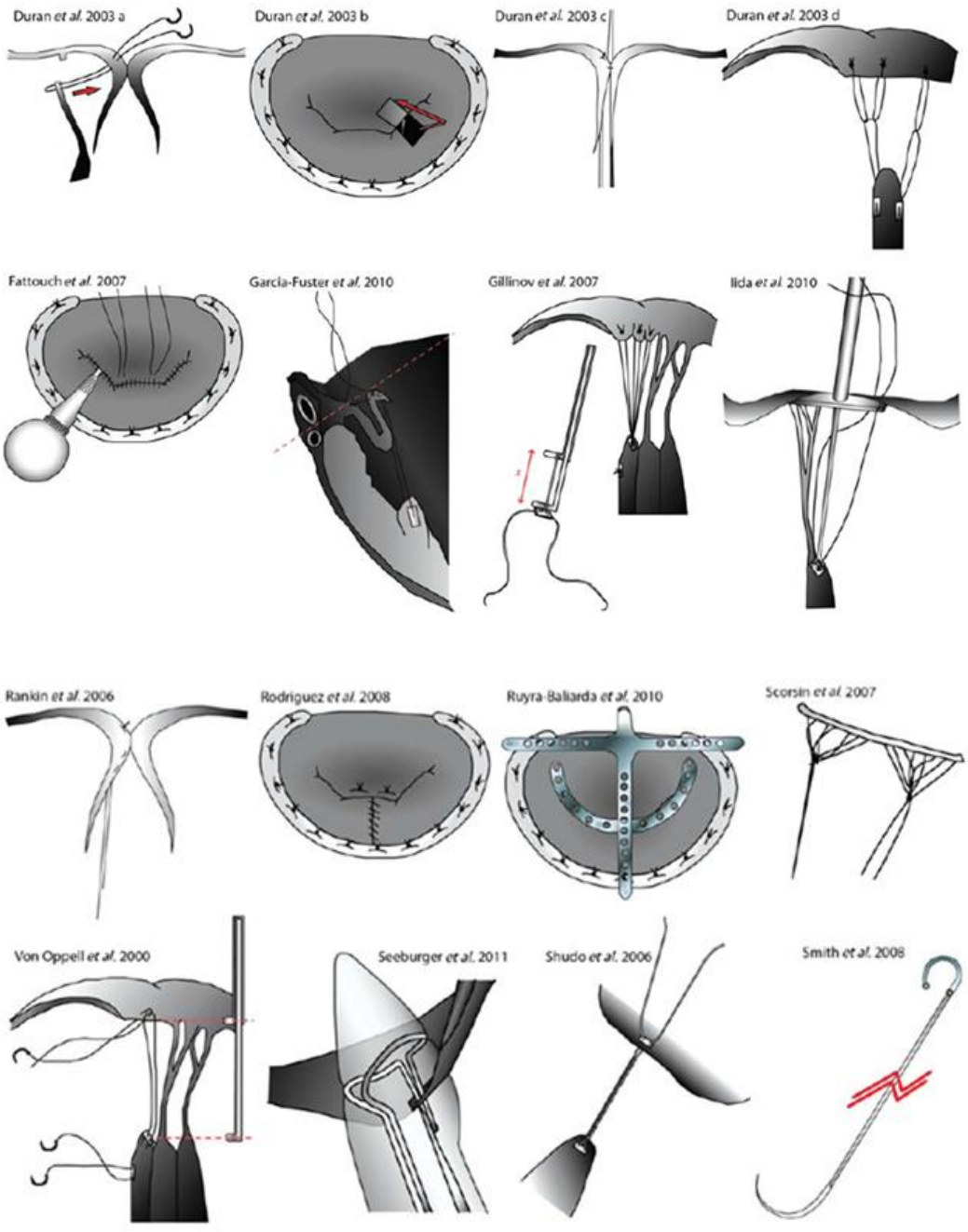

Figure 18A. Techniques for the repair of the anterior mitral leaflet.

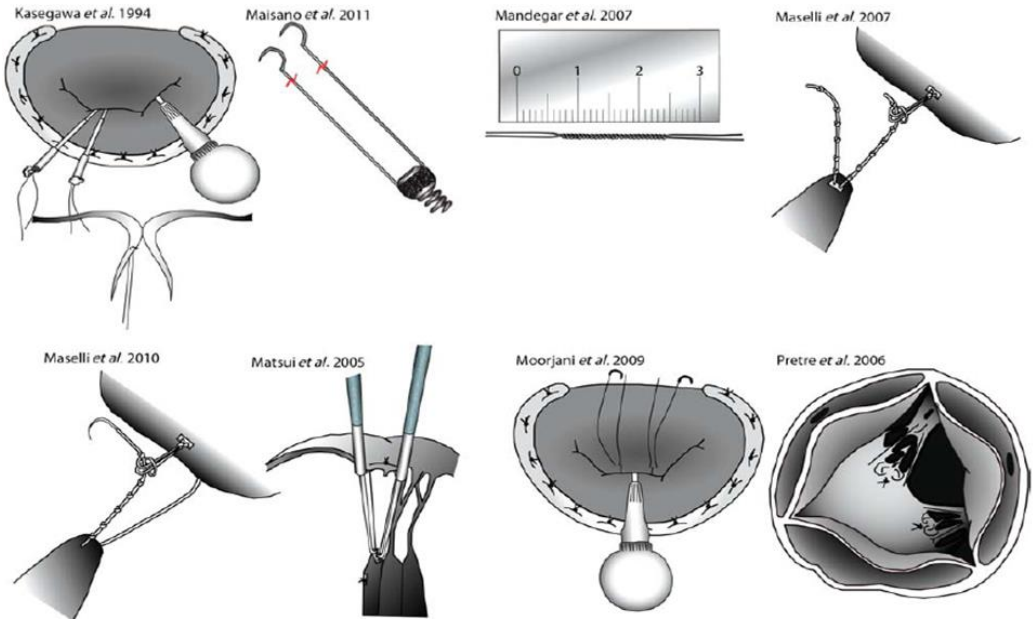

Figure 18B. Techniques for the repair of the anterior mitral leaflet.

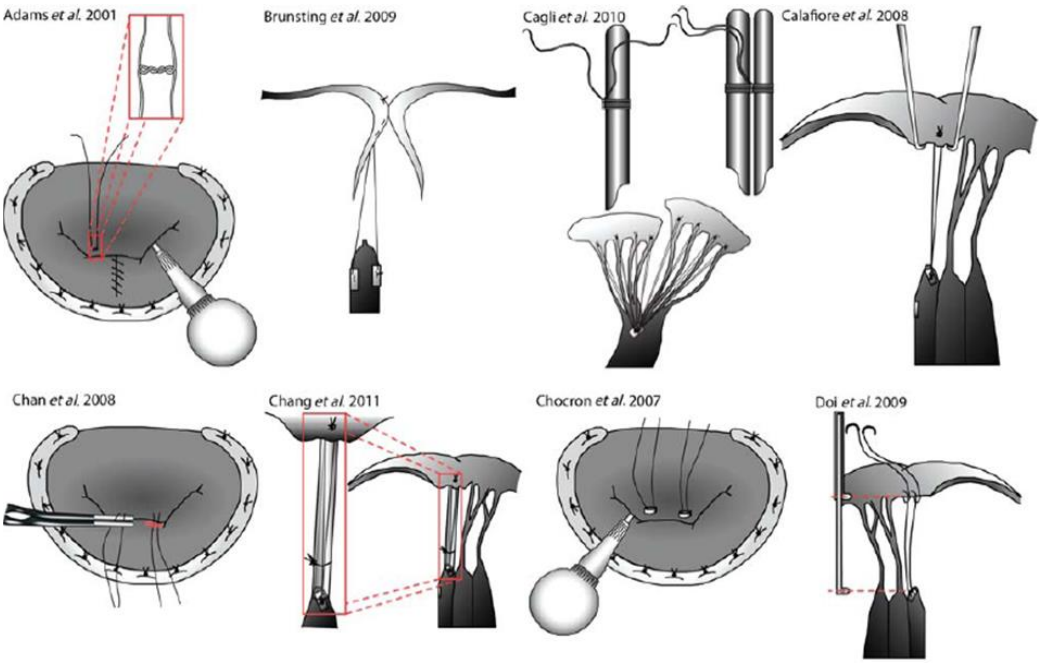

Figure 18C. Techniques for the repair of the anterior mitral leaflet.

Native MV Annulus Management

The management of the native MV annulus is fundamental in the setting of MVr. It is well known that lack of mitral annuloplasty [19] or no use of annuloplasty ring during MVr surgery are independent predictors of recurrent MR [20]. Other independent predictors of MV reoperation are shown in Table 3.

Several prosthetic rings are available for use in MVr in degenerative MR. Characteristics varies from model to model: open or closed; soft, rigid or semirigid; planar or saddle shaped. The device of choice depends on the surgeon's preference and experience. We usually employ soft open rings in order to preserve the physiological function of the mitro-aortic junction and to leave the mitro-aortic continuity undisturbed. Soft bands or semirigid closed rings can also be reshaped once they have been implanted to correct for instance asymmetrical annular enlargements. The development of precise 3D echocardiography has provided us with a new tool for MV analysis. For instance real-time three-dimensional TEE has increased our understanding of the distinct mechanisms underlying functional, ischemic or degenerative MR. In case of fibro-elastic deficiency (FED) or in Barlow's Disease (BD), the annular motion is substantially different. In FED, the saddle-shape and contractile function is relatively preserved, while in BD the annulus is remarkably flattened and hypodynamic. these findings may influence the choice of the repair technique and the selection of a particular annuloplasty ring [62]. The ring type and the size is related to the underlying MV disease (i.e., FED, BD) and is crucial in the position and reshaping of the MV coaptation that is due to the coaptation surface, the repositioning of the coaptation point among the antero-posterior MV diameter, and the coaptation depth (the distance from the annular plane to effective point of coaptation into the left ventricle). All these aspects are involved in a successful MVr (Figure 19).

Table 3. Independent predictors of MV reoperation

	Hazard Ratio (95% CI)	P value
Isolated anterior leaflets prolapse	5.04 (2.51-10-9)	<0.001
Myxomatous degeneration (per level)	1.54 (1.02-2.32)	0.04
Duran ring annuloplasty	3.23 (1.67-6.25)	0.001
Independent Predictors of recurrence of moderate/severe MV regurgitation		
Age by 5-y increments	1.33 (1.20-1.46)	<0.001
Isolated anterior leaflet prolapse	2.86 (1.66-1.90)	<0.001
Myxomatous degeneration (per level)	1.57 (1.19-2.07)	0.002
Repair without annuloplasty ring	2.13 (1.21-3.75)	0.009
CPB time (per 10 min)	1.11 (1.03-1.98)	0.007

From David TE, Armstrong S, McCrindle BW, Manlhiot C. 2013. Late outcomes of mitral valve repair for mitral regurgitation due to degenerative disease. *Circulation*. 127(14):1485-92. [19].

Anterior shifting of mitral leaflet coaptation toward the left ventricular outflow tract (LVOT) may lead to systolic anterior motion (SAM) and LVOT obstruction (LVOTO). The position of the coaptation line of the mitral leaflets is a dynamic condition and hence a potential target and end point for surgical strategies to prevent SAM/LVOTO post MV repair [63]. Some valvuloplasty techniques are more suitable to increase the risk of SAM in the post CPB period; for instance, the residual leaflet length strictly correlates with the degree of SAM. According to this study and that of Lee et al. [64], it should be expected that the "sliding leaflet technique," associated with quadrangular resection, as proposed by Jebara et al. [65], should reduce the incidence of SAM and LVOTO. By decreasing the size of the posterior mitral leaflet, coaptation will occur closer to the tip of the anterior leaflet and more posteriorly in the ventricular cavity, leaving less mitral tissue near the LVOTO [66].

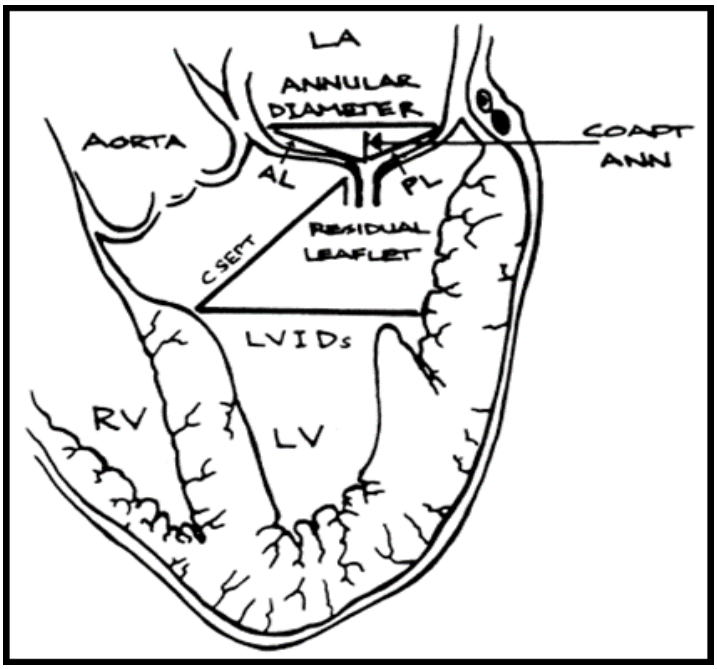

AL = anterior leaflet length; Ann Diam = annular diameter; CoaptAnn = distance from the mitral coaptation point to the annular plane; CSept = distance from the mitral coaptation point to the septum; LVIDs = left ventricular internal diameter in systole; PL = posterior leaflet length.

Figure 19. Schematic demonstrating the transesophageal echocardiographic measurements performed prior to and after mitral valve repair. The image was obtained from the esophageal location at zero degrees (horizontal) plane. Structures included the left atrium, left ventricle, mitral valve and the left ventricular outflow tract. Lengths of the anterior and posterior leaflets were obtained using the central scallops. From Adrew D. et al. [63].

In endoscopic MICS, performing surgery may be technically more challenging. However, the assessment of the valve is better than the standard sternotomy approach due to thoracoscopic magnification. The new generation of 3D systems for thoracoscopic surgery provide the feeling of depth that is lost with the traditional two-dimensional systems. Furthermore, the analysis of prolapsing segments, leaflet length and mobility and the determination of artificial neochordae length is facilitated by the use of videothoracoscopy.

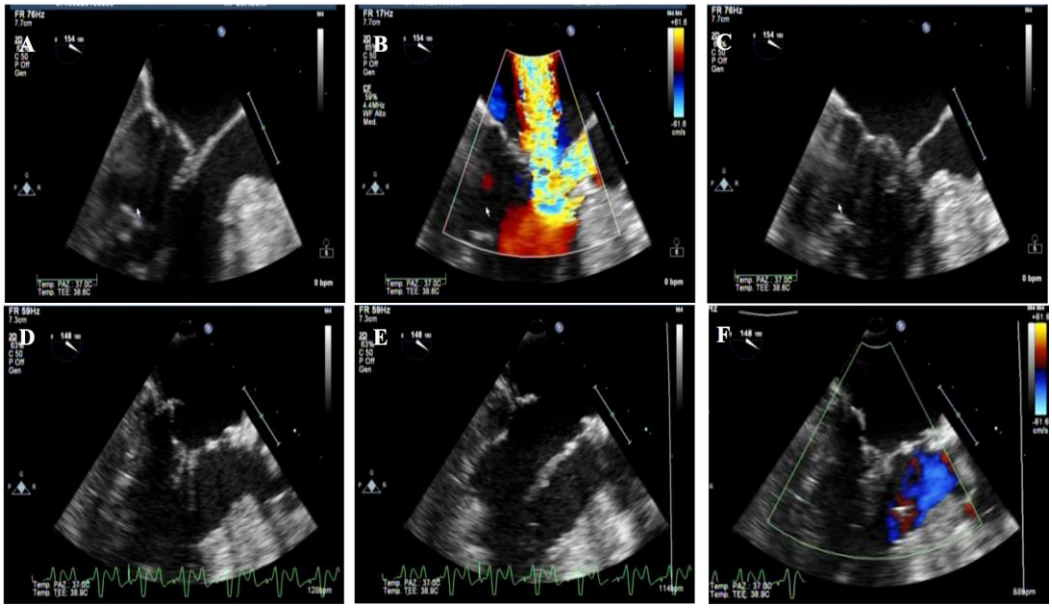

Figure 20. A, B, C Preoperative Echocardiogram - D, E, F postoperative Echocardiographic result [68].

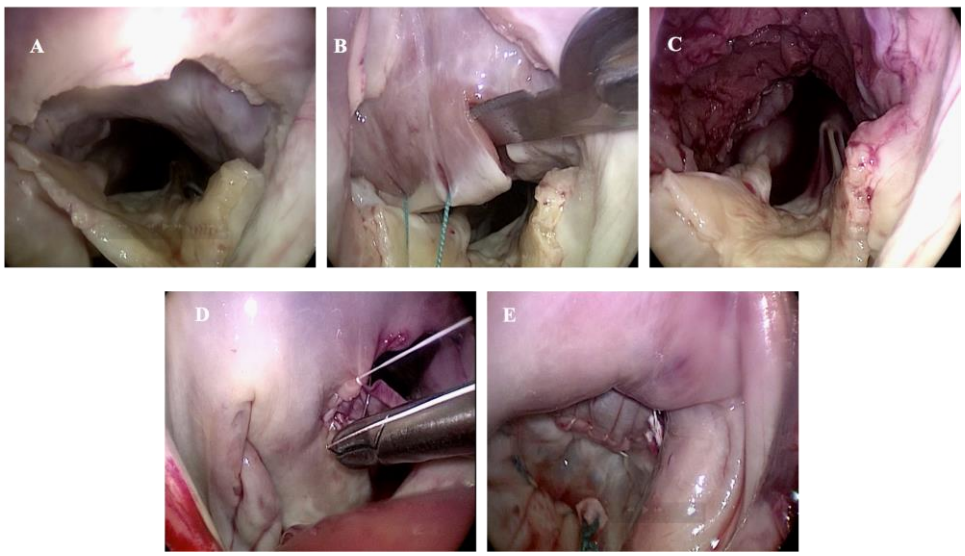

Figure 21. A: Anterior MV leaflet (AML) detachment from its base, B-C: LVOTO excision;
D: reconstruction and elongation of the AML with a xeno pericardial patch; E: final result AML [68].

As mentioned above, we are used to implant open soft mitral band in order to leave the mitro-aortic junction free and also to preserve the ability of subsequent modification of the ring size, if needed. The ring size choice is based on the annular diameter and shape (symmetrical or asymmetrical dilatation), on the posterior and anterior leaflet length and on their motility during the cardiac cycle and on the LVOT diameter and shape. The risk of SAM drives the choice towards an oversized ring, whereas the length of the posterior and anterior leaflets and the need for reduction of the antero-posterior annular diameter to achieve

coaptation may lead to an undersized ring. In the setting of degenerative MV disease a closed ring is usually chosen when a subsequent MV replacement may be contemplated. The MEMO 3D and MEMO 3D Rechord (Sorin-Livanova; London, UK) are semirigid closed mitral rings, that are very suitable for a valve-in-ring transapical procedure because of their ability to assume a perfect circular shape once the expandable valve has been released [67]. More complex techniques involving MV leaflets can be performed in endoscopic MICS; for example closure of pseudocleft with 6/0 GORE-TEX (GORE-TEX sutures; W.L. Gore & Associates, Inc, Flagstaff, Ariz) between two scallops to seal the coaptation surface; or a more complex extension of the anterior leaflet with pericardial patch and enlargement of the LVOT achieved by transmitral myectomy in order to avoid SAM and give a more natural movement of the leaflet during the cardiac cycle. The elongation of AMVL with patch is also used to "stiffen" the anterior leaflet thus reducing leaflet laxity, Figure 20A,B,C,D,E,F is representing pre and post-operative echocardiographic assessment Figures 21A, B, C, D, E represent intraoperative pictures [68].

REFERENCES

[1] Durham NC. Executive Summary. *STS National Database* 2003.

[2] Chitwood WR Jr, Gulielmos V. *What is minimally invasive cardiac surgery?* CTSnet.org. Accessed June 22, 2010.

[3] Felger JE, Nifong LW, Chitwood WR Jr. The evolution of and early experience with robot-assisted mitral valve surgery. *Surg Laparosc Endosc Percutan Tech* 2002;12:58-63.

[4] Youssef SJ1, Millan JA, Youssef GM, Earnheart A, Lehr EJ, Barnhart GR. The role of computed tomography angiography in patients undergoing evaluation for minimally invasive cardiac surgery: an early program experience. *Innovations (Phila)* 2015;10(1):33-8.

[5] Moodley S, Schoenhagen P, Gillinov AM, Mihaljevic T, Flamm SD, Griffin BP, Desai MY. Preoperative multidetector computed tomograpy angiography for planning of minimally invasive robotic mitral valve surgery: impact on decision making. *JTCVS* 2013;146(2):262-8.

[6] Enriquez-Sarano M, Akins CW, Vahanian A. Mitral regurgitation. *Lancet* 2009;373:1382-94.

[7] Kim HY, Baek SH, Je HG, Kim TK, Kim HJ, Ahn JH, Park SJ. Comparison of the single-lumen endotracheal tube and double-lumen endobronchial tube used in minimally invasive cardiac surgery for the fast track protocol. *J Thorac Dis* 2016;8(5):778-83.

[8] Chan EY1, Lumbao DM, Iribarne A, Easterwood R, Yang JY, Cheema FH, Smith CR, Argenziano M. Evolution of cannulation techniques for minimally invasive cardiac surgery: a 10-year journey. *Innovations (Phila)* 2012;7(1):9-14.

[9] Gillinov AM, Cosgrove DM, Blackstone EH, Diaz R, Arnold JH, Lytle BW, Smedira NG, Sabik JF, McCarthy PM, Loop FD. Durability of mitral valve repair for degenerative disease. *J Thorac Cardiovasc Surg* 1998;116:734-43.

[10] Suri RM, Schaff HV, Dearani JA, Sundt TM 3rd, Daly RC, Mullany CJ, Enriquez-Sarano M, Orszulak TA. Survival advantage and improved durability of mitral repair for leaflet prolapse subsets in the current era. *Ann Thorac Surg* 2006;82:819-26.

[11] David TE, Ivanov J, Armstrong S Christie D, Rakowski H. A comparison of outcomes of mitral valve repair for degenerative disease with posterior, anterior, and bileaflet prolapse. *J Thorac Cardiovasc Surg* 2005;130:1242-9.

[12] Carpentier A, Cardiac valve surgery-the "French correction." *J Thorac Cardiovasc Surg* 1983;86:323-37.

[13] Dreyfus GD, Souza Neto O, Aubert S. Papillary muscle repositioning for repair of anterior leaflet prolapse caused by chordal elongation. *J Thorac Cardiovasc Surg* 2006;132:578-84.

[14] Raanani E, Spiegelstein D, Sternik L, Preisman S, Moshkovitz Y, Smolinsky AK, Shinfeld A; Quality of mitral valve repair: Median sternotomy versus port-access approach. *J Thorac Cardiovasc Surg* 2010;140:86-90.

[15] Perier P, Hohenberger W, Lakew F, Batz G, Urbanski P, Zacher M, Diegeler A. Toward a New Paradigm for the Reconstruction of Posterior Leaflet Prolapse: Midterm Results of the "Respect Rather Than Resect" Approach. *Ann Thorac Surg* 2008;86:718 –25.

[16] Carpentier A, Relland J, Deloche A, Fabiani JN, D'Allaines C, Blondeau P, Piwnica A, Chauvaud S, Dubost C. Conservative management of the prolapsed mitral valve. *Ann Thorac Surg* 1978;26:294 –302.

[17] Carpentier A. The sliding leaflet technique. *Le Club Mitrale Newslett* 1988;I:5.

[18] Hopkins RA. Fleur de Lys Repair of Posterior Mitral Valve Leaflet. *Operative Techniques in Thoracic and Cardiovascular Surgery* 2008;13(2):68 - 73.

[19] David TE, Armstrong S, McCrindle BW, Manlhiot C. Late outcomes of mitral valve repair for mitral regurgitation due to degenerative disease. *Circulation* 2013;127(14): 1485-92.

[20] Shimokawa T, Kasegawa H, Katayama Y, Matsuyama S, Manabe S, Tabata M, Fukui T, Takanashi S. Mechanisms of recurrent regurgitation after valve repair for prolapsed mitral valve disease. *Ann Thorac Surg* 2011;91(5):1433-8.

[21] Zussa C. In: Zussa C, ed. Artificial chordae in mitral valve surgery (medical intelligence unit). RG Landes Co. Chapter 7-Artificial chordae *Clinical Experience* 1994;pg. 79–112.

[22] Zussa C, Polesel E, Rocco F, Valfré C. Artificial chordae in the treatment of anterior mitral leaflet pathology. *Cardiovasc Surg* 1997;5:125-8.

[23] Salvador L, Mirone S, Bianchini R, Regesta T, Patelli F, Minniti G, Masat M, Cavarretta E, Valfrè C. A 20-year experience with mitral valve repair with artificial chordae in 608 patients. *J Thorac Cardiovasc Surg* 2008;135:1280-7.

[24] Berrebi A. Mitral Valve Repair: Echocardiography is its Best Friend. *Rev Esp Cardiol*. 2011;64(7):554–556.

[25] Ibrahim M., Rao C. Athanasiou T. Artificial chordae for degenerative mitral valve disease: critical analysis of current techniques. *Interactive Cardio Vascular and Thoracic Surgery*. 2012;15:1019–1032.

[26] David TE. Artificial chordae. *Semin Thorac Cardiovasc Surg* 2004;16:161–8.

[27] Cimen S, Ketenci B, Ozay B, Demirtas M. Neo-chordae length adjustment in mitral valve repair. *Eur J Cardiothorac Surg* 2006;29:843–4.

[28] Tam R, Joshi P, Konstantinov IE. A simple method of preparing artificial chordae for mitral valve repair. *J Thorac Cardiovasc Surg* 2006;132:1486–7.

[29] Kudo M, Yozu R, Kokaji K, Kimura N. A simple method of prevention for systolic anterior motion in mitral valve repair by loop technique method. *Ann Thorac Surg* 2009;87:324–5.

[30] Isoda S, Osako M, Kimura T, Mashiko Y, Yamanaka N, Nakamura S, Maehara T. The "loop with anchor" technique to repair mitral valve prolapse. *Ann Thorac Cardiovasc Surg* 2012;18:170–3.

[31] Mohty D, Orszulak T, Schaff H, Avierinos J, Tajik J, Enriquez-Sarano M. Very long-term survival and durability of mitral valve repair for mitral valve prolapse. *Circulation* 2001;104:I1–7.

[32] Pretre R, Khatchatourov G, Kadner A, Genoni M. Application and adjustment of artificial chordae to the mitral valve using an approach through the aortic valve. *Ann Thorac Surg* 2006;82:761–2.

[33] Coutinho GF, Correia PM, Branco C, Antunes MJ. Long-term results of mitral valve surgery for degenerative anterior leaflet or bileaflet prolapse: analysis of negative factors for repair, early and late failures, and survival. *Eur J Cardiothorac Surg* 2016;50(1):66-74.

[34] Kasegawa H, Kamata S, Hirata S, Kobayashi N, Mannouji E, Ida T, Kawase M. Simple method for determining proper length of artificial chordae in mitral valve repair. *Ann Thorac Surg* 1994;57:237–8.

[35] Von Oppell UO, Mohr FW. Chordal replacement for both minimally invasive and conventional mitral valve surgery using premeasured Gore-Tex loops. *Ann Thorac Surg* 2000;70:2166–8.

[36] Adams DH, Kadner A, Chen RH. Artificial mitral valve chordae replacement made simple. *Ann Thorac Surg* 2001;71:1377–8.

[37] Duran CM, Pekar F. Techniques for ensuring the correct length of new mitral chords. *J Heart Valve Dis* 2003;12:156–61.

[38] Matsui Y, Fukada Y, Naito Y, Sasaki S, Yasuda K. A new device for ensuring the correct length of artificial chordae in mitral valvuloplasty. *Ann Thorac Surg* 2005;79:1064–5.

[39] Shudo Y, Taniguchi K, Takahashi T, Matsue H. Simple and easy method for chordal reconstruction during mitral valve repair. *Ann Thorac Surg* 2006;82:348–9.

[40] Rankin JS, Orozco RE, Rodgers TL, Alfery DD, Glower DD. Adjustable artificial chordal replacement for repair of mitral valve prolapse. *Ann Thorac Surg* 2006;81:1526–8.

[41] Chocron S. Removable clips for mitral valve repair. *J Thorac Cardiovasc Surg* 2007;133:1682–3.

[42] Mandegar MH, Yousefnia MA, Roshanali F. Preoperative determination of artificial chordae length. *Ann Thorac Surg* 2007;84:680–2.

[43] Scorsin M, Al-Attar N, Lessana A. A novel technique of utilizing artificial chordae for repair of mitral valve prolapse. *J Thorac Cardiovasc Surg* 2007;134:1072–3.

[44] Fattouch K, Bianco G, Sbraga F, Sampognaro R, Ruvolo G. Simple, safe and easy technique to ensure the correct length of artificial chordae in mitral valve repair. *Ann Thorac Surg* 2007;83:1902–3.

[45] Maselli D, De Paulis R, Weltert L, Salica A, Scaffa R, Bellisario A, Mingiano A, Celi S, Di Puccio F. A new method for artificial chordae length 'tuning' in mitral valve repair: preliminary experience. *J Thorac Cardiovasc Surg* 2007;134:454–9.

[46] Smith JM, Stein H. Endoscopic placement of multiple artificial chordae with robotic assistance and nitinol clip fixation. *J Thorac Cardiovasc Surg* 2008;135:610–14.

[47] Calafiore AM, Scandura S, Iacò AL, Contini M, Di Mauro M, Bivona A, Giordano G, Bosco P. A simple method to obtain the correct length of the artificial chordae in complex chordal replacement. *J Card Surg* 2008;23:204–6.

[48] Rodriguez E, Nifong LW, Chu MW, Wood W, Vos PW, Chitwood WR. Robotic mitral valve repair for anterior leaflet and bileaflet prolapse. *Ann Thorac Surg* 2008;85:438–44.

[49] Doi A, Iida H, Sunazawa T. Intracardiac calipers for artificial chordae replacement in mitral valve repair. *Ann Thorac Surg* 2009;87:326–8.

[50] Brunsting L, Rankin S, Braly K, Binford R. Robotic artificial chordae replacement for repair of mitral valve prolapse. *Innov Technol Tech Cardiothorac Vasc Surg* 2009; 4:229–232.

[51] Moorjani N, Viola N, Janusauskas V, Livesey S. Adjusting the length of artificial polytetrafluoroethylene chordae in mitral valve repair by a single loop technique. *J Thorac Cardiovasc Surg* 2009;138:1441–2.

[52] Ruyra-Baliarda X. Preliminary experience with the no prolapse system. A new device for ensuring the proper length of artificial chordae in mitral valve repair. *Interact Cardio Vasc Thorac Surg* 2010;10: 165–7.

[53] Cagli K. A simple method of making artificial chordal loops for mitral valve repair. *Ann Thorac Surg* 2010;89:e12–4.

[54] Garcia-Fuster R, Gil O, Vazquez A, Garcia A, Martinez-Leon J. The folding leaflet: a simple method for neochordal repair. *Ann Thorac Surg* 2010; 89:1682–4.

[55] Maselli D, Ficarra E, Weltert L, Barberi F, Scaffa R, Bellisario A, De Paulis R. A method to avoid knot-tying in artificial chordae implantation for mitral valve repair. *J Heart Valve Dis* 2010;19:249–53.

[56] Maisano F, Cioni M, Seeburger J, Falk V, Mohr FW, Mack MJ, Alfieri O, Vanermen H. Beating-heart implantation of adjustable length mitral valve chordae: acute and chronic experience in an animal model. *Eur J Cardiothorac Surg* 2011;40:840–7.

[57] Chang JP, Kao CL. Slit stent technique for ensuring the correct length of artificial chordae in mitral repair. *J Card Surg* 2011;26:259–60.

[58] Iida H, Sunazawa T, Doi A, Ishida K, Irabu S. A device for ensuring the neochordae replacement in mitral valve repair. *Ann Thorac Surg* 2010; 90:2071–2.

[59] Matsui Y, Kubota S, Sugiki H, Wakasa S, Ooka T, Tachibana T, Sasaki S. Measured tube technique for ensuring the correct length of slippery artificial chordae in mitral valvuloplasty. *Ann Thorac Surg* 2011;92:1132–4.

[60] Seeburger J, Leontjev S, Neumuth M, Noack T, Höbartner M, Misfeld M, Borger MA, Mohr FW. Trans-apical beating-heart implantation of neo-chordae to mitral valve leaflets: results of an acute animal study. *Eur J Cardiothorac Surg* 2012;41:173–6.

[61] Chan DT, Chiu CS, Cheng LC, Au TW. Artificial chordae: a simple clip and tie technique. *J Thorac Cardiovasc Surg* 2008;136:1597–9.

[62] Apor A, Nagy AI, Kovács A, Manouras A, Andrássy P, Merkely B. Three-dimensional dynamic morphology of the mitral valve in different forms of mitral valve prolapse –

potential implications for annuloplasty ring selection. *Cardiovascular Ultrasound.* 2015;14:32.

[63] Maslow AD, Regan MM, Haering JM, Johnson RG, Levine RA. Echocardiographic predictors of left ventricular outflow tract obstruction and systolic anterior motion of the mitral valve after mitral valve reconstruction for myxomatous valve disease, *Journal of the American College of Cardiology* 1999;34(7):2096-2104.

[64] Lee KS, Stewart WJ, Lever HM, Underwood PL, Cosgrove DM. Mechanism of outflow tract obstruction causing failed mitral valve repair. *Circulation* 1993;88:4–29.

[65] Jebara VA, Mihaileanu S, Acar C, Brizard C, Grare P, Latremouille C, Chauvaud S, Fabiani JN, Deloche A, Carpentier A. Left ventricular outflow tract obstruction after mitral valve repair. Results of the sliding leaflet technique. *Circulation* 1993;88:30–34.

[66] Kofflard MJ, van Herwerden LA, Waldstein DJ, Ruygrok P, Boersma E, Taams MA, Ten Cate FJ. Initial results of combined anterior mitral leaflet extension and myectomy in patients with obstructive hypertrophic cardiomyopathy. *J Am Coll Cardiol* 1996, 28:197–202.

[67] Bapat V. Mitral valve-in-ring: the good, the bad, and the ugly. *EuroIntervention* 2016;11(10):1092-4.

[68] Hinna Danesi T, Cresce G, Salvador L. *Minimally Invasive Correction of Degenerative Mitral Valve Regurgitation and Hypertrophic Obstructive Left Ventricular Cardiomyopathy -ISMICS* 2014 - (Boston, Massachusetts - USA 28-31 May 2014).

In: Encyclopedia of Surgery (22 Volume Set)
Editors: Andreas Lehrer and Kristin Mueller
ISBN: 978-1-53618-329-0
© 2020 Nova Science Publishers, Inc.

Chapter 425

MINIMALLY INVASIVE TRICUSPID VALVE AND AF ABLATION SURGERY

Chawannuch Ruaengsri, MD, Matthew R. Schill, MD and Ralph J. Damiano, Jr.*[*]*, MD
Division of Cardiothoracic Surgery, Washington University School of Medicine,
Barnes Jewish Hospital, St. Louis, MO, US

ABSTRACT

During the past two decades, the increasing popularity of minimally invasive techniques has had a dramatic impact on the surgical treatment of cardiac disease. Advances in endoscopic imaging and surgical instrumentation have enabled cardiac surgeons to perform complex procedures through small incisions. This chapter will summarize the current guidelines for surgical management of tricuspid valve disease and demonstrate our minimally invasive atrial fibrillation ablation (Cox-Maze IV procedure) technique for both stand-alone atrial fibrillation ablation and for patients undergoing concomitant tricuspid valve and/or mitral valve surgery. We will also discuss surgical results.

Keywords: tricuspid, atrial fibrillation, ablation

INTRODUCTION

Tricuspid valve (TV) disease often coexists with other valvular disease [1]. Functional incompetence of the TV, the most common condition, is commonly asymptomatic but progresses with time and may lead to annular and right ventricular (RV) dilatation. TV disease has been considered less clinically important than mitral or aortic valve pathology, and its management remains controversial [1]. Patients are only occasionally referred for isolated TV surgery, and most procedures are performed concomitant with other cardiac

[*] Corresponding Author's Email: damianor@wustl.edu.

operations. A minimally invasive surgical approach is feasible in most patients and is a very good approach to re-operative TV surgery in patients with a prior sternotomy and patent bypass grafts.

Table 1. Primary causes of tricuspid valve disease [2]

Tricuspid valve regurgitation
– Ebstein's anomaly
– AV canal defect
– Myxomatous degeneration
– Endocarditis
– Trauma (including iatrogenic)
– Tricuspid valve stenosis
– Congenital tricuspid atresia

Table 2. Secondary causes of tricuspid valve disease [2]

Tricuspid valve regurgitation
– Left-sided heart lesions (aortic valve disease, mitral valve disease)
– Congestive heart failure
– Pulmonary embolism
– Pulmonary hypertension
– Rheumatic heart disease
– Marfan's syndrome
– Right-sided ventricular infarction
– Tricuspid valve stenosis
– Carcinoid syndrome
– Rheumatic heart disease
– Right atrial myxoma
– Lupus erythematosus
– Endomyocardial fibrosis

INDICATIONS FOR TRICUSPID VALVE SURGERY

Tricuspid valve disease can arise from a variety of primary (Table 1) and secondary (Table 2) mechanisms. However, the management of the diseased TV is primarily determined by whether the primary physiology is stenosis or regurgitation.

Tricuspid Valve Regurgitation (TR)

TR is common and can arise from various causes. Primary TR is seen with congenital anomalies or acquired leaflet defects. Secondary TR develops in the setting of pressure

overload (primary or secondary pulmonary hypertension) or RV cardiomyopathies (infarction). Functional TR, defined as TR with an anatomically normal valve, is the most common form of tricuspid dysfunction. When the degree of regurgitation worsens, progressive volume overload distends the RV and the tricuspid annulus, producing more severe TR.

Because TR can vary in response to preload, afterload, and RV function [3], echocardiography and pulmonary artery pressure estimation are central to determining its management. It has been suggested that a tricuspid annulus diameter >40 mm (or 21 mm/m^2 measured in the 4-chamber view) indicates the need for TV repair (TVr) [4]. According to the European Society of Cardiology's (ESC) Guidelines on the Management of Valvular Heart Disease, "adding a tricuspid repair, if indicated during left-sided surgery, does not increase operative risks." [4]. The 2014 American Heart Association/American College of Cardiology guidelines recommend performing TV annuloplasty or replacement in patients with severe TR at the time of left-sided valve surgery (Class I) and TV annuloplasty for less than severe TR in patients with pulmonary hypertension or tricuspid annular dilatation undergoing left-sided valve surgery (class IIB) [5]. Tricuspid annuloplasty or replacement is reasonable for patients with severe primary TR who are symptomatic (Class IIa) and may be considered in asymptomatic patients with progressive right ventricular dysfunction (Class IIb).

Late onset TR can reflect intrinsic RV dysfunction or tricuspid annular dilatation. Functional TR has been found in upto 67% of patients undergoing left-sided valve surgery and is thought to be caused by increased afterload from left-sided heart pathology [6]. TR may progress after surgery if the TV is left untreated in patients with less than severe TR. Matsuyama et al. [7] reported significant TR (at least grade 3) on echocardiography performed late after mitral valve replacement (MVR) in 37% of patents with preoperative grade 2 TR. The incidence of echocardiographically moderate or severe late TR in rheumatic patients is even higher (68%) [6]. TR is diagnosed late after MVR, 10 years on average, but can appear as late as 24 years after the initial surgery [6, 8]. The ACC/AHA guidelines recommend considering reoperation for TR only if the regurgitation is severe and symptomatic, RV function is preserved, and severe pulmonary hypertension does not coexist (Class IIb) [5].

Although late TR has been reported most often in patients with rheumatic heart disease, it is not confined to rheumatic patients [9, 10]. Moderate or severe TR was reported in as many as 74% of patients three years after surgical repair of ischemic mitral regurgitation (MR) [10]. Dreyfus et al. [9] reported 34% late TR (grade 3 or 4) in a group of 163 patients with mixed MR etiology who were followed for five years after MV repair (MVr).

Tricuspid Valve Stenosis (TS)

TS produces a mechanical obstruction to right ventricular (RV) filling [11]. TS can be caused by rheumatic inflammation and accompanies rheumatic mitral stenosis in up to 30% of patients and can be associated with TR [12]. TS also may be secondary to carcinoid syndrome, intracardiac tumors or infective endocarditis. Clinically, TS is not well tolerated. Impairment to RV filling may produce symptoms of right-sided heart failure [11, 12]. Carcinoid valve lesions manifest as fibrous white plaques located on the valvular and mural endocardium. The valve leaflets are thickened, rigid, and reduced in area. Fibrous tissue

proliferation is present on the atrial and ventricular surfaces of the valve structure [13]. Surgical reports have recommended TV replacement (TVR) with a mechanical prosthesis in patients with carcinoid syndrome based on the assumed damage to bioprosthetic valves from vasoactive substances, but this has not been well established [14-16]. Mukhopadhyay et al. [17] reported a case producing features of TS because of an unusual presentation of primary antiphospholipid antibody syndrome presenting as intracardiac thrombus over the tricuspid valve. The ACC/AHA guidelines recommend TV surgery for patients with severe TS at the time of operation for left-sided valve disease (Class I, Level of Evidence C) and for symptomatic patients with severe TS (Class I, Level of Evidence C) [5].

Rheumatic Tricuspid Valve Disease

Rheumatic heart disease is still common in developing countries. Although the TV usually is not involved in rheumatic heart disease, its involvement is associated with mitral and/or aortic valve dysfunction and the TV is frequently both stenotic and regurgitant [18]. The TV will have diffusely thickened leaflets with or without fusion of commissures. Chordae tendinae will be thickened and shortened. Deformity of the valve tissue can lead to TS with coexisting TR.

ATRIAL FIBRILLATION IN PATIENTS WITH TRICUSPID VALVE DISEASE

Atrial fibrillation (AF) is a common complication in advanced valvular heart disease. Isolated severe TR is a rare disease, and the literature describing the natural history and management of this condition is sparse. The Framingham Heart Study found the prevalence of moderate or greater TR to be 0.28% in adult men and 1.44% in adult women [19]. However, the clinical impact of TR is very significant. Severe TR is associated with markedly reduced survival (38 ± 7% for severe TR vs. 70 ± 6% for less than severe TR at 10 years) [20]. As a result, the 2014 ACC/AHA guidelines state that surgical repair of symptomatic severe primary TR is reasonable (Class IIa recommendation), although this recommendation is not supported by randomized controlled trials or robust clinical data (level of evidence C) [5].

A history of AF is common in patients with both isolated primary and functional TR, with a prevalence of 40% and 44%, respectively [20, 21]. As many as 25% of patients with severe TR are in AF at the time of diagnosis, and primary TR due to a flail leaflet is associated with a 2.8% annual incidence of new AF [21]. AF in patients with TR is associated with a significant excess risk of mortality (hazard ratio 1.77, CI 1.14-2.79, $p = 0.01$) [20]. As a result, it is reasonable to treat AF at the time of TV surgery. However, evidence for a survival advantage in patients undergoing AF ablation at the time of surgery is lacking.

Surgical Ablation for AF Concomitant to Tricuspid Valve Surgery

For patients undergoing cardiac surgery, more than 50% of AF surgery is performed concomitant with MV surgery. AF is associated with reduced survival and increased risk of stroke [22-24]. The Cox-Maze procedure was originally designed as a concomitant procedure by Dr. James Cox for the treatment of AF in patients undergoing MV surgery. However, the complexity of the operation and the time required to complete the procedure limited its clinical application for many years to patients with lone AF. The ablation-assisted Cox-Maze IV procedure (CMIV) was introduced in 2002. The CMIV simplified the procedure by replacing most of the atrial incisions of the Cox-Maze lesion set with linear lines of ablation, making the operation technically easier and faster to perform [25]. Currently, more than 80% of these procedures are completed with the assistance of ablation technology, and more than 95% are performed as concomitant operations to other cardiac surgical procedures [22]. Our group has demonstrated that, for low-risk patients, the addition of a concomitant CMIV procedure does not increase the operative risk greater than that expected for MV surgery alone and produces a high degree of freedom from AF and antiarrhythmic medications in these patients [26].

Indications for Surgical Ablation of Atrial Fibrillation

The indications for catheter and surgical ablation of AF are detailed in the 2012 Expert Consensus Statement of the Heart Rhythm Society Task Force on Catheter and Surgical Ablation of Atrial Fibrillation [27]. Concomitant surgical ablation of AF at the time of other cardiac surgical procedures is indicated for 1) all symptomatic AF patients undergoing other cardiac surgical procedures, regardless of prior treatment with antiarrhythmic medications, and 2) selected asymptomatic AF patients undergoing cardiac surgery in which the ablation can be performed with minimal additional risk.

CRITERIA FOR USE OF A MINIMALLY INVASIVE APPROACH

The selection of a minimally invasive as opposed to a traditional surgical approach should be based on the presence of concomitant cardiac pathology, patient-specific anatomy, and the experience of the operating surgeon. Our practice is to perform a full biatrial Cox-Maze IV procedure through a minimally invasive right thoracotomy approach in patients undergoing concomitant mitral or tricuspid valve surgery. The Cox-Maze IV procedure is performed through a standard median sternotomy when combined with other concomitant procedures such as aortic valve replacement and coronary artery bypass grafting (CABG). Median sternotomy is reserved for patients with contraindications to a minimally invasive right mini-thoracotomy approach such as peripheral vascular disease that precludes femoral cannulation for cardiopulmonary bypass (CPB), a history of previous right thoracotomy, severe left ventricular dysfunction, or chest wall deformities.

TRICUSPID VALVE REPAIR TECHNIQUES AND APPROACHES

The principles of therapy for secondary TR include elimination of increased afterload to the RV (by correction of left-sided heart disease and restoration of left ventricular function) and correction of tricuspid annular dilatation, by tricuspid valve annuloplasty (suture or prosthetic ring annuloplasty). With rigid or semi-rigid prosthetic ring annuloplasty, the annulus is permanently fixed in a systolic position and the physiologic shape of the tricuspid valve is restored [28]. Flexible rings also may be used, but even though they decrease the size of tricuspid annulus, they are unable to restore its normal morphology. If severe valve tethering is present, the use of an adjunctive procedure such as enlargement of the anterior leaflet or TVR should be considered.

After an initial right atriotomy, the tricuspid valve should be inspected for asymmetrical dilatation in the posterior region and fixation of the septal annulus to the fibrous skeleton of the heart. In 1972, DeVega introduced a partial annuloplasty in the posterior region of annulus that consisted of a double continuous suture starting from the anteroseptal commissure and ending at the posteroseptal commissure [29]. The annuloplasty was nearly circumferential and ended in the region of the atrioventricular node. When TR meets criteria for repair, the current technique of choice is ring annuloplasty although suture annuloplasty is still performed by some surgeons. This technique utilizes a structured band to reduce the antero-posterior diameter of the tricuspid annulus. The ring is sized to the septal leaflet and carefully secured to avoid injury to the conduction system. Ring types most commonly used are those described by Carpentier-Edwards and colleagues (Carpentier-Edwards semirigid ring, MC3 3D ring, Carpentier-Edwards physio tricuspid ring, Edwards LifeSciences, Irvine, C [28]; Duran and Ubago (Duran flexible ring, Medtronic, Dublin, Ireland)[30]; McCarthy and Cosgrove (Cosgrove-Edwards flexible band, Edwards LifeSciences, Irvine, CA) [31]; and Kshettry and Kanda (Carbomedics Annuloflex ring, Sulzer Carbomedics, Inc., Austin, TX) [32].

Tricuspid valve ring annuloplasty improves long term survival, event-free survival, and survival free of recurrent TR compared with De Vega suture annuloplasty in a large series by Tang et al. of 702 patients who underwent TVr [33]. They also showed that TV ring annuloplasty was an independent predictor of long-term survival [33]. Among the different types of prosthetic rings, semi-rigid or rigid rings (either standard or 3D) have been associated with the best results and the lowest rate of recurrent TR. In two large series published by groups at Cleveland Clinic, the degree of postoperative grade 3+ or 4+ TR remained stable over time with the Carpentier-Edwards ring (12% at 5 years and 17% at 8 years) and rose constantly with De Vega procedure, with an overall rate of 24% at 5 years and 33% at 8 years [33, 34]. Evidence for the utility of TV ring annuloplasty during MV surgery and the tricuspid annulus diameter as a guide for TVr comes from a study by Dreyfus et al. [9] of 311 patients who underwent MVr. The TV annulus was measured intraoperatively with a ruler, from the anteroseptal commissure to the anteroposterior commissure. The TVr with a Carpentier-Edwards ring was performed regardless of the degree of TR if the tricuspid valve annulus diameter was >7 cm. TVr was performed in 48% of the patients, despite the fact that 88% had mild TR (grade <1 TR).

Tricuspid valve annuloplasty has been shown to add little time and complexity to MV surgery and has been associated with few additional complications [9, 33, 35]. In functional

TV disease, Singh et al. [35] showed that repair is better than replacement. If the TV needs replacement, the surgeon should excise or imbricate the anterior and posterior leaflets in order to retain the subvalvular apparatus. Sutures should be placed in the septal leaflet proper to avoid the conduction system. Bioprosthetic valves degenerate with time, and mechanical valves in the tricuspid position tend to thrombose. They reported a 5-fold risk of early death during the perioperative period with TVR, which also was an independent predictor of poor survival after surgery. Chang et al. [36] reported a large series of 360 patients with severe TR who underwent TVR (27%) or TVr (73%) [36]. Their study showed no difference in early mortality between the two approaches (TVR:TVr, 3.1%:3.4%, $p = 0.877$). Ten-year overall survival (TVR:TVr, 72%:70%, $p = 0.532$) and ten-year freedom from cardiac death (TVR:TVr, 76%:77%, $p = 0.715$) were not significantly different between the two groups. They concluded that TVR had acceptable early and late outcomes in patients with severe TR. TVR can be considered as a valid option with acceptable clinical outcomes in patients who are not suitable candidates for TVr [36]. Mechanical valve replacement may require permanent epicardial pacing lead placement later because percutaneous leads cannot be placed through a mechanical valve. In the Chang series, a mechanical prosthesis was used in 69 patients (71%) and a bioprosthesis in 28 patients (29%). They preferred a mechanical prosthesis when the patients had a previously implanted mechanical prosthesis in the left heart. A bioprosthetic valve was chosen when the patient life expectancy was less than 15 years [36].

MINIMALLY INVASIVE TRICUSPID VALVE REPAIR RESULTS

The increasing popularity of minimally invasive procedures has affected every surgical specialty. Advancements in cardiac imaging and special surgical instrumentation have enabled cardiac surgeons to perform complex cardiac surgery through small incisions. Minimally invasive approaches to the MV and the aortic valve either through a right mini-thoracotomy or a partial sternotomy have been well described. In addition to improving cosmesis, minimally invasive mitral valve surgery was pioneered with the intent of reducing morbidity, postoperative pain, postoperative blood loss, hospital length of stay, and the time required for patients to return to normal activity. However, there is a paucity of studies regarding minimally invasive TV operations. Kypson et al. [37] reported 33 consecutive patients who underwent TVr or TVR performed via a right mini-thoracotomy with 6% perioperative mortality and 3% conversion to median sternotomy. The largest reported series of 141 patients who underwent a TV operation via mini-thoracotomy was at Duke University between 1997 and June 2008 and revealed a 30 day mortality rate of 2.1%, a rate of conversion to median sternotomy of 3%, and a mean CPB time of 216 minutes [38].

Minimally invasive right mini-thoracotomy is an alternative approach for use in reoperative cases. Reoperative median sternotomy carries the potential for two different iatrogenic insults to the RV: 1) traumatic injury during surgical dissection of the heart, and 2) irreversible distention of an extremely thin and chronically volume overloaded RV, resulting in continuing right heart failure after removal of adherent scar tissue. A right lateral minithoracotomy approach in patients requiring reoperative RV surgery is the technique of choice at our institution. Pfannmuller et al. [39] reported the results of 48 patients who

underwent isolated TV operations after previous cardiac operations with minimally invasive access through a right lateral thoracotomy and showed a 30 day mortality rate of 0% in patients undergoing elective surgery and an early mortality rate of 4.2% for all patients. Five-year survival for patients after elective reoperative TV repair via minimally invasive access was 72.2% ± 10.0%, and five-year freedom from tricuspid valve-related reoperation was 88.1% ± 6.7%.

THE COX-MAZE IV PROCEDURE: SURGICAL TECHNIQUE

At our institution, bipolar radiofrequency energy and cryoablation have been used to replace most of the surgical incisions of the cut-and-sew Cox-Maze III procedure. Our current radiofrequency ablation-assisted procedure, termed the Cox-Maze IV, was introduced in 2002 and replicates the lesion set of the Cox-Maze III [40]. Our clinical results have shown that this modified procedure achieves the high success rate of the Cox-Maze III procedure while significantly reducing operative time and lowering complication rates [41-42].

When valvular heart disease is limited to the tricuspid position, it is reasonable in highly selected cases, particularly those with congenital heart disease, to use only incisions on the right-side for the Maze operation. Avoiding left atrial (LA) manipulation shortens CPB time and aortic cross-clamp (AoX) time. We usually perform the right atrial (RA) lesion set on the beating heart. However, in most patients who do not have congenital heart disease, we tend to perform a biatrial lesion set, since most patients have associated LA enlargement. The use of improved preoperative diagnostic modalities in the future may better inform this decision.

If a median sternotomy is performed, the Cox-Maze procedure is performed as shown in Figure 1 [40]. The superior vena cava (SVC) and inferior vena cava (IVC) are dissected and bicaval cannulation is performed. Both sets of pulmonary veins are dissected and encircled with umbilical tape. A bipolar radiofrequency clamp is used to isolate a cuff of atrial tissue surrounding the right and then the left pulmonary veins. The clamp is not released until an ablation time of less than ten seconds is achieved. This usually takes two-three ablations. We usually perform three sets of ablations in this manner for each ablation line. Pacing from the pulmonary veins while monitoring the surface electrocardiogram is used to confirm exit bock. Subsequently, the RA lesion set is performed as has been described previously [43]. If LA lesions are to be performed, they are performed on the arrested heart with an AoX in place (Figure 1B). The left atrium (LA) is dissected and opened in the interatrial groove. The bipolar radiofrequency clamp is used to make “roof” and “floor” lesions from the atriotomy to the left superior and inferior pulmonary veins, respectively. The clamp is also used to create an ablation from the inferior margin of the atriotomy toward the mitral annulus, taking care to avoid the circumflex coronary artery. As the bipolar clamp cannot reach the annulus itself, a bell-shaped cryoprobe is used to make an endocardial lesion to the mitral annulus and an epicardial lesion over the coronary sinus. The left atrial appendage (LAA) is managed by oversewing its orifice in two layers from an endocardial approach. If a MV procedure is performed, it is performed at this time. The LA is then closed with a running polypropylene suture. The patient is weaned from CPB and closed in standard fashion.

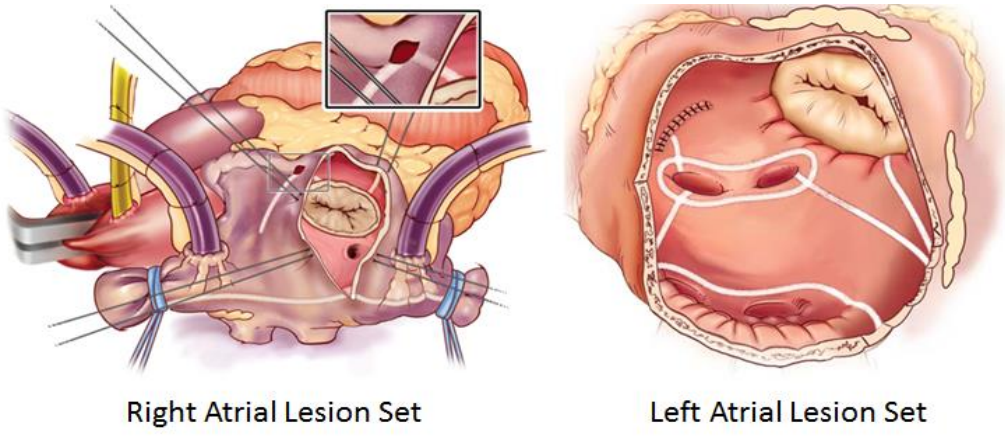

Figure 1. Standard right (A) and left (B) atrial lesion sets utilized for the Cox-Maze IV procedure. In the right atrium (A), radiofrequency ablation lines (white lines) extend from superior vena cava to inferior vena cava and along the right atrial free wall down to tricuspid valve annulus. In the left atrium (B), all ablation lines are performed with a bipolar radiofrequency clamp except for an endocardial cryoablation at the mitral annulus and an epicardial cryoablation over the coronary sinus (From Weimar T, Bailey MS, Watanabe Y, et al. The Cox-maze IV procedure for lone atrial fibrillation: a single center experience in 100 consecutive patients. *J Interven Card Electrophysiol*. 2011;31:47-54).

For the minimally invasive approach, exposure and access are obtained as follows. The patient is positioned supine, and general anesthesia is induced. A double-lumen endotracheal tube is used. Transesophageal echocardiography (TEE) is used to confirm the diagnosis of TR, examine for other pathology, and rule out a thrombus in the LAA. The right chest is elevated to a 30-45° angle. The patient is prepped and draped in sterile fashion. Femoral cannulation for CPB is obtained. The guidewires and cannulae are advanced into the descending thoracic aorta and the right atrium (RA) using TEE visualization. A 5-6 cm mini-thoracotomy is performed over the fourth intercostal space (ICS) lateral to the nipple in the mid-axillary line in men; a submammary incision is used in women (Figure 2). A small segment of the posterior fifth rib is removed, and a soft tissue retractor is used to improve visualization. No rib spreading is performed. A Blake drain is placed through the lateral chest wall and positioned in the posterior right pleural space. Carbon dioxide is infused through this drain to prevent air embolism. After the pericardium is opened, a thoracoscope is placed through a port in the fifth ICS near the posterior axillary line.

If a biatrial Cox-Maze procedure is planned, the oblique and transverse sinuses and the inter-atrial septum are mobilized. The right pulmonary veins are dissected and encircled with umbilical tape. Pacing thresholds are obtained. The right pulmonary veins are isolated using three sequential sets of ablations of a cuff of atrial tissue surrounding the veins with a bipolar radiofrequency device. Exit block is tested by pacing the pulmonary veins at two times the previously documented pacing threshold while monitoring the electrocardiogram for capture. Ablation is continued until exit block is documented.

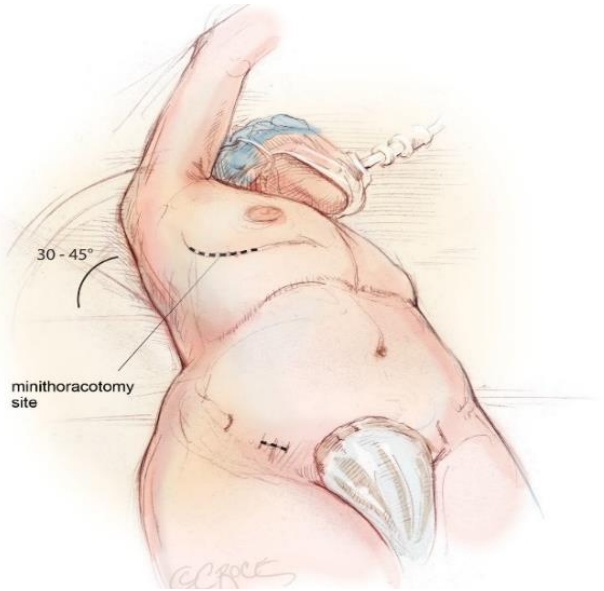

Figure 2. Patient positioning for the minimally invasive Cox-Maze IV procedure, performed through a 5–6 cm right mini- thoracotomy in the inframammary fold. A 2-cm subinguinal incision is used for femoral vessel cannulation for cardiopulmonary bypass (Robertson et al., *Annals of Cardiothoracic Surgery*, used with permission).

The RA lesion set is performed on the beating heart (Figure 2A). Although we usually perform the RA lesions through purse-string sutures, in the case of tricuspid annuloplasty a vertical atriotomy is made from just above the inter-atrial septum midway between the SVC and IVC and extending toward the AV groove near the free margin of the RV. The femoral venous cannula is withdrawn into the IVC under direct vision (Figure 3). A 20 french venous cannula is placed through a stab wound in the lateral chest wall and positioned into the SVC under direct vision. Umbilical tapes or direct clamping of the proximal cava can be used if there is venous blood flow into the RA obscuring the operative field, however this is usually not necessary as long as vacuum assist is used to augment venous drainage. The remaining lesions are then performed as described above. A bipolar radiofrequency clamp is placed through the atriotomy and is used to create two lesions: one up onto the SVC (Figure 4) and one down onto the IVC. The device is fired three times with slight changes in position for each lesion. A reusable linear cryoprobe or flexible disposable cryoprobe is placed endocardially from the upper end of the atriotomy down to the tricuspid annulus at the 1 o'clock position (Figure 5). This cryoablation is performed by freezing to -60°C for three minutes, as are all subsequent cryoablations. A purse-string placed at the base of the right atrial appendage (RAA). The RA is opened with a stab incision, and the bipolar radiofrequency clamp is used to make a lesion toward the SVC at least 2 cm away from the previous SVC lesion, and down the aortic side of the RAA to avoid the region of the SA node. An endocardial cryoablation is then made from the base of the RAA down to the tricuspid annulus at the 11 o'clock position with the linear or disposable cryoprobe. A ring tricuspid valve annuloplasty is then performed as described above, and the final result is shown in Figure 6. The atrium is closed with a running polypropylene suture.

If LA lesions are to be performed, they are performed on the arrested heart as shown in the schematic (Figure 7). The LA is dissected and opened in the interatrial groove. Exposure is obtained using an atrial lift retractor. The bipolar radiofrequency clamp is used to make "roof" and "floor" lesions from the atriotomy to the left superior and inferior pulmonary veins, respectively. The clamp is also used to create an ablation from the inferior margin of the atriotomy toward the mitral annulus, taking care to avoid the circumflex coronary artery. As the bipolar clamp cannot reach the annulus itself, cryoprobes are used to make an endocardial lesion to the mitral annulus and an epicardial lesion over the coronary sinus. The LA "box" is completed by using a T-shaped cryoprobe to create lesions behind the left pulmonary veins, along the lateral ridge, connecting the roof and floor lesions. The LAA is managed by oversewing its orifice in two layers from an endocardial approach. If a mitral valve procedure is performed, it is performed at this time. The LA is then closed with a running polypropylene suture. The patient is weaned from CPB and closed in standard fashion.

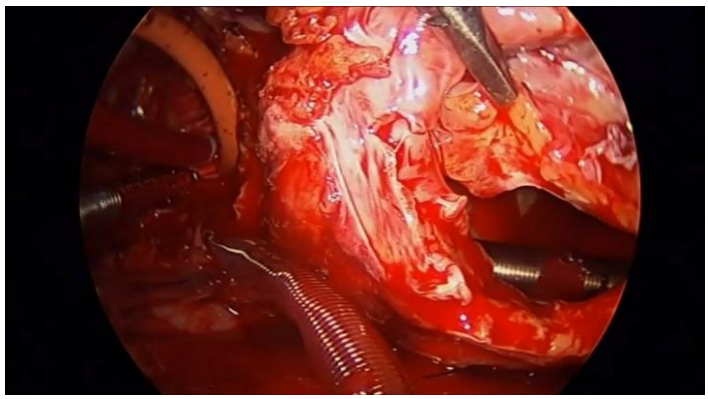

Figure 3. Right atrial cannulation and atriotomy. SVC cannula and cardioplegia cannula are visualized to the left. Transfemoral IVC cannula is visible within the atrium.

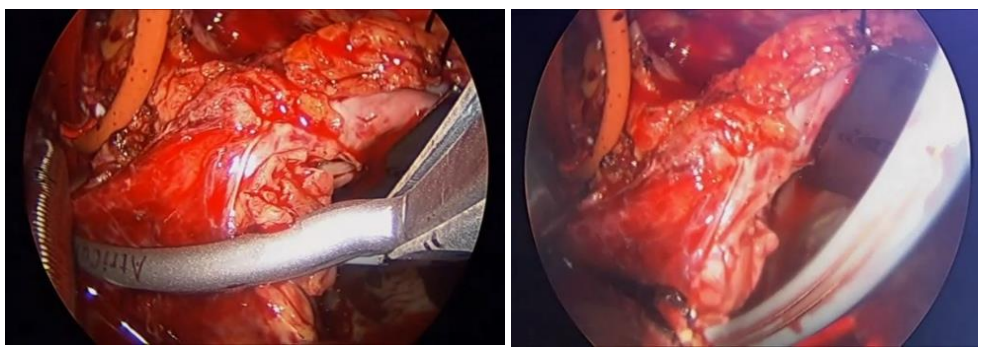

Figure 4. Left: Creation of the SVC lesion using a bipolar radiofrequency clamp. Right: Completed SVC ablation line.

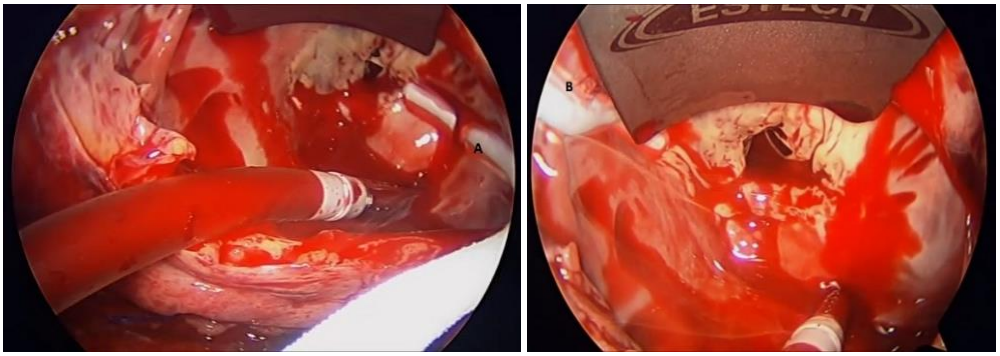

Figure 5. Left: Flexible cryoablation was placed from the midpoint of the right atrial incision down to the tricuspid annulus. Right: Completed tricuspid annulus ablation line.

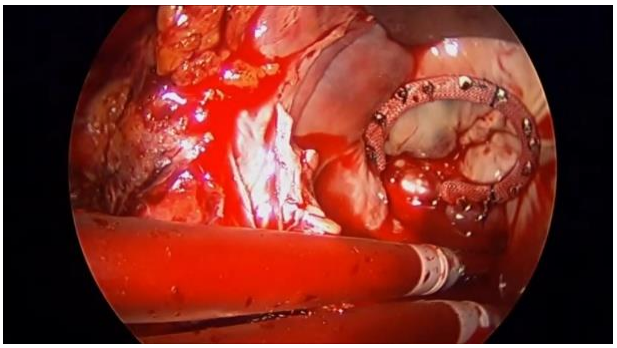

Figure 6. Completed right atrial Cox-Maze IV lesions and tricuspid ring annuloplasty.

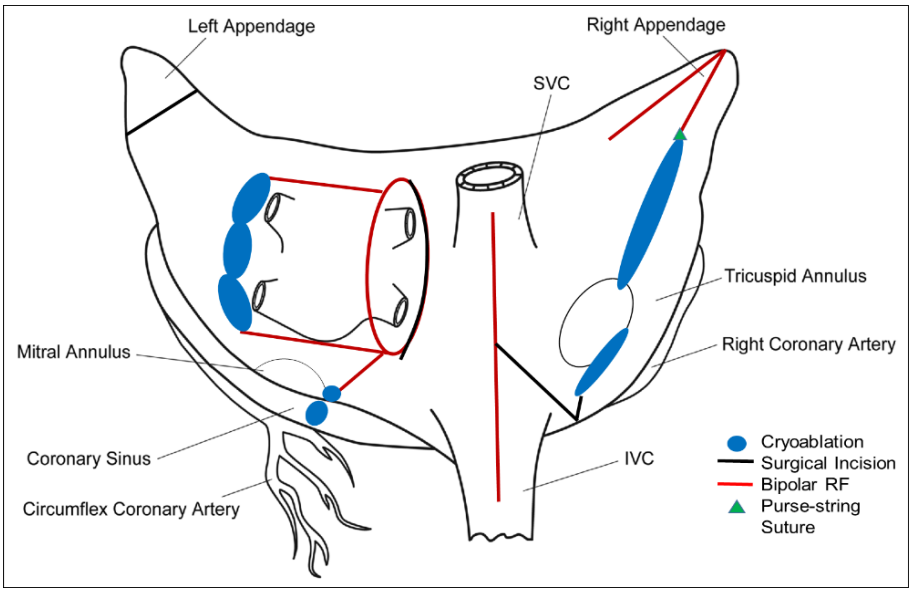

Figure 7. Schematic depicting the minimally invasive Cox-Maze IV lesion set modified for use with tricuspid valve annuloplasty. Adapted from Schill MR et al., *Innovations* (Phila) 2017, In Press. Used with permission.

THE COX-MAZE IV PROCEDURE: SURGICAL RESULTS

Our results from patients who underwent the Cox-Maze IV procedure have been encouraging. In a prospective, single-center trial from our institution, 91% of patients at 6-month follow-up were free from AF [25]. The Cox-Maze IV procedure significantly shortened the mean AoX times for a stand-alone Cox-Maze from 93 ± 34 minutes for the cut-and-sew Cox-Maze III to 47 ± 26 minutes for the Cox-Maze IV ($p<0.001$) [25]. A propensity analysis showed that there was no significant difference in freedom from AF at 3, 6, or 12 months postoperatively between the appropriately matched Cox-Maze III and IV groups [42]. A more recent prospective cohort study from our institution in 100 consecutive patients who underwent a stand-alone Cox-Maze IV procedure demonstrated postoperative freedom from AF of 93%, 90%, and 90% at 6, 12, and 24 months, respectively [40]. A report of over two decades of experience at our institution with both the Cox-Maze III and Cox-Maze IV procedures showed no difference in freedom from AF and a significantly decreased major complication rate between the two procedures [44].

The Cox-Maze IV procedure worked as well in patients with paroxysmal AF as it did for patients with longstanding persistent AF. Our most recent report of Cox-Maze IV data reviewed 576 consecutive patients who underwent this procedure between January 2002 and September 2014 [45]. All patients were followed with ECG, pacemaker interrogation or 24-hour Holter monitoring. Our 12-month rate of freedom from AF was 93%, with 85% of those patients also off all antiarrhythmic drugs, while our 5-year freedom from AF was 78%, with 66% of those patients also off all antiarrhythmic drugs. Comparisons of patients with paroxysmal versus non-paroxysmal AF on and off antiarrhythmic drugs were not significantly different at any time point [43]. Other groups have had similar results [46].

The Cox-Maze procedure has also been successful in reducing the incidence of stroke. In patients undergoing the Cox-Maze procedure, the preoperative incidence of neurological events has been high. In a report from our institution, 57 of 433 patients (13%) had experienced a preoperative neurological event. Despite this, there were only six neurological events during long-term follow-up (mean, 6.6 ± 5.0 years) in this cohort. The long-term stroke rate after the Cox-Maze procedure has been 0.2% per year despite the fact that the majority of patients had discontinued their anticoagulation therapy [47].

The Cox-Maze procedure is most commonly performed as a concomitant procedure [22]. Previous studies from our institution and others have documented high rates of restoration of sinus rhythm without increasing morbidity following concomitant procedures, including CABG, MV surgery, TV surgery, and aortic valve surgery [28, 48-56].

MINIMALLY INVASIVE COX-MAZE IV PROCEDURE AND TRICUSPID ANNULOPLASTY RESULTS

The published literature regarding the use of minimally invasive surgical ablation in the isolated TV disease population is sparse. Schaff and colleagues [57] at the Mayo Clinic published a series of 42 patients undergoing TVr or TVR with right-sided Cox-Maze procedure, and there were no instances of complete heart block or sinus node dysfunction requiring permanent pacemaker implantation. Follow-up of the first 18 patients showed that

all had NYHA class I symptoms. Early postoperative atrial arrhythmias occurred in 3 of 18 patients, and they were managed successfully with medication [57]. Late outcomes in the Mayo Clinic Cox-Maze series were similar to those reported by other centers, and the authors did not perform subgroup analysis of late outcomes in patients undergoing Cox-Maze and tricuspid valve procedures only.

We reviewed outcomes of minimally invasive TVr with concomitant Cox-Maze IV procedure at our institution. All patients gave informed consent for inclusion in our institutional database under a protocol approved by the Institutional Review Board. From July 2005 to August 2015, TVr or TVR with concomitant Cox-Maze IV procedure was performed in eight patients with severe TR and AF. Three patients had a history of prior cardiac surgery (orthotopic heart transplant, thoracic aortic aneurysm repair, CABG). Two patients received bioprosthetic TVR; the remainder were treated with ring annuloplasty. Four patients underwent concomitant MVr, one underwent concomitant MVR, and one underwent patch closure of a secundum atrial septal defect. In two of the three patients who underwent TV surgery alone, only the RA Cox-Maze lesions were performed; the remaining patients received the biatrial lesion set.

Postoperative outcomes were as to be expected in this high-risk group of patients. There was one operative mortality, a reoperative patient who underwent minimally invasive MVr, TVr and Cox-Maze IV. This patient developed pneumonia and respiratory failure and ultimately succumbed to recurrent episodes of ventricular tachycardia. Three patients required postoperative pacemakers, and two patients required reexploration for groin seromas. There were no other major complications. Six patients were alive at one year, and 5/6 were free from atrial tachyarrhythmias, all of whom had discontinued taking antiarrhythmic drugs. The one patient with five-year follow-up was free from atrial tachyarrhythmias and antiarrhythmic drugs and is alive at eleven years postoperatively. The Kaplan-Meier estimate of the median survival was 3.4 years.

CONCLUSION

The surgical treatment of secondary TR is still an object of debate. Severe TR should always be corrected at the time of left-sided heart surgery. In cases of less than severe regurgitation, the diameter of the tricuspid annulus (rather than the degree of regurgitation) should be the criterion to indicate the need of concomitant TVr. The minimally invasive approach has been shown to be safe, feasible, and reproducible in TV operations. It ensures low perioperative morbidity and mortality and low rates of TR recurrence. It also has similar benefits in reoperative procedures. However, most series in the literature are small and retrospective.

The right mini-thoracotomy Cox-Maze IV procedure is one of the only minimally invasive techniques that fully replicates the complete lesion set of the original Cox-Maze procedure. Long term outcomes of minimally invasive surgical ablation at our institution have matched those achieved with the standard median sternotomy approach [58]. The right mini-thoracotomy approach is familiar to many cardiac surgeons who perform minimally invasive MV and TV surgery and should therefore be generalizable to cardiac surgeons at large in the

future. A combination of these approaches to treat the patient with isolated TV disease and AF is feasible, but further prospective studies should be performed.

REFERENCES

[1] Tornos Mas P, Rodriguez-Palomares JF, Antunes MJ. Secondary tricuspid valve regurgitation: a forgotten entity. *Heart* (British Cardiac Society) 2015;101(22):1840-8.

[2] Greelish JP, Phillips BJ, Fang JC, Byrne JC. Tricuspid Valve Surgery in Right Heart Failure. *Contemporary Cardiology: Surgical Management of Congestive Heart Failure* 2005:97-122.

[3] Desai RR1, Vargas Abello LM, Klein AL, Marwick TH, Krasuski RA, Ye Y, Nowicki ER, Rajeswaran J, Blackstone EH, Pettersson GB. Tricuspid regurgitation and right ventricular function after mitral valve surgery with or without concomitant tricuspid valve procedure. *J Thorac Cardiovasc Surg* 2013;146(5):1126-32.

[4] Vahanian A, Alfieri O, Andreotti F, Antunes MJ, Barón-Esquivias G, Baumgartner H, Borger MA, Carrel TP, De Bonis M, Evangelista A, Falk V, Lung B, Lancellotti P, Pierard L, Price S, Schäfers HJ, Schuler G, Stepinska J, Swedberg K, Takkenberg J, Von Oppell UO, Windecker S, Zamorano JL, Zembala M; ESC Committee for Practice Guidelines (CPG).; Joint Task Force on the Management of Valvular Heart Disease of the European Society of Cardiology (ESC).; European Association for Cardio-Thoracic Surgery (EACTS). Guidelines on the management of valvular heart disease (version 2012): the Joint Task Force on the Management of Valvular Heart Disease of the European Society of Cardiology (ESC) and the European Association for Cardio-Thoracic Surgery (EACTS). *Eur J Cardiothorac Surg* 2012;42(4):S1-44.

[5] Nishimura RA, Otto CM, Bonow RO, Carabello BA, Erwin JP 3rd, Guyton RA, O'Gara PT, Ruiz CE, Skubas NJ, Sorajja P, Sundt TM 3rd, Thomas JD, Anderson JL, Halperin JL, Albert NM, Bozkurt B, Brindis RG, Creager MA, Curtis LH, DeMets D, Guyton RA, Hochman JS, Kovacs RJ, Ohman EM, Pressler SJ, Sellke FW, Shen WK, Stevenson WG, Yancy CW; American College of Cardiology; American College of Cardiology/American Heart Association; American Heart Association. 2014 AHA/ACC guideline for the management of patients with valvular heart disease: a report of the American College of Cardiology/American Heart Association Task Force on Practice Guidelines. *J Thorac Cardiovasc Surg* 2014;148(1):e1-e132.

[6] Porter A, Shapira Y, Wurzel M, Sulkes J, Vaturi M, Adler Y, Sahar G, Sagie A. Tricuspid regurgitation late after mitral valve replacement: clinical and echocardiographic evaluation. *J Heart Valve Dis* 1999;8(1):57-62.

[7] Matsuyama K, Matsumoto M, Sugita T, Nishizawa J, Tokuda Y, Matsuo T. Predictors of residual tricuspid regurgitation after mitral valve surgery. *Ann Thorac Surg* 2003;75(6):1826-8.

[8] Izumi C, Iga K, Konishi T. Progression of isolated tricuspid regurgitation late after mitral valve surgery for rheumatic mitral valve disease. *J Heart Valve Dis* 2002;11(3):353-6.

[9] Dreyfus GD, Corbi PJ, Chan KM, Bahrami T. Secondary tricuspid regurgitation or dilatation: which should be the criteria for surgical repair? *Ann Thorac Surg* 2005;79(1):127-32.
[10] Matsunaga A, Duran CM. Progression of tricuspid regurgitation after repaired functional ischemic mitral regurgitation. *Circulation.* 2005;112(9):I453-7.
[11] Goodwin JF, Rab SM, Sinha AK, Zoob M. Rheumatic tricuspid stenosis. *BMJ* 1957;2(5058):1383-9.
[12] Kitchin A, Turner R. Diagnosis and treatment of tricuspid stenosis. *BMJ* 1964;26:354-79.
[13] Heidi M. D, MD. Carcinoid heart disease: Medical and Surgical considerations. *Cancer Control* 2001;8(5):454-60.
[14] DiSesa VJ, Mills RM, Jr., Collins JJ, Jr. Surgical management of carcinoid heart disease. *Chest* 1985;88(5):789-91.
[15] Gutierrez FR, McKnight RC, Jaffe AS, Ludbrook PA, Biello D, Weldon CS. Double porcine valve replacement in carcinoid heart disease. *Chest* 1982;81(1):101-3.
[16] Knott-Craig CJ, Schaff HV, Mullany CJ, Kvols LK, Moertel CG, Edwards WD, Danielson GK. Carcinoid disease of the heart. Surgical management of ten patients. *J Thorac Cardiovasc Surg* 1992;104(2):475-81.
[17] Mukhopadhyay S, Suryavanshi S, Yusuf J, Chandrashekhar, Rastogi V, Trehan V, Kaul UA. Isolated thrombus producing tricuspid stenosis: an unusual presentation in primary antiphospholipid syndrome. *Indian Heart Journal* 2004;56(1):61-3.
[18] Bernal JM, Pontón A, Diaz B, Llorca J, García I, Sarralde A, Diago C, Revuelta JM. Surgery for rheumatic tricuspid valve disease: a 30-year experience. *J Thorac Cardiovasc Surg* 2008;136(2):476-81.
[19] Singh JP, Evans JC, Levy D, Larson MG, Freed LA, Fuller DL, Lehman B, Benjamin EJ. Prevalence and clinical determinants of mitral, tricuspid, and aortic regurgitation (the Framingham Heart Study). *Am J Cardiol* 1999;83(6):897-902.
[20] Topilsky Y, Nkomo VT, Vatury O, Michelena HI, Letourneau T, Suri RM, Pislaru S, Park S, Mahoney DW, Biner S, Enriquez-Sarano M. Clinical outcome of isolated tricuspid regurgitation. *JACC Cardiovasc Imaging* 2014;7(12):1185-94.
[21] Messika-Zeitoun D, Thomson H, Bellamy M, Scott C, Tribouilloy C, Dearani J, Tajik AJ, Schaff H, Enriquez-Sarano M. Medical and surgical outcome of tricuspid regurgitation caused by flail leaflets. J Thorac Cardiovasc Surg 2004;128(2):296-302.
[22] Gammie JS, Haddad M, Milford-Beland S, Welke KF, Ferguson TB Jr, O'Brien SM, Griffith BP, Peterson ED. Atrial fibrillation correction surgery: lessons from the Society of Thoracic Surgeons National Cardiac Database. *Ann Thorac Surg* 2008;85(3):909-14.
[23] Gillinov AM, Saltman AE. Ablation of atrial fibrillation with concomitant cardiac surgery. *Semin Thorac Cardiovasc Surg* 2007;19(1):25-32.
[24] Lee R, McCarthy PM, Wang EC, Vaduganathan M, Kruse J, Malaisrie SC, McGee EC Jr. Midterm survival in patients treated for atrial fibrillation: a propensity-matched comparison to patients without a history of atrial fibrillation. *J Thorac Cardiovasc Surg* 2012;143(6):1341-51.
[25] Gaynor SL, Diodato MD, Prasad SM, Ishii Y, Schuessler RB, Bailey MS, Damiano NR, Bloch JB, Moon MR, Damiano RJ Jr. A prospective, single-center clinical trial of a modified Cox maze procedure with bipolar radiofrequency ablation. *J Thorac Cardiovasc Surg* 2004;128(4):535-42.

[26] Saint LL, Damiano RJ Jr, Cuculich PS, Guthrie TJ, Moon MR, Munfakh NA, Maniar HS. Incremental risk of the Cox-maze IV procedure for patients with atrial fibrillation undergoing mitral valve surgery. *J Thorac Cardiovasc Surg* 2013;146(5):1072-7.

[27] Calkins H, Kuck KH, Cappato R, Brugada J, Camm AJ, Chen SA, Crijns HJ, Damiano RJ Jr, Davies DW, DiMarco J, Edgerton J, Ellenbogen K, Ezekowitz MD, Haines DE, Haissaguerre M, Hindricks G, Iesaka Y, Jackman W, Jalife J, Jais P, Kalman J, Keane D, Kim YH, Kirchhof P, Klein G, Kottkamp H, Kumagai K, Lindsay BD, Mansour M, Marchlinski FE, McCarthy PM, Mont JL, Morady F, Nademanee K, Nakagawa H, Natale A, Nattel S, Packer DL, Pappone C, Prystowsky E, Raviele A, Reddy V, Ruskin JN, Shemin RJ, Tsao HM, Wilber D; Heart Rhythm Society Task Force on Catheter and Surgical Ablation of Atrial Fibrillation. 2012 HRS/EHRA/ECAS expert consensus statement on catheter and surgical ablation of atrial fibrillation: recommendations for patient selection, procedural techniques, patient management and follow-up, definitions, endpoints, and research trial design: a report of the Heart Rhythm Society (HRS) Task Force on Catheter and Surgical Ablation of Atrial Fibrillation. Developed in partnership with the European Heart Rhythm Association (EHRA), a registered branch of the European Society of Cardiology (ESC) and the European Cardiac Arrhythmia Society (ECAS); and in collaboration with the American College of Cardiology (ACC), American Heart Association (AHA), the Asia Pacific Heart Rhythm Society (APHRS), and the Society of Thoracic Surgeons (STS). Endorsed by the governing bodies of the American College of Cardiology Foundation, the American Heart Association, the European Cardiac Arrhythmia Society, the European Heart Rhythm Association, the Society of Thoracic Surgeons, the Asia Pacific Heart Rhythm Society, and the Heart Rhythm Society. *Heart rhythm* 2012;9(4):632-96.e21.

[28] Carpentier A, Deloche A, Hanania G, Forman J, Sellier P, Piwnica A, Dubost C, McGoon DC. Surgical management of acquired tricuspid valve disease. *J Thorac Cardiovasc Surg* 1974;67(1):53-65.

[29] De Vega NG. [Selective, adjustable and permanent annuloplasty. An original technic for the treatment of tricuspid insufficiency]. *Revista espanola de cardiologia* 1972;25(6):555-6.

[30] Duran CG, Ubago JL. Clinical and hemodynamic performance of a totally flexible prosthetic ring for atrioventricular valve reconstruction. *Ann Thorac Surg* 1976;22(5):458-63.

[31] McCarthy JF, Cosgrove DM, 3rd. Tricuspid valve repair with the Cosgrove-Edwards Annuloplasty System. *Ann Thorac Surg* 1997;64(1):267-8.

[32] Kshettry VR, Kanda LT. Prospective study of mitral valve repair with the CarboMedics AnnuloFlex annuloplasty system: effectiveness and safety after one year. *J Heart Valve Dis* 2005;14(1):105-13.

[33] Tang GH, David TE, Singh SK, Maganti MD, Armstrong S, Borger MA. Tricuspid valve repair with an annuloplasty ring results in improved long-term outcomes. *Circulation* 2006;114(1):I577-81.

[34] Navia JL, Nowicki ER, Blackstone EH, Brozzi NA, Nento DE, Atik FA, Rajeswaran J, Gillinov AM, Svensson LG, Lytle BW. Surgical management of secondary tricuspid valve regurgitation: annulus, commissure, or leaflet procedure? *J Thorac Cardiovasc Surg* 2010;139(6):1473-82.

[35] Singh SK, Tang GH, Maganti MD, Armstrong S, Williams WG, David TE, Borger MA. Midterm outcomes of tricuspid valve repair versus replacement for organic tricuspid disease. *Ann Thorac Surg* 2006;82(5):1735-41.

[36] Chang HW, Jeong DS, Cho YH, Sung K, Kim WS, Lee YT, Park PW. Tricuspid Valve Replacement vs. Repair in Severe Tricuspid Regurgitation. *Circulation Journal* 2017;81(3):330-8.

[37] Kypson AP, Glower DD. Minimally invasive tricuspid operation using port access. *Ann Thorac Surg* 2002;74(1):43-5.

[38] Lee TC, Desai B, Glower DD. Results of 141 consecutive minimally invasive tricuspid valve operations: an 11-year experience. *Ann Thorac Surg* 2009;88(6):1845-50.

[39] Pfannmüller B, Davierwala P, Hirnle G, Borger MA, Misfeld M, Garbade J, Seeburger J, Mohr FW. Concomitant tricuspid valve repair in patients with minimally invasive mitral valve surgery. *Ann Cardiothorac Surg* 2013;2(6):758-64.

[40] Weimar T, Bailey MS, Watanabe Y, Marin D, Maniar HS, Schuessler RB, Damiano RJ Jr. The Cox-maze IV procedure for lone atrial fibrillation: a single center experience in 100 consecutive patients. *J Interven Card Electrophysiol* 2011;31(1):47-54.

[41] Mokadam NA, McCarthy PM, Gillinov AM, Ryan WH, Moon MR, Mack MJ, Gaynor SL, Prasad SM, Wickline SA, Bailey MS, Damiano NR, Ishii Y, Schuessler RB, Damiano RJ Jr. A prospective multicenter trial of bipolar radiofrequency ablation for atrial fibrillation: early results. *Ann Thorac Surg* 2004;78(5):1665-70.

[42] Lall SC, Melby SJ, Voeller RK, Zierer A, Bailey MS, Guthrie TJ, Moon MR, Moazami N, Lawton JS, Damiano RJ Jr. The effect of ablation technology on surgical outcomes after the Cox-maze procedure: a propensity analysis. *J Thorac Cardiovasc Surg* 2007;133(2):389-96.

[43] Robertson JO, Saint LL, Leidenfrost JE, Damiano RJ, Jr. Illustrated techniques for performing the Cox-Maze IV procedure through a right mini-thoracotomy. *Ann Cardiothorac Surg* 2014;3(1):105-16.

[44] Weimar T, Schena S, Bailey MS, Maniar HS, Schuessler RB, Cox JL, Damiano RJ Jr. The cox-maze procedure for lone atrial fibrillation: a single-center experience over 2 decades. *Circulation Arrhythmia Electrophysiol* 2012;5(1):8-14.

[45] Henn MC, Lancaster TS, Miller JR, Sinn LA, Schuessler RB, Moon MR, Melby SJ, Maniar HS, Damiano RJ Jr. Late outcomes after the Cox maze IV procedure for atrial fibrillation. *J Thorac Cardiovasc Surg* 2015;150(5):1168-76.

[46] Ad N, Holmes SD, Stone LE, Pritchard G, Henry L. Rhythm course over 5 years following surgical ablation for atrial fibrillation. *EJCTS* 2015;47(1):52-8.

[47] Pet M, Robertson JO, Bailey M, Guthrie TJ, Moon MR, Lawton JS, Rinne A, Damiano RJ Jr, Maniar HS. The impact of CHADS2 score on late stroke after the Cox maze procedure. *J Thorac Cardiovasc Surg* 2013;146(1):85-9.

[48] Gillinov AM, Gelijns AC, Parides MK, DeRose JJ Jr, Moskowitz AJ, Voisine P, Ailawadi G, Bouchard D, Smith PK, Mack MJ, Acker MA, Mullen JC, Rose EA, Chang HL, Puskas JD, Couderc JP, Gardner TJ, Varghese R, Horvath KA, Bolling SF, Michler RE, Geller NL, Ascheim DD, Miller MA, Bagiella E, Moquete EG, Williams P, Taddei-Peters WC, O'Gara PT, Blackstone EH, Argenziano M; CTSN Investigators. Surgical ablation of atrial fibrillation during mitral-valve surgery. *The New England Journal of Medicine* 2015;372(15):1399-409.

[49] Stulak JM, Sundt TM, 3rd, Dearani JA, Daly RC, Orsulak TA, Schaff HV. Ten-year experience with the Cox-maze procedure for atrial fibrillation: how do we define success? *Ann Thorac Surg* 2007;83(4):1319-24.

[50] Saint LL, Bailey MS, Prasad S, Guthrie TJ, Bell J, Moon MR, Lawton JS, Munfakh NA, Schuessler RB, Damiano RJ Jr, Maniar HS. Cox-Maze IV results for patients with lone atrial fibrillation versus concomitant mitral disease. *Ann Thorac Surg* 2012;93(3):789-94.

[51] Lawrance CP, Henn MC, Miller JR, Sinn LA, Schuessler RB, Damiano RJ, Jr. Comparison of the stand-alone Cox-Maze IV procedure to the concomitant Cox-Maze IV and mitral valve procedure for atrial fibrillation. *Ann Cardiothorac Surg* 2014;3(1):55-61.

[52] Damiano RJ Jr, Gaynor SL, Bailey M, Prasad S, Cox JL, Boineau JP, Schuessler RPl. The long-term outcome of patients with coronary disease and atrial fibrillation undergoing the Cox maze procedure. *J Thorac Cardiovasc Surg* 2003;126(6):2016-21.

[53] Ad N, Holmes SD, Massimiano PS, Pritchard G, Stone LE, Henry L. The effect of the Cox-maze procedure for atrial fibrillation concomitant to mitral and tricuspid valve surgery. *J Thorac Cardiovasc Surg* 2013;146(6):1426-34.

[54] Abreu Filho CA, Lisboa LA, Dallan LA, Spina GS, Grinberg M, Scanavacca M, Sosa EA, Ramires JA, Oliveira SA. Effectiveness of the maze procedure using cooled-tip radiofrequency ablation in patients with permanent atrial fibrillation and rheumatic mitral valve disease. *Circulation* 2005;112(9):I20-5.

[55] Henn MC, Lawrance CP, Sinn LA, Miller JR, Schuessler RB, Moon MR, Melby SJ, Maniar HS, Damiano RJ Jr. Effectiveness of Surgical Ablation in Patients With Atrial Fibrillation and Aortic Valve Disease. *Ann Thorac Surg* 2015;100(4):1253-9.

[56] Ad N, Henry L, Hunt S, Holmes SD. Do we increase the operative risk by adding the Cox Maze III procedure to aortic valve replacement and coronary artery bypass surgery? *J Thorac Cardiovasc Surg* 2012;143(4):936-44.

[57] Schaff HV, Dearani JA, Daly RC, Orszulak TA, Danielson GK. Cox-Maze procedure for atrial fibrillation: Mayo Clinic experience. *Semin Thorac Cardiovasc Surg* 2000;12(1):30-7.

[58] Lawrance CP, Henn MC, Miller JR, Sinn LA, Schuessler RB, Maniar HS, Damiano RJ Jr. A minimally invasive Cox maze IV procedure is as effective as sternotomy while decreasing major morbidity and hospital stay. *J Thorac Cardiovasc Surg* 2014;148(3): 955-61.

In: Encyclopedia of Surgery (22 Volume Set)
Editors: Andreas Lehrer and Kristin Mueller
ISBN: 978-1-53618-329-0
© 2020 Nova Science Publishers, Inc.

Chapter 426

CONTEMPORARY RESULTS IN MINIMALLY INVASIVE MITRAL VALVE SURGERY

Daniel Pereda*, MD and José L. Pomar, MD, PhD
Hospital Clínic, Department of Cardiovascular Surgery,
University of Barcelona. Barcelona, Spain

ABSTRACT

Minimally invasive mitral valve surgery (MIMVS) has been increasingly performed over the last 20 years, as growing support of evidence indicates that it provides excellent results, comparable to conventional mitral surgery performed through a full sternotomy. As our knowledge and expertise increases, MIMVS can now be offered to the vast majority of patients requiring a surgical intervention on their mitral valve, providing a better cosmetic result and a quicker recovery, with a similar risk profile and without a tradeoff in repair rate and durability. In fact, there is currently data supporting its feasibility and its role on many traditionally difficult subsets of indications such as: elderly patients, reoperations, endocarditis or Barlow's disease. In the present chapter we will review some of the most recent evidence on the current results of MIMVS.

Keywords: mitral valve surgery, postoperative complications, mortality, minimally invasive surgical procedures, treatment outcome

INTRODUCTION

Mitral valve (MV) surgery through a full sternotomy has been established over the years as the gold standard treatment for patients with all kinds of MV pathology requiring valve repair or replacement. Since the first cases performed in the mid-90's, many efforts have been made and many advances have been accomplished in the direction of reducing surgical aggression through minimally invasive approaches to repair or replace the mitral valve, while

* Corresponding Author's Email: dpereda@clinic.cat.

trying to maintain the excellent results and safety profile of conventional mitral surgery. The term minimally invasive mitral valve surgery (MIMVS) does not define a specific approach and many variations have been included under this term. These variations include surgical approaches other than a full median sternotomy such as partial upper or lower sternotomies or right/left small thoracotomies. Additionally, these operations can be performed with different degrees of thoracoscopic video-assistance and specifically designed instrumentation, including robotic telemanipulation. This surgical heterogeneity together with several different adaptations of cardiopulmonary bypass (CPB) and myocardial protection strategies, add to the difficulty in analyzing and comparing historical and current results of minimally invasive mitral valve repair (MIMVr).

Early and long-term results of MIMVS have improved over the years complemented by the advance in our knowledge of MV pathology and surgical repair, but also by a continuous improvement in other fields like: intraoperative imaging, instrument design, endoscopic high-definition video assistance, CPB, and more recently with high-definition 3D visualization or robotic telemanipulation. Currently, minimally invasive approaches to treat the MV are preferred over conventional surgery in many high-volume mitral valve surgery centers throughout the world, particularly in Europe. In these hospitals, most patients are now offered a minimally invasive approach to repair or replace their MV with excellent results and regardless of mitral disease complexity or patient risk profile. Some decisive factors responsible for this continuous improvement in MIMVS are: better preoperative evaluation of the patients, continuous refinement of specifically-designed cannulae for extracorporeal circulation (allowing a smoother introduction and significantly increased drainage with smaller outer diameters), routine intrathoracic CO_2 insufflation, alternative ways of tranthoracic aortic cross-clamping and re-engineered intra-aortic balloon occluders, improvement in myocardial protection protocols, the addition of techniques for atrial fibrillation ablation and increasing physician's skills as the result of the commitment of many surgeons to advanced MV repair (MVr) techniques. Very importantly, we have to acknowledge the perseverance of some pioneers, believers of this *minimally invasive philosophy*, and their contribution in developing educational programs, which have allowed the progression –although slow- of MIMVr within our surgical community.

MIMVr is undeniably appealing to both patients and physicians, holding the promise of improved cosmetic results, a shorter hospital stay, faster return to normal activities and less postoperative pain and blood loss, while maintaining the same high-quality results of conventional MV surgery through a full sternotomy. In this chapter, we will review the most recent evidence supporting MIMVr, particularly for degenerative mitral valve disease. We will pay special attention to safety and long-term durability of MVr, two of the most inquired aspects of MIMVS since the beginning of these operations. The main concerns that have been raised against these operations are a supposed higher rate of neurological complications and aortic dissection and a lower rate of MVr, with more valves being replaced. Detractors of MIMVr also claim it is more demanding technically and requires a long learning curve before achieving good results; while these statements may be true, and in fact the second has been beautifully described by the Leipzig group recently [1], current published evidence report excellent outcomes in terms of postoperative neurological complications, rate of successful repair and repair durability, that match in every aspect those of some of the best modern series of conventional mitral valve repair through a full sternotomy.

PERIOPERATIVE OUTCOMES AND NEUROLOGICAL COMPLICATIONS

Since the first developments on minimally invasive cardiac surgery in the early 90's, a strong debate started between its supporters and detractors. The discussion focused on its foreseen benefits in terms of decreased surgical trauma, improved patient recovery and shorter hospital stay, and the supposedly increased risks of neurological complications, worse rates of mitral repair, decreased repair durability and its greater technical complexity requiring a steep learning curve. This debate has been an intense and enduring one, and at times has even left the academic medical arena and has made it to the general public through the mass media [2].

One of the most controversial and criticized aspects of MIMVS has always been the possibility of an increased risk of postoperative stroke and neurological complications. Several factors have been pointed as playing a role in this increased risk, including the use of retrograde femoral perfusion, difficult cardiac deairing, embolization of subcutaneous fat debris from the port incisions and endovascular manipulation of the thoracic aorta with the use of endoaortic balloon occlusion (Figure 1).

With our current knowledge most of this risk has been reduced with better preoperative evaluation and patient selection, identifying those patients at increased risk of neurological complications such as older patients, patients with peripheral or carotid vascular disease and patients with a heavy burden of risk factors for atherosclerosis: smokers, diabetes mellitus, previous history of myocardial infarction or stroke. A focused medical anamnesis and preoperative clinical examination may reveal most of these risk factors and, for those patients at increased risk, a preoperative vascular imaging evaluation with MRI or CT can be obtained to help in the selection of the best surgical strategy to maximize safety (i.e., choosing axillary cannulation or direct aortic canulation in patients with abdominal aortic aneurysms or with a diseased bilateral iliac–femoral axis). Another area of improvement has been the widespread adoption of CO_2 insufflation. In its early experience, the Leipzig group reported an incidence of postoperative confusion of 18% that greatly improved after CO_2 insufflation was routinely performed [3]. In a study by Schneider et al. using trans-cranial Doppler in MIMVS (using endoaortic balloon occlusion and CO_2 insufflation) as compared to conventional surgery, no differences were found in the cerebral microembolic rate [4].

A meta-analysis published in 2008 by Modi et al. [5], compared the combined data from 11 case-control and 1 randomized clinical trial published between 1998 and 2005 (with some patients operated on as early as 1990). None of the individual studies included or the analysis of the pooled data (1641 patients OR = 0.46; 95%CI = 0.15-1.42; p = 0.18)) showed a significant difference in mortality between MIMVS and conventional surgery. Regarding the risk of postoperative stroke, there was no significant difference in neurological events on meta-analysis of 6 eligible studies (1801 patients. OR = 0.66; 95%CI = 0.23-1.93; p = 0.45). A significant difference favoring MIMVS was found in the rate of reoperation for bleeding (1553 patients. OR = 0.56; 95%CI = 0.35-0.9; p = 0.02). In this meta-analysis, when comparing the largest cohort series published on MIMVS to the Society of Thoracic Surgeons (STS) database data, mortality did not differ from that reported on the STS database for both MVr (2173 patients) and replacement (MVR)(979 patients): 1.1% in MVr and 4.9% in MVR vs. 1.5% in MVr and 5.5% in MVR, respectively. The incidence of neurological complications was also lower: 1.6% in MVr (1226 patients) and 2.3% in MVR (778 patients) vs. 1.9% in MVr and 3.2% in MVR.

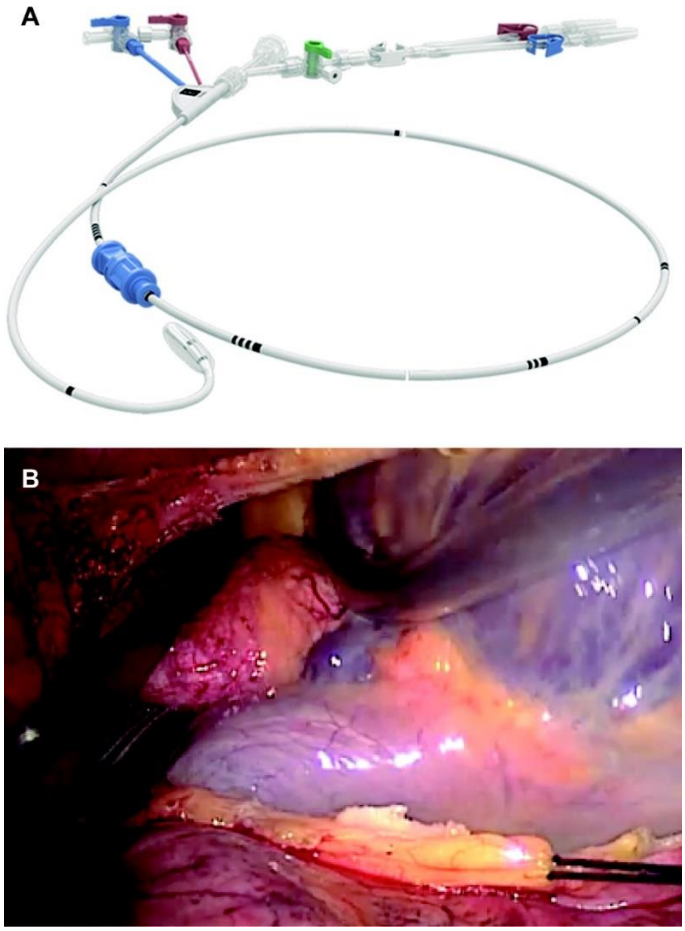

Figure 1. A: Intra-aortic balloon occlusion device (Edwards Intraclude, Edward Lifesciences, CA, USA). B: Transthoracic aortic clamp.

A more recent meta-analysis was published in 2011 by Cheng et al. [6]. It was limited to MIMVS performed through right minithoracotomy or a parasternal incision, thus excluding partial sternotomies. This meta-analysis included a larger pooled population from 35 published studies (18 with predominant use of endo-aortic balloon occlusion, 13 with predominant transthoracic aortic clamping and 4 using similarly both techniques). Perioperative mortality was similar with MIMVS and conventional surgery (13066 patients in 20 studies: 1.2% vs. 1.5% respectively; RR = 1.03, 95% CI = 0.75–1.42), as were long-term need for valvular reintervention and survival. In one hand, MIMVS was found to provide better results in terms of: less blood loss and transfusions, atrial fibrillation, chest wound infection, ventilation time, ICU (-0.8 days in average) and hospital (-2 days in average) length of stay, and reduced time to return to normal activities. On the other hand, MIMVS was found to be associated with an increased risk of stroke (12655 patients in 11 studies: 2.1% vs. 1.2%, RR = 1.79, 95% CI = CI 1.35–2.38), aortic dissection (0.2% vs. 0%), phrenic nerve palsy (3% vs. 0%), and groin infections (2% vs. 0%). MIMVS also required a longer duration of CPB (+33 min in average) and aortic cross-clamp (+21 min in average), with an overall longer procedural time (+0.8 hours in average).

These two meta-analyses of comparative studies together with large series published more recently represent the best evidence available on MIMVS. Only two small underpowered RCT have been conducted so far and were not able to find significant differences [7, 8]. The vast majority of comparative studies consist on small cohorts of unmatched patients with retrospective data collection and without any information on mid or long-term follow-up. Large institutional series provide longer follow-up data but lack a control group for comparisons. In this scenario, it is extremely difficult to obtain any solid conclusions regarding these infrequent -but critical- outcomes such as mortality and risk of stroke. Very large randomized trials would be necessary to have enough statistical power to elucidate these issues. As we all know, such trials are extremely difficult (if not impossible) to perform in cardiac surgery, so we will probably not be seeing such studies coming in our horizon on the near future. Despite these limitations it seems that, at least in high-volume centers of expertise, MIMVS can provide similar quality outcomes as the gold standard operation performed through a median sternotomy, with a better cosmetic result, increased patient satisfaction, less postoperative pain and blood loss, and a shorter length of hospitalization.

POSTOPERATIVE PAIN AND PATIENT RECOVERY

From the list of potential benefits of MIMVS, besides an irrefutable superior cosmetic result, a faster return to normal activities and less postoperative pain rank amongst the most consistently reported. In a study by Walther et al. [9], postoperative pain was similar after a right minithoracotomy as compared with a median sternotomy during the first two days after the operation and from the third day onwards the difference widened in favor of MIMVS. Glower et al. [10] reported decreased postoperative pain and a significantly faster return to normal activities after MIMVS (4 ± 2 weeks vs. 9 ± 1 week; $p = 0.01$). Interesting is the fact that in two different studies [11, 12], patients reoperated on with MIMVS after a previous full sternotomy reported that they felt their second procedure was less painful and had a faster recovery.

LENGTH OF HOSPITAL STAY AND COST

It is believed that patients recover faster from MIMVS than from a conventional operation through a full sternotomy and in fact, one of the most consistently found results in comparative studies is the reduction on the time patients spend in the ICU and in the hospital. In the 2008 meta-analysis by Modi et al. [5], the pooled analysis showed a trend towards a shorter postoperative saty after MIMVS (350 patients. OR = -0.73; 95%CI = -1.52 – 0.05; $p = 0.07$). These patients were more often discharged home, with less patients being sent to post-hospital rehabilitation facilities as compared with conventional surgery (9% vs. 33%) [13, 14]. The more recent meta-analysis by Cheng et al. [6] reported that duration of ICU (10435 patients in 18 studies: 1.6 vs. 2.4 days; $p < 0.0001$) and hospital stay (12249 patients in 26 studies: 6.9 vs. 8.9 days; $p < 0.00001$) were significantly reduced with MIMVS. In this study,

the duration of mechanical ventilation was also found to be significantly reduced after MIMVS (11434 patients in 18 studies: 12.6 vs. 19.9 hours; p = 0.002).

In terms of hospital costs there is little information available, since studies looking into this are scarce. A study from the United States reported that MIMVS reduced hospital costs (-$9160) [15]. However, operating room charges in this study were not time-dependent and this may have had an impact on the results, because the operating room time for MIMVS was 1.6 hours longer. Another study from Slovenia also reported that MIMVS had lower mean hospital cost [16], but none of these studies provided a comprehensive cost-effectiveness analysis. A more recent study by the Mayo Clinic group [17], compared costs in 370 propensity-matched pairs who underwent robotic or conventional MVr before and after implementing a program of improvement. Median length of stay for patients undergoing open repair was unchanged at 5.3 days before and after the program implementation, but was lower for robotic patients (3.5 vs. 3.4 days; p = 0.003). Despite the high costs of robotic technology, after the implementation of the program hospital costs became similar to that of open repair ($30606 vs. $31310; p = 0.876).

MITRAL VALVE REPAIR RATE AND REPAIR DURABILITY

A criticism that has been raised against MIMVr is that, due to its technical difficulty, more repairable valves are not spared and are replaced instead. In this same line of thought, it has been argued that repair results may be not as good as with open surgery, translating into a worse repair durability, with a higher incidence of recurrent mitral regurgitation (MR) on follow-up. MVr represents an excellent scenario for minimally invasive approaches, where the surgeon can get the most of the high-definition intracardiac video images, allowing an unparalleled exposure and visualization of the MV and the subvalvular apparatus. These advantages together with our current level of knowledge on MVr, particularly for the myxomatous mitral disease, have made results of MIMVr in high expertise mitral centers in terms of repair rate as good as those of conventional surgery in some of the best MVr series published [18-20].

In a recently published study, the Mayo Clinic group reported on their midterm results after robotic MIMVr for both isolated posterior leaflet prolapse (n = 289) and complex MVr (n = 198). They found a 100% repair rate and no conversions to sternotomy. Early mortality was 0.2% and the incidence of perioperative stroke for the entire cohort was 0.8%. Median echocardiographic follow-up was 362 days and 5-year freedom from recurrent regurgitation was 94.6% (96.2% simple; 92.7%, complex, $p = 0.67$) [21]. Another recently published series by Miceli et al. [22] reported on 703 patients undergoing MIMVS for degenerative mitral regurgitation: repair rate was 95.3% and they describe a mortality of 0.1%, a 1.3% risk of stroke, 1.8% of conversion to sternotomy and 4.4% of reoperation for bleeding. On follow-up, freedom from recurrent MR at 5 years was 93% and 5 year freedom from reoperation was 94%. Finally, Perier et al. [23] described another large series of MIMVr consisting of 842 patients with degenerative MR, and reported a 99.3% successful repair rate with a perioperative mortality of 0.2% and an incidence of stroke of 0.9%.

Current reported data indicate that in centers with a high volume of MVr and experienced in MIMVr, excellent results can be achieved in terms of quality of valve repair, repair rate

and repair durability (table 1). Once expertise is acquired, virtually all cases can be offered a MIMVr for all subsets of valve prolapse regardless of the complexity of the mitral pathology, including Barlow's disease. The generalized exception to this is the existence of significant valvular calcification. In these cases, general consensus is that they are still better served with a conventional approach, due to the difficulty in handling calcified tissues with MIMVS instrumentation.

SPECIAL SITUATIONS

Re-Operative Mitral Surgery

One of the biggest theoretical benefits of MIMVS is the avoidance of sternal re-entry in reoperations. This technique offers the advantage of requiring very little dissection of cardiac structures and adhesions (especially with the use of endo-aortic balloon occlusion) and is particularly attractive in the presence of patent coronary grafts. Several case-control studies have shown that MIMVS seems to be superior to redo-sternotomy in this scenario. Sharony et al. [26] found similar mortality but a lower rate of wound complications and transfusions, with a shorter postoperative stay. Similar results were found in other case-control studies in terms of duration of intubation, transfusions, and hospital stay [27] and even in mortality [28]. A recent study from the University of Pennsylvania group reported on their experience in reoperative mitral surgery, comparing MIMVS (n = 67) with a redo-sternonomy approach (n = 343); they found that MIMVS offered similar repair rates (19% vs. 22%), mortality (3% vs. 6%), stroke (3% vs. 3.1%) and a trend towards a shorter hospital stay (mean 11 days vs. 14 days; p = 0.07) [29]. In another large series published recently, Ricci et al. [30] reported on their results in 241 MIMVS reoperations; they found a mortality of 4.9% and an incidence of major stroke of 5.8%. In their experience, stroke rate dropped dramatically over time, and remained at 0% over the last two years of their series.

Despite all the theoretical advantages and the cumulative evidence supporting MIMVS for reoperations, the lack of studies showing clear benefits in hard end-points (such as in mortality and risk of stroke) together with the higher technical difficulty associated with these procedures have precluded the widespread use of MIMVS for reoperations in many institutions, although it will probably continue to increase.

Older Patients

Elderly patients have greater frailty and are at a particular high risk of complications after cardiac surgery. A recent meta-analysis reported a postoperative mortality of 13% after MVR and 7% after MVr, with a stroke rate of 4% and 3% respectively [31] (although data for isolated mitral surgery was not reported). Elderly patients are a particularly interesting population to whom MIMVr may offer an attractive perspective of a less traumatic operation and a faster recovery. Several studies have looked into this particular topic and seem to conclude in favor to MIMVr. Grossi et al [32]. reviewed 111 patients over 70 years of age

Table 1. Mitral repair for degenerative disease

Study	Year	Time span	Patients	Repair Rate	Neurological Complications	Mortality	5y freedom recurrent MR	Comments
Suri et al. (21)	2015	2008-2015	487	100%	0.8%	0.2%	94.6%	-100% degenerative disease. -100% robotic with transthoracic clamping.
Miceli et al. (22)	2015	2003-2011	703	95.3%	1.3%	0.1%	93%	-Direct aortic cannulation (87%), endo-aortic balloon (9%). -Intrathoracic aortic clamping. -Concomitant tricuspid operations in 11%.
Akowuah et al. (24)	2015	2003-2013	190		1.6%	1.1%	2.1% reoperated during follow-up (1–5 years)	
Perier et al. (23)	2013	2006-2012	842	99.3%	1.4% (major stroke 0.6%)	0.2%	Not reported	-100% Degenerative disease. -Tranthoracic clamping. -Concomitant tricuspid operations in 4%.
Grossi et al. (25)	2012	1995-2007	1282	NR	2.3%	1.1%*	Not reported	-Direct aortic cannulation in 69.3%. -Endoballoon in 29.1%. -Degenerative in 73.2%. *In patients with degenerative disease.
Pereda et al. (unpublished data)		2013-2015	102	100%	1%	0%	97.2% (1-4 years)	-Transthoracic clamping. -100% degenerative disease.

undergoing MIMVS and compared them to 259 patients on the same period having a redo-sternotomy; they found that MIMVS had a significantly lower risk of wound complications or **sepsis (1.8% vs. 7.7%; p = 0.027),** plasma transfusion (median 1.0 unit vs. 2.0 units; p = 0.04) and had a shorter hospital stay (11.6 days vs. 17.6 days; p = 0.001). Similarly, Tabata et al. [33] reported on MIMVr in 123 patients over 70 years of age, with a mortality of 1.6% and a 5-year survival of 87%. In 2013, the Leipzig group reported on their results in 191 octogenarians undergoing MIMVS [34], they found a perioperative mortality of 3.1% and no reported cases of stroke. Very recently, Minol et al. [35] reported on 34 octogenarian patients undergoing MIMVS (44.1% with concomitant tricuspid repair), with a postoperative mortality and a stroke rate both of 5.9% and no mortality in the isolated mitral subgroup. These results are particularly interesting now that an increasing number of elderly patients are being treated with transcatheter approaches and indicate that a substantial amount of patients can still be offered the possibility of a surgical MVr with excellent results in a minimally invasive fashion.

Endo-Aortic Balloon vs. Transthoracic Aortic Clamping

The use of the endo-aortic balloon occlusion device allows isolating the aortic root from the systemic perfusion and the delivery of antegrade cardioplegia, without the need to cross-clamp the aorta. Typically, it is retrogradely advanced from the femoral artery through a specially designed port on the arterial perfusion cannula and placed in the ascending aorta under trans-esophageal echocardiogram guidance. Once in place it is inflated to occlude the aorta, so the aortic root is excluded from circulation and antegrade cardioplegia is delivered through the tip of the device to arrest the heart. Great care must be taken to assure the balloon does not occlude the innominate artery (with the subsequent risk of neurological injury) nor migrates proximally with the risk of injuring the aortic valve. One of the main concerns regarding its use is the associated risk of aortic dissection. It has been shown that the risk of aortic dissection decreases greatly with experience, thus reflecting the existence of a learning curve. In the first report of the Port Access International Registry (PAIR) in 1999 [36], the incidence of aortic dissection was 1.3% and then decreased to 0.18% on the second half of the study (however, it has to be pointed that most patients in this study were coronary revascularizations and not mitral operations).

There are some studies that have looked into this issue, comparing cases performed with endo-aortic balloon occlusion or transthoracic aortic cross-clamping. Onnasch et al. [37] found a significant increase in neurological complications with the use of the balloon (8.1% vs. 1.8%; p = 0.05) and a higher mortality (5.2% vs. 3.1%; p < 0.04). After these findings, the Leipzig group abandoned intra-aortic occlusion in favor of the transthoracic clamp as their preferred method for non-redo cases. Similarly, other authors have also found better results using trans-thoracic clamping in terms of blood loss, operative times and costs [38, 39]. The endo-aortic balloon is an expensive piece of disposable equipment and the routine use of the transthoracic clamp has been shown to reduce costs on disposables up to $2.800 per case [39]. However, as mentioned before, the rate of complications related to the use of the balloon is tightly dependent on operator experience and many groups use the balloon as their preferred method, reporting very low complication rates after the learning curve is surpassed. In a recent multicentric report, Casselman et al. [40] described excellent results with the use of the

balloon when reviewing their most last 50 cases (all surgeons had already more than 100 procedures performed each) and with a 10.6% of redo-procedures: mortality 1.4%, stroke 0.8%, reoperation for bleeding 4.8% and no aortic dissections. However, even in their experienced hands, 2% of the patients required conversion to transthoracic clamping.

CONCLUSION

MIMVr has been increasingly performed over the last 20 years. There is growing evidence that it provides excellent results, comparable to conventional mitral surgery performed through a full sternotomy. MIMVr can now be offered to the vast majority of patients who have degenerative MR, providing a better cosmetic result, quicker recovery and without a tradeoff in repair rate and durability. It is also feasible in many traditionally difficult subsets of indications such as the elderly, reoperations, endocarditis or Barlow's disease. Large randomised controlled trials are underway and results from these are still awaited.

REFERENCES

[1] Holzhey DM, Seeburger J, Misfeld M, Borger MA, Mohr FW. Learning minimally invasive mitral valve surgery: a cumulative sum sequential probability analysis of 3895 operations from a single high-volume center. *Circulation* 2013; 128(5):483-91.

[2] King RT. New Keyhole Heart Surgery Arrived With Fanfare, but Was It Premature? *The Wall Street Journal*. May 5, 1999.

[3] Mohr FW, Falk V, Diegeler A, Walther T, van Son JA, Autschbach R. Minimally invasive port-access mitral valve surgery. *J Thorac Cardiovasc Surg* 1998; 115(3):567-74.

[4] Schneider F, Onnasch JF, Falk V, Walther T, Autschbach R, Mohr FW. Cerebral microemboli during minimally invasive and conventional mitral valve operations. *The Annals of thoracic surgery* 2000; 70(3):1094-7.

[5] Modi P, Hassan A, Chitwood WR, Jr. Minimally invasive mitral valve surgery: a systematic review and meta-analysis. *Eur J Cardiothorac Surg* 2008; 34(5):943-52.

[6] Cheng DC, Martin J, Lal A, Diegeler A, Folliguet TA, Nifong LW, Perier P, Raanani E, Smith JM, Seeburger J, Falk V. Minimally invasive versus conventional open mitral valve surgery: a meta-analysis and systematic review. *Innovations* (Phila) 2011; 6(2):84-103.

[7] Dogan S1, Aybek T, Risteski PS, Detho F, Rapp A, Wimmer-Greinecker G, Moritz A. Minimally invasive port access versus conventional mitral valve surgery: prospective randomized study. *Ann Thorac Surg* 2005; 79(2):492-8.

[8] El-Fiky MM, El-Sayegh T, El-Beishry AS, Abdul Aziz M, Aboul Enein H, Waheid S, Sallam IA. Limited right anterolateral thoracotomy for mitral valve surgery. *Eur J Cardiothoracic Surg* 2000; 17(6):710-3.

[9] Walther T1, Falk V, Metz S, Diegeler A, Battellini R, Autschbach R, Mohr FW. Pain and quality of life after minimally invasive versus conventional cardiac surgery. *Ann Thorac Surg* 1999; 67(6):1643-7.

[10] Glower DD, Landolfo KP, Clements F, Debruijn NP, Stafford-Smith M, Smith PK, Duhaylongsod F. Mitral valve operation via Port Access versus median sternotomy. *Eur J Cardiothorac Surg* 1998; 14:S143-7.

[11] Felger JE, Chitwood WR, Jr., Nifong LW, Holbert D. Evolution of mitral valve surgery: toward a totally endoscopic approach. *Ann Thorac Surg* 2001; 72(4):1203-8.

[12] Vleissis AA, Bolling SF. Mini-reoperative mitral valve surgery. *J Card Surg* 1998; 13(6):468-70.

[13] Mihaljevic T, Cohn LH, Unic D, Aranki SF, Couper GS, Byrne JG. One thousand minimally invasive valve operations: early and late results. *Ann Surg* 2004; 240(3):529-34.

[14] Cohn LH, Adams DH, Couper GS, Bichell DP, Rosborough DM, Sears SP, Aranki SF. Minimally invasive cardiac valve surgery improves patient satisfaction while reducing costs of cardiac valve replacement and repair. *Ann Surg* 1997; 226(4):421-6.

[15] Chitwood WR, Jr., Wixon CL, Elbeery JR, Moran JF, Chapman WH, Lust RM. Video-assisted minimally invasive mitral valve surgery. *J Thorac Cardiovasc Surg* 1997; 114(5):773-80.

[16] Gersak B, Sostaric M, Kalisnik JM, Blumauer R. The preferable use of port access surgical technique for right and left atrial procedures. *Heart Surg Forum* 2005; 8(5):E354-63.

[17] Suri RM, Thompson JE, Burkhart HM, Huebner M, Borah BJ, Li Z, Michelena HI, Visscher SL, Roger VL, Daly RC, Cook DJ, Enriquez-Sarano M, Schaff HV. Improving affordability through innovation in the surgical treatment of mitral valve disease. *Mayo Clin Proc* 2013; 88(10):1075-84.

[18] Castillo JG, Anyanwu AC, Fuster V, Adams DH. A near 100% repair rate for mitral valve prolapse is achievable in a reference center: implications for future guidelines. *J Thorac Cardiovasc Surg* 2012; 144(2):308-12.

[19] David TE, Armstrong S, McCrindle BW, Manlhiot C. Late outcomes of mitral valve repair for mitral regurgitation due to degenerative disease. *Circulation* 2013; 127(14):1485-92.

[20] Braunberger E, Deloche A, Berrebi A, Abdallah F, Celestin JA, Meimoun P, Chatellier G, Chauvaud S, Fabiani JN, Carpentier A. Very long-term results (more than 20 years) of valve repair with carpentier's techniques in nonrheumatic mitral valve insufficiency. *Circulation* 2001; 104(12 Suppl 1):I8-11.

[21] Suri RM, Taggarse A, Burkhart HM, Daly RC, Mauermann W, Nishimura RA, Li Z, Dearani JA, Michelena HI, Enriquez-Sarano M. Robotic Mitral Valve Repair for Simple and Complex Degenerative Disease: Midterm Clinical and Echocardiographic Quality Outcomes. *Circulation*. 2015; 132(21):1961-8.

[22] Miceli A, Murzi M, Canarutto D, Gilmanov D, Ferrarini M, Farneti PA, Solinas M, Glauber M. Minimally invasive mitral valve repair through right minithoracotomy in the setting of degenerative mitral regurgitation: early outcomes and long-term follow-up. *Ann Cardiothorac Surg* 2015; 4(5):422-7.

[23] Perier P, Hohenberger W, Lakew F, Batz G, Diegeler A. Rate of repair in minimally invasive mitral valve surgery. *Ann Cardiothorac Surg* 2013; 2(6):751-7.

[24] Akowuah E, Burdett C, Khan K, Goodwin A, Lage IB, El-Saegh M, Smailes T, Hunter S. Early and Late Outcomes After Minimally Invasive Mitral Valve Repair Surgery. *J Heart Valve Disease* 2015; 24(4):470-7.

[25] Grossi EA, Loulmet DF, Schwartz CF, Ursomanno P, Zias EA, Dellis SL, Galloway AC. Evolution of operative techniques and perfusion strategies for minimally invasive mitral valve repair. *J Thoracic Cardiovasc Surg* 2012; 143(4 Suppl):S68-70.

[26] Sharony R, Grossi EA, Saunders PC, Schwartz CF, Ursomanno P, Ribakove GH, Galloway AC, Colvin SB. Minimally invasive reoperative isolated valve surgery: early and mid-term results. *J Card Surg* 2006; 21(3):240-4.

[27] Bolotin G, Kypson AP, Reade CC, Chu VF, Freund WL Jr, Nifong LW, Chitwood WR Jr. Should a video-assisted mini-thoracotomy be the approach of choice for reoperative mitral valve surgery? *J Heart Valve Disease* 2004; 13(2):155-8.

[28] Burfeind WR, Glower DD, Davis RD, Landolfo KP, Lowe JE, Wolfe WG. Mitral surgery after prior cardiac operation: port-access versus sternotomy or thoracotomy. *Ann Thorac Surg* 2002; 74(4):S1323-5.

[29] labhajosyula P, Wallen T, Pulsipher A, Pitkin E, Solometo LP, Musthaq S, Fox J, Acker M, Hargrove WC 3rd. Minimally Invasive Port Access Approach for Reoperations on the Mitral Valve. *Ann Thorac Surg* 2015; 100(1):68-73.

[30] Ricci D, Pellegrini C, Aiello M, Alloni A, Cattadori B, D'Armini AM, Rinaldi M, Viganò M. Port-access surgery as elective approach for mitral valve operation in re-do procedures. *Eur J Cardiothorac Surg* 2010; 37(4):920-5.

[31] Andalib A, Mamane S, Schiller I, Zakem A, Mylotte D, Martucci G, Lauzier P, Alharbi W, Cecere R, Dorfmeister M, Lange R, Brophy J, Piazza N. A systematic review and meta-analysis of surgical outcomes following mitral valve surgery in octogenarians: implications for transcatheter mitral valve interventions. *EuroIntervention*: 2014; 9(10):1225-34.

[32] Grossi EA, Galloway AC, Ribakove GH, Buttenheim PM, Esposito R, Baumann FG, Colvin SB. Minimally invasive port access surgery reduces operative morbidity for valve replacement in the elderly. *Heart Surg Forum* 1999; 2(3):212-5.

[33] Tabata M, Cohn LH. Minimally invasive mitral valve repair with and without robotic technology in the elderly. *Am J Geriatric Cardiol* 2006; 15(5):306-10.

[34] Seeburger J, Raschpichler M, Garbade J, Davierwala P, Pfannmueller B, Borger MA, Mohr FW, Misfeld M. Minimally invasive mitral valve surgery in octogenarians-a brief report. *Ann Cardiothorac Surg* 2013; 2(6):765-7.

[35] Minol JP, Akhyari P, Boeken U, Kamiya H, Weinreich T, Sixt S, Gramsch-Zabel H, Lichtenberg A. Single-centre experience of mitral valve surgery via right lateral mini-thoracotomy in octogenarians. *Interact Cardiovasc Thorac Surg* 2016; 22(3):287-90.

[36] Galloway AC, Shemin RJ, Glower DD, Boyer JH Jr, Groh MA, Kuntz RE, Burdon TA, Ribakove GH, Reitz BA, Colvin SB. First report of the Port Access International Registry. *Ann Thorac Surg* 1999; 67(1):51-6.

[37] Onnasch JF, Schneider F, Falk V, Mierzwa M, Bucerius J, Mohr FW. Five years of less invasive mitral valve surgery: from experimental to routine approach. *Heart Surg Forum* 2002; 5(2):132-5.38.

[38] Aybek T, Dogan S, Wimmer-Greinecker G, Westphal K, Mortiz A. The micro-mitral operation comparing the Port-Access technique and the transthoracic clamp technique. *J Card Surg* 2000; 15(1):76-81.

[39] Reichenspurner H, Detter C, Deuse T, Boehm DH, Treede H, Reichart B. Video and robotic-assisted minimally invasive mitral valve surgery: a comparison of the Port-Access and transthoracic clamp techniques. *Ann Thorac Surg* 2005; 79(2):485-90.

[40] Casselman F, Aramendi J, Bentala M, Candolfi P, Coppoolse R, Gersak B, Greco E, Herijgers P, Hunter S, Krakor R, Rinaldi M, Van Praet F, Van Vaerenbergh G, Zacharias J. Endoaortic Clamping Does Not Increase the Risk of Stroke in Minimal Access Mitral Valve Surgery: A Multicenter Experience. *Ann Thorac Surg* 2015; 100(4):1334-9.

In: Encyclopedia of Surgery (22 Volume Set)
Editors: Andreas Lehrer and Kristin Mueller
ISBN: 978-1-53618-329-0
© 2020 Nova Science Publishers, Inc.

Chapter 427

ECHOCARDIOGRAPHIC PREDICTORS OF EARLY POSTOPERATIVE ATRIAL FIBRILLATION IN CORONARY ARTERY BYPASS SURGERY PATIENTS

Iana Simova[1,*], PhD, Tzvetana Katova[1], DSci, Anelia Nesheva[2], MD, Krasimira Hristova[1], MD, Velislava Kostova[1], PhD, Lyudmil Boyadzhiev[2], DSci and Nikolay Dimitrov[3], PhD

[1]Department of Noninvasive Cardiovascular Imaging and Functional Diagnostics, National Heart Hospital, Sofia, Bulgaria
[2]Cardiac Surgery Clinic, National Heart Hospital, Sofia, Bulgaria
[3]Department of Invasive Cardiology, National Heart Hospital, Sofia, Bulgaria

ABSTRACT

Background: Atrial fibrillation (AF) is the most common complication during the perioperative period of coronary artery bypass graft (CABG) surgery.

Objective: To evaluate the predictive power of different clinical and echocardiographic parameters for the occurrence of perioperative AF (POAF).

Methods: We studied 58 patients without previous history of AF undergoing elective CABG. We analyzed different demographic factors, clinical parameters, perioperative characteristics and the echocardiographic variables: left/right artial volume index (L/RAVI), left ventricular end-diastolic diameter, ejection fraction, tissue velocities at the mitral and tricuspid annulus during early and late diastolic filling (Em, Am, Et and At, respectively) as well as interatrial asynchrony time (IAA) and global functional index.

Results: Of 58 patients, 14 patients (24%) developed POAF. Demographic factors, clinical characteristics and perioperative variables didn't show a significant difference between patients with or without POAF. Patients with POAF had larger LAVI and RAVI and higher IAA. After a Linear Regression Analysis, IAA, LAVI, smoking and female

* Corresponding Author's Email: ianasimova@gmail.com; Fax: +35928229388.

gender turned out to be independent predictors for the occurrence of POAF. For IAA and LAVI we performed a ROC analysis and found that IAA values ≥ 32 ms had 100% sensitivity and 82% specificity, while LAVI values ≥ 29 ml/m^2 showed 86% sensitivity and 52% specificity for the occurrence of POAF.

Conclusion: For a relatively small patient group without previous history of AF and undergoing CABG surgery IAA, LAVI, smoking and female gender were independent predictors for the occurrence of POAF. The strongest predictor for POAF was IAA with the cut-off value of 32 ms.

Keywords: atrial fibrillation, coronary artery bypass surgery, echocardiography; perioperative period, interatrial asynchrony, left atrial volume index

INTRODUCTION

Atrial fibrillation (AF) is not only the most common form of supraventricular arrhythmia but also the most frequent complication after coronary artery bypass graft (CABG) surgery. Its prevalence ranges between 20 and 40% and it increases considerably the cost of treatment and lengthens the in-hospital stay [1-3]. Being itself a postoperative complication, AF can lead to a succession of other complications in this vulnerable period, namely: haemodinamic instability, exacerbation or occurrence of heart failure symptoms, bleeding from anticoagulation, increased incidence of myocardial infarction and thromboembolic complications, including stroke [4].

Previous history of AF is considered as one of the strongest predictors of the occurrence of this kind of arrhythmia in the perioperative period [5]. Many patients, however, develop their first episode of AF after CABG surgery.

Numerous studies have sought to identify predictors of AF after CABG. Their number is a proof of clinicians' futility to prevent the occurrence of postoperative AF (POAF) in unselected patients [2, 3, 6-9].

Regarding echocardiographic predictors of early POAF different studies have reported conflicting results: some of them finding a good correlation between the deviation in certain echocardiographic variables and the occurrence of POAF [10-12], while others have not been able to find such a relationship [13, 14]. These kinds of studies could be further subdivided to such that incorporate tissue Doppler imaging and measurement of myocardial deformation [10-11], and to studies evaluating more conventional echo-parameters [12-14].

The aim of the present study was to evaluate the prognostic significance of different clinical and echocardiographic parameters for the occurrence of POAF.

METHODS

Study Group

The study was prospective and the participants were consecutively enrolled. Our study group included 58 patients with no previous history of AF, evaluated between 02.2010 and 12.2011, who underwent elective CABG surgery. During the recruitment period 438 CABG

procedures were performed, of whom nearly one half were isolated coronary revascularization (211 cases). Baseline clinical characteristics of the patients are presented in Table 1.

Table 1. Demographic characteristics and risk factor distribution for the whole group of patients

Clinical variable	Distribution n = 58
Age – mean ± SD	64.4 ± 9.2
Male – n (%)	41 (71%)
BMI – mean ± SD	27.9 ± 4.4
AH – n (%)	56 (97%)
DM – n (%)	24 (41%)
Dyslipidemia – n (%)	54 (93%)
Family history of CAD – n (%)	11 (20%)
Smokers – n (%)	29 (50%)
COPD – n (%)	8 (14%)
History of MI – n (%)	32 (55%)
RCA stenosis – n (%)	52 (90%)
Digoxin use – n (%)	1 (2%)

SD – standard deviation; BMI – body mass index; AH – arterial hypertension; MI – myocardial infarction; COPD – chronic obstructive pulmonary disease; RCA – right coronary artery; n – number.

Inclusion criteria: patients admitted at our institution and scheduled for an elective CABG were considered eligible if they had no previous history of AF.

Exclusion criteria were the need for a combined surgical procedure (i.e., presence of a significant valvular heart disease, ascendic aortic aneurism requiring repair or congenital heart disease), history of AF or treatment with antiarrhythmic drugs class I or III, unstable clinical condition.

Beta-blockers and statins, as a part of the usual treatment in the presence of coronary artery disease (CAD) were continued in the perioperative period. Actually, all patients in our study group were taking beta-blockers and statins - two drug classes for which a prophylactic role against the occurrence of POAF has been suggested. Only one of the patients was taking a digitalis glycoside as a part of a heart failure regimen. Conventional monitoring was applied during the first postoperative days spent in Intensive Care Unit; later on patients were followed using telemonitoring till dehospitalization. AF was defined as fibrillation lasting more than one hour and precisely verified by skilled personnel.

Echocardiographic Evaluation

Standard transthoracic echocardiography was performed on the day before the scheduled operation in a left lateral position with a scanner Aloka Prosound SDD- α 10 and a 3.5 MHz transducer. The following echocardiographic parameters were studied: left artial volume index (LAVI) (ml/m^2) by two-plane area-length method in a four-chamber and two-chamber apical view obtained just before mitral valve opening, right artial volume index (RAVI) (ml/m^2) by the same method in a four-chamber apical view, left ventricular enddiastolic

diameter (LVEDD) (mm) and sum of the septal and posterior wall thickness (SpPW) (mm) in a parasternal long-axis view from two-dimensional guided M-mode tracings, ejection fraction (EF) (%) by biplane Simpson method, tissue velocities at the mitral and tricuspid annulus during early and late diastolic filling (Em, Am, Et and At, respectively) (cm/s) in an apical four-chamber view, the time from the onset of P wave on the surface ECG to the onset of A wave on the tissue velocity curve for the lateral segments of the mitral and tricuspid annulus (P-Am and P-At, respectively) (ms), the interatrial asynchrony time (IAA) measured as (P-Am) – (P-At) (ms) (Figure 1) and the global functional index (GFI) using the calculation (E/E')/S' (cm/s), where E is the transmitral early diastolic velocity and S' and E' are peak systolic and early diastolic tissue velocities, respectively – a mean value between the septal and lateral mitral annulus. All Doppler measurements were calculated as an average of three beats.

Statistics

We tested the distribution of continuous variables using the Kolmogorov-Smirnov test. Normally distributed data were presented as mean ± standard deviation (SD), whereas non-normally distributed data – as median and interquartile range (IQR) (the difference between the 25th and 75th percentile). Categorical variables were presented in percentage terms.

Clinical variables and echocardiographic parameters between the two studied groups (with or without AF) were compared using an independent samples t test for normally distributed data and the Mann-Whitney U test for non-normally distributed data. Categorical variables, presented in percentage terms, were compared with Chi square test.

We performed a multivariable analysis using Linear Regression Model using the stepwise procedure with a criteria to enter ≤ 0.05 and criteria to remove ≥ 0.1. The sensitivity and specificity for some of the continuous variables were assessed using the receiver operator characteristics (ROC) curve. We estimated the areas under the curve (AUC) with 95% confidence intervals (CI) under the nonparametric assumption. A two-tailed p value < 0.05 was considered statistically significant. Statistical analysis was performed using SPSS statistical software for Windows version 13.0.

Figure 1. Measurement of interatrial asynchrony (IAA): IAA = time (A) – time (B).

Ethics

Detailed preoperative echocardiographic evaluation was performed after an informed consent was obtained from the patients. The study was in accordance with the Declaration of Helsinki.

RESULTS

From the 58 patients we have studied, 14 (24%) developed POAF. Between these two groups of subjects (with or without POAF) we compared the following clinical factors and potential AF predictors in the perioperative period: age, gender, presence of arterial hypertension (AH), diabetes mellitus (DM), dyslipidemy, family history of early CAD, chronic obstructive pulmonary disease (COPD), smoking status, history of previous myocardial infarction (MI), preoperative use of digoxin, presence of a stenosis of the right coronary artery (RCA), aortic cross-clamp time, graft number, use of arterial graft – left internal mammary artery (LIMA), conventional on-pump versus off-pump CABG (OP-CABG), mechanical ventilation time, perioperative MI, postoperative pneumonia, need for intra-aortic balloon pump (IABP) and total amount of intravenous fluids – Table 2. Patients with and without POAF did not have a significant difference in any of the clinical parameters.

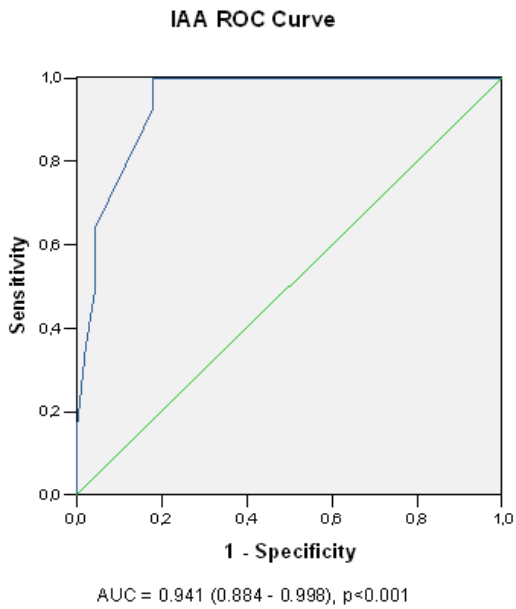

Figure 2. ROC analysis for IAA values regarding the occurrence of POAF. AUC - area under the ROC curve.

We further compared the preoperatively measured echocardiographic parameters (see Methods) between the groups of patients who did or did not develop postoperative arrhythmia – Table 3. Several of these parameters did show a significant difference between the groups – patients with POAF had larger LAVI and RAVI, longer time from the onset of P wave on the

surface ECG to the onset of A wave on the tissue velocity curve for the lateral segments of the mitral annulus (P-Am) and respectively higher value for the asynchrony index (IAA) compared to patients who did not develop POAF. When we performed a multivariable analysis with Linear Regression Model we found that the following variables were independent predictors for the occurrence of POAF: IAA, LAVI, smoking and female gender. IAA was included in all of the 4 models, created by the statistical software, LAVI - in 3 of them, smoking - in 2 of them and female gender - only in the last model, which combined all 4 variables and had the highest R square (0.92, $p < 0.001$). For the variable that differed most between both studied groups and at the same time was the most potent independent predictor for the occurrence of POAF - IAA, we then performed a ROC analysis - Figure 2. The area under the ROC curve (AUC) was high (0.941, $p < 0.001$) and the analysis showed us that IAA values ≥32 ms had 100% sensitivity and 82% specificity for the occurrence of POAF.

Table 2. Comparison of clinical factors and potential POAF predictors between patients with or without POAF

Clinical variable	POAF n = 14	No POAF n = 44	Significance (p)
Age – mean ± SD	67.1 ± 6	63.5 ± 9.9	ns
Male – n (%)	11 (79%)	30 (68%)	ns
BMI – mean ± SD	28.3 ± 3.4	26.9 ± 5.1	ns
AH – n (%)	14 (100%)	42 (96%)	ns
DM – n (%)	5 (36%)	19 (43%)	ns
Dyslipidemia – n (%)	13 (93%)	41 (93%)	ns
Family history of CAD – n (%)	3 (21%)	8 (18%)	ns
Smokers – n (%)	9 (64%)	20 (45%)	ns
COPD – n (%)	2 (14%)	6 (14%)	ns
History of MI – n (%)	8 (57%)	24 (55%)	ns
RCA stenosis – n (%)	13 (93%)	39 (87%)	ns
Digoxin use – n (%)	0	1 (2%)	ns
Aortic cross-clamp time (min) – mean ± SD	70.4 ± 24.5	69.1 ± 26.9	ns
Graft number – mean ± SD	3 ± 0.9	3.1 ± 0.8	ns
LIMA – n (%)	14 (100%)	43 (98%)	ns
OP-CABG – n (%)	1 (7%)	7 (16%)	ns
Mechanical ventilation time (hours) – mean ± SD	11.9 ± 2.8	15.4 ± 5.2	ns
Perioperative MI – n (%)	1 (7%)	6 (14%)	ns
Postoperative pneumonia – n (%)	0	2 (5%)	ns
IABP – n (%)	0	4 (9%)	ns
IV fluids (ml) – mean ± SD	3482 ± 913	3719 ± 1185	ns

SD – standard deviation; BMI – body mass index; AH – arterial hypertension; MI – myocardial infarction; COPD – chronic obstructive pulmonary disease; RCA – right coronary artery; LIMA – left internal mammary artery; OP-CABG – off-pump coronary artery bypass grafting; IABP – intra-aortic cross clamp; iv – intravenous; n – number; ns – statistically nonsignificant difference.

We performed also a ROC analysis for LAVI – another echocardiographic parameter that differed significantly between both groups and turned out to be an independent predictor for the occurrence of POAF (Figure 3). The AUC here was not so large – 0.713, $p = 0.017$; LAVI values ≥ 29 ml/m^2 showed 86% sensitivity and 52% specificity for the occurrence of POAF.

Table 3. Comparison of preoperatively measured echocardiographic between patients with or without POAF

Echocardiographic parameter	POAF n = 14	No POAF n = 44	Significance (p)
EF (%) – mean ± SD	62.9 ± 6.7	58.2 ± 8.9	ns
LVEDD (mm) – mean ± SD	50.4 ± 5.1	50.9 ± 5.8	ns
LAVI (ml/m^2) – mean ± SD	37.1 ± 9.1	30.8 ± 9.8	0.039
RAVI (ml/m^2) – mean ± SD	24 ± 6.6	19.4 ± 5.9	0.015
SpPW (mm) – mean ± SD	23.5 ± 2.9	22 ± 3.5	ns
Em (cm/s) – mean ± SD	8.9 ± 2.7	8.9 ± 2.7	ns
Am (cm/s) – mean ± SD	11.2 ± 2.8	10.7 ± 3.3	ns
Et (cm/s) – mean ± SD	10.3 ± 3.1	9.8 ± 2.9	ns
At (cm/s) – mean ± SD	15.1 ± 3.8	14.2 ± 4.1	ns
P-Am (ms) – mean ± SD	86.9 ± 14.4	68.9 ± 18.8	0.002
P-At (ms) – mean ± SD	43.9 ± 17	53.2 ± 19.6	ns
IAA (ms) – mean ± SD	43.6 ± 10.1	20 ± 12.6	< 0.001
GFI (cm/s) – mean ± SD	1.2 ± 0.3	1.5 ± 0.5	ns

SD – standard deviation; LAVI – left artial volume index; SpPW – sum of the septal and posterior wall thickness; Em – tissue velocity at the mitral annulus during early diastolic filling; Am – tissue velocity at the mitral annulus during late diastolic filling; Et – tissue velocity at the tricuspid annulus during early diastolic filling; ; At – tissue velocity at the tricuspid annulus during late diastolic filling; P-Am – the time from the onset of P wave on the surface ECG to the onset of A wave on the tissue velocity curve for the lateral segments of the mitral annulus; P-At – the time from the onset of P wave on the surface ECG to the onset of A wave on the tissue velocity curve for the lateral segments of the tricuspid annulus; IAA – interatrial asynchrony time; GFI – global functional index; ns – statistically nonsignificant difference.

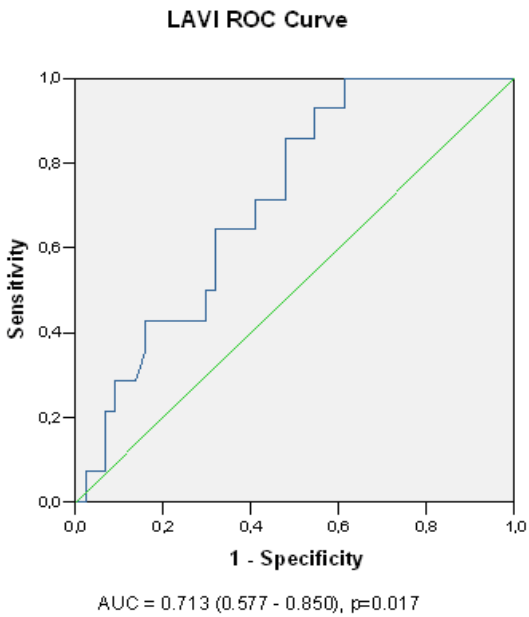

Figure 3. ROC analysis for LAVI values regarding the occurrence of POAF. AUC - area under the ROC curve.

DISCUSSION

In the present study with 58 elective CABG patients we observed a 24% incidence of POAF, which was comparable with the results from previous studies [1-3]. None of the demographic factors, clinical characteristics or perioperative parameters showed a significant difference between the groups of subjects with or without POAF. Patients with POAF, however, had larger atrial volumes (LAVI and RAVI) and more pronounced interatrial asynchrony (higher IAA values). From the multivariable Linear Regression Analysis IAA, LAVI, smoking and female gender turned out to be independent predictors for the occurrence of POAF. The ROC analysis for IAA and LAVI resulted in a statistically significant AUC, with a better predictive power (higher values for sensitivity and specificity) for the asynchrony index.

The possibility to predict the occurrence of POAF is very attractive. It would enable the clinician to detect a group of patients with a high risk for the development of this arrhythmia, to administer timely prophylactic antiarrhythmic therapy and to avoid the excessive morbidity imposed by this postoperative complication. On the other hand, patients who have low risk for the development of POAF could be spared the side effects of antiarrhythmic drugs.

There are some clinical factors that clearly identify a high risk group for POAF - e.g., previous history of AF, usually accompanied by atrial enlargement, LV systolic dysfunction and valvular involvement [5]. AF could, however, occur also in the early postoperative period of elective CABG patients without such risk factors.

Different clinical factors have been identified as possible predictors for POAF in clinical studies. In a prospective study of 302 CABG patients age, LA dimension, P wave morphology, failure to graft the RCA and postoperative adrenergic use were independently predictive of POAF [12]. In another study, which, however, had a retrospective design, 157 patients with POAF were compared with 191 subjects without such rhythm disorder after CABG [5]. The authors found a significant correlation between the occurrence of POAF and age >65 years, history of AF, presence of COPD, LV EF < 40%, proximal lesion of the RCA, bypass time > 120 min, significant intraoperative myocardial ischemia, positive fluid balance, and inotropic support with higher catecholamine doses.

In the present study the only clinical factors (outside the echocardiographic parameters) shown to be independently predictive for POAF, were female gender and smoking status. The female subgroup, however, was considerably small (17 patients) and the percentage of female patients and smokers was similar between the groups with or without POAF (t-statistics).

Studies regarding echocardiographic predictors for POAF give more consistent results, with left atrial volume or dimensions proven to have independent prognostic significance for the occurrence of this arrhythmia in the majority of studies [10, 11, 14], although there are also results pointing to the opposite. Tissue Doppler derived myocardial velocities and deformation indices have also been studied in this setting, the results generally showing that patients with POAF have reduced mechanical function of the atria compared to patients without perioperative arrhythmia [10, 11]. Other studies, however, have not found a correlation between tissue Doppler parameters and the occurrence of POAF [14].

Interatrial asynchrony has not been studied in the setting of CABG patients (determining therefore the main contribution of the present study). It has been evaluated, however, in a group of 37 patients with non-valvular paroxysmal AF, followed for 28 months [15]. During

this period 8 of the patients developed persistent AF. Significantly higher IAA values were present in this group, with the cut-off value IAA ≥ 34 ms showing the highest sensitivity and specificity for progression of paroxysmal to persistent AF.

In the present study we were able to prove that not only atrial enlargement but also interatrial dyssynchrony present in patients with a negative AF history have a predictive power for the development of supraventricular arrhythmia in the early postoperative period. It should be noted that the IAA cut-off value in our study (IAA ≥ 32 ms) was quite similar to the IAA cut-off value in the study by Sakabe et al. [15], although in a different clinical setting.

POAF episodes were not considered as an indication for long-term anticoagulation therapy in our group. At hospital discharge we recommended to these patients to perform an ambulatory Holter ECG or ECG telemonitoring in order to detect episodes of paroxysmal atrial fibrillation and to enable an optimal antithrombotic management.

The study had several limitations: the study group was considerably small, tissue Doppler derived indices were restricted to myocardial velocities and the occurrence of POAF was evaluated only in the early postoperative period (in fact - the most vulnerable one). We have not performed a long term follow-up in our patient group and do not have data about prognostic implication of POAF on mortality and future episodes of paroxysmal / persistent AF. As a result from the relatively small sample size the results of the present study should be interpreted with caution and our conclusion cannot be directly translated into a change in the patient care paradigm. The results from a larger study (presently ongoing in our institution) will be needed to either confirm or deny our findings. A deficiency of w-3 fatty acids and magnesium in the atrial tissue can also be a risk factor of AF among these patients.

In conclusion, for patients without previous history of AF and undergoing elective CABG surgery IAA, LAVI, smoking and female gender were independent predictors for the occurrence of POAF. The strongest predictor for POAF was IAA with the cut-off value of IAA ≥ 32 ms implying a significantly higher risk for this rhythm disorder.

REFERENCES

[1] Dunning J, Treasure T, Versteegh M, Nashev S. Guidelines on the prevention and management of de novo atrial fibrillation after cardiac and thoracic surgery. *Eur J Cardiothorac Surg* 2006; 30:852-872.

[2] Aranki SF, Shaw DP, Adams DH, Rizzo RJ, Couper GS, VanderVliet M, et al. Predictors of atrial fibrillation after coronary artery surgery: current trends and impact on hospital resources. *Circulation* 1996; 94:390–397.

[3] Mathew JP, Parks R, Savino JS, Friedman AS, Koch C, Mangano DT, et al., for the Multicenter Study of Perioperative Ischaemia Research Group. Atrial fibrillation following coronary artery bypass graft surgery: predictors, outcomes, and resource utilization. *JAMA* 1996; 276:300–306.

[4] Almassi GH, Schowalter T, Nicolosi AC, Aggarwal A, Moritz TE, Henderson WG, et al. Atrial fibrillation after cardiac surgery: a major morbid event? *Ann Surg* 1997; 226:501-511.

[5] Koletsis EN, Prokakis C, Crockett JR, Dedeilias P, Panagiotou M, Panagopoulos N, et al. Prognostic factors of atrial fibrillation following elective coronary artery bypass grafting: the impact of quantified intraoperative myocardial ischemia. *J Cardiothorac Surg* 2011; 6:127.

[6] Leitch JW, Thomson D, Baird DK, Harris PJ. The importance of age as a predictor of atrial fibrillation and flutter after coronary artery bypass grafting. *J Thorac Cardiovasc Surg* 1990; 100:338-342.

[7] Mendes LA, Connelly GP, McKenney PA, Podrid PJ, Cupples LA, Shemin RJ, et al. Right coronary artery stenosis: an independent predictor of atrial fibrillation after coronary artery bypass surgery. *J Am Coll Cardiol* 1995; 25:198-202.

[8] Sabzi F, Zokaei AH, Moloudi AR. Predictors of atrial fibrillation following coronary artery bypass grafting. *Clin Med Insights Cardiol* 2011; 5:67-75.

[9] Sovilj S, Van Oosterom A, Rajsman G, Magjarevic R. ECG-based prediction of atrial fibrillation development following coronary artery bypass grafting. *Physiol Meas* 2010; 31(5):663-668.

[10] Gabrielli L, Corbalan R, Córdova S, Enríquez A, Mc Nab P, Verdejo HE, et al. Left atrial dysfunction is a predictor of postcoronary artery bypass atrial fibrillation: association of left atrial strain and strain rate assessed by speckle tracking. *Echocardiography* 2011; 28(10):1104-1108.

[11] Tayyareci Y, Yildirimtürk O, Aytekin V, Memic K, Behramoglu F, Demiroglu IC, et al. Preoperative left atrial mechanical dysfunction predicts postoperative atrial fibrillation after coronary artery bypass graft operation – a velocity vector imaging-based study. *Circ J* 2010; 74(10):2109-2117.

[12] Haghjoo M, Basiri H, Salek M, Sadr-Ameli MA, Kargar F, Raissi K, et al. Predictors of postoperative atrial fibrillation after coronary artery bypass graft surgery. *Indian Pacing Electrophysiol J* 2008; 8(2):94-101.

[13] Gibson PH, Croal BL, Cuthbertson BH, Rae D, McNeilly JD, Gibson G, et al. Use of preoperative natriuretic peptides and echocardiographic parameters in predicting new-onset atrial fibrillation after coronary artery bypass grafting: a prospective comparative study. *Am Heart J* 2009; 158(2):244-251.

[14] Açil T, Cölkesen Y, Türköz R, Sezgin AT, Baltali M, Gülcan O, et al. Value of preoperative echocardiography in the prediction of postoperative atrial fibrillation following isolated coronary artery bypass grafting. *Am J Cardiol* 2007; 100(9):1383-1386.

[15] Sakabe K, Fukuda N, Fukuda Y, Morishita S, Shinohara H, Tamura Y. Interatrial dyssynchrony on tissue Doppler imaging predicts progression to chronic atrial fibrillation in patients with non-valvular paroxysmal atrial fibrillation. *Heart* 2009; 95:988-993.

In: Encyclopedia of Surgery (22 Volume Set)
Editors: Andreas Lehrer and Kristin Mueller
ISBN: 978-1-53618-329-0
© 2020 Nova Science Publishers, Inc.

Chapter 428

CYTOREDUCTIVE SURGERY AND HYPERTHERMIC INTRAPERITONEAL CHEMOTHERAPY FOR MUCINOUS TUMORS OF THE GASTROINTESTINAL TRACT

Amanda K. Arrington[1], MD and Joseph Kim[2,*], MD
[1]Department of Surgery, Marshall University, Huntington, WV, US
[2]Division of Surgical Oncology, SUNY Stony Brook,
Stony Brook, NY, US

ABSTRACT

The peritoneal cavity is the largest potential space in the body. With its own lymphatic and vascular systems, it is critical to appreciate the biology of the peritoneum to better understand how disease may spread. For example, benign or low-grade malignancies may spread along the peritoneal surface by exploiting the lymphatic flow patterns of peritoneal fluid. Any pathologic process involving the peritoneal cavity can easily disseminate throughout this space by means of unrestricted movement of fluid and cells. These varied mechanisms of disease spread necessitate a range of therapeutic options including the administration of intra-abdominal chemotherapies.

In the past, cancer dissemination to peritoneal surfaces (i.e., carcinomatosis) was universally lethal with limited survival. Peritoneal carcinomatosis constitutes 10-12% of colorectal cancer metastases and 40% of gastric cancer metastases. This chapter discusses the peritoneal surgical treatment options for mucinous peritoneal tumors of the gastrointestinal tract. Cytoreductive surgery (CRS) entails removing all visible disease within the abdomen. This is followed by administration of hyperthermic intraperitoneal chemotherapy (HIPEC). CRS/HIPEC has become a well-recognized, standardized method in a select patient population for treatment of mucinous carcinomatosis. An approach to this treatment strategy is detailed in this chapter. Though CRS/HIPEC by experienced surgeons has increased survival for patients with primary peritoneal cancers and peritoneal metastases, multimodality treatment options must always be considered.

* Corresponding Author's Email: joseph.kim1@ stonybrookmedicine.edu.

INTRODUCTION

The metastatic progression of malignant tumors of the gastrointestinal tract can occur by different mechanisms, including the hematogenous, lymphatic, and peritoneal surface routes. Benign or low-grade malignancies may also spread along the peritoneal surface by exploiting the flow patterns of peritoneal fluid. These varied mechanisms of disease spread necessitate a range of therapeutic options beyond the rote administration of systemic cytotoxic drugs. When cancers metastasize by the hematogenous and lymphatic routes, it is logical and intuitive to administer intravenous chemotherapies to achieve direct cytotoxic effects. However, when cancers progress exclusively or predominantly within the peritoneal cavity, the direct exposure of intravenous drug to tumor volume is limited; thus the cytotoxic effects are often suboptimal. Indeed, patients with predominance of peritoneal carcinomatosis, in contrast to visceral metastasis, often have poorer rates of overall survival because of the lower efficacy of systemic therapies in that setting [1]. Therefore, patients with peritoneal surface disease may benefit from a therapeutic approach that directly addresses its unique mechanism of disease progression.

In the 1970s a multidisciplinary approach to better manage intra-peritoneal cancer spread was developed [2-4]. This multimodal regimen consists of two major steps. In the first step, the surgical team performs operative resection to eradicate all sites of gross disease (i.e., cytoreductive surgery, CRS). In the second step, heated chemotherapy is instilled intraoperatively into the peritoneal cavity to eradicate all sites of microscopic disease (i.e., hyperthermic intraperitoneal chemotherapy, HIPEC). Although CRS and HIPEC are applied worldwide, there remains much debate and controversy regarding its indications, techniques, and efficacy. In this chapter we will examine CRS and HIPEC for mucinous gastrointestinal cancers while describing our experience on how to perform this complex multimodal treatment approach.

UNDERSTANDING THE PERITONEUM

It is critical to appreciate the biology of the peritoneum to better understand how disease may spread within the peritoneal cavity and how to optimally manage this disease. In its very simplest form, the peritoneum is the serous membrane supported by a thin layer of connective tissue that lines the abdominal cavity. It has both parietal and visceral components with the parietal peritoneum covering the inner surface of the abdominal walls, the diaphragm, and the pelvis; whereas the visceral peritoneum envelops the intraperitoneal organs and covers the anterior surface of retroperitoneal organs. The space between the parietal and visceral peritoneum is the peritoneal space; and within this space exists the fluid to lubricate the visceral surfaces. In its more complex form, the peritoneum doubles up to establish major extensions, including numerous mesenteries, the greater and lesser omentum, and complex ligamentous structures.

Figure 1. Operative photograph of a patient with appendiceal mucinous adenocarcinoma. The surgeon is holding the "omental cake." The small intestine is spared of disease.

There is an intricate relationship between the circulation of peritoneal fluid, the major peritoneal extensions, and the intra-peritoneal organs. The peritoneal fluid, which is <100 mL under physiologic conditions, is constantly produced as a transudate and resorbed through major pores in the large surface area of the peritoneum to create a steady-state circulation [5]. The typical pattern of circulation occurs with peritoneal fluid flowing up the right para-colic gutter and leading up to the right hemidiaphragm [6]. Major pores under the right hemi-diaphragm clear nearly 90% of peritoneal fluid. Not surprisingly, peritoneal surface disease may be frequently detected under the right hemi-diaphragm as tumor cells travel in the circulatory pattern of peritoneal fluid. The lesser and greater omentum also contribute to the steady-state peritoneal fluid circulation with sizeable pores throughout its large surface area [7, 8]. Thus, it is also a common location for both benign and malignant peritoneal disease spread. Massive replacement of the greater omentum by mucinous disease has been referred to as "omental cake" (Figure 1) [8, 9]. Finally, under pathologic conditions (e.g., cirrhosis, malignant ascites, etc.) peritoneal fluid may accumulate in the dependent areas of the peritoneal cavity (e.g., pelvis and lateral abdominal gutters), which are also frequent locations for peritoneal disease. Overall, the circulation of peritoneal fluid may help predict the progression of peritoneal surface disease (Figure 2).

MUCINOUS PERITONEAL TUMORS

Epithelial mucin-producing cells are at the core of the problem with mucinous peritoneal surface neoplasms. Mucins belong to a family of proteins also known as MUC glycoproteins. Intrinsically, these secreted mucins provide a physical barrier for epithelial cells lining the gastrointestinal tract and they contribute to the immune defense system on the mucosal surfaces [10-13]. These secreted mucins can accumulate and form voluminous gels slowly over months or years leading to a chronic condition that may elude detection until advanced stages of disease.

Pseudomyxoma peritonei (PMP) has been the term traditionally applied to the intraperitoneal dissemination of mucinous ascites from perforated mucinous cystadenoma of

the appendix [14]. In this condition, epithelial mucin-producing cells proliferate within the appendix, leading to occlusion of the lumen and expansion and eventual rupture of the appendix. If the mucinous cystadenoma is detected prior to rupture, simple appendectomy is sufficient to permanently eradicate disease (Figure 3). Extreme caution should be taken when laparoscopic appendectomy is attempted with large mucinous cystadenoma to avoid inadvertent rupture (Figure 4). When the appendix does rupture, which is frequently without symptoms, then semi-solid mucin may eventually fill the entire abdominal cavity leading to 'jelly belly' and 'omental cake.'

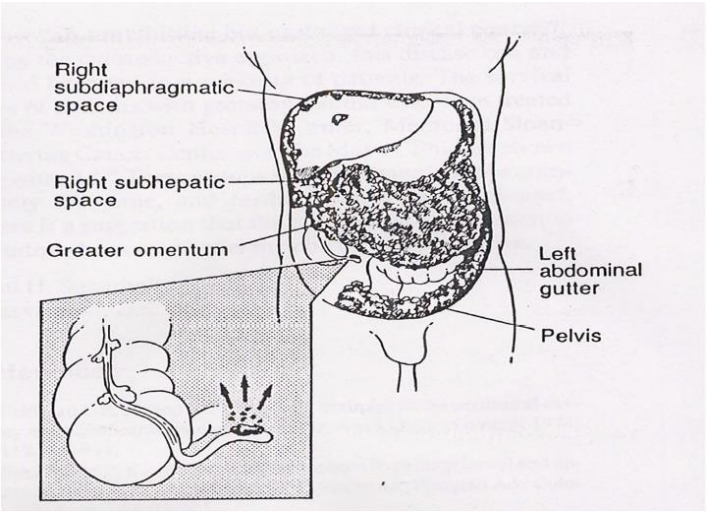

Figure 2. Typical locations of disease with peritoneal mucinous disease. Peritoneal surface disease from an appendiceal primary will follow the typical circulation of peritoneal fluid leading to disease under the hemi-diaphragms, omentum, and para-colic gutters. Gravity will also lead to disease in the pelvis.

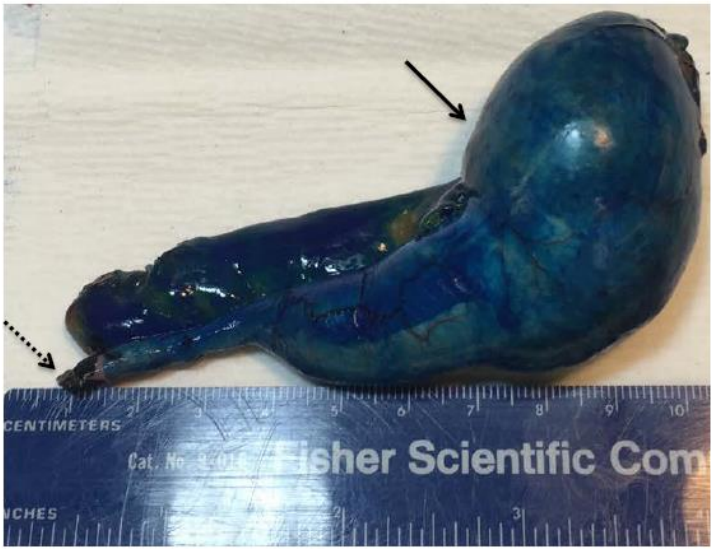

Figure 3. Appendiceal mucinous cystadenoma from laparoscopic appendectomy. The pathologic specimen has been stained blue. The solid arrow points to the mucinous cystadenoma. The dashed arrow shows the diameter of the non-diseased appendix.

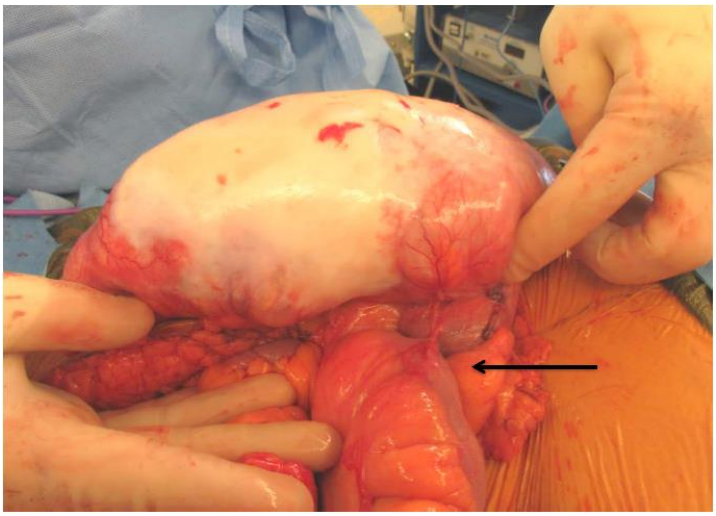

Figure 4. Massive appendiceal mucinous cystadenoma from open appendectomy. The solid arrow points to the terminal ileum. The base of the appendix was transected with a linear stapler.

The biologic aggressiveness of peritoneal surface disease has been classified to designate benign and low-grade malignant conditions together as disseminated peritoneal adenomucinosis (DPAM). In this schema, lesions are categorized as low-grade when they have scant simple to focally proliferative mucinous epithelium with minimal or little cytologic atypia or mitotic activity. In contrast, moderate or high-grade lesions of peritoneal mucinous carcinomatosis (PMCA) include lesions with more aggressive biologic disease that are composed of abundant mucinous epithelium with architectural and cytologic features of carcinoma. PMCA is typical for appendiceal mucinous adenocarcinoma or mucinous colorectal cancers and gastric cancers that violate the peritoneal cavity either by direct extension or by viscus rupture. This disease then spreads along the peritoneal surface with epithelial mucin-producing cells forming metastatic nodules in the absence of visceral metastases. The response to systemic therapies is generally poor and optimal management of these patients may include CRS and HIPEC in combination with systemic therapies [3, 4, 15-24].

CYTOREDUCTIVE SURGERY AND HEATED CHEMOTHERAPY

General Overview

Eradication of gross and microscopic disease by surgical resection and heated chemotherapy, respectively, are the principles of CRS and HIPEC. This treatment approach is ideally suited for disease processes that have peritoneal surface disease but lack visceral metastases; and generally excludes cancers that have metastasized outside the peritoneal cavity. Incomplete surgical resection of disease should be avoided since patients derive minimal to no survival benefit [1, 3, 16, 25-32]. As such, complete resection of all tumor volume to margin negative disease is the goal of CRS. The amount of disease burden may be estimated prior to surgical exploration with the Peritoneal Cancer Index (PCI). This scoring

system separates the abdominal cavity into 13 distinct regions. The operator assigns tumor burden scores for each of these regions based upon the Lesion Size (LS) of the tumor volume in each of those regions. The numerical value of these PCI scores have correlated with clinical outcomes; and patients with lower PCI scores generally fare better than patients with higher scores [33, 34].

Morbidity and Mortality of the Treatment Approach

Patients who undergo CRS and HIPEC may endure major physiologic stress from multi-visceral resection, rapid changes in fluid homeostasis, and alterations in body core temperature. Not surprisingly, there is considerable morbidity and mortality associated with this procedure with approximate rates approaching up to 50% and 5%, respectively [16, 21, 23, 24, 35-39]. Strategies to avoid unnecessary surgical steps and abandoning unsafe HIPEC protocols have improved the safety profile of these procedures without adversely impacting overall survival [40, 41]. In our practice we perform resection for grossly visible disease and generally avoid prophylactic or empiric resection except for the appendix and gallbladder. When disease is encountered on the surface of intra-peritoneal organs, we make concerted efforts to remove disease by stripping the peritoneal lining rather than resecting the entire organ en bloc. Finally, we avoid using D_5W in the hyperthermic perfusate, thus avoiding potentially serious electrolyte alterations.

Technique for Cytoreductive Surgery

For our cytoreduction procedures, we routinely use a generous midline incision with a Thompson retractor to provide full exposure. Once the peritoneal cavity is entered, mucin is typically removed with suction catheters. Tenacious, thick mucin may require manual removal using laparotomy pads. After initial exploration to rule out unresectable disease, we proceed with resection of all sites of gross disease. Regardless of detection of gross disease, we advocate mandatory resection of the greater and lesser omentum, appendix, and the gallbladder. We use a thermal energy device (Ligasure, Covidien) to remove the omentum by dividing the gastrocolic ligament close to the transverse colon from the hepatic to splenic flexures. The omentum is then divided along the greater curvature of the stomach while preserving the gastro-epiploic vessels. Appendectomy is performed using a linear stapling device, rather than using biodegradable suture to avoid its exposure to HIPEC. Similarly, titanium clips are placed on the cystic artery and duct during cholecystectomy.

For many patients, cytoreduction procedures will also require stripping of the right and occasionally left hemi-diaphragm. We use long Allis clamps to grasp the peritoneal lining of diaphragm and “strip” only gross disease. If the thoracic cavity is entered, we close the diaphragm around a red rubber catheter. A purse-string suture is placed around the catheter; and the catheter is removed and the suture tied down once the air in the thoracic cavity has been suctioned. Another common site of disease is on the liver surface. We have found that the bipolar hemostatic device (Aquamantys, Medtronic) is safe and effective for stripping Glisson’s capsule of the liver. Finally, the removal of intraperitoneal or retroperitoneal organs may sound contrary to the benign nature of low-grade malignancy; however, thick tenacious

mucinous disease may coat the pelvis, rectum, lesser curvature of the stomach, antrum of the stomach, the liver surface, and the porta hepatis. Therefore, it is common to perform major multi-visceral resection to completely remove disease even for patients with DPAM. Since mucinous disease tends to spare areas of active peristalsis, the small intestine is typically spared. In our experience we have identified lesions overlooked by other surgeons during combination operative resections. These examples of missed disease give us pause when considering laparoscopic HIPEC procedures.

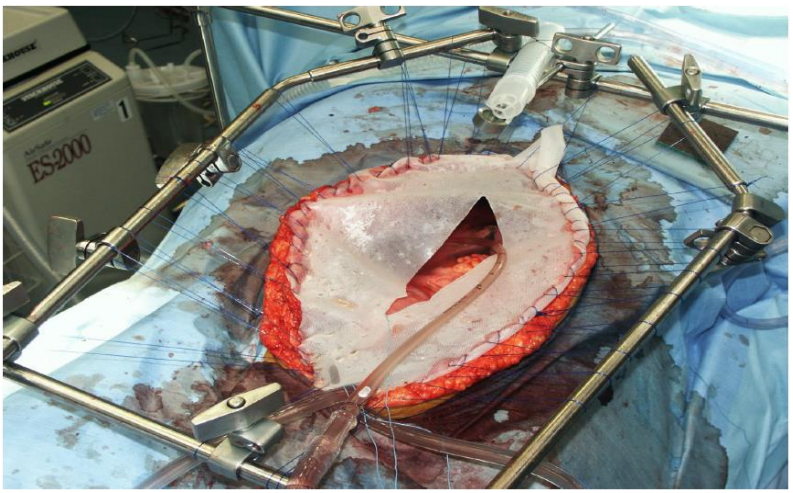

Figure 5. Open technique for hyperthermic intraperitoneal chemotherapy. Multiple sutures have been placed to suspend the skin to the retractor system. Inflow and outflow catheters have been placed through openings in the mesh. A smoke evacuator has been placed above the opening.

Figure 6. Closed technique for hyperthermic intraperitoneal chemotherapy. Inflow and outflow catheters have been placed into the abdominal cavity and the skin has been closed with a continuous running suture.

Administration of Heated Intraoperative Chemotherapy

The rationale to use intra-peritoneal chemotherapy is to eradicate microscopic disease with higher local concentrations of chemotherapy that may enhance cytoreduction, which may be further potentiated by the cytotoxic effects of heat [4, 15, 16]. Once gross resection of disease is completed and prior to anastomotic reconstruction, we perform HIPEC. Anastomoses should be delayed until after HIPEC is completed to avoid exposing the fresh anastomosis to the peritoneal dosage of chemotherapy. For colorectal and appendiceal tumors, we instill oxaliplatin or mitomycin C into our perfusion circuit, whereas cisplatin is used for gastric cancer. Mitomycin C may be the chemotherapeutic agent of choice for patients with peritoneal surface disease of colorectal origin with the American Society of Peritoneal Surface Malignancies (ASPSM) advocating its use for this disease [40-42].

HIPEC has been performed using an open platform, referred to as the coliseum technique (Figure 5), in which the abdomen is left open and the operator manually stirs the chemotherapy perfusate to ensure equal distribution throughout the abdominal cavity [16, 43, 44]. Because of institutional or state restrictions, the open technique has been abandoned in some centers. The alternate approach is the closed technique (Figure 6) [41, 43-47], which is our preferred technique. We employ the Genesis Medical system (Figure 7), which utilizes two inflow catheters connected by a Y connector to a single primary catheter; and a single outflow “lasso” catheter. In our experience this system rapidly achieves goal temperature when the catheters have been placed and the skin closed; and we have observed no interruptions in HIPEC secondary to system or catheter malfunction.

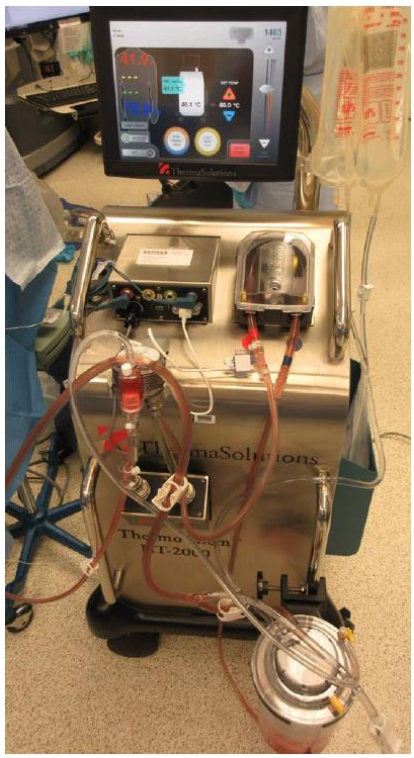

Figure 7. The Genesis Medical system for hyperthermic intraperitoneal chemotherapy.

Once closed, the abdomen is warmed with hyperthermic saline to 41-42°C. Once the target temperature is reached, chemotherapy is infused into the circuit and perfused for 30-90 minutes. Once the perfusion has been completed, the hyperthermic chemotherapy fluid is drained from the abdomen. Next, the skin is reopened and the final anastomoses are performed or ostomies constructed.

CONCLUSION

Multimodal therapies for patients with primary peritoneal cancers and peritoneal metastases are continuing to improve and evolve. Instead of representing rapidly fatal disease as in the past, contemporary management of DPAM and PMCA with CRS and HIPEC has improved survival in the hands of experienced surgeons. Importantly, the implementation of standardized protocols and advances in HIPEC delivery systems has resulted in decreased rates of morbidity and mortality. We recommend adhering to the guidelines from The American Society of Peritoneal Surface Malignancies (ASPSM) on the use of HIPEC in our difficult to manage patients. This organization has provided HIPEC guidelines on chemotherapy administration, timing, and dosage and temperature settings to improve patient safety [41, 42, 48]. Despite these past improvements, additional investigational studies are needed to further improve the outcomes of patients with mucinous peritoneal disease.

REFERENCES

[1] McQuellon RP, Loggie BW, Lehman AB et al.: Long-term survivorship and quality of life after cytoreductive surgery plus intraperitoneal hyperthermic chemotherapy for peritoneal carcinomatosis. *Ann. Surg. Oncol.* 10:155-62, 2003.

[2] Spratt JS, Adcock RA, Muskovin M et al.: Clinical delivery system for intraperitoneal hyperthermic chemotherapy. *Cancer Res*. 40:256-60, 1980.

[3] Sugarbaker PH: Surgical management of peritoneal carcinosis: diagnosis, prevention and treatment. *Langenbecks Arch. Chir*. 373:189-96, 1988.

[4] White SK, Stephens AD, Sugarbaker PH: Hyperthermic intraoperative intraperitoneal chemotherapy safety considerations. *AORN J*. 63:716-24, 1996.

[5] Dunn DL, Barke RA, Knight NB et al.: Role of resident macrophages, peripheral neutrophils, and translymphatic absorption in bacterial clearance from the peritoneal cavity. *Infect. Immun.* 49:257-64, 1985.

[6] Doherty GM: *Peritoneal Cavity, CURRENT Diagnosis and Treatment: Surgery* (ed. 13). New York, McGraw-Hill, 2010.

[7] Meyers MA, Oliphant M, Berne AS et al.: The peritoneal ligaments and mesenteries: pathways of intraabdominal spread of disease. *Radiology* 163:593-604, 1987.

[8] Healy JC, Reznek RH: The peritoneum, mesenteries and omenta: normal anatomy and pathological processes. *European radiology* 8:886-890, 1988.

[9] Mann WJ, Jr., Wagner J, Chumas J et al.: The management of pseudomyxoma peritonei. *Cancer* 66:1636-40, 1990.

[10] Semino-Mora C, Liu H, McAvoy T et al.: Pseudomyxoma peritonei: is disease progression related to microbial agents? A study of bacteria, MUC2 AND MUC5AC expression in disseminated peritoneal adenomucinosis and peritoneal mucinous carcinomatosis. *Ann. Surg. Oncol.* 15:1414-23, 2008.

[11] Fujishima Y, Goi T, Kimura Y et al.: MUC2 protein expression status is useful in assessing the effects of hyperthermic intraperitoneal chemotherapy for peritoneal dissemination of colon cancer. *Int. J. Oncol*. 40:960-4, 2012.

[12] Lo NS, Sarr MG: Mucinous cystadenocarcinoma of the appendix. The controversy persists: a review. *Hepatogastroenterology* 50:432-7, 2003.

[13] O'Connell JT, Hacker CM, Barsky SH: MUC2 is a molecular marker for pseudomyxoma peritonei. *Mod. Pathol*. 15:958-72, 2002.

[14] Chu DZ, Lang NP, Thompson C et al.: Peritoneal carcinomatosis in nongynecologic malignancy. A prospective study of prognostic factors. *Cancer* 63:364-7, 1989.

[15] Sugarbaker PH, Averbach AM, Jacquet P et al.: A simplified approach to hyperthermic intraoperative intraperitoneal chemotherapy (HIIC) using a self retaining retractor. *Cancer Treat. Res*. 82:415-21, 1996.

[16] Stephens AD, Alderman R, Chang D et al.: Morbidity and mortality analysis of 200 treatments with cytoreductive surgery and hyperthermic intraoperative intraperitoneal chemotherapy using the coliseum technique. *Ann. Surg. Oncol.* 6:790-6, 1999.

[17] Piso P, Bektas H, Werner U et al.: Improved prognosis following peritonectomy procedures and hyperthermic intraperitoneal chemotherapy for peritoneal carcinomatosis from appendiceal carcinoma. *Eur. J. Surg. Oncol*. 27:286-90, 2001.

[18] Ronnett BM, Yan H, Kurman RJS, B.M. et al.: Patients with pseudomyxoma peritonei associated with disseminated peritoneal adenomucinosis have a significantly more favorable prognosis than patients with peritoneal mucinous carcinomatosis. *Cancer* 92: 85-91, 2001.

[19] Glehen O, Kwiatkowski F, Sugarbaker PH et al.: Cytoreductive surgery combined with perioperative intraperitoneal chemotherapy for the management of peritoneal carcinomatosis from colorectal cancer: a multi-institutional study. *J. Clin. Oncol*. 22: 3284-92, 2004.

[20] Verwaal VJ: Long-term results of cytoreduction and HIPEC followed by systemic chemotherapy. *Cancer Journal* 15:212-5, 2009.

[21] Verwaal VJ, Bruin S, Boot H et al.: 8-year follow-up of randomized trial: cytoreduction and hyperthermic intraperitoneal chemotherapy versus systemic chemotherapy in patients with peritoneal carcinomatosis of colorectal cancer. *Ann. Surg. Oncol*. 15: 2426-32, 2008.

[22] Verwaal VJ, van Ruth S, de Bree E et al.: Randomized trial of cytoreduction and hyperthermic intraperitoneal chemotherapy versus systemic chemotherapy and palliative surgery in patients with peritoneal carcinomatosis of colorectal cancer. *J. Clin. Oncol*. 21:3737-43, 2003.

[23] Verwaal VJ, van Ruth S, Witkamp A et al.: Long-term survival of peritoneal carcinomatosis of colorectal origin. *Ann. Surg. Oncol*. 12:65-71, 2005.

[24] Verwaal VJ, van Tinteren H, van Ruth S et al.: Predicting the survival of patients with peritoneal carcinomatosis of colorectal origin treated by aggressive cytoreduction and hyperthermic intraperitoneal chemotherapy. *Br. J. Surg*. 91:739-46, 2004.

[25] Loggie BW, Fleming RA, McQuellon RP et al.: Cytoreductive surgery with intraperitoneal hyperthermic chemotherapy for disseminated peritoneal cancer of gastrointestinal origin. *Am. Surg*. 66:561-8, 2000.

[26] Witkamp AJ, de Bree E, Van Goethem R et al.: Rationale and techniques of intra-operative hyperthermic intraperitoneal chemotherapy. *Cancer Treat. Rev*. 27:365-74, 2001.

[27] Pilati P, Mocellin S, Rossi CR et al.: Cytoreductive surgery combined with hyperthermic intraperitoneal intraoperative chemotherapy for peritoneal carcinomatosis arising from colon adenocarcinoma. *Ann. Surg. Oncol*. 10:508-13, 2003.

[28] Shen P, Levine EA, Hall J et al.: Factors predicting survival after intraperitoneal hyperthermic chemotherapy with mitomycin C after cytoreductive surgery for patients with peritoneal carcinomatosis. *Arch. Surg*. 138:26-33, 2003.

[29] Glehen O, Cotte E, Schreiber V et al.: Intraperitoneal chemohyperthermia and attempted cytoreductive surgery in patients with peritoneal carcinomatosis of colorectal origin. *Br. J. Surg*. 91:747-54, 2004.

[30] Levine EA, Stewart JHt, Russell GB et al.: Cytoreductive surgery and intraperitoneal hyperthermic chemotherapy for peritoneal surface malignancy: experience with 501 procedures. *J. Am. Coll. Surg*. 204: 943-53; discussion 953-5, 2007.

[31] Smeenk RM, Verwaal VJ, Antonini N et al.: Survival analysis of pseudomyxoma peritonei patients treated by cytoreductive surgery and hyperthermic intraperitoneal chemotherapy. *Ann. Surg*. 245:104-9, 2007.

[32] Kusamura S, Baratti D, Virzi S et al.: Learning curve for cytoreductive surgery and hyperthermic intraperitoneal chemotherapy in peritoneal surface malignancies: analysis of two centres. *J. Surg. Oncol*. 107:312-9, 2013.

[33] Valle M, Federici O, Garofalo A: Patient selection for cytoreductive surgery and hyperthermic intraperitoneal chemotherapy, and role of laparoscopy in diagnosis, staging, and treatment. *Surg. Oncol. Clin. N. Am.* 21:515-31, 2012.

[34] Cascales Campos PA, Gil Martinez J, Galindo Fernandez PJ et al.: Perioperative fast track program in intraoperative hyperthermic intraperitoneal chemotherapy (HIPEC) after cytoreductive surgery in advanced ovarian cancer. *Eur. J. Surg. Oncol*. 37:543-8, 2011.

[35] Schmidt U, Dahlke MH, Klempnauer J et al.: Perioperative morbidity and quality of life in long-term survivors following cytoreductive surgery and hyperthermic intraperitoneal chemotherapy. *Eur. J. Surg. Oncol*. 31:53-8, 2005.

[36] Deraco M, Baratti D, Kusamura S: Morbidity and quality of life following cytoreduction and HIPEC. *Cancer Treat. Res*. 134:403-18, 2007.

[37] Spiliotis J, Rogdakis A, Vaxevanidou A et al.: Morbidity and mortality of cytoreductive surgery and hyperthermic intraperitoneal chemotherapy in the management of peritoneal carcinomatosis. *J. BUON* 14:259-64, 2009.

[38] Kerscher AG, Mallalieu J, Pitroff A et al.: Morbidity and mortality of 109 consecutive cytoreductive procedures with hyperthermic intraperitoneal chemotherapy (HIPEC) performed at a community hospital. *World J. Surg*. 34:62-9, 2010.

[39] Cascales Campos P: Morbidity and mortality outcomes of cytoreductive surgery and hyperthermic intraperitoneal chemotherapy in patients with primary and recurrent advanced ovarian cancer. *Eur. J. Surg. Oncol.*, 2013.

[40] Esquivel J, Sticca R, Sugarbaker P et al.: Cytoreductive surgery and hyperthermic intraperitoneal chemotherapy in the management of peritoneal surface malignancies of colonic origin: a consensus statement. Society of Surgical Oncology. *Ann. Surg. Oncol*. 14:128-33, 2007.

[41] Turaga K, Levine E, Barone R et al.: Consensus Guidelines from The American Society of Peritoneal Surface Malignancies on Standardizing the Delivery of Hyperthermic Intraperitoneal Chemotherapy (HIPEC) in Colorectal Cancer Patients in the United States. *Ann. Surg. Oncol*., 2013.

[42] Esquivel J, Piso P, Verwaal V et al.: American Society of Peritoneal Surface Malignancies opinion statement on defining expectations from cytoreductive surgery and hyperthermic intraperitoneal chemotherapy in patients with colorectal cancer. *J. Surg. Oncol*. 110:777-8, 2014.

[43] Sarnaik AA, Sussman JJ, Ahmad SA et al.: Technology for the delivery of hyperthermic intraoperative intraperitoneal chemotherapy: a survey of techniques. *Recent Results Cancer* Res. 169:75-82, 2007.

[44] Glehen O, Cotte E, Kusamura S et al.: Hyperthermic intraperitoneal chemotherapy: nomenclature and modalities of perfusion. *J. Surg. Oncol.* 98:242-6, 2008.

[45] Benoit L, Cheynel N, Ortega-Deballon P et al.: Closed hyperthermic intraperitoneal chemotherapy with open abdomen: a novel technique to reduce exposure of the surgical team to chemotherapy drugs. *Ann. Surg. Oncol*. 15:542-6, 2008.

[46] Roviello F, Pinto E, Corso G et al.: Safety and potential benefit of hyperthermic intraperitoneal chemotherapy (HIPEC) in peritoneal carcinomatosis from primary or recurrent ovarian cancer. *J. Surg. Oncol*. 102:663-70, 2010.

[47] Ortega-Deballon P, Facy O, Jambet S et al.: Which method to deliver hyperthermic intraperitoneal chemotherapy with oxaliplatin? An experimental comparison of open and closed techniques. *Ann. Surg. Oncol*. 17:1957-63, 2010.

[48] Esquivel J, Stojadinovic A, Levine EA: The American Society of Peritoneal Surface Malignancies (ASPSM). *Ann. Surg. Oncol*. 18 Suppl. 3:S218-9, 2011.

In: Encyclopedia of Surgery (22 Volume Set)
Editors: Andreas Lehrer and Kristin Mueller
ISBN: 978-1-53618-329-0
© 2020 Nova Science Publishers, Inc.

Chapter 429

EXFOLIATION SYNDROMEAND EXFOLIATIVE GLAUCOMA: FROM GENETICS TO SURGERY

Gábor Holló[1] , MD, PhD, DSc and Andreas Katsanos[2], MD, PhD
[1]Department of Ophthalmology, Semmelweis University, Budapest, Hungary
[2]Department of Ophthalmology, University of Ioannina, Ioannina, Greece

ABSTRACT

Exfoliation syndrome (XFS) is a genetically determined systemic condition characterized by the production and accumulation of an abnormal protein, the exfoliative material. Though XFS is a systemic elastosis, the most significant clinical consequences occur in the eye (nuclear cataract formation, Zinn'szonule fragility, increased risk for cataract surgery complications and exfoliative glaucoma[XFG]). XFG is the most common type of secondary open-angle glaucoma, and is characterized by elevated intraocular pressure with high fluctuation, and rapid progression. XFG is typically a disease of the elderly. In many cases XFG starts as a clinically unilateral disease in eyes with XFS. This chapter summarizes the current knowledge on genetics, environmental factors, clinical characteristics, medical, laser and surgical treatment options. It also addresses the significance of systemic vascular diseases associated with XFS and XFG, and the need for consultation between the ophthalmologist and cardiologist or general practitioner during long-term management of the disease.

INTRODUCTION

Open-angle glaucoma is one of the most important causes of severe irreversible visual field deterioration, decrease of vision related quality of life, and blindness [1-4]. Due to global population ageing along with increased life expectancy, glaucoma will have an ever increasing impact in the next decades. Since open-angle glaucoma is a group of progressive diseases, end-of-life glaucoma related blindness is not uncommon [5, 6]. This chapter deals with one type of the open-angle glaucoma, the most common secondary open-angle glaucoma, exfoliative glaucoma (XFG) [2-4, 7]. XFG is different from primary open-angle glaucoma; it develops from exfoliation syndrome (XFS), a systemic condition. For several

decades XFG was considered a rare type of glaucoma and frequently remained unrecognized by ophthalmologists. In the recent years, however, both research and clinical interest in XFG have dramatically increased so that awareness of XFG is heightened worldwide.

EXFOLIATION SYNDROME

Exfoliation (or "pseudoexfoliation") syndrome is a common genetically determined systemic condition characterized by the synthesis and accumulation of an abnormal protein, the exfoliation (or pseudoexfoliation) material (XFM). In XFS, elastin production and metabolism are disturbed, thus XFS is a systemic elastosis [3, 4]. Clinically, the signs of XFS are best detectable with slit lamp examination in the anterior segment of the eye after pupillary dilation. XFM appears on the anterior lens capsule in a typical distribution ("classic" XFS): a homogeneous central XFM area ("central disc") in the pupillary area surrounded by a transition zone containing some XFM. The transition zone reflects the brushing effect of pupil movements on the XFM. Outside the transition zone a peripheral zone of XFM deposition is seen (Figure 1).

Detection of XFM is difficult without pupil dilation, particularly because in the early stages of XFS the amount of XFM is small and its distribution less obvious. Clinically XFS is frequently unilateral: at the slit lamp it is detectable only in one eye. However, XFS is always a systemic disease: even in apparently unilateral cases, XFM is ultrastructurally detectable in both eyes and in several extraocular tissues and organs [3, 4, 8]. In approximately 38% of unilateral presentations, XFS becomes clinically detectable in the seemingly uninvolved fellow eye in a decade [9]. Clinically XFS (and XFG) typically appears after 60 years of age.



Figure 1. Distribution of exfoliation material on the lens surface. A, central disc; B, transition zone; C, peripheral zone.

XFM is also frequently detectable on the pupil margin [10, 11], the corneal endothelium [12], the zonules and the anterior chamber angle where pigment granules liberated from the iris tissue due to XFS are typically accumulated and distributed along undulating lines on and anterior to the Schwalbe's line (Sampaolesi' line) [3, 4, 11]. The loss of melanin granules results in the typical "moth-eaten" appearance of the pupillary margin in XFS. The zonules holding the crystalline lens are also frequently damaged in XFS due to elastosis [3, 4, 8, 11]. As a consequence, dislocation of the crystalline lens or a previously implanted artificial intraocular lens (in-the-bag IOL dislocation) is not uncommon in eyes with XFS. When the crystalline lens is dislocated towards the anterior chamber, pupillary block and secondary angle closure glaucoma can develop [13]. Development of nuclear cataract is also typical in XFS [14]. In addition, the disturbance of elastin metabolism diminishes the resistance of the lamina cribrosa [15, 16]; leads to decreased blood-aqueous barrier function in the iris, which results in localized vascular occlusions in the anterior iris layer [17]; and increases the postoperative inflammatory reaction after extracapsular cataract surgery [14]. However, the most significant complication of XFS is the development of intraocular pressure (IOP) elevation and XFG, the most common secondary open-angle glaucoma worldwide [8, 18, 19].

EXFOLIATIVE GLAUCOMA

XFG develops from XFS, but most XFS eyes do not eventually convert to XFG. Initially, IOP increases and exhibits high diurnal fluctuation [20]. Later, mild structural alterations (e.g., retinal nerve fiber layer thinning) become detectable with imaging devices [20-22]. Ultimately, the increased oxidative stress in the anterior chamber and pigment liberation from the iris lead to further, typically very significant IOP elevation, which (in part due to the elastosis-related weakening of the lamina cribrosa) results in severe glaucomatous neuroretinal rim damage, increased optic disc cupping, severe retinal nerve fiber layer loss and severe visual field deterioration, in many cases already prior to the first ophthalmology visit [18, 19, 23]. Since the presence of XFG is frequently unilateral or the severity of glaucomatous damage is remarkably asymmetrical, most patients do not realize unilateral visual field deterioration until it becomes very severe, or until the fellow eye suffers from central visual field deterioration [13, 23]. The progression rate of XFG is almost 3 times faster than that of high-pressure primary open-angle glaucoma, and 4 times higher than that of normal pressure glaucoma [24, 25].

ROLE OF GENETIC ALTERATIONS, ENVIRONMENTAL FACTORS AND OXIDATIVE STRESS IN THE DEVELOPMENT OF EXFOLIATION SYNDROME AND EXFOLIATIVE GLAUCOMA

XFS is a genetically determined condition. It has recently been shown that 2 common single nucleotide polymorphisms (SNPs) of the lysyl oxidase-like protein 1 (LOXL1) gene are responsible for almost 100% of the population-related risk of XFS [26, 27]. In most white populations the risk alleles are G153D and R141L [26, 27]. The LOXL1 protein is responsible for elastin production and turnover in the whole body, thus its disturbed

translation and dysfunction explain several characteristics of intraocular and systemic alterations in XFS [16, 28]. It is important to note, however, that there are different risk alleles in various populations and these are also common in healthy individuals in whom XFS never develops [26]. Thus, currently unknown environmental factors are also believed to take part in the development of XFS. Very recently a novel association between XFS and calcium signaling has been established: one SNP of the calcium voltage-gated channel subunit alpha1A gene (CACNA 1A) confers 1.16 times increased risk for XFS [29]. The exact mechanism of LOXL1 and CACNA1A polymorphisms causing XFS remains to be determined.

It is important to recognize that conversion from XFS to XFG is not genetically determined, thus any genetic screening for XFG is impossible. The conversion from XFS to XFG is considered a result of environmental factors [26, 30-32]. The common mechanism of all environmental factors seems to be increased oxidative stress in the anterior chamber [28, 30, 33]. According to the current hypothesis, increased sunshine exposure provokes production of oxidative stress markers (e.g., 8-ioprostaglandin F2α, endothelin 1) and depletion of antioxidant protection molecules (e.g., ascorbic acid) in the anterior chamber [33]. The oxidative stress, which is greater in XFG than in XFS, is supposed to cause nuclear cataract, dysfunction of the trabecular meshwork and zonular damage. The trabecular meshwork dysfunction is considered responsible for the IOP elevation and the large IOP fluctuation typical in XFG, and the zonular damage for phacodonesis, lens dislocation, or secondary angle closure glaucoma (when the luxated lens causes pupillary block or directly blocks the anterior chamber angle) [4]. Recently, based on population-based retrospective studies, it has been suggested that the amount of time spent outdoor in bright sunshine without sunglasses in young age (a proxy for ultraviolet light-induced oxidative stress in the anterior segment of the eye), high coffee consumption and decreased folate intake may be risk factors for the development of XFS and XFG in later life [30-32, 34, 35]. These hypotheses, however, require confirmation and further research. Figure 2 summarizes the proposed key mechanisms of the development of XFS and XFG.

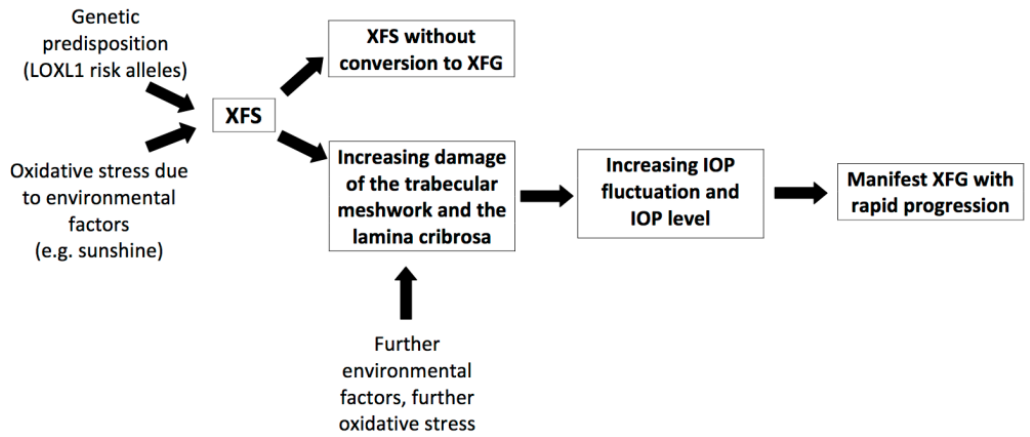

Figure 2. Key mechanisms involved in the pathophysiology of XFS and XFG.

GLOBAL HEALTH SIGNIFICANCE

It has been estimated that roughly 60 to 70 million people in the world have XFS. Approximately 25% of them have high IOP, and one third of them (i.e., 5-6 million people) have XFG in at least one eye [3, 7, 8]. The global impact of XFG becomes even more obvious considering the fact that approximately half of the patients with glaucoma remain undiagnosed [7, 8, 36]. This fact can have a profound effect on individual patients and healthcare resources alike, because XFG is often difficult to control and has a poor long-term prognosis. Irrespective of the risk for glaucoma, the global impact of exfoliation should also be seen in the light of increased risk for cataract formation and increased risk for complications during or after cataract surgery [14, 37].

Numerous reports in the last several years have contributed to the rejection of the notion that XFS and XFG are entities peculiar to Scandinavia. In fact, these conditions have been identified in diverse populations worldwide and XFG may account for 20-25% of open-angle glaucoma cases globally [3, 7, 8]. In particular, over half of open-angle glaucoma cases may be due to XFG in countries such as Norway, Iceland, Greece, Turkey and Saudi Arabia [7, 8].

The prevalence of XFS in the United States is generally comparable to that in Western Europe but significant racial variations exist, since the condition is much more prevalent in whites than persons of African origin, and Spanish-American men are almost six times more likely to have XFS compared to non-Spanish-Americans [36, 39].

It is puzzling that local variations in prevalence of exfoliation can be remarkable. In Nepal, for example, XFS was detected in 12% of the members of the Gurung ethnic group, but only in 0.24% of age-matched non-Gurungs [39]. Similarly, in the Middle Norway survey XFS prevalence values of 10.2%, 19.9% and 21% were observed in three population cohorts from different municipalities who were examined simultaneously using the same criteria, even though the municipalities were lying only about 100 kilometers apart [40]. Obviously, the interplay of genetic and environmental factors (epigenetics) is a major determinant of exfoliation prevalence. Well-designed population-based studies rather that frequency reports or studies with convenience samples are needed in order to explore possible etiological associations.

CLINICAL CHARACTERISTICS OF XFG

Patients with XFG are typically older than patients with primary open-angle glaucoma (POAG) [13, 19]. In fact, XFG is very uncommon before the age of 50. Because XFG has a fast rate of progression, serious visual deterioration or even terminal damage is often seen in some patients at diagnosis, occasionally with remarkable inter-eye asymmetry [13, 23]. Since IOP is typically very high in eyes with XFG, subjective symptoms reported by patients may include dull ocular or retrobulbar ache, clouding of vision due to corneal edema, or sudden severe visual deterioration due to branch- or central retinal vain occlusion [41, 42]. However, most XFG patients do not experience symptoms. IOP characteristics in XFG deserve particular mention: these eyes usually have higher mean, higher peak and larger 24-hour and intervisit IOP fluctuation compared to eyes with POAG [43-45]. Furthermore, IOP peaks in eyes with XFG often occur outside office hours and can therefore remain unnoticed in typical

clinical settings [45, 46]. As a consequence, single daytime IOP measurements every few months may be inadequate as a means of evaluating a patient's overall IOP characteristics or the response to therapy. In addition to the worse IOP characteristics in eyes with XFG, the purported elastosis-induced biomechanical alterations of the lamina cribrosa that may render the optic nerve more vulnerable to effects of IOP elevation are thought to underlie the poorer long-term prognosis compared to POAG [15, 16, 23, 25]. It should be noted that gradual or sudden IOP elevation in treated and seemingly well-controlled eyes with XFG may occur. Thus, close follow-up over the long term is necessary even in apparently well-controlled XFG patients [3, 19]. A notable difference between XFG and POAG is that the former is not associated with a higher risk of IOP elevation following steroid treatment [47].

Medical Treatment

Because XFG is a high-pressure glaucoma with unpredictable characteristics (e.g., high spikes outside office hours), achieving a sufficiently low IOP throughout the 24-hour cycle is frequently difficult [23, 44, 45]. Medical therapy should ideally be tailored to the particular needs of eye with XFG [48, 49]. Prostaglandin analogues are common first choices in open-angle glaucoma due to their efficacy, convenient once-daily administration and favorable safety profile[50-52]. A 3-month, multicenter, single masked, prospective, parallel group study with XFG patients compared the diurnal efficacy of evening-dosed latanoprost 0.005% versus timolol 0.5% administered twice daily [53]. The authors found that latanoprost provided marginally superior diurnal IOP reduction and smaller IOP fluctuation compared to timolol. Although the efficacy difference between latanoprost (reduction from untreated baseline 24.9 mmHg to 17.4 mmHg) and timolol (reduction from untreated baseline 24.7 mmHg to 18.3 mmHg) for the diurnal IOP did not reach statistical significance ($P = 0.07$), the IOP reduction at the 8 a.m. time-point was significantly greater with latanoprost (-8.5 mmHg vs. -6.0 mmHg).

The investigators of a 6-month, single masked, prospective, parallel group study with IOP measurements at 8 a.m., 10 a.m. and 4 p.m. compared the IOP lowering efficacy of evening-dosed latanoprost 0.005% and travoprost 0.004% and the dorzolamide 2%/timolol 0.5% fixed combination dosed twice daily, in patients with XFG [54]. The mean untreated daytime IOP in all groups varied between 23.8 mmHg and 25.7 mmHg and the mean IOP reduction was 8.2 mmHg for latanoprost, 9.3 mmHg for travoprost and 11.5 mmHg for the dorzolamide/timolol fixed combination. This result, however, may not be representative for the true 24-hour IOP lowering efficacy of these medications in XFG since 2 of the 3 time points coincided with the post-instillation peak efficacy period of the dorzolamide/timolol fixed combination, thus overestimation of IOP lowering effect of the fixed combination was possible.

In a 24-hour, investigator-masked, crossover trial made on XFG patients, latanoprost 0.005% and travoprost 0.004% lowered the mean untreated 24-hour IOP (25.1 mmHg) by 7.3 mmHg (30.8%) and 7.8 mmHg (31.1%), respectively [55]. The efficacy difference between the two treatments was statistically significant mostly due to the IOP difference at the 6 p.m. time point (17.9 mmHg on latanoprost *vs*16.7 mmHg on travoprost, $p < 0.01$).

In a 3-month, prospective, multicenter, investigator-masked, crossover trial comprising 129 XFG patients, the efficacy of latanoprost 0.005% and bimatoprost 0.03% was compared

[56]. The mean untreated diurnal IOP was 26.9 mmHg. Bimatoprost provided statistically and clinically significantly lower mean diurnal and individual time point IOP than latanoprost. The mean diurnal IOP values were 18.6 mmHg for latanoprost and 17.6 mmHg for bimatoprost. Only 34 patients (26.4%) on latanoprost versus 55 patients (42.6%) on bimatoprost achieved mean diurnal IOP < 17 mmHg. This difference is clinically relevant because a mean diurnal IOP < 17 mmHg has been shown to lower the risk of progression in XFG [25].

A 2-month, crossover, prospective, investigator-masked study conducted on treatment-naive XFG patients assessed the efficacy of latanoprost 0.005% dosed in the evening and dorzolamide/timolol fixed combination dosed twice daily[57]. The mean untreated IOP (measured at 10 a.m.) was 31.2 mmHg, which decreased by 40.2% to 18.9 mmHg with latanoprost and by 42.8% to 18.1 mmHg with the fixed combination (P = 0.21). The results indicate that the 2-hour post-instillation peak efficacy of the dorzolamide/timolol fixed combination and the 14-hour post-instillation efficacy of latanoprost monotherapy are comparable in XFG.

The efficacy of fixed combinations of a prostaglandin analogue (latanoprost 0.005%, travoprost 0.004%, bimatoprost 0.03% or tafluprost 0.0015%) and timolol 0.5% has also been investigated in XFG [58-61]. In general, the use of fixed combinations offers a number of advantages: convenient once daily dosing, decreased ocular tissue exposure to preservatives, reduced systemic absorption of timolol compared to twice daily administration, and increased efficacy compared to that of the individual constituents[52, 62, 63]. The investigators of a 3-month, 24-hour crossover study found that in XFG patients the evening dosed travoprost/ timolol fixed combination reduced the mean 24-hour IOP from 28.5 mmHg (untreated baseline) by 34.4% (9.8 mmHg), while the evening-dosed latanoprost/timolol fixed combination by 31.2% (8.9 mmHg) [58]. This difference was statistically significant (P < 0.001) [58]. In another crossover study, the mean 24-hour baseline IOP in a mixed population of POAG and XFG patients was 27.7 mmHg [59]. After 2 months of therapy, the mean 24-hour IOP was 19.2 ± 3.5 mmHg when the travoprost/timolol fixed combination was dosed in the morning, and 18.4 ± 3.3 mmHg when dosed in the evening (P = 0.001) [59]. In a 3-month, multicenter, prospective, single-masked, 24-hour crossover study conducted on XFG patients [60] the bimatoprost/timolol fixed combination was administered in the morning in one study phase, and in the evening in the other phase. The mean 24-hour IOP reduction from the mean untreated 24-hour value (29.03 mmHg) was 33.9% (9.84 mmHg) with morning dosing and 35.3% (10.2 mmHg) with evening dosing. This difference was statistically significant (P = 0.005). These results suggest that in XFG topical prostaglandin analog/timolol therapy is more effective when the drop is administered in the evening. Recently, the IOP lowering efficacy of morning-dosed preservative-free tafluprost/timolol fixed combination was evaluated in XFG patients who participated in a 6-month, randomized, double-masked, active controlled, parallel group, multicenter phase III study [61]. The mean untreated baseline IOP varied between 26.5 mmHg (4 p.m.) and 28.1 mmHg (8 a.m.). The mean time-wise IOP reduction ranged between 8.62 and 10.25 mmHg (31.8 to 36.7%), and the overall IOP reduction was 34.1%. The results discussed in this paragraph suggest that an IOP reduction of 31 to 36% from untreated baseline can be expected with once daily administration of all prostaglandin analogue/timolol fixed combinations. Currently there are no controlled data on the efficacy of combination therapy with 3 or more IOP lowering medications in XFG (e.g., a prostaglandin analogue and a topical carbonic anhydrase inhibitor/timolol fixed combination

or a prostaglandin analogue/timolol fixed combination and a topical carbonic anhydrase inhibitor).

Laser Treatment

Argon laser trabeculoplasty (ALT) exerts its IOP lowering effect by enhancing aqueous humor egress through the trabecular meshwork. It was initially hypothesized that the mode of action is mechanical distention of the collapsed trabecular meshwork [64, 65]. However, laser-induced enhancement of extracellular matrix turnover due to stimulation of trabecular cells has also been proposed [65]. Since energy absorption by melanin in the trabecular meshwork is necessary for ALT to be effective, patients with XFG are usually good candidates for this treatment because their eyes typically have debris laden, heavily pigmented anterior chamber angles.

ALT commonly provides significant IOP reduction in XFG eyes with high untreated IOP, at least in the first post-laser months or years [66-70]. Unfortunately, the hypotensive effect diminishes over time, conceivably due to the continuous accumulation of pigment granules and exfoliation material on the trabecular meshwork. A retrospective study evaluated the efficacy of ALT on 28 POAG and 26 XFG patients poorly controlled on medical treatment [70]. Failure was defined as IOP > 22 mmHg after 4 to 6 months following ALT, or need for filtering surgery. The authors found that despite an initially better response to ALT, patients with XFG eventually failed faster than patients with POAG. For instance, the cumulative probability of success after approximately 8 months was 59% and 77% for the XFG and POAG groups, respectively.

Another retrospective study compared the efficacy of ALT on 29 XFG eyes (mean follow-up time 23 months) and 66 POAG eyes (mean follow-up time 27 months) [67]. XFG patients had a greater percentage of IOP reduction in the first post-laser year compared to POAG patients. The IOP reduction in the XFG group varied between 28% and 38% (mean pre-laser IOP 25.8 mmHg), whereas in the POAG group it varied between 19% and 27% (mean pre-laser IOP 23.2 mmHg). The 1-year rate of failure (need for glaucoma filtering surgery; or an additional laser treatment; or IOP ≥ 22 mmHg; or IOP elevations up to 15% of the baseline IOP value in at least 2 visits) was 40% for POAG and 18% for XFG, while the 3-year failure rate for the groups was 58% and 47%, respectively (P = 0.89). The effect of ALT diminished over time and by three years both groups had comparable measures of success.

ALT was eventually proposed as primary treatment in patients with POAG [71]. A retrospective study also investigated the efficacy of ALT as primary therapy on 75 XFG and 93 POAG patients [66]. Using customized clinical criteria based on each patient's need for additional IOP lowering therapy, the probability of success (defined as no need for additional treatment) in the XFG group was 80% after 2 years, 54% after 5 years, and 36% after 8 years. The existing evidence suggests that in eyes with XFG and pre-laser IOP between 23 and 30 mmHg, clinicians can expect an approximately 20-40% pressure reduction from ALT during the first 4 post-laser years [66-68, 70].

Selective laser trabeculoplasty (SLT) employs a frequency-doubled Q-switched Nd-YAG laser to deliver low energy in brief pulses with a large spot diameter (400 μm) to the surface of the trabecular meshwork [72]. The precise mechanism by which SLT enhances aqueous humor outflow remains unknown. SLT is considered to selectively target the pigmented

trabecular meshwork cells without causing obvious coagulative or disruptive changes. Therefore the technique can be repeated in eyes previously treated with ALT or SLT [72, 73].

In eyes with POAG, the efficacy of SLT has been found similar to that of ALT [73]. However, there is limited information on the comparative efficacy of SLT and ALT in XFG. A 6-month randomized trial evaluated the efficacy of SLT versus ALT on 76 inadequately controlled XFG eyes and XFS eyes with ocular hypertension [74]. SLT and ALT resulted in similar IOP reductions (6.8 mmHg and 7.7 mmHg, respectively, P = 0.56) from the corresponding pre-laser baseline values (SLT: 23.1 mmHg, ALT: 25.2 mmHg, P = 0.03). Moreover, an identical proportion of patients (73%) achieved at least 20% IOP reduction with either treatment at the 6-month post-laser visit. Other reports suggest that XFG and POAG eyes respond to SLT similarly both when the procedures are used as primary [75] or adjunctive [76, 77] interventions.

It is important to note that ALT and SLT are seldom adequate treatments for patients with high-pressure XFG, especially when considering that a low target IOP (<17 mmHg) is needed to prevent progression on the long term [25]. Nonetheless, these techniques can be considered in elderly XFG patients with suboptimal compliance, in XFG patients intolerant to medical therapy and in XFG patients who are poor candidates for filtration surgery.

Surgical Treatment

Glaucoma surgery is mainly reserved for eyes insufficiently controlled with medical and/or laser treatment; cases in which progression develops on maximal tolerated medical and laser treatment; and in patients intolerant or non-compliant to medical therapy. For several years trabeculectomy (typically with adjuvant 5-fluorouracil or mitomycin C) has been considered the gold standard surgical procedure in XFG [78, 79]. Evidence suggests that the long-term survival of trabeculectomy in XFG may be longer than that in POAG [78, 80, 81], and glaucomatous progression after filtering surgery may be slower in XFG patients compared to POAG patients [19, 81].

Although non-penetrating techniques rarely achieve sufficiently low IOP to defer progression in patients with an aggressive glaucoma like XFG, they may still be an attractive alternative in few selected patients due to their favorable safety profile [82, 83]. In a randomized trial that comprised both POAG and XFG patients intraoperative use of mitomycin C increased the effectiveness of deep sclerectomy [84]. Thirty-six months postoperatively the mean IOP in eyes operated with and without adjunctive mitomycin C was 15.96 ± 1.71 mmHg and 18.71 ± 2.90 mmHg, respectively (P = 0.001). In a retrospective study that contained data on XFG eyes, the efficacy of the newly developed technique of CO_2 laser-assisted deep sclerectomy was found comparable to that of conventional deep sclerectomy [85]. The complete success rates (IOP < 18 mmHg without medication) were 73% in the CO_2 laser-assisted group and 71% in the control group, respectively, whereas the total success rate (IOP < 18 mmHg with/without medication) was 96% in the CO_2 laser-assisted group and 89% in the control group. A prospective study conducted on 24 XFG and 25 POAG patients investigated the efficacy of deep sclerectomy combined with various space-maintaining implants [86]. With a mean follow-up period of 19.9 months for the XFG group and 16.2 months for the POAG group, the proportion of eyes with complete success

(IOP < 19 mmHg without medication) was 60.7% in the XFG group and 37.9% in the POAG group.

The available evidence on the efficacy of viscocanalostomy in eyes with XFG is limited. In a prospective, non-randomized case series comprising 57 glaucomatous eyes (14 of them had XFG) an IOP < 21 mmHg without medication was observed in 60% of eyes after 60 months following viscocanalostomy [87]. Recently the efficacy of concurrent phacoemulsification and viscocanalostomy in 30 eyes of 22 patients with cataract and poorly controlled XFG was investigated [88]. The mean preoperative IOP was 25.3 mmHg. After a mean follow-up period of 18.6 months, success (IOP < 21 mmHg with/without medication) was achieved in all eyes and complete success (IOP < 21 mmHg without medication) was achieved in 90% of the eyes. In a subsequent prospective trial the efficacy of phacoemulsification combined with viscocanalostomy was evaluated in cataract patients with medically uncontrolled XFG or POAG [89]. The mean preoperative IOP was 24.5 mmHg for the XFG group (n = 30) and 21.7 mmHg for the POAG group (n = 30). The mean follow-up period was 19.7 months for both groups. At the last postoperative visit the XFG patients had significantly lower IOP than the POAG patients (49.7% vs. 30.9% IOP reduction, respectively).

The recently developed technique of ab-interno trabeculotomy with the Trabectome™ (Neomedix Inc., Tustin, CA, US) has been approved for the treatment of open angle glaucoma. A 12 months, prospective, non-randomized study evaluated the outcomes of Trabectome™ surgery alone and in combination with cataract surgery and intraocular lens implantation in XFG and POAG eyes [90]. For the "Trabectome™ surgery only" analysis the preoperative IOP was 29.0 mmHg and 25.5 mmHg for the XFG (n = 67) and the POAG group (n = 450; P < 0.01), and the IOP decreased by 12.3 ± 8.0 mmHg and 7.5 ± 7.4 mmHg in the XFG and POAG group, respectively (P < 0.01). The cumulative probability of success for the XFG and POAG groups was 79.1% and 62.9%, respectively (P = 0.004). In the "combined Trabectome™ plus cataract surgery" analysis the mean preoperative IOP was 21.7 mmHg and 19.9 mmHg for the XFG (n = 45) and the POAG (n = 263) group (P = 0.06), and the IOP decreased by 7.2 mmHg and 4.1 mmHg in the XFG and POAG groups, respectively (P < 0.01). The cumulative probability of success for the XFG and POAG group was 86.7% and 91.0%, respectively (P = 0.73). The results suggest that ab-interno trabeculotomy offers superior IOP control in XFG compared to POAG.

Trabecular aspiration is a technique specifically developed for the treatment of XFG based on the notion that surgical removal of the exfoliation material and pigment granules deposited on the intra-trabecular spaces should enhance aqueous humor outflow [91]. In a prospective trial with 22 eyes of 19 patients with uncontrolled XFG the mean preoperative IOP on medication (31.3 mmHg) was significantly lowered to 16.8 mmHg 18 months after trabecular aspiration [91]. Following the procedure, 45% of the patients required no IOP lowering medication. In the same study, the authors evaluated the efficacy of trabecular aspiration combined with phacoemulsification or extracapsular cataract surgery in 42 eyes of 36 patients with uncontrolled XFG and cataract. For these eyes the mean preoperative IOP on medication (32.4 mmHg) significantly decreased to 18.7 mmHg 2 years after the combined procedure [91]. In this subgroup, 54% of the participants did not need medication at the end of the 2-year follow-up period. In another prospective, controlled study the same authors compared the efficacy of phacoemulsification, combined phacoemulsification and trabecular aspiration, and combined phacoemulsification and trabeculectomy on 74 non-operated eyes

with XFG and cataract [92]. Failure was defined as the necessity for additional surgical or laser interventions (except for laser suture lysis), or the need for more than one medication to reach an individualized target pressure. After a 2-year follow-up period the proportions of successfully treated patients in the phacoemulsification alone group, the combined phacoemulsification and trabecular aspiration group, and the combined phacoemulsification and trabeculectomy group were 36%, 64% and 78%, respectively. The proportions of medication-free well-controlled patients 2 years after the above procedures were 9%, 38% and 65%, respectively.

Cataract surgery is frequently necessary in XFG due to nuclear cataract induced by increased oxidative stress in the anterior chamber [28, 30, 33]. In addition, cataract surgery offers a clinically significant IOP decrease in XFG and XFS eyes with elevated IOP [93-96]. It has been suggested that the IOP-lowering effect of cataract extraction in eyes with XFG and XFS is due to a combination of the following mechanisms: widening of the anterior chamber angle, removal of a large portion of the exfoliation-producing anterior capsule, decrease of irido-lenticular friction (which limits the release of pigment and exfoliation material postoperatively), aspiration of deposited debris from the trabecular meshwork during surgery, and enhancement of the trabecular outflow as a consequence of low-grade inflammation (the hypothesized mechanism being similar to that seen after argon laser trabeculoplasty [14, 93]). In a 2-year, multicenter, prospective cohort study the IOP-lowering effect of phacoemulsification was assessed in 71 cataract patients with exfoliation (29 patients had XFG) and 112 without exfoliation [93]. Eyes with XFS and XFG had a significantly larger IOP reduction than POAG patients and non-glaucomatous controls. Remarkably, the investigators found that the ocular hypotensive effect of cataract surgery in the exfoliation group was associated with the volume of the irrigating fluid. This suggests that the IOP-lowering effect of cataract surgery can be attributed to the intraoperative removal of debris. The results of this prospective study fit well to earlier data from retrospective case series [94, 95]. In another retrospective study conducted on 1122 XFS and XFG eyes followed for 7 years, the postoperative IOP reduction was proportional to the preoperative IOP [96]. A recent retrospective study found that the proportion of XFS patients who converted to XFG after phacoemulsification within the more than 6-year long follow-up period was lower than expected, and the mean IOP of eyes with exfoliation at the end of the follow-up period was 2.6 mmHg lower that the mean preoperative value [97].

However, cataract surgery in XFS and XFG is associated with several disease-specific surgical challenges [14, 19, 98]. These include Zinn'szonule laxity and/or fragility, phacodonesis, lens subluxation or luxation, inadequate mydriasis, hard nucleus, fragile capsule and increased risk of vitreous loss. In the postoperative period common complications include corneal edema due to exfoliation-related endotheliopathy, transient IOP elevation, postoperative fibrinous inflammatory reaction (mostly after extracapsular cataract extraction), anterior capsule phimosis and delayed in-the-bag intraocular lens subluxation or luxation.

VASCULAR ALTERATIONS IN XFS

An association between XFS and systemic vascular dysfunction or even vascular disease (capillary, medium and large artery dysregulation, increased plasma homocysteine level,

increased arterial stiffness and reduced distensibility, abnormal baroreflex sensitivity and heart rate regulation, increased risk for venous occlusions and aortic aneurisms) has been shown in several, but not all, populations [51, 99, 100, 101]. The relationship between systemic vascular disease and XFS is independent from the presence of XFG. In XFS, retinal vein occlusion is a part of the systemic vascular abnormalities. Since management of the vascular diseases associated with XFS exceeds the scope of the ophthalmologist, consultation with the patient's cardiologist, internist or general practitioner, who cannot detect XFS, is necessary. The ophthalmologist needs to indicate that the patient has XFS, and that XFS may represent a special risk for systemic venous occlusions and vascular diseases, thus special attention and care may be necessary after the first signs of systemic vascular disease are detected.

UNMET NEEDS IN THE TREATMENT OF EXFOLIATIVE GLAUCOMA

Similarly to primary open-angle glaucoma, the current treatment of XFG entails IOP reduction. Though therapeutic measures to decrease IOP are essential for the successful long-term management of XFG, disease progression remains common even when both the treated long-term mean IOP is low and the between-visit IOP fluctuation is small [25]. As discussed earlier in this chapter, increased oxidative stress plays a key role in the IOP elevation in XFG [33]. Therefore decrease of oxidative stress in the anterior chamber of the eye would be a potential disease-specific treatment in XFG. Unfortunately, currently no such treatment or prevention option exists except for use of sunglasses during outdoor activity.

CONCLUSION

Since XFS is a common condition, and XFG is an especially severe, rapidly progressing and common secondary open-angle glaucoma, better understanding of the pathophysiological processes in XFS and XFG and establishing a disease-specific targeted therapy of XFG would be of great clinical importance. Currently XFS is not considered a disease to treat, but rather a genetically determined condition to observe for conversion to XFG. In contrast, XFG requires effective IOP lowering treatment which needs to be introduced early in the course of the disease to prevent progression. In XFG, IOP reduction is satisfactory when the diurnal IOP curve shows no high peaks but low mean value (IOP < 17 mmHg) and low fluctuation, the visual field does not progress or the rate of progression is small, and the patient is adherent to the successful treatment. Even in such cases regular ophthalmological examinations are unavoidable, and ophthalmologists need to know that due to the continuous synthesis of XFM and the gradual buildup of pigment in the trabecular outflow system there is always a risk of sudden loss of IOP control, and a need to introduce a more complex IOP lowering medication, laser therapy or surgery. Since XFG is a disease of the elderly it is important to simplify therapy using fixed dose combination eye drops and minimal number of daily instillations, thus supporting adherence. Consulting with a glaucoma subspecialist is also important when optimal IOP control is not achievable in XFG because unnecessary delay prior to surgery results in unavoidable disease progression.

REFERENCES

[1] Bourne RR, Jonas JB, Flaxman SR, Keeffe J, Leasher J, Naidoo K, Parodi MB, Pesudovs K, Price H, White RA, Wong TY, Resnikoff S, Taylor HR; Vision Loss Expert Group of the Global Burden of Disease Study. Prevalence and causes of vision loss in high-income countries and in Eastern and Central Europe: 1990-2010. *Br. J. Ophthalmol*. 2014; 98:629-38.

[2] Tham YC, Li X, Wong TY, Quigley HA, Aung T, Cheng CY. Global prevalence of glaucoma and projections of glaucoma burden through 2040: a systematic review and meta-analysis. *Ophthalmology*. 2014;121: 2081-90.

[3] Ritch R. Exfoliation syndrome: the most common identifiable cause of open-angle glaucoma. *J. Glaucoma*. 1994;3:176-178.

[4] Ritch R, Schlötzer-Schrehardt U. Exfoliation syndrome. *Surv. Ophthalmol*. 2001;45:265-315.

[5] Peters D, Bengtsson B, Heijl A. Lifetime risk of blindness in open-angle glaucoma. *Am. J. Ophthalmol*. 2013;156:724-30.

[6] Ernest PJ, Busch MJ, Webers CA, Beckers HJ, Hendrikse F, Prins MH, Schouten JS. Prevalence of end-of-life visual impairment in patients followed for glaucoma. *Acta Ophthalmol*. (Scand.) 2013; 91: 738-43.

[7] Ringvold A. Epidemiology of exfoliation syndrome and exfoliative glaucoma. In: Holló G, Konstas AGP, editors. *Exfoliation syndrome and exfoliative glaucoma* (3rd edition). Savona: PubliComm; 2015; 25-31.

[8] Ritch R, Schlötzer-Schrehardt U, Allingham RR. Exfoliation syndrome and exfoliative glaucoma. In: Shaarawy TM, Sherwood MB, Hitchings RA, Crowston JG, editors. *Glaucoma*. 2nd edition. Elsevier Saunders; 2015; 357-65.

[9] Puska PM. Unilateral exfoliation syndrome: conversion to bilateral exfoliation and to glaucoma. A prospective 10-year follow-up study. *J. Glaucoma*. 2002;11:517-24.

[10] Schlötzer-Schrehardt U, Naumann GOH. Morphology of exfoliation syndrome. In: Holló G, Konstas AGP, editors. *Exfoliation syndrome and exfoliative glaucoma* (3rd edition). Savona: PubliComm; 2015; 33-42.

[11] Thygesen J. Title: Ocular clinical findings in exfoliation syndrome. In: Holló G, Konstas AGP editors. *Exfoliation syndrome and exfoliative glaucoma* (3rd edition). Savona: PubliComm; 2015; 139-48.

[12] Naumann GOH, Schlötzer-Schrehardt U. Title: Exfoliation keratopathy: corneal endothelial decompensation in exfoliation syndrome (3rd edition). In: Holló G, Konstas AGP, editors. *Exfoliation syndrome and exfoliative glaucoma*. Savona: PubliComm; 2015; 107-12.

[13] Irkec M. Clinical features of exfoliative glaucoma. In: Holló G, Konstas AGP, editors. *Exfoliation syndrome and exfoliative glaucoma* (3rd edition). Savona: PubliComm; 2015; 151-58.

[14] Teus MA, de Benito-Llopis L. Update on cataract surgery in exfoliation syndrome. In: Holló G, Konstas AGP, editors. *Exfoliation syndrome and exfoliative glaucoma* (3rd edition). Savona: PubliComm; 2015; 161-8.

[15] Moghimi S, Mazloumi M, Johari M, Abdi P, Fakhraie G, Mohammadi M, Zarei R, Eslami Y, Fard MA, Lin SC. Evaluation of Lamina Cribrosa and Choroid in

Nonglaucomatous Patients With Pseudoexfoliation Syndrome Using Spectral-Domain Optical Coherence Tomography. *Invest. Ophthalmol. Vis. Sci*. 2016;57:1293-300.

[16] Kim S, Sun KR, Lee JR, Lee KS. Evaluation of lamina cribrosa in pseudoexfoliation syndrome using spectral-domain optical coherence tomography enhanced depth imaging. *Ophthalmology* 2013;120:1798-803.

[17] Konstas AG, Marshall GE, Cameron SA, Lee WR. Morphology of iris vasculopathy in exfoliation glaucoma. *Acta Ophthalmol*. (Copenh.) 1993; 71: 751-9.

[18] Ritch R. From exfoliation syndrome to exfoliative glaucoma. In: Holló G, Konstas AGP, editors. *Exfoliation syndrome and exfoliative glaucoma* (3rd edition). Savona: PubliComm; 2015; 17-23.

[19] Holló G, Katsanos A, Konstas AG. Management of exfoliative glaucoma: challenges and solutions. *Clin. Ophthalmol*. 2015; 9: 907-19.

[20] Gumus K, Bozkurt B, Sonmez B, Irkec M, Orhan M, Saracbasi O. Diurnal variation of intraocular pressure and its correlation with retinal nerve fiber analysis in Turkish patients with exfoliation syndrome. *Graefes. Arch. Clin. Exp. Ophthalmol*. 2006; 244: 170-6.

[21] Dimopoulos AT, Katsanos A, Mikropoulos DG, Giannopoulos T, Empeslidis T, Teus MA, Holló G, Konstas AG. Scanning laser polarimetry in eyes with exfoliation syndrome. *Eur. J. Ophthalmol*. 2013; 23: 743-50.

[22] Kozobolis VP, Glynatsis M, Labiris G, Katsanos A, Fanariotis M, Koukoula S, Alvanos S, Toufexis G. Retinal nerve fiber layer thickness in patients with exfoliation, exfoliative glaucoma, and primary open angle glaucoma. *Eur. J. Ophthalmol*. 2010; 20: 142-8.

[23] Konstas AGP, Holló G, Astakhov YS, Teus MA, Akopov EL, Jenkins JN, Stewart WC. Presentation and long-term follow-up of exfoliation glaucoma in Greece, Spain, Russia, and Hungary. *Eur. J. Ophthalmol*. 2006; 16: 60-6.

[24] Heijl A, Bengtsson B, Hyman L, Leske MC, Early Manifest Glaucoma Trial Group. Natural history of open-angle glaucoma. *Ophthalmology* 2009; 116: 2271-6.

[25] Konstas AG, Holló G, Astakhov YS, Teus MA, Akopov EL, Jenkins JN, Stewart WC. Factors associated with long-term progression or stability in exfoliation glaucoma. *Arch. Ophthalmol*. 2004; 122: 29-33.

[26] Schlötzer-Schrehardt U. Genetics in exfoliation syndrome and exfoliative glaucoma. In: Holló G, Konstas AGP, editors. *Exfoliation syndrome and exfoliative glaucoma* (3rd edition). Savona: PubliComm; 2015; 57-76.

[27] Thorleifsson G, Magnusson KP, Sulem P, Walters GB, Gudbjartsson DF, Stefansson H, Jonsson T, Jonasdottir A, Jonasdottir A, Stefansdottir G, Masson G, Hardarson GA, Petursson H, Arnarsson A, Motallebipour M, Wallerman O, Wadelius C, Gulcher JR, Thorsteinsdottir U, Kong A, Jonasson F, Stefansson K. Common sequence variants in the LOXL1 gene confer susceptibility to exfoliation glaucoma. *Science*. 2007 Sep. 7; 317(5843):1397-400.

[28] Zenkel M, Krysta A, Pasutto F, Juenemann A, Kruse FE, Schlötzer-Schrehardt U. Regulation of lysyloxydase like 1 (LOXL1) and elastin-related genes by pathogenic factors associated with pseudoexfoliation syndrome. *Invest. Ophthalmol. Vis. Sci*. 2011; 52: 8488-95.

[29] Aung T, Ozaki M, Mizoguchi T, Allingham RR, Li Z, Haripriya A, Nakano S et al. A common variant mapping to CACNA1A is associated with susceptibility to exfoliation syndrome. *Nat. Genet*. 2015; 47: 387-92.

[30] Pasquale LR. Environmental factors in relation to exfoliation syndrome and exfoliative glaucoma. In: Holló G, Konstas AGP, editors. *Exfoliation syndrome and exfoliative glaucoma* (3rd edition). Savona: PubliComm; 2015; 95-104.

[31] Stein JD, Pasquale LR, Talwar N, Kim DS, Reed DM, Nan B, Kang JH, Wiggs JL, Richards JE. Geographic and climatic factors associated with exfoliation syndrome. *Arch. Ophthalmol*. 2011; 129: 1053-60.

[32] Pasquale LR, Jiwani AZ, Zehavi-Dorin T, Majd A, Rhee DJ, Chen T, Turalba A, Shen L, Brauner S, Grosskreutz C, Gardiner M, Chen S, Borboli-Gerogiannis S, Greenstein SH, Chang K, Ritch R, Loomis S, Kang JH, Wiggs JL, Levkovitch-Verbin H. Solar exposure and residential geographic history in relation to exfoliation syndrome in the United States and Israel. *JAMA Ophthalmol*. 2014; 132: 1439-45.

[33] Koliakos GG, Konstas AGP, Holló G. Biochemistry and genetics of exfoliation syndrome. In: Holló G, Konstas AGP, editors. *Exfoliation syndrome and exfoliative glaucoma* (3rd edition). Savona: PubliComm; 2015; 45-54.

[34] Xu F, Zhang L, Li M. Plasma homocysteine, serum folic acid, serum vitamin B12, serum vitamin B6, MTHFR and risk of pseudoexfoliation glaucoma: a meta-analysis. *Graefes Arch. Clin. Exp. Ophthalmol*. 2012; 250: 1067-74.

[35] Pasquale LR, Wiggs JL, Willett WC, Kang JH. The relationship between caffeine and coffee consumption and exfoliation glaucoma or glaucoma suspect: a prospective study in two cohorts. *Invest. Ophthalmol. Vis.Sci*. 2012; 53: 6427-33.

[36] Nolan W, Yip JL. Prevalence and geographical variations. In: Shaarawy TM, Sherwood MB, Hitchings RA, Crowston JG, editors. *Glaucoma* (2nd edition). Elsevier Saunders; 2015; 1-19.

[37] Konstas AG, Dimitrakoulias N, Kourtzidou O, Filidis K, Bufidis T, Benos A. Frequency of exfoliation syndrome in Greek cataract patients. *Acta Ophthalmol. Scand*. 1996; 74: 478-82.

[38] Jones W, White RE, Magnus DE. Increased occurrence of exfoliation in the male, Spanish American population of New Mexico. *J. Am. Optom. Assoc*. 1992; 63: 643-8.

[39] Shakya S, Koirala S, Karmacharya PCD. Pseudoexfoliation syndrome in Nepal: a hospital-based retrospective study. *Asia-Pacific J. Ophthalmol*. 2004; 16: 13-6.

[40] Ringvold A, Blika S, Elsås T, Guldahl J, Brevik T, Hesstvedt P et al. The Middle-Norway eye-screening study. I. Epidemiology of the pseudo-exfoliation syndrome. *Acta Ophthalmol*. (Copenh.) 1988; 66: 652-8.

[41] Harju M. Ocular hemodynamics in exfoliation syndrome and exfoliative glaucoma. In: Holló G, Konstas AGP, editors. *Exfoliation syndrome and exfoliative glaucoma* (3rd edition). Savona: PubliComm; 2015; 115-9.

[42] Cursiefen C, Hammer T, Küchle M, Naumann GO, Schlötzer-Schrehardt U. Pseudoexfoliation syndrome in eyes with ischemic central retinal vein occlusion. A histopathologic and electron microscopic study. *Acta Ophthalmol*. (Scand.) 2001; 79: 476-8.

[43] Konstas AG, Tsatsos I, Kardasopoulos A, Bufidis T, Maskaleris G. Preoperative features of patients with exfoliation glaucoma and primary open-angle glaucoma. The AHEPA study. *Acta Ophthalmol*. (Scand.) 1998; 76: 208-12.

[44] Konstas AG, Stewart WC, Stroman GA, Sine CS. Clinical presentation and initial treatment patterns in patients with exfoliation glaucoma versus primary open-angle glaucoma. *Ophthalmic Surg. Lasers*. 1997; 28: 111-7.

[45] Konstas AG, Mantziris DA, Stewart WC. Diurnal intraocular pressure in untreated exfoliation and primary open-angle glaucoma. *Arch. Ophthalmol.* 1997; 115: 182-5.

[46] Quaranta L, Katsanos A, Russo A, Riva I. 24-hour intraocular pressure and ocular perfusion pressure in glaucoma. *Surv. Ophthalmol*. 2013; 58: 26-41.

[47] Schlötzer-Schrehardt U, Naumann GOH. Pseudoexfoliation glaucoma. In: Grehn F, Stamper R, editors. *Glaucoma*. Berlin: Springer; 2004; 157-76.

[48] Konstas AGP, Tsironi S, Kozobolis VP. Medical therapy of exfoliative glaucoma. In: Holló G, Konstas AGP, editors. *Exfoliation syndrome and exfoliative glaucoma* (3rd edition). Savona: PubliComm; 2015; 171-80.

[49] Konstas AG, Katsanos A, Quaranta L, Mikropoulos DG, Tranos PG, Teus MA. Twenty-four hour efficacy of glaucoma medications. *Prog. Brain Res.* 2015; 221: 297-318.

[50] Ebstein RP, Stessman J, Eliakim R, Menczel J. The effect of age on beta-adrenergic function in man: a review. *Isr. J. Med. Sci*. 1985; 21: 302-11.

[51] Nieminen T, Uusitalo H, Mäenpää J, Turjanmaa V, Rane A, Lundgren S, Ropo A, Rontu R, Lehtimäki T, Kähönen M. Polymorphisms of genes CYP2D6, ADRB1 and GNAS1 in pharmacokinetics and systemic effects of ophthalmic timolol. A pilot study. *Eur. J. Clin. Pharmacol*. 2005; 61:811-9.

[52] Quaranta L, Biagioli E, Riva I, Rulli E, Poli D, Katsanos A, Floriani I. Prostaglandin analogs and timolol-fixed versus unfixed combinations or monotherapy for open-angle glaucoma: a systematic review and meta-analysis. *J. Ocul. Pharmacol. Ther*. 2013; 29: 382-9.

[53] Konstas AG, Mylopoulos N, Karabatsas CH, Kozobolis VP, Diafas S, Papapanos P, Georgiadis N, Stewart WC. Diurnal intraocular pressure reduction with latanoprost 0.005% compared to timolol maleate 0.5% as monotherapy in subjects with exfoliation glaucoma. *Eye* 2004;18:893-9.

[54] Parmaksiz S, Yüksel N, Karabas VL, Ozkan B, Demirci G, Caglar Y. A comparison of travoprost, latanoprost, and the fixed combination of dorzolamide and timolol in patients with pseudoexfoliation glaucoma. *Eur. J. Ophthalmol*. 2006; 16: 73-80.

[55] Konstas AGP, Kozobolis VP, Katsimpris IE et al. Efficacy and safety of latanoprost versus travoprost in exfoliative glaucoma patients. *Ophthalmology* 2007; 114: 653-7.

[56] Konstas AGP, Holló G, Irkec M, Tsironi S, Durukan I, Goldenfeld M, Melamed S. Diurnal IOP control with bimatoprost vs latanoprost in exfoliative glaucoma: a crossover observer-masked three-center study. *Br. J. Ophthalmol*. 2007; 91: 757-60.

[57] Konstas AG, Kozobolis VP, Tersis I, Leech J, Stewart WC. The efficacy and safety of the timolol/dorzolamide fixed combination vs. latanoprost in exfoliation glaucoma. *Eye* 2003; 17:41-6.

[58] Konstas AGP, Mikropoulos DG, Embeslidis TA, Dimopoulos AT, Papanastasiou A, Haidich AB, Stewart WC. 24-hour intraocular pressure control with evening-dosed travoprost/timolol, compared with latanoprost/timolol, fixed combinations in exfoliative glaucoma. *Eye* 2010; 24: 1606-13.

[59] Konstas AGP, Tsironi S, Vakalis AN, Nasr MB, Stewart JA, Nelson LA, Stewart WC. Intraocular pressure control over 24 hours using travoprost and timolol fixed

combination administered in the morning or evening in primary open-angle and exfoliative glaucoma. *Acta Ophthalmol*. (Scand.) 2009; 87: 71-6.

[60] Konstas AGP, Holló G, Mikropoulos D, Tsironi S, Haidich AB, Embeslidis T, Georgiadou I, Irkec M, Melamed S. Twenty-four hour intraocular pressure control with bimatoprost and the bimatoprost/timolol fixed combination administered in the morning, or evening in exfoliative glaucoma. *Br. J. Ophthalmol*. 2010; 94: 209-13.

[61] Holló G, Ropo A. Intraocular pressure decrease with preservative-free fixed and unfixed combination of tafluprost and timolol in pseudoexfoliative glaucoma. *Curr. Med. Res. Opin*. 2015; 31: 13-6.

[62] Konstas AGP, Quaranta L, Katsanos A, Voudouragkaki IC, Dutton GN. Fixed combination therapies in glaucoma. In: Shaarawy TM, Sherwood MB, Hitchings RA, Crowston JG, editors. *Glaucoma* (2nd edition). Elsevier Saunders; 2015; 583-92.

[63] Holló G, Katsanos A. Safety and tolerability of the tafluprost/timolol fixed combination for the treatment of glaucoma. *Expert Opin. Drug Saf*. 2015; 14: 609-17.

[64] Wise JB, Witter SL. Argon laser therapy for open angle glaucoma. A pilot study. *Arch. Ophthalmol*. 1979; 97: 319-22.

[65] Odberg T. Laser therapy of exfoliative glaucoma. In: Holló G, Konstas AGP, editors. *Exfoliation syndrome and exfoliative glaucoma* (3rd edition). Savona: PubliComm; 2015; 183-8.

[66] Odberg T, Sandvik L. The medium and long-term efficacy of primary argon laser trabeculoplasty in avoiding topical medication in open angle glaucoma. *Acta Ophthalmol*. (Scand.) 1999; 77:176-81.

[67] Threlkeld AB, Hertzmark E, Sturm RT, Epstein DL, Allingham RR. Comparative study of the efficacy of argon laser trabeculoplasty for exfoliation and primary open-angle glaucoma. *J. Glaucoma* 1996; 5: 311-6.

[68] Sherwood MB, Svedbergh B. Argon laser trabeculoplasty in exfoliation syndrome. *Br. J. Ophthalmol*. 1985; 69: 886-90.

[69] Gracner T. Intraocular pressure response of capsular glaucoma and primary open-angle glaucoma to selective Nd:YAG laser trabeculoplasty: a prospective, comparative clinical trial. *Eur. J. Ophthalmol.* 2002; 12: 287-92.

[70] Higginbotham EJ, Richardson TM. Response of exfoliation glaucoma to laser trabeculoplasty. *Br. J. Ophthalmol*. 1986; 70: 837-9.

[71] The Glaucoma Laser Trial (GLT). 2. Results of argon laser trabeculoplasty versus topical medicines. The Glaucoma Laser Trial Research Group. *Ophthalmology*. 1990; 97:1403-13.

[72] Latina MA, Sibayan SA, Shin DH, Noecker RJ, Marcellino G. Q-switched 532-nm Nd:YAG laser trabeculoplasty (selective laser trabeculoplasty): a multi-center, pilot, clinical study. *Ophthalmology* 1998; 105: 2082-8.

[73] Barkana Y, Belkin M. Selective Laser Trabeculoplasty. *Survey Ophthalmol.* 2007; 52: 634-54.

[74] Kent SS, Hutnik CM, Birt CM et al. A randomized clinical trial of selective laser trabeculoplasty versus argon laser trabeculoplasty in patients with pseudoexfoliation. *J. Glaucoma* 2015; 24: 344-7.

[75] Shazly TA, Smith J, Latina MA. Long-term safety and efficacy of selective laser trabeculoplasty as primary therapy for the treatment of pseudoexfoliation glaucoma compared with primary open-angle glaucoma. *Clin. Ophthalmol*. 2010; 5: 5-10.

[76] Goldenfeld M, Geyer O, Segev E, Kaplan-Messas A, Melamed S. Selective laser trabeculoplasty in uncontrolled pseudoexfoliation glaucoma. *Ophthalmic Surg. Lasers Imaging* 2011; 42: 390-3.

[77] Ayala M, Chen E. Comparison of selective laser trabeculoplasty (SLT) in primary open angle glaucoma and pseudoexfoliation glaucoma. *Clin. Ophthalmol.* 2011; 5: 1469-73.

[78] Konstas AG, Jay JL, Marshall GE, Lee WR. Prevalence, diagnostic features, and response to trabeculectomy in exfoliation glaucoma. *Ophthalmology* 1993; 100: 619-27.

[79] Kozobolis VP, Konstas AGP. Filtering surgery in exfoliative glaucoma. In: Holló G, Konstas AGP, editors. *Exfoliation syndrome and exfoliative glaucoma* (3rd edition). Savona: PubliComm; 2015; 191-7.

[80] Popovic V, Sjöstrand J. Course of exfoliation and simplex glaucoma after primary trabeculectomy. *Br. J. Ophthalmol*. 1999; 83: 305-10.

[81] Törnqvist G, Drolsum LK. Trabeculectomies. A long-term study. *Acta Ophthalmol*. (Copenh). 1991; 69: 450-4.

[82] Rulli E, Biagioli E, Riva I, Gambirasio G, De Simone I, Floriani I, Quaranta L. Efficacy and safety of trabeculectomy vs nonpenetrating surgical procedures: a systematic review and meta-analysis. *JAMA Ophthalmol*. 2013; 131: 1573-82.

[83] Roy S, Mermoud A. Deep sclerectomy. In: Shaarawy MT, Sherwood BM, Hitchings AR, Crowston GJ, editors. *Glaucoma* (2nd edition). Elsevier-Saunders; 2015: 945-59.

[84] Kozobolis VP, Christodoulakis EV, Tzanakis N, Zacharopoulos I, Pallikaris IG. Primary deep sclerectomy versus primary deep sclerectomy with the use of mitomycin C in primary open-angle glaucoma. *J. Glaucoma* 2002; 11: 287-93.

[85] Greifner G, Roy S, Mermoud A. Results of CO_2 laser-assisted deep sclerectomy as compared with conventional deep sclerectomy. *J. Glaucoma* 2016; 25: e630-8.

[86] Drolsum L. Deep sclerectomy in patients with capsular glaucoma. *Acta Ophthalmol.* (Scand.) 2003; 81: 567-72.

[87] Shaarawy T, Nguyen C, Schnyder C, Mermoud A. Five year results of viscocanalostomy. *Br. J. Ophthalmol*. 2003; 87: 441-5.

[88] Hassan KM, Awadalla MA. Results of combined phacoemulsification and viscocanalostomy in patients with cataract and pseudoexfoliative glaucoma. *Eur. J. Ophthalmol*. 2008; 18: 212-9.

[89] Awadalla MA, Hassan KM. Phacoviscocanalostomy in pseudoexfoliation glaucoma versus primary open-angle glaucoma. *Can. J. Ophthalmol*. 2011; 46: 77-82.

[90] Ting JL, Damji KF, Stiles MC; Trabectome Study Group. Ab interno trabeculectomy: outcomes in exfoliation versus primary open-angle glaucoma. *J. Cataract Refract. Surg*. 2012; 38:315-23.

[91] Jacobi PC, Dietlein TS, Krieglstein GK. Bimanual trabecular aspiration in pseudoexfoliation glaucoma: an alternative in nonfiltering glaucoma surgery. *Ophthalmology* 1998; 105:886-94.

[92] Jacobi PC, Dietlein TS, Krieglstein GK. Comparative study of trabecular aspiration vs. trabeculectomy in glaucoma triple procedure to treat pseudoexfoliation glaucoma. *Arch. Ophthalmol*. 1999; 117: 1311-8.

[93] Damji KF, Konstas AGP, Liebmann JM, Hodge WG, Ziakas NG, Giannikakis S, Mintsioulis G, Merkur A, Pan Y, Ritch R. Intraocular pressure following

phacoemulsification in patients with and without exfoliation syndrome: a 2 year prospective study. *Br. J. Ophthalmol*. 2006; 90: 1014-8.

[94] Merkur A, Damji KF, Mintsioulis G, Hodge WG. Intraocular pressure decrease after phacoemulsification in patients with pseudoexfoliation syndrome. *J. Cataract Refract. Surg*. 2001; 27: 528-32.

[95] Shingleton BJ, Heltzer J, O'Donoghue MW. Outcomes of phacoemulsification in patients with and without pseudoexfoliation syndrome. *J. Cataract Refract. Surg*. 2003; 29: 1080-6.

[96] Shingleton BJ, Laul A, Nagao K et al. Effect of phacoemulsification on intraocular pressure in eyes with pseudoexfoliation: single-surgeon series. *J. Cataract Refract. Surg*. 2008; 34:1834-41.

[97] Kristianslund O, Østern AE, Råen M, Sandvik GF, Drolsum L. Does cataract surgery reduce the long-term risk of glaucoma in eyes with pseudoexfoliation syndrome? *Acta Ophthalmol*. (Scand.) 2016; 94: 261-5.

[98] Shingleton BJ, Neo YN, Cvintal V, Shaikh AM, Liberman P, O'Donoghue MW. Outcome of phacoemulsification and intraocular lens implantation in eyes with pseudoexfoliation and weak zonules. *Acta Ophthalmol*. (Scand.) 2016 published online first, doi: 10.1111/aos.1311 0.

[99] Holló G. Exfoliation syndrome and systemic cardiovascular diseases. *J. Glaucoma* 2014; 23(Suppl. 1):S9-S11.

[100] Topouzis F, Wilson MR, Harris A, Founti P, Yu F, Anastasopoulos E, Pappas T, Koskosas A, Salonikiou A, Coleman AL. Risk factors for primary open-angle glaucoma and pseudoexfoliative glaucoma in the Thessaloniki Eye Study. *Am. J. Ophthalmol*. 2011; 152: 219-28.

[101] Andrikopoulos GK, Alexopoulos DK, Gartaganis SP. Pseudoexfoliation syndrome and cardiovascular diseases. *World J. Cardiol*. 2014;6: 847-54.

Reviewed by: Professor Barbara Cvenkel, MD, PhD
Department of Ophthalmology, University Medical Center Ljubljana

Commercial relationship: None of the authors has any relevant commercial relationship

In: Encyclopedia of Surgery (22 Volume Set)
Editors: Andreas Lehrer and Kristin Mueller
ISBN: 978-1-53618-329-0
© 2020 Nova Science Publishers, Inc.

Chapter 430

IgG4-Related Sclerosing Cholangitis in the Early Postoperative Period after Hepato-Biliary-Pancreatic Surgery: Screening Using Magnetic Resonance Cholangiography and Serum IgG4 Values

David Padilla-Valverde[1,*], MD, PhD,
Pedro Villarejo-Campos[1], MD, PhD, Carlos Marcote-Ibañez[2], MD,
Mercedes Molina[3], MD, Elena Buces[4], MD,
Francisco J. Redondo[5], MD, PhD and Maitane Múgica[6], MD

[1]Department of Surgery, University General Hospital, Ciudad Real, Faculty of Medicine, Castilla-La Mancha University, Spain
[2]Department of Interne Medicine, University General Hospital, "Marques de Valdecilla," Santander, Faculty of Medicine, University of Cantabria, Cantabria, Spain
[3]Department of Interne Medicine, University General Hospital," Alcazar de San Juan," Ciudad Real, Spain
[4]Clinic Analysis Department, University General Hospital, Ciudad Real, Spain
[5]Department of Anesthesiology, University General Hospital, Ciudad Real, Spain
[6]Department of Oncology, University General Hospital, "Marques de Valdecilla," Santander, University of Cantabria, Cantabria, Spain

Abstract

Introduction: Systemic autoimmune disease is a multisystem IgG4-type fibroinflammatory syndrome that is characterized by high levels of IgG4 and IgG4 lymphoplasmacytic multifocal infiltration. IgG4-related cholangitis is the biliary manifestation of this disease and is characterized by biliary stricture and jaundice. It can

* Corresponding Author's Email: marcote15@yahoo.es.

appear as a unique manifestation or be associated with autoimmune pancreatitis before and after surgical treatment.

Objective: The objective of this study is to understand the impact of IgG4-related sclerosing cholangitis after hepato-biliary-pancreatic resection in our population and identify non-invasive diagnostic methods, IgG-IgG4 serum values, and magnetic resonance cholangiography (MRC)) images to diagnose this entity in the early postoperative period in order to avoid aggressive and unnecessary treatment.

Material and Methods: The method used was a population-based case control study that included 109 patients who underwent liver resection. Biochemical and MRC images were obtained between the fifth and seventh postoperative days.

Parameters: Clinics: Age, sex, postoperative jaundice. Biochemicals: Total Bilirubin (BB), Alkaline phosphatase (ALP), Gamma Glutamyl Transferase (GGT), Immunoglobulin G (IgG), Immunoglobulin G4 (IgG4). Radiologic images: Magnetic Resonance (Philips Gyroscan Intera 1.5 T).

Results: The study included 109 patients were studied with a mean age of 59 ± 15 years. ALP: 142 ± 79 IU/L. BB: 1.5 ± 2 mg/dl. GGT: 188 IU/L. IgG: 948 ± 420 mg/dl (751-1560) mg/dl. IgG 4 ± 51 mg/dl (9-104) mg/dl.

Radiologic bile duct stenosis existed in six patients: In five patients, the stenosis was an intrahepatic stenosis, of which three cases were associated with postoperative collection, and in two patients, there was an image that was compatible with filling defects due to blood clots or residual stones. In other patients, extrahepatic biliary stenosis existed with an image compatible with a filling defect due to a blood clot or biliary lithiasis. There was no pathological elevation of IgG-IgG4 values in these patients.

There was a pathological elevation of IgG values in four patients, of whom only two patients presented elevated levels of IgG4, 397 mg/dl and 217 mg/dl, respectively. There was no relationship with clinical symptoms or pathological biochemical values.

Conclusion: In the early postoperative biliary complications, we should include bile leaks that cause edema, fibrosis, and secondary stenosis; ischemia by vascular injury; and surgical injury of the biliary system. According to our results and to the medical literature, we consider IgG4-related sclerosing cholangitis as a late postoperative complication. We should consider the involvement of another organ, usually the pancreas, to diagnose autoimmune cholangitis when there is a stenosis of unknown origin during the postoperative period.

Keywords: IgG4-related sclerosing cholangitis, postoperative stenosis bile duct, IgG4-related sclerosing disease

INTRODUCTION

In spite of improvements in hepato-biliary surgical techniques that have reduced biliary complications, early postoperative bile duct stenosis is still a serious problem that increases perioperative morbidity. Early complications include bile duct injury caused by erroneous sectioning or surgical clips and stenosis of the bile duct system due to ischemia because of injury to the hepatic artery and due to edema and fibrosis from bile leakage. Early cholangitis can also cause bile duct stenosis and late strictures. Some authors have referred to IgG4-related sclerosing cholangitis after surgery. They considered that surgical stress allowed for increased autoimmunity in patients with IgG4-related sclerosing disease [1-11]. It's important to reach an appropriate diagnosis of this entity as soon as possible in order to avoid late complications and/or unnecessary surgical treatment, but we don't know the early

postsurgical incidence. We can only see complications many days or even months after surgery.

We can suspect IgG4-related cholangitis in a patient with stenosis that is associated with other manifestations of IgG4-related diseases such as autoimmune pancreatitis. But, if IgG4-related cholangitis is the only autoimmune manifestation, we can only use biliary tract imaging that shows diffuse or segmental narrowing and elevated serum IgG4 values, greater than or equal to 135 mg/dl [1-4], as a probable preoperative diagnosis.

Our aim was to understand the value of magnetic resonance cholangiography findings and IgG4 serum values in the early postoperative period as screening tests for identifying IgG4-related sclerosing cholangitis.

IgG4-Related Disease (IgG4-RD) and IgG4-Related Cholangitis (IgG4-SC)

IgG4-related disease is a clinical entity that involves multiple organs, with an unknown etiology, but it is associated with infiltration of the organs by IgG4-positive cells. Organs with IgG4-related disease show diffuse or focal enlargement because of a great infiltration of lymphocytes, plasmacytes, and fibrosis. The organs can be affected synchronously or metachronously and include the pancreas, lacrimal glands, orbital soft tissue, eyes, extra-ocular muscle, salivary glands, pachymeninges, hypophysis, thyroid, arteries, mediastinum, retroperitoneum, mesentery, skin, lymph nodes, bile ducts, gallbladder, liver, lung, pleura, pericardium, kidney, breasts, and prostate.

The histopathological characteristics associated with IgG4-RD are a dense lymphoplasmacytic infiltrate, a storiform pattern of fibrosis, and an obliterative phlebitis. Other features that can appear include increased numbers of eosinophils and phlebitis without obliteration. But, the minimal criteria for diagnosis of IgG4-RD are the presence of elevated IgG4 plasmatic cells in the histopathological study, the existence of elevated IgG4 serum values, the effectiveness of glucocorticoid therapy, and the involvement of other organs.

IgG4-SC is a type of sclerosing cholangitis of unknown origin characterized by an intense infiltration of IgG4-positive plasmatic cells, obliterative phlebitis, and storiform fibrosis of the bile duct. These histopathological characteristics show a bile duct system with circular and symmetrical thickening of the bile duct wall.

The presence of infectious agents and autoimmunity are pathogenetic mechanisms in IgG4-SC. Interleukins 4, 5, 10, and 13 and TGF-β are overexpressed, and type 2 helper T (Th2) cells predominate. These cytokines allow for an elevated serum IgG4, IgE, eosinophilia, and fibrosis [12-15].

Definitive clinical diagnostic criteria of IgG4-related sclerosing cholangitis were established by the working group for this proposal in 2012 [1-3].

A diagnosis of IgG4-SC is realized using a combination of the following criteria:

- Biliary tract imaging revealing diffuse or segmental narrowing of the intrahepatic and/or extrahepatic bile duct. It exits thickening of the bile duct wall
- Elevated serum IgG4 concentrations, ≥135 mg/dl

- Coexistence of autoimmune pancreatitis and the involvement of other organs as dacryoadenitis, sialadenitis, and retroperitoneal fibrosis
- Histopathological findings: a) marked lymphocytic and plasma cells infiltration and fibrosis; b) infiltration of ≥IgG4-positive plasma cells/HPF; c) storiform fibrosis; and d) obliterative phlebitis
- Option: Effectiveness of steroid therapy since we can't obtain sufficient tissue to study from multiple patients.

The definitive diagnosis includes a combination of the criteria:

1 + 3
1 + 2 + 4a, 4b
4a, 4b, 4c
4a, 4b, 4d

The incidence of IgG4-SC is unclear because of the very small number of references in the medical literature that include only solitary centers, with few patients, and we don't know for sure if the associated stenosis of autoimmune pancreatitis (AIP) is due to lymphoplasmacitic infiltration or infiltration of the pancreas without bile duct thickness.

In Japan, the incidence of IgG4-RD is 0.28-1.08/100.000, with a prevalence of 336-1300 newly diagnosed patients per year. In eastern countries, autoimmune pancreatitis appears in 6% of the population. In western countries, the occurrence has been described in 11% of patients. In Japan, 75.9% of the patients with AIP show associated sclerosing cholangitis. In eastern countries, 26.6% of patients have a diagnosis of IgG4-SC not associated with AIP, and in western countries, the incidence is 8% [16-23]. Some authors [19, 21, 22] have referred the incidence of IgG4-SC with respect to benign hilar strictures that have been resected. They found an incidence level between 4.8% and 9.1%. Using our magnetic resonance cholangiography findings and IgG4 serum values in the early postoperative period, we didn't find any patients with IgG4-SC.

IgG4-Related Sclerosing Cholangitis After Surgery

In 2005, our group presented a patient who, after duodenopancreatectomy due to a lymphoplasmacytic pancreatitis pseudotumor, was admitted to our department because of obstructive jaundice at 75 days after surgery. At admission, the patient showed an elevated serum IgG value of 1520 mg/dl but a non-elevated serum IgG4 value of 28 mg/dl. Magnetic resonance cholangiography revealed dilatation of the intrahepatic biliary tract with no visualization of the hilar plate or the common bile duct. The case was resolved using methyl-prednisolone [5]. Wallis de Vries et al. [6] also reported a patient who presented with extensive stenosis of the intrahepatic biliary system after pancreaticoduodenectomy and was successfully treated using steroids. Marrache et al. [7] described three patients with severe cholangitis following pancreaticoduodenectomy. The three patients showed stenosis of the intrahepatic biliary system and the common bile duct. Only one patient presented with elevated IgG and IgG4 serum values.

Table 1. References in the Medical Literature about IgG4-related sclerosing cholangitis after hepato-bilio-pancreatic surgery

Authors/Journal	Year	n	Treatment	Clinic	Radiological findings	Presentation after surgery (days)
Padilla et al./Gut [5]	2005	1	PPCDP/AIP	Obstructive jaundice	EHBD-IHBD stenosis	75
Wallis de Vries et al./Ned Tijdschr Geeneskd [6]	2005	1	CDP/AIP	Cholangitis	IHBD stenosis	
Schmasmann et al./Gut [9]	2006	1	PPCDP/AIP	Obstructive jaundice	IHBD-EHBD stenosis	56
Marrache et al./Am J Gastroenterol [7]	2005	3	CDP/AIP	Obstructive jaundice (1) Cholangitis (2)	EHBD-IHBD stenosis	30-180-330
Alderlieste YA/Digestion [8]	2009	1	CDP/	Obstructive jaundice	IHBD stenosis	Few weeks
Padilla et al./Cir Esp [10]	2010	1	Left bisegmentectomy	Obstructive jaundice	CBD-IHBD stenosis	90
Ramia et al./Rev Esp Enferm Digest [11]	2011	1	Hepatojejunostomy	Cholangitis	IHBD stenosis	720

CDP: Cephalic Duodenopancreatectomy. PPCDPC: Pilorous Preserving Cephalic Duodenopancreatectomy. AIP: Autoimmune Pancreatitis. IHBD: Intrahepatic Biliary Duct. EHBD: Extrahepatic Biliary Duct. CBD: Common Biliary Duct.

In 2006, Schmassmann et al. [9] presented a patient who had been readmitted six weeks after pancreaticoduodenectomy due to jaundice. MR imaging showed intra and extra bile duct strictures, but the IgG4 serum values were normal. In 2009, Alderlieste et al. [8] described a patient with reoccurring jaundice after a Whipple procedure and abnormal IgG and IgG4 serum values. A diagnosis of stenosis and dilatation of the bile duct system was made in this case by percutaneous transhepatic cholangiography.

In 2010, we added a patient with jaundice after hepatic resection. In this patient, magnetic resonance imaging showed intrahepatic bile duct system stenosis. The serum values of IgG were elevated at 2060 mg/dl but the IgG4 serum values were normal at 37 mg/dl [10]. Ramia et al., [11] in 2011, described a male patient with cholangitis 24 months after hepatojejunostomy. MR imaging showed intrahepatic biliary duct system stenosis. In this case, the patient presented with elevated IgG4 serum values, 353 mg/dl. In all the cases, the sclerosing cholangitis appeared as late complications after surgery. For this reason, our aim was determining the value of magnetic resonance cholangiography (MRC) findings and IgG4 serum values in the early postoperative period after hepato-biliary-pancreatic surgery.

CASE-CONTROL STUDY PERFORMED BY OUR GROUP

We decided to perform a prospective study to determine the value of magnetic resonance cholangiography findings and IgG4 serum values in the early postoperative period after

hepato-biliary surgery, with the possibility of using them as screening tests for identifying IgG4-related sclerosing cholangitis. This was a population-based case control study that included 109 consecutive patients, operated on in our department by means of a liver resection that included at least two anatomical liver segments. We performed selective vascular exclusion before parenchyma resection. After resection, an intraoperative cholangiography was performed to provide a description of a normal bile duct system. A magnetic resonance cholangiography was performed in all patients on the seventh postoperative day. If pathological images were found, a percutaneous cholangiography and/or a retrograde endoscope cholangiography were performed for diagnosis and treatment, if possible. A serum sample was obtained from each patient on the seventh postoperative day for measuring the IgG4 values. Written informed consent was obtained from all patients. Those patients who refused to be included in the study, unstable haemodynamic patients, and claustrophobic patients were excluded.

Clinical diagnostic criteria of Igg4-related sclerosing cholangitis were established by the working group for this proposal in 2012 [3].

1. Biliary tract imaging revealing diffuse or segmental narrowing of the intrahepatic and/or extrahepatic bile duct. It exits thickening of bile duct wall
2. Elevated serum IgG4 concentrations, ≥135 mg/dl
3. Coexistence of autoimmune pancreatitis, dacryoadenitis, sialadenitis, and/or retroperitoneal fibrosis
4. Histopathological findings: marked lymphocytic and plasma cells infiltration and fibrosis; infiltration of ≥IgG4-positive plasma cells/HPF; storiform fibrosis; And obliterative phlebitis
5. Option: effectiveness of steroid therapy

For our study, a possible diagnosis would include the diagnostic items 1 and 2.

Clinical and biochemical parameters: · Age (years), sex (male/female), and pathological specimen diagnosis · Liver parameters that were obtained on the seventh postoperative day were BB (mg/dl), ALP (IU/L), and GGT (IU/L). · On the seventh postoperative day, serum samples were obtained and stored at -20°C for the measurements of IgA, IgM, and IgG subclasses. They were analyzed by a turbidimetric protein analyzer (SPAPLUS®). We used 135 mg/dl [1-4] as the serum IgG4 cut-off value for differential diagnosis.

Magnetic resonance imaging (MRI): All the patients fasted for six hours prior to the procedure, and images were obtained during apnea. MRI imaging was performed with a 1.5-T clinical imager (Philips Gyroscan Intera 1.5 T), on the seventh postoperative day. Patients were placed in a supine head-first position.

1. Multiplanar acquisition (axial, sagittal, and coronal images). Parallel images (SENSE)
2. T1 - GE. Axial. Cranial and caudal parallel saturation bands

We used sequences that were T2 weighted to depict fluid-containing biliary ducts. We also included half-fourier acquisition single-shot turbo spin. echo, HASTE.

T2 - S S h (HASTE) coronal. section thickness of 5 mm.

T2 - S S h (HASTE) axial section thickness of 5 mm.

T2 - TSE – Projection images. Section volumen of 50 mm. We obtained several slices (at least four), coronals, and coronal oblique planes, placed over an axial plane that includes the field of bile duct.

Image analysis: Images from MR cholangiography were viewed by three observers. Stricture was defined as the narrowing of the bile duct that explains abnormal and cholestatic liver parameters and a ductal caliber change. Intrahepatic and extrahepatic bile duct dilatation is defined as a diameter greater than 2 mm and 7 mm, respectively.

Classification of cholangiographic findings of IgG4-related sclerosing cholangitis: type 1. stenosis located in the lower part of the common bile duct; type 2. stenosis in the intra-hepatic and extra-hepatic bile ducts; type 3. stenosis in the hilar and the lower part of the common bile duct; type 4. hilar hepatic stricture [1].

Results: 109 patients were studied with a mean age of 59 ± 15 years old (range from 18 to 86 years old), being female patients in 55 cases. The biochemical values were: ALP: 142 ± 79. BB: 1.5 ± 2. GGT: 188. IgG: 948 ± 420 mg/dl, normal range (751-1560). IgG 4 ± 51 mg/dl, (15-198), normal range (9-104). IgG1:538 ± 323 mg/dl (122-2080). IgG2: 318 ± 177 mg/dl, (100-1130). IgG3: 64 ± 39 mg/dl (15-198). IgA: 258 ± 150 mg/dl (44-852). IgM: 132 ± 103 (184-439).

Pathological diagnosis of the resected specimens were:

Hepatocarcinoma, 6(5.5%). Cholangiocarcinoma, 5(4.6%). Colorectal hepatic metastasis, 41(37.6%). Non endocrine, non colorectal hepatic metastasis, 12(11%). Hemangioma, 2(1.8%). Nodal focal hyperplasia, 1(0.9%). Hepatic sarcoma, 1(0.9%). Hepatic hidatidosis, 25(22.9%). Gallbladder cancer, 12(11%). Hepatic cyst, 2(1.8%). Liver adenoma, 1(0.9%). Endocrine liver metastasis, 1(0.9%).

Radiologic stenosis of bile duct existed in six patients. In five of the patients there was an intrahepatic stenosis. In three cases, the stenosis were associated with postoperative collection. In two patient there was an image that was compatible with defect of filling by blood clot or residual stones. In the other patient existed extrahepatic biliary stenosis with a compatible image showing a filling defect by blood clot or biliary lithiasis. IgG and gG4 values were no pathologcical in these patients.

There was a pathological elevation of IgG values in only four patients, with a range from 1670 to 3210 mg/dl. However only two patients presented elevated levels of IgG4, 397 mg/dl and 217 mg/dl, respectively. There were not relation with clinical symptoms or pathological biochemical values in the four patients.

MAGNETIC RESONANCE CHOLANGIOGRAPHY (MRC)

This is a noninvasive radiologic method for diagnosing bile duct complications that is less time consuming and associated with less morbidity than endoscopic retrograde cholangiopancreatography (ERCP) and percutaneous transhepatic cholangiography (PTCH). MR cholangiography can also control the biliary duct above and below the level of obstruction.

One of the complications after surgery is a bile duct stricture that is defined as a narrowing of a focal segment of the bile duct that leads to a proximal biliary dilatation, more than 3 mm in the intrahepatic bile duct system and more than 7 mm in the extrahepatic bile duct system, and clinical characteristics of obstructive jaundice. An inflammatory response due to injury is the causing of collagen deposition, fibrosis, and later the formation of a bile duct stricture. In our hypothesis, we think that the surgical stress, the injury, and/or a secondary infection after surgery can allow, in some patients, an autoimmunity process with severe lymphoplasmacytic cells infiltration in the bile duct system and secondary bile duct stenosis. For this reason, we need to identify the start of the process in order to solve it.

Early complications after surgery that can be easily diagnosed by MRC include lithiasis retention, hemorrhage, hemobilia, bile leaks, bile duct injuries from excision or ligation, and bile collection. Strictures are the most common of the late complications.

In our patients, a radiologic bile duct stenosis existed in six patients. In five of the patients, there was an intrahepatic stenosis. In three cases, the etiology of the stenosis was a postoperative collection. In two patients, there was an image that was compatible with a filling defect due to a blood clot or residual stones. In the other patient, extrahepatic biliary stenosis due to a blood clot or biliary lithiasis existed. IgG and gG4 values were not pathological in any of these patients.

MR cholangiography can be useful to analyzes the anatomy of the biliary system and to detect bile duct complications such as stenosis. Some authors [24-32] propose radiologic features to diagnose IgG4-SC as common bile duct wall thickness greater than 2.5 mm, continuous involvement of the biliary system, absence of hepatic parenchymal complications, and gallbladder involvement. But, for a true diagnosis of IgG4-SC, we need to realize a combination with other diagnosis criteria.

IgG4 Serum Values

Since 2001, serum IgG4 values equal to or greater than 135 mg/dl have been widely used for diagnostic criteria of IgG4-related sclerosing cholangitis and discriminating from other pancreatic diseases [33-39]. Hamano et al. [39] reported with these values a high accuracy, 97%, sensitivity, 95%, and specificity, 97%, for identifying AIP with respect to pancreatic cancer.

In 2012, elevated serum IgG4 concentrations, ≥135 mg/dl, were used as Japanese clinical diagnostic criteria. However, this cutoff in IgG4-SC shows a lower specificity for diagnosis IgG4 with respect to cholangiocarcinoma [33-39]. Some cases of primary sclerosing cholangitis, 9%, and pancreatic cancer, 10%, also show high levels of serum IgG4 values. In a multicenter study in Japan, it was considered that a cutoff four times the upper limit of the normal serum values of IgG4 could be 100% specific for IgG4-sclerosing cholangitis. This cutoff is also used in western centers. They also described that values of IgG4 ≥ 207 mg/dl can diagnose types 3 and 4 IgG4-SC [36].

CONCLUSION

According to our results and to the medical literature, we should consider IgG4-related sclerosing cholangitis as a late postoperative complication. When there is the involvement of another organ, which is usually the pancreas, we should suspect a diagnosis of an autoimmune cholangitis, IgG4-SC, when there is a stenosis of unknown origin in the postoperative period.

REFERENCES

[1] Ohara H, Okazaki K, Tsubouchi H, Inui K, Kawa S, Kamisawa T et al. Clinical diagnostic criteria of IgG4-related sclerosing cholangitis. *J. Hepatobiliary Pancreat. Sci.* 2012;19:536-542.

[2] Okazaki O, Uchida K, Ikeura T, Takaoka M. Current concept and diagnosis of IgG4-related disease in the hapato-bilio-pancreatic system. *J. Gastroenterol*. 2013;48:303-314.

[3] Okazaki O, Uchida K, Koyabu M, Miyoshi H, Ikeura T, Takaoka M. IgG4 cholangiopathy. Current concept, diagnosis, and pathogenesis. *Journal of Hepatology* 2014;61:690-5.

[4] Kamisawa T, Okamoto A. IgG4-related sclerosing disease. *World J. Gastroenterol.* 2008;14:3948-3955.

[5] Padilla D, Cubo T, Villarejo P, Pardo R, Jara A, De la Plaza R et al. Response to steroid therapy of sclerosing colangitis after duodenpancreatectomy due to autoinmune pancreatitis. *Gut* 2005; 54: 1348-9.

[6] Wallis de Vries BM, Ter Borg E, Eeftinck Schattenkerk M, Eddes EH. A patient with sclerosing autoimmune pancreaticocholangitis as the cause of recurrent cholangitis following a pylorous-sparing pancreaticoduodenectomy. *Ned. Tijdschr. Geneeskd*. 2005;149:2888-9.

[7] Marrache F, Hammel P, O'Toole D, Cazals-Hatem D, Vullierme MP, Sibert A et al. Severe cholangitis following pancreaticoduodenectomy for pseudotumoral form of lymphoplasmacytic sclerosing pancreaititis. *Am. J. Gastroenterol*. 2005;100:2808-2813.

[8] Aldeslieste AY, Van den Elzen BDJ, Raws EAJ, Beuers U. Immunoglobulin G4-Associated colangitis: One variant of immunoglobulin G4-related systemic disease. *Digestion* 2009;79:220-228.

[9] Schmassmann A, Zehnder P, Gebbers JO, Wildisen A. Severe self limiting sclesosing cholangitis after pancreaticoduodenectomy due to autoimmune pancreatitis. *Gut* 2006, 55:1361-2.

[10] Padilla D, Menendez P, Villarejo P, Cubo T, Martin J. Autoimmune sclerosing colangitis after hepato-bilio-pancreatic surgery. *Cir. Esp.* 2010;87:391-3.

[11] Ramia-Angel JM, Sancho-Calatrava E, Ciampi-Topazo JJ, Santos-Blanco JM. Autoimmune IgG4-related cholangitis. *Rev. Esp. Enferm. Dig.* 2011;103:101-102.

[12] Moutsoupoulos HM, Fragoulis GE, Stone JH. *Overview of IgG4-related disease*. www.uptodate.com@2013UpToDate.

[13] Stone JH, Zen Y, DershpandeV. IgG4-related disease. *N. Engl. J. Med*. 2012;366:539-51.

[14] Kamisawa T, Zen Y, Pillai S, Stone JH. IgG4-related disease. *Lancet* 2015;385:1460-71.

[15] Kamisawa T, Okamoto A. Autoimmune pancreatitis: proposal of IgG4-related sclerosing disease. *J. Gastroenterol*. 2006;41:613-625.

[16] Hamano H, Arakura N, Muraki T, Ozaki Y, Kiyosawa K, Kawa S. Prevalence and distribution of extrapancreatic lesions complicating autoimmune pancreatitis. *J. Gastroenterol*. 2006;41:1197:1205.

[17] Uchida K, Masamune A, Shimosegawa T, Okazaki K. Prevalence of IgG4-related disease in Japan based on Nationwide Survey in 2009. *International Journal of Rheumatology* 2012. Doi:10.1155/2012/358371.

[18] Ghazale A, Chari ST, Zhang L, Smyrk TC, Takahashi N, Levy MJ et al. Immunoglobulin G4-Associated cholangitis: Clinical profile and response to therapy. *Gastroenterology* 2008;134:706-715.

[19] Fujita T, Kojima M, Gothoda N, Takahashi S, Nakagohri T, Konishi M et al. Incidence, clinical presentation and pathological features of benign sclerosing cholangitis of unknown origin masquerading as biliary carcinoma. *J. Hepatobiliary Pancreat. Surg*. DOI 10.1007/s00534-009-0115-5.

[20] Lazaridis KN. Sclerosing cholangitisepidemiology and etiology. *J. Gastrointest. Surg.* 2008; 12:417-9.

[21] Orvera CU, Blumgart LH, Darvishian F, Klimstra D, DeMatteo R, Fong Y et al. Clinical and pathologic features of proximal biliary strictures masquerading as hilar cholangiocarcinoma. *J. Am. Coll. Surg.* 2005; 6: 862-869.

[22] Erdogan D, Kloek JJ, Ten Kate FJW, Raws EAJ, Busch ORC,Gouma DJ et al. Immunoglobulin G4-related sclerosing cholangitis in patients resected for presumed malignant bile duct strictures. *Br. J. Surg*. 2009; 95:727-734.

[23] Webster GJM, Pereira SP, Chapman RW. Autoimmune pancreatitis/IgG4-associated cholangitis and primary sclerosing cholangitis-overlapping or separate diseases?. *J. Hepatology* 2009,51: 398-402.

[24] Katabathina VS, Dasyam AK, Dasyam N, Hosseinzadeh K. Adult bile duct strictures: Role of MR imaging and MR cholangiopancreatography in characterization. *Radiographics* 2014; 34; 565-585.

[25] Tokala A, Khalili K, Menezes R, Hirschfield G, Jhaveri KS. Comparative MRI analysis of morphologic patterns of bile duct disease in IgG4-related systemic disease versus primary sclerosing cholangitis. *AJR* 2014; 202:536-543.

[26] Ward J, Sheridan MB, Guthrie JA, Davies MH, Millson CE, Lodge JPA et al. Bile duct strictures after hepatobiliary surgery: Assesment with MR cholangiography. *Radiology* 2004; 231:101-108.

[27] Hoeffel C, Azizi L, Lewin M, Laurent V, Aubé C, Arrive L et al. Normal and pathologic features of the postoperative biliary tract at 3D MR cholangiopancreatography and MRI imaging. *Radiographics* 2006; 26:1603-1620.

[28] Nakazawa T, Ando T, Hayashi K, Naitoh I, Ohara H, Joh T. Diagnostic procedures for IgG4-related sclerosing cholangitis. *J. hepatobiliary Pancreat. Sci.* 2011;18:127-136.

[29] Nakazawa T, Naitoh I, Hayashi K, Okumura F, Miyabe K, Yoshida M et al. Diagnostic criteria for IgG4-related sclerosing cholangitis based on cholangiographic classification. *J. Gastroenterol*. 2012;47:79-87.

[30] Abdalian R, Heathcote EJ. Sclerosing cholangitis: A focus on secondary causes. *Hepatology* 2006;44:1063-1074.

[31] Nakazawa T, Ohara H, Sano H, Aoki S, Kobayashi S, Okamoto T et al. Cholangiography can discriminate sclerosing cholangitis with autoimmune pancreatitis from primary sclerosing cholangitis. *Gastrointestinal Endoscopy* 2004;60:937-44.

[32] Park MS, Kim KW, Yu J-S, Kim M-J, Kim KW, Lim JS et al. Early biliary complications of laparoscopic cholecistectomy: Evaluation on T2-weithted MR cholangiography in conjuction with Mangafodipir Trisodium-Enhanced eD T1-weithted MR cholangiography. *AJR* 2004; 183:1559-1566.

[33] Boonstra K, Culver EL, De Buy Wenninger LM, Van Heerde MJ, Van Erpecum KJ, Poen AC et al. Serum immunoglobulin G4 and Immunoglobulin G1 for distinguising Immunoglobulin G4-associated colangitis from primary sclerosing colangitis. *Hepatology* 2014;59:1954-1963.

[34] Hochwald SN, Hemming AW, Draganov P, Vogel SB, Dixon LR, Grobmyer SR. Elevation of serum IgG4 in western patients with autoimmune sclerosing pancreatocholangitis:aword of caution. *Ann. Surg. Oncol*. 2008;15:1147-1154.

[35] Hirano K, Kawabe T, yamamoto N, Nakai Y, Sasahira N, Tsujino T. Serum IgG4 concentrations in pancreatic and biliary diseases. *Clinica Chimica Acta* 2006;367:181-4.

[36] Ohara H, Nakazawa T, Kawa S, kamisawa T, Shiomosegawa T, Uchida K et al. Establishment of a serum IgG4 cut off value for the diferential diagnosis of IgG4-related sclerosing cholangitis: A Japanese cohort. *Journal of Gastroenterology and Hepatology* 2013;28:1247-1251.

[37] Oseini AM, Chaiteerakij R, Shire AM, Ghazale A, Kaiya J, Moser CD et al. Utility of serum immunoglobulin G4 in distinguishing immunoglobulin G4-associated cholangitis from cholangiocarcinoma. *Hepatology* 2011;54:940-948.

[38] Song TJ, Kim MH, Moon S-H, Eum JB, Park DH, Lee SS et al. The combined measurement of total serum Ig and IgG4 may increase diagnostic sensitivity for autoimmune pancreatitis without sacrificing specificity, compared with IgG4 alone. *Am. J. Gastroenterol.* 2010;105: 1655-60.

[39] Hamano H, Kawa S, Horiuchi A, Unno H, Furuya N, Akamatsu T et al. High serum IgG4 concentrations in patients with sclerosing pancreatitis. *N. Eng. J. Med*. 2001;344: 732-738.

BIOGRAPHICAL SKETCH

David Padilla-Valverde, MD, PhD

Affiliation: Head of Section of Digestive and General Surgery. Department of Surgery. University General Hospital, Ciudad Real, Spain

Chief of Traslacional Research Unit, University General Hospital, Ciudad Real, Spain

Professor of Surgery. Faculty of Medicine, Castilla La Mancha University, Spain

Education: Grade of Medicine and Surgery, Medicine Faculty, Autonoma University, Madrid 1987-1993

PhD University, Year:
Medicine and Surgery, Medicine Faculty, Autonoma University, Madrid 1995-1997.
Medicine and Surgery, University of Cordoba, Spain 1998-2001

Address:
University General Hospital, Ciudad Real, Spain
Avd Obispo Torija s/n
13005 Ciudad Real, Spain

Research and Professional Experience:

- "Test of safety and effectiveness in hemodynamic monitoring, fluid and drug distribution during the development of a model of laparoscopic access for cytoreductive surgery and hyperthermic intra-abdominal chemotherapy through a closed recirculating CO_2 in a porcine experimental model system" Foundation Eugenio Rodriguez Pascual, 2014. PI: David Padilla.
- Usefulness of hyperthermic chemotherapy using intraabdominal gemcitabine for inhibiting tumor progression in an experimental model of pancreatic peritoneal carcinomatosis, and their behavior respect to CD133 + CXCR4 + cancer stem cells. Fundacion Eugenio Rodriguez Pascual. Madrid 12/26/2012. PI: Dr David Padilla.
- FIS Project of Health Research, Institute of Health, Carlos III, Madrid, Spain. 2011. "Value of 18-FDG-PET-CT with intravenous contrast in the post-neoadjuvant restaging of patients with liver metastases" PI: Dr Ana Garcia Vicente.
- Development of independent clinical research, Department of Pharmacy and Health Products of the Ministry of Health, Social and Equality Policy. SAS/2377/2010 and SAS/2039/2009. "Intraperitoneal chemohyperthermia closed with paclitaxel in the treatment of ovarian carcinomatosis" PI: Dr Pedro Villarejo.
- Project of Health Research. Foundation for Health Research in Castilla La Mancha (DOCM No 124 of 16 June 2008): "Analysis of the prognosis - therapeutic utility of serum determination by polymerase chain reaction, PCR, and histologically by in situ, FISH, miR-21, microRNA21 in patients with colorectal cancer" (number PI-2008/16) hybridization PI: Dr David Padilla.
- Project: Gedi (Global Volume Diastolic) Versus PVC (Central Pressure Vein) In Control Blood Loss During Liver Resection Of Colorectal Metastasis who have received preoperative chemotherapy. IP: Dr Javier Redondo Calvo. Funding by Mutua Madrileña, Madrid, Spain. PI: DR Javier Redondo. 2013.
- "Selected avanced therapy for ovarian cancer using isolation, diagnosis and treatment of CD133 + CD44 + ovarian cancer stem cells after intra-abdominal citorreductive surgery and closed recirculation with CO_2 chemotherapy." Funding by AMUMA, Ciudad Real, 2014. PI: David Padilla-Valverde.
- "Individualized therapy in ovarian and pancreatic cancer by isolation, diagnosis and treatment of cancer stem cells after cytoreductive surgery and intraabdominal

chemohyperthermia closed recirculating with CO_2 chemotherapy." Funding by Roche Fundacion. 2014-2015. PIs: David Padilla-Valverde/Pedro Villarejo-Campos.

- Research project: "Technical and functional validation in animal model PRS equipment for treatment of peritoneal chemo-hyperthermia." 2009-2011. Departament of Animal Medicine and Surgery Autonomous University, Barcelona. Funding by: Biosurgical, SL. 2011.PI: Alberto Martinez.
- Research project: "Technical and functional validation in an animal model of the PRS equipment for chemo-hyperthermia bladder treatment." 2009-2011. Departament of Animal Medicine and Surgery. Autonomous University. Funding by: Biosurgical, SL. 2011. PI: Alberto Martinez.
- Principal co-investigator of the International LiverMetSurvey Project "Multidisciplinary treatment of colorectal liver metastases," 2007-2012. Funding by: Safonis Aventis. PI: Dr René Adams. 2007-2013.

Professional Appointments:

Line Cancer Research

- Co-principal investigator of the International Project, "LiverMetSurvey" "Multidisciplinary treatment of colorectal liver metastases," 2007-2016.
- Development of an Hipec Model for performing chemohyperthermia in patients with peritoneal carcinomatosis of gastrointestinal and ovarian origin.
- Development of filter systems for the isolation and treatment of tumor stem cells in drug recirculation during chemohyperthermia.
- Comprehensive Program, bi-directional and individualized treatment to improve the prognosis of tumors in advanced stage. Our group has technical and human resources to implement everywhere, everytime, an individualized program for patients with advanced pancreatic, bile duct, colorectal and ovarian cancer. We will perform surgical treatment, isolation, identification, characterization and tumor stem cell culture, by the use of locoregional chemohyperthermia.
- Research project: "Technical and functional validation in animal model of a PRS equipment for treatment of peritoneal chemohyperthermia." Department of Animal Medicine and Surgery. Autonomous University of Barcelona.
- Creation of the patent "recirculation system for hyperthermic perfusion and intra-abdominal chemotherapy, GST COMBAT PRS, Peritoneal QHT Team, GALMAZ SL" in a porcine model of peritoneal carcinomatosis (2009-2014).
- Development of a utility model for development of chemohyperthermia in patients with bladder cancer. Research project: "Technical and functional validation in animal model BRS bladder treatment equipment chemohyperthermia" (2009-2014). Department of Animal Medicine and Surgery. Autonomous University of Barcelona.
- Creation and development, of a murine model of peritoneal carcinomatosis with pancreatic neoplastic cell line, therapy with cytoreductive surgery and with intra-abdominal chemohyperthermia closed. Traslational Research Unit, Surgery Department and Laboratory Department of University General Hospital, Ciudad Real, Faculty of Medicine, UCLM.

Preclinical Development of anti-inflammatory and anti-cancer functionality of new synthetic products in collaboration with the, Castilla-La Mancha university, UCLM.

- "Treatment Of Sepsis And Septic Shock By Allicin (AJO Lyophilisate) + Black Garlic, as an adjuvant treatment to antibiotic treatment in An Experimental Model Of Bacterial Peritonitis."
- Allicin (AJO Lyophilisate) + Black Garlic As *In Vitro* Growth Inhibitor of cell lines colon carcinoma.
- Allicin + Black Garlic and Alterations of epithelial barrier function. Translational Research Unitand Surgery Group, HGUCR, Ciudad Real, Spain.

Implementation and Development of New Surgical Techniques

- Development and implementation of a program of cytoreductive surgery + HIPEC in ovarian and colon carcinomatosis.
- Developing a program of laparoscopic access Hepatobiliopancreatic Surgery (2009-2016).
- Developing a monitoring program of selective control of liver reserve in a model of volume restriction in liver surgery (2009-2016).
- Setting up a program of autologous islet Lagerhans transplant for patients with benign or malign pancreatic resection.

Agreements, Technological Merits

- Agreement between the Foundation "Mutua Madrileña" and the University General Hospital of Ciudad Real to promote collaboration in research, funding the study: GEDI (Global Volume diastolic) versus PVC (Central Pressure Vein) In Control Blood Loss During Liver Resection Of Colorectal Metastasis who have received preoperative chemotherapy PI: Dr Javier Redondo Calvo.
- Agreement between the Technology Institute of Environmental Chemistry (ITQUIMA), University of Castilla La Mancha and Translational Research Unit of the General Hospital of Ciudad Real. PIs: Dr. Javier Redondo, Dr. David Padilla, 2014-2016.

Patents

- Creation of an utility model "System for hyperthermic perfusion and recirculation intra-abdominal chemotherapy, GST COMBAT PRS, Peritoneal QHT Team, Galmaz S.L." porcine model of peritoneal carcinomatosis, 2008-2011, Faculty of Veterinary Medicine, Autonomous University, Barcelona. PI: Alberto Martínez Albalat/Dr Pedro Villarejo/Dr David Padilla.
- "Fluid Recirculation System," PCT/EP2011/006617 Biosurgical S.L. Creation and development of the patent "Agitation Apparatus" in a pig bladder carcinomatosis model, 2008-2011, Faculty of Veterinary Medicine, Autonomous University, Barcelona. PI: Alberto Martínez Albalat/Dr Pedro Villarejo/Dr David Padilla. "Agitation Apparatus," 1,220,306.

Others

- International Research Fellowship, Trauma Surgery and Intensive Care. Medical Center, University of Southern California. Los Angeles, California. 1998.
- International visitor, Liver Transplant Surgery Hepatobiliary and Pancreatic Surgery and, Department of Surgery. Queen Medical Hospital, Hong Kong.
- "Master in Medical and Clinical Management" (UNED), Spain. 2007-2009.
- Category C for the handling of animals used for experimental and other scientific purposes.

Current Development of Clinical Trials

- "GEDI (Global diastolic volume) versus PVC (Central venous pressure) in the control of blood loss and perioperative morbidity during liver parenchymal transection by hepatic neoplasms." PI: Dr Redondo Calvo.
- "Chemohyperthermia closed intraperitoneal paclitaxel in the treatment of ovarian carcinomatosis" No. EUDRACT: 2011-006319-69. PI: Dr Villarejo Campos.
- "Multicenter, randomized trial to evaluate the adjuvant effect of HIPEC-mitomycin C associated with surgery versus surgery alone in the T4 colorectal cancer." Colorectal carcinoma study. PI: Dr Sebastian Peña Ruffian.

Participation in Committees and Working Groups

- Working Group of Perioperative Medicine (2010-2012)
- Tissue Tumors Commission (2007-2011)
- Research Commission (2009-2011)
- Multidisciplinary Committee ofdigestive tumors (2007-2012)
- Coordinator of the Translational Research Unit, ITU, HGUCR, 2014-2016.
- Animal Experimentation Ethic Committee, HGUCR 2016 ·Member of Spanish Surgeon Society

Honors

- Top 20 awards, General Surgery and Digestive Diseases. Hospital Complex, Ciudad Real. Health and Consumer Affairs Ministry, 2004.
- Award for Best Scientific Communication in Medicine, "Angiogenesis and lymphangiogenesis in gastric cancer," presented at the XXI National Meeting of the Spanish Chapter of the ISDE (Madrid, April 2009).
- 2005 "Research projects Fiscam Award," "Serum growth factor of vascular endothelium in patients with colorectal cancer and its prognostic significance." 2005.
- Golden badge for David Padilla Valverde, as a member of hyperthermia Group, University General Hospital, Ciudad Real.
- Best Oral Communication Award, XVII National Meeting of the Spanish Association of Coloproctology, Mallorca, 2013, "Prognostic Utility of serum determination of microRNA-21 in patients with colorectal scanner functions."
- Prize for the best publication in 2013 in HGUCR: Villarejo-Campos P, D Padilla-Valverde, Martin RM, Menedez-Sanchez P, Cubo-Cintas T, Bondia-Navarro JA, Martín J. Serum VEGF and VEGF-C values before and after surgery postoperative treatment in gastric cancer. *Clin. Transl. Oncol*. 2012.

- "Dionisio Daza Chacon Award," 2013, for the study: Menendez p, Villarejo P, D Padilla Menendez JM, JA Rodriguez-Montes. "Diagnostic and prognostic utility of microRNA-21 in colorectal cancer." 2013.
- Best research work in health, University General Hospital, Ciudad Real, 2014, Development Of An Experimental Intraabdominal Chemohyperthermia Model With Closed Technique And CO_2 Recirculation System By Means Of Combat @ PRS-I.0.
- Accesit best oral communication "Utility of hyperthermic intra-abdominal chemotherapy by gemcitabine for inhibiting tumor progression in an experimental model of pancreatic peritoneal carcinomatosis, concerning their behavior with CD133 + CXCR4 + cancer stem cells." Biomedicina 2014, Ciudad Real, HGUCR, Spain.
- Accesit to best oral communication, "Utility of hyperthermic intra-abdominal chemotherapy by gemcitabine for inhibiting tumor progression in an experimental model of pancreatic peritoneal carcinomatosis, concerning their behavior with CD133 + CXCR4 + cancer stem cells." XX National Meeting of the Spanish Association of Surgeons, Granada 2015.
- Best communication, "Utility of hyperthermic intra-abdominal chemotherapy by gemcitabine for inhibiting tumor progression in an experimental model of pancreatic peritoneal carcinomatosis, concerning their behavior with CD133 + CXCR4 + cancer stem cells." IV National Congress of Surgical Oncology. SEOQ. Madrid, 2015.

Last Three Years Publications

- Garcia-Santos EP, Padilla-Valverde D, Villarejo-Campos P, Murillo-Lazar C, Fernandez-Grande E, Palomino-Muñoz T, Rodriguez-Martinez M,Amo-Salas M, Nuñez-Guerrero P, Sanchez-García S, Puerto-Puerto A, Martin-Fernandez J. The utility of hyperthermic intra-abdominal chemotherapy with gemcitabine for the inhibition of tumor progression in an experimental model of pancreatic peritoneal carcinomatosis in relation to their behavior with pancreatic cancer stem cells CD133 + CXCR4 + *Pancreatologya*, 2016. In Press.
- Intraperitoneal Hyperthermia Chemotherapy (HIPEC) for Peritoneal carcinomatosis of Ovarian Cancer Origin Fluids and CO_2 by a Recirculation Closed-Abdomen Technique (Combat PRS-1.0) Sanchez Garcia S, P Villarejo Campos, Padilla Valverde D, Martin *J. International Journal of Hyperthermia*, 2016; 7: 1-8. Articulo.
- Sanchez Garcia S, D Padilla Valverde, Villarejo Campos P, Martin Fernandez J, M Rojo Garcia, Rodriguez Martinez M, Experimental development of an intra-abdominal chemohyperthermia model with closed abdominal technique and CO_2 recirculation system by Means of PRS-I.0 *Combat. Surgery*, 2014; 155 (4): 719-25. Article.
- Pascual-Ramirez J, Sánchez García S, Gonzalez Ruiz de la Herran F, Villarejo Campos P, the Manzanara Cano Lopez C, Beech Palazuelo J, Valverde D Padilla, Martin Fernandez J. Security and efficiency of a closed-system, turbulent - intraperitoneal hyperthermic flow circuit for ovarian cytoreductive chemotherapy after surgery: perioperative outputs. *Arch. Gynecol. Obstet*., 2014, Feb. 1.DOI 10.1007/s00404-014-3153-4. Article.

- P Menendez, D Padilla, Villarejo P, Palomino T, P Nieto Menendez JM, JA Rodriguez-Montes. Prognostic Implications of serum microRNA-21 in colorectal cancer. *J. Surg. Oncol*. 2013 Nov; 108 (6): 369-73. Article.
- Menendez P, Villarejo P, D Padilla Menendez JM, JA Rodriguez Montes. Implications of the histological determination of microRNAs in the screening, diagnosis and prognosis of colorectal cancer. *J. Surg. Oncol*., 2013; 108: 70-3. Article.
- Menendez P, P Villarejo, Padilla D, Menedez J, Morales J. Diagnostic and prognostic significance of serum microRNAs in colorectal cancer. *J. Surg. Oncol.* 2013; 107: 217-2. Article.
- Garcia-Santos EP, MC Manzanares-Campillo, Padilla-Valverde D et al. Nesidioblastosis. A case of hyperplasia of the islets of Langerhans in the adult. *Pancreatology* 2013; 13: 544-8. Article.
- Villarejo-Campos P, D Padilla-Valverde, Martin RM, Menedez-Sanchez P, Cube. Tapes T, Bondia-Navarro JA, JM Fernandez. Serum VEGF and VEGF-C values before surgery and postoperative treatment after Transl. Oncol. in gastric cancer. *Clin* 2013; 15: 265-70. Article.
- New Roles of lymphangiogenesis in Cancer Spread. Villarejo-Campos P, D Padilla-Valverde, J. Sanchez Redondo – In: *The lymphatic System: Components, functions and diseases*. Ramirez C, Editor. Nova Science Publishers, 2016. Chapter Book.
- Villarejo Campos P, D Padilla Valverde, Eds. fatores gastric cancer and vascular endothelial growth. Prognostic value of serum levels of VEGF and VEGF-C. Saarbrucken, Alemania. Editorial Academic Spanish, 2013. Complete Book.
- Padilla D, JM Cano Garcia Red M, Palomar A. gastrointestinal stromal tumors (GIST). In: *Protocols Multidisciplinary Oncology*. Espinosa Arranz J. Aran Ediciones, Madrid 2013. pp. 510-15. CL.

In: Encyclopedia of Surgery (22 Volume Set)
Editors: Andreas Lehrer and Kristin Mueller
ISBN: 978-1-53618-329-0
© 2020 Nova Science Publishers, Inc.

Chapter 431

THE IMPACT OF SOCIAL MEDIA IN MEDICINE: AN EXAMINATION OF ORTHOPAEDIC SURGERY

Sergio M. Navarro[1], Heather S. Haeberle[1], Mary M. Cornaghie[1], Hafsah A. Hameed[1] and Prem N. Ramkumar[2,*]

[1]Department of Orthopaedic Surgery, Baylor College of Medicine, Houston, TX, US
[2]Orthopaedic & Rheumatologic Institute, Cleveland Clinic Foundation, Cleveland, OH, US

ABSTRACT

In medicine, the potential of social media is vast from a population health standpoint but limited by the concern of patient privacy. Orthopaedic surgery serves as an excellent case within medicine for its high volume, elective nature, less sensitive patient privacy concerns, and glaring need for patient reported outcomes. Furthermore, this increasingly popular modality serves as a revealing instrument for surveying the marketplace landscape, including hospital and surgeon perspective, to the end of characterizing and quantifying "word of mouth" effects in medicine as the health care economy becomes increasingly consolidated and competitive. Ultimately, the insights gained through our social media analysis of orthopaedic surgery may be applied to better understand and improve patient-perceived outcomes in all subspecialties of medicine and surgery.

Keywords: social media, orthopaedic surgery, outcomes

INTRODUCTION

Within the last decade, social media has exploded on the scene with the advent of continuous connectivity to web-based content and the popularization of mobile devices. Integrative platforms including Facebook, Twitter, and Instagram have invited users to

* Corresponding Author's Email: premramkumar@gmail.com.

connect online and readily publish content that includes their opinions and personal experiences. Initially used as a tool for individuals to connect with their personal networks, the rapid and broad adoption has facilitated the "small data" of individual social media content to be collected and analyzed as "big data." Many firms currently employ dedicated social media teams within their marketing department to gather and publish data as a way of readily engaging consumer bases and adapting to changing demands. In medicine, the potential of social media to provide population health data is vast but must be cautiously approached due to the concern of patient privacy and Health Insurance Portability and Accountability Act (HIPAA) regulations.

The subspecialty of orthopaedic surgery serves as an excellent case study for the power of social media within medicine for its high volume, elective nature, less sensitive patient privacy concerns, and glaring need for patient reported outcomes. Our studies have surveyed available social media channels primarily in the context of the orthopaedic patient for various injuries and deformities to arrive at generalizable conclusions that can be adapted to better meet patient expectations. In this chapter, we investigate the frequency, content, and value of the organic social media posts to the delivery of health care in the context of the patient, surgeon, and hospital in orthopaedics.

OVERVIEW OF SOCIAL MEDIA

The potential for the orthopaedic field to benefit from utilizing social media begins with understanding current social media platforms and the extent of their usership. In a 2016 article published by the New York Times discussing social media habits, it was reported that the average American has 5 active social media accounts and spends an average of 1 hour and 40 minutes a day browsing these sites [16]. Facebook continues to be the most popular of these social media platforms with a usership of 68% of adult Americans. Users reportedly spend an average of 50 minutes a day scrolling through newsfeeds, profiles, and posted photos or videos. While Facebook usage remains far ahead of that of other social media platforms, as the millennial generation expands their interest in social media, popularity of other social forums is surging. For example, 81% of millennials check Twitter at least once a day and 32% of the younger generations report that Instagram is the most important social media platform [7]. Twitter became popular for its novel concept of allowing users to share brief pieces of inconsequential information in a time sensitive manner, and now many rely on Twitter for major real-time news updates and events. In 2007, Twitter added the hashtag (#) feature because users wanted a way to be able to connect and interact with each other in groups regarding a specific topic. While Twitter executives did not want to divide the platform into groups, they did see potential in adding context to users' posts. By including a hashtag in a tweet, content may be filtered into groups based on shared context. Hashtags provide meta data for a twitter post, allowing users to access more information about current events and news both locally and worldwide. Because hashtags can be created and applied by any user, they have evolved into an effective way to follow any topic or conversation in real time.

As social media usership continues to increase, businesses have identified ways to tap into media platforms as a marketing approach. In 2016, over 50 million businesses were a

part of Facebook Business Pages and at least 2 million businesses use Facebook directly for advertising [7]. Facebook combines users' habits and interests to provide targeted advertising. This results in a powerful network for marketing that businesses are beginning to take advantage of. Besides directly using social media for advertising, businesses use the platform to share information about new additions to their services or as a platform for testimonials from clients. Social media can also provide businesses with valuable insight free of charge from potential consumers in real time about products, brands and services. In the past, firms would pay a substantial price for outside consulting agencies to provide such data from focus group interviews and surveys.

It is important to note that social media is ever changing. Ten years ago, providing content that could be rapidly disseminated to friends and family was the primary goal as Facebook developed the "status" and allowed photos or videos to be instantaneously shared with friends. Five years later, Instagram rose in popularity with the advent of photo and video-sharing through the use of photo editing with filters that glorify reality. Today, Snapchat and live streaming alternatives such as Facebook Live and Instagram Story are facilitating real-time unedited footage directly from a smartphone camera. According to survey data, in 2017, 43% of social media platforms plan to extend their content to include live streaming, up from 14% in 2016 [7]. The content of these live streaming events is difficulty to quantify as yet but represent new potential for capturing patient satisfaction and attitudes.

Patient Report Outcomes in Orthopaedic Surgery

Due to the increased cost and heavily elective nature of the field, orthopaedic surgery is under immense administrative scrutiny over outcomes. However, there is currently no perfect criteria to establish how effective, successful, or valuable a procedure is. Surgeons are instead relying on outcomes reported from patient to justify the benefits and costs of the rising demand for most orthopaedic procedures. These patient reported outcome measures (PROMs) are widely used in orthopaedics in an attempt to quantify the success of procedures. However, in a systematic review of 38 studies reporting on 47 different PROMs by Ramkumar et al., it was concluded that only 6 out of 38 surveyed studies acknowledged all of the "gold standard" metrics [13]. It is clear that a single, validated, reliable PROM including all of the "gold standard" measurements does not yet exist for orthopaedic procedures. Because no perfect functional measure exists, orthopaedic surgeons need an outcome metric that has both functional and subjective components. However, one of the limitations with the subjective PROM component is the difficulty of obtaining the data in a reliable and anonymous manner rather than a physician-administered measurement.

Thus far, the PROM has been one of the most successful assessments based on factors important to the patient's experience. A review study published by Nelson et al. reported that systematic use of PROMs led to enhanced communication and decision-making between patients and their physicians [10]. A large randomized trial across more than 20 primary care practices of 1,651 patients examining patient self-assessment data showed the use of PROMs improved the quality of interventional care received. Patients in this study reported that they felt their care had improved over the 2-year course of the assessment and that their doctors invested more time in interventional care [17]. Despite the perceived success of the PROMs,

they have some key limitations. Because patient outcomes are reported on a monitored health care platform, some patients may feel limited in their ability to be honest regarding their attitudes towards their physician experience. In addition, PROMs represent interval, not continuous, data that can be easily influenced by the attitude or mood of the patient at a given moment.

Role of Social Media in Orthopaedics

Social media platforms may offer unique insights into the patient perspective. Historically, word of mouth that has comprised physician referrals basis has occurred offline. Now, patients are rating and evaluating their doctors and surgeries publicly online. Given the complexity of medicine and health care, the gap between physicians' impressions of a patient's condition and the patient's own understanding of their conditions can be a barrier to satisfactory patient care. The healthcare community has recognized this disparity and attempted to address it with the advent of metrics that assess factors important to the patient's care. In addition, administration has begun to tie these patient satisfaction scores via the Press Ganey survey to physician and institution reimbursement [1,2]. Orthopaedic surgery, in particular, is challenging since establishing a satisfactory or ideal outcome remains difficulty to quantify and patient-dependent.

Social media analysis of patient posts can address some of the limitations of PROMs. First, given the nature of personal social media accounts to revolve around personal daily life activities, patients may feel more compelled to share honest opinions about their surgeries or their opinions of their physicians. Because platforms such as Instagram and Twitter were created for the purpose of sharing experiences, members of younger generations rely on these to connect with other members of their community. Physicians and healthcare organizations, limited by time and resources, could benefit from the virtual connections to patients through social media outlets. One study reported that patients feel more connected to their health care providers when their provider is accessible via a professional social media account [3]. In addition, the results of our forthcoming analysis in orthopaedic surgery show that patients most often use social media to document their personal priorities and outcomes.

While social media content analysis lacks full capacity to evaluate an orthopaedic intervention, it allows for quantification of benefit in ways that standard measures cannot. It can aid in establishing a mean timeline at which other patients undergoing the same surgery can expect to recover. Our analytical process of patient-centered social media posts provides the medical community with a novel way to measure the social media impact and perceptions of orthopaedic injuries and surgical intervention outside of the tradition PROM metrics. Additionally, social media analysis can be used to indirectly measure outcomes globally. The Global Social Media Impact Study sponsored by University College of London is investigating the use of social media in different countries across a 5-year span. The preliminary data reports that there is a stark difference in the content of various countries' social media posts. Some countries' social media usage focuses on economics by using social media to promote and sell clothing or home goods. Other countries primarily use social media as a means of news communication [5]. The variety of social media usage expands to health care consumption as well. For example, the UAE focuses on a patient-centered approach compared to the UK's universal health system [5]. These differences in health care delivery

have been identified by examining social media usage. In our work using social media outlets, we gained an improved understanding of patients, hospitals, and surgeons across various interventions and surgeries.

Social Media Methodology

Our research employs multimodal approaches to analyze data across social media platforms to assess the frequency and perspective from orthopaedic patients, surgeons, and hospitals. Analyses of published content on Instagram and Twitter by way of hashtag search represent a new method of gathering patient-reported outcomes with a unique firsthand view of unbiased patient attitudes that may corroborate or add to PROMs research. This analytical process provides the medical community with a novel way to prioritize how patients evaluate their recovery from orthopaedic surgery and share their care with the people they know. In a way, social media is able to capture the "word of mouth" effects that have historically generated referrals.

Filtering the public domain of Instagram and Twitter posts using relevant orthopaedic hashtags allows for a collection of a population of content referencing orthopaedic procedures, surgeons, and outcomes. After filtering for posts that featured only human subjects and referenced orthopaedics and musculoskeletal injuries, the authors were able to assess patient opinions and outcomes pre- and post- operatively. A categorical scoring system was used to analyze for the following: media perspective to determine who was publishing the post (patient, friend, or family of patient, business, or organization); tone (positive or negative); and content (education, advertisements, research, media coverage, or patient experience). Other methods may be used to quantify content and summarize outcomes. Secondary outcomes from social media included analysis of hospitals, subspecialty surgeons, and businesses as a surrogate of an analysis of the marketplace in health care. After data collection and scoring based on a set of parameters was completed, analysis was performed to assess the overall tone and content of patients' posts and absence or presence of reference to their surgeon or hospital.

Orthopaedic Patients on Social Media

Preliminary reports by the authors have indicated that the overwhelming majority of patients of orthopaedic surgeries tend to use social media to share personal photos following their operations with an overall positive tone. In the authors' preliminary report on total joint arthroplasty (TJA), including total knee arthroplasty (TKA) and total hip arthroplasty (THA), it was found that out of 1,287 posts that used social media to report on their primary joint replacement, 93.2% shared a message with a positive tone versus the 6.8% that posted with a negative attitude [15]. This trend may be due to the intentional effort of social media users to share only positive content, the actual positive effects of the joint replacement, or a combination of the two.

Patients across the subspecialties of orthopaedic surgery are relatively consistent in the type of posts they choose to share concerning their surgical experience. Nearly all of those who had undergone ACL surgery shared personal photos that were posted one week postoperatively, and the majority of these posts were associated with a positive tone [12].

Similar positive results were found with total knee arthroplasty patients, total hip arthroplasty patients, shoulder arthroplasty patients, rotator cuff patients, and ulnar collateral ligament reconstruction patients [14, 15].

The content of the images, however, varied slightly more but predominantly depicted rehabilitation, return to play (RTP), and surgical sites. ACL patients most commonly posted about rehabilitation followed closely by RTP and surgical site [12]. TJA patients posted equally about their rehabilitative journey as well as their return to activities of daily living (ADLs) [15]. Shoulder surgery patients (shoulder arthroplasty patients and rotator cuff repair patients) posted more so regarding their surgical site while patients of ulnar collateral ligament reconstruction (or "Tommy John" elbow surgery) posted more about their return to play. Understandably, these findings may be related to the nature of the patient population for the given surgery and their target social media audience [14].

Although most patients tend to focus on social media posts concerning their personal experience, a modest portion (23%) did also make references to their performing surgeons as well as the hospitals they were admitted to [14]. These references were commonly positive, reflecting the patient desire to include their physician as a contributor to their positive experience and to share that with their social circles. Outside of Instagram and Twitter social media use, patients often also take advantage of physician-rating websites to share their orthopaedic experiences. Five of the busiest physician-rating sites were analyzed for patient-published ratings and reviews for every orthopaedic surgeon listed. The overall orthopaedic surgeon rating was positive, ranking at 4.1/5 with no notable difference between academic and non-academic affiliated surgeons [9].

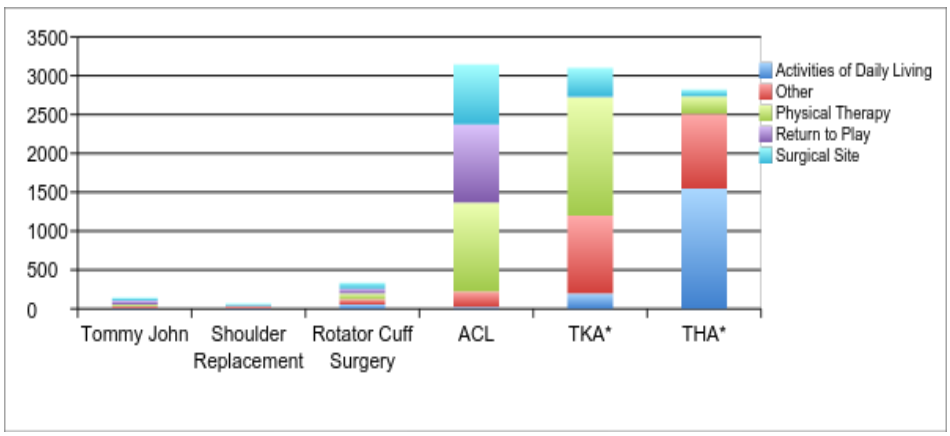

Other includes Education, Imaging, Industry Ads.
*Adjusted for six-month time frame to 2 year time frame.

Figure 1. Summary of analysis of patient social media content across six different orthopaedic procedures.

The use of social media data analytics may provide insights on how doctors and hospital organizations are using social media to enhance their practices by creating and maintaining an active social media presence. Indeed, an active social media presence may result in increased visibility that leads to increased elective surgical volume. One study by the authors evaluated the relative social media presence of surgeons specializing in shoulder and elbow surgeries. Less than half of surgeons who specialized in shoulder and elbow surgeries maintained active

Twitter accounts with an average of nearly 50 posts total. Among these surgeons maintaining a Twitter presence, the majority referenced their practice website and ways to schedule an appointment on their accounts. The study also found that all Top 5 US News and World Report orthopaedic surgery hospitals analyzed kept active Twitter accounts and participated much more, with an average of ~300 total posts. The content of the posts over a 2-year period focused more on education and community engagement rather than purely orthopaedic surgeries, with an even smaller amount related to shoulder and elbow surgeries [14]. Comparatively, more physicians specializing in ACL surgeries participated on social media via Twitter, although none were found to use Instagram. The hospitals analyzed in the context of ACL surgeries were found to use mostly Twitter and some used Instagram, where most of the posts on both platforms were centered on patients or celebrities [12].

Hospitals with a social media presence are working to capture the market and draw a greater patient population. This approach requires an investment of resources to adopt a connection between the hospital and online health consumers. The studies found that 19% of posts that hospitals shared on social media engaged with local community efforts and promoted prominent celebrities [14]. Additionally, hospitals often shared patient stories and experiences as a means to emphasize the importance of patient-centered health care. Similarly, there was an increased tendency to involve mid-level providers, such as physician assistants and nurse practitioners, in the hospital social media presence. This effort directly reflects the strategic response of hospitals to the growing number of non-physician providers who dedicate more bedside time to patients than physicians themselves and thus may act as a greater influence on the patient experience. Because potential patients now have the ability to easily compare several providers and hospitals with more information through better accessibility via the internet, hospitals that strategically invest resources into a social media presence may maintain an advantage with a higher likelihood to thrive in the healthcare market competition [12].

Limitations

Despite the conclusive findings through these social media analyses, it is important to note several limitations regarding patient posts based on population strata and personal biases, among others.

Social media use requires a population with access to smart phones and Internet as well as with sufficient technological literacy to navigate through the social media sphere. This may limit the population size of orthopaedic patients to a skewed population pool, which depending on the social media platform, may favor a higher proportion of younger patients. Additionally, social media users include both actively engaged participants and silent users who follow social media without contribution. Also, our studies were only able to capture public, not private, posts with hashtags, which understates the actual number of relevant posts [4].

Social media users maintain the potential to misrepresent and manipulate events in deliberate attempt to stage a public perception. To this end, one common criticism of frequent social media users is their predilection to glorify or self-promote themselves and their achievements, resulting in a false impression of reality that may either overstate the positive tone or exaggerate relatively minor negative events [12]. This may mean that individuals are

generally inclined to share material via social media when they feel an extreme sense of positivity or negativity associated with their experience. In an online community of social media users, there may be a trend to impress one another with their actions. Thus, this tendency to share extremely positive or negative experiences may skew the sample of posts analyzed in these studies.

It is important to note that a user may post multiple times with the same hashtag, resulting in a skew in the patient representation that may need to be adjusted in data content analysis. On this note, social media posts are often shared with a specific intention or directed purpose, which influences the content and tone of content on an ongoing basis. These limitations indicate a significant portion of orthopaedic patients whose presence on social media is greatly overshadowed by more active users.

Companies that utilize social media may also manipulate the messages they post to promote their products or services to their target patient audience. Stem cell therapy businesses that were studied were found to utilize a network of physicians that tend to advertise predominantly positive outcomes and broadly invite patients to seek treatments. Online strategies, such as the application of several hashtags, were employed by businesses to enhance visibility. However, the patient-published posts showed mixed results in visibility. This report highlighted that businesses were possibly leveraging social media with direct-to-consumer advertising that may mislead patients by illustrating only positive results without providing clear information regarding the risks, benefits, and limitations of the therapies. The authors proposed the need for increased regulation with sanctions to prevent businesses and physicians from advertising for therapies that as yet remain unproven [11].

Furthermore, the global coverage of social media may be diffuse and scattered. The analysis conducted on stem cell therapy content in social media showed that there was a preponderance of social media content centered from the United States, with secondary content located in the Indonesia, U.K., Canada. This means that penetrance of market and associated social media content may vary considerably according to the platform used and the target consumer group [11].

Another issue that arises when analyzing social media is the extent to which context plays a role on the meaning and interpretation of users' posts. Not only does this include the personal and social environment that influences an individual's post, but also the chronological context. With the progression of time comes advances in technology and proportional changes in the nature of social media. Although these changes occur gradually day-by-day, analyzing trends from a larger time scope too easily generalizes the transition and ignores important pivots in social media content. For example, realizing the change between posts of texts, pictures, and videos is second of importance to noting when and why social media users promoted the transition. However, evaluating these time-based changes requires constant and active analysis of individual social media and making connections, and this poses a difficulty in social media analysis.

OVERCOMING LIMITATIONS

To overcome these limitations, it is imperative to interpret data from these social media platforms qualitatively, not quantitatively. To do so, social media should be "listened" to, rather than used to support or reject a preconceived hypothesis. Large numbers of patients presenting a certain perception about orthopaedic care may offer important insight; however, even the few that seem to swim against the current can offer valuable constructive information that may result in long-term higher quality patient care. Acknowledging the presence of individuals who challenge the general consensus as well as understanding the context from which their sentiment stems provides indispensable insight into all recipients of orthopaedic care, not just the majority opinion. This integration of a qualitative approach to quantitative data will allow for directed improvements by addressing overlooked concerns and for better management of orthopaedic patient satisfaction [4].

A STEP INTO THE FUTURE

This research has the potential to affect the way physicians interact with their patients. Physicians and health care providers have the accreditation to speak on the topic of health care consumption. Physicians may feel that because of HIPAA concerns or hospital policy it is not permissible to share experiences and insight on social media platforms. Yet, physicians and healthcare providers should consider "owning" their own social media presence, using it as a tool to provide support to patients and their practices while still maintaining patient confidentiality.

This analysis of social media utilization in orthopaedic surgery serves as an excellent case study for the possibilities of future insight into other specialties and platforms. While social media may not be easily incorporated into every practice or hospital setting, there are certain referral-based medical and surgical subspecialties that may directly benefit from the insight that social media has to offer into their marketing portfolio.

In the future, social media data analysts expect the role of data science to become increasingly useful. A recent report published by the Harvard Business Review outlines that data scientists are becoming more proficient at leveraging social media data to make

decisions to improve advertising that result in increased consumer interest and revenue streams [8]. A similar strategy could be employed by academic and private hospital institutions and small private practices to improve patient interest in increasing referrals and gaining market access in new, innovative procedures.

Social media data analysts expect that social media platforms will continue to play a role in increased dialogue in the online marketplace, serving as a source of educational and informational utility to prospective patients and would-be-consumers. Furthermore, other social media platforms may play a role in "word of mouth" type referrals to follower and friend audiences, as they already do to some degree. Social data engineers have cited the role of friends in decision-making points, with determining what household appliances to purchase to which hospitals provide the best point-of-care for certain rare diseases. Finally, we expect to continue to see a growing role in terms of how feedback is based back to physicians, along with continued depiction of real time results from patients to prospective patients. Other specialties outside of orthopaedics have seen a growth in social media usage; in particular, dermatology and plastic surgery have seen growth in content across platforms [6].

CONCLUSION

Social media content has proven to be a unique and powerful tool for investigating the patient perspective, whether in orthopaedic surgery or other specialties. This data provides insights into the factors that are most important to patients, including ADLs and rehabilitation, which can guide patient counseling and improve expectation management with the enhanced understanding of outcomes. Furthermore, this increasingly popular modality serves as a revealing instrument for surveying the marketplace landscape, including hospital and surgeon perspective, to the end of characterizing and quantifying "word of mouth" effects in medicine as the health care economy becomes increasingly consolidated and competitive. Ultimately, the insights gained through our social media analysis of orthopaedic surgery may be applied to better understand and improve patient-perceived outcomes in all subspecialties of medicine and surgery.

REFERENCES

[1] Chughtai, M. et al. "Do Press Ganey Scores Correlate with Total Knee Arthroplasty-Specifc Outcome Questionnaires in Postsurgical Patients". *Journal of Arthroplasty* (2017). https://www.ncbi.nlm.nih. gov/pubmed/28189440.

[2] Chughtai, M. et al. "What Influences How Patients Rate Their Hospital After Total Knee Arthroplasty". *Surgical Technology International* (2016): 261-5. https://www. ncbi.nlm.nih.gov/pubmed/ 27042784.

[3] Farnan, J. M. et al. "Online Medical Professionalism: Patient and Public Relationships: Policy Statement from the American College of Physicians and the Federation of State Medical Boards*". Annals of Internal Medicine* 158(8) (2013): 620-627. http://annals.org/aim/ article/1675927/online-medical-professionalism-patient-public-relationships-policy-statement-from-american.

[4] Fournier, Susan et al. "To Get More Out of Social Media, Think Like an Anthropologist". *Harvard Business Review* (2016). https:// hbr.org/2016/08/to-get-more-out-of-social-media-think-like-an-anthropologist.

[5] Haynes, Neil. "The Value of Social Media". *Presented at the annual meeting for the American Anthropological Association conference* in Minneapolis, Minnesota, USA, November 2016.

[6] Li, Michael et al. "Better Questions to Ask Your Data Scientists". *Harvard Business Review* (2016). https://hbr.org/2016/11/better-questions-to-ask-your-data-scientists.

[7] Lister, Mary. "*40 Essential Social Media Marketing Statistics for 2017*". WordStream, January 20, 2017. Accessed February 14, 2017. http://www.wordstream.com/blog/ws/ 2017/01/05/social-media-marketing-statistics.

[8] McAfee, Andrew and Brynjolfsson, Erik. "Big Data: The Management Revolution". *Harvard Business Journal* (2012). https:// hbr.org/2012/10/big-data-the-management-revolution.

[9] Navarro, Sergio et al. "The Patient Experience: A Review of Orthopaedic Surgeon Quality on Physician-Rating Sites Orthopaedic Surgeons on Rating Sites". 2017 *Orthopedic Research Society Annual Meeting*. San Diego, CA, March 2017.

[10] Nelson, Eugene C., Eftimovska, Elena, Lind, Cristin et al. "Patient Reported Outcome Measures in Practice". *British Medical Journal* (2015).

[11] Ramkumar, Prem N. et al. "Cellular Therapy Injections in Today's Musculoskeletal Market: A Social Media Analysis. Submitted to *Clin Orthop Relat Res* (2017).

[12] Ramkumar, Prem N. et al. "Integrating Social Media and Anterior Cruciate Ligament Surgery: An Analysis of Patient, Surgeon, and Hospital Use". *The Journal of Arthroscopic and Related Surgery* 33 (3) (2017): 578-585. http://www.arthroscopy journal.org/article/ S0749-8063(16)30653-3/references.

[13] Ramkumar, P. N., Harris, J. D., Noble, P. C., "Patient-reported Outcome Measures after Total Knee Arthroplasty". *Journal of Bone and Joint Research* 4 (2015): 120-127.

[14] Ramkumar, Prem N. et al. "Social Media in Shoulder & Elbow Surgery: An Analysis of Patient, Surgeon, and Hospital Use". Submitted to *J Shoulder Elbow Surg* (2017).

[15] Ramkumar, Prem N. et al. "Social Media and Total Joint Arthroplasty: An Analysis of Patient Utilization on Instagram". Submitted *to J Arthroplasty* (2017).

[16] Stewart, James B. "Facebook Has 50 Minutes of Your Time Each Day. It Wants More". *New York Times,* May 5, 2016. Accessed February 16, 2016. https://www.nytimes.com/ 2016/05/06/business/ facebook-bends-the-rules-of-audience-engagement-to-its-advantage.html?_r=0.

[17] Wasson, J. H. Et al. "A randomized trial of the use of the patient self-assessment data to improve community practices". *Effective Clinical Practice* 2(1) (1999): 1-10. https://www.ncbi.nlm.nih.gov/ pubmed/10346547?access_num=10346547&link_type= MED& dopt=Abstract.

In: Encyclopedia of Surgery (22 Volume Set)
Editors: Andreas Lehrer and Kristin Mueller
ISBN: 978-1-53618-329-0
© 2020 Nova Science Publishers, Inc.

Chapter 432

QUALITY OF LIFE CHANGES RELEVANT TO EXTENT OF THYROID SURGERY

Fatima Z. Syed*, MD
Division of Endocrinology, Jefferson Medical College and Hospital,
Philadelphia, PA, US

ABSTRACT

One of the most frustrating facets of clinical thyroidology is to deal with the unhappy patients who have iatrogenic post-surgical hypothyroidism. These patients frequently have complaints of brain fog, weight gain and fatigue without any easy "fix."

These symptoms predominate frequently in the post-operative patient and are obviously real because they occur so frequently! "Prevention is better than cure" so we need to, where appropriate, minimize the extent of thyroid surgery as it would appear that some endogenous remaining thyroid hormone minimizes these symptoms as opposed to no endogenous thyroid function where these symptoms predominate. Future efforts need to be directed to more adequately defining appropriate thyroid hormone replacement and which compounds fare best? Finally perhaps the future rests on stem cell or related technique to retain endogenous thyroid hormone function?

Dr Syed addresses these issues in her narrative and provides some guide in minimizing extent of thyroid surgery where appropriate as well as attempts to appropriately replace physiological thyroid hormones and which compounds to use?

CASE REPORT ONE

Mrs. DS is a 65 year-old Caucasian female with history of well-controlled hypertension. Four years ago, she presented with a left sided two-centimeter thyroid nodule. Biopsy was consistent with papillary thyroid cancer, classical variant. She underwent a total thyroidectomy. Pathology was consistent with papillary cancer classic type 2cm in size. She did not have vascular invasion nor did she have any lymph node involvement. She did not

* Corresponding Author's Email: Fatima.syed@jefferson.edu.

receive radioactive iodine. Today, she presents to you for follow-up. At each visit in the last four years, she complains of fatigue, which did not exist prior to her surgery. Utilizing the Brief Fatigue Inventory, she states that she is fatigued at a score of 7/10 currently. At her worst, her fatigue is 10/10. Most of the time, she lives near a fatigue score of 8/10. She states that the fatigue affects her mood, her ability to exercise, and has interfered with work. She had planned on working into her 70s but states she feels so tired, she retired from her work as an accountant last year. She attributes the fatigue beginning after her thyroidectomy. She has been on a steady dose of levothyroxine 112 mcg for many years and has been biochemically euthyroid at your last five visits together. She ends the appointment by stating, "I wish I had never gotten my thyroid removed."

CASE REPORT TWO

Ms. Y is a 33 year-old East Asian female with history of papillary thyroid cancer status post total thyroidectomy here for follow-up. Three years ago, during a routine GYN visit, she was noted to have a right-sided thyroid nodule. She had no history of radiation in the past and she had no family history of thyroid cancer or other malignancies. She underwent a biopsy of the nodule, which came back as papillary thyroid cancer. She underwent total thyroidectomy and had a 3 cm nodule with classical PTC showing lymphovascular invasion. She received radioactive iodine as well. She comes today for follow-up. She is on levothyroxine at 100 mcg daily. She has been biochemically euthyroid for over one year. She complained of having low energy. She feels she is not functioning as well as she should and sleeps poorly at night. She screens negative for depression and has no other medical issues or stressors. She does have an eight month old daughter. However, her daughter is sleeping through the night and she does not believe motherhood is the source of her fatigue. She states that since her thyroidectomy and starting thyroid replacement, she has never felt the same.

CASE REPORT THREE

Mr. W is a 46 year-old who was diagnosed with papillary thyroid cancer, classic variant seven years ago upon discovering a palpable nodule on the right side of his thyroid whilst shaving one morning. He underwent biopsy, which showed the results as stated. He has no exposure to radiation. His mother also had papillary thyroid cancer and underwent total thyroidectomy. He was referred for surgery. It was ultimately decided that patient would undergo a right lobectomy as the nodule was only 2cm in size. Pathologically the right lobe showed 18mm papillary thyroid cancer without lymphovascular invasion. Post-operatively his thyroid function remained within normal range without the need for thyroid hormone replacement. He did however have minimal weight gain and complaint of fatigue in follow up.

INTRODUCTION

"I haven't been the same since my thyroid was removed." This is a common complaint endocrinologists hear from patients who have undergone total thyroidectomy. Before examining symptoms associated with thyroidectomy, it is first important to understand the role of the thyroid and the effects and treatment of hypothyroidism. The most common cause of hypothyroidism globally is iodine deficiency [1] Vanderpump, 2011. However, in the United States and other developed nations, the most common cause of hypothyroidism is autoimmune thyroid disease [2] Haugen et al., 2015. Amongst leadership in clinical guidelines, screening for hypothyroidism is not generally recommended. However, in cases of other autoimmune disease, family history, history of radiation, or personal history of thyroid surgery, screening of thyroid function is recommended. Of course, if a patient has symptoms of hypothyroidism, he or she should be screened [2, 3] Haugen et al., 2015, Garber et al., 2012.

Patients who have their thyroid gland surgically or radioactively removed require lifelong thyroid replacement [2] Haugen et al., 2015. Typically, thyroid replacement involves replacing levothyroxine at 1.6 micrograms/kilogram for all patients [4] Devdhar et al., 2011, regardless of the etiology of hypothyroidism. However, according to the American Thyroid Association, patients who have had surgical thyroidectomies may require more replacement [2] Haugen et al., 2015. This can be adjusted based on symptoms of the patient. Thyroid replacement is therefore based on both qualitative and quantitative measures.

Traditionally, patients that are status post thyroidectomies TSH are initially suppressed and then are maintained to be biochemically euthyroid [5] Massolt et al., 2016. However, in our case reports above, we find a common complaint amongst these patients is that they may not feel as they did before thyroidectomy, despite effective treatment of thyroid hormone replacement. The aim of this chapter is as follows:

1. Examine quality of life for patients who have undergone thyroidectomies
2. Understand the objective measurement tools of quality of life
3. Review treatment options of PTC and examine morbidity and mortality associated with PTC
4. Understand the perceptions of lobectomy versus thyroidectomy

OBJECTIVE MEASUREMENTS OF QUALITY OF LIFE

In evaluating patients with history of thyroidectomies, it is important to ask the symptoms the patient experiences as well as if those symptoms are tolerable or not. This can help guide supportive care for the patient. Several objective measures on quality of life can be applied to patients who have had total thyroidectomies.

Massolt et al. describe the following quality of life measures [5].

Thyroid Specific Patient Reported Outcome Measures (ThyPRO)

This is a qualitative survey containing eighty-five questions summarized in 13 scales. It accounts for cross-cultural [6, 7] Bukvić et al., 2015, Watt et al., 2015 and socio-economic validity [5] Massolt et al., 2016..

Multidimensional Fatigue Index (MFI-20)

This is a twenty-question survey which evaluates generalized fatigue, physical fatigue, mental fatigue, reduced motivation and reduced activity [5, 8] Massolt et al., 2016, Smets et al., 1996.

RAND-36

This is a validated Dutch survey on evaluating overall health in the prior thirty days [9] VanderZee et al., 1996. It consists of nine subclasses, including physical health problems, limitations of emotional and general health care needs.

Cancer Quality of Life Survey

This is a survey typically for patients before and after chemotherapy, however it is also helpful in evaluating depression and fatigue in patients with history of cancer [5] Massolt et al., 2016.

THYROIDECTOMY PATIENTS PERCEPTIONS OF QUALITY OF LIFE VS AGE NORMATIVE POPULATIONS

In a study by Husson et al, quality of life of patients with thyroidectomy is compared to age normative populations [10]. Consistently, it is found that patients with thyroidectomy have decreased quality of life compared to age normative populations. Patients with thyroid cancer have comparable life expectancies as patients without thyroid cancer [11], Links et al., 2005. Given the length of life expected by these patients, according to the study, any impacts to quality of life become concerning. The study aims to "assess [thyroid cancer specific] Health Related Quality of Life (HRQoL) among long-term thyroid cancer survivors and to compare this with the HRQoL of an age- and sex-matched normative population. Secondly, our aim was to investigate which clinical and socio-demographic characteristics and thyroid cancer specific problems were associated with HRQoL"[10] Husson et al., 2013.

The study surveyed patients over a twenty-year period of new patients diagnosed with thyroid cancer. It used objective surveys to assess disease specific symptoms. These scores were then compared with age and sex matched disease free controls. Confounding factors such as socio-economic status were addressed[10] Husson et al., 2013.

The study found that "Thyroid cancer survivors had significantly lower scores on physical, role, emotional, cognitive and social functioning ($p < 0.001$) compared to the normative population after adjusting for comorbidities. Sympathetic problems [feeling chilly (52%), hot flushes (40%)], neuromuscular problems [cramp legs (43%) and pain joints/muscles (64%)] and abrupt attacks of fatigue (50%) were the most often reported thyroid cancer specific complaints. Thyroid cancer specific neuromuscular, concentration, sympathetic and psychological problems explained 41–58% of the variance in HRQoL. Clinical and socio-demographic factors explained a small part of the variance in (thyroid cancer specific) HRQoL (1–27%)"[10] Husson et al., 2013.

Further studies have shown that patients with thyroid cancer who have undergone thyroidectomy are at higher risk of unemployment[12] Ratzon et al., 2016. Patients report fatigue as reasons for unemployment. It is difficult to correlate fatigue alone as reason for unemployment, which is a complicated issue. However, the correlation with thyroid cancer survivorship does indeed exist[12] Ratzon et al., 2016.

Overall, patients who have thyroid cancer and survived will likely have worse quality of life had they never had thyroid cancer and required a thyroidectomy [13] Lee et al., 2010. There is not objective data as to why patients with thyroidectomy have worsened quality of life. Obvious thought is that the thyroid is produces some endogenous substance [5] Massolt et al., 2016, which contributes to energy that is beyond thyroid hormone alone. Additionally, many with PTC have some component of autoimmune thyroid disease [2] Haugen et al., 2015. Autoimmunity itself may not disappear after surgery, and it is possible, this is causing the residual fatigue and impairment to perceived quality of life [5, 14] Massolt et al., 2016, Hirsch et al., 2009.

THYROIDECTOMY VERSUS LOBECTOMY IN TREATMENT OF THYROID CANCER AND EFFECTS ON QUALITY OF LIFE

According to a study done at Memorial Sloan Kettering over a twenty- year period, there was no difference in mortality in patients who received a total versus partial lobectomy for non-invasive thyroid cancer [15] Nixon et al., 2012. This study only included patients with thyroid cancers that were less than or equal to 4 cm in size and with no known invasion of lymph nodes or spread outside the neck. "A total of 361 patients were treated with lobectomy and 528 were treated with total thyroidectomy. As expected, the survival at 10 years was high in both groups of patients (93% in the lobectomy and 91% in the total thyroidectomy group). There were no significant differences in 10 year survival or thyroid cancer recurrence between the two groups of patients. Both age greater than 45 and male gender were predictive of a worse overall survival, while the type of surgery had no effect on survival" [15] Nixon et al., 2012.

According to Husson et al. and other studies, patients with lobectomy still report worse quality of life in comparison to those without thyroid cancer [10].

CONCLUSION

In all three cases, the commonality was that patients felt worse after thyroidectomy than before. There are many reasons this could be the case. In those with cancer survivorship in general, quality of life is perceived worse after cancer than before even decades after cure [16] Schlumberger M, 1999. Therefore, thyroid cancer, although mostly has high levels of long term survivorship, is not different than other cancers. Perhaps evaluating patients' quality of life before and after would be helpful in evaluating their perceptions of symptoms. Also in low risk thyroid cancer perhaps minimalistic surgery (lobectomy), leaving patients with some functioning thyroid tissue of their own, may alleviate some of the fatigue and weight gain attendant with total thyroidectomies without compromising longevity nor recurrence risk?

REFERENCES

[1] Vanderpump MP. The epidemiology of thyroid disease. *Br Med Bull.* 2011;99(1):39-51.

[2] Haugen BR, Alexander EK, Bible KC, Doherty GM, Mandel SJ, Nikiforov YE, . . . Wartofsky L. 2015 American Thyroid Association management guidelines for adult patients with thyroid nodules and differentiated thyroid cancer: the American Thyroid Association guidelines task force on thyroid nodules and differentiated thyroid cancer. *Thyroid.* 2015;26(1):1-133.

[3] Garber JR, Cobin RH, Gharib H, Hennessey,JV, Klein I, Mechanick JI, . . . Woeber KA. Clinical practice guidelines for hypothyroidism in adults: Cosponsored by the American Association of Clinical Endocrinologists and the American Thyroid Association. *Thyroid.* 2015;22(12):1200-1235.

[4] Devdhar M, Drooger R, Pehlivanova M, Singh G, Jonklaas J. Levothyroxine replacement doses are affected by gender and weight, but not age. *Thyroid.* 2011;21:821–827.

[5] Massolt ET, van der Windt M, Korevaar TI, Kam BL, Burger JW, Lehmphul I, …, Peeters RP. Thyroid hormone and its metabolites in relation to quality of life in patients treated for differentiated thyroid cancer. *Clin Endocrinol (Oxf).* 2016;5(13).

[6] Bukvić B, Živaljević V, Šipetić S, Diklić A, Taušanović K, Paunović I. Validation and cross-cultural adaptation of the questionnaire ThyPRO in thyroid patients in Serbia. *Vojnosanlt Pregl.* Jul 2015;72(7):583-8.

[7] Watt T, Barbesino G, Bjorner JB, Bonnema SJ, Bukvic B, Drummond R, …, Feldt-Rassmussen U. Cross-cultural validity of thyroid-specific quality-of-life patient-reported outcome measure, ThyPRO. *Qual Life Res.* Mar 2015;24(3):769-80.

[8] Smets EM, Garssen B, Cull A, de Haes JC. Application of multidimensional fatigue inventory (MFI-20) in cancer patients receiving radiotherapy. *Br J Cancer*. Jan 1996;73(2):241-5.

[9] VanderZee KI, Sanderman R, Heyink JW, de Haes H. Psychometric qualities of the RAND 36-Item Health Survey 1.0: a multidimensional measure of general health status. *Int J Behav Med.* 1996;3(2):104-22.

[10] Husson O, Haak HR, Bufart LM, Nieuwlaat WA, Oranje WA, Mols F, … van de Poll-Franse LV. Health-related quality of life and disease specific symptoms in long-term thyroid cancer survivors: a study from the population-based PROFILES registry. *Acta Oncol.* Feb 2013;52(2):249-58.

[11] Links TP, van TOL KM, Jager PL, Plukker TM, Piers DA, Boezen HM, … Sluiter WJ. Life expectancy in differentiated thyroid cancer: a novel approach to survival analysis. *Endocr Relat Cancer*. Jun 2005;12(2):273-80.

[12] Ratzon NZ, Uziely B, de Boear AG, Rottenberg Y. Unemployment risk and decreased income two and four years after thyroid cancer diagnosis: a population-based study. *Thyroid.* Sept 2016;26(9):1251-8.

[13] JI Lee, Kim SH, Tan AH, Kim HK, Jang HW, Hur KY, …, Kim SW. Decreased health-related quality of life in disease-free survivors of differentiated thyroid cancer in Korea. *Health Qual Life Outcomes.* 2010;8:101.

[14] Hirsch D, Ginat M, Levy S, Benbassat C, Weinstein R, Tsvetov G, …, Reicher-Atir R. Illness perception in patients with differentiated epithelial cell thyroid cancer. *Thyroid*. May 2009;19(5)459-65.

[15] Nixon IJ, Ganly I, Patel SG, Palmer FL, Whitcher MM, Tuttle RM, …, Shah JP. Thyroid Lobectomy for treatment of well differentiated intrathyroid malignancy. *Surgery*. Apr 2012;151(4):571-9.

[16] Schlumberger MJ. Diagnostic follow up of well differentiated thyroid carcinoma: historical perspectives and current status. *J Endocrinol Invest.* 1999;22(11 Suppl):3–7.

In: Encyclopedia of Surgery (22 Volume Set)
Editors: Andreas Lehrer and Kristin Mueller
ISBN: 978-1-53618-329-0
© 2020 Nova Science Publishers, Inc.

Chapter 433

ROBOTIC SURGERY FOR PROSTATE CANCER: FUNCTIONAL AND ONCOLOGICAL OUTCOMES IN A LAST GENERATION REFERRAL CENTER

Elio Mazzone, Riccardo Bientinesi, Carlo Gandi, and Pier Francesco Bassi and Emilio Sacco
Urologic Department, Agostino Gemelli Universitary Hospital Foundation, Catholic University Medical School of Rome, Italy

ABSTRACT

Objective. Robot-assisted laparoscopic radical prostatectomy (RARP) has been introduced from more than fifteen years and has rapidly become the main surgical option for localized prostate cancer. Our aim was to report complications, intraoperative outcomes, postoperative oncological and functional outcomes in a recent series of RARP performed in a robotic surgery referral centre of last generation.

Patients and Methods. Between January 2013 and January 2015, 164 consecutive patients (mean age 65.2 ± 6.8) underwent RARP at our centre. 52 RARP were performed with a nerve-sparing (NS) technique. Oncological outcomes were reported as positive surgical margins (PSM) and 1-yr biochemical disease-free survival (1y-bDFS). Biochemical recurrence was defined as a repeated prostate-specific antigen >0.2 ng/ml. Urinary continence was evaluated using the University of California-Los Angeles Prostate Cancer Index-Urinary Function (UF) score (1-100) and pad use. Sexual function was evaluated using the UCLA PCI-Sexual Function (SF) score (1-100) and the Erection Sufficient for Intercourse (ESI) criteria. To evaluate the learning curves, we equally divided patients into eight groups (case orders) based on the time of surgery and compared mean blood loss, mean operation time, functional results and PSM among patients groups.

Results. The mean intraoperative blood loss and the mean operative time were respectively 284.4 ± 110.4 ml and 146.5 ± 40.1 minutes. There were 1.2% major (Clavien III-IV) and 7.9% minor (Clavien I-II) postoperative complications, with no mortality. The overall prevalence of PSM was 30.5% (50/164). The PSM rate for pT2 and pT3 disease was 23.6% and 57.6%, respectively. At multivariate logistic regression analysis,

postoperative Gleason grade was the only independent predictor of PSM (OR 3.81; 95%CI 1.65-8.84; p = 0.002).

A nerve-sparing procedure did not affect the risk of PSM. In patients with at least 1-yr follow up, 1y-bDFS was 90.8%. At a median follow-up of 18 months, 71 patients (72%) were fully continents. The mean UCLA PCI-UF score was 71.3 ± 27.9 (0–100). On multivariable logistic regression, age (OR 0.881; 95%CI 0.79-0.98; p = 0.02) and pathologic Gleason Score (OR 0.118; 95%CI 0.05-0.69; p = 0.012) were independent predictors of continence recovery. Considering only patients who undergo NS technique, potency rate was 50% according to ESI criteria, and mean UCLA PCI-SF score was 46.5 ± 32.6 (1–100). The learning curve effect was observed for mean blood loss and mean operation time, which significantly decreased throughout case orders (p < 0.001). No significant learning curve effects were observed in oncological and functional outcomes.

Conclusion. RARP appears to be a safe procedure in last generation centres, with a very low complication rate and blood loss. Oncological and functional outcomes are overall in compliance with that reported in the recent literature. The learning curves analysis showed that intraoperative outcomes improve after a relatively small number of cases, while oncological and functional outcomes remain unchanged overtime and may need more time for further improvement. Long-term, prospective, and possibly randomized studies are needed.

1. INTRODUCTION

The history of robotic surgery started 20 years ago. Robotic surgery aims to improve the advantages and the results of the mini-invasive video-assisted surgery while simplifying the surgeon's job. Actually, the term tele-surgery is more specific because the surgeon manages instruments similar to those used in laparoscopy while remaining located at a specific console rather than at the operation table. The most recent and advanced *da Vinci*® surgical system (Intuitive Surgical, Inc.) is composed from three main parts. The first part is the console, set up on a distance from the operation table. The first operator controls the console while the assistant provides the instrumental equipment to the robotic hand and the inserting it to the patient's body. The second part is the surgical trolley equipped with four hands that are all capable of setting up a wide range of surgical instruments. The third part is the visualization system that provides a magnified three-dimensional image of an operation area. The use of the robot involves significant advantages in front of the video-assisted mini-invasive surgery. The *da Vinci*® robot increases the dexterity of the operator and allows more accurate eye-hand coordination, favours more ergonomic position of the console and improves vision with a three-dimensional image. In addition, the robot eliminates the trembling of the hands and improves the movement of the surgical instruments thanks to the *Endo-Wrist*® technological system. Comprehensively, the learning phase becomes faster, especially for surgeons experienced with video-assisted mini-invasive laparoscopic surgery. However, there are some disadvantages such as the loss of a tactile sensation and tension sensibility, which could provoke unperceived lacerations of organs or tissues. Furthermore, the positioning of the instrumentation atop the patient (the pre-operative preparatory procedures) requires some additional time and particular knowledge of the operational stuff, extending operative and narcosis time.

The first procedure of robot-assisted radical prostatectomy (RARP) was performed in Frankfurt, in May 2000, by a team of surgeons without any specific preparation in laparoscopy. The team followed partially the anterograde and partially the retrograde approach, similar to the retro-pubic radical prostatectomy (RP) technique originally described by Walsh and Campbell. Simultaneously, other European surgeons, with more experience in the laparoscopic field, reproduced with the new robot the Montsouris' anterograde and Heilbroon's retrograde technique. In the US, Menon, Guillenau and Vallancien performed the first 22 cases at the Vattikuti Institute of Urology (Detroit) applying the Montsouris' technique originally described by Gaston. For the following 18 cases, Menon et al. developed an original surgical technique that became the most common technique for the RARP, the Vattikuti Institute Prostatectomy (VIP) [1]. More than thousand operations were performed using the new anterograde and transperitonal technique. Just a few years after, Ahlering et al. made important modifications of the technique, introducing innovative method of dissection of the prostatic apex and control of the Santorini's venous complex with vascular clips. In the following years the attention focused on the development of a technique that could preserve the nerve fibers involved in sexual function and continence, the so-called "nerve-sparing" (NS) technique. In 2005, Kaul et al. [2] performed the first VIP NS operation that included the preservation of the prostatic nerve bundle. The same year, Ahlering group described a cauterisation-free NS technique using only the laparoscopic bulldog clips and FloSeal for the haemostasis. Another interesting NS technique, performed without use of clips and mono-polar electrocautery, was described by Chien et al. [3]

Our aim was to evaluate intraoperative outcomes, postoperative oncological and functional outcomes and complications in a recent series of RARP in order to display the results in a robotic surgery referral centre of last generation. Furthermore, we analysed the learning curves for RARP of a surgeon without previous laparoscopic experience.

2. MATERIALS AND METHODS

2.1. Study Characteristics

We performed a retrospective study using prospectively collected data at Urological Clinic of "Agostino Gemelli" Universitary Hospital Foundation of Rome. Between January 2013 and January 2015 all consecutive patients undergoing RARP for clinical localized prostate cancer (cT1-cT3N0M0) were included.

2.2. Surgical Technique

The procedures were performed by a single surgeon (P.F.B.) using a standard six-ports transperitoneal technique and the *da Vinci*® SI robotic system (Intuitive Surgical, Inc). The patient was placed in a dorsal lithotomy position with the lower limbs in slight abduction. Using the Hasson technique, a 12 mm port was introduced in abdominal cavity just above the umbilicus to induce pneumoperitoneum. Afterwards, under video assistance three 8 mm robotic trocars and an assistant 12-mm robotic trocar were introduced through a traversal line

passing 14 cm above the pubis, and one more assistant 5 mm port was placed in right hypochonder. The next steps were performed in chronologic order: (1) incision of the peritoneum of Douglas space freeing up the seminal vesicles and the deferens vas that were divided; (2) dissection of the Denovilliers fascia and separation of the posterior aspect of the prostate from the rectum until the prostate apex; (3) incision of the anterior peritoneum bilaterally to the umbilical vessels with access to the Retzius space; (4) prostatic defatting and incision of the endopelvic fascia with exposure of the prostate apex; (5) dissection of pubo-prostatic ligaments and preventive control of the dorsal vein complex of Santorini; (6) bladder-prostate dissection up to the level of the seminal vesicles previously freed-up using a bladder neck-sparing procedure; (7) control of the postero-lateral neurovascular bundles with Hemo-lock and completion of the anterograde prostate posterolateral dissection, with NS technique when indicated; (8) dissection of the prostate apex, urethral section and total prostate-vesiculectomy; (9) vesico-urethral anastomosis with barbed suture and Van Velthoven technique. The specimen was extracted through a small supraumbilical midline incision.

2.3. Outcomes and Variables

We considered mean blood loss and surgical time as intra-operative outcomes. Post-operative complications were classified using Clavien-Dindo score. In terms of cancer control, we considered positive surgical margins (PSM) and 1-year biochemical disease-free survival (1y-bDFS) as oncological outcomes. A PSM was defined as the extension of tumour to the inked surface of the specimen. All surgical specimens were evaluated by a single pathologist at the same institution. Recurrence was defined as a repeated prostate-specific antigen $\geq$0.2 ng/ml.

Urinary continence was evaluated by the Urinary Function score (questions from 2 to 6) of the University of California Los Angeles Prostate Cancer Index (UCLA-PCI-UF) [4]. Continence was defined as no pad use (answer 3 to question 4). Potency was evaluated by the Sexual Function score (questions from 7 to 10) of the UCLA-PCI questionnaire (UCLA-PCI-SF) [4]. Potency was defined using the Erection Sufficient for Intercourse (ESI) criteria. Each questions' score was converted into a scale from 0 to 100, higher score corresponding to better function.

For the evaluation of postoperative oncological and functional outcomes only patients with a minimum one-year follow-up were considered. Furthermore, only preoperatively potent patients who underwent RARP with NS technique and who did not receive postoperative radiotherapy or hormonal therapy were considered for potency evaluation.

To define a learning curve, we equally divided patients into eight groups (case orders) based on the time at surgery. Variables considered in the learning curves are the mean duration of the operation, mean blood loss, PSM and functional outcomes.

2.4. Statistical Analysis

Statistical analyses were performed with MedCalc statistic software. Continuous variables were reported as mean valued plus standard deviation (SD). Students' t test and

Pearson' chi-square test were utilized to compare continuous variables and categorical variables, respectively. To evaluate the variables as hypothetic predictive parameters of the considered outcomes, univariate and multivariate logistic regression analysis were performed. A p value < 0.05 was considered as statistical significance index.

3. RESULTS

Overall, 164 patients were included. The patients' mean age (±SD) was 65.2 (±6.8) years. Table 1 shows the most relevant patients baseline characteristics.

Table 1. Patients baseline characteristics (n = 164)

Mean age, years ± SD	65.2 ± 6.8
Mean prostate volume, ml ± SD	45.2 ± 18.0
Bioptic Gleason score, n (%)	
5	1 (0.6)
6	91 (55.5)
7	59 (36)
8	10 (6.1)
9	3 (1.8)
Clinical stage, n (%)	
T1	123 (75)
T2a	31 (18.9)
T2b	7 (4.3)
T2c	3 (1.8)
Charlson index, n (%)	
≤3	31 (18.9)
4	50 (30.5)
5	52 (31.7)
≥6	31 (18.9)
IIEF–5 score mean (1–25)	16.6 ± 7.4
PSA mean, ng/ml ± SD	8.8 ± 5.3
Mean PSA density, ng/ml/cc ± SD	0.15 ± 0.07
Risk class by D'Amico, n (%)	
Low risk	71 (43.3)
Intermediate risk	77 (46.9)
High risk	16 (9.8)

3.1. Operative Outcomes

The mean intraoperative blood loss and the mean operative time were 284.4 ± 110.4 ml and 146.5 ± 40.1 minutes, respectively.

In terms of postoperative complications, there were 1.2% major (Clavien III-IV) and 7.9% minor (Clavien I-II) events, with no mortality. We observed one rectal perforation (the only one intra-operative complication), which was repaired intra-operatively; 2 laparotomic explorations for postoperative haemorrhage; 4 bladder neck contractures; 2 external corps (Hemo-lock) in urethra that have been removed cystoscopically; 7 urinary fistulas with pelvic urinoma managed conservatively.

3.2. Oncological Outcomes

Table 2 displays the main pathological outcomes. The overall prevalence of PSM was 30.5% (50/164). Organ-confined prostate cancer (pT2) was found in 131 patients (80.1%), while remaining 33 patients (19.9%) had an extra-prostatic extension (pT3). The PSM rate for pT2 and pT3 disease was 23.6% and 57.6%, respectively. Apex was the most common PSM site (42%), followed by posterolateral site (30%).

Table 2. Pathological outcomes (n = 164)

Pathological Stage T, n (%)	
pT2a	17 (10.2)
pT2b	2 (1.2)
pT2c	112 (68.3)
pT3a	25 (15.2)
pT3b	8 (4.8)
Pathological stage N, n (%)	
N0	76 (46.3)
Nx	84 (51.2)
N1	4 (2.4)
Gleason score, n (%)	
6	66 (40.2)
7 (3+4)	72 (43.9)
7 (4+3)	18 (11.0)
8	8 (4.8)
PSM, n (%)	50 (30.5)
PSM location, n (%)	n = 50
Apex	21 (42)
Posterolateral	15 (30)
Others	14 (28)
Mean length PSM, mm ± SD	8.58 ± 7.81
EPE, n (%)	34 (27.7)

PSM: positive surgical margins.
EPE: extraprostatic extension.

Table 3. Patients with disease recurrence

N° pts	Age	PSA[1]	Type of Recurrence	pT	pN	PSM	Gleason score[2]	Therapy
1	67	4	Biochemical	2c	x	no	3+4	WW
2	61	7,3	Local	2c	0	yes	3+3	RT+HT
3	51	3,7	Biochemical	2c	x	no	3+3	RT+HT
4	75	8,7	Biochemical	2c	0	no	3+3	RT+HT
5	68	7	Biochemical	3b	0	yes	3+5	RT+HT
6	71	7	Local	2c	x	no	3+3	RT+HT
7	62	5	Biochemical	2c	x	yes	4+3	WW
8	67	4,4	Biochemical	2c	x	no	3+4	WW

[1] Preoperative Prostate specific antigen.
[2] Definitive Gleason score.
PSM: positive surgical margins; RT: radiotherapy; HT: hormonal therapy; WW: watchful waiting.

We evaluated the association between PSM and pathological, clinical and operative variables. D'Amico risk group ($p = 0.015$), bioptic Gleason Score ($p = 0.025$), pathological stage ($p = 0.007$) and pathological Gleason Score ($p < 0.001$) were significantly related with histopathological evidence of PSM. Patients who received a NS procedure did not show an increased risk of PSM ($p = 0.443$)

Accordingly, at univariate logistic regression analysis, D'Amico risk group (OR 2.27; 95% CI 1.33-3.89; $p = 0.002$), pathological stage (OR 2.13; 95% CI 1.33-3.42; $p < 0.001$) and pathological Gleason Score (OR 5.64; 95% CI 2.69-1.09; $p < 0.001$) were strongly associated with PSM finding, while a NS procedure did not affect the risk of PSM ($p = 0.089$). At multivariate logistic regression analysis, pathological Gleason score was the only independent predictor of PSM (OR 3.81; CI 1.65-8.84; $p = 0.002$).

Table 3 shows the clinical and pathological characteristics of patients with disease recurrence in the subgroup of 87 patients with at least 1 year of follow up. One year-bDFS was 90.8%. The median time of follow-up was 18 months. Disease recurrence was only biochemical in 6 patients (6.8%) and clinically detectable as localised relapse in 2 patients (2.3%).

3.3. Functional Outcomes

Evaluation of the urinary function included 92 patients (mean follow-up = 18 moths). According to our definition of continence, at last follow-up 71 patients (72%) were completely continent (Figure 1). Mean UCLA PCI-UF (Urinary Function) score was 71.3 ± 27.9. Patients that underwent monolateral nerve-sparing (MNS) technique (78.4 ± 28.0) and bilateral nerve sparing (BNS) technique (76.7 ± 25.3) showed higher scores than patients that underwent a non-NS technique (67.4 ± 28.2); however, the difference were not statistically significant ($p = 0.1226$) (Figure 2).

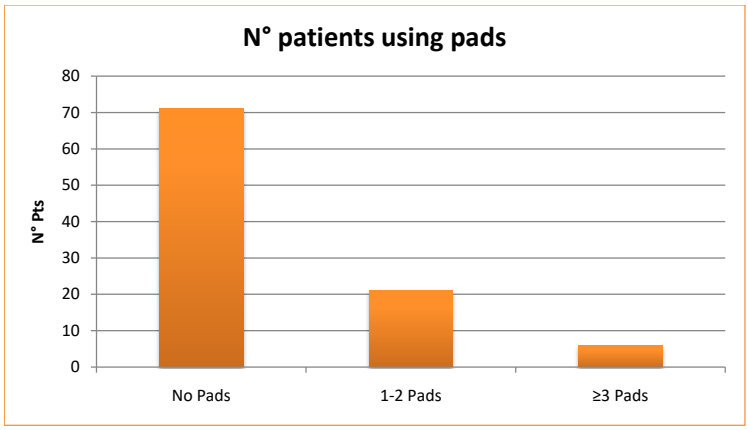

Figure 1. Percentages of patients using no pad, 1-2 pads or 3 or more pads daily at last follow-up.

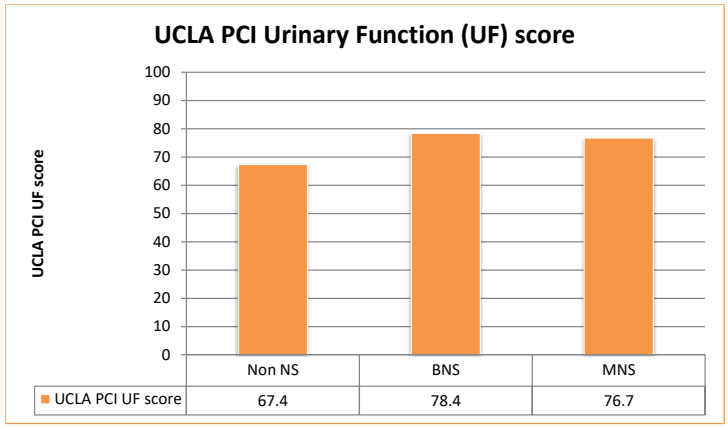

Figure 2. Mean UCLA PCI UF scores in patients undergoing non nerve-sparing (NS) procedure, monolatheral nerve-sparing (MNS) and bilatheral nerve-sparing (BNS).

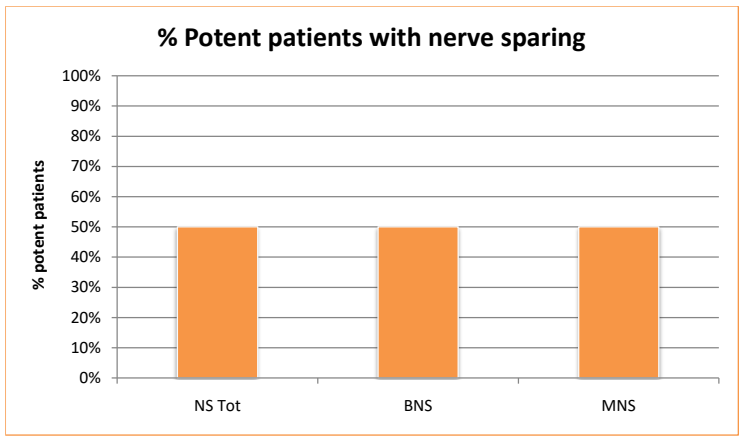

Figure 3. Percentages of potent patients considering ESI (Erection Sufficient for Intercourse) criteria for potency definition. The percentages for all patients undergoing a nerve-sparing procedure (NS tot), mono-latheral (MNS) and bilatheral NS procedure (BNS) are shown.

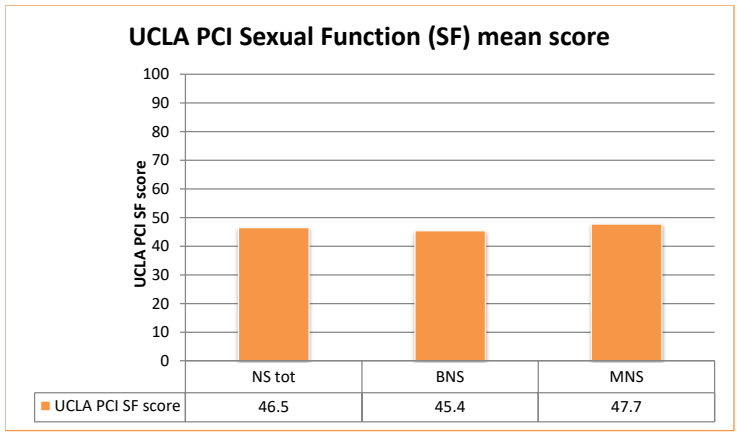

Figure 4. Mean UCLA PCI SF scores in all patients undergoing nerve-sparing procedure (NS tot), mono-latheral (MNS) and bilatheral NS procedure (BNS) are shown.

Variables included in the statistical analysis of continence recovery were age, age-adjusted Charlson comorbidity score, preoperative PSA, biopsy Gleason score, clinical stage, pathological Gleason score, pathological stage, radiotherapy, ormonotherapy and NS (yes/no). The results of the univariate logistic regression show that the older age (OR 0.906, 95% CI 0.84-0.97; p = 0.005), higher age-adjusted Charlson comorbidity score (OR 0.522, 95% CI 0.31- 0.86; p = 0.027), higher D'Amico risk class (OR 0.429, 95% CI 0.19-0.92; p = 0.026), higher preoperative PSA (OR 0.83, 95% CI 0.77-0.98; p = 0.022), higher pathological stage (OR 0.50, 95% CI 0.26-0.94; p = 0.019) and higher pathological Gleason score (OR 0.153, 95% CI 0.05-0.40; p < 0.0001) were associated to the continence outcome. At mutivariate analysis only age (OR 0.881, 95% CI 0.79-0.98; p = 0.020) and pathological Gleason score (OR 0.118, 95% CI 0.05-0.69; p = 0.012) were independent predictors for urinary continence.

Overall, 32 patients were included in the potency analysis. According to our definition of potency, 16 patients (50%) were potent. In the subgroup of 16 patients that underwent RARP with MNS technique, 8 (50%) resulted potent. An identical percentage of potency (50%) was observed in the subgroup 16 patients that underwent RARP with BNS technique (Figure 3). Overall, 50% of patients undergoing the NS procedure were potent at the last follow-up (average 18 months). The mean score of the UCLA PCI-SF for the patients undergoing NS technique was 46.2 ± 31.8. The corresponding values for the patients undergoing MNS and BNS technique were 47.7 ± 31.8 and 45.4 ± 32.6 (p = 0.8413), respectively (Figure 4).

Variables included in the statistical analysis of potency recovery in patients undergoing the NS procedure were age, age-adjusted Charlson comorbidity score, preoperative PSA, preoperative IIEF-5 score, biopsy Gleason score, clinical stage, pathological Gleason score and pathological stage. The results of the univariate logistic regression showed that only the pathological Gleason score was a predictor of potency recovery (OR 0.264, 95% CI 0.06-1.03; p = 0.037). At multivariate statistical analysis no variables resulted to be independent predictor of potency recovery.

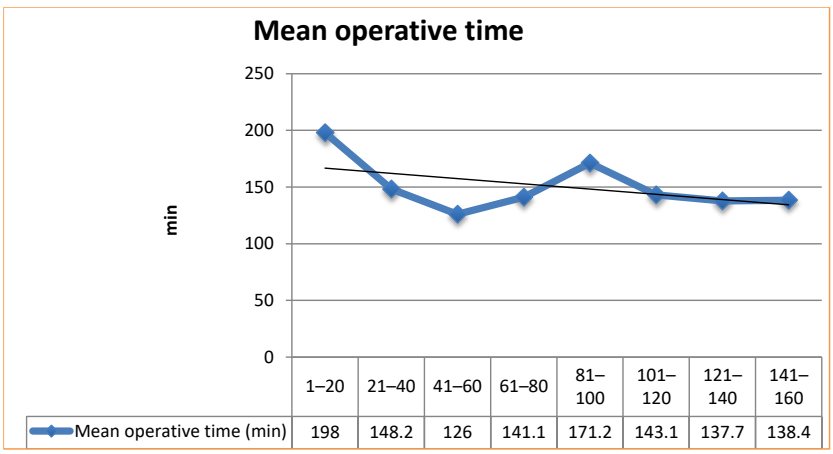

Figure 5. Mean operative time learning curve, dividing patients in eight groups.

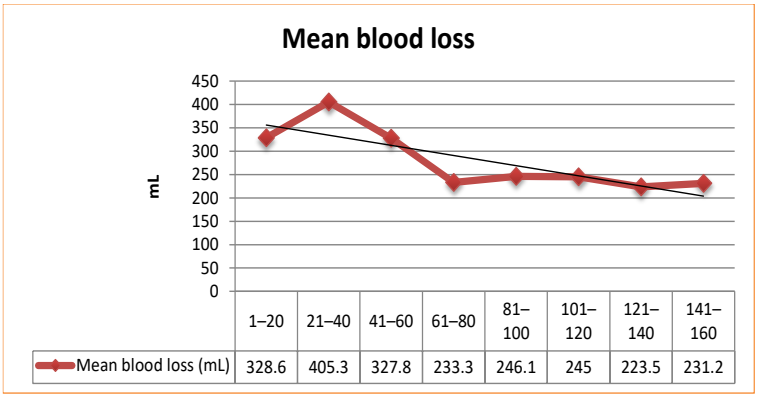

Figure 6. Mean operative blood loss learning curve, dividing patients in eight groups.

3.4. Learning Curves

A learning curve was observed for both operative time and blood loss (Figure 5, Figure 6). The mean operative time decreased from 198 ± 43 minutes for the first group to 126 ± 18 minutes for the third group, and then plateaued at about 138 minutes. The mean blood loss increases to the highest value of 405 ± 122 mL in the second group of patients and then decreased and plateaued at about 230 ml. The differences in operative time and blood loss between the first patients group and the last patients group were statistically significant ($p < 0.0001$) for both variables.

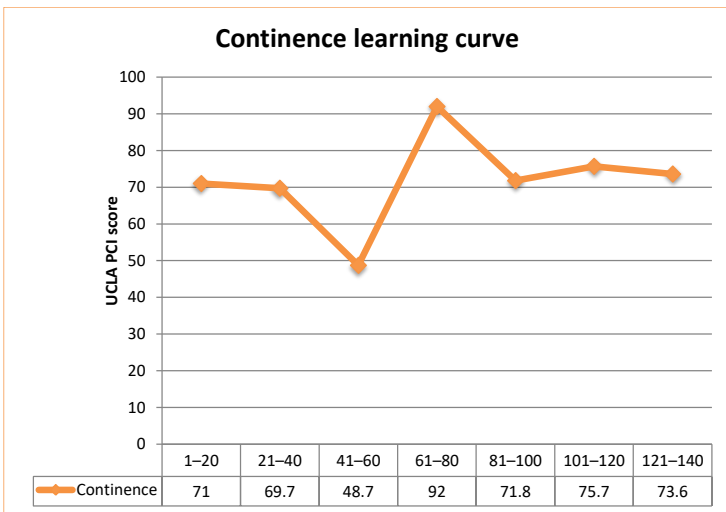

Figure 7. Continence learning curve considering UCLA PCI UF score, dividing patients in eight groups.

The UCLA-PCI-UF score showed a rising trend but there was not statistically significant difference between the first (71.0 ± 24.5) and the last group (73.6 ± 27.7; $p = 0.168$) (Figure 7). Regarding the sexual function, due to the limited sample ($n = 24$), patients were assigned

to 6 groups of 4 patients each. Similarly to the urinary continence, a statistically significant learning curve was not found for the UCLA-PCI-SF score: mean scores for the first and the last group were 70.7±25.8 and 46.5 ± 19.4 (p = 0.198), respectively (Figure 8). The PSM rate slightly decreased throughout the eight groups of patients, with no statistically significant differences among them (P = 0.213) (Figure 9).

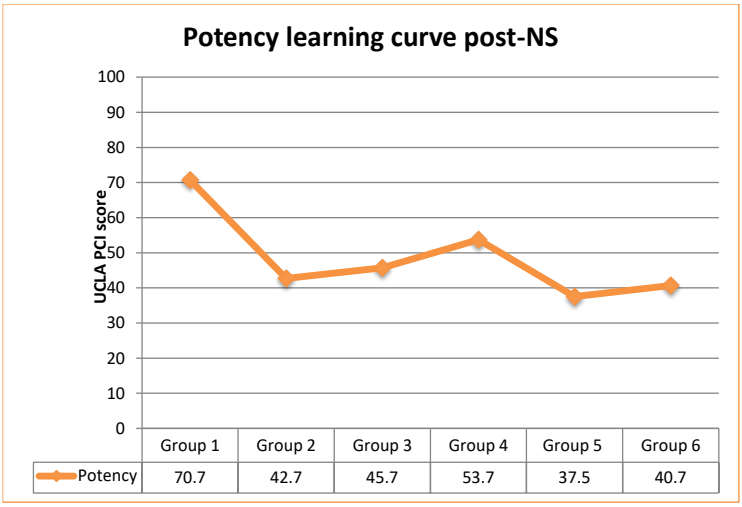

Figure 8. Potency learning curve considering UCLA PCI SF score in patients who underwent nerve-sparing procedure, dividing patients in six groups.

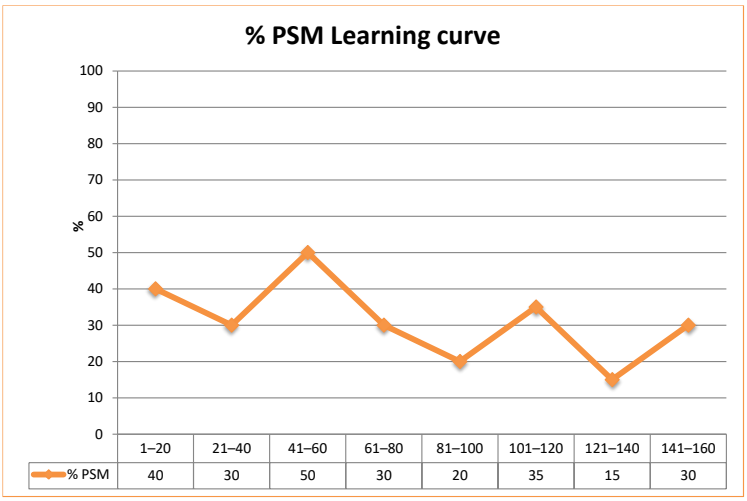

Figure 9. Percentage of positive surgical margins (PSM) dividing patients in eight groups.

4. Discussion

The analysis of the present surgical series of patients undergoing RARP in a referral centre of last robotic generation provided useful information about the evolution of the robotic surgery from its introduction more than fifteen years ago. In particular, we reported

complications, oncological and functional outcomes and evaluated the learning curve for several surgical parameters.

Major perioperative complications were very rare in our series. No conversion to open surgery was necessary indicating the high safety of RARP in modern series.

The presence of PSM in RP specimen is a known risk factor for disease recurrence and may generate patients anxiety. In the present series we observed a rate of PSM (30.5%), which is in the range of reported rates in the literature. In a collaborative review of PSM in RP, Yossepowitch et al. [5] selected 73 papers out of 768 and found PSM rates of 11–38%. These authors did not investigate differences among different surgical approaches.

Magheli et al. [6] reported on a group of 522 consecutive patients undergoing open RP, laparoscopic RP, and RARP at a single centre; while similar PSM rates were seen for open RP (14.4%) and laparoscopic RP (13.0%), a statistically significantly higher crude PSM rate of 19.5% was observed in the robotic RP group. In RARP series with sample size comparable to that of present study (Mottrie et al. 2007 [7], 183 cases; Atug et al. 2006 [8], 140 cases) the overall PSM rate varied between 16% and 26%, lower than our rate. The differences between different series may be explained by several factors such as differences in study population, surgical technique and protocol of anathomopatologic processing and reporting. It remains currently unclear whether RARP is superior, equivalent or inferior to open and laparoscopic RP with regard to oncological outcome [9]

The prognostic significance of PSM depends also on their location. The apex (42%) resulted to be the most frequent location in our series, followed by the postero-latheral site (30%). This pattern of PSM location is overall in adherence with that reported by some previous studies [10, 11, 12], although it remains a controversial point in the literature [13, 14]. In particular, Patel et al. reported that apex (36%) and postero-lateral sites (29%) were the most common PSM locations after RARP [15].

Our results did not indicate an association between the PSM and performing RARP with the NS technique. This is in disagreement with some previous findings [16] but in compliance with the results of other groups [17, 18]; as a result, this point remains controversial as well.

Few studies with small sample size have addressed clinical and pathological predictive factors for PSM after RARP. Pathological Gleason score was the only predictive risk factor for PSM at mutivariate analysis in our series. This is in compliance with some previous studies reporting that parameters related to tumour aggressiveness were strong predictor of PSM status [19, 20, 21]. Others found pathological stage and preoperative prostate specific antigen being the most important independent predictive factors for PSM after RARP [22].

In our series total continence rate settled at 72% at last follow-up. This finding is in the range of values reported by major series in the literature [9, 10, 7]. In several studies comparing the functional results after laparoscopic and robot RP, the percentage of complete continence was similar. This percentage varied between 80% and 95% after a follow-up of 12 months [23, 7]. The wide variation in post-prostatectomy continence rate reported in literature is due to multiple factors such as definition of continence, time to evaluation, surgical technique and patient population. A comparison can be done with the studies of Witz et al. [24] and Shikanov et al. [25], which applying the same continence definition criteria as our study reported rates of 69% [24] and 68% [25], therefore in line with our results. In our logistic model, age and pathological Gleason score were the only negative predictive independent parameters for the continence outcome. This may be explained by the worsening of the pelvic muscle function with ageing and by the more aggressive resection performed by

the surgeon in patients with more aggressive disease (higher length of urethra resected, complete resection of neurovascular bundles, resection of bladder neck) [26]. Novara et al. [27] reported a significant association at multivariate analysis between continence outcome and age (OR 1.076, p = 0.027) and Charlson comorbidity score (OR 1.635, p = 0.009), partly in adherence with our results. The negative impact of the age on postoperative urinary function was also confirmed in other RARP series [28, 29]. Stanford et al. [28] reported that the men younger than 60 year were significantly more continent within two years than the older ones; Talcott et al. [29] reported a rate of continence of 95% within 12 months among men younger than 65 year compared to a corresponding value of 85% among older patients.

We observed a potency rate of 50% among patients undergoing a NS RARP. The recent meta-analysis conducted by Ficarra et al. [30] reported for the studies using our definition criteria for sexual potency (ESI) a rate of potency within 12 months ranging from 39% to 90% among patients undergoing NS procedure, confirming the huge heterogeneity among studies. Nevertheless, our study did not demonstrate any statistically significant differences between MNS and BNS procedure, in disagreement with previous studies [7]. The superior efficacy of the BNS technique compared to the MNS technique remains rather controversial in the existing literature. Mottrie et al. [7] was one of the first to report the different results according to the techniques (47% MSN vs. 70% BNS). The meta-analysis of Ficarra et al. [30] reaffirmed the potential advantage of the bilateral technique in front of the monolateral, although without demonstrating statistically significant difference at multivariate analysis (OR: 2.07; 95% CI, 0.98-4.41; p value not reported). In our study only the pre-operative IIEF-5 and pathological Gleason score were associated to potency, partially confirming the existing findings in the literature regarding the association between the pre-operative sexual function and the post-operative potency recovery [31]. Nevertheless, no independent predictive factors of postoperative potency were identified at multivariate analysis indicating that other factors should be analysed such as nuances in surgical technique.

Our analysis of the learning curves showed that in modern series there is still a learning effect, however it is limited to the very early group of patients at least in terms of operative time and blood loss, plateauing after only 20 cases for the operative time and after 60 cases for the blood loss. Menon et al. [1] reported similar results on operative time that decreased after just 18 patients. Galli et al. [32] observed similar decrease after 20 laparoscopic RP cases.

A statistically significant learning curve was not found for postoperative outcomes such as PSM, potency and continence. These results confirm what has been already observed in other series [33]: both operative time and blood loss demonstrated a tendency to decrease rapidly in the first phase of the learning curve, while in terms of functional and oncological outcomes, the results remained stable. However, there is heterogeneity in the results reported in literature on this point. Although the learning curve for PSM for RARP is not known, Vickers et al. [34] have demonstrated the presence of multiple learning curves for open RP. A series of 450 RARP cases showed that PSM rates varied from 36% in the first 50 patients to 17.6% in case numbers 51–250 to 7.5% in case numbers 251–450 [35]. Another study of 3794 patients who underwent RARP demonstrated that PSM rates improved with increasing surgeon experience; >1600 cases were required to get a PSM rate <10%, suggesting that our series may be too small for the identification of a learning curve effect [36].

This study do have some limitations restricting the generalizability of the results such as the retrospective design, the relatively small sample size, the single-centre nature and missing

data on other variables that are likely to have influenced our findings, such as body mass index and tumor volume.

CONCLUSION

RARP is a safety and effective procedure in a last generation high-volume referral centre. The overall rate and severity of intra-operative and post-operative complications were very favourable. In terms of oncological and functional outcomes, our results were overall in compliance with that reported in recent literature. The learning curves analysis showed that intraoperative outcomes improve after a relatively small number of cases, while oncological and functional outcomes remain unchanged overtime and may need more time for further improvement. Long-term, prospective, and possibly randomized studies are needed.

REFERENCES

[1] Menon M, Shrivastava A, Tewari A, et al. Laparoscopic and robot assisted radical prostatectomy: establishment of a structured program and preliminary analysis of outcomes. *J Urol* 2002;168:945–9.

[2] Kaul S, Bhandari A, Hemal A, Savera A, Shrivastava A, Menon M. Robotic radical prostatectomy with preserva- tion of the prostatic fascia: a feasibility study. *Urology* 2005;66:1261–5.

[3] Chien GW, Mikhail AA, Orvieto MA, Zagaja GP, Sokoloff MH, Brendler CB, Shalhav AL. Modified clipless antegrade nerve preservation in robotic-assisted laparoscopic radical prostatectomy with validated sexual function evaluation. *Urology.* 2005 Aug;66(2):419-23.

[4] The UCLA Prostate Cancer Index: development, reliability, and validity of a health-related quality of life measure. Litwin MS, Hays RD, Fink A, Ganz PA, Leake B, Brook RH. *Med Care.* 1998 Jul; 36(7):1002-12.

[5] Yossepowitch O1, Bjartell A, Eastham JA, Graefen M, Guillonneau BD, Karakiewicz PI, Montironi R, Montorsi F. Positive surgical margins in radical prostatectomy: outlining the problem and its long-term consequences. *Eur Urol.* 2009 Jan;55(1):87-99.

[6] Magheli A, Gonzalgo ML, Su LM, Guzzo TJ, Netto G, Humphreys EB, Han M, Partin AW, Pavlovich CP. Impact of surgical technique (open vs laparoscopic vs robotic-assisted) on pathological and biochemical outcomes following radical prostatectomy: an analysis using propensity score matching. *BJU Int.* 2011 Jun;107(12):1956-62.

[7] Mottrie A, Van Migem P, De Naeyr G, Schatteman P. Robot-assisted laparoscopic radical prostatectomy: oncologic and functional results of 184 cases. *Eur Urol* 2007, 52(3):746-50.

[8] Atug F, Castle EP, Srivastav SK, Burgess SV, Thomas R, Davis R. Positive surgical margins in robotic- assisted radical prostatectomy: impact of learning curve on oncologic outcomes. *Eur Urol* 2006; 49: 866–71.

[9] Ficarra V, Novara G and Artibani W: Retropubic, laparoscopic, and robot-assisted radical prostatectomy: a systematic review and cumulative analysis of comparative studies. *Eur Urol* 2009; 55: 1037.

[10] Patel VR, Coelho RF, Rocco B, Orvieto M, Sivaraman A, Palmer KJ, et al. Positive surgical margins after robotic assisted radical prostatectomy: a multi-institutional study. *J Urol.* 2011 Aug;186(2):511-6.

[11] Smith JA Jr, Chan RC, Chang SS et al.: A comparison of the incidence and location of positive surgical margins in robotic assisted laparoscopic radical prostatectomy and open retropubic radical prostatectomy. *J Urol* 2007; 178: 2385.

[12] Guillonneau B, el-Fettouh H and Baumert H: Laparoscopic radical prostatectomy: oncological evaluation after 1,000 cases at Montsouris Institute. *J Urol* 2003; 169: 1261.

[13] Smith JA, Chan RC, Chang SS *et al*. A comparison of the incidence and location of positive surgical margins in robotic assisted laparoscopic radical prostatectomy and open retropubic radical prostatectomy. *J Urol* 2007; 178.

[14] Zorn KC, Gofrit ON, Orvieto MA *et al*. Robotic-assisted laparoscopic prostatectomy: functional and pathologic outcomes with interfascial nerve preservation. *Eur Urol* 2007; 51: 755–62.

[15] Patel VR, Coelho RF, Rocco B, Orvieto M, Sivaraman A, Palmer KJ, et al. Positive surgical margins after robotic assisted radical prostatectomy: a multi-institutional study. *J Urol.* 2011 Aug;186(2):511-6.

[16] Liss M, Osann K and Ornstein D: Positive surgical margins during robotic radical prostatectomy: a contemporary analysis of risk factors. *BJU Int* 2008; 102: 603.

[17] Ficarra V, Novara G and Seccoet S: Predictors of positive surgical margins after laparoscopic robot assisted radical prostatectomy. *J Urol* 2009; 182: 2682.

[18] Coelho RF, Chauhan S, Orvieto MA et al.: predictive factors for positive surgical margins and their locations after robot-assisted laparoscopic radical prostatectomy. *Eur Urol* 2010; 57: e53.

[19] Yang DY, Monn F, et al. Oncologic and quality-of-life outcomes with wide resection in robot-assisted laparoscopic radiacl prostatectomy. *Urol Oncol* 2014.

[20] Liss M, Osann K and Ornstein D: Positive surgical margins during robotic radical prostatectomy: a contemporary analysis of risk factors. *BJU Int* 2008; 102: 603.

[21] Ficarra V, Novara G and Seccoet S: Predictors of positive surgical margins after laparoscopic robot assisted radical prostatectomy. *J Urol* 2009; 182: 2682.

[22] Patel VR, Coelho RF, Rocco B, Orvieto M, Sivaraman A, Palmer KJ, et al. Positive surgical margins after robotic assisted radical prostatectomy: a multi-institutional study. *J Urol.* 2011 Aug;186(2):511-6.

[23] Salomon L, Sebe P, De La Taille A, et al. Open versus laparoscopic radical prostatectomy: part II. *BJU Int* 2004;94:244–50.

[24] Wiltz AL, Ahikanov S., Eggener SE et al.: Robotic radical prostatectomy in overweight and obese patients: oncological and validated functional outcomes. *Urology* 2009, 73:316.

[25] Shikanov SA, Zorn KC, Zagaja GP et al.: Trifecta outcomes after robotic-assisted laparoscopic prostatectomy. *Urology* 2009; 74:619.

[26] Kundu SD, Roehl KA, Eggener SE, Antenor JAV, Han M, Catalona WJ. Potency, continence and complications in 3,477 consecutive radical retropubic prostatectomies. *J Urol* 2004; 172: 2227– 31.

[27] Novara G, Ficarra V, D'elia C et al.: Evaluating urinary continence and preoperative predictors of urinary continence after robot assisted laparoscopic radical prostatectomy. *J Urol* 2010; 184.

[28] Stanford JL, Feng Z, Hamilton AS et al. Urinary and sexual function after prostatectomy for clinically localized prostate cancer: the Prostate Cancer Outcomes Study. *JAMA* 2000; 283: 354– 60.

[29] Talcott JA, Rieker P, Clark JA et al. Patient-reported symptoms after primary therapy for early prostate cancer: results of a prospective cohort study. *J Clin Oncol* 1998; 16: 275–83.

[30] Ficarra V, Novara G, Ahlering T, Costello A et al: Systematic review and meta-analysis of reporting potency rates after robot-assisted radical prostatectomy. *Eur Urol* 2012 May.

[31] Novara G, Ficarra V, D'Elia C, Secco S, Cavalleri S, Artibani W. Trifecta outcomes after robot-assisted laparoscopic radical prostatectomy. *BJU Int.* 2011 Jan;107(1):100-4.

[32] Galli S, Simonato A, Bozzola A, Gregori A et al.: Oncological outcomes and continence recovery after laparoscopic radical prostatectomy: 3 years follow-up in a "second generation center". *Eur Urol* 2007; 859-865.

[33] Ficarra V, Novara G, Cavalleri S, Aragona M, Artibani W. Evidence from robot-assisted radical prostatectomy: a systematic review. *Eur Urol* 2007 Jun; 45-56.

[34] Vickers A, Bianco F, Cronin A et al.: The learning curve for surgical margins after open radical prostatectomy: implications for margin status as an oncological end point. *J Urol* 2010; 183: 1360.

[35] Yee DS, Narula N, Amin MB, Skarecky DW, Ahlering TE. Robotassisted radical prostatectomy: current evaluation of surgical margins in clinically low-, intermediate-, and high-risk prostate cancer. *J Endourol* 2009;23:1461–5.

[36] Sooriakumaran P, John M, Wiklund P, Lee D, Nilsson A, Tewari AK. Learning curve for robotic assisted laparoscopic prostatectomy: a multi-institutional study of 3794 patients. *Ital J Urol Nephrol* 2011; 63:191–8.

In: Encyclopedia of Surgery (22 Volume Set)
Editors: Andreas Lehrer and Kristin Mueller
ISBN: 978-1-53618-329-0
© 2020 Nova Science Publishers, Inc.

Chapter 434

INTRATHECAL BACLOFEN PUMPS IN SPINAL DEFORMITY AND ORTHOPEDIC SURGERY

Jonathan Weyhenmeyer, MD and Albert Lee*, MD
Department of Neurosurgery, Indiana University School of Medicine
Goodman Campbell Brain and Spine,
Indianapolis, IN, US

By the nature of its use, the intrathecal baclofen pump is frequently implanted in children and adults with either an advanced spinal, pelvic or hip deformity who suffer from muscle spasticity. These deformities often lead to additional surgical procedures either simultaneously or after the implantation of the baclofen pump and intrathecal catheterization. For example, when performing an operation on the hip ipsilateral to a previously implanted baclofen pump, the orthopedic surgeon may ask that the implanted intrathecal pump be removed, the wound temporarily packed off, with subsequent replacement of the pump at the end of the case. Prior standard techniques for dealing with the catheter and pump system during this type of operation are not advisable with the new Medtronic Ascenda system, a pump system that is fully MRI compatible. Furthermore, spinal deformity surgery and its relation to the baclofen pump system must be well planned and implemented in order to prevent a cerebrospinal fluid (CSF) leak, inhibition of fusion and spinal instrumentation breakdown. In this chapter, we will describe each of the aforementioned scenarios and surgical maneuvers for mitigating complications and improving outcomes in this patient population.

Intrathecal catheterization for intrathecal drug delivery (IDD) of baclofen has become the standard of care for patients with medically refractory spasticity and dystonia secondary to congenital or acquired neurological abnormalities [1, 3, 5, 6]. Baclofen pumps are frequently implanted in children and adults with advanced spinal, pelvic and hip deformity to relieve spasticity encountered in cerebral palsy and other congenital or acquired syndromes of cerebral or spinal origin [7]. The implantation of baclofen pumps in patients with cerebral palsy has been shown to reduce the overall need for lower extremity orthopedic procedures

* Corresponding Author's Email: alee@goodmancampbell.com.

post-operatively, including procedures considered necessary prior to implantation of the baclofen IDD system [4]. Unfortunately, baclofen pump implantation does not completely remove the need for additional orthopedic surgical procedures occurring either simultaneously or after the implantation of the baclofen system. Given that orthopedic procedures are common following baclofen IDD system implantation, it is prudent to cover the stepwise operative techniques to reduce the risk of complications and operative failure.

At our institution, we utilize the Medtronic Ascenda catheter and Synchromed II pump system for intrathecal catheterization and drug delivery. It is MRI compatible without surgically removing the mechanical pump. The Ascenda catheter is an extremely durable catheter that rarely fractures, occludes or disconnects from the pump, thus helping to reduce the occurrence of catheter related complications. Prior studies have indicated that catheter related post-operative complications are the most common complications following IDD system implantation, with a rate of up to 20% at 5 years [10]. Unfortunately, the increased durability of the catheter has resulted in a higher number of CSF leaks secondary to the inability of the dura to form a water tight closure around the dura. As such, the risk of CSF leaks when implanting or revising the catheter are significantly increased in comparison to prior systems.

BACLOFEN INTRATHECAL DRUG DELIVERY IN MAJOR DEFORMITY SURGERY FOR SCOLIOSIS

There are a number of caveats and nuances when attempting a long segment deformity operation in patients with scoliosis and baclofen pumps previously placed for refractory spasticity. While baclofen pumps clearly help to relieve significant spasticity, they do not necessarily inhibit the progression of scoliotic deformity and in some instances, may increase the rate of progression of the underlying disease process [2]. In addition, previously implanted intrathecal catheters will increase the complexity of the deformity operation. Prior studies have shown an increased rate of post-operative complications in cerebral palsy patients undergoing deformity correction with prior baclofen pump implantation as compared to cerebral palsy patients without baclofen pumps. This increased complication risk also holds for patients receiving concomitant baclofen IDD systems at the time of their deformity operation. Multiple studies have indicated that patients with baclofen pumps are at an increased risk for CSF leaks [2, 8]. In addition, patients with baclofen IDD systems are at increased risk for re-operation stemming from CSF leaks, deep spinal infections, and baclofen IDD system failures [8]. Many of these complications require complete explanation of the baclofen system, putting the patient at high risk for baclofen withdrawal, and, as such, are life threatening.

When performing a spinal deformity operation, it is important that the spine surgeon coordinate with the surgeon who implanted the IDD system. The surgeon who implanted the system should know what vertebral level the tip of the catheter is located and the vertebral level at which the catheter enters the spinal dura. During the deformity operation, every attempt should be made to maintain the intrathecal catheter in the thecal sac at the level it was originally placed. Migrating the catheter caudal or cephalad may result in changes to the therapeutic effect of baclofen and may require an additional surgery increasing the risk of

infection and pseudoarthrosis. In addition, if the catheter is accidentally extracted during the surgery it will need to be replaced immediately in order to prevent overt baclofen withdrawal. As such, the surgeon who implanted the pump should be made aware that an additional operation may be necessary, and working with a surgeon who is comfortable with open spine operations and baclofen catheters is highly recommended for these types of deformity operations.

The previous standard of care in deformity surgery with a previously implanted baclofen IDD system where the catheter was ligated or removed and then replaced at the end of the operation should not be performed with the Ascenda catheter because CSF leak rates are much higher than originally thought. While the Ascenda catheter is clearly more resilient than prior iterations of intrathecal catheters, it is not capable of reliably functioning with two metal sutureless connectors as this may cause a motion induced fracture secondary to stress/strain phenomena. Post-operative CSF leaks following major scoliosis deformity are extremely difficult to deal with and lead to an increased fusion failure rate and an increased risk of infection, see Figures 1 and 2 displaying a large, persistent CSF leak in a young patient after deformity scoliosis surgery where the Ascenda catheter was placed and ligated during the operation.

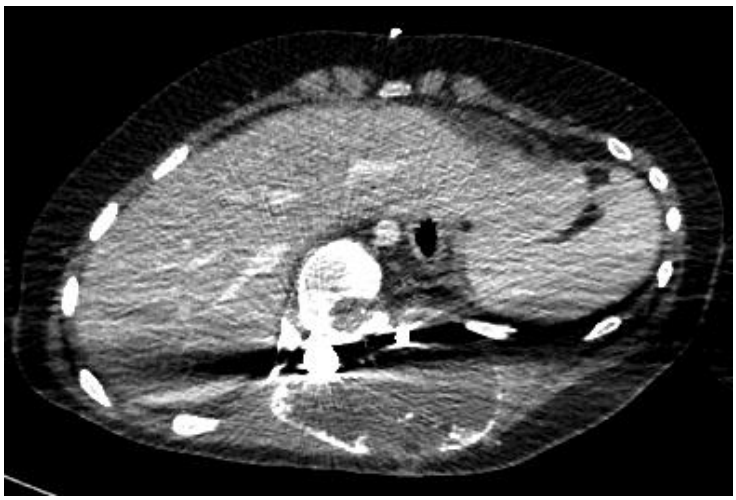

Figure 1. Axial CT slice showing a failed arthrodesis secondary to a persistent and large CSF leak stemming from a tied off intrathecal catheter. The osseous fusion has completely failed as it has been pushed out to the periphery (posterior and lateral) due to the large CSF leak.

The initial dissection to visualize and free the IDD catheter can be done with standard surgical technique using bovie electrocautery. The catheter will not be harmed if careful dissection is performed with dull instrumentation, e.g., sharp instruments and instruments with teeth should be avoided and bovie electrocautery should be utilized. The increased risk of CSF leak with the Medtronic Ascenda system is largely due to the inability of the dura around the inelastic Ascenda catheter to heal quickly enough to prevent the formation of a pseudomeningocele. It must be emphasized that CSF leaks with the Ascenda catheter are often resistant to traditional management techniques, e.g., bed rest, hydration, epidural blood patches, and complex surgical repair are often required to adequately seal the leak.

Figure 2. Sagittal reconstruction of the patient's CT scan displaying the osseous graft failure secondary to a large CSF leak. Note the significant posterior displacement of the graft material identified as the posterior hyperdensity.

Furthermore, the epidural blood patch, an often-utilized method for sealing a CSF leak is not a universally safe option following major deformity surgery for scoliosis. In total, these complications can result in the inhibition of osseous fusion, spinal instrumentation breakdown, and breakdown of the surgical wound with an increased rate of infection. The benefit of the Ascenda catheter system is that it has an extremely low occlusion rate, which does help with closure when removing old catheters and greatly reduces the risk of patients going into frank baclofen withdrawal. For these reasons, the authors highly recommend this system as the primary equipment in treating medically refractory spasticity over other available products.

ORTHOPEDIC HIP SURGERY FOLLOWING BACLOFEN PUMP PLACEMENT

Hip dysplasia is common in patients with cerebral palsy and the occurrence increases with increasing neurological involvement [9]. When performing an operation on the hip ipsilateral to a previously implanted baclofen pump, the orthopedic surgeon may ask that the implanted intrathecal pump be removed, the wound temporarily packed off, with subsequent replacement of the pump at the end of the case. This occurs in patients with spasticity and hip dysplasia that are small in stature and height as the pump or catheter may reside or pass

within the orthopedic surgeon's surgical field. Previously, the intrathecal catheter would be ligated prior to the orthopedic section of the case and then reconnected with a simple connector. Unfortunately, the Ascenda catheter, although more resilient, is not capable, of reliably functioning after being severed and reconnected. In addition, placing an Ascenda catheter and trying to ligate the catheter off, for future access to connect it to a pump in a delayed fashion may result in a constant CSF leak due to the catheter having an almost 0% occlusion rate. There is also an increased risk of catheter fracture with two surtureless metal connectors as noted above. As such, the pump must be removed and replaced after the conclusion of the orthopedic procedure. A case study is outlined below to further elicit the technical nuances and concerns for patients with baclofen pumps who require orthopedic intervention.

A 22-year-old male with a past medical history significant for cerebral palsy, bilateral hip dysplasia, and prior left sided baclofen pump placement was brought to the operating room for a left hip periacetabular osteotomy. A pre-operative pelvic X-ray showing prior right sided pelvic hardware, left sided femoral instrumentation and a left sided baclofen pump is shown in Figure 3. First, the patient was positioned for the orthopedic procedure, Figure 4. Next the patient is prepped and draped in the usual sterile fashion for the orthopedic procedure. Note that the abdominal pump pocket is also prepped and draped to allow for sterile removal and packing, Figure 5. Prior to the orthopedic segment of the operation, the abdominal pump incision is carefully opened and then bluntly dissected down to the pump. Every effort should be made to ensure that the catheter is not fractured or otherwise violated due to the aforementioned risk with catheter reconnection and distal ligation. Similar to deformity operations, the pump and catheter should be dissected out with blunt dissection and bovie electrocautery. Once the pump and catheter are well visualized, the pump should be carefully removed from the wound and subsequently disconnected from the catheter. A pair of hemostats are then placed on the catheter to prevent leakage of fluid through the catheter and to prevent the catheter from migrating out of the surgical field. The wound is then packed-off with antibiotic soaked gauze until the conclusion of the orthopedic procedure. The synchromed II pump is placed antibiotic solution until it is time to replace it in the patient, Figure 7. As shown in Figure 8, it is sometimes the case that the catheter may take a looping trajectory to the intrathecal space resulting in the catheter traversing the orthopedic wound. As such, the surgeon should not dissect the orthopedic wound with impunity, even after the baclofen pump has been removed, as there is still the potential for catheter injury. As previously mentioned, the Ascenda catheter is very resilient but may not withstand sharp dissection. Furthermore, the catheter is not always amenable to reconnection and fracturing the catheter at this point may necessitate the complete explanation and re-implantation of the entire system for reasons mentioned previously.

At the conclusion of the orthopedic procedure, the wound is reopened, the sterile packing is removed and the catheter with hemostat clamps is visualized. The catheter is cut within 1 cm proximal to where the hemostats were placed. The baclofen pump is then reconnected to the catheter. The pump is then placed back in the wound and sutured to the fascial layer. Antibiotic irrigation is then used to completely sterilize the wound and prevent infection. The wound is subsequently closed in the usual fashion. The pump in this case would need to be reprogrammed to reflect the operative changes made.

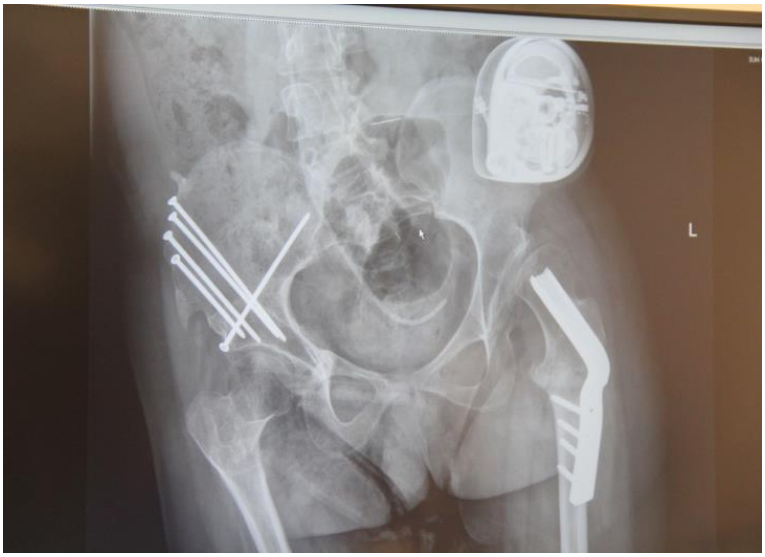

Figure 3. Pre-operative X-ray displaying the patients left sided baclofen pump and prior orthopedic instrumentation.

Figure 4. The patient is prepped and draped in the usual manner for the orthopedic procedure with the added caveat that the incision for baclofen pump is included within the field.

Figure 5. A skin incision is made over the previous pump incision. Blunt dissection is then used to identify the pump and catheter.

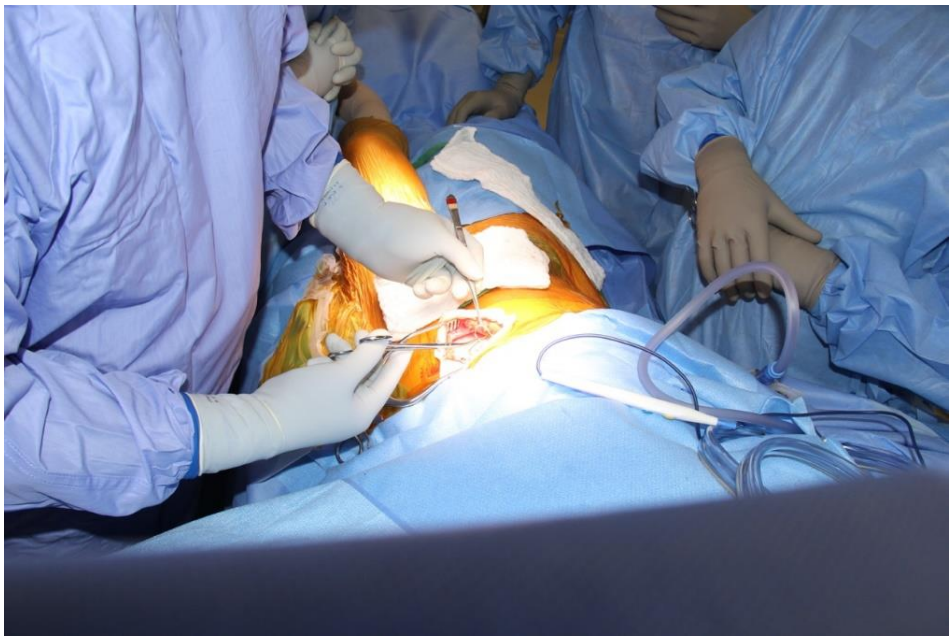

Figure 6. The catheter is identified and carefully manipulated so as to prevent fracture of the catheter. The catheter is then removed.

Figure 7. The pump is completely removed from the wound and washed with antibiotic solution.

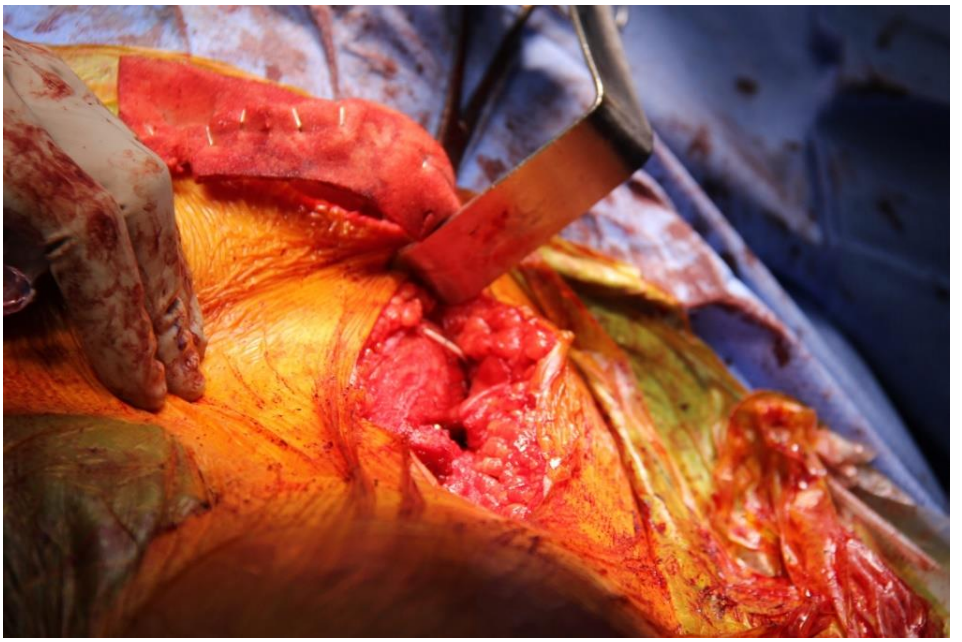

Figure 8. A section of the baclofen catheter is shown running through the orthopedic wound. The orthopedic wound is inferior to the pump wound and is in a horizontal orientation.

REFERENCES

[1] Albright AL, Cervi A, Singletary J: Intrathecal baclofen for spasticity in cerebral palsy. *JAMA* 265:1418-1422, 1991.

[2] Caird MS, Palanca AA, Garton H, Hensinger RN, Ayyangar RN, Drongowski A, et al: Outcomes of posterior spinal fusion and instrumentation in patients with continuous intrathecal baclofen infusion pumps. *Spine* (Phila Pa 1976) 33:E94-99, 2008.

[3] Coffey JR, Cahill D, Steers W, Park TS, Ordia J, Meythaler J, et al: Intrathecal baclofen for intractable spasticity of spinal origin: results of a long-term multicenter study. *J. Neurosurg.* 78:226-232, 1993.

[4] Gerszten PC, Albright AL, Johnstone GF: Intrathecal baclofen infusion and subsequent orthopedic surgery in patients with spastic cerebral palsy. *J. Neurosurg.* 88:1009-1013, 1998.

[5] Penn RD, Kroin JS: Long-term intrathecal baclofen infusion for treatment of spasticity. *J. Neurosurg.* 66:181-185, 1987.

[6] Penn RD, Savoy SM, Corcos D, Latash M, Gottlieb G, Parke B, et al: Intrathecal baclofen for severe spinal spasticity. *N. Engl. J. Med.* 320:1517-1521, 1989.

[7] Rawicki B: Treatment of cerebral origin spasticity with continuous intrathecal baclofen delivered via an implantable pump: long-term follow-up review of 18 patients. *J. Neurosurg*. 91:733-736, 1999.

[8] Segal LS, Wallach DM, Kanev PM: Potential complications of posterior spine fusion and instrumentation in patients with cerebral palsy treated with intrathecal baclofen infusion. *Spine* (Phila Pa 1976) 30:E219-224, 2005.

[9] Spiegel DA, Flynn JM: Evaluation and treatment of hip dysplasia in cerebral palsy. *Orthop. Clin. North Am.* 37:185-196, vi, 2006.

[10] Stempien L, Tsai T: Intrathecal baclofen pump use for spasticity: a clinical survey. *Am. J. Phys. Med. Rehabil.* 79:536-541, 2000.

In: Encyclopedia of Surgery (22 Volume Set)
Editors: Andreas Lehrer and Kristin Mueller
ISBN: 978-1-53618-329-0
© 2020 Nova Science Publishers, Inc.

Chapter 435

CONSERVATION SURGERY: OPEN PARTIAL LARYNGECTOMY

Alfredo Quintin Y. Pontejos, Jr.[1,*], Daryl Anne A. del Mundo[1], Soon Sue Rene[2], Andrea De Vito[3] and Sheng-Po Hao[4]

[1]Department of Otorhinolaryngology, University of the Philippines, Philippine General Hospital, Manila, Philippines
[2]Department of Otolaryngology-Head and Neck Surgery, Ng Teng Fong General Hospital, Jurong Community Hospital, NUHS Singapore
[3]Head&Neck Department, ENT Unit and Oral Surgery, Morgagni-Pierantoni Hospital, AUSL of Romagna, Forlì Italy
[4]Department of Otolaryngology Head and Neck Surgery, Comprehensive Oral Cancer Center Shin Kong Wu Ho-Su Memorial Hospital, Taiwan, School of Medicine, Fu-Jen University, Taiwan

KEY POINTS

- Open partial laryngectomies include: vertical partial laryngectomy and horizontal partial laryngectomy.
- Indications of supraglottic laryngectomy are: 1) lesions confined to the epiglottis and false vocal folds, 2) limited involvement of the aryepiglottic fold and 3) good pulmonary function.
- Indications for supracricoid laryngectomy include bilateral involvement of the vocal folds, minimal involvement of the anterior commissure, impaired mobility of the cords, T3 glottic lesions with minimal subglottic extension, and T4 tumors with limited thyroid cartilage invasion.
- Indications subtotal laryngectomy include glottic cancer (T2, T3) with significant subglottic extension reaching up to the cricoid cartilage.

* Corresponding Author's Email: docpontejosjr@yahoo.com.

Keywords: vertical partial laryngectomy, horizontal partial laryngectomy, supraglottic laryngectomy, supracricoid partial laryngectomy, subtotal laryngectomy with tracheohyoidopexy or tracheohyoidoepilgottopexy

INTRODUCTION

The beginnings of laryngectomy can be traced from the works of Solis-Cohen, Theodore Billroth, Gluck, Fraenkel, and Killian in the late 1800 and early 1900. During these early times, the survival rate after laryngectomy was 50% or less—mainly attributed to unsanitary surgical conditions. Mortality rate in the 1900's then decreased to 13% through the development of aseptic techniques and further refinement of the laryngectomy procedure. Particularly, laryngeal conservation surgery was introduced. Buck (1875) and Solis-Cohen (1868) in the US, Semon (1894) and Butlin (1895) in the UK, Okada in Tokyo, and Bruno in Germany were all early proponents of partial surgery [1]. The modified partial laryngectomy for anterior commissure was described by Clerf in 1940 and bilateral thyrotomy by Kemler in 1947 [1]. Frontolateral partial laryngectomy was promoted in France by Leroux-Robert in 1950–1970s [1]. Supraglottic surgery and hemilaryngectomy were among the first refined laryngeal conservation surgery techniques introduced by Justo Alonso in 1946 and Ogura in 1955, respectively [2]. Supracricoid partial laryngectomy (SCPL) was introduced by Majer and Reider in Vienna in 1959 [2]. Picquet gave more details of SCPL with cricohyoido-eppiglottopexy (CHEP)/cricohyoidopexy (CHP) in 1986, and different pioneers including Laccourreye and Brasnu further exposed the technique to the world in 1990 [2]. Conservation procedures for laryngeal cancer became more widely used until CO2 laser resection was eventually introduced in 1966 by Jako and Kleinsasser. The use of CO2 laser and SCPL reached their peak in the 1970's. Furthermore, treatment for laryngeal cancer had become more holistic with the role of radiotherapy having been investigated upon from the early 1990's through many larynx preservation trials (e.g., EORTC, RTOG, GORTEC, EORTC) [3].

We have come a long way from the time of Prof. Billroth and Solis-Cohen. Advances in surgical treatment of laryngeal cancer such as conservation laryngeal surgery procedures have further improved the quality of life of patients by preserving voice, in a good number of cases, without compromising survival. The surgical anatomy of the larynx is based on its skeleton and connective tissue barriers, the spaces delineated by these structures, and the soft tissue structures that include fat, musculature, vessels, nerves, and adnexa including the three laryngeal cartilages (epiglottis, thyroid, cricoid), hyoepiglottic ligament, thyrohyoid membrane, quadrangular membrane, conus elasticus, anterior commissure, and cricothyroid membrane [4].

The laryngeal framework of the larynx is compartmentalized, and this compartmentalization may be attributed to its unique embryology. The embryologic development of the larynx influences the pattern of metastatic spread of laryngeal cancer, and serves as the foundation for the principles of conservation surgery. The larynx develops from three branchial arches. Supraglottic structures are derived primarily from the buccopharyngeal primordium which develops from the third and fourth branchial arches. The glottis and subglottic areas are derived from the tracheobronchial primordium from the sixth branchial arch [4]. This serves

as the basis for supraglottic laryngectomy. The glottis is also vertically separated embryologically to left and right, thus serving as the basis for hemilaryngectomy.

TECHNIQUES

Open partial laryngectomies include: vertical partial laryngectomy (hemilaryngectomy); and horizontal partial laryngectomy, which include supraglottic laryngectomy, supracricoid partial laryngectomy with cricohyoidoepiglottopexy (CHEP) or cricohyoidopexy (CHP) and Subtotal Laryngectomy with Tracheohyoidopexy (THIP) or Tracheohyoido- epilgottopexy (THIEP). Laryngofissure with cordectomy has been completely replaced by Laser CO2 cordectomies (Transoral Laser Microsurgery, TLM).

1. Vertical Partial Laryngectomy (VPL): Hemilaryngectomy [5-7]

Indications and Contraindications

The indications for hemilaryngectomy include unilateral involvement of the vocal fold, non-involvement of the thyroid cartilage, non-involvement of the epiglottis and cricoid cartilage; and T1 and T2 glottic cancer. Contraindications for the procedure include involvement of the thyroid cartilage, bilateral involvement of the vocal folds, gross involvement of the arytenoid of the epiglottis or cricoid cartilage, or poor pulmonary function.

Technique

Make a horizontal incision at the midportion of the thyroid cartilage from the anterior border of the sternocleidomastoid (SCM). Develop the flap superiorly and inferiorly and separate the strap muscles in the midline to expose the thyroid cartilage 1 cm above the superior border and 1 cm below the inferior border. Cut the perichondrium 2 mm away from the involved side. Dissect free the perichondrium up to the posterior edge of the thyroid cartilage of the involved side. Draw a vertical line 2mm from the midline of the uninvolved side and cut the cartilage through and through from the upper to the lower edge of the thyroid cartilage. Open the thyroid cartilage like a book and with 3mm margin, cut the thyroid cartilage on the involved side preserving at least 0.5cm at its posterior edge. The specimen is taken out leaving the perichondrium intact then suture the perichondrium back to its original position (if there is too much space in the defect, you may insert a portion of the strap muscle underneath the perichondrium). Close the strap muscle to itself, put a penrose drain, and close the skin incision in layers.

Variants of Hemilaryngectomy

Modification is a frontolateral partial laryngectomy wherein the excision is extended to the other cord and the arytenoid cartilage in the involved side may be resected [5-6]. Another modification is the extended hemilaryngectomy wherein the excision may be extended to the pyriform sinus resulting in the removal of both the cricoarytenoid and thyroarytenoid muscles [5-6].

2. Horizontal Partial Laryngectomy (HPL)

1) Supraglottic Laryngectomy

Key Points

- The cut in the thyroid framework should not be midline.
- Avoid fracturing the thyroid cartilage.

Indications and Contraindications

Indications are as follows: 1) lesions confined to the epiglottis and false vocal folds, 2) limited involvement of the aryepiglottic fold and 3) good pulmonary function. Contraindications include involvement of the paraglottic space inferiorly, gross involvement of the valecullae and the base of tongue, and poor pulmonary function.

Technique

Make a horizontal incision at the midportion of the thyroid cartilage from the anterior border of the sternocleidomastoid (SCM) on both sides (if neck dissection needs to be done, an apron incision or U-incision may be done). Flaps are developed up to 1cm above the hyoid bone. The suprahyoid muscles are released, and the infrahyoid strap muscles are also released close to their insertion (Figure 1). The external perichondrium of the thyroid cartilage is then freed along the superior and lateral aspects of the thyroid lamina on the affected side (Figure 2). The thyroid cartilage is cut horizontally midway between the superior and inferior borders of the thyroid cartilage (Figure 3). The suprastructure is then removed after the pharynx is entered just above the superior border of the thyroid cartilage (Figure 4). Closure is done through approximation of the perichondrium of the thyroid cartilage. The remaining thyroid cartilage is sutured to the hyoid bone (Figure 5) or to the tongue base (if the hyoid bone is resected). Penrose drain is placed and closure is done in layers. A tracheostomy tube is placed around 2 cm above the sternal notch.

2) Supracricoid Partial Laryngectomy (SCPL) [8-9]

Key Points

- Use an oscillating saw if possible to cut the thyroid cartilage horizontally.
- There should be no tension in the apposition with the remaining thyroid cartilage to the hyoid bone or the base of tongue. The patient should therefore be placed on flexed position.
- Tracheostomy site is separate from the surgical incision.

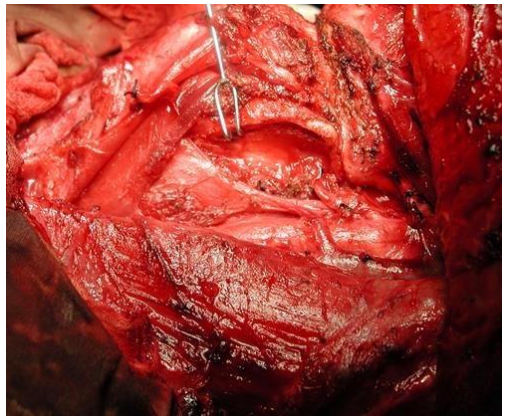

Figure 1. Suprahyoid muscles released, infrahyoid strap muscles released close to their insertion.

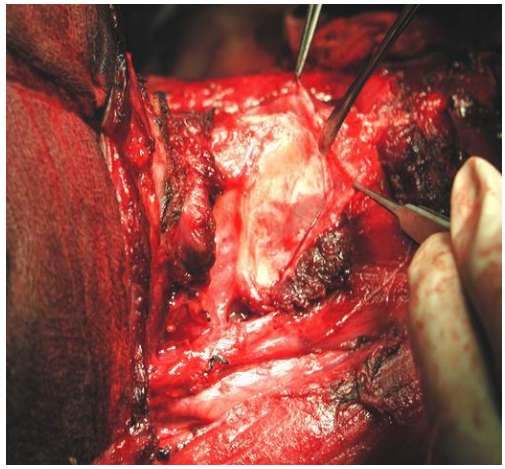

Figure 2. External perichondrium of the thyroid cartilage freed along the superior and lateral aspects of the thyroid lamina on the affected side.

Figure 3. Thyroid cartilage cut horizontally midway between the superior and inferior borders.

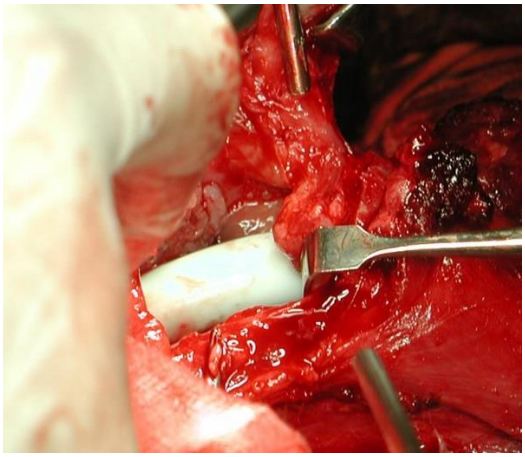

Figure 4. Suprastructure removed after the pharynx is entered just above the superior border of the thyroid cartilage.

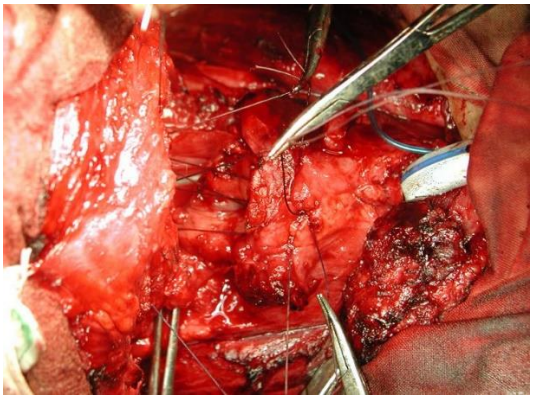

Figure 5. Remaining thyroid cartilage sutured to the hyoid bone.

Indications and Contraindications

Indications for supracricoid laryngectomy include bilateral involvement of the vocal folds, minimal involvement of the anterior commissure, impaired mobility of the cords, T3 glottic lesions with minimal subglottic extension, and T4 tumors with limited thyroid cartilage invasion. Contraindications include pre-operative evidence of severe pulmonary impairment, involvement of the cricoid cartilage, involvement of the hyoid bone, significant pre-epiglottic space involvement, fixation of both arytenoid cartilages, and invasion of the outer perichondrium of the thyroid cartilage.

Technique

Make a horizontal incision at the midportion of the thyroid cartilage from the anterior border of the sternocleidomastoid (SCM) on both sides (if neck dissection needs to be done, an apron incision or U- incision may be done) (Figure 6). Cut strap muscles close to their insertions and flap them down. Cut the inferior constrictor muscles parallel to the posterior edge of the thyroid cartilage, just 0.5cm above it. Free the inferior horn (Figure 7) with care not to injure the recurrent laryngeal nerve. Do isthmusectomy and mobilize the thyroid

cartilage up to the level of the carina. Separate the cricoid cartilage from the inferior border of the thyroid cartilage (Figure 8). Reinsert the tracheostomy tube at the cricothyroid incision (Figure 9). Enter the valleculae via an incision just below the hyoid bone. With the use of Metzembaum scissors, start cutting at the uninvolved side with 3mm margin moving from superior down to the inferior portion up to the lower edge of the thyroid cartilage. Crack open like a book the thyroid cartilage for direct visualization of the lesion and cut free the thyroid cartilage on the other side with a 3mm margin. After resection of the tumor and the involved thyroid cartilage, the remaining cricoid cartilage and hyoid bone can be visualized. Subsequent suturing and impaction of the hyoid bone to the cricoid cartilage is done with Vicryl-0 (one in the midline, the other 1cm from the midline to the left, and another 1cm to the right) (Figure 10). If there is still tension, you may do a suprahyoid release (which will give an additional 1.5cm length). There are two ways of reconstructing the neoglottis: 1) CHEP- cricohyoido-epiglottopexy: done when the cricoid is impacted to the hyoid with epiglottis still intact, and 2) CHP- cricohyoidopexy: done when the cricoid is impacted to the hyoid bone without an epiglottis. A penrose drain is placed and strap muscles are reanastomosed using Vicryl 3-0. Skin closure is done in layers. A tracheostomy tube is placed around 2 cm above the sternal notch.

Figure 6. Horizontal incision made at the midportion of the thyroid cartilage from the anterior border of the sternocleidomastoid (SCM) on both sides; cricoid and thyroid cartilage are marked.

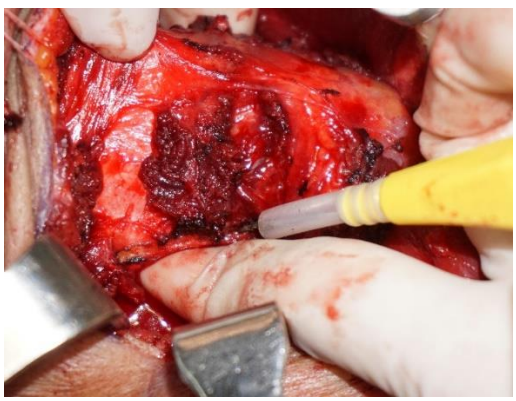

Figure 7. Inferior horn of the thyroid cartilage freed.

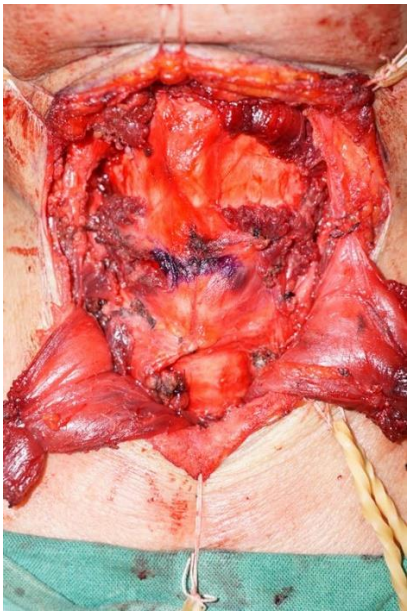

Figure 8. Inferior horn of the thyroid cartilage freed.

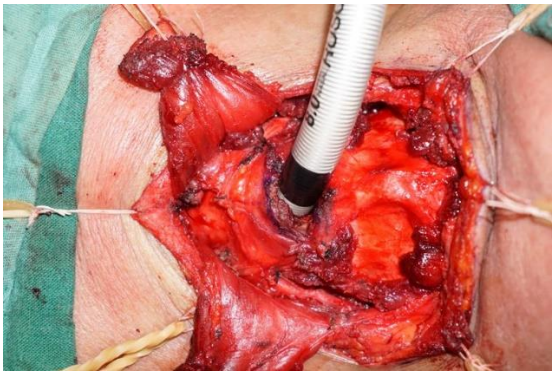

Figure 9. Reinsertion of the tracheostomy tube at the cricothyroid incision.

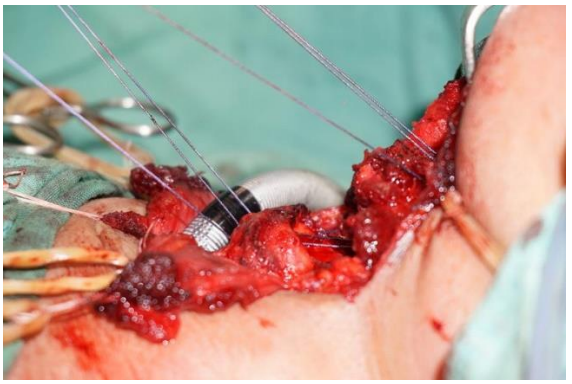

Figure 10. Subsequent suturing and impaction of the hyoid bone to the cricoid cartilage done with Vicryl-0 (one in the midline, the other 1cm from the midline to the left, and another 1cm to the right.

3) Subtotal Laryngectomy with Tracheohyoidopexy (THIP) or Tracheohyoidoepilgottopexy (THIEP)

Key Points

- There should be total removal of the thyroid cartilage.
- Ensure preservation of the recurrent laryngeal nerve.
- Ensure preservation of at least one arytenoid cartilage.
- Perform careful mobilization of the trachea.
- Impaction of cricoid/ trachea to the hyoid bone should be without tension.
- Suturing of cricoid to hyoid bone should be submucosal, ensuring that the epiglottis (if preserved) is well-anchored.
- Tracheostomy site is separate from the surgical incision.
- Use an oscillating saw if possible.
- Perichondrium must be preserved.
- Tracheostomy should be done in a separate incision.

Indications and Contraindications

The technique involves extending laryngeal resection beyond the limits of supracricoid laryngectomy. Indications include glottic cancer (T2, T3) with significant subglottic extension reaching up to the cricoid cartilage. An important contraindication is pre-operative evidence of severe pulmonary impairment.

The procedure entails resection of the cricoid cartilage but with preservation of the epiglottis if uninvolved, maintaining one or two cricoarytenoid units, and further suspension of the tracheal stump to the epiglottis and hyoid bone, or the hyoid bone alone.

Technique

Make a horizontal incision at the midportion of the thyroid cartilage from the anterior border of the sternocleidomastoid (SCM) on both sides (if neck dissection needs to be done, an apron incision or U-incision may be done). Cut strap muscles close to their insertions and flap them down. Cut the inferior constrictor muscles parallel to the posterior edge of the thyroid cartilage, just 0.5cm above it. Free the inferior horn with care not to injure the recurrent laryngeal nerve. Do isthmusectomy and mobilize the thyroid cartilage up to the level of the carina (See representative photos under supracricoid laryngectomy). The superior limit of the tumor is identified. If a THIP is to be performed, the pre-epiglottic space is removed by detaching the periosteum of the hyoid bone in its inferior portion to reach the mucosa of the vallecula, and the epiglottis is grasped and resected before performing pharyngotomy [10]. If a THIEP is to be performed, the pre-epiglottic space is incised along the superior edge of the thyroid cartilage and the epiglottis is preserved. The lower part of the resection involves separation of the cricoid ring from the trachea [10].

Tracheostomy is performed below the lower limit of the tumor, the endotracheal tube is reinserted through the tracheostomy and the resection proceeds differently according to whether one or two cricoarytenoid units are to be preserved [10]. If both cricoarytenoid units are to be preserved, suspension of the trachea to the hyoid bone is performed using five

double polyglactin suture stitches passed through the first and second tracheal ring (for THIEP), or through the pre-epiglottic space and through the base of the tongue encircling the hyoid bone (for THIP) [10]. The first stitch passes along the midline reaching to within 1 to 2 cm of the base of the tongue, whereas the lateral stitches should pass in front of the posterior cricoid plate through the base of the tongue close to the hyoid bone [10]. If only one cricoarytenoid unit is to be preserved, the pyriform fossa is reconstructed on the side of the sacrificed arytenoids before suspension of the trachea [10].

A Proposed Classification for Horizontal Partial Laryngectomy (HPL)

One of the advantages of supraglottic, supracricoid, and supratracheal laryngectomies is the possibility to customize the procedure to the specific extent of the disease, shifting from one HPL type to another intraoperatively. In extreme cases, in patients with a prior complete preoperative diagnostic workup, the procedure can be converted to a total laryngectomy intraoperatively. This results in a radical change in the patient's lifestyle after surgery and may lead to medicolegal issues regarding informed consent. To overcome these problems, a new classification of HPL has been proposed by the working committee on nomenclature of the European Laryngological Society, based on the craniocaudal extent of laryngeal structures resected (Table n°1) [11]. This could help the surgeon to refer to a surgical plan rather than to a single procedure, in the approach to HPL [12]. The proposed HPL classification system considers three types of partial horizontal laryngectomies: Type I (supraglottic), Type II (supracricoid) and Type III (supratracheal). HPL Type I can be extended to one arytenoid (A), the base of tongue (B), one vocal cord (C) or to a pyriform sinus (D); HPL Type II (a: with cricohoydoepiglottopexy or b: with cricohyoidopexy) can be extended to one arytenoid (A); HPL Type III (a: with cricohoydoepiglottopexy or b: with cricohyoidopexy) can be extended to one crico-arytenoid unit (A). This classification reflects and clarifies the complexity of HPL. All the possible HPL variations, in terms of extent of resection, are now clearly defined and can be reported in the informed consent.

Table 1. HPL classification proposal

TYPE I HPL: SUPRAGLOTTIC LARYNGECTOMY	TYPE II HPL: SUPRACRICOID LARYNGECTOMY	TYPE III HPL: SUPRATRACHEAL LARYNGECTOMY
TYPE I + A: extended to one arytenoid	TYPE IIa HPL: SUPRACRICOID LARYNGECTOMY with CRICOHYOIDO-EPIGLOTTOPEXY	TYPE IIIa HPL: SUPRATRACHEAL LARYNGECTOMY with TRACHEOHYOIDO-EPIGLOTTOPEXY
TYPE I + B: extended to base of the tongue	TYPE IIa + A HPL: SUPRACRICOID LARYNGECTOMY with CRICOHYOIDO-EPIGLOTTOPEXY extended to one arytenoid	TYPE IIIa + A HPL: SUPRATRACHEAL LARYNGECTOMY with CRICOHYOIDO-EPIGLOTTOPEXY extended to one arytenoid
TYPE I + C: extended to one vocal cord	TYPE IIb HPL: SUPRACRICOID LARYNGECTOMY with CRICOHYOIDOPEXY	TYPE IIIb HPL: SUPRATRACHEAL LARYNGECTOMY with CRICOHYOIDPEXY
TYPE I + D: extended to one pyriform sinus	TYPE IIb + A HPL: SUPRACRICOID LARYNGECTOMY with CRICOHYOIDOPEXY extended to one arytenoid	TYPE IIIb + A HPL: SUPRATRACHEAL LARYNGECTOMY with CRICOHYOIDOPEXY extended to one arytenoid

REFERENCES

[1] Thomas, L.; Drinnan, M., Natesh, B.; Mehanna, H.; Jones, T.; Paleri, V (2012). Open conservation partial laryngectomy for laryngeal cancer: A systematic review of English language literature. *Cancer Treatment Reviews*. 38: 203–211.

[2] Myers, E. (1997). Operative Otolaryngology: *Head and Neck Surgery*, Volume 1, Saunders.

[3] *International Federation of Head and Neck Oncology*, 2008 report.

[4] Armstrong, W.; Vokes, D.; Verma, S. (2015). Malignant Tumors of the Larynx. *Cummings Otolaryngology Head and Neck Surgery* 6th edition. Elsevier. Chapter 106 pp 1601-1602.

[5] Balatoni, Z.; Elo, J. (1999). Indication and surgical technique for extended hemilrayngectomy. *Eur. Arch. Otorhinolaryngol.* 256:400-402

[6] Johnson, J. (2014). Vertical Partial Laryngectomy. Head and Neck Surgery: Master Techniques in Otolaryngology- *Head and Neck Surgery*. Lippincott Williams and Wilkins Vol 1199-206.

[7] Ogura, J. H. (1963). Management of early cancer of the vocal cord --laryngofissure, hemilaryngectomy, irradiation. *Trans Pac. Coast Otoophthalmol. Soc. Annu. Meet.* 44:245-247.

[8] Eslava, E. M., Pontejos, A. Q. Y. Jr. (2004). A preliminary descriptive study of supracricoid laryngectomy with cricohyoidoepiglottopexy (SCL-CHEP) among laryngeal carcinoma patients at a tertiary hospital in Metro Manila from 1998-2002. *Philipp. J. Otolaryngol. Head Neck Surg.* 19:151-154.

[9] Laccourreye, H., Laccourreye, O., Weinstein, G, et al., (1990) Supracricoid laryngectomy with cricohyoidopexy: a partial laryngeal procedure for selected supraglottic and transglottic carcinomas. *Laryngoscope*. 100:735.

[10] Rizzotto, G.; Succo, G.; Lucioni, M.; Pazzaia, T. (2016). Subtotal Laryngectomy with Tracheohyoidopexy: a possible alteranative to total laryngectomy. *The Laryngoscope*. 116, 1907-1917.

[11] Succo, G., Peretti, G., Piazza, C., et al., (2014). Open partial horizontal laryngectomies: a proposal for classification by the working committee on nomenclature of the European Laryngological Society. *Eur. Arch. Otorhinolaryngol.* 271:2489-96.

[12] Giordano, L., Di Santo, D., Crosetti, E., Bertolin, A., Rizzotto, G., Succo, G., Bussi, M. (2016). Open partial horizontal laryngectomies: is it time to adopt a modular form of consent for the intervention? *Acta Otorhinolaryngol. Ital.* Oct; 36(5): 403–407. doi: 10.14639/ 0392-100X-76.

In: Encyclopedia of Surgery (22 Volume Set)
Editors: Andreas Lehrer and Kristin Mueller
ISBN: 978-1-53618-329-0
© 2020 Nova Science Publishers, Inc.

Chapter 436

EFFECT OF BARIATRIC SURGERY ON WEIGHT AND DIABETES

Natalia R. Moreno-Castellanos*, PhD
Department of Basic Sciences, Universidad Industrial de Santander,
Bucaramanga, Colombia

ABSTRACT

Bariatric surgery (BS) is a set of effective surgical procedures used for weight reduction and improvement of insulin sensitivity in morbidly obese patients, in comparison with non-invasive techniques such as drug treatment or changes in lifestyle. BS induces mechanical modifications, such as brain-mediated suppression of appetite, changes in gut hormones, microbiome and bile acids, which together, contribute to BS-associated improvement of glucose, lipid homeostasis and inflammation. Although the resolution of obesity-related metabolic comorbidities occurs well in advance of significant fat mass reductions, it is accepted that BS causes profound changes in the adipose tissue (AT) biology, which, in turn, strongly affect systemic glucose utilization and metabolic health leading to the improvement of insulin response in diabetic patients.

In this line, BS modifies the AT secretory profile and the expression of genes involved in the regulation of adipocyte metabolism, inflammation, and extracellular matrix organization, inducing adaptive changes in the AT. Notably, the degree of improvement, regarding to insulin sensitivity, after BS may depend on AT features at pre-surgery, such as adipocyte size and AT fibrosis; however, the reversion of insulin resistance strongly depends on the "pre-metabolic status" of individuals: "metabolically healthy obese" (MHO) or "metabolically unhealthy obese" (MUO).

Keywords: bariatric surgery, type 2 diabetes, weight, insulin sensitivity

* Corresponding Author's Email: natasmore1885@gmail.com.

INTRODUCTION

Over the last few decades, there has been a progressive increase in overweight and obesity, this tendency has become a serious problem for public health; mainly; because of its association with diseases, such as type 2 diabetes (T2D), cardiovascular diseases, hypertension, dyslipidemia among others [1, 2].

Obesity is a chronic, multi-factorial and recurrent disease, caused by abnormal or excessive fat accumulation, resulting in an altered metabolism and serious health consequences [3, 4] caused mainly by an imbalance between calories consumed and expended. Based on the Body Mass Index (BMI), the nutritional status of obese people can be classified as: overweight; BMI 30 to 34.9 kg/m^2, Grade I obesity; BMI 35 - 39.9 kg/m^2, Grade II obesity; BMI > 40 kg/m^2, Grade III Obesity or Morbid obesity, defined as a BMI higher than 40 kg/m^2 or 35 kg/m^2 [5].

In obesity, there is a lipid accumulation and hypertrophy of the adipocytes. Obese patients, with hypertrophic adipocyte, present a metabolic overload of intracellular and extracellular mechanisms (oxidation of energy substrates and protein synthesis, extracellular matrix expansion and angiogenesis), making them unable to meet metabolic demands. these mechanisms lead to: i) deficiencies in energy production and protein synthesis which, in turn, cause the activation of an intracellular inflammatory response, ii) endoplasmic reticulum (ER) stress and iii) increase in the mitochondrial production of ROS. The latter two, together with hypoxia and mechanical stress, generate the activation of inflammatory cascades (c-jun N-terminal kinase (JNK) and nuclear factor-κB (NF-κ B)) [6, 7]. Those alterations lead to: an increase the overproduction of pro-inflammatory adipokines (tumor necrosis factor (TNF), interleukin 6 (IL-6), monocyte chemoattractant protein-1 (MCP-1)), decrease adiponectin, amplification of oxidative stress and mechanical stress, development of chronic inflammation and a decrease in insulin signaling, causing insulin resistance (IR).

IR obese patients develop all the metabolic alterations associated with obesity. These patients are called “metabolically unhealthy obese” (MUO) [8], however, not all obese patients develop metabolic complications and IR. There is a type of obese individuals with a normal phenotype, “metabolically healthy obese” (MHO), who interestingly, maintains insulin sensitivity [9]. Specifically, MHO individuals are 13-29% of the obese population [10]. Characterized by maintaining insulin sensitivity, they have a normalized pattern of adipokines (including normal adiponectin levels), a reduction of adipose tissue (AT) fibrosis, smaller adipocytes in contrast with MUO adipocytes, a decrease in AT macrophage infiltration, a low inflammatory and lipid profile, and fasting glucose within normal ranges compared to MUO individuals [11-13]. These phenotypic features reduce the development of dyslipidemia, hypertension, IR, T2D, cardiovascular disease and, ultimately, metabolic syndrome.

There are different strategies to reduce obesity and pathologies associated therewith, the most common of which are reduction methods, such as diet and exercise. Both, improve body fat and body mass index, increase free fatty acids (FFA) oxidation, improve insulin sensitivity and glucose tolerance, have favorable effects on lipid profile, reduce hypertension and inflammation, increase adiponectin levels and reduce the basal levels of damage caused by oxidants [14]. Other common methods are drugs therapies (Omega-3 fatty acids, metformin,

inhibitors of angiotensin, etc.). These methods also promote weight loss and improve patient health, mainly relating to dyslipidemia and hypertension.

Interestingly, although the benefits of these methods in many cases are unsatisfactory. Actually, bariatric surgery (BS) is an effective treatment option for sustained weight loss, this medical procedure improves: hypertension, dyslipidemia, inflammatory status and reverts in the long term IR in obese patients (BS reverses IR and T2D in many patients in proportion to weight loss) [15],

Several studies consider that the improvement of IR may be associated with the remaining volume of the proximal stomach and malabsorptive state, BS caused metabolic changes in the intestine and the transit of food, including changes in the levels of gut hormones (glucagon-like peptide - 1 (GLP - 1) and peptide YY (PYY)), which positively affects insulin and glucose homeostasis [16]. Understanding the mechanisms underlying obesity and BS as the best effective treatment to weight loss is important, particularly the effect on IR patients improving their insulin sensitivity.

BARIATRIC SURGERY AND WEIGHT LOSS

There are several strategies to promote weight loss, but BS, is an effective surgical procedure used to reduce weight and improve health in patients with morbid obesity [17, 18]. These procedures are indicated mainly in obese patients with BMI $\geq$35 kg/m^2 and in which drug treatment and lifestyle modification have not been successful [19, 20].

BS surgical procedures are classified as restrictive, malabsorptive or mixed techniques. Restrictive methods consist of reducing size or gastric capacity, limiting food intake. Meanwhile, malabsorptive methods involve decreased absorption of nutrients by removing parts of the small intestine. Mixed methods combine both restrictive and malabsorptive techniques. The four techniques most used in BS include: adjustable gastric banding (restrictive technique, placing a band around the upper stomach), sleeve gastrectomy (restrictive technique, reducing stomach size by 25%), gastric bypass surgery (mixed method, creating a small stomach pouch, which can only contain small amounts of food and, in turn, connecting the small intestine to the stomach, thus reducing nutrient absorption) and biliopancreatic diversion (mixed technique, which reduces the stomach and creates a stomach pouch).

The effect of weight loss caused by BS is dependent on factors other than the BS method used. Those factors include, social factors such as age, gender, race, body composition, education, emotional state and activity [21]. Another factor that helps weight loss is the modification of the diet to prevent weight regain after BS [21]. All these factors lead to variations in the grade of weight loss between different patients. However, despite variations in weight loss among patients, patients lose weight significantly at 2 years, followed by a gradual weight reduction in the following years as a result of hormonal, cellular, metabolic and gene changes produced in response to the BS.

It has been suggested that acute caloric restriction that occurs just after BS with increases in some peptides associated with satiety (GLP-1, PYY, oxyntomodulin, gastrin) and decrease in factors associated with feeling hungry (ghrelin) promote weight loss [16]. Notably, it has been established that weight loss associated with BS induces changes in the AT which, in

turn, have a significant impact on the peripheral and general use of glucose and metabolic health [22, 23].

There have been a number of studies that have shown that BS induces important changes in the secretory profile of the AT, reflected in the weight loss [24]. Specifically, adiponectin increases significantly in relation to weight loss in patients undergoing BS, while leptin levels have been reduced. These changes have also been correlated with improved insulin resistance and normalization of the lipid profile in patients after surgery [23], indicating a recovery of alterations in the development of obesity in AT. Additionally, there have been studies that show both an increase [24] or decrease [25] in the pro-inflammatory cytokine tumor necrosis factor- α (TNF-α) after BS. The increase is due to the persistent inflammation after gastric bypass surgery, while decreasing TNF-α is explained by weight reduction and therefore, a reduction in the proinflammatory profile.

There are few studies about cellular and molecular changes that accompany weight loss after BS, especially in the medium and long term, but, they are not yet fully clarified mechanisms and molecular pathways involved in this process and, in particular, those that might contribute to improve the metabolic profile of obese patients undergoing BS. Specifically, a transcriptomic study by Dankel et al. showed an increase in expression of genes involved in pathways associated with the regulation of energy metabolism, as well as important gene changes related to the extracellular matrix after BS [26]. Other target studies have shown that weight loss after BS brings increase of proteins associated with lipid droplets, as CIDEC/FSP27, perilipin 1 (PLIN1), or lipogenic and mitochondrial genes [27].

Moreover, after BS, there are significant morphological changes, specifically in adipocyte size and/or related to the cytoskeleton, which greatly affect glucose utilization and/or fibrosis [28, 29]. This change in adipocyte size, after BS, is accompanied by cellular remodeling, which, in turn, involves cytoskeletal changes. In fact, although this field is not extensively studied, weight loss modifies some cytoskeletal proteins such as: vimentin, tubulin and actin, which in turn helps to normalize the metabolism [30] and increase adipogenesis in AT [31]. These changes, together, promote normalization of adipocyte functionality and thus promote weight reduction.

BARIATRIC SURGERY AND DIABETES

BS leads to improvement of blood sugar and remission of insulin resistance in patients with T2D, even before there have been significant reductions in weight [32]. Generally, short-term remission of diabetes occurs in 60-90% of patients. These ranges cannot be generalized to long-term results. Sjöström et al. published a prospective study in 25 surgical departments and 480 primary care centers in Sweden, called the study “Swedish Obese Subjects” (SOS), in order to determine the ranges of diabetes remission after BS compared to usual medical treatment after 10 and 18 years. The diabetes remission two years later was 16.4% in patients with medical control and 72.3% in patients after BS. At age 15, ranges remission of diabetes decreased to 6.5% for patients with medical management and 30.4% for patients undergoing BS [33]. Additionally, Buchwaldy et al. in a meta-analysis of 136 studies and 22,094 patients, compare different BS methods and found that, regardless of the procedure, BS improves or solves diseases such as T2D, hypertension and dyslipidemia in more than 80% of obese

patients [34]. Sugerman et al. in a study of 1,025 patients undergoing gastric "bypass", 2 years after BS, 83% of diabetic patients had fasting glucose of less than 120 mg/dI without the use of antidiabetic drugs [35].

Due to the existence of a large number of studies that support the effect of BS on diabetes remission and therefore, improving insulin sensitivity, clearly BS induces an improvement in remission of diabetes in the short term compared to other clinical methods. Restrictive methods, such as adjustable gastric band, show lower remission rates of diabetes and have an effect on glucose metabolism related to weight loss. Nevertheless, more complex procedures, such as, gastric bypass, alter the anatomy and neuroendocrine function. This surgery has higher remission rates even before weight loss, suggesting the presence of other mechanisms probably related to biochemical or endocrine disruption. The improvement in diabetes due to BS has been attributed to caloric restriction, changes in gut hormones, mechanical changes of the gastrointestinal system, appetite suppression mediated by changes in the central nervous system, and/or changes in the composition of bile acids and microbiota, adipose tissue modifications and metabolic status of subjects (MHO vs. MUO) before BS, taste receptors of the gut, genetic factors, insulin clearance and amino acids [36, 37].

Caloric Restriction

It is well know, that caloric restriction significantly improves glucose tolerance in diabetic patients. BS has been associated with improvements in fasting glucose and insulin signaling, occurring frequently in a short time after BS and even before significant weight loss. Obese patients undergoing BS or dieting at 500 kcal/day lose a similar amount of weight during the first 3 weeks and exhibit similar improvements in insulin sensitivity, acute secretion of insulin and beta cell action [38]. This mechanism partly explains remission of diabetes, which is common in all bariatric procedures. However, similar caloric intakes, decrease faster glucose plasma levels in procedures such as gastric bypass comparing with restrictive methods.

Glucagon and Glucagon-Like Peptide 2(GLP2)

Glucagon is a mechanism that improves glucose homeostasis after BS because it increases after stimulation by food in a postprandial state after gastric bypass. However, one year after gastric bypass and after fasting decreases, it could explain some of the long-term benefits of gastric bypass on glucose metabolism.

On the other hand, GLP-2 regulates gastric motility, gastric acid secretion, intestinal transport of hexose, glucagon secretion; increases absorption area and increase barrier function of the intestinal epithelium through inhibition of apoptosis in the enterocyte and crypt cell stimulation and proliferation. Rats' GLP-2 levels after bypass increase, which has been associated with high proliferation of crypt cells as early as 23 days after surgery. This clarifies how well the gastric bypass is tolerated and the low degree of macronutrients malabsorption [39]. However, the association of GLP2 with improved homeostasis after gastric bypass is not yet fully understood.

Incretins

Several studies have shown GLP-1 increase after gastric bypass, but not after adjustable gastric banding, weight loss or diet-induced. The GLP-1 increase is clearly related to the gastrointestinal anatomy alteration caused by the gastric bypass method [16, 40]. The early recovery of beta cells function has been associated with a higher GLP-1 secretion after-gastric bypass, although the cause has not yet been determined [41]. Studies about GIP changes after-BS have been inconsistent. In theory, the removal of duodenum, where most K enteroendocrine cells producing GIP are located, would lead to decreased GIP secretion after gastric bypass [42]. Instead, some studies have found increases in GIP [43], while in others have found decreases [42]. It is possible because different GIP secretion levels after surgery could be caused by variations in surgical technique, specifically, differences in the length of the Roux anastomosis, and blood sampling time.

Changes in Appetite Hormones

PYY is a polypeptide like GLP-1, found in L cells in the gastrointestinal tract, especially in colon and ileum. PYY function is primarily inhibitory, including stomach acid secretion, stomach emptying, intestinal transit rate, insulin secretion and exocrine pancreatic secretion. It also suppresses appetite and reduces food intake, promoting weight loss [44] and stimulating insulin activity [45]. PYY levels increased after gastric bypass, but not after adjustable gastric banding [46]. GLP-1 and PYY postprandial increase after BS, suggesting that gut hormones modulate appetite to enhance the sensitivity and insulin secretion, leading to reduction in food intake and contributing to achieving and maintaining better glycemia control [47].

Ghrelin is secreted by the gastric fundus and proximal small intestine. It acts on the hypothalamus, regulating appetite. Furthermore, it acts on the pancreatic islet where it is also produced, inhibiting insulin secretion. Ghrelin also stimulates appetite and reduces energy expenditure and fat catabolism. Among the mechanisms that regulate ghrelin secretion is body weight, which is inversely proportional to ghrelin amount, suggesting a major role in regulating long-term body weight. Several studies have reported decreases in ghrelin levels in fasting and postprandial post-gastric bypass; others have not found any change or even a low increase in ghrelin [48]. These apparently different results may be due to the post-surgery times studied, the amount of weight loss and sampling time (fasting vs. after meals).

Mechanical Changes of the Gastrointestinal System

One mechanism improving T2D after BS is the rapid delivery of nutrients not absorbed into the active distal intestine “ileal brake” that enhances the secretion of GLP-1 and PYY (hypothesis of the distal bowel). It is the most studied and probably one of the best theories supported by available evidence. It suggests that the arrival of nutrients to distal segments of the small intestine due to duodenum bypass and proximal jejunum, increases peptides secreted in the enteroendocrine “L” cells of the distal segments of the intestine (GLP-1 and PYY) [49]. This has been shown many times in experimental research, demonstrating high

levels of incretins after gastric bypass [46, 47]. It has also been shown, that patients in which ileal interposition is carried out, which locates rich ileal segments of "L" cells in proximal bowel segments, also have improved insulin sensitivity, improved glycemic control and plasma levels of GLP 1 and PYY, which further confirms the role of the stimulation of hindgut and confirms the role of distal intestine stimulation [50-52]. This effect (improvement in glucose metabolism and GLP-1 increased) also occurs after sleeve gastrectomy surgery, which does not include changes in the structure of intestinal transit, increases the rate of gastric emptying, which probably stimulates more distal segments of the small intestine. Ileal interposition in humans associated with gastrectomy has shown potential for the treatment of T2D in patients with BMI: 21-34kg/m^2 [53]. The exclusion of proximal nutrients in the small intestine (foregut hypothesis) has also been proposed as a euglycemia restorer. While gastric bypass nutrients promote exposure of the distal intestine, they also produce an exclusion of the proximal segments of the small intestine. Foregut theory suggests the existence of unknown hormones, whose effect would be antagonistic to incretins and insulin and would even promote insulin resistance [54]. This theory is based primarily on the results obtained with duodenal jejunal bypass; however, other studies with this procedure, do not have the same results in all animal models [55]. In addition, the results obtained with sleeve gastrectomy, in which these segments are not excluded, results similar to gastric bypass have found; this does not support this theory [56]. Less invasive endoscopic therapies have also been used for the treatment of T2D using a procedure of sleeve endoluminal in a rat model. Into the invasive therapies are included, gastric bypass, foregut bypass and early exposure to nutrients partially digested to the jejunum, Aguirre et al. showed that while rats undergoing gastric bypass surgery lost more weight than rats subjected to sleeve endoluminal, rats with sleeve endoluminal achieved greater improvement in glucose homeostasis [57]. In humans, they have shown reductions in glycated hemoglobin (HbA1c) subsequent to different types of endoluminal sleeves duodeno-jejunal. They are leading further research on safety, efficacy and long-term results.

Afipose Tissue and Metabolic Status of Subjects (MHO vs. MUO)

After gastric bypass, a significant weight and body fat reduction, including 50-60% reduction in visceral AT. Adiponectin, a protein of 244 amino acids secreted by white AT, is inversely proportional to body fat, BMI, waist-hip ratio, serum insulin and glucose levels [58], lower levels are closely related to insulin resistance and suspected to play a role in the pathogenesis of T2D. Many studies have shown an increase in adiponectin after gastric bypass, which is correlated with improvement in insulin resistance [59], adiponectin also increases in serum and AT levels after BS in both obese patients: MUO and MHO. These results together add further evidence to the beneficial effects of BS improving chronic systemic inflammation associated with obesity and insulin resistance [60].

On the other hand, metabolic conditions of patients after BS depend largely on AT characteristics of patients undergoing surgery. It has been established, that adipocytes size and degree of fibrosis before BS can affect the improvement of insulin resistance and reversion of T2D [28, 29]. In this regard, there are subtypes of obese individuals regarding the development of metabolic disease (MHO vs. MUO). It has been considered that to better understand the mechanism that improves insulin sensitivity after the BS, it is necessary to

explain the mechanisms underlying the maintenance of MHO phenotype. Some studies have failed at trying to attribute to changes in lifestyle (diet and physical activity) [61], while other studies have found that MHO individuals, in addition to maintaining insulin sensitivity, have greater capacity to adapt to calorie diets than MUO individuals [62]. Other studies have focused on explaining this phenotype by genetic modification [modification in some genes, such as adiponectin receptor 1 (AdipoR1) and hepatic lipase (LIPC)] [63] and other studies have attributed it to molecular changes in the AT. On the molecular level, it has been found that heat stress in MUO individuals leads to inflammation of AT and increased pro-inflammatory cytokines, hypertrophy, hyperplasia and AT dysfunction, while caloric overload in MHO individuals promotes hyperplasia, but does not increase adipocytes size, which is associated with the maintenance of a normal AT function and maintenance of insulin sensitivity [62].

Recently, our research group has shown that, compared to what was observed in obese MHO, the adipocytes of obese MUO individuals have less ability to prevent oxidative damage and excessive activity of the endoplasmic reticulum (i.e., ER stress) in obesity, this and proteasome dysfunction, carry an accumulation of oxidation and/or misfolding proteins in cells of MUO patients [64]. This proteasome dysfunction, which also occurs in animal models of insulin resistance and which can be induced in vitro by exposure to palmitate, is directly associated with the development of insulin resistance [64]. In addition, in another study we found that BS affects the AT of MUO and MHO in a different way. Moreno et al. determine the proteome of subcutaneous adipose tissue (SAT) in obese patients, with and without IR, before and one year after BS, to identify proteins that may be involved in metabolic changes in the AT. The AT of either MHO or MUO morbidly obese individuals exhibited proteomic signatures suggestive of functional recovery one year after surgery, yet there remained significant differences between the two groups of subjects at after BS, despite similar weight reductions, favorable adipokine profile and decreased inflammation. BS-induced weight loss evokes significant rearrangements in the metabolic activity, oxidative capacity, mitochondrial activity, cytoskeletal organization, and angiogenic capacity of AT in morbidly obese women. However, the most important part of this study is that surgery evokes selective changes in the AT of MUO morbidly obese subjects in a way that resembles, at least in some aspects, the AT in the MHO obese state, while MHO obese AT tends to acquire a lean-like phenotype. These phenotypic aspects of AT may be associated largely with the reversion of the T2D subjects in MUO after BS [60].

Bile Acids

Bile acids work as fat solubilizers and activate nuclear transcription factors that regulate genes involved in the metabolism of glucose and cholesterol. They can also activate TGR5, which is a receptor associated with a G protein activation, which regulates the secretion of GLP-1. Bile acids also act on Farnesoid X receptor, stimulating the secretion of fibroblast growth factor (FGF) 19 with subsequent inhibition of hepatic gluconeogenesis that result in the generation of glucose from certain non-carbohydrate carbon substrates. In prospective studies with humans and animals, Puornaras et al. conclude that gastric bypass but not the gastric banding, lead to faster delivery of bile acids into the terminal ileum, which causes an

increase in the total concentration of bile acids, plasma levels of GLP-1, PYY and FGF 19 [65].

Gut Microbiota

Recent data from studies in mice and small studies in humans have shown that the gut microbiota may play an important role in energy storage and in the development of obesity and associated complications [66]. BS, in particular, induces environmental, systemic and anatomical changes that may affect the composition of gut microbiota. Some studies suggest a change in intestinal microbiota after surgery to profiles most similar to lean subjects. However, these differences have also been found in obese patients undergoing low-calorie diets with restriction of carbohydrates or fats, so it is not clear whether the changes found after gastric bypass are secondary to the structural changes of the intestine, changes in hormone levels or due to diet after surgery [22, 66]. It remains to be clarified whether these changes in microbiota contribute to improving glucose homeostasis.

Genetic Factors

The melanocortin system is an integral component in the regulation of energy homeostasis. The loss of a single functional copy of the melanocortin receptor-4 gene (MC4R) is the most common mutation associated with obesity in humans. Mirshahi et al. found that subjects with I251L allele were more likely to lose weight during surgical and dietary interventions and had less insulin resistance. Published research on the role of MC4R in bariatric surgery involves few diabetic patients, so it is not clear whether MC4R has clinical significance in glycemic results [67]. Recently, fetal and adult ablation of transcription factor - Foxo1 in mouse enteroendocrine stem cells has led to the development of intestinal cells with the ability to produce insulin biologically active in response to glucose. In contrast to insulin-producing cells derived from embryonic stem cells, insulin-producing cells arising from the intestine showed a singular plasticity and ability to regenerate and produce insulin [68]. It is possible that BS, by changing hormonal signals and nutrients, have an influence on insulin secretion in the intestine through Foxo1 alterations.

Taste Receptors of the Gut

Taste receptors coupled with G-protein detect bowel luminal contents and send signals that regulate the expression of nutrient carriers and nutrient uptake, as well as release of gut hormones and neurotransmitters involved in the regulation of energy homeostasis and glucose. Sweet taste receptors, TAS1R2, have been altered in T2D and may increase the risk of postprandial hyperglycemia by increasing glucose uptake by cotransport Na +/glucose SGLT1 during hyperglycemia [69]. The fast discharge of undigested nutrients into the small intestine after gastric bypass can also affect the regulation of taste receptors or glucose transporters in L cells, leading to increased secretion of PYY and GLP-1 [70].

Insulin Clearance

The fast decrease in fasting glucose and fasting insulin after gastric bypass may be caused by an early improvement in hepatic glucose production and hepatic insulin sensitivity. Plasma FFA increases following BS are followed by a decrease in FFA plasma levels one year after BS, later contributing to the improvement of peripheral insulin sensitivity.

Amino Acids

Dietary macronutrients work as signaling molecules affecting eating behavior, enteric hormones, insulin release and sensitivity. Obesity and diabetes are known to alter the circulating levels of many metabolites. Metabolite profiles in diabetic patients have shown weight loss after gastric bypass, but not equal to weight loss induced by diet, which is associated with decreased plasma concentrations of fasting branched chain amino acids and their metabolites (C3 and C5) which correlate negatively with insulin sensitivity [71].

CONCLUSION

Bariatric surgery is as a treatment for sustained weight loss in morbidly obese subjects. Recently, development of new procedures and improved surgical techniques has found favorable results in T2D remission. In fact, the improvement of T2D with bariatric surgery reflects positive short- and long-term results. Nevertheless, among the different surgical techniques, gastric bypass clearly has the best results in weight loss and remission of diabetes. Although the results of bariatric surgery, in the management of T2D have been shown in many publications, the pathophysiological mechanisms are not fully understood. Nevertheless, the mechanisms considered important increasing sensitivity to insulin and weight loss include changes in caloric intake and glucose metabolism mediated primarily by changes in intestinal hormones released into specific segments, as well as genetic and mechanical mechanisms, AT modifications and clear differences between the initial metabolic states (MUO vs. MHO) of subjects before BS. The pathophysiological basics are constantly being researched and require further study for confirmation. However, it can be concluded that the improvement of diabetes and weight loss after BS implies a multifactorial complex process.

REFERENCES

[1] Hotamisligil, G.S. (2006). Inflammation and metabolic disorders. *Nature, 444*, 860-867.

[2] Flegal, K.M., Kit, B.K., Orpana, H. and Graubard, B.I. (2013). Association of all-cause mortality with overweight and obesity using standard body mass index categories: a systematic review and meta-analysis. *JAMA, 309*, 71-82.

[3] Fruhbeck, G., Mendez-Gimenez, L., Fernandez-Formoso, J.A., Fernandez, S. and Rodriguez, A. (2014). Regulation of adipocyte lipolysis. *Nutr Res Rev, 27*, 63-93.

[4] Fruhbeck, G., Toplak, H., Woodward, E., Yumuk, V., Maislos, M., et al. (2013). Obesity: the gateway to ill health - an EASO position statement on a rising public health, clinical and scientific challenge in Europe. *Obes Facts, 6*, 117-120.

[5] Expert Panel on the Identification, Evaluation, and Treatment of Overweight in Adults (1998) Clinical guidelines on the identification, evaluation, and treatment of overweight and obesity in adults. *WMJ, 97*, 20-21, 24-25, 27-37.

[6] Wellen, K.E. and Hotamisligil, G.S. (2005). Inflammation, stress, and diabetes. *J Clin Invest, 115*, 1111-1119.

[7] Gregor, M.F. and Hotamisligil, G.S. (2007). Thematic review series: Adipocyte Biology. Adipocyte stress: the endoplasmic reticulum and metabolic disease. *J Lipid Res, 48*, 1905-1914.

[8] Maury, E. and Brichard, S.M. (2010). Adipokine dysregulation, adipose tissue inflammation and metabolic syndrome. *Mol Cell Endocrinol, 314*, 1-16.

[9] Primeau, V., Coderre, L., Karelis, A.D., Brochu, M., Lavoie, M.E., et al. (2011). Characterizing the profile of obese patients who are metabolically healthy. *Int J Obes (Lond), 35*, 971-981.

[10] Badoud, F., Lam, K.P., Perreault, M., Zulyniak, M.A., Britz-McKibbin, P., et al. (2015). Metabolomics Reveals Metabolically Healthy and Unhealthy Obese Individuals Differ in their Response to a Caloric Challenge. *PLoS One, 10*, e0134613.

[11] Denis, G.V. and Obin, M.S. (2013). 'Metabolically healthy obesity': origins and implications. *Mol Aspects Med, 34*, 59-70.

[12] Muller, M.J., Lagerpusch, M., Enderle, J., Schautz, B., Heller, M., et al. (2012). Beyond the body mass index: tracking body composition in the pathogenesis of obesity and the metabolic syndrome. *Obes Rev, 13 Suppl 2*, 6-13.

[13] Dobson, R., Burgess, M.I., Sprung, V.S., Irwin, A., Hamer, M., et al. (2016). Metabolically healthy and unhealthy obesity: differential effects on myocardial function according to metabolic syndrome, rather than obesity. *Int J Obes (Lond), 40*, 153-161.

[14] Onat, A. (2011). Metabolic syndrome: nature, therapeutic solutions and options. *Expert Opin Pharmacother, 12*, 1887-1900.

[15] Garrido-Sanchez, L., Murri, M., Rivas-Becerra, J., Ocana-Wilhelmi, L., Cohen, R.V., et al. (2012). Bypass of the duodenum improves insulin resistance much more rapidly than sleeve gastrectomy. *Surg Obes Relat Dis, 8*, 145-150.

[16] Meek, C.L., Lewis, H.B., Reimann, F., Gribble, F.M. and Park, A.J. (2016). The effect of bariatric surgery on gastrointestinal and pancreatic peptide hormones. *Peptides, 77*, 28-37.

[17] Malkani, S. (2015). An update on the role of bariatric surgery in diabetes management. *Curr Opin Endocrinol Diabetes Obes, 22*, 98-105.

[18] Yu, J., Zhou, X., Li, L., Li, S., Tan, J., et al. (2015). The long-term effects of bariatric surgery for type 2 diabetes: systematic review and meta-analysis of randomized and non-randomized evidence. *Obes Surg, 25*, 143-158.

[19] Fried, M. (2013). Bariatric and metabolic surgery. *Minerva Endocrinol, 38*, 237-244.

[20] Fried, M., Yumuk, V., Oppert, J.M., Scopinaro, N., Torres, A., et al. (2014). [Interdisciplinary European guidelines on metabolic and bariatric surgery]. *Rozhl Chir, 93*, 366-378.

[21] Sarwer, D.B., Wadden, T.A., Moore, R.H., Baker, A.W., Gibbons, L.M., et al. (2008). Preoperative eating behavior, postoperative dietary adherence, and weight loss after gastric bypass surgery. *Surg Obes Relat Dis, 4*, 640-646.

[22] Clement, K. (2011). Bariatric surgery, adipose tissue and gut microbiota. *Int J Obes (Lond), 35 Suppl 3*, S7-15.

[23] Bays, H.E., Laferrere, B., Dixon, J., Aronne, L., Gonzalez-Campoy, J.M., et al. (2009). Adiposopathy and bariatric surgery: is 'sick fat' a surgical disease? *Int J Clin Pract, 63*, 1285-1300.

[24] Appachi, S., Kelly, K.R., Schauer, P.R., Kirwan, J.P., Hazen, S., et al. (2011). Reduced cardiovascular risk following bariatric surgeries is related to a partial recovery from "adiposopathy". *Obes Surg, 21*, 1928-1936.

[25] Cottam, D.R., Mattar, S.G., Barinas-Mitchell, E., Eid, G., Kuller, L., et al. (2004). The chronic inflammatory hypothesis for the morbidity associated with morbid obesity: implications and effects of weight loss. *Obes Surg, 14*, 589-600.

[26] Dankel, S.N., Fadnes, D.J., Stavrum, A.K., Stansberg, C., Holdhus, R., et al. (2010). Switch from stress response to homeobox transcription factors in adipose tissue after profound fat loss. *PLoS One, 5*, e11033.

[27] Moreno-Navarrete, J.M., Novelle, M.G., Catalan, V., Ortega, F., Moreno, M., et al. (2014). Insulin resistance modulates iron-related proteins in adipose tissue. *Diabetes Care, 37*, 1092-1100.

[28] Eriksson-Hogling, D., Andersson, D.P., Backdahl, J., Hoffstedt, J., Rossner, S., et al. (2015). Adipose tissue morphology predicts improved insulin sensitivity following moderate or pronounced weight loss. *Int J Obes (Lond), 39*, 893-898.

[29] Cotillard, A., Poitou, C., Torcivia, A., Bouillot, J.L., Dietrich, A., et al. (2014). Adipocyte size threshold matters: link with risk of type 2 diabetes and improved insulin resistance after gastric bypass. *J Clin Endocrinol Metab, 99*, E1466-1470.

[30] Bouwman, F.G., Claessens, M., van Baak, M.A., Noben, J.P., Wang, P., et al. (2009). The physiologic effects of caloric restriction are reflected in the in vivo adipocyte-enriched proteome of overweight/obese subjects. *J Proteome Res, 8*, 5532-5540.

[31] Chen, J.G., Spagnoli, A. and Torquati, A. (2012). Adipogenic differentiation of adipose tissue-derived human mesenchymal stem cells: effect of gastric bypass surgery. *Surg Endosc, 26*, 3449-3456.

[32] Panunzi, S., De Gaetano, A., Carnicelli, A. and Mingrone, G. (2015). Predictors of remission of diabetes mellitus in severely obese individuals undergoing bariatric surgery: do BMI or procedure choice matter? A meta-analysis. *Ann Surg, 261*, 459-467.

[33] Sjostrom, L., Peltonen, M., Jacobson, P., Ahlin, S., Andersson-Assarsson, J., et al. (2014). Association of bariatric surgery with long-term remission of type 2 diabetes and with microvascular and macrovascular complications. *JAMA, 311*, 2297-2304.

[34] Buchwald, H., Avidor, Y., Braunwald, E., Jensen, M.D., Pories, W., et al. (2004). Bariatric surgery: a systematic review and meta-analysis. *JAMA, 292*, 1724-1737.

[35] Sugerman, H.J., Wolfe, L.G., Sica, D.A. and Clore, J.N. (2003). Diabetes and hypertension in severe obesity and effects of gastric bypass-induced weight loss. *Ann Surg, 237*, 751-756; discussion 757-758.

[36] Seeley, R.J., Chambers, A.P. and Sandoval, D.A. (2015). The role of gut adaptation in the potent effects of multiple bariatric surgeries on obesity and diabetes. *Cell Metab, 21*, 369-378.

[37] Munzberg, H., Laque, A., Yu, S., Rezai-Zadeh, K. and Berthoud, H.R. (2015). Appetite and body weight regulation after bariatric surgery. *Obes Rev, 16 Suppl 1*, 77-90.

[38] Jackness, C., Karmally, W., Febres, G., Conwell, I.M., Ahmed, L., et al. (2013). Very low-calorie diet mimics the early beneficial effect of Roux-en-Y gastric bypass on insulin sensitivity and beta-cell Function in type 2 diabetic patients. *Diabetes, 62*, 3027-3032.

[39] le Roux, C.W., Borg, C., Wallis, K., Vincent, R.P., Bueter, M., et al. (2010). Gut hypertrophy after gastric bypass is associated with increased glucagon-like peptide 2 and intestinal crypt cell proliferation. *Ann Surg, 252*, 50-56.

[40] Gallwitz, B. (2016). Glucagon-like peptide-1 and gastric inhibitory polypeptide: new advances. *Curr Opin Endocrinol Diabetes Obes, 23*, 23-27.

[41] Nguyen, K.T., Billington, C.J., Vella, A., Wang, Q., Ahmed, L., et al. (2015). Preserved Insulin Secretory Capacity and Weight Loss Are the Predominant Predictors of Glycemic Control in Patients With Type 2 Diabetes Randomized to Roux-en-Y Gastric Bypass. *Diabetes, 64*, 3104-3110.

[42] Zhou, J., Hao, Z., Irwin, N., Berthoud, H.R. and Ye, J. (2015). Gastric inhibitory polypeptide (GIP) is selectively decreased in the roux-limb of dietary obese mice after RYGB surgery. *PLoS One, 10*, e0134728.

[43] Amouyal, C. and Andreelli, F. (2016). Increasing GLP-1 Circulating Levels by Bariatric Surgery or by GLP-1 Receptor Agonists Therapy: Why Are the Clinical Consequences so Different? *J Diabetes Res, 2016*, 5908656.

[44] Jones, K.W., Eller, L.K., Parnell, J.A., Doyle-Baker, P.K., Edwards, A.L., et al. (2013). Effect of a dairy- and calcium-rich diet on weight loss and appetite during energy restriction in overweight and obese adults: a randomized trial. *Eur J Clin Nutr, 67*, 371-376.

[45] Chandarana, K., Gelegen, C., Irvine, E.E., Choudhury, A.I., Amouyal, C., et al. (2013). Peripheral activation of the Y2-receptor promotes secretion of GLP-1 and improves glucose tolerance. *Mol Metab, 2*, 142-152.

[46] Korner, J., Inabnet, W., Febres, G., Conwell, I.M., McMahon, D.J., et al. (2009). Prospective study of gut hormone and metabolic changes after adjustable gastric banding and Roux-en-Y gastric bypass. *Int J Obes (Lond), 33*, 786-795.

[47] Ionut, V., Burch, M., Youdim, A. and Bergman, R.N. (2013). Gastrointestinal hormones and bariatric surgery-induced weight loss. *Obesity (Silver Spring), 21*, 1093-1103.

[48] Beckman, L.M., Beckman, T.R. and Earthman, C.P. (2010). Changes in gastrointestinal hormones and leptin after Roux-en-Y gastric bypass procedure: a review. *J Am Diet Assoc, 110*, 571-584.

[49] Rubino, F., Forgione, A., Cummings, D.E., Vix, M., Gnuli, D., et al. (2006). The mechanism of diabetes control after gastrointestinal bypass surgery reveals a role of the proximal small intestine in the pathophysiology of type 2 diabetes. *Ann Surg, 244*, 741-749.

[50] Patriti, A., Facchiano, E., Annetti, C., Aisa, M.C., Galli, F., et al. (2005). Early improvement of glucose tolerance after ileal transposition in a non-obese type 2 diabetes rat model. *Obes Surg, 15*, 1258-1264.

[51] Koopmans, H.S., Ferri, G.L., Sarson, D.L., Polak, J.M. and Bloom, S.R. (1984). The effects of ileal transposition and jejunoileal bypass on food intake and GI hormone levels in rats. *Physiol Behav, 33,* 601-609.

[52] Mason, E.E. (1999). Ileal [correction of ilial] transposition and enteroglucagon/GLP-1 in obesity (and diabetic?) surgery. *Obes Surg, 9,* 223-228.

[53] Shabbir, A. and Dargan, D. (2015). The success of sleeve gastrectomy in the management of metabolic syndrome and obesity. *J Biomed Res, 29,* 93-97.

[54] Kindel, T.L., Martins, P.J., Yoder, S.M., Jandacek, R.J., Seeley, R.J., et al. (2011). Bypassing the duodenum does not improve insulin resistance associated with diet-induced obesity in rodents. *Obesity (Silver Spring), 19,* 380-387.

[55] Cohen, R.V., Schiavon, C.A., Pinheiro, J.S., Correa, J.L. and Rubino, F. (2007). Duodenal-jejunal bypass for the treatment of type 2 diabetes in patients with body mass index of 22-34 kg/m^2: a report of 2 cases. *Surg Obes Relat Dis, 3,* 195-197.

[56] Nausheen, S., Shah, I.H., Pezeshki, A., Sigalet, D.L. and Chelikani, P.K. (2013). Effects of sleeve gastrectomy and ileal transposition, alone and in combination, on food intake, body weight, gut hormones, and glucose metabolism in rats. *Am J Physiol Endocrinol Metab, 305,* E507-518.

[57] Aguirre, V., Stylopoulos, N., Grinbaum, R. and Kaplan, L.M. (2008). An endoluminal sleeve induces substantial weight loss and normalizes glucose homeostasis in rats with diet-induced obesity. *Obesity (Silver Spring), 16,* 2585-2592.

[58] Esfahani, M., Movahedian, A., Baranchi, M. and Goodarzi, M.T. (2015). Adiponectin: an adipokine with protective features against metabolic syndrome. *Iran J Basic Med Sci, 18,* 430-442.

[59] Linscheid, P., Christ-Crain, M., Stoeckli, R., Reusch, C.E., Lutz, T.A., et al. (2008). Increase in high molecular weight adiponectin by bariatric surgery-induced weight loss. *Diabetes Obes Metab, 10,* 1266-1270.

[60] Moreno-Castellanos, N., Guzman-Ruiz, R., Cano, D.A., Madrazo-Atutxa, A., Peinado, J.R., et al. (2016). The Effects of Bariatric Surgery-Induced Weight Loss on Adipose Tissue in Morbidly Obese Women Depends on the Initial Metabolic Status. *Obes Surg, 26,* 1757-1767.

[61] Stefan, N., Haring, H.U., Hu, F.B. and Schulze, M.B. (2013). Metabolically healthy obesity: epidemiology, mechanisms, and clinical implications. *Lancet Diabetes Endocrinol, 1,* 152-162.

[62] Badoud, F., Perreault, M., Zulyniak, M.A. and Mutch, D.M. (2015). Molecular insights into the role of white adipose tissue in metabolically unhealthy normal weight and metabolically healthy obese individuals. *FASEB J, 29,* 748-758.

[63] Stefan, N., Kantartzis, K., Machann, J., Schick, F., Thamer, C., et al. (2008). Identification and characterization of metabolically benign obesity in humans. *Arch Intern Med, 168,* 1609-1616.

[64] Diaz-Ruiz, A., Guzman-Ruiz, R., Moreno, N.R., Garcia-Rios, A., Delgado-Casado, N., et al. (2015). Proteasome Dysfunction Associated to Oxidative Stress and Proteotoxicity in Adipocytes Compromises Insulin Sensitivity in Human Obesity. *Antioxid Redox Signal, 23,* 597-612.

[65] Pournaras, D.J., Glicksman, C., Vincent, R.P., Kuganolipava, S., Alaghband-Zadeh, J., et al. (2012). The role of bile after Roux-en-Y gastric bypass in promoting weight loss and improving glycaemic control. *Endocrinology, 153,* 3613-3619.

[66] Aron-Wisnewsky, J., Dore, J. and Clement, K. (2012). The importance of the gut microbiota after bariatric surgery. *Nat Rev Gastroenterol Hepatol, 9,* 590-598.
[67] Mirshahi, U.L., Still, C.D., Masker, K.K., Gerhard, G.S., Carey, D.J., et al. (2011). The MC4R(I251L) allele is associated with better metabolic status and more weight loss after gastric bypass surgery. *J Clin Endocrinol Metab, 96,* E2088-2096.
[68] Bouchi, R., Foo, K.S., Hua, H., Tsuchiya, K., Ohmura, Y., et al. (2014). FOXO1 inhibition yields functional insulin-producing cells in human gut organoid cultures. *Nat Commun, 5,* 4242.
[69] Gorboulev, V., Schurmann, A., Vallon, V., Kipp, H., Jaschke, A., et al. (2012). Na(+)-D-glucose cotransporter SGLT1 is pivotal for intestinal glucose absorption and glucose-dependent incretin secretion. *Diabetes, 61,* 187-196.
[70] Stearns, A.T., Balakrishnan, A., Rhoads, D.B. and Tavakkolizadeh, A. (2010). Rapid upregulation of sodium-glucose transporter SGLT1 in response to intestinal sweet taste stimulation. *Ann Surg, 251,* 865-871.
[71] Nguyen, K.T. and Korner, J. (2014). The sum of many parts: potential mechanisms for improvement in glucose homeostasis after bariatric surgery. *Curr Diab Rep, 14,* 481.

BIOGRAPHICAL SKETCH

Natalia R. Moreno-Castellanos

Education: MSc, PhD Biomedicine

Research and Professional Experience:

I obtained my MSc degree in Cell Biology, molecular and genetic at the University of Córdoba, Spain in 2010. I completed PhD studies at the University of Cordoba in 2015, under the supervision of Prof. Maria Malagón and Rafael Martinez, research based on the identification of new biomarkers of the adipose tissue in obesity and insulin resistance in a collaborative project between the Metabolic Research Laboratory of Navarra and the University of Córdoba. During this project, I applied different experimental techniques, which have allowed it to obtain original and new results on the effects of bariatric surgery on the molecular composition of adipose tissue and to identify and characterize for the first time, a new element of the cytoskeleton of adipocytes, in relation to the regulation of lipid metabolism, obesity and insulin resistance. These results have been collected in two publications one published at "Obesity Surgery" and other currently under review in the journal "Diabetes". In addition, as a result of other collaborations I participated as co-author in different journals, such as: "Antioxidants Redox Signaling", "Scientific Reports", "Molecular and Cellular Endocrinology", "Journal of Clinical Endocrinology and Metabolism "and" Current Vascular Pharmacology". Actually I have a position as a professor full time at the University Indrustrial de Santander, Department of Cell Biology, Colombia), at the same time I being member of the research group of the Spanish network of excellence for obesity and nutrition (CIBERobn). My research line is now focused on the study of genetic aspects on Diabetes Mody and their impact on physiology and pathophysiology in Colombian people and Obesity and metabolic diseases and its association with infectious diseases. Finally, I

presented results in different national conferences (4 communications type Oral Poster) and international (2 Poster type and one oral communication).

Professional Appointments: Full time Professor

Honors

1. 2 Scholarship granted by the Maimonides Institute of Biomedical Research of Cordoba (IMIBIC), Spain for a research stay in:
   - Metabolic Research Laboratory, under Dr. Gema Frühbeck supervision.
     University of Navarra, Pamplona, Spain.
     January 5th –April 5th 2014.
   - Network of Excellence for Functional Biomaterials and in the Centre for Research in Medical Devices (CURAM), under Dr. Abhay Pandit supervision.
     National University of Ireland, Galway, Ireland.
     June 1 th–August 30th 2015.
2. 1 Travel Grant, granted by the European Obesity society (EASO), for an Oral Communication (Functional characterization of novel cytoskeletal protein SEPT11 in murine and human adipocytes: role in lipid traffic), Sweden, Gotheburg, June 1th-June 4th.

Publications

1. Moreno-Castellanos N, Rodríguez A, Rabanal-Ruiz Y, Fernández-Vega A, López-Miranda J, Vázquez-Martínez R, Frühbeck G, Malagón MM. 2016. "The cytoskeletal protein septin 11 is associated with human obesity and is involved in adipocyte lipid storage and metabolism". *Diabetologia*. doi:10.1007/s00125-016-4155-5
2. Moreno-Castellanos N, Guzmán-Ruiz R, Cano DA, Madrazo-Atutxa A, Peinado JR, Pereira-Cunill JL, García-Luna PP, Morales-Conde S, Socas-Macias M, Vázquez-Martínez R, Leal-Cerro A, Malagón MM. 2015. "The Effects of Bariatric Surgery-Induced Weight Loss on Adipose Tissue in Morbidly Obese Women Depends on the Initial Metabolic Status". *Obes Surg*. doi: 10.1007/s11695-015-1995-x
3. Rodríguez A, Moreno NR, Balaguer I, Méndez-Giménez L, Becerril S, Catalán V, Gómez-Ambrosi J, Portincasa P, Calamita G, Soveral G, Malagón MM, Frühbeck G. 2015. "Leptin administration restores the altered adipose and hepatic expression of aquaglyceroporins improving the non-alcoholic fatty liver of ob/ob mice". *Scientific Reports* 5:12067. doi: 10.1038/srep12067.
4. Díaz-Ruiz A, Guzmán-Ruiz R, Moreno NR, García-Rios A, Delgado-Casado N, Membrives A, Túnez I, El Bekay R, Fernández-Real JM, Tovar S, Diéguez C, Tinahones FJ, Vázquez-Martínez R, López-Miranda J, Malagón MM. 2015. "Proteasome Dysfunction Associated to Oxidative Stress and Proteotoxicity in Adipocytes Compromises Insulin Sensitivity in Human Obesity". *Antioxid Redox Signal*. 23:597-612. doi: 10.1089/ars.2014.5939.
5. Ortega FJ, Mercader JM, Moreno-Navarrete JM, Nonell L, Puigdecanet E, Rodriquez-Hermosa JI, Rovira O, Xifra G, Guerra E, Moreno M, Mayas D, Moreno-Castellanos N, Fernández-Formoso JA, Ricart W, Tinahones FJ, Torrents D, Malagón MM, Fernández-Real JM. 2015. "Surgery-Induced Weight Loss Is

Associated With the Downregulation of Genes Targeted by MicroRNAs in Adipose Tissue" *J Clin Endocrinol Metab*. 100:E1467-1476. doi: 10.1210/jc.2015-2357.

6. Imbernon M, Whyte L, Diaz-Arteaga A, Russell WR, Moreno NR, Vazquez MJ, Gonzalez CR, Díaz-Ruiz A, Lopez M, Malagón MM, Ross RA, Dieguez C, Nogueiras R. 2014. "Regulation of GPR55 in rat white adipose tissue and serum LPI by nutritional status, gestation, gender and pituitary factors" *Mol Cell Endocrinol*. 383(1-2):159-69. doi: 10.1016/j.mce.2013.12.011.
7. Malagón MM, Díaz-Ruiz A, Guzmán-Ruiz R, Jiménez-Gómez Y, Moreno NR, García-Navarro S, Vázquez-Martínez R, Peinado JR. 2013. "Adipobiology for novel therapeutic approaches in metabolic syndrome". *Curr Vasc Pharmacol*.11:954-67. Review.

In: Encyclopedia of Surgery (22 Volume Set)
Editors: Andreas Lehrer and Kristin Mueller
ISBN: 978-1-53618-329-0
© 2020 Nova Science Publishers, Inc.

Chapter 437

BARIATRIC SURGERY: POSTOPERATIVE COMPLICATIONS

Carlos J. Ferrigni González, MD, J. Ruiz-Tovar, MD, PhD, J. González, MD, A. Garcia, MD and M. Duran Poveda, MD, PhD
Department of Surgery, University Hospital Rey Juan Carlos, Spain

ABSTRACT

Obesity is actually considered as a global epidemic disease associated with high physical and psychological morbidity. Bariatric surgery has proven to be the most effective and definitive treatment for this entity. In general, obese patients have poor physiologic reserve and this, added to their voluminous anatomy, leads to the development of complications in a different way than patients with normal BMI. Even in the presence of peritonitis, obese patients do not show clear symptoms, such as fever or abdominal pain and, when present, the diagnosis can be achieved when it is too late. The only significant clinical finding, as described by Mason, is the rapid pulse or tachycardia over 120 bpm; when an obese patient presents it in the first days after surgery, it is mandatory to rule out two complications, that can cause death if they are not quickly treated. These complications are intra-abdominal sepsis, and massive pulmonary embolism. Mason recommended in the presence of tachycardia to assess and treat "before the sun sets", this is, to solve before it is too late. The key for a good outcome in the management of complications, is to have a high index of suspicion when our patient "is not doing well" after surgery and having a low threshold for reintervention. Based on the published series of bariatric surgery, complications can be classified as perioperative (up to 30 days after the operation); immediate postoperative period (up to 6 months) and late (after 6 months). Additionally, based on the severity of the complication, it can be classified as severe (requiring reoperation or resulting in death) or mild. In this chapter we will focus on peri, postoperative and late complications.

INTRODUCTION

Obesity is actually considered as a global epidemic disease associated with high physical and psychological morbidity. Bariatric surgery has proven to be the most effective and definitive treatment for this entity. In general, obese patients have poor physiologic reserve and this, added to their voluminous anatomy, leads to the development of complications in a different way than patients with normal BMI. Even in the presence of peritonitis, obese patients do not show clear symptoms, such as fever or abdominal pain and, when present, the diagnosis can be achieved when it is too late. The only significant clinical finding, as described by Mason, is the rapid pulse or tachycardia over 120 bpm; when an obese patient presents it in the first days after surgery, it is mandatory to rule out two complications, that can cause death if they are not quickly treated.

PERI AND POSTOPERATIVE COMPLICATIONS

Leaks

Leaks can occur in the anastomosis, the staple line, or in cases of diathermic or mechanical injuries with laparoscopic instruments. Leaks are the most feared complication of bariatric surgery. Initially, they present only with tachycardia or may associate leukocytosis, neutrophilia and increased C-reactive protein; symptoms and signs of sepsis may appear later. The same signs may also be present in the setting of pulmonary embolism. The risk of leak ranges from 0.8% to 6%, but might be increased up to 35% in revisional bariatric surgery. Most leaks occur early, generally within the first week after surgery, but can occur up to a month after the operation [1-3]. The diagnosis of this complication can sometimes be a challenge. When a leak is unnoticed, the septic state progresses and the patients rapidly develop respiratory and renal failure [4]. As a general rule and it is the policy that we follow at our institution, once a leak is clinically suspected, even in cases without radiological confirmation, a surgical exploration must be performed, by laparoscopic approach when possible. How to diagnose this complication? In the case of patients with drainage, a change in the characteristics of the fluid can be observed, with outflow of intestinal contents or purulent discharge. We can also give a swallow of methylene blue dye and in case of extravasation, the diagnosis is achieved. However, it is not always a valid tool for diagnosis, since not all patients have drainage or they do not collect the site of the fistula. Computed tomography with IV and oral contrast (gastrografin), is the best imaging technique for the diagnosis of leak, with a sensibility for the diagnosis that reaches up to 86% [5]. It also allows to diagnose or at least provides indirect data of leak location, as in leaks located in the gastric remnant after a Gastric Bypass, where it does not reach the contrast. Another test that can be performed is an esophagus-gastro-duodenal transit with gastrografin. In some high-volume centers, the transit is first performed with gastrografin, then with Barium and finally a CT scan is performed, increasing thereby the percentage of diagnosed leaks.

In unstable patients, the treatment of leaks consist in emergency surgery, with different options ranging from drainage of the fluid collections adjacent to the fistula, resuture of the

leakage point or resection of the anastomosis and confection of a new one. In addition the treatment should include:

- Broad-spectrum antibiotic coverage
- Enteral access for feeding, most commonly a gastric feeding tube placed in the gastric remnant.

In a stable patient, a non-operative management of leaks can be chosen, including IV antibiotic therapy, absolute diet with nutritional support and percutaneous drainage of any existing collection. For the specific treatment of the fistula, endoscopic methods are available, such as the placement of endoprosthesis or sealing the fistula with fibrin or clips, all with different results, depending on the experience of endoscopist.

Different intraoperative techniques have been used to decrease the incidence of leaks, but there is no evidence that these methods reliably decrease the leak rate after bariatric surgery [6, 7].

Intestinal Obstruction and Internal Hernia

Internal hernia is a well-documented complication with an incidence rate of 1% to 9% of bariatric procedures performed. It is difficult to diagnose, usually presenting as intermittent and diffuse abdominal pain, which can be resolved spontaneously (spontaneous reduction of the hernia). Occasionally, it may cause vomiting, which forces the patient to attend frequently to the emergency room. In these cases, internal hernia is not always detected in the imaging tests. If progresses to incarceration, intestinal ischemia of the involved segment appears, with risk of strangulation and perforation. When there is a high clinical suspicion of if incarcerated internal hernia, exploring laparoscopy or laparotomy are mandatory [8]. Several types of internal hernia are most frequent: in Roux-en-Y Gastric Bypass, it is the Peterson hernia, located in the space between the alimentary loop and the mesocolon. These hernias can be theoretically prevented by closing this space with non-absorbable suture at the time of surgery. Steele et al., have reported that the antegastric antegrade assembly together with the closure of this space leads to fewer internal hernias than retrogastric and retrocholic assembly [9].

Other causes of early postoperative bowel obstruction are disorders in the jejuno-jejunal anastomosis of Roux-en-Y gastric bypass, that can be caused by angulation, edema of the anastomosis, obstruction by intraluminal clots or extraluminal adhesions. Clinical manifestations are vomits, abdominal distension and pain. Most of these etiologies can resolve with conservative management (nasogastric tube aspiration, fasting and hydroelectrolytic support). However, in some cases surgical treatment is necessary.

Hemorrhage

Significant bleeding after gastric bypass has been described in 0.4% to 4% of patients. The origin of this complication may be intraluminal, appearing as hematemesis, melena or

bright red blood per rectum, or intraperitoneal. It may present with hemodynamic stability or instability. In the first case, a conservative management is usually established, and in the second one a more aggressive treatment is necessary, implying interventional radiology or even an early reintervention to control the bleeding focus. Once confirmed the bleeding, antithrombotic prophylaxis must be discontinued and / or coagulation disorders corrected, in an attempt to control bleeding. The bleeding is most likely as a result of the use large staples in the distal stomach. Large staples are not adequate to seal small vessels. This has led many surgeons to reinforce the staple line by over-sewing, buttressing, or even both [10].

Stenosis

*C*linical presentation is similar to an obstruction and includes nausea, vomiting, abdominal pain, and dysphagia. A retrospective review of 230 patients found that the risk of stenosis following a LRYGB, BPDDS, or LSG is approximately 3.3%, 1.2%, and 3.5%, respectively [11]. In the case of Roux-en-Y gastric bypass, the most common site of stenosis is the gastrojejunal anastomosis. The cause of the stenosis is usually multifactorial, but mainly due to technical defect and / or ischemia. The management consists initially in endoscopic dilatation, resolving the stenosis in many patients. Surgery is reserved for the failure of endoscopic treatment [12].

In sleeve gastrectomy, the stenosis is mainly induced by cicatritial retraction. The *incisura angularis* is the most frequent site for the appearance of the stenosis. Nowadays there is consensus that this complication is associated with the caliber of bougie employed for the calibration of the gastric tube. In short- segment stenosis, repeated endoscopic dilatation may be useful. Longer stenoses and those ones not responding to endoscopic techniques, may require surgical resolution [13].

Stomal Obstruction

Acute stomal obstruction is an early complication that can occur in up to 14% of LAGB patients. Obstruction is usually caused by inclusion of excess perigastric fat, use of a narrow band for the thickness of the gastric tissue, or significant tissue edema. Patients usually present with persistent nausea, vomiting, and inability for oral intake. The diagnosis is confirmed with an upper gastrointestinal series, demonstrating no transit of contrast beyond the band. Acute stomal obstruction secondary to edema, can be conservatively treated with nasogastric tube aspiration, though it implies a risk for aspiration pneumonia and gastric ischemia. Persistent obstruction requires surgical revision or removal of the band. Meticulous removal of excess perigastric fat at the time of initial band placement may help to prevent this complication. The use of large diameter bands also reduces the incidence of acute postoperative obstruction [14].

Surgical Site Infection

Surgical site infections (SSIs) often present with the typical signs of cellulitis or peri-incisional necrosis. Some of them, specially in patients with Diabetes Mellitus, require an aggressive management, including ICU monitoring, IV antibiotic therapy and/or surgical debridement, since they can progress to necrotizing fasciitis with harmful consequences. Actually, with the laparoscopic approach, the incidence and severity of this complication has significantly decreased, though it must be always kept in mind that it may reflect a chronic fistula of intra-abdominal origin. Among laparoscopic techniques, wound infection rates vary depending upon the technique used, with a higher rate of wound infections associated with the use of circular stapling devices to create the gastrojejunostomy [15]. Signs of wound infections include unexplained fever, fluctuance, erythema, or purulent discharge. Treatment consists in opening the wound for drainage of infected fluid, debridement of any devitalized tissue, and antibiotics, when the surrounding skin presents signs of cellulitis [16].

Pulmonary Embolism

It is the second most feared complication in patients undergoing bariatric surgery. Fortunately, its incidence is very low, occurring between 1% and 2% of the cases, although with a mortality rate, that reaches up to 30%. Sometimes the diagnosis may pass undetected (subclinical pulmonary embolism). The most common risk factors associated with fatal PE include severe venous stasis disease, BMI >60, truncal obesity, and obesity-hypoventilation syndrome [17]. The patient presents dyspnea, with signs of sepsis sometimes indistinguishable from those observed in the case of a fistula. Thus, it is crucial to obtain a certain diagnosis. When pulmonary embolism is suspected, a chest CT scan, followed by an abdominal imaging study, is mandatory. Once a fistula is discarded and a pulmonary embolus is confirmed, anticoagulant treatment must be immediately started. When the patient's BMI does not allow the performance of a CT scan, in these cases the management must be aggressive, including exploring laparoscopy and if the intra-abdominal complication is ruled out, anticoagulation must be started. The best way to reduce the possibility of pulmonary thromboembolism is prevention, identifying any risk factors that must be treated preoperatively. Optimal strategies for preventing VTE/PE in bariatric surgery have not been clearly established. Most bariatric surgeons use both pneumatic compression devices and low molecular weight heparin. The current American Society of Bariatric and Metabolic Surgeons (ASMBS) guidelines regarding VTE prophylaxis state that all bariatric patients must receive mechanical prophylaxis and early postoperative deambulation is recommended. Additionally, the surgeon may routinely use pharmacological prophylaxis of either low molecular weight heparin or unfractionated heparin [18].

Pulmonary Complications

Pulmonary complications include pneumonia and acute respiratory failure. Atelectasis is common after all types of surgery that require general anesthesia and orotracheal intubation,

but is more prevalent in morbidly obese patients. The overall incidence of postoperative pneumonia is around 0.4%. The overall rate of acute respiratory failure (ARF) is 1.3%. The incidence is higher with open approach, when compared with laparoscopic one. Incidence is also higher after gastric bypass procedures than after restrictive procedures, and is more prevalent in patients with preoperative heart failure, chronic renal failure, peripheral vascular disease, chronic obstructive pulmonary disease (COPD), tobacco smoking, and diabetes. ARF is associated with a significantly higher in-hospital mortality rate compared with those who do not develop this complication. Early postoperative deambulation and respiratory physiotherapy are important to decrease the incidence of pulmonary complications. Preoperative identification of obstructive sleep apnea and initiation of continuous positive airway pressure (CPAP) therapy also reduces the risk of pulmonary complications in the postoperative course. CPAP should be used in the early postoperative period when it is clinically necessary [19].

Marginal Ulcers

They might appear in the gastrojejunal anastomosis of Roux-en-Y Gastric Bypass, commonly in the jejunal part. The mechanisms of development are not completely understood, but ischemia, tension in the anastomosis and / or *Helicobacter pylori* infection are usually involved [20]. Another important factor is the exposure of this anastomosis to the acid produced in the gastric pouch (when it is excessively large). The incidence of this complication ranges from 0.6% to 16% [21]. The clinical presentation includes pain, loss of appetite, excessive weight loss, nausea, vomiting, anemia and even perforation. As a preventive measure, proton pump inhibitors are used during the postoperative period for 3 months. Of the total number of patients presenting this complication, up to 1/3 would require revision surgery [21]. Risk factors for late presentation of a marginal ulcer include smoking, nonsteroidal antiinflammatory drugs (NSAID), or gastrogastric fistula formation. If NSAIDS are necessary, a concomitant use of a proton pump inhibitor is indicated [22].

Rhabdomyolysis

Rhabdomyolysis is a clinical and biochemical syndrome that includes increase of muscle enzymes, acute renal failure, compartimental syndrome and even death; notwithstanding some cases can be completely asymptomatic. It is produced by the damage and necrosis of the skeletal muscles when exposed to prolonged compression. This compression causes the release of substances (CK) to the plasma, that in excess are nephrotoxic. Its incidence in bariatric surgery is not clearly defined, ranging from 1.4% to 75% [23]. Risk factors identified include prolonged surgical time, extreme surgical positions, ASA III-IV, diabetes or hypertension [24].

Signs and symptoms usually appear during the first 24 hours after surgery. The suspected diagnosis is based on clinical manifestations (reddish-brown urine, gluteal and back pain, oliguria) and must be confirmed in laboratory tests with CK measurement. CK may reach 5-fold higher levels than normal ones [25]. The subsequent development of acute renal failure varies between 20-50%, with a mortality rate of nearly 20%. An early diagnosis of this

complication is essential for a successful outcome. Once the diagnosis of rhabdiomyolisis has been made, the treatment consists in intravenous hydration and forcing dieresis with osmotic diuretics, which seems to be the best measures to avoid fatal consequences [25].

LATE COMPLICATIONS

Late complications of bariatric procedures include cholelithiasis, incisional ventral hernia, nutritional deficiencies, neurological and psychiatric disorders.

Cholelithiasis

It occurs in up to 38% of patients within six months after surgery, giving symptoms in up to 41% of these patients. This incidence can be reduced to 2% with a six month course of ursodeoxycholic acid given prophylactically after weight-loss surgery. Cholecystectomy is not routinely indicated during the bariatric surgery, but it is advisable if the patient has symptomatic cholelithiasis preoperatively.

Another related complication is choledocholithiasis following a gastric bypass, with a more complex management. First of all, the diagnosis must be confirmed by ultrasonography or magnetic resonance cholangio-pancreatography (MRCP). Management can be difficult because of the impossibility of direct access to the duodenum. Current therapeutic options include endoscopic retrograde cholangiopancreatography (ERCP) assisted by laparoscopy (with entry into the gastric remnant), transhepatic percutaneous access or surgical approach to the bile duct [26, 27].

Ventral Incisional Hernia

The increase of the laparoscopic approach has raised the overall incidence of port-sites hernias. Considering the difficulty of a correct closure of the incisions added to the obesity status, a correct abdominal wall closure still remains a challenge for the bariatric surgeon [28]. Severe obesity is associated with an increase in intra-abdominal pressure and, therefore, a high risk of developing this type of hernia after a laparotomy. However, its incidence has significantly decreased with the laparoscopic approach (1.8%), when compared with open surgery (24%). To repair the hernia, it is advisable to wait until an adequate weight loss is achieved and post-surgical weight stabilization (more than one year). Early repairs should be considered only in complicated ventral hernias [29].

COMPLICATIONS OF SPECIFIC BARIATRIC PROCEDURES

Roux-en-Y Gastric Bypass

Gastric Remnant Distension

Gastric remnant distension is a rare, but potentially lethal complication with risk of perforation and peritonitis. Symptoms include pain, hiccups, abdominal distension in the left upper quadrant, tachycardia or dyspnea; nausea and vomiting are not frequent. Radiological evidence shows striking gastric remnant distention. The treatment consists in urgent decompression with performance of percutaneous or surgical gastronomy. If the gastrostomy is not feasible or a perforation is suspected, emergency surgery is indicated. Some studies recommend prophylactic gastrostomy in elderly, super-obese patients, patients with diabetic gastropathy and as part of revisional surgeries where gastric emptying might be delayed [30].

Dumping Syndrome

Dumping syndrome can occur in up to 50% of patients who undergo gastric bypass. There are two types of dumping syndrome: early and late [31].

Early dumping syndrome: has a rapid onset, within the first 15 minutes after ingestion and is the result of rapid emptying of food (hyperosmolar and sequestering liquid into the bowel), causing hypotension and reflex response of the sympathetic nervous system. Symptoms include abdominal pain, diarrhea, nausea, and tachycardia. Preventive measures include the suppression of sweet foods and replace them with foods rich in fiber, protein and complex carbohydrates. Usually these symptoms improve in 7 to 12 weeks after surgery.

Late dumping syndrome: is produced by the response of insulin to hyperglycemia, causing hypoglycemia 2 - 3 hours after food intake. Symptoms include dizziness, fatigue, sweating, and weakness. Treatment is similar to that of early dumping syndrome.

Change in Bowel Habits

Diarrhea is more common after malabsorptive procedures and may become uncontrollable in some cases. Constipation may occur in patients with a gastric band and in patients undergoing gastric bypass surgery. They usually improve these changes over time and with medical measures. Treatment with laxatives may be necessary for short periods of time to improve constipation [32].

Failure to Lose Weight and Weight Regain

The lack of weight loss after the Roux-en-Y gastric bypass is rare, and is often due to non-compliance with the postoperative diet. Among the causes of weight regain are eating disorders, development of a gastro-gastric fistula, enlargement of the pouch or dilation of the gastrojejunal anastomosis [33].

Laparoscopic Adjustable Gastric Banding

Early complications of this procedure appear in 1% to 12% of all performed procedures. Hemorrhage is very rare due to the almost lack of dissection of the tissues and there is no

possibility of anastomotic leakage. The iatrogenic perforation of the stomach appears in 0.5% of the cases [34]. The risk of thromboembolic events, such as deep venous thrombosis or pulmonary embolism is 0.1% (lower than in other procedures). Specific complications related to the band may occur days or even years after the procedure. Complications related to the port or tubing of the mechanism can occur in up to 11% of patients [35]. Prolapse of the stomach may be posterior (more common when the band is placed with the perigastric technique) or anterior (*pars flaccida* technique). Clinical manifestations include gastroesophageal reflux disease, oral intolerance, dysphagia and regurgitation. The diagnosis is usually made with an upper GI series. The first thing to do when confirming the diagnosis is to deflate the band, but the definitive treatment is usually surgical repositioning of the stomach and new plication or removal of the band and replacement by a new one, if necessary. When these symptoms appear immediately after increasing the band pressure in the outpatient clinic, the problem will be solved by reducing the volume of the band [36].

Erosion

Patients with this complication may have recurrent port infections, abdominal pain, gastroesophageal reflux, or a feeling of increase or decrease in band restriction after ingestion. The diagnosis is endoscopically achieved and the treatment consists in surgical removal of the band and closure of the gastric perforation. Other treatment option is the endoscopic removal of the band.

Esophageal Dilation

Esophageal dilation might be secondary to a excessively tight band or a prolapsed stomach. The incidence of esophageal dilatation ranges between 5% and 10% upon series [37, 38].

Laparoscopic Sleeve Gastrectomy

Bleeding

Most of the hemorrhages associated with this technique have their origin in the stapling line after the division of the stomach. Other sources of postoperative hemorrhage are short vessels during dissection of the major curvature and inadvertent splenic injury. In order to decrease the bleeding from the stapling line, many surgeons perform a reinforcement with over-sewing, buttressing or both [39].

Stenosis

Stenosis of a sleeve gastrectomy seems like an obstruction. Symptoms include dysphagia, vomiting, reflux, or regurgitation and may even lead to inability of oral intake with dehydration and malnutrition. The most frequent place of stenosis is the gastroesophageal union, followed by the *incisura angularis*. Diagnosis is obtained with upper gastrointestinal series and endoscopy. The most frequent cause of stenosis is the use of a very small bougie. The actual recommendation is to use a bougie of 36 to 40 Fr. We would recommend that the diameter of the bougie must be inversely proportional to the experience of the surgeon with this technique, meaning to use a bougie of greater caliber for the surgeon with less

experience. The treatment of this complication is endoscopic dilation when it is a short stenosis, but for long stenosis, surgery is usually necessary to correct the problem [40].

Gastric Leaks

Gastric leakage is the most feared complication and sometimes difficult to manage. They occur in up to 5.3% of patients. The causes may be tissue ischemia or scars with posterior perforation, generated by the use of hemostatic devices. Some leaks are caused by hyper-pressure generated by distal stenosis. Most of them are located at the gastroesophageal junction, where vascularization is compromised after the section of short gastric vessels; this would generate the ischemia that impels a correct healing of the tissue, leading to the appearance of the leak. Sleeve gastrectomy produces high intragastric pressure, even without stenosis, and this can increase the time necessary for the leak closure [41, 42]. If the patient is clinically stable, a conservative management with drainage of collections, antibiotherapy and total parenteral nutrition can be chosen until resolution of the leak. Other option is the placement of covered stents endoscopically, but it is not always feasible or successful [43].

Reflux

This complication occurs with typical symptoms such as burning pain, heartburn and regurgitation. It may appear early or late in the postoperative period. Initial treatment is with standard drugs used in GERD. If a stenosis is demonstrated, it can be treated by endoscopic dilatation to improve reflux. If the patient does not respond to adequate medical treatment no anatomical cause (stenosis or hiatal hernia) is demonstrated, conversion to a RYGB might be necessary [44].

Malabsortive Procedures

These procedures (Biliopancreatic Diversion and Duodenal Switch) present a higher rate of complications [45]. It is attributed in part to the greater complexity of the surgical technique and that these approaches are usually performed in patients with greater BMI. The marginal ulcer appears in up to 10% of BPD, and 1% to 3% of DS. Dreaded complications are the nutritional deficiencies that appear in the postoperative course, sometimes becoming so severe that they may cause mortality or the need for restitution to the normal anatomy of the gut [46. 47].

REFERENCES

[1] Stroh C, Köckerling F, Weiner R, et al. Are there gender-specific aspects of sleeve gastrectomy-data analysis from the quality assurance study of surgical treatment of obesity in Germany. *Obes Surg* 2012; 22:1214-9.

[2] Gentileschi P, Camperchioli I, D'Ugo S, et al. Staple-line reinforcement during laparoscopic sleeve gastrectomy using three different techniques: a randomized trial. *Surg Endosc* 2012; 26:2623-9.

[3] Lim RB, Blackburn GL, Jones DB. Benchmarking best practices in weight loss surgery. *Curr Probl Surg* 2010; 47:79-174.

[4] Gorecki P, Wise L, Brolin RE, et al. Complications of combined gastric restrictive and malabsorptive procedures: Part 1. *Curr Surg.* 2003;60(2):138-44.

[5] Sakran N, Goitein D, Raziel A, et al. Gastric leaks after sleeve gastrectomy: a multicenter experience with 2,834 patients. *Surg Endosc* 2013; 27: 240-245.

[6] Madan AK, Stoecklein HH, Ternovits CA, et al. Predictive value of uppergastrointestinal studies versus clinical signs for gastrointestinal leaks after laparoscopic gastric bypass. *Surg Endosc* 2007; 21:194-6.

[7] Gonzalez R, Sarr MG, Smith CD, et al. Diagnosis and contemporary management of anastomotic leaks after gastric bypass for obesity. *J Am Coll Surg* 2007; 204:47-55.

[8] Griffi th PS, Birch DW, Sharma AM, Karmali S. Managing complications associated with laparoscopic Roux-en-Y gastric bypass for morbid obesity. *Can J Surg* 2012; 55: 329-336.

[9] K. E. Steele, G. P. Prokopowicz,et al. Laparoscopic antecolic Roux-En-Y gastric bypass with closure of internal defects leads to fewer internal hernias than the retrocolic approach. *Surg Endosc 2008; 22: 2056–2061.*

[10] Wittgrove AC, Clark GW. Laparoscopic gastric bypass, Roux-en-Y- 500 patients: technique and results, with 3-60 month follow-up. *Obes Surg* 2000; 10:233-239.

[11] Parikh A, Alley JB, Peterson RM, et al. Management options for symptomatic stenosis after laparoscopic vertical sleeve gastrectomy in the morbidly obese. *Surg Endosc* 2012; 26:738-746.

[12] Campos JM, Mello FS, Ferraz AA, Brito JN, Nassif PA, Galvao- Neto Mdos P. Endoscopic dilation of gastrojejunal anastomosis after gastric bypass. *Arq Bras Cir Dig* 2012; 25: 283-289.

[13] Vilallonga R, Himpens J, van de Vrande S. Laparoscopic management of persistent strictures after laparoscopic sleeve gastrctomy. *Obes Surg* 2013; 2: 1655-1661.

[14] Gravante G, Araco A, Araco F, et al. Laparoscopic adjustable gastric bandings: a prospective randomized study of 400 operations performed with 2 different devices. *Arch Surg* 2007; 142:958-961.

[15] Nelson DW, Blair KS, Martin MJ. Analysis of obesity-related outcomes and bariatric failure rates with the duodenal switch vs gastric bypass for morbid obesity. *Arch Surg* 2012; 147:847-854.

[16] Bohdjalian A, Langer FB, Kranner A, et al. Circular- vs. linear-stapled gastrojejunostomy in laparoscopic Roux-en-Y gastric bypass. *Obes Surg* 2010; 20:440-446.

[17] Winegar DA, Sherif B, Pate V, DeMaria EJ. Venous thromboembolism after bariatric surgery performed by Bariatric Surgery Center of Excellence Participants: analysis of the Bariatric Outcomes Longitudinal Database. *Surg Obes Relat Dis* 2011; 7:181-8.

[18] American Society for Metabolic and Bariatric Surgery Clinical Issues Committee. ASMBS updated position statement on prophylactic measures to reduce the risk of venous thromboembolism in bariatric surgery patients. *Surg Obes Relat Dis* 2013; 9:493-497.

[19] Masoomi H, Reavis KM, Smith BR, et al. Risk factors for acute respiratory failure in bariatric surgery: data from the Nationwide Inpatient Sample, 2006-2008. *Surg Obes Relat Dis* 2013; 9:277-281.

[20] Rasmussen JJ, Fuller W, Ali MR. Marginal ulceration after laparoscopic gastric bypass: an analysis of predisposing factors in 260 patients. *Surg Endosc* 2007; 21: 1090-1094.

[21] D'Hondt MA, Pottel H, Devriendt D, et al. Can a short course of prophylactic low-dose proton pump inhibitor therapy prevent stomal ulceration after laparoscopic Roux-en-Y gastric bypass? *Obes Surg* 2010; 20: 595-599.
[22] Azagury DE, Abu Dayyeh BK, Greenwalt IT, Thompson CC. Marginal ulceration after Roux-en-Y gastric bypass surgery: characteristics, risk factors, treatment, and outcomes. *Endoscopy* 2011; 43:950-954.
[23] Chakravartty S, Sarma DR, Patel AG. Rhabdomyolysis in bariat- ric surgery: a systematic review. *Obes Surg* 2013; 23: 1333-1340.
[24] Lagandre S, Arnalsteen L, Vallet B, Robin E, Jany T, Onraed B, et al. Predictive factors for rhabdomyolysis after bariatric surgery. *Obes Surg* 2006; 16: 1365-1370.
[25] Merino I, Borrat X, Balust J, Delgado S, Lacy AM, Vidal J, et al. Rhabdomyolysis after bariatric surgery: a potentially fatal complication. *Br J Anaesth* 2009; 102: 283-284.
[26] Villegas L, Schneider B, Provost D, et al. Is routine cholecystectomy required during laparoscopic gastric bypass? *Obes Surg* 2004; 14:206-211.
[27] Hamad GG, Ikramuddin S, Gourash WF, Schauer PR. Elective cholecystectomy during laparoscopic Roux-en-Y gastric bypass: is it worth the wait. *Obes Surg* 2003; 13:76-81.
[28] Hass BE, Schrager RE. Small bowel obstruction due to Richter's hernia after laparoscopic procedures. *J Laparoendosc Surg* 1993; 3: 421-423.
[29] Lee S, Carmody B, Wolfe L, et al. Effect of location and speed of diagnosis on anastomotic leak outcomes in 3828 gastric bypass cases. *J Gastrointest Surg* 2007; 11:708-713.
[30] Nguyen NT, Ho HS, Palmer LS, Wolfe BM. A comparison study of laparoscopic versus open gastric bypass for morbid obesity. *J Am Coll Surg* 2000; 191:149-155.
[31] Ukleja A. Dumping syndrome: pathophysiology and treatment. *Nutr Clin Pract* 2005; 20:517-525.
[32] Potoczna N, Harfmann S, Steffen R, et al. Bowel habits after bariatric surgery. *Obes Surg* 2008; 18:1287-1296.
[33] Kalarchian MA, Marcus MD, Wilson GT, et al. Binge eating among gastric bypass patients at long-term follow-up. *Obes Surg* 2002; 12:270-275.
[34] Belachew M, Belva PH, Desaive C. Long-term results of laparoscopic adjustable gastric banding for the treatment of morbid obesity. *Obes Surg* 2002;12:564-568.
[35] Favretti F, Cadière GB, Segato G, et al. Laparoscopic banding: selection and technique in 830 patients. *Obes Surg* 2002;12:385-390.
[36] O'Brien PE, Dixon JB, Laurie C, Anderson M. A prospective randomized trial of placement of the laparoscopic adjustable gastric band: comparison of the perigastric and pars flaccida pathways. *Obes Surg* 2005;15(6):820-826.
[37] Ponce J, Paynter S, Fromm R. Laparoscopic adjustable gastric banding: 1,014 consecutive cases. *J Am Coll Surg* 2005;201:529-535.
[38] Dargent J. Esophageal dilatation after laparoscopic adjustable gastric banding: definition and strategy. *Obes Surg* 2005;15:843-848.
[39] Frezza EE, Reddy S, Gee LL, Wachtel MS. Complications after sleeve gas trectomy for morbid obesity. *Obes Surg 2009* 19:684-687.
[40] Dapri G, Cadière GB, Himpens J. Laparoscopic seromyotomy for long stenosis after sleeve gastrectomy with or without duodenal switch. *Obes Surg* 2009; 19:495-499.
[41] Arias E, Martínez PR, Ka Ming Li V, et al. Mid-term follow-up after sleeve gastrectomy as a final approach for morbid obesity. *Obes Surg* 2009; 19:544-548.

[42] Burgos AM, Braghetto I, Csendes A, et al. Gastric leak after laparoscopic sleeve gastrectomy for obesity. *Obes Surg* 2009; 19:1672-1677.

[43] Oshiro T, Kasama K, Umezawa A, et al. Successful management of refractory staple line leakage at the esophagogastric junction after a sleeve gastrectomy using the HANAROSTENT. *Obes Surg* 2010; 20:530-534.

[44] Langer FB, Bohdjalian A, Shakeri-Leidenmühler S, et al. Conversion from sleeve gastrectomy to Roux-en-Y gastric bypass--indications and outcome. *Obes Surg* 2010; 20:835-840.

[45] Buchwald H, Avidor Y, Braunwald E, et al. Bariatric surgery: a systematic review and meta-analysis. *JAMA* 2004;292:1724-1737.

[46] Hess DS, Hess DW, Oakley RS. The biliopancreatic diversion with the duodenal switch: results beyond 10 years. *Obes Surg* 2005;15:408-416.

[47] Bloomberg RD, Fleishman A, Nalle JE, Herron DM, Kini S. Nutritional deficien- cies following bariatric surgery: what have we learned? *Obes Surg* 2005;15:145-154.

In: Encyclopedia of Surgery (22 Volume Set)
Editors: Andreas Lehrer and Kristin Mueller
ISBN: 978-1-53618-329-0
© 2020 Nova Science Publishers, Inc.

Chapter 438

FOOD CHOICES AFTER BARIATRIC SURGERY: ARE THERE CHANGES IN ORAL MEDIUM CHARACTERISTICS AND FOOD PERCEPTION?

Elsa Lamy[1], Fernando Capela e Silva[1,2] and Isabel do Carmo[3]
[1]Institute of Mediterranean Agricultural and Environmental Sciences (ICAAM),
University of Évora, Évora, Portugal
[2]Department of Biology, University of Évora,
Évora, Portugal
[3]Faculty of Medicine, University of Lisbon,
Lisbon, Portugal

ABSTRACT

Bariatric surgery is, so far, the most effective method of sustained weight loss by obese patients. Although different studies have been performed with the aim of understanding the mechanisms by which bariatric surgery elicits weight loss, these are not completely understood. Dietary habits change in patients subjected to different types of bariatric surgery. It is known that bariatric surgery induces weight loss by restricting the amount of food the stomach can hold and/or by reducing nutrient absorption. However, in the recent years, evidence has emerged about variations in sensorial food perception in those patients, which may also be responsible for modifications in food acceptance and preference.

In this chapter, a revision of the studies concerning the effect of bariatric surgery procedures in overall oral food perception will be made, discussing how this may influence choices and dietary behavior. Attention will also been given to the potential effects of bariatric surgery on saliva composition, which may also influence oral perception. For a better framing of the theme, a review of the main endocrine-metabolic aspects of each type of bariatric surgery procedure, as well as physiology of taste and olfaction, will be made.

1. INTRODUCTION

Bariatric surgery is considered safe and the most effective method for sustained weight loss in treating morbid obesity. The different types of bariatric surgery are based in two main concepts: restriction and malabsorption. Restrictive procedures aim to regulate the amount of calories consumed by decreasing the gastric area capable of receiving food. The malabsorptive type reduces the area of intestine in contact with food, decreasing the absorption of nutrients and consequently energy (Elder and Wolfe, 2007). Some types of bariatric surgery procedures combine these two concepts. Independently of the type of surgery, the patient's understanding, motivation, and participation are key factors for the success of the intervention. To consider bariatric surgery as a restrictive and/or malabsorptive procedure is an oversimplification, and there is increasing evidence that factors such as neural and endocrine signaling pathways affecting appetite and satiety, including those affecting sensorial aspects and reward of food intake, are all operative to a variable extent in inducing weight loss (Wolfe et al., 2016).

The different types of bariatric surgery are Roux-en-Y gastric bypass (RYGB), sleeve gastrectomy, biliopancreatic diversion with duodenal switch and implantation of devices. In the latter case, the most common devices are adjustable gastric banding (which constricts the size of the gastric pouch and outlet), intermittent vagal blockade (where leads are placed around the vagal trunks at the diaphragm to produce an intermittent vagal blockade and an increase in satiety), and gastric balloons (which fill the stomach, leaving less space for food) (Buchwald, 2005; Elder and Wolfe, 2007; Ionut et al., 2013).

The effects of bariatric surgery comprise not only the direct effect on gastrointestinal capacity to receive, digest, and absorb foods, but also effects at the level of the complex interaction between signals from the gastrointestinal system, adipocytes, the central nervous system and hormones. Changes in post-ingestive responses occur (Quercia et al., 2014), which will be further presented in this chapter. Moreover, there is evidence that individuals submitted to bariatric surgery change their hedonic drive to consume palatable food, what appears to be also related to changes in the way in which they perceive food sensorial signs, namely taste (Pepino et al., 2014) and odors (Jurowich et al., 2014). Changes in food choices, with the establishment of healthier dietary habits, have been observed, such as an increased intake of protein-rich foods and vegetables and a reduced consumption of sugar and fat contained snacks (Ullrich et al., 2013).

The effect of bariatric surgery in oral food perception may include an effect on the constituents of oral medium responsible for taste and aroma perception. In this context, knowledge about changes in saliva composition may help us in understanding oral food perception changes. Based on this assumption, this chapter presents the main functions of this fluid, as well as factors affecting its composition and its relationship with oral food perception and ingestion. Although it has not yet much explored, our group has evidence that saliva composition changes in obesity (Lamy et al., 2015; Rodrigues et al., 2015) and that some of those changes appear to be reverted in individuals subjected to bariatric surgery (Lamy et al., 2015). Those studies will be reviewed and discussed in the context of possible influences of bariatric procedures in food perception.

2. BARIATRIC SURGERY

2.1. Bariatric Surgery, Weight Loss, and Eating Behavior

The main objective of bariatric surgery is weight loss, with the consequent treatment of the comorbidities associated with obesity and derived from excess body weight and adiposity.

As a weight loss procedure, the benefits of bariatric surgery are greater than those of lifestyle intervention and pharmaceutical management. It has the additional benefits of reducing risk factors for and leading to remission of comorbid conditions. Furthermore, the initial cost of bariatric surgery can be recovered within two years through reduced patient reliance on medication, fewer physician visits, increased employment, and increased productivity in the workplace.

There are a number of surgical procedures currently available to promote weight loss, together called bariatric surgery (reviewed in Buchwald, 2005; Elder and Wolfe, 2007; Ionut et al., 2013). In 2004, the consensus congress of the American Society for Metabolic and Bariatric Surgery concluded that: '*Bariatric surgery is the most effective therapy available for morbid obesity and can result in improvement or complete resolution of obesity comorbidities*' (Buchwald, 2005). In general, bariatric surgery reduces caloric intake by restricting the size of the stomach, limiting the absorption of nutrients in the intestine, or combining restrictive and malabsorptive components.

Different authors cite different percentages of weight loss after surgery, with some of them finding similar results for the various types of bariatric surgery and others reporting differences. The velocity of weight loss is also not consistent across different studies. Even so, there is generally rapid weight loss over the first six months, with maintenance, but at lower rate, of weight loss over time. After RYGB, 12% to 45% total decrease in body weight was reported three years after surgery (LABS, 2009). For the laparoscopic adjustable gastric band, a total body weight loss of 15.9%, at three years post-surgery was reported (Sjöström et al., 1999), whereas for gastric balloon most of the decrease in weight occurs during the initial months post-surgery, with reports of losses higher than 10% initial body weight after one year (Dogan et al., 2013).

Besides the changes in terms of the amount of food that an individual is able to eat and in nutrient absorption, weight loss requires the adoption of eating habits different from those practiced before surgery. General recommendations include the ingestion of very small, frequent and nutrient-dense meals and the avoidance of foods high in fat and/or sugar.

Alterations in dietary patterns appear to be one of the most documented effects of all bariatric surgical procedures. With the RYGB procedure, decreases in the consumption of the majority of sugar-containing foods and beverages, as well as in fatty foods, are reported (Molin Netto et al., 2017). For sleeve gastrectomy, improvements in healthy dietary habits were reported, namely with a short time between food intake and reduced appetite (Bužga et al., 2014). Using rats as an animal model, a decrease in the intake of dietary fat and a shift preference towards lower calorie-dense foods was observed after vertical sleeve gastrectomy (Wilson-Perez et al., 2013).

Bariatric surgery results in a decreased capacity in hold high amounts of food in one meal. However, some patients replace the high amounts of food in one meal by a frequent snacking of caloric food. It was shown that when this occurs, less weight is lost, or weight

regain may even occur (Leite Faria et al., 2009). Some authors also observed a greater preference for lower-calorie over higher-calorie after RYGB (le Roux and Bueter, 2014). Some authors observed that the decrease in the proportion of daily calorie intake from sweetened foods and beverages is higher after RYGB than after laparoscopic adjustable gastric banding surgery (Pepino et al., 2014).

It is also known that several extremely obese patients develop food addiction and that such food addiction may influence the efficacy of bariatric surgery in terms of weight loss. Nevertheless, it seems that bariatric surgery-induced weight loss may also help to treat food addiction, improving eating behavior in these patients (Pepino et al., 2014).

The main factors identified as responsible for dietary changes after bariatric surgery are: food intolerances, prevention of dumping syndrome symptoms, optimization of weight reduction, alteration of neuroendocrine regulation, and nutritional counselling and education about healthy choices (Molin Netto et al., 2017). The subsequent points will discuss aspects related to post-ingestive consequences and oral food perception, which may help to improve dietary habits.

2.2. Hormonal/Post-Ingestive Changes Induced by Bariatric Surgery

Bariatric surgery is coupled with changes in gut/gastro-intestinal hormones, which may also result in diverse changes in appetite/satiety control. This appears to be a reason for the sustained weight loss achieved with these procedures (Ionut et al., 2013). Complications such as hyperinsulinemia, resistance to insulin and diabetes type II are significantly attenuated after bariatric surgery, even before an amount of decrease in fat mass that could explain that. The mechanisms responsible for that are not completely understood, but gut hormones and peptides involved in the regulation of appetite/satiety have been implicated (Ionut et al., 2013).

The regulation of appetite/satiety, together with energy expenditure, is a complex process, involving central and peripheral signals (Coll et al., 2007; Perry and Wang, 2012). In the long-term regulation of satiety, two anorexigenic hormones – leptin and insulin – are the main intervenient, signaling the levels of energy stores (Perry and Wang, 2012; Rui, 2013). For short- to medium-term regulation, although the aforementioned hormones continue to play a role, gastrointestinal peptides/hormones are primarily responsible, acting both at nervous and circulatory level (Perry and Wang, 2012; Rui, 2013).

Ghrelin is produced by the endocrine cells of the gastric fundus and acts on the hypothalamic arcuate nucleus, promoting appetite and thus weight gain and stimulating growth hormone release (Kojima et al., 1999). During weight loss induced by diet, plasmatic levels of ghrelin are increased (Cummings et al., 2002). However, in the process of weight loss induced by surgery this is not necessarily true. The reduction of considerable stomach volume, as occurs in laparoscopic sleeve gastrectomy, results in significant reduction in ghrelin levels (Sista et al., 2016). In this case, the majority of the cells from the gastric fundus, which produce ghrelin, are removed. For Roux-en-Y gastric bypass the existing data present no consensus, with studies showing decreases in terms of both fasting and postprandial conditions after this type of surgery (Cummings et al., 2002; Geloneze et al., 2003), whereas others, by contrast, report increased levels of ghrelin (Kalinowski et al., 2017). For laparoscopic gastric banding, different studies also present different results, with

observation of: 1) slight or no differences in ghrelin levels (Hanusch-Enserer et al., 2003); 2) increased plasmatic ghrelin concentrations (Uzzan et al., 2007). The mechanisms involved in the release of ghrelin after bariatric surgery are not completely understood and the levels of insulin and insulin resistance before surgery may affect ghrelin release following surgical weight loss (McLaughlin et al., 2004).

Gastrin is a family of multiple peptides produced in the gastric antrum and duodenum by the enteroendocrine G cells. Their production responds to food ingestion, with increases in the secretion of acid and increases in satiety (Meek et al., 2016). Bariatric surgery involving decreased access of food to G cells appears to reduce gastrin levels, such as been observed in Roux-en-Y surgery (Sundbom et al., 2007). In other surgical practices, where G cells maintain contact with food, such as gastric banding, no changes in fasting gastrin concentration were observed (Shak et al., 2008).

At the level of intestine peptides such as cholecystokinin (CCK), gastric inhibitory peptide (GIP), glucagon-like peptide-1 (GLP-1), oxyntomodulin, and Peptide YY (PYY) are produced and contribute to regulating food intake (Meek et al., 2016). CCK is secreted in the duodenum by I cells, mainly in response to the presence of amino acids and fatty acids in the duodenum. CCK promotes bile secretion into the gut lumen, the release of digestive enzymes from the exocrine pancreas and a decrease in the rate of gastric emptying (Meek et al., 2016). As well as for the other gastrointestinal peptides/hormones, results from different studies and different types of bariatric surgery do not present the same results. A decrease was observed in CCK levels after the non-surgical bariatric technique duodenal-jejunal bypass linear, which mimics the exclusion of the proximal small intestine that occurs in Roux en-Y gastric bypass (de Jonge et al., 2016). However, other studies have shown increases in CCK levels after Roux-en-Y gastric bypass (Jacobsen et al., 2012). Sleeve gastrectomy was reported to result in increases in levels of CCK (Peterli et al., 2012). For gastric balloon surgery, there are reports of stimulation of CCK release (Feinle et al., 2002) and reports of reduced levels of this peptide after surgery (Mathus-Vliegen and de Groot, 2013).

Gastric inhibitory peptide (GIP), also known as glucose-dependent insulinotropic peptide, is another intestinal peptide produced by K cells, the majority of which are located in the duodenum and proximal jejunum, with smaller numbers also occurring throughout the entire small intestine (Baggio and Drucker, 2007). GIP is secreted in response to nutrient ingestion, especially glucose or fat (Baggio and Drucker, 2007), and it has an incretin effect, i.e., it induces insulin secretion in response to glucose in the duodenum. Bariatric procedures that reduce the contact of nutrients with parts of the intestine have been reported to result in a reduction in GIP secretion (Guidone et al., 2006), although this has been not observed in all studies (Laferrère et al., 2008). After biliopancreatic diversion, decreasing levels of GIP were also observed (Sarson et al., 1981), whereas after gastric banding, no change in fasting GIP concentrations were reported 6–12 months after surgery (Shak et al., 2008).

Similarly to GIP, GLP-1 has an incretin effect and is also secreted a few minutes after ingestion, augmenting insulin response and decreasing glucagon secretion. This peptide, secreted by intestinal endocrine L cells, induces satiety, while sustained GLP-1-receptor activation is associated with weight loss (Baggio and Drucker, 2007). An increase in postprandial GLP-1 response was observed after Roux-en-Y, not only after some time (le Roux et al., 2007), but also before weight loss (Laferrère et al., 2008). Nonetheless, laparoscopic adjustable gastric banding was not observed to induce an enhanced GLP-1 response (le Roux et al., 2007).

Peptide YY (PYY) belongs to the pancreatic peptide family and, similarly to GLP-1, is released postprandially by intestinal endocrine L-cells proportionally to the amount of calories ingested. The secretion of PYY induces satiety and reduces food intake. Malabsorptive bariatric surgery types, such as Roux-en-Y, appear to cause an increase in the stimulation of L-cells, increasing the postprandial response of PYY (Korner et al., 2005; le Roux et al., 2007). The same was not observed for restrictive types of bariatric surgery, such as adjustable gastric banding (le Roux et al., 2007).

Another intestinal peptide involved in the regulation of food intake that may be affected after bariatric surgery is oxyntomodulin, which is a peptide belonging to the enteroglucagon family of peptides and arises from post-translational processing of proglucagon in intestinal cells. The release of oxyntomodulin into blood responds to food ingestion, being proportional to the caloric content of the meal (Cohen et al., 2003). Jejuno-ileal bypass surgery results in a marked elevation of oxytomodulin levels (Sarson et al., 1981). The exaggerated increase in the levels of this peptide in Roux-en-Y surgery has been linked to the dumping syndrome, which is a side-effect greatly associated with this type of bariatric surgery (Meek et al., 2016).

During the previous description of the changes in gastrointestinal peptides/hormones paired with bariatric surgery, one of the hormonal modifications that were cited as a consequence of the altered secretion of these peptides is insulin secretion and sensitivity. As we started by stating, one of the metabolic complications derived from obesity that has considerable improvements with bariatric surgery is diabetes type II. These benefits in glucose metabolism are particularly evident and occur early in types of bariatric surgery that bypass contact with the proximal parts of intestine, such as Roux-en-Y (le Roux et al., 2007). On the other hand, when food makes contact with the stomach, as in adjustable gastric banding, improvements in insulin sensitivity and glucose metabolism emerge later, mainly paired with body weight reduction (Usinger et al., 2011). Changes in insulin levels and sensitivity may also affect appetite/satiety after bariatric surgery, as insulin participates in the regulation of food intake by acting at the level of hypothalamus, inducing satiety (Vetter et al., 2009).

3. ORAL FOOD PERCEPTION

3.1. Mechanisms Involved in Flavor Perception

The flavor of food, often confused with taste or aroma, is defined as the combination of tastes, smells, and trigeminal and tactile sensations, as well as the visual and auditory cues that we perceive when tasting food (Spence, 2015a). During ingestion, the flavor of the food is integrated with post-ingestive cues, influencing palatability and acceptance. This association of the post-ingestive signals with oral food perception is the basis for unconditioned stimulation, which is responsible for the acceptance of some naturally aversive stimuli, such as bitter and astringent ones, or for the rejection of some flavors that were pleasurable before a gastric disease (Beauchamp and Mennella, 2009).

Taste results from chemical stimulation at the level of taste receptor cells located on taste tissue in the tongue, palate and epiglottis. Smell respects the detection of volatile compounds in the upper region of the nose. Moreover, volatiles that are released during mastication in the

mouth can be detected through retronasal route, making what is defined as a food aroma. Concerning chemosensory stimulation, this occurs through activation of receptors in the mucosa in the mouth and nose.

It is important to note that oral food perception (at the level of taste, smell or aroma) involves different psychological components: sensory-discriminative and hedonic. The sensory-discriminative component relates to the capacity to detect and differentiate different qualities of stimulants, or the intensity with which these stimuli are perceived. On the other hand, the hedonic component relates to the satisfaction with that stimuli, i.e., how much they are liked or disliked (Spence, 2015a).

It is known that the hedonic component of oral food perception may be affected by different factors, but one of the factors already reported is the amount of sensory experience with a particular stimulus. It was observed that decreasing the habitual consumption (habitual contact) of food with particular sensorial characteristics may reduce preferences for those characteristics (Bertino et al., 1982).

3.2. Basics of Taste Anatomy and Physiology

A comprehensive description of the gustatory system is beyond the scope of this chapter and has been reviewed by different authors (e.g., Hadley et al., 2004; Breslin and Huang, 2006; Hornung, 2006). We will only introduce basic concepts that will be discussed later on.

In terms of taste anatomy, taste cells are organized in groups, with an onion shape, called taste buds. Each taste bud consists of approximately 100 taste cells belonging to four types: i) type I, with glia-like functions; ii) type II, considered to be taste cells, harboring the protein receptors for the basic tastes; iii) type III, which expresses the constituents of the synaptic vesicle machinery; iv) considered basal cells, believed to be stem cells that may replace mature cell types (Witt and Reutter, 2015).

At the moment, five types of basic tastes are unanimously considered: sweet, salty, bitter, sour, and umami or savory. A growing number of researchers now believe that metallic and fatty acid tastes deserve to be added to the list, while others have argued that there may be as many as 25 different basic tastes; however, these remain controversial (Spence, 2015a). Tordoff and colleagues (Tordoff et al., 2012) provided the first evidence for calcium taste transduction in the human oral cavity. However, some authors maintain that calcium signaling is a complex dynamic process in taste cells and in this context it is difficult to consider it as a taste quality (Medler, 2015). Research about the possible existence of the taste of fat and its regulation gained interest mainly due to the potential connection that this may have with the acceptance of or preference for fatty foods, which is particularly important in the context of obesity and public health. Fat taste has been proposed based on the observation that fatty acid receptors are present in the oral cavity, at taste bud level, specifically in the circumvallate and foliate papillae (Simons et al., 2011). One of the main concerns in defining fat as a taste is the fact that there is no obvious perceptual independence from other taste qualities, as some researchers claim that there is no well-defined perception of fatty acids (Galindo et al., 2012). Despite the lack of conclusion about fat as a taste, the oral perception of fatty acids has been demonstrated to be able to predict dietary behaviors related to fat consumption, both in human and animal models, suggesting a functional significance of oral fat perception (Keast and Costanzo, 2015).

Sweet, bitter, and umami taste transduction occurs through protein membrane receptors (Roper, 2007) attached to gustducin, a G protein composed of the products of the GNAT3 (α-subunit), GNB1 (β-subunit) and GNG13 (γ-subunit). The binding of tastant to membrane protein receptor results in an intracellular cascade that culminates in membrane depolarization and the release of signal to nerves that convey information to taste centers in the Central Nervous System (CNS) (Roper, 2007). Salty taste may be transduced by epithelial Na channels similar to those found in renal tissues, while sour transduction appears to be initiated by intracellular acidification acting on acid-sensitive membrane proteins (Roper, 2007).

Despite taste receptors having initially been identified in the oral cavity (mainly on the tongue), over recent years several studies have emerged referring to the presence of taste receptors in the organs of the gastrointestinal system and in other extra-gustatory tissues (Wu et al., 2002; Iwatsuki et al., 2012; Depoortere, 2014; Laffitte et al., 2014). Nutrient sensing at gut level appears to be important not only for digestion, but also for controlling food intake. TAS1Rs, which comprise sweet and umami taste receptors, have been detected in different endocrine cells from the intestine and X/A-like cells from the stomach, and their activation by nutrients results in gut hormone secretion, what may serve to regulate food intake (Janssen and Depoortere, 2013). Some studies have shown that the family of human bitter taste receptors (TAS2Rs) are not only expressed in mucous epithelial cells of the tongue, but also in epithelial cells of the stomach, small intestine, and colon (Rozengurt and Sternini, 2007; Behrens and Meyerhof, 2011; Prandi et al., 2013). These receptors are activated by molecules similar to the ones that activate them in oral cavity (e.g., quinine, denatonium benzoate). Intragastric infusion of denatonium benzoate in rodents produced flavor aversions, preventing future ingestion of other bitter compounds (Glendinning et al., 2008), raising the possibility that agonists of TAS2Rs might be useful in obesity, as they would potentially prolong satiety (Calvo and Egan, 2015).

3.2.1. Influences of Hormones and Gastrointestinal Peptides in the Taste System

In recent years the direct influence of hormones and peptides involved in the regulation of food intake and in taste perception has been suggested. CCK acts at the level of cholecystokinin receptor A, in taste cells, in an autocrine fashion. Its action appears to increase bitter signaling (Herness and Zhao, 2009) and to decrease sweetness (Hajnal et al., 2005). The peptide YY, which induces satiety after food ingestion, is produced at the level of both the intestine and cells in taste buds. Moreover, receptors for this peptide exist in taste cells (Hurtado et al., 2012) and, in mice, it was observed that a lack of PYY results in reduced preferences for fat oral perception (La Sala et al., 2013). GLP-1 and its receptors have been reported to be present in TAS1R-expressing cells (Martin et al., 2009), i.e., in cells expressing receptors for sweet and/or umami tastes. The functional action of this gastrointestinal peptide in sweet taste response has been reinforced by the observation that mice deficient in GLP-1 receptor have a decreased perception of sweeteners, either containing calories or artificial ones (e.g., sucralose), and an increased sensitivity to umami (Martin et al., 2009). Receptors for ghrelin, a gastric hormone that induces appetite, have been reported to be present in taste buds (Shin et al., 2010). It seems that ghrelin may decrease response to salty and sour tastes (Kang et al., 2011), as well as to the stimuli evoked by long-chain fatty acids (Shin et al., 2010).

The hormone leptin is greatly involved in the long-term regulation of energy balance, reflecting the adiposity levels of individuals. The studies about the role of this hormone in the

regulation of taste perception, gained interest, particularly in the case of sweet taste. A relation between plasma leptin levels and sweet taste has been proposed by different authors based on studies performed both in humans (Sanematsu et al., 2009) and rodents (Shigemura et al., 2004). However, studies are not totally in agreement: whereas some reported decreased responses to the sweet stimulus sucrose (Kawai et al., 2000; Yoshida et al., 2013), others reported an increased responsiveness (Lu et al., 2012), or no observable effects on sweet taste response (Glendinning et al., 2015). Sweet has been the basic taste most linked to leptin effects, with some authors arguing that this hormone does not influence the responses for the other basic tastes (Yoshida et al., 2015). However other studies observed that men of a regular weight who are sensitive to the bitter taste elicited by PTC (phenylthiocarbamide) or PROP (6-n-propylthyouracil) presented higher plasma (Wang et al., 2014) or saliva (Rodrigues et al., not published) leptin levels in comparison to their non-sensitive counterparts.

3.3. Basics of Aroma Perception

It is clear that olfaction is an important external signal used by humans to assess the palatability of foods and select foods in general. It has been suggested that as much as 75%–95% of the taste of food (i.e., as transduced by the gustatory receptors on the tongue) results from the stimulation of the olfactory receptors in the nose instead (Spence, 2015b). It has been argued that with a greater amount of the brain devoted to olfaction, humans may in many ways equal other animals in their olfactory abilities. It is important to distinguish between orthonasal smell when we sniff (which tells us about the aroma of food) and the retronasal smell when air is pulsed out from the back of the nose as we swallow. It is the retronasal aromas that are combined with gustatory cues to give rise to flavors (Spence, 2015b).

Olfactory receptors located on olfactory cilia bind odorants that have been dissolved in mucus in the olfactory region of the nose. Each receptor cell apparently expresses a single receptor, which recognizes a small number of odorants. Our olfactory sense plays an important role in eating behavior by modulating our food preferences and intake, while hunger or satiety may also influence how we perceive odors (Plailly et al., 2011; Tresserra-Rimbau et al., 2013).

Volatile molecules from foods are not only detected through the nose, but also via the retronasal route. Aroma release and perception is a complex process that is perceived in the oral cavity, during mastication of food, by the release of volatiles. During chewing the velum-tongue opens (le Roux and Bueter, 2014), allowing the passage of volatiles (aroma compounds) from the mouth to the nose, reaching receptor cells (Hannig et al., 2016). Aroma release and perception are affected by different factors, and the exact influence of each of these factors is not completely understood. A negative correlation between mastication and volatile release was reported in a study performed with flavored candies (Blissett et al., 2006). With flavored model cheese, Pionnier and colleagues observed a positive correlation between respiratory rate, chewing activity and aroma release (Pionnier et al., 2004). This effect of chewing activity has been supported more recently, in a study where different factors with potential effect in aroma release were tested and where masticatory behavior was observed as being the major factor (Feron et al., 2014).

Aroma perception depends not only on volatile release, but also on detection at receptor level. Factors that may influence this detection will influence perception. Adaptation appears to influence aroma perception: if the receptors were subjected to a constant level of stimulation by a particular volatile, then the response to that volatile would decrease with time (Baek et al., 1999).

Despite a lack of studies about the potential effect of hormones or gastrointestinal peptides in aroma perception, several studies report changes in olfactory function induced by hormones. For example, orexin was reported to increase olfactory sensitivity, whereas leptin reduces that sensitivity (Valladares Vega and Obregon Rivas, 2015).

Olfaction is modulated in response to changing levels of various molecules, such as ghrelin, orexins, neuropeptide Y, insulin, leptin, and cholecystokinin (Palouzier-Paulignan et al., 2012). The current known distribution of peripherally and centrally derived energy-signaling molecules and their receptors in the olfactory system are reviewed by Palouzier-Paulignan and colleagues (Palouzier-Paulignan et al., 2012).

3.4. Changes in Oral Food Perception after Bariatric Surgery

3.4.1. Changes in Taste Function

Changes in food preferences and dietary habits are associated to weight loss, both with or without bariatric surgery. Studies about changes in preferences after diet-induced weight loss reported increases in preferences for sweet, starchy, and high-fat foods. However, these were different for individuals who maintained a low-fat diet in comparison with those who maintained a low-carbohydrate diet (Martin et al., 2011). Others studies reported a decline in dietary preference for fat following a low-fat diet over six months (Ledikwe et al., 2007). However, these studies do not elucidate whether changes in preferences are influenced by stimuli perception at taste receptor level.

As in diet-induced weight loss, patients after bariatric surgery typically report changes in palatability of sweet and high-fat foods. Different studies have reported altered taste perception in bariatric surgery patients, which appears to depend on the type of bariatric procedure used. Different evidences emerge from different studies, which can be sometimes be related to the type of surgery and/or to the type of methodologies used to access taste – i.e., some studies evaluate taste perception through the evaluation of taste sensitivity, whereas others evaluate it through the perceived intensity, and others through preferences. By employing the forced choice three stimuli drop technique, Scruggs and colleagues (Scruggs et al., 1994) studied the effects of gastric bypass surgery in taste detection and observed a decrease in the detection thresholds for the basic tastes of sweet, bitter, salty, and sour, which means higher sensitivity for these four taste qualities. However, other authors reported decreased taste thresholds only for the sweet taste, but not for bitter (Burge et al., 1995). In terms of preferences, increased affinity for a salty taste was reported for bypass patients, whereas gastric banding patients had increased affinity for a sweet taste (Tichansky et al., 2006). Statistically significant improvements in the acuity for the different basic tastes (sweet, sour, salty, and bitter) were reported for obese patients after sleeve gastrectomy (Altun et al., 2016).

In one of the most recent and comprehensive studies, modifications in eating behavior was observed to be similar following Roux-en-Y or laparoscopic adjustable gastric banding (Pepino et al., 2014). However, when subjects were matched on the amount of weight lost, the contribution of the taste system towards those changes appears to differ. Whereas in Roux-en-Y surgery the hedonic value of sweet was significantly affected, in laparoscopic adjustable gastric banding this was not so evident: patients from Roux-en-Y surgery find the sweet taste less pleasurable than before (Pepino et al., 2014). However, the authors did not observe changes in taste sensitivity, suggesting that alterations in preferences could be not directly related to events at taste receptor level (Pepino et al., 2014).

3.4.2. Changes in Aroma/Odor Perception

Alterations in smell after bariatric surgery have been observed, but few data are available.

Richardson and colleagues (Richardson et al., 2012) observed that absolute olfactory dysfunction present in morbidly obese persons is not affected by weight loss, and data from other authors suggest that a substantial body weight loss per se does not affect olfactory perception. Their results point to the improvement of olfactory perception after sleeve gastrectomy but not Roux-en-Y gastric bypass (Jurowich et al., 2014). In a cohort of patients undergoing Roux-en-Y gastric bypass, it was reported that subjective changes in appetite, taste and smell are very common after this surgery (Graham et al., 2014).

Enck and colleagues (Enck et al., 2014) observed that bariatric surgery did not change odor sensitivity, but some morbidly obese patients exhibited abnormally low olfactory functions prior to and after surgery, concluding that olfactory functions in normal healthy volunteers and obese patients suffer only marginal effects with the manipulation of the hunger/satiety state.

Holinski and colleagues (Holinski et al., 2015) prospectively analyzed the orthonasal olfactory function and the gustatory function with psychophysical testing in highly obese adult patients undergoing laparoscopic bariatric surgery. In this study, about 25% of the morbidly obese patients were treated with hypnosis, with a significant decrease in discrimination and identification capacity. Six months after laparoscopic bariatric surgery, the olfactory function ability to discriminate was improved, and about 25% of morbidly obese individuals had limited gustatory function.

In another study the majority of patients presented taste and olfactory changes soon after surgery, independently of type of procedure (Zerrweck et al., 2016). Patients submitted to laparoscopic gastric bypass more often identified a different smell in food, and a higher percentage of excess weight loss was observed in individuals presenting any food aversion, especially in the laparoscopic gastric bypass group as compared with individuals submitted to laparoscopic sleeve gastrectomy.

Further studies are needed to understand if these changes are real, along with determining the durability of changes, and understanding the underlying mechanisms, influence of gender, obesity comorbidities, percentage of weigth loss, and whether they are related to the surgical procedures/techniques adopted (Makaronidis et al., 2016).

4. SALIVA: AN IMPORTANT FLUID IN ORAL FOOD PERCEPTION

4.1. Saliva Secretion, Composition, and Functions

Whole saliva is the secretion product of three pairs of major salivary glands (parotid, submandibular, and sublingual), numerous minor salivary glands (e.g., lingual, labial), and gingival crevicular fluid (Pedersen et al., 2002). This fluid, consisting of approximately 99% water, contains a wide variety of constituents, of organic and inorganic origin, as well as cells and microorganisms.

The three pairs of major salivary glands – parotid, submandibular, and sublingual – produce different secretions and have different contributions according to the type of stimulation. Parotid glands, located on each side of the face, under the ears, are serous in nature and produce a watery saliva, with little or no mucins. These glands have a higher contribution for total saliva following stimulation by mastication. Parotid secretion contains different constituents, including different salivary proteins, which include digestive enzymes such as amylase. Sublingual glands, located under the tongue, are mucous glands, with a secretion rich in mucins. Submandibular glands, which contribute to a high proportion of secretion for the total of saliva when resting, are mixed glands, with the resultant product having characteristics between parotid and sublingual secretion (reviewed in Proctor, 2016).

The inorganic part of human saliva comprises about 0.2–0.4% of the fluid. Ions such as Na^+, K^+, Mg^{2+}, Ca^{2+}, Cl^-, HCO_3^-, and HPO_3^{2-} are found in variable proportion in saliva. Bicarbonate (HCO_3^-) and phosphate ($PO4^{3-}$) ions have considerable buffering capacity and, together with proteins, participate in the regulation of salivary pH. When resting, saliva has a pH ranging between 5.75 and 7.05, increasing with stimulation of salivation to 8.0 (Singh Mamta et al., 2013). Saliva ionic composition is different in resting vs stimulated conditions. Whereas in non-stimulated conditions, saliva is slightly hypotonic, relative to plasma, when stimulated its composition is closer to that of plasma (Pedersen et al., 2002).

Proteins and peptides comprise an important part of the organic composition of saliva. Salivary proteins have diverse functions, namely protection for teeth and oral tissues, taste perception, and participation in ingestive and digestive processes (Humphrey and Williamson, 2001).

Considerable research has confirmed saliva to be one of the most important factors influencing oral health. Organic and inorganic constituents of saliva contribute to the protection of oral structures. Salivary glucose levels have been associated with poor oral health in diabetes mellitus patients. A positive correlation between salivary glucose levels and oral Candida carriage has been observed (Naik et al., 2014), which can result in acid production, with the resultant decrease in salivary pH (Darwazeh et al., 1991).

4.2. Relation between Saliva Composition and Food Intake: Potential Effect of Changes to Dietary Regimens

Saliva composition is dynamic in nature and is influenced by different factors, one of which is food intake. Physical and chemical stimulation, such as mastication and taste stimuli, strongly affect salivary gland functionality, with modifications in saliva constituents (Dawes

et al., 2000). Stimulation with different tastants has been observed to result in short-term variations in the levels of different salivary proteins (Neyraud et al., 2006). This salivary response appears to occur not only for oral stimulation with basic tastes, but also for other oral sensations, such as pungency and burning (Lorenz et al., 2011). In terms of masticatory activity, a positive relationship with the contribution of parotid glands has been observed, whereas submandibular glands are primarily responsible for unstimulated (resting) saliva. Long-term changes in masticatory activity also induce changes in salivary function and the resultant composition of secretion product (Pedersen et al. 2002).

The composition of diet is also a factor responsible for variations in type and amounts of saliva constituents. For example, in animals, it is well recognized that species with different dietary chemical composition present dissimilarities in their saliva composition (for a review, see Baptista et al., 2010). One of the most studied cases is the induction of salivary proline-rich proteins with the increased consumption of tannins (e.g., Lamy et al., 2008; Lamy et al., 2011). In humans, the exposure to polyphenolic compounds present in food and drink also seems to change salivary secretion and composition. Short-term exposure to tannic acid resulted in changes in salivary protein profile, which appeared to be different in individuals with high sensitivity to astringency, in comparison to those with low sensitivity for such sensation (Dinnella et al., 2010). Salivary amylase, PRPs, and cystatins have been proposed as salivary proteins and change in expression levels after stimulation with tannic acid solution (Dinnella et al., 2010).

For the same individual, changes in diet composition induce changes in saliva secretion and in the type and amount of compounds present in this fluid. A change from a standard diet to a high-fat diet over a long period results in changes in saliva protein composition, as was observed in a rat model (Rodrigues et al., 2015). This study did not test whether this was a direct result of the presence of higher amounts fat in the diet or an indirect result due to changes in the proportion of the other macro- and micronutrients, or even an indirect result of metabolic alterations in the animal. Nevertheless, in general, the study indicated the potential effects of changes in diet on saliva composition. A significant correlation between dietary and salivary fatty acid composition had already been observed before (Actis et al., 2005), showing that dietary fat may also change salivary constituents other than proteins.

The effect of changes in dietary patterns on saliva composition was studied by comparing an omnivore regimen with lactovegetarian and vegan regimens. A long-time change to a lactovegetarian diet was observed to induce changes in saliva secretion rate, buffer capacity and sodium concentration (Johansson and Birkhed, 1994). The observation of higher saliva secretion rates in vegetarian individuals in comparison with meat-eaters was hypothesized to be due to the slightly alkaline pH of most vegetable-driven foods (Amirmozafari et al., 2013). Concomitantly with changes in flow rate, decreases in peroxidase, catalase, and superoxide dismutase activities were also reported in saliva from vegetarian individuals (Amirmozafari et al., 2013).

It is not only the case that diet affects saliva secretion, as saliva secretion may affect dietary choices and nutritional status. A recent study observed that individuals with hyposalivation have, on average, nutritionally poorer alimentary habits, with a lower intake of vegetables and fish, polyunsaturated fatty acids, potassium, and vitamins D, E, and B6 (Iwasaki et al. 2016).

4.3. Saliva Changes Induced by Lifestyle Factors

Lifestyle factors, including exercise, are relevant in the context of obesity. Independent of diet, although possibly related to it, are lifestyle factors affecting oral medium characteristics, namely smoking, alcohol consumption, and physical exercise. The detrimental effect of chronic alcohol drinking on salivary proteins with defense functions is known. For example, chronic alcohol consumption decreases the levels of lactoferrin, peroxidase, immunoglobulin A and lysozyme (Waszkiewicz et al., 2012 a, b, c). A lesser level of glycosylation of salivary proteins from alcohol-dependent individuals was also cited, and suggested as a possible cause of an increased susceptibility to oral pathologies (Kratz et al. 2014). Physical exercise is known to produce alterations in salivary flow and protein composition. The higher viscosity of saliva produced during exercise is not a new discovery (Dawes, 1981). Despite such increase in viscosity having been primarily attributed to systemic dehydration after intense exercise, together with increased mouth breathing, which in turn reduces watery saliva content, increasing the concentration of salivary mucins and other proteins, a recent study has suggested that it is also a result of altered secretion of salivary mucin secretion (Ligtenberg et al., 2015). The effect of exercise on salivary secretion has been mainly studied at the level of salivary proteins with antimicrobial and mucosal defense functions. The effects at the level of salivary Immunoglobulin A (sIgA) secretion are reported by different authors, with prolonged, high-intensity exercise bouts decreasing sIgA secretion (Nieman et al., 2006), and short exercise bouts or low- to moderate-intensity exercise increasing sIgA levels (Allgrove et al., 2008). This indicates that not only the practice, but also the type and duration of exercise produce changes in salivary composition that may further affect the general functions and properties of saliva. The influences of physical exercise on salivary secretion may further differ according to the fitness of the individual (Kunz et al., 2015).

4.4. Saliva and Taste Perception

Saliva has a role in the oral perception of foods. This fluid is necessary to dissolve the substances that will be further transported to the places of reception/detection of taste (taste receptor cells in taste buds).

The involvement of saliva in oral food perception has begun to be studied in the context of astringency development, due to the participation of salivary proteins in the development of this sensation. Different salivary proteins have been identified as being involved in astringency from polyphenols, due to their affinity with these compounds: proline-rich-proteins (PRPs) (Williamson, 1994), histatins (Yan and Bennick, 1995), staterins, and cystatins (Soares et al., 2012), or even amylase (Soares et al., 2011). Of these, salivary PRPs have been the most studied in terms of interaction with polyphenols, constituting the main family of salivary proteins involved in astringency.

Apart from the proteins reported to be involved in astringency, other salivary proteins have been suggested as participating in oral food perception. The protein lipocalin 1, secreted by Von Ebner minor salivary glands, presents homology with hydrophobic molecule transporters, which are suggested as participating and helping in the concentration and transport of sapid molecules to taste cells (Schmale et al., 1990). Besides promoting lubrication, mucins, which are mainly high molecular weight glycoproteins, also participate in

the perception of food texture (Mese and Matsuo, 2007). Salivary amylase is a protein that is also involved in food perception. The involvement of this protein in food sensorial perception has been suggested by different authors, namely due to its influence on the perception of viscosity from starch-based foods (Engelen et al., 2007).

Carbonic anhydrase VI (CA VI) is a protein that is widely reported as being linked to bitter taste perception. Some authors observed that individuals with a deficit in CA VI presented altered anatomy of taste buds and taste function, and that such changes might be reversed by zinc treatment (Henkin et al., 1999). Moreover, this protein was observed in reduced levels in patients with taste dysfunction (Shatzman and Henkin, 1981). Levels of salivary CA VI have been also associated with differences between individuals in their capacity to taste the bitterness of the compound 6-n-propylthiouracil (PROP). Padiglia and colleagues (Padiglia et al., 2010), although they did not observe differences in the amounts of salivary CA VI between individuals sensitive and non-sensitive to the PROP bitter taste, observed differences between these groups in the capacity of salivary CA VI to bind zinc, which seems to affect its function. In the same line, a group of Italian researchers observed that different polymorphisms in the gene that codes for the salivary protein CA VI, which change the function of this enzyme, are related to the PROP taste response (Cabras et al., 2012). However, some controversy exists about the influence of this protein in bitter taste, with some studies lacking any observation of such a relationship (Feeney and Hayes, 2014).

Epidermal Growth Factor (EGF), secreted by parotid and submandibular glands, has been related to the morphological integrity of taste buds, being potentially involved in taste perception (Morris-Wiman et al., 2000). The possible interaction between salivary proteins and tastants, which can affect taste perception, was proposed for proteins such as histatin (Wada et al., 2010, cited by Dsamou et al., 2012). This protein was suggested as having an affinity with molecules such as quinine, possibly preventing it from reaching taste receptors. Melis and colleagues (Melis et al., 2013) reported the interaction of the molecule PROP with the amino acids arginine and lysine, suggesting that this interaction may induce changes in the conformation of the molecule, which may help it to interact with taste receptors.

A relationship between saliva composition and fat perception has been suggested, with the protein zinc-α2 glycoprotein being observed at higher levels in individuals with a high sensitivity to the taste of oleic acid (Mounayar et al., 2013).

Salivary cystatins, which had already been reported as possibly involved in astringency (Soares et al., 2012) were associated with the perception of caffeine bitter taste in adult men, with the individuals presenting lower sensitivity to this taste having higher levels of this salivary protein (Dsamou et al., 2012). It was suggested that the relationship of this protein to taste sensitivity is due to the activity of cystatins as protease inhibitors, preventing the action of proteases that may be needed for decreasing the tightness of the salivary film that covers taste receptors, and consequently allowing the tastants to access taste pores (Dsamou et al., 2012). This possible relationship between salivary cystatins and bitter taste perception was reinforced by studies reporting higher acceptance of bitter taste by children with high levels of salivary cystatins (Morzel et al., 2014; Mounayar et al., 2014). However, this issue needs to be deeply studied, as controversy exists in terms of the participation of salivary cystatins in the perception of bitter taste elicited by other compounds, such as PROP. In this case, some studies report no differences in salivary cystatin levels between individuals with high and low responsivity (Cabras et al., 2012), whereas our research team observed different salivary

responses in terms of cystatin secretion after stimulation with PROP bitter taste (data not published).

4.5. Changes in Saliva Composition in Obesity and Bariatric Surgery

Metabolic state can induce changes in saliva, with the consequent changes in the functions of this fluid. Nutritional condition and problems associated with it, such as malnutrition (Psoter et al., 2005), and obesity (Choromańska et al., 2015; Vors et al., 2015) have been observed as relating to changes in saliva composition.

Energy-protein deficit elicits changes in the levels of some salivary proteins, which is different according to the level of severity of malnutrition (Fonteles et al., 2012). Undernutrition in anorexia nervosa has been also associated with altered function of major and minor salivary glands, resulting in changes in the pH and composition of oral medium. Unstimulated flow rate is significantly lower in anorectic patients, with these individuals also presenting lower activities of enzymes such as collagenase and aspartate amino transferase (Elżbieta et al., 2015).

Saliva flow rate, total protein concentration and levels of salivary proteins such as alpha amylase, cystatins, and carbonic anhydrase VI (CA VI), among others, have been observed to be changed in obese individuals (Lamy et al., 2015; Rodrigues et al., 2015). Besides CA VI levels being elevated in obese individuals (Lamy et al., 2015; Vors et al., 2015), a strong positive correlation was observed between the levels of this protein and Body Mass Index (BMI), suggesting that salivary concentration of CA VI increases with BMI (Lamy et al., 2015). Higher levels of this protein, which have been associated with sensitivity to bitter taste, may suggest a relation between changes in obese saliva composition and bitter taste perception. Differences in the levels of salivary amylase, or salivary cystatins (Lamy et al., 2015), which have also been suggested as being related to oral food perception at the level of starchy foods (Mandel et al., 2010) and bitterness (Dsamou et al., 2012) respectively, supports this hypothesis. Vors and colleagues (Vors et al., 2015) reported lower lipolysis and higher proteolysis in the saliva of obese individuals in comparison with that of normal-weight subjects. Salivary lipolysis was reported as having a positive relation with fat intensity perception (Neyraud et al., 2012), which may suggest that saliva from obese individuals may result in different oral fat perception.

Various other nutrition-related pathologies have been also studied in terms of changes in saliva composition, which is beyond the scope of this chapter. This is reviewed in different publications (e.g., Javaid et al., 2016; Schipper et al., 2007; Zhang et al., 2013).

Despite the scarcity of studies about saliva composition after bariatric surgery, those that exist report partial reversion of the changes in this oral fluid composition that had been previously induced by obesity. Saliva total antioxidant status and the total amount of superoxide dismutase 2, which seems to be increased in obese patients, appears to decrease after bariatric surgery (Knaś et al., 2016), with the differences observed for the proteins salivary alpha-amylase and carbonic anhydrase VI in obese women no longer observed after gastric sleeve bariatric surgery (Lamy et al., 2015). Changes in saliva composition induced by bariatric surgery can also result in changes in food aroma perception. Aroma release is affected by several factors already mentioned in previous parts of this chapter. One of them appears to be saliva composition. An interesting study showed that the perception of aroma

by obese individuals may be altered in comparison with normal-weight subjects due to differences in saliva composition (Piombino et al., 2014). In that study, the different perception of wine aromas by obese individuals was related to the differences in their saliva protein composition, and a possible role of some of the proteins in binding volatiles, impeding them from accessing receptors, was hypothesized. Although potential changes in aroma perception after weight loss have not been evaluated, it is possible that they may also occur, as the saliva composition changes.

Based on the information set out above in relation to alterations in hormones and gastrointestinal peptides following bariatric surgery, about how hormones may influence taste perception and saliva secretion, and how taste and saliva may be related, more studies about saliva changes after different types of bariatric surgery may be useful for better understanding the modifications in oral food perception usually reported for this type of weight loss.

CONCLUSION

Bariatric surgery is, thus far, the most effective method for sustained weight loss and treatment of comorbidities associated to obesity. Although different factors contribute to this, differences in the way in which food is perceived at oral cavity level contribute to changes in dietary patterns. Oral food perception is influenced by hormonal parameters, and changes in these, resulting from bariatric surgery, have an influence at taste and odor level.

Although less well explored, saliva composition is also modified, at some level, after different types of bariatric surgery. Further studies are needed to better understand how these salivary changes are relevant to altered food perception and for the overall process of weight loss after bariatric surgery.

ACKNOWLEDGMENTS

This chapter is funded by FEDER financing through the Operational Programme for Competiveness Factors-COMPETE and national funding through FCT-Foundation for Science and Technology under the project UID/AGR/00115/2013 (ICAAM – University of Évora). The authors also acknowledge financial support from the Portuguese Science Foundation (FCT) in the form of Elsa Lamy FCT investigator contract IF/01778/2013. The Portuguese Science Foundation (FCT) played no role in the development of this work or in its submission for publication.

REFERENCES

Actis AB, Perovic NR, Defagó D, Beccacece C, Eynard AR. Fatty acid profile of human saliva: A possible indicator of dietary fat intake. *Arch Oral Biol.* 2005; 50(1):1-6.

Allgrove JE, Gomes E, Hough J, Gleeson M. Effects of exercise intensity on salivary antimicrobial proteins and markers of stress in active men. *J Sports Sci.* 2008; 26(6):653-61.

Altun H, Hanci D, Altun H, Batman B, Serin RK, Karip AB, Akyuz U. Improved gustatory sensitivity in morbidly obese patients after laparoscopic sleeve gastrectomy. *Ann Otol Rhinol Laryngol*. 2016; 125(7):536-40.

Amirmozafari N, Pourghafar H, Sariri R. Salivary defense system alters in vegetarian. *J Oral Biol Craniofacial Res.* 2013; 3(2):78-82.

Baek I, Linforth RS, Blake A, Taylor AJ. Sensory perception is related to the rate of change of volatile concentration in-nose during eating of model gels. *Chem Senses*. 1999; 24(2):155-60.

Baggio LL, Drucker DJ. Biology of incretins: GLP-1 and GIP. *Gastroenterology*. 2007; 132(6):2131-57.

Baptista ES, Lamy E, Mau M, Capela e Silva F, Coelho AV. Variation in salivary protein composition related to feeding behavior and its ecological implications. In: Zhang W, Liu H (Ed*). Behavioral and Chemical Ecology*. New York: Nova Science Publishers Inc; 2010. p.115-136.

Beauchamp GK, Mennella JA. Early flavor learning and its impact on later feeding behavior. *J Pediatr Gastroenterol Nutr*. 2009; 48(Suppl.1):S25-S30.

Behrens M, Meyerhof W. Gustatory and extragustatory functions of mammalian taste receptors. *Physiol Behav*. 2011; 105(1):4-13.

Bertino M, Beauchamp GK, Engelman K. Long-term reduction in dietary sodium alters the taste of salt. *Am J Clin Nutr*. 1982; 36(6):1134-44.

Blissett A, Hort J, Taylor AJ. Influence of chewing and swallowing behavior on volatile release in two confectionery systems. *J Texture Stud*. 2006; 37(5):476-96.

Breslin PA, Huang L. Human taste: Peripheral anatomy, taste transduction, and coding. *Adv Otorhinolaryngol*. 2006; 63:152-90.

Buchwald H. Bariatric surgery for morbid obesity: Health implications for patients, health professionals, and third-party payers. *J Am Coll Surg*. 2005; 200(4):593-604.

Burge JC, Schaumburg JZ, Choban PS, DiSilvestro RA, Flancbaum L. Changes in patients' taste acuity after Roux-en-Y gastric bypass for clinically severe obesity. *J Am Diet Assoc*. 1995; 95(6):666-70.

Bužga M, Zavadilová V, Holéczy P, Švagera Z, Švorc P, Foltys A, Zonča P. Dietary intake and ghrelin and leptin changes after sleeve gastrectomy. *Wideochir Inne Tech Maloinwazyjne*. 2014; 9(4):554-61.

Cabras T, Melis M, Castagnola M, Padiglia A, Tepper BJ, Messana I, Tomassini Barbarossa I. Responsiveness to 6-n-propylthiouracil (PROP) is associated with salivary levels of two specific basic proline-rich proteins in humans. *PLoS One.* 2012; 7(2):e30962. doi: 10.1371/journal.pone.0030962.

Calvo SS, Egan JM. The endocrinology of taste receptors. *Nat Rev Endocrinol.* 2015; 11(4):213–27.

Choromańska K, Choromańska B, Dąbrowska E, Bączek W, Myśliwiec P, Dadan J, Zalewska A. Saliva of obese patients – is it different*? Postepy Hig Med Dosw* (Online). 2015; 69:1190-5.

Cohen MA, Ellis SM, Le Roux CW, Batterham RL, Park A, Patterson M, Frost GS, Ghatei MA, Bloom SR. Oxyntomodulin suppresses appetite and reduces food intake in humans. *J Clin Endocrinol Metab*. 2003; 88(10):4696-701.

Coll AP, Farooqi IS, O'Rahilly S. The hormonal control of food intake. *Cell.* 2007; 129(2):251-62.

Cummings DE, Weigle DS, Frayo RS, Breen PA, Ma MK, Dellinger EP, Purnell JQ. Plasma ghrelin levels after diet-induced weight loss or gastric bypass surgery. *N Engl J Med*. 2002; 346(21):1623-30.

Darwazeh AM, MacFarlane TW, McCuish A, Lamey P-J. Mixed salivary glucose levels and candidal carriage in patients with diabetes mellitus. *J Oral Pathol Med.* 1991; 20(6):280-3.

Dawes C. The effects of exercise on protein and electrolyte secretion in parotid saliva. *J Physiol*. 1981; 320:139-48.

Dawes C, O'Connor AM, Aspen JM. The effect on human salivary flow rate of the temperature of a gustatory stimulus. *Arch Oral Biol*. 2000; 45(11):957-61.

de Jonge C, Rensen SS, Verdam FJ, Vincent RP, Bloom SR, Buurman WA, le Roux CW, Bouvy ND, Greve JW. Impact of duodenal-jejunal exclusion on satiety hormones. *Obes Surg*. 2016; 26(3):672-8.

Depoortere I. Taste receptors of the gut: emerging roles in health and disease. *Gut.* 2014; 63(1):179-90.

Dinnella C, Recchia A, Vincenzi S, Tuorila H, Monteleone E. Temporary modification of salivary protein profile and individual responses to repeated phenolic astringent stimuli. *Chem Senses.* 2010; 35(1):75-85.

Dogan UB, Gumurdulu Y, Akin MS, Yalaki S. Five percent weight lost in the first month of intragastric balloon treatment may be a predictor for long-term weight maintenance. *Obes Surg*. 2013; 23(7):892-6.

Dsamou M, Palicki O, Septier C, Chabanet C, Lucchi G, Ducoroy P, Chagnon MC, Morzel M. Salivary protein profiles and sensitivity to the bitter taste of caffeine. *Chem Senses.* 2012; 37(1):87-95.

Elder KA, Wolfe BM. Bariatric surgery: a review of procedures and outcomes. *Gastroenterology*. 2007; 132(6):2253-71.

Elżbieta P, Nadine S, Agnieszka S, Monika DW, Marta DK, Christian H. Salivary enzyme activity in anorexic persons – a controlled clinical trial. *Clin Oral Investig*. 2015; 19(8):1981-9.

Enck P, Rieber N, Sauer H, Klosterhalfen S, Mack I, Zipfel S, Teufel M. Almost nothing – not even bariatric surgery for obesity – changes olfactory sensitivity. *J Res Obesity* 2014; Article ID 491890, doi: 10.5171/2014.491890.

Engelen L, van den Keybus PA, de Wijk RA, Veerman EC, Amerongen AV, Bosman F, Prinz JF, van der Bilt A. The effect of saliva composition on texture perception of semi-solids. *Arch Oral Biol.* 2007; 52(6):518-25.

Feeney EL, Hayes JE. Exploring associations between taste perception, oral anatomy and polymorphisms in the carbonic anhydrase (gustin) gene CA6. *Physiol Behav*. 2014; 128:148-54.

Feinle C, Christen M, Grundy D, Faas H, Meier O, Otto B, Fried M. Effects of duodenal fat, protein or mixed-nutrient infusions on epigastric sensations during sustained gastric distension in healthy humans. *Neurogastroenterol Motil.* 2002; 14(2):205-13.

Feron G, Ayed C, Qannari EM, Courcoux P, Laboure H, Guichard E. Understanding aroma release from model cheeses by a statistical multiblock approach on oral processing. *PLoS One*. 2014; 9(4):e93113. doi: 10.1371/journal.pone.0093113.

Fonteles CS, Dos Santos CF, da Silva Alves KS, de Miranda Mota AC, Damasceno JX, Fonteles MC. Comparative proteomic analysis of human whole saliva of children with protein-energy undernutrition. *Nutrition.* 2012; 28(7-8):744-8.

Galindo MM, Voigt N, Stein J, van Lengerich J, Raguse JD, Hofmann T, Meyerhof W, Behrens M. G protein-coupled receptors in human fat taste perception. *Chem Senses*. 2012; 37(2):123-39.

Geloneze B, Tambascia MA, Pilla VF, Geloneze SR, Repetto EM, Pareja JC. Ghrelin: a gut-brain hormone: effect of gastric bypass surgery. *Obes Surg.* 2003; 13(1):17-22.

Glendinning JI, Elson AET, Kalik S, Sosa Y, Patterson CM, Myers MG Jr, Munger SD. Taste responsiveness to sweeteners is resistant to elevations in plasma leptin. *Chem Senses.* 2015; 40(4):223-31.

Glendinning JI, Yiin YM, Ackroff K, Sclafani A. Intragastric infusion of denatonium conditions flavor aversions and delays gastric emptying in rodents. *Physiol Behav.* 2008; 93(4-5):757-65.

Graham L, Murty G, Bowrey DJ. Taste, smell and appetite change after Roux-en-Y gastric bypass surgery. *Obes Surg.* 2014; 24(9):1463-8.

Guidone C, Manco M, Valera-Mora E, Iaconelli A, Gniuli D, Mari A, Nanni G, Castagneto M, Calvani M, Mingrone G. Mechanisms of recovery from type 2 diabetes after malabsorptive bariatric surgery. *Diabetes.* 2006; 55(7):2025-31.

Hadley K, Orlandi RR, Fong KJ. Basic anatomy and physiology of olfaction and taste. *Otolaryngol Clin North Am.* 2004; 37(6):1115-26.

Hajnal A, Covasa M, Bello NT. Altered taste sensitivity in obese, prediabetic OLETF rats lacking CCK-1 receptors. *Am J Physiol Regul Integr Comp Physiol.* 2005; 289(6):R1675-86.

Hannig C, Hannig M, Morzel M. Bioadhesion and oral fluids – perireceptor modulators of taste perception? In Guichard E, Salles C, Morzel M, Le Bon A-M. (Ed.), *Le Flavour: From Food to Perception.* Wiley-Blackwell, 2016, p.79-108.

Hanusch-Enserer U, Brabant G, Roden M. Ghrelin concentrations in morbidly obese patients after adjustable gastric banding. *N Engl J Med.* 2003; 348(21):2159-60.

Henkin RI, Martin BM, Agarwal RP. Efficacy of exogenous oral zinc in treatment of patients with carbonic anhydrase VI deficiency. *Am J Med Sci.* 1999; 318(6):392-405.

Herness S, Zhao FL. The neuropeptides CCK and NPY and the changing view of cell-to-cell communication in the taste bud. *Physiol Behav.* 2009; 97(5):581-91.

Holinski F, Menenakos C, Haber G, Olze H, Ordemann J. Olfactory and gustatory function after bariatric surgery. *Obes Surg*. 2015; 25(12):2314-20.

Hornung DE. Nasal anatomy and the sense of smell. *Adv Otorhinolaryngol.* 2006; 63:1-22.

Humphrey SP, Williamson RT. A review of saliva: normal composition, flow, and function. *J Prosthet Dent*. 2001; 85(2):162-9.

Hurtado MD, Acosta A, Riveros PP, Baum BJ, Ukhanov K, Brown AR, Dotson CD, Herzog H, Zolotukhin S. Distribution of Y-receptors in murine lingual epithelia. *PLoS One.* 2012; 7(9):e46358. doi: 10.1371/journal.pone.0046358.

Ionut V, Burch M, Youdim A, Bergman RN. Gastrointestinal hormones and bariatric surgery-induced weight loss. *Obesity* (Silver Spring). 2013; 21(6):1093-103.

Iwasaki M, Yoshihara A, Ito K, Sato M, Minagawa K, Muramatsu K, Watanabe R, Manz MC, Ansai T, Miyazaki H. Hyposalivation and dietary nutrient intake among community-based older Japanese. *Geriatr Gerontol Int.* 2016; 16(4):500-7.

Iwatsuki K, Ichikawa R, Uematsu A, Kitamura A, Uneyama H, Torii K. Detecting sweet and umami tastes in the gastrointestinal tract. *Acta Physiol* (Oxf). 2012; 204(2):169-77.

Jacobsen SH, Olesen SC, Dirksen C, Jørgensen NB, Bojsen-Møller KN, Kielgast U, Worm D, Almdal T, Naver LS, Hvolris LE, Rehfeld JF, Wulff BS, Clausen TR, Hansen DL, Holst JJ, Madsbad S. Changes in gastrointestinal hormone responses, insulin sensitivity, and beta-cell function within 2 weeks after gastric bypass in non-diabetic subjects. *Obes Surg*. 2012; 22(7):1084-96.

Janssen S, Depoortere I. Nutrient sensing in the gut: New roads to therapeutics? *Trends Endocrinol Metab*. 2013; 24(2):92-100.

Javaid MA, Ahmed AS, Durand R, Tran SD. Saliva as a diagnostic tool for oral and systemic diseases. *J Oral Biol Craniofacial Res.* 2016; 6(1):67-75.

Johansson G, Birkhed D. Effect of a long-term change from a mixed to a lactovegetarian diet on human saliva. *Arch Oral Biol*. 1994; 39(4):283-8.

Jurowich CF, Seyfried F, Miras AD, Bueter M, Deckelmann J, Fassnacht M, Germer CT, Thalheimer A. Does bariatric surgery change olfactory perception? Results of the early postoperative course. *Int J Colorectal Dis.* 2014; 29(2):253-60.

Kalinowski P, Paluszkiewicz R, Wróblewski T, Remiszewski P, Grodzicki M, Bartoszewicz Z, Krawczyk M. Ghrelin, leptin, and glycemic control after sleeve gastrectomy versus Roux-en-Y gastric bypass-results of a randomized clinical trial. *Surg Obes Relat Dis.* 2017; 13(2):181-188.

Kang K, Zmuda E, Sleeman MW. Physiological role of ghrelin as revealed by the ghrelin and GOAT knockout mice. *Peptides.* 2011; 32(11):2236-41.

Kawai K, Sugimoto K, Nakashima K, Miura H, Ninomiya Y. Leptin as a modulator of sweet taste sensitivities in mice. *Proc Natl Acad Sci USA.* 2000; 97(20):11044-9.

Keast RS, Costanzo A. Is fat the sixth taste primary? Evidence and implications. *Flavour*. 2015; 4(1):5. doi: 10.1186/2044-7248-4.

Knaś M, Maciejczyk M, Sawicka K, Hady HR, Niczyporuk M, Ładny JR, Matczuk J, Waszkiel D, Żendzian-Piotrowska M, Zalewska A. Impact of morbid obesity and bariatric surgery on antioxidant/oxidant balance of the unstimulated and stimulated human saliva. *J Oral Pathol Med.* 2016; 45(6):455-64.

Kojima M, Hosoda H, Date Y, Nakazato M, Matsuo H, Kangawa K. Ghrelin is a growth-hormone-releasing acylated peptide from stomach. *Nature.* 1999; 402(6762):656-60.

Korner J, Bessler M, Cirilo LJ, Conwell IM, Daud A, Restuccia NL, Wardlaw SL. Effects of Roux-en-Y gastric bypass surgery on fasting and postprandial concentrations of plasma ghrelin, peptide YY, and insulin. *J Clin Endocrinol Metab.* 2005; 90(1):359-65.

Kratz EM, Waszkiewicz N, Kaluza A, Szajda SD, Zalewska-Szajda B, Szulc A, Zwierz K, Ferens-Sieczkowska M. Glycosylation changes in the salivary glycoproteins of alcohol-dependent patients: A pilot study. *Alcohol Alcohol.* 2014; 49(1):23-30.

Kunz H, Bishop NC, Spielmann G, Pistillo M, Reed J, Ograjsek T, Park Y, Mehta SK, Pierson DL, Simpson RJ. Fitness level impacts salivary antimicrobial protein responses to a single bout of cycling exercise. *Eur J Appl Physiol.* 2015; 115(5):1015-27.

La Sala MS, Hurtado MD, Brown AR, Bohórquez DV, Liddle RA, Herzog H, Zolotukhin S, Dotson CD. Modulation of taste responsiveness by the satiation hormone peptide YY. *FASEB J.* 2013; 27(12):5022-33.

LABS. Longitudinal Assessment of Bariatric Surgery (LABS) Consortium, Flum DR, Belle SH, King WC, Wahed AS, Berk P, Chapman W, Pories W, Courcoulas A, McCloskey C,

Mitchell J, Patterson E, Pomp A, Staten MA, Yanovski SZ, Thirlby R, Wolfe B. Perioperative safety in the longitudinal assessment of bariatric surgery. *N Engl J Med.* 2009; 361(5):445-54.

Laferrère B, Teixeira J, McGinty J, Tran H, Egger JR, Colarusso A, Kovack B, Bawa B, Koshy N, Lee H, Yapp K, Olivan B. Effect of weight loss by gastric bypass surgery versus hypocaloric diet on glucose and incretin levels in patients with type 2 diabetes. *J Clin Endocrinol Metab.* 2008; 93(7):2479-85.

Laffitte A, Neiers F, Briand L. Functional roles of the sweet taste receptor in oral and extraoral tissues. *Curr Opin Clin Nutr Metab Care*. 2014; 17(4):379-85.

Lamy E, da Costa G, Capela e Silva F, Potes J, Coelho AV, Baptista ES. Comparison of electrophoretic protein profiles from sheep and goat parotid saliva. *J Chem Ecol.* 2008; 34(3):388-97.

Lamy E, da Costa G, Santos R, Capela e Silva F, Potes J, Pereira A, Coelho AV, Baptista ES. Effect of condensed tannin ingestion in sheep and goat parotid saliva proteome. *J Anim Physiol Anim Nutr*. (Berl). 2011; 95(3):304-12.

Lamy E, Simões C, Rodrigues L, Costa AR, Vitorino R, Amado F, Antunes C, do Carmo I. Changes in the salivary protein profile of morbidly obese women either previously subjected to bariatric surgery or not. *J Physiol Biochem*. 2015; 71(4):691-702.

le Roux CW, Bueter M. The physiology of altered eating behaviour after Roux-en-Y gastric bypass. *Exp Physiol.* 2014; 99(9):1128-32.

le Roux CW, Welbourn R, Werling M, Osborne A, Kokkinos A, Laurenius A, Lönroth H, Fändriks L, Ghatei MA, Bloom SR, Olbers T. Gut hormones as mediators of appetite and weight loss after Roux-en-Y gastric bypass. *Ann Surg.* 2007; 246(5):780-5.

Ledikwe JH, Ello-Martin J, Pelkman CL, Birch LL, Mannino ML, Rolls BJ. A reliable, valid questionnaire indicates that preference for dietary fat declines when following a reduced-fat diet. *Appetite.* 2007; 49(1):74-83.

Leite Faria S, de Oliveira Kelly E, Pereira Faria O, Kiyomi Ito M. Snack-eating patients experience lesser weight loss after roux-en-Y gastric bypass surgery. *Obes Surg.* 2009; 19(9):1293-6.

Ligtenberg AJ, Brand HS, van den Keijbus PA, Veerman EC. The effect of physical exercise on salivary secretion of MUC5B, amylase and lysozyme. *Arch Oral Biol.* 2015; 60(11):1639-44.

Lorenz K, Bader M, Klaus A, Weiss W, Görg A, Hofmann T. Orosensory stimulation effects on human saliva proteome. *J Agric Food Chem*. 2011; 59(18):10219-31.

Lu B, Breza JM, Nikonov AA, Paedae AB, Contreras RJ. Leptin increases temperature-dependent chorda tympani nerve responses to sucrose in mice. *Physiol Behav*. 2012; 107(4):533-9.

Makaronidis JM, Neilson S, Cheung W-H, Tymoszuk U, Pucci A, Finer N, Doyle J, Hashemi M, Elkalaawy M, Adamo M, Jenkinson A, Batterham RL. Reported appetite, taste and smell changes following Roux-en-Y gastric bypass and sleeve gastrectomy: Effect of gender, type 2 diabetes and relationship to post-operative weight loss. *Appetite.* 2016; 107:93-105.

Mandel AL, Peyrot des Gachons C, Plank KL, Alarcon S, Breslin PA. Individual differences in AMY1 gene copy number, salivary α-amylase levels, and the perception of oral starch. *PLoS One*. 2010; 5(10):e13352. doi: 10.1371/journal.pone.0013352.

Martin B, Dotson CD, Shin YK, Ji S, Drucker DJ, Maudsley S, Munger SD. Modulation of taste sensitivity by GLP-1 signaling in taste buds. *Ann N Y Acad Sci*. 2009; 1170:98-101.

Martin CK, Rosenbaum D, Han H, Geiselman PJ, Wyatt HR, Hill JO, Brill C, Bailer B, Miller BV 3rd, Stein R, Klein S, Foster GD. Change in food cravings, food preferences, and appetite during a low-carbohydrate and low-fat diet. *Obesity* (Silver Spring). 2011; 19(10):1963-70.

Mathus-Vliegen EM, de Groot GH. Fasting and meal-induced CCK and PP secretion following intragastric balloon treatment for obesity. *Obes Surg*. 2013; 23(5):622-33.

McLaughlin T, Abbasi F, Lamendola C, Frayo RS, Cummings DE. Plasma ghrelin concentrations are decreased in insulin-resistant obese adults relative to equally obese insulin-sensitive controls. *J Clin Endocrinol Metab*. 2004; 89(4):1630-5.

Medler KF. Calcium signaling in taste cells. *Biochim Biophys Acta*. 2015; 1853(9):2025-32.

Meek CL, Lewis HB, Reimann F, Gribble FM, Park AJ. The effect of bariatric surgery on gastrointestinal and pancreatic peptide hormones. *Peptides*. 2016; 77:28-37.

Melis M, Aragoni MC, Arca M, Cabras T, Caltagirone C, Castagnola M, Crnjar R, Messana I, Tepper BJ, Barbarossa IT. Marked increase in PROP taste responsiveness following oral supplementation with selected salivary proteins or their related free amino acids. *PLoS One*. 2013; 8(3):e59810. doi: 10.1371/journal.pone.0059810.

Mese H, Matsuo R. Salivary secretion, taste and hyposalivation. *J Oral Rehabil*. 2007; 34(10):711-23.

Molin Netto BD, Earthman CP, Farias G, Landi Masquio DC, Grotti Clemente AP, Peixoto P, Bettini SC, von Der Heyde ME, Dâmaso AR. Eating patterns and food choice as determinant of weight loss and improvement of metabolic profile after RYGB. *Nutrition*. 2017; 33:125-31.

Morris-Wiman J, Sego R, Brinkley L, Dolce C. The effects of sialoadenectomy and exogenous EGF on taste bud morphology and maintenance. *Chem Senses*. 2000; 25(1):9-19.

Morzel M, Chabanet C, Schwartz C, Lucchi G, Ducoroy P, Nicklaus S. Salivary protein profiles are linked to bitter taste acceptance in infants. *Eur J Pediatr*. 2014; 173(5):575-82.

Mounayar R, Morzel M, Brignot H, Tremblay-Franco M, Canlet C, Lucchi G, Ducoroy P, Feron G, Neyraud E. Salivary markers of taste sensitivity to oleic acid: a combined proteomics and metabolomics approach. *Metabolomics*. 2013; 10(4):688-96.

Mounayar R, Morzel M, Brignot H, Tremblay-Franco M, Canlet C, Lucchi G, Ducoroy P, Feron G, Neyraud E. Nutri-metabolomics applied to taste perception phenotype: human subjects with high and low sensitivity to taste of fat differ in salivary response to oleic acid. *OMICS*. 2014; 18(11):666-72.

Naik R, Ahmed Mujib BR, Raaju UR, Telagi N. Assesing oral candidal carriage with mixed salivary glucose levels as non-invasive diagnostic tool in type-2 Diabetics of Davangere, Karnataka, India. *J Clin Diagn Res*. 2014; 8(7):ZC69-72.

Neyraud E, Palicki O, Schwartz C, Nicklaus S, Feron G. Variability of human saliva composition: Possible relationships with fat perception and liking. *Arch Oral Biol*. 2012; 57(5):556-66.

Neyraud E, Sayd T, Morzel M, Dransfield E. Proteomic analysis of human whole and parotid salivas following stimulation by different tastes. *J Proteome Res*. 2006; 5(9):2474-80.

Nieman DC, Henson DA, Dumke CL, Lind RH, Shooter LR, Gross SJ. Relationship between salivary IgA secretion and upper respiratory tract infection following a 160-km race. *J Sports Med Phys Fitness.* 2006; 46(1):158-62.

Padiglia A, Zonza A, Atzori E, Chillotti C, Calò C, Tepper BJ, Barbarossa IT. Sensitivity to 6-n-propylthiouracil is associated with gustin (carbonic anhydrase VI) gene polymorphism, salivary zinc, and body mass index in humans. *Am J Clin Nutr.* 2010; 92(3):539-45.

Palouzier-Paulignan B, Lacroix MC, Aimé P, Baly C, Caillol M, Congar P, Julliard AK, Tucker K, Fadool DA. Olfaction under metabolic influences. *Chem Senses.* 2012; 37(9):769-97.

Pedersen AM, Bardow A, Jensen SB, Nauntofte B. Saliva and gastrointestinal functions of taste, mastication, swallowing and digestion. *Oral Dis.* 2002; 8(3):117-29.

Pepino MY, Bradley D, Eagon JC, Sullivan S, Abumrad NA, Klein S. Changes in taste perception and eating behavior after bariatric surgery-induced weight loss in women. *Obesity (Silver Spring, Md).* 2014; 22(5):E13-20.

Perry B, Wang Y. Appetite regulation and weight control: the role of gut hormones. *Nutr Diabetes*. 2012; 2:e26. doi: 10.1038/nutd.2011.21.

Peterli R, Steinert RE, Woelnerhanssen B, Peters T, Christoffel-Courtin C, Gass M, Kern B, von Fluee M, Beglinger C. Metabolic and hormonal changes after laparoscopic Roux-en-Y gastric bypass and sleeve gastrectomy: a randomized, prospective trial. *Obes Surg.* 2012; 22(5):740-8.

Piombino P, Genovese A, Esposito S, Moio L, Cutolo PP, Chambery A, Severino V, Moneta E, Smith DP, Owens SM, Gilbert JA, Ercolini D. Saliva from obese individuals suppresses the release of aroma compounds from wine. *PLoS One.* 2014; 9(1):e85611. doi: 10.1371/journal.pone.0085611.

Pionnier E, Chabanet C, Mioche L, Le Quéré J-L, Salles C. 1. In vivo aroma release during eating of a model cheese: relationships with oral parameters. *J Agric Food Chem*. 2004; 52(3):557-64.

Plailly J, Luangraj N, Nicklaus S, Issanchou S, Royet J-P, Sulmont-Rossé C. Alliesthesia is greater for odors of fatty foods than of non-fat foods. *Appetite.* 2011; 57(3):615-22.

Prandi S, Bromke M, Hübner S, Voigt A, Boehm U, Meyerhof W, Behrens M. A subset of mouse colonic goblet cells expresses the bitter taste receptor Tas2r131. *PLoS One.* 2013; 8(12):e82820. doi: 10.1371/ journal.pone.0082820.

Proctor GB. The physiology of salivary secretion. *Periodontol* 2000. 2016; 70(1):11-25.

Psoter WJ, Reid BC, Katza RV. Malnutrition and dental caries: A review of the literature. *Caries Res.* 2005; 39(6): 441-7.

Quercia I, Dutia R, Kotler DP, Belsley S, Laferrère B. Gastrointestinal changes after bariatric surgery. *Diabetes Metab.* 2014; 40(2):87-94.

Richardson BE, Vanderwoude EA, Sudan R, Leopold DA, Thompson JS. Gastric bypass does not influence olfactory function in obese patients. *Obes Surg*. 2012; 22(2):283-6.

Rodrigues L, Mouta R, Costa AR, Pereira A, Capela e Silva F, Amado F, Antunes CM, Lamy E. Effects of high fat diet on salivary α-amylase, serum parameters and food consumption in rats. *Arch Oral Biol.* 2015; 60(6):854-62.

Roper SD. Signal transduction and information processing in mammalian taste buds. *Pflugers Arch.* 2007; 454(5):759-76.

Rozengurt E, Sternini C. Taste receptor signaling in the mammalian gut. *Curr Opin Pharmacol.* 2007; 7(6):557-62.

Rui L. Brain regulation of energy balance and body weight. *Rev Endocr Metab Disord*. 2013; 14(4):387-407.

Sanematsu K, Horio N, Murata Y, Yoshida R, Ohkuri T, Shigemura N, Ninomiya Y. Modulation and transmission of sweet taste information for energy homeostasis. *Ann N Y Acad Sci.* 2009; 1170:102-6.

Sarson DL, Scopinaro N, Bloom SR. Gut hormone changes after jejunoileal (JIB) or biliopancreatic (BPB) bypass surgery for morbid obesity. *Int J Obes*. 1981; 5(5):471-80.

Schipper RG, Silletti E, Vingerhoeds MH. Saliva as research material: biochemical, physicochemical and practical aspects. *Arch Oral Biol*. 2007; 52(12):1114-35.

Schmale H, Holtgreve-Grez H, Christiansen H. Possible role for salivary gland protein in taste reception indicated by homology to lipophilic-ligand carrier proteins. *Nature.* 1990; 343(6256):366-9.

Scruggs D, Buffington C, Cowan G. Taste acuity of the morbidly obese before and after gastric bypass surgery. *Obes Surg.* 1994; 4(1):24-8.

Shak JR, Roper J, Perez-Perez GI, Tseng CH, Francois F, Gamagaris Z, Patterson C, Weinshel E, Fielding GA, Ren C, Blaser MJ. The effect of laparoscopic gastric banding surgery on plasma levels of appetite-control, insulinotropic, and digestive hormones. *Obes Surg*. 2008; 18(9):1089-96.

Shatzman AR, Henkin RI. Gustin concentration changes relative to salivary zinc and taste in humans. *Proc Natl Acad Sci USA*. 1981; 78(6):3867-71.

Shigemura N, Ohta R, Kusakabe Y, Miura H, Hino A, Koyano K, Nakashima K, Ninomiya Y. Leptin modulates behavioral responses to sweet substances by influencing peripheral taste structures. *Endocrinology.* 2004; 145(2):839-47.

Shin YK, Martin B, Kim W, White CM, Ji S, Sun Y, Smith RG, Sévigny J, Tschöp MH, Maudsley S, Egan JM. Ghrelin is produced in taste cells and ghrelin receptor null mice show reduced taste responsivity to salty (NaCl) and sour (Citric Acid) tastants. *PLoS One.* 2010; 5(9):e12729. doi: 10.1371/journal.pone.0012729.

Simons PJ, Kummer JA, Luiken JJ, Boon L. Apical CD36 immunolocalization in human and porcine taste buds from circumvallate and foliate papillae. *Acta Histochem*. 2011; 113(8):839-43.

Singh Mamta, Udita S, Bhasin GK, Rajesh P, Aggarwal SK. Oral fluid: Biochemical composition and functions: A review. *J Pharm Biomed Sci*. 2013; 37(37):1932-41.

Sista F, Abruzzese V, Clementi M, Carandina S, Amicucci G. Effect of resected gastric volume on ghrelin and GLP-1 plasma levels: a prospective study. *J Gastrointest Surg*. 2016; 20(12):1931-41.

Sjöström CD, Lissner L, Wedel H, Sjöström L. Reduction in incidence of diabetes, hypertension and lipid disturbances after intentional weight loss induced by bariatric surgery: the SOS Intervention Study. *Obes Res.* 1999; 7(5):477-84.

Soares S, Mateus N, de Freitas V. Interaction of different classes of salivary proteins with food tannins. *Food Res Int.* 2012; 49(2):807-13.

Soares S, Vitorino R, Osório H, Fernandes A, Venâncio A, Mateus N, Amado F, de Freitas V. Reactivity of human salivary proteins families toward food polyphenols. *J Agric Food Chem*. 2011; 59(10):5535-47.

Spence C. Multisensory flavor perception. *Cell.* 2015a; 161(1):24-35.

Spence C. Just how much of what we taste derives from the sense of smell? *Flavour*. 2015b; 4(1):30. doi: 10.1186/s13411-015-0040-2.

Sundbom M, Holdstock C, Engström BE, Karlsson FA. Early changes in ghrelin following Roux-en-Y gastric bypass: influence of vagal nerve functionality? *Obes Surg*. 2007; 17(3):304-10.

Tichansky DS, Boughter JD, Madan AK. Taste change after laparoscopic Roux-en-Y gastric bypass and laparoscopic adjustable gastric banding. *Surg Obes Relat Dis*. 2006; 2(4):440-4.

Tordoff MG, Alarcón LK, Valmeki S, Jiang P. T1R3: a human calcium taste receptor. *Sci Rep*. 2012; 2:496. doi: 10.1038/srep00496.

Tresserra-Rimbau A, Medina-Remón A, Pérez-Jiménez J, Martínez-González MA, Covas MI, Corella D, Salas-Salvadó J, Gómez-Gracia E, Lapetra J, Arós F, Fiol M, Ros E, Serra-Majem L, Pintó X, Muñoz MA, Saez GT, Ruiz-Gutiérrez V, Warnberg J, Estruch R, Lamuela-Raventós RM. Dietary intake and major food sources of polyphenols in a Spanish population at high cardiovascular risk: the PREDIMED study. *Nutr Metab Cardiovasc Dis*. 2013; 23(10):953-9.

Ullrich J, Ernst B, Wilms B, Thurnheer M, Schultes B. Roux-en Y gastric bypass surgery reduces hedonic hunger and improves dietary habits in severely obese subjects. *Obes Surg*. 2013; 23(1):50-5.

Usinger L, Hansen KB, Kristiansen VB, Larsen S, Holst JJ, Knop FK. Gastric emptying of orally administered glucose solutions and incretin hormone responses are unaffected by laparoscopic adjustable gastric banding. *Obes Surg*. 2011; 21(5):625-32.

Uzzan B, Catheline JM, Lagorce C, Airinei G, Bon C, Cohen R, Perret GY, Aparicio T, Benamouzig R. Expression of ghrelin in fundus is increased after gastric banding in morbidly obese patients. *Obes Surg*. 2007; 17(9):1159-64.

Valladares Vega M, Obregon Rivas AM. Association of olfactory sensitivity with energy intake: role in development of obesity. *Nutr Hosp*. 2015; 32(6):2385-9.

Vetter ML, Cardillo S, Rickels MR, Iqbal N. Narrative review: effect of bariatric surgery on type 2 diabetes mellitus. *Ann Intern Med*. 2009; 150(2):94-103.

Vors C, Drai J, Gabert L, Pineau G, Laville M, Vidal H, Guichard E, Michalski MC, Feron G. Salivary composition in obese vs normal-weight subjects: towards a role in postprandial lipid metabolism? *Int J Obes* (Lond). 2015; 39(9):1425-8.

Wang R, van Keeken NM, Siddiqui S, Dijksman LM, Maudsley S, Derval D, van Dam PS, Martin B. Higher TNF-α, IGF-1, and leptin levels are found in tasters than non-tasters. *Front Endocrinol* (Lausanne). 2014; 5:125. doi: 10.3389/fendo.2014.00125.

Waszkiewicz N, Zalewska A, Szajda SD, Szulc A, Kępka A, Minarowska A, Wojewódzka-Żelezniakowicz M, Konarzewska B, Chojnowska S, Supronowicz ZB, Ladny JR, Zwierz K. The effect of chronic alcohol intoxication and smoking on the activity of oral peroxidase. *Folia Histochem Cytobiol*. 2012a; 50(3):450-5.

Waszkiewicz N, Zalewska-Szajda B, Zalewska A, Waszkiewicz M, Szajda SD, Repka B, Szulc A, Kepka A, Minarowska A, Ladny JR, Zwierz K. Salivary lysozyme in smoking alcohol dependent persons. *Folia Histochem Cytobiol*. 2012b; 50(4):609-12.

Waszkiewicz N, Zalewska-Szajda B, Zalewska A, Waszkiewicz M, Szajda SD, Repka B, Szulc A, Kępka A, Minarowska A, Chojnowska S, Konarzewska B, Ładny JR, Kowzan U, Zwierz K. Decrease in salivary lactoferrin output in chronically intoxicated alcohol-dependent patients. *Folia Histochem Cytobiol*. 2012c; 50(2):248-54.

Williamson MP. The structure and function of proline-rich regions in proteins. *Biochem J*. 1994; 297 (Pt 2):249-60.

Wilson-Perez HE, Chambers AP, Sandoval DA, Stefater MA, Woods SC, Benoit SC, Seeley RJ. The effect of vertical sleeve gastrectomy on food choice in rats. *Int J Obes* (Lond). 2013; 37(2):288-95.

Witt M, Reutter K. Anatomy of the Tongue and Taste Buds. In Doty RL (Ed), *Handbook of Olfaction and Gustation*, Third Edition. John Wiley & Sons, Inc. 2015, p.637-664.

Wolfe BM, Kvach E, Eckel RH. Treatment of obesity: weight loss and bariatric surgery. *Circ Res.* 2016; 118(11):1844-55.

Wu SV, Rozengurt N, Yang M, Young SH, Sinnett-Smith J, Rozengurt E. Expression of bitter taste receptors of the T2R family in the gastrointestinal tract and enteroendocrine STC-1 cells. *Proc Natl Acad Sci*. 2002; 99(4):2392-7.

Yan Q, Bennick A. Identification of histatins as tannin-binding proteins in human saliva. *Biochem J*. 1995; 311(Pt 1):341-7.

Yoshida R, Niki M, Jyotaki M, Sanematsu K, Shigemura N, Ninomiya Y. Modulation of sweet responses of taste receptor cells. *Semin Cell Dev Biol.* 2013; 24(3):226-31.

Yoshida R, Noguchi K, Shigemura N, Jyotaki M, Takahashi I, Margolskee RF, Ninomiya Y. Leptin suppresses mouse taste cell responses to sweet compounds. *Diabetes.* 2015; 64(11):3751-62.

Zerrweck C, Zurita L, Álvarez G, Maydón HG, Sepúlveda EM, Campos F, Caviedes A, Guilbert L. Taste and olfactory changes following laparoscopic gastric bypass and sleeve gastrectomy. *Obes Surg*. 2016; 26(6):1296-302.

Zhang A, Sun H, Wang P, Wang X. Salivary proteomics in biomedical research. *Clin Chim Acta*. 2013; 415:261-5.

In: Encyclopedia of Surgery (22 Volume Set)
Editors: Andreas Lehrer and Kristin Mueller
ISBN: 978-1-53618-329-0
© 2020 Nova Science Publishers, Inc.

Chapter 439

INTEGRATIVE VIRTUAL REALITY THERAPY PRODUCES LASTING BENEFITS FOR A YOUNG WOMAN SUFFERING FROM CHRONIC PAIN AND DEPRESSION POST CANCER SURGERY: A CASE STUDY

Gregory House[1], PhD, Grigore C. Burdea[1,*], PhD,
Namrata Grampurohit[1], PhD, Kevin Polistico[1],
Doru Roll[1], Frank Damiani[2], MD,
Jasdeep Hundal[3], PsyD and Didier Demesmin[4], MD

[1]Bright Cloud International Corp,
Highland Park, NJ, US
[2]Roosevelt Care Center, Edison, NJ, US
[3]Hundal Neuropsychology Group, Watchung, NJ, US
[4]University Pain Medicine Center, Summerset, NJ, US

ABSTRACT

In this chapter we present a case study, which was part of an evaluation of the BrightArm Duo Rehabilitation System for treating the effects of chronic upper body pain following breast cancer surgery. The subject was a 22-year old woman with burning and stabbing pain in the right upper arm. Training consisted of playing custom bimanual 3D games while seated at a gravity-modulating robotic table. The therapy consisted of 16 sessions over eight weeks. Standardized assessments demonstrated a meaningful improvement in the motor, cognitive and emotive domains with a statistically significant reduction in pain. Gains transferred to daily activities enabling the subject to resume full time employment, driving and socializing.

[*] Corresponding Author's Email: president@brightcloudint.com.

INTRODUCTION

The psychological, social and behavioral impact of cancer at a young age can be tremendous (1). As the number of young cancer survivors increases, their quality of life after cancer treatment becomes an important concern (2). With improved detection and progress in management of breast cancer (3), the survivors need improved rehabilitation approaches to address and overcome the resulting complications from that treatment. Depression and chronic pain in shoulder and arm following breast cancer surgery are prevalent and can lead to life-long psychological, cognitive and physical impairments. It is important to have rehabilitation techniques that can produce long lasting benefits for women, while being gradated in difficulty, interactive and fun.

Virtual reality (VR) offers benefits for other diagnostic conditions and provides a new and unique opportunity in the rehabilitation of women with breast cancer. VR analgesia, pioneered by Hoffman (4) for burn wound care, has subsequently been used to reduce chemotherapy-related distress in women with breast cancer (5). Virtual reality has great potential for use in acute and chronic pain by providing a non-opioid 'virtual analgesic' response (6). Virtual reality therapy has been tried in breast cancer to alleviate symptoms during chemotherapy (5). However, to the authors' knowledge no clinical trials have been conducted to study VR effectiveness in breast cancer survivors with chronic upper body pain and related depression.

The BrightArm Duo Rehabilitation System (Bright Cloud International, New Jersey, USA) is an experimental robotic platform that modulates gravity loading on the upper extremities (UEs). The ability to unload gravity makes it appropriate for individuals with weak arms and diminished ability to grasp, such as those suffering from chronic UE pain. BrightArm Duo uses VR to engage the patient in upper body bimanual integrative exercises that provide motor and cognitive training and affective relief. This integrative virtual rehabilitation has been found to be beneficial in prior BrightArm Duo studies of elderly individuals with chronic stroke residing in skilled nursing facilities (7). These earlier studies have shown benefits to cognition and depression reduction, which in theory could benefit breast cancer survivors with the same type of impairments. Thus, a feasibility study was conducted (N=6) to explore the feasibility of BrightArm Duo Rehabilitation System for the treatment of chronic pain in breast cancer survivor post-surgery, and who also have depression and cognitive deficits. The case described here was the youngest subject participating in that study.

OUR STUDY

The BrightArm Duo Rehabilitation System consisted of a robotic rehabilitation table, two computerized forearm supports, a 27" monitor, a laptop computer for the therapist, a remote clinical server and a library of custom integrative rehabilitation games. The library of custom games was developed in Unity 3D (8) for uni-manual and bi-manual motor (shoulder, elbow, grasp), emotive (depression) and cognitive (executive function, focusing, short-term and delayed memory, working memory and task sequencing) training. The subject interacted with these serious games through active arm movement and power grasp, both being tracked in

real time. The forearms of the subject were placed onto low-friction supports outfitted with two 770 nm LED towers and a rubber pear bulb connected to an internal differential pressure sensor. The hand position was determined with better than 0.5 mm accuracy. Subject's grasp strength of the rubber pear was measured by the pressure sensor and communicated wirelessly to the laptop station at a data rate better than 40 packets per second. Each session, the system automatically adapted to the subject's forearm movement and grasp capabilities. Game difficulty, session duration, gravity unloading/loading (gravity assistance/resistance during training) on her upper extremity, were all gradated over the length of the training (7). Tilting upwards provided resistance when moving away from the trunk. Conversely, tilting downwards assisted weak arm movement.

Figure 1. BrightArm Duo Table tilted upwards with two arm supports for user interaction and therapist laptop rendering Pick & Place game to the 27" monitor. © Bright Cloud International Corp. Reprinted by permission.

Figure 2 shows the screen images of the nine games used in the study. In *Breakout 3D*, the subject bounced a virtual ball toward an array of crates using paddle avatars. The game trained shoulder abduction/adduction or flexion/extension depending on the orientation of the crates, as well as focusing and executive function. The matching card games *Card Island* and *Remember that Card* trained short-term and delayed visual and auditory memory, grasp strength, shoulder abduction/adduction, and shoulder flexion/extension. For *Musical Drums*, the subject controlled drum stick avatars to strike a series of notes that drifted across (up to four) drums. This game trained focusing and motor control. The *Xylophone* game trained short-term auditory and visual memory by having the subject repeat a sequence of musical notes using mallet avatars. In *Pick & Place*, the subject grasped a ball from among multiple choices and then moved it to a fixed target of matching color, using shoulder flexion/extension or abduction/adduction arm movements. The game trained working memory and motor control as subject was asked to follow an ideal straight line to the target. Playing *Arm Slalom* induced shoulder rotations in order to guide a skier avatar through a

downhill slalom course. In the *Avalanche* game, the subject controlled pickaxe and shovel avatars through grasp and arm movements. The task was to break and clear a series of ice walls so to free people trapped in a cottage. In *Treasure Hunt*, the subject used one or two shovel avatars to clear sand and uncover a series of buried treasures, before they were buried again by periodic sand storms.

Figure 2. Nine game screen images: a) Breakout 3D; b) Card Island; c) Remember that Card; d) Musical Drums; e) Xylophone; f) Pick & Place; g) Arm Slalom; h) Avalanche; i) Treasure Hunt. © Bright Cloud International Corp. Reprinted by permission.

Training Protocol

The feasibility study followed a single subject A1-B1-A2-A3 design with training (B1) consisting of a total of 16 sessions, two sessions per week for 8 weeks. Standardized assessments of motor, cognitive and emotive state were performed pre-training (A1), post-training (A2) and at 8-week follow-up (A3). The training sessions progressed from 20 minutes to 50 minutes in duration, and the BrightArm Duo robotic table was tilted upwards progressively from a minimum of 0° (horizontal) at the start of the protocol to a maximum of 20° in the last training sessions. This corresponded to gravity unloading at the beginning of the therapy then progressively increased gravity loading as the subjects trained in later sessions. The Western Institutional Review Board, an independent board overseeing research involving human subjects, reviewed and approved the study protocol in accordance with Federal Guidelines. The subject was recruited at the University Pain Medicine Center (Somerset, NJ) and training took place at Roosevelt Care Center, a clinical facility in Edison, NJ in summer 2015. The subject received a $25 monetary compensation for each session attended however to the authors' knowledge this was not her primary reason for participation. The subject was genuinely interested in this experimental therapy to help manage her upper body pain symptoms.

CASE STORY

The subject was a 22-year old single woman of a mixed race, African American and White, with post-surgical chronic pain for the preceding 9 years. This chronic pain was localized to right upper arm and was burning, throbbing and stabbing in nature. She occasionally also reported pain in lower back, upper back, breast, hip and neck which was described as nagging. The subject reported that moving made her pain worse and nothing made it better. She had severe depression, difficulty socializing and had one suicidal attempt. As a consequence of her pain she kept her right arm in a sling which resulted in employment difficulties. She worked as a certified nursing assistant in home health care with hourly work that she would have to cancel many times due to pain. She was recruited from the University Pain Medicine Center where she followed up routinely with a pain medicine physician with a reported pain level of 6 to 8 on Numerical Pain Rating Scale (9) and not undergoing any physical or occupational therapy at the time of her enrollment in the experimental study. The surgical procedure on her breast reported when she was 13 years old did not have any medical records for verification of diagnosis. She underwent lumpectomy of her right breast again in 2008 and cyst removal from left breast in 2007. She reported taking Tromodol 50 mg and Percocet 10 mg at pre-training. She had tried multiple therapies in the past as indicated in her clinical notes. These ranged from pain medications, to physical therapy twice a week for 10 weeks from January to April 2014, to home exercises.

Data Collection Instruments

Therapy session data (B1) included supported arm reach baseline on the BrightArm Duo table (as measured by overhead digital cameras used in tracking), power grasp strength baseline (as measured by a forearm support grasp sensor), heart rate and blood pressure. In addition B1 data included the number of active movements and grasp repetitions for each arm during a session, as well as game performance data (score, errors, completion time) collected during play. Pain was assessed using the Numeric Pain Rating Scale (NRS) administered verbally by the attending OT. This pain measure has validity in measuring cancer-related pain intensity (9). Skin temperature was measured during the sessions with basis wristwatch that was worn on the subject's unaffected arm. Blood pressure and pulse were measured before and after each session using Omron 7 Series upper arm blood pressure monitor.

Occupational therapy evaluations were done pre-training, post-training and at eight week follow-up by a blinded Senior Occupational Therapist (OT) consultant who was not training the subject. This OT evaluation involved assessment of upper extremity function using the Fulg-Meyer Assessment - Upper Extremity Section (FMA)(10), the Chedokee Arm and Hand Inventory – 9 (CAHAI-9)(11) for bimanual tasks and the Jebsen Hand Function Test (JHFT)(12) for hand function. Arm and hand range of motion were measured using mechanical goniometers, shoulder strength was assessed using wrist weights, grasp strength was measured with a Jamar mechanical dynamometer and a Jamar pinch meter. In addition the subject was assessed for her degree of independence in activities of daily living (ADL) involving the upper extremity, using the Upper Extremity Functional Index 20 (UEFI-20) (13).

Neuropsychological evaluations were done by a blinded research assistant under the supervision of a licensed clinical neuropsychologist pre-training, post-training and at follow-up. These were measures of depression severity, attention/concentration, processing speed, learning, memory, and executive function. The standardized measures used were the Beck Depression Inventory, Second Edition (BDI-II),(14) the Neuropsychological Assessment Battery Executive Functioning Module (Generation subtest) (15), the Hopkins Verbal Learning Test, Revised (HVLT-R) (16), the Brief Visuospatial Memory Test, Revised (BVMT-R) (17), the Trail Making Test A and B (TMT) (18). Alternate test forms were used whenever possible to minimize test-taking practice effects. Raw scores were utilized in all data analysis. Both evaluating clinicians were blinded to the therapy methodology and scope.

At the end of weeks 4 and 8 of VR training, the subject rated her experience on a custom paper-based subjective evaluation questionnaire with ten questions. The questions were: 1) "The system was easy to use?"; 2) "Playing games with my affected arm(s) was easy?"; 3) "I had no pain or discomfort in my upper body?"; 4)"Instructions given to me were useful?"; 5) "Playing games with both arms was easy?"; 6) "I was not bored while exercising?"; 7) "The length of the exercising in a day was appropriate?"; 8) "There were few technical problems?"; 9) "I would encourage others to used it?"; 10) "I liked the system overall?" Each question was rated on a 5-point Likert scale, from 1 meaning "strongly disagree" (least desirable outcome) to 5 meaning "strongly agree" (most desirable one). The subject could add free form comments on the evaluation form.

FINDINGS

The subject exercised a total of 20,130 active arm repetitions and 7,020 hand grasps. The BrightArm Duo tilt was gradually increased over the study span, from 0° initially to 20° upwards at the end. Figure 3a show active arm repetitions increased from about 320 in session 1 to over 1,500 repetitions in session 16 with peak activity around session 5 and 11. Hand grasps increased from 45 in session 1 to 971 by session 16. The intensity of play increased with session number as well. If session length is normalized to maximum duration of 51.2 minutes, arm movement and hand grasps would increase along a slope of 878 ($p=0.18$) and 1,011 ($p<0.001$) repetitions between session 1 and 16. The subject played a total of 412 games over a total of 567 minutes. The exercising duration steadily increased from 21.2 minutes/session at the start to 51.2 minutes/session at the end. Both game difficulty and subject performance increased over the study. Figure 3b illustrates how composite games scores increased from 43 (session 1) to 65 (session 16). The linear regression fit of the data points yielded a statistically significant trend line ($p<0.001$) corresponding to a 22 point increase in average game score from about 47 points in session 1 to about 69 points in session 16.

Pain and Skin Temperature Outcomes

The subject's reported pain and skin temperature were captured every session. Figure 4a illustrates the reported maximum upper extremity pain on the 10 point Numerical Pain Rating

Scale by session number. As seen by the statistically significant trend line (p=0.01), there was marked reduction in reported pain of 4.4 points over the course of the study. The increase in reported pain towards the end of the experimental therapy coincided with the subject stopping taking her pain medication. Figure 4b plots the average skin temperature by session number as measured at the wrist of the subject's unaffected arm. The linear regression fit of the data points yielded a statistically significant trend line (p=0.001) corresponding to a 10.25°F increase in skin temperature over the 16 sessions. This is indicative of increased blood flow to the upper extremities in response to increased use of the affected arm.

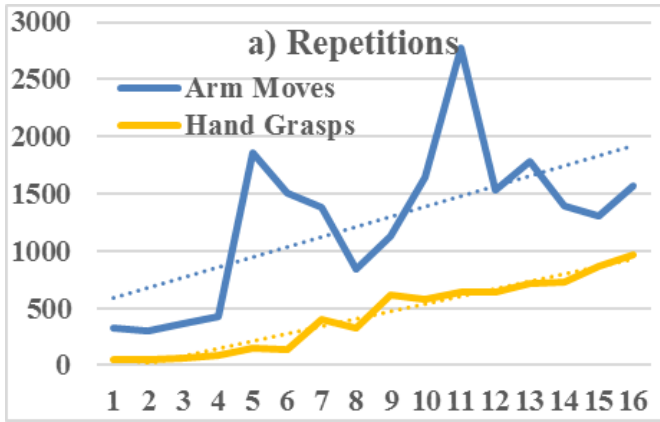

(a)

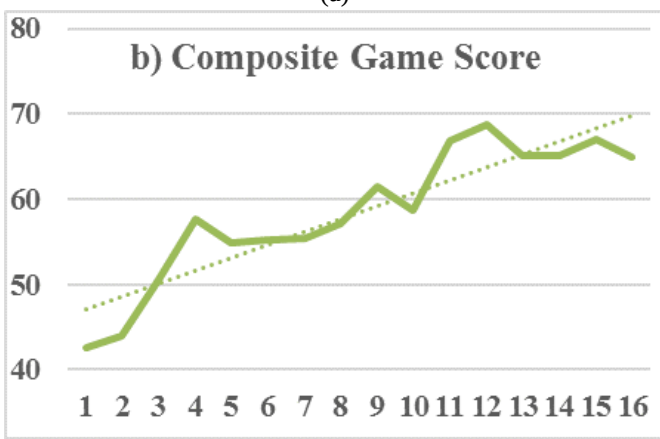

(b)

Figure 3. a) Arm and hand repetitions and b) composite game score by session number for the cancer survivor experiencing post-surgery chronic pain. © Bright Cloud International Corp. Reprinted by permission.

Upper Extremity Active Range of Motion

The subject's range of motion was evaluated for the affected and unaffected arms at pre-training (A1), post-training (A2) and follow-up (A3). The elbow and finger values were within normal limits. In Table 1, 10 of 12 range of motion measures improved at A2 and A3 relative to A1. The affected arm maintained substantial gains at A3: Abduction (111°),

Flexion (89°), Adduction (40°), External Rotation (31°), and Extension (19°). The unaffected arm improvements were more modest at A3: Flexion (16°), Abduction (10°), Extension (9°) with Internal Rotation moderately decreasing (20°). The minimal clinically important difference (MCID) is 8° for shoulder range of motion improvement (19).

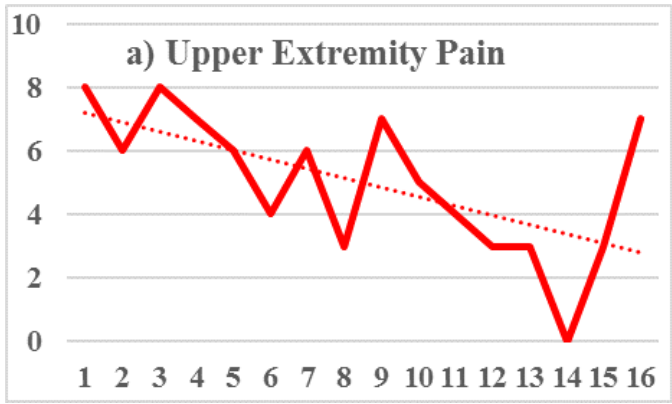

(a)

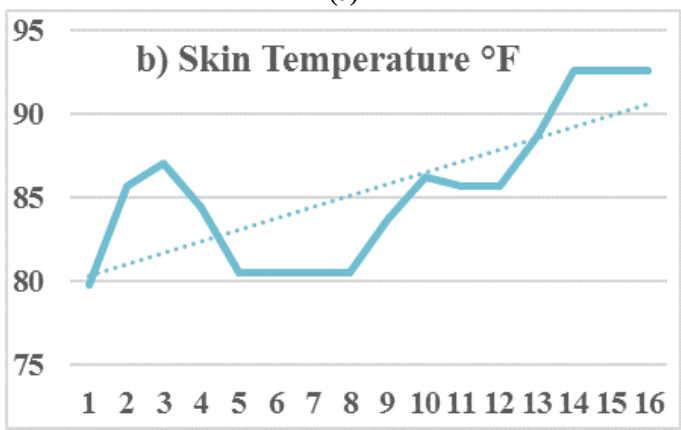

(b)

Figure 4. a) Maximum upper extremity pain and b) affected arm skin temperature by session for the cancer survivor experiencing post-surgery chronic pain. © Bright Cloud International Corp. Reprinted by permission.

Table 1. Shoulder range of motion (degrees) for the post-surgery cancer survivor experiencing chronic pain. © Bright Cloud International Corp. Reprinted by permission

	Affected Shoulder					Unaffected Shoulder				
Variable	A1	A2	A3	A2-A1	A3-A1	A1	A2	A3	A2-A1	A3-A1
Flexion	58	150	147	+ 92	+ 89	132	146	148	+ 14	+ 16
Extension	23	73	42	+ 50	+ 19	58	77	67	+ 19	+ 9
Abduction	27	157	138	+ 130	+ 111	140	148	150	+ 8	+ 10
Adduction	0	56	40	+ 56	+ 40	33	50	40	+ 17	+ 7
Internal rot.	38	55	40	+ 17	+ 2	70	68	50	– 2	– 20
External rot.	50	78	81	+ 28	+ 31	82	77	75	– 5	– 7

Upper Extremity Strength

Table 2 lists arm and hand strength for the affected and unaffected arms pre-training (A1), post-training (A2) and follow-up (A3). All ten strength measures improved or remained the same as compared to A1. At follow-up, the gains in grip strength compared to pre-training were 231.3 N and 97.9N for the affected and unaffected hands, respectively. These results are 200% to 400% the MCID of 49 N for hand grip (20). At follow-up, the affected and unaffected hand two-finger pinch improved 29.8 N and 20.0 N, respectively and the 3-jaw pinch improved 36.5N for both hands, compared to pre-training. The affected shoulder strength had an impressive gain from 4.4N at A1 to 31.1N at A3, a 700% increase. The unaffected shoulder strength improvement was from 31.1N to 44.5N represents a more modest 40% increase.

Table 2. Hand and arm strength for the post-surgery cancer survivor experiencing chronic pain. © Bright Cloud International Corp. Reprinted by permission

	Affected Shoulder					Unaffected Shoulder				
Variable	A1	A2	A3	A2-A1	A3-A1	A1	A2	A3	A2-A1	A3-A1
Hand Grip	68	262.4	299.4	+194.4	+231.3	115.7	218.0	213.5	+102.3	+97.9
Tip Pinch	0.0	31.1	29.8	+31.1	+29.8	11.1	23.6	31.1	+12.5	+20.0
3 Jaw Pinch	4.4	46.7	40.9	+42.3	+36.5	16.9	34.7	53.4	+17.8	+36.5
Ant. Deltoid	4.4	22.2	31.1	+17.8	+26.7	31.1	31.1	44.5	0.0	+13.3
Lat. Deltoid	4.4	22.2	31.1	+17.8	+26.7	31.1	31.1	44.5	0.0	+13.3

Upper Extremity Functional Assessments

Functional assessments also improved at post-training (A2) and follow-up (A3) relative to pre-training (A1). Fugl-Meyer Assessment scores were 47 (A1), 58 (A2) and 56 (A3). The 11 and 9 point improvement at A2 and A3 respectively meet the MCID criteria of 9 points (21). CAHAI-9 scores were 50 (A1), 63 (A2) and 63 (A3). The improvement of 13 points at A2 and A3 is twice the MCID of 6.3 points (22), and is indicative of improved ability to perform bimanual ADLs. The metric UEFI-20 measurements were 18 (A1), 58 (A2) and 42 (A3). The improvement of 40 and 24 points at A2 and A3 were three to five times the MCID of 8 points (13). The JHFT for the affected hand was 79 (A1), 35 (A2) and 39 (A3) seconds. The subject was able to complete the manual tasks of JHFT in half the time post-training, and the speed improvement was maintained at follow-up.

Cognitive and Emotive Outcomes

Table 3 lists emotive and cognitive measures evaluated pre-training, post-training and follow-up. There was a notable reduction in depression severity of 16 points (A2) and 6 points (A3). Both values were above MCID of 5 points for BDI-II (23). The Trail Making Test Part B showed a reduction in time from 128 seconds at A1 to 49 seconds at A3. This was indicative of improved attention and processing speed. HVLT-R which measures verbal

learning and memory was one cognitive measure that showed a systematic decline from 22 points at A1, to 20 points at A2, and 16 points at A3. This was offset by an increase in word generation from 5 at A1, to 6 at A2 and 9 at A3. There was a systematic increase BVMT-R, from 13 points at A1, to 18 points at A2 and 20 points at A3, indicative of improved visuo-spatial memory.

Table 3. Emotive and cognitive outcomes for the post-surgery cancer survivor experiencing chronic pain. *indicates sign reversed so all positive differences in table indicates improvement. © Bright Cloud International Corp. Reprinted by permission

Variable	A1	A2	A3	A2-A1	A3-A1	Variable	A1	A2	A3	A2-A1	A3-A1
BDI-II	37	21	31	*+ 16	* + 6	HVLT-R	22	20	16	– 2	– 6
TMT-A	20	22	22	* – 2	* – 2	BVMT-R	13	18	20	+ 5	+ 7
TMT-B	128	66	49	* + 62	* +79	Word Gen	5	6	9	+ 1	+ 4

Subject Attendance and Testimonial

The subject completed the 16 sessions of the protocol over a period of nine weeks. She postponed two sessions early on due to back pain related to work and unrelated to BrightArm training. She reported no side-effects from the VR therapy such as cyber sickness or headache. The subject evaluated the system by answering the ten questions. The average response was 3.6/5 at the two sampling times (week 4 and week 8). The lowest scores were for the questions: “I had no pain or discomfort in my upper body?” (1.5), “Playing games with my affected arm(s) was easy?” (2.0), “I would encourage others to used it?” (3.0), “The length of the exercising in a day was appropriate?” (3.5). The responses averaged a rating of 4 between week 4 and 8 for the questions: “The system was easy to use, “Playing games with both arms was easy?,” “There were few technical problems?,” “Instructions given to me were useful?.” The highest evaluation score was 5.0/5 for the questions: “I was not bored while exercising?” and “I liked the system overall?” which shows excellent technology acceptance of the BrightArm Duo.

At follow-up (A3) the subject was asked if she would provide a testimonial. In compliance to IRB Human Subject’s Regulations her identity is not disclosed, although she included her name in the email sent in late May 2015. This email is included here with subject’s approval, as it provides her opinion on the impact that the experimental therapy had on her life.

> “*I've just completed my 8 weeks of physical therapy. This therapy section helped me tremendously. Before I started this therapy my right arm had no use me and there was so much pain! There were things I couldn't do like driving, getting dressed, taking a shower, playing with my nephew....I was working on and off, I couldn't hang out with my friends, my life basically stopped, and it was very depressing. But now I'm driving, I'm back working full time, I'm catching up with friends AND there's no pain. I'm extremely happy with the results, this is my third time trying therapy for my arm and this the only one I saw results from. The therapy sessions consist of games....yes you are literally sitting in a chair in front of a computer playing games, though they were challenging it was also very fun, well for me it was. Dr. Burdea and his team gave me back my life because I*

thought it was over literally. I recommend everyone that's having this problem to try this therapy session, it works tremendously and it is fun (did I mention it's actually games you play on a computer) yes and everyone is very friendly. So thank you Bright Cloud International."

The subject was referring to BrightArm Duo in the physical therapy reported in this testimonial. She has compared VR games to the traditional physical therapy she had undergone in the past which did not work for her. The immersive games induced bilateral high repetitions and engaged the participant with rewarding feedback for effort. These features made the rehabilitation training with BrightArm Duo distinctly different from her prior traditional therapy.

DISCUSSION

Childhood cancer survivors have an increased risk of complications later in life and rehabilitation with better outcomes will greatly improve the quality of life in these women (24). In this study, the 22-year old female subject showed marked reduction in shoulder and arm pain of 4.4 points on the NRS scale which is much higher than the MCID of 2.17 for NRS established for people with surgical and post-surgical shoulder pain (25). This is an encouraging finding considering the impact of VR therapy on chronic pain in other conditions such as fibromyalgia has shown no benefits for pain intensity (26). However, the benefits of VR therapy in cancer related pain during acute painful procedures, hospitalization and chemotherapy has been studied and shown to be beneficial (27). Visual distraction has been one of the theories put forth for explaining these beneficial effects on pain (6). Although, in this study, the positive effect on pain intensity cannot be completely attributed to the phenomenon of visual distraction. As reported in literature (28), the distraction from pain could be insufficient to cause the accompanied improvements on motor and cognitive aspects of function measured at post-training and maintained at 8-week follow up. It is also likely that the 16-session protocol used in this study resulted in better outcomes than the 10-session protocol reported in other studies of VR in chronic pain of fibromyalgia (29).

Garcia-Palacios et al. (26) reported no benefit of VR therapy on depression in people with chronic pain due to fibromyalgia, whereas in this study, the depression scores decreased by 16 points on the BDI-II, which is a 32% improvement. The MCID for depression varies with initial severity (30) and has been estimated to be 32% for individuals with prolonged depression which fits the profile of the subject in this study. A recent review by Chirico et al. (27) summarizes the benefit of VR therapy in cancer on psychological variables such as state anxiety and painful procedures, the results of the present case study open the possibility to understand the impact of VR therapy in other variables such as depression. They also recommend including bio physiological variables in VR therapy research in cancer using biosensors for understanding physiological responses to the training. In this study, biosensors at the wrist of the unaffected arm showed a 10.25°F increase in skin temperature with the over the course of the 16 sessions conducted in the same indoor therapy room. This interesting finding is indicative of an increased thermal response during exercise that is likely during moderate to high intensity exercise (31) and was associated with improved outcomes

in the subject. This may indicate increased blood flow to the arm with a beneficial effect for overall health of the arm (32).

An average of 1,260 active arm repetitions and 440 hand grasps per session for the subject over the course of 16 sessions is an important characteristic of the BrightArm Duo therapy. This large number of induced arm repetitions has previously been reported (7) to benefit elderly stroke survivors in the chronic phase. The substantial benefits of this intensive therapy are indicative of application for chronic cancer pain populations as well. All standardized measures in this case study of range of motion, strength, UE function, attention, and memory improved at post-training. With the NRS pain level of 6 and 7 pre-training, the subject was unable to move her right arm and post training the regained range of motion in the arm along with simultaneous distraction from pain has shown to be the right combination of therapy for her. As seen from her own testimonial, the subject was able to transition to a full time job and returned to driving giving her maximal functional independence much desired at her young age.

A remarkable finding in this case study was that at 8-week follow up (A3) the majority of gains remained higher than A1, with no VR training for eight weeks (after A2). The subject did not report playing any form of videogames during the no-VR phase and enjoyed reading and socializing for recreation. The maintenance effect with VR therapy has been shown in prior studies in 48 hour follow-up (5), however, to the authors' knowledge, a 8-week follow up has not been reported previously. The study of VR maintenance effect for rehabilitation therapy programs is as critical for chronic pain conditions as it is for rehabilitation of conditions such as stroke. This case study is supportive of the feasibility of a longitudinal study protocol to study these maintenance effects of VR therapy in chronic pain and depression.

This study, part of an n=6 feasibility evaluation of the BrightArm Duo system for upper body chronic pain, has obvious limitations to generalizability. However, the information detailed in this case study brings forth the qualitative aspects associated with BrightArm Duo training especially in younger individuals and helps examine the feasibility of the VR therapy in this sample of cancer survivors. The therapists can benefit from an in-depth study of successful cases using BrightArm Duo system in rehabilitation to maximize benefits for their clients. In conclusion, initial findings demonstrate a meaningful reduction in chronic pain and physical, cognitive and psychological improvement for a young female subject. These outcomes suggest a need for controlled studies in young subjects with pain and depression associated to post-surgical treatment of breast cancer.

ACKNOWLEDGMENTS

Research reported here was supported by grant 1R43DA032224-01 from the National Institutes for Health/NIDA. We wish to thank Abby Eisner OT and Daniel Saldana who performed the clinical evaluations and Ms. Noreen Rana, the clinical coordinator for the study.

REFERENCES

[1] Zebrack BJ. Psychological, social, and behavioral issues for young adults with cancer. *Cancer* 2011;117(10 Suppl):2289–94.

[2] Quinn GP, Gonçalves V, Sehovic I, Bowman ML, Reed DR. Quality of life in adolescent and young adult cancer patients: a systematic review of the literature. *Patient Relat Outcome Meas* 2015;6:19–51.

[3] Kenyon M, Mayer D, Owens A. Late and long-term effects of breast cancer treatment and surveillance management for the general practitioner. *J Obstet Gynecol Neonatal Nurs* 2014;43(3):382–98.

[4] Hoffman HG, Doctor JN, Patterson DR, Carrougher GJ, Furness TA3rd. Virtual reality as an adjunctive pain control during burn wound care in adolescent patients. *Pain* 2000;85(1-2):305–9.

[5] Schneider S, Ellis M, Coombs W, Shonkwiler E, Folsom L. Virtual reality intervention for older women with breast cancer. *Cyberpsychol Behav* 2003;6(3):301–7.

[6] Triberti S, Repetto C, Riva G. Psychological factors influencing the effectiveness of virtual reality-based analgesia: a systematic review. *Cyberpsychol Behav Soc Netw* 2014;17(6):335–45.

[7] House G, Burdea G, Polistico K, Roll D, Kim J, Grampurohit N, et al. Integrative rehabilitation of residents chronic post-stroke in skilled nursing facilities: the design and evaluation of the BrightArm Duo. *Disabil Rehabil Assist Technol* 2016;11(8):683-94.

[8] Unity Technologies. *Unity Manual*. URL: http://docs.unity3d.com/Manual/ index.html.

[9] Paice JA, Cohen FL. Validity of a verbally administered numeric rating scale to measure cancer pain intensity. *Cancer Nurs* 1997;20(2):88–93.

[10] Duncan PW, Propst M, Nelson SG. Reliability of the Fugl-Meyer assessment of sensorimotor recovery following cerebrovascular accident. *Phys Ther* 1983;63(10):1606–10.

[11] Barreca S, Gowland C, Stratford P, Huijbregts M, Griffiths J, Torresin W, et al. Development of the Chedoke Arm and Hand Activity Inventory: theoretical constructs, item generation, and selection. *Top Stroke Rehabil* 2004;11(4):31–42.

[12] Jebsen RH, Taylor N, Trieschmann RB, Trotter MJ, Howard LA. An objective and standardized test of hand function. *Arch Phys Med Rehabil* 1969;50(6):311–9.

[13] Chesworth B, Hamilton C, Walton D, Benoit M, Blake TA, Bredy H, et al. Reliability and validity of two versions of the upper extremity functional index. *Physiother Can* 2014;66(3):243–53.

[14] Beck A, Steer R, Brown G. *Manual for Beck Depression Inventory*, 2nd ed. Antonio, TX: Psychology Corp, 1996.

[15] White T, Stern R. Neuropsychological Assessment Battery. Lutz, FL: *Psychological Assessment Resources*, 2003.

[16] Brandt J, Benedict R. Hopkins Verbal Learning Test Revised. Lutz, FL: *Psychological Assessment Resources*, 2001.

[17] Benedict R. Brief Visuospatial Memory Test Revised. Odessa, FL: *Psychological Assessment Resources*, 1997.

[18] Reitan R. Validity of the Trail Making Test as an indicator of organic brain damage. *Percept Motor Skills* 1958;8:271–6.

[19] Salamh P, Kolber M. The reliability, minimal detectable change and construct validity of a clinical measurement for quantifying posterior shoulder tightness in the post-operative population. *Int J Sports PhysTher*, 2012:7(6), 565–75.

[20] Lang CE, Edwards DF, Birkenmeier RL, Dromerick AW. Estimating minimal clinically important differences of upper-extremity measures early after stroke. *Arch Phys Med Rehabil*, 2008:89(9), 1693–1700.

[21] Arya KN, Verma R, Garg RK. Estimating the minimal clinically important difference of an upper extremity recovery measure in subacute stroke patients. *Top Stroke Rehabil*, 18 Suppl 1, 2011:599–610.

[22] Barreca SR. *Chedoke Arm and Hand Activity Inventory (CAHAI).* 2015, from http://www.cahai.ca/manual.html

[23] Hiroe T, Kojima M, Yamamoto I, Nojima S, Kinoshita Y, Hashimoto N, et al. Gradations of clinical severity and sensitivity to change assessed with the Beck Depression Inventory-II in Japanese patients with depression. *Psychiatry Res*, 2005:135(3), 229–35.

[24] Kenney LB, Yasui Y, Inskip PD, Hammond S, Neglia JP, Mertens AC, et al. Breast cancer after childhood cancer: a report from the Childhood Cancer Survivor Study. *Ann Intern Med* 2004;141(8):590–97.

[25] Michener L, Snyder A, Leggin B. Responsiveness of the numeric pain rating scale in patients with shoulder pain and the effect of surgical status. *J Sport Rehabil* 2011;20(1):115–28.

[26] Garcia-Palacios A, Herrero R, Vizcaino Y, Belmonte MA, Castilla D, Molinari, et al. Integrating virtual reality with activity management for the treatment of fibromyalgia: acceptability and preliminary efficacy. *Clin J Pain* 2015;31(6):564–72.

[27] Chirico A, Lucidi F, De Laurentiis M, Milanese C, Napoli A, Giordano A. Virtual reality in health system: Beyond entertainment. A mini-review on the efficacy of VR during cancer treatment. *J Cell Physiol* 2016;231(2):275–87.

[28] Loreto-Quijada, D, Gutiérrez-Maldonado J, Nieto R, Gutierrez-Martinez O, Ferrer-Garcia M, Saldana C, et al. Differential effects of two virtual reality interventions: distraction versus pain control. *Cyberpsychology Behav Soc Netw* 2014;17(6):353–8.

[29] Botella C, Garcia-Palacios A, Vizcaíno Y, Herrero R, Banos RM, Belmonte MA. Virtual reality in the treatment of fibromyalgia: a pilot study. *Cyberpsychol Behav Soc Netw* 2013;16(3):215–23.

[30] Button KS, Kounali D, Thomas L, Wiles NJ, Peters TJ, Welton NJ, et al. Minimal clinically important difference on the Beck Depression Inventory--II according to the patient's perspective. *Psychological Med*, 2015:45(15), 3269–79.

[31] Neves E, Vilaca-Alves J, Antunes N. Felisberto IM, Rosa C, Reis VM. Different responses of the skin temperature to physical exercise: Systematic review. Conference *Proc IEEE Eng Med Biol SocAnn Conf*, 2015:1307–10.

In: Encyclopedia of Surgery (22 Volume Set)
Editors: Andreas Lehrer and Kristin Mueller
ISBN: 978-1-53618-329-0
© 2020 Nova Science Publishers, Inc.

Chapter 440

IS MINIMALLY INVASIVE PARATHYROIDECTOMY FEASIBLE IN PATIENTS WITH PREVIOUS IPSILATERAL THYROID SURGERY?

Roberto de la Plaza Llamas*, José Manuel Ramia Ángel, Vladimir Arteaga Peralta, Cristina García Amador, Aylhín Joana López Marcano, Aníbal Armando Medina Velasco and Begoña González Sierra

Department of Surgery, Hospital General Universitario de Guadalajara, Guadalajara, Spain

ABSTRACT

Introduction. Prior ipsilateral thyroid surgery (PITS) has habitually been considered a contraindication for minimally invasive parathyroidectomy (MIP) in patients with primary hyperparathyroidism (PHPT).

Material and Methods. We performed an unlimited PubMed search updated on March 31, 2017, with the following strategy: ((Minimally invasive parathyroidectomy) OR (Focused parathyroidectomy) OR (Targeted parathyroidectomy)) AND ((Thyroid surgery) OR (Thyroidectomy) OR (Cervical endocrine surgery) OR (Reoperative neck)). A total of 563 articles were obtained.

Results. We found only four articles reporting MIP for PHPT in patients with PITS. Two of them correspond to the same series, which was recorded in full in the second article. Despite the limited results, we analyzed the studies in search of evidence supporting or contraindicating the use of MIP in patients with PITS.

In the literature on MIP, only 33 patients with PITS have been reported. Only one complication has been described, a temporary recurrent laryngeal nerve paralysis. All patients were discharged within 24 hours. Mean duration of the procedure and length of stay (in the studies in which it was recorded) did not differ from those cases without PITS.

* Corresponding Author's Email: rdplazal@sescam.jccm.es.

Conclusion. MIP seems to be a valid option in patients with PITS. Surgical difficulty does not appear to be increased in these patients. The limited dissection involved in MIP and the targeted nature of the technique in theory are clear advantages, with a decreased risk of complications, shorter hospital stay, and less scarring. There is also a saving on costs. However, further studies are required to reach firm conclusions.

1. INTRODUCTION

Minimally invasive parathyroidectomy (MIP) has been accepted as the procedure of choice for the majority of patients with primary hyperparathyroidism (PHPT) and single gland disease, and appears to have replaced bilateral neck exploration as the gold standard [1].

Prior central compartment surgery of the neck, such as parathyroid surgery via bilateral cervical exploration or total or ipsilateral thyroidectomy, is habitually considered a contraindication for MIP in patients with PHPT. This is because prior surgery may distort or eliminate the normal tissue planes, and may alter the location of the adenoma because of the scarring process accompanying the prior mobilization of the parathyroid glands or the thyroid [2]. Obviously this process is more pronounced in cases of ipsilateral thyroidectomy. It has generally held that reoperations for PHPT have lower cure rates (80% to 96%), higher rate of complications (5% to 10%), longer surgical time and higher costs significantly (2-3 times) than the first operation [3-7].

The aim of this chapter is to determine whether minimally invasive parathyroidectomy is feasible in patients with previous ipsilateral thyroid surgery (PITS), and to assess the results of series in which it has been applied.

2. MATERIAL AND METHODS

We performed an unlimited PubMed search updated on March 31, 2017, with the following strategy: ((Minimally invasive parathyroidectomy) OR (Focused parathyroidectomy) OR (Targeted parathyroidectomy)) AND ((Thyroid surgery) OR (Thyroidectomy) OR (Cervical endocrine surgery) OR (Reoperative neck)). A total of 563 articles were obtained.

Abstracts were reviewed and articles deemed relevant to the subject of this study were analyzed. Series containing patients who had undergone prior bilateral or ipsilateral surgery for adenoma removal were included. Series including contralateral thyroid surgery or surgery for other non-thyroidal causes were excluded, as were those that reported patients undergoing prior parathyroidectomy without thyroidectomy.

3. RESULTS

We found only four articles reporting MIP for PHPT in patients with PITS [1-2, 8-9]. Two of them [2, 8] correspond to the same series, which was recorded in full in the second article [2]. In all, 30 patients were studied (Table 1).

Briefly, the operative approach for MIP in the three series typically involved an incision of 2 to 4 cm, if possible taking advantage of the prior scar, although sometimes a caudal or cephalic incision was required [2]. Two types of approaches, central and lateral, were used. The central approach to the pretracheal fascia involved retracting the strap muscles laterally after separating them down the midline [2]. The lateral approach used the lateral aspect of the previous wound only and allows access to the deeper neck structures by entering the plane between the strap muscles and the sternocleidomastoid muscle [1-2, 9].

Norman et al. studied 21 patients referred for non-familial PHPT. Of these, 14 had persistent PHPT, three recurrent hyperparathyroidism and four PHPT without parathyroid surgery. The four patients with PHPT without parathyroid surgery were the only ones who had undergone PITS. All patients underwent a high-resolution sestamibi scan several weeks before the operation. The surgical procedure was radioguided MIP without intraoperative PTH monitoring (IOPTH). All patients were cured, as demonstrated by normal serum calcium and PTH levels after one week and three and six months after the procedure. Sixteen of the 21 patients were discharged within two hours of the operation. Four patients remained overnight as 23-hour admissions, mostly because their operations were performed late in the day and they were elderly [2].

In Dimas et al.'s retrospective study, 42 of 380 patients with PHPT had prior cervical surgery. Twenty-seven of these 42 were selected for MIP, while the other 15 underwent traditional cervical exploration. Selection criteria for MIP were unilateral single or two gland disease localized preoperatively by at least two imaging techniques. Imaging studies included high resolution neck ultrasound and sestamibi scan in most cases, and CT scan, selective venous sampling and MRI in seven patients. MIP was performed only when there was unilateral single or two gland disease and the adenoma(s) was preoperatively localized with two concordant imaging techniques, one of which necessarily was sestamibi scan. Endocrine neck operations had been performed previously in 24 patients in the first group (total or subtotal thyroidectomy) before the diagnosis of PHPT; one patient had a 2-stage planned unilateral approach under local anesthesia for parathyroid hyperplasia. Two patients had previously undergone surgery for other reasons: a highly positioned sternotomy and a tuberculosis neck mass with multiple abscesses. The type of operation performed included a unilateral approach under local anesthesia (22 cases) with one conversion to general anesthesia, and MIP under general anesthesia (5 cases). No gamma probes, IOPTH assays or frozen-section analyses were performed. Twenty-six of the 27 patients were normocalcemic after the operation. One patient had persistent PHPT. Mean duration of the procedure and length of stay were similar to those recorded in MIP in patients without previous neck surgery. No surgical complications or persistent hypoparathyroidism occurred. Mean hospital stay was approximately 20 hours (19-23 hours). All patients were considered for discharge on the first postoperative day after the morning measurement of blood calcium levels. Mean follow-up assessments at 40 months (4-89 months) did not reveal any recurrence [1].

In 62 patients operated on for PHPT, De la Plaza et al. used MIP with IOPTH in 55. Two patients had undergone prior total thyroidectomy for thyroid papillary carcinoma, one with central lymph node dissection. Preoperative localization was performed with sestamibi scan; ultrasound was negative in both patients. They were assigned to ambulatory MIP surgery with IOPTH, one radioguided. A temporary recurrent laryngeal nerve paralysis was recorded in another patient who underwent radio-surgery and who had previously undergone central lymph node dissection. Laryngoscopy performed at three months showed complete recovery, with normal mobility of the vocal cords [9].

Table 1. Patients in the literature underwent minimally invasive parathyroidectomy with previous ipsilateral thyroid surgery

	Authors/Year		
	Norman et al. 1998 [2]	Dimas et al. 2012 [1]	De la Plaza et al. 2015 [9]
Num. patients	4	24	2
Previous surgery	Ipsilateral thyroid lobectomy	Total or subtotal thyroidectomy	Total thyroidectomy (2). CLND (1)
Preoperative localization	Sestamibi scan	Two concordant imaging techniques (necessarily sestamibi scan)	Sestamibi scan
Complications	No	No	TRLNP (1)
Discharged	<23 hours (NS)	1 day	AS
Type of operation	MIRP	UALA: 22, MIP: 5	MIRP: 1, MIP: 1
IOPTH	No	No	Yes
Recurrence PHPT	No	No	No
Persistence PHPT	No	1	No
Follow-up (months)	6	40 (range 4-89)	18 and 25*

Central lymph node dissection: CLND; Temporary recurrent laryngeal nerve paralysis (TRLNP); NS: not specified; AS: ambulatory surgery; MIP: minimally invasive parathyroidectomy; UALA: unilateral approach under local anesthesia; MIRP: minimally invasive radioguided parathyroidectomy; IOPTH: intraoperative PTH monitoring.

* Updated data.

Taken together, the studies analyzed did not present evidence that contraindicated the use of MIP in patients with PITS.

4. DISCUSSION

With the use of preoperative imaging and IOPTH measurements, the surgical approach to PHPT has evolved from a standard bilateral exploration to a more focused image-directed approach [10]. However, surgery of the central compartment of the neck, particularly ipsilateral thyroidectomy, has been considered a contraindication for MIP.

MIP in patients with PITS has only rarely been reported in the literature. The published series of MIP either do not specify the history of PITS, automatically exclude patients with PITS [11] or warn that PITS may prevent the use of a minimally invasive approach [12]. The assignment of patients with persistent or recurrent PHPT to MIP is more common [13].

The search carried out in this chapter found that only 30 cases of MIP with PITS have been described in the literature, with a single case of morbidity [1-2, 9]. All patients were discharged within 24 hours. Mean duration of the procedure and length of stay, in the studies that specified them, did not differ from the cases without PITS [1]. In view of these results, the low level of use (or the low level of reporting) of focused parathyroidectomy in patients

with PITS comes as a surprise. This group of patients may represent a substantial proportion of the total: in Dimas et al.'s series, for example, 42 of 380 patients (11%) patients referred for PHPT had prior cervical surgery [1].

As we have seen, MIP has been carried out in patients with PITS even in cases in which only one preoperative localization study is available, with the support of radio-surgery and/or IOPTH [2, 9]. The European Society of Endocrine Surgeons recommends IOPTH assay for patients undergoing targeted parathyroidectomy on the basis of a single preoperative localization study [14]. If preoperative localization with sestamibi and ultrasound is not concordant and the surgeon wishes to perform a minimally invasive targeted procedure, IOPTH assay is recommended since the prevalence of multiglandular disease in this group is 17% [14-16].

MIP offers the following advantages: less scarring and thus better cosmetic results, less tissue dissection, lower level of pain, a significant decrease in the percentage of transient postoperative hypoparathyroidism to about 5% (compared with approximately 15 to 25% after bilateral neck exploration) and complete elimination of the risk of permanent hypoparathyroidism [17]. The biggest disadvantage is the risk of multiglandular disease.

CONCLUSION

The studies analyzed do not present any evidence to contraindicate MIP in patients with TIPS. Given its advantages over bilateral cervical exploration, MIP seems to be a valid option in patients with PITS, even when only one preoperative localization study has been performed. None of the 30 reports in the literature recorded any major surgical difficulties in patients with previous ipsilateral thyroid surgery. In theory, the limited dissection involved in MIP and the targeted nature of the technique represent advantages for the patient, with a lower risk of complications, shorter hospital stay and less scarring, and a decrease in costs. However, further studies are required to confirm these suppositions.

REFERENCES

[1] Dimas, S; Michas, S; Christakis, I; Augoustis, C; Alevizaki, M. Minimally invasive parathyroidectomy in patients with previous neck surgery. *Hormones* (Athens), 2012;11:160-5.

[2] Norman, J; Denham, D. Minimally invasive radioguided parathyroidectomy in the reoperative neck. *Surgery*, 1998;124:1088-92.

[3] Akerstrom, G; Rudberg, C; Grimelius, L; Johansson, H; Lundstrom, B; Rastad, J. Causes of failed primary exploration and technical aspects of reoperation in primary hyperparathyroidism. *World J Surg*, 1992;16:562-9.

[4] Jarhult, J; Nordenstrom, J; Perbeck, L. Reoperation for suspected primary hyperparathyroidism. *Br J Surg*, 1993;80:453-6.

[5] Shen, W; Duren, M; Morita, E; Higgins, C; Duh, QY; Siperstein, AE; Clark, OH. Reoperation for persistent or recurrent primary hyperparathyroidism. *Arch Surg*, 1996;131:861-9.

[6] Jaskowiak, N; Norton, JA; Alexander, HR; Doppman, JL; Shawker, T; Skarulis, M; Marx, S; Spiegel, A; Fraker, DL. A prospective trial evaluating a standard approach to reoperation for missed parathyroid adenoma. *Ann Surg*, 1996;224:308-22.

[7] Denham, D; Norman, J. Cost effectiveness of preoperative sestamibi scan for primary hyperparathyroidism is dependent solely on surgeon's choice of operative procedure. *J Am Coll Surg*, 1998;186: 293-304.

[8] Spiros, D; Nikolaos, R; Ioannis, C. Minimally invasive parathyroidectomy in patients with previous endocrine surgery. *JSLS*, 2011;15:499-503. doi:10.4293/108680811 X13176785204111.

[9] De la Plaza Llamas, R; Ramia Ángel, JM; Kühnhardt Barrantes, AW; Gonzales Aguilar, JD; Valenzuela Torres, J del C. Minimally invasive parathyroidectomy in patients with previous thyroid surgery. *Endocrinol Nutr*, 2015;62:414-6. doi: 10.1016/j.endonu.2015.05.001.

[10] Bilezikian, JP; Brandi, ML; Eastell, R; Silverberg, SJ; Udelsman, R; Marcocci, C; Potts, JT Jr. Guidelines for the management of asymptomatic primary hyperparathyroidism: summary statement from the Fourth International Workshop. *J Clin Endocrinol Metab*, 2014;99:3561-9. doi:10.1210/jc.2014-1413.

[11] Kandil, E; Malazai, AJ; Alrasheedi, S; Tufano, RP. Minimally invasive/focused parathyroidectomy in patients with negative sestamibi scan results. *Arch Otolaryngol Head Neck Surg*, 2012; 138: 223-5. doi:10.1001/archoto.2011.1419.

[12] Mihai, R; Barczynski, M; Iacobone, M; Sitges-Serra, A. Surgical strategy for sporadic primary hyperparathyroidism an evidence-based approach to surgical strategy, patient selection, surgical access, and reoperations. *Langenbecks Arch Surg*, 2009;394:785-98. doi: 10. 1007/s00423-009-0529-1.

[13] Karakas, E; Müller, HH; Schlosshauer, T; Rothmund, M; Bartsch, DK. Reoperations for primary hyperparathyroidism--improvement of outcome over two decades. *Langenbecks Arch Surg*, 2013; 398:99-106. doi:10.1007/s00423-009-0529-1.

[14] Bergenfelz, AO; Hellman, P; Harrison, B; Sitges-Serra, A; Dralle, H. European Society of Endocrine Surgeons. Positional statement of the European Society of Endocrine Surgeons (ESES) on modern techniques in pHPT surgery. *Langenbecks Arch Surg*, 2009;394:761-4. doi:10.1007/s00423-009-0533-5.

[15] Barczynski, M; Konturek, A; Cichon, S; Hubalewska-Dydejczyk, A; Golkowski, F; Huszno, B. Intraoperative parathyroid hormone assay improves outcomes of minimally invasive parathyroidectomy mainly in patients with a presumed solitary parathyroid adenoma and missing concordance of preoperative imaging. *Clin Endocrinol* (Oxf), 2007;66:878-85.

[16] Harrison, BJ; Triponez, F. Intraoperative adjuncts in surgery for primary hyperparathyroidism. *Langenbecks Arch Surg*, 2009;394: 799-809. doi:10.1007/ s00423-009-0532-6.

[17] Barczyński, M; Gołkowski, F; Nawrot, I. The current status of intraoperative iPTH assay in surgery for primary hyperparathyroidism. *Gland Surg*, 2015;4:36-43. doi:10.3978/j.issn. 2227-684X.2015.01.01.

In: Encyclopedia of Surgery (22 Volume Set)
Editors: Andreas Lehrer and Kristin Mueller
ISBN: 978-1-53618-329-0
© 2020 Nova Science Publishers, Inc.

Chapter 441

POSTOPERATIVE COGNITIVE DYSFUNCTION IN CARDIAC SURGERY: THE SELECTION OF TESTS AND STATISTICAL ISSUES

Anna G. Polunina[1,2,*] and Elena Z. Golukhova[1]
[1]A. N. Bakulev Scientific Center of Cardiovascular Surgery,
Russian Academy of Medical Sciences, Moscow, Russia
[2]Neuropsychology Department, Moscow Research Practical Center
for Prevention of Drug Addiction, Moscow, Russia

ABSTRACT

Postoperative cognitive dysfunction (POCD) is a mild form of perioperative ischemic brain injury, which emerges as memory decline and decreased attention during several months or even years after surgery. The present review summarizes our studies of POCD in patients after cardiac surgeries along with extensive review of the literature in this field. We found that at least three types of POCD may be outlined, and therefore tests sensitive to each type of POCD should be included into test batteries. Overall, the limitations of psychometric testing as a method of POCD definition include the lower baseline performance in cardiologic patients in comparison with matched healthy controls, the regression to the mean phenomenon and practice effects. Although the majority of studies of POCD have dichotomized cognitive outcome after surgery, classifying patients as "impaired" or "unimpaired," this approach has a range of serious limitations, leading to discrepancies in case classification by different dichotomous criteria. In the last part of the article we present the results of retrospective analysis of our data in order to illustrate that widely used conversion of raw test scores into z-scores for combining different tests into a 'cognitive domain' may contribute to discrepancies in the results of studies of surgery outcomes. The same is true for the factorization of raw scores. Consequently, analysis of the raw (mean) scores and standard deviations is obligatory for any meaningful conclusions to be made, and other mathematical approaches should be used cautiously as an additional option.

* Corresponding Author's Email: polunina.ag@gmail.com.

Keywords: brain ischemia, memory decline, mild cognitive dysfunction, psychometric testing, psychomotor speed slowing

INTRODUCTION

Post-operative cognitive dysfunction (POCD) is a mild form of perioperative ischemic brain injury, which emerges predominantly as memory decline during several months, or even years after surgery (Bergh, Bäckström, Jönsson, Havinder, & Johnsson, 2002; Newman, Stygall, Hirani, Shaefi, & Maze, 2007; Sotaniemi, Monomem, & Hokkanen, 1986; Tsai, Sands, & Leung, 2010; Vingerhoets, de Soete, & Jannes, 1995). In addition, patients commonly report decreased concentration, attention span, and psychomotor speed. Both patients and spouses of patients notice postoperative memory decline after several months or even 1 year after operation (Bergh et al., 2002; Kastaun et al., 2016). Negative effects on driving abilities during several months after uncomplicated cardiac surgeries, were registered (Ahlgren, Lundqvist, Nordlund, Aren, & Rutberg, 2003), and patients with preoperative mild cognitive deficits were shown to demonstrate changed functional capacity in 1 year after cardiac surgery (Messerotti Benvenuti et al., 2013).

In young patients, cognitive function tends to be restored to its preoperative levels, in about 6 – 12 months after surgery (Herrmann et al., 2000; Kastaun et al., 2016; Mahanna et al., 1996; Neville, Butterworth, James, Hammon, & Stump, 2001; Newman et al., 2001a), however, in some patients POCD may persist, or even progress after 5 years of their operation with negative effect on the quality of life (Newman et al., 2001b). Increased mortality rate during a median of 7 - 8 year follow-up in patients with POCD, which was registered in 3 months after operation, was also demonstrated (Evered, Silbert, Scott, Maruff, & Ames, 2016; Steinmetz, Christensen, Lund, Lohse, & Rasmussen, 2009). In the same patient population, risk of leaving the labor market prematurely was twice as high among patients with 1-week POCD in comparison with patients without POCD.

Improved surgical technologies appear to minimize the number of cases with severe neurological complications and POCD in recent years even in high risk patient cohorts, and some studies showed improvement of cognitive functioning after cardiac surgery (Cormack et al., 2012). Nevertheless, the optimal tools for assessment of neurological and neuro-psychological outcomes of surgical interventions are still needed at least when the effectiveness and the safety of surgical technologies and neuroprotective strategies are evaluated and compared. In addition, issues relating to the definition of POCD can be generalized to other fields where detection of subtle neuropsychological change is central (Lewis, Maruff, & Silbert, 2004).

Although some advanced neuroimaging and electrophysiological methods are available at present, the evaluation of patients with neuropsychological tests remains the most common approach for POCD definition. Using conventional pen and paper tests is much easier and cheaper in comparison with other diagnostic options, including computerized neuropsychological tests, and therefore any medical center all over the world may conduct research of POCD and compare neuropsychological consequences of different surgical and perfusion technologies.

Nevertheless, the evaluation of neurological outcomes of surgical interventions by perioperative psychometric testing is an intensively criticized approach. Experts point out the absence of a "gold standard" for effective application of this method in cardiac surgery studies (Arrowsmith, Grocott, Reves, & Newman, 2000; Blumenthal et al., 1995; Funder, Steinmetz, & Rasmussen, 2010; Collie, Darby, Falleti, Silbert, & Maruff, 2002; Lewis et al., 2004; Newman et al., 2007; Rasmussen et al., 2001; Slade, Sanchez, Townes, & Aldea, 2001; Tsai et al., 2010, Van Dijk et al., 2000), and many findings in this field were not confirmed by other similar studies, done by other research groups. Therefore, the contemporary methods of definition of POCD are considered to be highly arguable and unclear.

Here we summarize our experience with the evaluation of POCD in patients after coronary and open heart surgeries conducted in A. N. Bakulev Scientific Center of Cardiovascular Surgery in Moscow (Russia) in 2000 – 2010 (Bokeriia, Golukhova, Polunina, Davydov, & Begachev, 2005; Bokeriia et al., 2007; Bokeriia, Golukhova, & Polunina, 2009; Golukhova, Polunina, Lefterova, & Begachev, 2011; Golukhova, Polunina, Lefterova, Morelli, & Begachev, 2012; Polunina, 2008; Polunina, Golukhova, Guekht, Lefterova, & Bokeria, 2014) along with extensive review of the literature in this field. We found that at least three types of POCD may be outlined, and therefore tests sensitive to each type of POCD should be included into the batteries for studies of POCD. Also we discuss limitations of psychometric testing as a method of POCD definition, and these include lower baseline performance in patients with cardiac diseases in comparison with age and sex matched controls, regression to the mean phenomenon and practice effects, which may vary in magnitude in patients and healthy subjects. Although the majority of studies of POCD have dichotomized cognitive outcome after surgery, classifying patients as "impaired" or "unimpaired" on the basis of their baseline cognitive performance, this approach has a range of serious limitations, and considerable discrepancies in case classification by different dichotomous criteria of POCD were reported. In the last part of the article we present the results of the retrospective analysis of our data in order to illustrate that widely used conversion of raw test scores into z-scores for combining different tests into a 'cognitive domain' may contribute to discrepancies in the results of studies of surgery outcomes. The same is true for the factorization of raw scores, which have been used in few but very influential studies in this field.

PATHOPHYSIOLOGY AND TYPES OF POCD

In cardiac surgery POCD is caused predominantly by air and solid/fat particles microembolism emerging from the surgical wound and cardiopulmonary bypass, and the overall intraoperative microembolic load was shown to correlate with the cognitive decline after surgery in a range of studies (Barbut et al., 1997; Bokeriia et al., 2009; Fearn et al., 2001; Jacobs et al., 1998; Lee et al., 2003; Sylivris et al., 1998). Cerebral hypoperfusion, which impairs the clearance of microemboli from the cerebral circulation, (Blacker, Flemming, & Wijdicks, 2003; Caplan, & Hennerici, 1998; D'Agostino et al., 1996; Ganushchak, Fransen, Visser, De Jong, & Maessen, 2004; Omae, Mayzel-Oreg, Li, Sotak, & Fisher, 2000; Orlandi et al., 2005) and the systemic inflammatory response (Bruggemans, 2013; Parolari et al., 2007) are also discussed as important contributors to perioperative brain

damage. In addition, it was consistently shown, that pre-existing cerebrovascular disease with disturbed cerebral circulation considerably worsens effects of intraoperative brain ischemia on postoperative cognitive functioning (Evered, Silbert, Scott, Maruff, & Ames, 2016; Scott, Mathias, Kneebone, & Krishnan, 2016).

Neuroimaging studies consistently demonstrated an acute brain edema and global decrease of brain metabolism during the first three days after on-pump surgery (Anderson, Li, Hindmarsh, Settergren, & Vaage, 1999; Bendszus et al., 2002; Harris et al., 1998; Jacobs et al., 1998). In addition, 20 - 45% of on-pump patients demonstrated multiple small ischemic lesions postoperatively, and only 20% of them showed clinical signs of stroke or delirium (Bendszus et al., 2002; Floyd et al., 2006; Knipp et al., 2004; Restrepo et al., 2002; Stolz et al., 2004). Recently alterations in resting-state functional connectivity were demonstrated at 6-week follow-up after cardiac surgery (Browndyke et al., 2016). Hence, mild brain ischemic injury is common after on-pump surgery. Overall, the total volume of brain ischemic alterations correlated with clinical symptoms in several neuroimaging studies (Floyd et al., 2006; Stolz et al., 2004). It should be noted, that the problem of intraoperative cerebral microembolism, and POCD is not limited to cardiac surgery settings. For instance, the orthopedic surgery is associated with excessive fat microembolism (Scott et al., 2016; Kim et al., 2008; Koch et al., 2007; Koessler, Fabiani, Hamer, & Pitto, 2001). Indeed, any vessel or skin trauma may lead to air or fat embolism, especially when a wound is elevated in comparison to the heart level, and when multiple veins are open (Mirski, Lele, Fitzsimmons, & Toung, 2007): mini-invasive manipulations may induce massive microembolism (Dube et al., 2004; Sowell, Lovelady, Brogdon, & Wecht, 2007), and POCD is also commonly found after non-cardiac and off-pump surgeries (Newman, 2007; Rasmussen et al., 2001; Tsai et al., 2010). Newman and colleagues (2007) reported that studies of major surgery outcomes showed POCD in 26 – 33% of patients compared with 7% for minor surgery, when patients were evaluated on the 7th – 21st day after surgery.

Our previous analysis of literature and our own data showed that at least three types of perioperative brain ischemic damage may be registered in cardiac surgery patients (Polunina et al., 2014). First, left hemisphere structures are more prone to perioperative ischemic strokes and microembolism in comparison with right hemisphere ones (Atochin et al., 2004; Leker, Pollak, Abramsky, & Ben-Hur, 1999; Lee et al., 2003; Rasmussen, Sperling, Abildstrom, & Moller, 2002; Weinstein, 2001), and the same is true for strokes in general population (Foerch et al., 2005; Hedna et al., 2013; Naess, Waje-Andreassen, Thomassen, & Myhr, 2006). It was hypothesized that slower circulation and greater metabolic demands in the left hemisphere neuro-networks, compared to right hemisphere ones, may predispose left hemisphere structures to greater risk of functional decrement after ischemic events (Hedna et al., 2013). In a series of our studies we registered the postoperative decline of digit span and verbal short-term memory in both open heart and coronary artery surgery patient cohorts, and this type of cognitive dysfunction correlated with either the microembolic load at left middle cerebral artery or the length of cardiopulmonary bypass time (Bokeriia et al., 2007; Polunina et al., 2014).

Second, patients with high microembolic load may demonstrate more extensive neuropsychological deficit involving visuospatial functions, and this right hemisphere dysfunction correlated with the intraoperative microembolic load at right middle cerebral artery in our study (Bokeriia et al., 2007; Polunina et al., 2014). It should be noted, as opposite to the major trend with higher risk of left hemisphere damage, some cardiac surgery

centers reported postoperative strokes and decreased cerebral perfusion to be more prevalent in the right hemisphere in comparison with the left one (Chernov, Efimova, Efimova, Akhmedov, & Lishmanov, 2006; Jacobs et al., 1998; Korn-Lubetzki et al., 2007). These discrepancies mean that variations in surgical and perfusion technologies may considerably influence the distribution of intraoperative microemboli within the brain circulation system and therefore the localization of brain damage.

Finally, psychomotor slowing appears to occur predominantly in elderly patients with prominent atherosclerosis, and this cognitive deficit did not correlate with microembolic load in our study (Bokeriia et al., 2007). The analysis of the data of longitudinal studies showed that psychomotor slowing is very common at 1-week follow-up, and highly reversible at 1-month follow-up in the majority of cardiac surgery patients (Bokeriia et al., 2005). This dynamics is similar to the postoperative brain swelling reversibility (Anderson et al., 1999; Bendszus et al., 2002; Harris et al., 1998), and therefore it may be suggested that postoperative psychomotor slowing is caused by disturbed conductivity and neurochemical imbalances, rather than real brain damage. Overall, psychomotor slowing is a typical neuropsychological consequence of the aging process (Swan, LaRue, Carmelli, Reed, & Fabsitz, 1992), and deficit in this cognitive domain is especially prominent in atherosclerotic patients in general population (Lopez et al., 2003; Rankin, Kochamba, Boone, Petiti, & Buckwalter, 2003).

Hence, all three cognitive domains, i.e., digit span/verbal memory, visuospatial functions and psychomotor speed should be tested perioperatively in order to register these three types of POCD. It is a common approach in research of cardiac surgery outcomes to combine tests into separate "cognitive domains," however, to our opinion, most researchers prefer follow some imperfect psychometric tradition instead of taking neurological reality into account. Selection of optimal tests and appropriate statistical approaches are very important issues for registering subtle effects of intraoperative ischemia on brain functions in order to determine which surgical or anesthesiological technology is safer and therefore preferable.

SELECTION OF TESTS

The selection of tests remains problematic, and varies extensively between studies. Newman and colleagues (Newman et al., 2007) have counted 70 different neuropsychological tests which have been used in the studies of postoperative cognitive dysfunction, published before December 2005. Comparisons between studies are difficult because of the differences in the tests selected.

It should be noted that the ecological validity of a range of tests is also questionable. Several studies demonstrated a discrepancy between postoperative complaints in specific cognitive areas, and neuropsychological testing results (Dijkstra, & Jolles, 2002; Funder et al., 2010; Vingerhoets et al., 1995). For instance, Vingerhoets and colleagues (1995) did not find significant intergroup differences in performance on Rey Auditory Verbal Learning Test (RAVLT) between patients complaining of postoperative memory decline and patients not complaining in 1 year after surgery. And similar findings were characteristic for concentration, attention, and psychomotor speed domains in this study. At the same time, the group with cognitive complains had significantly higher anxiety and depression, as compared

to the patients without complains. Other research demonstrated that patients with greater cognitive demands had the most complaints concerning poor postoperative cognitive functioning (Funder et al., 2010).

In 1995 preliminary recommendations were given by the "Statement of Consensus on Assessment of Neurobehavioral Outcomes after Cardiac Surgery" (Murkin, Martzke, Buchan, Bentley, & Wong., 1995). The authors suggested four neuropsychological tests (Rey Auditory Verbal Learning Test, Trail Making Test parts A and B, and Grooved Pegboard test) as a core battery for research of POCD. This standard was used in many studies after 1995, and now the results of a considerable proportion of neuropsychological studies in the cardiac surgery field may be compared and analyzed.

In our analysis of 24 publications concerning neuropsychological outcomes of cardiac surgery (Polunina, 2008) we found that studies which used a test battery recommended by Statement of Consensus on Assessment of Neurobehavioral Outcomes after Cardiac Surgery (i.e., RAVLT, TMT A and B, and Pegboard test), showed significantly lower incidence of POCD after 1-3 months of follow-up, as compared to the studies which used Digit Span and Non-verbal memory tests (average incidence: 28 - 32% versus 45 – 52%). These data evidence, that selection of tests may considerably influence the findings in cardiac surgery outcome studies.

In our study (Polunina et al., 2014), we found that tests measuring auditory span were more sensitive to postoperative cognitive deficit, compared to word, or story learning. Moreover, in the same cohort of young patients after open heart operations, we found a strong correlation between postoperative changes of the performance on Digit Span Forward, and intraoperative microembolic load at left middle cerebral artery, whereas the correlation between postoperative changes of word list learning and microemboli only showed the same trend (Bokeriia et al., 2007). In CABG patients, we observed significant correlation between the length of cardiopulmonary bypass, and postoperative changes of performance on the Digit Span Forward, but not on word-learning or story-learning tests.

The similar results showed the analysis of literature data (Polunina, 2008), i.e., studies, which used Digit Span, demonstrated significantly higher POCD incidence, compared to studies which did not use Digit Span (mean POCD incidence: $45.7 \pm 23.3\%$ vs $26.2 \pm 18.0\%$, $t = 2.63$, $p = .013$). At the same time, studies which used RAVLT (word list learning), reported lower POCD incidence, compared to studies which did not use RAVLT (mean POCD incidence: $32.8 \pm 21.0\%$ vs $47.7 \pm 25.1\%$, $t = 1.81$, $p = .08$). Overall, Digit Span appears to represent neurological reality more efficiently in the context of the postoperative cognitive dysfunction, when compared to word-learning, or story-learning test paradigms. Although Digit Span is commonly referred to as an "attention span" test, whereas word list learning tests are considered to relate to "verbal memory" domain, both of these tests appear to be supported by normal functioning of left temporal cortical structures, and therefore are sensitive to the similar neurological functions.

In addition, we observed significant linear correlations between microembolic load at right middle cerebral artery and postoperative decline of the performance on Benton Visual Retention Test ($R = -0.39$, $p = 0.018$) and overall microembolic load and postoperative deficit in Block Design test ($R = -0.31$, $p = 0.04$) in the cohort of patients after open heart surgery (Polunina et al., 2014). This postoperative cognitive deficit was not typical for CABG cohort, and no correlations between visuospatial tests and microembolic load in this group were

found. It should be noted, that open heart operations were characterized by almost twice as large microembolic load at right MCA compared to the CABG group; therefore, a deficit of right hemisphere functions was related to a larger microembolic load to this brain structure in open heart patients.

Finally, in our study (Polunina et al., 2014) both patient groups showed post-operative slowing of performance on timed tests (i.e., Digit Symbol and TMT, parts A and B), and intraoperative microembolic load did not correlate with performance on timed tests. At the same time, there was a significant association between an older age and the slowing of psychomotor speed at the baseline and post-operative follow-up, i.e., this function was especially sensitive to the effects of 'on-pump' in elderly patients.

Analysis of literature data showed that 13 studies which used Pegboard test, for assessment of POCD during first week after cardiac surgery, found significant impairment of performance in the studied patient cohorts, whereas only 4 of 20 (5%) studies reported the same trend at their 1 – 3 month follow-up (Bokeriia et al., 2005). Very similar dynamics was characteristic of TMT A and B, Digit Symbol, Reaction time tasks, Letter-Cancellation, and Stroop test, (i.e., neuropsychological probes with high loading on psychomotor speed processes). Hence, psychomotor speed tends to normalize during first weeks after operations.

It should be stressed, that the battery of 10 tests was difficult to perform for patients at early postoperative follow-up in our first study, and therefore we used only 5 tests for the assessment of POCD in our second study. Digit Span and Block Design were easier to perform for our patients in comparison with word list learning test or Benton Visual Retention Test, therefore we had chosen these tools. Digit Symbol was chosen as a measure of psychomotor speed, as this test is well known and therefore more popular in Russia in comparison with TMT or Pegboard. Finally, we also included MMSE, as it proved to be an effective tool for measuring postoperative changes of global cognitive status. Overall, we found the same three types of POCS in the second study (Polunina et al., 2014). At the same time, the dropout rate among cardiac surgery patients was considerably lower in our second study in comparison with the first one.

Computerized tests appear to be more sensitive and precise for POCD diagnostics in comparison with conventional tests, and are preferable for studies in this field (Silbert et al., 2004). However, availability of computerized tests remains lower in comparison with conventional ones, and therefore the latter are more frequently used especially in medical centers with low research budget. Still, computerized battery of tests for POCD diagnostics should contain tests sensitive to three types of POCD, i.e., left hemisphere dysfunction (digit span), right hemisphere dysfunction (visuospatial functions), and easy motor and perceptual tests measuring psychomotor speed/reaction time.

LIMITATIONS OF PSYCHOMETRIC TESTING IN POCD STUDIES

It is an established fact that repeated neuropsychological evaluations lead to changes in performance, independent of any changes in underlying function or capacity, due to practice effect or regression to the mean phenomenon (Browne, Halligan, Wade, & Taggart, 1999; Collie et al., 2002; Funder et al., 2010; Rasmussen et al., 2001; Slade et al., 2001; 50-52).

The statistical phenomenon of ‘regression to the mean’ may considerably influence the results of studies of cardiac surgery outcomes (Browne et al., 1999), and it means that normal subjects with the lower performance at the first assessment would increase their results at the follow-up, whereas subjects with higher performance would decrease their results at repeated assessment, showing the trend to reach group means. The phenomenon ‘regression to the mean’ in cardiac surgery outcome research was demonstrated by Browne and colleagues (1999). In their study, authors observed significant decline of group mean score on delayed recall in Rey Auditory Verbal Learning Test (RAVLT) and significant improvement (practice effect) on the Trail Making Test part A (TMT A) score at three month follow-up after surgery. However, when subjects were divided into 3 baseline performance category (low, moderate and high), only high performers showed significant deterioration on RAVTL, whereas only low performers showed significant improvement (practice effect) on TMT A at 3 months follow-up. Moreover, high performers also slightly but significantly deteriorated on TMT A. Authors concluded, that the use of group mean data with appropriate control group mean data should be the method of choice in cardiac surgery research, as the phenomenon of regression toward the mean precludes dichotomous approach (impaired/non-impaired) to the analyses of cardiac surgery effects on cognitive functions.

Two other research groups also demonstrated prominent effects of preoperative cognitive performance on magnitude and direction of postoperative changes. In the study of Robson et al. (2000) baseline performance on all cognitive tests accounted for 47-82% of variance of postoperative changes, whereas aortic atheroma explained only 1-5% of independent variance of postoperative changes in four from seven cognitive scores. Newman et al. (2001a) reported significant association between baseline cognitive performance and postoperative changes of cognitive index in five years after surgery with considerably greater "impairment" signs in patients with high preoperative performance. Hence, phenomenon of regression to the mean represents very strong and consistently demonstrated trends in cardiac surgery outcome research and should not be ignored.

The magnitude of the practice effect considerably varies across the tests and patient cohorts. As it was already discussed, the practice effect during repeated neuropsychological evaluations is most prominent in low baseline performers (Browne et al., 1999). In addition, we registered the significant effect of a position of a test within a test battery on the study results. Practice effect at the follow-up assessment was most prominent when a test was administered at the beginning of testing (Polunina et al., 2014).

Another serious limitation of neuropsychological studies of surgery outcomes is the lower baseline cognitive performance in patient groups in comparison with controls. For instance, it was consistently shown that heart disease is a risk factor for dementia and cognitive dysfunction (Justin, Turek, & Hakim, 2013), and therefore matching healthy control subjects is very problematic. Also when effects of perioperative factors are studied, it is not uncommon that patients with more severe perioperative conditions are characterized by more prominent preoperative cognitive dysfunction in comparison with healthier controls, and the same is true for lost to follow-up patient cohorts in comparison with those, who were included in the studies (Funder et al., 2010; Puskas et al., 2007; Selnes & Gottesman, 2010). Hence, matching groups according to age and sex does not help to eliminate intergroup differences in baseline cognitive functioning in studies comparing cardiac surgery patients and normal controls.

Previously analyses of group means in cardiac surgery outcome research were criticized because "a group mean score reflects both the individuals whose performance is compromised due to POCD and those whose performance is enhanced as a consequence of practice; accordingly the net result may be no significant group differences from baseline score" (Murkin, J.M., Stump, D.A., Blumenthal, J.A., McKhann, G., 1997). At present several studies showed, that inclusion of a control group into a study protocol allows easily to overcome this problem (Keith et al., 2002a; Lee et al., 2003; Nagels et al., 2004). Moreover, in two studies the cardiac surgery group demonstrated absence of practice effect on memory tests in comparison with a control group, and these findings clearly indicated postoperative cognitive deficits, which might be overlooked in the absence of controls (Keith et al., 2002a; Lee et al., 2003).

DICHOTOMOUS CRITERIA OF POCD

The majority of studies of POCD have dichotomized cognitive outcome after surgery, classifying patients as “impaired” or “unimpaired” on the basis of their baseline cognitive performance. Multiple dichotomous criteria of POCD (impaired vs not impaired) were widely used in research of cardiac surgery outcomes. These included: 20% drop criterion in at least 1, 2 or more tests or cognitive domains (postoperative decline in test scores by at least 20% from baseline); 0.5 SD, 1 SD, 1.5 SD, 2 SD or 3 SD criterion of decline in at least 1, 2 or more tests or cognitive domains (SD – standard deviation); reliable change indexes (RCI); impairment in comparison to normative index in at least 1, 2 or more tests or cognitive domains; 1SD or 20% decline of composite z-score; decline of z-score>1.96 in 1 or 2 cognitive tests; 10% drop criterion in 1 or 2 tests or cognitive domains; 5 percentile decline in at least 1 or 2 cognitive domains; any decline in 1 or 2 tests; etc. The most commonly used techniques in studies of POCD are 1SD and 20% decline criteria.

Several studies compared the incidence of POCD according to different dichotomous criteria, and showed, that the incidence of “impaired” cases considerably varies when different criteria of POCD are applied (Browne et al., 1999; Bruggemans, Van de Vijver, & Huysmans, 1997; Kneebone et al., 1998; Mahanna et al., 1996; Raymond, Hinton-Bayre, Radel, Ray, & Marsh, 2006). It is obvious, that criterion of 0.5 SD would always classify more cases as impaired ones in comparison with 1 SD criterion, whereas 1 SD criterion would classify considerably more cases as POCD-positive in comparison with 1.5 SD, 2 SD or 3 SD criteria. The same trend is also true for the criteria defining POCD as decline in at least 1, 2, 3 or more tests.

Mahanna and colleagues (1996) used five different criteria to define neuropsychological deficits after cardiac surgery and found a sixfold difference in the incidence of deficits (3.4-19.4%). The authors showed that 20% drop criteria identified the largest proportion of patients with cognitive deficits in comparison with other three criteria of POCD. For instance, 34% patients exhibited cognitive deficit due to 20% drop criterion, whereas only 13.8% patients were classified as “impaired” by 1 SD criterion in 6 weeks after surgery. Similar trends were consistently found in the analyses of pre-discharge and 6 month follow-up data. Browne et al. (1999) also reported considerably larger incidence of decline on RAVLT or TMT A when 20% criterion was applied in comparison with 1 SD criterion both at pre-

discharge and 3 month follow-up. Rasmussen et al. (2001) also confirmed these findings by their data. Hence, at least three research groups found 20% decline criterion to be considerably less stringent in comparison with 1 SD criterion.

Important, that in the study of Mahanna and colleagues (1996) there was little agreement among the four measures of cognitive impairment tested in that study. Only 2.8% of the sample was rated as impaired by all four criteria and only 31.5% was consistently rated as non-impaired. The authors criticized the 1 SD criterion, because this method cannot show cognitive decline if a patient's baseline score is too low, and this was the reason why up to one third of the sample of Mahanna and colleagues (1996) was misclassified by 1 SD criterion.

More sophisticated dichotomous approaches were suggested for overcoming practice effect and regression to the mean during repeated neuropsychological evaluations (Bruggemans et al., 1997; Collie et al., 2002; Kneebone et al., 1998; Rasmussen et al., 2001; Raymond et al., 2006). The reliable change indexes (RCI) which provide criteria for meaningful change based on the calculated measurement error for each score. A patient's predicted retest score equals their pre-operative score plus mean practice effect detected in a matched control group. If the difference between the actual and expected retest score exceeds the likely variation based on matched controls, a significant change is considered to have occurred (Raymond et al., 2006).

Considerable discrepancies in case classification by 1 SD and reliable change indexes were reported as well (Bruggemans et al., 1997; Kneebone et al., 1998). In the study of Kneebone and colleagues (1998) RCI classified more patients as showing a postoperative decline in 7 of 11 neuropsychologic tests in comparison with the 1 SD method. At the same time, 1 SD criterion classified more patients as showing decline on California Verbal Learning Test in comparison with RCI.

The Standardized Regression-based technique (SRB) generates a regression equation to predict a patient's score change on the bases of preoperative performance, plus any demographic variables that contribute significantly to the prediction model in matched controls (Raymond et al., 2006). The expected change is therefore dependent on initial performance rather than mean practice effect. Raymond and colleagues (2006) compared RCI, SRB, 20% and 1 SD criteria in their study of outcomes of cardiac surgery. Patients were classified as impaired if they demonstrated deterioration on 2 or more of the nine test scores used. The SRB and RCI techniques classified more patients as declined than the SD or 20% methods on all scores of MicroCog except reaction time. The average incidence of decline across scores was 3.6% (SD method) and 4.2% (20% method), compared to 7.7% (RCI method) and 13.3% (SRB method).

Although RCI and SRB procedures seem to be logical in eliminating practice effect and regression to the mean effect, some authors argued that unlike strokes POCD is not a dichotomous event but occurs along a continuum (Keith & Puente, 2002b; Selnes & Gottesman, 2010). Moreover, the practice effect may be smaller in patients due to preoperative mild cognitive dysfunction in comparison with healthy subjects, whereas mean group practice effect of healthy controls instead of individual practice effects is calculated for RCI (Keith & Puente, 2002b; Newman et al., 2007).

The number of tests in a test battery and whether they were drawn from separate domains may also contribute to the magnitude of POCD incidence, when the definition of POCD involves a deterioration on a specified number of tests. We analyzed the data of 24

publications, which included 34 patient cohorts (Polunina, 2008), and the number of tests varied from 1 to 15 in these studies. We found that the magnitude of POCD incidence positively correlated with the total number of neuropsychological tests and the number of timed tests used in a study (Rs=.38 and .36, p=.03 and .04), however, only when patients were tested during the first postoperative week. The incidence of POCD at more delayed follow-up (1 - 3 months) did not correlate with the total number of neuropsychological tests used in a study (R=-.07, p=.65) and negatively correlated with the number of timed tests (R=-.41, p=.006). At the same time, strong correlations were found between the incidence of delayed POCD and the number of memory tests and/or the number of visuospatial tests (Rs=.62 and .69, ps=.000).

Hence, the dichotomous methods are far from being perfect for POCD studies. Methods taking into account practice effect and regression to the mean effects tend to show larger incidence of POCD in comparison with fixed criteria (1SD, 20%, etc.). The number and quality of tests in the test battery may significantly influence the results of studies of neurological outcomes of cardiac surgery.

Z-Scores, Factor Analysis and Raw Scores

Z-scores are expressed in terms of standard deviations from their means, and therefore z-scores have a distribution with a mean of 0 and a standard deviation of 1. In research of POCD, z-scores are commonly used when scores of several tests are summarized into a cognitive domain or a composite cognitive index. However, some authors convert raw scores into z-scores in order to determine changes of performance on individual tests or even to compare group means at preoperative testing and at follow-up (e.g., Hernandez et al., 2007). To our opinion, using z-scores instead of raw scores may contribute to inconsistencies in the results of studies of surgery outcomes. For instance, one of the studies compared mean z-scores of on-pump and off-pump coronary surgery patients and found somewhat worse outcomes in off-pump patients in comparison with on-pump ones at 6 month follow-up (Hernandez et al., 2007), whereas the general trend is opposite (Sun, Wu, Wang, & Jin, 2012).

Here we demonstrate the results of retrospective analysis of our data, which were presented in detail elsewhere (Bokeriia et al., 2007; Polunina et al., 2014), in order to show obvious discrepancies between the results of the analysis of raw and z-score data. The statistical coefficients are summarized in Table 1, and the dynamics of performance on three tests at 2-week follow-up is presented in Figures 1 – 3.

Overall, the intergroup differences in changes of raw and z-scores were similar in all analyses of variance. However, when the magnitude of change was calculated for each patient group separately, the results of statistical analyses differed considerably for Digit Span Forward and Benton Visual Retention Test.

The group means of Digit Span Forward raw scores declined significantly after both coronary and open heart surgeries, however, group means of z-scores did not show significant changes when the data of controls were either included into or excluded from the calculation of z-scores (Figure 1, Table 1). Both patient groups showed these negative effects of using z-scores instead of raw scores for defining postoperative changes of performance on Digit Span

Forward, and this trend was especially obvious for analyses of the data of the patient groups without controls. It should be stressed, that comparisons of patient groups are highly important when effects and safety of surgical technologies are evaluated.

Table 1. ANOVAs and paired t-tests of raw and z-scores, which were calculated with and without inclusion of the data of the healthy controls*

Test scores	Time/Group interaction with Controls	Time/Group interaction without Controls	Change after CABG (n=29)	Change after Open Heart (n=36)
Digit Span Forward				
raw scores	$F_{2,74}$=11.7, P<0.001	$F_{1,63}$= 0.46, P=0.830	t=3.52, **p=0.001**	t=3.84, **p<0.001**
z-scores with Controls	$F_{2,74}$=12.8, P<0.001	$F_{1,63}$= 0.08, P=0.775	t=1.58, p=0.125	t=1.36, p=0.183
z-scores without Controls	-	$F_{1,63}$= 0.11, P=0.746	t=0.36, p=0.721	t=-0.09, p=0.930
Benton Visual Retention Test				
raw scores	$F_{2,72}$=4.77, P=0.011	$F_{1,63}$= 3.70, P=0.059	t=0.76, p=0.456	t=4.59, **p<0.001**
z-scores with Controls	$F_{2,72}$=4.39, P=0.016	$F_{1,63}$= 3.72, P=0.058	t=-0.66, p=0.515	t=2.40, **p=0.022**
z-scores without Controls	-	$F_{1,61}$= 3.67, P=0.060	t=-1.13, p=0.268	t=1.63, p=0.112
Digit Symbol				
raw scores	$F_{2,74}$=30.9, P<0.001	$F_{1,63}$= 10.2, P=0.002	t=2.69, p=0.012	t=-1.49, p=0.146
z-scores with Controls	$F_{2,74}$=24.8, P<0.001	$F_{1,63}$= 9.32, P=0.003	t=3.65, p=0.001	t=0.18, p=0.858
z-scores without Controls	-	$F_{1,63}$= 10.2, P=0.002	t=2.36, p=0.026	t=-2.02, p=0.052

Abbreviation: *CABG*, coronary artery bypass grafting;

* Paired t-tests were calculated for each of two patient groups separately.

The similar trend characterized the dynamics of raw and z-scores on Benton Visual Retention test in patient cohort, which underwent open heart operations (Figure 2, Table 1). This patient group demonstrated significant decline of group mean raw score on Benton test in 2 weeks after surgery, and this trend was robust (t=4.59, p<0.001). Analysis of z-scores, which included controls, also showed significant differences between patient cohorts, but this trend was somewhat weaker (t=2.40, p=0.022). Finally, analysis of z-scores, which included only patients, did not demonstrate significant intergroup differences in perioperative dynamics of z-scores in two patient groups.

Interestingly, the patients after open heart operations did not demonstrate any real change of raw score on Digit Symbol test at postoperative follow-up. Nevertheless, analysis of z-scores derived in total patient cohort without controls showed significant improvement of patients after open heart operations due to real worsening of means of raw and z-scores in the cohort of patients after coronary surgeries.

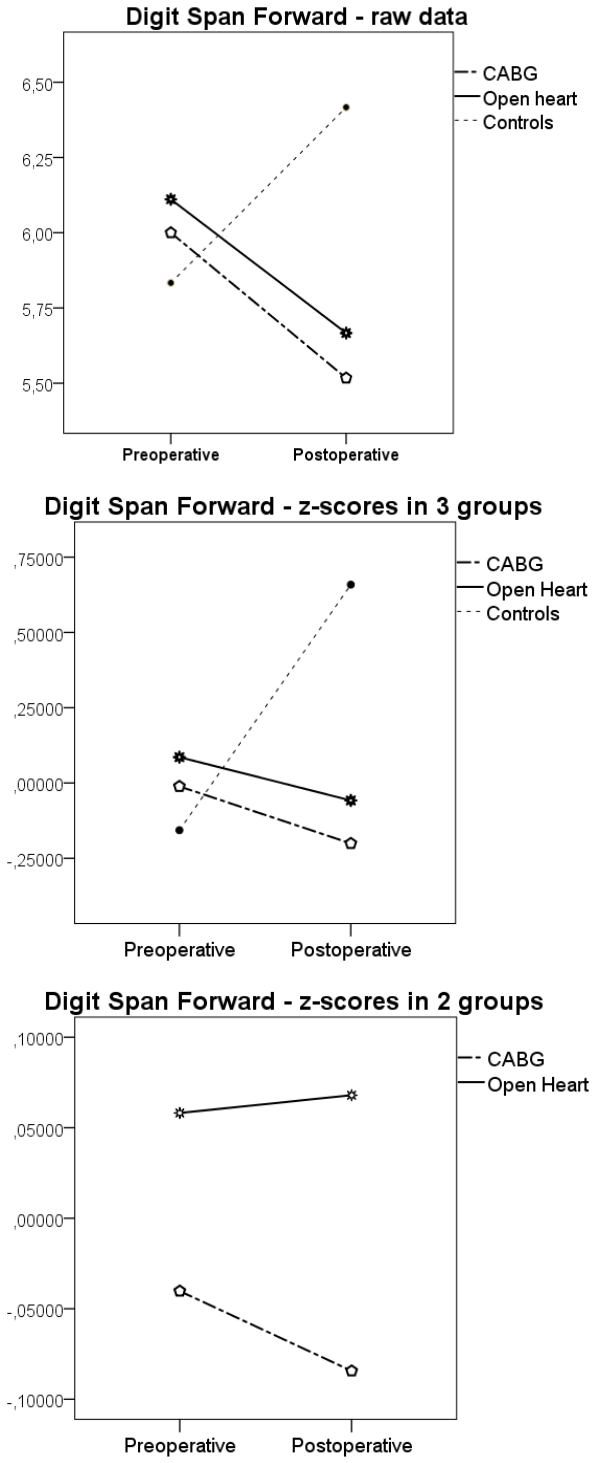

Figure 1. Changes of performance on Digit Span Forward test in patients after coronary surgery (n=29), patients after open heart operations (n=36) and healthy controls (n=12).

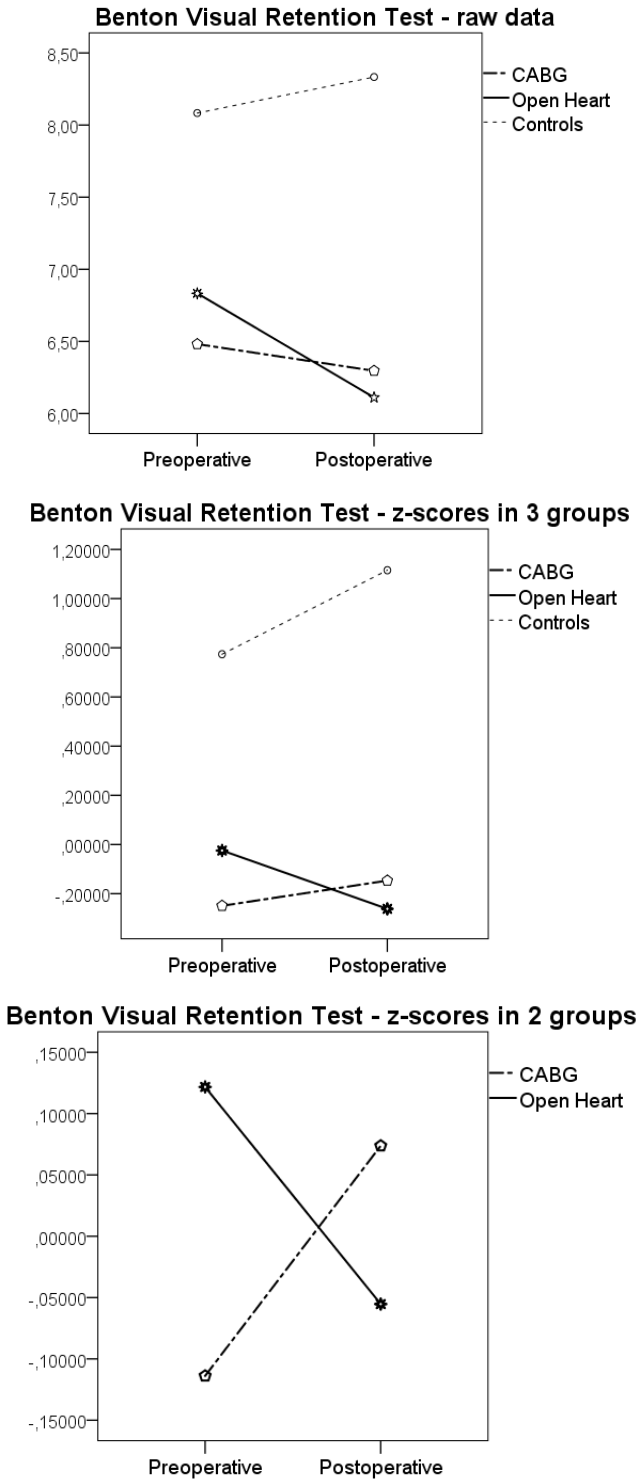

Figure 2. Changes of performance on Benton Visual Retention Test in patients after coronary surgery (n=29), patients after open heart operations (n=36) and healthy controls (n=12).

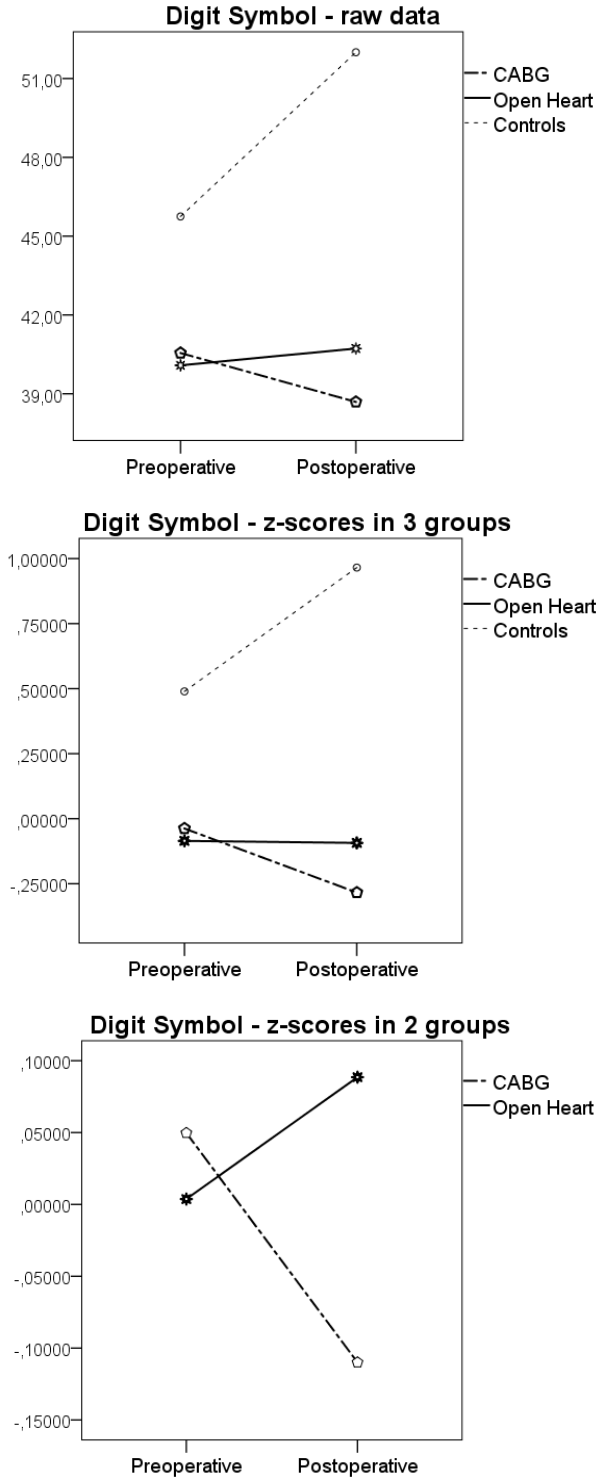

Figure 3. Changes of performance on Digit Symbol in patients after coronary surgery (CABG; n=29), patients after Open Heart operations (n=36) and healthy controls (n=12).

Overall, these data evidence, that z-scores should be used cautiously in research of subtle changes of cognitive functions. And analysis of z-scores should be performed as an additional option with obligatory comparison of its results with the results of analysis of raw neuropsychological scores.

Factor analysis is rarely used in research of cardiac surgery outcomes, however, some studies which used factor analysis are very influential and highly cited (Newman et al., 2001a; 2001b). The authors argued that each test loaded on each factor consistently at baseline and follow-up assessments, and therefore the cognitive domains also remained consistent throughout follow-ups in their study, which included 4 follow-ups (before discharge, in 6 weeks, 6 months and 5 years after surgery).

In our study (Polunina et al., 2014) we did not observe the consistency of the factor analysis results of preoperative and postoperative data (Table 2) perhaps due to lower number of subjects and inclusion of the controls into the analysis. However, if the term 'cognitive domain' relates to any objective reality then it may be expected that this entity would not be changed by inclusion of any category of subjects, especially normal controls, into the analysis.

Most important that key tests loaded differently on two factors, which were derived from preoperative and postoperative data. Both parts of Digit Span strongly loaded on the second factor, which explained 14.3% of neuropsychological variables at preoperative period. However, postoperative results of Digit Span Forward loaded predominantly on the first factor, whereas Digit Span Backward weakly loaded on two factors derived from postoperative data. Loadings of Digit Symbol distributed also differently at baseline and at postoperative follow-up. Nevertheless, the results of Word list learning test, Block Design test, Benton Visual Retention Test and some other tests demonstrated similar loading on two factors at both assessments.

Table 2. Factor analysis of neuropsychological variables at preoperative and postoperative assessments in the combined subject group (patients + controls, n=75)[#]

	Preoperative period		*Postoperative period*	
Neuropsychological variables	*Factor I*	*Factor II*	*Factor I*	*Factor II*
% of variance	41.0%	14.3%	51.3%	11.0%
Digit Symbol	0.508*	0.585*	0.784*	0.173
TMT A	-0.260*	-0.686*	-0.179	-0.852*
TMT B	0.097	-0.703*	-0.127	-0.821*
Benton Visual Retention Test	0.509*	0.285*	0.689*	0.209
Digit Span Forward	0.274*	0.711*	0.762*	0.342*
Digit Span Backward	0.356*	0.794*	0.575*	0.541*
MMSE	0.774*	0.189	0.724*	0.291*
Block Design test	0.664*	0.383*	0.629*	0.389*
Word list learning test	0.772*	0.056	0.772*	0.012
Logical memory test	0.756*	0.028	0.784*	0.162

[*] Significant Pearson's correlations between neuropsychological variables and extracted factors, $P<0.05$.

[#] The factor analysis of neuropsychological variables was conducted using principle component method, with varimax rotation.

These data evidence, that z-scores and factor analysis should be used cautiously in research of subtle changes of cognitive functions. And these mathematical methods should be performed as an additional option after obligatory analysis of raw scores is completed.

CONCLUSION

Studies of the associations between distribution of intraoperative microemboli in the cerebral circulation and postoperative cognitive changes showed that at least three types of POCD may be outlined, i.e., left hemisphere dysfunction with decline of digit span/verbal learning, right hemisphere dysfunction with decline of visuospatial processing and diffuse psychomotor slowing, which is most prominent in elderly atherosclerotic patients. Accordingly, tests sensitive to all these cognitive domains should be included into the test batteries in studies of POCD. Analysis of our data and the literature showed that short-term memory span tests (Digit Span Forward and Backward) are more effective, compared to word-learning and story-learning tests as a tool for registration of postoperative cognitive dysfunction. Non-verbal memory span tests may be recommended for future studies as a tool for evaluation of right hemisphere functions. Finally, a psychomotor speed test (e.g., Digit Symbol) should be included into test batteries, as a tool for evaluation of POCD, which is characteristic for early postoperative period and aging process. It is important to take into account, that administration of a test in the beginning of testing may increase practice effect at the follow-up assessment.

The limitations of psychometric testing as a method of POCD definition include the lower baseline performance in cardiologic patients in comparison with matched healthy controls, the regression to the mean phenomenon and practice effects. Although the majority of studies of POCD have dichotomized cognitive outcome after surgery, classifying patients as “impaired” or “unimpaired,” this approach has a range of serious limitations, leading to discrepancies in case classification by different dichotomous criteria. Conventional separate repeated measures ANOVAs on each raw score of cognitive variables with inclusion of control group is highly preferable. Whereas dichotomous criteria of POCD, z-scores and factorization of scores may be used as additional options, and the results of these analyses should be interpreted cautiously.

CONFLICT OF INTEREST

The authors declare that they have no conflict of interest.

REFERENCES

Ahlgren, E., Lundqvist, A., Nordlund, A., Aren, C., & Rutberg, H. (2003). Neurocognitive impairment and driving performance after coronary artery bypass surgery. *Eur J Cardiothorac Surg*, 23, 334-340.

Anderson, R.E., Li, T.Q., Hindmarsh, T., Settergren, G., & Vaage, J. (1999). Increased extracellular brain water after coronary artery bypass grafting is avoided by off-pump surgery. *J Cardiothorac Vascular Anesthesia*, 13, 698-702.

Arrowsmith, J.E., Grocott, H.P., Reves, J.G., & Newman, M.F. (2000). Central nervous system complications of cardiac surgery. *British Journal of Anaesthesia,* 84(3), 378-93.

Atochin, D.N., Murciano, J.C., Gürsoy-Ozdemir, Y., Krasik, T., Noda, F., Ayata, C., Dunn, A.K., Moskowitz, M.A., Huang, P.L., & Muzykantov, V.R. (2004). Mouse model of microembolic stroke and reperfusion. *Stroke,* 35(9), 2177-82.

Barbut, D., Lo, Y.W., Gold, J.P., Trifiletti, R.R., Yao, F.S., Hager, D.N., Hinton, R.B., & Isom, O.W. (1997). Impact of embolization during coronary artery bypass grafting on outcome and length of stay. *Ann Thorac Surg,* 63(4), 998-1002.

Bendszus, M., Reents, W., Franke, D., Mullges, W., Babin-Ebell, J., Koltzenburg, M., Warmuth-Metz, M., & Solymosi, L. (2002). Brain damage after coronary artery bypass grafting. *Arch Neurol,* 59, 1090-1095.

Bergh, C., Bäckström, M., Jönsson, H., Havinder, L., & Johnsson, P. (2002) In the eye of both patient and spouse: memory is poor 1 to 2 years after coronary bypass and angioplasty. *Ann Thorac Surg*, 74, 689-94.

Blacker, D.J., Flemming, K.D., & Wijdicks, E.F.M. (2003). Risk of ischemic stroke in patients with symptomatic vertebrobasilar stenosis undergoing surgical procedures. *Stroke*, 34, 2659-2663.

Blumenthal JA, Mahanna EP, Madden DJ, White WD, Croughwell ND, & Newman MF. Methodological issues in the assessment of neuropsychologic function after cardiac surgery. *Ann Thorac Surg* 1995;59:1345-1350.

Bokeriia, L.A., Golukhova, E.Z., Polunina, A.G., Davydov, D.M., & Begachev, A.V. (2005). Neural correlates of postoperative cognitive dysfunction in cardiac surgery. *Brain Research Reviews*, 50(2), 266-274.

Bokeriia, L.A., Golukhova, E.Z., Breskina, N.Y., Polunina, A.G., Davydov, D.M., Begachev AV, & Kazanovskaya SN. (2007). Asymmetric cerebral embolic load and postoperative cognitive dysfunction in cardiac surgery. *Cerebrovascular Diseases*, 23, 50-56.

Bokeriia, L.A., Golukhova, E.Z., & Polunina, A.G. (2009). Postoperative delirium in cardiac surgery: microembolic load is an important factor. *Ann Thorac Surg,* 88(1), 349-350.

Browndyke, J.N., Berger, M., Harshbarger, T.B., Smith, P.J., White, W., Bisanar, T.L., Alexander, J.H., Gaca, J.G., Welsh-Bohmer, K., Newman, M.F., & Mathew, J.P. (2016). Resting-State Functional Connectivity and Cognition After Major Cardiac Surgery in Older Adults without Preoperative Cognitive Impairment: Preliminary Findings. *J Am Geriatr Soc*, in press.

Browne, S.M., Halligan, P.W., Wade, D.T., & Taggart D.P. (1999). Cognitive performance after cardiac operation: implications of regression towards the mean. *J Thorac Cardiovasc Surg,* 117, 481-5.

Bruggemans, E.F., Van de Vijver, F.J.R., & Huysmans, H.A. (1997). Assessment of cognitive deterioration in individual patients following cardiac surgery: correcting for measurement error and practice effects. *J Clin Experiment Neuropsychology*, 19, 543-559.

Bruggemans, E.F. (2013). Cognitive dysfunction after cardiac surgery: pathophysiological mechanisms and preventive strategies. *Neth Heart J,* 21, 70-73.

Caplan, L.R., & Hennerici, M. (1998). Impaired clearance of emboli (washout) is an important link between hypoperfusion, embolism, and ischemic stroke. *Arch Neurol*, 55(11), 1475-82.

Chernov, V.I., Efimova, N.Y., Efimova, I.Y., Akhmedov, S.D., & Lishmanov, Y.B. (2006). Short-term and long-term cognitive function and cerebral perfusion in off-pump and on-pump coronary artery bypass patients. *Eur J Cardiothorac Surg*, 29(1), 74-81.

Collie, A., Darby, D.G., Falleti, M.G., Silbert, B.S., & Maruff, P. (2002). Determining the extent of cognitive change after coronary surgery: a review of statistical procedures. *Ann Thorac Surg*, 73, 2005-11.

Cormack, F., Shipolini, A., Awad, W.I., Richardson, C., McCormack, D.J., Colleoni L., Underwood M., Baldeweg T., & Hogan A.M. (2012). A meta-analysis of cognitive outcome following coronary artery bypass graft surgery. *Neuroscience and Biobehavioral Reviews*, 36, 2118-2129.

D'Agostino, R.S., Svensson, L.G., Neumann, D.J., Balkhy, H.H., Williamson, W.A., & Shahian, D.M. (1996). Screening carotid ultrasonography and risk factors for stroke in coronary artery surgery patients. *Ann Thorac Surg*, 62(6), 1714-23.

Dijkstra, J.B., & Jolles, J. (2002). Postoperative cognitive dysfunction versus complaints: a discrepance in long-term findings. *Neuropsychology Review*, 12(1), 1-13.

Dube, L., Soltner, C., Daenen, S., Lemariee, J., Asfar, P., & Alquier P. (2004). Gas embolism: an exceptional complication of radial arterial catheterization. *Acta Anaesthesiol Scand*, 48(9), 1208-10.

Evered, L.A., Silbert, B.S., Scott, D.A., Maruff P, & Ames D. (2016). Prevalence of Dementia 7.5 Years after Coronary Artery Bypass Graft Surgery. *Anesthesiology*, 125(1), 62-71.

Fearn, S.J., Pole, R., Wesnes, K., Faragher, E.B., Hooper, T.L., & McCollum, C.N. (2001). Cerebral injury during cardiopulmonary bypass: emboli impair memory. *J Thorac Cardiovasc Surg*, 121, 1150-60.

Floyd, T.F., Shah, P.N., Price, C.C., Harris, F., Ratcliffe, S.J., Acker, M.A., Bavaria, J.E., Rahmouni, H., Kuersten, B., Wiegers, S., McGarvey, M.L., Woo, J.Y., Pochettino, A.A., & Melhem, E.R. Clinically silent cerebral ischemic events after cardiac surgery: their incidence, regional vascular occurrence, and procedural dependence. *Ann Thorac Surg*, 2006, 81(60), 2160-6.

Foerch, C., Misselwitz, B., Sitzer, M., Berger, K., Steinmetz, H., Neumann-Haefelin, T; Arbeitsgruppe Schlaganfall Hessen. (2005). Difference in recognition of right and left hemispheric stroke. *Lancet*, 366(9483), 392-3.

Funder, K.S., Steinmetz, J., Rasmussen, L.S. (2010) Methodological issues of postoperative cognitive dysfunction research. *Seminars in Cardiothoracic and Vascular Anesthesia*, 14(2), 119-122.

Ganushchak, Y.M., Fransen, E.J., Visser, C., De Jong, D.S., & Maessen, J.G. (2004). Neurological complications after coronary artery bypass grafting related to the performance of cardiopulmonary bypass. *Chest*, 125(6), 2196-205.

Golukhova, E.Z., Polunina, A.G., Lefterova, N.P., Begachev, A.V. (2011). Electroencephalography as a tool for assessment of brain ischemic alterations after open heart operations. *Stroke Research and Treatment, Article ID* 980873.

Golukhova, E.Z., Polunina, A.G., Lefterova, N.P., Morelli, O.D., & Begachev, A.V. (2012). Electroencephalography as a tool for assessment of brain ischemic alteration after coronary artery bypass grafting. *Kreativnaya Kardiologia*, N1, 107-122.

Harris, D.N., Oatridge, A., Dob, D., Smith, P.L., Taylor, K.M., & Bydder, G.M. (1998). Cerebral swelling after normothermic cardiopulmonary bypass. *Anesthesiology*, 88(2), 340-5.

Hedna, V.S., Bodhit, A.N., Ansari, S., Falchook, A.D., Stead, L., Heilman, K.M., Waters, M.F. (2013). Hemispheric differences in ischemic stroke: is left-hemisphere stroke more common? *J Clin Neurol*, 9(2), 97-102.

Hernandez, F. Jr, Brown, J.R., Likosky, D.S., Clough, R.A., Hess, A.L., Roth, R.M., Ross, C.S., Whited, C.M., O'Connor. G.T., Klemperer, J.D. (2007). Neurocognitive outcomes of off-pump versus on-pump coronary artery bypass: a prospective randomized controlled trial. *Ann Thorac Surg*, 84(6), 1897-903.

Herrmann, M., Ebert, A.D., Galazky, I., Wunderlich, M.T., Kunz, W.S., & Huth, C. (2000). Neurobehavioral outcome prediction after cardiac surgery: role of neurobiochemical markers of damage to neuronal and glial brain tissue. *Stroke*, 31, 645-650.

Jacobs, A., Neveling, M., Horst, M., Ghaemi, M., Kessler, J., Eichstaedt, H., Rudolf, J., Model, P., Bönner, H., de Vivie, E.R, & Heiss, W-D. (1998). Alterations of neuropsychological function and cerebral glucose metabolism after cardiac surgery are not related only to intraoperative microembolic events. *Stroke*, 29, 660-667.

Justin, B.N., Turek, M., & Hakim, A.M. (2013). Heart disease as a risk factor for dementia. *Clin Epidemiol*, 26, 135-45.

Kastaun, S., Gerriets, T., Schwarz, N.P., Yeniguen, M., Schoenburg, M., Tanislav, C., & Juenemann, M. (2016) The Relevance of Postoperative Cognitive Decline in Daily Living: Results of a 1-Year Follow-up. *J Cardiothorac Vasc Anesth*, 30(2), 297-303.

Keith, J.R., Puente, A.E., Malcolmson, K.L., Tartt, S., Coleman, A.E., & Marks, H.F., Jr., (2002a). Assessing postoperative cognitive change after cardiopulmonary bypass surgery. *Neuropsychology*, 16, 411-421.

Keith, J.R., & Puente, A.E. (2002b). Deficiencies in the detection of cognitive deficits. *Neuropsychology*, 16(3), 434-439.

Kim, Y.H., Kim, J.S., Hong, K.S., Kim, Y.J., & Kim JH. (2008). Prevalence of fat embolism after total knee arthroplasty performed with or without computer navigation. *J Bone Joint Surg Am*, 90(1), 123-8.

Koessler, M.J., Fabiani, R., Hamer, H., Pitto, R.P. (2001). The clinical relevance of embolic events detected by transesophageal echocardiography during cemented total hip arthroplasty: a randomized clinical trial. *Anesth Analg*, 92(1), 49-55.

Koch, S., Forteza, A., Lavernia, C., Romano, J.G., Campo-Bustillo, I., Campo, N., Gold, S. (2007). Cerebral fat microembolism and cognitive decline after hip and knee replacement. *Stroke*, 38(3), 1079-81.

Kneebone, A.C., Andrew, M.J., Baker, R.A., Knight, J.L. (1998). Neuropsychologic changes after coronary artery bypass grafting: use of reliable change indices. *Ann Thorac Surg*, 65, 1320-5.

Knipp, S.C., Matatko, N., Wilhelm, H., Schlamann, M., Massoudy, P., Forsting, M., Diener, H. (2004). Evaluation of brain injury after coronary artery bypass grafting. A prospective study using neuropsychological assessment and diffusion-weighted magnetic resonance imaging. *Eur J Cardio-thorac Surg*, 25, 791-800.

Korn-Lubetzki, I., Oren, A., Asher, E., Dano, M., Bitran, D., Fink, D., Steiner-Birmanns, B. (2007). Strokes after cardiac surgery: mostly right hemispheric ischemic with mild residual damage. *J Neurol,* 254(12), 1708-13.

Leker, R.R., Pollak, A., Abramsky, O., Ben-Hur, T. (1999). Abundance of left hemispheric embolic strokes complicating coronary angiography and PTCA. *J Neurol Neurosurg Psychiatry*, 66, 116-7.

Lee, J.D., Lee, S.J., Tsushima, W.T., Yamauchi, H., Lau, W.T., Popper, J., Stein, A., Johnson, D., Lee, D., Petrovitch, H., Dang, C.R. (2003). Benefits of off-pump bypass on neurologic and clinical morbidity: a prospective randomized trial. *Ann Thorac Surg*, 76, 18-26.

Lewis, M., Maruff, P., Silbert, B. (2004). Statistical and conceptual issues in defining post-operative cognitive dysfunction. *Neuroscience and Biobehavioral Reviews*, 28, 433-440.

Lopez, O.L., Jagust, W.J., Dulberg, C., Becker, J.T., DeKosky, S.T., Fitzpatrick, A., Breitner, J., Lyketsos, C., Jones, B., Kawas, C., Carlson, M., Kuller, L.H. (2003). Risk factors for mild cognitive impairment in the cardiovascular health study cognition study. *Arch Neurol*, 60, 1394-1399.

Mahanna, E.P., Blumenthal, J.A., White, W.D., Croughwell, N.D., Clancy, C.P., Smith, R., Newman, M.F. (1996). Defining neuropsychological dysfunction after coronary artery bypass grafting. *Ann Thorac Surg*, 61, 1342-7.

Messerotti Benvenuti, S., Patron, E., Zanatta, P., Polesel, E., Bonfà, C., Palomba, D. (2013). Change in behavioral functional capacity is associated with preexisting cognitive function rather than with cognitive decline in patients 1 year after cardiac surgery. *Gen Hosp Psychiatry*, 35(2), 117-21.

Mirski, M.A., Lele, A.V., Fitzsimmons, L., & Toung, T.J. (2007). Diagnosis and treatment of vascular air embolism. *Anesthesiology*, 106(1), 164-77.

Murkin, J.M., Martzke, J.S., Buchan, A.M., Bentley, C., & Wong, C.J. (1995). A randomized study of the influence of perfusion technique and pH management strategy in 316 patients undergoing coronary artery bypass surgery. II. Neurologic and cognitive outcomes. *J Thorac Cardiovasc Surg*, 110(2), 349-62.

Murkin, J.M., Stump, D.A., Blumenthal, J.A., & McKhann, G. (1997). Defining dysfunction: group means versus incidence analysis - a statement of consensus. *Ann Thorac Surg*, 64, 904-5.

Naess, H., Waje-Andreassen, U., Thomassen, L., & Myhr, K.M. (2006). High incidence of infarction in the left cerebral hemisphere among young adults. *J Stroke Cerebrovasc Dis*, 15(6), 241-4.

Nagels, W., Demeyere, R., Van Hemelrijck, J., Vandenbussche, E., Gijbels, K., & Vandermeersch, E., (2004). Evaluation of the neuroprotective effects of S(+)-ketamine during open-heart surgery. *Anesth Analg*, 98, 1595-1603.

Neville, M.J., Butterworth, J., James, R.L., Hammon, J.W., & Stump, D.A. (2001). Similar neurobehavioral outcome after valve or coronary artery operations despite differing carotid embolic counts. *J Thorac Cardiovasc Surg*, 121, 125-36.

Newman, M.F., Kirchner, J.L., Phillips-Bute, B., Gaver, V., Grocott, H., Jones, R.H., Mark, D.B., Reves, J.G., & Blumenthal, J.A. (2001a). Longitudinal assessment of neurocognitive function after coronary artery bypass surgery. *N Engl J Med*, 2001a, 344, 395-9.

Newman, M.F., Grocott, H.P., Mathew, J.P., White, W.D., Landolfo, K., Reves, J.G., Laskowitz, D.T., Mark, D.B., & Blumenthal, J.A. (2001b). Report of the substudy assessing the impact of neurocognitive function on quality of life 5 years after cardiac surgery. *Stroke,* 32, 2874-81.

Newman, S., Stygall, J., Hirani, S., Shaefi, S., & Maze, M. (2007). Postoperative cognitive dysfunction after noncardiac surgery. *Anesthesiology,* 106, 572-90.

Omae, T., Mayzel-Oreg, O., Li, F., Sotak, C.H., & Fisher, M. (2000). Inapparent hemodynamic insufficiency exacerbates ischemic damage in a rat microembolic stroke model. *Stroke,* 31(10), 2494-9.

Orlandi, G., Fanucchi, S., Gallerini, S., Sonnoli, C., Cosottini, M., Puglioli, M., Sartucci, F., & Murri, L. (2005). Impaired clearance of microemboli and cerebrovascular symptoms during carotid stenting procedures. *Arch Neurol,* 62(8), 1208-11.

Parolari, A., Camera, M., Alamanni, F., Naliato, M., Polvani, G.L., Agrifoglio, M., Brambilla, M., Biancardi, C., Mussoni, L., Biglioli, P., & Tremoli, E. (2007). Systemic inflammation after on-pump and off-pump coronary bypass surgery: a one-month follow-up. *Ann Thorac Surg,* 84, 823-8.

Polunina, A.G. (2008). Selection of neurocognitive tests and outcomes of cardiac surgery trials. *Ann Thorac Surg,* 85(1), 362.

Polunina, A.G., Golukhova, E.Z., Guekht, A.B., Lefterova, N.P., & Bokeria, L.A. (2014). Cognitive dysfunction after on-pump operations: neuropsychychological characteristics and optimal core battery of tests, *Stroke Research and Treatment,* Article ID 302824.

Puskas, F., Grocott, H.P., White, W.D., Mathew, J.P., Newman, M.F., & Bar-Yosef, S. (2007). Intraoperative Hyperglycemia and cognitive decline after CABG. *Ann Thorac Surg* 2007;84:1467-73.

Rankin, K.P., Kochamba, G.S., Boone, K.B., Petiti, D.B., Buckwalter, J.G. (2003). Presurgical cognitive deficits in patients receiving coronary artery bypass graft surgery. *J Intern Neuropsycholog Soc,* 9, 913-924.

Rasmussen, L.S., Larsen, K., Houx, P., Skovgaard, L.T., Hanning, C.D., Moller, J.T. and the ISPOCD group. (2001). The assessment of postoperative cognitive function. *Acta Anaesthesiologica Scandinavica,* 45, 275-289.

Rasmussen, L.S., Sperling, B., Abildstrom, H.H., Moller, J.T. (2002). Neuron loss after coronary artery bypass detected by SPECT estimation of benzodiazepine receptors. *Ann Thorac Surg,* 74, 1576-80.

Raymond, P.D., Hinton-Bayre, A.D., Radel, M., Ray, M.J., Marsh, N.A. (2006). Assessment of statistical change criteria used to define significant change in neuropsychological test performance following cardiac surgery. *Eur J Cardio-thorac Surg,* 29, 82-88.

Restrepo, L., Wityk, R.J., Grega, M.A., Borowicz, L., Barker, P.B., Jacobs, M.A., Beauchamp, N.J., Hillis, A.E., McKhann, G.M. (2002). Diffusion- and perfusion-weighted magnetic resonance imaging of the brain before and after coronary artery bypass grafting surgery. *Stroke,* 33, 2909-2915.

Robson, M.J.A., Alston, R.P., Deary, I.J., Andrews, P.J.D., Souter, M.J., Yates, S. (2000). Cognition after coronary artery surgery is not related to postoperative jugular bulb oxyhemoglobin desaturation. *Anesth Analg,* 91, 1317-26.

Scott, J.E., Mathias, J.L., Kneebone, A.C., Krishnan, J. (2016). Postoperative cognitive dysfunction and its relationship to cognitive reserve in elderly total joint replacement patients. *J Clin Exp Neuropsychol,* 27, 1-14.

Selnes, O.A., & Gottesman, R.F. (2010). Neuropsychological outcomes after coronary artery bypass grafting. *J International Neuropsychological Society* 2010, 16, 221-226.

Silbert, B.S., Maruff, P., Evered, L.A., Scott, D.A., Kalpokas, M., Martin, K.J., Lewis, M.S., Myles, P.S. (2004). Detection of cognitive decline after coronary surgery: a comparison of computerized and conventional tests. *Br J Anaesth*, 92(6), 814-20.

Slade, P., Sanchez, P., Townes, B., Aldea, G.S. (2001). The use of neurocognitive tests in evaluating the outcome of cardiac surgery: some methodologic considerations. *J Cardiothorac Vasc Anesth*, 15(1), 4-8.

Song, Z., Fu, P., Chen, M., Bi, Q. (2016). Association of CT perfusion and postoperative cognitive dysfunction after off-pump coronary artery bypass grafting. *Neurol Res*, 38(6), 533-7.

Sotaniemi, K.A., Monomem, H., Hokkanen, T.E. (1986). Long-term cerebral outcome after open-heart surgery: a five-year neuropsychological follow-up study. *Stroke*, 17(3), 410-416.

Sowell, M.W., Lovelady, C.L., Brogdon, B.G., Wecht, C.H. (2007). Infant death due to air embolism from peripheral venous infusion. *J Forensic Sci*, 52(1), 183-8.

Steinmetz, J., Christensen, K.B., Lund, T., Lohse, N., Rasmussen, L.S.; ISPOCD Group. (2009). Long-term consequences of postoperative cognitive dysfunction. *Anesthesiology*, 110(3), 548-55.

Stolz, E., Gerriets, T., Kluge, A., Klövekorn, W.P., Kaps, M., Bachmann, G. (2004). Diffusion-weighted magnetic resonance imaging and neurobiochemical markers after aortic valve replacement. *Stroke*, 35, 888-892.

Sun, J.H., Wu, X.Y., Wang, W.J., Jin, L.L. (2012). Cognitive dysfunction after off-pump versus on-pump coronary artery bypass surgery: a meta-analysis. *J Int Med Res*, 40(3), 852-8.

Swan, G.E., LaRue, A., Carmelli, D., Reed, T.E., Fabsitz, R.R. (1992). Decline in cognitive performance in aging twins. *Arch Neurol*, 49, 476-481.

Sylivris, S., Levi, C., Matalanis, G., Rosalion, A., Buxton, B.F., Mitchell, A., Fitt, G., Harberts, D.B., Saling, M.M., Tonkin, A.M. (1998). Pattern and significance of cerebral microemboli during coronary artery bypass grafting. *Ann Thorac Surg*, 66, 1674-8.

Tsai, T.L., Sands, L.P., Leung, J.M. (2010). An update on postoperative cognitive dysfunction. *Adv Anesth*, 28(10), 269-284.

Van Dijk, D., Keizer, A.M.A., Diephuis, J.C., Durand, C., Vos, L.J., Hijman, R. (2000). Neurocognitive dysfunction after coronary artery bypass surgery: a systematic review. *J Thorac Cardiovasc Surg*, 120, 632-9.

Vingerhoets, G., de Soete, G., Jannes, C. (1995). Subjective complaints versus neuropsychological test performance after cardiopulmonary bypass. *J Psychosom Res*, 39(7), 843-53.

Weinstein, G.S. (2001). Left hemispheric strokes in coronary surgery: implications for end-hole aortic cannulas. *Ann Thorac Surg*, 71(1), 128-32.

In: Encyclopedia of Surgery (22 Volume Set)
Editors: Andreas Lehrer and Kristin Mueller
ISBN: 978-1-53618-329-0
© 2020 Nova Science Publishers, Inc.

Chapter 442

CURRENT ANESTHESIA CONCEPTS IN STRABISMUS SURGERY

***Monica del-Rio-Vellosillo*[1],[*] *and Jose Javier Garcia-Medina*[2,†]**

[1]Department of Anesthesia, University Hospital Virgen de la Arrixaca, El Palmar, Murcia, Spain

[2]Department of Ophthalmology, University Hospital Reina Sofia, Murcia, Spain and Department of Ophthalmology and Optometry, University School of Medicine, University of Murcia, Murcia, Spain

ABSTRACT

Strabismus is caused by the misalignment of extraocular muscles, and produces loss of binocular vision and amblyopia. This pathology can be inherited, developed or acquired, and can be associated with several comorbidities (neuromuscular diseases, congenital syndromes or cardiac diseases). Thus a suitable pre-anesthetic evaluation is important to assess each patient's individual requirements and their impact on perioperative morbidity.

Strabismus is the most frequent ocular surgery performed in childhood. This surgery aims to restore ocular alignment to maintain visual acuity, achieve a favorable esthetic result, improve depth perception, and to eliminate double vision, if present. This surgery also requires having to achieve anesthesia that provides akinesia, analgesia, and sometimes ocular hypotonia, to adjust sutures.

Strabismus surgery is characterized by being done in an outpatient setting. It implies the usual intraoperative and postoperative complications, which must be known to avoid them by prophylactic measures. The commonest complications are oculocardiac reflex, nausea, and vomiting and postoperative pain. Several studies have assessed the effectiveness of different drugs and anesthetic techniques, and the prophylactic measures to reduce these complications.

The different anesthetic techniques used include general anesthesia, retrobulbar anesthesia, peribulbar anesthesia, sub-Tenon´s anesthesia, or a combination of sedation/topical anesthesia, sedation/peribulbar anesthesia and sedation/local anesthesia.

[*] Corresponding Author's Email: monicadelriov@hotmail.com.
[†] Corresponding Author's Email: josegarciam@yahoo.com.

Each anesthetic technique offers several advantages and disadvantages, which are assessed in each case to choose the most suitable technique in each patient. Moreover, adequate surgeon experience in the technique is essential, as is suitable patient cooperation during the procedure.

INTRODUCTION

Strabismus is an ocular misalignment that produces loss of binocular vision and amblyopia (vision loss in a structurally normal eye) [1]. It is a relatively frequent pathology that can affect up to 3% of the general population. Its incidence in children lies between 2-7%, with an age prevalence of 2-4 years [1-5].

This pathology can be inherited, developmental or acquired, or may be associated with neuromuscular diseases. Children with strabismus or palpebral ptosis could either be at higher risk of malignant hyperthermia or related with any undiagnosed cardiomyopathy. So preanesthesia is required in these patients [6, 7]. It is the most frequently performed surgery in the pediatric population, and is usually done in outpatient settings [8].

The aims of surgery are to restore ocular alignment to maintain visual acuity (no amblyopia), provide cosmetic correction (orthotropia), confer depth perception (stereopsis), and eliminate double vision [3-5]. Visual maturation happens around the age of 5, so it is important to repair strabismus early in childhood [5].

This surgery can have side effects during intraoperative and postoperative management. One of the main problems associated with strabismus surgery is oculocardiac reflex (OCR), which appears more frequently in children due to a relative increase in vagal tone [9]. There are no data available about a precise OCR incidence estimates in adult strabismus surgery because the definition of OCR is not the same for all authors. Besides, most studies are based on data taken from pediatric populations [9]. OCR can be defined as a trigeminal vagal reflex that produces bradycardia, hypotension, dysrhythmias or sinoatrial arrest, associated with ocular muscle traction [10-13]. OCR is associated with postoperative nauseas and vomiting (PONV) from stimulating the oculometric reflex, with an incidence of 46-85% [14-16]. Several maneuvers have been studied to reduce OCR (preventing hypoxemia and hypercapnia, premedication with atropine or glycopyrrolate, and adequate anesthetic depth). However, no maneuver has proven effective, safe or acceptable [8, 15-17]. Treatment using atropine may cause a variety of cardiac arrhythmias [18].

Other side effects of this surgery include pain and PONV. PONV has an incidence of around 88% in these patients when they are not treated [19]. Postoperative PONV also depends on the anesthetic technique used, postoperative pain management and antiemetic therapy. Thus suitable knowledge and control of these factors by an anesthesiologist will enable safe and cost-effective anesthesia to be performed with quick awakening and minimal incidence of pain, nauseas and vomiting.

ANESTHETIC MANAGEMENT

There are several anesthetic techniques for strabismus surgery: general anesthesia, regional anesthesia (peribulbar anesthesia, retrobulbar anesthesia and sub-Tenon's block) and topical anesthesia.

The necessary fasting for surgery and parenteral separation lead to a period of perioperative anxiety in children. Suitable preoperative hydration reduces the incidences of intraoperative hypoglycemia and hypovolemia, and PONV. It is advisable to freely drink clear iv liquids until 2-3 hours preoperatively with iv crystalloids to lower PONV [4, 20]. In fact one published study recommends administering liquids at 30 mL/kg/h instead of at 10 mL/kg/h [21].

Perioperative anxiety can be managed with anxiolytics. In pediatric patients, ansiolysis is often administered from a protocol point of view after 18 months. There are several drugs used for premediction (e.g., oral midazolam). Another option is to allow parents to enter the operating room until anesthetic induction.

General Anesthesia

As immobilizing patients during strabismus surgery is important to avoid complications, general anesthesia is the anesthetic technique of choice in pediatric ocular surgery.

Both inhalation general anesthesia and intravenous general anesthesia have been used successfully in strabismus surgery. The most widely used inhalation anesthetics are sevoflurane, isoflurane or desflurane in air and oxygen. Desflurane offers a low blood/gas ratio, thus it allows quick anesthetic induction. However, this inhalation anesthetic has been associated with greater airway irritability when used in induction, so its use is more extended to maintain anesthesia. Nitrous oxide could increase perioperative nausea or vomiting, but this relation remains controversial [20, 22]. Sevoflurane seems to produce lower OCR incidence than propofol because this anesthetic depresses vagal activity. Hence it produces less bradycardia when manipulating extraocular muscles (EOM), along with a lower incidence of dysrhythmias in children compared with halothane [23, 24].

Propofol is an intravenous anesthetic of choice for strabismus surgery in older pediatric patients. It is an isopropyl phenol with quick onset and end of action. It does not produce analgesia, but generates minimum residual sedation and is a powerful antiemetic. However, if this drug is used only in induction and it is not used in anesthesia maintenance, no effect to diminish PONV is observed [25]. PONV lowers if used in anesthesia maintenance, but this can result in higher OCR incidence compared with other anesthetics [2, 12, 22, 26, 27].

Another intravenous anesthetic is ketamine. This drug is associated with fewer hemodynamic changes for strabismus surgery in pediatric patients [28], probably due to different mechanisms, which include the antagonism effect in N-methyl-D-aspartate receivers [29, 30], intrinsic analgesia and amnesic properties that protect the airway reflex [31, 32]. It has an analgesic effect at subanesthetic doses [30]. If low doses of this drug are used, thalamic sensory output and arousal increase [33], and duration is relatively quick-acting and short. Ketamina could avoid vagal stimulus, and could protect against parasymphatetic activity that induces OCR in patients who are more prone to develop it. So iv ketamine administration seems safe and useful for monitoring anesthesia care in outpatient settings [34].

Regarding neuromuscular relaxants, as surgery lasts 30-60 minutes, it is advisable to use neuromuscular relaxants that offer intermediate action, such as atracurium or rocuronium. One of the beneficial effects of rocuronium in such surgery is the vagolytic effect described in a published study, hence OCR incidence lowers if it is used at low doses [34]. Neuromuscular

relaxants, except for succinylcholine, reduce intraocular pressure (PIO) by relaxing EOM, which is something that we must bear in mind if strabismus surgery is accompanied by tonometry.

We can either perform endotracheal intubation or insert a laryngeal mask airway. Endotracheal intubation requires deeper anesthesia, increases PIO and results in a higher incidence of respiratory events during the postoperative period.

The effect of general anesthesia on EOM tone is that it can hinder ophthalmologists' ability to ensure the ocular position and to gage the extent of any necessary correction [35].

Regional Anesthesia

Although general anesthesia remains the most widely used anesthetic technique in strabismus surgery, more and more ophthalmologists perform this surgery with regional anesthesia in adult patients. It is also one of the more painful ophthalmological surgery types that can benefit from the postoperative analgesia offered by this kind of anesthesia. Furthermore, it enables us to explore and correct surgery results with awake patients before surgery ends [36].

Regional anesthesia is used with general anesthesia in children. Several studies have confirmed that using preoperative regional blocks avoids having to resort to intraoperative anesthetics and opioids, contributes to postoperative analgesia, and allows faster recovery, which is important in outpatient surgery [37-40]. Moreover, a drop in OCR incidence has been observed due to the sensitive block of afferent pathways, as well as a drop in PONV, which is the commonest complication in strabismus surgery [28, 41].

In order to successfully perform strabismus surgery under regional anesthesia, working with a surgeon who is sufficiently competent in the anesthetic technique is essential, as is suitable patient contribution during the procedure [36].

Several types of regional anesthesia are used in ocular surgery: peribulbar, retrobulbar, and sub-Tenon's blocks.

Peribulbar and Retrobulbar Anesthesias

Peribulbar anesthesia is performed to inject the anesthetic drug (6-8 ml) into the orbit around the equatorial line of the eyeball. Retrobulbar anesthesia is performed to inject anesthetic drug (3-4 ml) into the orbit, and even further behind the eyeball, where nerves manage eye movement and sensitivity.

Both anesthetic techniques incur the risk of producing major complications, such as the intravenous or subarachnoid injection of local anesthetic, or ocular complications such as perforating the eyeball, optic nerve damage and retrobulbar bleeding, with possible loss of vision [42-45].

Moreover, anesthetic techniques produce anatomical distortion and akinesia if large volumes of local anesthetics are injected into the orbital space, which implies problems to properly fit ocular alignment. Other complications are miotoxicity by local anesthetic as it can produce fibrosis or muscular hypertrophy [46].

Peribulbar anesthesia, compared with retrobulbar anesthesia, requires a large volume of local anesthetic, but peribulbar anesthesia complications are minor because the needle used is shorter [47].

Sub-Tenon's Block

This anesthetic technique offers similar conditions for anesthesia and ocular akinesia to peribulbar anesthesia, but has a lower major complication rate and produces less pain when applied [48-50]. However, some patients have complained about conjunctival incision or Tenon's capsule and EOM traction [51]. The commonest complication is subconjunctival bleeding, although the same peribulbar anesthesia complications have also been described with this technique [52].

It is done with local anesthetics, which are injected into the back Tenon's capsule. The analgesic effect of sub-Tenon's anaesthesia is apparently due to the blockage of ciliary ganglia and short posterior nerves to the EOM [53]. As this regional anesthetic technique is performed under direct vision, it provides a safe effective anesthesia and entails a minimal risk of serious complications [54, 55].

This technique is a safe method to reduce PONV, postoperative pain, and to provide better adult patient satisfaction compared to general anesthesia [53]. It also allows faster hospital discharge [56]. Its effectiveness to reduce OCR is controversial. Some studies have observed a lower incidence of OCR, and therefore of PONV [57], but other studies have not observed this effect [58].

Sub-Tenon's block allows eyes to be aligned according to patient satisfaction at the time of surgery [51]. This anesthetic technique, compared with topical anesthesia, allows more patient and surgeon comfort.

Topical Anesthesia

It is a non invasive technique with very few adverse effects and allows effective anesthesia on the ocular surface. Insertion of needles, which happens in regional anesthesia, is avoided by this anesthetic technique and general anesthesia is also avoided.

Many studies about successful topical anesthesia in strabismus surgery for adults have been published, while most studies supplement the technique with sedation, which is either intravenous hypnotic or opioid, and have been used to avoid potential patient discomfort with muscular traction or conjunctiva manipulation [36].

Despite usually being a well-tolerated anesthetic technique, cases of discomfort have been described with dissection and manipulation of rectus muscles. This can be avoided if muscles are carefully manipulated, or combined with greater sedation or local anesthetic administration. If local anesthetic is managed in gel, it can increase its penetration [59-64].

Given the stress that this anesthetic technique produces in surgeons, the recommendation is that surgeons have sufficient experience in EOM surgery before they apply it [62].

Lack of akinesia and patient collaboration allow ocular alignment to be more accurately fitted and the incidence of reoperation lowers [60, 61, 63-65]. A lower OCR incidence has been observed [60, 61, 64, 66].

Contact topical anesthesia is a variant of traditional topical anesthesia with drops. It allows greater local anesthetic penetration on the ocular surface after applying a gelatin sponge soaked with local anesthetic. This anesthetic technique provides a more comfortable and deeper anesthesia [36], although it is true that some patients feel uncomfortable with muscular traction [9]. As with traditional topical anesthesia, lack of akinesia allows better suture adjustment. Although some studies have been published that report lower incidences

for PONV and OCR, and good pain control [9], more research is needed to assess these points. Besides, this technique needs to be compared with all the other techniques used in strabismus surgery [36].

Suitable patient monitoring by anesthesiologists is advisable to assess good pain control and the possible appearance of side effects, plus the safety matter of being able to convert to general anesthesia if any complication occurs [62].

PREVENTING AND TREATING POSTOPERATIVE PAIN

Excessive postoperative pain produces nausea, distress and delays patients being discharged from recovery rooms. Preventing and treating postoperative pain in strabismus surgery is a challenge for anesthesiologists. Pain that occurs after strabismus surgery comes from the conjunctival area, Tenon's capsule, sclera and stretched muscles [57]. Different regional anesthesia techniques, combined with general anesthesia, have contributed to reduce postoperative pain.

Opioids are drugs that are often used in strabismus surgery, but must be used very carefully because they produce nausea and vomiting, which could cause respiratory depression by excessive sedation and could delay patient discharge [67].

Some studies report good pain control without using opioids, such as ibuprofen or ketorolac, and even indicate a similar degree of effectiveness to morphine and pethidine, but with low PONV incidence [68-70]. Ketorolac has been demonstrated in some studies as the most effective compared with ibuprofen or paracetamol [71]. Ketorolac is a non steroidal anti-inflammatory drug (NSAIDs) that interferes with prostaglandins by blocking cyclo-oxygenase. Ketorolac is effective for 45 minutes when administered intravenously, and has a 6-hour half-life. Administering this drug at the beginning of surgery, instead of at the end, improves its effectiveness because strabismus surgery duration is short. One disadvantage with this drug is a higher risk of bleeding because it produces less platelet aggregation, which is a common side effect with NSAIDs. Topical analgesia using drops with NSAIDs has proven effective in some studies [72], but not in others [73, 74].

Some possible reactions produced by NSAIDs are: angioedema, rhinitis, and exacerbation of asthma or bronchospasm [75-79]. So this should be considered in asthmatic patients because a proportion of them (20%) are sensitive to aspirin and other NSAIDs [80, 81]. These reactions have been observed in ophthalmologist procedures and after administering NSAIDs such as ibuprofen, diclofenac and ketorolac [82]. Hence they are not highly recommended in strabismus surgery.

PREVENTING AND TREATING POSTOPERATIVE NAUSEA AND VOMITING

Although anesthesiologists are aware of this complication in postoperative strabismus surgery, its incidence is still too high.

In the last few decades, different guides have attempted to standardize its management in the clinical practice, but no clear algorithm has been found.

PONV incidence in childhood lies between 33.2% and 82%, and its incidence is double in adults [83-87]. This high incidence explains antiemetic prophylaxis instead of treatment [84, 88, 89].

Although there are many causes of PONV, surgery type has a strong influence [22]. Strabismus surgery and ear-nose-throat, such as adenoidectomy or tonsillectomy, are associated with a PONV incidence of between 54-82%, and with a post-prophylaxis incidence of 33-36% [21, 83]. PONV in strabismus surgery is due to EOM traction producing the oculoemetic reflex [90]. Joo et al. demonstrated that there was no relation between the number of muscles operated in strabismus surgery and PONV [91].

PONV can result in a range of complications, including wound dehiscence, dehydration, electrolyte imbalance, subconjunctival bleeding, delayed patient discharge, likely readmission, or even pulmonary aspiration [69, 92].

Anesthesiologists can reduce the risk of PONV with different therapeutic managements [88]: 1) avoiding volatile anesthetics and preferably using total intravenous anesthesia (TIVA) with propofol; 2) preferably using regional anesthesia or combined with general anesthesia to use postoperative opioids less; 3) multimodal therapy for postoperative pain to use postoperative opioids less; 4) avoiding nitrous oxide; 5) suitable hydration; 6) avoiding neostigmine.

The use of NSAIDs in multimodal analgesia is controversial because of the higher risk of bleeding during surgery, although some studies have proved that that the incidence of bleeding after its use is no higher, as well as a lower PONV incidence [93].

Regarding hydration, several studies have demonstrated that high doses of intravenous liquids (30 ml/kg/h) for strabismus surgery have been associated with a lower emesis incidence than standard therapy (10 ml/kg/h), and with a lower PONV incidence, from 54% to 22% [21, 83].

Other factors that have been demonstrated to lower PONV incidence are gastric emptying under general anesthesia and prolonged postoperative fasting [94-96].

Different drugs can reduce PONV, such as droperidol, 5-HT3 antagonists (ondansetron), dimenhydrinate, dexamethasone and metoclopramide [20, 97]:

1) Droperidol: is a butyrophenone that produces the central antagonism of the receptors of dopamine in the chemoreceptor trigger zone. Because of side effects, like prolonged sedation, extrapiramidal side effects, agitation, anxiety and prolonged QT, this drug has been recommended as a recue therapy if PONV is only refractory [98]. QT prolongation is a contradiction for its use.
2) 5-HT3 antagonists: are first-line drugs recommended for PONV. Ondansetron is one of the most frequently used and most effective, and is a serotonin central antagonist of the 5-HT3 receptor [89, 99, 100, 101]. Its use is associated with minimal side effects, absence of sedation and extrapiramidal effects. This drug could have a dose-dependent effect, and is able to lower PONV incidence, even with low doses at 0.1–0.15 mg/kg iv [102].

   The main concern lies in the possibility of triggering cardiac dysrhythmias by QT prolongation. However, some studies have proven QT prolongation as being insignificant when using therapeutic doses of this drug [103].

   A drop in PONV incidence up to 50% has been observed after using a 5-HT3 antagonist [101]. Other studies have indicated a minor PONV incidence when

tropisetron is combined with dexamethasone (PONV of 24.4%), compared to tropisetron alone (PONV of 53%) [104]. A clear advantage has been also observed with ramosetron (PONV of 8.3%) over ondansetron (PONV of 21.3%) [105]. Even in strabismus surgery, PONV with ramosetron was 9% [91, 106].

3) Dimenhydrinate: is an antihistamine drug with an antiemetic effect. It is a cheap drug with good antiemetic effectiveness [107]. It may have a similar effect to 5-HT3 receptor antagonists, dexamethasone and droperidol. However, this drug could produce greater sedation and require better observation during the postoperative period. In fact its duration and dose-response have not yet been studied [108].
4) Dexamethasone: is a glucocorticoid used for PONV. No consensus about a dose-response relationship has been reached from published studies. Some studies have shown no difference with the various doses used (0.0625, 0.125, 0.25, 0.5 or 1 mg/kg until a maximum dose of 24 mg) [109, 110]. Instead other studies have found a reduced PONV dose-response and have favored higher dexamethasone doses of up to 0.5mg/kg [111]. Hence nowadays more randomized dose-control trials are necessary to recommend suitable doses of this drug in such cases [112]. The remarkable side effects of this drug are tumor lysis syndrome, a serious complication with low dexamethsone doses, which produce hyperkalemia, hyperuricemia, hypocalcemia and hyperphosphatemia, which could result in kidney failure, cardiac arrhythmias, seizures, and even death [113]. Toxic effects have also been observed in children with hematologic cancer who received dexamethasone [114, 115]. This drug also causes a higher blood glucose concentration [116].
5) Metoclopramide: is a benzamide that acts as a central peripheral dopaminergic antagonist to increase the lower esophageal sphincter tone and to enhance gastric motility. The side effects of metoclopramide include sedation and extrapiramidal effects.

   Available studies that analyze the effectiveness of metoclopramide compared to other drugs are limited, so we must be careful with their results. It has been demonstrated to be an effective drug, and one with no dose dependency. Ondansetron has been shown in some studies to be more effective than metoclopramide at doses of 0.5 mg/kg [117]. So metoclopramide should not be used routinely as a prophylactic drug.

   The risk factors for PONV are: previous PONV or a family history of PONV, duration of anesthesia (> 30 minutes), age (≥ 3 years), underlying diseases (e.g., general sickness), female sex, no smoking, use of volatile anesthetic, use of opioids during the perioperative and postoperative periods, and kind of surgery (strabismus surgery, orchiopexy and tonsilloadenoidectomy) [118, 119].

   Several factors can increase PONV incidence in strabismus surgery: visual disturbances, anesthetic technique and oculoemetic reflex. Oculoemetic reflex is a central reflex due to ocular muscle manipulation, which has been described by Van den Berg et al. [69].

   Risk factors should be treated to lower PONV incidence and to make a good pharmacological prophylaxis with antiemetics, by maintaining it for the first 24 h in strabismus surgery [91]. Doses and administration times are important, as is performing a good combination of different kinds of drugs to optimize the effect.

REFERENCES

[1] Engle EC. The genetic basis of complex strabismus. *Pediatr Res.* 2006;59:343-348.

[2] Mills MD. Perianesthesia care of adult and pediatric strabismus surgery patients. *J Perianesth Nurs.* 1998;13:16-25.

[3] Huddleston KR. Strabismus repair in the pediatric patient. *AORN J*. 1994;60:754-760.

[4] McGoldrick KE. Principles of ophthalmic anesthesia. *J Clin Anesth*. 1989;1:297-312.

[5] Donahue SP. Clinical practice. Pediatric strabismus. *N Engl J Med*. 2007;356:1040-1047.

[6] Strazis KP, Fox AF. Malignant hyperthermia: a review of published cases. *Anesth Analg*. 1993;77:297-304.

[7] Michelides M, Moore AT. The genetics of strabismus. *J Med Genet*. 2004;41:641-646.

[8] McGoldrick KE, Gayer SI. Anesthesia and the eye. In: BarashPG, Cullen BF, Stoelting RK, editors. *Clinical anesthesia*. 5th ed. Philadelphia: Lippencott Williams & Wilkins; 2006. p. 974-96.

[9] Vallés-Torres J, García-Martín E, Peña P, Abadía B, Pablo LE, Martínez-Diestre MD. Anestesia tópica de contacto en cirugía de estrabismo. *Rev Esp Inves Oftalmol.* 2013;1:9-11.

[10] Allison CE, De Lange JJ, Koole FD, Zuurmond WW, Ros HH, van Schagen NT. A comparison of the incidence of the oculocardiac and oculorespiratory reflexes during sevoflurane or halothane anesthesia for strabismus surgery in children. *Anesth Analg*. 2000; 90:306-310.

[11] Choi SH, Lee SJ, Kim SH, Kim JH, Kwon HH, Shin YS, Lee KY. Single bolus of intravenous ketamine for anesthetic induction decreases oculocardiac reflex in children undergoing strabismus surgery. *Acta Anaesthesiol Scand*. 2007;51:759-762.

[12] Choi SR, Park SW, Lee JH, Lee SC, Chung CJ. Effect of different anesthetic agents on oculocardiac reflex in pediatric strabismus surgery. *J Anesth*. 2009;23:489-493.

[13] Chung CJ, Lee JM, Choi SR, Lee SC, Lee JH. Effect of remifentanil on oculocardiac reflex in paediatric strabismus surgery. *Acta Anaesthesiol Scand*. 2008;52: 1273-1277.

[14] Blanc VF, Hardy JF, Milot J, Jacob JL. The oculocardiac reflex: a graphic and statistical analysis in infants and children. *Can Anaesth Soc J*. 1983;30:360-369.

[15] Donlon JV, Doyle JDJ. Anesthesia for eye, ear, nose and throat surgery. In: Miller RD, editor. *Anesthesia*. New York: Churchill Livingstone; 1990. p. 2001-2023.

[16] Wier PM, Munro HM, Reynolds PI, Lewis IH, Wilton NC. Propofol infusion and the incidence of emesis in pediatric outpatient strabismus surgery. *Anesth Analg*. 1993;76:760-764.

[17] Steib A, Karcenty A, Calache E, Franckhauser J, Dupeyron JP, Speeg-Schatz C. Effects of subtenon anesthesia combined with general anesthesia on periopera-tive analgesic requirements in pediatric strabismus surgery. *Reg Anesth Pain Med*. 2005;30:478-483.

[18] Mirakhur RK, Jones CJ, Dundee JW, Archer DB. Intramuscular or intravenous atropine or glycopyrrolate for prevention of OCR in children during squint surgery. *British Journal of Anaesthesia*. 1982;54:1059.

[19] Lin DM, Furst SR, Rodart A. A double-blinded comparison of metoclopramide and droperidol for prevention of emesis following strabismus surgery. *Anesthesiology.* 1992;76:357.

[20] Williams AR, Conroy JM. The anesthetic management of the pediatric strabismus patient. *J AAPOS*. 1998;2:113-115.

[21] Goodarzi M, Matar MM, Shafa M, Townsend JE, Gonzalez I. A prospective randomized blinded study of the effect of intravenous fluid therapy on postoperative nausea and vomiting in children undergoing strabismus surgery. *Paediatr Anaesth.* 2006;16:49-53.

[22] Kovac AL. Management of postoperative nausea and vomiting in children. *Paediatr Drugs.* 2007;9:47-69.

[23] Oh AY, Yun MJ, Kim HJ, Kim HS. Comparison of desflurane with sevoflurane for the incidence of oculocardiac reflex in children undergoing strabismus surgery. *Br J Anaesth*. 2007;99:262-265.

[24] Gürkan Y, Kiliçkan L, Toker K. Propofol-nitrous oxide versus sevoflurane-nitrous oxide for strabismus surgery in children. *Paediatr Anaesth*. 1999;9:495-499.

[25] Hamunen K, Vaalamo MO, Maunuksela EL. Does propofol reduce vomiting after strabismus surgery in children? *Acta Anaesthesiol Scand*. 1997;41:973-977.

[26] Tramer M, Moore A, McQuay H. Prevention of vomiting after paediatric strabismus surgery: a systemic review using the numbers-needed-to-treat method. *Br J Anaesth*. 1995;75:556-561.

[27] Hahnenkamp K, Honemann CW, Fischer LG, Durieux ME, Muehlendyck H, Braun U. Effect of different anaesthetic regimes on the oculocardiac reflex during paediatric strabismus surgery. *Paediatr Anaesth*. 2000;10:601-608.

[28] Chhabra A, Pandey R, Khandelwal M, Subramaniam R,Gupta S. Anesthetic techniques and postoperative emesis in pediatric strabismus surgery. *Reg Anesth Pain Med.* 2005;30:43-47.

[29] Krystal JH, Karper LP, Seibyl JP, Freeman GK, Delaney R, Bremner JD, Heninger GR, Bowers MB, Jr, Charney DS. Subanesthetic effects of the noncompetitive NMDA antagonist, ketamine, in humans. Psychotomimetic, perceptual, cognitive, and neuroendocrine responses. *Arch Gen Psychiatry*. 1994;51:199-214.

[30] Suzuki M, Tsueda K, Lansing PS, Tolan MM, Fuhrman TM, Ignacio CI, Sheppard RA. Small-dose ketamine enhances morphine induced analgesia after outpatient surgery. *Anesth Analg*. 1999;89:98-103.

[31] White PF, Way WL, Trevor AJ. Ketamine, its pharmacology and therapeutic uses. *Anesthesiology*. 1982;56:119-136.

[32] Green SM, Johnson NE. Ketamine sedation for pediatric procedures: Part 2, Review and implications. *Ann Emerg Med*. 1990;19:1033-1046.

[33] Carlsson M, Carlsson A. Schizophrenia: a subcortical neurotransmitter imbalance syndrome? *Schizophr Bull*. 1990;16:425-432.

[34] Mizrak A, Erbagci I, Arici T, Avci N, Ganidagli S, Oner U. Dexmedetomidine use during strabismus surgery in agitated children. *Med Princ Pract*. 2011;20:427-432.

[35] Lili X, Zhiyong H, Jianjun S. Asleep-awake asleep technique in children during strabismus surgery under sufentanil balanced anesthesia. *Paediatr Anaesth.* 2012; 22:1216-1220.

[36] Vallés-Torres J, Garcia-Martin E, Gil-Arribas LM, Fernández Tirado FJ, Pablo Júlvez LE. Local and regional anesthesia techniques in strabismus surgery: advantages and disadvantages. *Arch Soc Esp Oftalmol.* 2013;88:331-333.

[37] Ates Y, Unal N, Cuhruk H, Erkan N. Postoperative analgesia in children using preemptive retrobulbar block and local anesthetic infiltration in strabismus surgery. *Reg Anesth Pain Med.* 1998;23:569-574.

[38] Sheard RM, Mehta JS, Barry JS, Bunce C, Adams GW. Subtenons lidocaine injec-tion for postoperative pain relief after strabismus surgery inchildren: a pilot study. *J AAPOS*. 2003;7:38-41.

[39] Subramaniam R, Subbarayudu S, Rewari V, Singh RP, Madan R. Usefulness ofpre-emptive peribulbar block in pediatric vitreoretinal surgery:a prospective study. *Reg Anesth Pain Med*. 2003;28:43-47.

[40] Chhabra A, Sinha R, Subramaniam R, Chandra P, Narang D, Garg SP. Comparison ofsub-Tenon's block with i.v. fentanyl for paediatric vitreoretinalsurgery. *Br J Anaesth*. 2009;103:739-43.

[41] Deb K, Subramaniam R, Dehran M, Tandon R, Shende D. Safety and efficacy of peribulbar block as adjunct to generalanaesthesia for paediatric ophthalmic surgery. *Paediatr Anaesth.* 2001;11:161-167.

[42] Rodriques-Coleman H, Spaide R. Ocular complications of needle perforations during retrobulbar and peribulbar injections. *Ophthalmol Clin North Am*. 2001;14:573-579.

[43] Parulekar MV, Berg S, Elston JS. Adjunctive peribulbar anaesthesia for paediatric ophthalmic surgery: are the risks justified? *Paediatr Anaesth*. 2002;12:85-86.

[44] Wong DH. Regional anaesthesia for intraocular surgery. *Can J Anaesth*. 1993;40:635-657.

[45] Troll GF. Regional ophthalmic anesthesia: safe techniques and avoidance of complications. *J Clin Anesth*. 1995;7:163-172.

[46] Guyton DL. Strabismus complications from local anesthetics. *Semin Ophthalmol*. 2008;23:298-301.

[47] Ripart J, Lefrant JY, de La Coussay JE, Prat-Pradal D, Vivien B, Eledjam JJ. Peribulbar versus retrobulbar anesthesia for ophthalmic surgery: an anatomical comparison of extraconal and intraconal injections. *Anesthesiology*. 2001;94:56-62.

[48] Eke T, Thompson JR. The national survey of local anaesthesia for ocular surgery. II. Safety profiles of local anaesthesia techniques. *Eye* (Lond). 1999;13 Pt 2:196-204.

[49] Winder S, Noble DW, Sim MJ, Church WH. Sub-Tenon's versus peribulbar anaesthesia for cataract surgery. *Eye* (Lond).1998;12 Pt 3a:486-488.

[50] Clarke JP, Roberton G, Plummer J. Sub-Tenon block. A learning curve of 100 cases. *Anaesth Intensive Care.* 2006;34:450-452.

[51] Kiliç A, Gürler B. Subtenon lidocaine vs topical proparacaine in adult strabismus surgery. *Ann Ophthalmol (Skokie).* 2006;38:201-206.

[52] Kumar CM, Williamson S, Manickam B. A review of sub-Tenon's block: Current practice and recent development. *Eur J Anaesthesiol*. 2005:567-577.

[53] Snir M, Bachar M, Katz J, Friling R, Weinberger D, Axer-Siegel R. Combined propofol sedation with sub-Tenon's lidocaine/mercaine infusion for strabismus surgery in adults. *Eye (Lond).* 2007;21:1155-1161.

[54] Guise PA. Sub-tenon anesthesia: a prospective study of 6,000 blocks. *Anesthesiology*. 2003;98:964-968.

[55] Anderson CJ. Circumferential perilimbal anesthesia. *J Cataract Refract Surg*. 1996;22:1009-1012.
[56] Greenberg MF, Pollard ZF. Adult strabismus surgery under propofol sedation with local versus general anesthesia. *J AAPOS*. 2003;7:116-120.
[57] Bakr RH, Abdelaziz HM. Subtenon bupivacaine injection for postoperative pain relief following pediatric strabismus surgery: a randomized controlled double blind trial. *Middle East J Anaesthesiol*. 2015;23:91-99.
[58] Tuzcu K, Coskun M, Tuzcu EA, Karcioglu M, Davarci I, Hakimoglu S, Aydın S, Turhanoglu S. Effectiveness of sub-Tenon's block in pediatric strabismus surgery. *Braz J Anesthesiol.* 2015;65:349-352.
[59] Diamond GR. Topical anesthesia for strabismus surgery. *J Pediatr Ophthalmol Strabismus*. 1989;26:86-90.
[60] Merino P, Gómez de Liaño P, Isasi M, Zamora J. Topical anesthesia in strabismus surgery. *Acta Estrabológica*. 1998;3:76-80.
[61] Kim S, Yang Y, Kim J. Tolerance of patients and postoperative results: Topical anesthesia for strabismus surgery. *J Pediatr Ophthalmol Strabismus*. 2000;37:344-348.
[62] Seijas O, Gomez de Liano P, Merino P, Roberts CJ, Gomez de Liano R. Topical anesthesia in strabismus surgery: A review of 101 cases. *J Pediatr Ophthalmol Strabismus.* 2009;46:218-222.
[63] Thorson JC, Jampolsky A, Scott AB. Topical anesthesia for strabismus surgery. *Trans Am Acad Ophthalmol Otolaryngol*. 1966;70:968-972.
[64] Hakim OM, El-Hag YG, Haikal MA. Strabismus surgery under augmented topical anesthesia. *J AAPOS*. 2005;9:279-284.
[65] Weston B, Enzenauer RW, Kraft SP, Gayowsky GR. Stability of the postoperative alignment in adjustable-suture strabismus surgery. *J Pediatr Ophthalmol Strabismus*. 1991;28:206-211.
[66] Ruta U, Gerding H, Mollhoff T. Effect of locally applied lidocaine on expression of the oculocardiac reflex. *Ophthalmologe.* 1997;94:354-359.
[67] Padda GS, Cruz OA, Krock JL. Comparison of postoperative emesis, recovery profile, and analgesia in pediatric strabismus repair. *Ophthalmology*. 1997;104:419-424.
[68] Munro HM, Riegger LQ, Reynolds PI, Wilton NCT, Lewis IH. Comparison of the analgesic and emetic properties of ketorolac and morphine for paediatric outpatient strabismus surgery. *Br J Anaesth.* 1994;72:624-628.
[69] Van den Berg AA, Lambourne A, Clyburn PR. The oculoemetic reflex: a rationalization of postophthalmic anaesthesia vomiting. *Anaesthesia*. 1989;44:110-117.
[70] Shende D, Das K. Comparative effects of intravenous ketorolac and pethidine on perioperative analgesia and postoperative nausea and vomiting (PONV) for paediatric strabismus surgery. *Acta Anaesthesiol Scand*. 1999;43:265-269.
[71] Morrison NA, Repka M. Ketorolac versus acetaminophen or ibuprofen in controlling postoperative pain in patients with strabismus. *Ophthalmology.* 1994;101:915-918.
[72] Snir M, Axer-Siegel R, Frilling R, Weinberer D. Efficacy of diclofenac versus dexamethasone for treatment after strabismus surgery. *Ophthalmology*. 2000;107: 1884-1888.
[73] Kim J, Azavedo L, Bhananker S, Bonn G, Splinter W. Amethocaine or ketorolac eye drops provide inadequate analgesia in pediatric strabismus surgery. *Can J Anaesth*. 2003;50:819-823.

[74] Bridge HS, Montgomery CJ, Kenendy RA, Merrick PM. Analgesic efficacy of ketorolac 0.5% ophthalmic solution (Accular) in paediatric strabismus surgery. *Paediatr Anaesth.* 2000;10:521-526.

[75] Jenkins C. Recommending analgesics for people with asthma. *Am J Therapeutics*. 2000;7:55-61.

[76] Sharir M. Exacerbation of asthma by topical diclofenac. *Arch Ophthalmol*. 1997; 115:294-295.

[77] Sitenga GL, Ing EB, Van Dellen RG, Younge BR, Leavitt JA. Asthma caused by topical application of ketorolac. *Ophthalmology*. 1996;103:890-892.

[78] Hebert WG, Scopelitis E. Ketorolac precipitated asthma. *South Med J*. 1994;87:282-283.

[79] Chen AH, Bennett CR. Ketorolac induced bronchospasm in an aspirin-intolerant patient. *Anesth Progress*. 1994;41:102-107.

[80] Taussig LM, Landau LI. *Pediatric respiratory medicine*. St Louis, Mosby; 1999, pp. 3, 918.

[81] Levy S, Volans G. The use of analgesics in patients with asthma. *Drug Safety*. 2001; 24:829-841.

[82] Antonicelli L, Tagliabracci A. Asthma death induced by ibuprofen. *Monaldi Arch Chest Dis.* 1995;50:276-278.

[83] Elgueta MF, Echevarria GC, De la Fuente N, Cabrera F, Valderrama A, Cabezón R, Muñoz HR, Cortinez LI. Effect of intravenous fluid therapy on postoperative vomiting in children undergoing tonsillectomy. *Br J Anesth*. 2013;110:607-614.

[84] Apfel CC, Kranke P, Piper S, Rüsch D, Kerger H, Steinfath M, Stöcklein K, Spahn DR, Möllhoff T, Danner K, Biedler A, Hohenhaus M, Zwissler B, Danzeisen O, Gerber H, Kretz FJ. Nausea and vomiting in the postoperative phase. Expert- and evidence-based recommendations for prophylaxis and therapy. *Anaesthesist*. 2007; 56:1170-1180.

[85] Eberhart LH, Morin AM, Guber D, Kretz FJ, Schäuffelen A, Treiber H, Wulf H, Geldner G. Applicability of risk scores for postoperative nausea and vomiting in adults to paediatric patients. *Br J Anaesth*. 2004; 93:386-392.

[86] Hamid SK, Selby IR, Sikich N, Lerman J. Vomiting after adenotonsillectomy in children: a comparison of ondansetron, dimenhydrinate, and placebo. *Anesth Analg*. 1998; 86:496-500.

[87] Lerman J. Surgical and patient factors involved in postoperative nausea and vomiting. *Br J Anaesth*. 1992; 69:24S-32S.

[88] Gan TJ, Diemunsch P, Habib AS, Kovac A, Kranke P, Meyer TA, Watcha M, Chung F, Angus S, Apfel CC, Bergese SD, Candiotti KA, Chan MT, Davis PJ, Hooper VD, Lagoo-Deenadayalan S, Myles P, Nezat G, Philip BK, Tramèr MR; Society for Ambulatory Anesthesia. Consensus guidelines for management of postoperative nausea and vomiting. *Anesth Analg*. 2014;118:85-113.

[89] Bolton CM, Myles PS, Nolan T, Sterne JA. Prophylaxis of postoperative vomiting in children undergoing tonsillectomy: a systematic review and meta-analysis. *Br J Anaesth*. 2006; 97:593-604.

[90] Kenny GN. Risk factors for postoperative nausea and vomiting. *Anaesthesia*. 1994;49(Suppl):6-10.

[91] Joo J, Park S, Park HJ, Shin SY. Ramosetron versus ondansetron for postoperative nausea and vomiting in strabismus surgerypatients. *BMC Anesthesiol*. 2016 Jul 22;16:41.

[92] Olutoye O, Watcha MF. Management of postoperative vomiting in pediatric patients. *Int Anesthesiol Clin*. 2003;41:99-117.

[93] Cardwell ME, Siviter G, Smith AF. Nonsteroidal anti-inflammatory drugs and perioperative bleeding in paediatric tonsillectomy. *Cochrane Database Syst Rev*. 2013;7:CD003591.

[94] Chukudebelu O, Leonard DS, Healy A, McCoy D, Charles D, Hone S, Rafferty M. The effect of gastric decompression on postoperative nausea and emesis in pediatric, tonsillectomy patients. *Int J Pediatr Otorhinolaryngol*. 2010;74:674-676.

[95] Jones JE, Tabaee A, Glasgold R, Gomillion MC. Efficacy of gastric aspiration in reducing posttonsillectomy vomiting. *Arch Otolaryngol Head Neck Surg*. 2001;127:980-984.

[96] Radke OC, Biedler A, Kolodzie K, Cakmakkaya OS, Silomon M, Apfel CC. The effect of postoperative fasting on vomiting in children and their assessment of pain. *Paediatr Anaesth*. 2009;19:494-499.

[97] Höhne C. Postoperative nausea and vomiting in pediatric anesthesia. *Curr Opin Anaesthesiol*. 2014;27:303-308.

[98] Henzi I, Sonderegger J, Trame` r MR. Efficacy dose–response and adverse effects of droperidol for prevention of postoperative nausea and vomiting. *Can J Anaesth*. 2000;47:537-551.

[99] Gan TJ, Meyer T, Apfel CC, Chung F, Davis PJ, Eubanks S, Kovac A, Philip BK, Sessler DI, Temo J, Tramèr MR, Watcha M; Department of Anesthesiology, Duke University Medical Center. Consensus guidelines for managing postoperative nausea and vomiting. *Anesth Analg*. 2003;97:62-71.

[100] Schnabel A, Eberhart LH, Muellenbach R, Morin AM, Roewer N, Kranke P. Efficacy of perphenazine to prevent postoperative nausea and vomiting: a quantitative systematic review. *Eur J Anaesthesiol*. 2010;27:1044-1051.

[101] Engelman E, Salengros JC, Barvais L. How much does pharmacologic prophylaxis reduce postoperative vomiting in children? Calculation of prophylaxis effectiveness and expected incidence of vomiting under treatment using Bayesian metaanalysis. *Anesthesiology*. 2008;109:1023-1035.

[102] Schroeter E, Schmitz A, Haas T, Weiss M, Gerber AC. Low dose droperidol in children. Rescue therapy for persistent postoperative nausea and vomiting. *Anaesthetist*. 2012;61:30-34.

[103] Mehta D, Sanatani S, Whyte SD. The effects of droperidol and ondansetron on dispersion of myocardial repolarization in children. *Paediatr Anaesth*. 2010;20:905-912.

[104] Liechti M, Feurer R, Gross D, Schmitz A, Stutz K, Gerber A, Weiss M. Prevention of postoperative nausea and vomiting in children following adenotonsillectomy, using tropisetron with or without low-dose dexamethasone. *J Anesth*. 2007;21:311-316.

[105] Park YV, Yang YE, Byon HJ, Kim JT, Kim HS. Comparison of the efficacy of ramosetron and ondansetron in the prophylaxis of postoperative vomiting in children receiving fentanyl by patient-controlled analgesia after orthopedic surgery: a randomized controlled trial. *Pediatr Anesth*. 2013;23:360-364.

[106] Byon HJ, Lee SJ, Kim JT, Kim HS. Comparison of the antiemetic effect of ramosetron and combined ramosetron and midazolam in children: a double- blind, randomised clinical trial. *Eur J Anesthesiol.* 2012;29:192-196.

[107] Kranke P, Morin AM, Roewer N, Eberhart LH. Dimenhydrinate for prophylaxis of postoperative nausea and vomiting: a metaanalysis of randomized controlled trials. *Acta Anaesthesiol Scand*. 2002;46:238-244.

[108] Welters ID, Menges T, Graf M, et al. Reduction of postoperative nausea and vomiting by dimenhydrinate suppositories after strabismus surgery in children. *Anesth Analg*. 2000;90:311-314.

[109] Kim MS, Cote´ CJ, Cristoloveanu C, Roth AG, Vornov P, Jennings MA, Maddalozzo JP, Sullivan C. There is no dose escalation response to dexamethasone (0.0625–10 mg/kg) in pediatric tonsillectomy or adenotonsillectomy patients for preventing vomiting, reducing pain, shortening time to first liquid intake, or the incidence of voice change. *Anesth Analg.* 2007;104:1052-1058.

[110] Hermans V, DePooter F,DeGroote F, De Hert S, Van der Linden P. Effect of dexamethasone on nausea, vomiting, and pain in paediatric tonsillectomy. *Br J Anesth*. 2012;109:427-431.

[111] Czarnetzki C, Elia N, Lysakowski C, Dumont L, Landis BN, Giger R, Dulguerov P, Desmeules J, Tramèr MR. Dexamethasone and risk of nausea and vomiting and postoperative bleeding after tonsillectomy in children: a randomized trial. *JAMA.* 2008;300:2621-2630.

[112] Steward DL, Grisel J, Meinzen-Derr J. Steroids for improving recovery following tonsillectomy in children. *Cochrane Database Syst Rev*. 2011;CD003997.

[113] Howard SC, Jones DP, Pui CH. The tumor lysis syndrome. *N Engl J Med*. 2011; 364:1844-1854.

[114] McDonnell C, Barlow R, Campisi P, Grant R, Malkin D. Fatal peri-operative acute tumour lysis syndrome precipitated by dexamethasone. *Anaesthesia*. 2008;63:652-655.

[115] Osthaus WA, Linderkamp C, Bünte C, Jüttner B, Sümpelmann R. Tumor lysis associated with dexamethasone use in a child with leukemia. *Paediatr Anaesth.* 2008;18:268-270.

[116] Gnatzy R, Hempel G, Hebestreit A, Kaisers UX, Philippi-Höhne C. The effect of intraoperative administration of dexamethasone for PONV prophylaxis on perioperative blood glucose level in obese and normal weight children. *ESPA Meeting*, Best Free Paper Session. Stresa, Italy; 2012.

[117] Bolton CM, Myles PS, Carlin JB, Nolan T. Randomized, double-blind study comparing the efficacy of moderate-dose metoclopramide and ondansetron for the prophylactic control of postoperative vomiting in children after tonsillectomy. *Br J Anaesth*. 2007;99:699-703.

[118] Eberhart LH, Geldner G, Kranke P, Morin AM, Schäuffelen A, Treiber H, Wulf H.The development and validation of a risk score to predict the probability of postoperative vomiting in pediatric patients. *Anesth Analg*. 2004;99:1630-1637.

[119] Apfel CC, Heidrich FM, Jukar-Rao S, Jalota L, Hornuss C, Whelan RP, Zhang K, Cakmakkaya OS. Evidence-based analysis of risk factors for postoperative nausea and vomiting. *Br J Anaesth*. 2012;109:742-753.

In: Encyclopedia of Surgery (22 Volume Set)
Editors: Andreas Lehrer and Kristin Mueller
ISBN: 978-1-53618-329-0
© 2020 Nova Science Publishers, Inc.

Chapter 443

BRAIN MAPPING AND NEURO-MONITORING IN LOW GRADE GLIOMA SURGERY: CURRENT CHALLENGES AND FUTURE PERSPECTIVES

Christian Brogna[1,2,*], MD, PhD, Noemia Pereira[3], Eduardo C. Ribas[4], MD, PhD, Holly Jones[5], Francesco Vergani[1], MD, PhD, Sanj Bassi[1], Keyoumars Ashkan[1] and Ranj Bhangoo[1]

[1]Department of Neurosurgery, King's College Hospital, London, UK
[2]Maurice Wohl Clinical Neuroscience Institute, King's College London, London, UK
[3]London Neuro Monitoring, London, UK
[4]Discipline of Neurosurgery, Department of Neurology, University of São Paulo, Medical School (FMUSP), Albert Einstein Hospital, São Paulo, Brazil
[5]Department of Anaesthesia, King's College Hospital, London, UK

ABSTRACT

Low grade gliomas (LGGs) are infiltrative primary brain tumors with a typical slow evolution. LGGs occur in young and otherwise healthy patients, which poses a great challenge for the neurosurgeon in maximizing resection while preserving neurological functions, namely increasing time to progression and overall survival while preserving patient's quality of life. Brain mapping, intra-operative advanced cortical and subcortical mapping for motor, language and higher order functions as well as mapping stimulation protocols currently in use in the Department of Neurosurgery - Neuro-oncology, King's College Hospital are presented. Future challenges in brain mapping are also discussed in light of the current knowledge on the actual distant propagation of direct electrical stimulation as a methodology to study the brain connectome organization.

Keywords: low grade gliomas, brain mapping, neuromonitoring, white matter, connectome

[*] Corresponding Author's Email: christian.1.brogna@kcl.ac.uk.

INTRODUCTION

Intra-operative mapping for resection of infiltrating low grade gliomas (LGGs) located in eloquent regions of the brain such as motor, language and higher order functions is nowadays considered mandatory in order to achieve maximal tumor resection, while preserving neurological functions (Figure 1) and consequently improving quality of life to those patients [1].

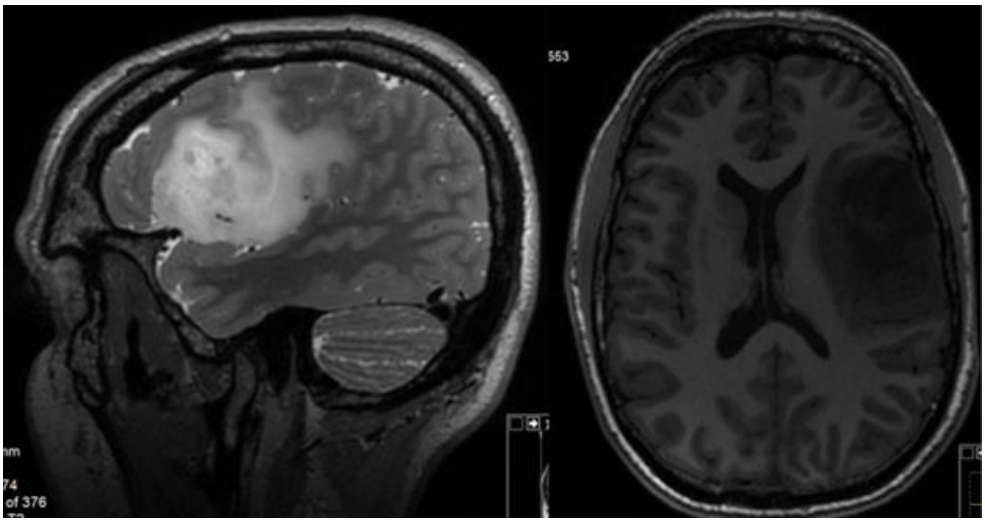

Figure 1. MRI T2-weighted (left image) and T1-weighted (right image) showing a typical low grade glioma of the left opercular region with involvement of both motor and language cortical and subcortical structures.

Cortical and subcortical brain mapping requires an *a priori* knowledge of the cortical and subcortical anatomy, namely the white matter tracts, which integrity is required to preserve the functions. Correct stimulation parameters and a detailed preoperative strategy are mandatory in viewing of maximizing the tumor resection [2, 3, 4].

Hence, we discuss in this chapter the value of LGGs' extent of resection, and how to acquire the complex three-dimensional white matter fibers anatomical knowledge necessary to adequately perform mapping throughout the surgical resection. We provide an historical perspective of the brain mapping techniques and we analyze the anesthetic and neurophysiological protocol for brain cortical and subcortical mapping of motor, language and higher order functions that we currently use in our Department of Neurosurgery – Neuro-oncology, King's College Hospital. We also briefly discuss the cortico-cortical evoked potentials as a future tool for online *in vivo* mapping of the brain connectome.

LOW GRADE GLIOMAS: VALUE OF EXTENT OF RESECTION

Infiltrating LGGs are slow growing brain tumors which affect young and middle aged adults. They present with seizures and only rarely they manifest with neurological deficits, regardless the fact that LGGs grow continuously. The linear diameter growth rate of the

lesion is on average 4mm/year [5, 6]. When volumetric analysis is performed, the linear volumetric growth is 0,187 cm3/month [7]. LGGs inevitably transform to higher grades malignancy which is associated with high rates of morbidity and mortality [8].

The surgical and oncological strategy and timing of treatment of LGGs has been controversial. A cohort study population-based compared the survival outcomes in two Norwegian regions where different surgical approaches were applied. It has demonstrated a remarked advantage in favor to early surgical resection compared to watchful waiting strategy [9]. In fact, the median survival in the watchful waiting strategy cohort was 5.8 years compared to 14.4 years in the cohort of patients where early resection was advocated. In those watchful waiting strategy, the survival rate was of 60% for biopsy patients, while for those receiving early surgery was of 74%. Moreover, the effect of early resection is sustained after adjustment for molecular markers according to the new WHO classification of low grade tumors. Those data favor an early LGGs resection strategy in order to achieve a higher survival outcome.

Not only early resection of LGGs seems to play a crucial role in patients' outcome but also the extent of resection. The malignant transformation rate of LGGs ranges from 4 to 29 months, being 45% within 5 years from the diagnosis. Smith et al. demonstrated that individuals with at least 90% extent of resection have an extended time progression free survival and a 5-year survival rate of 97%, compared with patients with less than 90% extent of resection which showed a 5-year survival rate of only 76% [1] (Figure 2).

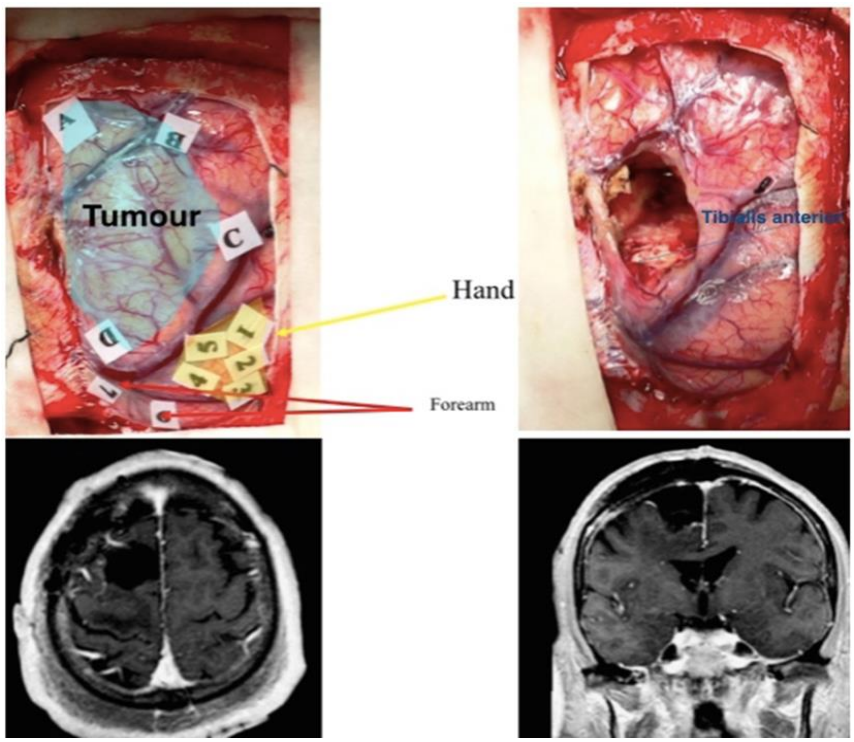

Figure 2. Early postoperative MRI within 24 h from the surgery showing complete resection of a right supplementary motor area low grade glioma. Intraoperative cortical mapping of hand and forearm (top left image). Intraoperative subcortical mapping of the corticospinal tract and in particular of the tibialis anterior muscle during tumor resection (right top image).

In light of the abovementioned data, low grade gliomas pose a unique challenge: maximizing extent of resection while preserving neurological functions. In order to achieve the oncological benefits from maximizing extent of resection, accurate intraoperative mapping should be performed either in anaesthetized or awake patients according to the structures involved by the tumor as well as patient's wishes taking to account job, hobbies and cultural background.

WHITE MATTER FIBER DISSECTION AS A PROPEDEUTIC TRAINING TO LGGS SURGERY

The white matter of the brain consists of myelinated bundles of nerve fibers, known as fascicles or tracts (Figure 3). These fibers form a complex three-dimensional architecture within the hemispheres. *Brain mapping of the different brain compartments and subcortical structures cannot be performed without an in-depth understanding of the white matter fiber system.*

To ensure consistency and reliability of brain mapping to effectively guide the surgical resection, direct electrical stimulation (DES) cannot be applied without a strong *a priori* hypotheses and a detailed knowledge of how white matter fiber systems and networks are organized. Precise neuroanatomical hypotheses are then confirmed with DES [10].

The white matter fiber dissection technique performed according to Joseph Klingler allows the surgeon to build the anatomical mental imagery to be coupled with current state of the art knowledge about networks sub serving different brain functions as motor and language. Mastering this dissection technique is mandatory in order to tailor surgical strategy to each patient according to tumor relationships with white matter tracts as well as vascular and subarachnoid spaces' anatomy [11].

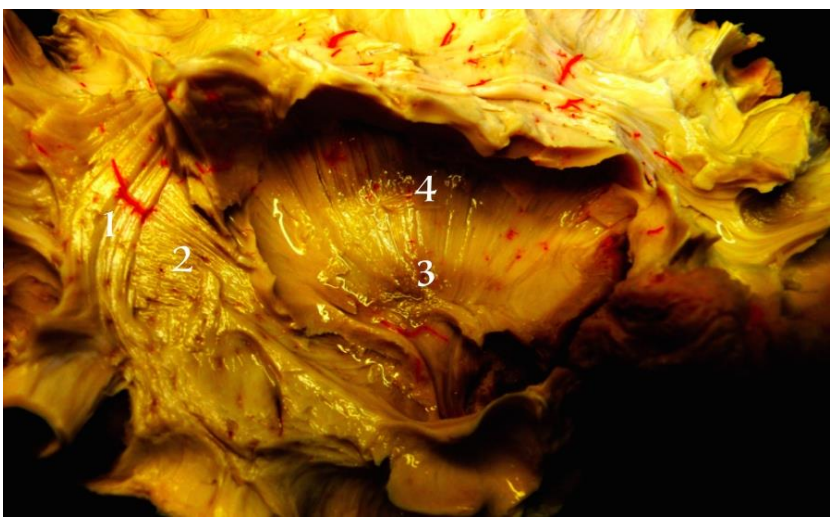

Figure 3. White matter fiber dissection technique as per Joseph Klingler's methodology. This technique unveils the complex three-dimensional architecture of the white matter fiber system of the brain, which is propaedeutic to intraoperative brain cortical and subcortical mapping. 1: arcuate fasciculus, 2: inferior fronto-occipital fasciculus, 3: claustrum, 4: external capsule.

HISTORICAL PERSPECTIVES OF BRAIN MAPPING TECHNIQUES

Brain mapping using Direct Electrical Stimulation (DES) of the neural structures finds his pioneers in Fritsch and Hitzig in 1870. They stimulated the motor cortex of dogs and were able to elicit movements. In 1874, Ferrier characterized the brain's motor centers in macaque, and later on in 1901 Sherrington and Grunbaum replicated the same experiment in great apes. In 1917 Leyton and Sherrington noticed that different motor area representations such as fingers, forearm and arm overlap within the precentral gyrus.

Krause and Cushing in 1909 were the first group to perform DES in the human brain eliciting motor responses, and a decade later, in 1919, Vogt and Vogt tried to link brain functions to the anatomy using DES. Later, in 1937 Penfield and Boldrey described a simplified representation of the somatotopy of the body on the cortical surface, calling it "Homunculus." In 1957, Purpura et al. attempted to use DES to study the contribution of dendritic potentials in the modulation of the electrical activity output at the brain surface [10]. In 1960s the use of electrical microstimulation (EMS) refined the methodology for studying the brain in animal models, however, it is not currently used in humans.

DES is nowadays performed to guide the surgeon in cortical and subcortical mapping of eloquent functional areas including motor, sensory and language throughout the LGGs resection (Figure 4).

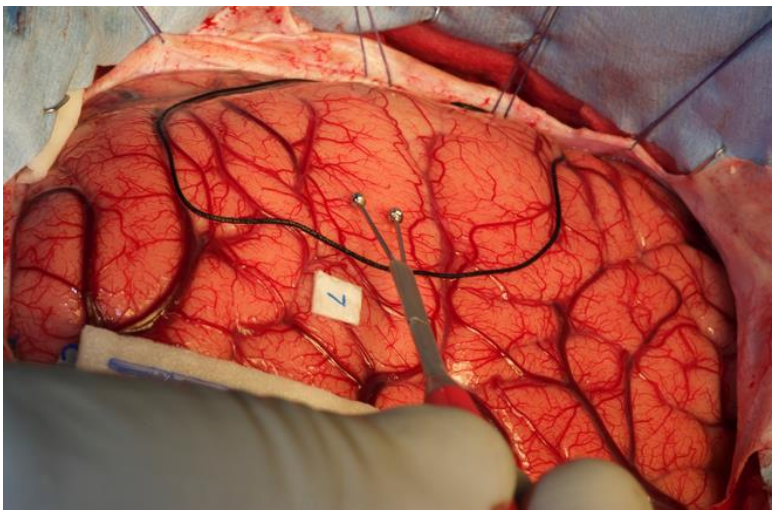

Figure 4. Direct cortical stimulation (DES) mapping with a bipolar probe for cortical and subcortical language mapping. Patient is awake performing specific language tasks. DES of language areas causes a transient perturbation of the network. The black line indicates the tumor boundaries defined using intraoperative ultrasound. The number 7 on the cortical surface represents a cortical site which when stimulated caused transient nominum dysphasia.

THE USE OF INTRAOPERATIVE NEUROMONITORING AND NEUROLOGICAL OUTCOME IMPROVEMENT

Seven retrospective studies, class III evidence, have demonstrated the impact of intraoperative neurophysiological monitoring in order to achieve improved neurologic

outcome for language [12-18] and motor functions [16, 17, 18] in LGGs resection. In 2003, Duffau et al. investigated cortical and subcortical language and motor mapping in 103 resections of LGGs, in which 94% of the cases resulted in favorable functional results [17]. 3 years later, a follow up study by the same group reported no permanent deficits in patients that received insular LGGs surgery with motor and/or language mapping. Yordanova et al. reported a surgical approach using DES mapping to extend the resection beyond the MRI boundaries of the tumor. This led to supra-total resections of 15 out of 17 cases, which improved progression free survival (PFS) rate compared to a control group of patients undergoing total resections of LGGs [14]. Even though functional mapping seems to favor neurological outcomes, patients with tumors in eloquent areas identified through DES mapping exhibited decreased overall survival in comparison with tumors in non-eloquent locations, due to the limitations dictated by highly functional structures as for example the corticospinal tract or the arcuate fasciculus [12] (Figure 2). Sarubbo et al. reported no permanent deficits in thei patients and a 78% of volumetric resection achieved and Karnofsky Performance Status improved in 8 out of 12 patients [13].

Benedictis et al. reported 9 cases in which patients underwent a second awake craniotomy demonstrating that the extent of resection could be improved in all 9 cases. This result suggest that a process of plasticity may take place [15].

A study of motor mapping in LGGs identified subcortical tracts in 89% of 26 LGGs. In the 11% where corticospinal tracts could not be identified the gross total resection (GTR) rate improved from 44 to 67% [16]. The identification of subcortical tracts was directly correlated with higher probability of immediate postoperative deficits, which however usually resolved within 1 month [16] (Figure 5).

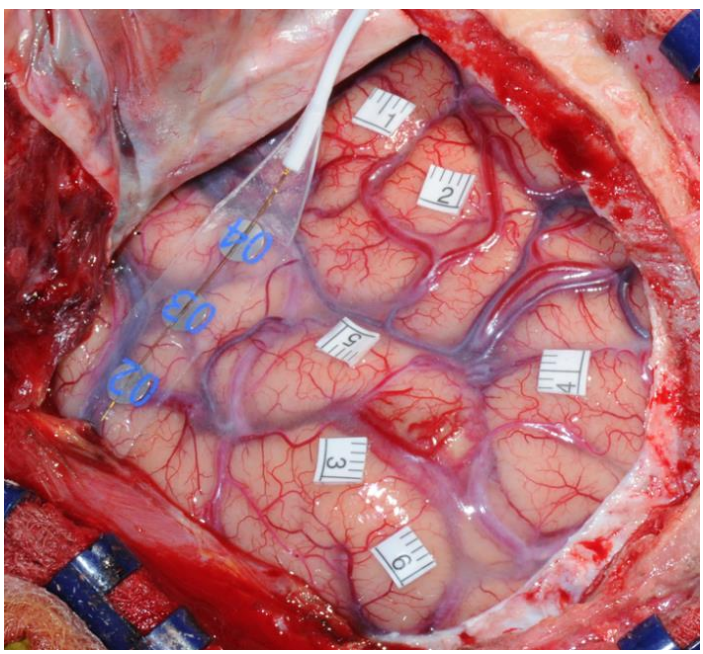

Figure 5. Direct cortical stimulation for motor and language mapping. A strip electrode of 4-contact channels is placed over the precentral gyrus for continuous monitoring of MEPs throughout tumor resection as an adjunct electrophysiological tool to ensure safety.

ANAESTHESIA DURING BRAIN MAPPING IN ASLEEP AND AWAKE PATIENTS

While brain mapping of primary motor functions and corticospinal tract can be performed with the patient anaesthetized, higher order functions as language require the patient to be awake and collaborative with the surgeon while resection of the tumor is carried out.

Awake craniotomy can be undertaken awake from the beginning to the end or with the asleep-awake-asleep or the asleep-awake-awake protocols. The setup of the anaesthesia is similar in all three protocols, with placement of two venous cannulas, an arterial cannula and a urinary catheter.

In awake only craniotomy, sedatives are often used to relieve the boredom for the patient and to enable them to tolerate staying still for prolonged periods. The drugs to maintain this state must not interfere with the conscious state below minimal sedation. Dexmedetomidine is an ideal anaesthetic, as it is short acting and titratable. Other drugs such as propofol and remifentanil can be used but they are more depressant on the respiratory system. Longer acting drugs such as midazolam need to be used with care as they are less titratable. No sedation at all can be given but all patients will need adequate local anaesthetic to tolerate pins and craniotomy while awake.

Delivering adequate oxygen without interfering with the patient's ability to communicate needs to be considered. Oxygen masks muffle the voice and nasal speculums can irritate, both have limitations on the maximal delivery of oxygen concentrations. Thrive/optiflow is a well tolerated delivery system of humidified high oxygen concentration via the nasal route. The disadvantage is that currently there is not a simple way to monitor the end tidal carbon dioxide and respiratory parameters.

In the asleep-awake-asleep/awake technique, the advantage is that pinning and bone flap removal can be done easily and quickly under general anaesthesia, waking the patient only when the tumor resection is performed. Placing a laryngeal mask airway (LMA) instead of an endotracheal tube is an ideal airway technique if the patient is suitable (i.e., not too obese). This allows smooth emergence while in pins with the open skull and avoids the need for muscle relaxation and reversal. Optiflow or other oxygenation devices need to be placed from the outset to ensure they are sitting correctly after removal of the airway. As with awake craniotomy, dexmedetomidine is ideal as it preserves respiratory function and is easily titratable. As before, the drugs propofol and remifentanyl are used for both the GA and sedation. The use of depth of anaesthesia monitoring allows anaesthetics to be titrated to effect to allow quick intraoperative wake up. During the awake phase anaesthetics can be stopped completely or titrated to effect to maintain patients comfort.

After removal of the tumor, a joint decision between the surgeon, anaesthetist and patient takes place as to whether the patient remains awake/sedated or returns to GA for closure of the craniotomy. An LMA is needed in this situation due to the position and open cranium.

As with any awake case, signage on the operating doors and minimal movement of staff around the theatre help to keep an atmosphere of calm. Keeping the patient warm is important and temperature should be monitored to prevent hyperthermia.

Careful patient selection and preoperative education is vital to the success of awake craniotomy. Close cooperation between surgeon, anaesthetist, neurophysiologist and speech and language therapist is vital to maintain safety and smooth running of the surgery.

METHODOLOGY FOR FUNCTIONAL MAPPING

Neurophysiological monitoring and mapping in brain tumor surgery involves simultaneous acquisition of continuous electroencephalography (EEG), electrocorticography (ECoG), multichannel recording of free-running electromyographic activity (EMG), motor-evoked potentials (MEPs), and somatosensory evoked potentials (SSEPs). It can be done either under general anaesthesia or awake state. We preferentially perform awake craniotomies only when language mapping and higher order functions mapping are required, which include asleep-awake-asleep anaesthesia protocol.

In asleep-awake-asleep protocol, cortical motor mapping is first performed with the patient asleep which produces more reliable results. In fact, the voluntary movements of the patient make the interpretation of the MEPs responses more challenging. Moreover, the conscious sedation used in awake patients have antiepileptic properties that affect the interpretation of the stimulation. Following cortical motor mapping, cortical and subcortical language mapping is performed with the patient awake as well as motor subcortical mapping.

Given the epileptogenic effect of direct electrical cortical stimulation, ice-cold saline is used in case of stimulation-triggered after-discharges, aborting triggered epileptiform or epileptic activity.

SSEPS AND PHASE-REVERSAL

SSEPs are obtained by stimulation of peripheral nerves, the most commonly used being the median nerve at the wrist and posterior tibial nerve at the ankle (Figure 6). For stimulation of the peripheral nerves we use subdermal needles (Friend Hip Medical, 13 mm length) and a constant current stimulator (ISIS Neurostimulator, InomedGmbH) integrated into a ISIS Xpress System (Figure 7). The electrical stimulus delivered is a positive pulse form of 0.2-0.5 msec width, delivered at a frequency of 3.1 or 3.7 Hz, averaged at least 20-200 stimulation trials. Current intensity is increased until thumb muscle twitches are observed.

Mean EP traces are obtained by averaging electrophysiological signals time-locked to the DES. Evoked potentials (EP) are recorded by subdermal corkscrew needles (Friend Hip Medical, 0.6 mm diameter) positioned in the postcentral parietal regions (C3', C4', Cz', Fz), according with the 10-20 International Electrode System. Electrodes may need to be repositioned to other locations due to bone flap. SSEPs in brain procedures are useful for detecting vascular injury during tumor resection.

The functional mapping protocol starts with the accurate identification of the central sulcus by SSEPs phase reversal technique. This technique is performed by stimulation of the median nerve or ulnar nerve (in case of arterial line), and recording through a strip electrode of 4-6 contacts (Dixi medical, France). The contacts are placed over the exposed cortex (or epidurally) at the level of the hand area on the convexity, in a perpendicular position. For more median exposure towards the inter hemispheric fissure, posterior tibial nerve stimulation can be used.

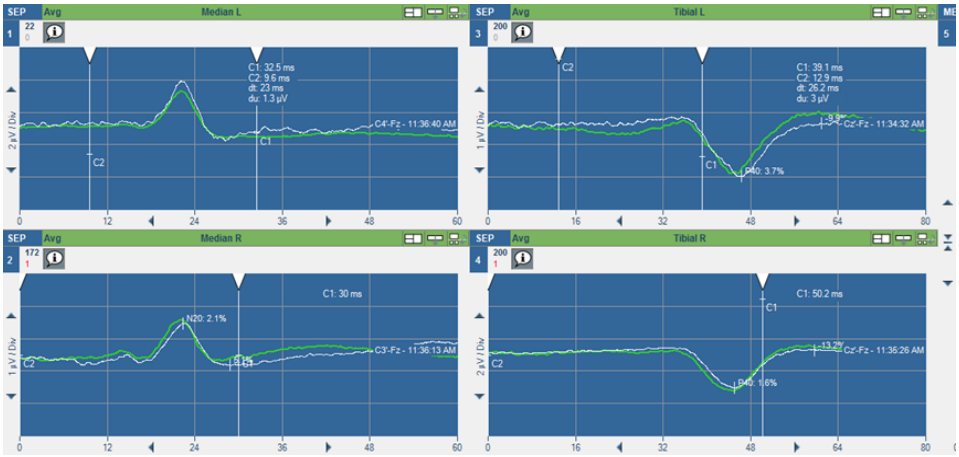

Figure 6. SSEP responses at baseline and closing. Left windows – Left and right median nerve responses (N20 waveforms). Right windows – Left and right posterior tibial nerve responses (P40 waveforms). Green traces: baseline responses.

EP responses are recorded using a monopolar derivation with the reference electrode, subdermal corkscrew needle, placed on the contralateral mastoid. Reversal in polarity of the scalp-recorded median or tibial thalamocortical SSEPs is observed at about 19 msec after the stimulation of the contralateral nerves (Figure 7).

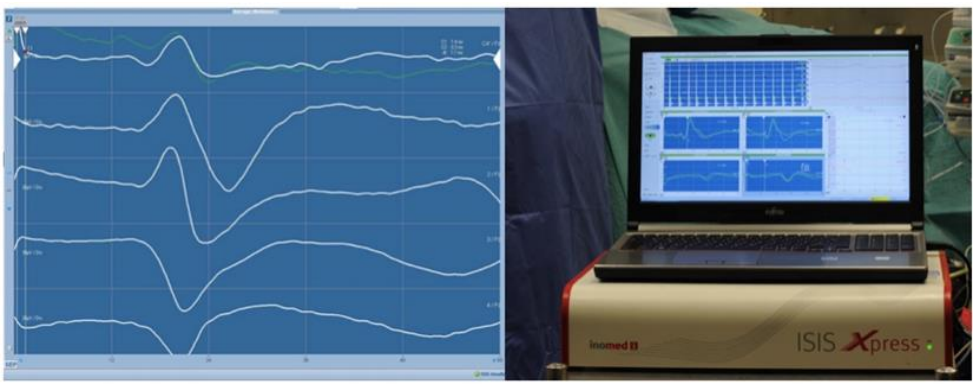

Figure 7. Median nerve SSEP phase reversal technique using 4-contact (1,2,3,4) strip electrode and referential recording (Fz), with reference electrode on the contralateral mastoid. Phase reversal is observed between contact 2 and 3. The electronegative potentials seen at contact 1 and 2 represents the N19/22 thalamocortical potential obtained in the postcentral somatosensory cortex. Scalp SSEPs responses displayed on the top (N20 waveform) helps to distinguish somatosensory responses from motor responses. Right image: ISIS Xpress System, InomedGmbH.

CORTICAL AND SUBCORTICAL MOTOR MAPPING

Following identification of the central sulcus via the phase-reversal technique, DES is applied to the primary motor cortex using a monopolar probe or bipolar probe. We preferentially use the monopolar probe (Inomed, InomedGmbH) as this provides a homogeneous radiant spreading electric field, which increase the probability of stimulating

nervous tissue at more distant sites and, therefore, provides higher sensitivity [19]. Moreover, it seems to be less epileptogenic (Figure 8).

Anodal train-of-five stimulation is used at 1 Hz frequency, with 0.5 msec pulse width, and 2 msec duration, using a constant current stimulator (ISIS Xpress System, Inomed GmbH) [20]. The primary motor cortex is first identified at the motor threshold defined at the lowest intensity allowing MEPs recorded in the contralateral hemibody muscles. This is followed by a higher stimulation, normally in our department we use 10 mA, for identification of supplementary motor regions. Lastly, higher-stimulus intensity is applied to the surroundings of the regions to be resected for safer "entry zone."

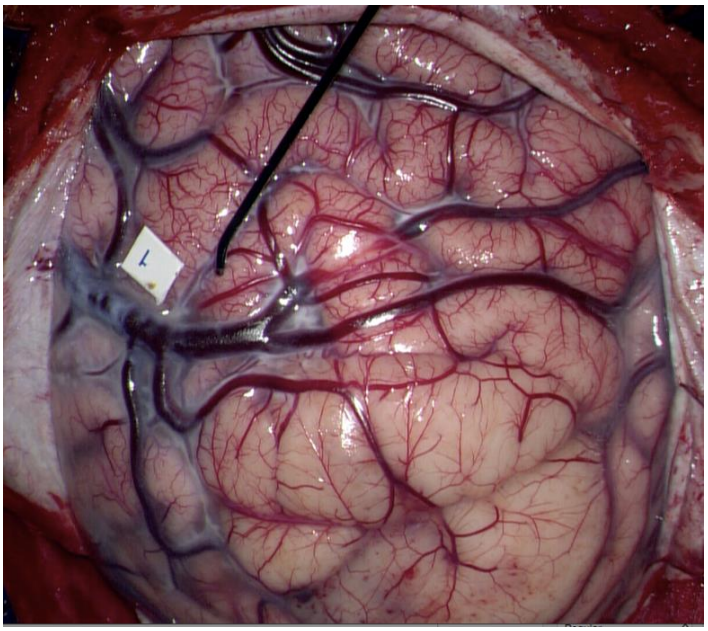

Figure 8. Monopolar probe is used for DES of the primary motor cortex. Number 1 showing a positive response from flexor carpi ulnaris muscle of the hand. Tumor can be appreciated behind the Vein of Troland running in the central sulcus in this particular case.

MEP responses time-locked to the DES of the motor areas are recorded using subdermal needle electrodes (Friend Hip Medical, 13 mm or 17 mm length) inserted in face, upper and lower limbs muscle groups of the contralateral hemibody, connected to a multichannel EMG recording (Figure 10). For facial muscles we use orbicularis oculi, orbicularis oris, tongue and masseter. For upper limb we use deltoid, biceps, brachioradialis, flexor carpi ulnaris, dorsal interosseous, thenar and hypothenar. For the lower limb we include quadriceps, anterior tibialis, gastrocnemius and abductor hallucis. Moreover, free-run EMG of voluntary motor activity is run using the same muscle groups.

Subcortical mapping of the corticospinal tract can be achieved using the train-of-five technique and cathodal stimulation (Figure 9). We normally set a current intensity of 10 mA and, after a motor response is detected, a stepwise resection towards the corticospinal tract is achieved decreasing the current up to the limit of 5 mA. For a quicker detection, we increase the frequency of stimulation to 2 Hz.

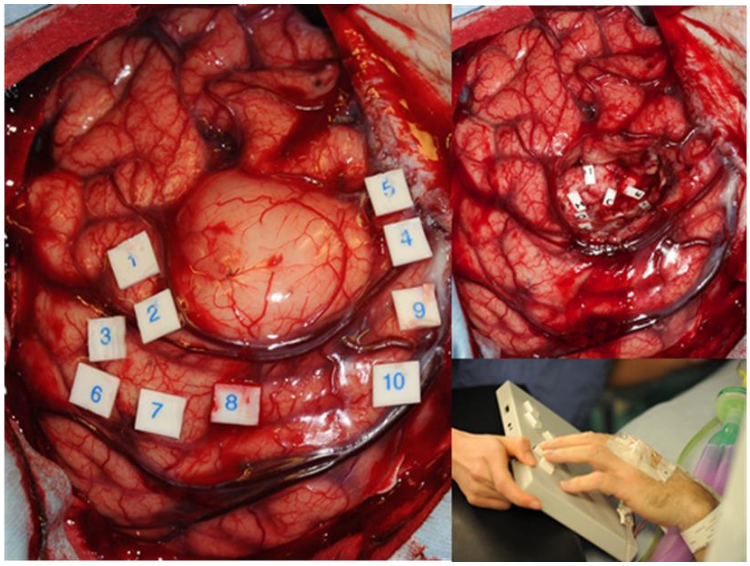

Figure 9. Cortical and subcortical mapping of the hand and foot over the precentral gyrus while the patient performs awake finger-tapping test for fine motor movements intraoperative assessment.

Throughout tumor resection, MEPs are run repeatedly to continuously assess the functional integrity of the motor pathways. MEPs are obtained using a strip electrode (4-6 electrodes) placed over the precentral cortex and using the train-of-five technique (Figure 10). Each contact is tested with a vertex reference.

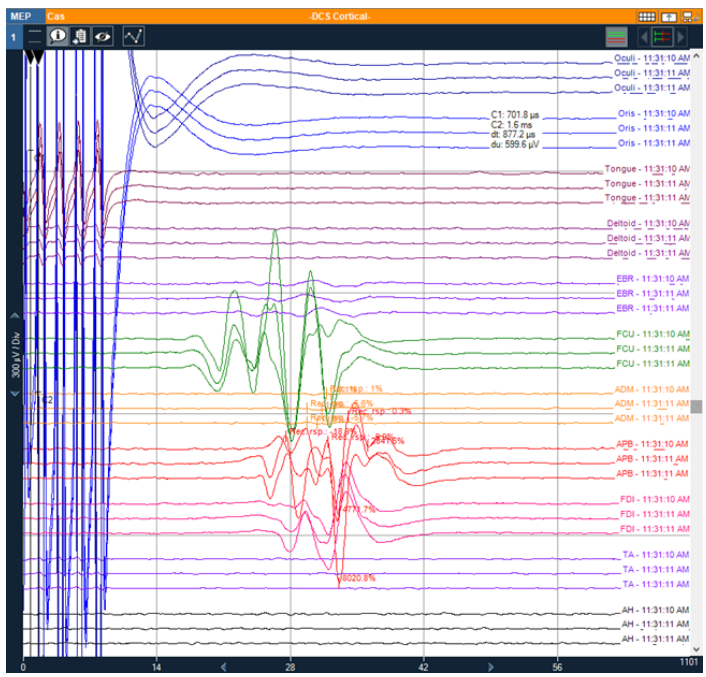

Figure 10. MEP responses obtained from stimulation of the primary motor cortex through a strip electrode (4- contacts). MEPs were recorded continuously throughout procedure. Motor responses were recorded from flexor carpi ulnaris (FCU), abductor pollicis brevis (APB) and first distal interosseous (FDI) muscles. Scale: 70 msec, 300µV/DIV.

CORTICAL AND SUBCORTICAL LANGUAGE MAPPING

DES applied to the cortical and subcortical structures essential for speech functions is able to inhibit part of the network during few seconds.

For speech mapping we perform the Penfield stimulation technique using a bipolar probe (2 mm diameter ball tips, spaced 5 mm apart, InomedGmbH) (Figure 4). Biphasic square wave pulses of 1 msec duration are applied at a frequency of 50 Hz (Europe) for 5-8 sec using a constant current stimulator (ISIS Neurostimulator, Inomed GmbH). The threshold of current is set at the minimal current to evoke language errors without triggering after discharges in the electrocorticography (ECoG), in an incremental fashion of 2 mA. If the ventral premotor cortex can be exposed, the threshold is defined during a counting task. DES is applied during a comprehensive language testing such as verbal fluency, repetition, visual object naming, sentence comprehension, and word generation.

To distinguish motor arrest, speech arrest, and anomia, free-run EMG recordings are accomplished alongside with DES. Subdermal needles (Friend Hip Medical, 13 mm length) are placed on the *orbicularis oris* muscle and *masseter*.

EEG AND ECOG

EEG and ECoG are used complementary to monitor depth of anaesthesia, and spontaneous or triggered after discharges minimizing the risk of stimulation-triggered seizures (Figure 5). EEG is recorded by subdermal corkscrew needles positioned in the postcentral parietal regions, used simultaneously for SSEP, recordings of each hemisphere referred to a midfrontal electrode for referential derivation. For the ECoG recording, a subdural strip electrode (Dixi medical, France) is placed over the exposed cortex (Figure 5). ECoG is also helpful for ruling out non-convulsive but focal seizures throughout resection. EEG and ECoG recordings are filtered (bandpass 0.5 – 100 Hz) running at sensitivity of 30 mm/sec (Figure 11).

EMG modality parallel with EEG and ECoG also allows for early detection of the spreading of muscle activation over a limb as a sign of seizures.

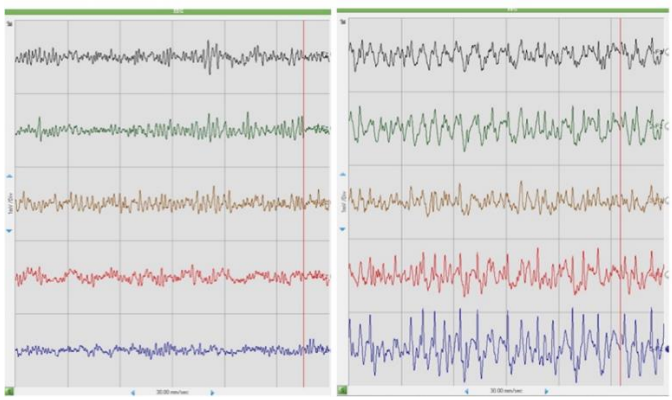

Figure 11. ECoG recorded during speech mapping. Left window – Baseline ECoG. Right window – electric seizure induced during speech mapping using 7 mA current intensity. The channels are numbered 1 through 5, with the top being channel 1. Reference electrode on the contralateral mastoid. The recording settings for the ECoG are: Low-frequency filter 0.5 Hz, high-frequency filter 100 Hz, and sensitivity 1 mV/Div.

HIGHER ORDER COGNITIVE FUNCTIONS: INTRAOPERATIVE MAPPING

Patients receiving awake surgery with language intraoperative mapping still experience post surgical neurocognitive deficits when a more accurate neuropsychological assessment is performed [21, 22]. Therefore, there is a need for mapping higher order functions intraoperatively, specifically in the context of performing a supra total resection, in order to be able to accurately balance the extent of resection against quality of life preservation.

Specific tests should be tailored to each individual patient, for example according to the characteristics of his/her job, due to the constraints given by the intraoperative fatigue and consequently the limitation of the tests that can be performed. For example, mapping calculation (multiplication and subtraction) has been used as an intraoperative test for a school teacher with a lesion involving the left parietal lobe, in order to preserve her from developing dyscalculia [23].

Dissociation between language tested by picture naming and nonverbal comprehension tested by a semantic task of association has been demonstrated. Specifically, for surgery involving the dominant posterior temporo-visual areas naming test might be of importance [24].

Moreover, it has been shown that executive functions are often impaired after brain surgery [21, 22] affecting cognitive domains as decision making, and planning of complex strategy. Therefore, several intraoperative tests have been proposed to task recent memory -by performing stimulation during storage, encoding or retrieval in lesions within the temporoparietal and frontal sites-; to task attention -testing ocular saccades in patients with lesions involving the frontal eye fields eliciting stimulation or suppression of ocular deviation-; to task visuoverbal congruent and incongruent judgment in lesions of the prefrontal cortex.

Non ultimately maintenance of visuospatial attention by eliciting transient partial neglect intraoperatively is paramount in all cognitive domains in order to receive the correct stimuli to be processed from the environment. In this context a fronto-parietal network with a line bisection task and reaching test could be mapped intraoperatively in the non-dominant hemisphere (Figure 12).

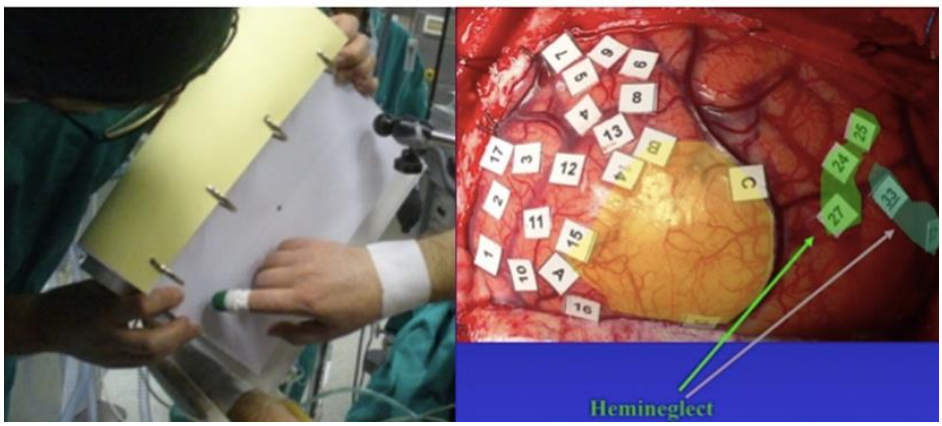

Figure 12. Intraoperative Bisection line test while patient awake used to map the non dominant Fronto-parietal networks.

CORTICO-CORTICAL AND AXONO-CORTICAL EVOKED POTENTIALS

In 1935 Foerster and Altenburger were the first to use electrocorticography (ECoG) to record electrophysiological responses to DES in various parts of the brain distant from the motor areas [10]. However how the stimulus induced by electrical stimulation is propagated still remains unknown. Recording evoked potentials generated by DES far away from where the stimulus is applied represents a way to have an in-depth view on stimulus propagation (Figure 13). In particular, DES can be used to probe the spatio-temporal connectivity and the dynamics of short and long range networks in vivo and in real time. This approach requires the combination of electrophysiological recordings -EEG or EcoG- with the stimulation technique (Figures 5, 13).

Figure 13. Combination of DES and intraoperative Stealth guided EEG recording is used to probe the spatio-temporal connectivity and the dynamics of short and long range networks in real time during brain surgery.

Matsumoto et al. [25] observed that low-frequency cortical application of DES (1Hz, constant current and alternating rectangular wave pulses lasting 0.3 ms) induces cortico-cortical evoked potentials (CCEPs) around 10-50 ms after stimulation.

The evoked potentials were observed in contiguous cortical areas whose centers were up to 3 cm apart linked by subcortical pathways. Single pulse DESs were delivered to certain functional areas of the cortex and CCEPs were measured by averaging the EcoG signal recorded at other sites.

Keller et al. [26] found that non contiguous and distant brain cortical areas even 5 cm apart exhibited strong evoked potentials (lasting from 10 to 30 ms) with low frequency DES. More interestingly Keller et al. demonstrated that low frequency fluctuations in BOLD signal in functional resting state MRI are representative of the brain's functional architecture when correlated with CCEP findings. As a consequence, low frequency DES can propagate in long

range networks with functional relevance through subcortical pathways and not only grey matter.

In our experience we were able to elicit also axono-cortical evoked potentials ACEPs) when stimulating at the subcortical level -the arcuate fasciculus- while recording from the ventral premotor cortex (Figure 5). This mean that probably the electrical stimulus, applied with DES at a subcortical level while distal cortical recording is achieved, can propagate through discrete subcortical pathways.

While CCEPs and ACEPs recording in neuro-oncology is still at an early stage, however they represent in our perspective a valuable tool to study the human connectivity *in vivo* and eventually guide low grade glioma resection also based on the dynamics of the whole network.

FUNCTIONAL PLASTICITY OF ADULT CORTEX: A STRATEGY TOWARDS EXTENDING LGG RESECTION?

Plasticity is an inherent feature of the human brain. Defined as the ability to change in response to experience, brain plasticity allows for the development and maintenance of nervous system function [27]. In particular, involvement of brain plasticity in clinical recovery from ischemic stroke [28] and infiltrative brain tumors has been clearly described [29]. However, those findings are derived from non-invasive studies conducted with functional MRI (fMRI), positron emission tomography (PET) and transcranial magnetic stimulation (TMS).

DES of brain cortex and subcortical structures during low grade glioma surgeries in patients receiving two or more brain mapping surgeries can be used as a direct tool to examine functional reorganization.

A longitudinal study comparing cortical brain mapping in two different surgeries in the same patient showed that nearly 40% of patients demonstrated a rearrangement of their functional maps between initial and repeated surgeries [30]. More interestingly patients who showed loss of function at one or more stimulation sites still exhibited intact or stable motor and speech function at the time of repeat surgery.

Tumor volumes at time of the initial surgery were significantly smaller in patients who exhibited functional reorganization (34.1+-23 cm3 in those with reorganization vs 69.9+-32,2 cm3 in those who did not, p=0.02) [30], possibly meaning that brain plasticity reserve decrease when tumors reach a critical volume. As a consequence, early surgery for low grades might be warranted in order to use at best the inherent plastic potentials of the brain cortex for functional recovery. However, mechanisms of functional rearrangement still need to be understood [31].

Advances in non-invasive methods as fMRI, TMS and Magnetoencephalography as well as in CCEPs invasive recordings could perhaps lead to careful observation of functional reorganization, with the aim to perform a more aggressive resection once functional circuits has been redistributed in areas not necessarily infiltrated by the lesion.

A STEP BACK: IS THERE A BIOPHYSICAL RATIONALE FOR DES?

While Electrical Microstimulation (EMS) is applied to animal fundamental neuroscience experiments, DES is performed on humans in the operating theatre. It is sometimes wrongly assumed that EMS and DES induce similar effects and findings in animal models are wrongly translated into humans.

At the current state of the art there is no solid biophysical rationale for setting the stimulation parameters in EMS and DES, probably due to historical, methodological and technical constraints. EMS and DES techniques are applied differently to the nervous tissue and use very different parameters. Moreover, even though DES is used effectively in tumors resection, the underlying electrophysiological effects needs to be yet defined.

The gap between empirical intraoperative DES and EMS in a laboratory setting offers an invaluable opportunity to gain insights on how DES perturbs a large functional network with physiological and behavioral relevance [10]. In particular, the study of CCEPs and ACEPs and the propagation of the stimulus along the white matter pathways will probably offer an invaluable tool for an in-depth understanding on the relationships between DES and neural networks.

CONCLUSION

At the state of the art intraoperative neuromonitoring coupled with direct cortical and subcortical stimulation for brain mapping of motor, language and higher order functions represents the gold standard to achieve maximal resection of low grade gliomas while preserving neurological functions, hence patient's quality of life.

In depth knowledge of the neuroanatomy of white matter fibers, by means of white matter fiber dissection technique, as well as of principles and interpretation of intraoperative neuromonitoring and brain mapping protocols is mandatory in order to correctly and effectively perform intraoperative mapping.

An *a priori* hypothesis of the functional networks possibly involved by the tumour is *conditio sine qua non* for the neurosurgeon to operate on intrinsic low grade brain tumors.

Stimulus spreading of DES is still matter of debate. Research on CCEPs and ACEPs could represent a valuable tool to unveil widespread and bilateral networks on line and in vivo, namely the dynamics of brain connectivity.

REFERENCES

[1] Smith JS, Chang EF, Lamborn KR, Chang SM, Prados MD, Cha S, Tihan T, Vandenberg S, McDermott MW, Berger M. Role of extent of resection in the long-term outcome of low-grade hemispheric glioma (2008). *J Clin Oncol.* 2008 Mar 10;26(8):1338-45. doi: 10.1200/JCO.2007.13.9337.

[2] Sarubbo S, De Benedictis A, Merler S, Mandonnet E, Barbareschi M, Dallabona M, Chioffi F, Duffau H. Structural and functional integration between dorsal and ventral

language streams as revealed by blunt dissection and direct electrical stimulation (2016). *Hum Brain Mapp.* 2016 Nov;37(11):3858-3872. doi: 10.1002/hbm.23281.

[3] Martino J, De Witt Hamer PC, Vergani F, Brogna C, de Lucas EM, Vázquez-Barquero A, García-Porrero JA, Duffau H. Cortex-sparing fiber dissection: an improved method for the study of white matter anatomy in the human brain (2011). *J Anat.* Oct; 219(4):531-41. doi: 10.1111/j.1469-7580.2011.01414.x.

[4] Martino J, Brogna C, Robles SG, Vergani F, Duffau H. Anatomic dissection of the inferior fronto-occipital fasciculus revisited in the lights of brain stimulation data (2010). *Cortex.* May;46(5):691-9. 0.1016/j.cortex.2009.07.015.

[5] Duffau H, Pallud J, Mandonnet E. Evidence for the genesis of WHO grade II glioma in an asymptomatic young adult using repeated MRIs (2011). *Acta Neurochir* (Wien) 153:473–477.

[6] Mandonnet E1, Delattre JY, Tanguy ML, Swanson KR, Carpentier AF, Duffau H, Cornu P, Van Effenterre R, Alvord EC Jr, Capelle L. Continuous growth of mean tumor diameter in a subset of grade II gliomas (2003). *Ann Neurol.* Apr;53(4):524-8.

[7] Potts MB, Smith JS, Molinaro AM, Berger MS. Natural history and surgical management of incidentally discovered low-grade gliomas (2012). *J Neurosurg*. Feb;116(2):365-72. doi: 10.3171/2011.9.JNS111068.

[8] Sanai N, Chang S, Berger MS. Low-grade gliomas in adults. (2011). *J Neurosurg.* Nov;115(5):948-65. doi: 10.3171/2011.7.JNS101238.

[9] Jakola AS, Skjulsvik AJ, Myrmel KS, Sjåvik K, Unsgård G, Torp SH, Aaberg K, Berg T, Dai HY, Johnsen K, Kloster R, Solheim O. Surgical resection versus watchful waiting in low-grade gliomas (2017). *Ann Oncol.* May 5. doi: 10.1093/annonc/mdx230.

[10] Vincent M, Rossel O, Hayashibe M, Herbet G, Duffau H, Guiraud D, Bonnetblanc F. The difference between electrical microstimulation and direct electrical stimulation - towards new opportunities for innovative functional brain mapping? (2016). *Rev Neurosci.* 2016 Apr 1;27(3):231-58. doi: 10.1515/revneuro-2015-0029.

[11] Martin J, Brogna C. *Anatomy of the white-matter pathways* (2011). Wien. Springer-Verlag, 27-41.

[12] Chang EF, Clark A, Smith JS et al. (2011) Functional mapping- guided resection of low-grade gliomas in eloquent areas of the brain: improvement of long-term survival. Clinical article. *J Neurosurg* 114(3):566–573.

[13] Sarubbo S, Latini F, Panajia A et al. (2011) Awake surgery in low-grade gliomas harboring eloquent areas: 3-year mean follow- up. *Neurol Sci* 32(5):801–810.

[14] Yordanova YN, Moritz-Gasser S, Duffau H (2011) Awake surgery for WHO Grade II gliomas within ‘‘noneloquent’’ areas in the left dominant hemisphere: toward a ‘‘supratotal’’ resection. Clinical article. *J Neurosurg* 115(2):232–239.

[15] De Benedictis A, Moritz-Gasser S, Duffau H (2010) Awake mapping optimizes the extent of resection for low-grade gliomas in eloquent areas. *Neurosurgery* 66(6):1074–1084: (discussion 1084).

[16] Carrabba G, Fava E, Giussani C et al. (2007) Cortical and subcortical motor mapping in rolandic and perirolandic glioma surgery: impact on postoperative morbidity and extent of resection. *J Neurosurg Sci* 51(2):45–51.

[17] Duffau H, Capelle L, Denvil D et al. (2003) Usefulness of intra- operative electrical subcortical mapping during surgery for low- grade gliomas located within eloquent

brain regions: functional results in a consecutive series of 103 patients. *J Neurosurg* 98(4):764–778.

[18] Duffau H, Taillandier L, Gatignol P, Capelle L (2006) The insular lobe and brain plasticity: lessons from tumor surgery. *Clin Neurol Neurosurg* 108(6):543–548.

[19] Bello L, Riva M, Fava E, Ferpozzi V, Castellano A, Raneri F, Pessina F, Bizzi A, Falini A, Cerri G. (2014) Tailoring neurophysiological strategies with clinical context enhances resection and safety and expands indications in gliomas involving motor pathways *Neuro Oncol.* 2014 Aug;16(8):1110-28. doi: 10.1093/neuonc/not327.

[20] Taniguchi, A.M., Cedzich, C., and Schramm, J. (1993). Modification of cortical stimulation for motor evoked potentials under general anesthesia: technical description. *Neurosurgery* 32, 219–226.

[21] du Boisgueheneuc F, Levy R, Volle E, et al. (2006) Functions of the left superior frontal gyrus in humans: a lesion study. *Brain* 129(pt 12):3315-3328.

[22] Teixidor P, Gatignol P, Leroy M, Masuet-Aumatell C, Capelle L, Duffau H. (2007). Assessment of verbal working memory before and after surgery for low-grade glioma. *J Neurooncol.* 2007;81(3):305-313.

[23] Duffau H, Denvil D, Lopes M, et al. (2002) Intraoperative mapping of the cortical areas involved in multiplication and subtraction: an electrostimulation study in a patient with a left parietal glioma. *J Neurol Neurosurg Psychiatry.* 73(6):733-738.

[24] Gatignol P, Capelle L, Le Bihan R, Duffau H. (2004). Double dissociation between picture naming and comprehension: an electrostimulation study. *Neuroreport.* 15(1):191-195.

[25] Kunieda T, Yamao Y, Kikuchi T, Matsumoto R. (2015). New Approach for Exploring Cerebral Functional Connectivity: Review of Cortico-cortical Evoked Potential. *Neurol Med Chir* (Tokyo). 55(5):374-82.

[26] Entz L, Tóth E, Keller CJ, Bickel S, Groppe DM, Fabó D, Kozák LR, Erőss L, Ulbert I, Mehta AD. (2014). Evoked effective connectivity of the human neocortex. *Hum Brain Mapp.* Dec;35(12):5736-53.

[27] Paqual-Leone A. (2005). The plasticity of brain human cortex. *Ann Rev Neurosci* 28: 377-401.

[28] Talelli P, Greenwood RJ, Rothwell JC (2006). Arm function after stroke: neurophysiological correlates and recovery mechanisms assessed by transcranial magnetic stimulation. *Clin Neurophysiol* 117:1641–1659.

[29] Krieg SM, Sollmann N, Hauck T, Ille S, Meyer B, Ringel F (2014). Repeated mapping of cortical language sites by preoperative navigated transcranial magnetic stimulation compared to repeated intraoperative DCS mapping in awake craniotomy. *BMC Neurosci* 15:20.

[30] Southwell DG, Froemke RC, Alvarez-Buylla A, Stryker MP, Gandhi SP (2010): Cortical plasticity induced by inhibitory neuron transplantation. *Science* 327:1145–1148.

[31] Robles SG, Gatignol P, Lehéricy S, Duffau H (2008). Long-term brain plasticity allowing a multistage surgical approach to World Health Organization Grade II gliomas in eloquent areas. *J Neurosurg* 109:615–624.

BIOGRAPHICAL SKETCH

Christian Brogna, MD, PhD

Affiliation:

Department of Neurosurgery - Neuro-oncology - King's College Hospital
Department of Basic and Clinical Neuroscience
Maurice Wohl Clinical Neuroscience Institute
King's College London Institute of Psychiatry, Psychology & Neuroscience

Education:

Dr. Christian Brogna completed his neurosurgical training in 2009 at "La Sapienza" University of Rome, Italy. He studied Neuroanatomy under the mentorship of Prof. Guilherme Ribas in Sao Paulo, Brasil. He did a fellowship in awake surgery and brain mapping with Prof. Hugue Duffau, CHU de Montpellier, France. He trained with Prof. Ugur Ture, Istanbul, in advanced Microneurosurgical Techniques in Brain Tumour Surgery. Mr. Christian Brogna earned his PhD in Neuroscience in 2013.

Business Address:

125 Coldharbour Lane
London SE5 9NU
United Kingdom
christian.1.brogna@kcl.ac.uk

Research and Professional Experience:

Dr. Christian Brogna is an expert in complex brain and spinal cord tumour surgery. In particular he operates on brain tumours located in highly eloquent areas of the brain, for example those areas involved in motor and language functions in order to preserve patient's quality of life. He conducts research in advanced techniques in brain and spinal cord mapping for safe tumour resection.

Professional Appointments:

Dr. Christian Brogna currently operates on Brain and Spinal Cord Tumours in the Department of Neurosurgery, King's College Hospital. Dr Christian Brogna has an academic appointment with King's College London University and is responsible for translational neurosurgical research in neuro-oncology.

Publications from the Last 3 Years:

1) Lavrador JP, Brogna C, Vergani F, Greenway F, Aizpurua M, Bhangoo R. 5-ALA fluorescence in intraparenchymal endodermal cysts. *Acta Neurochir* (Wien). 2017 May
2) Lavrador JP, Brogna C, Vergani F, Hasegawa H, Aizpurua M, Bhangoo R. Third-ventricle enterogenous cyst presentation mimicking a colloid cyst: uncommon presentation of a rare disease and literature review. *Acta Neurochir* (Wien). 2017 Mar;159(3):465-468.
3) Brogna C, Thakur B, Fiengo L, Tsoti SM, Landi A, Anichini G, Vergani F, Malik I. Mini Transsternal Approach to the Anterior High Thoracic Spine (T1-T4 Vertebrae). *Biomed Res Int*. 2016;2016:4854217. doi: 10.1155/2016/4854217. Epub 2016 Apr 27.
4) Brogna C, Fiengo L, Türe U. Achille Louis Foville's atlas of brain anatomy and the Defoville syndrome. *Neurosurgery*. 2012 May;70(5):1265-73; discussion 1273.
5) Martino J, Brogna C, Robles SG, Vergani F, Duffau H. Anatomic dissection of the inferior fronto-occipital fasciculus revisited in the lights of brain stimulation data. *Cortex*. 2010 May;46(5):691-9.
6) Martino J., Brogna C. (2011) Anatomy of the white-matter pathways. In: Duffau H. (eds) *Brain Mapping*. Springer, Vienna.

In: Encyclopedia of Surgery (22 Volume Set)
Editors: Andreas Lehrer and Kristin Mueller
ISBN: 978-1-53618-329-0
© 2020 Nova Science Publishers, Inc.

Chapter 444

THE EFFECTS OF LIPOIC ACID ON WOUND HEALING IN A UTERINE INJURY RAT MODEL: CLINICAL PERSPECTIVES IN OBSTETRIC SURGERY

Asli Goker [*] ***and Naci Kemal Kuscu***
Department of Obstetrics and Gynecology, Manisa Celal Bayar University,
Manisa, Turkey

ABSTRACT

Healing of the uterus after an obstetric or gynaecologic intervention is of great importance to maintain further pregnancies. Wound healing of the uterine tissue has not been widely studied but is gaining more importance with increasing caesarean rates in modern times.

Alpha lipoic acid, an anti-inflammatory and antioxidant compound has been studied in many fields of treatment. Wound healing is shown to be enhanced by alpha lipoic acid. A study on the effect of alpha lipoic acid on wound healing in a rat model and a general overlook about the compound has been reported.

Keywords: uterine injury, alpha lipoic acid, wound healing

INTRODUCTION

The uterus is a unique female genital organ which serves for fertility. Trauma to the uterus may cause infertility, miscarriage or uterine rupture in a pregnancy.

The most frequent causes of uterine damage are caesarean section (CS), myomectomy and curettage. Uterine wound healing is of vital importance because dehiscence of uterine scars or rupture during a subsequent pregnancy or parturition may be life threatening for mother and/or baby.

[*] Corresponding Author's Email: asligoker@gmail.com.

Uterine wound healing has not been widely studied and there are not well designed and convincing articles about the subject. Little is known on the mechanisms and factors influencing adequate tissue regeneration.

Various molecules which may have positive impact on uterine wound healing have been studied: a promising compound is Alpha Lipoic Acid (ALA) and the first experimental study on its effect on a full thickness injury in a rat model will be discussed later.

INTERVENTIONS TO THE UTERUS

Uterine fibroids are the most common benign tumours of women after the third decade with a prevalence rate of 20–50%, based on post-mortem studies (Laughlin, Schroeder, and Baird 2010, Novak, Novak, and Woodruff 1979). In modern times women tend to postpone their pregnancies after reaching a certain career status and thus their childbearing years coincide with the time of high fibroid incidence (Schmidt et al., 2012).

Approximately 5-10% of the infertile patients have fibroids (Benecke et al., 2005) and some of them undergo myomectomy either by laparoscopy, laparotomy or robotic surgery.

The major concern about myomectomy is the risk of uterine rupture in a subsequent pregnancy, and this risk is not related to the mode of surgery. A history of myomectomy leads to prefer CS in pregnant women especially if more than 50% of the myometrium has been exposed during the surgery (Roopnarinesingh, Suratsingh, and Roopnarinesingh 1985). Uterine rupture may cause the displacement of the foetus into the abdominal cavity leading to perinatal demise and maternal haemorrhage causing blood transfusions, hysterectomy or even maternal death.

The precise risk of uterine rupture in a pregnancy following myomectomy remains unknown but is reported as high as the risk in a patient with previous CS. The risk increases when it is an intramural fibroid (Brady, Stanic, and Styer 2013).

The risk of uterine rupture during trial of labour after myomectomy is reported as 0.47% - 0.8% mainly occurring before 36 weeks of gestation (Gambacorti-Passerini et al., 2016, Kim et al., 2016). However, it is indicated by the World Fibroid Registry that most uterine ruptures after myomectomy are not reported especially if no complication occurred (Kim et al., 2016). Most reported cases do not include silent ruptures (Kim et al., 2016). There are cases of spontaneous uterine rupture, at 20 weeks of gestation with a myomectomy-pregnancy interval of 6 years (Pakniat, Soofizadeh, and Khezri 2016).

An increase in hospitalization due to fibroids is estimated to increase 23% by year 2050 (Wechter et al., 2011). Open, laparoscopic or hysteroscopic myomectomies are recommended even in asymptomatic infertile women if the cavity is distorted (American Society for Reproductive Medicine 2017). Since physicians will continue to perform myomectomies, the risk of uterine rupture in future pregnancies will remain as a major and a life-threatening problem.

Another uterine intervention is CS and it is among the most common surgical operations worldwide. Even though it is life-saving in most cases, maternal complications may arise and future pregnancies may be affected.

There is no supporting evidence that CS has maternal and/or perinatal benefits and the World Health Organization (WHO) is trying to maintain a certain rate of CS procedures.

Though CS is of great benefit in many conditions, it is still debatable to perform in uncomplicated deliveries due to increase in maternal complications in subsequent pregnancies and financial costs. The WHO statement on CS concludes that caesarean sections are saving maternal and infant lives, at population level they should be performed only when required for medically indicated reasons.

Rates exceeding 10% are not associated with reductions in maternal and newborn mortality rates, therefore more research is needed to understand the health effects of CS on immediate and future outcomes (World Health Organization 2017). Despite this statement, caesarean section rates range from 3% in Western Africa to 42.9% in Southern America and almost 20% of women worldwide give birth by CS (Betran et al., 2016). The most frequent indications for elective CS are fear of vaginal birth and physicians' fear of facing a litigation (Habiba et al., 2006).

Elective repeat CSs are associated with increased risk of uterine rupture, placental invasion anomalies and placenta previa (Barger et al., 2012). Vaginal birth after caesarean (VBAC) was considered as a good alternative method to decrease repeat CSs, however VBAC rates dropped since mid 1990's due to health care providers' choice (Tsai and Wu 2017). The American College of Obstetrics and Gynaecology (ACOG) has recently released Practice Bulletin 184 and reported that women can avoid major abdominal surgery and have lower rates of haemorrhage, thromboembolism and infection with a successful VBAC.

The risk of hysterectomy, bowel-bladder injury, abnormal placentation and infection may decrease with VBAC in women who are planning future pregnancies. The final statement of ACOG is "Most women with one previous caesarean delivery with a low-transverse incision are candidates for and should be counselled about and offered trial of labour after caesarean" (Committee on Practice Bulletins-Obstetrics 2017) and therefore the rate of uterine rupture or dehiscence which contribute to maternal and neonatal morbidity or mortality may decrease.

Since physicians will continue to perform myomectomy and CS, the significance of good wound healing is of great importance to achieve a durable incision site. Wound healing is a process involving complex interactions of mediators. Following tissue injury, keratinocytes migrate to the injury site and then granulation formation by fibroblasts and endothelial cells and neovascularization occur. Blood vessels are repaired, restored and regenerated (Fosen and Thom 2014).

The classic steps of wound healing comprise inflammation, proliferation and remodelling. In mammals, reactions to trauma is repair and regeneration with numerous molecules participating in the process (Tonnesen, Feng, and Clark 2000).

The female reproductive tract is constantly exposed to tissue injury. Menstruation and parturition are physiological injuries whereas gynaecologic or obstetric procedures such as curettage, myomectomy, hysteroscopic resection and CS are widely applied and traumatic interventions. Initiation of endometriosis is another example of inflammatory response and healing of menstrual wounds (Leyendecker, Wildt, and Mall 2009). Similarly, fibroids are found to represent keloids in abnormal healing and disordered collagen fibril organization (Leppert et al., 2004). Therefore, understanding the mechanism of the endometrial, myometrial and serosal regeneration of the uterus is of great importance.

WOUND HEALING

Skin lesions are widely studied to understand the mechanism of wound healing but so far there is little information on uterine pathways. Even though most wounds heal with scar formation, this is usually not the case in endometrial repair, like the absence of granulation formation or blood clots (Salamonsen 2003).

The healing of foetuses is without scar formation, however in anti-inflammatory deficient foetuses, wounds heal with scarring. This indicates a role for inflammation in the scar formation (Liechty et al., 2000).

The major molecules participating in wound healing are growth factors, cytokines, extracellular matrix molecules and matrix degrading enzymes (Salamonsen 2003). Endometrial repair includes stromal mitoses, re-epithelization, vascular repair, proteolytic enzymes, growth factors, endothelin, inflammatory cells and chemokines.

An important modulator related to angiogenesis is vascular endothelial growth factor (VEGF) which is found to be expressed during post-menstrual repair (Graubert et al., 2001). A study investigating uterine injury in humans' reports that healing may result by myometrial hyperplasia, elastosis or myofiber disarray (Roeder, Cramer, and Leppert 2012). What is known regarding the underlying mechanisms of healing in female genital tract is that inflammation and angiogenesis are key points in uterine wound healing. Despite this, further studies are necessary to better investigate this complex process.

ALPHA LIPOIC ACID

Alpha lipoic acid (ALA) is an organosulfur compound derived from octanoic acid and its R-enantiomeric form is synthetized endogenously. Plants, animals and human tissues rich in mitochondria synthesize ALA and it is present in reduced, oxidized and disulfuric forms (Biewenga, Haenen, and Bast 1997).

Under physiological conditions, ALA is amphipathic which allows it to pass the blood-brain barrier and show its effects both in an aqueous and lipid environment (Wada, Shintani, and Ohlrogge 1997). This versatility clearly has advantages on other hydrophilic or hydrophobic antioxidants. The antioxidant property of ALA has shown to enhance vascular functions in diabetic skin lesions and diabetic kidneys (Lateef et al., 2005, Micili, Ergur, et al., 2013).

Numerous trials and experiments are carried out about the possible therapeutic fields of ALA such as cancer (Yang et al., 2017, Nur, Naziroglu, and Deveci 2017, Alpay et al. 2016), polycystic ovary syndrome (Genazzani et al., 2017), diabetes (Jurisic-Erzen et al., 2017), tissue regeneration (Mazroa et al., 2015, Ekinci et al., 2014, Aydin et al., 2014, Chen et al., 2012) and protection from ischemia/reperfusion damage (Lv et al., 2017, Ambrosi et al., 2016). Most studies have found positive impact on molecular and tissue levels.

Clinical use of ALA seems to be promising in many clinical conditions which involve inflammation, oxidation and tissue damage in their pathophysiology. Experimental and clinical trials have shown that ALA decreases growth factor receptor bound protein-2 in lung cancer cells, increases apoptosis and ROS production by activating TRPV-1 in breast cancer, decreases insulin, glucose and HOMA index levels in polycystic ovary syndrome, increases

TGF-beta in femoral fracture model, controls inflammatory reaction, enhances elastic fiber synthesis and improves angiogenesis in mesh application (Yang et al., 2017, Nur, Naziroglu, and Deveci 2017, Genazzani et al. 2017, Mazroa et al., 2015, Aydin et al., 2014).

After oral intake, ALA is quickly and nearly completely absorbed, however due to hepatic first-pass effect its bioavailability is limited (Locher, Busker, and Borbe 1995). Recent experiments investigated the vaginal administration of ALA to verify its distribution in uterine and cervical tissues after vaginal application of ALA to rats. Samples of the endometrium, myometrium and perimetrium have shown that normal histomorphological structure had been maintained and the stroma was consistent with the oestrus cycle of the rats. This indicates that ALA reaches uterine tissues when applied vaginally and does not impair the histomorphologic structure. Immunohistochemical studies of the endometrium have shown staining of simple columnar epithelium, endometrial glands and stroma with anti-ALA antibody, showing us that vaginal route for ALA is effective in reaching target tissues of uterus (Micili et al. 2018).

The safety of ALA in animals and humans have been shown by numerous other studies (Rahimifard et al., 2015, Cremer et al., 2006, Parente et al., 2017).

The most important function of ALA is its antioxidant effect by scavenging oxidants, regenerating endogenous antioxidants, chelating transition metals and repairing oxidative damage (Monastra et al., 2016). Besides anti-inflammatory and immunomodulatory effects, ALA has been shown to have angiogenetic stimulating features (Paradells et al., 2015).

FULL THICKNESS INJURY IN A RAT MODEL

The VEGF family is specific to endothelial cells and takes part in cell proliferation, migration and differentiation (Neufeld et al., 1999). In addition, VEGF plays an important role in angiogenesis during the granulation process of wound healing (Nissen et al., 1998). Considering that VEGF plays an important role in angiogenesis and ALA is a potential anti-inflammatory and antioxidant compound it has been used in an experimental model.

In a study, Cilaker et al., produced a full thickness injury in the uterus, mimicking CS or myomectomy with the endometrium disposed (Micili, Goker, et al., 2013). Alpha lipoic acid was used to determine its effects on the healing process due to its numerous features.

The authors studied VEGF and smooth muscle actin (SMA), a marker for fibrogenesis and myofibroblast generation. The alpha form of SMA is present in fibroblasts and myoepithelial properties which are active in wound healing by contracting the edges of the injury site (Cherng, Young, and Ma 2008).

Besides angiogenetic induction in tissues, VEGF is essential for re-epithelization of the endometrium, and has been used in tissue engineering and wound healing (Ferrara and Kerbel 2005, Ferrara 2004, Fan et al., 2008). Lin et al., showed that, after injection of collagen into a scarred rat uterus, VEGF promoted remodelling of the scarred uterus including, the regeneration of endometrium, muscular cells and vascularization and improved pregnancy outcomes (Lin et al., 2012).

The experimental study by Cilaker et al was carried out on Wistar albino rats which were randomly assigned to five study groups. Group 1: control group, group 2: uterine scar group 15 days, group 3: uterine scar + ALA treatment 15 days, group 4: uterine scar group 30 days,

group 5: uterine scar + ALA treatment 30 days. The experiment was done on day of diestrus phase. Full thickness injury was modified from Lin et al.'s model (LİN). After full-thickness injury was created on the uterine horns of the rats.

Alpha Lipoic acid treatment was administered as fresh solutions by oral gavage. According to study groups 15 or 30 days later relaparotomy was performed to retrieve uterine horns for histological examination and immunohistochemistry.

The thickness of the regenerative uterine wall in Control group uterus (687.5 ± 85.7 μm) was higher than all other groups ($p< 0.001$). The uterine wall thickness was significantly higher in the US15d+ALA (483.4 ± 45.7 μm) and US30d + ALA (619.1 ± 61.4 μm) groups when compared to the US15d (248.3 ± 56.8 μm) and US30d groups (503.9 ± 56.5 μm), respectively ($p< 0.001$). No significant difference was observed between US15d + ALA and US30d groups ($p = 0.571$).

The percentage of α-SMA positive area in US15d + ALA (20.3 ± 1.54) and US30d + ALA (28.1 ± 2.98) groups was significantly higher than US15d (15.2 ± 3.20) and US30d groups (21.07 ± 1.59) ($p< 0.001$, $p< 0.001$).

The percentage of VEGF positive area in US15d + ALA (23.3 ± 2.92) group was significantly higher than US15d group (16.0 ± 1.95) ($p< 0.001$) and US30d + ALA (25.8 ± 2.59) group was significantly higher than US30d group (21.3 ± 1.94) ($p< 0.001$).

Groups treated with ALA had a comparable uterine wall thickness with control which was a similar result to Li et al.'s bFGF treatment group.

A significant increase in α-SMA expression both by immunohistochemical and biochemical methods lead us to conclude that ALA has an enhancing effect on smooth muscle cell regeneration. An increase in the expression of tissue α-SMA refers to an increase in myofibroblast activity, thus ALA may have a triggering effect on fibrogenesis during wound healing.

A study by Buhimschi et al., demonstrated regenerative ability as histological, mitotic and functional differences in mice strains with different healing capacities (Buhimschi et al., 2010). They showed that, the site of uterine scar was active and underwent significant remodelling transformation even at 15 days post caesarean delivery which was equivalent to 7.5 months in humans. The risk of uterine rupture from the incision site due to dehiscence is highest in the postoperative first 2 years in humans (Stamilio et al., 2007).

The study by Cilaker et at., evaluated the effect of ALA at day 15 and 30 after uterine full thickness injury and have seen a significant healing in the group treated with ALA for 15 days. These results propose a possible positive effect of ALA on uterine wound healing and point out a probable clinical use of this molecule to accelerate tissue regeneration after surgery.

CONCLUSION

Many studies showed the positive effect of ALA on wound healing. Supplementation with oral ALA has been shown to down-regulate chronic inflammatory state by changing the protease/anti-protease levels, to decrease the matrix metalloproteinase 9 expression and to increase levels of PDGF-BB contributing to the treatment of dermal wound repair (Alleva et al., 2008).

Treatment with ALA has been shown beneficial for fracture healing in an animal model (Aydin et al., 2014).

The study by Cilaker et al opens a new scenario for ALA clinical use in gynaecology and obstetrics representing the first experimental example on the use of oral ALA for uterine injury healing.

Further experimental and clinical studies on this field of application are warranted to further investigate the efficacy of ALA and the development of new ALA-based drugs and/or medical devices may represent an opportunity for clinicians and patients.

REFERENCES

Alleva, R., M. Tomasetti, D. Sartini, M. Emanuelli, E. Nasole, F. Di Donato, B. Borghi, L. Santarelli, and J. Neuzil. 2008. "Alpha-Lipoic acid modulates extracellular matrix and angiogenesis gene expression in non-healing wounds treated with hyperbaric oxygen therapy." *Mol. Med.* 14 (3-4):175-83. doi: 10.2119/2007-00095.Alleva.

Alpay, M., B. Yurdakok-Dikmen, G. Kismali, and T. Sel. 2016. "Antileukemic effects of piperlongumine and alpha lipoic acid combination on Jurkat, MEC1 and NB4 cells in vitro." *J. Cancer Res. Ther.* 12 (2):556-60. doi: 10.4103/0973-1482.151936.

Ambrosi, N., V. Arrosagaray, D. Guerrieri, P. D. Uva, J. Petroni, M. B. Herrera, J. L. Iovanna, L. Leon, C. Incardona, H. E. Chuluyan, and D. H. Casadei. 2016. "Alpha-Lipoic Acid Protects Against Ischemia-Reperfusion Injury in Simultaneous Kidney-Pancreas Transplantation." *Transplantation* 100 (4):908-15. doi: 10.1097/TP.00 00000000000981.

American Society for Reproductive Medicine. 2017. "Removal of myomas in asymptomatic patients to improve fertility and/or reduce miscarriage rate: a guideline." *Fertil. Steril.* 108 (3):416-425. doi: 10.1016/j. fertnstert.2017.06.034.

Aydin, A., Z. Halici, A. Akoz, A. Karaman, I. Ferah, Y. Bayir, A. M. Aksakal, E. Akpinar, J. Selli, and H. Kovaci. 2014. "Treatment with alpha-lipoic acid enhances the bone healing after femoral fracture model of rats." *Naunyn Schmiedebergs Arch. Pharmacol.* 387 (11):1025-36. doi: 10.1007/s00210-014-1021-1.

Barger, M. K., A. Nannini, J. Weiss, E. R. Declercq, P. Stubblefield, M. Werler, and S. Ringer. 2012. "Severe maternal and perinatal outcomes from uterine rupture among women at term with a trial of labor." *J Perinatol* 32 (11):837-43. doi: 10.1038/jp.2012.2.

Benecke, C., T. F. Kruger, T. I. Siebert, J. P. Van der Merwe, and D. W. Steyn. 2005. "Effect of fibroids on fertility in patients undergoing assisted reproduction. A structured literature review." *Gynecol. Obstet. Invest.* 59 (4):225-30. doi: 10.1159/000084513.

Betran, A. P., J. Ye, A. B. Moller, J. Zhang, A. M. Gulmezoglu, and M. R. Torloni. 2016. "The Increasing Trend in Caesarean Section Rates: Global, Regional and National Estimates: 1990-2014." *PLoS One* 11 (2):e0148343. doi: 10.1371/journal.pone.0148343.

Biewenga, G. P., G. R. Haenen, and A. Bast. 1997. "The pharmacology of the antioxidant lipoic acid." *Gen. Pharmacol.* 29 (3):315-31.

Brady, P. C., A. K. Stanic, and A. K. Styer. 2013. "Uterine fibroids and subfertility: an update on the role of myomectomy." *Curr. Opin. Obstet. Gynecol.* 25 (3):255-9. doi: 10.1097/GCO.0b013e3283612188.

Buhimschi, C. S., G. Zhao, N. Sora, J. A. Madri, and I. A. Buhimschi. 2010. "Myometrial wound healing post-Cesarean delivery in the MRL/MpJ mouse model of uterine scarring." *Am. J. Pathol.* 177 (1):197-207. doi: 10.2353/ajpath.2010.091209.

Chen, S. A., H. M. Chen, Y. D. Yao, C. F. Hung, C. S. Tu, and Y. J. Liang. 2012. "Topical treatment with anti-oxidants and Au nanoparticles promote healing of diabetic wound through receptor for advance glycation end-products." *Eur. J. Pharm. Sci.* 47 (5):875-83. doi: 10.1016/j.ejps.2012.08.018.

Cherng, S., J. Young, and H. Ma. 2008. "Alpha-smooth muscle actin (alfa-SMA)." *J. Am. Sci.* 4 (4):7-9.

Committee on Practice Bulletins-Obstetrics. 2017. "Practice Bulletin No. 184: Vaginal Birth After Cesarean Delivery." *Obstet. Gynecol.* 130 (5):e217-e233. doi: 10.1097/aog. 0000000000002398.

Cremer, D. R., R. Rabeler, A. Roberts, and B. Lynch. 2006. "Long-term safety of alpha-lipoic acid (ALA) consumption: A 2-year study." *Regul. Toxicol. Pharmacol.* 46 (3):193-201. doi: 10.1016/j.yrtph.2006. 06.003.

Ekinci, M., H. H. Cagatay, E. Ceylan, S. Keles, Y. Koban, G. Gokce, U. Huseyinoglu, E. Ozcan, and M. E. Oba. 2014. "Reduction of conjunctival fibrosis after trabeculectomy using topical alpha-lipoic acid in rabbit eyes." *J. Glaucoma* 23 (6):372-9. doi: 10.1097/IJG. 0000000000000052.

Fan, X., S. Krieg, C. J. Kuo, S. J. Wiegand, M. Rabinovitch, M. L. Druzin, R. M. Brenner, L. C. Giudice, and N. R. Nayak. 2008. "VEGF blockade inhibits angiogenesis and reepithelialization of endometrium." *FASEB J.* 22 (10):3571-80. doi: 10.1096/fj.08-111401.

Ferrara, N. 2004. "Vascular endothelial growth factor: basic science and clinical progress." *Endocr. Rev.* 25 (4):581-611. doi: 10.1210/er.2003-0027.

Ferrara, N., and R. S. Kerbel. 2005. "Angiogenesis as a therapeutic target." *Nature* 438 (7070):967-74. doi: 10.1038/nature04483.

Fosen, K. M., and S. R. Thom. 2014. "Hyperbaric oxygen, vasculogenic stem cells, and wound healing." *Antioxid. Redox. Signal.* 21 (11):1634-47. doi: 10.1089/ars.2014.5940.

Gambacorti-Passerini, Z., A. C. Gimovsky, A. Locatelli, and V. Berghella. 2016. "Trial of labor after myomectomy and uterine rupture: a systematic review." *Acta. Obstet. Gynecol. Scand.* 95 (7):724-34. doi: 10.1111/aogs.12920.

Genazzani, A. D., K. Shefer, D. Della Casa, A. Prati, A. Napolitano, A. Manzo, G. Despini, and T. Simoncini. 2017. "Modulatory effects of alpha-lipoic acid (ALA) administration on insulin sensitivity in obese PCOS patients." *J. Endocrinol. Invest.* doi: 10.1007/s40618-017-0782-z.

Graubert, M. D., M. A. Ortega, B. Kessel, J. F. Mortola, and M. L. Iruela-Arispe. 2001. "Vascular repair after menstruation involves regulation of vascular endothelial growth factor-receptor phosphorylation by sFLT-1." *Am. J. Pathol.* 158 (4):1399-410.

Habiba, M., M. Kaminski, M. Da Fre, K. Marsal, O. Bleker, J. Librero, H. Grandjean, P. Gratia, S. Guaschino, W. Heyl, D. Taylor, and M. Cuttini. 2006. "Caesarean section on request: a comparison of obstetricians' attitudes in eight European countries." *BJOG* 113 (6):647-56. doi: 10.1111/j.1471-0528.2006.00933.x.

Jurisic-Erzen, D., G. Starcevic-Klasan, D. Ivanac, S. Peharec, D. Girotto, and R. Jerkovic. 2017. "The effects of alpha-lipoic acid on diabetic myopathy." *J. Endocrinol. Invest.* doi: 10.1007/s40618-017-0720-0.

Kim, H. S., S. Y. Oh, S. J. Choi, H. S. Park, G. J. Cho, J. H. Chung, Y. S. Seo, S. Y. Jung, J. E. Kim, S. H. Chae, and H. S. Hwang. 2016. "Uterine rupture in pregnancies following myomectomy: A multicenter case series." *Obstet. Gynecol. Sci.* 59 (6):454-462. doi: 10.5468/ ogs.2016.59.6.454.

Lateef, H., M. N. Aslam, M. J. Stevens, and J. Varani. 2005. "Pretreatment of diabetic rats with lipoic acid improves healing of subsequently-induced abrasion wounds." *Arch. Dermatol. Res.* 297 (2):75-83. doi: 10.1007/s00403-005-0576-6.

Laughlin, S. K., J. C. Schroeder, and D. D. Baird. 2010. "New directions in the epidemiology of uterine fibroids." *Semin. Reprod. Med.* 28 (3):204-17. doi: 10.1055/s-0030-1251477.

Leppert, P. C., T. Baginski, C. Prupas, W. H. Catherino, S. Pletcher, and J. H. Segars. 2004. "Comparative ultrastructure of collagen fibrils in uterine leiomyomas and normal myometrium." *Fertil. Steril.* 82 Suppl. 3:1182-7. doi: 10.1016/j.fertnstert.2004.04.030.

Leyendecker, G., L. Wildt, and G. Mall. 2009. "The pathophysiology of endometriosis and adenomyosis: tissue injury and repair." *Arch. Gynecol. Obstet.* 280 (4):529-38. doi: 10.1007/s00404-009-1191-0.

Liechty, K. W., H. B. Kim, N. S. Adzick, and T. M. Crombleholme. 2000. "Fetal wound repair results in scar formation in interleukin-10-deficient mice in a syngeneic murine model of scarless fetal wound repair." *J. Pediatr. Surg.* 35 (6):866-72; discussion 872-3. doi: 10.1053/jpsu.2000.6868.

Lin, N., X. Li, T. Song, J. Wang, K. Meng, J. Yang, X. Hou, J. Dai, and Y. Hu. 2012. "The effect of collagen-binding vascular endothelial growth factor on the remodeling of scarred rat uterus following full-thickness injury." *Biomaterials* 33 (6):1801-7. doi: 10.1016/j.biomaterials. 2011.11.038.

Locher, M., E. Busker, and H. O. Borbe. 1995. "Metabolism of Alpha-Lipoic Acid İn Human Volunteers." *Naunyn Schmiedebergs Arch. Pharmacol.* 351:R52.

Lv, C., S. Maharjan, Q. Wang, Y. Sun, X. Han, S. Wang, Z. Mao, Y. Xin, and B. Zhang. 2017. "Alpha-Lipoic Acid Promotes Neurological Recovery after Ischemic Stroke by Activating the Nrf2/HO-1 Pathway to Attenuate Oxidative Damage." *Cell Physiol. Biochem.* 43 (3):1273-1287. doi: 10.1159/000481840.

Mazroa, S. A., S. A. Asker, W. Asker, and M. Abd Ellatif. 2015. "Effect of alpha lipoic acid co-administration on structural and immunohistochemical changes in subcutaneous tissue of anterior abdominal wall of adult male albino rat in response to polypropylene mesh implantation." *Int. J. Exp. Pathol.* 96 (3):172-82. doi: 10.1111/ iep.12127.

Micili, S. C., B. U. Ergur, C. Ozogul, S. Sarioglu, H. A. Bagriyanik, K. Tugyan, C. Pekcetin, U. Sonmez, I. Tekmen, G. Erbil, G. G. Akdogan, D. Ozyurt, and Z. Buldan. 2013. "Effects of lipoic acid in an experimentally induced hypertensive and diabetic rat model." *Clin. Exp. Hypertens* 35 (5):373-81. doi: 10.3109/10641963.2012.732647.

Micili, S. C., A. Goker, O. Sayin, P. Akokay, and B. U. Ergur. 2013. "The effect of lipoic acid on wound healing in a full thickness uterine injury model in rats." *J. Mol. Histol.* 44 (3):339-45. doi: 10.1007/s10735-013-9485-8.

Micili, S. C., A. Goker, K. Kuscu, B. U. Ergur, and A. Fuso. 2018. "Alpha-lipoic acid vaginal administration contrasts inflammation and preterm delivery in rats." *Reproductive Sciences.* Accepted.

Monastra, G., S. De Grazia, S. Cilaker Micili, A. Goker, and V. Unfer. 2016. "Immunomodulatory activities of alpha lipoic acid with a special focus on its efficacy in preventing miscarriage." *Expert Opin. Drug Deliv.* 13 (12):1695-1708.

Neufeld, G., T. Cohen, S. Gengrinovitch, and Z. Poltorak. 1999. "Vascular endothelial growth factor (VEGF) and its receptors." *FASEB J.* 13 (1):9-22.

Nissen, N. N., P. J. Polverini, A. E. Koch, M. V. Volin, R. L. Gamelli, and L. A. DiPietro. 1998. "Vascular endothelial growth factor mediates angiogenic activity during the proliferative phase of wound healing." *Am. J. Pathol.* 152 (6):1445-52.

Novak, E., E. R. Novak, and J. D. Woodruff. 1979. "Myoma and other benign tumors of the uterus." In *Novak's Gynecologic and Obstetric Pathology*, 260-278. Philadelphia, USA: W.B. Saunders.

Nur, G., M. Naziroglu, and H. A. Deveci. 2017. "Synergic prooxidant, apoptotic and TRPV1 channel activator effects of alpha-lipoic acid and cisplatin in MCF-7 breast cancer cells." *J. Recept. Signal Transduct. Res.* 37 (6):569-577. doi: 10.1080/10799893.2017.1369121.

Pakniat, H., N. Soofizadeh, and M. B. Khezri. 2016. "Spontaneous uterine rupture after abdominal myomectomy at the gestational age of 20 weeks in pregnancy: A case report." *Int. J. Reprod. Biomed. (Yazd)* 14 (7):483-6.

Paradells, S., I. Zipancic, M. M. Martinez-Losa, M. A. Garcia Esparza, F. Bosch-Morell, M. Alvarez-Dolado, and J. M. Soria. 2015. "Lipoic acid and bone marrow derived cells therapy induce angiogenesis and cell proliferation after focal brain injury." *Brain Inj.* 29 (3):380-95. doi: 10.3109/02699052.2014.973448.

Parente, E., G. Colannino, O. Picconi, and G. Monastra. 2017. "Safety of oral alpha-lipoic acid treatment in pregnant women: a retrospective observational study." *Eur. Rev. Med. Pharmacol. Sci.* 21 (18):4219-4227.

Rahimifard, M., M. Navaei-Nigjeh, M. Baeeri, F. Maqbool, and M. Abdollahi. 2015. "Multiple protective mechanisms of alpha-lipoic acid in oxidation, apoptosis and inflammation against hydrogen peroxide induced toxicity in human lymphocytes." *Mol. Cell Biochem.* 403 (1-2):179-86. doi: 10.1007/s11010-015-2348-8.

Roeder, H. A., S. F. Cramer, and P. C. Leppert. 2012. "A look at uterine wound healing through a histopathological study of uterine scars." *Reprod. Sci.* 19 (5):463-73. doi: 10.1177/1933719111426603.

Roopnarinesingh, S., J. Suratsingh, and A. Roopnarinesingh. 1985. "The obstetric outcome of patients with previous myomectomy or hysterotomy." *West Indian Med. J.* 34 (1):59-62.

Salamonsen, L. A. 2003. "Tissue injury and repair in the female human reproductive tract." *Reproduction* 125 (3):301-11.

Schmidt, L., T. Sobotka, J. G. Bentzen, and A. Nyboe Andersen. 2012. "Demographic and medical consequences of the postponement of parenthood." *Hum Reprod Update* 18 (1):29-43. doi: 10.1093/humupd/ dmr040.

Stamilio, D. M., E. DeFranco, E. Pare, A. O. Odibo, J. F. Peipert, J. E. Allsworth, E. Stevens, and G. A. Macones. 2007. "Short interpregnancy interval: risk of uterine rupture and complications of vaginal birth after cesarean delivery." *Obstet. Gynecol.* 110 (5):1075-82. doi: 10.1097/01.AOG.0000286759.49895.46.

Tonnesen, M. G., X. Feng, and R. A. Clark. 2000. "Angiogenesis in wound healing." *J. Investig. Dermatol. Symp. Proc.* 5 (1):40-6. doi: 10.1046/ j.1087-0024.2000.00014.x.

Tsai, H. T., and C. H. Wu. 2017. "Vaginal birth after cesarean section-The world trend and local experience in Taiwan." *Taiwan J. Obstet. Gynecol.* 56 (1):41-45. doi: 10.1016/j.tjog.2016.03.007.

Wada, H., D. Shintani, and J. Ohlrogge. 1997. "Why do mitochondria synthesize fatty acids? Evidence for involvement in lipoic acid production." *Proc. Natl. Acad. Sci. U S A* 94 (4):1591-6.

Wechter, M. E., E. A. Stewart, E. R. Myers, R. M. Kho, and J. M. Wu. 2011. "Leiomyoma-related hospitalization and surgery: prevalence and predicted growth based on population trends." *Am. J. Obstet. Gynecol.* 205 (5):492 e1-5. doi: 10.1016/j.ajog.2011.07.008.

World Health Organization. 2017. http://who.int/en/.

Yang, L., Y. Wen, G. Lv, Y. Lin, J. Tang, J. Lu, M. Zhang, W. Liu, and X. Sun. 2017. "Alpha-Lipoic acid inhibits human lung cancer cell proliferation through Grb2-mediated EGFR downregulation." *Biochem Biophys. Res. Commun.* 494 (1-2):325-331. doi: 10.1016/j.bbrc.2017. 10.030.

In: Encyclopedia of Surgery (22 Volume Set)
Editors: Andreas Lehrer and Kristin Mueller
ISBN: 978-1-53618-329-0
© 2020 Nova Science Publishers, Inc.

Chapter 445

SEX DIFFERENCES IN TERMS OF EATING BEHAVIORS, BIOLOGICAL AND PSYCHOLOGICAL FEATURES: A REVIEW IN THE BARIATRIC SURGERY POPULATION

Gabriela S. Figueiredo, Marta F. Lourdes, Paulo P. P. Machado, PhD and Eva M. Conceição*, PhD
School of Psychology, University of Minho,
Braga, Portugal

ABSTRACT

Bariatric surgery has showed to be a successful weight loss treatment, which has been mainly performed on women. Sex entails differences on biological, behavioral and psychological features along with social-cultural factors that might be important in predicting outcomes after surgery, as well as on the (re)emergence of eating-related problems and psychopathology in the post-operative time. However, research addressing sex differences after bariatric surgery is scarce. The aim of this chapter is to summarize the existing literature on sex differences in obesity and bariatric surgery population.

Men and women are biologically different in terms of body fat distribution and gonadal hormones. For example, male patients have higher body mass index and higher probability of developing medical complications following gastric bypass surgery in all weight ranges, whereas in women obesity-related risk factors, for instance pregnancy or menopause, may play a role in the physiological and behavioral consequences of appetite and weight regulation. These differences lead to diverse behaviors and attitudes towards food.

Regarding eating behavior, although eating disorders, such as bulimia and anorexia nervosa, have been reported in men, they are usually more prevalent in women.. However, women tend to report higher levels of loss of control over eating, while men tend to report more overeating without loss of control. Women also tend to report more

* Corresponding Author's Email: econceicao@psi.uminho.pt.

compensatory behavior such as vomiting or dieting. Likewise women tend to engage more often than man in body checking behaviors.

In the psychological perspective, women are more likely to acknowledge a history of depression, social anxiety, psychological and psychiatric treatment. Furthermore women have more negative thoughts about themselves, and their weight has a greater influence on body image and self-esteem. Similarly, men and women differ on motivations for undergoing bariatric surgery.

Considering all of these aspects, clinical practice and follow-up evaluation should be sex adjusted, and sex should be investigated as a predictor of adjustment to treatment, quality of live and psychological distress after surgery. Understanding such differences and their impact would allow the development of tailored assessment and interventions pre- and post-surgery.

Keywords: bariatric surgery, sex differences, eating behaviors

1. INTRODUCTION

Obesity, classified when Body Mass Index (BMI) is equal or above 30 (Libeton, Dixon, Laurie, & O'Brien, 2004; Moyer, 2012) is currently reaching epidemic proportions in developed and developing countries. While the prevalence of individuals with excessive weight (BMI 25-29.9kg/m^2) has been kept stable, the percentage of individuals with obesity (BMI $\geq$ 30kg/m^2) and extreme obesity (BMI $\geq$ 40kg/m^2) have greatly increased over the past years (Mitchell & de Zwaan, 2005). The problem of overweight and obesity is not limited to adults, and is also a concern among children and adolescents. Obesity is considered the most common nutritional issue worldwide and the most significant contributor for mortality rates surpassing malnutrition and infection diseases (Lau et al., 2007). The causes of obesity are both complex and multifactorial, with genetic, social and environmental factors playing a role. In recent decades, sedentary lifestyles and overeating have exceeded the physical work and the regular physical activity benefits for weight control, resulting in a rapid increase of obesity prevalence seen in the last twenty years. These factors allow to conclude that this increment was motivated mainly by social and environmental causes, and not so much by genetic factors (Lau et al., 2007).

The problem of obesity goes far beyond the aesthetic and body image issue as people with excessive weight or obesity present increased risk for developing a great variety of health conditions, such as hypertension, type 2 diabetes, dyslipidemia, kidney stone, coronary heart disease, stroke, osteoarthritis and some types of cancer (Moyer, 2012). The increasing number of patients needing effective treatments for obesity results in a great demand for health services, and in larger health expenses of these patients. Despite the associated mortality risks and medical morbidity, obesity is also associated with heavy psychosocial consequences such as low self-esteem and self-worth, negative emotions, anxiety, insecurity, negative self-belief, powerlessness and apathy, depression and stress (Hemmingsson, 2014).

Pharmacological treatment, physical activity, diet and behavioral interventions are some of the available treatments (Tsai & Wadden, 2005), but changing and maintaining a healthy lifestyle is still the key for long-term treatment of obesity. However, both the patient and the professionals responsible for treatment face several barriers for long-term maintenance of treatment outcomes (Lau et al., 2007). Such barriers include time constraints, medical

comorbidities (mental health, sleep, pain, cardiovascular, respiratory or digestive disease and endocrine disorders), socioeconomic status, medication, alcohol and substance abuse, and the acceptance of obesity as a chronic disease (Mauro, Taylor, Wharton, & Sharma, 2008). Fortunately, these barriers include aspects that can be modified in order to facilitate adherence to treatments. Thus, identifying and addressing such aspects is crucial for patients to make the lifestyle changes required and adhere to therapy.

When concerning patients with severe obesity (BMI≥40) or with BMI over 35kg/m^2 with two medical conditions associated (such as hypertension or diabetes), bariatric surgery is considered the most effective treatment (Mitchell & de Zwaan, 2005; Niego, Kofman, Weiss, & Geliebter, 2007). Nevertheless, this surgical procedure requires harsh changes in the patient's nutritional pattern and lifestyle. In fact, some authors consider that patients who do not engage in the necessary changes, should be considered not suitable for this treatment (Kushner & Roth, 2003). Furthermore, high surgical risk status, advanced age, endocrine disorders, other comorbidities not treated, as well as addictive behaviors, are some of the contraindications for bariatric surgery (Mitchell & de Zwann, 2005). Currently, there are a variety of surgical procedures available, which are in constant evolution, influenced by literature results, and medical team of each site (Angrisani et al., 2015). Such techniques differ in terms of their restrictive or malabsorptive nature.

Studies suggest that, for the majority of patients, bariatric surgery has significant effects on long-term weight loss and is associated with a reduction in overall mortality (Sjöström et al., 2004). This surgical treatment results in significant weight reduction, and is consequently accompanied by significant improvements in several comorbid conditions associated with obesity, including diabetes, hypertension, dyslipidemia, vascular disease and sleep apnea (Chang et al., 2014). Additionally, each type of surgery can be performed using minimally invasive techniques such as laparoscopic surgery, or as an open surgery. Procedures performed laparoscopically are less invasive, decreasing the time spent in hospital as well as the recovery time for patients (Colquitt, Pickett, Loveman, & Frampton, 2014).

Adjustable Gastric Banding (AGB) is considered a purely restrictive procedure and involves the placing of an adjustable plastic and silicone ring around the proximal opening of the stomach, immediately below the gastroesophageal junction, creating an approximate 20 ml upper gastric pouch. This restrictive surgery is the least invasive for obesity treatment. However, success rates are lower than 50% and failure rates reach 40% at 7 years after treatment. Therefore, a rising number of authors consider that AGB should not be the procedure of choice for treating patients with excessive obesity (Papamargaritis, Pournaras, & Le Roux, 2010).

In turn, in Sleeve Gastrectomy (SG), a restrictive procedure as well, the stomach is transected vertically creating a gastric tube and leaving a 150-200ml pouch. The remaining stomach is excised (Papamargaritis et al., 2010). This procedure leads to weight loss by restraining food ingestion, presenting lower risks when compared to other procedures which implicate the implantation of medical devices and malabsorptive procedures (Braghetto et al., 2007). The percent excessive weight loss for SG varies from 33% to 90% and appears to be sustained up to 3 years. The expected mortality rate is 0-3.3%, and major complications are thought to range from 0% to 29% (average 12.1%) (Shi, Karmali, Sharma, & Birch, 2010).

In Roux-en-Y Gastric Bypass (RYGB) the stomach is divided into the upper stomach pouch, which is 15–30 mL in volume, and the lower stomach pouch, gastric remnant. The stomach pouch is then anastomosed to a distal part of the intestine, eliminating absorption of

food in the proximal intestine (Papamargaritis et al., 2010). This procedure consists in the combination of restrictive and malabsorption techniques, in which patients lose about 60% to 80% of their excessive weight in the first year of treatment. In about 80% of the patients the long-term stabilization of weight occurs by the time when 50% to 60% of weight loss has occurred (Mitchell & de Zwaan, 2005).

In 2013, the surgical procedures made more frequently worldwide were RYGB, 45%, followed by SG, 37% and AGB, 10%. No other surgical procedure exceeded 2.5%. Additionally, the literature mentions that in 2013, 95,7% of bariatric surgeries were preformed laparoscopically, allowing shorter staying at the hospital and less complications when compared to the open approach technique (Angrisani et al., 2015).

Despite the success of this surgical treatment in inducing weight loss and weigh loss maintenance in the long-term, the variability of weight outcomes is still of concern (Mitchell & de Zwaan, 2005), and research has sought to investigate the factors associated with poorer results.

Accumulating evidence suggests that sex might be an important factor in understanding the effectiveness of bariatric surgery, and that there are different predictors of success for men and women. Focusing on the importance of sex differences would lead to health and economic improvements of treatments and other support mechanisms for these patients (Lovejoy & Sainsbury, 2008).

In this context, the distinction between the terms “sex” and “gender” should be taken into consideration. The term “sex” refers to differences between men and women that result from the chromosomal complement, the sexual organs and the effects of hormones; the term “gender” refers to an individual’s identity, cultural and behavioral expectations, associated with being a man or a woman (Lovejoy & Sainsbury, 2008).

In the United States, the overall age-adjusted prevalence of obesity has been considered to be higher in women (40.4%) than in men (35.0%) in the recent years of 2013-2014 (Flegal, Kruszon-Moran, Carroll, Fryar, & Ogden, 2016). There seems to be a sex-specific variation regarding obesity prevalence, as for men obesity prevalence varies according to smoking status, with lower prevalence among men who are current smokers than in men who never smoke; for women, education level such as holding a college degree, has been significantly related to a lower risk of obesity (Flegal et al., 2016).

Globally, 85% of the bariatric procedures are performed in women (Buchwald, Estok, Fahrbach, Banel, & Sledge, 2007). Yet, the majority of studies present significant improvements in weight loss for both men and women, showing evidence that bariatric surgery should be encouraged for eligible men. Although, male sex has traditionally been acknowledged as a significant independent risk factor for the development of cardiovascular diseases (and other comorbid diseases), these conditions can be improved after surgery highlighting that men with severe obesity can potentially benefit from bariatric surgery even more than women (Kennedy-Dalby, Adam, Ammori, & Syed, 2014).

The aim of this paper is to summarize the main findings, possible explanations and gaps in the existing literature on differences between men and women in the bariatric surgery population. This chapter is divided into three main sections: (1) differences in biological factors - this section focuses on variances in physiological aspects, weight loss, the effectiveness of treatment in the resolution of comorbidities and complications after surgery, life expectancy and mortality rates; (2) differences on behavioral aspects in terms of eating behavior, eating disorders and problematic eating behaviors; and (3) comparison of

psychological aspects such as depressive and anxiety symptoms, body image dissatisfaction, childhood sexual abuse, motivation for surgery and health help-seeking behavior.

2. BIOLOGICAL FACTORS

2.1. Weight Loss

Weight loss is predicted by different factors and sex is not an exception, particularly because there are distinct variables that have an impact on long-term weight loss (Bekheit et al., 2014).

Clear evidence shows that a higher pre-surgical BMI predicts an increased weight loss (Andersen, Aadland, Nilsen, & Våge, 2014). Male patients with morbid obesity undergoing weight loss treatment tend to lose significantly higher amounts of body weight than women, corresponding also to a higher fraction of their initial body weight (Sartorio, Maffiuletti, Agosti, & Lafortuna, 2005). Men with obesity undergoing weight loss treatment have a higher aerobic capacity which could explain the increased weight loss. Also it is important to note that weight loss in men with morbid obesity consists of a similar amount of reduction in fat mass and fat-free mass, whereas women lose fat mass almost entirely, and fat-free mass appears to be maintained (Sartorio et al., 2005).

Empirical research shows that two years after bariatric surgery men have a higher mean percentage of excessive BMI loss (76.7% to 78.9%), while women lose between 74.8% and 78.8% kg/m² (Perrone et al., 2016).

In the study of Andersen and colleagues (2014) with patients who underwent SG, different predictors of weight loss at 2 years were found for both sexes. Older men without diabetes showed lower percentage of excess BMI loss, whereas for women lower BMI loss was mainly predicted by unemployment and anxiety and/or depression. Additionally, Perrone and colleagues (2016) showed empirical evidence that SG is more effective in male than in female patients in terms of the percent excess BMI loss after 24, 36 and 60 months since surgery.

However, there is evidence that highlights the absence of significant differences between men and women in the mean percentage of excess BMI loss after RYGB (Bekheit et al., 2014; Perrone et al., 2016), and also 24 months after SG (65.8% kg/m² in men vs 72.9% kg/m² in women; Kennedy-Dalby et al., 2014). Although Tymitz, Kerlakian, Engel and Bollmer (2007) found no significant differences between men and women in their BMI after RYGB, male patients continued to weigh more and lost more pounds than females at 6 and 12 months post operation.

Physiological and behavioral differences (such as body composition, physical activity and others sex-specific characteristics described elsewhere in this chapter) between men and women could explain such differences in weight outcomes after bariatric surgery (Perrone et al., 2016).

2.2. Effectiveness of the Treatment on Comorbidities and Surgery Complications

Diseases such as diabetes mellitus type II, hypertension, cardiovascular disease and sleep apnea syndrome are all associated with obesity (Tymitz et al., 2007), and these are also the most common comorbid conditions presented by bariatric surgery patients. Significant differences in preoperative comorbidities and complications rates are observed between male and female patients (Stroh et al., 2012). Men tend to have increased preoperative incidence of these conditions when compared to women (Livingston et al., 2002; Stroh et al., 2013).

Male sex and weight status are considered to be significant preoperative risk factors for the development of severe life-threatening complications following RYGB. For example, the risk of severe life-threating adverse outcomes increases from 7% in a male patient with 200-lb, up to 13% for a 600-lb male patient, while for a 200-lb female patient the risk rises from 4% to 7.5% when compared to a 600-lb women (Livingston et al., 2002).

Concerning sex differences in perioperative variables, no significant differences have been found on length of hospital stay, intensive care unit stay, overall leaks or other medical conditions such as bowel obstruction, gastrointestinal bleed, wound infection, pulmonary failure, deep vein thrombosis or pulmonary embolism (Tymitz et al., 2007). Although men have a significantly longer anesthesia time, operative time and length during RYGB (Tymitz et al., 2007), for SG no differences on mean operating time are observed between the two sexes (Stroh et al., 2012). Regarding AGB, no sex-specific aspect regarding perioperative complications rates were found (Stroh et al., 2013).

When measuring improvements in comorbidities after SG and RYGB, studies showed great reductions but similar outcomes for both sexes (Kennedy-Dalby et al., 2014; Perrone et al., 2016). However, despite similar improvements in both sexes, remission rates of hypertension after AGB seem to be higher for female patients. Additionally to achieve similar remission rates of comorbidities (e.g., hypertension and diabetes), men have to significantly lose more weight and need longer continuous treatments during the post-operative period (Livingston et al., 2002) compared to female patients (Stroh et al., 2013). In fact, because of the low postoperative remission rates of these comorbidities in men Stroh and colleagues (2013) suggested that AGB may not be a good option for men with a BMI above 45 kg/m2, hypertension and/or sleep apnea, and/or diabetes.

Regarding postoperative complications of bariatric surgery, the literature suggests that male sex has a higher probability of developing life-threatening complications following RYGB surgery in all weight ranges (Livingston, Huerta, Arthur, Lee, & Shields, 2002). According to Stroh and colleagues (2012), female sex has a protective effect against complications, while men have significantly higher overall complication and mortality rates because of their higher BMI and higher incidence of comorbidities.

2.3. Life Expectancy and Mortality Rates

Life expectancy is markedly shortened by obesity, particularly among young adults. Being overweight rises the risk of mortality from 6 to 12 times (Fontaine, Redden, Wang, Westfall, & Allison, 2003).

Marked sex and race differences were observed in the estimation of years of life lost (YLL). The YLL index is defined as the difference between the number of years an individual would be expected to live if not obese, and the number of years expected to live if with obesity. White men aged 20 years with BMI greater than 45 are estimated to have 13 YLL compared to white men in the same age with BMI of 24. White women aged 20 to 30 years and BMI over 45 are expected to have 8 YLL due to obesity. Further findings with black population suggest that overweight and obesity may not decrease life expectancy until a BMI of approximately 32-33 for men and 37-38 for women. For example, black men aged 20 years with BMI over than 45 are expected to have 20 YLL, while black women in the same conditions have 5 YLL (Fontaine et al., 2003). Either way, regardless of race, women have less YLL due to obesity when compared to men. However among white men, the number of YLL was generally constant across ages, compared to white women where a higher variance is observed (Fontaine et al., 2003).

Regarding mortality rates after bariatric surgery, studies present a marked decreased over the years, owing to the surgeon experience and to the annually increased performance of these procedures (Buchwald et al., 2007). The risk of early death after surgery is further associated with advanced age, lower number of bariatric procedures performed by the surgeon, and male sex (Flum et al., 2005).

Mortality rates are significantly higher for men than women within the first weeks of surgery (4.74% vs 0.13%, respectively) (Buchwald et al., 2007), at 30 days (3.7% vs 1.5%, respectively), 90 days (4.8% vs 2.1%, respectively) and 1 year (7.5% vs 3.7%, respectively) after surgery (Flum et al., 2005). Male sex has been associated with higher mortality rates either after laparoscopic or open procedures (Tymitz et al., 2007). Additionally, male patients undergoing RYGB have a 3-fold higher risk of mortality than women. Although there is little research on the factors underlying these differences, differences in body composition and diminished physiologic tolerance to stress in men have been suggested (Livignston et al., 2002). Curiously, higher incidences of comorbidities in male sex was not associated with higher perioperative morbidity and mortality rates (Tymitz et al., 2007).

2.4. Physiological Differences

Sex differences in obesity can be explained in part by differences in body fat distribution, composition, and chromosomal factors and gonadal hormones which influence appetite. However behavioral and socio-cultural aspects may also play a role (Lovejoy & Sainsbury, 2008).

It is widely accepted that biological factors determine that men tend to be taller, larger, heavier and also to present a greater BMI (Grilo, Masheb, Brody, Burke-Martindale, & Rothschild, 2005; Livingston et al., 2002; Stroh et al., 2013). Both before and after bariatric surgery, men's BMI remains significantly higher than women's (Mahony, 2008; Stroh et al., 2012). Women tend to be shorter, weigh less, and have less fat-free mass and more fat mass than men (Lovejoy & Sainsbury, 2008). Notwithstanding, BMI has been considered an inaccurate estimate of body composition (Lovejoy & Sainsbury, 2008), and the use of other methods that reflect body fat and lean content have been encouraged, especially when comparing men and women whose body composition differs, even at the same absolute weight and height.

Regarding body composition, men and women with obesity differ when gaining weight. Males display concomitant increases in fat-mass and fat free mass, while women present a significant increase in fat-mass with a minimal increase in fat free mass (Lafortuna, Maffiuletti, Agosti & Sartorio, 2005). The literature also points to sex differences in body fat distribution. Men with obesity and postmenopausal women tend to accumulate more abdominal and visceral fat, whereas premenopausal women have greater inferior body gluteo-femoral fat (Després et al., 2008). These differences may be a result of differences in sex hormones between men and women. Estrogen reduces visceral fat in both men and women Yet, opposite effects of sex hormones on fat distribution in men and women are seen, decreasing visceral fat in men, but increasing in women (Lovejoy & Sainsbury, 2008).

Pregnancy and menopause are specify moments in a women's life with physiological and behavioral consequences on appetite and weight regulation that confer an elevated risk of obesity in women (Lovejoy & Sainsbury, 2008). The prevalence of maternal obesity has increased along with the obesity epidemic worldwide. In the United States, nearly one in two women in childbearing age are overweight or obese. It is observed that non-Hispanic black women at childbearing age are 2.25 times more likely to be overweight or obese when compared to non-Hispanic white women. Some socio-cultural factors may explain the racial and ethnical disparity such as educational attainment, household income, and stability of health insurance coverage (Vahratian, 2009).

Furthermore, the majority of women in developed countries gain more weight than what is recommended during pregnancy. Excess weight gain in pregnancy is of concern in part because it is associated with increased long-term risk of obesity for the mother (Amorim, Rössner, Neovius, Lourenço, & Linné, 2007).

Besides the health impact of maternal overweight and obesity for the women herself, the consequences for the newborn are also of concern. Increased maternal BMI has been associated with increased infant mortality rates, rising from 2.4/1000 among women with normal weight to 5.8/1000 among women with obesity (BMI over 40.0) (Johansson et al., 2014). Also the incidence of type-one diabetes in children with non-diabetic parents can be partly explain by maternal overweight or obesity (Hussen, Persson, & Moradi, 2015). Children of women who exceeded gestational weight gain recommendations are 46% more likely to be overweight or obese at 2-5 years of age. However, if gestational weight gain is below recommendations, especially among normal weight women, there is also an increased risk (23%) of subsequent childhood overweight/obesity (Sridhar et al., 2014).

Men's and women's weight varies and increases gradually during adulthood. Women experience a serious weight increase when pregnant, changing weight trajectory in short-term compared to what would be expected in the absence of pregnancy (Yakusheva, Kapinos, & Weiss, 2017). Obesity in midlife women can be predicted by the failure to lose weight gain 6 months after child-birth and excessive weight gain (Rooney, Schauberger, & Mathiason, 2005). Women who experience weight increases during pregnancy greater than the recommendations tend to retain on average 4.1 kg more in the long-term (up to 15 years) than women with normal weight gain. Women with pre-pregnancy overweight or obesity tend to maintain higher BMI after pregnancy.

Stress seems to be another important factor with relation to obesity and sex differences. Stress has been related to overeating and the development of obesity and abdominal fat accumulation. Sex hormones interact in different ways in response to stress hormones

between pre- and postmenopausal women, however much is still unknown (Lovejoy & Sainsbury, 2008).

Questions related to sex differences in obesity, energy homeostasis and central regulation of appetite have important physiological and clinical relevance for the treatment of these patients (Lovejoy & Sainsbury, 2008). For instances, sex specific physical activity recommendations for weight control could be necessary. Sex-related differences on physical exercise capacity have been observed and related to the marked differences in body composition between men and women. In men with obesity, muscle capacity and strength to perform anaerobic exercise is higher than in women with obesity (Lafortuna et al., 2005). Data available suggest that men and women different in the way physical activity impacts appetite and energy-regulating hormones leading to a different impact on food intake after exercising and different effects on body fat loss for men and women. Women seem to increase food intake in response to the increased energy expenditure after exercising, although no changes in appetite are observed. As a results, the energy deficit from exercising is compensated and hampering weight loss. Men do not seem to increase food intake and seem to experience decrease in appetite, resulting in weight loss because of the energy deficit maintained after exercising. This model partially explains how the practice of physical activity results in different weight trajectories for men and women, and why it is more difficult for women to lose body fat. However, further research is still needed to verify and add evidence to these aspects (Hagobian & Braun, 2010).

3. BEHAVIORAL VARIABLES

After bariatric surgery, the development of eating disorders seems to be a severe postoperative problem (Conceição et al., 2013; Marino et al., 2012). Moreover, in the clinical practice different forms of disordered eating are regularly detected, which do not meet the necessary diagnostic criteria to be considered a full-syndrome psychological disorder, but have a significant impact on daily functioning (Conceição et al., 2014b). Subsyndromal presentations of disordered eating are probably more frequent, but few studies have described and classified them (Marino et al., 2012). However, studies suggest that these maladaptive eating behaviors can reduce or reverse the success of surgery, resulting in difficulties in weight maintenance, medical and psychological morbidity in the long-term (Conceição et al., 2017b; Niego et al., 2007). Thus, further attention should be focused on this area with the aim of systematically investigating the correlates of eating pathology in the bariatric population, and identifying possible rick factors that may compromise the success of these procedures.

3.1. Eating Disorders

The development of bulimia nervosa and anorexia nervosa have been described in women after bariatric surgery. Although no cases were described in men, evidence from the non-bariatric population estimates a lifetime prevalence rate of bulimia nervosa of up to 1.5% and 0.5%, and anorexia nervosa of up to 2.2% and 0.24% in women and men, respectively

(Smink, Van Hoeken, & Hoek, 2012). Considering this literature, health professionals should also consider screening for eating disorders among men undergoing bariatric surgery.

Binge-eating disorder (BED), is the second most common psychiatric diagnosis in bariatric surgery population (Sarwer et al., 2004), and its lifetime prevalence is estimated to be up to 3.6% for women and 2.1% for men (Smink et al., 2012). According to the Diagnostic and Statistical Manual of Mental Disorders (5th ed.; DSM-5; American Psychiatric Association, 2013) BED is defined as binge-eating (BE) - "eating in a discrete period of time (within a 2 hour period), an amount of food that is definitely larger than most people would eat in a similar period of time under similar circumstances… [with] a sense of lack of control over eating during the episode." This loss of control aspects is characterized as "being unable to stop eating or control what or how much was consumed" (Colles, Dixon, & O'Brien, 2008b).

Niego and colleagues (2007) found a high prevalence of BE and BED in patients undergoing weight loss surgery, and suggested that following surgery, maladaptive and psychological distressing eating behaviors continue to be common for many patients. Furthermore, the same authors proposed an association between BE before and after surgery, and indicated that patients sustaining BED or BE after surgery have poorer weight loss outcomes than patients who never had these behaviors or patients who remitted (Niego et al., 2007)..

Given that a higher percentage of patients undergoing bariatric surgery are women (Zizza, Herring, Stevens, & Carey, 2003), research on these eating disorders in men is scarce. However, when assessing the prevalence of eating disorder symptoms in the overweight community, Striegel-Moore and colleagues (2009) found significant sex differences on most behavioral eating disorder symptoms, with more women than men reporting loss of control over eating and more men than women reported overeating. Both sexes presented high levels of inappropriate compensatory behaviors, although with higher frequency for women. There were no sex differences on laxatives and exercise practice behavior (Striegel-Moore et al., 2009).

In turn, when investigating the psychological factors associated with binge eating in men and women, some authors found that depression plays an important role in the maintenance of binge eating symptomatology among both sexes. Women were more depressed than men, felt more negatively about themselves because their weight, and spend more time dieting, while men reported being less disturbed about their weight (Mazzeo, Saunders, & Mitchell, 2006).

Night eating syndrome (NES), recently included in the DSM-5 as an otherwise specified eating disorder, is characterized by conscious episodes of evening or nighttime hyperphagia, manifested by the ingestion of at least 25% of food consumption after the evening meal and/or nocturnal awakening. NES has been associated with emotional distress when reported at least two times per week (5th ed.; DSM-5; American Psychiatric Association, 2013). Studies found that 6 out of 10 subject with NES before surgery may develop this behavior after surgery, and that NES is more prevalent in men than women (Colles, Dixon, & O'Brien, 2008a). Also, the impact of NES in the weight maintenance is still unclear (Conceição et al., 2015), as this area remains understudied.

According to these data, eating disorders and particular BED are serious condition with impact on the bariatric surgery outcomes, and despite the sex differences described, men should also be target population for the screening of these problems.

3.2. Problematic Eating Behaviors

Grazing has received an increased interest among clinicians and researchers for its high occurrence (Conceição et al., 2014a; Conceição et al., 2014b) and association with poor weight loss or weight regain following bariatric surgery.

After surgery, the gastric capacity is reduced and eating large quantities of food, necessary for the diagnosis of BED, is likely impossible. Even though, patients may learn to circumvent these conditions imposed by surgery by eating more frequently, emerging a new behavior labeled grazing- Grazing is characterized by the repetitively eating of modest amounts of food in an unplanned and repetitive manner throughout a period of time (Conceição et al., 2014a). Colles, Dixon and O'Brien (2008a), assessed the nature and development of a variety of eating behaviors before and after surgery, and found that 26.4% of participants before surgery, and 38% of participants at 12 months after surgery reported grazing. In patients undergoing this treatment, grazing appears as a factor strongly associated with poor weight loss and with weight regain. This behavior is relatively frequent among the bariatric papulation, as well as among nonclinical samples (Conceição et al., 2014a). Nevertheless, when estimating sex differences, similar scores were found for both sexes in the repetitive eating questionnaire [Rep(eat)-Q] designed to assess grazing behavior (Conceição et al., 2017a).

Emotional eating is characterized by eating in response to emotional distress (Fischer et al., 2007; Lindeman & Stark, 2001). This behavior was found preoperatively in both females and males (Hörchner, Tuinebreijer, & Kelder, 2002). This emotional eating pattern is estimated to be present in 38% of bariatric population (Miller-Matero et al., 2014), but there are still mixed findings regarding its association with weight loss after bariatric surgery. Although some authors did not find such association (Fischer et al., 2007), increasing evidence suggests that eating in response to emotional cues has a negative impact in weight loss (Lindeman & Stark, 2001). Despite being more frequent in women, both sexes seem to report this behavior (Gade, Hjelmesaeth, Rosenvinge, & Friborg, 2014), highlighting the need for attention i both men and women.

4. PSYCHOLOGICAL VARIABLES

4.1. Depressive and Anxiety Disorders

Individuals with obesity tend to present higher rates of mood and anxiety disorders in comparison with the community population (Mühlhans, Horbach, & de Zwaan, 2009). In general, female bariatric surgery candidates are more likely to report a history of depression (45.7% for women vs. 17.4% for men), social anxiety (23.2% of women vs. 10.4% of men), as well as a history of psychotherapy (36.5% of women vs. 15.9% of men) (Mahony, 2008).

Depressive disorder is the most common psychopathology diagnosed in bariatric surgery population (Sarwer, et al., 2004), which is associated with unhealthy lifestyle, poor physical activity, lower social interaction and higher caloric intake behavior, resulting in long term weight regain. Depression itself explains about 4% weight loss variance in bariatric patients (Legenbauer, et al., 2009).

Research supports that the presence of preoperative depressive disorder predicts postoperative depressive symptomatology at 24-36 months. However, preoperative depression was not found to be a predictor of short term depression (6-12 months after surgery; de Zwann et al., 2011). Within the first years of surgery substantial improvements are observed, particularly in patients with higher baseline depressive symptomatology who tend to experience larger reductions (de Zwann et al., 2011; Mitchell et al., 2014). However, studies also suggest a gradual increase of such symptoms after 12-36 months of surgery (Mitchell et al., 2014; White et al., 2015).

Reduction in depressive symptoms has been positively related to changes in BMI (Mitchell et al., 2014). Increased levels of postoperative depressive symptoms are associated with poorer weight outcomes 6 to 12 months following surgery, as well as with greater eating disorders symptoms and poor quality of life 24 month after surgery(White et al., 2015).

On the contrary, anxiety seems to have a different course of evolution in bariatric patients when compared to depression. In general, the prevalence of anxiety disorders seems to be maintained following surgery (de Zwaan et al., 2011). The presence of preoperative anxiety tends to predict postoperative anxiety disorders (de Zwaan et al., 2011). Regarding its association with weight loss, preoperative lifetime anxiety was found to be a predictor of poor weight loss after surgery, while postoperative anxiety disorder showed no association with the degree of weight loss at any follow-up time-point (de Zwaan et al., 2011).

Comorbid psychiatric problems can co-occur in bariatric surgery candidates. The presence of baseline, lifetime and current anxiety and depressive disorders have been negatively associated with the degree of weight loss after surgery. Accordingly, patients with anxiety and depressive disorders tend to lose less weight after surgery (de Zwaan et al., 2011). Women with a diagnosis of anxiety and/or depression had a lower percentage of excess of BMI loss than those without these diagnoses, while no such association was observed for men (Andersen et al., 2014).

Empirical evidence suggests that sex and socioeconomic status may be moderators of depressive symptoms in obesity: women with obesity tend to report greater depression levels within high socioeconomic status, but reduced depression among low socioeconomic status women. Such association with socioeconomic level was not observed in men (Faith, Matz, & Jorge, 2002).

4.2. Body Image Dissatisfaction

The perception of men's and women's body image along with emotional factors seems to play a significant role in the development, maintenance and treatment of obesity, as well as in preventive strategies (Lovejoy & Sainsbury, 2008).

Literature relating to body image dissatisfaction among obese and bariatric patients remains mixed (Grilo et al., 2005). Among patients with extreme obesity seeking bariatric surgery, females tend to report significantly higher levels of body image dissatisfaction (Grilo et al., 2005), to diet more, and to be more likely to allow their weight to interfere with how they feel about themselves (Mahony, 2008; Mazzeo et al., 2006).

For both men and women undergoing bariatric surgery, body image dissatisfaction seems to be correlated with greater frequency of binge eating disorder, higher depression levels and low self-esteem. Predictors such as sex, binge eating disorder and self-esteem explain 56% of

body image dissatisfaction variance in men, and 33% in women. Body image dissatisfaction is thought to be under multifactorial influence, highlighting the importance of global adult functioning in understanding body image dissatisfaction as a whole (Grilo et al., 2005).

Patients undergoing bariatric surgery, regardless of sex, tend to improve significantly their perception of body image within the first 6 months, mainly due to major weight loss, positively influencing quality of life (Nickel et al., 2017). Nonetheless, after surgery patients face body deformities and loose skin, which has been associated with overall impairment in sexual functioning, body image and depressive symptomatology, as well as with greater weight regain in women (Ramalho et al., 2015). Undergoing plastic and reconstructive surgery for body contouring is known to improve both quality of life and body image (Song et al., 2006). Women (75%) are the ones who seek such treatments the most and show more interest in body contouring surgeries thanmen (68%) (Kitzinger et al., 2012). Nonetheless, only 6% of patients after bariatric surgery fully complete this type of surgery (Altieri et al., 2017).

In the matter of body checking and body avoidance in the community sample, significant differences between sexes have been reported, with women being more likely engage in these behaviors. About one in five women check their body size at least "very often," as for men statistics points that one in ten engaging in the same behaviors (Striegel-Moore et al., 2009).

4.3. Childhood Sexual Abuse

Childhood sexual abused (CSA) victims are more likely to suffer from extreme obesity (Gustafson & Sarwer, 2004), and history of CSA is considered to be a possible threat for successful weight loss after bariatric surgery (Larsen & Geenen, 2005). The majority of victims tend to be female (32% female and 14% male in general population), whereas males tend to suffer more physical abuse than females (Briere & Elliott, 2003).

The relation between weight loss after treatments and CAS is unclear. Sexual abused is considered a psychosocial risk factor for conditions under which obesity may be caused, exacerbated or maintained (Wiederman, Sansone, & Sansone, 1999). Women with obesity and history of CSA tend to lose less weight after a behavioral weight management program, than women without such history (King, Clark, & Pera, 1996). On the other hand, Larsen and Geenen (2005) suggested that CAS did not appear to impact weight outcomes after bariatric surgery in women. With mixed data no clear position has been establish (Livhits et al., 2012).

Contrary to expectations, sexually abuse women with obesity seem to display less weight fluctuations when compared to not abused women with obesity (Wiederman et al., 1999). The ideal-current body weight discrepancy (i.e., body dissatisfaction), seems to be predicted by the interaction between obesity and sexual abuse in women. Women with obesity and history of sexual abuse report relatively less current body dissatisfaction compared to non-sexual abused obese women. Accordingly, Wiederman and colleagues (1999) showed that women with obesity and history of sexual abuse seem comfortable about their weight and appearance, and only a small percentage wanted to look slimmer. The authors justify these apparent discrepancies with the adaptive function of obesity as a defense mechanism to protect themselves from sexual advances, sexual proposals or sexual relationships. Accordingly, women with obesity and history of sexual abuse are less motivated to lose weight, being willing to look less attractive, to avoid physically intimate relationships. Additionally, these

women showed to be psychologically more comfortable at a higher weight, which reduce anxiety-trauma association (Wiederman et al., 1999).

Although women with CAS who are candidates for bariatric surgery seem to experience no increased anxiety compared to non-CAS candidates, the literature suggests that these patients need additional psychological treatment for their mental health (Larsen & Geenen, 2005).

Finally, research has showed that male individuals with eating disorders, such as binge eating disorder who suffered sexual abuse experience greater body dissatisfaction when compared to women in the same conditions (Grilo & Masheb, 2001).

4.4. Motivation for Surgery and Health Help-Seeking Behavior

Health issues dominate the general motivation for seeking surgery. Nonetheless, Libeton and colleagues (2004) found that men and women differ on the reasons for seeking bariatric surgery. Generally, men were more likely than women to be motivated by medical problems, while women seem to indicate aesthetical aspects. The first reason that women indicate for undergoing bariatric surgery is to improve appearance, followed by health concerns, medical condition, physical limitation, embarrassment and physical fitness. Whereas for men, the most important reasons are medical condition and health concerns, followed by physical fitness, physical limitation, and finally embarrassment and appearance (Libeton et al., 2004).

Help-seeking is a complex phenomenon with multiple influencing factors aside from sex, such as age, ethnicity, lifestyle choices, masculine ideology and identity, perceptions shaped by social and cultural factors, and core beliefs (Galdas, Cheater, & Marshall, 2004).

The literature in not consensual regarding the differences between men and women in health help-seeking behaviors in the community population. Many studies report that men underuse health services in comparison with women, others find increased help seeking in men, and one study found no significant difference between sexes. More than just sex, other aspects, such as occupational and socioeconomic status, may play a role (Galdas et al., 2004).

Studies supporting that men tend to underutilize healthcare services, suggest some delay in help seeking when they feel sick and the same is expected for weight loss treatments (Galdas et al., 2004). Possible socio-cultural believes are exalted to understand such differences. Although men tend to have higher risk behaviors for obesity, they tend to ignore heath symptoms through denial, normalization, under-evaluation. Physical symptoms are the most determining factors for seeking medical help, while emotional symptoms are a minor concern, delaying treatment seeking for depression (Möller-Leimkühler, 2002). Men tend to report higher substance abuse (Alavi, Mehrdad, & Makarem, 2016), and tend to use more emergency services than a multidisciplinary and continuous health care (Corney, 1990). These reasons may also explain the reduced number of men seeking bariatric surgery treatment for obesity. Despite of these assumptions there is no evidence of men being less willing to search health services or treatments than women (Macintyre, Ford, & Hunt, 1999).

CONCLUSION

Changes in behavior and lifestyle patterns have occurred worldwide in the recent decades, especially regarding to the importance of physical activity and habits of food consumption, which lead to increased risk for the development of a variety of diseases. Currently the incidence and prevalence of obesity, is considered to be the XXI century epidemic (Satia-Abouta, 2003).

All around the world, countries struggle to deal with increasing population overweight and obesity. Understand sex differences and their impact would allow the development of tailored assessments, strategies and interventions pre and post bariatric surgery, requiring specific screening methods to facilitate positive outcomes (Mazzeo et al., 2006).

Bariatric surgery is considered equally safe in men and women (Tymitz et al., 2007). Although all patients should complete a battery of pre surgical exams, and pass through a psychological evaluation to help identify patients at risk for postsurgical psychological or behavioral problems, it is possible to anticipate some sex-specific aspects and present a more efficient service from the counseling view.

Each patient is different and should be considered as such, but from the start women with obesity are biologically in disadvantage, compared to men, regarding weight regulation and also bariatric surgery outcomes. This disadvantage is mainly due to body composition and distribution, muscle capacity and strength for physical exercise, energy homeostasis, pregnancy and menopause. Men undergoing non-surgical treatments and surgical treatments for obesity tend to lose more weight than women. However, men with obesity have more preoperative risk factors, lower comorbidities remission rates, higher postoperative complications and higher risk of mortality. In turn, women with obesity have higher prevalence of eating disorders as well as problematic eating behaviors.

Psychological variables play an important role for both sexes influence all the various aspects of success in bariatric surgery. Pre-operative anxiety, postoperative depression and the presence of both, lead to lower weight loss after surgery and women are the ones with greater probability of reporting a history of such mental disorders. Body image dissatisfaction seems to be prominent in women with extreme obesity, which is considered to be the first reason for undergoing bariatric surgery in women, to improve appearance which is related with body image dissatisfaction. However, the majority of bariatric surgery candidates are dissatisfied with their image. The presence of a traumatic event like sexual abuse, most prevalent in women, is considered to be a psychosocial risk for undergoing bariatric surgery due to the relation with the condition of being obese has in these women.

All of these differences could in parte explain some of the inconsistent results found in previous studies over the treatment of obesity.

This chapter allows the reader to have a complete overview on sex differences in obese and bariatric populations, gathering recent scientific information that supports the clear need for monitoring men and women in health care. Psychological counseling should be considered indispensable for these higher risk population in developing effective strategies, and adjusted interventions to sex-specificities.

It is also important to study future possible bariatric surgery candidates in order to predict and prevent with specialized interventions the increase in obesity and diminish the prevalence of eating disorders, in which sex differences still plays an important role. Other populations

such as adolescents with obesity, who are at increased risk of choosing and reproducing maladaptive behaviors in food consumption and emotional management as seen in the family, peers and role models.

REFERENCES

Alavi, S. S., Mehrdad, R., & Makarem, J. (2016). Prevalence of substance abuse/alcohol consumption and their predictors among patients admitted in operating rooms of a general educational hospital, Tehran, Iran. *Asian Journal of Pharmaceutical Research and Health Care*, *8(S1)*, 63-71. doi:10.18311/ajprhc/2016/7651.

Altieri, M. S., Yang, J., Park, J., Novikov, D., Kang, L., Spaniolas, K., ... Pryor, A. (2017). Utilization of body contouring procedures following weight loss surgery: A study of 37,806 patients. *Obesity Surgery*, 1-7. doi: 10.1007/s11695-017-2732-4.

American Psychiatric Association. (2013). *Diagnostic and statistical manual of mental disorders* (5th ed.). Washington, DC: Author.

Amorim, A. R., Rössner, S., Neovius, M., Lourenco, P. M., & Linné, Y. (2007). Does excess pregnancy weight gain constitute a major risk for increasing long-term BMI? *Obesity*, *15*(5), 1278–1286. doi:10.1038/oby.2007.149.

Andersen, J. R., Aadland, E., Nilsen, R. M., & Våge, V. (2014). Predictors of weight loss are different in men and women after sleeve gastrectomy. *Surgery Endoscopy*, *24*(4), 594-598. doi:10.1007/s11695-013-1124-7.

Angrisani, L., Santonicola, A., Iovino, P., Formisano, G., Buchwald, H., & Scopinaro, N. (2015). Bariatric Surgery Worldwide 2013. *Obesity Surgery*, *25*(10), 1822-1832. doi:10.1007/s11695-015-1657-z.

Bekheit, M., Katri, K., Ashour, M. H., Sgromo, B., Abou-ElNagah, G., Abdel-Salam, W. N., … Kayal, E. E. (2014). Gender influence on long- term weight loss after three bariatric procedures: Gastric banding is less effective in males in a retrospective analysis. *Surgery Endoscopy*, *28*(8), 2406-2411. doi:10.1007/s00464-014-3489-7.

Braghetto, I., Korn, O., Valladares, H., Gutiérrez, L., Csendes, A., Debandi, A., … Brunet, L. (2007). Laparoscopic Sleeve Gastrectomy: Surgical Technique, Indications and Clinical Results. *Obesity Surgery*, *17*(11), 1442-1450. Retrieved from https://doi.org/10.1007/s11695-008-9421-2.

Briere, J., & Elliott, D. M. (2003). Prevalence and psychological sequelae of self-reported childhood physical and sexual abuse in a general population sample of men and women. *Child Abuse & Neglect*, *27*, 1205-1222. doi:10.1016/j.chiabu.2003.09.008.

Buchwald, H., Estok, R., Fahrbach, K., Banel, D., & Sledge, I. (2007). Trends in mortality in bariatric surgery: a systematic review and meta-analysis. *Surgery*, *142*(4), 621-635. doi: 10.1016/j.surg.2007.07.018.

Chang, S.-H., Stoll, C. R. T., Song, J., Varela, J. E., Eagon, C. J., & Colditz, G. A. (2014). The effectiveness and risks of bariatric surgery. *JAMA Surgery*, *149*(3), 275. Retrieved from https://doi.org/10.1001/jamasurg.2013.3654.

Colles, S. L., Dixon, J. B., & O'Brien, P. E. (2008a). Grazing and loss of control related to eating: two high-risk factors following bariatric surgery. *Obesity*, *16*(3), 615–22. Retrieved from https://doi.org/10.1038/oby.2007.101.

Colles, S. L., Dixon, J. B., & O'Brien, P. E. (2008b). Loss of control is central to psychological disturbance associated with binge eating disorder. *Obesity, 16*(3), 608–614. Retrieved from https://doi.org/10.1038/oby.2007.99.

Colquitt, J. L., Pickett, K., Loveman, E., & Frampton, G. K. (2014). Surgery for weight loss in adults. *The Cochrane Library, 8*, 1-47. doi:10.1002/14651858.CD003641.pub4.

Conceição, E. M., Mitchell, J. E., Engel, S. G., Machado, P. P. P., Lancaster, K., & Wonderlich, S. A. (2014a). What is "grazing"? Reviewing its definition, frequency, clinical characteristics, and impact on bariatric surgery outcomes, and proposing a standardized definition. *Surgery for Obesity and Related Diseases, 10*(5), 973–982. Retrieved from https://doi.org/10.1016/j.soard.2014.05.002.

Conceição, E. M., Mitchell, J. E., Machado, P. P. P., Vaz, A. R., Pinto-Bastos, A., Ramalho, S., … Freitas, A. C. (2017a). Repetitive eating questionnaire [Rep(eat)-Q]: Enlightening the concept of grazing and psychometric properties in a Portuguese sample. *Appetite, 117*, 351-358. doi:10.1016/j.appet.2017.07.012.

Conceição, E. M., Mitchell, J. E., Pinto-Bastos, A., Arrojado, F., Brandão, I., & Machado, P. P. (2017b). Stability of problematic eating behaviors and weight loss trajectories after bariatric surgery: a longitudinal observational study. *Surgery for Obesity and Related Diseases, 13*(6), 1063-1070. Retrieved from https://doi.org/10.1016/j.soard.2016.12.006.

Conceição, E. M., Utzinger, L. M., & Pisetsky, E. M. (2015). Eating disorders and problematic eating behaviors before and after bariatric surgery: Characterization, assessment and association with treatment outcomes. *European Eating Disorders Review, 23*(6), 417–425. Retrieved from https://doi.org/10.1002/erv.2397.

Conceição, E., Mitchell, J. E., Vaz, A. R., Bastos, A. P., Ramalho, S., Silva, C., … Machado, P. P. P. (2014b). The presence of maladaptive eating behaviors after bariatric surgery in a cross sectional study: Importance of picking or nibbling on weight regain. *Eating Behaviors, 15*(4), 558–562. Retrieved from https://doi.org/10.1016/j.eatbeh.2014.08.010.

Conceição, E., Orcutt, M., Mitchell, J., Engel, S., Lahaise, K., Jorgensen, M., … Wonderlich, S. (2013). Eating disorders after bariatric surgery: A case series. *International Journal of Eating Disorders, 46*(3), 274–279. Retrieved from https://doi.org/10.1002/eat.22074.

Corney, R. H. (1990). Sex differences in general practice attendance and help seeking for minor illness. *Journal of psychosomatic research, 34*(5), 525-534. Retrieved from https://doi.org/10.1016/0022-3999(90)90027-2.

Després, J. P., Lemieux, I., Bergeron, J., Pibarot, P., Larose, E., Rodes-Cabau, J., … Poirier, P. (2008). Abdominal obesity and the metabolic syndrome: contribution to global cardio-metabolik risk. *Arteriosclerosis, Thrombosis, and Vascular Biology, 28*, 1039–1049. doi:10.1161/ATVBAHA.107.159228.

de Zwaan, M., Enderle, J., Wagner, S., Mühlhans, B., Ditzen, B., Gefeller, O., … Müller, A. (2011). Anxiety and depression in bariatric surgery patients: A prospective, follow-up study using structured clinical interviews. *Journal of Affective Disorders, 133*, 61-68. doi:10.1016/j.jad.2011.03.025.

Faith, M., Matz, P., & Jorge, M. (2002). Obesity – depression associations in the population. *Journal of Psychosomatic Research, 53*, 935-942. Retrieved from https://doi.org/10.1016/S0022-3999(02)00308-2.

Fischer, S., Chen, E., Katterman, S., Roerhig, M., Bochierri-Ricciardi, L., Munoz, D., … Le Grange, D. (2007). Emotional eating in a morbidly obese bariatric surgery-seeking

population. *Obesity Surgery, 17*(6), 778–784. Retrieved from https://doi.org/10.1007/s11695-007-9143-x.

Flegal, K. M., Kruszon-Moran, D., Carroll, M. D., Fryar, C. D., & Ogden, C. L. (2016). Trends in obesity among adults in the united states, 2005 to 2014. *JAMA, 315*(21), 2284-2291. doi:10.1001/jama.2016.6458.

Flum, D. R., Salem, L., Elrod, J. A. B., Dellinger, E. P., Cheadle, A., & Chan, L. (2005). Early mortality among medicare beneficiaries undergoung bariatric surgical procedures. *JAMA, 294*(15), 1903-1908. Retrieved from https://jamanetwork.com/pdfacess.ashx?url=/data/journals/jama/4996/.

Fontaine, K. R., Redden, D. T., Wang, C., Westfall, A. O., & Allison, D. B. (2003). Years of life lost due to obesity. *JAMA, 289*, 187-193. Retrieved from http://jamanetwork.com/journals/jama/fullarticle/195748.

Gade, H., Hjelmesaeth, J., Rosenvinge, J. H., & Friborg, O. (2014). Effectiveness of a Cognitive Behavioral Therapy for Dysfunctional Eating among Patients Admitted for Bariatric Surgery: A Randomized Controlled Trial. *Journal of Obesity, 2014.* Retrieved from https://doi.org/10.1155/2014/127936.

Galdas, P. M., Cheater, F., & Marshall, P. (2005). Men and health help-seeking behavior: literature review. *Journal of Advanced Nursing, 49*, 616-623. doi:10.1111/j.1365-2648.2004.03331.x.

Grilo, C. M., Masheb, R. M., Brody, M., Burke-Martindale, C. H., & Rothschild, B. S. (2005). Binge eating and self-esteem predict body image dissatisfaction among obese men and women seeking bariatric surgery. *International Journal Eatind Disorder*, *37*, 347-351. doi:10.1002/eat.20130.

Grilo, C. M., & Masheb, R. M (2001). Childhood psychological, physical, and sexual maltreatment in outpatinets with binge eating disorder: Frequency and associations with gender, obesity, and eating-related psychopathology. *Obesity Research*, *9*(5), 320-325. doi:10.1038/oby.2001.40.

Gustafson, T. B., & Sarwer, D. B. (2004). Childhood sexual abuse and obesity. *Obesity reviews*, *5*(3), 129-135. doi:10.1111/j.1467-789X.2004.00145.x.

Hagobian, T. A., & Braun, B. (2010). Physical activity and hormonal regulation of appetite: Sex differences and weight control. *Exercise and Sport Sciences Reviews, 38*(1), 25-30. doi:10.1097/JES.0b013e3181c5cd98.

Hemmingsson, E. (2014). A new model of the role of psychological and emotional distress in promoting obesity: Conceptual review with implications for treatment and prevention. *Obesity Reviews, 15*(9), 769–779. Retrieved from https://doi.org/10.1111/obr.12197.

Hörchner, R., Tuinebreijer, W., & Kelder, H. (2002). Eating Patterns in Morbidly Obese Patients Before. *Obesity Surgery*, *12*, 108–112. doi:10.1381/096089202321144676.

Hussen, H., Persson, M., & Moradi, T. (2015). Maternal overweight and obesity are associated with increased risk of type 1 diabetes in offspring of parents without diabetes regardless of ethnicity. *Diabetologia*, *58*(7), 1464-1473. doi: 10.1007/s00125-015-3580-1.

Johansson, S., Villamor, E., Altman, M., Edstedt, A., Granath, F., & Cnattingius, S. (2014). Maternal overweight and obesity in early pregnancy and risk of infant mortality: a population based cohort study in Sweden. *BJM*, *349*, 1-12. doi:10.1136/bmj.g6572.

Kennedy-Dalby, A., Adam, S., Ammori, B. J., & Syed, A. A. (2014) Weight loss and metabolic outcomes of bariatric surgery in men versus women - A matched comparative

observational cohort study. *European Journal of Internal Medicine, 25*(10), 922-925. doi:10.1016/j.ejim.2014.10.020.

King, T. K., Clark, M. M., & Pera, V. (1996) History of sexual abuse and obesity treatment outcome. *Addictive Behaviors, 21*(3), 283-290. Retrieved from https://doi.org/10.1016/0306-4603(95)00058-5.

Kitzinger, H. B., Abayev, S., Pittermann, A., Karle, B., Kubiena, H., Bohdjalian, A., ... Frey, M. (2012). The prevalence of body contouring surgery after gastric bypass surgery. *Obesity surgery, 22*(1), 8-12. doi:10.1007/s11695-011-0459-1.

Kushner, R., & Roth, J. (2003). Assessment of the obese patient. *Endocrinology & Metabolism Clinics of North America, 32*(4), 915-933. doi:10.1016/S0889-8529(03)00068-9.

Lafortuna, C. L., Maffiuletti, N. A., Agosti, F., & Sartorio, A. (2005). Gender variations of body composition, muscle strenght and power output in morbid obesity. *International Journal of Obesity, 29*(7), 833-841. doi:10.1038/sj.ijo.0802955.

Larsen, J. K., & Geenen, R. (2005). Childhood sexual abuse is not associted with a poor outcome after gastric banding for severe obesity. *Obesity Surgery, 15*(4), 534-537. Retrieved from https://doi.org/10.1381/0960892053723277.

Lau, D. C., Douketis, J. D., Morrison, K. M., Hramiak, I. M., Sharma, I. M., & Ehud, U. (2007). Canadian clinical practice guidelines on the management and prevention of obesity in adults and children [summary]. *CMAJ, 176*(8), S1-S13 doi:10.1503/cmaj.061409.

Legenbauer, T., de Zwaan, M., Beneckec, A., Mühlhansb, B., Petraka, F., & Herpertza, S. (2009). Depression and anxiety: their predictive function for weight loss in obese individuals. *Obesity Fact, 2*, 227-234. doi:10.1159/00022678.

Libeton, M., Dixon, J. B., Laurie, C., & O'Brien, P. E. (2004). Patient motivation for bariatric surgery: Characteristics and impact on outcomes. *Obesity Surgery, 14*, 392-398. doi:10.1381/096089204322917936.

Lindeman, M., & Stark, K. (2001). Emotional eating and eating disorder psychopathology. *Eating Disorders, 9*(October), 251–259. Retrieved from https://doi.org/10.1080/10640260127552.

Livhits, M., Mercado, C., Yermilov, I., Parikh, J. A., Dutson, E., Mehran, A., ... Gibbons, M. M. (2012). Preoperative predictors of weight loss following bariatric surgery: systematic review. *Obesity surgery, 22*(1), 70-89. doi:10.1007/s11695-011-0472-4.

Livingston, E. H., Huerta, S., Arthur, D., Lee, S., De Shields, S., & Heber, D. (2002). Male gender is a predictor of morbidity and age a predictor of mortality for patients ubdergoing gastric bypass surgery. *Annals of Surgery, 236*(5), 576-582. doi:10.1097/01.SLA.0000033321.22614.D6.

Lovejoy, J. C., & Sainsbury, A. (2008). Sex differences in obesity and the regulation of energy homeostasis. *Obesity Reviews, 10*(2), 154-167. doi:10.1111/j.1467-789X.2008.00529.x.

Macintyre, S., Ford, G., & Hunt, K. (1999). Do womenover-report'morbidity? Men's and women's responses to structured prompting on a standard question on long standing illness. *Social science & medicine, 48*(1), 89-98. Retrieved from https://doi.org/10.1016/S0277-9536(98)00292-5.

Mahony, D. (2008). Psychological gender differences in bariatroc surgery candidates. *Obesity Surgery, 18*, 607-610. doi: 10.1007/s11695-007-9245-5.

Marino, J. M., Ertelt, T. W., Lancaster, K., Steffen, K., Peterson, L., de Zwaan, M., & Mitchell, J. E. (2012). The emergence of eating pathology after bariatric surgery: A rare outcome with important clinical implications. *International Journal of Eating Disorders, 45*(2), 179–184. Retrieved from https://doi.org/10.1002/eat.20891.

Mauro, M., Taylor, V., Wharton, S., & Sharma, A. M. (2008). Barriers to obesity treatment. *European Journal of Internal Medicine*, 19(3), 173–180. Retrieved from https://doi.org/10.1016/j.ejim.2007.09.011.

Mazzeo, S. E., Saunders, R., & Mitchell, K. S. (2006). Gender and binge eating among bariatric surgery candidates. *Eating Behaviors, 7*(1), 47–52. Retrieved from https://doi.org/10.1016/j.eatbeh.2005.05.008.

Miller-Matero, L. R., Armstrong, R., McCulloch, K., Hyde-Nolan, M., Eshelman, A., & Genaw, J. (2014). To eat or not to eat; is that really the question? An evaluation of problematic eating behaviors and mental health among bariatric surgery candidates. *Eating and Weight Disorders, 19*(3), 377–382. Retrieved from https://doi.org/10.1007/s40519-014-0118-3.

Mitchell, J. E., & de Zwaan, M. (2005). *Bariatric surgery: a guide for mental health professionals.* New York: Routledge.

Mitchell, J. E., King, W. C., Chen, J., Devlin, M. J., Flum, D., Garcia, L., … Yanovski, S. (2014). Course of depressive symptoms and treatment in the longitudinal assessments of bariatric surgery (LABS-2) study. *Obesity Journal*, *22*(8), 1799-1806. doi:10.1002/oby.20738.

Möller-Leimkühler, A. M. (2002). Barriers to help-seeking by men: a review of sociocultural and clinical literature with particular reference to depression. *Journal of Affective Disorders*, *71*(1), 1-9.

Moyer, V. A. (2012). Screening for and management of obesity in adults: U.S. preventive services task force recommendation statement. *Annals of Internal Medicine, 157*, 373-378. doi: 10.7326/0003-4819-157-5-201209040-00475.

Mühlhans, B., Horbach, T., & de Zwaan, M. (2009). Psychiatric disorders in bariatric surgery candidayes: a review of the literature and results of a German prebariatric surgery sample. *General Hospital Psychiatry, 31*, 414-421. doi:10.1016/j.genhosppsych.2009.05.004.

Nickel, F., Schmidt, L., Bruckner, T., Büchler, M. W., Müller-Stich, B. P., & Fischer, L. (2017). Influence of bariatric surgery on quality of life, body image, and general self-efficacy within 6 and 24 months—a prospective cohort study. *Surgery for Obesity and Related Diseases*, *13*(2), 313-319. Retrieved from https://doi.org/10.1016/j.soard.2016.08.017.

Niego, S. H., Kofman, M. D., Weiss, J. J., & Geliebter, A. (2007). Binge eating in the bariatric surgery population: A review of the literature. *International Journal of Eating Disorders, 40*, 349-359. doi:10.1002/eat.20376.

Papamargaritis, D. K., Pournaras, D. J., & Le Roux, C. W. (2010). Techniques, assessment, and effectiveness of bariatric surgery in combating obesity. *Open Access Surgery*, *3*(October), 123-136. doi:10.2147/OAS.S7195.

Perrone, F., Bianciardi, E., Benavoli, D., Tognoni, V., Niolu, C., Siracusano, A., … Gentileschi, P. (2016). Gender influence on long-term weight loss and comorbidities after laparoscopic sleeve gastrectomy and roux-en-y gastric bypass: a prospective study with a 5-year follow-up. *Obesity Surgery*, *26*, 276-281. doi:10.1007/s11695-015-1746-z.

Ramalho, S., Bastos, A. P., Silva, C., Vaz, A. R., Brandão, I., Machado, P. P. P., & Conceição, E. (2015). Excessive skin and sexual function: Relationship with psychological variables and weight regain in women after bariatric surgery. *Obesity Surgery*, *25*(7), 1149-1154. doi:10.1007/s11695-014-1514-5.

Rooney, B. L., Schauberger, C. W., & Mathiason, M. A. (2005). Impact of perinatal weight change on long-term obesity and obesity-related illness. *Obstetrics and Gynecology*, *106*(6), 1349-1356. doi:10.1097/01.AOG.0000185480.09068.4a.

Sartorio, A., Maffiuletti, N. A., Agosti, F., & Lafortuna, C. L. (2005). Gender- related changes in body composition, muscle strength and power output after a short-term multidisciplinary weight loss intervention in morbid obesity. *Journal of Endocrinological Investigation*, *28*(8), 494-501. Retrieved from https://link.springer.com/article/10.1007/BF03347236.

Satia-Abouta, J. (2003). Dietary acculturation: definition, process, assessment, and implications. *International Journal of Human Ecology*, *4*(1), 71-86. Retrieved from https://pdfs.semanticscholar.org/f27d/6b1251ccd68eaf504d1be8faac924f848c8c.pdf.

Sarwer, D. B., Cohn, N. I., Gibbons, L. M., Magee, L., Crerand, C. E., Raper, S. E., … Wadden, T. A. (2004). Psychiatric diagnoses and psychiatric treatment among bariatric surgery candidates. *Obesity Surgery*, *14*, 1148-1156. doi:10.1381/0960892042386922.

Shi, X., Karmali, S., Sharma, A. M., & Birch, D. W. (2010). A review of laparoscopic sleeve gastrectomy for morbid obesity. *Obesity Surgery*, *20*(8), 1171-1177. doi: 10.1007/s11695-010-0145-8.

Sjöström, L., Narbro, K., Sjöström, D., Karason, K., Larsson, B., Wedel, H., … Carlsson, L. M. S. (2004). Effects of Bariatric Surgery on Mortality in Swedish Obese Subjects. *New England Journal of Medicine*, *351*(21), 2159–2169. Retrieved from https://doi.org/10.1056/NEJMoa1208410.

Smink, F. R., Van Hoeken, D., & Hoek, H. W. (2012). Epidemiology of eating disorders: incidence, prevalence and mortality rates. *Current Psychiatry Reports*, *14*(4), 406-414. doi: 10.1007/s11920-012-0282-y.

Song, A. Y., Rubin, J. P., Thomas, V., Dudas, J. R., Marra, K. G., & Fernstrom, M. H. (2006). Body image and quality of life in post massive weight loss body contouring patients. *Obesity*, *14*(9), 1626-1636. doi: 10.1038/oby.2006.187.

Sridhar, S. B., Darbinian, J., Ehrlich, S. F., Markman, M. A., Gunderson, E. P., Ferrara, A., & Hedderson, M. M., (2014). Maternal gestational weight gain and offspring risk for childhood overweight or obesity. *American Journal of Obstetrics and Gynecology*, *211*(3), 259.e1-259.e8. Retrieved from http://dx.doi.org/10.1016/j.ajog.2014.02.030.

Striegel-Moore, R. H., Rosselli, F., Perrin, N., DeBar, L., Wilson, G. T., May, A., & Kraemer, H. C. (2009). Gender Difference in the prevalence of eating disorer symptoms. *International Journal of Eating Disorders*, *42*(5), 471-474. doi:10.1002/eat.20625.

Stroh, C., Groh, C., Weiner, R., Ludwing, K., Wolff, S., Kabelitz, M., & Manger, T. (2013). Are there gender-specific aspects of gastric banding? Data analysis from the quality assurance study of the surgical treatment of obesity in Germany. *Obesity Surgery*, *23*(11), 1783-1789. doi:10.1007/s11695-013-0964-5.

Stroh, C., Köckerling, F., Weiner, R., Horbach, T., Ludwig, K., Dressler, M., ... Lippert, H. (2012). Are there gender-specific aspects of sleeve gastrectomy—data analysis from the

quality assurance study of surgical treatment of obesity in Germany. *Obesity surgery*, *22*(8), 1214-1219. doi: 10.1007/s11695-012-0681-5.

Tsai, A. G., & Wadden, T. A. (2005). Systematic review: An evaluation of major commercial weight loss programs in the United States. *Annals of Internal Medicine*, *142*(1), 56-66. Retrieved from https://doi.org/10.7326/0003-4819-142-1-200501040-00012.

Tymitz, K., Kerlakian, G., Engel, A., & Bollmer, C. (2007). Gender differences in early outcomes following hand-assisted laparoscopic Roux-en-Y gastric bypass surgery: gender differences in bariatric surgery. *Obesity Surgery*, *17*, 1588-1591. Retrieved from https://link.springer.com/article/10.1007/s11695-007-9296-7.

Vahratian, A. (2009). Prevalence of overweight and obesity among women of childbearing age: results from the 2002 national survey of family growth. *Maternal and Child Heath Journal*, *13*, 268-273. doi: 10.1007/s10995-008-0340-6.

White, M. A., Kalarchian, M. A., Levine, M. D., Masheb, R. M., Marcus, M. D., & Grilo, C. M. (2015). Prognostic significance of depressive symptoms on weight loss and psychosocial outcomes following gastric bypass surgery: A prospective 24-month follow-up study. *Obesity Surgery*, *25*(10), 1909-1916. doi:10.1007/s11695-015-1631-9.

Wiederman, M. W., Sansone, R. A., & Sansone, L. A., (1999). Obesity among sexually abused women: an adaptive function for some?. *Women & Health*, *29*(1), 89-99. Retrieved from http://dx.doi.org/10.1300/J013v29n01_07.

Yakusheva, O., Kapinos, K., & Weiss, M. (2017). Maternal weight after childbirth versus aging-related weight changes. *Women's Health Issues*, *27*(2), 174-180. Retrieved from https://doi.org/10.1016/j.whi.2016.12.001.

Zizza, C. a, Herring, A. H., Stevens, J., & Carey, T. S. (2003). Bariatric surgeries in north Carolina, 1990 to 2001: a gender comparison. *Obesity Research*, *11*(12), 1519–25. Retrieved from https://doi.org/10.1038/oby.2003.203.

In: Encyclopedia of Surgery (22 Volume Set)
Editors: Andreas Lehrer and Kristin Mueller
ISBN: 978-1-53618-329-0
© 2020 Nova Science Publishers, Inc.

Chapter 446

THE LEAN SIX SIGMA METHODOLOGY: APPLICATIONS IN THORACIC SURGERY

Luca Bertolaccini*[*]*, MD, PhD, Barbara Bonfanti, MD, Jury Brandolini, MD, Francesca Calabrese, MD, Sergio Nicola Forti Parri, MD, Kenji Kawamukai, MD, Nicola Lacava, MD and Piergiorgio Solli, MD, PhD
Department of Thoracic Surgery, Maggiore Teaching Hospital, Bologna, Italy

ABSTRACT

Six Sigma and Lean are two prominent quality improvement methodologies that have been validated across several areas of healthcare. Despite a slow initial uptake within the surgical unit, the use of Lean and Six Sigma has increased markedly. The Six Sigma quality improvement methodology, is a data-driven approach developed by the Motorola Corporation that seeks to improve outcomes by eliminating the variation within a process. To date, clinical use of the Six Sigma methodology has focused on efficiency issues, but the application of the Six Sigma method has been used successfully to improve clinical results and to reduce surgical complications in repetitive procedures. Therefore, the use of this methodology in the healthcare arena has focused mainly on areas of business operations, throughput, and case management and has focused on efficiency outcomes.

After the revision of the methodology, the chapter presents a brief clinical example of the use of Lean Six Sigma as a quality improvement method in the reduction of the complications during and after VATS major procedures. Using the Lean Six Sigma methodology, the multidisciplinary teams could identify multiple modifiable points across the surgical process. These process improvements could be applied to different surgical specialities and could result in a measurement, from a statistical point of view, of the surgical quality.

Using the Lean Six Sigma methodology, thoracic surgeons could identify multiple modifiable points across the surgical process. Process improvements based on these

[*] Corresponding Author's Email: luca.bertolaccini@gmail.com.

findings could be applied to different surgical specialities and could result in a measurement, from a statistical point of view, of surgical quality.

Keywords: medical statistics, statistical analysis, thoracic surgery, Six Sigma methodology

1. INTRODUCTION

Six Sigma and Lean are two prominent quality improvement methodologies that have been validated across several areas of healthcare. Despite a slow initial uptake within the surgical unit, the use of Lean and Six Sigma has increased noticeably [1].

2. SIX SIGMA IS A QUALITY EVALUATION METHODOLOGY

Six Sigma was developed by the Motorola Corporation in 1986 and aims to improve the quality by identifying and correcting the causes of errors [1]. The Six Sigma approach attempts to drive production failures to six standard deviations (sigma) from the mean or 3.4/1,000,000 defects per products. The term Six Sigma reflects the statistical objective of the approach, namely striving to achieve a negligible number of defects, corresponding to the probability associated with a corrected Six Sigma value for the standard curve. Applying the standard curve, Six Sigma attempts to relegate defects and quality problems to the very tails of the distribution, making such problems rare exceptions in a process that operates almost without defects. The Six Sigma level of performance is not possible in biological systems, but its methodology applies to repetitive procedures. The roots of Six Sigma as a measurement standard can be traced back to Carl Frederick Gauss who introduced the concept of the standard curve. Six Sigma as a measurement standard in product variation can be traced back to 1920 when Walter Shewhart showed that three sigma from the mean is the point where a process requires correction. The Six Sigma methodology has gained wide popularity because it has proven to be successful not only in improving quality but also at producing significant cost savings along with those improvements. As mentioned earlier, to achieve the Six Sigma objective, a process must not produce more than 3.4 defects per million opportunities to produce such defects, where a defect is defined as an unacceptable outcome produced by the process under scrutiny [2].

3. THE LEAN PROCESS STRATEGY

The Lean process strategy is attributed to the Toyota Production System where specific types of manufacturing “waste,” which absorb personnel, resources, or time but do not add value to the overall processor to the end user of the service or product are eliminated. Lean is a process that continually reduces waste and improves workflow to efficiently produce a product or service that is perceived to be of high value to those who use it. The successful application of Lean and Six Sigma management tool is not limited to manufacturing but has been applied to the customer and financial service industries and the government.

Increasingly, Lean and Six Sigma are being used in the healthcare industry. Like other industries, the use of these tools can be applied to several aspects of health care, including finance, inventory management, information processing, outpatient clinics, and inpatient setting [3]. Lean focuses on reducing wasteful or non-value-added steps in a process, and Six Sigma reduces process variation through the application of statistical methods. In many quality improvement projects, these different tools are complementary, which has led to merging them into a single strategy, the Lean Six Sigma methodology [3].

3.1. The Lean Six Sigma Methodology

Recently, in healthcare Lean Six Sigma was used to improve the organisation and quality of care and to reduce costs. Lean Six Sigma offers the roadmap of DMAIC (define, measure, analyse, improve, control) as an improvement methodology and a conceptual organisational framework with specific roles for project leaders and project owners to improve processes. The DMAIC phases are milestones for the improvement project and integrate statistical quality tools and techniques like failure mode and effect analysis and statistical process control. Process and outcome measurements are combined with project metrics into a systematic review process so that that management can deal with the progress of the projects. The five DMAIC phases are [2].

- Define
  The Define phase of the DMAIC roadmap concerns the definition of the problem to be solved. The project charter determined the project leader, process owners, scope, timeline, and auxiliary members of the project team. To put the problem in perspective, a Supplier, Input, Process, Output, and Customer analyses were made, leading to a detailed flowchart of the process at the micro level. The process leader did a stakeholder analysis, to chart the stakes and the influence of the people involved.
- Measure
  To quantify the current process performance, we need appropriate measurements, the so-called critical to quality indicators in Lean Six Sigma terms. A critical to quality flow down was used to translate the rationale underlying the project into performance indicators and strategic focal points. The critical to quality flow down resulted in a measurement plan to determine the current performance, the number of clinical intakes and throughput time of the process.
- Analyse
  The Analyse phase aimed to arrive at a data-based diagnosis of the current process performance.
- Improve
  After the process was diagnosed, the project team determined objectives for interventions to eliminate waste and to reduce waiting times.
- Control
  The new process is actively monitored, to assure that better results are retained [4].

The power of Lean Six Sigma lies in its empirical data-driven approach (and its focus on using quantitative measures of how the system is performing) to achieve the goal of process improvement and variation reduction. The distribution of a characteristic in Six Sigma has usually assumed Gaussian for continuous variables and Poissonian for discrete variables. To date, the use of the Lean Six Sigma methodology in the health-care arena has focused mainly on areas of business operations (nurse recruitment), throughput (emergency department and diagnostic radiology wait times), and case management (improvement of test scheduling) [5]. The clinical use of the Lean Six Sigma methodology has focused on efficiency outcomes, such as reducing the length of hospital stay in stroke patients, but the application of the Lean Six Sigma corporate improvement method was successfully used to improve clinical outcomes and to reduce surgical complication in repetitive procedures [2].

A clinical example of the use of Lean Six Sigma as a quality improvement method, developed from previous experience in other specialities [6], can be employed to reduce the complications resulted during and after lobectomies. A surgical team was assembled and trained in the Lean Six Sigma methodology. This team assured committed and consistent leadership to overcome the complications. The surgical team firstly generated a Supplier, Input, Process, Output, and Customer table for surgery process. To achieve the performance objective, the surgical team first determined by brainstorming the critical to quality factors, i.e., the factors that may influence the objective. The surgical team determined the metrics to measure existing process.

The metrics to be chosen for a Six Sigma study were the total number of performed in the unit and the number of complications. Data were collected for a period of *x* years. In this period, *s* VATS major procedures were performed on *n* patients. Complications had been noted as they occurred. The surgical team identified c types of complications and classified them as when (e.g., intraoperatively and/or postoperatively), and how soon they occur (e.g., acute, sub-acute and/or chronic). Then, sources and root-causes of these complications are tabulated by type. To measure the current sigma level of a complication, the surgical team calculated the current defects per million opportunities and sigma levels for each complication type. Normal distribution underlies Six Sigma's statistical assumptions [7].

4. How to Conduct a Study with the Lean Six Sigma Methodology?

Lean and Six Sigma are favourite strategies used by leaders in the industry to improve efficiency, quality, and return. Thus, literature offers some recommendations when conducting studies implementing Lean and/or Six Sigma methodologies to improve the quality of the evidence. The training involved staff members in data collection and statistical methods and engage individuals proficient in research methodology. The determination of the study protocol, including the outcomes that will be measured, a priori with the intention of conducting an objective and impartial empirical study should be done. Documenting this initial protocol in the final report reduces the likelihood of selective outcome reporting, subsequently minimising the risk of bias. Measure a diverse set of outcomes that do not only measure the intended benefits of the study should be added. Report all measured outcomes, including adverse outcome(s), in natural units alongside the net cost savings of the project.

Judgments about confidence in effect estimates should be based, as far as possible, on estimates of resource use rather than on estimates of the costs of those resources. Data should be collect data in three phases: before, during, and after quality improvement implementation. Measure outcomes for at least one year after study completion reduce the risk of observational bias and ensure sustainability. A similar period should be followed when collecting data before quality improvement implementation. Avoid uncontrolled before-and-after study designs whenever possible. If randomised trials cannot be conducted, a time-series design is recommended. Measure and compare the final trend of the data to help determine whether improvements are sustainable. Conduct thorough statistical analysis of the data, including calculating P values and 95% confidence intervals for all measured outcomes (wherever practical) to ensure that results are statistically significant and to estimate precision and conduct follow-up studies to further ensure that the results are sustainable [8].

CONCLUSION

Using the Lean Six Sigma methodology, thoracic surgeons could identify multiple modifiable points across the surgical process. Process improvements based on these findings could be applied to different surgical specialities and could result in a measurement, from a statistical point of view of surgical quality.

REFERENCES

[1] Mason SE, Nicolay CR, Darzi A. The use of Lean and Six Sigma methodologies in surgery: A systematic review. *Surgeon* 2015;13:91-100.

[2] Bertolaccini L, Rizzardi G, Filice MJ, et al. 'Six Sigma approach' - an objective strategy in digital assessment of postoperative air leaks: a prospective randomised study. *Eur J Cardiothorac Surg* 2011;39:e128-32.

[3] Cima RR, Brown MJ, Hebl JR, et al. Use of lean and six sigma methodology to improve operating room efficiency in a high-volume tertiary-care academic medical center. *J Am Coll Surg* 2011;213:83-92; discussion 93-4.

[4] Niemeijer GC, Flikweert E, Trip A, et al. The usefulness of lean six sigma to the development of a clinical pathway for hip fractures. *J Eval Clin Pract* 2013;19:909-14.

[5] Bertolaccini L, Terzi A. eComment: the Six Sigma approach: from mobile phones to chest tubes. *Interact Cardiovasc Thorac Surg* 2011;13:493.

[6] Sahbaz I. Deployment of Six Sigma Methodology in Phacoemulsification Cataract Surgeries. *International Review of Management and Marketing* 2014;4:123-31.

[7] Bertolaccini L, Viti A, Terzi A. The Statistical point of view of Quality: the Lean Six Sigma methodology. *J Thorac Dis* 2015;7:E66-8.

[8] Amaratunga T, Dobranowski J. Systematic Review of the Application of Lean and Six Sigma Quality Improvement Methodologies in Radiology. *J Am Coll Radiol* 2016;13:1088-95.

In: Encyclopedia of Surgery (22 Volume Set)
Editors: Andreas Lehrer and Kristin Mueller
ISBN: 978-1-53618-329-0
© 2020 Nova Science Publishers, Inc.

Chapter 447

MECHANICAL VENTILATION IN PATIENTS AFTER CARDIAC SURGERY

Javier Barrenechea Gutiérrez*[*],
Pía Antequera Gorrini and Max Varela González
Physical Medicine and Rehabilitation Department and Coronary Intensive Critical Unit,
Clinica Alemana de Santiago, Chile

ABSTRACT

Mechanical ventilation is used to treat patients who undergo procedures and/or surgeries in order to maintain ventilatory support and thus achieve adequate tissue oxygenation and reduce the risk of post-operative complications. In cardiac surgery, the application of ventilatory strategies such as titration of tidal volume, use of moderate PEEP and early extubation protocol is part of the process that takes place in most hospitals.

1. CARDIAC SURGERY AND MECHANICAL VENTILATION

Cardiac surgery has been performed since the middle of the last century, and the use of an extracorporeal circulation system or cardiopulmonary bypass (CPB) is a relevant element considering its impact on the pathophysiology of the surgical process. Mortality in patients undergoing cardiac surgery is less than 2%, with a similar rate of incidence in acute lung injury (ALI) and acute respiratory distress syndrome (ARDS) [1].

This procedure triggers several physiological reactions, including cardiac injury due to the surgical manipulation and a marked systemic inflammatory response, which is triggered by the cardiopulmonary bypass and reperfusion mechanisms during and after surgery [2]. In addition, it can generate some frequent inflammatory processes as a result of the surgery, which can contribute to post-operative complications, such as myocardial dysfunction,

[*] Corresponding Author's Email: jbarrenecheag@udd.cl.

respiratory failure, renal and hepatic dysfunction, neurological alterations, bleeding and finally a possible multiple organ failure [3].

Cardiopulmonary bypass in cardiac surgery produces profound physiological changes, not only in the circulatory system but also in other systems. Recovery from the physiological homeostasis of these changes can take hours or even days in patients with uncomplicated conditions. For this reason, it is a common practice to keep patients on ventilatory support, sedated until the day after surgery [4].

Pulmonary dysfunctions are among the most common post-operative complications. About 25% of the patients who do not have severe post-operative cardiac dysfunction have some alteration or pulmonary complication for at least one week after surgery [5]. The greatest proportion of this disability is related to CPB, which generally leads to excessive interstitial pulmonary edema resulting in abnormal gas exchange [6] decreased pulmonary compliance and increased intrapulmonary shunt [7].

1.1. Mechanical Ventilation

The main objective of mechanical ventilation during cardiac surgery and after the period in CPB is to ensure optimal oxygenation with adequate CO2 removal and avoid post-operative pulmonary complications [8].

Mechanical ventilation with the use of increased tidal volume (VT) (10 - 15 mL/kg predicted body weight) has traditionally been recommended to prevent hypoxemia and atelectasis in anesthetized patients. There is, however, considerable evidence from experimental and observational studies that mechanical ventilation, particularly with high tidal volume, causes alveolar overdistension, and may initiate pulmonary-induced injury associated with ventilation [9]. The ARDS Network is one of the studies that generated a break in the programming of mechanical ventilation, this was done in patients with ARDS, in which when comparing use of tidal volume (VT) to 6 mL vs. 12 mL/kg weight, patients with low VT had lower mortality than the group with a high VT [10].

Additionally, the application of alveolar recruitment strategies and positive end-expiratory pressure (PEEP) titration were implemented as useful tools in the treatment of patients with ARDS [9]. Then, Amato et al. brought the importance of measuring the distension pressure or "driving pressure" as a parameter for estimating lung damage into the discussion. They established that a driving pressure lower than 15 cmH20 reduces mortality in patients with ARDS [11]. Another parameter to be taken into account is the plateau pressure, with the American Thoracic Society consensus recommending a value <30 cmH20 [12].

In 2010, a randomized controlled trial in patients undergoing invasive mechanical ventilation (IMV) without ARDS compared patients with tidal volume titration of 6 vs. 10 mL/kg predicted body weight. The study showed that the plasma levels of interleukin 6 (IL-6) decrease significantly in patients with low VT. In addition, over the days on IMV the group with VT of 6 mL/Kg predicted body weight had a lower oxygenation index, a lower lung damage score, and from the point of view of pulmonary mechanics had a better static compliance and a lower minute volume on the 4th day on IMV [13].

In 2012 Serpa Neto et al. conducted a review of studies on patients on mechanical ventilation without ARDS, in which titration of the tidal volume close to 6 vs. 10 mL/Kg

predicted weight produced less ventilation-induced pulmonary damage, as well as lower mortality, lower pulmonary infection and a lower degree of atelectasias [14].

All these parameters must be taken into account at the time of titration of mechanical ventilation in post-cardiac surgery patients who do not have ARDS, who generally have healthy lungs, subjected to stress such as surgery.

1.2. Mechanical Ventilation in Cardiac Surgery

Despite the benefits offered by mechanical ventilation in the care of the critical patient, it is not exempt from adverse effects, as this alone can cause damage, in severe ill patients and others of lesser severity who are exposed to prolonged mechanical ventilation, known as ventilation-induced lung injury (VILI). This may indicate that the marked pulmonary dysfunction following cardiac surgery is the result of two noxae that trigger an "insult" to the lungs: 1) the cardiac surgery procedure, with or without CPB and 2) mechanical ventilation to the lung in an inflammatory environment [7]. Mechanical ventilation in patients after cardiac surgery is a short-term process, depending on the severity of the patient's condition, and may be between 4 and 8 hours, but it is not necessary to stop applying protocols and maintain "protective ventilation parameters" used in critically ill patients as in ARDS to avoid VILI.

Protective mechanical ventilation in patients undergoing cardiac surgery is not limited to the reduction of tidal volume. It involves an assisted-controlled ventilatory technique, with a low tidal volume (6-8 mL/Kg predicted weight), associated with high PEEP and the limitation of the inspired oxygen fraction. This programming is maintained during cardiopulmonary bypass and to which alveolar recruitment maneuvers can be added, thus being the major components of ventilatory management in patients after cardiac surgery [8].

In 2000 Chaney et al. published one of the first articles related to protective mechanical ventilation in patients undergoing cardiac surgery, and determined that pulmonary mechanic parameters were reduced in airway pressures, both plateau and peak. Furthermore, titration of the tidal volume would attenuate pulmonary dysfunctions such as decreased compliance and increased intrapulmonary shunt, commonly seen in patients after exposure to cardiopulmonary bypass [15].

Lellouche et al. conducted a prospective study on patients after cardiac surgery and analyzed the association between high tidal volume and some organic dysfunction (prolonged mechanical ventilation, hemodynamic instability and renal failure), in addition to prolonged stay in the intensive care unit. Patients in the group with the highest tidal volume had the longest time on mechanical ventilation (7.4 vs.6.0 hours in group <10 mL), renal failure and longer stay in the intensive care unit. In addition, they found that obesity (BMI> 30) and being female were risk factors at the time of setting the mechanical ventilation. This may be due to the fact that a higher VT is frequently programmed in these patients [16].

In relation to the inflammatory response at the systemic level in patients undergoing surgery, Zupancich et al. studied the effects of high VT and low PEEP vs. low VT and high PEEP. With respect to the inflammation process, after 6 hours in invasive mechanical ventilation the concentrations of interleukin-6 (IL-6) and interleukin-8 (IL-8) were higher in the group of patients with high VT and low PEEP. From the point of view of pulmonary mechanics, the group of patients treated with low VT and high PEEP presented lower plateau pressures and minute volume [17].

The study conducted by Sundar et al. in 2011 compared the time to extubation in patients undergoing cardiac surgery with protective ventilation and limitation of the VT at 6 vs. 10 mL/kg predicted weight. A higher proportion of patients with protective ventilation was out of mechanical ventilation at 6 hours after surgery (37.3 vs. 20.3%) and also after 8 hours (53.3 vs. 31.1% in control group) [1].

1.3. Post-Operative Alveolar Recruitment

Pulmonary dysfunction after cardiac surgery is a constant. Its appearance increases the occurrence of respiratory complications and delays rehabilitation. It is for this reason that ventilatory strategies have been proposed that seek to reduce, as far as possible, these respiratory complications. Further on in this chapter, we will analyze how the presence of PEEP can prevent alterations in tissue oxygenation. Likewise, the use of small periods of high inspiratory pressures to open the collapsed alveolus, followed by a relatively high level of PEEP to keep it open associated with a low level of tidal volume, seems able to accelerate lung function recovery [18].

In the post-operative period of cardiac surgery, the use of PEEP of 5 cmH20 and the decrease in VT can lead to hypoxemia due to atelectasis, which in the case of this surgery is approximately 6 times more frequent than for abdominal surgery [19]. When the tidal volume is decreased, atelectasis can be prevented with the implementation of PEEP slightly higher than 5 cmH20 (8 to 12 cmH20), particularly in obese patients with reduced thoracic compliance [8].

It is important to prevent atelectasis because the recurrence of cyclic alveolar opening in inspiration and closure in expiration caused by the presence of atelectasis is among the major causes of lung inflammation and ventilation-induced damage [7, 20].

Positive end-expiratory pressure (PEEP) aids in preventing alveolar collapse and the consequent formation of atelectasis, but it also generates hemodynamic changes that are important to consider when setting the PEEP. Ventilation with positive pressure restricts the filling of the right ventricle by an increase in intrathoracic pressure, restricting venous return to the thorax and thereby reducing cardiac output. As the heart rate does not change with PEEP, the drop in systemic cardiac output is then a result of the reduction in left ventricular stroke volume. Therefore, the discussion of the change in PEEP-induced cardiac output should be analyzed for changes in stroke volume and its determinants: preload, afterload, contractility and ventricular compliance [21].

The concept of “open lung”, which involves the application of small periods of high inspiratory pressure to open the collapsed alveolus associated with a relatively high PEEP to keep the alveolus open and low VT, is one of the strategies used in patients undergoing cardiac surgery with and without extracorporeal circulation. Bolzan et al. showed that patients with both early (immediately after intubation) and late (30 minutes after arrival to an ICU) open lung had better results in lung function, higher value in forced vital capacity (FVC) and forced expiratory volume in the first second (FEV1), than those subjected to conventional ventilation. In relation to functional capacity measured through the 6-minute walk test, the group with early open lung was significantly higher than in the late open lung group, and this was significantly higher than the conventional ventilation group in terms of meters walked in the preoperative evaluation [22].

The use of alveolar recruitment is a widely implemented technique in patients with ARDS; however, it is also applicable in patients undergoing cardiac surgery. A randomized study on patients undergoing cardiac surgery without extracorporeal circulation (off-pump), separated into 3 groups: i) conventional ventilation (VT 8 ml/Kg ideal weight, PEEP 0 in operating room and PEEP 5 in ICU piece), ii) late open lung (tidal volume 6 mL/Kg ideal weight, PEEP 10) with increase in re-expansion maneuvers reaching inspiratory peak pressures of 40 cmH20 for 15 seconds and iii) early open lung, with post-intubation beginning with re-expansion maneuvers with inspiratory pressures peak of 40 cmH20 (tidal volume 6 mL/Kg ideal weight and PEEP 10), reducing the PEEP to 5 if it made the process of bypass surgery difficult. The lung capacity results measured by spirometry on days 1, 3 and 5 indicated that patients undergoing early and late open lung had better results in forced vital capacity (FVC) and forced expiratory volume in one second (FEV1) on days 1, 3 and 5 than the conventional ventilation group [18].

A similar study carried out in 2005 by Miranda et al. in which alveolar recruitment was applied to an early open lung group, another late open lung group and a third group with conventional therapy. The application according to the open lung ventilation concept was associated with a greater post-operative functional residual capacity than that obtained with conventional ventilation [23].

A study has also reported on patients with hypoxemia after cardiac surgery, subject to titration of the tidal volume at 6 mL/kg ideal weight. They were divided into groups with intensive recruitment strategy and moderate recruitment strategy. The intensive recruitment group received 3 cycles of inflation (60 seconds) in pressure control mode with PEEP 30 cmH20 and driving pressure of 15 cmH20, with a respiratory rate (RR) of 15x', and then the PEEP was lowered to 13 cmH20, driving pressure to achieve 6 mL/Kg ideal weight of tidal volume and RR to maintain PaCo2 between 35 and 45 mmHg. Patients in the moderate recruitment strategy group received 3 cycles followed by 30 seconds with CPAP 20 cmH20 and subsequently ventilation with volume control mode PEEP 8; VT of 6 mL/kg ideal weight, RR to maintain PaCO2 between 35 and 45 mmHg. Patients under intensive recruitment had fewer points on the pulmonary complications score. The occurrence and severity of post-operative complications in the intensive recruitment group was lower than in the moderate recruitment group. In addition, the intensive recruitment group had fewer days of stay in the ICU and days of hospitalization. In terms of mechanical and arterial gases, the intensive recruitment group had a better PaO2:FiO2 ratio, better pulmonary compliance and lower driving pressure than the other groups [24].

Lago Borges et al. compared the use of PEEP in 3 groups, PEEP in 5, 8 and 10 cmH20, with a tidal volume between 6 to 8 mL/Kg ideal weight. The group with PEEP 10 had better lung compliance and lower airway resistance (although with no statistically significant difference), increasing oxygenation and decreasing the occurrence of hypoxemia [25].

Dongelmans et al. compared the use of PEEP of 10 cmH20 vs. 5 cmH20 (both groups with VT between 6 - 8 mL/kg ideal weight) in the period following cardiac surgery. The group of patients with high PEEP presented better pulmonary compliance and better oxygenation than the group with low PEEP, but this did not reduce the time to extubation, caused by an increase in the time of use of propofol for sedation [26].

2. EXTUBATION AND THE FAST-TRACK PROCESS

To perform early extubation or fast-tracking, a multidisciplinary team is required as well as a consolidated process with assessment tools and goals to be met in the post-operative period so as to reduce errors and make the right decisions when extubating the patient.

The "fast-track" process began in the early 1990s; it has no standard definition but usually aims to extubate the patient within 6-8 hours after surgery [27], and involves several components of care during cardiac anesthesia and in the post-operative period. The ultimate goal is early post-operative extubation, which may reduce the days of stay in the intensive care unit and in the hospital [28] and possibly decrease the rate of ventilator-related pneumonia [29].

In 2016 Cove et al. published an article detailing the early extubation process carried out in the surgical center. Carrying out the fast-track process with a multidisciplinary team managed to reduce the time to extubation by 35% in a study group compared to the patients in their own institution who underwent surgery prior to application of the protocol. In addition, the mechanical ventilation time was reduced by 24% in the pressure support mode as were the days of stay in the ICU [30].

Bansal et al. performed a retrospective review of their patients undergoing fast-track extubation, taking 7.3 hours as the cut-off time. Those who spent less time on mechanical ventilation had fewer ICU days and hospital days [29].

Reyes et al. implemented a protocol with patients for early extubation (between 7 and 11 post-operative hours) and a control group with conventional management who extubated the morning after the day of surgery. In the early extubation group, the average time to extubation was 8.52 hours compared to 19 hours in the conventional group [4].

In 2014, Probst et al. conducted a study on post-operative management and the time of early extubation between a post-anesthetic care unit (PACU) and the ICU. Both presented the same criteria for extubation. The median extubation in the PACU was 90 min vs. 478 min in the ICU. One of the important differences was that in the PACU, the nurse-patient and therapist-patient relationships were both1:3, with the therapist being an anesthetist, whereas in the ICU the nurse-patient relationship was 1:2 and therapist 1:12 [31]. The development of the PACU as a place for post-operative work has better results if it has limited hours (12 vs. 24 hours), since in limited hours the intubation times are shortened, the stays in intermediate units are shortened and costs are reduced, unlike a PACU with unlimited hours (24 hours) [27].

A review by Wong et al. compared the fast-track and the conventional therapy groups. The results showed that the group with a low dose vs. a high dose of analgesia had no significant differences in post-operative complications such as myocardial infarction, cerebrovascular accident and re-intubation, nor did the groups associated with time-directed extubation protocols after surgery. In addition, the fast-track process associated with a low dose of analgesia decreases mechanical ventilation times (4.3 vs. 10.5 h), and the same occurs with the groups associated with the post-operative time-directed extubation protocol (3.7 vs. 8.8 h). Furthermore, mechanical ventilation times and days of stay in the ICU are reduced [28, 30, 32, 33].

On the other hand, there is a range of patients who are not candidates for a fast-track process, such as those who underwent a cardiogenic shock, dialysis-dependent patients, or

who have a Euroscore greater than 10 [31]. Those with previous risk factors such as ejection fraction <35%, pre-operative or post-operative cardiac assist devices and post-operative cardiopulmonary instability (high inotropic support, lactate> 5 mmol/L, Horowitz Index under 200) [34, 35]. In addition, there are independent risk factors that can cause the fast-track process to fail, such as those patients over 70 years of age, duration of surgery, cross-clamp time and being female [36].

2.1. Fast-Track Inclusion Criteria

- Elective surgeries [36]
- Hemodynamically stable (SBP > 90 mmHg, HR <120 bpm, adrenaline or noradrenaline < 0.04 mcg/kg/min), T° > 36°C, without bleeding [31, 36].

The requirements to perform extubation depend on the protocol that exists in each unit, but generally there are 3 aspects to consider: hemodynamic, respiratory and neurological stability.

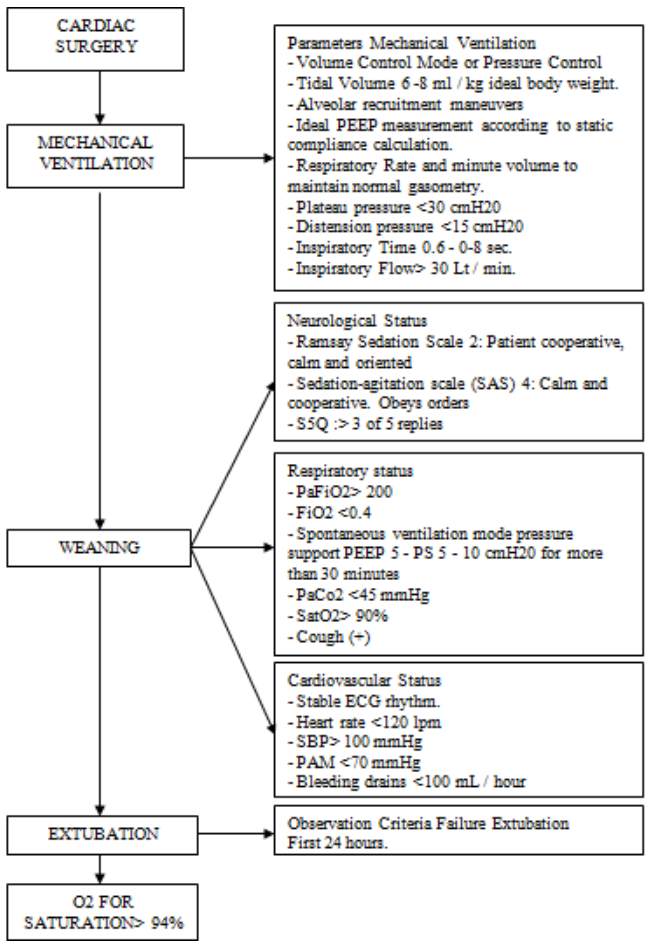

Figure 1. Proposal for mechanical ventilation management of patients after cardiac surgery.

Hemodynamic stability presents without uncontrolled arrhythmias, normal electrocardiogram, bleeding drains <100 mL/hour and a T° ≥ 36°C. From the neurological point of view, the patient must cooperate and follow indications, without neurological deficit (Ramsay Sedation Scale2, SAS 4). From the respiratory point of view, the patient must have a spontaneous respiratory rate between 10-20 resp/min, FiO2 <40%, acceptable blood gases (PaO2 ≥ 100 mmHg, PaCO2 ≤40 mmHg), PEEP 5 with inspiratory support pressure 5 to 10 cmH20 for a time of at least 30 minutes, normal lactate and normal chest radiograph [26, 36].

In addition, one should be alert to the possible spontaneous ventilation test failure criteria, such as the pulse>20 bpm>pre-wean rate for >5 minutes, respiratory rate ≤7 or ≥35 for 5 minutes, SatO2 <92% or PaO2 <60 mmHg for more than 5 minutes, marked use of accessory muscle and/or abdominal paradox, marked distress, subjective dyspnea or agitation, arrhythmias on the ECG or chest pain [37].

CONCLUSION

Mechanical ventilation in patients after cardiac surgery is a complex process which must be undertaken by a multidisciplinary team and with an established protocol to assist in rehabilitation. The mechanical ventilation techniques and modes used in critical patients are also tools used after cardiac surgery. Titration of the tidal volume (6 - 8 mL/Kg ideal weight), application of alveolar recruitment protocols, use of ideal PEEP in relation to pulmonary mechanics and an established fast-track protocol comprise the ideal process to be applied in patients after cardiac surgery. The application of these concepts reduces the times in mechanical ventilation, days of stay in the ICU and days of hospitalization, aiding in a faster and more efficient rehabilitation of patients.

REFERENCES

[1] Sundar, S., Novack, V., Jervis, K., Bender, P., Lerner, A., Panzica, P., et al. (2011). Influence of low tidal volume ventilation on time to extubation in cardiac surgical patients. *Anesthesiology*. 114, 1102–1110.

[2] Suleiman, M., Zacharowski, K. and Angelini, G., (2008). Inflammatory response and cardioprotection during open-heart surgery: the importance of anaesthetics. *British Journal of Pharmacology*. 153, 21–33.

[3] Paparella, D., Yau, T. M., Young, E., (2002). Cardiopulmonary bypass induced inflammation: pathophysiology and treatment. An update. *European Journal of Cardio-thoracic Surgery*. 21, 232–244.

[4] Reyes, A., Vega, G., Blancas, R., Morató, B., Moreno, J. L., Torrecilla, C., et al. (1997). Early vs Conventional Extubation After Cardiac Surgery With Cardiopulmonary Bypass. *Chest*. 112, 193-201.

[5] Taggart, D. P., El-Fiky, M., Carter, R., et al. (1993). Respiratory dysfunction after uncomplicated cardiopulmonary bypass. *Ann. Thorac. Surg*. 56, 1123-1128.

[6] Apostolakis, E., Filos, K. S., Koletsis, E., Dougenis, D., (2010). Lung Dysfunction Following Cardiopulmonary Bypass. *J. Card. Surg*. 25, 47-55.

[7] Miranda, D., Gommers, D., Papadakos, P., Lachmann, B., (2007). Mechanical Ventilation Affects Pulmonary Inflammation in Cardiac Surgery Patients: The Role of the Open-Lung Concept. *Journal of Cardiothoracic and Vascular, Anesthesia*. 21, 279-284.

[8] Lellouche, F., Delorme, M., Bussières, J., Ouattara, A., (2015). Perioperative ventilator strategies in cardiac surgery. *Best, Practice, & Research, Clinical, Anaesthesiology*. 29, 381-95.

[9] Futier, E., Constantin, J-M., Paugam-Burtz, C., Pascal, J., Euri, M., Neuschwander, A., et al. (2013). A Trial of Intraoperative Low-Tidal-Volume Ventilation in Abdominal Surgery. *N. Engl. J. Med*. 369, 428-437.

[10] The Acute Respiratory Distress Syndrome Networks. (2000). Ventilation with lower tidal volumes as compared with traditional volumes for acute lung injury and the acute respiratory distress syndrome. *N. Eng. J. Med*. 342, 1301-1308.

[11] Amato, M., Meade, M., Slutsky, A., Brochard, L., Costa, E., Schoenfeld, D., et al. (2015). Driving Pressure and survival in the acute respiratory distress syndrome. *N. Eng. J. Med*. 372, 747-55.

[12] Fan, E., Del Sorbo, L., Goligher, E., Hodgson, C., Munshi, L., Walkey, A., et al. (2017). An Official American Thoracic Society/European Society of Intensive Care Medicine/Society of Critical Care Medicine Clinical Practice Guideline: Mechanical Ventilation in Adult Patients with Acute Respiratory Distress Syndrome. *Am. J. Respir. Crit. Care Med*. 195, 1253–1263.

[13] Determann, R., Royakkers, A., Wolthuis, E., Vlaar, A., Choi, G., Paulus, F., et al. (2010). Ventilation with lower tidal volumes as compared with conventional tidal volumes for patients without acute lung injury: a preventive randomized controlled trial. *Critical Care*. 14, R1.

[14] Serpa, A., Oliveira, S., Manetta, J., Moura, V., Crepaldi, D., et al. (2012). Association Between Use of Lung-Protective Ventilation With Lower Tidal Volumes and Clinical Outcomes Among Patients Without Acute Respiratory Distress Syndrome A Meta-analysis. *JAMA*. 308, 1651-1659.

[15] Chaney, M., Nikolov, M., Blakeman, B., Bakhos, M., (2000). Protective Ventilation Attenuates Postoperative Pulmonary Dysfunction in Patients Undergoing Cardiopulmonary Bypass. *Journal of Cardiothoracic, and Vascular, Anesthesia*. 14, 514-518.

[16] Lellouche, F., Dionne, S., Simard, S., Bussières, J., Dagenais, F., (2012). High Tidal Volumes in Mechanically Ventilated Patients Increase Organ Dysfunction after Cardiac Surgery. *Anesthesiology*. 116, 1072–82.

[17] Zupancich, E., Paparella, D., Turani, F., Munch, C., Rossi, A., Massaccesi, S., (2005). Mechanical ventilation affects inflammatory mediators in patients undergoing cardiopulmonary bypass for cardiac surgery: A randomized clinical trial. *J. Thorac. Cardiovasc. Surg*. 130, 378-83.

[18] Bolzan, D., Trimer, R., Begot, I., Nasrala, M., Forestieri, P., Mendez, V., et al. (2016). Open lung ventilation improves clinical outcomes in offpump coronary artery bypass surgery. A randomized controlled trial. *Journal of Cardiothoracic, and Vascular, Anesthesia*. 30, 702-708.

[19] Celebi, S., Köner, O., Menda, F., Korkut, K., Suzer, K., Cakar, N., (2007). The Pulmonary and Hemodynamic Effects of Two Different Recruitment Maneuvers after Cardiac Surgery. *Anesth. Analg*. 104, 384 –90.

[20] Dreyfuss, D., Saumon, G., (1998) Ventilator-induced Lung Injury. Lessons from Experimental Studies. *Am. J. Respir. Crit. Care Med*. 157, 294–323.

[21] Luecke, T., Pelosi, P., (2005). Positive end-expiratory pressure and cardiac output. *Critical Care*. 9, 607-621.

[22] Bolzan, D., Gomes, W., Rocco, I., Viceconte, M., Nasrala M., Pauletti, H., et al. (2016). Early Open-Lung Ventilation Improves Clinical Outcomes in Patients with Left Cardiac Dysfunction Undergoing Off-Pump Coronary Artery Bypass: a Randomized Controlled Trial. *Braz. J. Cardiovasc. Surg.* 31, 358-364.

[23] Miranda, D., Struijs, A., Koetsier, P., Van Thiel, R., Schepp, R., Hop, W., et al. (2005). Open lung ventilation improves functional residual capacity after extubation in cardiac surgery. *Crit. Care Med*. 33, 2253-2258.

[24] Costa, A., Hajjar, L., Volpe, M., Fukushima, J. T., et al. (2017). Effect of Intensive vs Moderate Alveolar Recruitment Strategies Added to Lung-Protective Ventilation on Postoperative Pulmonary Complications. A Randomized Clinical Trial. *JAMA*. 317, 1422-1432.

[25] Lago, D., Da Silva, V., De Albuquerque, M., Pereira, T., Pereira dos Santos, N., Mendes, I., et al. (2013). Effects of different PEEP levels on respiratory mechanics and oxygenation after coronary artery bypass grafting. *Rev. Bras, Cir. Cardiovasc*. 28, 380-385.

[26] Dongelmans, D., Hemmes, S., Kudoga, A., Veelo, D., Binnekade, J., Schultz M., (2012). Positive end-expiratory pressure following coronary artery bypass grafting. *Minerva. Anestesiol*. 78, 790-800.

[27] Graß, C., Stretti, F., Zakhary, W., Turton, E., Sgouoropoulou, S., Mende, M, et al. (2017). Impact of the post-anesthetic care unit opening hours on fast-track success in cardiac surgery. *Minerva. Anestesiol*. 83, 155-164.

[28] Wong, W., Lai, V., Chee, Y., Lee, A., (2016) Fast-track cardiac care for adult cardiac surgical patients. *Cochrane Database of Systematic, Reviews*. Issue 9.

[29] Bansal, S., Thai, H., Hsu, C., Sai-Sudhakar C., Goldman, S., Rhenman, B., (2015). Fast Track Extubation Post Coronary Artery Bypass Graft: A Retrospective Review of Predictors of Clinical Outcomes. *World Journal of Cardiovascular, Surgery*. 3, 81-86.

[30] Cove, M., Ying, C., Taculod, J., Oon, S., Oh, P., Kollengode, R., et al. (2016). Multidisciplinary Extubation Protocol in Cardiac Surgical Patients Reduces Ventilation Time and Length of Stay in the Intensive Care Unit. *Ann, Thorac, Surg*. 102, 28–34.

[31] Probst, S., Cech, C., Haentschel, D., Scholz, M., Ender, J., (2014) A specialized post-anaesthetic care unit improves fast-track management in cardiac surgery: a prospective randomized trial. *Critical, Care*. 18:468.

[32] Richey, M., et al. (2017). Implementation of an Early Extubation Protocol in Cardiac Surgical Patients Decreased Ventilator Time But Not Intensive Care Unit or Hospital Length of Stay. *Journal of Cardiothoracic, and Vascular, Anesthesia*. 32, 739-744.

[33] Ender, J., Borger, M., Scholz, M., Funkat, A. K., Anwar, N., Sommer, M., et al. (2008). Cardiac Surgery Fast-track Treatment in a Postanesthetic Care Unit. *Anesthesiology*. 109, 61–66.

[34] Constantinides, V., Tekkis, P., Fazil, A., Kaur, K., Leonard, R., Platt, M., et al. (2006). Fast-track failure after cardiac surgery: development of a prediction model. *Crit. Care Med*, 34, 2875–2882.

[35] Akhtar, M., Hamid, M., (2009). Success and failure of fast track extubation in cardiac surgery patients of tertiary care hospital: one year audit. *J. Pak. Med. Assoc*. 59, 154–156.

[36] Zakhary, W., Lindner, J., Sgouropoulou, S., Eibel, S., Probst, S., Scholz, M., et al. (2015). Independent Risk Factors for Fast-Track Failure Using a Predefined Fast-Track Protocol in Preselected Cardiac Surgery Patients. *Journal of Cardiothoracic and Vascular, Anesthesia*. 29, 1461–1465.

[37] Fitch, Z., Debesa, O., Ohkuma, R., Duquaine, D., Steppan, J., Schneider, E., et al. (2014). A protocol-driven approach to early extubation after heart surgery. *J. Thorac. Cardiovasc. Surg*. 147, 1344-50.

In: Encyclopedia of Surgery (22 Volume Set)
Editors: Andreas Lehrer and Kristin Mueller
ISBN: 978-1-53618-329-0
© 2020 Nova Science Publishers, Inc.

Chapter 448

IMPROVEMENT OF CARDIOVASCULAR RISK FACTORS AFTER BARIATRIC SURGERY

Jaime Ruiz-Tovar[1] and Carolina Llavero[2]
[1]Department of Surgery, Centro de Excelencia para el Estudio y Tratamiento de la Obesidad, Valladolid, Spain
[2]Department of Surgical Nursery, Hospital del Sureste, Madrid, Spain

ABSTRACT

Impaired glucose tolerance, hypertension, and dyslipidemia have been described as metabolic syndrome (MetS). MetS is associated with an increased cardiovascular risk. A close association between morbid obesity and MetS has been highlighted in several clinical studies. Disease risk increases with increasing body mass index (BMI). However, BMI can be misleading for certain body constitutions. Thus, other parameters have been proposed as predictors of cardiovascular risk. Among them, the adiposity, the Framingham Index and the Atherogenic Index (Triglycerids/HDL-c.).

Bariatric surgery has been shown to be effective in achieving and maintaining weight change and reducing obesity-related comorbidities. Malabsorptive procedures (biliopancreatic diversion and duodenal switch) have been associated with the greatest reduction of cardiovascular risk, associated with a greatest improvement in obesity-related comorbidities (diabetes mellitus, hypertension and dyslipidemia). On the other hand, the lowest improvement is obtained after restrictive procedures (Adjustable gastric banding (AGB). However, despite sleeve gastrectomy is also considered a restrictive procedure, the reported improvement of cardiovascular risk reduction is greater than after AGB, as a certain hormonal effect is also involved in this technique-

In this chapter we will review the current evidence of obesity-related comorbidities and cardiovascular risk factor index after different bariatric approaches.

INTRODUCTION

More than 2/3 of the U.S. population is overweight or obese. Obesity is on the rise and the incidence is increasing most rapidly in the morbidly obese population, i.e., those with

BMIs exceeding 40 kg/m2. Epidemiological studies estimate the prevalence of morbid obesity around 0.5%, but this rate is probably underestimated, as many morbidly obese subjects are not under any medical control. Only surgery results in substantial, long-term weight loss for obese individuals. Therefore, the performance of bariatric procedure has increased exponentially in the last 2 decades; from less than 9,000 procedures in 1993 to a high of over 115,000 in 2004. It is estimated that 220,000 weight-loss surgeries were performed in 2008. Actually, the number of bariatric procedures performed is even higher [1].

Impaired glucose tolerance, hypertension, and dyslipidemia have been described as metabolic syndrome (MetS). MetS is associated with an increased cardiovascular risk. A close association between morbid obesity and MetS has been highlighted in several clinical studies. Disease risk increases with increasing body mass index (BMI) [2].

Bariatric surgery has been shown to be effective in achieving and maintaining weight change and reducing obesity-related comorbidities. Malabsorptive procedures (biliopancreatic diversion and duodenal switch) have been associated with the greatest reduction of cardiovascular risk, associated with a greatest improvement in obesity-related comorbidities (diabetes mellitus, hypertension and dyslipidemia). On the other hand, the lowest improvement is obtained after restrictive procedures (Adjustable gastric banding (AGB). Despite sleeve gastrectomy is also considered a restrictive procedure, the reported improvement of cardiovascular risk reduction is greater than after AGB. It has been hypothesized that a certain hormonal effect is also involved in this technique [3].

Disease risk increases with increasing body mass index (BMI). However, BMI can be misleading for certain body constitutions. Thus, other parameters have been proposed as predictors of cardiovascular risk. Among them, the adiposity, the Framingham Index and the Atherogenic Index (Triglycerids/HDL-c.) [2, 4].

Diabetes Mellitus

Bariatric surgical procedures are effective interventions for treating type 2 diabetes. Improvement in metabolic control is often evident within days to weeks following bariatric procedures, most likely reflecting an alteration in metabolism that is independent of weight loss [5].

Three randomized trials illustrate the efficacy of weight loss surgery versus medical therapy alone:

- Obese patients with uncontrolled type II diabetes, undergoing a RYGB or a SG plus medical therapy, were significantly more likely to achieve the main outcome of a glycated hemoglobin level of 6% or less at 12 months, compared with patients managed by intensive medical therapy alone (42% versus 37% versus 12%, respectively) [6].
- A randomized trial of 60 patients also found that obese diabetic patients undergoing a bariatric operation had better control than medical management alone. Obese patients (BMI ≥35) with a history of diabetes for five or more years and a glycated hemoglobin level ≥7%, undergoing a RYGB or biliopancreatic diversion (BPD), were significantly more likely to achieve the study endpoint of remission of diabetes

at two years, compared with patients managed by medical therapy alone (75% versus 95% versus 0%, respectively) [7].

- A randomized trial that included 120 patients demonstrated that a RYGB procedure was superior to intensive medical management alone in achieving the main outcome measure of a glycated hemoglobin level of less than 7%. (75% versus 32%) [8]. Results following RYGB operation are promising and several trials are in progress to evaluate the procedure for patients with BMI <35 and poorly controlled type 2 diabetes [9, 10]. Efficacious control of type 2 diabetes has also been demonstrated following a SG or an AGB.

In 2011, the American College of Surgeons Bariatric Surgery Center Network (ACSBSCN) found that the remission or improvement was for patients undergoing RYGB, SG, and AGB. In a prospective, longitudinal study, that included bariatric-specific data from more than 100 participating institutions and 28,616 obese diabetic patients, remission or improvement in diabetes at 12 months was achieved in 83% of patients undergoing a RYGB, 55% undergoing SG, and 44% undergoing an AGB [11]. This result has been corroborated by other studies demonstrating one-year remission or improvement of diabetes in 40% to 75% of patients who underwent a SG or an AGB [12, 13]. SG is an alternative procedure to RYGB for patients with BMI <50, the extremes of ages, and smokers.

In addition to glycemic control, improvement in distal peripheral neuropathy was identified following RYGB. An improvement or normalization of the Neuropathy Symptom Score (NSS) and the Neuropathy Deficit Score (NDS) in all patients has been found [14].

Hypertension

The association between obesity and the development of hypertension is well established. Weight loss, whether by an intensive lifestyle-medical modification program or by a bariatric operation, improves obesity-linked hypertension or contributes to remission. Patients undergoing a bariatric surgery plus intensive lifestyle medical management were able to achieve a similar reduction in systolic blood pressure at 12 months compared with patients managed with lifestyle medical modification alone [15]. While intensive lifestyle modification resulting in weight loss appears beneficial for resolution of hypertension, this is unfortunately not feasible for all patients, due to reasons such as lack of motivation or inability to exercise.

Data are unclear as to whether or not RYGB offers the highest resolution or reduction of hypertension of bariatric operations, as illustrated by several studies [16].

Dyslipidemia

Obesity-linked dyslipidemia is a well-established risk factor for cardiovascular disease [17]. The most commonly encountered dyslipidemias in obese individuals include hypertriglyceridemia, decreased HDL-cholesterol values, and increased LDL-cholesterol particles [18]. Multiple studies have demonstrated improved lipid profiles following bariatric

procedures. The most extensively studied procedure is the RYGB. Mean total cholesterol levels decreased by 16%, triglyceride levels decreased by 63%, LDL- cholesterol levels decreased by 31%, total cholesterol/HDL-cholesterol risk ratio decreased by 60%, and HDL-cholesterol levels increased by 39%. In addition, over 80% of patients requiring lipid lowering medications preoperatively, no longer required medical therapy [19]. Malabsorptive procedures obtain at least similar results of improvement of dyslipidemia. A recent study of our group has demonstrated that after SG, HDL-cholesterol values increase and Triglycerides levels decreased significantly. However, total and LDL-cholesterol remained unaltered of present nonsignificant improvements. Notwithstanding, mainly based on the HDL-cholesterol increase, the cardiovascular risk index present a significant improvement after surgery [2].

PREDICTIVE MARKERS OF OBESITY AND CARDIOVASCULAR DISEASE IN MORBIDLY OBESE PATIENTS

BMI and Adiposity

In the 19th century, Adolphe Quetelet observed that the relative weight of the human was proportional to the square of the height. This relation was denominated Quetelet Index and later on, Body Mass Index (BMI) [20, 21]. The cut-off points of the BMI are very useful for epidemiological studies, but it does not represent an accurate measure of the body composition. Frequently, it underestimates obese subjects as just overweight ones. Based on a study performed on more than 6.000 subjects, investigators of the University Clinic of Navarra (Spain) developed an equation to calculate the body fat percentage, also known as adiposity, without depending on sophisticated technology and just based on anthropometric values easily obtained [22, 23]. The new formula, also known as CUN-BAE (Clínica Universidad de Navarra-Body Adiposity Estimator) is an approach to the fat composition and classifies it according previously established ranges. With this new classification, it has been demonstrated that subjects considered as lean or with overweight (BMI<30 Kg/m^2) in reality present elevated adiposity ranges, which might explain certain comorbidities associated with the metabolic syndrome [22].

Several studies have analyzed the impact of adiposity on cardiovascular risk, realizing that BMI associated or not to the waist circumference is less effective than adiposity determination [23, 24]. However, the actual devices to measure adiposity (bioelectric impedance, hydrostatic weight, pletismography, double-energy X-ray absorciometry, …) are often not available in all media, the measures are estimative and imply elevated sanitary costs [25, 26].

CUN-BAE formula has exposed that nearly one third of subjects classified as lean by the BMI, present an elevated adiposity, and 80% of patients classified as overweight, are really obese ones [22-24].

Thus, BMI does not define the obesity grade as an excess of adiposity, but a weight excess, without discriminating between fat, water and muscle. Despite BMI and adiposity present a certain degree of correlation, it is only moderate in morbidly obese patients before undergoing bariatric surgery and slightly increases in postoperative determinations. The

effectiveness of bariatric surgery is not just limited to the reduction of body adiposity, but, when achieving it, the risk of suffering a cardiovascular event is also reduced [27].

Framingham Score and Castelli Index

In our medium, there are two indices, predictive of cardiovascular risk: Triglycerids/HDL-cholesterol (TG/HDL) ratio (Castelli Index) and the Framingham score, which analyzes age, gender, total cholesterol, HDL-cholesterol, tobacco habit and systolic arterial pressure. It has been considered that Framingham score is the most accurate method to calculate the cardiovascular risk, but its application is more complex than other scores [27]. Therefore, the TG/HDL index is preferred by many clinicians, as it can be numerically quantified and is not expressed as the probability of suffering a cardiovascular event, like the Framingham score. Diverse studies have shown that a TG/HDL index >3 is associated with increased cardiovascular risk. A previous study of our group has demonstrated that TG/HDL index correlates with the adiposity grade before and after bariatric surgery, but it does not correlate with BMI at any state. This reflects that both, adiposity and TG/HDL index, are better predictors of cardiovascular risk than BMI [4, 28, 29].

Serum Cortisol

Cortisol plays a role in the adiposity and finally in obesity development. Circulating serum levels of cortisol are higher among obese subjects with or without metabolic syndrome, than in lean ones. Cortisol induces the differentiation and proliferation of human adipocytes and their receptors are more profuse in the visceral adipose tissue than in the subcutaneous one. Moreover, cortisol contributes to the distribution of the fat from the peripherical depots to the central ones; it activates lipolysis and the release of free fatty acids to the blood circulation, increasing the risk of ateromatosis and consequently, the cardiovascular risk.

Weight loss reduces the serum cortisol levels down to normal ranges. According to this, cortisol levels might be considered as reflection of cardiovascular disease. Previous studies of our group demonstrated that the decrease in the adiposity directly correlates with the reduction in the cortisol levels. From the 6th month, the decrease in serum cortisol correlates with a reduction in the cardiovascular risk [2, 4, 30, 31]. All these data confirm the hypothesis that cortisol is an accurate predictor of cardiovascular risk in morbidly obese patients undergoing bariatric surgery.

Vitamin D

In the last decade, actions of vitamin D different than those related with the bone metabolism, have been discovered. These actions have been denominated as non-calcemic actions. These findings demonstrate that vitamin D has diverse functions, corresponding to a hormone rather than an inert vitamin [32, 33].

Deficiencies in vitamin D in obese patients are associated with metabolic syndrome and disorders in lipid levels (cholesterol and triglycerids). This suggests that vitamin D is a

modifiable factor amenable for correction, which may imply a benefit in the cardiovascular risk of these patients [30].

Vitamin D stores mostly in the adipose tissue in obese patients, leading often to a secondary hyperparathyroidism. As they lose weight, the serum values of vitamin D increase. This explains the inverse correlation between the adiposity reduction and the increase of plasmatic levels of vitamin D after bariatric surgery [30].

REFERENCES

[1] Encinosa, WE; Bernard, DM; Du, D; Steiner, CA. Recent improvements in bariatric surgery outcomes. *Med Care*, 2009, 47, 531-5.

[2] Ruiz-Tovar, J; Oller, I; Tomas, A; et al. Midterm impact of sleeve gastrectomy, calibrated with a 50-Fr bougie, on weight loss, glucose hemostasis, lipid profiles and comorbidities in morbidly obese patients. *Am Surg*, 2012, 78, 969-74.

[3] Schauer, PR; Kashyap, SR; Wolski, K; et al. Bariatric surgery versus intensive medical therapy in obese patients with diabetes. *N Engl J Med*, 2012, 366, 1567-76.

[4] Zubiaga, L; Ruiz-Tovar, J; Diez-Tabernilla, M; et al. Fórmula CUN-BAE y factores bioquímicos como marcadores predictivos de obesidad y enfermedad cardiovascular en pacientes pre y post gastrectomía vertical. *Nutr Hosp*, 2014, 30, 281-6.

[5] Rubino, F. Is type 2 diabetes an operable intestinal disease? A provocative yet reasonable hypothesis. *Diabetes Care*, 2008, 31, Suppl 2, S290-6.

[6] Schauer, PR; Kashyap, SR; Wolski, K; et al. Bariatric surgery versus intensive medical therapy in obese patients with diabetes. *N Engl J Med*, 2012, 366, 1567-76.

[7] Mingrone, G; Panunzi, S; De Gaetano, A; et al. Bariatric surgery versus conventional medical therapy for type 2 diabetes. *N Engl J Med*, 2012, 366, 1577-85.

[8] Ikramuddin, S; Korner, J; Lee, WJ; et al. Roux-en-Y gastric bypass vs intensive medical management for the control of type 2 diabetes, hypertension, and hyperlipidemia: the Diabetes Surgery Study randomized clinical trial. *JAMA*, 2013, 309, 2240-9.

[9] Rubino, F; Kaplan, LM; Schauer, PR; et al. The Diabetes Surgery Summit consensus conference: recommendations for the evaluation and use of gastrointestinal surgery to treat type 2 diabetes mellitus. *Ann Surg*, 2010, 251, 399-405.

[10] Kenngott, HG; Clemens, G; Gondan, M; et al. DiaSurg 2 trial - surgical vs. medical treatment of insulin-dependent type 2 diabetes mellitus in patients with a body mass index between 26 and 35 kg/m2: study protocol of a randomized controlled multicenter trial - DRKS00004550. *Trials*, 2013, 14, 183.

[11] Hutter, MM; Schirmer, BD; Jones, DB; et al. First report from the American College of Surgeons Bariatric Surgery Center Network: laparoscopic sleeve gastrectomy has morbidity and effectiveness positioned between the band and the bypass. *Ann Surg*, 2011, 254, 410-20.

[12] Dixon, JB; O'Brien, PE; Playfair, J; et al. Adjustable gastric banding and conventional therapy for type 2 diabetes: a randomized controlled trial. *JAMA*, 2008, 299, 316-23.

[13] Ahn, SM; Pomp, A; Rubino, F. Metabolic surgery for type 2 diabetes. *Ann N Y Acad Sci*, 2010, 1212, E37-45.

[14] Müller-Stich, BP; Fischer, L; Kenngott, HG; et al. Gastric bypass leads to improvement of diabetic neuropathy independent of glucose normalization--results of a prospective cohort study (DiaSurg 1 study). *Ann Surg*, 2013, 258, 760-5.

[15] Ikramuddin, S; Korner, J; Lee, WJ; et al. Roux-en-Y gastric bypass vs intensive medical management for the control of type 2 diabetes, hypertension, and hyperlipidemia: the Diabetes Surgery Study randomized clinical trial. *JAMA*, 2013, 309, 2240-9.

[16] Zhang, N; Maffei, A; Cerabona, T; et al. Reduction in obesity-related comorbidities: is gastric bypass better than sleeve gastrectomy? *Surg Endosc*, 2013, 27, 1273-80.

[17] Anderson, KM; Castelli, WP; Levy, D. Cholesterol and mortality. 30 years of follow-up from the Framingham study. *JAMA*, 1987, 257, 2176-80.

[18] Joshi, AV; Day, D; Lubowski, TJ; Ambegaonkar, A. Relationship between obesity and cardiovascular risk factors: findings from a multi-state screening project in the United States. *Curr Med Res Opin*, 2005, 21, 1755-61.

[19] Nguyen, NT; Varela, E; Sabio, A; et al. Resolution of hyperlipidemia after laparoscopic Roux-en-Y gastric bypass. *J Am Coll Surg*, 2006, 203, 24-9.

[20] Frühbeck, G; Diez-Caballero, A; Gómez-Ambrosi, J; et al. Preventing obesity. Doctors underestimate obesity. *BMJ*, 2003, 326, 102-3.

[21] Frühbeck, G. Screening and interventions for obesity in adults. *Ann Intern Med*, 2004, 141, 245-6.

[22] Gómez-Ambrosi, J; Silva, C; Catalán, V; et al. Clinical usefulness of a new equation for estimating body fat. *Diabetes Care*, 2012, 2, 383-8.

[23] Catalán, V; Gómez-Ambrosi, J; Ramírez, B; et al. Proinflammatory cytokines in obesity: impact of type 2 diabetes mellitus and gastric bypass. *Obes Surg*, 2007, 17, 1464-74.

[24] Catalán, V; Gómez-Ambrosi, J; Rodríguez, A; et al. Increased circulating and visceral adipose tissue expression levels of YKL-40 in obesity-associated type 2 diabetes are related to inflammation: impact of conventional weight loss and gastric bypass. *J Clin Endocrinol Metab*, 2011, 96, 200-9.

[25] Flegal, KM; Shepherd, JA; Looker, AC; et al. Comparisons of percentage body fat, body mass index, waist circumference, and waist-stature ratio in adults. *Am J Clin Nutr*, 2009, 89, 500-8.

[26] Basterra, FJ; Bes, M; Segui, M; Forga, L; Martínez, JA; Martínez, MA. Tendencias de la obesidad, diabetes mellitus, hipertensión e hipercolesterolemia en España, 1997-2003. *Med Clin (Barc)*, 2007, 129, 405-8.

[27] Fields, DA; Goran, MI; McCrory, MA. Body-composition assessment via air-displacement plethysmography in adults and children: A review. *Am J Clin Nutr*, 2002, 75, 453-67.

[28] Carbajo, MA; Castro, MJ; Kleinfinger, S; et al. Effects of a balanced energy and high protein formula diet (Vegestart complet®) *vs.* low-calorie regular diet in morbid obese patients prior to bariatric surgery (laparoscopic single anastomosis gastric bypass): A prospective, double-blind randomized study. *Nutr Hosp*, 2010, 25 (6), 939-48.

[29] O'Donnela, C; Elosuab, R. Factores de riesgo cardiovascular. Perspectivas derivadas del Framingham Heart Study. *Rev Esp Cardiol*, 2008, 61, 299-310.

[30] Ruiz-Tovar, J; Oller, I; Galindo, I; et al. Change in Levels of C-Reactive Protein (CRP) and Serum Cortisol in Morbidly Obese Patients After Laparoscopic Sleeve Gastrectomy. *Obes Surg*, 2013, 23, 764-9.

[31] Frankenfield, DC; Rowe, WA; Cooney, RN; et al. Limits of body mass index to detect obesity and predict body composition. *Nutrition*, 2001, 17, 26-30.

[32] Clare-Grace, PD; Vincent, R; Aylwin, SJ. High prevalence of vitamin D insufficiency in a United Kingdom urban morbidly obese population: implications for testing and treatment. *Surg Obes Relat Dis*, 2013, 29. pii:S1550-7289(13)00257-8.

[33] Ruiz-Tovar, J; Oller, I; Tomas, A; et al. Mid-term effects of sleeve gastrectomy on calcium metabolism parameters. Vitamin D and parathormone (PTH) in morbid obese women. *Obes Surg*, 2012, 22 (5), 797-801.

In: Encyclopedia of Surgery (22 Volume Set)
Editors: Andreas Lehrer and Kristin Mueller
ISBN: 978-1-53618-329-0
© 2020 Nova Science Publishers, Inc.

Chapter 449

THE EFFECTS OF EXERCISE PROGRAMS ON CARDIOVASCULAR RISK FACTORS IN PATIENTS UNDERGOING BARIATRIC SURGERY

Artur Marc Hernández[1], PhD and Jaime Ruiz-Tovar[2], MD, PhD
[1]Laboratory of Training Analysis and Optimization. Sports Research Center. Miguel Hernández University, Elche, Alicante, Spain
[2]Department of Surgery, University Hospital Rey Juan Carlos, Mostoles, Madrid, Spain

ABSTRACT

In recent decades, obesity levels have increased worldwide, increasing the prevalence of morbid obesity. This type of obesity is associated with a large number of comorbidities that increase the mortality risk of the patients who suffer it. Therefore, it is necessary to apply a treatment to this type of population. Bariatric surgery has proven to be an effective method, generating large weight reductions and improving cardiovascular risk factors, thus increasing the life expectancy of patients who undergo it. However, this surgery has certain disadvantages. On the one hand, some factors, such as total weight, comorbidities associated with obesity or low cardiorespiratory fitness, are associated with a greater number of surgical complications and a higher rate of intra and postoperative mortality. On the other hand, one of the most common problems after surgery is the weight regain, which is associated with a relapse in different comorbidities, such as diabetes mellitus.

Physical activity has been proved to be an effective tool for reducing total weight and improving cardiovascular risk factors and cardiorespiratory fitness, which can reduce the incidence of these surgical complications. In addition, the performance of physical activity after surgery enhances its effects, generating greater reductions in total weight and cardiovascular risk factors. Furthermore, physical activity has shown to be a factor of great importance for weight maintenance, and, therefore, can be a key point to avoid recurrences in different comorbidities. Although cardiorespiratory exercise at low and moderate intensities has been classically recommended for weight loss, this trend is currently changing. In recent years, several studies have determined that performing exercise at high intensities, adding resistance training to an exercise program, generates greater losses of fat mass and reductions in cardiovascular risk factors compared to traditional recommendations.

1. INTRODUCTION

Definition of Obesity, Resting Metabolic Rate and Body Tissues

Obesity is defined as an excess of fat mass that is associated with high risks for health [1]. This excess of fat mass occurs due to a prolonged state under a positive energy balance, that is, when energy intake is greater than daily energy expenditure. There are 3 components that will determine this daily energy expenditure [2]:

1. *Thermic effect of feeding*: this concept refers to the energy expenditure that is produced by the ingestion of food. It is the energy consumed in digesting, absorbing, using and storing nutrients [3]. This energy cost is different for each macronutrient, being very low for fats (0-3%), medium for carbohydrates (5-10%) and higher for proteins (20-30%) (4). It contributes around 10% to the daily energy expenditure [2].
2. *Thermic effect of activity*: refers to the energy consumed due to physical activity (PA), therefore, it is a factor that varies greatly depending on individuals. It is especially important, because it is directly related to the activity performed, hence it has influence the basal metabolic rate (RMR). For example, PA can increase the FFM, in this way generates an increase in the RMR [5]. It has been reported that this component contributes between 15-30% to daily energy expenditure [2].
3. *Resting metabolic rate*: is the energy consumed by the body for maintaining physiological functions (body temperature, breathing, and other vital functions). It can be a key factor in controlling obesity, since it is the component that contributes the most to daily energy expenditure (60-75%) [2]. It is mainly determined by the FFM [6].

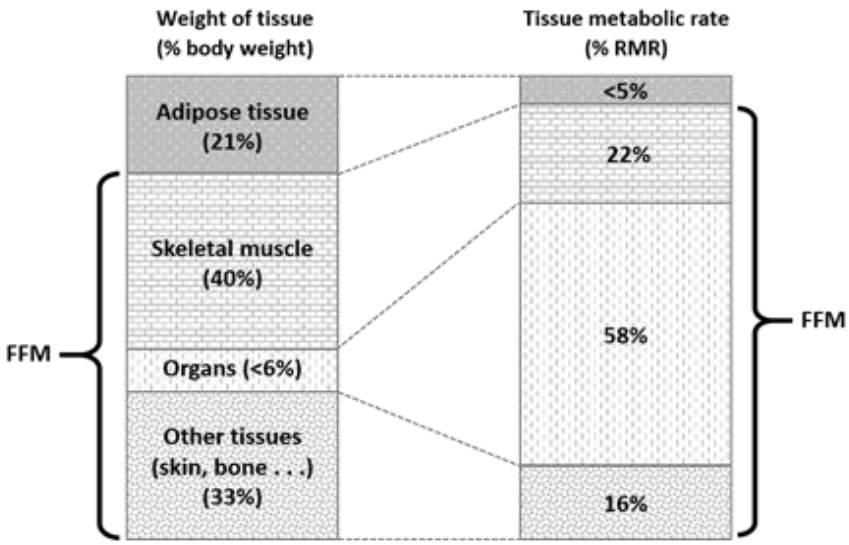

Abbreviations: RMR, resting metabolic rate; FFM, fat free mass.

Figure 1. Distribution of body tissues and contribution of each tissue to the resting metabolic rate. Adapted from Dullo et al. [11].

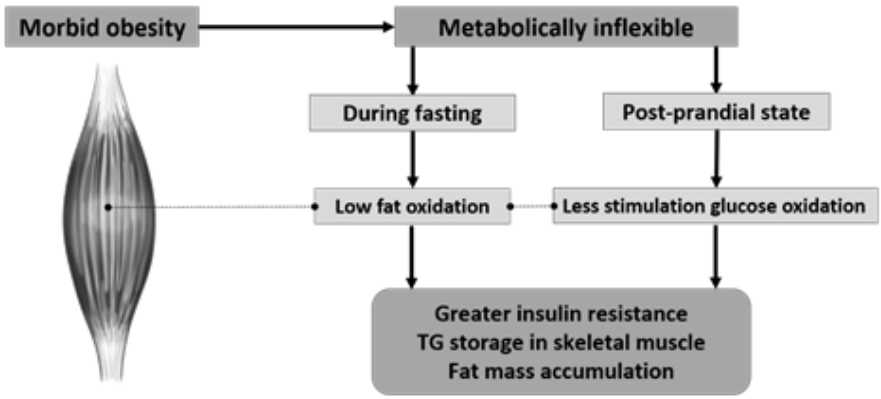

Figure 2. Skeletal muscle metabolism in patients with morbid obesity. Adapted of kelley et al. [229].

The body is integrated of different tissues. It is distinguished between adipose tissue and fat-free mass, which is composed by organs, other tissues such as skin or bones, and skeletal muscle (Figure 1). The latter is of great importance, and in recent decades has been recognized as a powerful endocrine organ [7, 8]. Among other aspects, skeletal muscle is responsible for eliminating approximately 75% of glucose after meal [9], and has an important storage function, since 80% of the body's glycogen is stored in it [10]. On the other hand, it consumes a large amount of energy at rest, about 22% of the RMR [11], which comes mainly from the oxidation of fatty acids [12]. However, in obese patients, especially in subjects with morbid obesity, it has been seen that those functions are damaged, and they are metabolically inflexible. That is, during fasting they have a low capacity to fat oxidation, which can be 58% lower than in lean subjects [13], and in a postprandial state have a lower oxidation of glucose. This will cause greater insulin resistance, storage of triglycerides in the muscle and accumulation of fat mass (Figure 2) [9, 14].

Obesity Prevalence

Progress has led to changes in society that have generated an obesogenic environment. On the one hand, the mechanization of industries and the emergence of computers have contributed to a decrease in PA at work, and an increase in sedentary jobs [15]. In addition, new forms of leisure and transportation have appeared, which are more sedentary, such as the television or the use of the car. All this causes that the levels of PA of the population have greatly decreased. For example, in the United States, PA levels decreased from 235.2 MET-hours/week in 1965 to 159.5 MET-hours/week in 2009 [16]. On the other hand, economic development and global trade liberalization have provoked changes in dietary patterns [17], where the "Western diet" has been imposed, which is a type of diet characterized by high intake of fat, added sugars, refined carbohydrates and animal-source foods [18]. In addition, energy intake in the world has increased from 2358 Kcal/day/capita to 2803 Kcal/day/capita between 1964 and 1999 [19].

These factors have led to the fact that, in recent decades, obesity levels have increased greatly in all regions of the world [20, 21].

From 572 million people with overweight or obesity in 1980, it has been estimated an increase to 1.46 billion in 2008, of which 508 million were obese [22]. While other studies concluded that in 2015 there were 603.7 million people with obesity [23]. And the forecasts are not positive, if the trend continues, it is estimated that in the year 2030, 57.8% of the world population will suffer from obesity or overweight, and 19.7% will be obese [24].

However, the problem is even greater, since levels of morbid obesity (Body Mass Index (BMI) ≥40 $kg \cdot m^{-2}$) are also increasing acutely. Different countries show relative raises in morbid obesity of between 33-200% [25–27]. For instance, in Australia, morbid obesity increased from 1.4% to 3.1% between 1995 and 2012 [28], in Canada, it increased from 0.3% registered in 1985 to 1.6% in 2011 [29], while in the United States this increase was from 0.9% to 3.5% between 1990 and 2008 [30]. It is estimated that, if this trend continues, morbid obesity will affect 6% of men and 9% of women of the world's population in the year 2025 [31].

These high levels of obesity generate great health risks. It has been widely reported that excess weight is a determining factor in the development of type 2 diabetes mellitus [32], hypertension [33], hyperlipidemia [34] and cardiovascular risk [35]. Particularly, above all, this risk is greater with a higher BMI. Subjects with a BMI greater than 35 $kg \cdot m^{-2}$ have a risk 42.1 times higher than subjects with a normal weight [36]. Furthermore, 51.3% of subjects with morbid obesity suffer from hypertension, meanwhile 62.5% suffer from dyslipidemia [34]. All these factors contribute to the fact that obesity is directly associated with mortality (Figure 3) [37, 38]. Indeed, a high BMI caused 4 million deaths worldwide in 2015, of which, about 70% were due to cardiovascular disease [23]. In addition, the risk of mortality increases with the BMI, with a hazard ratio of 1.45 for class I obesity and 2.76 for class III obesity [39].

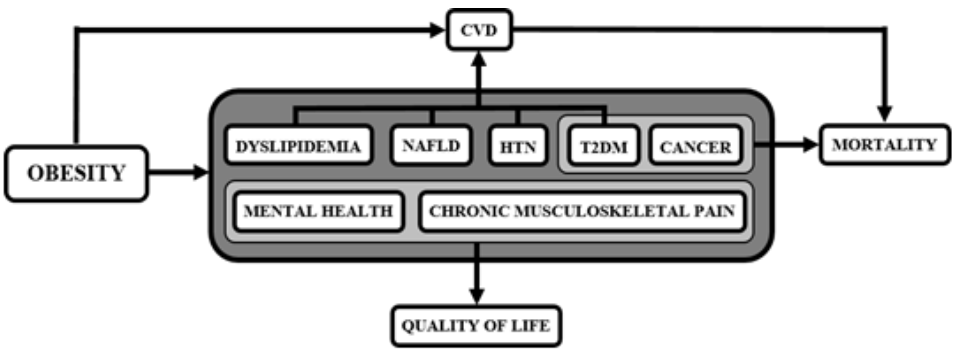

Abbreviations: CVD, cardiovascular disease; NAFLD, nonalcoholic fatty liver disease; HTN, hypertension; T2DM, type 2 diabetes mellitus.

Figure 3. Most common health consequences caused by obesity.

These aspects show the need to reduce the obesity levels of the population. Normally, through of the use of drugs, diet and PA, reductions in the body weight of obese patients are achieved [40]. But in extreme cases, such as morbid obesity, sometimes these methods are not enough [41], and an effective alternative is bariatric surgery (BS).

Bariatric Surgery

Bariatric surgery is a surgical procedure that consists of a reduction in the capacity of food intake (intragastric balloon, vertical banded gastroplasty etc.), a decrease in the absorption capacity of nutrients (biliopancreatic diversion), or well, in a combination of both (gastric bypass) [42, 43]. This surgery is performed on individuals with a BMI ≥ 40 $kg \cdot m^{-2}$ or whit a BMI ≥ 35 $kg \cdot m^{-2}$ associated with some comorbidity, such as diabetes, hypertension or obstructive sleep apnea (OSA) [44].

The first surgery was performed in Sweden in 1952, by Viktor Henrikson, and it was malabsorptive type [45]. This was followed by a process of development of the surgery, giving rise to the first mixed surgery (gastric bypass) in 1966, and to the first restrictive surgery in 1971, both performed by Edward E. Mason [46]. From this point, BS has evolved, until now it is considered one of the most effective treatments for morbid obesity [47]. In fact, in recent decades, the number of surgeries has increased in parallel with the increase of morbid obesity. In only 16 years (between 1997-2013) the number of surgeries has raised from 40,000 to 468,609 worldwide (Figure 4) [47]. Currently, of all these surgeries performed, the most frequently performed surgical techniques are sleeve gastrectomy and gastric bypass [47], the latter being considered the gold standard of surgery for obesity [48].

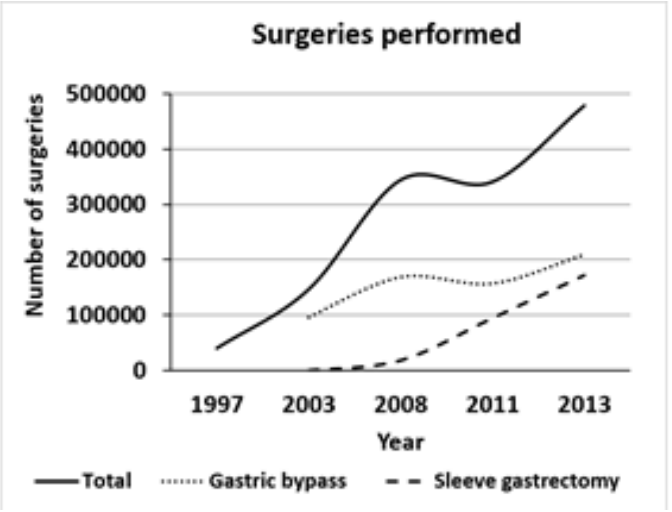

Figure 4. Evolution bariatric surgery.

Sarcopenic Obesity

Sarcopenic obesity refers to a disproportion between the amount of lean mass and fat mass, in which the fat mass exceeds the weight that lean mass could support [49]. It has a multifactorial origin. On the one hand, sarcopenic obesity is reached when the total weight is increased at the expense of an increase in fat mass. On the other hand, it is reached when, for example, subjects with morbid obesity lose a large amount of weight, with a large decrease in FFM, but they are still obese subjects [50], which is common in bariatric patients.

This sarcopenic obesity causes certain disadvantages. On the one hand, subjects with sarcopenic obesity may have impaired functional capacity [49]. On the other hand, the loss of FFM can lead to a decrease in the RMR, and therefore, induce an increase in fat mass [51]. Last, sarcopenic obesity influences in the cardiometabolic health of the patients. Subjects suffering from sarcopenic obesity have higher levels of blood pressure and greater insulin resistance than subjects with obesity or sarcopenia, as well as an increased risk of developing diabetes mellitus [52, 53]. As a result of all this, sarcopenic obesity increases the risk of suffering cardiovascular disease and mortality risk, which is higher compared to subjects who are only obese or sarcopenic [52, 54, 55].

2. Exercise before Bariatric Surgery

Cardiovascular Risk Factors and Operative Complications

Normally, patients who are waiting for BS usually suffer from different comorbidities. Among others, it has been reported that 34-54.9% suffer from hypertension, 22-44.8% of OSA, 18-33.7% have type 2 diabetes mellitus and 7.4-50.2% of dyslipidemia [56–58]. On the one hand, this comorbidities such as hypertension, diabetes and hyperlipidemia are associated with mortality at 30 days after surgery [59–61]. On the other hand, these contribute to increase the risk of suffering post-operative complications. In a recent study, it is shown that 48% of patients who suffered postoperative complications had hypertension, and 30% had dyslipidemia [62]. In addition, hypertension and hyperlipidemia are shown as predictors of postoperative complications [62]. While in other studies, it is noticed that 52.9% of patients with diabetes and 57.6% of patients with OSA suffered moderate complications after surgery [63]. In turn, the preoperative weight is also a predictor of mortality and complications of surgery [61, 64], showing a greater risk of mortality with an increase in body mass index [65].

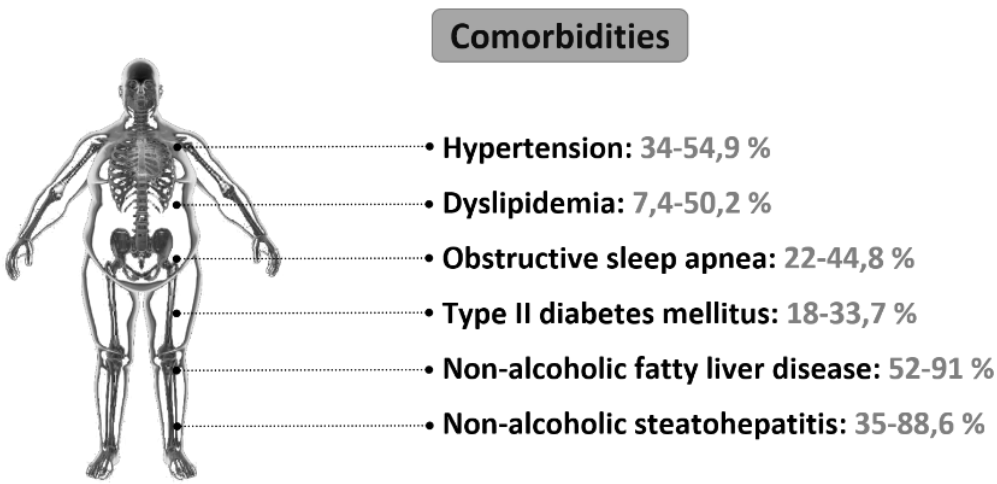

Figure 5. Percentage of subjects with specific comorbidities in patients waiting for bariatric surgery.

Along with this, it has been reported that between 52% and 91% of patients awaiting BS have non-alcoholic fatty liver disease, while between 35% and 88.6% suffer from non-alcoholic steatohepatitis [66–70]. These liver diseases, together with high levels of visceral fat can cause certain disadvantages and complicate the surgical process. On the one hand, deposits of fat tissue in the liver turn it into a more fragile organ. Which increases the risk of injury and hemorrhage due to surgical manipulation [71, 72]. On the other hand, a greater hepatic volume, especially a greater volume of the left liver lobe, difficult the approach to the gastroesophageal junction and the visualization of top portion of the stomach and the retroesophageal area [71, 73]. In fact, in gastric bypass, a larger size of the liver has been shown to be the main responsible for the conversion of laparoscopy to open surgery in 48% of cases, while steatohepatitis is a predictor of this conversion [74, 75].

In addition to comorbidities, the functional status of patients also contributes to an increased risk of morbidity/mortality, showing that subjects who are dependent or partially dependent have a greater risk of suffering complications in the surgical process [59, 76–78]. This suggests that physical fitness level at the time of the operation may be relevant, although unfortunately, there are few data on this subject in bariatric patients. In mixed intra-abdominal surgical procedures, it has been shown that an anaerobic threshold <11 $ml \cdot kg^{-1} \cdot min^{-1}$ show a cardiovascular mortality ratio of 18%, however, when the anaerobic threshold is ≥11 $ml \cdot kg^{-1} \cdot min^{-1}$, the mortality ratio decrease until 0.8% [79]. Furthermore, an anaerobic threshold <10.1 $ml \cdot kg^{-1} \cdot min^{-1}$ predicts the number of complications [80]. In bariatric surgery, one study reported that patients with a greater number of complications, and a longer hospital stay, have a lower anaerobic threshold (with a mean of 9.9 $ml \cdot kg^{-1} \cdot min^{-1}$) [81]. While in another study, it was concluded that patients with a peak oxygen consumption of less than 15.8 $ml \cdot kg^{-1} \cdot min^{-1}$ had a greater risk of suffering post-operative complications [82].

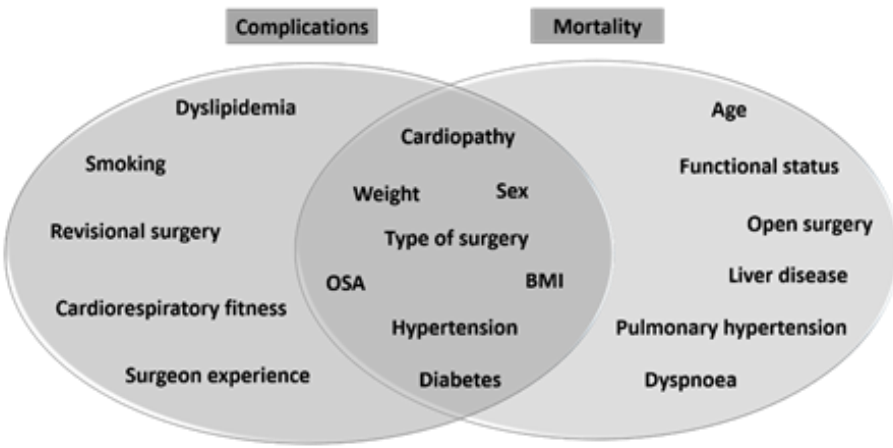

Figure 6. Factors that influence in the complications and in mortality of bariatric surgery.

All of these comorbidities associated with morbid obesity increase the risk of suffering complications, in fact, their effects are added up, since it has been shown that the greater the number of morbidities in a patient, the greater the risk of mortality [76, 77]. Consequently, surgery is not risk-free. In a meta-analysis conducted in 2014 that included 16,156 patients undergoing BS, complications were found in 17% of the surgeries performed, being 13% for

sleeve gastrectomy, and 21% for gastric bypass [83]. This same study showed a perioperative mortality rate of 0.08% and a postoperative mortality of 0.31% [83].

To sum up, patients awaiting BS are associated with a high number of comorbidities. This, together with a very high weight, an inadequate functional status and a low physical condition, increase the risk of mortality and of suffering intra and postoperative complications. In addition, aspects such as a large liver size, a fatty liver, and a large amount of visceral fat, hinder the surgical process. Therefore, strategies must be pursue to maximize weight loss, reduce the number of comorbidities and increase the physical fitness in patients awaiting BS. The achievement of these objectives could increase the safety of patients and facilitate surgery. Both factors would allow to reduce the number of intra and postoperative complications, and reduce the time of the operation and the stay at the hospital, thus reducing the costs associated with the BS.

Usual Care before Surgery

Normally, in order to decrease these comorbidities associated with obesity and, thereby, decline the number of complications and the operative mortality rate, it is recommended to reduce the weight prior to surgery. This can have great advantages. On the one hand, it can reduce liver size between 5.3-18.7%, between 25.5-40% of the fat tissue deposited in the liver and approximately 17% of visceral fat [71, 84–86]. This can lead to a decrease in the duration of surgery [48, 73, 87], the number of intra and postoperative complications [48, 87–90] and generate a shorter hospital stay after surgery [87]. For this reason, many centers use restrictive or very restrictive diets in a period between 2-6 weeks prior to surgery. However, highly restrictive diets may cause the body shift into a catabolic state, producing that, a great part of the weight loss may be due to the loss of FFM, which can be approximately 40% of it [91]. This loss of FFM can lead to sarcopenic obesity [50], a state linked to a low functional capacity [51], a reduced RMR [92, 93] and an increase in insulin resistance [53]. Therefore, strategies should be applied that are able to provoke fat mass loss, maintenance FFM and generate a reduction in the comorbidities associated with obesity. Exercise can be an effective tool for this surgery.

It has been widely demonstrated that the addition of an exercise program to a nutritional intervention generates greater reductions in weight, fat mass and visceral fat compared to use a nutritional intervention in isolation [94–97], avoiding also FFM loss [96, 98]. Similarly, exercise by itself has shown to be effective both in achieving reductions in both visceral fat and fat deposited in the liver [97, 99, 100], aspects that, as we have seen, could facilitate the surgical process. At the same time, the implementation of an exercise program has been reported to be useful in achieving reductions in blood pressure, diabetes and waist circumference levels [101–103], as well as improvements in OSA [104, 105], which, could help to reduce the risk of suffering intra and postoperative complications. While, in turn, exercise is one of the most effective methods to obtain improvements in the functional capacity and cardiorespiratory fitness of individuals, which, as we have seen, are powerful predictors of surgical risk.

Physical Activity Levels in Patients Awaiting Bariatric Surgery

Despite the benefits that PA entails, patients awaiting BS show very low levels. Some studies have reported that 90% of patients are sedentary [106], while in others it is shown that candidates for bariatric surgery spend approximately 80% of the time in sedentary behaviors [107]. In fact, if you compare the levels of PA between subjects with a normal weight, and patients waiting for surgery, it is observed that only ~13% of the subjects in a normal weight do not perform moderate or vigorous PA, while this figure rises to ~68% in patients awaiting BS [108].

Therefore, it can be considered that very few of the patients have a healthy lifestyle. Studies have shown that only 4.5% of patients awaiting surgery meet the weekly recommendations for PA (≥150 min/week). Although other studies report higher percentages, only 20% of the candidates are considered active or very active (109), or perform some type of PA [110]. However, of this PA that is performed, the one that is carried out largely is walking, between 44% and 95% of the total time allocated to the activity, followed by other activities such as gardening or playing with children [109, 111]. These activities do not include resistance training, and are made at low intensities. So, we should ask ourselves if the PA that bariatric patients perform is adequate to generate fat mass losses and health benefits.

Exercise in Patients Awaiting Bariatric Surgery

Unfortunately, currently, there is a few research in which the effects of exercise have been studied in patients awaiting BS. Most studies in which an exercise program has been applied, have shown reductions in the total weight of the subjects who participated. On the one and, a resistance training generates reductions of between 1.41-7.5% total weight, from 5.3-12.5% fat mass and between 3.86-7.8% waist circumference [112–115]. On the other hand, the realization of an exercise program that combines aerobic and resistance training, of 8 or 12 weeks duration, has shown to achieve reductions of weight, fat mass and visceral fat, with a maintenance of fat-free mass [116, 117]. In turn, a training program that included only aerobic exercise at low intensities also generated reductions in the total weight of the patients [118]. Besides, one aspect of great importance that many of the studies have in common is that there is an improvement in physical fitness, especially in the cardiorespiratory fitness [112, 114–117, 119, 120].

If the number of studies in patients awaiting BS is low, the quantity of studies examining the effects of exercise on cardiovascular risk factors (CVRF) in this population is still lower. However, in these studies there is a trend of exercise to improve CVRF. For example, a resistance training after surgery, that consisted of 3 series per exercise of 60 seconds to muscle failure, performed 3 times a week for 12 or 16 weeks, generated reductions in blood glucose of ~10% [114, 115], and showed a tendency to decrease the levels of total cholesterol (8.1%), LDL (-6.3%) and TG (-7.6%) [112].

Aerobic training has also proven to be an effective tool. In a 6-month study, patients were given a supervised training session a week in which 30 minutes of low-intensity aerobic exercise was performed and they were encouraged to do this in their homes. The results of this study showed reductions in total cholesterol, LDL cholesterol, triglycerides, blood glucose and blood pressure, resulting a great reduction of the CVR (-4.4 units) [118]. In

another study, a program of PA focused on AT, 2 days per week for 4 months, was added to the usual care, besides subjects were encouraged to increase the number of steps walked every day. This patients had reductions in CVRF, which caused a decrease in cardiovascular risk (-3.4 units), while the control group did not show any improvement. On the contrary, it had an increase in blood glucose and triglycerides [120]. In addition, shorter training programs can also generate certain benefits. By only 7 days performing a 60 minutes of aerobic training at 65% of maximum oxygen consumption has been reduced fasting insulin concentrations and the insulin area under the curve during the oral glucose tolerance test, what indicates that there has been an improvement in the action of insulin [121].

Although there are few studies in the literature, these studies show potential benefits in patients who perform exercise before surgery. On the one hand, exercise causes reductions in weight and in comorbidities associated with obesity, while it increases in cardiorespiratory fitness, which could greatly help to reduce operative complications and hospital stay after BS. On the other hand, decreases in waist circumference indicate that visceral fat is also being reduced, thus facilitating the surgical process. Therefore, the health system should seriously consider the inclusion of exercise programs prior to surgery.

3. EXERCISE IN PATIENTS UNDERGOING BARIATRIC SURGERY (SHORT-TERM)

Benefits and Disadvantages of Bariatric Surgery in the Short-Term

It has been widely argued that BS generates great benefits. In the short-term, BS causes large weight losses, causing reductions of between 20-35 kg three months after the intervention [122–124], and between approximately 35-50 kg a year after surgery, reducing to a great extent fat mass [125–127], and visceral fat [128]. Furthermore, after BS, decreases in liver volume and fatty liver levels are also generated [129, 130]. Along with this, improvements in CVRF have also been widely reported, such as decreases in resting blood pressure, glycosylated hemoglobin, LDL cholesterol, and increases in HDL cholesterol [131–133]. The results of a meta-analysis covering more than 22,000 patients showed complete remissions in 76.8% of diabetic subjects, of 61.7% of hypertensive patients, of 85.7% of patients with OSA, and a reduction of hyperlipidemia in 70% of patients [134]. All this will reduce the risk of heart disease [135, 136]. But not only physiological improvements are achieved, psychological improvements are also generated, such as increases in mental health, increased self-esteem or a decrease in depression levels [137, 138].

However, BS has, in the short-term, some disadvantages. After surgery, especially when it is malabsorptive, there is a deficiency of certain micronutrients. After gastric bypass, iron deficits have been reported in 49% of patients, of vitamin B12 in 70%, of calcium in 10%, and of Vitamin D in 50%, as well as decreases in bone mineral density [139, 140]. However, in this chapter, greater emphasis will be placed on the FFM losses. Many studies show reductions of around 10 kg of fat-free mass a year after surgery [125, 127, 141–144]. These reductions in fat-free mass can cause, among other factors, a greater insulin resistance, a decrease in the RMR and favor the accumulation of fat mass [51]. In fact, a low RMR has

been associated with weight regain in bariatric patients [145–147], which is one of the most common problems in this population, as it will be seen later [110, 148–150].

Physical Activity Levels in Patients Undergoing Bariatric Surgery in the Short-Term

As seen above, most patients awaiting BS have a sedentary behavior. However, it has been widely reported that in the short-term after BS, patients increase their PA levels [151–155]. In some studies it has been shown that the percentage of patients who did not perform any PA decreased from 37.4% to 7.6% a year after surgery [156]. Other studies have reported increases between 1225 and 2749 steps/day a year after surgery [155, 157], increasing from 30% to 46% of subjects who performed at least 150 minutes of PA per week [157]. The most frequently activity performed after surgery is walking, 54.7% of patients, while only 12.7% report performing weight lifting [157]. This, as it will be seen later, may be of great importance in weight loss and the reduction of comorbidities after surgery. However, in the same way as before surgery, subjects perform little strength training, and the intensity that can be reached walking may not report the best benefits.

Exercise in Patients Undergoing Bariatric Surgery in the Short-Term

As we have seen, after surgery, a series of disadvantages are generated, which could be minimized or even avoided by performing structured exercise appropriately. Unfortunately, there are currently few studies on this, and most of them are observational studies. These studies show greater reductions in weight in subjects who perform PA after surgery [158–160], noting that only 150 minutes per week of moderate or intense PA per week are sufficient to generate greater weight losses [161]. In addition, both higher volumes and higher PA intensities performed after bariatric surgery are associated with greater weight losses [162]. However, in the short term after surgery, the important issue is not weight loss, since both patients who perform exercise and those who do not it, have large reductions in total weight. This point should focus on the FFM, although the availability of studies on this is still scarcer, since few studies analyze the effects of exercise on body composition after surgery. They have found that a greater increase in leisure time PA, was directly associated with a smaller decrease in fat-free mass [153]. While another reported that only the completion of 30 minutes 3 or more times per week showed to be effective to increase the FFM [163]. Here the volume also seems to be important, since it has been shown that the subjects who increased their steps/day more after surgery obtained skeletal muscle maintenance [164].

However, nowadays, some research has emerged on this subject. These studies show that patients who participate in a post-surgery exercise program avoid or reduce the FFM loss [165–168], although occasionally, the difference between experimental group and control group is not significant [169, 170]. In most of these studies there is only one intervention group in which an exercise program is applied, therefore, it is not established what type of exercise can be more effective after surgery. Nevertheless, one study compared a control group and two experimental groups, one of them performed only aerobic training, and the other combined aerobic and resistance training. The results showed that the group that

included resistance training was the one that lost the least FFM, meanwhile the control group had the greatest reduction [168]. Therefore, although volumes and intensities are still to be determined, it seems that resistance training can be a determining factor in the maintenance of the FFM.

Avoiding the loss of FFM can be of great importance, both in the short and long term. On the one hand, as we have seen previously, the FFM (specifically the skeletal muscle) plays a fundamental role in the organism, so its maintenance could generate additional benefits to the surgery in the cardiometabolic profile of the patients, as well as a greater functional capacity. On the other hand, maintaining the FFM could prevent or minimize the reduction of RMR that is generated after surgery [171], and it has been associated with certain long-term problems, such as weight recovery [172, 173].

Although, after surgery there is an improvement in functional capacity (evaluated by the 6-minute walk test) [174], this is not the case when aerobic capacity is measured by oxygen consumption. It can be observed that in the studies that analyze oxygen consumption after surgery, there are increases when the results are normalized to the total weight of patients. Probably, these increases are due to the great weight loss that occurs, and not to an improvement in cardiorespiratory fitness, since absolute oxygen consumption does not increase [175, 176]. However, in studies in which an exercise program is applied, it can be seen how patients who perform it have greater rises in normalized oxygen consumption to weight, and increases in consumption of oxygen in absolute values [177–179]. The improvement of cardiorespiratory capacity can be of great importance in CVRF, since it is associated with a lower cardiometabolic risk [180, 181].

As previously shown, BS, by itself, generates large improvements in cardiometabolic risk factors. However, there is a proportion of patients to whom the BS fails for reducing certain comorbidities. Some authors have called these patients as resistant to bariatric surgery [182]. These patients, besides not showing improvements in cardiometabolic parameters, have lower weight losses after surgery. Although the reasons for this variability between patients are not clear yet, there are different common aspects in the "non-responsiveness to surgery," such as gender, age or preoperative weight, emphasizing an inadequate PA, since it is a factor that can be modified.

However, although the role of the exercise on CVRF remains to be determined, due to the lack of studies, it seems that it can have a positive effect. In an observational study it was obtained that, one year after surgery, total and LDL cholesterol were higher in the sedentary subjects (<1,250 Mets/14 days), while the HDL cholesterol, although the difference was not significant, showed a tendency to be higher in active subjects (75.5 $mg \cdot dl^{-1}$ vs 68.6 $mg \cdot dl^{-1}$) [106]. Another study showed that, also one year after surgery, patients who reported an average of 96.8 minutes of aerobic exercise per week had a higher resolution of diabetes and OSA than patients who had an average of 21.1 minutes per week [183]. In addition, positive associations have been found between the number of daily steps and insulin sensitivity, and between the increase in daily minutes of PA and HDL cholesterol 9 months after surgery [184].

Recently, some experimental studies have emerged on this subject. In these studies, in the short-term (6-9 months), there are no differences between patients participating in an exercise program, and those who do not, showing all patients similar improvements in lipid profile and blood pressure levels at rest [178, 179]. However, after surgery, exercise seems to be effective in glucose metabolism. In one study, a 12-week exercise program was performed, in which

2000 kcal a week was tried to consume by aerobic exercise at 60-70% of VO_{2max} [178]. The results of this study showed a reduction in the incremental area under the curve postprandial blood glucose response in the experimental group. In turn, other studies have shown greater improvements in insulin sensitivity by performing only ~120 minutes of aerobic exercise per week, at an intensity of 60-70% [179, 185].

Although the limited availability of studies in this regard does not allow to reach a clear conclusion, it seems that the performance of aerobic exercise in the short term after surgery (6-9 months) produces additional benefits in the improvement of glycemic control. While, between 9-12 months after BS, it is observed that PA can contribute to increase HDL cholesterol, and a higher resolution of various comorbidities, such as diabetes. This seems to indicate that the use of exercise programs can help improve the cardiovascular profile in patients who do not respond adequately to surgery.

4. Exercise in Patients Undergoing Bariatric Surgery (Medium and Long-Term)

Benefits and Disadvantages of Bariatric Surgery in the Medium and Long-Term

Bariatric surgery generates diverse benefits, which decrease the risk of suffering a cardiovascular disease [135, 136], and in the long term it contributes to the fact that subjects with morbid obesity undergoing BS show an increase of approximately 7 years in their life expectancy [186].

However, one of the biggest disadvantages after BS is weight regain, which is shown above in all studies that have a follow-up period ≥5 years [187]. Weight regain occurs in a large proportion of patients (19.2% -58.5%) [110, 148–150], and it is positively associated with the postoperative period, [110, 188] that is, the longer after surgery, greater weight regain. Therefore, it can be seen how patients decrease from 70% of EWL in the second year of surgery to 42% at 10 years. While other studies have shown that 6 years after surgery, 64% of patients had a% EWL below 50% [189].

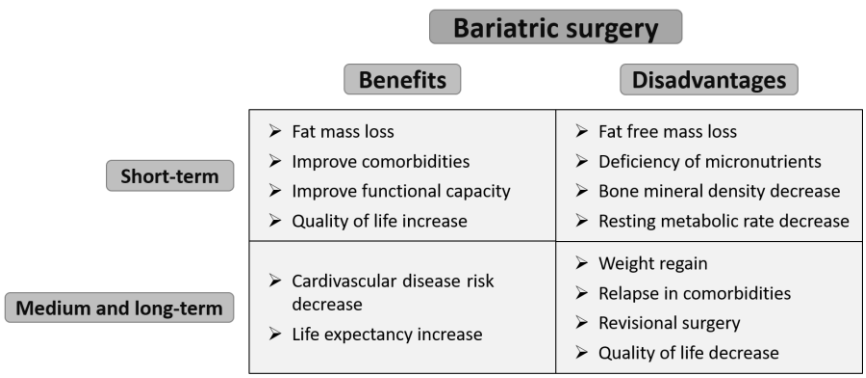

Figure 7. Benefits and disadvantages of bariatric surgery.

On the one hand, weight regain can lead to revisional surgery, which has been seen between 15.4% and 36% of patients [148, 150, 190]. On the other hand, weight regain can be accompanied by relapses in different comorbidities [191]. One study showed that the incidence in diabetes, hypertension and hypertriglyceridemia increased from 1% to 7%, from 24% to 41% and from 8% to 17% respectively between the 2nd and the 10th year of the surgery [192]. Similar results have been shown in the short-term, observing how the complete remission of diabetes decreased from 50.7% patients a year after surgery to 20% at 5 years, while the complete remission of the cholesterolemia decreased from 40% to 26.1% [193]. Furthermore, type 2 diabetes mellitus relapse ranges have been obtained from 19% to 35.1% of patients [194–196], and these relapses have been associated with weight regain [195, 197]. While, regarding hypertension, Benaiges et al. showed a range of relapse in 21.9% of patients between the 1st and 3rd year of surgery, with these patients showing a lower% EWL than subjects who did not relapse [198].

Physical Activity Levels in the Medium and Long-Term after Bariatric Surgery

Although there are few studies that analyze changes in PA levels in the medium and long term, it seems that over time they tend to decrease. Sjöström et al. found as the proportion of subjects who were active in leisure time and work increased after surgery, reaching a peak around the year of the same, and that from this moment began to reduce, until at 10 years, there was a great reduction in this proportion [192]. In turn, another study showed an increase in steps/day (+1526.8) and in the percentage of patients who performed 150 minutes of moderate or intense activity per week (+10.2%) two years after surgery. However, between the 2nd and the 3rd year of surgery both variables were significantly reduced (-278.9 steps/day; -7.1%, respectively) [199]. In a long-term study it was reported that at ~9 years of surgery, although 71.8% of patients reported being more active than before CB, but only 11.7% of patients performed ≥10,000 steps/day (daily recommendation), while 36.6% performed less than 5000 steps/day. In addition, 7 years after surgery, only 48% of patients reported performing ≥1 exercise session per week, while the average time spent sitting turned out to be 7.3 hours per day (200). So, it can be concluded that in the medium and long term there is a decrease in the levels of PA, there being a large proportion of patients who are not very active, and spend much of their time in sedentary behavior.

Exercise in Patients Undergoing Bariatric Surgery in the Medium and Long-Term

From our knowledge, there are few studies that investigate the role of exercise on CVRF in the medium and long term after BS. However, as we have seen above, weight control can be of great importance for CVRF, and exercise can be a fundamental tool for this. In one study, PA was evaluated 36 months after surgery, and it was found that subjects who performed between 0 and 59 minutes of aerobic exercise had an EWL of 33%, while those who performed ≥150 minutes had an EWL of 54'1%, which is considered a successful weight

loss [183]. Herman et al. showed that patients who reported ≥1 weekly sessions of at least 30 minutes of moderate or vigorous exercise were more likely to maintain at least 50% of their initial weight loss (OR: 2.6), and had a lower probability of weight regain than less active subjects (OR: -3'1) [201]. In another study that modified the behavior of the patients, modifying eating habits and increasing levels of PA, it was obtained that the subjects of the experimental group had a greater weight loss at 12 months after surgery, and subsequently, they got a maintenance of the lost weight. However, subjects who did not change their habits showed a decrease in their %EWL between 12 and 36 months after surgery (from 57.5% to 49.1%) [202].

Although the majority of studies regarding this topic are observational, some experimental study has also been carried out. In one study, patients who had <50% EWL after 3 years or more of surgery were recruited. The experimental group underwent a 6-month behavioral intervention that consisted in reducing caloric intake, and in the prescription, a PA program. The results of this study showed a significant decrease in %EWL after the intervention only in the experimental group (-6.6% EWL) [203]. Last, in one study an exercise program that combined aerobic and resistance training at moderate intensities was applied in patients who had a BMI ≥ 30 between 12-24 months after surgery. The group that performed the exercise program had reductions in weight and resting blood pressure, while in the control group there was a tendency to increase weight [204].

In the studies it is observed that adding exercise to BS generates greater weight loss and that it is an effective tool to achieve weight maintenance that has been lost through surgery. In addition, exercise can be an efficient method to generate weight loss in patients with an inadequate weight loss or who suffer from weight regain.

5. ORIENTED NEW TRENDS TRAINING TO HEALTH

Traditionally, to achieve weight loss in obese people, it has been recommended to perform aerobic exercise at moderate intensities, without giving much importance to the resistance, defending the volume of aerobic activity as a determining factor. While some authors stated that for achieving weight loss should be performed 5 days a week of aerobic activity, with a minimum duration of 60 minutes per session [205]. Other organizations, such as the ACSM in its position stand in 2009, proposed that performing 150-250 minutes per week of PA at moderate intensity will result in modest weight reductions, but that greater than 250 minutes per week is when the greatest benefits are achieved [206]. However, the role of resistance training on weight loss has not been given more relevance [206, 207].

Currently, this trend is changing, and it seems that there are other methods that can be more effective than aerobic training. Resistance training increases fat-free mass, and with it the RMR (208), so it can be very important both to generate weight loss and to avoid weight gain. In addition, it has been shown to be as effective in reducing CVRF as aerobic training [209]. Therefore, if resistance training is added to aerobic training, it can be an effective strategy for weight and cardiometabolic control. In recent years, research has emerged that confirms this theory. It has been found that, by combining resistance and aerobic training in the same training program, greater reductions in weight, fat mass, waist circumference and abdominal fat are achieved than through aerobic training in isolation [210–214]. Generating

at the same time increases in fat-free mass [212–214]. Even the benefits of CVRF are also greater when both types of training are combined [102, 215].

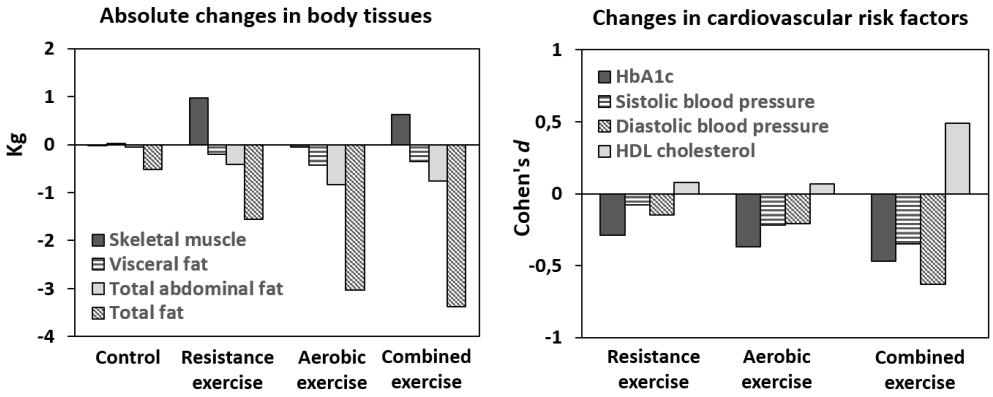

Figure 8. Impact of different exercise modalities on body tissues and cardiovascular risk factors. Dates obtained from Davidson et al. [230] and Snowling et al. [231].

On the other hand, training intensity is showing itself as a decisive component. Currently, numerous research are reporting the benefits of high intensity interval training (HIIT). HIIT is a type of exercise that combines short periods at high intensities and low intensities in the same training session, thus, when applying recovery periods, training time in more intense areas is prolonged in relation to continuous training [216]. The greater the intensity of aerobic training, the greater will be the increase in excess post-exercise oxygen consumption (EPOC) [217]. The increase in EPOC, in turn, has been related to a greater mobilization of fatty acids [218], in both healthy and obese subjects [219, 220]. This means that HIIT is an effective method to achieve fat loss as continuous training at moderate intensities [221]. Other benefits are also attributed to it, as it decreases insulin sensitivity [220, 222], reduces cholesterol [222–224], glycemia [225] and blood pressure levels [224, 226], in addition to achieving greater increases in cardiorespiratory capacity than through continuous training at moderate intensities [227]. All this results in that this type of training helps reduce the risk of suffering cardiometabolic pathologies [228].

However, one of the main advantages of HIIT is that all these results are achieved in 40% less training time than if continuous training were employed [221], which leaves more time in a training session so that other capacities can be worked on, as the strength. As we have seen previously, resistance training can provoke great benefits, but training intensity is also important. In studies with obese subjects who train at intensities between 70-80% of the repetition maximum (RM), gains of fat-free mass are obtained [212–214]. A recent review that analyzes the effects of training intensity, has concluded that the intensities that cause more favorable changes in body composition and in certain CVRF are between 75-80% of the RM for resistance training, and above 75% VO_{2max} for aerobic training, and not between 55-75%, as has been traditionally prescribed [96].

Therefore, adding an exercise program to a nutritional intervention can be an effective strategy to maximize the results in weight loss and in the improvement of CVRF. The inclusion of strength training in an exercise program can avoid reductions in FFM, while aerobic training at high intensities can, among other benefits, generate greater losses of fat

mass. Consequently, for an exercise program to be as efficient as possible and generate the greatest benefits in the CVRF, it should combine both types of exercise (resistance and aerobic training), initiated at moderate intensities, but progressing to train at high intensities.

CONCLUSION

Exercise may be of great importance in the control of CVRF in bariatric patients. This control of the CVRF can be done in different ways. On the one hand, exercise by itself generates improvements in glycemic control, hypertension, lipid profile and other comorbidities associated with obesity. On the other hand, when a nutritional intervention is combined with exercise, large weight losses occur, which is associated with an improvement in comorbidities.

Furthermore, it is important to notice that cardiorespiratory fitness is a very high importance for cardiovascular risk factors, and the fact of rising it is able to prevent to some degree, cardiovascular diseases. In the same way, skeletal muscle is a powerful endocrine organ that must not be forgotten. It has relevant functions such as elimination of post-prandial glucose, glucose storing or a high oxidation of fatty acids at rest. For that reason, in these patients who have a high cardiovascular risk, exercise must be aimed at the rising of cardiorespiratory fitness, maintaining skeletal muscle levels and rising muscular quality.

However, due to different disadvantages that BS can present, the objectives of the exercise should be different at each stage of the surgery. Prior to surgery, it should be sought to generate greater losses of fat mass, especially of visceral fat, and to help reduce the comorbidities associated with obesity, in addition to increasing cardiorespiratory fitness. All this will reduce the surgical risk, and can help to decrease the number of complications and mortality in these patients, as well as a shorter hospital stay, which could reduce the health cost of the operation.

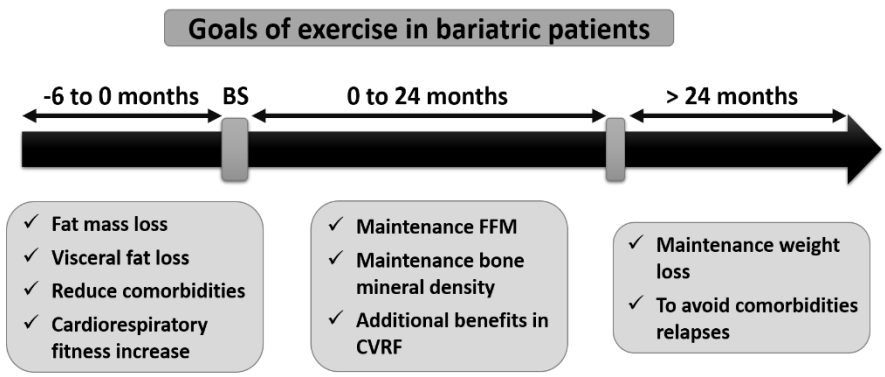

Figure 9. Exercise goals before and after bariatric surgery.

Bariatric surgery generates large losses of fat mass by itself, therefore, after surgery (especially in the first months), exercise should be oriented mainly to the maintenance of FFM, of the RMR and of the bone mineral density, for that reasons, the resistance training is

fundamental. In addition, exercise can help by reducing comorbidities in patients who fail through bariatric surgery.

Normally, after BS there is a point of maximum weight loss, which is usually reached between 12-24 months after surgery. At this point, exercise should focus on maintaining the weight loss through BS. Possibly, this would be an effective strategy to avoid relapse in comorbidities that occurs in some patients, since these relapses are associated with weight regain.

REFERENCES

[1] Sellen D. Physical status: the use and interpretation of anthropometry. Report of a WHO Expert Committee. *WHO Technical Report.* 1998. p. 1–452.

[2] Poehlman E. A review: exercise and its influence on resting energy metabolism in man. *Med Sci Sport Exerc*. 1989;21(5):515–25.

[3] Pinheiro Volp AC, Esteves de Oliveira F., Duarte Moreira Alves R, Esteves E., Bressan J. Energy expenditure: components and evaluation methods. *Nutr Hosp*. 2011;26(3):430–40.

[4] Tappy L. Thermic effect of food and sympathetic nervous system activity in humans. *Reprod Nutr Dev*. 1996;36(4):391–7.

[5] Strasser B, Schobersberger W. Evidence for Resistance Training as a Treatment *Therapy in Obesity*. 2011;2011.

[6] Illner K, Brinkmann G, Heller M, Bosy-Westphal a, Müller MJ. Metabolically active components of fat free mass and resting energy expenditure in nonobese adults. *Am J Physiol Endocrinol Metab*. 2000;278(2):E308–15.

[7] Pedersen BK, Febbraio MA. Muscles, exercise and obesity: Skeletal muscle as a secretory organ. *Nat Rev Endocrinol.* Nature Publishing Group; 2012;8(8):457–65.

[8] Kim TN, Choi KM. The implications of sarcopenia and sarcopenic obesity on cardiometabolic disease. *J Cell Biochem*. 2015;116(7):1171–8.

[9] Houmard JA, Pories WJ, Dohm GL. Severe obesity: evidence for a deranged metabolic program in skeletal muscle? *Exerc Sport Sci Rev.* 2013;40(4):204–10.

[10] Jensen J, Rustad PI, Kolnes AJ, Lai YC. The role of skeletal muscle glycogen breakdown for regulation of insulin sensitivity by exercise. *Front Physiol*. 2011;2:1–11.

[11] Dulloo AG, Jacquet J, Solinas G, Montani J, Schutz Y. Body composition phenotypes in pathways to obesity and the metabolic syndrome. *Int J Obes.* Nature Publishing Group; 2010;34(S2):S4–17.

[12] Saltin B, Helge JW. Skeletal muscles, physical activity and health. *Orthopade*. 2000;29(11):941–7.

[13] Hulver MW, Berggren JR, Cortright RN, Dudek RW, Thompson RP, Pories WJ, et al. Skeletal muscle lipid metabolism with obesity. *Am J Physiol Endocrinol Metab*. 2003;284(4):E741-7.

[14] Kelley DE, Goodpaster B, Wing RR, Simoneau J a. Skeletal muscle fatty acid metabolism in association with insulin resistance, obesity, and weight loss. *Am J Physiol*. 1999;277(6 Pt 1):E1130–41.

[15] Church TS, Thomas DM, Tudor-locke C, Katzmarzyk PT, Conrad P, Rodarte RQ, et al. Trends over 5 Decades in U.S. Occupation-Related Physical Activity and Their Associations with Obesity. *PLoS One.* 2011;6(5):1–7.

[16] Ng SW, Popkin BM. Time use and physical activity: A shift away from movement across the globe. *Obes Rev*. 2012;13(8):659–80.

[17] Malik VS, Willett WC, Hu FB. Global obesity: trends, risk factors and policy implications. *Nat Rev Endocrinol*. Nature Publishing Group; 2013;9(1):13–27.

[18] Popkin BM. Nutrition Transition and the Global Diabetes Epidemic. *Curr Diab Rep*. 2015;15(9):64.

[19] Vasileska A, Rechkoska G. Global and Regional Food Consumption Patterns and Trends. *Procedia-Social Behav Sci* [Internet]. 2012;44:363–9.

[20] Prentice A, Ph D, Jebb S, Ph D. Energy Intake/Physical Activity Interactions in the Homeostasis of Body Weight Regulation. *Nutr Rev*. 2004;62(7):S98-104.

[21] Ng M, Fleming T, Robinson M, Thomson B, Graetz N, Margono C, et al. Global , regional , and national prevalence of overweight and obesity in children and adults during 1980–2013: a systematic analysis for the Global Burden of Disease Study 2013. *Lancet.* 2014;384(9945):766–81.

[22] Stevens GA, Singh GM, Lu Y, Danaei G, Lin JK, Finucane MM, et al. National , regional , and global trends in adult overweight and obesity prevalences. *Popul Health Metr*. 2012; 10 (1) 1–16.

[23] GBD 2015 Obesity Collaborators. Health Effects of Overweight and Obesity in 195 Countries over 25 Years. *N Engl J Med.* 2017;377(1):1–15.

[24] Kelly T, Yang W, Chen C-S, Reynolds K, He J. Global burden of obesity in 2005 and projections to 2030. *Int J Obes*. 2008;32(9):1431–7.

[25] Lear SA, Wu CH. Prevalence and trends of adult obesity in the US, 1999-2012. *ISRN Obes*. 2014;2014:1–6.

[26] Sturm R, Hattori A. Morbid obesity rates continue to rise rapidly in the United States. *Int J Obes* (Lond). 2013;37(6):889–91.

[27] Basterra-Gortari FJ, Beunza JJ, Bes-Rastrollo M, Toledo E, García-López M, Martínez-González MA. Increasing trend in the prevalence of morbid obesity in Spain: from 1.8 to 6.1 per thousand in 14 years. *Rev española Cardiol.* 2011;64(5):424–6.

[28] Keating C, Backholer K, Gearon E, Stevenson C, Swinburn B, Moodie M, et al. Prevalence of class-I , class-II and class-III obesity in Australian adults between 1995 and 2011-12. *Obes Res Clin Pract.* 2015;9(6):553–62.

[29] Twells LK, Gregory DM, Reddigan J, Midodzi WK. Current and predicted prevalence of obesity in Canada: a trend analysis. *C open.* 2014;2(1):E18-26.

[30] Finkelstein EA, Khavjou OA, Thompson H, Trogdon JG, Pan L, Sherry B. Obesity and Severe Obesity Forecasts Through 2030. *Am J Prev Med*. 2012;42(6):563–70.

[31] NCD Risk Factor Collaboration. Trends in adult body-mass index in 200 countries from 1975 to 2014: a pooled analysis of 1698 population-based measurement studies with 19·2 million participants. *Lancet*. NCD Risk Factor Collaboration. Open Access article distributed under the terms of CC BY; 2016;387(10026):1377–96.

[32] Hu F, Manson J, Stampfer M, Colditz G, Liu S, Solomon C, et al. Diet, lifestyle, and the risk of type 2 diabetes mellitus in women. *N Engl J Med*. 2001;345(11):790–7.

[33] Brown CD, Higgins M, Donato KA, Rohde FC, Garrison R, Obarzanek E, et al. Body mass index and the prevalence of hypertension and dyslipidemia. *Obes Res*. 2000;8(9):605–19.

[34] Bays HE, Toth PP, Kris-Etherton PM, Abate N, Aronne LJ, Brown WV, et al. Obesity, adiposity, and dyslipidemia: A consensus statement from the National Lipid Association. *J Clin Lipidol*. 2013;7(4):304–83.

[35] Fock KM, Khoo J. Diet and exercise in management of obesity and overweight. *J Gastroenterol Hepatol.* 2013;28(Suppl 4):59–63.

[36] Chan JM, Rimm EB, Colditz GA, Stampfer MJ, Willett WC. Obesity, Fat Distribution, and Weight Gain as Risk Factors for Clinical Diabetes in Men. *Diabtes Care*. 1994;17(9):961–9.

[37] Patel A V, Hildebrand JS, Gapstur SM. Body Mass Index and All-Cause Mortality in a Large Prospective Cohort of White and Black U.S. Adults. *PLoS One*. 2014;9(10):e109153.

[38] Flegal KM, Graubard BI, Williamson DF, Gail MH. Cause-specific excess deaths associated with underweight, overweight, and obesity. *JAMA.* 2007;298(17):2028–37.

[39] The Global Mortality Colaboration TGM. Body-mass index and all-cause mortality: individual-participant-data meta-analysis of 239 prospective studies in four continents. *Lancet.* 2016;388(10046):776–86.

[40] Avenell a, Broom J, Brown TJ, Poobalan a, Aucott L, Stearns SC, et al. Systematic review of the long-term effects and economic consequences of treatments for obesity and implications for health improvement. *Health Technol Assess*. 2004;8(21):iii–iv, 1-182.

[41] Rubio M, Martínez C, Vidal O. Documento de consenso sobre cirugía bariátrica. *Rev Esp Obes*. 2004;4:223–49.

[42] Sasaki A, Wakabayashi G, Yonei Y. Current status of bariatric surgery in Japan and effectiveness in obesity and diabetes. *J Gastroenterol*. 2014;49(1):57–63.

[43] Jaunoo S, Southall P. Bariatric surgery. *Obes Surg*. 2010;8(2):86–9.

[44] Khwaja HA, Bonanomi G. Bariatric surgery: techniques, outcomes and complications. *Curr Anaesth Crit Care*. 2010;21(1):31–8.

[45] Baker MT. The History and Evolution of Bariatric Surgical Procedures. *Surg Clin North Am*.2011;91(6):1181–201.

[46] González-gonzález JJ, Sanz-álvarez L, García C. La obesidad en la historia de la cirugía. *Cir Esp*. 2008;84(4):188–95.

[47] Angrisani L, Santonicola A, Iovino P, Formisano G, Buchwald H, Scopinaro N. Bariatric Surgery Worldwide 2013. *Obes Surg*. 2015;25(10):1822–32.

[48] Blackburn GL, Hutter MM, Harvey AM, Apovian CM, Boulton HRW, Cummings S, et al. Expert panel on weight loss surgery: executive report update. *Obesity* (Silver Spring). 2009;17(5):842–62.

[49] Cauley JA. An Overview of Sarcopenic Obesity. *J Clin Densitom*. 2015;18(4):499–505.

[50] Prado CMM, Wells JCK, Smith SR, Stephan BCM, Siervo M. Sarcopenic obesity: A Critical appraisal of the current evidence. *Clin Nutr*. 2012;31(5):583–601.

[51] Parr EB, Coffey VG, Hawley JA. "Sarcobesity": A metabolic conundrum. *Maturitas*. 2013;74(2):109–13.

[52] Curvello-silva K, Barreto-medeiros JM. Association between sarcopenic obesity and cardiovascular risk : where are we ? *Nutr Hosp*. 2016;33(5):1245–55.

[53] Srikanthan P, Hevener AL, Karlamangla AS. Sarcopenia exacerbates obesity-associated insulin resistance and dysglycemia: Findings from the national health and nutrition examination survey III. *PLoS One*. 2010;5(5).

[54] Kim J-H, Cho JJ, Park YS. Relationship between Sarcopenic Obesity and Cardiovascular Disease Risk as Estimated by the Framingham Risk Score. *J Korean Med Sci*. 2015;30(3):264–71.

[55] Wannamethee SG, Atkins JL. Muscle loss and obesity: the health implications of sarcopenia and sarcopenic obesity. *Proc Nutr Soc*. 2015;(December 2014):1–8.

[56] Livingston EH. Procedure incidence and in-hospital complication rates of bariatric surgery in the United States. *Am J Surg*. 2004;188(2):105–10.

[57] Goergen M, Arapis K, Limgba A, Schiltz M, Lens V, Azagra JS. Laparoscopic Roux-en-Y gastric bypass versus laparoscopic vertical banded gastroplasty : results of a 2-year follow-up study. *Surg Endosc*. 2007;21(4):659–64.

[58] Jonathan F, Kole KL, Yenumula PR, English WJ. Predicting Risk for Serious Complications With Bariatric Surgery Results from the Michigan Bariatric Surgery Collaborative. *Ann Surg*. 2011;254(4):633–40.

[59] Benotti P, Wood GC, Winegar DA, Petrick AT, Still CD, Argyropoulos G, et al. Risk factors associated with mortality after Roux-en-Y gastric bypass surgery. *Ann Surg*. 2014;259(1):123–30.

[60] Nguyen NT, Nguyen B, Smith B, Reavis KM, Elliott C, Hohmann S. Proposal for a bariatric mortality risk classification system for patients undergoing bariatric surgery. *Surg Obes Relat Dis*. 2013;9(2):239–46.

[61] Fernandez AZ, Demaria EJ, Tichansky DS, Kellum JM, Wolfe LG, Meador J, et al. Experience with over 3 ,000 open and laparoscopic bariatric procedures. *Surg Endosc*. 2004;18(2):193–7.

[62] Coblijn UK, Karres J, Raaff CAL De, Castro SMM De, Lagarde SM, Tets WF Van, et al. Predicting postoperative complications after bariatric surgery : the Bariatric Surgery Index for Complications , BASIC. *Surg Endosc*. Springer US; 2017;31.

[63] Martins-filho ED, Ferraz B, Ferraz EM. Evaluation Of Risk Factors In Superobese Patients Submitted To Conventional Fobi-Capella Surgery. *Arq Gastroenterol*. 2008;45(1):3–10.

[64] Livingston EH, Ko CY. Assessing the Relative Contribution of Individual Risk Factors on Surgical Outcome for Gastric Bypass Surgery : A Baseline Probability Analysis. *J Surg Res*. 2002;105(1):48–52.

[65] Ramanan B, Gupta PK, Gupta H, Fang X, Forse RA. Development and validation of a bariatric surgery mortality risk calculator. *J Am Coll Surg* . Els2012;214(6):892–900.

[66] Caiazzo R, Lassailly G, Leteurtre E, Baud G, Verkindt H, Raverdy V, et al. Roux-en-Y Gastric Bypass Versus Adjustable Gastric Banding to Reduce Nonalcoholic Fatty Liver Disease. *Ann Surg*. 2014;260(5):893–9.

[67] Machado M, Marques-vidal P, Cortez-pinto H. Hepatic histology in obese patients undergoing bariatric surgery. *J Hepatol*. 2006;45(4):600–6.

[68] Losekann A, Weston AC, Carli LA De, Espindola MB, Pioner SR, Coral GP. Nonalcoholic fatty liver disease in severe obese patients, subjected to bariatric surgery. *Arq Gastroenterol*. 2013;50(4):285–9.

[69] Reha J, Lee S, Hofmann LJ. Prevalence and predictors of nonalcoholic steatohepatitis in obese patients undergoing bariatric surgery: a Department of Defense experience. *Am Surg.* Elsevier Inc.; 2014;80(6):595–9.

[70] Cordeiro L, Campos J, de Paula P, Vilar L, Lopes E, de Arruda P, et al. Nonalcoholic steatohepatitis on preoperative period of gastric bypass: lack of correlation with degree of obesity. *Arq Bras Cir Dig.* 2013;26(1):39–42.

[71] Wissen J Van, Bakker N, Doodeman HJ. Preoperative Methods to Reduce Liver Volume in Bariatric Surgery : a Systematic Review. *Obes Surg*. 2016;26(2):251–6.

[72] Fris RJ. Preoperative Low Energy Diet Diminishes Liver Size. *Obes Surg.* 2004;14(9):1165–70.

[73] Martínez-Ramos D, Salvador-Sanchis JL, Escrig-Ros J. Pérdida de peso preoperatoria en pacientes candidatos a cirugía bariátrica. Recomendaciones basadas en la evidencia. *Cir Esp*. 2012;90(3):147–55.

[74] Schwartz ML, Drew RL, Chazin- M. Factors Determining Conversion from Laparoscopic to Open Roux-en-Y Gastric Bypass. *Obes Surg.* 2004;14(9):1193–7.

[75] Schwartz ML, Drew RL, Chazin-Caldie M. Laparoscopic Roux-en-Y Gastric Bypass : Preoperative Determinants of Prolonged Operative Times , Conversion to Open Gastric Bypasses , and Postoperative Complications. *Obes Surg*. 2003;13(5):734–8.

[76] Asad M, Roman K, Johnson S, Afthinos JN, Gibbs KE. Perioperative risk factors for 30-day mortality after bariatric surgery : is functional status important? *Surg Endosc*. 2013;27(5):1772–7.

[77] Consortium LA of BS (LABS), Flum D, Belle S, King W, Wahed A, Berk P, et al. Perioperative Safety in the Longitudinal Assessment of Bariatric Surgery. *N Engl J Med*. 2009;361(5):445–54.

[78] Turner PL, Saager L, Dalton J, Abd-Elsayed A, Roberman D, Melara P, et al. A nomogram for predicting surgical complications in bariatric surgery patients. *Obes Surg*. 2011;21(5):655–62.

[79] Older P, Smith R, Courtney P, Hone R. Preoperative evaluation of cardiac failure and ischemia in elderly patients by cardiopulmonary exercise testing. *Chest.* 1993;104(3):701–4.

[80] Snowden CP, Prentis JM, Anderson HL, Roberts DR, Randles D, Renton M, et al. Submaximal Cardiopulmonary Exercise Testing Predicts Complications and Hospital Length of Stay in Patients Undergoing Major Elective Surgery. *Ann Surg*. 2010;251(3):535–41.

[81] Hennis PJ, Meale PM, Hurst RA, Doherty AFO, Otto J, Kuper M, et al. Cardiopulmonary exercise testing predicts postoperative outcome in patients undergoing gastric bypass surgery. *Br J Anaesth.* 2012;109(4):566–71.

[82] McCullough PA, Gallagher MJ, DeJong AT, Sandberg KR, Trivax JE, Alexander D, et al. Cardiorespiratory fitness and short-term complications after bariatric surgery. *Chest.* 2006;130(2):517–25.

[83] Chang S, Stoll CRT, Song J, Varela JE, Eagon CJ, Colditz GA. The Effectiveness and Risks of Bariatric Surgery An Updated Systematic Review and Meta-analysis, 2003-2012. *JAMA Surg*. 2014;149(3):275–87.

[84] Colles SL, Dixon JB, Marks P, Strauss BJ, Brien PEO. Preoperative weight loss with a very-low-energy diet : quantitation of changes in liver and abdominal fat by serial imaging 1–3. *Am J Clin Nutr.* 2006;84(2):304–11.

[85] Edholm D, Kullberg J, Haenni A, Karlsson FA, Ahlström A, Hedberg J, et al. Preoperative 4-week low-calorie diet reduces liver volume and intrahepatic fat, and facilitates laparoscopic gastric bypass in morbidly obese. *Obes Surg*. 2011;21(3):345–50.

[86] Patel NS, Doycheva I, Peterson MR, Hooker J, Kisselva T, Schnabl B, et al. Effect of Weight Loss on Magnetic Resonance Imaging Estimation of Liver Fat and Volume in Patients With Nonalcoholic Steatohepatitis. *Clin Gastroenterol Hepatol*. 2015;13(3): 561–568.e1.

[87] Tarnoff M, Kaplan LM, Shikora S. An evidenced-based assessment of preoperative weight loss in bariatric surgery. *Obesity Surgery*. 2008;18(9):1059–61.

[88] Benotti PN, Still CD, Wood C, Akmal Y, King H, El Arousy H, et al. Preoperative Weight Loss Before Bariatric Surgery. *Arch Surg*. 2014;144(12):1150–5.

[89] Anderin C, Gustafsson UO, Heijbel N, Thorell A. Weight Loss Before Bariatric Surgery and Postoperative complications. *Ann Surg*. 2015;261(5):909–13.

[90] Gerber P, Anderin C, Thorell A. Weight loss prior to bariatric surgery : An Updated Review of the Literature. *Scand J Surg*. 2014;104(1):33–9.

[91] Nielsen LV, Nielsen MS, Schmidt JB, Sjodin AM. Efficacy of a liquid low calorie formula diet in achieving preoperative target weight loss before bariatric surgery. *J Nutr Sci*. 2016;5:E-22.

[92] Menozzi R, Bondi M, Baldini A, Venneri MG, Velardo A, Del Rio G. Resting metabolic rate, fat-free mass and catecholamine excretion during weight loss in female obese patients. *Br J Nutr*. 2000;84(4):515–20.

[93] Sparti A, Delany JP, De La Bretonne J a., Sander GE, Bray G a. Relationship between resting metabolic rate and the composition of the fat-free mass. *Metabolism*. 1997;46(10):1225–30.

[94] Wu T, Gao X, Chen M, Van Dam RM. Long-term effectiveness of diet-plus-exercise interventions vs. diet-only interventions for weight loss: A meta-analysis: Obesity Management. *Obes Rev*. 2009;10(3):313–23.

[95] Volek JS, Vanheest JL, Forsythe CE. Diet and exercise for weight loss: a review of current issues. *Sport Med*. 2005;35(1):1–9.

[96] Clark JE. Diet, exercise or diet with exercise: comparing the effectiveness of treatment options for weight-loss and changes in fitness for adults (18–65 years old) who are overfat, or obese; systematic review and meta-analysis. *J Diabetes Metab Disord*. 2015;14:31.

[97] Vissers D, Hens W, Taeymans J, Baeyens J-P, Poortmans J, Van Gaal L. The effect of exercise on visceral adipose tissue in overweight adults: a systematic review and meta-analysis. *PLoS One*. 2013;8(2):e56415.

[98] Stiegler P, Cunliffe A. The role of diet and exercise for the maintenance of fat-free mass and resting metabolic rate during weight loss. *Sport Med*. 2006;36(3):239–62.

[99] Mahady SE, George J. Exercise and diet in the management of nonalcoholic fatty liver disease. *Metabolism*. Elsevier B.V.; 2015;65(8):1172–82.

[100] Oliveira CP, Sanches PDL, Abreu-silva EO De, Marcadenti A. Nutrition and Physical Activity in Nonalcoholic Fatty Liver Disease. *J Diabetes Re*. 2016;2016.

[101] Bacchi PE, Moghetti NC, Zanolin ME, Milanese C, Faccioli N, Trombetta M, et al. Metabolic Effects of Aerobic Training and Resistance Training in Type 2 Diabetic Subjects. *Diabetes Care*. 2012;35(4):676–82.

[102] Schwingshackl L, Missbach B, Dias S, König J, Hoffmann G. Impact of different training modalities on glycaemic control and blood lipids in patients with type 2 diabetes: A systematic review and network meta-analysis. *Diabetologia.* 2014;57(9): 1789–97.

[103] Schwingshackl L, Dias S, Strasser B, Hoffmann G. Impact of different training modalities on anthropometric and metabolic characteristics in overweight/obese subjects: A systematic review and network meta-analysis. *PLoS One*. 2013;8(12): e82853.

[104] Iftikhar I, Kline C, Youngstedt S. Effects of Exercise Training on Sleep Apnea : A Meta-analysis. *Lung*. 2014;192(1):175–84.

[105] Aiello KD, Caughey WG, Nelluri B, Sharma A, Mookadam F, Mookadam M. Effect of exercise training on sleep apnea: A systematic review and meta-analysis. *Respir Med*. Elsevier Ltd; 2016;116:85–92.

[106] Ruiz-Tovar J, Zubiaga L, Llavero C, Diez M, Arroyo A, Calpena R. Serum cholesterol by morbidly obese patients after laparoscopic sleeve gastrectomy and additional physical activity. *Obes Surg.* 2014;24(3):385–9.

[107] Bond DS, Unick JL, Jakicic JM, Vithiananthan S, Pohl D, Roye GD, et al. Objective Assessment of Time Spent Being Sedentary in Bariatric Surgery Candidates. *Obes Surg*. 2011;21(6):811–4.

[108] Bond D, Jakicic J, Vithiananthan S, Thomas J, Leahey T, Sax H, et al. Objective Quantification of Physical Activity in Bariatric Surgery Candidates and Normal-Weight Controls. *Surg Obes Relat Dis*. 2010;6(1):72–8.

[109] King WC, Belle SH, Eid GM, Dakin GF, Inabnet WB, Mitchell JE, et al. Physical activity levels of patients undergoing bariatric surgery in the Longitudinal Assessment of Bariatric Surgery study. *Surg Obes Relat Dis*. 2008;4(6):721–8.

[110] Freire RH, Borges MC, Alvarez-Leite JI, Toulson Davisson Correia MI. Food quality, physical activity, and nutritional follow-up as determinant of weight regain after Roux-en-Y gastric bypass. *Nutrition*. 2012;28(1):53–8.

[111] Freire RH, Borges MC, Alvarez-Leite JI, Toulson Davisson Correia MI. Food quality, physical activity, and nutritional follow-up as determinant of weight regain after Roux-en-Y gastric bypass. *Nutrition*. 2012;28(1):53–8.

[112] Delgado Floody P, Caamaño Navarrete F, Jerez Mayorga D, Campos Jara C, Ramírez Campillo R, Osorio Poblete A, et al. Efectos de un programa de tratamiento multidisciplinar en obesos mórbidos y obesos con comorbilidades candidatos a cirugía bariátrica. *Nutr Hosp.* 2015;31(5):2011–6.

[113] Delgado Floody P, Jerez Mayorga D, Caamaño Navarrete F, Osorio Poblete A, Thuillier Lepeley N, Alarcón Hormazábal M. Doce semanas de ejercicio físico intervalado con sobrecarga mejora las variables antropométricas de obesos mórbidos y obesos con comorbilidades postulantes a cirugía bariátrica. *Nutr Hosp.* 2015;32(5): 2007–11.

[114] Delgado Floody P, Cofré Lizama A, Alarcón Hormazábal M, Osorio Poblete A, Caamaño Navarrete F, Jerez Mayorga D. Evaluación de un programa integral de cuatro meses de duración sobre las condiciones preoperatorias de pacientes obesos candidatos a cirugía bariátrica. *Nutr Hosp*. 2015;32(3):1022–7.

[115] Delgado Floody P, Jerez Mayorga D, Caamano Navarrete F, Concha Diaz M, Ovalle Elgueta H, Osorio Poblete A. [Effectiveness of Comprehensive Treatment on the

Preoperative Conditions of Obese Women Candidates for Bariatric Surgery]. *Nutr Hosp*. 2015;32(6):2570–5.

[116] Ortega LS, Juan CS, García AA. Valoración de un programa de ejercicio físico estructurado en pacientes con obesidad mórbida pendientes de cirugía bariátrica. *Nutr Hosp*. 2014;29(1):64–72.

[117] Baillot A, Mampuya WM, Comeau E, Méziat-Burdin A, Langlois MF. Feasibility and impacts of supervised exercise training in subjects with obesity awaiting bariatric surgery: A pilot study. *Obes Surg.* 2013;23(7):882–91.

[118] Marcon ER, Gus I, Neumann CR. Impacto de um programa mínimo de exercícios físicos supervisionados no risco cardiometabólico de pacientes com obesidade mórbida. *Arq Bras Endocrinol Metabol*. 2011;55(5):331–8.

[119] Adair JD, Wollner SB, DaCosta ME, Blackburn GL. Progressive Resistance Training for Patients with Class III Obesity. *Obes Weight Manag*. 2010;6(3):115-8.

[120] Marcon ER, Baglioni S, Bittencourt L, Lopes CLN. What Is the Best Treatment before Bariatric Surgery ? Exercise, Exercise and Group Therapy , or Conventional Waiting : a Randomized Controlled Trial. *Obes Surg*. 2016;27(3):763–73.

[121] Hickey M, Gavingan K, McCammon M, Tyndall G, Pories W, Israel R, et al. Effects of 7 days of exercise training on insulin action in morbidly obese men. *Clin Exerc Physiol*. 1999;1:24–8.

[122] De Aquino LA, Pereira SE, De Souza Silva J, Sobrinho CJS, Ramalho A. Bariatric surgery: Impact on body composition after Roux-en-Y gastric bypass. *Obes Surg*. 2012;22(2):195–200.

[123] Adamczyk P, Bužga M, Holéczy P, Švagera Z, Šmajstrla V, Zonča P, et al. Bone mineral density and body composition after laparoscopic sleeve gastrectomy in men: A short-term longitudinal study. *Int J Surg.* 2015;23(Pt A):101–7.

[124] Belfiore A, Cataldi M, Minichini L, Aiello ML, Trio R, Rossetti G, et al. Short-Term Changes in Body Composition and Response to Micronutrient Supplementation After Laparoscopic Sleeve Gastrectomy. *Obes Surg*. 2015;25(12):2344–51.

[125] Otto M, Elrefai M, Krammer J, Weiß C, Kienle P, Hasenberg T. Sleeve Gastrectomy and Roux-en-Y Gastric Bypass Lead to Comparable Changes in Body Composition after Adjustment for Initial Body Mass Index. *Obes Surg*. 2015;26(3):479–85.

[126] Calleja-Fernández A, Pintor-de-la-Maza B, Diez-Rodríguez R, Vidal-Casariego A, Urioste-Fondo A, Cano-Rodríguez I, et al. Relationship Between Diet and Body Composition After Biliopancreatic Diversion. *Obes Surg*. 2015;25(11):2093–9.

[127] Carey DG, Pliego GJ, Raymond RL. Body composition and metabolic changes following bariatric surgery: effects on fat mass, lean mass and basal metabolic rate: six months to one-year follow-up. *Obes Surg*. 2006;16(12):1602–8.

[128] Kim MK, Kim W, Kwon HS, Baek KH, Kim EK, Song KH. Effects of bariatric surgery on metabolic and nutritional parameters in severely obese Korean patients with type 2 diabetes: A prospective 2-year follow up. *J Diabetes Investig*. 2014;5(2):221–7.

[129] Busetto L, Tregnaghi A, Marchi F De, Segato G, Foletto M, Sergi G, et al. Liver Volume and Visceral Obesity in Women with Hepatic Steatosis Undergoing Gastric Banding. *Obes Res*. 2002;10(5):408–11.

[130] Cazzo E, Pareja JC, Chaim EA. Nonalcoholic fatty liver disease and bariatric surgery : a comprehensive review. *Sao Paulo Med J*. 2017;135(3):277–95.

[131] Gasteyger C, Suter M, Calmes J. Changes in body composition, metabolic profile and nutritional status 24 months after gastric banding. *Obes Surg* . 2006;16(3):243–50.
[132] Domienik-Karłowicz J, Lisik W, Rymarczyk Z, Dzikowska-Diduch O, Chmura A, Demkow U, et al. The short-term effect of bariatric surgery on non-invasive markers of artery function in patients with metabolic syndrome. *Diabetol Metab Syndr*. 2015;7(1):76.
[133] Lubrano C, Cornoldi A, Pili M, Falcone S, Brandetti F, Fabbrini E, et al. Reduction of risk factors for cardiovascular diseases in morbid-obese patients following biliary-intestinal bypass: 3 years' follow-up. *Int J Obes Relat Metab Disord*. 2004;28(12): 1600–6.
[134] Braunwald E, Jensen MD, Fahrbach K. Bariatric Surgery. *JAMA*. 2015;292(14):1724.
[135] Kwok CS, Pradhan A, Khan MA, Anderson SG, Keavney BD, Myint PK, et al. Bariatric surgery and its impact on cardiovascular disease and mortality: a systematic review and meta-analysis. *Int J Cardiol*. 2014;173(1):20–8.
[136] Major P, Kowalczuk A, Wysocki M, Osadnik S, Pędziwiatr M, Głuszewska A, et al. Effects of bariatric surgery on cardiovascular risk factors among morbidly obese patients. *Pol Przegl Chir*. 2017;89(1):41–9.
[137] Omotosho P, Mor A, Shantavasinkul PC, Corsino L, Torquati A. Gastric bypass significantly improves quality of life in morbidly obese patients with type 2 diabetes. *Surg Endosc*. 2016;30(7):2857–64.
[138] Burgmer R, Petersen I, Burgmer M, Zwaan M De, Wolf AM, Herpertz S. Psychological Outcome Two Years after Restrictive *Bariatric Surgery*. 2007;785–91.
[139] Abdeen G, le Roux CW. Mechanism Underlying the Weight Loss and Complications of Roux-en-Y Gastric Bypass. Review. *Obes Surg.* 2016;26(2):410–21.
[140] Stein EM, Silverberg SJ. Bone Loss After Bariatric Surgery: Causes, Consequences and Management. *Lancet Diabetes Endocrinol*. 2014;2(2):165–74.
[141] De Luis DA, Pacheco D, Izaola O, Terroba MC, Cuellar L, Martin T. Clinical results and nutritional consequences of biliopancreatic diversion: Three years of follow-up. *Ann Nutr Metab*. 2009;53(3–4):234–9.
[142] Andreu A, Moizé V, Rodríguez L, Flores L, Vidal J. Protein intake, body composition, and protein status following bariatric surgery. *Obes Surg.* 2010;20(11):1509–15.
[143] Ciangura C, Bouillot J-L, Lloret-Linares C, Poitou C, Veyrie N, Basdevant A, et al. Dynamics of change in total and regional body composition after gastric bypass in obese patients. *Obesity* (Silver Spring). 2010;18(4):760–5.
[144] Carrasco F, Ruz M, Rojas P, Csendes A, Rebolledo A, Codoceo J, et al. Changes in bone mineral density, body composition and adiponectin levels in morbidly obese patients after bariatric surgery. *Obes Surg.* 2009;19(1):41–6.
[145] da Silva FBL, Gomes DL, e Carvalho KMB. Poor diet quality and postoperative time are independent risk factors for weight regain after Roux-en-Y gastric bypass. *Nutrition*. 2016;32:1–4.
[146] Odom J predictors of weight regain after bariatric surgery, Zalesin KC, Washington TL, Miller WW, Hakmeh B, Zaremba DL, et al. Behavioral Predictors ofWeight Regain after Bariatric Surgery. *Obes Surg.* 2010;20(3):349–56.
[147] Faria SL, Kelly E, Faria OP. Energy Expenditure and Weight Regain in Patients Submitted to Roux-en-Y Gastric Bypass. *Obes Surg.* 2009;19(7):856–9.

[148] Felsenreich DM, Langer FB, Kefurt R, Panhofer P, Schermann M, Beckerhinn P, et al. Weight loss, weight regain, and conversions to Roux-en-Y gastric bypass: 10-year results of laparoscopic sleeve gastrectomy. *Surg Obes Relat Dis*. b 2016;12(9):1655–62.

[149] Tamboli RA, Breitman I, Marks-Shulman PA, Jabbour K, Melvin W, Williams B, et al. Early weight regain after gastric bypass does not affect insulin sensitivity but is associated with elevated ghrelin. *Obesity*. 2014;22(7):1617–22.

[150] Bohdjalian A, Langer FB, Shakeri-Leiden Mühler S, Gfrerer L, Ludvik B, Zacherl J, et al. Sleeve gastrectomy as sole and definitive bariatric procedure: 5-Year results for weight loss and ghrelin. *Obes Surg.* 2010;20(5):535–40.

[151] Herring LY, Stevinson C, Davies MJ, Biddle SJ, Sutton C, Bowrey D, et al. Changes in physical activity behaviour and physical function after bariatric surgery: A systematic review and meta-analysis. *Obes Rev.* 2016;17(3):250–61.

[152] Wouters EJ, Larsen JK, Zijlstra H, Van Ramshorst B, Geenen R. Physical activity after surgery for severe obesity: The role of exercise cognitions. *Obes Surg*. 2011;21(12):1894–9.

[153] Vatier C, Henegar C, Ciangura C, Poitou-Bernert C, Bouillot JL, Basdevant A, et al. Dynamic relations between sedentary behavior, physical activity, and body composition after bariatric surgery. *Obes Surg.* 2012;22(8):1251–6.

[154] Silver HJ, Torquati A, Jensen GL, Richards WO. Weight, dietary and physical activity behaviors two years after gastric bypass. *Obes Surg*. 2006;16(7):859–64.

[155] Colles SL, Dixon JB, O'Brien PE. Hunger Control and Regular Physical Activity Facilitate Weight Loss After Laparoscopic Adjustable Gastric Banding. *Obes Sur*. 2008;18(7):833–40.

[156] Rosenberger PH, Henderson KE, White MA, Masheb RM, Grilo CM. Physical activity in gastric bypass patients: associations with weight loss and psychosocial functioning at 12-month follow-up. *Obes Surg.* 2011;21(10):1564–9.

[157] King W, Hsu J, Belle S, Courcoulas A, Eid G, Flum D, et al. Pre- to Post-operative Changes in Physical Activity: Report from the Longitudinal Assessment of Bariatric Surgery-2. Surg *Obes Relat* Dis. 2012;8(5):522–32.

[158] Jacobi D, Ciangura C, Couet C, Oppert J-M. Physical activity and weight loss following bariatric surgery. *Obes Rev*. 2011;12(5):366–77.

[159] Egberts K, Brown W a, Brennan L, O'Brien PE. Does exercise improve weight loss after bariatric surgery? A systematic review. *Obes Surg*. 2012;22(2):335–41.

[160] Livhits M, Mercado C, Yermilov I, Parikh J a, Dutson E, Mehran A, et al. Exercise following bariatric surgery: systematic review. *Obes Surg*. 2010;20(5):657–65.

[161] Evans RK, Bond DS, Wolfe LG, Meador JG, Herrick JE, Kellum JM, et al. Participation in 150 min/wk of moderate or higher intensity physical activity yields greater weight loss after gastric bypass surgery. *Surg Obes Relat Dis.* 2007;3(5):526–30.

[162] Moya M, Hernández A, Sarabia JM, Sánchez-martos MA, Hernández-davó JL, López-grueso R, et al. Bariatric Surgery, Weight Loss and the Role of Physical Activity : a Systematic Review. *Eur J Hum Mov*. 2014;32:145–60.

[163] Metcalf B, Rabkin R a., Rabkin JM, Metcalf LJ, Lehman-Becker LB. Weight Loss Composition: The Effects of Exercise following Obesity Surgery as Measured by Bioelectrical Impedance Analysis. *Obes Surg.* 2005;15(2):183–6.

[164] Carnero EA, Dubis GS, Hames KC, Jakicic JM, Houmard JA, Coen PM, et al. Randomized Trial Reveals that Physical Activity and Energy Expenditure are Associated with Weight and Body Composition after RYGB. *Obe*s (Silver Spring). 2017;25(7):1206–16.

[165] Daniels P, Burns RD, Brusseau TA, Hall MS, Adams TD, Eisenman P, et al. Effect of a randomised 12-week resistance training programme on muscular strength , cross-sectional area and muscle quality in women having undergone Roux-en-Y gastric bypass. *J Sports Sci.* Routledge; 2017;1–7.

[166] Campanha-versiani L, Aparecida D, Pereira G, Ribeiro-samora GA, Ramos AV, Fatima M, et al. The Effect of a Muscle Weight-Bearing and Aerobic Exercise Program on the Body Composition , Muscular Strength , Biochemical Markers , and Bone Mass of Obese Patients Who Have Undergone Gastric Bypass Surgery. *Obes Surg*. 2017;27(8):2129–37.

[167] Muschitz C, Kocijan R, Haschka J, Zendeli A, Pirker T, Geiger C, et al. The Impact of Vitamin D, Calcium, Protein Supplementation, and Physical Exercise on Bone Metabolism after Bariatric Surgery: The BABS Study. *J Bone Miner Res*. 2016;31(3): 672–82.

[168] Hassannejad A, Khalaj A, Mansournia MA, Tabesh MR, Alizadeh Z. The Effect of Aerobic or Aerobic-Strength Exercise on Body Composition and Functional Capacity in Patients with BMI ≥ 35 after Bariatric Surgery : a Randomized Control. Obes Surg. *Obesity Surgery*; 2017;27(11):2792–801.

[169] Castello V, Simões RP, Bassi D, Catai AM, Arena R, Borghi-Silva A. Impact of aerobic exercise training on heart rate variability and functional capacity in obese women after gastric bypass surgery. *Obes Surg*. 2011;21(11):1739–49.

[170] Stegen S, Derave W, Calders P, Van Laethem C, Pattyn P. Physical fitness in morbidly obese patients: effect of gastric bypass surgery and exercise training. *Obes Surg*. 2011;21(1):61–70.

[171] Faria SL, Faria OP, Buffington C, De Almeida Cardeal M, Rodrigues De Gouvêa H. Energy expenditure before and after Roux-en-Y gastric bypass. *Obes Surg*. 2012;22(9):1450–5.

[172] Sumithran P, Proietto J. The defence of body weight: a physiological basis for weight regain after weight loss. *Clin Sci* (Lond). 2013;124(4):231–41.

[173] Browning MG, Franco RL, Cyrus JC, Celi F, Evans RK. Changes in Resting Energy Expenditure in Relation to Body Weight and Composition Following Gastric Restriction : A Systematic Review. *Obes Surg*. 2016;26(7):1607–15.

[174] Wiklund M, Olsén MF, Olbers T, Cider Å. Physical fitness and physical activity in swedish women before and one year after roux-en-y gastric bypass surgery. *Open Obes J*. 2015;6(1):38–43.

[175] Lund MT, Hansen M, Wimmelmann CL, Taudorf LR, Helge JW, Mortensen EL, et al. Increased post-operative cardiopulmonary fitness in gastric bypass patients is explained by weight loss. *Scand J Med Sci Sports*. 2015;n/a-n/a. A.

[176] Wilms B, Ernst B, Thurnheer M, Weisser B, Schultes B. Differential changes in exercise performance after massive weight loss induced by bariatric surgery. *Obes Surg*. 2013;23(3):365–71.

[177] Huck CJ. Effects of Supervised Resistance Training on Fitness And Functional Strength in Patients Succeeding Bariatric Surgery. *J strength Cond Res.* 2015;29(3): 589–95.

[178] Shah M, Snell PG, Rao S, Adams-Huet B, Quittner C, Livingston EH, et al. High-volume exercise program in obese bariatric surgery patients: a randomized, controlled trial. *Obesity* (Silver Spring). 2011;19(9):1826–34.

[179] Coen PM, Tanner CJ, Helbling NL, Dubis GS, Hames KC, Xie H, et al. Clinical trial demonstrates exercise following bariatric surgery improves insulin sensitivity. *J Clin Invest*. 2015;125(1):248–57.

[180] Wei M, Kampert JB, Barlow CE, Nichaman MZ, Gibbons LW, Paffenbarger RS, et al. Relationship between low cardiorespiratory fitness and mortality in normal-weight, overweight, and obese men. *JAMA.* 1999;282(16):1547–53.

[181] DeFina LF, Haskell WL, Willis BL, Barlow CE, Finley CE, Levine BD, et al. Physical Activity Versus Cardiorespiratory Fitness: Two (Partly) Distinct Components of Cardiovascular Health? *Prog Cardiovasc Dis*. 2015;57(4):324–9.

[182] Gilbertson NM, Paisley AS, Kranz S, Weltman A, Kirby JL, Hallowell PT, et al. Bariatric Surgery Resistance: Using Preoperative Lifestyle Medicine and/or Pharmacology for Metabolic Responsiveness. *Obes Surg. Obesity Surgery*; 2017;27(12):3281–91.

[183] Shada AL, Hallowell PT, Schirmer BD, Smith PW. Aerobic exercise is associated with improved weight loss after laparoscopic adjustable gastric banding. *Obes Surg*. 2013;23(5):608–12.

[184] Wefers JF, Woodlief TL, Carnero EA, Helbling NL, Anthony SJ, Dubis GS, et al. Relationship among physical activity, sedentary behaviors, and cardiometabolic risk factors during gastric bypass surgery-induced weight loss. *Surg Obes Relat Dis Off J Am Soc Bariatr Surg*. 2016;1–10.

[185] Woodlief TL, Carnero EA, Standley RA, Distefano G, Anthony SJ, Dubis GS, et al. Dose Response of Exercise Training Following Roux-en-Y Gastric Bypass Surgery : A Randomized Trial. *Obes* (Silver Spring). 2015;23(12):2454–61.

[186] Schauer DP, Arterburn DE, Livingston EH, Coleman KJ, Ph D, Sidney S, et al. Impact of bariatric surgery on life expectancy in severely obese patients with diabetes: A Decision analysis. *Ann Surg.* 2016;261(5):914–9.

[187] Magro DO, Geloneze B, Delfini R, Pareja BC, Callejas F, Pareja JC. Long-term weight regain after gastric bypass: A 5-year prospective study. *Obes Surg*. 2008;18(6):648–51.

[188] Gomes DL, de Almeida Oliveira D, Dutra ES, Pizato N, de Carvalho KMB. Resting Energy Expenditure and Body Composition of Women with Weight Regain 24 Months After Bariatric Surgery. *Obes Surg*. 2015.

[189] Himpens J, Dobbeleir J, Peeters G. Long-term results of laparoscopic sleeve gastrectomy for obesity. *Ann Surg*. 2010;252(2):319–24.

[190] Sarela AI, Dexter SPL, O'Kane M, Menon A, McMahon MJ. Long-term follow-up after laparoscopic sleeve gastrectomy: 8-9-year results. *Surg Obes Relat Dis.* 2012;8(6):679–84.

[191] Shah M, Simha V, Garg A. Review: long-term impact of bariatric surgery on body weight, comorbidities, and nutritional status. *J Clin Endocrinol Metab* 2006;91(11): 4223–31.

[192] Sjöström L, Lindroos A, Peltonen M, Torgerson J, Bouchard C, Carlsson B, et al. Lifestyle, Diabetes, and Cardiovascular Risk Factors 10 Years after Bariatric Surgery. *N Engl J Med.* 2004;351(26):2683–93.

[193] Golomb I, Ben David M, Glass A, Kolitz T, Keidar A. Long-term Metabolic Effects of Laparoscopic Sleeve Gastrectomy. *JAMA Surg*. 2015;150(11):1051–7.

[194] Arterburn DE, Bogart A, Sherwood NE, Sidney S, Coleman KJ, Haneuse S, et al. A multisite study of long-term remission and relapse of type 2 diabetes mellitus following gastric bypass. *Obes Surg*. 2013;23(1):93–102.

[195] Brethauer SA, Aminian A, Romero-Talamás H, Batayyah E, Mackey J, Kennedy L, et al. Can diabetes be surgically cured? Long-term metabolic effects of bariatric surgery in obese patients with type 2 diabetes mellitus. *Ann Surg*. 2013;258(4):628-36-7.

[196] Dogan K, Betzel B, Homan J, Aarts EO, Ploeger N, de Boer H, et al. Long-Term Effects of Laparoscopic Roux-en-Y Gastric Bypass on Diabetes Mellitus, Hypertension and Dyslipidaemia in Morbidly Obese Patients. *Obes Surg*. 2014;24(11):1835–42.

[197] Jimenez A, Casamitjana R, Flores L, Viaplana J, Corcelles R, Lacy A, et al. Long-Term Effects of Sleeve Gastrectomy and Roux-en-Y Gastric Bypass Surgery on Type 2 Diabetes Mellitus in Morbidly Obese Subjects. *Ann Surg*. 2012;256(6):1023–9. A

[198] Benaiges D, Sagué M, Roux JAF, Pedro-botet J, Ramón JM, Chillarón JJ, et al. Predictors of Hypertension Remission and Recurrence After Bariatric Surgery. *Am J Hypertens*. 2016;29(5):653–9.

[199] King WC, Chen J, Bond DS, Belle SH, Courcoulas AP, Patterson EJ, et al. Objective Assessment of Changes in Physical Activity and Sedentary Behavior : Pre- Through 3 Years Post-Bariatric Surgery. *Obes* (Silver Spring). 2015;23(6):1143–50.

[200] Herman KM, Carver TE, Christou N V, Andersen RE. Keeping the weight off: Physical activity, sitting time, and weight loss maintenance in bariatric surgery patients 2 to 16 years postsurgery. *Obes Surg*. 2014;24(7):1064–72.

[201] Herman KM, Carver TE, Christou N V., Andersen RE. Keeping the weight off: Physical activity, sitting time, and weight loss maintenance in bariatric surgery patients 2 to 16 years postsurgery. *Obes Surg*. 2014;24:1064–72.

[202] Papalazarou A, Yannakoulia M, Kavouras S a, Komesidou V, Dimitriadis G, Papakonstantinou A, et al. Lifestyle intervention favorably affects weight loss and maintenance following obesity surgery. *Obesity (*Silver Spring). 2010;18(7):1348–53.

[203] Kalarchian MA, Marcus MD, Courcoulas AP, Cheng Y, Levine MD, Josbeno D. Optimizing long-term weight control after bariatric surgery : a pilot study. *Surg Obes Relat Dis*. Elsevier Inc.; 2012;8(6):710–5.

[204] Herring LY, Stevinson C, Carter P, Biddle SJH, Bowrey D, Sutton C, et al. The effects of supervised exercise training 12 – 24 months after bariatric surgery on physical function and body composition: a randomised controlled trial. *Int J Obes.* Nature Publishing Group; 2017;41(6):909–16.

[205] Hainer V, Toplak H, Mitrakou A. Treatment modalities of obesity: what fits whom? *Diabetes Care*. 2008;31(Suppl 2):S269-277.

[206] Donnelly JE, Blair SN, Jakicic JM, Manore MM, Rankin JW, Smith BK. Appropriate Physical Activity Intervention Strategies for Weight Loss and Prevention of Weight Regain for Adults. *Medicine and Science in Sports and Exercise*. 2009. p. 459–71.

[207] Jakicic JM, Clark K, Coleman E, Donnelly JE, Foreyt J, Melanson E, et al. American College of Sports Medicine position stand. Appropriate intervention strategies for weight loss and prevention of weight regain for adults. *Med Sci Sports Exerc*. 2001;33(12):2145–56.

[208] Tresierras M a, Balady GJ. Resistance training in the treatment of diabetes and obesity: mechanisms and outcomes. *J Cardiopulm Rehabil Prev*. 2008;29:67–75.

[209] Strasser B, Schobersberger W. Evidence for resistance training as a treatment therapy in obesity. *J Obes*. 2011;482564.

[210] Schwingshackl L, Dias S, Strasser B, Hoffmann G. Impact of different training modalities on anthropometric and metabolic characteristics in overweight/obese subjects: a systematic review and network meta-analysis. *PLoS One*. 2013;8(12):e82853.

[211] Ho SS, Dhaliwal SS, Hills AP, Pal S. The effect of 12 weeks of aerobic, resistance or combination exercise training on cardiovascular risk factors in the overweight and obese in a randomized trial. *BMC Public Health.* 2012;12:704.

[212] Willis LH, Slentz C a, Bateman L a, Shields a T, Piner LW, Bales CW, et al. Effects of aerobic and/or resistance training on body mass and fat mass in overweight or obese adults. *J Appl Physiol.* 2012;113(12):1831–7.

[213] Sanal E, Ardic F, Kirac S. Effects of aerobic or combined aerobic resistance exercise on body composition in overweight and obese adults: Gender differences. A randomized intervention study. *Eur J Phys Rehabil Med*. 2013;49(1):1–11.

[214] Park S-K, Park J-H, Kwon Y-C, Kim H-S, Yoon M-S, Park H-T. The effect of combined aerobic and resistance exercise training on abdominal fat in obese middle-aged women. *J Physiol Anthropol Appl Human Sci*. 2003;22(3):129–35.

[215] Dâmaso AR, Campos RMDS, Caranti DA, de Piano A, Fisberg M, Foschini D, et al. Aerobic plus resistance training was more effective in improving the visceral adiposity, metabolic profile and inflammatory markers than aerobic training in obese adolescents. *J Sports Sci.* 2014;32:1–11.

[216] Buchheit M, Laursen PB. High-intensity interval training, solutions to the programming puzzle: Part I: cardiopulmonary emphasis. *Sports Med.* 2013;43(5):313–38.

[217] Laforgia J, Withers RT, Gore CJ. Effects of exercise intensity and duration on the excess post-exercise oxygen consumption. *J Sports Sci.* 2006;24(12):1247–64.

[218] Børsheim E, Bahr R. Effect of exercise intensity, duration and mode on post-exercise oxygen consumption. *Sport Med*. 2003; 33(14):1037–60.

[219] Perry CGR, Heigenhauser GJF, Bonen A, Spriet LL. High-intensity aerobic interval training increases fat and carbohydrate metabolic capacities in human skeletal muscle. *Appl Physiol Nutr Metab*. 2008;33(6):1112–23.

[220] Whyte LJ, Ferguson C, Wilson J, Scott R a., Gill JMR. Effects of single bout of very high-intensity exercise on metabolic health biomarkers in overweight/obese sedentary men. *Metabolism.* 2013;62(2):212–9.

[221] Wewege M, van den Berg R, Ward RE, Keech A. The effects of high-intensity interval training vs. moderate-intensity continuous training on body composition in overweight and obese adults: a systematic review and meta-analysis. *Obes Rev*. 2017;18(6):635-646.

[222] Racil G, Ben Ounis O, Hammouda O, Kallel A, Zouhal H, Chamari K, et al. Effects of high vs. moderate exercise intensity during interval training on lipids and adiponectin levels in obese young females. *Eur J Appl Physiol*. 2013;113(10):2531–40.

[223] Alvarez L, Ramírez-Campillo R, Flores O, Henríquez-Olguín C, Campos J, Carrasco V, et al. Metabolic response to high intensity exercise training in sedentary hyperglycemic and hypercholesterolemic women. *Rev Med Chil*. 2013;141(10):1293–9.

[224] Paoli A, Pacelli QF, Moro T, Marcolin G, Neri M, Battaglia G, et al. Effects of high-intensity circuit training, low-intensity circuit training and endurance training on blood pressure and lipoproteins in middle-aged overweight men. *Lipids Health Dis*. 2013;12(3):131.

[225] Jelleyman C, Yates T, O'Donovan G, Gray LJ, King JA, Khunti K, et al. The effects of high-intensity interval training on glucose regulation and insulin resistance: A meta-analysis. *Obes Rev*. 2015;16(11):942–61.

[226] Batacan RB, Duncan MJ, Dalbo VJ, Tucker PS, Fenning AS. Effects of high-intensity interval training on cardiometabolic health: a systematic review and meta-analysis of intervention studies. *Br J Sports Med*. 2016;51(6):494–503.

[227] Milanović Z, Sporiš G, Weston M. Effectiveness of High-Intensity Interval Training (HIT) and Continuous Endurance Training for VO2max Improvements: A Systematic Review and Meta-Analysis of Controlled Trials. *Sport Med*. 2015;45(10):1469–81.

[228] Kessler HS, Sisson SB, Short KR. The potential for high-intensity interval training to reduce cardiometabolic disease risk. *Sport Med.* 2012;42(6):489–509.

[229] Kelley DE. Skeletal muscle fat oxidation: timing and flexibility are everything. *J Clin Invest*. 2005;115(7):1699–702.

[230] Davidson LE, Hudson R, Kilpatrick K, Kuk JL, McMillan K, Janiszewski PM, Lee S, Lam M, Ross R. Effects of exercise modality on insulin resistance and functional limitation in older adults: a randomized controlled trial. *Arch Intern Med*. 2009;26;169(2):122-31.

[231] Snowling NJ, Hopkins WG. Effects of different modes of exercise training on glucose control and risk factors for complications in type 2 diabetic patients: a meta-analysis. *Diabetes Care*. 2006; 29(11):2518- 2527.

In: Encyclopedia of Surgery (22 Volume Set)
Editors: Andreas Lehrer and Kristin Mueller
ISBN: 978-1-53618-329-0
© 2020 Nova Science Publishers, Inc.

Chapter 450

NEAR-INFRARED SPECTROSCOPY AS A TOOL TO DETECT CEREBRAL ISCHEMIA DURING CAROTID SURGERY

Bozidarka L. Zaric[1], Milan Obradovic[1], Dragana Unic-Stojanovic[2], Ayman El-Menyar[3], Hassan Al-Thani[3], Djordje Radak[2] and Esma R Isenovic[1,*]

[1]Institute of Nuclear Sciences Vinca, University of Belgrade, Laboratory of Radiobiology and Molecular Genetics, Mike Petrovica Alasa 12-14, Belgrade, Serbia
[2]Department of Vascular Surgery, Dedinje Cardiovascular Institute, Belgrade University
[3]Department of Trauma and Vascular Surgery, Hamad Medical Corporation, Doha, Qatar

ABSTRACT

The pathogenesis and progression of acute cerebral ischemia (CI) is a complex process involving oxidative stress. During CI, loss of oxygen occurs and the brain becomes unable to adapt to the resultant anaerobic metabolism. Also, levels of ATP (adenosine triphosphate) in the brain fall within few minutes and removal of metabolic products slows down. Reactive oxygen species (ROS) are involved in the irreversible disruption of the function of cellular macromolecules and the initiation of cellular signaling pathways after CI. There are two types of CI: focal ischemia (localized to specific regions of the brain) and global ischemia involving a larger area of the brain. In patients with carotid atherosclerotic disease, carotid endarterectomy (CEA) is the surgical procedure used to reduce the risk of stroke. During and after a CEA, cerebral monitoring is important in order to ensure appropriate and prompt management of perioperative complications such as stroke, embolization, dissection of the arterial wall and acute arterial occlusion. During cross-clamping of the internal carotid artery (ICA), prompt

* Corresponding Author's Email: isenovic@yahoo.com.

detection of cerebral hypoperfusion can guide surgeons to modify their surgery technique accordingly. Near-infrared spectroscopy (NIRS), a non-invasive monitoring method, allows continuous real-time monitoring of cerebral hemoglobin oxygen saturation (ScO_2) in a small area of the frontal cortex. This monitoring tool is based on the principle that some biological materials, including the skull, are relatively permeable to near-infrared light. This spectroscopic method is applied in many medical diagnostic fields.

Keywords: carotid endarterectomy, cerebral ischemia, neuromonitoring, near-infrared spectroscopy

1. CEREBRAL ISCHEMIA (CI)

Brain function relies on aerobic metabolism in order to meet its substantial energy needs and cerebral tissue is highly sensitive to brief periods of ischemia [1, 2]. Focal ischemia as a result of occlusion of an artery in the brain is the most common type of stroke [3]. A major artery obstruction usually causes tissue infarction with non-selective loss of cells including astrocytes, neurons, and oligodendrocytes in the affected parts of the brain, due to the disrupted mitochondrial function and release of apoptogenic proteins [4]. Different parts of the brain have different sensitivity thresholds for ischemic cell damage [1, 2]. Also, particular populations of neurons such as pyramidal CA1 neurons (CA refers to *cornu Ammon*, Latin for Ammons horn) are more sensitive to ischemia, as well as the hippocampus, while more resistant neurons are dentate granule neurons [1, 2]. The brain is in general very sensitive to oxygen deprivation; the parts such as the amygdala, prefrontal cortex, and hippocampus are structurally and biochemically sensitive to stress, however, these changes are mainly reversible [5].

Cerebral damage secondary to brain ischemia is multifactorial. The physiological, biochemical, genetic and molecular changes disturb brain normal activities through a degradation of cellular integrity mediated by calcium overload, apoptosis, ionic imbalance, oxidative stress and excitotoxicity mediated by glutamate [6-8]. These processes affect cell organelle function such as membranes, nuclei, lysosomes, endoplasmic reticulum, and mitochondria and leads to damage of vascular elements, glia cells and neurons [6]. Mitochondrial function in focal ischemia is disturbed by the impaired inflow of oxygen and glucose to the tissues and additionally modified by ischemia-induced changes in mitochondrial features [6, 9]. The limited ability of cells to synthesize adenosine triphosphate (ATP) leads to a deterioration of cellular responses to the activity of other damaging factors and can affect cell death pathways. In cases of CI, death and dysfunction of cerebral neurons and neurological defect can be repressed by size and location of the affected cerebral region [6, 8].

There is a critical level of brain tissue oxygen tension and blood flow [6]. The decrease in blood flow, either permanent or temporary, to a certain part of the brain induces ischemic brain changes [6]. It is well-known that time-dependent neuronal events are initiated by cerebral blood flow reduction [6, 10, 11]. Blood flow in the brain tissue is normally about 45 to 60 ml blood/100g/min [6]. The need for oxygen in the brain of an adult human compromise about 20% of the total oxygen requirement, whereas its relative size, is 2% of the total body size [12]. Glucose and ATP concentrations during the first 5 min of arterial occlusion fall

markedly [13]. Also, there is an imbalance in the levels of adenosine monophosphate (AMP), adenosine diphosphate (ADP) and ATP [4]. Cerebral phosphocreatine presents, for a brief time period, a source of energy that provides ATP production from ADP in a creatine kinase catalyzed reaction. In normal brain functioning creatine is synthesized in the brain and is used to form phosphocreatine in a reaction catalyzed by creatine kinase [14]. It has been documented that pretreatment with creatine improves severe anoxic or ischemic damage that is caused by anoxic depolarization which is a consequence of decreased of ATP and is mainly electrophysiological event [14]. Phosphocreatine may have a neuroprotective effect on focal cerebral ischemia-reperfusion (IR) injury which may be connected with apoptosis while phosphocreatine pretreatment alleviates neurobehavioral score and brain swelling [15].

After middle cerebral artery occlusion, a rapid deterioration of cellular energy state was observed (ATP content was lowered to 20-40% of control value) [13]. There are available data [16] which demonstrate that certain compounds, such as N-tert-Butyl-α-phenylnitrone, markedly improve recovery of the cerebral energy status after transient and focal ischemia. Reduced levels of cellular ATP during CI consequently cause the failure to maintain ionic gradients and the depolarization of neurons and other brain cells [6, 17]. Disturbed availability of ADP and AMP levels have the consequence of changing lactate concentrations and this is associated with rising extra- and intracellular pH values [13]. Energy in the brain is generated from glycolysis and oxidative phosphorylation [6]. Reduction of oxygen and glucose supply (by lowering ATP levels) leads to membrane depolarization and changes in the concentration gradients of Na^+ and K^+ across the plasma membrane resulting in activation of voltage-gated calcium channels [6]. This results in an excessive release of excitatory amino acids (in particular glutamate) to the extracellular space [6, 18].

Cerebral ischemia as a stress factor activates the hypothalamic-pituitary-adrenal (HPA) axis [19-21]. According to several reports, HPA axis activation is one of the first prominent responses to ischemic insult [19-21]. It was shown that increases in the HPA axis activity may cause a prolonged and considerable increase in the concentration of extracellular glutamate that is followed by the death of central neurons [6, 22-24]. Transient acute CI during the period of carotid artery cross-clamping, as part of carotid endarterectomy (CEA), may lead to an activation of the HPA axis with endocrine function abnormalities and hypermetabolic stress reaction [25, 26]. This reaction induces hemodynamic, inflammatory, metabolic and immunologic changes in order to maintain homeostasis and facilitate recovery [25].

Impaired neuronal function by an excessive release of glutamate at synapses activated by glutamate receptors represents a pathophysiological mechanism called excitotoxicity [22]. Excitotoxicity is described as cell death caused by excitatory amino acids [6], and these processes are essential for the development of CI [27, 28]. Excitotoxicity contributes to the synthesis of free radicals due to impaired mitochondrial function [6]. There is a high concentration of glutamate in the central nervous system (CNS), particularly in presynaptic regions of different hypothalamic nuclei [27]. Under physiological conditions, glutamate plays an important part in the modulation of neuroendocrine secretion [27, 29], while under pathophysiological conditions, such as CI, the role of glutamate in modulating stress reactions and hormone release has not been well-explained yet [27]. Poor functional outcomes have been reported following elevated catecholamine levels that, in turn, aggravate CI [21, 30].

Ischemic brain injury is characterized by several mechanisms that cause ionic imbalance, excitotoxicity, apoptosis and oxidative/nitrosative stresses resulting in cell death [31]. These

processes lead to disruption of membrane integrity, loss of cellular homeostasis and cell death by necrosis or apoptosis [31]. Numerous studies suggest that oxidative stress is a major occurrence that leads to cerebral damage induced by CI [6, 32-34]. During treatment of CI, there is a need to consider the relationship between metabolic rate, oxygen free radicals produced by metabolism and oxygen concentration [35].

2. CEA AND CI

The ideal sites for atherosclerosis generation are those of supra-aortic arteries, particularly regions at the carotid bifurcation, which may cause significant stenosis and may be the cause of acute CI, responsible for about 20% of all strokes [36-39]. There are different patterns of the progression of atherosclerotic disease i.e., it could be slow or remain stable for a long time [36]. The main aim of performing CEA is to prevent the development of potentially fatal embolic and thrombotic stroke. CEA is a well-established surgical procedure for carotid artery stenosis, during which plaques that are clogging the artery are removed [36]. CEA is an established procedure in individuals with high-grade stenosis of the carotid arteries but complications and adverse outcomes are possible and must be maintained at low levels. The main complications are major stroke and death [40, 41].

Carotid artery stenosis may cause a cerebral embolism, one of the 3 main causes of stroke. The obstructive material is most often a blood clot but it may be a fat globule, air bubble, tissue, or clump of bacteria. The efficacy of CEA has been proved to prevent stroke in patients with atherosclerotic carotid bifurcation stenosis [36, 38, 42]. The benefits of CEA in females without symptoms are significantly less than for men [36]. During the procedure of CEA, the surgeon opens the artery and removes the area of plaque. There is a newer minimally invasive procedure, endovascular stenting, that uses a balloon to expand the blood vessel followed by inserting a stent to maintain the patency of the site [43].

The benefits of CEA depend on the incidence of adverse neurological events during the intraoperative and postoperative period. Approximately 80% of strokes are due to ischemic changes [44]. One of the important surgical complications during CEA is hemorrhage or hyperperfusion syndrome due to the sudden increase in perfusion of vasculature distal to the site of the stenosis [45]. Also, during or after CEA, stroke may occur due to cerebral blood flow reduction and cerebral hypoperfusion throughout the period of cross-clamping of the internal carotid artery. Otherwise, the most common causes of the post-operative cerebral events include cerebral hyperperfusion syndrome (CHS) and thromboembolism. The development of thrombotic obstruction could be explained with increased and repeated accumulation of clotting factors, primarily fibrinogen, calcium and fatty deposits [46]. Observed lower levels of cerebral blood flow (range: 20-40% of reference values) may be tolerated for several hours with complete recovery of all functions after reperfusion [47]. Comorbidities such as heart failure and diabetes significantly increase the risk of unwanted complications during or after CEA [48].

Importantly, the degree of metabolic and endocrine reactions in response to the stress of surgery, have been reported to be proportional to the poor postoperative outcome because of potential adverse systemic effects, such as impaired oxygen supply-demand ratio, immune dysfunction and increased catabolism. Serum cortisol levels are proportional to the degree of

stress, and represent an endocrine and sympathetic nervous system response to stress [49 75]. This condition may be directly associated with possible CI during cross-clamping of the internal carotid artery [25].

3. NEAR-INFRARED SPECTROSCOPY (NIRS) IN CI AND CEA

3.1. NIRS in General

NIRS, first proposed by Jobsis in 1977, is a technique that enables the measurement of oxygen and deoxyhemoglobin concentration in the brain using light from the near-infrared spectrum which can penetrate the skull [50]. The first NIRS study in humans was published in 1985 by Ferrari and colleagues [51]. After the United States Food and Drug Administration (FDA) approval in 1993, the first commercially available NIRS device, INVOS 3100 was marketed [52]. Near-infrared light was then used to measure regional cerebral tissue oxygenation [52].

The application of NIRS is based on the fact that near-infrared light when passing through the skin and skull, may be absorbed by certain biological molecules in the brain [53]. These methods include a monitor and self-adhesive pads that consist of the detector and NIRS-emitting light source sensor. These self-adhesive pads are usually applied to the skin of the forehead for noninvasive measuring cerebral oxygenation. The emitted light may be absorbed, scattered, reflected or redirected. Proteins such as hemoglobin, cytochrome, and bilirubin are the primary light-absorbing molecules in tissue. The light spectrum changes in contact with hemoglobin molecules and these changes are directly proportionate to the level of hemoglobin oxygenation. According to the Lambert-Beer law, measurement of tissue hemoglobin oxygen saturation is determined by the difference in intensity between a transmitted and received light delivered at specific wavelengths [52]. The intensity of transmitted light depends on the concentration of the substance through which the light passes as well as the distance between the light source and the absorbing substance. The amount of light detected by the photodetector decreases with increasing the concentration of chromophores, and with the increasing distance light travels through a substance. According to the Lambert-Beer law, the distance that a light passes between the transmitting source and detector, the concentration of chromophore as well as the absorption coefficient of the chromophore are the main determinants of the absorption level of the emitted light [52].

Cerebral NIRS devices are designed to measure average tissue oxygen saturation and to provide information about hemoglobin saturation in venous, capillary and arterial blood. For the cerebral cortex, average tissue hemoglobin is distributed in a proportion of 70% venous and 30% arterial, based on correlations between positron emission tomography and NIRS [54]. NIRS-based cerebral oximetry measures the percentage of the oxygenated chromophore hemoglobin to total hemoglobin (including oxygenated and deoxygenated hemoglobin), expressed as cerebral tissue oxygen saturation (ScO_2), in the area about 2 cm below the scalp. This method basically uses the fact that oxygenated (HbO_2) and deoxygenated hemoglobin absorption properties are different: oxygenated hemoglobin absorbs less red light at wavelength 600-750 nm and more infrared light at wavelength 850-1000 nm, compared with deoxygenated hemoglobin that absorbs light at wavelength 740 nm [55]. Usually, two

detectors and emitter are used: the proximal detector detects photons reflected from superficial tissues (bone and extra-cerebral tissue) and the distal one detects those from deeper tissues. The space between the sensor and light source is one of the determinants of the spatial resolution of the emitted light. After "banana-shaped" course of the light, from the emitter to the detector, the monitor using the appropriate algorithms, differentiates the two forms of oxygenated and deoxygenated hemoglobin in order to determine the regional cerebral tissue oxygen saturation (ScO_2) in the frontal lobes [56].

There are several approved NIRS devices including the following: (INVOS™, Somanetics/Covidien, Inc, Boulder, CO; EQUANOX™, Nonin Medical Inc, Plymouth, MN; FORE-SIGHT™, CAS Medical Systems, Branford, CN; NIRO, Hamamatsu Photonics, Hamamatsu City, Japan; CerOx™, Ornim Medical, Lod, Isreal; the TOS-96, Tostec, Tokyo, Japan) [57]. NIRS is easily applicable in all patients at low cost because it provides information about cerebral oxygenation without the need for specialized personnel. NIRS has also been applied in cardiac surgery where it provides valuable information that might lead to reduced neurologic complications and improved patient outcomes [58]. Nevertheless, the clinical application of NIRS has concerns like oversampling volume and sources of extracranial contamination. Commercially available equipment employs principles of optical attenuation from several wavelengths of light by 3 different spectroscopy principles: time-resolved, phase-resolved and spatially resolved spectroscopy. Quantification is enabled by various algorithms [59]. NIRS may be used at different sites for measuring oxygen saturation. Non-invasive cerebral oximetry uses NIRS for the measurement of regional oxygen saturation in the frontal lobe, which includes an area of the brain which is most prone to hypoxemia as a watershed area between the anterior and middle cerebral artery territories. ScO_2 is primarily an indicator of the equilibrium between cerebral oxygen supply and demand. The obtained value provides information about cerebral tissue saturation. Although, venous blood may represent on average 70-75% of the volume of the total blood in the measured brain tissue in the frontal lobe, there is inter-individual variability in measured regional ScO_2 [60].

3.2. NIRS in CEA

It is crucial to evaluate cerebral blood flow during CEA, but it remains challenging to correctly evaluate cerebral blood flow in the operating room. Recently, a high accuracy NIRS has enabled precise cerebral blood flow estimation following injection of indocyanine green (ICG) [61]. NIRS together with indocyanine green kinetics measurement (NIRS-ICG) can predict the development of postoperative hyperperfusion (CHP) in patients who underwent CEA and carotid artery stenting [62]. Most patients undergoing CEA have sufficient intra-cerebral collateral blood flow to tolerate clamping of one of the carotid arteries. In subjects with poor circulation, the risk of CI can be reduced by shunt placement. However, placement of the shunt is sometimes technically difficult and may carry a risk of arterial dissection, shunt thrombosis or air embolism [63, 64]. Shunt placement is more complicated in patients under general anesthesia (GA) where there is no possibility of monitoring neurological function. In that case, surrogate markers are normally used [65]. Stump pressure (SP) is a widely used method but the cutoff pressure when shunting is necessary is still matter of debate and various thresholds have been proposed [66].

NIRS has sufficient sensitivity and specificity in predicting CI and the need for hemodynamic optimization and shunt placement making it an alternative to SP measurement [65]. Blood pressure augmentation and perfusion improving via collateral circulation have inter-individual variability and is difficult to determine in advance of surgery.

There are numerous devices applicable for cerebral function monitoring, aiming for timely detection of CI during and after surgery [67]. The monitoring tool should provide information about adequate brain perfusion, oxygenation, and neurophysiological function, especially during carotid clamping and shunting. Intraoperative monitoring is useful as guiding technique (for selective usage of shunting) and anesthesia (correction of arterial blood pressure, partial pressure of carbon dioxide in arterial blood ($PaCO_2$), systemic arterial oxygen saturation, cardiac output (CO), hemoglobin concentration), while monitoring during postoperative period provides fast reaction, if the signs of either increased or decreased, cerebral blood flow are present [68]. In one study included 60 patients undergoing CEA [59] , there was a significant correlation between changes in regional cerebral oxygenation and changes in Transcranial Doppler (TCD) measured cerebral blood flow velocity ($r = 0.56$, $p < 0.0001$) during internal carotid artery clamping. This study supports the reliability of NIRS in detecting changes in cerebral oxygenation. There was no correlation between skin laser Doppler flow velocity and cerebral tissue oxygenation during external carotid artery clamping. The sensitivity of NIRS measured cerebral tissue oxygenation for detecting intracranial and extracranial flow changes was 87.5% and 0%, respectively. The specificity of these measurements were 100% and 0%, respectively [59]. Another study involved 596 patients who underwent CEA under GA reported that an 11.7% (cutoff point of 12% decrease in ScO_2) decrease from baseline in ScO_2 had a sensitivity of 75% and a specificity of 77% with a positive predictive value of 37% and a negative value of 98% for detecting neurological complications [69].

NIRS still has some limitations such as a lack of published data if it can detect embolic insult [69] which represents a significant factor in determining patient outcome. Advantages of using NIRS during CEA is real-time measurement, noninvasiveness and simplicity of use. We conclude that NIRS is a reasonable choice for monitoring cerebral hypoperfusion during and after CEA.

3.3. Other Methods for Monitoring Cerebral Function during and after CEA

During CEA surgery, carotid artery cross-clamping and temporary cessation of cerebral blood flow are tolerated, but in some patients with decreased collateral perfusion through insufficient blood flow via the circle of Willis, CI may still develop. Shunt insertion may prevent cerebral hypoperfusion during carotid clamping. For patients undergoing CEA surgery under GA, there is no clear recommendation for using a shunt during carotid artery cross-clamping. Based on results of cerebral perfusion, surgeons are able to give the proper recommendation about the application of shunt [70-73]. Shunting represents a risk for possible adverse effects such as intimal damage or dissection, distal embolization and acute occlusion. So, selective shunting may be a better choice over routine shunting [74]. During CEA cross-clamping, monitoring of cerebral perfusion and function may be performed by the using various methods, including electroencephalography (EEG), transcranial Doppler (TCD), measurement of the stump pressure (SP, the blood pressure measured in the internal

carotid artery distal to the cross clamp), somatosensory evoked potentials (SSEPs), regional cerebral oxygen saturation monitoring (NIRS - ScO_2) or direct neurological monitoring of the awake patient during carotid cross-clamping.

The measurement of evoked potentials and electroencephalography (EEG) are a useful technique for neurophysiological function monitoring; SP measurements and TCD provide information about hemodynamic status, and NIRS provides data on cerebral oxygenation status and balance between regional O_2 supply and demand [58]. Each monitoring technique has its strengths and weaknesses. The main advantage of performing surgery under local anesthesia is that the patient is awake during carotid artery cross-clamping, providing direct neurological monitoring with less shunt use which is accepted as "gold standard" [57]. This type of neurological monitoring has certain disadvantages in cases of a patient that is non-cooperative, claustrophobic, with neurologic diseases, or unable to remain still and follow instructions. A meta-analysis reported that the best neurological monitoring and brain function assessment was found by the combined use of SP and either EEG or TCD [75]. Although these methods are associated with the highest sensitivity and specificity for cerebral ischemia detection, there are difficulties with their application in clinical practice because they require special skills. TCD measures local blood flow velocity in a cerebral artery and is useful for correct diagnosis of hypoperfusion, thrombosis, hyperperfusion or embolic load. The interpretation of TCD results depends on who performs the test. TCD cannot be used in about 15-20% patients due to the lack of a transtemporal window attributed to temporal hyperostosis [76]. Also, there is a high risk of dislocation of the TCD probe due to proximity of the surgical field. GA and surgical diathermy may change SSEPs and EEG signals and may cause wrong diagnosis [52]; this is a disadvantage of these 2 techniques. For EEGs an experienced team is required for correct readings. Another disadvantage is that this method of monitoring is time-consuming. Measurement of SP after carotid artery clamping is also a useful method for cerebral blood flow assessment, but it is not widely accepted because it presents a discontinuous monitoring variable that cannot detect ischemia developing later during the performance of the arterectomy [52] and the results are affected by arterial pressure, partial pressure of carbon dioxide, type of anesthetic agent and the other factors [52].

Moritz and colleagues [77] conducted a prospective study (48 patients were included) with a goal of comparing the accuracy and efficiency of different neurological monitoring techniques in detecting cerebral ischemia during CEA. They compared the results of TCD, SEP, NIRS, EEG monitoring and SP, with awake clinical monitoring as the gold standard of monitoring of the level of cerebral perfusion during arterial clamping. NIRS, TCD and stump pressure exhibited similar accuracy, while SSEPs monitoring is least accurate in the detection of the onset of ischemia. The main disadvantage of this analysis is that monitoring of the level of cerebral perfusion and function during arterial clamping during CEA is particularly useful in patients operated under GA while in the Moritz et al. study surgery was performed under LA [77].

A recently published systematic review included 6 randomized controlled studies, involving 1270 patients, that compared routine shunting with selective shunting and no shunting in patients undergoing CEA [78].

CONCLUSION

Cerebral monitoring during CEA provides useful information regarding changes in cerebral blood flow and cerebral function, which might otherwise be missed. NIRS is a non-invasive monitoring method that may provide useful information on the most appropriate management during the procedure and postoperative recovery period. Currently, NIRS is used in many centers as the primary cerebral monitor during carotid surgery, not only for decision-making about the placement of a shunt but also to manage systemic physiological variables in order to optimize cerebral perfusion and oxygenation. In this chapter, we present the literature related to NIRS and its practical use, evaluation and reliability for the detection of clamping ischemia and in the prevention of clamping-related neurologic deficits. However, there is a need for large scale randomized trials to support these observations.

ACKNOWLEDGMENTS

This work is supported by grant No. 173033 (to E.R.I.) and No. 41002 (Dj.R) from the Ministry of Science, Republic of Serbia.

REFERENCES

[1] Mattson, MP; Duan, W; Pedersen, WA; Culmsee, C. Neurodegenerative disorders and ischemic brain diseases. *Apoptosis*, 2001, 6, 69-81.

[2] Woodruff, TM; Thundyil, J; Tang, SC; et al. Pathophysiology, treatment, and animal and cellular models of human ischemic stroke. *Mol Neurodegener*, 2011, 6, 11.

[3] Smith, EE. Cerebral Amyloid Angiopathy as a Cause of Neurodegeneration. *J Neurochem*, 2017, 21, 14157.

[4] Sims, NR; Muyderman, H. Mitochondria, oxidative metabolism and cell death in stroke. *Biochim Biophys Acta*, 2010, 1, 80-91.

[5] Andrew, S; James, L. Vasopressin and its role in critical care. *Oxford Journals*, 2008, 8, 134-13.

[6] Breton, RR; Rodríguez, JCG. editors. Excitotoxicity and Oxidative Stress in Acute Ischemic Stroke, *Acute Ischemic Stroke: InTech*, 2012.

[7] Moustafa, RR; Baron, JC. Pathophysiology of ischaemic stroke: insights from imaging, and implications for therapy and drug discovery. *Br J Pharmacol*, 2008, 153, S44-S54.

[8] Lo, EH; Dalkara, T; Moskowitz, MA. Mechanisms, challenges and opportunities in stroke. *Nat Rev Neurosci*, 2003, 4, 399-415.

[9] Lee, DR; Helps, SC; Macardle, PJ; Nilsson, M; Sims, NR. Alterations in membrane potential in mitochondria isolated from brain subregions during focal cerebral ischemia and early reperfusion: evaluation using flow cytometry. *Neurochem Res*, 2009, 34, 1857-66.

[10] Erecinska, M; Silver, IA. Tissue oxygen tension and brain sensitivity to hypoxia. *Respir Physiol*, 2001, 128, 263-76.

[11] Heiss, WD. Flow thresholds of functional and morphological damage of brain tissue. *Stroke*, 1983, 14, 329-31.

[12] Markus, HS. Cerebral perfusion and stroke. *J Neurol Neurosurg Psychiatry*, 2004, 75, 353-61.

[13] Folbergrova, J; Memezawa, H; Smith, ML; Siesjo, BK. Focal and perifocal changes in tissue energy state during middle cerebral artery occlusion in normo- and hyperglycemic rats. *J Cereb Blood Flow Metab*, 1992, 12, 25-33.

[14] Balestrino, M; Lensman, M; Parodi, M; et al. Role of creatine and phosphocreatine in neuronal protection from anoxic and ischemic damage. *Amino Acids*, 2002, 23, 221-9.

[15] Li, T; Wang, N; Zhao, M. Neuroprotective effect of phosphocreatine on focal cerebral ischemia-reperfusion injury. *J Biomed Biotechnol*, 2012, 168756, 13.

[16] Folbergrova, J; Zhao, Q; Katsura, K; Siesjo, BK. N-tert-butyl-alpha-phenylnitrone improves recovery of brain energy state in rats following transient focal ischemia. *Proc Natl Acad Sci U S A*, 1995, 92, 5057-61.

[17] Hansen, AJ; Nedergaard, M. Brain ion homeostasis in cerebral ischemia. *Neurochem Pathol*, 1988, 9, 195-209.

[18] Rothman, SM; Olney, JW. Glutamate and the pathophysiology of hypoxic--ischemic brain damage. *Ann Neurol*, 1986, 19, 105-11.

[19] Neidert, S; Katan, M; Schuetz, P; et al. Anterior pituitary axis hormones and outcome in acute ischaemic stroke. *J Intern Med*, 2011, 269, 420-32.

[20] Olsson, T; Marklund, N; Gustafson, Y; Nasman, B. Abnormalities at different levels of the hypothalamic-pituitary-adrenocortical axis early after stroke. *Stroke*, 1992, 23, 1573-6.

[21] Fassbender, K; Schmidt, R; Mossner, R; Daffertshofer, M; Hennerici, M. Pattern of activation of the hypothalamic-pituitary-adrenal axis in acute stroke. Relation to acute confusional state, extent of brain damage, and clinical outcome. *Stroke*, 1994, 25, 1105-8.

[22] Choi, DW; Rothman, SM. The role of glutamate neurotoxicity in hypoxic-ischemic neuronal death. *Annu Rev Neurosci*, 1990, 13, 171-82.

[23] Dirnagl, U; Iadecola, C; Moskowitz, MA. Pathobiology of ischaemic stroke: an integrated view. *Trends Neurosci*, 1999, 22, 391-7.

[24] Lipton, P. Ischemic cell death in brain neurons. *Physiol Rev*, 1999, 79, 1431-568.

[25] Marrocco-Trischitta, MM; Tiezzi, A; Svampa, MG; et al. Perioperative stress response to carotid endarterectomy: the impact of anesthetic modality. *J Vasc Surg*, 2004, 39, 1295-304.

[26] Wilmore, DW. editor. *Homeostasis* (bodily changes in trauma and surgery). 14th ed. Philadelphia: WB Saunders, 1991.

[27] He, M; Chen, M; Wang, J; et al. Relationship between glutamate in the limbic system and hypothalamus-pituitary-adrenal axis after middle cerebral artery occlusion in rats. *Chin Med J (Engl)*, 2003, 116, 1492-6.

[28] Milton, SL; Thompson, JW; Lutz, PL. Mechanisms for maintaining extracellular glutamate levels in the anoxic turtle striatum. *Am J Physiol Regul Integr Comp Physiol*, 2002, 282, R1317-23.

[29] Yan, P; Xu, J; Li, Q; et al. Glucocorticoid receptor expression in the spinal cord after traumatic injury in adult rats. *J Neurosci*, 1999, 19, 9355-63.

[30] Sander, D; Winbeck, K; Klingelhofer, J; Etgen, T; Conrad, B. Prognostic relevance of pathological sympathetic activation after acute thromboembolic stroke. *Neurology*, 2001, 57, 833-8.

[31] Kanekar, SG; Zacharia, T; Roller, R. Imaging of stroke: Part 2, Pathophysiology at the molecular and cellular levels and corresponding imaging changes. *AJR Am J Roentgenol*, 2012, 198, 63-74.

[32] Siesjo, BK; Zhao, Q; Pahlmark, K; et al. Glutamate, calcium, and free radicals as mediators of ischemic brain damage. *Ann Thorac Surg*, 1995, 59, 1316-20.

[33] Lin, MT; Beal, MF. Mitochondrial dysfunction and oxidative stress in neurodegenerative diseases. *Nature*, 2006, 443, 787-95.

[34] Niizuma, K; Endo, H; Chan, PH. Oxidative stress and mitochondrial dysfunction as determinants of ischemic neuronal death and survival. *J Neurochem*, 2009, 109 Suppl 1, 133-8.

[35] Cherubini, A; Polidori, C; Benedetti, C; et al. Association Between Ischemic Stroke and Increased Oxidative Stress. *2nd Virtual Congress of Cardiology Argentine Federation of Cardiology*; 2nd Virtual Congress of Cardiology.

[36] Liapis, CD; Bell, PR; Mikhailidis, D; et al. ESVS guidelines. Invasive treatment for carotid stenosis: indications, techniques. *Eur J Vasc Endovasc Surg*, 2009, 37, 1-19.

[37] Inzitari, D; Eliasziw, M; Gates, P; et al. The causes and risk of stroke in patients with asymptomatic internal-carotid-artery stenosis. North American Symptomatic Carotid Endarterectomy Trial Collaborators. *N Engl J Med*, 2000, 342, 1693-700.

[38] Barnett, HJ; Taylor, DW; Eliasziw, M; et al. Benefit of carotid endarterectomy in patients with symptomatic moderate or severe stenosis. North American Symptomatic Carotid Endarterectomy Trial Collaborators. *N Engl J Med*, 1998, 339, 1415-25.

[39] Bogousslavsky, J; Van Melle, G; Regli, F. The Lausanne Stroke Registry: analysis of 1,000 consecutive patients with first stroke. *Stroke*, 1988, 19, 1083-92.

[40] Barnett, HJM; Taylor, DW; Haynes, RB; et al. Beneficial effect of carotid endarterectomy in symptomatic patients with high-grade carotid stenosis. *N Engl J Med*, 1991, 325, 445-53.

[41] MRC European Carotid Surgery Trial: interim results for symptomatic patients with severe (70-99%) or with mild (0-29%) carotid stenosis. European Carotid Surgery Trialists' Collaborative Group. *Lancet*, 1991, 337, 1235-43.

[42] Risk of stroke in the distribution of an asymptomatic carotid artery. The European Carotid Surgery Trialists Collaborative Group. *Lancet*, 1995, 345, 209-12.

[43] Ederle, J; Dobson, J; Featherstone, RL; et al. Carotid artery stenting compared with endarterectomy in patients with symptomatic carotid stenosis (International Carotid Stenting Study): an interim analysis of a randomised controlled trial. *Lancet*, 2010, 375, 985-97.

[44] Donnan, GA; Fisher, M; Macleod, M; Davis, SM. Stroke. *Lancet*, 2008, 371, 1612-23

[45] van Mook, WN; Rennenberg, RJ; Schurink, GW; et al. Cerebral hyperperfusion syndrome. *Lancet Neurol*, 2005, 4, 877-88.

[46] Shahar, E; Chambless, LE; Rosamond, WD; et al. Plasma lipid profile and incident ischemic stroke: the Atherosclerosis Risk in Communities (ARIC) study. *Stroke*, 2003, 34, 623-31.

[47] Lakhan, SE; Kirchgessner, A; Hofer, M. Inflammatory mechanisms in ischemic stroke: therapeutic approaches. *J Transl Med*, 2009, 7, 97.

[48] Tu, JV; Wang, H; Bowyer, B; et al. Risk factors for death or stroke after carotid endarterectomy: observations from the Ontario Carotid Endarterectomy Registry. *Stroke*, 2003, 34, 2568-73.

[49] Fareau, GG; Vassilopoulou-Sellin, R. Hypercortisolemia and infection. *Infect Dis Clin North Am*, 2007, 21, 639-57.

[50] Jobsis, FF. Noninvasive, infrared monitoring of cerebral and myocardial oxygen sufficiency and circulatory parameters. *Science*, 1977, 198, 1264-7.

[51] Ferrari, M; Giannini, I; Sideri, G; Zanette, E. Continuous non invasive monitoring of human brain by near infrared spectroscopy. *Adv Exp Med Biol*, 1985, 191, 873-82.

[52] Murkin, JM; Arango, M. Near-infrared spectroscopy as an index of brain and tissue oxygenation. *Br J Anaesth*, 2009, 103.

[53] Fischer, GW; Silvay, G. Cerebral oximetry in cardiac and major vascular surgery. *HSR Proc Intensive Care Cardiovasc Anesth*, 2010, 2, 249-56.

[54] McCormick, PW; Stewart, M; Goetting, MG; Balakrishnan, G. Regional cerebrovascular oxygen saturation measured by optical spectroscopy in humans. *Stroke*, 1991, 22, 596-602.

[55] Casati, A; Spreafico, E; Putzu, M; Fanelli, G. New technology for noninvasive brain monitoring: continuous cerebral oximetry. *Minerva Anestesiol*, 2006, 72, 605-25.

[56] Vretzakis, G; Georgopoulou, S; Stamoulis, K; et al. Cerebral oximetry in cardiac anesthesia. *J Thorac Dis*, 2014, 6, 2072-1439.

[57] So, VC; Poon, CC. Intraoperative neuromonitoring in major vascular surgery. *Br J Anaesth*, 2016, 117.

[58] Pennekamp, CW; Immink, RV; den Ruijter, HM; et al. Near-infrared spectroscopy to indicate selective shunt use during carotid endarterectomy. *Eur J Vasc Endovasc Surg*, 2013, 46, 397-403.

[59] Al-Rawi, PG; Smielewski, P; Kirkpatrick, PJ. Evaluation of a near-infrared spectrometer (NIRO 300) for the detection of intracranial oxygenation changes in the adult head. *Stroke; a journal of cerebral circulation*, 2001, 32, 2492-500.

[60] Yu, Y; Lu, Y; Meng, L; Han, R. Monitoring cerebral ischemia using cerebral oximetry: pros and cons. *J Biomed Res*, 2015, 28, 20150096.

[61] Kato, S; Yoshitani, K; Ohnishi, Y. Cerebral Blood Flow Measurement by Near-Infrared Spectroscopy During Carotid Endarterectomy. *J Neurosurg Anesthesiol*, 2016, 28, 291-5.

[62] Nakagawa, I; Park, HS; Yokoyama, S; et al. Indocyanine green kinetics with near-infrared spectroscopy predicts cerebral hyperperfusion syndrome after carotid artery stenting. *PLoS One*, 2017, 12.

[63] Connolly, JE; Kwaan, JH; Stemmer, EA. Improved results with carotid endarterectomy. *Ann Surg*, 1977, 186, 334-42.

[64] Green, RM; Messick, WJ; Ricotta, JJ; et al. Benefits, shortcomings, and costs of EEG monitoring. *Ann Surg*, 1985, 201, 785-92.

[65] Jonsson, M; Lindstrom, D; Wanhainen, A; Djavani Gidlund, K; Gillgren, P. Near Infrared Spectroscopy as a Predictor for Shunt Requirement During Carotid Endarterectomy. *Eur J Vasc Endovasc Surg*, 2017, 53, 783-91.

[66] Calligaro, KD; Dougherty, MJ. Correlation of carotid artery stump pressure and neurologic changes during 474 carotid endarterectomies performed in awake patients. *J Vasc Surg*, 2005, 42, 684-9.

[67] Radak, D; Sotirovic, V; Obradovic, M; Isenovic, ER. Practical use of near-infrared spectroscopy in carotid surgery. *Angiology*, 2014, 65, 769-72.
[68] O'Brien, MS; Ricotta, JJ. Postoperative treatment of patients undergoing carotid endarterectomy. *J Vasc Nurs*, 1994, 12, 1-5.
[69] Mille, T; Tachimiri, ME; Klersy, C; et al. Near infrared spectroscopy monitoring during carotid endarterectomy: which threshold value is critical? *Eur J Vasc Endovasc Surg*, 2004, 27, 646-50.
[70] Bond, R; Rerkasem, K; Counsell, C; et al. Routine or selective carotid artery shunting for carotid endarterectomy (and different methods of monitoring in selective shunting). *Cochrane Database Syst Rev*, 2002, 2.
[71] Bellosta, R; Luzzani, L; Carugati, C; Talarico, M; Sarcina, A. Routine shunting is a safe and reliable method of cerebral protection during carotid endarterectomy. *Ann Vasc Surg*, 2006, 20, 482-7.
[72] Roseborough, GS. Pro: Routine shunting is the optimal management of the patient undergoing carotid endarterectomy. *J Cardiothorac Vasc Anesth*, 2004, 18, 375-80.
[73] Nguyen, TQ; Lind, L; Harris, EJ. Jr. Selective shunting during carotid endarterectomy. *Vascular*, 2005, 13, 23-7.
[74] Karasu, A; Kuscu, DY; Bakac, G; et al. Carotid endarterectomy with regional anesthesia: an audit of 71 cases. *Turk Neurosurg*, 2009, 19, 21-8.
[75] Guay, J; Kopp, S. Cerebral monitors versus regional anesthesia to detect cerebral ischemia in patients undergoing carotid endarterectomy: a meta-analysis. *Can J Anaesth*, 2013, 60, 266-79.
[76] Grubhofer, G; Plochl, W; Skolka, M; et al. Comparing Doppler ultrasonography and cerebral oximetry as indicators for shunting in carotid endarterectomy. *Anesth Analg*, 2000, 91, 1339-44.
[77] Moritz, S; Kasprzak, P; Arlt, M; Taeger, K; Metz, C. Accuracy of cerebral monitoring in detecting cerebral ischemia during carotid endarterectomy: a comparison of transcranial Doppler sonography, near-infrared spectroscopy, stump pressure, and somatosensory evoked potentials. *Anesthesiology*, 2007, 107, 563-9.
[78] Chongruksut, W; Vaniyapong, T; Rerkasem, K. Routine or selective carotid artery shunting for carotid endarterectomy (and different methods of monitoring in selective shunting). *Cochrane Database Syst Rev*, 2014, 23.

BIOGRAPHICAL SKETCH

Prof. Dr. Esma R. Isenovic

Affiliation:

Vinca Institute of Nuclear Sciences, University of Belgrade, Laboratory of Radiobiology and Molecular Genetics, Mike Petrovica Alasa 12-14, Belgrade, Serbia

Education:

- Post-doctoral fellow. Hypertension and Research Division, Henry Ford Hospital, Detroit, Michigan, USA; 1998-2000.

- Post-doctoral visiting scientist , Metabolic Research Unit, University of California, San Francisco, CA, USA; 1997-1997.
- Ph.D. (Molecular Biology), Faculty of Biology, University of Belgrade, Yugoslavia; 1992-1996.
- M.Sci. (Molecular Biology), Faculty of Natural Sciences and Mathematics, University of Belgrade, Yugoslavia; 1987-1992.
- B.Sc. (General Biology), Faculty of Natural Sciences and Mathematics, University of Belgrade, Yugoslavia; 1982-1987.

Business Address:

Vinca Institute of Nuclear Sciences, University of Belgrade, Laboratory of Radiobiology and Molecular Genetics, Mike Petrovica Alasa 12-14, Belgrade, Serbia

Research and Professional Experience:

- Visiting Professor, University of St Andrews, School of Medicine, St. Andrews, Scotland, UK, 2013-2013.
- Visiting Professor, The Pharmaceutical Research Institute at Albany, Albany College of Pharmacy and Health Sciences, One Discovery Drive, Rensselaer, New York 12144, 2010-2010.
- Visiting Professor , CNRS UMR 7131 & Univ Pierre and Marie Curie, Hôpital Broussais, Paris, France; CNRS UMR 7131 & Univ Pierre and Marie Curie, Hôpital Broussais, Paris, France ; 2006., 2007., 2008., 2009., 2012.
- Visiting Professor, CNRS UMR 7131 & Univ Pierre and Marie Curie, Hôpital Broussais, Paris, France;.
- Visiting scientist, Institute of Pathological Physiology, University of Ljubljana, Laboratory for Neuroendocrinology- Molecular Cell Physiology, Ljubljana, Slovenia; 2005-2005.
- Tenure-truck position-Associate Professor (Research), Institute Vinca, Belgrade, Department for Radioisotopes, Serbia; 2004-2006. Research Assistant Professor, Principal Research Scientist, Department of Medicine, SUNY-HSC at Brooklyn, Brooklyn, NY, USA; 2000-2003.
- Tenure-track position-Assistant Professor (Research), Institute Vinca, Department for radioisotopes, Belgrade, Serbia; 1998-2003.
- Research Scientist, Institute Vinca, and Department for molecular biology and endocrinology, Belgrade, Serbia; 1998-2000.
- Postgraduate fellowship, Centre International de Formation en Biotechnologie, Bussières-Badil, France, 1990-1990.

Professional Appointments:

- Visiting Research Professor, The Pharmaceutical Research Institute at Albany, Albany College of Pharmacy and Health Sciences, One Discovery Drive, Rensselaer, New York 12144, 2014-current
- Director of Laboratory for Molecular genetics and Radiobiology, Institute Vinca, University of Belgrade, Belgrade, Serbia, January 2014-current

- Professor of Biochemistry (tenure), Faculty of Stomatology in Pančevo, University Business Academy, Novi Sad, Serbia, 2014- current
- Associate Dean for Science, Faculty of Stomatology in Pančevo, University Business Academy, Novi Sad, Serbia, 2014-current
- Deputy Director of Institute Vinca, Belgrade, Serbia, January-December 2013.
- Professor of Molecular Endocrinology, Course for Doctoral students, Faculty of Biology, University of Belgrade, 2012-current
- Professor (Research) Institute Vinca, 2007-current
- Visiting Research Assistant Professor, University of Illinois at Chicago, Department of Medicine, Chicago, USA, 2006¬2007
- Tenure position-Professor (Research), Head of Laboratory for Endocrinology, Hypertension and Metabolic Diseases, Institute Vinca, Department of Molecular genetics and radiobiology, Belgrade, Serbia; 2007.- current.
- Associate Professor of Research; Institute Vinca Belgrade, 2004-2006.
- Assistant Professor of Research Department of Medicine, SUNY-HSC at Brooklyn, Brooklyn, NY; 2000-2003.
- Instructor for Biochemistry Course, Faculty of Natural Science, Group for Molecular Biology, University of Belgrade, Yugoslavia 1986-1987.
- Teaching assistant for Biochemistry Course, Faculty of Natural Science, Group for Molecular Biology, University of Belgrade, Yugoslavia; 1986-1987.

Honors:

- Award for the best senior scientist in 2015. Institute Vinca, University of Belgrade
- Deutscher Akademischer Austauschdienst-DAAD Fellowship, 2011.
- The first prize –The best presentation of the best technological innovation. Ministry of Sciences Serbia; 2008.
- Award for the workshop-Training-Planning of Business, Republic of Serbia; 2006.
- Competency based Economies through Formation of Enterprise (CEFE) supported by German Center for Technical Cooperation-Award for CEFE training-Manager (completed 1st module of training), 2005.
- European co-operations in the field of scientific and technical research-COST. Grant Award for short-term scientific mission (STMS), 2005.
- NIH postdoctoral fellowship. NIH, USA; 1998.
- Foundation for Open Society “George Soros “International Conference of Biochemistry and Molecular Biology, San Francisco, CA; Travel Award, 1996.
- International Center for Genetic Engineering and Biotechnology, China National Center for Biotechnology, Development, Beijing, China; Scholarship for postgraduate education, 1995.
- Centre International de Formation en Biotechnologies, Bussiere-Badil, France; Scholarship for postgraduate education, 1990.

Publications Last 3 Years (2015-2017):

Chapters:

(1) Ivana Resanovic, Milan Obradovic, Julijana Stanimirovic, Desanka Cenic-Milosevic, Branislava Vukovic, Djordje Radak, Esma R. Isenovic (2017): Nitric oxide and abdominal aortic aneurysm, in book: *"Advances in Medicine and Biology*" (Editor: Leon V. Berhardt), Volume 119, p. 219-248. ISBN: 9781536111057 Nova Science Publishers Inc. New York.

(2) Milan Perovic, Miroslava Gojnic Dugalic, Milan Obradovic, Esma R. Isenovic (2017): Ultrasonography: contemporary and supplementary screening method for gestational diabetes, in book: "*Gestational Diabetes: Risk Factors, Management and Outcomes*" (Editor: Irene Coleman), p117-p134, ISBN:978-1-53610-786-9, Nova Science Publishers Inc, New York.

(3) Mohamed Abdel Aleem Haidara, Milan Obradovic, Emina Sudar-Milovanovic, Anastasija Panic, Milan Perovic, Desanka Cenic-Milosevic, Ema Aleksic, Jasmina Milic, Hanaa Zaki Yassin, Bahjat Al-Ani, and Esma R. Isenovic (2017): The Protective Effects of the Primary Female Sex Hormone Estradiol, in book: "*Estradiol: Synthesis, Functions and Effectiveness*" (Editor: Lindsey Henderson), 33-68, ISBN 978-1-53612-322-7. Nova Science Publisher Inc, New York.

(4) Milan Obradovic, Julijana Stanimirovic, Anastasija Panic, Bozidarka Zaric, Esma R. Isenovic (2016): NA+/K+-ATPase, Sodium/potassium-adenosine triphosphatase, in book: "*Encyclopedia of Signaling Molecules*", 2nd Edition, (Editor: Sangdun Choi); p-1-6, ISBN-978-1-4614-6438-9; Springer, New York.

(5) Andreja Trpkovic, Milan Obradovic, Nina Petrovic, Radoslav Davidovic, Emina Sudar-Milovanovic, Esma R. Isenovic (2016): CRP, C reactive protein, in book: "*Encyclopedia of Signaling Molecules*", 2nd Edition, (Editor: Sangdun Choi); p 1-5, ISBN-978-1-4614-6438-9, Springer New York.

(6) Milica M. Labudović Borović, Milan M. Obradović, Jelena T. Kostić, Ivan V. Zaletel, Dejan G. Milašinović, Marija Stojanović, Slavica S. Mutavdžin, Milena Vesković, Dragan Opačić, Dejan Radaković, Nela S. Puškaš, Tatjana S. Radosavljević, Saša D. Borović, Zvezdana Z. Kojić, Ljiljana Šćepanović, Božidarka Zarić, Esma R. Isenović (2016): Myocardial Na^+ K^+-ATPase and SERCA: Clinical and Pathological Significance From a Cytological Perspective, in book: "Regulation of Membrane Na, K ATPase" (Editors: Sajal Chakraborti and Naranjan S. Dhalla) under the Series "*Advances in Biochemistry in Health and Disease*", p. 113-144. ISBN 978-3-319-24748-9, Springer, New York.

Papers:

(1) Milan Obradovic, Bozidarka L. Zaric, Emina Sudar-Milovanovic, Branislava Ilincic, Edita Stokic, Milan Perovic, and Esma R. Isenovic (2017): PCSK9 and hypercholesterolemia: Therapeutical approach. *Current Drug Targets. (in press).*

(2) Dj. Radak, M. Neskovic, P. Otasevic and E.R. Isenovic (2017): Renal dysfunction following endovascular aortic aneurysm repair. 2017 Nov 16, *Current Vascular Pharmacology (in press).*doi: 10.2174/1570161115666171116163203.

(3) Edita Stokic, Andrea Romani, Branislava Ilincic, Aleksandar Kupusinac, Zoran Stosic, Esma R. Isenovic (2017): Chronic Latent Magnesium Deficiency in Obesity Decreases

Positive Effects of Vitamin D on Cardiometabolic Risk Indicators. 2017 Aug 21, *Current Vascular Pharmacology (in press).* doi: 10.2174/ 1570161115666170821154841.

(4) Milan Perovic, Milan Obradovic, Ivana Resanovic, Esma R. Isenovic (2017): Relationship between vitamin D and metalloproteinases (MMPs) in acute myocardial infarction (AMI)-Editorial. 2017 Oct 4, *Current Vascular Pharmacology (in press).* doi: 10.2174/ 1570161115999171004111230.

(5) Gluvic Z, Zaric B, Resanovic I, Obradovic M, Mitrovic A, Radak Dj, Isenovic ER (2017): Link between Metabolic Syndrome and Insulin Resistance. *Current Vascular Pharmacology*. 15(1):30-39.

(6) Djordje Radak, Niki Katsiki, Ivana Resanovic, Aleksandra Jovanovic, Emina Sudar-Milovanovic, Sonja Zafirovic, Shaker A. Mousa, Esma R. Isenovic (2017): Apoptosis and Acute Brain Ischemia in Ischemic Stroke. *Current Vascular Pharmacology*. 15(2):115-122.

(7) Djordje Radak, Nenad Djukic, Slobodan Tanaskovic, Milan Obradovic, Desanka Cenic-Milosevic, Esma R Isenovic (2017): Should we be concerned about the inflammatory response to endovascular procedures? *Current Vascular Pharmacology*. 15(3):230-237.

(8) Aleksandra Jovanovic, Emina Sudar-Milovanovic, Milan Obradovic, Samantha J Pitt, Alan J Stewart, Sonja Zafirovic, Julijana Stanimirovic, Djordje Radak, Esma R Isenovic (2017): Influence of a high-fat diet on cardiac iNOS in female rats. *Current Vascular Pharmacology*. 15 (5):491-500.

(9) Petrovic Nina, Sercan Ergün, Esma R. Isenovic (2017): Levels of microRNA heterogeneity in Cancer Biology. *Molecular Diagnosis & Therapy*. Vol. 21 (5):511–523.

(10) Edita Stokic, Aleksandar Kupusinac, Dragana Tomic-Naglic, Dragana Miljenic, Branka Kovacev-Zavisic, Biljana Srdic-Galic, Sanja Soskic and Esma R Isenovic (2017): Vitamin D and Dysfunctional Adipose Tissue in Obesity (Authors' Reply). *Angiology*. 68(6):561.

(11) Stanimirovic J, Obradovic M, Panic A, Petrovic V, Alavantic D, Melih I, Isenovic ER. (2017): Regulation of hepatic Na^+/K^+-ATPase in obese female and male rats: involvement of ERK1/2, AMPK, and Rho/ROCK. 2017 Aug 17, *Molecular and Cellular Biochemistry*. *(in press).* doi: 10.1007/s11010-017-3157-z.

(12) Aleksandra Jovanovic, Milan Obradovic, Emina Sudar Milovanovic, Alan J. Stewart, Samantha J. Pitt, Dragan Alavantic, Ema Aleksic and Esma R. Isenovic (2017): Changes in cardiac Na^+/K^+-ATPase expression and activity in female rats fed a high fat diet. *Molecular and Cellular Biochemistry*. 436(1-2): 49-58.

(13) Petrovic Nina, Davidovic Radoslav, Bajic Vladan, Obradovic Milan, Isenovic R Esma (2017): MicroRNA in breast cancer: The association with *BRCA1/2*. *Cancer Biomarkers*. 2017 19 (2):119-128.

(14) Vladan Bajic, Biljana Spremo-Potparevic, Lada Zivkovic, Andrea Cabarkapa, Jelena Kotur-Stevuljevic, Esma Isenovic, Dusan Sredojevic, Ivana Vukoje, Vesna Lazic, S. Phillip Ahrenkiel, Jovan M. Nedeljkovic (2017): Surface-modified TiO2 nanoparticles with ascorbic acid: Antioxidant properties and efficiency against DNA damage *in vitro*. *Colloids and Surfaces B: Biointerfaces.* 155: 323–331.

(15) Emina Sudar-Milovanovic, Sonja Zafirovic, Aleksandra Jovanovic, Jovana Trebaljevac, Milan Obradovic, Desanka Cenic-Milosevic and Esma R. Isenovic (2017): Hormonal

Regulation of Nitric Oxide (NO) in Cardio-Metabolic Diseases. *Current Pharmaceutical Design*. 23(10):1427-1434.

(16) Milan Obradovic, Julijana Stanimirovic, Anastasija Panic, Nikola Bogdanovic, Emina Sudar-Milovanovic, Desanka Cenic-Milosevic and Esma R Isenovic (2017): Regulation of Na^+/K^+-ATPase by estradiol and IGF-1 in cardio-metabolic diseases. *Current Pharmaceutical Design*; 23(10):1551-1561.

(17) Sonja Zafirovic, Milan Obradovic, Emina Sudar-Milovanovic, Aleksandra Jovanovic, Julijana Stanimirovic, Alan J. Stewart, Samantha J. Pitt and Esma R. Isenovic (2017): 17ß-Estradiol protects against the effects of a high fat diet on cardiac glucose, lipid and nitric oxide metabolism in rats. *Molecular and Cellular Endocrinology*. Vol. 446(c): p. 12-20.

(18) Branislava Ilinčić, Edita Stokić, Zoran Stošić, Nevena Eremić Kojić, Niki Katsiki, Dimitri P Mikhailidis, Esma R. Isenovic (2017): Vitamin D Status and Circulating Biomarkers of Endothelial Dysfunction and Inflammation in Non-Diabetic Obese Individuals: a pilot study. *Archives of Medical Science*. 13, 1: 53–60.

(19) Stanimirovic J, Obradovic M, Jovanovic A, Sudar-Milovanovic E, Zafirovic S, Pitt SJ, Stewart AJ, Isenovic ER. (2016): A high fat diet induces sex-specific differences in hepatic lipid metabolism and nitrite/nitrate in rats. *Nitric Oxide: Biology and Chemistry*. 54:51-9.

(20) Predrag Vujovic, Iva Lakic, Nebojsa Jasnic, Tanja Jevdjovic, Sinisa F. Djurasevic, Esma R. Isenovic and Jelena Djordjevic (2016): Effects of starvation on the prolactin level in the rat pituitary and hypothalamus. Comparison to the galanin expression. *Archives of Biological Sciences.* 68: 117-123.

(21) Vladan Bajic, Emina Sudar Milovanovic, Biljana Spremo-Potparevic, Lada Zivkovic, Zorka Milicevic, Julijana Stanimirovic, Nikola Bogdanovic and Esma R. Isenovic (2016): Treatment of Alzheimer's Disease: Classical Therapeutic Approach. *Current Pharmaceutical Analysis*. Vol. 12 (2): 82-90

(22) Milan Obradovic, Zoran Gluvic, Emina Sudar-Milovanovic, Anastasija Panic, Jovana Trebaljevac, Vladan Bajic, Milos Zarkovic and Esma R Isenovic (2016): Nitric Oxide as a Marker for Levo-Thyroxine Therapy in Subclinical Hypothyroid Patients. *Current Vascular Pharmacology* 14(3):266-70.

(23) Djordje Radak, Slobodan Tanasković, and Niki Katsiki, Esma R. Isenović (2016): Protective Role of Diabetes Mellitus on Abdominal Aortic Aneurysm Pathogenesis: myth or reality? *Current Vascular Pharmacology.* 14(2):196-200.

(24) Emina Sudar Milovanovic, Milan Obradovic, Aleksandra Jovanovic, Bozidarka Zaric, Sonja Zafirovic, Anastasija Panic, Djordje Radak, Esma R. Isenovic. (2016): Benefits of L-Arginine on cardiovascular system. *Mini Reviews in Medicinal Chemistry*. 16(2):94-103.

(25) Dragana Unic-Stojanovic, *Esma R. Isenovic*, Miomir Jovic, Vera Maravic-Stojkovic, Milica Miljkovic, Tamara Gojkovic, Biljana Milicic, Nikola Bogdanovic, Djordje Radak (2016): Copeptin levels do not correlate with cross clamping time in patients undergoing carotid endarterectomy under general anesthesia. *Angiology*. 67(10):951-960.

(26) Milan Obradovic, Andreja Trpkovic, Vladan Bajic, Sanja Soskic, Aleksandra Jovanovic, Julijana Stanimirovic, Milos Panic, and Esma R. Isenovic (2015):

Interrelatedness between C-reactive protein and oxidized LDL. *Clinical Chemistry and Laboratory Medicine.* 53(1):29-34.

(27) Milan Obradovic, Sonja Zafirovic, Aleksandra Jovanovic, Emina Sudar Milovanovic, Shaker A. Mousa, Milica Labudovic-Borovic and Esma R. Isenovic (2015): Effects of 17β-estradiol on cardiac Na^+/K^+-ATPase in high fat diet fed rats. *Molecular and Cellular Endocrinology*. 416:46-56.

(28) Branko Filipović, Branka Šošić-Jurjević, Vladimir Ajdžanović, Jasmina Živanović, Esma Isenović, Florina Popovska-Perčinić, Verica Milošević (2015): Tamoxifen stimulates calcitonin producing thyroid C cells and prevents 1 trabecular bone loss in a rat model of androgen deficiency. *Journal of Anatomy*. 226(5):489-96.

(29) Manfredi Rizzo, Nicola Abate, Manisha Chandalia, Ali A. Rizvi, Rosaria V. Giglio, Dragana Nikolic, Antonella Gammazza Marino, Ignazio Barbagallo, Esma R. Isenovic, Maciej Banach, Giuseppe Montalto, Giovanni Li Volti (2015): Liraglutide Reduces Oxidative Stress And Restores Heme Oxygenase-1 And Ghrelin Levels In Patients With Type 2 Diabetes: a prospective pilot study. *Journal of Clinical Endocrinology & Metabolism.* 100(2):603-606.

(30) Vladan Bajic, Biljana Spremo-Potparevic, Lada Zivkovic, Esma R.Isenovic, and Thomas Arendt (2015): Cohesion and the Aneuploid Phenotype in Alzheimer's disease: A Tale of Genome Instability. *Neuroscience & Biobehavioral Reviews.* 55:365-374.

(31) Andreja Trpkovic, Ivana Resanovic, Julijana Stanimirovic, Djordje Radak, Shaker A. Mousa, Desanka Cenic-Milosevic, Danimir Jevremovic, and Esma R. Isenovic (2015): Oxidized low-density lipoprotein as a biomarker of cardiovascular diseases. *Critical Reviews in Clinical*

(32) Milan Obradovic, Emina Sudar, Sonja Zafirovic, Julijana Stanimirovic, Milica Labudovic-Borovic, and Esma R. Isenovic (2015): Estradiol *in vivo* induces changes in cardiomyocytes size in obese rats. *Angiology*. 66(1):25-35.

(33) Milan Perovic, Miroslava Gojnic, Biljana Arsic, Igor Pantic, Tomislav Stefanovic, Gordana Kovacevic, Milica Kovacevic, Eliana Garalejic, Stefan Dugalic, JovanaRadakovic, Uros Babic, Esma R. Isenovic (2015): Relationship Between Mid-Trimester Ultrasound Fetal Liver Length Measurements And Gestational Diabetes Mellitus. *Journal of Diabetes.* 7(4):497-505.

(34) Obradovic M, Bogdanovic N, Radak D, Isenovic ER (2015): Oxidative Stress in Pathophysiological Conditions. *Current Vascular Pharmacology*. 13 (2): 226-228.

(35) Haidara MA, Assiri AS, Yassin HZ, Ammar HI, Obradovic MM, Isenovic ER (2015): Heart Failure Models: Traditional and Novel Therapy. *Current Vascular Pharmacology.* 13(5):658-69.

(36) Edita Stokić, Aleksandar Kupusinac, Dragana Tomić-Naglić, Branka Kovačev Zavišić, Milena Mitrović, Dragana Smiljenić, Sanja Soskić, Esma Isenović (2015): Obesity and vitamin D deficiency: trends to promote a more proatherogenic cardiometabolic risk profile. *Angiology*. 66(3):237-43.

(37) Ivana Krdžić, Nadežda Čovičković-Šternić, Niki Katsiki, Esma R.Isenović, Đorđe Radak (2015): Correlation of carotid artery disease severity and vasomotor response of cerebral blood vessels. *Angiology.* 66(5):481-7.

(38) Andreja Trpkovic, Julijana Stanimirovic, Rizzo Manfredi, Ivana Resanovic, Sanja Soskic, Danimir Jevremovic and Esma R. Isenovic (2015): High sensitivity C-reactive protein and statin initiation. *Angiology*. 66(6):503-7.

(39) Matic P, Jolic S, Tanaskovic S, Soldatovic I , Katsiki N, Isenovic E, Radak Dj (2015): Chronic Venous Disease And Comorbidities. *Angiology*. 66(6):539-44.

(40) Stokic Edita, Kupusinac Aleksandar, Tomic-Naglic Dragana, Smiljenic Dragana, Kovacev-Zavisic Branka, Srdic-Galic Biljana, Soskic Sanja, and Isenovic R. Esma (2015): Vitamin D and dysfunctional adipose tissue in obesity. *Angiology*. 66(7):613-8.

(41) Vladan Bajic, Biljana Spremo-Potparevic, Lada Zivković, Emina Sudar, Sonja Zafirovic, Milan Obradovic and Esma R. Isenovic (2015): Non-Classical Therapeutic Approach in the Treatment of Alzheimer'sDisease: A Mini Review. *Letters in Drug Design & Discovery*. 12 (2): 158-164.

(42) Emina Sudar, Aleksandra Jovanovic, Misirkic M, Vucicevic L, Janjetovic K, Esma R. Isenovic (2015): Effects of intracerebroventricularly (ICV) injected ghrelin on cardiac inducible nitric oxide synthase activity/expression in obese rats. *Experimental and Clinical Endocrinology & Diabetes*. 123 (10), pp. 581-588.

(43) Julijana Stanimirovic, Milan Obradovic, Sonja Zafirovic, Ivana Resanovic, Nikola Bogdanovic, Zoran Gluvic, Shaker A. Mousa and Esma R. Isenovic (2015) Effects of altered hepatic lipid metabolism on regulation of hepatic iNOS. *Clinical Lipidology*. 10:167-175.

(44) Andreja Trpkovic, Julijana Stanimirovic, Ivana Resanovic, Petar Otasevic, Danimir Jevremovic, Radak Djordje, and Esma R. Isenovic (2015): High sensitivity C-reactive protein and cardiovascular risk prediction. *Current Pharmaceutical Analysis*. 11(1): 60-65.

(45) Miomir Jovic, Dragana Unic-Stojanovic, Esma R. Isenovic, Rizzo Manfredi, Olivera Cekic, Nenad Ilijevski, Srdjan Babic, and Djordje Radak (2015): Anesthetics and cerebral protection in patients undergoing carotid endarterectomy. *Journal of Cardiothoracic and Vascular Anesthesia* 29(1):178-184.

(46) Zoran Gluvic, Emina Sudar, Jelena Tica, Aleksandra Jovanovic, Sonja Zafirovic, Ratko Tomasevic, and Esma R. Isenovic (2015): Effects of Levothyroxine Replacement Therapy on Parameters of Metabolic Syndrome and Atherosclerosis in Hypothyroid Patients: A Prospective Pilot Study. *International Journal of Endocrinology*. Vol. 2015, Article ID 147070, 9 pages, 2015. doi:10.1155/2015/147070

In: Encyclopedia of Surgery (22 Volume Set)
Editors: Andreas Lehrer and Kristin Mueller
ISBN: 978-1-53618-329-0
© 2020 Nova Science Publishers, Inc.

Chapter 451

INTRAOPERATIVE AND POSTOPERATIVE ANALGESIC SCHEMES IN BARIATRIC SURGERY

Esther García Villabona[1], MD, Carmen Vallejo Lantero[1], MD and Graciela García Villabona[2], MD

[1]Anesthesiology Department, Hospital Universitario de La Princesa, Madrid, Spain

[2]Anesthesiology Department, Hospital Universitario Marqués de Valdecilla, Santander, Spain

ABSTRACT

The term multimodal analgesia refers to the simultaneous use of multiple analgesic methods or drugs. Pain from surgery has three major components: tissue injury, nociceptor stimulation, and activation of central pathways. Because of these integrated processes, a multimodal approach typically deploys interventions such as local anesthesia, a nonsteroidal anti-inflammatory drug, or an opioid so as to achieve a combination of analgesic chemotherapy.

Keywords: preemptive analgesia, multimodal analgesia, adjuvants

KEY POINTS

1. Thoracic epidural analgesia (T6-T11) still remains the gold standard for postoperative pain control in patients undergoing open bariatric surgery.
2. Patients scheduled for gastric bypass surgery or sleeve gastrectomy are often enrolled in an opioid free regimen. This protocols combine several non-opioid analgesic treatments in order to eliminate, or at least minimize opioid dosing. In the case of laparoscopic bariatric surgery this works remarkably well.
3. These regimens include drugs that can stabilize the sympathetic nervous system, including alpha-2 agonists (clonidine and dexmedetomidine), locoregional

anesthetics given intravenously (lidocaine or procaine), magnesium, and gamma-aminobutyric acid modulators (gabapentin).

4. Regional techniques may also play an important role. A transversus abdominis plane block is an efferent block of the anterior abdominal wall that could reduce pain when employed in the context of multimodal analgesia.
5. Other components of the analgesic schemes for bariatric surgery are: ketamine, acetaminophen, NSAID's and glucocorticoids.
6. If an opioid must be used, it is recommended to use small doses of short-acting opioids such as alfentanil or fentanyl.

INTRODUCTION

Morbid obesity increases the risks of anesthesia and surgery including cardiovascular, thromboembolic, pulmonary, and gastrointestinal impairment. Obesity also carries an increased risk of postoperative hypoxemia and complex management issues, which may contribute to the difficulty of pain treatment. It is important for this population to ambulate soon after their surgery. By encouraging this patient population to move their legs, sit up, and stand, we can reduce the risk of postoperative complications.

In this chapter, we describe the multimodal, evidence-based and procedure-specific analgesic regimens which should be the standard of care, with the aim to achieve optimal analgesia with minimal side effects to facilitate the achievement of ERAS objectives (early mobilization and feeding).

INTRAOPERATIVE PERIOD

Using a unimodal pain treatment method, it may be difficult to attain adequate analgesia without inhibiting normal functions (movement or gastrointestinal function) or producing other side effects (sedation or nausea) related to large-dose opioid requirements.

Preemptive analgesia (or preemptive antinociception) refers to the concept that blocking neuronal pathways before or during surgery, can reduce or eliminate the hyperexcitability of these pathways and pain memory during recovery. Preemptive analgesia can be achieved by multiple methods, e.g., infiltrating local anesthetic into surgical wounds. This techniques improves postoperative pain relief and decreases the total opioid requirement, thus reducing undesirable side effects.

Most common side effects of opioids are well known: respiratory depression, pruritus, nausea and vomiting, ileus, constipation, urinary retention, tolerance by desensitization, immediate hyperalgesia that may evolve into chronic pain syndrome, reduced cardiac output, dizziness, somnolence and short-duration central muscle stiffness. Opioid induced ventilatory impairment is well known by anesthesiologists and is easily treated in the post-anesthesia care unit, but this complication is still problematic postoperatively, especially in the bariatric surgery population. Another side effect is pharyngeal muscle weakness, contributing to obstructive breathing patterns in every patient. This side effect should certainly be avoided in obese patients and patients with obstructive sleep apnea (OSA), given the potential for

aggravation and further breathing obstruction. Accordingly recommendations for anesthesiologists are to avoid or minimize the perioperative use of opioids in these patients.

If no opioids are used during surgery, fewer opioids are needed to achieve a pain-free recovery, as addiction has not yet destroyed the mu receptor system. Opioid induced hyperalgesia and chronic pain syndromes are more frequent when high-dose opioids are used perioperatively [1].

- Thoracic epidural analgesia (TEA):

Initiation of neuroaxial blockade before surgery and its maintenance throughout surgery decreases the need for anesthetic agents, opioids and muscle relaxants. Compared with parenteral opioids, epidural blockade has shown to provide better postoperative static and dynamic analgesia for the first 72 h, to accelerate the recovery of gastrointestinal function, to reduce insulin resistance and impact positively on cardiovascular and respiratory complications.

However, it also has side effects like: hypotension, urinary retention, pruritus and motor blockade. Although detrusor function can be impaired in patients receiving this technique, it has been shown that early removal of a urinary catheter (on postoperative day 1) does not increase the risk of bladder recatheterization and urinary infection.

The same benefits have not been observed after laparoscopic procedures, especially in a context of an ERAS program. However, thoracic epidural analgesia might still be valuable in patients at risk of respiratory complications, or in those with high probability of conversion to laparotomy.

- Continuous wound infusion:

Continuous wound infusion of local anesthetic after open abdominal surgery has been shown to improve postoperative analgesia and reduce opioid consumption. Regarding laparoscopic abdominal surgery, it has been demonstrated that pain intensity was similar among patients receiving epidural and wound infusion of local anesthetic.

Despite these promising results, there are several aspects related to this techniques which need to be clarified. It remains to be established if the analgesic effect observed in these trials is mainly driven by the bolus of local anesthetic given at the end of surgery of by the infusion of local anesthetic during the postoperative period.

- TAP block:

Significant reduction of pain intensity and opioid consumption after ultrasound-guided single-shot TAP block has been observed but it is limited to the first 24 hours after surgery. TAP blocks can also be performed by surgeons from the peritoneal cavity before closing the abdominal wall, or laparoscopic guided. Only few studies have reported a reduction of some of the opioid side effects, but these results have not been reproduced consistently.

Optimal timing, choice of local anesthetic, dosing and volumes remain unknown. However, it seems that a minimal volume of 15 ml is required to achieve satisfactory

analgesia with single-shot TAP block. Ropivacaine 0.2% (8–10 ml/h) can be infused for 48–72 h through a multihole catheter.

- Intraperitoneal local anesthesia:

It has been shown to improve postoperative analgesia, reduce shoulder pain and opioid consumption after laparoscopic gastric surgery.

- Opioids:

The primary objective should be to minimize or avoid the use of opioids wherever possible. Under general anesthesia, patients are unconscious and do not perceive pain. Although there is no pain perception, surgery induced activation of nociceptive reflex arcs has hemodynamic consequences. Using opioids to reduce the hemodynamic changes should be resisted as much as possible, as hyperalgesia can develop acutely and opioid-related side effects can occur at very low doses.

Control of blood pressure and heart rate at intubation and during surgery by beta-blockers, calcium channel blockers, or lidocaine should be encouraged rather than using opioids without a specific indication other than intraoperative tachycardia or hypertension [4].

- Multimodal analgesia:

A multimodal analgesia regimen is based on routine use of NSAID's and paracetamol (PO o intravenously). It should be adopted if not contraindicated in patients undergoing open or laparoscopic bariatric surgery with the aim to reduce opioid consumption and their dose-dependent side effects that impair recovery.

Acetaminophen (paracetamol) has shown to improve postoperative analgesia, have an opioid-sparing effect, but not to reduce opioids side effects.

Concerns have been raised about the cardiovascular risk and delayed bone healing associated with the use of NSAID's and COX-2 inhibitors. The evidence is inconclusive and does not support the avoidance of short perioperative treatment in patients with low cardiovascular risk.

High-dose of systemic steroids have also shown promising results, when used carefully in patients undergoing gastrointestinal surgery. Perioperative intravenous ketamine and gabapentinoids have also shown opioid sparing properties. However, the risk of side effects such as dizziness and sedation should be considered.

Gabapentin or pregabalin should be considered as part of a multimodal analgesia protocol. Both medications are associated with reduced opioid requirements and appear effective when administered as a preoperative dose. It is difficult to determine optimal doses, because higher doses might be more effective, but they might also be associated with more sedation. They are only available in oral form, potentially limiting their use in the immediate postoperative period. Dose reductions are recommended in patients with impaired renal function.

Intravenous ketamine has been evaluated as a part of multimodal analgesia. It has been found in several studies that ketamine IV infusions were associated with decreased

postoperative pain medications use compared with placebo, and with a decreased risk of persistent postsurgical pain. If administered perioperatively, ketamine is associated with increased risk of hallucinations and nightmares.

Glucocorticoid steroids may have analgesic properties possibly related to anti-inflammatory properties and should be considered as part of a multimodal perioperative pain protocol. The concern for significant hyperglycemia (>180 mg/dL) in bariatric patients has not been confirmed [3].

Dexmedetomidine is a highly selective α2-agonist. It is approximately 8 times more specific to α2 adrenergic receptors than clonidine and its elimination half-life is much shorter. This medication should be administered cautiously as several cardiovascular effects may occur. For example, dexmedetomidine should be given over at least 10 minutes, as hypertensive episodes may otherwise be provoked. Nonetheless, a generally hypotensive effect of dexmedetomidine (as well as clonidine) may be observed later as well. In addition, bradycardia may commonly occur, and even cases of asystole have been reported. Importantly, the use of dexmedetomidine is contraindicated in patients with higher degree AV-blocks. While there are certainly many benefits associated with the use of dexmedetomidine in the perioperative setting, caution is required [6].

- Intravenous lidocaine:

In view of its antinociceptive and anti-inflammatory properties, systemic administration of lidocaine as adjuvant to systemic opioids has been shown to improve postoperative analgesia, reduce opioid consumption and speed surgical recovery.

Side effects are directly related to serum levels, and are more pronounced in patients with liver dysfunction, pulmonary diseases when the predominant problem is carbon dioxide retention, and congestive heart failure [4].

INTRAOPERATIVE CLINICAL MANAGEMENT

Gabapentin 150–300 mg can be given as premedication orally and continued the next day postoperatively, when the patient can take oral medication. Dexmedetomidine loading dose of 0.25 μg/kg is given 15 minutes before induction. The dose is further increased to 0.5 or 1 μg/kg and continued with 0.5–1 μg/kg/h, if the procedure takes longer than two hours. Rapid awakening requires the use of the lowest possible dexmedetomidine dose (<0.5 μg/kg), frequently without maintenance doses.

Clonidine has a much longer half-life and is therefore less suitable for short procedures.

Lidocaine 1.5 mg/kg and magnesium 40 mg/kg given at induction and by infusion (lidocaine or procaine 1–3 mg/kg/h and magnesium 5–15 mg/kg/h) further improve the multimodal approach.

Ketorolac (0.5 mg/kg) or diclofenac (150mg) and dexamethasone (10 mg) should be administered before surgery to reduce inflammation. The use of propofol combined with a sympathetic block is possible but requires high propofol doses, while inhalational anesthetics can be given below one minimum alveolar concentration value.

Most of these doses are calculated for lean body weight or ideal body weight +20%, which is easier to calculate instead of total body weight [1].

POSTOPERATIVE CLINICAL MANAGEMENT

Epidural blockade should be tested before surgery or in the immediate postoperative period to avoid non-functioning epidurals and unnecessary opioid administration. The addition of opioids to local anesthetic has shown to improve postoperative analgesia. Although epidural solution containing morphine increases the risk of urinary retention.

However, the use of low dose of local anesthetics (bupivacaine 0.1 mg/ml) and lipophilic opioids (e.g., fentanyl) seem to provide optimal analgesia with minimal side effects. Epidural morphine in adjunct to local anesthetic can be preferred to lipophilic opioids to increase segmental analgesia spread and could be recommended for long midline incisions. Epidural infusions can be continued for 48-72, gradually reducing infusion rates and until the recovery of gastrointestinal function.

Adding adrenaline (1.5–2.0 lg/ml) to epidural mixture of local anesthetic and fentanyl improves postoperative analgesia, especially during mobilization and coughing, and reduces pruritus and nausea.

Hypotension induced by epidural blockade should be treated with vasopressors as first choice provided the patient is not hypovolaemic. Orthostatic hypotension associated with postoperative epidural analgesia does not impair the ability to ambulate [2].

When waking the patient up, give a loading dose of paracetamol and continue with paracetamol 1gr every 6 hours for several days, if needed. Add a non-steroidal anti-inflammatory drug (NSAID) such as diclofenac (75 mg every 12 hours) for up to the first two days. Continue with oral gabapentine (150-300 mg / day) when possible.

Continue the sympathetic block by loading up with an extra dose of clonidine (75-150 μg), lidocaine 1 mg/Kg, and ketamine 25 mg at the end of anesthesia if not already done.

It is better to keep giving these in a continuous infusion bag or pump over the next 10-24 hours. Medication choices for infusion include clonidine (0,1 μg/Kg/h) or dexmedetomidine (0,1 μg/Kg/h), ketamine (0,05 mg/Kg/h) and magnesium (5 mg/Kg/h).

Dexmedetomidine and procaine are shorter acting and therefore preferable. A continuous infusion of dexmedetomidine, magnesium, ketamine or lidocaine might require follow-up on a high dependency care unit.

The exact duration of the lidocaine infusion providing optimal analgesia and facilitating also recovery remains unknown. Systemic toxicity is rare, but continuous cardiovascular monitoring is required.

Be aware that although most of these drugs are given postoperatively below sedation levels, dose reduction may be required if residual sedation persists postoperatively in older and frail patients [1].

OPIOID ANALGESIA

Although one of the main analgesic goals for the bariatric surgery today is minimization of opioid use, one must recognize that opioids are still an important analgesic option. However, their role is less central when compared to traditional care where opioids where the main analgesic options for postoperative pain management.

For opioid-naïve patients who are not yet tolerating oral intake, patients ideally would have one of the main local anesthetic based options and multimodal analgesia before utilizing short-acting IV opioids for rescue analgesia. After these, opioid-naïve patients are tolerating oral intake, then short-acting oral opioids can be added for breakthrough pain after a scheduled regimen of nonopioid analgesics such as gabapentin, acetaminophen, NSAIDs, and other multimodal analgesic agents.

Thus, although some chronic pain patients will benefit from a PCA, the assumption that IV opioids via PCA should be a standard part of postoperative recovery is not necessarily valid in this case, and should be reconsidered [5].

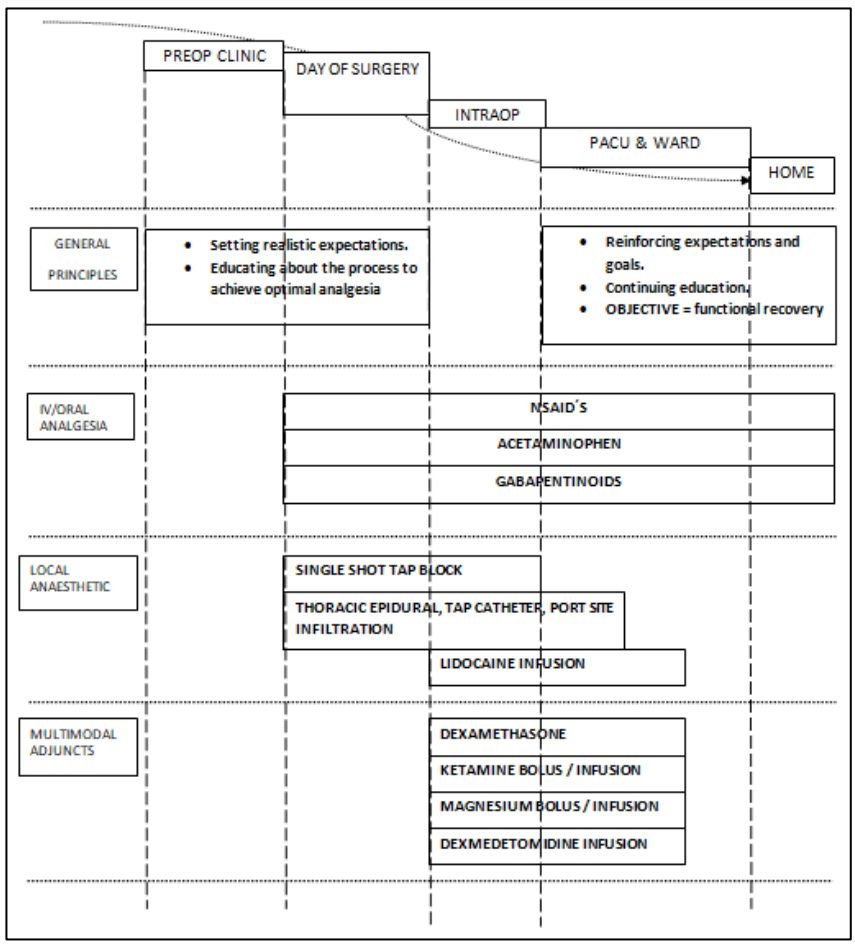

Figure 1. Analgesia scheme for bariatric surgery patients.

REFERENCES

[1] Mulier J. Opioid free general anesthesia: A paradigm shift? *Rev Esp Anestesiol Reanim*. 2017 Oct; 64(8):427-430.

[2] Feldheiser A, Aziz O2, Baldini G, Cox BP, Fearon KC, Feldman LS, Gan TJ, Kennedy RH, Ljungqvist O, Lobo DN, Miller T, Radtke FF, Ruiz Garces T, Schricker T, Scott MJ, Thacker JK, Ytrebø LM, Carli F. Enhanced Recovery After Surgery (ERAS) for gastrointestinal surgery, part 2: consensus statement for anaesthesia practice. *Acta Anaesthesiol Scand*. 2016 Mar; 60(3):289-334.

[3] Chou R, Gordon DB, de Leon-Casasola OA, Rosenberg JM, Bickler S, Brennan T, Carter T, Cassidy CL, Chittenden EH, Degenhardt E, Griffith S, Manworren R, McCarberg B, Montgomery R, Murphy J, Perkal MF, Suresh S, Sluka K, Strassels S, Thirlby R, Viscusi E, Walco GA, Warner L, Weisman SJ, Wu CL. Management of Postoperative Pain: A Clinical Practice Guideline From the American Pain Society, the American Society of Regional Anesthesia and Pain Medicine, and the American Society of Anesthesiologists' Committee on Regional Anesthesia, Executive Committee, and Administrative Council. *J Pain*. 2016 Feb; 17(2):131-57.

[4] McEvoy MD, Scott MJ, Gordon DB, Grant SA, Thacker JKM, Wu CL, Gan TJ, Mythen MG, Shaw AD, Miller TE. Perioperative Quality Initiative (POQI) I Workgroup. American Society for Enhanced Recovery (ASER) and Perioperative Quality Initiative (POQI) joint consensus statement on optimal analgesia within an enhanced recovery pathway for colorectal surgery: part 1-from the preoperative period to PACU. *Perioper Med (Lond)*. 2017 Apr 13; 6:8.

[5] Scott MJ, McEvoy MD, Gordon DB, Grant SA, Thacker JKM, Wu CL, Gan TJ, Mythen MG, Shaw AD, Miller TE. Perioperative Quality Initiative (POQI) I Workgroup. American Society for Enhanced Recovery (ASER) and Perioperative Quality Initiative (POQI) Joint Consensus Statement on Optimal Analgesia within an Enhanced Recovery Pathway for Colorectal Surgery: Part 2-From PACU to the Transition Home. *Perioper Med (Lond)*. 2017 Apr 13; 6:7.

[6] Mauermann E, Ruppen W, Bandschapp O. Different protocols used today to achieve total opioid-free general anesthesia without locoregional blocks, *Best Pract Res Clin Anaesthesiol*. 2017; doi: 10.1016/j.bpa.2017.11.003.

In: Encyclopedia of Surgery (22 Volume Set)
Editors: Andreas Lehrer and Kristin Mueller
ISBN: 978-1-53618-329-0
© 2020 Nova Science Publishers, Inc.

Chapter 452

MULTIMODAL ANALGESIA AND ADJUVANT ANALGESIC TREATMENT IN BARIATRIC SURGERY

Carmen Vallejo Lantero*, MD and Esther García Villabona, MD
Anesthesiology Department, Hospital Universitario de La Princesa,
Madrid, Spain

ABSTRACT

Increasing numbers of patients with morbid obesity are presenting for surgery and their acute pain management requires an evidence-based clinical update. The pathophysiology of obesity, typical co-morbidities and the high prevalence of obstructive sleep apnea make safe analgesic management difficult in these patients. Multimodal, evidence-based and procedure-specific analgesic regimens should be standard of care, with the aim to achieve optimal analgesia with minimal side effects. The perioperative use of non-opioid adjuvants appears to offer further improvements in patient's safety and outcomes.

Keywords: multimodal analgesia, adjuvant analgesics, pain management, bariatric surgery, obesity, postoperative pain, opioid-sparing

INTRODUCTION

With increasing awareness of both short- and long-term problems associated with liberal perioperative opioid administration, the need for routinely and clinically feasible alternatives is greater than ever. Opioids still represent the mainstay of any perioperative analgesic treatment plan. However, opioids can provoke severe side effects. Some of these side effects like postoperative nausea and vomiting (PONV) are obvious; others are not so manifest. Hyperalgesia and postoperative respiratory depression caused by opioids are of concern, yet often go unnoticed. Postoperative desaturation episodes are far more prevalent than generally

* Corresponding Author's Email: c.vallejo_26@hotmail.com.

appreciated, especially in patient groups with specific risk factors like morbid obesity (MO) or obstructive sleep apnea (OSA). Furthermore, undesirable side effects like constipation, urinary retention, and drowsiness may significantly impede an uneventful postoperative course [1].

In the obese patient, the goal of postoperative pain management is provision of comfort, early mobilization and improved respiratory function without causing inadequate sedation and respiratory compromise. The pathophysiology of obesity, typical co-morbidities and the high prevalence of OSA amongst obese patients make safe analgesic management difficult. In particular, pain control after bariatric surgery is a major challenge [2].

In times of ever more ERAS® (enhanced recovery after surgery) protocols emerging, the primary reliance on analgesic agents with such suboptimal side effect profile seems out-of-date. Although an opioid-free anesthesia and analgesia regimen long seemed elusive, newer truly multimodal protocols enable opioid-free (or at least opioid-sparing) anesthesia for certain types of operations. Multimodal, evidence-based and procedure-specific analgesic regimens should be standard of care, with the aim to achieve optimal analgesia with minimal side effects [3]. In patients with MO, these specific outcomes would also not be desirable, they are probably essential.

Though overall evidence is limited, multimodal analgesia with a step-wise, severity-based, opioid-sparing approach appears to improve acute pain management in morbid obesity. The perioperative use of non-opioid adjuvants appears to offer further improvements in patient's safety and outcomes [4].

GOALS OF POSTOPERATIVE ANALGESIA IN MORBID OBESITY

Pain management of the obese patient in the perioperative setting is of great importance for not only the comfort, but also the outcome of patients. After bariatric surgery, pain is the most frequent postoperative problem, even if this surgery was performed laparoscopically. Adequate analgesia provides comfort for patients and this is an important treatment goal, but analgesia should also allow early mobilization, which, in turn, reduces the risk of deep vein thrombosis (DVT), pressure ulcers and respiratory complications including pneumonia [2].

The main risks for this patient group are perceived to be respiratory complications [5]. In MO, conventional opioid-based acute pain during intraoperative and post-operative pain management is associated with the risk of sedation, airway obstruction, and respiratory depression. Site of surgery (bariatric surgery) and co-existing OSA, which is very common in this population, are risk factors contributing to the increased incidence of pulmonary complications in obese patients [6]. Goals of postoperative analgesia should be the ability to comply with respiratory physiotherapy and early mobilization.

MULTIMODAL ANALGESIA IN OBESE PATIENT

The concept of multimodal analgesia was introduced more than a decade ago as a technique to improve analgesia and reduce the incidence of opioid-related adverse events. Multimodal techniques for pain management include the administration of two or more drugs

that act by different mechanisms for providing analgesia. These drugs may be administered via the same route or by different routes.

Multimodal analgesia involves the concurrent use of primarily non-opioid analgesics to take advantage of the additive, if not synergistic, effects that produce superior analgesia while decreasing opioid use and opioid-related side effects. Also, a key component of multimodal pain management is the utilization of regional analgesic techniques, including peripheral and field blocks and neuraxial blocks [7]. Recent data on the efficacy and safety of multimodal pain management strategies for weight loss surgery are consistent with this accepted approach of opioid-sparing postoperative analgesia in the general surgical patient population [8].

The ASA task force on acute pain management in 2012 recommended that multimodal pain analgesia should be included for the management of perioperative pain whenever possible [9]. It is widely accepted adjuvants such as ketamine, lidocaine and pregabalin, directed to avoid acute hyperalgesia, plays a major role in the treatment of acute pain in MO.

ACUTE PAIN MANAGEMENT IN OBESE PATIENT

The role of multimodal analgesia and non-opioid adjuvant therapy has been shown to be beneficial in a variety of procedure-specific postoperative pain management protocols.

Acute pain management modalities can be divided into systemic analgesics and regional anesthesia techniques. The systemic analgesics have been further described as per the World Health Organization (WHO) Step Ladder approach- foundational, intermediate, opioid and adjuvant analgesics. This stepwise, severity based, opioid-sparing approach will be useful in all patients; more so in those with MO.

SYSTEMIC MEDICATIONS

Acetaminophen and NSAIDs

Non opioid analgesics should be considered wherever possible.

- *Acetaminophen* is an important foundational World Health Organization (WHO) Step I whose mechanism of action is still not completely understood. It is highly selective and has an additive and not necessarily synergistic effect when combined with NSAIDs. It has been repeatedly shown to decrease opiod requirements in the perioperative setting and even contribute to shorter length of stay. The half-life of paracetamol does not change in obese patients, and plasma concentration measurements suggest that dosing according to the ideal weight is appropriate. IV acetaminophen is an attractive option in the perioperative period. It can be administered independent of enteral intake. *(Recommendation Grade B) [4]*.
- *Ketorolac.* Cyclo-oxygenase inhibitors, as well non-selective NSAIDs such as selective coxibs, are the most widely used component of multimodal analgesia. The non-steroidal anti-inflammatory drugs are highly effective analgesics with the lowest numbers needed to treat (NNT) of all classes. Ketorolac administered regularly post-

operatively can result in lower opioid consumption in patients with MO *(Recommendation Grade C)* [4]. The perioperative use of ketorolac alone or in combination with local anesthesia leads to significant improvement of postoperative pain control [2]. Similarly, an intraoperative infusion of ketorolac reduced pain scores and decreasing the incidence of postoperative nausea and vomiting (PONV).

Further studies of dose, safety and side effects specific to MO are needed.

Intermediate Analgesics: Tramadol and Tapentadol

Tramadol and Tapentadol are both intermediate-potency (WHO Step II) analgesics that may benefit surgical patients due to their multimodal mechanisms of action. Tramadol may be particularly useful when combined with acetaminophen *(Recommendation Grade B)* [4].

The use of tapentadol has not been yet reported specifically in this patient population. This is a newer molecule, related to tramadol but promisingly lacks the serotonergic effects of the latter, so reducing nausea, vomiting and interactions with anti-depressant medications.

Opioids Analgesics

Use of opioids for post-operative pain in patients with MO presents a challenge. Nevertheless, to achieve satisfactory pain control in obese patients after surgery, the employment of opioids is in some cases inevitable. Through the review of the literature base on the evidence available for the management of acute pain on MO, the current recommendations conclude that in case of use of opioid, PCA should be limited to patients with moderate to severe postoperative pain, probably when oral opioid therapy is not possible. Basal or continuous opioid infusions in patients with MO and particularly those with undiagnosed or untreated OSA should be avoided. Patients with suspected sleep disordered breathing must be observed with overnight monitoring of respiratory adequacy, during the entire time PCA is used *(Recommendation Grade C)* [4].

Adjuvants Analgesics

Gabanoids: Pregabalin/Gabapentina

Gabanoids, gabapentin and pregabalin, are anticonvulsants but are also called neuromodulators, as they reduce neuronal excitability by inhibiting the α-2-δ subunit of calcium-gated channels on presynaptic axons. Both of them plays a role as a component of multimodal analgesia in non obese patients. In MO patients, single preoperative adminstration of 150 mg pregabalin resulted in improved analgesia, opioid-sparing and reduced adverse effects such as nausea and vomiting [2]. Similarly, preoperative administration of 100 mg of gabapentin also produced significantly lower pain scores in recovery with less nausea-vomiting compared with placebo. However, pregabalin and gabapentin may be associated with increased sedation and postoperative respiratory depression.

There is no consensus for dose, frecuency or duration treatment. Their use in the perioperative period requires careful assessment of the risk-benefit in patients with MO and/or OSA *(Recommendation Grade C)* [4].

Nevertheless, although several single clinical trials report that gabanoids decrease the postoperative use of opioids, the Pfizer multi-centric phase III program failed to confirm these findings and to demonstrate any effectiveness in three different models. Nevertheless, the use of gabanoids for acute pain is extensive, even if it is not an approved indication. Recently, the non-approved use of gabanoids has been questioned [7].

NMDA Antagonist

With the discovery of the N-methyl-D-aspartate (NMDA) receptor and its links to nociceptive pain transmission and central sensitization, there has been renewed interest in utilizing noncompetitive NMDA receptor antagonists as potential antihyperalgesic agents.

Ketamine, magnesium, methadone, and dexamethasone all have NMDA-blocking ability, but ketamine has emerged as a frontrunner in the perioperative period [7].

- *Ketamine* has been a well known general anesthetic and analgesic drug. A review of available trials concluded that ketamine alone or added to morphine/hydromorphone showed mild improvement in postoperative analgesia while reducing opioid requirements along with reducing postoperative nausea and vomiting (PONV) [10]. An IV bolus before incision and then a continuous infusion is an effective option for postoperative pain control. If the infusion is administered over a prolonged period of time (48 hours) for more invasive and routinely painful procedures, patients can be at lower risk for developing persistent postoperative pain in the subsequent months. Low doses of ketamine (0,1-0,5 mg/kg) used in morbid obese lead to a significant reduced opioid consumption and reduced need for rescue analgesia importantly *(Recommendation Grade C)* [4]. Limiting factors for ketamine are co-existing severe arterial hypertension and cardiac failure, although the induction of hypertension by low-dose ketamine is unlikely.
- *Magnesium:* The magnesium ion was the first agent discovered to be an NMDA channel blocker. At very high doses, perioperative intravenous magnesium sulfate has been reported to reduce postoperative morphine consumption but not postoperative pain scores. However, as the magnesium ion crosses the blood–brain barrier poorly in humans, it is not clear whether the therapeutic effect is related to the NMDA antagonist effect studied in the central nervous system [11].

Alpha-2 Adrenergic Agonists

Alpha-2 adrenergic activation represents an intrinsic pain control network of the central nervous system. In bariatric surgery it was demonstrated that the use of alpha2-agonists leads to a reduction in postoperative opioid consumption, less respiratory depression, shorter PACU stay, less use of antiemetics, and a favourable cardiovascular stability.

- *Dexmedetomidine* is an α 2 receptor agonist with sedative and analgesic sparing properties. Various studies in MO population have shown safety of dexmedetomidine infusion perioperatively and the capacity to minimize narcotic requeriments, length

of stay after laparoscopic bariatric procedures and the risk of developing PONV *(Recommendation Grade B)* [4,12].

- *Clonidine.* Due to the many side effects of systemic clonidine administration (hypotension, bradycardia, and sedation), the spinal route is preferred. When clonidine is used as a premedication, it has found to be more sedating and associated with bradycardia and hypotension. Clonidine has been used in a limited number of studies in patients with MO.

When comparing pain scores, quantity of analgesic consumption, PONV and patient satisfaction, a single study reported comparable benefits between clonidine and dexmedetomidine [4]. Up to date it remains unclear if there is a clinical difference between the two substances, of which dexmedetomidine possesses a much higher specificity of the alpha2-adrenoceptor. Optimal dosing strategies are lacking providing the best balance between perioperative analgesia, patient safety, and quick recovery. Nonetheless alpha2-agonist appear to be one of the most tempting tools in the anaesthesiologist's arsenal to reduce perioperative opioid consumption [11].

Lidocaine

Lidocaine has analgesic effect, anti-hyperalgesic and anti-inflammatory properties, which makes it use as a general anesthetic adjuvant. Lidocaine is capable of reducing nociception and/or cardiovascular responses to the surgical stress, and postoperative pain and/or analgesic requirements. If the exact mechanism of action remains not fully explained; bolus then continuous lidocaine infusion has clear analgesic benefits. Lidocaine is one of major drug for opioid reduced anesthesia (ORA) or opioid free anesthesia (OFA) procedures. It clearly improves the postoperative outcomes with increased patient satisfaction. Such procedure takes place wisely in the ERAS protocols [13]. With recommended protocols, safety will be as great as his efficacy. Very little information is available in patients with morbid obesity indicating a significant decrease in opioid consumption in PACU and at 24 hours post analgesia regimen *(Grade B)* [4], but few studies are available and optimal dosing schedule in patients with morbid obesty is yet to be determined..

REGIONAL TECHNIQUES

Utilizing regional anesthesia to block peripheral or central nerves is an effective option to reduce or eliminate the need for opioids. A continuous infusion of local anesthetics should be considered in patients requiring prolonged analgesia, who are at risk of local anesthetic overdose, and in whom motor function needs to be preserved, like patients undergoing lower extremity joint replacement. Other benefits of continuous nerve block include reduction in hospital resource utilization, decreased risk of nausea and vomiting, early discharge, and improvement in patient satisfaction.

Neuroaxial Techniques

Neuroaxial techniques for pain management have been shown in numerous studies to be highly efficient in reducing opioid-related complications.

Thoracic Epidural Analgesia (TEA)

(T6-T11) remains the gold standard for postoperative pain control in patients undergoing open abdominal surgery. Initiation of neuroaxial blockade before surgery and its maintenance throughout surgical intervention decreases the need for anaesthetic agents, opioids and muscle relaxants [3]. Continuation of regional anesthesia techniques into the postoperative period to provide analgesia is regarded particular useful in obese patients undergoing open bariatric surgery. Compared with parenteral opioids, epidural blockade has shown to provide better postoperative static and dynamic analgesia for the first 72 h, to accelerate the recovery of gastrointestinal function, to reduce insulin resistance and impact positively on cardiovascular and respiratory complications [3]. Epidural analgesia in patients submit to open bariatric surgery resulted in better pain scores, patient satisfaction, early recovery and ambulation *(Recommendation Grade B)* [4]. The same benefits have not been observed after laparoscopic procedures, especially in a context of an ERAS programme. However, TEA might still be valuable in patients at risk of respiratory complications, in those with high probability of conversion to laparotomy, or requiring transverse or Pfannenstiel-like incisions [3].

Intrathecal (IT) Analgesia

IT morphine is a valuable analgesic technique to improve early postoperative analgesia and facilitates surgical recovery. However, compared with systemic opioids, the incidence of pruritus and respiratory depression (although rare) is increased. Postoperative urinary retention is also more frecuent. In the light of these side effects, in the context of an multimodal analgesic regimen other regional anaesthesia technique could be favoured [3].

TAP Blocks

Transvesus abdominis plane (TAP) block has been studied as a potential technique to aid with pain management in bariatric surgery. Field blocks are non-specific, and the local anesthetic mixture is administered in fascial planes between muscles. It has been shown to reduce morphine use and PONV in abdominal surgery *(Recommendation Grade C, especially laparoscopic procedures)* [4]. Other studies have found limited or no statistically significant difference in outcomes with this block. One potential explanation may be that, there is no significant added benefit of TAP block if local anesthetic is also infiltrated at trocar insertion sites. Like all regional techniques, the efficacy of TAP block is also operator dependent, and in patients with morbidly obesity the performance of TAP blocks may be more difficult. However, TAP blocks can also be performed by surgeons from the peritoneal cavity before closing the abdominal wall, or laparoscopic guided.

Intraperitoneal and Wound Modalities

Continuous administration of local anesthetic has been reported at wound and/or intraperitoneal infusions.

Some studies that examines the use of continuos bupivacaine wound infusion in laparoscopic weight loss surgery (WLS) lasting up to 96 hours. There was a statistically significant decrease in opioid consumption, but this benefit was not sustained beyond the infusion and there was no improvement in patient pain scores.

On the other hand, intraperitoneal bupivacaine infusions have found a statistically improvement in pain scores and total opioid consumption. Likewise, the use of a one-time spray of bupivacaine applied at the esophagueal hiatus once the pneumoperitoneum is establish, resulted in statistically significant decreased in analgesic consumption, incluiding shoulder tip pain. For this reasons, these loco-regional analgesic modalities contribute to optimizing pain in open abdominal and laparoscopic surgical procedures (Recommendation Grade C). Further investigations, standarization and technique refinement are required [4].

CONCLUSION

A multimodal analgesia regimen should de used in patients undergoing open and laparoscopic abdominal procedures with the aim to reduce opioid consumption and their dose-dependent side effects that impair recovery. Analgesic techniques should aim to not only provide optimal pain control, but also to facilitate the achievement of important milestones such as early mobilization. This is of particular importance in this patient population because of the risks of airway obstruction and respiratory insufficiency, otherwise inherent to an opioid centric acute pain management protocols. Opioid-sparing analgesic strategies, including regional analgesia techniques, should be implemented in a context of a multimodal analgesic regimen [3].

REFERENCES

[1] Mauermann E, Ruppen W, Bandschapp O. Different protocols used today to achieve total opioid-free general anesthesia without locoregional blocks. *Best Pract Res Clin Anaesthesiol* 2017; doi: 10.1016/j.bpa.2017.11.003.

[2] Schung SA, Rayman A. Posoperative pain management of the obese patient. *Best Pract Res Clin Anaesthesiol* 2011; 25:73-81.

[3] Feldheiser A, Aziz O, Baldini G, et al. Enhanced Recovery after Surgery (ERAS) for gastrointestinal surgery, part 2: consensus statement for anaesthesia practice. *Acta Anaesthesiol Scand* 2016; 60:289-334.

[4] Budiansky AS, Margarson MP. Acute pain management in morbid obesity- an evidence based clinical update. *Surg Obes Relat Dis* 2017; 13:523-532.

[5] Smetana GW. Postoperative pulmonary complications: an update on risk assessment and reduction. *Cleve Clin J Med* 2009; 76(4):60–S65.

[6] American Society of Anesthesiologists. Practice guidelines for the perioperative management of patients with obstructive sleep apnea. *Anesthesiology* 2006; 104:1081-1093.

[7] Wardhan R, Chelly J. Recent advances in acute pain management: understanding the mechanisms of acute pain, the prescription of opioids, and the role of multimodal pain therapy. *F1000Res* 2017; 6:2065 (doi: 10.12688/f1000research.12286.1).

[8] Schumann R, Jones SB, Cooper B, et al. Update on best practce recommendations for anesthesic perioperative care and pain management in weight loss surgery, 2004-2007. *Obesity* 2009; 17:889-894.

[9] American Society of Anesthesiologists Task Force on Acute Pain Management: Practice guidelines for acute pain management in the perioperative setting: an updated report by the American Society of Anesthesiologists Task Force on Acute Pain Management. *Anesthesiology* 2012; 116(2):248–73.

[10] Wang L, Johnston B, Kaushal A, et al. Ketamine added to morphine or hydromorphone patient-controlled analgesia for acute postoperative pain in adults: a systematic review and meta-analysis of randomized trials. *Can J Anaesth* 2016; 63(3):311–25.

[11] Buvanendran A, Kroin JS. Multimodal analgesia for controlling acute postoperative pain. *Curr Opin anaesthesiol* 2009; 22:588–593.

[12] Tonner PH. Additives used to reduce perioperative opioid consumption1: Alpha2-agonists. *Best Pract Res Clin Anaesthesiol* 2017; doi: 10.1016/j.bpa.2017.10.004.

[13] Estebe JP. Intravenous lidocaine. *Best Pract Res Clin Anaesthesiol* 2017; doi: 10.1016/j.bpa.2017.05.005.

In: Encyclopedia of Surgery (22 Volume Set)
Editors: Andreas Lehrer and Kristin Mueller
ISBN: 978-1-53618-329-0
© 2020 Nova Science Publishers, Inc.

Chapter 453

IMPLICATIONS OF LAPAROSCOPIC APPROACH ON POSTOPERATIVE PAIN AFTER BARIATRIC SURGERY

Pablo Priego*, MD, PhD
Department of General Surgery, Division of Esophagogastric and Bariatric Surgery,
Ramón y Cajal University Hospital, Madrid, Spain

ABSTRACT

Laparoscopy has shown to have special benefits to obese patients because of less blood loss, earlier mobilization, reduced postoperative pain, shorter hospital stay and faster convalescence in comparison with the open procedure. Moreover, the risk of intraabdominal adhesions and incisional hernia has cleared decreased. Pain management is a significant component of postoperative care. The traumatic effect of the surgical incision, the mobilization of intraabdominal viscera during surgery, and some of the metabolic responses that accompany surgery are the main responsible in the occurrence of postoperative pain and complications. Implications of laparoscopic approach against open procedure on postoperative pain after bariatric surgery are presented in this chapter.

Keywords: open, laparoscopy, bariatric surgery, postoperative pain, analgesia, gastric bypass

INTRODUCTION

The number of bariatric procedures has recently risen up, not only because an increase of the number of obese patients, but also because of the exponential growth up in the number of laparoscopic surgeries performed. In USA, Nguyen et al., [1] using NIS data estimated that the percentage of bariatric procedures performed laparoscopically increased from 2.1% in 1998 to 17.9% in 2002. Nowadays, it is not very common to perform a bariatric surgery through an open approach.

* Corresponding Author's Email: papriego@hotmail.com.

Laparoscopy has shown to have special benefits to obese patients because of less blood loss, earlier mobilization, reduced postoperative pain, shorter hospital stay and faster convalescence in comparison with the open procedure. Moreover, the risk of intraabdominal adhesions and incisional hernia has clearly decreased [2].

However, when comparing the outcomes of a bariatric operation performed by two different approaches, it is essential to choose which outcome measures are determinant for clinical practice. Nguyen et al., [3], argue that sometimes, the most common measurements outcome include operative time and length of hospital stay. Furthermore, and although a short surgical time is preferred, this is not always correlated with a better operative outcome. In the same way, the hospital stay can be misleading because it only represents the time of hospitalization that it is considered to be safe before a patient is discharge home. For these reasons, these two parameters would not be as good enough in order to show the superiority to one technique over the other. From the patient's view better measures will be the postoperative pain and duration of the convalescence.

Pain management is a significant component of postoperative care. The traumatic effect of the surgical incision, the mobilization of intraabdominal viscera during surgery, and some of the metabolic responses that accompany surgery are the main responsible in the occurrence of postoperative pain. Moreover, postoperative pain may also be a pointer to the development of certain complications like atelectasia, pneumonia, deep vein thrombosis, pulmonary embolism and cardiovascular events [4].

Implications of laparoscopic approach against open procedure on postoperative pain after bariatric surgery are presented in this chapter.

OPEN VS. LAPAROSCOPIC BARIATRIC SURGERY

Since the introduction of laparoscopic surgery, a wide variety of techniques have been performed via this approach because of the advantages it offers, i.e., earlier mobilization, reduced postoperative pain, shorter hospital stay, better cosmetic results and faster convalescence in comparison with the open procedure. Moreover, the risk of intraabdominal adhesions and incisional hernia has clearly decreased [2].

Therefore, surgeons began using the different techniques that existed for treating obesity through the laparoscopic approach [5, 6]. *Gastric banding* was the first laparoscopic technique described which became extremely popular due to its relatively low technical difficulty and low initial morbidity and mortality rates [7-9]. However, long-term results regarding weight loss and late complications were worse than with other bariatric procedures.

Another of the procedures performed via laparoscopy was *Vertical banded gastroplasty* [10, 11]. This technique was not difficult to perform by laparoscopy and had low morbidity and mortality rates, but the long-term results were worse than with gastric bypass and nowadays it is not a common option for treatment of obese patients, due to the discomfort it causes the patient and the high incidence of staple-line disruption.

Gastric bypass (GB) was initially developed in USA by Masson and Ito in the 1960s [12]. Although GB resulted in durable weight loss and had evident advantages like better weight loss than after purely restrictive procedures, low incidence of protein-calorie malnutrition, rapid improvement of resolution of weigh-related comorbidities and appetite

reduction; postoperative pain and wound-related complications such as infection (8%) and incisional hernia (20%) were disgusting problems.

Laparoscopic gastric bypass (LGBP) was first introduced by Wittgrove et al., [13] in 1994 and since then has become more commonly performed than open gastric bypass (OGB).

Although there are several restrictive (gastric band, sleeve gastrectomy) and malabsortive weight loss operations (duodenal switch, SADI-s, biliopancreatic diversion…), most of studies comparing open vs. laparoscopic approach are related to GB, because nowadays it is the most common bariatric procedure all around the world.

From the beginning, clinical studies [6, 14, 15] demonstrated that LGBP was a safe and effective alternative to OGB for the treatment of morbid obesity. Moreover, laparoscopy showed a lot of advantages against the traditional open approach. On the other hand, LGBP showed that this was a complex operation associated with a long learning curve and with a possible increase in the rate of internal hernia [16-18].

Most part of studies that compare open vs. laparoscopy in bariatric surgery are too old (final of the 90s and beginning of 21st century), because nowadays, there is not discussion about the advantages of this minimally invasive approach in the treatment of these obese patients. Indeed, current studies are concerning about differences in postoperative pain and cosmetic results between the single-port and the traditional laparoscopic approach [19, 20]. Other studies present that the implementation of Enhanced Recovery After Surgery (ERAS) programs [21] in treatment of obese patients is a safe issue, obtaining similar results to standard care in terms of complications, reoperations, mortality and readmissions; with less postoperative pain and earlier hospital discharge. Other studies are referred to the decrease of postoperative pain associated with the intraoperative peritoneal infusion with ropivacaine [22] and the postoperative advantages of free opioids anesthesia [23]. However, these items have been described in other chapters of the book.

In order to understand differences between open and laparoscopic approach in bariatric surgery, it is essential to differentiate some technical aspects that are going to affect clinical outcomes [3].

The first difference between these two approaches is the method of access (length and number of abdominal incisions). OGB is usually performed through a supraumbilical midline incision, whereas LGBP is performed through five-six small abdominal incisions for trocars.

Second difference is the method of exposure. During OGB, the methods of exposure are abdominal wall retractors and mechanical retractors of intraabdominal organs. On the other hand, in LGBP, methods of exposure are the pneumoperitoneum to create a working space and gravity for moving of intraabdominal organs.

Finally, the last difference is the extent of operative trauma. By reducing the length of the surgical incision and avoiding the needed of abdominal wall retractors, it is logical that operative trauma is less in after LGBP in compare to OGB.

Although physiopathological basis of postoperative pain have been presented in Chapter 1, we cannot avoid that there are some physiopathological differences between open and laparoscopic surgery that influences in the development of postoperative pain.

Surgical injury often results in accumulation of edema (third-space fluid), and the degree of third-space fluid accumulation is often proportional to the extent of surgical trauma. Indeed, intra-abdominal pressure after LGBP is significantly lower than after OGB on postoperative days 1, 2, and 3. Moreover, the magnitude of the systemic stress response (interleukin-6 levels) is significantly lower after LGBP than after OGB.

Providing a high quality pain treatment is a major challenge in health care. Despite the developments in pain management, postoperative pain is still a clinical problem [24-26]. Poorly managed pain reduces quality of life, causes unneeded suffering, and can extend time of discharge from hospital [27]. The importance of evaluating postoperative pain with consideration given to type of surgery and the patient's perspective cannot be overemphasized. Postoperative pain is an important measurement of outcome because it can be measured objectively. The degree of postoperative pain after OGB is associated with the length of the surgical incision, the extent of operative dissection, and operative trauma [26]. Hence, laparoscopic procedures that minimize surgical tissue trauma are associated with less pain than laparotomies [29-30].

While some outcomes such as pulmonary complications, duration of hospital stay and convalescence appear to be better with the laparoscopic approach [31, 32], few prospective trials have investigated the effect of LGBP on postoperative pain and bowel function.

One of the first studies that compare open vs. laparoscopic approach in bariatric surgery was the study of Joris et al., [33]. They compared a group of 30 obese patients undergoing laparoscopic or open gastroplasty (15 in each group). Postoperative pain, measured on a visual analogue scale (VAS), and opioid consumption were recorded during the first two days after operation. Tests of pulmonary function were performed and SpO2 was measured 4 h after surgery and on days 1, 2 and 3 after operation. Results confirmed that in the laparoscopy group, requirements for postoperative opioid were 50% less; pain intensity during mobilization and on coughing was significantly less after laparoscopy. Forced vital capacity, forced expiratory volume in 1 s and peak expiratory flow rate were reduced significantly less after laparoscopic gastroplasty than after open gastroplasty. Moreover, SpO_2 values were significantly greater in the laparoscopy group.

El Shoraby et al., [34], performed a prospective study in which patients were assigned to LGBP (33 cases) or OGB (20 cases). All patients received patient controlled analgesia (PCA) with intravenous morphine and rectal naproxen 500 mg every 12 hours. Postoperative analgesia was assessed daily using a VAS at rest, on walking and coughing. The amount of morphine used during the first 48 hours, the time of return of gastrointestinal motility and the time until first oral food intake were recorded. Patients undergoing LGBP requested less morphine and showed lower VAS pain scores than patients undergoing OGB. The return of bowel movement in the laparoscopic group occurred 1 day earlier than in the open group. The time to first passage of gas and oral food intake was shorter after laparoscopic than after OGB. Moreover, patients in the laparoscopic group were discharged 1.5 days earlier than patients in the open group.

Fisher [35] randomly selected bariatric surgery patients, consisting of 20 OGB, 19 LGBP, and 21 laparoscopic adjustable gastric banding (LAGB). LAGB patients returned to normal activity levels earlier than gastric bypass patient's irrespective of approach. Moreover, recovering from surgery was significantly sooner than OGB patients. However, perceived differences in recovery time between OGB and LGBP patients did not affect their time to resumption of normal activity.

Finally, Nguyen et al., [3] performed a randomized study in which seventy obese patients were randomly assigned to undergo LGBP (n = 36) or OGB (n = 34). Pulmonary function studies were performed preoperatively and on postoperative days 1, 2, 3, and 7. Oxygen saturation and chest radiographs were performed on both groups preoperatively and on postoperative day 1. Postoperative pain was evaluated using a VAS and the amount of

narcotic consumed was recorded. LGBP patients had significantly less impairment of pulmonary function than OGB patients on the first three postoperative days. By the 7th postoperative day, all pulmonary function parameters in the LGBP group had returned to within preoperative levels, but only one parameter (peak expiratory flow) had returned to preoperative levels in the OGB group. Moreover, on the first postoperative day, LGBP patients used less intravenous morphine sulfate than OGB patients (46 +/- 31 mg versus 76 +/- 39 mg, respectively), and VAS pain scores at rest and during mobilization were lower after LGBP than after OGB. Fewer patients after LGBP than after OGB developed hypoxemia (31% versus 76%) and segmental atelectasia (6% versus 55%). All results were statistically significant.

Recovery is a very important outcome parameter and can be measured by questioning the patients' time to return to activities of daily living. Nguyen et al., [15] reported that LGBP patients had a more rapid return to activities of daily living than OGB patients. Furthermore, and based on the SF-36 health survey and the Moorehead-Ardelt Quality-of-Life questionnaire it has shown that recovery based on physical and social functioning at 1 and 3 months postoperatively was significantly faster after LGBP compared to OGB. In addition, patients undergoing laparoscopic surgery perceived their overall health to be better than that of OGB patients when the survey was measured at 1 month postoperatively. Moreover, LGBP patients had more sexual interest or resumed sexual activity earlier than OGB patients at 3 months postoperatively, hence demonstrating a faster recovery.

However, and although LGBP is considered as a minimally invasive procedure, most of the patients complain of abdominal pain after surgery [36-38]. Cho et al., [36], have reported that 98.94% of patients were found to have pain in the first 24 hours of post-surgery, 60% at the end of the first week and 29.5% still had pain four weeks after the surgery. The highest incidence of abdominal pain was in left upper quadrant. Moreover, 45% of patients were admitted to the emergency department complaining of abdominal pain. About 54.1% of these patients were referred again for the second time and 22.6% were admitted for the third time, all due to abdominal pain.

Eidy et al., [39], analyzed the distribution and frequency of post LGBP pain in 190 morbidly obese patients. The results of the study were similar to those published by Cho et al., Left upper quadrant was found to be the most prevalent site for pain, probably related to the insertion of drainage.

There are many reasons for pain after gastric bypass surgeries, several of which could be related to the behavioral eating patterns, such as rapid eating [40], food intolerance, like rice, vegetables, fruits, pasta, gluten and lactose intolerance, some deficiencies like folate and vitamin B12 deficiencies [41] and finally bacterial overgrowth [42]. Other etiologies could be constipation and lower abdominal pain due functional changes of the gastrointestinal tract after surgery, retroesternal pain, biliar colics because of de novo gallbladder stones, ulcers in gastric pouch, gastroesophageal reflux disease (GERD), anastomotic stenosis, trocar site hernia, adhesions band, incisional hernia, intussusceptions, omental torsion, infarction, internal hernia and bezoars.

Similar to other minimal invasive operations, the late pain following GB surgery is a serious problem. Chronic postsurgical pain (CPSP) has been defined as pain persisting for more than 3 months after expected healing time. CPSP of the surgical site after bariatric surgery has been reported in up to 50% of the patients.

Finally, Kumar et al., [4], performed a review of the literature in order to identify follow-up studies on pain and bariatric surgery. Sixteen studies were included for further analysis with over 2000 subjects (60% of them were on bypass surgery). "Short term" studies with data on pain within 3 months after surgery were randomized controlled trials comparing surgical techniques or analgesia. Although pre-operative pain status had not been documented, peri-operative pain management was reported in detail. In 8 observational studies, pain data were available exceeding 3 months after surgery ("long term" studies). While pre-operative pain data were reported in the latter studies, in over half the anatomic location of the pain had not been specified. Authors concluded that an accurate estimation of the incidence of CPSP after bariatric surgery was not possible based on the available data. The reason is that number of comparable studies was low and the anatomic location of the pain had not been specified. Moreover, data on pain between 1 week and 6 months after surgery (time point after measured pain is defined as chronic) were lacking.

To end up, the laparoscopic approach has shown to have special benefits to obese patients because of less blood loss, earlier mobilization, reduced postoperative pain, shorter hospital stay and faster convalescence in comparison with the open procedure. Nowadays, there is no discussion about whether laparoscopy should be the treatment of choice for bariatric patients. However, and although laparoscopic gastric bypass is considered as a minimally invasive procedure, many patients complain of abdominal pain after surgery, and chronic postsurgical pain has been reported in up to 50% of the patients. Despite the developments in pain management, postoperative pain is still a clinical problem.

REFERENCES

[1] Nguyen NT, Root J, Zainabadi K, et al., Accelerated growth of bariatric surgery with the introduction of minimally invasive surgery. *Arch Surg*. 2005; 140:1198-1202.

[2] Allvin R, Rawal N, Johanzon E, and Bäckström R. Open versus Laparoscopic Surgery: Does the Surgical Technique Influence Pain Outcome? *Results from an International Registry. Hindawi Publishing Corporation Pain Research and Treatment*. Volume 2016, Article ID 4087325, 5 pages. http://dx.doi.org/10.1155/2016/4087325.

[3] Nguyen N. Open vs laparoscopic procedures in bariatric surgery. *J Gastrointest Surg* 2004; 8: 393-395.

[4] Kumar N, Soekarman D, Singh R, Bashah MM, Abou Samra AB, Marcus MAE. Peri-operative pain in patients experiencing bariatric surgery. *Med Clin Arch* 2017, 1(1):2-4.

[5] Encinosa WE, Bernard DM, Steiner CA. Advances in bariatric surgery for obesity: laparoscopic surgery. *Adv Health Econ Health Serv Res.* 2007; 17:131-148.

[6] Luján JA, Frutos MD, Hernández Q, et al., Laparoscopic versus open gastric bypass in the treatment of morbid obesity: a randomized prospective study. *Ann Surg*. 2004; 239(4):433-437.

[7] Belachew M, Legrand M, Vincent, et al., Laparoscopic Adjustable gastric banding. *World J Surg* 1998; 22: 955-963.

[8] O'Brien PE, Brown WA, Smith A, et al., Prospective study of a laparoscopically placed, adjustable gastric band in the treatment of morbid obesity. *Br J Surg* 1999; 86: 113-118.

[9] Dargent J. Laparoscopic adjustable gastric banding: lessons from the first 500 patients in a single institution. *Obes Surg* 1999; 9: 446-452.
[10] Hess DW, Hess DS. Laparoscopic vertical banded gastroplasty with complete transection of the staple line. *Obes Surg* 1994; 4: 44-46.
[11] Lönroth H, Dalenbäck J, Haglind E, et al., Vertical banded gastroplasty by laparoscopic technique in the treatment of morbid obesity. *Surg Laparosc Endosc* 1996; 6: 102-107.
[12] Mason EE, Ito C. Gastric bypass in obesity. *Surg Clin North Am*. 1967; 47:1345–1351.
[13] Wittgrove AC, Clark GW, Tremblay LJ. Laparoscopic gastric bypass, Roux-en-Y: preliminary report of five cases. *Obes Surg*. 1994; 4(4):353-357.
[14] Higa KD, Boone KB, Ho T. Complications of the laparoscopic Rouxen-Y gastric bypass: 1,040 patients—what have we learned? *Obesity Surg* 2000; 10:509 –513.
[15] Nguyen NT, Goldman C, Rosenquist CJ, et al., Laparoscopic versus open gastric bypass: a randomized study of outcomes, quality of life, and costs. *Ann Surg*. 2001; 234(3):279-289, discussion 289-291.
[16] Banka G, Woodard G, Hernandez-Boussard T, Morton JM. Laparoscopic vs Open Gastric Bypass Surgery Differences in Patient Demographics, Safety, and Outcomes. *Arch Surg*. 2012; 147(6):550-556.
[17] Weller WE, Rosati C. Comparing outcomes of laparoscopic versus open bariatric surgery. *Ann Surg*. 2008; 248(1):10-15.
[18] Westling A, Gustavsson S. Laparoscopic vs Open Roux –en-Y Gastric Bypass: A prospective, randomized trial. *Obes Surg* 2001; 11: 284-292.
[19] Moreno-Sanz C, Morandeira-Rivas A, Sedano-Vizcaino C, Tenías-Burillo JM, Román-Ortíz C, de la Espada JB. Single-incision laparoscopic bariatric surgery: a systematic review. *Surg Obes Relat Dis.* 2015; 11(1):248-257.
[20] Morales-Conde S, Del Agua IA, Moreno AB, Macías MS. Postoperative pain after conventional laparoscopic versus single-port sleeve gastrectomy: a prospective, randomized, controlled pilot study. *Surg Obes Relat Dis.* 2017; 13(4):608-613.
[21] Ruiz-Tovar J, Muñoz JL, Royo P, Duran M, Redondo E, Ramirez JM; Grupo Español de Rehabilitación Multimodal (GERM). Implementation of the Spanish ERAS program in bariatric surgery. *Minim Invasive Ther Allied Technol.* 2018; 8:1-8.
[22] Ruiz-Tovar J, Gonzalez J, Garcia A, Cruz C, Rivas S, Jimenez M, Ferrigni C, Duran M Intraperitoneal Ropivacaine Irrigation in Patients Undergoing Bariatric Surgery: a Prospective Randomized Clinical Trial. *Obes Surg.* 2016; 26(11):2616-2621.
[23] Barajas JS, Gonzalez D. Pain management in weight loss surgery: aiming for multimodal approach. *Adv Obes Weight Manag Control* 2016, 5(2): 00125.
[24] Benhamou D, Berti M, Brodner G, et al., Postoperative Analgesic THerapy Observational Survey (PATHOS): a practice pattern study in 7 central/southern European countries. *Pain* 2008; 136 (1-2): 134–141.
[25] Hartog CS, Rothaug J, Goettermann A, Zimmer A, and Meissner W. Room for improvement: nurses' and physicians' views of a post-operative pain management program. *Acta Anaesthesiologica Scandinavica* 2010; 54(3):277–283.
[26] Fletcher D, Fermanian C, Mardaye A, Aegerter P. A patient-based national survey on postoperative pain management in France reveals significant achievements and persistent challenges. *Pain* 2008; 137 (2): 441–451.
[27] Taylor RS, Ullrich K, Regan S et al., The impact of early postoperative pain on health-related quality of life. *Pain Practice* 2013; 13 (7): 515–523.

[28] Nguyen NT, Goldman C, Rosenquist CJ, et al., Laparoscopic versus open gastric bypass: a randomized study of outcomes, quality of life, and costs. *Ann Surg*. 2001; 234(3):279-289, discussion 289-291.

[29] Karayiannakis AJ, Makri GG, Mantzioka A, et al., Postoperative pulmonary function after laparoscopic and open cholecystectomy. *Br J Anaesth* 1996; 77:448-452.

[30] Joris J, Cigarini I, Legrand M, et al., Metabolic and respiratory changes after cholecystectomy performed via laparotomy or laparoscopy. *Br J Anaesth* 1992; 69:341-345.

[31] Nguyen N, Lee S, Goldman C, et al., Comparison of pulmonary function and postoperative pain after laparoscopic versus open gastric bypass: a randomized trial. *J Am Coll Surg* 2001; 192: 469-476; discussion 476-477.

[32] Antoniou SA, Antoniou GA, Koch OO, Köhler G, Pointner R, Granderath FA. Laparoscopic versus Open Obesity Surgery: A Meta-Analysis of Pulmonary Complications. *Dig Surg* 2015; 32:98–107.

[33] Joris JL, Hinque VL, Laurent PE, et al., Pulmonary function and pain after gastroplasty performed via laparotomy or laparoscopy in morbidly obese patients. *Br J Anaesth* 1998; 80: 283-288.

[34] El Shobary H, Christou N, Backman SB, Gvocdic B, Schricker T. Effect of Laparoscopic versus Open Gastric Bypass Surgery on Postoperative Pain and Bowel Function. *Obes Surg* 2006; 16:437-442.

[35] Fisher BL. Comparison of recovery time after open and laparoscopic gastric bypass and laparoscopic adjustable banding. *Obes Surg.* 2004; 14(1):67-72.

[36] Cho M, Kaidar-Person O, Szomstein S, Rosenthal RJ. Emergency room visits after laparoscopic Roux-en-Y gastric bypass for morbid obesity. *Surg Obes Relat Dis.* 2008; 4(2):104–109.

[37] Kellogg TA, Swan T, Leslie DA, Buchwald H, Ikramuddin S. Patterns of readmission and reoperation within 90 days after Roux-en-Y gastric bypass. *Surg Obes Relat Dis.* 2009; 5(4):416–423.

[38] Agaba EA, Gentles CV, Shamseddeen H, Sasthakonar V, Kandel A, Gadelata D, et al., Retrospective analysis of abdominal pain in postoperative laparoscopic Roux-en-Y gastric bypass patients: is a simple algorithm the answer? *Surg Obes Relat Dis.* 2008; 4(5):587–593.

[39] Eidy M, Pazouki A, Raygan F, Ariyazand Y, Pishgahroudsari M, Jesmi F. Functional abdominal pain syndrome in morbidly obese patients following laparoscopic gastric bypass surgery. *Arch Trauma Res*. 2014 Mar 20; 3(1):e13110.

[40] Foster A, Richards WO, McDowell J, Laws HL, Clements RH. Gastrointestinal symptoms are more intense in morbidly obese patients. *Surg Endosc.* 2003; 17(11):1766–1768.

[41] Walker SP, Wein P, Ihle BU. Severe folate deficiency masquerading as the syndrome of hemolysis, elevated liver enzymes, and low platelets. *Obstet Gynecol.* 1997; 90 (4 Pt 2):655–657.

[42] Ishida RK, Faintuch J, Paula AM, Risttori CA, Silva SN, Gomes ES, et al., Microbial flora of the stomach after gastric bypass for morbid obesity. *Obes Surg.* 2007; 17(6):752–758.

In: Encyclopedia of Surgery (22 Volume Set)
Editors: Andreas Lehrer and Kristin Mueller
ISBN: 978-1-53618-329-0
© 2020 Nova Science Publishers, Inc.

Chapter 454

PERITONEAL LAVAGE AND LAPAROSCOPIC SLEEVE GASTRECTOMY SURGERY

Lorea Zubiaga[1,*], MD, PhD and Jaime Ruiz-Tovar[2], MD, PhD
[1]Inserm U1190, Lille 2 University, Lille, France
[2]Surgery Department, Autonoma University, Madrid, Spain

ABSTRACT

To prevent or remove bacterial proliferation after different abdominal surgeries, different solutions for peritoneal lavage have been proposed. This procedure is usually described on laparotomic surgery, but it is not current practice on laparoscopic procedures. Peritoneal lavage may reduce bacterial contamination, but does not completely eliminate them. The addition of antibiotic agents might further reduce the bacterial contamination. Despite surgical-site infection is a relatively rare complication after bariatric surgery, antibiotic lavage does not show its effect on this issue. However, the eventual reduction in the bacterial contamination reduces the inflammatory response and consequently diminishes the postoperative pain.

Keywords: peritoneal lavage, antibiotic solution, postoperative pain, acute-phase reactants, peritoneal contamination, surgical site infection

INTRODUCTION

Following laparotomy, abdominal surgery develops some degree of peritoneal contamination and surgical site infection (SSI) due to complex processes involving injured tissues and peritoneum. For most patients, peritoneal contamination and SSI have no clinical consequences due to the effectiveness of the patient's own immune response and prophylaxis with intravenous antibiotics, but SSI is associated with increased health care resource utilization and, in some cases, the peritoneal contamination is the prelude to infectious

* Corresponding Author's Email: loreazubiaga@gmail.com.

problems that go unnoticed until it is too late. [1] It is assumed that many of these processes of SSI have been significantly reduced by the shift from conventional laparotomy to laparoscopic surgery. [2]

Surgical site infection (SSI) is one of the most common complications of abdominal surgery. It is associated with longer hospital stays, lower quality of life and increased morbidity and mortality and sanitary cost. Centers for disease control (CDC) defines SSI as infection that occurs in or near the surgical incision during the first 30 days, or up to one year, if an implant has been left in place. [3] SSI occurs when the bacterial inoculum exceeds the ability of the immune system to control it. Contamination in abdominal surgery comes from the skin or target organs being treated. The abdominal organs are typically the gastrointestinal tract, a system that coexists with a significant number of microbes that under normal conditions are contained by the immune system, but in cases of surgical aggression can become highly virulent pathogens.

The determinants of infection are the surgeon, the pathogen and the patient. [3, 4] The surgeon is the main modulator of the surgical infection. Their experience and ability can reduce the inoculum to dimensions controllable by the body's defenses. A proper surgical procedure includes careful tissue management, good hemostasis, no unnecessary lengthening of surgical time and minimizing extravasation of gastrointestinal contents. Patients´ dependent factors include comorbidities, obesity, smoking, and old age.

Many surgeons have adopted peritoneal lavage on different abdominal surgeries, mainly by laparotomy and/or peritonitis conditions. [5] This lavage usually consists of peritoneal irrigation with a variable volume of warm 0.9% sodium chloride physiologic solution (Saline Solution –SS-). The main mechanism of action of these lavages is to remove large accumulations of infectious material (feces, pus, necrotic tissue, etc.) and to dilute as much as possible the bacterial charge and other materials, that promote bacterial proliferation (e.g., blood) at the peritoneum. However, the effects of lavage have been widely studied, but with controversial results yet. [5-7] Peritoneal lavage can be altered by three basic variables: volume of irrigation fluid, timing of delivery and/or solution composition. Therefore, flushing the peritoneal cavity may also reduce the bacterial load and possibly minimize the risk of SSI. [8] Obviously, the efficacy of peritoneal irrigations in peritonitis is unclear. Moreover, the prophylactic effect of lavage in elective clean contaminated surgery is even less well understood than in peritonitis, because few relevant studies have been conducted.

Cases of undiagnosed serious abdominal infections are also common in obese patients undergoing bariatric surgery, as in many cases they are patients with a series of comorbidities (such as diabetes and dyslipemia) that aggravate the basal situation. [9] Gastric leak after sleeve gastrectomy is associated with significant and prolonged morbidity, remaining one of the most feared complications. Based on the data from International Sleeve Gastrectomy Expert Panel Consensus Statement 2011, the leak rate was near to 1.06%, but the leak rate can vary between 1% and 3% for primary procedure and more than 10% in revision techniques. [10] A gastric leak can present as peritonitis, abscesses, cutaneous or other fistulas, sepsis, organ failure and even death.

Furthermore performing a lavage with large amounts of SS is not a frequent procedure in laparoscopic bariatric surgery, since achieving the total and correct aspiration of all the infused serum is not easy in obese patients. The obese patients have an important amount of visceral adipose tissue, which makes any maneuver in the abdominal cavity even more difficult. Above all, it is precisely the visceral fat of obese patients that has a high capacity to

hide the bacterial niches and reproduce process of infection, which are difficult to diagnose and treat. For this reason, it has been proposed to use antibiotic solutions for the peritoneal lavage.

PERITONEAL LAVAGE WITH ANTIBIOTIC SOLUTIONS

Several antibiotics have been used for peritoneal lavage in diverse pathologies. The most widely investigated pathologies, in which antibiotic solutions were used was peritonitis. [8, 11] Up to our knowledge, our group was the first one to investigate the effect of peritoneal lavage with antibiotic solutions in bariatric surgery. We evaluated the effects of peritoneal lavage with physiologic saline solution (SS) or an antibiotic solution (AS) (clindamycin–gentamicin) on post-operative pain, acute-phase reactants and SSI. The microbiologic impact of both irrigations on peritoneal contamination was also determined.

A randomized study was performed with the following inclusion criteria were body mass index (BMI) either >40kg/m2 or >35kg/m2 with co-morbidities associated with obesity and undergoing laparoscopic sleeve gastrectomy (LSG) as a bariatric procedure. Exclusion criteria were documented uncontrolled psychiatric disorders, active infection or malignant disease, gastroesophageal reflux and other concomitant pathologies considered to be a contraindication to perform the LSG. A pre-operative diagnosis of chronic renal failure (because of the risk of nephrotoxicity associated with intraperitoneal gentamicin absorption) was also considered an exclusion criterion.

The surgical technique was performed as usual for LSG: A longitudinal resection from the angle of His to approximately 3 to 4 cm cranially to the pylorus was performed using a 40 French bougie inserted along the lesser curve. A staple line inversion was performed with a continuous over-sewing of polypropylene 3-0 before extracting the bougie. The remnant stomach was extracted through the 12-mm port site located in the right hypochondrium. The aponeurotic defect of only the 12-mm port site was closed using two simple sutures of poly-dioxanone (size 2) and the skin of all port sites with staples.

The lavage was performed with an irrigation-aspiration device immediately prior to closure of the port sites. In Group 1, irrigation of the entire abdominal cavity was performed with 500 mL of SS. In Group 2, lavage was carried out with the AS, including gentamicin (240 mg) and clindamycin (600mg) dissolved in 500mL of physiologic saline. In both groups, the solution was allowed to stand in the abdominal cavity for 3 min. Pre-operative systemic prophylaxis was performed in all the patients with cefazoline 3g intravenously and another dose of cefazoline.

Prior to any lavage, a microbiologic sample was obtained from the peritoneal surface (parietal and visceral from the gastric tube) with a swab introduced through the 12-mm port site (sample 1). After the assigned lavage and aspiration of the irrigation liquid, a new microbiologic sample was obtained from the peritoneum and the visceral surface of the gastric tube (sample 2). The drainage volume on the second day was collected in a syringe for microbiologic study (sample 3).

Table 1. Baseline features of the patients

	SS	AS	P
N	40	40	
Mean Age (±SD)	41.6 ±7.1	44.6 ±7.4	0.541
BMI (±SD)	46.9 ±7.5	48.7 ±7.6	0.732
Female/male	30/10	32/8	0.689
Comorbidities (%)			
T2D	8 (20)	9 (22.5)	0.781
Hypertension	10 (25)	10 (25)	1
Dyslipidemia	7 (17.5)	8 (20)	0.772
SAHS	6(15)	5 (12.5)	0.745

(SS: Saline Solution; AS: Antibiotic Solution; SD: Standard Deviation; BMI: Body Mass Index; T2D: Type 2 Diabetes; SAHS: sleep apnea/hypopnea syndrome).

The clinical variables investigated were age, gender, co-morbidities, complications (gastric leak, incisional SSI, and organ-space SSI), post-operative pain assessed 24 hours after surgery by the Visual Analog Scale for Pain (VAS) and morphine needs, occurrence of post-operative nausea or vomiting, analytical variables determined 24 hours after surgery (C-reactive protein [CRP]; white blood cell [WBC] count and lactic acid) compared to hospital stay. Microbiologic variables consisted of cultures of the three extracted samples.

Incisional SSI was defined as the presence of a purulent discharge from any of the surgical sites confirmed with culture. An epidemiology nurse blinded to the treatment groups determined incisional SSI. Infection surveillance was extended for 30 days after discharge. Organ-space SSI was defined as a fluid collection on a contrast-enhanced computed tomography (CT) scan in a patient presenting with fever, tachycardia, abdominal pain, or septic status. The evidence of oral contrast extravasation on a CT scan was considered a leak rather than an organ-space SSI. A radiologist blinded to the treatment group determined the diagnosis of organ-space SSI and leak in case there was one.

A total of 80 patients were included in the study, 40 in each group. The sample consisted of 62 females and 18 males with a mean age of 43 ± 7.2 years. Pre-operative BMI of 47.8 Kg/m^2 ± 7.7 Kg/m^2. The distribution of age, gender, BMI, and co-morbidities was similar in both groups (Table 1).

The post-operative complication rate was 3.7%, consisting of two leaks at the Hiss angle junction (one in each group), satisfactorily resolved with conservative treatment. In SS group one deceased occurred due to pulmonary embolism despite correct thromboembolic prophylaxis. There were no significant differences in the morbidity or mortality rates in the two groups. Given that the hospital stay, pain perception, and laboratory values of the three patients presenting with complications might be altered, as intra-abdominal infection can lead to elevation of all of them, these patients were excluded from the analysis of post- operative pain, laboratory values of acute-phase reactants, and microbiologic study.

The median post-operative pain score 24 hours after surgery was 3.5 (range 2–7) in Group SS and 1.5 (range 0–4) in Group AS ($p = 0.021$). Morphine administration was required in two patients in Group SS and 0 in Group AS ($p = 0.15$). Post-operative nausea or vomiting appeared in five patients (13%) in Group AS and 4 (10%) in Group SS ($p = 0.72$).

The laboratory data 24 hours after surgery are shown in the graphic below (Figure 1). The WBC count also was significantly higher in Group SS (mean difference 1,930/mm3; 95% CI

145–66,839; p = 0.029). The mean CRP concentration also was higher in Group SS (mean difference 27.3 mg/L; 95% CI 16.4–71.2; p = 0.036). Finally, the mean lactic acid concentration also was higher in Group SS (mean difference 0.34 mg/L; 95% CI 0.1–0.7; p = 0.049). The median hospital stay was 3.5 days (range 3–5 days) in Group SS and 2.5 days (range 2–4 days) in Group AS (p = 0.05).

The culture of sample 1 (before any lavage) was positive in seven cases (18.4%) in Group SS and eight cases (20.5%) in Group AS (p = 0.77). The culture of sample 2 (after lavage) was positive in 18.4% of the patients in Group SS and 0 in Group AS (p = 0.006). The culture of sample 3 (drainage discharge) was positive in three patients (7.9%) in Group SS and 0 in Group AS (p = 0.08). The microorganism detected was *Escherichia coli* in all cases. No significant association between microbiologic contamination and clinical or analytical variables could be demonstrated.

In case of peritonitis a peritoneal lavage is mandatory to obtain prompt and fast resolution of the severe infection. [6] In fact, the ideal peritoneal lavage solution should be effective, easy to apply and with low posterior complications or adhesions formation. Several studies tried to establish effective protocols of peritoneal lavage; some authors focused on the effect of temperature, the volume of solution or different methods, such as cyclic intraperitoneal lavage by bi-luminal drainages. Meanwhile, no method has been universally accepted yet. [12] Some authors showed that peritoneal lavage with saline, antibiotics, or antiseptics solution does not influence the outcome following laparotomies for peritonitis. Having so few conclusions in laparotomic surgery, it is evident that much less evidence exists in laparoscopic one. [1]

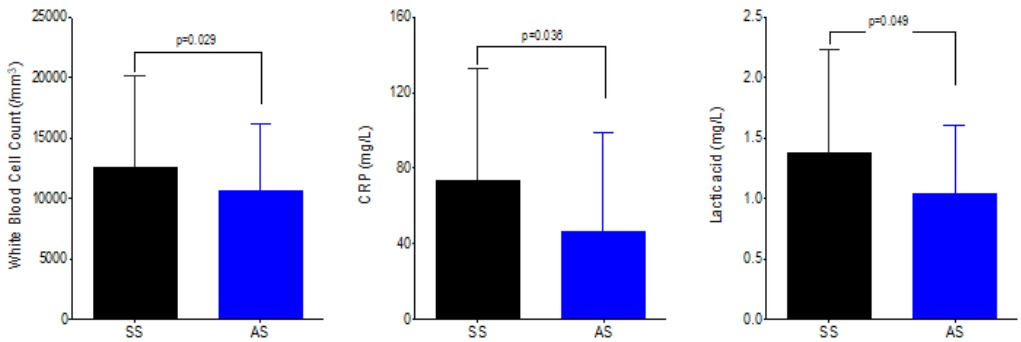

Figure 1. Laboratory data 24 hours after surgery.

The LSG is considered a clean-contaminated procedure, because the stomach is divided during this procedure. Thus, peri-operative systemic antibiotic prophylaxis is usually administered. In this sense, the SSI rate after laparoscopic surgery is significantly lower than that after conventional surgery, and this is especially relevant in morbidly obese subjects, as this condition itself is a risk factor for post-operative SSI. In this study, the highest contamination rate was 20% in both groups and the only micro-organism that grew in the cultures was *E. coli*. Thus, the peritoneal contamination in laparoscopically performed operations is much lower than conventional open surgeries and not only reduces the incisional SSI. [9] The abdominal wound is an important problem in obese patients, not only by the size of the skin-peritoneum damage, but also as the subcutaneous fatty tissue is easily colonized

by skin flora. It is evident that laparoscopy must be the elective approach for obese patients. In this way, the contamination of SSI is reduced to the intestinal saprophytic flora in the peritoneum and contamination of the subcutaneous tissue is avoided.

The concept of antibiotic irrigation is focused on reduction of SSI on wound. It seems to make no sense when performed in patients undergoing laparoscopic bariatric surgery with such a low contamination rate compared with colorectal surgery. [11] The fact that, SSI rates are not as high as in contaminated procedures reveals that host immunity can control contamination in most cases. The host as an aggression identifies the microorganism contamination, and it produces an inflammatory response. Surgical dissection indeed is an aggression sufficient to start an inflammatory response, but bacterial contamination might contribute to the increase and prolong it. [5]

Among several markers of inflammation, CRP has been studied widely to investigate its accuracy for the diagnosis of bacterial infection and the associated inflammatory response. [14, 15] The protein is an acute-phase reactant, synthesized by the liver, mainly in response to interleukin-6, which is produced not only during infection, but also in many types of inflammation, including the normal course after open or laparoscopic abdominal surgery. This fact justifies the higher concentrations of CRP observed in the post-operative course of most patients, even those having uncomplicated surgery. [14] Furthermore, CRP elevation is predictive of infective post-operative complications. In our series, the elevated CRP concentrations were markers of greater contamination. [16]

For fibrinogen, we could not find an effect like that reported for other acute-phase reactants. However, the accuracy of fibrinogen measurement for the diagnosis of inflammatory response secondary to bacterial infection or contamination seems to be lower, as reported by other authors. [17, 18]

Post-operative pain is a clinical reflection of tissue damage and the consequent inflammatory response. Local release of cytokines by the inflammatory cells stimulates nociceptive nervous receptors, and these trigger pain perception. Thus, a greater inflammatory response increases pain. After surgery the pain perception evaluated by VAS correlates directly with inflammatory cytokines concentrations. [19] In the present study, we could not demonstrate any association between pain, analytical values, and contamination. However, the reduction of all these parameters in the group of patients, who underwent antibiotic irrigation, indicates that the clinical relevance of these procedures beyond the improvement of acute-phase reactants is the reduction of post-operative pain. [20]

According to the results obtained, we believe that peritoneal lavage with antibiotic solution can be recommended in patients undergoing laparoscopic sleeve gastrectomy, and probably other bariatric procedures, but the latter hypothesis must be confirmed in similar studies conducted in other bariatric operations. Another limitation of this study is the small sample, which we used in order to obtain significant results on SSI reduction, one of the principal objectives of the study. More studies must be conducted with larger samples to confirm these hypotheses.

CONCLUSION

Intraperitoneal irrigation with a gentamicin and clindamycin solution in patients undergoing LSG leads to less alteration of acute-phase reactants, decrease postoperative pain and shorter hospital stay. Peritoneal lavage with antibiotic solutions can be considered an effective tool in the multimodal analgesia for bariatric surgery.

REFERENCES

[1] Chopra T. Epidemiology and outcomes associated with surgical site infection following bariatric surgery. *Am J Infect Control* 2012;40(9) (2012):815-9.

[2] Markides G. Laparoscopic versus open appendectomy in adults with complicated appendicitis: systematic review and meta-analysis." *World J Surg* 2010;34(9):2026-40.

[3] Henriksen NA. Clinical relevance of surgical site infection as defined by the criteria of the Centers for Disease Control and Prevention. *J Hosp Infect* 2010;75(3):173-7.

[4] Norman G. Intracavity lavage and wound irrigation for prevention of surgical site infection. *Cochrane Database Syst Rev.* 2017:CD012234.

[5] Qadan M. Meta-analysis of the effect of peritoneal lavage on survival in experimental peritonitis. *Br J Surg* 2010; 97(2):151-9.

[6] Platell C. The influence of lavage on peritonitis. *J Am Coll Surg* 2010;191:672–80.

[7] Adam U. Programmed lavage as a basic principle in therapy of diffuse peritonitis. *Langenbecks Arch Surg* 1997; 382:S18-21.

[8] Edmiston CE. Intra-Operative Surgical Irrigation of the Surgical Incision: What Does the Future Hold-Saline, Antibiotic Agents, or Antiseptic Agents? *Surg Infect (Larchmt)* 2016; 17(6):656-664.

[9] Doyle SL. Obesity and post-operative complications in patients undergoing non-bariatric surgery. *Obes Rev* 2010;11(12):875-86.

[10] Rosenthal RJ. Sleeve Gastrectomy Expert Panel. International Sleeve Gastrectomy Expert Panel Consensus Statement: best practice guidelines based on experience of >12,000 cases. *Surg Obes Relat Dis* 2012;8(1):8-19.

[11] Ruiz-Tovar J. Effect of peritoneal lavage with clindamycin-gentamicin solution on infections after elective colorectal cancer surgery. *J Am Coll Surg* 2012; 214(2):202-7.

[12] Sortini D. Role of peritoneal lavage in adhesion formation and survival rate in rats: an experimental study. *J Invest Surg* 2006; 19(5):291-7.

[13] Ruiz-Tovar, J. Prevention of surgical site infection in abdominal surgery. A critical review of the evidence. *Cir Esp* 2014; 92(4):223-31.

[14] Muñoz JL. C-Reactive Protein and Procalcitonin as Early Markers of Septic Complications after Laparoscopic Sleeve Gastrectomy in Morbidly Obese Patients Within an Enhanced Recovery After Surgery Program. *J Am Coll Surg* 2016; 222(5):831-7.

[15] Woeste G. Increased serum levels of C-reactive protein precede anastomotic leakage in colorectal surgery. *World J Surg* 2010; 34:140-6.

[16] Welsch T. C-reactive protein as early predictor for infectious postoperative complications in rectal surgery. *Int J Colorectal Dis* 2007; 22:1499–507.

[17] Feng S. Hyperfibrinogenemia in appendicitis: a new predictor of perforation in children. *Pediatr Surg Int* 2014; 30(11):1143-7.
[18] Glantzounis GK. Laparoscopic surgery-induced changes in oxidative stress markers in human plasma. *Surg Endosc* 2001; 15:1315–9.
[19] Ruiz-Tovar J. Evaluation of postoperative pain after laparoscopic cholecystectomy: Correlation between visual analogic scale (VAS) and systemic stress markers determined in a routine blood analysis. *Surg Chron* 2013;18:209–12.
[20] Ruiz-Tovar J. Effect of Peritoneal Lavage with Clindamycin-Gentamicin Solution on Post-Operative Pain and Analytic Acute-Phase Reactants after Laparoscopic Sleeve Gastrectomy. *Surg Infect (Larchmt)* 2016; 17(3):357-62.

In: Encyclopedia of Surgery (22 Volume Set)
Editors: Andreas Lehrer and Kristin Mueller
ISBN: 978-1-53618-329-0
© 2020 Nova Science Publishers, Inc.

Chapter 455

PROPHYLAXIS OF DEEP-VEIN THROMBOSIS IN BARIATRIC SURGERY

Jaime Ruiz-Tovar*, MD, PhD and Carolina Llavero
Obesity Unit, Garcilaso Clinic, Madrid, Spain

ABSTRACT

Obesity is associated with an increased risk of thromboembolic events. Venous thromboembolisms are the most common postoperative medical complications after bariatric surgery. Moreover, most bariatric procedures actually are performed by laparoscopic approach, implying an increased intraabdominal pressure during the surgical procedure that may favor the development of thrombus. The incidence of deep vein thrombosis (DVT) after laparoscopic bariatric surgery is about 3%. The prolonged anti-Trendelenburg position is considered the most important risk factor for venous thromboembolisms.

DVT is probably the most easily detected complication associated with venous thromboembolism, as it tends to appear with unilateral pain in the lower limb, associated with gastrocnemic edema and tenderness. DVT alone is not a life-threatening condition, but its main risk is migration of the thrombus and the development of pulmonary embolism (PE).

Therefore, bariatric surgery is considered a high-risk procedure for thromboembolic events. Actual recommendations are to include low molecular weight heparins (LMWH) and compression stockings in the primary prophylaxis of thromboembolic events.

INTRODUCTION

According to the World Health Organization (WHO), there are 1.6 billion overweight and 400 million obese people worldwide. Bariatric surgery has demonstrated to be the most effective and sustainable method for the regulation of morbid obesity, superior to both

* Corresponding Author's Email: jruiztovar@gmail.com.

pharmaceutical interventions and combinations of diet and lifestyle regimens. Therefore, the number of bariatric procedures performed, mainly in developed countries, is increasing every year [1, 2].

Obesity itself is associated with an increased risk of thromboembolic events. Moreover, most bariatric procedures are actually performed by a laparoscopic approach, implying an increased intraabdominal pressure during the surgical procedure that may favor the development of thrombus. Therefore, bariatric surgery is considered a high risk procedure for thromboembolic events [3, 4].

MORBID OBESITY AS RISK FACTOR

It has been determined that obesity is associated with a hypercoagulability status. Morbidly obese patients present increased fibrinogen levels that may reach twofold the normal value. It has been proved that venous circulation flow is slower in the infradiaphragmatic territory and especially in the lower limbs. Both facts, associated with disorders in several coagulation factors, favor the appearance of venous thrombosis, thrombophlebitis, and thromboembolic events, mainly pulmonary thromboembolisms (PE), which are the first cause of mortality in obese patients.

Venous stasis and hypercoagulability improve with weight loss, mostly after bariatric surgery. This improvement is achieved several months after the surgical procedure, when an important weight reduction has been obtained. More than 90% of patients undergoing any bariatric procedure present a relevant reduction of their hypercoagulability.

PE is also the most frequent cause of mortality in the immediate postoperative course of any kind of surgery in obese patients. Thus, they are considered as high-risk subjects, requiring intense prophylactic measures (mechanical and pharmacological) [5-7].

LAPAROSCOPIC BARIATRIC SURGERY

Venous thromboembolism is the most common postoperative medical complication after bariatric surgery. The incidence of deep vein thrombosis (DVT) after laparoscopic bariatric surgery is about 3% and that of pulmonary embolism (PE) is less than 1%. However, mortality associated with PE is estimated to be between 50% and 75% [8-10].

In laparoscopic abdominal surgery, the increase of intraabdominal pressure by the pneumoperitoneum, the prolonged operation time, and the anti-Trendelenburg position are considered risk factors for venous thromboembolisms. Moreover, hypercapnia induces vasoconstriction. It has been also demonstrated that surgical dissection induces the release of procoagulant cytokines. Other causes of venous thromboembolism after bariatric surgery is dehydration, especially after restrictive procedures, when patients hardly drink [11].

CLINICAL MANIFESTATIONS AND DIAGNOSIS

Venous thromboembolisms are often a challenging issue for the medical staff. DVT is probably the most easily detected complication associated with venous thromboembolism, as

it tends to appear with unilateral pain in the lower limb, associated with gastrocnemic edema and tenderness.

DVT alone is not a life-threatening condition, but its main risk is migration of the thrombus and the development of PE. The gold standard method for the diagnosis of DVT is Doppler ultrasonography (US).

PE usually appears with sudden unexplained dyspnea without any relevant features at the physical examination and on X-ray plain films. Laboratory data may show increased levels of D dimers, which present high sensitivity but low specificity for the suspicion of PE. The gold standard test for the diagnosis is a contrast-enhanced thoracic computed tomography (CT) scan showing a filling defect in the pulmonary arteries or their branches [11].

ANTITHROMBOEMBOLIC PROPHYLAXIS (PRIMARY PROPHYLAXIS)

Venous thromboembolisms are life-threatening conditions. Several measures, including prophylactic low molecular weight heparins (LMWH) and compressive stockings, are adopted to reduce their incidence. Up to the present there is no consensus about the optimal dosage of LMWH in the antithromboembolic prophylaxis for patients undergoing bariatric surgery. The dosage must be adjusted according to the weight of the patient, implying the need of administration of high preoperative doses.

Intra- and postoperative bleeding is one of the main complications of bariatric surgery. Many surgeons fear these complications and administer lower doses of LMWH than that recommended by most groups (Enoxaparin 0.5 mg/kg/day or Bemiparin 5000 UI/day or Dalteparin 50 UI/kg/day or Nadroparin 4100 UI/day) [12-15]. However, other authors report that this dose is insufficient because these patients are at high risk of developing thrombotic events [16-18].

The postoperative prolongation of prophylaxis is also a debated issue as some authors defend that a prolongation of 5-7 days is enough, whereas others report the need for maintaining it during 1 month, considering laparoscopic bariatric surgery as a high-risk procedure performed in high-risk patients [19-21]. In our opinion, a preoperative dose of 0.5 mg/kg/day administered 12 h before surgery and maintained postoperatively for 1 month is an adequate scheme for pharmacological antithromboembolic prophylaxis. We also fear intraoperative bleeding, but at these doses, it is not especially relevant in our experience. However, a postoperative thromboembolic event is a life-threatening condition for us that, once established, could be very difficult to manage.

Compression stockings must be maintained during the surgical event and postoperatively until the patient is able to make a proper ambulation [22, 23].

SCREENING FOR ASYMPTOMATIC VENOUS THROMBOEMBOLISM (SECONDARY PROPHYLAXIS)

As has already been mentioned, venous thromboembolisms are asymptomatic in many cases. In DVT it is especially important to achieve an early diagnosis to avoid the

development of life-threatening conditions, such as PE. With this aim, our group performed a prospective observational study of 100 consecutive patients undergoing laparoscopic sleeve gastrectomy as a bariatric procedure. DVT and porto-spleno-mesenteric vein thrombosis (PSMVT) were investigated 3 months after surgery with Doppler US and contrast-enhanced abdominal CT scan. The results of this study revealed that 2% presented unnoticed DVT and 1% unnoticed PSMVT. All these patients were asymptomatic. According to these results, we concluded that a routine postoperative screening with Doppler US or contrast-enhanced CT seems to be unnecessary [24].

REFERENCES

[1] Colquitt J. L., Picot J., Loveman E. et al. Surgery for obesity. *Cochrane Database Syst Rev* 2009; 2, CD003641.

[2] Martın Duce A., Dıez Del Val I. [*Surgery for morbid obesity. Clinical Guidelines of the Spanish Surgical Association*]. *Aran*, 2007, Madrid.

[3] Avenell A., Brown T. J., McGee M. A. et al. What are the long-term benefits of weight reducing diets in adults? A systematic review of randomized controlled trials. *J Hum Nutr Diet* 2004; 17:317-335.

[4] Rewers M., Zaccaro D., D'Agostino R. et al. Insulin Resistance Atherosclerosis Study investigators. Insulin sensitivity, insulinemia, and coronary artery disease: the Insulin Resistance Atherosclerosis Study. *Diabetes Care* 2004; 27:781-787.

[5] Solomon H., Liu G. Y., Alami R. et al. Benefits to patients choosing preoperative weight loss in gastric bypass surgery: new results of a randomized trial. *J Am Coll Surg* 2009; 208:241-245.

[6] Mhuircheartaigh J., Abedin S., Bennett A. E. et al. Imaging features of bariatric surgery and its complications. *Semin Ultrasound CT MR* 2013; 34:311-324.

[7] Switzer N. J., Mangat H. S., Karmali S. Current trends in obesity: body composition assessment, weight regulation, and emerging techniques in managing severe obesity. *J Interv Gastroenterol* 2013; 3:34-36.

[8] Stroh C., Birk D., Flade R. et al. Evidence of thromboembolism prophylaxis in bariatric surgery: results of a quality assurance trial in bariatric surgery in Germany from 2005 to 2007 and review of literature. *Obes Surg* 2009; 19:928-936.

[9] Melinek J., Livingston E., Cortina G. et al. Autopsy findings following gastric bypass surgery for morbid obesity. *Arch Pathol Lab Med* 2002; 126:1091-1095.

[10] Chan M. M., Hamza N., Ammori B. J. Duration of surgery independently influences risk of venous thromboembolism after laparoscopic bariatric surgery. *Surg Obes Relat Dis* 2013; 9:88-93.

[11] Cottam D. R., Mattar S. G., Barinas-Mitchell E. et al. The chronic inflammatory hypothesis for the morbidity associated with morbid obesity: implications and effects of weight loss. *Obes Surg* 2004;14: 589-600.

[12] Brotman D. J., Shihab H. M., Prakasa K. R. et al. Pharmacologic and mechanical strategies for preventing venous thromboembolism after bariatric surgery: a systematic review and meta-analysis. *JAMA Surg* 2012; 148:675-686.

[13] Ikesaka R., Delluc A., Le Gal G. et al. Efficacy and safety of weight-adjusted heparin prophylaxis for the prevention of acute venous thromboembolism among obese patients undergoing bariatric surgery: a systematic review and meta-analysis. *Thromb Res* 2014; 133:682-687.

[14] Becattini C., Agnelli G., Manina G. et al. Venous thromboembolism after laparoscopic bariatric surgery for morbid obesity: clinical burden and prevention. *Surg Obes Relat Dis* 2012; 8:108-115.

[15] Erviti J. [*Low-molecular weight heparins*] In: [*Pharmacotherapeutic informative bulletin of Navarra*]. http://www.cfnavarra.es/WebGN/SOU/publicac/BJ/textos/v6n5.htm.

[16] Gomez-Ambrosi J., Salvador J., Rotellar F. et al. Increased serum amyloid A concentrations in morbid obesity decrease after gastric by-pass. *Obes Surg* 2006;16:262-269.

[17] O'Brien K. D., Brehm B. J., Seeley R. J. et al. Diet induced weight loss is associated with decreases in plasma serum amyloid A and C-reactive protein independent of dietary macronutrient composition in obese subjects. *J Clin Endocrinol Metab* 2005;90:2244-2249.

[18] Ruiz-Tovar J., Oller I., Tomas A. et al. Midterm impact of sleeve gastrectomy, calibrated with a 50-Fr bougie, on weight loss, glucose hemostasis, lipid profiles and comorbidities in morbidly obese patients. *Am Surg* 2012; 78:969-974.

[19] Chivot C., Robert B., Lafaye N. et al. Laparoscopic sleeve gastrectomy: imaging of normal anatomic features and postoperative gastrointestinal complications. *Diagn Interv Imaging* 2013;94:823-834.

[20] Langer F. B., Reza Hoda M. A., Bohdjalian A. et al. Sleeve gastrectomy and gastric banding: effects on plasma ghrelin levels. *Obes Surg* 2005; 15:1024-1029.

[21] Rosenberg J. M., Tedesco M., Yao D. C. et al. Portal vein thrombosis following laparoscopic sleeve gastrectomy for morbid obesity. *JSLS* 2012; 16:639-643.

[22] Singh P., Sharma M., Ghandhi K. et al. Acute mesenteric vein thrombosis after laparoscopic gastric sleeve. *Surg Obes Relat Dis* 2010; 6:107-108.

[23] Huerta S., Li Z., Livingston E. H. Outcome of portal injuries following bariatric operations. *Obes Surg* 2006; 16:105-109.

[24] Alsina E., Ruiz-Tovar J., Alpera M. R. et al. Incidence of deep vein thrombosis and thrombosis of the portal-mesenteric axis after laparoscopic sleeve gastrectomy. *J Laparoendosc Adv Surg Tech* A 2014; 24:601-605.

In: Encyclopedia of Surgery (22 Volume Set)
Editors: Andreas Lehrer and Kristin Mueller
ISBN: 978-1-53618-329-0
© 2020 Nova Science Publishers, Inc.

Chapter 456

ANESTHETIC CONSIDERATIONS IN PEDIATRIC CARDIAC SURGERY

Carolina Passos Diniz[1], MD and Juliana Torres Pacheco[2,*], MD
[1]Beneficência Portuguesa Hospital,
São Paulo, Brazil
[2]Pediatric Cardiac Intensive Care Unit, Beneficência Portuguesa Hospital,
São Paulo, Brazil

INTRODUCTION

The congenital cardiovascular anesthesiologist's central role is to design an anesthetic strategy for a patient who often has limited cardiovascular reserve and constitutes a key component for optimal perioperative care of these complex patients.

PREOPERATIVE CONSIDERATIONS

It's mandatory to understand the type of congenital heart disease and evaluate the patient's functional status (Table 1), since it reveals their cardiopulmonary reserve [1, 2].

RISK STRATIFICATION

There are a few risk stratification tools available to access the risk of postoperative death in children undergoing cardiac surgery. They are: Risk Adjustment for Congenital Heart Surgery (RACHS-1) score (Table 2), the Basic Aristotle Complexity Score, and the Society of Thoracic Surgeons and the European Association for Cardiothoracic Surgery Mortality score (STS-EACTS score) (Table 3) [3-6].

According to Pacheco JT et al. [7], our CICU showed a 23.3% mortality in patients RACHS-1 category 6 in a 4-year analysis.

* Corresponding Author's Email: julianatpacheco@gmail.com.

Table 1. General preoperative care

Informed consent	Involves patient's and parent's knowledge of the upcoming intervention, reducing their anxiety and improving their involvement with postoperative care.
History and physical examination	Gestational age at birth. Previous surgery and hospital staying Anesthetic experiences and complications Diagnostic and therapeutic interventions Non-cardiac problems and syndromes Current medications Food allergies Evaluation of vital signs, cardiac rhythm, and pre- and post-ductal oxygen saturations, if there is any unrepaired defect.
Preoperative exams	Imaging studies and cardiac catheterization, and electrocardiographic evaluation are required in most interventions. Laboratory tests are based on the extent of surgery/procedure, signs and symptoms.
Fasting	Follows ASA (American Society of Anesthesiologists) guidelines.

Table 2. Procedures according to RACHS-1 category

Risk Category 1

1. Partially anomalous pulmonary venous connection surgery
2. Coarctation repair at age >30 d
3. Patent ductus arteriosus surgery at age >30 d
4. Atrial septal defect surgery (including ostium secundum, sinus venosus, and PFO closure)

Aortopexy

Risk Category 2

1. Left ventricular to right atrial shunt repair
2. Common atrium closure
3. Transection of pulmonary artery
4. Repair of pulmonary artery stenosis and Pulmonary outflow tract augmentation
5. Coarctation repair at age ≤30 d
6. Repair of aorta-pulmonary window
7. Vascular ring surgery
8. Glenn procedure
9. Total repair of tetralogy of Fallot
10. Repair of total anomalous pulmonary veins at age >30 d
11. Repair of unspecified septal defect
12. Ventricular septal defect repair (with or without pulmonary artery banding removal or pulmonary valvotomy or infundibular resection)
13. Ostium primum atrial septal defect repair
14. Atrial septal defect and ventricular septal defect repair
15. Repair of coronary artery fistula
16. Right ventricular infundibulectomy
17. Pulmonary valve replacement, valvotomy or valvuloplasty
18. Aortic valvotomy or valvuloplasty at age >30 d
19. Subaortic stenosis resection

Risk Category 3

1. Repair of anomalous coronary artery with intrapulmonary tunnel
2. Closure of semilunar valve, aortic or pulmonary
3. RV or LV to pulmonary artery conduit
4. Repair of double-outlet right ventricle with or without repair of right ventricular obstruction
5. Fontan procedure
6. Repair of transitional or complete atrioventricular canal with or without valve replacement
7. Pulmonary artery banding
8. Repair of tetralogy of Fallot with pulmonary atresia
9. Repair of cor triatriatum
10. Systemic to pulmonary artery shunt
11. Atrial or arterial switch operation
12. Reimplantation of anomalous pulmonary artery
13. Annuloplasty Repair of coarctation and ventricular septal defect closure
14. Excision of intracardiac tumor
15. Repair of anomalous coronary artery without intrapulmonary tunnel
16. Tricuspid valve repositioning for Ebstein anomaly at age >30 d
17. Tricuspid valve replacement, valvotomy or valvuloplasty
18. Valvectomy of tricuspid valve
19. Mitral valve replacement, valvotomy or valvuloplasty
20. Aortoplasty
21. Ventriculomyotomy
22. Left ventricular outflow tract patch
23. Ross procedure
24. Aortic valve replacement

Risk Category 4

1. Aortic valvotomy or valvuloplasty at age ≤30 d
2. Konno procedure
3. Repair of complex anomaly (single ventricle) by ventricular septal defect enlargement
4. Repair of total anomalous pulmonary veins at age ≤30 d
5. Atrial septectomy repair of transposition, ventricular septal defect, and subpulmonary stenosis
6. Atrial switch operation with ventricular septal defect closure
7. Atrial switch operation with repair of subpulmonary stenosis
8. Arterial switch operation with pulmonary artery band removal
9. Arterial switch operation with ventricular septal defect closure
10. Arterial switch operation with repair of subpulmonary stenosis
11. Repair of truncus arteriosus
12. Repair of hypoplastic or interrupted arch without ventricular septal defect closure
13. Repair of hypoplastic or interrupted aortic arch with ventricular septal defect closure
14. Transverse arch graft
15. Unifocalization for tetralogy of Fallot and pulmonary atresia
16. Double switch

Risk Category 5

1. Tricuspid valve repositioning for neonatal Ebstein anomaly at age ≤30 d
2. Repair of truncus arteriosus
3. Repair of interrupted arch

Risk Category 6

1. Stage 1 repair of hypoplastic left heart syndrome (Norwood operation)
   Damus-Kaye-Stansel procedure

Source: Jenkins, K. J. et al. 2002. *J. Thorac. Cardiovasc. Surg.* 123(1):110-8.

Table 3. Procedures according to STAT score

Risk Category 1

1. ASD repair (primary closure or patch repair)
2. Partial and Intermediate (transitional) AVSD repair
3. PAPCV repair
4. Aortic stenosis, subvalvar repair
5. ICD (AICD) implantation
6. Double chamber right ventricle repair
7. VSD repair (primary closure or patch repair)
8. Vascular ring repair
9. Coarctation repair (end to end anastomosis or interposition graft)
10. Aortic valve replacement (bioprosthetic or mechanical)
11. Pulmonary valve replacement
12. Conduit reoperation
13. TOF repair (no ventriculotomy and no transanullar patch
14. Fontan (lateral tunnel, fenestrated)
15. Aneurysm of sinus of Valsalva repair

Risk Category 2

1. PDA closure
2. LV to aorta tunnel repair
3. Tricuspid, mitral, aortic or pulmonary valvuloplasty
4. Tricuspid valve replacement
5. Truncal valve replacement
6. 1½ Ventricular repair
7. Arrhythmia surgery - surgical ablation
8. Permanent pacemaker implantation
9. Ross procedure
10. Aortopexy
11. Bidirectional Glenn procedure
12. Pulmonary artery reconstruction (plasty)
13. Fontan connection (external conduit, atriopulmonary connection and nonfenestrated lateral tunnel)
14. Atrial fenestration closure
15. Aortic root replacement (valve sparing or mechanical prothesis)
16. Conduit placement (including LV to PA)
17. Extended coarctation repair (end to end anastomosis or subclavian flap)
18. Anomalous origin of coronary artery repair
19. RVOT procedure
20. Aortic aneurysm repair
21. Congenitally corrected TGA repair
22. AP window repair
23. TOF repair (with ventriculotomy and transannular patch)
24. Aortic root replacement (bioprosthetic)
25. Supravalvar aortic stenosis repair
26. Pericardiectomy
27. LV aneurysm repair
28. Pulmonary artery origin from ascending aorta (hemitruncus) repair

29. Atriosseptectomy
30. PAPVC (scimitar) repair
31. Ligation of pulmonary artery
32. Coronary artery fistula ligation
33. Mitral stenosis and supravalvar mitral ring repair
34. Systemic venous stenosis repair
35. Cor triatriatum repair
36. Multiple VSD repair
37. Atrial baffle procedure (non-Mustard, non-Senning)
38. Partial left ventriculectomy (LV volume reduction surgery - Batista)
39. TOF repair with RV-PA conduit

Risk Category 3

1. Lung transplantation
2. Occlusion MAPCA(s)
3. Coarctation repair + VSD repair
4. Konno procedure
5. Coarctation repair with patch aortoplasty
6. PA, reconstruction (plasty), branch, central (within the hilar bifurcation)
7. Pulmonary artery or RV aneurysm repair
8. Ventricular septal fenestration
9. Shunt ligation and takedown
10. Hemi-Fontan procedure
11. Total AVSD repair
12. Anomalous systemic venous connection repair
13. ASO or Mustard procedure
14. Truncal valve valvuloplasty
15. Pulmonary embolectomy
16. ASD partial closure
17. Rastelli operation
18. Conduit placement (ventricle to aorta and RV to PA)
19. Aortic valve replacement (homograft)
20. REV
21. Pulmonary artery sling repair
22. Pulmonary atresia-VSD (including TOF, PA repair)

Risk Category 4

1. Mitral valve replacement
2. Pericardial drainage procedure
3. Aortic arch repair
4. Fontan revision or conversion (redo Fontan procedure)
5. DOLV and DORV (intraventricular tunnel) repair
6. ASO + aortic arch repair
7. PA debanding
8. ASO and VSD repair
9. Cardiac tumor resection
10. Heart transplantation
11. Coronary artery bypass
12. TOF-absent pulmonary valve repair

Table 3. (Continued)

13. Tricuspid valve excision (without replacement)
14. Modified BT Shunt or central shunt
15. AVSD + TOF repair
16. Ross-Konno procedure
17. Senning procedure
18. Ebstein's repair
19. Aortic arch repair + VSD repair
20. PA banding
21. Aortic root replacement with homograft
22. Unifocalization MAPCA(s)
23. Aortic dissection repair
24. Congenitally corrected TGA repair (VSD closure and LV to PA conduit)
25. Pulmonary atresia + VSD + MAPCA repair
26. ASD or VSD creation/enlargement
27. HLHS biventricular repair
28. TAPVC repair
29. Pulmonary venous stenosis repair
30. Interrupted aortic arch repair
31. Arterial switch procedure and VSD repair + aortic arch repair
32. Truncus arteriosus repair
33. Atrial septal fenestration
34. Tricuspid valve closure (exclusion, univentricular approach)
Risk Category 5
1. Damus-Kaye-Stansel procedure (creation of AP anastomosis without arch reconstruction)
2. Heart and lung transplantation
3. Congenitally corrected TGA repair (atrial switch + Rastelli operation or Double switch)
4. Norwood procedure
Truncus + IAA repair

Source: O'Brien, S. M. et al. *J. Thorac. Cardiovasc. Surg.* 138(5):1139-53.

ANESTHETIC AGENTS

The adequate choice of the anesthetic agent aims to preserve patients' hemodynamics. The most commonly used drugs are [8, 9, 10]:

- Opioids and benzodiazepines: the tendency to early extubation favors lower opioid doses (10-20 μg/kg of Fentanyl or equivalent). High doses (50-75 μg/kg) might be used in selected cases. Midazolam provides sedation and amnesia with hemodynamic stability.
- Volatile agents: Isoflurane, sevoflurane and desflurane at end-tidal. All volatile agents may depress myocardial contractility and cardiac output at high doses and should be used with caution.

- Ketamine: administration can be intravenous (IV) or intramuscular (IM). Induction dose of 1-2 mg/kg IV or 5-10 mg/kg IM, and maintenance dose of 1-5 mg/kg/hour are indicated.
- Dexmedetomidine: loading dose of 0.5-1 μg/kg given over 10 minutes, followed by a maintenance of 0.2-0.7 μg/kg/hour is commonly used as a coadjuvant.
- Propofol: caution must be taken with prolonged infusion and it should be indicated only in patients with adequate cardiovascular reserve.
- Etomidate: reserved to few patients with very limited cardiac reserve.

PERIPOPERATIVE CONSIDERATIONS

PREMEDICATION

- Premedication is the first step to relax the patient, facilitate separation from parents, and enhance their composure having their child calm before the procedure. Numerous sedative-hypnotics may be used.
- Midazolam is commonly administered by different routes (intranasally 0.3mg/kg, orally 0.5–1mg/kg, IV 0.05 - 0,1 mg/kg). The oral route is well tolerated and easily administered.
- Intranasal dexmedetomidine (0.5–1 μg/kg) has also been used. The onset of action is delayed at 45 minutes.
- Ventilation and oxygenation should be monitored.

ANTIBIOTIC PROPHYLAXIS

- All cardiac surgery should receive antibiotic prophylaxis 30 to 60 minutes before surgical incision (see Chapter 16).
- Cefuroxime 50mg/kg q8h in case of hospital stay up to 7 days.
- Associate Vancomycin 15mg/kg q6h in case of hospital admission longer than one week.
- Antibiotics should be admnistered for 24 hours after surgery, except in case of open chest, when they should be discontinued only 24h after closed chest.

INDUCTION AND MAINTENANCE

- A superficial vein at any site is cannulated before induction or during inhalation induction of anesthesia.
- Induction can be achieved by inhalation of a volatile anaesthetic agent.
- Secure airway, arterial line and central venous access are obtained. Multi-lumen catheters are recommended.
- Some access sites (superior vena cava) in small infants with single-ventricular pathologies might be preserved.
- Patients receiving inotropes and vasodilators have the potential to significantly deteriorate with anesthetic exposure.
- Pulmonary hypertension increases the perioperative risk in patients with congenital heart disease. [11]

MONITORING

- Heart and respiratory rate, arterial line, CVP, pulse oximetry, continuous EKG, capnography, urine output, central temperature, cerebral and somatic oximetry, BIS, and left atrium and pulmonary pressure pressure if necessary.
- Coagulation point-of-care testing, activated clotting time (ACT), blood gas analysis, lactate, venous oxygen saturation, electrolytes, red blood cell count, and glycemia should be monitored during the surgery.

CORTICOSTEROIDS

- Limits the inflammatory response after bypass and may reduce the need for inotropes.
- Methylprednisolone is the drug of choice, 30mg/kg prior to CPB and at the start of CPB.

ANTIFIBRINOLYTIC THERAPY

- Both ε-aminocaproic acid and tranexamic acid appear effective in reducing bleeding and transfusion in cyanotic patients. [12]
- Dose: 50-100mg/kg/dose IV

HEPARIN

- Heparin injection precedes the cannulation of the great vessels.
- 300–400 units/kg is injected to reach a target ACT > 480 seconds prior to the initiation of CPB.
- Additional heparin doses: 200–400 units/kg in the circuit, and 50–100 units/kg ongoing administration every 30–120 minutes.

CPB

- After CPB is initiated, mechanical ventilation is discontinued. Anesthetic drugs can be added to the bypass circuit to maintain general anesthesia during CPB. Anticoagulation, fluid balance, organ perfusion, core temperature and cardioprotection are of particular importance.
- Use of the pH-stat strategy in infants undergoing deep hypothermic cardiopulmonary bypass is associated with lower postoperative morbidity, improved oxygen delivery, reduced ventilator dependence, and reduced ICU stays when compared to Alpha-stat. [13,14]
- During rewarming, inotropes might be initiated (milrinone and epinephrine are the preferred drugs for prevention and treatment of LCOS). Normal temperature is reached, heart is filled, ventilation is resumed, vasoactive drugs are titulated, and possible cardiac arrhythmias are treated before separation from bypass is initiated. [15]

POST CPB

- Modified ultrafiltration after CPB is commonly employed to decrease blood transfusion requirement, reduce cytokines, decrease tissue edema, improve myocardial perfusion, and reduce pulmonary vascular resistance.
- Surgical repair is assessed by transesophageal echocardiogram (TEE).
- Pulmonary hypertension, if present, must be treated.
- Heparin reversal is achieved with protamine and other coagulation disturbances are treated.
- Some patients fail to wean off CPB, despite an asserted surgical technique and all resources used, and ECMO is eligible.

POSTOPERATIVE CONSIDERATIONS

- The main goal when treating children who have undergone surgery for congenital heart disease is maintaining adequate tissue oxygenation, which is accomplished by maintaining systemic oxygen delivery and minimizing oxygen consumption [1, 16].

- To optimize oxygen delivery, improve sedation and analgesia, treat hyperthermia, it's advisable to consider muscle relaxation in critically ill patients under mechanical ventilation and blood transfusions [15].
- Increased oxygen consumption usually occurs in systemic inflammatory response and low cardiac output syndrome, bleeding, ischemia–reperfusion injury, postoperative myocardial dysfunction, right ventricular failure due to acute pulmonary hypertension, and decreased coronary perfusion [17].
- Postoperative management should consider limitations of the cardiovascular reserve in neonates, hematocrits targets and cardiovascular physiology after surgery.
- If coagulation, electrolytes, temperature and hemodynamics are normalized, and individual factors are considered, extubation may be performed in the operating room or programmed for the first hours after surgery [3].
- Early extubation and spontaneous ventilation are particularly desirable in patients undergoing bidirectional Glenn anastomosis, Fontan operations and Tetralogy of Fallot repair [17].
- Fast-track protocols also includes early extubation. For fast-tracking, prior to a balanced anesthetic technique, limit opioid use and prefer non-opioid analgesics or opioid-sparing drugs such as dexmedetomidine, in a multimodal pain management strategy. Typical benefits include less sedation, lower inotropic support, fewer mechanical ventilation-associated complications, more rapid patient mobilization, reduced parental stress, decreased length of ICU and hospital stay, and possibly cost savings [18].
- The transport from the OR to CICU must follow a systematic approach. Before leaving, remember to check before leaving the OR the drugs pump, the thresholds of the pacemaker, the airway equipment, the transport monitor, and to organize the lines.
- After arriving in the CICU, the anesthesiologist should report the patient's information and the operative course (anesthetic problems, ETT size and position, line locations, size and any problems, times of CPB, XC and DHCA, weaning from CPB and any issues, echo findings post-CPB, pacemaker settings, inotrope infusions, blood products given and last antibiotic time).

REFERENCES

[1] Kang, N., Cole, T., Tsang, V., Elliott, M. and de Leval, M. 2004. "Risk stratification in paediatric open-heart surgery." *Eur. J. Cardiothorac. Surg.* 26(1):3-11.

[2] Simsic, J. M., Cuadrado, A., Kirshbom, P. M. and Kanter, K. R. 2006. "Risk adjustment for congenital heart surgery (RACHS): is it useful in a single-center series of newborns as a predictor of outcome in a high-risk population?" *Congenit. Heart Dis.* 1(4):148-51.

[3] Jenkins, K. J. 2004. "Risk adjustment for congenital heart surgery: the RACHS-1 method." *Semin. Thoracic Cardiovasc. Surg. Pediatr. Card. Surg. Annu.* 7(1):180-4.

[4] Jenkins, K. J., and Gauvreau, K. 2002. "Center-specific differences in mortality: preliminary analyses using the Risk Adjustment in Congenital Heart Surgery (RACHS-1) method." *J. Thorac. Cardiovasc. Surg.* 124(1):97-104.

[5] Jenkins, K. J., Gauvreau, K., Newburger, J. W., Spray, T. L., Moller, J. H. and Iezzoni, L. I. 2002. "Consensus-based method for risk adjustment for surgery for congenital heart disease." *J. Thorac. Cardiovasc. Surg.* 123(1):110-8.

[6] O'Brien, S. M., Clarke, D. R., Jacobs, J. P., Jacobs, M. L., Lacour-Gayet, F. G., Pizarro, C., Welke, K. F. et al. 2009. "An empirically based tool for analyzing mortality associated with congenital heart surgery." *J. Thorac. Cardiovasc. Surg.* 138(5):1139-53.

[7] Pacheco, J. T., Fuenmayor, G., Pereira, M. E. N. T., Khader, H. M., Furlanetto, B. H., Furlanetto, G., Bezerra, R. F., da Silva, L. F. and da Silva, J. P. 2018. "Pediatric cardiac surgical mortality rate from a Brazilian reference center." *Paper presented at XXXIX Congress of Cardiology Society of São Paulo,* São Paulo, Brazil, May 31-June 2.

[8] Nicolson, S. C., Stevem, J. M., Kurth, C. D., Krucylak, C. P. and Jobes, D. R. 1994. "Anesthesia for noncardiac surgery in infants with hypoplastic left heart syndrome following hemi-Fontan operation." *J. Cardiothorac. Vasc. Anesth*. 8(3):334-6.

[9] LeRiger, M., Naguib, A., Gallantowicz, M. and Tobias, J. D. 2012. "Dexmedetomidine controls and junctional ectopic tachycardia during tetralogy of fallot repair in an infant." *Ann. Card. Anaesth.* 15(3):224-8.

[10] Liu, Y., Bian, W., Liu, P., Zang, X., Gu, X. and Chen, W. 2018. "Dexmedetomidine improves the outcomes in paediatric cardiac surgery: a meta-analysis of randomized controlled trials." *Interact. CardioVasc. Thorac. Surg.* 26(5):852-858.

[11] Bates, K. E., Mahle, W. T., Bush, L., Donohue, J., Gaies, M. G., Nicolson, S. C., Shekerdemian, L. et al. 2019. "Variation in implementation and outcomes of early extubation practices after infant cardiac surgery." *Ann. Thorac. Surg.* 107(5):1434-40.

[12] Koster, A., Faraoni, D., and Levy, J. H. 2015. "Antifibrinolytic therapy for cardiac surgery: an update." *Anesthesiology* 123(1):214-21.

[13] Duebener, L. F., Hagino, I., Sakamoto, T., Mime, L. B., Stamm, C., Zurakowski, D., Schäfers, H. J., and Jonas, R. A. 2002. "Effects of pH management during deep hypothermic bypass on cerebral microcirculation: alpha-stat versus pH-stat." *Circulation* 106(suppl I):I-103-8.

[14] du Plessis, A. J., Jonas, R. A., Wypij, D., Hickey, P. R., Riviello, J., Wessel, D. L., Roth, S. J. et al. 1997. "Perioperative effects of alpha-stat versus pH-stat strategies for deep hypothermic cardiopulmonary bypass in infants." *J. Thoracic Cardiovasc. Surg.* 114(6):991-1000.

[15] Gomes, W. J. and Buffolo, E. 1993. "Acid-base control in hypothermia." *Rev. Bras. Cir. Cardiovasc.* 8(3):189-94.

[16] Cavalcante, C. T., de Souza, N. M. G., Pinto, V. C. Júnior, Branco, K. M., Pompeu, R. G., Teles, A. C., Cavalcante, R. C., and de Andrade, G. V. 2016. "Analysis of surgical mortality for congenital heart defects using RACHS-1 risk score in a Brazilian single center." *Braz. J. Cardiovasc. Surg.* 31(3):219-25.

[17] Steven, J. M. Nicolson, S. C. 2003. "Anesthetic management for HLHS." In: *Hypoplastic left heart syndrome*, edited by Rychik J. et al, 167-91. Kluwer Academic Publishers.

[18] da Cruz, E. M., Ivy, D. and Jaggers, J. 2014. *Pediatric and Congenital Cardiology, Cardiac Surgery and Intensive Care.* Volume 2. Springer-Verlag London.

In: Encyclopedia of Surgery (22 Volume Set)
Editors: Andreas Lehrer and Kristin Mueller
ISBN: 978-1-53618-329-0
© 2020 Nova Science Publishers, Inc.

Chapter 457

CARDIAC SURGERY POSTOPERATIVE ARRHYTHMIAS

Carla Daina[1], MD, Joan Sanchez-de-Toledo[1,2], MD and Lucas Saenz[2,*], MD

[1]Pediatric Intensive Care Unit, Vall d'Hebron Hospital, Barcelona, Spain
[2]Cardiac Intensive Care Unit, Children's Hospital of Pittsburgh, Pittsburgh, US

INTRODUCTION

Cardiac arrhythmias are one of the most frequent postoperative complications after congenital heart surgery. Its incidences are estimated between 10-50% with a mortality that can reach up to 12%. The recognition and treatment of arrhythmias during the postoperative period is key after congenital heart surgery. Abnormal high and low heart rate arrhythmias (tachyarrhythmia and bradyarrhythmia, respectively) and the loss of atrioventricular synchrony are characteristic of some rhythms that can compromise cardiac output and therefore complicate the postoperative care of children with congenital heart disease.

BRADYARRHYTHMIAS

The most frequent bradyarrhythmias after cardiac surgery are:

- Sinus node dysfunction, usually transitory.
- Pharmacological bradyarrhythmia.
- AV block with its distinctive degrees.

* Corresponding Author's Email: SanchezDeToledoJ@upmc.edu.

1. Sinus node dysfunction:

It is caused by a dysfunction of the pacemaking mechanism within the sinus node, resulting in low heart rhythm with prolonged pauses or with a nodal escape rhythm.

Usually this appears after surgical manipulation of the right atrium. In most cases it is a temporal rhythm, but in some cases it can become a permanent rhythm.

2. Atrioventricular block (AVB):

AV block presents an alteration of the normal electrical conduction paths through the AV node. It can be present during or after surgeries affecting the left ventricular outflow track, interventricular septum and especially after Tetralogy of Fallot repair.

Classification:

2.1. *First degree*: P-R interval is enlarged but all the P waves are conductive and go through the AV node. Nonetheless, there is a delay in the electrical conduction. Does not produce important clinical alterations and does not require urgent treatment.

2.2. *Second degree:* Mobitz 1: (Wenkebach): Characterized by progressive enlargement of PR interval until a P wave does not depolarize the ventricle. Hemodynamically is usually well tolerated. Mobitz 2: Represents a progressive dysfunction of the AV node. An intermittent AV block develops and there is risk it will develop into a complete AV block.

2.3. *Third degree or complete AV block:* There is a loss of AV conduction. None of the P waves are producing a ventricle depolarization. A state of atrioventricular asynchrony is present. The ventricular escape rate rhythm will define the hemodynamic status of the patient.

Table 1. Drugs for bradyarrhythmia and their doses

Drugs	Indications	Doses	Secondary effects
Atropine	Sinus bradycardia AV block	Bolus: 0.01-0.02 mg/kg (min 0.1 mg, max 2 mg)	Tachycardia Paradoxical bradycardia
Epinephrine	Asystole (CPR) Extreme bradycardia	Bolus: 0.01 mg/kg Continuous infusion: 0.05-2 mcg/kg/min	Tachycardia Arterial hypertension Arrhythmias
Isoproterenol	AV block	Continuous infusion: 0.01-0.05 mcg/kg/min	Tachycardia Arrhythmias

The postoperative management is based on the utilization of sequential pacemaker, and for this reason temporary pace wires should be placed during the surgical procedure. The current recommendations are to place atrioventricular wires to secure adequate heart rate and AV synchrony. In case the AV wires are dysfunctional, chronotropic medications such as Isoproterenol, Atropine and Epinephrine could be used while pacemaker wires are restored to functional capacity or as new probes are placed (endocavitary or external).

Permanent pacemaker is indicated when a second-degree AV block (Mobitz 2) or complete AV block are present for more than 2 weeks.

TACHYARRHYTHMIAS

Tachyarrhythmias are the most common arrhythmias during the post-operative course. Etiology is usually multifactorial, including intra- and perioperative factors. In the last three decades, the therapeutical advances in this field have been few, and today the therapeutical options are limited. A practical way to classify these types of arrhythmias is to describe their etiopathology and location.

1. Etiopathology classification (Figure 1):
   1.1. Reentrant tachyarrhythmias
   1.2. Automatic tachyarrhythmias.

Classifying these arrhythmias into automatic and reentrant has a special interest from a clinical point of view and defines its therapeutic approach in the intensive care unit. *Reentrant tachyarrhythmias* are frequent in the neonatal period and less frequent during the immediate post-operative time. This class of arrhythmias appears suddenly and end in the same way, a phenomenon called “on-off.” Heart rates are fixed, and they usually respond to pharmacological and electrical cardioversion. On the other hand, *automatic tachyarrhythmias* are the most prevalent arrhythmias in the post-operative period. They usually appear in a progressive manner (“warm-up”) and dissipates slowly overtime (“cool down”). These types of arrhythmias are refractory to pharmacological treatment and characteristically also to electrical cardioversion.

2. Classification based on location (Figure 2):
   2.1. Atrial arrhythmias
   2.2. Conduction arrhythmias
   2.3. Ventricular Arrhythmias.

The mechanism of action and location are important concepts that lead to a rapid diagnosis. For this reason, P/QRS ratio (Figure 2) is being used to identify the location of the arrhythmia and the proper differential diagnosis in most of the cases (Figure 3).

It is important to be aware of the most common associations between arrhythmias and surgical procedures (Table 2).

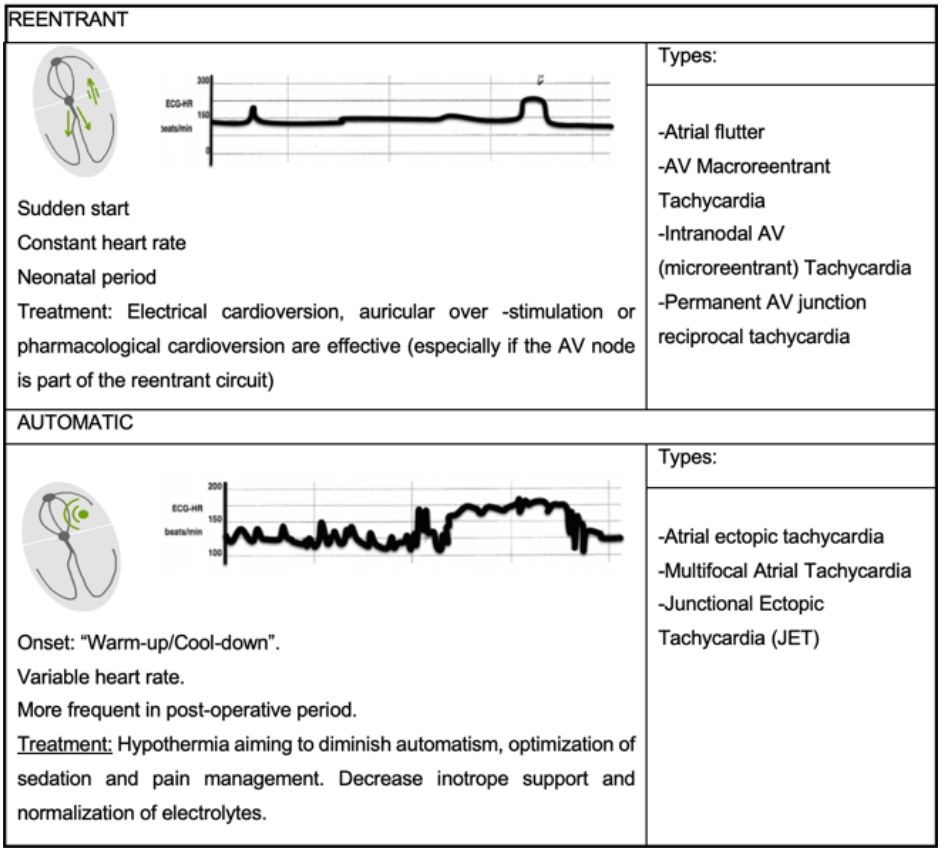

Figure 1. Tachyarrhythmias classification based on etiopathology *(Mechanism of Action).*

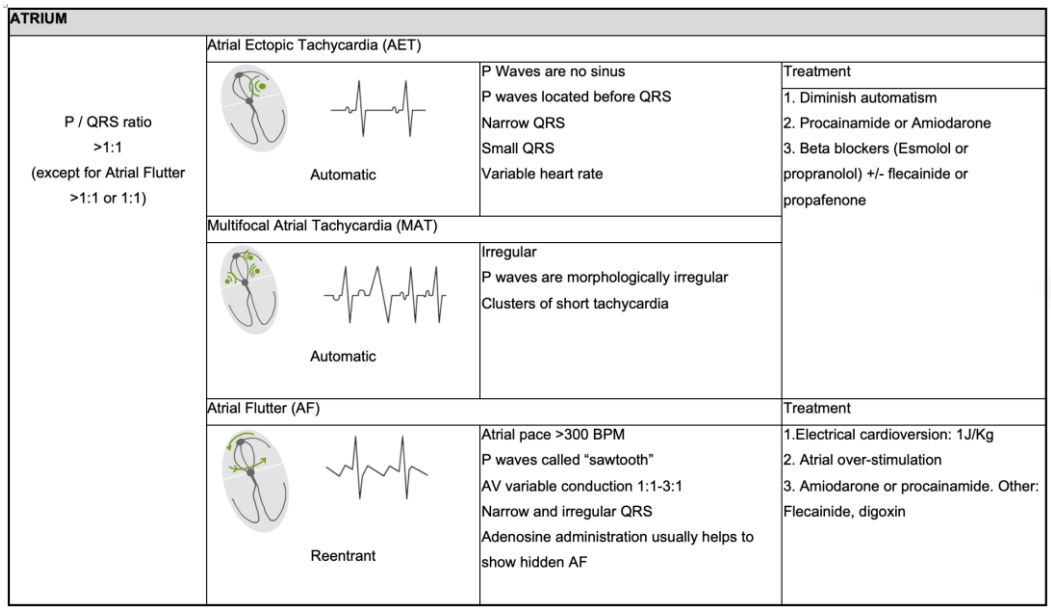

Figure 2. (Continued).

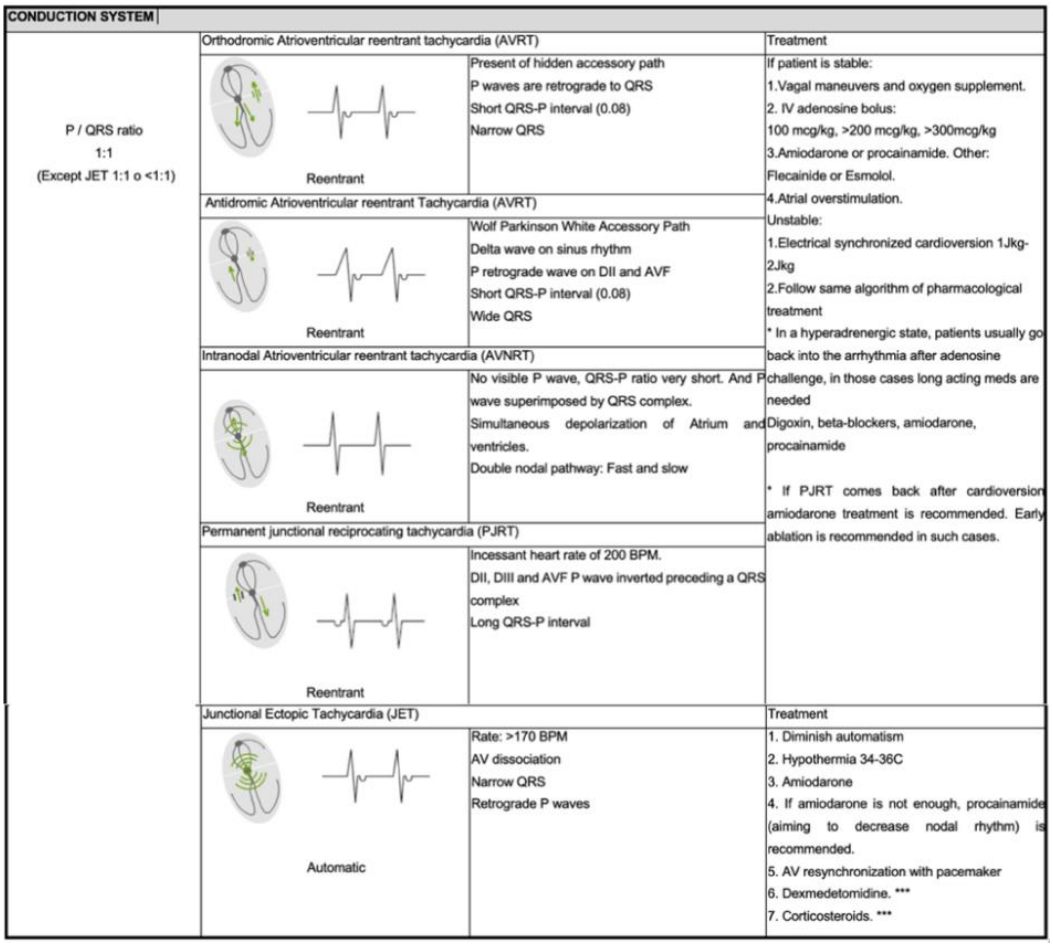

CONDUCTION SYSTEM			
P / QRS ratio 1:1 (Except JET 1:1 o <1:1)	Orthodromic Atrioventricular reentrant tachycardia (AVRT)		Treatment
	Reentrant	Present of hidden accessory path P waves are retrograde to QRS Short QRS-P interval (0.08) Narrow QRS	If patient is stable: 1.Vagal maneuvers and oxygen supplement. 2. IV adenosine bolus: 100 mcg/kg, >200 mcg/kg, >300mcg/kg 3.Amiodarone or procainamide. Other: Flecainide or Esmolol. 4.Atrial overstimulation. Unstable: 1.Electrical synchronized cardioversion 1Jkg-2Jkg 2.Follow same algorithm of pharmacological treatment * In a hyperadrenergic state, patients usually go back into the arrhythmia after adenosine challenge, in those cases long acting meds are needed Digoxin, beta-blockers, amiodarone, procainamide * If PJRT comes back after cardioversion amiodarone treatment is recommended. Early ablation is recommended in such cases.
	Antidromic Atrioventricular reentrant Tachycardia (AVRT)		
	Reentrant	Wolf Parkinson White Accessory Path Delta wave on sinus rhythm P retrograde wave on DII and AVF Short QRS-P interval (0.08) Wide QRS	
	Intranodal Atrioventricular reentrant tachycardia (AVNRT)		
	Reentrant	No visible P wave, QRS-P ratio very short. And P wave superimposed by QRS complex. Simultaneous depolarization of Atrium and ventricles. Double nodal pathway: Fast and slow	
	Permanent junctional reciprocating tachycardia (PJRT)		
	Reentrant	Incessant heart rate of 200 BPM. DII, DIII and AVF P wave inverted preceding a QRS complex Long QRS-P interval	
	Junctional Ectopic Tachycardia (JET)		Treatment
	Automatic	Rate: >170 BPM AV dissociation Narrow QRS Retrograde P waves	1. Diminish automatism 2. Hypothermia 34-36C 3. Amiodarone 4. If amiodarone is not enough, procainamide (aiming to decrease nodal rhythm) is recommended. 5. AV resynchronization with pacemaker 6. Dexmedetomidine. *** 7. Corticosteroids. ***

VENTRICULAR			
P / QRS ratio <1:1	Ventricular tachycardia (VT)		Treatment
		Wide QRS complex P waves do not precede QRS Capture ventricular beats Last > 30 secs	1.<u>Unstable:</u> Electrical synchronized cardioversion. 1 J/kg <u>Stable:</u> Amiodarone 2. Lidocaine 3. Procainamide *Torsade de pointes: IV magnesium sulfate 15-30mg/kg over 20 minutes
	Ventricular Fibrillation (VF)		Treatment
		Irregular and chaotic rhythm Hemodynamic shock	Cardiopulmonary reanimation (CPR) 1.Defibrillation: 4J/Kg 2. Epinephrine: 0.01mg/kg IV After 3 to 5 defibrillation attempts Amiodarone IV 5mg/kg + Epinephrine IV 0.01 mg/kg

Figure 2. Tachyarrhythmias classification based on location.

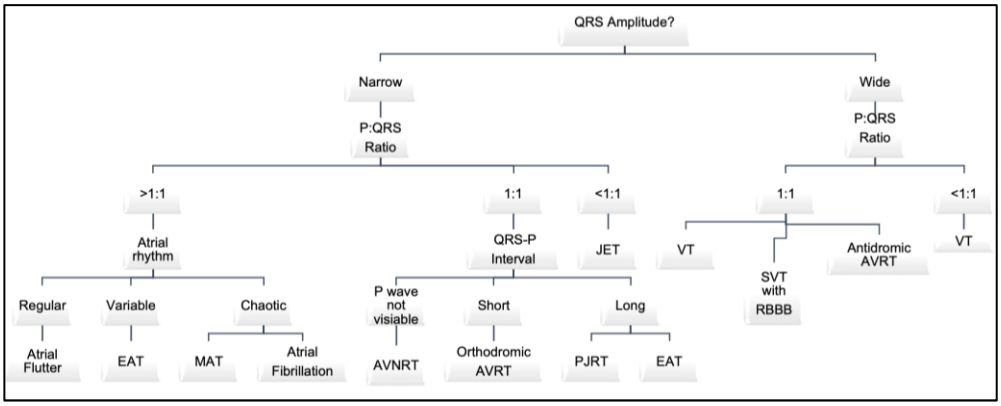

QRS Amplitude: Narrow: <80 ms; Wide: >80 ms.; *EAT*: Ectopic Atrial Tachycardia.; *MAT*: Multifocal Atrial Tachycardia.; *AF*: Atrial fibrillation; *AVNRT*: Atrioventricular Nodal Reentrant Tachycardia; *AVRT*: Atrioventricular Reentrant Tachycardia; *PJRT*: Permanent Junctional Reciprocating Tachycardia; *VT*: Ventricular Tachycardia; *SVT*: Supraventricular Tachycardia; *RBBB*: Right Bundle Branch Block

Figure 3. Tachyarrhythmias differential diagnosis.

Table 2. Congenital heart surgery and respectively associated arrhythmias

Surgery/Diagnosis	Common arrhythmias
Ebstein Anomaly	Atrial arrhythmias Ventricular arrhythmias
Pulmonary Atresia (single ventricle)	Atrial arrhythmias
Atrioventricular septal defects	AV block JET
Atrial Septal defect	AV node dysfunction Atrial Reentrant Tachycardia RBBB JET
Ventricular septal defect	RBBB AV block JET
Double outlet right ventricle	AV block Ventricular tachycardia
Aortic Stenosis	AV Block
Fontan	Sinus node dysfunction Atrial Reentrant Tachycardia
Heterotaxy	Complete AV block
Norwood	JET
LVOT repair	LBBB
Total anomalous pulmonary venous connection	Sinus node dysfunction Atrial arrhythmias JET
Senning/Mustard	Atrial reentrant tachycardia
Tetralogy of Fallot	RBBB JET Ventricular tachycardia
Transposition of the great arteries	Sinus node dysfunction Atrial arrhythmias Complete AV block Ventricular tachycardia
Truncus Arteriosus	AV block JET Ventricular Tachycardia

JUNCTIONAL ECTOPIC TACHYCARDIA

Junctional ectopic tachycardia (JET) is the most common arrhythmia with hemodynamic consequences in the postoperative period. It usually appears with the first 24 to 48 hours, it is intermittent, and it could last between 2-5 days. It has an incident variation between 10-50%, with an important associated morbidity and mortality up to 13.5%.

Definition

Defined as an automatic tachyarrhythmia with origin in the AV node, it is considered a narrow QRS arrhythmia with a heart rate of >170 PBM plus an AV dissociation. Occasionally P retrogrades waves can be seen in an auriculogram (Figure 4).

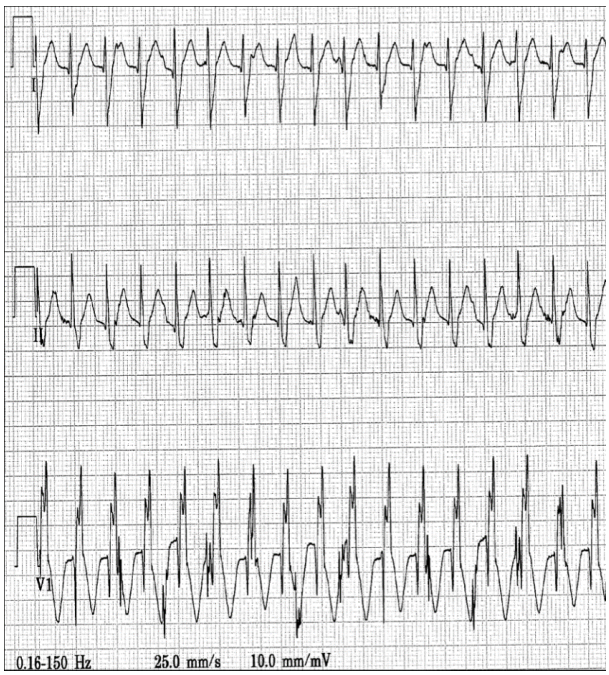

Figure 4. Diagnostic Auriculogram for a JET.

Risk Factors

- Predominant in neonates and infants
- Highly complex surgeries with prolonged surgical times, including CPB >100 minutes
- Myocardial ischemia: Post-operative patients with high inotropic support (>2 inotropes meds), hyperlactatemia (>20 mg/dl)
- Other factors: Hyperthermia, Hypomagnesemia.

TGA repair, AVSD repair and TOF repair are the most common surgical procedures associated with JET.

Traumatism of the AV node and/or the His system has been postulated as the main cause of JET, however the real mechanism is unknown. The endogenous or exogenous adrenergic release is extremely important in the physiopathology mechanism and the increase of automatism.

The modulation of the sympathetic system and inflammatory process are of benefit in the post-operative period, to ensure restoration of normal organic function. The combination of AV asynchronicity and elevated heart rates leads to a poor cardiac output and haemodymic instability.

Treatment

A more physiological heart rate is the main goal of the treatment. If cardiac output is compromised, reestablishing AV synchrony with pacemaker is a priority.

Therefore, it is advised to:

1. Use strategies to diminish the endogenous and exogenous catecholamine release, including:
   a) Sedation and analgesia optimization
   b) Reduction of any exogenous catecholaminergic support.
   c) Keeping electrolytes within the normal range is advised (Mg and Ca). Magnesium supplementation during CPB has been associated with less postoperative JET.
   d) Avoiding hyperthermia and keeping a relatively low temperature (35-36ºC)
   e) Corticosteroids have been suggested as a treatment, however there is not enough evidence to recommend them.
   f) Decreasing the nodal rhythm with antiarrhythmics. Amiodarone is the recommended medication. Procainamide could be contemplated.
   g) Using dexmedetomidine as a coadjutant in the management of sedation during the post-operative period. This agent has also been associated with a preventive medication for post-operative JET.

2. Pace sequentially to restore AV synchrony.

The main goal is to reestablish AV synchrony. In the majority of the cases when the nodal frequency has diminished to <150, atrial stimulation (AAI or AOO) is enough to restore AV synchrony. If this situation does not happen, it is necessary to use a pacemaker on a sequential modality (DDD).

ARRHYTHMIA TREATMENT

Post-operative arrhythmia management is based on a combination of pharmacological therapy and sequential pacemaker.

The pharmacological treatment is wide. Vaughan Williams' antiarrhythmic drugs classification (Table 3) is the most used one and it is based on the drug's mechanism of action. This classification is incomplete since it does not include alpha adrenergic blockers, cholinergic agonist and ionic supplements. In 1991, the European Cardiology Society proposed a new classification, however, Vaughan Williams' is still the most used classification.

Table 3. Vaughan-Williams' drugs antiarrhythmics classification

Class		Mechanism of action and effects	Indications	Anti arrhythmic	Dose	Adverse effects
I	A	NA channel blocker (phase 0) Decreased Heart Rate Increased action potential duration Increased QT Moderate decrease in conduction AV block	SVT Ventricular arrhythmias Pre-excitation syndrome JET Atrial fibrillation	Procainamide *Others* *Quinidine* *Disopyramide*	Bolus: 3-15 mg/kg in 30 min (max 100 mg) P: 20-80 mcg/kg/min	Lupus-like syndrome Hypotension Arrhythmias
	B	Shortened repolarization period Increased refractory period Decreased automaticity Minimal decrease in conduction AV block	Ventricular arrhythmias Digoxin intoxication	Lidocaine *Others* *Phenytoin* *Mexiletine* *Tocainide*	Bolus: 1 mg/kg (repeat dose each 10 min, max 5 doses) P: 10-50 mcg/kg/min	Bradycardia Hypotension CNS effects
	C	Increased refractory period Decreased cardiac heart rate Important reduction of conduction Prolongation of PR and QRS Decrease of LVEF	Supra ventricular arrhythmias. Atrial Fibrillation. Pre-excitaction síndrome. Ventricular arrhythmias	Propafenone	Bolus: 1-2 mg/kg in 15 min (max 140 mg) P: 4-8 mcg/kg/min	Hypotension Bradycardia Arrhythmias
				Flecainamide	Bolus: 2-4 mg/kg in 30 min (max 150 mg) P: 0.25-1 mg/kg/h	Hypotension Arrhythmias

Class	Mechanism of action and effects	Indications	Anti arrhythmic	Dose	Adverse effects
II	Beta adrenergics antagonist: Beta-blockers				
	Decreased heart automaticity Decreased Heart rate Decreased conduction speed Prolonged AV refractory period Decrease LVEF	SVT Ventricular Extrasystole	Esmolol	Bolus: 0.1-0.5 mg/kg in 2-4 min P: 50-300 mcg/kg/min	Hypotension Bradycardia Bronchospasm
			Propanolol	Bolus: 0.1 mg/kg c/6h IV in 5 min (max 1 mg/dose)	

Table 3. (Continued)

Class	Mechanism of action and effects	Indications	Anti arrhythmic	Dose	Adverse effects
III	Potassium (K+) channel blockers Prolonged action potential Delayed repolarization Decreased heart rate	Reentrant arrhythmias Pre-excitation Syndrome Ventricular arrhythmias JET	Amiodarone	Bolus: 5 mg/kg in 20 mins (up to 20 mg/kg) P: 5-20 mg/kg/day	Thyroid toxicity Hepatic Toxicity Bradycardia Hypotension
			Solatol	Bolus: 1.5 mg/kg P: 2-4 mg/kg/day	Long QT
IV	Ca+ channel blockers Decreased conduction speed Prolonged refractory period AV block	Atrial Arrhythmias Supraventri-cular arrhythmias	Verapamil	Bolus: 0.1-0.2 mg/kg in 2 min 2-3x doses. P: 1-5 mcg/kg/min	Hypotension Bradycardia Cardio pulmonary arrest Restricted use in children
			Diltiazem	Bolus: 0.25 mg/kg in 2 min P: 0.1-0.3 mg/kg/h	
Others	Slows conduction time through AV node, interrupting the re-entry pathways and restoring normal sinus rhythm	SVT	Adenosine	Bolus: 1st 0.1 mg/kg, 2nd 0.2 mg/kg, 3rd 0.3 mg/kg	Bronchospasm Prolonged asystole in heart transplant recipients
Others	Na and Ca intracellular bioavailability. Decreased conduction in both sinus node and AV node. Decreased sympathetic tone	Atrial Fibrillation Supraventricular arrhythmias	Digoxin	Bolus: slow 15 mcg/kg 5-10 min (up to 0.5 mg)	Bradycardia AV Block Ventricular Arrhythmia
	Alpha 2- agonist	Nodal tachycardia JET	Dexmedeto-medine	Bolus: 0.5-1 mcg/kg in 10 min P: 0.2-0.7 mcg/kg/h	Hypotension Bradycardia Sedative

CARDIAC PACEMAKER

Temporal Pacemaker

Post-operative temporal pacemakers are routinely used after pediatric cardiac surgery. Bradyarrhythmias, complete heart blocks, AV asynchronicity and atrial overstimulation are some of the scenarios where pacemakers are useful.

Temporal bicameral pacemakers with epicardial leads are widely accepted for postoperative patients.

Programable parameters:

1. Voltage (mA): The energy emitted by the pacemaker to generate an electrical impulse in the heart.

Voltage range is between 0.1 to 25 mA, with an average starting point of 10 mA. This threshold must be evaluated daily and needs to be programmed 2 points above the threshold

for safety issues. This threshold represents the stimulus needed to create a P or QRS on the ECG that would produce a contraction.

2. Sensibility (mV): Refers to the capacity of pacemaker to detect the heart's own electrical activity. Range is between 0.4 to 20 mV. Average start points: Atrial: 0.5 mV, Ventricular: 2 mV. This threshold must be evaluated daily and set to half of the sensibility threshold. Sensibility threshold: minimal sensibility required to sense all P waves and all QRS complexes.
3. Frequency: The Cardiac Frequency a pacemaker provides.
4. AV Interval: Time between atrial to ventricle stimulation. It varies according to heart rate. Range between 50 to 300 mseg.
5. Atrial tracing: The capacity to stimulate ventricle after a native atrial impulse.
6. Post ventricular atrial refractory period (PVARP): The time after a QRS in which the pacemaker cannot react to an atrial stimulus.
7. Maximum rate: Maximum rate of ventricular tracing that the pacemaker will reach. This depends on the total atrial refractory period (TARP) (TARP = AV time + PVARP).

Pacemaker modalities are defined by three initial letters:

*Stimulated chamber**-Sensed chamber-Stimulated mode***

*Chambers: A: atrium. V: ventricle. D: dual O: none
**Stimulated Mode: Defined as the pacemaker's response to the detected cardiac activity. I: inhibited. T: triggered. D: Dual. O: none.
The modality that should be used depends on the following factors:

1. If atrial/ventricular wire is available.
2. Type of arrhythmia (if the nodal function is preserved and the goal is to increase heart rate to increase cardiac output modalities with atrial sensing and stimulation are preferred (AAI/AOO). In case of AV block, an AV sequential modality is advised (DDD, DVI, VDD, VVI) (Figure 5).

Other Pacemaker Functions

Atrial overdriving pacing: could be used to revert reentrant tachycardias.

Reentrant atrial (Atrial Fibrillation): Atrial overstimulation (rate 10-30% faster). If the atrial capture is confirmed (when P waves of different shapes are seen), stimulation should be stopped.

Underdrive pacing (inducing a refractory period at the myocardial tissue involved on the reentrant circuit) or overdrive pacing (provoking an atrial anterograde depolarization) could terminate SVT.

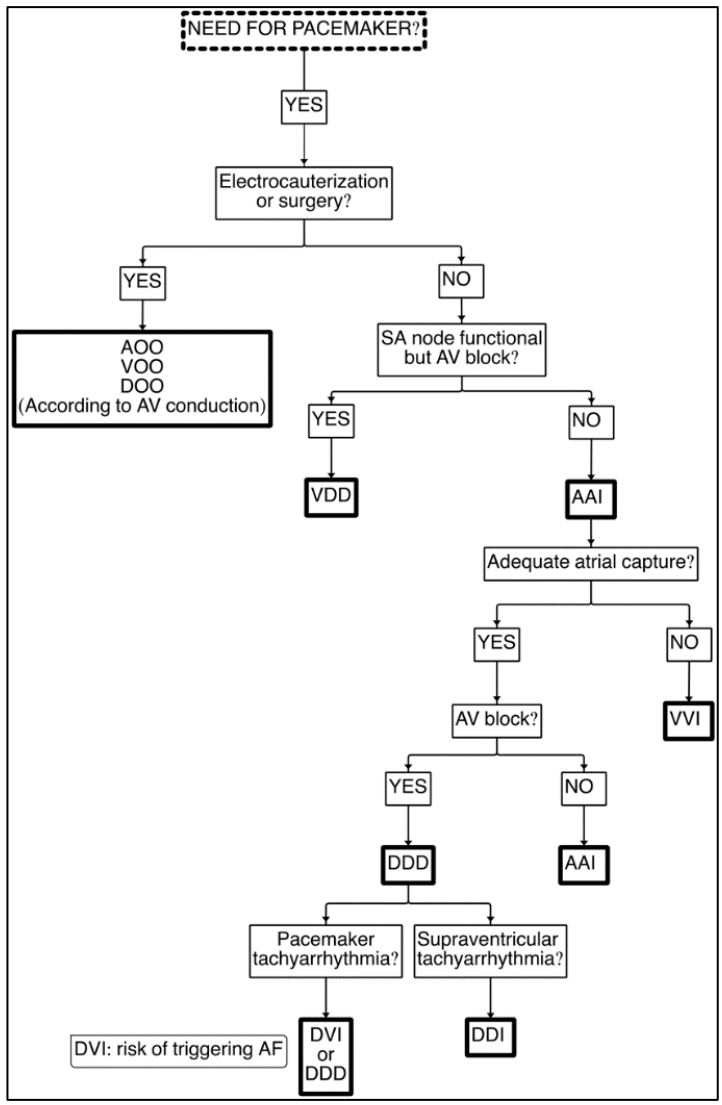

Figure 5. Post-operative selection of Pacemaker modality.

DETECTION AND SOLUTION OF PROBLEMS

Stimulation failure: There is no electrical output nor pacemaker spikes on the ECG.

Reasons: Wire or battery dysfunction, crosstalk, inhibition or over sensing. These sensing issues can be solved by changing to asynchrony mode.

Capture failure: There is electrical output but there is not myocardial contraction.

Reasons: Myocardial fibrosis, ischemia, metabolic imbalance (hyperglycemia, hyperpotassemia, acidosis, alkalosis), antiarrhythmics.

Treatment: change polarity of the wires, correct underlying causes, check pacemaker output and refractory periods.

Sensed failure: Generated by the same reasons as those for capture failure.

It can be solved by correcting underlying causes, reviewing refractory times and sensed threshold set. Under-sensing could cause the pacemaker to compete with the intrinsically electrical activity. Over-sensing could cause the pacemaker to be inhibited and therefore cause ventricular pauses to appear.

Pacemaker wires usually start to fail after several days of being implanted, notorious especially after 5 days of being in place. The reason for this could be the inflammation generated in the surrounding myocardial tissue.

Pacemaker induced Wenckebach effect: This effect is produced as the atrial rhythm overcomes the maximum heart rate setting. P wave becomes closed and jumps into a PVARP, and the ventricular cable does not respond to this P wave. Adjusting the AV interval and the PVARP will increment the maximum rate and will avoid this.

Induced Pacemaker Tachycardia "endless loop": On DDD or VDD, an endless loop tachycardia can be induced through a retrograde VA conduction. Usually it is started from a ventricular extrasystole that conducts retrograde to the atrium. If this activity is sensed by the pacemaker, an AV interval is generated and a subsequent ventricular stimulation is reached, leading to an endless loop tachycardia and perpetual AV node retrograde circuit. A none sense mode (DVI or VVI) or an increase in PVARP will finish the endless circuit.

Fibrillation Induction: If a stimulus under a unicameral asynchronic modalities (AOO, VOO) is generated and reaches the myocardial repolarization phase, an AF or VF can be induced. "Cross talk": On Dual Sensed modalities a stimulus that is generated on one of the other wires is detected, and therefore the subsequent chamber stimulus is erroneously inhibited. A decreased sensibility or output intensity can terminate the error.

Other emergency alternatives: Transcutaneous pacemaker or Transesophageal pacemaker. Transesophageal pacemaker allows a transitory atrial pacing. It could easily move. Atrial capture output has to be >10 mA.

DEFIBRILLATION AND CARDIOVERSION

Defibrillation: Random non-synchronized shock: Used to treat ventricular fibrillation or pulseless ventricular tachycardia. Dose: 4J/Kg.

Cardioversion: Synchronized shock discharged with the next R wave. Used to treat SVT or ventricular tachycardia associated with hemodynamic instability or/and refractory pharmacological cardioversion.

Patch and paddles are used to monitor the rhythm before and after the shock is given. Both have the same thoracic impedance; however, patch is preferred since they are more secure and effective.

The contact surface between patch/paddles and thorax should be always be highest. Paddle/Patch should not be in touch with each other. Preferable positions are: Right infraclavicular position for the first one, and the second should be placed in the heart apex location or left middle axillary line. In small patients, one anterior and the other posterior is recommended. Usually there are use indications over the patch/paddles and they can be placed in inverted positions without problem.

Procedure

1. Turn on and select synchronic or non-synchronic mode
2. Check Rhythm. In the case that you need to use synchronized cardioversion, check sensing is adequate to capture R waves. If necessary, adjust sensibility.
3. Select amount of energy to use and charge.
4. Check rhythm and proceed to cardiovert or defibrillate if necessary.
5. Secure your surroundings, avoid health care personnel in contact with patient at the time of shock. Check for sources of free oxygen and continue with invasive mechanical ventilation.
6. Shock: Keep discharge bottom press until you can prove shock has been given. There could be a gap between the order and the discharge during synchronized cardioversion.

Cardiac Post-Operative Peculiarities

Paddle/Patch should be separated 12 cm from internal/DAI pacemaker. In patients with external pacemakers it is recommended to disconnect it before giving a shock.

REFERENCES

Andreasen, J. B., Johnsen, S. P. and Ravn, H. B. 2008. "Junctional ectopic tachycardia after surgery for congenital heart disease in children." *Intensive Care Med* 34(5):895-902.

Beerman, L., Arora, G., Park, S. C. 2010. "Arrhythmias in the Intensive Care Unit." In *Critical Care of Children with Heart Disease*, edited by Muñoz, R. A., Morell, V. O., Da Cruz, E. M., Vetterly C., 619-636. New York: Springer London Dordrecht Heidelberg.

Brugada, J., Blom, N., Sarquella-Brugada, G., Blomstrom-Lundgvist, C., Deanfield, J., Janousek, J., Abrams, D. et al., 2013. "Pharmacological and non-pharmacological therapy for arrhythmias in the pediatric population: EHRA and AEPC-Arrhythmia Working Group joint consensus statement." *Europace* 15(9):1337-82.

Cannon, B. C., Snyder, C. S. 2013. "Disorders of cardiac rhythm and conduction." In *Moss and Adams' Heart Disease in infants, children, and adolescents*, edited by Allen, H. D., Driscoll, D. J., Shaddy, R. E., Feltes, T. F., 441-472. Philadelphia: Lippincott Williams and Wilkins, Wolters Kluwer.

Carrillo, A., Lopez-Herce, J., Sancho, L., Solana, L. J. 2013. "Arritmias." In *Pediatric intensive care manual*, edited by Lopez-Herce, J., Calvo, C., Rey, C., Rodriguez, A., Baltodano, A., 218-30. Madrid: Publimed.

Lopez-Herce, J., Urbano, J., Santiago, M. J., Lopez, J. 2013. "Marcapasos." In *Pediatric intensive care manual*, edited by Lopez-Herce, J., Calvo, C., Rey, C., Rodriguez, A., Baltodano, A., 965-71. Madrid: Publimed.

Makhoul, M., Oster, M., Fischbach, P., Das, S. and Deshpande, S. 2013. "Junctional ectopic tachycardia after congenital heart surgery in the current surgical era." *Pediatr Cardiol* 34(2):370-4.

Moffett, B. S., Salvin, J. W. and Kim, J. J. 2016. "Pediatric Cardiac Intensive Care Society 2014 Consensus Statement: Pharmacotherapies in Cardiac Critical Care Antiarrhythmics." *Pediatr Crit Care Med* 17(3 Suppl 1):S49-58.

Reade, M. C. 2007. "Temporary epicardial pacing after cardiac surgery: a practical review. Part 2: Selection of epicardial pacing modes and troubleshooting." *Anaesthesia* 62(4):364-73.

Skippen, P., Sanatani, S., Froese, N. and Gow, R. M. 2010. "Pacemaker therapy of postoperative arrhythmias after pediatric cardiac surgery." *Pediatr Crit Care Med* 11(1):133-8.

In: Encyclopedia of Surgery (22 Volume Set)
Editors: Andreas Lehrer and Kristin Mueller
ISBN: 978-1-53618-329-0
© 2020 Nova Science Publishers, Inc.

Chapter 458

AVIATION AND CARDIAC SURGERY: REVIEW OF THEIR RELATIONSHIPS. IMPLICATION ON COMPLEXITY THEORY AND ETHICAL CONSIDERATIONS

Roberto Battellini[1], MD, Michael S. Firstenberg[2], MD and Mauricio Perez-Martinez[3], MD

[1]Hospital Italiano de Buenos Aires,
Buenos Aires, Argentina
[2]Cardiothoracic and Vascular Surgery, The Medical Center of Aurora and Rose Hospital,
Aurora, CO, US
[3]Department of Surgery, Swedish Medical Center,
Denver, CO, US

ABSTRACT

The cardiac surgery operating room is an environment characterized by a high degree of complexity with respect to human-technological and human-human interfaces. Both aviation and surgery, in order to live in these environments, require integrated strategic planning. Leadership is crucial, and the lack of the latter can obstruct the "situational awareness" necessary for the prevention of mistakes and for recovery in critical situations, like in the case of Air France Flight 447 which crashed into the Atlantic Ocean on June 1, 2009 while traveling from Rio de Janeiro (Brazil) to Paris (France) [1]. Given that aviation is more advanced than surgery in the resolution of communication and leadership problems, many believe that among other surgeons and pilots, that transferring the systems from the first to the second helps substantially to approach its international security standard, even if it does not solve the problem in its entirety. In the following article, after analyzing two particular examples, we discuss similarities and differences between both activities; and we propose, thanks to the analysis of the literature, a foundation for understand. Good leadership recognizes problems, prevents and recovers from them, mainly without looking for blame.

Keywords: aviation industry, cardiac surgery, medical error, safety systems, zero error incidence, six sigma

1. Introduction: What Is Complexity?

The Chaos Theory is a denomination shared by various sciences that deal with complex dynamic systems which are very sensitive to the variations in the initial conditions. Small variations within these conditions may implicate a significant difference in the behavior of the system, making prediction impossible [2] (Figure 1).

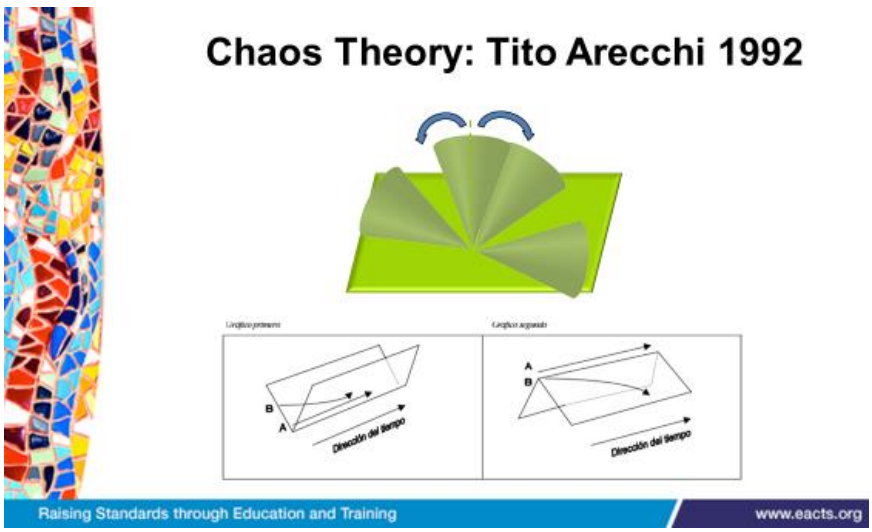

Figure 1. Above: Poincare assured that little changes in the initial conditions can produce big changes towards the end. Below: Tito Arecchi 1992: small variations at the beginning can produce a totally different trajectory. Example: a tear in the aorta while cannulating a patient to initiate cardiopulmonary bypass, retrograde cardioplegia that does not enter the coronary by sliding the catheter, etc. [2].

In 1984, Perrow published his theory on "Normal Accidents", exposing the complexity of interaction, where catastrophes are inevitable in complex systems that are intimately related. He predicted that in these scenarios mistakes can happen in many ways and are impossible to predict. The failure of a single component can have multiple consequences downstream, for example the complex patient that suffers various cycles of medical mistakes. In these systems there's few possibilities of substituting or reassigning personnel due to the high level of specialization, closed personal communication and decreased comprehension of some processes [3]. According to Sigston, there is a point in any self-regulating organization, that once a level of stability is surpassed, it results in the collapse to the next hierarchical level. Close to, or when reaching this point, a change can happen that within itself is insignificant, but in a system it could lead to a massive, fast and disruptive transformation. This, which can be applied to the pathophysiology of carcinogenesis, can also be relevant for other topics within healthcare, per example, forgetting to give heparin to initiate extracorporeal circulation, causing total thrombosis of the circuit resulting in death of the patient. If we think in complexity, we would be able to solve problems that escape linear thinking. This prior statement coincides with the modern analysis of accidents: they are a result of an alignment of conditions and events, each single one necessary but none of them sufficient by themselves. If there can be mistakes within a system, it is complex. Even more, it is frequent that the best people commit the worst mistakes due to an excess of self-confidence (Psychological Complexity) [4].

2. PART 1: COMPLEXITY IN AVIATION AND MEDICINE: THE UNCERTAINTY OF FLIGHT AND SURGERY

As an introduction, the following two stories exemplify how the individuals did not comprehend the existing complexity due to a lack of a systemic focus.

1. Flight AF 447/2009 Rio to Paris: During this transatlantic flight, a storm formed ice crystals on the airspeed gauge (Pitot Tube), causing the autopilot to disengage. The two young pilots in charge, not fully understanding the problem, acted asynchronously and did not ask for help on time. At the last moment, the captain realizes the problem; unfortunately, it is too late. This accident was later explained through the black box recordings [1].

   While analyzing this horrible catastrophe, it is notable how the intense psychological stress, which also occurs in cardiac surgery, tended to obstruct the part of the brain responsible for creative thinking. Immediately relying in the familiar, well-practiced, and usually ineffective protocols. The mistake resided in part because of the difficulties in communication between machine and man: the pilots were not trained for that eventuality (a stall alarm). Dynamic decisions in not fully understood critical situations require non-linear thinking.
2. A Patient in Cardiac PACU (Post-Anesthesia Care Unit). Back in the 1980's, a surgeon from the US donated to a local institution in Argentina a series of pressure cuffs that compressed IV fluids to 300 mmHg. These were used to purge the catheter used for blood draws from an arterial line. Previously, the pressure cuffs used only

compressed to 170 mmHg. The nurses used this pressure to periodically flush the arterial line in order to prevent thrombosis. Every time the plastic sachet was half empty, the nurses would open it and let air in to provide volume and put on the cuff again. An accident never occurred due to the previous low-pressure system. After the introduction of the new models, there was a series of patients who underwent operations requiring cardiopulmonary bypass (CPB) and then, post-operatively, transferred to recovery, that once they were awake and neurologically intact, they were extubated. In these patients, after the blood was drawn for the arterial blood gases and subsequent flushing of the line, they started experiencing seizures, and in a few, coma. The directors of PACU, thinking in a linear manner, thought the root cause was in an inappropriately managed CPB or an inadvertent flush of air in the heart. It was not until they hired an external investigator, similar to the Line Operations Safety Audit in the aviation industry, to perform a comprehensive investigation [5]. What was observed was that the introduction of this new method of flushing the arterial lines introduced IVF fluids to such a high pressure that it surpassed the pressure in the aortic arch and injected air into the carotids.

"When you change the way you look at things, the things you look at, change."

Max Planck 1918

3. COMPLEXITY IN THE OR

The Cardiac Surgery OR is an environment characterized by a high level of complexity with respect to the human-technological and human to human interfaces. These surgical procedures require coordinated efforts with multiple groups of people, all working under stress and time limitations (the longer the time the heart is static to fix a defect, the higher the mortality). The main, sophisticated technological factor is the extracorporeal circulation (ECC), in which both the coagulation cascade and the immunological interaction between blood and the plastic lines intervene, always unpredictable. The composition of the OR team is continuously changing, unlike the teams in the aviation industry, which can bring serious communication deficiencies going in and out of the ECC. Whether is low flows, complete cardiac arrest or flushing the heart, a minimal mistake can serious adverse events that can even lead to a coma.

It is known that cardiac surgeons make a life or death decision every 10 seconds during an operation. The majority would be in agreement that 75% of the outcomes are attributed to making the correct decisions and 25% in surgical technique. Surgeons should permanently maintain a conscience of the situation at hand, in other words, the degree of accuracy in which perception follows reality (situational awareness) [6].

Other sophisticated technologies that require similar control to that of aviation is ECMO (extracorporeal membrane oxygenation), which permits prolonging the ECC for various days outside of the operating, and "Cell Saver" blood conversation systems. It is because of these technologies that bloodless (i.e., without the need for transfusions) surgeries have been possible, even heart transplants and complex re-operative surgery. The transesophageal echocardiogram permits to control step by step the functional outcomes of off-pump heart surgery (i.e., cardiac surgery without the use of cardiopulmonary bypass or ECC) - it is the situational awareness, like flight controllers in aviation that enable such complex procedures.

Let us imagine the process of a heart transplant, and we will be convinced of how complex it can be.

By the end of the 1990's modern technologies emerged like the video-assisted robotics and combined endovascular techniques that are performed in hybrid operating rooms with intraoperative radiology. The actions of a team influence the necessities and functions of the others. All members of the Team should work in coordination having the same goal and technological interphase. Once again, a miscommunication can be catastrophic [7, 8].

4. SIMILARITIES AND DIFFERENCES BETWEEN AN AIRPLANE AND THE CARDIAC OR: LEADERSHIP IN BOTH

Both environments need integrated, strategical planning, with interdisciplinary microenvironments of professional development. Cardiac Surgery and the corresponding anesthesia practice in an OR with a "open door" to many people; aviation, on the other hand, practices inside a cockpit that are closed to the influence of other individuals.

The personnel in an airplane is usually smaller than that of a cardiac surgery OR: in a transatlantic flight three pilots fly in the cockpit, while in cardiac surgery 10 to 15 people from different specialties intervene during a case (surgeon, assistants, technologists, perfusionists, nurses, anesthesiologists, etc.). It has been estimated that around 100 individuals intervene in a complete perioperative period [6]. The teams involved are heterogeneous, even in their ways of communicating, however the complementation increases because of the subspecialties of skills involved. As the number of people involved increases, the complexity of their interactions also increases; the intricacies of inter-human relationships grow exponentially and not linearly, and therefore potentially reducing the quality of leadership [9]. The lack of leadership can impede recovery from mistakes in critical circumstances. Cardiac surgery is "Aviation and something more": human beings are more complex than an airplane, and they don't have a complete instruction manual.

Both fields require intense focus to be able to navigate a crisis or emergency situation, often with little information. Treating complications and emergencies can be compared to flying in a storm – an unpredictable scenario that most pilots avoid. Cardiac surgeons frequently encounter these situations, aortic ruptures and dissections are common examples. In the specialty of cardiac surgery there is a lot of unpredictability, and in cases of surgical emergencies, you have to fly, even with bad weather. This is a fundamental difference when compared to aviation, even though emergencies can always appear midflight. An example of excellence in leadership in aviation is the conduct of the pilots of US Airways flight 1549 "The Miracle on the Hudson" in which an Airbus A320, after taking off from LaGuardia Airport in New York struck a flock of Canadian geese. This resulted in a catastrophic engine failure and the need to land emergently in the Hudson River on January 15, 2009. The captain trained all his life for an eventuality that might never happened to him, the predictability of the unpredictable: landing in water [10].

In the cockpit, the pilots' functions are usually superimposed, to a certain degree (they allow substitution), in the OR it should be that way, however because of administrative and economic issues, this is not always the case. If the plane falls, the pilot falls with it. In commercial aviation there's multiple lives at risk; in surgery, there's only one (usually).

Accidents in aviation are public, highly noted and generate public demands for investigation and repairs. As a result, economic resources to investigate these incidents are more available, while in iatrogenic adverse events, it is completely the opposite (**Error! Bookmark not defined.**). Safety in medicine is considered a priority for some people in medicine, but is not considered an obligation for all [11].

In aviation, safety is the priority, and a safe landing, in which everyone walks away, is the only acceptable solution. For surgery, there's a broad spectrum of acceptable outcomes, most of time determined by the initial condition of the patient. It is important to remember that patients are different biologically, disease processes differ, and even sometimes we perform surgery on patients on the brink of death, not even knowing their initial condition. This scenario does not occur in aviation, where you always know your initial condition, and if they are not favorable you can simply cancel or delay the flight – or, at least in the setting of icy conditions, take the time to prepare and optimize for the journey as long as necessary to ensure a good outcome. While the concept of "optimization" exists in surgery, sometimes it is the unfavorable conditions that drive the need for urgent or emergent surgery – thereby, by definition, defining a situation of increased risk. Probably the closest analogy in the aviation world, is a plane taking off in the middle of a hurricane to prevent damage and loss of life from existing conditions in which the risk of remaining on the ground is greater than the risk of leaving – although, such circumstances are extremely rare.

5. TRANSLATIONAL CULTURE FROM AVIATION TO CARDIAC SURGERY

5.1. Culture of Safety: In the Air and in the Operating Room

The science of human factors, a prominent cornerstone in the aviation industry [12], has not yet found its place in Medicine; but it could still profoundly change the comprehension and execution of the decisions made in surgery [13]. Looking for the factors that are unpredictable or complex that relates both, specifically - human error - which often defines complexity. It drives to mistakes due to unexpected or misunderstood problems, if they exceed the cognitive capacity of the individuals or the Team [1]. In this day and age, in both medicine and aviation, society does not want to give room to mistakes – the concept of a learning curve does not exist, nor despite it's crucial historical importance, is barely acknowledged. Pilots, much like physicians, and especially surgeons, are expected to be perfect as soon as they complete their "simulation" training. But, experience and judgment develop and mature over time. This had entrusted doctors with the burden of understanding and dealing with the disease. Although it is known that they are human, new technological wonders have created an expectation of absolute perfection. Patients, who have the comprehensible necessity of considering their doctor infallible, have colluded (agreed) with these to deny the existence of the error and reject the uncertainty. However in medicine this has to be tolerated, since paradoxically, only uncertainty is definite [14].

Of course, the paradox in this concept is that while "pilot error" is often the final variable in most airline crashes, surgeons often be blamed for poor outcomes, despite the under-recognized reality that they often have very little influence on the final outcome other than

helping to guide a patient through an operation or hospitalization in which hundreds of providers have some impact on the final outcome. The closest analogy in the aviation world is recognizing the safe landing of a flight is determined by everyone from the baggage handlers, the ticket agents, to the flight attendants – and, of course, the mechanics.

Considering the error theory, there are authors who, like Fabri, assert that most of these are cognitive in nature [15]. Others, like Wiegmann, who analyze similar systems, propose that an error results from the disruptions of surgical flow provoked by miscommunications, external distractions, and failure of surgical equipment [16].

The culture that the aviation industry has in terms of safety is definitely something that could easily translate into surgery. The impossible to reach safety rate of the aviation industry (0.017/100,000 flights/year in the US) seduces the need for translation to healthcare. Especially with the medical institutes of the US estimate that yearly around 44,000 to 98,000 people die because of medical mistakes [17]. The report of not just accidents, but also of "near misses" is key in this. The CHIRP program (Confidential Human Factors Incident Reporting) permits the reporting of non-punitive human mistakes and near misses [18, 19]. This has been extrapolated to surgery with good results [11]. Helmreich, a psychologist dedicated to the study of human factors in aviation and surgery, has observed multiple surgical procedures in which he recorded many situations in which communication and team work are suboptimal, parallel to those observed in the cockpit. Rogers, an anesthesiologist and also a pilot, suggested that we do not let ourselves be seduced by moving unviable systems in a different environment [20]. On the contrary, Gaba, also a pilot and a pioneer of simulation in medicine, thinks that if concepts and practices from aviation cannot be transferred directly, it is possible and necessary for appropriate translation and adaptation [20].

Also, there is an existing observational audit translatable to the OR: LOSA or Line Operations Safety Audit, also a project of Helmreich [21] – see the following link for details (www.psy.utexas.edu/psy/helmreich/nasaut.htm). LOSA consists of an audit where expert observers sit down in the cockpit of normal flights to assess threats to safety, mistakes and their handling. These audits identified an average of two threats and two mistakes per flight. More than half of the mistakes where due to violations of already established rules – and finding that was somewhat unexpected.

5.2. Simulations

In aviation, every major incident is followed by a simulation of its causes to avoid a subsequent event, becoming a part of training. Moreover, there is a redesign of all equipment involved. In surgery, complications are considered habitual, and apart from being discussed extensively, they are not reported; most of the time due to fear of personal or professional repercussions or false sense of elevated (or need to preserve) self-esteem. In aviation, the simulators constitute a structured part of training, and surgery is catching up thanks to this. The pilots practice without risk, and they learn to develop strategies to recover from a mistake. They don't fly in airplanes in which they did not have extensive simulation training in first – and to which they are periodically and objectively re-tested. In cardiac surgery, as in other areas of surgery, there are multiple instances in which a surgeon has to operate for circumstances in which he/she has not trained due to multiple reasons – the least of which,

unlike flying in which a pilot can always abandon a flight, once an operation is started and the patient is placed on cardiopulmonary bypass, it is difficult to turn back without fixing the problem(s) at hand. Unfortunately, the complexity of biologic systems is almost impossible to simulate for now. These don't offer the same amount of realism that an aviation simulation would, despite extensive and growing literature attempting to simulate "real world" critical medical/surgical events. We can comfortably say we are still in very early and primitive in the field [22]. The future of surgical education is hybrid simulators between plastic materials and biologic organs. The sphere in which the greatest achievements in training have been obtained is in emergencies involving cardiopulmonary bypass – in part due to the mechanical nature of the technology [23, 24].

5.3. Sterile Cockpit Protocol

In commercial and military aviation, a compulsory protocol of a "Sterile Cockpit" was instituted during periods of high mental demand – specifically, during takeoff and landing. During a "Sterile Cockpit" there are standardized protocols for communication, language and call-back in order to decrease ambiguity. In 2010, Wadhera et al. translated these concepts to the Mayo Clinic, defining eight critical events during cardiopulmonary bypass, implementing the NASA Task Load Index, and decreasing significantly any potential opportunities for miscommunication [25]. Emphasis was made on communication during key actions, like clamping and unclamping of the aorta (i.e., intentionally stopping and re-starting the heart in a manner that limits myocardial injury and, all the while, maintaining adequate oxygenation blood flow to the remainder of the body). The authors concluded that unlike aviation, in cardiac surgery there's no exact time that can be conveniently defined as the main high risk or stress period for the whole team. In Figure 2, from Wadhera, the difference in mental demand in the OR according to the NASA TLI is demonstrated. However, unlike aviation, in cardiac surgery, high-stress situations are different for each component of the team at different times of the procedure. Also, cockpits are not equal: in an airplane it is closed and there's no intervention from the public; in the OR, the door is continuously opening and closing which permits entry and exiting.

Wadhera suggests that effective communication should be structured by defining periods of high mental tension and transferring the sterile cockpit concept to the operating room. The surgeon has to have more creativity than a pilot, not being able to put "autopilot", since a good "landing" (or weaning, to use the technical term) from cardiopulmonary bypass depends mainly on what has been repaired in the heart during the "surgical flight". Wadhera made emphasis to focus in critical events during the procedure rather than on defined periods: Heparinization/ starting CPB/ Aortic Clamping/ Cardioplegia/ Flushing / Stopping CPB. Interestingly, the cultures of operating rooms are often such the surgeon who insists on total silence during such key periods if often view negatively almost in a manner similar to flight attendants not understanding the need for pilots to singularly focused on landing an airplane and being unaware of the consequences of what happens if the plane does not land safely. In fact, most "bad outcomes" after surgery rarely occur in the operating room, even though operative events might initiate the path of a downward spiral that manifests much later in the Intensive Care Unit and often far away (in both time and distance) from those involved in the key triggering events.

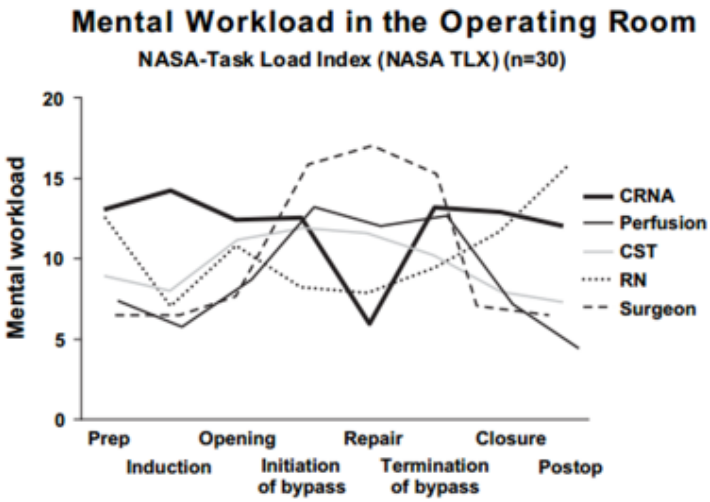

Source: *J Thorac Cardiovasc Surg* 2010;139:312-9.

Figure 2. Results of National Aeronautics and Space Administration Task Load Index *(NASA TLX)* show widely divergent cognitive workload measures during course of typical case. *CRNA,* certified registered nurse anesthetist; *CST,* certifies surgical technologist; *RN,* registered nurse; *Prep,* surgical preparation; *Postop,* postoperative.

5.4. NASA Model "Threat and Error" Applied to Cardiac Surgery

Hickey suggested considering each operation like a flight. He analyzed 524 flights/patients. He found 763 preoperative "threats" (atypical morphology, multiple lesions, comorbidities) in 72% of the patients (flights). Only 51% of these resulted in an error. In the remaining 257, he observed 430 errors in proficiency or judgment. In 173 (67%) of these, the mistakes were consecutive. Of those, in 60% (n=110; 21% of total), subsequent cycles of additional errors occurred. These cycles containing multiple errors were associated with surgical complications including death in 1.3%. The conclusion is that one unsolved error drives further cycles of errors and dangerous complications [26]. This coincides with the "Swiss Cheese" theory that is also parallel to the nuclear industry disasters (i.e., Chernobyl) and NASA flights that ended in tragedy (Challenger) [27]. In respect to medical mistakes, Hickey mentions that our profession has been stubborn on its focus, instead of adopting a systemic solution we have epitomized that of personal attacks, that at the same time discourages reporting and inhibits the investigation of systemic conditions that produce or result in an error that otherwise could be fixed – unless, of course, such "errors" can be directly attributed to the obvious actions (or inactions) of a single individual. He concludes that two thirds of errors are consecutive and a fifth of the patients suffer cycles of error that are associated with complications [26]. However, a pilot that crashes his plane – even if he/she survives – probably does not get to fly again, while the surgeon who experiences an intra-operative death is often expected to resume operating as if nothing adverse has occurred. Not to mention the rarely of the term "co-pilot error" when describing airline crashes and the potential similarities to medicine in which many providers have some impact on an eventual outcome.

5.5. Mission Analysis: "Crew Resource Management"

In the early 1980s, due to several aviation disasters, the concept of "CRM" or "Crew Resource Management" was developed in the United States to improve performance and promote safety [28]. These strategies to improve safety and teamwork can be translated to surgery [6]. In "Briefing and debriefing in the Operating Room using fighter pilot crew resource management", McGreevy suggests two steps. In the first part, or Briefing (instructions), the military pilots explain in advance to their squad not only what they are going to do or expect what will happen, but what could happen and the measures to be taken in each case. In cardiac surgery, an example would be, if immediately after sternotomy a patient would become unstable, how to immediately initiating CPB would be considered or performed. The "debriefing" (reflection) is a wave of introspection similar to brainstorming about what went as expected or not – especially when such discussions involve equipment issues or a formal acknowledgement of those events that "went well" as opposed to those that did not. This is in order to avoid repeating mistakes (not to mention, praising good or effective Teamwork) but also suggesting a role in inducing a positive cultural change. In 2017, Powell-Dunford made a search in PubMed using the terms: Aviation, CRM, and patient safety. This search concluded in 22 relevant manuscripts [29]. Cardiac surgeons are described by McGreevy in 2007 as the fighter pilots of Medicine [30]. A key element in this process (rather than emphasizing the glamorous 'movie star' concept) is to identify mission objectives, benefiting from military CRM. Perhaps the most important thing is to emulate aviation by incorporating surgical specialty services in human factors and psychological aspects in patient safety (11). Investigation is essential in medicine; curiously, it has been historically specific to diseases and not to the study of errors, which are involved across diseases and specialties. Finally, video and autopsies in cardiac surgery would be the equivalent of black boxes in aviation – and yet, fewer and fewer autopsies are being requested, let alone performed, out of fear of finding something that the surgeon could have or should have done differently or better. The paradox is akin to trying to learn to be better when we prefer to not know the answers to the questions of why something did not go as planned.

6. PART 2: BIOETHICAL ANALYSIS: IS IT POSSIBLE AND SHOULD WE ATTEMPT TO REDUCE HUMAN ERRORS IN CARDIAC SURGERY WHILE IMITATING AVIATION?

6.1. Background and Theoretical Framework

The human error is an added product of human activity, and it can result in an unintentional chain reaction of tragic events. Even back in 100 A.C., the Latin proverb would say: "Errare Humanum Est" – translated into the commonly used term – "to error is human". The modern concept of medical error arises mainly after the theories of Popper in 1967. His main school of thought was that knowledge grows by accumulation. Acknowledging mistakes and discarding old and wrong theories will provide a larger opportunity for growth. In "Conjectures and Refutations" [31] he referred to science, but a prior joint article with

McIntyre in 1983 [32] includes a powerful comment: "we must learn from mistakes, and how to look for them." "Mistakes will help the scientist grow in terms of knowledge. Each one owes their enrichment thanks to others' criticism, and being reasonable is to be prepared to listen." Learning only from personal mistakes would be a long and painful process, and of unnecessary cost to patients. Experiences must be stored in such a way that doctors learn from the mistakes of others. We should not feel loss of self-esteem or shame to comment on mistakes to others. This philosophy is followed in Aviation, but why is it not the same in medicine? In 1990 James Reason [33] extensively studied the human error in nuclear centers such as Chernobyl and the Challenger tragedy (also discussed above). In 1994 [34] Mary Sue Bogner translated this knowledge to human error in medicine and that was the starting point for a tsunami of literature in the topic. The notion of malpractice-error is changing and also the guilt paradigm of the doctor due to the fact that in the majority of times variables not related to patients and procedures can be involved in certain deaths. In 1996, Marc de Leval asked about the role of human factors in medical outcomes [35, 36], and recalling Chernobyl, he postulates that a negative outcome can be observed and investigated as an accident. With the report, *to err is human, building a Safer Health System (IOM report 1999)* [37] there are no more excuses not to include this issue in hospitals and forcing the designing processes of care in order to avoid error.

Cardiac Surgery can be considered a complex social and technical system [38, 39] that assimilates that of high-risk businesses, such as the aerospace industry. The etiology of surgical errors is deeply enrooted in the effectiveness of teamwork. As discussed above, Wiegmann and colleagues postulated in 2007 that disruptions in team work was the only independent predictor of surgical errors [40]. Now a days, medical mistakes account for the third leading cause of deaths in the United States [41]. These issue are just being recognized, but hard to imagine being 'new', just in 2001 Carthey and de Leval [39] recognized that reporting critical incidents and near misses based on taxonomies of human error was in childhood stages in the field of Cardiac Surgery – while the rest of medicine was even less mature. After Makary published his work, the questions started to be asked: "why not investigate what aviation can teach us in order to reduce surgical mistakes?"

7. OUR PROPOSITION FROM KANTIAN ETHICS

In "Fundamental Principles of the Metaphysics of Morals", Kant states: [42] "You may want your maxim to become a universal law". We start to think what the good surgeon or the patient would like regarding the analysis and prevention of medical errors; which, as a human being, should be understood by all? This is reaffirmed by the position "To err is human, building a safer health system". It is a categorical imperative. Kant says it when he writes: "The imperative says, what possible action for me is good, and represents the practical rule in relation to a will". "The categorical imperative declares the action objectively necessary in itself ... ." We must put ourselves in the place of the patients in general: would they want the services of a surgical "Team" to have a "Situational awareness", controlling errors and disturbances of the flow during a procedure? Every rational man (or woman) would speculate that, like cockpit checklists, he/she could help. Summing up the Kantian thesis, the moral value of an act is not related to the result of it, but is valid if it is done or conducted from a

sense of duty or obligation. *Thus, a surgical error should be forgiven if there was ample pre-operative planning and care by the surgeon, regardless of the final result*. In fact, doctors have no obligation to results provided the system and processes are in place and function effectively to mitigate against such events – much like how airplane crashes are becoming less frequent and are more and more being considered "never events". Extrapolating Kant to our day, we should try to prevent all errors, and in case of committing them, communicate them. In this Robert C. Mavroudis agrees, in an article referring to Kantian ethics and surgery in 2005 [43]. Society should defend the medical profession and not instigate or lead negative changes. This is how we come to the Platonic idea of virtue, which applies to society in its entirety. Physicians cannot be required to be more virtuous than the society from which they come. The extreme of this concept is reflected in the views of some that if a surgeon is not directly responsible for at least "some" deaths, then he/she is not giving enough patients the opportunity to extent their life in the face of challenging and complex problems.

8. From Utilitarian Ethics

The English school of Utilitarianism bases its moral on the utility or result of an act before the motive. John Stuart Mill, disciple of Bentham, emphasized that the quality of "The Good" result matters. For him, "The Good", widely constructed, is not only the good of the particular individual but that of the entire society. Mill insisted on the principle of equality, "what ultimately gives happiness is the sense that one was a good person who acted in accordance with his conscience by treating others well" (also in Mavroudis 2005) [43]. Thus, utilitarian ethics would also be in favor of doing everything possible to reduce human error in medicine. If the good has more weight than the bad, the act would be morally correct. Some believe that perhaps a combination of Kant and Stuart Mill would represent the ideal: an act well motivated by a Kantian imperative, with an acceptable result (Mill), and correctly communicating the results to the patient (Kant), and if there were future errors, rescue them (Kantian imperative and Millerian utilitarianism).

9. Other Ethics

Santo Tomas de Aquino says, in "Bioética", by Diego Gracia, p. 211 [44]: "The good of the people is more important than the good of one man". "He who seeks the common good of the multitude, consecutively seeks his own particular good". It would seem that Miller took it from Santo Tomas. This justifies this proposal, given that through research in aeronautics, by means of translation, it will be possible to reduce the incidence of errors in the operating room.

In the "Emilio" by Rousseau, it states: "Historical societies are the consequence of a BAD social contract, but it is not said anywhere that it is not possible to build a new society on a GOOD social contract" [44]. Would this new contract be one of goodwill, where doctors learn from our mistakes and we can communicate them without fear? (McIityre and Popper, 1983) [32].

10. COMMENT

Although it is universally known, as mentioned above, that "Errare humanum est", reinforced by the "To err is Human" of the NHI, 1999 [37]. The standard of medical practice has evolved to the point where only perfection seems to be accepted by the public, as people are impressed by the current safety in commercial aviation. This also seems to be the opinion of the press. This feeling was instilled in medical surgeons through medical school and residency. The science of human error is not taught during the curriculum in medicine, students are allowed to believe that error is avoidable and that every mistake is error – and a concept informally emphasized in some training programs that despite their actions, inactions, and co-morbidities, patients should not be held accountable for their own outcomes. Surgeons do not have the power to control all results, even in intensive care units. Mavroudis reported in 2005, 1.7 errors were committed per day per patient in an intensive care unit in the USA [43]. Therefore, it is a "categorical imperative" to prepare comparative works of this type. Not doing it would be, according to Banja, entering a medical narcicism [45] and making us believe that we are all perfect. For the public, cursing to the individual is more emotionally satisfying than blaming institutions, but this is not the way to be better [33].

SUMMARY AND CONCLUSION

1. Both, cardiac surgery and aviation develop in complex environments.
2. Given the more heterogeneous human environment, added to the greater number of personnel involved in the operating room and the greater biological variability of the human being, the possibilities of error in cardiac surgery are more unpredictable.
3. Aviation has become more methodical and systemic to solve safety issues, and there are various reasons for that: the pilot's life is at risk, tragedies are public and there are more resources to investigate – not to mention the consequences, both in terms of lost of life and the financial costs (direct and indirect) of a crash are substantial. Nevertheless, aviation accepts the inevitability of an error – but still strives to avoid them.
4. Physician tend not to recognize error or fatigue, and together with patients make a pact to acknowledge this. Systems must be put into place to recognize and appropriately manage both. Unlike how pilots are restricted in their work hours and conditions, the surgeon/hero is often a martyr to endless work hours in extremely adverse conditions. As a society, medicine must overcome this cultural barrier.
5. Adopting the systems from aviation and translating them to surgery gets everyone closer to a standard and culture of safety, even though it does not solve the whole problem. Research on human factors, especially the psychology of safety, has a very important role that we must develop, enlarging the "islands of excellence in a sea of invisible faults".

REFERENCES

[1] *AF 447 Final report* 2012: www.bea.aero/enquetes/flight.af.447/rapport.final.en.php.

[2] Arecchi FT. Coherence, complexity and creativity: the dynamics of decision making. In: *Decision theory and choices: A complexity approach 2010* (pp. 3-21). Springer, Milano.

[3] Perrow C. Normal Accidents: living with high risk technologies. New York basic books 1984. En : *Human error, Reason 1990*. Cap. 7 Latent errors and systems disasters.

[4] Bogner MS. *Human Error in Medicine*. Erlbaum publishers, New Jersey 1994.

[5] Helmreich, R.L. *Line Operations Safety Audit* (www.psy.utexas.edu/psy/helmreich/nasaut.htm.

[6] Marvil P, Tribble C. Lessons from crew resource management for cardiac surgeons. Editorial. *The Heart Surgical Forum* 2017;20(2) Epub April 2017.

[7] Bogner MI, Helmreich RL, Schaefer HG. Team performance in the operating room. In: Bogner, M, ed. *Human Error in Medicine*. Hillsdale, NJ: Laurence Erlbaum 1994.

[8] ElBardissi AW, Wiegmann DA, Dearani JA, Daly RC, Sundt TM. Application of the human factor analysis and classification system methodology to the cardiovascular surgery operating room. *Ann Thorac Surg* 2007;83:1412-9.

[9] Pendharkar P, Roger J. An empiric study of the impact of team size on software development effort. *Inf Technol manage* 2007;253-62.

[10] Eisen LA, Savel, RH. What went right: lessons for the intensivist from the crew of US Airways Flight 1549. *Chest* 2009;136:910-7.

[11] Kapur N, Parand A, Soukup T, Reader T, Sevdalis N. Aviation and healthcare: a comparative review with implications to patients safety. *Journal of the Royal Society of MedicinOpen*.2015;0(0): 1-10.

[12] Schappell S, Wiegmann D. The human factor analysis and classification system. HFACS levels. *Human Factors* 2007;49:227.

[13] Eltorai AS. Lessons from the sky: an aviation-based framework for maximizing the delivery of quality anesthetic care. *J Anesth* 2018 Feb23 doi: 10.1007/s00540-018-2467-y Epub ahead of print.

[14] Simpkin A. Tolerating uncertainty-The next medical revolution?. *NEJM*;2016: 375:1713-15).

[15] Fabri PJ, Zayas-Castro JL. Human error, not communication and systems underlies surgical complications. *Surgery* 2008;144:557-65.

[16] Wiegmann D, ElBardissi AW, Dearani JA, Daly RC, Sundt TM. Disruption in surgical flow and their relationship to surgical errors: an exploratory investigation. *Surgery* 2007;142:658-65.

[17] Helmreich RL. On error management: lessons from aeronautics. *BMJ* 2000;320:781-785.

[18] Eidt JF. The aviation model of vascular surgery education. Presidential address. *J Vasc Surg* 2012;55:1801-1809.

[19] Rogers J. Have we gone too far in translating ideas from aviation to patient safety?. *BMJ* 2011;342:c7309.

[20] Gaba D. Have we gone too far in translating ideas from aviation to patient safety? NO. *BMJ* 2011:342:c7310).

[21] Helmreich RL. On error management: lessons from aeronautics. *BMJ* 2000;320:781-785.
[22] Feins R. Simulation-based training in cardiac surgery. *Ann Thorac Surg* 2017;103:302-21.
[23] Riley JB, Winn BA, Hurdle MB. A computer simulation of cardiopulmonary bypass: version two. *J ExtraCorpor Technol* 1984;16:130-136.
[24] Stevens LM, Cooper JB, Raemer DB, Schneider RC, Frankel AS, Berry WR, Agnihotri AK. Educational program in crisis management for cardiac surgery teams including high realism simulation. *J Thorac Cardiovasc Surg* 2012;144:17-24.
[25] Wadhera R, Hendrickson-Parker S, Burkhart HM, Greason KL, Neal JR, Levenick K, Wiegmann D, Sundt T. Is the sterile cockpit concept applicable to cardiovascular surgery intervals or critical events? The impact of protocol-driven communication during cardiopulmonary bypass. *J Thorac Cardiovasc Surg* 2010;139:312.
[26] Hickey EJ, Nosikova Y, Pham Hung E, Gritti M, Schwarz S, Caldarone C, Redington A, Van Arsdell GS. National Aeronautics Space Administration "threat and error" model applied to pediatric cardiac surgery: error cycles precede 85% of patient deaths. *J Thorac Cardiovasc Surg* 2015;149: 496-507.
[27] Reason JT. *Human Error*. Cambridge University Press 1990.
[28] Ricci M. Is aviation a good model to study human errors in health care?. Editorial. *Am J Surg* 2012;203:798-801.
[29] Powell-Dunford N, McPherson MK, Pina JS, Gaydos SJ. Transferring aviation practices into clinical medicine for the promotion of high reliability. *Aerosp Med hum Perform* 2017 May 1;88(5):487-491.
[30] McGreevy J. Briefing and Debriefing in the operating room using fighter pilot crew resource management. *J Am Coll Surg* 2007;205:169-76.
[31] Popper KR. Quantum mechanics without "the observer". In: *Quantum theory and reality 1967* (pp. 7-44). Springer, Berlin, Heidelberg.
[32] McIntyre N. and Popper KR. The critical attitude in Medicina: the need for a new ethics. *BMJ* 1983:287:1919-23.
[33] Reason J. *Human Error*. Cambridge University Press, 1999.
[34] Bogner MS. *Human Error in Medicine*, Lawrence Erbium 1994.
[35] de Leval MR. Human factors and surgical outcomes: A Cartesian dream. *Lancet* 1997;349: 723-25.
[36] Marc de Leval: The Edgar Mannheimer Invited Guest Lecture, Congreso Aleman de Cirugía Cardíaca. Dresden 1967.
[37] Kohn LT, Corrigan JM, Donaldson MS et al. *To err is human. Building a safer health system*. Institute of Medicine, Washington DC, National Academy Press 1999.
[38] De Leval M, Carthey J, Wright D, Farewell V, Reason J. Human factors and cardiac surgery: a multicenter study. The *Journal of Thorac and Cardiovasc Surg* 2000; 119:661-72.
[39] Carthey J, De Leval, M, Reason J. The Human factor in cardiac surgery: errors and near misses in a high technology medical domain. *Ann Thorac Surg* 2001;72:300-5.
[40] Wiegmann DA, El Bardissi AW, Dearani JA, Sundt TM. Disruptions in surgical flow and their relationship to medical errors: an exploratory investigation. *Surgery* 2007; 142:658-6512.

[41] Makary M, Daniel M. Medical Error-the third leading cause of death in the US. *BMJ* 2016; 353:2139.
[42] Emmanuel Kant. *Fundamentación Metafísica de las costumbres*. Ed Porrúa, México 1990, trad. Francisco Larroyo, 7a ed. Pág. 28.
[43] Mavroudis RC. "Should surgical errors always be disclosed to the patient? *Ann Thorac Surg* 2005;80: 399-408.
[44] Thomasma DC. Clinical Bioethics in a Post Modern Age. In: *Clinical Bioethics* 2005 (pp. 3-20). Springer, Dordrecht.
[45] Banja John. Medical errors and Medical Narcissism. Sudbury, Mass, Jones and Bartlett, 2005.ISBN 0-7637-8631-7 Commentary in: *N Eng J Med*. Book Review 2005;353:324

.

In: Encyclopedia of Surgery (22 Volume Set)
Editors: Andreas Lehrer and Kristin Mueller
ISBN: 978-1-53618-329-0
© 2020 Nova Science Publishers, Inc.

Chapter 459

THE EARLY HISTORY OF TREATMENT OF KERATOCONUS BY SURGERY

T. Jurkiewicz[1,*], C. Fabio[1] and A. S. Marty[2]
[1]Lyon, France
[2]Bordeaux, France

ABSTRACT

Keratoconus had been described for the first time in 1748 by a German oculist, Buchard Mauchard, who named this disease "staphyloma diaphanum", but it was in 1854 that John Nottingham made the first complete description of the pathology.

The first treatments were intended to stop the progression of the disease. Doctors created ointments based on plant extracts or molecules. It was also at this time that the first surgical protocols appeared, aimed at increasing visual acuity and reducing the cone.

For this purpose, several protocols have been developed in the early and middle 19th century in order to modulate the shape of the iris or to create scar tissue at the cone. The first surgical approach was resting on pupil displacement and change of the shape of the iris to increase visual acuity. The second surgical approach was developed from the mid of the 19th century. These protocols relied on the creation of corneal scars or the removal of the cone-containing part to modify its shape.

But these interventions showed unreliable and contradictory results and were gradually abandoned. The first major revolution in the surgical management of these patients came with keratoplasty.

Keywords: history, keratoconus, surgery, iridotomy, cauterization

* Corresponding Author's Email: tristan.jurkiewicz1@gmail.com.

1. INTRODUCTION

Our current knowledge gives us a better understanding of the apparition mechanism, risk factors, and treatments of keratoconus, but during the 18th and 19th century, it was a less known, and misunderstood disease. Its causes were still mysterious and the treatments were disputed.

The first data about this disease came from the doctoral dissertation of a German oculist, Buchard Mauchard, written in 1748 [1]. He wrote the first known report on this ectasy which he called "staphyloma diaphanum". But it was not until 1854 that a first clear description of keratoconus was made by John Nottingham [2].

In the 19th century, the lack of theoretical knowledge and the difficulties of exploring visual function led to the formulation of several contradictory hypotheses on the causes and consequences of this disease.

Indeed, a limited number of tools available for the cornea's functional exploration have led to two theories. The first considered keratoconus as a thickening of the cornea, with several authors including Adams and Himly then naming it hyperkeratosis [3, 4].

The second hypothesis was that the keratoconus causes a thinning of the cornea and was defended by Wardrop, who was also the first to evoke it [5]. His hypothesis has been confirmed a few years later in 1830 by Rudolph Wagner when performing a corneal dissection of a keratoconus patient. He mentioned a thinning of the stroma at the cone's level [5]. Hulke performed a second dissection in 1859 and describe a thinning of the anterior elastic lamina (now called Bowman's membrane) [6, 7].

Finally, some authors mentioned a keratoconus comorbidity with intraocular hypertension, which, according to them, would explain the corneal deformation [8]. Other authors evoked a keratoconus associated hypotonia [6, 9].

In that time, doctors also suspected a link between the disease onset, the use of accommodation and a higher blood flow at the head level, which make them believe of a possible predisposition for some trades such as seamstress, or cook [5, 10].

Regarding the disease's probable causes, several hypotheses have been already mentioned like genetic component presence. The descriptions of familial cases of keratoconus present in the literature at this period support this particular track.

Other factors are also highlighted such as the simultaneous apparition of certain diseases, alcoholism or being generally vulnerable [5].

Authors also tend to agree on the disease onset, which occurs most often in the youth and early adulthood, but may also occur later, in rare cases up to 50 years [10]. Its discontinuous progression has already been mentioned [3].

The first statistical study on keratoconus prevalence happened in 1850. Prevalence can be defined as a measure of a population's health status. It is the total number of disease's case at a certain moment or over a given period. For a pathology, prevalence is determined by relating the present number of disease case to the studied population.

This study by Dr. White Cooper included all cases of keratoconus detected in different hospitals or clinics that he was informed of (between 1824 and 1850). These data mainly concerned institutions located in the United Kingdom but also in Macao.

He concluded on a general prevalence of keratoconus of 1/1 077, out of 208 970 cases that he could compile on the basis of the transmitted results. He had already evoked at the

time a different prevalence of the disease in different countries, but these results were unreliable.

He found a prevalence of 1/1 090 in London against 1/4 515 in Scotland, or 1/405 in Dublin. He also mentioned a trend toward increased prevalence in warmer countries and in Asia, based on the prevalence he had obtained for Macao (1/308) [3, 10, 11].

This study prefigured modern studies about keratoconus epidemiology, as the overall proportion found here is not far from certain current studies. But many factors must also be taken into account: although the mentioned hypotheses are still relevant, detection tools were not reliable, the medical staff was not always well trained, especially for this rare disease, access to care was difficult for some populations and the living and environmental conditions were also very different at the time.

All of this proves us that the knowledge of that time was rather weak and blurry even if it seemed that an evolution was starting. The numerous and contradictory hypotheses supported by the different researchers could lead to misunderstandings and the creation of treatments which were at best useless and at worst could cause an eye loss, as we will see later.

2. TREATMENT OF KERATOCONUS IN THE 19TH AND EARLY 20TH CENTURY

Treatments could be divided into different categories: optical treatments, medical treatments, and surgical treatments.

2.1. Optical Treatments

The first optical treatments were not recognized as effective because of that time's technological limitations, preventing the creation of glasses optimally correcting strong ametropia (including astigmatism that poses the most problems in the correction) [3, 12].

However, glasses were still recommended at least in the early stages of the disease where they could still be useful [13, 14].

2.2. Medical Treatments

These treatments consisted of instillations of certain substances in the form of miotics, aiming to reduce the ocular tension or to put the pupil in miosis.

Irritating topicals (like infusions of tobacco leaves, zinc sulphate solution ...) were also in use; nervetheless these treatments had debatable effects with many possible undesirable effects.

Some other treatments described as "hygienic" consisted in a set of recommendations, such has walks and accommodation, for reducing the disease progression rate.

Eye compression by a rubber band, with or without the complementary use of miotics, was another medical treatment that was profusely cited by many works of the late 19th century.

2.3. Surgical Treatments

For the doctors, surgical treatments represented the most solid and effective way to treat keratoconus. Many protocols were set up with different goals, including corneal flattening and restoration of vision.

The first surgical techniques were developed in the early and middle 19th century: most of them relied on pupil displacement and iridectomy (change of the shape of the iris, also called iridodesis) to increase visual acuity.

2.3.1. First Surgical Attempts at the Beginning of the 19th Century

Lowering the Eye Tone

Considering that an ocular hypertonia could be the origin of keratoconus, some surgeons proposed protocols to lower the tension. Wardrop submitted a protocol based on the puncture of the anterior chamber several times through the top of the cone, but this technique did not allow a maintained flattening of the durable cone. Indeed, as soon as the punctures stopped the cornea resumed its shape [5].

Displacement of the Pupil

In 1840, Tyrrell moved the pupil to the periphery so that the patient could use a corneal area with normal curvature.

He made an incision in the anterior chamber and drew the iris to pass through it. He then excised the prolapse part of the iris: the pupil obtained was more or less regular at the periphery. But there were many accidents (like ocular inflammation due to herniation of the iris, or increased intraocular pressure, making an iridectomy mandatory for these patients, which affected a little more their vision) [15].

Iridectomy

Other procedures were attempted in a similar approach such as sectioning a small portion of the iris to allow reuse of a corneal portion unaffected by keratoconus. This procedure was used by surgeons such as Bowman or Walton, who recommended it in the early stages of the disease in addition to wearing an optical correction [16].

This operation's purpose was for the patient to reuse unused corneal portions with normal curvature to improve his vision. Several surgeons have tried this procedure with variable and non-reproducible results [3, 5]. This procedure was also used complementary to other surgical procedures [17].

Iridodesis

Donders was the first to consider the idea of suppressing ametropia by using a pinhole, made with a diaphragm pierced with a hole or a thin slit.

But it had disadvantages for orienting oneself into space with far vision to go into space because of the very limited visual field [18]. Bowman draw inspiration from this work to design a protocol to reduce the pupillary opening to a narrow slit like a cat pupilthat hee named “iridodesis” [19].

He opened the anterior chamber at both ends and incarcerated the iris in the two incisions to obtain the deformation of the iris in a narrow slit.

Critchett picked up the idea of incarcerating the iris only on one side, forming a simple iridodesis [5, 20].

However, these procedures caused many accidents and inconveniences because of the incarceration of the iris in the sclero-corneal limb. Moreover, there was a great risk of causing a glaucoma via the hernia iris.

2.3.2. Techniques Developed from the Mid of the 19th Century

Other techniques were developed around the middle of the 19th century following the failures of the previously mentioned methods. These new techniques relied more on the creation of corneal scars or the removal of the cone-containing part to modify its shape.

They were based on observations of patients with hydrops, who, after healing and a period of time to decrease opacity, got a better acuity with a less conical corneal shape.

Creation of Scar Tissue

Several surgeons have relied on cases of corneal scarring that have reduced the curvature of the cornea:

De Graefe’s procedure consisted of creating a scar to try to smooth the cornea. He excised a corneal flap 2 to 3 mm long without penetrating the anterior chamber.

After two days of rest for the patients, he cauterized the wound chemically with a silver nitrate pencil during three to four days. After this stage, he completely crossed the cornea and repeated this process for a few days before allowing to the cornea to heal, causing a whitish scar to appear [5, 21].

Many variations of this method have emerged: [22] Meyer, for example, modified the protocol by no longer excising the vertex of the cone but performing lateral excision [19, 23].

Bowman, in order to avoid painful daily cauterization, suggested to replace the excision of the cornea by the trepanation of almost the whole thickness of the cornea [18].

Finally, tattooing techniques were created, using the perforation of the cornea with needles coated with Indian ink [24]. But all these methods provoked the appearance of a corneal leucoma causing a strong loss of visual acuity for the patient.

Compression Healing

Another surgical technique involved the section of an oval area of the cornea at the center whose edges were approximated by the use of a silver wire. But the use of these wires could lead to numerous infections and edematous complications [5].

Therefore other surgeons preferred trying to heal by compressing the cornea to avoid them [12]. The operated eye was covered with a cloth and compression was performed with a rubber band.

Finally, one of the derived techniques consisted of the total section of an oval zone of the cornea not in the central part but in the lower middle part and the use of compression to help the healing of the cornea.

After this procedure, the vertex of the cone moves from a central position to a lower corneal position and decreases. The cornea resumed a form closer to normal according to the authors [23, 25].

Creation of Scar Tissue by Corneal Cautery

Another procedure derived from the creation of corneal scar is used by the French surgeon Gayet. He preferred this method because it made it possible to avoid the disadvantages of nitrate, whose action is difficult to limit once applied and which could be printed in the cornea. One of the main objectives of this method was to reduce the size of the scar while keeping the efficiency of the cautery process.

Other surgeons quickly adopted the use of thermo-cautery or Galvano-cautery and several derivatives of this protocol were created [3, 26].

Some surgeons used this method with perforation of the cornea by cautery [27] but this had serious consequences including cases of glaucoma.

Non-perforated corneal cauterization protocols have been developed with the aim of reducing these undesirable effects: the risk of developing glaucoma could then be reduced while keeping the efficiency of the process [19, 28].

After reviewing them, we can say that all these methods caused the occurrence of a more or less central corneal scar. Visual acuity was mostly decreased instead of being increased, causing visual discomfort. Some methods were as long and painful as the De Graefe or Bowman procedure and caused a central scar preventing any vision with the operated eye. Moreover, the cornea remained irregular with strong astigmatism and the results of these methods remained difficult to predict.

The various surgical procedures enumerated so far exposed patients to serious complications in the iris and cornea with delicate operative procedures.

Even if the operation was successful with sagging of the cone, the results obtained in the visual acuity were poor because of strong astigmatism but also because of the corneal scar created.

CONCLUSION

At the end of the 19th century and the beginning of the 20th century, several surgical approaches for treating keratoconus remained: one of the most common is a synthesis of medical procedures (compression and use of myotic) and surgery in cases of aggravation (cauterization or scar tissue creation).

However, these methods did not guarantee good vision and a conservation of the patients' ability to remain autonomous because of possible residual corneal scars, but also of possible adverse effects (like infections or glaucoma). Improvement in glasses manufacture at the end of the 19th century made the increase of patients' visual acuity possible. Although important progress has been made during these centuries, the prognosis of patients remained bad in the long term. It is only in the first half of the 20th, after the possibility of performing corneal

transplants with better success rates was developed, that surgeons have been able to provide a more perennial solution to their patients, thus making it possible to stop the disease while preserving a certain visual acuity. The first corneal transplant was performed in 1901 by Dr. Zinn. But it was not until 1936 that a corneal transplant in an advanced case of keratoconus was successfully performed.

REFERENCES

[1] Mauchart B. D. *Staphyloma Vexatum Nomen*. Tübingen: Erhardt, 1748.

[2] Nottingham J. *Practical Observations on Conical Cornea: and on the Short Sight, and Other Defects of Vision Connected with it*. London: J Churchill, 1854.

[3] Charmoille L. J. B. [*Keratoconus and its treatment with igneous cauterization*]. 1903 [Thesis]; Nancy.

[4] Desmarre L. A. [Transparent conical staphyloma, or pellucid conicity of the cornea]. In: Desmarre L. A. [*Practical and theoretical treatise on eye diseases*]. Paris: Germer Bailliere; 1847; 344-8.

[5] Adams W. On the restoration of vision, when injured or destroyed in consequence of the cornea having assumed a conical form. *J Sci Arts.* 1817; 2: 402-7.

[6] Bénaky N. B. [*Keratoconus and its correction by conical glasses*]. 1881 [Thesis]; Lyon.

[7] Petresco G. [*Keratoconus and its treatment with miotics and compression*]. 1887 [Thesis]; Paris.

[8] Bowman W. On conical cornea. *Ophthalmic Hosp rep and J R Lond Ophthalmic Hosp.* 1859; 9: 157.

[9] De Graefe. [Keratoconus], traduction Delacroix. *Ann Ocul.* 1867; 60: 135-6.

[10] Cooper W. On conical cornea. *Lond J Med.* 1950 May; 2(17): 208-19.

[11] Cooper W. On conical cornea. *Lond J Med.* 1950 May; 2(18): 523-38.

[12] Abadie. [*Treaty of eye diseases*]. 1st edition. Paris: Librairie octave doin; 1876.

[13] Sattler R. The surgical treatment of conical cornea. *JAMA.* 1900; 35(7): 397-400.

[14] Dor H. [On contact lenses]. *Lyon méd.* 1892 Dec; 71(49): 467-70.

[15] Tyrrell F. *A practical work on the diseases of the eye and their treatment, medically, topically, and by operation*. 2nd edition. London: John Churchill; 1840.

[16] Walton H. On conical cornea. *Brit Med J*. 1863 Jun; 1(130); 643-4.

[17] Young G. A surgical method of dealing with keratoconus. *Br J Ophthalmol.* 1924; 8(6):270-2.

[18] Donders F. C. *On the anomalies of accommodation and refraction of the eye*. 1st edition. London: The new Sydenham Society; 1864.

[19] Bowman W. On conical cornea and its treatment by operation. *Ophtalimic Hosp Rep.* 1859; 2(9): 157.

[20] Crichett A. *Conical cornea: its surgical evolution*. 1st edition. London: Morton and Burt; 1903.

[21] Bader C. Treatment of conical cornea by removal of the top of the cone. *Lancet.* 1872 Jan; 99(2525): 73-5.

[22] Fluch E. *Text book of ophthalmology*. 1st edition. New York: D Appelton and cie; 1892.
[23] Grandclément M. [Keratoconus treated by tattooing the apex of the conical cornea]. *Lyon méd.* 1896 May; 81(11): 363-6.
[24] De Wecker L. [The eye drill and its application]. *Ann Ocul.* 1872; 68(8): 137-40.
[25] De Wecker L. [Removal of total staphyloma from the cornea]. *Ann Ocul.* 1873; 70(4): 51-5
[26] Gayet A. C. [Treatment of keratoconus with igneous cautery]. *Lyon méd.* 1879; Jan; 30(6): 193-4.
[27] Knapp A. Etiology and treatment of keratoconus. *Trans Am Ophthalmol Soc.* 1929; 27: 63-72.
[28] Knapp H. Galvanocautery for keratoconus. *JAMA.* 1900 Aug; 35(7): 400-2.

In: Encyclopedia of Surgery (22 Volume Set)
Editors: Andreas Lehrer and Kristin Mueller
ISBN: 978-1-53618-329-0
© 2020 Nova Science Publishers, Inc.

Chapter 460

THE RETROSIGMOID APPROACH: FROM THE MICROSURGICAL ANATOMY TO THE SURGERY

Francesca Graziano, Enrico Lo Bue, Lara Brunasso, Alessia Lombardo, Rosario Maugeri and Domenico G. Iacopino
Neurosurgical Clinic, AOUP "Paolo Giaccone", PostGraduate Residency Program in Neurosurgery, Department of Biomedicine Neurosciences and Advanced Diagnostic (BiND), School of Medicine, University of Palermo, Palermo, Italy

ABSTRACT

The retrosigmoid approach has been widely described and utilized for access to various pathologies of the posterior fossa and the cerebellopontine angle. This approach gives a better view of the CPA and allows early identification of various neurovascular structures, more complete removal of lesions, less morbidity, and better functional results in terms of cochlear and facial nerve preservation. Many authors advocate it as the procedure of choice during vestibular nerve section, microvascular decompression, surgery for vestibular schwannomas, non-acoustic tumors, or insertion of auditory brain stem implants.

1. MICROSURGICAL ANATOMY OF THE CEREBELLOPONTINE ANGLE

In skull base neurosurgery, the retrosigmoid approach has been widely described and utilized for access to various pathologies of the posterior fossa and the cerebellopontine angle [1]; thus, it was defined by Mostafa B E et al. as the keyhole to the Cerebello-Pontine Angle (CPA) [2]. The cerebellopontine angle is located between the superior and inferior limbs of the cerebellopontine fissure formed by the petrosal cerebellar surface folding around the pons and middle cerebellar peduncle [3]. This approach gives a better view of the CPA and allows early identification of various neurovascular structures, more complete removal of lesions, less morbidity, and better functional results in terms of cochlear and facial nerve preservation [2]. Surgery of the posterior fossa has evolved over the years with a shift toward a more

minimally invasive approach [4]. Many variations of the technique have been described to tailor the procedure in relation to patient's pathology [5. 6]. Many authors advocate it as the procedure of choice during vestibular nerve section, microvascular decompression, surgery for vestibular schwannomas, non-acoustic tumors, or insertion of auditory brain stem implants [5. 6].

1.1. Osseus and Muscolar Relationships

When dealing with cerebellopontine angle approaches, surgeons initially confront the occipital and temporal bones and their related structures. Careful exposure, in particularly of bony sutures and others osseous prominences and depression, enables these sites to be used as important landmarks for surgical orientation and for restricted and appropriate CPA approaches (Figure 1) [7]. The occipital bone, situated at the back and lower part of the cranium, surrounds a large oval aperture, the foramen magnum, through which the cranial cavity communicates with the vertebral canal. The convex external surface of occipital bone has several prominences and lines on which the muscles of neck attack. The largest prominence, the external occipital protuberance or inion, is situated at the central portion of the external surface. A vertical ridge, the external occipital crest, descends from the inion to the midpoint of the posterior margin of the foramen magnum, with the nuchal ligament attached. Along the superior nuchal lines, which extend laterally and horizontally from the external occipital protuberance, the trapezius muscle inserts medially and the sternocleidomastoid muscle inserts laterally. The splenius capitis muscle, partially covered by the trapezius and sternocleidomastoid muscles, inserts on the lateral third of the superior nuchal line. The inferior nuchal lines run laterally from the midpoint of the crest. Below each inferior nuchal line, the rectus capitis posterior minor and major muscles are inserted, respectively, medially and laterally. The semispinalis capitis muscle inserts in the area between the superior and inferior nuchal lines and is situated, with the longissimus capitis muscle, deep to the splenius capitis and sternocleidomastoid muscle. Therefore, there are 4 muscular planes, which are from surface to depth: sternocleidomastoid and trapezius muscles; splenius capitis muscle; semispinalis capitis and longissimus capitis muscles; rectus capitis posterior minor, rectus capitis posterior major, inferior oblique and superior oblique muscles. The suboccipital triangle (SOT) is formed by 3 of the 4 muscles of the deepest plane: medially by the rectus capitis posterior major, laterally by the superior oblique muscle, and inferiorly by the inferior oblique muscle (Figure 2) [8]. The internal concave surface of occipital bone, in particularly of the squamous part, is deeply concave and has a prominence, the internal occipital protuberance, near its center. The *cruciform eminence* divides the endocranial surface of the occipital squama into four fossae. The *internal occipital protuberance* lies at the center of the cruciform eminence. The *internal occipital crest* is the inferior arm of the cruciform eminence. *Transverse sulci* form the transverse arms of the cruciform eminence. The occipital bone articulates with six bones: the two parietals, the two temporals, the sphenoid, and the atlas. The lambdoid, occipitomastoid, and parietomastoid sutures are united at the asterion and separate the occipital, parietal, and temporal bones (Figure 1) [7]. The asterion has been widely used as a landmark for all posterolateral approaches to the cranial base. Classically, the asterion has been cited as an external landmark for the transverse sigmoid junction (TSSJ). The relationship between the cranial sutures and

venous sinuses can be used in surgical planning [7]. Posterior fossa craniotomies can constitute a risk of injury to the sinus complex due its location [9]. Localization of the venous sinuses, TSSJ and emissary vein is of utmost importance in the retrosigmoid approach to avoid damage to the venous structures of the region [10].

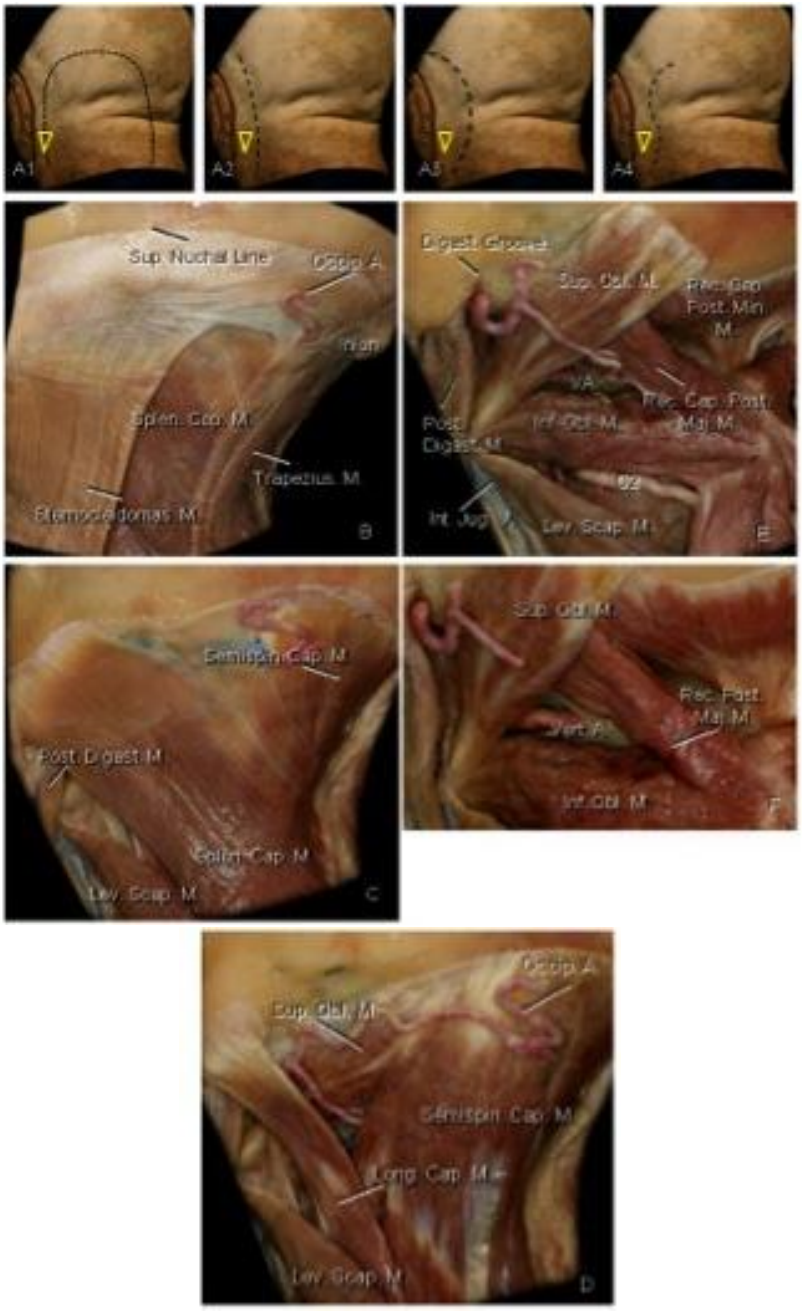

Figure 1. Temporal occipito-parietal bone surfaces. Upper: Adult cadaveric embolmed head with brain and suture lines saved to show their relationship. Lower: Lateral surface of an adult skull showing the junction of lambdoid, occipitomastoid, and parietomastoid sutures to form the asterion.

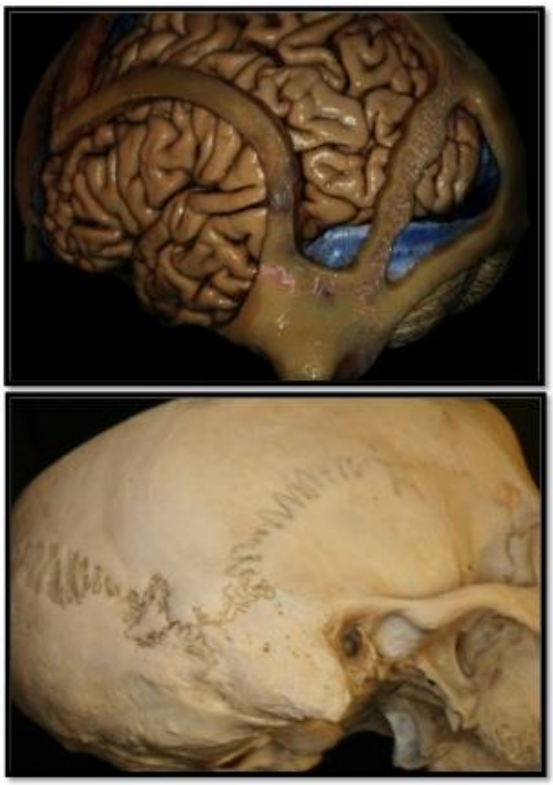

Abbreviations: sup. Superior, occip. occipital, a. artery, spleen. splenium, cap. sapitis, m. muscle, digast. digastric, obl. Oblique, rec. rectus, post. Posterior, min. minor, VA. Vertebral artery, inf. Inferior, maj. Major, int. internal, jug. Jugular, v. vein, lev. Levatoris, scap. Scapula, semispin. Semispinalis, long. Longus

Figure 2. Muscolar relationship on posterior fossa and skin incision. Adult cadaveric embolmed head. A1, A2, A3, A4: type of skin incision, reversed hockey stich, linear, C shaped, and lazy S respectively. The reversed yellow triangle indicates the mastoid tip. B, C, D, E, F: muscular planes showed in a stepwise fashion.

1.2. CPA and Its Compartments

1.2.1. CPA Upper Neurovascolar Complex

In the CPA, identification of the cranial nerves that arise from the brainstem and of their vascular relationships within the upper, middle and lower aspects of CPA cisternal space is mandatory [7]. The CPA neurovascular complex includes the pons, trigeminal nerve, supracerebellar artery (SCA) and superior petrosal veins. The most common operation directed to the upper neurovascular complex is exsposure and decompression of the posterior root of the trigeminal nerve. The posterior trigeminal root joins the brainstem about halfway between the lower and upper borders of the pons [7]. Today, it is generally agreed that the most common cause of classical trigeminal nevralgia TN is compression of the trigeminal nerve by a blood vessel, usually an artery, in the cerebellopontine cistern. This phenomenon is commonly referred to as neurovascolar conflict. A neurovascular conflict should be

considered a normal neuroanatomic variant in patients with facial pain not fulfilling the TN diagnostic criteria [11]. More than one artery can compress the nerve. In a few cases the SCA will compress the rostral surface of the nerve and the anterior inferior cerebellar artery (AICA) will compress the caudal surface [7]. The SCA arises in front of the midbrain, usually from the basilar artery near the apex. It passes below the oculomotor and trochlear nerves and above the trigeminal nerve to reach the cerebellomesencephalic fissure [3].

The transverse pontine veins are the most frequent veins to compress the trigeminal nerve. The transverse veins are tributaries of the superior petrosal veins, the largest and most frequently encountered veins in the posterior fossa.

1.2.2. CPA Middle Neurovascolar Complex

The middle complex includes the AICA, pons, middle cerebellar peduncle, cerebellopontine fissure, petrosalsurface of the cerebellum and the abducens, facial and vestibulocochlear nerves. The AICA originated from the Basilar artery (98.1%) or from the vertebral artery (1.9%) as a single (92.3% of CPAs) or duplicate (7.7%) artery [12]. It courses together with the abducens, facial and vestibulocochlear nerves to reach the surface of the middle cerebellar peduncle, where it courses along the cerebellopontine fissure and terminates by supplying the petrosal surface of the cerebellum.

In most cases, the AICA passes below the facial and vestibulocochlear nerves as it encircles the brainstem. However, it may also in other cases pass above or between these nerves in its course around the brainstem. The veins on the side of the brainstem that have a predictable relationship to the facial and vestibulocochlear nerves are the veins of the pontomedullary sulcus, the veins of the cerebellomedullary fissure, middle cerebellar peduncle and cerebellopontine fissure.

Operations directed to the middle complex are for the removal of acoustic neuromas and other tumors and for the relief of hemifacial spasm. The facial and adjacent cranial nerves are the neural structures at greatest risk during acoustic neuroma removal. The facial nerve is stretched around the anterior half of the tumor capsule. The nerve infrequently is found on the posterior surface of the tumor [3].

1.2.3. CPA Lower Neurovascular Complex

The lower complex includes the posterior inferior cerebellar artery (PICA), the medulla, inferior cerebellar peduncle, cerebellomedullary fissure, suboccipital surface of the cerebellum, and the glossopharyngeal, vagus, spinal accessory and hypoglossal nerves.

The PICA arises at the medullary level from the vertebral artery, encircles the medulla, passing together with to the glossopharyngeal, vagus, spinal accessory and hypoglossal nerves to reach the surface of the inferior cerebellar peduncle. The glossopharyngeal, vagus, spinal accessory, and hypoglossal nerves arise from the medulla along the margin of the inferior olive. The PICA has a complex relationship to these nerves. The proximal part of the PICA passes around or between and often stretches or distorts the rootlets of the nerves in the lower complex. At the anterolateral medulla, the PICA passes around or between the rootlets of the hypoglossal nerve. At the posterolateral margin of the medulla, it passes between the fila of the glossopharyngeal, vagus and spinal accessory nerves. The vertebral artery courses anterior to the nerves in the lower neurovascular complex. The hypoglossal rootlets usually pass behind the vertebral artery. However, some hypoglossal rootlets infrequently pass

anterior to the artery. If the vertebral artery is elongated or tortuous and courses laterally to the olive, it will stretch the hypoglossal rootless over its posterior surface. The close relationships of the PICA and vertebral artery to the glossopharyngeal and vagus nerves makes it logical to explore these relationships in glossopharyngeal neuralgia. The glossophayngeal nerve arises as one rootlet from the upper medulla, just caudal to the origin of the facial nerve. In a few cases, however, it originates as two rootlets, which can remain separates through their course to the dura. The vagus nerve arises below the glossopharyngeal nerve and is composed of multiple combinations of large and small rootlets [13]. It may be difficult to distinguish the lower vagal fibers from the upper accessory rootlets because the vagal and cranial accessory fibers usually enter the vagal meatus as a single bundle. The rootlets forming the hypoglossal nerve arise in a nucleus whose rostral portion sits deep to the hypoglossal triangle in the floor of the fourth ventricle.

2. The Retrosigmoid Approach: A Step by Step Description

2.1. Patient Positioning

The patient is placed supine or in the park-bench or sitting position [7]. Most patients are placed in a supine-oblique position, where the patient lies supine with the shoulder that is ipsilateral to the tumor elevated enough to allow the head to be turned parallel to the floor with no excessive tension on the neck [14]. A sand bag or a foam roll can be placed under the ipsilateral shoulder to minimize rotation of the neck [7]. The patient's head is rotated toward the contralateral side and is supported on a Mayfield three-point fixation device to obtain simultaneous flexion and rotation [7]. If the patient's body habitus (e.g., significant limitation of neck motion) precludes this positioning, the modified park-bench position can be considered, where the patient is placed in a lateral position with the head supported outside the surgical table by the Mayfield head holder. The dependent arm is then supported on a swing attached to the Mayfield and an axillary roll under it prevents brachial plexopathies. The ipsilateral shoulder can be taped to minimize its profile [7]. The use of sitting position has almost been abandoned because it is associated with a significant risk of air embolism, even if it offers a clean surgical field because blood and CSF drain away from it. Here, the head is slightly fixed and rotated toward the ipsilateral side [7]. The sitting position can be uncomfortable for the surgeon, leading to early interruption of the procedure. Instead, in the supine position or the modified park-bench position the operating table is turned so that the surgeon can sit behind the patient's head with his or her feet under the table. An armrest for the surgeon is also placed for the arm nearest the vertex [7].

2.2. Skin Incision

The skin incision consists of a 4–5 cm curvilinear skin incision made at the retroauricular region, and it was made to cross over the asterion at the upper third point of incision, being 1–2cm lateral to the greater occipital nerve and just medial to the lesser occipital nerves [15]. The inferior limb of the skin incision was directed laterally to avoid direct or indirect injury to

the lesser occipital nerves [15]. The operative field became deeper with a linear skin incision because of the thickness of the subcutaneous tissue when retracted. Accordingly, the curvilinear incision was preferable for closing up the operative field after retracting the skin flap [15]. As the operative results have improved remarkably, the patients have begun to focus on the postoperative discomfort around the craniectomy site. One major drawback of the conventional retrosigmoid craniectomy is a possible (7–50%) postoperative headache due to the long skin incision and the large craniectomy [15, 16, 17, 18, 19, 20, 21]. Such postoperative headache may occur by adhesion of cervical musculature to dura mater with the resultant traction during neck motion, injuries to greater and/or lesser occipital nerves, or chemical meningitis by bone chips during drilling [21]. To reduce the rate of such complications and thereby improve surgical outcomes, various skin incisions and scalp flaps have been proposed as possible alternatives to the standard straight or S-shaped approach (Figure 1) [22].

To reduce postoperative headache and scalp and neck discomfort from injury to these nerves, a modified technique for a 4-cm C-shaped skin incision was developed and initially tested by Salvatore Chibbaro [23]. This modified skin incision has a medial convexity and is usually placed 8 cm laterally to the external occipital protuberance (EOP) and medially to the mastoid groove and the pinna, with the lower edge terminating 1.5-2 cm above the mastoid tip [23]. The main neural structures at risk when performing the skin incision for a minicraniotomy via retrosigmoid approach (mCRSA) are the lesser occipital nerve (LON) and the greater auricular nerve (GAN) [24, 25]: the LON runs approximately 7 cm lateral to the EOP and 3 cm medial to the mastoid process tip and provides sensorial innervation of the occipital, mastoid, and temporal regions; the GAN may have a mastoid branch running approximately 9 cm lateral to the EOP, whereas the principal trunk may be located 1cm above to the mastoid tip [24, 25]. Following a careful subperiosteal dissection, the muscle flaps are then reflected superiorly and inferiorly and retracted with stitches. After creation of a burr hole at the transverse- sigmoid sinus junction [23], a circular craniotomy approximately 2.5 cm in diameter is done, exposing the underlying dura mater, which is opened in a C-shaped fashion with the base protecting the sinus junction [23].

Asterion is a precise landmark for determining the skin incision and localizing the apex of the triangular craniectomy. It has been defined as the junction of the lambdoid, parietomastoid, and occipitomastoid sutures [27, 28], and it is easily identified as the site of slight digital depression which could be palpated through the skin behind the mastoid process at the level of zygomatic root (on the extending line from the zygomatic root to the superior nuchal line).

2.3. Bone Drilling

A retrosigmoid craniectomy usually extends from the lower margin of the transverse sinus down to the foramen magnum, behind the sigmoid sinus. In the past, the main concern during the retrosigmoid approach for CPA lesions was focused on the preservation of VIIth and VIIIth cranial nerves [15, 16, 20]. A circular craniectomy is made below asterion, overlapping the back portion of mastoid process, using a 6 mm-steel burr and a 4 mm Kerrison rongeur. The craniectomy 2 cm in width is enough to explore around V nerve or VII–VIII nerve complex and to achieve a total removal for the CPA tumors (such as

vestibular schwannomas, meningiomas or cholesteatomas), while the craniectomy is a little bit enlarged downward to explore the lower CPA. A steel burr is mainly used until exposure of dura mater, while a diamond burr and Kerrison rongeurs are used for resecting the marginal inner table of the skull. The lateral border of the triangular craniectomy is approximately at the posterior margin of the sigmoid sinus, while the upper border is approximately at the inferior margin of the transverse sinus. Usually, bony removal over asterion proceeded to delineate the transverse-sigmoid junction and it is completed when the margin of the sigmoid sinus is exposed. Therefore, the final landmark of craniectomy of the subasterional approach is not exactly the asterion, but the margin of the transverse-sigmoid junction. Venous bleeding from the diploic vein, the epidural space and/or the mastoid emissary vein occurred consistently during high-speed drilling but is controlled easily using bone wax. Such hemostasis technique is indispensable for this approach (Figure 2) [15].

2.4. Dura Opening and Intradural Exposure

After the craniectomy, the dura is exposed and opened under the microscope in two possible ways. Or the dura is cut as an anteriorly based semicircular U-shaped flap, with a wide base toward the sigmoid sinus [7, 2]; this semilunar incision starts from the level of the jugular bulb and ends at the level of transverse sinus; it must be parallel and almost 1 mm posterior to the sinuses [29]. Or the dura could be also opened in a cruciate fashion and the flaps held aside with suture [30]. At the end of incisions, dura mater could be hanged anteriorly to the skin flap with sutures and stay sutures are placed on the dural edge to enhance exposure [1, 29]. The idea of making additional cuttings appears to be not necessary; furthermore, this will facilitate dura closure afterwards, at the end of surgical approach (Figure 3) [31]. When the dura cut is done, the posterior fossa dura maintains its position on the moist surface of the cerebellum, and a wet cottonoid is placed on the top of the dura to prevent drying. After its placement, it's necessary to perform intermittent irrigation of the cottonoid and the dura; this procedure ensures to avoid the desiccation of tissues [1].

CSF Drainage Maneuvers

Neurosurgery experience showed that an important maneuver in retrosigmoid approached surgery is a sufficient drainage of CSF. After anesthesia is induced, it is appropriate to perform a CSF drain because this procedure helps minimize the retraction on the cerebellum, averts a postoperative CSF leak, decreases the pressure of the posterior fossa and facilitates the access to the lesion [7, 32]. However, in some patients, it appears to be difficult to drain the CSF because of the possibility that a fulminant cerebellar swelling may to occur after the dura mater incision; in addition, when an excessive cerebellar retraction for drainage of CSF is attempted, an unexpected cerebellar injury could be induced. Method usually used to obtain an operative corridor into the posterior fossa consists in opening the lateral cerebellomedullary cistern or the lateral cerebellopontine cistern, or cistern magna (that now results obsolete) [32]. Anyway, in alternative the placement of a lumbar drain could be a valid tool, indeed, before opening the dura mater, the lumbar drainage is opened to drain 20 to 30 cc of CSF, that is sufficient for cerebellum relaxation, than it could closed and againg opened as the surgery may require [7].

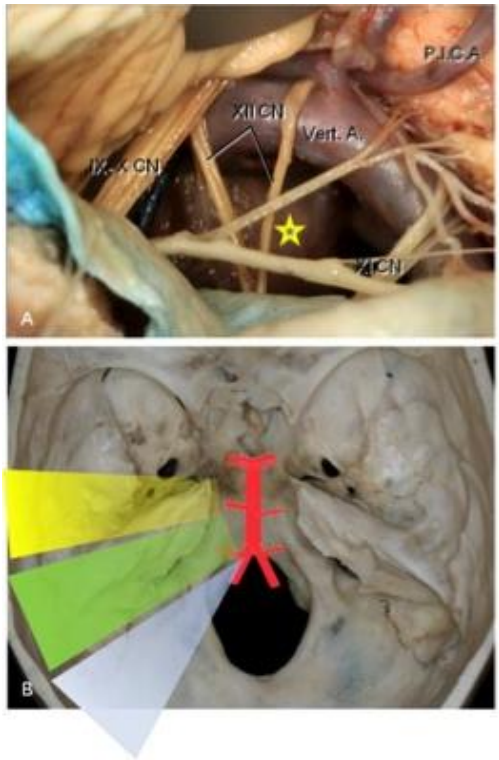

Figure 3. Intradural view and surgical approaches to posterior fossa. A. Lower exposure during retrosigmoid approach: intradural microsurgical view of the lower neurovascular complex. B. Upper view of an adult cranial fossa. The different surgical routes to the posterior fossa are showed. Yellow rectangle: Supratemporal approach-upper neurovascular complex; Green rectangle: Retrosigmoid approach- middle neurovascular complex; Light blue triangle: Lower retrosigmoid or Far lateral approach-lower neurovascular complex.

Cerebellar Retractors Placement

Retractors allow neurosurgeons to work within confined spaces, unhindered by an assistant's hand, by applying a constant force to reposition structures that would otherwise impinge on the operative line of sight [33]. However, because retractor-induced tissue edema and injury remain sources of neurosurgical morbidity, the utility of fixed retraction comes at a price; furthermore, fixed retractors require time to adjust and readjust repeatedly as the exposure demands [29].

In retrosigmoid approach, retraction of the cerebellum through retractors is seldom necessary.

The benefit of its usage is in order to obtain an adequate surgical exposure, that allows the surgeon to visualize the extremely important structures in the CP angle. In particular, the direction of the application of brain spatulas for surgery admit to see different parts in the various compartments of the CP angle. Positioning retractors laterally permits to have an exposure of the middle neurovascular complex; it could be used for a lesion in the midportion of the CP angle, such as a vestibular schwannoma. Positioning retractors from top-down permits to have an exposure of the upper neurovascular complex, parallel to the superior petrosal sinus; it could be used for a microvascular decompression operation for trigeminal

neuralgia. Positioning retractors from bottom-up permits to have an exposure of the lower neurovascular complex; it could be used in hemifacial spasm, because the facial nerve root exit zone is located only a few millimeters above the glossopharyngeal nerve and the PICA is commonly a compressing vessel [3]. However, in the vestibular schwannoma surgery through posterior fossa, cerebellar retraction is usually maintained for several hours, and this could provoke a cerebellar injury [29].

Because of the need to find a safe and effective solution to avoid the possibility of injury due to its utilization, now cerebellar retractors are not required in posterior fossa approaches because of refinements of the surgical and neuroanesthesia [29]. Indeed, when adequate conditions such as patient positioning, adequate anesthesia techniques, and surgical manipulations are applied in posterior fossa approach (except for neurovascular decompression and some of the acoustic neuroma surgeries), cerebellar retractors are not needed [29]. For example, a surgical manipulation, in which their usage is not required, consists in suturing the dura anteriorly over the sigmoid sinus because this maneuver could allow the maximal anterior exposure [1]. Moreover, another option is to insert a spatulum fixed by a Leyla-retractor and gain insight to the CP angle to hold (not retract!) the cerebellum [31].

2.5. Tumor Exposure and Removal

In the first moments of the dissection, when it is easiest to distinguish tumor from surrounding tissues, arachnoid adhesions are released and the cerebellum and lower cranial nerves are separated from the tumor. Once the cranial nerves have been identified, the tumor is morcellized from its core through ultrasonic aspiration, which is especially helpful when resecting the core of the tumor because it allows the removal of its smaller fragments. An important procedure during tumor removal is the monitoring of the facial nerve. If there are some evidence of its irritation, the surgeon should think about changing the area of dissection; in facts, after the facial nerve identification, it is important to perform a dissection of it from the tumor with a round knife. The facial nerve is usually displaced anteriorly against the anterior rim of the internal auditory canal, and this spot is most susceptible to injury during dissection [7]. After brain tumor removal, hemostasis could be performed using hemostat such as TachoSil, a sponge with an active yellow side coated with human thrombin and human fibrinogen. Its effect can be enhanced and supported by an autologous fibrin sealant to cover the surgical bed and to achieve dural closure, repair of dural defects, and to fill “dead spaces” with the same product [34, 35]. The microscopical approach may gain some advantages from the endoscopic technique. The application of neuroendoscopy will likely reflect less-invasive alternatives of traditional skull base approaches and may enhance the surgical view along deep or tight corridors not well visualized with the binocular microscopic view [36].

2.6. Closure Techniques

Once tumor removal is complete and hemostastis is obtained, the tack-up dural sutures applied during the dural opening phase are cut and the dura could be closed with 4-0 woven

nylon suture; in order to guarantee a major stability, a patch of blood-impregnated microfibrillar collagen hemostat is layered on top of the dural closure filling the craniectomy defect [7, 1]. Another way to make duroplasty is using the autologous pericranium graft, inserting it through the defect as an underlay hourglass-shaped plug. For obtaining this, the graft harvested has to be slightly larger than the dural defect, in order to have its edges under the dural plane and then it is fixed under operative microscope magnification with separated stitches (with an "inside-to-outside" direction) to the dura mater, using a 3-0 running silk. After that, the inserted patch was augmented with one layer of absorbable hemostats, with small pieces of surgical patches and with dural sealant [34]. In consideration of the thinness and fragility of pericranium in some population, like children, it could be another option to use ligamentum nuchae as graft; it could be more robust than pericranium, but this statement needs to be considered with caution and the understanding that this may not be true for all age groups [38]. When the duroplasty is complete, the bony defect could be filled with different materials, that reduce the risk of postoperative headache, such as: acrylic muscle, fibrin glue, wax or polymethyl methacrylate (PMMA). The muscles are then closed in layers primarily using their respective fascial planes with interrupted 2-0 woven polyglactic acid suture [1]. During closure, the aponeurotic fascia that was dissected before, could be an extra layer that helps to achieve a more hermetic closure [7, 39, 40]. The deep layer of the skin is closed with inverted, interrupted sutures, in which the staples are used to approximate the skin. Antibiotic ointment is applied to the staples and a 5x 3x 7cm island-type dressing is placed over the staple line; since this is not a pressure dressing, it can be removed the day after surgery [1].

REFERENCES

[1] Venable, et al. Primary Dural Closure for Retrosigmoid Approaches. *J Neurol Surg B*., 2017.

[2] Mostafa, BE; El Sharnoubi, M; Youssef, AM. The Keyhole Retrosigmoid Approach to the Cerebello-Pontine Angle: Indications, Technical Modifications, and Results. *Skull Base*, Volume 18, Number 6, 2008.

[3] Rhoton, AL. The Cerebellopontine Angle and Posterior Fossa Cranial Nerves by the Retrosigmoid Approach. *Neurosurgery*, 2000, 47, S93–129.

[4] Wackym, PA; King, WA; Meyer, GA; Poe, DS. Endoscopy in neuro-otologic surgery. *Otolaryngol Clin North Am*, 2002, 35, 297–323.

[5] Magnan, J; Barbieri, M; Mora, R; et al. Retrosigmoid approach for small and medium-sized acoustic neuromas. *Otol Neurotol*, 2002, 23, 141–145.

[6] Miyazaki, H; Deveze, A; Magnan, J. Neuro-otologic surgery through minimally invasive retrosigmoid approach: endoscope assisted microvascular decompression, vestibular neurotomy, and tumor removal. *Laryngoscope*, 2005, 115, 1612–1617.

[7] Bambakidis, NC; Megerian, CA; Robert, F; Spetzler, F. S*urgery of the cerebellopontine Angle*.

[8] Campero, A; Villalonga, JF; Elizalde, RL; Ajler, P. The Nuchal Lines as Anatomic Landmarks to Dissect the Muscles in the Far Lateral Approach. *World Neurosurg*, 2018, 113, 188–94.

[9] Uz, A; Ugur, HC; Tekdemir, I. Is the asterion a reliable landmark for the lateral approach to posterior fossa? *J Clin Neurosci*, 2001, 8, 146–7.

[10] da Silva, EB; Leal, AG; Milano, JB; da Silva, LFM; Clemente, RS; Ramina, R. Image-guided surgical planning using anatomical landmarks in the retrosigmoid approach. *Acta Neurochir* (Wien), 2010, 152, 905–10.

[11] Di Stadio, A; Dipietro, L; Toffano, R; Burgio, F; De Lucia, A; Ippolito, V; Garofalo, S; Ricci, G; Martines, F; Trabalzini, F; Della Volpe, A. Working memory function in children with single side deafness using a bone-anchored hearing implant: A case-control study. *Audiology and Neurotology*, (2018), 23 (4), pp. 238-244.

[12] Kim, HN; Kim, YH; Kim, GR; Park, IY; Chung, IH. Variability of the Surgical Anatomy of the Neurovascular Complex of the Cerebellopontine Angle. *Ann Otol Rhinol Laryngol*, 1990, 99, 288–96.

[13] Tarlov, IM. Structure of the nerve roots: II. Differentation of sensory from motor roots; observations on identification of function in roots of mixed cranialnerves. *Arch Neurol Psychiatry*, 1937, 37, 1338.

[14] Ojemann, RG. Retrosigmoid Approach to Acoustic Neuroma (Vestibular Schwannoma). *Neurosurgery*, vol 48, No 3, March 2001.

[15] Scorpecci, A; Massoud, M; Giannantonio, S; Zangari, P; Lucidi, D; Martines, F; Foligno, S; Di Felice, G; Minozzi, A; Luciani, M; Marsella, P. Otogenic lateral sinus thrombosis in children: proposal of an experience-based treatment flowchart. *European Archives of Oto-Rhino-Laryngology*, (2018), 275 (8), pp. 1971-1977.

[16] Fukuhara, T; Silverman, DA; Hughes, GB; Kinney, SE; Newman, CW; Sandridge, SA; et al. Vestibular nerve sectioning for intractable vertigo: efficacy of simplified retrosigmoid approach. *Otol Neurotol.*, 2002, 23, 67-72.

[17] Malignant paroxysmal positional vertigo. De Stefano A, Kulamarva G, Dispenza F. *Auris Nasus Larynx.*, 2012 Aug, 39(4), 378-82. doi: 10.1016/j.anl.2011.07.008. Epub 2011 Aug 30.

[18] Canal switch and re-entry phenomenon in benign paroxysmal positional vertigo: difference between immediate and delayed occurrence. Dispenza F, DE Stefano A, Costantino C, Rando D, Giglione M, Stagno R, Bennici E. *Acta Otorhinolaryngol Ital.*, 2015 Apr, 35(2), 116-20.

[19] Vertigo in childhood: a methodological approach. Dispenza F, De Stefano A. *Bratisl Lek Listy*., 2012, 113(4), 256-9. Review.

[20] Silverman, DA; Hughes, GB; Kinney, SE; Lee, JH. Technical modifications of suboccipital craniectomy for prevention of postoperative headache. *Skull Base.*, 2004, 14, 77-84.

[21] Schaller, B; Baumann, A. Headache after removal of vestibular schwannoma via the retrosigmoid approach: a long-term follow-up-study. *Otolaryngol Head Neck Surg.*, 2003, 128, 387-395.

[22] Jannetta, PJ; McLaughlin, MR; Casey, KF. Technique of microvascular decompression; technical note. *Neurosurg Focus*., 2005, 18, E5.

[23] Salvatore, Chibbaro; et al. Retrosigmoid Approach: Investigating the Role of a C-Shaped Skin Incision and Muscle Flaps in Improving Functional Outcome and Reducing Postoperative Pain. *World Neurosurg*., (2017).

[24] Tomasello, F; Esposito, F; Abbritti, RV; Angileri, FF; Conti, A; Cardali, SM; et al. Microvascular decompression for trigeminal neuralgia: technical refinement for complication avoidance. *World Neurosurg.*, 2016, 94, 26-31.

[25] Lee, M; Brown, M; Chepla, K; Okada, H. Gatherwright J, Totonchi A, et al. An anatomical study of the lesser occipital nerve and its potential compression points: implications for surgical treatment of migraine headaches. *Plast Reconstr Surg.*, 2013, 132, 1551-1556.

[26] Tubbs, RS; Loukas, M; Shoja, MM; Bellew, MP; Cohen-Gadol, AA. Surface landmarks for the junction between the transverse and sigmoid sinuses: application of the "strategic" burr hole for suboccipital craniotomy. *Neurosurgery*., 2009, 65, (6 suppl), 37-41 [discussion: 41].

[27] Bannister, LH; Berry, MM; Collins, P; Dyson, M; Dussek, JE; Ferguson, MWJ. (eds) Gray's anatomy. 38th edn. *Churchill Livingstone*, New York, 1995, 561.

[28] Aysun, Uz; Hasan Caglar Ugur, I. brahim Tekdemir. Is the asterion a reliable landmark for the lateral approach to posterior fossa? *Journal of Clinical Neuroscience*, (2001), 8(2), 146–147.

[29] Nebil, Goksu; Yildirim, A. Bayazit; Ismet, Bayramoglu; Berrin, Isik; Metin, Yilmaz; Omer, Kurtipek; Kemal, Uygur. Surgical exposure in retrosigmoid approach: do we need cerebellar retractors? *Surgical neurology*, 65, (2006), 631-634.

[30] Roberto, A; Cueva, Bill Mastrodimos. *Approach design and closure techniques to minimize cerebrospinal fluid leak after cerebellopontine angle tumor surgery.*, 26, 1176-1181, 2005, Otology & Neurotology, Inc.

[31] Marcos, Tatagiba; Florian, Roser; Martin, U. Schuhuman; Florian, H. Ebner. Vestibular schwannoma surgery via the retrosigmoid transmeatal approach. *Acta Neurochir*, (2014), 156, 421-425.

[32] Chang, Kyu Park; Sung, Ho Lee; Bong, Arm Rhee; Seok, Keun Choi. Puncture of Cerebellar Horizontal Fissure for Retrosigmoid Approach: a prospective and quantitative analysis. *Operative Neurosurgery*, 0, 1-4, 2017.

[33] Robert, F. Spetzler, Nader Sanai. The quiet revolution: retractorless surgery for complex vascular and skull base lesions. *J Neurosurg*, 116, 291-300, 2012.

[34] Graziano, F; Maugeri, R; Iacopino, DG. Intraparenchymal brain hemorrhage: "birdlime" effect usefulness. *World Neurosurg.*, (2018), 120, 598.

[35] Graziano, F; Certo, F; Basile, L; Maugeri, R; Grasso, G; Meccio, F; Ganau, M; Iacopino, DG. Autologous fibrin sealant (Vivostat (®)) in the neurosurgical practice: Intracranial surgical procedure. *Surg Neurol Int.*, 2015, May 12, 6, 77.

[36] Russo, VM; Graziano, F; Quiroga, M; Russo, A; Albanese, E; Ulm, JA. Minimally invasive supracondylar transtubercular (MIST) approach to the lower clivus. *World Neurosurg*., (2012), 77, 5/6, 704-712.

[37] Mastronardi, L; Cacciotti, G; Caputi, F; Roberto, R; Tonelli, MP; Carpineta, E; Fukushima, T. Underlay hourglass-shaped autologous pericranium duroplasty in "key-hole" retrosigmoid approach surgery: Technical report. *Surg Neurol Int*., 2016, Mar 10, 7, 25.

[38] Cools, MJ; Quinsey, CS; Elton, SW. *Ligamentum nuchae as a graft material for duroplasty in patients with Chiari malformation type I*. Published online July 13, 2018; DOI: 10.3171/2018.5.PEDS18301.

[39] Management of labyrinthine fistula in chronic otitis with cholesteatoma: Case series Dispenza, F., Mazzucco, W., Bianchini, S., Mazzola, S., Bennici, E. (2015) *EuroMediterranean Biomedical Journal*, 10 (21), pp. 255-261.

[40] Determinants of failure in the reconstruction of the tympanic membrane: a case-control study. Dispenza F., Battaglia A.M., Salvago P., Martines F. *Iranian J of Otorhinolaryngol*., 2018, 30, 341-346.

In: Encyclopedia of Surgery (22 Volume Set)
Editors: Andreas Lehrer and Kristin Mueller
ISBN: 978-1-53618-329-0
© 2020 Nova Science Publishers, Inc.

Chapter 461

FACIAL NERVE RESTORATION AFTER VESTIBULAR SCHWANNOMA SURGERY

S. Taliente[1], M. Maruccia[2], R. Guarino[1], R. Elia[2], G. Giudice[2] and Nicola Quaranta[1]

[1]Division of Otolaryngology, Department of BMS, Neuroscience and Sensory Organs University of Bari, Bari, Italy
[2]Division of Plastic and Reconstructive Surgery, Department of Emergency and Organ Transplantation, University of Bari, Bari, Italy

ABSTRACT

Facial nerve (FN) palsy represents the most frequent complication of VS surgery, therefore all of the professionals involved in the treatment of VS should be aware of its implications and treatment. Several treatments have been described for the management of facial nerve paralysis. The choice of the repair technique depends on various factors, including the type and site of lesion, the time elapsed from the injurious event, the patient's expectations and the rehabilitation. Post-operative facial nerve paralysis can be treated with static and dynamic techniques.

Static techniques are based on the passive correction of muscle deficits without restoring their movement, while dynamic techniques aim to restore the active function of the affected mimic muscles, through the restoration of the muscular innervation or their replacement with free or pedunculated muscle flaps.

INTRODUCTION

Vestibular Schwannoma (VS) is one of the most difficult brain tumours to remove. They account for the 85-92% of cerebellopontine angle tumours, 93.1% of intracranial nerve Schwann cell tumour and 7.79-19.64%, of intracranial tumours [1].

Over the past 25 years VS surgery has undergone immense changes and the progressive improvement of surgical instruments and techniques have drastically reduced the mortality rate [2].

The focus of the surgery has passed from the preservation of "life" to the preservation of "quality of life" with more attention to the preservation of the cranial nerves function.

Facial nerve (FN) palsy represents the most frequent complication of VS surgery, therefore all of the professionals involved in the treatment of VS should be aware of its implications and treatment [3].

The effect of FN palsy are both clinical and psychological. From a clinical point of view facial palsy induces oral incompetence, collapse of the nasal valve, dysfunctional lacrimation up to possible serious ophthalmic complications like corneal ulceration [4] while the loss of facial expression and the alteration of the muscular tone and movements reduce significantly the quality of life of these patients [5].

The treatment of VS has changed in the last 20 years; small tumours are managed conservatively, while surgery is reserved for medium-large sized VS and radiologically growing tumours [6].

In VS surgery the facial nerve is at high risk of lesion due to its intimate relationship with the tumour. The introduction of the operating microscope by William House [7] and the use of facial nerve neurophysiological monitoring [8] has considerably decreased the incidence of postoperative facial palsy [6, 9].

However, facial nerve outcome after VS surgery is influenced by several factors and the size of the tumours represents the most important one [1, 10]. Additional factors that can influence the prognosis of FN function have been reported, such as the patient's age and comorbidities, the extent of tumour removal (complete vs partial removal), the gross anatomy of the tumour (cystic vs non cystic form) [10].

CLASSIFICATION AND TREATMENT

Several classifications have been proposed to categorize facial nerve function such as the FaCE Scale [11], the Facial Disability Index [FDI] [12], Sunnybrook's staging system [13]; still, the most utilized classification is the House-Brackmann grading system [14].

In 2003 Kanzaki et al. [15] proposed a modification of the HB scale for reporting facial nerve outcome after VS surgery (Table 1).

Table 1. Kanzaki et al. Tokyo classification

Grade I		Normal facial function in all areas
Grade II	Gross:-	Slight weakness noticeable on close inspection
	Synkinesis*	Very slight-noticeable on close inspection when the mouth is protruded forcibly
	At rest:-	Normal symmetry and tone
	Motions:	a) Forehead: Moderate to good function
		b) Eye: complete closure with minimal effort
		c) Mouth: Slight asymmetry
Grade III A	Gross:-	Obvious but not disfiguring difference between the two sides.
	Synkinesis*	*Slight* noticeable but not complete when the mouth protruded forcibly. Some contracture and/or hemifacial spasm may be present.
	At rest:-	Normal symmetry and tone
	Motions:	a) Forehead: slight to moderate movements
		b) Eye: complete closure with effort *eye comfortable and in good condition with or without lubricants*
		c) Mouth: Weak with maximum effort

Grade I		Normal facial function in all areas
Grade III B	Gross:-	Obvious but not disfiguring difference between the two sides.
	Synkinesis*	*Moderate* eye close completely when the mouth is protruded forcibly some contracture and/or hemifacial spasm may be present
	At rest:-	Normal symmetry and tone
	Motions:	a) Forehead: slight to moderate movements
		b) Eye: complete closure with effort *eye dry and uncomfortable with evidence of exposure keratitis requiring lucricants and possibly tarsorrhaphy*
		c) Mouth: Weak with maximum effort
Grade IV	Gross:-	Obvious weakness and disfiguring asymmetry
	Synkinesis*	*Severe_*- Apparent mass motion whilst speaking
	At rest:-	Normal symmetry and tone
	Motions:	a) Forehead: None
		b) Eye: incomplete closure
		c) Mouth: Asymmetry with maximum effort
Grade V	Gross:-	Barely perceptible or no motion
	At rest:-	Asymmetry
	Motions:	a) Forehead: none
		b) Eye: none or incomplete closure
		c) Mouth: Slight or no movement
Grade VI		No movement. No tone.

* Synkinesis can be assessed by observed the degree of the eye closure when the mouth moves or by forcible protrusion of the lips. Synkinesis may include contracture and/or hemifacial spasm.

Several treatments have been described for the management of facial nerve paralysis. The choice of the repair technique depends on various factors, including the type and site of lesion, the time elapsed from the injurious event, the patient's expectations and the rehabilitation possibilities [16].

Facial Nerve paralysis after VS surgery can immediate or delayed.

- Immediate paralysis is related to intraoperative trauma of the nerve. In case the nerve is intact and responds to intraoperative electrical stimulation, a post-operative palsy is treated with post-operative steroids (e.g., dexamethasone i. v. at 4 mg every 6 hours during 48 hours).

In cases of intraoperative interruption of the nerve, immediate reconstruction gives the best long term results [17] (see below).

- Occasionally a *delayed paralysis* can present several days after the surgery. High-dose of steroids are indicated and recovery is possible in most cases [18].

Facial Nerve Repair Techniques

- Intraoperative repair

In case of intraoperative interruption of the nerve immediate reconstruction is indicated, being direct end-to-end anastomosis the preferred technique [18].

- Direct end-to-end anastomosis (or primary neurorrhaphy)

Direct end-to-end anastomosis (or primary neurorrhaphy) is considered the best option in case of acute post-traumatic facial nerve palsy in terms of recovery outcomes [19, 20].

After the removal of the VS, nerve stumps are identified and brought together. It is essential to avoid any tension between the two nerve stumps (proximal and distal), and to have a sufficient and useful contact between the endoneural surfaces. No difference has been shown between epineural and fascicular repair in terms of functional result in case of monofascicular nerve stumps. In polyfascicular nerve stumps, an interfascicular repair secures an optimal alignment of the nerve ends. Nerve repair is carried out using non-resorbable 8-10/0 suture.

To avoid tension between the two stumps in translabyrinthine surgery it is possible to free the second and third portion of the nerve from its bony channel and reroute it in the cerebellopontine angle where the two stumps are anastomosed. Since direct suturing, especially in the cerebello-pontine angle, is most of the time difficult, fibrin glue and temporalis fascia can be used instead of sutures [21].

- Interposition nerve grafts

When the nerve anastomosis cannot be performed without tension or there is a nerve gap, an interposition (or cable) nerve graft is used.

The sural nerve, the great auricular nerve or the medial antebrachial cutaneous nerve are the most common donor sites of nerve grafts because they are long, unbranched and they are not associated with critical sensory deficit. Both sides of the nerve graft is co-opted in an end-to-end fashion to the ends of the two stumps. Also in this case the fibrin glue and fascia are used instead of sutures.

Immediate repair of the facial nerve leads to HB grade 3 in most of the cases [22].

POST-OPERATIVE FACIAL NERVE REHABILITATION

Post-operative facial nerve paralysis can be treated with static and dynamic techniques.

Static techniques are based on the passive correction of muscle deficits without restoring their movement, while dynamic techniques aim to restore the active function of the affected mimic muscles, through the restoration of the muscular innervation or their replacement with free or pedunculated muscle flaps.

Static Reanimation

Static reanimation is used to achieve symmetry or a slightly overcorrection at rest on the normal side without providing animation. Static procedures are a good option for repairing specific cosmetic or functional deficits of the peri-orbital, perioral and to address nasal obstruction due to nasal valve collapse [22].

Although dynamic reanimation should be the gold standard, in a subset of patients, static techniques may be more appropriate. For patients with significant comorbidities, a shortened life span, advanced age, patients who are not good candidates for prolonged general anaesthesia, or in whom free muscle transfer may not be appropriate, static correction can still provide improved symmetry and function [23].

Rehabilitating the eye is one of the most important immediate needs in facial paralysis. Paralytic lower eyelid ectropion/retraction and lack of upper eyelid closure contribute to lagophthalmos and lacrimal dysfunction. A gold or platinum weight can be placed in a submuscolar pocket along the superior margin of the tarsal plate (Figure 1). Other techniques to improve the paralyzed eye include tarsorrhaphy, lateral canthopexy; a modification of a tarsoconjunctival flap has also been described to repair ectropion and lagofhtalmos [24, 25].

Functional deficits related to midface flaccidity include external nasal valve collapse and nasal obstruction, and lip ptosis with associated drooling and speech difficulty. The entire midface cheek complex also becomes ptotic and displaced inferiorly exacerbating lower eyelid and lip ptosis.

Figure 1. Gold weight. Note the gold weight on the upper eyelid, placed at a submuscolar pocket along the superior margin of the tarsal plate.

Static suspension with slings can be used. Slings can be made of fascia (tensor fascia latae), tendon (palmaris longus) or prosthetic material such as Gore-Tex®. The graft is attached to the temporal fascia or to the zygoma. Midface subperiostal lifts may also be beneficial.

Dynamic Reanimation

The aims of a dynamic procedure are to restore voluntary movement, especially the smile, resting tone and facial symmetry.

Reconstructive modalities for facial paralysis can be classified by two basic criteria: the first is whether the reconstruction is based on the facial nerve or on a different cranial nerve and the second is whether the working muscle unit is the original facial musculature or a transferred muscle flap.

Reanimation based on the facial nerve can be on the ipsilateral or contralateral nerve depending on the presence of a functional and usable branch or stump. The duration of paralysis is the determinant for the need for muscle transfer or transplant: if it is less than 12 months, the facial musculature is assumed to be able to be reinnervated. Muscles become irreversibly atrophic by 24 months, in which case muscle replacement is indicated. Even if surgical techniques for dynamic nervous resuscitation have been improved in the recent years, it is still very difficult to obtain an House Brackmann grade better than grade 3 [26].

Reinnervation

The aim of reinnervation procedures is to re-establish the input to facial nerve stumps using donors other than the native facial nerve. This procedure is useful when the proximal stump of the nerve is no longer available for example in very large tumours with distorted anatomy.

Figure 2. Hypoglossal-to-facial nerve transfer (post-operative result). A HB grade III is achieved (note the complete closure of the right eye) at 12 months of follow up.

Hypoglossal (XII) - to - Facial (VII) Nerve Transfer

The VII nerve is identified at the stylomastoid foramen and transected, while the XII nerve is divided distally, reflected upward and sutured with the VII nerve. Alternatively the XII nerve is partially divided in order to avoid tongue atrophy and a great auricular nerve "jump graft" can be coopted between the XII and the VII nerve. In this case an end-to-side anastomosis is performed, although a tongue dysfunction may occur in the 25% of the patients and the transfer may lead to an unnatural appearing activation of the intact facial musculature [27, 28].

After 12-months an HB grade 3 with synkinesis can be achieved (Figure 2).

Masseter to Facial Nerve Transfer

Masseterine nerve (or the masseteric branch of the trigeminal nerve) has become most recently a good donor site to innervate facial musculature because of its anatomic location, relative easy dissection and the facial nerve results [4, 29, 30].

VII-VII Cross Facial Nerve Grafting (CFNG)

The CFNG technique uses branches of contralateral functioning facial nerve to innervate paralyzed muscles. A nerve graft (e.g., sural nerve graft) connects healthy peripheral nerve branches to corresponding branches of specific muscle groups on paralyzed sides. CFNG can be performed as one stage or two-stages procedure. In the first stage the selectively neurectomized branches of the unaffected facial nerve provide motor fibers through CFNGs; after 9-12 months and after electrophysiological confirmation, secondary microcoaptation takes place with corresponding branches of the affected facial nerve. If denervation is longer than 6 months, a partial hypoglossal-to-facial nerve graft can be combined to CFNG two-stages procedure to prevent atrophy and loss of motor endplates ('babysitter' of the facial muscles, as described by Terzis [31]).

Local Muscle Transposition

Muscle transposition is performed when there is irreversible muscolar atrophy and fibrosis, due to the long denervation period.

Temporalis Muscle Transfer

It is still considered the best choice for facial rehabilitation due to the greater excursion of movement and adaptability to orbit. The muscle with its fascial extensions can be transferred and sutured to eyelids, ala of nose, oral commissure, and upper and lower lips. Labbè et al. [32] described a lengthening myoplasty: the tendon is rerouted to the corner of the mouth and additional length is achieved by repositioning the muscle's origin on the skull.

Masseter Muscle Transfer

It is a valuable option for the rehabilitation of the buccal complex. It is possible to recover an acceptable smile, a raising of the upper lip and the buccal angle. The muscle is, indeed, released from the mandible and transposed to the orbicularis oris resulting in a lateral vector.

Digastric Muscle Transfer

The anterior digastric tendon is mobilized and inserted into orbicularis oris at inferior vermilion border. The technique can be applied in case of isolated mandibular branch palsy to restore lower lip depression function.

Microneurovascular Muscle Transposition

The microneurovascular muscle transfer is indicated in case of long-standing facial paralysis, when facial muscles cannot gain useful function after reinnervation. The main advantage of a free functional muscle transfer vs local muscle transfer is the possibility to control precisely the origin, insertion, tension and location of the muscle. The procedure can be performed in one stage if the motor nerve is directly sutured to a branch of the contralateral facial nerve. The functional improvement is visible within few months, avoiding nerve grafts and a second operation. Nevertheless, there is a lack of suitable muscle (long neurovascular bundle), except for children. The two stage procedure involves a CFNG before harvesting a free muscle flap.

The following muscles may be used as free functioning transfers:

- Gracilis muscle: it is considered the gold standard for rehabilitating the oral commissure [16, 33-35] (Figure 3)
- Pectoralis minor
- Latissimus dorsi muscle, that allows recovery of facial symmetry, muscle tone and expression similar to the traditional temporalis muscle transfer [36]
- Serratus anterior
- Rectus abdominis
- Rectus femoris
- Sartorius
- Abductor hallucis.

Figure 3. Free gracilis muscle transfer for smile restoration (intraoperative views). A. Harvest of free gracilis muscle flap. The photograph shows the dominant vascular pedicle (asterisk) and the gracilis motor nerve. Note the marker sutures placed at 1cm intervals, to insert the muscle at the in situ tension. B. Scheme of the free gracilis muscle flap inset. The muscle is transferred to the cheek pocket. The vascular pedicle is anastomosed to the facial vessels and the motor nerve coaptation is made to the masseteric nerve.

CONCLUSION

The aim of vestibular schwannoma surgery is total tumour removal with the preservation of the facial nerve integrity and minimal postoperative morbidity.

If a facial reanimation is necessary, immediate nerve repair yields the best outcomes.

If the denervation time is less than 12-18 months, facial muscle can be reinnervated through reinnervation procedures.

If the denervation is over 24 months, CFNGs are used for neurotization of free or pedicled vascularized muscle transfer for facial muscle substitution (Figure 4).

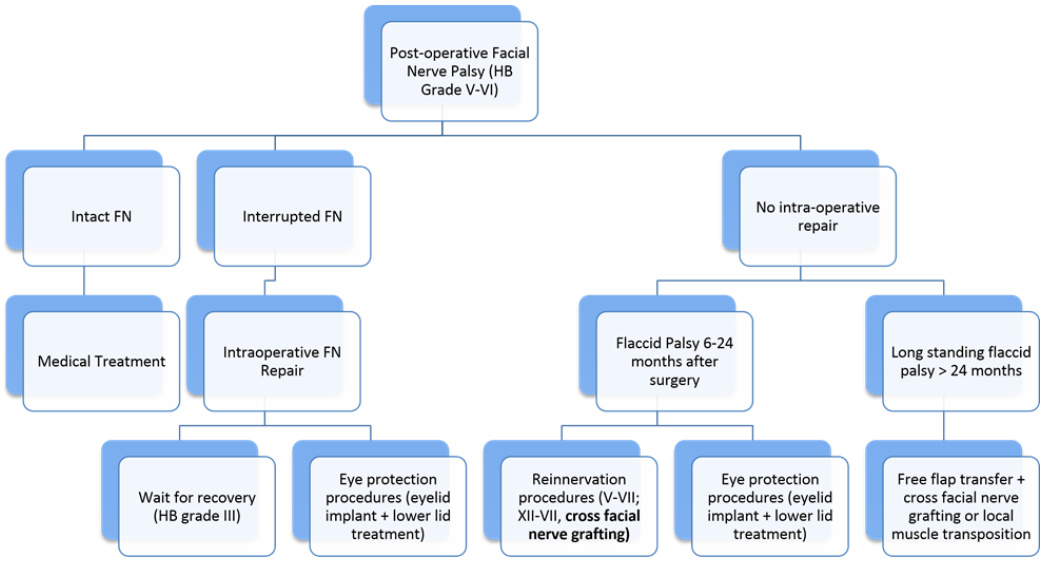

Figure 4. Facial reanimation treatment algorithm.

Revision and ancillary procedures along with early and long term follow up are essential to determine the functional and aesthetic outcome.

REFERENCES

[1] Samii M, Matthies C. Management of 1000 vestibular schwannomas (acoustic neuromas): surgical management and results with an emphasis on complications and how to avoid them. *Neurosurgery*. 1997;40(1):11-21.

[2] Falcioni M, Fois P, Taibah A, Sanna M. Facial nerve function after vestibular schwannoma surgery. *J. Neurosurg*. 2011;115(4):820-826.

[3] Dandinarasaiah M, Prasad SC, Piccirillo E, et al. Facial Nerve Outcomes Following Total Excision of Vestibular Schwannoma by the Enlarged Translabyrinthine Approach. *Otol. Neurotol. Off Publ. Am. Otol. Soc. Am. Neurotol. Soc. Eur. Acad. Otol. Neurotol*. 2019;40(2):226-235.

[4] Hadlock TA, Cheney ML, McKenna MJ, Facial reanimation surgery. In: Nadol Jr JP, Mckenna MJ editors. *Surgery of the ear and temporal bone*. Philadelphia (PA). Lippincott Williams and Wilkins; 2005. pp 461-472.

[5] Dey JK, Ishii LE, Byrne PJ, Boahene KDO, Ishii M. Seeing is believing: objectively evaluating the impact of facial reanimation surgery on social perception. *The Laryngoscope*. 2014;124(11):2489-2497.

[6] Sampath P, Holliday MJ, Brem H, Niparko JK, Long DM. Facial nerve injury in acoustic neuroma (vestibular schwannoma) surgery: etiology and prevention. *J. Neurosurg*. 1997;87(1):60-66.

[7] House WF. Acoustic neuroma. Case summaries. *Arch. Otolaryngol. Chic. Ill.* 1960. 1968;88(6):586-591.

[8] Delgado TE, Bucheit WA, Rosenholtz HR, Chrissian S. Intraoperative monitoring of facila muscle evoked responses obtained by intracranial stimulation of the facila nerve: a more accurate technique for facila nerve dissection. *Neurosurgery*. 1979;4(5):418-421.

[9] Nicoli F, D'Ambrosia C, Lazzeri D, et al. Microsurgical dissection of facial nerve in parotidectomy: a discussion of techniques and long-term results. *Gland Surg*. 2017;6(4):308-314.

[10] Grey PL, Moffat DA, Palmer CR, Hardy DG, Baguley DM. Factors which influence the facial nerve outcome in vestibular schwannoma surgery. *Clin. Otolaryngol. Allied Sci*. 1996;21(5):409-413.

[11] Kahn JB, Gliklich RE, Boyev KP, Stewart MG, Metson RB, McKenna MJ. Validation of a patient-graded instrument for facial nerve paralysis: the FaCE scale. *The Laryngoscope*. 2001;111(3):387-398.

[12] VanSwearingen JM, Brach JS. The Facial Disability Index: reliability and validity of a disability assessment instrument for disorders of the facial neuromuscular system. *Phys. Ther*. 1996;76(12):1288-1298.

[13] Neely JG, Cherian NG, Dickerson CB, Nedzelski JM. Sunnybrook facial grading system: reliability and criteria for grading. *The Laryngoscope*. 2010;120(5):1038-1045.

[14] House JW, Brackmann DE. Facial nerve grading system. *Otolaryngol. - Head Neck Surg. Off J. Am. Acad. Otolaryngol. - Head Neck Surg*. 1985;93(2):146-147.

[15] Kanzaki J, Tos M, Sanna M, Moffat DA, Monsell EM, Berliner KI. New and modified reporting systems from the consensus meeting on systems for reporting results in vestibular schwannoma. *Otol. Neurotol. Off Publ. Am. Otol. Soc. Am. Neurotol. Soc. Eur. Acad. Otol. Neurotol*. 2003;24(4):642-648.

[16] Boahene K. Facial reanimation after acoustic neuroma resection: options and timing of intervention. *Facial Plast. Surg. FPS*. 2015;31(2):103-109.

[17] Mehta RP. Surgical treatment of facial paralysis. *Clin. Exp. Otorhinolaryngol*. 2009;2(1):1-5.

[18] Slattery III WH, Brandt M. Acoustic Neuromas and Facial Paralysis. In: *The facial nerve*. pp 155-163 (chapter 20) Ed. Thieme 2014.

[19] Bailey BJ, Johnson JT, Newlands SD. *Head & Neck Surgery - Otolaryngology*. Philadelphia, PA: Lippincott Williams & Wilkins; 2006.

[20] Divi V, Deschler DG. Re-animation and rehabilitation of the paralyzed face in head and neck cancer patients. *Clin. Anat. N Y N*. 2012;25(1):99-107.

[21] Sanna M, Khrais T, Mancini F et al. Facial Nerve Reanimation. In: *The facial nerve in temporal bone and lateral skull base microsurgery*. 2006. cap 5: pp 43-60.
[22] Prasad SC, Balasubramanian K, Piccirillo E, et al. Surgical technique and results of cable graft interpositioning of the facial nerve in lateral skull base surgeries: experience with 213 consecutive cases. *J. Neurosurg*. 2018;128(2):631-638.
[23] Lafer MP, O TM. Management of Long-Standing Flaccid Facial Palsy: Static Approaches to the Brow, Midface, and Lower Lip. *Otolaryngol. Clin. North Am*. 2018;51(6):1141-1150.
[24] Sufyan AS, Lee HBH, Shah H, Nunery WR, Kokoska MS, Shipchandler TZ. Single-stage repair of paralytic ectropion using a novel modification of the tarsoconjunctival flap. *JAMA Facial Plast. Surg*. 2014;16(2):151-152.
[25] Homer N, Fay A. Management of Long-Standing Flaccid Facial Palsy: Periocular Considerations. *Otolaryngol. Clin. North Am*. 2018;51(6):1107-1118.
[26] Rabie AN, Ibrahim AMS, Kim PS, et al. Dynamic rehabilitation of facial nerve injury: a review of the literature. *J. Reconstr. Microsurg*. 2013;29(5):283-296.
[27] Viterbo F, Amr AH, Stipp EJ, Reis FJ. End-to-side neurorrhaphy: past, present, and future. *Plast. Reconstr. Surg*. 2009;124(6 Suppl):e351-358.
[28] Darrouzet V, Dutkiewicz J, Chambrin A, Stoll D, Bébéar JP. [Hypoglosso-facial anastomosis: results and technical development towards end-to-side anastomosis with rerouting of the intra-temporal facial nerve (modified May technique)]. *Rev. Laryngol. - Otol. - Rhinol*. 1997;118(3):203-210.
[29] Henstrom DK. Masseteric nerve use in facial reanimation. *Curr. Opin. Otolaryngol. Head Neck Surg*. 2014;22(4):284-290.
[30] Klebuc MJA. Facial reanimation using the masseter-to-facial nerve transfer. *Plast. Reconstr. Surg*. 2011;127(5):1909-1915.
[31] Terzis JK, Tzafetta K. The "babysitter" procedure: minihypoglossal to facial nerve transfer and cross-facial nerve grafting. *Plast. Reconstr. Surg*. 2009;123(3):865-876.
[32] Labbé D, Huault M. Lengthening temporalis myoplasty and lip reanimation. *Plast. Reconstr. Surg*. 2000;105(4):1289-1297.
[33] Harris BN, Tollefson TT. Facial reanimation: evolving from static procedures to free tissue transfer in head and neck surgery. *Curr. Opin. Otolaryngol. Head Neck Surg*. 2015;23(5):399-406.
[34] Ciudad P, Agko M, Manrique OJ, et al. The retrograde transverse cervical artery as a recipient vessel for free tissue transfer in complex head and neck reconstruction with a vessel-depleted neck. *Microsurgery*. 2017;37(8):902-909.
[35] Nicoli F, Chilgar RM, Sapountzis S, et al. Reconstruction after orbital exenteration using gracilis muscle free flap. *Microsurgery*. 2015;35(3):169-176.
[36] Tate JR, Tollefson TT. Advances in facial reanimation. *Curr. Opin. Otolaryngol. Head Neck Surg*. 2006;14(4):242-248.

INDEX

#

3D custom implants, 2311, 2312, 2322
3d fluoroscopy, 2211
3D laparoscopy, 2786
3D models, 682, 684, 687, 2260, 2270, 2275, 2280, 2281, 2293, 3244
3D printed, 2300, 2303, 2306, 2314, 2322, 2323, 2324, 4023
3D printing, 659, 959, 964, 2223, 2275, 2276, 2277, 2293, 2295, 2311, 2319, 2321, 2322, 2323, 2551, 2552, 2984, 3242, 3548, 3574, 4073
3d reconstruction, 755, 2189, 2271, 2280
3D slicer, 645, 646, 647, 648, 652, 655, 661
3-dimensional imaging, 796, 2551, 2561, 3365
3-dimensional printing, 2551
3 McVay, 6140
3D Cine PC MRI, 5881, 5886
46XX, 1599, 1600, 1601, 1602, 1603, 1604, 1605, 1607
5-aminolevulinic acid, 680, 689, 711, 3083

α

α-SMA, 7122

β

β-cell function, 2120, 2121, 2124, 2125, 2126, 2130, 2164, 2173, 2174, 2175, 2176, 2178, 2181, 2182, 2730, 2731

A

abdominal compartment syndrome, 3859, 3920, 3927, 3928, 3929, 4046, 4836, 4930
abdominal flaps, 1407, 2583, 2591, 2593, 2604, 2645, 2674
abdominal wall allotransplantation, 3657
aberrant left arteria subclavia, 4757
aberrant right subclavian artery, 4765, 4782, 4783
ab-interno trabeculotomy, 6890
ablation, 547, 563, 574, 627, 705, 706, 707, 710, 716, 717, 1224, 1228, 1232, 1294, 1347, 1536, 1556, 1709, 1711, 1712, 1715, 1718, 1719, 1739, 1886, 1902, 2093, 2098, 2336, 2360, 2363, 2364, 2421, 2504, 2513, 2514, 2515, 2783, 2791, 2922, 3002, 3133, 3134, 3155, 3357, 3700, 3776, 4198, 4954, 4955, 4958, 4959, 4960, 4961, 4972, 4973, 5471, 5811, 5816, 6045, 6046, 6055, 6057, 6318, 6319, 6320, 6324, 6594, 6697, 6744, 6747, 6754, 6755, 6760, 6770, 6773, 6825, 6828, 6829, 6832, 6833, 6835, 6836, 6837, 6838, 6840, 6841, 6842, 6843, 6846, 6985, 7272
ABO-incompatibility, 5464
above-knee femoropopliteal bypass, 4895
abscess, 378, 777, 780, 1096, 1102, 1163, 1164, 1165, 1179, 1237, 1238, 1307, 1309, 1514, 1517, 1520, 1522, 1525, 1528, 1548, 1571, 1693, 1886, 1922, 1952, 2039, 2040, 2083, 2093, 2098, 2099, 2116, 2411, 2443, 2447, 2450, 2481, 2495, 2502, 2523, 2742, 2805, 2809,2811, 2824, 2826, 3160, 3161, 3162, 3192, 3864, 4025, 4036, 4056, 4380, 4383, 4477, 4479, 4481, 4560, 4674, 4689, 4899, 4946, 4986, 5577, 5578, 5579, 5581, 5952, 5957, 5958, 5959, 5960, 5961, 5962, 5968, 5973, 5975, 5983, 5985, 5986, 5991, 5994, 5995, 6002, 6003, 6004, 6005, 6006, 6007, 6008, 6010, 6013, 6015, 6019, 6024, 6177, 6182, 6284, 6288, 6291, 6293, 6317, 6330, 6486, 6760, 6766
accessory nostril, 5493, 5494, 5496
acclimatization, 3303, 3304, 3311, 3434
accuracy of image-guided maxillary positioning, 665
acellular collagen matrix, 2565, 2566, 2569

acellular dermal matrix, 2566, 2574, 2575, 2577, 2578, 2579, 2592, 2602, 2616, 2627, 3542, 3553
acetaminophen, 2480, 2486, 2520, 2530, 2531, 2532, 2533, 2535, 2536, 2537, 2538, 2545, 2719, 3309, 3420, 3746, 3755, 3760, 3761, 3865, 3872, 4589, 4590, 4786, 5458, 6179, 6180, 6192, 6195, 6197, 6200, 7092, 7230, 7232, 7235, 7239, 7240
acetyl-L-carnitine, 3791, 3798
acid ceramidase, 3541, 3548, 3554
acid-base imbalance, 3314, 3898
acid-base, 559, 577, 711, 2801, 2826, 3027, 3097, 3276, 3313, 3314, 3316, 3317, 3318, 3323, 3324, 3325, 3326, 3328, 3329, 3332, 3333, 3335, 3526, 3623, 3626, 3644, 3702, 3825, 3898, 4528, 6008, 7278
acidosis, 260, 2124, 2896, 3025, 3099, 3110, 3314, 3317, 3320, 3323, 3324, 3325, 3326, 3327, 3328, 3329, 3333, 3418, 3527, 3783, 3792
acidosis, 3816, 3859, 4018, 4785, 4976, 5612, 7290
active components, 3451, 3454, 3458, 7194
actively engaged, 6925
active-passive function, 3452, 3453, 3454
activities of daily living, 924, 1035, 1036, 1040, 1041, 1042, 1052, 1058, 1872, 2025, 3907, 4051, 4345, 5579, 5882, 6230, 6245, 6924, 7041, 7251
acupuncture, 2533, 2539, 3163, 3164, 3165, 4521, 5609, 5610, 5611, 5612, 5613, 5614, 5615, 5616
acute aortic dissection, 5442, 5443, 5448, 6552
acute artery occlusion, 4723, 4725
acute complications, 776, 784, 785, 2035, 2055, 2077
acute experiments, 3431
acute hydrocephalus, 927, 931, 932, 937, 938, 942, 943, 944, 958, 1019, 3802, 3861, 3862, 3863
acute limb ischemia, 3701, 4726, 4748, 4826, 4833, 4872, 4877, 4878, 4881, 4889, 4924, 4992
acute liver failure, 2866, 2878, 2880, 2882, 2886, 3641, 3750, 3751, 3752, 3754, 3755, 3756, 3759, 3760, 3761, 3763, 3774, 3865, 3872, 3873, 6622
acute mesenteric ischemia, 3666, 3683, 3684, 3713, 3718, 4727, 4839, 4840, 5008
acute myocardial infarction, 3104, 3342, 3698, 3699, 3705, 4978, 5007, 5442, 5446, 6423, 7225
acute pancreatitis, 1237, 1238, 1239, 1240, 1241, 1242, 1285, 1288, 1970, 2892, 2893, 2894, 2895, 2896, 2904, 2905, 2906, 2907, 2909, 2910, 2911, 2912, 2913, 3112, 3681, 3705, 3920, 4996, 5457, 5458, 5461, 6298
acute respiratory distress syndrome, 2796, 3666, 3675, 3716, 3844, 3845, 3922, 4038, 4629, 4713, 4812, 4836, 4976, 4979, 5007, 5457, 5458, 5936, 7157, 7165
acute-phase reactants, 4503, 7255, 7257, 7258, 7260, 7261
Adamkiewicz artery, 4781
adaptation, 236, 239, 240, 241, 248, 741, 870, 871, 872, 874, 875, 883, 985, 1493, 1603, 1672, 1675, 1743, 1947, 2123, 2147, 2156, 2168, 2186, 2731, 2817, 2912, 2967, 3100, 3280, 3304, 3310, 3450, 3675, 4382, 5009, 5275, 6018, 6090, 6126, 6188, 6331, 6332, 6391, 6578, 6702, 6728, 6799, 6936, 6988, 7018, 7301
adenocarcinoma, 712, 1104, 1257, 1262, 1263, 1266, 1267, 1268, 1269, 1271, 1272, 1274, 1275, 1276, 1277, 1282, 1284, 1291, 1292, 1314, 1316, 1317, 1318, 1330, 1334, 1337, 1338, 1634, 1885, 1886, 1901, 2329, 2343, 2443, 2451, 2906, 2969, 2971, 3152, 3350, 4159, 4288, 4407, 4412, 4436, 4489, 4689, 5558, 5804, 5833, 5834, 5842, 5843, 5844, 5845, 5846, 5847, 5944, 5947, 5948, 5962, 6020, 6078, 6079, 6080, 6081, 6084, 6085, 6086, 6324, 6871, 6873, 6879
adenoid hypertrophy, 1536, 1681, 1683, 1686
adenoidectomy, 1460, 1535, 1536, 1554, 1555, 1683, 1686, 1687, 1702, 2461, 2463, 2464, 2466, 2469, 2472, 2473, 2483, 2484, 2485, 2487, 2488, 2489, 2492, 2493, 2496, 2499, 2507, 2508, 2509, 2510, 2514, 2515, 2516, 2523, 2524, 2527, 2529, 2530, 2531, 2536, 2539, 2540, 2543, 2546, 2549, 7087
adenoids, 1533, 1534, 1683, 1687, 2495, 2515
adenoma, 1104, 1193, 1194, 1196, 1198, 1199, 1200, 1201, 1203, 1204, 1205, 1210, 1212, 1213, 1219, 1251, 1475, 2418, 3321, 3746, 4322, 5641, 5642, 5643, 5646, 5647, 5648, 5649, 5650, 5651, 5652, 5676, 5688, 5773, 6090, 6094, 6099, 6100, 6101, 6114, 6115, 6116, 6120, 6130, 6132, 6907, 7052, 7053, 7056
adenomatous polyps, 1332, 1895
adhesion, 8, 10, 70, 75, 166, 167, 180, 374, 397, 897, 906, 938, 984, 1433, 1565, 1593, 1732, 2367, 2368, 2371, 2489, 2802, 2826, 2954, 2965, 2997, 3011, 3017, 3047, 3070, 3075, 3076, 3088, 3097, 3099, 3106, 3107, 3108, 3110, 3177, 3341, 3374, 3490, 3496, 3507, 3572, 3655, 3680, 4105, 4487, 4691, 4692, 4702, 4703, 4710, 4712, 4955, 4956, 5153, 5572, 5576, 5607, 5744, 5956, 5969, 6205, 6279, 6510, 6651, 6688, 6689, 6690, 6694, 6707, 6708, 6709, 6791, 7261, 7325
adhesive vein ablation, 4934
adipocyte, 163, 165, 166, 167, 168, 175, 176, 177, 178, 179, 523, 526, 2152, 2158, 2160, 2170, 6977, 6978, 6980, 6986, 6987, 6988, 6992
adipogenic, 3570, 6415, 6422, 6570, 6988
adiponectin, 163, 167, 168, 170, 171, 172, 175, 179, 180, 184, 2114, 2131, 2145, 2152, 2158, 2159,

2162, 2163, 2170, 2171, 2172, 3709, 5353, 5354, 5361, 5395, 5397, 5423, 6699, 6702, 6978, 6980, 6983, 6984, 6990, 7202, 7208
adipose-derived stem cells, 2561, 2562, 2563, 3443, 3538, 3555, 6411, 6412, 6423, 6424, 6425, 6426, 6427, 6429, 6430
adjustable banded RYGB, 801
adjustable gastric band, 138, 151, 154, 157, 158, 159, 160, 168, 169, 170, 173, 174, 181, 182, 183, 184, 189, 191, 197, 200, 206, 222, 237, 245, 250, 256, 257, 258, 260, 769, 795, 796, 799, 800, 808, 809, 812, 818, 840, 869, 874, 875, 1565, 2134, 2163, 2174, 2184, 2185, 2680, 2681, 2714, 2722, 2832, 4550, 4583, 5015, 5045, 5344, 5360, 5384, 6355, 6356, 6360, 6367, 6397, 6979, 6981, 6982, 6989, 7005, 7006, 7010, 7011, 7014, 7019, 7028, 7169, 7170, 7174, 7252, 7253
adjustable gastric banding, 157, 158, 159, 160, 168, 170, 173, 181, 182, 183, 184, 197, 200, 206, 222, 237, 245, 250, 256, 795, 796, 799, 808, 809, 818, 840, 869, 874, 875, 1565, 2163, 2174, 2184, 2185, 2680, 2681, 2722, 2832, 4583, 5015, 5045, 5344, 5360, 5384, 6356, 6360, 6367, 6397, 6979, 6982, 6989, 7005, 7006, 7010, 7014, 7019, 7028, 7169, 7170, 7174, 7252, 7253
adjuvant analgesics, 7237, 7239
adjuvants, 3120, 3200, 4587, 4588, 4589, 4590, 4593, 7229, 7237, 7238, 7239, 7240
adrenal lesion angiography, 1208
adrenal lesion CT, 1208
adrenal lesion imaging, 1208
adrenal lesion MRI, 1208
adrenal lesion nuclear imaging, 1208
adrenal lesion US, 1208
adrenal, 688, 696, 1207, 1208, 1209, 1210, 1211, 1212, 1213, 1214, 1215, 1218, 1219, 1220, 1221, 1222, 1286, 1325, 1336, 1352, 1528, 1589, 1590, 1599, 1600, 1603, 1604, 1605, 1607, 1608, 2763, 3323, 3425, 3650, 3895, 4318, 4319, 5641, 5642, 5643, 5645, 5647, 5648, 5649, 5650, 5651, 5652, 5762, 5764, 5951, 5983, 6046, 6047, 7211, 7218
ADS (acronimus of author's name) palpebral area, 6436
advancement of genioglossus, 1535
adverse events, 215, 408, 500, 508, 532, 538, 549, 553, 563, 564, 565, 566, 567, 571, 578, 619, 626, 1450, 1460, 1464, 1469, 1470, 1662, 1688, 1952, 2005, 2024, 2035, 2044, 2091, 2531, 3899, 4051, 4523, 4524, 4588, 4655, 4659, 4691, 4705, 4888, 5382, 5468, 5919, 6017, 6069, 6072, 6102, 6171, 6172, 6183, 6474, 6487, 6493, 7238, 7298, 7300
aerocele, 4012
Afghanistan, 3990, 4012, 4014, 4015, 4023, 4032, 4033, 4037, 4041, 4042, 4929
agarose, 707, 2954, 3541, 3728
aggrecan, 3540, 3541, 3549, 4807
aggrecanase, 3543, 3547
aggregation, 948, 982, 983, 984, 989, 1076, 1519, 1851, 2637, 2801, 2802, 2821, 2826, 2995, 3076, 3077, 3079, 3080, 3081, 3084, 3095, 3096, 3098, 3099, 3100, 3101, 3102, 3108, 4674, 4818, 4887, 4955, 4956, 5468, 5930, 6482, 6715, 7086
AHA/ASA, 3933, 3945
airway obstruction, 214, 218, 424, 426, 433, 449, 1309, 1448, 1476, 1874, 1875, 1877, 1908, 2392, 2495, 2500, 3402, 3890, 3893, 4453, 4588, 5504, 5543, 5545, 6217, 6219, 7238, 7244
alar batten graft, 438, 441, 449, 5485, 5499, 5500, 5502
alcian blue, 3541
alginate beads, 3541
alimentary limb, 782, 783, 784, 785, 788, 822, 823, 826, 828, 829, 835, 839, 849, 851, 871, 873, 1866, 1996, 2000, 2003, 2733, 2832, 4579, 4604, 4609, 5097, 5098, 5107, 5124, 5125, 5126, 5127, 5129, 5133, 5147, 5148, 5150, 5156, 5157, 5158, 5159, 5217, 5219, 5220, 5229, 5234, 5235, 5236, 5238, 5243, 5244, 5246, 5369, 5390, 6356
allogeneic, 351, 1695, 1696, 1734, 1744, 2633, 2917, 2923, 2924, 2934, 2935, 2936, 2984, 3000, 3001, 3263, 3264, 3268, 3269, 3292, 3294, 3297, 3300, 3440, 3543, 3544, 3588, 3600, 3602, 3609, 3639, 3649, 3652, 3654, 3655, 3659, 3660, 3664, 3721, 3722, 3727, 3728, 3729, 3730, 3731, 3739, 3740, 3757, 5911, 6472
allotransplantation, 2928, 2936, 3349, 3372, 3441, 3606, 3640, 3647, 3648, 3653, 3655, 3656, 3657, 3658, 3661, 3662, 3663, 3664, 3712, 3731
alpha lipoic acid, 7117, 7120, 7121, 7123, 7125
ALS/ALG/ATG, 3652
alterations of the lamina cribrosa, 6886
altered anatomy, 146, 813, 1200, 1841, 1948, 2001, 2005, 2016, 7023
alveolar recruitment maneuvers, 7159
alveolar recruitment, 7158, 7159, 7161, 7164
Amadeus® system, 695
ambulatory selective vein ablation under local anesthesia, 4964
ambulatory, 215, 218, 256, 626, 1308, 1309, 1429, 1430, 1434, 1435, 1436, 1438, 1439, 1443, 1444, 1445, 1446, 1447, 1448, 1449, 1450, 1451, 1453, 1454, 1455, 1456, 1457, 1458, 1459, 1460, 1461, 1462, 1463, 1464, 1465, 1466, 1467, 1468, 1469, 1470, 1471, 1472, 1554, 1595, 1761, 1775, 1777, 1789, 1790, 1791, 1792, 1793, 1794, 1803, 1809,

1819, 1825, 1828, 1896, 2046, 2297, 2492, 2523, 2524, 2527, 2529, 2535, 2536, 2539, 2544, 2545, 2549, 2558, 2727, 2845, 3388, 3406, 3409, 3419, 4369, 4389, 4524, 4579, 4887, 4964, 4973, 5299, 5512, 5871, 5872, 5874, 5878, 5880, 6262, 6867, 7054, 7093
ameloblastoma, 1698, 1707
America, 88, 446, 447, 450, 451, 498, 539, 561, 563, 580, 597, 661, 726, 767, 914, 918, 940, 1187, 1188, 1189, 1453, 1454, 1575, 1577, 1733, 1856, 1868, 1881, 1902, 1903, 1904, 1954, 2048, 2114, 2116, 2244, 2525, 2536, 2744, 2792, 3132, 3144, 3159, 3165, 3194, 3195, 3199, 3202, 3208, 3231, 3234, 3249, 3275, 3880, 3910, 4012, 4040, 4052, 4057, 4338, 4341, 4502, 4647, 4651, 4673, 4725, 4864, 5269, 5314, 5491, 5627, 5784, 5785, 5786, 5971, 5972, 5973, 5976, 6237, 6248, 6516, 6524, 6538, 6757, 7119, 7147
American Society of Anesthesiologists, 218, 1443, 1444, 1465, 1472, 1841, 1874, 1880, 2536, 4587, 4593, 4617, 4656, 4664, 5788, 5794, 5795, 5796, 5797, 5934, 6306, 7236, 7245, 7270
amiodarone, 6503, 7286, 7288
amputation, 66, 517, 1336, 1466, 1467, 2312, 2313, 3166, 3171, 3174, 3176, 3177, 3181, 3182, 3184, 3193, 4614, 4722, 4818, 4871, 4872, 4873, 4874, 4889, 4893, 4900, 4909, 4920, 4921, 4932, 4975, 5002, 5003, 5004, 5005, 5006, 5012, 5013, 5558, 5561, 5724
amyotrophic lateral sclerosis, 1838, 1848, 1858, 1866, 1871
anaplastic thyroid carcinoma, 5676
anastomotic leak, 137, 140, 143, 145, 156, 158, 814, 2708, 2710, 2718, 2720, 2742, 4164, 4231, 4305, 4306, 4312, 4314, 4330, 4495, 4531, 4568, 4637, 4638, 4640, 4689, 5100, 5200, 5829, 5944, 5951, 5952, 5956, 5972, 5985, 5986, 6002, 6003, 6005, 6006, 6007, 6009, 6010, 6011, 6012, 6024, 6025, 6284, 6285, 6314, 6701, 6703, 6704, 7003, 7005, 7006, 7261
anastomotic leakage, 814, 2718, 4330, 4495, 4531, 4568, 4637, 4638, 4640, 5829, 5972, 6701, 6703, 6704, 7003, 7261
anastomotic pseudoaneurysm, 4981, 4986
anastomotic ulcers, 4569, 4582, 5181
anatomic landmark-based registration, 665
anatomic resection, 2333, 2334, 2335, 2343, 2345, 2346, 2353, 2354, 2356, 2358
anatomical resection, 2334, 2339, 2341, 2353, 2358, 2359, 2364, 2368, 2371, 2880, 6076
anesthetists, 5204, 6454
aneurysm of the abdominal aorta, 4728, 4827, 4830, 4834, 4844
aneurysm of the descending aorta, 4790
aneurysm rerupture, 931
aneurysm rupture risk, 4828
aneurysm surgery, 882, 924, 957, 958, 960, 961, 962, 963, 964, 965, 995, 1061, 1663, 3179, 4760, 5010
aneurysms of splanchnic arteries, 4812, 4843, 4844
aneurysms of superior mesenteric, 4844
angio-embolization, 1698, 2068, 2069
angiogenic factors, 2996, 3560, 3566, 3568, 3570
angioplasty, 985, 1001, 1004, 1010, 1012, 1014, 1016, 1017, 1410, 3699, 4037, 4038, 4211, 4723, 4741, 4789, 4790, 4813, 4820, 4841, 4843, 4850, 4856, 4863, 4865, 4869, 4872, 4873, 4875, 4886, 4892, 4894, 4904, 4908, 4918, 4934, 4940, 4948, 4969, 4970, 4971, 4978, 4992, 4994, 5007, 6596, 6602, 7074
animal models of SAH, 1069
anion gap, 3324, 3325, 3326, 3333
annulus fibrosus, 2986, 3007, 3539, 3551
antagonists, 221, 222, 881, 974, 984, 987, 988, 1030, 1452, 1891, 1895, 2655, 2921, 3036, 3274, 3298, 3547, 3651, 3710, 3712, 3793, 4515, 4516, 4517, 4518, 4519, 4521, 4522, 4525, 4563, 4565, 4572, 4589, 4978, 5397, 6197, 6587, 6588, 6589, 6591, 6600, 6605, 7087, 7088, 7241
antecolic, 140, 839, 2000, 2001, 2003, 2737, 4300, 4604, 4606, 4607, 4609, 4610, 5085, 5094, 5164, 5173, 5221, 5245, 5246, 7005
anterior cruciate ligament, 23, 24, 27, 1466, 1468, 2252, 3358, 3542, 6252
anterior fusion, 5577, 5578, 5579
anterior right mini-thoracotomy, 6500, 6510, 6528, 6544
anterior right thoracotomy, 6454, 6463, 6466, 6478, 6485, 6494, 6496, 6520
anti-aging, 6411, 6412, 6416, 6417, 6422, 6427
antibiotic prophylaxis, 451, 1862, 1868, 1930, 2033, 2036, 2040, 2041, 2042, 2046, 2048, 2049, 2050, 3384, 3419, 3615, 3616, 3956, 4031, 4390, 4499, 4501, 4502, 4503, 4641, 4643, 4644, 4645, 4654, 4658, 4686, 4702, 4990, 5086, 6260, 6261, 7259
antibiotic solution, 584, 4501, 4679, 4688, 4690, 6959, 6962, 7255, 7257, 7260, 7261
anticoagulant, 1043, 1446, 1465, 1923, 2033, 2656, 2757, 3101, 3862, 3902, 4886, 4900, 4924, 4978, 4980, 4991, 5000, 5465, 5913, 5929, 5930, 6027, 6999
anticoagulation, 141, 952, 973, 1014, 1614, 1725, 1863, 1864, 1865, 1868, 1869, 2033, 2036, 2037, 2067, 2072, 2648, 2996, 3034, 3725, 3864, 3902, 4043, 4297, 4369, 4457, 4857, 4879, 4900, 4948, 4967, 4968, 5926, 5928, 6020, 6244, 6539, 6617, 6837, 6860, 6867, 6999

antiemetics, 4511, 4514, 4515, 4516, 4517, 4519, 4520, 4521, 4522, 4524, 4558, 7088, 7241
antimetabolites, 3650
antimicrobial sutures, 4701, 4706
antioxidant proteins, 3791, 6418
antioxidants, 3029, 3033, 3522, 3785, 3791, 3798, 4629, 5355, 5371, 6416, 6419, 6991, 7120, 7121
antiplatelet therapy, 951, 952, 958, 1864, 1869, 1873, 1923, 2037, 4211, 4856, 4871, 4887, 4888, 4900, 4961, 4978, 4991, 4999, 5912, 5916
antiplatelet treatment, 945, 1864
antiplatelet, 945, 951, 952, 958, 1864, 1865, 1869, 1873, 1923, 2033, 2037, 2067, 3862, 4083, 4211, 4818, 4826, 4856, 4871, 4887, 4888, 4900, 4924, 4961, 4978, 4991, 4999, 5912, 5913, 5915, 5916, 5917, 6590
antireflux therapy, 5505, 5506, 5507, 5510
antiseptic gargle, 2042
antiseptic(s), 107, 584, 1430, 1431, 1911, 2042, 2046, 2047, 2052, 2237, 3177, 3194, 3196, 3626, 4390, 4612, 4634, 4635, 4647, 4648, 4650, 4652, 4663, 4666, 4672, 4673, 4674, 4676, 4677, 4678, 4680, 4681, 4684, 4685, 4687, 4691, 4701, 4702, 4703, 4709, 4710, 4711, 4712, 4717, 4718, 4719, 4990, 6255, 6556, 6790, 7259, 7261
antithrombotic therapy, 1861, 1862, 1863, 1868, 5912
anti-torsion suture, 2738
antrochoanal polys, 1683
aortic aneurysm, 1084, 1086, 1087, 1088, 1090, 1489, 1505, 3346, 3369, 3376, 3379, 3466, 3467, 3468, 3469, 3476, 3671, 3674, 3677, 3685, 3697, 3702, 3708, 3710, 4188, 4596, 4614, 4723, 4744, 4748, 4760, 4769, 4777, 4778, 4779, 4781, 4782, 4790, 4791, 4792, 4793, 4796, 4805, 4806, 4807, 4808, 4809, 4811, 4812, 4813, 4817, 4827, 4828, 4836, 4845, 4846, 4847, 4848, 4875, 4976, 4996, 5007, 5008, 5009, 5011, 5448, 5896, 5897, 5898, 5904, 5905, 5906, 5907, 5920, 6470, 6487, 6551, 6552, 6553, 6555, 6559, 6566, 6567, 6568, 6744, 6749, 6750, 6838, 6847, 7224, 7272
aortic arch aneurysm, 4753, 4769, 4780, 4806
aortic arch, 1174, 1296, 1479, 1481, 2847, 2854, 3385, 3464, 3686, 4753, 4754, 4755, 4756, 4757, 4758, 4759, 4760, 4761, 4762, 4763, 4765, 4767, 4768, 4769, 4770, 4771, 4772, 4774, 4775, 4776, 4777, 4778, 4779, 4780, 4781, 4782, 4784, 4787, 4788, 4790, 4791, 4796, 4797, 4801, 4803, 4806, 4855, 5441, 5442, 5443, 5894, 6488, 6489, 6555, 6564, 7273, 7274, 7298
aortic banding, 2839, 2846, 2854
aortic coarctation, 2845, 4759, 4781, 4782, 4787, 4788, 4789, 4795, 4799, 4805, 4809
aortic development, 4754, 4782
aortic dissection, 1101, 4203, 4753, 4760, 4765, 4766, 4770, 4777, 4779, 4781, 4792, 4793, 4794, 4795, 4806, 4808, 4809, 4839, 4878, 4918, 5441, 5442, 5443, 5444, 5445, 5448, 5881, 5886, 5897, 5899, 5900, 5903, 5904, 5905, 5907, 5936, 6493, 6553, 6555, 6720, 6723, 6766, 6782, 6846, 6848, 6853, 6854, 7274
aortic surgery, 1881, 3686, 3700, 3707, 3714, 4762, 4777, 4779, 4825, 4826, 4827, 5007, 5011, 5882, 5912, 5913, 5919, 5920, 6474, 6551, 6552, 6553, 6566, 6568
aortic valve replacement, 4621, 6453, 6457, 6461, 6471, 6472, 6473, 6474, 6479, 6485, 6494, 6499, 6507, 6508, 6509, 6515, 6516, 6517, 6519, 6520, 6524, 6525, 6526, 6527, 6528, 6533, 6535, 6536, 6538, 6545, 6546, 6547, 6548, 6549, 6561, 6566, 6567, 6568, 6750, 6751, 6753, 6788, 6795, 6829, 6843, 7079, 7271, 7272, 7273
aortic valve surgery, 6453, 6471, 6472, 6473, 6474, 6475, 6479, 6481, 6483, 6485, 6486, 6487, 6488, 6489, 6490, 6491, 6492, 6496, 6507, 6508, 6510, 6516, 6520, 6524, 6525, 6532, 6541, 6543, 6717, 6837
aortobifemoral bypass, 4811, 4813, 4822, 4823, 4824, 4825, 4826, 4988, 4990, 4995, 4996, 4998
aortocaval fistula, 2839, 2840, 2859, 2863
aortoiliac atherosclerosis, 4811, 4812, 4813, 4814, 4815, 4816, 4818, 4833, 6775
aortoiliac endarterectomy, 4821, 4822, 4824
aortoiliac occlusive disease, 4814, 4818, 4821, 4824, 4833, 4838, 4845
AoX and CPB, 6538, 6541, 6543, 6545
apixaban, 1864
appetite-hormones, 2173
aquaporin-4, 3767, 3770, 3776, 3779, 3841, 3849, 3854
arbitrary Lagrangian-Eulerian, 3461
area of scleral, 6434
Argon laser trabeculoplasty, 6888, 6897
ARTEMIS, 3131, 3156
arterial reconstructions, 4721, 4723, 4739, 4813, 4818, 4833, 4846, 4884, 4916, 4981, 4984, 4988, 4990, 4991
arterial spin labeling, 1162, 3337, 3357, 3807
arteriovenous fistula, 895, 936, 1179, 1347, 1656, 1658, 1663, 3357, 3371, 3812, 4729, 4745, 4904, 4905, 4918, 4922, 4932, 4934, 4935, 4968, 4969, 4970, 5000, 5012
arteriovenous malformation, 878, 908, 936, 940, 941, 963, 964, 965, 1066, 1067, 1179, 1180, 1183, 1351, 1609, 1653, 1654, 1656, 1662, 1663, 2562, 4738, 5892

arthroplasty planning, 2275
arthroplasty, 11, 12, 102, 709, 733, 1455, 1456, 1466, 1575, 1670, 2199, 2200, 2210, 2250, 2251, 2275, 2283, 2290, 2291, 2293, 2294, 2295, 2297, 2299, 2307, 2308, 2309, 2320, 2331, 2332, 2708, 2710, 2715, 2724, 3134, 3137, 3138, 3154, 3155, 3156, 3539, 4621, 4699, 5560, 5561, 5867, 5868, 5869, 5872, 5873, 5874, 5878, 5879, 5880, 6246, 6263, 6273, 6274, 6275, 6923, 6924, 6928, 6929, 7076
arthroscopy, 732, 1457, 1458, 1466, 1467, 1470, 2210, 2218, 2221, 2225, 2237, 2246, 2247, 2249, 2250, 2251, 2257, 2259, 2262, 2264, 2267, 2268, 2272, 3149, 3435, 3554, 4621, 6251, 6252, 6253, 6254, 6256, 6257, 6258, 6259, 6260, 6261, 6262, 6710, 6929
articular cartilage, 3538, 3552
as non-human primates, 3611
ascenda, 6955, 6956, 6957, 6958, 6959
ascites, 1038, 1102, 1248, 1262, 1267, 1328, 1336, 1724, 1840, 1849, 1851, 1853, 1854, 1855, 1858, 1859, 1866, 1918, 1949, 1973, 1977, 1981, 2334, 2348, 2364, 2365, 2366, 2369, 2888, 2896, 2968, 2974, 2975, 2977, 3754, 3757, 3865, 3926, 4479, 4480, 4481, 4990, 5336, 5368, 5377, 5379, 5402, 5404, 6133, 6134, 6135, 6136, 6137, 6138, 6139, 6140, 6141, 6142, 6143, 6144, 6279, 6286, 6309, 6622, 6627, 6629, 6630, 6651, 6654, 6655, 6657, 6658, 6660, 6871
aspirin, 412, 413, 947, 948, 950, 951, 952, 982, 984, 1010, 1516, 1519, 1614, 1683, 1864, 1869, 1873, 1923, 2033, 2037, 2074, 3203, 3309, 3422, 4818, 4856, 4867, 4900, 4956, 4968, 5912, 5913, 5916, 5918, 5933, 6180, 6192, 6243, 6244, 6248, 7086, 7093
association between XFS and systemic vascular dysfunction, 6891
atelectasis, 142, 214, 218, 1239, 2392, 2718, 2726, 2727, 2804, 3306, 3893, 3896, 4141, 4566, 4655, 4661, 4979, 6069, 6074, 6075, 6242, 6477, 6718, 6789, 6999, 7158, 7160
atherosclerosis, 164, 166, 167, 168, 176, 177, 178, 420, 767, 2136, 2820, 3357, 3366, 3370, 3466, 3475, 3476, 3478, 3754, 3762, 4508, 4749, 4765, 4791, 4811, 4813, 4814, 4815, 4818, 4826, 4828, 4840, 4841, 4842, 4843, 4847, 4852, 4866, 4872, 4873, 4875, 4876, 4877, 4881, 4888, 4901, 4902, 4903, 4905, 4906, 4907, 4908, 4975, 4976, 4992, 4996, 5006, 5286, 5362, 5413, 5429, 5441, 5442, 5443, 5445, 5446, 5448, 5789, 5904, 5905, 6101, 6243, 6474, 6609, 6699, 6702, 6704, 6755, 6847, 7061, 7212, 7219, 7228, 7266
atherosclerotic plaques, 3341, 4738, 4742, 4763, 4839, 4840, 4850
atherothrombotic complications, 4981
ATP synthase, 3782, 3783, 3789
atraumatic technique, 310, 3009, 3011, 3018
atrial fibrillation, 716, 717, 1863, 2804, 3133, 3134, 3154, 3155, 4187, 4198, 4199, 4214, 4725, 4839, 4872, 4901, 4905, 4906, 6069, 6217, 6292, 6464, 6505, 6509, 6514, 6515, 6523, 6744, 6755, 6760, 6773, 6774, 6784, 6825, 6828, 6833, 6840, 6841, 6842, 6843, 6846, 6848, 6859, 6860, 6867, 6868, 7284, 7287
atrial overdriving pacing, 7289
atriotomy, 4193, 6730, 6731, 6734, 6739, 6747, 6748, 6780, 6781, 6795, 6797, 6803, 6830, 6832, 6834, 6835
atrioventricular asynchrony, 7280
atrioventricular block, 7280
atrioventricular synchrony, 7279
atropine, 1449, 2818, 2819, 3276, 3283, 3878, 7082, 7089, 7280, 7281
audiovisual format, 6329, 6336, 6339
augmented reality, 646, 647, 661, 663, 679, 680, 686, 709, 710, 3129, 3244, 3256, 3257, 4467
auricular reconstruction, 2560, 5475
auscultation, 4723, 4729, 4882, 4903, 4927
autologous breast reconstruction, 1405, 1407, 1413, 1417, 1424, 2583, 2592, 2602, 2603, 2604, 2613, 2614, 2636, 2637, 2645, 2646, 2676
autologous chondrocyte implantation, 3537, 3538, 3540, 3543, 3551
autologous platelet-enriched fibrin, 3543, 3546
automatic instrument inserting function, 738, 742
automatic tachyarrhythmias, 7281
autonomy, 1471, 1843, 3289, 6327, 6382, 6387
autoregulation, 967, 972, 980, 981, 985, 994, 999, 1075, 3075, 3392, 3403, 3705, 3711, 3766, 3767, 3806, 3807, 3808, 3809, 3812, 3813, 3814, 3819, 3826, 3827, 3830, 3836, 3843, 3852, 3855, 3866, 3869, 3888, 3889, 3897, 3912, 3953, 3992, 4005, 4035, 4041, 4045, 4046, 4082, 4097, 4850, 5789, 5887, 6651
AV access, 4934, 4938, 4940, 4941, 4942, 4943, 4946, 4947
AV fistula, 4934, 4937, 4945, 4967
AV graft, 4934, 4936, 4937, 4941, 4945
AVF failure, 4938, 4941a laser Doppler perfusion imaging technology, 3091
aviation industry, 3473, 7296, 7298, 7300, 7301
axolotl, 3541, 3550, 3553

B

Babylon, 3159
baby-sitter procedure, 1667, 1668, 1669
back pain, 283, 286, 287, 295, 313, 340, 927, 3539, 4490, 4726, 4791, 4829, 5571, 5572, 5576, 5586, 6161, 6162, 6163, 6164, 6165, 6166, 6167, 6168, 6170, 6185, 6207, 6210, 6214, 7000, 7046
BAGUA, 5165, 5179, 5180, 5181, 5378
ballistic head trauma, 4012
balloon remodelling, 945, 947
balloon-assisted endoscopy, 1996, 2000
band failures, 782
barbed suture, 1429, 4244, 4248, 4249, 4250, 4251, 4256, 4274, 4275, 4276, 4322, 4478, 4488, 4496, 4607, 4610, 5085, 5096, 5099, 5182, 5198, 5199, 5200, 6942
barbiturates to lower ICP, 3860
barbiturates, 1450, 3272, 3513, 3529, 3805, 3812, 3860, 3866, 3870, 3899, 3950, 3951, 3953, 3960, 3967, 3970, 3972, 3973, 3976, 3986, 3988, 3997, 3998, 4096
bariatric experimental surgery, 2775, 2835
bariatric surgical methods, 2831, 2836
barrow institute study, 945
Basic Aristotle Complexity Score, 7269
Bassini or McVay herniorrhaphy, 6140
BCR-ABL1 fusion gene, 5653, 5658, 5659, 5660, 5661
BCR-ABL1-positive, 5654, 5655
beauty, 388, 395, 568, 580, 585, 596, 597, 605, 606, 613, 632, 6373, 6374, 6375, 6378, 6379
below-knee femoropopliteal bypass, 4895
Bentall procedure, 6487, 6551, 6568
benzodiazepines, 1445, 1450, 1876, 1877, 1883, 2393, 3203, 7274
BEST TRIP, 3805
bifurcated (reverse Y-shaped) Dacron graft, 4831
bile acids, 219, 223, 231, 2173, 2174, 2178, 2180, 2182, 2185, 2186, 2891, 3529, 5361, 5375, 5392, 5425, 6362, 6977, 6981, 6984
bile duct ligation, 2865, 2866, 2886, 2887, 2888, 2891, 2901, 2907, 3348, 3746, 3757, 3760
biliary tree, 822, 1286, 1560, 1995, 1996, 1998, 2345, 2771, 2882, 2901, 3523, 5821, 5822, 5823, 5836, 5842
biliopancreatic diversion with duodenal switch, 144, 808, 819, 2184, 2693, 2695, 2702, 2705, 2723, 2745, 2757, 2832, 2837, 4546, 5016, 5204, 5396, 6356, 6360, 6365, 6368, 7010
biliopancreatic diversion, 140, 144, 152, 173, 186, 188, 189, 191, 195, 196, 197, 198, 199, 202, 204, 237, 256, 774, 801, 806, 808, 818, 819, 830, 840, 868, 874, 875, 2107, 2160, 2174, 2175, 2183, 2184, 2680, 2681, 2693, 2695, 2702, 2705, 2723, 2745, 2757, 2832, 2833, 2837, 4546, 4601, 5016, 5204, 5227, 5229, 5234, 5246, 5344, 5359, 5360, 5385, 5387, 5389, 5390, 5396, 6355, 6356, 6360, 6365, 6368, 6370, 6372, 6979, 7007, 7010, 7013, 7169, 7170, 7181, 7202, 7249
biliopancreatic limbs, 1996
Billroth, 221, 222, 858, 1951, 1987, 2832, 3188, 3189, 3190, 3191, 3195, 5164, 5942, 6966
bi-maxillary advancement, 1535
binder, 489, 553, 1510, 1943, 2025, 2026, 3403, 3776, 3926, 5994, 6179, 6180
bioactive, 1, 10, 11, 25, 69, 71, 72, 73, 74, 75, 77, 78, 80, 84, 85, 86, 89, 90, 93, 99, 100, 223, 343, 346, 1730, 1732, 1745, 1751, 2155, 2324, 2325, 3541, 3562, 3566, 3572, 3578, 6224, 6364, 6416
biochemical markers, 1210, 1769, 2798, 3565, 5351
bioengineering, 70, 73, 2983, 3000, 3002, 3004, 3005, 3007, 3449, 3476, 3566, 6423
biologic, 8, 69, 70, 73, 75, 134, 345, 1136, 1433, 1434, 2022, 2299, 2352, 2445, 2520, 2757, 3001, 3206, 3207, 3239, 3294, 3341, 3433, 4181, 4377, 4598, 4601, 4744, 5010, 5576, 5639, 5959, 5981, 5983, 6004, 6006, 6018, 6019, 6021, 6171, 6172, 6177, 6181, 6423, 6528, 6703, 6873, 7302
biological factors, 345, 2175, 4490, 7132, 7135
biomarkers, 986, 994, 998, 2351, 2361, 2822, 2827, 2940, 2963, 3046, 3070, 3215, 3235, 3352, 3354, 3406, 3429, 3435, 3488, 3494, 3495, 3505, 3511, 3549, 3563, 3573, 3662, 3674, 3814, 3836, 3864, 3986, 5261, 5264, 5331, 5333, 5335, 5340, 5341, 5347, 5352, 5353, 5354, 5355, 5651, 6039, 6364, 6702, 6705, 6991, 7207, 7225, 7226
biomaterials, 70, 73, 76, 86, 88, 343, 346, 349, 351, 1433, 1436, 1729, 1731, 1734, 1746, 2425, 2965, 2966, 2984, 3001, 3002, 3003, 3004, 3005, 3006, 3349, 3365, 3402, 3444, 3546, 3552, 3560, 3563, 3566, 3572, 3574, 3737, 3738, 3740, 3741, 3742, 3743, 4072, 6413, 6423, 6424, 6992, 7125
biomechanical testing, 308, 3557, 3565, 3570, 3573
biopsychosocial, 2380, 6171, 6172, 6185
bladder cancer, 695, 1353, 2724, 3143, 3154, 3432, 3444, 4345, 4347, 4350, 4360, 4361, 4362, 5424, 5428, 5429, 6913
bladder exstrophy, 5593, 5594, 5595, 5596, 5597, 5598, 5599
blast injury, 4011, 4012, 4013, 4014, 4015, 4017, 4018, 4020, 4021, 4023, 4026, 4029, 4034, 4037
blast, 705, 3116, 3406, 3776, 3968, 3969, 4011, 4012, 4013, 4014, 4015, 4017, 4018, 4019, 4020, 4021, 4023, 4025, 4026, 4029, 4030, 4034, 4036, 4037, 4039, 4040, 4043, 4932, 5654, 5655, 5660

bleeding rates, 2513, 2521, 2522, 4311
blood flow velocity, 980, 996, 3461, 3800, 3822, 7215, 7216
blood type-incompatible, 5464, 5468
blood viscosity, 413, 3076, 3077, 3079, 3081, 3094, 3096, 3098, 3103, 3107, 3110, 3112, 3806, 4785, 4786, 4850, 4955, 4956
blood-brain barrier, 906, 967, 981, 997, 1073, 1160, 1659, 3351, 3370, 3666, 3690, 3703, 3766, 3776, 4000, 4556, 4850, 7120
body image dissatisfaction, 642, 7133, 7140, 7143, 7146
body mass index, 144, 151, 159, 163, 164, 172, 176, 179, 206, 209, 211, 241, 262, 263, 264, 295, 313, 322, 499, 503, 505, 512, 772, 794, 803, 813, 827, 1460, 1465, 1487, 1601, 1867, 2089, 2150, 2157, 2171, 2172, 2572, 2674, 2677, 2684, 2690, 2692, 2695, 2730, 2735, 2745,2832, 4239, 4248, 4263, 4348, 4500, 4527, 4533, 4537, 4562, 4596, 4617, 4625, 4643, 4664, 5046, 5086, 5265, 5274, 5333, 5335, 5345, 5348, 5415, 5417, 5465, 5643, 5758, 6031, 6351, 6352, 6354, 6360, 6362, 6431, 6861, 6864, 6952, 6978, 6986, 6987, 6990, 7032, 7129, 7169, 7170, 7174, 7175, 7176, 7182, 7196, 7257
bomb blast, 4011, 4012, 4013, 4014, 4015, 4016, 4017, 4026
bone defect, 70, 72, 73, 121, 122, 123, 128, 134, 347, 1737, 1740, 1742, 1743, 1749, 1751, 1752, 2200, 2210, 2293, 2294, 2295, 2296, 2297, 2299, 2300, 2304, 2307, 2315, 2318, 3366, 3368, 3559, 3567, 3568, 3570, 3575, 3576, 3577, 3578, 3579, 3581, 3988, 6097
bone flap resorption, 3905, 3915, 4000, 4001, 4008, 4078, 4086, 4087, 4090
bone fractures, 70, 86, 1375, 1768, 3539, 3557, 3559, 3568, 3570, 3574, 6232, 6235, 6236
bone grafting, 119, 131, 351, 1733, 1737, 1738, 1739, 1740, 1741, 1744, 1751, 1752, 2262, 2298, 2308, 2309, 3559, 3566, 5578
bone lengthening, 6, 11, 30, 37, 46, 49, 52, 54, 55, 56, 57, 64, 66, 67, 74, 101
bone marrow stimulation, 3537, 3540, 3542, 3546, 3548, 3549
bone marrow transplantation, 2915, 2916, 2917, 2918, 2921, 2935, 2936, 2937, 3268, 3292, 3295, 3298, 3299, 3348, 3661, 3662, 3664, 3696
bone marrow, 6, 10, 74, 75, 322, 350, 351, 1168, 1734, 1845, 1869, 2153, 2195, 2209, 2232, 2233, 2244, 2245, 2915, 2916, 2917, 2918, 2921, 2923, 2924, 2926, 2931, 2933, 2935, 2936, 2937, 2990, 2997, 3085, 3107, 3263, 3268, 3269, 3286, 3287, 3292, 3295, 3298, 3299, 3301, 3348, 3358, 3363, 3372, 3415, 3537, 3538, 3539, 3540, 3541, 3542, 3543, 3544, 3546, 3548, 3549, 3552, 3554, 3555, 3558, 3561, 3566, 3567, 3570, 3574, 3578, 3580, 3599, 3648, 3650, 3652, 3653, 3655, 3657, 3660, 3661, 3662, 3663, 3664, 3696, 3734, 5249, 5253, 5307, 5429, 5650, 5653, 5654, 5655, 5656, 5657, 5658, 5659, 5660, 5661, 5662, 5663, 5667, 5706, 5707, 5796, 6412, 6423, 6424, 6556, 7126
bone marrow-derived mesenchymal stem cells, 3538, 3542, 3554, 3555, 3558, 3566, 3570, 6412
bone mineral density, 10, 79, 83, 84, 85, 283, 292, 293, 1776, 3348, 3563, 3566, 3569, 5429, 6225, 6226, 7186, 7193, 7201, 7202
bone morphogenetic protein, 174, 1731, 1735, 3538, 3543, 3549, 3552, 3553, 3555, 3560, 3561, 3566, 3576
bone pain, 1195, 1314, 5609, 5610, 5611, 5614, 5773, 6051, 6052, 6054, 6055
bone remodeling, 125, 3373, 3546, 3559, 3560, 3561, 3564
bone sarcomas, 2312
bone tumor, 2311, 2312, 2314, 2315, 2317, 2318, 2319, 2321, 2330, 2331, 3559, 5516, 5533, 5560, 5561, 5563, 5568, 5666, 5667, 5673, 5721, 5722, 5727, 5729, 5731, 5732, 5736, 5738
botulinum toxin type A, 537, 538, 539, 554, 555, 556, 557, 1753, 1759, 1760, 1762
botulinum toxin, 353, 362, 537, 538, 539, 540, 541, 542, 543, 544, 546, 547, 548, 549, 550, 551, 552, 553, 554, 555, 556, 557, 569, 570, 573, 1041, 1044, 1045, 1311, 1753, 1759, 1760, 1761, 1762, 1763, 1800, 1811, 1899, 2098, 2452, 2707, 3122, 3128, 3538, 6590, 6608
boundary condition, 3461, 3462, 3463, 3476, 5886, 5887, 5888, 5892, 5893, 5894, 5896
bovine, 561, 562, 563, 565, 566, 571, 574, 1592, 1724, 1737, 1738, 1745, 1749, 1752, 2565, 2567, 2575, 2757, 2770, 2936, 2940, 2953, 2999, 3024, 3025, 3058, 3086, 3358, 3480, 3484, 3507, 3541, 3543, 3552, 3554, 3652, 3662, 3739, 4548, 4549, 4745, 4827, 4946, 4966, 5328, 5918, 5923, 5928, 6505, 6536, 6540, 6541
bowel obstruction, 145, 146, 259, 779, 1092, 1093, 1107, 1336, 1342, 1845, 1851, 1852, 1853, 1855, 1858, 1952, 1987, 1989, 2009, 2010, 2011, 2019, 2020, 2074, 2743, 2747, 4599, 4603, 4607, 4609, 4628, 4674, 4691, 4823, 5747, 5749, 5986, 6011, 6997, 7006, 7134
box trainer simulators, 2770, 2779
box trainer, 702, 2770, 2777, 2779
bradyarrhythmia, 7279, 7280
brain death, 3040, 3046, 3060, 3070, 3480, 3488, 3507, 3510, 3812, 3875, 3891, 3908, 3915

brain ischemia, 3357, 3792, 3827, 3839, 3847, 3889, 3892, 3895, 7058, 7060, 7210
brain mapping, 1166, 1167, 7097, 7098, 7100, 7101, 7103, 7111, 7112, 7113, 7115
brain oxygen delivery, 3841, 3842
Brain Trauma Foundation, 3804, 3824, 3844, 3845, 3854, 3950, 3959, 3970, 3988, 4002, 4006, 4038, 4046, 4047, 4066, 4067, 4104
brainstem, 889, 992, 1171, 1180, 1613, 1636, 1883, 1884, 3401, 3700, 3766, 3817, 3820, 3879, 3895, 3932, 3940, 4021, 4022, 4024, 4119, 4120, 4121, 4122, 4123, 4124, 4125, 4126, 4127, 4128, 4129, 4130, 4131, 4132, 4133, 4134, 4135, 4138, 4512, 6101, 7322, 7323
breaks, 431, 1732, 1889, 2078, 2080, 2140, 3306, 4614
breast reconstruction, 456, 471, 480, 489, 494, 500, 509, 512, 514, 1366, 1405, 1406, 1407, 1408, 1409, 1410, 1411, 1412, 1413, 1414, 1415, 1416, 1417, 1418, 1419, 1421, 1422, 1423, 1424, 1425, 1426, 2551, 2552, 2555, 2559, 2560, 2561, 2562, 2563, 2565, 2566, 2567, 2569, 2571,2572, 2574, 2575, 2576, 2577, 2578, 2579, 2583, 2584, 2586, 2587, 2590, 2591, 2592, 2593, 2594, 2595, 2596, 2597, 2598, 2599, 2600, 2601, 2602, 2603, 2604, 2605, 2607, 2608, 2612, 2613, 2614, 2615, 2616, 2626, 2628, 2629, 2630, 2631, 2635, 2636, 2637, 2639, 2640, 2641, 2642, 2643, 2644, 2645, 2646, 2647, 2648, 2649, 2661, 2663, 2666, 2668, 2669, 2670, 2673, 2674, 2675, 2676, 4698, 6376, 6379, 6420, 6774
BREAST-Q, 603, 608, 2585, 2592, 2593, 2596, 2600, 6373, 6376, 6377, 6378, 6379, 6380
bronchoscopy, 1319, 2389, 2390, 2391, 2392, 2395, 2397, 2398, 2399, 2401, 2402, 2500, 3890, 4147, 4160, 4453, 6062, 6063, 6081
buccal mucosa graft, 4342, 6153, 6158
bumper, 1867, 1912, 1913, 1914, 1915, 1917, 1928, 1929, 1942, 1943, 1944, 1950, 1952, 1963, 1965, 1969, 1998, 1999, 2002, 2014, 2018, 2019, 2027, 2028, 2029, 2030, 2031, 2032, 2035, 2044, 2047, 2051, 2052, 2060, 2064, 2066, 2071, 2079, 2081, 2083, 2084, 2089, 2091, 2092, 2093, 2094
Bundesarbeitsgemeinschaft Rehabilitation, 1036
buprenorphine, 2841, 2850, 2853, 2859, 2862, 2973, 3274, 3275, 3280, 3281, 3283, 3284, 3290, 3294, 3295, 3297, 3298, 3299, 3300, 3309, 3311, 3384, 3385, 3388, 3396, 3420, 3421, 3630
Burch Colposuspension, 4367, 4382, 4383, 4384, 4393, 4394
Burch urethropexy, 4382
buried bumper syndrome, 1969, 2029, 2031, 2035, 2047, 2083, 2084, 2085, 2089
buried bumper, 1915, 1969, 2029, 2031, 2035, 2047, 2083, 2084, 2085, 2089
buttressing, 141, 149, 1721, 2445, 2754, 2757, 4297, 4545, 4548, 4549, 6998, 7003
bypasses to crural vessels, 4895

C

C. difficile, 2041
Cachexia, 1849, 1857
CAD/CAM technology, 666, 4074
caesarean section, 3166, 4567, 4716, 7117, 7119, 7124
calcineurin, 2919, 3414, 3440, 3628, 3630, 3637, 3648, 3650, 3660, 3662, 3757
calcium ATPase, 3788
calcium channel blockers, 1004, 1311, 2655, 3027, 3785, 4561, 4766, 7232
calcium channels, 983, 2841, 3782, 6587, 6588, 6604, 7211
calcium voltage-gated channel subunit alpha1A gene (CACNA 1A), 6884
caloric restriction, 6981
calpains, 3788, 3797
calvarial defect, 1750, 3348, 3362, 3373, 3563, 3568, 4075, 6428
calvarium, 4072
Candida, 2039, 2048, 2060, 2073, 2807, 4616, 4985, 7020
Canine fossa puncture, 2404, 2407, 2408, 2418, 2459
capacitance, 3451, 3452, 3454, 3457, 3459, 3463, 3468
caprine, 3373, 3432, 3443, 3445
capsular contracture, 463, 476, 478, 479, 482, 485, 486, 487, 488, 492, 493, 494, 581, 582, 585, 586, 587, 2565, 2566, 2569, 2571, 2572, 2574, 2589, 2590, 2612, 2637
carbon dioxide, 212, 216, 374, 687, 1075, 1080, 1087, 1166, 1876, 1924, 1936, 1969, 1999, 2058, 2072, 2073, 2099, 2393, 2502, 2506, 2534, 2719, 2781, 2968, 2979, 3285, 3292, 3417, 3806, 3859, 3878, 3890, 3895, 3908, 3928, 3999, 4147, 4215, 4424, 4528, 4629, 4712, 4885, 5279, 5793, 6357, 6427, 6502, 6512, 6521, 6522, 6529, 6593, 6608, 6759, 6769, 6833, 7103, 7215, 7216, 7233
carcinomatosis, 936, 1096, 1267, 1851, 1853, 1855, 1918, 1987, 1989, 1990, 2011, 2968, 2975, 2979, 4422, 4691, 6291, 6295, 6643, 6869, 6870, 6873, 6877, 6878, 6879, 6880, 6912, 6913, 6914, 6915, 6916
cardiac arrhythmias, 1038, 1311, 3273, 3276, 4518, 4529, 7082, 7088, 7279

cardiac resynchronization therapy, 3152, 4198, 4200, 6611, 6612, 6618, 6619
cardiac risk assessment, 1873, 5972
cardiopulmonary bypass, 3628, 3629, 3634, 3637, 3639, 3675, 4190, 4191, 4194, 4202, 4203, 4204, 4206, 4207, 4214, 4771, 4777, 4799, 4809, 5909, 5910, 5931, 5933, 5934, 5935, 5936, 6469, 6476, 6505, 6513, 6521, 6538, 6557, 6558, 6566, 6583, 6588, 6600, 6605, 6713, 6730, 6743, 6744, 6758, 6762, 6773, 6797, 6829, 6834, 6846, 7059, 7060, 7062, 7075, 7076, 7079, 7157, 7158, 7159, 7164, 7165, 7278, 7296, 7298, 7302, 7309
cardiopulmonary resuscitation, 3295, 3797, 3926, 3929
cardiovascular risk factors, 160, 179, 180, 206, 767, 771, 772, 2169, 2185, 2679, 2682, 2706, 4818, 4979, 5383, 5392, 5396, 5415, 5416, 5428, 6051, 6120, 6367, 6702, 7175, 7177, 7185, 7192, 7193, 7202, 7207
cardioversion, 1867, 3401, 6775, 7281, 7291, 7292
carnosic acid, 3791, 3798
carotid artery disease, 1082, 1083, 4725, 4728, 4867, 7227
carotid artery injury, 2500, 4017, 6106, 6107
carotid artery surgery, 4849
carotid artery, 878, 879, 880, 886, 887, 888, 889, 891, 892, 895, 914, 928, 946, 1010, 1011, 1071, 1082, 1083, 1084, 1085, 1088, 1089, 1195, 1477, 1479, 1480, 1481, 1521, 1610, 1611, 1660, 1687, 1978, 2500, 2818, 3140, 3179, 3342, 3379, 3380, 3477, 3584, 3586, 3621, 3692, 3725, 3812, 4017, 4723, 4725, 4726, 4728, 4738, 4754, 4757, 4783, 4812, 4849, 4850, 4853, 4858, 4860, 4863, 4864, 4865, 4866, 4867, 4868, 4869, 4881, 4946, 4984, 4999, 5000, 5011, 5518, 5519, 6089, 6096, 6099, 6103, 6106, 6107, 6108, 6500, 7211, 7212, 7214, 7215, 7216, 7219, 7220, 7221, 7227
carotid cavernous fistula, 4017, 6089, 6091, 6099, 6104
carotid endarterectomy, 1089, 3831, 4742, 4831, 4849, 4850, 4856, 4857, 4858, 4860, 4862, 4863, 4865, 4866, 4868, 4982, 4999, 5011, 7209, 7210, 7211, 7218, 7219, 7220, 7221, 7226, 7228
carotid occlusive disease, 4849
cartilage degeneration, 3547
cartilage regeneration, 3540, 3544, 3551, 3552
cartilage trauma, 3540
cataract surgery, 1710, 1715, 1717, 1718, 1719, 1720, 1880, 5850, 5851, 5853, 5855, 6696, 6697, 6881, 6883, 6885, 6890, 6891, 6893, 6899, 7091
cataract, 1710, 1714, 1715, 1717, 1718, 1719, 1720, 1880, 3172, 3173, 3186, 5850, 5851, 5852, 5853, 5854, 5855, 6687, 6689, 6696, 6697, 6698, 6881, 6883, 6885, 6890, 6891, 6893, 6895, 6898, 6899, 7091, 7092, 7155
catheter associated urinary tract infections, 3901
causes of weight regain, 827, 871, 2689, 7002
cauterization, 496, 1610, 2031, 2415, 2421, 2464, 2485, 2521, 3165, 4424, 6033, 7311, 7315, 7316, 7317
CEAP classification, 4951, 4952, 4965
cell therapy, 2561, 3246, 3443, 3480, 3499, 3547, 3548, 3555, 3557, 3562, 3566, 3569, 3570, 3578, 3580, 3653, 4888, 6262, 6413, 6926
cellular properties, 3080
cellulitis, 143, 524, 1528, 2086, 2098, 2665, 3142, 4674, 4730, 4953, 4955, 4967, 6999
central cannulation, 6463, 6465, 6514, 6519
central line associated bloodstream infections, 3901
cerebral aneurysm, 877, 882, 907, 913, 915, 916, 917, 918, 919, 935, 939, 940, 945, 955, 956, 960, 962, 963, 964, 965, 967, 1015, 1017, 1032, 1077, 1663, 2380, 3254, 3474
cerebral arteries, 885, 886, 890, 893, 897, 901, 903, 904, 914, 935, 951, 980, 1004, 1005, 1073, 1612, 3767, 4037, 4775, 6102
cerebral blood flow, 905, 911, 964, 971, 972, 975, 976, 994, 997, 1015, 1069, 1070, 1071, 1072, 1073, 1074, 1075, 1161, 1165, 1166, 1175, 1610, 1632, 3092, 3338, 3356, 3370, 3666, 3689, 3702, 3707, 3711, 3773, 3781, 3783, 3787, 3789, 3792, 3794, 3796, 3806, 3811, 3825, 3827, 3828, 3830, 3831, 3839, 3842, 3844, 3847, 3848, 3849, 3855, 3866, 3868, 3870, 3888, 3889, 3890, 3891, 3899, 3921, 3925, 3929, 3953, 3958, 3988, 3992, 4005, 4046, 4048, 4053, 4077, 4086, 4096, 4105, 4857, 6099, 7210, 7212, 7214, 7215, 7216, 7217
cerebral edema, 1169, 1170, 3317, 3319, 3769, 3770, 3774, 3775, 3776, 3777, 3788, 3789, 3809, 3813, 3819, 3820, 3841, 3848, 3854, 3855, 3861, 3864, 3865, 3866, 3867, 3868, 3879, 3885, 3891, 3900, 3917, 3919, 3927, 3932, 3934, 3938, 3947, 3956, 3959, 3963, 3964, 3968, 3987, 3992, 3996, 3997, 4006, 4007, 4014, 4030, 4035, 4037, 4045, 4046, 4050, 4071, 4077, 4078, 4090, 4101, 4114, 4423, 5000, 5778
cerebral hypoperfusion, 967, 993, 3805, 3823, 3919, 3932, 4999, 7059, 7210, 7212, 7215
cerebral ischemia, 911, 962, 977, 982, 990, 991, 995, 998, 999, 1015, 1033, 1173, 1181, 1611, 1613, 1614, 3101, 3689, 3690, 3691, 3692, 3701, 3711, 3712, 3713, 3778, 3781, 3787, 3788, 3790, 3792, 3796, 3797, 3814, 3829, 3830, 3838, 3842, 3847, 3860, 3908, 3947, 3963, 3993, 4105, 4723, 4762, 4875, 7209, 7210, 7211, 7216, 7217, 7218, 7220, 7221

cerebral metabolic rate for glucose, 3783
cerebral metabolic rate of oxygen, 972, 3789, 3807, 3811, 4048
cerebral microdialysis, 3809, 3814, 3815, 3817, 3820, 3829, 3835, 3845, 3846, 3847, 3848, 3864, 3889
cerebral oedema, 906, 967, 968, 3990
cerebral palsy, 1753, 1754, 1760, 1761, 1762, 1763, 1765, 1766, 1767, 1768, 1769, 1771, 1772, 1773, 1775, 1776, 1777, 1779, 1780, 1781, 1787, 1789, 1790, 1791, 1792, 1793, 1794, 1799, 1800, 1801, 1802, 1810, 1811, 1812, 1813, 1815, 1816, 1819, 1824, 1827, 1828, 1829, 1830, 2546, 3666, 3688, 3689, 3690, 3701, 3705, 5854, 5867, 5868, 5872, 5874, 5878, 5879, 5880, 6955, 6956, 6958, 6959, 6963
cerebral perfusion pressure, , 968, 972, 980, 994, 1009, 1074, 1075, 3784, 3794, 3799, 3800, 3810, 3822, 3823, 3825, 3826, 3827, 3828, 3830, 3837, 3848, 3850, 3851, 3852, 3867, 3869, 3887, 3889, 3891, 3894, 3909, 3912, 3913, 3929, 3958, 3962, 3964, 3975, 3981, 3987, 3990, 3993, 4006, 4019, 4052, 4068, 4104, 4134
cerebral perfusion, , 881, 946, 968, 972, 980, 985, 989, 991, 992, 993, 994, 1009, 1015, 1071, 1074, 1075, 1451, 1643, 3364, 3784, 3794, 3799, 3800, 3805, 3810, 3815, 3822, 3823, 3825, 3826, 3827, 3828, 3829, 3830, 3837, 3848, 3850, 3851, 3852, 3867, 3869, 3887, 3889, 3891, 3894, 3909, 3912, 3913, 3927, 3929, 3958, 3962, 3964, 3970, 3975, 3981, 3987, 3990, 3993, 4006, 4019, 4046, 4052, 4058, 4059, 4068, 4096, 4104, 4109, 4110, 4134, 4760, 4761, 4763, 4764, 4765, 4777, 4778, 6558, 6564, 6565, 7061, 7075, 7215, 7216, 7217, 7218
cerebral pressure reactivity index, 3855
cerebral protection strategies, 4753
cerebral protection, 4071, 4753, 4761, 4762, 4763, 4764, 4862, 7221, 7228
cerebral vasospasm, 881, 884, 925, 939, 962, 967, 968, 971, 976, 979, 982, 985, 987, 988, 990, 998, 1001, 1015, 1016, 1019, 1020, 1023, 1066, 1073, 1074, 1075, 1076, 1077, 3825, 3900, 4037, 4038, 4040, 6100, 6104, 6108
cerebral veins, 885, 898, 899, 900, 901, 902, 1662
cerebral venous thrombosis, 1184, 3372, 3864, 3872
cerebrospinal fluid (CSF) leak, 1614, 1695, 1705, 1706, 2435, 3903, 4017, 4031, 4042, 6089, 6091, 6163, 6955, 7331
cerebrospinal fluid, 905, 934, 938, 940, 943, 981, 987, 1019, 1020, 1023, 1024, 1039, 1043, 1070, 1073, 1074, 1614, 1654, 1695, 1705, 1706, 2111, 2435, 3314, 3774, 3778, 3786, 3792, 3796, 3800, 3801, 3802, 3814, 3822, 3829, 3836, 3869, 3883, 3889, 3903, 3911, 3940, 3950, 3951, 3970, 4017, 4031, 4041, 4042, 4058, 4072, 4081, 4090, 4096, 4796, 4809, 5790, 6089, 6091, 6117, 6163, 6206, 6955, 7331
cerebrovascular pressure reactivity, 3808, 4082
cervical cancer, 3136, 3154, 4399, 4400, 4402, 4405, 4412, 4413, 4414, 4418, 4425, 4432, 4433, 4435, 4436, 4438, 4439, 4440, 4441, 4444, 4445
charing cross venous ulcer questionnaire, 4954
Chilaiditi syndrome, 1987
childhood sexual abuse, 7133, 7141, 7146, 7147
chimerism, 2925, 2926, 2927, 2929, 2931, 2932, 2933, 2934, 2936, 3291, 3293, 3425, 3605, 3628, 3639, 3642, 3643, 3644, 3647, 3650, 3652, 3653, 3654, 3655, 3656, 3659, 3660, 3661, 3662, 5758
China, 288, 645, 662, 749, 767, 1615, 1617, 1709, 1749, 2360, 2729, 3023, 3030, 3031, 3038, 3039, 3159, 3163, 3164, 3200, 3202, 3647, 3658, 3731, 3732, 3738, 3818, 3938, 3941, 4048, 4049, 4062, 4063, 4750, 5491, 5629, 5803, 5832, 6411, 6581, 6597, 7223
chitosan, 92, 3543, 3545, 3546, 3548, 3549, 3552, 3553, 3566, 3572, 3728
CHIVA- conservative ambulatory hemodynamic management of varicose veins, 4965
chlorhexidine, 1430, 1862, 1908, 3385, 3416, 3417, 3884, 4369, 4390, 4633, 4634, 4636, 4648, 4649, 4650, 4652, 4676, 4678, 4679, 4686, 4691, 4692, 4712, 4718, 4719, 4720, 6255
choanal atresia, 1691, 1692, 1704, 1705
cholangiocarcinoma, 1589, 1893, 2865, 2866, 2901, 2904, 2905, 2908, 2912, 2913, 5259, 5799, 5800, 5801, 5802, 5803, 5804, 5805, 5806, 5807, 5808, 5809, 5811, 5812, 5813, 5814, 5815, 5816, 5817, 5819, 5823, 5830, 5831, 5832, 5833, 5834, 5835, 5836, 5838, 5839, 5842, 5843, 5844, 5845, 5846, 5848, 6907, 6908, 6910, 6911
cholelithiasis, 145, 260, 1240, 2741, 2763, 2770, 2897, 2905, 2909, 4537, 4538, 4539, 4540, 4541, 4542, 4543, 7001
chondrocyte morphology, 3546
chondrocyte phenotype, 3541, 3543, 3544
chondrocytes, 3537, 3538, 3539, 3540, 3541, 3543, 3544, 3545, 3546, 3547, 3548, 3549, 3550, 3551, 3552, 3553, 3554, 3555, 3561, 6412
chondrogenesis, 73, 3540, 3541, 3542, 3543, 3547, 3548, 3549, 3550, 3551, 3552, 3553, 3554, 3555, 3561, 3568
chondrogenic, 3537, 3539, 3541, 3542, 3543, 3544, 3545, 3546, 3548, 3550, 3551, 3553, 3554, 3555, 3570, 5672, 6415, 6570

chondrosarcoma, 2312, 2314, 2331, 5665, 5666, 5667, 5669, 5670, 5671, 5672, 5673, 5674, 5711, 5712
chordoma, 1636, 5563, 5564, 5565, 5566, 5567, 5568, 5569, 6090
chronic complications, 1434, 2077, 2088, 5445, 6002, 6359
chronic hydrocephalus, 938, 1019, 1021, 1023, 1024, 1025
chronic mesenteric ischemia, 4727, 4840, 4848
chronic myeloid leukemia, 5653, 5654, 5662, 5663
chronic pain, 267, 269, 286, 297, 320, 347, 836, 1493, 3281, 3297, 4141, 4479, 4491, 5012, 5571, 5612, 5613, 5868, 5878, 6161, 6164, 6169, 6170, 6171, 6185, 6186, 6200, 6203, 6214, 7038, 7041, 7043, 7044, 7045, 7046, 7047, 7048, 7230, 7231, 7235
chronic rhinosinusitis, 1683, 1685, 1686, 1687, 1688, 1701, 1702, 2403, 2406, 2412, 2429, 2430, 2433, 2438, 2439, 2457
chronic venous insufficiency, 4730, 4749, 4877, 4920, 4933, 4934, 4949, 4950, 4951, 4957, 4967
circular anastomosis, 4917, 5101, 5129, 5130, 5137
circulatory arrest, 3490, 3519, 3667, 3692, 3705, 4762, 4777, 4778, 4809, 4978, 4991, 5912, 5924, 5935, 5936, 6470
claudication, 4724, 4811, 4813, 4815, 4816, 4818, 4821, 4838, 4845, 4846, 4871, 4872, 4873, 4874, 4880, 4881, 4882, 4885, 4886, 4887, 4889, 4897, 4899, 4900, 4901, 4906, 4908, 4945, 4987
clear cell chondrosarcoma, 5665, 5666, 5668, 5669, 5670, 5671, 5672, 5673
clear cell papillary renal cell carcinoma, 5631, 5639, 5640
cleft palate, 603, 608, 1526, 1541, 1694, 1733, 1740, 2463, 3187, 3242, 5537, 5538, 5539, 5540, 5541
clinical assessment, 91, 1361, 1634, 3105, 3151, 3282, 3326, 3327, 3816, 3867, 3893, 3894, 4810
clinical evaluation, 711, 776, 993, 1025, 1145, 1148, 1149, 1361, 1466, 1469, 1719, 1790, 1958, 2107, 2264, 2307, 3235, 3773, 3911, 5727, 6051, 6226, 6426, 6742, 6788, 7048
clinical examination, 398, 427, 564, 666, 928, 971, 991, 992, 1002, 1069, 1154, 1314, 1359, 1364, 1370, 1780, 1784, 1881, 2245, 2456, 2653, 2970, 3638, 3802, 3804, 3820, 3876, 3877, 3878, 3880, 3885, 3900, 3909, 3927, 3928, 4060, 4721, 4722, 4746, 4749, 4903, 4950, 5482, 5713, 5834, 6257, 6260, 6847
clinical versus experimental sepsis, 2795
clinically not invasive. Pathology revealed a Masaoka stage I, 5861
clitoris, 3162, 4383, 5766, 6147, 6148, 6149, 6154, 6158
clogged, 1900, 2030, 2080
clogging, 1837, 1947, 1960, 1967, 1969, 1973, 2030, 2461, 3095, 7212
clopidogrel, 947, 948, 951, 955, 1614, 1864, 1869, 1923, 2033, 2037, 2074, 4818, 4856, 4867, 4900, 5912, 5916, 5934
closed-loop, 1326, 2171, 3408, 3463, 3464, 3465, 3468, 3470, 3472, 3473, 3744
closure of mesenteric defects, , 839, 2736, 4603, 4607, 4609, 4610
closure of the defect, 806, 836, 2743, 4238, 4606, 4607
clousure, 2425, 4671
CNS tumors, 1632, 1633, 1634, 1642, 1643, 1645, 5454, 6105
CO2 laser resection, 6966
coagulation complications, 4980
coagulopathy, 268, 444, 1179, 1465, 1469, 1840, 1891, 1918, 1949, 1980, 2068, 2827, 3614, 3643, 3752, 3802, 3864, 3865, 3866, 3867, 3876, 3879, 3883, 3891, 3894, 3899, 3909, 3910, 3918, 3958, 4018, 4019, 4025, 4082, 4348, 4457, 4530, 4571, 4836, 4853, 5912, 5918, 5923, 5924, 5926, 5932, 5936, 5937, 5982, 6003, 6009, 6135, 6243, 6285, 6291, 6622, 6627, 6630, 6646, 6651
coblation, 2484, 2504, 2505, 2507, 2513, 2514, 2515, 2516, 2520, 2521, 2523, 2526, 2534, 2540
Cochrane Handbook, 3972
codeine, 2520, 2530, 2531, 2532, 2536, 2537, 2545, 6208
cognition, 1061, 1063, 1605, 3795, 3877, 3914, 6242, 6244, 7038, 7074, 7077, 7078
cognitive deficits, 992, 1057, 1058, 1059, 1060, 1064, 1067, 3289, 3906, 7038, 7058, 7065, 7076, 7078
cognitive plasticity, 1057
cognitive therapy, 3906
coils, 883, 886, 945, 946, 947, 948, 949, 950, 953, 954, 955, 1065, 1095, 1136, 2394, 3356, 3358, 3359, 4486, 4739, 6111, 6642, 6659
collagen-glycosaminoglycan, 3544, 3566, 3573
collagen-induced arthritis, 3568
colocutaneous fistula, 1991, 2073, 2092, 2093, 2094, 2101, 5995, 6025
colocutaneous fistulae, 1991, 2092, 5995, 6025
colonic injury, 1991, 2064, 2066, 2071
colonic ischemia, 4836, 4847, 4997
colonic, 223, 226, 1094, 1098, 1099, 1209, 1489, 1505, 1559, 1562, 1909, 1984, 1987, 1991, 1992, 2009, 2015, 2018, 2064, 2066, 2067, 2071, 2092, 2093, 2095, 2709, 2724, 2725, 2880, 2903, 2979,

3198, 3390, 4223, 4224, 4225, 4228, 4556, 4559, 4560, 4562, 4565, 4568, 4639, 4836, 4847, 4997, 5259, 5594, 5748, 5939, 5941, 5981, 5982, 5983, 5984, 5986, 5987, 5988, 5989, 5990, 5992, 5997, 5998, 6002, 6003, 6006, 6009, 6014, 6018, 6025, 6026, 6362, 6880, 7032
colonoscope, 1949, 1950, 1962, 1963, 1965, 1991, 1992, 2002, 2014, 2015, 2094, 2101
colonoscopy, 1094, 1862, 1984, 1990, 1991, 1992, 1994, 2001, 2020, 2069, 2092, 2093, 2094, 2791, 4490, 4494, 4847, 5957, 5982, 5993, 5997
colonoscopy-assisted percutaneous endoscopic gastrostomy, 1991, 1994, 2020
colorectal liver metastases, 1588, 1589, 1595, 1597, 1598, 2375, 2376, 2903, 2911, 3519, 3534, 5817, 6623, 6624, 6625, 6632, 6633, 6634, 6645, 6646, 6913
colorectal surgery, 1091, 1486, 1489, 1492, 1505, 2375, 2707, 2708, 2709, 2710, 2713, 2714, 2715, 2716, 2719, 2722, 2723, 2725, 2761, 2764, 2774, 2784, 2788, 3135, 3148, 4230, 4233, 4235, 4568, 4614, 4615, 4620, 4637, 4639, 4640, 4644, 4654, 4658, 4669, 4689, 4690, 4692, 4702, 4703, 4704, 4705, 4706, 4714, 4716, 5975, 5991, 6004, 6009, 6012, 6014, 6015, 6019, 6020, 6021, 6026, 6393, 6407, 6703, 7236, 7260, 7261
colpotomy, 4379, 4423, 4424, 4478
combined posterior and anterior approach, 5563
combined surgical technique, 90
combined technique of limb lengthening, 1, 43
combined technique, 1, 7, 8, 10, 30, 43, 47, 85, 89, 90, 100, 103, 107, 118, 122
common bile duct (CBD) stricture, 2865
common carotid artery, 1071, 1477, 1479, 1480, 1978, 3357, 3361, 3380, 3381, 3584, 3586, 3686, 3689, 3692, 4726, 4754, 4757, 4783, 4850, 4869, 4917, 4999, 6564, 6565, 6792
communicating veins, 4949, 4952
communication, 425, 489, 620, 647, 652, 762, 833, 959, 1041, 1042, 1045, 1048, 1116, 1120, 1122, 1223, 1239, 1241, 1244, 1250, 1260, 1325, 1465, 1470, 1516, 1606, 1695, 1729, 1738, 1750, 1847, 2018, 2140, 2155, 2465, 2489, 2536, 2537, 2722, 2767, 2945, 3147, 3245, 3250, 3777, 3875, 3877, 3891, 3893, 3898, 3902, 4038, 4091, 4097, 4207, 4240, 4369, 4467, 4827, 4875, 5496, 5539, 5941, 5984, 6064, 6162, 6244, 6255, 6325, 6326, 6327, 6329, 6336, 6338, 6339, 6340, 6382, 6386, 6390, 6457, 6571, 6721, 6728, 6915, 6916, 6921, 6922, 6992, 7028, 7295, 7297, 7298, 7301, 7302, 7308, 7309
co-morbidity, 235, 238, 1475, 1503, 2180, 2694, 2699, 4561, 4889, 6014, 6069, 6239, 6240, 6246, 6248, 6354
comparator, 3975, 3976
compartment syndrome, 588, 3620, 3859, 3917, 3918, 3919, 3925, 3927, 3928, 3929, 4046, 4386, 4836, 4879, 4898, 4924, 4940, 4975, 4981, 6259
compensatory reserve, 3800, 3801, 3802
complete cytoreduction, 2979, 6278, 6280, 6281, 6284, 6286, 6288, 6293, 6294, 6303, 6306, 6307, 6318
complete tonsillectomy, 2493, 2544, 2545
complex regional pain syndrome, 6164, 6171, 6172, 6187, 6189, 6203, 6205, 6213, 6214, 6259
composite tissue allotransplantation, 3441, 3647, 3648, 3660, 3661, 3663
composite tissue, 1423, 2934, 3268, 3441, 3647, 3648, 3649, 3656, 3659, 3660, 3661, 3662, 3663, 3664
compression fractures, 267, 269, 279, 280, 283, 286, 291, 296, 297, 298, 301, 302, 303, 304, 306, 307, 309, 310, 314, 319, 320, 321, 322, 326, 327, 339, 340, 341, 347, 348, 5592, 6221, 6225, 6226, 6227
compression therapy, 4953, 4954, 4955
compromised bone repair, 3574
computational fluid dynamics, 3450, 3475, 3476, 3477, 5881, 5883, 5884, 5904, 5907, 5908
computational, 732, 752, 755, 756, 2255, 3143, 3354, 3449, 3450, 3451, 3452, 3454, 3460, 3461, 3462, 3464, 3465, 3468, 3469, 3471, 3472, 3473, 3474, 3475, 3476, 3477, 3478, 3571, 3574, 3579, 3799, 5780, 5881, 5883, 5884, 5888, 5889, 5895, 5898, 5902, 5903, 5904, 5905, 5907, 5908
computed tomography angiography, 1088, 1406, 1417, 1426, 2562, 2638, 3363, 4872, 4875, 4884, 4903, 4976, 5894, 6784, 6820
computer-aided surgery, 645, 646, 661
computer-assisted surgery, 680, 681, 708, 727, 728, 732, 2260, 2320, 2330, 4291, 4314
computerized tomography, 1067, 1107, 1332, 1612, 1770, 1983, 2456, 3825, 3850, 3879, 4137, 4138, 4760, 4791, 4801, 4802, 5302, 5599, 5957, 6110, 6638
confocal microscopy, 1719, 2939, 2941, 2948, 2955, 2957, 2958, 2960, 2961, 3082, 3085, 3087
congenic, 2920, 3422, 3431
congenital abnormalities, 1235, 1730, 4738, 5494, 5537
congenital adrenal hyperplasia, 1599, 1600, 1607, 1608, 5758, 5762
congenital anomalies, 103, 263, 1296, 1319, 1688, 1693, 1739, 4756, 4757, 4776, 5742, 5747, 6826

congenital defect, 1695, 1747, 5594, 5741, 5747, 5750
congenital heart disease, 4805, 5881, 5885, 5886, 5890, 5909, 5924, 5925, 5936, 6553, 6832, 6861, 7269, 7276, 7278, 7279, 7292
congenital lower limb length discrepancy, 41, 51, 52, 65
congenital malformations, 261, 598, 1681, 1691, 1693, 4782, 5593, 5594
congenital melanocytic nevus, 5475, 5476, 5479
congestive HF, 2839, 2862, 3672
connectome, 7097, 7098
conscious sedation, 1875, 1883, 1949, 2045, 2395
conscious sedation, 6749, 7104
consumers, 3236, 6921, 6925, 6928
continuous cerebral blood flow, 3889
continuous electroencephalography, 3832, 3889, 4097, 7104
contraindications, 257, 268, 296, 308, 322, 541, 1180, 1209, 1262, 1359, 1363, 1413, 1422, 1540, 1541, 1544, 1655, 1837, 1839, 1840, 1841, 1844, 1855, 1861, 1917, 1918, 1932, 1949, 1969, 2010, 2015, 2195, 2283, 2355, 2367, 2390, 2586, 2587, 2591, 2735, 3864, 3866, 3880, 4188, 4189, 4348, 4449, 4533, 4712, 4713, 4714, 4786, 4800, 4864, 4889, 4958, 5165, 5181, 5458, 5820, 5821, 5965, 6020, 6062, 6063, 6070, 6148, 6253, 6506, 6542, 6645, 6755, 6756, 6760, 6766, 6775, 6776, 6829, 6967, 6968, 6970, 6973, 7131
contralateral hematoma, 3903, 3984
controlling eat disorders, 169
conus medullaris syndrome, 5585, 5586, 5589, 5590, 5591, 5592
conventional carotid endarterectomy, 4858, 4868
conventional ultrasound, 5334, 6635
conventional ventilation, 7160, 7161
conversion from XFS to XFG, 6884
conversion to laparotomy, 4399, 4404, 4410, 4418, 6291, 6396, 6397, 6398, 6399, 6400, 6401, 6402, 6403, 6404, 6405, 6406, 7231, 7243
core body temperature, 3405, 3878
Cor-Knot, 4193, 4195, 6463, 6502, 6733, 6735, 6738, 6739
corneal cautery, 7316
corneal transplantation, 1709, 1714, 1718
coronary artery bypass surgery, 3154, 3715, 4216
coronary artery bypass surgery, 5881, 5882, 5920, 5931, 5932, 5933, 5934, 6555, 6597, 6601, 6606, 6610, 6843, 6860, 6868, 7073, 7077, 7079, 7165
coronary artery ligation, 2840, 2841, 3355, 3672, 3708
coronary heart disease, 179, 238, 249, 763, 1038, 1872, 4800, 4845, 4888, 5286, 5383, 5413, 5881, 5888, 5893, 5894, 5895, 7130
coronary ligation, 3347, 3705
cortical mapping, 7099
corticosteroids, 295, 313, 444, 984, 1329, 1522, 1852, 1858, 2394, 2497, 2927, 2930, 3307, 3319, 3539, 3566, 3568, 3650, 3757, 3777, 4103, 4453, 4515, 4517, 5708, 5951, 5958, 5983, 6004, 6010, 6194, 7286
coupled momentum method, 3461, 3475
covered PEG, 2045
CPB and AoX, 6540, 6542, 6543, 6736, 6764
cranial nerve palsies, 992, 4017
cranial vault reconstruction, 6665, 6666, 6679, 6681
craniofacial injuries, 4014, 4024
cranioplasty, 1043, 1621, 3766, 3848, 3872, 3905, 3915, 3952, 3953, 3954, 3984, 3991, 3995, 4000, 4001, 4008, 4026, 4034, 4036, 4039, 4041, 4043, 4060, 4061, 4068, 4071, 4072, 4073, 4074, 4075, 4076, 4077, 4078, 4079, 4081, 4083, 4085, 4086, 4087, 4090, 6429, 6667, 6675, 6676, 6678, 6683, 6684
craniosynostosis, 6665, 6666, 6667, 6669, 6671, 6672, 6673, 6674, 6675, 6676, 6679, 6680, 6681, 6682, 6683, 6684, 6685
CRASH model, 4094, 4095, 4111
critical illness, 1037, 1040, 1045, 1054, 1507, 2442, 2826, 3335, 3943, 4569, 4629
critical limb ischemia, 3346, 4724, 4727, 4811, 4812, 4813, 4814, 4815, 4816, 4873, 4874, 4877, 4881, 4886, 4908, 4909, 4915, 6172, 6428
critical size defects, 3562
cross-clamp times (AoX), 6538
cross-facial nerve graft, 1665, 1666, 1667, 1668, 1669, 1670, 1671, 1672, 1673, 1674, 1675, 1676, 1677
cryoablation, 1886, 3154, 3395, 3409, 4199, 6055, 6775, 6784, 6832, 6833, 6834, 6836
cryoischemia, 3774
cryopreserved, 3028, 3747, 3759, 4001, 4023, 4060, 4946, 4988, 4989, 5010
cryotherapy, 420, 623, 624, 629, 1349, 1527, 2087, 6051
CSF leak, 1679, 1688, 1695, 3884, 3984, 4018, 4022, 4023, 4024, 4025, 4036, 6118, 6119, 6120, 6122, 6179, 6956, 6957, 6958, 6959, 7326
CT classifications, 4120
CT-angiography, 1612, 4721, 4722, 4734, 4737, 4738, 4739, 4746, 4817, 4883
Cushing, 877, 878, 879, 997, 1071, 1208, 1213, 1220, 1610, 3959, 3963, 3970, 3972, 3988, 4013,

4030, 4795, 6090, 6101, 6105, 6110, 6118, 6121, 6129, 6546, 7101
custom implants, 587, 2275, 2276, 2293, 2323, 5876
customized cranial implant, 4073, 4074, 4077
cut and push', 2089, 2094
Cutan section, 2834, 2835
cut-and-push' method, 2081
CV5 GORE-TEX, 6733
cyanoacrylate, 386, 390, 882, 1436, 1736, 1892, 4667, 4668, 4669, 4670, 4711, 4714, 4962, 5923, 6641
CyberKnife® system, 705
cyclooxygenase-2, 3538, 3558, 3560, 3566, 4491, 4515, 4559, 4567, 4568
cyclosporin A, 2922, 3639, 3786, 3791, 3794, 3795, 3796, 3798
cynomolgus, 2816, 2923, 2934, 2936, 2938, 3263, 3264, 3282, 3287, 3291, 3292, 3293, 3294, 3296, 3297, 3299, 3301, 3391, 3396, 3397, 3402, 3403, 3405, 3408, 3433, 3542, 3695, 3697, 3725
cystectomy, 691, 695, 713, 2715, 2724, 3134, 3143, 3151, 3154, 4317, 4322, 4323, 4337, 4338, 4345, 4346, 4347, 4349, 4360, 4361, 4362, 4363, 4481, 4482, 4493, 6029, 6030, 6031, 6032, 6033, 6034, 6035, 6036, 6037, 6038, 6039, 6040, 6041, 6042, 6043
cytochrome c, 3075, 3786, 3796
cytokines, 87, 164, 165, 166, 167, 174, 176, 178, 180, 253, 907, 988, 994, 2104, 2105, 2152, 2170, 2714, 2801, 2807, 2918, 2919, 2921, 2928, 2989, 2990, 3011, 3013, 3025, 3047, 3050, 3070, 3076, 3107, 3117, 3119, 3120, 3263, 3285, 3490, 3497, 3499, 3507, 3522, 3539, 3560, 3561, 3565, 3568, 3570, 3600, 3650, 3651, 3653, 3655, 3673, 3677, 3680, 3723, 3736, 3751, 3866, 4491, 4506, 4677, 4687, 5254, 5255, 5256, 5257, 5260, 5267, 5290, 5333, 5343, 5354, 5359, 5397, 5612, 5659, 5706, 6279, 6303, 6357, 6413, 6428, 6646, 6651, 6699, 6700, 6702, 6703, 6903, 6984, 7120, 7175, 7260, 7264
cytoreduction, 1855, 2977, 2979, 4422, 4444, 6278, 6280, 6281, 6282, 6285, 6287, 6288, 6289, 6290, 6291, 6292, 6293, 6294, 6295, 6296, 6297, 6298, 6301, 6302, 6306, 6307, 6308, 6309, 6310, 6311, 6312, 6313, 6314, 6315, 6317, 6318, 6322, 6323, 6324, 6874, 6876, 6878, 6879
cytoskeleton, 3012, 3019, 5291, 6980, 6991

D

da Vinci skills simulator, 2779, 3146, 3243
da Vinci surgical system, 3153, 3243, 3255, 4398
da Vinci surgical system, 6774
da Vinci, 691, 692, 693, 694, 695, 696, 697, 698, 699, 701, 702, 712, 715, 1210, 2779, 2780, 3146, 3149, 3152, 3153, 3154, 3155, 3156, 3157, 3238, 3243, 3255, 4147, 4157, 4161, 4173, 4174, 4176, 4179, 4181, 4182, 4184, 4193, 4220, 4223, 4225, 4230, 4235, 4240, 4241, 4254, 4263, 4264, 4292, 4293, 4306, 4313, 4336, 4339, 4370, 4371, 4387, 4395, 4398, 4399, 4406, 4407, 4420, 4423, 4431, 4434, 4447, 4448, 4450, 4451, 4452, 4453, 4458, 4459, 4466, 4468, 4471, 4492, 6393, 6407, 6408, 6409, 6532, 6533, 6534, 6616, 6617, 6758, 6759, 6774, 6783, 6940, 6941
da Vinci® Single-Site Instrumentation kit, 699
da Vinci® Surgical System, 691, 692, 693, 694, 695, 696, 697, 698, 699, 701, 702, 6393
dabigatran, 1864
dacryocystorhinostomy, 1689, 1703, 1704, 2411, 2412
daily cognition, 3906
damage control surgery, 4018, 4019, 6391
damage mechanisms, 3790, 3836
DAS59, 6373, 6378, 6380
data integration, 3799, 3821, 4467
de novo lipogenesis, 5256, 5272, 5273, 5275, 5278, 5284, 5367
DeBakey classification, 4794
debranching, 4771, 4772, 4773, 4774, 4779, 4791, 4796, 5441
debridement, 113, 116, 143, 500, 1237, 1418, 1513, 1526, 1569, 1570, 1571, 1572, 1573, 1574, 2098, 2642, 2643, 2644, 2658, 2659, 2662, 2663, 2665, 2669, 3539, 3540, 3543, 3567, 3569, 3580, 3864, 3996, 4012, 4013, 4021, 4023, 4029, 4030, 4075, 4083, 4618, 4619, 4712, 4713, 4924, 4987, 5431, 5432, 5433, 5435, 5436, 5437, 5438, 5439, 5559, 5577, 5578, 5579, 5582, 5583, 5962, 6195, 6253, 6258, 6262, 6464, 6465, 6570, 6999
decannulation, 1040, 1047, 1049, 6496, 6731, 6733, 6736, 6748, 6781
decellularization, 2983, 2984, 2985, 2986, 2987, 2988, 2991, 2992, 2993, 2994, 2995, 2996, 2997, 2998, 2999, 3000, 3001, 3002, 3003, 3004, 3005, 3006, 3007
DECIMAL, 3862, 3934, 3935, 3937, 3938, 3945, 4064, 4068, 4102, 4115
decision making, 470, 681, 682, 861, 1136, 1231, 1790, 1824, 1844, 1848, 1854, 1867, 1871, 1900, 1904, 2346, 2439, 2443, 2523, 2540, 2548, 2567, 2576, 2597, 3438, 3800, 3839, 3875, 3892, 3893, 3902, 3909, 3943, 3961, 4026, 4097, 4098, 4099, 4100, 4105, 4136, 4467, 4672, 4967, 5822, 5926, 6339, 6340, 6341, 6384, 6386, 6485, 6582, 6638, 6719, 6784, 6820, 7109, 7308

declaration of Helsinki, 1755, 1781, 1796, 1803, 1818, 3224, 6194, 6326, 6863
decompressive hemicraniectomy, 967, 968, 1043, 3777, 3779, 3780, 3818, 3820, 3833, 3848, 3849, 3868, 3945, 3946, 3995, 4007, 4065, 4068, 4079, 4092, 4102, 4108, 4109, 4114, 4115
decompressive laparotomy, 3901, 3914, 3917, 3923, 3924, 3925, 3926, 3927, 3929
DECRA trial, 3950, 3952, 3953, 3954, 3955, 3960, 3961, 3968, 3989, 4047, 4110
DECRA, 3766, 3805, 3859, 3949, 3950, 3951, 3952, 3953, 3954, 3955, 3959, 3960, 3961, 3968, 3969, 3974, 3975, 3976, 3977, 3978, 3979, 3980, 3982, 3983, 3985, 3986, 3989, 4013, 4047, 4051, 4059, 4062, 4065, 4092, 4096, 4102, 4109, 4110, 4115, 4116, 4136
deep sclerectomy, 6889, 6898
deep sedation, 3907, 6655
deep sedation, 972, 995, 1874, 1875, 1876
deep vein thrombosis, 137, 415, 1725, 2312, 3138, 3306, 3892, 4039, 4042, 4505, 4506, 4509, 4530, 4729, 4730, 4731, 4748, 4749, 4958, 4981, 5103, 6240, 6244, 6247, 6248, 7134, 7238, 7248, 7263, 7264, 7267
deep veins, 4729, 4736, 4920, 4948, 4949, 4950, 4952, 5017
deeply hypothermic circulatory arrest, 4762
defibrillation, 1867, 6478, 6496, 6503, 6618, 6745, 7291
deformability, 2257, 2801, 2802, 2826, 2827, 3076, 3077, 3078, 3079, 3084, 3095, 3096, 3098, 3099, 3102, 3103, 3108, 3112
deformity, 5576, 5577, 5578, 5579, 5581, 5582, 5583, 5586, 5597, 5602, 5713, 5733, 5868, 5869, 5876, 5942, 6221, 6222, 6223, 6224, 6230, 6266, 6267, 6272, 6273, 6477, 6666, 6677, 6679, 6683, 6717, 6776, 6828, 6955, 6956, 6957, 6958, 6959
dehiscence, 378, 413, 508, 531, 581, 582, 583, 584, 586, 826, 1467, 1542, 1614, 2312, 2412, 2413, 2624, 2635, 2636, 2642, 2650, 2668, 3017, 3629, 4318, 4425, 4478, 4496, 4512, 4547, 4566, 4567, 4599, 4697, 4704, 4705, 5141, 5437, 5472, 5473, 5476, 5597, 5950, 6003, 6004, 6005, 6008, 6009, 6010, 6182, 6454, 6545, 6567, 6781, 7087, 7117, 7119, 7122
dehydration, 149, 1179, 1184, 1848, 1995, 2000, 2428, 2472, 2489, 2499, 2500, 2519, 2521, 2523, 2524, 2529, 2534, 2546, 2859, 2860, 3268, 3278, 3308, 3313, 3315, 3319, 3329, 3330, 3331, 3420, 3421, 4506, 4879, 4941, 4963, 4977, 5000, 5306, 5309, 5311, 5315, 5326, 5329, 5511, 5923, 6018, 7003, 7022, 7087, 7264
delayed cortical ischemia, 979
delayed union, 90, 131, 133, 134, 3559, 3562, 3566, 3567
DeMeester score, 1896
dementia, 908, 1624, 1838, 1840, 1843, 1844, 1846, 1850, 1855, 1857, 1858, 2108, 2115, 3879, 6247, 7064, 7075, 7076
demineralized bone matrix, 1735, 2308, 2314, 3558, 3559, 3569
dental anxiety, 6333, 6334, 6340, 6342, 6343
dental extractions, 6334
dental office, 1518, 6332
depression, 432, 542, 545, 580, 603, 634, 637, 981, 982, 988, 1041, 1044, 1045, 1065, 1067, 1370, 1606, 1667, 1668, 1669, 1677, 1876, 1877, 1878, 1888, 2095, 2108, 2109, 2121, 2166, 2487, 2499, 2530, 2531, 2537, 3282, 3307, 3309, 3323, 3328, 3418, 3783, 3817, 3832, 3860, 3864, 3890, 3899, 3905, 3915, 3941, 3954, 4035, 4086, 4517, 4588, 4590, 4757, 4843, 5610, 6162, 6185, 6198, 6210, 6331, 6574, 6576, 6687, 6688, 6932, 6934, 7037, 7038, 7041, 7042, 7045, 7047, 7048, 7049, 7050, 7061, 7086, 7130, 7133, 7138, 7139, 7140, 7142, 7143, 7145, 7147, 7148, 7186, 7230, 7237, 7238, 7240, 7241, 7243, 7320, 7325
descending aorta injury, 4781
descending aorta, 272, 1009, 3382, 3598, 3686, 3687, 4753, 4755, 4756, 4757, 4758, 4759, 4761, 4765, 4766, 4769, 4770, 4771, 4777, 4781, 4782, 4783, 4787, 4790, 4796, 4797, 4800, 4801, 4803, 5442, 5443, 5445, 6495, 6566, 6722, 6737, 6745, 6760, 6761, 6766, 6779
desensitization, 2670, 3392, 5463, 5464, 5465, 5467, 7230
destabilization of medial meniscus, 3538, 3542, 3547
DESTINY, 968, 3862, 3935, 3936, 3937, 3938, 3941, 3945, 3946, 3990, 4061, 4064, 4068, 4092, 4097, 4102, 4103, 4109, 4111, 4115, 4116
DESTINY II, 3946, 4061, 4068, 4097, 4103, 4109, 4111, 4116
detection of XFM, 6882
determining hepatic clearance and drug metabolism, 3512
developing countries, 773, 774, 2107, 2708, 3256, 4056, 4067, 4630, 4672, 5557, 5558, 5581, 6341, 6346, 6367, 6369, 6828, 7130
deviated nose, 5481, 5484, 5485
dexamethasone, 443, 1452, 1453, 1462, 1476, 1852, 2533, 2538, 2539, 2726, 3415, 3643, 3728, 3864, 4515, 4516, 4517, 4519, 4520, 4521, 4522, 4524, 4525, 5545, 5628, 5779, 5812, 5813, 5817, 6569, 6570, 6571, 6647, 7087, 7088, 7092, 7094, 7095, 7233, 7241, 7335

dexmedetomidine, 972, 975, 1445, 1450, 1454, 1877, 1878, 1883, 1884, 3274, 3275, 3276, 3284, 3859, 4520, 4591, 4593, 6208, 7090, 7103, 7229, 7233, 7234, 7241, 7242, 7275, 7277, 7278, 7286
diabetes mellitus, 137, 159, 164, 176, 177, 181, 182, 206, 219, 221, 238, 503, 763, 771, 772, 917, 1059, 1258, 1487, 1524, 1570, 1868, 2037, 2105, 2117, 2157, 2158, 2183, 2184, 2677, 2681, 2692, 2729, 2820, 2831, 3558, 3565, 3681, 3721, 3722, 3737, 3739, 3742, 4239, 4353, 4530, 4562, 4617, 4620, 4664, 4765, 4792, 4806, 4876, 4894, 4902, 4933, 4934, 4976, 4980, 4985, 5006, 5230, 5269, 5333, 5387, 5400, 5409, 5415, 5420, 5677, 5789, 6194, 6354, 6585, 6601, 6699, 6702, 6847, 6863, 6988, 7020, 7027, 7134, 7169, 7170, 7175, 7177, 7182
diagnostic imaging, 682, 931, 933, 934, 960, 993, 1059, 1080, 1127, 1145, 1189, 1320, 1364, 2189, 2190, 2277, 3340, 3364, 3684, 5842, 5957, 6046, 6053, 6163, 6655, 6657
diarrhea, 147, 150, 223, 225, 226, 228, 232, 233, 257, 816, 837, 853, 854, 862, 863, 1097, 1102, 1452, 2066, 2074, 2092, 2093, 2108, 2111, 2113, 2115, 2448, 2926, 2929, 3267, 3316, 3317, 3319, 3323, 3325, 3326, 3327, 3330, 3651, 4490, 4541, 4562, 4716, 5618, 5627, 5953, 5957, 5969, 6018, 6184, 6345, 6347, 6349, 6359, 6361, 6362, 7002
dichotomized, 3936, 3937, 3938, 3941, 3973, 3979, 3983, 4100, 4111, 4126, 7057, 7059, 7065, 7073
diclofenac sodium, 6191, 6192, 6193, 6195, 6197, 6198, 6200
dicrotic wave, 3801, 3886
DIEP flap, 1363, 1366, 1407, 1408, 1411, 1412, 1413, 1414, 1415, 1416, 1417, 1423, 1424, 1425, 2551, 2552, 2554, 2555, 2558, 2559, 2560, 2583, 2585, 2589, 2591, 2592, 2593, 2594, 2595, 2603, 2604, 2605, 2608, 2613, 2637, 2639, 2641, 2644, 2645, 2646, 2647, 2667, 2674, 2675
diffuse injuries on FLAIR, 4120
DiGeorg syndrome, 4787
digital subtraction angiography, 882, 946, 950, 951, 953, 956, 964, 1002, 1069, 1079, 1081, 1088, 1089, 1612, 1622, 1653, 1654, 1663, 3361, 3363, 3929, 4721, 4734, 4735, 4746, 4872, 4884, 4886, 4903, 6090, 6091, 6094
dilates, 4827, 4838, 6588
dimethylfumarate, 3791
direct costs, 2691, 4402
direct iliac endarterectomy, 4824, 4825
direct PEJ, 1896, 1960, 2003
direct percutaneous endoscopic jejunostomy, 1834, 1866, 1888, 1900, 1922, 1947, 1953, 1954, 1955, 1960, 1970, 2006, 2007, 2021
disabling claudication, 4818
disc herniation, 720, 3539, 5572, 5592, 6181, 6204, 6213
discomfort, 149, 155, 443, 475, 522, 541, 563, 604, 616, 619, 625, 674, 728, 792, 1241, 1325, 1435, 1439, 1440, 1441, 1444, 1446, 1467, 1496, 1498, 1499, 1510, 1511, 1852, 1878, 2045, 2061, 2083, 2456, 2464, 2474, 2478, 2491, 2499, 2520, 2521, 2584, 2585, 2594, 2618, 2661, 2672, 2786, 3248, 3290, 3297, 3311, 3434, 3445, 4086, 4245, 4563, 4566, 4615, 4724, 4725, 4727, 4729, 4730, 4731, 4737, 4875, 4903, 4953, 5267, 5368, 5618, 5752, 6148, 6178, 6234, 6328, 6527, 6570, 6695, 6774, 6782, 7042, 7046, 7085, 7248, 7316, 7325
dislocation, 131, 148, 805, 1010, 1515, 1526, 1545, 1688, 1689, 1815, 1816, 1817, 1819, 1820, 1824, 1825, 1826, 1827, 1828, 1829, 1921, 1922, 2196, 2234, 2251, 2252, 2257, 2263, 2264, 2265, 2291, 2294, 2298, 2301, 2325, 2414, 2500, 3161, 3182, 3285, 3564, 4786, 4893, 5522, 5867, 5868, 5869, 5871, 5874, 5875, 5876, 5879, 5880, 6883, 6884, 7216
dislodged, 2019, 2022, 2025, 2092, 2098, 2099, 3882, 3932, 4713, 6488
dislodgement, 1848, 1922, 1943, 1952, 1969, 1980, 1988, 1998, 2003, 2025, 2026, 2027, 2035, 2057, 2059, 2060, 2061, 2062, 2064, 2073, 2078, 2087, 2099, 2100, 2102, 3631, 3882, 6002, 6495, 6613, 6675, 6678, 6793, 6795
disorder of sex development 46XX, 1600
disorder of sex development, 1599, 1600, 5758
displacement, 10, 17, 23, 79, 90, 92, 97, 100, 259, 282, 344, 441, 475, 486, 581, 586, 671, 705, 782, 1012, 1163, 1171, 1245, 1252, 1255, 1278, 1309, 1313, 1318, 1370, 1373, 1479, 1515, 1680, 1686, 1694, 1699, 1815, 1826, 1828, 1829, 1866, 1960, 1961, 1963, 1966, 2196, 2212, 2298, 2433, 2465, 3089, 3285, 3387, 3573, 3852, 4012, 4046, 4928, 5237, 5327, 5485, 5603, 6099, 6175, 6210, 6230, 6234, 6252, 6442, 6679, 6737, 6958, 7118, 7175, 7311, 7314
distress, 522, 523, 632, 634, 636, 637, 638, 639, 640, 1528, 1529, 1552, 1606, 1690, 1691, 1704, 2057, 2167, 2521, 2524, 2585, 2588, 2593, 2710, 2803, 2853, 3219, 3247, 3248, 3249, 3250, 3261, 3269, 3279, 3280, 3285, 3290, 3292, 3297, 3309, 3310, 3311, 3421, 3423,3434, 3445, 3666, 3826, 3831, 3888, 3905, 4058, 4098, 4110, 4113, 4812, 4836, 4980, 5007, 5457, 5747, 5756, 6185, 6189, 6332, 6378, 6380, 7038, 7086, 7130, 7138, 7139, 7146, 7164, 7165
diurnal IOP curve, 6892
diverticulum of Kommerell, 4782, 4783, 4784

diverting stoma, 6005
DNA vaccine(s), 3115, 3119, 3120, 3126, 3127, 3128
DNA, 2110, 2113, 2350, 2351, 2879, 2964, 2966, 2986, 2987, 2988, 2998, 2999, 3009, 3014, 3021, 3036, 3115, 3116, 3117, 3118, 3119, 3120, 3122, 3123, 3125, 3126, 3127, 3128, 3217, 3263, 3322, 3351, 3428, 3540, 3573, 3650, 3651, 3733, 3791, 5257, 5259, 5278, 5279, 5393, 5459, 5581, 5684, 6347, 6357, 6418, 7225
docking, 122, 124, 128, 130, 131, 1716, 4163, 4174, 4175, 4176, 4192, 4203, 4221, 4240, 4241, 4242, 4245, 4247, 4249, 4252, 4253, 4254, 4255, 4294, 4306, 4312, 4320, 4385, 4404, 4405, 4406, 4407, 4408, 4449, 4466, 4472, 4476, 4487, 6778
domain optical coherence tomography, 1717, 3093, 6894
dorzolamide/timolol fixed combination, 6886, 6887
double aortic arch, 4756, 4757, 4758
double lumen aorta, 4758, 4759
double needle, 6446, 6448
double-PEG gastropexy, 1984
doxapram, 3307
doxycycline, 229, 3543, 3547, 3552, 4688, 4713
DREAM, 2134, 4812, 4838
dressings, 107, 128, 129, 131, 407, 414, 500, 518, 622, 623, 1746, 1969, 2047, 2086, 2631, 2669, 3016, 3196, 3924, 4018, 4668, 4682, 4694, 4696, 4698, 4709, 4710, 4711, 4712, 4713, 4714, 4715, 4716, 4717, 4719, 4987, 6259
drug disposition, 3479, 3480, 3481, 3485, 3487, 3500, 3510, 3513, 3514
drug-eluting stents, 4892, 4893, 5916
DSD 46XX, 1599, 1600, 1601, 1602, 1603, 1604, 1605, 1607
dual-innervation, 1665, 1666, 1672
ductus arteriosus, 4754, 4757, 4758, 4759, 4782, 4784, 4785, 4786, 4787, 4788, 4789, 4790, 4802, 7270
dumping syndrome, 147, 158, 257, 259, 759, 837, 2719, 2730, 2733, 2743, 2744, 4546, 5086, 5180, 5390, 6356, 6361, 7002, 7006, 7012, 7014
duodenal switch, 140, 144, 157, 158, 202, 237, 774, 791, 801, 808, 811, 814, 818, 819, 820, 851, 865, 875, 1565, 2174, 2184, 2678, 2686, 2695, 2706, 2730, 2743, 2745, 2747, 2832, 2833, 2837, 4314, 4316, 4551, 4552, 4579, 4585, 5015, 5203, 5227, 5344, 5385, 5390, 5391, 5392, 5396, 6355, 6360, 6368, 6370, 7005, 7006, 7007, 7169, 7170, 7249
duodenojejunal bypass, 2729, 2736, 2743, 2745, 2746
duodenojejunostomy bypass, 2729
duplex ultrasonography, 1081, 1083, 1084, 1088, 4721, 4734, 4746, 4749, 4875, 4886, 4948
dura scar, 5572
duraplasty, 2426, 3769, 3771, 3958, 3970, 3972, 3988, 3989, 3995, 3996, 3997, 3998, 3999, 4000, 4001, 4003, 4004, 4006, 4007, 4035, 4048, 4050, 4060
dV-Trainer, 2780, 3155, 3238, 3243
DWI infarct volume, 3937
dysplasia, 31, 43, 47, 847, 1104, 1258, 1351, 1817, 1818, 1819, 1825, 1828, 1829, 1886, 1901, 2233, 2240, 2241, 2245, 2246, 2249, 2250, 2252, 2260, 2265, 2280, 2283, 2284, 2291, 2304, 2901, 4379, 4477, 4784, 4785, 4786, 4804, 4842, 4902, 5515, 5516, 5522, 5523, 5533, 5534, 5535, 5536, 5686, 5776, 5784, 5785, 5867, 5868, 5875, 5984, 5989, 5997, 5998, 6958

E

early and delayed injury, 905
early extubation, 6726, 7157, 7162, 7167, 7274, 7277, 7278
early postoperative period, 143, 147, 444, 1571, 1724, 1757, 1773, 1999, 2742, 3307, 3329, 4522, 4540, 4607, 4826, 4978, 4979, 4980, 4982, 4985, 5000, 5840, 6294, 6319, 6866, 6867, 6902, 6903, 6904, 6905, 7000, 7073
early vascular complications, 4981
eating behaviors, 7130, 7137, 7138, 7139, 7145
eating disorders, 843, 870, 1766, 2121, 2694, 5230, 6358, 6369, 7002, 7129, 7132, 7137, 7138, 7140, 7142, 7143, 7145, 7149
echocardiogram, 1725, 1873, 4189, 4190, 4194, 5102, 6486, 6789, 6798, 6819, 6853, 7298
echocardiography, 1873, 1881, 2489, 2824, 2853, 3338, 3340, 3403, 3584, 3587, 3606, 3607, 3638, 4198, 4202, 4203, 4206, 4207, 4761, 4766, 4776, 4784, 4785, 4801, 4804, 4886, 5881, 5883, 5884, 5885, 5886, 5894, 5901, 5903, 5908, 6461, 6469, 6470, 6471, 6474, 6477, 6479, 6480, 6484, 6495, 6501, 6513, 6522, 6555, 6617, 6713, 6717, 6725, 6726, 6733, 6734, 6744, 6745, 6757, 6758, 6770, 6775, 6789, 6790, 6817, 6821, 6827, 6833, 6860, 6861, 6868, 7076
ectopic models, 3562
ectropion, 378, 380, 383, 384, 6439, 6449, 6451
effectiveness of the treatment, 1497, 1498, 1501
efficiency, 90, 103, 662, 684, 685, 689, 843, 844, 854, 1096, 1323, 1436, 1444, 1446, 1470, 1581, 1584, 1766, 1769, 1772, 1773, 1774, 1811, 2143, 2419, 2588, 2768, 2769, 2793, 2992, 3002, 3125, 3130, 3152, 3210, 3246, 3342, 3355, 3374, 3522,

3751, 4261, 4265, 4266, 4363, 4369, 4404, 4405, 4406, 4424, 4431, 4466, 4978, 4979, 5467, 5890, 5892, 5901, 6118, 6122, 6123, 6307, 6333, 6361, 6408, 6475, 6590, 6636, 6714, 6783, 6916, 7151, 7154, 7155, 7216, 7225, 7316
Egypt, 2692, 2694, 3159, 3162, 3163, 4780
elastance function, 3452, 3453, 3454
elasticity, 6, 10, 71, 79, 344, 345, 364, 402, 565, 576, 883, 907, 983, 1378, 2253, 2956, 2988, 3001, 3078, 3084, 3356, 3363, 3451, 3541, 3547, 3548, 4996, 5311, 5337, 5338, 5511, 6231, 6330, 6416
electrical injury, 5432, 5434, 5435, 5438, 5440
electrocardiogram, 1872, 1876, 1880, 3277, 3338, 3343, 3375, 3376, 3402, 3405, 3420, 3422, 3637, 4872, 4879, 6832, 6833
electrocautery, 364, 444, 1409, 1527, 1866, 1867, 2091, 2343, 2493, 2494, 2497, 2499, 2501, 2502, 2506, 2507, 2508, 2510, 2515, 2516, 2519, 2520, 2521, 2523, 2525, 2527, 2534, 2784, 3017, 4077, 4194, 4203, 4204, 4205, 4223, 4230, 4252, 4430, 5926, 6092, 6462, 6562, 6594, 6609, 6667, 6791, 6941, 6957, 6959
electrocoagulation, 1886, 6029, 6031, 6033, 6038, 6042
electroencephalography, 995, 3402, 3815, 3832, 3889, 5777, 5780, 5784, 7075, 7076, 7215, 7216
electrolytes disorders, 3314
electrolytes, 971, 973, 1602, 2820, 3276, 3278, 3308, 3313, 3314, 3316, 3317, 3329, 3330, 3331, 3333, 3481, 3484, 3895, 4024, 4879, 4882, 4886, 4939, 5656, 5956, 6013, 7277, 7286
electromagnetic tracking systems, 683
electron microscopy, 488, 2988, 3059, 3573, 3695, 3786, 3837, 3840, 5291, 5307, 5311, 5702, 5707, 6593
electron transport chain, 3782, 3783, 3786, 3787, 3788, 3789, 3790
electrophysiological monitoring, 999
electrophysiology, 717, 957, 961, 3478, 3815, 3839
electrosurgery, 1867, 2498, 2504, 2505, 2511, 2516, 4242, 4247, 4255
elephant trunk procedure, 4765, 4769, 4770, 4777, 4806
elephant trunk, 4765, 4769, 4770, 4771, 4774, 4777, 4778, 4779, 4791, 4806, 6470
embolectomy, 4741
embolism, 137, 141, 142, 143, 145, 157, 215, 268, 290, 296, 318, 321, 343, 346, 414, 420, 531, 1012, 1038, 1203, 1444, 1451, 1587, 1588, 1644, 1661, 3065, 3191, 3306, 3932, 4039, 4195, 4390, 4529, 4725, 4762, 4763, 4777, 4840, 4852, 4863, 4864, 4877, 4879, 4893, 4898, 4901, 4905, 4919, 4927, 4979, 4984, 5919, 6089, 6226, 6243, 6248, 6259, 6491, 6492, 6539, 6556, 6683, 6769, 6826, 6833, 6999, 7060, 7075, 7076, 7077, 7079, 7212, 7214, 7324
emesis, 1449, 1450, 1452, 2011, 2497, 2719, 3396, 3400, 3404, 4512, 4515, 4516, 4524, 5746, 7087, 7089, 7090, 7092, 7094
encapsulation, 2984, 3721, 3722, 3723, 3724, 3728, 3730, 3731, 3736, 3737, 3739, 3740, 3741, 3743, 3744
encephaloceles, 1692, 1693, 1694, 1695, 1705, 1706, 4036
end tidal CO2, 1876, 1883, 3807, 3859, 3884
endarterectomy, 1089, 4721, 4723, 4742, 4743, 4821, 4824, 4841, 4843, 4849, 4850, 4851, 4856, 4857, 4858, 4859, 4860, 4861, 4862, 4863, 4864, 4865, 4866, 4867, 4868, 4869, 4875, 4879, 4885, 4887, 4894, 4897, 4909, 4999, 5011, 7219, 7220, 7221
endoballoon, 4190, 6734, 6736, 6737, 6852
endobronchial ultrasound, 1721, 2389, 2390, 2398, 2399, 2400, 2402
endobronchial valves, 2389, 2390, 2393, 2397, 2400, 2401
endochondral ossification, 3545, 3561, 3567, 3571, 3574
endoclip technique, 1966
end-of-life, 1848, 4136, 6382, 6385, 6387, 6388, 6881, 6893
endoleak, 1081, 1082, 1086, 1087, 1090, 4773, 4774, 4784, 4837, 4838, 4893
endoluminal, 858, 1995, 2004, 2687, 2791, 2792, 2793, 3131, 3360, 4585, 4941, 4945, 5100, 5943, 6012, 6983, 6990
endometrial cancer, 698, 714, 3136, 4399, 4400, 4401, 4402, 4403, 4404, 4405, 4407, 4408, 4409, 4410, 4411, 4412, 4418, 4419, 4420, 4422, 4432, 4433, 4434, 4435, 4436, 4437, 4438, 4441, 4442, 4443, 4445, 6277, 6407, 6408
endometrioma, 4490, 4493, 6031, 6032, 6033, 6034, 6035, 6037, 6038, 6039, 6040, 6041
endometriosis, 1096, 3149, 3153, 4471, 4477, 4483, 4489, 4490, 4491, 4492, 4493, 4494, 4497, 6029, 6030, 6031, 6032, 6035, 6037, 6038, 6040, 6041, 6042, 7119, 7125
endometrium, 1601, 2968, 3321, 4407, 4486, 4487, 4489, 4490, 5757, 6304, 7121, 7124
EndoSAMURAI®, 703
endoscope, 366, 374, 484, 694, 700, 701, 703, 704, 706, 716, 728, 742, 788, 789, 792, 957, 958, 963, 1326, 1335, 1337, 1483, 1648, 1681, 1682, 1832, 1833, 1903, 1908, 1911, 1913, 1914, 1916, 1917, 1923, 1924, 1927, 1936, 1938, 1940, 1941, 1942, 1944, 1948, 1950, 1951, 1962, 1963, 1964, 1965,

1966, 1967, 1968, 1986, 1992, 1996, 1997, 1998, 2002, 2003, 2014, 2017, 2020, 2021, 2044, 2045, 2046, 2069, 2099, 2404, 2785, 2786, 3131, 3132, 3389, 4147, 4204, 4206, 4207, 4210, 4242, 4452, 4476, 5303, 5405, 6061, 6089, 6090, 6101, 6102, 6109, 6118, 6121, 6122, 6210, 6211, 6667, 6670, 6681, 6682, 6683, 6745, 6749, 6763, 6906, 7329
endoscopic mucosal resection, 703, 1886
endoscopic procedure, 354, 691, 759, 850, 1235, 1535, 1854, 1862, 1863, 1866, 1867, 1869, 1879, 1908, 1922, 1960, 1967, 1983, 2033, 2055, 2058, 2067, 2074, 2750, 3243, 4177, 5403, 5458
endoscopic retrograde cholangiopancreatography, 146, 1863, 1996, 2075, 4540, 6907, 7001
endoscopic sinus surgery, 1679, 1682, 1702, 2403, 2404, 2406, 2407, 2408, 2409, 2417, 2418, 2419, 2423, 2427, 2434, 2437, 2439, 2455, 2459, 2460
endoscopic surgery, 680, 700, 710, 711, 712, 715, 716, 1536, 1679, 2009, 2022, 2099, 2404, 2405, 2409, 2410, 2420, 2423, 2777, 2785, 2787, 2790, 3151, 3156, 4199, 4448, 6105, 6682
endoscopic ultrasound (EUS) without fine needle aspiration (FNA), 1863
endoscopic ultrasound, 1288, 1289, 1291, 1293, 1294, 1333, 1334, 1336, 1338, 1863, 1898, 1998, 2017, 2021, 2402, 4160, 4262, 4276, 5835
endoscopic-assisted minimally invasive craniectomy (EAC), 6667
endoscopic-laparoscopic interdisciplinary training entity (ELITE), 2780
endoscopic-surgery, 6757
endotension, 4837
endothelial progenitor cells, 2984, 2997, 3338, 3358, 3362, 3566, 3571
endothelium-derived P-selectin, 3076
EndoTower, 2779
endotracheal suctioning, 3890, 3912
endovascular aneurysm repair, 1080, 1084, 1086, 1088, 1090, 4805, 4812, 4836, 4838, 4845, 4931
endovascular intervention, 1002, 1014, 1080, 4038, 4742, 4759, 4774, 4784, 4786, 4791, 4795, 4800, 4802, 4844, 4856, 4885, 4892, 4893, 4938, 4992, 5008, 5899
endovascular method, 4791, 4795
endovascular techniques, 1611, 4057, 4058, 4775, 4850, 4856, 4871, 4875, 4897, 4900, 5011, 7299
endovascular treatment, 884, 919, 945, 946, 952, 954, 955, 1001, 1012, 1014, 1015, 1016, 1017, 1027, 1028, 1031, 3864, 3944, 3945, 4066, 4721, 4723, 4738, 4739, 4746, 4800, 4806, 4810, 4811, 4813, 4819, 4821, 4831, 4834, 4837, 4843, 4844, 4863, 4864, 4869, 4871, 4875, 4878, 4879, 4890, 4892, 4893, 4897, 4900, 4904, 4930, 4932, 4940, 4942, 6090, 6091, 6104, 6106, 6107, 6744
endovenous ablation procedures, 4958
endovenous heat-induced thrombosis, 4961
endovenous laser therapy, 611, 615, 616, 625, 4934, 4960
endovenous laser treatment, 4957, 4959
endovenous steam ablation, 4958, 4960
end-to-end, 1412, 1620, 1670, 1673, 2730, 3188, 3587, 3591, 3592, 3594, 3595, 3624, 4330, 4789, 4822, 4823, 4858, 4966, 4998, 5002, 5748, 5827, 5839, 5942, 5954, 5973, 5974, 5976, 5986, 5996, 5997, 6016, 7335
energy metabolism, 249, 964, 991, 1510, 2110, 2178, 2181, 2182, 3321, 3438, 3524, 3707, 3711, 3781, 3782, 3783, 3785, 3786, 3787, 3788, 3789, 3790, 3791, 3792, 3797, 3835, 3841, 3842, 3847, 6980, 7194
enhanced recovery after surgery, 1773, 1778, 2708, 2710, 2714, 2723, 2724, 2727, 4555, 4556, 5016, 5064, 5086, 5102, 5165, 5230, 5840, 7238
enteral feeding, 1039, 1774, 1831, 1837, 1844, 1849, 1850, 1869, 1893, 1900, 1905, 1917, 1921, 1923, 1930, 1948, 1950, 1957, 1960, 1970, 1995, 2000, 2011, 2019, 2023, 2024, 2034, 2035, 2036, 2060, 2074, 2077, 2088, 2092, 2093, 2095, 2098, 3900, 3901, 4024, 4567, 4627, 4632
enteral nutrition, 997, 1773, 1774, 1835, 1837, 1838, 1840, 1848, 1849, 1857, 1869, 1888, 1931, 1951, 1955, 1957, 1970, 1994, 2000, 2009, 2010, 2023, 2025, 2034, 2036, 2039, 2067, 2078, 2080, 2089, 2449, 3314, 3330, 3899, 4565, 4572, 4581, 4627, 4629, 4630, 4631, 5950, 6008, 6013, 6017, 6024, 6026
enterocutaneous fistula, 1952, 2064, 3925, 5955, 5956, 5958, 5963, 6001, 6002, 6003, 6006, 6009, 6011, 6012, 6021
enterocutaneous fistulae, 5955, 5956, 6009, 6021
enteroenteric, 1103, 5956, 5958, 5984, 6020, 6027
enterography, 1104, 1105, 1107, 1108, 5956, 5961, 6008
enteropathy-associated T-cell lymphoma, 5618, 5630
eosinophilic esophagitis, 1890, 1902
epidemiology, 249, 285, 286, 287, 288, 326, 477, 492, 913, 1108, 1570, 1626, 1789, 1858, 1900, 1901, 2596, 2598, 2744, 3713, 3987, 4005, 4045, 4056, 4057, 4064, 4066, 4167, 4257, 4388, 4458, 4541, 4543, 4570, 4611, 4615, 4619, 4620, 4621, 4641, 4651, 4671, 4673, 4683, 4684, 4720, 4747, 4806, 4827, 4834, 4874, 4881, 4890, 4905, 4929, 5265, 5361, 5410, 5427, 5448, 5454, 5455, 5479, 5592, 5627, 5630, 5662, 5945, 5993, 6058, 6079,

6086, 6105, 6236, 6578, 6628, 6771, 6893, 6895, 6936, 6990, 7125, 7149, 7258, 7261, 7313
epidural, 255, 272, 275, 296, 348, 993, 1168, 1179, 1448, 1458, 1569, 1571, 1573, 1724, 3853, 3864, 3883, 3903, 3914, 4017, 4020, 4025, 4076, 4083, 4095, 4112, 4129, 4131, 4524, 4559, 4562, 4563, 4592, 4655, 4796, 4889, 5457, 5459, 5460, 5461, 5572, 5575, 5576, 5777, 5840, 6137, 6163, 6164, 6169, 6170, 6172, 6177, 6178, 6179, 6180, 6181, 6182, 6203, 6206, 6208, 6209, 6210, 6211, 6213, 6227, 6242, 6484, 6667, 6724, 6957, 6958, 7229, 7231, 7234, 7243, 7326
epiglottectomy, 1535
epileptic seizures, 927, 928, 931, 932, 939, 991, 992, 995, 1027, 1028, 1029, 1030, 1031, 1043, 1767
epinephrine, 508, 519, 520, 533, 994, 1207, 1214, 1446, 1455, 1525, 1684, 1687, 2500, 2679, 2800, 3277, 3477, 4075, 6195, 6690, 6691, 7280, 7281
epiphora, 1689, 1690, 1694, 1695, 2411, 2412, 2431, 3162, 6439
epitheliotropism, 5619, 5626
equine, 3334, 3541, 3550, 3551, 3553, 3554, 6505, 6540
erectile function, 696, 2619, 3141, 4346, 6147, 6154, 6156, 6157
erection, 1603, 3393, 3394, 3402, 3404, 3410, 3658, 4816, 6147, 6154, 6939, 6942, 6946
erosions, 158, 787, 795, 1838, 1890, 2028, 4245, 5940, 5952
erythema, 143, 366, 571, 616, 621, 622, 1365, 1518, 1571, 1861, 1891, 2060, 2084, 2642, 2661, 2665, 2668, 3012, 3281, 4618, 4619, 4674, 4731, 4953, 4967, 5368, 5374, 5791, 5942, 6181, 6702, 6999
erythrocyte aggregation, 2801, 2802, 3079, 3080, 3098, 3099, 3112
erythromycin, 983, 1899, 3861, 4565, 4638
ESCAPE, 3933, 4066
esophageal adenocarcinoma, 1314, 1885, 1886, 1887, 1901, 4167, 4575
esophageal Varices, 1301, 1892
esophagectomy, 1486, 1559, 1887, 1951, 1954, 1955, 2006, 2036, 4159, 4160, 4162, 4163, 4164, 4165, 4166, 4167, 4168, 4169, 5943
esophagitis, 149, 153, 1302, 1304, 1888, 1889, 1890, 1900, 1901, 1902, 2067, 2684, 2736, 2742, 2747, 4575, 4576, 4578, 5940
esophagogastroduodenoscopy, 265, 1309, 1314, 1334, 1923, 2736, 4174, 5939
esophagus, 148, 256, 702, 704, 800, 806, 812, 833, 834, 847, 1197, 1295, 1296, 1297, 1298, 1299, 1300, 1301, 1305, 1308, 1309, 1310, 1311, 1312, 1313, 1315, 1316, 1318, 1320, 1323, 1336, 1767, 1772, 1832, 1885, 1886, 1887, 1888, 1889, 1890, 1891, 1895, 1896, 1900, 1901, 1902, 1908, 1913, 1914, 1916, 1917, 1932, 1944, 1963, 1965, 1977, 1978, 1979, 2012, 2017, 2018, 2019, 2684, 2686, 2735, 2742, 2747, 2752, 2763, 2776, 2832, 2834, 2835, 2870, 2871, 3190, 3191, 3387, 3388, 4159, 4161, 4163, 4164, 4167, 4168, 4171, 4173, 4174, 4177, 4178, 4179, 4180, 4182, 4556, 4570, 4575, 4577, 4578, 4579, 4756, 4762, 4781, 5064, 5068, 5078, 5101, 5114, 5115, 5116, 5180, 5181, 5360, 5363, 5405, 5513, 5939, 5940, 5941, 5942, 5943, 5945, 5946, 5947, 6996
estimated blood loss, 517, 520, 521, 2347, 3139, 3140, 3142, 3143, 4166, 4263, 4286, 4319, 4332, 4334, 4354, 4355, 4356, 4377, 4404, 4408, 4410, 4414, 4419, 4472, 4561, 5788, 5793, 5860, 6005, 6292, 6306, 6310, 6318, 6667, 6669
ETCO2, 1876, 3878, 3890, 3893, 3899
ethical considerations, 1923, 3245, 3250, 4115, 4117
ethic(s), 17, 199, 492, 1064, 1600, 1603, 1605, 1635, 1755, 1781, 1796, 1803, 1818, 1844, 1845, 1846, 2783, 2790, 2791, 3167, 3202, 3224, 3232, 3234, 3237, 3241, 3247, 3248, 3249, 3251, 3253, 3254, 3255, 3256, 3257, 3258, 3288, 3311, 3440, 3443, 3659, 3943, 4101, 4105, 4107, 4116, 4117, 4467, 6375, 6381, 6382, 6383, 6385, 6386, 6387, 6388, 6863, 6915, 7305, 7306, 7309
etiopathogenesis, 277, 302, 3429, 3432, 4787, 4793, 5247, 5255, 5267
etomidate, 1450, 7275
Europe, 286, 472, 478, 594, 599, 878, 914, 918, 919, 982, 1542, 1789, 1869, 2338, 2428, 2445, 2567, 3031, 3049, 3142, 3159, 3165, 3169, 3173, 3181, 3187, 3189, 3192, 3193, 3195, 3197, 3252, 3492, 3495, 3974, 4066, 4105, 4108, 4116, 4199, 4623, 4683, 4725, 4815, 4864, 5266, 5269, 5345, 5628, 5780, 5800, 5803, 5814, 6144, 6166, 6206, 6505, 6538, 6728, 6846, 6885, 6893, 6987, 7108
European Cooperative Acute Stroke Study 3 (ECASS III), 3933
Eurotherm, 3951
euthanasia, 2970, 3248, 3261, 3284, 3285, 3292, 3296, 3298, 3422, 3429, 3434
EVAR I, 4838
eversion carotid endarterectomy, 4857, 4860, 4862, 4863, 4868
evidence based, 532, 2713, 2715, 4516, 4556, 4593, 6382, 7244
evidence-based practice, 446, 2536, 6214, 6251, 6262, 6384, 6385
ex vivo patient-derived, 2939, 2948
ex vivo, 350, 534, 702, 704, 1588, 1591, 1596, 2774, 2775, 2784, 2790, 2926, 2939, 2943, 2944, 2946, 2948, 2949, 2962, 2964, 2977, 2993, 3005, 3024,

3036, 3039, 3046, 3051, 3052, 3053, 3054, 3055, 3056, 3057, 3061, 3062, 3063, 3064, 3065, 3066, 3068, 3070, 3071, 3086, 3097, 3145, 3240, 3286, 3293, 3340, 3344, 3345, 3351, 3357, 3359, 3368, 3436, 3437, 3488, 3497, 3498, 3499, 3500, 3503, 3505, 3509, 3519, 3520, 3528, 3529, 3533, 3534, 3537, 3541, 3554, 3573, 3612, 3655, 3658, 3754, 3759, 3760, 3836, 6413, 6420, 6422
excessive fat tissue, 2831
excitotoxicity, 3767, 3788, 3797, 3837, 3841, 4096, 7210, 7211, 7217
excluded stomach, 142, 804, 833, 836, 851, 852, 1996, 1997, 1998, 2005, 2006, 21685043, 5044, 5084, 5226
exercise programs, 7186, 7189
exfoliation (or pseudoexfoliation) material, 6882
exfoliation syndrome, 6881, 6893, 6894, 6895, 6896, 6897, 6898, 6899
exfoliative glaucoma, 6881, 6893, 6894, 6895, 6896, 6897, 6898
experiment animals, 3313, 3314, 3315, 3316, 3317, 3329, 3331, 3332
experiment, 8, 10, 13, 17, 22, 23, 122, 123, 124, 654, 659, 660, 661, 662, 702, 703, 745, 881, 1720, 1744, 2783, 2881, 2978, 3009, 3017, 3026, 3120, 3157, 3198, 3213, 3218, 3246, 3247, 3280, 3289, 3308, 3309, 3313, 3314, 3315, 3316, 3317, 3329, 3331, 3332, 3379, 3398, 3414, 3416, 3431, 3433, 3456, 3457, 3466, 3469, 3472, 3473, 3584, 3627, 3628, 3638, 3655, 3658, 3673, 6331, 6608, 7074, 7101, 7122
experimental drugs, 3220, 5419
experimental laparoscopy, 2762
experimental SAH, 1069
experimental study, 1, 6, 25, 27, 30, 64, 76, 121, 134, 293, 343, 1073, 1075, 1750, 1752, 2321, 2329, 2603, 2673, 2792, 2833, 2911, 3372, 3445, 3650, 3698, 3704, 3708, 3717, 3766, 3778, 3779, 3849, 4692, 5432, 5691, 6227, 6710, 7041, 7118, 7121, 7191, 7261
experimental surgery, 2775, 2787, 2789, 2831, 3009, 3014, 3018, 3115, 3159, 3237, 3238, 3239, 3240, 3241, 3245, 3246, 3247, 3248, 3250, 3251, 3252, 3257, 3258, 3300, 3303, 3304, 3308, 3313, 3317, 3330, 3332, 3337, 3339, 3349, 3359, 3375, 3413, 3414, 3424, 3427, 3428, 3429, 3430, 3432, 3434, 3436, 3439, 3440, 3442, 3444, 3642, 3645
experimental wound models, 3009
EXTEND-IA, 3933
external bolster, 2028, 2029, 2030, 2080, 2081, 2084, 2085, 2095
external bumper, 1915, 1917, 1928, 1929, 1943, 1950, 1963, 1969, 2029, 2030, 2031, 2047, 2083, 2084
external carotid arteries, 4852, 4917
external ventricular drain, 938, 943, 983, 1020, 1021, 1023, 1024, 1620, 3801, 3802, 3855, 3869, 3883, 3884, 3897, 3911, 3913
extracapsular tonsillectomy, 2473, 2483, 2484, 2492, 2493, 2495, 2497, 2502, 2505, 2507, 2513, 2514, 2519, 2521
extracellular matrix molecules, 7120
extracellular matrix, 76, 1378, 1731, 1732, 1734, 2943, 2983, 2985, 3001, 3002, 3004, 3012, 3020, 3021, 3538, 3539, 3543, 3546, 3549, 3554, 3567, 3570, 3572, 4674, 4792, 5254, 5289, 5290, 5659, 5717, 5985, 6554, 6888, 6977, 6978, 6980, 7120, 7123
extracorporeal circulation, 4761, 4762, 4763, 4765, 4766, 4768, 4770, 4773, 4774, 4794, 4797, 4799, 6538, 6542, 6846, 7157, 7160, 7161, 7297, 7298
extracranial meningioma, 5449, 5450, 5453, 5454
extrapleural pneumonectomy, 1721, 1722, 1726, 1727
extravascular fluids, 3314
extraventricular drainage, 3911, 3950
extubation, 210, 213, 214, 218, 1449, 2492, 2499, 2545, 2741, 3618, 3904, 5545, 6476, 6477, 6481, 6714, 6726, 7160, 7161, 7162, 7163, 7164, 7166, 7167, 7277
ex-vivo liver perfusion model, 3509, 3510
ex-vivo machine perfusion, 3043
ex-vivo perfusion, 2987, 2992, 3061, 3480

F

FACE-Q, 6373, 6377, 6380
facial fractures, 1528, 4024
facial nerve, 355, 356, 357, 360, 362, 371, 398, 399, 400, 401, 404, 417, 1528, 1665, 1666, 1667, 1668, 1669, 1670, 1671, 1672, 1673, 1674, 1675, 1676, 1677, 2561, 3191, 5518, 6437, 6438, 6445, 6446, 6447, 6450, 7319, 7323, 7324, 7328, 7333, 7334, 7335, 7341, 7342
facial pain, 1685, 1688, 1697, 1700, 2379, 2431, 2436, 7323
facial reanimation, 1666, 1670, 1672, 1673, 1674, 1675, 1676, 1677, 6450, 7341, 7342, 7343
facial transplantation, 3647, 3653, 3656, 3657
fail back surgery syndrome, 6203
failed back surgery syndrome, 6161, 6162, 6168, 6169, 6170, 6171, 6172, 6187, 6212, 6213, 6214
failing heart, 2862, 6618

false aneurysm, 4827, 4828, 4882, 4884, 4932, 4942, 4975, 4995, 4996, 6567
familial adenomatous polyposis, 1895, 3442
Fas Binding Factor 1, 4792
fasting, 169, 181, 186, 189, 191, 192, 193, 195, 196, 197, 198, 199, 200, 201, 203, 222, 226, 228, 257, 260, 764, 765, 766, 767, 769, 784, 785, 787, 1472, 1491, 1506, 1602, 1773, 1908, 1917, 2004, 2105, 2119, 2128, 2134, 2141, 2142, 2143, 2144, 2146, 2147, 2148, 2149, 2150, 2151, 2152, 2153, 2159, 2160, 2162, 2167, 2174, 2177, 2178, 2185, 2453, 2681, 2705, 2717, 2725, 2732, 2734, 2741, 2808, 3276, 3303, 3307, 3329, 3389, 4057, 4513, 4533, 4557, 4628, 5274, 5275, 5277, 5279, 5281, 5283, 5285, 5392, 5643, 6365, 6978, 6981, 6982, 6986, 6997, 7012, 7013, 7029, 7031, 7083, 7087, 7094, 7179, 7186, 7270
Fast-Track Process, 7162
fatty acids, 231, 1430, 2105, 2120, 2124, 2134, 2143, 2156, 2180, 3330, 3431, 4627, 4629, 4703, 5253, 5257, 5261, 5262, 5266, 5267, 5270, 5271, 5273, 5274, 5275, 5276, 5277, 5278, 5279, 5280, 5282, 5283, 5284, 5319, 5367, 5371, 5393, 5423, 5424, 5425, 5426, 5427, 5429, 5950, 5972, 6192, 6357, 6361, 6699, 6702, 6867, 6978, 7013, 7015, 7016, 7021, 7127, 7173, 7179, 7192, 7193
fatty liver, 154, 160, 2910, 2998, 3033, 5248, 5261, 5262, 5263, 5264, 5266, 5271, 5272, 5273, 5274, 5276, 5277, 5278, 5280, 5281, 5282, 5283, 5285, 5298, 5299, 5300, 5334, 5340, 5341, 5343, 5344, 5347, 5348, 5352, 5354, 5355, 5357, 5358, 5361, 5362, 5363, 5365, 5366, 5367, 5371, 5372, 5374, 5375, 5379, 5381, 5383, 5384, 5385, 5388, 5389, 5396, 5400, 5410, 5411, 5413, 5418, 5424, 5427, 5428, 5429, 5430, 6630, 6633, 6704, 6992, 7180, 7184, 7186, 7197, 7199, 7201
felines develop an, 3432
femoral artery, 2280, 2285, 2286, 2344, 2818, 2819, 3171, 3381, 3382, 3384, 3385, 3386, 3395, 3677, 3692, 3693, 3751, 4190, 4195, 4203, 4728, 4739, 4743, 4744, 4745, 4788, 4796, 4799, 4812, 4819, 4820, 4823, 4825, 4826, 4863, 4872, 4873, 4879, 4884, 4885, 4893, 4894, 4895, 4897, 4913, 4921, 4922, 4932, 4988, 4989, 4995, 4996, 5004, 6151, 6152, 6217, 6488, 6491, 6493, 6521, 6529, 6558, 6566, 6729, 6731, 6732, 6733, 6734, 6736, 6737, 6743, 6745, 6750, 6754, 6762, 6765, 6766, 6779, 6789, 6792, 6794, 6797, 6853
femoral head resection, 5867, 5868, 5869, 5878, 5879
femoral sheath, 6732
femorofemoral cross over bypass, 4825, 4826, 4838
femoropedal bypass, 4895
femtosecond laser, 1709, 1710, 1711, 1712, 1713, 1714, 1715, 1717, 1718, 1719, 1720
femtosecond-laser-assisted cataract surgery, 1716
fertility, 253, 256, 261, 262, 1600, 3431, 3696, 3709, 4412, 4413, 4432, 4481, 4486, 4487, 4492, 4493, 4494, 4497, 5990, 6029, 6030, 6036, 6037, 6038, 6039, 6040, 6042, 7117, 7123
fever, 143, 776, 777, 779, 806, 997, 1045, 1096, 1097, 1102, 1451, 1571, 1573, 2055, 2057, 2061, 2431, 2464, 2473, 2484, 2491, 2495, 2742, 2799, 2812, 2926, 3164, 3168, 3195, 3267, 3306, 3318, 3319, 3328, 3330, 3401, 3812, 3815, 3818, 3833, 3878, 3889, 3896, 3900, 3904, 3910, 3913, 4329, 4566, 4612, 4986, 5435, 5558, 5568, 5618, 5625, 5702, 5703, 5706, 5911, 5957, 5960, 6011, 6012, 6182, 6192, 6641, 6660, 6995, 6996, 6999, 7258
fibrin, 141, 364, 365, 374, 393, 407, 408, 409, 410, 411, 412, 413, 418, 419, 906, 907, 909, 1436, 1437, 1519, 1746, 2426, 2444, 2445, 2452, 2754, 2809, 2814, 3011, 3020, 3342, 3541, 3543, 3546, 3548, 3551, 3560, 3566, 3568, 3571, 3572, 3579, 3614, 3889, 4213, 4246, 4250, 4251, 4256, 4357, 4548, 4674, 4876, 5002, 5468, 5918, 5923, 5927, 5960, 6011, 6104, 6137, 6142, 6205, 6421, 6428, 6997, 7328, 7329, 7331
fibrinogen, 172, 413, 414, 1437, 2445, 2801, 3011, 3020, 3076, 3078, 3079, 3080, 3098, 3099, 3103, 3110, 3560, 3614, 3776, 3866, 4357, 4506, 4876, 4956, 5463, 5465, 5466, 5467, 5468, 5469, 5918, 5923, 5926, 5927, 6704, 7212, 7260, 7264, 7328
fibroblast growth factor, 99, 100, 615, 2186, 3020, 3538, 3543, 3547, 3555, 3558, 3559, 3561, 3566, 3579, 3704, 3734, 5352, 6413, 6984
fibroblasts, 564, 905, 906, 910, 1433, 1734, 1736, 2105, 2111, 2414, 2965, 2993, 2994, 3011, 3012, 3544, 3545, 3548, 3560, 3561, 3570, 3643, 3656, 4675, 5659, 6411, 6413, 6415, 6416, 6417, 6418, 6426, 6427, 6428, 7119, 7121
fibrocartilage, 3010, 3358, 3540, 3542, 3544, 3546, 3548, 3561, 3562, 6230
fibroids, 4471, 4484, 4485, 4486, 4487, 4496, 7118, 7119, 7123
fibromuscular dysplasia, 1351, 4814, 4842, 4853, 4876, 4902
fibrostenotic, 5950, 5951, 6007
fibrous dysplasia, 31, 43, 47, 5515, 5516, 5522, 5523, 5529, 5530, 5533, 5534, 5535, 5536
Finney, 5954, 5964, 5965, 5966, 5967, 5968
first assistant, 1562, 1563, 4407, 5018, 5021, 5033, 5036, 5037, 5038, 5039, 5040, 5066, 5068, 5072, 5144, 5184, 5187, 5188, 5190, 5191, 5239, 6458
Fisher and Veronesi, 1579

fistulae, 221, 1429, 1433, 1434, 1440, 1639, 1644, 1648, 1656, 1663, 1706, 1738, 1918, 1984, 1991, 2018, 2073, 2085, 2086, 2093, 2097, 2098, 2106, 2442, 2445, 2449, 3189, 4394, 4744, 4922, 4968, 4969, 4970, 4971, 4981, 4985, 5000, 5011, 5955, 5956, 5957, 5958, 5959, 5960, 5975, 5995, 6001, 6006, 6007, 6012, 6013, 6015
fistulogram, 2061, 6013
fixed combinations of a prostaglandin analogue, 6887
flap failure, 2601, 2608, 2612, 2635, 2639, 2643, 2657, 5435, 5439
flexible intramedullary bioactive coating, 69
flexible intramedullary nailing, 1, 26, 29, 30, 48, 49, 74, 75, 76, 78, 80, 83, 87, 88, 95
flexible LMA, 2463, 2465
floating craniotomies, 4056
FLOW 800, 1631, 1632, 1633, 1634, 1635, 1637, 1638, 1639, 1640, 1641, 1642, 1643, 1645, 1646, 1647, 1649, 1651, 1659, 1662, 1663
flow cytometry, 2926, 2939, 2941, 2957, 2959, 2960, 2961, 3446, 3739, 7217
flow diverter, 945, 950, 951, 952, 953, 955, 956
flow rates, 972, 985, 2656, 3049, 3052, 3214, 3274, 3455, 3456, 3495, 3498, 3523, 6596
fluid therapy, 975, 1445, 1461, 2710, 2718, 3277, 3278, 3297, 3313, 3314, 3317, 3318, 3319, 3323, 3329, 3330, 3332, 3333, 3334, 3385, 4564, 4654, 4660, 7090, 7093
fluid-structure interactions, 3461, 3472
fluorescence-guided surgery, 689, 710, 3338, 3353, 3369, 3373
fluoroscopic guidance, 323, 1950, 1959, 1963, 1968, 1978, 1979, 1992, 1994, 2019, 2215, 4486, 5782, 5961, 6641, 6750
fluoroscopic, 267, 322, 325, 706, 726, 782, 784, 1236, 1327, 1772, 1866, 1944, 1950, 1959, 1963, 1966, 1968, 1978, 1979, 1992, 1994, 2014, 2016, 2018, 2019, 2051, 2071, 2212, 2215, 2216, 2221, 2224, 2225, 2260, 2265, 2272, 2282, 4486, 5782, 5961, 6125, 6641, 6750
fluoroscopy, 322, 346, 646, 705, 706, 717, 726, 782, 783, 1297, 1328, 1335, 1336, 1346, 1655, 1770, 1854, 1932, 1943, 1950, 1954, 1955, 1958, 1960, 1966, 1967, 1977, 1978, 1979, 1980, 1983, 1984, 1990, 1991, 1992, 1993, 1994, 1997, 1998, 2001, 2002, 2003, 2005, 2006,2007, 2013, 2014, 2015, 2017, 2080, 2095, 2096, 2211, 2212, 2213, 2214, 2215, 2217, 2218, 2219, 2221, 2222, 2223, 2224, 2225, 2260, 2271, 2282, 2344, 3137, 3156, 3361, 4190, 6110, 6126, 6179, 6208, 6209, 6210, 6211, 6268, 6539, 6613, 6655
focused parathyroidectom, 7051, 7052, 7054, 7056
folate, 147, 222, 224, 226, 231, 256, 258, 259, 3404, 6352, 6362, 6363, 6371, 6884, 7251, 7254
follow-up support, 2689, 2692, 2697, 2698
Fontaine classification, 4815, 4816, 4880
foregut, 1296, 1311, 1866, 1885, 1895, 1950, 1953, 1996, 2142, 2144, 2147, 2154, 2176, 2729, 2731, 4183, 5939, 5940, 5941, 5942, 5944, 5945, 6983
formats, 2277, 3235, 3340, 6326, 6328, 6329, 6336
Fountaine classification, 4815
Fourier, 1717, 3090, 3093, 3817
fracture healing, 72, 74, 3349, 3557, 3558, 3559, 3560, 3561, 3562, 3565, 3567, 3568, 3570, 3571, 3574, 3575, 3576, 3577, 3578, 3579, 3580, 3581, 5606, 6230, 6231, 6234, 7123
free air, 1092, 1098, 1099, 2058, 2059, 2073, 5962
free flap, 1405, 1406, 1408, 1410, 1411, 1412, 1413, 1417, 1419, 1421, 1422, 1424, 1426, 1427, 1734, 2560, 2562, 2587, 2591, 2592, 2594, 2597, 2601, 2604, 2607, 2608, 2609, 2611, 2612, 2613, 2614, 2635, 2636, 2637, 2639, 2640, 2641, 2642, 2643, 2644, 2646, 2647, 2648, 2650, 2651, 2657, 2658, 2662, 2663, 2665, 2673, 2675, 4043, 4449, 5432, 5433, 5440, 5515, 6158
frontal encephaloceles, 4017
frontal lifting, 6446
fronto-orbital bandeau, 4024
frozen elephant trunk, 4771, 4774
Full Outline of UnResponsiveness (FOUR) Score, 3879
functional anatomy, 276, 885, 1666, 2872, 3406
functional capillary density, 3073, 3084, 3086, 3088
functional free muscle transfer, 1670
functional rhinoplasty, 439, 446, 447, 449, 637, 1535, 1536
fundamental anatomic, 3432
fundic gland polyps, 1339, 1894
fundoplication, 1896, 2791, 4184, 4580, 5078, 6401
futility, 1611, 4098, 4101, 4105, 4107, 4117, 6860
future laparoscopy, 2762
future lingual tonsil hypertrophy, 2543

G

gait analysis, 1761, 1779, 1780, 1781, 1782, 1786, 1788, 1790, 1791, 1792, 1793, 1794, 1796, 1797, 1799, 1800, 1801, 1802, 1803, 1805, 1808, 1809, 1810, 1811, 1812, 1813, 6261
gastric acidity, 2047, 2053, 4580
gastric bypass surgery, 147, 155, 156, 157, 161, 198, 206, 224, 231, 232, 249, 250, 251, 265, 771, 795, 796, 839, 841, 1505, 2006, 2103, 2105, 2106, 2113, 2114, 2115, 2132, 2133, 2134, 2137, 2148, 2155, 2156, 2158, 2159, 2160, 2161, 2163, 2165,

2166, 2167, 2168, 2169, 2171, 2172, 2184, 2185, 2186, 2701, 2724, 2726, 2731, 2745, 2746, 2747, 4305, 4306, 4508, 4535, 4541, 4543, 4601, 4609, 5411, 6352, 6354, 6355, 6358, 6360, 6361, 6363, 6368, 6370, 6979, 6980, 6983, 6988, 6991, 7002, 7018, 7027, 7028, 7030, 7033, 7034, 7129, 7147, 7150, 7198, 7203, 7204, 7205, 7229, 7254, 7266
gastric outlet obstruction, 149, 1329, 1332, 1337, 1338, 1852, 1858, 1893, 1903, 1904, 1908, 1947, 1957, 1962, 1969, 1999, 2000, 2010, 2018, 2021, 2024, 5950, 5952
gastric plication, 801, 806, 820, 2831, 2832, 2833, 2834, 2836, 2837
gastric stenosis, 2683, 2684, 2687, 2688
gastric twist, 2683, 2684, 2687
gastric ulceration, 259, 2047, 2091
gastric ulcers, 1896, 1897, 2067
gastric varices, 1303, 1891, 1892, 1903
gastritis, 221, 222, 791, 792, 1038, 1328, 1334, 1888, 1890, 1891, 1894, 2067, 2733, 2735, 4564, 4580, 4840, 5203, 5618
gastrocolic fistula, 819, 2093, 2094, 2101
gastrocutaneous fistula, 2032, 2036, 2073, 2098, 2101
gastroesophageal reflux disease, 153, 160, 761, 797, 841, 1296, 1308, 1309, 1314, 1450, 1682, 1686, 1766, 1767, 1885, 1895, 1904, 2700, 2742, 2747, 2763, 4171, 4569, 4570, 4573, 4575, 4580, 4582, 4583, 4584, 4585, 5063, 5084, 5086, 5181, 5230, 5360, 5512, 7003, 7251
gastroesophageal reflux, 150, 153, 160, 256, 761, 797, 841, 1296, 1308, 1309, 1314, 1320, 1450, 1682, 1686, 1766, 1767, 1838, 1885, 1895, 1904, 2700, 2742, 2747, 2763, 3402, 4171, 4560, 4569, 4570, 4573, 4575, 4580, 4582, 4583, 4584, 4585, 5063, 5084, 5086, 5181, 5214, 5230, 5360, 5510, 5512, 5513, 5940, 5943, 5964, 7003, 7251, 7257
gastrointestinal stromal tumors, 1897, 1904
gastrointestinal T-anchor(s), 1916, 1934, 1935, 1936, 1937, 1939, 1940, 1958, 1985, 1997, 1998, 2001, 2002, 2003, 2013, 2014, 2017, 2026, 2027, 2040, 2097, 2100
gastrojejunal anastomosis, 139, 144, 147, 816, 845, 847, 849, 856, 1996, 1999, 2000, 2002, 2733, 2743, 4573, 4606, 5095, 5097, 5114, 5141, 5142, 5161, 5244, 5245, 6409, 6998, 7000, 7002, 7005
gastro-jejunostomy, 1948, 2022, 5164, 5177, 5943, 5950
gastroparesis, 983, 1045, 1834, 1898, 1899, 1900, 1904, 1905, 1922, 1924, 1947, 1948, 1951, 1957, 1962, 1970, 2009, 2011, 2020, 2023, 3390, 4556, 4560, 4562
gastropexy, 1832, 1855, 1934, 1936, 1937, 1938, 1939, 1940, 1941, 1943, 1958, 1984, 1990, 1997, 2006, 2009, 2012, 2013, 2014, 2015, 2020, 2021, 2046, 2049, 2051, 2052, 2097, 2099
GCS motor, 3804, 3855, 3856, 4083, 4125, 4126, 4127, 4131, 4134, 4136
gender dysphoria, 1605, 6154, 6158
gender reassignment surgery, 1600, 6149, 6151, 6157
gene gun, 3115, 3116, 3117, 3118, 3119, 3120, 3121, 3122, 3127, 3128
gene therapy, 1729, 1730, 3015, 3023, 3063, 3115, 3120, 3121, 3122, 3124, 3127, 3128, 3365, 3368, 3370, 3515, 3543, 3569, 3759, 3760, 6596
general surgery, 728, 1464, 2670, 2761, 2764, 3243, 3667, 3929, 4292, 4469, 4709, 4710, 5165, 5794, 6328, 6393, 6396, 6407, 6408, 6454, 6759
generalities, 2339
genital reconstructive surgery, 6147
genomic post-conditioning, 3791
genomic, 2351, 2352, 2962, 3021, 3432, 3791, 5640, 5651, 5687, 5699
German phase model, 1036
ghrelin, 170, 171, 172, 173, 181, 183, 184, 758, 830, 871, 2004, 2121, 2131, 2140, 2141, 2142, 2154, 2155, 2156, 2157, 2158, 2159, 2160, 2161, 2162, 2163, 2164, 2165, 2166, 2167, 2168, 2169, 2170, 2171, 2172, 2173, 2176, 2177, 2181, 2182, 2184, 2185, 2678, 2679, 2680, 2681, 2689, 2697, 2702, 2704, 2705, 2714, 2723, 2730, 2731, 2732, 2745, 2775, 2831, 2832, 2833, 2834, 3710, 4509, 4557, 4559, 5271, 5361, 5371
ghrelin, 6979, 6982, 7012, 7016, 7018, 7026, 7027, 7028, 7029, 7031, 7033, 7034, 7203, 7227, 7228, 7267
giant cell tumor of the bone, 5732
giant hemangioma, 5751, 5752, 5754, 5756
glandular section, 2834, 2835
Glasgow Coma Scale, 921, 922, 932, 992, 1525, 2796, 3784, 3786, 3836, 3843, 3854, 3879, 3910, 3919, 3940, 3942, 3953, 3960, 3972, 3978, 3998, 4018, 4094, 4103, 4112, 4120, 4123, 4129
Glasgow Coma Scale score, 3784, 3843, 3919, 3940, 3942, 3972, 3978
Glasgow Outcome Scale, 924, 1029, 1064, 3786, 3818, 3840, 3842, 3843, 3845, 3960, 3968, 3973, 3979, 3982, 3989, 3996, 4047, 4110, 4111, 4123, 4131
Glasgow Outcome Score, 883, 921, 924, 1059, 1065, 3855, 4025, 4038, 4091, 4095, 4129
glial cells, 967, 1163, 3767, 3782, 4556, 4851

gliomas, 1161, 1162, 1164, 1165, 1169, 1186, 1188, 1189, 1635, 1636, 1639, 1640, 1643, 1646, 1647, 1692, 1693, 1694, 1706, 7097, 7098, 7113, 7114
Glissonian approach, 2341, 2342
Glucagon, 172, 2115, 2146, 2147, 2148, 2156, 2161, 2165, 2168, 2732, 2745, 5281, 6981, 6989
glucagon-like peptide - 1 (GLP - 1), 6979
gucagon-lke peptide 2(GLP2), 6981
glucagon-like-polypeptide (GLP-1), 2731
glutamate, 994, 3032, 3703, 3767, 3775, 3782, 3784, 3786, 3787, 3788, 3794, 3797, 3814, 3816, 3820, 3837, 3841, 3844, 3846, 3854, 4096, 5612, 7210, 7211, 7218, 7219
glyburide, 3773, 3779, 3942, 3946
glycolysis, 1163, 1488, 3322, 3513, 3529, 3674, 3782, 3783, 3785, 3787, 3837, 5278, 5281, 7211
glycosaminoglycan, 3012, 3541, 3566, 3573
goat, 3007, 3111, 3358, 3432, 3542, 3544, 3557, 7030
gold-standard, 1082, 1083, 2991, 4384, 5301, 5332, 6655
good laboratory practice, 3202, 3210, 3232, 3428, 3434, 3439
Gott shunt, 4797, 4798, 4803
Göttingen minipig, 3388, 3406, 3537, 3542
gracilis muscle flap, 1672
grading scales, 924, 931, 938, 992
gradual rewarming, 3050, 3496, 3509, 3524, 3525, 3899
graft-versus-host (GVH) responses, 2915
granuloma formation, 566, 571, 578, 6182
granulomas, 391, 566, 571, 578, 2406, 5940, 5942, 6211
gravitational valve, 1019, 1022, 1025
groin flap, 2562, 5431, 5432, 5433, 5434, 5435, 5436, 5437, 5438, 5439, 5440, 6159
growth and differentiation factor, 1736, 3558, 3566, 3569
growth differentiation factor, 3538, 3543, 3549
growth factors, 74, 615, 1437, 1732, 1735, 1737, 1747, 2899, 2919, 2995, 3011, 3025, 3052, 3498, 3537, 3538, 3539, 3541, 3542, 3543, 3546, 3559, 3561, 3562, 3563, 3568, 3570, 3574, 3682, 3751, 4001, 4889, 5923, 6010, 6019, 6279, 6303, 6411, 6413, 6415, 6416, 6417, 6418, 6419, 6420, 6428, 7120
g-tube, 1931, 1932, 1933, 1938, 1943, 1944, 1969, 2000
guided bone regeneration, 1730, 1734, 1748, 1749, 1750, 1751, 1752
guided tissue regeneration, 1729, 1730, 1731, 1749, 1750, 1751, 1752
guidewire(s), 334, 882, 1834, 1911, 1912, 1913, 1914, 1921, 1926, 1927, 1933, 1937, 1938, 1941, 1942, 1950, 1959, 1962, 1963, 1964, 1965, 1966, 1968, 1977, 1978, 1979, 1980, 1986, 1992, 1997, 2003, 2018, 2043, 2045, 2067, 2080, 2085, 2094, 2095, 2099, 2100, 4203, 4959, 6493, 6617, 6655, 6722, 6745, 6779, 6793, 6833
gunshot wound, 285, 287, 1733, 2197, 3176, 3189, 3190, 3193, 3971, 3988, 4011, 4012, 4015, 4026, 4028, 4029, 4031, 4083
gut microbiome, 2173, 2178, 2180, 2181, 2182, 2186, 2187
gynecologic oncology, 698, 2979, 3155, 4292, 4398, 4400, 4401, 4404, 4413, 4422, 4431, 4432, 4433, 4435, 4437, 4440, 4468
gynecologic surgery, 698, 1425, 4331, 4342, 4368, 4371, 4384, 4389, 4398, 4399, 4471, 4472, 4474, 4476, 4685, 6037, 6407
gynecology, 253, 691, 698, 699, 714, 715, 1425, 1599, 1607, 2114, 2761, 2967, 3134, 3135, 3136, 3157, 3177, 3182, 3189, 3195, 3243, 3390, 3988, 4258, 4340, 4367, 4368, 4387, 4389, 4390, 4397, 4398, 4399, 4401, 4407, 4433, 4434, 4435, 4436, 4437, 4438, 4441, 4471, 4472, 4476, 4480, 4495, 4496, 4497, 4693, 4844, 5472, 6280, 6389, 7117, 7149

H

H. pylori, 144, 788, 791, 792, 1893, 1894, 1896, 1897, 2736, 4573, 4574, 5940
HAMLET, 3862, 3937, 3938, 3945, 4065, 4068, 4069, 4098, 4102, 4115
Hampshire, 3248, 3254, 3431
hand hygiene, 3884, 3904, 4647, 4651
hand-assisted laparoscopic surgery, 2370, 5991, 6015, 6026
hand-sewn anastomosis, 2738, 4197, 4210, 4301, 5141, 5223, 5224, 5225, 5986, 6003, 6006, 6010, 6011
hand-sewn, 2451, 2736, 2738, 4164, 4197, 4210, 4230, 4301, 4305, 4306, 4314, 4582, 5096, 5099, 5141, 5142, 5161, 5223, 5224, 5225, 5954, 5963, 5967, 5974, 5986, 5996, 6003, 6005, 6006, 6008, 6009, 6010, 6016, 6024, 6461
hard callus, 3559, 3560, 3561
hardware, 148, 362, 364, 646, 652, 656, 719, 731, 1571, 1573, 1715, 1900, 1984, 2215, 2219, 2222, 2304, 2777, 3131, 3143, 3243, 3340, 3354, 3360, 3473, 3889, 4077, 4875, 5872, 6164, 6171, 6172, 6176, 6177, 6178, 6182, 6184, 6185, 6186, 6959
hashtags, 6920, 6923, 6925, 6926

head and neck squamous cell carcinoma, 1945, 3428, 3432, 3447, 4460
head injury, 1171, 1189, 1522, 3191, 3395, 3396, 3766, 3772, 3775, 3779, 3794, 3796, 3823, 3824, 3825, 3826, 3827, 3828, 3829, 3831, 3843, 3847, 3848, 3849, 3850, 3867, 3869, 3870, 3900, 3903, 3909, 3912, 3913, 3914, 3949, 3956, 3958, 3959, 3962, 3963, 3975, 3987, 3988, 3989, 4005, 4006, 4007, 4008, 4015, 4025, 4029, 4030, 4034, 4035, 4037, 4038, 4039, 4040, 4041, 4060, 4066, 4067, 4068, 4088, 4101, 4103, 4104, 4114, 4116, 4120, 4121, 4122, 4124, 4125, 4126, 4127, 4130, 4131, 4132, 4134, 4136, 4137, 4138, 4139, 4140, 4926
HeADDFIRST, 3938, 3939
health help-seeking behavior, 7133, 7142, 7146
heart and lung transplantation, 3611, 7274
heart failure, 142, 143, 164, 176, 179, 253, 520, 973, 1038, 1508, 1769, 1857, 1863, 1872, 1881, 2126, 2825, 2839, 2840, 2846, 2850, 2854, 2859, 3315, 3317, 3379, 3381, 3464, 3474, 3629, 3666, 3672, 3684, 3705, 3708, 3864, 4214, 4528, 4529, 4784, 4788, 4789, 4790, 4834, 4836, 4878, 4922, 4941, 4943, 4944, 4955, 4977, 4978, 5854, 5892, 5912, 5918, 6138, 6217, 6618, 6619, 6719, 6773, 6774, 6826, 6827, 6831, 6860, 6861, 7000, 7212, 7233
heart machine preservation, 3060
heart models, 3244, 3452, 3474
heart transplantation, 3023, 3029, 3036, 3042, 3044, 3059, 3123, 3425, 3477, 3586, 3587, 3588, 3589, 3590, 3598, 3599, 3600, 3601, 3604, 3605, 3606, 3607, 3608, 3627, 3628, 3629, 3639, 3642, 3643, 3644, 3650, 3663, 5926, 7273
Heineke-Mikulicz, 5944, 5964, 5965, 5966
hemangioma-like vessels, 5751, 5752, 5753, 5754, 5755
hemangiomas, 267, 1096, 1168, 1183, 1219, 1698, 1707, 5751, 5754, 5755
hematemesis, 144, 148, 777, 1334, 2067, 2091, 2742, 3865, 6654, 6997
hematocrit, 141, 172, 2638, 2896, 3074, 3076, 3077, 3080, 3081, 3084, 3097, 3098, 3276, 4786, 4888, 4939, 4982, 5464, 5467, 5633, 5655, 5703, 5790, 5792, 5913, 5914, 5915, 5918, 5926, 5931, 5933, 5934, 5970
hematogenous spread, 2354, 4947, 6278, 6301, 6302
hematopoietic stem cells, 3263, 3442, 3558, 3560, 3571, 5628, 5653, 5654, 5661
hemedex, 3806
hemodynamic stability, 1445, 1448, 1449, 2066, 3891, 6998, 7164, 7274
hemorheology, 2821, 2824, 3073, 3102, 3103, 3105, 3106, 3111, 3112
hemorrhagic stroke, 916, 3773, 3779, 3788, 3818, 3819, 3851, 4073, 4078, 5000
hemorrhagic, 47, 916, 1015, 1149, 1178, 1179, 1180, 1182, 1190, 1213, 1215, 1243, 1255, 1284, 1611, 1626, 2110, 2495, 2820, 2894, 2896, 2906, 2911, 2913, 2968, 2974, 3084, 3104, 3107, 3108, 3111, 3682, 3683, 3684, 3703, 3767, 3771, 3773, 3779, 3788, 3818, 3819, 3822, 3851, 3853, 3861, 3864, 3868, 3872, 3903, 3918, 3984, 4039, 4048, 4053, 4073, 4078, 4083, 4084, 4087, 4088, 4089, 4125, 4135, 4136, 4479, 4480, 4549, 4550, 4553, 4580, 4766, 4826, 4843, 4931, 4982, 5000, 5643, 5648, 5685, 5728, 5783, 5795, 5954
hepatectomy technique, 2866
hepatic artery aneurysms, 4844
hepatic encephalopathy, 3756, 3865, 3866, 3872, 3873, 6139
hepatic metastases, 1271, 1272, 1278, 1593, 1595, 1597, 2375, 2880, 2910, 3509, 3527, 3528, 6301, 6302, 6303, 6304, 6309, 6316, 6324
hepatic resection, 704, 716, 1224, 1504, 1505, 1587, 1588, 1589, 1590, 1597, 1598, 2334, 2335, 2336, 2337, 2338, 2345, 2346, 2350, 2354, 2355, 2356, 2357, 2358, 2359, 2360, 2373, 2374, 2375, 2873, 2874, 2878, 2880, 2881, 2882, 2912, 4262, 5811, 5816, 6287, 6301, 6302, 6304, 6305, 6309, 6310, 6311, 6312, 6315, 6317, 6319, 6321, 6322, 6323, 6623, 6624, 6625, 6626, 6627, 6629, 6631, 6632, 6633, 6637, 6643, 6646, 6647, 6648, 6650, 6651, 6657, 6662, 6905
hepatocellular-steatosis, 5287
hepatocyte transplantation (HTx), 3747
hepatocyte, 1226, 2886, 2891, 2907, 2908, 2964, 2988, 2989, 3002, 3003, 3034, 3057, 3593, 3594, 3745, 3746, 3747, 3748, 3749, 3750, 3751, 3753, 3754, 3755, 3756, 3757, 3758, 3759, 3760, 3761, 3762, 3763, 3866, 5248, 5251, 5253, 5254, 5255, 5256, 5258, 5260, 5261, 5262, 5284, 5288, 5289, 5294, 5318, 5346, 5351, 5352, 5358, 5359, 5367, 5391, 5421, 5423, 5424, 5425, 5800, 6416, 6622, 6624, 6628, 6630, 6641, 6651
hepatopancreatobiliary surgery, 2866
hepatosplenomegaly, 1866, 1987, 2069, 5702
herniation, 259, 260, 547, 556, 586, 720, 779, 780, 782, 783, 784, 785, 787, 792, 793, 800, 802, 807, 824, 833, 948, 1044, 1170, 1305, 1721, 2013, 2014, 2018, 2020, 2239, 2593, 2752, 2763, 3268, 3539, 3766, 3772, 3773, 3801, 3804, 3819, 3836, 3837, 3839, 3852, 3856, 3861, 3863, 3864, 3866, 3878, 3879, 3880, 3890, 3903, 3932, 3939, 3940, 3941, 3942, 3953, 3954, 3958, 3980, 3991, 3995, 3996, 3999, 4002, 4003, 4016, 4018, 4024, 4025, 4036, 4037, 4038, 4042, 4046, 4049, 4050, 4082,

4127, 4129, 4131, 4245, 4376, 4598, 4599, 4602, 4606, 5382, 5573, 5594, 5968, 6206, 7314
heterotopic abdominal heart transplantation, 3587, 3588, 3627, 3637
hiatal hernia(s), 150, 158, 760, 761, 780, 782, 785, 787, 792, 793, 797, 806, 809, 824, 841, 1296, 1308, 1320, 1450, 1866, 1887, 1888, 1902, 1918, 1984, 2012, 2014, 2018, 2019, 2024, 2069, 2684, 2736, 2752, 2776, 4184, 4295, 4313, 4575, 4576, 4577, 4578, 4584, 5019, 5068, 5089, 5152, 5181, 7004
high dose barbiturates, 3898, 3899
high income countries, 4055, 4056
high-grade invasive transitional cell carcinoma, 3432
high-grade sarcoma, 5721, 5722, 5725, 5726, 5727, 5728
high-order models, 3449, 3450, 3460, 3462, 3471, 3473
hinge craniectomy, 4023
hip arthroplasty, 732, 733, 1456, 1575, 1670, 2275, 2276, 2282, 2283, 2290, 2291, 2295, 2307, 2308, 2309, 2319, 3134, 4621, 5874, 5880
hip dislocation, 1815, 1816, 1820, 1824, 1825, 1826, 1827, 1828, 2196, 2197, 2242, 2285, 5867, 5868, 5869, 5870, 5879, 6241
hip dysplasia, 1819, 1829, 2242, 2245, 2258, 2263, 2276, 6958, 6959, 6963
hip fractures, 287, 2209, 2210, 6239, 6244, 6245, 6247, 6248, 6249, 7155
hip fusion, 5868, 5869, 5876, 5878, 5880
hip imaging, 2212, 2227
hip oncology, 2312
hip reconstruction, 1815, 1816, 1817, 1823, 1824, 1825, 1826, 1827, 1828
hip revision arthroplasty, 2293
hip surgery, 1447, 1824, 1826, 1830, 2189, 2211, 2249, 2265, 2271, 2275, 2293, 2294, 2300, 2308, 2309, 5878, 5879, 5880, 6243, 6246
hiperglycemia, 4653
histology, 4, 347, 478, 555, 576, 905, 1140, 1160, 1267, 1339, 1530, 1700, 1723, 1725, 1726, 1748, 1890, 1895, 2397, 2459, 2891, 2896, 2928, 3037, 3054, 3056, 3057, 3058, 3060, 3268, 3357, 3358, 3366, 3371, 3526, 3557, 3563, 4141, 4159, 4343, 4407, 4412, 4491, 5247, 5269, 5287, 5301, 5330, 5334, 5347, 5351, 5354, 5359, 5360, 5361, 5368, 5370, 5372, 5375, 5376, 5383, 5396, 5410, 5479, 5523, 5639, 5701, 5702, 5738, 5804, 5841, 5858, 5863, 5864, 5865, 5942, 6056, 6310, 6316, 6426, 6595, 6598, 6603, 6633, 7197
histopathological techniques, 2850, 3573
histopathology, 515, 1187, 1188, 1583, 2458, 2460, 2580, 3356, 3707, 4137, 4867, 5287, 5298, 5300, 5301, 5453, 5651, 5683, 5699, 5701, 5702, 5703, 5704, 5721, 5728, 5732, 5738
hollow viscus injury, 2055, 2057, 2058
HOPES trial, 3818
horizontal partial laryngectomy, 6965, 6966, 6967
hormonal study, 5086
host-versus-graft, 2915, 2916, 2931
HPB anatomy, 2865
HPB models, 2865
HPB research, 2865
human diseases, 349, 2865, 2921, 2967, 3073, 3209, 3337, 3375, 3401, 3428, 3429, 3430, 3446, 3557
Hürthle cell adenoma, 5676, 5688
Hürthle cell tumor, 5676, 5685, 5687, 5688
Hürthle cell, 5675, 5676, 5678, 5679, 5682, 5684, 5685, 5687, 5688
husbandry, 2977, 3248, 3259, 3260, 3265, 3266, 3267, 3290, 3291, 3292, 3419, 3434, 3439
hyaline cartilage, 2228, 2236, 2238, 3537, 3538, 3544, 3545, 3546, 3549, 3555
hyaluronic acid, 557, 559, 561, 562, 569, 570, 572, 574, 575, 576, 577, 578, 618, 627, 1378, 2533, 2539, 2625, 3054, 3056, 3057, 3538, 3539, 3543, 3545, 3558, 3562, 3566, 3572, 3576, 5353, 5354, 5366, 6420
hybrid procedure, 700, 4211, 4897
hydrocephalus, 897, 898, 927, 931, 932, 934, 937, 938, 942, 943, 944, 958, 959, 964, 972, 1019, 1021, 1022, 1023, 1024, 1025, 1037, 1038, 1043, 1044, 1053, 1065, 1169, 1180, 1615, 1618, 3395, 3396, 3771, 3779, 3818, 3819, 3820, 3852, 3861, 3862, 3863, 3900, 3903, 3905, 3914, 3940, 3952, 3953, 3969, 3984, 3998, 4000, 4025, 4034, 4036, 4072, 4085, 4087, 4088, 4089, 6118
hydrodynamic method, 3115, 3123, 3125
hydrogel, 478, 479, 492, 1433, 2047, 2053, 3545, 3546, 3551, 3562, 3565, 3569, 3571, 3572, 3577, 3580, 3727, 3728, 3730, 3741, 6424, 6426
hydrogen peroxide, 1969, 2031, 3790, 4676, 4684, 4712, 5252, 6418, 6428, 7126
hydrosalpinx, 4479, 6029, 6036, 6038, 6039
hydroxyapatite, 7, 8, 10, 11, 12, 70, 71, 72, 75, 76, 79, 86, 87, 92, 102, 324, 559, 565, 572, 576, 618, 620, 2284, 2324, 2331, 2332, 2625, 3353, 3558, 3559, 3563, 3566, 3569, 3572, 3573, 3579, 5528, 6227
hyoid suspension, 1535
hyonatraemia, 3317
hyperchloremia, 3319, 3321, 3325, 3326, 3334
hyperchloremic metabolic acidosis, 3320, 3325, 3326, 3333

hyperemia, 127, 1769, 3766, 3767, 3777, 3807, 3809, 3812, 3839, 3842, 3992, 4082, 5459, 5488, 5490, 5952, 6205
hyperkalemia, 3033, 3319, 3320, 3325, 3334, 3859, 3897, 7088
hypermagnesemia, 3323
hypermetabolism, 1772, 1773, 3814
hypernatraemia, 3318
hyperosmolar therapy, 3809, 3861, 3864, 3867, 3897, 3898, 3993
hyperoxia, 2824, 3790, 3797, 3798, 3814, 3827, 3830, 4654
hyperphosphatemia, 3322, 3334, 7088
hyperplastic polyps, 1332, 1894
hyperthermia, 1038, 3400, 3839, 3876, 3878, 3891, 3896, 3909, 3935, 5000, 6913, 6915, 6916, 7082, 7089, 7103, 7277, 7285, 7286
hypertrophic cartilage, 3544, 3574
hypertrophic differentiation, 3540, 3541, 3543, 3544
hypertrophy, 165, 178, 241, 385, 426, 445, 496, 498, 506, 510, 514, 557, 1194, 1229, 1328, 1348, 1349, 1493, 1496, 1507, 1536, 1537, 1538, 1540, 1543, 1548, 1550, 1554, 1555, 1681, 1682, 1683, 1686, 1687, 1691, 1701, 2115, 2163, 2234, 2240, 2431, 2457, 2469, 2472, 2488, 2489, 2495, 2496, 2507, 2514, 2516, 2519, 2540, 2548, 2840, 2845, 2846, 2853, 2859, 2863, 3545, 3549, 3554, 4529, 4788, 4790, 5253, 5510, 5825, 5910, 5914, 6163, 6469, 6623, 6625, 6631, 6633, 6640, 6642, 6643, 6644, 6645, 6647, 6648, 6651, 6978, 6984, 6989, 7084
hyperventilation, 958, 3326, 3328, 3777, 3807, 3811, 3825, 3827, 3859, 3866, 3870, 3891, 3894, 3898, 3899, 3900, 3936, 3958, 3963, 3967, 3970, 3972, 3976, 3993, 4096, 4104, 4105, 4979
hypoalbuminemia, 224, 225, 232, 862, 4624, 4630, 5377, 5378, 5380, 5381, 5382, 5392, 5950
hypochloremia, 3318
hypodensity, 1173, 3820, 3933, 3935, 3937
hypofibrinogenemia, 5463, 5468
hypogastric plexus, 4425, 4426, 4428, 4999
hypoglossal nerve, 1550, 1551, 1557, 1666, 1667, 1668, 1669, 7323
hypokalemia, 3319, 3325, 3330, 3331, 3333, 3334, 5647, 5983
hypomagnesemia, 989, 3320, 3322, 3323, 7285
hyponatremia, 971, 977, 3317, 3332, 3333, 3334, 3864, 3898, 4785, 6131
hypopharyngeal surgery, 1533, 1535, 1547
hypophosphatemia, 91, 100, 3322, 3331, 3334
hypothermic liver perfusion, 3070
hypothermic machine perfusion, 3043, 3045, 3046, 3053, 3063, 3064, 3065, 3066, 3067, 3069, 3070, 3479, 3480, 3488, 3502, 3503, 3504, 3505, 3506, 3509, 3510, 3520, 3527, 3528, 3529, 3530, 3532, 3533, 3534
hypovolemia, 1100, 1102, 1350, 1529, 2640, 2663, 2896, 3099, 3315, 4660, 4661, 4979, 4980, 5791, 6137, 6216, 7083
hysterectomy classes, 4413
hysterectomy, 714, 1454, 1600, 1603, 1604, 2715, 3134, 3136, 3145, 3150, 3151, 3153, 3154, 3155, 4367, 4368, 4371, 4376, 4377, 4379, 4380, 4386, 4389, 4390, 4391, 4392, 4395, 4398, 4399, 4400, 4402, 4403, 4405, 4407, 4408, 4410, 4412, 4413, 4422, 4423, 4425, 4430, 4432, 4433, 4434, 4435, 4436, 4437, 4438, 4439, 4440, 4441, 4442, 4444, 4445, 4472, 4474, 4477, 4478, 4484, 4486, 4488, 4493, 4495, 4496, 4497, 4567, 4614, 5792, 6029, 6035, 6036, 6037, 6038, 6042, 6043, 6148, 7118, 7119

I

iatrogenic crouch gait, 1788, 1794, 1801, 1802, 1803, 1804, 1806, 1807, 1808, 1809, 1810
iatrogenic vascular injuries, 4911
ICP monitoring, , 992, 1020, 3771, 3801, 3802, 3803, 3804, 3805, 3812, 3813, 3815, 3819, 3841, 3852, 3854, 3855, 3860, 3863, 3866, 3880, 3885, 3912, 3936, 3950, 3959, 3971, 3984, 3986, 4002, 4003, 4058, 4059, 4095
ICP waveform, 3881, 3885, 3886, 3887, 3897
IgG4-related sclerosing cholangitis, 6902, 6903, 6905, 6906, 6907, 6908, 6909, 6910, 6911
IgG4-related sclerosing disease, 6902, 6909, 6910
ileal pouch-anal anastomosis, 5981, 5990, 5992, 5998
ileocecal valve, 221, 828, 843, 857, 1091, 1103, 1104, 2808, 2809, 2832, 4556, 4560, 5183, 5184, 5185, 5186, 5217, 5218, 5229, 5234, 5235, 5954, 5963, 6018, 6279
ileorectal anastomosis, 5987, 5988, 5989, 5990, 5998, 6014
ileus, 146, 997, 1092, 1094, 1854, 2009, 2010, 2020, 2230, 2709, 2799, 2804, 3143, 3860, 4318, 4330, 4347, 4376, 4408, 4419, 4555, 4556, 4558, 4559, 4560, 4561, 4562, 4563, 4564, 4565, 4566, 4567, 4568, 4637, 4638, 4639, 5742, 5968, 5986, 5998, 6012, 6014, 6310, 6314, 7230
Iliac artery aneurysms, 4833
Ilizarov apparatus, 121, 122, 123, 131, 132, 133, 134
Ilizarov method, 2, 6, 7, 30, 46, 47, 48, 49, 67, 90, 99, 101, 122, 134
image-based, 663, 683, 2320, 3449, 3477, 3592, 6534

Image-guided interventions, 662, 708, 710
image-guided surgery, 674, 676, 680, 681, 708, 1229, 2418, 6110
imagery techniques, 3337
immersed boundary, 3461, 3474, 3475, 3478, 5887
immobility, 567, 3270, 3902, 3907, 4729, 5439, 5557, 6203, 6215, 6230, 6243
immune tolerance, 3611, 3647, 3651, 3652, 3653, 3654, 3655
immunologic, 1654, 2544, 2781, 2806, 2817, 2887, 3422, 3432, 3435, 3587, 3597, 3609, 3613, 3681, 5467, 6181, 7211
immunostaining, 2987, 5291, 5326, 5327, 5328, 5329, 5628, 5641, 5693, 5697, 5698, 5701, 5702, 5703, 5705, 5706, 5707, 5708, 5745, 5769
immunosuppressants, 2922, 3433, 3441, 3722, 5463, 5464, 5465, 5983, 5995, 6194
immunosuppression, 1734, 1861, 1867, 2033, 2043, 2095, 2364, 2812, 2919, 2922, 2927, 2929, 2930, 2931, 2933, 2935, 2983, 2989, 2999, 3245, 3263, 3266, 3286, 3287, 3294, 3401, 3422, 3590, 3592, 3602, 3605, 3612, 3613, 3614, 3626, 3627, 3628, 3629, 3634, 3637, 3641, 3647, 3649, 3650, 3652, 3654, 3656, 3659, 3661, 3663, 3721, 3722, 3725, 3727, 3728, 3730, 3731, 3734, 3738, 3739, 3742, 3743, 3757, 3899, 4072, 4642, 4643, 4985, 5399, 5401, 5403, 5413, 5467, 5943, 5959, 5961, 6018
immunosuppressive therapy, 3121, 3276, 3279, 3401, 3593, 3601, 3606, 3647, 3650, 3654, 3656, 3657, 4643, 5951, 5961, 6017
immunosuppressive, 2078, 2917, 2928, 3109, 3121, 3264, 3276, 3279, 3286, 3287, 3400, 3401, 3414, 3433, 3588, 3592, 3593, 3595, 3596, 3597, 3601, 3606, 3611, 3612, 3618, 3627, 3629, 3639, 3643, 3645, 3647, 3650, 3651, 3652, 3654, 3655, 3656, 3657, 3658, 3662, 3663, 3696, 3722, 3740, 3742, 3757, 3791, 3795, 4643, 4841, 5412, 5467, 5942, 5943, 5950, 5951, 5961, 5969, 5983, 5987, 6004, 6006, 6017, 6022
impaction, 308, 784, 1373, 1527, 1890, 2243, 2295, 2296, 2297, 2298, 2308, 2309, 3318, 6192, 6195, 6196, 6197, 6971, 6972, 6973
implantable cardiac defibrillator, 1867
implantable cardiac devices, 1861
improvised explosive device, 4012
Impulse Acoustic Radiation Force/Share Wave Elastography (ARFI/SWE), 5331
in intracranial pressure, 902, 905, 928, 938, 972, 980, 1009, 1060, 3407, 3784, 3831, 4009, 4019, 4038, 4042, 4511
In vitro, 72, 1572, 2050, 2116, 2943, 2944, 2963, 2965, 2980, 3001, 3006, 3015, 3080, 3106, 3212, 3213, 3226, 3232, 3447, 3449, 3455, 3458, 3462, 3464, 3466, 3472, 3473, 3475, 3476, 3478, 3541, 3549, 3554, 3562, 3735, 3762, 3767, 4490, 6413, 6607, 6914
incision management, 4693, 4698, 4699
incisional hernia, 146, 4237, 4595, 4600
increased intracranial pressure, , 927, 967, 968, 972, 1043, 3796, 3822, 3824, 3848, 3958, 3968, 4053, 4065, 4102, 4115, 5778, 6666
incretins, 2105, 2143, 2156, 2158, 2160, 2173, 2731, 6982, 6983, 7026
India, 705, 767, 1532, 1559, 1615, 1616, 1617, 1629, 1649, 2580, 3159, 3166, 3167, 3180, 3794, 3835, 3848, 3872, 4062, 4063, 4068, 4776, 5629, 5909, 5910, 6107, 6108, 6191, 7031
indication for DC, 3772, 3859
indications of multimodal monitoring, 3799
indirect costs, 286, 764, 4402, 5332
individualized treatment, , 991, 29663799, 3867, 5420, 6913
indocyanine green, 680, 689, 963, 965, 1294, 1406, 1419, 1420, 1426, 1427, 1613, 1631, 1632, 1633, 1642, 1653, 1654, 1662, 1663, 2341, 2343, 2356, 2357, 2366, 2371, 2555, 2653, 2659, 2675, 2676, 3353, 4162, 4164, 4324, 4338, 4397, 4406, 4443, 6102, 6108, 6630, 6632, 6646, 6653, 7214, 7220
induced pluripotent stem cells, 2984, 2990, 3538, 3544, 3552, 3558, 3566, 3570, 3736, 6428
inductance, 3451, 3452, 3454, 3457, 3463
infectious AAA, 4828
inferior turbinate hypertrophy, 1682, 1691, 1701
inferior vena cava, 139, 218, 272, 296, 687, 1092, 1301, 1352, 1587, 1588, 1589, 1596, 1597, 1598, 1725, 2343, 2447, 2771, 2867, 2868, 2869, 2870, 2872, 2874, 2875, 2885, 3338, 3342, 3415, 3422, 3444, 3510, 3517, 3584, 3586, 3592, 3594, 3612, 3616, 3631, 3633, 3642, 3687, 3746, 3920, 4191, 4193, 4262, 4428, 4917, 4918, 4923, 4946, 4953, 5249, 5890, 6216, 6219, 6480, 6654, 6655, 6722, 6723, 6730, 6747, 6780, 6793, 6803, 6832, 6833
inflammation process, 5742, 7159
inflammatory environment, 255, 2918, 7159
inflammatory response, 73, 76, 165, 169, 173, 183, 565, 615, 994, 997, 1437, 1441, 1690, 2110, 2269, 2709, 2714, 2783, 2812, 2813, 2814, 2815, 2816, 2822, 2827, 3000, 3011, 3013, 3026, 3035, 3037, 3051, 3076, 3309, 3356, 3366, 3494, 3497, 3559, 3606, 3671, 3716, 3737, 3758, 3763, 3767, 3878, 3900, 4334, 4558, 4642, 4671, 4675, 4691, 4696, 4892, 5255, 5367, 5457, 5458, 5460, 5615, 5911, 6065, 6192, 6348, 6350, 6475, 6482, 6515, 6570, 6702, 6713, 6714, 6715, 6908, 6978, 7119, 7159, 7164, 7225, 7255, 7260
inflatable prostheses, 6154, 6156

informed consent, 471, 1633, 1726, 1755, 1781, 1796, 1803, 1818, 1843, 2016, 2392, 2657, 2735, 3224, 3225, 3732, 3977, 3985, 3990, 4097, 4105, 4109, 4116, 5393, 5572, 6055, 6194, 6195, 6325, 6326, 6327, 6328, 6329, 6335, 6336, 6339, 6340, 6341, 6382, 6387, 6694, 6838, 6863, 6906, 6974, 7270
inguinal and liver cirrhosis, 6134
inguinal ligament, 4728, 4731, 4921, 5433, 6178, 6493, 6732, 6792
inhalation anesthetic agent, 1452
innovations, 714, 1430, 1533, 1587, 1588, 1834, 2193, 2323, 2334, 2559, 2781, 3199, 3242, 3250, 3251, 3445, 4157, 4158, 4167, 4168, 4215, 4217, 4368, 4387, 4464, 5390, 5780, 6070, 6071, 6497, 6499, 6507, 6508, 6536, 6547, 6605, 6618, 6707, 6749, 6820, 6836, 6854
insonation, 993, 3803, 3806, 4816
inspection, 426, 791, 965, 1316, 1681, 1690, 1886, 2343, 2463, 2841, 2845, 3012, 3210, 3228, 3303, 3305, 4147, 4195, 4210, 4422, 4723, 4727, 4731, 4732, 4860, 4882, 5149, 5604, 5776, 5963, 6122, 6184, 6198, 6243, 7334
inspiratory support pressure, 7164
insulin resistance and secretion, 2173
insulin sensitivity, 164, 165, 167, 168, 169, 177, 178, 179, 182, 195, 1506, 2120, 2122, 2123, 2124, 2126, 2128, 2130, 2132, 2133, 2134, 2136, 2150, 2152, 2153, 2161, 2170, 2172, 2173, 2174, 2175, 2177, 2181, 2182, 2184, 2185, 2187, 2678, 4508, 4531, 4628, 5285, 5348, 5392, 5418, 5423, 5425, 6977, 6978, 6979, 6981, 6983, 6986, 6988, 6989, 7014, 7029, 7124, 7188, 7189, 7192, 7194, 7203, 7205, 7266
insulin-like growth factor, 2105, 2115, 3024, 3025, 3538, 3543, 3551, 3552, 3558, 3559, 3561, 3566, 4793, 5397, 6065, 6416
integration, 69, 344, 656, 681, 694, 708, 960, 1053, 1059, 1117, 1154, 1430, 1433, 1437, 1633, 1656, 1662, 1732, 1741, 1745, 2284, 2322, 2324, 2351, 2352, 2359, 2414, 2786, 3132, 3145, 3362, 3540, 3547, 3548, 3559, 3752, 3758, 3799, 3800, 3821, 4212, 4245, 4317, 4438, 4450, 4653, 5528, 5534, 6108, 6132, 6927, 7112
intensive care therapy, 971, 3949
intensive recruitment strategy, 7161
interact, 684, 714, 1052, 1808, 1877, 2164, 2190, 2985, 2986, 3003, 3041, 3373, 3473, 3485, 3642, 3652, 3713, 3761, 3902, 4669, 4777, 4778, 4930, 4969, 5008, 5258, 5706, 5906, 5935, 5936, 6072, 6497, 6525, 6608, 6798, 6813, 6823, 6856, 6920, 6927, 7023, 7136, 7155, 7278
interatrial asynchrony, 6859, 6860, 6862, 6865, 6866
internal bolster, 2029, 2080, 2081
internal carotid artery, 879, 880, 886, 887, 888, 889, 891, 892, 895, 914, 928, 946, 1010, 1011, 1071, 1089, 1610, 1611, 1687, 2415, 2417, 2500, 3612, 3624, 3772, 3816, 3817, 3863, 3932, 4097, 4456, 4725, 4726, 4728, 4812, 4831, 4850, 4863, 4864, 4867, 4999, 5788, 6089, 6106, 6107, 7209, 7212, 7213, 7215, 7216
internal fistulae, 5955, 5956, 5957, 5958
internal hernia(s), 140, 259, 779, 783, 784, 796, 800, 824, 836, 839, 846, 2736, 2738, 2743, 2747, 4546, 4603, 4604, 4605, 4606, 4607, 4608, 4609, 4610, 5237, 5360, 5382, 5390, 6997, 7005, 7249, 7251
internal mammary, 454, 497, 693, 1148, 1149, 1150, 1405, 1408, 1409, 1410, 1411, 1412, 1414, 1420, 1421, 1422, 1423, 1424, 1427, 2558, 2560, 2562, 2608, 2613, 2637, 2639, 2642, 2644, 2656, 3686, 4197, 4201, 4202, 4203, 4204, 4206, 4207, 4215, 4745, 4814, 4904, 4905, 4943, 5912, 6504, 6521, 6525, 6566, 6581, 6582, 6585, 6590, 6593, 6595, 6598, 6599, 6600, 6601, 6602, 6603, 6604, 6605, 6606, 6607, 6608, 6609, 6610, 6767, 6779, 6793, 6804, 6863, 6864
internal retention-bumper, 1912, 1913
International Cartilage Repair Society, 3538, 3548
interrupted aortic arch, 4756, 4758, 4759, 4760, 4777, 7271, 7274
interventional radiography, 877
intervertebral disc, 273, 316, 344, 1168, 3538, 3546, 3547, 3551, 3552, 3555, 3567, 4375, 5572, 5574, 5615, 6206, 6208
intestinal lymphoma, 5617, 5625, 5628
intestinal obstruction, 846, 1306, 1952, 1994, 2002, 2003, 3318, 3319, 5618, 5625, 5741, 5742, 5744, 5746, 5747, 5748, 5749, 5750, 5964, 6002
intra-abdominal hypertension, 3901, 3927, 3928, 4930
intra-abdominal pressure, 146, 3375, 3390, 3409, 3901, 3917, 3918, 3920, 3927, 3928, 4046, 4540, 4544, 4575, 5231, 5233, 5793, 6134, 6135, 7001, 7249
intra-abdominal septic complications, 5983, 5985, 6001, 6006, 6007, 6008, 6023
intra-aortic counterpulsation, 973, 985
intracapsular tonsillectomy technique, 2483
intracapsular tonsillectomy, 2471, 2472, 2473, 2475, 2483, 2484, 2485, 2486, 2487, 2492, 2494, 2496, 2500, 2502, 2504, 2506, 2507, 2509, 2513, 2514, 2515, 2516, 2519, 2520, 2521, 2522, 2523, 2524, 2530, 2532, 2534, 2538, 2541, 2543
intracapsular, 1194, 2250, 2471, 2472, 2473, 2475, 2483, 2484, 2485, 2486, 2487, 2490, 2492, 2494,

2496, 2500, 2502, 2504, 2506, 2507, 2509, 2510, 2513, 2514, 2515, 2516, 2519, 2520, 2521, 2522, 2523, 2524, 2525, 2526, 2527, 2530, 2532, 2534, 2535, 2538, 2540, 2543, 2549, 6240
intracerebral hematoma, 958, 1615, 1620, 3850, 3867, 3989, 4025, 4027
intracerebral hemorrhage, 915, 916, 1031, 1075, 1180, 1191, 3405, 3666, 3688, 3773, 3780, 3815, 3820, 3831, 3861, 3871, 3883, 3980, 4016, 4018, 4082, 4851, 5000, 5011, 5783
intracerebral pressure, 3781
intracranial aneurysm, 877, 879, 884, 914, 916, 919, 920, 924, 925, 928, 934, 938, 939, 940, 941, 945, 947, 954, 955, 956, 957, 962, 964, 965, 974, 976, 1017, 1031, 1032, 1054, 1062, 1066, 1067, 1072, 1077, 1611, 2384, 3251, 4788
intracranial hypertension, 1070, 3395, 3396, 3756, 3759, 3765, 3766, 3775, 3777, 3784, 3790, 3793, 3803, 3804, 3808, 3809, 3823, 3824, 3825, 3827, 3835, 3836, 3842, 3851, 3852, 3856, 3858, 3865, 3868, 3872, 3876, 3880, 3883, 3885, 3890, 3891, 3892, 3895, 3896, 3897, 3898, 3899, 3900, 3901, 3903, 3909, 3913, 3914, 3929, 3950, 3952, 3954, 3956, 3958, 3959, 3961, 3962, 3964, 3987, 3988, 3989, 3990, 3991, 3992, 3993, 3994, 3996, 3997, 3999, 4002, 4003, 4005, 4007, 4009, 4011, 4013, 4014, 4017, 4020, 4022, 4035, 4045, 4046, 4049, 4050, 4052, 4054, 4065, 4067, 4068, 4089, 4096, 4100, 4102, 4104, 4109, 4115, 4116, 4136, 4139
Intracranial infection, 3900
intracranial pressure (ICP) monitor, 3836, 3880, 3889, 3949, 4056
intracranial pressure monitor transducers, 3881
intracranial stent, 945, 947, 948, 952
intragastric balloon, 2832, 4530, 4533, 7027, 7031, 7181
intramedullary nailing, 1, 2, 14, 26, 28, 29, 30, 37, 47, 48, 49, 69, 74, 75, 76, 78, 80, 81, 83, 85, 87, 88, 90, 91, 95, 101, 102, 121, 122, 134, 135, 6240
intraocular pressure, 3375, 3376, 3403, 3404, 3407, 3408, 3410, 3666, 3694, 5791, 5792, 5793, 5795, 5797, 6881, 6883, 6894, 6896, 6897, 6898, 6899, 7084, 7314
intraoperative angiography, 957, 960, 963, 964, 965, 1660, 1663, 2560, 2675
intraoperative electrophysiology, 957
intraoperative imaging, 682, 686, 709, 957, 958, 961, 1280, 1417, 1419, 2211, 2321, 2345, 3353, 6110, 6111, 6112, 6124, 6846
intraoperative MRI, 1169, 1189, 6109, 6111, 6126, 6127, 6128, 6132
intraoperative PTH monitoring, 7053, 7054
intraperitoneal bleeding, 2742, 4843
intrapulmonary shunt, 7158, 7159
intrathecal baclofen pump, 6955, 6963
intrathecal drug delivery, 6165, 6214, 6955
intravascular fluids, 3314
Introducer method, 1997
introducer technique, 1908, 1916, 1931, 1932, 1933, 1944, 1945, 1998, 2042, 2043, 2044, 2046, 2051, 2052
introducer, 323, 879, 1005, 1833, 1890, 1908, 1911, 1916, 1917, 1921, 1931, 1932, 1933, 1934, 1937, 1938, 1941, 1942, 1943, 1944, 1945, 1984, 1985, 1986, 1987, 1994, 1997, 1998, 1999, 2010, 2032, 2040, 2042, 2043, 2044, 2046, 2047, 2049, 2050, 2051, 2052, 2079, 2097, 4959, 6210, 6790, 6793, 6797
intussusception, 779, 824, 835, 841, 4582, 5746, 6020, 6027
invasive breast carcinoma, 5689, 5697, 5698
investigational new drug, 3202, 3207, 3211, 3212, 3220, 3222, 3234
ionic edema, 3766, 3767, 3770, 3854
IOP elevation, 6883, 6884, 6886, 6888, 6891, 6892
IOP reduction, 6886, 6887, 6888, 6889, 6890, 6891, 6892
Iraq, 3990, 4012, 4013, 4014, 4023, 4029, 4032, 4033, 4037, 4041, 4042, 4929, 5491
iridectomy, 7314
iridodesis, 3187, 7314, 7315
iridotomy, 7311
ischemia-reperfusion injury, 2675, 3026, 3027, 3028, 3029, 3030, 3039, 3041, 3067, 3105, 3106, 3108, 3109, 3111, 3499, 3502, 3607, 3665, 3666, 3697, 3698, 3699, 3700, 3702, 3703, 3704, 3705, 3706, 3708, 3709, 3710, 3713, 3714, 3715, 3717, 3718, 6319
ischemic cerebral stroke, 3863
ischemic pain, 4724, 4877, 4889, 4901, 4914, 4927
ischemic preconditioning, 2850, 2913, 3665, 3666, 3697, 3699, 3701, 3704, 3705, 3708, 3710, 3713, 3715, 3716, 3718, 3665, 3666, 3668, 3700, 3705, 3708, 3711, 3712, 3714, 3715, 3716, 3717, 3718, 3719, 3797, 6633
ischemic stroke, 1173, 1176, 1611, 3370, 3667, 3688, 3706, 3710, 3773, 3787, 3815, 3817, 3818, 3820, 3832, 3833, 3862, 3863, 3864, 3931, 3932, 3934, 3944, 3945, 3947, 3959, 3980, 4056, 4057, 4058, 4066, 4071, 4084, 4085, 4087, 4089, 4092, 4097, 4099, 4100, 4108, 4109, 4111, 4112, 4114, 4115, 4725, 4726, 4852, 4866, 5428, 6288, 7060, 7074, 7075, 7076, 7111, 7217, 7219
Ishimaru classification, 4755, 4756, 4772, 4773

islet transplantation, 3030, 3037, 3040, 3721, 3722, 3723, 3726, 3728, 3731, 3732, 3733, 3734, 3736, 3737, 3738, 3741, 3742, 3743, 3744
isogenic, 3431
isolated kidney perfusion, 3480, 3481, 3504
isolated perfusion, 3052, 3498, 3510, 3514, 3527
Isolation of aortic branches, 4758
Isoproterenol, 7280, 7281

J

jaboulay, 5964, 5966, 5968
janeway gastrostomy, 1831, 1832, 2027
Japan, 661, 688, 689, 702, 703, 707, 711, 712, 713, 716, 737, 913, 914, 941, 1228, 1561, 1611, 1615, 1616, 1617, 1675, 1892, 1977, 2039, 2044, 2045, 2046, 2052, 2349, 2360, 2363, 2368, 2377, 2561, 2781, 2926, 3030, 3087, 3115, 3159, 3163, 3164, 3165, 3166, 3198, 3200, 3254, 3255, 3495, 4062, 4063, 4778, 5371, 5454, 5630, 5800, 5803, 5806, 5808, 5809, 5838, 5845, 5848, 5865, 6029, 6061, 6073, 6081, 6084, 6086, 6089, 6254, 6421, 6632, 6789, 6904, 6908, 6910, 7196, 7214
jejunal extension, 1834, 1888, 1893, 1896, 1900, 1910, 1922, 1947, 1953, 1954, 1958, 1959, 1960, 1961, 1962, 1963, 1964, 1965, 1966, 1967, 1968, 1969, 1970, 1971, 2000, 2002, 2003, 2006, 2018, 2029, 2083, 2096
jejunal feeding extension, 1834, 1958, 2002, 2011
Jejunal feeding tubes, 1957
jejunoileal, 158, 159, 817, 2147, 2775, 5236, 5270, 5377, 5385, 5746, 5953, 5954, 5962, 5964, 6010, 6016, 6990, 7033
jejunojejunostomy, 140, 848, 855, 1996, 2736, 4296, 4299, 4300, 4607, 5085, 5098, 5099
joints, 82, 91, 99, 273, 275, 278, 310, 613, 704, 743, 1172, 1371, 1372, 1754, 1757, 1767, 1780, 1786, 1787, 1788, 1816, 1823, 1826, 1827, 1828, 2195, 2196, 2199, 2214, 2221, 2227, 2228, 2232, 2237, 2249, 2253, 2272, 3139, 3157, 3173, 3179, 3183, 3184, 3188, 3191, 3194, 3539, 3541, 3542, 3545, 3548, 3578, 4712, 5005, 5439, 5565, 5566, 5568, 5573, 5597, 5608, 5738, 6112, 6260, 6577, 6708, 6935
jugular venous oxygen saturation, 3811, 3827, 3828, 3889, 3899
jump gait, 1779, 1780, 1781, 1787, 1807, 1808
junctional ectopic tachycardia, 7278, 7285, 7292, 7293
juvenile nasopharyngeal angiofibroma, 1696, 1697, 1706, 5536

K

kartogenin, 3543, 3545, 3548, 3552
keratinocytes, 2105, 2116, 3012, 3545, 6413, 6415, 7119
keratoconus, 7311, 7312, 7313, 7314, 7316, 7317, 7318
ketamine, 972, 975, 1450, 1452, 1461, 1530, 1878, 1884, 2533, 2538, 2818, 2819, 2973, 3271, 3272, 3273, 3274, 3275, 3276, 3284, 3294, 3296, 3300, 3301, 3380, 3385, 3387, 3398, 3418, 3620, 3630, 4515, 4589, 4591, 6200, 6484, 7077, 7083, 7089, 7090, 7230, 7232, 7234, 7239, 7241, 7245, 7275
ketogenic diet, 3791, 5422, 5428
ketone bodies, 260, 3782, 3791, 5275, 5276, 5279, 5367
key findings, 3073, 3955
keystone flap, 5471
kidney donor, 3041, 5464
kidney transplantation, 1097, 2885, 2910, 3023, 3025, 3027, 3028, 3031, 3036, 3038, 3039, 3040, 3044, 3050, 3051, 3063, 3066, 3067, 3068, 3069, 3238, 3480, 3488, 3496, 3497, 3501, 3502, 3504, 3505, 3506, 3532, 3584, 3589, 3590, 3591, 3592, 3599, 3601, 3602, 3604, 3606, 3607, 3608, 3609, 3614, 3668, 3671, 3681, 3717, 5463, 5464, 5465, 5468, 5469, 6703
kinetic energy, 1711, 1808, 2190, 4039, 4120, 4122, 4134
Kirschner wire, 24, 27, 90, 2319, 3558, 5601, 5602, 6231, 6232
Kono-S anastomosis, 5953, 5954, 5973, 5986
K-wire, 99, 364, 374, 3566, 5601, 5602, 5604, 5606, 5607, 5608, 6231, 6232, 6237
kyphotic deformity, 291, 322, 324, 5577, 5578, 5581, 5582, 5583, 5587

L

labiopalatoschisis, 5544
labioschisis, 5544
lab-on-a-chip, 2940, 2941
laboratory animals, 881, 1069, 2775, 2894, 2910, 3109, 3233, 3237, 3238, 3247, 3250, 3257, 3266, 3267, 3293, 3294, 3297, 3310, 3311, 3375, 3377, 3397, 3407, 3418, 3434, 3442, 3445, 3446, 3701
lactate, 495, 501, 994, 1163, 1164, 1165, 1488, 2799, 2801, 2819, 2881, 2991, 3044, 3045, 3048, 3051, 3059, 3076, 3098, 3110, 3278, 3326, 3399, 3409, 3491, 3497, 3502, 3510, 3522, 3525, 3526, 3622, 3624, 3681, 3685, 3697, 3782, 3783, 3784, 3787, 3789, 3792, 3793, 3795, 3800, 3810, 3811, 3814,

3820, 3831, 3837, 3838, 3841, 3844, 3846, 3847, 3849, 3850, 3891, 4480, 4563, 4802, 5656, 6051, 6052, 7163, 7164, 7211
laminectomy, 5566, 5571, 5572, 5575, 5576, 5585, 5589, 5590, 6161, 6167, 6181, 6203
landing zones, 4755, 4756
landrace, 3431
langerhans cell histiocytosis, 5701, 5702, 5703, 5708, 5709
laparoendoscopic single-site surgery, 679, 698, 714, 715, 4387
laparoscopic adjustable gastric banding, 157, 158, 159, 168, 170, 173, 181, 182, 183, 184, 196, 199, 245, 250, 256, 795, 796, 808, 809, 874, 875, 1565, 2133, 4583, 5045, 5062, 5348, 5387, 6360, 6367, 6370, 7005, 7006, 7012, 7013, 7019, 7034, 7205, 7250, 7253
laparoscopic adrenalectomy, 710, 1208, 1209, 1210, 1220, 1221, 6408
laparoscopic hepatobiliary surgery, 2770, 2771
laparoscopic nephrectomy, 2775, 2776, 2781, 3155, 4337, 4353, 4363, 4364, 5793
laparoscopic one-anastomosis bypass, 5179
laparoscopic Roux-en-Y gastric bypass, 138, 144, 157, 158, 160, 206, 779, 795, 808, 812, 818, 838, 839, 841, 844, 1565, 2004, 2005, 2133, 2137, 2160, 2166, 2171, 2185, 2680, 2681, 2722, 2723, 2759, 4315, 4533, 4534, 4538, 4542, 4543, 4546, 4581, 4582, 4585, 4608, 4609, 5085, 5101, 5141, 5161, 5418, 6409, 7005, 7006, 7032, 7034, 7150, 7175, 7197, 7254
laparoscopic simulator, 2761, 2762, 2768, 2777, 2789, 2790, 2791, 2793, 3254
laparoscopic sleeve gastrectomy, 139, 156, 159, 172, 195, 206, 218, 794, 795, 797, 808, 812, 818, 819, 820, 840, 1565, 2004, 2166, 2171, 2172, 2680, 2681, 2683, 2684, 2688, 2692, 2702, 2703, 2704, 2705, 2709, 2714, 2722, 2723, 2726, 2729, 2746, 2747, 2758, 2759, 2837, 2838, 4315, 4316, 4501, 4503, 4508, 4509, 4538, 4542, 4544, 4550, 4551, 4552, 4553, 4583, 4584, 5015, 5063, 5178, 5358, 5360, 5363, 5384, 5387, 5412, 5416, 5417, 6369, 6370, 6409, 6701, 6704, 7004, 7007, 7012, 7019, 7026, 7148, 7149, 7174, 7200, 7201, 7203, 7205, 7257, 7260, 7266, 7267
laparoscopic suturing, 1939, 1984, 2765, 2766, 2777, 2788
laparoscopic table, 2971
laparoscopic technique, 143, 696, 1219, 1438, 1947, 2342, 2451, 2763, 2768, 2774, 2784, 2789, 2881, 3130, 3134, 3709, 4172, 4173, 4219, 4230, 4291, 4306, 4393, 4464, 4603, 5203, 5968, 5986, 5991, 5992, 6010, 6395, 6409, 6999, 7248, 7253
laparoscopic training, 2763, 2775, 2776, 2777, 2778, 2779, 2781, 2783, 2788, 2790, 2793, 3254
laparotomies, 2973, 2974, 3163, 4400, 4410, 4595, 7250, 7259
LapMentor II, 2778
LapSim, 2778, 3243
large animal model, 1071, 1073, 2821, 2824, 2915, 2918, 2921, 2925, 2928, 2930, 2932, 2994, 3068, 3265, 3294, 3295, 3296, 3385, 3413, 3422, 3427, 3428, 3429, 3430, 3439, 3441, 3443, 3444, 3526, 3548, 3551, 3553, 3585, 3602, 3611, 3612, 3613, 3614, 3618, 3628, 3629, 3630, 3643, 3691, 3697, 3700, 3756
large animal, 1071, 1072, 1073, 2783, 2807, 2810, 2816, 2821, 2824, 2840, 2893, 2915, 2918, 2920, 2921, 2922, 2925, 2928, 2930, 2932, 2969, 2994, 3068, 3125, 3245, 3259, 3262, 3264, 3268, 3286, 3294, 3295, 3296, 3307, 3317, 3318, 3327, 3328, 3334, 3385, 3388, 3398, 3399, 3413, 3422, 3427, 3428, 3429, 3430, 3432, 3433, 3434, 3435, 3439, 3441, 3442, 3443, 3444, 3526, 3542, 3548, 3551, 3553, 3562, 3585, 3594, 3598, 3602, 3611, 3612, 3613, 3614, 3618, 3627, 3628, 3629, 3630, 3638, 3643, 3654, 3668, 3673, 3677, 3684, 3688, 3690, 3691, 3697, 3700, 3730, 3755, 3756
large artery occlusion, 3931, 3932, 3933
laryngeal surgery, 1533, 1535, 6966
laryngeal transplantation, 3657, 3663
laryngopharyngeal reflux, 5505, 5506, 5508, 5513
laryngovide ostroboscopy, 5506
larynx, 1476, 1479, 1480, 1521, 1551, 1702, 2516, 2527, 2842, 2987, 3002, 3190, 3191, 3276, 3620, 3647, 3648, 3657, 3660, 3904, 4017, 4019, 4448, 4449, 4457, 5506, 6966, 6975, 7330
laser in situ keratomileusis, 389, 1709, 1718, 1719
laser speckle imaging, 3083, 3092, 3103, 3107, 3109
late complications, 445, 773, 774, 839, 846, 1334, 4005, 4595, 4833, 4976, 4981, 5381, 5382, 6902, 6905, 6908, 6995, 7001, 7248
latency, 1049, 1449, 2880, 2897, 2903, 3146, 3147, 3878
lateral collateral ligament, 3433, 6252
latissimus dorsi, 1407, 1666, 1672, 1674, 1677, 2562, 2563, 2583, 2589, 2591, 2595, 2601, 2602, 2603, 2612, 2643, 2646, 2648, 2658, 4699, 6151, 6152, 6158, 7340
LC-non-ascites:, 6141
leadership, 4466, 6381, 6382, 6383, 6384, 6385, 6386, 6387, 6388, 6389, 6390, 6391, 6575, 6933, 7154, 7295, 7299
leakage of CSF, 4087
left anterior descending (LAD) artery ligation, 2839
left atrial volume index, 6860

left coronary artery ligation, 2840, 2841, 2850
left internal mammary artery graft, 6519
left ventricular bypass, 4796, 4797, 4803
leg pain, 4730, 4949, 5558, 5571, 5572, 5573, 5576, 5585, 5586, 5589, 6166, 6208, 6210
legal requirement, 6327, 6328
length of hospital stay, 794, 2046, 2708, 2713, 2714, 2715, 2717, 2718, 2720, 2721, 2761, 3135, 3136, 3140, 3143, 4157, 4355, 4356, 4401, 4402, 4404, 4405, 4408, 4409, 4415, 4416, 4417, 4418, 4419, 4487, 4501, 4563, 4565, 4625, 4633, 4637, 4656, 4660, 4663, 4672, 5833, 5840, 5985, 5991, 5992, 6004, 6063, 6064, 6067, 6242, 6245, 6396, 6397, 6398, 6399, 6400, 6401, 6402, 6403, 6404, 6405, 6406, 6454, 6471, 6669, 6675, 7134, 7154, 7248
leptin, 163, 165, 168, 170, 171, 172, 173, 175, 176, 177, 181, 182, 184, 1777, 2104, 2105, 2114, 2120, 2145, 2151, 2152, 2156, 2157, 2159, 2160, 2162, 2163, 2165, 2166, 2170, 2179, 2181, 2187, 2679, 2681, 2831, 2832, 2833, 2837, 3565, 3566, 3577, 3578, 3579, 5271, 5361, 6699, 6702, 6980, 6989, 6992, 7012, 7016, 7018, 7026, 7028, 7029, 7030, 7033, 7034, 7035
leukocytosis a, 2061, 3287
Levosimendan, 976
Lichtenstein 9, 6140
Lichtenstein hernioplasty, 6138, 6140, 6141
life expectancy, 164, 253, 256, 286, 844, 1153, 1487, 1768, 1844, 1847, 1849, 1853, 1854, 1856, 1887, 1893, 1900, 1949, 2023, 2093, 2284, 2323, 2433, 3237, 3239, 3563, 3864, 4057, 4812, 4821, 4838, 5375, 5560, 5964, 6046, 6053, 6277, 6520, 6528, 6555, 6578, 6831, 6881, 6937, 7132, 7134, 7135, 7177, 7189, 7205
ligating device, 2095, 2096
limb salvage, 1085, 2321, 2323, 2331, 4893, 4894, 4897, 4909, 4925, 4926, 4931, 5431, 5557, 5558, 5561
limb transplantation, 3122, 3124, 3125, 3128, 3649, 3653, 3654, 3655, 3656, 3661, 3664
limitations of multimodal monitoring, 3799
lindegaard ratio, 3806
lingual surgery, 1535
liver anatomy, 1230, 2340, 2341, 2357, 2364, 2770, 2867, 2873, 2885
liver biopsy, 1224, 1225, 5258, 5259, 5267, 5268, 5301, 5302, 5303, 5304, 5314, 5315, 5318, 5330, 5332, 5336, 5337, 5338, 5343, 5344, 5346, 5347, 5351, 5358, 5368, 5410, 6136, 6144, 6310, 6648
liver engineering, 2988
liver fibrosis, 2339, 2351, 2891, 2905, 2910, 3363, 5258, 5266, 5268, 5273, 5287, 5294, 5298, 5302, 5335, 5338, 5341, 5367, 5371, 5384, 5400, 5421, 5425, 5427, 5429
liver steatosis, 2888, 5268, 5270, 5271, 5274, 5343, 5344, 5345, 5346, 5347, 5349, 5354, 5357, 5358, 5360, 5365, 5373, 5374, 5379, 5383
liver-histology, 5247
local complications, 4975, 4976, 4981
local nonvascular complications, 4981
local vascular complications, 4981
longevity, 165, 353, 359, 362, 366, 394, 397, 405, 406, 415, 469, 471, 498, 506, 509, 528, 540, 564, 568, 574, 617, 626, 627, 1960, 1969, 2162, 2171, 2276, 2466, 3059, 3060, 3233, 6263, 6264, 6267, 6578, 6936
loop ileostomy, 4230, 5988, 6011
Los Angeles classification, 1889, 1902
low cardiac output syndrome, 6797, 7277
low grade glioma(s), 7097, 7098, 7099, 7100, 7111, 7112
low molecular weight heparins, 4505, 4507, 4509, 5917, 7263, 7265
lower and middle income countries, 4056
lower BMI, 174, 194, 2522, 2734, 5046, 5404, 5405, 7133
lower extremity, 88, 95, 111, 1087, 1088, 1089, 1492, 1725, 1789, 1791, 1792, 1828, 2224, 2670, 3692, 4174, 4240, 4253, 4386, 4563, 4668, 4724, 4729, 4730, 4745, 4747, 4750, 4813, 4821, 4846, 4872, 4873, 4879, 4880, 4889, 4906, 4907, 4925, 4929, 4930, 4931, 4932, 4936, 4937, 4945, 4948, 4950, 4951, 4957, 4984, 4988, 5002, 5008, 5012, 5557, 5565, 6237, 6955, 7242
lower limb ischemia, 1089, 3671, 3674, 3704, 3718, 4871, 4872, 4873, 4874, 4875, 4878, 4880, 4909, 5011
lower-profile, 1913
low-intensity pulsed ultrasound, 49, 3558, 3566, 3570, 3576, 3581
low-order models, 3449, 3450, 3451, 3463, 3471
low-profile, 1932, 2027, 6095, 6103, 6489
lubricin, 3543
lumbar canal stenosis, 5573, 5585, 5589, 5591
lumbar drain, 938, 958, 983, 1019, 1020, 1023, 3911, 4025, 7326
lumbar pain, 1472, 5572, 6162, 6203, 6204, 6208, 6210
lumped-parameter, 3449, 3450, 3451, 3452, 3458, 3468, 3477
Lundberg type A, 3800, 3802, 3887
lung capacity, 111, 1725, 2392, 3921, 7161
lung machine preservation, 3060, 3061
lung transplantation, 2428, 2431, 2436, 2439, 2781, 3023, 3039, 3044, 3063, 3585, 3587, 3597, 3598,

3599, 3601, 3603, 3604, 3605, 3606, 3607, 3629, 3630, 3631, 3637, 3638, 3644, 3645, 3675, 3677, 3708, 7273, 7274
lymphadenectomy, 713, 1360, 1561, 1578, 1582, 1583, 1586, 1721, 3134, 3136, 3151, 4142, 4161, 4162, 4165, 4167, 4168, 4223, 4269, 4323, 4350, 4362, 4404, 4405, 4408, 4418, 4420, 4422, 4429, 4430, 4435, 4436, 4437, 4439, 4440, 4442, 4443, 4444, 4445, 5801, 5803, 5805, 5806, 5807, 5808, 5810, 5819, 5826, 5833, 5838, 5839, 5843, 5844, 5845, 5846, 6066, 6068, 6071, 6085
lymphatic secretion, 4990

M

machine organ preservation, 3038, 3045, 3046
machine perfusion, 3039, 3042, 3043, 3044, 3045, 3046, 3050, 3052, 3053, 3055, 3057, 3058, 3059, 3060, 3061, 3062, 3064, 3065, 3066, 3067, 3068, 3069, 3070, 3071, 3480, 3481, 3488, 3489, 3491, 3492, 3494, 3495, 3499, 3500, 3501, 3502, 3503, 3504, 3505, 3506, 3507, 3509, 3510, 3511, 3512, 3515, 3516, 3519, 3520, 3521, 3522, 3523, 3524, 3526, 3527, 3528, 3529, 3530, 3532, 3533, 3534, 3535
macro-hemorheological changes, 3098
magnesium, 217, 974, 977, 983, 989, 990, 2655, 2953, 3031, 3315, 3322, 3323, 3896, 6013, 6372, 6867, 7224, 7230, 7233, 7234, 7241, 7286
magnetic resonance angiography, 956, 1088, 1184, 1366, 1367, 1418, 1426, 3338, 3359, 3363, 3466, 3879, 3932, 4812, 4817, 4867, 4873, 4875, 4883, 4903
magnetic resonance elastography, 5341
magnetic resonance spectroscopy, 1187, 1188, 3783, 3784, 3792, 3794, 3841, 5268, 5283, 5332, 5348, 5349, 5359, 5775, 6132
major histocompatibility complex, 2916, 2924, 2937, 2938, 3250, 3296, 3299, 3422, 3433, 3584, 3585, 3599, 3600, 3612, 3614, 3628, 3639, 3644, 3663, 3714, 3716, 3731
malabsorption, 220, 223, 225, 228, 229, 230, 232, 258, 260, 758, 828, 840, 861, 862, 865, 866, 867, 870, 874, 1774, 2002, 2107, 2109, 2112, 2139, 2145, 2147, 2154, 2175, 2775, 5203, 5204, 5360, 5390, 5391, 5950, 5953, 5957, 5964, 5969, 5984, 6018, 6347, 6348, 6351, 6355, 6356, 6358, 6360, 6361, 6362, 6365, 6366, 6981, 7010, 7132
malabsorptive interventions, 261
malate dehydrogenase, 3786
malignant bowel obstruction, 1845, 1851, 1852, 1855, 1858, 1989, 2009, 2010, 2011, 2020
malignant MCA syndrome, 3932, 3933, 3934, 3935, 3940
malignant pleural mesothelioma, 1721, 1722, 1726, 1727
malignant stroke, 988, 3778, 3931, 3932, 3938, 4064
Mallory-Den bodies, 5287
mammalian target, 3648, 3650
Mandibular advancement, 1535
Marfan syndrome, 915, 916, 917, 4760, 4791, 4792, 4795, 4806, 4807, 4808, 6553, 6555, 6568
marginal organs, 2989, 3038, 3511
marginal ulcers, 144, 759, 783, 788, 825, 840, 846, 847, 848, 2730, 4569, 4573, 4581, 4582
masseteric nerve, 1666, 1667, 1669, 1671, 1672, 1673, 1675, 1677, 2381, 6438, 6445, 6450, 7343
masseteric, 401, 557, 1666, 1667, 1669, 1671, 1672, 1673, 1675, 1677, 2381, 6438, 6445, 6446, 6450, 7343
massive rotator cuff tear, 6707, 6708, 6709, 6710, 6711
mass-lesion, 3951
mastectomy, 458, 477, 490, 494, 496, 509, 514, 1135, 1136, 1406, 1408, 1409, 1414, 1415, 1416, 1420, 1423, 1577, 1578, 1579, 1581, 1582, 1584, 1585, 2552, 2556, 2558, 2560, 2565, 2566, 2567, 2568, 2569, 2570, 2571, 2572, 2573, 2574, 2575, 2576, 2577, 2578, 2583, 2584, 2586, 2587, 2588, 2591, 2593, 2594, 2595, 2596, 2597, 2598, 2599, 2601, 2602, 2605, 2608, 2609, 2612, 2613, 2617, 2625, 2632, 2636, 2637, 2639, 2643, 2647, 2650, 2658, 2661, 2662, 2663, 2674, 2675, 4685, 5690, 5691, 5696, 5698, 6148, 6376, 6379, 6420, 6421
maternal and neonatal outcomes, 259, 263, 264
matrix degrading enzymes, 7120
matrix metalloproteinases, 2911, 3012, 3538, 3539, 6553, 6554
mature cystic teratoma, 6034, 6035, 6040
maxillofacial surgery, 72, 675, 676, 686, 1513, 1532, 1729, 1730, 1743, 2321, 6339, 6341, 6343
MAXIO® system, 705
MCA perforation model, 1069, 1071
McVay hernia repair, 6140
mean arterial pressure, 972, 992, 996, 1877, 1878, 2796, 2799, 3621, 3803, 3810, 3837, 3851, 3852, 3854, 3993, 4038, 4660, 6218
mechanical bowel preparation, 4637, 4639, 4640, 4689, 6011
mechanical heart valve, 1863, 6546
mechanical ventilation, 110, 210, 212, 214, 932, 1036, 1039, 1875, 1877, 1879, 1891, 2035, 2391, 2803, 2818, 2825, 2843, 3037, 3347, 3365, 3694, 3807, 3891, 3892, 3894, 3898, 3904, 3907, 3912, 3914, 3929, 3954, 4059, 4571, 4581, 5458, 5923,

6216, 6477, 6503, 6506, 6515, 6543, 6850, 6863, 6864, 7157, 7158, 7159, 7160, 7162, 7163, 7164, 7165, 7277, 7292
mechanical-chemical ablation technique, 4961
mechanicochemical vein ablation, 4934
mechanism of action, 177, 982, 1878, 2151, 3014, 3280, 5045, 5165, 5922, 5923, 6179, 6603, 7239, 7242, 7256, 7281, 7287, 7288
medial sternotomy, 4761, 4767, 4773
medical community, 2190, 2585, 3980, 6922, 6923
medical error, 3907, 7296, 7304, 7305, 7309, 7310
medical statistics, 7152
medical treatments, 38, 642, 1843, 3218, 3272, 3968, 3971, 6222, 6416, 7313
medical-treatment of NASH, 5419
melanocortin, 2129, 6985
melanocyte, 5475
melanoma, 1161, 1183, 1218, 1357, 1358, 1359, 1360, 1364, 1365, 1583, 1585, 1586, 3119, 3128, 3355, 3516, 3518, 3527, 3528, 3529, 3530, 3531, 3533, 3535, 5479, 6278, 6417, 6418, 6419, 6428
melatonin, 3791, 3798
melena, 141, 144, 777, 1334, 2067, 2091, 2742, 6654, 6997
memory decline, 7057, 7058, 7061
meningitis, 1030, 1038, 1614, 1688, 1693, 1694, 1695, 2411, 2414, 2805, 2810, 2811, 2815, 2825, 2826, 2828, 3841, 3843, 3849, 3865, 3872, 4017, 4025, 4036, 4059, 4065, 4087, 4102, 4115, 5778, 6089, 6091, 6117, 6211, 7325
mesenchymal stem cells, 70, 73, 74, 76, 350, 351, 1749, 2925, 2937, 2990, 3003, 3337, 3357, 3361, 3441, 3506, 3538, 3540, 3545, 3551, 3552, 3553, 3554, 3555, 3558, 3566, 3567, 3570, 3575, 3577, 3578, 3580, 3661, 3662, 6413, 6423, 6424, 6429, 6430, 6988
mesenteric ischemia, 690, 3666, 3684, 3703, 3706, 3707, 3716, 3718, 3920, 4727, 4811, 4812, 4839, 4841, 6019
Mesh plug hernia repair, 6140
meta-analyses, 186, 192, 202, 477, 492, 974, 983, 984, 1208, 1220, 1495, 1597, 1957, 2040, 2128, 2150, 2335, 2336, 2727, 2762, 2763, 3934, 3939, 3940, 3943, 4004, 4346, 4414, 4515, 4524, 4627, 4644, 4645, 4697, 4703, 5918, 5985, 6014, 6064, 6065, 6066, 6069, 6360, 6510, 6543, 6544, 6849
metabolic acidosis, 260, 2928, 3320, 3322, 3324, 3325, 3326, 3327, 3333, 3897, 3898, 4785, 6288
metabolic alkalosis, 3324, 3326, 3327
metabolically healthy obese, 6977, 6978, 6990
metabolically unhealthy obese, 6977, 6978
metaclopromide, 1899
metacognition, 3906
methicillin-resistant *Staphylococcus aureus*, 1570, 1575, 1862, 1868, 2037, 2041, 2050, 4239
methodology, 103, 186, 242, 366, 436, 496, 622, 1208, 1246, 1654, 1656, 2155, 2156, 2941, 2967, 3053, 3058, 3059, 3073, 3074, 3082, 3084, 3085, 3101, 3125, 3438, 3439, 3474, 3575, 3603, 3812, 3846, 3910, 3928, 3972, 3981, 4031, 4097, 4121, 4128, 4130, 4157, 4301, 4320, 4678, 4703, 4797, 4803, 4865, 5406, 5419, 5420, 5423, 5427, 5778, 5780, 5782, 5783, 5784, 6328, 6380, 6638, 6923, 7042, 7097, 7100, 7101, 7104, 7151, 7152, 7153, 7154, 7155, 7308
methoxamine and phenylephrine, 6584
methyl methacrylate, 2951, 3728, 4023, 4077, 5873
metoidioplasty, 6147, 6149, 6150, 6153, 6154, 6157, 6158
MIAVR centers, 6454
Michelassi, 5964, 5965, 5967, 5973, 5974, 5976, 5977, 5979, 5997, 6024, 6025
micro-dissected tissue, 2939, 2940, 2941, 2948, 2952, 2955
micro-hemodynamic features, 3084
micro-rheology, 3074, 3101
micro-ultrasound devices, 3094
microbiology, 503, 1701, 2397, 2430, 3200, 3721, 4499, 4500, 4611, 4615, 4618, 4619, 4620, 4641, 4642
microcirculation, 911, 1069, 1070, 1071, 1072, 1238, 1365, 1655, 2638, 2801, 2824, 2826, 2828, 2829, 2892, 2894, 2895, 3028, 3041, 3048, 3065, 3073, 3074, 3075, 3076, 3078, 3079, 3081, 3083, 3084, 3085, 3087, 3089, 3090, 3091, 3092, 3097, 3098, 3099, 3100, 3101, 3102, 3103, 3104, 3105, 3106, 3107, 3108, 3109, 3110, 3111, 3112, 3492, 3605, 3678, 3680, 3697, 3700, 3715, 3717, 3808, 3845, 4105, 4877, 4882, 4885, 4916, 4954, 5006, 5458, 5459, 5461, 5924, 6630, 6633, 7278
microcirculatory inflammation, 3073
microcirculatory perfusion, 2828, 3073, 3084, 3091, 3111, 5458, 5459
microcomputed tomography, 3362, 3365, 3368, 3558
microdebrider adenoidectomy, 2461
microdialysis, 994, 999, 1455, 3783, 3784, 3786, 3789, 3792, 3793, 3794, 3796, 3814, 3815, 3817, 3820, 3827, 3829, 3830, 3831, 3836, 3837, 3838, 3839, 3840, 3841, 3842, 3843, 3845, 3846, 3847, 3850, 3889, 4096
microfluidic device, 2939, 2941, 2942, 2943, 2945, 2946, 2947, 2948, 2949, 2951, 2952, 2954, 2957, 2963
microfluidics, 2940, 2941, 2942, 2943, 2946, 2966, 3743
microfracturing, 3537, 3539, 3540, 3543, 3548

micromass, 3537, 3541
microsurgery, 680, 702, 713, 728, 904, 1189, 1366, 1367, 1405, 1406, 1419, 1422, 1423, 1425, 1426, 1427, 1653, 1674, 1675, 1676, 1718, 2551, 2561, 2597, 2600, 2639, 2646, 2647, 2675, 2882, 2908, 2910, 2913, 3109, 3156, 3241, 3252, 3253, 3255, 3257, 3419, 3425, 3583, 3585, 3601, 3602, 3603, 3604, 3605, 3606, 3607, 3608, 3609, 3649, 3661, 4448, 4455, 4459, 4460, 4461, 4897, 5474, 5601, 5850, 6126, 6130, 6131, 6132, 6451, 6967, 7343
microsurgery techniques, 1406, 2551, 3241
microvascular dysregulation, 4082
microvasculature, 3075, 3082, 3084, 3090, 3093, 3112, 3514
Midazolam, 1454, 1876, 3275, 3283, 3284, 4520, 7274
mid-facial reconstruction, 5515, 5516, 5518, 5528, 5535
middle cerebral artery, 881, 887, 888, 889, 890, 892, 896, 899, 902, 932, 935, 945, 963, 965, 968, 969, 972, 985, 993, 1071, 1182, 1183, 1611, 1640, 1641, 3666, 3688, 3690, 3691, 3692, 3694, 3698, 3712, 3769, 3772, 3777, 3778, 3789, 3797, 3806, 3833, 3841, 3849, 3863, 3871, 3931, 3932, 3935, 3938, 3944, 3945, 3946, 3980, 3989, 4004, 4014, 4026, 4030, 4061, 4065, 4068, 4089, 4097, 4101, 4102, 4114, 4115, 4854, 4858, 6098, 6104, 7060, 7062, 7211, 7214, 7218
middle meatal antrostomy, 2403, 2404, 2405, 2407, 2456, 2457
mild cognitive dysfunction, 7058, 7066
military, 2035, 2233, 3031, 3130, 3143, 3147, 3165, 3171, 3172, 3174, 3176, 3180, 3181, 3183, 3184, 3187, 3188, 3189, 3190, 3192, 3193, 3194, 3196, 3950, 3968, 3969, 3971, 3980, 4011, 4012, 4013, 4014, 4018, 4019, 4021, 4022, 4023, 4024, 4025, 4026, 4027, 4028, 4029, 4033, 4037, 4039, 4040, 4041, 4042, 4914, 4931, 4932, 5469, 7302, 7304
military cranial surgery, 4013
military surgery, 3180, 3181, 3187, 3188, 3189, 3190, 3194, 4011, 4014
millennials, 6920
mini-Bentall, 6551, 6566, 6567
mini gastric bypass, 774, 814, 822, 857, 858, 1565, 2701, 2832, 2837, 4539, 5163, 5177, 5178, 5179, 5201, 5377, 5378, 5386, 5387, 5388, 5390
mini-sternotomy, 6456, 6470, 6480, 6510, 6515, 6516, 6540, 6551, 6552, 6555, 6556, 6566, 6740, 6758
mini-thoracotomy, 4198, 4212, 4214, 6061, 6473, 6509, 6510, 6516, 6520, 6525, 6528, 6531, 6532, 6548, 6552, 6566, 6614, 6615, 6616, 6619, 6713, 6727, 6729, 6751, 6754, 6755, 6756, 6758, 6759, 6760, 6762, 6763, 6764, 6774, 6788, 6791, 6795, 6796, 6797, 6800, 6803, 6829, 6831, 6833, 6838, 6842, 6856
minimal access, 292, 402, 418, 1559, 2423, 4153, 4364, 4444, 6071, 6454, 6464, 6474, 6516, 6525, 6526, 6551, 6560, 6566, 6567, 6713, 6740
minimally invasive aortic valve replacement, 6453, 6461, 6462, 6471, 6472, 6473, 6474, 6476, 6499, 6507, 6508, 6509, 6517, 6524, 6535, 6538, 6546, 6548, 6567
minimally invasive approach, 290, 299, 315, 822, 1065, 1131, 1195, 2006, 2443, 2456, 2789, 2792, 3136, 4157, 4172, 4237, 4239, 4248, 4257, 4288, 4330, 4345, 4350, 4367, 4382, 4401, 4405, 4410, 4412, 4413, 4448, 4467, 4477, 5858, 5920, 6015, 6062, 6063, 6251, 6407, 6459, 6463, 6466, 6470, 6471, 6473, 6474, 6499, 6504, 6505, 6506, 6507, 6509, 6510, 6516, 6519, 6520, 6524, 6525, 6527, 6537, 6538, 6543, 6545, 6547, 6667, 6669, 6679, 6682, 6714, 6741, 6751, 6756, 6787, 6797, 6798, 6831, 6833, 6838, 6845, 6846, 6850, 7054, 7249, 7320
minimally invasive cardiac surgery, 696, 6491, 6524, 6757, 6758, 6787, 6799, 6800, 6820, 6847
minimally invasive parathyroidectomy, 1193, 1195, 1204, 7051, 7052, 7054, 7055, 7056
minimally invasive surgery, 646, 661, 680, 713, 719, 1319, 1535, 1800, 1813, 2343, 2443, 2761, 2763, 2767, 2768, 2776, 2780, 2785, 2788, 2980, 3129, 3130, 3131, 3136, 3142, 3144, 3150, 3257, 3445, 3871, 4160, 4172, 4173, 4174, 4183, 4187, 4233, 4345, 4360, 4398, 4421, 4431, 4432, 4436, 4438, 4464, 4466, 4471, 4563, 4615, 4640, 4641, 4664, 5969, 6061, 6251, 6292, 6454, 6475, 6477, 6482, 6487, 6501, 6519, 6541, 6543, 6566, 6567, 6701, 6714, 6715, 6717, 6756, 6800, 6802, 7252
minimally invasive surgical procedures, 692, 1559, 4196, 6845
minimum information, 6329
minor complications, 100, 391, 441, 530, 581, 960, 1688, 1690, 1845, 1854, 1922, 1952, 1980, 1990, 2023, 2055, 2077, 2411, 2456, 2590, 3142, 4360, 4959, 6137, 6141, 6142, 6314
mirror separation of branches, 4758
missile, 3971, 4011, 4012, 4018, 4020, 4026, 4029, 4040, 4042, 4137
MISTELS/FLS trainer, 2779
MIST-VR system, 3243
mitochondria, 1197, 1199, 3027, 3065, 3075, 3503, 3558, 3671, 3673, 3748, 3781, 3785, 3786, 3788, 3789, 3790, 3791, 3795, 3798, 3840, 5252, 5256, 5279, 5285, 5333, 5367, 5676, 5684, 7120, 7127, 7210, 7217

mitochondrial permeability transition pore, 3666, 3673, 3785, 3790, 3795
mitochondrial respiration, 3086, 3513, 3785, 3837
mitral regurgitation, 4188, 4193, 6470, 6719, 6720, 6723, 6741, 6773, 6774, 6784, 6785, 6787, 6799, 6802, 6817, 6820, 6821, 6827, 6840, 6850, 6855
mitral valve, 693, 696, 697, 713, 3133, 3134, 3149, 3153, 3154, 3157, 3444, 3478, 4187, 4188, 4189, 4192, 4194, 4195, 4196, 4197, 4198, 4199, 4776, 4787, 5901, 6470, 6474, 6482, 6490, 6525, 6536, 6567, 6713, 6719, 6722, 6723, 6725, 6727, 6728, 6736, 6737, 6739, 6740, 6741, 6742, 6743, 6749, 6750, 6751, 6754, 6756, 6757, 6758, 6759, 6760, 6765, 6766, 6768, 6771, 6772, 6773, 6776, 6781, 6783, 6784, 6785, 6787, 6798, 6799, 6800, 6803, 6804, 6806, 6807, 6814, 6817, 6818, 6820, 6821, 6822, 6823, 6824, 6825, 6826, 6827, 6831, 6835, 6839, 6841, 6842, 6843, 6845, 6846, 6854, 6855, 6856, 6861, 7271, 7273
mitral valve (MV) repair, 6713, 6773
mitral valve prolapse, 3153, 4199, 6725, 6742, 6773, 6785, 6822, 6823, 6855
mitral valve surgery, 697, 3133, 4188, 4189, 4192, 4196, 4198, 5901, 6470, 6474, 6536, 6713, 6727, 6728, 6740, 6741, 6742, 6743, 6749, 6750, 6751, 6756, 6757, 6758, 6768, 6771, 6772, 6784, 6785, 6787, 6798, 6799, 6803, 6820, 6821, 6822, 6825, 6831, 6839, 6841, 6842, 6845, 6846, 6854, 6855, 6856
model of hepatic metastases of colon carcinoma, 2865
models of acute liver failure, 2865, 2880, 2886, 3754
models of cirrhosis, 2865
models of hepatocellular carcinoma, 2865
modification of the target organ, 3515
modified Rankin Scale, 947, 1046, 1051, 1064, 1659, 3934, 4108
modiolus, 6443, 6444
monitored anesthesia care, 1460, 1871, 1874, 4519
monitoring neurochemistry, 3841
monocyte chemoattractant protein-1, 3011, 3558, 3569, 5612, 5614, 6978
monolayer, 2941, 2943, 2944, 2956, 3117, 3537, 3541, 3544, 3727
monomorphic epitheliotropic intestinal T-cell lymphoma, 5617, 5630
monopolar cautery tonsillectomy, 2493
Monro-Kellie doctrine, 3800, 3852, 3970
morphine, 972, 1453, 1462, 1877, 1883, 2531, 2532, 2537, 2538, 2727, 2818, 3203, 3281, 3309, 3418, 3420, 3421, 3485, 3506, 4332, 4350, 4515, 4521, 4567, 4591, 5459, 5614, 5796, 6198, 6203, 6207, 6208, 6210, 6211, 6212, 6214, 6242, 6248, 7086, 7090, 7092, 7234, 7241, 7243, 7245, 7250, 7251, 7258
morphology, 70, 299, 306, 388, 557, 580, 585, 917, 919, 1125, 1135, 1139, 1142, 1254, 1272, 1273, 1314, 1348, 1362, 1554, 1612, 1748, 1904, 2199, 2210, 2234, 2235, 2237, 2238, 2239, 2240, 2244, 2250, 2251, 2276, 2283, 2771, 2802, 2892, 2903, 2944, 2961, 3034, 3076, 3082, 3096, 3349, 3547, 3570, 3573, 3600, 3696, 3786, 3796, 4132, 4133, 4736, 4807, 4850, 4867, 5305, 5327, 5626, 5628, 5632, 5675, 5701, 5707, 5712, 5804, 5893, 5902, 6149, 6181, 6182, 6471, 6554, 6593, 6790, 6823, 6830, 6866, 6893, 6894, 6988, 7031, 7303
mortality rates, 138, 143, 145, 501, 1421, 1725, 1840, 1841, 1843, 1850, 1854, 1892, 2053, 2056, 2336, 2338, 2808, 2891, 2894, 2895, 2927, 3403, 3519, 3904, 4057, 4165, 4286, 4530, 4576, 4616, 4672, 4833, 4865, 4997, 5006, 5401, 5831, 5839, 5890, 5944, 5988, 6090, 6133, 6138, 6311, 6462, 6543, 6642, 6655, 7119, 7130, 7132, 7134, 7135, 7136, 7149, 7248, 7258
mosaicplasty, 3537, 3540, 3543, 3548
mouth gag, 2486, 2494, 2497, 2498, 2499, 2500, 2514, 2523, 4451, 4452, 4453, 5543, 5544
MR angiography, 945, 952, 956, 1081, 1088, 1176, 1178, 1180, 1358, 1612, 3094, 3372, 3820, 4887
MR CLEAN, 3933, 4066
MrBot®, 707
mucocele, 1688, 1703, 2427, 2428, 2429, 2430, 2431, 2432, 2433, 2434, 2437, 2438, 2459
mucosal healing, 443, 5940, 6013, 6017
multidisciplinary approach, 73, 826, 1039, 1040, 1223, 1600, 1601, 1605, 1607, 1769, 1776, 1867, 1993, 2315, 2437, 2565, 2568, 4078, 4419, 4630, 5046, 5402, 5535, 5878, 5985, 6243, 6870
multilevel occlusive disease, 4823
multilevel orthopedic surgery, 1757, 1780, 1781, 1788, 1793, 1794, 1801, 1802, 1810, 1815, 1816
multilevel surgery, 1533, 1535, 1539, 1756, 1757, 1760, 1761, 1762, 1763, 1779, 1780, 1788, 1792, 1798, 1811, 1812, 1817
multimodal analgesia, 211, 214, 1444, 1453, 1461, 2536, 2719, 4587, 4588, 4589, 4590, 4592, 4593, 7087, 7229, 7230, 7232, 7235, 7237, 7238, 7239, 7240, 7244, 7245, 7261
multimodal monitoring and clinical outcomes, 3799
multimodal monitoring, 998, 3799, 3800, 3833, 3839, 3846, 3888, 3900, 4059, 4096
multimodal, 211, 214, 623, 959, 991, 998, 999, 1042, 1045, 1181, 1444, 1452, 1453, 1458, 1461, 1902, 1994, 2092, 2101, 2106, 2530, 2536, 2718, 2719, 2724, 2727, 3271, 3280, 3282, 3283, 3296, 3604, 3799, 3800, 3802, 3812, 3818, 3821, 3831, 3833,

3839, 3846, 3869, 3888, 3900, 3910, 3986, 4040, 4059, 4065, 4096, 4101, 4115, 4159, 4511, 4515, 4587, 4588, 4589, 4590, 4592, 4593, 5458, 5816, 6870, 6877, 6923, 7087, 7229, 7230, 7232, 7233, 7235, 7237, 7238, 7239, 7240, 7243, 7244, 7245, 7253, 7261, 7277
multiorgan failure, 3866, 4546, 4812, 4836, 6797
multiple compartment syndrome, 3917, 3919, 3922, 3927, 3929, 4052
multiple organ dysfunction syndrome, 2823, 2829, 3101, 3685, 4976, 4977, 4980
multiple-hits hypotheses, 5247
multiscale, 3449, 3450, 3451, 3462, 3463, 3464, 3466, 3468, 3469, 3470, 3472, 3476, 3477, 3562, 3575, 3737, 5906
murine, 179, 1074, 2153, 2186, 2810, 2817, 2822, 2823, 2824, 2825, 2829, 2863, 2901, 2918, 2919, 2936, 2937, 2978, 2981, 2995, 3016, 3021, 3036, 3264, 3270, 3272, 3301, 3341, 3342, 3346, 3347, 3349, 3351, 3362, 3366, 3368, 3369, 3373, 3374, 3409, 3425, 3442, 3543, 3548, 3549, 3555, 3563, 3568, 3571, 3575, 3577, 3578, 3581, 3599, 3600, 3601, 3603, 3605, 3609, 3693, 3699, 3700, 3703, 3706, 3714, 3716, 3759, 3768, 3769, 3770, 3772, 3773, 5260, 5262, 5425, 5426, 6413, 6414, 6415, 6424, 6631, 6633, 6913, 6992, 7028, 7125
muscle sling, 5515, 5516, 5529, 5530, 5534
muscle strength, 108, 246, 247, 1485, 1487, 1491, 1492, 1494, 1497, 1501, 1507, 1508, 1509, 1510, 1757, 1808, 2123, 2382, 6705, 7149
muscle transposition, 6434, 7339
musculocutaneous latissimus dorsi flap, 6147, 6158
music therapy, 1041, 1042, 4516
mutant, 2887, 3122, 3431, 3569, 5707
myelolipomatous metaplasia, 5641, 5642, 5643, 5650, 5651
myocardial infarction, 144, 262, 767, 768, 771, 1444, 1450, 1451, 1486, 1872, 1873, 1881, 2650, 2673, 2681, 2840, 2853, 3133, 3142, 3338, 3341, 3346, 3347, 3355, 3360, 3364, 3369, 3401, 3407, 3666, 3667, 3671, 3684, 3701, 3703, 3705, 3712, 3713, 3716, 3717, 4211, 4214, 4529, 4826, 4836, 4857, 4863, 4864, 4873, 4874, 4881, 4901, 4905, 4976, 4977, 4978, 5007, 5414, 5447, 5448, 5882, 5893, 5914, 6217, 6776, 6782, 6847, 6860, 6861, 6863, 6864, 7162
myocardial ischemia, 997, 1725, 2840, 2863, 3108, 3671, 3673, 3674, 3702, 3703, 3705, 3711, 3716, 4202, 4904, 4905, 6217, 6589, 6866, 6868, 7285
myofascial pain, 2379, 2380, 2383
myomectomy, 714, 3134, 3135, 3148, 3149, 4432, 4486, 4487, 4488, 4494, 4497, 6035, 6037, 6043, 7117, 7118, 7119, 7121, 7123, 7124, 7125, 7126
myometrium, 3391, 4486, 4487, 4488, 4493, 4494, 7118, 7121, 7125

N

NABIS:H, 3818
N-acetylasparate, 3784
nailing, 1, 2, 6, 7, 13, 14, 15, 23, 24, 25, 26, 28, 29, 30, 33, 35, 37, 47, 48, 49, 69, 77, 78, 79, 81, 85, 87, 88, 89, 90, 91, 95, 101, 102, 121, 122, 125, 128, 131, 133, 134, 135, 3443, 3574
naked DNA, 3115, 3116, 3122, 3123, 3124, 3127, 3128
nanomaterials, 3546, 3548
nasal defect, 5487, 5489, 5490, 5491, 5550
nasal dermoids, 1692, 1693, 1705
nasal endoscopy, 426, 1681, 1682, 1683, 1688, 1689, 1690, 1691, 1693, 1694, 1695, 1697, 1698, 2431, 5503
nasal polypectomy, 1535
nasal reconstruction, 448, 5487
nasal septal flap, 5487, 5488, 5489, 5490
nasal surgery, 422, 423, 437, 440, 444, 445, 451, 598, 1533, 1535, 1536, 1553, 5499, 5500, 5503
nasal valve surgery, 450, 1535, 1536, 5499, 5504
nasal valve, 421, 423, 424, 425, 426, 437, 438, 439, 440, 445, 446, 448, 449, 450, 1535, 1536, 5485, 5499, 5500, 5502, 5503, 5504, 7334
NASH/NADFL etiopathogenesis, 5247
NASH-disgnosis, 5351
nasolabial flap, 5487, 5488, 5489, 5490, 5491
naso-lacrimal duct cysts, 1690
naso-lacrimal duct obstruction, 1689
National Health Service, 2697, 6453
National Institute of Neurological Disorders and Stroke (NINDS) trial, 3933
National Institutes of Health Stroke Scale (NIHSS) scores, 3932
natural orifice translumenal endoscopic surgery, 712, 715, 716, 2761, 2762, 2774, 2784, 2785, 2789
navigation, 645, 646, 647, 648, 649, 652, 653, 654, 656, 659, 661, 662, 663, 665, 666, 667, 668, 669, 670, 671, 672, 673, 674, 675, 676, 679, 682, 683, 685, 686, 687, 688, 689, 697, 705, 706, 708, 709, 710, 716, 717, 719, 720, 721, 722, 725, 726, 727, 728, 729, 730,731, 732, 733, 734, 960, 1166, 1169, 1366, 1654, 2212, 2217, 2224, 2225, 2251, 2260, 2264, 2272, 2311, 2313, 2316, 2318, 2319, 2320, 2321, 2322, 2323, 2324, 2329, 2330, 2331, 2332, 2345, 2357, 2397, 2398, 2401, 2778, 2779, 3148, 6111, 6112, 6246, 6263, 6264, 6266, 6267, 6269, 6272, 6273, 6274, 6275, 7076

near-infrared fluorescence, 680, 689, 710, 711, 1158, 2785, 3351, 3352, 4168, 4324, 4356, 4364
near-infrared spectroscopy, 999, 3074, 3083, 3092, 3103, 3811, 3813, 3889, 7210, 7220, 7221
near-infrared spectroscopy/ diffuse correlation spectroscopy, 3889
neck dilatation, 4838
necrotizing fasciitis, 389, 2030, 2039, 2050, 2055, 4674, 6999
negative pressure wound therapy, 1573, 4693, 4698, 4699, 5009, 5847
neointimal hyperplasia, 4826, 4968, 4991, 4992
neophalloplasty, 6147, 6151, 6158
neophallus, 6147, 6148, 6149, 6150, 6151, 6152, 6153, 6154, 6155, 6157
neoplasm, 1165, 1243, 1254, 1258, 1260, 1261, 1272, 1273, 1274, 1275, 1282, 1283, 1288, 1290, 1294, 1897, 1977, 1996, 2313, 2315, 2342, 2343, 2348, 2395, 2488, 2495, 2736, 3140, 4436, 5567, 5630, 5631, 5638, 5639, 5642, 5648, 5653, 5654, 5657, 5661, 5663, 5675, 5676, 5678, 5679, 5682, 5686, 5687, 5688, 5707, 5709, 5713, 5731, 5732, 5754, 5836, 5950, 5952, 5962, 6051, 6052, 6053, 6054, 6055, 6056
neourethra, 6150, 6153
nerve-sparing RH, 4425, 4426
neurobiochemistry, 3835, 3836
neurocritical care, 924, 975, 991, 992, 993, 998, 1032, 1033, 1034, 3794, 3827, 3836, 3839, 3841, 3855, 3867, 3869, 3962, 3965, 3990, 4058, 4059, 4067
neurodegenerative, 1838, 1842, 1843, 1850, 2164, 3354, 3359, 7217, 7219
neurodiagnostics, 3879
neurogenic pulmonary edema, 929, 996, 997, 3893
neuromodulation, 6169, 6170, 6171, 6175, 6180, 6181, 6185, 6186, 6187, 6188, 6189, 6214
neuromonitoring, 881, 958, 962, 3811, 3815, 3829, 3835, 3839, 3841, 3842, 3848, 3869, 3968, 3986, 5010, 5572, 5575, 5576, 7097, 7101, 7112, 7210, 7220
neurons, 166, 981, 982, 989, 995, 1451, 1671, 2143, 2165, 2386, 3117, 3686, 3693, 3767, 3782, 3787, 3788, 3837, 3854, 3876, 4082, 4556, 4561, 5459, 5586, 5612, 6197, 6590, 7210, 7211, 7218
neuro-oncological surgery, 1632, 1635, 1642, 1645
neuroprotection, 979, 981, 982, 984, 3691, 3692, 3701, 3711, 3775, 3787, 3791, 3795, 3797, 3798, 3850, 3963
neuropsychology, 1041, 1042, 7037, 7074, 7075, 7076
neurorehabilitation, 1035, 1036, 1037, 1040, 1041, 1043, 1053, 1054, 1055, 3690
NeuroTouch, 3243
neurotrauma, 1074, 3775, 3776, 3777, 3779, 3792, 3793, 3794, 3795, 3796, 3797, 3798, 3824, 3825, 3826, 3829, 3832, 3846, 3847, 3849, 3850, 3868, 3870, 3910, 3911, 3914, 3915, 3929, 3962, 3967, 3988, 3989, 4009, 4013, 4030, 4053, 4066, 4067, 4068, 4078, 4088, 4089, 4090, 4093, 4096, 4100, 4101, 4103, 4104, 4116, 4117, 4119, 4123, 4124, 4126, 4127, 4137, 4138, 4139
neurovascular bundle, 1514, 4247, 4249, 4250, 4346, 4383, 4923, 5432, 6152, 6154, 6942, 6951
Niobe® Navigation System, 706
nipple reconstruction, 2584, 2615, 2616, 2618, 2619, 2620, 2621, 2624, 2625, 2627, 2630, 2631, 2632, 2633, 2634
nitric oxide, 166, 1531, 2796, 2823, 2826, 2828, 2829, 2863, 2904, 2995, 3019, 3027, 3074, 3075, 3102, 3107, 3111, 3499, 3502, 3767, 3777, 3790, 3866, 4559, 4808, 6200, 6569, 6583, 6585, 6590, 6601, 6604, 6607, 6608, 6622, 7224, 7226, 7228
nitroglycerin, 2647, 2907, 6584, 6585, 6586, 6587, 6591, 6592, 6594, 6596, 6599, 6600, 6602, 6603, 6604, 6605, 6608, 6609, 6733
nitrous oxide, 1449, 1450, 1452, 1459, 1461, 2969, 3197, 3198, 3389, 3621, 4512, 4515, 4524, 7083, 7087, 7090
N-methyl-D-aspartate receptor, 3298, 3788
no special type, 5689, 5690
non alcoholic fatty liver disease, 5262, 5270, 5272, 5349, 5373
non invasive test, 5351
non-absorbable running, 4604, 4607
non-absorbable suture, 458, 806, 834, 836, 2444, 2738, 2809, 2834, 2972, 2973, 3386, 3616, 3618, 4603, 4606, 4607, 5062, 5065, 5102, 5968, 6447, 6997
non-acoustic tumors, 7319, 7320
non-alcoholic fatty liver disease, 160, 5247, 5261, 5263, 5264, 5265, 5266, 5271, 5272, 5283, 5284, 5285, 5286, 5290, 5298, 5300, 5332, 5340, 5343, 5347, 5348, 5349, 5354, 5357, 5361, 5362, 5371, 5372, 5374, 5384, 5386, 5389, 5396, 5400, 5410, 5413, 5414, 5427, 5428, 5429, 6628, 7183
non-alcoholic steatohepatitis, 5247, 5262, 5264, 5265, 5266, 5285, 5298, 5300, 5348, 5354, 5383, 5389, 5393, 5396, 5400, 5411, 5412, 5414, 5427, 5428, 5429, 5430, 6354, 7183
non-Hodgkin lymphoma, 5625, 5630
non-maturation of AVF, 4938
non-penetrating techniques, 6889
non-pharmacological treatment, 5609
non-rigid registration, 683, 684, 709
non-ruptured AAA, 4829

non-steroidal anti-inflammatory agents, 2033, 2530
non-steroidal anti-inflammatory drugs, 1902, 2520, 2529, 2532, 2727, 3280, 3309, 3420, 3487, 3538, 3558, 3565, 3566, 4486, 4549, 4574, 4588, 4590, 6191, 6192, 6478, 6570, 7239
nonunion, 121, 122, 123, 124, 125, 128, 130, 131, 133, 134, 135, 290, 2317, 3559, 3564, 3570, 3573, 3575, 3578, 3579, 3580
norepinephrine, 1207, 2110, 2128, 2800, 3514, 3529, 3618, 3794, 3810, 4517, 5277, 6193, 6584, 6589, 6606
normalized elastance, 3452, 3453, 3454
normothermia, 2638, 3050, 3496, 3525, 3818, 3828, 3833, 3859, 3861, 3891, 3895, 3896, 3936, 3967, 3970, 4024, 4038, 4656, 4658, 4660, 4661, 5924, 5925, 6136, 6594, 6609
normothermic machine perfusion, 3479, 3509
normovolemia, 4653, 4654, 4660, 4661
NOTES technique, 2102, 2774, 2776, 2786
novel oral anticoagulants, 1864, 1869
Nrf2, 3791, 3798, 7125
nuclear cataract, 6881, 6883, 6884, 6891
nucleus pulposus, 3543, 3547, 5587, 6164
nursing care, 995, 1036, 1037, 1039, 1052, 2024, 3875, 3876, 3896, 3899, 3903, 3904, 3905, 3908, 3911, 4111, 4629, 5867, 5868, 5869, 5872, 6215, 6243
nursing interventions, 3888, 3897, 3904, 3912
nursing therapy, 1042
nutritional support, 228, 230, 1767, 1773, 1837, 1838, 1843, 1844, 1848, 1849, 1850, 1867, 1907, 1948, 1951, 1953, 2034, 3331, 3332, 3333, 3334, 3901, 4623, 4628, 4629, 4631, 5950, 5956, 5971, 5983, 6013, 6646, 6997

O

obstructive sleep apnea syndrome, 210, 213, 1554, 1555, 2495, 2530
obstructive sleep apnea, 143, 153, 160, 164, 209, 210, 211, 213, 215, 216, 218, 1553, 1554, 1555, 1556, 1557, 1878, 1885, 2473, 2486, 2488, 2492, 2493, 2495, 2507, 2513, 2516, 2519, 2522, 2529, 2530, 2531, 2535, 2540, 2543, 2549, 2684, 2730, 3134, 3140, 4449, 4528, 4587, 4593, 5086, 5409, 6354, 7000, 7181, 7230, 7237, 7238, 7245
occupational therapy, 1036, 1041, 7041
occupational, 287, 633, 1036, 1037, 1041, 1042, 1065, 2649, 3906, 3907, 3915, 5602, 7041, 7142
of rapamycin, 3605, 3648, 3650
omentectomy, 3136, 4398, 4399, 6292, 6309
Ommaya-Gennarelli hypothesis, 4120
oncological resection, 5471, 5472
one anastomosis gastric bypass, 5373, 5378, 5388, 5390
one anastomosis gastric bypass, 844, 858
one-to-one, 1866, 1910, 1926
online community, 6926
open abdomen, 3917, 3924, 3925, 6880
open aortic surgery, 4761
open lung, 3828, 7160, 7161, 7165, 7166
open surgery, 681, 685, 689, 693, 696, 713, 829, 1034, 1130, 1208, 1429, 1433, 1486, 1502, 1609, 2215, 2343, 2367, 2443, 2762, 2763, 2764, 2980, 3090, 3130, 3136, 3143, 4142, 4193, 4219, 4220, 4232, 4233, 4291, 4306, 4316, 4342, 4362, 4386, 4404, 4414, 4432, 4441, 4464, 4472, 4540, 4547, 4560, 4664, 4772, 4791, 4800, 4802, 4809, 4811, 4819, 4821, 4831, 4833, 4838, 4841, 4845, 4848, 4871, 4893, 4894, 4900, 4958, 5523, 5534, 5825, 5968, 5977, 5985, 5986, 5993, 5996, 6003, 6014, 6015, 6016, 6025, 6061, 6063, 6065, 6066, 6067, 6069, 6221, 6223, 6225, 6251, 6252, 6260, 6529, 6850, 6950, 7001, 7131, 7183
open-angle glaucoma, 6881, 6883, 6885, 6886, 6892, 6893, 6894, 6896
open-loop, 3463
operating table, 106, 107, 706, 707, 2968, 2972, 2977, 3131, 3137, 3623, 4021, 4174, 4190, 4240, 4253, 4292, 4475, 4495, 4860, 5017, 5065, 5087, 5143, 5182, 5187, 5204, 5781, 5782, 5849, 5850, 5853, 5854, 6112, 6215, 6255, 6761, 7324
Operation Enduring Freedom, 4012, 4033, 4034
Operation Iraqi Freedom, 4012, 4033, 4034
opioid-sparing, 1452, 4520, 4587, 4588, 4589, 4590, 4591, 4593, 7232, 7237, 7238, 7239, 7240, 7244, 7277
optic nerve sheath diameter, 3803, 3823
optical coherence tomography, 1715, 1717, 1719, 6594, 6609
optical tracking systems, 683
optical treatments, 7313
or insertion of auditory brain stem implants, 7319, 7320
or tracheohyoidoepilgottopexy, 6973
oral antibiotic prophylaxis, 4637, 4639
oral squamous cell carcinoma, 3428, 3432, 3444
oral surgery, 414, 1518, 1519, 1521, 1532, 1748, 6200, 6334, 6335, 6336, 6337, 6339, 6340, 6341, 6572
oral tract therapy, 1036
organ engineering, 2984, 2985, 2989, 2991, 2996, 2999, 3001, 3002, 3004, 3006
organ preservation, 2984, 3023, 3024, 3025, 3026, 3027, 3028, 3030, 3031, 3032, 3035, 3037, 3038, 3039, 3048, 3051, 3061, 3062, 3063, 3069, 3491,

3492, 3494, 3498, 3500, 3501, 3509, 3519, 3524, 3525, 3528, 3533, 3618
organ transplantation, 351, 2488, 2916, 2983, 2984, 2999, 3023, 3024, 3025, 3030, 3031, 3036, 3042, 3044, 3065, 3122, 3163, 3199, 3265, 3294, 3425, 3499, 3503, 3583, 3584, 3585, 3587, 3591, 3598, 3600, 3603, 3611, 3639, 3650, 3660, 3662, 3667, 3731
organotypic tissue, 2940
oropharyngeal surgery, 1533, 1535
orthop(a)edic surgery, 729, 730, 731, 734, 1464, 1469, 1470, 1753, 1755, 1756, 1757, 1760, 1761, 1762, 1780, 1781, 1788, 1792, 1794, 1808, 1810, 1811, 1813, 1816, 2223, 2276, 2295, 2311, 2315, 2321, 2721, 3137, 3138, 3139, 3177, 3183, 3188, 3189, 3245, 4678, 6244, 6249, 6251, 6253, 6261, 6262, 6391, 6919, 6920, 6921, 6922, 6923, 6925, 6927, 6928, 6963, 7060, 7094
orthopedic surgical treatment, 1780
orthotopic liver transplantation, 1224, 3058, 3123, 3528, 3592, 3594, 3600, 3601, 3602, 3603, 3605, 3606, 3607, 3609, 3639, 3640, 3641, 3642, 3643, 3644, 3645, 3678, 3745, 3746, 3763, 5385, 5414, 5418, 5811, 5813
Oryctolagus cuniculus, 2816, 3431
osmolality, 974, 2193, 3032, 3110, 3278, 3315, 3316, 3318, 3325, 3866, 3891, 3894
osmolar gap, 3325
osmotherapy, 3950, 3951, 3954, 4058, 4096
Osteoarthritis Research Society International, 3538, 3548
osteoarthritis, 30, 137, 1507, 1902, 2189, 2198, 2217, 2227, 2228, 2234, 2238, 2240, 2241, 2244, 2245, 2249, 2250, 2252, 2262, 2264, 2272, 2301, 3338, 3348, 3358, 3360, 3361, 3366, 3369, 3440, 3441, 3442, 3445, 3537, 3538, 3539, 3541, 3548, 3549, 3550, 3551, 3552, 3553,3554, 3555, 6197, 6200, 6234, 6253, 6258, 6259, 6261, 6262, 6354, 6553, 7130
osteoblasts, 70, 73, 74, 3558, 3559, 3560, 3561, 3563, 3568, 3570, 3653, 5522, 5671, 5672, 6222, 6412
osteoclasts, 125, 126, 1745, 3558, 3560, 3561, 3563, 3573, 5738
osteogenesis imperfecta, 13, 14, 15, 23, 25, 26, 27, 28, 33, 69, 76, 77, 80, 82, 83, 85, 87, 88, 3558, 3567, 3575, 3577, 5791, 5796, 6788
osteogenesis, 1, 2, 6, 9, 13, 14, 15, 23, 25, 26, 27, 28, 33, 49, 69, 70, 73, 74, 75, 76, 77, 80, 82, 83, 85, 87, 88, 122, 134, 1729, 3362, 3558, 3559, 3560, 3562, 3565, 3566, 3567, 3568, 3570, 3575, 3577, 4001, 5747, 5791, 5796, 6236, 6679, 6684, 6685, 6788
osteogenic, 70, 73, 74, 76, 345, 1736, 3565, 3566, 3569, 3570, 3572, 3579, 3580, 6415, 6422, 6570, 6788
osteomyelitis, 30, 268, 278, 1527, 1575, 3566, 3567, 3574, 3579, 4072, 4073, 4076, 4078, 4375, 4376, 4391, 4886, 4946, 5436, 5778, 6206
osteonectin, 3568
osteoporosis, 81, 125, 277, 278, 279, 280, 282, 286, 287, 288, 293, 295, 297, 298, 305, 310, 311, 313, 316, 319, 321, 322, 326, 340, 346, 347, 348, 1373, 1777, 1829, 2125, 2232, 2233, 2283, 3363, 3367, 3557, 3559, 3563, 3565, 3566, 3568, 3570, 3577, 3650, 5774, 5983, 6206, 6221, 6222, 6223, 6225, 6226, 6227, 6230, 6236, 6239
osteo-vascular injuries, 4911, 4921
otolaryngology, 421, 446, 447, 448, 449, 450, 451, 607, 685, 686, 1483, 1533, 1534, 1538, 1554, 1675, 1700, 1701, 1703, 1706, 1858, 2115, 2409, 2461, 2464, 2469, 2471, 2480, 2483, 2487, 2492, 2493, 2509, 2510, 2511, 2515, 2516, 2519, 2524, 2525, 2526, 2527, 2529, 2532, 2536, 2537, 2538, 2539, 2540, 2541, 2543, 2549, 3134, 3139, 3140, 3154, 4447, 4460, 4461, 5455, 5506, 5536, 5541, 6433, 6451, 6684, 6965, 6975, 7333, 7342
outcome metric, 6921
ovarian cancer, 2965, 2967, 2968, 2969, 2977, 2978, 2979, 2980, 2981, 3136, 3153, 4398, 4399, 4420, 4443, 4444, 4478, 4479, 4481, 6030, 6039, 6043, 6277, 6278, 6279, 6280, 6281, 6282, 6284, 6285, 6286, 6287, 6288, 6289, 6290, 6291, 6292, 6293, 6294, 6295, 6296, 6297, 6298, 6301, 6302, 6303, 6304, 6305, 6306, 6307, 6308, 6309, 6310, 6312, 6314, 6315, 6316, 6317, 6318, 6319, 6320, 6321, 6322, 6323, 6879, 6880, 6912, 6913
ovarian cysts/tumors, 6029, 6031, 6034, 6035
ovarian malignancies, 6029, 6036, 6038, 6042, 6284
ovarian tumors, 1254, 2968, 2969, 2980, 6030, 6033, 6034, 6036, 6037, 6038, 6324
ovariectomized, 3348, 3367, 3563, 3566, 3568, 3570, 3571, 3577, 3578
oversewing, 2444, 2754, 2756, 4312, 4545, 4548, 4549, 6294, 6832, 6835
over-the-guidewire technique, 1965, 1966
over-the-scope clip, 2007, 2032, 2036, 2093, 2095, 2098, 2101
overtube, 2044, 2045, 2047, 2052, 2067, 2068, 2075
overweight, 137, 138, 155, 164, 168, 177, 183, 195, 216, 247, 249, 253, 254, 255, 256, 262, 263, 264, 535, 600, 774, 1549, 1601, 2127, 2129, 2132, 2137, 2160, 2171, 2186, 2601, 2730, 2735, 2744, 4441, 4505, 4528, 4575, 4588, 5283, 5284, 5333, 5346, 5366, 5371, 5410, 5412, 5415, 5418, 5421, 6352, 6353, 6367, 6632, 6699, 6702, 6953, 6978,

6986, 6987, 6988, 6989, 7130, 7134, 7135, 7136, 7138, 7143, 7146, 7149, 7150, 7169, 7172, 7180, 7195, 7196, 7199, 7200, 7205, 7207, 7208, 7263
ovine, 2803, 2828, 3432, 3571, 6711
ovotesticular disorder of sexual development, 5757, 5770
oxidation, 240, 2123, 2152, 2160, 3321, 3351, 3791, 5253, 5255, 5256, 5258, 5266, 5275, 5277, 5278, 5279, 5281, 5282, 5285, 5314, 5315, 5329, 5367, 5423, 5425, 6978, 6984, 7120, 7126, 7179, 7193, 7208
oxidative phosphorylation, 3026, 3027, 3322, 3781, 3782, 3783, 3788, 3789, 3790, 7211
oxidative stress, 167, 173, 182, 1773, 2103, 2107, 2111, 2113, 2114, 2562, 2781, 2888, 3032, 3098, 3105, 3408, 3683, 3696, 3702, 3703, 3716, 3718, 3781, 3789, 3791, 3792, 3797, 3798, 3839, 5255, 5256, 5258, 5263, 5277, 5279, 5343, 5351, 5353, 5367, 5371, 6371, 6415, 6417, 6418, 6427, 6604, 6630, 6883, 6884, 6891, 6892, 6978, 7209, 7210, 7212, 7219, 7262
oxygen consumption, 240, 971, 1490, 1491, 1497, 2817, 3014, 3050, 3054, 3055, 3056, 3093, 3103, 3496, 3679, 3693, 3733, 3807, 3811, 4105, 4528, 5252, 5560, 5913, 5924, 7183, 7186, 7188, 7192, 7207, 7276, 7277
oxygen delivery, 240, 2817, 2829, 3099, 3321, 3523, 3812, 3813, 3815, 3828, 3899, 3900, 4660, 5910, 5913, 7276, 7277
oxygen metabolic index, 3786
oxygen tensions, 3092
oxygenation extraction fraction, 3786
oxyntomodulin, 2145, 2147, 2155, 2157, 2158, 2163, 2164, 2168, 2171, 2175, 2185, 5370, 6979, 7013, 7014, 7026

P

P waves, 7280, 7289
pacemaker, 835, 1897, 1924, 1984, 2043, 3134, 3628, 3634, 4561, 4614, 4854, 5345, 6496, 6523, 6538, 6543, 6544, 6614, 6615, 6764, 6790, 6797, 6837, 7272, 7277, 7281, 7286, 7287, 7288, 7289, 7290, 7291, 7292, 7293
pain management, 217, 1446, 1454, 1461, 1513, 1757, 2380, 2385, 2499, 2529, 2530, 2532, 2535, 2536, 2537, 2539, 2708, 3270, 3280, 3282, 3284, 3291, 3296, 3420, 4453, 4515, 4587, 4588, 4589, 4591, 4592, 4593, 5457, 5458, 5459, 5460, 5461, 5611, 5614, 5878, 6168, 6198, 6242, 6569, 7237, 7238, 7239, 7243, 7244, 7245, 7247, 7248, 7250, 7252, 7253, 7277
palatal surgery, 1534, 1535, 1536, 1538, 1540, 1541, 1544
palatoplasty, 1556, 5540, 5541, 5543, 5544
palatoschisis, 5543, 5544
palliation, 1848, 1852, 1853, 1854, 1858, 1893, 1903, 1948, 2018, 2021, 2392, 2393, 3450, 3468, 3474, 3476, 5839, 5846
palliative care, 1269, 1843, 1847, 1856, 1857, 2078
palliative surgery, 1466, 1824, 5867, 5868, 5878, 6878
pancreas anatomy, 2875
pancreatic transplantation, 2875, 3023, 3044
pancreatitis, 221, 260, 783, 1237, 1238, 1239, 1240, 1241, 1242, 1244, 1245, 1246, 1247, 1248, 1249, 1250, 1253, 1254, 1261, 1268, 1269, 1270, 1271, 1275, 1278, 1285, 1288, 1289, 1292, 1293, 1334, 1891, 1947, 1948, 1957, 1970, 2021, 2126, 2135, 2735, 2865, 2875, 2892,2893, 2894, 2895, 2896, 2904, 2905, 2906, 2907, 2909, 2911, 2913, 3106, 3681, 3682, 3699, 3711, 3716, 4263, 4537, 4538, 4540, 4541, 4840, 5457, 5459, 5461, 5833, 5841, 5946, 6293, 6902, 6903, 6904, 6905, 6906, 6909, 6910, 6911
pancytopenia, 2112, 2926, 3651, 5653, 5654, 5655, 5656, 5659, 5662, 5702
para-aortic lymphadenectomy, 3136, 4398, 4399, 4405, 4407, 4408, 4428, 4445
paraesophageal hernias, 1305, 1307, 1888, 4172, 4174
paralysis, 44, 210, 213, 292, 362, 547, 589, 890, 1014, 1449, 1459, 1466, 1475, 1551, 1665, 1667, 1668, 1669, 1671, 1673, 1674, 1675, 1676, 1677, 1980, 2446, 3161, 3176, 3380, 3417, 3630, 3686, 3687, 3698, 3807, 3913, 3923, 3950, 3951, 3953, 3972, 4035, 4058, 4095, 4524, 4725, 4771, 4840, 4878, 4901, 4927, 5598, 6177, 6180, 6449, 6450, 6451, 7051, 7054, 7333, 7335, 7342
paralytics, 3879, 3896, 3898, 3993
paralyzed eye, 6434
parenchymal ICP monitor, 4023
parenteral nutrition, 150, 854, 1857, 1955, 1957, 1970, 2010, 2067, 2442, 2449, 2453, 2928, 3314, 3330, 3331, 3332, 3333, 3334, 4625, 4628, 4631, 5267, 5358, 5951, 5956, 5958, 5964, 5969, 5972, 6012, 6013, 6022, 6294, 6349, 7004
Parkinson disease, 1848
Parry–Romberg Syndrome, 5481, 5482
partial cardiopulmonary bypass, 4799
partial portal vein ligation, 2886, 2888
partial tonsillectomy, 2471, 2483, 2487, 2502, 2516, 2521, 2534, 2540, 2543
passive component, 3452, 3454

patent ductus arteriosus, 4776, 4781, 4782, 4784, 4785, 4786, 4787, 4804, 4805, 5742, 5747, 7270
patent protection, 3201, 3202, 3205, 3222, 3223, 3234
pathobiology, 2915, 3259, 3429, 4692, 6524, 7218
pathogenesis, 297, 416, 488, 905, 907, 1058, 1647, 1691, 1693, 1696, 1754, 1824, 1901, 1970, 2158, 2177, 2253, 2335, 2351, 2403, 2759, 2830, 2859, 2895, 2904, 2906, 2912, 3011, 3097, 3360, 3541, 3543, 3557, 3592, 3703, 3705, 3711, 3716, 3790, 3873, 4167, 4340, 4489, 4546, 4550, 4552, 4570, 4793, 4806, 4808, 5247, 5255, 5258, 5259, 5260, 5262, 5263, 5264, 5272, 5274, 5280, 5289, 5298, 5353, 5367, 5371, 5479, 5641, 5651, 5659, 5662, 5701, 5702, 5707, 5708, 5709, 5742, 5750, 5771, 5790, 5795, 5814, 5879, 5959, 5985, 5994, 6130, 6135, 6295, 6652, 6710, 6909, 6983, 6987, 7209, 7226
pathogens, 1045, 1573, 1686, 2047, 2107, 2801, 2803, 2825, 2999, 3016, 3037, 3197, 3266, 3286, 3416, 3423, 3613, 3732, 4611, 4615, 4616, 4648, 4660, 4669, 4674, 4679, 4696, 6700, 7256
patient blood management, 1882
patient positioning, 960, 1119, 1456, 2215, 3895, 3897, 3903, 4013, 4060, 4207, 4210, 4240, 4242, 4245, 4247, 4249, 4265, 4319, 4322, 4329, 4331, 4332, 4334, 4404, 4406, 4464, 4474, 5791, 5849, 5855, 6111, 6215, 6218, 6745, 6766, 6777, 6782, 6834, 7328
patient reported outcome measures, 2575, 2599, 6921
patient satisfaction, 159, 353, 357, 359, 360, 364, 366, 367, 368, 370, 372, 404, 405, 422, 424, 426, 442, 446, 463, 464, 477, 482, 487, 495, 496, 498, 505, 511, 513, 527, 530, 532, 537, 540, 565, 567, 568, 569, 570, 578, 579, 584, 585, 587, 589, 601, 613, 619, 623, 636, 641,1446, 1449, 1458, 1467, 1469, 1555, 1878, 1879, 2574, 2576, 2583, 2584, 2593, 2596, 2597, 2598, 2599, 2600, 2601, 2602, 2603, 2614, 2631, 2636, 2644, 2674, 2676, 4173, 4388, 4477, 4511, 4592, 5164, 5476, 5500, 5990, 6167, 6168, 6183, 6263, 6329, 6383, 6384, 6386, 6415, 6464, 6484, 6504, 6507, 6520, 6525, 6567, 6713, 6749, 6764, 6771, 6787, 6849, 6855, 6921, 6922, 6927, 7085, 7242, 7243
patient-specific, 730, 734, 1663, 1958, 2277, 2330, 2941, 2943, 2990, 2999, 3242, 3244, 3253, 3255, 3449, 3450, 3460, 3474, 3476, 3477, 3799, 3805, 3809, 4079, 4364, 4513, 5458, 5788, 5893, 5894, 5895, 5897, 5904, 5906, 5907, 6176, 6273, 6829
PbtO2, 3800, 3809, 3810, 3811, 3812, 3813, 3814, 3815, 3820, 3846, 3855, 3889, 3998
P-DC, 3971, 3972
PDGF-BB, 7122
PEAK plasmablade, 2493
pediatric autoimmune neuropsychiatric disorders associated with streptococcal infections, 2472
pediatric colonoscope, 1949, 1950, 1962, 1963, 1965, 2014
pediatric sleep apnea, 2471, 2496, 2543
pediatric surgery training, 2776, 2781
pedicles, 106, 271, 272, 273, 274, 275, 278, 279, 282, 322, 331, 332, 497, 501, 506, 510, 512, 513, 1414, 2341, 2342, 2343, 2344, 2622, 2875, 2881, 2882, 2884, 3679, 4283, 4284, 4348, 5437, 6443, 6594
peel-away sheath, 1833, 1931, 1933, 1934, 1937, 1942, 1943, 1977, 1978, 1980, 2043, 4190, 6617
PEG Rescue, 2019, 2099, 2100
PEGASUS, 4003
pellet cultures, 3541, 3547
pelvic exenteration, 4422, 4444, 6286, 6321
pelvic ischemia, 4823, 4838
pelvic lymphadenectomy, 713, 3154, 4362, 4405, 4410, 4413, 4428, 4429, 4438, 4439, 4440, 4442
pelvic oncology, 2312
pelvic organ prolapse, 4367, 4388, 4390, 4391, 4392, 4395, 4471, 4477
pelvic osteotomy, 1817, 1824, 1825, 1827, 1829, 2249, 2263, 5594, 5595, 5596, 5597, 5599
pelvic reconstruction, 2312, 2318, 2324, 5565, 5569
penetrating brain injury, 4011, 4031, 4037, 4039, 4042, 4043
penetrating, 335, 337, 737, 888, 1268, 1269, 1289, 1319, 1345, 1709, 1714, 1718, 2064, 2421, 2490, 2498, 3117, 3268, 3927, 3971, 4011, 4012, 4013, 4014, 4015, 4017, 4018, 4019, 4020, 4021, 4022, 4023, 4024, 4025, 4026, 4029, 4030, 4031, 4032, 4037, 4039, 4040, 4042, 4043, 4136, 4580, 4614, 4674, 4808, 4912, 4917, 4918, 4919, 4930, 5307, 5448, 5985, 6001, 6002, 6003, 6006, 6007, 6017, 6018, 6021, 6023, 6157, 6259, 7315
penile allotransplantation, 3658
penile prosthesis, 3658, 6147, 6151, 6152, 6154, 6156, 6157, 6158, 6159
penis, 1344, 1349, 3376, 3393, 3394, 3622, 3647, 3648, 3658, 3659, 3663, 3664, 6147, 6149, 6151, 6152, 6154, 6157, 6158, 6159
peptic ulcer disease, 1329, 1893, 1896, 1987, 5940, 5941, 5964
peptide YY, 172, 2156, 2159, 2161, 2162, 2165, 2170, 2172, 2185, 2678, 2731, 2732, 5370, 6979, 7013, 7014, 7016, 7029
percentage of lipid content, 5343, 5345, 5346, 5347
percussion wave, 3801, 3886

percutaneous drainage, 141, 146, 150, 1242, 4689, 5846, 5961, 5962, 5975, 5976, 5985, 5994, 5995, 6002, 6007, 6008, 6021, 6024, 6997
percutaneous endoscopic gastrojejunostomy, 1958, 1959, 2021
percutaneous endoscopic jejunostomy, 1834, 1835, 1861, 1866, 1888, 1900, 1922, 1947, 1953, 1954, 1955, 1960, 1970, 1971, 2006, 2007, 2010, 2021
percutaneous hepatic perfusion, 3516
percutaneous jejunal feeding tube, 1841
percutaneous radiologic gastrostomy, 1970, 1985, 1989, 1990, 2040, 2042, 2049, 2051
perforating veins, 4949, 4952
perform adjunctive profundoplasty, 4823
perfusion solutions, 3055
periappendicular, 1096
peribulbar anesthesia, 7081, 7082, 7084, 7085
pericranial vascularized flaps, 4024
periodic fever with apthous stomatitis, 2472
perioperative care, 217, 765, 924, 1445, 1453, 1873, 2708, 2710, 2713, 2714, 2715, 2716, 2722, 2724, 2725, 3278, 3304, 3309, 3963, 4593, 4639, 4656, 5839, 5842, 5846, 6134, 6143, 6246, 6684, 7245, 7269
perioperative management, 733, 1456, 1594, 1863, 1868, 2334, 2907, 3766, 3836, 4543, 4588, 4593, 6144, 6240, 6640, 7245
perioperative period, 143, 164, 213, 1451, 1454, 1774, 1874, 2497, 2665, 2718, 3329, 4419, 4519, 4527, 4591, 4626, 4627, 4654, 4655, 4656, 4659, 4789, 4834, 5007, 5575, 5789, 5791, 5917, 5923, 5935, 5969, 6240, 6243, 6831, 6859, 6860, 6861, 6863, 7239, 7241, 7299
peripheral arterial (occlusive) disease, 4873
peripheral arterial disease, 1082, 1083, 1084, 1085, 1088, 1089, 1872, 4723, 4727, 4747, 4750, 4812, 4813, 4818, 4845, 4873, 4876, 4881, 4882, 4884, 4901, 4907, 4908, 4934, 4959, 4976, 5006, 6776
peripheral artery aneurysms, 4726, 4727
peripheral blood mononuclear cells, 2931, 3538, 3543, 3544, 3551, 3658
peri-procedural management, 2091
peristomal infection, 1854, 1861, 1862, 1932, 1944, 2039, 2040, 2041, 2042, 2043, 2044, 2045, 2046, 2047, 2049, 2051, 2052, 2053
peritoneal contamination, 1952, 2814, 4501, 4690, 5960, 7255, 7257, 7259
peritoneal irrigation, 4687, 4688, 4689, 4691, 7256
peritoneal lavage, 2099, 4501, 4503, 4673, 4683, 4686, 4687, 4688, 4690, 4692, 7255, 7256, 7257, 7259, 7260, 7261
peritonitis, 146, 784, 834, 843, 846, 847, 857, 1038, 1854, 1918, 1952, 1970, 1977, 2015, 2016, 2021, 2025, 2030, 2035, 2039, 2042, 2055, 2058, 2060, 2065, 2066, 2072, 2073, 2078, 2083, 2084, 2089, 2091, 2092, 2093, 2098, 2099, 2742, 2796, 2803, 2805, 2806, 2807, 2808, 2809, 2810, 2813, 2814, 2815, 2819, 2822, 2823, 2824, 2825, 2829, 4482, 4561, 4686, 4687, 4688, 4689, 4690, 4691, 4692, 4703, 4706, 4727, 4840, 4918, 4984, 4997, 5748, 5952, 5962, 5983, 6007, 6011, 6135, 6654, 6914, 6995, 6996, 7002, 7256, 7257, 7259, 7261
peroxynitrite, 3098, 3767, 3775, 3790, 3795
persist, 150, 151, 260, 404, 599, 600, 1969, 2093, 2097, 2107, 2149, 2384, 2661, 3046, 3294, 3329, 3783, 3917, 4088, 4726, 4864, 4963, 4990, 5467, 5468, 5958, 6359, 6612, 7058
persistent fifth aortic arch, 4756, 4758, 4759, 4775, 4776
personalized approach, 2119, 2939, 2940
pethidine, 3309, 7086, 7092
pH, 932, 994, 1308, 1309, 1503, 1509, 1889, 1896, 1904, 2035, 2047, 2085, 2180, 2187, 2428, 2561, 2801, 2896, 2953, 2971, 2994, 3030, 3056, 3061, 3098, 3106, 3284, 3308, 3323, 3325, 3326, 3328, 3333, 3338, 3375, 3377, 3389, 3390, 3408, 3410, 3483, 3485, 3527, 3671, 3728, 3787, 3789, 3795, 3806, 3828, 3829, 3854, 4571, 4576, 4579, 4585, 4722, 5227, 5230, 5306, 5308, 5317, 5327, 5512, 5654, 5660, 5661, 6136, 6586, 7020, 7021, 7024, 7049, 7077, 7195, 7205, 7211, 7222, 7278
phalanges, 108, 5601, 5602, 5607, 5608
phalloplasty, 6147, 6148, 6149, 6151, 6154, 6156, 6157, 6158, 6159
phantom, 654, 659, 660, 699, 716, 732, 2780, 2790, 3462, 3466, 3467, 3468, 3469, 3472, 3473, 6164
pharmaceuticals, 2444, 3202, 3203, 3224, 3230, 3233, 3235, 3284, 3572, 3726, 6690
pharmacology, 1033, 1654, 1868, 1883, 1904, 2120, 2121, 2123, 2130, 2165, 2173, 2538, 2745, 2962, 3194, 3202, 3213, 3215, 3217, 3220, 3230, 3232, 3233, 3234, 3236, 3241, 3252, 3270, 3384, 3388, 3397, 3398, 3400, 3402, 3405, 3406, 3423, 3425, 3437, 3444, 3445, 3532, 3660, 3872, 4719, 5972, 6025, 6199, 6422, 6572, 6600, 6607, 6991, 7090, 7123, 7164, 7205, 7224, 7225, 7226, 7227
pharyngitis and cervical adenitis, 2472
phase model, 1035, 1036
Philadelphia (Ph) chromosome, 5654, 5660
phlebectomy, 615, 625, 626, 4921, 4958, 4964, 4973
phlegmasia, 4730, 4731, 4878
phlegmon, 4985, 5952, 5965, 5973, 6011
phospholipase A2, 3707, 3788, 3797, 6569, 6570
photoacoustic tomography, 3093, 3373
photodynamic therapy, 624, 2389, 2390, 2391, 2398, 2400, 2401

phylogenetically, 2886, 3428
physical activity, 131, 164, 168, 193, 194, 235, 236, 237, 238, 239, 240, 242, 243, 244, 245, 246, 247, 248, 249, 250, 251, 600, 1488, 1504, 1771, 2122, 2123, 2130, 2132, 2133, 2134, 2166, 2481, 2486, 2546, 2699, 3396, 4253, 4724, 4871, 4887, 4888, 4900, 5411, 5414, 5415, 5419, 5421, 5422, 5426, 5428, 5869, 6183, 6354, 6499, 6984, 7130, 7133, 7137, 7139, 7143, 7146, 7177, 7178, 7194, 7195, 7200, 7203, 7204, 7205, 7206
physical examination, 128, 426, 1113, 1125, 1135, 1145, 1179, 1601, 1605, 1761, 1769, 1771, 1803, 1809, 1865, 2227, 2228, 2264, 2495, 2653, 2684, 2743, 2841, 3305, 3311, 3313, 3316, 3573, 3918, 3920, 4073, 4507, 4721, 4722, 4723, 4727, 4728, 4731, 4733, 4734, 4815, 4833, 4882, 4923, 4938, 4939, 4950, 5442, 5453, 5454, 5465, 5494, 5496, 5500, 5502, 5564, 5565, 5586, 5589, 5611, 5618, 5654, 5678, 5690, 5703, 5732, 5743, 5752, 5753, 5758, 6050, 6051, 6052, 6054, 6055, 6163, 6204, 6744, 7265, 7270
physiologic signals, 3375, 3377, 3401
physiological differences, 3450
physiotherapy, 1036, 1040, 1041, 1042, 1045, 1756, 1762, 2385, 2435, 3893, 5165, 5204, 5572, 5604, 5607, 5614, 6212, 6477, 6482, 6715, 6718, 7000, 7238
pig breeds, 3431
pigtail, 1986, 1989, 2011, 2012, 2078, 2079, 3433
pioglitazone, 2134, 2135, 5269, 5419, 5420, 5423, 5424, 5426, 5428, 5429
PITS, 7051, 7052, 7053, 7054, 7055
pituitary adenoma, 2420, 2425, 6090, 6092, 6094, 6097, 6098, 6099, 6100, 6101, 6102, 6103, 6105, 6106, 6107, 6108, 6109, 6110, 6111, 6114, 6115, 6116, 6118, 6119, 6120, 6121, 6123, 6124, 6125, 6126, 6127, 6128, 6129, 6130, 6131, 6132
pituitary, 878, 888, 936, 1038, 1044, 1054, 1445, 1530, 1697, 2141, 2161, 2420, 2424, 2425, 2426, 2460, 2838, 3895, 5792, 6089, 6090, 6091, 6092, 6093, 6094, 6095, 6096, 6097, 6098, 6099, 6100, 6101, 6102, 6103, 6105, 6106, 6107, 6108, 6109, 6110, 6111, 6113, 6114, 6115, 6116, 6118, 6119, 6120, 6121, 6123, 6124, 6125, 6126, 6127, 6128, 6129, 6130, 6131, 6132, 6993, 7211, 7218, 7226
plasma viscosity, 2801, 2802, 3076, 3078, 3094, 3098, 3100, 3106, 3112
plastic surgery, 375, 413, 417, 419, 446, 447, 448, 449, 450, 451, 456, 466, 470, 490, 491, 505, 507, 510, 594, 602, 605, 606, 607, 641, 1357, 1358, 1362, 1365, 1366, 1422, 1423, 1424, 1425, 1426, 1427, 1540, 1655, 1673, 1674, 1676, 2552, 2575, 2578, 2579, 2613, 2614, 2645, 2646, 2647, 2648, 2674, 2675, 2676, 3167, 3177, 3183, 3186, 3187, 3188, 3189, 3190, 3252, 3447, 4077, 5480, 5497, 5500, 5540, 6373, 6374, 6375, 6377, 6378, 6379, 6391, 6411, 6412, 6419, 6422, 6425, 6426, 6428, 6429, 6430, 6680, 6708, 6928
plastic wound protectors, 4663, 4664
plateau waves, 3802
platelet-derived, 1731, 1750, 3558, 3561, 3566, 4976, 4991, 5011, 5257, 6584
platelet-rich plasma, 387, 419, 1521, 1735, 1750, 3538, 3543, 3546, 3548, 3549, 3551, 3554, 3566, 3568, 3576, 6426
pleuropericardotomy, 3926
plication, 402, 405, 406, 415, 761, 801, 804, 806, 808, 817, 820, 827, 833, 836, 840, 1541, 2095, 2833, 2834, 2836, 2837, 4178, 4179, 4244, 4379, 4381, 6738, 6774, 6781, 6805, 7003
pneumaturia, 5957
pneumonia, 137, 142, 145, 777, 796, 1028, 1037, 1038, 1042, 1309, 1490, 1491, 1503, 1525, 1767, 1772, 1857, 1953, 1957, 2006, 2024, 2025, 2033, 2035, 2434, 2436, 2499, 2500, 2805, 2810, 2815, 3197, 3287, 3307, 3328, 3654, 3898, 3904, 3913, 3914, 3922, 4141, 4165, 4561, 4566, 4580, 4689, 5703, 5870, 5871, 6014, 6064, 6065, 6240, 6242, 6285, 6288, 6314, 6464, 6477, 6660, 6718, 6838, 6863, 6864, 6998, 6999, 7162, 7238, 7248
pneumoperitoneum, 212, 687, 689, 690, 1327, 1438, 1562, 1563, 1984, 2057, 2058, 2059, 2066, 2072, 2073, 2367, 2368, 2750, 2780, 2781, 2968, 2973, 2978, 2979, 2980, 2981, 3141, 3928, 4221, 4230, 4244, 4369, 4385, 4407, 4422, 4424, 4489, 4506, 4530, 4592, 4605, 5017, 5047, 5062, 5065, 5088, 5143, 5167, 5168, 5183, 5206, 5231, 5233, 5962, 6941, 7244, 7249, 7264
point of care devices, 5910, 5929
polyester o proly-propylene mesh, 6140
polymers, 72, 482, 1732, 2943, 3079, 3080, 3566, 3572, 3728, 3730, 5326, 5923, 6231
polyneuropathy, 1037, 1038, 1040, 1045, 1054, 2137
polypropylene mesh, 2600, 2776, 2792, 4238, 4256, 4376, 4377, 4391, 4392, 4601, 6138, 7125
polyps, 1096, 1104, 1108, 1332, 1339, 1536, 1681, 1683, 1684, 1686, 1701, 1702, 1894, 1895, 1904, 2404, 2405, 2407, 2428, 2429, 2430, 2431, 2434, 2436, 2438, 3171, 5511, 6020
polytetrafluorothylene, 6707
polytrauma, 3565, 4012, 4019, 4038, 4039
polyurethane, 479, 492, 1433, 2087, 2571, 2578, 2600, 3566, 3568, 3572, 3581, 4712, 4713, 4947, 5778, 6181, 6709
popliteofibular, 3433
popliteus tendon, 3433

poppy seed, 5957
porcine animal models, 2776, 2782, 2790
port access, 697, 700, 714, 4197, 6616, 6727, 6729, 6736, 6738, 6739, 6740, 6741, 6772, 6784, 6799, 6842, 6854, 6855, 6856
portal systemic shunt, 2865
positive end-expiratory pressure, 2726, 2796, 4786, 6719, 7158, 7160, 7166
positron emission tomography, 681, 1095, 1109, 1147, 1148, 1157, 1231, 1292, 1321, 1341, 1360, 1365, 1509, 2316, 2980, 3338, 3339, 3365, 3369, 3370, 3584, 3592, 3783, 3793, 3807, 3827, 3831, 3832, 3837, 3842, 3847, 4160, 4722, 4903, 4976, 4987, 5775, 5814, 6073, 6077, 6084, 6086, 7111, 7213
POSSUM score, 6020
posterior cerebral artery, 886, 887, 889, 890, 891, 893, 894, 897, 903, 948, 949, 3932, 5791, 6101
posterior stabilization, 290, 5563, 5574, 5577, 5578, 5585, 5589
postischemic syndrome, 4911
postoperative care, 131, 443, 2480, 2486, 2491, 2741, 3303, 3306, 3637, 4077, 4453, 5840
postoperative course, 146, 150, 408, 443, 582, 776, 821, 1377, 1403, 2464, 2520, 2521, 4506, 4550, 4560, 4689, 4836, 5181, 5371, 5978, 6094, 6139, 6289, 6317, 6348, 6349, 6628, 6700, 6701, 6703, 7000, 7004, 7029, 7238, 7264
postoperative Ileus, 4555, 4558, 4562, 4568
postoperative management, 2448, 2735, 3304, 3493, 3903, 4999, 5008, 5840, 5978, 6185, 6281, 6311, 6588, 6628, 7082, 7277, 7281
postoperative nausea and vomiting, 1443, 1445, 1460, 1461, 1462, 1773, 2717, 2726, 4511, 4516, 4520, 4521, 4523, 4524, 4525, 4558, 4564, 4590, 4661, 7090, 7092, 7093, 7094, 7095, 7237, 7240, 7241
postoperative recovery, 134, 486, 1485, 1486, 2507, 2593, 2715, 2716, 2717, 2724, 2809, 3143, 4367, 4525, 5402, 6180, 6325, 6330, 6335, 6338, 6340, 7217, 7235
postoperative stenosis bile duct, 6902
post-pyloric nutrition, 1957
post-tonsillectomy bleed, 2500, 2521, 2522, 2532
povidone-iodine, 488, 494, 2042, 2046, 2051, 2846, 4650, 4676, 4681, 4692
powered adenoidectomy, 2461, 2463, 2464, 2467, 2468
P-R interval, 7280
prasugel, 1864
preclinical models, 2151, 2941, 2943, 3218, 3372, 3773
preemptive analgesia, 3282, 7229, 7230
pregnancy, 253, 254, 255, 256, 257, 258, 259, 260, 261, 262, 263, 264, 265, 496, 497, 935, 936, 1179, 1347, 1531, 2706, 2918, 3390, 3391, 3392, 3431, 3690, 3712, 3717, 3733, 3864, 4368, 4378, 4385, 4389, 4392, 4479, 4485, 4486, 4488, 4730, 4843, 4950, 4959, 5086, 5288, 5494, 5522, 5537, 5538, 5742, 5747, 6031, 6033, 6036, 6037, 6038, 6194, 6346, 6359, 7117, 7118, 7121, 7126, 7129, 7136, 7143, 7144, 7146
prehabilitation, 1485, 1492, 1506, 1507, 2716, 2722, 2725, 5402
prehospital care, 4012, 4055, 4056, 4057, 4058, 4066, 4103
preoperative anxiety, 6325, 6328, 6329, 6332, 6334, 6335, 6339, 6340, 7140
preoperative assessment, 378, 381, 388, 499, 518, 637, 825, 1104, 1154, 1291, 1293, 1609, 1805, 1861, 2638, 4188, 4196, 4245, 4530, 4532, 5016, 5064, 5142, 5181, 5204, 5230, 6072, 6248, 6629, 6634, 6638, 6663, 6802
preoperative bath and shower, 4633
preoperative hair removal, 4633, 4634, 4636
pre-postoperative care, 3303
preservation solution, 1594, 2989, 3023, 3025, 3026, 3027, 3028, 3029, 3030, 3031, 3032, 3033, 3034, 3035, 3039, 3040, 3042, 3048, 3051, 3052, 3062, 3066, 3068, 3479, 3491, 3492, 3497, 3498, 3501, 3504, 3505, 3522, 3528, 3616, 3622
preservation technique, 3059, 3479, 3481, 3488, 3489, 3527, 3528, 3629, 6793
pressure reactivity index, 3807, 3851, 3855, 3888, 3889, 4097
pressure–volume curve, 3800, 3801
prevalence of exfoliation, 6885
prevalence of XFS, 6885
previous ipsilateral thyroid surgery, 7052, 7054, 7055
primary brain injury, 3876, 3971, 4059, 4093
primary hyperparathyroidism, 1194, 1203, 1204, 1205, 1530, 3321, 5773, 7051, 7052, 7055, 7056
primary malignant giant cell tumor, 5721, 5729
primary minimally invasive AVR, 6520
primary open-angle glaucoma, 6881, 6883, 6885, 6892, 6895, 6896, 6897, 6898, 6899
primary snoring, 1542, 2472, 2473
primary-DC, 3971
primates, 1069, 1076, 1077, 2780, 2798, 2813, 2814, 2816, 2821, 2872, 2916, 2923, 2928, 2934, 2936, 2999, 3259, 3260, 3263, 3266, 3268, 3273, 3275, 3277, 3281, 3282, 3283, 3285, 3292, 3297, 3298, 3301, 3304, 3310, 3399, 3402, 3404, 3406, 3410, 3413, 3428, 3429, 3430, 3433, 3434, 3435, 3439, 3440, 3441, 3443, 3537, 3538, 3542, 3553, 3557,

3558, 3563, 3564, 3565, 3585, 3598, 3612, 3613, 3618, 3638, 3639, 3689, 3727, 3728, 3738, 3743, 4005
primitive aortic arch, 4754, 4756, 4757, 4790
problematic eating behaviors, 6358, 7132, 7143, 7145, 7148
procainamide, 7286, 7287
proctocolectomy, 5793, 5797, 5981, 5982, 5987, 5988, 5989, 5990, 5991, 5997, 5998, 6014
proficiency, 2397, 2765, 2767, 2768, 2769, 2779, 2780, 2789, 3145, 3240, 3243, 3253, 4165, 4166, 4167, 4214, 4257, 4404, 4405, 4406, 4431, 7303
profundoplasty, 4823, 4894, 4897, 4996
progesterone, 984, 3391, 3791, 3798, 4485, 4491, 5253, 5689, 5690, 5694
prognostic value, 995, 1157, 1339, 1421, 1880, 2372, 3503, 3813, 3832, 3846, 3850, 3944, 4119, 4123, 4124, 4125, 4130, 4138, 4139, 5467, 5809, 5903, 6632, 6661, 6917
programmable flow pump, 3457, 3458
progression rate of XFG, 6883
proinflammatory, 167, 178, 253, 2170, 3013, 3050, 3494, 3497, 3499, 3522, 3539, 3560, 3561, 3565, 3717, 4105, 4559, 4687, 5254, 5256, 5258, 5260, 5266, 5267, 5611, 5612, 5613, 5950, 5959, 6424, 6700, 6980, 7175
prolypropylene prosthesis:Gilbert 6, 6140
prone position, 106, 331, 724, 2220, 2366, 2859, 3896, 3913, 4038, 4161, 4167, 4169, 5579, 5787, 5788, 5789, 5790, 5792, 5795, 6183, 6208, 6209, 6210, 6215, 6216, 6217, 6218, 6219
prophylactic antibiotics, 1570, 1574, 1861, 1867, 1908, 2040, 2041, 2043, 2046, 2047, 2049, 2665, 2888, 4654, 4661, 4664, 6018, 6137, 6251, 6254, 6477
prophylactic hypothermia for TBI, 3861
prophylactic mesh, 4595, 4596, 4597, 4598, 4600, 4601, 4602
propofol, 212, 213, 971, 972, 975, 1443, 1448, 1449, 1450, 1452, 1454, 1458, 1459, 1460, 1875, 1876, 1877, 1879, 1883, 1884, 1908, 2398, 2718, 2819, 3274, 3275, 3276, 3284, 3291, 3293, 3296, 3859, 3870, 3892, 3897, 4515, 4519, 4520, 4522, 5545, 6245, 7083, 7087, 7089, 7090, 7091, 7092, 7103, 7161, 7233, 7275
prostaglandin analogues, 6886
prostaglandin receptors, 4785
Prostar, 6731, 6744, 6745, 6746, 6748, 6749, 6750
prostate cancer, 695, 717, 1353, 2939, 2940, 2952, 2954, 2956, 2959, 3149, 3341, 3350, 3372, 4345, 4346, 4347, 4360, 4403, 4489, 5424, 5429, 5609, 5610, 6939, 6941, 6944, 6954
prostate, 688, 695, 705, 707, 709, 717, 733, 1167, 1344, 1348, 1349, 1353, 1355, 2312, 2458, 2939, 2940, 2952, 2953, 2954, 2956, 2959, 2960, 3149, 3341, 3350, 3372, 4321, 4338, 4345, 4346, 4347, 4348, 4360, 4361, 4403, 4489, 5424, 5429, 5609, 5610, 5656, 6192, 6903, 6939, 6941, 6942, 6943, 6944, 6950, 6952, 6954
prostatectomy, 687, 691, 692, 695, 696, 699, 710, 711, 712, 713, 2708, 2775, 2784, 2939, 2952, 3134, 3141, 3142, 3149, 3150, 3152, 3153, 3154, 3157, 4317, 4321, 4322, 4337, 4345, 4346, 4360, 4361, 4444, 5793, 5797, 6407, 6939, 6941, 6950, 6952, 6953, 6954
prostheses, 11, 478, 488, 492, 579, 582, 586, 587, 588, 1437, 1730, 1735, 2276, 2283, 2284, 2314, 2316, 2318, 2321, 2324, 2578, 2587, 2600, 3003, 3900, 4198, 4693, 4744, 4745, 4746, 4768, 4771, 4774, 6147, 6150, 6154, 6156, 6157, 6159, 6272, 6509, 6514, 6516, 6517, 6520, 6527, 6533, 6537, 6538, 6539, 6542, 6543, 6544, 6545, 6547
prosthesis breast reconstruction, 2583
prosthetic grafts, 4723, 4745, 4746, 4813, 4821, 4823, 4875, 4918, 4931
prosthetic interposition arthroplasty, 5874, 5878, 5879
prosthetic materials, 2195, 4023, 6710
protective mechanical ventilation, 7159
proteomic, 2351, 2352, 3432, 3796, 6418, 6427, 6984, 7028, 7031
protocol design, 3434
proton pump inhibitors, 153, 219, 221, 222, 834, 1889, 1901, 2085, 2741, 4572, 4574, 5512, 5943, 5956, 7000
proximal femoral resection arthroplasty, 5868, 5869, 5871, 5878
pseudoaneurysm, 1081, 1237, 1239, 1241, 1242, 1244, 4017, 4736, 4760, 4776, 4827, 4893, 4898, 4918, 4923, 4930, 4932, 4942, 4943, 4981, 4986, 4998, 6089, 6091, 6098, 6099, 6104, 6107
pseudocarcation, 4790
psychological effect, 2607, 5493, 5496
psychometric testing, 7057, 7058, 7059, 7073
psychomotor speed slowing, 7058
PTFE augmentation, 6707, 6709
PTFE patches for massive rotator cuff tears, 6709
PTFE patches, 1591, 6707, 6709
pull method, 1944, 1945, 1997, 2000, 2043, 2044, 2047, 2048, 2051, 2052
pull technique, 1907, 1916, 1917, 1932, 1944, 1949, 1996, 2002, 2043, 2044, 2045, 2052
pull, 241, 335, 337, 401, 402, 448, 475, 835, 836, 1378, 1514, 1515, 1523, 1529, 1724, 1833, 1834, 1855, 1890, 1907, 1908, 1912, 1913, 1914, 1916,

1917, 1921, 1922, 1930, 1932, 1943, 1944, 1945, 1947, 1949, 1950, 1953, 1974, 1981, 1984, 1986, 1987, 1988, 1996,1997, 2000, 2002, 2010, 2012, 2019, 2022, 2032, 2041, 2042, 2043, 2044, 2045, 2046, 2047, 2048, 2050, 2051, 2052, 2061, 2062, 2079, 2083, 2094, 2100, 2672, 2687, 2738, 4226, 4713, 4741, 4955, 5212, 5853, 6223, 6463, 6692, 6745, 6748, 6763, 6793
pulmonary compliance, 3060, 3347, 3364, 3372, 3921, 4528, 7158, 7161
pulmonary dysfunction(s), 3921, 6776, 7158, 7159, 7160
pulmonary embolism, 137, 141, 142, 143, 145, 157, 268, 290, 296, 318, 343, 346, 414, 420, 531, 1038, 1444, 1451, 3138, 3872, 4039, 4042, 4506, 4529, 4530, 4738, 4977, 6226, 6243, 6244, 6247, 6248, 6284, 6660, 6826, 6995, 6996, 6999, 7003, 7134, 7248, 7258, 7263, 7264
pulmonary hygiene, 3893
pulmonary hypertension, 997, 1724, 1725, 1876, 1878, 2817, 3376, 3381, 3405, 3411, 3621, 3677, 4189, 4784, 6736, 6755, 6769, 6775, 6826, 6827, 7277
pulmonary infection, 2430, 3893, 3901, 7159
pulmonary thromboembolisms, 4506, 7264
pulsatility index, 3803, 3822, 3823, 6659
pulse examination, 4728
pupil, 359, 1716, 3168, 3174, 3176, 3179, 3181, 3182, 3183, 3185, 3186, 3187, 3188, 3189, 3190, 3191, 3803, 3860, 3877, 3878, 3879, 3898, 3908, 3910, 3953, 3996, 4018, 4047, 5851, 5853, 6434, 6440, 6694, 6882, 6883, 7311, 7313, 7314
pupillometer, 3878, 3910
push, 241, 1477, 1780, 1786, 1788, 1805, 1808, 1834, 1890, 1907, 1921, 1922, 1923, 1927, 1928, 1930, 1932, 1955, 1981, 1984, 1987, 1994, 1996, 2000, 2042, 2043, 2048, 2051, 2081, 2088, 2089, 3143, 3383, 3526, 4142, 4324, 4336, 6216, 6254, 6621, 6622, 6639, 6733, 6768, 6793
pyruvate dehydrogenase complex, 3782, 3789, 3790
pyruvate, 994, 3110, 3699, 3782, 3784, 3785, 3789, 3790, 3800, 3810, 3814, 3831, 3837, 3838, 3844, 3845, 3849

Q

quantification of benefit, 6922
quarantine, 3266, 3267, 3303, 3305, 3311
QuikClot, 2521, 2526

R

R0 resection, 4164, 4165, 5808, 5810, 5811, 5820, 5821, 5822, 5835, 5836, 5841, 5842, 5858, 5862, 5863, 6278, 6282, 6283, 6284, 6286, 6290, 6293, 6309, 6310, 6311, 6317, 6319, 6623
rabbit model, 1070, 1074, 2776, 2781, 2791, 3361, 3441, 3542, 3546, 3547, 3549, 3551, 3552, 3553, 3555, 3563, 3570, 3581, 5572, 5959
rabbit, 347, 1070, 1074, 1075, 2776, 2781, 2789, 2790, 2791, 2806, 2807, 2813, 2816, 2909, 2969, 2979, 3004, 3106, 3218, 3311, 3341, 3361, 3374, 3398, 3418, 3421, 3424, 3429, 3431, 3441, 3537, 3541, 3542, 3543, 3544, 3545, 3546, 3547, 3549, 3551, 3552, 3553, 3555, 3557, 3563, 3565, 3567, 3569, 3570, 3573, 3574, 3577, 3579, 3581, 3674, 3676, 3680, 3685, 3686, 3687, 3692, 3699, 3714, 3717, 3754, 5572, 5959, 6603, 6698, 6710, 7124
Rachmawati, 5505
radial forearm free flap, 6147, 6158
radical hysterectomy, 714, 3136, 3154, 4399, 4400, 4413, 4415, 4416, 4425, 4433, 4435, 4436, 4438, 4439, 4440, 4441, 4444, 4445
radiculopathy, 268, 293, 6161, 6162, 6170, 6181, 6188
radiofrequency ablation, 707, 709, 716, 1228, 1232, 1556, 1886, 2493, 2502, 2540, 2790, 4957, 4958, 4960, 4972, 5811, 6055, 6164, 6258, 6311, 6313, 6318, 6319, 6320, 6324, 6832, 6833, 6840, 6842, 6843
radiofrequency of varicose veins, 4934
radiotelemetry, 3375, 3378, 3387, 3391, 3400, 3402, 3404, 3407, 3408
radiotherapy, 705, 1099, 1475, 1514, 1523, 1551, 1579, 1581, 1582, 1585, 1688, 1726, 2312, 2314, 2316, 2391, 2565, 2566, 2567, 2568, 2569, 2570, 2571, 2572, 2573, 2574, 2575, 2576, 2577, 2578, 2579, 2587, 2588, 2591, 2595, 2596, 2597, 2599, 2602, 2635, 2639, 2644, 2645, 2650, 2661, 2965, 2971, 3400, 3696, 4348, 4455, 4457, 4625, 4865, 5529, 5609, 5611, 5613, 5672, 5682, 5695, 5708, 5728, 5732, 5815, 5832, 6030, 6117, 6118, 6120, 6122, 6128, 6129, 6131, 6578, 6788, 6936, 6942, 6944, 6947, 6966
randomization, 3860, 3935, 3936, 3950, 3951, 3954, 3960, 3974, 3975, 3976, 3977, 3978, 4094, 6195
rapid deployment, 6454, 6473, 6508, 6537, 6538, 6539, 6541, 6542, 6543, 6547, 6568
rat models, 1075, 2774, 2901, 2925, 2994, 3572, 3585, 3606, 3768, 3769, 3772, 3841, 5612
rat stomach, 2834, 2835, 2836

reactive oxygen species, 2111, 2175, 2801, 3014, 3020, 3024, 3026, 3032, 3415, 3522, 3666, 3671, 3789, 3790, 5256, 5275, 5279, 6418, 6651, 7209
readmission, 169, 209, 211, 242, 1050, 1450, 1451, 1464, 1468, 1469, 1470, 1688, 1853, 2442, 2514, 2519, 2521, 2523, 2524, 2715, 2720, 2722, 3907, 4248, 4287, 4313, 4404, 4408, 4419, 4615, 4663, 5381, 5992, 6002, 7087, 7254
recellularization, 2983, 2984, 2985, 2988, 2991, 2992, 2993, 2994, 2995, 2997, 2998, 2999, 3000, 3001, 3005, 3007
recombinant or transgenic, 3431
reconstruction infection, 4981
reconstruction thrombosis, 4981
recurrent tonsil infections, 2543
red blood cell deformability, 2801, 2802, 2826, 3076, 3078, 3095, 3098, 3099, 3100, 3102, 3106, 3108
red blood cell deformability, 4956
redox state, 3092, 3791
reentrant tachyarrhythmias, 7281
refeeding syndrome, 3331, 3334, 4629
refractory intracranial hypertension, 3841, 3870, 3899, 3900, 3902, 3908, 3923, 3950, 3957, 3959, 3970, 3988, 3993, 3997, 3998, 3999, 4002, 4003, 4006, 4007, 4047, 4048, 4050, 4051, 4053, 4056, 4068, 4087, 4090
regeneration, 5748, 5824, 5830, 6246, 6411, 6412, 6413, 6414, 6415, 6420, 6423, 6424, 6425, 6426, 6621, 6622, 6623, 6624, 6625, 6628, 6630, 6632, 6633, 6634, 6643, 6644, 6645, 6648, 6649, 6650, 6651, 6653, 6654, 7119, 7121, 7122
registration, 645, 646, 647, 649, 652, 653, 654, 655, 658, 659, 660, 661, 662, 663, 664, 665, 666, 667, 668, 669, 671, 674, 675, 676, 682, 683, 684, 686, 687, 689, 705, 708, 709, 720, 725, 730, 731, 734, 735, 756, 995, 1230, 1606, 1643, 2255, 2317, 2320, 2321, 3203, 3361, 3397, 3908, 4037, 6271, 6451, 7073
regrowth rates, 2519, 2522
regulations, 1036, 3160, 3171, 3203, 3210, 3229, 3237, 3239, 3248, 3249, 3250, 3256, 3260, 3261, 3262, 3269, 3279, 3288, 3303, 3434, 3447, 6920, 7046
regulatory and ethical considerations, 3259, 3290
rehabilitation chain, 1036
reintegration, 1036, 1037, 1052, 1057, 1058, 1059, 1063, 4001
remote ischemic preconditioning, 3665, 3666, 3697, 3701, 3702, 3704, 3705, 3706, 3708, 3710, 3713, 3715, 3718
remote vascular complications, 4981
renal cell carcinoma, 691, 1183, 1218, 1221, 1286, 1294, 3142, 3150, 4364, 5631, 5639, 5640, 6045, 6052, 6054, 6056, 6058, 6059
renal physiology, 3332, 3480, 3500
rendezvous, 1987, 1989, 2006, 2011, 2012, 2018
renovascular hypertension, 4843
re-operation(s), 211, 500, 582, 585, 586, 587, 599, 774, 794, 809, 811, 821, 843, 856, 871, 1480, 1482, 2225, 2589, 2720, 4172, 4332, 4565, 4909, 5379, 5568, 5571, 5572, 5780, 5912, 5914, 5970, 5990, 6001, 6004, 6008, 6009, 6012, 6013, 6016, 6021, 6117, 6118, 6119, 6120, 6122, 6128, 6141, 6170, 6212, 6284, 6288, 6291, 6306, 6319, 6470, 6474, 6507, 6519, 6520, 6760, 6763, 6765, 6772, 6781, 6787, 6806, 6845, 6851, 6854, 6856, 6956, 7052, 7056, 7249
reoperative neck, 7051, 7052, 7055
re-operative surgery, 2699, 6487, 6519, 7298
replacement PEG, 2032, 2079
RESCUE-ASDH trial, 3961
RESCUEicp trial, 3805, 3859, 3860, 3959, 3960, 3961, 3968, 3974, 3975, 3977, 3979, 3980, 3983, 3985, 4004, 4013, 4050, 4051, 4096, 4110
research and development, 3139, 3201, 3202, 3208, 3209, 3211, 3223, 3229, 3234, 3442
resection arthrodesis, 5557, 5558, 5560, 5561, 5562
residual growth, 13, 14, 17, 20, 24, 52, 53, 54, 55, 56, 57, 61, 63, 64, 67, 1825
residual volumes, 2025
resistor-capacitor-resistor, 3450, 3458
resorption, 127, 343, 440, 445, 454, 624, 1021, 1043, 1378, 1734, 1740, 1742, 1744, 1745, 1751, 1936, 2294, 2299, 2432, 2625, 2966, 3321, 3558, 3561, 3565, 3572, 3905, 4000, 4001, 4072, 4073, 4078, 4081, 4086, 4087, 4090, 5611, 6230, 6420
respiratory acidosis, 3324, 3326, 3327, 3328
respiratory alkalosis, 3324, 3326, 3328
restraint, 3282, 3303, 3304, 3305, 3377, 3379, 3393
restrictive procedures, 142, 209, 211, 215, 256, 259, 261, 762, 2107, 2121, 2175, 2679, 4506, 4546, 5165, 5181, 6345, 6347, 6356, 7000, 7010, 7169, 7170, 7248, 7264
retractorless neurosurgery, 957
retrobulbar anesthesia, 5851, 7081, 7082, 7084, 7091
retrocolic, 139, 140, 1235, 2000, 4326, 4604, 4606, 4607, 4609, 5829, 7005
retroesophageal diverticulum, 4757
retrograde cerebral perfusion, 4763, 4765, 4777, 4778
retroperitoneal approach, 1209, 2296, 4326, 4339, 4355, 4796, 4823, 4824, 4825, 4834, 4846
return to presurgical activity level, 2543

revascularisation, 618, 1089, 4823, 4872, 4884, 4889, 4897, 4906, 4908, 4909, 4944
Revised (Lee) Cardiac Risk Index, 1872
revision arthroplasty planning, 2293
rhabdomyosarcoma, 1700, 5711, 5712, 5718, 5719, 5720
rhesus, 1743, 2816, 2923, 2928, 2935, 2993, 3004, 3263, 3281, 3291, 3293, 3295, 3296, 3300, 3397, 3433, 3660, 5464
rheumatoid arthritis, 1520, 3539, 3558, 3559, 3565, 3566, 3568, 3578, 4876, 5615
rhinomanometry, 426, 437, 441, 1682, 5482, 5485, 5499, 5500, 5501, 5502, 5503, 5504
rhinoplasty, 421, 422, 424, 425, 426, 427, 428, 429, 430, 434, 437, 438, 439, 440, 441, 442, 443, 444, 445, 446, 447, 448, 449, 450, 451, 452, 594, 598, 602, 605, 607, 631, 634, 636, 637, 638, 640, 642, 643, 1535, 1536, 1693, 1695, 1705, 3167, 3179, 3187, 5486, 5496, 5499
rhinosinusitis, 1683, 1685, 1686, 1687, 1688, 1698, 1701, 1702, 1750, 2403, 2407, 2417, 2424, 2427, 2428, 2431, 2438, 2459, 2469, 2480
right aortic arch, 4754, 4756, 4757, 4758, 4776, 4782
right brachiocephalic artery, 6737
right internal mammary graft, 6523
right minithoracotomy, 6509, 6517, 6526, 6747, 6772, 6798, 6848, 6849, 6855
rigid registration, 683, 684, 709, 730
risk adjustment for congenital heart surgery (RACHS-1) score, 7269
risk of bleeding, 1182, 1864, 1869, 1922, 2033, 2037, 2067, 2074, 2492, 2520, 2532, 2537, 2538, 2757, 2843, 2882, 4360, 4550, 4590, 4769, 4788, 5464, 5467, 5468, 5911, 5913, 5915, 5916, 5917, 5918, 5920, 5921, 5922, 5925, 5926, 5929, 6020, 6519, 7086, 7087
risk score, 157, 215, 915, 1461, 1841, 4511, 4514, 4523, 4534, 5847, 6047, 6524, 6544, 7093, 7095, 7278
risks and benefits, 444, 2033, 2127, 2508, 2645, 3898, 4072, 4420, 4487, 4493, 4744, 6326, 6350, 6680
rivaroxaban, 1864, 6246
RNA Interference, 3023
robot-assisted surgery, 691, 708, 727, 728, 3129, 3135, 3149, 3243, 4157, 4158, 4434, 6407
robotic adrenalectomy, 1208, 1210
robotic natural orifice transluminal surgery, 701
robotic scrub nurse, 738
robotic single-site surgery, 699, 714
robotic-assisted, 679, 680, 681, 691, 692, 695, 697, 698, 701, 708, 712, 713, 714, 715, 2784, 3146, 3148, 3149, 3151, 3152, 3153, 3154, 3155, 3157, 4142, 4151, 4153, 4157, 4162, 4167, 4168, 4199, 4210, 4211, 4216, 4231, 4234, 4238, 4239, 4240, 4243, 4244, 4245, 4246, 4247, 4248, 4249, 4250, 4251, 4252, 4253, 4254, 4255, 4256, 4257, 4315, 4342, 4345, 4346, 4361, 4362, 4363, 4372, 4376, 4377, 4379, 4382, 4384, 4386, 4388, 4389, 4391, 4393, 4394, 4395, 4399, 4402, 4432, 4433, 4435, 4436, 4437, 4438, 4440, 4443, 4444, 4449, 4459, 4460, 4468, 4472, 4477, 4497, 5992, 5999, 6324, 6407, 6408, 6785, 6856, 6952, 6953
robotics, 663, 691, 699, 703, 712, 714, 715, 727, 728, 732, 733, 734, 747, 1210, 1221, 2315, 3130, 3131, 3132, 3136, 3137, 3139, 3143, 3144, 3145, 3149, 3150, 3152, 3154, 3155, 3156, 3212, 4149, 4171, 4172, 4174, 4181, 4196, 4199, 4212, 4213, 4215, 4220, 4231, 4238, 4258, 4296, 4315, 4316, 4330, 4336, 4342, 4345, 4359, 4360, 4388, 4395, 4432, 4433, 4434, 4435, 4437, 4438, 4440, 4441, 4442, 4444, 4459, 4463, 4464, 4465, 4467, 4469, 4495, 6292, 6298, 6393, 6394, 6395, 6396, 6406, 6407, 6408, 6536, 6785, 7299
rodent models, 2863, 2865, 2886, 2967, 2968, 2969, 3264, 3358, 3379, 3422, 3425, 3428, 3545, 3576, 3585, 3598, 3611, 3727, 3734, 3769, 3773, 3774
RoSS, 418, 570, 578, 755, 1023, 1635, 1648, 1662, 2005, 2007, 2264, 2265, 2272, 2392, 2401, 2599, 2780, 2863, 2994, 3004, 3005, 3007, 3243, 3369, 3377, 3406, 3742, 3835, 4288, 4289, 4968, 5576, 5796, 5913, 5931, 5934, 5974, 5996, 6106, 6213, 6486, 6497, 6519, 6524, 6993, 7076, 7208, 7271, 7272, 7274
rotator cuff, 1456, 1466, 6707, 6708, 6709, 6710, 6711, 6924R0 resection, 1262, 1269, 1723
Roth n, 2094
rule of rescue, 4111, 4117
rumen, 3307
ruminants, 3307, 3322, 3326, 3332, 3334, 3429, 3570
rupture of AAA, 4834, 4836
Rutherford classification, 4815, 4816, 4881, 4889R
Adams Cowley Shock Trauma Center, 3856, 4134

S

sacrectomy, 5563, 5565, 5568, 5569
sacrocolpopexy, 3134, 3151, 4371, 4372, 4376, 4377, 4378, 4379, 4380, 4381, 4382, 4385, 4387, 4388, 4389, 4391, 4392, 4395
sacrum, 271, 276, 2196, 2231, 2313, 2325, 2328, 2329, 2330, 4371, 4375, 4378, 4379, 4473, 5563, 5564, 5565, 5566, 5569, 5611, 6224
SADIS, 5389

safe tract, 1833, 1835, 1910, 1911, 1912, 1917, 1930, 1950, 1952, 1962, 1971, 1997, 1998, 2002, 2003, 2012, 2074
safety systems, 7296
Safranin-O, 3541
salpingectomy, 4371, 4478, 4481, 4496, 6029, 6035, 6036, 6037, 6038, 6042, 6043
scar tissue, 567, 1438, 1440, 1542, 2296, 2316, 2547, 2661, 2970, 2974, 3012, 3546, 4077, 4489, 4710, 4877, 5289, 5488, 5526, 5571, 5572, 5573, 5575, 5611, 6188, 6205, 6831, 7311, 7316
scar, 357, 358, 364, 374, 385, 386, 388, 402, 404, 407, 415, 418, 436, 444, 445, 452, 453, 458, 459, 460, 461, 462, 463, 465, 466, 467, 484, 485, 495, 496, 502, 503, 504, 505, 506, 508, 513, 514, 531, 567, 605, 614, 625, 629, 1131, 1133, 1140, 1251, 1252, 1362, 1365, 1366, 1412, 1413, 1414, 1415, 1416, 1417, 1424, 1438, 1439, 1440, 1476, 1542, 1543, 1544, 1581, 1746, 2296, 2316, 2547, 2585, 2620, 2625, 2633, 2644, 2648, 2661, 2671, 2785, 2819, 2970, 2974, 2992, 3010, 3012, 3016, 3017, 3386, 3546, 4023, 4077, 4489, 4675, 4710, 4877, 4952, 4964, 5289, 5432, 5473, 5488, 5502, 5526, 5571, 5572, 5573, 5574, 5575, 5576, 5611, 5781, 6151, 6156, 6188, 6205, 6425, 6426, 6454, 6524, 6688, 6690, 6692, 6698, 6831, 7053, 7120, 7121, 7122, 7125, 7311, 7315, 7316
scarring, 358, 359, 360, 362, 363, 366, 369, 378, 383, 385, 388, 407, 413, 436, 443, 453, 454, 459, 460, 463, 464, 465, 476, 485, 506, 509, 566, 572, 621, 1109, 1298, 1362, 1409, 1424, 1439, 1536, 1539, 1548, 1738, 1739, 2105, 2106, 2436, 2457, 2473, 2484, 2489, 2548, 2549, 2618, 2624, 2636, 2637, 2639, 2643, 2644, 2660, 2671, 2672, 3009, 3011, 3019, 3021, 3142, 4187, 4300, 4313, 4360, 4716, 4719, 5571, 5576, 5952, 6117, 6121, 6122, 6124, 6149, 7052, 7055, 7120, 7124, 7315
sclerosing rhabdomyosarcoma, 5711, 5717, 5719, 5720
sclerostin, 3566, 3568, 3574, 3576, 3578
sclerotherapy, 611, 615, 616, 625, 627, 1535, 1892, 4954, 4963, 4964, 4973
scoliosis, 103, 104, 106, 108, 111, 114, 118, 119, 280, 287, 475, 499, 1575, 1733, 1816, 2065, 3567, 5854, 5868, 5876, 6217, 6218, 6788, 6956, 6957, 6958
S-DC, 3971, 3972
secondary brain injury, 991, 3800, 3805, 3806, 3807, 3808, 3809, 3812, 3813, 3817, 3825, 3839, 3875, 3876, 3878, 3879, 3880, 3888, 3890, 3891, 3892, 3893, 3900, 3902, 3903, 3904, 3905, 3909, 3927, 3949, 3950, 3951, 3952, 3953, 4058, 4088, 4093, 4096, 4110
secondary extracranial meningioma, 5449, 5450, 5453, 5454
secondary malignant, 5731, 5732, 5736, 5737, 5738, 5739
secondary-DC, 3971
second-look gastroscopy, 1915
secretory carcinoma, 5689, 5690, 5699
sedation, 323, 519, 614, 616, 971, 972, 975, 992, 995, 998, 1445, 1448, 1450, 1452, 1454, 1460, 1474, 1621, 1871, 1874, 1875, 1876, 1877, 1878, 1879, 1882, 1883, 1884, 1908, 1949, 2013, 2019, 2045, 2390, 2392, 2393, 2395, 2402, 2531, 3267, 3274, 3276, 3418, 3422, 3434, 3804, 3807, 3859, 3870, 3889, 3892, 3895, 3896, 3897, 3898, 3902, 3923, 3925, 3936, 3950, 3951, 3954, 3958, 3967, 3970, 3972, 3976, 3993, 4002, 4035, 4058, 4095, 4518, 4519, 4522, 4533, 4588, 4590, 4592, 5783, 6198, 6210, 6242, 6245, 6248, 7081, 7083, 7085, 7086, 7087, 7088, 7090, 7091, 7092, 7103, 7161, 7164, 7230, 7232, 7234, 7238, 7240, 7242, 7274, 7277, 7286
sedatives, 971, 972, 993, 1450, 1876, 1877, 3248, 3274, 3879, 3884, 3892, 3898, 4655, 6254, 7103
segmental absence of intestinal musculature, 5741, 5742, 5749, 5750
segmental resection, 703, 1525, 1527, 2356, 2883, 2885, 4494, 5836, 5952, 5954, 5963, 5964, 5965, 5988, 5989, 5998, 6014, 6016
seizures, 927, 928, 931, 932, 939, 991, 992, 995, 1027, 1028, 1029, 1030, 1031, 1032, 1033, 1034, 1043, 1173, 1614, 1615, 1618, 1654, 1655, 1767, 2015, 2129, 2496, 3140, 3317, 3323, 3397, 3690, 3691, 3812, 3815, 3831, 3839, 3841, 3876, 3877, 3879, 3889, 3896, 3897, 3900, 3901, 3903, 3904, 3905, 3984, 4030, 5776, 5777, 5780, 5781, 5792, 7088, 7098, 7108, 7298
selective antegrade cerebral perfusion, 4763, 4777, 4778, 6564, 6565
selective laser trabeculoplasty, 6888, 6898
semi-closed femoropopliteal endarterectomy, 4894
semi-rigid, 6, 2067, 4193, 4665, 6147, 6154, 6156, 6157, 6830
Sensei® robotic catheter, 706
sensory nerves, 357, 359, 360, 366, 617, 1665, 1666, 1670, 2386, 3699, 5459, 5461
sensory protection, 1670, 1676
sensory-to-motor innervation, 1666, 1670
sentinel lymph node biopsy, 1112, 1156, 1157, 1360, 1405, 1409, 1421, 1427, 1482, 1586, 2577, 4402, 4442
sentinel lymph node, 714, 1112, 1148, 1149, 1152, 1156, 1157, 1158, 1360, 1405, 1409, 1421, 1427,

1482, 1583, 1586, 2571, 2577, 2580, 4398, 4402, 4407, 4431, 4442, 4443, 4445, 5680, 5700
SEP-Robot, 3243
septoplasty, 443, 451, 1535, 1536, 2485, 5499, 5502, 5503, 5504
septorhinoplasty surgery, 5481
septorhinoplasty, 443, 451, 5481, 5482, 5484, 5485, 5499, 5500
serum markers, 2890, 3889, 5353, 5744
seventh intersegmental artery, 4754, 4758
severe disability, 305, 924, 3805, 3860, 3909, 3931, 3938, 3941, 3955, 3959, 3960, 3961, 3962, 3968, 3973, 3979, 3980, 3982, 3983, 3984, 3985, 4049, 4051, 4055, 4056, 4061, 4062, 4064, 4066, 4069, 4086, 4091, 4093, 4096, 4099, 4100, 4101, 4107, 4108, 4109, 4110, 4111, 4113, 4114, 4126, 4130, 4920
severe traumatic brain injury, 975, 3765, 3777, 3779, 3792, 3793, 3794, 3795, 3796, 3797, 3823, 3824, 3825, 3826, 3829, 3830, 3832, 3835, 3848, 3850, 3868, 3869, 3870, 3875, 3880, 3909, 3911, 3912, 3914, 3929, 3955, 3957, 3962, 3964, 3967, 3968, 3972, 3987, 3988, 3989, 3990, 3992, 4005, 4006, 4007, 4008, 4009, 4039, 4040, 4046, 4052, 4053, 4054, 4056, 4066, 4067, 4069, 4088, 4090, 4092, 4101, 4103, 4104, 4107, 4108, 4109, 4111, 4112, 4114, 4116, 4117, 4119, 4140
sex differences, 1608, 2927, 6342, 7129, 7130, 7132, 7134, 7135, 7136, 7137, 7138, 7139, 7143, 7145, 7146, 7147
sex reassignment surgery, 6148, 6158
shearing, 280, 2106, 3078, 3094, 3095, 3096, 3953
sheep models, 2774
sheep, 28, 87, 293, 1669, 2774, 2798, 2806, 2807, 2813, 2814, 2816, 2817, 2823, 2824, 2827, 2828, 2991, 3111, 3242, 3249, 3428, 3430, 3432, 3440, 3444, 3445, 3540, 3542, 3543, 3544, 3550, 3557, 3563, 3564, 3565, 3573, 3578, 3580, 3689, 3690, 3695, 3698, 3700, 3705, 3709, 3712, 3717, 3722, 6709, 7030
sheep-based simulator, 3242
shivering, 3420, 3812, 3815, 3828, 3896, 3898, 3899, 3913, 4655
short gut syndrome, 5964, 5965, 6001, 6002, 6012, 6018, 6019, 6021
short soft palate, 2463
shoulder surgery, 1447, 6707, 6924
side-to-side, 849, 1620, 1670, 1676, 2738, 2860, 2861, 3623, 4209, 4936, 5108, 5173, 5954, 5963, 5965, 5966, 5967, 5968, 5974, 5976, 5977, 5986, 5996, 6011, 6016, 6024
sigmoidoscopy, 1862, 5957
signs, 5567, 5568, 5575, 5589, 5594, 5617, 5618, 5625, 5627, 5641, 5643, 5648, 5654, 5655, 5691, 5695, 5703, 5707, 5741, 5743, 5744, 5746, 5747, 5748, 5758, 5833, 5836, 5868, 5869, 5925, 5940, 5944, 5952, 5957, 5961, 6004, 6011, 6018, 6051, 6052, 6054, 6055, 6143, 6178, 6204, 6293, 6347, 6364, 6365, 6622, 6630, 6658, 6702, 6788, 6882, 6892, 6996, 6999, 7000, 7005, 7010, 7060, 7064, 7215, 7270
silico modeling, 3439
silver nitrate, 2031, 2079, 2086, 2087, 2097, 2492, 3184, 5317, 7315
SIMENDO VR, 2779
simulation training, 2390, 2397, 2402, 2777, 2791, 3145, 7301
simulation, 288, 703, 709, 729, 918, 959, 964, 1719, 2251, 2253, 2255, 2260, 2261, 2264, 2270, 2272, 2273, 2275, 2277, 2278, 2281, 2285, 2286, 2287, 2288, 2313, 2319, 2320, 2344, 2390, 2397, 2399, 2402, 2691, 2763, 2764, 2765, 2770, 2777, 2778, 2779, 2780, 2788, 2789, 2791, 2793, 2794, 3015, 3145, 3150, 3152, 3240, 3241, 3242, 3243, 3244, 3251, 3252, 3253, 3254, 3255, 3256, 3257, 3258, 3358, 3437, 3453, 3462, 3463, 3469, 3470, 3472, 3473, 3475, 3476, 3562, 3573, 3580, 4026, 4032, 4468, 5882, 5884, 5886, 5887, 5888, 5892, 5893, 5898, 5902, 5905, 5907, 6072, 6407, 6638, 7300, 7301, 7309
simulation-based training, 2777, 2788, 2794, 3251, 7309
simvastatin, 984, 990, 2707, 2708, 3566, 3577
single incision laparoscopic surgery, 2761, 2784, 2785, 2792, 5986
single nucleotide polymorphisms (SNPs) of the lysyl oxidase-like protein 1 (LOXL1) gene, 6883
single ventricle, 3464, 3465, 3468, 3474, 3476, 3477, 5890, 7271, 7284
single-event multilevel orthopedic surgery, 1793, 1794, 1801, 1802, 1815, 1816
sinking skin flap syndrome, 1037, 1038, 1043, 1053, 4072, 4077
sinonasal malignancies, 1700, 1707
sinonasal meningioma, 5449, 5454
sinonasal polyposis, 1683
sinotubular junction, 4203, 4756, 6556, 6557, 6559, 6566, 6737, 6753, 6794
sinus node dysfunction, 6837, 7279, 7280, 7284
sinusitis, 1515, 1517, 1701, 1702, 1738, 1739, 1838, 2403, 2404, 2405, 2406, 2407, 2408, 2418, 2424, 2434, 2438, 2439, 2455, 2456, 2457, 2458, 2459, 2460, 2472, 2491, 5529
situs inversus, 1559, 1560, 1561, 1562, 1563, 1564, 1565, 1566

six sigma methodology, 7155
six sigma, 7155, 7296
skeletal deformities, 1754, 1802, 3567
skin antiseptics, 4633, 4634, 4635, 4651
skin burns, 1361, 4961
skin fixed dynamic reference frame, 719
skin graft, 1466, 1745, 1746, 2616, 2625, 2627, 2631, 2643, 2663, 3012, 3013, 3425, 3656, 3659, 3925, 4343, 5432, 5437, 5475, 5476, 5479, 5480, 5847, 6152
skin incision, 128, 332, 333, 356, 377, 385, 388, 401, 463, 505, 600, 720, 722, 729, 959, 1404, 1415, 1476, 1547, 1581, 1862, 1911, 1926, 1928, 1940, 1950, 1974, 2028, 2046, 2053, 2067, 2084, 2818, 2847, 2849, 3385, 3396, 3398, 3563, 4149, 4568, 4668, 4702, 4860, 4945, 6456, 6458, 6462, 6463, 6468, 6493, 6500, 6511, 6521, 6556, 6557, 6558, 6560, 6752, 6762, 6763, 6766, 6792, 6800, 6803, 6804, 6961, 6967, 7322, 7324, 7325
skull base neurosurgery, 7319
skull base reconstruction, 1687, 1693, 1695, 1696, 1700, 4037, 6107
skull base surgery, 1687, 1695, 1701, 2384, 2413, 2419, 2420, 2423, 2425, 2426, 3139, 3140, 3242, 6106, 6107, 6127, 6450
sleep disordered breathing, 2472, 2492, 2495, 2513, 2530, 2540, 2543, 4588, 4590, 7240
small animal models, 2780, 2821, 2839, 2915, 3346, 3368, 3413, 3423, 3507, 3542, 3583, 3598, 3608, 3613, 3691
small animal, 27, 1075, 2780, 2781, 2783, 2821, 2831, 2839, 2901, 2915, 2971, 2977, 2980, 3094, 3115, 3245, 3277, 3291, 3297, 3307, 3317, 3318, 3320, 3324, 3326, 3334, 3335, 3346, 3347, 3351, 3353, 3360, 3363, 3364, 3365, 3366, 3367, 3368, 3369, 3370, 3371, 3374, 3399, 3413, 3416, 3419, 3420, 3423, 3429, 3483, 3507, 3542, 3562, 3583, 3585, 3587, 3592, 3598, 3606, 3608, 3613, 3673, 3678, 3691, 3696, 3756
small bowel obstruction, 145, 779, 1093, 1107, 2010, 2709, 3718, 4419, 4566, 4599, 4603, 4606, 4608, 4609, 6020, 7006
small bowel transplantation, 2915, 2916, 2928, 2933, 2937, 3591, 3595, 3596, 3599, 3601, 3603, 3604, 3606, 3607, 3608, 3685
small bowel volvulus, 2064
small intestinal bacterial overgrowth, 219, 220, 221, 223, 224, 225, 226, 229, 230, 231, 232, 233, 6018, 6352, 6358, 6361, 6362, 6363, 6366, 6371
small intestine, 144, 220, 222, 223, 226, 228, 229, 231, 232, 703, 875, 1103, 1323, 1897, 1951, 1961, 1964, 2107, 2109, 2112, 2120, 2143, 2144, 2145, 2146, 2154, 2176, 2177, 2180, 2181, 2182, 2678, 2832, 2835, 2933, 2935, 2987, 3004, 3030, 3110, 3111, 3145, 3188, 3330, 3390, 3606, 3670, 3685, 3698, 3711, 3713, 3747, 4556, 4557, 4558, 4559, 4827, 4833, 4839, 4840, 4998, 5017, 5087, 5097, 5098, 5145, 5146, 5165, 5229, 5256, 5618, 5627, 5628, 5742, 5747, 5944, 5948, 5956, 5962, 5963, 5976, 6018, 6020, 6351, 6355, 6356, 6357, 6361, 6362, 6368, 6371, 6871, 6875, 6979, 6982, 6985, 6989, 7013, 7016
small midline thymoma with sharp borders and a clear tissue plane between the thymoma and the aorta, 5861
small right sided thymoma with sharp borders, 5861
small-for-size syndrome, 2881, 6626, 6631, 6649, 6653, 6661
smoking, 142, 144, 211, 381, 389, 393, 412, 413, 414, 419, 420, 499, 500, 510, 512, 783, 788, 834, 848, 913, 914, 917, 1080, 1314, 1411, 1451, 1487, 1503, 1570, 2393, 2572, 2586, 2588, 2590, 2591, 2601, 2635, 2637, 2644, 2645, 2650, 2662, 2674, 2716, 2725, 2736, 3565, 3566, 4057, 4239, 4367, 4376, 4457, 4513, 4573, 4574, 4582, 4617, 4624, 4630, 4642, 4644, 4744, 4814, 4818, 4826, 4828, 4845, 4857, 4864, 4871, 4876, 4887, 4888, 4900, 5006, 5086, 5632, 5970, 5971, 5986, 6001, 6003, 6007, 6016, 6018, 6019, 6021, 6045, 6077, 6084, 6120, 6139, 6179, 6428, 6523, 6702, 6859, 6860, 6863, 6864, 6866, 6867, 7000, 7022, 7034, 7088, 7132, 7256
snare, 1333, 1461, 1911, 1912, 1913, 1914, 1916, 1926, 1927, 1928, 1935, 1940, 1941, 1950, 1959, 1962, 1963, 1964, 1965, 1966, 1992, 1997, 2002, 2003, 2045, 2046, 2099, 2100, 2499, 2510, 3673, 4209, 6779
social media presence, 6924, 6925, 6927
social media, 2691, 6919, 6920, 6921, 6922, 6923, 6924, 6925, 6926, 6927, 6928
Society of American Gastrointestinal and Endoscopic Surgeons, 714, 2764, 4257, 4258, 4662
Society of Thoracic Surgeons and the European Association for Cardiothoracic Surgery Mortality score (STS-EACTS score), 7269
sodium/glutamate co-transporter, 3787, 3788
sodium/potassium ATPase, 3782, 3788
soft callus, 3560, 3569
solid organ injury, 139, 777, 1924
solid organ, 139, 351, 777, 1363, 1924, 2055, 2916, 2925, 2926, 2928, 2931, 3009, 3024, 3038, 3264, 3271, 3287, 3516, 3583, 3584, 3585, 3596, 3597, 3598, 3641, 3647, 3648, 3649, 5413, 5957, 5959, 6639
sondergaard groove, 6729, 6730, 6731, 6803

Sox9, 3538, 3541
spasticity, 1044, 1753, 1754, 1755, 1757, 1759, 1761, 1762, 1763, 1767, 1780, 1787, 1797, 1808, 5874, 6955, 6956, 6958, 6963
spectroscopy, 993, 999, 1142, 1163, 1164, 1187, 1188, 2640, 3080, 3083, 3091, 3092, 3093, 3110, 3112, 3368, 3607, 3698, 3794, 3811, 3813, 3830, 3836, 3889, 5283, 5331, 5333, 5335, 5343, 5344, 5345, 5347, 5348, 5349, 5360, 5363, 5383, 5426, 6112, 7209, 7210, 7213, 7214, 7220, 7221
speech therapy, 1041, 1042, 2548, 4453, 5538, 5539
sphenoid, 888, 890, 891, 898, 1680, 1685, 1687, 1688, 1691, 1695, 1696, 1697, 1700, 2381, 2410, 2413, 2415, 2416, 2417, 2418, 2419, 2420, 2421, 2422, 2423, 2424, 2425, 2429, 2430, 2431, 2456, 2459, 4017, 4022, 4037, 5453, 5516, 5517, 5522, 5529, 6091, 6092, 6096, 6097, 6101, 6103, 6105, 6107, 7320
spinal cord injury, 116, 1510, 2709, 3338, 3341, 3363, 3376, 3393, 3401, 3666, 3686, 3687, 3698, 3707, 3712, 3713, 3798, 3890, 4571, 4772, 4789, 4796, 4797, 4802, 4990, 5585, 5592, 6181, 6184
spinal cord stimulation, 4889, 6161, 6168, 6169, 6170, 6171, 6186, 6187, 6188, 6189, 6203, 6207, 6212, 6214
spinal navigation system, 719
spinal surgery, 116, 269, 293, 350, 351, 1571, 1574, 1575, 1772, 2212, 2725, 4614, 5572, 5576, 5795, 5796, 6207, 6213, 6215, 6217, 6218, 6219
spindle cell/sclerosing RMS, 5712, 5719
spine surgery, 103, 119, 269, 276, 343, 350, 351, 726, 734, 1570, 1572, 1574, 1575, 2271, 2272, 3134, 3137, 4681, 5787, 5788, 5789, 5790, 5791, 5792, 5793, 5794, 5795, 5796, 5797, 6169, 6177, 6204, 6215, 6217, 6218
splanchnic arteries, 4811, 4812, 4813, 4814, 4839, 4843, 4844, 6583
splanchnic artery aneurysms, 4812, 4843, 4844
spleen, 139, 689, 1209, 1212, 1235, 1563, 1565, 2075, 2446, 2488, 2752, 2756, 2757, 2834, 2877, 2915, 2920, 2923, 2930, 2933, 3079, 3120, 3269, 3350, 3360, 3431, 3593, 3625, 3679, 3698, 3734, 3751, 3756, 4281, 4307, 4839, 5019, 5020, 5021, 5089, 5152, 5155, 5249, 5334, 5625, 5656, 5659, 5660, 5707, 5930, 6278, 6279, 6280, 6282, 6284, 6285, 6288, 6294, 6295, 6297, 6307, 6409, 6638, 6658, 6659, 6660, 6664, 7322
splenectomy, 139, 689, 701, 710, 814, 1249, 1262, 1559, 1564, 1568, 1892, 2344, 2370, 2371, 2777, 2820, 2930, 3134, 3189, 4262, 4263, 4276, 4614, 4643, 5463, 5464, 5467, 5469, 6277, 6278, 6280, 6281, 6282, 6283, 6284, 6285, 6286, 6287, 6288, 6289, 6290, 6291, 6292, 6293, 6294, 6295, 6296, 6297, 6298, 6299, 6306, 6308, 6312, 6313, 6317, 6405, 6409, 6649, 6659, 6661, 6664
splenic artery aneurysms, 4843
splenic metastases, 6278, 6280, 6286, 6287, 6291, 6294, 6295, 6296
splinting, 443, 445, 451, 1759, 3571, 5602
split-thickness skin grafts, 5475, 5476, 6151
spondylitis tuberculosis, 5577, 5578, 5582
spring-mediated cranioplasty, 6666, 6667, 6675, 6676, 6683, 6684
stabilization, 303, 3571, 4766, 5578
STAI test, 6328, 6336
STAI-S, 6338
STAI-T, 6338
stamm gastrostomy, 1831, 1832, 2048, 2059, 2061, 2063
standardization, 775, 1223, 1227, 1560, 2716, 2749, 2750, 2992, 3045, 3100, 3102, 3434, 3436, 3439, 3440, 3512, 3579, 4443, 4545, 4681, 4686, 5391, 5663, 6327, 6657, 6659, 6757
stanford classification, 4765, 4794
staphylococcus aureus, 444, 1569, 1570, 1575, 1686, 1862, 1868, 2037, 2041, 2050, 2430, 2807, 3558, 3567, 3574, 3579, 3580, 3581, 4239, 4611, 4615, 4616, 4617, 4985, 6177
stapled anastomosis, 4163, 5085, 5164, 5963, 5974, 5986, 6003, 6010, 6024
stapled, 157, 822, 834, 835, 845, 1096, 1832, 2446, 3634, 3637, 4163, 4164, 4179, 4230, 4274, 4283, 4301, 4302, 4305, 4306, 4546, 4552, 4573, 4582, 5085, 5094, 5095, 5100, 5114, 5161, 5164, 5954, 5963, 5966, 5974, 5976, 5977, 5986, 5996, 6003, 6005, 6008, 6009, 6010, 6016, 6023, 6024, 6406, 6409, 7005
stasis, 142, 220, 231, 782, 806, 883, 901, 928, 1176, 1309, 1310, 1412, 2011, 2429, 2803, 3079, 3096, 3098, 3319, 3322, 3342, 3494, 3694, 4506, 4539, 4582, 4733, 4949, 4950, 4978, 5252, 5870, 5898, 5963, 6999, 7264
state anxiety, 5012, 6328, 6332, 6333, 6334, 6336, 6337, 6338, 6339, 7047
static suspension, 6448, 7337
statistical analysis, 17, 38, 624, 671, 1166, 1185, 1805, 3247, 3433, 3442, 4004, 4064, 4094, 4111, 4122, 4132, 5479, 5863, 5895, 6522, 6862, 6947, 7089, 7152, 7155
steatohepatitic hepatocellular carcinoma, 5287, 5299
steatosis, 151, 154, 1271, 2180, 2900, 2912, 3519, 3531, 3748
stent-assisted coiling, 945
stenting, 298, 301, 302, 303, 305, 306, 307, 310, 311, 320, 341, 949, 950, 955, 1085, 1089, 1262, 1276, 1285, 1705, 1843, 1844, 1852, 1853, 1854,

1873, 1893, 1899, 1903, 1904, 2010, 2018, 2700, 3279, 3608, 3865, 4197, 4342, 4384, 4838, 4841, 4843, 4846, 4850, 4856, 4863, 4864, 4865, 4866, 4868, 4869, 4892, 4904, 4969, 4978, 4992, 4994, 5011, 5485, 5839, 5846, 5847, 5916, 6487, 6490, 6612, 6619, 6783, 7078, 7212, 7214, 7219, 7220
sternal position, 3306
stiff knee gait, 1793, 1794, 1795, 1797, 1798, 1799
strabismus surgery, 7081, 7082, 7083, 7084, 7085, 7086, 7087, 7088, 7089, 7090, 7091, 7092, 7093, 7094, 7095
stress doses, 5951
stress related gastritis, 1890
stress ulcers, 1902, 4569, 4570, 4572, 4579, 4580
stress urinary incontinence, 4367, 4376, 4377, 4382, 4384, 4388, 4394
stress, 3895, 3905, 3943, 4034, 4037, 4114, 4120, 4122, 4262, 4305, 4367, 4369, 4376, 4377, 4382, 4384, 4388, 4393, 4394, 4466, 4562, 4569, 4570, 4571, 4572, 4574, 4579, 4580, 4581, 4629, 4658, 4755, 4766, 4788, 4814, 4826, 4935, 4937, 4970, 5256, 5261, 5262, 5264, 5279, 5353, 5401, 5443
stretching, 6, 564, 1544, 1711, 1757, 1759, 2994, 3279, 3453, 3767, 3953, 4082, 5611
stricture, 221, 691, 797, 846, 1268, 1297, 1304, 1311, 1314, 1317, 1344, 1349, 1689, 1893, 1896, 1897, 1908, 1917, 1932, 1936, 1950, 1974, 2016, 2017, 2018, 2081, 2743, 2905, 3183, 3189, 3618, 3630, 4302, 4305, 4311, 4325, 4328, 4330, 4334, 4335, 4342, 4343, 4560, 4920, 4992, 5141, 5940, 5941, 5947, 5950, 5954, 5960, 5964, 5965, 5966, 5967, 5968, 5970, 5977, 5985, 5991, 6002, 6003, 6011, 6012, 6352, 6363, 6477, 6717, 6901, 6907, 6908
strictureplasty, 5939, 5943, 5944, 5945, 5946, 5947, 5949, 5952, 5953, 5954, 5963, 5964, 5965, 5966, 5967, 5968, 5970, 5971, 5973, 5974, 5976, 5977, 5979
stripping, 1382, 1388, 1393, 1403, 2435, 2456, 2457, 2655, 3564, 3570, 4712, 4920, 4934, 4957, 4958, 4960, 4963, 4964, 4971, 4972, 4973, 4990, 6032, 6033, 6037, 6039, 6040, 6041, 6286, 6874
stroke, 5791, 5792, 5885, 5910, 5914, 5918, 5931, 5934, 6100, 6216, 6217, 6218, 6241, 6243, 6463, 6470, 6476, 6478, 6505, 6515, 6525, 6717, 6742, 6776, 6781, 6782, 6797, 6829, 6837, 6842, 6847, 6848, 6849, 6850, 6851, 6852, 6853, 6854, 6857, 6860, 7038, 7048, 7049, 7050, 7060, 7074, 7075, 7076, 7077, 7078, 7079, 7114, 7125, 7130, 7154, 7160, 7209, 7210, 7212, 7217, 7218, 7219, 7220, 7225
subarachnoid haemorrhage, 877, 885, 886, 896, 897, 898, 900, 905, 908, 909, 911, 913, 916, 917, 918, 920, 921, 924, 927, 928, 931, 932, 933, 935, 936, 937, 938, 940, 941, 943, 945, 949, 963, 968, 971, 974, 975, 976, 979, 987, 988, 989, 990, 991, 1001, 1016, 1019, 1020, 1023, 1024, 1025, 1027, 1028, 1032, 1034, 1035, 1037, 1044, 1045, 1050, 1057, 1060, 1061, 1062, 1064, 1065, 1067, 1068, 1069, 1070, 1071, 1072, 1073, 1075
subarachnoid, 6089, 6100, 6108, 6205, 7084, 7100
subcapsular tonsillectomy, 2543
subdural hygromas, 4000, 4084, 4085
sub-normothermic machine perfusion, 3050, 3479, 3481, 3496, 3500, 3520, 3527
suboccipital decompression, 3863, 3940, 3970
sub-Tenon´s anesthesia, 7081
subtotal colectomy, 5987, 5988, 5989, 5990, 5992, 5998, 6014
subtotal laryngectomy with tracheohyoidopexy, 6966
subzygomatic triangle, 6436, 6438, 6445, 6450
succinate dehydrogenase, 3786
suffocation, 3307
sulforaphane, 3791, 3798
supercharging, 1406, 1412, 1665, 1666, 1669, 1671, 2638, 2657
superficial circumflex iliac artery flap, 5432, 5434
superficial thrombophlebitis, 4731, 4749, 4957, 4967
superficial vein thrombosis, 4729, 4730
superficial veins, 902, 1301, 4730, 4731, 4732, 4948, 4958, 4965, 4967
superior mesentery artery, 3921
supernumerary nostril, 5493, 5494, 5496, 5497
superoxide, 344, 1076, 3076, 3097, 3105, 3790, 3837, 6347, 6348, 6363, 6416, 7021, 7024
supraaortic branches, 4755, 4760, 4768, 4771, 4772, 4773, 4774, 4806, 4886
supracervical hysterectomy, 3151, 4371, 4376
supracricoid laryngectomy, 6965, 6970, 6973, 6975
supracricoid partial laryngectomy, 6966, 6967
supraglottic laryngectomy, 4449, 4459, 6965, 6966, 6967
supraglottoplasty, 1535
suprastructure maxillectomy, 5515, 5516, 5524, 5529, 5531, 5533, 5534
SUR1-TRPM4, 3767
sural nerve, 1669, 1672, 4958
surgery for distal cholangiocarcinoma, 5843
surgical approach, 4029, 4145, 4153, 4160, 4173, 4221, 4326, 4352, 4355, 4400, 4401, 4402, 4403, 4407, 4409, 4412, 4418, 4420, 4421, 4440, 4448, 4458, 4460, 4494, 4596, 4689, 4761, 4767, 4769, 4772, 4796, 4797, 4800, 4803, 4904, 4923, 5401, 5402
surgical debridement, 1237, 1569, 1570, 1572, 1573, 2642, 4924, 5578, 6999

surgical equipment, 695, 877, 3240, 4319, 6395, 6396, 6397, 6398, 6399, 6400, 6401, 6402, 6403, 6404, 6405, 6406, 6724, 6770, 7301
surgical hand antisepsis, 4647, 4648, 4651
surgical hip dislocation, 2249, 2250, 2257
surgical navigation system, 645, 646, 647, 661, 665, 679, 683, 685, 727, 729
surgical planning systems, 684
surgical risk, 137, 185, 295, 313, 604, 645, 661, 924, 938, 1872, 2414, 2566, 3725, 3754, 4527, 4528, 4530, 4532, 4533, 4572, 4606, 5346, 5778, 6020, 6134, 6192, 6241, 6535, 6538, 6541, 6776, 7131, 7184, 7193
surgical robotics, 691, 712, 727, 732, 733, 3131, 3133, 3137, 3139, 3143, 3144, 3148, 3153, 3156, 4238, 4317, 4434, 4467
surgical simulators, 3237, 3239, 3242, 3251, 4142, 4465
surgical site infection(s), 137, 143, 1574, 1575, 1831, 2572, 2665, 3417, 3618, 3904, 3905, 3914, 4072, 4075, 4078, 4237, 4239, 4248, 4252, 4390, 4408, 4499, 4502, 4503, 4598, 4611, 4612, 4613, 4617, 4619, 4620, 4621, 4623, 4624, 4630, 4631, 4633, 4635, 4636, 4637, 4640, 4641, 4642, 4644, 4645, 4647, 4651, 4652, 4653, 4656, 4657, 4659, 4660, 4661, 4662, 4663, 4668, 4669, 4670, 4671, 4672, 4675, 4681, 4682, 4683, 4685, 4686, 4693, 4694, 4698, 4699, 4701, 4705, 4706, 4707, 4709, 4710, 4716, 4718, 4720, 6001, 6002, 6003, 6004, 6022, 6023, 6178, 6999, 7255, 7256, 7261
surgical skin prep, 1862, 4647
surgical skin preparation, 4647
surgical team, 489, 503, 822, 844, 959, 1207, 1208, 2300, 2499, 2617, 2764, 3621, 3658, 4031, 4099, 4146, 4188, 4319, 4406, 4407, 4408, 4450, 4547, 4616, 4648, 4649, 4657, 4925, 5188, 5270, 5593, 6151, 6288, 6308, 6317, 6394, 6728, 6733, 6740, 6743, 6744, 6870, 6880, 7154
surgical therapy, 1195, 1595, 1686, 1896, 2010, 2088, 2433, 3146, 3972, 4371, 4784, 4791, 4795, 4824, 4940, 4957, 5785, 5815, 6063, 6157, 6527
surgical time, 702, 1377, 1404, 1429, 1430, 1434, 1538, 1551, 2281, 2296, 2317, 2322, 2503, 2523, 2665, 2673, 3136, 4401, 4607, 6395, 6514, 6666, 6675, 6677, 6942, 7000, 7052, 7248, 7256, 7285
surgical tissue handling, 3009
surgical wound infections, 1570, 4619, 4630, 4651
surgical-site infection, 4620, 4627, 4639, 4662, 4668, 4683, 4687, 4693, 4701, 4706, 4707, 6177, 7255
surveillance, 44, 245, 261, 998, 1082, 1084, 1085, 1086, 1087, 1088, 1089, 1119, 1120, 1126, 1127, 1225, 1292, 1343, 1364, 1574, 1824, 1828, 1829, 1886, 1887, 1892, 1895, 1898, 1900, 1901, 2592, 2595, 2598, 2731, 2970, 3226, 3310, 3548, 3588, 3904, 4066, 4612, 4613, 4614, 4615, 4617, 4618, 4620, 4621, 4683, 4706, 4805, 4828, 4847, 4938, 5010, 5267, 5338, 5770, 5804, 5931, 5969, 5993, 5997, 6045, 6046, 6049, 6050, 6051, 6053, 6054, 6056, 6057, 6059, 6079, 6086, 6137, 6176, 6420, 6649, 7049, 7258
sus scropha domesticus, 3431
suspension, 361, 364, 370, 384, 402, 404, 405, 418, 439, 448, 450, 514, 1378, 1535, 1543, 1546, 1547, 1548, 1556, 2500, 2738, 2809, 2810, 2814, 2815, 2818, 2819, 2959, 3076, 3095, 3103, 3117, 3141, 3537, 3541, 3749, 4371, 4378, 4379, 4380, 4388, 4392, 4393, 4395, 4452, 6422, 6434, 6442, 6447, 6448, 6973
sutureless cardiac valves, 6499
sutureless valve, 6465, 6472, 6473, 6505, 6507, 6509, 6512, 6515, 6517, 6528, 6534, 6535, 6536, 6538, 6539, 6540, 6542, 6543, 6544, 6545, 6548
sutureless, 4364, 6463, 6465, 6472, 6499, 6500, 6503, 6505, 6507, 6508, 6509, 6510, 6512, 6514, 6515, 6516, 6517, 6527, 6528, 6531, 6532, 6533, 6534, 6535, 6536, 6537, 6538, 6539, 6540, 6541, 6542, 6543, 6544, 6545, 6546, 6547, 6548, 6549, 6688, 6698, 6957
swallow evaluation, 3904
swallowing dysfunction, 1775, 3904, 3914
SWIFT-PRIME, 3933
swine, 2771, 2772, 2773, 2774, 2794, 2887, 2924, 2928, 2931, 2932, 2933, 2934, 2935, 2936, 2981, 3016, 3019, 3021, 3064, 3258, 3259, 3261, 3264, 3267, 3268, 3269, 3270, 3273, 3276, 3277, 3278, 3279, 3280, 3282, 3283, 3284, 3285, 3286, 3287, 3292, 3293, 3294, 3295, 3296, 3298, 3299, 3300, 3301, 3334, 3431, 3444, 3446, 3447, 3530, 3605, 3612, 3614, 3627, 3628, 3630, 3637, 3638, 3639, 3640, 3641, 3642, 3643, 3644, 3645, 3650, 3653, 3655, 3656, 3659, 3660, 3661, 3662, 3705, 3794, 4030
symptomatic aneurysms, 4812, 4829, 4843
synaptic activity, 3782
synchromed, 6212, 6956, 6959
syndrome of acute circulatory failure, 4975, 4976, 4977
syndrome of inadequate antidiuresis, 974
syndrome of the trephine, 1053, 3905, 3915, 3954, 3956, 3984, 4025, 4036, 4041, 4072, 4085, 4086, 4090
syndrome of the trephined, 1053, 3905, 3915, 3954, 3956, 3984, 4025, 4041, 4072, 4085, 4086, 4090
systemic inflammatory response syndrome, 997, 2742, 2796, 2798, 4976, 4980

systemic inflammatory response, 169, 173, 183, 997, 2742, 2796, 2798, 3016, 3677, 3718, 4660, 4976, 4980, 5008, 7059, 7157, 7277

T

T2*GRE (Star Gradient Echo), 4120
T2WI (T2 Weighted Image), 4120
tachyarrhythmia, 3711, 7279, 7285
TACS (Trans-Atlantic Inter-Society Consensus) criteria, 4819
tailored approaches, 957, 959, 961
T-anchors, 1840, 1916, 1934, 1935, 1936, 1937, 1939, 1940, 1958, 1985, 1997, 1998, 2001, 2002, 2003, 2013, 2014, 2017, 2026, 2027, 2097, 2099, 2100
targeted delivery of a transgene, 3515
task trainer, 2777
Taylor spatial frame, 30, 49
TD-198946, 3543, 3545, 3548
techniques of liver resection, 2866
teleosts, 3562
telesurgery, 693, 694, 702, 712, 733, 1221, 3129, 3132, 3146, 3147, 3149, 3152, 3153, 3154
temporal muscle atrophy, 2379
temporal myoplasty, 6439, 6442
temporomandibular joint, 666, 1541, 2379, 2384, 2385, 3538, 6438
tendon, 24, 44, 378, 1550, 1757, 1761, 1779, 1780, 1782, 1787, 1789, 1792, 1795, 1797, 1798, 1799, 1801, 1803, 1804, 1808, 1809, 1812, 1813, 2231, 2236, 2237, 2241, 2988, 3017, 3018, 3183, 3323, 3648, 3649, 3653, 4191, 4333, 4728, 4935, 5431, 5432, 5439, 5586, 5589, 5602, 5604, 5606, 5729, 6256, 6257, 6258, 6443, 6450, 6707, 6709, 6710, 6711
Teratoma, 1699
terminal ileum, 223, 258, 1097, 1103, 2810, 3172, 3596, 5940, 5949, 5950, 5954, 5969, 5971, 5981, 5982, 5985, 6002, 6015, 6873, 6984
tertiary ACS, 3920
tertiary, 818, 968, 1194, 1310, 1503, 1573, 1601, 1930, 2341, 2355, 2373, 2488, 2521, 2526, 2609, 2612, 2613, 2727, 3814, 3862, 3920, 4047, 4066, 4233, 4356, 4435, 4791, 5324, 5332, 5535, 5536, 5629, 5750, 5774, 6289, 6290, 6291, 6294, 6295, 6298, 6302, 6317, 6318, 6324, 6390, 6975, 7155, 7167
Tessier no. 3 cleft, 5549, 5551, 5553
TGF-β signalling, 3542
the articular processes, 273
the intervertebral foramina, 272, 275, 276
the laminae, 273
the retrosigmoid approach, 7319, 7321, 7325, 7330
the spinous process, 273, 279
the vertebral body, 267, 271, 272, 274, 279, 282, 289, 290, 291, 296, 299, 301, 306, 308, 309, 314, 315, 318, 321, 322, 323, 324, 333, 334, 335, 336, 337, 339, 345, 5579, 6207, 6225
therapeutic plasma exchange, 5463, 5464, 5465, 5466, 5469
therapeutic response, 1010, 2939, 2940, 2946, 2948, 2962, 2963, 2964, 3216, 5690, 5697
third molar, 1526, 6191, 6192, 6193, 6194, 6195, 6197, 6198, 6199, 6200, 6325, 6328, 6329, 6330, 6334, 6335, 6336, 6338, 6339, 6340, 6341, 6343, 6570
thirty-day mortality, 2056
thoracic endovascular aortic repair, 4780, 5441, 5442, 5448, 5920
thoracic epidural analgesia, 4564, 5457, 5458, 7229, 7231
thoracic outlet syndrome, 4725, 4730, 4901, 4903, 4904, 4910, 4941
thoracic surgery, , 697, 714, 728, 1303, 1722, 4142, 4150, 4151, 4157, 4169, 4189, 4614, 5860, 6061, 6063, 6064, 6070, 6071, 6072, 6471, 6472, 6473, 6474, 6507, 6508, 6536, 6548, 6854, 6867, 7152
thoracotomy, 112, 697, 713, 714, 1311, 1724, 2840, 2851, 2852, 2853, 2854, 2855, 3133, 3309, 3381, 3383, 3384, 3385, 3386, 3405, 3408, 3637, 3672, 3673, 3686, 3687, 4141, 4142, 4145, 4146, 4150, 4159, 4168, 4197, 4210, 4761, 4769, 4770, 4771, 4777, 4786, 4789, 4796, 4797, 4931, 5579, 6062, 6063, 6066, 6068, 6069, 6070, 6071, 6072, 6077, 6468, 6477, 6478, 6490, 6493, 6494, 6497, 6509, 6510, 6511, 6516, 6532, 6611, 6613, 6614, 6615, 6616, 6618, 6717, 6724, 6741, 6751, 6752, 6754, 6758, 6761, 6763, 6766, 6776, 6782, 6787, 6791, 6800, 6802, 6829, 6831, 6832, 6834, 6838, 6854, 6856
three- hits hypotheses, 5247
three smile classification, 6435
three-dimensional laparoscopy, 2784
thromboembolic complications, 950, 952, 2716, 3295, 4566, 4942, 4981, 5926, 5928, 6860
thromboembolic event risk, 1862
thromboembolic events, 255, 415, 960, 2055, 2736, 4505, 4506, 5065, 6027, 6244, 6246, 6285, 6292, 7003, 7263, 7264
thromboembolic prophylaxis, 4505, 5086, 7258
thromboembolism, 142, 157, 261, 420, 1010, 1615, 1837, 1863, 2033, 2638, 2673, 2719, 3896, 4042, 4043, 4506, 4507, 4508, 4509, 4530, 4725, 4749, 4771, 4849, 4850, 4888, 4906, 4908, 4967, 5791, 5933, 6003, 6019, 6027, 6217, 6243, 6246, 6249,

6539, 6999, 7005, 7119, 7212, 7264, 7265, 7266, 7267
thromboembolytic drugs, 3787
through-the-snare technique, 1963, 1964, 1965, 1966
thyroid surgery, 1474, 1476, 1478, 1482, 1483, 6573, 6575, 6931, 6933, 7051, 7052, 7056
thyroid, 386, 1167, 1183, 1193, 1194, 1195, 1196, 1197, 1198, 1199, 1200, 1201, 1202, 1204, 1296, 1473, 1474, 1475, 1476, 1477, 1478, 1479, 1480, 1481, 1482, 1483, 1484, 1530, 1547, 1548, 1772, 1978, 2458, 2488, 3139, 3140, 3156, 3186, 3191, 3321, 3355, 3361, 3658, 4614, 5675, 5676, 5677, 5679, 5680, 5681, 5682, 5683, 5684, 5686, 5687, 5688, 5703, 5773, 5774, 6097, 6573, 6574, 6575, 6576, 6577, 6578, 6579, 6903, 6931, 6932, 6933, 6934, 6935, 6936, 6937, 6965, 6966, 6967, 6968, 6969, 6970, 6971, 6972, 6973, 7051, 7052, 7054, 7056, 7227, 7288
thyroidectomy, 1473, 1479, 1480, 1481, 1483, 3134, 3140, 3152, 3156, 3157, 4464, 5678, 5682, 5773, 6573, 6574, 6575, 6576, 6577, 6931, 6932, 6933, 6934, 6935, 6936, 7051, 7052, 7053, 7054
tibia, 2, 3, 4, 5, 7, 8, 9, 13, 14, 16, 17, 20, 21, 22, 23, 31, 32, 33, 35, 42, 46, 47, 53, 54, 55, 56, 57, 60, 63, 77, 80, 85, 89, 90, 91, 92, 99, 122, 123, 125, 126, 135, 728, 1089, 1782, 1795, 1804, 2228, 3564, 3571, 3572, 3578, 4886, 5004, 5432, 5560, 5561, 5721, 5722, 5723, 5724, 5727, 5732, 5736, 6252, 6264, 6265, 6266, 6269, 6271
tidal volume, 2819, 2843, 2846, 2854, 3274, 3388, 3621, 3924, 6719, 7157, 7158, 7159, 7160, 7161, 7164, 7165
tidal wave, 3801, 3886
tier-based protocols, 3958
timolol, 6886, 6887, 6896, 6897
TIPS, 1892, 1970, 2005, 2324, 2551, 2556, 4244, 4338, 4608, 6650, 7055
tissue engineering, 73, 74, 86, 87, 349, 351, 1729, 1730, 1731, 1732, 1747, 1748, 1749, 2989, 2993, 3000, 3002, 3003, 3004, 3005, 3006, 3007, 3348, 3444, 3445, 3546, 3552, 3553, 3554, 3570, 3572, 3574, 3581, 3740, 4946, 6258, 6413, 6419, 6420, 6423, 6424, 6425, 6429, 6430, 7121
tissue inhibitors of metalloproteinases, 3543, 3547
tissue plasminogen activator, 2655, 3341, 3817, 3832, 3933, 3944
tissue regeneration, 2, 4, 6, 10, 74, 87, 1730, 1731, 1738, 1747, 1749, 1750, 1751, 1752, 1773, 3009, 3012, 3540, 3549, 3574, 4678, 4685, 7118, 7120, 7122
tissue viability imaging, 3093, 3109
Tissular 12, 6140
titanium implants, 301, 1736, 4023
titanium mesh plate, 5515, 5534
titanium mesh, 322, 323, 324, 325, 327, 1733, 1741, 1748, 2299, 2562, 4024, 4072, 5515, 5528, 5529, 5530, 5532, 5533, 5534, 5536, 5578, 5579
titration metabolic acidosis, 3326
T-lesion, 3932
tobacco and papillomavirus exposure, 3432
tongue edema, 2498, 5543, 5544
tongue, 890, 1521, 1522, 1529, 1531, 1533, 1534, 1535, 1543, 1547, 1548, 1549, 1550, 1551, 1552, 1556, 1557, 1667, 1669, 1746, 1766, 2109, 2111, 2463, 2464, 2465, 2467, 2468, 2472, 2473, 2474, 2475, 2477, 2485, 2490, 2491, 2494, 2498, 2500, 2506, 2549, 2829, 2854, 3101, 3139, 3155, 3184, 3191, 3197, 3307, 3648, 3877, 3890, 4448, 4449, 4451, 4455, 4457, 4459, 5510, 5526, 5543, 5544, 5545, 5546, 6968, 6974, 7014, 7016, 7017, 7020, 7035, 7106
topical anesthesia, 1884, 2402, 5851, 5854, 7081, 7082, 7085, 7092
topical antibiotics, 4503, 4678, 4679, 4681, 4685, 4691, 4709, 4710, 4714, 4716, 4717, 4718, 4719, 6690
topographical anatomy, 514, 885, 3186
torsion deformities, 80, 85, 90, 1780, 1782, 1784, 1786, 4990
torus tubarius, 1681, 2464, 2468, 2469
total hip arthroplasty, 732, 733, 1575, 2210, 2276, 2282, 2284, 2290, 2291, 2301, 2307, 2308, 2309, 2331, 2332, 3134, 3138, 3154, 3155, 5868, 5869, 5874, 5880, 6246, 6247, 6923, 6924, 7076
total hysterectomy, 4376, 4379, 4422, 6304, 6309
total knee replacement, 11, 3152, 4621, 6253, 6263, 6266, 6267, 6271, 6272, 6273, 6274
toxic megacolon, 5982, 5983, 5987, 5988, 5997
trabecular aspiration, 6890, 6898
trabeculectomy, 6889, 6890, 6898, 7124
Trabucco 37, 6140
tracheohyoidoepilgottopexy, 6966, 6973
tracheostomy, 110, 111, 1476, 1482, 1528, 1529, 1535, 1557, 1691, 2818, 3621, 3893, 3922, 3939, 4450, 4456, 4771, 6523, 6968, 6971, 6972, 6973
tract maturity, 2059, 2078
traction method, 2032
trait anxiety, 6326, 6332, 6333, 6334, 6336, 6337, 6338, 6343
tramadol hydrochloride, 6192, 6199
trans-catheter aortic valve replacement (TAVR), 6454, 6528
transcellular fluids, 3314
transcranial doppler ultrasonography, 4078
transcranial doppler, 4078, 4858, 4859

transforming growth factor beta, 2912, 3538, 3539, 3543, 3553, 3555, 3558, 3559, 3561, 3566, 4808
transfusion triggers, 5909, 5910
transfusion, 141, 502, 519, 530, 696, 779, 1570, 1593, 1688, 1874, 1882, 2069, 2367, 2410, 2411, 2715, 2938, 3023, 3133, 3139, 3141, 3142, 3157, 3194, 3195, 3621, 3894, 3910, 4031, 4318, 4323, 4349, 4356, 4357, 4358, 4383, 4408, 4547, 4590, 4656, 4796, 4875, 4928, 4979, 5465, 5467, 5468, 5469, 5597, 5656, 5794, 5909, 5910, 5911, 5912, 5913, 5914, 5915, 5916, 5917, 5918, 5919, 5920, 5921, 5922, 5923, 5924, 5925, 5926, 5927, 5928, 5930, 5931, 5932, 5933, 5934, 5935, 5936, 5982, 6003, 6005, 6136, 6142, 6241, 6243, 6306, 6310, 6314, 6472, 6505, 6506, 6509, 6514, 6520, 6527, 6649, 6665, 6667, 6669, 6676, 6787, 6788, 6797, 6853
transgenders, 6147, 6148, 6154, 6156, 6157, 6158
transgenic, 1069, 1071, 1073, 1076, 2816, 2862, 2897, 2899, 2900, 2910, 2918, 3116, 3117, 3125, 3292, 3350, 3364, 3366, 3367, 3380, 3392, 3414, 3422, 3424, 3542, 3563, 3569, 3585, 3598, 3613, 3619, 3640, 3641, 3643, 3644, 3708, 3769, 5936
transient elastography, 5379, 6663
transient ischaemic attack(s), 4726, 4849, 4867, 6241
transillumination, 1854, 1866, 1888, 1909, 1910, 1925, 1962, 1974, 1983, 1984, 1987, 1990, 1994, 1997, 1998, 2001, 2002, 2003, 2012, 2017, 2074, 2095, 3085, 5747
transition from acute care, 3907, 3908
transitional meningioma, 5449, 5451
translational animal model, 3427, 3429, 3430, 3435, 3436, 3437, 3438, 3439, 3445
translational research, 349, 2782, 2790, 3339, 3362, 3427, 3429, 3431, 3432, 3439, 3440, 3441, 3442, 3443, 3444, 3445, 3446, 3447, 3606, 3690
transoesophageal echocardiography, 6733, 6734
trans-PEG technique, 1967
trans-percutaneous endoscopic gastrostomy technique, 1968
transphyseal sliding nailing, 13
transsexual, 6147, 6148, 6157, 6159
transsphenoidal surgery, 2423, 2424, 2426, 6089, 6090, 6096, 6098, 6103, 6105, 6106, 6108, 6109, 6110, 6111, 6113, 6114, 6117, 6119, 6120, 6121, 6123, 6124, 6125, 6126, 6127, 6128, 6130, 6131, 6132
transverse aortic constriction, 2840, 2853, 4808
transverse processes, 271, 272, 274, 279
traumatic aneurysm, 3172, 4037, 4040, 4911, 4922, 4927, 4928, 6106, 6108
traumatic arteriovenous fistula, 4911, 4913, 4922
traumatic brain injury management, 4056
traumatic brain injury, 968, 975, 988, 992, 1044, 1049, 1054, 1871, 3349, 3372, 3376, 3394, 3406, 3408, 3765, 3775, 3776, 3777, 3779, 3780, 3781, 3783, 3787, 3792, 3793, 3794, 3795, 3796, 3797, 3798, 3799, 3800, 3803, 3822, 3823, 3824, 3825, 3826, 3827, 3828, 3829, 3830, 3831, 3836, 3846, 3847, 3849, 3850, 3851, 3852, 3867, 3868, 3869, 3870, 3875, 3889, 3894, 3909, 3910, 3911, 3912, 3913, 3914, 3915, 3919, 3929, 3949, 3950, 3955, 3956, 3957, 3958, 3962, 3963, 3964, 3968, 3986, 3987, 3988, 3989, 3990, 3991, 4004, 4005, 4006, 4007, 4008, 4009, 4014, 4029, 4030, 4032, 4041, 4042, 4043, 4045, 4052, 4053, 4054, 4056, 4065, 4066, 4067, 4068, 4071, 4081, 4088, 4089, 4090, 4099, 4102, 4103, 4104, 4105, 4114, 4115, 4116, 4119, 4120, 4121, 4136, 4138, 4139, 4140, 4571
traumatic brainstem injury, 4119, 4120, 4138, 4139
treatment outcome, 104, 542, 840, 883, 898, 948, 952, 953, 954, 1059, 1063, 1064, 1065, 1187, 1780, 1815, 1816, 2763, 3439, 3555, 4365, 4863, 4882, 4932, 5009, 5455, 5513, 6845, 7130, 7145, 7147
tricarboxylic acid, 622, 623, 3782, 3785, 3789, 3837
Trichostatin A, 3543, 3547
triclosan-coated sutures, 4701, 4703, 4704, 4705, 4706, 4707
tricuspid, 1725, 3475, 3628, 4196, 4758, 5902, 5905, 6554, 6725, 6735, 6751, 6752, 6756, 6760, 6773, 6775, 6784, 6793, 6797, 6800, 6825, 6826, 6827, 6828, 6829, 6830, 6831, 6832, 6833, 6834, 6836, 6837, 6838, 6839, 6840, 6841, 6842, 6843, 6852, 6853, 6859, 6862, 6865, 7271, 7272, 7274
triiodothyronine, 3406, 3541, 3543, 3548
trimoxazole solution, 2041
trocar position, 1563, 4222, 4228, 4240, 4253, 4254, 4423, 4598, 5205, 6530
trocar, 32, 79, 139, 140, 267, 335, 336, 337, 687, 700, 715, 737, 741, 742, 744, 745, 746, 779, 824, 833, 1209, 1562, 1563, 1936, 1937, 1938, 1939, 1973, 1974, 1984, 1985, 2043, 2051, 2092, 2404, 2683, 2684, 2687, 2742, 2743, 2747, 2750, 2751, 2752, 2756, 2758, 2769, 2773, 2968, 2970, 2973, 2976, 2979, 3090, 3385, 3388, 4174, 4221, 4222, 4228, 4238, 4240, 4241, 4242, 4244, 4245, 4247, 4249, 4253, 4254, 4266, 4267, 4274, 4305, 4307, 4310, 4328, 4331, 4348, 4355, 4369, 4370, 4371, 4379, 4387, 4422, 4423, 4431, 4452, 4464, 4475, 4476, 4540, 4591, 4598, 4599, 4600, 4601, 4602, 5029, 5033, 5034, 5035, 5036, 5046, 5062, 5065, 5080, 5086, 5088, 5089, 5123, 5168, 5205, 5212, 5231, 5233, 5239, 5242, 5859, 6256, 6292, 6528, 6529, 6530, 6531, 6534, 6734, 6941, 7243, 7251
true equinus gait, 1779, 1780, 1781, 1787

TubeClear® System, 2031, 2082
tumor necrosis factor- α (TNF-α), 6980
tumoral injection, 2974
turbinate surgery, 1535
turner syndrome, 4787, 4795, 5758, 6555
two-hits hypotheses, 5247
type 2 diabetes mellitus, 159, 164, 177, 181, 182, 206, 238, 763, 771, 772, 2105, 2130, 2131, 2132, 2135, 2136, 2137, 2158, 2171, 2183, 2678, 2681, 2702, 2703, 2714, 2729, 2745, 2746, 3575, 3576, 5086, 5178, 5230, 5265, 5266, 5333, 5358, 5359, 5366, 5387, 5391, 5428, 7034, 7174, 7175, 7180, 7182, 7190, 7195, 7206
type 2 diabetes, 152, 159, 164, 166, 177, 178, 179, 180, 181, 182, 185, 192, 193, 194, 195, 196, 197, 198, 199, 200, 201, 202, 203, 204, 205, 206, 207, 238, 256, 763, 771, 772, 825, 841, 1445, 2105, 2119, 2120, 2130, 2131, 2132, 2133, 2134, 2135, 2136, 2137, 2156, 2157, 2158, 2159, 2160, 2162, 2163, 2166, 2167, 2168, 2170, 2171, 2172, 2173, 2174, 2175, 2176, 2179, 2180, 2181, 2183, 2184, 2185, 2187, 2678, 2681, 2682, 2702, 2703, 2714, 2729, 2745, 2746, 2775, 3356, 3365, 3575, 3576, 3725, 4529, 4534, 5086, 5178, 5180, 5230, 5248, 5265, 5266, 5273, 5282, 5333, 5358, 5359, 5360, 5362, 5366, 5374, 5387, 5391, 5415, 5418, 5428, 6367, 6977, 6978, 6987, 6988, 6989, 6990, 7028, 7030, 7034, 7130, 7170, 7171, 7174, 7175, 7180, 7182, 7190, 7195, 7200, 7201, 7202, 7206
type I endoleak, 4775, 4837, 4838
TYPE I HPL
SUPRACRICOID LARYNGECTOMY, 6974
type II endoleak, 4775, 4780, 4837
TYPE II HPL
SUPRAGLOTTIC LARYNGECTOMY, 6974
type III endoleak, 4837
TYPE III HPL
SUPRATRACHEAL LARYNGECTOMY, 6974
Type IV, 53, 1518, 1697, 1896, 3750, 4837, 4853
Type of grafts, 4744
Type V endoleak, 4837
Types of anxiety, 6333

U

UHS approach, 6464, 6470, 6500, 6505, 6522, 6754, 6756
ulceration, 144, 157, 259, 498, 499, 780, 788, 789, 792, 824, 834, 1084, 1312, 1325, 1329, 1330, 1336, 1338, 1539, 1548, 1893, 1894, 1950, 2027, 2028, 2047, 2085, 2092, 2105, 2929, 4313, 4569, 4570, 4571, 4572, 4573, 4574, 4579, 4580, 4581, 4582, 4723, 4815, 4816, 4851, 4881, 4886, 4906, 4933, 4949, 4950, 4952, 4956, 4957, 5142, 5558, 5620, 5691, 5867, 5868, 5871, 5941, 5942, 5943, 6016, 6194, 6352, 6363, 6479, 7005, 7006, 7334
ulcers, 144, 759, 760, 783, 788, 825, 840, 846, 847, 848, 1103, 1329, 1330, 1746, 1766, 1845, 1850, 1890, 1896, 1897, 1902, 1904, 2067, 2110, 2650, 2673, 2730, 2743, 2832, 3165, 3651, 4569, 4570, 4573, 4574, 4580, 4581, 4675, 4713, 4724, 4727, 4731, 4733, 4808, 4816, 4881, 4897, 4905, 4951, 4952, 4953, 4954, 4956, 5448, 5723, 5940, 5963, 5970, 6017, 6026, 6193, 6243, 6245, 6246, 6247, 7000, 7238, 7251
ultra-rapid metabolizer, 2531
ultrasound imaging, 727, 732, 1082, 1084, 1086, 1090, 3340, 3352, 3362, 3363, 3365, 3374, 3387, 3462
ultrasound-assisted percutaneous endoscopic gastrostomy, 1994
umbilical cord, 2990, 3301, 3409, 3543, 3545, 3552, 3554, 3566, 3570, 3667, 3689, 3709, 4174, 6423
unilateral iliofemoral bypass, 4825
unsatisfactory implant reconstruction, 2612, 2614
upper airway obstruction, 214, 218, 1877, 1908, 2472, 2493, 2495, 2496, 3328, 4528, 5543, 5544
upper extremity vascular disorders, 4872, 4901
upper extremity, 79, 627, 1149, 3663, 3674, 4292, 4724, 4730, 4745, 4872, 4901, 4902, 4903, 4905, 4925, 4934, 4936, 4937, 4945, 4947, 4990, 5012, 5432, 5434, 5438, 5602, 7039, 7041, 7042, 7044, 7049, 7050
upper gastrointestinal bleeding, 1329, 1902, 2021, 2067, 2075, 2101, 4580, 4581, 5379
upper gastrointestinal series, 145, 148, 149, 2700, 2746, 4574, 5181, 5952, 6998, 7003
upper hemisternotomy, 6462, 6466, 6469, 6485, 6500, 6508, 6526, 6751, 6752
upper, 6519, 6520
upsizing, 2085, 2448
urethra, 1344, 1345, 1346, 1348, 1349, 1606, 3393, 3394, 4230, 4321, 4322, 4346, 4348, 5594, 5598, 6150, 6153, 6156, 6158, 6943, 6951
urethral plate, 6149, 6153
urethral reconstruction, 6150, 6158
urethral tubularization, 6153
urethroplasty, 1603, 1604, 1606, 4343, 5758, 5760, 6152, 6153, 6158
URO Mentor, 2779
urogynecology, 4292, 4342, 4367, 4368, 4369, 4383, 4385, 4387, 4388
urologic laparoscopic training, 2775
urology, 690, 701, 711, 712, 713, 715, 728, 1220, 1294, 1341, 1346, 1355, 1585, 1607, 2761, 2764, 2774, 2784, 2788, 2790, 2792, 2793, 3023, 3134,

3140, 3145, 3146, 3151, 3153, 3156, 3182, 3243, 3332, 3705, 4324, 4337, 4338, 4339, 4340, 4341, 4342, 4343, 4345, 4360, 4361, 4362, 4363, 4364, 4365, 4366, 4367, 4394, 4434, 4693, 5595, 5639, 6045, 6158, 6390, 6407, 6941, 6952, 6953
uroradiology, 1341, 1355
ursodeoxycholic acid, 145, 4538, 4539, 4541, 4544, 5424, 5427, 5429, 7001
USA-PEG, 1990
uterine fibroids, 3191, 7118, 7123, 7125
uterine injury, 7117, 7120, 7123, 7125
uterine rupture, 4488, 7117, 7118, 7119, 7122, 7123, 7124, 7125, 7126
uterine wound, 7117, 7118, 7120, 7122, 7126
uterosacral ligament suspension, 4379, 4380, 4392, 4393, 4478
uterus, 259, 1601, 1604, 3184, 3194, 3391, 3585, 3600, 3667, 3695, 3697, 3712, 3717, 4222, 4378, 4379, 4380, 4392, 4407, 4423, 4424, 4425, 4427, 4445, 4472, 4473, 4474, 4475, 4477, 4478, 4485, 4486, 4487, 6030, 6035, 6036, 6037, 6304, 7117, 7118, 7119, 7121, 7122, 7125, 7126

V

valve conduit, 6560, 6561, 6562, 6565, 6567
varices, 1243, 1246, 1301, 1302, 1303, 1320, 1891, 1892, 1903, 1990, 1994, 2369, 2370, 2377, 3183, 3184, 4767, 4971, 6477, 6630, 6632, 6654, 6655, 6656, 6660, 6717
varicose vein surgery, 4957
varicose veins, , 627, 3179, 4730, 4731, 4732, 4733, 4737, 4749, 4921, 4950, 4951, 4952, 4953, 4954, 4956, 4958, 4959, 4960, 4962, 4963, 4964, 4965, 4967, 4971, 4972, 4973
vascular endothelial growth factor, 995, 1867, 2160, 2904, 3020, 3021, 3341, 3348, 3499, 3560, 3579, 3710, 6058, 6413, 6607, 7120, 7124, 7125, 7126
vascular graft, 2997, 3635, 3645, 4721, 4744, 4745, 4746, 4890, 4898, 4909, 5009, 6154, 6708, 6710
vascular pathophysiology, 1631, 1632, 1645
vascular postoperative complications, 4975
vascular resection, 1594, 5810, 5819, 5835, 5839
vascular ring, 4756, 4757, 4758, 4783, 7270, 7272
vascular trauma, 1073, 4810, 4911, 4912, 4914, 4915, 4917, 4918, 4924, 4925, 4928, 4929, 4930, 4931
vasogenic edema, 1173, 1177, 1183, 3766, 3767, 3776, 3852, 3853, 3854, 3946
vasospasm, 881, 882, 884, 922, 923, 924, 925, 937, 939, 962, 967, 971, 972, 973, 976, 979, 980, 982, 983, 984, 985, 986, 987, 988, 989, 990, 991, 992, 993, 994, 995, 998, 1001, 1002, 1014, 1015, 1016, 1017, 1019, 1020, 1023, 1028, 1030, 1043, 1066, 1067, 1069, 1070, 1071, 1072, 1073, 1074, 1075, 1076, 1077, 1081, 1419, 1614, 2637, 2655, 2675, 3025, 3622, 3777, 3816, 3817, 3825, 3895, 4017, 4037, 4903, 6089, 6100, 6108, 6181, 6581, 6582, 6583, 6584, 6585, 6586, 6588, 6593, 6594, 6596, 6597, 6598, 6600, 6601, 6602, 6604, 6605, 6606
Vaughan Williams' antiarrhythmic drugs classification, 7287
vegetative survivors, 3949, 3952, 3955, 4110
vegetative, 922, 924, 1038, 1843, 1844, 3766, 3805, 3836, 3860, 3949, 3952, 3955, 3959, 3960, 3968, 3973, 3979, 3980, 3982, 3983, 3984, 3985, 4045, 4046, 4049, 4051, 4055, 4093, 4095, 4096, 4100, 4110, 4111, 4113, 4114, 4125, 4126, 4130, 4131
velopharyngeal insufficiency, 2484, 5537, 5538
VenaSeal closure system, 4962
venoactive drugs, 4955, 4956
venous clinical severity score, 4952
venous disability score, 4953
venous disease, 1084, 4723, 4729, 4731, 4734, 4736, 4749, 4934, 4941, 4949, 4950, 4951, 4952, 4956, 4963, 4970, 4972
venous reflux, 4736, 4950, 4952, 4965
venous segmental disease score, 4953
venous stasis ulcers, 4730, 4733
venous thromboemboli, 142, 157, 420, 1863, 2638, 2650, 2656, 2673, 2719, 2727, 4039, 4042, 4043, 4408, 4505, 4506, 4507, 4508, 4509, 4530, 4931, 5143, 6001, 6003, 6019, 6021, 6027, 6239, 6241, 6243, 6246, 6247, 6248, 6249, 6262, 7005, 7263, 7264, 7265, 7266, 7267
venous thromboembolism, 142, 157, 420, 1863, 2638, 2650, 2656, 2673, 2719, 2727, 4039, 4042, 4043, 4408, 4505, 4506, 4507, 4508, 4509, 4530, 5143, 6001, 6003, 6019, 6027, 6241, 6243, 6247, 6248, 6249, 6262, 7005, 7263, 7264, 7265, 7266, 7267
venous thromboembolus, 6002
venting, 1540, 1541, 1848, 1852, 1853, 1854, 1855, 1858, 1859, 1958, 1959, 2009, 2010, 2011, 2096, 4768, 6485, 6490, 6491, 6492, 6529, 6534, 6566, 6736, 6753, 6776
ventral rectopexy, 4382, 4393
ventricular assist device, 1984, 3450, 3454, 3464, 3465, 3474, 3475, 3477, 3629, 5913, 5933, 5936
ventricular drain, 938, 943, 983, 1019, 1020, 1021, 1023, 1024, 1620, 3855, 3869, 3889, 3911, 3958
ventricular-peritoneal (VP) shunt, 1984
ventriculoperitoneal shunt, 1019, 1021, 1024, 1025, 3865, 4001, 4085

ventriculostomy, 943, 944, 1019, 1021, 1023, 1024, 3134, 3396, 3822, 3828, 4023, 4026, 4035
vertebral body augmentation, 348, 6221, 6224, 6225
Vertical Partial Laryngectomy (VPL) Hemilaryngectomy, 6965, 6966, 6967
vertical sleeve gastrectomy, 140, 157, 222, 841, 1995, 2681, 2775, 4305, 4311, 6355, 6356, 6359, 6360, 6361, 6365, 7005, 7011, 7035
very low density lipoprotein, 3759, 5273
Vesicouterine Fistula, 4384, 4386, 4394
vestibular schwannomas, 7319, 7320, 7325
VHI-10, 5506, 5507, 5508, 5510, 5512
viability assessment, 3504, 3534
video assisted thoracoscopic techniques and robotic surgery, 6611, 6613
video trainers, 2775, 2777
videoangiography, 963, 965, 1631, 1632, 1633, 1636, 1637, 1639, 1640, 1642, 1643, 1644, 1645, 1646, 1647, 1648, 1649, 1650, 1651, 1653, 1654, 1656, 1659, 1662, 1663
Villalta scale, 4954
VIPAR system, 3244
viral diseases, 3286, 3567
virtual model of the hip, 2223, 2250, 2257
virtual models, 684, 708, 2223, 2249, 2253, 2254, 2257, 2261, 2262, 2267
virtual reality models, 2769
virtual reality, 680, 2769, 2770, 2777, 2778, 2780, 2786, 2788, 2790, 2791, 2793, 3145, 3146, 3149, 3251, 3252, 3253, 3255, 3257, 3258, 3906, 4026, 4465, 6395, 6407, 6637, 6638, 7038, 7049, 7050
virtual surgery, 2786, 3469, 5881, 5884, 5888, 5889, 5890, 5891, 5894, 5903
virtual-reality trainer, 2767
visceral ischemia, 3717, 4813, 4835, 4981, 4984
viscocanalostomy, 6890, 6898
visual field deterioration, 6881, 6883
vitamin E, 225, 1768, 2110, 5369, 5392, 5419, 5420, 5423, 5424, 5426, 5428, 5429, 6180
vitamin K, 223, 258, 1030, 1519, 1863, 2107, 2112, 2804, 2889, 2904, 5917
vivisection, 3240, 3249, 3252, 3253, 3255
voice therapy, 5505, 5506, 5507, 5508, 5509, 5510, 5511, 5512, 5513
volatile agents, 2718, 7274
vulvar cancer, 4422, 4432, 5474
vulvar reconstruction, 5471, 5473, 5474

W

war, 883, 1348, 2717, 2917, 3160, 3169, 3170, 3180, 3183, 3192, 3193, 3194, 3196, 3197, 3203, 3649, 3980, 4011, 4012, 4013, 4019, 4023, 4024, 4029, 4030, 4033, 4034, 4035, 4040, 4041, 4634, 4875, 4925, 5012
warfarin, 1519, 1863, 1864, 1923, 2033, 4967, 5920
water balance, 3316, 3317, 3332, 3333
weaning, 1024, 1039, 1042, 1043, 1045, 1047, 1049, 1050, 1054, 1622, 3397, 3431, 3904, 4058, 5459, 6478, 6503, 6719, 6723, 6748, 6754, 6764, 6770, 7277, 7302
weight implant, 6438, 6439
weight regain rate, 2691, 2694
weight regain, 147, 243, 247, 248, 251, 759, 761, 765, 766, 774, 780, 790, 801, 803, 805, 811, 812, 813, 814, 823, 824, 827, 828, 829, 839, 840, 841, 843, 850, 851, 857, 865, 866, 869, 870, 871, 872, 874, 2121, 2123, 2132, 2139, 2164, 2175, 2689, 2690, 2691, 2692, 2693, 2694, 2695, 2696, 2697, 2698, 2699, 2700, 2701, 2702, 2703, 2705, 2706, 2708, 2714, 4313, 4547, 5204, 5360, 5363, 5378, 5381, 6979, 7012, 7139, 7141, 7145, 7149, 7177, 7187, 7189, 7190, 7191, 7194, 7200, 7202, 7203, 7204, 7205, 7207
Wenkebach, 7280
western diet, 5273, 5276, 5282, 5421, 7179
white matter fibers, 7098, 7112
white matter, 900, 901, 1167, 1173, 1176, 1182, 1188, 3371, 3667, 3688, 3690, 3691, 3698, 3772, 3779, 3812, 3842, 3849, 3953, 4127, 4131, 4136, 7097, 7098, 7100, 7112, 7113
WHO AB thymoma. This was removed by VATS, 5861
WHO B2 thymoma. This was removed by VATS, 5861
Willis circuit, 4764, 4775, 4796
wound dressing, 1752, 2047, 2053, 4698, 4710, 4712, 4713, 4714, 4715, 4716, 6749
wound irrigation, 4671, 4672, 4675, 4676, 4677, 4678, 4679, 4680, 4681, 4682, 4684, 4685, 4686, 4694, 7261
wound management, 1573, 2676, 4671, 4672, 4674, 4675, 4676, 4678, 4682
wound physiology, 3009
wounding, 2116, 3009, 3010, 3011, 3015, 3016

X

xenogeneic, 2999, 3000, 3294, 3404, 3543, 3544, 3548, 3629, 3641, 3660, 3721, 3722, 3723, 3727, 3728, 3729, 3730, 3731, 3755
xenograft models, 2897, 2899, 2900, 2956, 2966, 2967, 2969, 2976, 3438, 3445
xenograft(s), 1525, 1596, 1734, 2575, 2897, 2899, 2900, 2901, 2940, 2941, 2944, 2945, 2956, 2962, 2963, 2964, 2965, 2966, 2967, 2968, 2969, 2974,

2976, 2977, 2978, 2980, 3342, 3350, 3356, 3362, 3367, 3369, 3373, 3400, 3401, 3403, 3438, 3445, 3446, 3540, 3560, 3566, 3574, 3639, 3640, 3642, 3645, 3660, 3725, 3730, 3737, 3740, 3741, 3743, 4745, 4827, 4946, 6430, 6709
xenotransplantation, 2936, 3007, 3268, 3276, 3291, 3292, 3297, 3298, 3301, 3400, 3401, 3405, 3433, 3443, 3608, 3611, 3613, 3628, 3629, 3638, 3640, 3641, 3642, 3643, 3644, 3645, 3722, 3725, 3731, 3732, 3733, 3736, 3738, 3739, 3741, 3742, 3743, 3744, 3761, 3762, 3763
XX DSD, 5757, 5762, 5765

Y

years isolated hepatic perfusion, 3509
Yorkshire, 2389, 2580, 3294, 3431

Z

zero error incidence, 7296
Zeus robotic surgical systems, 4398
Zeus, 711, 3129, 3130, 3131, 3146, 3147, 3152, 4319, 4398, 4399, 6639, 6758
ZEUS® Surgical System, 692, 696
zinc deficiency, 1769, 2112, 2113, 6345, 6346, 6347, 6348, 6349, 6350, 6351, 6352, 6358, 6359, 6360, 6361, 6363, 6364, 6365, 6366, 6368, 6369, 6370, 6371, 6372
zinc oxide, 2031, 2085
zinc, 165, 168, 180, 348, 1769, 2031, 2085, 2103, 2107, 2112, 2113, 2115, 2116, 2117, 3289, 3338, 3354, 4717, 6345, 6346, 6347, 6348, 6349, 6350, 6351, 6352, 6357, 6358, 6359, 6360, 6361, 6362, 6363, 6364, 6365, 6366, 6368, 6369, 6370, 6371, 6372, 7023, 7028, 7032, 7033, 7313
Zollinger-Ellison syndrome, 1236, 1329, 1330, 1896

Encyclopedia of Surgery

(22 Volume Set)

Andreas Lehrer
Kristin Mueller
Editors

nova science publishers

www.novapublishers.com

ISBN 978-1-53618-329-0

本书版权归Nova Science所有